

# ESTHETIC DENTISTRY

A CLINICAL APPROACH TO TECHNIQUES AND MATERIALS



انتشارات شایان نمودار

# ESTHETIC DENTISTRY

A CLINICAL APPROACH TO TECHNIQUES AND MATERIALS

**Kenneth W. Aschheim, DDS, FACD**

Assistant Clinical Professor, Department of Dentistry  
Mount Sinai School of Medicine of New York University  
Assistant Attending Dentist, The Mount Sinai Hospital  
Private Practice  
New York, New York

**Barry G. Dale, DMD, FACD**

Assistant Clinical Professor, Department of Dentistry  
Mount Sinai School of Dental Medicine of New York University  
Assistant Attending Dentist, The Mount Sinai Hospital  
New York, New York  
Private Practice  
Englewood, New Jersey

SECOND EDITION

With 975 illustrations

 **Mosby**

*A Harcourt Health Sciences Company*

St. Louis Philadelphia London Sydney Toronto



انتشارات شایان نمودار



A Harcourt Health Sciences Company

Editor-in-Chief: John Schrefer  
Editor: Penny Rudolph  
Developmental Editor: Kimberly Frare  
Project Manager: Linda McKinley  
Senior Production Editor: Rene S. Saller  
Design Manager: Amy Buxton  
Designer: Michael Warrell

SECOND EDITION

Copyright© 2001 by Mosby, Inc.

Previous edition copyrighted 1993.

All rights reserved. No part of this publication may be reproduced, stored in a retrieval system, or transmitted, in any form or by any means, electronic, mechanical, photocopying, recording, or otherwise, without prior written permission from the publisher.

Permission to photocopy or reproduce solely for internal or personal use is permitted for libraries or other users registered with the Copyright Clearance Center, provided that the base fee of \$4.00 per chapter plus \$.10 per page is paid directly to the Copyright Clearance Center, 222 Rosewood Drive, Danvers, MA 01923. This consent does not extend to other kinds of copying, such as copying for general distribution, for advertising or promotional purposes, for creating new collected works, or for resale.

Printed in the United States of America.

Mosby, Inc.  
11830 Westline Industrial Drive  
St. Louis, Missouri 64146

Library of Congress Cataloging in Publication Data

Esthetic dentistry : a clinical approach to techniques and materials / [edited by] Kenneth W Aschheim, Barry G. Dale.-2nd ed.

p. ; cm.

Includes bibliographical references and index.

ISBN 0-323-00162-9 (hard cover)

1. Dentistry-Aesthetic aspects. I. Aschheim, Kenneth W II. Dale, Barry G.

[DNLM: 1. Esthetics, Dental. 2. Dental Materials. 3. Dental Restoration, Permanent.

WU 100 E79 2000]

RK54 .E88 2000

617.6-dc21

00-048046

01 02 03 04 05 OW / KPT 9 8 7 6 5 4 3 2 1



# CONTRIBUTORS

Fred B. Abbott, DDS, MDS, FACD  
Life Member, American College of  
Prosthodontics  
Former Associate Professor  
Northwestern University  
School of Dentistry  
Chicago, Illinois  
Practice Limited to Prosthodontics  
Salisbury, Maryland

Nellie Abbott, PhD, RN  
Former Associate Administrator  
Nursing Hospital of University of  
Pennsylvania  
Former Associate Dean  
Nursing Practice  
University of Pennsylvania  
School of Nursing  
Philadelphia, Pennsylvania

Milton B. Asbell, DDS, MSc, MA  
Clinical Associate Professor  
Department of Community  
Dentistry  
Temple University  
School of Dentistry  
Staff, Department of Dental  
Medicine  
Einstein Medical Center  
Philadelphia, Pennsylvania

Jerry B. Black, DMD, MS, FACD  
Private Practice  
Birmingham, Alabama

Phillip Bonner, DDS  
President  
Bonner Communications, Inc.  
Atlanta, Georgia

Daniel Buchbinder, MD, DMD  
Professor of Oral, Maxillo-Facial  
Surgery and Otolaryngology  
Department of Dentistry  
Division of Oral, Maxillo-Facial  
Surgery  
Mount Sinai School of Medicine  
Head, Division of Oral, Maxillo-  
Facial Surgery  
Department of Dentistry  
Mount Sinai Medical Center  
New York, New York

Trudy M. Burke, DDS, MS  
Clinical Assistant  
Department of Restorative and  
Prosthodontic Sciences  
New York University  
College of Dentistry  
New York, New York

Vincent Celenza, DMD  
Diplomate  
American Board of Prosthodontics  
Private Practice  
Manhattan, New York

Charles I. Citron, DDS, MScD  
Director of Pediatric Dentistry  
Dental Department  
New York Hospital Medical Center  
of Queens  
Queens, New York

David R. Federick, DMD, MScD  
Adjunct Associate Professor  
Department of Fixed Prosthodontics  
University of Texas  
School of Dentistry  
Houston, Texas  
Adjunct Clinical Assistant Professor  
Department of Restorative Dental  
Sciences  
Boston University, Goldman School  
of Dental Medicine  
Boston, Massachusetts

Mark Edward Jensen, BS, MS, DDS,  
PhD, FACD, FADM, CBGD, DABFD  
Director  
Minnesota Dental Research  
Associates  
St. Paul, Minnesota

Mark P King, DDS, MS  
Assistant Professor  
University of Texas, Dental Branch  
Houston, Texas

Richard J. Lazzara, DMD, MScD  
Assistant Professor  
Department of Periodontics and  
Implant Regeneration  
University of Maryland  
Baltimore, Maryland

Enrique Lenchewski, DDS  
Assistant Clinical Professor  
Department of Implant Dentistry  
New York University  
New York, New York  
Assistant Attending  
Department of Dentistry  
Mount Sinai Medical Center  
New York, New York

Charles Andrew Lennon, DMD  
Assistant Attending Dentist  
(Prosthodontist)  
Oral and Maxillofacial  
Reconstructive Department  
New York Hospital  
New York, New York



- Edward C. McNulty, DMD, MDS,  
FACD, FICD  
Clinical Associate Professor  
Chairman, Orthodontic  
Department  
New York University  
College of Dentistry  
New York, New York  
Co-Chief, Orthodontic Division  
Department of Surgery (Dental)  
Lenox Hill Hospital  
New York, New York  
Senior Attending Staff  
Dental Clinic  
Greenwich Hospital  
Greenwich, Connecticut
- Richard D. Miller, DDS, FICD  
Former Associate Clinical Professor  
Division of Restorative and  
Prosthodontic Sciences  
New York University  
College of Dentistry  
New York, New York  
Attending Staff  
Department of Surgery-Section of  
Oral Surgery  
Greenwich Hospital  
Greenwich, Connecticut
- Ross W. Nash, DDS  
Clinical Instructor  
Department of Restorative  
Dentistry  
Medical College of Georgia  
School of Dentistry  
Augusta, Georgia
- Francis V Panno, BS, DDS, FACP,  
FICD, FACD  
Professor and Head  
Division of Restorative and  
Prosthodontic Sciences  
New York University  
New York, New York  
Professor and Chairman  
Department of Prosthodontics and  
Occlusion  
New York University  
College of Dentistry  
New York, New York
- Mitchell S. Pines, DDS  
Clinical Professor  
Department of Dental Materials  
Science  
Graduate School of Arts and  
Sciences  
New York University  
New York, New York
- Burton R. Pollack, DDS, MPH, JD  
Dean and Professor  
School of Dental Medicine  
SUNY at Stony Brook  
Stony Brook, New York
- Stephan S. Porter, DDS, MSD, MS  
Director of Clinical Dentistry  
Implant Innovations  
Palm Beach Gardens, Florida
- Gregory E. Rauscher, MD  
Professor  
Department of Plastic Surgery  
Hackensack University Medical  
Center  
Hackensack, New Jersey  
Professor  
Department of Plastic Surgery  
University of Medicine and Den-  
tistry of New Jersey  
University Hospital  
Newark, New Jersey
- Edwin S. Rosenberg, BDS,  
H.Dip.Dent., DMD  
Professor  
Department of Implant Dentistry  
New York University  
School of Dental Medicine  
New York, New York
- Bruce A. Singer, BS, DDS  
Clinical Assistant Professor  
Department of General Restorative  
Dentistry  
University of Pennsylvania  
School of Dental Medicine  
Philadelphia, Pennsylvania  
Albert Einstein Medical Center,  
North Division  
Jenkintown, Pennsylvania
- Robert A. Strauss, DDS  
Associate Professor and Chief, Resi-  
dency Training Program  
Department of Oral and  
Maxillofacial Surgery  
Medical College of Virginia  
Virginia Commonwealth University  
Richmond, Virginia
- Van P Thompson, DDS, PhD  
Associate Dean for Research  
Department of Prosthodontics and  
Biomaterials  
University of Medicine and Den-  
tistry of New Jersey  
Newark, New Jersey
- James Torosian, DMD  
Assistant Professor  
Department of Periodontics  
Temple University  
School of Dentistry  
Philadelphia, Pennsylvania
- Richard D. Trushkowsky, DDS,  
FAGD, FADM  
Director of Operative Dentistry  
Dental Department  
Staten Island University Hospital  
Staten Island, New York
- Michel G. Venot, DCD, DDS,  
MScD, FICD  
Adjunct Associate Professor  
Department of Restorative  
Dentistry  
Case Western Reserve University  
School of Dentistry  
Cleveland, Ohio  
Staff Maxillofacial Prosthodontist  
Department of Dental Service  
Veteran Administration Medical  
Center  
Cleveland, Ohio
- Morton Wood, DDS, MEd  
Chairman  
Department of Restorative  
Dentistry  
University of Maryland  
Dental School  
Baltimore, Maryland
- Ira D. Zinner, DDS, MSD  
Diplomate, American Board of  
Prosthodontics  
Fellow, American College of  
Prosthodontists  
Clinical Professor  
Division of Restorative and  
Prosthodontic Sciences  
New York University  
College of Dentistry  
New York, New York



# FOREWORD

---

The change in dentistry from need-based dentistry to elective dentistry has made a significant impact on the profession and the public perception of dentists. It is estimated that up to one half of the dentistry accomplished at this time is elective. Much of this treatment is what would be considered to be esthetic dentistry including bleaching, bonding, veneers, tooth-colored inlays and onlays, nonmetallic crowns and fixed prostheses, orthodontics, surgical procedures, and many other procedures.

Dentists and their staff must be proactive in their patient educational activities to stimulate patients to desire these elective procedures. If dentists wait for patients to

ask for the procedures, practice activity can be influenced negatively.

Many of the procedures in current esthetic dentistry are not taught or are taught minimally in dental schools because of the shortage of curriculum time. Practitioners must learn many of these clinical concepts and techniques independently after dental school graduation.

This book will assist interested persons in becoming updated in the broad scope of esthetic dentistry. Self-instruction is perhaps the best way to cope with the expanding area of esthetic dentistry.

GORDON J. CHRISTENSEN, DDS, MSD, PhD

*In memory of my parents, David and Edith Aschheim; together they pointed me in the right direction. And to my wife, Susan, her parents, Herb and Edith Margulis, and my children, Sara and Joshua, without whom I could not continue to find the way. KWA*

*To my parents, Jack and Frances Dale, who built a strong foundation, and to my wife, Ellen, my son, Adam, and my daughter, Chelsea, who assure me the stars. BGD*

# PREFACE

Dental restorations exhibiting exquisite esthetics and physiologic function are well within the province of today's dentist. However, either most of the information in the vast area of esthetic dentistry has changed dramatically since the education of most practitioners, or the information was simply unavailable during their formal dental training. In fact, the myriad choices of techniques and materials available initially may appear overwhelming. In reality, when properly organized, this body of knowledge is easily managed. This, then, was the challenge in preparing this book: to create a definitive, all-encompassing, single source of information presented in a clinically relevant, easy-to-use format.

Resolution of a cosmetic dental problem requires the practitioner to determine a diagnosis, formulate a treatment plan, and select the appropriate instruments and materials. Treatment must then be performed in an orderly fashion with an understanding of proper clinical technique and specific material manipulations. The competent clinician approaches any cosmetic dilemma in this manner. We therefore organized this text to duplicate this sequence of thought processes and clinical operations.

A troubleshooting guide (Section I) quickly directs the practitioner to appropriate information in this textbook. It permits diagnosis and treatment planning at a glance and provides cross-references to more detailed discussions of material selection and clinical technique.

Section II, "Principles of Esthetics," lays the foundation of basic esthetic principles. A detailed discussion of the fundamentals of esthetics and the relevancy to dentistry is presented. The principles are referred to throughout the textbook to link clinical relevancy to basic theory.

Section III, "Esthetic Materials and Techniques," aids in selecting the correct materials for a specific clinical situation. The concise discussion of basic material science

enables the clinician to fully understand the ramifications of using the various materials currently available. Further, this serves as a basis of comparison, enabling an effective evaluation of new materials as they are introduced. Detailed step-by-step clinical techniques delineate appropriate armamentarium and include specific procedural nuances and numerous highlighted Clinical Tips. This facilitates a sound clinical approach. Also included is a comprehensive discussion of special considerations, indications, and contraindications for each technique and material presented, as well as numerous case presentations.

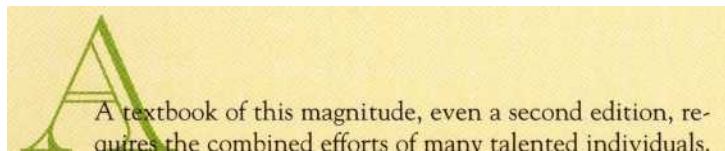
Section IV, "Esthetics and Other Clinical Applications," is a specialty-oriented section that presents an overview of other clinical applications by eminent practitioners. Included are such dental specialties as orthodontics, periodontics, and oral and maxillofacial surgery. Also included are emerging fields such as implantology, implant surgery, and laser surgery as well as other clinically relevant topics such as dental photography and plastic surgery. The clinical relevance to the esthetic dentist is stressed by using case studies, sample laboratory prescriptions, office forms, and clinical techniques. Advanced techniques and criteria are presented to aid the dentist in determining when to refer a patient for specialty care.

Section V, "Esthetic Practice Management," details important patient psychology, marketing, and jurisprudence information. Today's clinician will find this section helpful in meeting the challenges facing dentistry and in managing a successful dental practice.

As our profession enters the twenty-first century, esthetic dentistry offers a new era of doctor and patient satisfaction and excitement. We hope we have shared our own enthusiasm in the pages of this text.

KENNETH W ASCHHEIM, DDS, FACD  
BARRY G. DALE, DMD, FACD

# ACKNOWLEDGMENTS



A textbook of this magnitude, even a second edition, requires the combined efforts of many talented individuals.

We are grateful to the pioneers of esthetics who have preceded us. We owe an enormous debt to the gifted clinicians of today who seek to expand the envelope of knowledge. These people are our contributors. Without their willingness and ability to surpass all expectations and their sharing in the common goal of creating a "state-of-the-art" text, this volume would not be possible.

First and foremost, we wish to thank our esteemed contributors. Their enormous effort is greatly appreciated. We feel privileged to have had the opportunity to work closely with such talented individuals. We are grateful to Dr. Rella Christensen and the Clinical Research Associates Staff for generously providing the resource list. We also would like to extend special thanks to Dr. Gordon Christensen for honoring us by contributing the foreword.

We were particularly impressed with each and every one of the individuals we had the pleasure of working with at Mosby/Harcourt. They all exhibited the highest degree of professionalism, while at the same time maintaining a sense of humor and good will during this arduous task. We are greatly indebted to Penny Rudolph and Linda Duncan and the executives at Mosby/Harcourt for agreeing to undertake the second edition. We also want to thank Kimberly Frare, our developmental editor, and Rene Saller, our production editor, who kept us on track after we were continuously faced with the realization that in 6 years we had forgotten just how much work went into producing a textbook. We would also like to thank Amy Buxton, our designer, and the entire production department who took a manuscript and some photographs and created a true work of art. In addition, we wish to thank everyone else at Harcourt, from Marketing to Production, from the Art Department to the Editorial Department, without whose efforts this book could not have been a success.

We also wish to thank all the laboratory technicians and manufacturers' representatives who supplied us with much of the necessary technical information. We must extend a special thank you to Adrian Jurim at Jurim Dental Studios; the late Jack Karp, Beth Karp, and Arthur Saltzman at Americus Dental Labs; Zwe Padeh at Studio 46; and Steven Pigiaccelli and Eva Pop of Marotta Dental

Studio, our reservoirs of information for some of the laboratory aspects of dental esthetics. An additional thank you goes to Barry Mermelstein and Fred Gebert of Patterson, Inc., and Benco, Inc., and Cliff Marsh of J and B Dental Services and Supply for providing us with information about many of the products in this textbook.

A special note of gratitude goes to Debbie Baer, Evelyn Rosa, Wandee Gonzales, Diane Korn, Catherine Hill, Rachele DiMaso, and Millie Errante, as well as former and present dental assistants and office managers who helped "mind the store" while we worked on the book and also aided us in compiling many of the clinical cases necessary for this text. We also owe particular gratitude to Dr. Jack Hirsch, who, despite seeing his office overrun twice with "bookwork," was still able to provide much appreciated insight and guidance. An additional thank you to Ellen Horowitz Dale and Eric Zaidins, Esq., for their advice and counsel.

We owe much to our colleagues at the Department of Dentistry of The Mount Sinai/NYU Medical Center for their continued support and guidance, especially Dr. Jack Klatell, Dr. Daniel Buchbinder, and the attending and support staff for providing the resources and encouragement necessary to produce this text.

A note of appreciation must be extended to our medical illustrator, Caroline Meinstein, whose first edition illustrations stood the test of time. Her good spirits, combined with her excellent technical skills, were an integral part of conveying many of the techniques illustrated in the book.

Finally, we wish to thank our families. After 4 years of work on the first edition, they still gave us 4 more years of support and encouragement to allow us to update this textbook. Their unwavering love, encouragement, and moral support not only made our lives easier but was ultimately the most important force ensuring a successful result.

This is not merely a book of our experiences with dental esthetics but a work of the combined experiences of all of the above. Through their efforts, we hope we have been able to describe the state of esthetic dentistry today and perhaps lay a basic framework for the esthetic dentist of tomorrow.

Kenneth W. Aschheim, DDS, FACD  
Barry G. Dale, DMD, FACD



# CONTENTS

## SECTION ONE TROUBLESHOOTING

TROUBLESHOOTING GUIDE, 1

## SECTION TWO PRINCIPLES OF ESTHETICS

1 INTRODUCTION TO ESTHETICS, 23

*Milton B. Asbell*

2 FUNDAMENTALS OF ESTHETICS, 27

*Bruce A. Singer*

## SECTION THREE ESTHETIC MATERIALS AND TECHNIQUES

3 DENTIN BONDING AGENTS, 41

*Mark E. Jensen*

4 COLOR MODIFIERS AND OPAQUERS, 53

*Jerry B. Black*

5 COMPOSITE RESIN: FUNDAMENTALS AND DIRECT TECHNIQUE RESTORATIONS, 69

*Richard D. Trushkowsky*

6 COMPOSITE RESIN: INDIRECT TECHNIQUE RESTORATIONS, 97

*Ross Nash*

7 CERAMOMETAL: FULL COVERAGE RESTORATIONS, 113

*Ira D. Zimmer*

*Francis V. Panno*

*Richard D. Miller*

*Mitchell S. Pines*

*Trudy M. Burke*

8 PORCELAIN: FULL COVERAGE RESTORATIONS, 137

*Vincent Celenza*

*Charles A. Lennon*

9 PORCELAIN LAMINATE VENEERS AND OTHER PARTIAL COVERAGE RESTORATIONS, 151

*Kenneth W Aschheim*

*Barry G. Dale*

10 ADHESIVE RESIN BONDED CAST RESTORATIONS, 185

*Morton Wood*

*Van Thompson*

11 ACRYLIC AND OTHER RESINS: PROVISIONAL RESTORATIONS, 199

*David R. Federick*

12 ACRYLIC AND OTHER RESINS: REMOVABLE PROSTHESES, 227

*Michel G. Venot*

13 BLEACHING AND RELATED AGENTS, 247

*Barry G. Dale*

*Kenneth W Aschheim*

## SECTION FOUR ESTHETICS AND OTHER CLINICAL APPLICATIONS

14 ESTHETICS AND ORAL PHOTOGRAPHY, 269

*Kenneth W. Aschheim*

*Mark P. King*

15 ESTHETICS AND ELECTROSURGERY, 289

*Mark P. King*

16 ESTHETICS AND IMPLANT PROSTHETICS, 301

*Richard J. Lazzara*

*Stephan S. Porter*

17 PEDIATRIC DENTISTRY, 329  
*Charles I. Citron*

18 ESTHETICS AND PERIODONTICS, 349  
*Edwin S. Rosenberg*  
*James Torosian*

19 ESTHETICS AND ORTHODONTICS, 379  
*Edward C. McNulty*

20 ESTHETICS AND ORAL AND MAXILLOFACIAL SURGERY, 411  
*Daniel Buchbinder*

21 ESTHETICS AND IMPLANT SURGERY, 429  
*Enrique Lenchewski*

22 ESTHETICS AND LASER SURGERY, 441  
*Robert A. Strauss*

23 ESTHETICS AND PLASTIC SURGERY, 451  
*Gregory E. Rauscher*

24 ESTHETICS AND ADVANCED TECHNOLOGY, 459  
*Kenneth W Aschheim*

SECTION FIVE ESTHETIC PRACTICE  
MANAGEMENT

25 ESTHETICS AND PSYCHOLOGY, 485  
*Fred B. Abbott*  
*Nellie Abbott*

26 ESTHETICS AND DENTAL MARKETING, 499  
*Phillip Bonner*

27 ESTHETICS AND DENTAL JURISPRUDENCE, 509  
*Burton R. Pollack*

SECTION Six APPENDIXES

App A CUSTOM STAINING, 523  
*Kenneth W Aschheim*  
*Barry G. Dale*

App B NINETY-SECOND RUBBER DAM  
PLACEMENT, 531  
*Barry G. Dale*

App C SMILE ANALYSIS, 541  
*Barry G. Dale*  
*Kenneth W Aschheim*

App D SAMPLE LEGAL FORMS, 543

App E LIST OF MANUFACTURERS, 555

INDEX, 583

# I

SECTION ONE

---

## TROUBLESHOOTING GUIDE



انتشارات شایان نمودار

# TROUBLESHOOTING GUIDE

**T**HIS EFFICIENT treatment planning aid cross references each of the following esthetic problems to the appropriate chapter or chapters, which provide more detailed technique and material information.

The guide is divided into the following categories:

## Tooth Related Problems

---

### ***Size and Shape Problems***

- Abrasion, 3
- Aged teeth-worn, 3
- Anterior tooth-chipped or fractured, 3
- Attrition, 3
- Chipped tooth, 3
- Erosion, 4
- Extruded tooth, 4
- Feminine teeth-excessive, 4
- Fractured tooth, 4
- High smile line, 5
- Large tooth, 5
- Long tooth, 5
- Malformed teeth-mild, 5
- Malformed teeth-severe, 6
- Masculine teeth-excessive, 6
- Narrow tooth, 6
- Peg lateral incisor, 6
- Short tooth, 6
- Small tooth, 7
- Wide tooth, 7

### ***Position Problems***

- Anterior flared teeth-major, 7
- Anterior flared teeth-minor, 7
- Crowding, 7-8
- Diastemata, 8
- Excessive spacing, 8
- Extruded tooth, 8
- High smile line, 9
- Long tooth, 9
- Midline disharmony, 9-10
- Migrated teeth, 10
- Multiple diastemata, 10
- Open bite-mild, 10
- Open bite-severe, 10
- Overbite/overjet, 10
- Spacing, 10-11
- Traumatic injury-luxation, 11

**Coloring Problems**

- Aged (dark) teeth, 11
- Coloration, 11
- Congenital discoloration, 11
- Discoloration, 11-12
- Endemic fluorosis, 12
- Endodontic discoloration, 12
- Fluorosis, 12
- Post-endodontic discoloration, 12-13
- Staining, 13
- Tetracycline discoloration, 13
- Tooth color-too dark, 13
- Tooth color-too light, 13-14
- Traumatic discoloration, 14
- White spots, 14

**Missing Teeth**

- Migrated teeth-multiple, 14
- Migrated tooth-single, 15
- Multiple missing teeth, 15
- Single missing tooth, 15
- Traumatic injury-avulsion, 15

**Caries**

- Carious restoration margins, 15
- Carious tooth, 15

**Repairs**

- Acrylic veneer facing-dislodgment, 16
- Carious restoration margins, 16
- Porcelain fractures-ceramometal-full coverage restorations, 16

**Non-Tooth-Related Problems****Periodontal Problems**

- Gingival asymmetry, 16
- Gingival hypertrophy, 16

- Gingival inflammation, 16
- Gingival recession, 16
- High frenum attachment with or without diastema, 16
- High smile line, 16
- Mobile teeth, 16

**Dermatologic Problems**

- Aging, 17
- Bruising, 17
- Scars, 17
- Wrinkles, 17

**Facial Contours and Skeletal Problems**

- Asymmetry, 18
- Bimaxillary prognathism/protrusion, 18
- Excessive lip support, 18
- Facial asymmetry, 18
- Hypogenia, 18
- Insufficient lip support, 18
- Macrogenia problem, 18
- Mandibular prognathism/protrusion, 18
- Mandibular retrognathism/retrusion, 19
- Maxillary prognathism/protrusion, 19
- Maxillary retrognathism/retrusion, 19
- Open bite-mild, 19
- Open bite-severe, 19
- Orthodontic therapy, 19
- Orthognathic surgery, 19
- Prognathism, 19
- Protrusion, 19
- Retrognathism, 19
- Retrusion, 19

Clinical conditions that are common to more than one category are appropriately repeated.



Problem	Solution	Chapter Number and Title	
<b>TOOTH-RELATED PROBLEMS</b> <b>Size and Shape Problems</b>	Direct composite resin restoration	Ch 4 Color modifiers and opaquers Ch 5 Composite resin—fundamentals and direct technique restorations	
	Indirect composite resin restoration	Ch 6 Composite resin—indirect technique restorations	
	<b>Abrasion</b>	Ceramometal restoration	Ch 7 Ceramometal—full coverage restorations
	All-porcelain restoration	Ch 8 Porcelain—full coverage restorations	
	Porcelain laminate veneer or partial coverage restoration	Ch 9 Porcelain laminate veneers and other partial coverage restorations	
<b>Aged teeth—worn</b>	Direct composite resin veneers	Ch 4 Color modifiers and opaquers Ch 5 Composite resin—fundamentals and direct technique restorations	
	Indirect composite resin veneers	Ch 6 Composite resin—indirect technique restorations	
	Ceramometal—full coverage restorations	Ch 7 Ceramometal—full coverage restorations	
	All-porcelain restorations	Ch 8 Porcelain—full coverage restorations	
	Porcelain laminate veneers or partial coverage restorations	Ch 9 Porcelain laminate veneers and other partial coverage restorations	
<b>Anterior tooth—chipped or fractured</b>	Cosmetic recontouring	Ch 2 Fundamentals of esthetics	
	Direct composite resin veneer	Ch 4 Color modifiers and opaquers Ch 5 Composite resin—fundamentals and direct technique restorations	
	Indirect composite resin veneer	Ch 6 Composite resin—indirect technique restorations	
	Ceramometal restoration	Ch 7 Ceramometal—full-coverage restorations	
	All-porcelain restoration	Ch 8 Porcelain—full-coverage restorations	
	Porcelain laminate veneer	Ch 9 Porcelain laminate veneers and other partial coverage restorations	
<b>Attrition</b>	Direct composite resin veneer (in selected cases)	Ch 4 Color modifiers and opaquers Ch 5 Composite resin—fundamentals and direct technique restorations	
	Indirect composite resin restoration (in selected cases)	Ch 6 Composite resin—indirect technique restorations	
	Ceramometal restoration	Ch 7 Ceramometal—full coverage restorations	
	All-porcelain restoration (in selected cases)	Ch 8 Porcelain—full coverage restorations	
	Porcelain laminate veneer or partial coverage restoration (in selected cases)	Ch 9 Porcelain laminate veneers and other partial coverage restorations	
<b>Chipped tooth</b>	Cosmetic recontouring	Ch 2 Fundamentals of esthetics	
	Direct composite resin restoration	Ch 4 Color modifiers and opaquers Ch 5 Composite resin—fundamentals and direct technique restorations	

<b>Problem</b>	<b>Solution</b>	<b>Chapter Number and Title</b>
<b>Chipped tooth—cont'd</b>	Indirect composite resin restoration	Ch 6 Composite resin—indirect technique restorations
	Ceramometal restoration	Ch 7 Ceramometal—full coverage restorations
	All-porcelain restoration	Ch 8 Porcelain—full coverage restorations
	Porcelain laminate veneer or partial coverage restoration	Ch 9 Porcelain laminate veneers and other partial coverage restorations
<b>Erosion</b>	Direct composite resin restoration	Ch 4 Color modifiers and opaquers Ch 5 Composite resin—fundamentals and direct technique restorations
	Indirect composite resin restoration	Ch 6 Composite resin—indirect technique restorations
	Ceramometal restoration	Ch 7 Ceramometal—full coverage restorations
	All-porcelain restoration	Ch 8 Porcelain—full coverage restorations
	Porcelain laminate veneer or partial coverage restoration	Ch 9 Porcelain laminate veneers and other partial coverage restorations
<b>Extruded tooth</b>	Cosmetic recontouring	Ch 2 Fundamentals of esthetics
	Ceramometal restoration (possibly combined with endodontic and periodontal therapy)	Ch 7 Ceramometal—full coverage restorations
	All-porcelain restoration (possibly combined with endodontic and periodontal therapy)	Ch 8 Porcelain—full coverage restorations
	Porcelain laminate veneer or partial coverage restoration (possibly combined with endodontic and periodontal therapy; sufficient tooth structure must be present)	Ch 9 Porcelain laminate veneers and other partial coverage restorations
	Gingival recontouring—(if necessary)	Ch 15 Esthetics and electrosurgery Ch 18 Esthetics and periodontics Ch 22 Esthetics and laser surgery
	Gingival grafting—(if accompanied by recession)	Ch 18 Esthetics and periodontics
	Artificial gingiva—(if accompanied by recession)	Ch 18 Esthetics and periodontics
	Orthodontic therapy	Ch 19 Esthetics and orthodontics
Orthognathic surgery	Ch 20 Esthetics and oral and maxillofacial surgery	
<b>Feminine teeth—excessive</b>	Cosmetic recontouring	Ch 2 Fundamentals of esthetics
<b>Fractured tooth</b>	Cosmetic recontouring	Ch 2 Fundamentals of esthetics
	Direct composite resin restoration	Ch 4 Color modifiers and opaquers Ch 5 Composite resin—fundamentals and direct technique restorations
	Indirect composite resin restoration	Ch 6 Composite resin—indirect technique restorations
	Ceramometal restoration	Ch 7 Ceramometal—full coverage restorations
	All-porcelain restoration	Ch 8 Porcelain—full coverage restorations
	Porcelain laminate veneer or partial coverage restoration	Ch 9 Porcelain laminate veneers and other partial coverage restorations

Problem	Solution	Chapter Number and Title
<b>High smile line</b>	Cosmetic recontouring	Ch 2 Fundamentals of esthetics
	Gingival recontouring—(with restoration—see <i>Long tooth</i> )	Ch 15 Esthetics and electrosurgery Ch 18 Esthetics and periodontics Ch 22 Esthetics and laser surgery
	Oral surgery (with restoration—see <i>Long tooth</i> )	Ch 20 Esthetics and oral and maxillofacial surgery
<b>Large tooth</b>	Cosmetic recontouring	Ch 2 Fundamentals of esthetics
	Direct composite resin restoration	Ch 4 Color modifiers and opaquers Ch 5 Composite resin—fundamentals and direct technique restorations
	Indirect composite resin restoration	Ch 6 Composite resin—indirect technique restorations
	Ceramometal restoration	Ch 7 Ceramometal—full coverage restorations
	All-porcelain restoration	Ch 8 Porcelain—full coverage restorations
	Porcelain laminate veneer or partial coverage restoration	Ch 9 Porcelain laminate veneers and other partial coverage restorations
<b>Long tooth</b>	Cosmetic recontouring	Ch 2 Fundamentals of esthetics
	Direct composite resin restoration	Ch 4 Color modifiers and opaquers Ch 5 Composite resin—fundamentals and direct technique restorations
	Indirect composite resin restoration	Ch 6 Composite resin—indirect technique restorations
	Ceramometal restoration (possibly combined with endodontic and periodontal therapy)	Ch 7 Ceramometal—full coverage restorations
	All-porcelain restoration (possibly combined with endodontic and periodontal therapy)	Ch 8 Porcelain—full coverage restorations
	Porcelain laminate veneer or partial coverage restoration (possibly combined with endodontic and periodontal therapy) (sufficient tooth structure must be present)	Ch 9 Porcelain laminate veneers and other partial coverage restorations
	Gingival grafting—(if accompanied by recession)	Ch 18 Esthetics and periodontics
	Artificial gingiva	Ch 18 Esthetics and periodontics
	Orthodontic therapy	Ch 19 Esthetics and orthodontics
	Orthognathic surgery	Ch 20 Esthetics and oral and maxillofacial surgery
<b>Malformed teeth—mild</b>	Cosmetic recontouring	Ch 2 Fundamentals of esthetics
	Direct composite resin restorations	Ch 4 Color modifiers and opaquers Ch 5 Composite resin—fundamentals and direct technique restorations
	Indirect composite resin restorations	Ch 6 Composite resin—indirect technique restorations
	Ceramometal—full coverage restorations	Ch 7 Ceramometal—full coverage restorations
	All-porcelain restorations	Ch 8 Porcelain—full coverage restorations
	Porcelain laminate veneers or partial coverage restorations	Ch 9 Porcelain laminate veneers and other partial coverage restorations



<b>Problem</b>	<b>Solution</b>	<b>Chapter Number and Title</b>
<b>Malformed teeth—severe</b>	Direct composite resin restorations	Ch 4 Color modifiers and opaquers Ch 5 Composite resin—fundamentals and direct technique restorations
	Indirect composite resin restorations	Ch 6 Composite resin—indirect technique restorations
	Ceramometal—full coverage restorations	Ch 7 Ceramometal—full coverage restorations
	All-porcelain restorations	Ch 8 Porcelain—full coverage restorations
	Porcelain laminate veneers or partial coverage restorations	Ch 9 Porcelain laminate veneers and other partial coverage restorations
<b>Masculine teeth—excessive</b>	Cosmetic recontouring	Ch 2 Fundamentals of esthetics
<b>Narrow tooth</b>	Cosmetic recontouring	Ch 2 Fundamentals of esthetics
	Direct composite resin restoration	Ch 4 Color modifiers and opaquers Ch 5 Composite resin—fundamentals and direct technique restorations
	Indirect composite resin restoration	Ch 6 Composite resin—indirect technique restorations
	Ceramometal restoration	Ch 7 Ceramometal—full coverage restorations
	All-porcelain restoration	Ch 8 Porcelain—full coverage restorations
	Porcelain laminate veneer or partial coverage restoration	Ch 9 Porcelain laminate veneers and other partial coverage restorations
<b>Peg lateral incisor</b>	Direct composite resin restoration	Ch 4 Color modifiers and opaquers Ch 5 Composite resin—fundamentals and direct technique restorations
	Indirect composite resin restoration	Ch 6 Composite resin—indirect technique restorations
	Ceramometal restoration	Ch 7 Ceramometal—full coverage restorations
	All-porcelain restoration	Ch 8 Porcelain—full coverage restorations
	Porcelain laminate veneer or partial coverage restoration	Ch 9 Porcelain laminate veneers and other partial coverage restorations
<b>Short tooth</b>	Cosmetic recontouring	Ch 2 Fundamentals of esthetics
	Direct composite resin restoration	Ch 4 Color modifiers and opaquers Ch 5 Composite resin—fundamentals and direct technique restorations
	Indirect composite resin restoration	Ch 6 Composite resin—indirect technique restorations
	Ceramometal restoration	Ch 7 Ceramometal—full coverage restorations
	All-porcelain restoration	Ch 8 Porcelain—full coverage restorations
	Porcelain laminate veneer or partial coverage restoration	Ch 9 Porcelain laminate veneers and other partial coverage restorations
	Gingival recontouring	Ch 15 Esthetics and electrosurgery Ch 18 Esthetics and periodontics Ch 22 Esthetics and laser surgery

<b>Problem</b>	<b>Solution</b>	<b>Chapter Number and Title</b>
<b>Small tooth</b>	Cosmetic recontouring	Ch 2 Fundamentals of esthetics
	Direct composite resin restoration	Ch 4 Color modifiers and opaquers Ch 5 Composite resin—fundamentals and direct technique restorations
	Indirect composite resin restoration	Ch 6 Composite resin—indirect technique restorations
	Ceramometal restoration	Ch 7 Ceramometal—full coverage restorations
	All-porcelain restoration	Ch 8 Porcelain—full coverage restorations
	Porcelain laminate veneer or partial coverage restoration	Ch 9 Porcelain laminate veneers and other partial coverage restorations
	Gingival recontouring	Ch 15 Esthetics and electrosurgery Ch 18 Esthetics and periodontics Ch 22 Esthetics and laser surgery
<b>Wide tooth</b>	Cosmetic recontouring	Ch 2 Fundamentals of esthetics
	Direct composite resin restoration	Ch 4 Color modifiers and opaquers Ch 5 Composite resin—fundamentals and direct technique restorations
	Indirect composite resin restoration	Ch 6 Composite resin—indirect technique restorations
	Ceramometal restoration	Ch 7 Ceramometal—full coverage restorations
	All-porcelain restoration	Ch 8 Porcelain—full coverage restorations
	Porcelain laminate veneer or partial coverage restoration	Ch 9 Porcelain laminate veneers and other partial coverage restorations
<b>POSITION PROBLEMS</b> <b>Anterior flared teeth—major</b>	Orthodontic therapy	Ch 19 Esthetics and orthodontics
<b>Anterior flared teeth—minor</b>	Direct composite resin restorations	Ch 4 Color modifiers and opaquers Ch 5 Composite resin—fundamentals and direct technique restorations
	Indirect composite resin restorations	Ch 6 Composite resin—indirect technique restorations
	Ceramometal—full coverage restorations	Ch 7 Ceramometal—full coverage restorations
	All-porcelain restorations	Ch 8 Porcelain—full coverage restorations
	Porcelain laminate veneers or partial coverage restorations	Ch 9 Porcelain laminate veneers and other partial coverage restorations
	Orthodontic therapy	Ch 19 Esthetics and orthodontics
<b>Crowding</b>	Cosmetic recontouring	Ch 2 Fundamentals of esthetics
	Direct composite resin restorations	Ch 4 Color modifiers and opaquers Ch 5 Composite resin—fundamentals and direct technique restorations
	Indirect composite resin restorations	Ch 6 Composite resin—indirect technique restorations

Problem	Solution	Chapter Number and Title
<b>Crowding—cont'd</b>	Ceramometal—full coverage restorations	Ch 7 Ceramometal—full coverage restorations
	All-porcelain restorations	Ch 8 Porcelain—full coverage restorations
	Porcelain laminate veneers or partial coverage restorations	Ch 9 Porcelain laminate veneers and other partial coverage restorations
	Orthodontic therapy	Ch 19 Esthetics and orthodontics
<b>Diastemata</b>	Direct composite resin restorations	Ch 4 Color modifiers and opaquers Ch 5 Composite resin—fundamentals and direct technique restorations
	Indirect composite resin restorations	Ch 6 Composite resin—indirect technique restorations
	Ceramometal—full coverage restorations	Ch 7 Ceramometal—full coverage restorations
	All-porcelain restorations	Ch 8 Porcelain—full coverage restorations
	Porcelain laminate veneers or partial coverage restorations	Ch 9 Porcelain laminate veneers and other partial coverage restorations
	Orthodontic therapy	Ch 19 Esthetics and orthodontics
<b>Excessive spacing</b>	Direct composite resin veneers	Ch 4 Color modifiers and opaquers Ch 5 Composite resin—fundamentals and direct technique restorations
	Indirect composite resin veneers	Ch 6 Composite resin—indirect technique restorations
	Ceramometal—full coverage restorations	Ch 7 Ceramometal—full coverage restorations
	All-porcelain restorations	Ch 8 Porcelain—full coverage restorations
	Porcelain laminate veneers	Ch 9 Porcelain laminate veneers and other partial coverage restorations
	Orthodontic therapy	Ch 19 Esthetics and orthodontics
<b>Extruded tooth</b>	Cosmetic recontouring	Ch 2 Fundamentals of esthetics
	Ceramometal restoration (possibly combined with endodontic and periodontal therapy)	Ch 7 Ceramometal—full coverage restorations
	All-porcelain restoration (possibly combined with endodontic and periodontal therapy)	Ch 8 Porcelain—full coverage restorations
	Porcelain laminate veneer or partial coverage restoration (possibly combined with endodontic and periodontal therapy)(sufficient tooth structure must be present)	Ch 9 Porcelain laminate veneers and other partial coverage restorations
	Gingival recontouring—electrosurgery (if necessary)	Ch 15 Esthetics and electrosurgery Ch 18 Esthetics and periodontics Ch 22 Esthetics and laser surgery
	Gingival grafting—(if accompanied by recession)	Ch 18 Esthetics and periodontics
	Artificial gingiva—(if accompanied by recession)	Ch 18 Esthetics and periodontics
	Orthodontic therapy	Ch 19 Esthetics and orthodontics
	Orthognathic surgery	Ch 20 Esthetics and oral and maxillofacial surgery

<b>Problem</b>	<b>Solution</b>	<b>Chapter Number and Title</b>
<b>Generalized spacing</b>	Direct composite resin veneers	Ch 4 Color modifiers and opaquers Ch 5 Composite resin—fundamentals and direct technique restorations
	Indirect composite resin veneers	Ch 6 Composite resin—indirect technique restorations
	Ceramometal—full coverage restorations	Ch 7 Ceramometal—full coverage restorations
	All-porcelain restorations	Ch 8 Porcelain—full coverage restorations
	Porcelain laminate veneers	Ch 9 Porcelain laminate veneers and other partial coverage restorations
	Orthodontic therapy	Ch 19 Esthetics and orthodontics
<b>High smile line</b>	Cosmetic recontouring	Ch 2 Fundamentals of esthetics
	Gingival recontouring—electrosurgery (with restoration—see Long Tooth)	Ch 15 Esthetics and electrosurgery Ch 18 Esthetics and periodontics Ch 22 Esthetics and laser surgery
	Oral surgery (with restoration—see Long Tooth)	Ch 20 Esthetics and oral and maxillofacial surgery
<b>Long tooth</b>	Cosmetic recontouring	Ch 2 Fundamentals of esthetics
	Direct composite resin restoration	Ch 4 Color modifiers and opaquers Ch 5 Composite resin—fundamentals and direct technique restorations
	Indirect composite resin restoration	Ch 6 Composite resin—indirect technique restorations
	Ceramometal restoration (possibly combined with endodontic and periodontal therapy)	Ch 7 Ceramometal—full coverage restorations
	All-porcelain restoration (possibly combined with endodontic and periodontal therapy)	Ch 8 Porcelain—full coverage restorations
	Porcelain laminate veneer or partial coverage restoration (possibly combined with endodontic and periodontal therapy)(sufficient tooth structure must be present)	Ch 9 Porcelain laminate veneers and other partial coverage restorations
	Gingival recontouring—electrosurgery (if necessary)	Ch 15 Esthetics and electrosurgery Ch 18 Esthetics and periodontics Ch 22 Esthetics and laser surgery
	Gingival grafting—if accompanied by recession)	Ch 18 Esthetics and periodontics
	Artificial gingiva—if accompanied by recession)	Ch 18 Esthetics and periodontics
	Orthodontic therapy	Ch 19 Esthetics and orthodontics
Orthognathic surgery	Ch 20 Esthetics and oral and maxillofacial surgery	
<b>Midline disharmony</b>	Cosmetic recontouring	Ch 2 Fundamentals of esthetics
	Direct composite resin restoration	Ch 4 Color modifiers and opaquers Ch 5 Composite resin—fundamentals and direct technique restorations

<b>Problem</b>	<b>Solution</b>	<b>Chapter Number and Title</b>
<b>Midline disharmony— cont'd</b>	Indirect composite resin restoration	Ch 6 Composite resin—indirect technique restorations
	Ceramometal—full coverage restorations	Ch 7 Ceramometal—full coverage restorations
	All-porcelain restorations	Ch 8 Porcelain—full coverage restorations
	Porcelain laminate veneer	Ch 9 Porcelain laminate veneers and other partial coverage restorations
	Orthodontic therapy	Ch 19 Esthetics and orthodontics
<b>Migrated teeth</b>	Orthodontic therapy	Ch 19 Esthetics and orthodontics
<b>Multiple diastemata</b>	Direct composite resin veneers	Ch 4 Color modifiers and opaquers Ch 5 Composite resin—fundamentals and direct technique restorations
	Indirect composite resin veneers	Ch 6 Composite resin—indirect technique restorations
	Ceramometal—full coverage restorations	Ch 7 Ceramometal—full coverage restorations
	All-porcelain restorations	Ch 8 Porcelain—full coverage restorations
	Porcelain laminate veneers	Ch 9 Porcelain laminate veneers and other partial coverage restorations
	Orthodontic therapy	Ch 19 Esthetics and orthodontics
<b>Open bite—mild</b>	Direct composite resin veneers	Ch 4 Color modifiers and opaquers Ch 5 Composite resin—fundamentals and direct technique restorations
	Indirect composite resin veneers	Ch 6 Composite resin—indirect technique restorations
	Ceramometal—full coverage restorations	Ch 7 Ceramometal—full coverage restorations
	All-porcelain restorations	Ch 8 Porcelain—full coverage restorations
	Porcelain laminate veneers	Ch 9 Porcelain laminate veneers and other partial coverage restorations
	Orthodontic therapy Orthognathic surgery	Ch 19 Esthetics and orthodontics Ch 20 Esthetics and oral and maxillofacial surgery
<b>Open bite—severe</b>	Orthodontic therapy	Ch 19 Esthetics and orthodontics
	Orthognathic surgery	Ch 20 Esthetics and oral and maxillofacial surgery
<b>Overbite/overjet</b>	Orthodontic therapy	Ch 19 Esthetics and orthodontics
	Orthognathic surgery	Ch 20 Esthetics and oral and maxillofacial surgery
<b>Spacing</b>	Direct composite resin veneers	Ch 4 Color modifiers and opaquers Ch 5 Composite resin—fundamentals and direct technique restorations
	Indirect composite resin veneers	Ch 6 Composite resin—indirect technique restorations
	Ceramometal—full coverage restorations	Ch 7 Ceramometal—full coverage restorations

<b>Problem</b>	<b>Solution</b>	<b>Chapter Number and Title</b>
<b>Spacing—cont'd</b>	All-porcelain restorations	Ch 8 Porcelain—full coverage restorations
	Porcelain laminate veneers	Ch 9 Porcelain laminate veneers and other partial coverage restorations
	Orthodontic therapy	Ch 19 Esthetics and orthodontics
<b>Traumatic injury—luxation</b>	Temporary splinting	Ch 17 Pediatric dentistry
<b>COLOR PROBLEMS</b>		
<b>Aged (dark) teeth</b>	Direct composite resin veneers	Ch 4 Color modifiers and opaquers Ch 5 Composite resin—fundamentals and direct technique restorations
	Indirect composite resin veneers	Ch 6 Composite resin—indirect technique restorations
	Ceramometal—full coverage restorations	Ch 7 Ceramometal—full coverage restorations
	All-porcelain restorations	Ch 8 Porcelain—full coverage restorations
	Porcelain laminate veneers	Ch 9 Porcelain laminate veneers and other partial coverage restorations
	Bleaching	Ch 13 Bleaching and related agents
<b>Coloration</b>	Direct composite resin veneers	Ch 4 Color modifiers and opaquers Ch 5 Composite resin—fundamentals and direct technique restorations
	Indirect composite resin veneers	Ch 6 Composite resin—indirect technique restorations
	Ceramometal—full coverage restorations	Ch 7 Ceramometal—full coverage restorations
	All-porcelain restorations	Ch 8 Porcelain—full coverage restorations
	Porcelain laminate veneers	Ch 9 Porcelain laminate veneers and other partial coverage restorations
	Bleaching	Ch 13 Bleaching and related agents
	Prophylaxis (extrinsic stains)	Ch 13 Bleaching and related agents
<b>Congenital discoloration</b>	Direct composite resin veneer	Ch 4 Color modifiers and opaquers Ch 5 Composite resin—fundamentals and direct technique restorations
	Indirect composite resin veneer	Ch 6 Composite resin—indirect technique restorations
	Ceramometal restoration	Ch 7 Ceramometal—full coverage restorations
	All-porcelain restoration	Ch 8 Porcelain—full coverage restorations
	Porcelain laminate veneer	Ch 9 Porcelain laminate veneers and other partial coverage restorations
	Bleaching	Ch 13 Bleaching and related agents
<b>Discoloration</b>	Direct composite resin veneers	Ch 4 Color modifiers and opaquers Ch 5 Composite resin—fundamentals and direct technique restorations
	Indirect composite resin veneers	Ch 6 Composite resin—indirect technique restorations

<b>Problem</b>	<b>Solution</b>	<b>Chapter Number and Title</b>
<b>Discoloration—cont'd</b>	Ceramometal—full coverage restorations	Ch 7 Ceramometal—full coverage restorations
	All-porcelain restorations	Ch 8 Porcelain—full coverage restorations
	Porcelain laminate veneers	Ch 9 Porcelain laminate veneers and other partial coverage restorations
	Bleaching	Ch 13 Bleaching and related agents
	Prophylaxis (extrinsic stains)	Ch 13 Bleaching and related agents
<b>Endemic fluorosis</b>	Direct composite resin veneers	Ch 4 Color modifiers and opaquers Ch 5 Composite resin—fundamentals and direct technique restorations
	Indirect composite resin veneers	Ch 6 Composite resin—indirect technique restorations
	Ceramometal—full coverage restorations	Ch 7 Ceramometal—full coverage restorations
	All-porcelain restorations	Ch 8 Porcelain—full coverage restorations
	Porcelain laminate veneers	Ch 9 Porcelain laminate veneers and other partial coverage restorations
	Bleaching	Ch 13 Bleaching and related agents
<b>Endodontic discoloration</b>	Direct composite resin veneers	Ch 4 Color modifiers and opaquers Ch 5 Composite resin—fundamentals and direct technique restorations
	Indirect composite resin veneers	Ch 6 Composite resin—indirect technique restorations
	Ceramometal—full coverage restorations	Ch 7 Ceramometal—full coverage restorations
	All-porcelain restorations	Ch 8 Porcelain—full coverage restorations
	Porcelain laminate veneers	Ch 9 Porcelain laminate veneers and other partial coverage restorations
	Bleaching	Ch 13 Bleaching and related agents
<b>Fluorosis</b>	Direct composite resin veneer	Ch 4 Color modifiers and opaquers Ch 5 Composite resin—fundamentals and direct technique restorations
	Indirect composite resin veneer	Ch 6 Composite resin—indirect technique restorations
	Ceramometal restoration	Ch 7 Ceramometal—full coverage restorations
	All-porcelain restoration	Ch 8 Porcelain—full coverage restorations
	Porcelain laminate veneer	Ch 9 Porcelain laminate veneers and other partial coverage restorations
	Bleaching	Ch 13 Bleaching and related agents
<b>Post-endodontic discoloration</b>	Direct composite resin veneer	Ch 4 Color modifiers and opaquers Ch 5 Composite resin—fundamentals and direct technique restorations
	Indirect composite resin veneer	Ch 6 Composite resin—indirect technique restorations

<b>Problem</b>	<b>Solution</b>	<b>Chapter Number and Title</b>
<b><i>Post-endodontic discoloration—cont'd</i></b>	Ceramometal restoration	Ch 7 Ceramometal—full coverage restorations
	All-porcelain restoration	Ch 8 Porcelain—full coverage restorations
	Porcelain laminate veneer	Ch 9 Porcelain laminate veneers and other partial coverage restorations
	Bleaching	Ch 13 Bleaching and related agents
<b><i>Staining</i></b>	Direct composite resin veneer	Ch 4 Color modifiers and opaquers Ch 5 Composite resin—fundamentals and direct technique restorations
	Indirect composite resin veneer	Ch 6 Composite resin—indirect technique restorations
	Ceramometal restoration	Ch 7 Ceramometal—full coverage restorations
	All-porcelain restoration	Ch 8 Porcelain—full coverage restorations
	Porcelain laminate veneer	Ch 9 Porcelain laminate veneers and other partial coverage restorations
	Bleaching	Ch 13 Bleaching and related agents
	Prophylaxis (extrinsic stains)	Ch 13 Bleaching and related agents
<b><i>Tetracycline discoloration</i></b>	Direct composite resin veneer	Ch 4 Color modifiers and opaquers Ch 5 Composite resin—fundamentals and direct technique restorations
	Indirect composite resin veneer	Ch 6 Composite resin—indirect technique restorations
	Ceramometal restoration	Ch 7 Ceramometal—full coverage restorations
	All-porcelain restoration	Ch 8 Porcelain—full coverage restorations
	Porcelain laminate veneer	Ch 9 Porcelain laminate veneers and other partial coverage restorations
	Bleaching	Ch 13 Bleaching and related agents
<b><i>Tooth color—too dark</i></b>	Direct composite resin veneer	Ch 4 Color modifiers and opaquers Ch 5 Composite resin—fundamentals and direct technique restorations
	Indirect composite resin veneer	Ch 6 Composite resin—indirect technique restorations
	Ceramometal restoration	Ch 7 Ceramometal—full coverage restorations
	All-porcelain restoration	Ch 8 Porcelain—full coverage restorations
	Porcelain laminate veneer	Ch 9 Porcelain laminate veneers and other partial coverage restorations
	Bleaching	Ch 13 Bleaching and related agents
	Prophylaxis (extrinsic stains)	Ch 13 Bleaching and related agents
<b><i>Tooth color—too light</i></b>	Direct composite resin veneer	Ch 4 Color modifiers and opaquers Ch 5 Composite resin—fundamentals and direct technique restorations
	Indirect composite resin veneer	Ch 6 Composite resin—indirect technique restorations



Problem	Solution	Chapter Number and Title
<b>Tooth color—too light—cont'd</b>	Ceramometal restoration	Ch 7 Ceramometal—full coverage restorations
	All-porcelain restoration	Ch 8 Porcelain—full coverage restorations
	Porcelain laminate veneer	Ch 9 Porcelain laminate veneers and other partial coverage restorations
	Bleaching (white spot lesions)	Ch 13 Bleaching and related agents
	Prophylaxis (extrinsic stains)	Ch 13 Bleaching and related agents
<b>Traumatic discoloration</b>	Direct composite resin veneer	Ch 4 Color modifiers and opaquers Ch 5 Composite resin—fundamentals and direct technique restorations
	Indirect composite resin veneer	Ch 6 Composite resin—indirect technique restorations
	Ceramometal restoration	Ch 7 Ceramometal—full coverage restorations
	All-porcelain restoration	Ch 8 Porcelain—full coverage restorations
	Porcelain laminate veneer	Ch 9 Porcelain laminate veneers and other partial coverage restorations
Bleaching	Ch 13 Bleaching and related agents	
<b>White spots</b>	Direct composite resin veneer	Ch 4 Color modifiers and opaquers Ch 5 Composite resin—fundamentals and direct technique restorations
	Indirect composite resin veneer	Ch 6 Composite resin—indirect technique restorations
	Ceramometal restoration	Ch 7 Ceramometal—full coverage restorations
	All-porcelain restoration	Ch 8 Porcelain—full coverage restorations
	Porcelain laminate veneer	Ch 9 Porcelain laminate veneers and other partial coverage restorations
	Bleaching	Ch 13 Bleaching and related agents
Prophylaxis (extrinsic stains)	Ch 13 Bleaching and related agents	
<b>MISSING TEETH PROBLEMS</b>		
<b>Migrated teeth—multiple</b>	Direct composite resin veneer	Ch 4 Color modifiers and opaquers Ch 5 Composite resin—fundamentals and direct technique restorations
	Indirect composite resin veneer	Ch 6 Composite resin—indirect technique restorations
	Ceramometal—full coverage restorations	Ch 7 Ceramometal—full coverage restorations
	All-porcelain restorations (experimental)	Ch 8 Porcelain—full coverage restorations
	Porcelain laminate veneer	Ch 9 Porcelain laminate veneers and other partial coverage restorations
	Acid etched retained ceramometal restoration	Ch 10 Adhesive resin bonded cast restorations
	Removable prosthesis	Ch 12 Acrylic and other resins—removable prostheses
	Orthodontic therapy	Ch 19 Esthetics and orthodontics

Problem	Solution	Chapter Number and Title
<b>Migrated tooth—single</b>	Direct composite resin veneer	Ch 4 Color modifiers and opaquers Ch 5 Composite resin—fundamentals and direct technique restorations
	Indirect composite resin veneer	Ch 6 Composite resin—indirect technique restorations
	Ceramometal—full coverage restorations	Ch 7 Ceramometal—full coverage restorations
	All-porcelain restorations (experimental)	Ch 8 Porcelain—full coverage restorations
	Porcelain laminate veneer	Ch 9 Porcelain laminate veneers and other partial coverage restorations
	Acid etched retained ceramometal restorations	Ch 10 Adhesive resin bonded cast restorations
	Removable prosthesis	Ch 12 Acrylic and other resins—removable prostheses
	Orthodontic therapy	Ch 19 Esthetics and orthodontics
<b>Multiple missing teeth</b>	Ceramometal—full coverage restorations	Ch 7 Ceramometal—full coverage restorations
	All-porcelain restorations (experimental)	Ch 8 Porcelain—full coverage restorations
	Acid etched retained ceramometal restorations	Ch 10 Adhesive resin bonded cast restorations
	Removable prosthesis	Ch 12 Acrylic and other resins—removable prostheses
	Implant retained restorations	Ch 16 Esthetics and implant prosthetics Ch 21 Esthetics and implant surgery
<b>Single missing tooth</b>	Ceramometal restoration	Ch 7 Ceramometal—full coverage restorations
	All-porcelain restorations (experimental)	Ch 8 Porcelain—full coverage restorations
	Acid etched retained ceramometal restoration	Ch 10 Adhesive resin bonded cast restorations
	Removable prosthesis	Ch 12 Acrylic and other resins—removable prostheses
	Implant retained restorations	Ch 16 Esthetics and implant prosthetics Ch 21 Esthetics and implant surgery
<b>Traumatic injury—avulsion</b>	Temporary splinting	Ch 17 Pediatric dentistry
<b>CARIES</b> <b>Carious restoration margins</b>	See Repairs	
<b>Carious tooth</b>	Direct composite resin restoration	Ch 4 Color modifiers and opaquers Ch 5 Composite resin—fundamentals and direct technique restorations
	Indirect composite resin restoration	Ch 6 Composite resin—indirect technique restorations
	Ceramometal restoration	Ch 7 Ceramometal—full coverage restorations
	All-porcelain restoration	Ch 8 Porcelain—full coverage restorations
	Porcelain laminate veneer or partial coverage restoration	Ch 9 Porcelain laminate veneers and other partial coverage restorations

Problem	Solution	Chapter Number and Title
<b>REPAIRS</b>		
<i>Acrylic veneer facing—dislodgment</i>	Acrylic veneer repair	Ch 4 Color modifiers and opaquers
<i>Cariou restoration margins</i>	Porcelain bonding agents	Ch 4 Color modifiers and opaquers
<i>Porcelain fractures—ceramometal—full coverage restorations</i>	Porcelain bonding agents	Ch 4 Color modifiers and opaquers
<b>NON-TOOTH-RELATED PROBLEMS</b>		
<b>Periodontal problems</b>		
<i>Gingival asymmetry</i>	Gingival recontouring—electrosurgery	Ch 15 Esthetics and electrosurgery Ch 18 Esthetics and periodontics Ch 22 Esthetics and laser surgery
	Artificial gingiva	Ch 18 Esthetics and periodontics
	Gingival grafting—(if caused by recession)	Ch 18 Esthetics and periodontics
<i>Gingival hypertrophy</i>	Gingival recontouring	Ch 15 Esthetics and electrosurgery Ch 18 Esthetics and periodontics Ch 22 Esthetics and laser surgery
<i>Gingival inflammation</i>	Evaluate restoration margins and contours	Ch 5 Composite resin—fundamentals and direct technique restorations
	Evaluate restoration margins and contours	Ch 6 Composite resin—indirect technique restorations
	Evaluate restoration margins and contours	Ch 7 Ceramometal—full coverage restorations
	Evaluate restoration margins and contours	Ch 8 Porcelain—full coverage restorations
	Evaluate restoration margins and contours	Ch 9 Porcelain laminate veneers and other partial coverage restorations
	Evaluate restoration margins and contours	Ch 11 Acrylic and other resins—provisional restorations
	Periodontal therapy	Ch 18 Esthetics and periodontics
	Evaluate medical status	
<i>Gingival recession</i>	Gingival graft	Ch 18 Esthetics and periodontics
	Artificial gingiva	Ch 18 Esthetics and periodontics
<i>High frenum attachment with or without diastema</i>	Frenectomy	Ch 19 Esthetics and orthodontics Ch 22 Esthetics and laser surgery
<i>High smile line</i>	Gingival recontouring—electrosurgery (possibly with restoration—see Long Tooth)	Ch 15 Esthetics and electrosurgery Ch 18 Esthetics and periodontics Ch 22 Esthetics and laser surgery
	Oral surgery (possibly with restoration—see Long Tooth)	Ch 20 Esthetics and oral and maxillofacial surgery
<i>Mobile teeth</i>	Ceramometal—full coverage restorations	Ch 7 Ceramometal—full coverage restorations
	Splinting	Ch 18 Esthetics and periodontics

Problem	Solution	Chapter Number and Title
<b>DERMATOLOGIC PROBLEMS</b>	Restore lip support—direct composite resin restorations	Ch 4 Color modifiers and opaquers Ch 5 Composite resin—fundamentals and direct technique restorations
	Restore lip support—indirect composite resin restorations	Ch 6 Composite resin—indirect technique restorations
	Restore lip support—ceramometal restorations	Ch 7 Ceramometal—full coverage restorations
	Restore lip support—all-porcelain restorations	Ch 8 Porcelain—full coverage restorations
	Restore lip support—porcelain laminate veneers	Ch 9 Porcelain laminate veneers and other partial coverage restorations
	Restore lip support—removable prostheses	Ch 12 Acrylic and other resins—removable prostheses
	Lip augmentation	Ch 20 Esthetics and oral and maxillofacial surgery
	Skin resurfacing	Ch 20 Esthetics and oral and maxillofacial surgery Ch 22 Esthetics and laser surgery
	Plastic surgery	Ch 23 Esthetics and plastic surgery
<b>Aging</b>	Restore lip support—direct composite resin restorations	Ch 5 Composite resin—fundamentals and direct technique restorations
	Restore lip support—indirect composite resin restorations	Ch 6 Composite resin—indirect technique restorations
	Restore lip support—ceramometal restorations	Ch 7 Ceramometal—full coverage restorations
<b>Bruising</b>	Restore lip support—all-porcelain restorations	Ch 8 Porcelain—full coverage restorations
	Restore lip support—porcelain laminate veneers	Ch 9 Porcelain laminate veneers and other partial coverage restorations
	Restore lip support—removable prostheses	Ch 12 Acrylic and other resins—removable prostheses
<b>Scars</b>	Restore lip support—porcelain laminate veneers	Ch 9 Porcelain laminate veneers and other partial coverage restorations
	Restore lip support—removable prostheses	Ch 12 Acrylic and other resins—removable prostheses
	Skin resurfacing	Ch 20 Esthetics and oral and maxillofacial surgery Ch 22 Esthetics and laser surgery
<b>Wrinkles</b>	Plastic surgery	Ch 23 Esthetics and plastic surgery
	Skin resurfacing	Ch 20 Esthetics and oral and maxillofacial surgery
	Cosmetic skin resurfacing	Ch 22 Esthetics and laser surgery
	Plastic surgery	Ch 23 Esthetics and plastic surgery
	Skin resurfacing	Ch 20 Esthetics and oral and maxillofacial surgery
	Cosmetic skin resurfacing	Ch 22 Esthetics and laser surgery
	Plastic surgery	Ch 23 Esthetics and plastic surgery
	Skin resurfacing	Ch 20 Esthetics and oral and maxillofacial surgery
Cosmetic skin resurfacing	Ch 22 Esthetics and laser surgery	

<b>Problem</b>	<b>Solution</b>	<b>Chapter Number and Title</b>
<b>FACIAL CONTOURS AND SKELETAL PROBLEMS</b>  <i>Asymmetry</i>	Orthodontic therapy	Ch 19 Esthetics and orthodontics
	Orthognathic surgery	Ch 20 Esthetics and oral and maxillofacial surgery
	Plastic surgery	Ch 23 Esthetics and plastic surgery
<i>Bimaxillary prognathism/protrusion</i>	Orthodontic therapy	Ch 19 Esthetics and orthodontics
	Orthognathic surgery	Ch 20 Esthetics and oral and maxillofacial surgery
	Plastic surgery	Ch 23 Esthetics and plastic surgery
<i>Excessive lip support</i>	Orthodontic therapy	Ch 19 Esthetics and orthodontics
	Orthognathic surgery	Ch 20 Esthetics and oral and maxillofacial surgery
	Plastic surgery (severe)	Ch 23 Esthetics and plastic surgery
<i>Facial asymmetry</i>	Orthognathic surgery	Ch 20 Esthetics and oral and maxillofacial surgery
	Plastic surgery	Ch 23 Esthetics and plastic surgery
<i>Hypogenia</i>	Orthognathic surgery	Ch 20 Esthetics and oral and maxillofacial surgery
	Plastic surgery	Ch 23 Esthetics and plastic surgery
<i>Insufficient lip support</i>	Restore lip support—direct composite resin restorations	Ch 4 Color modifiers and opaquers Ch 5 Composite resin—fundamentals and direct technique restorations
	Restore lip support—indirect composite resin restorations	Ch 6 Composite resin—indirect technique restorations
	Restore lip support—ceramometal restorations	Ch 7 Ceramometal—full coverage restorations
	Restore lip support—all-porcelain restorations	Ch 8 Porcelain—full coverage restorations
	Restore lip support—porcelain laminate veneers	Ch 9 Porcelain laminate veneers and other partial coverage restorations
	Restore lip support—removable prostheses	Ch 12 Acrylic and other resins—removable prostheses
	Orthodontic therapy	Ch 19 Esthetics and orthodontics
	Orthognathic surgery (severe)	Ch 20 Esthetics and oral and maxillofacial surgery
	Plastic surgery (severe)	Ch 23 Esthetics and plastic surgery
<i>Macrogenia problem</i>	Orthognathic surgery	Ch 20 Esthetics and oral and maxillofacial surgery
	Plastic surgery	Ch 23 Esthetics and plastic surgery
<i>Mandibular prognathism/protrusion</i>	Orthodontic therapy	Ch 19 Esthetics and orthodontics
	Orthognathic surgery	Ch 20 Esthetics and oral and maxillofacial surgery
	Plastic surgery	Ch 23 Esthetics and plastic surgery

<b>Problem</b>	<b>Solution</b>	<b>Chapter Number and Title</b>
<b>Mandibular retrognathism/retrusion</b>	Orthodontic therapy	Ch 19 Esthetics and orthodontics
	Orthognathic surgery	Ch 20 Esthetics and oral and maxillofacial surgery
	Plastic surgery	Ch 23 Esthetics and plastic surgery
<b>Maxillary prognathism/protrusion</b>	Orthodontic therapy	Ch 19 Esthetics and orthodontics
	Orthognathic surgery	Ch 20 Esthetics and oral and maxillofacial surgery
	Plastic surgery	Ch 23 Esthetics and plastic surgery
<b>Maxillary retrognathism/retrusion</b>	Orthodontic therapy	Ch 19 Esthetics and orthodontics
	Orthognathic surgery	Ch 20 Esthetics and oral and maxillofacial surgery
	Plastic surgery	Ch 23 Esthetics and plastic surgery
<b>Open bite—mild</b>	Direct composite resin veneers	Ch 4 Color modifiers and opaquers Ch 5 Composite resin—fundamentals and direct technique restorations
	Indirect composite resin veneers	Ch 6 Composite resin—indirect technique restorations
	Ceramometal—full coverage restorations	Ch 7 Ceramometal—full coverage restorations
	All-porcelain restorations	Ch 8 Porcelain—full coverage restorations
	Porcelain laminate veneers	Ch 9 Porcelain laminate veneers and other partial coverage restorations
	Orthodontic therapy	Ch 19 Esthetics and orthodontics
	Orthognathic surgery	Ch 20 Esthetics and oral and maxillofacial surgery
<b>Open bite—severe</b>	Orthodontic therapy	Ch 19 Esthetics and orthodontics
	Orthognathic surgery	Ch 20 Esthetics and oral and maxillofacial surgery
<b>Prognathism</b>	Orthodontic therapy	Ch 19 Esthetics and orthodontics
	Orthognathic surgery	Ch 20 Esthetics and oral and maxillofacial surgery
	Plastic surgery	Ch 23 Esthetics and plastic surgery
<b>Protrusion</b>	Orthodontic therapy	Ch 19 Esthetics and orthodontics
	Orthognathic surgery	Ch 20 Esthetics and oral and maxillofacial surgery
	Plastic surgery	Ch 23 Esthetics and plastic surgery
<b>Retrognathism</b>	Orthodontic therapy	Ch 19 Esthetics and orthodontics
	Orthognathic surgery	Ch 20 Esthetics and oral and maxillofacial surgery
	Plastic surgery	Ch 23 Esthetics and plastic surgery
<b>Retrusion</b>	Orthodontic therapy	Ch 19 Esthetics and orthodontics
	Orthognathic surgery	Ch 20 Esthetics and oral and maxillofacial surgery
	Plastic surgery	Ch 23 Esthetics and plastic surgery

SECTION TWO

# PRINCIPLES OF ESTHETICS



انتشارات شایان نمودار

# INTRODUCTION TO ESTHETICS

Milton B. Asbell

**T**HE SEARCH FOR BEAUTY can be traced to the earliest civilizations. Dental art has long been part of the quest to enhance the esthetics of the teeth and mouth. Assyrio-Babylonian cuneiform tablets dating from the dawn of recorded history advise the following:

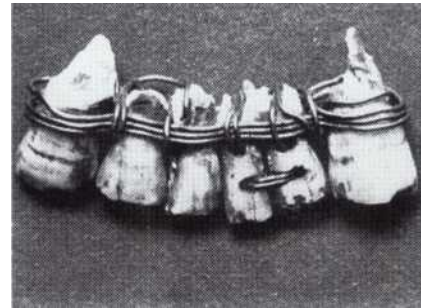
*"If a man's teeth become yellow . . . thou shalt bray together "salt of Akkad," anmi, lolium, pine-turpine with these, with thy fingers shalt bur his teeth."*

Writing in the ninth century BC, the author of the Song of Solomon (4:2) offers a poetic description of dental esthetics:

*"Thy teeth are like a flock of well-selected sheep, which are come up from the washing, all of which bear twins, and there is not one among them that is deprived of her young."*

Both the Phoenicians (approximately 800 BC) and Etruscans (approximately 900 BC) carefully carved animal tusks to simulate the shape, form, and hue of natural teeth for use as pontics (Fig. 1-1). The Central and South American Mayas (approximately 1000 AD) beautified themselves by filing the incisal edges of their anterior teeth into various shapes and designs (Figs. 1-2 and 1-3). They also placed plugs of iron pyrites, obsidian, and jade into the labial surfaces of the maxillary anterior teeth (Fig. 1-4). This practice was common among both sexes, and tooth mutilation is still practiced in some societies (Figs. 1-5 and 1-6).

During the Roman Empire dental cosmetic treatment was available only to the affluent classes. Oral hygiene was practiced primarily by women for reasons of beauty rather than dental health. Mouthwashes, dentifrices, and toothpicks were common in Roman boudoirs,



*Fig. 1-1.* Ancient Phoenician "bridge." Pontics are extracted central and lateral incisors that are attached to the remaining canines with wires. (From Ring ME: Dentistry: an illustrated history, New York, 1985, Harry N. Abrams.)



*Fig. 1-2.* Ancient painting depicting a probable method of preparing teeth used by the Mayas about 1000 AD. (From Ring ME: Dentistry: an illustrated history, New York, 1985, Harry N. Abrams.)



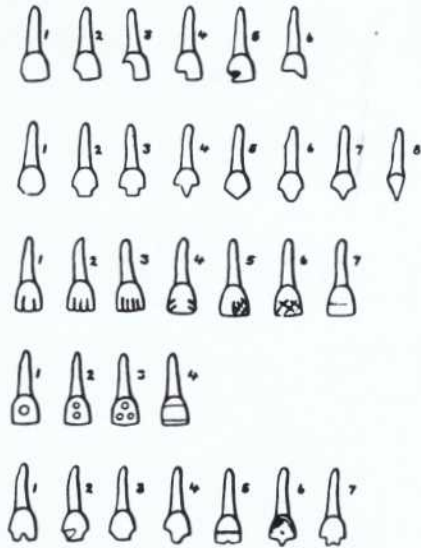


Fig. 1-3. Various forms of tooth mutilation that were considered beautification techniques. (From Weinberger BW: An introduction to the history of dentistry, vol 1, St Louis, 1948, Mosby.)

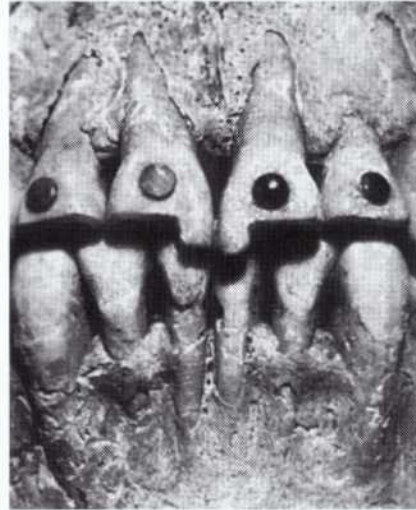


Fig. 1-4. Mayan specimen dating to approximately 1000 AD showing multiple inlays and turquoise restorations. (Courtesy Museo Nacional de Antropologia, Mexico City.)

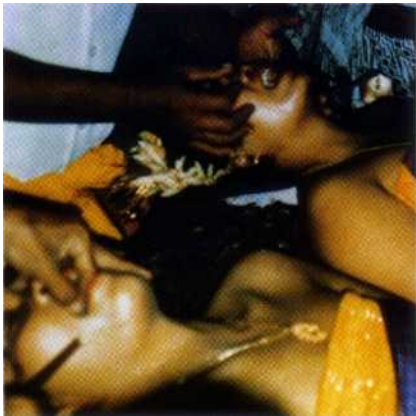

Fig. 1-5. Photograph taken in 1987 showing traditional filing of the maxillary anterior teeth designed to beautify Polynesian brides.

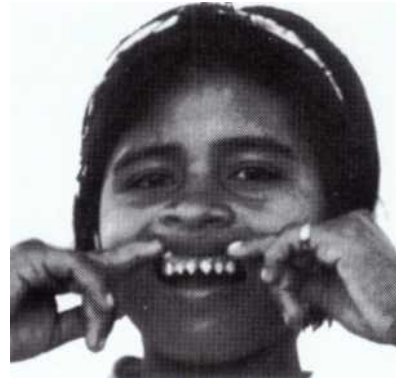

Fig. 1-6. Ticuana tribal tooth mutilation. (From Ring ME: Dentistry: an illustrated history, New York, 1985, Harry N. Abrams. )

and when teeth were lost, they were replaced with substitutes of bone or ivory carved to the likeness of the missing ones.

Interest in dental esthetics was virtually absent during the Middle Ages. It was not until the eighteenth century that dentistry was recognized as a separate discipline and its various branches were established. The leader of the movement to modernize and promote dentistry was Pierre Fauchard (1678-1761) of France. He, together with several colleagues, advocated such esthetic practices as proper oral hygiene and the use of gold shell crowns

with enamel "veneers." They also introduced a technique for the manufacture of mineral (as opposed to ivory or bone) "incorruptible" teeth for use in dentures. In England *The British Journal* carried the following advertisement (1724):

*"The incomparable powder for cleaning the teeth which has given great satisfaction to most of the nobility and gentry for above these twenty years . . . it, at one using, makes the teeth as white as ivory, and never black or yellow."*

1767 November 5.  
**ROBERT WOOFFENDILE,**  
 SURGEON DENTIST, lately from LONDON, (who was  
 instituted by THOMAS BERDMORE, Esq; Operator for  
 the Teeth to his Britannick Majesty):  
**B**E G S leave to inform the Public, that he perform  
 all operations on the TEETH, GUMS and SOCKETS  
 likewise in ARTIFICIAL TEETH, so as to escap  
 discernment and without the least inconvenience, a  
 Mrs. HUNT's, opposite to where Mr. Roberdeau lately  
 lived, in Second Street.  
 N. B. As he intends going to England the latter en  
 of next week, returns thanks to the public for thei  
 favours.

Fig. 1-7. Colonial United States advertisement that appeared in the *Pennsylvania Chronicle and Universal Advocate* on November 5, 1767, selling "artificial teeth, so as to escape discernment."

*Boston* *Gazette*  
 COURSE JOURNAL  
 MONDAY SEPTEMBER 5 1768

**WHEREAS** many Persons are so  
 unfortunate as to lose their Fore-Teeth by Accident, and  
 otherways, to their great Detriment, not only in Looks,  
 but speaking both in Public and Private:—This is to in-  
 form all such, that they may have them re-placed with  
 false Ones, that looks as well as the Natural, and answers  
 the End of Speaking to all Intents, by **PAUL REVERE,**  
 Goldsmith, near the Head of Dr. Clarke's Wharf, Boston.  
 \* \* \* All Persons who have had false Teeth fixt by Mr.  
 John Baker, Surgeon-Dentist, and they have got loose (as  
 they will in Time) may have them fastened by the above,  
 who learnt the Method of fixing them from Mr. Baker.

Fig. 1-8. Paul Revere's advertisement for his services as a dentist (dated September 5, 1768). (From *Ring ME: Dentistry: an illustrated history*, New York, 1985, Harry N. Abrams.)

## ESTHETICS IN THE UNITED STATES

In the colonial United States, primitive dental conditions prevailed for almost a century (from roughly 1670 to 1770) until the arrival of "operators for the teeth," dental professionals who had been trained in Europe. They brought with them not only medications for toothache but also prescriptions for toothpowder "to make teeth white" and "attend to your teeth and preserve your health and beauty." They claimed their toothpowder "[prepared] and [fixed] real enameled teeth, the best contrivance yet to substitute the loss of natural ones" (Figs. 1-7 and 1-8). Transplantation of teeth between patients was practiced, with donors being paid for their trouble: "Any person that will dispense of the front teeth, five guineas for each" (Fig. 1-9).

Cosmetic dentistry did not meet with universal acceptance, however. The following is an official edict published by His Britannic Majesty at Perth Amboy, New Jersey:



Fig. 1-9. Eighteenth-century Thomas Rowlandson etching depicting the transplantation of a tooth from a maid to her mistress. (Courtesy National Library of Medicine, Bethesda, Md.)



Fig. 1-10. George Washington's denture. (Object courtesy of National Museum of Dentistry, Baltimore, MD. Image courtesy of National Museum of American History, Smithsonian Institution.)

"All women of whatever age, rank, profession or degree, whether virgins, maids, or widow, who after this Act shall impose upon, seduce and betray unto matrimony any of His Majesty's subjects by virtue of cosmetics, scents, washes, paints, artificial teeth, false hair or high-heeled shoes, shall incur the penalty of the law in force against witchcraft and like misdemeanors."

Competent dental practitioners could be found in the leading cities of the United States by the early years of the nineteenth century. The introduction of mineral teeth in 1817 was soon followed by the manufacture of porcelain teeth. Dentures were fabricated with a gingival component made of carved ivory or animal bone that was designed for adaptation to ivory or bone bases (Fig. 1-10). These denture bases were common until the 1850s, when various alternative materials were introduced to afford more esthetic results. The technique of mounting artificial teeth on gold or platinum fused with a continuous pink gingival body made of porcelain was patented in the

nineteenth century. "Auroplasty;" colored gutta-percha; "parkesine," a celluloid-like material; "cheoplasty," an alloy of tin, silver, and bismuth; "rose pearl;" collodion; pink hecolite; and even tortoise shells were used for esthetic effect in dentistry. Vulcanite was the first universally acceptable denture material. Patented by Nelson Goodear in 1851, it was made by heating caoutchouc (Indian rubber) with sulphur, resulting in a firm yet flexible material. Vulcanite, which was relatively inexpensive and simple to make, propelled the use of dentures out of the luxury category by allowing for relatively inexpensive and simple fabrication. Synthetic materials such as vinyl acrylic resins, copolymer acrylic resins, and styrene acrylic resins were introduced about 1934.

In the late nineteenth century various techniques used in esthetic fixed prosthodontics were introduced. The open-faced crown was invented around 1880, the interchangeable porcelain facing (a ridged facing that fitted into a grooved pontic) was developed in the 1880s, and the porcelain jacket crown came into vogue in the early 1900s. The three-quarter crown was introduced in 1907.

Practitioners of operative dentistry sought more esthetic material than the gold, lead, tin, and platinum in use in the late nineteenth century. One option was "Hill's Stopping," a mixture of bleached gutta-percha, carbonates of lime and quartz, plastic, bone, and fused glass. Porcelain was another option in restorative material. By 1897 a relatively modern composition of silicate cement was developed. It consisted of powdered aluminum and zinc oxide mixed with phosphoric and hydrofluoric acid. After being briefly abandoned because it was difficult to manage and became brittle, it resurfaced in modified form in 1904 and revolutionized operative dentistry. The inventive combination of acid-soluble glasses blended with a liquid containing phosphoric acid produced dentistry's first truly translucent restorative material. Further modifications continued until 1938, when the American Dental Association (ADA) published its definitive specification of acceptability known as "ADA Specification No. 9." This was the first cosmetic dental material to be accepted by the ADA. However, newer and more exciting innovations were about to arrive.

In the 1930s chemically activated acrylic resins were developed. In the 1940s acrylic-veneer facings came into widespread use. By the 1970s composite resins virtually replaced acrylic resins and silicate cements as "permanent" restorations. Refinements of this basic formula of resin matrix and glass filler are currently in use.

Acid etching, often called *bonding*, radically changed cavity treatment by emphasizing conservation of tooth structure. It also allowed for the numerous veneering techniques introduced in the 1970s. Variations include direct resin veneers, commercially produced acrylic "shells," and laboratory-processed veneers of resin and porcelain.

Research continues. Study groups, societies, journals, and continuing education courses dedicated to the discipline of cosmetic dentistry have proliferated. Undoubtedly, the quest for the elusive ultimate restoration will continue to reveal new vistas in the art and science of esthetic and cosmetic dentistry.

## BIBLIOGRAPHY

- Asbell MB: *A bibliography of dentistry in America: 1790-1840*, Cherry Hill, NJ, 1973, Sussex House.
- Asbell MB: *Dentistry: a historical perspective*, Pittsburgh, 1988, Dorrance & Co.
- Bremmer MDK: *The story of dentistry*, New York, 1954, Dental Items of Interest.
- Foley GPH: *Foley's footnotes: a treasury of dentistry*, Wallingford, PA, 1972, Washington Square East Publishing.
- Guerini V: *A history of dentistry from the most ancient times until the end of the eighteenth century*, Philadelphia, 1969, Lea & Febiger.
- Herschfeld J: The progress of esthetic restorations in dentistry, unpublished paper.
- Kanner L: *Folklore of the tooth*, New York, 1934, Macmillan.
- Prinz H: *Dental chronology. A record of more important historic events in the evolution of dentistry*, Philadelphia, 1945, Lea & Febiger.
- Ring ME: *Dentistry: an illustrated history*, New York, 1985, Harry N. Abrams.
- Weinberger BW: *An introduction to the history of dentistry, vols 1 and 2*, St Louis, 1948, Mosby.

# FUNDAMENTALS OF ESTHETICS

Bruce A. Singer

**T**HE DEVELOPMENT OF NEW MATERIALS and techniques in dentistry has required the enlightened practitioner to develop new artistic skills. The restorative dentist manipulates light, color, illusion, shape, and form to create an esthetic outcome. Expertise in these areas differentiates the technically proficient dentist from one practicing a higher level of care and artistry.

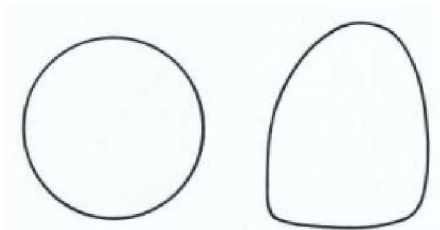


Fig. 2-1. Unidirectional, unnatural lighting throws no shadows. Only length and width are represented.

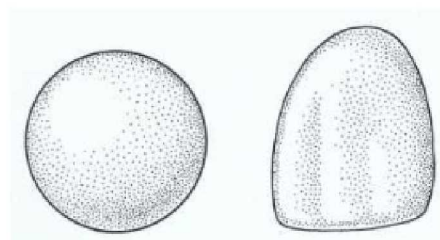


Fig. 2-2. Natural lighting is multidirectional. It throws shadows and therefore promotes a feeling of depth—a three-dimensional effect.

## LIGHT AND SHADOW

Objects cannot be distinguished without light. When lit, most objects (Fig. 2-1) exhibit two dimensions—length and width. True natural light, however, is multidirectional; it reveals texture and throws shadows, adding the lifelike third dimension of depth (Fig. 2-2). Therefore *the communication of form is by shadow*. A comparison of Figures 2-1 and 2-2 makes this concept apparent. Dental restorations can *mimic* the shadows of adjacent teeth to create a shape that blends with the surrounding tooth forms. Shadow manipulation can make poorly shaped teeth esthetically pleasing.

## THE PRINCIPLES OF COLOR

In 1666, Sir Isaac Newton observed that white light passing through a prism divided into an orderly pattern of colors now termed the *spectrum*. He also discovered that these colors produced white light when passed back through the prism, proving that all spectral colors were in the original beam.'

Color, as the eye interprets it, is either a result of absorption or reflection. In absorption a white light is passed through a filter. The colors that pass through the filter and reach the eye are perceived as the color of the filter. In reflection, as with solid objects, the color that we see is the portion of the spectrum that is reflected back to the eye.

Light entering the eye stimulates the photoreceptor rods and cones in the retina. The energy is converted through a photochemical reaction into nerve impulses



Fig. 2-3. Hue is the name of the color.



Fig. 2-5. Value is the brightness of a shade. A low value is darker than a high value.



Fig. 2-4. Chroma is the saturation or amount of hue.

and carried through the optic nerve into the occipital lobe of the cerebral cortex. The rod cells are responsible for interpreting brightness differences and value. The cone cells function in hue and chroma interpretation. If the light source contains all the colors of the spectrum, a true reading occurs. If the light source is deficient in a certain color, a false reading occurs (see the section on Metamerism later in this chapter). Precise description of these colors and organization of their interrelationships, however, did not occur until 249 years after Newton's work. Robert Louis Stevenson, one of the most concise writers in the English language, demonstrated the problems of describing color: "red-it's not Turkish and it's not Roman and it's not Indian, but it seems to partake of the two last."<sup>2</sup> In 1915 Albert Henry Munsell created an orderly numeric system of color description that is still the standard today. In this system color is divided into three parameters-hue, chroma, and value.<sup>1</sup>

### Hue

Hue (Fig. 2-3) is the name of the color. Roy G. Biv (Red, Orange, Yellow, Green, Blue, Indigo, Violet) is an acronym for the hues of the spectrum. In the younger permanent dentition, hue tends to be similar throughout the mouth. With aging, variations in hue often occur because of intrinsic and extrinsic staining from restorative materials, foods, beverages, smoking, and other influences.

### Chroma

Chroma (Fig. 2-4) is the saturation or intensity of hue; therefore it can only be present with hue. For example, to increase the chroma of a porcelain restoration more of that hue is added. Chroma is the quality of hue that is most amenable to decrease by bleaching. Almost all hues are amenable to chroma reduction in vital and non-vital bleaching.<sup>4</sup> In general, the chroma of teeth increases with age.

### Value

Value (Fig. 2-5) is the relative lightness or darkness of a color. A light tooth has a high value; a dark tooth has a low value. It is not the *quantity* of the "color" gray, but rather the *quality* of brightness on a gray scale.<sup>5</sup> That is, the shade of color (hue plus chroma) either seems light and bright or dark and dim. It is helpful to regard value in this way because the use of value in restorative dentistry does not involve adding gray but rather manipulating colors to increase or decrease amounts of grayness.

**CLINICAL TIP.** Value is the most important factor in shade matching. If the value blends, small variations in hue and chroma will not be noticeable.<sup>5</sup>

## COLOR (HUE) RELATIONSHIP

### The Color Wheel

Hues, as used in dentistry, have a relationship to one another that can be demonstrated on a color wheel. The relationships of primary, secondary, and complementary hues are graphically depicted by the color wheel (Fig. 2-6).

### Primary Hues

The primary hues-red, yellow, and blue-form the basis of the dental color system. In dentistry the metal oxide pigments used in coloring porcelains are limited in forming certain reds; therefore pink is substituted. The primary hues and their relationships to one another form the basic structure of the color wheel.

### Secondary Hues

The mixture of any two primary hues forms a secondary hue. When red and blue are mixed they create violet, blue and yellow create green, and yellow and red create orange. Altering the chroma of the primary hues in a mixture changes the hue of the secondary hue produced. Primary and secondary hues can be organized on the color wheel with secondary hues positioned between primary hues.

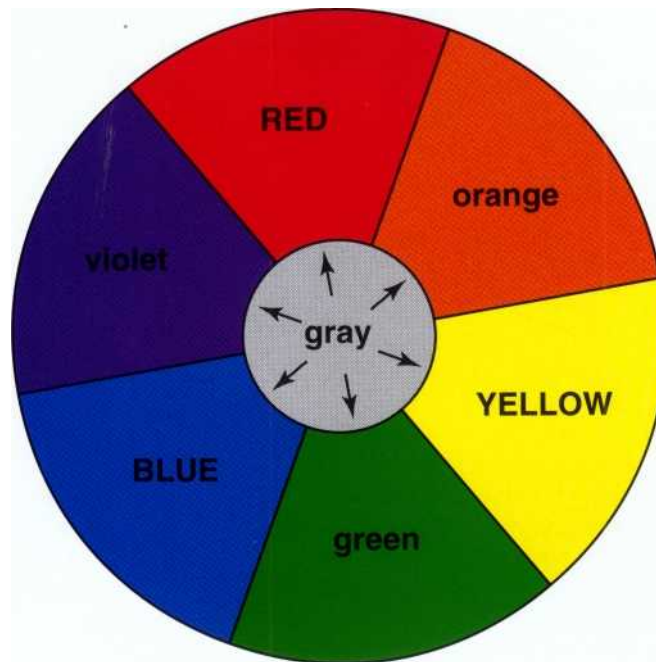


Fig. 2-6. The color wheel. The primary colors (red, yellow, and blue), mixed two at a time, produce the secondary colors (orange, green, and violet). Opposite colors on the color wheel cancel each other out and produce gray.

## Complementary Hues

Colors directly opposite each other on the color wheel are termed *complementary hues*. A peculiarity of this system is that a primary hue is always opposite a secondary hue and vice versa. When a primary hue is mixed with a complementary secondary hue, the effect is to "cancel" out both colors and produce gray. *This is the most important relationship in dental color manipulation.*

**CLINICAL TIP.** To change hue, lessen chroma, or lower value, place the complementary hue over the color to be modified.

When a portion of a crown is too yellow, lightly washing with violet (the complementary hue of yellow) produces an area that is no longer yellow. The yellow color is canceled out and the area will have an increased grayness (a lower value). This is especially useful if the body color of a crown has been brought too far incisally and more of an incisal color is desired toward the cervical area. If a cervical area is too yellow and a brown color is desired, washing the area with violet cancels the yellow. This is followed by the application of the desired color, in this case brown.

Complementary hues also exhibit the useful phenomenon of intensification. When complementary hues are placed next to one another, they intensify one another and appear to have a higher chroma. A light orange

line on the incisal edge intensifies the blue nature of an incisal color.

## Hue Sensitivity

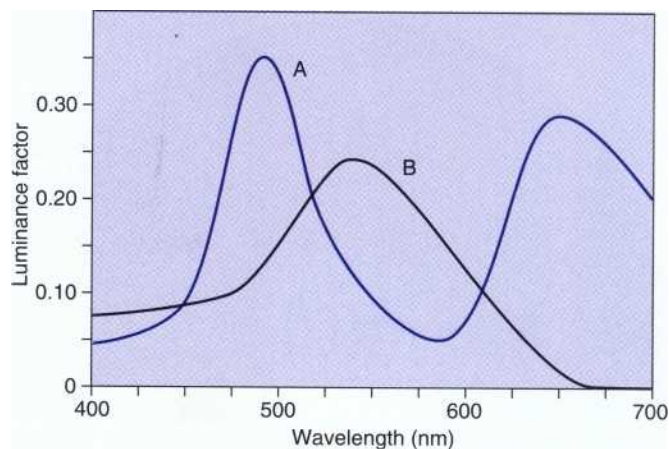
After 5 seconds of staring at a tooth or shade guide, the eye accommodates and becomes biased. If a person stares at any color for longer than 5 seconds and then stares away at a white surface or closes his or her eyes, the image appears, but in the complementary hue. This phenomenon, known as *hue sensitivity*, adversely affects shade selection.

**CLINICAL TIP.** After 5 seconds, look away or stare briefly at a blue surface (such as a patient napkin). This will readapt your vision to the orange-yellow portion of the spectrum, the portion most involved in color matching.

## Metamerism

**Basic Theory.** Metamerism is a phenomenon that can cause two color samples to appear as the same hue under one light source, but as unmatched hues under a different light source.

There is more than one way to produce a color. It can either be pure, or a mixture of two other colors (e.g., pure green versus a mix of blue and yellow). Pure green reflects light in the green band, but the green mixture



**Fig. 2-7.** The spectral curves of two metameric green surfaces that appear identical but exhibit different reflection properties. Surface B reflects light in the green wavelengths and, thus, appears green. Surface A, on the other hand, reflects both cyan and yellow light, which also results in the perception of a green surface. As long as all the required wavelengths of light are present, these two metameric pairs look identical. If, however, the incident light is deficient in either the yellow or cyan, Surface A will not appear green and the colors will not match. (Adapted from Preston JD, Bergen SF: Color science and dental art: a self-teaching program, St Louis, 1980, Mosby.)

reflects light in the blue and yellow bands simultaneously. If both colors are exposed to a light with a full color spectrum they will appear similar. If, however, they are exposed to a light source that does not contain light in the blue band, the two colors will appear dissimilar. True green will still appear green, but the mixture will appear yellow because without a source of light in the blue band the blue component of the mix is not visible to the eye. A spectral curve is a measure of the wavelength of light reflected from a surface. It reveals the actual component colors reflected from an object (Fig. 2-7).<sup>5</sup>

**Clinical Relevance.** Metamerism complicates the color matching of restorations. A shade button may match under incandescent lighting from the dental operatory lamp but not under fluorescent lighting in the patient's workplace.

**CLINICAL TIP.** The best approach to color matching is to use three light sources.

A color selection that works well under a variety of lights is preferred to a match that is exact under one source of light but completely wrong under others. Usually, three sources of light are available in the dental operatory:

1. Outside daylight through a window
2. Incandescent lighting from the dental operatory lamp
3. Cool white fluorescent lighting from overhead fixtures

Color-corrected fluorescent lamps more closely approximate natural daylight and some practitioners prefer them as the standard in dental operatories. If the entire office is illuminated by color-corrected fluorescent lamp, one room should have cool white fluorescent lighting for comparative shade matching. The color match that holds up the best in these three lights is the best choice.

**CLINICAL TIP.** If the patient spends a great deal of time in one lighting situation, that light source should take precedence during shade selection.

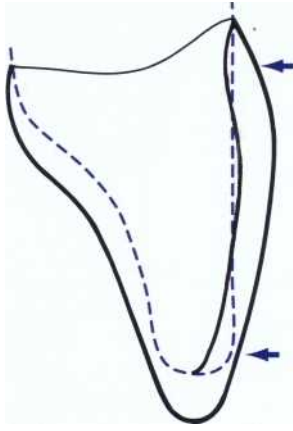
## Opacity

**Basic Theory.** An opaque material does not permit any light to pass through. It reflects all the light that is shined on it.

**Clinical Relevance.** A porcelain-fused-to-metal restoration must have a layer of opaque porcelain applied to the metal substructure to prevent the color of the metal from appearing through the translucent body and incisal porcelains. Improper tooth reduction results in two unacceptable results:

1. An ideally contoured restoration with minimal porcelain thickness and too much opaque porcelain, resulting in a "chalky" appearance
2. A bulky, poorly contoured restoration with ideal porcelain thickness

Tooth reduction must be sufficient to allow enough room for an adequate bulk of body and incisal porcelains (Fig. 2-8).



**Fig. 2.8.** The arrows indicate underprepared areas in a typical full crown or veneer preparation. Underpreparation results in opaque areas in the finished restoration. The correct preparation is illustrated by the solid line.

**CLINICAL TIP.** The usual areas of underpreparation are the cervical one third and, if a second plane of reduction is not placed, the incisofacial aspect of the preparation.

### Translucency

Translucent materials allow some light to pass through them. Only some of the light is absorbed. Translucency provides realism to an artificial dental restoration.

### Depth

**Basic Theory.** In restorative dentistry, depth is a spatial concept of color blending combining the concepts of opacity and translucency. In the natural dentition, light passes through the translucent enamel and is reflected out from the depths of the relatively opaque dentin.

**Clinical Relevance.** White porcelain colorants used in color modification are opaque. Gray porcelain colorants are a mixture of black and white. A tooth restoration with a white opaque colorant on the surface appears artificial because it lacks the quality of depth that would be seen if the opaque layer were placed *beneath* a translucent layer of porcelain. Similarly, a bright restoration (high value) in need of graying (a decrease in value) **would appear falsely** opaque if it were simply painted gray. Adding a complementary hue, however, both decreases the value and adds to the translucency. If characterization needs to be added to porcelain to represent white hypoplastic spots or gray amalgam stains, white or gray col-

orant can be used, but with the knowledge that translucency will be reduced in these areas.

Depth may be problematic if translucent composite resins are used to restore Class III or IV cavities that extend completely from facial to lingual surfaces. The restoration may appear gray or overly translucent. However, if a more opaque composite resin is placed on the lingual portion of the restoration and then overlaid with a translucent resin, a natural illusion of depth results.

## THE PRINCIPLES OF FORM

### Perception

As we look at a tooth in an environment of other teeth we perceive unconsciously many qualities of that tooth. Perceptions about color, size, shape, age, and gender are based on certain natural biases indigenous to an individual's cultural background. Perceptual biases can be divided into two types: cultural and artistic.

### Cultural Biases

Cultural biases are naturally occurring environmental observations about the world around us. We perceive (and believe) that darker, heavily worn, highly stained, longer teeth belong to an older person because we know that teeth naturally darken, wear, and stain in grooves and along the cervical area with age, and that they lengthen because of gingival recession. We perceive (and believe) rounded, smooth-flowing forms are feminine, whereas harsher, more angular forms are masculine.

**Masculine and Feminine.** Culturally defined masculine qualities may enhance the appearance of a woman (many feminine fashions include a modification of a shirt and tie). However, usually these masculine nuances look best on a woman with stereotypically feminine features. Square, angular anterior teeth, therefore, may be desirable for a more "feminine" woman, but on other women this tooth shape may not be as flattering. In Western culture, contrast evokes a certain allure. With no contrast, the allure is gone.

**The Golden Proportion.** Western civilization has drawn the conclusion that for objects to be proportional to one another the ratio of 1 : 1.618 is esthetically pleasing. Much has been hypothesized from this ratio, from the mathematical relationship of the chambers of the nautilus shell to facial proportions. As a general rule, if the *apparent* (see the section on The Law of the Face later in this chapter) size of each tooth, as observed from the frontal view, is 60% of the size of the tooth anterior to it, the relationship is considered to be esthetically pleasing. That is, if the *apparent* width of the central incisor is





*Fig. 2-9. The principle of illumination: light approaches and dark recedes. The illusion of contour is produced as cosmetics are applied to the face or shadows are drawn on a drawing.*

1.608, the lateral incisor and canine should be 1.0 and .608 respectively.<sup>7</sup>

### Artistic Biases

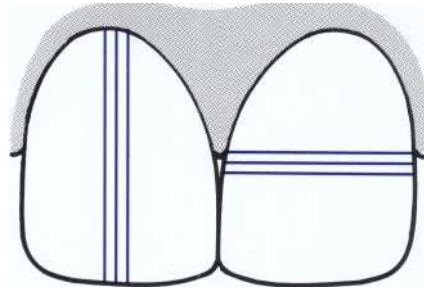
Artistic biases are inherent in our perception of form. The most important of these is the perception that light approaches and dark recedes; this is the *principle of illumination*.<sup>8</sup> The light areas in Figure 2-2 appear to come forward, whereas the darker areas appear to recede. This produces the illusion of a third dimension (depth) despite the two-dimensional nature (length and width) of the printed page. This bias applies equally to clothes, cosmetics, and teeth. The purpose of cosmetics is to give contour to the face (Fig. 2-9).

The second artistic bias of great importance in dentistry is the use of horizontal and vertical lines. A horizontal line makes an object *appear* wider, whereas a vertical line makes an object *appear* longer (Fig. 2-10). This can be termed the *principle of line*.

These cultural and artistic biases are so entrenched in our subconscious thought that they are unavoidable and automatic. Artistic manipulation of these biases allows the cosmetic dentist to fool the eye of the observer when fabricating artificial esthetic restorations.

### Illusion

Illusion is the art of changing perception to cause an object to appear different than it actually is. Teeth can be



*Fig. 2-10. The principle of line: horizontal lines created by cervical staining, texturing, white hypoplastic lines, and straight incisal edges create the illusion of width; vertical lines created by narrowing the face of the tooth, carving the incisal edges to slope cervically, and deepening the incisal embrasures create the illusion of length.*

made to appear wider, narrower, smaller, larger, shorter, longer, older, younger, masculine, or feminine. An understanding of the basic principles of perception and their use in controlling illusion must precede their use.

## USING THE PRINCIPLES OF PERCEPTION TO CONTROL ILLUSION

### Principle of Illumination

The principle of illumination can be manipulated by the dentist to change the apparent size and shape of a tooth through illusion. This bias is the key to *The Law of the Face*.

### The Law of the Face

The law of the face is the most important single concept in shaping dental restorations. Understanding this concept and its interplay with the concept of light and dark enables the esthetic dentist to shape all esthetic restorations correctly.

The *face* of a tooth is the area on the facial surface of anterior and posterior teeth that is bounded by the transitional line angles as viewed from the facial (buccal) aspect (Fig. 2-11). The transitional line angles mark the transition from the facial surface to the mesial, cervical, distal, and incisal surfaces. The tooth surface slopes lingually toward the mesial and distal approximating surfaces and toward the cervical root surface from these line angles. Often no transitional line angle appears on the incisal portion of the facial surface; in this case the face is bounded by the incisal edge or the occlusal tip. Shadows created as light strikes the labial surface of the tooth begin at the transitional line angles. *These shadows delineate the boundaries of the face.*

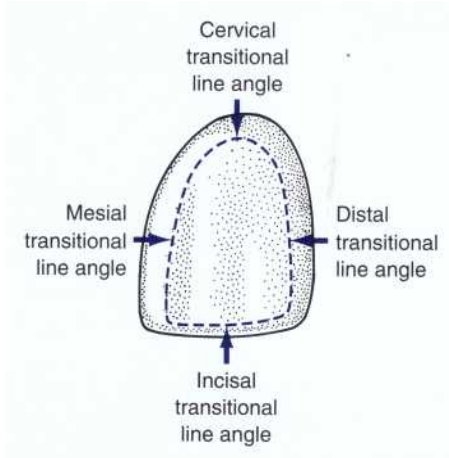


Fig. 2-11. The face of the tooth is bound by the transitional line angles.

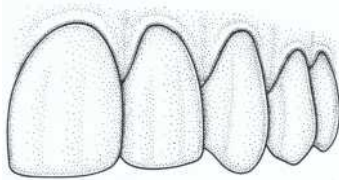


Fig. 2-12. From a frontal view the canine displays only the mesial portion of the tooth, up to and including the midlabial ridge.

The apparent face of a tooth is the portion that is visible to the viewer from any single view. The perimeter of the apparent face is dictated by the position of **the viewer relative to** the tooth. For example, from the front view the entire incisor faces are visible, but usually only the mesial half of the faces of the maxillary canines are visible from this angle (Fig. 2-12).

The *law of the face* states that in order to make dissimilar teeth appear similar, the dentist should make the apparent faces equal (Figs. 2-13 and 2-14). Creating equal apparent faces in two dissimilar adjacent teeth produces dissimilar areas outside the transitional line angles (i.e., outside the faces). These dissimilarities are esthetically acceptable because they are **essentially invisible; the similar faces of the teeth catch** the light and appear to protrude, whereas the dissimilar areas are in shadow and appear to recede (see Fig. 2-14). Through cultural biases we are conditioned to expect the faces of contralateral teeth to be equal even though exposed roots may be unequal in length. The six teeth in Figure 2-13 are dissimilar. Shaping the maxillary right central incisor, lateral incisor, and canine so that their faces equal those of **the maxillary left central incisor, lateral incisor, and canine produces the illusion that** these teeth are equal.

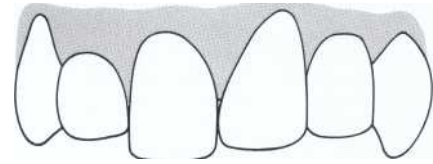


Fig. 2-13. Teeth with numerous disharmonious esthetic problems.

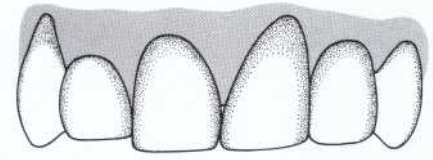


Fig. 2-14. Selective grinding of the incisal edges, moving the labial prominence of the left canine mesially and altering the transitional line angles to make the apparent faces equal, creates an illusion of harmony.

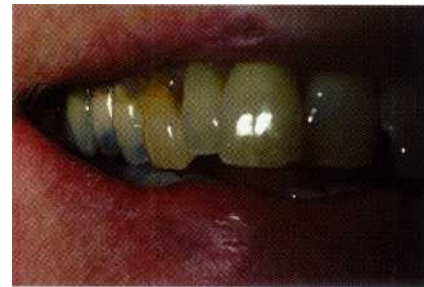

Fig. 2-15. The porcelain-fused-to-metal crown restoring the maxillary right second premolar has been darkened at the gingival third to create the illusion of a discolored restoration. The root surface appears to recede because it has a lower (darker) value.

**CLINICAL TIP.** Equal faces can be most effectively created by shaping the labial surface to reposition the transitional line angles. This promotes a natural shadow.

When the transitional line angle cannot be repositioned on a ceramic restoration, the artistic principle of illumination can be employed. A portion of the tooth can be stained darker to create the illusion that the transitional line angle has been moved and that the portion of the tooth is receding. In reality the tooth contour remains unchanged (Fig. 2-15). *Only the "apparent face" should be manipulated, not the actual face.* This becomes particularly significant in posterior regions where the apparent face significantly differs from the actual face (see the section on canines and the law of the face later in this chapter).

### Alteration of the Face-Incisors

For clarity, the tooth to be mimicked is referred to as the *guide tooth* and the tooth to be altered as the *related tooth*.

#### Armamentarium

- Pencil
- Greenstones (porcelain)
- Multifluted carbides or finishing diamonds (tooth structure, composite resin)
- Aluminum oxide disks in varying coarseness, 4 grits are preferred (i.e., Sof-Flex, 3M Inc.) (tooth structure, acrylic, composite resin)
- Diamond disks (porcelain modification)
- Porcelain stains

#### Clinical Technique

1. Outline the face of the guide tooth with a pencil.
2. Examine the related tooth from the incisal angle to determine the buccolingual dimensions.
3. If sufficient tooth structure (or restorative material) is available, flatten the labial surface to the same level of protrusion as **the guide tooth** using green stones, multifluted carbides, finishing diamonds, or coarse disks.
4. Using a pencil, draw a mirror image of the face of the guide tooth onto the related tooth.
5. Carve back toward the proximal surfaces from the boundaries of the face using greenstones, multifluted carbides, finishing diamonds, and coarse disks followed by diamond disks and successively finer aluminum oxide disks. If this is not possible, shade the restorative material a darker color in the areas lateral to the face (pencil lines). Surface staining can be employed on porcelain. A resin with a lower value or increased chroma should be used on composite resin.

### Canines and the Law of the Face

The concept of the apparent face becomes more important when dealing with teeth posterior to the incisor teeth. From a frontal view only a portion of the canine and posterior teeth are visible (see Figure 2-12). In the frontal view the canine face is bounded by the mesial transitional line angle, the cervical transitional line angle, and the midlabial ridge. Usually the distal half of the tooth is not visible from a frontal view. The left and right side views cannot be seen simultaneously and are of secondary importance. Four steps are required to blend a poorly shaped canine into a smile.

### Alteration of the Face-Canines

For clarity, the tooth to be mimicked is referred to as the *guide tooth* and the tooth to be altered as the *related tooth*.

#### Armamentarium

The same setup as for alteration of the face (incisors) is used.

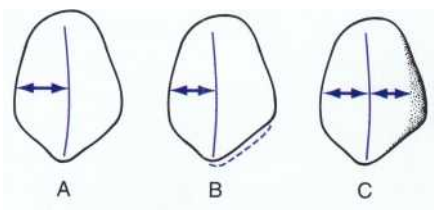
#### Clinical Technique

1. Using the frontal view, **outline the apparent face of the guide tooth (the contralateral canine) with a pencil** (Fig. 2-16, A).
2. Again looking from the front, draw a mirror image of the apparent face of the guide tooth onto the related canine with a pencil.
3. Using these lines, move the midlabial ridge of the related tooth either mesially or distally to approximate the amount of tooth structure shown on the guide canine. Because only the area mesial to this ridge is seen from the frontal view, the viewer extrapolates the full size of the tooth as twice that size (Fig. 2-16, B).
4. From the side view, if the mesial half of the related tooth has been made smaller by mesial movement of **the midlabial ridge, make the distal half of the face equal by locating the distal transitional line angle in a symmetric position to the mesial transitional line angle by carving the** tooth structure back toward the lingual area from the distal transitional line angle (Fig. 2-16, C).

### Principle of Line

Horizontal lines—in the form of cervical staining, texturing, white hypoplastic lines, or long, straight incisal edges—create the illusion of width. Widening the face also produces an illusion of width (Fig. 2-17).

Vertical lines in the form of accentuated developmental grooves, hypoplastic lines, and vertical texturing accentuate height. Incisal edges of anterior teeth carved to slope cervically toward the distal area with larger in-



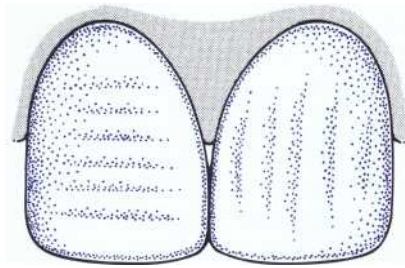
*Fig. 2-16. From a frontal view the canine appears too wide. Several steps are required to create the illusion of a narrower tooth. A, Preoperative view of the canine with the width delineated by an arrow. B, The midlabial ridge is moved mesially, creating the illusion of a narrower tooth. The incisal tip is also moved mesially by removing tooth structure from the distal aspect of the incisal edge. C, The distal transitional line angle is moved mesially until the distal face is equal to the mesial face. The canine now appears narrower from both the frontal and side views.*

cisal embrasures and narrower (mesiodistally) incisal edges create an illusion of increased height. Narrowing the face also creates this illusion (see Fig. 2-17). These same concepts apply for clothing and makeup. Individuals wearing clothing with vertical lines appear thinner. Conversely, horizontal stripes accentuate width. To "lengthen" and "slim" the nose with cosmetics, a light highlighter is applied in a vertical line down the center bridge of the nose. Then a darker contour shade of makeup is applied on each side of the nose to make that area recede.<sup>9</sup>

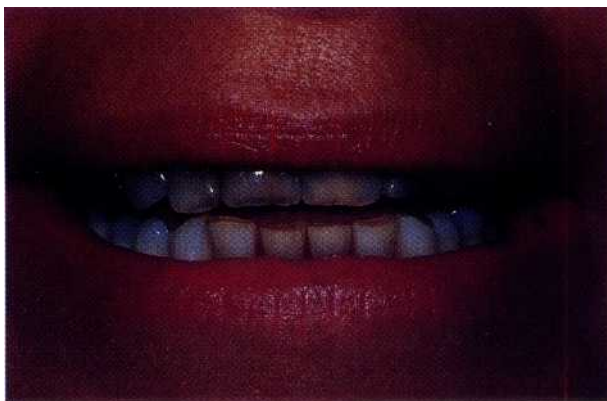## Age

The Western negative cultural bias toward age is a sensitive issue for patients seeking esthetic care and must be considered.

**Older Teeth.** Older teeth (Fig. 2-18) have the following characteristics:



*Fig. 2-17. The principle of line can be used to create the illusion of a longer or shorter tooth. Stain lines, texturing, and modification of the face and incisal edge all contribute to the illusion.*



*Fig. 2-18. Older teeth are smoother, darker, shorter, have worn incisal edges, and are more characterized.*

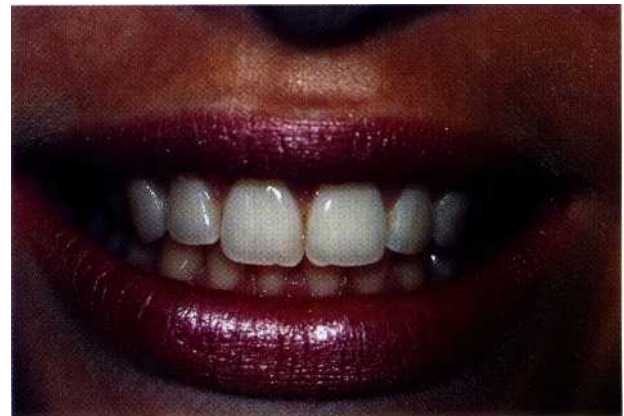1. They are smoother.
2. They are darker (i.e., not as bright, lower value).
3. They have a higher saturation (higher chroma).
4. They are shorter incisally (less tooth shows when the patient is smiling).
5. They are longer gingivally (although they may be shorter incisally).
6. They exhibit more wear, even on incisal edges with small incisal embrasures.
7. They have wider, more open gingival embrasures.
8. They are more characterized.

The lower incisors exhibit flat broad incisal edges, which show a dentin core.

**Younger Teeth.** Younger teeth (Fig. 2-19) have the following characteristics:

1. They are more textured.
2. They are lighter (i.e., brighter, higher value).
3. They have a lower saturation (lower chroma).
4. They have a gingival margin at approximately the cemento-enamel junction.
5. They have incisal edges that make the laterals appear shorter than the incisors or canines.
6. They have significant incisal embrasures.
7. They have small gingival embrasures.
8. They have light characterization, often with white hypoplastic lines or spots.

Clinically, the ultimate esthetic goal is to make artificial prostheses appear natural. (This should elicit a third



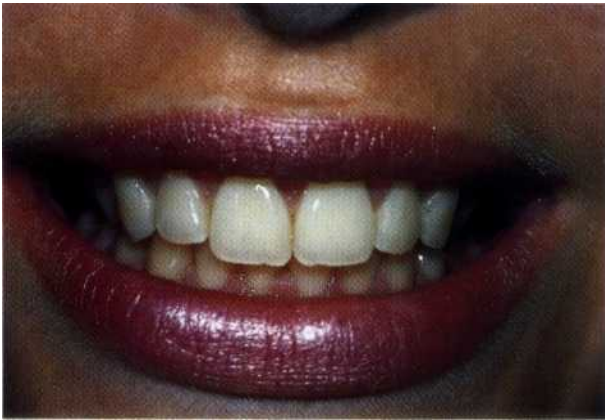*Fig. 2-19. Younger teeth are brighter and more textured, have lower chroma, and have gingival margins at the cemento-enamel junction. They have pronounced incisal embrasures, small gingival embrasures, and are only lightly characterized. Lateral incisors are shorter than the central incisors and the canines. These feminine-looking teeth are more rounded at the transitional line angles and have pronounced incisal embrasures.*

party response of "What beautiful teeth you have," rather than an observer noticing an artificial substitution.) Beautiful natural teeth or artificial substitutes should be harmonious with the patient's personality, age, and gender.

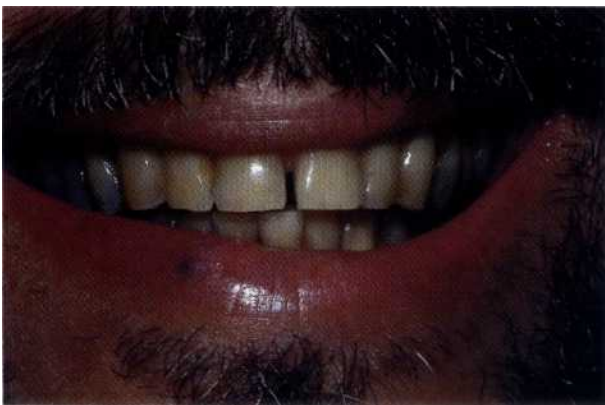### Gender

Lombardi<sup>1</sup> described a theory of anterior esthetics in which he proposed that the age, gender, and personality of a person was reflected in the shape and form of the teeth. Factually, the concept of sexual dimorphism is difficult to prove or disprove. This concept should be considered in the light of cultural bias.

**Feminine.** Feminine teeth are more rounded, both on the incisal edges and at the transitional line angles. The incisal embrasures therefore are more pronounced. The incisal edges are more translucent and white hypoplastic striations may be used to give the illusion of delicacy (Fig. 2-20). The translucency on the incisal edges appears as a



*Fig. 2-20. Feminine-looking teeth are more rounded and translucent, giving an appearance of delicacy.*



*Fig. 2-21. Masculine-looking teeth are more angular and have a higher chroma, square incisal edges, and darker craze lines.*

gray line in the incisal one-eighth of the facial surface paralleling the incisal edge with a white hypoplastic rim on the edge.

**Masculine.** Masculine teeth are more angular and rugged. In older men chroma is greater and body color often extends to the incisal edges. The incisal embrasures are more squared and not as pronounced. Characterization is often stronger, incorporating darker craze lines (Fig. 2-21).

Cultural and artistic biases are central to understanding dental esthetics. They must be thoroughly understood so that the dentist can use these biases artistically to create illusions to satisfy the esthetic demands of the patient. Only then can the technically proficient dentist rise to the level of an artist, providing a higher level of care.

### LABORATORY COMMUNICATIONS

Many practical methods are available to enhance communication with the dental laboratory. Shape and texture can be communicated by intraoral photographs or slides. Desired form may also be conveyed with video imaging technology (see Chapter 25). Shape is perhaps best communicated three dimensionally. Preoperative study models, wax-ups for development of the provisional phase, and models of provisional restorations are helpful. Models of the seated bisque bake allow the technician to see the relation of tooth shape to the soft tissue.

Desired color can be communicated by demonstration or prescription, with demonstration being by far the most accurate method. Custom-colored shade tabs sent to the laboratory as a three-dimensional prescription are most effective. They can be shaded with the same materials used in chairside dental porcelain staining with the only modification being the use of a product such as Ceramco Stain Set (Ceramco, Dentsply) as a liquid medium (see Appendix A). The same technique can be used to communicate final coloring when the case is at the bisque bake stage.

### REFERENCES

1. Waltke R: Color in the human dentition, New Rochelle, 1977, Jelenko.
2. Clark EB: Tooth color selection, DADA, p. 1065, June 1933.
3. Munsell AH: A grammar of color, New York, 1969, Van Nostrand Reinhold.
4. Feinman RA, Goldstein RE, Garber DA: Bleaching teeth, Chicago, 1987, Quintessence.
5. Preston JD, Bergen SF: Color science and dental art: a self-teaching program, St Louis, 1980, Mosby.
6. Sproull RC: Color matching in dentistry. Part 111. Color control, J Prosthet Dent 31:146, 1974.

7. Feigenbaum N, Moppet KW: A complete guide to dental bonding, East Windsor, 1984, Johnson and Johnson.
8. Lombardi RE: Visual perception and denture esthetics, J Prosthet Dent 29:363, 1973.
9. Jackson C: Color me beautiful makeup book, New York, 1988, Ballantine Books.

## BIBLIOGRAPHY

- Adams A: Artificial-light photography, Hastings-on-Hudson, 1968, Morgan and Morgan.
- Agoston GA: Color theory and its application in art and design, New York, 1979, Springer-Verlag.
- Appleby DS, Craig C: Subtleties of contour: a system for recognition and correction, Compend Contin Ed 7:109, 1986.
- Beder OE: Esthetics-an enigma, J Prosthet Dent 25:588, 1971.
- Bergen SF, McCasland J: Dental operator lighting and tooth color discrimination, JADA 94:130, 1977.
- Ceramco stain system manual, East Windsor, 1977, Johnson and Johnson.
- Culpepper WD: A comparative study of shade-matching procedures, J Prosthet Dent 24:166, 1970.
- Culpepper WD: Esthetic factors in anterior tooth restoration, J Prosthet Dent 30:576, 1973.
- De Van M: Methods of procedure in a diagnostic service to the edentulous patient, JADA 29:1981, 1942.
- Edwards B: Drawing on the artist within: a guide to innovation, invention, imagination, and creativity, New York, 1986, Simon and Schuster.
- Edwards B: Drawing on the artist within: an inspirational and practical guide to increasing your creative powers, New York, 1986, Simon and Schuster.
- Edwards B: Drawing on the right side of the brain: a course in enhancing creativity and artistic confidence, New York, 1979, St. Martin's Press.
- Feigenbaum N, Moppet KW: A complete guide to dental bonding, East Windsor, 1984, Johnson and Johnson.
- Friedman M: Staining and shade control of dental ceramics. Part I, Trends and Techniques April 1987.
- Friedman M: Staining and shade control of dental ceramics. Part II, Trends and Techniques, p. 24, May 1987.
- Frush JP, Fisher RD: The age factor in dentogenics, J Prosthet Dent 7:5, 1957.
- Frush JP, Fisher RD: Dentogenics: its practical application, J Prosthet Dent 9:914, 1959.
- Frush JP, Fisher RD: The dysesthetic interpretation of the dentogenic concept, J Prosthet Dent 8:558, 1958.
- Frush JP, Fisher RD: How dentogenic restorations interpret the sex factor, J Prosthet Dent 6:160, 1956.
- Frush JP, Fisher RD: How dentogenics interprets the personality factor, J Prosthet Dent 6:441, 1956.
- Frush JP, Fisher RD: Introduction to dentogenic restorations, J Prosthet Dent 5:586, 1955.
- Garber DA, Goldstein RE, Feinman RA: Porcelain laminate veneers, Chicago, 1988, Quintessence.
- Goldstein RE: Change your smile, Chicago, 1987, Quintessence.
- Goldstein RE: Esthetics in dentistry, Philadelphia, 1976, JB Lippincott.
- Held R: Readings from Scientific American-image, *object*, and illusion, San Francisco, 1974, WH Freeman.
- Light and film, New York, 1970, Time-Life Books.
- Pincus CL: Cosmetics-the psychological fourth dimension in full mouth rehabilitation, Dent Clin North Am, March 1967.
- Ricketts RM: The golden divider, J Clin Ortho 15:752, 1981.
- Rogers LR: Sculpture, Toronto, 1969, Oxford University Press.
- Sorensen JA, Torres TJ: Improved color matching of metal-ceramic restorations. Part I. A systematic method for shade determination, J Prosthet Dent 58:133, 1987.
- Sorensen JA, Torres TJ: Improved color matching of metal-ceramic restorations. Part II. Procedures for visual communication, J Prosthet Dent 58:669, 1987.
- Sorensen JA, Torres TJ: Improved color matching of metal-ceramic restorations. Part III. Innovations in porcelain application, J Prosthet Dent 59:1, 1988.
- Sproull RC: Color matching in dentistry. Part I. The three-dimensional nature of color, J Prosthet Dent 29:416, 1973.
- Sproull RC: Color matching in dentistry. Part II. Practical applications of the organization of color, **J Prosthet Dent 29:556, 1973.**
- Swedlund C: Photography, New York, 1974, Holt, Rinehart and Winston.
- Torlakson J, Gordon J: Deepening the third dimension, The Artist's Magazine 6:50, 1989.



# III

SECTION THREE

---

## ESTHETIC MATERIALS AND TECHNIQUES



انتشارات شایان نمودار

# DENTIN BONDING AGENTS

Mark E. Jensen

**T**HE SEARCH FOR ideal dental adhesives is probably as old as dentistry itself. Significant advances in adhesive dentistry have steadily progressed over the past four decades. The bonding of bis-GMA resin to etched enamel<sup>1</sup> introduced esthetic restorations without the need for mechanical retention form. An obvious goal was to develop an adhesive material that bonds to dentin with a strength at least equal to that of resin bonded to etched enamel. Creating this strong bond is extremely difficult because dentin is only about 50% inorganic by volume compared with the approximately 98% mineral content of enamel. The remaining volume of dentin is primarily water and collagen. In addition, a freshly prepared dentin surface is physically altered by instrumentation during operative procedures (smear layer) (Fig. 3-1). This mechanically altered surface is relatively homogeneous with occluded dentinal tubular openings. Achieving a biocompatible bond to moist dentin while preventing bacterial invasion is critical.



Fig. 3-1. Scanning electron micrograph (SEM) of dentin surface with "smear-layer" produced from cavity preparation.

## HISTORIC PERSPECTIVE

Five distinct generations of dentin bonding agents have evolved. The first generation was developed in the late 1950s and early 1960s and was composed of polyurethanes, cyanoacrylates, glycerophosphoric acid dimethacrylate, and NPG-GMA (N-phenyl glycine and glycidymethacrylate). All these materials were disappointing clinical failures. In vitro shear bond strengths were only approximately 10 to 20 kg/cm<sup>2</sup>. Nearly two decades later, second-generation dentin bonding materials were introduced (Scotchbond, Dentin Bonding Agent, Creation Bonding Agent, Dentin-Adhesit, Bondlite, and Prisma Universal Bond). Most were halophosphorus esters of bis-GMA that were designed to adhere to the mineral portion of the dentin as a phosphate-calcium bond. In vitro bond strengths of these materials were reported to be 30 to 90 kg/cm<sup>2</sup>.<sup>2,3</sup> The bond, however, was hydrolyzed over time in the oral environment, which contributed to their poor clinical success.<sup>3-7</sup>

The third-generation dentin bonding agents flooded the market in the early 1980s. Bowen introduced a novel oxalate dentin bonding system in 1982.<sup>8</sup> Originally, this system was cumbersome and unpredictable, but it demonstrated a marked improvement, with bond strengths of 100 to 150 kg/cm<sup>2</sup>. The acidified ferric oxalate in this system was believed to be a source of marginal discoloration, and the complicated series of reagents made the system clinically cumbersome. Bond strengths improved, with modifications close to that of composite resin bonded to etched enamel at 200 to 220 kg/cm<sup>2</sup>. Still, clinical success was not satisfactory.

Fourth-generation dentin bonding agents are probably the closest to an ideal dentin bond. The effect on the pulp of conditioning the dentinal surface was long an issue.<sup>9,10</sup> Clinical procedures were simplified by the





simultaneous etching of the enamel surface and conditioning of the dentin. This "total etch technique" improved the bond strength to dentin as well."

Fifth-generation bonding agents are essentially a modification of the fourth generation materials. They are self-priming "one-bottle" systems allowing faster and easier clinical application.<sup>12</sup>

### IDEAL CHARACTERISTICS OF A DENTIN BONDING AGENT

The ideal dentin bonding agent should achieve the following:

1. Bond to dentin with an equal or greater strength than that of a composite resin bonded to etched enamel
2. Rapidly attain (within a few minutes) maximum bond strength to permit finishing and polishing procedures and postoperative patient functioning within a reasonable time frame
3. Be biocompatible and nonirritating to the pulp
4. Prevent microleakage
5. Exhibit long-term stability in the oral environment
6. Be easy to apply and clinically forgiving

Despite dramatic improvements in dentin bonding agents, clinical techniques are still confusing, despite the fact that research and product information on the subject has dramatically increased. An electronic Medline search using the phrase "dentin bonding" lists over 650 abstracts written between 1993 and early 1998. A search with a single search engine on the World Wide Web using the keywords "dentin" and "adhesive" produced more than 36,000 web pages with up-to-date research, discussion groups, and promotional information.

### PRODUCT SELECTION

Sufficient laboratory and animal data to predict clinical performance of dentin bonding agents are currently lacking. In addition, no large-scale controlled clinical human trials comparing the performance of these materials currently exist. Fortunately, however, some progress has been made in attempting to support scientifically the clinical choice between bonding agents. The American Dental Association (ADA) Acceptance Program was extended to include "Dentin and Enamel Adhesive Materials." The ADA states, "These guidelines should distinguish those adhesive materials that provide valid long-term adhesion to tooth structure from others that either provide none or for which those properties are short lived".<sup>13</sup> The acceptance process is complex, requiring FDA-510K or PMA (Pre-Market Approval), product information/descriptions, quality control requirements, laboratory and

biologic evaluation parameters, and clinical trials. At least two independent studies are required, evaluating which produce measurements at baseline, 6 months (Provisional Acceptance) and 18 months (Full Acceptance).

The ADA standard requires a minimum of 30 restorations (25 patients) at placement (baseline), 20 patients at 6 months, and 15 patients at 18 months. Even though the current ADA "guidelines for Dentin and Enamel Adhesive Materials" involve only a small number of patients and do not specify levels of performances, clinicians should use only these ADA-accepted products to ensure at least minimal levels of scientific scrutiny. In addition, the use of only ADA-accepted products may encourage greater manufacturer participation in this program. A product's acceptance status can be determined by contacting the ADA (<http://www.ada.org>).

### AVAILABLE DENTIN BONDING PRODUCTS

Dentin bonding agents are available in both multicomponent (Box 3-1) and single-component systems (Box 3-2). Multicomponent systems are the most reliable at the present time but require more time and steps to complete. The single-component systems are a simplification of the wet-bonding process and are easier to use, but they produce less reliable results.

### Indications

Products with ADA acceptance can be expected to perform well in the "saucer-shaped" Class V preparations that have been evaluated. However, including mechanical retention in even these situations is prudent. Mechanical retention can be achieved with small rotary instruments in conventional preparations with converging cavity walls, retention "dimples" or "grooves," or air abrasive units that can be carefully manipulated to provide undercut areas. Most clinical data about dentin bonding agents refer to these minor operative dental procedures. A dentin bonding agent is also indicated on all exposed dentin whenever a composite resin material will be used for adhesion to the tooth structure. The only exception is in extremely deep preparations wherein the dentin tubular diameters are large and the vital pulp tissue is less than 1.0 mm from the surface. In these cases, a resin-ionomer liner is recommended. When cavosurface margins are on dentin or cementum, achieving the best possible bond is particularly important to reduce, if not eliminate, microleakage, thereby reducing the effects of pulpal irritation, postoperative sensitivity, marginal discoloration, and recurrent caries.

Indications for clinical applications of dentin bonding agents are as follows:

## BOX 3-1

## MULTICOMPONENT PRODUCTS

Adhesive by Choice/Enhanced (Mirage Dental Systems)	Clearfil Liner Bond V (Kuraray/J. Morita USA)	Permaquick (Ultradent)
AeliteBond (Bisco)	Creation 3 In One (Den-Mat)	PowerBond (Cosmedent)
All-Bond 2 (Bisco)	Dentastic (Pulpdent)	Prime & Bond NT Dual Cure (Dentsply/Caulk)
Amalgambond Plus (Parkell)	Dent Bond (Denpac)	ProBond (Dentsply/Caulk)
Ana Norm (Nordicka)	Denthesive II (Heraeus Kulzer)	Restobond (Lee)
A.R.T. (Coltene/Whaledent)	Dentin Bond LC (Bosworth)	Scotchbond Multi-Purpose Plus (3M)
AsepBond (KHS)	DiamondBond (DMR)	Syntac (Ivoclar-Vivadent)
Bond-It! (Jeneric Pentron)	Dual Cured Scotchbond (3M)	Tenure (Den-Mat)
Bondlite (Kerr)	Encore Bond (Centrix)	Tooth Adhesive (Cosmedent)
C-Bond (Megadenta)	Imperva Bond (Shofu)	Wet Bond (Mirage Dental Systems)
Clearfil Liner Bond (Kuraray/J. Morita USA)	OptiBond/OptiBond FL (Kerr)	X-R Primer/X-R Bond (Kerr)
Clearfil New Bond (Kuraray/J. Morita USA)	PAAMA 2 (SDI)	
	PC Bond (Health-Dent)	
	Permagen (Ultradent)	

## BOX 3-2

## SINGLE COMPONENT PRODUCTS

Bond-1 (Jeneric Pentron)	Gluma One Bond (Heraeus Kulzer)
Dentastic Uno (Pulpdent)	Single Bond (3M)
Dent Bond Single Step (Denpac)	Solobond M (Voco)
One-Step (Bisco)	Syntac Single Component (Ivoclar-Vivadent)
OptiBond Solo Plus (Kerr)	Tenure Quick (Den-Mat)
Prime & Bond NT (Dentsply/Caulk)	Excite (Ivoclar/Vivadent)
PQ1 (Ultradent)	

- All direct composite resin restorations- anterior and posterior
- Indirect (as well as direct/indirect) composite restorations -laboratory processed inlays/onlays and veneers
- Indirect ceramic restorations and alloys that are to be resin-bonded- inlays/onlays
- Amalgam restorations-if isolation can be achieved so that the bonding process is not contaminated; all dentin bonding systems can be used to bond amalgam to the prepared tooth
- Post and core restorations (composite resin, ceramic and amalgam) of endodontically treated teeth- both prefabricated and indirect
- Retrograde fillings after apicoectomy-when isolation is possible; both composite resin and amalgam can be used for the retrograde filling material
- Fixed prostheses (precious alloy, nonprecious alloy, resin-bonded prostheses, composite resin prosthesis, fiber-reinforced composite resin prosthesis [Targis-Vectris or Sculpture Fibercore] and all ceramic prostheses and laminate veneers)
- Desensitization of exposed dentin

### THEORY AND PRACTICE OF BONDING TO DENTIN

Attempts to bond to the smear layer (a mechanically altered layer of tooth structure that coats the surface of the prepared dentin surface, occluding the dentinal tubules, after rotary instrument preparation) were doomed to failure because this layer is itself only weakly attached to the dentin (Fig. 3-2). The total etch technique has proved to produce a stronger bond. Enamel and dentin are etched concomitantly. The etching process removes the smear layer completely and demineralizes the surface of the dentin to a depth of approximately 5 to 10 microns, creating a collagen "scaffolding" with wide-open tubules. The deeper mineralized dentin has an irregular hydroxyapatite




Fig. 3-2. SEM of dentin with smear layer prior to bonding. Note areas of dentin tubules are barely visible. (Courtesy Ivoclar/Vivadent.)

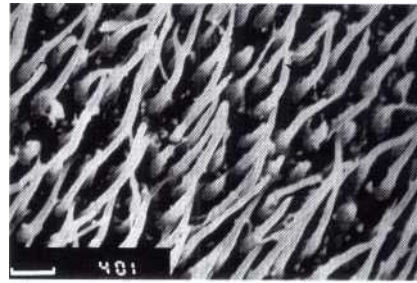


Fig. 3-4. SEM of dentin bonded composite restoration after demineralization with acid to remove dentin. Note tubular extensions of resin that penetrated into the opened dentinal tubules to the irregular hydroxyapatite surface, thus creating a bond. (Courtesy Nelson J. Gendusa, Parkell.)

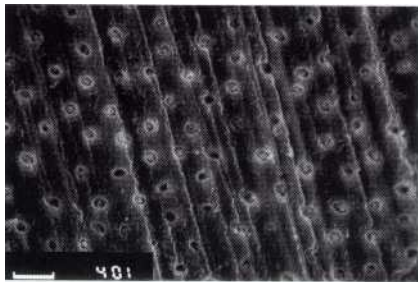


Fig. 3-3. SEM after application of primer (Syntac), showing resin has penetrated smear layer and formed a hybrid surface. (Courtesy Ivoclar/Vivadent.)

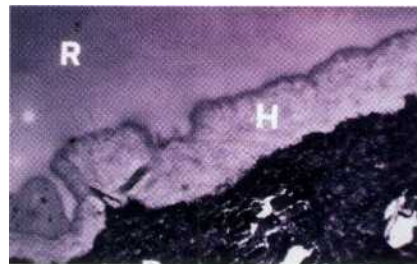


Fig. 3-5. TEM of Amalgambond Plus showing resin (R), layer of bonding agent/tooth structure, hybrid (H) layer, and hydroxyapatite crystals in the under-calcified dentin below.

surface. The key to bonding is the infiltration of this collagen matrix and tubules through the mineralized layer of dentin (Fig. 3-3). Except for nonvital teeth, dentin is moist with tubular fluid. After the etching acid is rinsed away, bonding must be performed on a "wet" dentin surface. If the dentin is overdried the collagen will collapse producing an inadequate bond.

**CLINICAL TIP.** Even nonvital dentin is moist in the oral environment and should not be completely desiccated or an inadequate bond will result. Both nonvital and vital dentin should be treated with the wet bonding.

The priming agent (or bonding resin itself, in the case of "single-bottle" agents) must be somewhat hydrophilic, or have an affinity for water. These resin materials are actually hydrophobic but can be considered to be more hydrophilic than previous materials. The primer or bonding resin infiltrates the moist collagen and penetrates the tubules to the peritubular area, which was demineralized in the etching process (Fig. 3-4). Bonding is believed to be primarily a micromechanical interlocking of resin into the mineral portion or the dentin. Recent evidence indicates that bonding agents also form covalent bonds with the molecular structure of the collagen.14

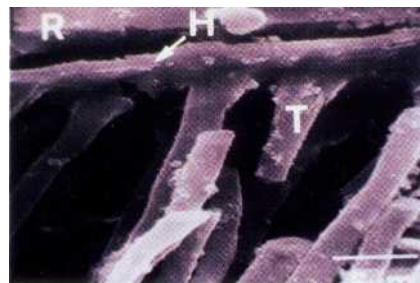
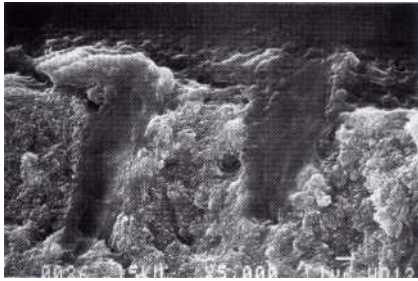
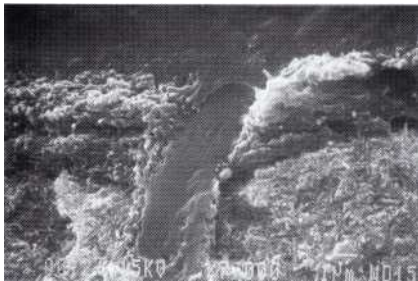


Fig. 3-6. SEM of Amalgambond Plus specimen showing resin (R), hybrid layer of bonding material/tooth component (H), and tubular extensions (T) of bonding material. (Courtesy Nelson J. Gendusa, Parkell.)

Some of the earliest dentin bonding agents to have hydrophilic components were those containing 4-META. The somewhat hydrophilic material allowed bonding resin to penetrate the moist collagen surface and flow into the "wet" tubules, creating a real hybrid or transition layer. This transition layer can be seen in both transmission electron micrograph (TEM) (Fig. 3-5) and scanning electron microscopy (SEM) (Fig. 3-6) of a 4-META/



*Fig. 3-7. SEM of multicomponent bonding agent (Scotchbond Multi-Purpose Plus) after total-etch of dentin. Scotchbond Multi-Purpose Plus provides a reliable bond to etched dentin by using a primer with an activating component of ethanol-based solution of sulfonic acid salt plus a photo-initiator. The adhesive component consists of an adhesive of bis-GMA and HEMA with a photo-initiator and a catalyst component of bis-GMA with a peroxide chemical initiator. (Courtesy Robert L. Erickson.)*



*Fig. 3-8. SEM of single-component bonding agent "one-bottle" approach (Single Bond, 3M, Inc.) showing interface between resin and etched dentin. The bonding agent is composed of bis-GMA, HEMA, ethanol, water, diacrylates, photo-initiator, methacrylate functional copolymer of polyacrylic acid and polyitaconic acids. (Courtesy Robert L. Erickson.)*

MMA-TBB-containing product (Amalgambond Plus, Parkell, Inc.). The creation of transition layers, or hybrid layers, of dentin and bonding agent can be seen in the SEM for both the multicomponent (Scotchbond Multi-Purpose Plus 3M, Inc.) (Fig. 3-7) and "single-bottle" materials (Single Bond, 3M, Inc.) (Fig. 3-8).

A recent study indicates that in vitro and in vivo dentin bond strengths may be comparable.<sup>15</sup> Another study indicates that coronal and apical dentin adhesion is high but cervical root dentin bond strengths are significantly lower.<sup>16</sup> Other work shows bond strengths vary considerably depending on the depth of the dentin; bonding to deep dentin is significantly weaker than superficial dentin.<sup>17</sup> Similarly, differences have been found with deciduous dentin.<sup>18</sup> The latter study suggests that less etching time is appropriate for deciduous dentin.

Other applications including successful retrograde fillings<sup>1,22</sup> amalgam to dentin bonding,<sup>23</sup> use with post and cores<sup>24,25</sup> and use with all types of indirect restorations luted with composite resin cements.<sup>26</sup>

## GENERAL CONSIDERATIONS AND PROCEDURES

Cavity preparation, basing (to achieve a protective layer when the preparation is 0.5 mm. or less from the pulp) to eliminate resin penetration to the pulp, and composite restorative material placement are generally identical for all dentin **bonding agents and involve three essential steps.**

### *Clean the Preparation*

The tooth surfaces must be clean (use of cavity cleansers and disinfectants is encouraged) and remain completely noncontaminated during the procedure, or clinical failure is to be expected. Isolation is absolutely necessary. Should contamination occur at any step, the entire process must be repeated, beginning with **the thorough surface cleansing achieved with a prophylaxis brush** or cup and pumice. Pumice used with a cup or brush removes the contaminated resin, leaving a clean dentin surface.

### *Etch the Tooth Surface*

The manufacturers' suggested etching gel should always be used. Generally, etching gel is 30% to 40% orthophosphoric acid (some evidence indicates that greater than 37% acid denatures the collagen). The etchant should be applied to both enamel and dentin and allowed to remain for only 15 to 20 seconds. The gel must then be thoroughly rinsed away with the air/water spray. A thorough rinse with a water stream alone is satisfactory but must be complete and not abbreviated so that no acid gel remains on the treated surface. Excess water can be evacuated, or the preparation can be blotted dry, without air drying. Small sponges or applicator tips can be used to remove excess water, leaving the surface moist but not soaking wet. If an air syringe is used to the point of complete dryness, it should be followed with a water-saturated small sponge or nonlinting applicator tip **applied to the** dry surface to remoisten the dentin. An air spray can be used to gently remove the pooled water, but care must be taken to leave a moist surface.

### *Apply Dentin Bonding Agent*

A dentin bonding agent (either primer/bonding resin or primer followed by bonding resin) is applied. Primers from single-bottle as well as multicomponent systems are

essentially applied in the same way. Protocols from the specific manufacturer should be followed, but this generally involves applying the primer or resin with a brush or applicator tip continuously for 15 to 20 seconds. A scrubbing action is not warranted, but gentle agitation or light rubbing seems to facilitate the infiltration into the etched dentin surface. About 5 to 10 seconds of a gentle stream of air after the resin has been applied evaporates the solvent (either acetone or ethanol-based systems).

**CLINICAL TIP.** Do not blast the surface with air, proceed gently without using maximum air pressure. The step is designed to simply vaporize the solvent without blowing the primer or resin off the tooth surface. Generally, single-bottle techniques require at least two applications, and evidence indicates that several more may facilitate a higher bond strength.

**CLINICAL TIP.** The dentin surface must appear very shiny after the last coat of material has been applied. If this shiny appearance is not evident, the dentin is not sealed and another coat must be applied.

Single-bottle agents should be light-cured for 10 to 20 seconds. The dentin surface should appear uniformly shiny with a complete coat of bonding resin; otherwise additional coats should be applied to achieve this appearance. When the single-bottle agents are used with indirect restorations, pooling of resin in any line angles or on any surfaces must be eliminated. Improper pooling will prevent the indirect restoration from seating properly. An applicator tip can be drawn across the surface to prevent pooling, or excess adhesive can be blotted away. Use of the air syringe to thin the resin is not advised because overdrying (instead of solvent evaporation) may occur. If air drying with a gentle stream from the air-syringe is performed, it must be carried out with great caution to prevent desiccation. If the single-bottle agent is properly applied and light-cured on the tooth, the indirect restoration can be completely seated because the bonding layer is thin enough to leave the surface essentially unaltered.

Multi-component systems, in general, cannot be light-cured on the tooth when using an indirect restorative technique because a much thicker layer is present and the restoration will not completely seat. The multi-component dentin bonding agents must be light-cured with the luting resin after seating the restoration to prevent incomplete seating of the restoration.

## CLINICAL PROCEDURES

Procedures for the fourth and fifth generations of dentin bonding agents are quite similar. The following step-by-

step procedure outlines the clinical application of a multi-component bonding agent that has received full acceptance by the ADA.

### Clinical Technique for Multi-Component Bonding Agents

Example Product:	Composition
Primer	25% Tetraethylene glycol dimethacrylate 4% Maleic acid 71% Acetone and water
Adhesive	35% Polyethylene glycol dimethacrylate 5% Glutaraldehyde 60% Water 60% bis-GMA
Light-cured bonding resin	40% triethylene glycol dimethacrylate

#### Armamentarium

##### Standard dental setup

- Explorer
- Mouth mirror
- Periodontal probe
- Suitable anesthesia
- Rubber dam setup
- High-speed handpiece and burs

Low-speed handpiece, burs, mandrel, and polishing disks

Light-curing resin-ionomer base or Dycal if needed for deep areas

Etching gel-orthophosphoric acid

Dental bonding primer (e.g., Syntac Primer (Ivoclar-Vivadent))

Dental bonding adhesive (e.g., Syntac Adhesive (Ivoclar-Vivadent))

Composite resin of choice (e.g., Heliobond (Ivoclar-Vivadent) (see Chapter 5))

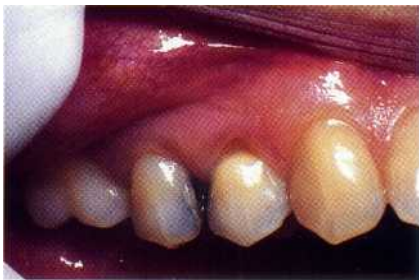#### Clinical Technique

1. Examine the area to determine the extent of carious lesion and evaluate periodontal health (Fig. 3-9).
2. Administer local anesthesia if necessary.
3. Isolate the lesion with rubber dam. Nonlatex dams (e.g., Hygienic Company) are preferred because of increasing concerns about latex allergies.

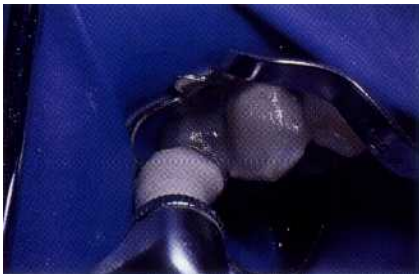**CLINICAL TIP.** If a rubber dam will not be used, the preparation to be bonded must have adequate isolation or the denting bonding approach cannot successfully be used. Retraction cords can be packed, or troughing with a carbon dioxide laser (see Chapter 22) can be used to gain an isolated field in which to operate successfully.

4. Clean the tooth surface with a nonfluoridated flour of pumice for adequate shade visualization and promotion of a surface free of plaque, debris and calculus (Figs. 3-9 and 3-10).
5. Prepare the cavity in a conventional manner with high-speed air turbine and appropriate burs (Fig. 3-11).
6. Use a low-speed air turbine and round burs to remove all decay.

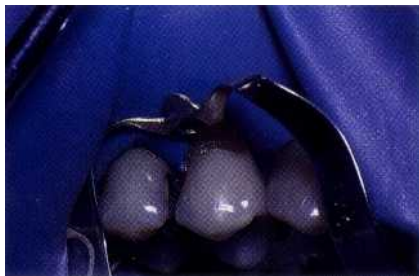**CLINICAL TIP.** Caries detection dyes are appropriate to use, especially in areas where visualization is difficult, such as tunnel preparations. Continue until all dentin is noncarious.



*Fig. 3-9.* Preoperative view of Class V abfraction lesion.



*Fig. 3-10.* The tooth is isolated and cleaned with plain nonfluoridated pumice.

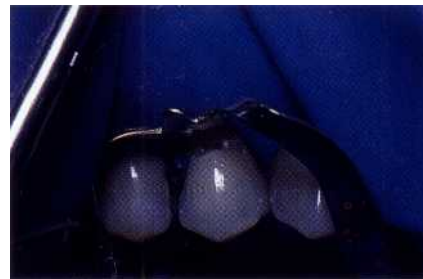

*Fig. 3-11.* The tooth is prepared with high-speed air turbine.

7. Use burs to place slots, grooves, or retention points for mechanical retention (Fig. 3-12). Use of non-retentive saucer-shaped designs is not advised. An enamel bevel is also advisable.
8. In deep cavity preparations (within approximately 0.5 mm of the pulp), place an acid-resistant calcium hydroxide base or resin-ionomer base to protect the pulpal tissues. This based area should be kept to a minimum to expose an adequate amount of exposed dentin for bonding (Fig. 3-13).
9. Place orthophosphoric etching gel (total etch technique) over entire cavity preparation for 15 to 20 seconds (Fig. 3-14).



*Fig. 3-12.* A low-speed air turbine is used to completely remove the caries and to place mechanical retention such as slots, grooves, or dimples.



*Fig. 3-13.* A resin-ionomer base/liner or acid-resistant calcium hydroxide liner is placed in extremely deep areas.



*Fig. 3-14.* To achieve a total etch, orthophosphoric acid gel is placed on the entire preparation for 15 seconds.

10. Wash the etching gel away with an air/water spray for 20 seconds (Fig. 3-15). See the preceding section on the application of dentin bonding agents.
11. Assure moist (not soaking wet) dentin by blotting dry with a sponge, dry applicator, or cotton pellet.

**CLINICAL TIP.** Do not air dry. An alternative approach is to briefly air dry the surfaces to visualize the frosty appearance of the etched enamel and immediately reapply water on a sponge or applicator to remoisten the dentin. To ensure the moistness of the dentin surface, extreme care must be taken if an air stream is used.

12. Apply the primer to all surfaces with a brush or small applicator, adding more primer during the process (Fig. 3-16), for 20 seconds with a gentle agitating action. Do not use a forceful scrubbing action!
13. Gently evaporate the solvents with a very light stream of air.
14. Apply the adhesive over the entire preparation for a second time; a gentle stream of air should be used to evaporate the solvents for 15 seconds.
15. Apply a thin layer of bonding resin (Heliobond), and remove excess with sponge or applicator (Fig.

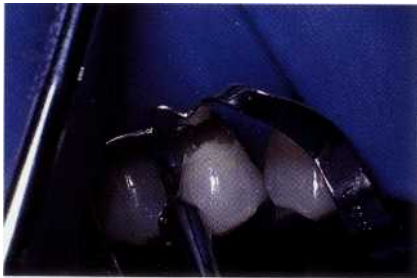

Fig. 3-15. The etched cavity preparation is thoroughly washed for 15 to 20 seconds.

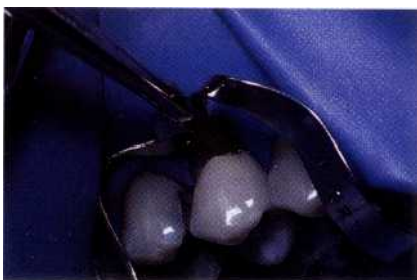

Fig. 3-16. The dentin primer is applied to all surfaces with a brush, using a gentle agitation action. Multiple applications of the primer ensure that the tooth has been amply primed. A gentle stream of air is used to evaporate the solvent.

3-17). If this is a filled adhesive and does not require an additional layer of resin, then light cure as indicated in following step.

**CLINICAL TIP.** Do not blow the resin away with an air spray. Use a small sponge, applicator, or even an endodontic paper point to remove excess resin.

16. Photocure the resin with a light-curing unit for 15-20 seconds (Fig. 3-18).

**CLINICAL TIP.** Be sure to maintain a daily or weekly schedule that is comfortable for adequate testing of the photo-curing unit with a radiometer to ensure adequate intensity of light output. Each time a new lamp is installed, it should be tested as well. Radiometers include the Curing Radiometer (Demetron/Kerr), Cure Rite (EFOS), Coltolux Light Meter (Coltene/Whaledent), and the built-in testing unit in the XL-3000 photo-curing unit (3M).

17. Restore the cavity preparation with your choice of composite resin restorative materials (Fig. 3-19).
18. Finish and polish the restoration with carbide burs and polishing disks.
19. An additional layer of resin may be applied and photocured to "heal" surface cracks produced during finishing and polishing and possible microscopic

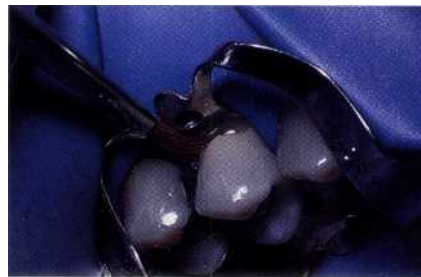

Fig. 3-17. A thin layer of bonding resin is applied with a brush. Excess resin is removed with an applicator or paper point. The resin must not be blown too thin.

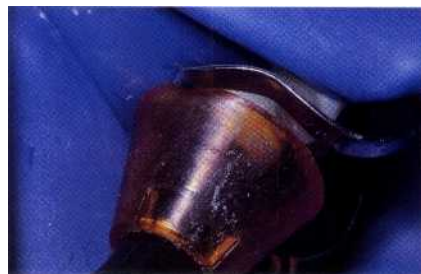

Fig. 3-18. The bonding agent is photo-cured for 15-20 seconds.

marginal discrepancies that may later show marginal staining. Other resins are manufactured specifically for this purpose; however, most new "filled" bonding agents can be used instead.

**Clinical Technique for Single-Bottle**

**Bonding Agents**

Example Product:	Single Bond (3M, Inc.)
Composition:	bis-GMA Hydroxyethylmethacrylate Ethanol Water Diacrylates Photo-initiator Methacrylate functional copolymer of polyacrylic and polyitaconic acid (polyalkenoic acid)
Light-cured bonding resin:	60% bis-GMA 40% triethylene glycol dimethacrylate

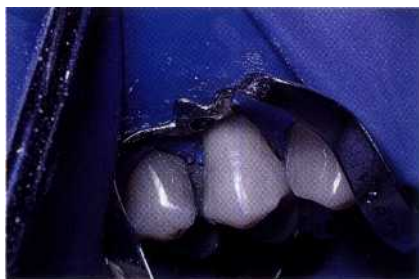**Armamentarium**

The same as for multi component systems except with substitution of appropriate single-bonding system.

**Clinical Technique**

1. Examine the area to determine the extent of the carious lesion and evaluate periodontal health (Fig. 3-20).
2. Administer local anesthetic as necessary.
3. Isolate the lesion with a rubber dam. A nonlatex dam (e.g., Hygienic Company) is preferred because of increasing concerns about latex allergies.

**CLINICAL TIP.** If a rubber dam will not be used, the preparation to be bonded must have adequate isolation or the denting bonding approach cannot successfully be used. Retraction cords can be packed or troughing with a carbon dioxide laser (see Chapter 22) can be used to gain an isolated field in which to operate successfully.

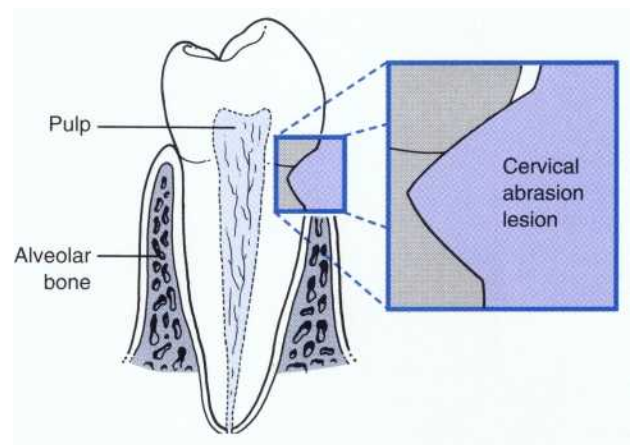


*Fig. 3-19. The chosen composite resin restorative material is applied in increments and finished with carbide burs, followed by polishing disks. A final glaze of bonding resin may be applied to seal the marginal microgaps and cracks that may remain after finishing.*

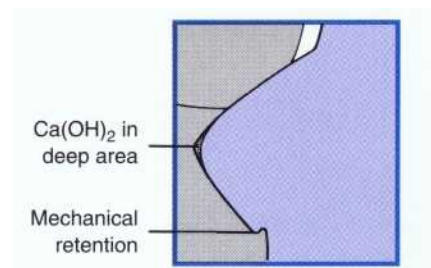
4. Clean the tooth surface with nonfluoridated pumice.
5. Prepare the cavity in a conventional manner with high-speed air turbine and appropriate burs.
6. Use a low-speed air turbine and round burs to remove all decay.

**CLINICAL TIP.** Use of caries detection dyes are appropriate to use, especially in areas such as tunnel preparations where visualization is difficult. Continue until all dentin is noncarious.

7. Use burs to place slots, grooves, or retention points for mechanical retention. Use of nonretentive saucer-shaped designs is not advised. An enamel bevel is advisable.
8. In deep cavity preparations, (within approximately 0.5 mm of the pulp), place an acid-resistant calcium hydroxide base or resin-ionomer base to protect the pulpal tissues. This based area should be kept to a minimum to expose an adequate amount of exposed dentin for bonding (Fig. 3-21).



*Fig. 3-20. Tooth with cervical abfraction/abrasion lesion involving dentin/cementum at the gingival cavosurface margin.*



*Fig. 3-21. After preparation, which maximizes mechanical retention, the pulp is protected by placing a resin-ionomer liner or acid resistant calcium hydroxide liner in deep areas of preparation.*

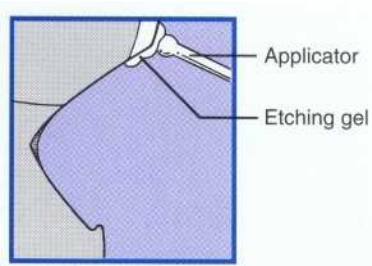


9. Place orthophosphoric etching gel (total etch technique) over entire cavity preparation for 15 to 20 seconds (Fig. 3-22).
10. Wash the etching gel away with an air/water spray for 20 seconds (Fig. 3-23). See the preceding section on the application of dentin bonding.
11. Assure moist (not soaking wet) dentin by blotting dry with a sponge dry applicator or cotton pellet.

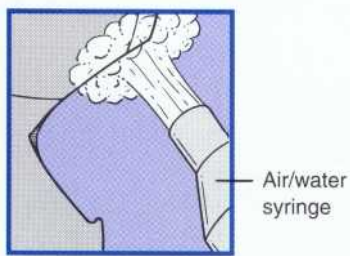
**CLINICAL TIP.** Do not air dry. An alternative approach is to briefly air dry the surfaces to visualize the frosty appearance of the etched enamel and immediately reapply water on a sponge or applicator to remoisten the dentin. To ensure that the dentin surface is moist, extreme care must be taken if an air stream is used.

12. Apply single-bottle adhesive (e.g., Single Bond, 3M, Inc.) with enough material to keep the cavity preparation saturated with adhesive for 20 seconds (according to manufacturer's instructions) (Fig. 3-24).

**CLINICAL TIP.** Be sure to rewet your brush or applicator frequently during this time to reapply additional adhesive to the preparation.

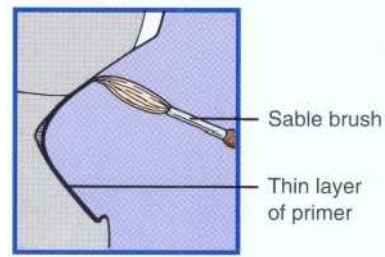


*Fig. 3-22. The etching gel is placed over the entire surface of the cavity preparation for 15 to 20 seconds. The clinician should ensure that no voids caused by air bubbles exist.*

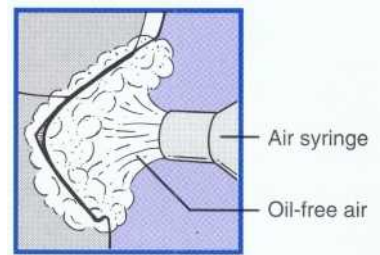


*Fig. 3-23. The etching gel is thoroughly washed off with the water syringe. The preparation is blotted with a dry applicator to leave moist (not dripping wet) dentin or dried briefly with air, with moisture reapplied with a damp applicator.*

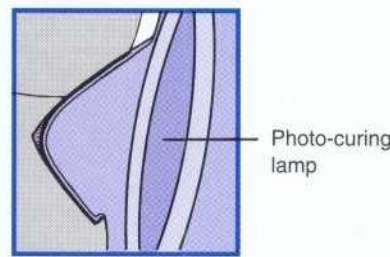
13. Gently evaporate the solvents with a very light stream of air for 5 to 10 seconds (Fig. 3-25).



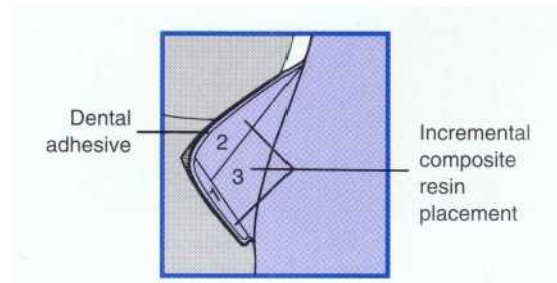
*Fig. 3-24. Single-component bonding agent is applied with a brush to the entire cavity preparation for 20 seconds with a gentle agitation action.*



*Fig. 3-25. The solvent evaporates from the bonding agent with application of gentle air. The surface should appear shiny at this point. If not, agent should be applied a second time.*



*Fig. 3-26. The resin bonding agent is light-cured for 10 seconds.*



*Fig. 3-27. The cavity is restored with chosen composite resin material using incremental placement technique to minimize the effects of polymerization shrinkage.*

14. Light-cure the bonding agents for 10 seconds (Fig. 3-26). Some manufacturers recommend a second application, which requires repeating steps 12 through 14.

**CLINICAL TIP.** If the preparation margins are on dentin or cementum, apply a second coating of Single Bond (3M, Inc.), using the same procedure.

15. Place the composite restoration in increments to reduce the effects of polymerization shrinkage (Fig. 3-27).
16. Finish and polish the restoration with carbide burs and polishing disks.
17. An additional layer of resin may be applied and photocured to "heal" surface cracks produced during finishing and polishing and possible microscopic marginal discrepancies that may later show marginal staining. Other resins are manufactured specifically for this purpose; however, most new "filled" bonding agents can be used instead.

## DESENSITIZERS

Conventional treatments (when restorations are not indicated) for exposed dentin or cementum that results in tooth sensitivity include desensitizing toothpastes with potassium nitrate and topical fluorides. These methods are relatively inexpensive and often effective.

Dentin bonding agents can be used to place a thin, varnishlike coating on the dentin, thereby eliminating the problem. This approach can also "desensitize" crown and cavity preparations in indirect techniques.

Clinical examination proved earlier bonding agents very successful in alleviating sensitivity on root surfaces.<sup>27</sup> (If small abfractions exist, it is best to eliminate the problem with the bonding agent and a small restoration for a definitive treatment). The agent must be of minimal film thickness to allow indirect restorations to be fully seated. Therefore use of a specific dedicated product for indirect restorations is advised (Box 3-3). Desensitizing agents are not recommended for restorative care. Exposed root surfaces can be treated with any dentin bonding agent provided a layer of resin is placed over the surface to form an effective seal. Single-component systems may adequately

occlude the tubules and result in desensitization, but an added layer of surface resin may provide a better seal for the tubules.

### Clinical Technique

Example Product: All Bond DS (Bisco)  
 Composition: Primer A: NTG-GMA, acetone, ethanol  
 Primer B: BPDm, acetone  
 Cavity cleanser: 2% chlorhexidine digluconate (Cavity Cleanser, Bisco)

### Armamentarium

The same as for multicomponent systems except with the substitution of an appropriate desensitizing bonding system.

### Clinical Technique

1. Examine the area to be certain the dentin is free of caries.
2. Clean the surface, if possible, with plain pumice and water.
3. Rinse the sensitive area after rubbing with the cleanser included in the kit for smear layer removal cleanser (2% chlorhexidine digluconate)
4. Air dry, but do not desiccate.
5. Mix the two primers together, and gently apply 5 to 6 coats without drying between applications.

**CLINICAL TIP.** The bonding agent will actually be penetrating the tubules, and the patient may experience some discomfort, including a cold sensation caused by the evaporation of the acetone. Inform patients of this before beginning treatment, and reassure them that it is a normal part of the process.

6. After the 5 to 6 **coats are applied, air dry for 15 seconds** and light-cure for 20 seconds.
7. Test the patient's sensitivity with the air syringe to see whether the problem is resolved. If not, reapply 5 to 6 more coats and repeat the process. The resin must adequately penetrate the tubules and completely occlude them to achieve desensitization. A layer of Bis-GMA bonding resin may be added to improve the seal.

sox 3-3

## DENTIN BONDING AGENTS MARKETED FOR DESENSITIZATION

All Bond Ds (Bisco)  
 D/Sense (Centrix)  
 Desenzal (Lang)  
 Superseal (Phoenix)  
 Health-Dent Desensitizer (Healthdent)

Microprime (Danville Materials)  
 Gel-Kam Dentin Bloc (Colgate)  
 Gluma Desensitizer (Heraeus Kulzer)  
 Hurriseal (Beutlich Pharma)

## CONCLUSION

Dentin bonding agents have dramatically improved in recent years. The major breakthrough has been the "total etch" technique, in which the smear layer is removed simultaneously with the enamel etching. The primers and bonding agents of multicomponent systems and combined primer/agent of one-bottle systems provide a dramatic bond to both the collagen and etched hydroxyapatite of the dentin. Although the dentin bonding agents do not yet meet the criteria for "ideal" materials, they are certainly close. Hopefully, more controlled clinical trials will be forthcoming, allowing material and technique choices to be made on a sound scientific basis.

## REFERENCES

- Buonocore MG, Wileman W Brudevold F: Simple methods of increasing adhesion of acrylic filling materials to enamel surfaces, *J Dent Res* 34:849, 1955:
- Asmussen E: Clinical relevance of physical, chemical and bonding properties of composite resins, *Oper Dent* 10:61, 1985:
- Fan PL: Dentin bonding systems: an update, *J Am Dent Assoc* 114:91, 1987:
- Doering JV, Jensen ME: Clinical evaluation of dentin bonding materials on cervical "abrasion" lesions, *J Dent Res* 65:173, 1986.
- Tyas MJ, Beech DR: Clinical performance of three restorative materials for non-undercut cervical abrasion lesions, *Aust Dent J* 30:260, 1985.
- Dennison JB, Ziemiecki TL, Charbeneau GT: Retention of unprepared cervical restorations utilizing a dentin bonding agent: two year report, *J Dent Res* 65:173, 1986:
- Ziemiecki TL, Dennison JB, Charbeneau, GT Clinical evaluation of cervical composite resin restorations placed without retention, *Oper Dent* 12:27, 1987:
- Bowen RL, Cobb EN, Rapson JE: Adhesive bonding of various materials to hard tooth tissues: improvement in bond strength to dentin, *J Dent Res* 61:1070, 1982:
- Cox CF: Evaluation and treatment of bacterial microleakage, *Am J Dent* 7:293, 1994.
- Goracci C, Mori G, Bazzucchi M: Marginal seal and biocompatibility of a fourth-generation bonding agent, *Dent Mater* 27:129, 1995:
- Kanca J: Resin bonding to wet substrate. I. Bonding to dentin. *Quint Int* 23:39, 1992:
- Ferrari M, Goracci G, Garcia-Godoy F: Bonding mechanism of three "one-bottle" systems to conditioned and unconditioned enamel and dentin, *Am J Dent* 10:224, 1997.
- American Dental Association, Council on Dental Materials: Revised acceptance program guidelines for dentin and enamel adhesive materials, Chicago, 1994, The Association.
- Xu J et al: An FT-Raman spectroscopic investigation of dentin and collagen surfaces modified by 2-hydroxyethyl-methacrylate, *J Dent Res* 76:596, 1997:
- Mason PN and others: Shear bond strength of four dental adhesives applied in vivo and in vitro, *J Dent* 24:217, 1996:
- Yoshiyama M et al: Regional bond strengths of resins to human root dentin, *J Dent* 24:435, 1996.
- Tam LE, Yim D: Effect of dentine depth on the fracture toughness of dentine-composite adhesive surfaces, *J Dent* 25:339, 1997:
- Royse MC, Ott NW, Mathieu GP: Dentin adhesive superior to copal varnish in preventing microleakage in primary teeth, *Pediatric Dent* 18:440, 1996:
- de Araujo FB, Garcia-Godoy F, Issao M: A comparison of three resin bonding agents to primary tooth dentin, *Pediatric Dent* 19:253, 1997.
- Nor JE et al: Dentin bonding: SEM comparison of the dentin surface in primary and permanent teeth, *Pediatric Dent* 19:246, 1997:
- Jon YT, Pertl C: Is there a best retrograde filling material? *Dent Clin North Am* 41:555, 1997.
- Rud J, Rud V, Munksgaard EC: Retrograde root filling with dentin-bonded modified resin composites, *J Endod* 22:477, 1996:
- Hasegawa T, Retief H: Shear-bond strengths of two commercially available dentin-amalgam bonding agents, *J Dent* 24:449, 1996:
- Mendoza DB et al: Root reinforcement with a resin-bonded pre-formed post, *J Prosthet Dent* 78:410, 1997:
- Christensen GJ: Posts and cores: state of the art, *J Am Dent Assoc* 129:96, 1998.
- Christensen GJ: Seating nonmetal crowns or fixed partial dentures with resin cement, *J Am Dent Assoc* 129:239, 1998:
- Jensen ME, Doering JV: A comparative study of two clinical techniques for treatment of root surface sensitivity *Gen Dent* 35:128, 1987.



# COLOR MODIFIERS AND OPAQUERS

Jerry B. Black

**T**

THE INTRODUCTION OF the acid-etch technique in 1955<sup>1</sup> and the bis-GMA resin by Bowen in 1962<sup>2</sup> set the stage for a new era in dentistry. As the chairside or direct bonding technique gained impetus, many dentists were lacking in a basic knowledge of dental anatomy, a subject that had traditionally been relegated to the laboratory technician. In addition to a focus on external anatomic features, dentists began to appreciate internal anatomy and the individual roles that enamel and dentin play in the determination of tooth color. The facial enamel could be visualized as a translucent window through which light could pass and reflect off the dentin background. The direct bonded veneer became, in a sense, the anatomic equivalent of the facial enamel. The challenge to reproduce normal shades stimulated interest in the components of color: hue, chroma, and value.

Enamel reduction and the desire for reversibility were debated subjects in the early days of direct enamel bonding. It became obvious that, to prevent overcontouring, enamel reduction was often necessary to provide space for color modifiers, opaquers, and the veneer resin. At least one study showed that even minimal enamel reduction resulted in a significant increase in the shear bond strength between etched enamel and composite resin.<sup>3</sup>

In cases involving intrinsically stained teeth, efforts concentrated on opaquing or masking the dark background: In 1982 Black<sup>4</sup> described a definitive technique that included enamel reduction and masking of severe tetracycline stain in the fabrication of direct bonded composite resin veneers. Color modifiers and opaquers helped create highly esthetic and realistic restorations.

## HISTORY

The first color modifiers (Estilux Color, Heraeus Kulzer, Inc., USA) were introduced in 1982: These low-chroma, tooth-colored tints expanded the possibilities for shade matching, characterization, and opaquing. Two years later, high-chroma color modifiers were introduced by Heraeus Kulzer, Inc., USA (Durafill Color) and Den-Mat Corp. (Rembrandt). When diluted with low-viscosity bonding resins, these color modifiers allowed unlimited variation of chroma and more flexibility.

In 1984 Cosmedent, Inc., introduced its Creative Color and Renamel opaquing system.

In 1987 Heraeus Kulzer, Inc., USA introduced Durafill Color VS, a series of highly pigmented Vita opaque shades. When coordinated with corresponding Vita composite resin, these provide a high degree of color predictability in the composite resin veneer: Bisco, Inc., recently introduced Bicolor color modifiers. These are highly pigmented, heavy filled (50%) microfilled liquids available in eight shades. Recently, Heraeus Kulzer, Inc., introduced "Effect" color. These are intense opaque color modifiers that can be used to make dark stains and characterize composite resins.

The need for intense metal opaquers prompted the introduction of many products, including Heliocolor Opaque (Vivadent USA, Inc.) Prisma Metal Opaque (Caulk/Dentsply), Panavia (J. Morita USA, Inc.), and C & B Metabond (Parkell).

## CHEMISTRY

Most of the visible light-cured color modifiers contain metal oxide pigments suspended in a low viscosity



bis-GMA resin or a mixture of bis-GMA and urethane dimethylacrylate resins. Moderate opaquers, such as Du-rafill VS (Heraeus Kulzer, Inc., USA), contain 20% to 30% microfilled pigmented bis-GMA resin by weight. Heliocolor Opaque (Vivadent USA, Inc.) is supplied in solid opaque tablets, which are used with diethyl ketone solvent for complete opaquing of metal and for intensely stained teeth. The opaquing tablets contain titanium dioxide, iron oxide, and polymethyl methacrylate.

Recently introduced metal opaques, such as C & B Metabond II (Parkell), are reported to chemically bond resin opaquers to nickel-chromium alloys and to amalgam. The bond is mediated through a 4 META component. Panavia contains a modified ester of bis-GMA, which provides chemical adhesion to nonprecious alloys, tin-plated noble alloys, porcelain, tooth enamel, and un-etched dentin. Because the long-term strength of these adhesive formulations is unknown, wherever possible mechanical retention should be used in addition to chemical adhesion.

### GENERAL CONSIDERATIONS

Color modifiers can be mixed with composite resins to change their shades; however, this procedure can result in the following:

1. Incorporation of air, which may result in surface porosity
2. Decreased filler loading
3. Increased curing times because of the pigments in the modifiers

The introduction of composite resins in an extended range of shades, including Vita shades, makes the admixing of color modifiers with composite resins seldom necessary.

The color characteristic of a natural tooth is the result of the subtle interplay of light reflected from the underlying dentin through the relatively translucent enamel. This phenomenon is simulated through the creative use of opaquers and color modifiers that are subsequently overlaid with a relatively translucent composite resin.

**CLINICAL TIP.** The rough enamel surface created by diamond burs should be smoothed with fine diamond burs or flexible disks before placing an opaquer. This allows the opaquer to flow evenly over the prepared surface and results in a uniform background.

**CLINICAL TIP.** Always mask out in very thin layers and be certain to observe the required curing time for each layer. Thicker layers result in incomplete curing and uneven layers caused by pooling of the material:

### INDICATIONS FOR COLOR MODIFIERS

The most frequently used color modifiers are white, gray, yellow, yellow-brown, blue, and red. Table 4-1 provides the visual effects of available color modifiers.

Visual effects of color modifiers.

Color	Indications
Yellow-orange	Creates illusion of narrowness Simulates craze lines
Yellow-brown	Masks blue tetracycline stains
Blue, gray, violet	Simulates translucency Decreases value or brightness
White	Increases the brightness of any color modifier Simulates craze lines Simulates enamel hypocalcifications; white spots
Red, pink	Masks yellow spots Simulates gingival tones Enhances vitality Masks blue tetracycline stains

**CLINICAL TIP.** Because most color modifiers have high chromas, they must be diluted with a low viscosity resin before use:

#### *Yellow and Yellow-Brown*

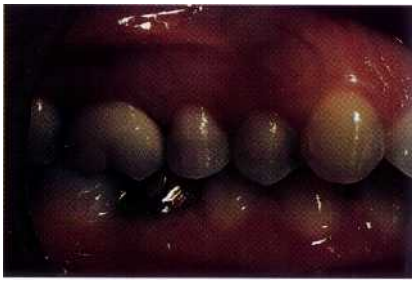These shades are most often used in the cervical one third of the crown (Figs. 4-1 to 4-3). Sometimes they are used along proximal surfaces to create the illusion of narrowness (see Chapter 2). They can also be used to simulate craze lines. Because yellow is the complementary color of violet, it is effective in neutralizing and masking blue-gray tetracycline stains (see Chapter 2). Yellow can also be used in combination with white to mask brown tetracycline stains.

#### *Blue, Gray, or Violet*

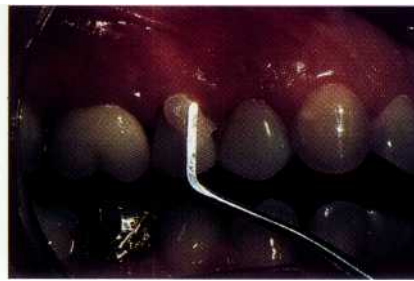These shades are used on the incisal one third of the tooth to simulate translucency (compare Figs. 4-4 and 4-5). They can also be used to reduce value (brightness).

#### *White*

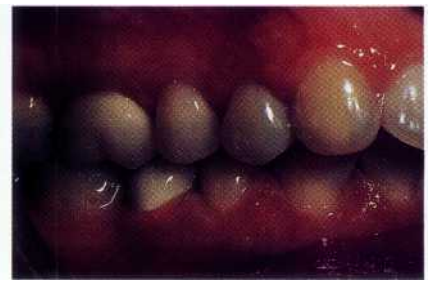White is used to increase the value (brightness) of any color modifier. It can also be effectively used to simulate craze lines and enamel hypocalcifications (Figs. 4-6 to 4-9). White can be effectively used to mask yellow stains (Figs. 4-10 and 4-11).



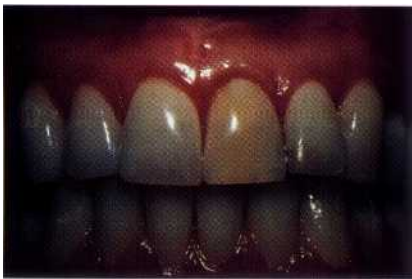*Fig. 4-1. Preparation of the maxillary right first and second premolars for direct bonded veneers:*



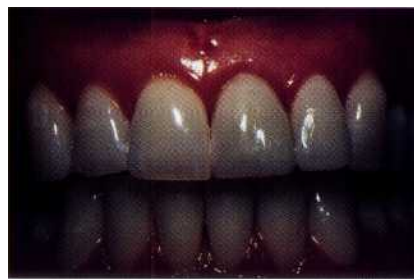*Fig. 4.2. The color of the cervical one third of the veneers must harmonize with the adjacent teeth: A diluted yellow-brown color modifier (Durafill) was placed on the cervical one third and overlaid with Durafill VS A-30.*



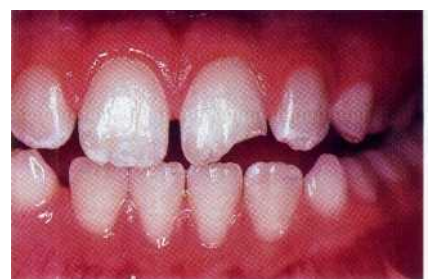*Fig. 4-3. Color harmony from the maxillary right first molar to the maxillary right canine has been established.*



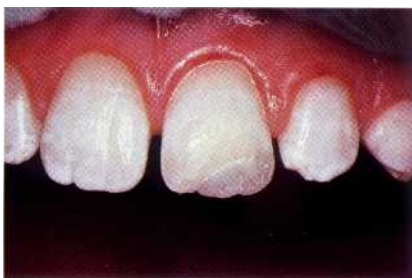*Fig. 4-4. Intrinsic yellow discoloration of maxillary left central incisor.*



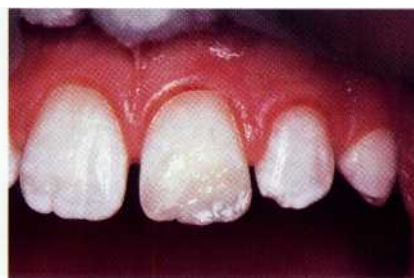*Fig. 4-5. White color modifier was used to mask the yellow background, and blue color modifier was added to the incisor to simulate translucency:*



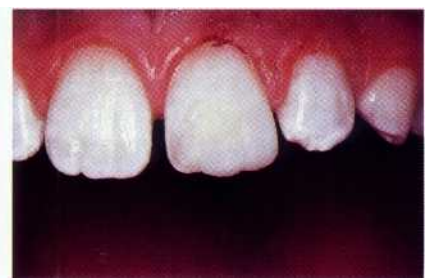*Fig. 4-6. Fractured distoincisor angle. Adjacent teeth exhibit white hypoplastic enamel areas: (Courtesy Dr. William Mopper.)*



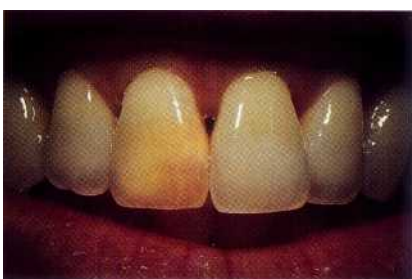*Fig. 4-7. A layer of Multifill VS (Kulzer, Inc., USA) is placed on the lingual wall and cured. (Courtesy Dr. William Mopper.)*



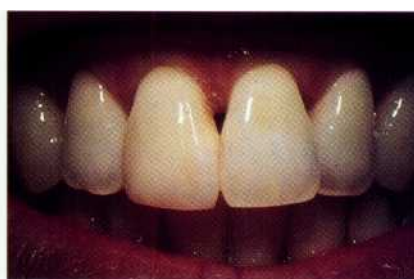*Fig. 4-8. Creative Color white is added to simulate the hypoplastic areas. (Courtesy Dr. William Mopper.)*



*Fig. 4-9. The completed restoration. (Courtesy Dr. William Mopper.)*



*Fig. 4-10. A maxillary right central incisor with intrinsic yellow discoloration:*



*Fig. 4-11. White color modifier is used to mask the yellow background.*

### *Red or Pink*

Red or pink simulates gingival tones, enhances vitality, and can neutralize blue tetracycline stains (see Chapter 2).

#### CLASS III AND CLASS IV RESTORATIONS

Truly "invisible" Class III and Class IV restorations are possible only through proper cavity preparation in conjunction with proper color matching (Figs. 4-12 and 4-13).<sup>5</sup> Blending the color of the restorative resin into the color of the tooth is essential. Color modifiers are indispensable in fine tuning the final color.

In Class III or Class IV cavity preparations involving a through-and-through loss of both the labial and lingual enamel, the final restoration can exhibit undesirable "shine-through" (Fig. 4-14). This shine-through occurs because the missing lingual tooth structure is replaced by a composite resin that is more translucent than the original dentin. The result is a visible outline of the restoration. Shine-through can be prevented by careful cavity preparation, the judicious use of color modifiers and opaquers, and a "sandwich" of various types of composite resins.

##### Armamentarium

- Standard dental setup:
  - Rubber dam
  - Cotton rolls
  - Explorer
  - High-speed handpiece
  - Low-speed handpiece
  - Mouth mirror
  - Periodontal probe
  - 2 X 2 gauze
- Mylar matrix strips
- Wooden or plastic wedge (optional)
- Assorted round carbide dental burs
- Flame-shaped, tapered, and ovoid coarse diamonds for cavity preparations.
- Oil-free pumice
- Rubber prophyl cup
- Cavity liner (optional)
- Acid etchant
- Bonding agent of choice (see Chapter 3)
- Composite resin placement instruments (e.g., 8A, Hu-Friedy, American Dental, Brasseler USA; IPC-I, Premier Dental Products, Inc.; Goldstein Series 1-4 and mini 1 and 3, GC International Corp.)
- Hybrid composite resin of choice (see Chapter 5)
- Microfilled composite resin of choice (see Chapter 5)
- Diamond finishing burs
  - For microfilled composite resins, low-speed, water-cooled diamond burs are best for trimming and fin-

ishing. For small particle hybrid composite resins, high-speed tungsten carbide burs and low-speed, water-cooled diamond burs are recommended.

- 12-fluted finishing burs (e.g., 7901-Premier OR ET -9 and ET OSI ovoid; Brasseler USA)
- Finishing and polishing disks (e.g., Sof-Lex, 3M; Super Snaps, Shofu Dental Corp.; or Flexi-Discs, Cosmedent, Inc.)
- Finishing and polishing strips
  - Metal backed (e.g., Compo Strips, Premier Dental Products Co.) or plastic backed (e.g., Sof-Lex, 3M or Flexi Strips, Cosmedent, Inc.)
- EP Esthetic
- Rubber wheels, cups, and points containing abrasives
  - Medium grit rubber wheels for prepolishing (e.g., Burlew, J.E Jelenko & Company), or complete systems (e.g., Shofu Dental Corp.; Vivadent USA, Inc.; Brasseler USA; Heraeus Polishing System (Brasseler USA) Kulzer Inc., USA; Cosmedent, Inc.; Enhance; L.D. Caulk Co.; Brasseler USA).
- Composite resin polishing paste (containing aluminum oxide)
- Dry felt wheel
- Padded discs (e.g., Cosmedent, Inc.)
- Color modifiers and opaquers
  - Color modifiers: yellow, yellow-brown, white, blue, gray, violet (e.g., Durafill VS, Heraeus Kulzer, Inc. USA; Creative Color, Cosmedent Inc.; Porcelite Color Modifiers, Kerr Manufacturing Co.; Prisma Enhancers, Caulk Dentsply; Bicolor modifiers, Bisco, Inc.; Effect Color, Heraeus Kulzer, Inc.)

##### Clinical Technique

1. Administer local anesthesia (optional).
2. Cleanse the tooth and neighboring teeth with pumice.
3. Determine the appropriate shade while the teeth are wet with saliva.
4. Isolate the lesion with a rubber dam.
5. Prepare the cavity in a conventional manner (Fig. 4-15).
6. Round the cavosurface angle and place a long bevel to create an invisible transition from resin to tooth (Fig. 4-16).

**CLINICAL TIP.** If the enamel is very translucent, create a longer and deeper bevel: If the tooth is more opaque, the bevel can be shorter and less pronounced:

7. Place a pulp protection as necessary (see Chapter 5). Place dentin bonding agent according to the manufacturer's instructions.

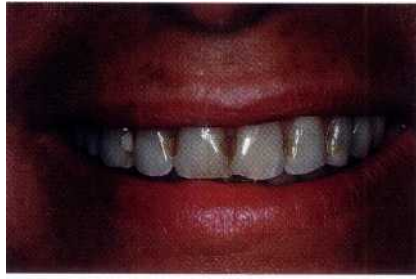

Fig. 4-12. Preoperative view of discolored Class III composite resin restorations. (Courtesy Dr: William Mopper.)

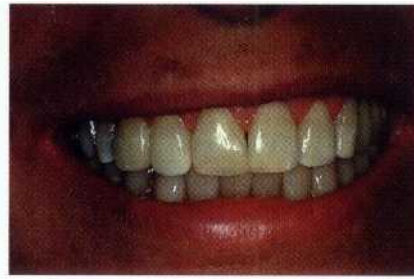

Fig. 4-13. Postoperative view of "invisible restoration." (Courtesy Dr: William Mopper.)

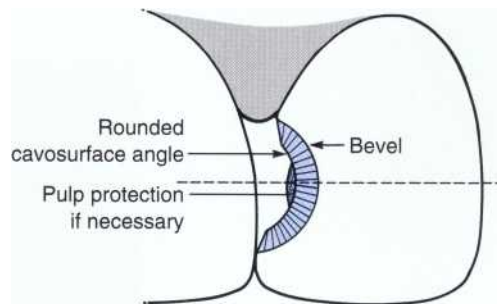


Fig. 4-14. Typical Class III preparation with a through-and-through loss of both the labial and lingual enamel. The line denotes the cross-section area of subsequent drawings:

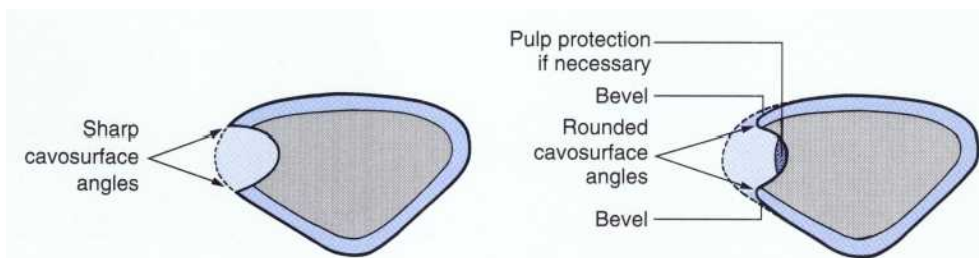


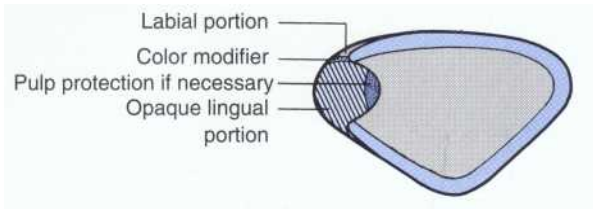
Fig. 4-13.. The cavity is prepared in a conventional manner:

Fig. 4-16. The cavosurface angle is rounded, and a long bevel is placed to facilitate an invisible transition from resin to tooth:

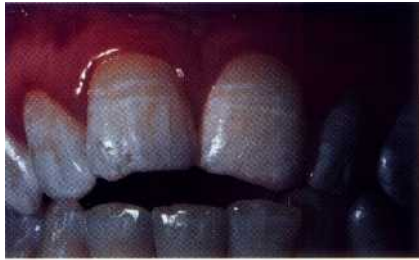**CLINICAL TIP.** Avoid the use of opaque lining materials beneath very translucent enamel: They interfere with the transmission of light through the enamel into the underlying tooth structure or composite resin:

8. To prevent "shine-through," place a more opaque hybrid composite resin in the lingual portion of the preparation.
9. Build up the resin to the level of the original dentoenamel junction.
10. If necessary, place custom tinting resins over this layer and blend the background color of the resin with the color of the tooth (Fig. 4-17).





*Fig. 4-17. An opaque composite resin is placed on the lingual portion of the restoration: This is followed by color modifiers or opaques (if necessary) and completed with a labial veneer of a microfilled composite resin.*



*Fig. 4-18. Maxillary central incisors in open-bite relationship:*

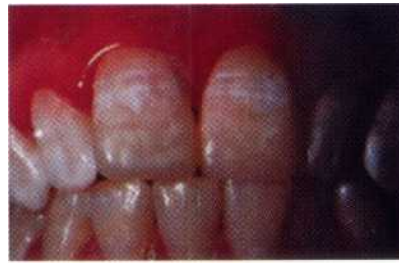**CLINICAL TIP.** Always apply color modifiers in very thin layers and be certain to observe the required curing time for each layer. Thicker layers result in incomplete curing and uneven layers caused by pooling of the material:

**CLINICAL TIP.** Chroma (intensity) must be appropriately diluted with a bonding resin to create a tooth-colored hue:

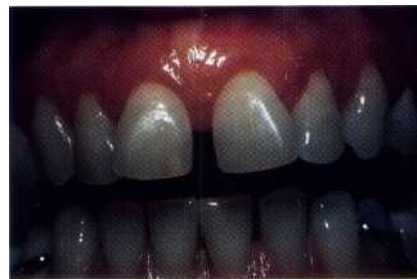**CLINICAL TIP.** Place custom tints, such as gray, blue, or violet, to simulate incisal translucency in Class IV restorations: Place yellow or yellow-brown custom tints for fine tuning the background color: Place white for increasing value (Figs. 4-18, 4-19):

11. To complete the restoration, fill the remaining labial portion with a translucent microfilled composite resin.
12. Contour the restoration.
13. Prepolish the restoration with rubber wheels or cups.
14. Smooth with a microfine diamond in a low-speed handpiece with water cooling.
15. Polish with disks or strips.

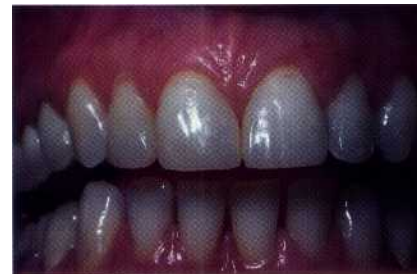**CLINICAL TIP.** An excellent final high gloss can be obtained by using a dry felt wheel or padded disk without paste on the dry composite resin surface:



*Fig. 4-19. A lingual wall of Multifill VS was first created: Durafill VS (white) was then used to simulate white hypoplastic enamel areas: A Multifill VS (incisal) overlay on the labial surface completed the restoration.*



*Fig. 4-20. Malposed maxillary right and left central incisors with a 2-mm diastema.*



*Fig. 4-21. The distal surface was re-contoured and a mesial partial composite resin veneer (Durafill VS) was placed: Usually a matching composite resin shade can be blended into the tooth without the need for color modifiers:*

### DIASTEMA CLOSURES

A microfilled composite resin is the material of choice for diastema closure because of its excellent polishability and enamel-like luster (Figs. 4-20 and 4-21). If the diastema is very large, the lingual surface of the composite resin could be subjected to high functional stress in patients with heavy centric contacts. In these cases, the dentist

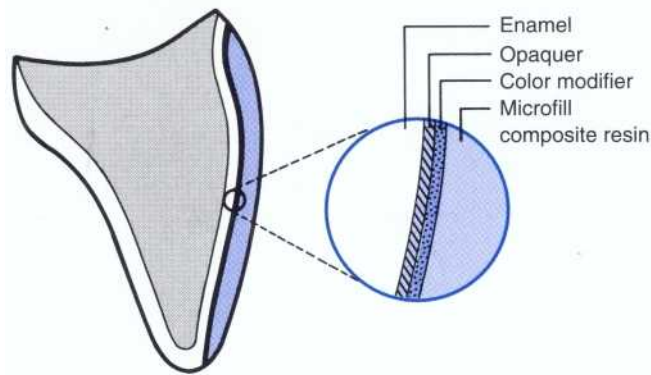


Fig. 4-22. Cross-sectional view of a direct labial veneer when incisal lengthening was not required:

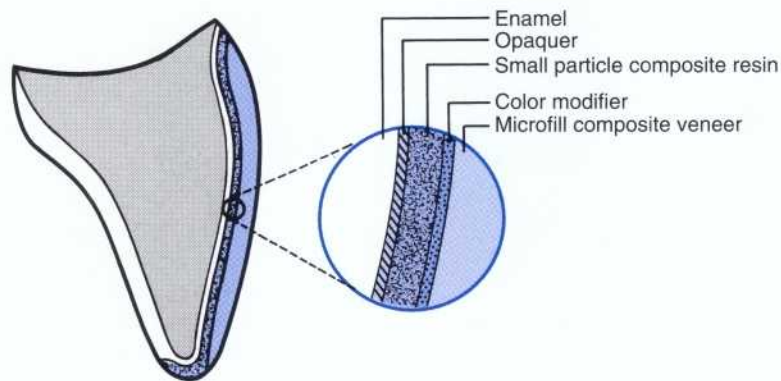


Fig. 4-23. Cross-sectional view of a direct labial veneer when incisal lengthening was required:

may elect to use a hybrid composite resin for the entire restoration or a hybrid on the lingual portion overlaid on the labial surface with a microfilled composite resin. Shine-through is usually not a problem in diastema closure because of the labiolingual thickness of the add-on composite resin in the body area of the clinical crown. In many cases, some translucency is desirable because the composite resin thins out at the incisal edge. If shine-through is a problem, follow the procedure described for the Class III and Class IV restorations.

### DIRECT LABIAL VENEERS

Direct composite resin veneers can be divided into two types: those that require incisal lengthening and those that do not. If tooth length is to be maintained, place an opaque or color-modifying layer underneath a microfilled layer (Fig. 4-22). If incisal lengthening is required, materials are used in the following order, from lingual to labial (Fig. 4-23):

1. Opaquer
2. Hybrid or small particle composite resin

3. Color modifiers
4. Microfilled composite resins

The shades and distribution of color modifiers are related to the three zones of the clinical crown: Each of the three zones may require a different combination of colors based on the individual requirements of the tooth to be restored (Fig. 4-24). A color modifier with a high value (usually white), can make teeth appear larger and more prominent in the arch (Fig. 4-25). A gray tint lowers value, which creates a less prominent appearance (Fig. 4-26).

In addition, teeth can be made to appear narrow by staining the interproximal surfaces yellow-brown or orange. This results in the central aspect appearing relatively lighter, that is, a higher value (Fig. 4-27) (see Chapter 2). Staining the central vertical axis of the crown makes the lateral aspects appear lighter, and therefore the entire crown appears wider (Fig. 4-28).

#### Armamentarium

Use the same dental setup as for Class III and Class IV composite resin restorations with the following exceptions:

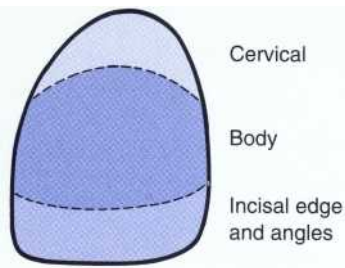


Fig. 4-24. The three zones of the clinical crown:

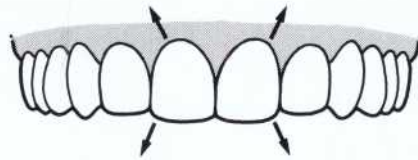


Fig. 4-25. Using a color modifier with a high value (usually white), teeth can be made to appear larger and more prominent in the arch.

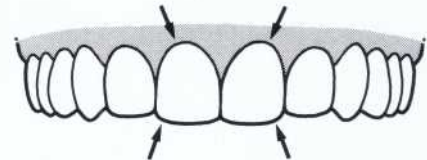


Fig. 4-26. Using a color modifier with a low value (usually gray), teeth can be made to look less prominent in the arch:

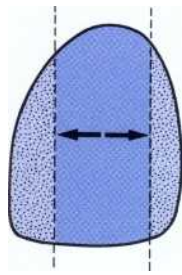


Fig. 4-27. Teeth can be made to appear narrow by staining the interproximal surfaces yellow-brown or orange:

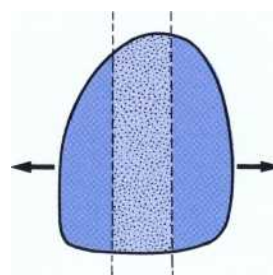


Fig. 4-28. Teeth can be made to appear wider by staining the central vertical axis yellow-brown or orange.

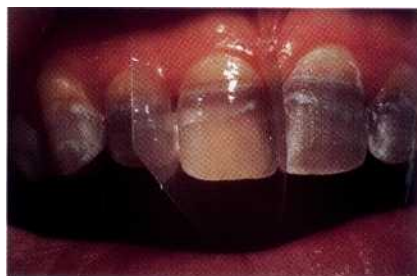- Assorted diamond burs for the preparation, such as 850-014, 6850-016, 8392-016, 8392-016EF, and Nixon II Kit (Brasseler USA)
- Retraction cord
- Ultrapak No. 0 (Ultradent Products, Inc.)
- Gingibraid No. 0 (Van R Products, Inc.)
- Mylar strips (optional)
- Wooden or clear plastic wedges (optional)
- Opaquers or color modifiers, as dictated by the individual case. Opaquers for tetracycline and other severe intrinsic stains include the following: Durafill VS (Kulzer, Inc., USA), Creative Color (Cosmedent, Inc.), Tetrapaque (Den-Mat Corp.), Prisma Enhancers (Caulk/Dentsply), Command Opaque (Kerr Manufacturing Co.), and Heliomolar Opaque (Vivadent USA, Inc.), and Biscolor modifiers (Bisco, Inc.)
- Artist's brushes

**Clinical Technique**

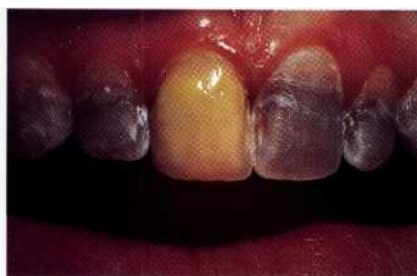1. Administer local anesthesia (optional).
2. Cleanse the tooth and neighboring teeth with pumice.
3. Determine the appropriate shade while the teeth are wet with saliva.
4. Isolate the area to maintain a dry field.

**CLINICAL TIP.** A rubber dam is not recommended for direct labial veneers, because the creative (artistic) nature of the work requires an unobstructed view of the patient to harmonize tooth color and form with the patient's face: Moisture can usually be controlled with cotton rolls, cheek retractors, and retraction cord:

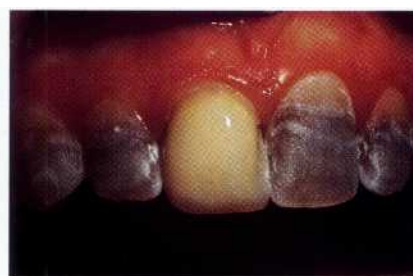5. Prepare the teeth (Fig. 4-29). The need for enamel reduction depends upon the reason for veneering.
  - a. If the reason for veneering is to close diastemata and change the length of teeth with a blending shade of composite resin, minimal or no enamel reduction is necessary.
  - b. If the reason for veneering is to effect a color change, enamel reduction is usually necessary to create space for color modifiers and veneer resins. In most cases, reduce the enamel by 0.3 mm in the gingival one third, and by 0.5 mm in the body area. Depth-cutting diamonds (Nixon II Kit, Brasseler USA) can be used to establish appropriate levels of enamel reduction. (If the **intrinsic discoloration is severe, as in the case of tetracycline stain, reduce the enamel** by 0.5 mm in the gingival one third and by 1.0 mm in the body.) The gingival margin must be subgingival for major



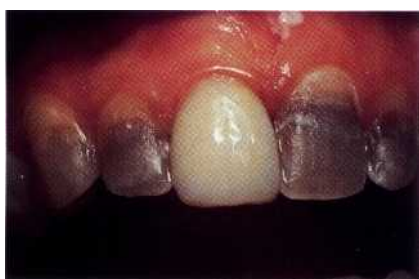*Fig. 4-29. Preparation of severe tetracycline stained teeth for direct bonded labial veneers. The maxillary right central incisor has been etched and Durafill bond placed and cured.*



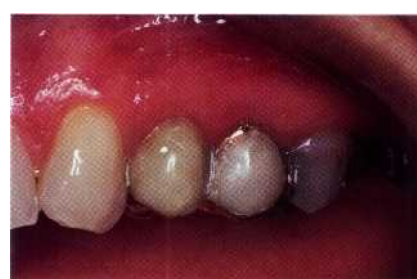*Fig. 4-30. To neutralize the blue-gray tetracycline stain, a complementary color (Durafill VS [yellow]) was placed.*



*Fig. 4-31. Estilux Color (white) was placed over the yellow to create a normal dentin background color.*



*Fig. 4-32. Durafill VS A-10 was used to complete the veneer.*



*Fig. 4-33. Preoperative view of defective acrylic veneer gold crowns with an inadequate opaquer. The gold can be seen through the composite resin. (Courtesy Dr. William Mopper.)*

color changes. In all other cases the gingival margin should be supragingival if possible.

6. Place the opaquers and color modifiers (Figs. 4-30 and 4-31).
7. Finish and polish (see the section on Class III and Class IV restorations).

**CLINICAL TIP.** It is usually better to complete one veneer at a time, including final polishing (Fig. 4-32). This allows for precise evaluation of the final color and prevents bonding through the contact area. Uncured resin from the adjacent veneer will not bond readily to the highly polished resin surface of the finished veneer.

8. To minimize the **possibility of chipping, eliminate all premature centric contacts and all interferences in labial excursive movements.** Provide for cuspid guidance whenever possible.

#### REPAIR OF ACRYLIC VENEER CROWNS

Partial or total separation of the acrylic veneer from an otherwise serviceable crown or bridge is common. Composite resin can be used to restore the veneer; however, an adequate layer of opaquer is necessary to conceal the

metal (Fig. 4-33). Both mechanical and chemical retention assist in preventing dislodgment of the restorative material.

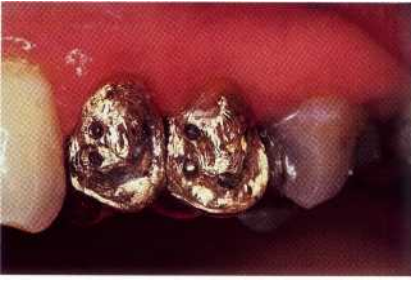#### Armamentarium

Use the same dental setup as for Class III and Class IV composite resin restorations with the following exceptions:

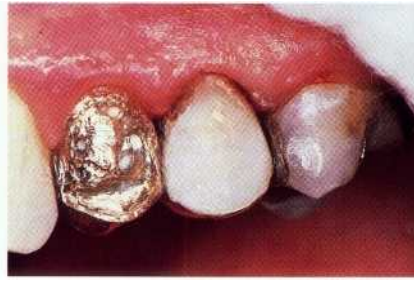- Small round or inverted cone high-speed tungsten carbide burs for providing mechanical retention (e.g., No. 1 round or 33 $\frac{1}{2}$  inverted cone bur)
- Metal coupling agent (e.g., C & B Metabond, Parkell, or Goldlink, DenMat)
- Bonding resin of choice
- Composite resin of choice
- Composite resin instruments (same as those listed under Direct Labial Veneers)
- Composite resin color opaquer of choice
- Composite resin color modifiers of choice

#### Clinical Technique

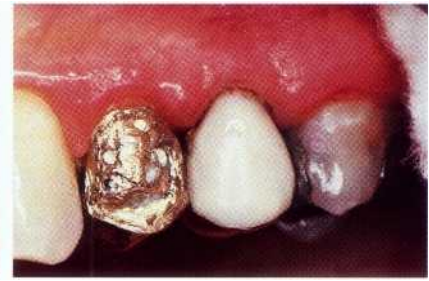1. Cleanse the tooth and neighboring teeth with pumice.



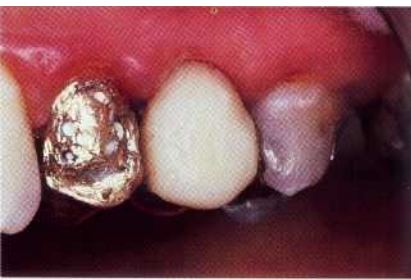*Fig. 4-34. Retention holes are placed through the metal into dentin. (Courtesy Dr. William Mopper.)*



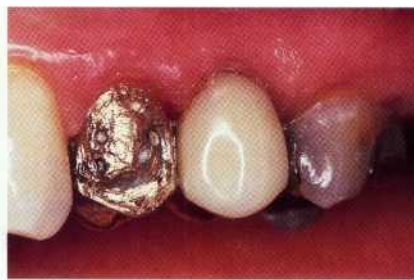*Fig. 4-35. After treatment with a metal bonding agent, a layer of opaquer is placed. (Courtesy Dr. William Mopper.)*



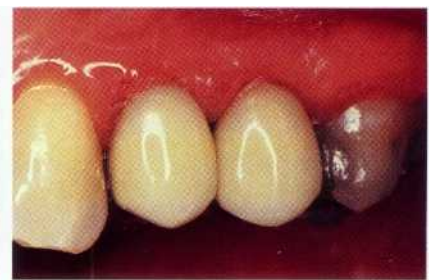*Fig. 4-36. Color modifiers are placed over the opaque resin. (Courtesy Dr. William Mopper.)*



*Fig. 4-37. Incremental layers of composite resin are added. (Courtesy Dr. William Mopper.)*



*Fig. 4-38. Postoperative view of the repair. (Courtesy Dr. William Mopper.)*



*Fig. 4-39. Postoperative view of the repair of the adjacent tooth. (Courtesy Dr. William Mopper.)*

2. Determine the appropriate shade while the teeth are wet with saliva.
3. Using a water-cooled, high-speed, small, round, or inverted cone bur, remove any remaining acrylic.
4. Place retention grooves around the entire peripheral margin. Place four to six retention holes in the metal, penetrating through the metal and into the dentin (Fig. 4-34). Coupling agents may preclude the need for penetration into dentin.

**CLINICAL TIP.** It is important to seal the entire labial or buccal surface with composite resin to ensure an adequate seal and prevent marginal leakage through the retention holes.

5. **For all remaining steps maintain a dry operating field.**

**CLINICAL TIP.** It is often difficult to match shades when a rubber dam is used. However, it is vital to maintain a dry field to ensure maximum bond strength.

6. Treat and coat the exposed metal surface with a 4 *META* coupling agent and opaquer, according to the manufacturer's recommendation (e.g., C & B Metabond) (Fig. 4-35).
7. Place a color modifier (if necessary) to adjust the background color (Fig. 4-36).

**CLINICAL TIP.** Always apply color modifiers in very thin layers and be certain to observe the required curing time for each layer. Thicker layers result in incomplete curing and uneven layers caused by pooling of the material.

8. Apply the composite resin in increments (Fig. 4-37).
9. Finish and polish (Figs. 4-38 and 4-39).

## PORCELAIN REPAIRS

### Repair of Fractured Porcelain with No Exposed Metal

Recent advances in silane coupling agents and opaquers and color modifiers have allowed for the repair of porcelain fractures of ceramometal restorations.

#### Armamentarium

Use the same dental setup as for Class III and Class IV composite resin restorations with the following exceptions:

- Microetcher (Danville Engineering) or hydrofluoric acid etching gel
- Silane
- Bonding resin of choice
- Composite resin of choice
- Composite resin instruments (same as those listed under Direct Labial Veneers)
- Color modifiers of choice

#### Clinical Technique

1. Cleanse the tooth and neighboring teeth with pumice. Determine the appropriate shade while the teeth are wet with saliva.
2. Using water-cooled, high-speed coarse diamonds, remove any loose porcelain and place a broad 2-mm bevel in the porcelain around the fracture site. Featheredge the porcelain peripheral to the bevel.

**CLINICAL TIP.** Featheredging beyond the beveled porcelain facilitates the blending of the resin into the porcelain.

3. For all of the remaining steps maintain a dry operating field.
4. Sandblast or etch the prepared porcelain with hydrofluoric acid gel for 3 to 6 minutes, according to the manufacturer's instructions.

**CLINICAL TIP.** Although hydrofluoric acid for dental use is buffered, it should be handled with care. When applying it to teeth, take precautions to avoid contact with skin and mucosal surfaces (e.g., use a rubber dam or protective gel).

5. Apply silane to the prepared porcelain.
6. Let dry according to manufacturer's instructions.
7. Apply bonding resin; gently remove excess with an air syringe and cure.
8. Apply the composite resin in increments.
9. Apply color modifiers (if necessary).

**CLINICAL TIP.** Always apply color modifiers in very thin layers and be certain to observe the required curing time for each layer. Thicker layers result in incomplete curing and uneven layers caused by pooling of the material.

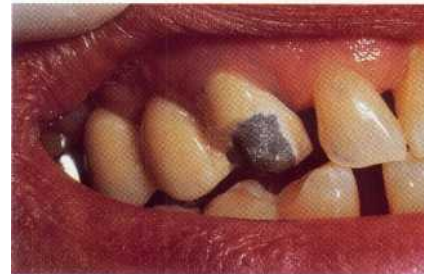10. Complete the application of composite resin.
11. Finish and polish.

### Repair of Fractured Porcelain with Exposed Metal

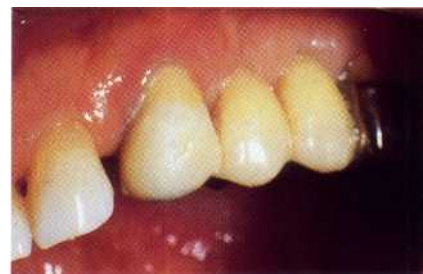The use of metal bonding agents (Table 4-2) has greatly enhanced the ability to repair porcelain that has fractured and exposed metal (Figs. 4-40 and 4-41).

#### Metal bonding agents

Product	Manufacturer
C & B Metabond	Parkell
Panavia OP (nonprecious only)	J. Morita USA, Inc.
Gold Link	Den-Mat Corp.
Alloy Primer	Kuraray Co., Ltd.



**Fig** *Fractured porcelain veneers with exposed metal. The metal was roughened with a coarse diamond. The porcelain was beveled, featheredged, etched, and silanated.*



*The completed repair.*

## Armamentarium

Use the same dental setup as used for Class III and Class IV composite resin restorations, but also needed are the following:

- Small round or inverted cone high-speed tungsten burs for providing mechanical retention
- Metal opaquer of choice

## Clinical Technique

1. Cleanse the tooth and neighboring teeth with pumice.
2. Determine the appropriate shade while the teeth are wet with saliva.
3. Using water-cooled, high-speed diamonds remove any loose porcelain and place a broad 2-mm bevel in the porcelain around the fracture site. Feather-edge the porcelain peripheral to the bevel.

**CLINICAL TIP.** Featheredging beyond the bevel porcelain will facilitate the blending of the resin into the porcelain.

4. Retention can be accomplished in one of two ways:
  - a. Place retentive holes through the metal.
  - b. Use a coarse diamond or a microetcher to roughen the metal surface and remove the oxide layer.
5. For all remaining steps maintain a dry operating field.
6. Sandblast or etch the prepared porcelain with hydrofluoric acid gel for 3 to 6 minutes, according to the manufacturer's instructions.

**CLINICAL TIP.** Although hydrofluoric acid for dental use is buffered, handle it with care. When applying it to teeth, take precautions to avoid contact with skin and mucosal surfaces (e.g., use a rubber dam or protective gel).

7. Apply silane to the prepared porcelain.
8. Let dry according to manufacturer's instructions.
9. Apply a thin layer of the metal opaquer of choice.

**CLINICAL TIP.** Panavia OP will not set in the presence of oxygen. Cover the Panavia with Oxyguard for 2 to 3 minutes, then rinse off the Oxyguard and dry.

**CLINICAL TIP.** It is not necessary to apply a bonding resin between the metal opaquer and the composite resin.

10. Incrementally apply the composite resin of choice.
11. Apply color modifiers (if necessary).

**CLINICAL TIP.** Always apply color modifiers in very thin layers and be certain to observe the required curing time for each layer. Thicker layers result in incomplete curing and uneven layers caused by pooling of the material.

12. Complete the application of the composite resin.
13. Finish and polish.

## REPAIR OF CERAMOMETAL MARGINS

### *Cervical Addition to Exposed Metal Crown Margins or Restorations of Recurrent Caries Around Ceramometal Margins*

Restorations of ceramometal margins are especially complex because of the necessity for bonding to cementum, dentin, metal, and porcelain (Fig. 4-42). The clinician should be aware of the importance of following the proper sequence in the use of the material, because the materials have specific chemistries or formulations for specific functions.

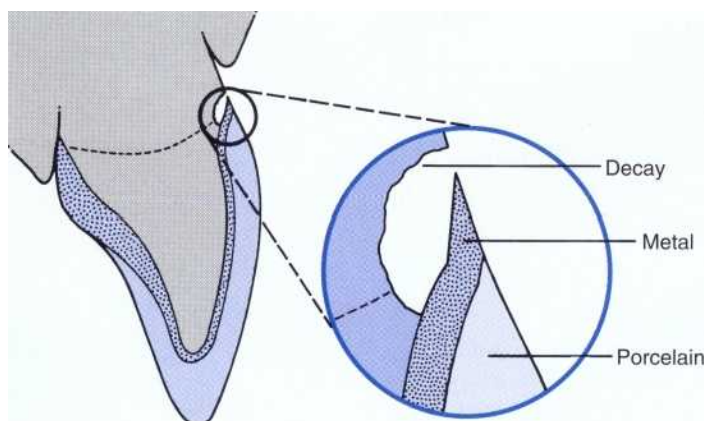


Fig. 4-42. Recurrent caries around ceramometal margins.

### Armamentarium

Use the Ammentarium listed under Repair of Acrylic Veneer Crowns, Porcelain Repairs, and Repair of Fractured Porcelain with Exposed Metal, but also needed are the following:

- Dentin bonding agent (see Chapter 3)
- Metal opaquer of choice

### Clinical Technique

**CLINICAL TIP.** It is often difficult to place a rubber dam on these types of restorations (Fig. 4-43). Take extra care to maintain a dry field and avoid contact with skin and mucosal surfaces.

1. Cleanse the tooth and neighboring teeth with pumice.
2. Determine the appropriate shade while the teeth are wet with saliva.
3. Prepare the tooth. Remove the metal collar to greatly simplify the restoration. Hold a coarse diamond at an angle to the crown and tooth, create a long bevel on the adjacent portion of the porcelain, and remove the metal collar. The crown margin should be located at a cervical level (Fig. 4-44). Featheredge the incisal porcelain and bevel the gingival margin (Fig. 4-45). A retention groove can be optionally placed in the gingival wall (Fig. 4-46).

**CLINICAL TIP.** Featheredging beyond the beveled porcelain facilitates the blending of the resin into the porcelain.

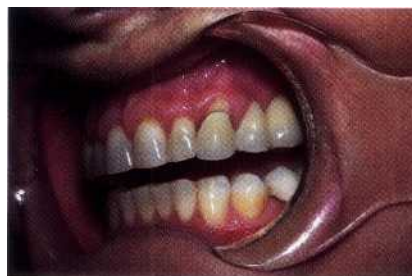4. For all remaining steps maintain a dry operating field.

5. Sandblast or etch the prepared porcelain with hydrofluoric acid gel according to the manufacturer's instructions.

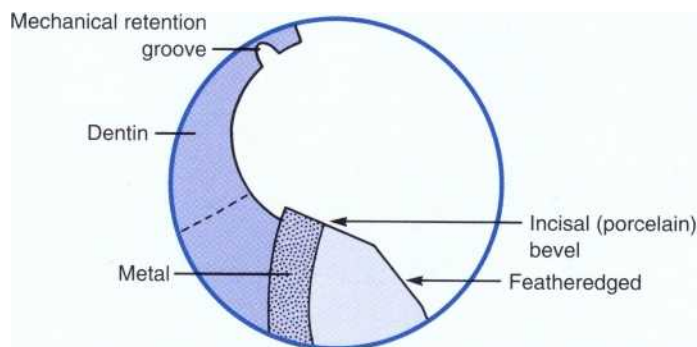
**CLINICAL TIP.** Although hydrofluoric acid for dental use is buffered, it should be handled with care. When applying it to teeth, take precautions to avoid contact with skin and inucosal surfaces (e.g., use a rubber dam or protective gel).

6. Rinse and dry thoroughly.
7. Apply silane to the prepared porcelain (Fig. 4-47).
8. Let dry according to the manufacturer's instructions.
9. If significant metal is exposed, apply the metal opaquer of choice in thin layers.

**CLINICAL TIP.** Panavia OP will not set in the presence of oxygen. Cover the Panavia with Oxyguard for 2 to 3 minutes, then rinse off the Oxyguard and dry.

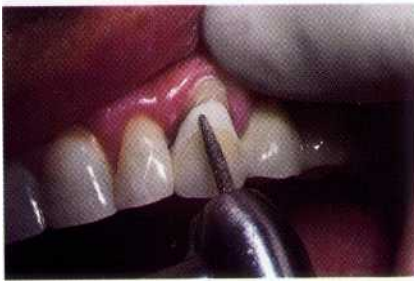

*Fig. 4-43. Exposed ceramometal crown margin with class V caries.*

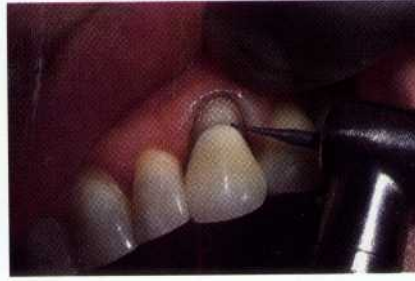

*Fig. 4-44. The prepared tooth following removal of the metal collar and placement of a long bevel and featheredge on the porcelain. A retention groove can be optionally placed in the gingival floor.*

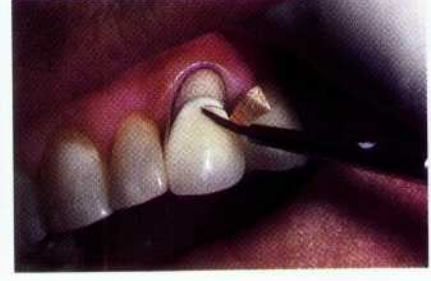



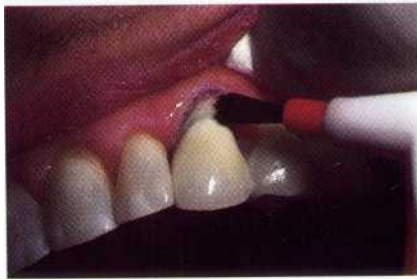*Fig. 4-45. A bevel and feathered edge were placed on porcelain.*



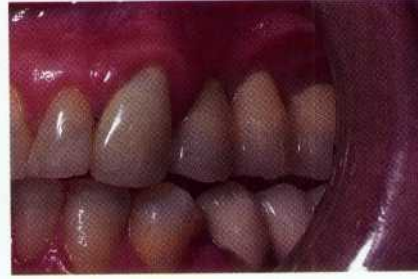*Fig. 4-46. Class V preparation and caries removal. Note retraction cord in place.*



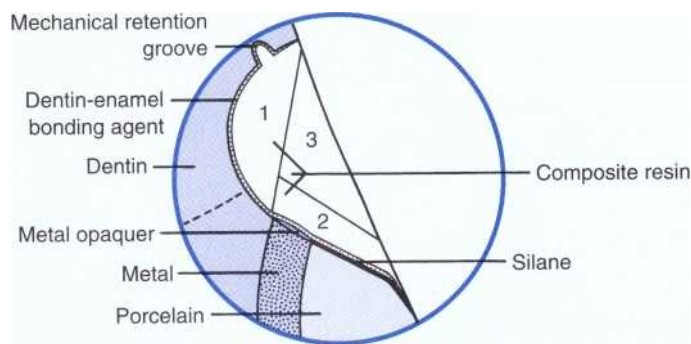
*Fig. 4-47. The etched porcelain was silanated.*



*Fig. 4-48. Application of Durafill bonding resin.*



*Fig. 4-49. The completed restoration with Durafill VS A-30.*



*Fig. 4-50. The completed restoration showing metal opaquer, silanated porcelain, dentin bonding agent, and incremental placement of composite resin.*



10. If exposed dentin remains, apply a dentin bonding agent to the exposed dentin and enamel only (Fig. 4-48).
11. Incrementally apply the composite resin of choice (Fig. 4-49).

**CLINICAL TIP.** In general, more opaque composite resins are needed in the cervical area (e.g., Cervical Opaque Composite Shade BO [brown] or YO [yellow], Kulzer, Inc., USA).

12. Apply color modifiers (if necessary).
13. Complete the application of composite resin.
14. Finish and polish (Fig. 4-50).

**CLINICAL TIP.** Always apply color modifiers in very thin layers and be certain to observe the required curing time for each layer. Thicker layers result in incomplete curing and uneven layers caused by pooling of the material.

### *Alternative Use of Glass Ionomer Cement for the Repair of Exposed Metal Crown Margins or Restorations of Recurrent Caries Around Ceramometal Margins*

#### Armamentarium

Use the armamentarium listed under Cervical Addition to Exposed Metal Crown Margins or Restorations of Recurrent Caries, but also needed are the following:

- Dentin bonding agent (see Chapter 3)
- Metal opaquer of choice
- Polyacrylic acid (e.g., Dentin Conditioner, GC International Corp.; Polyacrylic Conditioner, Ultradent Products, Inc., Durelon Liquid, ESPE Premier Sales Corp.)
- Glass ionomer cement of choice (see Chapter 7)

#### Clinical Technique

1. Cleanse the tooth and neighboring teeth with pumice.
2. Determine an appropriate shade while the teeth are wet with saliva.
3. Using a low-speed round carbide bur, excavate all recurrent decay within the dentin and around the margins and metal substructure.
4. Place pulp protection if necessary.
5. Place a long bevel on the most occlusal portion of the porcelain and **featheredge the porcelain below the bevel.**
6. For all remaining steps maintain a dry operating field.

**CLINICAL TIP.** It is often difficult to place a rubber dam on these types of restorations. Take extra care to maintain a dry field and avoid contact with skin and mucosal surfaces.

**CLINICAL TIP.** Although hydrofluoric acid for dental use is buffered, handle it with care. When applying it to teeth, take precautions to avoid contact with skin and mucosal surfaces (e.g., use a rubber dam or protective gel).

7. Rinse and dry thoroughly.
8. Place glass ionomer restoration of choice. Use a light-cured resin to protect the surface while setting.
9. Apply silane to the prepared porcelain.
10. Let dry according to the manufacturer's instructions.
11. If significant metal is exposed, apply a thin layer of primer followed by a thin layer of metal opaquer.
12. Apply a dentin bonding agent to any remaining exposed dentin.

**CLINICAL TIP.** Panavia OP will not set in the presence of oxygen. Cover the Panavia with Oxyguard according to manufacturer's instructions, then rinse off the Oxyguard and dry.

13. Incrementally apply the composite resin of choice.

**CLINICAL TIP.** In general, more opaque composite resins are needed in the cervical area (e.g., Cervical Opaque Composite Shade BO [brown] or YO [yellow] Kulzer, Inc. USA).

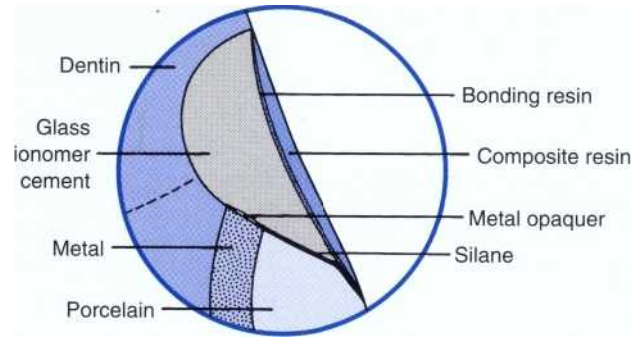
14. Apply color modifiers (if necessary).

**CLINICAL TIP.** If needed, use color modifiers to fine tune the background color or for custom tinting prior to the application of the last (surface) layer of composite resin.

15. Complete the application of composite resin.
16. Finish and polish (Fig. 4-51).

## CONCLUSION

Composite resins have vastly increased the range of options available to the dentist. The use of color modifiers and opaquers along with agents capable of bonding to porcelain or metal, have allowed the dentist to not only create an "invisible filling" but also greatly improve the esthetics of the patient's existing dentition.



*Fig. 4-51. The completed restoration showing metal opaquer, silanated porcelain, glass ionomer base, bonding agent, and single layer of composite resin.*

## REFERENCES

1. Buonocore MG: A simple method of increasing the adhesion of acrylic filling materials to enamel surfaces, *J Dent Res* 34:849, 1955.
2. Bowen RL: Dental filling material comprising vinyl silane treated fused silica and a binder consisting of the reaction product of bisphenol and glycidyl acrylate. US Patent 3,006,112, 1962.
3. Schneider RM, Messer LB, Douglas WH: The effect of enamel surface reduction in vitro on the bonding of composite resin to permanent human enamel. *J Dent Res* 60:895, 1981.
4. Black JB: Esthetic restoration of tetracycline stained teeth, *J Am Dent Assoc* 104:846, 1982.
5. Belvedere PC: Universal material, wide shade range makes for invisible anterior restorations, *Restor Dent* 3:4, 1989.



# COMPOSITE RESIN

## Fundamentals and Direct Technique Restorations

Richard D. Trushkowsky

**I**N 1955, MICHAEL BUONOCORE published the first paper in the *Journal of Dental Research* describing the technique of placing an unfilled resin (Serviton) on the labial surface of incisor teeth after conditioning with two different types of acid. Conditioning with phosphoric acid resulted in a hundredfold increase in retention of the non-adhesive resin to the labial surface compared to the control.<sup>1</sup> In 1950 a Swiss chemist named Osaka Hagger developed the first enamel and dentin bonding agent based on glycerophosphoric acid dimethacrylate<sup>2</sup>; in addition, Buonocore devised a phosphate-based adhesive resin in an attempt to bond composite resins to dentin.<sup>3</sup> However, bond strengths were only 2 to 3 MPa, whereas the bond strengths obtained with acid-etched enamel were 15 to 20 MPa. Rafael Bowen obtained the first clinically significant bond strengths in the early 1980s. He obtained measured bond strengths to dentin of 14 MPa.<sup>4</sup> The ability to bond reliably to dentin and enamel, in addition to the development of composite resins, led to a new era in restorative dentistry.

### HISTORY

In 1938, Castan, who was working for DeTrey-Zurich, invented the epoxy resins that are the basis for current composite resins. S.A. Leader introduced an incremental layering technique involving an auto-cured acrylic resin in Britain in 1948, and light-curing catalysts based on alpha-diketone amines were invented by ICI in Britain.<sup>5</sup> Acrylic filling materials containing aluminosilicate glass filler were formulated in the 1950s. The silicate glass was precoated with polymer (or primed with silane). Al-

though this process improved the material's physical properties, the materials were still hard to manipulate. In 1962, Raphael Bowen synthesized a new resin, a dimethacrylate (2,2-bis-[4(1-hydroxy-3-methacryloxypropyloxy-phenyl)]-propane, referred to as *bis-GMA*).<sup>6</sup> Bis-GMA is a reaction product of bisphenol A and a glycidyl methacrylate.

Bis-GMA was only originally available in a chemically cured system as a powder-liquid or paste-paste formulation. Ultraviolet- (UV-) cured resins were developed in 1972. This form of curing allowed adequate working time because the setting time was under the control of the clinician. Light-activated composite resins were reported by Michael Buonocore in 1970 and introduced by L.D. Caulk in 1971. Visible light-cured systems have exponentially increased composite resin use and improved on problems inherent in UV systems. Composite resins have undergone continuous development, but they still remain similar to the original formulation by Bowen.<sup>7</sup> Nevertheless, many improvements have been made in the resin and filler compositions. A general trend has been to reduce filler particle size and optimize its distribution, which improves the physical properties.<sup>8</sup>

Composite resins were originally used only in the anterior dentition. Composite resins can now be used posteriorly and can adhere to enamel, dentin, cementum, previously placed composite resins, porcelains, and metals.

Composite materials have also been indicated for posterior laboratory restorations.<sup>9</sup> Heat, and in some cases nitrogen under pressure, is often combined with light in laboratory polymerization to improve the physical properties of the restoration. A high degree of marginal accuracy can be achieved with these current

restorative systems, wear on opposing teeth is reduced, and surface properties improve.

### BASIC CHEMISTRY

Composite literally means "of distinct phases." Composite resins have four main components: (1) a matrix phase (dimethacrylate resin), (2) polymerization initiators (activated either chemically or by visible light), (3) a dispersed phase of filler and tints, and (4) a coupling phase that results in the adherence of the matrix to the filler particles (e.g., silanes). A diluent (e.g., triethylene glycol dimethacrylate, or TEG-DMA) is often added to control viscosity to make the resin more flexible and less brittle.'

In 1974, Foster and Walker introduced another difunctional resin, urethane dimethacrylate. (NOTE: A difunctional molecule has two reactive groups for polymerization.) Its low viscosity allows an increase in filler loading without the need for the addition of low-molecular-weight monomers to lower viscosity. However, urethane dimethacrylate is more brittle and undergoes more polymerization shrinkage than bis-GMA.S

Initiators are also added to produce the free radicals necessary for polymerization. Heat-activated systems split benzoyl peroxide to form free radicals. In chemically activated systems, benzoyl peroxide is split by a tertiary aromatic amine (acting as an electron donor) into free radicals. UV light-activated systems use a 365-nm UV light source to split benzoin methyl ether into free radicals without tertiary amines. Visible light-cured systems utilize a  $468 \pm 20$  nm light source to excite camphor quinones or other diketones to react with an aliphatic amine to start a free radical reaction. This amine is more color stable than the aromatic amine in chemically cured composite resins.

Chemical activation results in the least uniform curing of the resin systems. Air incorporation during mixing weakens the resin because oxygen inhibits polymerization. Mixing also causes voids, which may result in increased surface roughness and long-term discoloration.

The dispersed phase, or inorganic filler component, is responsible for the improved physical properties; the fracture resistance, wear resistance, polymerization shrinkage, water sorption, and coefficient of thermal expansion improve as the amount of filler in the composite increases. Common filler particles include quartz, lithium, aluminum silicate, borosilicate, barium, and other glasses. These particles range in size from 0.5 to 10  $\mu$ m.

In the final, or coupling phase, the properties of a composite resin improve as the attraction of the filler to the resin matrix increases. The adhesion between resin and filler transfers stress between both components. Silanes, which are bipolar molecules, are often used to bring the two phases together.

### PARTICLE SIZE

The type and size of the filler particles used in a composite resin affect its handling properties and longevity. Composite resins originally contained very large particles (15 to 100  $\mu$ m). Quartz was the most commonly used filler in the first generation of composite resins. It has excellent esthetics and durability, but its lack of radiopacity is a distinct drawback, especially for posterior resins. It is also difficult to obtain a smooth surface with quartz because polishing causes exposure of the large, irregular particles, and plucking these filler particles from the surface causes increased roughness and staining. In addition, masticatory stress is transferred through these filler particles to the resin matrix, causing microcracks in the resin matrix." The sizes of the particles in microfilled composite resins have been reduced to about 1 to 5  $\mu$ m (small particles). Heavy-metal glasses such as strontium and barium are smaller, radiopaque, easier to grind, and softer, resulting in improved polishability and decreased roughness and staining.

Microfilled resins were developed in the late 1970s to improve polishability. They are produced from silicon dioxide ash (fumed silica) or by adding colloidal sodium silicate to water and hydrochloric acid (colloidal silica). Microfills can either be homogeneous (i.e., formed by adding the microfiller directly to the resin) or heterogeneous (i.e., formed by compressing the microfiller into clumps and adding the clumps to heated resin). These prepolymerized resin filler blocks are ground and added to unpolymerized resin, which also contains microfiller.

Hybrid composite resins combine particles of different sizes; small particles (0.6 to 5  $\mu$ m) and 0.04  $\mu$ m microfillers are added to the resin matrix. The shape of the filler particle determines its properties. Irregularly shaped particles cause stress concentration at the area where the particle is angled.' Spherical particles distribute stress between the filler and the matrix more uniformly.

Radiopacity is desirable in Class II and Class III restorations. However, this can be detrimental when veneering the labial area of a tooth; radiographic contrast is reduced, making caries detection more difficult.

Different composite resins have different degrees of fill and radiopacity and different shades. Hybrid composite resins and microfilled resin placement both have advantages and disadvantages. Hybrid composite resin is less technique sensitive than microfilled resin and shrinks less on polymerization. Therefore less microleakage would occur at the gingival margin of Class II or Class III restorations if the shrinkage and strength of the dentin bonding were the only considerations. Paradoxically, several in vitro studies have shown that microfilled resins can produce a better seal than hybrid resins." " In addition, resins with a low Young's modulus (rigidity), such as Silux Plus, produce a better seal than many hybrid composite resins.'<sup>314,15</sup>

The microfiller particles in the resin matrix may increase the stress-bearing capacity and reduce microcrack propagation. Increased filler loading by weight also increases physical properties. The addition of microfiller particles allows the production of a relatively smooth surface. This, combined with high translucency, allows the use of a hybrid resin in critical esthetic areas.

In an attempt to overcome the disadvantages of self-cured glass ionomers, new generations of the materials have been developed. The new materials are hybrids of conventional glass ionomer cements and visible light-activated resin. The term *resin-modified glass ionomer* refers to materials that are set with an acid-base reaction in addition to photochemical polymerization. Materials that contain glass ionomer ingredients but do not exhibit an acid-base reaction are called *polyacid-modified resin composites*, or *compomers*. The compomers have a relatively high bond strength and fluoride release. Because their modulus of elasticity is close to that of tooth structure, the strain capacity of the restoration is increased and its deformation under a load is prevented, preserving adhesion at the margins of the restoration. The strength of compomers is higher than that of resin-modified glass ionomers but lower than composites. Flowable composites, or new, low-viscosity resin composite materials have also been introduced. However, their mechanical properties are about 60% to 90% as strong as those of conventional composites. Flowable composites are created by retaining the same size of traditional hybrid composites but reducing the filler content and increasing the resin, thereby reducing the viscosity of the mixture. Flowable composites are very useful for minimally invasive techniques, especially those used in conjunction with air abrasion. Some clinicians have recommended their use under Class I and Class II composites to achieve an initial seal and, as a result of their reduced modulus of elasticity, to reduce strain in the final restoration. The physical properties of currently available materials vary widely. However, some flowable materials have a filler content approaching that of conventional composite resins.

#### GENERAL CONSIDERATIONS: ACID ETCHING

Mature enamel contains 96% to 97% inorganic material (mainly hydroxyapatite) by weight. The rest is mainly water (~4%) and organic material or collagen (~1%). The enamel's surface is usually covered by an organic pellicle,<sup>15</sup> which makes bonding difficult because of its low reactivity." Etching enamel with phosphoric acid raises the critical surface tension and increases the bonding area and roughness, allowing the hydrophobic resins to penetrate the porosities of the dry etched enamel." Some important acid etching considerations include the following:

1. Liquid acid etchants must be applied repeatedly because they have a tendency to dry on the tooth surface. Gel etchants can be left in place for the required time.
2. The top layer of fluoride-rich enamel is removed with a diamond bur, and a pumice is used to remove plaque. A commercial prophylaxis paste can be used if it does not contain oils or is water soluble. Fluoridated water can be used for rinsing."
3. Rubber dam isolation or other precautions are necessary to minimize gingival fluid contamination or ambient moisture.
4. Etchants should be applied for 15 seconds. If this does not produce a frosted appearance on the enamel after washing and drying, etch repeatedly in 15-second increments until the frosted appearance is obtained. Recent studies have shown that shorter etching times produce the same or greater adhesive strength than the originally suggested 60 seconds.<sup>16</sup> In addition, morphologic studies have shown significant differences in etching results based on the viscosity of the etchant.<sup>21,22</sup> A liquid or a thin gel produced a more even etch pattern than a thick gel. In addition, the thin gel seemed to have the best defined etch pattern. Etching for too long produces insoluble reaction products and a weak bond.'
5. Some reports have stated that agitation with a soft brush may alter the etching pattern.<sup>22</sup> Mechanical agitation of the etching agent allows fresh acid to be in constant contact with the enamel,<sup>23</sup> which increases the amount of enamel that dissolves. The agitation of etchant may also aid in removing residual precipitates. Other studies have concluded that agitation has no effect on the outcome of the etch .'s
6. Shiny areas that appear after etching indicate the presence of old composite resins. The resins can be removed with a diamond bur and etched again to obtain the appropriate frosted surface.
7. An effective bond between composite resin and etched enamel can be achieved with a short rinse of the etchant from the etched enamel surface. Studies have concluded a 2- to 5-second rinse per tooth surface should sufficiently cleanse gel-etched enamel, resulting in adequate shear bond strength .<sup>16</sup> Rinsing for 1 second from a smooth enamel surface resulted in essentially no microleakage.<sup>2-9</sup>
8. Bleaching teeth before bonding may adversely affect bond strengths and result in increased microleakage. Hydrogen peroxide may denature proteins in the organic components of dentin and enamel. The presence of oxygen, a breakdown product of hydrogen peroxide, has been associated with the reduction in bond strength. Oxygen can inhibit the curing of composite resins and reduce adhesion. The oxygen

remains trapped in the porous enamel. Dentin traps oxygen longer than enamel because it is more porous. Waiting 1 to 2 weeks after bleaching allows tensile bond strengths to return to a value comparable to that of unbleached dentin.<sup>20</sup> Saliva, with its high remineralization capacity, may increase remineralization of bleached enamel.<sup>31</sup> Peroxide is an oxidant and may react with the highly organic smear layer and interfere with bonding and hybrid layer formation. Surface porosity and formation of precipitates increase as bleaching time increases. Bleaching may also increase the microleakage of previously placed composite resin. The leakage appears to be specific to the cementum-dentin margin<sup>32</sup> and is not reversed after subsequent exposure to saliva. Water-clearing solvents such as acetone and ethanol-based adhesive systems can reverse the effects of bleaching on bond strengths.<sup>33</sup>

### ENAMEL AND ENAMEL-DENTIN BONDING

Bonding agents are unfilled or lightly filled composite resins that improve the bond between a viscous composite resin and the microporosities created in the etched enamel. Application of a bonding agent reduces microleakage. Dentin-enamel bonding agents are more hydrophilic and can strengthen the bond between composite resin and dentin.

Etching enamel surfaces with phosphoric acid results in a superficial etched zone and underlying qualitative and quantitative porous zone.<sup>34</sup> The depth of the etched zone and the amount of the surface enamel removed during this etching procedure depend on the acid concentration, duration of the etching process, and the chemical composition of the etchant.<sup>3</sup> Adhesion to dentin is more of a challenge. Previous dentin bonding systems did not yield high bond strengths in the laboratory or prevent microleakage. Newer dentin-enamel adhesive systems use a phosphoric acid to condition the dentin, and then the primer resins in acetone, alcohol, or aqueous solution are placed on the dentin and allowed to diffuse into the few micrometers of tissue rendered porous by acid conditioning. This will result in the formation of a hybrid zone.<sup>35</sup>

The physical integrity of collagen is a key factor in bonding to dentin. The phosphoric acid used during the removal of the smear layer denatures the exposed collagen. The degree of denaturation depends on the phosphoric acid concentration and exposure time. The demineralized and denatured collagen fibers collapse easily during air drying and lose their permeability to resin monomers. Effective priming is needed to reexpand the collapsed collagen network and allow permeation of bonding monomers. In addition, acid-denatured collagen

fibers are susceptible to hydrolysis unless they are sufficiently enveloped by the primer. Reexpanding the collagen fibers is accomplished by strict adherence to the manufacturer's instructions during this critical stage.

Optimal bond strength is derived from the complete resin's diffusion into the chemically altered dentin. Moisture plays a significant role in achieving optimal bond strength for some of the resins in fourth-generation dentin bonding.<sup>36-38</sup> Bonding to dry dentin reduces potential bond strengths because of collagen collapse. Increased microleakage occurs in cervical areas because the bond between the composite resin and cervical dentin or cementum is much weaker than the bond to the occlusal enamel.<sup>39,40</sup>

Brushing on only a thin layer of bonding agent may be better than air drying, which can incorporate air into the composite resin and inhibit curing. Air drying from a triple syringe can also incorporate moisture into the preparation (see Chapter 3).

**CLINICAL TIP.** Dry with a syringe that is not connected to a water line or with a hair dryer to prevent moisture contamination.

### POLYMERIZATION SHRINKAGE

The polymerization reaction consists of three stages: (1) initiation, (2) propagation, and (3) termination. Initiation occurs when the camphorquinones are promoted to a free radical state. When the free radical camphorquinone reacts with a monomer molecule, it forms a bond that converts the monomer to a free radical state. Propagation occurs when this camphorquinone-monomer-free radical complex reacts with another monomer and converts it into another free radical. This chain reaction terminates when two free radical complexes react with each other to form a stable bond. Ideally, the termination should not occur too quickly so that the free radical complex can react with many monomers, thus creating longer, more flexible polymer chains. If termination occurs too rapidly, the chains are too short (and therefore less flexible). Reducing the number of available free radicals can minimize early termination of the reaction. This makes it more likely that the free radicals will react with a monomer and increase chain length rather than react with other free radicals and terminate the polymerization reaction.

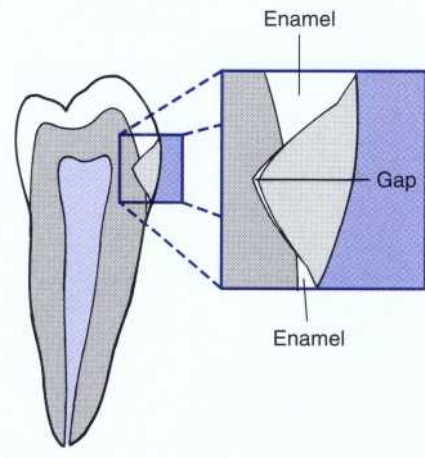
A major drawback of using composite resin as a direct restorative material is polymerization shrinkage. Linear polymerization shrinkage (i.e., a straight-line measurement of shrinkage) is approximately 0.4% to 1.6%.<sup>41</sup> Commercial materials contract by 2% to 5% by volume during setting. Volumetric shrinkage is related to the density of the material—the higher the filler content by

weight, the less volumetric shrinkage. Volumetric shrinkage is determined by placing a sample in a liquid (usually water or mercury) and measuring the displacement before and after the reaction. Cracks in enamel margins caused by polymerization shrinkage have been reported.<sup>42</sup> Polymerization shrinkage may cause marginal gaps, promoting postoperative sensitivity, marginal staining and recurrent caries. Composite resin shrinkage is dictated by the volume fraction (the relative amounts of filler and resin material) of the polymerized resin, its composition and the completeness of the curing reaction.

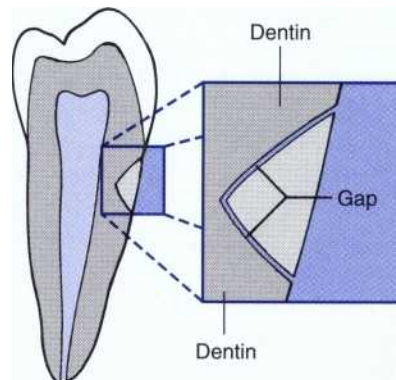
Several techniques to overcome this problem include the use of self-cured materials or glass ionomers that have slower setting rates than light-cured composite resins.<sup>43,44</sup> Application of an intermediate layer of a low-viscosity resin or a resin-modified glass ionomer cement between the dentin and the restoration has been shown to relieve polymerization stress by 20% to 50%.<sup>45</sup> A gradual transition in modulus of elasticity from dentin through the bonded interface to the restoration resin appears to be desirable. Bulk placement may result in less shrinkage, but if the surfaces remain bonded the resin composite has internal stress that can be alleviated by initial flow. The total shrinkage and its stress field are a result of the combined effect of the contraction of all the incremental layers and the deformation of the surrounding tooth structure of the final restoration. When the restoration is in full contact with the cavity, the polymerization contraction of each individual filling increment will cause some deformation of the cavity, forcing the cavity wall inward and downward and decreasing the cavity volume.<sup>46</sup> However, currently it is still believed that incremental layer placement is the best way to prevent internal stress caused by polymerization shrinkage of composite resins.

#### DENTIN BONDING AND POLYMERIZATION SHRINKAGE

The placement of bonded composite resins into cavity preparations leads to a competition between polymerization contraction forces and the bond to tooth structure. If the lesion is completely surrounded by enamel (Fig. 5-1), the stress is relieved by detachment of composite resin from the dentin; however, marginal integrity in enamel is maintained. If the lesion is completely contained within the root surface (Fig. 5-2) and polymerization shrinkage forces exceed the instantaneous strength of the dentin bonding agent, the restoration may leak and will most likely dislodge. The most common clinical situation involves a restoration that is bonded to enamel incisally and to the root structure at the gingival margin (Fig. 5-3). If the dentin bond is not instantaneous and not stronger than the composite resin shrinkage, a contraction gap



*Fig. 5-1. In a restoration completely surrounded by enamel, polymerization contraction causes composite resin to detach from the dentin. Although a gap may form under the restorations, the marginal integrity in the enamel is maintained. If the dentin bonding agent could be formulated to be as strong as an enamel bonding agent, the composite resin could break away from the enamel or cause the enamel rods to pull out. If the enamel and dentin bonds hold, they could place the tooth and resin under tremendous stress.*

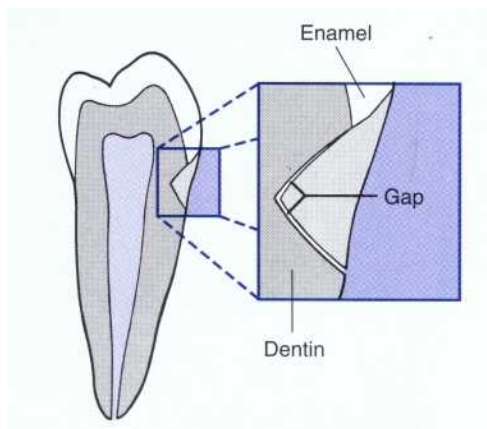


*Fig. 5-2. If the restoration is completely contained within the root surface and polymerization shrinkage forces exceed the instantaneous strength of the dentin bonding agent, a gap may form around the entire restoration, possibly leading to leakage and restoration failure.*

forms at the gingival margin and the restoration will probably leak at that location.

The amount of stress development can be controlled to some extent by the configuration factor, (or *C-factor*—the ratio of bound to unbound surfaces of adhesive restorations); the use of bases; the size, shape, and position of increments placed in the cavity; and the type of





*Fig. 5-3. The most commonly seen clinical situation: a restoration bonded to enamel incisally and to the root at the gingival margin. If the dentin bond is not instantaneous and is not stronger than the composite resin shrinkage, a contraction gap forms at the gingival margin, resulting in restoration failure. (Modified from Davidson CL, Kemp-Shulte CM: Shortcomings of composite resins in Class V restorations, J Esthet Dent IA, 1986.)*

resin curing (i.e., light cured or chemically cured). Studies have found no significant difference in marginal integrity utilizing a self-cured composite resin (P-10) and a light-cured composite resin (Z-100).<sup>47</sup> Ideally, the C-factor should be kept as low as possible by the use of chemically cured resin and low-modulus liners.<sup>48</sup> Reestablishment of marginal seals may occur as a result of gradual expansion of the composite resin as a result of water sorption; however, this depends on the configuration of the cavity and the resin volume. Polymerization is rapid, whereas this process is slower and allows bacterial invasion to occur. Water sorption may cause erosion of the filler and matrix, possibly resulting in a reduction in strength stiffness and wear resistance.<sup>49</sup>

A linear relationship between light intensity and polymerization contraction has been demonstrated. Reduced rates of polymerization during the maturation of the bond between the tooth structure and the composite may allow for increased flow of material and less stress formation, which may disrupt the bond **between the tooth and restoration**.<sup>50-54</sup> Some reports state that even thin layers of composite resin, such as those produced under porcelain inlays, can produce shrinkage stress that challenges the dentin bond.<sup>55</sup>

Recent studies have suggested that the physical characteristics of composite resins can be improved by using a soft-start technique beginning at 100 mW for 20 seconds followed by 40 to 60 seconds of 700 mW or greater. Studies indicate a laser could be used as the light source of the

soft-start polymerization technique. The use of the Elipar High Light Dual (manufactured by ESPE) produces significantly better marginal integrity and the lowest leakage.<sup>56</sup> The Elipar High Light two-step curing unit provides a period of 12-second, low-intensity (approximately 150 mW/cm<sup>2</sup>), slow-start polymerization and a 28-second high intensity (approximately 800 mW/cm<sup>2</sup>) final cure. The two-phase cure allows flow at the free surface and better marginal integrity in Class V resin restorations but does not ultimately reduce the internal stress of the composite resin.

## LINERS AND BASES

Traditionally, liners and bases have been used under restorations. However, new developments in liners and bases and an increased understanding of pulp biology have changed the indications for use of these materials.

The current generation of dentin bonding agents has significantly reduced the need for protective liners and bases. However, despite dramatic improvements since their introduction, modern dentin bonding agents leak immediately when bonded to superficial dentin. Nearly all dentin bonding agents show significant loss of bond strength when bonding to deep rather than superficial dentin.<sup>5,57</sup> This difference is a result of the amount of intertubular and peritubular dentin found at different dentinal depths. Deep dentin has more peritubular dentin and more surface moisture.

In some specific instances, placement of a liner may be warranted. Calcium hydroxide is still useful for direct pulp capping as a stimulus for reparative dentin formation, despite its inability to provide a permanent seal against bacterial invasion. This inability to form a permanent seal may be caused by tunnel defects that form **in reparative dentin and the eventual dissolution of the calcium hydroxide** after long-term placement.<sup>58,59</sup> Tunnels in a dentin bridge are inactive vascular channels that were once active. The number and sizes of vessels injured by exposure determine the number of tunnels formed during the healing process.

**CLINICAL TIP.** After any pulpal exposure the preparation should be disinfected with Concepsis (Ultradent) and then dried. Alternatively, 2.625% sodium hypochlorite can be applied and then rinsed off with water. (Sodium hypochlorite also helps create homeostasis.) An adequate amount of calcium hydroxide to cover the exposure should be applied, and then a small amount of light-cured resin, modified glass ionomer should be used to cover the calcium hydroxide, creating a bacterial barrier.<sup>60,61</sup> The preparation is then etched and primed and adhesive is applied.

**CLINICAL TIP.** The use of any calcium hydroxide should be kept to a minimum because it dissolves over time, resulting in an unsupported restoration."

Light-cured glass ionomers are useful as liners because of their good compressive strength, adhesiveness to dentin, and ability to release fluoride and chemically bond to the composite restoration. Glass ionomers are useful for eliminating undercuts and developing the ideal thickness for indirect ceramic restorations. They are also useful, as indicated in the previous Clinical Tip, as part of the direct pulp-capping process. In deep-cavity preparations, placement of glass ionomers reduces the bulk of composite resin, resulting in less stress. In addition, if the gingival margin is on dentin, a better seal may be obtained with light-cured, resin-modified glass ionomers (e.g., Vitrebond using the "open sandwich" technique). The release of fluoride may reduce instances of recurrent caries.<sup>63,64</sup>

**CLINICAL TIP.** Placing resin ionomers, such as Vitremer (3M), in the gingival portion of Class II, Class III, and Class V composite restorations (the "open-sandwich technique") may be a practical method of reducing microleakage, especially apical to the cementum-enamel junction.

**CLINICAL TIP.** If postoperative sensitivity is anticipated because of the preparation depth, a glass ionomer, light-cured resin-modified glass ionomer, or resin ionomer can be used as a dentin replacement. The material should be built up to resemble the form of an "ideal" cavity preparation.

### Marginal Bevels

1. Enamel margins of composite resin restoration are beveled in most cases. Beveling enamel provides an increased surface area for etching, resulting in increased retention and reduced microleakage. The beveling exposes the ends of enamel rods, which is optimal for acid etching.<sup>65</sup> Bevels should be prepared with a medium grit diamond bur.
2. Beveling provides a gradual transition between the composite resin restoration and the tooth. Bevels of 45 degrees and 1 to 2 mm wide are used in facial areas, whereas a smaller (0.5-mm) bevel is used in other areas. (A wider bevel is placed on the facial surface to achieve better blending in the esthetic zone.)
3. Bevels (on the occlusal surface) should be avoided in Class I and Class II restorations because thin composite resin margins are subject to fracturing. Widening the preparation to allow a bevel may extend the restoration into areas of occlusal function and possibly increase wear.
4. Areas at the cervical margin with only a thin layer of enamel should not be beveled because thin areas of enamel may be removed. It is always desirable to terminate the restoration on enamel rather than cementum or dentin.<sup>39,40</sup>

### FINISHING

Finishing involves margination, contouring, and polishing. The primary goals are good contour, occlusion, smoothness, and appropriate embrasure form.'

**CLINICAL TIP.** Adequate contouring of a restoration before polymerization is essential for minimizing finishing time and reducing damage to the composite resin. (Finishing procedures can cause microcracks.) Damage to the composite resin results in a higher wear rate, an increased fracture rate, and a greater tendency for opening of margins.

The bonding agent should cover all etched enamel surfaces. Etched enamel that is not covered with resin may take as long as 2 to 3 months to remineralize, leaving the tooth surface vulnerable to discoloration. Running a composite resin knife, a number 12 Bard Parker blade, or a gold foil finishing instrument from the enamel to the composite resin will remove all unattached bonding agent. (These instruments are also excellent for removing small proximal overhangs in Class II restorations before finishing with aluminum oxide strips [see Fig. 5-17].) This will leave a small step, which can be finished with composite resin finishing diamonds or disks. The restoration can have a lifelike appearance. Finishing burs, diamonds, rubber points, and disks can be used to create lobes, ridges, and surface texture. To produce a textured surface, a slight excess of composite is left after finishing. A micron diamond can be used to produce the desired texture. A polishing cup and polishing paste are then used to bring out the luster, although care should be taken not to destroy the created texture.

The restoration is smoothed with rubber polishing instruments for the anterior surface and points and cups for the posterior surface. Metal or plastic finishing strips can be used interproximally. Some controversy surrounds whether burs or diamonds are best for finishing composite resins. Diamonds are usually preferred because finishing burs are more damaging to the surface, causing more plucking of filler particles. These defects result in staining or loss of surface luster. Micron diamonds at slow speeds (with water spray to prevent clogging of the diamonds) can be used for excess removal and contouring and to provide a smooth surface with minimal resin damage. A variety of shapes, sizes, and degrees of fineness are available. White and green stones can loosen the fillers from

the resin matrix and need to be used with copious amounts of water to prevent heat buildup.

## POLISHING

Achievement and maintenance of a smooth surface on a restoration will improve esthetics and in addition reduce plaque and stain formation.<sup>66</sup> Several studies have suggested certain techniques may be suitable for specific materials.<sup>67</sup> Differences in surface smoothness has been demonstrated using identical finishing systems with different composite resins.<sup>68</sup>

Microfilled composite resins can be polished with disks. The tooth surface should be wet when using coarse disks and dry when using superfine disks. The heat from the dry disk procedure produces a durable, highly cured smear layer of resin over the microfill. However, aggressive use of disks may destroy the previously created texture. A composite resin polishing paste can be used if necessary for 15 to 30 seconds using a rubber cup moistened with water. Small particle hybrids are polished with fine diamonds, flexible disks, and a very fine polishing paste (e.g., Luminescence, Premier).

**CLINICAL TIP.** Surface-penetrating sealants (e.g., Fortify, Bisco Corp.; Optiguard, Kerr Corp.) can be used to repair surface defects created during finishing, which improves the wear of posterior composite resins and decreases microleakage around Class V composite resins.<sup>69</sup> In addition, the composite resin **that is closest to the light is often the** most polymerized and therefore the hardest part of the restoration. Because this layer is removed with occlusal adjustment and polishing, placement of the sealant and postcuring are necessary.<sup>10"</sup>

**CLINICAL TIP.** It is impossible to overcure a composite resin. An additional 60-second cure is recommended if the tooth is dark or if a dark shade of composite resin is used. The additional cure is most beneficial after the restoration is finished to its final form.

## TECHNIQUES AND MATERIALS

### *Class I Composite Resin Restorations*

#### Armamentarium

Standard dental setup  
 Explorer  
 Mouth mirror  
 Cotton forceps  
 Anesthesia (if necessary)  
 Rubber dam setup  
 High-speed handpiece  
 Slow-speed handpiece

Burs: carbide (e.g., #557, #330, #4, S.S. White, Inc.)  
 Diamond: coarse and medium grit (e.g., Brassler, Axis, Premier)

37% phosphoric acid

Placement and carving instruments (e.g., instruments by Hu-Friedy, Inc.; Cosmedent, Inc.; Coltene-Whaledent, Inc.; Premier, Inc.; Thompson, Inc.; Almore, Inc.)

- Suitable liner (if necessary) (e.g., Vitrebond, 3M, Inc.; Vivaglass Liner, Vivadent, Inc.; Fuji Lining LC, Fuji, Inc; Ionosit, Zenith/DMG, Inc.)
  - Suitable base (if necessary) (e.g., Vitromer Cement, 3M, Inc.; Fuji II LC, Fuji, Inc.)
- Articulating paper or wax (e.g., Bausch BK 01, Bausch, Inc.; Accufilm II, Parkell, Inc.)
- Radiopaque composite resin or microfilled resin designed for posterior use (e.g., Surefil, Caulk/Dentsply; Z-100, 3M, Inc.; Herculite XRV or Prodigy, Kerr, Inc.; Heliomolar and Tetric Ceram, Ivoclar/Vivadent, Inc.; Solitaire, Heraeus-Kulzer, Inc.; Alert, Jeneric Pentron, Inc.; SternOmega Composite LC, Sterngold, Inc.)
- Oil-free pumice (Moyco, Inc.)
- Cavity disinfectant (e.g., Tublicid Red, Global Dental Products, Inc.; Consepsis, Ultradent, Inc.)
- Composite resin placement syringe (e.g., Centrix Syringe, Centrix Inc.)
- Glycerin gel (e.g., Liquid Strip, Ivoclar/Vivadent, Inc.)
- Finishing instruments (e.g., Esthetic Trimming Kit, Brasseler, Inc; Raptor System, Bisco, Inc; Two Striper MPS Kit, Premier, Inc.)
  - Polishing instruments (D\*Fine, Clinicians Choice; Diacomp, Brasseler; Flexi [points, cups, and wheels], Cosmedent, Inc.; Composite Technique Kit, Shofu, Inc; Diagloss, Diagloss Axis.)
- Polishing paste materials (e.g., Luminescence, Premier, Inc.; Prisma Gloss, Caulk, Inc.; Diamond Polishing Paste, Shofu, Inc.)

#### Clinical Technique

1. Cleanse the tooth with pumice.
2. Evaluate the shade of the tooth before isolation (from the middle third of tooth).
3. Use articulating paper to determine the location of occlusal contacts so that they can be avoided, if possible, during preparation.

**CLINICAL TIP.** If the occlusal surface is intact, fabricate a registration of the occlusal surface with a clear polyvinyl siloxane bite material (e.g., Memesil, Kulzer, Inc.; Transbite, SciCan) or a thermoplastic button. (This step decreases the need for subsequent carving and occlusal adjustment.)"

4. Administer local anesthetic if necessary.
5. Isolate the area with a rubber dam.

**CLINICAL TIP.** The preparation does not have to be extended to dentin for retention.

6. Place an appropriate liner or base if necessary. See section on liners and bases in this chapter.

**CLINICAL- TIP.** After any pulpal exposure the preparation should be disinfected with Concepsis (Ultradent) and then dried. Alternatively, 2.625% sodium hypochlorite can be applied and then rinsed off with water. (Sodium hypochlorite also helps create hemostasis.) An adequate amount of calcium hydroxide to cover the exposure should be applied, and then a small amount of light-cured resin-modified glass ionomer should be used to cover the calcium hydroxide, creating a bacterial barrier.<sup>60,61</sup> The preparation is then etched and primed and adhesive is applied.

**CLINICAL TIP.** The use of any calcium hydroxide should be kept to a minimum because it dissolves over time, resulting in an unsupported restoration.<sup>62</sup>

**CLINICAL TIP.** If postoperative sensitivity is anticipated because of the preparation depth, a glass ionomer, light-cured resin-modified glass ionomer, or resin ionomer can be used as a dentin replacement. The material should be built up to resemble the form of an "ideal" cavity preparation.

7. Etch the enamel and dentin for 15 seconds. See section on acid etching in this chapter.
8. Wash with water and/or water/air spray for a minimum of 10 seconds for gel or liquid etchants. See section on acid etching in this chapter.
9. Air dry the enamel and blot the dentin, leaving it slightly moist. The cavity preparation can be disinfected with a cavity disinfectant and the excess blown off and blotted with a cotton pellet. However, in some systems the smear layer is not removed but only modified, and bond strengths may decrease as a result of disinfection.<sup>73,74</sup>
10. Repeat the procedure if the enamel does not have a frosted white appearance after air drying. If the dentin is dry, moisten the dentin again with a cotton pellet moistened with water.
11. Place the dentin-enamel bonding agent according to the manufacturer's instructions.
12. With a syringe, place an increment of a dentin shade posterior composite against the pulpal floor and against one of the buccal cusps. Light cure for 40 seconds through the cusp. Build up the other buccal cusp and subsequently the lingual cusps in a

similar manner. This creates appropriate fissure position and depth.

**CLINICAL TIP.** When composite resin is initially cured with an attenuated light, a better interface between the composite resin and tooth surface is created. Curing through the tooth structure provides the light attenuation. Because polymerization shrinkage occurs toward the bonded surface, curing through the tooth may allow the composite resin to better adapt. See the complete discussion on this topic in the conclusion of this chapter.

**CLINICAL TIP.** The triangular ridges usually have a whitish hue and elevated value. An AI or a pedodontic shade may be preferred in building up this area. The in-between ridge pits usually have a higher chroma and usually match the dentin shade or cervical third of the tooth.<sup>75</sup>

**CLINICAL TIP.** A two-step bonding agent is a better lubricant than alcohol for preventing composite resin from sticking to the plastic instrument. Alcohol, or a one-step bonding agent (which contains a solvent), should not be used because it could weaken the composite resin. This consideration is particularly important for Class II restorations, which are subject to heavy occlusal stress.

**CLINICAL TIP.** A Centrix-type syringe is the preferred instrument for composite resin placement. It reduces the chance of bubble formation and eliminates composite resin "pullback" that occurs when the material is placed with hand instruments.

13. Place tints and opaques to achieve a natural appearance. Place brown and ochre tints into pits and **fissure and white** or colored opaques at the crest of triangular ridges (e.g., Kolor+, Kerr; Creative Color, Cosmedent).
14. Place a layer of an enamel/incisal composite resin to build up the final contour. This anatomic layering technique reduces stress within the adhesive interface.
15. Place glycerin to reduce the air-inhibited layer. Light cure for 40 seconds.

**CLINICAL TIP.** The previously fabricated occlusal registration can be used at this time. It is pressed back into position, and the resin is light cured for 60 seconds from the occlusal direction. Occlusal adjustments are minimal when this technique is used.

16. Finish the restoration. See section on finishing in this chapter.<sup>16</sup>

17. Polish the restoration. See section on polishing in this chapter.
18. Sealant and postcuring procedures are the following:
  - A. Rinse off polishing debris with water; air dry.
  - B. Etch for 15 seconds.
  - C. Rinse with water for a minimum of 10 seconds.
  - D. Air dry the surface. (If the surface is not enamel, leave it moist.)
  - E. Apply sealant (e.g., Fortify, Bisco Corp.; Cpti-guard, Kerr Corp).
  - F. Air thin.
  - G. Light cure for 40 seconds.

**CLINICAL TIP.** The composite resin that is closest to the light is often the most polymerized and therefore the hardest part of the restoration. Because this layer is removed with occlusal adjustment and polishing, placement of the sealant and postcuring are necessary.<sup>70,71</sup> Postcuring and placement of the sealant reduce wear on the restoration.<sup>71,71</sup>

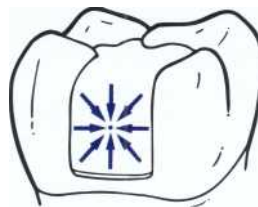### Class II Composite Resin Restorations

Improved clinical performance has been a result of more durable dentin bonding<sup>77-79</sup> and improvement in composite resins.<sup>80-82</sup> However, despite these resin improvements, composite resins remain technique sensitive.<sup>83</sup> Failures often involve inadequate proximal contours and contacts, microleakage, secondary caries, postoperative sensitivity, occlusal wear, marginal degradation, and bulk fracture of the material.<sup>84</sup>

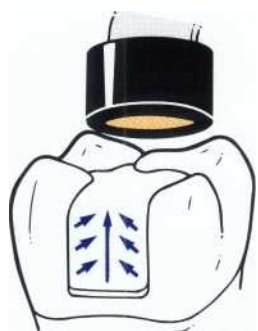**Occlusal Wear.** In the 1960s, high wear rates made the composite resins unacceptable for restoring occlusal surfaces.<sup>85</sup> However, recent formulations have reduced the wear rate for many materials to 7 to 10  $\mu\text{m}$  per year. The composite resins have been made radiopaque, allowing the detection of excess material and recurrent decay.<sup>86</sup> The addition of ytterbium trifluoride provides an element of fluoride release (e.g., Heliomolar).

**Postoperative Sensitivity.** Postoperative sensitivity was initially attributed to inadvertent acid etching of the dentin.<sup>87</sup> However, recent research has shown that pulp inflammation is primarily caused by bacterial microleakage resulting from a breakdown of marginal integrity of the restoration.<sup>88</sup>

Light-cured composite resins are generally used for posterior restorations because they are more resistant to occlusal wear. Unlike chemically cured resins, which contract toward the geometric center (Fig. 5-4), light-cured resins shrink toward the light source (Fig. 5-5). The portion of the composite resin closest to the light hardens first, pulling the composite resin away from the gingival margin. However, see the discussion (Versluis) in the conclusion at the end of this chapter. This process results in leakage, especially if the restoration ter-



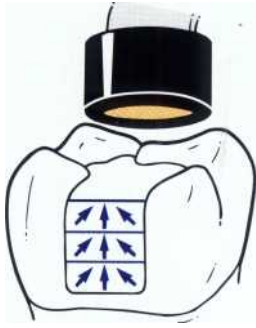**Fig. 5-4.** Chemically cured composite resin shrinks toward the geometric center of the mass. (This may only occur if the composite is not bonded. Versluis thinks that composites shrink toward the adhesively bound surfaces.) This process leaves a small contraction gap at the gingival margin. The composite resin is strongly bonded to enamel on the buccal and lingual walls, preventing the formation of gaps at these walls; however, stresses may be set up in the tooth and the composite resin.



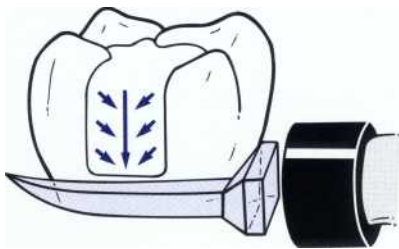
**Fig. 5-5.** Photocured composite resin shrinks toward the light source because the composite resin closest to the light hardens first. This pulls the softer composite resin from the gingival areas, creating a gap. The mass of composite resin being pulled to the occlusal area is twice that found in chemically cured resins (see Fig. 5-4); therefore the gingival contraction gap is roughly twice as large. Versluis thinks that composites shrink toward the adhesively bound surfaces. However, if the contraction is toward bound surfaces and not toward the light, this would not occur.

minates on dentin or cementum.<sup>89-92</sup> When present, cervical enamel bonds poorly compared to occlusal enamel. Sometimes enamel prisms can actually be torn during shrinkage toward the occlusal surface.

Incremental curing reduces but does not eliminate the gingival shrinkage (Fig. 5-6). A plastic wedge acting as a fiberoptic guide can further reduce the gap<sup>93</sup> (Fig. 5-7), especially in combination with incremental placement of resins<sup>94</sup> (Figs 5-8 and 5-9). However, the plastic wedges do not adapt to varying tooth morphology and may loosen during manipulations of the restorative material. Lutz et al<sup>95</sup> differed from Barkmeier<sup>95</sup> and found wedges with a reflecting core to be more effective in pro-



*Fig. 5-6. Incremental curing reduces but does not completely eliminate the gingival contraction gap.*



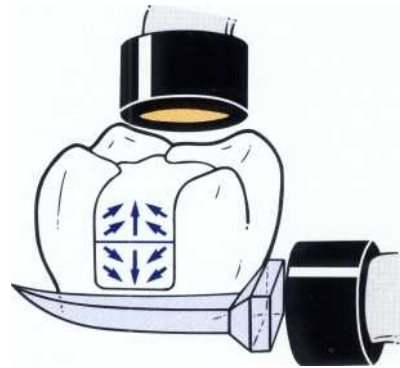
*Fig. 5-7. A plastic wedge, which acts as a fiberoptic extension, can pull the composite resin gingivally to minimize gap formation.*

ducing better polymerization than clear wedges. Lutz stated that light reflecting wedges reversed the shrinkage vectors 180 degrees (by directing them toward the enamel margins<sup>16</sup>).

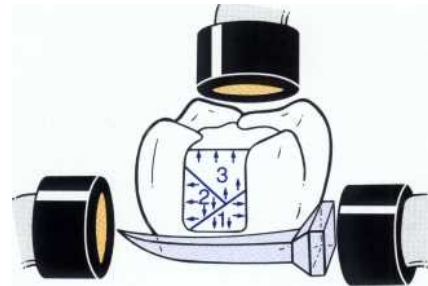
Use of retention grooves has been recommended to reduce gingival margin microleakage.<sup>97</sup> However, these grooves were no benefit with an incremental technique. In general the clinician should minimize the size of the cavity preparation so that only carious areas are encompassed. Extension of the gingival floor or embrasure area or extension into other grooves on the occlusal surface are unwarranted. The pulpal floor need only be as deep as the dimension of the lesion, because composite resin has a relatively low elastic modulus and incorporation of the energy-absorbing properties of dentin are not needed.<sup>98</sup>

Evidence suggests that shrinkage can pull cusps together, creating postoperative sensitivity. If this occurs, bisecting the restoration (from mesial to distal) to the occlusal floor permits the cusps to spring back and eliminates the sensitivity.

**CLINICAL TIP.** Placing a sectional matrix decreases sensitivity because an overly tightened circumferential matrix can pull the cusps together (i.e., Palodent Matrix and Bitine Ring, Darway, Inc. and Composi-Tight, Garrison, Inc.).



*Fig. 5-8. Although not ideal, this incremental technique, should reduce the gingival contraction gap and the stress better than a two-increment technique involving only occlusal curing. The first layer is placed and photocured through the plastic wedge. A second layer is placed and cured occlusally. Two improvements could be made in the most gingival increment. First, regardless of tooth color, a light-color resin should be used to ensure additional curing depth. Second, before adding the final increment, a second, occlusal cure of the first increment should be performed to ensure complete hardening of the mass. (Modified from Lutz F et al: Improved proximal margin adaptation of Class II composite resin restorations, Quint Int 17:659, 1988.)*



*Fig. 5-9. A technique that takes advantage of composite resin contraction and uses only one 11- to 13-mm cured light tip. The first increment can be pulled lingually and gingivally (via the light-reflecting wedge directing light at a 90-degree angle to the light tip) before an additional occlusal cure. The second increment is pulled buccally and gingivally before it too receives an additional occlusal cure. The final increment is hardened occlusally after placing a ball of prepolymerized composite to act as an internal wedge. Additional occlusal increments may be necessary in large teeth. This design also minimizes pulling together of the cusps.*

Research suggests that a layering procedure can minimize cusp contraction. Buildup of individual cusps prevents the cusps from being pulled together. Although many clinicians advocate a layering buildup of the composite resin to minimize the amount of polymerization

shrinkage and reduce the possibility of enamel fracturing, several studies advocate bulk placement of composite resin in Class II preparations.<sup>99</sup> Two of these studies utilized a dual-cured material (Marathon, Den-Mat Corp). It was theorized that shrinkage occurs toward the center of its mass, and the slightly warmer surface of the tooth may initiate polymerization at the junction between the wall of the preparation and the composite resin.<sup>100,101</sup> However, further research is necessary to validate this concept.

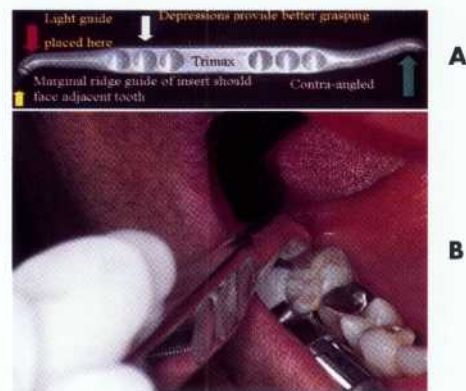
**Tight Proximal Contacts.** Placement of the posterior composite resins depends on the matrix for correct interproximal contour. Unlike an amalgam restoration, a circumferential band is not necessary and a contoured segmental matrix may be preferred. In a mesial-occlusal-distal (MOD) composite resin restoration, the wedge and matrix should initially be placed on the distal side only, which displaces the tooth slightly in a mesial direction. (Placing a wedge and matrix simultaneously on the mesial surface would interfere with and prevent some of this mesial displacement and increase the chance of an open, or "light," contact.) Similarly, when the mesial surface is filled, no wedge or matrix should be present at the distal surface.

**CLINICAL TIP.** A small, egg-shaped ball of prepolymerized composite resin (shaped and cured on the finger) can be wedged into unpolymerized composite resin (at increment 3) against the axial wall and the band. The composite resin ball acts as an additional wedge<sup>102,103,105</sup> placing pressure from within on the axial wall and the matrix. A plugger is used to exert active downward pressure and expose increment 3 (unpolymerized) to the curing light. The mesial box is restored in a similar manner, with the composite resins joined at the occlusal area.

**CLINICAL TIP.** When new composite resin is added within 5 minutes of placement of uncontaminated cured composite resin, chemical adhesion is as strong as it would be if the two resins had been placed simultaneously.<sup>106,107</sup>

**Strengthening Cusps.** A dentist may think that a strong dentin-enamel bond and high composite resin tensile strength can tie the buccal and lingual cusps together to strengthen the tooth. However, research on this topic is equivocal. One study has shown that this method causes less reinforcement because of thermal cycling.<sup>108</sup>

**Contact Forming Devices.** Various devices and instruments have been manufactured to aid in achieving a tight contact (e.g., Contact Pro, C.E.J.; Beta Quartz Inserts, Lee<sup>109</sup>; Belvedere Contact Former, American Eagle; Composite Contact Instrument, Premier; Light-Tip, Denbur<sup>111,112</sup>; Trimax, AdDent, Intra-wedge, made chair-



A, Trimax contact forming instrument, AdDent, Inc. B, Trimax instrument in position. The light from the curing unit is transmitted through the adjustable light conducting tip into the composite resin.

side) (Fig. 5-10). These instruments are made of a wide variety of materials and shapes, and they all have a range of advantages and disadvantages.

Most of the instruments reduce the bulk of composite resin, thereby reducing polymerization shrinkage. They also expedite contact formation. However, the contact formed is not always at the correct height, dimension, and position.<sup>110</sup> Devices such as the Light Tip permit curing at the critical gingival area.

### Multiple-Step Buildup Technique

#### Armamentarium

Use the same dental setup as for Class I restorations with the following exceptions:

- Mylar matrix strip (possibly the contoured variety), a sectional matrix and Bitine ring, or a retainerless matrix system (e.g., AutoMatrix II, L.D. Caulk; Super-Mat, Premier) that can be preloaded with a wide variety of bands (pediatric, metal, combination, and transparent)
- Light-reflecting wedge (Cure-Thru, Premier Dental Products, Co.; Luciwedge, Coltene/Whaledent) or a contoured Sycamore Wedge (Premier)
- Radiopaque composite resin or microfilled resin designed for posterior use (e.g., Heliomolar RO, Ivoclar/Vivadent, Inc; Surefil, Caulk/Dentsply, Inc.; Herculite XRV, Kerr, Inc.; Charisma-F, Heraeus-Kulzer, Inc.; Alert, Jeneric Pentron, Inc; Tetric Ceram, Ivoclar/Vivadent, Inc.; SternOmega composite LC, Sterngold, Inc.; Solitaire, Heraeus-Kulzer, Inc.; Filtek P60, Filtek P250, 3M)

#### Clinical Technique

1. Determine the appropriate shade of the tooth while it is wet with saliva.
2. Cleanse the tooth with pumice and clean the proximal surface with a strip where necessary.

3. Before cavity preparation, use articulating paper to ensure that the cavity design avoids including occlusal contacts where possible.

**CLINICAL TIP.** If the occlusal surface is intact, fabricate a registration of the occlusal surface with a clear polyvinyl siloxane bite material or a thermoplastic button.

4. Administer local anesthesia if necessary.
5. Place a rubber dam. When warranted, the preparation may be *entirely* based in enamel, because extension into dentin for retention is not necessary.
6. Place appropriate liner and base if necessary. See section on liners and bases in this chapter.

**CLINICAL TIP.** After any pulpal exposure the preparation should be disinfected with Concepsis (Ultradent) and then dried. Alternatively, 2.625% sodium hypochlorite can be applied and then rinsed off with water. (Sodium hypochlorite also helps create hemostasis.) An adequate amount of calcium hydroxide to cover the exposure should be applied, and then a small amount of light-cured resin-modified glass ionomer should be used to cover the calcium hydroxide, creating a bacterial barrier.<sup>60,61</sup> The preparation is then etched and primed and adhesive is applied.

**CLINICAL TIP.** The use of any calcium hydroxide should be kept to a minimum because it dissolves over time, resulting in an unsupported restoration.<sup>62</sup>

**CLINICAL TIP.** If postoperative sensitivity is anticipated because of the preparation depth, a glass ionomer, light-cured resin-modified glass ionomer, or resin ionomer can be used as a dentin replacement. The material should be built up to resemble the form of an "ideal" cavity preparation.

**CLINICAL TIP.** Placing resin ionomers, such as Vitremer (3M), in the gingival portion of Class I, Class III, and Class V composite restorations (the "open-sandwich technique") may be a practical method of reducing microleakage, especially apical to the cementum-enamel junction.

7. Etch the enamel and dentin for 15 seconds. See section on acid etching in this chapter.
8. Wash with water and/or water/air spray for a minimum of 10 seconds for gel or liquid etchants. (See section on acid etching in this chapter.)
9. Air dry the enamel and blot the dentin leaving it slightly moist. The cavity preparation can be disinfected with a cavity disinfectant and the excess blown off and blotted with a cotton pellet. However, in some systems the smear layer is not re-

moved but only modified, and bond strengths may decrease during disinfection.<sup>73,74</sup>

10. Repeat the procedure if the enamel does not have a frosted white appearance after air drying. If the dentin is dry, moisten the dentin again with a cotton pellet moistened with water.
11. Place selected matrix, retainer, and wedge.
12. Place the appropriate dentin-enamel bonding agent.
13. A thin layer of a flowable composite resin (e.g., Tetric Flow, Ivoclar/Vivadent; Flow-It, Jeneric-Pentron) can be placed at the gingival margin and all axial walls, which allows curing of the initial thin layer of composite resin to seal these critical areas. However, research has not demonstrated any reduced microleakage.<sup>113,114</sup>
14. Depending on the composite resin used, the subsequent step may vary. Materials such as Surefil are recommended for bulk placement if the curing depth is not greater than 5 mm. Other materials may require a layered buildup of the composite resin in 2-mm increments.

**CLINICAL TIP.** If the first two layers are not be part of the labial display, use a light-color resin to ensure more complete light penetration and subsequent polymerization.

**CLINICAL TIP.** Place an incremental layer of composite resin on the lingual wall; it should not touch the buccal wall (see Fig. 5-9). Use bonding agent, rather than alcohol, to prevent the composite resin from sticking to the plastic instrument. See the Clinical Tip on bonding resin and alcohol in the section on Class I composite resin restorations.

**CLINICAL TIP.** Place the composite resin with a Centrix-type syringe (see Fig. 5-14). See the Clinical Tip on Centrix syringes in the section on Class I composite resin restorations.

15. Cure from the lingual direction for 60 seconds if a 2-mm layer of composite resin is the initial increment. During bulk placement, cure proximally for 60 seconds if the areas (buccal and lingual surfaces) are accessible to the light, and then cure the occlusal surface for 60 seconds.

**CLINICAL TIP.** Use an 11- to 13-mm angle-tip light to ensure that the light exposes the lingual surface and the wedge (if a light conducting wedge is used), which optimizes light direction vectors and polymerization (see arrows in Fig. 5-8).

16. Cure from the occlusal direction for 60 seconds for incremental placement.



17. Remove the wedge and place it buccally.
18. Place a second layer of composite resin on the buccal wall. It should not touch the lingual wall.
19. Cure from the buccal direction for 60 seconds.
20. Cure from the occlusal direction for 60 seconds.
21. Shape a small piece of posterior composite resin into an egg-shape ball on a gloved finger and polymerize the resin.

**CLINICAL TIP.** Wash and dry your gloves before beginning this procedure so that no powder remains on the surface.

22. Place the resin into the proximal box, and push the ball into the uncured resin so that it contacts the axial wall and the mylar strip. This forms an internal wedge to further tighten the contact with the adjacent tooth. Remove the excess composite resin with an interproximal carver. See section on finishing in this chapter.

**Alternative method:** If a contact-forming instrument is used, the proximal box is filled and the instrument inserted and torqued toward the adjacent tooth (see Fig. 5-10). An interproximal carver is used to remove the excess material. The composite is then light cured and the remainder of the box filled.

23. Cure from the occlusal direction for 60 seconds.
24. Add additional increments as necessary. The shade of these increments should blend with the surrounding tooth structure. The final increment should be a translucent layer (enamel replacement).

**CLINICAL TIP.** The previously fabricated occlusal registration can be used at this time. It is pressed back into position, and the resin is light cured for 60 seconds from the occlusal direction. Occlusal adjustments are minimal when this technique is used.

**CLINICAL TIP.** In a mesial-occlusal-distal preparation, fill the distal portion first and place the mylar or metal strip and wedge in the distal area only. It is usually not necessary for the matrix to encircle the tooth; the absence of the band and wedge in the mesial area ensures tighter distal contact. Remove the distal matrix and repeat the process in the mesial area.

25. Adjust the occlusion and contour the restoration. See section on finishing in this chapter.
26. Polish the restoration. See section on polishing in this chapter.

27. Sealant and postcuring procedures are the following:
  - A. Rinse off polishing debris with water; air dry.
  - B. Etch for 15 seconds.
  - C. Rinse with water for a minimum of 10 seconds.
  - D. Air dry the surface. (If the surface is not enamel, leave it moist.)
  - E. Apply sealant (e.g., Fortify, Bisco Corp.; Opti-guard, Kerr Corp.).
  - F. Air thin.
  - G. Light cure for 40 seconds.

**CLINICAL TIP.** Although not mandatory, sealing can increase wear and stain resistance. Sealants should be cured in 40-second increments.

**CLINICAL TIP.** The composite resin that is closest to the light is often the most polymerized and therefore the hardest part of the restoration. Because this layer is removed with occlusal adjustment and polishing, placement of the sealant and postcuring are necessary.<sup>70,71</sup> Postcuring and placement of the sealant reduce wear on the restoration.<sup>70,71</sup>

### *Class III Composite Resin Restorations*

Class III restorations include the simple two-surface lingual approach situation and the three-surface labial approach situation. The three-surface through-and-through preparation presents shade matching and blending challenges because of darkness "show through" from the back of the mouth. A radiopaque composite resin material should be used to aid in the detection of recurrent decay.

#### Armamentarium

Use the same dental setup as for Class I restorations with the following exceptions:

- Conventional mylar strip, stop strips (mylar anterior bands with an integrated stopper to secure the matrix band between adjacent teeth) (Premier, Inc.)
- Strip aids (Premier, Inc.)
- Wedges (desirable if near the gingiva) (Premier, Inc.)
- Hybrid composite resin (e.g., Renamel, Cosmedent Inc.; Z-100, 3M, Inc.; TPH Spectrum, Cautk/Dentsply, Inc.; Tetric, Ivoclar, Inc.)
- Microfilled composite resin (e.g., Silux Plus, 3M, Inc.; Durafill, Kulzer, Inc.; Renamel, Cosmedent, Inc.; Epic-TMPT, Parkell, Inc.)

#### Clinical Technique

1. Pumice the tooth and clean the proximal surface with a strip where necessary.
2. Determine the appropriate shade of the tooth while it is wet with saliva.
3. Apply local anesthesia if necessary.

4. Place a rubber dam.
5. Determine the direction of access depending on the extent of decay, and prepare the tooth as conservatively as possible.
6. Place appropriate liner or base if necessary. See section on liners and bases in this chapter.

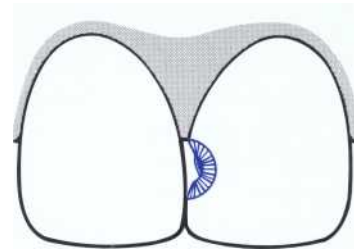
**CLINICAL. Tip.** After any pulpal exposure the preparation should be disinfected with Concepsis (Ultradent) and then dried. Alternatively, 2.625% sodium hypochlorite can be applied and then rinsed off with water. (Sodium hypochlorite also helps create hemostasis.) An adequate amount of calcium hydroxide to cover the exposure should be applied, and then a small amount of light-cured resin-modified glass ionomer should be used to cover the calcium hydroxide, creating a bacterial barrier.<sup>60,61</sup> The preparation is then etched and primed and adhesive is applied.

**CLINICAL TIP.** The use of any calcium hydroxide should be kept to a minimum because it dissolves over time, resulting in an unsupported restoration.<sup>62</sup>

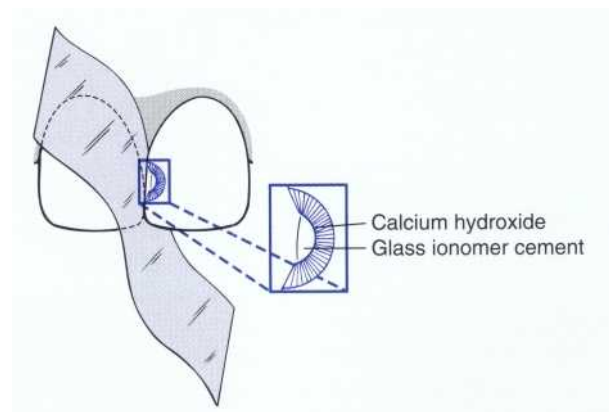
**CLINICAL TIP.** If postoperative sensitivity is anticipated because of the preparation depth, a glass ionomer, light-cured resin-modified glass ionomer, or resin ionomer can be used as a dentin replacement. The material should be built up to resemble the form of an "ideal" cavity preparation.

**CLINICAL TIP.** Placing resin ionomers, such as Vitremer (3M), in the gingival portion of Class II, Class III, and Class V composite restorations (the "open-sandwich technique") may be a practical method of reducing microleakage, especially apical to the cementum-enamel junction.

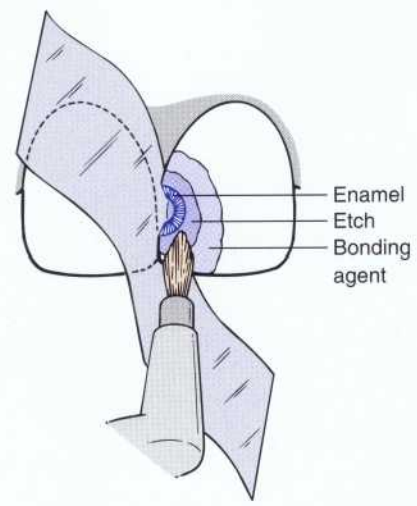
7. Place a bevel of 1 to 2 mm on all visible margins with a medium grit diamond to aid in creating an invisible restoration (Fig. 5-11).
8. Place 0.5-mm bevels on nonvisible margins except in areas that are in occlusion. No bevel is necessary on cementum.
9. Place appropriate liner and base if applicable (Fig. 5-12). See section on liner and bases in this chapter.
10. Etch the preparation with 37% phosphoric acid several millimeters past the bevel for 15 seconds (Fig. 5-13). Protect the adjacent teeth with a mylar strip.
11. Wash with water and/or water/air spray for a minimum of 10 seconds for gel or liquid etchants. See section on acid etching in this chapter.
12. Air dry the enamel and blot the dentin, leaving it slightly moist. The cavity preparation can be



**Fig. 5-11.** Because the lesion is completely surrounded by enamel, the final preparation does not require an undercut. Note the bevel around the entire preparation.



**Fig. 5-12.** A mylar strip is placed, and calcium hydroxide or a glass ionomer cement or both can be placed if necessary.



**Fig. 5-13.** A brush being used to apply acid etchant to enamel and dentin followed by a wash, dry, and the use of a different brush for the application of an enamel dentin bonding agent. The gel etchant can also be applied with a syringe and needle.



disinfected with a cavity disinfectant and the excess blown off and blotted with a cotton pellet. However, in some systems the smear layer is not removed but is only modified, and bond strengths may decrease during disinfection.<sup>73,74</sup>

13. Repeat the procedure if the enamel does not have a frosted white appearance after air drying. If the dentin is dry, moisten the dentin again with a cotton pellet moistened with water.
14. Place the primers and adhesive resin according to the manufacturer's directions and light cure for 20 seconds.

*Placing the Restorative Material*

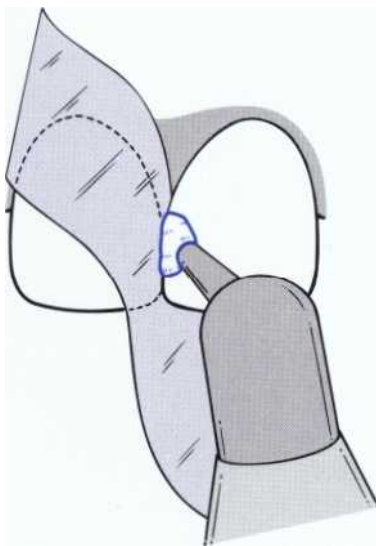
The cavity can be filled in one or two increments, depending on its size and configuration.

**Type I Class III Restorations:  
Lingual Access Only**

1. Place the mylar strip interproximally and inject hybrid composite resin (dentin replacement).

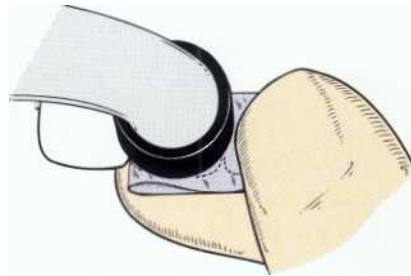
**CLINICAL TIP.** Use bonding agent rather than alcohol to present the composite resin from sticking to the plastic instrument. See the Clinical Tip on bonding resin and alcohol in the section on Class I composite resin restorations.

**CLINICAL TIP.** Place the composite resin with a Centrix-type syringe (see Fig. 5-14). See the Clinical Tip on Centrix syringes in the section on Class I composite resin restorations.

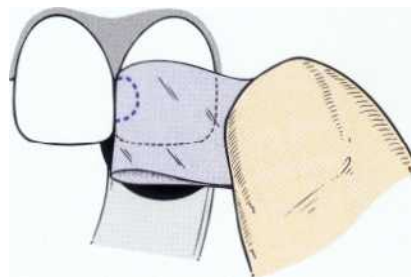


*Fig. 5-14.* Application of the composite resin with a syringe minimizes "pullback," which often occurs when hand-held instruments are used.

2. Overfill the cavity slightly and pull the mylar strip to the facial to properly adapt the composite resin.
3. Wrap the strip around the proximal surface, keeping it tightly adapted at the gingival margin. (A wedge can be used to stabilize the strip or minimize excess, but this may also cause gingival bleeding.)
4. Hold one finger on the facial side of the mylar strip and compress the strip. The strip will "bow out" to contact the adjacent tooth.
5. Cure from the labial direction for 60 seconds. The labial area therefore is fully cured, whereas the lingual area is partially cured (Fig. 5-15).
6. Remove the gloved finger from the mylar strip and cure from the lingual direction for 60 seconds (Fig. 5-16).
7. Contour and finish the restoration (Figs. 5-17 to 5-19). See section on finishing in this chapter.
8. Polish the restoration. See section on polishing considerations in this chapter.

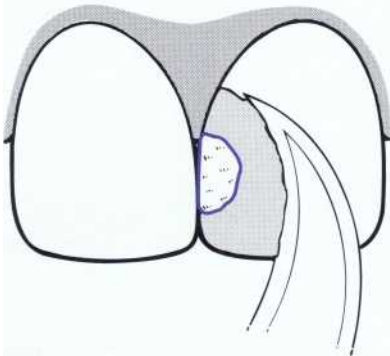


*Fig. 5-15.* The mylar strip is pulled tightly with finger pressure to minimize subsequent finishing. Placement of a wedge to reduce gingival composite resin excess is optional. Note that the index finger exerts labial pressure against the mylar strip. In addition to reducing composite resin excess, the labial direction of force moves the central incisors slightly labially during the polymerization. When the pressure is released, the tooth springs back, which can partially compensate for the thickness of the mylar strip and ensure a tight contact area.

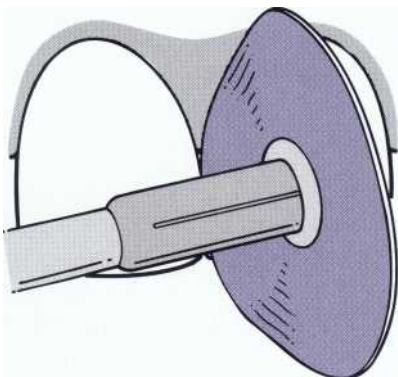


*Fig. 5-16.* After 60 seconds of labial curing, the lingual resin has partially hardened. A 60-second lingual cure completes the process.

9. Sealant and postcuring procedures are the following:
- Rinse off polishing debris with water; air dry.
  - Etch for 15 seconds.
  - Rinse with water for a minimum of 10 seconds.
  - Air dry the surface. (If the surface is not enamel, leave it moist.)



*Unbonded resin flash and small resin overhangs are removed with a Bard-Parker blade or composite resin knife before the final polishing. The hand-held instrument is always moved from the tooth to the composite resin.*



*Shaping and polishing can be done with diamonds, burs, disks, or rubber wheels. This step is followed by application of composite resin polishing paste using a prophylaxis cup or felt wheel.*



*The finished restoration.*

- Apply sealant (e.g., Fortify, Bisco Corp; Opti-guard, Kerr Corp.).
- Air thin.
- Light cure the labial and lingual surfaces for 60 seconds each.

**CLINICAL TIP.** The composite resin that is closest to the light is often the most polymerized and therefore the hardest part of the restoration. Because this layer is removed with occlusal adjustment and polishing, placement of the sealant and postcuring are necessary.<sup>70,71</sup> Postcuring and placement of the sealant reduce wear on the restoration.<sup>70,71</sup>

Because a Class III restoration is usually not in a high-stress area, the labial and lingual portions can be restored with a microfiller. Optimal results can be achieved utilizing a sandwich technique. A microfill is used on the labial and lingual surfaces, and a tooth-colored, opaque, or hybrid composite in between. The microfills are easier to polish, they retain a smooth surface, and they maintain their luster over a long period. However, either a microfill or hybrid can be used alone effectively.

**Type 2 Class III Restorations: Facial Access.** A microfill composite resin or a combination of hybrid resin overlaid with a microfill composite resin can be used.

- Place the mylar strip interproximally and inject the hybrid or microfilled composite.
- Pull the mylar strip to the lingual and adapt it to the lingual surface.
- Place your thumb on the lingual surface and forefinger on the labial surface. Bow the matrix toward the adjacent tooth. If using only one increment, allow sufficient excess to cover the facial bevel. If a combination of hybrid and microfill are used, inject the hybrid and then the microfill.
- Light cure.
- Use a small amount of opaque to cover the demarcation between the tooth structure and resin.
- A translucent microfill can be placed as the last layer (enamel).

**Type 3 Class III Restoration: Through-and-Through**

- Place a mylar strip interproximally and hold it against the lingual surface. Inject either an opaque microfill or a hybrid resin (dentin replacement).
- Place a translucent microfill or hybrid from the facial direction over the previously placed uncured resin and slightly overfill.
- Wrap the strip around the tooth, making sure it is adapting to the gingival margin.

- Squeeze with your thumb and forefinger and cure for 40 seconds labially and lingually. (The lingual material can also be placed separately to fill the lingual half to two thirds of the preparation. It is then light cured for 40 seconds.) The enamel replacement material and opaque can be placed if necessary so that no demarcation is created between the restoration and tooth structure. Contour with an interproximal carver to the proper anatomic form. A sable hair brush can be used to blend the material with the adjacent tooth structure."

### Class IV Composite Resin Restorations

Class IV restorations involve the labial, incisal, and lingual surfaces. Polymerization shrinkage is not a problem because no area of the restoration is enclosed. Hybrid composite resins are ideal because they have superior physical properties and can be overlaid to achieve esthetically pleasing results.

**CLINICAL TIP.** Porcelain laminate veneers, full-coverage porcelain, or ceramometal crowns should be considered for patients with heavy bruxism or lack of adequate enamel for retention. Hybrid composite resin can be used to build up mandibular anterior surfaces if the occlusion is favorable.

Most hybrids can be polished to an acceptable level. However, hybrids do not maintain their luster, and the surface will need periodic renewal and polishing. The hybrid composite resins are used as dentin replacements because of their opacity, which prevents darkness "show through" from the posterior of the oral cavity.

Occlusal adjustment or cosmetic recontouring, which creates adequate clearance for the composite resin's thickness, may be required before placement of the restoration.

**Single-Step Buildup Technique.** The Class IV single-step technique is similar to the Class III single-step technique. See the preceding section for a complete discussion of the limitations of this technique. This technique includes the use of opaque to limit the gray "show through" from the mouth's posterior and the addition of tints and color modifiers.

#### Armamentarium

Use the same dental setup as for the Class III multiple-step technique with the following exceptions:

Clear crown or incisal matrix (Premier)

#### Clinical Technique

Use the same clinical technique as described in the Class III single-step buildup technique; an incisal matrix or a clear crown form can also be used to aid in the buildup of the incisal corner.

### Multiple-Step Buildup Technique

#### Armamentarium

Use the same dental setup as for Class I restorations with the following exceptions:

Mylar strip

Posterior, small-particle, hybrid composite resin

Optional microfill composite resin (e.g., Silux Plus, 3M, Inc.; Durafill, Kulzer Inc.; Renamel, Cosme-dent, Inc.)

#### Clinical Technique

- Pumice the teeth and clean the proximal surface with a strip where necessary.
- Determine the appropriate shade of the tooth while it is wet with saliva.
- Administer local anesthesia if necessary.
- Place a rubber dam.

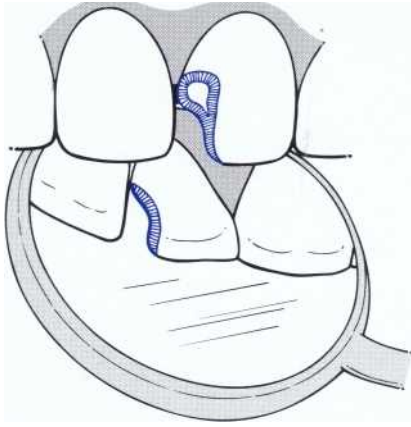
**CLINICAL TIP.** After any pulpal exposure the preparation should be disinfected with Concepsis (Ultradent) and then dried. Alternatively, 2.625% sodium hypochlorite can be applied and then rinsed off with water. (Sodium hypochlorite also helps create hemostasis.) An adequate amount of calcium hydroxide to cover the exposure should be applied, and then a small amount of light-cured resin-modified glass ionomer should be used to cover the calcium hydroxide, creating a bacterial barrier.<sup>60,61</sup> The preparation is then etched and primed and adhesive is applied.

**CLINICAL TIP.** The use of any calcium hydroxide should be kept to a minimum because it dissolves over time, resulting in an unsupported restoration.<sup>12</sup>

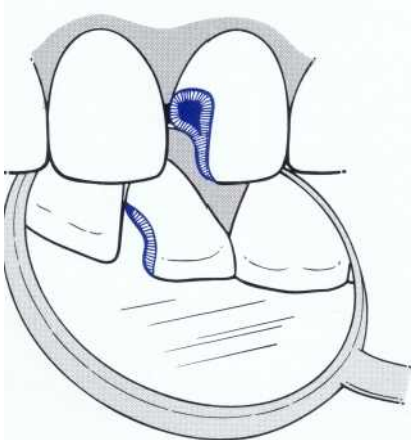
- Place liner or base where appropriate (Fig. 5-20). See section on liners and bases in this chapter.
- Place a 2- to 3-mm long chamfer about 0.3 mm deep around the entire margin. Place a scalloped bevel on the esthetic areas of the chamfer to help disguise the margins. Bevel the gingival margin only if beveling does not entirely remove the enamel. Avoid placing the lingual chamfer under an occlusal load (Fig. 5-21).

**CLINICAL TIP.** Cavity disinfectants may adversely affect bond strength. Verify compatibility with the disinfectant and bonding agent manufacturers.

- Etch the enamel and dentin for 15 seconds. See section on acid etching in this chapter.
- Wash with water and/or water/air spray for a minimum of 10 seconds for gel or liquid etchants. See section on acid etching in this chapter.

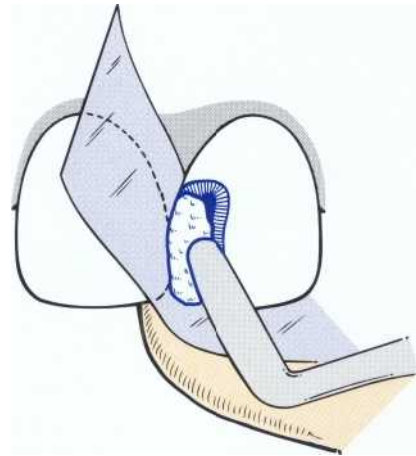


*Fig. 5-20. Calcium hydroxide should be placed only in areas close to the pulp and is followed by the placement of a radiopaque resin-modified glass ionomer base in the area immediately surrounding the exposure. This step seals the area, and a "total etch" process is used to seal the remaining tooth structure. Etch the preparation slightly beyond the chamfer. Wash, dry, and paint bonding agent beyond the area of the etch.*



*Fig. 5-21. A chamfer bevel has been placed completely around the periphery of the restoration. Should the fracture extend to the root surface, a bevel is not placed at the gingiva, but a gingival retention groove is placed to aid retention and to minimize microleakage.*

9. Air dry the enamel and blot the dentin leaving it slightly moist. The cavity preparation can be disinfected with a cavity disinfectant and the excess blown off and blotted with a cotton pellet. However, in some systems the smear layer is not removed but only modified, and bond strengths may decrease during disinfection.<sup>73,74</sup>
10. Repeat the procedure if the enamel does not have a frosted white appearance after air drying. If the



*Fig. 5-22. Pack a small increment of hybrid resin against the lingual mylar matrix (wedging is optional), and support with the finger. This increment can be placed with the plastic instrument or a syringe.*

dentin is dry, moisten the dentin again with a cotton pellet moistened with water.

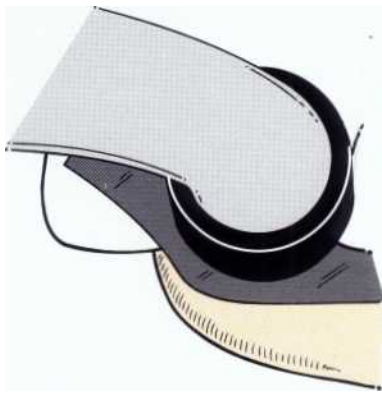
11. Place the appropriate dentin-enamel bonding agent.
12. To eliminate lingual finishing, closely adapt the mylar strip to the tooth with a gloved finger.
13. Place the posterior, small-particle, hybrid composite resin against the mylar strip. If a translucent incisal area is desired, this layer can be built up with a translucent hybrid material. Place a dentin shade and add internal stain and opaque if necessary to duplicate the internal coloring of the adjacent tooth. Place an amount that leaves sufficient room for a continuous overlay of microfilled composite resin (Fig. 5-22).

**CLINICAL TIP.** Use bonding agent rather than alcohol to prevent the composite resin from sticking to the plastic instrument. See the Clinical Tip on bonding resin and alcohol in the section on Class I composite resin restorations.

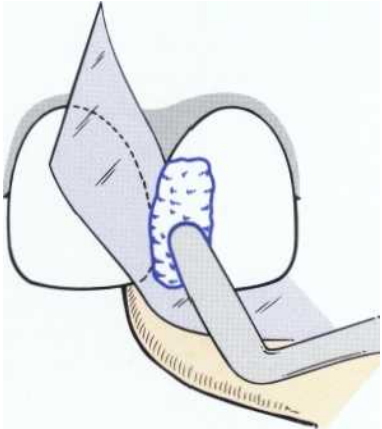
14. Cure the composite resin from the labial surface and then the lingual surface to form a lingual wall (Fig. 5-23).

**CLINICAL TIP.** Place the composite resin with a Centrix-type syringe (see Fig. 5-14). See the Clinical Tip on Centrix syringes in the section on Class I composite resin restorations.

15. Place the microfilled composite resin over the previously placed hybrid composite resin (Fig. 5-24). The microfilled composite resin may consist of a body shade and a final, clear translucent incisal shade.

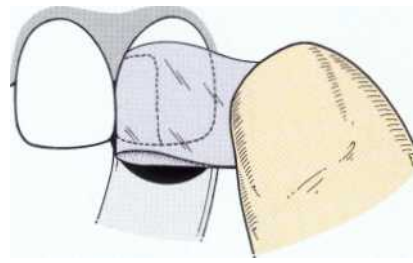


*Fig. 5-23. The increment is cured from the labial aspect first, followed by the lingual. Pressure from the finger against the mylar matrix can assure good adaptation and can minimize lingual finishing.*

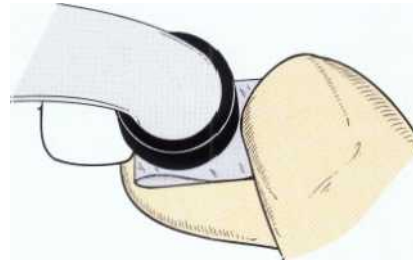


*Fig. 5-24. A second increment can be packed against the hardened lingual wall. The increment can be made of either a hybrid or microfilled resin. If necessary a layer of tint or opaque can be sandwiched between these two layers.*

16. Shape the composite as much as possible with a sable hair brush.
17. Cure the microfilled composite resin from the lingual direction (Fig. 5-25) and then from the labial and incisal directions (Fig. 5-26).
18. Create the final texture and contour and then finish (Figs. 5-27 and 5-28). See section on finishing in this chapter.
19. Polish the restoration. See section on polishing in this chapter.
20. Sealant and postcuring procedures are the following:
  - A. Rinse off polishing debris with water; air dry.
  - B. Etch for 15 seconds.
  - C. Rinse with water for a minimum of 10 seconds.



*The second increment should be cured from the lingual aspect. Wrapping the matrix band around the labial surface is optional but usually minimizes the amount of finishing and provides a realistic curve of composite resin around the interproximolabial areas.*



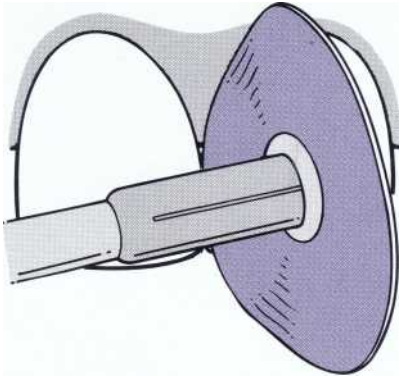
*The labial and incisal aspects should then be cured again. The mylar strip is removed and the occlusion adjusted. Because the surface next to the light is the hardest, it is sometimes removed during bite adjustment and a final, additional cure is advisable.*

- D. Air dry the surface. (If the surface is not enamel, leave it moist.)
- E. Apply sealant (e.g., Fortify, Bisco Corp.; Optiguard, Kerr Corp.).
- E Air thin.
- G. Light cure the labial and lingual surfaces for 60 seconds each.


**CLINICAL TIP.** The composite resin that is closest to the light is often the most polymerized and therefore the hardest part of the restoration. Because this layer is removed with occlusal adjustment and polishing, placement of the sealant and postcuring are necessary. <sup>70,71</sup> Postcuring and placement of the sealant reduce wear on the restoration. <sup>70,71</sup>

### *Class V Composite Restorations*

**Single-Step Buildup Technique.** The Class V single-step technique is similar to the Class III single-step technique. This technique is recommended for preparations in which the margins are entirely in enamel. A finite element stress analysis of three filling techniques by



*Labial flash is removed with a Bard-Parker blade or composite resin knife in an enamel-to-composite resin direction. Creation of developmental grooves or texturing is best accomplished with micron diamonds or knife-edge disks. Finishing is accomplished with burs, diamonds, disks, and rubber cusps. Final polishing can be accomplished with a composite resin polishing paste.*



*The final restoration.*

Winkler et al<sup>16</sup> concluded that bulk filling is indicated in restorations that are sufficiently shallow to be cured to their full depth. The highest stress levels developed during the curing process, and bulk filling resulted in the lowest maximum normal transient stress compared to three horizontal increments and three wedge-shape increments.

#### Armamentarium

Use the same dental setup as for the Class V multiple-step buildup technique with the following exceptions:

Class V cervical matrix (i.e., Cure-Thru, Premier Dental Products, Co.)

#### Clinical Technique

Use the same clinical technique as that described for the Class V multiple-step buildup technique, except place all the composite in a single increment. Apply pressure with a cervical matrix and cure the composite resin, or shape and sculpt the composite resin with an interproximal carver before curing.

### Multiple-Step Buildup Technique

#### Armamentarium

Use the same dental setup as for Class I restorations. However a microfilled resin may be preferable because its high modulus of elasticity permits flexing of the restoration, and its high polishability permits excellent soft tissue response." A flowable microfill that allows appropriate contour may be ideal for this procedure (e.g., Renamel Flowable Microfill, Cosmedent, Inc.). The tooth can be isolated with a rubber dam and a #212 rubber dam clamp or retraction cord and cotton rolls.

#### Clinical Technique

1. Pumice the teeth and clean the involved proximal surface with a sand paper strip.
2. Determine the shade of the tooth while it is wet.
3. Administer local anesthesia if necessary.
4. Place a rubber dam or retraction cord and cotton rolls if adequate isolation can be achieved.

**CLINICAL TIP.** After any pulpal exposure the preparation should be disinfected with Concepsis (Ultradent) and then dried. Alternatively, 2.625% sodium hypochlorite can be applied and then rinsed off with water. (Sodium hypochlorite also helps create hemostasis.) An adequate amount of calcium hydroxide to cover the exposure should be applied, and then a small amount of light-cured resin-modified glass ionomer should be used to cover the calcium hydroxide, creating a bacterial barrier.<sup>60,61</sup> The preparation is then etched and primed and adhesive is applied.

**CLINICAL TIP.** The use of any calcium hydroxide should be kept to a minimum because it dissolves over time, resulting in an unsupported restoration."

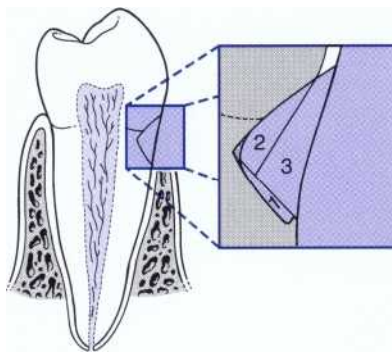
**CLINICAL TIP.** If postoperative sensitivity is anticipated because of the preparation depth, a glass ionomer, light-cured resin-modified glass ionomer, or resin ionomer can be used as a dentin replacement. The material should be built up to resemble the form of an "ideal" cavity preparation.

5. Place appropriate liner and base if indicated. See section on liners and bases in this chapter.
6. Place bevels with a medium grit diamond bur around the periphery if the restoration has borders made entirely of enamel. In esthetic areas, 1- to 2-mm bevel should be placed, however, the gingival margin should not be beveled if the enamel margin is thin. Beveling permits a gradual transition from the composite resin to the enamel.



7. Place a retention groove at the gingival margin if the Class V restoration ends on the root surface, and use a low-modulus material to ensure retention in the event that the dentin bonding fails. Beveling the gingival margin on cementum is usually undesirable.

**CLINICAL TIP.** Placing resin ionomers, such as Vitremer (3M), in the gingival portion of Class II, Class III, and Class V composite restorations (the "open-sandwich technique") may be a practical method of reducing microleakage, especially apical to the cementum-enamel junction.



*Fig. 5-29. If the preparation extends onto the root surface, a gingival groove is placed to aid in retention should the dentin bond fail. The clinical situation dictates the necessity of the groove. Heavy occlusal forces and lack of enamel at the gingival margin make groove placement advisable. Neither the first nor the second layer touches the bonded enamel, therefore polymerization shrinkage does not place the enamel bond in competition with the dentin bond. Furthermore, use of increments ensures better light penetration and less shrinkage. The final increment, which should also be the thinnest, covers the entire preparation to eliminate a layering effect. The final increment is the enamel replacement. A thinner layer shrinks less, thus helping to maintain marginal integrity.*

8. Etch the enamel and dentin for 15 seconds. See section on acid etching in this chapter.
9. Wash with water and/or water/air spray for a minimum of 10 seconds for gel or liquid etchants. See section on acid etching in this chapter.
10. Air dry the enamel and blot the dentin, leaving it slightly moist. The cavity preparation can be disinfected with a cavity disinfectant and the excess blown off and blotted with a cotton pellet. However, in some systems the smear layer is not removed but only modified, and bond strengths may decrease during disinfection.<sup>73,74</sup>
11. Repeat the procedure if the enamel does not have a frosted white appearance after air drying. If the dentin is dry, moisten the dentin again with a cotton pellet moistened with water.
12. Place the appropriate dentin-enamel bonding agent.
13. If the restoration is large, place the composite resin in increments that will minimize stress in the restoration and gap formation from polymerization shrinkage. Place an initial pie-shape increment entirely on the root surface (Fig. 5-29). The bonding agent and composite resin must fill the cervical retention groove if one is deemed necessary.

**CLINICAL TIP.** Use bonding agent rather than alcohol to prevent the composite resin from sticking to the plastic instrument. See the Clinical Tip on bonding resin and alcohol in the section on Class I composite resin restorations.

**CLINICAL TIP.** Place the composite resin with a Centrix-type syringe (see Fig. 5-14). See the Clinical Tip on Centrix syringes in the section on Class I composite resin restorations.

14. Place a second increment on the occlusal enamel bevel; extend it to the axial wall and polymerize.

15. Add a third layer to build the tooth form. This layer can be translucent so that it is similar to the enamel layer.
16. Continue adding and polymerizing composite resin as necessary until the restoration is slightly overfilled.
17. Place a previously fabricated matrix to decrease the amount of excess material. Use an interproximal carver to remove excess composite resin.
18. Contour and finish the restoration. See section on finishing in this chapter.
19. Polish the restoration. See section on polishing in this chapter.
20. Sealant and postcuring procedures are the following:
  - A. Rinse off polishing debris with water; air dry.
  - B. Etch for 15 seconds
  - C. Rinse with water for a minimum of 10 seconds.
  - D. Air dry the surface.
  - E. Apply sealant (e.g., Fortify, Bisco Corp; Opti-guard, Kerr Corp.).
  - E. Air thin.
  - G. Light cure for 40 seconds.

**CLINICAL TIP.** The composite resin that is closest to the light is often the most polymerized and therefore the hardest part of the restoration. Because this layer is removed with occlusal adjustment and polishing, placement of the sealant and postcuring are necessary.<sup>70,71</sup> Postcuring and placement of the sealant reduce wear on the restoration.<sup>70,71</sup>

## CLINICAL CASES

### *Postorthodontic Therapy*

An 18-year-old female patient presented with an open bite limited to the left anterior segment after her orthodontic treatment (Fig. 5-30). Her medical history was noncontributory. The teeth could not undergo further orthodontic treatment because some apical resorption had already occurred. A maxillary growth problem had not been addressed, and surgical intervention may have been needed to achieve a more esthetic appearance.

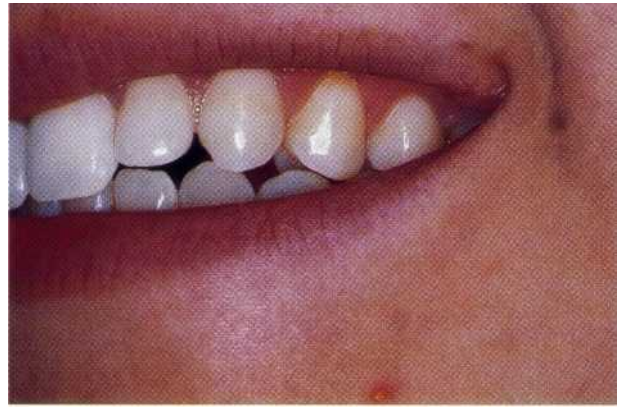Placing a hybrid composite resin on the lingual surface lengthened the maxillary left lateral incisor. Opaque and white tints were used to mimic the adjacent teeth. A medium translucent microfill was overlaid on the labial surface to build out the tooth to an appropriate contour. Surface irregularities were added with a fine micron diamond after the initial finishing and polishing. An aluminum oxide polishing paste and buffing wheel with water were used to obtain luster while maintaining the original contour and texture. The final result (Fig. 5-31) permitted the patient to smile with bilateral symmetry.

### *Matrix Use for Establishing Occlusal Anatomy*

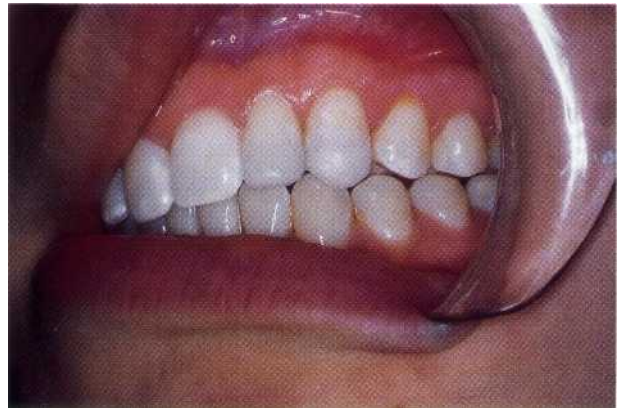A 16-year-old female patient presented with decay in tooth #18. Before excavation of the tooth, the occlusal anatomy was intact, allowing clear bite registration material to be used as an index to establish appropriate anatomic form and occlusion. The bite registration material was syringed onto the tooth requiring restoration and onto adjacent teeth if present. (This acts as a stop.) This procedure can be done while waiting for anesthesia. After completing the excavation (Fig. 5-32), the appropriate dentin bonding materials were placed, and the composite resin was built up as previously described. A translucent enamel layer was placed as the final increment, and the matrix was pressed into position. (The matrix itself can be removed, as can excess material at the interface between the composite resin and tooth structure, before curing.) The composite resin was then light cured through the matrix (Fig. 5-33), and penetrating sealant was placed (Fig. 5-34).

### *Class II Posterior Composite*

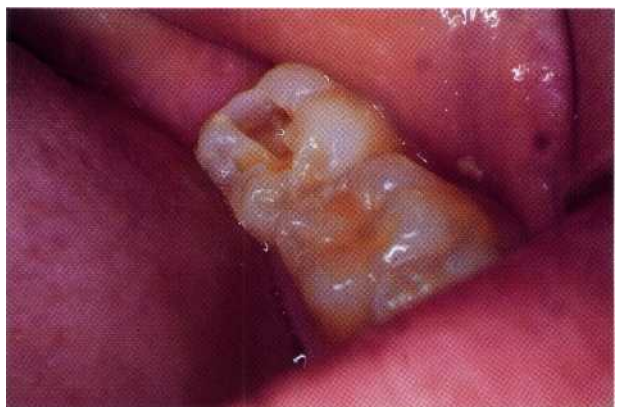
A 16-year-old male patient presented with extensive decay on tooth #30. The large size of the lesion was such that an indirect restoration would have been preferable, but financial constraints and concerns about the long-term vitality of the tooth resulted in placement of a direct composite resin. The extensive distal-occlusal-lingual composite restored the original anatomic structure and helped strengthen the remaining tooth structure (Fig. 5-35).



*Fig. 5-30. Preoperative view of an 18-year-old female with a left lateral anterior open bite after orthodontic treatment.*



*Fig. 5-31. Postoperative view of patient after incisal lengthening and labial veneering with composite resin.*



*Fig. 5-32. Excavation of tooth #18.*

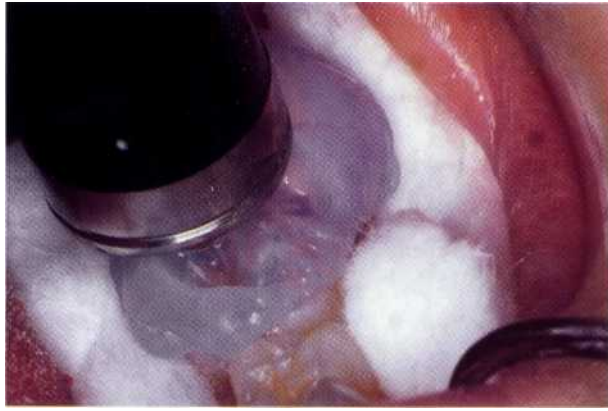


Fig. 5-33. A clear bite registration material is utilized to register the anatomy of the occlusal surface.

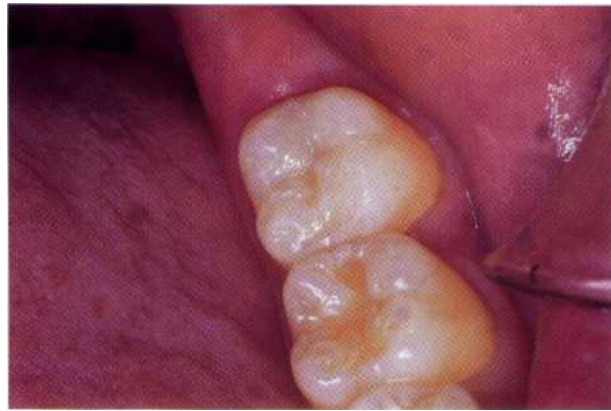

Fig. 5-34. Postoperative view of the final restoration demonstrating reproduction of the original occlusal anatomy.

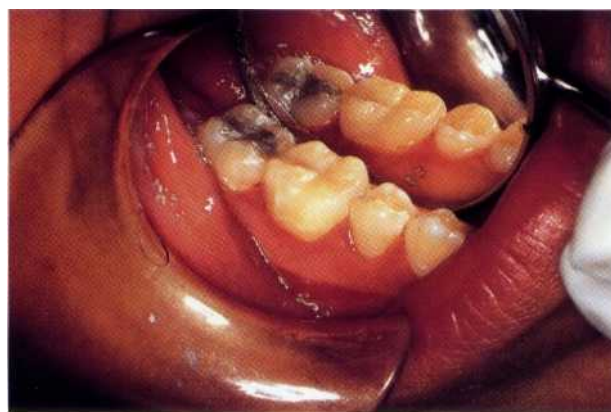


Fig. 5-35. Postoperative view of tooth #30 in a 16-year-old male with an extensive distal-occlusal-lingual composite resin restoring the tooth to function.

### CONCLUSION

The indications for composite resins are constantly increasing. The advances in dentin bonding and numerous improvements in resin and filler composition have fueled this expansion. Composite resins have improved handling, superior esthetics, reduced wear, and satisfactory long-term clinical performance.

One of the drawbacks of composite resins, especially in Class II restorations, is polymerization shrinkage. Nearly 10 years ago, Ehrnford developed a method by which posterior composite resins could be condensed into a cavity preparation in a manner similar to that used for conventional amalgam.<sup>82</sup> However, the clinical performance was less than satisfactory. Recently, Med USA (San Antonio, Texas) developed a material that emulates the handling properties of amalgam. The polymer rigid organic matrix material (PROMM) contains organized domains of interconnecting ceramic fibers that form rigid skeletons. These domain networks are more resistant to condensing and masticatory forces. The final structure consists of a three-dimensional network of ultrathin ceramic fibers and a continuous phase of selected polymer. The light-conducting characteristics of the ceramic fibers allow polymerization to a depth of 6 mm. This system is not yet commercially available, although but several studies have found some reduction in polymerization shrinkage and no reduction in physical properties such as diametrical tensile strength, compressive strength, flexural strength, and flexural modulus.<sup>118,119</sup>

Several new packable composite resins have been introduced. Alert is a highly filled composite resin with a balanced combination of conventional filler (ground barium borosilicate) and "chopped" glass fibers (microfilaments about 6 μm in diameter and 60 to 80 μm long) with approximately a 5-mm depth of cure. The resin matrix is a polycarbonate dimethacrylate (PCDM).<sup>120</sup> The Alert kit contains dose strips of single, double, and triple spills, a composite resin carrier, and plugger/carver. A flowable composite resin (Flow-It) is provided to ensure intimate contact with all line and point angles. A surface-penetrating sealant is also provided (Protect-It) to seal microcracks formed as result of the composite resin finishing process.

SureFil uses a multimodal particle-size distribution with blends of selected distribution of particles that are fine, medium, and coarse. When a particulate ceramic phase is incorporated into a high-volume fraction in the composite, a minimal quantity of resin fills the interstices between the compacted particles, thus providing a continuous matrix phase. The optimal contact between filler particles allows any stress transfer within the composite to be mediated by the ceramic particles and particle contacts as well as the resin matrix phase.<sup>121</sup> This is a result of the interlocking of these particles.

Solitaire has porous particles that allow penetration by the resin material. Because the rough surface of the particles do not flow readily over adjacent particles when subjected to a load, higher pressure is needed for condensation.<sup>123</sup> In addition, Leinfelder indicated that Solitaire undergoes a slower rate of polymerization during the first few seconds of curing regardless of the light intensity (soft-start polymerization). The rates of curing and shrinkage are substantially less because flow or relaxation in the direction of the cavity walls has occurred resulting in more uniform stress in the material, less stress on the margins, and a reduction in gap formation. Kerr has released a packable material that is related to Prodigy (Prodigy condensable) but is more highly filled because of modifications in the surface chemistry using a dispersant and theological control additive.

Further evaluation needs to be done to determine the optimum consistency of composite resin materials that pack like amalgam because a thick composite resin may have problems with voids and wall adaptation.<sup>123</sup>

In addition to the new packable composite resins, leucite-reinforced prefabricated ceramic inserts have been introduced to reduce the deficiencies of Class II composite resins (SoniSys, Ivoclar/Vivadent, Inc.).<sup>124</sup> The inserts are available in three sizes corresponding to a set of safe-side, diamond-coated cutting tips. The inserts provide more ideal margins because the diamonds create the bevels (by refining the proximal and gingival margins) by cutting the ends of the enamel rods (for effective bonding). Predictable contacts are also achieved. Further research is needed to evaluate the efficacy of this technique in reducing problems associated with Class II posterior composite resin placement.

Light-activated resins rely on adequate light intensity to polymerize sufficiently.<sup>125</sup> Light passing through composite resins is absorbed and scattered, resulting in attenuation of the intensity and reduction of the light polymerization effectiveness. Sufficient light is critical now with bulk placement of composite resins.<sup>126</sup> Composites can be placed in bulk if adequate curing can be achieved, a factor that varies depending on the individual composite and cavity configuration. Factors affecting depth of cure include filler type, size, and loading; light transmission attenuation; type, thickness, and shade of the restorative resin; exposure time and distance from the light source; and light intensity.<sup>126</sup> A study by Vargas et al<sup>127</sup> indicated that hybrid resins polymerize more completely and to a greater depth than microfills with any light source. However, resin polymerization by an argon laser allowed reduced exposure time. Conventional lights emit broader wavelengths (between 400 and 520 nm). However, this study did not indicate that the greater portion of energy in effective wavelengths for absorption by camphorquinones makes argon lasers a more efficient light source for photoinitiation (in regards to complete-

ness of cure). However, dentin-enamel bond values were higher, and compressive strengths and diametrical tensile strengths were also high.<sup>129</sup> In addition, many of the **current restorative** techniques are based on the theory that composites shrink toward the light. However, Versluis et al concluded that composites do not shrink toward light, and the direction of shrinkage is predominately determined by cavity shape and bond quality.<sup>130</sup> In addition, "effective shrinkage" of restrained composites is different from that of "free composites." None of the currently available direct restorative materials can fill the requirements of a perfect restorative material. However, composite resin can provide high-quality restorations in the anterior area and are usually amalgam alternatives for small posterior restorations (depending on the occlusion and enamel availability). Enamel remaining at the gingival margin and rubber dam isolation are preferred. Arch position is also important because molars wear more than premolars as a result of increased forces. An initial restoration can be made with direct composite to reduce the amount of tooth structure removed. Replacement of an amalgam may require an inlay or onlay depending on the buccal-lingual dimensions of the restoration. Nanocomposite resins or modified resins such as silicon compounds, orthospirocarbonates, ormocers, and epoxides may comprise the material of the future.<sup>131</sup>

## REFERENCES

1. Buonocore MG: A simple method of increasing the adhesion of acrylic filling materials to enamel surfaces, *J Dent Res* 34:849, 1955.
2. Roulet J-F: Adhesive techniques: the standard for the restoration of anterior teeth. In Degrange M, Roulet J-F, editors: *Minimally invasive restorations with bonding*, Carol Stream, 111, 1997, Quintessence.
3. Buonocore M et al: A report on a composite resin capable of bonding to human dentin surfaces, *J Dent Res* 35:846, 1956.
4. Bowen RL et al: Adhesive bonding of various materials to hard tooth tissues. Improvement in bond strength to dentin, *J Dent Res* 61:1070, 1982.
5. Albers HF: *Tooth-colored restoratives*, ed 8, Santa Rosa, Calif, 1996, Alto Books.
6. Dietschi D, Dietschi J-M: *Current developments in composite materials and techniques*, *Pract Perio Aethet Dent* 8:603, 1996.
7. Touati B, Pissis P: UInlay colle en resine composite, *Cahiers de Prothese* 48:29, 1984.
8. Touati B: Une nouvelle application du collage en prothese conjointe: inlays, onlays et couronnes jacket en resine composite, *Revue d'Odonto-Stomatologie* 3:171, 1984.
9. Crispin B: *Contemporary esthetic dentistry practice fundamentals*, Tokyo, 1994, Quintessence.

10. Leinfelder KF: Posterior composites state-of-the art applications, *Dent Clin North Am* 137:411, 1993.
11. Davidson CL, DeGee AJ: Relaxation of polymerization contraction stresses by flow in dental composites, *J Dent Res* 63:146, 1984.
12. Davidson CL, Kemp-Scholte CM: Shortcomings of composite resins in Class V restorations, *J Esthet Dent* 1:1, 1989.
13. Crim GA: Effect of composite resin on the microleakage of Scotchbond 2 and Gluma, *Am J Dent* 5:215, 1988.
14. Kemp-Scholte CM, Davidson CL: Marginal sealing of contraction gaps in Class V composite resin restorations, *J Dent Res* 67:841, 1988.
15. Major IA, Fejerskov O, editors: *Human oral embryology and histology*, Copenhagen, 1986, Menkaart.
16. Stanford JW: Bonding of restorative materials to dentine, *Int Dent J* 35:133, 1985.
17. Jendresen MD, Glantz PO: Clinical adhesiveness of selected dental materials, *Acta Odontologica Scandinavica* 39:39, 1981.
18. Buonocore MG: Retrospection on bonding, *Dent Clin North Am* 25:243, 1981.
19. Rowland GF et al: The influence of topical stannous fluoride application on the tensile strength of pit and fissure sealants, *J Pedodont* 4:9, 1979.
20. Barkmeier WW et al: Effects of 15 versus 60 seconds enamel acid conditioning on adhesion and morphology, *Op Dent* 11:111, 1986.
21. Garcia-Godoy F, Gwinnett AJ: Penetration of acid solution and gel in occlusal fissures, *J Am Dent Assoc* 114:809, 1987.
22. Baharav H et al: The efficiency of liquid and gel acid etchants, *J Prosthet Dent* 60:545, 1988.
23. Baharav H et al: The continuing brushing acid etch technique, *J Prosthet Dent* 57:147, 1987.
24. Mixson JM et al: The effects of variable wash times and techniques on enamel composite resin bond strength, *Quint Int* 19:279, 1988.
25. Bates D et al: Effects of acid etch parameters on enamel topography and composite resin-enamel bond strength, *Pediatr Dent* 4:106, 1982.
26. Mixson JM et al: The effects of rinse volumes and air water pressure on enamel-composite resin bond strengths, *J Prosthet Dent* 62:522, 1989.
27. Summitt JB et al: Effect of rinse time on microleakage between composite and etched enamel, *J Op Dent* 18:37, 1992.
28. Holtan JR et al: Influence of different etchants and etching times on shear bond strength, *Oper Dent* 20:94, 1995.
29. Schulein TM et al: Rinsing times for a gel etchant related to enamel/composite bond strength, *Gen Dent*, July-August, 1996.
30. Titley KC et al: Adhesion of composite resin to bleached and unbleached bovine material, *J Dent Res* 67:1523, 1988.
31. Smidt A et al: Effects of bleaching agents on microhardness and surface morphology of tooth enamel, *Am J Dent* 11:83, 1998.
32. Rotstein J et al: Effect of bleaching agents on organic components of human dentin and cementum, *J Endo* 18:290, 1992.
33. Swift EJ, Perdigo J: Effects of bleaching on teeth and restorations, *Compend Contin Educ Dent* 19:815, 1998.
34. Silverstone LM, Dogon IL, editors: *Proceedings of International Symposium on the Acid Etch Technique*, St Paul, Minn, 1991, North Central Publishing.
35. Nakabayashi N: Resin reinforced dentin due to infiltration of monomer into the dentin at the adhesive interface *J Japan Dent Mat Device* 1:78, 1982.
36. Gwinnett AJ, Matsui A: A study of enamel adhesives. The physical relationship between enamel and adhesive, *Arch Oral Biol* 12:1615, 1967.
37. Swift E, Triolo PT Bond strength of Scotchbond Multipurpose to moist dentin and enamel. *Am J Dent* 5:318, 1992.
38. Gwinnett AJ: Moist versus dry dentin. Its effect on shear bond strength, *Am J Dent* 5:127, 1992.
39. Jensen ME, Chan DCN: Polymerization shrinkage and microleakage. In Vanherle G, Smith DC, editors: *International Symposium on Posterior Composite Resin Dental Restorative Materials*, Netherlands, 1985, Peter Szulc.
40. Crim GA, Mattingly SL: Microleakage and the Class V composite cavosurface, *J Dent Child* 47:333, 1980.
41. Shigehiga I: Posterior restorations: ceramics or composites. In Nakajima H, Tani Y, editors: *Transaction Third International Congress on Dental Materials*, 1997.
42. Yoshikawa T et al: Study on marginal integrity of the composite restoration, *Japan J Conserv Dent* 32:639, 1989.
43. Davidson CL, deGee AJ: Relaxation of polymerization contraction stresses by flow in dental composites, *J Dent Res* 63:146, 1984.
44. Trushkowsky RD, Gwinnett AJ: Microleakage of Class V composite resin sandwich, and resin-modified glass ionomers, *Am J Dent* 9:96, 1996.
45. Kemp-Scholte CM, Davidson CL: Marginal integrity related to bond strength and strain capacity of composite resin restorative systems, *J Prosthet Dent* 64:658, 1990.
46. Verhis A et al: Does an incremental filling technique reduce polymerization shrinkage stress? *J Dent Res* 75:871, 1996.
47. Browning WD, Halter TK: Microleakage in self-cured and light-cured posterior composite resins, *J Dent Res*, p 1367, 1998.
48. Fan PL et al: Alternative interpretations of water sorption values of composite resins, *J Dent Res* 64:78, 1985.
49. Soderholm KJ et al: Hydrolytic degradation of dental composite, *J Dent Res* 63:1248, 1984.
50. Bouschlicher MR et al: Effect of composite type, light intensity, configuration factor and laser polymerization on polymerization contraction forces, *Am J Dent* 10:88, 1997.

51. Gorracci G et al: Curing light intensity and marginal leakage on composite resin restorations, *Quint Int* 27:355, 1996.
52. Curtis, Jr JW: Curing efficiency of the turbo tip, *Gen Dent* 43:428, 1995.
53. Newcomb J et al: Self start polymerization using VLC or argon lasers, *J Dent Res* 77:1396, 1998.
54. Degues M et al: Marginal adaptation in Class V composite restorations with four curing units, *J Dent Res* 77:1395, 1998.
55. Feilizer AJ et al: Setting stress in composite resin in relation to configuration of the restoration, *J Dent Res* 66:1636, 1987.
56. Strydom C et al: Laboratory evaluation of the Gluma 3-step bonding system, *Am J Dent* 8:893, 1995.
57. Tao L et al: Pulpal pressure and bond strengths of Superbond and Gluma, *Am J Dent* 4:73, 1991.
58. Cox CF et al: Tunnel defects in dentin bridges: their formation following direct pulp capping, *Op Dent* 21:4, 1996.
59. Cox CF et al: Re-evaluating pulp protection: calcium hydroxide vs. cohesive hybridization, *J Am Dent Assoc* 125:823, 1994.
60. Hilton TJ: Cavity sealers, liners and bases: current philosophies and indications for use, *Op Dent* 21:134, 1996.
61. Pameijer CH, Stanley HR: The disastrous effects of the "total etch" technique in vital pulp capping in primates, *Am J Dent* 11:545, 1998.
62. Leinfelder KF et al: Use of  $\text{Ca}(\text{OH})_2$  for measuring microleakage, *Dent Mat* 2:121, 1986.
63. Miller MB et al: Effectiveness of restorative materials on microleakage of Class II composites, *J Esthet Dent* 8:107, 1996.
64. Aboushala A, Kugel G, Hurley E: Class II composite resin restoration using glass ionomer liners: microleakage studies, *J Clin Pediatr Dent* 21:67, 1996.
65. Speiser A et al: The etched butt-joint margin, *J Dent Child* 44:42, 1977.
66. Strassler HE et al: Current concepts in polishing composite resins, *Pract Perio Aesthet Dent* 5:12, 1993.
67. Boghosian AA et al: Rotary finishing of microfilled and small particle hybrid composite resin, *J Am Dent Assoc* 115:299, 1987.
68. Stoddard JW et al: An evaluation of polishing agents for composite resins, *J Prosthet Dent* 65:491, 1991.
69. Ratanapridakul K et al: Effect of finishing on in vivo wear rate of posterior composite resin, *J Am Dent Assoc* 118:333, 1989.
70. Kawai K, Leinfelder KF: Effect of surface penetrating sealant on composite wear, *Dent Mat* 9:108, 1993.
71. Dickinson GL, Leinfelder KF: Assessing the long term effects of surface-penetrating sealant, *J Am Dent Assoc* 120:68, 1993.
72. Trushkowsky RD: Use of a clear matrix to minimize finishing of posterior composite resin, *Am J Dent* 10:111, 1997.
73. Gwinnett AJ: Effect of cavity disinfection on bond strength to dentin, *J Esthet Dent* 4:11, 1992.
74. Meiers JC, Shook LW: Effects of disinfectants on the bond strength of composite to dentin, *Am J Dent* 9:11, 1996.
75. Fahl NF: Tetric Ceram Direct posterior composite restorations—a great idea, *AACD J*, Fall, p 8, 1997.
76. Dietchi D: Anatomical application of a new direct Ceromer, *Signature* 4:8, 1997.
77. Gwinnett AJ: Bonding basics: what every clinician should know, *Esthet Dent Up* 5:35, 1994.
78. Leinfelder K: Dentin adhesives: the newest generation, *Esthet Dent Up* 5:50, 1994.
79. Cox CI, Suzuki S: Biological update of  $\text{Ca}(\text{OH})_2$  bases, liners and new adhesive systems, *Esthet Dent Up* 5:29, 1994.
80. Suzuki S, Leinfelder K: An in vitro evaluation of a copolymerizable type of microfilled composite resin, *Quint Int* 25:59, 1994.
81. Fick JD et al: Adhesives and non-shrinking dental resins of the future, *Quint Int* 24:632, 1993.
82. Leinfelder KF et al: A new polymeric rigid material, *J Cal Dent Assoc* 24:78, 1996.
83. Leinfelder K: After amalgam what? Other materials fall short. *J Am Dent Assoc* 125:586, 1994.
84. Jordan RE, Suzuki M: Posterior composite restorations: where and how they work best, *J Am Dent Assoc* 122:31, 1991.
85. Eames WB et al: Clinical comparison of composite amalgam and silicate restorations, *J Am Dent Assoc* 89:111, 1974.
86. Leinfelder K: Posterior composite resins: the materials and their clinical performance, *J Am Dent Assoc* 126:63, 1995.
87. Erick J, Welch F: Dentin adhesives: do they protect the dentin from acid etching? *Quint Int* 17:533, 1986.
88. Suzuki S, Cox CF: Cohesive bonding between dental clinicians and researchers. In Shimono M et al, editors: *Proceedings of International Conference on Dentin Pulp Complex and International Meeting on Clinical Topics on Dentin*, 1995, Quintessence.
89. Vanharle G et al: Overview of the clinical requirements for post composite resin restorative materials, Netherlands, 1985, Peter Szulc.
90. Jensen ME, Chan DCN: Polymer shrinkage and microleakage. In Vanharle G: *Overview of the clinical requirements for post composite resin restorative materials*, Netherlands, 1985, Peter Szulc.
91. Gross JD et al: Microleakage of post composite restorations, *Dent Mat* 1:7, 1985.
92. Lue JL et al: Margin quality and microleakage of Class II composite resin restorations, *J Am Dent Assoc* 14:49, 1987.
93. Lutz F et al: Improved proximal margin adaptation of Class II composite resin restorations by the use of light reflecting wedges, *Quint Int* 17:659, 1986.

94. Koenigsberg S et al: The effect of three filling techniques on marginal leakage around class II composite resin restorations in vitro, *Quint Int* 20:117, 1989.
95. Barkmeier WW Cooley RL: Curing ability of plastic wedges, *J Esthet Dent* 1:51, 1989.
96. de Goes MF et al: Optical transmittance of reflecting wedges, *Am J Dent* 5:78, 1992.
97. Ben-Amar A et al: The effect of retention grooves on gingival marginal microleakage in Class II posterior composite restorations, *J Oral Rehab* 15:325, 1988.
98. Leinfelder KFI: A conservative approach to placing posterior composite resin restorations, *J Am Dent Assoc* 127:743, 1996.
99. Scherer W, Leinfelder KF: Bulk placement of composite resin in Class II preparations, *Esthet Dent Up* 7:28, 1996.
100. Godder B et al: Direct shrinkage composite placement, *Gen Dent* 43:444, 1995.
101. Versluis A: Does an incremental filling technique reduce shrinkage stress? *J Dent Res* 75:871, 1996.
102. Trushkowsky RD: A panoramic overview of Class II posterior composite placement techniques, Part I *Dentistry Today* 14:60, 1995.
103. Trushkowsky RD: A panoramic overview of Class II posterior composite placement techniques, Part II *Dentistry Today* 14:74, 1995.
104. Feinman RA: Class II composite resin restorations using the prepolymerized ball technique, *Pract Periodont Aesthet Dent* 1(suppl):5, 1983.
105. Feinman RA: The plunging ball technique. Class II direct composite resins, *Pract Periodont Aesthet Dent* 4:43, 1982.
106. Bouschilicher MR et al: Surface treatment techniques for resin composite repair, *Am J Dent* 10:279, 1997.
107. Boyer DB: Buildup and repair of light cured composites: bond strength, *Int Assoc Dent Res Abstr*, p 949, 1984.
108. Eackle WS: Effects of thermal cycling on fracture strengths of microleakage in teeth restored with bonded composite resin, *Dent Mat* 2:114, 1986.
109. Donly KJ et al: An in vitro investigation of the effects of glass inserts on the effective composite resin polymerization shrinkage, *J Dent Res* 68:1234, 1989.
110. Eichmiller FC: Clinical use of beta-quartz glass inserts, *Compend Contin Educ Dent* 8:568, 1992.
111. Ericson D, Derand T Reduction of cervical gaps in Class II composite resin restorations, *J Prosthet Dent* 70:219, 1993.
112. Ericson D, Derand T Increase of in vitro curing depth of Class II composite resin restorations, *J Prosthet Dent* 70:219, 1993.
113. Walshaw PR, McComb D: Microleakage in Class 2 composite resins with low-modulus intermediate materials, *J Dent Res* 77(abstr):204, 1998.
114. Russell RR, Mazer RB: Microleakage of Class II restorations using a flowable composite as liner, *J Dent Res* 77(abstr):203, 1998.
115. Miller MB: Class III composite restorations, *Dent Today* 16:58, 1997.
116. Winkler MM et al: Finite element **analysis of three filling techniques for Class V light cured composite restorations**, *J Dent Res* 75:1477, 1996.
117. C Prati et al: Marginal morphology of Class V composite restorations, *Am J Dent* 10:231, 1997.
118. Rowley J et al: The effect PRIMM on physical properties of dental composites, *J Dent Res* 77(abstr):515, 1998.
119. Craigo RA et al: Effect of PRIMM on polymerization shrinkage of composite, *J Dent Res* 77(abstr):516, 1998.
120. Leinfelder K, Prasad A: New composite for restoring posterior teeth, *Dent Today* 17:112, 1998.
121. Watts DC: The structural scope of biomaterials as amalgam alternatives. In Proceedings of conference on clinically appropriate alternatives to amalgam: biophysical factors in restorative decision-making, *Transaction* 9:51, 1996.
122. Nash RW Radz GM: A report on a new condensable composite resin, *Compend Contin Educ Dent* 19:230, 1998.
123. Opdam NJM et al: Cavity wall adaptation and voids in adhesive Class I composite resin restorations, *Dent Mat* 12:230, 1996.
124. Haase SL: An innovative approach to Class II preparation and restoration, *Signature* 5:16, 1998.
125. Ruggeberg FA et al: Factors affecting cure at depths within light activated composite resins, *Am J Dent* 6:91, 1993.
126. Ruggeberg FA, Craig RG: Correlation of parameters used to estimate monomer conversion in a light-cured composite, *J Dent Res* 67:932, 1988.
127. Bayne SC et al: Update on dental composite restorations, *J Am Dent Assoc* 125:687, 1994.
128. Vargas MA et al: Polymerization of composite resins: argon laser vs. conventional light, *Operative Dent* 23:87, 1998.
129. Powell GL et al: The use of an argon laser for polymerization of composite resin, *J Esthet Dent* 1:34, 1989.
130. Versluis A et al: Do dental composites always shrink toward the light? *J Dent Res* 77:1435, 1998.
131. Hickel R et al: New direct restorative materials, *Int Dent* J48:3, 1998.



# COMPOSITE RESIN: INDIRECT TECHNIQUE RESTORATIONS

Ross Nash

**I**N SOME CASES, indirect composite resin restorations offer distinct advantages over direct composite resin restorations. Technology is continually evolving, and the use of laboratory-processed composite resin can be expected to increase significantly.

## BASIC CONCEPTS

When a composite resin is cured, polymerization shrinkage occurs in the resin matrix. With the direct technique, such shrinkage can cause a marginal gap where the bond strength is the weakest, such as at the dentin-composite resin interface. When composite resin is cured in the laboratory by light, heat, or other methods, the shrinkage occurs before the restoration is bonded into place; thus only a thin layer of luting composite resin is subject to shrinkage at the tooth-restoration interface. This results in less marginal gap, which reduces the likelihood of marginal leakage, sensitivity, recurrent decay, and staining. In addition, studies have shown that some laboratory techniques (such as those that use pressure or vacuum plus heat or light catalysts and those that use heat processing after or simultaneously with light) produce a greater degree of polymerization than that achieved with light alone.<sup>1-4</sup> Thus the physical properties of tensile strength and hardness may be improved, providing for longer lasting and stronger restorations.<sup>1</sup>

Indirect techniques allow the dentist to incorporate the skills of the cosmetic dental laboratory technician. The rapid advances in composite resin technology are expected to produce materials that not only rival the beauty and physical properties of porcelain, but that also solve

the problems associated with this time-proven material. For example, porcelain is harder than tooth structure and can cause it to wear during function. Composite resin does not cause accelerated wear of opposing natural tooth structure. Also, after porcelain has been bonded into place, it is difficult to return the surface to the original luster after an adjustment. Composite resin can be adjusted and repolished easily. Laboratory-processed composite resin can be repaired with light-cured composite resin.

Compared with other techniques, indirect techniques may allow better control over interproximal contours and contacts; and, although meticulous attention to detail is important, indirect composite resin procedures may be less technique sensitive than direct ones.

## BASIC CHEMISTRY

All composite resins are composed of filler particles in a resin matrix. The filler particles may range in size from 0.04  $\mu\text{m}$  to over 100  $\mu\text{m}$ . They provide the strength, and the resin matrix binds them together and bonds them to the tooth structure. The filler material may be very small silica particles, as in microfilled resins, or larger quartz or glass particles, as in small particle composite and hybrid resins. The resin matrix may be composed of bisphenol A diglycidylether methacrylate resin (introduced by Ray Bowen in 1962), urethane dimethacrylate, or similar polymers. Many combinations of resin and filler particles have been tried. In general, the higher the filler content (expressed as a percentage of weight), the greater the strength, and the smaller the filler particles, the greater the surface polishability.<sup>6,7</sup>



## COMPOSITE RESIN SYSTEMS

Three types of composite resin material are available for use in indirect techniques: microfilled resins, small particle composite resins and hybrid resins (Table 6-1). All show excellent wear resistance, but small particle composite resins and hybrid resins can be etched to produce micro-mechanical retention. They also can be silanated to enhance the bond strength. One manufacturer of a reinforced microfilled resin inlay-onlay provides a special bonding agent to increase the bond strength of its material. None of the current systems has proved superior to the others, and all produce good results when used properly.

A new category of processed composite resin recently was introduced. Polymer-glass, Polymer-ceramic, and ceromer (ceramic-optimized polymer) are all terms used to describe these materials. In reality, they are all composite resins with improved properties. Several systems also have incorporated fiber reinforcement to allow fabrication of metal-free fixed partial dentures.

*ArWass*

Artglass (Heraeus Kulzer, Inc.) is a polyglass, an indirect restorative material with improved resin and filler technology designed as an alternative to porcelain (Fig. 6-1). It is described as consisting of multifunctional methacrylates, bifunctional monomers, 20% silica fillers, and microglass fillers. The silica filler reportedly reduces slumping and improves sculptability. A high-output strobe light is used to cure the material.

Artglass is available in sixteen Vita Lumin shades. It can be used for metal and nonmetal crowns and fixed partial dentures and for inlays, onlays, and veneers. Repairs can be performed intraorally using Artglass liquid and Charisma tight-cured composite resin.

*BelleGlass HP*

BelleGlass HP (Kerr Lab, Sybron Dental Specialties dual cure indirect polymer-ceramic is a low-wear, high-strength microhybrid for inlays, onlays, anterior veneers,

**Table 6-1.** Indirect composite resins.

Name	Manufacturer	Composite type	Resin type	Curing method	Type of fabrication	Use
Artglass	Heraeus Kulzer, Inc.	Polyglass	Proprietary	Light	Indirect	Crowns, inlays, onlays, laminate veneers, veneers on metal substructures
BelleGlass HP	Kerr Lab, Sybron Dental Specialties	Polymer-ceramic	Bis-GMA	Light, heat, and pressure	Indirect	Crowns, inlays, onlays, laminate veneers, veneers on metal substructures, multiple-unit metal-free fiber-reinforced restorations
Clearfil CR Inlay	Kuraray, Inc.	Hybrid	Bis-GMA	Light and heat	Indirect	Inlays and onlays
Coltene Inlay/Onlay	Coltene, Inc.	Hybrid	Bis-GMA	Light and heat	Indirect/Direct/indirect	Inlays and onlays Laminate veneers
Cristobal	Dentsply Ceramco, Inc.	Bioglass polymer	Bis-GMA, TEDMA, UDDMA	Light	Indirect	Crowns, inlays, onlays, laminate veneers, veneers on metal substructures, multiple-unit metal-free restorations
Sculpture	Jeneric/Pentron, Inc.	Polymer-ceramic	PCDMA	Light, heat, and vacuum	Indirect	Crowns, inlays, onlays, laminate veneers, veneers on metal substructures, multiple-unit metal-free fiber (Fibrekor)—reinforced restorations
Targis	Ivoclar	Ceramic-optimized polymer (Ceromer)	Bis-GMA	Light, vacuum, and pressure	Indirect	Crowns, inlays, onlays, laminate veneers, multiple-unit metal-free fiber (Vectris)—reinforced restoration veneers on metal substructures
TrueVitality	Den-Mat, Inc.	Hybrid	Modified bis-GMA	Heat, light, self	Direct, direct/indirect, indirect	Crowns, inlays, onlays, laminate veneers, multiple-unit metal-free restorations
Visio-Gem	ESPE Premier, Inc.	Microfill	Bis-GMA	Light and vacuum	Indirect	Inlays and onlays, laminate veneers on metal substructures

implants, full coverage crowns, metal-free fixed partial dentures, long-term provisional restorations, or splints. The opalescence of belleGlass HP is reported to achieve optimal shade matching capabilities. The physical properties are reported to include the strength of porcelain combined with an average wear rate of 1.2 to 1.5  $\mu\text{m}$  per year. This material can achieve a cure of 98.5% with the use of a fiber-optic light, a heat level of 140° C, and pressure of 60 pounds per square inch (psi) in a nitrogen environment. This curing percentage exceeds that which can be achieved with a single entity, such as a fiber optically driven light. The high flexural strength of this material is reported to offer far greater fracture resistance than unsupported porcelain. Use of this polymer-ceramic has undergone **more than 5 years of in vitro** clinical documentation. A reinforcing fiber material (Connect) is recommended for use in metal-free fixed partial dentures made with belleGlass HP (Fig. 6-2).




Fig. 6-1. Artglass (Heraeus Kulzer, Inc.).



Fig. 6.2. Connect (Kerr Lab, Sybron Dental Specialties).

### Clearfil CR Inlay

Clearfil CR Inlay (Kuraray Co., Ltd.) is a hybrid composite resin that is filled 86.5% by weight (Fig. 6-3). Available in six shades, this light-cured composite resin has been formulated with extra body to make condensing and carving easier. Its heavier body allows for buildup and minimizes sag. The inlay is processed in the CRC-100 Curing Oven (Kuraray). Four available stains allow for final shade adaptation.

The inlay is bonded into place with CR Inlay Cement, a dual-cured luting composite resin. Light irradiation for 40 seconds per surface sets the cement and stabilizes the inlay, and additional curing beneath the restoration ensures a secure bond. It is recommended that vinyl polysiloxane impression material be used because of its low deformation, and extra-hard plaster stone is recommended for the model. Intraoral repairs can be accomplished with Clearfil Photoposterior light-cured composite resin (Kuraray, Inc. USA).

### Coltene Inlay System

The Coltene Inlay system (Coltene AG) was first designed for direct/indirect application (Fig. 6-4). Separating medium is placed on a tooth prepared with divergent walls and without undercuts. A composite resin inlay is fabricated directly in the tooth removed and placed in a special oven that provides heat at 120° C and light for 7 minutes, followed by cooling for 1 minute. The material recommended to lute the restoration is Brilliant Dentin, a hybrid composite resin with shades that correspond to the Vita-Lumin guide.

This system also has been adapted for indirect use. An impression is made, and a working model is poured. A light-cured composite resin inlay, onlay, or labial veneer is fabricated on the model, heat treated, and bonded to



Fig. 6-3. Clearfil CR Inlay (Kuraray Co., Ltd.).



Fig. 6-4. Coltene Inlay System (Coltene AG).

the prepared tooth. The inlay may be fabricated in the office, avoiding the need for temporization, or the dentist may place a provisional restoration and have the patient return after the restoration has been fabricated in the office or dental laboratory. Intraoral repairs can be accomplished with Brilliant light-cured hybrid composite resin.

### Cristobal

Cristobal (Dentsply Ceramco, Inc.) is a patented bioglass polymer material designed for fixed prosthetic restorations, including single crowns with or without metal support, fixed partial dentures, fixed partial dentures on implants, inlays, onlays, and laminate veneers. The system includes a metal primer, adhesive liquid, Opaquer liquid, intense color liquid (12 shades), Opaquer powder (20 shades), a modeling liquid, an oxygen barrier, a dentin opaque core (19 shades), a dentin core (17 shades), an incisal core (16 shades), a transparent core (four shades), an opalescent core (four shades), and a gingival core (one shade).

Cristobal is composed of barium glass particles, 74.2% by weight, with an average particle size of 0.7  $\mu$ m in a matrix of bis-GMA, TEDMA and UDDMA. It is reported to have very low polymerization shrinkage (0.12% after 24 hours), a low wear rate (less than 5  $\mu$ m per year) and high compressive and flexural strengths. Cristobal's cure rate is reported to be 92.6% by light cure alone. The manufacturer has suggested that this material can be used for three-unit anterior fixed partial dentures without the use of reinforcing media.

### Sculpture

Sculpture (Jeneric/Pentron, Inc.), a polymer-ceramic, is reported to have very low water sorption and high wear resistance. The low water sorption is reported to afford greater stain resistance. Sculpture uses a PCDMA chem-



Fig. 6-5. Fibrekor (Jeneric/Pentron, Inc.).

istry featuring high fracture toughness and low polymerization shrinkage. Sculpture is a shock-absorbing restorative material that is used in conjunction with osseointegrated implants. It is said to truly challenge the esthetics of porcelain while offering user-friendly handling, excellent marginal integrity, and polishability.

The material is polymerized in the Cure-Lite Plus or the hands-free Spectra Lite. The surface of the Sculpture restoration is glazed by means of light curing in a pressure vessel under a nitrogen atmosphere. The final curing in the heat curing unit under vacuum is reported to raise the mechanical properties to their optimum level and also to virtually eliminate residual monomers. These processes are said to give the material color stability and resistance to plaque retention. Sculpture restorations are fluorescent.

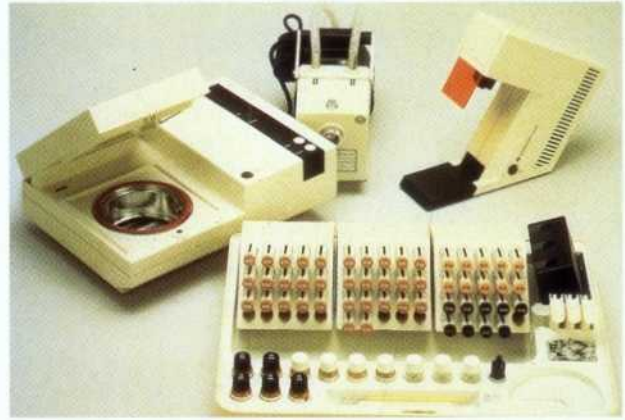
This particular material also is incorporated into the Fibrekor system (Fig. 6-5). Fibrekor is a fiber-reinforced composite that is used as a framework material for metal free substructures. A structure of Sculpture composite is built over these frameworks to fabricate multiunit fixed partial dentures. Fibrekor fibers provide the necessary structural strength and rigidity, and Sculpture composite offers the desired esthetics and wear resistance. Fibrekor incorporates a preimpregnated technology to chemically bond unidirectional glass fibers to a resin matrix. The net result of Fibrekor frameworks is reported to be very high flexural strength and excellent cohesive bonding between Fibrekor and Sculpture. Fibrekor is visible light and heat curable. It is available in five translucent shades and two sizes. Before polymerization, it exhibits very little memory. This allows easy placement of the strips on working dies during fabrication of the framework.

### Targis

Targis (Ivoclar, AG) is a ceromer (ceramic-optimized polymer) system for the fabrication of inlays, onlays, ve-



Targis (Ivoclar, AG).



Visio-Gem (ESPE Dental AG).

neers, and single- and multiple-unit metal-free restorations (Fig. 6-6). It is provided in base, dentin, and incisal shades. Targis is processed using a heat and light oven calibrated for ideal polymerization (Targis Power). The Targis system also offers Targis Link, which is used to form a bond to underlying metal substructures or frameworks that are not easily hydrolyzed and therefore are stable in the oral cavity. Targis Ceromer material can then be added directly to the metal frameworks, a combination that is ideal for longer span multiple-unit restorations or implant restorations.

Vectris, the fiber-reinforced composite (FRC) component of the Targis system, is used as the framework for the metal-free restorations. Vectris is manufactured and woven in three different patterns, each positioning the fibers for the ideal transfer and resistance of force, depending on the intended use. Vectris Pontics, which are unidirectional, 14  $\mu$ m, preimpregnated fibers used over the pontic space in multiple-unit restorations, are reported to provide the greatest flexural strength. Vectris Singles and Frames have a "satin weave" and overlay the abutments and pontic areas to provide resistance to torque and homogeneous distribution of forces. Once the correct positioning of the FRC has been determined and the FRC is in place in a silicone mold, the entire framework is processed under vacuum, light, and pressure in the proprietary VS I processing unit to ensure precise fit to the die and to eliminate excess monomer. After the framework has been processed, Targis ceromer is added to complete the restoration.

### TrueVitality

TrueVitality (Den-Mat, Inc.) is a hybrid composite resin with three curing modes: heat curing, self curing, and light curing. It is reported to be a true universal material that can be used for a wide array of clinical applications, ranging from simple direct restorations to more elaborate

indirect procedures such as inlays, onlays, fixed partial dentures, crowns, and laminate veneers. The manufacturer indicates that it also allows dentists to perform indirect inlays and onlays in the office without requiring special equipment.

TrueVitality is reported to have a wear rate less than half that of amalgam; high compressive, tensile, and flexural strengths; a 3 mm depth of cure; and low water sorption. It is radiopaque and comes in a wide variety of Vita-Lumin shades.

### Visio-Gem

Visio-Gem (ESPE Dental AG) is a light and vacuum-cured microfilled composite resin designed for laboratory fabrication over metal substructures for crowns and fixed partial dentures (Fig. 6-7). It also is recommended for indirect composite resin laminate veneers, inlays, onlays, and jacket crowns. It has been used to fabricate custom denture teeth and long-term provisional restorations. A large number of shades are available that correspond to the Vita-Lumin and Bioform shade guides.

Initial curing during buildup procedures is done with a direct visible light source, called the Visio Alpha unit. Final polymerization takes place in a light and vacuum chamber, called the Visio Beta unit. The vacuum allows complete curing of the oxygen-inhibited layer and results in greater color stability and enhanced physical properties.

## ANTERIOR VENEERS

Indirect composite resin veneers are the treatment of choice in many situations:

- Abrasion considerations. Many composite resins wear much like natural tooth structure and do not cause iatrogenic wear of the opposing dentition.

- Darkly stained teeth. Indirect composite resin can cover dark color without opaquing agents while retaining a vital appearance.
- Conservation of tooth structure. Tooth preparation for composite resin laminate veneers can be more conservative than that for porcelain alternatives because composite resin does not require 0.5 mm thickness, as does porcelain. Composite resin can be much thinner in spots and still function well.
- Fabrication alternatives. Indirect composite resin laminate veneers can be fabricated either in the office or in the dental laboratory. They can be light cured or processed. They can be made of micro-filled, small particle, or hybrid composite resin. The glass in the small particle or hybrid composite resin can be etched with hydrofluoric acid, which provides micromechanical retention rivaling that of etched porcelain.
- Chairside repairs. These restorations can be repaired at the chairside with light-cured composite resins.

The technique described below is for a light-cured hybrid composite resin that is heat tempered, etched with 10% hydrofluoric acid gel, and treated with silane. The silane chemically bonds to the remaining glass particles and then to the luting composite resin, which is used to attach the veneer to the etched enamel surface of the tooth. (Note that techniques may vary among manufacturers.)

#### Armamentarium

- Mirror
- Explorer
- Metal "plastic" instrument
- #12 surgical blade
- Bard parker handle
- Anterior scaler
- Medium grit flame or chamfer diamond bur
- Vinyl polysiloxane impression material
- Irreversible hydrocolloid impression material
- Maxillary and mandibular full arch impression trays
- Die stone
- Hybrid composite resin
- Light-cured or dual-cured luting composite resin
- Toaster oven or Coltene oven
- 12- and 30-fluted carbide finishing burs
- Fine finishing diamond burs
- Rubber composite resin polishing cups
- Composite resin finishing disks
- Composite resin polishing paste
- 10% hydrofluoric gel
- 37% phosphoric acid gel
- Dentin-enamel bonding resin
- Silane coupling agent
- Intraoral light-curing unit
- Oil-free pumice

#### Clinical Technique

1. Clean the tooth and the neighboring teeth with pumice.
2. Select the desired shades of composite resin while the teeth are wet with saliva.
3. Determine the desired alignment of the teeth.
4. Prepare the eight maxillary anterior teeth by removing small amounts of enamel with a medium grit flame or chamfer diamond bur. If only minimum preparation is necessary to improve alignment and increase facial contour, remove only 0.25 to 0.50 mm of enamel from the facial area and none from the incisal area (Fig. 6-8). If incisal reduction is necessary, remove 1 to 1.5 mm (Fig. 6-9).

**CLINICAL TIP.** A definite chamfer margin is not necessary, because composite resin veneers can be fabricated with feather-edged margins.

5. Make a full arch impression of the prepared teeth with a vinyl polysiloxane impression material. No retraction cord is needed because the margins are placed at the gingival crest.
6. Make a full arch irreversible hydrocolloid opposing impression.

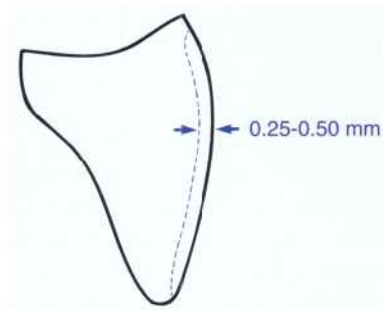


Fig. 6-8. Anterior preparation without incisal reduction.

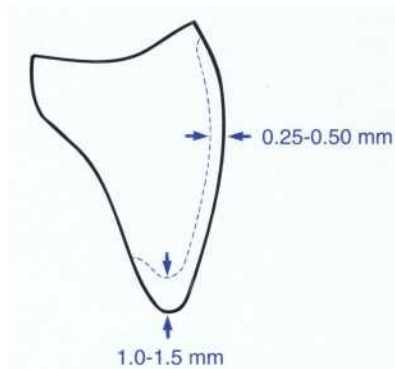


Fig. 6-9. Anterior preparation with incisal reduction.

7. Place a provisional restoration if needed (see Chapter 9, Porcelain-Laminate Veneer and Other Partial Coverage Restorations.)
8. Pour stone models of both the prepared and the opposing arches. Veneers can be fabricated on the stone model by using a separating medium or on a flexible model as described below.
9. After the stone is fully set, soak the model of the prepared arch in water for 10 minutes and make an irreversible hydrocolloid impression of the model.

**CLINICAL TIP.** Soaking the stone in water before making the irreversible hydrocolloid impression prevents the irreversible hydrocolloid from adhering to the stone.

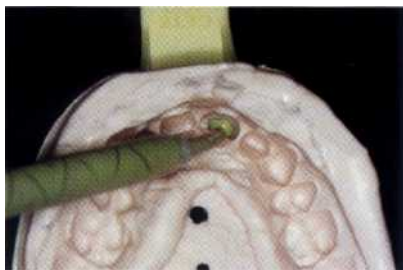10. Inject a vinyl polysiloxane impression material (medium to heavy viscosity) into the irreversible hydrocolloid impression and form a flexible model (Fig. 6-10). This technique was first developed by Dr. K. Michael Rhyne for use in indirect composite resin inlay fabrication.

**CLINICAL TIP.** A flexible working model does not require a separating medium, nor is it susceptible to breakage. The chance of chipping the restoration upon removal from the working model is slight.

11. On the flexible model, fabricate composite resin veneers using a technique similar to that described for direct intraoral application (Fig. 6-11).

**CLINICAL TIP.** To achieve a vital, natural appearance, apply layers of dentin, enamel, and incisal shades and cure each layer for 40 seconds (Fig. 6-12).

12. Remove the veneers from the flexible model.
13. Contour and polish the veneers using 12- and 30-fluted finishing carbide burs in a high-speed hand-piece or porcelain contouring and polishing wheels on a lathe.

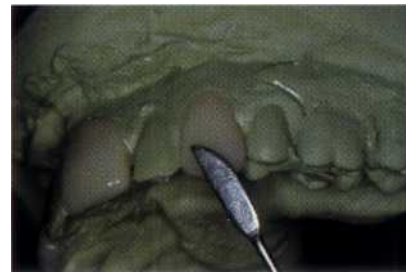

**Fig. 6-10.** Vinyl polysiloxane is injected into an alginate impression of a stone model of prepared teeth.

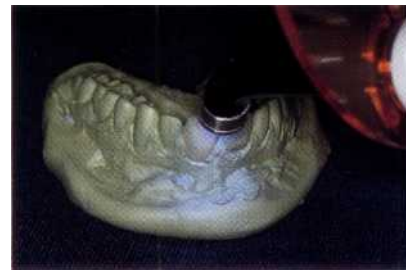**CLINICAL TIP.** Fabricating every other veneer to completion before fabricating the adjacent veneer allows for good interproximal contours and contacts.

14. Place the veneers on the original stone model to check the fit and margins; adjust further if necessary (Fig. 6-13).
15. Heat treat the veneers in boiling water or a heat device, such as the Coltene unit, for 10 minutes to achieve the heat-curing benefits.
16. Acid etch the lingual side of the veneers with 10% hydrofluoric acid gel for 30 seconds (Fig. 6-14) or lightly sandblast with a microetcher or air abrasion unit and rinse thoroughly.

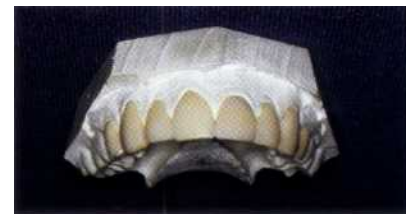**CLINICAL TIP.** Handle hydrofluoric acid carefully because it is caustic.



**Fig. 6-11.** Composite resin is applied to the flexible model.



**Fig. 6-12.** Composite resin veneer is light cured.



**Fig. 6-13.** Eight indirect composite resin veneers on a stone model.

17. Evaluate the internal surfaces of the veneers to ensure that an etched surface has been achieved (Fig. 6-15).

**CLINICAL TIP.** At the delivery appointment, use cheek and lip retractors to isolate the teeth. With this technique, no cotton rolls or rubber dam is needed.

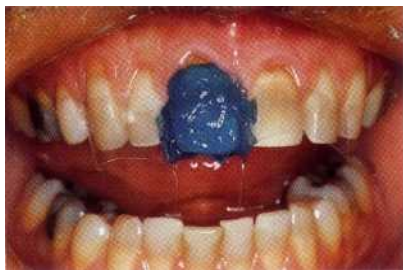
18. Clean the teeth with No. 4 fine pumice in a prophylaxis cup, rinse, and dry with water-free and oil-free air.
19. Use 37% phosphoric acid for 15 seconds to etch the enamel and remove the smear layer from any exposed dentin surface of the first central incisor (Fig. 6-16).
20. Rinse thoroughly.
21. Leave the tooth surface slightly moist for wet bonding.
22. Using a brush, apply silane coupling agent to the internal surface of the veneers and air dry.



*Hydrofluoric acid gel (10%) is applied for 30 seconds.*

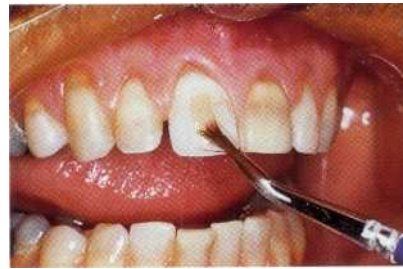

*Etched internal surface of the hybrid composite resin veneer.*

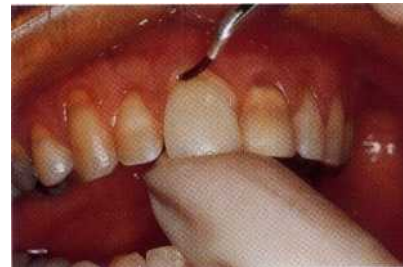

*Enamel surface is etched with 37% phosphoric acid.*

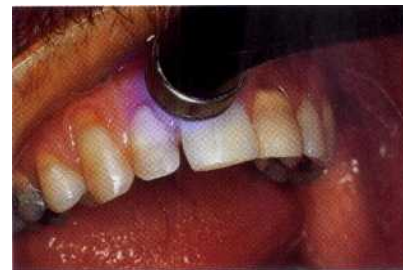23. Liberally coat the etched surfaces with a hydrophilic primer from a fourth generation dentin and enamel bonding agent (Fig. 6-17) and dry the primer with oil-free and water-free air until the surface appears glossy without being wet. This indicates that the "hybrid" layer has been established in the dentin and the enamel is thoroughly coated with the resin in the primer.
24. Paint a thin layer of bonding resin onto the internal surface of the veneers.
25. Apply a luting composite resin to the internal surface of one of the veneers. Place the veneer on the prepared tooth and remove excess luting composite resin with a brush dipped in bonding agent (Fig. 6-18).
26. Light cure for 40 seconds on the facial and lingual surfaces of the tooth (Fig. 6-19).



*Fig. 6.17. Bonding resin is applied to the etched enamel.*

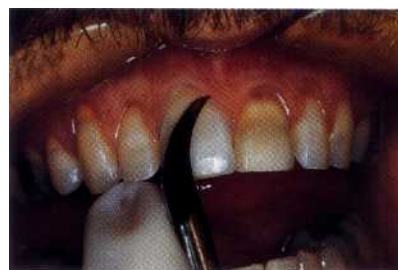

*Excess luting composite resin is removed with a brush dipped in bonding agent.*

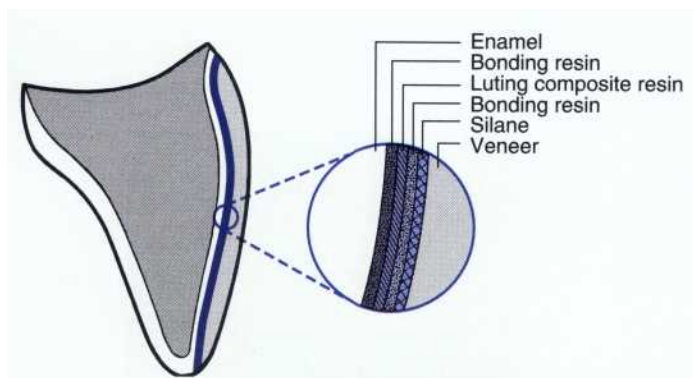


*Fig. 6-19. Luting composite resin is light cured.*

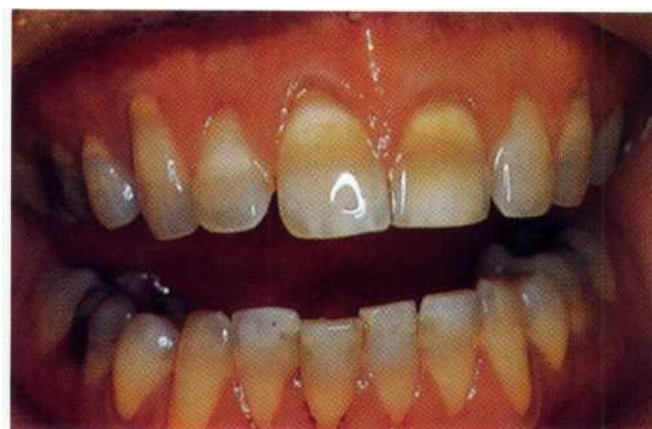27. Remove excess cured luting composite resin with a #12 surgical blade or a scaler (Fig. 6-20).
28. Place the other veneers in the same fashion.
29. Finish the margins with 12- and 30-fluted carbide finishing burs, fine diamonds, rubber polishing cups, finishing disks, or other composite resin finishing techniques (Figs. 6-21 to 6-23).



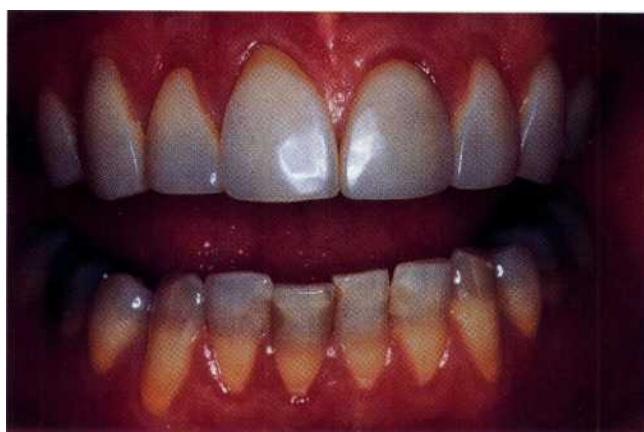*Fig. 6-20. Excess cured luting composite resin is removed with a #12 surgical blade.*



*Fig. 6-21. Final anterior restoration with various layers displayed.*



*Fig. 6-22. Preoperative view of tetracycline-stained teeth.*



*Fig. 6-23. Postoperative view of eight indirect composite resin veneers.*





## POSTERIOR INLAYS AND ONLAYS

Composite resin inlays and onlays are the treatment of choice in many situations:

- **Esthetic considerations.** A bonded restoration can provide esthetics and function of high quality and may be a long-lasting alternative to full coverage or the porcelain counterparts.
  - **Structural considerations.** A bonded restoration returns nearly all the original strength to the tooth and holds the remaining tooth structure together. An amalgam restoration that merely fills a space does not strengthen the tooth but rather actually forms a wedge that eventually can cause fracturing of the tooth.
  - **Abrasion considerations.** Because some composite resins have been shown to wear at about the same rate as natural tooth structure, they could be the material of choice for restorative purposes. However, long-term clinical data are not yet available, therefore caution and clinical judgement should be exercised at the present time.
  - **Conservation of tooth structure.** Onlay preparations have the advantage of requiring the removal of less tooth structure than for a full crown.
  - **Supragingival margins.** Onlay preparations have supragingival margins and therefore infringe less on the periodontal apparatus than restorations with subgingival margins.
  - **Chairside repairs.** These restorations can be repaired at the chairside with light-cured composite resins.
- With the advent of strong bonding agents and appropriate restorative materials, indirect composite resins can provide long-lasting alternatives to full crowns or conventional cast onlays.

### Direct/Indirect Technique: Fabrication

#### Armamentarium

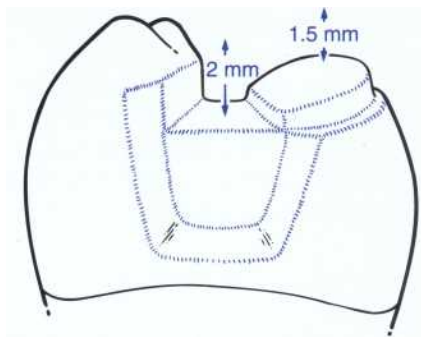
The armamentarium is the same as that listed for anterior veneers.

#### Clinical Technique

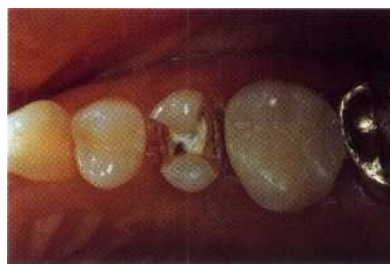1. The preparation is similar to that for a gold inlay or onlay; however, the divergent walls must have rounded angles and no sharp corners (Fig. 6-24).

**CLINICAL TIP.** No retentive grooves or parallel walls are needed, because the restoration will be bonded into place (Fig. 6-25).

2. Provide at least 1.5 mm of clearance on the prepared occlusal surface.



**Fig. 6-24.** Posterior onlay preparation. Note the rounded line angles designed to reduce internal stress.



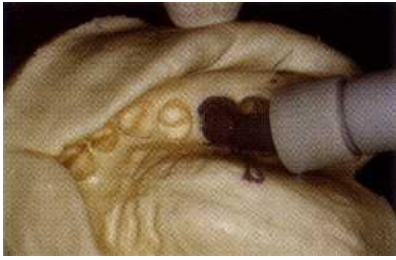**Fig. 6-25.** Tooth prepared for indirect composite resin veneer.

3. No bevels are needed, and slightly tapering or butt joint margins are best.
4. Areas prepared closer than 0.5 mm to the pulp should be lined with calcium hydroxide, and undercuts should be filled with glass ionomer cement or another appropriate liner or base.

**CLINICAL TIP.** Do not use solutions containing eugenol, which can interfere with the chemistry of the resins.

**CLINICAL TIP.** Undercuts in the preparation make removal impossible; carefully inspect the preparation before placing composite resin and block out or remove undercuts.

5. Apply a separating medium or glycerin to the entire tooth.
6. Place a light-cured hybrid composite resin directly into the prepared tooth using normal direct placement technique.
7. Remove the restoration from the tooth using a large spoon or other instrument.
8. Heat treat the inlay or onlay.
9. Place the inlay or onlay according to the placement technique described later.



Vinyl polysiloxane is injected into an alginate impression.

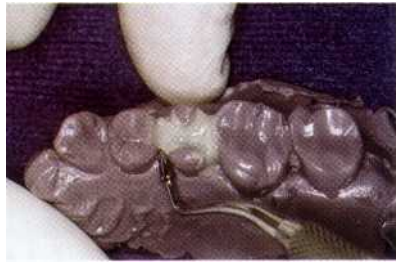

Fig. 6-2 Fabrication of the composite resin inlay.

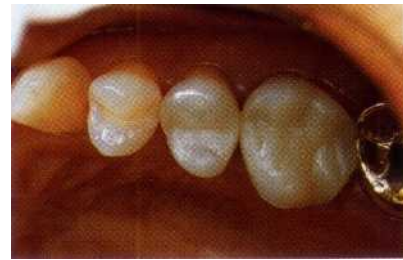

Fig. 6-28. Composite resin inlay bonded into place.

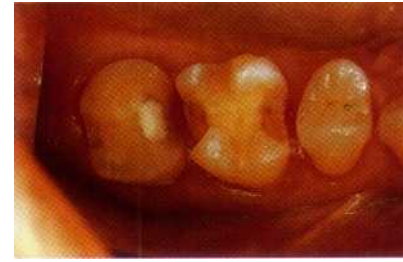

Fig. 6-29. Prepared teeth.

### *Indirect Technique: Flexible Model Fabrication*

A completely indirect technique that can be performed in one appointment and that does not require a provisional restoration can be accomplished using a flexible model technique.

#### Armamentarium

The armamentarium is the same as that listed for anterior veneers.

#### Clinical Technique

1. The first four steps are identical to those given in the preceding section on direct/indirect technique.
2. Make an irreversible hydrocolloid impression that captures all of the margins of the preparation.
3. Inject a firm-setting vinyl polysiloxane impression material into the irreversible hydrocolloid impression to form a flexible model (Fig. 6-26).
4. Fabricate a composite resin inlay using light-cured hybrid composite resin (Fig. 6-27).
5. Heat treat the restoration.
6. Place the inlay or onlay according to the placement technique described below. (Fig. 6-28).

### *Placement Technique*

The preparation and placement of inlays or onlays are identical whether they are fabricated in the office or at

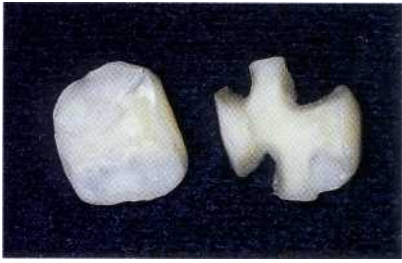
the dental laboratory using the commercial processes described.

#### Armamentarium


The armamentarium is the same as that listed for anterior veneers.

#### Clinical Technique

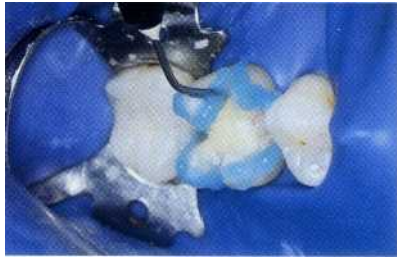1. Remove the provisional restorations, if any (Fig. 6-29).
2. Place the definitive restorations on a clean, dry surface (Fig. 6-30).
3. Place a rubber dam.
4. Thoroughly clean the prepared tooth with pumice.
5. Use 37% phosphoric acid to etch the enamel margins (Fig. 6-31) and to remove the smear layer from the prepared dentin surfaces. Rinse thoroughly and leave the tooth surfaces moist to allow wet bonding.
6. Liberally coat the etched surfaces with a hydrophilic primer from a fourth generation dentin and enamel bonding agent (Fig. 6-32) and dry the primer with oil-free and water-free air until the surface appears glossy without being wet. This indicates that the "hybrid" layer has been established in the dentin and the enamel has been thoroughly coated with the resin in the primer.
7. Apply a dual-curing bonding resin to the dentin and enamel surfaces and the internal surface of the onlay (Fig. 6-33).



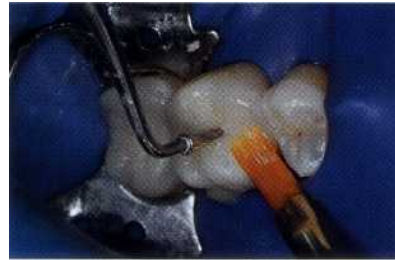*Fig. 6-30. Internal surfaces of laboratory-fabricated composite resin onlays.*



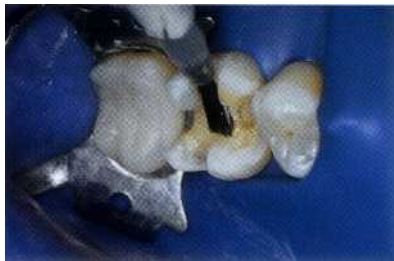*Fig. 6-34. Mixing of the dual-cured luting composite resin.*



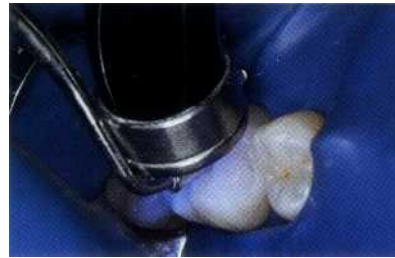*Fig. 6-31. Enamel margins are etched with 37% phosphoric acid gel.*



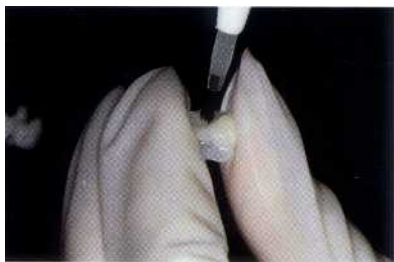*Fig. 6-35. Excess luting composite resin is removed with a brush dipped in bonding agent.*



*Fig. 6-32. Dentin primer is applied.*



*Fig. 6-36. Luting composite resin is light cured with a visible light source.*



*Fig. 6-33. Bonding resin is applied to the internal surface of the onlay.*

8. Mix a dual-cured luting composite resin and apply it to the inner surface of the restoration or to the surface of the prepared tooth (Fig. 6-34).
9. Place the restoration and remove excess luting composite resin with a brush dipped in bonding agent (Fig. 6-35).

10. While the onlay is held in place with an instrument, run dental floss through the proximal areas, pulling in the facial or lingual direction to remove excess resin.
11. Cure the restoration for 40 seconds on the occlusal, facial, and lingual surfaces (Figs. 6-36 and 6-37).
12. Excess cured luting composite resin can be removed with a surgical blade (Fig. 6-38), a scaler, or carbide finishing burs.

**CLINICAL TIP.** The dual-cured luting composite resin will continue to cure, but finishing can begin 4 minutes after light curing.

13. Adjust the occlusion with carbide finishing burs (Fig. 6-39).
14. Polish the finished and adjusted surfaces with normal composite resin polishing techniques, including the use of final polishing paste (Figs. 6-40 to 6-43).

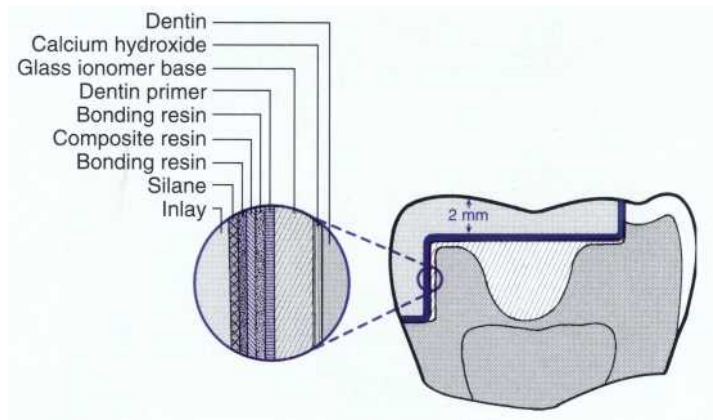


Fig. 6-37. Final posterior restoration with various layers displayed. Note that the glass ionomer base is used to restore the restoration to "ideal" depth.

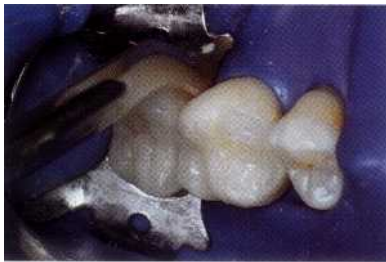
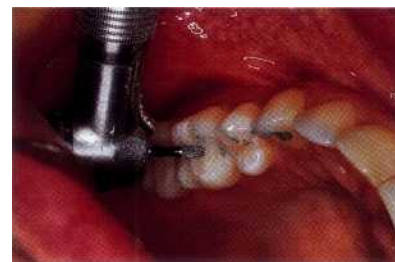
Fig. 6-38. Excess cured luting composite resin is removed with a #12 surgical blade.



Occlusion is adjusted with a carbide finishing bur.

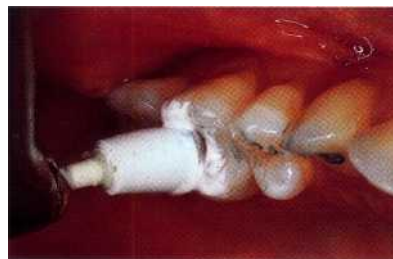


Fig. 6-4( Composite resin onlays are polished with composite resin polishing paste.

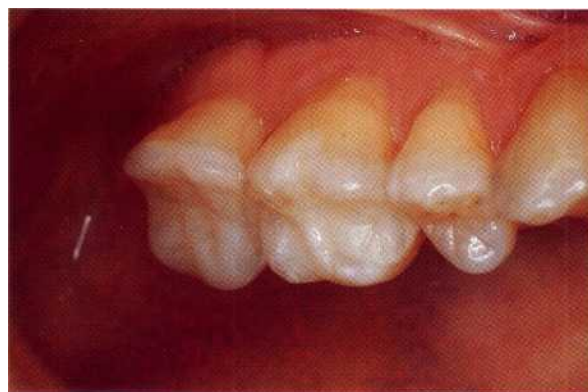
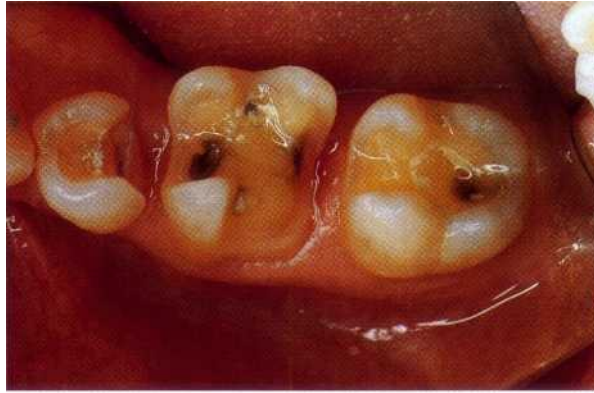
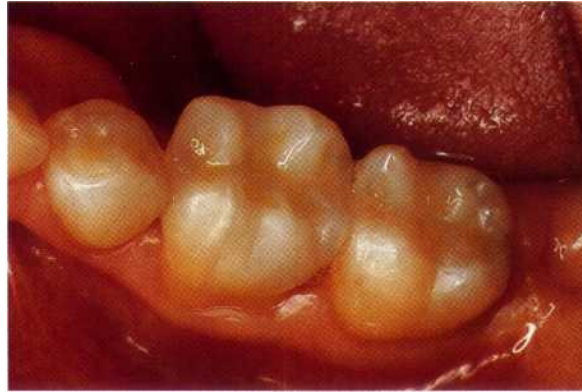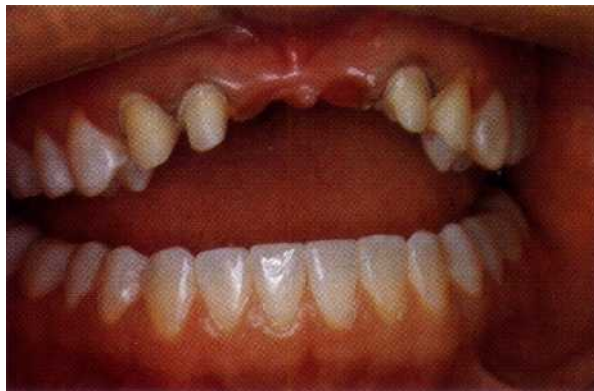Fig. 6-4 Completed onlays.



*Preparation of the mandibular arch for two inlays and one onlay.*



*Fig. 6-43. Finished restorations.*



*Fig. 6-44. Teeth prepared for a six-unit metal-free fixed partial denture.*

#### MULTIPLE-UNIT METAL-FREE FIXED PARTIAL DENTURE RESTORATION

A 32-year-old man required a restoration after traumatic loss of the maxillary incisors. The patient wanted a metal-free restoration. The teeth were prepared for a six-unit fixed partial denture, and an impression was made. The

laboratory constructed a fiber-reinforced metal-free polymer-ceramic fixed partial denture, Sculpture/Fibrekor (Jeneric/Pentron, Inc.).

The restoration was luted into place with a dentin bonding agent and a composite resin cement (Figs. 6-44 to 6-46).

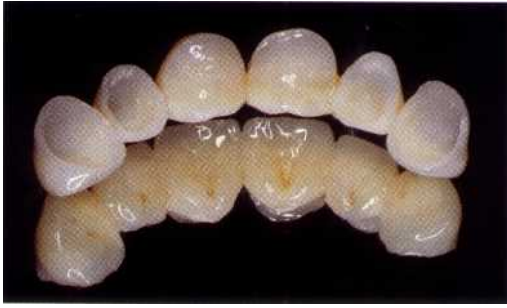

Fig. 6-45. Fiber-reinforced metal-free polymer-ceramic fixed partial denture ready for placement.

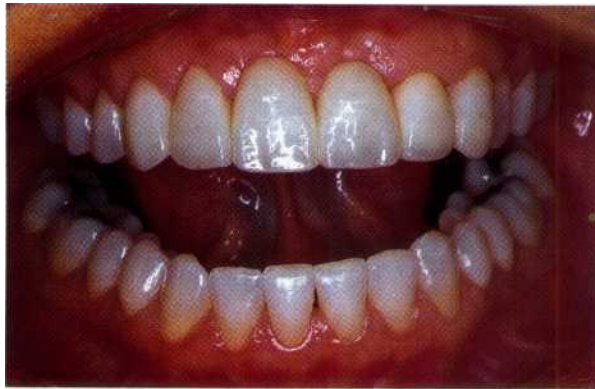

Fig. 6-46. Fiber-reinforced metal-free polymer-ceramic fixed partial denture in place.

## THE FUTURE

Composite resins have a promising future in dentistry. The technology is progressing rapidly, and composite resins that rival porcelain in every way are expected within the next 5 years. Systems will be available for office and laboratory use, and both esthetic and functional requirements will be met. The need for metal support will be eliminated, and bonding agents will ensure strong, long-lasting adhesion to tooth structure.

## REFERENCES

1. Wendt SL: Time as a factor in the heat curing of composite resins, *Quintessence Int* 20:259, 1989.
2. Watts DC: The Coltene direct inlay system: a report on the properties of the inlay composite material resulting from different curing conditions, Coltene seminar, September 1-13, 1988.
3. Duke ES, Norling BK: Vacuum curing of light activated composite veneering resin, USAF Medical Center and University of Texas HSC published report, San Antonio, Texas.

4. Lappalainen R: Wear of dental restorative and prosthetic materials in vitro, *Dent Mater* 5(1):35, 1989.
5. Wendt SF: The effect of heat used as a secondary cure upon the physical properties of three composite resins, *Quintessence Int* 18:351, 1987.
6. Ibsen RL, Nevill K: *Adhesive restorative dentistry*, Philadelphia, 1974, WB Saunders.
7. Albers HE *Tooth colored restoratives*, ed 7, Cotati, Calif, Alto Books.
8. Simonsen R, Barouch E, Geib M: Cusp fracture resistance from composite resin in Class 11 restorations, *J Dent Res* 62:761, 1983.

## BIBLIOGRAPHY

- Berge M: Properties of prosthetic resin-veneer materials processed in commercial laboratories, *Dent Mat* 5:77, 1989.
- Bonner P, Kanca J: Dentist reveals methods for fabricating the direct resin inlay, *Cosmet Dent Gen Pract* 5:1, 1989.
- Christensen GJ: Tooth-colored inlays and onlays, *J Am Dent Assoc* 9:12E, 1988.
- Dimberio RD: A new crown and bridge veneering material, *Quintessence Dent Tech* 4:27, 1979.
- First International Symposium on the Clinical Applications of Laboratory Light Cured Composites, December 13, 1984, Valley Forge, Pa.
- Gallegos LI, Nicholls JI: In vitro two-body wear of three veneering resins, *Quintessence Int* 20:259, 1989.
- Gross J, Malacmacher L: Posterior composite resins: the technique, *Dentique 1:1*, 1985.
- James DF: An esthetic inlay technique for posterior teeth, *Quintessence* 14:725, 1983.
- Jones RM, Moore BK: A comparison of the physical properties of four prosthetic veneering materials, *Prosthet Dent* 61:38, 1989.
- Kanca J: The single visit heat processed indirect composite resin inlay, *J Esthet Dent* 1:13, 1988.
- Lappalainen R, Yil-Urpo A, Seppa L: Wear of dental restorative and prosthetic materials in vitro, *Dent Mat* 5:35, 1989.
- Michl RJ: Isosit: a new dental material, *Quintessence Int* 9:1, 1978.
- Miller M et al: Indirect resin systems, *Reality* 4:52, 1989.
- Nash R: Restorative options for good aesthetics, *Dent Today* 3:1, 1987.
- Nash R: Hybrid composites: excellent for veneers, *Lab Man Today* 4:34, 1988.
- Nash R, Oaten R: Indirect techniques for composites, *Lab Man Today* 4:35, 1988.



# CERAMOMETAL FULL COVERAGE RESTORATIONS

Ira D. Zinner, Francis V Panno, Richard D. Miller, Mitchell S. Pines, and Trudy M. Burke

**T**O THE PATIENT, the cosmetics of anterior fixed prosthodontics are usually more important than the functional or technical aspects of the restoration. The finest fitting restoration with exquisite porcelain carvings can meet with total patient dissatisfaction if it does not conform to the expected esthetic results.

## BASIC CHEMISTRY

The basic chemical components of ceramometal porcelains are potassium-sodium aluminosilicate glasses (Table 7-1). Combinations of metallic and nonmetallic oxides are added as opacifiers (Table 7-2).

The conventional all-ceramic and acrylic resin full and partial coverage restorations, although esthetically pleasing, can fail under heavy occlusal stress because of low tensile and shear strengths.<sup>1</sup> Newer porcelain materials are stronger but still cannot be used to create multiple-unit fixed prostheses.<sup>2</sup> Full cast restorations offer sufficient strength but lack the esthetic appearance required in today's society. Ceramometal dental restorations, however, offer both strength and acceptable appearance.<sup>3</sup>

The strength of the porcelain-to-metal bond is close to the tensile strength of the opaquing porcelain. Fracture usually occurs within the body of the porcelain. If this is not the case, an error in fabrication technique usually is to blame.<sup>4</sup> Ceramic and metal alloys must have properties that allow for both physical and chemical compatibility. The fusion temperature of the ceramic (usually 100° to 150° C) is lower than the metal casting temperature, which prevents the cast metal substructure from melting during porcelain application. Ceramometal

porcelains contain more soda and potash than typical all-ceramic blends; this increases thermal expansion to a level compatible with the metal alloy (the coefficient levels of thermal expansion for several porcelains are presented in Box 7-1). The coefficient of thermal expansion of the ceramic is 13 to 14 × 10<sup>-6</sup>/°C. This should be approximately 0.5 to 1 × 10<sup>-6</sup>/°C less than the coefficient of thermal expansion of the casting alloy, which places the brittle ceramic into slight compression at the ceramometal interface when it cools. Ceramic is much stronger under compression than under tension.<sup>5</sup> In addition, because it is brittle and tends to form minor stress-concentrating defects, the ceramic is much stronger when applied to a rigid metal framework. This framework, upon wetting with porcelain, reduces the internal ceramic defects and supports the brittle porcelain, thus adding strength to the restoration.<sup>6</sup> Conversely, the metal of a knife-edged finishing line or a bevel contains insufficient bulk to resist small deflections during seating. Porcelain should not be applied to these thin margins because if resistance to seating is encountered, flexing of the metal can cause the porcelain to flake off.<sup>7</sup>

*Ingredients of dental porcelains.*

Ingredient	Dental Porcelain (% Weight)	Decorative Porcelain (% Weight)
Feldspar	81	15
Quartz	15	14
Kaolin	4	70
Metallic pigment	<1	1

Modified from Craig RG, editor: *Restorative dental materials*, ed 10, St Louis, 1997, Mosby.



Composition Of dental ceramics for fusing to high-temperature alloys.

Compound	Biodent Opaque BG 2 (%)	Ceramco Opaque 60 (%)	V.M.K. Opaque 121 (%)	Biodent Dentin BD 27 (%)	Ceramco Dentin T 69 (%)
SiO <sub>2</sub>	52	55	52.4	56.9	62.2
Al <sub>2</sub> O <sub>3</sub>	13.55	11.65	15.15	11.8	13.4
CaO	-	-	-	0.61	0.98
K <sub>2</sub> O	11.05	9.6	9.9	10	11.3
Na <sub>2</sub> O	5.28	4.75	6.58	5.42	5.37
TiO <sub>2</sub>	3.01	-	2.59	0.61	-
ZrO <sub>2</sub>	3.22	0.16	5.16	1.46	0.34
SnO <sub>2</sub>	6.4	15	4.9	-	0.50
Rb <sub>2</sub> O	0.09	0.04	0.08	0.10	0.06
BaO	1.09	-	-	3.52	-
ZnO	-	0.26	-	-	-
UO <sub>3</sub>	-	-	-	-	-
B <sub>2</sub> O <sub>3</sub> , CO <sub>2</sub> and H <sub>2</sub> O	4.31	3.54	3.24	9.58	5.85
Total	100	100	100	100	100

Modified from Craig RG, editor: Restorative dental materials, ed 10, St Louis, 1997, Mosby.

## BOX 7-1

### PORCELAIN COEFFICIENT OF THERMAL EXPANSION

#### Low Coefficient

Ceramco  
Denpac  
Vita  
Excelco

#### Medium Coefficient

Pencraft  
Duceram  
Synspak

#### High Coefficient

Biobond  
Williams  
Crystar

Opaque porcelains, which mask the metal coping, contain metallic oxide opacifiers. New opaque porcelains can be used effectively in layers as thin as 100  $\mu\text{m}$ . However, this opaque porcelain must be covered by at least 1 mm of body porcelain to mask its reflectiveness.

Vitrification in ceramic restorations refers to a liquid phase caused by reaction or melting which, on cooling, forms a glassy phase. If this formation is disturbed by the addition of too much modifying oxide, devitrification (crystallization) can occur.<sup>4</sup> The ceramic porcelains are sensitive to devitrification because of their alkali content, which can cause clouding with additional porcelain fir-

ings. Repeated firing of high-expansion ceramometal porcelains at maturing temperature increases the likelihood of devitrification.<sup>4</sup>

Traditional dental ceramometal porcelains were formulated as a compromise between optimum properties and metal compatibility. The coefficient of thermal expansion of the porcelain had to be raised to approximate that of the ceramometal alloy. The ceramic metal had to be alloyed to cast at a higher temperature than conventional gold-copper alloys so that it could withstand the higher porcelain firing temperatures and reduced thermal expansion to meet that of the porcelain. The development of low-fusing porcelain systems has changed the character of ceramic-metal restorations. New porcelains have been formulated with lower fusing temperatures and a higher coefficient of thermal expansion to be compatible with conventional American Dental Association (ADA) type IV-like dental gold alloys. In 1993 the "Golden Gate System" (Degussa AG) introduced the first low-fusing porcelain/type IV gold ceramometal system. This was made possible by the development of Ducera's low-fusing ceramic, Duceram, which was matched to a new type IV ceramic alloy, Degunorm (Degussa AG). Degunorm alloy is based on the conventional gold, platinum, silver, and copper dental gold alloys. The gold and platinum content was raised to 82.9% by weight and the copper reduced to 4.4%. The casting temperature is similar to that for conventional dental golds, and the coefficient of thermal expansion, at 16.8 m/m. °C, is 15% to 20% higher than conventional ceramic alloys. The low-fusing ceramic Duceragold (Ducera) was formulated so that the coefficient of thermal expansion matches its corresponding dental metal alloy Degunorm. The porcelain fuses below 800° C. The low-fusing porcelain is produced by hydrothermal processing of the dental glass



*Low-fusing dental porcelain systems.*

Ceramic	Firing temperature (° F)	Coefficient of thermal expansion (mm/m . °C)
Carrara (Elephant Industries)	1562	6
Duceragold (Ducera)	1400-1436	15.8
Duceram (Ducera)	1220-1270	11-12

that allows hydroxyl ions to incorporate into the glass lattice. The high thermal expansion is achieved by homogenization of fine leucite crystals in the glass matrix.\* This process produces porcelain with a smoother surface than conventional dental ceramometal porcelains. This smoother surface is claimed to be less abrasive to the natural dentition. The homogeneous, dense surface is easier to polish than conventional dental porcelain and may be more compatible with soft tissue (Table 7-3).

## CERAMOMETAL ALLOYS

Ceramometal alloy must be sufficiently thick to prevent deflection (i.e., it must be rigid). This implies that an ideal ceramometal alloy has a high modulus of elasticity. However, even though the modulus of elasticity for dental alloys varies greatly, the practical savings in using stiffer materials is minimal because even the more flexible ceramometal alloys can be reduced to **the minimum coping thickness** of 0.5 mm and still be clinically acceptable. Ceramometal alloys should not melt during porcelain application or exhibit creep at high temperatures. (Creep is a time-dependent strain that occurs under stress<sup>9</sup> and results in deformation or flow of the material. It is shown by a material that continues to deform even though the stress on it remains the same.)

**CLINICAL Tip.** A thin marginal apron may distort during porcelain application, resulting in an inaccurate fit. To prevent this, copings should be waxed with thick margins and then thinned (after porcelain application) during final finishing.

When a ceramometal alloy is heated during porcelain firing, its modulus of elasticity must be high (rigid) enough to resist metal deformation. However, as the restoration cools, the alloy should be able to deform a small amount to relieve the stress produced by the ther-

mal contraction of the porcelain. If the alloy's modulus of elasticity is too high, it will be unginging and will not relieve this stress; thus the stress would remain within the porcelain and may lead to crazing.'

Creep is seen in metals at temperatures close to their melting point. Creep can be controlled by avoiding extremely long firing cycles. High-temperature creep is flow that occurs at elevated temperatures. For gold alloys, high-temperature creep occurs at about 1800° F It can be reduced by varying alloy composition so that a dispersion strengthening effect occurs at the high temperature.'''

As with all intraoral restorative metals, the ceramometal alloy should be resistant to tarnish and corrosion.'

### *Classification of Ceramometal Alloys*

The two basic types of ceramometal alloys are the precious alloys and the base metal alloys.

**Precious Alloys** Because original ceramometal restorations contained high proportions of noble metal, their clinical characteristics are well documented; they show good resistance to oxidation, tarnish, and corrosion.<sup>4</sup> The noble metals are gold, platinum, palladium, iridium, rhodium, osmium, and ruthenium. Their physical properties are all similar, although the non-gold noble alloys require a modified investment to withstand the higher casting temperatures. Ceramic alloys are very hard and strong compared with ADA type I, type II, and type III gold; they are similar to type IV gold. The coefficient of thermal expansion of ceramic alloys is less than that of any of the four types of gold. The noble metals and silver are often referred to as precious metals.

**Base Metal Alloys** Base metal alloys consist of nickel, chromium, molybdenum, cobalt, and beryllium. They can be used to obtain satisfactory fit, but laboratory procedures for base metals are much more technique sensitive than those for the noble alloys. High casting shrinkage of the base metal alloys necessitates special investments and casting methods. When nickel-based alloys are subjected to heat treatment during the porcelain firing cycles, the strength and hardness of the alloy diminishes. The base metal alloys' oxide thickness is more difficult to control, which creates problems with additional porcelain firings.'

Dental ceramometal restorative alloys may be further classified by their major constituents and the chronology of their development (Tables 7-4 and 7-5 ).<sup>7</sup>

### **Group 1: Gold Noble**

#### *Composition*

1. 96% to 98% noble metal
  - a. 84% to 86% gold
  - b. 4% to 10%, platinum
  - c. 5% to 7% palladium
2. 2% to 3% base metal

\*Meier O et al: A new metal-ceramic system: some aspects of materials technology, Dental Labor, XLI, Helf, 1993.

Group	% Noble Metal	Contains Silver (Greening)	Technique Sensitivity	Porcelain Type (Coefficient of Thermal Expansion)	Color	Minimum Thickness (mm)
1	96-98	No	Low	Conventional	Yellow	.5
2	80	Yes	Low	Conventional	White	.5
3	53-60	Yes	Medium	High	White	.5
4	90	No	Low	Low or Conventional	White	.5
5	0	No	High	Conventional	White	.4
6	0	No	Medium to High	Conventional	White	.5
7	78-88	Some contain Ag	Medium	Conventional	White	.5
8	0	No	High	Very Low ?	White	?
9	84-92	Some contain Ag	Low	Very High, Low Fusing	Yellow	.5

Table 7-5. Properties of ceramometal alloys.

Group	Type	Example	Au (%)	Pt (%)	Pd (%)	Ag (%)	Cr (%)	Ni (%)	Co (%)	Be (%)	Ti (%)
1	Gold noble	Jelenko O*	88	5	6	1					
		Degudent†	78	10	9	1					
		Rx CG‡	87	7	5	1					
		Bio 86‡	86	11							
2	White noble	Cameo*	53		27	16					
		Ceramco White	51		31	15					
		RxWCG‡	52		30	14					
3	Palladium silver	Jelstar*			60	28					
		Degustar			52	38					
		Rx Palladent B*			60	28					
4	Gold palladium	Olympia*	52		39						
		Deva M†	47		45						
		RxSF 45	45		45						
5	Nickel chromium	Rexillium‡						75	14	2	
		Genesis					27		53		
6	Cobalt	Nouarex‡					25		55		
		Legacy*	2		85	1					
7	High palladium	Deguplus2	1	1	80						
		Aspen‡	6	1	75	7					
		R/1‡									100
8	Titanium	R/2‡									90
		Bio 75G‡	75	9							
9	Ceramic Type IV Gold	Degunorm†	73.8	9		9.2					

(S) = Soft, (H) = Hard, (F) = Hardness after firing. Values are rounded to nearest whole number. Data supplied by manufacturers.

\*Manufactured by J.F. Jelenko and Co.

†Manufactured by Degussa Dental, Inc.

‡Manufactured by Jeneric/Penton, Inc.

*Properties* Gold noble alloys, which were developed in the 1950s, are weaker and have less sag resistance (the property of a ceramometal alloy to resist flow under its own weight during soldering and porcelain application) than the more recently developed ceramometal alloys. Gold noble alloys are the easiest to cast and solder and have a yellow color that aids in obtaining the lighter tooth color shades. These alloys are the most costly because of their high noble metal content. The Group 1 alloys were developed by both J.E. Jelenko and Co. and J. Aderer, Inc.'

#### Group 2: White Noble

##### Composition

1. 80% noble metal
  - a. 51% to 54% gold

- b. 0% platinum
  - c. 26% to 31% palladium
2. 14% to 16% silver

*Properties* Platinum, the most costly metal, was eliminated in the Group 2 alloys. The gold content was reduced and the palladium portion increased. The overall noble metal proportion was reduced by adding silver. These alloys have improved mechanical properties with higher strength and greater sag resistance. They are easy to fabricate and are less costly than Group I alloys. However, the silver may cause some porcelain greening, and the gray color of the alloy makes it harder to obtain lighter tooth color shades.<sup>2</sup> The Group 2 alloys were developed by Joseph Tuccillo in 1976 at J.E. Jelenko and Co.<sup>12</sup>

Proprietary Metals	Melting Range (EF)	Casting Temperature (EF)	Vickers Hardness	Yield Strength (psi)	Elongation (%)	Coefficient of Thermal Expansion	Density (gm/cm <sup>3</sup> )
0	2100-2150	2300	182	65,300	5	14.7	19.2
2	2100-2300	2550	200	68,150(S) 84,100(H)	7(S) 3(H)		18
0	2100-2150	2300	165	40,000	5		18.5
3	1870-2030		190(S) 215(H)	74800(S) 84500(H)	9(S) 7.5(H)	14.5	18.9
4	2200-2300	2400	220	80,000	10	14.7	16.7
3	2300-2345	2550	130(S) 220(H) 220(F)	30,450(S) 61,630(H)	35(S) 10(H)		14.5
4	2200-2300	2400	220	80,000	10		13.8
12	2250-2380	2500	189	67,000	20	14.8	10.7
10	2100-2250	2550	200(S) 250(H) 220(F)	56,550(S) 81,200(H)	25(S) 10(H)		11.2
12	2200-2275	2500	165	80,000	10		10.5
9	2320-2380	2450	220	83,000	20	14.1	13.5
8	2230-2390	2550	185(S) 275(H) 260(F)	53,650(S) 94,250(H)	31(S) 10(H)		14.4
10	2200-2300	2550	250	80,000	10	14.6	13.5
9	2250-2350	2500	240	74,000	9-12		7.8
20	2415-2550	2600	350	61,000	9	14.6	8.8
20	2425-2475	2675	260	90,000	7		8.8
12	2020-2360	2450	270	95,500	20	14.2	11
18	2110-2355		260(F) 260(F) 260(F)	83,380(S) 83,350(H)	30(S) 30(H)		11.5
11	2115-2275		250	80,000	21		11
Slight	3035		175	50025	15	9.85	4.51
10	2800-3000		330	129920	9	10.22	4.51
16	1841-1967	2192-2237	125(S) 200(H)	40029(S) 63089(H)	22(S) 14(H)	16.6	16.7
8	1650-1815	2010	230(C) 150(S) 200(H)	49300(S) 72500(H)	14(S) 6(H)	16.4	16.7

**Group 3: Palladium-Silver Alloys***Composition*

1. 53% to 60% noble metal
  - a. 0% gold
  - b. 0% platinum
  - c. 53% to 60% palladium
2. 30% to 37% silver
3. 10% base metals

**Properties** These alloys contain palladium, silver, and a small amount of base metals. They are easy to cast and solder, have acceptable mechanical properties, and are the least expensive of the noble alloys. The coefficient of thermal expansion of palladium-silver alloys is higher than that of gold alloys, necessitating the use of porcelains with a correspondingly higher coefficient of shrinkage. The silver content may cause greening of the porcelain, requiring judicious use of metal conditioners.<sup>13</sup> Metal conditioner is an opaque porcelain with a high concentration of pink pigment that is used to negate the green discoloration of the porcelain caused by the silver content. These alloys can absorb gases in their liquid state and then release the gases during solidification, which may cause bubbles to form in the porcelain during its application.<sup>13</sup> Palladium alloys are prone to carbon contamination, which affects the porcelain-to-metal bond; therefore carbon blocks and graphite crucibles must not be used with these materials. This problem can be minimized by not overheating the alloy and not holding the molten metal for long periods before casting. The Group 3 alloys were developed by Clyde Ingersol of Williams Gold Inc., in 1975.<sup>14</sup>

**Group 4: Gold-Palladium Alloys***Composition*

1. 90% noble metals
  - a. 45% to 52% gold
  - b. 38% to 45% palladium
2. 0% silver
3. 10% base metals

**Properties** Both silver and platinum were eliminated from Group 4 alloys. The mechanical properties (e.g., modulus of elasticity, yield strength), the ease of fabrication, and the dimensional accuracy make these the most promising of all the noble alloys. They have a lower coefficient of thermal expansion than Group 1, 2, or 3 alloys, making them compatible only with lower shrinkage porcelains. The Group 4 gold-palladium alloys were developed by Paul Cascone at J.E. Jelenko and [Co. in 1978.](#)<sup>15</sup> In 1985, the alloy was improved<sup>15</sup> by increasing the coefficient of thermal expansion, making it more compatible with conventional porcelains. These alloys are white gold in color.

**Group 5: Nickel-Chromium Alloys***Composition*

1. 0% noble metal

2. 100% base metal
  - a. 60% to 82% nickel
  - b. 11% to 20% chromium
  - c. 2% to 9% molybdenum
  - d. 0% to 2% beryllium

**Properties** The use of nickel-based alloys was explored in the 1950s, but lack of a suitable investment and technique delayed their successful development. Advancements in casting investments and the soaring gold prices of the 1970s spurred the acceptance of nickel alloys. These alloys are comprised of nickel, chromium, molybdenum, and beryllium. The beryllium-containing alloys, in general, cast better and have a greater porcelain-to-metal bond strength than the non-beryllium-containing alloys. This accounts for the great degree of difference in mechanical properties in this group. These alloys are the hardest, they have a very high modulus of elasticity, and they have a higher melting temperature than the other alloy groups. The presence of nickel introduces the possibility of nickel hypersensitivity in allergic patients, and the small amount of beryllium adds the hazard of beryllium toxicity in the dental laboratory if proper ventilation is not established. Laboratory procedures are extremely technique sensitive.<sup>16</sup> These alloys produce suitable restorations when nickel hypersensitivity is not a problem and when a low-cost alloy is desired. The dental laboratory should be knowledgeable about the proper handling of these alloys.

**Group 6: Cobalt-Based Alloys***Composition*

1. 0% noble metal
2. 100% base metal
  - a. 55% to 64% cobalt
  - b. 25% to 34% chromium
  - c. 2% to 9% molybdenum

**Properties** In general, the castability, solderability, and porcelain-to-metal bond strength of the cobalt-based alloys are not as good as those of the nickel-based, beryllium-containing alloys. Cobalt-based alloys are harder and more technique sensitive than Group 5 alloys.<sup>17</sup>

**Group 7: High-Palladium Alloys***Composition*

1. 78% to 88% noble metal
  - a. 76% to 88% palladium
  - b. 0% to 2% gold
2. 0% to 1% silver
3. 12% to 22% base metal

**Properties** The high palladium-containing alloys are extremely hard and have a very high yield strength. They do not cast as well as the gold alloys and are more technique sensitive in laboratory fabrication. These alloys are compatible with most porcelain systems.

**Group 8: Titanium****Composition**

1. Titanium
2. Trace elements iron and oxygen

**Properties** Titanium casting requires specialized equipment, and all new alloy must be used with each casting (i.e., the buttons from previous castings cannot be reused). The color of titanium is white. The ceramic technique requires a special low-fusing porcelain and use of a bonding agent. The porcelain can be fired in a conventional porcelain furnace but only at a lower temperature and slower heating rate than for conventional porcelain. The special porcelain has a lower color value. When the value is raised, the opacity is increased.

**Group 9: Type IV Gold Yellow Ceramic Alloys****Composition**

1. 84% to 92% noble metal
  - a. 70% to 75% gold
  - b. 9% platinum
  - c. 0% palladium
2. 0% to 10% silver
3. 8% to 16% other metals

**Properties** With the introduction in the 1990s of low-fusing ceramics such as the "Golden Gate System" (Degussa), conventional type IV-like gold alloys could be used for ceramometal applications. The restorative dentist can reduce the number of different dental metal alloys used in a patient's mouth by using similar metals for ceramometal applications, endodontic dowels, full cast crowns, inlays, and onlays, thus reducing the incidence of galvanic reactions while controlling wear. These alloys have excellent castability and are easy to solder. The yellow color aids in achieving light porcelain shades. They are less expensive than the original high gold yellow ceramic alloys but are more costly than palladium-silver or non-precious ceramic alloys. The coefficient of thermal expansion did not have to be lowered for porcelain compatibility because of the development of new high-expansion, low-fusing porcelains.

## BASIC CONSIDERATIONS IN FULL COVERAGE PREPARATIONS

*Medicolegal Considerations*

Before beginning any tooth preparation, the restorative dentist should discuss thoroughly with the patient the patient's expectations and cosmetic desires. A thorough history, as well as the patient's attitude toward previous treating clinicians, should be recorded. In addition, a full series of radiographs (parallel cone technique) should be taken, using appropriate instrumentation.

Ideally, two sets of diagnostic casts should be made. One set should be mounted on a semiadjustable articulator using verified oral records, and the second set should be used for a diagnostic wax-up to demonstrate the desired esthetic results to the patient. If the patient's expectations are unrealistic or if the patient's opinion differs from that of the dentist, the dentist should be able to advise the patient and explain the limitations in terms of the cosmetic result. If the patient cannot accept the result set forth by the dentist, no further dentistry should be pursued with the patient (see Chapters 26 and 28).

*Photography*

Close-up photographs should be taken before any dental treatment as part of the patient's record. They may be used to aid communication between the dentist and the laboratory technician. Photographs also should be taken after treatment is complete, and they should be kept as part of the patient's record (see Chapter 14).

*Periodontal Considerations*

Unesthetic, pathologic periodontal structures preclude a cosmetic result. Therefore before any fixed prosthodontic procedures are begun, all periodontal tissues should be in a state of optimal health.

Inflammation often is caused by temporary cement or by impression material that remains in the gingival sulcus area or by placement of less than optimal provisional restorations. Areas of deficiency usually involve margins, the height and width of gingival embrasures, contours, and polishing and finishing of the transitional prosthesis. Corrections should be made before proceeding with construction of the definitive restorations.

Definitive restorations should have optimum contours, correct emergence profiles, properly placed contact areas between teeth, and marginal integrity. The gingival margins of the six maxillary anterior teeth should be symmetric wherever possible; this may require periodontal plastic surgery to obtain the desired result.

*Diagnostic Models*

Before tooth preparation begins, an irreversible hydrocolloid impression should be made of the arch to be prepared. If changes are required for cosmetic purposes, an additional diagnostic cast is altered with white carving wax to create the desired effect. If soft tissue modifications are anticipated, these changes should be included on the cast using pink base-plate wax. The completed diagnostic wax-up of the desired soft and hard tissue changes may then be used by the periodontist as a guide for treatment planning and case presentation (see Chapters 15 and 18).

### *Tooth Reduction*

The laboratory technician must be given sufficient room for both metal and porcelain, even if intentional prophylactic endodontics is necessary. Opaquing porcelain need be only 100  $\mu\text{m}$  thick, but unless it is covered by an optimum thickness of surface porcelain, the final restoration will appear flat and unlikelike.<sup>16</sup> Insufficient tooth reduction forces the laboratory technician to create either an overcontoured, periodontally unacceptable restoration or a properly contoured, unesthetically opaque restoration.<sup>6</sup> In either case, underreduction prevents duplication of natural tooth contours and in the gingival one third precludes the proper emergence profile necessary to ensure gingival health.<sup>7,8</sup>

Overreduction is also undesirable because it can lead to insufficient retention and resistance form, as well as an increased risk of pulpal involvement. In addition, if porcelain is thicker than 1.5 mm because of inadequate tooth structure or insufficient metal buildup, the risk of porcelain failure is greater.

### *Provisional Restorations*

The provisional restoration should serve as a guide in determining the proper esthetics and function of the definitive prosthesis. Both the dentist and the patient should select an acrylic shade. An impression of the diagnostic wax-up should be used to create a die stone cast. The designated teeth are prepared by the dentist on a second diagnostic cast. A heat-cured acrylic resin shell is fabricated in the laboratory to the desired shape and shade of the future restorations, as depicted by the diagnostic wax-up. (See Chapter 11 for alternative methods.)

An all-acrylic resin transitional restoration is appropriate only for short-term use. If provisional restorations are used for a prolonged period, they should be constructed of more durable materials, such as a gold thimble or less costly, non-precious metal thimble splinted substructure casting with a heat-cured acrylic resin superstructure. The acrylic is attached to the substructure by means of acrylic resin retention beads. This type of restoration can withstand long-term use with the varying occlusal, functional, and parafunctional forces that may be brought to bear on it. This type of provisional restoration also is used after periodontal surgery or implant placement that requires a prolonged healing period to allow evaluation of questionable teeth with a guarded prognosis. In addition, this method of provisional splinting can be used as a fixed orthodontic retainer after adult tooth movements to create a favorable esthetic and functional result.

Because the acrylic resin shell usually is brittle, the dentist should cut away the interproximal sections of acrylic material with a fluted wax carving bur. This 3-fluted bur is used because it does not clog when carving or cutting acrylic resin. After tooth preparation, the den-

tist lines the entire shell with autopolymerizing acrylic resin of the same shade. The autopolymerizing resin imparts some plasticity to the restoration and reinforces the brittle shell, reducing the chance of breakage.

Tooth reduction, especially in the area influencing the incisal guidance, is verified with the transitional prosthesis. If the section incisal to the cingulum becomes thin or perforated, this area must be reprepared. If tooth preparation does not allow adequate room for the final restorative materials, the functional movements, and esthetic considerations, the tooth must be further prepared and the provisional restoration readapted with autopolymerizing acrylic resin of the selected shade.

The marginal termination of the provisional fixed restoration should be at the end of the preparation. Overextension causes periodontal problems, gingival recession, and a compromised esthetic result." Underextended provisional margins result in tooth sensitivity, possible pulpal damage, and the growth of gingival tissue over the shoulder of the preparation."

Carvings of the provisional prostheses should simulate those of the definitive porcelain-fused-to-metal restoration in terms of size, shape, and occlusal contact. If any alterations are to be made because of either the patient's or the dentist's desires, they should be performed on the provisional restoration prior before completion of the definitive fixed restoration.

For enhanced cosmetic effect and to simulate nature in the transitional restorations, the labial embrasures are deepened, the incisal embrasures are opened, rounded, and made to be of varying depths, and the gingival embrasures are carved to accommodate a healthy gingival papilla. A straight emergence profile should be carved in the gingival one third of the restoration. Enhanced individuality can be created with interproximal orange-brown or brown acrylic stains. In addition, many of these restorations can be stained with decalcification or fracture lines to simulate nature in an elderly patient.

The restorations are contoured, polished, and cemented with a temporary cement. A cement is chosen that allows easy removal of the restoration and sedation of the prepared tooth. The patient is dismissed, and the esthetics, tooth contours, gingival health, and occlusion are evaluated at the next office visit.'

Often more than one set of provisional restorations is necessary because of sequential alterations for creation of the desired cosmetic result. The restorative dentist should use the provisional restoration as a template, or guide, for the height, shade, and shape of the definitive prosthesis, as well as for incisal guidance.

### *Finishing Lines*

Five types of finishing lines can be used for full coverage porcelain-fused-to-metal restorations:

1. A knife-edged finishing line preparation (Fig. 7-1).
2. A chamfer preparation (Fig. 7-2).
3. A full shoulder preparation (Fig. 7-3).
4. A full shoulder with a bevel preparation (Fig. 7-4).



Fig. 7-1. Tapered knife-edged preparation.



Fig. 7-2. Chamfer preparation.

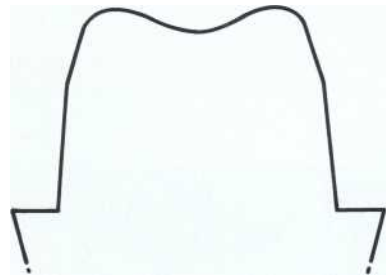


Fig. 7-3. Full shoulder preparation.

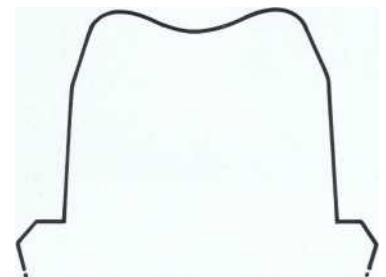


Fig. 7-4. Full shoulder with bevel preparation.

5. A full shoulder with a bevel and a facial butt joint preparation.

**Knife-Edged Finishing Line** The knife-edged preparation is a tapered preparation that has maximum tooth reduction at the occlusal or incisal portion and tapers to zero cutting at the gingival termination. It is accomplished by inclining the cutting instrument at the occlusal end while maintaining no tooth reduction at the gingival termination of the preparation. The greater the tooth reduction, the more tapered the preparation becomes. This usually results in an overtapered preparation with insufficient tooth reduction in the gingival one third for optimum periodontal health when using ceramometal full coverage restorations. This type of finishing line should be used only after periodontal surgery that results in long clinical crowns that terminate apically onto root structure. If a shoulder and bevel were to be created at this apically positioned margin, an overprepared tooth and pulpal exposure is likely.

**CLINICAL TIP.** To create a knife-edged finishing line on elongated teeth, first prepare a full shoulder preparation at the cemento-enamel junction to ensure removal of adequate tooth structure. Then prepare a bevel or knife-edged finishing line to the desired gingival margin.

**Chamfer Preparation** A chamfer preparation reduces more tooth structure in the gingival one third than does the knife-edged preparation. However, it does not allow as much room as the full shoulder preparation for the buttressing of metal that is necessary to produce the rigid metallic framework for porcelain. The rounded-end chamfer stone produces the same type of finishing line cut independent of the angle of handpiece placement. This allows for ease of preparation despite varying soft tissue heights and for the creation of a consistent gingival contour. If, however, a chamfer stone is used to create a deep chamfer yielding a low-stress concentration preparation, a reverse lip may be cut. A "low-stress concentration preparation" is one in which the walls are more parallel than in a "high-stress concentration preparation," and the angle of the shoulder is 90 to 110 degrees with an internal rounded-line angle. Removing this lip may result in a preparation that is more subgingival than desired. A more tapered chamfer preparation results in a "high stress concentration-type" preparation. A "high stress concentration-type" preparation is overly tapered, and the shoulder to axial wall line angle is less than 90 degrees. The shoulder slopes incisally. This type of preparation and the knife-edged finishing line may result in marginal metal distortion during firing, depending on the depth of the gingival portion of the preparation.

**Full Shoulder Preparation** The full shoulder preparation has the same attributes as the full beveled shoulder preparation without the disadvantages of the anterior bevel. It is used for a butt joint ceramic-type restoration.

**Full Shoulder with Bevel Preparation** The ideal preparation for a porcelain-fused-to-metal restoration is a full shoulder with a bevel. The main difference between a shoulder preparation and a chamfer preparation in the gingival one third is the additional tooth reduction needed to create a shoulder between the horizontal and vertical line angles formed by the shoulder and the axial wall. The additional reduction provides room for additional metal, which buttresses the shoulder and supports the porcelain. The shoulder preparation may have a shoulder of 90 to 120 degrees. The advantages of a full shoulder with bevel preparation include the following:

- Adequate room is created in the gingival one third for proper contouring of the restoration to maintain periodontal health, and a straight emergence profile is achieved (Fig. 7-5).
- Room is created in the gingival one third for proper porcelain application and esthetics.
- A buttress of metal is created in the gingival area to prevent distortion of the metallic framework during the baking of porcelain and the seating of castings.
- A more parallel, less tapered preparation is created, which enhances retention of the restoration.<sup>19</sup>

#### Bevel Types (Table 7-6)

**45-degree facial bevel** To avoid displaying a labial metal collar, a facial 45-degree bevel and a full shoulder can be prepared. Proximally and lingually, an 80-degree bevel (Fig. 7-6) is cut. The porcelain and metal are brought to a common termination with predictable fit, contour, and color. Because the vertical amount of marginal metal is so narrow, the opaque is barely visible in the finished restoration. The 45-degree bevel is like a



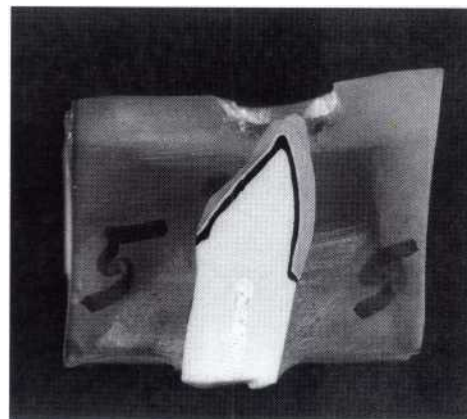
**Fig. 7.5.** Optimal interproximal form for biologic contours of definitive full coverage restorations. The contact area allows for an occlusal embrasure and a gingival embrasure, which allows room for a healthy interproximal papilla. An internal view of the castings shows a beveled shoulder with the same thickness throughout the preparation. The gingival embrasure has a wide contact area to aid cleansability and enhance the health of the surrounding interproximal papilla. The buccolingual embrasure enhances food deflection and periodontal health.

sloped shoulder and allows creation of the desired esthetic result. Also, from a laboratory viewpoint, it is less technique sensitive than a butt joint (Fig. 7-7). A porcelain margin accumulates less plaque, results in less margin exposure caused by gingival recession over time, and is less objectionable cosmetically. Porcelain stacking and firing does not distort the facial margin of the 45-degree bevel. The 45-degree bevel with porcelain over the metal collar has greater esthetic potential and the same marginal adaptation as the 80-degree bevel with an all-metal collar.<sup>10</sup>

**80-degree facial bevel with porcelain covering metal collar** The complete bevel prepared with a plug finishing bur has a convergence angle of 80 degrees or greater (Fig. 7-8). Porcelain baked onto this labial apron will fracture off as a result of flexure of the metal in the apron area.

**Table 7-6.** Finishing line variations for shoulder and shoulder with bevel preparations


Type	Indications
Butt joint	Anterior splints up to six units.
45-Degree facial bevel	Esthetics is paramount; this is a preferred substitute for a butt joint. It also is less technique sensitive.
80-Degree facial bevel with porcelain	Not recommended because of possibility porcelain will fracture.
80-Degree facial bevel with metal	For short preparations to increase retention, endodontic teeth with posts, better closing angles, and postperiodontally treated teeth with long clinical crowns.



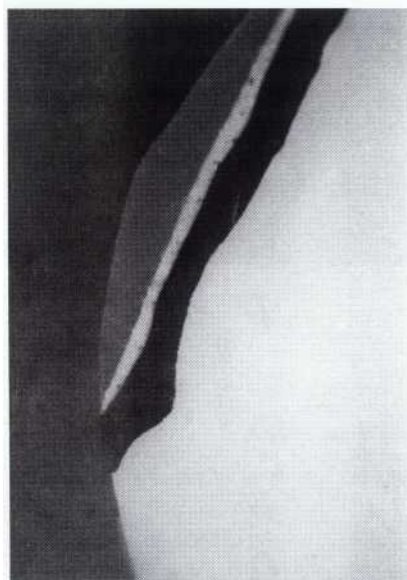
**Fig. 7-6.** Specimen sectioned for light microscopic examination shows a full shoulder preparation with a facial 45-degree bevel and a proximal and lingual 80-degree bevel. Black is metal; white is opaquer; gray is porcelain.



**80-degree facial bevel with metal collar** For small and large splints or fixed prostheses, a full shoulder with a 360-degree encirclement by a bevel is required for closure at the termination of the preparation. The bevel should extend only about 0.5 mm into the labial sulcus area (Fig. 7-9). The metal collar is not a limiting factor in the fab-



*Fig. 7-7.* Magnified view of a prepared tooth showing a facial margin with a 45-degree bevel (original magnification  $\times 25$ ).



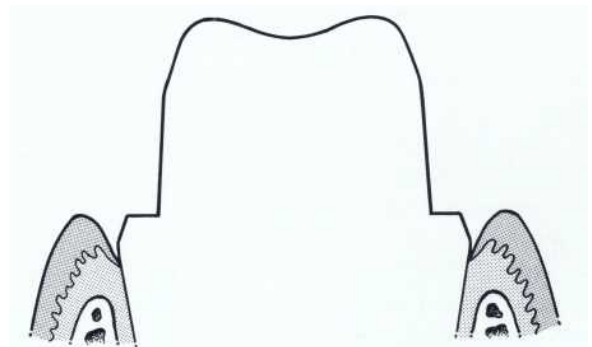
*Fig. 7-8.* Magnified view of a prepared tooth showing a lingual margin with an 80-degree bevel and a metal collar (original magnification  $\times 25$ ).

rication of a fixed prosthesis. It can be used in a single full coverage restoration or for fixed partial prostheses.

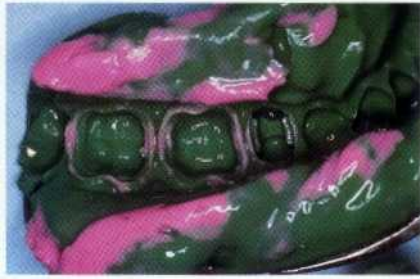**Full shoulder with a bevel and a facial butt joint preparation** The bevel is prepared on the proximal and lingual surfaces of the preparation but not on the facial surface. The labial surface terminates in a butt joint shoulder finishing line to avoid showing a labial metal collar. In addition, for porcelain to be esthetically acceptable, 1.5 mm of thickness must be obtained for the opaque layer and body porcelain. This space does not exist at the margin of a bevel or knife-edged finishing line preparation if optimum crown contours are created. This type of finishing line is satisfactory for single- or multiple-unit splints of up to six units, especially when the labial gingival tissue is thin or almost transparent. A butt joint is not recommended for splints of more than six units because of the contraction of the metal during baking of the porcelain and the concomitant lack of marginal integrity.

### *Impression Considerations*

The preferred method of impressing full coverage preparations uses elastomeric materials. Tissue management is accomplished by preparing the teeth as described below and by creating both the bevel and room in the sulcular area for the impression material through gingival rotary curettage using a 12-fluted blunted plug finishing bur. Gingival retraction cords are not used for gingival retraction but for maintaining the newly created space at the time of impressing. If the soft tissues are healthy and the margins of the preparation were not extended more than 0.5 mm into the gingival sulcus, the gingiva will not bleed during impression making. Only a No. 1 or No. 2 cord is necessary to maintain the sulcular space for the elastomeric materials (Fig. 7-10). An opposing irreversible hydrocolloid impression is also made. The dies of the individual preparations should be trimmed by the dentist, not the technician.



*Fig. 7-9.* Proper placement of the finishing line. The bevel should extend only about 0.5 mm into the labial sulcus area.

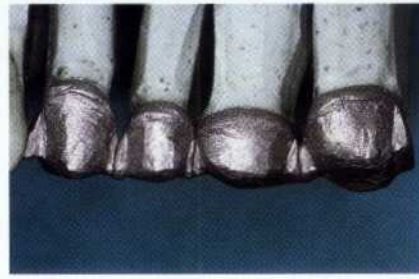

*Fig. 7-10.* To obtain adequate impressions of the gingival margin, a No. 1 or No. 2 retraction cord is necessary to maintain the sulcular space.

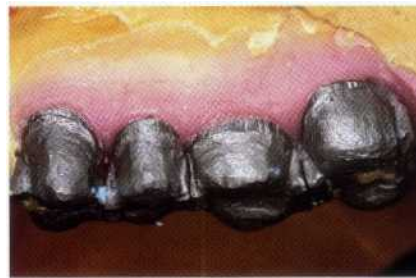Before the cast is sectioned for trimming preparation dies, the models should be mounted in an "indexed" mounting system (i.e., Accu-Trac or Pindex Systems, Coltene/Whalident; Di-Lok System, Di-Equi Corp.). An impression of a tooth is not complete until a likeness of the prepared tooth is given to the laboratory technician for crown fabrication. If the responsibility of die preparation is given to the technician, errors in marginal placement are likely to occur. Therefore the clinician should take the time to prepare the dies before wax-up. Models can be returned from the laboratory with removable dies ready for trimming, or the dentist can send completed casts using a die relating system. In most cases a cast can be poured and indexed and the dies trimmed in the same day with little change in schedule. One layer of die spacer is painted over the die, down to but not including the shoulder and bevel. A thin layer of cyanoacrylate or die hardener is then painted in the ditched area, up to but not including the termination of the bevel, to prevent chipping or scraping away of this area during laboratory procedures. The full arch articulated casts with trimmed dies are then sent to the laboratory for wax-up and fabrication of the ceramometal castings.

### *Framework Considerations*

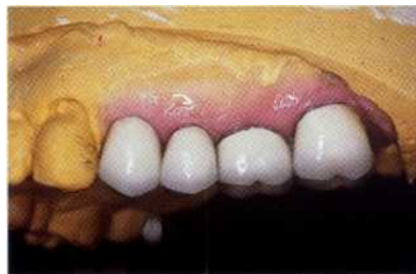One of the very important steps in the construction of a ceramometal restoration is the design of the metal framework. The metal frame must resemble the completed restoration except for the labial, lingual, and occlusal surfaces of abutments and pontics, which are 1.5 mm smaller, and the incisal surface, which is 2 mm smaller, to allow for the support of porcelain and creation of a uniform shade. The connection areas are placed toward the lingual surface with adequate room for opaque, porcelain, and a deep facial embrasure in order to create individuality and the illusion of depth in the definitive porcelain-fused-to-metal restoration. If the dentist is concerned about porcelain fracture, the connection areas can be waxed, cast up to the occlusal surface posteriorly for sup-



*Fig. 7-11.* To prevent porcelain fracture, the metal support in the crown must be adequate. The area most commonly involved in porcelain breakage is the interproximal area, where many crowns are devoid of metal. Dies show castings with metal contacts and adequate support for the porcelain.



*Fig. 7-12.* Dies transferred to a soft tissue model for porcelain margin definition and the creation of proper crown contour.



*Fig. 7-13.* Completed crowns with properly supported porcelain. Note that the crowns are well contoured and have adequate space for the interdental papilla.

port, and to occlusally contact the opposing teeth (Figs. 7-11 to 7-13). If the metal is gold plated, it can mimic the interproximal occlusal embrasure space. Anteriorly, the connection areas should not interfere with the gingival embrasures or incisally with translucency or the incisal embrasure.

The work authorization should specify the placement and height of interproximal struts, the presence of metal

occlusal contacts (when fabricating a posterior ceramometal restoration), and the type of metal desired. For anterior restorations the work authorization should also include the need for metal lingual contact, depending on the individual anterior guidance factors. Posteriorly, the contact areas between adjacent teeth or restorations should be in metal, not porcelain. If the contact point is porcelain instead of metal and the porcelain marginal ridge area fractures, a food impaction area will result, and the crown must be replaced. For **this reason, the interproximal metal struts** on individual crowns should extend to within 1 mm of the occlusal surface of the porcelain and should contain the contact area or point that is required. When the technician returns the ceramometal casting to the dentist, it should be **tried in the mouth for gingival fit, contour, occlusion**, and contact with adjacent teeth. The adaptation of the internal surface of the casting should be checked using Cavitec cement (Kerr/Sybron, Inc.), Multiform paste, or a polysiloxane paste (i.e., Pressure Indicating Material, Coltene, Inc.), as indicating materials. Next, using a small bur, the dentist should scribe the termination of porcelain on the labial surface of the casting at the facial gingival margin. This mark is a guide for the technician for terminating facial porcelain because no porcelain should be baked onto the apron of the crown casting; this area is thin and flexible, and porcelain baked on it will fracture. By scribing the termination of the veneering material intraorally, allowance is made for a small gold collar or finishing line that is hidden in the sulcus area.

**CLINICAL TIP.** Intraoral scribing eliminates the laboratory guesswork about subgingival termination of the porcelain and results in maximal esthetics.

**CLINICAL TIP.** After the porcelain veneer has been baked and glazed, a gold-plating solution may be used to impart a yellow color to gray ceramometal casting. The gray color of the metal adds a darkness to the gingiva. The plated yellow gold color gives a softer, "self-masking" appearance that is more acceptable to the patient (Fig. 7-14).

### Pontic Design

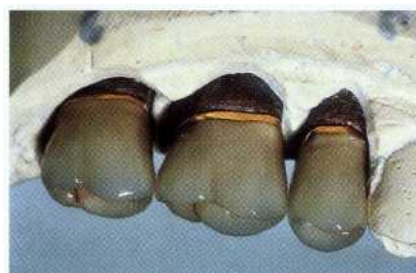**Sanitary Pontic** The sanitary pontic (Fig. 7-15, D) with no tissue contact is an alternative to the ridge lap pontic. It has the occlusal form and function of the tooth it replaces but has a rounded gingival surface that does not extend to the residual ridge. This pontic is used when an esthetic replacement is not required. However, it may be used in mandibular molar areas. Maintenance of a hygienic condition of the ridge generally is satisfactory when the pontic, with rounded contours, is kept 2 to 3 mm above the ridge. When the

pontic tissue clearance is less than 2 mm, it contributes to food entrapment.

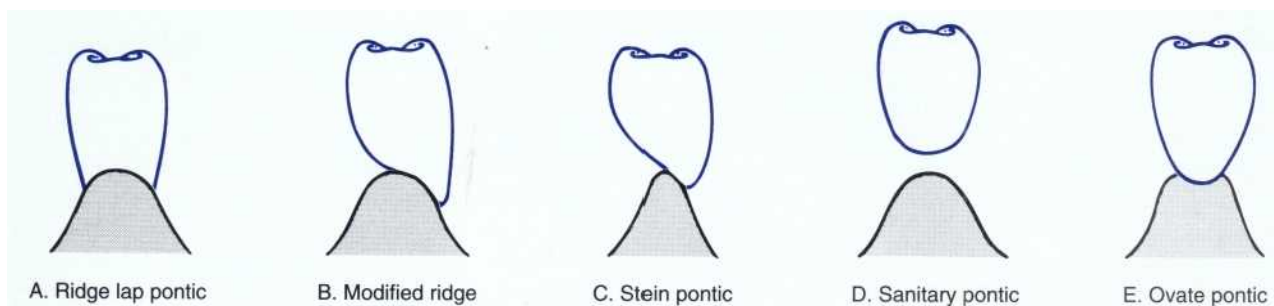
**Ridge Lap Pontic** Ante stated, "A pontic must restore the dentition to proper form and function while preserving the esthetic quality of the tooth it replaces, ensure its sanitation, and be biologically acceptable to the tissue."<sup>21</sup> Ideally, a pontic would exactly duplicate the tooth it replaces. However, the residual ridge over which the pontic will be placed usually is convex.<sup>22</sup> Consequently, that surface of the pontic contacting the mucosa would be concave if the pontic were to recreate the natural tooth shape at the gingival area. This maximum tissue contact pontic design, known as the ridge lap or saddle pontic (Fig. 7-15, A), is undesirable because a concave surface is difficult to clean, resulting in soft tissue irritation with concomitant periodontal problems.<sup>23</sup>

**Modified Ridge Lap Pontic** In the modified ridge lap design (Fig. 7-15, B),<sup>24</sup> the facial aspect of the pontic **assumes the shape of the replaced tooth** and contacts the soft tissue only on the buccal half of the ridge. This allows for maximum esthetics. The tissue contact is minimal, and the underside of the pontic does not follow the convex anatomy of the residual ridge, as in the ridge lap design. Instead, a rounded convex surface unites with the lingual portion of the pontic in a smooth design that is easily cleaned. Despite improved esthetics and control of sanitation, some problems surface soon after insertion of the fixed prosthesis:

- Despite hygienic procedures, the concave tissue surfaces of the pontics invariably become coated with plaque and debris. The corresponding ridge surfaces usually become red and inflamed.<sup>25</sup>
- The triangular area of the lingopalatal surface traps food particles and also annoys the patient's tongue.



*Fig. 7-14. Buccal view of maxillary second premolar and first and second molars. Optimum biologic contours enhance periodontal health. The 80-degree bevels are not covered by porcelain. Interproximal contact areas are placed in the occlusal one third of the tooth. The gray color of the metal is plated with a yellow gold color to give a softer appearance.*



**Fig. 7-15.** Relationship of poetic design to residual ridge. *A, Ridge lap poetic.* This type of poetic demonstrates unacceptable excess tissue contact and is difficult to maintain hygienically. *B, Modified ridge lap poetic.* This type of poetic demonstrates acceptable esthetics and works best with broad edentulous ridges. *C, Stein poetic.* This type of poetic, which is designed for sharp edentulous ridges, demonstrates minimal tissue contact and acceptable esthetics. It is contraindicated in edentulous ridges with broad buccolingual dimensions. *D, Sanitary poetic.* This type of poetic is 2 to 3 mm distant from the ridge. This design is easily cleaned and allows for a free flow of food beneath the poetic. However, it exhibits unacceptable esthetics. *E, Ovate poetic.* This type of poetic exhibits excellent esthetics and function. It produces minimal tissue contact and is very hygienic. However, if ridge resorption occurs, deterioration of esthetics results.

The poetic may not provide adequate air seal for desired or correct phonation.

The space that exists between poetic and ridge or poetic and abutment may permit droplets of saliva to be forced through during speech sounds, causing annoyance and embarrassment.<sup>16</sup>

**Stein Poetic** The Stein poetic (Fig. 7-15, C) is a variation of the modified ridge lap poetic. It is designed for sharp edentulous ridges, exhibits minimal tissue contact, and offers acceptable esthetics. It is contraindicated in edentulous ridges with broad buccolingual dimensions.

**Ovate Poetic** The most functional and esthetic poetic is the ovate poetic (Fig. 7-15, E). It requires plastic reconstructive surgery of the ridge to create a concavity. In the preparation of an ovate poetic, an egg-shaped concavity is produced on the tissue surface that blends into the cervical one third of the poetic, and the tissue surface of the poetic is glazed and polished to a smooth finish. When properly placed, the poetic appears to emerge from the surgically created corpus of the ridge, affording a more natural and pleasing effect. Cleansing of soft tissue and the poetic is expedited and effective. A properly contoured ovate poetic automatically creates interdental papillae that fill the embrasures, thereby eliminating the dark space triangles between teeth, reducing the escape of saliva during speech, and reducing occasional lisping sounds. The ovate poetic is a necessity in patients with a high smile line. It is contraindicated in or against a knife-edged ridge. It is important that the residual ridge be capable of augmentation in buccolingual thickness to contain the ovate poetic within the body of the ridge (see Chapter 18).

## BASIC CONSIDERATIONS IN TOOTH FORM

### *Patient Personality and Gender*

Dentists are obligated to acquaint themselves with all personality factors that can be gleaned from patients. The oral examination, the history, and the many aspects relevant to the patient's esthetic requirements and expectations should serve the dentist well in the attempt to provide the most esthetic and functional prosthesis possible.

Endless combinations and variations of physical attributes exist in men and women, but a complete analysis also accounts for personality factors. In general, masculinity is associated with vigorous, strong, and robust qualities, whereas femininity is translated in terms of softness, delicacy, and curvature of anatomic form (see Chapter 2).

By selecting and modifying a tooth form, the dentist is creating an image for the patient. By placing the two maxillary central incisors boldly in a dominating position, around which the lateral incisors are rotated and elevated slightly above the plane of occlusion, the sense of vigorous domination is established in the position of the maxillary central incisors. A small maxillary lateral incisor confers the appearance of femininity, whereas lateral incisors that are almost as broad as central incisors confer ruggedness and masculinity. A patient with a "delicate" appearance often has lighter skin and consequently lighter teeth.

The maxillary canines are important because they are easily visible from a frontal or lateral view, and they serve as a gateway to the posterior teeth. By turning the tip of the canine inward, one may prevent a toothy, and possibly anthropoidal appearance<sup>27</sup>; however, the mesial aspect of the canine should not be hidden when viewed from directly in front of the patient.

An important factor to consider in all cases is the patient's age. The dentist is seeking to create, when necessary, the desired illusion of a natural tooth in the oral environment. Age and concomitant changes bring challenges to the creative dentist attempting to fabricate an artistically acceptable prosthesis. Studying changes wrought by time and their visibility in relation to the planned porcelain restoration may suggest appropriate modifications, such as cuspal reductions caused by wear, reduction of translucent incisal edges of anterior teeth, color change, possible change in the shape of papillae and, of course, changes in chroma and value.

A study of the position of natural teeth reveals the following<sup>27</sup>:

1. Roundness of the arch form denotes femininity; squareness denotes masculinity.
2. The incisal edges of the maxillary teeth of women follow the curve of the lower lip.
3. When women speak, smile, or laugh, they expose more maxillary teeth than men do. The maxillary first premolars should be contoured to conform with the canines.
4. In men, a square incisal silhouette with prominence of the maxillary central incisors and canines may indicate a bolder and more vigorous personality.

It is an inspiring challenge to the dentist to duplicate as closely as possible the qualities of the natural teeth, resulting in unobtrusive functional and harmonious restorations (see Chapter 2).

### Alignment of the Gingival Margins

A bilaterally balanced alignment of the gingival margins usually enhances the cosmetic result. When discrepancies are visible, the patient should be referred for periodontal correction before tooth preparation begins (see Chapters 15 and 18).

## HUE, CHROMA, AND VALUE

Preston and Bergen<sup>28</sup> have provided the following definitions:

*Hue*: "That dimension of color used to distinguish one family of color from another." By the common names, the physical hue order is violet, blue, green, yellow, orange, and red. Hue usually is defined by the color family name.

*Chroma*: "That quality by which one distinguishes a weak hue from a stronger, more intense hue. It is the amount of a basic hue added to gray. If more colorant is added, a stronger, more intense hue (higher chroma) results." Chroma also is referred to as "saturation." Chroma denotes the concentration

or strength of the basic hue. Intense color indicates a higher chroma, or saturation.

*Value*: "That quality by which one distinguishes a light color from a dark color; a gray scale that extends from black to white. It has nothing to do with the amount of gray in a color, only the relative level of brightness, lightness, or brilliance. It is not a quantitative but rather a qualitative description.

Value is found by comparing the chosen color to a color of similar brightness." Colors of low value are more like black; colors of high value are more like white. Value, a quality of grayness, is an important factor of color, both to the dentist and the technician, who should be able to separate value from other dimensions and detect and control differences that could prove disastrous to shade matching.

One of the simplest modifications is to raise the chroma of the dominant hue. The modification of the chroma that is 100 high is more difficult. If a lower chroma is needed, the color must be neutralized by its complement. The most obvious color one might use to raise value is white. The technician should be fully versed in the many ways of managing dentists' requests for modifications and characterizations, and communication should be completely clear (see Chapter 2 and Appendix A).

Poor esthetics is exacerbated when too light a shade has been selected and modified by staining and coloring; this combination creates artificiality.

The dentist should differentiate the hue, value, and chroma of the patient's natural teeth and apply these factors to the porcelain tooth or teeth to be fabricated.<sup>29</sup> Concentrating on these aspects for 5-second intervals helps prevent retinal fatigue (retinal adaptation) and allows shade differences to be more readily detected. One very important factor that the dentist must communicate to the technician is the type of tooth enamel being matched (i.e., opaque, translucent, dull, or highly reflective). No matter how beautifully the color has been incorporated into the porcelain restoration or how skillfully the tooth has been contoured, a high glossy glaze is incompatible with the appearance of the enamel of the surrounding teeth if the latter are comparatively dull.

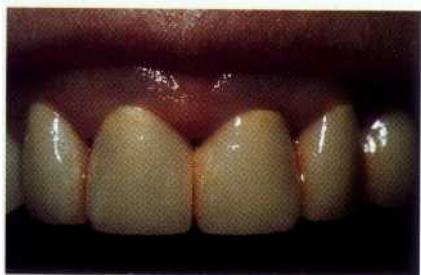Ceramometal procedures require the thinnest layer of porcelain opaquing materials that still block out the metal casting surface. Covering this opaque masking with a thin layer of translucent body and incisal porcelain permits the restoration to become highly reflective. As such, the tooth cannot be compatible with its adjacent natural teeth.

**CLINICAL TIP.** To compensate for high light reflection (which results when thin layers of translucent porcelain are used to cover an opaque mask), select shades that are slightly lower in value than the surrounding teeth." This should not reduce the brightness of the restoration.

Positioning the restoration more lingually and increasing the incisal curvature directs the light in various directions away from the viewer. The contour and texture of the outer porcelain surface defines the character of the restoration and contributes vitality to its appearance. Each tooth is individualized and characterized by a distinct outline form. The incisal form and tooth position influence esthetics more than any other aspect, because the tooth is silhouetted against the dark shadow of the oral cavity.

### *Creation of Dental Illusions*

The apparent size of the teeth (length and width) may be influenced by the contours of the teeth and the effects of light reflections (Fig. 7-16). For example, the maxillary central incisors reflect light anteriorly, superiorly, inferiorly, and laterally. By contouring the facial or labial aspects to deflect the light in directions other than forward (e.g., by curving the lateral aspects into embrasures), the tooth may be made to appear narrower and longer. Using contouring to reflect light superiorly in the gingival one third and inferiorly in the incisal curve should give the illusion of a shorter, broader maxillary tooth. In the case of malpositioned teeth, it may be necessary to create the illusion of a wider tooth in a small space. This can be effected by bringing the contact points as far labially as possible and flattening the surfaces to reflect all the light labially. Similarly, a diastema can be eliminated by porcelain crowns that make contact in lingually positioned embrasure and that have narrow facial aspects to reflect a smaller tooth. The curves moved laterally into the embrasures allow the light to be deflected away from the viewer<sup>16</sup> (see Chapter 2). The facial forms of the adjacent



*Fig. 7-16. Illusions can be used to enhance teeth, especially when a very light shade is used. The labial surfaces are curved, the interproximal areas are stained orange-brown to enhance individuality, and the incisal length and curvature follow the smile line of the lower lip. The contour of the gingival one third presents a straight emergence profile to enhance the health of the surrounding soft tissues. Adequate interproximal room is provided for the gingival papilla and gingival embrasures.*

crowns should curve into one another in the areas of the proximal contact rather than be separated by a thin, straight disk.

Surface texturing that is similar to adjacent natural teeth is an important feature of the restored tooth. It produces an interplay of light and creates pleasant color matching experiences.

Horizontal and vertical lines affect the apparent width or length of the tooth being fabricated.

In addition to the variables of color and contour, the technician should be informed of all aspects involving the compatibility of the porcelain with various aspects of the remaining natural teeth.

A removable partial denture affords the advantage of trial seating in determining the size and form of the restorative teeth.

**CLINICAL TIP.** Surface texturing on the restorations should be slightly more emphasized than that on the adjacent tooth being matched because light is reflected differently from tooth enamel and glazed enamel.

Corrections can be made in wax in the process of repositioning, reshaping, or replacing the denture teeth. In fixed prosthodontics, temporary acrylic resin coverage serves a similar diagnostic function. By adjusting the plastic, the dentist may satisfy the patient's esthetic expectations. An impression and a poured stone model may serve as further instructional guidance for the laboratory technician.

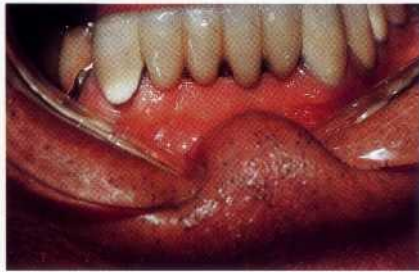
A valuable aid in creating esthetic restorations is to place a degree of importance on the patient's personality. Esthetic factors usually correlate with the patient's facial form and degree of facial symmetry. Rounded, blunt, or sharp distoincisor line angles of incisor teeth greatly affect the visual perception of facial esthetics. Incisal embrasures should vary from one side of the tooth and arch to the other. The degree of space from the mesiolabial incisal line angle must contain both horizontal and vertical variations of this space.

Extrinsic staining and shading highlight or illuminate the cosmetic result only when all the above factors have been satisfied. Incisal translucency, enamel hypocalcifications, enamel crazing lines, and areas of wear can be accurately created in an esthetic restoration. Overcharacterization can mar the result and produce an unwanted, unsightly effect.

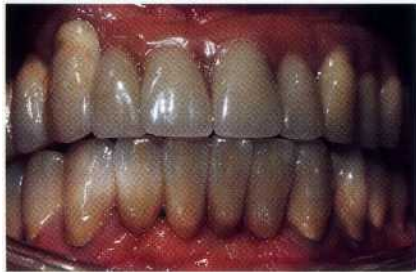Poor esthetics occur when the teeth lack individuality. Poor esthetics are exacerbated by shade, staining, or coloring that is too light and by a lack of proper embrasures, surface texture, and contours. When all the above occur, the restoration appears flat, unindividualized, and of uniform color, giving the appearance of a single mass of porcelain, or what is known as "Chicklets" (Figs. 7-17 and 7-18). An acceptable cosmetic result is obtained as follows:

Avoid flatness by optimum fabrication of the curvature of the labial surfaces, which reflect light differently.

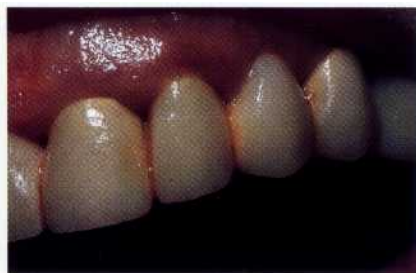Use deep orange-brown stain interproximally to enhance the individuality of the prosthesis (Fig. 7-19).



*Fig. 7-17. Preoperative view of a mandibular fixed porcelain-fused-to-gold restoration that required replacement because of recurrent caries. The restoration appears as a single mass of porcelain and lacks individualization of the teeth and proper color characterization. Placing the pontics on the crest of the residual ridge creates dark spaces.*



*Fig. 7-18. Postoperative view shows a prosthesis with overlapping of the mandibular incisors, which greatly improves the esthetics. Brown and orange-brown staining of the interproximal and labial surfaces diffuses the reflected light and enhances the individuality within the restoration. Open gingival and incisal embrasures have been maintained, and proper placement over the residual ridge creates optimal esthetics.*



*Fig. 7-19. Deep orange-brown stain highlights the individuality within the restorations. Incisal embrasures are open, and curvature and incisal length follow the smile line from the central incisors to the canines.*

Create deep incisal embrasures for individuality; the length and curvature of the incisal surfaces should follow the smile line of the lower lip.

Avoid gingival inflammation by providing adequate interproximal space for the papillae and gingival embrasures. The gingival terminations must not be overextended or shy of the margin or too bulky, which results in gingival problems. The labial gingival heights must be the same. The porcelain-fused-to-metal restorations should aid in maintenance of an optimal periodontal environment.<sup>10</sup>

## MANAGEMENT OF MALALIGNED TEETH

### Diastemata

Several methodologies may be used to create a favorable cosmetic result when diastemata are present or when teeth are rotated. The optimum method of treatment is to use adult orthodontics, whether minor tooth movement or full-banded complete therapy (see Chapter 19).

**CLINICAL TIP.** If porcelain-fused-to-metal restorations are fabricated to close existing diastemata without prior orthodontics and if the occlusogingival height is not great, the resultant crowns will appear short and square. This may create a more unfavorable esthetic result than maintaining the diastemata.

After tooth movement is complete, the teeth are held in place for at least 6 months by a fixed retainer. If the teeth are to be covered eventually, metal and acrylic resin fixed provisional restorations may be used as the fixed retainer. The major problem with adult orthodontics for closure of diastemata or correction of rotated or overlapped anterior teeth is the common need for splinting the teeth to maintain their positions after tooth movement, because they have a tendency to revert to their original positions.

### Protruded Teeth

When a tooth is labially protruded, the surrounding facial soft tissue is thin; this is especially common with the maxillary canines. Orthodontic therapy is the treatment of choice (see Chapter 19). If this tooth is to be covered with a restoration for realignment and cosmetics without orthodontic treatment, sufficient tooth structure must be removed to allow not only for metal and porcelain but also for the realignment. Prophylactic endodontic therapy is often necessary. Also, the facial margin of the restoration cannot be carried subgingivally without the risk of gingival recession resulting from the thinness of this facial soft tissue. In addition, a pronounced labial



bulge at the gingival margin of the definitive restoration cannot be avoided because of the facial angulation of the underlying root.

**CLINICAL TIP.** In addition to the anticipated cosmetic result, the patient must know the risks and the problems involved in placing porcelain-fused-to-metal restorations on malaligned or spaced anterior teeth without prior orthodontic treatment. These problems can be demonstrated on a diagnostic wax-up before any irreversible dental procedures are performed.

## Tooth Reduction

### Armamentarium

#### Standard dental setup

- Explorer
- Mouth mirror
- Periodontal probe
- Appropriate anesthesia
- High-speed handpiece
- Low-speed handpiece
- Suitable size impression trays
- Diamond burs
- A football-shaped diamond stone, coarse or medium (e.g., 63-68-023 large or 63-68-016 small, Brasseler USA).
- A shoulder diamond stone or a cylinder stone (e.g., 835-010, Brasseler USA).
- A 1-mm diameter shoulder diamond with a 3-degree taper (e.g., 6847-016 [Brasseler USA] for molars or the smaller 811-033 [Brasseler USA] for premolars). The 45-degree bevel is formed with the Premier two-striper DCB.5.

### Clinical Technique

1. Administer the appropriate anesthesia.
2. Create two 1-mm, 3 degree-taper labial guide cuts with the shoulder diamond bur. The first cut follows the facial angle from the height of contour to the incisal edge. The second cut parallels the long axis of the tooth from the gingival margin to the height of contour. This ensures sufficient removal of tooth structure and a 3-degree taper.
3. For anterior teeth, prepare a third depth guide cut on the lingual surface from the gingival margin to the height of the cingulum, using the same shoulder diamond stone as for the labial surface. Prepare a fourth depth guide cut from the height of the cingulum to the incisal edge with a 1.2-mm shoulder stone.
4. For posterior teeth, prepare two depth guide cuts on the lingual surface as described for the facial surface. Create an additional depth cut at least 1.5 mm deep on the occlusal surface to ensure adequate occlusal reduction.

**CLINICAL TIP.** To ensure sufficient room for incisal or occlusal porcelain and to prevent a restoration from being too protrusive, remove at least 1.5 mm of tooth structure from the incisal one third of the labial surface.

5. Finish the preparation, except for the area incisal to the cingulum of the anterior teeth, by following the depth guide grooves.

**CLINICAL TIP.** Follow the height of contour of the soft tissues labially, lingually, and proximally. If the preparation extends too deeply within the sulcus, the sulcular epithelium and gingival attachment will be damaged, resulting in gingival inflammation and recession. Preparations that extend too far subgingivally in the interproximal portions and those that do not follow the contour of the soft tissues may result in interproximal inflammation and facial gingival recession.

6. For anterior teeth, reduce the height of the incisal edge by at least 2 mm.
7. For anterior teeth, prepare the area from the incisal edge to the cingulum with a football-shaped stone. The depth of preparation in this area must accommodate for the incisal guidance created in the diagnostic wax-up and also provide room for the metal, opaque, and porcelain of the restoration. If the pulp is large, a metal lingual surface may have to be used to avoid pulp exposure.
8. For the anterior teeth, verify tooth reduction, especially that area influencing the incisal guidance, with the transitional prosthesis. If the section incisal to the cingulum becomes thin or perforated, reprepare this area or alter the treatment plan (e.g., metal lingual, intentional endodontics, or selective grinding of opposing teeth before impressing the preparation).
9. Contour and polish the provisional restorations and cement them with a sedative temporary cement (see Chapter 11).
10. Dismiss the patient and evaluate the esthetics, tooth contours, gingival health, and occlusion at the next office visit.

## Bevel Placement

Once the esthetics of the provisional restorations are acceptable to both the dentist and the patient, create a finishing line.

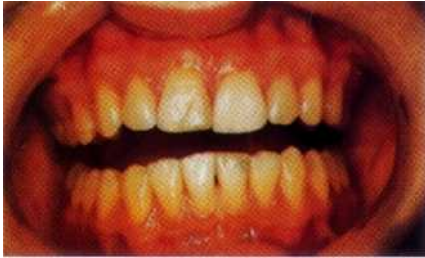### Armamentarium

- Standard dental setup. See the above section on tooth reduction.
- Blunted 12-fluted steel finishing bur (i.e., GTB 300.11-14, Brasseler USA, or 152-010, Busch), which is manufactured with a blunted tip or a fine diamond bur (i.e., 8863-012, Brasseler USA)

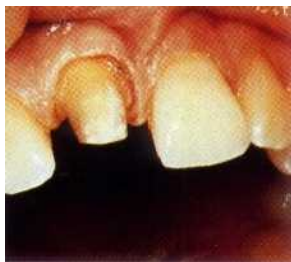

**Clinical Technique**

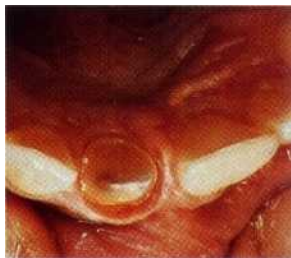1. Prepare a bevel on the mesial, palatal, and distal margins with a blunted 12-fluted steel plug or fine diamond finishing bur (Figs. 7-20 to 7-23).



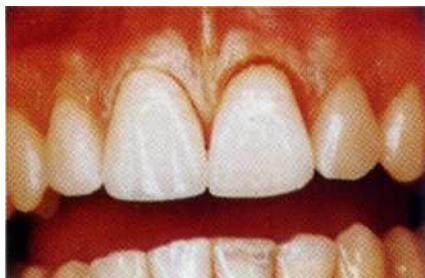*Fig. 7-20. Preoperative view of unesthetic right central incisor requiring a full coverage restoration.*



*Fig. 7-21. The tooth in is prepared with a labial butt joint and a mesial, distal, and lingual full shoulder with an 80-degree bevel.*



*Fig. 7-22. Palatal view of the patient shown in Fig. 7-20.*



*Fig. 7-23. The provisional restoration is contoured, polished, and cemented with a sedative temporary cement. A gingivectomy was performed to improve soft tissue esthetics.*

2. Use a clockwise direction for beveling and a counterclockwise rotation for gingival curettage.
3. Hold the bur parallel to the path of insertion. The bevels and subgingival buccal shoulder must not violate the biologic width (see Chapter 18).

**Tissue Management and Impressioning****Agmamentarium**

Standard dental setup. See the above section on tooth reduction.

No. 1 gingival retraction cord

No. 2 gingival retraction cord

Suitable impression material

**Clinical Technique**

1. The preparation of the bevel creates adequate room in the sulcular area for the impression material.

**CLINICAL TIP.** Gingival retraction cords are not used for gingival retraction at the time of impressioning, but rather to maintain the space created while beveling.

2. No gingival bleeding should occur at the time of impression making. If the soft tissues are healthy and were managed without extending the margins of the preparation more than 0.5 mm into the gingival sulcus, the gingiva will not bleed.
3. Only a No. 1 or No. 2 cord is necessary to maintain the sulcular space for the impression material.
4. The single strand of cord should be fully visible when in place. It is not used for retraction, but rather to maintain the prepared sulcus.
5. Make a final impression of the preparations.
6. Make an irreversible hydrocolloid impression of the opposing arch.
7. Before sectioning the cast for trimming preparation dies, the models should be mounted in an "indexed" mounting system (i.e., Accu-Trac or Pindex Systems, Coltene/Whaldent; Di-Lok System, Di-Equi Corp.).
8. After securing the dies, trim and ditch them below the end of the preparation.

**CLINICAL TIP.** To ensure proper delineation of the margin, the dentist should trim the individual dies. Models can be returned from the laboratory with removable dies ready for trimming, or the dentist can send completed casts using an "indexed" mounting system (i.e., Accu-Trac or Pindex Systems, Coltene/Whaldent; Di-Lok System, Di-Equi Corp.). With practice, casts usually can be poured and indexed and the dies trimmed in one day, with little alteration in the practitioner's schedule.

## Die Trimming and Preparation

### Armamentarium

- Denture vulcanite bur
- No. 6 handpiece round bur
- Die spacer, 0.25-mm thickness (George Taub Products)
- Cyanoacrylate

### Clinical Technique

1. Trim the die first with a vulcanite bur.
2. Ditch below the bevel with a No. 6 round bur.
3. Paint a single layer of die spacer over the entire die, except for auxiliary grooves, the shoulder, and the bevel.
4. Paint a thin layer of cyanoacrylate or die hardener over the termination of the bevel to prevent chipping or scraping away of this area during laboratory procedures.
5. Articulate the full arch casts (with trimmed dies) and send instructions to the laboratory for wax-up and fabrication of the ceramometal castings.

## Work Authorization

The work authorization should specify the placement and height of interproximal struts, metal occlusal contacts (when fabricating a posterior ceramometal restoration), and the type of metal the dentist wants. For anterior restorations, the work authorization should also include the need for metal lingual contact, depending on the individual anterior guidance factors. It should be emphasized to the laboratory that the contact areas between adjacent teeth or restorations should be in metal and not in porcelain in the distal of the first premolars and all other posterior teeth.

**CLINICAL TIP.** If the contact point is in porcelain instead of **metal and the porcelain marginal ridge area fractures, a food impaction area results, and the** crown must be remade. Therefore the interproximal metal struts on individual crowns should extend up to within 1 mm of the occlusal surface of the porcelain and should contain the contact area or point that is required.

## Try-In of Castings

### Armamentarium

- Standard dental setup. See the above section on tooth reduction.
- Indicating paste
- Cavitec cement (Kerr/Sybron, Inc.) or Multiform paste (Surgident, Corp.) or polysiloxane material (i.e., Pressure spot indicator, Coltene/Whaldent)
- No. 1 round bur

### Clinical Technique

1. Check the adaptation of the internal surface of the casting using Cavitec cement, Multiform paste, or a polysiloxane material as the indicating material.
2. Check the castings in the mouth for gingival fit, contour, occlusion, and contact with adjacent teeth.
3. Using a small bur, scribe the desired location of the termination of porcelain on the labial surface of the casting, at the facial gingival margin.

**CLINICAL TIP.** A scribed line serves as a guide for the technician for the cervical termination of facial porcelain and allows the thin metal collar or finishing line to be hidden in the sulcus area.

**CLINICAL TIP.** With a small No. 1 round bur, scribe the porcelain termination line on the labial surface of the casting at the facial gingival margin. This line serves as a guide for the technician for the cervical termination of the facial porcelain and allows the thin metal collar or finishing line to be hidden within the sulcus area.

## Soft Tissue Models and Shade Selection

**CLINICAL TIP.** Crown contours are critical for establishing esthetics and maintaining gingival health. A soft tissue cast is helpful in this regard, especially in anterior teeth. Create the soft tissue model after the castings are tried in and found to be clinically acceptable.

### Armamentarium

- Standard dental setup. See the above section on tooth reduction.
- Suitable luting agent
- Autopolymerizing acrylic resin (i.e., Duralay, Reliance Corp.)
- Suitable impression material (i.e., irreversible hydrocolloid)
- Metal retention device (i.e., flat-headed screws or bent dowel pins)
- Soft Denture Reline Acrylic (e.g., Coe Soft, Kerr Manufacturing Co.)
- Self-curing pink acrylic (i.e., Jet Pink Acrylic, Lang Dental Manufacturing Co.)
- Yellow stone

### Clinical Technique

1. Lute the castings together intraorally with red autopolymerizing acrylic resin.
2. Make an overall irreversible hydrocolloid impression with the castings reseated firmly into the index.
3. Flow a soupy mix of red autopolymerizing acrylic resin into the occlusal two thirds of the casting and

insert a flat-headed screw or bent dowel pin into the stone cast for retention.

4. Cover the gingival area surrounding the castings with a mixture of two parts resilient autopolymerizing denture liner and one part hard pink autopolymerizing acrylic resin.<sup>31</sup>

**CLINICAL TIP.** Apply the mixture with a standard disposable syringe. Then sprinkle acrylic beads onto the surface to facilitate union with the subsequent die stone cast.

5. Make an irreversible hydrocolloid impression of the provisional restoration and send models to the laboratory.
6. Select a shade and prepare a proper laboratory prescription, including required characterization (see sections in this chapter on basic considerations in tooth form and hue, chroma, and value; see also Chapter 2).

**CLINICAL TIP.** Use intrinsic rather than extrinsic stains, because intrinsic staining is not eliminated when the crown is reshaped by the clinician or technician. Also, intrinsic stains have a more realistic appearance than surface stains.

## Procelain Try-In

### Armamentarium

- Standard dental setup. See the above section on tooth reduction.

### Clinical Technique

1. The laboratory should only use low-speed hand-piece fine green stones or fine diamond stones to re-carve the bisque bake porcelain.
2. Correct the points or areas of contact until unwaxed extra fine dental floss just snaps through.
3. Refine the crown contours intraorally with appropriate high-speed diamond stones and copious amounts of water to avoid overheating and fracturing the veneering material.
4. Refine the occlusion. If the cast is inaccurate, make another impression. If the articulation is incorrect, remount the case before returning it to the laboratory.

**CLINICAL TIP.** Perform extensive additions directly on the model, using ivory wax. Take an irreversible hydrocolloid impression of these altered restorations and make a cast. This creates a guide for the technician to make the required alterations.

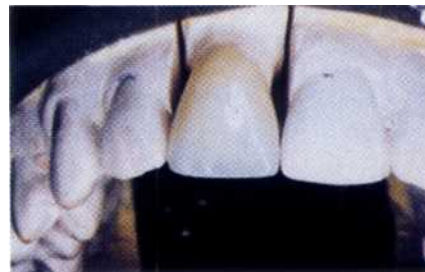5. When splinting a posterior quadrant, the metal interproximal struts can be maintained up to and in-

cluding the occlusal surface for maintenance of occlusal stability in patients with a high risk of porcelain fracture (see the section in this chapter on framework considerations). Correct centric occlusal discrepancies on the articulator on which the casts had been previously mounted, according to verified maxillomandibular recordings.


6. Correct small discrepancies in eccentric movements intraorally.
7. Return the bisque bake restoration to the laboratory with the proper work authorization, including the required changes and a shade guide tab or a drawing of the selected color indicating placement of gingival, body, and incisal shades and character variations (Figs. 7-24 and 7-25).

**CLINICAL TIP.** To maintain a natural appearance and surface texture, use the natural glaze of the porcelain rather than painting on a low-temperature glaze after applying surface stains.

**CLINICAL TIP.** If the original bisque bake does not match the selected color, return the chosen shade guide tab to the laboratory. As an alternative, an acrylic resin stain kit (e.g., Minute Stain, George Taub Products) can be used to modify an acrylic shade guide tab to the correct shade of the provisional restoration.



*Fig. 7-24. The crown is inspected for marginal fit, porcelain imperfections, and proper esthetics.*



*Fig. 7-25. The internal aspect of the crown shows a clearly defined finishing line and labial porcelain.*

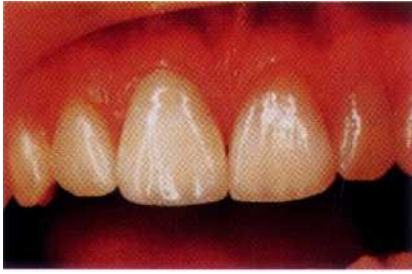

Fig. 7-26. The final restoration.

### Trial Cementation and Final Cementation

Trial cementation is used in multiple-unit cases for final evaluation of esthetics and occlusion and to detect any processing errors. If these factors are satisfactory, the restoration is placed with the definitive cement (Fig 7-26).

### CONCLUSION

The procedures described in this chapter involve newer concepts and techniques. The diagnostic phase permits consultation and treatment planning among several disciplines. The introduction of new surgical and prosthetic techniques permits the solution of more problems with greater patient satisfaction.

The clinician should discuss treatment plans and esthetic goals directly with the patient in order to achieve a satisfactory result. The surgeon is responsible for ensuring that all prosthetic and esthetic goals are clearly defined. Thus preprosthetic and presurgical planning and joint consultations should occur as often as needed to determine the resolution of problems that may affect the result. Such problems may include the feasibility of the design of the pontics, the design of the provisional prosthesis, the nature of the ridge deformity and potential reconstruction, and unexpected complications.

### REFERENCES

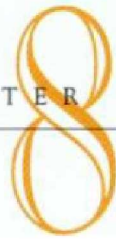1. Craig RG: Restorative dental materials, ed 10, St Louis, 1997, Mosby.
2. Asgar K: Casting materials. International State of the Art Conference on Restorative Dental Materials, National Institutes of Health, Bethesda, Md, Sept 8-10, pp. 105-123, 1986.
3. Phillips RW: Skinner's science of dental materials, ed 8, Philadelphia, 1982, WB Saunders.
4. McLean JW: The science and art of dental ceramics, vol 2, Bridge design and laboratory proceedings in dental ceramics, Chicago, 1980, Quintessence.

5. Cascone PJ: The theory of bonding for porcelain to metal systems. In Yamaha H, Grenoble, P: Dental porcelain: the state of the art. University of Southern California Conference Proceedings, a compendium of the Colloquium held at the University of Southern California School of Dentistry on Feb. 24-26, Los Angeles, Calif., 1977.
6. Perel ML: Periodontal considerations of crown contours, 3 Prosthet Dent 26:627, 1971.
7. Wheeler RC: Complete crown form and the periodontium, 3 Prosthet Dent 11:722, 1961.
8. Yuodelis RA, Weaver JD, Sapkos S: Facial and lingual contours of artificial crown restorations and their effects on the periodontium, 3 Prosthet Dent 29:61, 1973.
9. Avner SH: Introduction to physical metallurgy, New York, 1974, McGraw Hill.
10. Williams DY: Materials in clinical dentistry, New York, 1979, Oxford University Press.
11. Vickery RC, Badinelli LA: Nature of attachment forces in porcelain-gold systems, J Dent Res 47:683, 1968.
12. Tuccillo JJ: Dental restorations combining dental porcelain and improved white gold alloy, US Patents No 3,961,420 and No 3,981,723 (1976).
13. Tuccillo JJ: Comments at the International State of the Art Conference on Restorative Dental Materials, National Institutes of Health, Bethesda, Md., Sept. 8-10, pp. 151-155, 1986.
14. Ingersoll CJ: Tarnish-resistant palladium base dental casting alloy, US Patent No 113,929,474 (1975).
15. Cascone PJ: Low dental alloy, US Patents No 4,523,262, and No 4,539,176, (1978, 1985).
16. Eissman HS, Rudd KD, Marrow RM: Dental laboratory procedures in fixed partial dentures, vol 2, St Louis, 1980, Mosby.
17. Schwartz H: Anterior guidance and aesthetics in prosthodontics, Dent Clin North Am 31:323, 1987.
18. Zinner ID, Trachtenberg DI, Miller RD: Provisional restorations in fixed prosthodontics, Dent Clin North Am 33:355, 1979.
19. Panno FV: Preparation and management of full coverage restorations for combination fixed removable prostheses, Dent Clin North Am 31:505, 1987.
20. Panno FV et al: Evaluation of the 45-degree labial bevel with a shoulder preparation, 3 Prosthet Dent 56:655, 1986.
21. Ante IH: The fundamental principles of design and construction of crown and bridge prostheses, Dent Items Interest 1:215, 1928.
22. Atirams H, Kopezyk R, Kaplan A: Incidence of anterior ridge deformities in partially edentulous patients, 3 Prosthet Dent 57:191, 1987.
23. Stein RS: Pontic-residual ridge relationships: a research report, J Prosthet Dent 16:251, 1966.
24. Langer B, Calagna L: The subepithelial connective tissue graft, 3 Prosthet Dent 44:363, 1980.
25. Hirschberg SM: The relationship of oral hygiene to embrasure and pontic design: a preliminary study, 3 Prosthet Dent 27:26, 1972.

26. Seibert IS, Cohen DW: Periodontal considerations in preparation for fixed and removable prosthodontics, *Dent Clin North Am* 31:529, 1987.
27. Heartwell CM, Rahn AD: *Syllabus of complete dentures*, ed 4, Philadelphia, 1986, Lea & Febiger.
28. Preston JD, Bergen SF: *Color science and dental art*, St Louis, 1980, Mosby.
29. Pincus CL: Achieving the ultimate esthetic smile, Proceedings of the Second International Congress of Prosthodontics, Las Vegas, Nev, Oct. 19-21, 1979.
30. Seide LI, editor: *A dynamic approach to restorative dentistry*, Philadelphia, 1980, WB Saunders.
31. Pameijer JHN: *Periodontal and occlusal factors in crown and bridge procedures*, Amsterdam, 1985, Dental Center for Postgraduate Courses.



انتشارات شایان نمودار



# PORCELAIN-FULL COVERAGE RESTORATIONS

Vincent Celenza and Charles A. Lennon

## ALL-CERAMIC RESTORATIONS

Current technology in dental ceramics is advancing at a rapid pace, constantly producing new materials for the restoration of the single tooth. Feldspathic porcelains fused to a cast metal substructure, the so-called "metal-ceramic crown," has long been the industry standard; this is due primarily to its predictable long-term strength characteristics. All-ceramic systems have been a focus of interest, because they offer esthetic possibilities that may be difficult to achieve with metal-ceramic systems. The ideal material, regardless of whether it contains metal, should be strong, have excellent fit, and have lifelike esthetic qualities. The primary drawback to all-ceramic systems has been their strength and the fact they are limited to a single unit.

### *Porcelain Jacket Crowns*

The earliest all-ceramic system was the porcelain jacket crown, which is still in widespread use. The methodology used in the creation of these restorations may not satisfy current dental requirements, specifically fit. The use of platinum foil is technique sensitive, and the fit of the restoration may be regarded as an "approximation" to the die. Color modification after foil removal is difficult, and flexural breakages occur with greater frequency than in metal-ceramic restorations because of low tensile strength.

Nevertheless, porcelain jacket crowns have been used successfully for many years despite their apparent shortcomings. Improvements include upgrades in fabrication technique; the development of stronger ceramic sys-

tems; the ability to **internally etch the restoration, thereby increasing retention to the tooth and possibly limiting crack propagation within the crown**; better cements; and the ability to achieve more lifelike esthetics. This expanding knowledge base has facilitated optimum selection of restorative material. Tooth preparation design, soft tissue control, impressioning, and provisionalization techniques have all improved. The net result is a more gratifying experience for dentists and patients.

### *Dicor*

Dicor is an all-ceramic system first developed in the 1980s to answer a need for improved fit and color. It had qualities unavailable in other materials at the time of its inception. However, over time, breakage became an increasing problem. It was also very difficult to achieve depth in an externally colored system. Although still available, other systems have proved to be stronger, more lifelike, and more versatile (Figs. 8-1 to 8-3).<sup>3-6</sup>

### *IPS Empress*

Empress (Ivoclar-Williams) is a leucite-reinforced pressed ceramic that, like Dicor, is waxed to full contour but is then "pressed" in a special oven, not cast. Fit is excellent and marginal openings of less than 30  $\mu\text{m}$  can routinely be achieved.<sup>7</sup> If the core is cut back or waxed and pressed to less than full contour, porcelains may be baked in layers to achieve depth of color in the final restoration (the "layering technique"). This material is particularly well suited for posterior inlays and onlays and, like Dicor, a simple acid etching of all the internal aspects of the



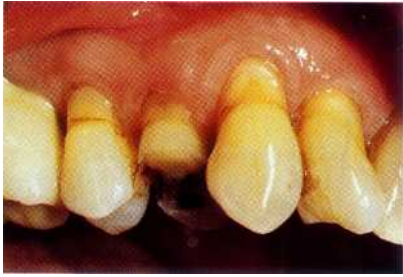

Fig. 8-1. Buccal cusp fracture of the first premolar.

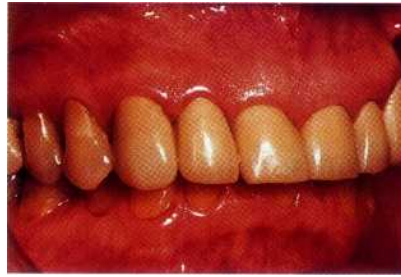

Fig. 8-4. These six anterior porcelain fused to metal full crowns were to be replaced for esthetic reasons.

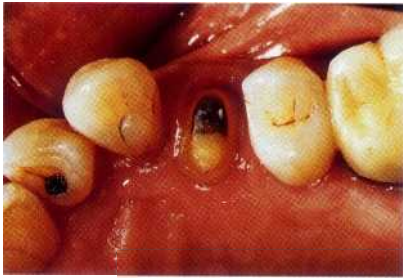

Fig. 8-2. Occlusal view the tooth preparation for a full coverage all-ceramic restoration.

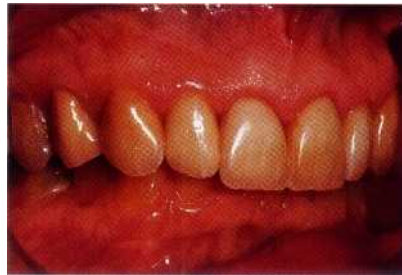

Fig. 8-5. The final Empress (pressed ceramic) full crowns in place for six anterior teeth and the first premolars. Among the changes made was a correction to labial flaring.

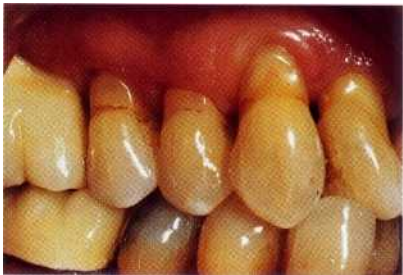

Fig. 8-3. The final Dicor (cast glass ceramic) restoration works well in this low value situation. (Ceramics by Mr. Marino Patrk.)

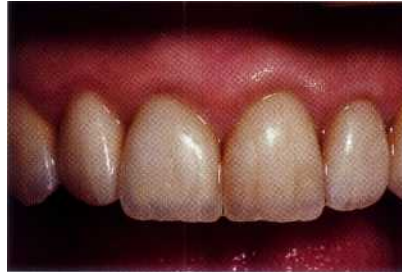

Fig. 8-6. Surgical correction to elevate the gingival margin especially over the left central and lateral helped reduce bilateral disharmony/asymmetry and improve overall tooth proportions. (Ceramics using the layering technique by Mr. Akiko Miyuki.)

restoration enhances retention. Empress has proven clinically strong enough for anterior full coverage restorations (Figs. 8-4 to 8-6) and labial porcelain veneers", but posterior full coverage restorations are not as reliable and operator discretion is advised. 9 "

### In-Ceram

Infiltration ceramics, In-Ceram (Vita-Vident), was created to solve the strength limitations of all-ceramic systems. 12-15 A fine-grained Al<sub>2</sub>O<sub>3</sub> powder in suspension is applied to a special die material. The densely packed

particles achieve even greater density after "sintering." The glass infiltration results in a high-strength core, which forms the substructure for porcelain buildup. The Alpha veneering porcelains developed to be compatible with the aluminous oxide core include opacious dentins, colored body modifiers and colored, opal, and translucent incisals.

The resultant restoration may have a somewhat opacious effect as a result of the dense internal core. This ef-

feet is desirable when blocking or masking unwanted underlying colors, such as dark or discolored dentin or cast metal cores.<sup>16</sup> The opacious effect may be minimized by creating thinner cores (possibly impacting strength, however) and by reducing the tooth structure adequately during preparation to provide maximum thickness of porcelain over the core material.

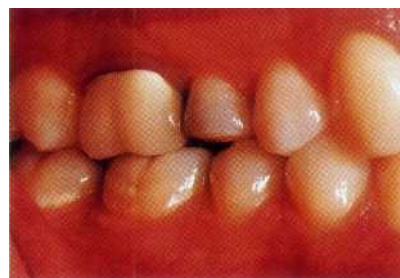A variant of the conventional In-Ceram, called In-Ceram Spinell, creates a more translucent or lower-value final effect. A magnesium-oxide material replaces the aluminum-oxide core material. Strength is somewhat lower than In-Ceram but is still stronger than most other all-ceramic systems. Internal acid etching is not possible with these systems, although sandblasting coupled with a composite resin cement improves mechanical retention. Nevertheless, sufficient axial wall height is necessary for proper retention of the restoration. This material has currently proven to be strong enough for single unit applications both anteriorly and posteriorly when sufficient material thickness is present.<sup>9,17</sup> Both systems may be used for inlays, but In-Ceram Spinell, because of its translucent nature, has better esthetics for this application.

In-Ceram is an excellent all-ceramic system. However, it is limited like any system by the clinical skill of the dental operator, the accuracy with which the restoration is technically created, and the skill and talent of the ceramist for final esthetics (Figs. 8-7 and 8-8).

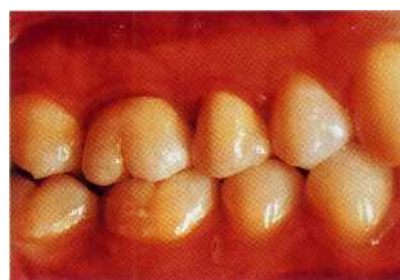### Procera

The newest all-ceramic system is Procera AllCeram (Nobel Biocare, Inc.).<sup>18</sup> Unique to this method is the use of computer-assisted design and computer-assisted manufacturing (CAD/CAM) to fabricate a densely sintered, high-purity aluminum oxide coping, which is later veneered with porcelain. A scanner "reads" the stone die into a specialized unit that processes the data and creates either a two-dimensional cross-section or a three-dimensional view on a computer monitor. The shape of the crown (e.g., an emergence profile angle) may be selected and modified before actual coping fabrication (CAD). The production unit in Sweden receives this information via a modem and the coping is fabricated there.

The primary advantage in this methodology is the ability to ensure quality control in the coping manufacturing process using industrial standards, which eliminates the many operator variables possible in coping fabrication. The marginal preparation design may be more chamfer-like than a true shoulder because of the increased strength of this sintered understructure. The CAD/CAM technology is not limited to aluminum oxide cores but may also be used to fabricate metal copings. This application is still in design stages, but it is hoped that metal foundation frameworks may be fabricated using a probe and a modem for multi-unit implant prostheses.



*Fig. 8-7. Preoperative appearance of the second premolar and first molar. Both teeth had been endodontically treated.*



*Fig. 8-8. In-Ceram crowns on the upper right first molar and second premolar are an appropriate restorative choice in this high value, "creamy" tooth shade situation.*

## ELECTROFORMING

### Considerations in All-Ceramic Restorations

Electroforming or galvanoceramics involves a thin (0.2 mm) gold metallic substructure for porcelain restorations, which imparts a warm glow that helps to control gray or value problems in the final esthetics. Gold ions are electrolytically deposited onto a special die in a technique similar to electroplating. The simple but technique-sensitive process results in a gold matrix of uniform thickness and extreme accuracy that may mask unwanted understructure color influences ..... The fit of the coping to the die may be within 15 to 20  $\mu\text{m}$  and is limited only by the handling and care taken in the duplication of the original die." When combined with an all-porcelain shoulder technique, excellent esthetics may be achieved. Areas for further investigation include studying the nature of the porcelain to gold bond and the strength of the final restoration so that this unique system may be properly categorized (Figs. 8-9 to 8-12).

### Light Absorption and Refraction

The metal component of porcelain-fused-to-metal restorations prevents the transmission of light. Even diffusion of light through the porcelain is diminished when



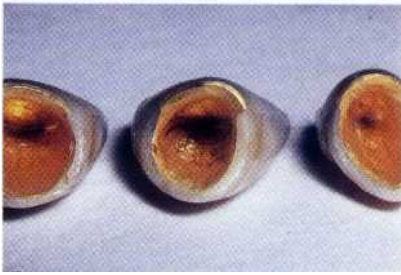

Fig. 8-9. The internal view of electroformed crowns demonstrates sections of the shoulder with ceramic or gold extensions incorporating a bevel if desired.

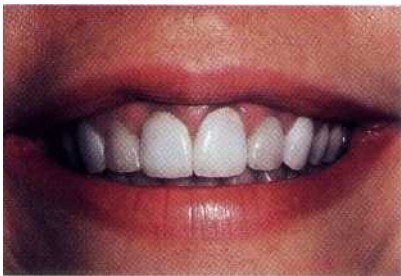

Fig. 8-10. Preoperative photo demonstrating opaque porcelain veneers on the central incisors and canines.

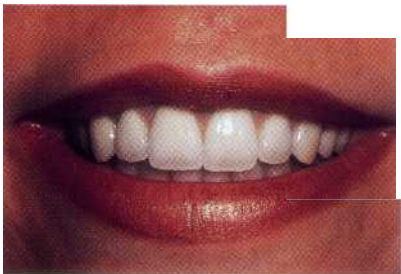


Fig. 8-11. Full coverage electroformed crowns on all anterior and premolar teeth. This restoration type was **selected because the gold metal component provided the best method** of developing esthetics uninfluenced by underlying tooth colors.

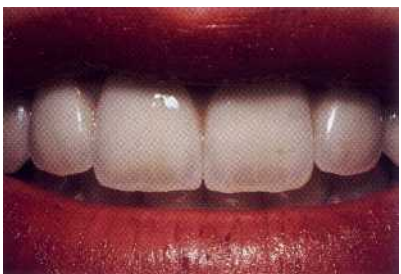

Fig. 8-12. Life-like esthetics may be achieved with "warm" gold metal substructure. (Ceramics by Mr. Naoki Aiba.)

metal is present beneath the veneering porcelain.<sup>35</sup> The marginal soft tissues adjacent to subgingivally placed metal collars often appear dark, especially if the gingival tissues are thin. This effect may occur in porcelain-fused-to-metal restorations with labial butt joint designs, because the small amount of porcelain covering the metal is opaque and creates a shadow of the root surface by blocking the normal transmission of light through the labial gingival tissues.<sup>36</sup>

All-ceramic crowns and natural teeth allow the transmission of light to occur because of the absence of a metal coping. This light transmission quality varies with different materials. For example, feldspathic porcelains characteristically refract light differently than cast glass or pressed ceramics and natural enamel. The unorganized, random crystalline form of porcelain refracts approximately 25% of the available light and opacifying porcelain refracts even less. Cast glass (Dicor) and pressed glass (Empress) refract as much as 75% of entering light, because its organized crystalline form has a refractive index similar to that of enamel.<sup>37-41</sup> Continuing research in dental materials in conjunction with improvements in technique have narrowed the gap considerably between restorations that look like "caps" and restorations that look like teeth.

### *Biocompatibility*

Rough, uneven, porous surfaces may encourage bacterial colonization. Poor metal margins, improperly glazed porcelains, and rough acrylics contribute to gingival inflammation." Clinically, superb gingival response and esthetics routinely occur under the following conditions: excellent marginal fit, controlled margin placement, and porcelain fabricated to properly refract light.

### *Control of Margin Placement*

The gingival extent of the interproximal shoulder of a full crown restoration may be deeper than ideal because of caries or a preexisting deep restoration. A bevel extends the ideal preparation further subgingivally. Deep subgingival margins complicate retraction, impression techniques, and margin evaluation. Biologic width violation and compromised oral hygiene access can result in gingival inflammation, pocket formation, and other periodontal problems.<sup>31,41-44</sup> Elimination of the bevel decreases the depth of the finishing line by an amount equal to the length of the bevel. However, this compromises the marginal integrity of a ceramometal crown, because the "slip-joint" effect of the cast metal bevel to the prepared bevel tooth surface is lost.<sup>48-51</sup> Retention is also decreased.

Improvements in investment materials and fabrication procedures for the newest all-ceramic materials have resulted in accurate fits to butt joint or rounded shoulder preparations, thus eliminating the need for a bevel. These technique-sensitive procedures, however, leave little or

no room for error by either the clinician or the laboratory technician.

### *Ideal Preparation Requirements*

Preparations for single tooth restorations have evolved primarily with the goal of creating excellent natural esthetics. Retention is aided by parallel axial wall design, dentin bonding techniques (see Chapter 3), and acid etching the internal portion of the restoration if possible.<sup>52</sup> The finishing line is 90 degrees to the external, unprepared, axial root surface, a "butt joint" preparation design. Thin margins or beveled preparations are contraindicated, because they would create an unacceptably weak ceramic margin. Additionally, the level of technical difficulty required to create a porcelain margin would be extreme and it would provide no particular advantage.

Perhaps the most difficult aspect of the butt joint preparation design is the shoulder or actual butt joint. When viewed from the occlusal, adequate reduction is mandatory to guard against breakage during function, because thin areas tend to chip as the tooth flexes. A minimum 360 degrees shoulder width of 1 mm is critical; however, 1.5 mm is ideal, because the restoration will be thicker and therefore stronger. In addition, greater thickness always provides the ceramist with a better opportunity to achieve more lifelike esthetics. However, greater material thickness achieved by more axial reduction than recommended may lead to pulpal involvement and can weaken the tooth considerably increasing the chances of the tooth literally snapping off during function.

## TECHNIQUE

### Armamentarium

#### Standard dental setup:

- Explorer
- Mouth mirror
- Periodontal probe
- Suitable anesthesia
- High-speed handpiece
- Low-speed handpiece
- Diamond burs: "Great White" (S.S. White Co.)
- Chamfer, long round end taper No. 5856L-31/018 (Brasseler)
- Cingulum reduction bur No. 6368-31/023 football (Brasseler)
- Occlusal reduction bur No. 35010-5 egg and No. 30006-106 (Brasseler)
- White polishing points, No. 649-FG-420 (Brasseler)
- Protection/visualization cord: ex. No. 000 Ultrapak, black, nonimpregnated (Ultradent, Inc.)

Deflection/retraction cord: ex. No. 1 Ultrapak, non-impregnated, (Ultradent, Inc.)

Gingetage packing instrument: ex. No. 1 (Polard, Vic Dental Products, Inc.) or Hu-Friedy cord placement instrument No. 3 (serrated)

Scissors

Cotton pliers

### Clinical Technique

#### *Anterior preparation*

1. Place protection cord; see the section on impressioning in this chapter
2. Reduce the tooth a minimum of
  - a. 1.0 mm labially and axially
  - b. 1.5 mm incisally
  - c. 1.5 mm palatally to create sufficient space for material thickness to resist tensile (lateral) forces

(Axial reduction on the labial surface follows two planes.)

**CLINICAL TIP.** Ensure all prepared surfaces are smooth, rounded, and flowing. Avoid creating sharp comers (Figs. 8-13 and 8-14).

**CLINICAL TIP.** Pay particular attention to the labial-to-lingual transition at the prepared incisal edge. Avoid thin edges or sharp points in this area; these can easily lead to crown seating problems, because often these areas are not precisely replicated in the stone die. If the die is an exact reproduction of the clinical tooth, you can appreciate how easily thin or pointed stone areas may inadvertently be abraded. This in turn will lead to inaccurate internal aspects of crowns with excess material at the incisal edge. This excess material will prevent full crown seating. Stress concentrations may also occur at these points<sup>53</sup> (see Figs. 8-27 and 8-28).

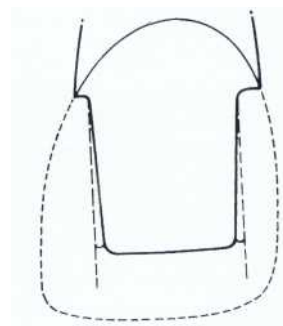


Fig. 8-13. Facial view of anterior preparation.

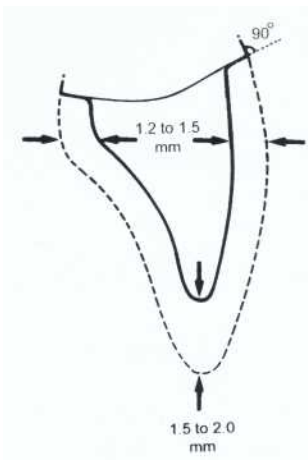


Fig. 8-14. Lateral view of anterior preparation.

**Posterior preparation**

1. Place protection cord; see the section on impressing in this chapter
2. Reduce the tooth a minimum of
  - a. 1.0 to 1.5 mm axially<sup>54,55</sup>
  - b. 1.5 to 2.0 mm occlusally to allow for sufficient bulk to resist tensile (lateral) forces
  - c. Axial reduction on the buccal and lingual surfaces follows two planes.

**CLINICAL TIP.** Ensure all prepared tooth surfaces are smooth, rounded, and flowing, avoiding sharp corners where stress concentrations may occur (Fig. 8-15).

**CLINICAL TIP.** "Scoop out" posterior occlusal reduction buccolingually. This ensures adequate occlusal thickness of the restoration while avoids sacrificing axial wall height or restricting the ceramist from creating anatomic groove carving (Figs. 8-16 and 8-17).

**CLINICAL TIP.** Marginal design may be either a shoulder or rounded shoulder with even reduction 360 degrees around the tooth for strength. Inadequate reduction may lead to failure caused by flexural movement during function (Fig. 8-18).

**CLINICAL TIP.** Terminate the finishing line of the preparation entirely on sound tooth structure." Ending on cements, bases, or metallic substructures does not ensure a positive seal against microleakage. Crown lengthening procedures alone or in combination with forced eruption procedures can help enhance marginal integrity while avoiding violations of biologic attachment dimensions. 51 3"




Fig. 8-15. The bottom two burs are round-ended and are well suited for posterior reduction. A conventional occlusal-reduction diamond shaped bur is not.

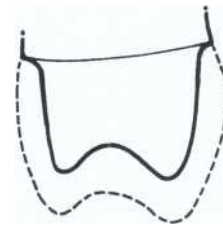


Fig. 8-16. Lateral view of posterior preparation.

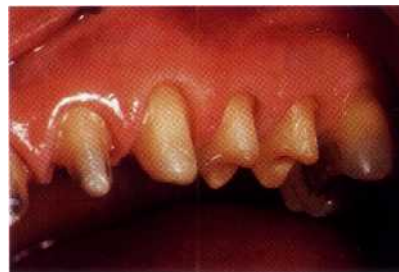
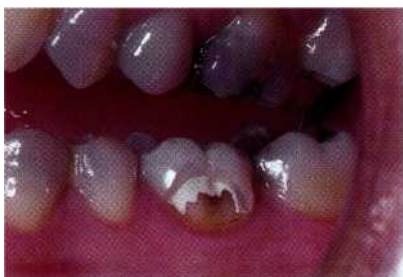
Fig. 8-17. Posterior occlusal reduction should be "scooped-out" buccolingually as is evident in these premolar preparations. This ensures adequate occlusal thickness while not sacrificing axial wall height or restricting the ceramist during anatomic groove carving.

**Impressing: Double Cord Technique**

The butt joint or rounded shoulder preparation design allows little or no room for error in reading the final preparation in die material. Therefore the entire extent of the prepared tooth must be clearly visible in the impression. Additionally, to create accurate marginal fit and to control emergence profile, impressing a small amount of unprepared tooth structure beyond the finishing line is of equal importance. When compared with preparation designs incorporating bevels, full and partial shoulder preparations, sloping shoulders, or chamfer design preparations require a greater level of technical expertise to



*Fig. 8-18. Tooth flexure or crown bending during function is the most reasonable explanation for this fracture failure .*

achieve accurate fits, because less room for error exists. Excellent impressing requires superior performance in tooth preparation and soft tissue control.

#### Armamentarium

- Standard dental setup including burs, cord placement instrument, cords, scissors, and cotton pliers; see the section on tooth preparation in this chapter
- Suitable hemostatic agent (Hemodent)
- Scissors
- Plastic instrument to be used for soft tissue deflection
- Suitable impression material (e.g., Impregum with Permadyne)

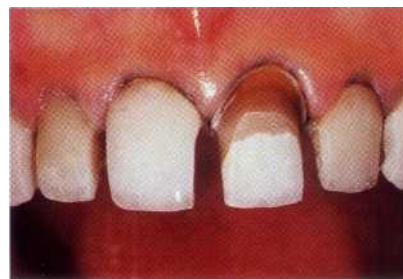#### Clinical Technique

1. Gently place the thin No. 000, contrasting color (black) cord, which was previously dipped into a hemostatic liquid agent (Hemodent) (Fig. 8-19).

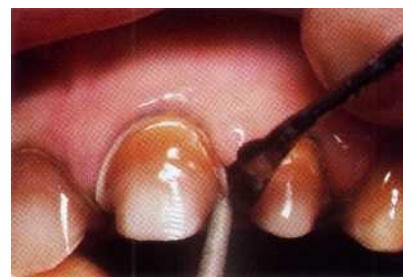**CLINICAL TIP.** Ensure the intrasulcular placement of this cord before the initiation of any subgingival tooth preparation. This will protect the subjacent junctional epithelial attachment.

**CLINICAL TIP.** To further guard against soft tissue trauma, use a plastic instrument held in the hand not holding the handpiece to deflect the gingival cuff away from the rotating bur (Fig. 8-20). This allows bloodless preparation even in subgingival areas.

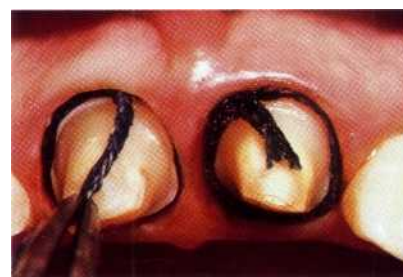After tooth preparation has been completed, true retraction needs to be accomplished to create room for the impression material lateral to the tooth and beyond the finishing line. Lateral displacement of the gingival cuff is accomplished by the placement of the second, wider cord. Because the true purpose of this cord is to displace tissue, this cord is referred to as the *retraction* or *deflection cord*.



*Fig. 8-19. Previously placed labial porcelain veneers could not block the dark underlying tetracycline staining without being unnaturally opaque. Before the completion of tooth preparation, No. 000 Ultrapak black "protection or visualization" cords have been placed.*



*Fig. 8-20. A deflection instrument is recommended to protect the gingiva while tooth preparation in marginal or subgingival areas are refined.*



*Fig. 8-21. The second cord, the true "retraction" cord, is removed just before syringing impression material (different case). Note how an axial unprepared tooth surface apical to the finish line is clearly exposed while the original, thin, black, protection cord remains during the impression. The displacement or deflection of marginal soft tissues (the definition of retraction) has created space for impression material.*

2. Place the second deflection/retraction cord. This is nonimpregnated and dry but is moistened with air/water spray after placement.
3. Remove the retraction cord after at least 4 minutes, while leaving the protection cord in place. Make the impression with any standard impression material (Fig. 8-21).

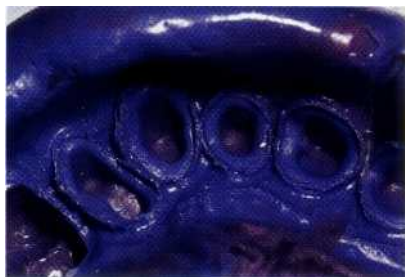

Fig. 8-22. Final impression showing, most importantly for butt joint preparation designs, captured unprepared tooth structure beyond the finishing line.

- Carefully inspect the impression for completeness, absence of voids or obvious distortions, and the capture of unprepared tooth structure beyond the finishing line (Fig. 8-22).

**CLINICAL TIP.** Supragingival preparation designs simplify impression procedures and whenever possible are the preferred designs from both restorative and periodontal standpoints.<sup>59-61</sup> Consider supragingival preparations when axial wall height is sufficient and esthetic demands permit.

## PROVISIONAL RESTORATIONS

Properly contoured and well-fitting provisional restorations may be regarded as templates for final restorations. These provisional restorations should protect prepared tooth structure and maintain the tooth's position in the arch. Fit is particularly critical when margins are placed subgingivally, because slight openings or short margins allow gingival tissues to proliferate and invaginate into any acrylic opening. Undercontouring of the provisional restoration allows soft tissue overgrowth circumferentially, which will invariably result in trapping of soft tissue tags during restoration try-in. Soft tissues that interfere with full seating at the final case delivery visit should be retracted and/or removed prior to cementation procedures. Failure to remove these tags, which prevent full seating of the crown and create an area of potential marginal leakage, can result in restoration failure (see Chapter 11).

**CLINICAL TIP.** Study casts of provisional restorations; record tooth length, width, emergence profile, contour, esthetic arrangement, occlusion, and incisal guidance (disclusion). This information may be very helpful to laboratory technicians in the fabrication of final restorations especially in the anterior region.<sup>62-65</sup>

## Die Preparation

All aspects of the prepared tooth must be captured in the impression and faithfully reproduced in die stone. Tooth preparation design determines die preparation design. "Ditching" beneath the finishing line is indicated for the bevel preparation (Fig. 8-23). Burnishing of wax margins may be best accomplished to ensure closed margins after casting. Ditching is contraindicated in butt joint or shoulder preparation designs (Fig. 8-24), because this process would result in weak, friable, and thin die stone at the finish line. Furthermore, unprepared tooth structure captured apical to the finish line provides valuable information pertaining to the emergence profile of the tooth.

**CLINICAL TIP.** Use a large rubber wheel (Brasseler porcelain polisher white No. 0301-220) to "clear" excess stone away from the finish line for dies with shoulder preparation designs. Leave untouched the unprepared tooth structure that is clearly discernable near the finish line. Avoid "ditching" in the classic sense, utilizing a round bur or something similar.

## Crown Try-in and Placement

### Contacts

#### Armamentarium

Standard dental setup:  
 Colored spray powder (e.g., Occlude, Pascal Co., Inc.)  
 Unwaxed dental ribbon  
 Polishing wheels (e.g., Brasseler porcelain polisher white No. 0301-220, pink No. 0306-220, "dialite" R17D)

#### Clinical Technique

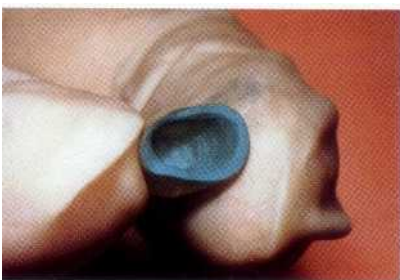- Try in the final crown with gentle finger pressure.
- Check margins with an explorer tip to confirm full seating.
- Check contact areas with floss while holding the crown in place. (Ask an assistant to hold the crown in place with a finger while the operator passes floss through the contact area.)
- Locate areas of tight contact by applying a light powder mist of Occlude (Pascal Co., Inc.) indicator powder to the interproximal surfaces of the crown.
- Reseat the crown, remove it, and observe the interrupted powder area created by the tight contact.
- Adjust the "mark" with polishing wheels.
- Reseat the crown and check the contact area with floss.
- Recheck the margin with an explorer.
- If the contact is light, make corrections by firing add-on porcelains.



*Fig. 8-23.* This die of a shoulder with a bevel tooth preparation for a conventional porcelain fused to metal restoration has been "ditched" in the standard way and is now ready for coping waxing.



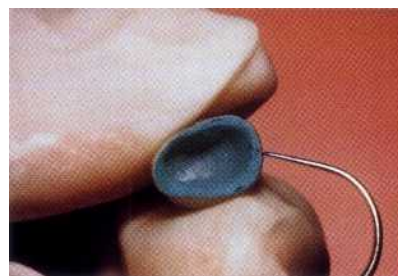
*Fig. 8-24.* A rubber wheel may be used in this fashion to obviate the margin for an all-ceramic shoulder restoration. Unprepared tooth structure, which is clearly discernible near the finish line, should be left untouched. Note that the margin will not be "ditched," because this would create a weak and vulnerable margin area. Ditching would also lose unprepared axial tooth structure in the stone die, resulting in the loss of important information necessary to create a proper emergence profile.



*Fig. 8-25.* Occlude powder (Pascal Co., Inc.) sprayed on the shoulder to mark binding or high spots.

#### Internal Fit

Because the color of conventional silicones or indicator pastes closely approximates the internal color of all-ceramic crowns, they are ineffective in detecting areas in which the restoration binds. However, because the occlusal surface and all axial surfaces have been die-spaced, the only area of the crown that may interfere with full seating is the unspaced shoulder (Figs. 8-25 and 8-26).



*Fig. 8-26.* After crown seating, binding areas on the shoulder are revealed. These may be very carefully adjusted using a fine diamond stone in a slow-speed handpiece.

This explains why crowns made on a spaced die frequently completely seat on a second unspaced die.

#### Armamentarium

Standard dental setup

Colored indicator spray (e.g., Occlude, Pascal Co., Inc.)

Fine diamond bur to be used at slow speed for internal adjustment (e.g., Brasseler 247F-009)

#### Clinical Technique

1. Spray the internal aspect of the crown with a thin mist of a colored spray especially on the shoulder and incisal edge area.
2. Try on the crowns with gentle finger pressure.
3. Remove the crown and carefully inspect all areas for rub marks.
4. Gently adjust the binding areas with a fine diamond using slow speed.
5. Repeat, if necessary.
6. Check the margins with an explorer tip to confirm full seating.

**CLINICAL TIP.** A binding area or rub internally at the incisal edge is generally indicative of a discrepancy between the tooth and the die. The best and easiest way to compensate for this is to modify the tooth intraorally rather than try to grind out the incisal-most portion of the crown. The rub mark noted in the crown will correlate with a colored mark left at the exact offending area of the tooth. This is easily ground away at slow speed and without anesthesia in most cases (Figs. 8-27 and 8-28).

#### Occlusal Adjustments

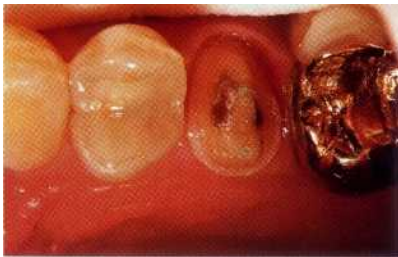Once interproximal contacts and internal fit are satisfactory, make occlusal corrections.

#### Armamentarium

Standard dental setup



*Fig. 8-27. After crown seating, Occlude powder is rubbed off onto the tooth at a sharp occlusal internal point.*



*Fig. 8-28. The corresponding green powder marks on the tooth depict areas that act as a fulcrum, about which the crown rocks and is prevented from fully seating. In these cases, it is easier to adjust the tooth itself than to thin out the crown internally at these points.*

Two-color, double-sided articulating paper (Accu-film II)  
 Fine diamond burs, football-shaped and small fine (e.g., Brasseler No. 8368-016)  
 Green stones (e.g., IC3 and ICI Shofu Dental Corp.)  
 Rubber wheels (e.g., Brasseler porcelain polishers, white No. 0301-220, pink No. 0306-220)  
 7-(m-thick metal foil (Almore Co.)  
 Hemostat

#### Clinical Technique

1. With two-color, double-sided articulating paper in place, have the patient gently "tap" his or her (dry) teeth into occlusion.
2. Remove the paper.
3. Have the patient close his or her mouth again. This causes a superimposition of the opposing occlusal markings. In this way, the thickness of the paper is compensated for and only "true" contacting surfaces superimpose.

**CLINICAL TIP.** Do not adjust other marks; these are erroneously caused by the thickness of the paper.

**CLINICAL TIP.** Wipe both sides of the articulating paper with a thin film of Vaseline. This facilitates the transfer of the colorant to the tooth surface.

**CLINICAL TIP.** Make sure the red side of the articulating paper marks the arch where the restoration is being placed and the opposing occlusal contact (in black) is superimposed. It is more difficult to read if done in reverse.

4. Adjust the restoration with fine diamonds and rubber wheels, where necessary.
5. Confirm occlusal contact by asking the patient to close down on a strip of Artus foil held in place by a hemostat. With the patient's teeth held in the fully closed position, a slight tug on the interposed foil with the hemostat should prove contact is present. Check the teeth adjacent to the crown being placed in the same manner to verify that those teeth are not prevented from making full contact.

#### Color

The luting agent may have an effect on the final coloration of the restoration, especially in the case of Dicor or Empress because of their translucency. These restorations tend to be lower in value when compared with metal ceramic systems or systems with reinforced internal cores. For example, the clinician should evaluate the color of an Empress crown with a translucent luting agent (e.g., Dual or Variolink) as well as a more opacious cement (e.g., Panavia) before actual final cementation to better predict the esthetic result. On the other hand, In-Ceram and Procera, with their reinforced aluminous-oxide core designs, tend to be less translucent. They tend to be "milky" and are relatively unaffected by the color of the luting agent selected. The qualities that differentiate these materials may be used to advantage. For example, when using full coverage to restore a tooth where the adjacent teeth to be "matched" have low value characteristics, Empress would probably produce the best results because of its inherent translucency, especially in the cervical one third of the tooth. This is technically a difficult effect to create with materials that are inherently high value or bright. Similarly, In-Ceram, Procera, or electroformed crowns would probably best match teeth that are brighter, creamier, or more opacious, especially in the cervical one third. Additionally, these materials can better mask unwanted underlying tooth influences, such as dark dentin or cast cores, than can the more translucent materials.

If color modifications beyond that which may be achieved through luting agents alone are necessary, these restorations may be stained, tinted, or characterized and refired in the ceramic oven.



	Internally etchable?	Permit light transmission?
Leucite-reinforced crowns (Dicor/Empress)	Yes	Yes
Alumina-reinforced crowns (In-ceram-Procera)	No	No
Metal-reinforced crowns (Electroformed)	No	No

**CLINICAL TIP.** Compare the degree of brightness or translucency of the cervical third of the tooth to be restored with the adjacent teeth. This determination will help determine which restorative material will likely be the most esthetic choice.

have different characteristics. A thorough working knowledge of the use of these materials will allow the practitioner to fully benefit from current dental technology to ultimately achieve the best results and deliver the finest care for patients.

## LUTING

Low viscosity luting agents are the preferred materials to secure any of the aforementioned restorations. High-viscosity cements such as polycarboxylates are generally considered too thick and may create hydrostatic pressures, which could interfere with or prevent full seating of the restoration. Composite resin luting agents, such as Dual, Variolink, or Panavia, or glass ionomer cements such as Fuji or Ketac, may be used for permanent restoration placement. Dicor and Empress permit light curing through the restoration; thus light-activated cements may be considered. These restorations may also be internally acid etched, which when combined with a total tooth-etching procedure and composite luting agent, is probably the most retentive system currently available.

Electroformed crowns have metal cores and therefore do not permit light transmission. Some have claimed that tin plating may enhance cement to metal restoration bonds, but this has not been clearly demonstrated. The teeth may be etched if desired, and an auto-curing composite cement selected.

In-Ceram and Procera crowns are not internally etchable. Sandblasting, which microscopically roughens the internal surface thereby increasing mechanical retention, is recommended to maximize retention of these crowns.<sup>66</sup> The decision whether or not to etch enamel and/or dentin for any of these crown systems is left to the practitioner (Table 8-1).

## CONCLUSION

It is possible to create strong, well-fitting, and lifelike restorations using any of a number of presently available alternatives to conventional porcelain fused to metal restoration materials. However, the available materials

## REFERENCES

1. Jones DW: The strength and strengthening mechanisms of dental ceramics. In McLean JW editor: *Dental ceramics: proceedings of the First International Symposium on Ceramics*, Chicago, 1983, Quintessence.
2. Rosenstiel SF et al: Strength of a dental glass-ceramic after surface coating, *Dent Mater* 9:274, 1993.
3. Adair PJ, Grossman DG: The castable ceramic crown, *Int J Periodontics Restorative Dent* 4:32, 1984.
4. Grossman DG: The science of castable glass ceramics. In Preston JD, editor: *Perspectives in dental ceramics*, Chicago, 1988, Quintessence, p 117.
5. Adair PJ, Hoeksta KE: Fit evaluation of a castable ceramic, *J Dent Res* 61:345, 1982.
6. Malament KA, Grossman DG: Bonded vs. non-bonded Dicor crowns: four-year report, *J Dent Res* 71:321, 1992.
7. Leinfelder KF et al: Clinical assessment of pressed ceramic restorations, *Contemp Esthetic Dent* 3:1, 1997.
8. Fradeani M: Six-year follow-up with Empress veneers, *Int J Periodontics Restorative Dent* 18:216, 1998.
9. McLean JW Kedge MI: High-strength ceramics, *Quintessence Int* 18:97, 1987.
10. Anusavice KJ: Recent developments in restorable dental ceramics, *J Am Dent Assoc* 124:71, 1993.
11. Hankinson JA, Capetta EG: Five years' clinical experience with a leucite-reinforced porcelain crown system, *Int J Periodontics Restorative Dent* 14:139, 1994.
12. McLaren E: All-ceramic alternatives to conventional metal-ceramic restorations, *Compend Contin Educ Dent* 19:307, 1998.
13. Sadoun M: *All-ceramic bridges with slip casting technique*, Presented at the Seventh International Symposium of Ceramics, Paris, Sept 1988.
14. Claus H: Vita In-Ceram, a new system method for producing alumina oxide crown and bridge substructures, *Quintessence Zahntech* 16:35, 1990.



15. Huls A: All-ceramic restorations with the In-Ceram system: six years of clinical experience, VITA Zahnfabrik H. Rauter GmbH & Co. Gottingen, Germany, Feb 1995.
16. McLaren E: The skeletal buildup technique: a systemic approach to the three-dimensional control of shade and shape, *Prac Periodont Aesthet Dent* 10:587, 1998.
17. Seghi RR, Sorenson JA: Relative flexural strength of six new ceramic materials, *Int J Prosthodont* 8:239, 1995.
18. Oden A, Andersson M.: A new all-ceramic crown, *Acta Odontol Scand* 51:59, 1993.
19. Zeng K, Oden A, Rowcliffe D: Flexural test on dental ceramic, *Int J Prosthodont* vol 4, 1996.
20. May K, Russel M, Lang B: Precision of fit of the Procera AllCeram crown, *J Prosthet Dent* 4, 1996.
21. White S, Caputo A, Chun Li Z, Yu Zhao X: Modulus of rupture of the Procera All-Ceramic system, *J Esthet Dent* 8:3, 1996.
22. Wagner WC, Chu TM: Biaxial flexural strength and indentation fracture toughness of three new dental core ceramics, *J Prosthet Dent* 76:140, 1996.
23. May K, Razoog M, Lang B, Wang R: Marginal fit: the Procera AllCeram crown, abstract 2379, *Inter Assoc Dent Res ADR* 1997.
24. Prestapino V, Ingber A, Kravitz J: Clinical and laboratory considerations in the use of a new all-ceramic restorative system, *Prac Periodont Restor Dent* 10:567, 1998.
25. Razzoog ME, Lang B: Research evaluations of a new all-ceramic system, *Prac Periodont Esthet Dent (suppl)*1, p 1, Jan-Feb 1998.
26. Sadan A, Hegenbarth EA: A simplified and practical method for optimizing aesthetic results utilizing a new high-strength all-ceramic system, *Prac Periodont Esthet Dent (suppl)*1, p 4, Jan-Feb 1998.
27. Rogers OW Armstrong BW: Electroforming a gold matrix for indirect inlays, *J Prosthet Dent* 11:959, 1961.
28. Rogers OW: The electroformed gold matrix inlay technique, *Aust Dent J* 15:316, 1970.
29. Rogers OW: Porosity in gold cast against an electroformed gold matrix in an inlay technique, *Aust Dent J* 22:100, 1977.
30. Rogers OW: The dental application of electroformed pure gold. 1. Porcelain jacket crown technique, *Aust Dent J* 24:163, 1979.
31. Rogers OW: The dental application of electroformed pure gold. II. A. Porcelain inlay. B. Cast copings with adaptable electroformed gold margins, *Aust Dent J* 25:1, 1980.
32. Rogers OW: The dental application of electroformed pure gold. III. An investigation into an alternative ceramic bonding system for base metal alloys, *Aust Dent J* 25:205, 1980.
33. Vence B: Electroforming technology for galvanoceramic restorations, *J Prosthet Dent* 77:444, 1997.
34. Setz J, Diehl J, Weber H: The marginal fit of cemented galvanoceramic crowns, *Int J Prosthodont* 2:61, 1989.
35. McLean J: The science and art of dental ceramics, vol 2, Chicago, 1980, Quintessence.
36. Geller W Kwiakowski S: The Willi's glass crown: a new solution in the dark and shadowed zones of esthetic porcelain restorations, *Quintessence Dent Technol* 11:233, 1987.
37. Adair PJ, Grossman DG: Esthetic properties of lost tooth structure compared to ceramic restorations, *J Dent Res* 61:293, 1982.
38. Grossman DG, Adair PJ, Pameijar CH: Evaluation of the color of a cast ceramic restorative material, *J Dent Res* 59:542, 1980.
39. Malament KA: The cast-ceramic crown. In Preston JD, editor: *Perspectives in dental ceramics*, Chicago, 1988, Quintessence.
40. Grossman DG: Cast glass ceramics, *Dent Clin North Am* 29:725, 1985.
41. Sorenson JA: Rationale for comparison of plaque-retaining properties of crown systems, *J Prosthet Dent* 62:264, 1989.
42. Flores-de Jacoby L, Zafiroopoulos GG, Ciancio S: The effect of crown margin location on plaque and periodontal health, *Int J Periodontics Restorative Dent* 9:197, 1989.
43. Nevins M: Interproximal periodontal disease-the embrasure as an etiological factor, *Int J Periodontics Restorative Dent* 2:9, 1982.
44. Ingber JS, Rose LF, Coslet JG: The biologic width-a concept in periodontics and restorative dentistry, *Alpha Omega* 10:62, 1977.
45. Kramer GM: A consideration of root proximity, *Int J Periodontics Restorative Dent* 6:9, 1987.
46. Kramer GM: Rationale of periodontal therapy. In Goldman MM et al: *Periodontal therapy*, ed 6, St Louis, 1980, Mosby.
47. Gargiulo AW, Wentz FM, Orban B: Dimensions and relations of the dentogingival junction in humans, *J Periodontol* 32:261, 1961.
48. Shillingburg MT, Jacobi R, Brockett SE: *Fundamentals of tooth preparation*, Chicago, 1987, Quintessence.
49. Panno FV et al: Evaluation of the 45 degree labial bevel with a shoulder preparation, *J Prosthet Dent* 56:655, 1986.
50. Rosner D: Furcation placement and reproduction of bevels for gold casting, *J Prosthet Dent* 13:1160, 1963.
51. Wagenburg BD, Eskow RN, Langer B: Exposing adequate tooth structure for restorative dentistry, *Int J Periodont Restorative Dent* 9:323, 1989.
52. Jensen ME: Preliminary research report on etched-porcelain resin bonded restorations, Iowa City, Iowa, 1996, University of Iowa.
53. Kelly JR, Campbell SD, Bowen HK: Fracture surface analysis of dental ceramics, *62:536, 1989.*
54. Friedlander LD et al: The effect of tooth preparations design on the breaking strengths of Dicor crowns, Part 1, *Int J Prosthet Dent* 3:159, 1990.

55. Doyle MG et al: The **effects of tooth preparation design on the breaking strength of Dicor crowns**, Part 11, *Int J Prosthet Dent* 3:241, 1990.
56. Nevins M, Skurrow HM: The intracrevicular restorative margin, the biologic width, and the maintenance of the gingival margin, *Int J Periodontics Restorative Dent* 4:30, 1984.
57. Ingber JS: Forced eruption. Part 11, a method of treating non-restorable teeth-periodontal and restorative considerations, *J Periodontol* 47:203, 1976.
58. Pontoriero R, Celenza F Jr: Rapid extrusion with fiber resection, a combined orthodontic-periodontic treatment modality, *Int J Periodontics Restorative Dent* 7:30, 1987.
59. Silness J: Fixed prosthodontics and periodontal health, *Dent Clin North Am* 24:317, 1980.
60. Wilson RD: **Intracrevicular restorative dentistry**, *Int J Periodontics Restorative Dent* 3:40, 1983.
61. Waerbaug J: Tissue reactions around artificial crowns, *J Periodontol* 54:172, 1983.
62. Skurrow HM, Nevins M: The rationale of the periodontal provisional biologic trial restoration, *Int J Periodontol Restorative Dent* 8:1, 1988.
63. Reider CE: The use of provisional restorations to develop and achieve expectations, *Int J Periodontol Restorative Dent* 9:2, 1989.
64. Shavell H: Mastering the art of tissue management **during provisionalization and biologic final impressions**, *Int J Periodontol Restorative Dent* 3:25, 1988.
65. Gane D, Levine JB: Imaging the esthetic case: a structured three-step analysis, *Esthetic Dentistry Update* 6(4): 85, 1995.
66. Chiche GJ: Application of microetching to all-ceramic crown techniques, *Pract Periodont Esthet Dent* 10:5, 626, 1998.



انتشارات شایان نمودار

# PORCELAIN LAMINATE VENEERS AND OTHER PARTIAL COVERAGE RESTORATIONS

Kenneth W. Aschheim and Barry G. Dale

**I**N THE NINETEENTH CENTURY, porcelain inlays were introduced as an esthetic alternative to metallic restorations. These inlays were formed either by grinding a solid porcelain block<sup>1</sup> or more commonly by fusing porcelain chips to a platinum-gold foil matrix.<sup>1</sup> Extremely brittle restorations, they were contraindicated in high-stress areas. Their imprecise fit resulted in a visible cement line and caries susceptibility because of cement washout. In addition, the absence of an adhesive cement limited these restorations to preparations that provided sufficient frictional retention.

Porcelain use decreased following the introduction of silicate cements in 1908. Although silicates, a combination of silica alumina and calcium fluoride, showed significant solubility in salivary fluids, the fluoride component provided anticariogenicity. Acrylic resins, introduced in 1946, immediately replaced silicate resins as the esthetic material of choice. Although they exhibited better long-term retention, they did not contain fluoride, which resulted in an increased incidence of recurrent decay. Advances in acrylic resin systems, compared with earlier restorations, controlled some of the polymerization shrinkage, but they still exhibited poor overall dimensional stability. In addition, like silicates, acrylic resins required mechanical retention. The introduction of the acid-etch technique and filled composite resins further diminished the use of porcelain as an internal restorative material. Porcelain, in the form of all-porcelain and porcelain-fused-to-metal restorations, was relegated to full coverage restorations.

In the late 1970s, direct and indirect laminate veneers were introduced. Direct veneers, which used light-cured composite resin to overlay the entire facial surface, allowed great flexibility in both shaping and shading teeth. However, they were time consuming and required substantial artistic skill. In addition, they exhibited poor color stability and wear resistance.

Indirect or preformed veneers attempted to overcome some of these limitations.<sup>1</sup> Composed of acrylic, they were treated with ethyl acetate, methylene chloride, or methyl methacrylate and then luted to the etched tooth with a composite resin. Although they exhibited greater color stability and stain resistance than early direct composite resin veneers, the composite resin-to-laminate veneer bond proved to be a fatal weak link.<sup>4</sup> The acrylic veneer also exhibited a dull and monochromatic appearance, poor abrasion resistance,<sup>5</sup> and resulted in unsatisfactory gingival inflammation.

## PORCELAIN-BONDED RESTORATIONS

Early research<sup>6</sup> indicated that it was possible to chemically bond silica to acrylic or bis-GMA using a silane coupling agent (see below). Most research<sup>7,8,9</sup> focused on the direct chemical bonding of porcelain teeth to acrylic denture bases. Early silane bonds prevented seepage of oral fluids between the porcelain-acrylic interface.<sup>10</sup> However, differences in the coefficient of thermal expansion between porcelain and acrylic caused bond



deterioration during bench cooling of the heat-cured acrylic.

The need for a technique to repair ceramometal restorations with debonded porcelain prompted interest in the composite resin to porcelain bond. It was discovered that no bond formed between the glazed porcelain and composite resin, even with silane, " , " unless the surface was roughened.<sup>14</sup>

In 1983 the porcelain-laminate veneer was introduced." It combined the esthetic and positive tissue response of porcelain with the adhesive strength of acid etch retained restorations and the convenience of a laboratory-fabricated restoration. Since that time, posterior inlays and onlays, multiple units for splinting, and even all-porcelain bridges have been advocated by some, with variable results.<sup>16,17,18</sup>

### BASIC CHEMISTRY

The porcelain-bonded restoration consists of four components:

1. An internally etched porcelain veneer
2. An acid etched enamel surface
3. A silane-coupling agent
4. A composite resin luting cement

#### Porcelain

Dental porcelains are composed of natural feldspar (both potassium and sodium alumino-silicate glasses).<sup>19</sup> Early porcelain-laminate veneers utilized the same porcelains used in all-porcelain restorations. In recent years, high-strength porcelains specifically designed for bonded restorations have been introduced. These materials are stronger than conventional porcelains and composite resin and have a hardness comparable with that of enamel."

Some manufacturers claim that high-strength porcelains have sufficient strength for use as all-porcelain bridges." For a complete discussion of dental porcelains see Chapter 8.

#### Acid Etching

Retention of the acid-etch retained porcelain restoration is accomplished by the creation of microporosities in both the porcelain and enamel. Porcelain porosities are derived from treating the internal surface of the restoration with a 10% acid solution, such as hydrofluoric acid (HFA). Studies show that etching with or without the use of a silane coupling agent greatly increases bond shear strength, which can even surpass resin-enamel bond strength (Table 9-1).<sup>20,21</sup>

Salivary contamination of the etched porcelain can significantly reduce bond strength, even after cleaning

Table 9-1. Effects of etching and silane on bond shear strength.

Group	Etch	Silane	Bond shear strength
A	Yes	No	2907 ± SD 165
B	Yes	Yes	3485 ± SD 340
C	No	No	564 ± SD140
D	No	Yes	978 ± SD390

Modified from Hsu CS, Stangel I, Nathanson D: Presentation at the 63rd session of the International Association of Dental Research.

with acetone.<sup>22</sup> Application of 37% phosphoric acid for 15 seconds has been shown to restore the etched surface.<sup>22</sup> The etched surface is stable over extended periods. One study<sup>22</sup> demonstrated that a 7-day delay between etching and silane application/veneer cementation did not reduce bond strength when the laminate veneers were kept in a dry environment (e.g., a simple plastic box).

#### Silane Coupling Agents

The function of a coupling agent is to alter the surface of a solid to facilitate either a chemical or physical process.' ° Numerous silane coupling agents exist and are used in dentistry to increase the shear strength of the porcelain-to-composite resin bond.

These agents are believed to be capable of chemically bonding to silica in both the porcelain laminate veneer and the composite resin matrix. Scanning electron micrographs reveals that silane and etching eliminate the polymerization contraction gap, which forms in both etched, nonsilanated and unetched, silanated restorations by allowing the resin to better wet the surface.<sup>21</sup> An in vitro study using two different types of feldspathic porcelain concluded that silane combined with the action of hydrofluoric acid gel is the most effective surface treatment for ceramics.<sup>23</sup> Another in vitro study found that a single reapplication of silane maintained the bond strength of resin to porcelain when final cementation was preceded by a 5-minute, nonactivated resin try-in procedure and a 3-minute acetone cleaning.<sup>24</sup>

#### Composite Resin Luting Cements

initially, laminate veneers were retained with auto-curing composite resins. Light-activated composite resin luting cements provided increased working time." Most resin cements are thinned versions of previously available restorative resins.<sup>26</sup> (See Chapter 5.) Numerous viscosities are available, with medium viscosity being the most popular. Different shades and opacities allow for color modification of the restoration.

Light-activated resins are ideally suited for most laminate veneers. However, they require sufficient light from a curing light to initiate curing. Therefore they should not be used when the light must travel through a thickness of porcelain that exceeds the manufacturer's recommendations. Factors affecting this maximum depth include the specific light source, the age of the bulb, the shade and opacity of the laminate, and the shade and opacity of the composite resin cement.

This is particularly problematic in the gingival floor and axial wall areas of the interproximal box of porcelain inlays or onlays. The light source cannot be positioned perpendicular to the interproximal surface because of the approximating tooth; therefore light rays entering this region at an angle may be required to penetrate 4 to 8 mm of porcelain.<sup>21</sup> In both these cases, a dual-cured composite resin luting system should be used. Laser light sources may penetrate deeper than conventional light sources, but their use may raise issues concerning the rapidity of the composite resin cure. (For a complete discussion see Chapter 5.)

### BASIC LABORATORY TECHNIQUE

Porcelain-laminate veneers can be fabricated by the laboratory in one of four ways: platinum foil backing, refractory models, direct castings, or CAD-CAM machining.

**Platinum Foil Backing.** This method can also be used to construct the all-porcelain crown. A very thin layer of platinum foil is placed on the die. The porcelain is layered on the foil. Then the porcelain-foil combination is removed from the die and fired in an oven. Before try-in, the foil is removed and the porcelain is etched."

The use of platinum foil permits the porcelain to be repeatedly removed from and replaced onto the die during restoration fabrication. This permits easier access to the proximal margins. In addition, the thickness of foil creates a space for opaques and tinting agents.

**Refractory Models.** The use of refractory models is the most commonly used method of porcelain laminate veneer fabrication.<sup>27</sup>

The restoration is fired directly on a refractory die. This eliminates the platinum layer but makes repeated firings difficult once the laminate veneer has been removed from the die.

The advantages of the refractory model include tighter contacts and the absence of the gap created by the use of platinum foil. The disadvantages are less room for coloring agents and more difficulty in adjusting proximal areas by the technician.

**Direct Castings.** Cast ceramic restorations are fabricated using the "lost wax" technique. This eliminates the

need for multiple firings but requires extrinsic staining for coloration (see Chapter 8).

**CLINICAL TIP.** Use a platinum layer to make repeated firings easier after the laminate veneer has been removed from the die.

**CAD/CAM Machining.** Ceramic restorations can be manufactured either in the dental office or in the laboratory. A model or video image of the preparation is required, and the restoration always requires modification of the surface porcelain to obtain proper color esthetics. (For a complete discussion see the section on CAD/CAM systems in Chapter 24.)

### ADVANTAGES OF BONDED PORCELAIN RESTORATIONS

The main advantages of bonded porcelain restorations are the following:

1. *Excellent esthetics.* Porcelain offers unsurpassed esthetics and inherent color control. In addition, unlike direct laminate veneers, the porcelain laminate veneers depend less on the esthetic skill of the dentist.
2. *Excellent long-term durability.* Porcelain is both abrasion resistant and color stable. In addition, porcelain has excellent resistance to fluid absorption.
3. *Inherent porcelain strength.* Porcelain exhibits excellent compressive, tensile, and shear strengths when bonded to enamel.
4. *Marginal integrity.* Porcelain restorations bonded to enamel exhibit exceptional marginal integrity.
5. *Soft tissue compatibility.* Properly polished porcelain is highly biocompatible with gingival tissue.
6. *Minimal tooth reduction.* Anterior porcelain laminate veneers are considerably more conserving of tooth structure than porcelain-fused-to-metal and all-porcelain full coverage restorations.

### DISADVANTAGES OF BONDED PORCELAIN RESTORATIONS

The primary disadvantages of bonded porcelain restorations are the following:

1. *Time.* Multiple visits are required.
2. *Cost.* Laboratory involvement and additional chair time are required when compared with direct restorations, resulting in higher costs to the patient.
3. *Fragility.* Although strong when bonded to the tooth, bonded porcelain restorations are extremely fragile during the try-in and cementation stages.

4. *Lack of repairability.* Porcelain restorations are difficult, if not impossible, to repair.
5. *Difficulty in color matching.* Although porcelain restorations are color-stable, precise matching of a desired shade to an adjacent tooth can be difficult. In addition, shade alteration is impossible after cementation.
6. *Irreversibility.* Tooth reduction, although often minimal, is required.
7. *Inability to trial cement the restoration.* Unlike traditional indirect restorations, bonded porcelain restorations cannot be temporarily retained with a provisional cement for evaluation purposes.

### INDICATIONS

Porcelain laminate veneers may be indicated in areas traditionally restored with single crowns or composite resin veneers for the following:

1. Correcting diastemata
2. Masking discolored or stained teeth
3. Masking enamel defects
4. Correcting malaligned or malformed teeth

Porcelain inlays and onlays may be indicated in areas traditionally restored with amalgams, single-unit cast restorations, and composite resins

1. For the esthetic restoration of large posterior teeth with adequate tooth structure
2. As a conservative esthetic alternative to full coverage restorations in teeth requiring onlaying of cusps
3. As a more durable alternative to posterior composite resin restorations
4. As a less periodontally invasive alternative to full and partial coverage restorations with subgingival margins
5. In "amalgam phobic" patients

### CONTRAINDICATIONS

Porcelain laminate veneers may be contraindicated for the following:

1. Patients who exhibit tooth wear as a result of bruxism
2. Short teeth
3. Teeth with insufficient or inadequate enamel for sufficient retention (e.g., severe abrasion)
4. Existing large restorations or endodontically treated teeth with little remaining tooth structure
5. Patients with oral habits causing excessive stress on the restoration (e.g., nail biting, pencil biting)

Porcelain inlays and onlays may be contraindicated for the following:

1. Patients who exhibit bruxism
2. Short teeth

3. Insufficient or inadequate enamel for sufficient retention
4. Exceedingly thin buccal or lingual walls
5. Endodontically treated teeth with little remaining tooth structure
6. Patients with oral habits causing excessive stress on the restoration (e.g., nail biting, pencil biting)

### DIAGNOSTIC AND TREATMENT PLANNING AIDS

Porcelain laminate veneers can be used to change any or all of the following characteristics of a single tooth or multiple teeth:

1. Color (including characterizations and degree of polychromaticity)
2. Size
3. Shape
4. Position within the arch

#### Wax and Paint Simulation

White orthodontic wax and acrylic paint provide an extremely effective diagnostic and patient education aid. This is especially helpful when evaluating the treatment of single or multiple diastemas, and fractured, misshaped, or malpositioned teeth. The wax can be used to quickly and inexpensively simulate (and thereby "preview") the effects of porcelain laminate veneer placement.

**CLINICAL TIP.** Prediction of the anticipated outcome of porcelain laminate veneer placement without the use of a preliminary wax simulation is deceptively difficult even for the experienced dentist. You may want to use a wax "preview," which often reveals a favorable prognosis for a clinical situation that initially appears unmanageable with porcelain laminate veneers.

#### Armamentarium

- White orthodontic tray wax (Hygienic Corp.)
- Mars Black artist's acrylic paint (Liquidtex, Inc.)
- Plastic instrument (Plastic Instrument PF4, Henry Schein, Inc.)
- One-piece lip retractor (e.g., Self-Span, Ellman International Manufacturing Co. or Expandex, Parkell, Inc.)
- Cotton-tipped applicator

#### Clinical Technique

1. Isolate the teeth with a one-piece lip retractor (Fig. 9-1).
2. Dry thoroughly with an air syringe.

**CLINICAL TIP.** Squeeze a  $\frac{1}{8}$ -inch strip of orthodontic wax between the thumb and index fingers. This will quickly form a thin "veneer-shaped" piece of wax.

3. Apply the wax to the teeth and grossly mold to shape with the index finger.
4. Refine the wax with the plastic instrument (Figs. 9-2 and 9-3).

**CLINICAL TIP.** Simulate shortening of the teeth by applying an appropriate amount of black artist's acrylic paint to the dried tooth surface, using the wooden end of a cotton-tipped applicator (Fig. 9-4). Turn off the examination light and have the patient separate the teeth until they do not exhibit vertical overlap (Fig. 9-5). Squinting augments the illusion.

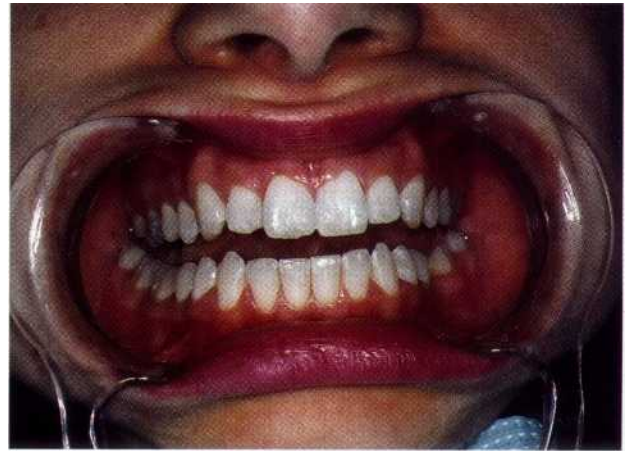

Fig. 9-3. The diastema is closed with white orthodontic tray wax.

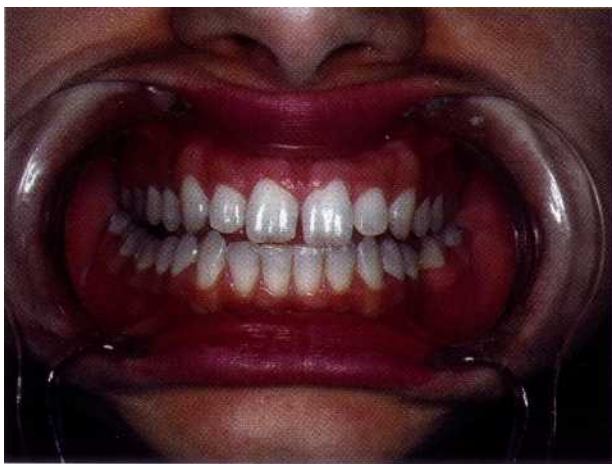

Fig. 9-1. The patient presented with a midline diastema. She also thought her teeth were too long.

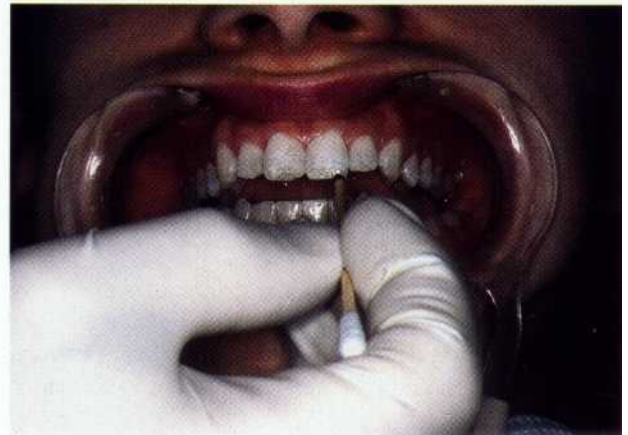

Fig. 9-4. Mars black acrylic paint is applied to the teeth with the wooden end of a cotton-tipped applicator.

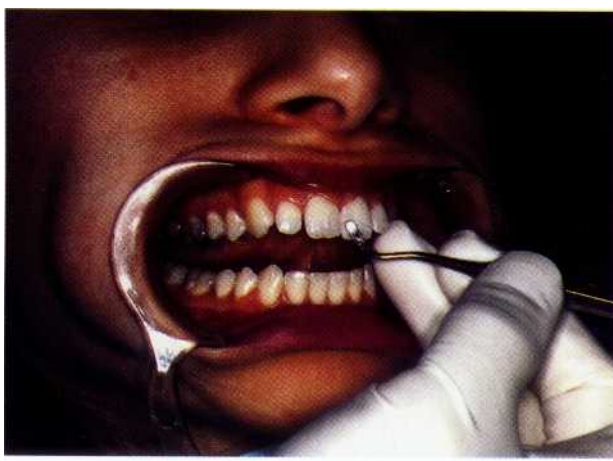

Fig. 9-2. The wax is refined with a plastic instrument.

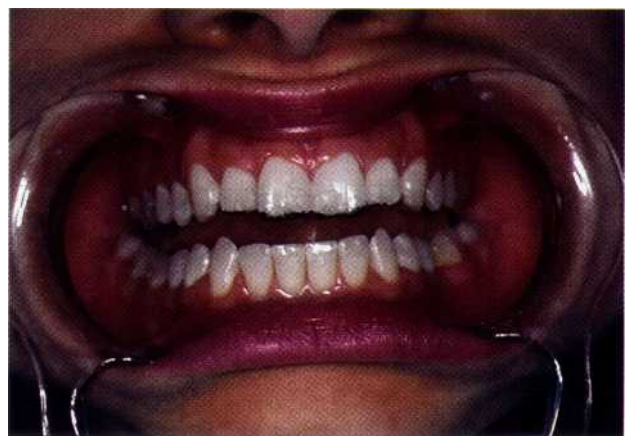

Fig. 9-5. The black acrylic paint helps the patient envision the esthetic effect of shortening the teeth.

## Computer Imaging

Computer imaging provides a two-dimensional prediction similar to the three-dimensional preview provided by wax simulation and acrylic paint. This system has the added advantage of previewing the effects of color and characterization changes and providing a more lifelike prognostication. Computer imaging systems can also provide instant printouts of the predicted changes (see Chapter 24).

## Patient Education

**Photography.** One of the most effective patient education tools is a book or photograph album containing before and after images of representative cases. These educational materials can be purchased commercially or be produced by the dentist (see also Chapter 14).

**Demonstration Models.** Sample porcelain laminate veneers fabricated to fit on prepared denture teeth or stone models are valuable patient education aids. They effectively demonstrate the conservative nature of this technique and the lifelike appearance of the final restorations.

## TOOTH PREPARATION

The outline form of the porcelain laminate veneer tooth preparation depends largely on the degree of desired color alteration. This consideration particularly influences the location of the interproximal and gingival finish lines.

### Static Area of Visibility versus Dynamic Area of Visibility

The entire labial tooth surface, including the gingival area and the area immediately labial to the contact area with the adjacent tooth (the labial embrasure), is visible if the available light and the perspective of the viewer is optimal. This static area of visibility occurs when the patient is seated in the dental chair under adequate lighting and with the lips fully retracted. The static area of visibility significantly differs from the actual dynamic area of visibility exhibited during normal function.

The dynamic area of visibility of the labial embrasure is partially a function of viewing perspective. It is particularly influenced, however, by shadows cast from surrounding structures. The lip, adjacent tooth contour and position, and gingival architecture, as well as the contour, shade, and position of the tooth under observation are all important factors (Fig. 9-6).

The dynamic area of visibility of the gingival area is governed by the position of the lip during maximal smiling (the high smile line).

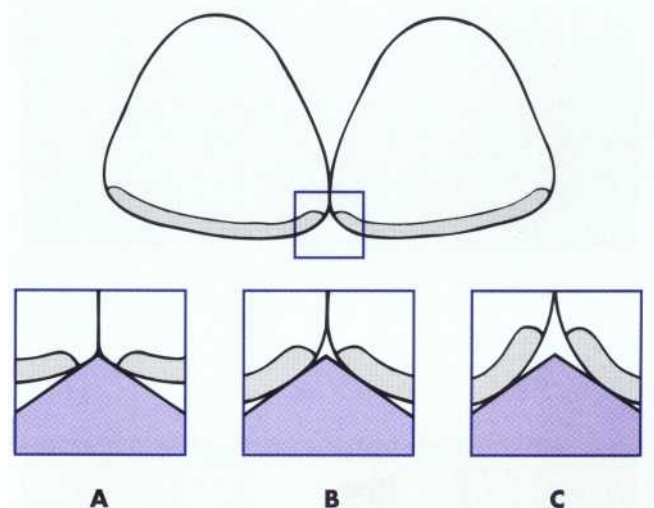
## Minimal or No Color Change

**Proximal Finishing Lines.** A proximal chamfer finishing line is preferred except when diastemata are present. Proximal areas adjacent to diastemata should receive a feather-edged finishing line (Fig. 9-7).

**Proximal Contact Area.** When the shade difference between the tooth (after preparation) and the desired final restoration is minimal, proximal chamfer finish lines are placed slightly labial (approximately 0.2 mm) to the contact areas of the adjacent tooth. This provides for the following:

1. Ease in evaluating marginal fit during the try-in stage
2. Access for performing and evaluating finishing procedures
3. Access for home care (margins in "self-cleansing" area)
4. Ease in evaluating marginal integrity during follow-up maintenance visits

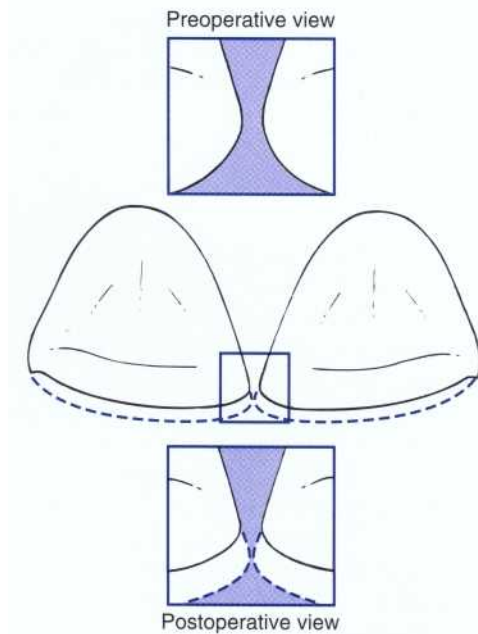
The major disadvantage of this design is the possibility of eventual staining at the tooth-restoration interface. However, the factors influencing the dynamic area of visibility often negate this disadvantage. See the section on static versus dynamic area of visibility in this chapter.



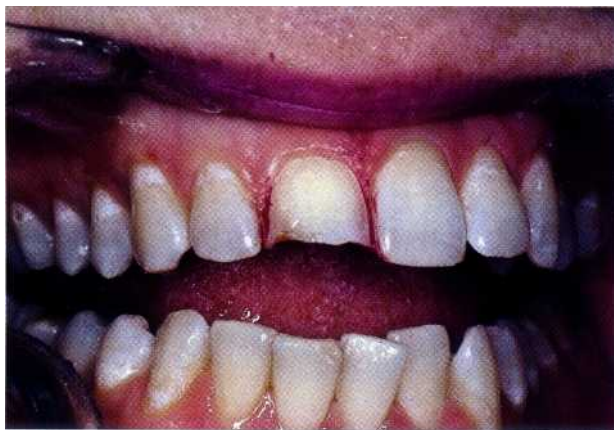*Fig. 9-6. The dynamic area of visibility of the labial embrasure is influenced by the depth of the embrasure space and by the shadow cast by surrounding structures including the tooth itself. A, The entire embrasure space is visible. The margins of the laminate veneers illustrated in the figure will be visible. To hide this margin, the finishing line must be placed into the contact area. B, The embrasure space is only partially visible. The margins of the porcelain laminate veneers illustrated in the figure are just within the nonvisible area. C, The majority of the embrasure space is not visible. The margins of the porcelain laminate veneer illustrated in the figure need not have been placed as deeply into the interproximal area.*



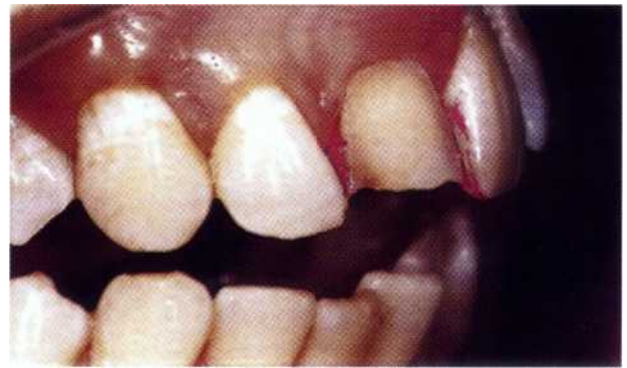**Proximal Subcontact Area.** The proximal subcontact area (PSCA) consists of the interproximal tooth structure, which is immediately gingival to the contact area with the adjacent tooth. This area is usually not visible from a direct frontal view of the tooth (Fig. 9-8) and is therefore often left underprepared or totally unprepared. It is visible, however, from an oblique view. Therefore preparation of the PSCA is essential<sup>28</sup> and is particularly crucial when the final restoration significantly differs in shade from that of the unprepared tooth structure (Figs. 9-9 to 9-12).



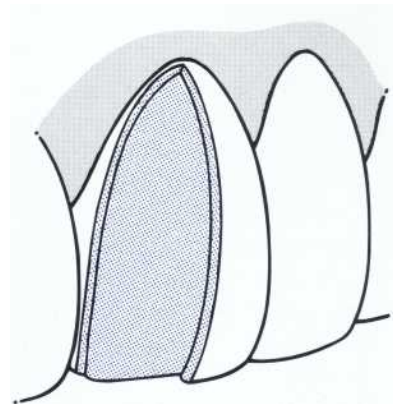
*Fig. 9-7. Feather-edged proximal finishing lines are used in proximal areas adjacent to diastemata.*



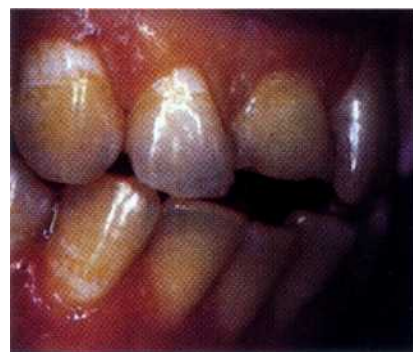*Fig. 9-8. A partially prepared tooth shows that the proximal subcontact area is not visible when the tooth is observed from a direct frontal view.*



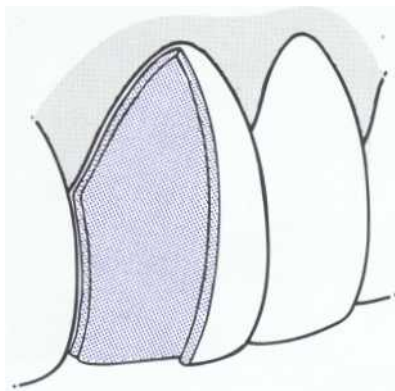
*Fig. 9-9. The same preparation as shown in Fig. 9-8 viewed from an oblique angle. The proximal subcontact area is often overlooked during tooth preparation. The red dye on the proximal surfaces delineates the area that must be reduced to hide the margin of the subsequent restoration.*



*Fig. 9-10. The proximal subcontact area is visible only from an oblique perspective and is often left unprepared or underprepared.*



*Fig. 9-11. The tooth shown in Fig. 9-8 following removal of the red dye by tooth reduction in the proximal subcontact area.*



*Fig. 9-12. Proper extension of the preparation into the proximal subcontact area.*

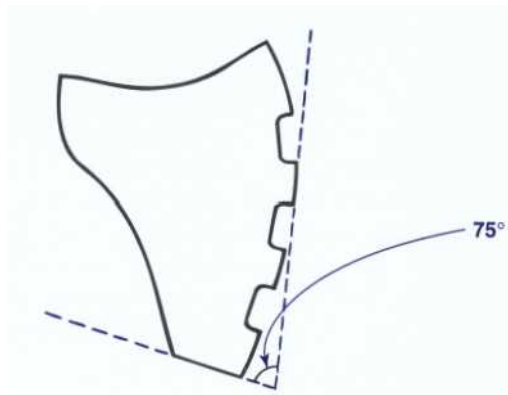
**CLINICAL TIP.** View the preparation of the PSCA from all oblique angles to ensure adequate extension into this often-overlooked area.

**Diastemata.** The proximal area adjacent to a diastema should receive a feather-edged finishing line (see Fig. 9-7). This finishing line extends from the incisal edge to a point adjacent to the height of the gingival papilla.

**Gingival Finishing Lines.** A chamfer is preferred for all gingival finishing lines. Supragingival finishing lines provide the same advantages as proximal finishing lines, which terminate labial to the contact areas. In addition, impressions are easier to make with supragingival preparations as compared with subgingival preparations. Supragingival finishing lines also increase the likelihood that restoration margins will end on enamel. The major disadvantage, however, is that any subsequent staining or color changes at the restoration margin will be visible. Therefore supragingival margins are limited to clinical situations when this area remains concealed by the lip during maximum smiling (high lip line).

When the entire clinical crown is included in the labial display, the gingival margin should be placed 0.1 mm below the free gingival margin. If gingival recession is anticipated, the gingival finishing line can be extended deeper subgingivally as long as the biologic width is not violated.

**CLINICAL TIP.** Evaluate critically the true position of the lip during maximum smiling! (the high lip line) before planning supragingival finishing lines. The true lip position may be deceptive. Patients with unattractive smiles often habitually adapt a high lip line position, which is significantly less revealing of tooth structure than is anatomically possible. After porcelain laminate veneers are placed, the high lip line may significantly elevate, because the patient's psychological barriers to full smiling have dissipated.



*Fig. 9-13. A butt incisal finishing line should slope approximately 75 degrees gingivally from the labial to provide resistance to restoration displacement and to provide for adequate thickness of porcelain at the margin to prevent restoration fracture.*

**Incisal Preparation.** Incisal reduction should ideally provide for 1 mm of porcelain thickness. Therefore if the incisogingival height of the final restoration is to be 0.5 mm longer than the existing tooth, only 0.5 mm of incisal reduction is required. If the preoperative teeth are to be lengthened by 1 mm, only a rounding of **the incisal edge and placement of a finishing line are required.**

A butt joint finishing line provides for the proper thickness of porcelain at the margin to prevent restoration fracture. The finishing line should slope slightly gingivally (approximately 75 degrees from the labial). This augments resistance to labial displacement of the final restoration (Fig. 9-13).

After ideal preparation, the incisal outline of the tooth, when viewed from the labial aspect, should be identical to the incisal outline of the proposed final restoration, except for a 1-mm incisal reduction. This allows for an even thickness of porcelain. Incisal line angles must be rounded to reduce internal restoration stresses.

**Labial Depth Reduction.** A labial reduction of approximately 0.5 to 0.7 mm is sufficient for most maxillary teeth and 0.3 mm for smaller teeth, such as mandibular incisors, if adequate thickness of enamel is present. Inadequate thickness of enamel, such as in the gingival one third of the tooth, may require a more conservative tooth reduction. Teeth or portions of rotated tooth surfaces that are in lingual version require proportionately less reduction. Preparation into dentin is sometimes necessary; however, this should involve less than 50% retention of the prepared surface.<sup>20</sup> The effect of dentin exposure on the clinical longevity of porcelain laminate veneers remains to be investigated.<sup>29</sup>

The entire finishing line should ideally remain in enamel.

### Major Color Change

In addition to considerations of preparation design for minimal color changes, major color differences between the prepared tooth and the desired final restoration may also require other adjustments. Visibility of the contact area may necessitate extension of the interproximal finishing line into the contact area to a depth of approximately one half the labiolingual dimension of the contact area. See the sections on minimal or no color change and static versus dynamic area of visibility in this chapter. The gingival finishing line can be extended 1 mm subgingivally, assuming the biologic width is not violated. Supragingival margins are indicated, however, if this area remains concealed by the lip during maximal smiling (high smile line). See the preceding Clinical Tip. The preparation depth may be increased if sufficient thickness of enamel is present. This will allow for an increased thickness of porcelain or additional layers of die spacer to increase the available space for an opaque cement.

**CLINICAL TIP.** Tetracycline discoloration occurs in the dentin. The prepared tooth may be darker than the original tooth shade, because the deep tooth preparation that is often necessary in these cases removes a significant amount of the "masking" enamel.

#### Armamentarium

Basic dental setup:  
 Explorer  
 High-speed handpiece  
 Low-speed handpiece  
 Mouth mirror  
 Periodontal probe  
 Suitable anesthesia (if necessary)  
 One-piece lip retractor (e.g., Self-Span, Ellman International Manufacturing Co.; Expandex, Parkell, Inc.)  
 High-speed (friction grip) diamond three-tiered depth cutting burs (e.g., LVS-1 [0.3 mm depth cut] and LVS-2 [0.5 mm depth cut], Brasseler, Inc.)  
 High-speed (friction grip) two-grit burs (LVS-3, LVS-4, Brasseler, Inc.)  
 High-speed (friction grip) diamond wheel bur (e.g., 5909, Brasseler, Inc.)  
 Unwaxed regular dental floss  
 Interproximal abrasive strips (Sof-Flex Strips No. 1954 coarse/medium, 3M, Inc.)  
 Sharp pencil  
 Retraction cord packer (e.g., Fischer's Ultrapak Packer, Ultradent Products, Inc.)  
 Nonimpregnated gingival retraction cord (e.g., Ultrapak No. 0 or No. 1, Ultradent Products, Inc.; Gingibraid No. 0 or No. 1, Van R, Inc.)  
 Gingival retraction instrument (e.g., Zekrya, Foremost Dental Manufacturing, Inc.) (optional)



Fig. 9-14. Preoperative view of a patient with multiple diastemata and discolored teeth.

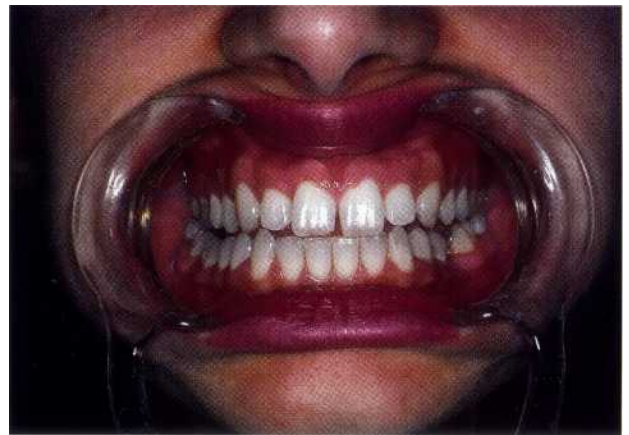

Fig. 9-15. Close-up view of the patient in Fig. 9-14.

#### Clinical Technique

1. Evaluate the high lip line (Figs. 9-14 to 9-16). See the Clinical Tip in the section on gingival finishing lines.
2. Administer suitable anesthesia (if necessary).
3. Prepare three horizontal surface depth cuts in the labial surface with a friction grip three-tiered LVS-1 or LVS-2 depth cutting diamond (Figs. 9-17 and 9-18). Depth cuts should be 0.5 to 0.7 mm deep for "ideal" teeth, and 0.3 mm deep for mandibular incisors. Lingually positioned teeth and those with thin enamel require less reduction. See the section on labial depth reduction in this chapter.

**CLINICAL TIP.** When the three-tiered depth cutting bur is held tangentially to the surface of the tooth, only the middle section of the bur penetrates to its entire depth. This is due to the tooth's convex labial surface (Figs. 9-19 and 9-20). To avoid under-preparation, position the bur two additional times to ensure complete penetration of each section of the bur (Figs. 9-21 to 9-24).

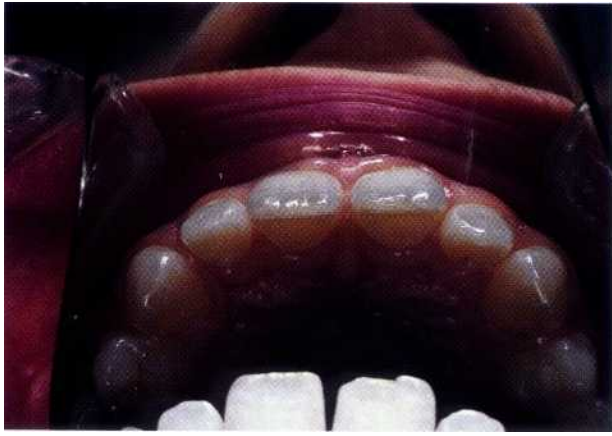

Fig. 9-16. Incisal view of the patient in Fig. 9-14.

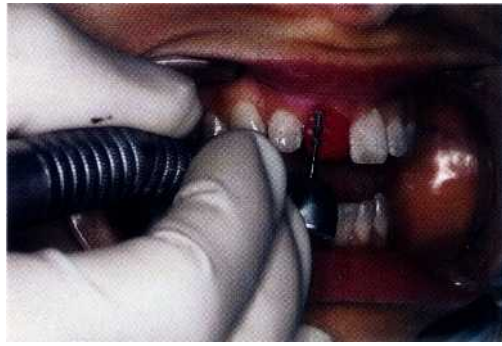

Fig. 9-17. Three horizontal depth cuts are prepared in the labial surface.

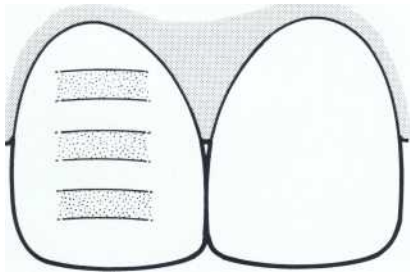


Fig. 9-18. Three horizontal depth cuts are prepared in the labial surface.

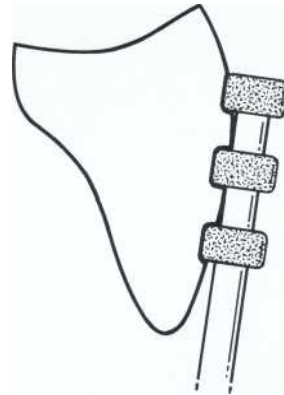

Fig. 9-19. When the three-tiered depth cutting bur is held tangentially to the surface of the tooth, only the middle section of the bur penetrates to its entire depth.

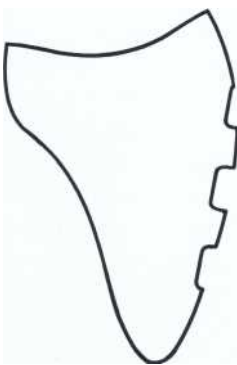

Fig. 9-20. Only the middle section of the tooth is prepared to the full depth because of the convex labial surface. The incisal and gingival portions of the tooth are underprepared.

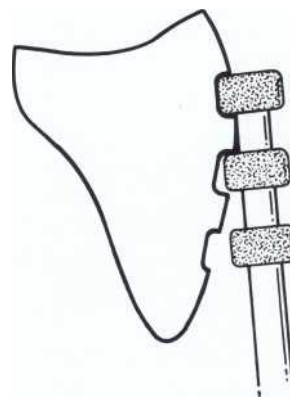
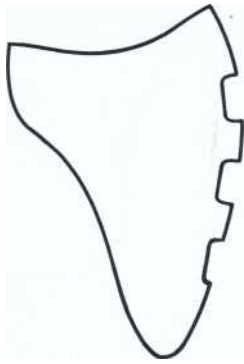
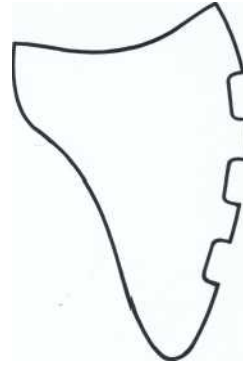

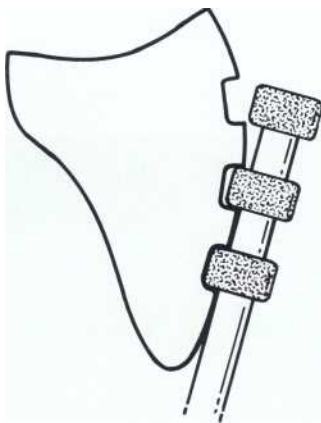
Fig. 9-21. The bur is angled a second time to complete the gingival depth cut.



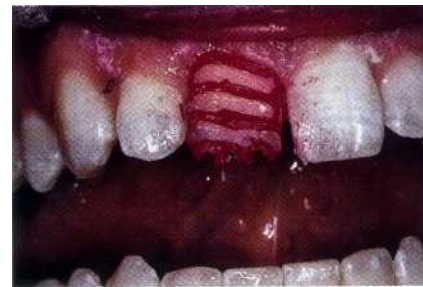*Fig. 9-22. The tooth after two depth cuts. The incisal portion of the tooth remains underprepared.*



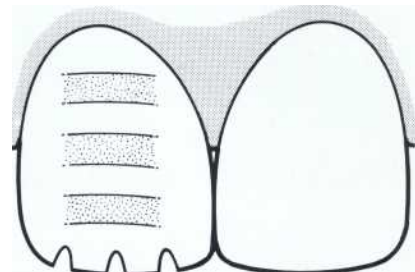
*Fig. 9-24. The three depth cuts are equally deep.*



*Fig. 9-23. The bur is angled for the third time to complete the incisal depth cut.*



*Fig. 9-25. Three vertical depth cuts are prepared in the incisal edge.*

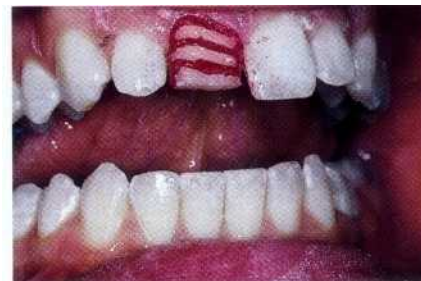

*Fig. 9-26. Three vertical depth cuts are prepared in the incisal edge.*

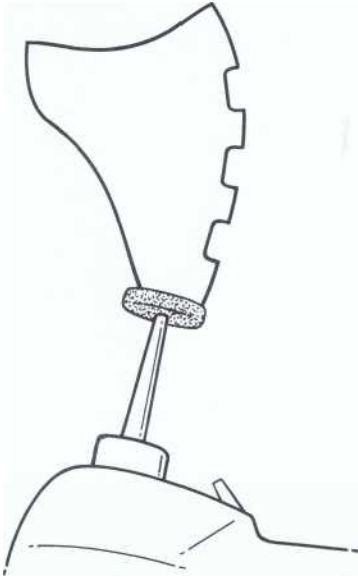
4. Prepare three incisal depth cuts with an WS-3 or WS-4 diamond bur (Figs. 9-25 and 9-26). (The incisal reduction should create a preparation that is 1 mm shorter than the desired final restoration.)
5. Using the depth cut as a guide, prepare the incisolingual finishing line to a modified butt joint with the diamond wheel bur (Figs. 9-27 and 9-28). The labioincisolingual angle should be approximately 75 degrees (see Fig. 9-13).

**CLINICAL TIP.** To prevent overreduction, draw pencil lines into the prepared enamel guide cuts (Fig. 9-29). Labial reduction is complete immediately after the pencil lines are removed by the action of the reduction bur.

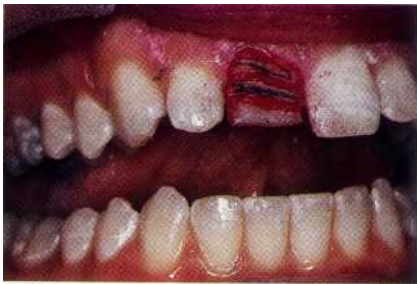6. Using the depth cuts as a guide, prepare the labial surface with an LVS-3 or LVS-4 diamond bur (Figs. 9-30 and 9-31).
7. Prepare the proximal chamfer finishing lines.



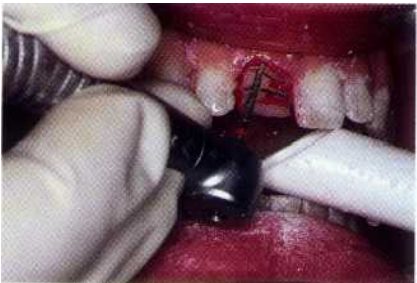*Fig. 9-27. The incisolingual finishing line was prepared to a modified butt joint using the depth cut as a guide.*



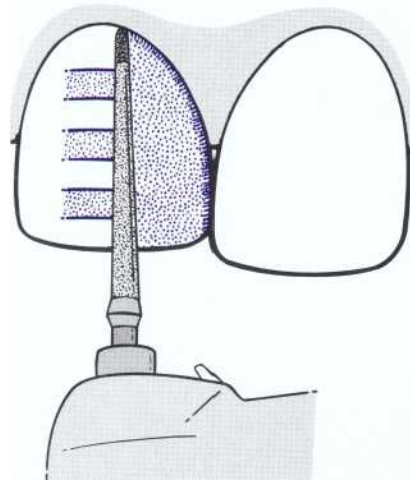
**Fig. 9-28.** An incisal butt joint angled approximately 75 degrees from the labial provides for adequate thickness of porcelain at the margin and resistance to displacement of the restoration.



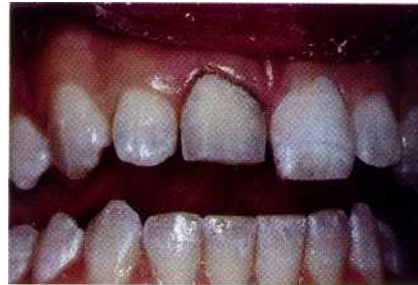**Fig. 9-29.** To prevent overreduction, pencil lines can be drawn into the prepared enamel guide cuts. Labial reduction is complete immediately after the pencil lines are removed by the action of the reduction bur.



**Fig. 9-30.** The labial surface is prepared using the horizontal depth cuts as a guide.

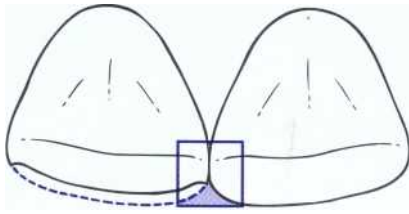


**Fig. 9-31.** The labial surface is prepared using the horizontal depth cuts as a guide.

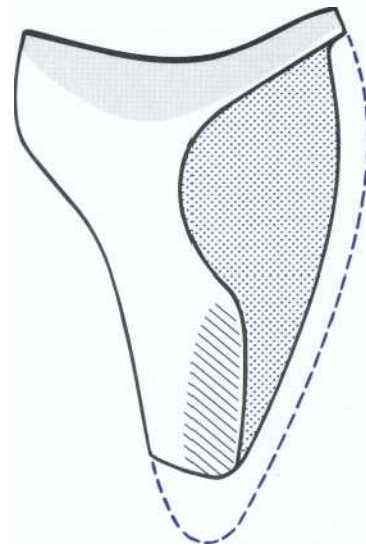


**Fig. 9-32.** The feather-edged finishing line is prepared adjacent to the diastemata. (See incisal view, Figs. 9-7 and 9-47.)

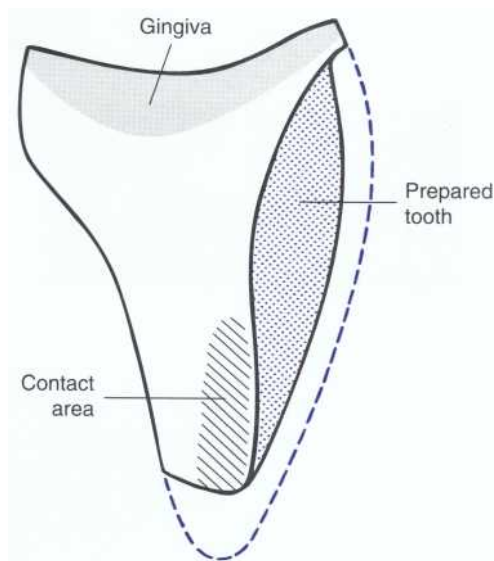
- A. For *diastema*: Prepare a feather-edged finishing line with an LVS-3 or LVS-4 diamond bur. The finishing line should terminate as far to the lingual aspect as possible without creating an undercut area, and it should extend from the incisal edge to the point adjacent to the height of the gingival papilla (Fig. 9-32, see also Fig. 9-7).
- B. For *minimal or no color change and no diastema*, see the section on minimal or no color change in this chapter.
  - i. Prepare the proximal chamfer finishing line with an LVS-3 or LVS-4 diamond bur to approximately 0.2 mm labial to contact area (Figs. 9-33 and 9-34).
  - ii. Prepare the proximal subcontact area with an LVS-3 or LVS-4 diamond bur (Fig. 9-35).
- C. For *major color change and no diastema*, see the section on major color change in this chapter.



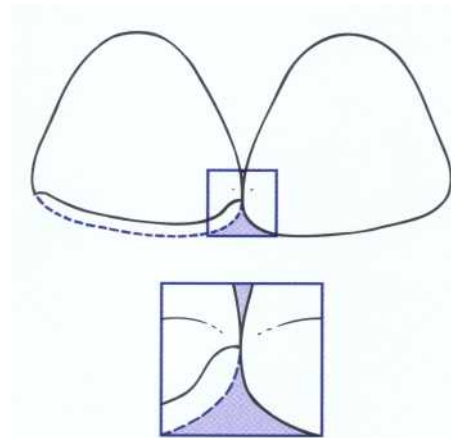
**Fig. 9-33.** If the final porcelain laminate veneer will be similar in color to that of the prepared tooth, the proximal finishing line terminates 0.2 mm labial to the contact area.



**Fig. 9-35.** Proximal representation of porcelain laminate veneer preparation shown in Fig. 9-34 after proper reduction of the proximal subcontact area.



**Fig. 9-34.** Proximal representation of porcelain laminate veneer preparation before reduction of the proximal subcontact area. The proximal finishing line terminates 0.2 mm labial to the contact area because the final porcelain laminate veneer will be similar in color to that of the prepared tooth. The contact area is indicated with diagonal lines.

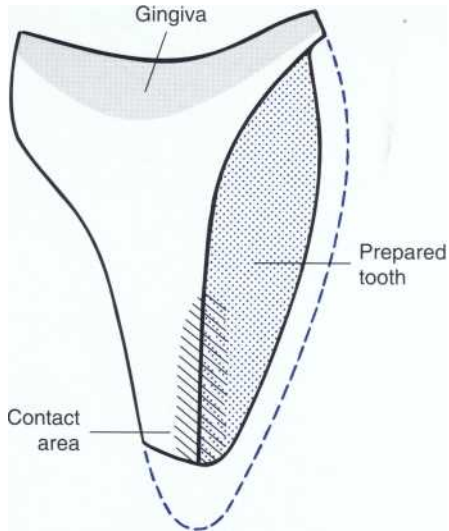


**Fig. 9-36.** If the final porcelain laminate veneer will significantly differ in color from that of the prepared tooth, the proximal finishing line terminates within the interproximal contact area at a depth of one half the labiolingual dimension of the contact area.

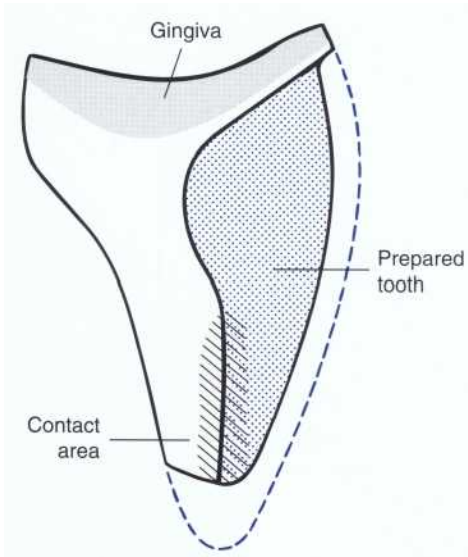
- i. Prepare the proximal chamfer finishing line with an LVS-3 or LVS-4 diamond bur to a depth of one half the labiolingual dimension of the interproximal contact area (Figs. 9-36 and 9-37).
- ii. Prepare the proximal subcontact area with an LVS-3 or LVS-4 diamond bur (Fig. 9-38).

**CLINICAL TIP.** Be certain that unprepared tooth structure in the proximal subcontact area is not visible from all oblique viewing perspectives. See the Clinical Tip in the section on proximal subcontact area and see Figs. 9-8 to 9-12.

8. Prepare the gingival finishing line.
  - A. For supragingival preparations: Prepare the gingival finishing line to the desired location.

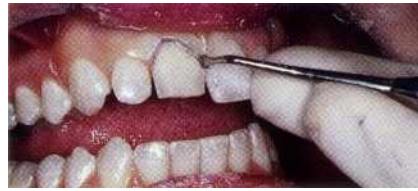

**Fig. 9-37.** Proximal representation of porcelain laminate veneer preparation before reduction of the proximal subcontact area. The proximal finishing line terminates within the interproximal contact area at a depth of one-half the labiolingual dimension of the contact area because the final porcelain laminate veneer will be significantly different in color from that of the prepared tooth.

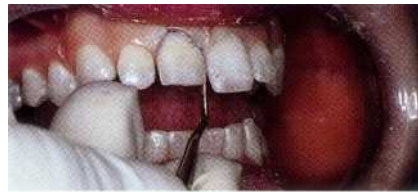

**Fig. 9-38.** Proximal representation of porcelain laminate veneer preparation shown in Fig. 9-37 after proper reduction of the proximal subcontact area.

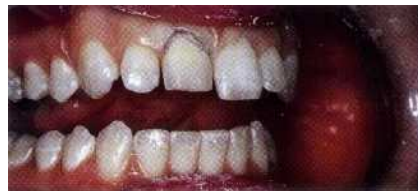**B. For subgingival margins:** Gently place gingival retraction cord (Fig. 9-39). The cord should extend into the sulcus of the interproximal papil-



**Fig. 9-39.** Retraction cord is placed.



**Fig. 9-40.** The cord should extend into the sulcus of the interproximal papillae beyond the proximal finishing line.



**Fig. 9-41.** When retraction cord is placed, the gingiva will not only be retracted labially, but usually also gingivally as the pencil line demonstrates. The pencil line was drawn at the level of the free gingival margin prior to cord placement (see Fig. 9-32).

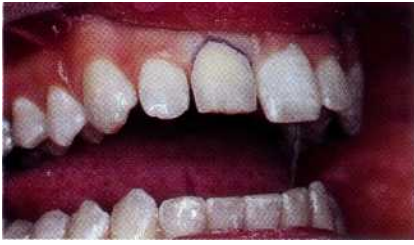lae beyond the proximal finishing line (Fig. 9-40).

**CLINICAL TIP.** For subgingival preparations, draw a line with a sharpened pencil at the present location of the gingival margin (currently at the level of the free gingival margin).

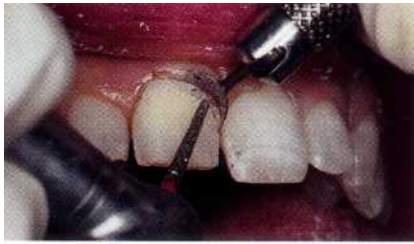**CLINICAL TIP.** When the retraction cord is placed, the gingiva will be retracted not only labially but usually also gingivally (Fig. 9-41).

9. Extend the gingival finishing line (for subgingival preparations only) approximately 0.1 mm subgingivally with an LVS-3 or LVS-4 Diamond bur

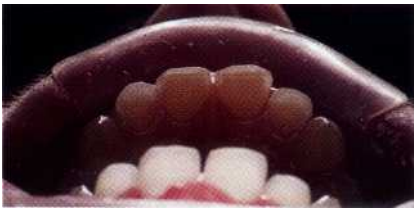



*Fig. 9-42. Properly prepared subgingival finishing line.*



*Fig. 9-43. The gingiva can be gently retracted with the gingival retraction instrument.*



*Fig. 9-44. The incisal line angle is rounded to prevent internal stresses within the porcelain laminate veneer.*

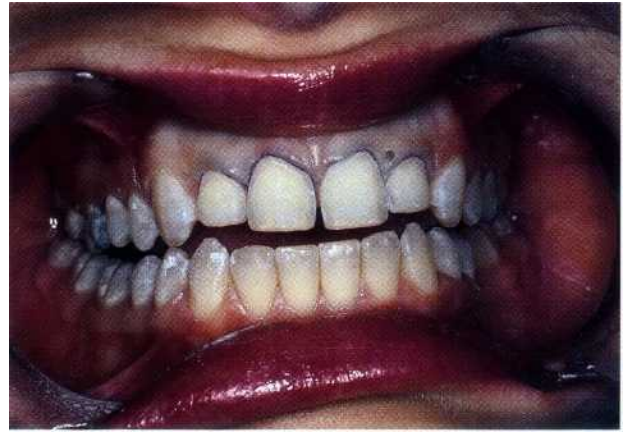(Fig. 9-42). Use the pencil line as a guide; see the preceding two Clinical Tips. Severely discolored teeth may require a 1-mm subgingival extension of the finishing line.

---

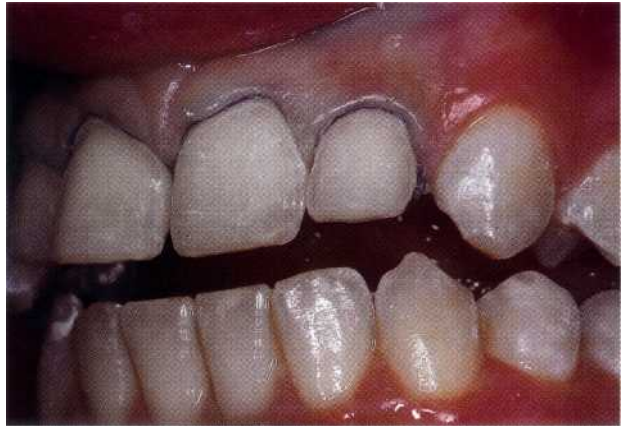**CLINICAL TIP.** Gently retract the gingiva with the gingival retraction instrument (Fig. 9-43).

10. Round the incisal line angles with an LVS-3 or LVS-4 diamond bur. The thinner LVS-5 or LVS-6 diamond bur may be necessary to access line angles that are close to adjacent teeth (Figs. 9-44 to 9-48).

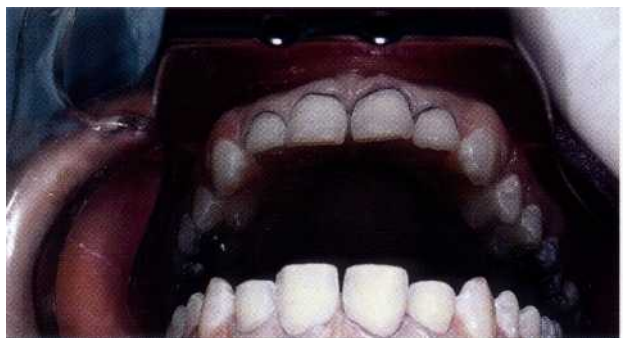**CLINICAL TIP.** Rounding the incisal line angles reduces the internal stress and therefore the fracture potential of the final restoration."



*Fig. 9-45. Teeth prepared for porcelain laminate veneers. The proximal subcontact area is not visible from this direct frontal view.*



*Fig. 9-46. The same preparation as shown in Fig. 9-44 viewed from an oblique angle. The proximal subcontact area chamfer preparation between the maxillary left central and lateral incisor has been properly extended. The proximal chamfer finishing line terminates approximately 0.2 mm labial to the contact area between these two teeth. All incisal edges have been rounded.*



*Fig. 9-47. Incisal view of the final preparations.*

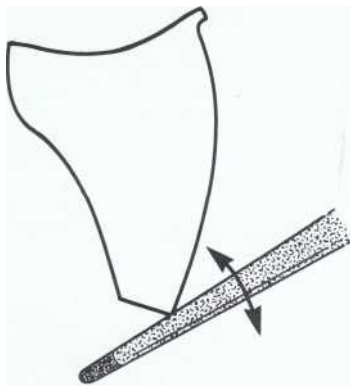


Fig. 9-48. Incisal view demonstrating clearly defined palatal finishing lines.

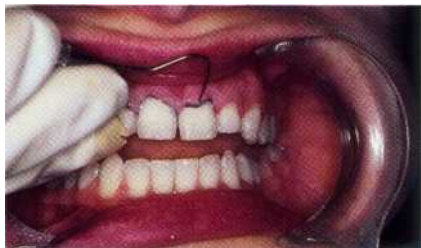

Fig. 9-49. Retraction cord should be removed immediately after impressions are made.

### IMPRESSIONING

#### Armamentarium

- Retraction cord packer (e.g., Fischer's Ultrapak Packer, Ultradent Products, Inc.)
- Nonimpregnated gingival retraction cord (e.g., Ultrapak No. 0 or No. 1, Ultradent Products, Inc.; Gingibraid No. 0 or No. 1, Van R)
- Scissors
- Elastomeric impression material

#### Clinical Technique

1. Gently place a retraction cord in the sulcus unless previously placed during preparation.

**CLINICAL TIP.** Position the cord just beneath the finishing line to avoid interfering with capturing the entire gingival margin in the impression.

2. Make the impression with any accurate elastomeric impression material.

**CLINICAL TIP.** Leave the retraction cord in place during impressioning. It is usually removed in the impression. However, be certain that all remaining cord is removed before proceeding to the next step (Fig. 9-49).

### PROVISIONAL RESTORATIONS

The placement of provisional restorations is usually unnecessary because of the conservative nature of porcelain laminate veneer preparations (Figs. 9-50 and 9-51). A patient's desire for provisional restorations is often based on expectations or previous experience with crown and bridge procedures, rather than actual esthetic necessity. In many cases the improved contour of the prepared teeth and the possible removal of surface discolorations after preparation results in enhanced esthetics when compared with the preoperative appearance. These considerations, as well as any additional fees for provisional restorations, should be discussed in the initial consultation.

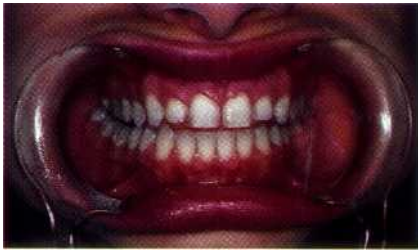If a provisional restoration is deemed necessary, the gingival termination of the provisional restoration should not impinge upon the gingival tissue to prevent gingival inflammation or recession.

Provisional restoration fabrication involves the use of a template and light-cured composite resin. A preoperative study model is made from an irreversible hydrocolloid impression. If the preoperative tooth contours are esthetically unacceptable, appropriate recontouring or wax buildup is accomplished. The modified model is duplicated and a clear plastic matrix is fabricated by either the Ellman Press-Form system or a vacuum former unit (see Chapter 11). An alternate method involves the fitting of individual celluloid (clear) crown forms over the prepared teeth (see Chapter 11). The appropriate palatal and proximal surfaces of the crown form or matrix are then removed.

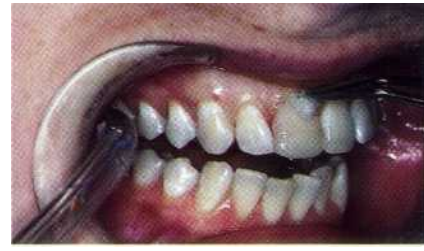**CLINICAL TIP.** The retention of the restoration is solely mechanical in nature. Therefore a single multi-tooth provisional restoration will be more effectively retained than separate single-tooth provisional restorations.

#### Armamentarium

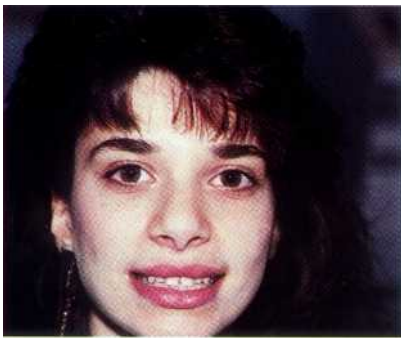- Basic dental setup; see section on major color change
- Plastic matrix or celluloid crown forms (see Chapter 11)
- Sable brush (No. 0)
- Bonding agent
- Hybrid composite resin (e.g., Herculite, Kerr, Inc.)
- Fine diamond finishing burs (e.g., ET Burs, Brasseler, Inc.; Micron Finishing System, Premier Dental Products Co.)



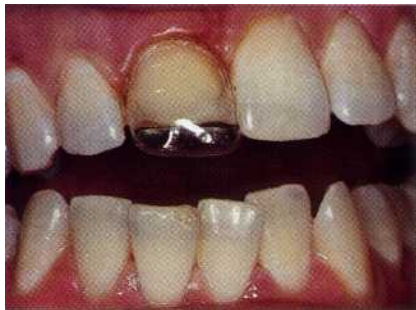*Fig. 9-50. The placement of provisional restorations is usually unnecessary because of the conservative nature of porcelain laminate veneer preparations.*



*Fig. 9-53. Excess composite resin is removed with a cotton pellet moistened with bonding agent.*



*Fig. 9-51. Full face view of patient in Fig. 9-50.*



*Fig. 9-52. A patient with a single prepared maxillary incisor who required a provisional restoration. A trimmed celluloid crown form is positioned over the prepared tooth.*

#### Clinical Technique

1. Fit the plastic matrix over the prepared teeth (Fig. 9-52).

**CLINICAL TIP.** The matrix margins should allow for easy removal of excess composite resin.

2. Remove the matrix and place the appropriate shade of composite resin into the matrix.

**CLINICAL TIP.** It is not necessary to etch the enamel, prime the dentin surfaces, or place bonding agent on the teeth before placing the composite resin. Retention of the provisional restoration is solely mechanical.

3. Place the matrix and resin onto the prepared teeth. (If multiple celluloid crown forms are used, all should be placed before curing; after curing, the restoration will be a single solid unit.)
4. Remove excess composite resin from the entire buccal, lingual, and proximal surfaces (Fig. 9-53).

**CLINICAL TIP.** Dip a sable brush or cotton pellet in bonding agent and wipe off all excess composite resin before curing. In addition featheredge the composite resin on the palatal surfaces with the wetted brush. Precise, smooth marginal adaptation ensures minimal adjustment after curing and prevents gingival inflammation.

5. Light cure all surfaces for a minimum of 60 seconds each.

**CLINICAL TIP.** Light-cured resin cannot be damaged by excessive light exposure. It is therefore preferable to err on the side of longer exposure times.

6. Verify and correct the occlusion with high speed diamond finishing burs.

**CLINICAL TIP.** Adjustments of the provisional restoration must not alter the previously prepared tooth. If this would not be possible, remove the entire restoration and place a new restoration, making certain that all excess composite resin is removed before curing.

7. Recontour with high-speed diamond finishing burs (if necessary).
8. Instruct the patient that the provisional restoration is for esthetic purposes only and that careful limited function is required (Figs. 9-54 and 9-55).

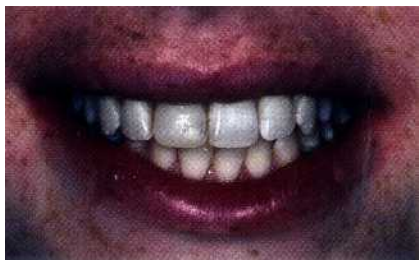

Fig. 9-54. The provisional restoration (labial view).

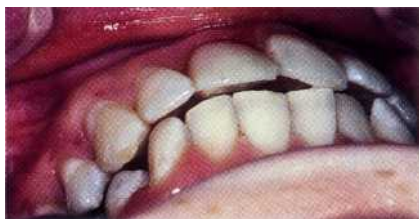

Fig. 9-55. The provisional restoration (incisal view).

**CLINICAL TIP.** If the provisional restoration dislodges, recement it with a noneugenol temporary cement. Alternatively, etch a 1-mm diameter area of midlabial surface enamel and lute the provisional restoration into place with a low-viscosity resin cement.

## LABORATORY COMMUNICATIONS

### *Natural versus Idealized Artificial Appearance*

Natural teeth are polychromatic and characterized. Canines are usually slightly lower in value or higher in chroma than incisors and premolars. These can be disturbing insights for patients who often desire an idealized artificial appearance (monochromatic, white "chiclets"). Both of these alternatives, and the myriad options in between, should be discussed before a final shade selection is made. It may be helpful to elicit the opinion of the patient's friend or family member.

### *Shade*

**CLINICAL TIP.** Include in the laboratory prescription both the shade of the tooth after tooth reduction and the desired final restoration shade. This allows the laboratory technician to attempt to compensate for the underlying discoloration.

To achieve the desired shade change, the percentage of opaquing porcelain and the amount of die spacer can be appropriately adjusted by the dental laboratory techni-

cian. The specific ratios vary depending on the type and brand of materials used. Close communication with the dental laboratory technician is essential in this regard.

**CLINICAL TIP.** It is easier to "darken" (lower the value and increase the chroma) than to "lighten" a porcelain laminate veneer by use of internal modification with luting resin. Therefore select the "lighter" alternative when in doubt about a final shade (see Chapter 2).

### *Shape*

Indicate the desired shape and size of each individual porcelain laminate veneer. As a general rule, feminine teeth are more rounded, less textured, and smaller than masculine teeth; however, this is not always appropriate nor is it always desired by the patient (see Chapter 2). Therefore specific characterizations should be specified diagrammatically, or in writing, on the laboratory prescription.

### *Texture*

Texturing scatters reflected light and produces a more natural appearance. If not all of the teeth in the labial display are to be restored, the laboratory personnel should be instructed to match the texture of the adjacent teeth.

**CLINICAL TIP.** Lack of texturing can produce an artificial appearance, because scattering of light is diminished or absent.

### *Characterization of Porcelain Laminate Veneers*

Characterization and polychromaticity of porcelain laminate veneers can be accomplished by the laboratory technician through the use of different shades of porcelain or by surface staining. Additional modifications can also be accomplished by the dentist at the time of cementation through the use of internal color-modifying agents.

A combination of composite resin color modifiers, opaquers, and different shades of luting cements can be layered between the prepared tooth and the restoration to create a polychromatic effect. However, it is difficult to maintain continuity from tooth to tooth with this technique. Even slight variations in the ratios and relative positioning of these agents and differences in the spacing between the porcelain and the tooth surface can influence the final appearance. This is further complicated because the uncured shade-modifying materials are spread by compression from the seating of the porcelain laminate veneer and not by direct manual placement and subsequent curing before overlaying (as with direct composite resin laminate veneers).

Characterization and polychromaticity of porcelain-laminate veneers, including body, gingival, and incisal shading and the degree of opacity, is therefore best incorporated directly into the porcelain by the laboratory technician. The relative thinness of the veneer, however, may limit the extent of polychromaticity attainable in the porcelain. Internal resin shading ideally should be limited to the minor changes that can be accomplished through the use of a single homogeneous shade of luting cement.

### TRY-IN CONSIDERATIONS

The porcelain laminate veneers should be tried in and evaluated either with water-soluble, noncuring try-in paste (if available) or with the actual luting agent.

The water-soluble, noncuring try-in paste has the advantage of allowing unlimited time to evaluate the effect of the differing shades. If desired, a number of porcelain laminate veneers, each with a different shade of try-in paste, may be simultaneously evaluated. The pastes will approximate the color of the corresponding luting cement.

The actual luting cement can be used to evaluate the effects of different shades. However, the evaluation must be performed quickly so that the material does not begin to cure.

Whether water-soluble, noncuring try-in paste or the actual luting agent is used, the final result may vary from that which is visualized during this evaluation procedure. This occurs for the following reasons:

1. The shade of the try-in paste may not precisely match that of the corresponding luting resin.
2. The shade of the luting resin may change immediately following curing.
3. The shade of the cured resin may change over time.

To partially compensate for these phenomena, a sample of each shade of luting resin should be bench-cured and placed in water and any relative changes noted. These changes can be recorded and considered at the time of try-in to help predict the eventual appearance of the final restoration. For example, if the chosen shade of uncured luting agent or try-in paste is higher in value than the corresponding cured sample, the final restoration will probably be similarly affected and appropriate compensation should be considered. However, other factors, such as the metameric influence (see Chapter 2) of the porcelain and dentin, the thickness of the luting agent layer, and the degree of opacity of the porcelain will further complicate this assessment. These considerations are generally more significant when attempting to match unprepared or previously restored adjacent teeth than when an entire labial display is being restored.

### Armamentarium

Oil-free pumice  
 Water-soluble try-in paste or composite resin luting cement (Insure, Cosmedent, Inc.)  
 Extra-fine diamond bur for adjusting porcelain laminate veneers during try-in (Laminate Veneer Kit, Brasseler; Micron Finishing System Diamond Burs MF1, MF2, MF3, Premier Dental Products Co.)  
 Cotton-tipped applicators  
 Acetone or alcohol  
 Double-sided clear adhesive tape (e.g., double-sided tape, 3M, Inc.)

### Clinical Technique

1. Inspect the porcelain laminate veneers for cracks and imperfections. Place the veneers on the model and verify appropriate fit individually and collectively (Figs. 9-56 and 9-57).

**CLINICAL TIP.** Although the porcelain laminate veneers will be cemented with an appropriately shaded luting cement, precise restoration margins are necessary to minimize the exposure of the composite resin cement, which may discolor over time.

2. Remove the provisional restoration with a hemostat. Break the brittle composite resin into smaller fragments if it cannot be removed in one piece.
3. Pumice all areas of the prepared teeth (Fig. 9-58). Rinse thoroughly with water and leave wet.

**CLINICAL TIP.** Prophylaxis pastes contain oil that may contaminate the tooth surface. Therefore do not substitute prophylaxis pastes for oil-free pumice."

4. Moisten the teeth and the internal surfaces of the porcelain laminate veneers with water. Glycerin, a more viscous liquid, may be used if greater retention of the porcelain laminate veneer is desired during this stage.
5. Place the porcelain laminate veneers on the teeth and evaluate for proper fit and color (Fig. 9-59). Adjustments to the fit can be made with a fine diamond bur.

**CLINICAL TIP.** Whenever possible, **delay adjustments until after the porcelain laminate veneers are bonded into place** because of the fragile nature of these restorations before bonding. Therefore perform only those adjustments that are necessary for proper seating of the restorations at this time. Porcelain laminate veneers are much less susceptible to fracture after bonding.

6. Verify shade.

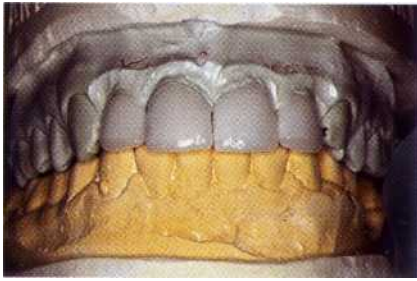


Fig. 9-56. The porcelain laminate veneers positioned on the laboratory model (labial view).

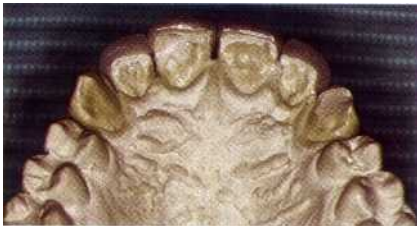

Fig. 9-57. The porcelain laminate veneers positioned on the laboratory model (palatal view).

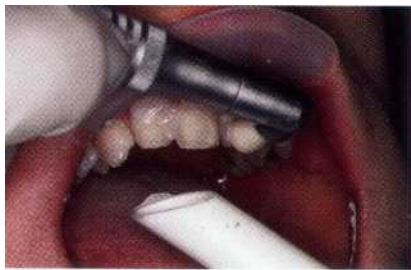

Fig. 9-58. All areas of the prepared teeth are pumiced.

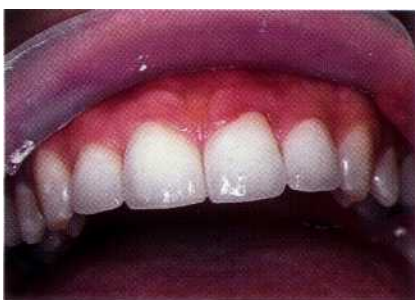

Fig. 9-59. The porcelain laminate veneers are placed on the prepared teeth and evaluated for proper fit and appearance.

A. *If the shade is correct:* Verify that untinted luting resin will be acceptable by placing untinted water-soluble try-in paste or the actual resin luting

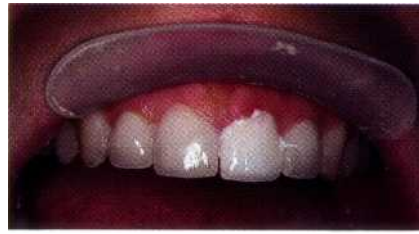

Fig. 9-60. If different shade modifications are evaluated simultaneously in adjacent porcelain laminate veneers, comparisons can be easily visualized.

ing cement into the internal surface of the porcelain laminate veneers and placing the veneers on the teeth.

**CAL TIP.** If the resin luting cement is used to preview the final result, care must be taken to work quickly so that the material does not begin to cure.

**CLINICAL TIP.** Because the shade of the resin luting cement can change immediately upon polymerization and after time, correlate the final choice of resin cement with bench-cured shade samples. See the section on try-in considerations in this chapter.

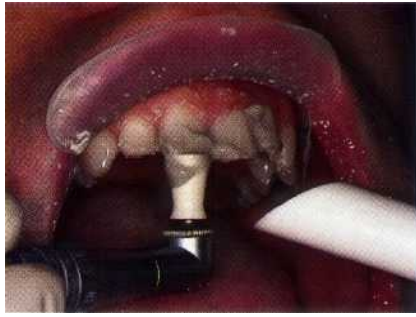B. *If the shade must be altered:* Place the appropriate shade of water-soluble try-in paste or the actual resin luting cement into the internal surface of the porcelain laminate veneers and place the veneers on the teeth.

**CLINICAL TIP.** If the resin luting cement is used to preview the final result, take care to work quickly so that the material does not begin to cure.

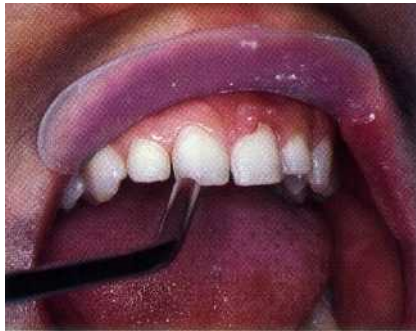**CLINICAL TIP.** By evaluating different shades simultaneously in adjacent porcelain laminate veneers, you can easily visualize comparisons (Fig. 9-60). This is best accomplished with try-in pastes that allow unlimited working time.

**CLINICAL TIP.** Because the shade of the resin luting cement can change immediately upon polymerization and after time, correlate the final choice of resin cement with bench-cured shade samples. See the section on try-in considerations in this chapter.

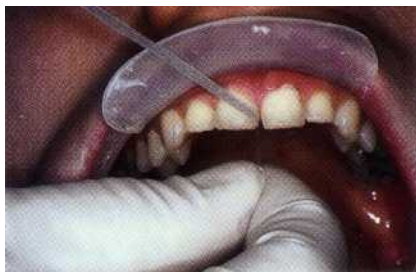**CLINICAL TIP.** If you cannot attain an acceptable shade, the laminate veneer can be custom stained in the office (see below) or by the laboratory.



*Fig. 9-61. The teeth are pumiced to remove all traces of the try-in paste or luting agent.*



*Fig. 9-62. Following a thorough water wash, the teeth are dried with oil-free air.*



*Fig. 9-63. Proximal surfaces are cleaned with a finishing strip.*

7. Clean the internal surfaces with a cotton-tipped applicator followed by a water spray, and finally in an ultrasonic cleaner with acetone or alcohol. Apply 37% phosphoric acid for 15 seconds to remove any salivary contamination from the etched surface.

**CLINICAL TIP.** The "etching" of the etched porcelain surface of a porcelain laminate veneer is much more durable than the "etching" of etched enamel. Cleaning (as described in the preceding step) will not damage the etched surface.

8. Clean the teeth again with oil-free pumice (Fig. 9-61); wash and dry with oil-free air (Fig. 9-62).

9. Clean proximal surfaces with a finishing strip (Fig. 9-63); wash and dry thoroughly with oil-free air.

### CUSTOM LABORATORY STAINING

A large discrepancy in hue or chroma requires custom staining either at chairside or by the laboratory technician. Most laminate veneers are fabricated on a refractory model, which is destroyed when the veneer is removed, so a new model must be fabricated.<sup>31</sup>

#### Armamentarium

Basic dental setup; see the section on major color change  
 Low-speed green stone  
 Basic custom shading setup (see Appendix A)  
 Porcelain laminate investment material  
 Sandblaster (e.g., Microetcher, Danville Engineering)  
 Porcelain etch (10% hydrofluoric acid)

#### Clinical Technique

1. Mix investment material and carefully place a small amount of investment on the lingual aspect of the porcelain laminate veneer.
2. Shape the remaining investment into a block and place the porcelain laminate veneer on this block with the labial side of the restoration facing out.
3. Trim excess investment to completely expose the labial surface. This is best done before the investment sets.
4. Carefully remove the glaze on the buccal surface with a low-speed green stone.
5. Modify the porcelain laminate veneer as necessary and fire (see Appendix A).
6. After "bench cooling," carefully remove the porcelain laminate veneer from the investment.
7. Carefully sandblast the internal aspect of the porcelain laminate veneer to remove any remaining investment material.
8. Try-in the porcelain laminate veneer. If the shade is still not acceptable, repeat steps 1 through 7.
9. Verify with the porcelain manufacturer whether re-etching of the internal aspect of the porcelain laminate veneer with hydrofluoric acid is necessary. Do not allow the etchant to contact the external surfaces.

### CEMENTATION

#### Armamentarium

Basic dental setup; see the section on major color changes  
 Oil-free pumice

**Interproximal abrasive strips (Sof-flex Strips, 3M, Inc.)**

Dead soft matrix strips (e.g., dead soft metal matrix strip, DenMat) or clear plastic matrix strips (e.g., Clear Mylar Strips, Patterson, Inc.)

Silane coupling agent

Dentin/enamel bonding agent (e.g., One-Step, Bisco, Inc.)

Set of shaded resin luting cement (e.g., Insure, Cosmedent, Inc.)

Composite resin carving instruments (e.g., TCA, TCB, TCD, American Dental Manufacturing)


**Clinical Technique**

**CLINICAL TIP.** Placement of a porcelain laminate veneer on an incorrect tooth can easily occur after the luting cement is applied. This is particularly true for canine teeth restorations, which easily can be transposed. To avoid this, draw and **label circles** on the bracket table cover (Fig. 9-64) or a mixing pad, or affix the laminate veneers to double-sided clear adhesive tape in the correct order.

1. Apply silane coupling agent to the internal surface of all the porcelain laminate veneers according to the manufacturer's instructions (Figs. 9-65 and 9-66).

**CLINICAL TIP.** The resin/porcelain bond is enhanced when the silane coupling agent is applied to the porcelain surface according to the manufacturer's instructions.

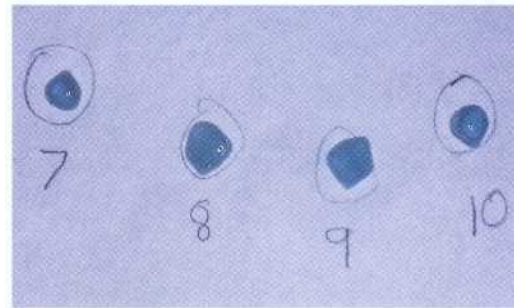
**CLINICAL TIP.** Restore both central incisors simultaneously, then proceed distally. Should minor errors in porcelain laminate veneer positioning occur, they will therefore be located as far from the midline as possible, where any necessary compensatory adjustments will be less visible.



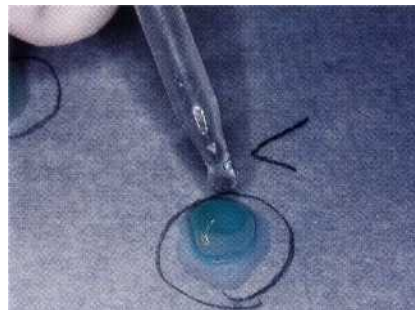
*Fig. 9-64. Placement of a porcelain laminate veneer on an incorrect tooth can easily occur after the luting cement is applied. To avoid this, draw and label circles on the bracket table cover.*

2. If the tooth surface has been contaminated, pumice the labial and lingual tooth surfaces again.
3. Place matrix strips between the first teeth to be restored and the adjacent teeth (Fig. 9-67).
4. Etch the enamel and dentin for 15 seconds (Fig. 9-68). (See Chapter 5.)

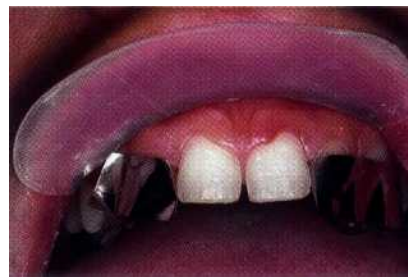**CLINICAL TIP.** Controlled positioning of the 37% phosphoric acid is facilitated by the use of a gel.



*Fig. 9-65. Some silane coupling agents require acid etch activation of the porcelain surface.*



*Fig. 9-66. Silane coupling agent is applied to the internal surface of the porcelain laminate veneer according to the manufacturer's instructions.*



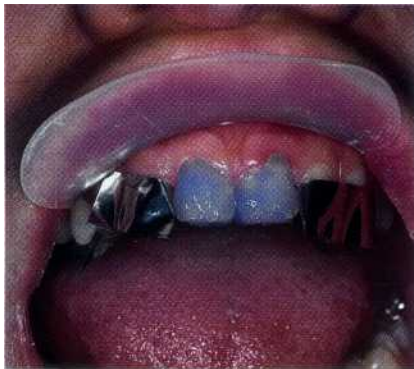*Fig. 9-67. Matrix strips are placed between the first teeth to be restored and the adjacent teeth.*



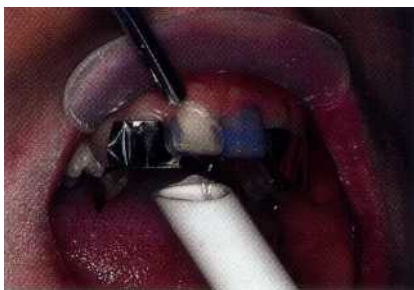5. Wash with water and or water/air spray for a minimum of 10 seconds for gel or liquid etchants (Fig. 9-69). (See Clinical Tip in the section on acid etch considerations in Chapter 5.)
6. Air dry (Fig. 9-70). Repeat the etching process and rewash the enamel if it is not "frosty" white. Repeat if necessary.
7. Place new matrix strips between all interproximal areas (Fig. 9-71).
8. Rewet the dentin with a cotton pellet.
9. Apply bonding agent to the internal surface of the porcelain laminate veneers according to the manufacturer's instructions (Fig. 9-72).
10. Apply preselected shade of luting cement to the internal surface of the porcelain laminate veneer (Fig. 9-73).

**CLINICAL TIP.** Place the porcelain laminate veneers underneath an opaque cup to prevent premature curing of the resin.

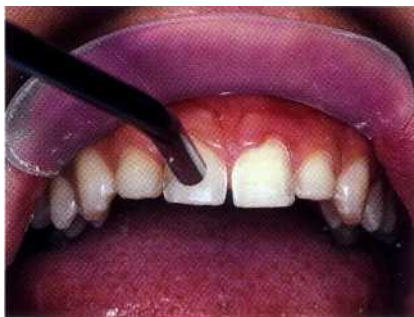11. Place dentin/enamel bonding agent onto the tooth according to the manufacturer's instructions (Fig. 9-74).



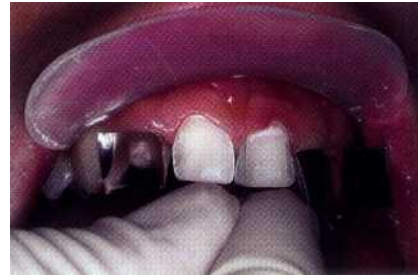*Fig. 9-68.* The enamel is etched with 37% phosphoric acid for 15 seconds.



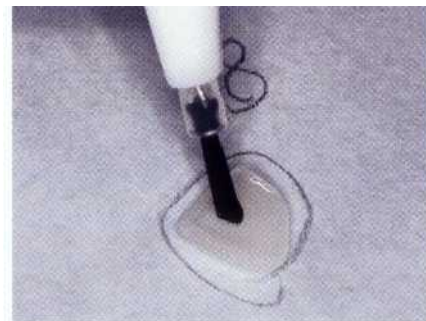
*Fig. 9-69.* The etchant is removed with water.



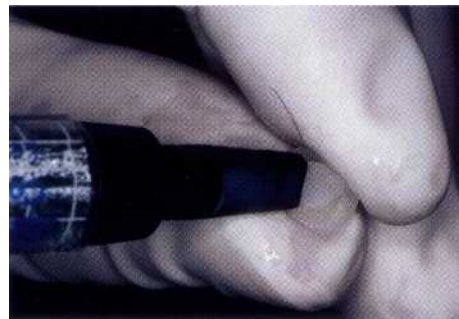*Fig. 9-70.* The preparation is dried with oil-free air.



*Fig. 9-71.* Fresh matrix strips are placed into all interproximal areas.



*Fig. 9-72.* Bonding agent is applied to the internal surface of the porcelain laminate veneers according to the manufacturer's instructions.



*Fig. 9-73.* The preselected shade of luting cement is applied to the internal surface of the porcelain laminate veneer.

12. Carefully place the porcelain laminate veneers onto the teeth and fully seat to place.

**CLINICAL TIP.** To ensure proper seating of the porcelain laminate veneer, first use finger pressure with a pulsing motion on the incisal edge in an incisogingival direction. Then press with a pulsing motion on the labial surface in a labiolingual direction. Repeat these steps as necessary

13. Hold the porcelain laminate veneer in place and cure the incisal tip from a labial direction for 10 seconds (Fig. 9-75).

14. Remove excess luting cement with a sable brush moistened with bonding agent (Fig. 9-76).

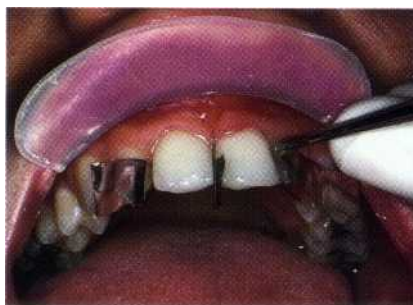**CLINICAL TIP.** Dipping the brush into bonding agent before removing excess cement prevents "pulling" of the cement, which could create marginal voids.

15. Cure the remaining luting cement from the buccal, lingual, and incisal directions according to the manufacturer's instructions (Figs. 9-77 and 9-78).

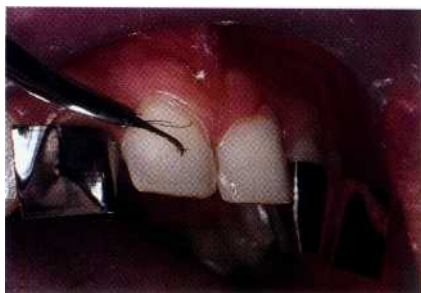**CLINICAL TIP.** Light-cured resin cannot be damaged by excessive light exposure. It is therefore preferable to err on the side of longer exposure times.

16. Remove the matrix strips.  
 17. Remove excess flash with composite resin carving instruments (Figs. 9-79 and 9-80).  
 18. Repeat steps 2 to 17 for the remaining porcelain laminate veneers. Two adjacent teeth can be placed simultaneously.

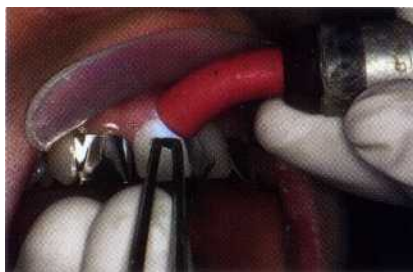**CLINICAL TIP.** Try-in the restorations that will be luted next. Even minimal amounts of excess luting agent from the previously luted porcelain laminate veneers can prevent the proper seating of subsequent veneers (Figs 9-81 and 9-82).



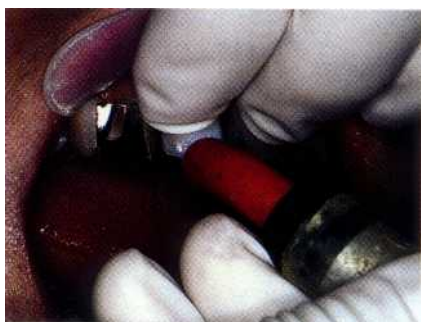*Fig. 9-76. The excess luting agent is removed from marginal areas with a sable brush moistened with bonding agent.*



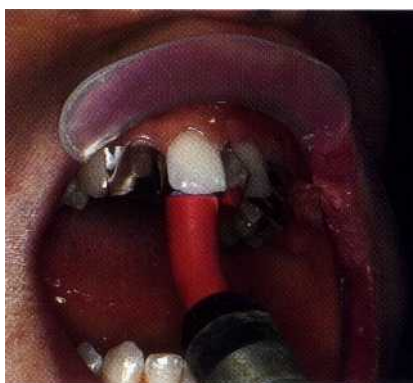*Fig. 9-74. Bonding agent is applied to the tooth structure according to the manufacturer's instructions.*



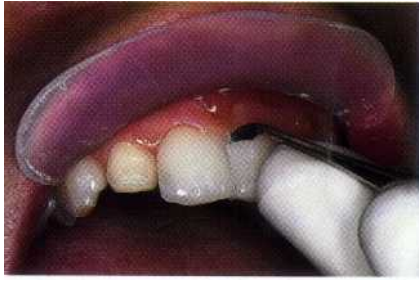*Fig. 9-77. The luting cement is cured from the buccal direction.*



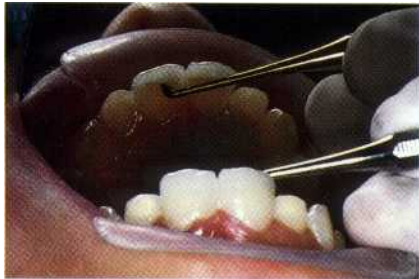*Fig. 9-75. The restoration is carefully seated onto the prepared tooth and the incisal tip is cured from the incisolabial direction for 10 seconds.*



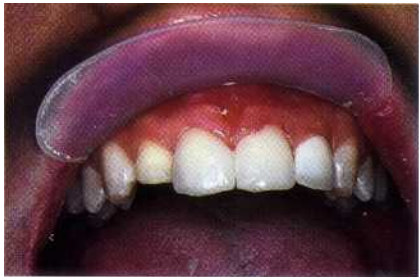*Fig. 9-78. The remaining luting cement is cured from the palatal direction.*



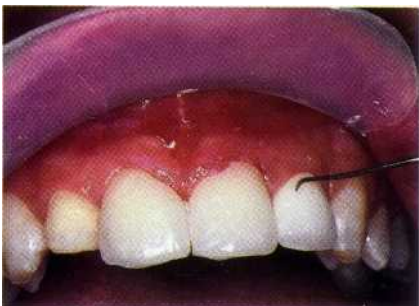*Fig. 9-79. Excess cured composite resin is initially removed from the marginal areas with composite resin carving instruments.*



*Fig. 9-80. Excess cured composite resin is removed from the palatal marginal areas.*



*Fig. 9-81. The open margin at the gingival area on the maxillary left lateral incisor restoration indicates improper seating, which is caused by excess luting cement on the distal aspect of the maxillary left central incisor restoration.*



*Fig. 9-82. After removal of the interference the maxillary left lateral incisor restoration seats properly.*

## FINISHING AND POLISHING

Marginal discrepancies immediately after cementation of indirect restorations are, to some degree, inevitable. Postcementation intraoral finishing of both porcelain and resin at the tooth-restoration interface can be accomplished with rotary instruments. Scanning electron microscope and spectrographic reflectance analyses reveal that adjusted porcelain can attain a surface smoothness that is superior to that of glazed porcelain if a specific protocol is followed.<sup>33</sup> This protocol is outlined below and involves the use of progressively finer abrasives. Finishing and polishing instruments include diamond burs, a 30-fluted carbide bur and a 2- $\mu$ m to 5- $\mu$ m particle size diamond polishing paste on a webbed rubber prophylaxis cup.

### Armamentarium

Composite resin carving instruments (e.g., TCA, TCB, TCD, American Dental Manufacturing)

Diamond finishing burs (Micron Finishing System Diamond Burs MR, MF2, MF3, Premier Dental Products Co.)

30-fluted carbide bur (e.g., ETUF6 and 379UF, Brasseler, Inc.)

Interproximal abrasive strips (Sof-Flex Strips, 3M, Inc.)

Unwaxed regular dental floss

Porcelain polishing paste (e.g., Truluster, Brasseler, Inc.; Instaglaze, George Taub Products)

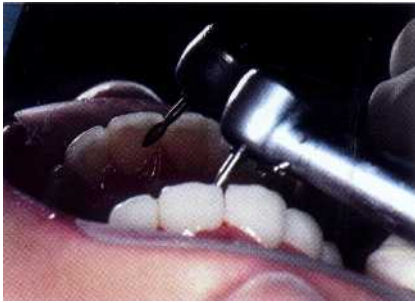Webbed rubber prophylaxis cup (e.g., Young Dental Mfg. Co.)

### Clinical Technique

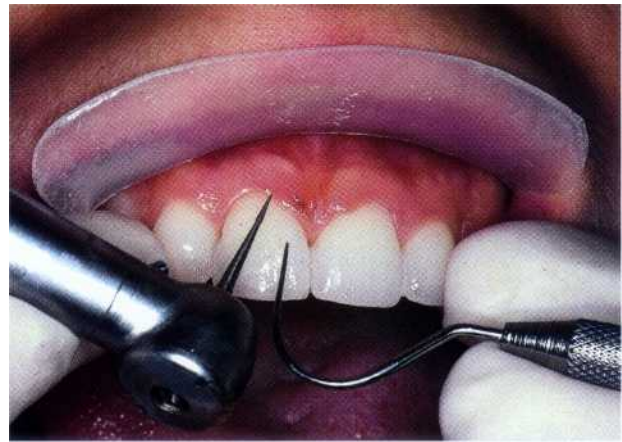1. Carefully finish the facial margins with the M1 finishing diamond in a high-speed handpiece at low speed (regulated by applying appropriate pressure on the rheostat) with water coolant.
2. Finish the lingual areas with a fine "football-shaped" diamond (Fig. 9-83).
3. Dry the marginal areas to evaluate for smoothness and repeat steps 1 and 2 if necessary.

**CLINICAL TIP.** Hold the finishing instruments (composite resin carving instruments or the handpiece) in the dominant hand (right hand for right-handed dentists, left hand for left-handed dentists) and the evaluation instrument (explorer) in the other hand. This allows for efficient repetitive alternations between the evaluation instrument and the finishing instrument. If all instruments are held with only the dominant hand, repeated instrument transfers can become tedious, resulting in inadvertent overlooking of restorative material overhangs (Figs. 9-84 to 9-87).

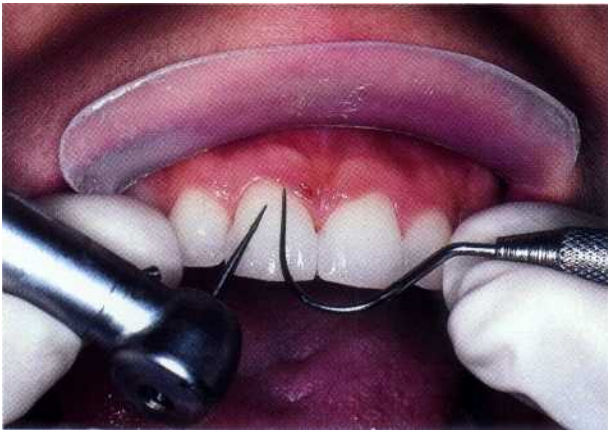4. Evaluate the occlusion with articulating paper in both centric occlusion and in all eccentric excursions.




*Fig. 9-83. Palatal margins are finished with a football-shaped diamond bur.*



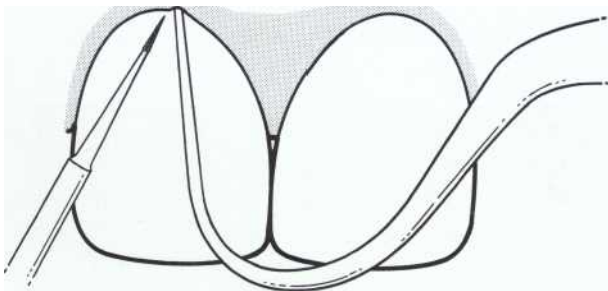
*Fig. 9-86. The polishing instrument is held in the dominant hand while the explorer is held in the other hand. Two-handed instrumentation expedites the tedious, repetitive "margin polishing/margin evaluation" process.*



*Fig. 9-84. The finishing instrument is held in the dominant hand while the explorer is held in the other hand. Two-handed instrumentation allows for efficient repetitive alternation between the evaluation instrument and the finishing instrument. This expedites the tedious, repetitive "margin polishing/margin evaluation" process.*



*Fig. 9-87. The polishing instrument is held in the dominant hand while the explorer is held in the other hand. Two-handed instrumentation expedites the tedious, repetitive "margin polishing/margin evaluation" process.*



*Fig. 9-85. The finishing instrument is held in the dominant hand while the explorer is held in the other hand. Two-handed instrumentation allows for efficient repetitive alternation between the evaluation instrument and the finishing instrument. This expedites the tedious, repetitive "margin polishing/margin evaluation" process.*

- Adjust porcelain, if necessary, with an extra-fine "football-shaped" diamond bur.
- 5. Repeat steps 1 through 4, substituting first an M2 finishing diamond, then an M3 finishing diamond, and lastly, a 30-fluted carbide bur.

**CLINICAL TIP.** Do not substitute a 9- or 12-fluted carbide bur, which tends to chip or cleave the porcelain, for the recommended 30-fluted carbide bur.<sup>34</sup>

**CLINICAL TIP.** Whenever possible, centric occlusion stops and excursive movements should be on natural tooth surfaces. This may not be possible with certain occlusal schema, such as canine-protected occlusion (Figs. 9-88 to 9-90).

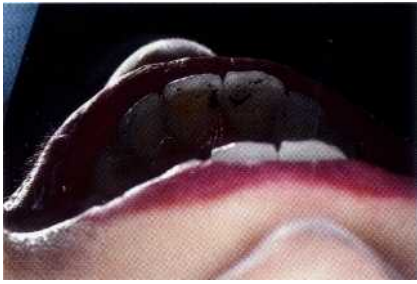

Fig. 9-88. Centric occlusion and excursive movements are evaluated for prematurities.

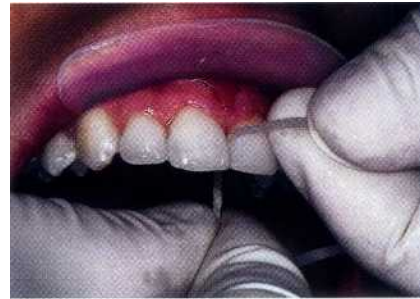

Fig. 9-91. The proximal areas are finished with finishing strips.

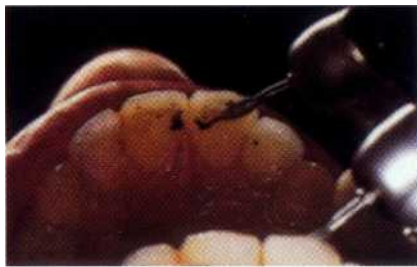

Fig. 9-89. Prematurities are removed with a football-shaped diamond.

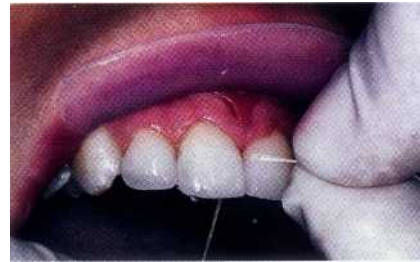


Fig. 9-92. The interproximal contact area is evaluated with unwaxed dental floss.

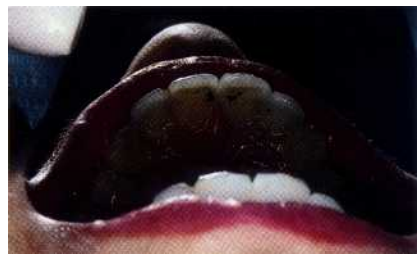

Fig. 9-90. Whenever possible, the centric occlusion stop should be only on natural tooth structure and the restoration should be out of occlusion during excursive movements. This is particularly important if the opposing teeth are not restored with porcelain.

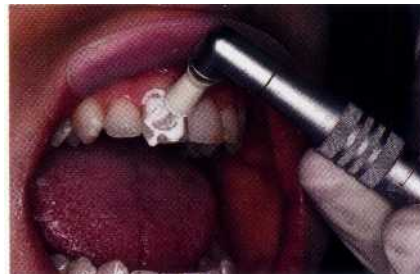

Fig. 9-93. The restoration is polished with diamond polishing paste on a webbed prophylaxis cup.

6. Finish and polish the proximal areas with interproximal abrasive strips (Fig. 9-91).
7. Evaluate the interproximal contact areas with unwaxed dental floss (Fig. 9-92) and repolish if necessary.
8. Polish with a diamond polishing paste on a prophylaxis cup using intermittent pressure to prevent heat buildup (Fig. 9-93).

**CLINICAL TIP.** Defer cosmetic recontouring, if possible, for approximately 1 to 2 weeks after porcelain laminate veneer placement. The initial dramatic cosmetic change can elicit in the patient a psychologic ambivalence and a desire to reestablish the previous appearance. Allowing the patient time to adjust to the new appearance usually eliminates this initial reaction. (This familiar response is commonly seen after the creation of a drastically new hair-style.) Recontouring at this time therefore may result in overcorrection.

9. Reevaluate the finishing and polishing procedures in approximately 1 to 2 weeks for additional marginal discrepancies that may have been obscured by

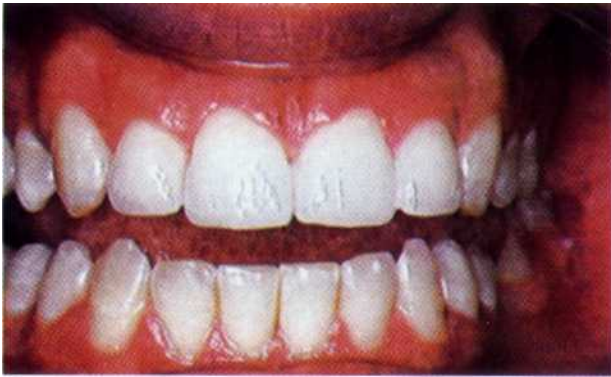

Fig. 9-94. The final porcelain laminate veneer restorations.

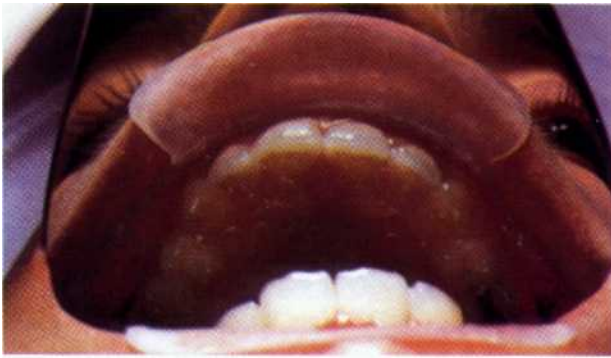
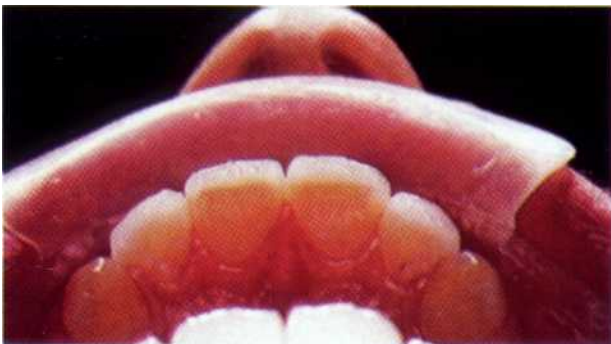
Fig. 9-95. Incisal view of the patient shown in Fig. 9-94



Palatal view of the patient shown in Fig. 9-94.

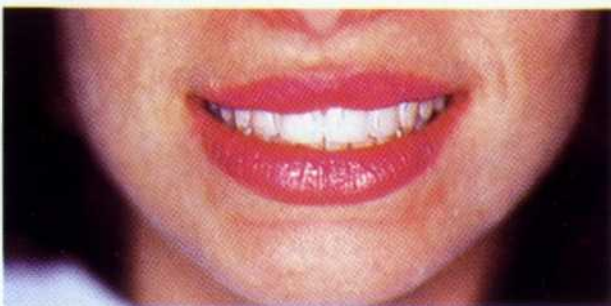

Fig. 9-97. Anterior view of the patient shown in Fig. 9-94.



Fig. 9-98. Full face view of the patient shown in Fig. 9-94.

gingival bleeding or may result from subsequent water sorption by excess luting resin (Figs. 9-94 to 9-98).

### POSTERIOR PORCELAIN INLAYS AND ONLAYS

Porcelain inlay and onlay cavity design is similar to that used for gold inlays and onlays, except that all line angles other than finishing lines must be rounded, and bevels are contraindicated. In addition, adequate thickness must be provided to prevent porcelain fracture. Unlike gold restorations, frictional retention is unnecessary, because porcelain restorations are bonded into place.

#### Clinical Technique for the First Visit

See Fig. 9-99.

#### Armamentarium

Basic dental setup for porcelain laminate veneers

(see the section on major color change)

Burs: medium grit tapered diamond bur (e.g., 6847-

016, Brasseler, Inc.), medium grit flame or chamfer diamond bur (e.g., 6856-018, Brasseler, Inc.)

Retraction cord packer (e.g., Fischer's Ultrapak Packer, Ultradent Products, Inc.)

Nonimpregnated gingival retraction cord (e.g., Gingibraid No. 0, No. 1, or No. 2, Van R, Inc.)

Suitable hemostatic agent (optional) (e.g., Asstringent, Ultradent Products, Inc.)

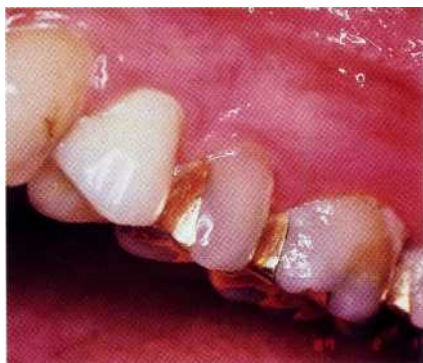Scissors

Elastomeric impression material

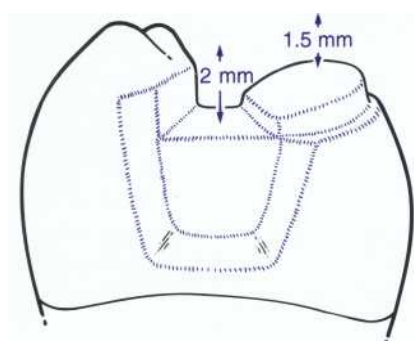
Suitable provisional restorative material (e.g., Fermit N, IvOclar, Inc.)

#### Clinical Technique

1. Administer suitable anesthesia.



*Fig. 9-99. The inlay in the second premolar presented with an unesthetic labial display of gold. (Courtesy Dr. Brian Pollack.)*



*Fig. 9-100. The tooth is prepared in a manner similar to that for a gold inlay/onlay preparation. Divergent walls and rounded internal line angles reduce stress in the restoration.*

2. Prepare the tooth in a manner similar to a gold inlay or onlay preparation. Provide divergent walls and *round* all internal line angles to reduce stress (Fig. 9-100).

**CLINICAL TIP.** Because the restoration will be bonded into place, no retentive grooves or parallel walls are needed.

3. Provide 1.5 mm of occlusal clearance.

**CLINICAL TIP.** Because the occlusion can be adjusted only after cementation, it is often difficult at the try-in stage to predict if the thickness of porcelain will be adequate after occlusal adjustment of the bonded restoration. Therefore verify adequate occlusal reduction at the time of preparation. This prevents the need for overadjustment and subsequent increased fracture susceptibility, because of inadequate occlusal clearance.

**CLINICAL TIP.** Beveled finishing lines create thin areas of porcelain, which may result in porcelain fracture, and are therefore contraindicated. Use butt joint margins.

4. Areas prepared closer than 0.5 mm to the pulp should be lined with calcium hydroxide.
5. Undercuts should be filled with glass ionomer cement or another appropriate liner or base.

**CLINICAL TIP.** Do not use materials containing eugenol, because eugenol can interfere with the chemistry of the bonding resins.

6. Verify that no undercuts exist in the preparation.
7. Gently place a nonimpregnated No. 0 retraction cord in the sulcus.
8. Place a No. 1 or No. 2 cord over the No. 0 cord.
9. Remove only the second cord before impressing.

**CLINICAL TIP.** Make sure that the remaining cord lies beneath the finishing lines to avoid interfering with the capture of the entire gingival margin in the impression.

10. Make the impression with any accurate crown and bridge impression material.

**CLINICAL TIP.** The first retraction cord is left in place during the impressing procedure. It is usually removed by the impression material. However, be certain that all remaining cord is removed before proceeding with the next step.

11. Make a counter impression and obtain a suitable bite registration.
12. Place a provisional restoration and dismiss the patient. Materials containing eugenol are contraindicated.
13. Send the impressions and models to the laboratory for fabrication of the restoration.

### *Clinical Technique for the Second Visit*

#### Armamentarium

Basic dental setup; see the section on major color changes in this chapter  
 Colored spray powder (e.g., Occlude, Pascal Co., Inc.)  
 Pumice  
 Extra-fine diamond burs for adjusting porcelain inlays and onlays during try-in (Laminate Veneer kit, Brasseler; Micron Finishing System Diamond Burs MF1, MF2, MF3, Premier Dental Products Co.)  
 Cotton-tipped applicators  
 Acetone or alcohol  
 Interproximal abrasive strips (Sof-Flex Strips, 3M, Inc.)

- Silane coupling agent Multi-Purpose Etching System (with one-step silanating agent, Cosmedent, Inc.)
- Dentin/enamel bonding agent
- Dual-cured or self-cured luting cement
- Composite resin carving instruments (e.g., TCA, TCB, TCD, American Dental Manufacturing)
- Dead soft matrix strips (e.g., DenMat, Inc.) or clear plastic matrix strips (e.g., Patterson, Inc.)
- 30-fluted carbide burs (Brasseler, Inc.)
- Unwaxed regular dental floss
- Porcelain polishing paste (e.g., Truluster, Brasseler, Inc., Instaglaze, George Taub Products, Inc.)
- Webbed rubber prophylaxis cup

#### Clinical Technique

1. Remove the provisional restoration and thoroughly cleanse the tooth.
2. Gently try-in the restoration and adjust the internal aspects and contact areas to allow for complete seating.

**CLINICAL TIP.** The unbonded porcelain restoration is very fragile. Take care to prevent inadvertent breakage. Do not use a bite stick or have the patient use biting pressure to seat the restoration.

**CLINICAL TIP.** If the restoration is difficult to manipulate with fingers, you can temporarily lute it on the occlusal surface with sticky wax to a small amalgam plugger. This is particularly helpful when preparing the internal surface for final cementation.

**CLINICAL TIP.** Use a colored spray powder (e.g., Occlude) to reveal binding areas.

3. Verify that the restoration is completely seated and that all the margins are adequately sealed. A radiograph is helpful to ensure proper interproximal seating and marginal adequacy.
4. Use dental floss to verify the accuracy of the contact areas.

**CLINICAL TIP.** Do not adjust the occlusion at this time. Occlusal adjustment must be performed after cementation.

5. Shade evaluation and adjustment are accomplished in a manner similar to that for porcelain laminate veneers. See the section on try-in considerations in this chapter.
6. Clean the internal surfaces of the restoration with a cotton-tipped applicator followed by a water spray,

and finally in an ultrasonic cleaner with acetone or alcohol. Apply 37% phosphoric acid for 15 seconds to remove any salivary contamination from the etched surface.

**CLINICAL TIP.** The "etching" of the etched porcelain surface of a porcelain laminate veneer is much more durable than the "etching" of etched enamel. Cleaning (as described in the preceding step) will not damage the etched surface.

7. Place a rubber dam. Place interproximal matrix strip.
8. Place the restoration on a clean, dry surface.
9. Apply silane coupling agent to the internal surface of the restoration according to the manufacturer's instructions.

**CLINICAL TIP.** Application of the silane coupling agent enhances the resin/porcelain bond.

10. Thoroughly clean the prepared tooth with pumice.
11. Etch the enamel and dentin for 15 seconds (see section on acid etch considerations in Chapter 5).

**CLINICAL TIP.** Controlled positioning of the 37% phosphoric acid is facilitated by the use of a gel.

12. Wash with water and or water/air spray for a minimum of 10 seconds for gel or liquid etchants (see Clinical Tip in the section on acid etch considerations in Chapter 5).
13. Air dry. Repeat the etching process and rewash the enamel if it is not "frosty" white. Repeat if necessary.
14. Replace the matrix strip.
15. Rewet the dentin with a cotton pellet (moistened with water if it is dry).
16. Apply dentin/enamel bonding agent to the base (if present), dentin, enamel, and internal surface of the restoration according to the manufacturer's instructions.
17. Apply a self-cured or dual-cured luting composite resin to the internal surface of the restoration according to the manufacturer's instructions.

**CLINICAL TIP.** Use a self-cured or dual-cured luting cement because the light source may not penetrate all internal surfaces.

18. Place the restoration on the tooth and seat with finger pressure using pulsing motion; remove excess luting composite resin with a brush dipped in bonding agent.

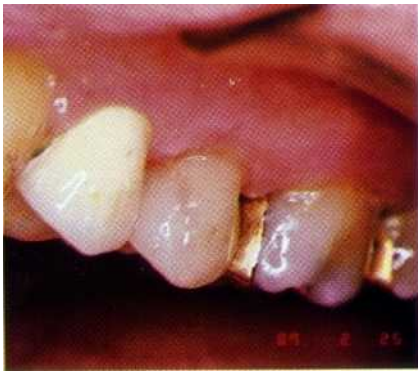

**CLINICAL TIP.** Dipping the brush into bonding agent before removing excess cement prevents "pulling" of the cement, which could create marginal voids.

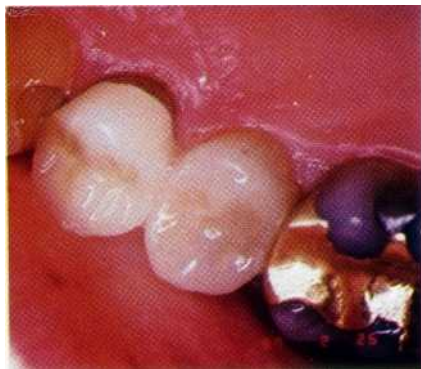19. While the onlay is held in place with an instrument, run dental floss through the proximal areas and pull to the facial or lingual aspect to remove excess resin.
20. Cure the restoration on the occlusal, facial, and lingual surfaces for 40 seconds each if using a dual-cured system. Remove matrix strips.

**CLINICAL TIP.** Light-cured resin cannot be damaged by excessive light exposure. It is therefore preferable to err on the side of longer exposure times.

21. Excess cured luting composite resin can be removed with a surgical blade, scaler, composite resin carving instruments, or with diamond finishing burs.
22. Adjust the occlusion with diamond finishing burs.
23. Finish and polish in a manner similar to that for porcelain laminate veneers (Figs. 9-101 and 9-102).



**Fig. 9-101.** A porcelain onlay was fabricated to replace the gold inlay shown in Fig. 9-99. (Courtesy Dr. Brian Pollack.)



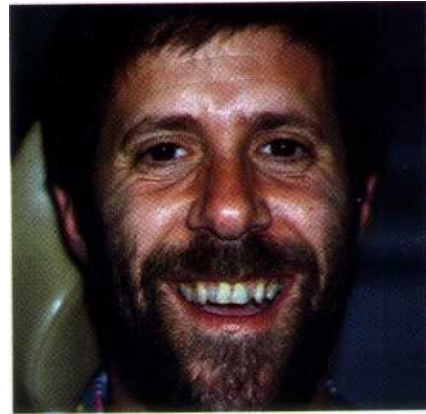**Fig. 9-102.** Occlusal view of porcelain onlay. (Courtesy Dr. Brian Pollack.)

See the section on finishing and polishing in this chapter.

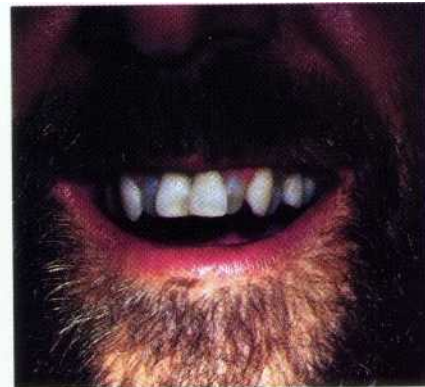## CLINICAL CASE STUDIES

### *Case Study 1*

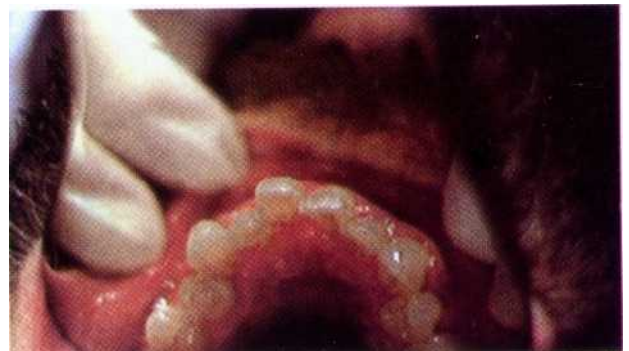A 43-year-old male presented with malpositioned maxillary anterior teeth (Figs. 9-103 to 9-105). His medical



**Fig. 9-103.** Patient presented with anterior crowding. The patient refused orthodontic treatment.



**Fig. 9-104.** Close-up view of patient shown in Fig. 9-103.



**Fig. 9-105.** Incisal view of patient shown in Fig. 9-103.

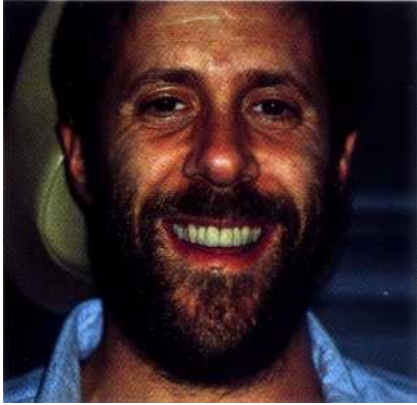history was not contributory. The patient refused orthodontic care, which was presented as the treatment of choice.

An initial chairside wax-up predicted a favorable prognosis for treatment with porcelain laminate veneers. The veneers were placed on the maxillary left first premolar and the four incisors. The patient's slight mandibular prognathism permitted the palatally positioned teeth to be significantly "brought labially" with the porcelain

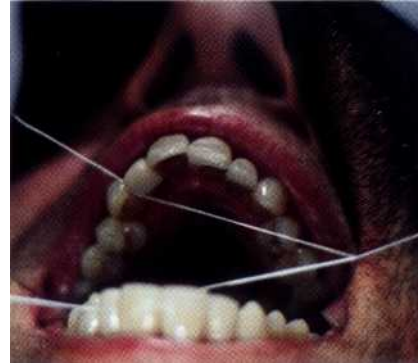laminate veneers without creating a Class 11 appearance (Figs. 9-106 to 9-109).

### Case Study 2

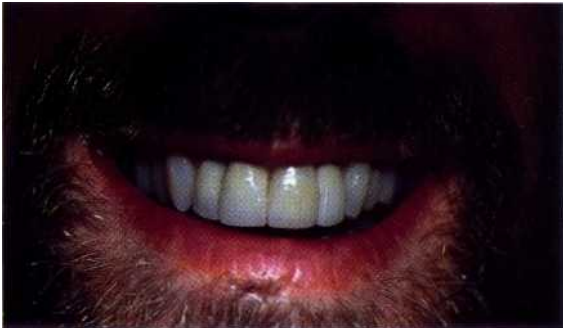A 33-year-old male presented with discolored maxillary teeth and a midline diastema (Fig. 9-110). His medical history was noncontributory. The incisors were restored with porcelain laminate veneers (Fig. 9-111).



*Fig. 9-106. Full face view of the patient shown in Fig. 9-103, 3 years after porcelain laminate veneer placement on the four maxillary incisors and the left first premolar.*



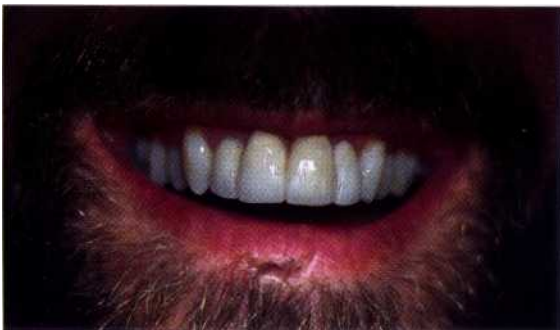*Fig. 9-109. Incisal view, 3 years postoperative, of the patient shown in Fig. 9-105. Floss is easily negotiated through all contact areas.*



*Fig. 9-107. Close-up view of the patient shown in Fig. 9-106.*



*Fig. 9-110. This patient exhibited discolored teeth and a midline diastema.*



*Fig. 9-108. Close-up view of the patient shown in Fig. 9-106 showing a high smile line.*



*Fig. 9-111. The four incisors were restored with porcelain laminate veneers.*

## CONCLUSION

Significant advances in porcelain technology have permitted increased versatility in its use as a restorative material. When combined with acid-etch bonding techniques, porcelain laminate veneers and partial coverage restoration have become a more conservative and highly esthetic alternative to full coverage restoration in appropriate clinical situations.

## REFERENCES

- McGehee WH, True HA, Inskipp EF: A textbook of operative dentistry, ed 3, New York, 1950, The Blakiston Co.
- Fauce FG: Tooth restorations with preformed laminated veneers, J Texas Dent Assoc 53:30, 1977.
- Boyer DB, Chakley Y: Bonding between acrylic laminates and composite resins, J Dent Res 61:489, 1982.
- Cannon, ML, Marshall GW Jr, Marshall SJ, Cooley RO: Surface resistance to abrasion of preformed laminate resin veneers, J Prosthet Dent 52:323, 1984.
- Bowen RL: Report 6333. Development of silica resin direct filling material, Washington DC, 1958, National Bureau of Standards.
- Paffenberger GC, Sweeney WT, Bowen RL: Bonding porcelain teeth to acrylic denture bases, J Am Dent Assoc 74:1018, 1967.
- Semmelman JO, Kull PR: Silane bonding of porcelain teeth to acrylic, J Am Dent Assoc 76:69, 1968.
- Meyerson RL: The effects of silane bonding of acrylic resin to porcelain on porcelain structures, J Am Dent Assoc 78:113, 1969.
- Quinn F, McConnell RJ, Byrne D: Porcelain laminates: a review, Br Dent J 161:61, 1986.
- Newbury R, Pameijer CH: Composite resin bonded to porcelain with silane solution, J Am Dent Assoc 96:288, 1978.
- Highton RM, Caputo AA, Matyas J: The effectiveness of porcelain repair systems, J Prosthet Dent 42:292, 1979.
- Barreto MT, Bottaro BF: A practical approach to porcelain repair, J Prosthet Dent 48:349, 1982.
- Jochen DG, Caputo AA: Composite repair of porcelain teeth, J Prosthet Dent 38:673, 1977.
- Simonsen RJ, Calamia JR: Tensile bond strength of etch porcelain, J Dent Res 62:297, 1983.
- Jordan RE, Suzuki M, Senda A: Clinical evaluation of porcelain laminate veneers: a four year recall report, J Esthet Dent 1:126, 1989.
- Calamia JR: Etch porcelain veneers: the current state of the art, Quintessence Int 16:5, 1985.
- Jenkins CBG, Abousch YEY: Clinical durability of porcelain laminate over 8 years, J Dent Res 67:1081, 1987.
- Phillips RW: Skinner's science of dental materials, ed 7, Philadelphia, 1973, WB Saunders, p 526.
- Hsu CS, Stangel I, Nathanson D: Shear bond strength of resin to etch porcelain, J Dent Res 64:296, 1985.
- Garber DA, Goldstein RE, Feinman RE: Porcelain-laminate veneers, Chicago, 1988, Quintessence.
- Nichols JI: Tensile bond of resin cements to porcelain veneers, J Prosthet Dent 60:443, 1988.
- Horn HR: Porcelain-laminate veneers bonded to etched enamel, Dent Clin North Am 27:671, 1983.
- Jardel V, Degrange M, Picard B, Derrien G: Correlation of topography to bond strength of etched ceramic, Int J Prosthodont 12:59, 1999.
- Della Bona A, Northeast SE: Shear bond strength of resin bonded ceramic after different try-in procedures, J Dent 22:103, 1994.
- Christensen G, editor: Porcelain veneers, cementation kits, Clin Res Assoc Newsletter 12:7:3, 1988.
- Plant CG, Thomas GD: Porcelain facings, a simple clinical and laboratory method, Br Dent J 163:231, 1987.
- Wildgoose DG, Winstanley RB, van Noort R: The laboratory construction and teaching of ceramic veneers: a survey, J Dent 25:119, 1997.
- Nixon RL: Tooth preparation for porcelain veneers, Forum Esthet Dent 4:5, 1986.
- Brunton PA, Richmond S, Wilson NH: Variations in the depth of preparations for porcelain laminate veneers, Eur J Prosthodont Restor Dent 5:89, 1997.
- Highton R, Caputo AA, Matayas J: A photoelastic study of the stresses on porcelain laminate preparations, J Prosthet Dent 58:157, 1987.
- Calamia JR: Materials and techniques for etch porcelain facial veneers, Alpha Omegan 4:81, 1988.
- Scharf J: In-office custom staining of porcelain laminate veneers, Dent Today 9:28, 1990.
- Haywood VB et al: Polishing porcelain veneers: an SEM and specular reflectance analysis, Dent Mater 4:116, 1988.



# ADHESIVE RESIN BONDED CAST RESTORATIONS

Morton Wood and Van Thompson

**C**ONVENTIONAL CERAMOMETAL FIXED PROSTHODONTICS require the removal of substantial amounts of tooth structure so that the resulting restorations are strong, appropriately contoured, and esthetic. However, alternatives that remove less tooth structure are desirable.

The primary goal of the resin bonded prosthesis is conservation of tooth structure. In addition, a bonded

restoration may be more esthetic than conventional ce-ramometal fixed partial dentures, because the facial enamel of **the abutment teeth** is not prepared. Original designs for bonded fixed partial dentures had minimal, if any, preparation of enamel. The latest designs incorporate a more detailed preparation of enamel but are still highly conservative and do not involve the facial enamel.

## HISTORICAL PERSPECTIVE AND PHILOSOPHY

### *Bonded Pontics*

Early attempts to conserve tooth structure when replacing missing anterior teeth with a fixed restoration led to the use of acid-etched retained pontics. Limited to short anterior spans, these pontics were attached to the adjacent abutment teeth with composite resin that was bonded to etched enamel in the approximal contact areas and was mechanically retained within the pontic. A variety of techniques and materials were advocated, including the use of acrylic denture teeth (with and without retentive pins),<sup>1</sup> composite resin,<sup>2</sup> and the patient's natural extracted tooth.<sup>3</sup> These pontic replacements preserved vital tooth structure; however, the failure rate was ex-

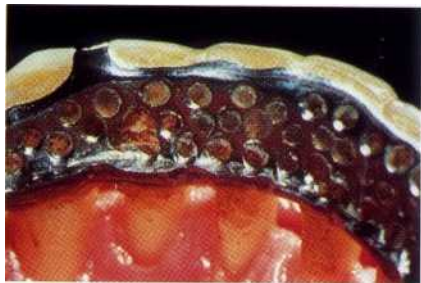cessively high, and they now are used only as temporary re-

### *Cast Perforated Fixed Partial Dentures (Mechanical Retention)*

Rochette<sup>4</sup> first introduced the cast perforated, resin bonded periodontal splint in 1973. Castings were retained by a "sandwich" of unfilled acrylic resin that bonded to etched enamel and mechanically locked into flaring perforations in the metal (Fig. 10-1). This gross mechanical attachment provided improved retention when compared with the bonded pontic replacements, because the metal framework engaged a much broader surface area for enamel bonding.

This design could be adapted to include a porcelain-fused-to-metal pontic.<sup>5</sup> Initially patients who had little or no opposing arch occlusal contact were selected. In addition, no tooth modifications were performed and the framework was extended to cover a maximum amount of the lingual surface. The restorations were bonded using a heavily filled composite resin as a luting medium. Livaditis<sup>6</sup> later used cast perforated fixed partial dentures placed in full occlusion to replace posterior teeth. He extended the perforated retainer framework from the lingual surfaces over the occlusal surfaces and into the interproximal surfaces adjacent to the edentulous areas. He advocated minimal enamel preparation to increase the surface area for retention and develop an occlusogingival path of insertion free from undercuts. The path of insertion was obtained by lowering the proximal and lingual height of contour on the abutment teeth.





*Fig. 10-1.* This perforated cast periodontal splint was designed with a rest seat for the lingual plate of a removable partial denture. The resin locks into the perforations, which flare outward from the tooth surface. Wear and staining of the resin in the area of the perforations are common.

Although cast perforated fixed partial dentures showed promise, several disadvantages accompanied their use:


1. The mechanical retention of resin to metal perforations was often weaker than the resin to enamel bond.' The retention of retainers was therefore only as strong as the resin-to-metal mechanical bond.
2. Perforations weakened the framework, resulting in cracking between the holes and flexing of the retainers. To compensate, an undesirably thick metal wing was required.
3. The resin in the exposed perforations was subject to wear, stain, and plaque accumulation, requiring periodic replacement of the surface layer of composite resin.

### *Etched Cast Resin Bonded Fixed Partial Dentures (Micromechanical Retention)*

Based on the work of Tanaka et al<sup>9</sup> on pitting corrosion for retaining acrylic resin facings, Thompson and Livaditis developed a technique for the electrolytic etching of nickel-chromium (Ni-Cr) and chromium-cobalt (Cr-Co) alloys.<sup>10</sup> The lack of perforations to serve as escape vents for the composite resin required a new "cementing type" of composite resin (e.g., Comspan, Caulk/Dentsply). A moderately filled (60% by weight) composite resin, with a film thickness of approximately 20  $\mu\text{m}$ , allowed good strength and full seating of the cast retainers."

Etched cast retainers provide several advantages over cast perforated restorations:

1. Retention is improved because the bond between resin and etched metal is twice as strong as the bond between resin and etched enamel.
2. The absence of perforations allows for thinner retainers, which resist flexing.
3. The oral surface of the cast retainers are highly polished, resist plaque accumulation, and are impervious to wear.



*Fig. 10-2.* This incisal view diagram noticeably outlines the proximal preparation design for anterior teeth. The "proximal wrap around" is a two-plane reduction that follows the natural contour of the teeth. The dotted line shows the outline of the porcelain that will cover the metal framework.

Guidelines for optimum design were empirically derived. The first generation of etched cast designs included an "interproximal wrap around" concept, developed to resist occlusal forces and provide a broader area for bonding. Enamel preparations consisted of creating occlusal clearance, placing occlusal and cingulum rests, and lowering the lingual and proximal height of contour, thus creating proximal extensions. Frameworks seated in an occlusogingival direction and resisted faciolingual displacement (Fig. 10-2).

The current, second-generation design combines the basic concepts of earlier techniques with the addition of parallel grooves in the interproximal areas and shallow but distinct gingival chamfers.

Second-generation mouth preparations, in an effort to minimize failures, do not preserve as much tooth structure as their predecessors. Nevertheless, they still do not extend into dentin and are true to conservative design principles.

## BASIC PRINCIPLES

### *Adhesion Fixed Partial Dentures (Chemical Bonding)*

One limitation of the etched cast resin bonded technique is that the etching process is limited to Ni-Cr and Cr-Co alloys. The etching of these alloys requires strict attention to details and has been a problem for many dental laboratories." An improved adhesive system allows bonding directly to a casting alloy without the **need for etching or incorporating gross mechanical retention.**<sup>13</sup>

**Panavia (Kuraray, America) is an adhesive paste, bisphenol-diglycidyl methacrylate-based composite resin.** It eliminates laboratory etching procedures and expands the number of alloys that can be used for resin bonded restorations. Panavia has shown excellent bonds to air-abraded Ni-Cr and Cr-Co alloys, as well as to tin-plated gold, tin-plated ceramic gold, and tin-plated gold palladium-based alloys."

Another adhesive resin is Super Bond C&B (Sun Medical), based on a methyl methacrylate polymer powder and methyl methacrylate liquid modified with the adhesion promoter, 4-methacryloxyethyl trimellitic anhydride (4-META). It requires a tri-n-butylborane (TBB) catalyst system. Super Bond has the highest initial bond strengths to base metal alloys of any adhesive resin system, but some concern exists about hydrolytic stability and the possible resultant loss of bond strength over time.<sup>6</sup>

Panavia has a tensile bond strength to etched enamel (10 to 15 MPa) that is comparable with the bond strengths of traditional bis-GMA low film thickness composite resins, such as Comspan (Caulk/Dentsply) and Rely x resin cement (3M, Inc.). The combination of etching metal and using the adhesive Panavia does not improve the strength of the tensile bond to the alloy; this bond strength is actually slightly lower than that of bonds to air-abraded alloys,<sup>6</sup> because the etching removes some of the oxides essential for the chemical bonds. Tensile bond strengths of Panavia to tin-plated high gold ceramic alloys are lower than either the etched or air abraded nickel-chromium-beryllium (Ni-Cr-Be) alloys (18 to 30 MPa); however, they are still greater than the bond to etched enamel.

Although the adhesive materials have not yet shown the same degree of long-term clinical bonding (since 1983 in Japan) as the conventional composite resins (1980 in the United States), the laboratory data supports their efficacy by demonstrating stable bond strengths upon aging in water.<sup>4,15</sup>

Recently, some have advocated a new adhesive method for bonding resin to metal that involves the flame application of a silica-carbon layer to the metal surface. A silane coating can be applied to this treated metal, which provides a surface to which composite resin will bond. The system, which involves a coating-oven-timer system and associated chemistry, has been marketed to the dental laboratory industry as the Silicoater (Kulzer, Inc.).<sup>16</sup> In the laboratory, the strength of the bonds to base metal alloys with this system are high and appear stable, whereas the strength of the bonds to noble metal, although initially high, may degrade with thermal cycling.<sup>19</sup> Clinical trials using this bond system for the metal are in progress.

Changing the method of attachment of the resin to the metal framework does not change the design of the framework itself; the short-term limiting factor in the system is still the bond of resin to enamel, and the long-term limiting factor is the fatigue strength of the luting composite resin. Mechanical retention based on the framework design is necessary to limit the stress on the bond interfaces and the composite resin.

### Maximum Enamel Coverage

The University of Maryland Dental School criteria for resin bonded cast restorations includes coverage of maxi-

imum enamel surface, as long as occlusion, esthetics, and periodontal health are not compromised. Retention, despite the overall success, is only as strong as the resin-to-enamel bond.<sup>20,21</sup> Because the strength of the resin-to-enamel bond cannot be increased, it is critical to add mechanical retention for long-term success.<sup>22</sup> Bond failures in the first or second year usually result from inadequate enamel coverage, contamination of the enamel during bonding, or improper etching of the metal. Fixed partial dentures that debonded at 5 to 7 years seemed to demonstrate a variety of failure causes, which has led to the speculation that long-term failures may result from possible fatigue failure of the composite resin. Failure is evident by separation at either the resin-to-enamel interface or the resin-to-metal interface, or a cohesive failure may occur through the resin itself. The fatigue phenomenon in composite resin is well known. The strength of composite resin is reduced to approximately 60% of its original strength after load cycling (similar to occlusal loading).<sup>23</sup> It is therefore inappropriate to rely solely upon bonding to lingual enamel for retention of the prosthesis.

**CLINICAL TIP.** When it comes to mechanical retention (e.g., surface area of covered enamel, retention grooves), more is better than less.

### Gingival Chamfer

The gingival chamfer should be no greater than 0.2 to 0.5 mm and should not extend into dentin. The resulting preparation allows a slight bulk of metal in the gingival one third. This lowers stress in the resin to enamel bond<sup>24</sup> by limiting metal flexing and providing a positive gingival stop. It also provides a useful guide for the laboratory technician when developing finishing lines and establishing proper contour in this area.

### Cingulum and Occlusal Rests

Rests serve the same function as the gingival chamfer in terms of positive seating, a gingival stop, and a guide for the laboratory technician.

### Interocclusal Clearance

Interocclusal clearance of 0.5 mm in all excursions is required to ensure adequate thickness of the metal framework.

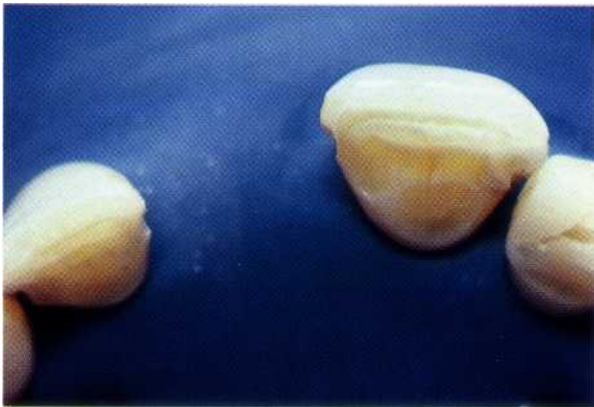### Retention Grooves

Retention grooves, placed only in enamel, protect against rotational forces in the same way that the grooves in a three-quarter cast crown do. The placement of grooves is especially critical when abutment teeth have short clinical crowns, when the occlusion is heavy, or when

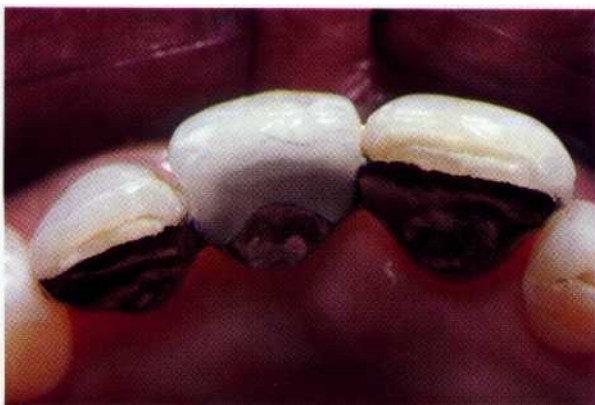esthetics or occlusion prevents adequate surface area from being included. Grooves in anterior abutment teeth should be designed with minimal proximal extension to the facial surface (Figs. 10-3 and 10-4).

### Path of Insertion

The existing heights of contour are visible when examining surveyed casts. Lowering the lingual and proximal heights of contour allows the restoration to cover a greater surface area. Upon completion of this and other aspects of tooth preparation, a distinct incisal (occlusal)/gingival path of insertion, which is free of undercuts, should exist.



*Fig. 10-3.* The completed preparation of this second generation design includes a chamfer margin in the gingulum area and a shallow tapered groove just lingual to the proximal contact area. The marginal ridge distal to the edentulous area is reduced and a second groove placed in an accessible area. When a groove and chamfer finishing line are incorporated, a gingulum notch is not required.



*Fig. 10-4.* The postoperative view of the bonded prosthesis demonstrates adequate retention, open embrasure form, and a retentive design that should resist dislodgment.

### Provisional Restorations

Because provisional restorations are not required, resin bonded bridges should be fabricated as soon as possible to prevent tooth movement.

**CLINICAL TIP.** To prevent supereruption of opposing teeth against the lingual or occlusal preparation, place composite resin spacers.

### Reversibility

The second generation preparation is retentive and conservative but not as reversible as earlier designs. Reversibility, however, becomes less significant as clinical studies continue to demonstrate the long-term success of these restorations.<sup>24a</sup>

### Unit Size

The same principles that are used in determining the number of abutments needed for proper periodontal support of **conventional fixed partial dentures are applied** to bonded prostheses. It is not necessary to add abutments merely to increase the size of the bonded area. Sufficient retention can be created by preparing the abutment teeth with retention components, such as grooves and rests (or, as in the case of short clinical crowns in the posterior region, by onlaying). The replacement of two missing anterior teeth can be considered routine. Replacement of two maxillary central incisors requires double abutting, using both the lateral incisors and the canines for the requisite periodontal support. Replacement of more than two missing maxillary anterior teeth requires extreme caution. Replacement of all mandibular incisors is routine and can be accomplished with only the canines as abutments if the occlusion is limited.

Posterior restorations should be limited to one pontic using bonded retainers, unless inlaying or onlaying the abutment teeth is planned. When multiple posterior pontics are present, the forces of occlusion can create high stresses on the resin and the resin-to-enamel bond, unless extensive mechanical retention is used to dissipate these forces.

### Adhesive Systems versus Etch Systems

Adhesive systems offer clinical convenience but require base metal or tin-plated noble metal. Base metal must be air abraded (50  $\mu$ m alumina at a minimum of 60 psi of air pressure) to allow bonding. Surface contamination with saliva during try-in reduces the bond strength by up to 50%. The bond strengths can be returned to normal by repeated air abrading of the metal surface or by the use of hot detergent solution. An **air-abrasive instrument** in the

dental office is almost a requisite for the adhesive system. This system can be used with palladium- or gold-based alloys, assuming they are properly tin-plated. In addition, gold- or palladium-based metal frameworks must be thicker than those of base metals to compensate for the relatively lower elastic modulus and yield strength of these alloys.

Salivary contamination does not appreciably degrade the bond of the etched metal system. The micromechanical retention is not compromised by a salivary protein coat, as is the case in the chemical bond adhesive system. The disadvantage of the etch system is the requirement for careful and critical laboratory techniques involving strong acids. In addition, no chairside etching techniques provide an adequate degree of three-dimensional relief on the base metal alloy surface for good bonding. Good laboratory support is mandatory. In addition, not all base metal alloys can be used in this technique.

### Tooth Mobility

Mobile teeth tend to debond, making them frequently inadequate abutments for resin bonded prostheses. However, if mobile teeth must be incorporated into the design, they should be prepared with as much retention as possible. To prevent faciolingual displacement, the retainer should cover as much enamel surface as possible and incorporate retentive designs (e.g., distinct grooves, multiple rests, incisal hooks).<sup>25</sup> In general, when the framework is seated, the abutment teeth must not be displaced out of the framework by the occlusion in any direction. This requirement is particularly important on mobile teeth. In addition, the connector-to-retainer transitional area should be thick to prevent fatigue failure of the metal framework on mobile abutment teeth. It is possible for splints to fail with the bonding remaining intact because of metal fatigue.

## TOOTH PREPARATION

### Anterior Preparations

#### Armamentarium

Standard dental setup:

- Explorer
- Mouth mirror
- Periodontal probe
- High-speed handpiece
- Low-speed handpiece

Surveyed and articulated study models

Diamond burs

- Round-ended, tapered (small and medium diameter with carbide tips)
- Bullet- or football-shaped
- Round

Carbide burs

- #6 round
- #35 inverted cone
- #169 and #169L
- #700 and #701

Tapered and ovoid 12-fluted finishing burs

Custom or stock impression trays

Impression materials

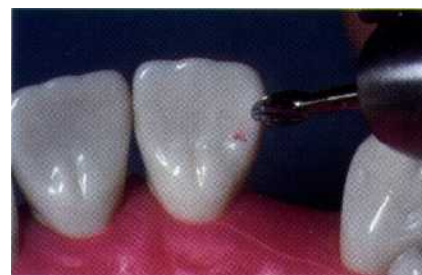Anterior restorative composite resin kit

#### Clinical Technique

1. Before any tooth reduction, survey and evaluate the models to determine where to create retention, lower the height of contour, place proximal extensions, position cingulum rests, locate proximal grooves, and provide occlusal clearance.

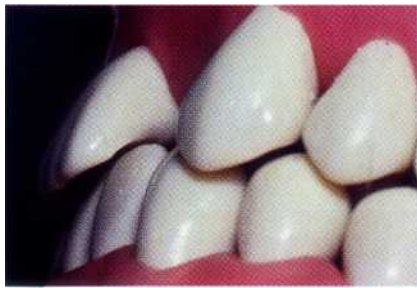**CLINICAL TIP.** Interocclusal clearance should be at least 0.5 mm to 1 mm in both centric and eccentric movements of the mandible. In the maxillary anterior, the clearance usually can be obtained by reducing the lingual enamel of the abutment teeth. If enamel is thin or if the abutment teeth are sensitive, obtain clearance by reducing the incisal edges of mandibular anterior teeth. Depending on the anatomy of the teeth, use a tapered, ovoid, or football-shaped diamond bur to create the lingual clearance (Fig. 10-5). Verify the clearance visually or with wax (Fig. 10-6).

2. Because no provisional restorations are used, bond a light-cured composite resin to the incisal edges of the opposing anterior teeth to maintain the clearance. The resin can be easily removed for try-in appointments or after bonding procedures. Mandibular anterior abutment teeth seldom need incisal clearance, because the framework engages only the lingual and proximal areas.
3. Using a small tapered diamond bur, create a shallow lingual chamfer within 1 mm of the gingival crest. The chamfer should be approximately 0.25 mm

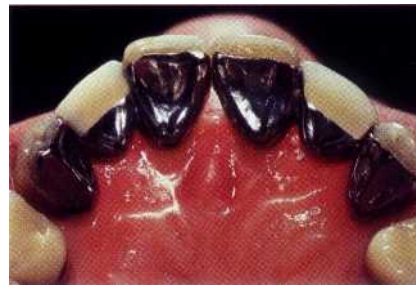

*Fig. 10-5. The occlusal contact is marked with articulating paper so that only a minimal amount of enamel is removed for lingual clearance. An ovoid diamond or 12-fluted carbide bur can be used for this reduction.*

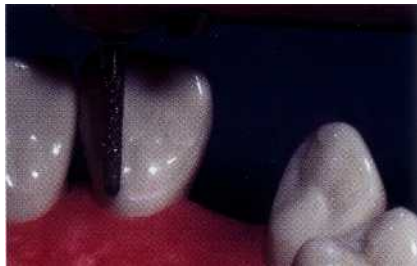



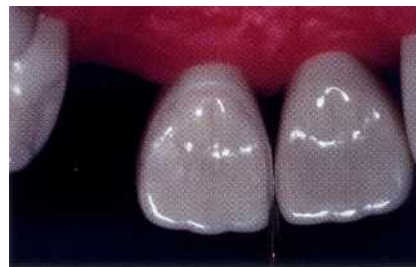*Fig. 10-6.* The ideal clearance is 0.5 to 1.0 mm. The clearance can be verified visually or confirmed with wax. Check for adequate clearance in centric occlusion and in excursive movements.



*Fig. 10-8.* These restorations are still successfully bonded after 7 years, partly because the frameworks had maximum extension especially over mesial and distal marginal ridges.



*Fig. 10-7.* A tapered diamond or carbide-tipped bur (#383-012 Brasseler) assists the creation of the lingual chamfer. This chamfer finishing line extends from the mesiolingual line angle to the distal marginal ridge.



*Fig. 10-9.* Using a #169L bur, create the proximal groove, making sure that it does not extend too far to the facial aspect or penetrate into dentin.

deep, without penetrating into dentin or creating a subgingival margin (Fig. 10-7).

4. Using the same diamond bur, create proximal extensions as far to the facial aspect as esthetics allow.

**CLINICAL TIP.** If a standard framework design would allow metal to be visible in the labial display, modify the technique to cover the area with porcelain. The preparation should allow the metal framework to be fabricated shy of the facial area. Etch, silanate, and bond the proximal area of the porcelain pontic to the etched enamel of the abutment teeth with the cementing composite resin. =

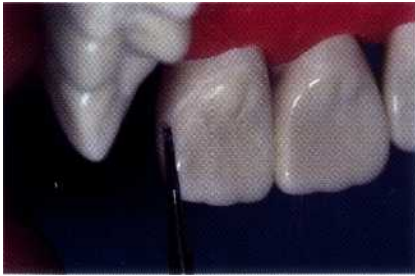5. When a tooth has a distinct cingulum, place a well-defined cingulum rest with an inverted cone bur, running from mesial to distal marginal ridges. When this retentive notch is used, the chamfer can be eliminated from the preparation. This has been verified in photoelastic model studies.<sup>24</sup> When lingual anatomy is shallow or not distinct, use proximal grooves and a chamfer.

**CLINICAL TIP.** The proximal reduction is a critical aspect of the preparation. It determines the path of insertion and the amount of "wrap around" that can be achieved, especially when combined with a retainer design that is extended over the marginal ridges on tooth surfaces not adjacent to the edentulous space (Fig. 10-8).

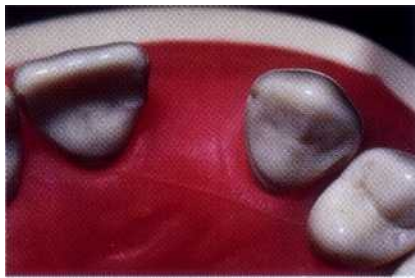6. Proximal grooves are best used when abutment teeth are short or subject to excessive occlusal forces. To properly prepare the grooves, place a #169L bur just lingual to the contact area and parallel to the long axis of the tooth (Fig. 10-9) toward the facial. The bur should penetrate no deeper than the diameter of the bur; otherwise the metal of the final restoration will create a gray shadow through the enamel. Place tapered, parallel grooves on both the proximal area and the marginal ridge opposite the edentulous area (Fig. 10-10). The preparation should resemble a shallow three-quarter crown preparation (Fig. 10-11).

### Posterior Preparations

Conceptually anterior and posterior preparations are similar, except that the design and retentive features for pos-



*Fig. 10-10.* The groove should be parallel with the long axis of the tooth and also parallel to the groove that will be placed on the canine.



*Fig. 10-11.* The completed preparations on both the central incisor and the canine resemble modified three-quarter crown preparations.

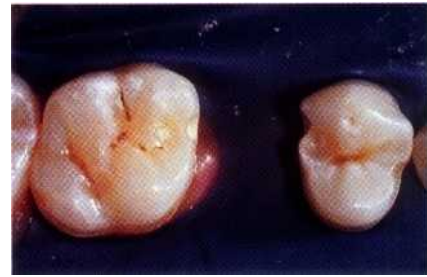terior teeth are more extensive because of tooth morphology and the need to resist forces of posterior occlusion. Extensive occlusal clearance is usually not required, because framework extensions to the occlusal surface are usually limited to the rest seat areas and lingual slope of the lingual cusp.

#### Armamentarium

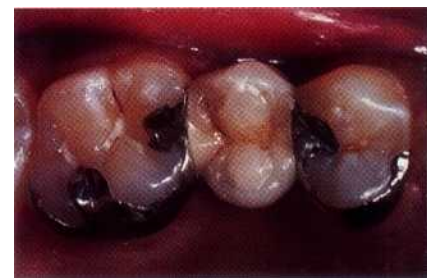- Standard dental setup; see the section on anterior preparations in this chapter

#### Clinical Technique

1. Before tooth reduction, survey and evaluate the models to determine where to create retention, place interproximal extensions, position occlusal rests, locate grooves, and provide occlusal clearance.
2. Use a #6 round bur for molars or a #4 round bur for premolars. Penetrate the fossa next to the marginal ridge and reduce the tooth sufficiently to obtain 0.5 to 1.0 mm of occlusal clearance in the marginal ridge area. Angle the bur gingivally toward the center of the tooth and, although it does not penetrate the dentin, the resulting rest seat should have distinct walls that provide retention and resistance form. In addition, occlusal rest seats aid in providing a positive seating for the casting. These rests re-
- semble those for removable partial dentures but are more distinct (Figs. 10-12 and 10-13).
3. Use a tapered diamond bur to reduce the lingual and proximal heights of contour and establish the occlusogingival path of insertion. The lingual finishing line should be no less than 1.0 mm above the crest of the gingiva. The proximal "wings" of the casting should be approximately 3.0 to 5.0 mm in occlusogingival length and should never impinge on the soft tissue. Increase this occlusogingival height whenever possible by extending the casting as high toward the occlusal surface as the opposing occlusion will allow. Thus the casting will extend up the lingual slope of the lingual cusp. Adherence to these guidelines allows for proper contouring of castings and the embrasure form should allow ease of cleansing.
4. To improve retention, prepare a groove or a shallow slot in the proximal surface buccal to the occlusal rest seat. Place a #700 bur along the long axis of the tooth and penetrate to a depth of one half the bur. When abutment teeth are short or if additional retention is needed, place a second groove similarly



*Fig. 10-12.* An occlusal view of these completed posterior preparations demonstrates the placement of multiple occlusal rest seats. The premolar has mesial and distal rests, whereas the molar has rests on the mesial and lingual surfaces. Note the distinct chamfer finishing line that extends from the facial extent of the edentulous area to the opposite lingual proximal line angle.



*Fig. 10-13.* The occlusal view of the completed restoration highlights the placement of multiple occlusal rests.

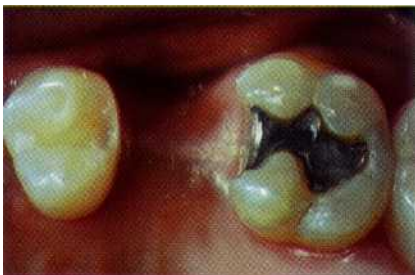on the linguoproximal line angle opposite the initial groove. All grooves must be shallow, distinct, and parallel. If the grooves are not parallel, they can be realigned by using a #701 to one half its depth. Alternatively, a second occlusal rest can be placed distal to the edentulous space on the abutment tooth (see Fig. 10-12).

### Miscellaneous Preparations

Ideal abutment teeth are not always available for use in resin bonded restorations. Abutment teeth commonly have existing restorations, are rotated or tilted, and are sometimes too short to have an adequate retentive design.

When an existing restoration is present, it must be evaluated for overall quality and marginal integrity. If it is not adequate, it should be replaced before the restoration is fabricated. Small Class III composite resins that appear to be sound can be incorporated into the design, as long as the framework fully covers the restoration and the resin is roughened just before bonding. If anterior teeth have extensive Class III or Class IV composite resin restorations, they should not be used as abutment teeth.

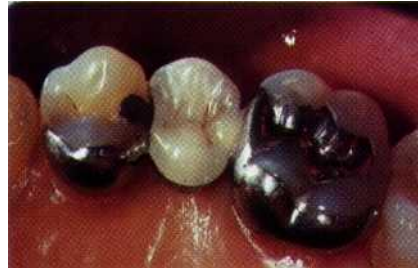Posterior teeth with amalgam restorations often require variations in basic techniques. Small or moderate Class I amalgams seldom cause a serious problem because alternative sites for rest seats can usually be found.<sup>25</sup> Large Class I or small two-surface Class II amalgams adjacent to the edentulous area require the amalgam to be partially removed and the remaining walls flared to accept an inlay component (Figs. 10-14 and 10-15). The remaining amalgam functions as a base and the surrounding enamel walls provide adequate resin bonding surface area. Again, it is important that the amalgam restoration be completely covered by the framework. The amalgam functions as a high elastic modulus base for the metal; a glass ionomer would be inadequate in this regard. The luting resin Panavia has a moderate bond to dental amalgam as a result of the high tin composition of the amalgam.



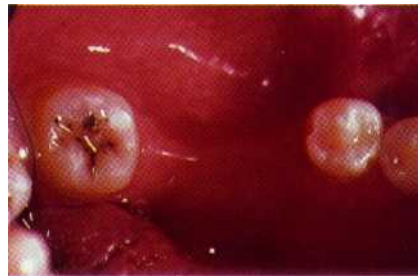*Fig. 10-14. The completed preparation demonstrates the removal of part of the two-surface amalgam in the molar. Not only does the inlay form itself provide retention but also the enamel walls provide additional surface for resin bonding.*

Defective existing dental amalgam restorations may be removed and replaced with a posterior composite resin restoration. The shallow inlay preparation for the bonded retainer should still be incorporated in the design.

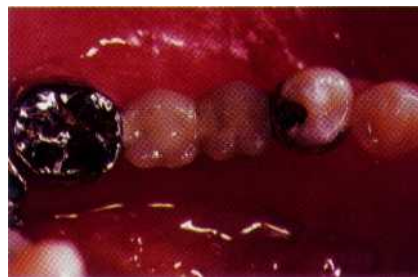A bonded onlay may be warranted for teeth with extensive restorations or tilted teeth (Figs. 10-16 and 10-17). The enamel must be reduced by 1.0 mm and ver-



*Fig. 10-15. The completed restoration demonstrates the outline form for the inlay, as well as the conventional lingual extension. This design is extremely retentive, even though the bond of resin to amalgam is not as strong as resin to etched enamel.*



*Fig. 10-16. Because of the shortness and mesial tilting of the molar, an onlay retainer was designed to extend over the entire occlusal surface as well as portions of the buccal, lingual, mesial, and distal surfaces. The premolar was also short and, as a result, it has mesial and distal grooves and a distinct distoocclusal rest seat.*



*Fig. 10-17. Postoperative view of the bonded fixed partial denture.*

ified in excursive movements of the mandible. Composite resin is bonded to the opposing cusp tips to prevent supereruption or mesial drifting of the onlaid tooth. A shallow chamfer helps to define the gingival margin and later helps provide a definitive finishing line for the metal.

## Impressions

Impression techniques for resin bonded restorations are similar to those used for conventional crown and fixed partial denture restorations, except that anesthetics and retraction cords are seldom used.

### Armamentarium

Standard dental setup; see the section on anterior preparations in this chapter  
Suitable impression agent (e.g., reversible hydrocolloid, rubber base, condensation silicone, vinyl polysiloxane, or polyether)

### Clinical Technique

1. Inject a light body or syringe material around the abutment teeth using great care to capture any grooves, slots, or rests.

**CLINICAL TIP.** Use only accurate elastomeric impressions, such as rubber base, condensation silicone, vinyl polysiloxane, polyether, or reversible hydrocolloid. Irreversible hydrocolloid is not indicated; avoid it as a final impression material.

2. Load a heavy body or tray material into a custom or stock tray and seat it. All finishing lines are supragingival, which allows for easy capture of the details of each abutment tooth.

**CLINICAL TIP.** The low tear strength of vinyl polysiloxane and polyether is a limitation when taking impressions of multiple abutment teeth. Often these materials tear in the interproximal embrasure and the finishing line may be lost. The high tear strength of polysulfide rubber is generally more convenient in this regard, particularly for periodontal splint impressions.

**Laboratory Techniques.** Impressions may be poured in an investment material to develop a refractory cast; however, most technicians prefer to work with stone models.

**CLINICAL TIP.** Conventional trimmed and indexed dies are not recommended. The model is therefore very stable and allows the technician to develop anatomic contours with open and cleansible embrasure form.

Laboratory technicians draw the outline lightly with a wax pencil in a color that contrasts with the pattern (Fig. 10-18) and fabricate an acrylic resin pattern. The completed pattern can be sprued with a runner bar and auxiliary sprues, or with one large sprue with a reservoir attached to the pontic."

Base metal alloys historically have been used for resin bonded prostheses because of their etching characteristics. However, the etching conditions for each alloy vary, and each requires different acids, current densities, or etching times. These alloys are contraindicated in patients with known metal sensitivities.

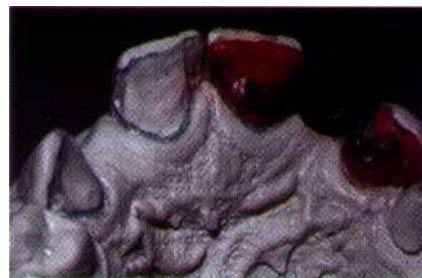**CLINICAL TIP.** Review the patient's medical history concerning reactions to metals. For patients with pierced ears this is particularly important. If they can tolerate only pure gold posts, they likely have a nickel sensitivity. Inexpensive gold posts are nickel plated and then coated with a thin gold layer. The nickel diffuses through the gold and sensitizes some individuals.

Gold- and palladium-based alloys may be selected if the dental laboratory has the facilities for tin-plating (see below) or "silicoating."

**CLINICAL TIP.** Enter into the patient's record the composition of the alloy used by the laboratory and the brand name.

**CLINICAL TIP.** In cases involving longer spans, or postorthodontic or periodontal splinting, a metal framework try-in is essential to verify the fit and occlusion prior to porcelain application.

Because of the wide variability and quality of commercial laboratory work, the etching work is often performed less than ideally.<sup>12</sup> The adhesive system that uses



*Fig. 10-18. This cast demonstrates a pencil outline on the right side and a completed pattern on the left. The outline covers a broad area of enamel and extends just facial to the proximal grooves. Because the teeth are short and the surface area for bonding is limited, the retainers extend closer to the gingiva than is ideal.*

Panavia resin (or Silicoater, Kulzer, Inc.) provides more consistent results and eliminates the need for a chemical or electrolytic etching process. If an adhesive bonding system is selected, the framework only requires air abrasion after each firing of porcelain or if contaminated by saliva.

### *Esthetic Try-In*

When Comspan (Caulk/Dentsply) was first introduced in 1980, it was a very translucent composite resin that allowed the darkened etched metal to cause graying or dark shadowing in the incisal area of anterior teeth. The graying was not always visible when the fixed partial denture was tried in but was often evident following bonding. As a result of the graying problem, most of the commonly used bis-GMA composite resins now contain opaques to mask the color changes.<sup>28</sup> **Despite the use of opaques, obtaining a pleasing esthetic result necessitates an esthetic try-in with a simulated bonding.**

#### Armamentarium

- Standard dental setup; see the section on anterior preparations in this chapter
- Stones and burs to adjust the metal and contour the porcelain
- Composite resin bonding kit that includes translucent *and* opaque resins
- Air brush (optional) (e.g., Micro Etcher, Danville Engineering)
- Eugenol or glycerin
- Plastic filling instrument
- Porcelain staining kit
- Acetone in a glass beaker
- Ultrasonic bath
- Alcohol wipes
- Battery-operated tin-plating device (e.g., Micro Tin, Danville Engineering)
- Panavia Kits (Kuraray, America), TC (tooth colored), and opaque

#### Clinical Technique

1. Alter the metal framework where necessary before using the cementing resins.

**CLINICAL TIP.** If the framework does not fit, do not rely upon the composite resin cement to fill the gaps. Bond only well-adapted retainers.

2. If the interproximal metal is visible, reduce it toward the lingual surface. The porcelain can be etched to provide retention in these areas.
3. Evaluate the lingual and gingival extension of the framework and reduce or recontour where necessary.
4. To preview the final esthetic result and determine whether the resin has adequate opacity to mask the

gray metallic shadowing, trial bond the restoration with an inhibited composite resin (see below). Both translucent and opaque resins should be available in a composite resin bonding system, allowing for regulation of the amount of opacity.

**CLINICAL TIP.** Use translucent resins in the interproximal area, because most opaque resins will leave a visible, high value line in this area.

**CLINICAL TIP.** Although opaque resins are effective in preventing incisal graying, too much opaqueness can increase the color value of the abutment teeth and make them appear lighter than the pontic.

5. Using a spatula dipped in eugenol, mix the opaque catalyst and base resins in equal proportions. Eugenol is a powerful inhibitor of the setting reaction of composite resins; the mix will not set but will remain quite viscous. Eugenol only partially inhibits the setting reaction of Panavia; **therefore use one paste (A) for the try-in** from TC or opaque, and mix as necessary. Load the metal retainers with the inhibited resin and seat the fixed partial denture on the *unetched* abutment teeth.
6. Most resins mask the gray metal at a thickness of 25 to 50  $\mu\text{m}$ . If, however, the mixture is too opaque and the abutment teeth appear too light, prepare a second inhibited mix, incorporating some of the translucent resin with the opaque resin.

**CLINICAL TIP.** Use opaque resins for all posterior restorations so that any excess flash can be visualized and removed.

7. Trial and error will determine the correct proportion of translucent to opaque resin.

**CLINICAL TIP.** Esthetic anterior restorations are best created by using opaque and translucent resins for the lingual and interproximal areas, respectively. The Panavia system is excellent because it is available both as opaque Panavia and translucent Panavia TC

8. Remove the inhibited resin from the metal retainers by rinsing in acetone or placing in an ultrasonic bath with acetone.
9. Clean the teeth of the eugenol/resin mix by wiping them thoroughly with gauze dipped in alcohol.
10. Once the ideal ratio of translucent to opaque resins is obtained, record it in the patient's record so that it can be used during the actual bonding.

**CLINICAL TIP.** Use simulated bonding to control the color value of the abutment teeth in conjunction with characterization and staining of the porcelain-fused-to-metal pontic. After placing the correct combination of inhibited resins, apply porcelain stains to the pontic section to produce the most natural color blend. Remove the inhibited composite resin from the interproximal area of the pontic. The resin that remains on the metal surface does not have to be washed away with acetone, because it will be burned off in the porcelain oven when the pontic is glazed.

### *Preparation of the Fixed Partial Denture for Final Cementation*

After the fixed partial denture is glazed, the inner surface of the metal is air abraded and the oral side polished. If an acid-etched fixed partial denture is used, the metal is either chemically or electrolytically etched at this stage. Use of an adhesive system and a metal framework cast in a base metal alloy necessitates a freshly air-abraded surface for good bonding.

Laboratory systems are available for tin-plating the gold- or palladium-based casting alloys. The laboratory professional masks the area not to be plated and then, using conductive tweezers, places the fixed partial dentures in the tin-plating bath. The automatic system then indicates when the tin-plating is completed. The tin-coated surface is only slightly lighter in color than the air-abraded surface. Coating that is too thick is light gray to white in color and will lower bond strength. The strength of the bond of Panavia or Superbond to the tin-plated surface is not as high as that for base metal alloys, but it is very stable in water.

**CLINICAL TIP.** If the esthetics are acceptable at the esthetic try-in stage and if an adhesive system is to be used with a base metal alloy, the restoration does not have to be returned to the laboratory. After cleaning, abrade the metal with an air brush and cement the restoration.

**CLINICAL TIP.** A small battery operated system for tin-plating in the dental office is available (Micro Tin, Danville Engineering).

## BONDING

The most essential prerequisite for bonding is maintaining a dry field. Many early failures of resin bonded fixed partial dentures are attributed to enamel contamination after etching and before the application of bonding agents. To ensure consistent and predictable results, rubber dam isolation is essential.

**CLINICAL- TIP.** When punching holes in the rubber dam, leave extra material in the pontic area so that the fixed partial denture can fully and passively seat without tension from the dam acting to unseat it.

### *Panavia Bonding*

#### Armamentarium

Standard dental setup; see the section on anterior preparations in this chapter  
 Rubber dam setup  
 Mylar matrix strips  
 Panavia Kit (Kuraray, America)

#### Clinical Technique

1. Place a rubber dam, taking care to invert it at all gingival margins and making certain that it will not impinge on bonded areas.
2. Pumice the abutment teeth; rinse and dry.
3. Protect the adjacent teeth by lightly wedging mylar strips between them and the abutment teeth.
4. Etch the teeth according to the manufacturer's instructions

**CLINICAL TIP.** Once teeth are etched, proceed immediately to bonding.

5. Rinse the abutment teeth for 20 seconds.
6. Air-dry the teeth with an oil-free air spray. Apply the air until the area is dry and the teeth appear frosty. Either the dentist or assistant maintains the dry area until ready to paint the teeth with the ED primer resin from the Panavia kit (Fig. 10-19).
7. The dentist lightly dries the ED primer on the teeth after 60 seconds. The assistant mixes the pastes.

**CLINICAL TIP.** Panavia is extremely oxygen inhibited because it sets anaerobically. Keep it in thin layers to provide a long working time (Fig. 10-20).

8. With a flat brush the assistant paints the inside of the castings with a thin layer of the resin. (Fig. 10-21).
9. Apply the opaquer to the full lingual area of the metal and then apply the Panavia TC to the interproximal area of the retainer.
10. Holding the fixed partial denture by the pontic, quickly transfer it from the assistant to the dentist, who seats it and holds it in place.

**CLINICAL TIP.** Coordinate the bonding sequence with the dental assistant so that each stage proceeds efficiently.

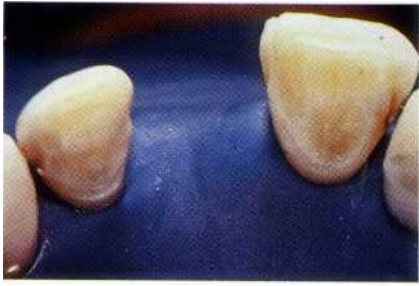

Fig. 10-19. With a rubber dam properly inverted, the abutment teeth are etched, rinsed, and dried, revealing the characteristically frosty-appearing enamel.

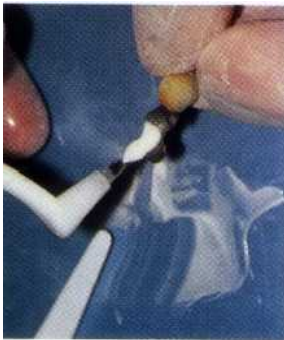

Fig. 10-20. When Panavia is properly mixed, it should have a smooth, creamy appearance. When kept in thin layers on the mixing pad, the material has an extended working time. The thin film of Panavia should be applied to the framework using a disposable brush.

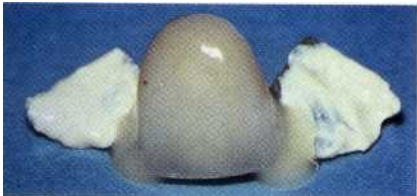

Fig. 10-21. When combining the opaque and translucent resins, place the opaque resin on the body of the retainer and use the translucent resin in the interproximal areas so that a visible opaque line on the facial surface does not result.

11. After 60 seconds, wipe away the excess resin with a second stiff pointed brush. The thin layer of resin that flows beyond the casting margins does not easily set unless it pools. Continue wiping until the metal, tooth, embrasure areas, and soft tissues are free of cementin, resin (Fig. 10-22).

**CLINICAL TIP.** When removing the excess, be careful not to wipe the opaquer through the facial embrasure.

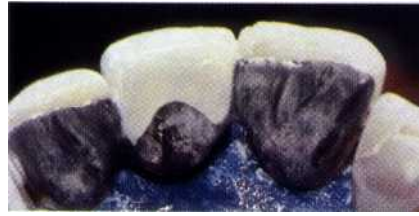

Fig. 10-22. After seating the restoration, use a clean pointed brush to wipe away all excess resin. The framework should be held in place so the debridement process does not dislodge the restoration before it is bonded.

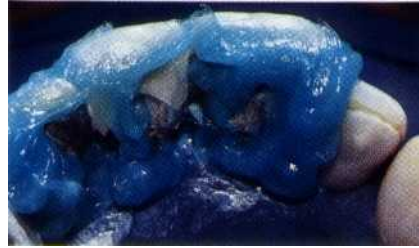


Fig. 10-23. After all excess resin is removed place liberal amounts of OxyGuard II over all exposed margins. The gel seals the resin from the air and has an accelerator included, permitting the resin to set quickly.

12. Inject the "blue-green" Oxyguard 11 gel (polyethylene glycol) around the margins of the castings (Fig. 10-23). This gel seals the area from air and accelerates the set of the resin. Hold the restoration in place for approximately 3 minutes.
13. Wipe and rinse the gel from the teeth.
14. Because excess resin can be removed effectively before it sets, little hard resin should be left to remove. Excess resin can be removed using scalars, curettes, and rotary instruments. Finishing burs or composite resin finishing stones are effective for this purpose.

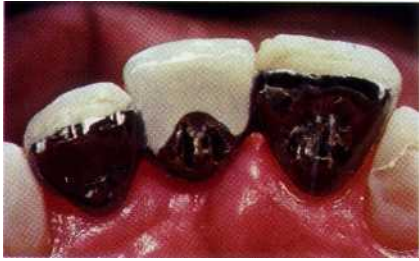**CLINICAL TIP.** If rubber points are used, avoid overheating the metal, because this may soften the resin and lead to debonding.

15. Remove the rubber dam and verify the occlusion. Provide patients with instructions on using floss threaders or other periodontal aids to keep the tissues healthy (Fig. 10-24).

### Adhesive Bonding

#### Armamentarium

The armamentarium is the same as that listed for Panavia bonding, with the following exceptions:



*Fig. 10-24.* After all excess resin is removed, the rubber dam is removed and the occlusion verified.

Adhesive bonding system (e.g., Nexus, sds Kerr)  
Dental bonding systems (e.g., Optibond Solo Plus, sds Kerr; 3M, Inc.; Tenure, Den-Mat)

#### Clinical Technique

Use the same Clinical Technique as that described for Panavia bonding, with the following exceptions:

1. When dentin is exposed, etch the tooth as usual and use a dental bonding system on all surfaces.
2. Light cure the bonding agent.
3. Apply the luting resin in a normal fashion. When using Tenure, mix bottles A and B and apply the normal luting resin directly to the coated dentin.
4. Be careful not to contaminate the gingival and lingual bonding surfaces with saliva or crevicular fluid. If any question exists, etch the enamel again to avoid compromising the bond to enamel.

**CLINICAL TIP.** Do not rely on dentin bonding unless an exposed dentin area is surrounded by enamel.

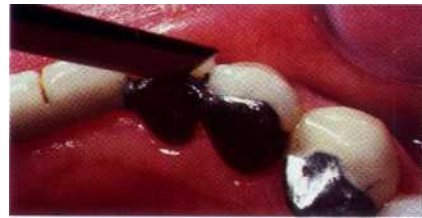#### Follow-up Visits

Regular checks are necessary for debonding or other problems with the restoration. Patients should learn to notify the dentist if they become aware of changes in feel or fit of the fixed partial denture. Early detection of debonding is critical.

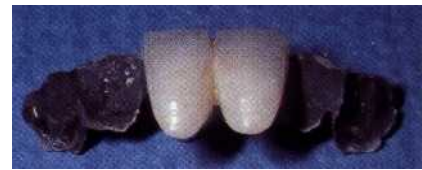If debonding (full or partial) is detected, remove the entire restoration and rebond it or make a new one. To remove a bonded restoration, take advantage of the low shear strength of the cementing composite resin and direct a controlled high-impact blow along the path of insertion on each abutment tooth.

**CLINICAL TIP.** To best remove a bonded restoration, place a straight chisel at the occlusal or incisal edge of the retainer at the metal-enamel interface (Fig. 10-25).

the long axis of the tooth. During the tapping procedure, make sure that either the dentist or the assistant supports the tooth to ensure safe removal of the restoration (Fig. 10-26).



*Fig. 10-25.* A bonded restoration can be easily removed when using a mallet and directing sharp taps along the long axis of the tooth at the incisal aspect of the metal-enamel junction.



*Fig. 10-26.* Observation of the removed fixed partial denture reveals that the resin is still attached to the etched metal. This is typical of partial debond failures, which are the result of enamel contamination during the bonding process.

#### CONCLUSION

Resin bonded prostheses can be used for a wide variety of clinical situations. They provide long-term esthetically pleasing restorations when proper case selection, design, and bonding conditions are followed. Although resin bonding is less complicated than conventional fixed prosthodontics, the procedures are technique-sensitive and demand careful attention to details.

The authors wish to thank Mr. Victor Stryzak, for his technical and laboratory assistance.

#### REFERENCES

1. Ibsen RL: One-appointment technique using an adhesive composite, *Dent Surv* 37:28, 1973.
2. Portnoy J: Constructing a composite pontic in a single visit, *Dent Surv* 49:30, 1973.
3. Ibsen RL: Fixed prosthetics with a natural crown using an adhesive composite, *J South Cal State Dent Assoc* 41:100, 1973.
4. Jordan RE et al: Temporary fixed partial dentures fabricated by means of the acid-etch resin technique: a report of 86 cases followed up to three years, *J Am Dent Assoc* 96:994, 1978.
5. Rochette AL: Attachment of splint to enamel of lower anterior teeth, *J Prosthet Dent* 30:418, 1972.



6. Howe DF, Denehy GE: Anterior fixed partial dentures utilizing the acid etch technique and a cast metal framework, *J Prosthet Dent* 37:28, 1977.
7. Livaditis GJ: Cast metal bonded bridges for posterior teeth, *J Am Dent Assoc* 101:926, 1980.
8. Williams VD, Drennon DG, Silverstone LM: The effect of retainer design on the retention of filled resin in acid-etched fixed partial dentures, *J Prosthet Dent* 48:417, 1982.
9. Tanaka T et al: Pitting corrosion for retaining resin facings, *J Prosthet Dent* 42:282, 1979.
10. Livaditis GJ, Thompson VP: Etched casting: an improved retentive mechanism for resin bonded retainers, *J Prosthet Dent* 47:52, 1982.
11. Levine WA: An evaluation of the film thickness of resin luting agents, *J Prosthet Dent* 62:175, 1989.
12. Hussey DL et al: The quality of bonded retainers from commercial laboratories, *J Dent Res* 68:919, 1989.
13. Yamashita A: A dental adhesive and its clinical application, vol 2, Tokyo, 1983, Quintessence.
14. Omura I et al: Adhesive and mechanical properties of a new dental adhesive, *J Dent Res* 63:233, 1984.
15. Thompson VP, Grolman KM, Liao R: Bonding of adhesive resins to non-precious alloys, *J Dent Res* 64:314, 1985.
16. Ohno H et al: The adhesion mechanism of dental adhesive resin to the alloy-experimental evidence of the deterioration of bonding ability due to adsorbed water to the oxide layer, *Dent Mater J* 5:211, 1986.
17. Thompson VP: Cast bonded retainers. In SHY Wei, editor: *Pediatric dentistry: total patient care*, Philadelphia, 1988, Lea & Febiger.
18. Hansson O: The silicoater technique for resin-bonded prostheses: clinical and laboratory procedures, *Quintessence Int* 20:85, 1989.
19. Ruyter IE, Waarli M: The adhesion mechanism of the silicoating technique, *J Dent Res* 68:891, 1989.
20. Thompson VP, Wood M, de Rijk WG: Bonded bridge recalls and Weibull distributions: results averaging seven years, *J Dent Res* 68:920, 1989.
21. Verzijden CW, Creugers NH: Survival rate of resin-bonded bridges: a 5-year evaluation, *J Dent Res* 68:920, 1989.
22. Crispin BJ, Fisher DW, Avera S: Etched metal bonded restorations: three years of clinical follow-up, *J Dent Res* 65:311, 1986.
23. Draughn RF: Fatigue and fracture mechanics of composite resin. In Vanherle G, Smith DC, editors: *International symposium on posterior composite resin dental restorative materials*, St. Paul, Minn, 1985, 3M Co.
24. Seto BO, Caputo AA: Photoelastic analysis of stresses in resin-bonded cingulum rest seats, *J Prosthet Dent* 56:460, 1986.
- 24a. DeRijk WG, Wood M, Thompson VP: Maximum likelihood estimates for the lifetime of bonded prostheses, *J Dent Res* 75:1700, 1996.
25. Wood M: Etched castings an alternative approach to treatment, *Dent Clin North Am* 29:393, 1985.
26. Williams HA, Caughman WF, Pollard BL: The esthetic hybrid resin-bonded bridge, *Quintessence Int* 29:623, 1989.
27. Wood M, Thompson VP, Mager LS: Etched casting resin bonded retainers: design and fabrication (1), *Quintessence Dent Technol* 7:409, 1982.
28. Wood M, Thompson VP: Masking tooth color changes of etched castings, *J Dent Res* 62:305, 1983.



# ACRYLIC AND OTHER RESINS

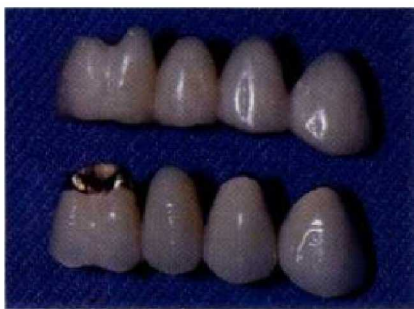## Provisional Restorations

David R. Federick

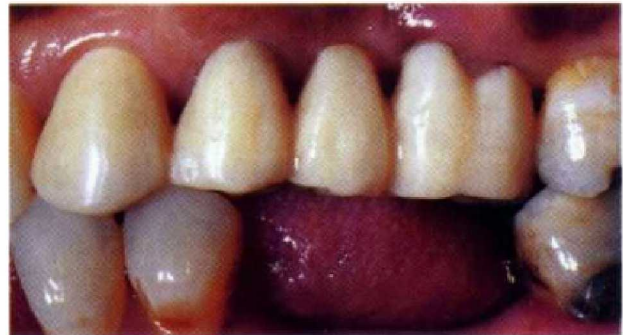**A**CHIEVEMENT OF ESTHETIC and functional excellence in fixed prosthodontics is the reward for meticulous attention to detail at each stage of treatment. A high-quality provisional restoration is crucial to this success. The interim crown or fixed partial denture must be a mirror image of the definitive restoration, with the only variable being the material (Figs. 11-1 and 11-2). Failure to do so may result in periodontal damage, pulpal irritation, occlusal aberrations, and patient dissatisfaction (Fig. 11-3).

### BASIC CONCEPTS

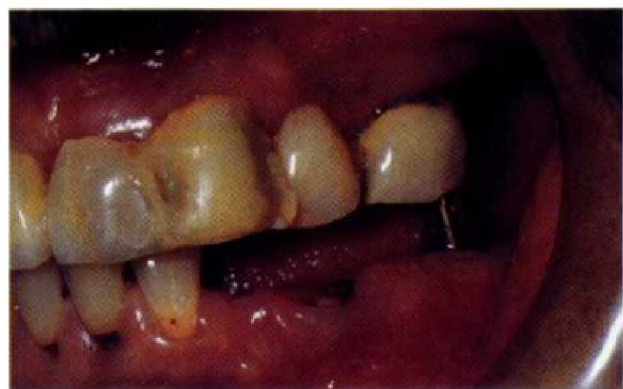The provisional (treatment) restoration provides for the following:



*Fig. 11-1. Note the similarity between the acrylic resin maxillary provisional splint (top) and the porcelain-fused-to-gold fixed partial denture (bottom).*



*Fig. 11-2. Intraoral view of four-unit acrylic resin provisional splint (canine through first molar).*



*Fig. 11-3. Unacceptable provisional restoration exhibiting poor contour, open margins, gingival impingement, and unacceptable esthetics.*

1. Pulp protection and sedation of the prepared abutments while the cast restorations are being fabricated. An adequate thickness of acrylic resin and good marginal integrity affords protection against thermal insult and bacterial and salivary invasion of the dentinal tubules.
2. Evaluation of the tooth preparation and parallelism of abutments. Designing the treatment restoration to be similar to the final cast restoration gives the operator an immediate opportunity to assess (and correct if necessary) the tooth preparation for undercuts, adequate enamel/dentin reduction, and mutual paths of insertion.
3. Immediate replacement of missing or extracted teeth. The inclusion of pontics in the provisional restoration provides immediate replacements in edentulous spaces, which aids in stabilizing and preventing drifting of abutments.
4. Improvement of esthetics in interrupted and debilitated dentitions. The provisional restoration provides immediate coverage with an esthetic resin crown for malaligned, eroded, discolored, poorly restored, and damaged abutments.
5. A healthy environment for the periodontium. Crowded and malaligned abutments, overhanging margins of existing restorations, and areas of erosion or abrasion are replaced with properly contoured resin crowns compatible with periodontal health.
6. A means of evaluation and reinforcement of the patient's oral home care in maintaining an interim fixed restoration as a prerequisite to the permanent restoration. The patient's dexterity and motivation may be inadequate to provide the meticulous daily **preventive maintenance necessary to care for a fixed partial denture**. In these cases, placing a removable prosthesis may be prudent.
7. Facilitation of periodontal therapy by providing access to and total visibility of surgical sites. Removal of the provisional restoration gives the periodontist an unobstructed surgical field in which to perform soft and hard tissue corrective procedures.
8. Stabilization of mobile teeth during and after periodontal therapy. The splinting action of joining two or more teeth increases resistance to an applied force and offers a stabilizing effect and reorientation of stress vectors.' This action is important when fibers of the periodontal ligaments are in the process of reattaching to the cementum of a periodontally treated abutment. A tooth made stable by a splinting procedure may undergo a reinsertion of periodontal fibers, whereas a mobile abutment has little chance of reattachment.'
9. Facilitation of development and evaluation of an occlusal scheme. Various occlusal schemes and ex-

cursive guides can be evaluated by adding acrylic resin to or removing acrylic resin from the occlusion and contours of the provisional restoration.

10. Evaluation of vertical dimension, phonetics, freeway space, and esthetics. The information gleaned during the alteration and finalization of the provisional restorations can be used to develop the subsequent cast restorations.
11. Aid in determining the prognosis of questionable teeth. Changes in mobility patterns, osseous graft "takes," redefined lamina dura, periodontal ligament thickness, success of endodontic therapy, success of hemisection and bicuspidization procedures, pocket depth decreases, and alleviation of signs and symptoms of periodontal disease may be determined during the provisional restorative phase of therapy. These factors aid the clinician in making decisions about retaining questionable abutments.

#### REQUIREMENTS FOR A PROVISIONAL RESTORATION

The interim acrylic resin restoration must maintain gingival health. The basic requirements of a morphologically correct and physiologically acceptable provisional restoration are as follows:

1. Marginal adaptation. Marginal adaptation is achieved by careful attention to the details of the acrylic margins and reline/remargination procedures when applicable.
2. Retention. A temporary cement must always be used to ensure a barrier to intrusion of saliva and bacteria. Thick layers of cement do not correct a poorly made, ill-fitting provisional restoration.
3. Strength and durability. An acrylic resin provisional restoration must withstand the test of time if an extended period of service becomes necessary.
4. Nonporous and dimensional stability. A good grade of acrylic resin that is properly polymerized provides a superior restoration capable of extended service.
5. Esthetics. Attention to anatomic details encourages a patient's cooperation and acceptance of the provisional restoration.
6. Physiologic contours and embrasures. Adequate sluiceways and deflecting contours (that are not overcontoured) enhance the health of the periodontium.
7. Ease of refinement. Ease of refinement is especially important for a patient with a periodontal prosthesis whose provisional splint is fabricated and delivered before periodontal surgery. The healing periodontium usually exhibits controlled gingival recession for pocket elimination. The abutments

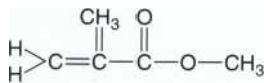
- must then be altered by apically extending the finishing lines and relining the original provisional splint to cover the newly exposed tooth surfaces.
8. Biologic occlusion. The occlusal scheme developed in the provisional restoration must include a stable centric occlusion, an acceptable vertical occlusion dimension, unobstructed excursive movements, and proper cusp-fossae development for efficient mastication.
  9. Compatibility with supporting tissues. Rough, unpolished margins, overcontoured crowns, impinged embrasures, and a poor fit must be avoided in the provisional restoration to promote periodontal health.
  10. Ease of cleaning by the patient. The patient must be able to maintain a plaque-free environment using routine preventive home care devices and techniques. Advise patients that extended use of chlorhexidine oral rinses stains acrylic resin restorations.

**CLINICAL TIP.** A final layer (glaze) of the light-cured, unfilled methyl methacrylate resin PALASEAL (Kulzer, Inc.) produces the best resistance to staining.

## BASIC CHEMISTRY

### *Auto-Cured Resin in Provisional Restorations*

Acrylic polymers were introduced to dentistry in 1937, primarily as a denture base material. Polymethyl methacrylates are supplied in powder and liquid components. The powder (polymer) is polymethyl methacrylate plus benzoyl peroxide (initiator). The liquid (monomer) is methyl methacrylate plus hydroquinone (inhibitor). Other temporization materials are supplied in powder/liquid or paste/paste form.



The selection of an acrylic resin for crown and bridge temporization is based on many factors. Shade availability, handling ease, polymerization time, exothermic heat production, and anticipated length of service of the provisional restoration are major considerations. The operator may choose an extended putty stage resin to facilitate manipulations and may prefer a rapid-set resin for repairs. The properties of the various classes of acrylic resins available for crown and bridge temporization should be evaluated and compared before selection (Table 11-1) s

### *Setting Stages of Auto-Cured Resin (Power/Liquid)*

1. Doughy, or putty, stage. In the doughy, or putty, stage a mixture of acrylic resin can be manipulated by hand, sticks to nonlubricated fingers, and has lost all surface gloss.
2. Rubbery stage. In the rubbery stage the resin is 60% to 70% **set and can** be removed from the mouth. The excess is easily trimmed with sharp scissors and immediately repositioned over the abutments for complete polymerization.

### *Light-Cured Resin in Provisional Restorations*

Bis-GMA type restorative materials have definite applications in short-term crown and bridge temporization. Unlimited working time and favorable manipulative properties may make light-cured composite resins an alternative to conventional auto-cured crown and bridge resins. Bis-GMA provisional resins may also be used in the following situations:

1. For intraoral repair of fractured provisional fixed partial dentures
2. For reestablishing proximal and contact areas
3. For remargination procedures
4. For veneering conventional acrylic resin provisional crowns and bridges to provide an exceptionally esthetic and durable restoration

**CLINICAL TIP.** When auto-cured or light-cured composite resins or both are used in the previously mentioned applications, a primer layer of bonding primer should be placed on the polymethyl methacrylate to be repaired or veneered.

## TECHNIQUES AND MATERIALS

### *Preformed Crowns and Crown Forms*

An acceptable interim restoration can be produced using polycarbonate, a celluloid strip, or metallic crowns. Although this procedure may result in gingival abuse if improperly performed (Figs. 11-4 to 11-6), a cautious clinician who allots adequate time for the procedure can produce a serviceable restoration (Table 11-2).

### *Polycarbonate Crowns (Anterior Teeth and Premolars)*

To achieve adequate retention, fit, and physiologic contours, the preformed crown must be altered, relined, and trimmed and polished before cementation.

#### Armamentarium

- Standard dental setup (Tables 11-3 and 11-4)
- Cotton rolls

**Table 11-1.** Properties of acrylic resins for provisional restorations

Material	Curing Shrinkage	Strength	Exothermic Heat	Stiffness	Reline and Repair Strength	Color Stability	Stain Resistance	Polishability	Abrasion Resistance	Cost
Polymethyl methacrylate	Medium	High	High	High	Excellent	High	High	High	Medium-high	Low
Polyethyl methacrylate	Medium	Medium-high	Medium-high	Medium	Excellent	Medium-high	Medium-high	Medium-high	Medium	Low
Polyvinyl methacrylate	Medium	Medium	Medium	Medium	Excellent	Medium	Medium	Medium	Medium	Low
Isobutyl methacrylate	Medium	Medium	Medium	Medium	Excellent	Medium	Medium	Medium	Medium	Low
Bis-GMA composite resins (auto cured)	Low	Medium	Low	Medium (brittle)	Poor	Medium	Low-medium	Medium-high	Medium	High
Bis-GMA (dual cured or light cured)	Low	Medium	Low	Medium (brittle)	Poor	Medium-high	Low-medium	Medium-high	Medium	High

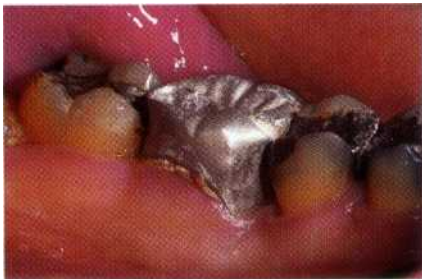

Fig. 11-4. Poorly adapted metallic provisional crown on the mandibular molar.

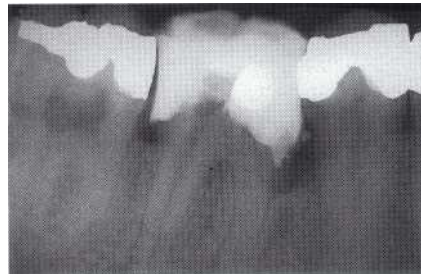


Fig. T 1-5. Radiograph of metallic provisional crown seen in Fig. 11-4. Marginal irregularities have contributed to peri-odontal damage.

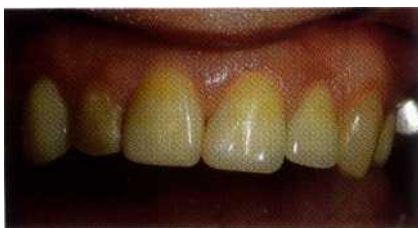

Fig. 11-6. Relined stock polycarbonate crowns cemented on the prepared left maxillary lateral incisor and both maxillary central incisors. Surface color correction pigment has been applied.

*Preformed crowns and crown forms.*

Type	Brand	Manufacturer
Polycarbonate	ION Crown (anterior and premolar)	3M Dental Products
	SDI Crowns	Svenska Dental Instrument
	B-Crowns (anterior)	H.J. Bosworth Co.
	Molar-B-Crowns (posterior)	H.J. Bosworth Co.
Plastic/acetate	Alu-Plast (tooth color, posterior)	Carlisle Labs
	Caulk Crown Forms	L.D. Caulk Co.
	Crown Forms (anterior/posterior)	Den-Mat Corp.
	Strip Crowns (anterior/posterior)	Premier Dental Products
	Odus Pella	E.C. Moore Co., Inc.
	Crown Forms	Interstate Dental Co.
	Strip Crowns	3M-Unitek
Metal	Aluminum Crowns	Parkell Biomaterials Co.
	ISOFORM (posterior)	3M Dental Products
	Unitek Crowns	3M Dental Products
	Gold Anodized	3M Dental Products
	Java Crown (Epoxy-coated, aluminum)	Java Crown, Inc.
	Stainless Steel and Aluminum	Denovo Co.

*Miscellaneous materials and devices.*

Brand	Manufacturer
Identic Syringable Impression System	Cadco Dental Co.
Burlew Dry Foil	Jelenko Dental Co.
Aquapres	Lang Dental Mfg. Co.
Triad VLC System	Dentsply Lab Products
Metal/Mesh Reinforcing Bars	Ellman International Mfg.
Hand Instruments	3M Dental Products
Perfectone Molds	George Taub Dental Products
Novatech Collection	Hu-Friedy Dental Corp.
Flexible Dappen Dish	George Taub Dental Products
	Pulpdent Corp.
	Patterson Dental Products
Dr. David Federick Bur Kit	Brasseler, Inc. USA
Electric Dental Engines 5,000-35,000	Bell International
	Patterson Dental Products
Titanium Alloy Temporary Posts	Coltene/Whaledent International

*Crown removers.*

Brand	Manufacturer
Kline Crown Remover	Brasseler, Inc. USA
Baade Pliers	S.S. White
Wynman Crown Gripper	Premier Dental Mfg.
Morrell Crown Remover	Premier Dental Mfg.
Crown Remover	Ellman International Mfg.
Automatic Crown Removers	J.S. Dental Products
Richwell Crown Removers	Almore Dental Co.

- Dappen dish (silicone)
- Explorer
- High-speed handpiece
- Low-speed handpiece
- Mouth mirror
- Periodontal probe
- 2" x 2" gauze
- Crown and bridge scissors (Brasseler, Inc. USA)
- Petroleum jelly or silicone liquid (Table 11-5)
- Acrylic resin of choice (Table 11-6)
- Polycarbonate crown kit (3M, Inc.)
- Polycarbonate crown mold guide
- Boley gauge (optional) (Henry Schein, Inc.)
- No. 8 Hollenback carver
- Acrylic bur setup low-speed straight handpiece
- Low-speed tapered carbide bur-rounded tip, 4-mm base (e.g., H79E-040 carbide "E" cutter, Brasseler, Inc. USA)

- Low-speed tapered carbide bur-rounded tip, 2.3-mm base (e.g., H261D-023 carbide "D" cutter, Brasseler, Inc. USA)
- Low-speed diamond bur-pointed tip 3.7-mm base (e.g., 852-037 medium grit diamond, Brasseler, Inc. USA)
- Low-speed round carbide bur-rounded (No. 10) tip, 2.7-mm head (e.g., H 1-027 carbide cutter, Brasseler, Inc. USA)
- Low-speed straight carbide bur-flat (No. 557) tip, 1-mm base (e.g., H31-010 carbide cutter, Brasseler, Inc. USA)
- Low-speed inverted cone carbide bur-flat (No. 34) tip, 0.8-mm base (e.g., H2-008 carbide cutter, Brasseler, Inc. USA)
- Acrylic finishing setup. See the section on finishing in this chapter.
- Shade correction setup (optional). See the section on color correction and shade characterization in this chapter.
- Temporary cementation setup. See the section on cementation of provisional restorations in this chapter.

Brand	Manufacturer
High Spot (spray)	Cadco Dental Products
Mizzy (spray)	Buffalo Dental Co.
Crown & Bridge Lube	Cadco Dental Products
Masque	HJ Bosworth Co.

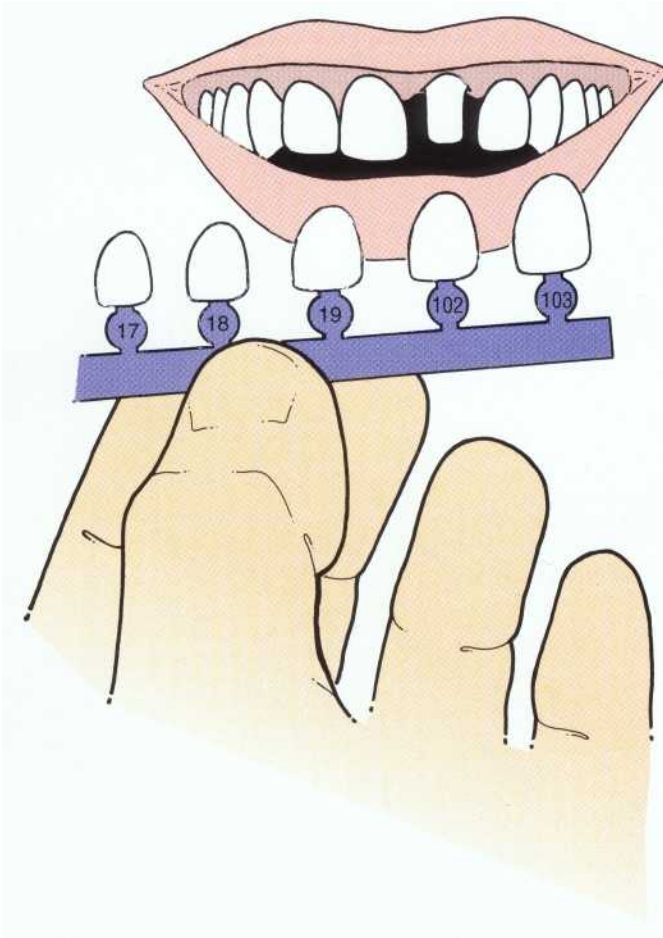
Clinical Technique

1. Select the correct size crown from the kit. A mold guide or Boley gauge (Henry Schein, Inc.) facilitates the selection (Fig. 11-7).

Type	Brand	Manufacturer
Methyl methacrylate	Duralay	Reliance Dental Mfg. Co.
	Jet	Lang Dental Mfg. Co.
	Tab	Kerr Syborn Corp.
	True	H.J. Bosworth Co.
	Alike (radiopaque)	Coe Dental Mfg. Co.
	Cold-Pac	Matloid Dental Mfg. Co.
	Duracryl	Masel Dental Mfg.
Ethyl methacrylate	Temporary Bridge Resin	L.D. Caulk Co.
	Splintline Lang	Lang Dental Mfg. Co.
Vinyl ethyl methacrylate	Snap	Parkell Biomaterials Co.
	Trim	H.J. Bosworth Co.
	Provisional C & B Resin	Cadco Dental Products
Bis-GMA (auto cured)	Dura-Seal	Reliance Dental Mfg. Co.
	Kind	Den-Mat
	Pro-Temp	Premier Dental Products
	Temphase	Sybron Kerr
	Luxatemp	Zenith Foremost
	Super-T	American Consolidated Mfg.
Bis-GMA (light cured)	Light Cured	Mirage Chameleon Dental
	Triad (light cured)	Dentsply Dental Products
	GC Manifest LC	GC Corp.
	RAP System	DMD Systems
	Isotemp (DC)	3M
	Astron LC (dual cured)	Astron Dental Corp.
Iso-butyl	Temp Plus	Ellman International Mfg.
	Aristocrat HTC Resin	Patterson Dental Products

2. Adjust the crown gingivally and proximally with a low-speed diamond or carbide bur (e.g., H79E040, H261D023, 852037, Brasseler, Inc. USA), and remove a thin layer of internal acrylic with a hand-piece round bur (02710, Brasseler, Inc. USA) so that it fits over the prepared tooth and does not bind (Figs. 11-8 and 11-9).
3. Protect the dentin and adjacent soft tissue with a layer of petroleum jelly or silicone liquid.
4. Fill the crown shell with a mixture of acrylic resin. Wait until the surface monomer dissipates (i.e., the surface sheen disappears), and then carefully seat it on the preparation. As a guide to proper seating, note that the incisal edge or occlusal surface relates correctly to the adjacent teeth.

**CLINICAL TIP.** For easier clean up, use a rubber or silicone dappen dish instead of glass. (Acrylic does not stick to rubber or silicone.)

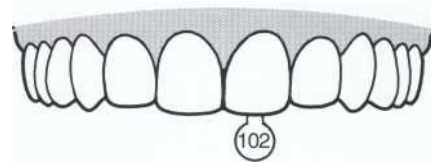


*Fig. 11-7. Mold guide used to select stock preformed polycarbonate crowns.*

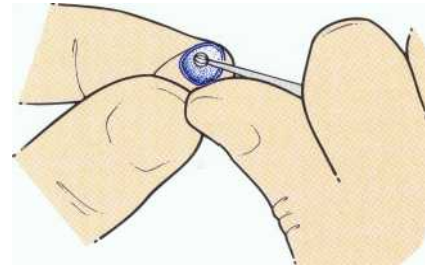
5. When the reline acrylic resin achieves the rubbery stage, trim excess away from the margin with a No.  $\frac{1}{2}$  Hollenback carver (Fig. 11-10).

**CLINICAL TIP.** While the acrylic is setting, remove and replace the temporary crown. This will accomplish the following:

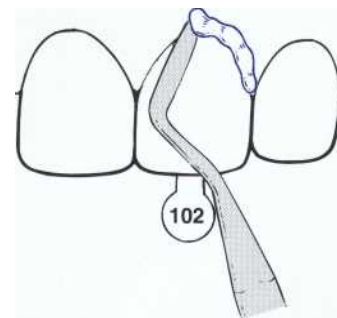
1. Protect the tooth from the exothermic reaction of the setting resin.
2. Prevent the temporary crown from locking into undercuts of adjacent teeth.
3. Prevent the temporary crown from locking onto resin core material.
6. Remove the unit when the reline material has set.
7. Trim and smooth.



*Fig. 11-8. Polycarbonate crown shell adjusted to fit over preparation and align with adjacent teeth.*



*Fig. 11-9. No. 8 round carbide bur being used to remove internal layer before relining.*



*Fig. 11-10. No.  $\frac{1}{2}$  Hollenback carver being used to trim excess reline resin at putty stage.*



8. Reline or remarginate if necessary. See the section on remargination in this chapter.
9. Finish and polish the restoration. See the section on finishing in the chapter.
10. Custom stain or characterize if necessary. See the section on color correction and shade characterization in this chapter.
11. Cement (Fig. 11-11). See the section on cementation of provisional restorations in this chapter.

### Celluloid (Clear) Strip Crown (Anterior Teeth and Premolars)

#### Armamentarium

- Standard dental setup. See the section on preformed crowns and crown forms in this chapter.
- Petroleum jelly or silicone liquid
- Acrylic resin of choice (see Table 11-6)
- Celluloid crown kit (3M, Inc.)
- Boley gauge (optional)
- Crown and bridge scissors (e.g., No. 325, Brasseler, Inc. USA)
- No. 7 Flollenback carver
- Acrylic bur setup. See the section on preformed crowns and crown forms in this chapter.
- Acrylic finishing setup. See the section on finishing procedures in this chapter.
- Shade correction setup (optional). See the section on color correction and shade characterization in this chapter.
- Temporary cementation setup. See the section on cementation of provisional restorations in this chapter.

#### Clinical Technique

The clinical technique is similar to that described for polycarbonate crowns with the following exceptions:

1. Trim the appropriate strip crown with scissors to achieve the correct length (Fig. 11-12).
2. Perforate the incisal edge with an explorer, and open the proximal surfaces with a #6 round bur so that the acrylic resin establishes proximal contacts (Fig. 11-13).




Fig. 11-11. Completed restoration.

**CLINICAL TIP.** While the acrylic is setting, remove and replace the temporary crown. See the preceding Clinical Tip.

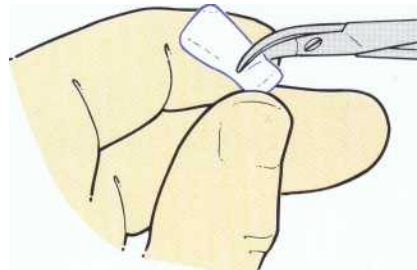
3. After the acrylic resin has set, remove the restoration, cut away the celluloid shell, and finish.

### Modified Metal Crown (Posterior Teeth)

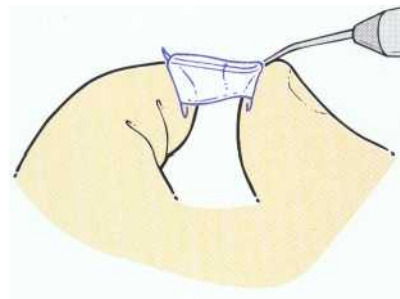
Manufactured metallic shell crowns present a challenge to the restorative dentist. They are seldom morphologically accurate and require considerable alterations to achieve even minimal acceptability. Cutting, bending, and crimping the metal often results in a ragged, thick margin that readily retains plaque. The metal occlusal surface is not easily corrected to obtain a functional occlusal relationship. An esthetic result is impossible. These crowns are best used as a matrix only.

#### Armamentarium

- Standard dental setup. See the section on preformed crowns and crown forms in this chapter.
- Petroleum jelly or silicone liquid
- Acrylic resin of choice (see Table 11-6)
- Metal crown kit (3M Isoform Kit, 3M, Inc.)
- Crown and bridge scissors (e.g., No. 325, Brasseler, Inc. USA)



Gingival adjustment using a curved crown and bridge scissors.



Incisal edge being perforated with explorer.

- No. 1/2 Hollenback carver
- Acrylic bur setup. See the section on preformed crowns and crown forms in this chapter.
- Acrylic finishing setup. See the section on finishing procedures in this chapter.
- Shade correction setup (optional). See the section on color correction and shade characterization in this chapter.
- Temporary cementation setup. See the section on cementation of provisional restorations in this chapter.

Clinical Technique

1. Select a metal crown that is one size too large for the available space.
2. Trim the gingival contour with a curved crown and bridge scissors so that the crown is 1 mm above the occlusion of the adjacent teeth when seated. (Use marginal ridge relationships as a guide.) Leave the metal at least 1 mm apical to the tooth preparation margin (Fig. 11-14).
3. Using a large, round carbide, cut a window of approximately 6 to 8 mm in diameter from inside the metal crown into each proximal surface. This will permit resin to establish the proximal contacts with the adjacent teeth. The preformed metallic crown serves as a matrix for the acrylic resin (Fig. 11-15).
4. Protect the dentin and adjacent soft tissue with a layer of petroleum jelly or silicone liquid.
5. Mix the appropriate shade of acrylic resin in a dappen dish and fill the altered metal crown.

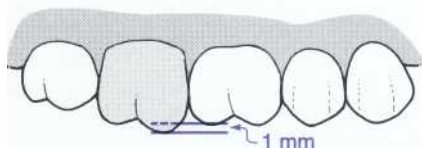


Fig. 11-14 Occlusal surface is left 1 mm in superocclusion. Metal margin extends at least 1 mm apical to preparation margin.



Fig. 11-15 Preformed metal crown that has been altered to serve as a matrix for the acrylic resin.

CLINICAL TIP. For easier clean up, use a rubber or silicone dappen dish instead of glass. (Acrylic does not stick to rubber or silicone.)

6. When the acrylic is doughy, seat the metal crown 1 mm in superocclusion onto the prepared tooth (Fig. 11-16).

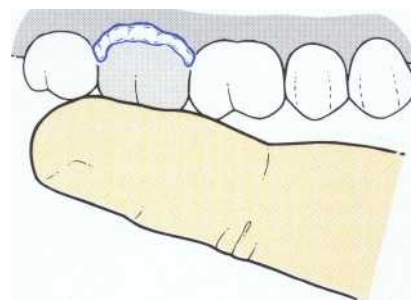
CLINICAL TIP. While the acrylic is setting, remove and replace the temporary crown. See the Clinical Tip in the section on preformed crowns and crown forms.

7. Remove excess resin at the margins and at the interproximal areas with a sharp Hollenback carver.
8. When the acrylic is fully polymerized, remove the metallic crown and reline with resin.
9. Strip off the metal shell. Do not leave the metal crown over the acrylic resin. Use the metal crown only as a matrix in the development of the interim acrylic resin crown.
10. Trim to the ideal anatomic shape and occlusion.
11. Reline or remarginate if necessary. See the section on remargination in this chapter.
12. Finish and polish restoration. See the section on finishing procedures in this chapter.
13. Custom stain if necessary. See the section on color correction and shade characterization in this chapter.
14. Cement. See the section on cementation of provisional restorations in this chapter.

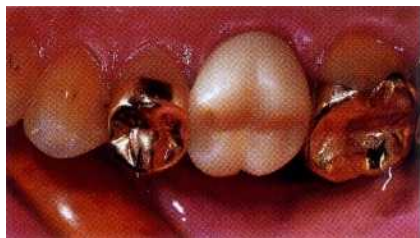This technique yields an esthetic, well-contoured provisional crown that is significantly superior to a crudely adjusted, unesthetic, ill-fitting, preformed metallic crown (Fig. 11-17).

Direct Preparation/Impression Technique

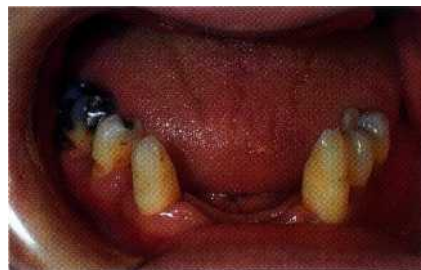The use of an impression is the most popular method of positioning polymerizing acrylic resin over tooth preparations to produce a multiunit provisional splint. Any elastic



11-16. Altered metal preformed crown carrying acrylic resin.



*Fig. 11-17. Esthetic acrylic resin provisional crown made via metal preformed crown matrix technique.*



*Fig. 11-18. Mandibular dentition before rehabilitation.*

impression material in a stock impression tray is acceptable. Either the direct or indirect method may be performed.

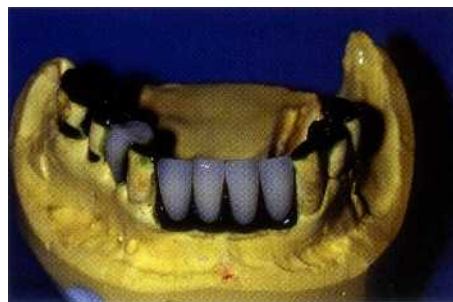
**CLINICAL TIP.** Use of a C-silicone (e.g., Coltene Rapid or Coltene Speedex) may not require the support of an impression tray if a minimal thickness of 5 mm is used in the matrix.

#### Armamentarium

Standard dental setup. See the section on preformed crowns and crown forms in this chapter.  
 Petroleum jelly or silicone liquid  
 Acrylic resin of choice (see Table 11-6)  
 Impression material: irreversible hydrocolloid or silicone impression material  
 No. 15 scalpel  
 Acrylic bur setup. See the section on preformed crowns and crown forms in this chapter.  
 Acrylic finishing setup. See the section on finishing procedures in this chapter.  
 Shade correction setup (optional). See the section on color correction and shade characterization in this chapter.  
 Temporary cementation setup. See the section on cementation of provisional restorations in this chapter.

#### Clinical Technique

1. Make an impression of the unprepared abutments using irreversible hydrocolloid or silicone impression material in a stock tray.
2. Remove unnecessary elastic material from the impression (e.g., interproximal tags, border extensions) to make reseating easier.
3. Store until tooth preparation is completed.
4. Prepare teeth.
5. Protect the prepared abutments with petroleum jelly or silicone emulsion.
6. Pour a mixture of acrylic resin into the impression and when no sheen is present, carefully insert the impression to ensure full and accurate seating over the preparations.



*Fig. 11-19. Corrected diagnostic cast. Before making the elastic impression, inlay wax and denture teeth were used to restore occlusal anatomy, increase the vertical dimension of occlusion, and replace missing teeth.*

7. Remove the splint at the rubbery stage, and trim any excess resin with sharp scissors.
8. Return the splint to the impression and position the tray over the preparations.
9. When fully set, remove the splint and finish in the usual manner.
10. Reline or remarginate if necessary. See the section on remargination in this chapter.
11. Finish and polish the restoration. See the section on finishing procedures in this chapter.
12. Custom stain or characterize if necessary. See the section on color correction and shade characterization in this chapter.
13. Cement. See the section on cementation of provisional restorations in this chapter.

#### *Indirect/Direct Technique*

Secure preoperative diagnostic casts for patients with coronally debilitated teeth or edentulous spaces. The cast can be corrected to the ideal anatomic form using inlay wax, resin, denture teeth, or preformed polycarbonate or metallic crowns. The corrected cast serves as the model, which is impressed. The impression is used to position the polymerizing acrylic resin onto the prepared teeth (Figs. 11-18 and 11-19).

Type	Brand	Laboratory
Vacuum	OmniVac	Howmedica Corp.
	StaVac	Buffalo Dental Co.
	Dentiformer	Patterson Dental Products
Manual	Press-Form Kit	Ellman International Mfg.

#### Armamentarium

The armamentarium is the same as that listed for the direct technique.

#### Clinical Technique

Use the same clinical technique as that described for the direct technique, except use the corrected cast as the source of the impression.

### Plastic Matrix Technique

Some clinicians think that elastic materials are inadequate and inaccurate for carrying acrylic resin during the fabrication of provisional splints. Disadvantages include the following:

1. Voids and bubbles that are not easily detected until the polymerization of the resin is complete, yielding a porous, unesthetic surface
2. Occlusal discrepancies caused by distortion or incomplete reseating of the impression
3. Cumbersome procedures allowing minimal or no visibility or access to the polymerizing resin

The use of a clear plastic matrix (Table 11-7) to carry acrylic resin eliminates these disadvantages and provides the following additional advantages:

1. The clear matrix serves as a tooth preparation (reduction) guide.
2. Acrylic resin polymerizes into a smooth, void-free surface against the plastic.
3. The matrix is reusable for fabrication of replacement provisional restorations.
4. Auxiliary personnel can easily make the matrix.
5. The matrix is inexpensive to produce.<sup>4</sup>

### Ellman Press-Form System (Fig. 11-20)

#### Armamentarium

Standard dental setup. See the section on preformed crowns and crown forms in this chapter.

Petroleum jelly or silicone liquid

Acrylic resin of choice (see Table 11-6)

Diagnostic cast

Press-Form System (Ellman International Mfg. Co.)

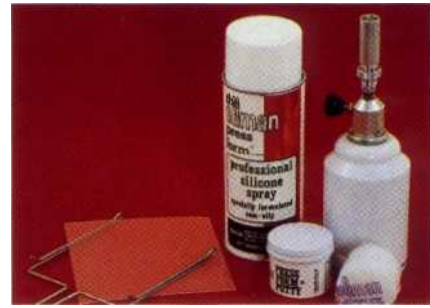

Fig. 11-20. Components of Ellman Press-Form Kit.

Plastic sheets (in various sheet thickness): 0.02 inch for short spans, 0.03 inch for medium spans, 0.04 inch for long spans

Blue inlay wax (optional)

Bunsen burner

Denture or metallic crown forms or polycarbonate crowns (optional)

Clay or Mortite (Mortite, Inc.)

Acrylic bur setup. See the section on preformed crowns and crown forms in this chapter.

Acrylic finishing setup. See the section on finishing procedures in this chapter.

Shade correction setup (optional). See the section on color correction and shade characterization in this chapter.

Temporary cementation setup. See the section on cementation of provisional restorations in this chapter.

### Clinical Technique

1. Prepare a stone or plaster cast.
2. Make any necessary corrections to the tooth structure (Fig. 11-21).

**CLINICAL TIP.** If the coronal anatomy must be corrected with inlay wax, duplicate the cast in plaster or stone before adapting the heated plastic sheet. However, if resin denture teeth or preformed crowns are used to correct the original cast, it is not necessary to duplicate the cast before adapting the heated plastic.

3. Block out peripheral undercuts with clay or Mortite (Mortite, Inc.) stripping.
4. Select the appropriate plastic sheet. Use a 0.02-inch plastic sheet for a one- to six-unit splint. For longer spans use a 0.03- to 0.04-inch thick sheet.
5. Securely insert the plastic sheet into the frame.
6. Use silicone spray to coat the cast and both sides of the plastic sheet.
7. Heat the plastic sheet on one side until opacity begins to disappear (2 to 4 seconds).

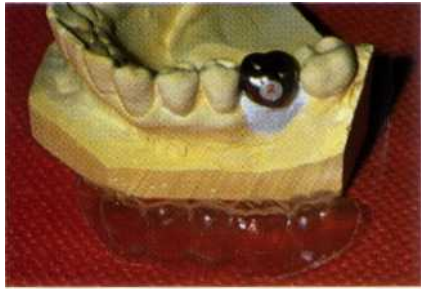

Fig. 11-21. NiChro preformed metal crown was used to correct edentulous space on diagnostic cast before adapting heated plastic sheet.

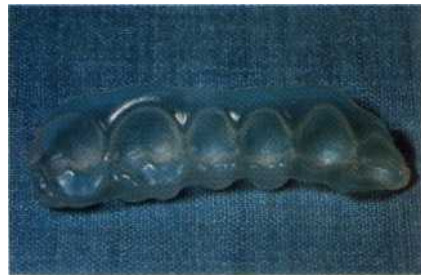

Fig. 11-22. Borders are trimmed to within 2 to 3 mm of gingival margins.

**CLINICAL TIP.** Do not allow the sheet to overheat or sag excessively, which causes it to tear or buckle. This creates a distorted, inaccurate matrix that may also adhere to the cast

8. Place the plastic sheet on the cast, and aggressively apply putty for 10 seconds to mold the sheet to the cast.
9. Allow the sheet to cool for 20 seconds; peel away the putty and lift the sheet off the cast.
10. Trim the plastic sheet with scissors.

**CLINICAL TIP.** Trim the borders to within 2 to 3 mm of the gingival margins (Fig. 11-22). Include one tooth mesial and one tooth distal to the terminal abutments of the fixed partial denture. If no teeth are adjacent to terminal preparations, leave a 5-mm "drape" of plastic covering the distal soft tissue area. Carefully round all sharp corners of the matrix to prevent intraoral soft tissue lacerations.

11. Prepare the teeth.
12. Protect the prepared abutments with petroleum jelly or silicone emulsion.
13. Pour a mixture of acrylic resin into the matrix.

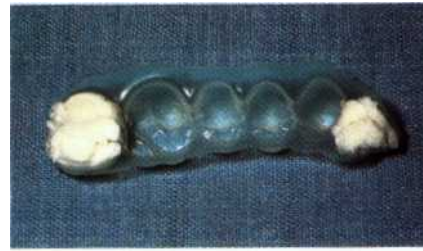

Fig. 11-23. Wads of wet paper towels are placed into stent adjacent to terminal abutments.

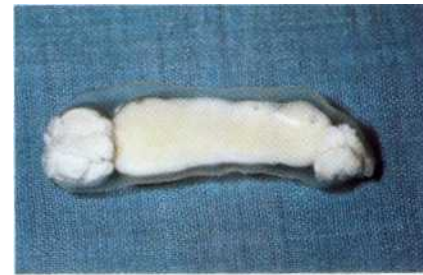


Fig. 11-24. Acrylic is placed in stent.

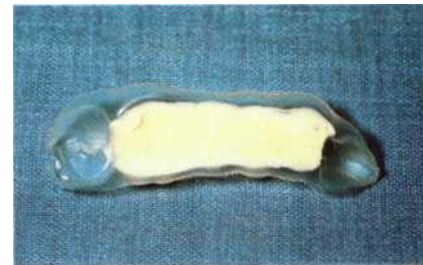

Fig. 11-25. When surface sheen disappears, paper towels are removed and stent and acrylic are ready to be carefully seated over preparation.

**CLINICAL TIP.**

1. Place wet wads of paper towels into the stent adjacent to the terminal abutments (Fig. 11-23), which confines the resin until it reaches the putty stage.
2. Place the acrylic in the stent (Fig. 11-24).
3. When the surface sheen disappears, remove the paper towels (Fig. 11-25).
4. Carefully seat the stent and acrylic over the preparation in the correct path of insertion.
14. Carefully position the plastic matrix carrying the acrylic resin over the preparations to ensure full and accurate seating.
15. **Seat the matrix with finger pressure only on the plastic extensions** over the unprepared teeth adjacent to the terminal abutments.

16. Remove and replace to avoid locking into an undercut.
17. Remove the matrix and resin at the rubbery stage so that excess resin can be trimmed with sharp scissors.
18. Return the resin splint to the plastic matrix, and reseat both over the preparation.

**CLINICAL TIP.** While the acrylic is setting, remove and replace the matrix/resin and direct a stream of water over the matrix containing the polymerizing acrylic resin. See the Clinical Tip in the section on preformed crowns and crown forms.

19. When fully set, remove the splint and finish in the usual manner.
20. Remarginate if necessary. See the section on remargination in this chapter.
21. Finish and polish the restoration. See the section on finishing procedures in this chapter.
22. Custom stain or characterize if necessary. See the section on color correction and shade characterization in this chapter.
23. Cement. See the section on cementation of provisional restorations in this chapter.

### *Vacuum Former Unit*

The vacuum former unit (Fig. 11-26) is particularly suited to producing long-span matrices. The technique involving the vacuum former unit is more time consuming than the hand-molded method and yields a closely adapted sheet.

#### Armamentarium

The armamentarium is the same as that listed for the Eilman Press-Form System with the exception of the use of a vacuum forming unit (i.e., Dental Vacuum Forming Unit, Buffalo Dental Mfg. Co., Inc.).

#### Clinical Technique

1. Prepare a stone or plaster cast.

**CLINICAL TIP.** The coronal anatomy can be corrected on the model. See the Clinical Tip in the section on plastic matrix technique.

2. Preheat the unit by activating the calrod element (heating element).
3. Drill a hole 1 inch in diameter in the center of the palate of a maxillary cast. A mandibular cast should be a horseshoe shape.
4. Block out peripheral undercuts with clay or Mortite (Mortite, Inc.) stripping.
5. Spray the cast with silicone.



11-26. Vacuum former unit (Omnivac Corp.).

6. Select the plastic sheet. Use a 0.02-inch plastic **sheet for** a one- to six-unit splint. For longer spans use a 0.04- to 0.06-inch thick sheet.
7. Secure the plastic sheet into the frame, and reposition the frame upward to the highest position just below the calrod.
8. Allow the plastic sheet to sag only 0.5 inch before guiding the frame with the sheet down over the cast.

Do not allow the sheet to overheat or sag excessively, which causes it to tear or buckle. This creates a distorted, inaccurate matrix that may also adhere to the cast.

9. Quickly **lower the frame over the** cast.
10. Activate the vacuum.

**CLINICAL TIP.** Leave the calrod element on for an additional 30 seconds, and vacuum for 1 minute. This step allows for proper adaptation and cooling of the plastic.

11. When the sheet has cooled, remove it from the cast. Cut away the excess sheet material to aid in removal.
12. Trim the plastic sheet (Figs. 11-27 and 11-28).

**CLINICAL TIP.** Trim the borders to within 2 to 3 mm of the gingival margins. See the Clinical Tip in the section on plastic matrix technique.

13. Prepare the teeth.
14. Protect the prepared abutments with petroleum jelly or silicone emulsion.
15. Pour a mixture of acrylic resin into the impression (see Figs. 11-23 through 11-25).

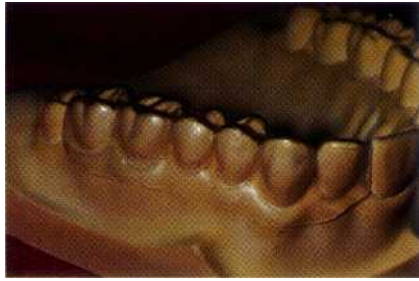

Fig. 11-27. Adapted and trimmed clear plastic matrix: facial view.

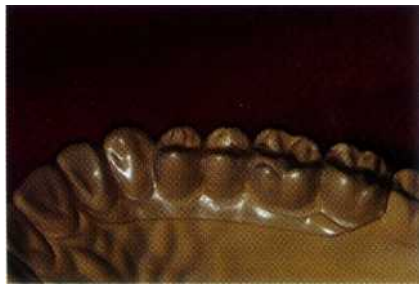

Fig. 11-28. Adapted and trimmed clear plastic matrix: palatal view.

**CLINICAL TIP.** Place wet wads of paper towels into the stent on the teeth adjacent to terminal abutments. See the Clinical Tip in the section on plastic matrix technique.

16. Carefully position the plastic sheet carrying the preparations to ensure full and accurate seating.
17. Remove the matrix and resin at the rubbery stage so that the excess resin can be trimmed with sharp scissors.
18. Return the splint to the plastic sheet and reseal both over the preparation.
19. When fully set, remove the splint and finish in the usual manner.
20. Reline or remarginate if necessary. See the section on remargination in this chapter.
21. Finish and polish the restoration. See the section on finishing procedures in this chapter.
22. Custom stain or characterize if necessary. See the section on color correction and shade characterization in this chapter.
23. Cement. See the section on cementation of provisional restorations in this chapter.

### Indirect Technique

Employing the indirect technique allows a clinician to avoid direct contact between freshly cut dentin with the



Fig. 11-29. Components of the Identic Syringable Impression System.

acrylic resin monomer or avoid the potentially damaging effect of the exothermic heat of polymerization on pulpal tissue. This method should also be considered when making long-span splints of six or more units (and fresh extraction sites are present) or to decrease chair time for both patient and dentist. The method involves securing an impression of the prepared teeth, preparing a quick-set plaster cast, and making the provisional restoration on the cast.

### Advantages

1. The prepared teeth and tissues do not have contact with surface monomer and polymerization heat.
2. Leaving the resin splint on the cast throughout the procedure minimizes polymerization shrinkage; distortion is minimized.
3. Oral contaminants (e.g., blood, saliva) do not contact polymerizing acrylic resin.
4. An auxiliary staff member can perform this extra-oral procedure, thereby freeing the dentist for other productive procedures.

### Disadvantages

1. The procedure is time consuming.
2. Extra materials and devices and increased cost are involved.

### Armamentarium

Standard dental setup. See the section on pre-formed crown and crown forms in this chapter.  
 Cord placement instrument  
 No. 0, 00, 000 gauge retraction cord  
 Impression material: irreversible or reversible hydrocolloid or silicone impression material (e.g., Identic Syringable System, Cadco) (Fig. 11-29)  
 Petroleum jelly or silicone liquid  
 Tin foil substitute (e.g., Al-Kote, Caulk, Inc.; Coe-Sep, Coe/ICI Dental, Inc.; Liquid Foil, Lang Dental)

Acrylic resin of choice (see Table 11-6)

Acrylic bur setup. See the section on preformed crowns and crown forms in this chapter.

Acrylic finishing setup. See the section on finishing procedures in this chapter.

Shade correction setup (optional). See the section on color correction and shade characterization in this chapter.

Temporary cementation setup. See the section on cementation of provisional restorations in this chapter.

#### Clinical Technique

1. Prepare the teeth.
2. Place the retraction cord into the sulcus below the preparation margins (0, 00,000 gauge)
3. Make a full arch impression using an elastomeric impression material.

**CLINICAL TIP.** To secure a more accurate impression (especially of the marginal detail), use the Cadco Identic Syringable Impression System.

**CLINICAL TIP.** The hydrocolloid component can be boiled in any device that boils water. Thus any office without the standard hydrocolloid preparation units can still use this technique. After boiling the hydrocolloid, temper it in a standard water bath for 20 minutes at the temperature recommended by the manufacturer (usually 150° F). For convenience, the Dry Processor 11 (Cadco VanR) can be used to prepare the hydrocolloid cartridges of the Identic Syringable System. The Dry Processor II boils, tempers, and stores the cartridges.

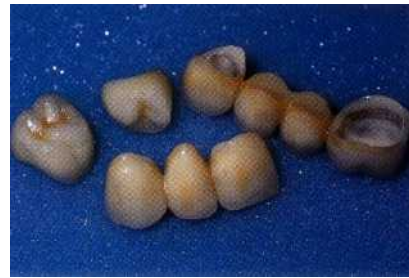4. Have the assistant mix Identic Alginate with cold water and fill a stock impression tray. (Water-cooled trays are not required in this technique.)
5. Using a syringe, place tempered Identic syringable hydrocolloid around the prepared tooth, taking care to fill the sulci, and place the tray containing the alginate over the teeth.
6. Leave the tray in place for 2 minutes.
7. Pour the impression with a fast set plaster or stone.

**CLINICAL TIP.** Use slurry water (i.e., water mixed with a small amount of finely ground set plaster, such as waste water from a model trimmer) to accelerate the cast setting.

8. Trim the cast.
9. Apply a tin foil substitute.
10. Using any of the techniques listed previously, construct the provisional restoration on the model as if it was being done intraorally.

**Table 11-8.** Laboratory-processed custom provisional shells.

Brand	Laboratory
Resista-Temps	Indianapolis: (317) 248-2476
Temp Limited	Florida: (800) 248-3677
Glidewell Laboratories (Bio-Temp)	California: (800) 854-8261



**Fig. 11-30.** Dental laboratory-produced shells that are to be relined with auto-cured acrylic resin and placed on prepared abutments.

11. Reline or remarginate if necessary. See the section on remargination in this chapter.
12. Finish and polish the restoration. See the section on finishing procedures in this chapter.
13. Custom stain or characterize if necessary. See the section on color correction and shade characterization in this chapter.
14. Cement. See the section on cementation of provisional restorations in this chapter.

#### Laboratory-Produced Shell and Reline Technique

The professional dental laboratory can assist the dentist in achieving excellence with acrylic resin provisional restorations (Table 11-8). The dentist relines a processed acrylic resin shell (provided by the laboratory) with an auto-cured resin on the prepared teeth. The shell can be auto cured or heat processed on study casts to the dentist's prescription. Heat processing provides increased strength, durability, and stain resistance and is particularly appropriate for long-term use. Another technique uses hollow plastic denture teeth as "veneers" to which the laboratory adds resin to fill out the shell's proximal and lingual contours (Fig. 11-30). A length of 15-gauge, half-round stainless steel wire can be incorporated into multiple-unit splints to add strength and stiffness.

Kevlar (FibreFlex) and Polyethylene Fiber (Ribbond) reinforcement can also be used. Nylon mesh (Splint-Grid) and Splint Bars (Ellman International Mfg.



Co.) also provide a degree of reinforcement to acrylic resin provisional fixed partial dentures.

#### Armamentarium

- Standard dental setup. See the section on preformed crowns and crown forms in this chapter.
- Diagnostic cast
- Acrylic resin of choice (see Table 11-6)
- Acrylic bur setup. See the section on preformed crowns and crown forms in this chapter.
- Acrylic finishing setup. See the section on finishing procedures in this chapter.
- Shade correction setup (optional). See the section on color correction and shade characterization in this chapter.
- Temporary cementation setup. See the section on cementation of provisional restorations in this chapter.

#### Clinical Technique

1. Provide the dental laboratory with preoperative diagnostic casts, centric occlusion and protrusive records, shade and characterization information, and detailed instructions for the production of an acrylic resin shell.
2. The technician corrects anatomic contour on the study casts.
3. The technician underprepares the abutments on the cast (with a 1-mm reduction) to provide space for resin.
4. The technician fabricates the splint using one of the various previously described methods.
5. Initial finishing can be performed before sending the restoration to the dental office.
6. Reline intraorally on the prepared abutments.
7. Finish and polish the restoration. See the section on finishing procedures in this chapter.
8. Custom stain or characterize if necessary. See the section on color correction and shade characterization in this chapter.
9. Cement. See the section on cementation of provisional restorations in this chapter.

### Provisional Restorations for Coronally Debilitated Teeth

When minimal coronal dentin is available, the retention of the provisional restoration is compromised. Standard retention techniques must be altered or augmented to compensate for a lack of resistance and retentive form.

**Endodontically Treated Teeth.** Between the required two appointments, a provisional restoration is mandatory (especially for anterior teeth) for restorations involving a dowel and core. It is not always feasible to immediately provide a final dowel and core for endodontically treated teeth before temporization.

1. If the restorability of a tooth is questionable, an interim post/crown is less expensive than a restoration that may subsequently be lost with tooth removal.
2. During lengthy periodontal treatment periods of questionable teeth, the interim resin post/core is mandatory.

When fabrication or placement of a dowel/core is delayed, a titanium alloy temporary post may be used to add retention to the acrylic resin provisional restoration. Accessory temporary aluminum pins are also available (Para-Post systems, Coltene/Whaledent) (Fig. 11-31). These devices are incorporated into provisional restorations during reline techniques (Fig. 11-32). The provisional titanium alloy post/crown must be monitored (as must any temporarily cemented provisional restoration) regularly for cement washout and caries development.

**Nonendodontically Treated Teeth.** To provisionally restore teeth that, despite having little coronal structure, do not require endodontic therapy, an interim pin-retained, light-cured composite resin "crown" may be used. This restoration can later be prepared as a pin-retained core on which a ceramometal restoration can be placed (Figs. 11-33 and 11-34).

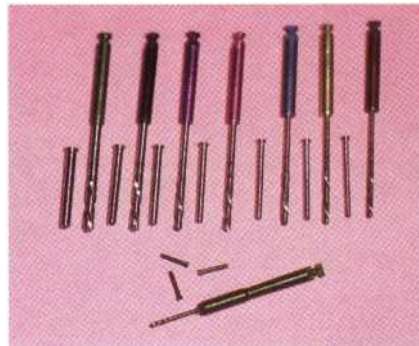

Fig. 11-31 Titanium-alloy temporary posts and aluminum temporary pins (Coltene/Whaledent International) are available to provide retention for acrylic resin provisional crowns for endodontically treated teeth.

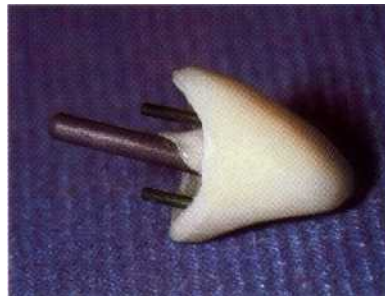


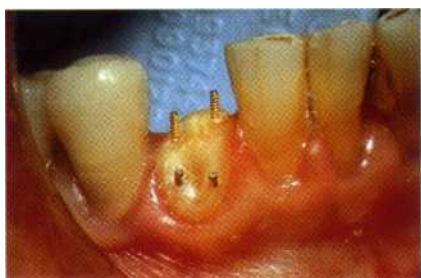Fig. 11-32 Temporary posts and pins have been added to provisional restoration to increase retention and resistance.

## Provisional Restorations for Edentulous Spaces

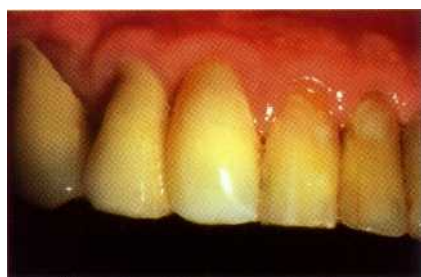**Pontic Design.** Interproximal contact areas are constructed wider buccolingually than the solder joint of the permanent splint to provide strength for the splint. The tissue-contacting surface of a pontic must be flat or convex (never concave) to permit efficient cleansing with floss and other home care devices (Fig. 11-35). See discussion on pontic design in Chapter 7.

## Temporization of Osseointegrated Imj

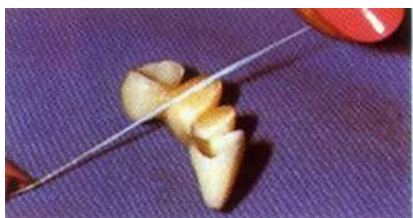After the prescribed healing period required for osseointegration, the reentry surgical procedure is performed, and healing abutments are placed. The patient may be required to wear a modified relined interim removable prosthesis before placement of the final restoration. This may



*Fig. 11-33.* Coronally debilitated canine with four Link-Plus Retention Pins (Coltene/Whaledent). The tooth is vital; however, limited finances did not permit elective endodontic treatment and dowel-core placement.

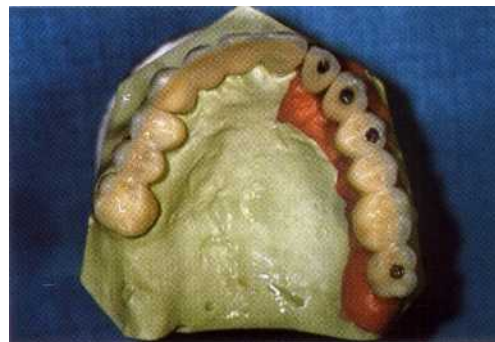

*Fig. 11-34.* Interim light-activated composite resin veneer crown retained with bonding agent and retention pins.

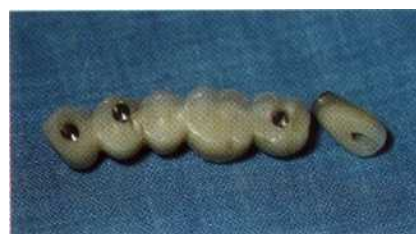

*Fig. 11-35.* Proper pontic contour (tissue side) is conducive to cleansing with dental floss.

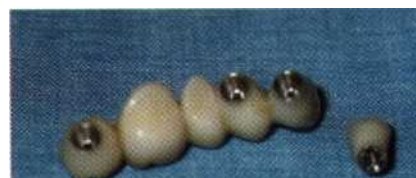be particularly desirable when implants are in the anterior sextant. One solution to this scenario is the placement of an interim acrylic resin fixed prosthesis incorporating temporary cylinders (Figs. 11-36 to 11-39 and



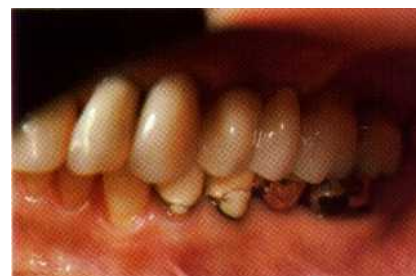*Fig. 11-36.* Titanium temporary cylinder for conical abutment with acrylic resin crowns: teeth #10, #11, #12, #13, #14, and #15 on master cast.



*Fig. 11-37.* Occlusal view of provisional restorations for conical abutments.



*Fig. 11-38.* Gingival view of provisional restorations for conical abutments.



*Fig. 11-39.* Provisional restorations containing titanium temporary cylinders secured to conical abutments with gold retention screws.

Table 11-9). These components may be used by the dentist in a direct chairside fabrication of an acrylic resin prosthesis or when prescribed for laboratory fabrication.'

Whether fabricated directly (chairside) or by a dental technician, the acrylic resin prosthesis provides many benefits to the patient. Wearing a modified fixed prosthesis when indicated eliminates the need for healing abutments. The patient can immediately use the osseointegrated implants with a preview of the final prosthesis. Function and esthetics can be altered in the interim restoration until the patient and clinician are satisfied. In addition, this "fixed-type" prosthesis provides an excellent training and evaluation guide for the home care regimen. It may also be retained as a backup prosthesis in case repair or modifications are required for the definitive prosthesis.

**Intraoral (Direct) Technique**

The intraoral technique is a modification of the plastic matrix technique, which uses either a vacuum former unit or an Ellman Press-Form System. It requires the fabrication of a clear plastic matrix that represents the correct anatomic form desired in the provisional restoration.

**Armamentarium**

The armamentarium is the same as that listed for the vacuum former unit or Ellman Press-Form System with the following exceptions:

- Appropriate retention screws
- Guide pin (Implant Innovations, Inc.)
- Titanium temporary cylinder (Implant Innovations, Inc.)
- Cotton pellets and silicone plugs, Access-Blocker (Implant Innovations, Inc.), or Fermit (Vivadent, USA)

**Clinical Technique**

1. Secure the appropriate temporary cylinders to the abutments. Determine the reduction in height necessary, remove cylinders, and adjust them with a sintered diamond disk.
2. Secure to implant with guide pin.
3. Use the clear plastic matrix to carry acrylic resin intraorally (cut a hole in the matrix to allow it to seat over the cylinder).
4. Allow the resin to set to just after the rubbery stage before unscrewing and removing the assembly. Allow complete exothermic polymerization to occur extraorally.
5. When fully set, contour the acrylic resins and refine the occlusion.
6. Finish and polish the restoration. See the section on finishing procedures in this chapter.
7. Custom stain or characterize if necessary. See the section on color correction and shade characterization in this chapter.
8. Insert and secure the restoration with retention screws. The access opening can be obturated with Access-Blocker (Implant Innovations, Inc.), cotton pellets and silicone plugs, or Fermit (Vivadent, USA).

**Indirect Technique**

The professional dental laboratory can produce acrylic resin interim restorations that seat directly to the implant head or to abutments secured to implants.

**Armamentarium**

The armamentarium is the same as that listed for the indirect technique with the following exceptions:

Cylinder type	Code	Clinical application
Temporary retention cylinder	#TRC30	Screws into standard abutment Retains a soft-relined transitional removable prosthesis
Temporary bridge head	#TB700	Screws into standard abutment; may be prepared like a core to retain a cemented provisional restoration
Standard abutment temporary cylinder	#TC300	Retains a provisional restoration to standard abutment via screws
Tapered abutment temporary cylinder	#TTC30	For construction of screw-retained provisional restorations on tapered abutments
Conical temporary cylinder	#CC300 #CNC30 (single tooth)	For fabrication of screws retained provisional restorations on conical abutments and Estheticone
Nonrotating temporary cylinder	#NTC30	For construction of screws retained fixed crowns or nonrotating abutments
Implant temporary cylinder and screw	#ITCH1 (hexed) #ITCH0 (nonhexed)	Cylinder seats directly on implant For placing fixed provisional restorations on implants without using abutments

Impression material: polyether or vinyl polysiloxane  
 Irreversible hydrocolloid  
 Periphery wax or injectable silicone  
 Appropriate retention screws  
 Access-Blocker (Implant Innovations, Inc.)  
 (optional)

#### Clinical Technique

1. Fabricate a short-term removable prosthesis. This is usually a modified or relined existing removable partial prosthesis.
2. Make a polyether or vinyl polysiloxane impression of the impression coping.
3. Make an irreversible hydrocolloid impression of the opposing arches; make interocclusal records and select the correct shade.
4. Connect the abutment analogs or implant analogs to the impression copings.
5. Pour impressions; articulate the master and opposing casts.
6. Attach temporary cylinders to analogs and complete a full-contour wax-up.
7. Invest, boil out, flask, pack with resin, and process.
8. Recover and finalize the prosthesis.
9. Deliver the custom prosthesis to the patient.
10. Secure the restorations to the abutments or implants with retention screws.

#### Remargination

If marginal discrepancies are noted, an intraoral repair procedure (remargination) is required.

##### Armamentarium

Standard dental setup. See the section on preformed crowns and crown forms in this chapter.  
 Dappen dish  
 Universal Polishing Paste (Ivoclar, Inc.)  
 Assorted red sable brushes (No. 00 to No. 2)  
 Acrylic resin of choice (see Table 11-6)  
 Acrylic bur setup. See the section on preformed crowns and crown restorations in this chapter.

##### Clinical Technique

1. Roughen the resin surrounding the defect with an acrylic cutting bur.
2. Mix a moderately fluid acrylic resin, and paint it onto the dry defect area.
3. Additional mixed resin may be placed in the gingival sulcus adjacent to the defect.
4. Seat the splint so that the fluid resin sets in the defect.
5. Remove when set; trim and finish the restoration to the correct margins.

**CLINICAL TIP.** Light-cured resins are an excellent, efficient material for repairing marginal defects. If light-cured composite resins are used to remarginate defects (or restore contacts, repair fractures, and adjust occlusal defects) of polymethyl methacrylate provisional restorations, the defect must first be primed with bonding primer before the composite resin is applied.

#### Finishing and Polishing Procedures

To ensure biologic compatibility the provisional restoration must be finished so that the contour and marginal excellence approach that of the final cast restoration. Various laboratory carbides, diamond stones, and diamond-coated disks are used to establish physiologically acceptable contours (Table 11-10 and Fig. 11-40). Following intraoral occlusal adjustment to establish centric relation and excursive border movement, the occlusal surfaces are refined and defined with burs. See the acrylic bur setup discussion in the section on preformed crowns and crown forms in this chapter. Correct esthetic coronal anatomic shape is achieved with a series of flat planes rather than rounded surfaces (Fig. 11-41).

Facial textures, supplementary anatomy, and development grooves are sculpted with carbide burs. Smoothing is accomplished with a slurry of medium pumice on a wet chamois wheel with a dental laboratory lathe.

##### *Finishing and polishing.*

Brand	Manufacturer
Cutting/Finishing Bur	Ellman International Mfg.
Pure Buff Lathe Wheels	Almore Dental Co.
Sof-Lex Discs	3M Dental Products
Fine Pumice	Kerr Sybron Co.
White Diamond Bar	Laboratory Products
Sulci Discs	Burlew Co.



*Fig. 11-40. Dr. Federick Temporization Kit (Brasseler, Inc. USA) containing the following straight handpiece laboratory cutting instruments: two diamond disks, two carbide burs, one diamond bur.*

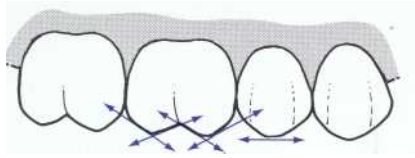


Fig. 11-41. Subtle flat planes that meet at gentle angles create esthetic excellence in provisional restoration. Note occlusal embrasures.

- 11. Acrylic resin glaze

Brand	Manufacturer
Touchup Liquid	Lang Dental Mfg. Co.
Cyanodent (Fast/Slow) Glaze	Ellman International Mfg.
Snap Liquid Glaze	George Taub Dental Products
Temp-Glaze	Parkell Biomaterials Co.
	Ellman International Mfg.

Shade alteration kits.

Brand	Manufacturer
Minute Stain Kit	George Taub Dental Products
Jet Adjusters	Lang Dental Mfg. Co.
Prisma Tints (LC)	LD Cauck

To avoid breaking the acrylic resin splint, all smoothing and polishing must be done on the slow-speed lathe setting. Interproximal surfaces are smoothed and polished with pumice wheels, sand paper, cuttle, and Sof-Lex (3M, Inc.) disks on a straight handpiece. High-luster polishing is accomplished with a dry rag wheel coated with Universal Polishing Paste, a white diamond bar (Laboratory Products, Inc.) on the dental lathe, or glazing resin (Table 11-11). However, custom staining is always performed **after polishing but before glazing.**

*Color Correction and Shade Characterization*

To create an exceptionally esthetic, lifelike acrylic resin provisional restoration that pleases the most demanding patient, the operator can apply surface colorants (Table 11-12). This is readily accomplished with the Taub Minute Stain Kit (George Taub Products) (Fig. 11-42) or the Lang jet Adjuster Kit (Lang Dental Mfg. Co., Inc.) (Fig. 11-43).

These quick-setting, colored acrylic liquids are applied with a brush to modify the shades of acrylic provisional restorations. The stains adhere or bond to all dental resins, including ethyl and methyl methacrylate,



Fig. 11-42. Taub Minute Stain Kit.



Fig. 11-43. Lang Jet Adjuster Kit.

polycarbonates, vinyl methacrylate copolymers, resin crowns and laminates, denture bases, acrylic denture teeth, and composite resins. These stains can be applied intraorally or extraorally.

Armamentarium

- Standard dental setup. See the section on pre-formed crowns and crown forms in this chapter.
- Assorted red sable brushes (No. 00 to No. 2)
- Acrylic color correction kit (Taub Minute Stain Kit or Lang jet Adjuster Kit)

Clinical Technique

1. Finish and polish the restoration. See the section on finishing in this chapter.
2. Make certain the surface is clean.

**CLINICAL TIP.** Gently shake bottles of stain to disperse pigments. Only shake bottles vigorously when intense, concentrated colors are desired.

3. Dip the brush into the bottle, wipe off excess pigment at the bottle neck, and bleed additional excess from the brush onto the ceramic or glass mixing slab. Pigments should be evenly dispersed with a very light, quick brush stroke. Additional layers can be applied following 10-second drying periods.

Type	Brand	Manufacturer	
Eugenol	ZOE Plus	Interstate Dental Co., Inc.	
	ZOE	Cadco Dental Mfg.	
	Flow-Temp	Premier Dental Products	
	TempBond	Kerr Sybron Corp.	
	Trial Cement	Opatow Corp.	
	Embonte	Cadco Dental Mfg.	
	TempoCem	Zenith/DMG	
	Temrex	Interstate Dental Co., Inc.	
	Noneugenol	Zone	Cadco Dental Mfg.
		Nogenol	Coe Dental Mfg.
Freegenol		G.C. Dental Co.	
Flex-Span CMT		Jeneric-Pentron	
TempBond Clear		Kerr Sybron	
Neo-Temp		Teledyne-Getz	
Provicol		Sabra Dental Products	

### Cementation

Cements with or without eugenol can be used for cementation of provisional restorations (Table 11-13). Cements containing eugenol are indicated for relief of pulpal sensitivity. However, the eugenol may inhibit the setting of the acrylic during subsequent relining and remargination procedures. Noneugenol formulations are easier to remove from the acrylic resin.

#### Armamentarium

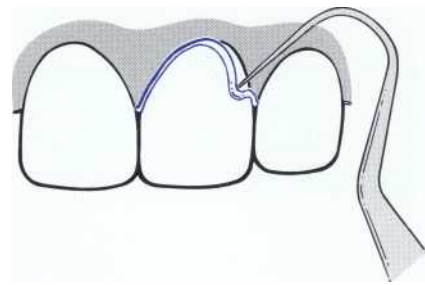
- Standard dental setup. See the section on preformed crowns and crown forms in this chapter.
- Cord placement instrument (optional)
- No. 0 gauge retraction cord (optional)
- Temporary cement: noneugenol or eugenol type
- Petroleum jelly or mineral oil
- Dental floss
- Dental floss threader
- Cement removal instrument
- Small cement spatula
- No.  $\frac{1}{2}$  Hollenback or red sable brushes
- #7 wax spatula

#### Clinical Technique

1. Isolate the teeth with cotton rolls, and dry them with the air syringe.

**CLINICAL TIP.** Lubricate the provisional splint externally with mineral oil or petroleum jelly to facilitate the removal of excess cement after setting.

**CLINICAL TIP.** Place lengths of dental floss between the prepared teeth before cementation of the splint to facilitate dislodging interproximal excess cement.



*Fig. 11.44. Retrieval of cord that was placed before cementation of provisional restoration. This technique aids in debridement of excess temporary cement.*

**CLINICAL TIP.** Place a section of nonimpregnated retraction cord into the sulcus before cementation of the provisional restoration. Retrieving this cord during excess cement removal ensures that no cement remains; however, failure to remove the cord can have adverse periodontal consequences (Fig. 11-44).

2. Prepare a eugenol or noneugenol temporary cement according to the manufacturer's instructions.
3. Deliver a thin film of cement to the restoration with a #7 wax spatula or plastic instrument (Brasseler, Inc. USA).
4. Seat the restoration on the preparations and direct the patient to gently close into the centric occlusal position.
5. After the cement has set, gently remove the excess with an explorer or No.  $\frac{1}{2}$  Hollenback carver. Floss threaders and unwaxed dental floss effectively cleanse cement from interproximal spaces.
6. Make certain no excess subgingival cement remains because it may contribute to gingival irritation and recession.

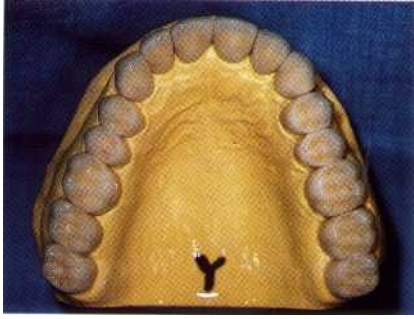


Fig. 11-45. Maxillary (full arch) provisional restorations.

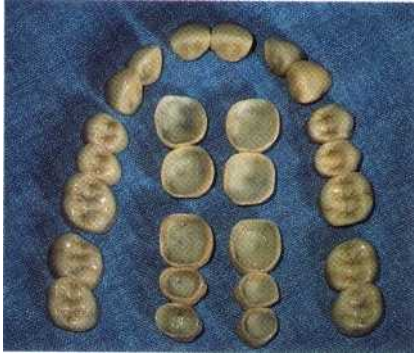

Fig. 11-46. Custom, processed polymethyl methacrylate provisional restorations.

### Laboratory Prescription

Properly fabricated provisional restorations can be used as a three-dimensional laboratory prescription. A stone cast duplicate of the cemented provisional restorations aids the dental technician in developing crown contour, emergence profile, transitional line angles, proportion, lip and smile lines, disclusion guides, and esthetics in the definitive restoration (Figs. 11-45 and 11-46). This serves to minimize chairside adjustments and remakes. An acrylic tab accurately conveys the desired shade to the laboratory.

### Modular Transitional Implants

Patients seeking implant-retained prostheses are often hesitant to initiate treatment because of the lengthy osseointegration period requiring the use of a removable interim prosthesis. This factor may cause patients to seek alternative care. It is now possible to offer patients the option of never being without an implant-supported transitional prosthesis between the time of the initial implant placement and stage 2 surgical exposure. The Modular Transitional Implant and Prosthetic System (MTI-MP) from Dentatus USA provides a new system for the implantologist and restorative dentist to deliver the following benefits:

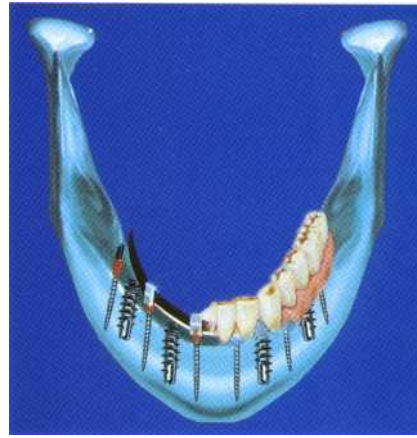


Fig. 11-47. Schematic diagram of the Modular Transitional Implant and Prosthetic System (MTI-MP) components.

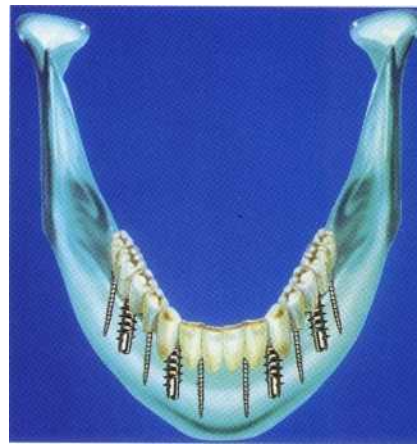
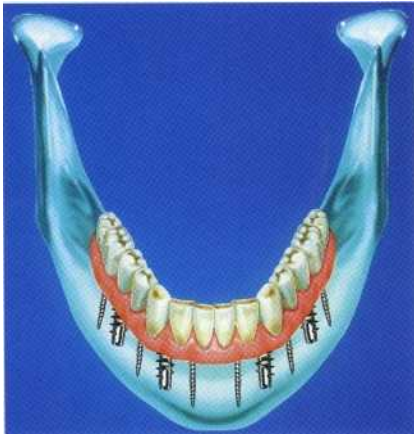


Fig. 11-48. Schematic diagram of Modular Transitional Implant and Prosthetic System (MTI-MP) implant retained provisional fixed partial denture.

1. The MTI-MP provides immediate interim stable restorations immediately after implant placement (Fig. 11-47).
2. The MTI-MP eliminates the need to wear a tissue-supported prosthesis that may transmucosally "load and stress" the submerged implants.
3. The MTI-MP implant prosthesis presents a preview of the definitive prosthesis and can be altered to analyze the form desired in the final restoration.
4. The pure titanium MTI-MP implants serve as stabilizers for bone and membranes in guided tissue regeneration procedures.

The MTI-MP system is not currently accepted by the American Dental Association (ADA), but it is FDA 510K approved. The system contains components that permit implantologists and restorative dentists to fabricate fixed and removable immediate interim implant-retained restorations (Figs. 11-48 and 11-49).



*Fig. 11-49. Schematic diagram of Modular Transitional Implant and Prosthetic System (MTI-MP) implant retained provisional removable partial denture.*

## CLINICAL CASES

### Direct Technique

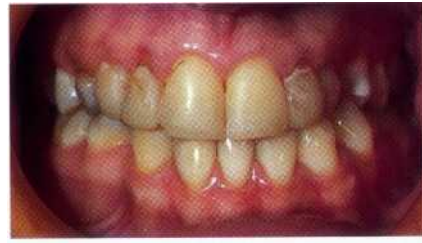A 28-year-old woman had poorly repaired maxillary dentition. She had some missing teeth (a congenital condition) and retained deciduous teeth (Fig. 11-50). After consultation with the woman, porcelain-fused-to-gold prostheses were selected as treatment. Corrected and duplicated diagnostic casts were prepared to secure clear plastic matrices for the maxillary left and right quadrants (Figs. 11-51 and 11-52). The abutments were prepared for porcelain-fused-to-metal retainers, nonsalvageable teeth were extracted (Fig. 11-53), and maxillary left and right acrylic resin provisional splints were produced using the clear plastic matrix technique (Fig. 11-54).

### Indirect/Direct Technique: Laboratory Processed

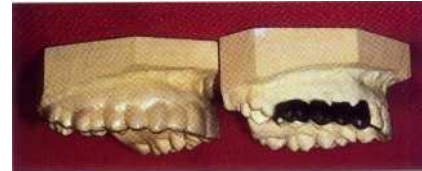A 24-year-old woman had severe gingival irritation surrounding six clinically unacceptable maxillary anterior porcelain jacket crowns (Fig. 11-55). A six-unit laboratory processed acrylic resin shell splint was fabricated (Fig. 11-56). The existing porcelain jackets were removed, the abutments were reprepared, and the acrylic resin shell was relined to fit the preparations. Conventional finishing techniques were employed to achieve an esthetic, biologically compatible interim provisional fixed partial denture (Fig. 11-57).

### Maxillary Rehabilitation

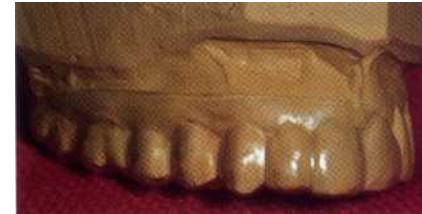A 46-year-old woman had very high expectations regarding the esthetics of her planned maxillary dental reconstruction (which would be composed of three fixed partial



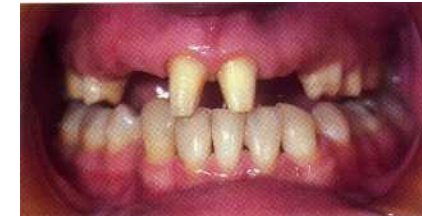*Fig. 11-50. Preoperative photograph of poorly restored maxillary dentition.*



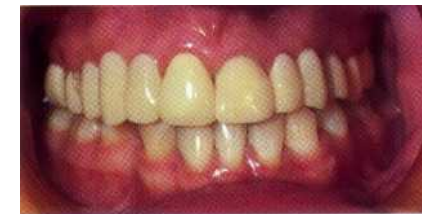*Fig. 11-51. Corrected maxillary right diagnostic cast that was duplicated before obtaining clear plastic matrix.*



*Fig. 11-52. Stone duplicate of corrected study cast with maxillary right clear plastic matrix.*

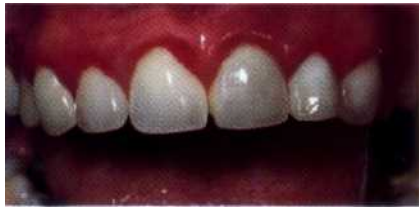

*Fig. 11-53. Prepared abutments for porcelain-fused-to-gold retainers 2 months after extractions.*

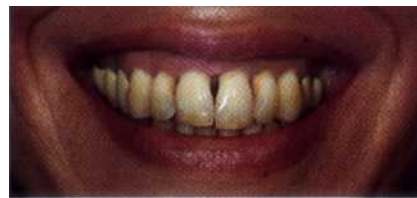

*Fig. 11-54. Maxillary left and right acrylic resin provisional splints cemented to abutments.*

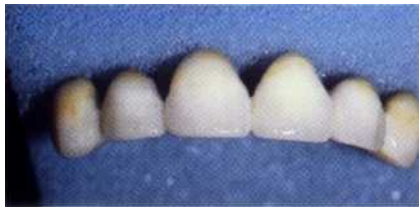



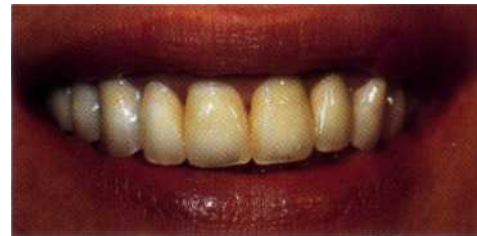*Fig. 11-55. Poorly contoured maxillary anterior porcelain jacket contributing to severe gingival inflammation and hyperplasia.*



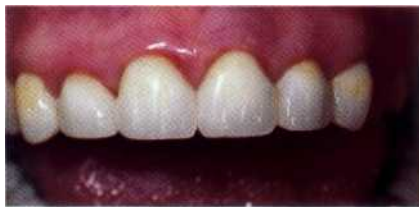*Fig. 11-58. Pretreatment photograph of patient scheduled for removal of central and lateral incisors and complete maxillary fixed prosthetic reconstruction.*



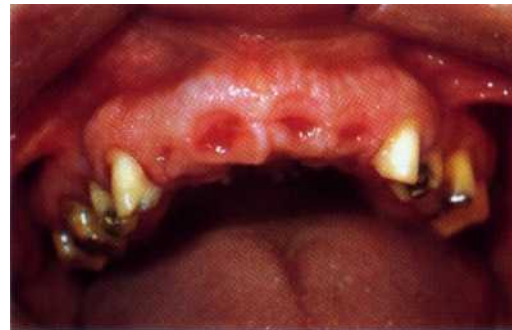*Fig. 11-56. Laboratory-produced shell splint.*



*Fig. 11-59. Maxillary acrylic resin provisional splints (three sextants) cemented with ZONE temporary cement.*



*Fig. 11-57. Photograph 1 week after cementation of relined laboratory-produced acrylic resin shell splint. Note favorable soft tissue response.*

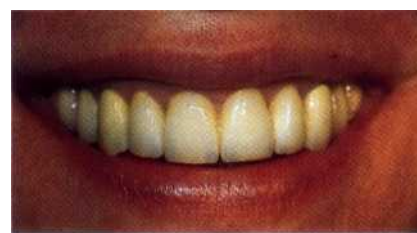

*Fig. 11-60. Photo showing ovate poetic receptor sites teeth #7, #8, #9, and #10 created by periodontal therapy and maintained by custom acrylic resin provisional restorations.*

dentures). She was particularly concerned about the emergence profile of her central and lateral incisor poetics, noting that the replacement teeth (poetics) of her friends' similar dental restorations appeared "very fake." To ensure the ideal esthetic emergence of the poetic gingival collars in the definitive porcelain/gold restorations, the anterior provisional restoration was designed with ovate poetics for the central and lateral incisor poetics. The periodontist created ideal ovate poetic tissue receptor sites. The sites were maintained by the provisional restoration contours, which were captured in the impressions that produced the master crown and bridge cast and were beautifully restored by a master dental technician/ceramist (Figs. 11-58 to 11-61).

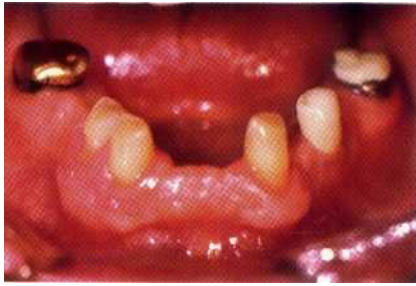*Laboratory-Produced Shell and Reline Technique*

A 64-year-old patient requested a mandibular dental reconstruction consisting of fixed partial dentures. The pre-

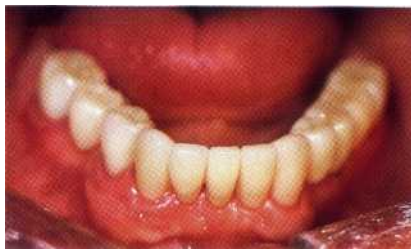

*Fig. 11-61. Posttreatment photograph of completed maxillary fixed partial denture reconstruction.*

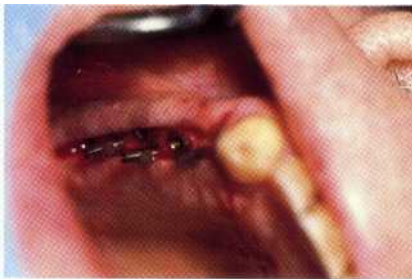treatment photograph (Fig. 11-62) reveals six available abutment teeth and multiple edentulous spaces. Custom BioTemps were fabricated and relined intraorally to the full coverage prepared abutments, teeth #18, #20, #22, #27, #28, and #30 (Fig. 11-63).



*Fig. 11-62. Pretreatment photograph of a debilitated dentition. Restorative treatment plan involves placing three fixed partial dentures.*



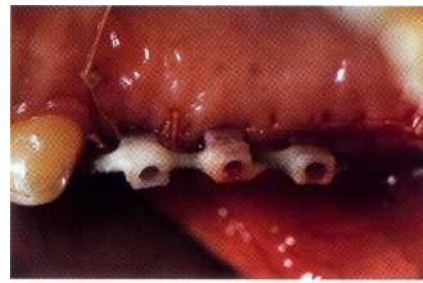*Fig. 11-63. Direct relined BioTemp splints cemented intraorally with ZONE temporary cement. Abutments are teeth #18, #20, #22, #27, #28, and #30.*



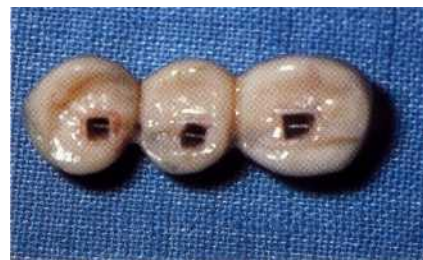*Fig. 11-64. Three Modular Transitional Implant and Prosthetic System (MTI-MP) titanium transitional implants placed palatal to definitive root-form implants in maxillary right sextant.*

### *MTI-MP Case*

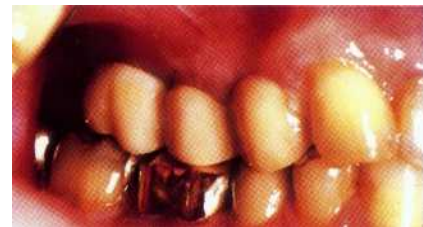A 63-year-old man requested an interim fixed partial denture in a partially edentulous region (of teeth #3, #4, and #5) immediately following stage 1 implant surgery. He refused to wear a removable partial denture (stayplate) or to remain partially edentulous during the integration period. It was determined that an acrylic resin fixed interim partial denture, retained by three Dentatus MTI-MP titanium transitional implants, would best satisfy his needs. The interim fixed partial denture was fabricated using the prosthetic components of the Dentatus MTI-MP system (Figs. 11-64 to 11-67).



*Fig. 11-65. TI Connector Bar and Modular Transfer Copings splinted with polymethyl methacrylate acrylic resin. Splint is retained in slotted heads of Modular Transitional Implant and Prosthetic System (MTI-MP) transitional implants.*



*Fig. 11-66. Undersurface of the polymethyl methacrylate fixed provisional splint showing the connector bar in each retainer.*



*Fig. 11-67. One-week postoperative view of three-unit (teeth #3, #4, and #5) polymethyl methacrylate provisional splint retained by three Modular Transitional Implant and Prosthetic System (MTI-MP) titanium transitional implants.*

## CONCLUSION

An esthetic, biologically compatible, physiologically sound interim restoration satisfies the patient, ensures tissue health, and favorably enhances the final restoration delivery and cementation times. Experience gained during this critical phase of therapy aids the clinician in accepting perioprosthetic challenges confidently.

The restorative dentist must never rationalize that the acrylic resin provisional restoration is "only temporary," a mindset that can easily lead to failure of treatment goals. The acrylic resin provisional restoration

should be considered a "permanent restoration made of temporary material."

#### REFERENCES

1. Federick DR, Capilto AA: Stress distribution to the supporting tissues of abutment stabilized with fixed splints, *J Cal Dent Assoc* 8:33, 1980.
2. Amsterdam M, and Fox L: Provisional splinting: principals and techniques, *Dent Clin North Am* 4:73, 1959.
3. Burgess JO: Provisional materials, *The Dental Advisor*, vol. 12, no. 1, 1995.
4. Federick DR: Temporization, *The Dental Advisor*, vol. 9, no. 1, 1992.
5. Federick DR: Provisional/transitional implant retained fixed restorations, *J Calif Dent Assoc* 23:19, 1995.
6. Schneider DN: Full-coverage temporization-an outline of goals, methods, and uses (Part 1), *Quint Int* 11:27, 1980.

#### BIBLIOGRAPHY

- Adams WK: A temporary fixed partial denture, *J Prosthet Dent* 24:571, 1970.
- Antonoff SJ, Levine H: Fabricating an acrylic resin fixed prosthesis for an allergic patient, *J Prosthet Dent* 45:678, 1981.
- Ban M et al: A new temporary crown and bridge resin, *Br Dent J* 141:269, 1976.
- Barghi N, Simmonds EW: The marginal integrity of the temporary acrylic resin crown, *J Prosthet Dent* 36:274, 1976.
- Baumhammers A: Temporary and **semi-permanent splinting**, **Springfield, 111, 1971, Thomas C. Thomas.**
- Behrend DA: Temporary protective restorations in crown and bridge work, *Aust Dent J* 12:411, 1967.
- Bell TA: Light-cured composite veneers for provisional crowns and fixed partial dentures, *J Prosthet Dent* 61:266, 1989.
- Berglin GM: A technique for fabricating a fixed provisional prosthesis on osseo-integrated fixtures, *J Prosthet Dent* 61:347, 1989.
- Binkley CJ et al: Reinforced heat-processed acrylic resin provisional restorations, *J Prosthet Dent* 57:689, 1987.
- Braden LC: Indirect temporary acrylic restorations for fixed prosthodontics, *J Am Dent Assoc* 105:1026, 1982.
- Braden M, Clark RL: An ethyleneimine derivative as a temporary crown and bridge material, *J Dent Res* 50:536, 1971.
- Brotman IN: Contoured temporary aluminum shell crown, *Dent Survey* 28:807, 1952.
- Burgess JO: Provisional materials, *Dental Advisor*, Vol 12, No 1, 1995.
- Caidwell WK: A temporary fixed partial denture, *J Prosthet Dent* 24:571, 1970.
- Campagni WV: Technique for cementation of provisional restorations, *J Prosthet Dent* 54:13, 1985.

- Campagni WV et al: Provisional restorations, *J Cal Dent Assoc* 16:16, 1988.
- Cathcart J: Immediate acrylic jacket crowns by the direct-indirect technique, *Dent Dig* 56:342, 1950.
- Chalifoux PR: Temporary crown and fixed partial dentures: new methods to achieve esthetics, *J Prosthet Dent* 61:411, 1989.
- Christensen LC: Color characterization of provisional restorations, *J Prosthet Dent* 46:631, 1981.
- Cleveland J, King C, Contino S: Custom shading for temporary-coverage restorations, *J Prosthet Dent* 32:425, 1974.
- Cleveland JL, Richardson JT: Surface characterization of temporary restorations: guidelines for quality ceramics, *J Prosthet Dent* 37:643, 1977.
- Cohn LA: Staining acrylic resin restorations, *J Prosthet Dent* 7:400, 1957.
- Cooly RL: Etched-retained natural crown as a temporary fixed partial denture, *Gen Dent* 29:323, 1982.
- Cottle KL: Temporary bridge or inlay, *Dent Survey* 39:3541, 1963.
- Crispin BJ, Caputo AA: Color stability of temporary restorative materials, *J Prosthet Dent* 42:27, 1979.
- Crispin BJ et al: The marginal accuracy of treatment restorations: a comparative analysis, *J Prosthet Dent* 44:283, 1980.
- Dahi BL et al: Biological tests of a temporary crown and bridge material, *J Oral Rehabil* 1:299, 1983.
- Davidoffi JR: Heat-processed acrylic resin provisional restorations: an in-office procedure, *J Prosthet Dent* 48:673, 1982.
- Defines DN: Direct provisional restoration technique, *J Prosthet Dent* 59:395, 1988.
- Dill G, Schmidt J, King C: A technique for temporary bridge construction, *South Car Dent J* 27:22, 1969.
- Doherty MJ: Fabrication of an acrylic and metal band provisional restoration, *J Prosthet Dent* 41:109, 1979.
- Donaldson D: Gingival recession associated with temporary crowns, *J Periodont* 44:691, 1973.
- Donaldson D: The etiology of gingival recession associated with temporary crowns, *J Periodont* 45:468, 1974.
- Donovan TE et al: Physical properties of acrylic resin polymerized by four different techniques, *J Prosthet Dent* 54:522, 1985.
- Eliman I: Compression-formed plastic shells for temporary splints, *Dent Dig* 77:334, 1971.
- Etkins BJ: Temporization, *Ariz Dent* 3(24):17, 1978.
- Federick DR: The provisional fixed partial denture, *J Prosthet Dent* 34:520, 1975.
- Federick DR: The processed provisional splint in periodontal prostheses, *J Prosthet Dent* 33:553, 1975.
- Federick DR: Rationale and requirements for the provisional (treatment) restoration in fixed prosthodontics, *Isr Dent Med* 26:5, 1977.
- Federick DR: Temporization, *Dental Advisor*, Vol 9, No 1, 1992.

- Federick DR: Provisional/transitional implant retained fixed restorations, *J Cal Dent Assoc* 23:19, 1995.
- Feinberg E: Full mouth *restoration in daily practice*, Philadelphia, 1971, Lippincott.
- Fiasconaro J, Skerman H: Vacuum-fired prostheses: a temporary fixed bridge or splint, *J Am Dent Assoc* 76:74, 1968.
- Fisher D, Dewhirst F, Schillingburg H: Indirect temporary restorations, *J Am Dent Assoc* 72:160, 1971.
- Naimon FH: Intraoral fabrication of temporary coverage for crown and bridge (part 11), *Quint Int* 8:19, 1977.
- Naimon FH: Intraoral fabrication of temporary coverage for crown and bridge (part III), *Quint Int* 8:23, 1977.
- Naimon FH: Intraoral fabrication of temporary coverage for crown and bridge (part IV), *Quint Int* 8:31, 1977.
- Nayyar A, Edwards WS: Fabrication of a single anterior intermediate restoration, *J Prosthet Dent* 39:574, 1978.
- Nayyar A, Edwards WS: Fabrication of a single posterior intermediate restoration, *J Prosthet Dent* 39:688, 1978.
- Oliva R: Custom shading of temporary acrylic resin jacket crown, *J Prosthet Dent* 44:154, 1980.
- Pokorny DK, Rote MG: Temporary resin crowns and bridges, *Dent Survey* 54:52, 1978.
- Portera JJ: Immediate fixed temporization utilizing extracted natural dentition, *J Prosthet Dent* 45:286, 1981.
- Povlich J: Temporary coverage in crown and bridge, *J North Car Dent Soc* 53:22, 1970.
- Preston JD: A systematic approach to the control of esthetic form, *J Prosthet Dent* 35:393, 1976.
- Prichard JF: *Advanced periodontal disease*, ed 2, Philadelphia, 1972, WB Saunders.
- Richardson JT, Cleveland JL, Cox WB: Metal shell temporization: effective and protective, *Dent Survey* 53:34, 1977.
- Robinson FB et al: Marginal fit of direct temporary crowns, *J Prosthet Dent* 47:390, 1982.
- Rosenstiel SF, Gegauff AG: Effect of provisional cementing agents on provisional resins, *J Prosthet Dent* 59:29, 1988.
- Rubin M: Full coverage: the provisional and final restorations made easier, *J Prosthet Dent* 8:664, 1958.
- Rubinstein MN: Immediate acrylic temporary crown and bridge, *Dent Dig* 60:12, 1954.
- Rudick GS: Fabrication and duplication of a temporary acrylic resin splint, *J Prosthet Dent* 28:318, 1972.
- Sakiad M: An esthetic provisional cast gold and acrylic splint, *J Prosthet Dent* 4:653, 1954.
- Samarni SIA, Harris WT: Provisional restorations for traumatically injured teeth, *J Prosthet Dent* 44:36, 1980.
- Schmidt J et al: Anterior temporary coverage, *South Car Dent* 327:5, 1969.
- Schneider DN: Full coverage temporization-an outline of goals, methods and uses (part 1), *Quint Int* 11:27, 1980.
- Schneider DN: Full coverage temporization-an outline of goals, methods and uses (part II), *Quint Int* 11:35, 1980.
- Schneider DN: Full coverage temporization-an outline of goals, methods and uses (part III), *Quint Int* 11:31, 1980.
- Segat L: Protection of prepared abutments between appointments in crown and bridge prosthodontics, *J Mich Dent Assoc* 44:32, 1962.
- Shavell NM: Mastering the art of provisionalization, *J Cal Dent Assoc* 7:44, 1979.
- Shillingburg HT et al: Indirect temporary restorations, *J Am Dent Assoc* 82:160, 1971.
- Silvestri AR, Gagnon WW: Improved temporary restorations for onlay preparations, *J Prosthet Dent* 37:4327, 1977.
- Smith CC, McGhay RM: Techniques for making a template for temporary restorations, *J Prosthet Dent* 47:214, 1982.
- Sochat P, Schwartz M: The provisional splint-trouble shooting, *J South Cal Dent Assoc* 41:92, 1973.
- Sotera AJ: Direct technique for fabricating acrylic resin temps using the omnivac, *J Prosthet Dent* 29:577, 1960.
- Stein LB: The status of temporary fixed-splinting procedures in the treatment of periodontally involved teeth, *J Periodont* 31:217, 1960.
- Stein R, Glickman I: Prosthetic considerations essential for gingival health, *Dent Clin North Am* 4:177, 1960.
- Talkov L: Temporary acrylic fired bridgework and splints, *J Prosthet Dent* 2:693, 1952.
- Talkov L: The copper band splint, *J Prosthet Dent* 6:245, 1956.
- Taylor AG: Temporary protection of prepared abutment teeth, *Royal Can Dent Corps Quart* 2:8, 1961.
- Tjan AHL et al: Marginal accuracy of temporary composite crowns, *J Prosthet Dent* 58:417, 1987.
- Tracy WW: Simplified procedure for temporary crown, *NY J Dent* 25:191, 1955.
- Troendle KB et al: Temporary replacement of missing maxillary incisors, *J Prosthet Dent* 55:277, 1986.
- Tylman SD: *Theory and practice of crown and bridge prosthodontics*, ed 5, St Louis, 1965, Mosby.
- Utley JL: Chairside fabrication of an acrylic resin temporary crown, *J Prosthet Dent* 54:736, 1985.
- Vahidi F: The provisional restoration, *Dent Clin North Am* 31:363, 1987.
- Vahidi F: The provisional restoration, *NYJ Dent* 51:208, 1985.
- Waerhaug J: Effect of rough surfaces on gingival tissue, *J Dent Res* 35:323, 1956.
- Waerhaug J, Zander NA: Reaction of gingival tissue to self curing acrylic restorations, *J Am Dent Assoc* 54:760, 1957.
- Waerhaug J: Temporary restorations: advantages and disadvantages, *Dent Clin North Am* 24:305, 1980.
- Weinberg L: *Atlas of crown and bridge prosthodontics*, St Louis, 1965, Mosby.
- Weinberg LA: Esthetics and the gingivae in full coverage, *J Prosthet Dent* 10:737, 1960.
- Weiner S: Fabrication of provisional acrylic resin restorations, *J Prosthet Dent* 50:863, 1983.
- Wilkie ND: The search for the practical, *J Prosthet Dent* 32:251, 1974.
- Willis J: Gold temporary crowns simplified, *J South Cal Dent Assoc* 40:51, 1972.

Wilson IE, Werrin SR, Groom GS: Temporary coverage using the double-arch impression technique, *Gen Dent* 31:273, 1983.

Wood M et al: Visible light-cured composite resins: an alternative for anterior provisional restorations, *J Prosthet Dent* 54:192, 1984.

Wright WE: Provisional restoration, *J Cal Dent Assoc* 16:18, 1988.

Wright WE et al: The role of restorative dentistry in the prevention of periodontal failures, *J Cal Dent Assoc* 13:68, 1985.

Yuodelis RA et al: Provisional restorations: an integrated approach to periodontics and restorative dentistry, *Dent Clin North Am* 24:285, 1980.

Ziebart G: A modified "shell" type of temporary acrylic filled partial denture, *J Prosthet Dent* 27:667, 1972.



انتشارات شایان نمودار

# ACRYLIC AND OTHER RESINS

## Removable Prosthesis

Michel G. Venot

**C**OMPLETE DENTURE SERVICE can be a frustrating experience for restorative dentists not familiar with the goals and the emotional background of edentulous patients seeking oral rehabilitation.<sup>1</sup> These individuals have usually experienced a progressive breakdown of the appearance and function of their teeth; rarely have they lost all their teeth at once. Thus these losses have been accepted as natural and even normal events of life. Some denture wearers have resigned themselves to accepting the increased isolation caused by the inability to smile and socialize during meals.<sup>2</sup>

The edentulous population is generally older and has lower levels of education and income than the average population.<sup>3</sup> This group is often skeptical of denture treatments because of previous bad experiences. However, the majority of denture wearers are satisfied with their prostheses.<sup>4-8</sup> The most frequently reported overall complaint is pain in the mandibular arch,<sup>9</sup> although poor esthetics is the leading reason for dissatisfaction among women.<sup>10</sup> Patients frequently have high expectations regarding their ability to chew food with their new prostheses. Unfortunately, regardless of the complexity of the denture technique used, the maximum biting force possible with maxillary and mandibular prostheses does not exceed one fifth of the amount generated by natural teeth.<sup>11</sup> General dentists should take the time to present in detail the advantages of implant therapy to their edentulous patients. Failing to do so could be construed as a promise of functional success without implant therapy. The dental profession should be concerned by the very low rate of conversion to implant-supported prostheses,<sup>12</sup> especially considering the bone preservation and increased quality of life provided by these devices, as well as their functional superiority.<sup>14,11</sup>

In addition, dentists should be aware that some patients disguise their esthetic complaints with more socially acceptable complaints about function.<sup>13</sup> Dentists should not assume that advancing age diminishes a patient's interest in esthetics. The media portrays a large, white smile as the means for improving personal relationships.<sup>14</sup> This message is often included in television advertisements for denture adhesives. The barrier between excellent esthetics and function is becoming more vague for this population with limited dental knowledge. Thus providing satisfactory denture esthetics to patients should be the primary concern. Unfortunately, in dental schools, dentists are not taught to emphasize complete denture esthetics. The high number of resets or remakes reported can be traced to three major problems:

1. The patient's desires were not evaluated or were poorly communicated to technicians (or both).<sup>15</sup>
2. The prosthetic teeth were not approved by the patient before being set.<sup>16</sup>
3. An undirected technician tends to emphasize a mechanistic approach.

The key to maximizing patient satisfaction is striving for excellent patient-dentist interactions.<sup>17</sup> The first step toward this goal is to eliminate any promise of a complete restoration of function (which cannot be predicted) and to concentrate on esthetics (which can be promised). Thus explaining denture limitations visually with a model of resorbed mandibles (Zenza, Davie) is critical. Patients who cannot accept the functional limitations inherent in complete dentures should not be treated. The second step is for the dental professional to listen to the patient's wishes<sup>18</sup> and translate them into practical guidelines for the technician. A patient's ability to accurately

assess problems with dentures is often grossly underestimated by clinicians." The third step is to have the patient actively participate in the rehabilitation."

### THE FIRST APPOINTMENT

The quality of the patient-dentist interaction is primarily determined at the first appointment. At this stage the prospective patient has the best opportunity to express goals and aspirations, and the practitioner has the best opportunity to evaluate the esthetic problems present in the existing dentures." However, edentulous patients may have a difficult time describing their wishes" and accepting the limitations of dentures because of limited knowledge of and trust in dentistry. Patients should bring photographs of their natural teeth (even if they were taken many years previously and were esthetically unacceptable) because photographs facilitate dialogue.<sup>211</sup> In the United States, wedding photographs were commonly available even early in the twentieth century. These photographs are often large and show wide smiles, which are helpful during oral rehabilitation. In addition, the office business manager should always encourage edentulous patients to bring a family member who can act as a facilitator. However, denture wearers themselves are often unac-

ceptable facilitators because they have inadequate restorations and often reinforce the negative treatment outlook common to edentulous patients.

**CLINICAL TIP.** The business manager should ask the prospective patient to bring photographs showing their natural teeth, even with teeth with unacceptable esthetics. Large photographs and side views are most helpful. A person the patient trusts can help with the tooth selection.

A well-designed, properly administered questionnaire allows patients to express their concerns and aspirations and expedites the evaluation process.<sup>29</sup> Furthermore, questionnaires can reduce confrontations and identify patients with negative psychologic profiles." Patients who feel emotionally secure tend to prefer natural-looking dentures. Meanwhile, patients with lower self-esteem are more likely to select the "Hollywood" look, or the "perfect-looking" smile, as a means of seeking emotional compensation. Patients' esthetic preferences are influenced by their ethnic and cultural backgrounds as well.<sup>3'</sup>

A denture questionnaire should be short and uncomplicated. A visual analogue scale is an easily understood format.<sup>31-31</sup> The benefits of completing the questionnaire must be clearly presented orally and in writing; otherwise patients may consider it an invasion of privacy (Fig. 12-1).

Patient's Name: \_\_\_\_\_

How many dentures have you had? \_\_\_\_\_ When was (were) your denture(s) made? \_\_\_\_\_

With my dentures, I can chew

Nothing  25% of the time  50% of the time  75% of the time  Anything I want

When I wear my dentures, I experience pain

Never  25% of the time  50% of the time  75% of the time  All the time

With my new dentures, I expect to chew

Nothing  25% of the time  50% of the time  75% of the time  Anything I want

With my new dentures, I expect to experience pain

Never  25% of the time  50% of the time  75% of the time  All the time

Please look into a mirror and evaluate the following:

I am \_\_\_\_\_ satisfied with the appearance of my dentures.

Not at all  25%  50%  75%  Extremely

I want a smile that appears (check all that apply)

Natural  Perfect (like entertainers')  Exactly the same as my previous teeth or dentures  I do not care

I expect to be \_\_\_\_\_ satisfied with the look of my new dentures.

Not at all  25%  50%  75%  Extremely

How much stress have you experienced during the last 12 months?

None  Some  Quite a bit  A lot

Please list anything else about your smile that you wish to discuss:

\_\_\_\_\_

\_\_\_\_\_

Signature: \_\_\_\_\_ Date: \_\_\_\_\_

Fig. 12-1. Denture questionnaire.

A patient's desires should be determined by the questionnaire and the interview. The advantages of implants as they relate to the functional goals of each specific patient should be presented visually with models of implant-supported restorations. Then the patient's experience with their dentures should be compared to the objective findings gathered by examining the prosthesis in the mouth and the patient's oral condition. The result of this investigation provides an estimate of the success of the proposed prosthesis. After the patient and dentist have agreed that the treatment has a significant chance of success, they should proceed with the tooth selection before the fee is presented. See section on fee presentation in this chapter.

### EVALUATION OF EXISTING DENTURE ESTHETICS

Esthetic problems and patient concerns are more readily discovered when the existing dentures are being worn."

#### Armamentarium

- Basic dental setup
  - Explorer
  - Mouth mirror
  - Patient mirror
- Questionnaire (see Fig. 12-1)
- Polaroid or digital camera (see Chapter 14)
- Alma Gauge (Dentsply Inc.)
- Disposable plastic template for Alma Gauge
- Thin, indelible marker (available at office supply stores) (Sharpie Fine Point, Sanford)
- Alcohol gauze
- White orthodontic wax (Modern Material, Haerus) or light-cured composite resin (Tetric, Ivoclar North America)

#### Clinical Technique

1. Take a Polaroid photograph of the patient's smile and a second photograph of the lateral profile while the teeth are in occlusion. These photographs facilitate dialogue by helping the patient understand the suggested changes.
2. Observe the lip support and vertical dimension of occlusion by examining the patient's profile while the patient is standing.
3. Palpate the anterior border of the maxillary denture to evaluate its thickness.
4. Place the tip of the index finger over the subnasion (junction of the columella of the nose with the upper lip) and the pad of the finger over the lip. The pad should be more anterior than the maxillary incisal edges when the lip is properly supported by the labial flange of the denture. (When the upper lip is properly supported, it protrudes in relation to the subnasion.)
5. While looking at the patient's profile, ask the patient to count from 50 to 70 very slowly.

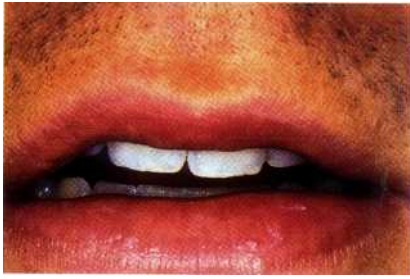
6. The incisal edges of the maxillary central incisors should lightly contact at or near the wet line of the lower lip while the "F" sound is pronounced (Fig. 12-2).
  - A. While the "S" sound is being pronounced, the maxillary and mandibular central incisors should be separated by about 1 mm of space. A slightly lingual position of the mandibular incisors with respect to their maxillary counterparts is acceptable.<sup>36</sup> See the discussion on denture limitations in this chapter.
  - B. An average of 3 mm of space should be present between the maxillary and mandibular first premolars when the patient is at rest. An exaggerated space between the premolars may indicate an insufficient vertical dimension of occlusion."
  - C. Move the maxillary incisors forward when they are lingual to the mandibular incisors ("S") and to the wet line ("F") unless the patient displays marked orthognathic discrepancies.
7. Observe the face of the patient and note any irregular features .11,39
  - A. Marked discrepancy in the level of the corners of the mouth compromises the esthetics.
  - B. Have the patient open the mouth slightly without activating the lip musculature. Note the relationship of the mandibular canines to the corners of the mouth.

**CLINICAL TIP.** The incisal edges of mandibular canines tend to be located at the level of or slightly superior to the corners of the mouth when the lips are relaxed and barely separated (Fig. 12-3). When the vertical positions of the right and the left corners of the mouth are asymmetrical, maintain parallelism between the occlusal and horizontal planes, and position the canine incisal edges at a level that is midway between the left and right corners of the mouth.

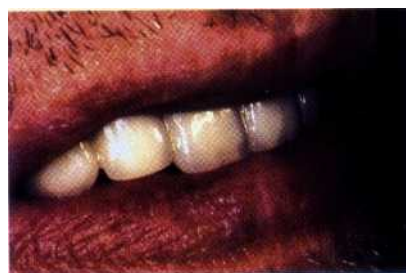

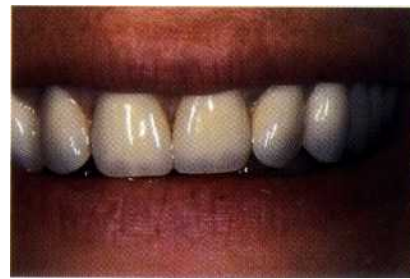Fig. 12-2. The incisal edges should barely contact the lower lip at the wet-dry line when the "F" sound is pronounced. The lower denture must also be in the mouth to properly test the position of the upper anterior teeth. In this picture, the central incisors are positioned correctly antero-posteriorly but are slightly too long because their edges are compressing the lower lip.





*Fig. 12-3. The incisal edges of mandibular canines tend to be located at the level of or slightly superior to the corners of the mouth when the lips are relaxed and barely separated.*

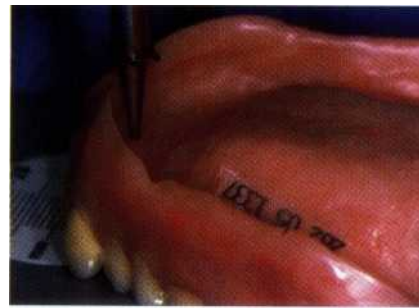

*Fig. 12-4. The edges of the upper anterior teeth follow the contour of the lower lip and fill the space between the upper and lower lips while the mouth is in a smile. This "ideal" situation cannot be created when the patient has a short upper lip (i.e., a "gummy" smile) and a highly convex lower lip (i.e., an excessive overbite). Recreating the patient's original smile using old pictures should satisfy the patient who requests a natural smile.*

- C. If the incisal edges are located higher than (hidden by) the upper lip, the clinician places the pad of the thumb on the incisal edges of the patient's maxillary central incisors with the upper lip at rest to determine the relationship of the incisal edges to the lip.
- D. Incisal edges more than 1 mm shorter than the lip in young or middle-aged females may indicate that the incisors need to be moved inferiorly or anteriorly (or both) to improve their visibility.
- E. **Observe the vertical dimension of occlusion by asking the patient to bring teeth together.**
- E. Ask the patient to smile.
  - i. Determine whether the patient feels that the amount of tooth being displayed is sufficient.
  - ii. Record the position of the corners of the mouth, the curvature of the lower lip, and the muscle tone of the upper lip (Fig. 12-4).

**CLINICAL TIP.** A flaccid or long upper lip compromises maxillary esthetics. This condition is more common in men more than 60 years of age.

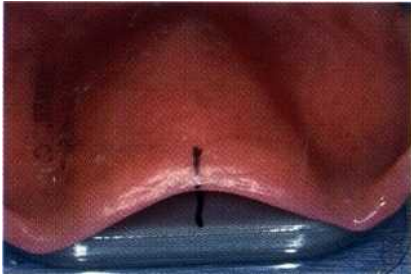
- iii. Note defects in the dental composition (e.g., midline, incisal edges, vertical and anteroposterior inclinations).
- iv. Record the number of posterior teeth displayed and the size of the buccal corridor (the black space between the cheeks and the buccal aspect of the maxillary posterior teeth that is visible when the patient smiles).
- v. Register the orientation of the occlusal plane. A reverse occlusal plane may indicate enlarged tuberosities requiring pre-prosthetic surgery.
- vi. Examine the prosthetic teeth to determine whether they are the proper proportion,



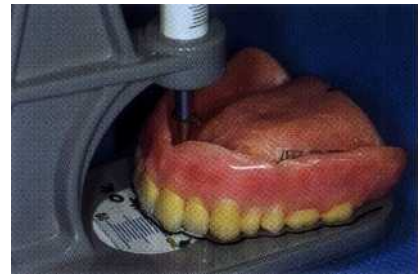*Fig. 12-5. The pointer is positioned in the concavity of the incisal papilla while the posterior teeth contact the base of the instrument. The distances from the central incisors to the incisal papilla in the vertical and the horizontal planes are read on the instrument scales.*

shape, hue, and value with regard to the face.

- vii. Note the amount of artificial gingiva. Excessive display of gingiva requires a larger tooth mold when possible or a detailed reproduction of the marginal gingiva with staining (or both) to prevent the "denture look."
- 8. Remove the maxillary prosthesis from the mouth.
- 9. Evaluate the position of the maxillary anterior denture teeth by using the Alma Gauge. This tool allows the registration of the position of the incisal edges of the central incisors vertically and horizontally with regard to the incisal papilla (Fig. 12-5).
  - A. Place a disposable plastic template over the base to allow the transfer of the buccal outline of all maxillary teeth.
  - B. With a thin, indelible marker, mark the posterior midline of the maxillary denture and the template (Fig. 12-6).

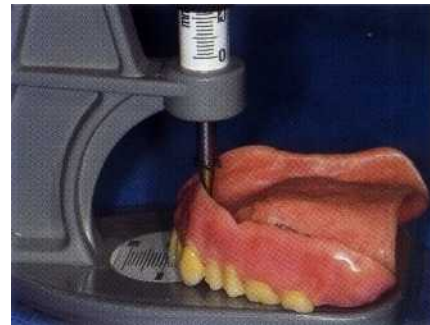


*Fig. 12-6.* To facilitate the setup of the new prosthesis, the palatal midline is transferred onto the template before scribing the outline of the denture.



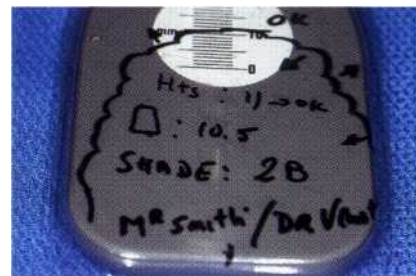*Fig. 12-7.* The buccal contour of the existing denture is marked on the template with an indelible marker. An alcohol wipe removes any ink that contacts the teeth.

- C. Position the denture over the template so that both marks coincide.
- D. Depress the pointer into the anterior depression of the denture created by the reproduction of the incisal papilla contour.
- E. With the pen, transfer the buccal contour to the template (Fig. 12-7).
- E. Immediately remove any ink that may have spilled over the prosthetic teeth with alcohol gauze.
- G. Read the height between the incisal papilla and the maxillary central incisors on the pointer scale and write it on the template (Fig. 12-8).
- H. Write the shade of the existing denture on the template. Indicate modifications of the existing dentures that should be incorporated into the new prosthesis (Fig. 12-9).



*Fig. 12-8.* The vertical distance between the incisal papilla and the edge of the central incisors is read before being written on the template.

**CLINICAL TIP.** The incisal edges of denture teeth that are replacing the central incisors should be 8 to 10 mm anterior to the middle of the incisal papilla. "They are rarely positioned between 6 and 8 mm in the natural dentition." When the papilla has been involved in the resorption process, use the posterior aspect of the papilla and position the incisal edges 12 to 13 mm anterior to this point."



*Fig. 12-9.* The denture shade, the height of the central incisor, and the desired modifications are written on the template, which is sent to the lab with the prescription for the new denture.

A patient may have dentures that appear to be in an Angle Class I relationship. However, if the anteroposterior distance between the incisive papilla and the incisal edges of the central incisors measures less than 6 mm, the patient actually has a Class II jaw relationship. Bringing the maxillary anterior teeth anteriorly to recreate the original lip support may create phonetic and masticatory problems because the mandibular teeth cannot be brought forward. (See the discussion on limitations of denture esthetics in this chapter.) In contrast, a patient who requests more tip support than that given by maxillary central incisors placed 10 mm in

front of the incisal papilla cannot be accommodated without compromising the retention of the maxillary prosthesis and placing excessive forces on the premaxilla.

10. Present the proposed modifications after giving a mirror to the patient.<sup>47</sup> To further illustrate the modifications, add wax or some cured, unbound composite resin to the anterior denture teeth.<sup>48,49</sup> White orthodontic wax can also be placed on the occlusal of

the posterior mandibular teeth to simulate an increase in the vertical dimension of occlusion.<sup>50</sup>

11. Take a Polaroid photograph of the patient's profile and smile.
12. At this stage, present the value of postinsertion treatments. Regular relines not only enhance stability and comfort but also help maintain optimal facial esthetics.
13. Have the items listed in the armamentarium available before proceeding to the next step.

### PRESENTATION OF PROGNOSIS

#### Armamentarium

Basic dental setup. See section on evaluation of existing denture esthetics in this chapter.

Alma Gauge template of the existing maxillary complete denture, including its shade and the height of the central incisor

Frontal and profile Polaroid photographs of patient  
Photographs of the patient's natural teeth

The questionnaire (see Fig. 12-1)

The dentist's list of recommended changes regarding the lip support, the vertical dimension of occlusion, the prosthetic tooth selection, and the dental composition, as well as any implant recommendations that have been made

A list of the expected functional limitations

A list of required preprosthetic treatments

#### Clinical Technique

1. To convince prospective patients that their expectations have been fully understood, repeat their complaints in their own words.
2. Present the procedures that can be done without difficulty and then the procedures requiring preparatory work, describing them visually and verbally in understandable terms. Take great care to explain results that cannot be achieved.
3. Encourage patients to voice their feelings about the consultation by asking open-ended questions.
4. **Let a patient's advocate explain the information presented.**
5. **At this stage, give patients** their three options.
  - A. Accept the treatment plan.
  - B. Refuse some of the preprosthetic treatment, and accept the limitations resulting from this decision.
  - C. Refuse the proposed treatment because goals cannot be met or because they do not understand the proposed plan. Patients who choose this option should be referred to a specialist. To be successful, dentures must be completely accepted by patients because they have functional limitations, affect self-esteem, and are removable.

**CLINICAL TIP.** Be very Suspicious of patients who do not care about the esthetics of their dentures. They may have medical conditions (e.g., dementia, Alzheimer's), life-threatening diseases (e.g., terminal cancer), or mental problems that could interfere with the success of a new prosthesis.<sup>51</sup> Some patients in **these situations** may not want to be **treated and may have been sent to the dentist** by a family member.

6. **Start the tooth selection process when the dentist and patient are** satisfied that the treatment outcomes will be successful.
7. Refrain from disclosing the fee before the prosthetic tooth selection is completed. The delay provides the practitioner with more time to evaluate how difficult it will be to obtain satisfactory results. It also allows more time to establish rapport between the prospective patient and the practitioner.

### TOOTH SELECTION TECHNIQUES

Practitioners must become more involved in the tooth selection process because technicians do not have all the necessary information, such as the patients' preferences, to perform it successfully.<sup>52-54</sup> Moreover, technicians select the teeth after the third appointment, providing no opportunity for patients to approve the shade, size, and shape of the prosthetic teeth before they are ground and set in wax.

**CLINICAL TIP.** The number of reset and remade dentures can be greatly reduced by selecting the denture tooth mold at the first appointment and showing the actual teeth (on the manufacturers' packaging) to the patient at the second appointment.

Tooth selection is especially critical when matching prosthetic teeth to natural teeth.<sup>55</sup> Technicians do not **see the existing dentures**, which limits their ability to match them for patients who want duplicates.

Objectively, the actual look of **the artificial teeth is not as important as the way they are arranged**.<sup>56</sup> However, patients want to be involved in the selection because it is a feature of denture construction that they can partly control.<sup>57</sup> Securing patients' approval of the prosthetic teeth at an appointment other than the dental composition **try-in is beneficial because patients have difficulty separating both entities when they are presented together.**

#### *Shade Selection*

The two most important esthetic features of a prosthetic tooth are anatomic shape and shade layering. Among the anatomic problems noted in some popular brands are the limited thickness and contour of the incisal edges and

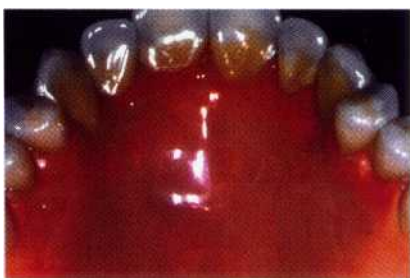
proximal contacts. Maxillary canines often have a flat facial contour" with an unrealistic cusp tip characterized by a lack of lingual cusp bulge. This creates a dark space mesially, especially because the mandibular canine should not touch the denture construction. Unfortunately, shade layering rarely captures the complexity and translucency expected from crown and bridge master technicians.

Denture teeth that do not have a full lingual contour compound the problem because they prevent the transmission of light and the proper resonance with the oral cavity. Furthermore, they do not reproduce the natural lingual contour of teeth, negatively impacting phonetics,<sup>59</sup> increasing the weight of the dentures, and producing occlusal interference by the excessive acrylic shrinkage they create. Reduced lingual contour may also reduce lip support, because the technician can easily place the anterior maxillary artificial teeth too lingually.<sup>60</sup> Reinforced acrylic prosthetic teeth produced by some European manufacturers (Ivoclar, Lactona) have a full lingual contour in their anterior molds and can be purchased one set at a time directly from the manufacturer or its distributor (Fig. 12-10).

**CLINICAL TIP.** Select a prosthetic tooth with a full lingual contour for maximum comfort and esthetics. Evaluate various manufacturers' product lines, and select the posterior anatomic type that is appropriate for the patient.

The shades of a full lingual contour denture tooth brand (Antaris/Postaris, Ivoclar North America) are integrated in a shade system including all porcelain, composite, and porcelain-fused-to-metal products to maximize the esthetics of combined fixed-removable rehabilitations.

Other esthetic problems involve differences in layering, color, and tooth height between anterior and posterior teeth. Brands with these problems must be rejected because the majority of patients display teeth beyond the canines. Brand selection is also controlled by the choice of available posterior teeth. Some of the most esthetic



**Fig. 12-10.** Full, lingually contoured prosthetic teeth provide a more natural contour for the tongue, help reduce the weight of the prosthesis, and improve esthetics because the light is not obstructed by the denture base. The use of less denture base acrylic results in fewer processing errors.

teeth brands may not carry flat posterior teeth or teeth designed for a balanced, lingualized occlusion. Using teeth from different molds is necessary when duplicating a natural smile from a photograph if selective grinding cannot adequately reshape the denture teeth.<sup>58</sup> However, it is rarely necessary to order different shades because manufacturers have often placed added chroma (pigments) in the canines. In addition, setting teeth in different planes or angles or both reflects the light in different directions, giving the illusion of the teeth being of different values, or lightness. Composite stains can also be applied to the facial aspect of the artificial teeth at the try-in appointment for patient approval.

The choice of tooth material is becoming simpler because the abrasion resistance of some newer teeth has greatly improved and the esthetics of the better cross linked acrylic teeth reduces the need for porcelain teeth. The reduced manual dexterity of some older patients should be taken into consideration before selecting a porcelain reconstruction. Furthermore, the availability of porcelain denture teeth in the United States is limited, making the replacement of broken porcelain teeth increasingly difficult. Patients who have worn porcelain teeth successfully are often reluctant to give them up because they are not aware of or refuse to believe that acrylic materials have improved. Composite resin teeth have not proven to be a reasonable compromise between acrylic and porcelain because of poor chemical bonding to the denture base and their relative brittleness.

**CLINICAL TIP.** Dentists should not use the word plastic to describe prosthetic teeth. The terms *acrylic* and *medical resin* have better connotations.

The tooth selection process begins with shade selection. The shade guides used are preselected from manufacturers offering posterior teeth that are appropriate for patients' functional needs. Color-corrected light is recommended for denture construction and is required when crown and fixed bridge work are present.

Shade guides should be organized by hue (color) rather than value (lightness) because the former is a major distinguishing factor among the four patient groups identified in the questionnaire and interview. Mini pull-out shade guides are less confusing (Chromascope, Ivoclar North America) because only the appropriate hue is presented to the patient.<sup>61</sup> Other shade guides could be reorganized accordingly (Fig. 12-11).

**CLINICAL TIP.** The neck of the shade tabs is often markedly darker than the body. Remove the neck to avoid getting a negative reaction from the patient.

1. Patients who want a Hollywood smile want the whitest teeth available, and their choices are restricted to value and opacity. However, these patients



*Fig. 12-11. Initially, using the hue to select the denture tooth shade is more effective than using value, or lightness. Patients can have input on hue, and it can be somewhat modified as appropriate for the patient's ethnicity.*

should be made aware that denture teeth will look whiter when set in a high-chroma denture base.<sup>62</sup>

2. Patients who want the same teeth that are in an existing denture can present a unique problem. Prosthetic tooth color deteriorates in the mouth. In addition, a brand may no longer be available or a specific shade guide may not be part of the dentist's armamentarium. Patients who cannot be accommodated in the dental office must visit the dental laboratory, which carries a more comprehensive shade guide selection.
3. Indifferent patients should be treated as part of the second group if they have an existing denture and as part of the first group if they have never worn dentures.
4. Selection for a natural smile is initially directed by the ethnicity of the patient and modified to match the individual: African Americans tend to have a yellow hue, Asians a grayer hue, and Caucasians red-yellow and gray hues. All ethnic groups should receive a hue complementing their facial skin. Using the mini guides for the appropriate hue, the dentist makes the choice of value and chroma first so that it blends with the skin and is appropriate for the patient's age. The dentist justifies the choice to the patient and the patient advocate, who approves or modifies it. The importance society places on teeth even impacts patients who want natural smiles.

**CLINICAL TIP.** Practitioners should not be surprised or upset when patients select an unrealistic value, even when they have already approved a natural hue and dental composition.

**CLINICAL TIP.** Be aware that shade guides are made differently than the actual denture teeth. Thus they often do not represent the true color and layering of the prosthetic teeth. This is yet another reason that the actual mold should be shown to patients before it is set in wax.

## Mold Selection

**Beginning the Mold Selection.** After choosing the shade, select the mold for the six maxillary anterior teeth.

### Armamentarium

- Basic dental setup. See section on evaluation of existing denture esthetics in this chapter.
- Mold guide or mold chart
- Boley gauge
- Flexible ruler

### Clinical Technique

1. If available, use a model of the natural teeth before extraction.
2. When natural mandibular teeth are present, measure the width of the six anterior teeth and multiply this dimension by 1.3 and 1.38. The width of the maxillary anterior mold is between these two values in a Class I occlusion.<sup>63</sup>
3. Although it is accurate, do not use the traditional technique of transcribing the corners of the mouth to a well-contoured maxillary rim. When this technique is used, patients are not able to approve the prosthetic teeth before the wax try-in. Mold selection should be based on external landmarks.
  - A. The most accurate technique involves using photographs of the patient's original smile, a technique that is especially useful when treating women who are more likely to have a high smile line. Find an external landmark that has not been modified by aging and is readily measured on the photograph and patient (e.g., the center of the pupils,<sup>64</sup> the outer aspect of the ala of the nose, and the inner canthus of the eyes) (Fig. 12-12). Most photographs are not taken perpendicular to the frontal plane. Therefore one of the ala may not be completely visible, or the angle of the photograph may create a distortion (Fig. 12-13). Measuring the distance between the center of the patient's pupils when the patient is seated in the dental chair is difficult without an optometrist's tool; measuring this distance on photographs is also difficult because of flash reflection. The most useful landmark may be the inner canthus of the eyes because they are easy to find and measure on the patient and the photographs; moreover, the measurement is stable from the young adult stage.
  - B. Record the distance between the selected landmarks to the tenth of a millimeter with the thin points of a Boley gauge (Masel Inc.).
  - C. Calculate the magnification factor necessary to obtain the size of the actual teeth by dividing the patient's measurement by the one taken from the photograph.



Fig. 12-12. The external landmark most helpful in establishing the **coefficient of multiplication** of a picture is often the inner canthus of the eye. The level of magnification and the appropriate measuring tool are selected as a function of the picture size. 1, Interpupillary distance; 2, ala of the nose; 3, inner canthus distance.



Fig. 12-13. The full width between the ala cannot be measured accurately because the head is tilted toward the left. This picture shows the norm rather than the exception.

Size of natural teeth =

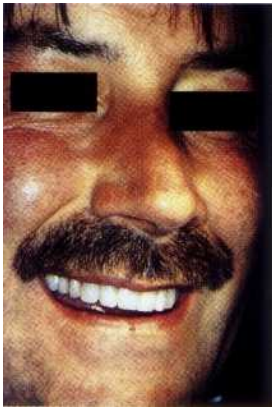$$\frac{\text{Size of photographed teeth} \times \text{Patient's landmark distance}}{\text{Photograph landmark distance}}$$

- D. Use the tips that follow to limit errors.
- i. Select the largest photograph available to reduce the multiplication error.
  - ii. Use magnification tools. For smaller photographs a stereo microscope measuring in hundredths of millimeter may be needed.
  - iii. Measure the width of a group of anterior teeth rather than each individual tooth. Search for a mold using the patient's measurement when a landmark matches a group of anterior teeth (e.g., inner canthus of the eye equaling the width of the six anterior teeth). This technique eliminates the need to use the multiplication technique that was required in the previous step.

- iv. Use the width of the four maxillary incisors on the photograph. In the mouth, maxillary incisors tend to be arranged on a flat surface that is similar to that of a two-dimensional photograph; also, the distal portion of the canine is rarely visible.
4. Select the shape of the natural teeth.
5. Find the possible molds with similar widths on the appropriate section of the selected mold guide.
6. Evaluate the height of the central incisor to finalize the mold selection. Some interpretation usually is required to establish the height of the maxillary central incisor because its neck is rarely visible. When the smiling lip line is high, estimate the percentage of the tooth height covered by the lip. When the lip line is low, use the 4:5 ratio between the width and the height, which is preferred by the majority of patients,<sup>65</sup> the 9:10 ratio, which is the average width to length ratio in the Caucasian population,<sup>66</sup> or the 3 : 5 ratio (also known as the *golden proportion*) .<sup>67</sup> The lack of precision regarding this dimension is not as much of a problem as it may seem, because the upper lip covers at least the same amount of tooth structure as it does in a photograph.

The plethora of techniques used when photographs of natural teeth are not available indicate that no techniques are completely effective. The better ones rely either on a statistical relationship between external facial landmarks and natural teeth or on emotional factors such as duplicating the natural teeth of a same-sex sibling (which is preferable to a daughter or son) .<sup>68</sup> The least desirable methods involve using averages with a wide standard of deviation from the mean<sup>66</sup> when the averages are related to body size<sup>61</sup> or averages based on sex **differences<sup>70</sup> or anatomic structures that are visible on the cast** of the maxillary edentulous ridge (because of variations intrinsic to extraction techniques and the resorption of the premaxilla)." The techniques based on the golden proportion<sup>72</sup> seek to create anatomic relationships that do not necessarily exist in dentate patients.<sup>73</sup> The relationship between the bizygomatic width and the sizes of the maxillary central incisor and six maxillary anterior teeth has been used to develop an instrument called *the Trubyte Tooth Indicator* (Dentsply Trubyte).<sup>74</sup> This instrument tends to produce molds that are larger than natural teeth<sup>71,16</sup> but larger molds **are more likely to be rejected by patients, even when dentists are satisfied** with them .<sup>58,65</sup>

The better mold selection techniques for edentulous patients who do not have photographs and would like to change their existing dentures include measuring the distance between the ala of the nose. This distance is equivalent to the width of the six maxillary anterior teeth on **a curve when multiplied** by 1.31.<sup>77</sup> The usefulness of this technique may be somewhat limited for African Americans and Asians because this ratio was based on a

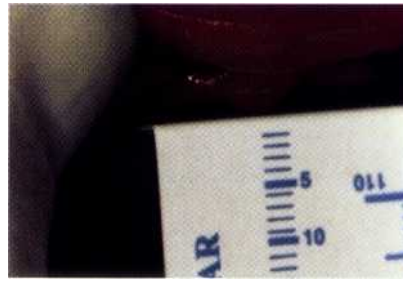

*Fig. 12-14. The anterior teeth typical of a "Hollywood" smile are slightly narrower than the original teeth; the display of the posterior teeth is maximized. This approach tends to please patients interested in this type of smile.*

Caucasian population. One manufacturer used the same distance based on a different ratio to develop a mold selection technique and an instrument called the *Alameter* (Geneva 2000). Another approach is to match the inner canthus distance to the width of the four maxillary anterior teeth (O.P.A. Ruler, Ivoclar North America). Although the scientific basis for this method is lacking, patients frequently approve molds selected by this method because they are somewhat smaller than the natural teeth.

**CLINICAL TIP.** When no objective techniques are available (e.g., casts, photographs, extracted teeth, radiographs) to help in the selection of the artificial teeth, begin by using the patient's evaluation of the existing denture combined with dental clinical judgment.

To determine the tooth shape in the absence of old photographs, patients' preferences should take precedence over any theories based on creating harmony with the outline of their face," their sex, or their personality<sup>79</sup> because these theories have not been validated in patients who have teeth.<sup>80-82</sup> Interestingly, the sexual approach of the dentogenic theory,<sup>83,84</sup> which uses square teeth for men and ovoid teeth for women,<sup>85</sup> seems to be intuitively endorsed by the public. A severely tapered shape tends to be rejected by patients.<sup>65,78</sup> Obviously, the final shape of the denture tooth can be modified by the gingival wax-up.<sup>80,86</sup> Patients requesting a perfect smile are more likely to be satisfied with smaller anterior teeth (because they enhance the presentation of the posterior teeth) and square teeth with little difference in size between the maxillary lateral and the central incisors (Fig. 12-14). This group of patients generally does not bring



*Fig. 12-15. Place the measuring device lightly against the incisal papilla. The ruler should be moved anteriorly to simulate the proper lip support.*

photographs because they are dissatisfied with the esthetics of their original smiles.

**Completing the Mold Selection.** To complete the mold selection, the length of the central incisor must be established.

#### Armamentarium

Basic dental setup. See section on evaluation of existing denture esthetics in this chapter.

Papillometer (Geneva 2000) and the O.P.A. Ruler (Ivoclar North America)

#### Clinical Technique

1. If available, use a model of the natural teeth before extraction.
2. Measure the length from the existing denture.
3. Ask the patient to smile. Evaluate the smile if the length needs to be modified to limit the denture base display or restore a pleasing proportion with the face.
4. Use the phonetics tests to determine whether the maxillary central incisors need to be shortened or lengthened.
5. In the absence of dentures, the minimal height of the central incisor that is needed to prevent the display of artificial gingiva is the space available between the lip at rest and the lip smiling. The tools available to facilitate this measurement are the Papillometer and the [O.P.A. Ruler](#). Both of these instruments support the lip during the readings, making the instruments more accurate than a tongue blade. They are placed under the lip against the incisal papilla (Fig. 12-15); the difference between the lip at rest (Fig. 12-16) and smiling (Fig. 12-17) is the vertical dimension of the smile zone. When this minimal height is more than the height needed to create a tooth in proportion to its width (i.e., more than two thirds of the width), a display of denture base is expected and a custom wax-up and coloring

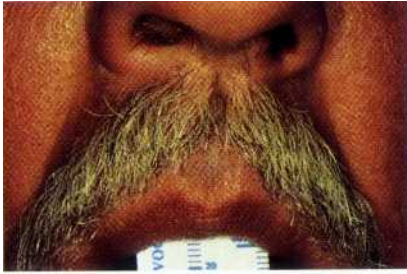


Fig. 12-16. Measurement of the distance between the incisal papilla and the lip at rest. This distance is compared with the vertical reading of the Alma Gauge.

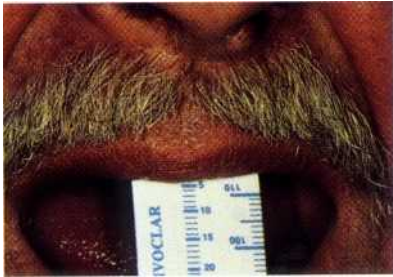

Fig. 12-17. The height difference between the lip at rest and the lip during a smile is the minimal height of the anterior prosthetic teeth that is necessary to minimize gingival display.

of the denture base should be anticipated. For patients with a long or flaccid upper lip, the minimal length is not a significant esthetic factor, and the mold selection is completed using the previous discussed ratios.

Molds for patients who want exact duplications of their current dentures is easily obtained from an impression of the dentures. This technique is also used to obtain molds for indifferent patients.

## FEE PRESENTATION

When making an appointment, patients must be informed that a consultation fee will be assessed at the end of the first appointment. This fee, which should be a true representation of the time spent, is levied regardless of whether the patient decides to proceed with the recommended treatment. A compromise between no compensation (which is too often accepted by practitioners) and a fair one might be to apply this fee toward treatment. Setting a low consultation fee to attract patients should be avoided because the tactic is easily recognized by patients and reduces the likelihood that even satisfied patients will refer other patients.

Patients should not be offered different fees based on the quality of their prosthetic teeth or any necessary customization of the denture base. Patients do not buy teeth or laboratory work; they buy a service that is designed to enhance the quality of their lives. The fee for this service depends on the difficulty in achieving this goal. Thus many fee schedules are possible, but only one is appropriate for a specific patient and dental team. Generalized pricing and material-based fees are unfair for the patient or the dentist and can send an inappropriate message to the patient.

**CLINICAL TIP.** Delay the presentation of treatment fees until after tooth selection in order to maximize the value of the service to the patient and to better evaluate the difficulty of the case.

**CLINICAL TIP.** Complete dentures should be paid in full before being inserted into the mouth to encourage the patient to adjust to the new prosthesis.

Some patients may unconsciously avoid adjusting to a new denture to justify meeting any remaining financial commitments. Furthermore, the exchange of money after approval of the trial denture reminds patients that they are co-responsible for the success of the prostheses.

Patients who have high expectations for functional success in spite of refusing preliminary treatments (e.g., implants) often object to this approach. Dentists must present again the functional limitations that the patient has created by refusing the recommended preparatory work. The number of the postinsertion visits included in the treatment fee should be disclosed at this time. The fee for any additional visits that may be requested must also be presented. Dentists should refuse to give any guarantees about function, although they should guarantee that no fee has to be paid patients who are unsatisfied with the esthetics at the try-in stage.

## DENTAL COMPOSITION

The dental composition varies according to the treatment goals of each patient.

1. For patients who want to duplicate the dental composition of the existing dentures or for indifferent patients with existing dentures, the technician needs two items.
  - A. Alma Gauge template
  - B. Cast of the existing maxillary denture
2. For indifferent patients without prostheses, prescribe a neutral dental composition.
3. For patients interested in receiving a perfect smile, the arrangement should maximize lip support,



especially at the canine area, and the visibility of maxillary posterior teeth. The latter is accomplished by placing the posterior teeth more buccally while respecting the functional limitations imposed by the neutral zone.

4. For the patient who wants a natural smile, the technician needs several photographs.
  - A. Provide the technician with two types of photographs.
    - i. One type of photograph should be of the patient smiling with natural teeth (frontal and lateral views if possible).
    - ii. The other type of photograph should be of the patient wearing the existing dentures (smiling for the frontal view and in occlusion for the lateral view).
  - B. Show the patient any changes in facial features that have occurred since the photograph was taken that may prevent a display of teeth similar to the one portrayed by the natural teeth photograph. Point out changes in lip support and length and any discrepancies in the upper lip coverage between the left and right sides while smiling.
  - C. Compare the curve of the incisal edges to the curve of the lower lip. Symmetry between both of these lines<sup>87, 88</sup> is not always present in natural dentition, especially in older patients, although a straight incisal outline is readily identified as indicative of dentures and should be avoided. Insufficient selective grinding on the incisal edges to simulate occlusal wear compounds this problem.
  - D. Often a space is present between the incisal edges and the lower lip, despite the ideal that dictates they should have light contact. In addition, the maxillary anterior teeth can be partly covered by the lower lip while smiling.
  - E. Although duplicating the natural dentition's lateral incisor edge levels in relation to the central incisor edges is usually accepted by patients, the duplication of the rotations and overlap of the lateral incisors may not result in a "perfect" smile.

**CLINICAL TIP.** Point out the rotation of the maxillary lateral incisors and mandibular anterior teeth on the photograph to the patient. Present them as marks of individuality.

5. Technicians should note the inclination of the maxillary canines, the location and surface of the contact areas, and the size of the buccal corridor to be recreated. In addition, lateral views should not be ignored because they provide valuable information about the buccolingual inclination of the cen-

tral incisors and inclination of the occlusal plane in relation to the Camper plane.

Creating a natural composition without photographs of the natural smile is a difficult challenge. Anatomic difficulties (e.g., a "gummy" smile caused by a severe Class II occlusion and a hyperactive upper lip) may not be apparent at the diagnostic stage. Although patients may accept the duplication of their own dental variations (when they are pointed out in their photographs), patients are less likely to endorse rotations and malpositions without some justification. (Photographs of models and closeups of teeth depicting these natural variations are readily available in popular magazines.) Thus patients who desire natural smiles and do not have photographs require more treatment time. Following are treatment considerations for these patients.

1. Limit the modifications to the maxillary lateral incisors and the mandibular anterior teeth. The variability in tooth shape between the natural maxillary left and right lateral incisors is more common in females than males.<sup>89</sup> Overlap of the lateral incisors should be based on the amount of light desired on the central incisors and canines. To make the central incisors more visible, place the mesial portion of the lateral incisors behind them. The same approach is valid for positioning the maxillary canines. They are less visible when the distal portion of the lateral incisors is placed over them. The neck of the lateral incisor is usually lingual to the neck of both neighboring teeth; bringing it to a more buccal position flattens the arrangement and makes the canines less visible. Placing teeth in different planes and removing excess wax between anterior teeth enhances the illusion of separation."

**CLINICAL TIP.** The natural interdental papilla is not flat; it is convex, which leaves a small space in the anteroposterior dimension on which the light may reflect back, creating the illusion of separation between teeth.

2. Keep the vertical inclinations of the maxillary anterior teeth similar to the ideal inclination until the changes to the lateral incisors have been approved. The exception to this rule is for patients with very tapered faces, especially with osseous Class II relationships. In these patients the facial outline of the canines should follow the outline of the face, which means the canine tips are lingual to the necks.
3. The incisal edge line should follow the contour of the lower lips when the patient is smiling. However, be prepared to assess and modify the vertical height of the incisal edges and the anteroposterior inclination of the central incisors by using the phonetics tests<sup>90</sup> and to prevent contact between the anterior teeth during lateral and lateral-protrusive movements.

4. Do not prescribe the more obvious modifications such as diastema, overlap, or mesiodistal inclination of central incisors; removal of the second premolar; placement of gold restorations; or treatment of gingival recession unless the patient indicates interest after looking at photographs illustrating these modifications. Explain that these imperfections give character to the smile and are not just signs of the aging process.<sup>61</sup>

**CLINICAL TIP.** Do not attempt to explain verbally the irregularities that will be used to enhance a natural look. Use photographs of previously completed cases or of models to communicate with the patient.

### INFORMATION NEEDED BY THE TECHNICIAN TO SET THE PROSTHETIC TEETH

Unless otherwise indicated, the technician will assume that the maximum overbite allowed between the anterior teeth is 2 mm. Be careful to keep the border of the anterior flange of the maxillary record base thin to avoid displacing the superior aspect of lip upward and forward. Use the contouring of the wax rims to determine the overjet. Dentists should know in which arch the technician first sets the anterior teeth. If the technician sets the mandibular arch first (European approach), practitioners should begin by establishing the mandibular rim at the corners of the mouth with the patient at rest, then adjust the height of the maxillary rim to establish the vertical dimension of occlusion. If the technician prefers to set the maxillary anterior teeth first, the dentist should first adjust the maxillary rim to reflect the ideal length of the anterior teeth before modifying the mandibular rim for the vertical dimension of occlusion. In either situation the maxillary rim should reflect the lip support desired (even when the Alma Gauge has already provided this information), and the facial midline should be marked.

**CLINICAL TIP.** The patient should stand up when the practitioner is scribing the midline on the rim. This prevents the distortion that may be created when the patient is approached from the side.

Mark the vertical plane by scribing it on the wax rim. If using a face-bow,<sup>91</sup> the reference plane of choice should be either the Camper plane or the horizontal plane, with the patient standing with the head erect. Inform the technician of the characteristics of the plane used. Use of the Frankfort plane can lead to major errors in the anteroposterior inclination of the anterior teeth used by an uninformed technician.<sup>92</sup> Another esthetic problem that

may be encountered when using a face-bow is the difference in height of the patient's ears, which gives an inclination to the maxillary cast. Using the Camper plane with an esthetic bow (Universal Face-bow, Ivoclar North America) overcomes these limitations. The technician must have the following information:

1. The type of smile the patient desires (e.g., natural, Hollywood)
2. The prosthetic teeth approved by the patient
3. The Polaroid photographs, which should have the desired modifications written or drawn on them (and the photograph of the natural smile when appropriate)
4. The Alma Gauge template with the desired modifications written on it; allows the technician to create the proper lip support and the correct vertical placement of the maxillary central incisors

Some practitioners personally set the six maxillary anterior teeth in the wax before sending the mounted cast to the laboratory.<sup>93</sup> Although this approach solves many problems and improves dentist-patient interactions, it also has some limitations. Besides the obvious skills it requires, the extra time spent in the dentist's office may result in a higher fee, which can be an obstacle for some patients.

The **record bases** must provide good stability and retention. If they do not, the approval phase is compromised. A processed base fabricated on a duplicated master cast is required when traditional techniques for the record base are not effective. The wax used to set the teeth should be very rigid to allow for evaluation of the dentures at home (Set-Up Wax, Dentsply Inc.; Set-Up Wax, Genova 2000).

### WAX TRY-IN

This scope of this chapter is limited to the patient's approval of the setup.

#### Armamentarium

Basic dental setup. See the section on evaluation of existing denture esthetics in this chapter.

Wall-mounted mirror

Bunsen burner

No. 7 wax spatula

Patient's advocate

#### Clinical Technique

1. Remind patients of the mutually accepted goals before placing the setup intraorally, especially when major changes between the existing dentures and the new ones were prescribed.
2. Acknowledge the mental and physical efforts that will be needed to adjust to the changes.

3. Reassure patients that they should not feel pressured to accept the setup, and no payment is due until they are satisfied with the esthetics. This approach enhances the quality of the patient-dentist interaction.
4. The dentist must be satisfied with the trial dentures before presenting them to patients. In particular, proper lip support and vertical dimension of occlusion must be evident.<sup>94</sup> Pay special attention to the anterior border of the maxillary denture. It should be thin to prevent distortion of the upper lip.<sup>95</sup>
5. Ensure that the wax-up is sufficiently complete to allow for effective inspection. Details such as rugae and opened embrasure space must be present in the wax-up for patients' approval.

**CLINICAL TIP.** Do not give patients a hand-held mirror because this encourages them to examine the dentures too closely. Instead, place patients in front of a well-lit, large mirror that is on a wall and has a small table in front of it. This encourages a more overall evaluation of the denture esthetics.

6. Provide a chair and a glass of iced water for patients so that they can be seated and swallow any excess saliva. These steps help patients devote the necessary time to the evaluation process.
7. Inform patients that they are being left alone to give them a chance to evaluate the setup.
8. When invited back in the room, stand behind patients and refrain from speaking.

**CLINICAL TIP.** Wait for the patient's comments.

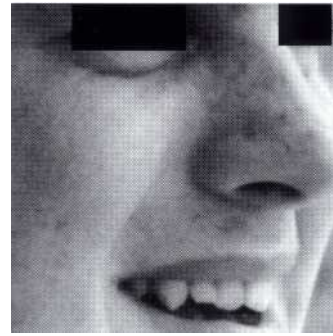
9. Address the concerns immediately if possible.
10. When patients and practitioners are satisfied, invite the advocate to join the discussion. Try to avoid the involvement of the advocate before patients have approved the setup because the interaction between patients and advocates can blur the responsibility for the treatment and change patients' goals.
11. Select the shade of the denture base by matching it to the color of the ridges. Show the chosen shade to patients for their approval.
12. When all parties have agreed on the setup, ask patients to take the trial dentures home for family approvals'

**CLINICAL TIP.** Many patients do not want to proceed with this step because they have fully accepted the dentures, they do not want to challenge their dentist, or they wish to avoid an additional office visit. However, it is critical to have all the family members see and approve the dentures when extensive modifications have been made. The family usually provides the emotional support needed during the adaptation phase.

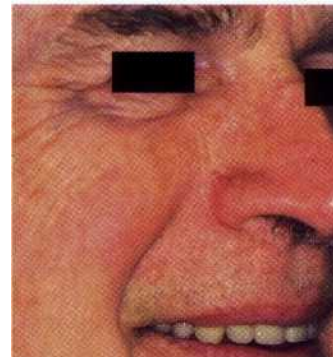
13. Consider the wax try-in phase complete when patients have returned the trial dentures and paid the entire fee.

### CUSTOM LABORATORY SERVICES

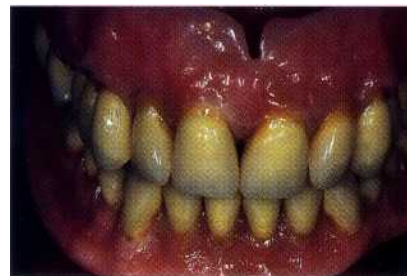Custom laboratory services include the wax-up and tinting of the denture base and the selective grinding and tinting of the prosthetic teeth. Effective customization re-



*Fig. 12-18. Old black and white photograph of a patient with natural teeth.*



*Fig. 12-19. Photograph of the patient in Figure 12-18 after oral rehabilitation.*



*Fig. 12-20. An enhanced wax-up of the denture base recreates the gingival contour of natural teeth. Custom tinting the denture base further improves esthetics and greatly increases the value of the services provided.*

sulting in a natural denture base requires a highly skilled technician. Custom bases for Caucasians require a detailed gingival wax-up because tints alone do not give the illusion of a natural contour. The opposite is true for the darker tints used in bases for African-Americans; in these bases a detailed wax-up would look excessive when combined with the darker tint. A high-quality photograph of the gingiva and the facial skin helps the technician by showing the intensity of the skin chroma. Customized services are not used for patients requesting an exact duplication of their current dentures and are rarely used for indifferent patients or those who would like a Hollywood smile. The value of using these customizations has been questioned for patients with a low lip line. However, patients do frequently remove the prostheses from their mouths—the positive mental effect of seeing a beautifully finished prosthesis cannot be ignored.

The customization of denture teeth can be divided in two stages: (1) customization that takes place before placing the teeth in wax and (2) customization that takes place after processing. The first customization should be made during the grinding of the proximal surfaces and tinting of the proximal surfaces and neck of the teeth. The second customization is the selective adjustment and tinting of the incisal edges and fossae to increase the appearance of separation between the teeth. Customized coloring of denture teeth should be performed with a composite resin system that has a high-intensity light and coupling agent for longevity (Targis, Ivoclar North America). A thick coat of clear resin should be placed over the stains for protection and proper esthetics<sup>96</sup> (Figs. 12-18 to 12-20).

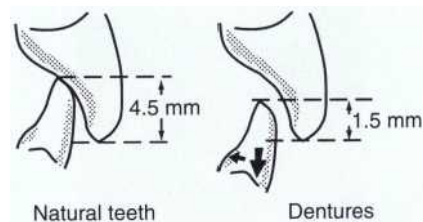
## LIMITATIONS OF DENTURE ESTHETICS

Tooth placement, occlusal embrasures, and lip support can be readily incorporated into denture construction. These factors can cause some patients to have unrealistic expectations about tooth placement in relation to improvements in muscle support. They seem unaware of the predicted and inevitable decreases in chewing function. Regardless of these unrealistic expectations, it is true that esthetics in dentures may be jeopardized by the limited overbite required for a balanced occlusion and the prevention of contact between anterior teeth during lateral and lateral-protrusive movements. The average central incisor overbite in Class I patients (with teeth) who have not received orthodontic treatment is 4.25 millimeters, with a range of 3 to 6 mm,<sup>97</sup> whereas the proper amount of denture overbite taught in dental schools is 1.5 to 2 mm (Fig. 12-21). To reduce the impact of this situation, consider the following:

1. Inform patients with a long or flaccid upper lip about the esthetic effects of this condition.
2. Restore the vertical dimension of occlusion (OVD) to improve facial appearance and reduce the

amount of vertical overlap. Be aware that the traditional physiologic rest position technique to establish OVD may not maximize the restoration of the vertical dimension of occlusion.<sup>98</sup>

3. The incisal edges of the mandibular anterior teeth and the cusp tips of the mandibular canines should remain at or slightly below the corners of the mouth when the mandible is at rest and the perioral musculature is relaxed. It may be difficult to achieve this goal when a maxillary denture has been opposing a reduced number of mandibular teeth (a condition known as *combination syndrome*)<sup>28,99</sup> because the latter have often extruded too far to be corrected by simple coronoplasty. This problem can be resolved with fixed prosthetic restorations. Crown lengthening may have to precede the fixed prosthetic phase. Orthognathic surgery is advantageous in the most severe cases.
4. The mandibular canines can be inferiorly repositioned as much as 2 mm below the corners of the mouth if the upper lip is not long. However, lowering the mandibular anterior teeth increases the angle of the occlusal plane, which may cause the dentures to become unstable. Limit the angle of the occlusal plane to a maximum of +10 degrees compared to the Camper plane.<sup>100</sup>
5. Attempt to increase the overjet to further reduce the incisal angle. This approach has some limitations because it may compromise lip support and proper phonetics.
6. Use steep posterior teeth or increase the curves of compensation or both (Spee and Wilson). To prevent denture instability, establish the occlusion on casts that have been mounted with a face-bow on a programmed semiaadjustable articulator.<sup>28</sup> Create the curve of Spee by raising the distal region of the most posterior teeth, not by lowering the other posterior teeth below the plane of occlusion. The latter



**Fig. 12-21.** The lower anterior teeth must not be set or left extruded. Otherwise, the display of the upper teeth is compromised—no anterior overbite should be present. (The anterior maxillary incisal edges must not contact the anterior mandibular incisal edges.) An anterior overbite creates lateral and protrusive interferences that compromise the stability of the prostheses and create excessive pressure on the premaxilla, leading to accelerated bone resorption.

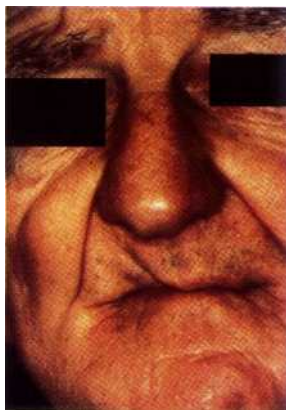approach compromises proper esthetics by placing the cusp tips of the maxillary premolars below the canine edge.

A significant portion of the edentulous population is older, meaning that advanced bone resorption and loss of muscle tone are the rule rather than the exception.<sup>93,94</sup> The recreation of a broad, large smile is difficult because of the commonly seen long or flaccid upper lip. Attempts to display maxillary teeth results in a grotesque smile (Fig. 12-22). Instead, mandibular anterior teeth should be the primary focus when attempting to create a natural smile. Rotations and lingual and buccal inclinations may be required to achieve a convincing result.<sup>101,102</sup> Using selective grinding and tints simulates incisal wear.

Distortion of the mouth corners while smiling and upper lip defects are more frequently encountered in older patients.<sup>103</sup> Distortion of the mouth corners requires raising the incisal edge of the maxillary anterior teeth to even out the amount of tooth displayed between both sides of the mouth. Setting the teeth facing the localized upper lip defect more buccally, which increases the lip support, may solve problems resulting from upper lip defects (Figs. 12-23 and 12-24).



Fig. 12-22- A long, flaccid upper lip is common in older patients, especially men. Lowering the occlusal plane results in a grotesque appearance.



Note the upper lip defect that is visible with the existing denture.

Setting the prosthetic teeth in the previous position of the natural teeth is difficult in the presence of a highly resorbed mandibular ridge.<sup>104,105</sup> Esthetic and phonetic problems can result from setting mandibular anterior teeth lingual to their natural counterparts in an attempt to limit the negative impact of the mentalis muscle on denture stability<sup>106</sup> (Fig. 12-25).

To verify the lingual position of the mandibular anterior teeth, transfer the location of the mental nerve on the denture base of the existing mandibular dentures. Frequently the canine or mesial half of the first premolar is above the nerve instead of between the first and the second premolars. The lack of lower lip support makes it less visible, and the upper lip tends to roll lingually at rest, thus compromising the esthetics of both lips. Another problem that can result from this anatomic condition is the inability to properly phonate sibilant sounds because the mandibular anterior teeth are lingual rather than fac-

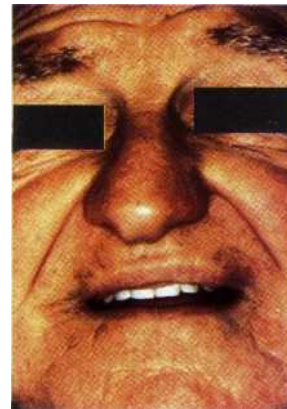

Fig. 12-24. The lateral and central incisors facing the defect have been moved more buccally. The lip defect is not visible.

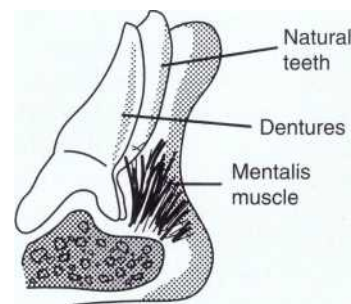


Fig. 12-25. As mandibular resorption increases, the mandibular anterior teeth must be set more lingually to reduce the denture instability caused by the mentalis muscle. Lower lip support is compromised. Upper lip support may also have to be reduced because the maxillary anterior teeth have been positioned lingually to avoid phonation problems.

ing the maxillary teeth. If the patient's tongue fails to adjust to the situation, moving the acrylic in a position that is lingual to the maxillary anterior teeth can sometimes be helpful.

The duplication of an existing denture that was not designed to properly preserve bone presents an ethical dilemma and is a challenge for any practitioner to explain to a patient. A classic example demonstrates this situation: a patient with a large maxilla and normal mandible had teeth that were set in a Class I relationship. Ten years later, the patient arrives in a dentist's office with excessive mandibular anterior bone resorption resulting from the contact of the anterior teeth. The patient's mandibular anterior teeth must be set lingually relative to the original setup to prevent displacement of the mandibular denture by the mentalis muscle. Patients with this type of dental arrangement often prefer an anterior chewing pattern. Dentists should assume that such patients will not accept the necessary overjet needed to preserve premaxillary bone. Only individuals who accept mandibular implant placement should be treated. When the overbite is not too steep, an alternative is to relin the dentures and relieve the incisal edges of the mandibular anterior teeth.

Recreating a smile from photographs is difficult because fewer choices of large maxillary anterior teeth molds are available today than in previous years.<sup>11</sup> This problem causes the premolars to be more visible than the original ones and narrow the smile width.<sup>12</sup> Another major obstacle to advanced esthetic modifications in denture construction is the lack of qualified technicians. The reduced number of qualified dental teams is one reason the role of denturism is expanding in the United States.<sup>13</sup> The decline in the number of edentulous patients during the 1970s, the poor compensation of technicians, the difficulties dentists have communicating with patients (which has resulted in unacceptable numbers of remade dentures), and the fact that technicians are not able to work directly with their patients are factors that have resulted in a shortage of highly skilled complete denture technicians. Dentists must be prepared to compensate handsomely for the privilege of working with the few technicians who can interpret the information discussed. The time saved as a result of the clinical expertise provided by these technicians is well worth their fee. Furthermore, an interest in esthetics is reaching a larger number of edentulous patients. They are ready to pay a fair fee if they are convinced they will receive a superior service.

## CONCLUSION

Edentulous patients have frequently been treated as second-class patients because they can be difficult to satisfy, because the financial rewards can be limited, and most

importantly because the training the dentists receive is often focused on function, which is unrealistic for some patients.<sup>14</sup> With the advent of implant dentistry, the functional limitations have been eliminated for healthy patients. Proper esthetics helps patients to adjust to the functional limitations of their prostheses.<sup>11</sup> Patients must be allowed to participate in the design of their smile if they are to form a strong patient-dentist relationship.<sup>15</sup>

As mentioned in the chapter, patients who are interested in having natural smiles should provide photographs of their own teeth. Regardless, dentists must consider the age of the patients when the photographs were taken so that, for example, an 80-year-old patient is not given a 20-year-old smile.<sup>16</sup> In addition, dentists must be aware that family members may react negatively to extensive esthetic modifications. A long and thorough approval stage for the trial dentures can control this dilemma.

The practice of advanced denture esthetics is ideal for dentists who enjoy the challenge of creating a positive relationship with patients who initially have a negative outlook on planned treatment and do not appreciate the dental efforts. Practitioners must have the humility to accept the esthetic decisions of their patients (as long as they do not compromise bone preservation); practitioners can help restore or break down their patients' self-image. Dentists must understand that the difficulties involved with fabricating prostheses are minor in comparison with the trials that patients must endure to make their prostheses successful. Finally, dentists need the moral fortitude to accept failure as they explore the possibilities of the art of complete dentures.

## REFERENCES

1. Koper A: Human factors in prosthodontics patients, *J Prosthet Dent* 30:678, 1973.
2. Pilling LF: Emotional aspects of prosthodontics patients, *J Prosthet Dent* 30:514, 1973.
3. Bloomberg S, Lindquist LW: Psychological reactions to edentulousness and treatment with jawbone-anchored bridges, *J Prosthet Dent* 68:251, 1983.
4. Friedman N, Landesman H, Wexler M: The influence of fear, anxiety and depression on the patient's adaptive response to complete dentures (part I), *J Prosthet Dent* 58:687, 1987.
5. US Public Health Service, National Institute of Dental Research: *Oral health of United States adults: national findings*, NIH Publications 87-2868, Washington, DC, 1987, US Government Printing Office.
6. Burt BA: Epidemiology of dental diseases in the elderly, *Clin Geriat Med* 8:447, 1992.
7. Berg E: The influence of some anamnestic, demographic and clinical variables on patient acceptance of new complete dentures, *Acta Odont Scand* 42:119, 1984.

8. Jonkman RE, Van Waas MA, Kalk W: Satisfaction with complete immediate dentures and complete immediate overdentures. A one year survey, *J Oral Rehab* 22:791, 1995.
9. Palmquist S, Soderfeldt B; Arnbjerg D: Subjective need for implant dentistry in a Swedish population aged 45-69 years, *Clin Oral Implants Res* 2:99, 1991.
10. Turner W: Personal communication, 1994.
11. Lassila V, Holmbund I, Koivumaa KK: Biting force and its correlations in different denture types, *Acta Odontol Stand* 43:127, 1985.
12. Gibbs CH et al: Limits of human bite strength, *J Prosthet Dent* 56:226, 1986.
13. Survey of general dentists and prosthodontists regarding the conversion rate from conventional complete denture to implant supported overdenture, *Dental Products Report*, May 1996.
14. de Grandmont P et al: Within subject comparisons of implant supported mandibular prostheses: psychometric evaluation, *J Dent Res* 73:1096, 1994.
15. Zarb GA, Schmitt A: The edentulous predicament. 1: a prospective study of the effectiveness of implant-supported fixed prostheses, *J Am Dent Assoc* 127:59, 1996.
16. Berg E, Johnsen TB, Ingebretsen R: Patients motives and fulfillment of motives in renewal of complete dentures, *Acta Odontol Stand* 42:235, 1984.
17. Ament P, Ament A: Body image in dentistry, *J Prosthet Dent* 24:362, 1970.
18. Kalk W de Baat C: Patient's complains and satisfaction 5 years after complete denture treatment, *Community Dent Oral Epidemiol* 18:27, 1990.
19. Sheets CG: Modern dentistry and the esthetically aware patient, *J Am Dent Assoc* 1987. Spec No 103E.
20. Taylor TD et al: Prosthodontics survey (part 1): removable prosthodontics laboratory survey, *J Prosthet Dent* 52:598, 1984.
21. Venot MG, Armenio C, Jasenuvicius R: The laboratory prescription in complete denture, *J Dent Technol* 13(7):28, 1996.
22. Seiffert I et al: Evaluation of psychologic factors in geriatrics patients, *J Prosthet Dent* 12:516, 1962.
23. Hirsch B, Levin B, Tiber N: Effects of dentist authoritarianism on patient evaluation of dentures, *J Prosthet Dent* 30:745, 1973.
24. Chamberlain BB, Razzoog ME, Robinson E: Quality of care: compared perceptions of patient and prosthodontist, *J Prosthet Dent* 52:744, 1984.
25. Hirsch B, Levin B, Tiber N: Effects of patient involvement and esthetic preference on denture acceptance, *J Prosthet Dent* 28:127, 1972.
26. Landa LS: Practical guidelines for complete denture esthetics, *Dent Clin North Am* 21:285, 1977.
27. Hock DA: Qualitative and quantitative guides to the selection and arrangement of the maxillary anterior teeth, *J Prosthodont* 2:106, 1992.
28. Zarb GA et al: *Boucher's* prosthodontic treatment for edentulous patients, ed 11, St Louis, 1997, Mosby.
29. Nassif J: A self administered questionnaire-an aid in managing complete denture patients, *J Prosthet Dent* 40:363, 1978.
30. Levin B, Landesman HM: A practical questionnaire for predicting denture success or failure, *J Prosthet Dent* 35:124, 1976.
31. Tau S, Lowental U: Some personality determinants of denture preference, *J Prosthet Dent* 44:10, 1980.
32. Linde C, Isacson G, Jonsson BG: Outcome of 6-week treatment with transcutaneous electric nerve stimulation compared with splint on symptomatic temporomandibular joint disk displacement without reduction, *Acta Odontol Stand* 53:92, 1995.
33. Lysell L et al: Rating the preventive indication for mandibular third-molar surgery. The appropriateness of the visual analogue scale, *Acta Odontol Stand* 53:60, 1995.
34. Smedberg JI et al: A clinical and radiological two-year follow-up study of maxillary overdentures on osseointegrated implants, *Clin Oral Implants Res* 4:39, 1993.
35. McNamara JA, Brust EW, Riolo ML: Soft tissue evaluation of individuals with an ideal occlusion and a well-balanced face. In McNamara Jr, JA, editor: *Esthetics and the treatment of facial form*, Ann Arbor, Mich, 1992, University of Michigan.
36. Pound ES: Let /s/ be your guide, *J Prosthet Dent* 38:482, 1977.
37. Silverman MM: Vertical dimension must not be increased, *J Prosthet Dent* 2:188, 1952.
38. Lundquist DO, Luther WW: Occlusal plane determination, *J Prosthet Dent* 23:489, 1970.
39. Wright CR: Evaluation of the factors necessary to develop stability in mandibular dentures, *J Prosthet Dent* 16:414, 1966.
40. Harper RN: The incisive papilla, *J Dent Res* 27:661, 1948.
41. Martone AL: The phenomenon of function in complete denture prosthodontics. Clinical application of concepts of functional anatomy and speech science to complete denture prosthodontics (part VII). Recording phases of denture construction, *J Prosthet Dent* **13:211, 1963**.
42. Murray CG: Anterior tooth positions in prosthodontics, *Aust Dent J* 22:113, 1977.
43. Mersel A, Ehrlich J: Connection between incisive papilla, central incisor and rugae canine, *Quint Int* 12:1327, 1981.
44. McGee GF: Tooth placement and base contour in denture construction, *J Prosthet Dent* 10:561, 1960.
45. Watt MD: *Designing complete dentures*, Philadelphia, 1976, WB Saunders.
46. Ehrlich J, Gazit E: Relationship of the maxillary central incisors and canines to the incisive papilla, *J Oral Rehab* 2:309, 1975.

47. Manji I: Boxed commentary, *Dent Practice Finance* 1:27, 1998.
48. Small BW: How communication can affect aesthetic outcome, *Pract Periodontics Aesthet Dent* 4:11, 1992.
49. Sprigg RH: Diagnosis using the patient's existing dentures, *J Prosthet Dent* 49:152, 1983.
50. Akerly WB: Recording jaw relationship in edentulous patients, *Dent Clin North Am* 40:53, 1996.
51. Brewer A: Selection of denture teeth for esthetics and function, *J Prosthet Dent* 23:368, 1970.
52. Shelley JJ, Plummet KD: Removable prosthodontics laboratory survey, *J Prosthet Dent* 67:567, 1992.
53. Basket RM, Ogden AR, Ralph JP: Complete denture prescription-an audit of performance, *Br Dent J* 174:278, 1993.
54. St Arnault FD, Allen DL: Dental laboratory work authorization forms: a survey, *J Prosthet Dent* 64:497, 1990.
55. Shotwell JL, Johnston WJ, Swarts RG: Color comparisons of denture teeth and shade guides, *J Prosthet Dent* 56:31, 1986.
56. Nelson AA: The esthetic triangle in the arrangement of teeth, *Nod Dent Assn* 9:392, 1922.
57. Krajickek DD: Natural appearance for the individual denture patient, *J Prosthet Dent* 10:205, 1960.
58. Hardy IR: Ways and means of avoiding obvious artificiality, *J Am Dent Assoc* 26:1289, 1939.
59. Gysi A: **Practical application** of research results in denture construction, *J Am Dent Assoc* 16:199, 1929.
60. Esposito SL: Esthetics for the denture patient, *J Prosthet Dent* 44:608, 1980.
61. Lloyd PM: Complete denture therapy for the geriatric patient, *Dent Clin North Am* 40:239, 1986.
62. Millstein PL, Harlan J, Nathanson D: Color effect of denture base on denture tooth materials, *J Oral Rehab* 15:173, 1988.
63. McArthur DR: Determining approximate size of maxillary anterior artificial teeth when mandibular anterior teeth are present (part 1): size relationship, *J Prosthet Dent* 53:216, 1985.
64. Wehner PJ, Hickey JC, Boucher CO: Selection of artificial teeth, *J Prosthet Dent* 18:222, 1967.
65. Brisman AS: Esthetics: a comparison of dentist's and patient's concepts, *J Am Dent Assoc* 100:345, 1980.
66. Shillinburg HT, Kaplan MJ, Grace CS: Tooth dimension-a comparative study, *J South Calif Dent Assoc* 40:830, 1972.
67. Ash M: *Wheeler's Dental anatomy, physiology, and occlusion*, ed 7, 1992, WB Saunders.
68. Heimansohn H: A prosthetic donor system from daughter to mother, *Dental Dig*, December, p 511, 1968.
69. Gant SM, Lewis AB, Kerewsky RS: The magnitude of the relationship between tooth size and body size, *Arch Oral Biol* 13:129, 1968.
70. Gam SM, Lewis AB, Kerewsky RS: Sex difference in tooth shape, *J Dent Res* 46:1470, 1967.
71. Strack R: *Handbook of complete denture prosthetics*, Liechtenstein, 1994, Ivoclar.
72. Levin EI: Dental esthetics and the golden proportion, *J Prosthet Dent* 40:244, 1978.
73. Mitchener RW: Selection of the width of the maxillary six anteriors, *Ill Dent J* 1:38, 1990.
74. House MM, Loop JL: *Form and color harmony in the dental art*, Whittier, Calif, 1939, Private printing.
75. LaVere AM et al: Denture tooth selection: an analysis of the natural maxillary central incisor compared to the length and width of the face (part I), *J Prosthet Dent* 67:661, 1992.
76. LaVere AM et al: Denture tooth selection: an analysis of the natural maxillary central incisor compared to the length and width of the face (part II), *J Prosthet Dent* 67:810, 1992.
77. Hoffman Jr, W Bomberg TJ, Hatch RA: The interalar width as a guide in denture construction, *J Prosthet Dent* 55:219, 1986.
78. Williams JL: A new classification of human tooth forms, with special reference to a new system of artificial teeth, *Dent Cosmos* 56:627, 1914.
79. Frush JP, Fisher RD: How dentogenic restorations interpret the personality factor, *J Prosthet Dent* 6:441, 1956.
80. Seluk LW Brodbelt HW, Walker GF: A biometric comparison of face shape with denture tooth form, *J Oral Rehab* 14:139, 1987.
81. Mavroskoufis F, Ritchie, GM: The face form as a guide for the selection of maxillary central incisors, *J Prosthet Dent* 43:501, 1980.
82. Tjan AH, Miller GD, The JG: some esthetic factors in a smile, *J Prosthet Dent* 51:24, 1984.
83. Frush JP, Fisher RD: How dentogenic restorations interpret the sex factor, *J Prosthet Dent* 6:160, 1956.
84. Frush JP, Fisher RD: Dentogenics: its practical application, *J Prosthet Dent* 9:94, 1959.
85. Marunick MT, Chamberlain BB, Robinson CA: Denture aesthetics: an evaluation of layman's preferences, *J Oral Rehab* 10:339, 1983.
86. French FA: The selection and arrangement of the anterior teeth in prosthetic dentures, *J Prosthet Dent* 587, 1951.
87. Pound E: Applying harmony in selecting and arranging teeth, *Dent Clin North Am* 6:241, 1962.
88. Frush JP, Fisher RD: Introduction to dentogenic restorations, *J Prosthet Dent* 5:586, 1955.
89. Gam SM, Lewis AB, Kerewsky RS: Sex difference in tooth shape, *J Dent Res* 46:1470, 1967.
90. Pound E: Utilizing speech to simplify a personalized denture service, *J Prosthet Dent* 24:586, 1970.
91. Mendez AJ: Application of prosthodontics techniques in private practice, *J Prosthet Dent* 54:730, 1985.
92. Wilkie ND: The anterior point of reference, *J Prosthet Dent* 41:488, 1979.
93. Vig RG: The denture look, *J Prosthet Dent* 11:9, 1961.



94. Tautin FS: Denture esthetics is more than tooth selection, *J Prosthet Dent* 40:127, 1978.
95. Maritato FR, Douglas JR: A positive guide to anterior tooth placement, *J Prosthet Dent* 14:848, 1964.
96. Hardy IR: Problem solving in denture esthetics, *Dent Clin North Am* 24:305, 1960.
97. McHorris WH: Importance of the anterior teeth, *J Gnathology* 1(1):34, 1982.
98. Kois JC, Phillips, KM: Occlusal vertical dimension: alteration concerns, *Compendium Cont Dent Edu* 18(12):1169, 1997.
99. The glossary of prosthodontic terms, ed 7, *J Prosthet Dent* (suppl), St Louis, Mosby.
100. Karkazis HC, Polyzois GL: A study of the occlusal plane orientation in complete denture construction, *J Oral Rehab* 14:399, 1987.
101. Vig RG, Brundo GC: The kinetics of anterior tooth display, *J Prosthet Dent* 39:502, 1978.
102. Cade RE: The role of the mandibular teeth in complete denture esthetics, *J Prosthet Dent* 42:368, 1976.
103. Lombardi RE: Method for classification of errors in dental esthetics, *J Prosthet Dent* 32:501, 1973.
104. Hooper BL: Prosthodontia as a fine art, *Digest* 767, 1927.
105. Pound E: The lost arts in the fallacy of the ridges, *J Prosthet Dent* 4:6, 1954.
106. Sharry JJ: *Complete denture prosthodontics*, ed 2, New York, 1968, McGraw Hill.
107. Baer ML, Reynolds MA: Comparison of anterior tooth width in natural and artificial dentitions, *J Prosthodont* 66:84, 1992.
108. LaVere AM et al: Denture tooth selection: size matching of natural anterior tooth width with artificial denture teeth, *J Prosthet Dent* 67:661, 1992.
109. Survey of the time spent by general dentists and prosthodontists making complete dentures, *Dental Products Report*, May 1996.
110. Davis EL et al.: Expectations and satisfactions of denture patients, *J Prosthet Dent* 55:59, 1986.
111. Culpepper WD, Mitchell PS, Blass MS: Esthetic factors in anterior tooth restoration, *J Prosthet Dent* 30:576, 1973.
112. Hirsch B, Levin B, Tiber N: Effects of patient involvement and esthetic preference on denture acceptance, *J Prosthet Dent* 30:127, 1972.
113. Lammie GA: Aging changes and the complete denture, *J Prosthet Dent* 6:450, 1956.



# BLEACHING AND RELATED AGENTS

Barry G. Dale and Kenneth W Aschheim

**E**STHETIC IMPROVEMENT of acceptably shaped but discolored teeth by chemical means is highly desirable because of its conservative nature. The chemical agents and specific procedures used depend on a number of factors, including the type, intensity, and location of the discoloration.

## HISTORY

A professional response to the unrelenting quest for whiter teeth dates back at least 2000 years. First century Roman physicians maintained that brushing teeth with urine, particularly Portuguese urine, whitened teeth.<sup>1</sup> In the 1300' the most requested dental service, other than extraction, was tooth whitening. After abrading the enamel with coarse metal files, barber-surgeons would apply "aquafor-tis," a nitric acid solution, to whiten the teeth. This common practice continued into the eighteenth century.<sup>1</sup>

In the late 1800' the combination of hydrogen peroxide, ether, and electricity was reported to be an effective method of lightening teeth.<sup>2</sup> Around 1916 hydrochloric acid was used successfully to treat "Colorado brown stain" (endemic fluorosis).<sup>3</sup> In 1937 the combination of five parts 100% hydrogen peroxide with one part ether and heat was reported as a treatment for this same type of discoloration.<sup>1</sup> Two years later, successful bleaching of fluorosis staining using 30% hydrogen peroxide, ether, and heat was described.<sup>1</sup> In 1966 the use of hydrochloric acid combined with hydrogen peroxide was advocated.<sup>6</sup> Not until 1970 was hydrogen peroxide demonstrated to be effective for the treatment of dentinal discoloration as well.<sup>7</sup>

## TYPES OF DISCOLORATION: MECHANISM, APPEARANCE, AND TREATMENT

### Tetracycline Staining

The broad spectrum tetracycline group of antibiotics was first introduced in 1948 for use in the treatment of respiratory illnesses. However, tooth discoloration caused by incorporation of systemic tetracycline into tooth structure was not reported until 1956 .a

**Mechanism.** The exact mechanism of tetracycline staining is not completely understood. It is hypothesized to occur by the joining of the tetracycline molecule with calcium through a chelation process and a subsequent incorporation into the hydroxylapatite crystal of the tooth during the mineralization stage of development.<sup>9-12</sup> A second theory maintains that the discoloration involves a binding of the tetracycline to tooth structure by a metal-organic matrix combination of the tetracycline complex.<sup>13,14</sup> Although some tetracycline accumulates within the enamel, it is primarily deposited in the dentin<sup>15</sup> because of the large surface area of the dentin apatite crystals compared with enamel apatite crystals.<sup>16</sup> However, enamel hypoplasia also can result.<sup>17</sup>

Extracted tetracycline-stained rat, 18 dog,<sup>19</sup> and primary human teeth<sup>10</sup> darkened when exposed to sunlight. Interestingly, further exposure to various light sources (sunlight, or incandescent or ultraviolet lights) produces a subsequent lightening of the tetracycline stain.<sup>1,18,20-23</sup> It has been postulated that tetracycline incorporated into hydroxylapatite, when oxidized by light (photo-oxidation), produces the red quinone product



4-a, 12-a anhydro-4-oxo-4-dedimethylaminotetracycline (AODTC).<sup>24,25</sup> Continued photo-oxidation of AODTC photolyzes, or bleaches, the red quinone.<sup>24</sup> Addition of diluted hydrogen peroxide yields an irreversible bleaching of the red quinone as well.<sup>24</sup>

**Appearance.** Tetracycline discoloration may be yellow, yellow-brown, brown, gray, or blue. The intensity of the staining varies widely. Distribution of discoloration usually is diffuse, and severe cases may exhibit banding. The staining usually is bilateral and affects multiple teeth in both arches.

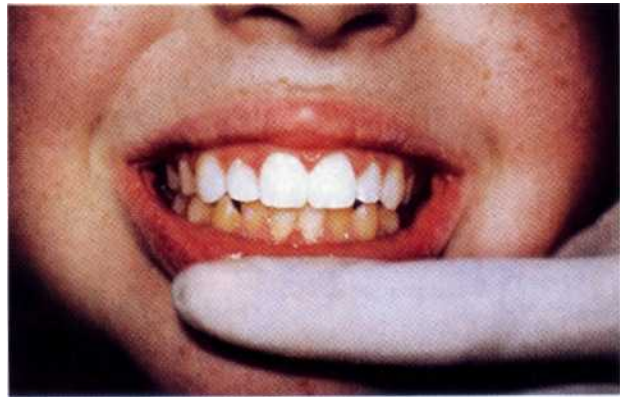The hue and severity of tooth discoloration depend on four factors associated with tetracycline administration:

1. Age at the time of administration: Anterior primary teeth are susceptible to discoloration by systemic tetracycline from 4 months in utero through 9 months postpartum. Anterior permanent teeth are susceptible from 3 months postpartum through age 7 years.<sup>26</sup>
2. Duration of administration: The severity of the staining is directly proportional to the length of time the medication was administered."<sup>27</sup>
3. Dosage: The severity of the staining is directly proportional to the administered dosage.<sup>26,29,30</sup>
4. Type of tetracycline: Coloration has been correlated with the specific type of tetracycline administered:<sup>31</sup>
  - A. Chlortetracycline (Aureomycin): Gray-brown stain
  - B. Dimethylchlortetracycline (Ledermycin): Yellow stain
  - C. Doxycycline (Vibramycin): Does not cause staining
  - D. Oxytetracycline (Terramycin): Yellow stain
  - E. Tetracycline (Achromycin): Yellow stain

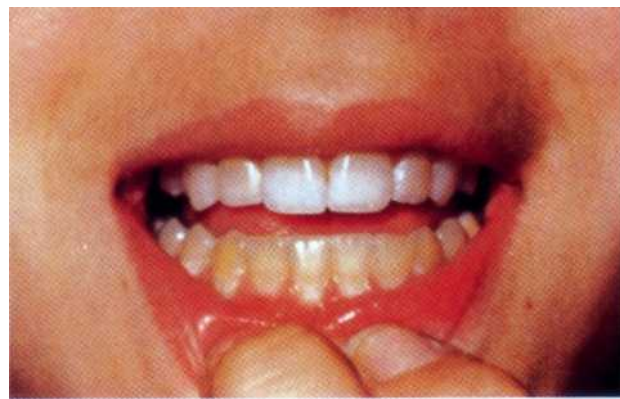Yellow tetracycline staining slowly darkens to brown or gray-brown when exposed to sunlight. Therefore the anterior teeth of children often darken first, while the posterior teeth, because of reduced exposure to sunlight, darken more slowly.<sup>32</sup> In adults, however, natural photo-bleaching of the anterior teeth (see the preceding mechanism section under tetracycline staining) has been observed, particularly in individuals whose teeth are excessively exposed to sunlight because of maxillary lip insufficiency.<sup>21</sup> Hypocalcified white areas of varying opacity, size, and distribution also may be present.

Tetracycline staining has been classified into three groups:<sup>33</sup>

1. First-degree stains. First-degree stains are light yellow, light brown, or light gray and are uniform throughout the clinical crown. No banding is present (Fig. 13-1).
2. Second-degree stains. Second-degree stains are more intense than first-degree stains. No banding is present (Fig. 13-2).



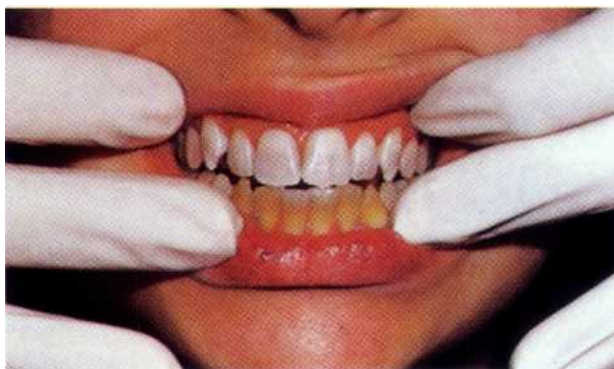*Fig. 13-1.* First-degree tetracycline staining after bleaching. The mandibular arch remains untreated and serves as a comparative control.



*Fig. 13-2.* Second-degree tetracycline staining after bleaching. The mandibular arch remains untreated and serves as a comparative control.

3. Third-degree stains. Third-degree stains are intense, and the clinical crown exhibits horizontal color banding. Bleaching generally is not performed because of the time involved and the poor prognosis. However, although less than **ideal results are to be expected**, the outcome may be esthetically satisfactory to the patient. The yellow-brown to brown component generally responds better than the blue to blue-gray component (Fig. 13-3).

**Treatment Considerations.** Acid/abrasion techniques are not indicated for the removal of tetracycline stains because the discoloration primarily resides in the dentin. In general, the results of bleaching yellow, yellow-brown, and brown stains are more favorable than those with blue-gray to gray stains. When teeth show any combination of yellow, brown, blue, or gray stains, the blue and gray components may remain to some degree despite a



*Fig. 13-3. Third-degree tetracycline staining with typical banding pattern. The maxillary arch was bleached. The mandibular arch remains untreated and serves as a comparative control. Note the complete removal of the yellow-brown component and the partial removal of the more tenacious blue-gray band. Although a less than ideal result was achieved, it was esthetically satisfactory to the patient, who desired no additional treatment.*

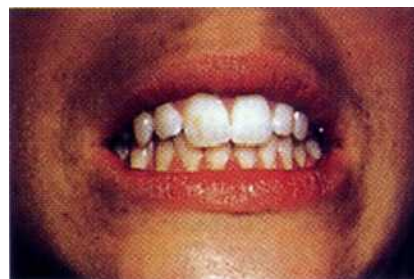more favorable bleaching of the yellow and brown components (see Fig. 13-3). In addition, less intense stains have a better prognosis and usually bleach more quickly. Teeth with diffuse staining generally respond better than those with banding.

### Ultraviolet Photo-Oxidation

Laboratory evidence that photo-oxidation is both the cause of and a "cure" for tetracycline staining suggests that light alone is potentially a viable treatment for some tooth discolorations. In vitro ultraviolet (UV) irradiation of tetracycline-stained rat dentin produced complete stain removal after 24 hours of exposure.<sup>21</sup> However, UV light does not penetrate enamel easily. Other sources of higher intensity UV light, such as deuterium arc sources or UV lasers, may overcome this obstacle, but problems such as high temperature generation, skin and mucosal burns, eye damage, potential carcinogenicity, and structural damage to enamel and dentin have not yet been suitably addressed, making this an unacceptable alternative at this time.<sup>21</sup>

### Fluorosis

**Mechanism.** Endemic fluorosis, or mottling, is caused by the presence of excessive systemic fluoride during enamel matrix formation and calcification.<sup>34,35</sup> Fluorosis is actually a form of enamel hypoplasia<sup>34</sup> hence the white spotting. Darker discoloration occurs through extrinsic staining of the hypoplastic enamel. Thus the darker stains occur only after tooth eruption." A fluoride concentra-



*Fig. 13-4. Extrinsic environmental staining may be similar in appearance to developmental discoloration (see Fig. 13-12).*

tion of 0.7 to 1.2 parts per million (ppm) in the municipal water supply maximizes the caries-preventive benefits of fluoride while minimizing the likelihood of mild dental fluorosis.<sup>36</sup>

**Appearance.** Staining usually is bilateral and affects multiple teeth in both arches. Fluorosis presents as mild, intermittent white spotting, chalky or opaque areas, yellow or brown staining of varying degrees and, in the severest cases, surface pitting of the enamel.<sup>33,35</sup>

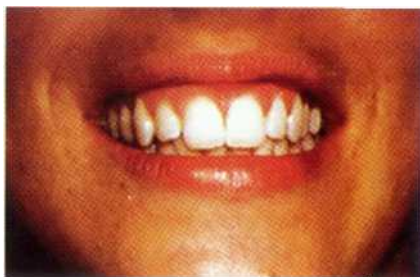**Treatment Considerations.** It has been suggested that bleaching and acid/abrasion systems are effective for treating superficial fluorosis stains.<sup>37</sup> It has been proposed that a more conservative approach may be to attempt home bleaching first, followed by selective acid/abrasion if that is still required.<sup>38</sup> It also has been reasoned that treatment time, financial considerations, and the patient's lifestyle may indicate the use of acid/abrasion as the initial treatment, followed by bleaching.<sup>39</sup> (See the section on white spot lesions later in this chapter.)

### Extrinsic Environmental Stains

**Mechanism.** Essentially limited to enamel, extrinsic environmental staining is caused by a variety of factors, including food, beverages, and tobacco products.

**Appearance.** Environmental staining affects multiple teeth and appears as yellow or brown stains of varying intensities. The staining is diffuse, but pits and other enamel defects may be more intensely stained because of inadequate oral hygiene procedures on these concave "protected" surfaces (Fig. 13-4).

**Treatment Considerations.** Superficial extrinsic staining often can be removed by proper home care or with routine professional prophylaxis (Fig. 13-5 see also Fig. 13-4).



Some extrinsic stains may be eliminated by simple prophylaxis.

### Staining of Pulpal Etiology: Trauma or Necrosis

**Mechanism.** Intrinsic staining results from the deposition of hemorrhagic by-products into the dentinal tubules after pulpal trauma<sup>40-42</sup> or necrosis."

**Appearance.** Discoloration of pulpal origin can be red, yellow, yellow-brown, brown, gray, or black. Obviously, discoloration is limited to the pulpally involved tooth or teeth (Fig. 13-6).

**Treatment Considerations.** Acid/abrasion techniques are not indicated for stains of pulpal etiology.

### Staining after Endodontic Therapy

**Mechanism.** Staining that occurs after endodontic therapy can be caused by excessive hemorrhaging during pulp removal or by decomposition of pulpal tissue following incomplete extirpation.<sup>40,47</sup>

**CLINICAL TIP.** Careful removal of all tissue and debris from the sometimes elusive pulp horns and lateral extensions of the pulp chamber may reduce the likelihood of subsequent tooth discoloration (Fig. 13-7).

Various endodontic medicaments and sealers containing barium, iodine, or silver also may cause discoloration, as can gutta-percha.<sup>40,43-45</sup>

**CLINICAL TIP.** Careful removal of all remnants of endodontic filling materials and sealers from the pulp chamber may reduce the likelihood of subsequent tooth discoloration.

**Appearance.** Discoloration of pulpal origin can appear red, yellow, yellow-brown, brown, gray, or black. Discoloration from endodontic medicaments and sealers ranges from orange-red to dark red, or gray to black." Discoloration obviously is limited to the endodontically treated tooth or teeth (Fig. 13-8).

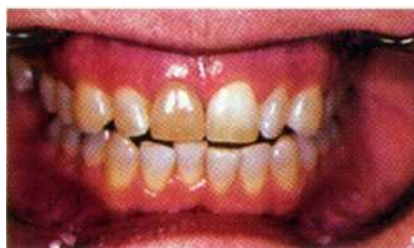

Fig. 13-6. Intrinsic staining results from the deposition of hemorrhagic by-products and decomposition of pulpal tissue into the dentinal tubules after pulpal trauma (also see Fig. 13-25).

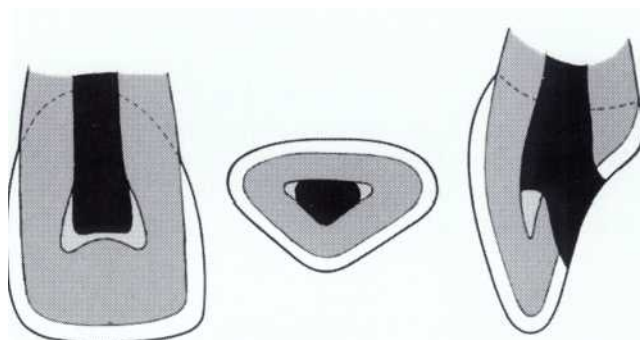


Fig. 13-7. Elusive pulp horns and lateral extensions of the pulp chamber often remain untouched during routine endodontic access preparation. (The access preparation is highlighted in black.) Careful removal of tissue and debris from these areas may help prevent subsequent tooth discoloration.

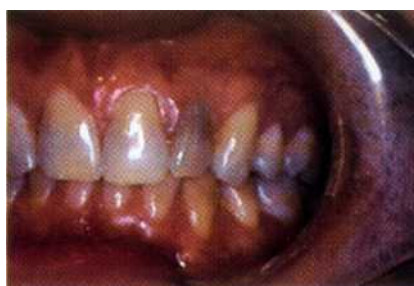

Fig. 13-8. Intrinsic staining results from the deposition of hemorrhagic by-products and from endodontic medicaments deposited into the dentinal tubules.

**Treatment Considerations.** Acid/abrasion techniques are not indicated for stains of pulpal etiology. The absence of pulp tissue allows for placement of bleaching agents directly into the pulp cavity. Staining caused by medications, sealers, and filling materials generally is less amenable to bleaching than staining resulting from biologic causes.<sup>46</sup> In an in vitro, intracoronary bleaching study in which a combination of sodium perborate and 30% hydrogen peroxide was used in teeth stained with one of

seven different sealers, the teeth were markedly improved after bleaching, although some color regression occurred after 6 months.<sup>47</sup>

### *Staining from Pre-eruption Trauma: Direct and Indirect*

**Mechanism.** Discoloration of a permanent tooth may occur after trauma to its primary counterpart.<sup>48</sup> Blood breakdown products from the traumatized site can infiltrate the developing enamel during the calcification stage.<sup>32</sup> Also, the apex of the primary tooth may directly traumatize the ameloblasts or the enamel matrix. Discoloration of a permanent tooth also may result from jaw fractures associated with the developing dentition, periapical inflammation of a primary tooth, or other infections in the area of a developing tooth bud."

**Appearance.** Discoloration usually is white or yellow-brown and often sharply demarcated or spotty rather than diffuse.<sup>48</sup> This discoloration can closely mimic that caused by endemic fluorosis or tetracycline ingestion; however, it usually is limited to the facial enamel surface of one or two teeth, usually the maxillary incisors.<sup>49</sup> Enamel defects also may be present if the ameloblasts or the enamel matrix was disturbed.<sup>12</sup>

**Treatment Considerations.** A normal response to pulp vitality testing can aid in distinguishing between staining induced by developmental trauma and that arising from pulpal etiology.

### *White Spot Lesions*

**Mechanism.** White spot enamel lesions can be developmental, acquired, or a combination of the two. Developmental lesions result from alterations that occur during the matrix formation or calcification stages of tooth development. Endemic fluorosis and trauma are two of the most common causes, but developmental disturbances during this period caused by genetic disorders, febrile and other illnesses, and unknown factors also occur. The term "dysmineralization" has been proposed to refer to these lesions because of the difficulty often encountered in determining the precise nature of these mineralization abnormalities.<sup>50</sup>

Acquired white spot lesions occur after tooth eruption. One source of such lesions may be localized discoloration from chronic stasis of bacterial plaque around fixed orthodontic appliances in patients with poor oral hygiene.<sup>50</sup>

**Appearance.** White spot lesions manifest as discrete areas that are lighter than the surrounding normocalcified enamel (Fig. 13-9). The intensity of the lesion varies from mildly decreased chroma to opaque chalky white.

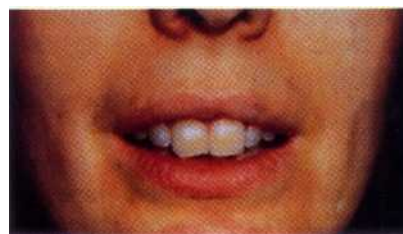

Fig. 13-9. Congenital white spot lesions. Note that brown developmental discoloration also is present (see also Fig. 13-10).

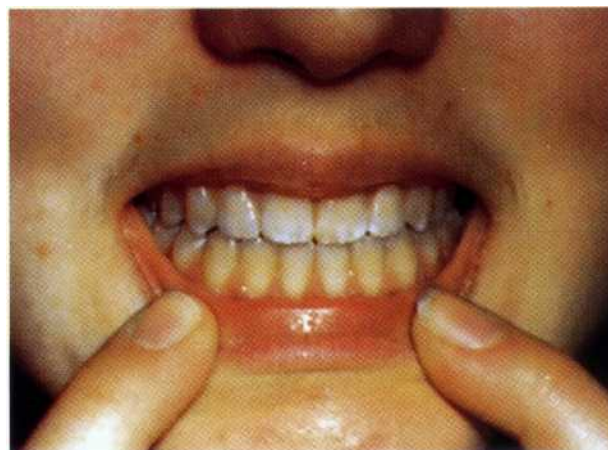

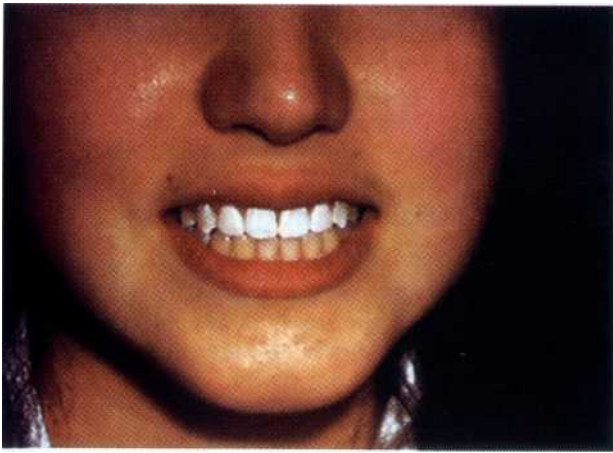Fig. 13-10. Congenital white spot lesions.

Size, distribution patterns, and penetration depth vary greatly.

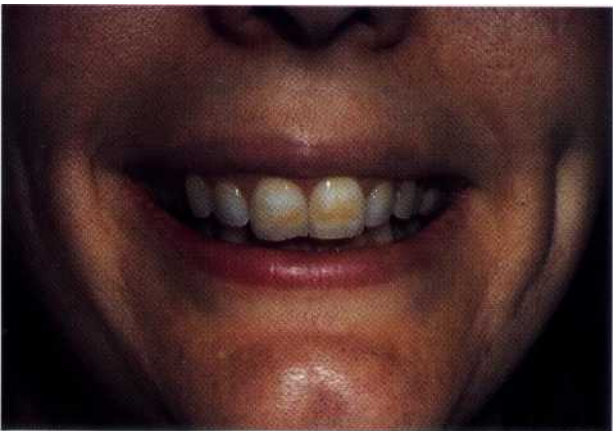**Treatment Considerations.** For treatment planning purposes, a tooth with localized white spot lesions can often be considered a mosaic of light areas on a background of normocalcified tooth structure. If the background tooth structure is a desirable color, acid/abrasion techniques may be considered. (See the section on acid application with mechanical abrasion [acid/abrasion] later in this chapter.) However, if the background color is undesirable, a bleaching system may be appropriate. In this situation, the contrasting white spot lesions may become significantly less noticeable and esthetically more acceptable after a successful bleaching of the normocalcified background area (Figs. 13-10 to 13-14). (See the general considerations section under acid application with mechanical abrasion [acid/abrasion] later in this chapter.)

### *Staining from Silver Amalgam*

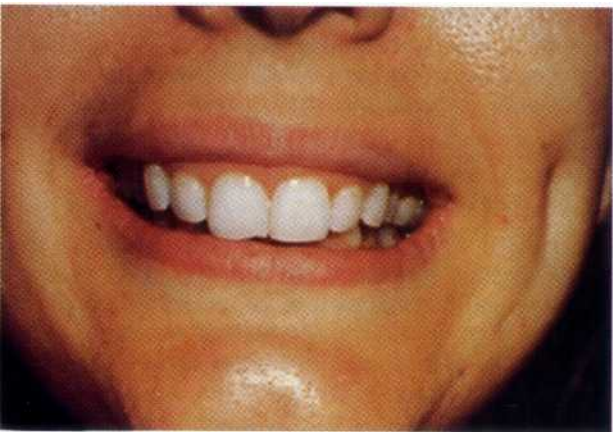**Mechanism.** Tooth discoloration from silver amalgam is caused primarily by the visibility of a restoration through relatively translucent tooth structure. To varying



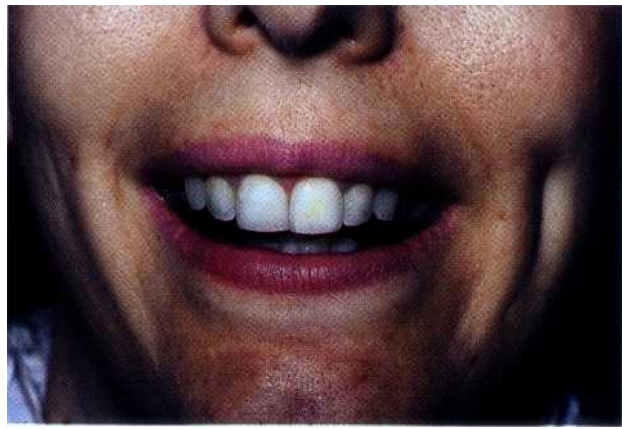*Fig. 13-11. The same patient as in Fig. 13-10 after bleaching. Lightening of the "background" color eliminates the perceptual impact of the white spot lesions.*



*Fig. 13-12. Central incisors exhibit both brown and white developmental discolorations.*



*Fig. 13-13. The same patient as in Fig. 13-12 after bleaching. Whitening of the "background" color and removal of the brown stain eliminates the perceptual impact of the white spot lesions, creating an esthetically pleasing result.*



*Fig. 13-14. The same patient as in Fig. 13-12 after cosmetic recontouring.*

degrees it also may be caused by direct staining of the tooth structure by the reaction products of intraoral sulfides and the copper or silver ions of the amalgam.

**Appearance.** Tooth discoloration from silver amalgam is gray to black.

**Treatment Considerations.** Tooth discoloration from silver amalgam is not routinely amenable to bleaching. Restorative treatment is the usual solution.

#### *Other Discolorations*

Numerous other types of discoloration can result from a plethora of causes. Some chromogenic bacteria may cause yellow, orange, brown-black, or green stains.<sup>51,52</sup> Salivary components can cause brown stains.<sup>53</sup> Sulfmethemoglobin, a blood pigment breakdown product, can cause a green coloration to remnants of Nasmyth's membrane.<sup>31,51</sup> Chlorophyll in dental plaque also may cause green stains.<sup>31</sup> The deposition of porphyrin into developing dentin in patients with erythropoietic porphyria, an inborn error of metabolism, may result in a red, purplish brown, or brownish discoloration.<sup>54</sup> Phenylketonuria, another inborn error of metabolism, can produce brown discolorations.<sup>31</sup> Erythroblastosis fetalis, a syndrome resulting from Rh incompatibility in an infant, is characterized by the hemolysis and breakdown of the infant's blood, producing jaundice. These pigments may produce an intrinsic blue, brown, or green discoloration.<sup>55</sup> Thalassemia and sickle cell anemia may cause similar discolorations.<sup>31</sup> Amelogenesis imperfecta may result in yellow or brown stains.<sup>51</sup> Dentinogenesis imperfecta can cause brownish violet, yellowish, or gray discolorations.<sup>56</sup> Generalized yellow or gray coloration may not result from a pathologic entity but may simply be a variant within the normal range of tooth shade (Figs. 13-15 and 13-16). Some discolorations are of unknown origin.

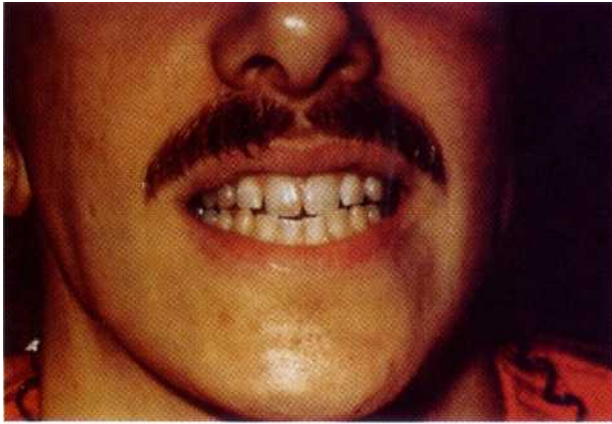


Fig. 13-15. Generalized yellow coloration of nonpathologic etiology.

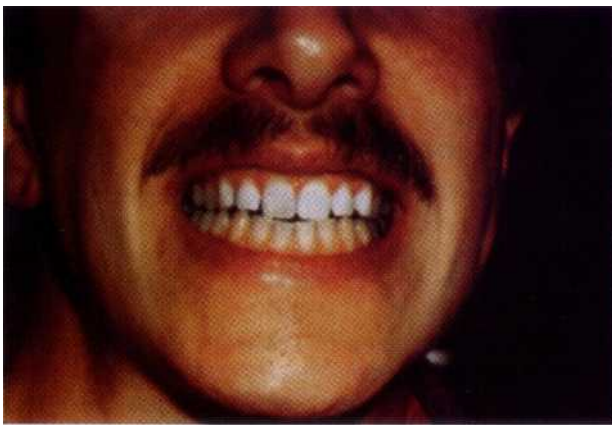


Fig. 13-16. The same patient as in Fig. 13-15 after bleaching. The untreated mandibular arch serves as a control.

**Treatment Considerations.** The precise etiology of many stains is not always discernible. This may complicate the generation of a reasonable treatment plan and prognosis. Some discolorations may be treated with routine prophylaxis. Stains resulting from erythropoietic porphyria and erythroblastosis fetalis sometimes can be treated successfully with bleaching agents.<sup>54,55</sup> Treatment of discoloration resulting from amelogenesis imperfecta and other etiologies that interfere with normal matrix formation or calcification of enamel often is less effective.<sup>55</sup> Also, treatment often is contraindicated if the current structural integrity of the tooth is sufficiently compromised. The prognosis for the treatment of generalized coloration of nonpathologic origin is highly unpredictable.

## TREATMENT MODALITIES

As with any therapeutic treatment, proper diagnosis should be attempted before a course of treatment is pro-

mulgated. Although the etiology of a specific tooth discoloration may be difficult to discern, an accurate history and evaluation of the factors discussed earlier (see the section on discolorations: mechanism, appearance, and treatment considerations in this chapter) help in establishing a differential diagnosis. The presence or absence of pulp tissue is also a treatment planning factor. Even with a definitive diagnosis, however, the ultimate outcome can be unpredictable.

Currently, only three methods of stain removal are available:

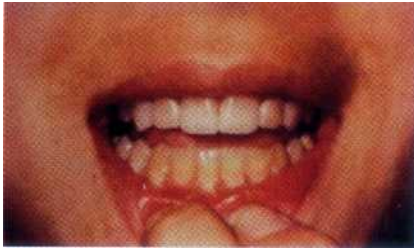- *Acid application with mechanical abrasion (acid/abrasion):* Acid/abrasion techniques are enticingly efficient because of the short treatment times. However, the nonselective, destructive nature of this procedure limits its application to only the most superficial discolorations. Obviously, whether a discoloration is superficial enough to be treated in this way can only be determined through trial and error,<sup>50</sup> and patients should be so informed. (See the section on acid application with mechanical abrasion [acid/abrasion] later in this chapter.)
- *Bleaching systems:* Bleaching systems can also be used to treat superficial staining and are the only technique available for deeper enamel stains and for staining of the dentin. Repeated treatment applications often are necessary. Vital bleaching is accomplished either completely in the dental office (office or "power" bleaching) or outside of the dental office (home bleaching). (See the sections on office bleaching ["power" bleaching] and dentist-prescribed at home bleaching later in this chapter.) Nonvital teeth can be bleached with an intracoronal technique. (See the section on nonvital bleaching later in this chapter.)
- *Combination therapy:* The use of bleaching techniques and acid application/mechanical abrasion consecutively may provide the desired clinical result in some cases. (See the general considerations section under acid application with mechanical abrasion [acid/abrasion] later in this chapter.)

## General Considerations

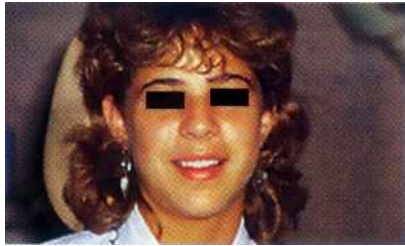If the mandibular and maxillary arches are similarly discolored, it may not be necessary to treat the discoloration of the mandibular teeth. In some cases, the lower lip completely hides the mandibular arch during normal function (Figs. 13-17 and 13-18).

During function the coloration of the mandibular arch often is obscured because of shadowing from the upper lip, particularly in Angle Class I and Class II horizontal overjet relationships. The visual perception of the mandibular teeth is further reduced by the continuous motion of the mandible during speaking; the maxillary arch remains relatively stable in space during function.





*Fig. 13-17. Patient with second-degree tetracycline staining after bleaching of the maxillary teeth.*



*Fig. 13-18. The same patient as in Fig. 13-17. A full lower lip hides the mandibular arch during function, precluding the need for mandibular bleaching.*

These factors may permit an esthetically acceptable result despite significantly contrasting shades between the maxillary and mandibular arches.

#### *Acid Application with Mechanical Abrasion (Acid/Abrasion)*

Acid/abrasion is a relatively simple procedure that removes tooth structure and stain simultaneously. Techniques vary and include at least one commercially produced set of armamentarium.

**Hydrochloric Acid.** Although hydrochloric acid is not a true bleaching agent, its applications warrant inclusion in any discussion of tooth discoloration treatments.

Hydrochloric acid is a potent decalcification agent. Nonselective in nature, it decalcifies both the tooth structure and the accompanying stains. When hydrochloric acid is used in conjunction with abrasive agents, the affected enamel is completely removed, along with the stain.

In one study, five repetitions of a 5-second acid/pumice application with a wooden stick in vitro removed 112  $\mu\text{m}$  of tooth structure.<sup>56</sup> This resulted in an 11% loss of enamel thickness, assuming a permanent incisor midlabial enamel thickness of approximately 1 mm." It has been suggested that enamel losses of 25%<sup>57</sup> and 30%<sup>58</sup> are clinically acceptable.

It has been postulated that hydrochloric acid applied to the enamel surface does not penetrate the pulpal tissue.<sup>59,60</sup> The acid may form a calcium or phosphorous salt precipitate that limits further penetration of the acid into the dentin. In addition, these salts may further neutralize the acid.<sup>59</sup>

Scanning electron microscopy performed after in vitro treatment with 18% hydrochloric acid and Italian ground pumice revealed a "smeared" enamel surface with tooth structure loss from both chemical erosion and mechanical abrasion.<sup>61</sup> Qualitative elemental analysis of this same enamel surface demonstrated a chemical pattern similar to unetched enamel and an absence of any foreign residue.<sup>61</sup>

**General Considerations.** Safety considerations include patient cooperation, careful gingival isolation, minimal duration of exposure of the tooth structure to the acid, minimal mechanical abrasion, and meticulous protection of the dentist, patient, and personnel from the acid.

The preponderance of the early literature deals with the use of acid and acid/abrasion techniques for the treatment of superficial brown fluorosis staining.<sup>4,6,58,62-70</sup> Treatment with a commercially available proprietary product has been used for these stains and for white spots and streaks associated with fluorosis, superficial white dysmineralizations, and many white decalcifications associated with chronic stasis of dental plaque (such as those following orthodontic banding in patients with poor oral hygiene)."

Hydrochloric acid treatment of superficial enamel stains resulting from developmental disturbances of the enamel has been suggested,<sup>72</sup> although not for most amelogenesis imperfecta defects.<sup>71</sup> Acid/abrasion techniques are not indicated for stains or discolorations that reside deeper in the enamel or in dentin, for those acquired from food, beverages, or tobacco,<sup>72</sup> or for caries underlying a decalcified region.<sup>71</sup>

If white spot lesions cover significant areas of the labial surface, patients may mistakenly consider the darker, normocalcified areas to be the discoloration, rather than the white spot lesions. Successful removal of these white spot lesions may result in a darker overall result." It is also possible that deep enamel may be unpredictably removed in areas of hypocalcification.<sup>72</sup> This may necessitate the use of composite resin to restore lost surface contour or to protect exposed dentin. It has been estimated that 50% to 75% of white enamel defects are superficial enough to be removed successfully with acid/abrasion.<sup>71</sup>

It has been proposed that a more conservative approach to the removal of yellow-brown fluorosis staining may be to attempt home bleaching first, followed by selective acid/abrasion if that is still required.<sup>38</sup> It also has been reasoned that treatment time, financial considerations, and the patient's lifestyle may indicate the use of acid/abrasion

as the initial treatment, followed by bleaching.<sup>39</sup> (See the section on white spot lesions earlier in this chapter.)

**Other Abrasion Techniques.** Mechanical abrasion using rotary instrumentation without acid and pumice is an alternative approach.<sup>73</sup> However, special care must be taken with this technique to avoid ditching, alteration of labial contours, and excessive enamel reduction.

### Acid Abrasion<sup>14</sup>

#### Armamentarium

Protective glasses with side shields (for patient and operator)  
 Heavy rubber dam  
 Copal varnish (e.g., Copalite, Cooley & Cooley, Ltd.)  
 36% hydrochloric acid USP (available from chemical supply house)  
 Two glass dappen dishes  
 Distilled water  
 Flour of pumice  
 Sodium bicarbonate powder USP  
 Tongue blade  
 Cotton-tipped applicator  
 1.1% neutral sodium fluoride (e.g., Prevident, Colgate-Hoyt Laboratories)  
 Fine fluoridated prophylaxis paste  
 Superfine aluminum oxide polishing disc (e.g., Soflex, 3M, Inc.)

#### Clinical Technique

**CLINICAL TIP.** WARNING: Protective glasses with side shields must be worn by the patient, dentist, and any auxiliary personnel while working with hydrochloric acid. The dentist and auxiliary personnel should wear rubber gloves, and the patient must be draped. The procedure is contraindicated for uncooperative patients and for teeth that are sensitive to temperature changes or acidic liquids or foods. This technique should not be attempted if the operatory is not equipped with a high-volume evacuation system and a water syringe.

1. Apply a heavy rubber dam to the teeth to be bleached.
2. Seal the labial and lingual (or palatal) rubber dam margins with copal varnish.
3. Prepare an 18% hydrochloric acid solution by mixing equal volumes of 36% hydrochloric acid and distilled water in a dappen dish.

**CLINICAL TIP.** Always add acid to water; adding water to acid can cause splattering because of the exothermic reaction that occurs upon mixing.

4. Add flour of pumice to the acid solution to make a thick, Nvet paste.

**CLINICAL TIP.** WARNING: Hydrochloric acid should never be passed over or held in the region of the patient's face, nor should any mixture containing the acid or any instrument that has come in contact with it.

5. Prepare a thick paste of sodium bicarbonate and water.
6. Place sodium bicarbonate paste on the rubber dam to help neutralize any splashed acid.
7. Apply the acid/pumice mixture to the labial enamel with a wooden tongue blade. Simultaneously use a cotton-tipped applicator to absorb any excess solution.

**CLINICAL TIP.** The tongue blade can be cut or split to better adapt to the facial surface.

**CLINICAL TIP.** WARNING: Rotary instrumentation of any type (e.g., a prophylaxis cup on a slow-speed hand-piece) is strictly contraindicated because of the danger of splattering the acid.

8. With firm finger pressure on the tongue blade, grind the mixture into the enamel.

**CLINICAL TIP.** Total acid contact time should not exceed 5 seconds.

9. Rinse carefully and thoroughly with water for 10 seconds while carefully evacuating with the high-powered suction.
10. Evaluate for excessive enamel wear by viewing, with a mirror, the labial surface from an incisal direction.
11. Wet the tooth with saliva and evaluate for appropriate color change.

**CLINICAL TIP.** White enamel discoloration usually is more visible on dry tooth structure than when the tooth is wets<sup>o</sup>; thus color evaluation of dry teeth may result in overtreatment and unnecessary removal of enamel.

12. If the color change is esthetically acceptable, skip to step 14.

**CLINICAL TIP.** To avoid excessive wear, limit the acid/abrasion application to a maximum of five attempts. However, if no change is observed after the third attempt, discontinue treatment and skip to step 14.

13. If the color change is unacceptable, repeat steps 6 through 13. These steps should not be performed more than five times.

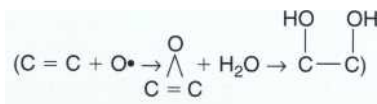
14. Polish with a fine fluoride prophylaxis paste and superfine aluminum oxide composite resin polishing discs.
15. Apply a 1.1 % neutral sodium fluoride gel for 4 minutes.

### Office Bleaching ("Power" Bleaching)

Bleaching of vital teeth in the dental office (often referred to as "power" bleaching) involves the application of bleaching agents (usually 30% to 35% hydrogen peroxide) in liquid or gel form.

**Hydrogen Peroxide.** The exact mechanism of discoloration removal is not entirely understood, but likely includes oxygen-releasing, mechanical cleansing action<sup>53</sup> and oxidation or reduction reactions. Tetracycline staining, more specifically, may be bleached through an oxidative degradation of the quinone ring<sup>24</sup> (see the section on tetracycline under types of discoloration: mechanism, appearance, and treatment considerations earlier in this chapter). The mechanisms will differ according to the type of discoloration involved and the chemical and physical environment present at the time of action (e.g., pH, temperature, cocatalysts, lighting, and other conditions).<sup>75</sup>

Depending on conditions, hydrogen peroxide can release free radicals ( $\text{H}_2\text{O}_2 \rightarrow \text{H}\cdot + \cdot\text{OOH}$  or  $\text{H}_2\text{O}_2 \rightarrow \text{HO}\cdot + \cdot\text{OH}$ ); perhydroxyl anions ( $\text{H}_2\text{O}_2 \rightarrow \text{H}^+ + \cdot\text{OOH}^-$ ); or a combination of free radicals and anions ( $\text{HOO}\cdot + \text{O}_2^{1-} \rightarrow \text{O}_2^{\cdot-} + \text{H}_2\text{O}$  in a basic solution and  $\text{HOO}\cdot \rightarrow \text{O}_2^{\cdot-} + \text{H}^+$  in an acidic solution).<sup>75</sup> These compounds tend to be attracted to electron-rich alkene (double) bonds and form epoxides that are unstable and can form alcohols.



Double bonds can create discoloration; therefore breaking these bonds often eliminates discoloration. In addition, more water-soluble compounds are created, which are more easily removed.<sup>76</sup> Hydrogen peroxide also increases the permeability of tooth structure, thereby increasing the movement of ions through the tooth.<sup>77</sup> This probably occurs because of the low molecular weight of hydrogen peroxide and its ability to denature proteins.<sup>77</sup>

**General Considerations.** The efficacy of bleaching teeth with heat and hydrogen peroxide is well documented.<sup>7,33,78-81</sup> Goldstein observed no known loss of tooth vitality after 30 years of bleaching over 30,000 vi-

tal teeth.<sup>82</sup> It has been suggested that although mild thermal sensitivity is a common sequela of bleaching, no long-term irreversible pulpal effects have been demonstrated in relevant clinical studies.<sup>87</sup>

**Treatment Methods.** Treatment methods generally involve the use of 35% hydrogen peroxide in either liquid or gel form. The *thermocatalytic* technique involves the use of a spatula- or paddle-shaped heating element, which is approximately the size of a single tooth (Fig. 13-19). After 35% hydrogen peroxide is applied to the tooth surface, the heating element is positioned over the tooth. Each tooth is treated individually and in sequence. In the *thermophotocatalytic* technique, a rheostatically controlled heating lamp provides heating and lighting of an entire arch. When bleaching teeth without heat or light, the 35% hydrogen peroxide is combined with a proprietary component to produce a gel.

Power bleaching is also used in combination with at home bleaching.<sup>82,83</sup> It has been proposed that a certain segment of the population whose lifestyles are not amenable to home treatment can be treated exclusively by in-office power bleaching.<sup>82</sup>

**Restorative Implications.** In some cases discoloration has returned after successful or partly successful treatment. Subsequently placed porcelain or composite resin laminate veneers may not prevent color regression of the underlying tooth structure, and the restorative materials may not completely mask the visual display of any such changes. The esthetic effects of such color regression depend on the amount of regression and the degree of translucency of the overlying restoration. This must be considered if discoloration removal therapy is followed by restorative treatment of any kind.

It also has been demonstrated that applying hydrogen peroxide to bovine tooth structure diminishes the bond strength between unfilled resin and acid-etched enamel.<sup>81-86</sup> Presumably, oxygen inhibition of resin polymerization and the creation of voids in the resin tags may be caused by residual hydrogen peroxide or peroxide-related substances in the interprismatic enamel areas



Fig. 13-19. Bleaching unit with paddle-shaped heating attachment (Union Broach).

after bleaching.<sup>85,86</sup> This residual substance apparently is not removed either by a 1-minute water rinse or by thoroughly drying the surface.<sup>86</sup> However, the changes within the tooth structure that cause the diminished bond strength seem to be reversible.<sup>84</sup> The most common recommendation is to postpone placing bonded restorations for 1 to 2 weeks after bleaching.<sup>87-89</sup>

**Clinical Approaches.** Numerous office bleaching products and techniques have been proposed. The American Dental Association (ADA) Seal of Acceptance program includes a category for in-office bleaching. The acceptance program is ongoing, and products are continually added and eliminated.

**CLINICAL TIP.** Stereo headphones playing the patient's choice of music or the use of video glasses (e.g., I-Glass, I-Glass, Inc.) often help the patient pass the time pleasantly while bleaching is performed in the office.

### *Laser-Assisted Bleaching*

Bleaching with an argon laser, a carbon dioxide laser, or a combination of the two" as a light source was recently introduced, but sufficient long-term or controlled clinical studies of safety and effectiveness currently are lacking.<sup>87</sup> Laser-assisted bleaching may be no more effective than nonlaser techniques.<sup>83</sup>

### *Dentist-Prescribed At Home Bleaching*

Patient self-application of bleaching agents performed at home is perhaps the most popular method of bleaching vital teeth. It is alternately referred to as "home bleaching" or "matrix bleaching."

**Carbamide Peroxide.** Ten percent carbamide peroxide (also known as hydrogen peroxide carbamide, carbamide urea, urea hydrogen peroxide, urea peroxide, perhydrol urea, and perhydelure) breaks down into approximately 3% hydrogen peroxide and 7% urea.<sup>90</sup> Carobopol and other thickeners often are incorporated to enhance the material's properties<sup>90</sup> to produce a gel or paste.

**General Considerations.** The bleaching agent is held against the teeth by means of a custom-fabricated tray. Techniques vary as to the frequency, timing, number of applications, and duration of treatment.

The retention of bleaching material within the custom tray when the tray is worn overnight was initially questioned.<sup>91,92</sup> However, a later study with a newer generation material reported a retention of over 60% of active material after more than 4 hours of use.<sup>90</sup>

The ADA Seal of Acceptance is given to a product that meets the program's criteria for safety and effectiveness.<sup>93</sup> Acceptance of a dentist-prescribed at home bleaching product includes a review of the instructions provided with the product.<sup>93</sup> The acceptance program is ongoing, and products are continually added and eliminated.

The mutagenic potential<sup>94</sup> of the free radicals released by hydrogen peroxide, as well as their ability to potentiate the effects of known carcinogens, have also been reported.<sup>95</sup> Therefore the use of any known carcinogen, such as tobacco or alcohol, is a consideration (at the time of the preparation of this manuscript, the American Dental Association was in the process of updating the specific recommendations regarding tobacco and alcohol use in relation to bleaching and should be consulted in this regard). In addition, this technique should not be used by pregnant women.<sup>96</sup> Calculus should be removed<sup>96</sup> and if the prophylaxis traumatizes the tissues, bleaching should be delayed 1 to 2 weeks.<sup>96</sup> Teeth to be bleached should be free of caries and have no defective restorations.

The patient should be informed that existing restorations will not whiten. **Restorations matched to teeth after** bleaching may become esthetically unacceptable if postbleaching color regression occurs in the surrounding natural tooth structure.

Patients should be instructed to discontinue treatment and to contact the dentist if sensitivity of the teeth or gingiva occurs.<sup>96</sup> Other precautions may exist as well, some of which may be discussed in the manufacturer's instructions and enclosures.

**Custom Tray Fabrication.** The current ADA Seal of Acceptance program for dentist-prescribed at home bleaching products includes acceptance of the instructions for use. (The acceptance covers a specific product; acceptance of similar products by the same manufacturer should not be inferred.) Although these instructions differ among specific manufacturers, many of the basic concepts behind these procedures are similar in nature. The step-by-step technique that follows, although adapted from only one product, is helpful in demonstrating the implementation of some of these concepts.

**Clinical Approach.** This technique was adapted from the Instructions for the Use of Opalescence (Ultradent Products, Inc.).

**CLINICAL TIP.** The specific current manufacturer's instructions and enclosures (including patient use instructions) for products adhering to the ADA acceptance program may be updated periodically and therefore should be consulted. Instructions for products from other manufacturers will be different and should be consulted.

## Armamentarium

- Fast-set plaster or dental stone
- Model trimmer
- Block-out material (LC Block-Out (REF/UP 240), Ultradent Products, Inc.)
- Hand-held intraoral light or curing device (Ultra-Lume, Ultradent Products, Inc.)
- Tray material (Sof Tray 0.035 inch, Ultradent Products, Inc.)
- Vacuum former unit (Ultra-Form or EconoForm, Ultradent Products, Inc.)
- Small tactile scissors (Ultra-Trim scissors, Ultradent Products, Inc.)
- Serrated plastic trimmers (Ultradent Utility Cutters, Ultradent Products, Inc.)
- Portable torch (Blazer Micro Torch, Ultradent Products, Inc.)

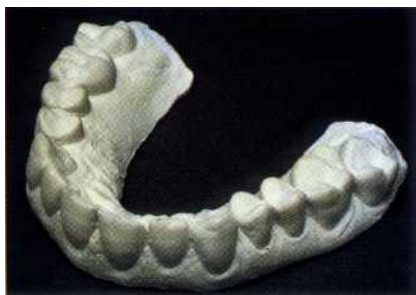Clinical Technique

**CLINICAL TIP.** WARNING: Before bleaching is begun, teeth should be free of caries and defective restorations.

1. Pour the impression of the arch with fast-set plaster or dental stone. Irreversible hydrocolloid must be poured shortly after making the impression to ensure accuracy.

**CLINICAL TIP.** The model base ultimately is reduced to within a few millimeters of the gingival margins. To save time, use only the minimum amount of stone necessary to ensure removal of the set stone from the impression without fracture.

2. Trim the base of the model parallel to the occlusal table on a model trimmer to within a few millimeters of the gingival margins. The palate and tongue areas are removed (Fig. 13-20).
3. Allow the model to dry for 2 hours.



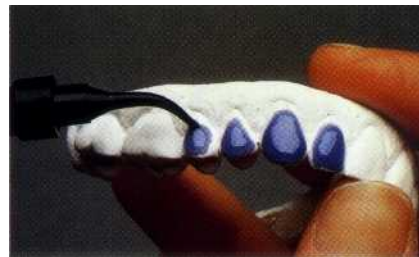*Fig. 13-20.* The base of the model is trimmed parallel to the occlusal table to within a few millimeters of the gingival margins. The palate and tongue areas are removed. (Courtesy Ultradent Products, Inc.)

4. Apply approximately 0.5-mm thickness of block-out material to the desired labial surfaces to provide reservoir spaces in the tray as follows:
  - A. Approximately 1.5 mm from the gingival line
  - B. Do *not* extend onto the incisal edges and occlusal surfaces (Fig. 13-21).

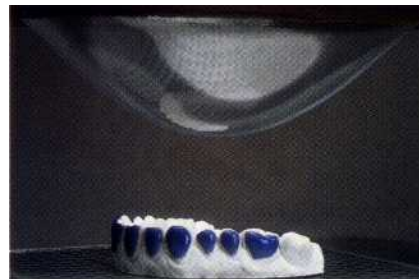**CLINICAL TIP.** Extending the block-out material onto the incisal edges or occlusal surfaces can cause the margins of the tray to open upon occluding and/or the tray to impinge on the soft tissues. Patients may experience less tooth discomfort from tray pressures with reservoirs because of reduced "orthodontic" pressures.

5. Cure the block-out material for approximately 2 minutes (Ultra-Lume). A hand-held intraoral light can be used, and each tooth is exposed for approximately 20 to 40 seconds. Wipe off the oxygen-inhibited layer.
6. Heat the tray material on the vacuum former unit until it sags approximately 2<sup>1</sup>/<sub>2</sub> inches (Fig. 13-22). Activate the vacuum and adapt the softened tray material over the model. Cool and remove the model.

**CLINICAL TIP.** Use a serrated plastic trimmer to initially remove the bulk of the tray material. This facilitates the final precise trimming with the small tactile scissors.



*Fig. 13-21.* Spacing for reservoirs is created on the model. (Courtesy Ultradent Products, Inc.)



*Fig. 13-22.* The tray material is heated on a vacuum former unit. (Courtesy Ultradent Products, Inc.)

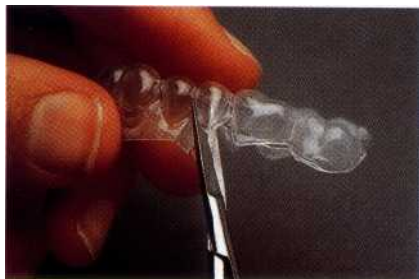7. Trim the tray material carefully and precisely 0.25 to 0.33 mm occlusal from the gingival margin with small tactile scissors. Scallop around the interdental papilla (Fig. 13-23).
8. Place the tray on the model and check the tray extensions. Gently flame polish the edges one quadrant at a time with the torch (Fig. 13-24).
9. While still warm, hold the periphery of each segment firmly against the model for 3 seconds with a water-moistened finger.

**CLINICAL TIP.** If an area is short of the desired length, gently heat and push the tray material to the desired location. If the material becomes too thin, a new tray should be fabricated.

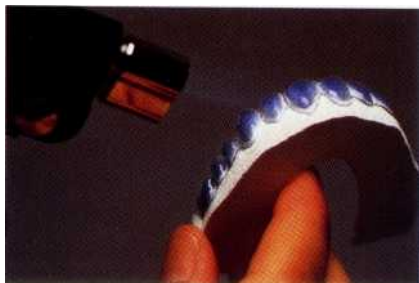
**Restorative Implications.** For a discussion of restorative implications, see the section on office bleaching ("power" bleaching) earlier in this chapter.

### *Over-the-Counter Unsupervised At Home Bleaching*

Many home bleaching products are available over the counter or through mail order, print, radio, and television advertisements. This approach is not recommended. Overuse and abuse are a concern."



*Fig. 13-23. The tray material is trimmed. (Courtesy Ultradent Products, Inc.)*



*Fig. 13-24. The tray is flamed to facilitate adaptation to the model. (Courtesy Ultradent Products, Inc.)*

### *Nonvital Tooth Bleaching*

The agents traditionally involved in the lightening of discolored nonvital teeth are sodium perborate and 30% to 35% hydrogen peroxide used alone or in combination." The most commonly used agent has been reported to be 30% hydrogen peroxide.<sup>98</sup> The techniques commonly used include the thermocatalytic technique, in which the bleaching solution is heated from within the pulp chamber with a hot instrument,<sup>97</sup> heated externally with a floodlight apparatus, or a combination of the two; and the "walking bleach" technique, in which the materials are sealed within the pulp chamber for 3 to 7 days.<sup>97</sup> These techniques are repeated until an appropriate result is achieved."

**External Cervical Root Resorption.** External root resorption is a possible sequela of internal bleaching. Hydrogen peroxide occasionally has been associated with this development." The exact cause or causes of this response are still not entirely understood, although a number of mechanisms have been postulated:

1. In 10% of all teeth, the cemento-enamel junction is defective or absent, resulting in a portion of the tooth being devoid of cementum coverage.<sup>99</sup> Thirty-five percent hydrogen peroxide may denature the dentin, invoking a foreign body response by elements in the approximating gingival tissue, which may result in cervical resorption.<sup>100</sup>
2. Internally applied 35% hydrogen peroxide may directly contact the periodontal membrane by passing through patent dentinal tubules<sup>101</sup> or through lateral root canals or accessory foramina." This may elicit an inflammatory reaction, ultimately resulting in cervical resorption.
3. Bleaching agents may infiltrate between the gutta-percha and the root canal walls. They could then communicate with the periodontal membrane through the dentinal tubules, lateral canals, or apex. This may invoke a resorptive process anywhere along the root area, including the apical regions.
4. Heat application during treatment may invoke a resorptive process."
5. Thirty-five percent hydrogen peroxide mixed with sodium perborate can lower the pH in the periodontal membrane area,<sup>102</sup> which may increase the likelihood of cervical resorption.

It also has been demonstrated in vitro that when heat is combined with 35% hydrogen peroxide/sodium perborate paste during an internal bleaching technique, not only is the crown bleached, but also the entire root surface. Significantly less of the root surface is bleached when the heat is omitted.<sup>103</sup> This may suggest that heat facilitates the permeation of bleaching agent, in all directions, thus possibly increasing the likelihood of external cervical root resorption through some of the above mechanisms.

Tooth discoloration often is the result of a traumatic injury to the tooth, and resorption may be a sequela of the original trauma. Resorption also can be caused by orthodontic treatment or surgery, particularly when involving the cements-enamel junction area.<sup>104</sup>

**Bleaching Materials and Technique.** The literature is equivocal about the efficacy of the various techniques. Two in vitro studies have found intracoronal placement of 30% to 35% hydrogen peroxide (Superoxol) in combination with sodium perborate provided, after two applications, results that were superior to a sodium perborate/water combination,<sup>41,105</sup> although one of these studies showed equal results after three applications.<sup>105</sup> Another in vitro study found equal results after two applications.<sup>106</sup> In an in vitro study, the success rates for teeth treated intracoronal with a sodium perborate/30% hydrogen peroxide combination, a sodium perborate/3% hydrogen peroxide combination, and a sodium perborate/water combination were found to be essentially equal after 1 year.<sup>107</sup>

It has been stated, however, that the traditional thermocatalytic technique with 30% hydrogen peroxide is faster and more effective.<sup>108</sup> The thermocatalytic method has been described as recently as 1995 when the "walking bleach" technique is unsuccessful.<sup>109</sup> In a 1995 literature review of external resorption following intracoronal placement of hydrogen peroxide (thermocatalytic method in most cases), none included the prior placement of a protective base, and many reported previous dental trauma.<sup>109</sup> Sodium perborate/30% hydrogen peroxide combinations are also described.<sup>110</sup> However, cemental exposure to 30% to 35% hydrogen peroxide, especially in combination with high heat, increasingly is being discouraged for dentists performing intracoronal bleaching to reduce the potential for external root resorption.<sup>111</sup> Sodium perborate mixed with water is potentially safer.<sup>87</sup>

An in vitro quantitative analysis of bleaching materials disclosed that after 3 days, further color change was minimal. It was concluded that the interval between bleaching visits could be reduced to reflect this finding.<sup>98</sup>

**Acid Etching.** In an in vitro study, the removal of the smear layer with phosphoric acid did not significantly change the efficacy of intracoronal bleaching with a sodium perborate/water combination (37% phosphoric acid)<sup>112</sup> or a 35% hydrogen peroxide/sodium perborate combination (37% phosphoric acid).<sup>113</sup> Another in vitro study with a 30% hydrogen peroxide/sodium perborate combination (50% phosphoric acid) had similar results.<sup>114</sup>

**Calcium Hydroxide.** The literature is equivocal on whether calcium hydroxide placed within the pulp chamber can raise the pH of the microenvironment of the ex-

ternal tooth surface,<sup>102,115</sup> or whether it has no effect.<sup>116</sup> Increasing the alkalinity of the external root surface may be advantageous, because polymorphonuclear leukocytes and osteoclasts function best at a slightly acidic pH, elaborating acid hydrolases, which leads to demineralization of hard tissue components and prevents formation of new hard tissue.<sup>102</sup> It has been suggested that if this pH change occurred in the periodontal membrane, external root resorption could result.<sup>117</sup> The mechanism of the recalcification and the role of calcium hydroxide are not completely understood.<sup>118</sup> Calcium hydroxide placed intracoronal has effectively treated cervical root resorption<sup>115,116</sup> but it has also been reported to be ineffective.<sup>119</sup> Intracoronal placement of calcium hydroxide following bleaching has been suggested.<sup>102,115</sup>

**Protective Base.** A 2- to 2.5-mm protective base<sup>119</sup> should be placed over the gutta-percha root canal obliteration; however, the literature is equivocal about the material of choice, its exact positioning and design, and even about its ultimate efficacy in preventing external cervical root resorption.

The dentinal tubules terminate at the external root surface at a point incisal to the level at which they leave the pulp chamber. The dentinal tubules progress in a slightly incisal direction from their point of origin at the pulp chamber to their point of termination at the external root surface. Some have advocated, therefore, that the protective base be placed at a point 1mm apical to the level of the cements-enamel junction,<sup>41</sup> slightly apical to the gingival margin,<sup>120</sup> or 1 mm incisal to the incisal extent of the epithelial attachment.<sup>120</sup> It has also been proposed that the base extend to a point corresponding to the level of the cements-enamel junction, and that if further cervical bleaching is necessary, the base outline can be gradually repositioned and bleaching can be continued with bleaching materials milder than 30% hydrogen peroxide.<sup>121</sup> It would seem reasonable, therefore, that the more coronally the base is placed, the less may be the chance of external cervical root resorption, but the greater the chance of esthetic compromise.<sup>122</sup> The practitioner must use clinical judgment on this point.

If the patient's lip covers a portion of the tooth during all functions, the base can be positioned even more coronally than the above landmarks.

**CLINICAL TIP.** If the gingival portion of the clinical crown is not visible during function or maximum smiling, the incisal termination of the base can be appropriately positioned to further reduce the chance of external cervical root resorption. Explaining this advantage may help the patient overcome psychologic ambivalence about possibly leaving a segment of the tooth unbleached. However, see the next Clinical Tip.

**CLINICAL TIP.** The position of the lip during maximum smiling (the high lip line) may be deceptive. Patients with unattractive smiles often habitually adapt a high lip line position that is significantly less revealing of tooth structure than is anatomically possible. After cosmetic improvement the high lip line may significantly elevate because the psychological barriers inhibiting full smiling have been removed.

The vertical height of the cemento-enamel junction, the epithelial attachment, and the marginal gingiva at the interproximal area generally is coronal to the level on the labial and lingual surfaces. The protective base should follow the outline of these incisogingival contours. It should extend to a level coronal to the marginal gingiva and cemento-enamel junction on the lingual or palatal aspect because this surface need not be bleached. A method of creating a base with a coronal contour that follows a specific design has been described.<sup>120</sup> The base resembles a bobsled tunnel mesiodistally and a ski slope buccolingually.<sup>120</sup> Glass ionomer cement<sup>9</sup> and polycarboxylate cement<sup>9</sup> have been suggested as protective base materials.

**Other Considerations.** Macrophages may play a role in external root resorption. It has been postulated that external root resorption is found infrequently when only **sodium perborate and water are used because sodium perborate has an inhibitory effect** on macrophage adhesion.<sup>122</sup>

**Proper Endodontic Treatment.** A properly sealed Endodontic filling is a prerequisite for bleaching. Silver points may be dislodged during the preparatory stages and must be replaced with gutta-percha prior to bleaching.

**Possible Future Materials.** A material containing the enzymes amylase, lipase, and trypsin with disodium edetate was found to be 40% as effective as hydrogen peroxide in lightening blood-stained teeth in vitro.<sup>98</sup>

#### Armamentarium

- Orabase Plain (Colgate-Hoyt Laboratories)
- Protective glasses for the patient and operator
- Medium or heavy rubber dam
- Rubber dam frame
- Rubber dam clamps
- Waxed dental floss
- Glass slab
- Cement spatula
- Periodontal probe
- Flat-ended "plastic" instrument
- Sodium perborate powder USP (e.g., Sultan, Inc.; also available at some local pharmacies)
- Temporary restorative material (e.g., Cavit, ESPE-Premier Sales Corp.; Provit, Svedia, USA)

- Calcium hydroxide powder USP (Eli Lilly & Co.)
- Sterile water (Abbott Laboratories)
- Material for protective base (e.g., polycarboxylate cement, glass ionomer cement)
- Toothbrush and toothpaste

#### Clinical Technique

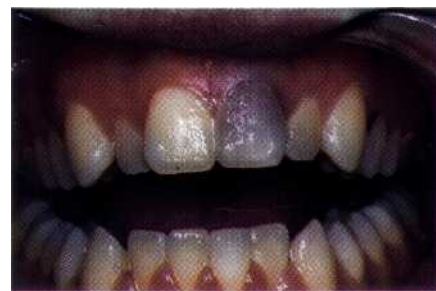1. Evaluate the high smile line.

**CLINICAL TIP.** The position of the lip during maximum smiling (the high lip line) may be deceptive. Patients with unattractive smiles often habitually adapt a high lip line position which is significantly less revealing of tooth structure than is anatomically possible. After cosmetic improvement the high lip line may significantly elevate because the psychological barriers inhibiting full smiling have been removed.

2. If the cervical area of the tooth remains hidden by the lip during maximum smiling and functioning, consult with the patient about bleaching only the visible portions of the crown.

**CLINICAL TIP.** If the gingival portion of the clinical crown is not visible during function or maximum smiling, the incisal termination of the base should be appropriately positioned to further reduce the chance of external cervical root resorption. Explaining this advantage may help the patient overcome psychological ambivalence about leaving a segment of the tooth unbleached.

3. Position the protective glasses over the patient's eyes.
4. Apply Orabase Plain to the labial and lingual (or palatal) gingiva.
5. Isolate the tooth with a rubber dam (Figs. 13-25, 13-26).
6. Apply additional Orabase Plain to the rubber dam and the tooth.



*Fig. 13-25. Preoperative view of staining caused by the deposition of hemorrhagic by-products into the dentinal tubules following pulpal trauma.*



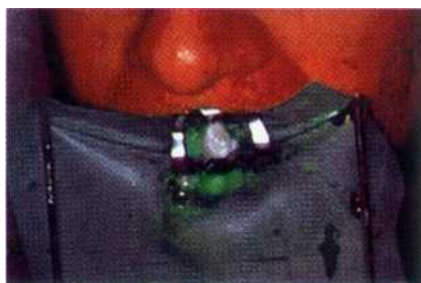

Fig. 13-26. Tooth after rubber dam isolation and placement of Orabase Plain.



Fig. 13-27. Occlusal view of access opening with gutta-percha in place. The appropriate amount of gutta-percha must be removed before the bleaching agent is placed in the chamber.

7. Remove the access restoration and any remaining pulp tissue from the crown (Fig. 13-27). Leave a slight undercut in the access opening to retain the temporary restorative material that will be placed later.

**CLINICAL TIP.** When performing initial endodontic therapy, carefully remove all tissue, debris, endodontic sealers, and filling materials from the sometimes elusive pulp horns and lateral extensions of the pulp chamber. This may help prevent subsequent tooth discoloration (see Fig. 13-7).

8. Remove excess gutta-percha and endodontic sealer. Remove gutta-percha to 2 to 2.5 mm gingival to the gingival-most point on the coronal extension of the planned base. (See the section on protective base earlier in this chapter.)

**CLINICAL TIP.** Select the landmark on the labial surface of the tooth that will determine the gingival-most point of the coronal surface of the planned base. Use a periodontal probe to measure the length on the labial surface of the tooth from the above point to a reference point on the incisal tip. Add a minimum of 2 mm to this measurement. Use this final measurement and incisal reference point intracoronally to determine the precise amount of gutta-percha to remove.

9. Place a 2- to 2.5-mm thick protective base that conforms to the predetermined design and location (see the section on protective base earlier in this chapter) as follows:
  - A. Measure the distance between a reference point on the incisal edge and the desired labial landmark (see the section on protective base earlier in the chapter).
  - B. Transfer this measurement intracoronally to determine the corresponding coronal positioning of the base.
  - C. Repeat steps A and B for locations between the midlabial and lateral extremes to create a base that conforms to the contour of the desired landmarks (see the section on protective base earlier in the chapter).
  - D. The palatal (lingual) extension of the base should be coronal to the corresponding palatal cemento-enamel junction and gingival margin (see the section on protective base earlier in the chapter).
  - E. The base should resemble a bobsled tunnel mesiodistally and a ski slope buccolingually.<sup>120</sup>

**CLINICAL TIP.** Because only the labial portion of the tooth must be bleached, extend the lingual and proximal portions of the base as coronally as possible. This may further reduce the chance of external cervical root resorption.

10. Mix a thick paste of sodium perborate and sterile water on a glass slab and place the mixture into the tooth.
11. Tamp the mixture into place with a moist cotton pellet so that appropriate space is provided for the temporary restorative material.

**CLINICAL TIP.** To ensure an intimate seal of the temporary restorative material, be certain that the walls of the access opening have been cleared of bleaching material.

12. Seal the access with temporary restorative material.
13. Schedule the next appointment for the patient for 3 days later.
14. If a successful result is achieved after 3 days, skip to step 16.
15. Isolate the tooth with rubber dam, remove the temporary filling, and carefully wash the internal tooth chamber with water. If a successful result has not been achieved after 3 days, repeat steps 10 through 14. After three attempts, the likelihood of further whitening generally is minimal.
16. Isolate the tooth with rubber dam, remove the temporary filling, and carefully wash the internal tooth chamber with water. Mix a thick paste of calcium hydroxide powder and sterile water and place the mixture into the tooth.

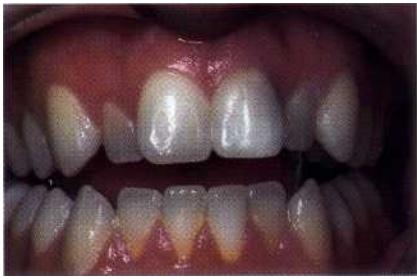

Fig. 13-28. Result 6 months after treatment.

17. Tamp the paste into place with a moist cotton pellet so that appropriate space is provided for the temporary restorative material.
18. Seal the access with temporary restorative material.
19. Schedule the next appointment for the patient for 7 to 14 days later.
20. After 7 to 14 days, remove the calcium hydroxide paste and restore the tooth (Fig. 13-28). (See the section on restorative implications under office bleaching ["power" bleaching] earlier in this chapter.)

**Restorative Implications.** For a discussion of restorative implications, see the section on restorative implications under office bleaching ("power" bleaching) earlier in this chapter.

**Postoperative Complications.** Because external cervical root resorption may occur even years after bleaching,<sup>91</sup> periodic follow-up radiographs are necessary. Cervical resorption has been treated with calcium hydroxide therapy,<sup>15,116</sup> although it has been suggested that this technique will be ineffective if there is communication between the oral cavity and the resorptive lesion.<sup>15</sup> It has also been suggested that calcium hydroxide therapy is ineffective (see the section on calcium hydroxide earlier in the chapter). Resorption also has been treated with surgical repair,<sup>TS</sup> orthodontic extrusion,<sup>115</sup> and surgical crown lengthening.<sup>115</sup>

## CONCLUSION

Bleaching agents or acid/abrasion techniques are effective, conservative approaches to the removal of unesthetic discolorations from vital and nonvital teeth. As with all types of therapeutic modalities, proper diagnosis and treatment planning are essential.

The author wishes to acknowledge the generous help of Dr. Ilan Rotstein, Professor and Acting Chairman, Department of Endodontics, Hebrew University-Hadassah Faculty of Dental Medicine, in the preparation of this chapter.

## REFERENCES

1. Panati C: Panati's extraordinary origins of everyday things, New York, 1987, Harper & Row.
2. Westlake A: Bleaching teeth by electricity, Am J Dent Sci 29:101, 1895.
3. Adams TC: Enamel color modifications by controlled hydrochloric acid pumice abrasion: a review with case summaries, Indiana Dent Assoc J 66:23, 1987.
4. Ames JW. Removing stains from mottled enamel, J Am Dent Assoc 24:1674, 1937.
5. Younger HB: Bleaching fluorine stain from mottled enamel, Texas Dent J 57:380, 1939.
6. McInnes J: Removing brown stain from teeth, Ariz Dent J 12:13, 1966.
7. Cohen BA, Parkins FM: Bleaching tetracycline-stained teeth, Oral Surg Oral Med Oral Pathol 19:465, 1970.
8. Schwachman H, Schuster A: The tetracyclines: applied pharmacology, Pediatr Clin North Am 3:295, 1956.
9. Albert A, Rees CW: Avidity of the tetracyclines for the cations of metals, Nature 177:433, 1956.
10. Finerman GAM, Milch RA: In vitro binding of tetracyclines to calcium, Nature 198:486, 1963.
11. Stewart DJ: The effects of tetracyclines upon the dentition, Br J Dermatol 76:374, 1964.
12. Weinstein L: Antimicrobial agents. In Goodman LS, Gilman A, editors: The pharmacologic basis of therapeutics, New York, 1975, Macmillan.
13. Sayegh FS, Gassner E: Sites of tetracycline deposition in rat dentin, J Dent Res 46:1474, 1967.
14. Sayegh FS: H3-proline and tetracycline as marking agents in the study of reparative dentine formation, Oral Surg 23:221, 1967.
15. Milch RA et al: Bone localization of the tetracycline, J Natl Cancer Inst 18:87, 1957.
16. Urist M, Ibsen K: Chemical reactivity of mineralized tissue with oxytetracycline, Arch Pathol 76:484, 1963.
17. Martin NO, Barnard PD: The prevalence of tetracycline staining in erupted teeth, Med J Aust 1:1286, 1969.
18. Bridges JB, Owens PDA, Stewart DJ: Tetracycline and teeth: an experimental investigation into five types in the rat, Br Dent J 1:306, 1969.
19. Walton RE et al: External bleaching of tetracycline stained teeth in dogs, J Endodont 8:536, 1982.
20. Stewart DJ: Teeth discolored by tetracycline bleaching following exposure to daylight, Dent Practitioner 20:309, 1969.
21. Lin LC, Pitts DL, Burgess LW: An investigation into the feasibility of photobleaching tetracycline-stained teeth, J Endodont 14:293, 1988.
22. Ibsen KH, Urist MR, Sognnaes RF: Differences among tetracyclines with respect to the staining of teeth, J Pediatr 67:459, 1988.
23. Wallman IS, Hilton HB: Teeth pigmented by tetracycline, Lancet 1:827, 1962.

24. Davies AK et al: Photochemical oxidation of tetracycline in aqueous solution, *J Chem Soc Perkin Trans 2*:369, 1979.
25. Davies AK et al: Photo-oxidation of tetracycline adsorbed on hydroxyapatite in relation to the light-induced staining of teeth, *J Dent Res* 65:936, 1985.
26. Moffitt JM et al: Prediction of tetracycline-induced tooth discoloration, *J Am Dent Assoc* 88:547, 1974.
27. Genet MT Effects of administration of tetracycline in pregnancy on the primary dentition of the offspring, *J Oral Med* 25:75, 1970.
28. Swallow JN: Discoloration of primary dentition after maternal tetracycline ingestion in pregnancy, *Lancet* 2:611, 1964.
29. Grossman ER, Walchek A, Freeman H: Tetracycline and permanent teeth: the relation between dose and tooth color, *Pediatrics* 47:567, 1971.
30. Wehman J, Porteous JR: Tetracycline staining of teeth: a report of clinical material, *J Dent Res* 42:1111, 1963.
31. Eisenberg E, Bernick SM: Anomalies of the teeth with stains and discolorations, *J Prevent Dent* 2:7, 1975.
32. McEvoy SA: Chemical agents for removing intrinsic stains from vital teeth. II. Current techniques and their clinical application, *Quintessence Int* 20:379, 1989.
33. Jordan RE, Boksmann L: Conservative vital bleaching treatment of discolored dentition, *Compend Contin Ed Dent* 5:803, 1984.
34. Stewart, RE, et al: Pediatric dentistry, St Louis, 1982, Mosby, p 87.
35. Swift EJ: A method for bleaching discolored vital teeth. *Quintessence Int* 19:607, 1988.
36. US Department of Health and Human Services, Public Health Service: Review of fluoride: benefits and risks, Report of the Ad Hoc Subcommittee on Fluoride, Washington, DC, February 1991.
37. McEvoy SA: Chemical agents for removing intrinsic stains from vital teeth. I. Technique development, *Quintessence Int* 20:323, 1989.
38. Dunn JR: Dentist-prescribed home bleaching: current status, *Compend Contin Educ Dent* 18:760, 1998.
39. McEvoy SA: Combining chemical agents and technique to remove intrinsic stains from vital teeth, *Gen Dent* 46:168, 1998.
40. Grossman LI, Oliet S, del Rio CE: Endodontic practice, ed 11, Philadelphia, 1988, Lea & Febiger.
41. Ho S, Goerig AC: An in vitro comparison of different bleaching agents in the discolored tooth, *J Endodont* 15:106, 1989.
42. Imber S, Gorfil C: A one visit bleaching technique for the endodontically treated tooth, *Refuat Hoshinayim* 4:7, 1986.
43. Crane DL: The walking bleach technique for endodontically treated teeth, *Chi Dent Soc Rev* 77:49, 1984.
44. Gutierrez J, Guzman M: Tooth discoloration in endodontic procedures, *Oral Surg* 26:706, 1968.
45. Nutting EB, Poe GS: Chemical bleaching of discolored endodontically treated teeth, *Dent Clin North Am* 11:655, 1967.
46. Sommer FS, Ostrander FD, Crowley ML: Clinical endodontics, ed 3, Philadelphia, 1966, WB Saunders.
47. Van der Burgt TP, Plasschaert AJM: Bleaching of tooth discoloration caused by endodontic sealers, *J Endodont* 12:231, 1986.
48. Andreasen JO et al: The effect of traumatic injuries to the primary teeth on their permanent successors: a **clinical and histologic study of 117 injured permanent teeth**, *Scand J Dent Res* 79:219, 1971.
49. McEvoy SA: Bleaching stains related to trauma or periapical inflammation, *Compend Contin Ed Dent* 7:420, 1986.
50. Croll TP: Enamel microabrasion for removal of superficial dysmineralization and decalcification defects, *J Am Dent Assoc* 120:411, 1990.
51. Shafer WG, Hine MK, Levy BL: A textbook of oral pathology, ed 3, Philadelphia, 1974, WB Saunders.
52. Finn SB: Clinical pedodontics, ed 4, Philadelphia, 1973, WB Saunders.
53. Faunce F: Management of discolored teeth, *Dent Clin North Am* 27:657, 1983.
54. Feinman RA, Goldstein RE, Garber DA: Bleaching teeth, Chicago, 1987, Quintessence.
55. Goldstein RE: Bleaching teeth: new materials, new role, *J Am Dent Assoc* 115:44E, 1987.
56. Waggonner WF et al: Microabrasion of human enamel in vitro using hydrochloric acid and pumice, *Pediatr Dent* 11:319, 1989.
57. Croll TP, Cavanaugh RR: Enamel color modification by controlled hydrochloric acid-pumice abrasion. II. Further examples, *Quintessence Int* 17:157, 1986.
58. Bailey RW Christen AG: Effects of a bleaching technique on the labial enamel of human teeth stained with endemic dental fluorosis, *J Dent Res* 49:168, 1970.
59. Griffen RE et al: Effects of solutions used to treat dental fluorosis on permeability of teeth, *J Endodont* 3:139, 1977.
60. Baumgartner JC, Reid DE, Pkett AB: Human pulpal reaction to the modified McInnes bleaching technique, *J Endodont* 9:527, 1983.
61. Olin PS, Lehner CR, Hilton JA: Enamel surface modification in vitro using hydrochloric acid pumice: an investigation, *Quintessence Int* 19:733, 1988.
62. Bailey RW Christen AG: Bleaching of vital teeth stained with endemic dental fluorosis, *Oral Surg* 26:871, 1968.
63. Colon PG: Improving the appearance of severely fluorosed teeth, *J Am Dent Assoc* 86:1329, 1973.
64. Colon PG: Removing fluorosis stain from teeth, *Quintessence Int* 2:89, 1971.
65. Douglas WA: A history of dentistry in Colorado: 1859-1959, *J Col State Dent Assoc* 38:19, 1960 (book review).

66. McCloskey RJ: A technique for removal of fluorosis stains, *J Am Dent Assoc* 109:63, 1984.
67. McMurray CA: Removal of stains from mottled enamel of teeth, *Texas Dent J* 59:293, 1941.
68. Raper HR, Manser JG: Removal of brown stain from fluorine mottled teeth, *Dent Digest* 47:390, 1941.
69. Smith HV, McInnes JW: Further studies on methods of removing brown stain from mottled teeth, *J Am Dent Assoc* 29:571, 1942.
70. Wayman BE, Cooley RL: Vital bleaching technique for treatment of endemic fluorosis, *Gen Dent* 29:424, 1981.
71. Croll TP: Enamel microabrasion: observations after 10 years, *J Am Dent Assoc (supplement)* 128:45S, 1997.
72. McEvoy SA: Removing intrinsic stains from vital teeth by microabrasion and bleaching, *J Esthet Dent* 7:1006, 1995.
73. Coll JA, Jackson P, Strassler HE: Comparison of enamel microabrasion techniques: Prema Compound versus a 12-fluted finishing bur, *J Esthet Dent* 3:180, 1991.
74. Croll TP, Cavanaugh RR: Enamel color modification by controlled hydrochloric acid-pumice abrasion. 1. Technique and examples, *Quintessence Int* 17:81, 1986.
75. Feinman RA, Madray G, Yarborough D: Chemical optical and physiologic mechanisms of bleaching products: a review, *Pract Periodont Aesthetics* 3:32, 1991.
76. Loudon GM: *Organic chemistry today*, Reading, Mass, 1984, Addison-Wesley.
77. Arwill T et al: Penetration of radioactive isotopes through the enamel and dentine. II. Transfer of  $^{22}\text{Na}$  in fresh and chemically treated dental tissues, *Odontol Rev* 20:47, 1969.
78. Christensen GJ: Bleaching vital tetracycline-stained teeth, *Quintessence Int* 9:13, 1978.
79. Ingle JI, Taintor JF: *Endodontics*, ed 3, Philadelphia, 1965, Lea & Febiger.
80. Reid JS, Newman P: A suggested method of bleaching tetracycline-stained vital teeth, *Br Dent J* 142:261, 1977.
81. Wilson CF, Seale NS: Color change following vital bleaching of tetracycline-stained teeth, *Pediatr Dent* 7:205, 1985.
82. Goldstein RE: In-office bleaching: where we came from, where we are today, *J Am Dent Assoc (supplement)* 128:11S, 1997.
83. Garber DA: Dentist-monitored bleaching: a discussion of combination and laser bleaching, *J Am Dent Assoc (supplement)* 128:26S, 1997.
84. Titley KC et al: Adhesion of composite resin to bleached and unbleached bovine enamel, *J Dent Res* 67:1523, 1988.
85. Titley KC et al: Scanning electron microscopy observations on the penetration and structure of resin tags in bleached and unbleached bovine enamel, *J Endodont* 17:72, 1991.
86. Torneck CD et al: The influence of time of hydrogen peroxide exposure on the adhesion of composite resin to bleached bovine enamel, *J Endodont* 16:123, 1990.
87. Heymann H: Nonrestorative treatment of discolored teeth: reports from an international symposium, *J Am Dent Assoc (supplement)* 128:Introduction, 1997.
88. Swift E: Restorative considerations with vital tooth bleaching, *J Am Dent Assoc (supplement)* 128:60S, 1997.
89. Swift EJ, Perdigao J: Effects of bleaching on teeth and restorations, *Compend Contin Educ Dent* 19:815, 1998.
90. Haywood V: Nightguard vital bleaching: current concepts and research, *J Am Dent Assoc (supplement)* 128:19S, 1997.
91. Tooth bleaching, home use products: update report, *Clinical Research Associates Newsletter* 13(12), 1989.
92. Ploeger BJ et al: Quantitative in vivo comparison of five carbamide peroxide bleach gels, Abstract No 889, *J Dent Res* 70:376, 1991.
93. Burrell K: ADA supports vital tooth bleaching-but look for the seal, *J Am Dent Assoc (supplement)* 128:3S, 1997.
94. Berry JH: What about whiteners? Safety concerns explored, *J Am Dent Assoc* 121:223, 1990.
95. Weitzman SA et al: Effects of hydrogen peroxide on oral carcinogenesis in hamsters, *J Periodontol* 57:685, 1986.
96. Instructions for use of Opalescence, Ultradent, Inc, (product received American Dental Association Seal of Acceptance), South Jordan, UT.
97. Rotstein I, Lehr Z, Gedalia I: Effect of bleaching agents on inorganic components of human dentin and cementum, *J Endodont* 18:290, 1992.
98. Marin PD, Heithersay GS, Bridges TE: A quantitative comparison of traditional and nonperoxide bleaching agents, *Endod Dent Traumatol* 14:64, 1998.
99. Bhaskar SN, editor: *Orban's oral histology and embryology*, ed 11, St Louis, 1999, Mosby.
100. Lado EA, Standley HR, Weisman MI: Cervical resorption in bleached teeth, *Oral Surg* 55:78, 1983.
101. Harrington GM, Natkin E: External resorption associated with bleaching of pulpless teeth, *J Endodont* 5:344, 1979.
102. Kehoe JC: pH reversal following in vitro bleaching of pulpless teeth, *J Endodont* 13:6, 1987.
103. Freccia W et al: An in vitro comparison on nonvital bleaching techniques in the discolored tooth, *J Endodont* 8:70, 1982.
104. Heithersay GS: Invasive cervical resorption: an analysis of potential predisposing factors, *Quintessence Int* 30:83, 1999.
105. Rotstein I et al: In vitro efficacy of sodium perborate preparations used for intracoronal bleaching of discolored nonvital teeth, *Endod Dent Traumatol* 7:177, 1991.
106. Weiger R, Kuhn A, Lost C: In vitro comparison of various types of sodium perborate used for intracoronal bleaching of discolored teeth, *J Endodont* 20:338, 1994.
107. Rotstein I, Mor C, Friedman S: Prognosis of intracoronal bleaching with sodium perborate preparation in vitro: 1-year study, *J Endodont* 19:10, 1993.

108. Rotstein I et al: Histological characterization of bleaching-induced external resorption in dogs, *J Endodont* 17:436, 1991.
109. Baratieri LN et al: Nonvital tooth bleaching: guidelines for the clinician, *Quintessence Int* 26:597, 1995.
110. Abbott PV Aesthetic considerations in endodontics: internal bleaching, *Practic Periodontol Aesthet Dent* 9:833, 1997.
111. Horn DJ, Hicks ML, Bulan-Brady J: Effect of smear layer removal on bleaching of human teeth in vitro, *J Endodont* 24:791, 1998.
112. Casey LJ et al: The use of dentinal etching with endodontic bleaching procedures, *J Endodont* 15:535, 1989.
113. Tronstad L et al: pH changes in dental tissues after root canal filling with calcium hydroxide, *J Endodont* 2:17, 1981.
114. Fuss Z, Szajkis S, Tagger M: Tubular permeability to calcium hydroxide and to bleaching agents, *J Endodont* 15:362, 1989.
115. Gimlin DR, Schindler G: The management of post-bleaching cervical resorption, *J Endodont* 16:292, 1990.
116. Montgomery S: External cervical resorption after bleaching a pulpless tooth, *Oral Surg Oral Med Oral Pathol* 57:203, 1984.
117. Latcham NL: Postbleaching cervical resorption, *J Endodont* 12:262, 1986.
118. Friedman S: Surgical-restorative treatment of bleaching-related external root resorption, *Endod Dent Traumatol* 5:63, 1989.
119. Rotstein I: Personal communication, e-mail, July 22, 1999.
120. Steiner DR, West JD: A method to determine the location and shape of an intracoronal bleach barrier, *J Endodont* 20:304, 1994.
121. Rotstein I et al: Effect of different protective base materials on hydrogen peroxide leakage during intracoronal bleaching in vitro, *J Endodont* 18:114, 1992.
122. Jimenez-Rubio A, Segura JJ: The effect of the bleaching agent sodium perborate on macrophage adhesion in vitro: implications in external cervical root resorption, *J Endodont* 24:229, 1998.



# IV

SECTION FOUR

---

## ESTHETICS AND OTHER CLINICAL APPLICATIONS



انتشارات شایان نمودار

# ESTHETICS AND ORAL PHOTOGRAPHY

Kenneth W Aschheim and Mark P King

**D**ental photography has always been an important potential adjunct to dental records. However, before the advent of recent esthetic procedures, the dental camera could have been considered a dispensable item. With today's technologic advances and the proliferation of new procedures, yesterday's luxury item, the 35-mm dental camera or the digital camera, has become part of today's indispensable armamentarium.

With the advent of computers, digital cameras, and color printers, the use of film as a storage medium is on the decline. However, it is unclear how rapidly this transition will occur, because digital cameras have not been able to reproduce the quality and convenience of conventional photography. A full understanding of conventional photography allows the dentist to better understand the limitations of digital photography (see the section on digital cameras later in this chapter).

## HISTORY OF CONVENTIONAL PHOTOGRAPHY

In the early half of the twentieth century, dental photography was limited to the professional photographer's studio. Before the early 1960s, dental photography was impractical because of a lack of proper through-the-lens viewing, lighting complications, exposure difficulties, and affordability.

The first 35-mm single lens reflex (SLR) camera became available just before World War II. These cameras, which incorporate a mirror and a prism, allow the photographer to see the same image that the lens is "viewing" (Figs. 14-1 and 14-2). Non-SLR cameras (called range

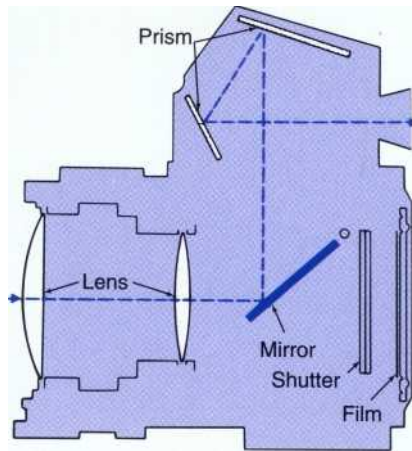
finder cameras) use a viewing window located 3 to 4 inches above the film plane. This means that the image the viewer sees and the image the film exposes are not identical. This problem is referred to as parallax, and it makes accurate closeup dental photography impossible (Fig. 14-3).

A camera system that is practical for use in dentistry must be lightweight, have adequate lighting mounted on the end of the lens barrel, be automatic enough to factor out most of the technical problems for the user, have a high degree of image-accuracy, and be affordable. Most of these problems were not solved until the advent of the bellows system in the early 1960s. This camera has a short-mount lens attached to an accordion-like tube that expands and contracts to achieve the desired magnification. The automatic macro lens was soon developed as a more practical approach than the racking system of the bellows.

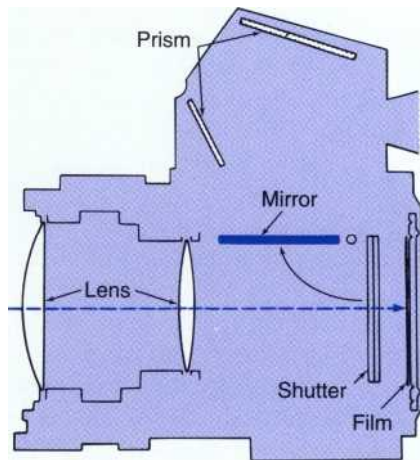
Today, the basic high quality conventional closeup camera system is composed of a 35-mm SLR camera body, a macro lens (or a short-mount lens for the bellows system) in the 100-mm range, a ring light or point source flash mounted on the end of the lens barrel, and a power source, either separate or encased in the light unit. Modern through-the-lens metering systems automatically determine the proper setting for a given film type and lighting condition and some are autofocus. Electronic cameras remove almost all manual control of the parameters of photography. The operator has only to shoot to produce good, accurate dental photographs.

Automatic focus 35-mm SLR cameras have become less expensive and have improved in accuracy. However, the combined costs of the automatic camera and the

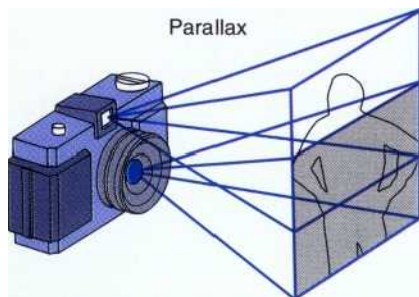




*Fig. 14-1.* A single lens reflex (SLR) camera with the mirror in the view-finding position. In this position the mirror and prism mechanism allows the viewer to see the exact same image as the camera lens.



*Fig. 14-2.* An SLR camera with the mirror in the "exposing" position. In this position the mirror is lifted out to allow light to expose the film.



*Fig. 14-3.* The parallax problem of range finder (any non-SLR) cameras.

automatic lens still make these units expensive compared with most manual focus systems. If the clinician is willing to accept a unit that requires some manual input, manual focus cameras give extremely satisfying results at an affordable price.

## USES OF DIGITAL AND CONVENTIONAL DENTAL PHOTOGRAPHY

### Quality Control

Dental photography can be an effective quality control measure. The magnified image in a dental photograph often highlights imperfections that the clinician may have overlooked; such feedback is an excellent learning device.

### Patient Records

Photographs are an effective treatment planning adjunct. With a thorough medical history, intraoral charting, study models, radiographs, and intraoral and extraoral photographs, the treatment planning may be accomplished almost as if the patient were present. In addition, attaching a photograph to the outside of the patient's record facilitates instant recall of that patient by all staff members.

### Case Presentation

Photographs of the patient's current condition enhance the patient's understanding of a proposed treatment plan, especially when accompanied by a portfolio of before and after photographs of similar, successfully treated cases. In addition, the acceptance of treatment plans may increase through this approach. Digital photographs combined with the proper software can even be used to predict clinical results (see Chapter 24).

### Treatment Documentation

Before and after photographs provide accurate visual documentation. The dentist should obtain a release from the patient to display these photographs (especially full face photographs) for any other purpose (see Appendix D).

### Laboratory Communication

A color photograph or slide of the restorative case facilitates communication with the laboratory. Photographing the shade tab adjacent to the teeth to be restored makes the chances of success higher. A good camera and Kodachrome 64 film will not capture the subtle differences between shades with 100% accuracy, but the important parameter is the shade of the tab relative to the shade of the tooth. When the laboratory technician compares the



actual tab with the photograph, appropriate adjustments can be made. If the image is converted into electronic form, the information can be sent to the laboratory via a modem.

### Insurance

Submitting color prints for insurance claims may increase the chances of treatment plan acceptance. Often the condition in question is not radiographically evident, although a color photograph presents the situation clearly. A claim can be made for reimbursement for the photographs just as for radiographs (American Dental Association [ADA] Code 00471).

### Education

Photography can be used for conferring with a colleague or for lecturing at dental meetings or study clubs, or in table clinics. It can be used in publications or, as mentioned above, in patient consultation. Again, a signed release is necessary before any such use of photographs.

### Community Service

Presentation to local organizations raises the dental health consciousness of the community, improves the image of the profession, and expands the dentist's future patient base by creating a greater awareness of advances in dentistry.

### Marketing

Photography has a tremendous capacity to help any dental practice grow more effectively through internal and external marketing. Just being photographed may make a patient feel more important. After treatment has been completed, before and **after color prints** can be sent in attractive and inexpensive frames. Before and after photographs of some dramatic esthetic cases can be included in a patient newsletter. Representative esthetic cases can be illustrated in a three-panel brochure format fairly inexpensively and purchased in small quantities. These can then be mailed to individuals in the community, as well as given to patients who visit the office. Photographs significantly enhanced the effectiveness of a practice's web site (see the section on the Internet in Chapter 26).

Children in the practice can be rewarded for good oral hygiene by having their pictures placed on a bulletin board in the waiting room. Displays of representative cases can be placed throughout the office to be seen by other patients.

Presentations to civic clubs and other organizations are greatly enhanced when slides and photographs are used.

If the practitioner involves the staff in this area of the practice, the collective creative capacity of the group can be tapped.

### Medicolegal Concerns

Any and every form of record keeping is vital for defense litigation. Color photographs can be critical in esthetic treatments because the quality of the end result is subjective.

## BASIC PRINCIPLES

### Terminology

It is possible to use equipment that is so automated the operator needs no particular knowledge to achieve the desired results. However, knowledge of the workings of the camera, whether digital or conventional, is advantageous (Fig. 14-4). Some elements are common to both, whereas others are unique.

**Shutter** The shutter is a device inside a conventional camera body that opens and closes, allowing light to strike the film for a selected period of time. This predetermined period is referred to as shutter speed. The various shutter speeds are indicated on a dial located on the camera body. Each shutter speed is exactly one half the speed of the next highest one on the dial. In dental photography, a flash is used to produce the necessary light. In flash photography, only a single, predetermined synchronized shutter speed is used for proper exposures. This usually is indicated either by a different color on the dial or by a broken arrow. This speed usually is  $1/125$  or  $1/60$  of 1 second and is indicated on a dial or readout on the camera body. This eliminates one of the variables the operator must control to achieve the desired quality of the resulting image. In closeup photography, most of these variables are preset, and therefore little manipulation of the

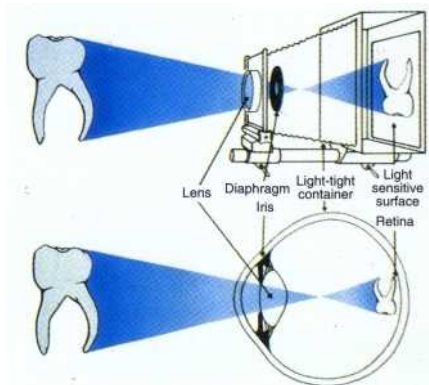


Fig. 14-4. An SLR camera mechanism "sees" in a manner similar to the human eye.

camera system is necessary to achieve quality in the finished product. Digital cameras do not have shutters in the mechanical sense; instead, the shutter speed is controlled electronically.

**Aperture** The aperture is an opening inside the lens that controls the amount of light that strikes the film. The terms "aperture setting," "aperture size," and "f-stop" are synonymous. These terms refer to the size of the opening of the aperture selected by the operator (or by the camera in a fully automated system) (Fig. 14-5). The various aperture settings are indicated on a dial on the lens or on a display on the camera body. Each change in the aperture settings allows exactly one half the amount of light to reach the film as the next larger size aperture on the dial. However, the larger the aperture, the smaller the corresponding f-stop number, which indicates the amount of opening. This is because the f-stop number is a ratio of the focal length of the lens to the diameter of the opening at a particular f-stop. In dental photography the usual images are close up or full face, therefore only two aperture settings are necessary, again factoring out most of the variables. Fully automated systems set these openings for the operator, which means the operator need have no knowledge whatsoever of this function.

The sometimes confusing relationship between f-stop number and shutter speed is easily clarified by using the analogy of a water faucet. If the handle controlling the length of time the faucet remains on is likened to the shutter in the camera, and the size of the opening of the faucet through which the water runs is likened to the aperture size, it is immediately apparent that the amount of water that exits the system is a result of two variables. When the circular opening of the faucet is left open for 2 seconds, a specific volume of water is collected. If the opening is reduced to one half that size, the faucet would have to remain on for twice as long (i.e., 4 seconds) to collect the same volume of water. Therefore the total volume of water collected is controlled by the total area of the size of the opening and the length of time the orifice is allowed to remain open. This is exactly how the camera and lens system works to control the amount of light that reaches the film. Because the shutter speeds are re-

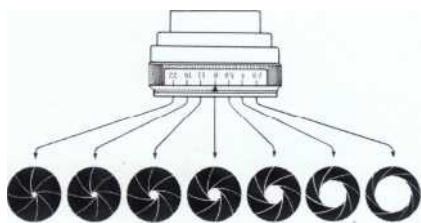


Fig. 14-5. F-stop numbers are inversely related to the size of the aperture; that is, a lower number means a larger opening.

lated by increments of two when traveling up or down the dial and the aperture settings are also related by increments of two, several combinations of shutter speed and aperture size result in exactly the same amount of light reaching the film. Digital cameras have an electronic aperture that controls the amount of light reaching the sensor (electronic "film").

**Focus** Focus refers to the degree of clarity of the image on the film. This clarity is controlled in one of two ways. If the operator wishes to have a uniform magnification of all the photographs in a series, the magnification is chosen and the focus is adjusted by moving the camera away from or closer to the subject until the image is in focus. The chosen magnification remains unchanged. If this uniformity is not important, focus is achieved by rotating the lens barrel. Digital cameras, which use conventional lenses, require focusing in a similar manner.

**Lens** The lens refers to the barrel mounted on the camera body, which houses the lens optics that control the focus of the image on the film. Dental photography, whether conventional or digital, requires a macro lens to achieve closeup images. The term *macro lens* refers to a closeup lens. (See the section on macro lens later in this chapter.)

**Focal Length** The focal length of a lens is the distance from the film to the optical center of the lens, measured in millimeters (Fig. 14-6). For all practical purposes, this optical center coincides with a point at the center of the aperture. For the most accurate images in conventional dental closeup photography, the appropriate focal lengths are 90 to 120 mm for 35-mm cameras and 60 to 80 mm for APS cameras. (See the section on advanced photo system later in this chapter.)

**Film Speed** The term *film speed* refers to the relative sensitivity of the film to the available light. The higher the film speed, the more sensitive the film is to the light. For example, a film speed of 64 requires less light for the desired exposure than one of 25. A lower film speed produces less graininess in the finished photograph, therefore the lowest film speed that will render the desired result is preferred. Flash photography is best used with film speeds made to simulate daylight situations. The appropriate film speeds are ASA 100 or less. The film speed is indi-

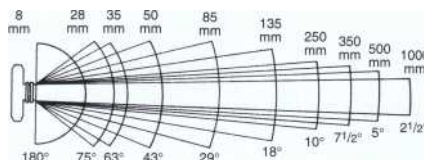


Fig. 14-6. A representative range of focal lengths of various lenses used in photography.

cared on the film by the designation ASA, ISO, or DIN. These abbreviations refer to the international organizations that control these parameters of film production. (See the section on film later in this chapter.)

**DX Settings** All currently manufactured 35-mm film has DX encoding printed on its outer case. These markings, similar to the "bar codes" found on most consumer products, represent the exact ASA rating of the film. DX-capable cameras automatically scan this code.

**Exposure** *Exposure* refers to the amount of light that must reach the film to produce a proper photograph. This single most important principle of photography is controlled by four factors, and it determines the success of the end results. The four factors are shutter speed, aperture size, light source, and film speed.

As previously discussed, several combinations of aperture settings and shutter speeds can result in the same amount of light entering the camera. When photographing in natural lighting, this is important; however, in flash photography, the shutter speed is fixed because it must be synchronized with the camera flash. Therefore only the aperture can be varied. A full face photograph requires more light than a closeup because the film is farther from the subject. This means that a larger aperture size (smaller f-stop number) is required for the full face photograph than for the closeup. An average range is f22 for the closeup and f5.6 for the full face. The f-stop for any particular camera can be one f-stop on either side of these numbers, depending on the camera, film, film speed, type of macro lens, light source, and possible use of filters.

**Light Source** The third factor affecting exposure is the light source. In closeup photography, the usual light source is either a point source or a ring light (Fig. 14-7). The point source is mounted on a rotating bracket on the end of the lens. It is rotated around the lens to achieve the most advantageous lighting for each photograph.



Fig. 14-7. Lester Dine Nikon N70 body with a modified Kiron 105-mm lens with both a point source and a ring light.

Generally, this type of flash creates a visual environment that is similar to natural light, producing an image with more shadows and with greater depth, contrast, and texture. The operator must be completely familiar with the proper position for the point light, or an entire series of photographs can be ruined. This can be very disconcerting, because the practitioner does not always have a second chance.

The other type of flash lighting used in closeup photography is the ring light. The ring light completely encircles the end of the lens barrel and gives more even lighting, resulting in a flatter surface with less depth, **contrast, and texture**. The major advantage of the ring light is that its position remains unchanged, resulting in one less variable for the operator to control.

No consensus has been reached regarding the light source to choose for dental use. The operator should make an informed choice and please only himself or herself. Fortunately, some suppliers offer both light sources with their standard systems because in some clinical situations, one is preferred over the other.

At least one company, Nikon, offers a graded ring flash unit. One side of the ring flash produces more light than the other, resulting in an image with all the elements of even lighting, depth, contrast, and texture. **Minnolta's Maxxum ring flash has switches that individually control the left, right, top, and bottom tubes.** The Maxxum automatically increases the total light output to compensate for any tubes that are turned off. If only a single tube is left on, the system acts as a point flash. (These units are discussed in a subsequent section.)

Altering any of the above variables can achieve any combination of results, from completely natural appearing photographs to surrealistic images. In flash photography the only variable that can be changed is the aperture setting. The single shutter speed is determined by the manufacturer and is never changed. The flash unit produces a set amount of light, and the film speed setting on the camera should never differ from the speed indicated on the film itself.

**Depth of Field** The depth of field is the range of distance from the lens within which objects appear in focus (Figs. 14-8 and 14-9). In dental photography, the more



Fig. 14-8. Small depth of field, large aperture size (f12.8).



44). Large depth of field, small aperture size

(f/32).

depth of field achieved, the sharper the image in front of and behind the specific object being focused on. In flash photography the two variables that control depth of field are the aperture size and the distance from the focused image. The smaller the aperture (larger f-stop) and the greater the distance from the focused image, the more depth of field. Because closeups have a very bright light source, smaller openings can be used. This results in the maximum depth of field appearing on the photographs where it is desired. As the operator moves farther from the subject for full face photographs, the lighting requirements demand a larger aperture size, but the greater distance from the image helps compensate for this larger opening, thus maintaining good depth of field. To achieve the maximum depth of field, the photographer should focus one third the distance into the desired depth of field.

**Magnification** Magnification indicates the relationship between the size of the image on the film and the size of the actual image. These relationships are expressed in ratios. If the size of the photographed image on the film is exactly the same as the actual image, the magnification is 1:1. A magnification of 1:2 means the image on the film is one half the actual size of the object. Most closeups are taken at approximately 1:1.2 or 1:1.5, and full face views usually are in the 1:8 to 1:10 range. Uniform magnification should be used when documenting various stages of a dental case, because this makes viewing these photographs much easier. Most cameras have magnification indicator markings.

**Composition** The term composition simply refers to the content of the photograph. The image should contain only those items intended for viewing. Often magnification is the only variable that needs to be changed to achieve proper composition. Superfluous objects in slides or prints are very distracting.

**Advanced Photo System** In response to advances in digital technology, a new film format called the Advanced Photo System (APS) was developed by a consortium of film manufacturers. When matched with a new

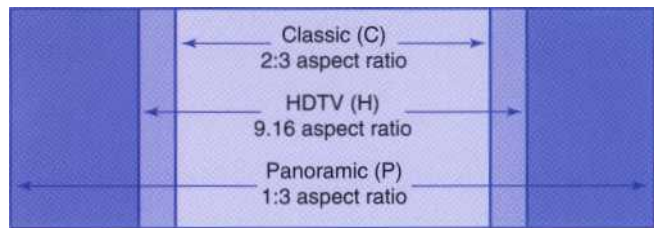


Fig. 14-10. APS film has three different film aspect ratios, a "C" (Classic) format (2 x 3 aspect ratio), an "H" (HDTV or "Group") format (9 x 16 aspect ratio), and a "P" (Panoramic) format (1 x 3 aspect ratio).

APS camera and processing system, this film incorporates several new technologic features. For example, a new "drop-in" film cartridge eliminates the film leader and the need to thread film. An "automatic reject device" prevents accidental loading of exposed or processed film, eliminating double exposures. The cartridge allows unlimited rewinding of the film, enabling the changing of film midroll as subjects and lighting conditions warrant. Cartridges are available in 15, 25, and 40 exposures.

APS film is smaller than standard 35-mm film. The negative format of APS film is 24-mm wide, with an image size of 16.7 x 30.2 mm, compared with 35-mm film that is 35-mm wide and has an image size of 24 x 36 mm. However, manufacturers claim that advances in film emulsion technology have eliminated any degradations of image quality caused by the smaller film area when the APS film is enlarged to 35-mm print size.

Exposure information is stored magnetically on a thin layer on the back of the film and optically on the film emulsion. This information, called Picture Quality Information Exchange (PQIX), or simply IX, records the selected picture size (see below), the light source used (natural light or flash), and the date, time, and optional titles from the "data back" of the camera. Film manufacturers claim that photofinishing equipment can use the IX exposure information to make adjustments that improve the quality of the photographs.

APS cameras and films have three different film sizes or aspect ratios (Fig. 14-10): a "C" (Classic) format, with a 2 x 3 aspect ratio that is similar to a standard 35-mm print; an "H" (HDTV or "Group") format, with a 9 x 16 aspect ratio; and a "P" (Panoramic) format, with a 1 x 3 aspect ratio. The user selects the desired size, and the choice is encoded on the film to ensure the return of the correct photograph size. However, because the widest P format is always recorded on the film, the user can later have reprints made in a different format.

APS film is returned from the processor along with a thumbnail-sized image color "proof" sheet (index print). The index print, the film cassette, and the back of each

*Photo CD master disk resolutions.*

Base level	Resolution	Type
Base*16	1024 × 1536 pixels	HDTV (high resolution)
Base*4	512 × 768 pixels	HDTV (medium resolution)
Base	256 × 384 pixels	NTSC (TV resolution)
Base/4	128 × 192 pixels	Thumbnail
Base/16	16 × 24 pixels	Small thumbnail

print have the same identification number, which makes reprint ordering simple.

Current APS systems have only limited usefulness in dentistry. Because APS was designed for the consumer market, APS films are limited to color photographs; no slide (reversal) films are currently available. Also, only a few APS cameras have interchangeable lenses. However, should the APS format gain in popularity, more of these products will become available.

**Photo CD System** In the late 1980s, Kodak released a digital standard to deliver 35-mm photographic images on compact disk (CD-ROM). A CD player displays photographic-quality images on home televisions, or a CD-ROM-XA drive displays them on a computer. The photograph is released in five different resolutions (Table 14-1). The acceptance of this format in the consumer market has been limited, but it has had some degree of success in the professional and computer market. With the convergence of photography and computer technology, Photo CD could increase in popularity.

## DIGITAL CAMERAS

Despite recent advances in film photography, film as an image storage media is being challenged by digital photography, in which the image is stored on magnetic or optical storage devices. (See Chapter 24 for a complete discussion of intraoral imaging systems and computer imaging systems.)

Digital photography has both advantages and disadvantages. Some of the advantages are:

- Instant photographs are produced.
- Material costs are lower.
- The need to develop film is eliminated.
- Images can be previewed before the picture is taken.
- Only desired images are printed.
- Instant image duplication is possible without degradation of images.
- Images can be manipulated by computer.
- Images can be transmitted over telephone lines.
- Images can be placed on the Internet.



*Fig. 14-11. A digital camera modified for dental use. (Courtesy SciCam, Inc.)*

- Waste is reduced because poor images can be deleted.
- Some of the disadvantages are:
- A significant learning curve is involved.
  - Startup costs are higher than conventional photography.
  - Additional time is required for the operator to print pictures.
  - The risk of data loss is greater because no hard copy exists unless a printed copy is produced. (However, see the next disadvantage.)
  - Printers cannot create "archive quality" images.
  - The resolution is lower than with standard film.
  - The technology is still evolving.

Despite its disadvantages, digital photography is increasing in popularity. Many manufacturers are modifying standard digital cameras for dental use (Fig. 14-11). (See the following section and Chapter 24 for a complete discussion of digital cameras.)

## OTHER METHODS OF DIGITIZING FILM

Digital cameras use an electronic sensor to replace film. Digital scanners reflect a light off a photograph and onto a charged couple device (CCD), which transmits the information to a computer. Specialized scanners (or specialized attachments to standard scanners) can similarly scan radiographs and slides.

## Summary

Optimal photographs can be produced if the clinician has a proper understanding of the equipment and the mechanisms of photography. Proper film selection, correct exposure, depth of field, and composition are essential. When a flash is used as a light source, the process is significantly simplified because most other variables cannot be altered; exposure is controlled only by the aperture setting, depth of field is automatically determined by the chosen focus point, and composition and magnification are determined by personal preference. Attention to these easily controlled variables makes dental photography simple and satisfying.

## BASIC ARMAMENTARIUM

The basic equipment required for proper dental photography is a 35-mm SLR camera body or digital camera, a macro lens, a flash unit, accessories such as mirrors and lip retractors, and the appropriate film.

### 35-mm SLR Camera Body

The camera body's only function is to hold and advance the film and to trip the shutter for the proper amount of time. Because the shutter speed for flash photography is predetermined by the manufacturer, the camera body's function is greatly simplified compared with nondental photography. For these reasons, the operator need not make a large expenditure on this part of the system. The main consideration is that the camera body must be compatible with the macro lens chosen. To achieve this compatibility, most manufacturers make bodies with interchangeable mounts. Novices should purchase camera bodies produced by major manufacturers.

### APS Cameras

The APS camera system is relatively new. Early models were a non-SLR type with noninterchangeable lenses, which made them difficult to adopt for dental use. Newer SLR types are similar to 35-mm SLR cameras and have similar requirements. Novices should purchase camera bodies produced by major manufacturers.

### Digital Cameras

The digital camera body is quite different from a 35-mm SLR camera. The camera body has many more functions. Instead of film, the image is directed onto an electronic sensor, called a charged couple device (CCD). Optical viewfinder devices are found on less costly models and suffer from the same parallax problems as non-SLR earn-

eras (see Fig. 14-3, as well as the section on the history of conventional photography earlier in this chapter). Electronic viewfinders are more accurate but add weight and expense and consume more battery power. The camera must have some type of internal storage device, usually a specialized type of electronic memory. The camera also must have some method to transfer the image to a computer (e.g., "port," memory slot). Most have built-in flash systems and noninterchangeable lenses that are poorly suited for dentists. Therefore most are modified with specialized flashes and add-on lenses for dental use. Some include additional software to enhance the camera's usefulness. Novices should purchase a camera from a dental reseller who will modify the cameras of major electronics manufacturers.

### Bellows System

The bellows system is unsurpassed for image quality, but many clinicians find the modern 90- to 120-mm macro lenses more practical and less time-consuming. The slight increase in image accuracy with the bellows system compared with the macro lens is not of significant consequence to most clinicians. Bellows-type cameras are becoming increasingly difficult to purchase.

### Macro Lens

Macro refers to the closeup focusing capability of the macro lenses. Several reliable macro lenses are on the market that perform well in dentistry. They commonly have a focal length range of 90 to 120 mm. These lenses produce less distortion and allow more comfortable working lengths than lenses with shorter or longer focal lengths. At least one manufacturer sells a 55-mm lens. This focal length works well for most dental purposes, although the working distance for closeup views is short and full face views are distorted.

Magnification capability is the second important factor in choosing a lens. Many good macro lenses achieve a 1:1 magnification without additional converters or extenders to expand the magnification range. Some older models produce only 1:2 magnification and require extenders to achieve 1:1 magnification.

### Flash

To obtain proper lighting effects in intraoral photographs, the light must be mounted on the end of the lens barrel; otherwise the lips will cause harsh shadows. The choice for proper lighting is either a point or a ring flash (see Fig. 14-7), depending on the operator's needs and preferences (see the section on light source earlier in this chapter). Both units can be incorporated into the same system, al-

lowing for personal preference in each situation; the added expense of having both types of flash units is minimal.

### Data Back

Many 35-mm SLR cameras offer an optional data back. This device replaces the back of the camera and is capable of permanently imprinting on the film the time and date the picture was taken. APS and digital cameras store this information automatically. Some units can imprint exposure information (i.e., shutter speed and aperture setting) in order to permanently record the optimal camera setting required for different lighting conditions. Although the data back can be switched off, once the data are imprinted on the "film," of non-APS or non-digital cameras, they cannot be removed. In some situations printed information may detract from the esthetics of the photograph.

### Retractors and Mirrors

Proper lip and cheek retractors are made of clear plastic (Fig. 14-12). The clear plastic allows the tissue to be seen through the retractor (reducing visual distraction), and the double end allows versatility because the two ends can be different sizes. Plastic retractors can be reshaped with an acrylic bur to any size the operator finds useful. Sometimes metal retractors can be used in combination with buccal mirrors (long slender mirrors that reflect buccal views and fit between the zygomatic arch and the lower border of the mandible).

Front surface glass mirrors perform best because they produce a clearer single image view, compared with the double (shadowed) view of back surface mirrors. Chrome plated mirrors also perform well but require a larger aperture setting for proper exposure because they do not reflect light as brightly as glass mirrors.

Two differently shaped mirrors are required, one for full occlusal views and one for buccal and lingual views (Fig. 14-13). The clinician with a practice composed of all age groups probably needs at least two sizes of each.

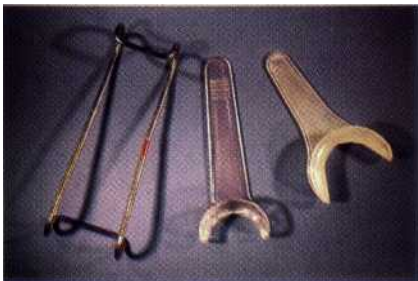

Fig. 14-12. Plastic and metal retractors.

**CLINICAL TIP.** To determine the type of mirror, place an explorer directly onto the mirror's surface. On a front surface mirror, the "tips" will meet. On a back surface mirror, a space will be seen between the tips, which represents the distance between the glass and the reflecting surface on the back.

**CLINICAL TIP.** A commonly encountered problem is mirror fogging caused by the patient's breath. This can be eliminated either by soaking the mirrors in warm water or by having the assistant gently blow air from the syringe onto the mirror while it is in use.

**CLINICAL TIP.** If saliva comes in contact with the mirror's surface, the mirror must be removed and cleaned to avoid a significant distraction on the finished photograph.

### Film

Several manufacturers make film that is appropriate for dental purposes. However, some have not been manufacturing film long enough to guarantee archival (longevity) quality. Kodak produces a wide range of 35-mm film that is ideally suited for dental purposes (Fig. 14-14). The

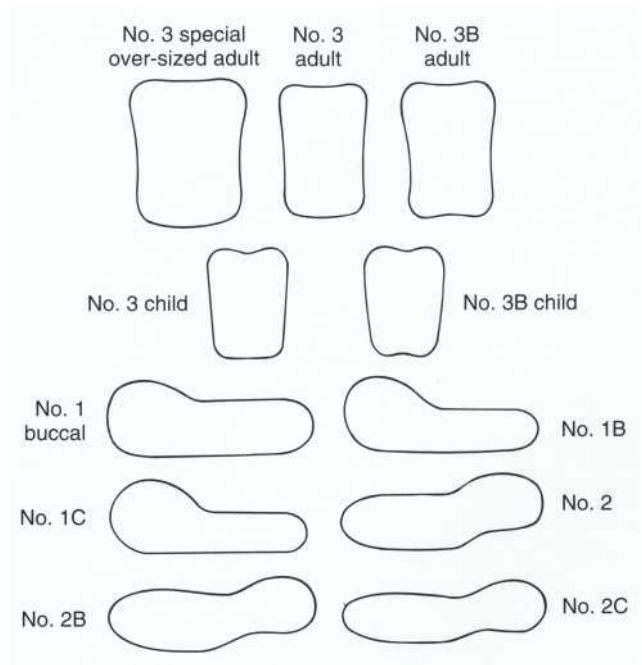


Fig. 14-13. Various dental mirrors. No. 3 Special Oversized Adult; No. 3 Child; No. 3 Adult; No. 313 Adult; No. 313 Child; No. 1 Buccal; No. 1B; No. 1C; No. 213; No. 2; No. 2 C.



Fig. 14-14. Recommended Kodak film for slides and prints.

proper film for flash photography is daylight film of 100 ASA or lower, such as Kodacolor 100 for prints and Kodachrome 64 or 25 for slides. The difference in grain between 64 and 25 is undetectable, but the tooth and tissue tones are more correct with Kodachrome 64. Kodachrome 64 is unsurpassed for photographing the human body because of its correct red coloration and unequalled worldwide consistency of manufacturing and developing. When speed of processing is the top priority, Ektachrome 100 is useful; however, the tooth and tissue tones are incorrect without the use of filters, and the archival quality is inferior compared with other films.

If the practitioner wants only prints, Kodacolor 100 is the only film needed. However, if slides are also desired, Kodachrome 64 can be used exclusively because a good custom color laboratory can render an extremely high quality print from a properly exposed slide.

Currently, APS film is limited to color photography; no slide film is available. The film is available from numerous manufacturers in 100, 200, and 400 ASA.

Several types of instant Polaroid films **are available for different cameras and needs.** The Lester Dine Instant Model 4 camera (Lester Dine, Inc.) uses type 600+ and 779 film. Special versions of the 600 series film are available. The 600 Notepad Film has an added line on the bottom of the film for annotation; the 600 Write On Film and 600 AlterImage Film (matte finish) have special writing and drawing surfaces; and the 600 Copy&Fax Film has a surface with a special built-in halftone screen that ensures that details on the photograph are not lost when photocopied or faxed. For dental use the 779 produces more consistent color than the 600 series film at a similar cost. The Polaroid Macro 5 uses Polaroid's Spectra Film (which can only be used in a Spectra series camera), which produces higher definition instant color prints than the 600+ and 779 films.

Polaroid Type 691 film produces instant  $3\frac{1}{4} \times 4\frac{1}{4}$  inch slide transparencies. Polaroid Polachrome, an instant slide film used in 35-mm cameras, requires some additional hardware for instant self-developing. The quality is sharp but grainy and lacks color brilliance.

MultiSpeed 35-mm slide films (e.g., Fuji Fujichrome MS 100/1000 Professional) can be set for 100 to 1000 ASA and still provide sharp, accurate color balance.

Digital photography does not use film; "film speed" is a function of the CCD light sensor. (See Chapter 24 for a complete discussion of CCD light sensors.)

### Summary

The crucial choice of components for dental photography are the macro lens, the flash unit, and the film. Mirrors, retractors, and the camera body are important, but the specific selection from among the available choices is less critical.

### AVAILABLE CAMERA SYSTEMS

If employee turnover is high, a simple system may be a good choice. If the clinician will be making most of the photographs, a higher quality, more complex camera may be preferable.

The following section covers a representative sample of cameras, including the important major differences. Any combination of cameras, macro lenses, and flash units may be used in dentistry, but suppliers that exclusively serve the profession simplify the choices. Some listed equipment can be obtained wholesale through mail order but require some investigation by the purchaser. It is important to check with the manufacturer before purchasing to ensure that any optional equipment is still available and to determine if enhancements have been made to the cameras and if noted limitations still exist.

**CLINICAL TIP.** The dental camera should be readily available, stored either in a wall-mounted bracket or on a counter near the work area. If the camera is not readily available, it will not be used. It is not advisable for the dental camera to double as a recreational camera, because it probably will be at home when needed.

### *Nikon 120-mm Medical Nikkor*

When combined with an automatic or a manual Nikon camera body unit, the Nikon 120-mm Medical Nikkor lens is unsurpassed for ease of use and quality. Every aspect of closeup photography is fully automatic. The extremely high quality ring light built into the lens is specifically designed for precise lighting for closeup pictures. The ring flash is graded so that one side of the flash emits more light than the other; this creates an image that is more three dimensional than those obtained with conventional ring lights while simultaneously producing more even light distribution than is available with point lights. This lens can be used only for closeup photography



(magnifications from 2: 1 to 1:11) and has a minimum aperture of f-32, which allows for maximum depth of field. Because the f-stops are harnessed to the magnification, the operator need only select the desired magnification, move the camera toward or away from the subject until the images is in focus, and engage the shutter. This unit can be used with either AC or DC power. The lens has a mottling light that illuminates the field for preview before exposure. A data button also is provided that will print the magnification on the film. An optional data back will print additional characters. This unit can be obtained through mail order or from local retail camera stores.

### *Minolta Maxxum*

The Minolta Maxxum is available in several different models. Currently in its fourth generation, the Maxxum 800si is the most popular si-series camera for dental use. All Maxxums must be paired with a special 100-mm macro lens (focal range of 1:1 to infinity) and a special autofocus macro ring flash (Fig. 14-15). The ring light consists of four individually controlled tubes. When a single tube is used, the camera automatically increases the light output to simulate a point flash. Like most other autofocus cameras, the Maxxum may require manual focusing on some very close subjects. The camera has a built-in quartz data back and built-in creative expansion card system; the expansion card system, an option in previous models, customizes the camera for different conditions (e.g., sports, portraits, closeups, landscapes, night portraits). The camera is available through mail order or from local retail camera stores.

### *Yashica Dental Eye III*

The Yashica Dental Eye III has become one of the most popular clinical cameras because it is easy for the beginner to use (Fig. 14-16). This camera has a highly advanced ring flash system permanently affixed to its 100-mm macro lens. The Yashica Dental Eye III can focus from 1:1 to 1:15 and has a one-f-stop exposure compensation, DX autosensing, and a motorized film loading, advance, and rewind system. It has an adjustable three-element ring flash for shadow or shadowless photographs, an illuminated viewfinder, and a built-in data back. The Yashica Dental Eye III (manufactured by Kyocera International) is available from mail order houses or selected retailers.

### *Lester Dine*

Lester Dine has been involved with dental closeup equipment for many years. The company provides quality equipment while keeping choices simple. One unit uses a



Fig. 14-15. Minolta Maxxum 800si.



Fig. 14-16. Yashica Dental Eye III.

Nikon N70 body with a modified Kiron 105-mm lens and a ring light, a point light, or both (see Fig. 14-7). Unlike the Medical Nikkor, the Lester Dine unit focuses from 1:1 to infinity. This lens has a minimum aperture of f-32 for maximum depth of field. The proper magnification for each photograph is conveniently marked on the lens barrel. This unit requires the user to change the f-stop for different exposures. This is an excellent choice for the user who wants both dental and recreational use from the camera. The N70 camera body has a built-in motor drive, automatic film loading, automatic ASA setting, and a data back.

Lester Dine was one of the first retailers to introduce an APS system. The company's APS system consists of their modified Kiron 105-mm lens and ring light, a point light, and a Nikon Pronea APS Camera (Fig. 14-17). The system also includes a Dine APS Photo Digitizer and a complete image archiving software package. The same lens/flash combination is available with a less expensive Pentax ZX50. The company also offers a complete line of dental photography accessories and a "how to" guide for the beginner or for those wishing to improve their technique. Lester Dine is located at 351 Hiatt Drive, Palm Beach Gardens, FL, 33418, (407) 624-9100.



Fig. 14-17. Lester Dine APS system.




Fig. 14-18. Polaroid Macro 5.

### Polaroid Macro 5

The Polaroid Macro 5 is an SLR, autoexposure camera (Fig. 14-18). It has five preset magnification dials for 300% magnification (quadrant views), 200% magnification (full anterior teeth view), 100% magnification (full mouth and occlusal views), 40% magnification (full face view), and 20% magnification (head, neck, and shoulder views). The camera has two built-in, converging electronic flash units that can be used individually (for side-lit shadowed photographs) or in combination (for front-lit shadowless photographs). It has a microprocessor-controlled exposure system that automatically sets the camera for the correct exposure, a date/time data back, and a grid screen viewfinder for consistent framing of the subject. It uses Polaroid's high-definition Spectra film. The Polaroid Macro 5 can be purchased through mail order catalogs and local retail camera stores or from Lester Dine.

### Lester Dine Instant Model 4

The Lester Dine Instant Model 4 camera is made by Polaroid and has been altered for dental closeup use. It is a simple frame and shoot camera that takes closeup and full face standard views. It can focus 2 to 20 inches from the

subject and has a magnification ratio of 2:1, 1:1, and 5: 1. The Lester Dine Instant Model 4 can be purchased from Lester Dine.

### Other Systems

Many other systems are available from companies such as Washington Scientific Camera (615 Wood Ave., Sumner, WA, 98390, [2531863-2854] and Adolph Gasser (5733 Geary Boulevard, San Francisco, CA, 94121, [4151751-0145]), as well as from many other fine local and mail order dealers that offer a wide range of systems that can be customized for dental use.

### Summary

Many cameras and lenses for dental use can be purchased at a local camera store, but the necessary ring light may or may not be available, and the point light will not be available because it is a customized component specifically made for closeup use. Companies familiar with the specific requirements of good dental photography provide the necessary equipment. It is discouraging to purchase equipment and later find that it is unsuitable for good macro dental photography.

## INTRAORAL TECHNIQUE

The posttreatment photograph can be repeated at any time, but the pretreatment photograph can never be reproduced. A good photograph is the product of proper equipment, organization, a procedural checklist, and good technique. It is important that the procedure be organized and simplified to reduce the learning curve for new employees. The techniques are very similar for conventional and digital photography. Differences are noted.

**CLINICAL TIP.** The dental camera should be readily available, stored either in a wall-mounted bracket or on a counter near the work area. If the camera is not readily available, it will not be used. It is not advisable for the dental camera to double as a recreational camera, because it probably will be at home when needed.

**CLINICAL TIP.** The camera should be stored at room temperature (e.g., not by a window in direct sunlight) because excessive heat can adversely affect the film.

A simplified checklist will prevent error:

1. Load the film and set the proper ASA (conventional film only).
2. Turn on the power unit.

3. Check the film advance and shutter speed for flash synchronization (conventional film only).
4. Set the f-stop (conventional film only).
5. Position the subject, flash, retractors, and mirrors.
6. Choose the desired magnification.
7. Focus while correcting the magnification.

**CLINICAL TIP.** The single most common beginner's error is incorrect choice of magnification. A typical magnification error involves including the nose and chin in a frontal view of the oral cavity. This extraneous information is distracting for the viewer. The photographer must decide what the photograph should contain and choose the magnification that eliminates everything else.

8. Release the shutter.

(NOTE: Many automatic and digital cameras eliminate some of these steps.)

**CLINICAL TIP.** Good intraoral photographs should appear as if the camera were aimed directly at the desired subject regardless of whether mirrors were used. The photographs should be devoid of mirror edges, fingers or thumbs, fog, saliva, lip retractors, or any elements other than the desired aspect of the oral cavity.

**CLINICAL TIP.** Lip retractors are not always easily eliminated, but clear retractors are an excellent compromise. Some photographs may require only the patient's assistance, whereas others require assistance from the patient, the photographer and one or even two staff members.

### *Anterior (Frontal) View*

The anterior or frontal view is the most common view used in dental photography (Fig. 14-19). It ranges from a single tooth to a full face view.

**CLINICAL TIP.** A more relaxed or casual view without lip retractors is useful and appropriate for esthetic dentistry, especially when designed for patient viewing (Figs. 14-20 to 14-22). Never show patients with lips retracted when illustrating esthetic dentistry for patient viewing.

#### Armamentarium

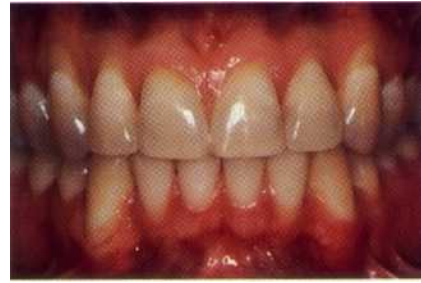Appropriate 35-mm SLR camera body or APS camera or digital camera (see above)

Appropriate macro lens (see above)

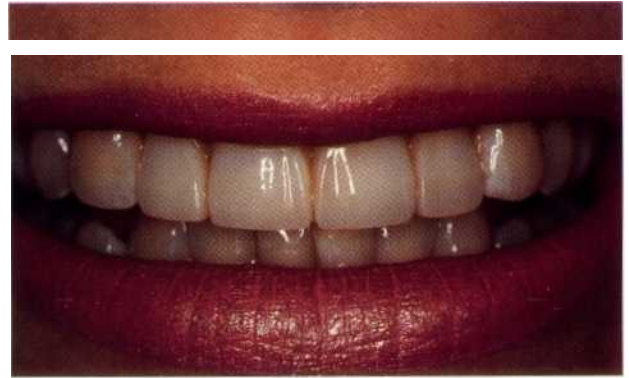Appropriate film (see above)

Appropriate retractors (see above)

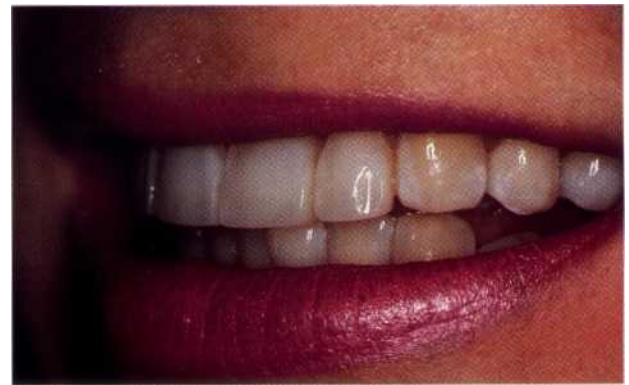(See the section on the basic armamentarium earlier in this chapter.)



*Fig. 14-19. Anterior (frontal) view (1:2 magnification).*



*Fig. 14-20. Relaxed, casual buccal view without lip retractors.*



*Fig. 14-21. Relaxed, casual three-quarter view without lip retractors.*

#### Clinical Technique

1. Seat the patient semi-upright with the head turned toward the photographer.
2. Place retractors at the corners of the mouth and pull gently outward and forward so that the buccal tissue is away from the teeth.

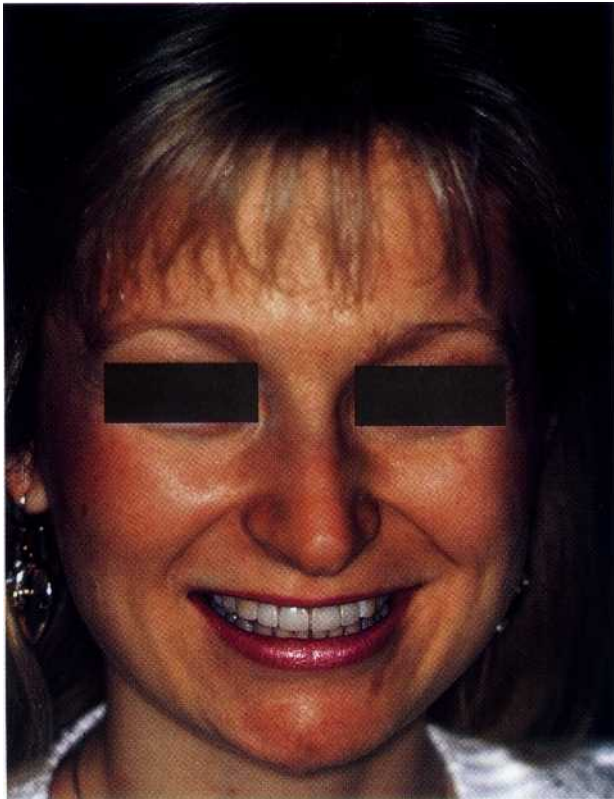


Fig. 14-22. Relaxed, casual full face view without lip retractors.

3. If a point light is used, it should be at the 3 o'clock or 9 o'clock position to create a sense of depth with shadows.
4. Set the **f-stop** (conventional film only).
5. Hold the camera so that the **occlusal plane is perpendicular and centered horizontally to the plane of the film** (or CCD).
6. Align the patient's midline with the center of the frame. Adjust the magnification (usually 1:2). Compose the photograph to include all relevant teeth and soft tissue.
7. Focus the camera while correcting the magnification.

**CLINICAL TIP.** To achieve maximum sharpness of the image, focus the camera on the canines, not the central incisors.

### Maxillary Occlusal View

The maxillary occlusal view is the most difficult view to obtain and requires patience (Fig. 14-23). This photograph usually requires assistance from two staff members.

#### Armamentarium

Appropriate 35-mm SLR camera body or APS camera or digital camera (see above)

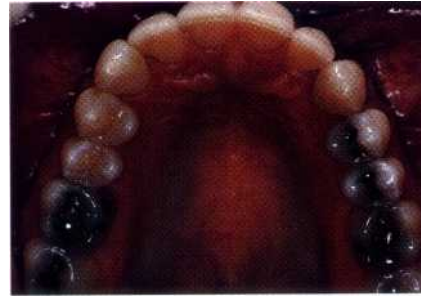

Fig. 14-23. Maxillary occlusal view (1:2 magnification).

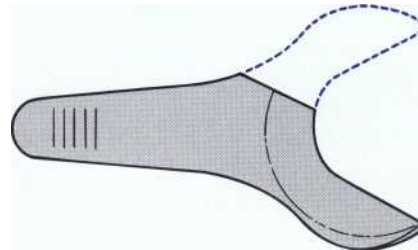


Fig. 14-24. A standard cheek retractor can be modified by removing a flange from one of its sides. This provides more working space and allows for better visualization of the dental arch.

Appropriate macro lens (see above)

Appropriate film (see above)

Appropriate retractors (see above)

Appropriate mirrors (see above)

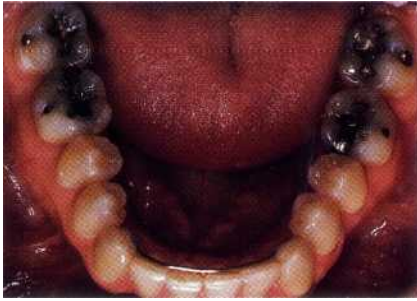(See the section on the basic armamentarium earlier in this chapter.)

#### Clinical Technique

1. **Seat the patient in a semi-upright position with the head turned toward the photographer.**
2. Instruct one of the assistants to gently rotate the retractors upward and outward.

**CLINICAL TIP.** A standard set of retractors can be modified by removing the flange on one side of the retractor (Fig. 14-24), such that when the retractor is rotated toward the desired arch, no interference comes between the mirror and the retractor.

3. **Instruct the other assistant to rest** a full-arch mirror on the maxillary tuberosity, not on the teeth. The mirror should diverge from the occlusal plane as much as possible so that the camera can be held 90 degrees to the plane of the mirror.
4. If a point light is used, it should be at the 9 o'clock or 3 o'clock position.
5. Set the f-stop (conventional film only).



*Fig. 14-25. Mandibular occlusal view (1:2 magnification).*

6. Hold the camera so that the plane of the film (or CCD) is parallel to the full arch in view.
7. Align the midline of the palate with the center of the frame and adjust the magnification (usually 1:2). Compose the photograph to include all relevant teeth and soft tissue.
8. Focus on **the premolar area while correcting** the magnification.

### *Mandibular Occlusal View*

The mandibular occlusal **view is the reverse of the** maxillary occlusal view (Fig. 14-25).

#### Armamentarium

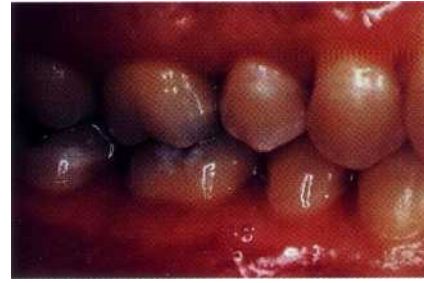
Appropriate 35-mm SLR camera body or APS camera or digital camera (see above)  
 Appropriate macro lens (see above)  
 Appropriate film (see above)  
 Appropriate retractors (see above)  
 (See the section on the basic armamentarium earlier in this chapter.)

#### Clinical Technique

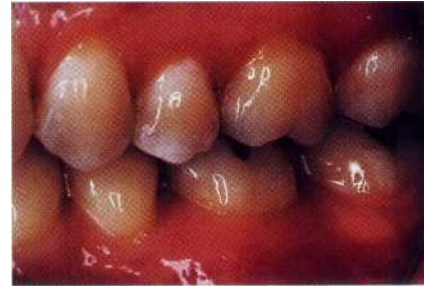1. Seat the patient in the supine position, parallel to the floor.
2. Tip the patient's head back slightly and turn it toward the photographer so that the occlusal plane is parallel to the floor.
3. Rotate the retractors gently downward toward the mandible and outward.

**CLINICAL TIP.** When photographing the mandibular occlusal view, use the same altered lip retractors described for the maxillary view. See the preceding Clinical Tip.

4. Rest a full-arch mirror on the retromolar pad not on the teeth.
5. The mirror should diverge from the occlusal plane as much as possible so that the camera can be held 90 degrees off the plane of the mirror.



*Fig. 14-26. Right buccal view (1:1.2 to 1:1.5 magnification).*



*Fig. 14-27. Left buccal view (1:1.2 to 1:1.5 magnification).*

6. If a point light is used, it should be at the 9 o'clock or 3 o'clock position.
7. Set the f-stop (conventional film only).
8. Hold the camera so that the plane of the film is parallel to the full arch in view.
9. Align the midline of the tongue with the center of the frame and adjust the magnification (usually 1:2). Compose the photograph to include all relevant teeth and soft tissues.
10. Focus on the premolar area while correcting the magnification.

### *Buccal View*

Buccal views are ideal for photographing the patient's centric occlusion (Figs. 14-26 and 14-27).

#### Armamentarium

Appropriate 35-mm SLR camera body or APS camera or digital camera (see above)  
 Appropriate macro lens (see above)  
 Appropriate film (see above)  
 Appropriate retractors (see above)  
 (See the section on the basic armamentarium earlier in this chapter.)

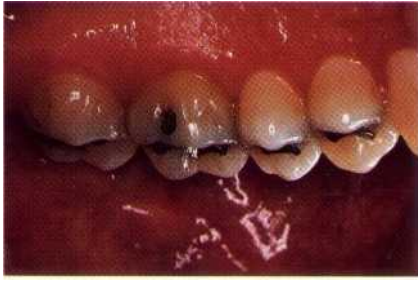

Fig. 14-28. Maxillary left lingual view (1:1.2 to 1:1.5 magnification).

#### Clinical Technique

1. Seat the patient in a semi-upright position with the head facing straight for left buccal views and toward the photographer for right buccal views (reverse for left-handed dental units).
2. Place a buccal mirror distal to the last tooth in the arch. Move it as laterally as possible while at the same time retracting the lip. The mirror also serves as a retractor.

**CLINICAL TIP.** Buccal views can be taken without mirrors if a view of **the distal end of the terminal** molar is not required.

3. If a mirror is used, passively hold a single retractor on the side opposite the mirror.
4. If no mirror is used, pull the retractor on the side being photographed as distally as comfortably possible for the patient. Passively hold the retractor on the side that is not being photographed.
5. If a point source light is used, place it on the same side of the camera as the mirror.
6. Set the f-stop (conventional film only).
7. Hold the camera so that the plane of the film (or CCD) is as perpendicular to the mirror as possible.
8. Set the magnification (usually 1:1.5 to 1:2). Compose the photograph to include from the distal area of the canine to the most posterior tooth, with the plane of occlusion parallel to the film plane and in the middle of the frame.
9. Focus the camera on the premolar area while correcting the magnification.

#### Lingual View

Lingual views of the maxilla (Figs. 14-28 and 14-29) or the mandible (Figs. 14-30 and 14-31) are obtained similarly.

#### Armamentarium

Appropriate 35-mm SLR camera body or APS camera or digital camera

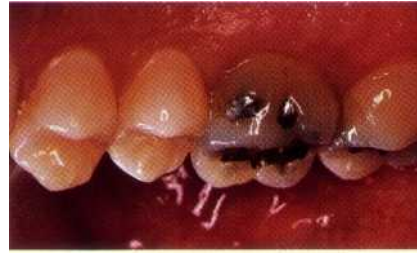

Fig. 14-29. Maxillary right lingual view (1:1.2 to 1:1.5 magnification).

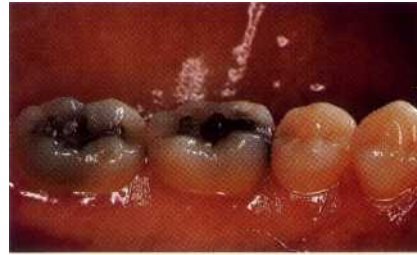


Fig. 14-30. Mandibular left lingual view (1:1.2 to 1:1.5 magnification).

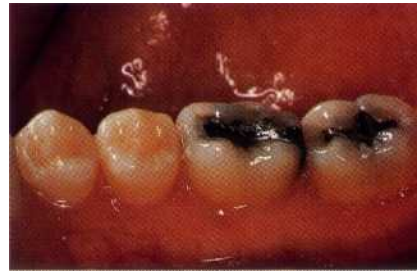

Fig. 14-31. Mandibular right lingual view (1:1.2 to 1:1.5 magnification).

Appropriate macro lens

Appropriate film

Appropriate retractors

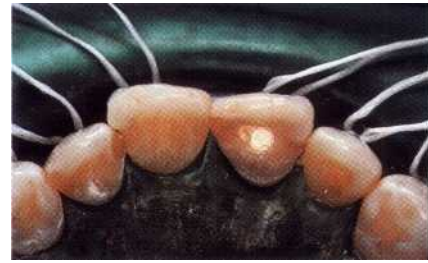
(See the section on the basic armamentarium earlier in this chapter.)

#### Clinical Technique

1. Position the patient semi-upright with the head facing straight for right views and toward the photographer for left views (reverse for left-handed dental units).
2. Place retractors at the corners of the mouth, rotated toward the photographed arch and passive on the opposite side.
3. For a mandibular photograph, place a mirror between the tongue and the quadrant being photo-

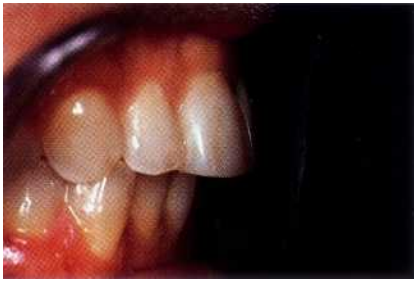

Fig. 14-32. Lateral view.



g. 14-34. Incisal quadrant view.

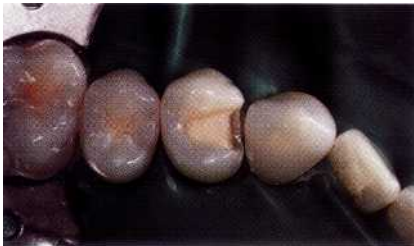

Fig. 14-33. Occlusal quadrant view.

tographed, distal to the terminal tooth, parallel to the long axis of the teeth, and pushed laterally as much as possible. For a maxillary photograph, place the mirror against the palate in the midline, distal to the terminal tooth, parallel to the long axis of the teeth, and pushed as laterally as much as possible.

4. If a point source light is used, place it on the same side of the camera as the mirror.
5. Set the f-stop (conventional film only).
6. Hold the camera so that the plane of the film is as perpendicular to the mirror as possible.
7. Set the magnification (usually 1:1.5 to 1:1.2). Compose the photograph to include from the distal area of the canine to the most posterior tooth, with the plane of occlusion parallel with the film plane and in the middle of the frame.
8. Focus the camera on the distal side of the canine while correcting the magnification.

### Other Views

Any of the above views can be modified to meet the needs of the user. Usually only changes in magnification and composition are necessary to suit specific needs. For example, if only an occlusal view of a quadrant is necessary, the buccal or lingual mirror can be used in a similar manner as that described for the full-arch occlusal view, along with a modification in the magnification. For a view of only the premaxilla, only the necessary portion of a full-arch mirror is used and the magnification is adjusted (1:1.2). The creativity of the photographer can allow for any other specific views that are needed (Figs. 14-32 to 14-34).

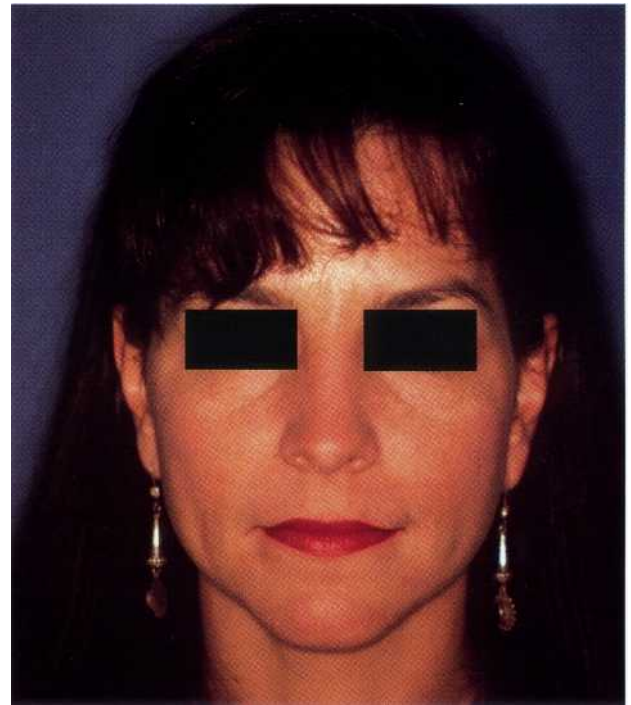

Fig. 14-35. Full face view(1: 10 magnification).

### EXTRAORAL TECHNIQUE

Good, finished full face and profile photographs require a pleasant colored background. An art store can furnish art paper in a number of suitable colors. The best usually is a pastel color that contrasts with normal hair color and skin tones. A soft blue is the best overall. This paper can be taped to the wall in the operatory and removed as needed.

#### Full Face View (Fig. 14-35)

##### Armamentarium

- Appropriate 35-mm SLR camera body or APS camera or digital camera (see above)

- Appropriate lens (see above)
- Appropriate film (see above)
- Appropriate background (optional)  
(See the section on the basic armamentarium earlier in this chapter.)

#### Clinical Technique

1. Position the patient approximately 18 to 24 inches in front of the background to help minimize shadows.
2. Position the head such that a line from the ala of the nose to the tragus of the ear is parallel to the floor.
3. If a point source light is used, place it at the 12 o'clock position.
4. Set the f-stop (conventional film only).
5. Position the camera vertically at the level of the patient's eyes.

**CLINICAL TIP.** Many cameras feature a "red eye" reduction flash. Pulsating the flash before taking the photograph causes the subject's iris to contract, thus eliminating the reflection of light off the retina and minimizing the "red eye" effect seen in some photographs.

6. Set the magnification (usually 1:10). Compose the photograph to include from the inferior border of the hyoid to above the top of the head.
7. Focus the camera on the patient's eyes while correcting the magnification.
8. Take a photograph with the teeth in occlusion.
9. Take a second photograph with the patient smiling.

#### Profile View (Fig. 14-36)

##### Armamentarium

- Appropriate 35-mm SLR camera body or APS camera or digital camera (see above)
- Appropriate lens (see above)
- Appropriate film (see above)
- Appropriate background (optional)  
(See the section on the basic armamentarium earlier in this chapter.)

#### Clinical Technique

1. Position the patient approximately 18 to 24 inches in front of the background to help minimize shadows.
2. Position the head such that a line from the ala of the nose to the tragus of the ear is parallel to the floor. The teeth should be in occlusion.

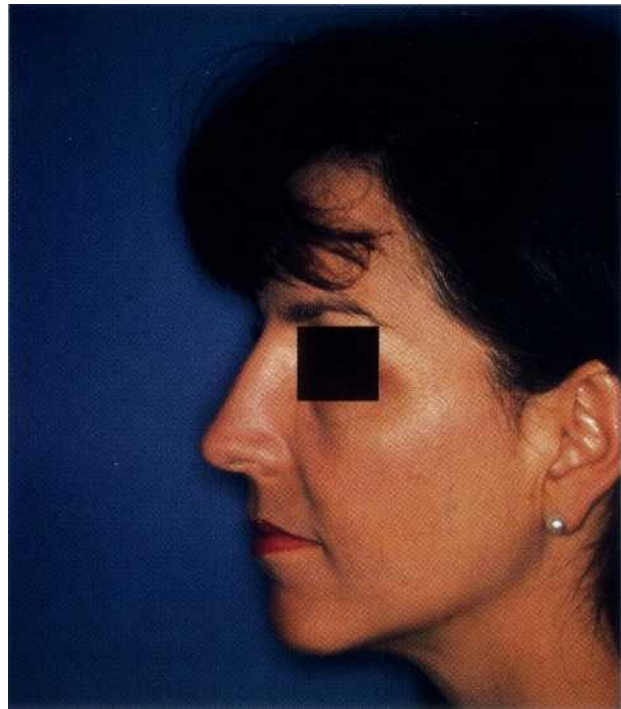


Fig. 14-36. Profile view(1:10 magnification).

**CLINICAL TIP.** The head should be turned slightly toward the photographer so that the off-side eyelash is just visible. This avoids the appearance of the patient looking away from the camera.

3. If a point source light is used, place it on the side of the camera that the patient is facing. The camera should be in a vertical position at the level of the patient's eyes.
4. Set the f-stop (conventional film only).
5. Set the magnification (usually 1:10). Compose the photograph so that the profile dominates the center of the frame, with the area just behind the ear visible.
6. Focus the camera on the patient's eyes while correcting the magnification.

**CLINICAL TIP.** A more relaxed or casual view without lip retractors is useful and appropriate for esthetic dentistry, especially when designed for patient viewing (see Figs. 14-20 to 14-22). Never show patients with lips retracted when illustrating esthetic dentistry for patient viewing.

#### TECHNICAL ERRORS

Some of the problems commonly encountered in the finished photograph can be caused by technical errors. Table



www.pdfbooks.ir

Problem	Possible causes
Incomplete image	Improperly loaded film Improper shutter speed for flash synchronization
Black image	Improperly loaded film Inadequate initial film advance Improperly connected flash Broken flash
Shadows	Improperly positioned point flash Extraneous overhead lighting reflected into mirrors, disrupting the flash
Improper exposure	Weak flash batteries Improperly set flash Incorrect f-stop Improperly set ASA
Out of focus image	Improperly focused Fog on the mirror Camera movement Patient movement

14-2 presents some of the major mistakes made in using the camera and lens system; however, this is not meant to be an exhaustive list.

### CONCLUSION

The clinical use of photography in dentistry has many practical and profitable applications. The clinician should analyze how the camera will be used and select a system accordingly. Through photography, the rewards of dentistry are experienced at a higher level of quality for everyone.

### BIBLIOGRAPHY

- Freedman G: Standardization in dental photography, *Compend Contin Educ Dent* 10:682, 1989.
- Freehe CL: Symposium on dental photography, *Dent Clin North Am* 27:3, 1983.
- Gehrman RE: *Dental photography*, Tulsa, 1982, Penn Well Publishing.
- Goodlin RM: *The complete guide to dental photography*, Montreal, 1987, Michael Publishing.
- Hook S: The camera is a practice builder, *Dent Econ* 77:71, 1987.
- Swift EJ Jr, Quiroz L, Hall SA: An introduction to clinical photography, *Quintessence Int* 18:859, 1987.



انتشارات شایان نمودار

# ESTHETICS AND ELECTROSURGERY

Mark P King

**E**STHETIC EVALUATION of the oral cavity often concentrates on the color, spacing, and arrangement of the teeth without considering the architecture of the soft tissue. The gingival architecture is just as important as other parameters to good overall esthetics.

## CONCEPTIONS AND MISCONCEPTIONS

Electrosurgery allows for easy, quick, safe alteration or removal of living tissue from the oral cavity with little or no bleeding. The esthetic results can be remarkable. Electrosurgery can also be used for gingivoplasty; hyperplastic tissue removal; mucoperiosteal surgery; overhanging tissue excision in Class I, II, III, IV, and V lesions; frenuli removal; sulcus expansion; hemorrhage control; endodontic procedures; bleaching; root sensitivity; and biopsy excisions. Yet electrosurgery is one of the least frequently used techniques in the contemporary dental armamentarium because of misconceptions caused by fear and inadequate knowledge.

## BASIC CONCEPTS

Electrosurgery is the surgical application of fully controlled, partially self-limiting, high-frequency, electrically generated heat energy to living tissue to alter or remove it for therapeutic purposes, while permitting and promoting desirable tissue repair.<sup>1</sup>

### *Brief History*

Before 1891 the instruments used for heat-generated surgical alteration or removal of organic tissue were crude,

uncontrollable, flame-heated cautery instruments.<sup>1</sup> In 1891 D'Arsonval discovered that alternating current oscillating at frequencies higher than 10,000 cycles per second produced no potentially lethal neuromuscular pain or shock.<sup>1</sup> D'Arsonval's experiments led to the development of the spark-gap generator, which eventually evolved into electrosurgery. In 1907 Doyen et al. were the first to use extremely-high-frequency current (3 million cycles per second) in combination with an active and passive electrode to achieve suitable surgical cutting ability. However, this cutting current, utilizing spark-gap generators, proved to be of poor quality. In 1908 DeForrest created the first radio-tube high-frequency apparatus. In 1920 this led to a more refined apparatus, which used three electrode vacuum tubes to produce a much finer cutting current than those available previously.<sup>2</sup> Dr. George A. Wyeth used this latest technology to develop the endotherm knife, which was the prototype electronic scalpel capable of delivering true surgical cutting energy. In the 1960s William Coles, an engineer, converted these vacuum tubes into solid state transistors, and the first pure continuous cutting current became available to dentistry.<sup>1</sup> This fully rectified filtered current has revolutionized electrosurgical cutting because of its ability to produce very low levels of heat energy. Modern technology has ushered in an era of potentially problem-free electrosurgical cutting procedures.

### *Mechanism of Action*

A major misconception about electrosurgical cutting energy is that it is simple household electrical current. Everyday electricity is an alternating current, which cycles or oscillates from positive to negative 60 times per second



(60 Hertz [Hz]). If this current were applied to living tissue, it would cause cell membrane polarization to change 60 times per second. This repeated polarization of the cell membrane would result in contraction of muscle tissue and would be painful and potentially lethal. This reaction occurs at frequencies of up to 10,000 cycles per second (10 kilohertz [KHz]).<sup>4</sup> Electrosurgical units convert household current into an electromagnetic radiofrequency (RF) wave, which oscillates at a rate of 2 to 4 million cycles per second (2 to 4 millihertz [MHz]). Since it is impossible for a cell to depolarize at this rate, the electrical resistance of the tissue produces localized intracellular heating without the accompanying muscle contraction.<sup>4</sup>

As the RF wave leaves the unit, it travels from the active electrode (the handpiece), through the tissue, to the passive electrode in contact with the patient, and then back to the unit. Both electrodes remain at room temperature throughout the process. The passive electrode is often incorrectly referred to as the "ground." The dental chair is grounded, and no additional grounding is necessary. The passive electrode simply allows smoother and more efficient passage of current through the patient. At the proper current setting the RF wave passes through the tissue and produces a slight rise in temperature, which causes the volatilization of one cell layer and leaves adjacent cell layers intact.<sup>4</sup> If the current is set too low, it will result in drag (the inability of the electrode to cut the tissue efficiently); if it is set too high, it will create sparking and result in excessive heat at the tissue site.<sup>4</sup> Absolute familiarization with the unit is crucial to achieve optimal results.

### Current Types

With alternating current (including RF current), electric flow changes direction during each cycle. The amplitude of the current also changes continuously, exhibiting a classic sine wave pattern on an oscilloscope. Because the sine wave pattern type of current causes excessive tissue damage, it is not suitable for dental purposes and must be modified by the electrosurgical unit. At present, four basic types of current are used in dentistry, each for a specific application.

**Sparking Current.** An alternating current, sparking current is a disorganized high-frequency wave that causes localized but superficial destruction of cells (fulguration) (Fig. 15-1). It is used in the removal of fistulas and cystic growths.

**Partially Rectified Current.** Unlike alternating current, partially rectified current pulses but does not change direction (Fig. 15-2). During the first half of the cycle, partially rectified current flows in one direction while continuously changing amplitude. During the second half

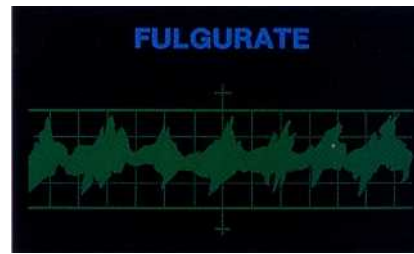

Fig. 15-1. Sparking current. (Courtesy Ellman International Manufacturing Co.)




Fig. 15-2. Partially rectified current. (Courtesy Ellman International Manufacturing Co.)

of the cycle, no current flow occurs. This type of current coagulates tissue.

**Fully Rectified Current.** During the first half of the cycle, fully rectified current is identical to partially rectified current. However, unlike partially rectified current, this flow is repeated again during the second half of the cycle (Fig. 15-3). Because this current incises and coagulates at the same time, it is used to cut edematous tissue.

**Fully Rectified Filtered Current.** Fully rectified filtered current exhibits the same properties as fully rectified current except that the change in amplitude is reduced (Fig. 15-4). On an oscilloscope the "peaks of the hills" have been eliminated, forming a more continuous flow in one direction. It is the current of choice for esthetic gingival recontouring because it provides the cleanest incision.

### Lateral Heat

During an electrosurgical procedure, inadvertent heating of tissue adjacent to the surgical site is possible. This lateral heating results from the resistance of the adjacent cells to RF wave current flow. By controlling the electrode size, the time it contacts the tissue, and the type and intensity of the current and by keeping the tissue moist, this heating can be minimized. The electrode should be in contact with the tissue for a maximum of 1 to 2 seconds, with 5 to 10 seconds between each application.




Fig. 15-3. Fully rectified current. (Courtesy Ellman International Manufacturing Co.)




Fig. 15-4. Fully rectified filtered current. (Courtesy Ellman International Manufacturing Co.)

**CLINICAL TIP.** To dissipate excess heat and cool the adjacent tissue, moisten the tissue with water, saliva, or saline solution before beginning the procedure.

The power should be set at the lowest level that still allows the electrode to move through the tissue smoothly. Thin, straight, bendable needle electrodes with fully rectified filtered cutting current should be used.<sup>4</sup>

### Applicable Research

The literature is one source of misconceptions about electrosurgery. Several investigators<sup>5-8</sup> have reported adverse postoperative effects of electrosurgery. Notably missing from many of these studies were descriptions of waveform, machine type, size and shape of electrode, and the speed of the electrode movement through the tissue. These variables must be properly controlled, and their omission leaves these studies flawed.<sup>9</sup>

Many more investigators have reported overwhelmingly positive postoperative responses to electrosurgery.<sup>10-19</sup> When the electrode briefly contacted the oral cavity in a conventional manner, regardless of the current level, no conduction changes were detected in the heart during monitoring' and no damage was seen histologically in the dental pulps of animals.<sup>20-21</sup> When the therapist is equally competent in the use of both electrosurgery and scalpel surgery, postoperative healing is comparable.<sup>22,24</sup> However,

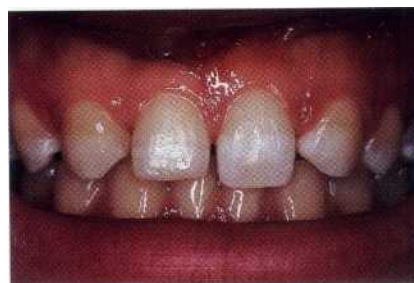

Fig. 15-5. Preoperative view of unesthetic gingival margins.

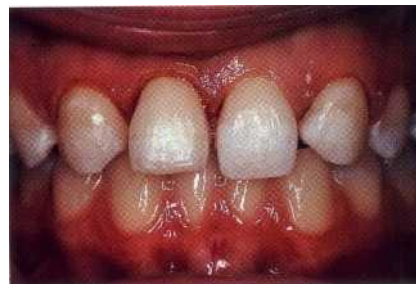

Fig. 15-6. Postoperative view immediately following surgery.

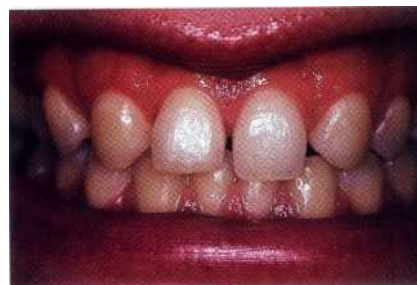

Fig. 15-7. Postoperative view following healing.

in deep resection procedures with approximation to bone, electrosurgery is contraindicated because of delayed wound healing.<sup>24</sup>

The overwhelming conclusion in **evaluation of the literature is that when the variables in electrosurgery are properly controlled, uneventful postoperative** healing is the final result (Figs. 15-5 to 15-7).

### Basic Equipment

Electrosurgery units deliver various surgical modalities, depending on the currents they produce. Choosing a unit that delivers all four current types is advised. Several modern, multiple-circuit, fully rectified units are available that utilize vacuum-tube power generators and solid-state transistorized components to deliver these currents (Fig. 15-8). A proper unit should provide the following:



Fig. 15-8. Electrosurgical unit. (Courtesy Ellman International Manufacturing Co.)



Fig. 15-9. Electrodes are available in a multitude of shapes. For esthetic dental work a thin, straight, bendable needle electrode is used. (Courtesy Ellman International Manufacturing Co.)

1. A current selector switch with definitive "clicks" to indicate the type of current being used
2. A separate current intensity switch that allows for continuous, linear adjustments in power
3. An insulated passive electrode to create the most efficient cutting and the least problematic postoperative healing. (These electrodes can be incorporated into the dental chair to decrease patient apprehension.)
4. A foot pedal control, rather than a handpiece control, for activation. (A handpiece control requires the fingers to flex for activation, which may interfere with proper hand positioning.)
5. Thin, straight, bendable needle electrodes (Fig. 15-9)

## DIAGNOSIS AND TREATMENT PLANNING

### Indications

If the clinician is careful to employ proper probing techniques and respect for the biologic width, electrosurgery may be used to recontour any gingival architecture that is not conducive to good esthetics or periodontal health.

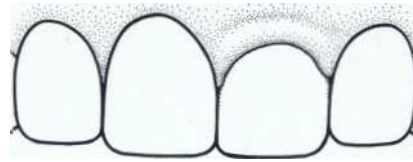


Fig. 15-10. Excess tissue caused by ectopic eruption of the maxillary left central incisor.

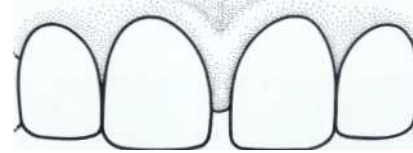


Fig. 15-11. An apically malpositioned papilla between the maxillary central incisors makes diastema closure difficult.

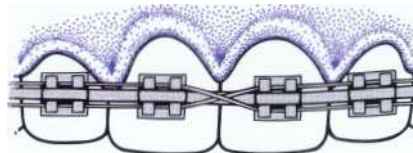
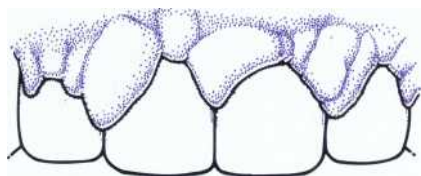


Fig. 15-12. Inflamed, hypertrophied gingiva during orthodontic treatment.

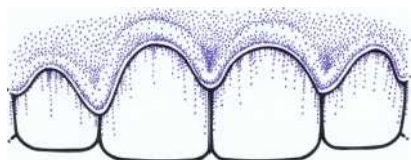
The biologic width extends from the alveolar crest and includes 2 mm of gingival attachment and 1 to 2 mm of gingival sulcus. This biologic width must not be violated. Electrosurgery can be performed only on gingiva with a sulcus depth exceeding this amount. Electrosurgery can be used to change gingival contours for esthetic purposes alone, periodontal treatment alone, or periodontal treatment as a precursor to esthetic treatment. Any periodontal treatment required for improved gingival health should precede esthetic treatment.

Electrosurgery is indicated when improper contours result from any of the following causes and when the biologic width will not be violated:

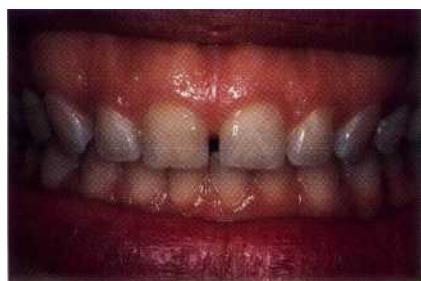1. Excess tissue caused by ectopic eruption or incomplete passive eruption of one or more teeth (Fig. 15-10)
2. Hypertrophied or malpositioned papilla (Fig. 15-11)
3. Inflamed, hypertrophied gingiva during or after orthodontic treatment (Fig. 15-12)
4. Any hypertrophied tissue from drug therapy, such as Dilantin (Fig. 15-13)
5. Any hypertrophied tissue of pathologic origin, including poor oral hygiene (Fig. 15-14)



*Fig. 15-13. Hypertrophied gingival tissue during Dilantin drug therapy.*

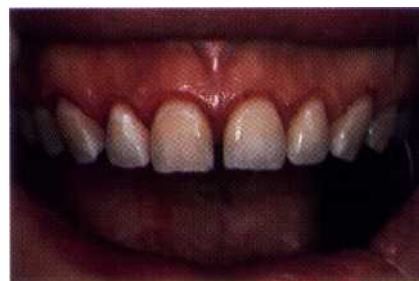

*Fig. 15-14. Hypertrophied tissue caused by poor oral hygiene.*



*Fig. 15-15. Excess tissue caused by incomplete passive eruption.*

**Excess Tissue Caused by Ectopic Eruption or Incomplete Passive Eruption.** One of the most frequently overlooked dental problems is excess tissue caused by ectopic eruption or incomplete passive eruption of one or more teeth (Fig. 15-15). If the eruptive force of the tooth either is misdirected or dissipates before the height of contour emerges, the gingival crest remains incisal to this height of contour. The result is inadequate crown length for proper esthetics. In the classic case, all maxillary anterior teeth are involved and the patient displays excess gingiva. Treatment of this situation depends on the cause of the excess gingiva. This excess can result from incomplete passive eruption of the teeth, insufficient lip height, overgrowth of the maxilla, or a combination of these factors. If probing reveals a sulcus of 1.5 mm or less or the radiographs reveal that the alveolar bone is in an inappropriate position, electrosurgery is contraindicated. Orthognathic or periodontal surgery involving bone removal should be considered as an alternative. If probing reveals excess gingival sulcus and the crestal bone is in the correct position, electrosurgery alone



*Fig. 15-16. Postoperative view following electrosurgical procedure.*

may solve the problem; otherwise, a combination of electrosurgery and periodontal or orthognathic surgery may be required (Fig. 15-16). (See also Chapters 18 and 20).

When improper gingival height exists around teeth because of ectopic eruption, orthodontic repositioning usually will not correct this defect. Surgical recontouring is commonly required after orthodontic treatment is completed.

**Hypertrophied or Malpositioned Papilla.** Proper restorative closure of diastema requires access to the most gingival and interproximal areas of the involved teeth. If the papilla is positioned either too far incisally or too far facially, this enamel is inaccessible and an imbalance occurs in the restored teeth between the mesiodistal width at the cervical area compared with the incisal area. Electrosurgery can quickly make this enamel available.

**Inflamed, Hypertrophied Gingiva During or After Orthodontic Treatment.** Inflamed, hypertrophied gingiva that occurs during or after orthodontic treatment is treated in the same manner as other redundant tissue.

**Hypertrophied Tissue Caused by Drug Therapy.** Hypertrophied tissue that is caused by drug therapy, such as the use of Dilantin, is treated in the same manner as other redundant tissue.

**Hypertrophied Tissue Resulting from Pathologic Condition or Poor Oral Hygiene.** Hypertrophied tissue that results from a pathologic condition or poor oral hygiene is treated in the same manner as other redundant tissue.

**CLINICAL TIP.** Treatment planning is important if electrosurgery is used in combination with esthetic restorative treatment. Although it may be possible to complete both electrosurgical and restorative procedures at the same appointment, best results are achieved with a 1- to 2-week healing period before the initiation of restorative treatment.

## Contraindications

Contraindications for electrosurgery are as follows:

1. Electrosurgery should not be performed within 16 feet of a pacemaker of unknown frequency and/or shielding or any other implanted electronic device that is sensitive to RF waves (implantable cardiac defibrillators, etc.). Some devices (e.g., coaxially shielded pacemakers) may be sufficiently shielded for electrosurgery to be used safely. Therefore it is mandatory to check with the patient's physician or the manufacturer of the device before using electrosurgery. This safety warning is for the patient, operator, auxiliary staff, family members, or other persons who may be within 16 feet of the unit (even in adjacent rooms) during the procedure.
2. Electrosurgery should not be performed when the patient has undergone radiation therapy of the head and neck. Because radiation therapy results in a decrease in vascularization, electrosurgery, as well as all oral surgery, carries an increased risk of osteonecrosis.
3. Because of the danger of explosion, electrosurgery should not be performed in the presence of certain chemicals, such as ethanol and chloroform.'

## Advantages

The many advantages of electrosurgery include the following:

1. No pressure is needed for tissue separation.
2. The incision is smooth.
3. Access to remote regions of the oral cavity is easier than with other surgical modalities.
4. Tissue separation occurs with less coagulation. Scalpel incisions result in a great deal of coagulation because of trauma to the tissue, resulting in a large wound, more shrinkage, and resulting scar tissue postoperatively. Electrosurgery lessens the effects of all these healing steps because of less initial trauma upon incision and therefore less coagulation.
5. Coagulation control allows better visibility.
6. Little or no scar tissue results.
7. Sterility is more easily controlled. All bacteria in the line of the incision are volatilized at the electrode in a manner similar to that of the cell (tissue) layer.
8. Electroplaning of tissue is possible. With this approach, the electrode is placed just tangent to the tissue and used to remove, or plane off, a minimal layer of tissue in a manner similar to a carpenter's plane.
9. Electrosurgery allows completion of the planned restorative procedures in the same appointment if this is absolutely necessary. See the preceding Clinical Tip.

## Nitrous Oxide Analgesia

With some simple precautions, nitrous oxide can be used safely and with consistent results in conjunction with electrosurgery.' This type of analgesia should be used with great caution. The oropharynx should be draped with slightly moist gauze to avoid the accumulation of oxygen in the oral cavity. Any metal restorations in the surgical area should be coated with petrolatum, and contact should be avoided because of the potential for excessive sparks to ignite any accumulated oxygen.

## CLINICAL APPLICATIONS

In an ideal gingival architecture of the maxillary anterior teeth, the gingival heights of the central incisors and canines are equal and the gingival height of the lateral incisor is just slightly incisal to the central incisor or canine height. If the first premolar is included in the recontouring, the gingival height should be approximately 1 to 2 mm incisal to that of the canine. Precise application of instrumentation and technique cannot be overemphasized. Strict adherence to a few simple concepts ensures consistently successful results.

### Armamentarium

- Standard dental setup
- Cotton rolls
- Explorer
- Alcohol sponges
- Plastic mouth mirror
- Periodontal probe
- 2 x 2 gauze
- Appropriate electrosurgical unit
- Thin, straight, bendable needle electrodes
- Passive electrode
- Extra-small bite block
- Plastic high-volume suction tip
- Topical anesthetic
- Local anesthetic
- Straight edge
- Hydrogen peroxide
- Tincture of benzoin and myrrh
- Aromatic oil (various flavors of fruit or flowers)

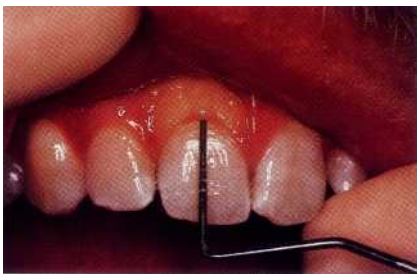
### Clinical Technique

1. Administer topical anesthetic followed by local anesthetic. Profound anesthesia is critical for a completely painless procedure.
2. Select a thin, straight, bendable needle electrode. Ensure that the needle electrode is completely seated into the handle of the handpiece to prevent the metal of the shaft from touching the soft tissues of the lips and cheeks. Place the insulated passive plate under patient's thigh. Be certain that no metal

objects are in the patient's pockets or on undergarments because if these metal objects can cause a burn if they touch the plate. (The thigh is preferred because in extremely thin individuals who have a sharp scapula or vertebral eminence, the thin layer of tissue may be burned if the plate is placed under the shoulder.)' If the plate is insulated and properly placed, no untoward events will occur.'

**CLINICAL TIP.** The operator must be in a comfortable position to ensure a steady hand motion. The patient's head must be low enough to allow the operator's upper arms to hang comfortably at his sides with the elbows bent at 90 degrees or more. This keeps tension off the muscles and relaxes the upper arm.

3. Stabilize the dentition with an extra-small bite block to ensure that the mandible does not move during the procedure.
4. Place moist cotton rolls on either side of the maxillary labial frenum to retract the upper lip from the operating area. Keep everything (tissue, cotton rolls, etc.) moist to minimize the temperature change of the tissues. Also, moist cotton rolls will not stick to soft tissue during *any* procedure, thus preventing tearing of the tissue.
5. Probe the sulcular area of the appropriate teeth to determine the orientation of the gingival attachment and the depth of the sulcus (Fig. 15-17).
6. As a guide for the surgically repositioned gingival height of the involved teeth, use a maxillary anterior tooth that is not included in the surgical procedure and that has an appropriately esthetic crown length.
7. Hold a straight-edge tangent to the gingival height of the guide tooth and parallel to the pupils of the patient's eyes to determine the necessary amount of gingiva to be removed on the other teeth to achieve symmetry (Fig. 15-18).



*Fig. 15-17.* The sulcular area is probed to determine the orientation of the gingival attachment and the depth of the sulcus.

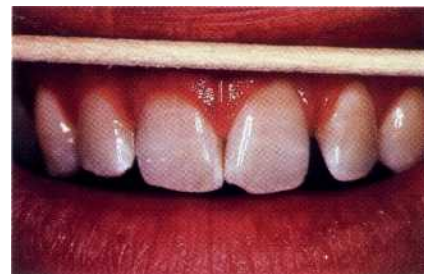**CLINICAL TIP.** While orienting for the incision, disregard the occlusal plane because many patients have worn their teeth at uneven angles. Orientation with this uneven angle would result in subsequent uneven gingival orientation.

8. Probe the affected teeth to reconfirm whether sufficient gingiva exists to perform electrosurgery and leave proper sulcular depth. Do not remove gingiva apical to the cemento-enamel junction.
9. If absolute symmetry cannot be realized, then remove as much gingiva as possible while leaving at least 1 mm of sulcus. This will result in optimal possible esthetic results in these cases.

**CLINICAL TIP.** If all the maxillary anterior teeth are to be included in the surgical procedure, the tooth with the most incisally positioned gingival attachment becomes the guide for the surgically repositioned gingival height. This eliminates the possibility of violating the biologic zone on any of the teeth and also ensures the most esthetic crown length and symmetric architecture on all teeth.

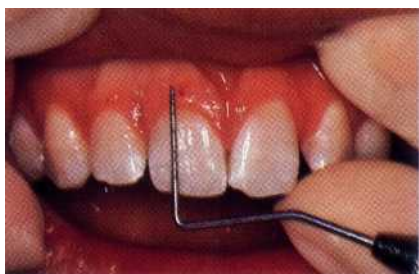
**CLINICAL- TIP.** In anterior teeth the height of the curvature of the incision is slightly toward the distal area of the tooth. The exception to this rule occurs in extremely square teeth, in which the gingival curvature is symmetric from mesial to distal.

10. After orienting with the pupils and determining the amount of tissue to remove, penetrate the gingival thickness at the desired height with an explorer at a right angle to the long axis of the teeth. With a periodontal probe, confirm that surgery to this new gingival height will not violate the biologic zone, while leaving the sulcus at least 1 mm **deep** (Fig. 15-19).

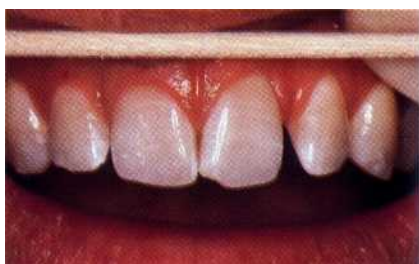

*Fig. 15-18.* Holding a straight edge tangent to the gingival height and parallel to the pupils of the patient's eyes helps determine the amount of gingiva to be removed for symmetry.





*Fig. 15-19.* The gingiva is penetrated at the predetermined position with an explorer at a right angle to the long axis of the tooth.

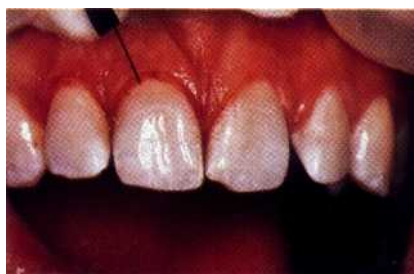

*Fig. 15-20.* The practitioner should confirm that the height of the marks will result in the desired symmetry.

**CLINICAL TIP.** Care should be taken not to make the teeth too long. The mesiodistal width of central incisors averages 80% of their gingivoincisal height. During electro-surgery, be sure to account for any planned widening of the central incisors caused by bonding or laminating techniques.

11. These gingival penetrations will bleed slightly.
12. Reorient with the pupils, and confirm that surgery at the height of these penetrations will result in the desired symmetry (Fig. 15-20). If the penetrations are asymmetric, repeat the orientation procedure until the desired balance is achieved.
13. Activate the electrosurgical unit, and allow it to warm up for a short period of time. Set the current selector switch on fully rectified filtered current. The separate current intensity switch should be set to maximize cutting efficiency. (Sufficient practice sessions on a cut of beef or a calf mandible will determine this setting.) Perform electrosurgery only when completely familiar with all aspects of the surgical equipment and the procedure.

**CLINICAL TIP.** Reanesthetize the papilla immediately before making the incision. This ensures complete anesthesia of any collateral innervation and also hydrates the tissue, which allows for better cutting conditions.



*Fig. 15-21.* With the handpiece held at a 45-degree angle toward the incisal aspect of the tooth, a smooth, pressureless hand motion should begin the incision.

**CLINICAL TIP.** Keep the tissue and the surrounding areas slightly moist with saliva, water, or saline (see step 4). A dry field creates additional heat and may cause tissue damage.

14. Before the initial incision, make a few practice cutting motions to help visualize the desired gingival contour.

**CLINICAL TIP.** The odor resulting from electrosurgical cutting of organic tissue can be strong. To mask this odor, place a 2 x 2 gauze impregnated with a pleasant smelling aromatic oil just under the nose. Many patients, however, do not find these strong smelling aromatic oils pleasant; consult the patient immediately before surgery regarding preferences.

15. When properly oriented for the incision, activate the foot rheostat.
16. Wait momentarily for the current surge to pass, and then begin the incision.
17. With the handpiece held at a 45-degree angle toward the incisal area of the tooth, begin the incision with a smooth, pressureless hand motion (Fig. 15-21). Hold the electrode tip extremely close to the tooth without touching it. Contacting the unevenly textured tooth surface with the electrode tip will cause drag and lead to an uneven incision. The spark-gap completes the current connection, thus initiating the incision.

**CLINICAL TIP.** The intensity of the electrical current must be at a level that creates neither drag (too low) nor sparking (too high).

18. The depth of the incision should be reached on each individual pass of the electrode. However, the length of the incision does not have to be completed in one motion. Three to four short connected incisions will complete the procedure. To prevent overheating, the

needle electrode should contact the tissue for not more than 1 to 2 seconds at a time while constantly in motion. Always allow 5 to 10 seconds between reapplication of the electrode at the same tissue site to prevent overheating of the tissue.

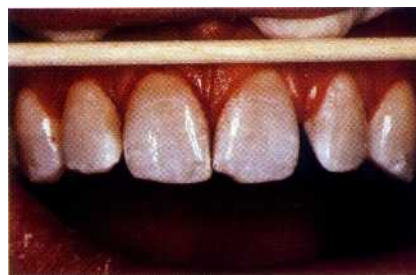**CLINICAL TIP.** Particular attention should always be paid to the speed and time of electrode contact with the tissue; these are the most important aspects of the entire procedure.

**CLINICAL TIP.** Remove any accumulation of tissue on the electrode with an alcohol-moistened sponge. Never allow tissue remnants to remain on the electrode while cutting.

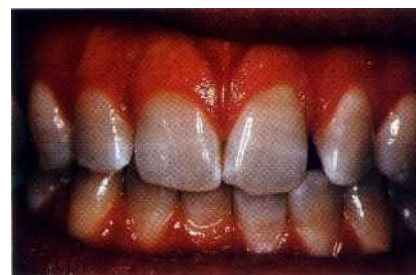19. Care should always be taken not to overincise the tissue; it cannot be replaced. After completion of the initial incision, use the **straight edge to confirm the new gingival height for accuracy (Fig. 15-22)**. If needed, make necessary adjustments to achieve desired final results.
20. Surgery is incomplete until the site is completely cleansed. This includes removing all tissue tags with the electrode, curette, scaler, explorer, or any sharp sterile instrument; thorough cleansing with water or saline; and placement of surgical dressing of 4 or 5 separate air-dried layers of tincture of benzoin and myrrh if needed. If the patient has good gingival health, as well as good overall physical health, this dressing is not required.
21. Under normal conditions, the tissues involved in electrosurgery should heal in 7 to 14 days (Fig. 15-23).
22. **If the tissues were inadvertently overheated during the procedure, adverse tissue reactions, such as pain, swelling, excessive inflammation, or infection, can occur; however, these reactions are rare.** Also, overheating the tissues results in grossly delayed healing; thus use of a periodontal pack may be considered. Smoking and drinking are contraindicated because they can delay healing.
23. Postoperative instructions include cleansing with 3% hydrogen peroxide, mixed on a cotton swab with a small amount of regular toothpaste, and rinsing with warm saline solution two to three times daily for the first week. The patient should maintain a bland diet for a few days.

**CLINICAL TIP.** Direct application of the toothbrush to the surgical site is contraindicated until healing is completed.

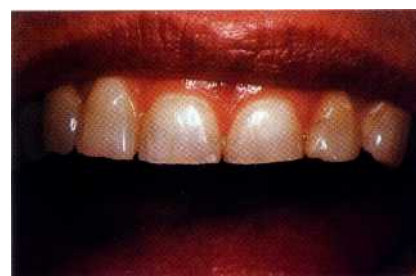24. If the patient experiences postoperative pain, prescribe an appropriate analgesic. Infections can be controlled with antibiotics.



*Fig. 15-22. The new gingival height is confirmed for accuracy using the straight edge.*



*Fig. 15-23. Under normal conditions the tissues involved in electrosurgery should heal in 7 to 14 days.*



*Fig. 15-24. A 45-year-old woman with poor gingival architecture.*

## CLINICAL CASES

A 45-year-old female presented with previously fractured maxillary left and right central incisors and maxillary left lateral incisor. Her medical history was noncontributory. These teeth had subsequently overerupted, creating an imbalance in the gingival architecture of her maxillary anterior teeth (Fig. 15-24). The patient requested cosmetic bonding. Probing revealed 4-mm sulci around the central incisors and a 3-mm sulcus around the left lateral incisor. Electrosurgery was indicated on all three teeth to achieve a more balanced gingival architecture prior to a bonding procedure (Fig. 15-25).

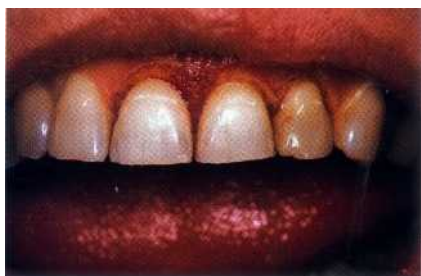

Fig. 15-25. Postoperative view immediately after surgery.

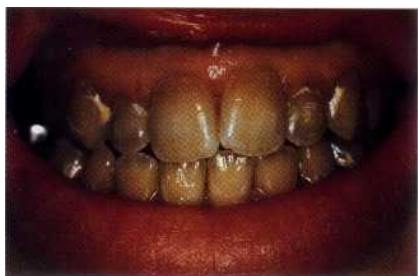

Fig. 15-26. A 22-year-old woman with tetracycline staining of all teeth and a gingival imbalance of all maxillary anterior teeth.

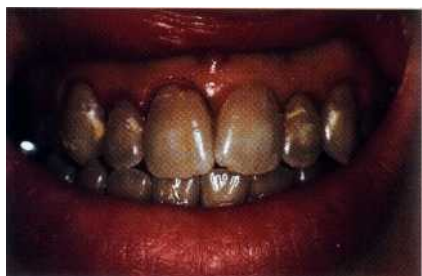

Fig. 15-27. Postoperative view immediately after surgery.

A 22-year-old female presented with tetracycline stains of all teeth and a gingival imbalance of all maxillary anterior teeth (Fig. 15-26). The patient requested cosmetic bonding. Probing revealed 4-mm sulci around the right and left lateral incisors and 3-mm sulci around the right and left canines and right central incisor. Electrosurgery was indicated on all involved teeth to achieve a more balanced gingival architecture prior to cosmetic bonding (Fig. 15-27).

### CONCLUSION

The architecture of the gingiva must be included in the assessment of the patient undergoing esthetic procedures.

Electrosurgery allows for dramatic soft tissue changes with a great degree of confidence.<sup>25</sup>

The clinician can gain skill rapidly with adequate practice. Proper familiarization with the equipment and adherence to precise rules for application of this equipment allow the operator to approach each surgical case in a confident and relaxed manner. As the operator's proficiency in electrosurgery increases, the recognition of anesthetic gingival defects will become almost automatic.

### REFERENCES

1. Cringer MJ: *Electrosurgery in dentistry*, ed 2, Philadelphia, 1975, WB Saunders.
2. Malone WF: *Electrosurgery in dentistry*, Springfield, Ill, 1974, Charles C Thomas.
3. Pollack BF: Understanding dental electrosurgery, *NY State Dent J* 50:340, 1984.
4. Krause-Hohenstein U: Electrosurgery: fundamental requirements for successful use, *Quint Int* 14:1, 1983.
5. Nixon KC, Adkins KF, Keys DW: Histological evaluation of effects produced in alveolar bone following gingival incision with an electrosurgical scalpel, *J Periodontol* 46:40, 1975.
6. Simon BI et al: The destructive potential of electrosurgery on the periodontium, *J Periodontol* 47:342, 1976.
7. Robertson PB et al: Pulpal and periodontal effects of electrosurgery involving cervical metallic restorations, *Oral Surg* 46:702, 1978.
8. Pope JW et al: Effects of electrosurgery on wound healing in dogs, *Periodontics* 6:30, 1968.
9. Williams VD: Electrosurgery and wound healing: a review of the literature, *J Am Dent Assoc* 108:220, 1984.
10. Coelho DH, Cavallaro J, Rothchild EA: Gingival recession with electrosurgery for impression making, *J Prosthet Dent* 33:422, 1975.
11. Malone WF, Manning JL: Electrosurgery in restorative dentistry, *J Prosthet Dent* 20:417, 1968.
12. Armstrong SR et al: The clinical response of the gingival tissues to electrosurgical displacement procedures, *Tenn Dent Assoc J* 48:271, 1968.
13. Klug RG: Gingival tissue regeneration following electrical retraction, *J Prosthet Dent* 16:955, 1966.
14. Schieda JD, DeMarco JJ, Johnson LE: Alveolar bone response to the electrosurgical scalpel, *J Periodontol* 43:225, 1972.
15. Fisher DW: Conservative management of the gingival tissue for crowns, *Dent Clin North Am* 29:273, 1976.
16. Stark MM et al: The effects of retraction cords and electrosurgery upon blood pressure and tissue regeneration in rhesus monkeys, *J Dent Res* 56:881, 1977.
17. Aremband D, Wade AB: A comparative wound healing study following gingivectomy by electrosurgery and knives, *J Periodontal Res* 8:42, 1973.

18. Kalkwarf KL, Krejci RF, Wentz FM: Healing of electrosurgical incisions in gingiva: early histologic observations in adult men, *J Prosthet Dent* 46:662, 1981.
19. Schneider AR, Zaki AE: Gingival wound healing following experimental electrosurgery: an electron microscope investigation, *J Periodontol* 45:685, 1974.
20. Beube FE: *Periodontology*, New York, 1953, MacMillan.
21. Agnew RG, Kaiser WF: Effects upon the dental pulp of the macacus rhesus of externally applied high-frequency electrosurgical currents, *J Dent Res*, 1952 (abstract #105).
22. Malone WF, Eisenmann D, Kusek J: Interceptive periodontics with electrosurgery, *J Prosthet Dent* 22:555, 1969.
23. Eisenmann D, Malone WF, Kusek J: Electron microscopic evaluation of electrosurgery, *Oral Surg, Oral Med, Oral Pathol* 29:660, 1970.
24. Glickman I, Imber LR: Comparison of gingival resection with electrosurgery and periodontal knife-a biometric and histologic study, *J Periodont* 41:142, 1970.
25. Strong D: Esthetics enhanced with electrosurgery, *NY State Dent J* 50:358, 1984.



انتشارات شایان نمودار

# ESTHETICS AND IMPLANT PROSTHETICS

Richard J. Lazzara and Stephan S. Porter

**L**ONG-TERM SUCCESS RATES for osseointegrated dental implants have been well documented.<sup>1,2</sup> However, the esthetic restoration of the dental implant has lagged behind its biologic counterpart.

The original Branemark protocol required that several millimeters of titanium be exposed above the soft tissue. However, these early Swedish implants were originally placed into totally edentulous, severely resorbed ridges. The borders of the subsequent restoration were apical to the lip and smile line and did not present an esthetic problem. Acrylic denture flanges and acrylic teeth were used to replace the lost natural teeth and alveolar bone. Interpore's IMZ type restoration with its IME (intermobile element) also requires at least 1 mm of plastic and a small amount of titanium to be exposed supragingivally. Ridge-lapping is a way of covering these exposed elements, but this creates difficulties in oral hygiene.

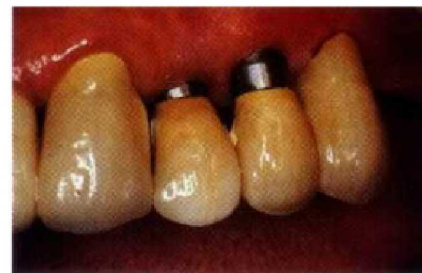Because of the exposed metal or plastic elements, the early Branemark and the IMZ technique resulted in restorations with flat, apical contours and crowns that were shorter than the adjacent teeth. This further compromised esthetics (Fig. 16-1).

Implant surgery is divided into two stages. Stage 1 involves placement of the implant. This is typically followed by a healing period, with the implants submerged, during which the process of osseointegration occurs.

Following stage 1 surgery, if the implants are submerged below the crest of the alveolar bone, the denture can be replaced immediately, as long as adequate relief is provided in the denture over the surgical site. The denture should be relined with a soft material to improve denture stabilization and to facilitate soft tissue healing. The patient thereby leaves the office esthetically com-

fortable. In the maxillary arch particularly, the denture that is placed immediately following stage 1 surgery acts as a healing stent to provide an appropriate amount of pressure on the surgical site. In the mandibular arch, some incision designs such as vestibular incisions produce increased swelling and make denture function difficult. In these cases, the mandibular denture serves a purely cosmetic purpose.

In stage 2 surgery, the implants are exposed and, after the soft tissue is allowed to heal, the prosthesis is fabricated. During stage 2 surgery, a final abutment or temporary healing abutment is connected to the implant. If a final abutment is placed, use of a temporary crown will cover the abutment until the final prosthesis can be placed. The temporary crown prevents tissue growth over the abutment and prevents debris accumulation in the area of the abutment retaining screw. If the implants are to be restored



*Fig. 16-1. The implant restorations using standard techniques exhibit flat apical contours as well as crowns that are shorter than the adjacent teeth. In addition, exposed metal creates an unesthetic result.*

with a removable partial denture or a complete denture, a temporary retention cylinder can be used in place of a healing abutment. The temporary retention cylinder provides increased retention of the denture by creating an O-ring effect in the soft relined denture material, which adds stability to the transitional appliance until final abutment connection and denture placement are achieved.

### ACCEPTANCE

Implantology and implant prosthetics are exciting and rapidly evolving fields. A number of organizations, including the Food and Drug Administration (FDA) and the American Dental Association (ADA), are currently involved with evaluation and acceptance (both provisional and full) of these devices.

However, it is the responsibility of the dentist to be adequately trained and experienced in the placement and use of these implants, to exercise proper judgment in the case selection, and to provide the patient with appropriate information for informed consent (see Chapter 27).

Currently, the number of manufacturers receiving provisional and complete ADA acceptance is limited. As more long-term clinical studies become available, more manufacturers are expected to receive acceptance for a wider array of applications. The exact type and extent of acceptance for each device is available from the ADA.

### TERMINOLOGY

An implant restoration consists of three stages. The first stage is the implant itself, which is placed in the bone and becomes osseointegrated. Once osseointegration has taken place, a mechanism must extend the implant through the soft tissue. This transmucosal extension, or second stage, is called an abutment. Abutments come in a variety of different types, each designed to manage a particular clinical situation at that location. The abutment generally consists of an abutment and an abutment retaining screw. The abutment retaining screw maintains the abutment's position on the implant. The abutment provides an area of retention similar to a prepared tooth for cementation of a crown or attachment of a prosthetic retaining screw. The third stage, or restoration, is attached to the underlying abutment by either cementation to the abutment or by a prosthetic retaining screw. A premachined gold cylinder may be used, which becomes incorporated into the final prosthesis. This final prosthesis will contact the abutment or second stage during placement of the prosthesis. The use of a machined cylinder reduces potential laboratory error.

The final restoration is held in place by cement or by a prosthetic retaining screw. Prosthetic retaining

screws are generally constructed of gold alloy or titanium. They are recessed internally within the occlusal surface of the crown and are seated on the gold cylinder, thus holding the final restoration in place on the second stage or abutment. Some clinical situations typically related to angle correction necessitate the fabrication of a custom cast abutment, which is constructed at the implant level. The final prosthesis is placed directly on this custom abutment. The final prosthesis or prosthetic superstructure may be cemented to the custom abutment or screw retained.

### MATERIALS

To provide successful osseointegration, the implant material must be biocompatible. The most popular biocompatible material used in implant dentistry today is titanium, either commercially pure titanium or titanium alloy. Typically commercially pure titanium is used. Titanium has proven to be biocompatible in long-term evaluations and documentation reporting on the success and longevity of dental implants.<sup>3,4</sup> Titanium is lightweight and noncorrosive (because of its oxide layer); it seems to be the most predictable material for manufacturing implants and implant components.

#### Implant Surface Modifications

Implant surface modifications, including surface coatings, can be divided into two general categories: additive types and subtractive types of surface preparations.

**Additive Surface Modifications.** Commercially pure titanium implants can be plasma sprayed with titanium particles on the surface, thereby maintaining the titanium surface for osseointegration as well as greatly increasing the surface area for attachment of bone to the implant. Titanium plasma sprayed (TPS) implants are generally cylindrical in shape and are available with an external hexagon, which provides maximum prosthetic options and stability.

The use of sintered beads applied to the surface of dental implants has become more popular recently. This technology claims to have originated in the orthopedic application for joint replacement implant components. However, the long-term clinical result of such coatings in dental applications is currently not known.

Hydroxyapatite (HA) has also been used as a surface coating on dental implants. Long-term documentation of results with this material does show improved stability of the HA material, but it still appears that hydroxyapatite may slowly resorb from the surface of the implant and therefore may not provide a long-term stable surface coating.

**Subtractive Surface Modifications.** **Grit blasting the implant surface results in an increase in the surface roughness**, which produces increased surface area. Grit blasting has been used alone or followed by application of hydrochloric (HCL) and sulfuric (H<sub>2</sub>SO<sub>4</sub>) acids, which increase the microstructure of the roughened surface. Documentation evaluating the clinical response of these types of surface preparation methods indicates that both surface modifications can provide long-term clinical success and functionality of the implant.

Generally, the screw-type implant has been well documented for use in dense bone or where stability at the time of placement is critical. The use of a screw-type implant provides engagement of cortical bone to provide maximum stability and the most predictable precise placement.

## TYPES OF IMPLANT RESTORATIONS

### *Overdenture-Retained Prosthesis: Clip Bar*

Using implants as overdenture abutments and retainers for bar and clip prostheses is a cost-effective method of improving the stability of the denture.

**CLINICAL TIP.** An implant retained denture may provide the best lip support and speech control for the patient.

Denture implant restorations are generally constructed by connecting the implant abutments with a gingival bar and using an overdenture clip for retention.

1. Lip support requirements. Especially in the maxillary arch, a fixed prosthesis may be inadequate to provide sufficient lip support in **the anterior regions because of resorption of the maxillary** ridges. The use of an overdenture provides the option of extending the labial flange to provide for additional lip support. This will maximize esthetics and facial contours.
2. Psychologic concerns. Patients who have worn removable appliances for many years sometimes feel that a removable appliance allows them better access for oral hygiene. They are accustomed to removing their appliance during oral hygiene procedures. These patients may feel more comfortable having a removable prosthesis and are primarily concerned about the stability of the denture more so than the appearance.
3. Financial concerns. **The overdenture is usually the least expensive alternative for the restoration of multiple osseointegrated implants in** an edentulous arch. Because the bar requires fewer laboratory procedures, laboratory costs are reduced considerably. Retentive abutments, such as O-ring or Dal-Ro (3i,

Implant Innovations, Inc.), eliminate the need for a laboratory constructed substructure, and therefore a conventional denture may be constructed for the patient and the attachments cold-cured intraorally.

### Contraindications

1. Psychologic concerns. Many patients have a psychologic aversion to wearing a removable appliance. **This aversion can be extremely strong and these patients may try to avoid a removable prostheses at all costs.**
2. Hyperactive gag reflexes. The overdenture requires the extension onto the tuberosity area of the maxillary arch and onto the posterior retromolar area of the mandibular arch. Placement into these areas may activate the patient's gag reflexes.
3. Unilaterally edentulous areas. When a patient presents with a unilateral edentulous area, an overdenture is not indicated because it is not possible to adequately stabilize the appliance. Therefore a fixed restoration should be considered in such situations.
4. Poor supporting bone. **As with any implant, adequate** bone type and configuration must be available.

### *Overdenture-Retained Prosthesis: O-Ring*

These abutments screw directly into the implant and provide a basis for the retention of the overdenture. They do not require laboratory construction of bars and connections but rather provide immediate connection to the denture. **They are usually in the form of an O-ring** or hall-and-socket attachment (Dal-RO, 3i, Implant Innovations, Inc.; Overdenture Kit, Nobel Biocare, Inc.). These abutments screw directly into the implant and provide stable retention of a mandibular overdenture.

### Indications

1. Simplicity requirements. The overdenture abutments provide a more simplistic approach to the retention of overdentures, because they do not require impressions or laboratory procedures and construction of gingival bars.
2. Excessive space between or inadequate arrangement of implants. Individual retentive abutments are indicated when too much space exists between implant locations or if a gingival bar would have to be constructed in a circular fashion. These allow retention of the overdenture without construction of oversized or poorly designed bars.

### Contraindications

1. Maintenance requirements. O-rings must be changed periodically, because they tend to wear during extended usage.
2. Nonparallel implant orientation. Because these abutments have male posts extending above the

implant, they must be relatively parallel to prevent damage to the retaining rings and to allow proper seating.

3. Immobility requirements. O-rings and ball-and-socket attachments allow some movement of the overdenture. If the patient requires absolute immobility to the overdenture, multiple implants and bars should be used to provide a greater area of support for stabilizing the denture.

### *Crown and Bridge Type: Single Tooth*

The single tooth replacement is one of the most challenging esthetic restorations. An antirotational mechanism must be present for stability.

**CLINICAL TIP.** An implant with a built-in antirotational mechanism eliminates the need for external stabilization extensions and is essential for the maintenance of a diastema.

1. Conservation of tooth structure requirements. The usual alternative to a single tooth replacement is either a conventional or acid-etch resin composite retained bridge. These require the removal of tooth structure.
2. Diastema maintenance. Maintaining adjacent diastemata prevents overcontouring contact areas or placement of a palatal bar.
3. Existing clinically acceptable adjacent bridgework. In some instances a single tooth must be removed and the adjacent multiple unit bridgework is clinically acceptable. Conventionally, this would require replacement of the adjacent fixed bridge to replace this single tooth. Generally, this also includes extending the bridgework one tooth beyond the edentulous area. Placement of a single implant allows the preservation of the clinically acceptable fixed bridge, as well as avoids the preparation of an additional tooth adjacent to the new edentulous area.

#### Contraindications

1. Poor supporting bone. As with any implant, adequate bone type and configuration must be available.
2. Restoration of adjacent teeth is necessary for other reasons. If adjacent teeth require extensive rehabilitation, a fixed bridge should be considered.

### *Crown and Bridge Type: Small Span Bridge*

Small span, unilateral fixed bridges eliminate the need for removable partial dentures and provide stable abutments for fixed bridgework. This includes bridges supported solely by implants or by a combination of implants and

the natural teeth connected by some type of retrievable mechanism.

#### Indications

1. Unilateral edentulous posterior or anterior areas. A unilateral fixed prosthesis can be placed in edentulous posterior or anterior areas to avoid the use of removable partial dentures. If the adjacent natural dentition is in need of preparation and is stable, several implants can be placed to support a fixed prosthesis in addition to the natural dentition. However, the appropriateness of splinting natural teeth to implant borne restorations still requires further research.
2. Large edentulous area with unprepared adjacent natural teeth. In this situation an independent implant-supported bridge can be constructed using an adequate number of implants to provide maximum stability. It is especially important to provide an appropriate number of implant abutments to resist lateral occlusal forces.

#### Contraindications

1. Poor supporting bone. An adequate number of implants must be placed to support a fixed prosthesis. As with any implant, adequate bone type and configurations must be available.
2. Inadequate interarch space. An adequate amount of interarch distance must exist between the residual ridge and the opposing occlusion to provide room for the restorative components. This is especially important in the posterior regions when implants are placed in the tuberosity area and mandibular posterior areas.

### *Crown and Bridge Type: Full Arch Bridge*

Full arch crown and bridge restoration can be constructed on osseointegrated implants, assuming adequate supporting structure and realization of an acceptable esthetic result. Under ideal circumstances a patient can convert from a complete denture to a totally fixed restoration.

#### Indications

1. Adequate ridge height. Full arch crown and bridge restoration can be considered only for totally edentulous patients when adequate ridge height is present to produce a normally sized and shaped final restoration. Minimal resorption of the residual ridge permits the final restoration to be toothlike in both size and shape. This is the ideal situation for using a conventional crown and bridge restoration supported by osseointegrated dental implants.



### Contraindications

1. Moderate to severe ridge resorption. In the case of moderate to severe bone resorption, a fixed restoration requires replacement of more than just tooth crowns. Root dimension and alveolus height must be replaced. This is difficult to achieve using a conventional crown and bridge restoration because of framework considerations. In addition, because the ridges generally recede in a lingual or palatal direction, as well as in an apical direction, unusual contours would be required in the final restoration or in the final fixed bridge. This is difficult to restore with conventional metal and porcelain type restorations.
2. The need for extensive cantilevering. In totally edentulous patients, implants are generally placed anterior to both the mental foramen and the maxillary sinus. This requires extensive distal cantilevering to provide some posterior occlusion. Fixed restorations using conventional crown-and-bridge-type procedures with porcelain and metal have no shock-absorbing effect when in occlusion, and the extensive cantilevering may affect the stability of the porcelain surface and the implant itself.
3. Inadequate lip support. The prosthesis may not adequately support the lip in the vestibular area and may produce a soft tissue crease under the nose.

### Hybrid Type

The hybrid restoration of osseointegrated dental implants involves components of both the complete removable denture and the traditional fixed restoration. It consists of a metal framework supporting denture teeth. Denture acrylic is processed around the denture teeth, connecting them to the metal framework. This allows replacement of the lost alveolar structures as well as root structures in the edentulous patient with moderate to severe bone resorption. Generally, these restorations are associated with extensive cantilevering at the distal aspects of the restoration.

### Indications

1. Totally edentulous arches with moderate to severe resorption. This hybrid prosthesis is used in moderately to severely resorbed edentulous patients, because it provides maximum flexibility when positioning the teeth, despite the location of the implants. The denture teeth can be placed in the proper position to provide lip support and occlusal function; this position may not be directly over the implants themselves.
2. Lip support, speech, and air control requirements. The hybrid prosthesis provides sufficient bulk to the restoration to adequately seal areas that otherwise may potentially cause disturbances in air control

and speech. The hybrid prosthesis can provide adequate bulk for lip support, especially in severely resorbed areas of the anterior maxilla.

### Contraindication

1. Minimal ridge resorption. In the case of minimal ridge resorption, the hybrid prosthesis is contraindicated, because the open apical surface of the hybrid prosthesis will be displayed during function.

## TYPES OF ABUTMENTS

### Screw-retained prosthesis

The screw-retained final prosthesis uses a screw to attach the abutment to the implant. A second screw attaches the prosthesis to the abutment. All components are easily removed and thus readily retrievable (Fig. 16-2).

### Indication

1. Retrievability requirements. A screw retained final prosthesis is indicated when frequent removal of the implant prosthesis is desired.

### Contraindications

1. Inadequate arch space. If inadequate room is available for placement of a gold cylinder, an alternative type of prosthesis must be considered, combining the abutment and crown.

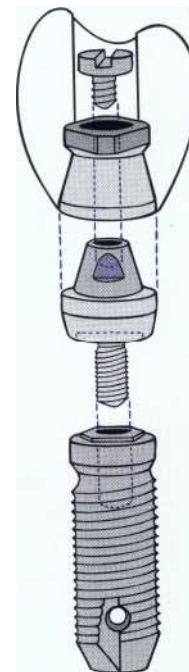


Fig. 16-2. Screw-retained prosthesis.

- Occlusal esthetic requirements. When maximum esthetics of the occlusal surface of the final restoration are indicated, a screw-retained prosthesis should not be used, because the screw access opening must be filled with a composite resin-type material. This can partially compromise the final esthetics of the occlusal portion of the restoration.

### Cement-Retained Prosthesis

The cement-retained prosthesis can be used on osseointegrated dental implants. However, it is important to maintain retrievability of the entire system, and therefore the prosthesis should be cemented with a transitional type cement. The second stage, or abutment, should be screwed into the implant and not cemented to maintain adequate retrievability. These second stage abutments can be custom-made using UCLA-type abutments or pre-constructed abutment posts (see below).

#### Indications

- Accessibility. The cement-retained prosthesis should be utilized in posterior areas where accessibility with screwdrivers may be difficult. The cement-retained prosthesis is easier to seat and to impression than other types of abutments.
- Simplicity requirements. The cement-retained prosthesis more clearly parallels conventional crown-and-bridge technique. Impressions, laboratory technology, and final restoration seating are similar to conventional procedures. In addition, impression copings, analogs, gold cylinders, and screws are not needed.

#### Contraindication

- Inadequate interarch distance. An adequate amount of interarch distance provides sufficient retention when using the cement retained prosthesis. There should be a minimum of 5 to 7 mm of abutment exposed supragingivally to provide adequate retention for the final restoration. When a reduced amount of interarch distance is available, a screw-retained prosthesis should be utilized.

### UCLA-Type Retained Prosthesis

The UCLA-type prosthesis, first developed at UCLA (i.e., Unique Castable Long Abutment, 3i, Implant Innovations, Inc., or UCLA Abutment, Implant Support Systems) reduces the three-stage system by combining the final restoration and abutment phase (Fig. 16-3). It consists of a castable abutment with a large retaining screw that screws directly into the implant for most implant types. For implant systems with a coronal hexagonal elevation, this type of abutment should be used for single tooth replacement and custom post construction.

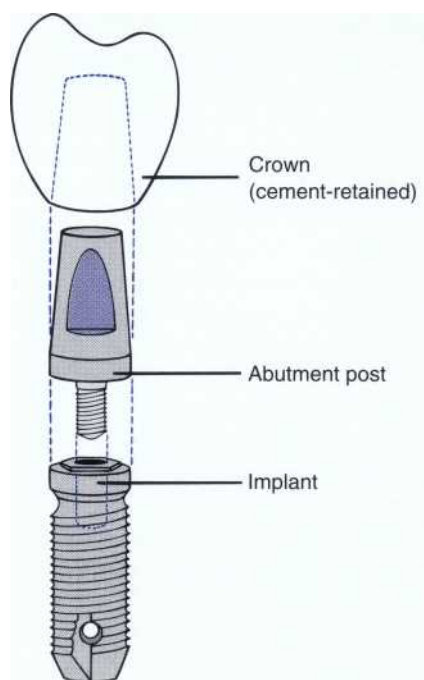


Fig. 16-3. Cement-retained UCLA-type prosthesis.

#### Indications

- Single tooth replacement. The UCLA-type abutment should be used for single-tooth abutment restorations in which tissue height extends less than 4 mm above the implant. This will allow adequate stability of impression copings and provide ease of prosthetic procedures.
- Improper implant angulation. This abutment can be used when the angulation of the implant is inappropriate and when less than 4 mm of tissue height exists. This can ideally position the abutment for construction of the most esthetic and optimally positioned final restoration.
- Minimal tissue height. In cases of minimal tissue height, the UCLA-type abutment is indicated, because it allows porcelain to be carried to within less than 1 mm of the coronal aspect of the implant surface. This will maximize esthetics by bringing restorative material below the level of the soft tissue.

#### Contraindication

- More than 4 mm of tissue height. The UCLA-type abutment should not be utilized for single-tooth or custom post construction in such a case. Most available impression copings are designed for use when tissue height extends less than 4 mm above the coronal aspect of the implant. When tissue height exceeds 4 mm, it limits the ability of the impression material to properly engage the impression coping.

## PREOPERATIVE PLANNING

To obtain ideal esthetic results it is critical that the restorative dentist, in conjunction with the surgeon, formulate a preoperative plan. This plan culminates in the fabrication of a surgical guide stent. However, a number of factors must be considered first.

### Mounted Model Analysis

Mounted models will facilitate the evaluation of interarch distance and location of opposing occlusion. In the fully edentulous patient, preoperative models mounted with occlusal rims indicate the desired lip support and occlusal requirements of the final prosthesis. This influences the shape and angle of the final restoration. For example, the rims will clinically demonstrate the amount of facial inclination of the restoration necessary for proper lip support and a functional occlusion.

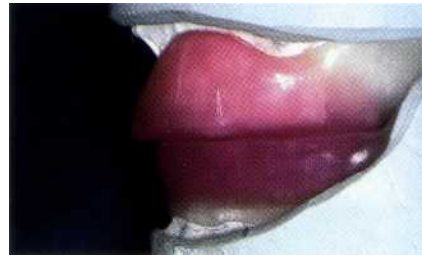
Preoperative mounted models can influence decisions concerning the type of final restoration to be used. For example, if the final tooth position will be facial to the residual mandibular ridge, a hybrid-type prosthesis may be considered, as opposed to a conventional crown and bridge restoration.

In the maxillary arch, an occlusal rim (Fig. 16-4) demonstrates the amount of facial positioning required of the replacement tooth to properly support the maxillary lip relative to the residual ridge. In this way, it helps determine whether a conventional crown and bridge prosthesis, a hybrid prosthesis, or an overdenture should be constructed to best support the lip.

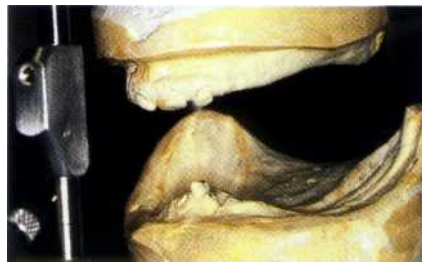In the fully edentulous patient, it may be necessary to construct a trial tooth setup to precisely determine final tooth position. This is especially true when the location of the teeth is changed both in the arch to be reconstructed with the osseointegrated dental implant and in the opposing arch, which may be restored conventionally. Because tooth position in the maxillary arch will affect the mandibular teeth, the location must be determined precisely before constructing the mandibular guide stent. In those cases, a wax try-in of the maxillary and mandibular teeth should be constructed as part of a diagnostic workup before constructing a stent and placing implants (Figs. 16-5 and 16-6).

The guidelines for selection of a conventional crown and bridge prosthesis, hybrid prosthesis, or overdenture prosthesis after study model analysis follow.

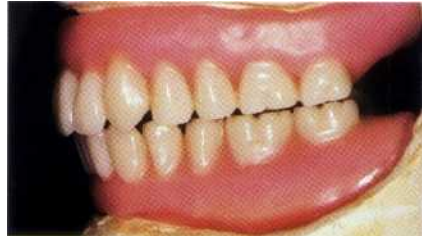1. Patient's desire for fixed restoration. To many patients, the avoidance of a removable appliance is paramount.
2. The size of the framework involved. This may eliminate the possibility of using a conventional crown and bridge-type prosthesis because of the amount of metal necessary.



*Fig. 16-4. Mounted models and an occlusal rim should be used during the preoperative phase for patients undergoing osseointegrated dental implant therapy. This will give an indication of the final tooth position relative to the residual ridge.*



*Fig. 16-5. The maxillary tooth position of the patient shown in Fig. 16-4 will be changed. This will, in turn, affect the final position of the mandibular teeth.*



*Fig. 16-6. A tooth setup is important in the preoperative evaluation of the final tooth position, especially when changing the position of both the maxillary and mandibular teeth.*

3. Amount of interarch distance. The amount of interarch distance is important, because moderate to severe resorption requires a hybrid prosthesis or overdenture. If providing adequate lip support is critical, an overdenture is generally necessary, especially in the case of severe resorption. This is especially true in the maxillary anterior region, where proper support of the maxillary lip and the area under the nose is critical.
4. Number and location of implants. For construction of a conventional crown and bridge-type prosthesis,

implants must be positioned in tooth locations. In addition, the implants must be adequately spaced in the anterior and posterior regions to provide adequate stabilization.

**CLINICAL TIP.** Do not use a conventional crown and bridge-type procedure when placing six implants anterior to the mental foramen. This causes the cantilever to create stress upon both the implants and the prosthesis.

5. Strength and dimension of supporting bone. When severe resorption has taken place, especially in the mandibular posterior region of totally edentulous patients, placing an overdenture is best. An anterior fixed appliance can develop significant functional forces that may overstress the mandible, which thins posteriorly. This may cause fracture of the mandible because of an overload of the anterior region with a fixed restoration.

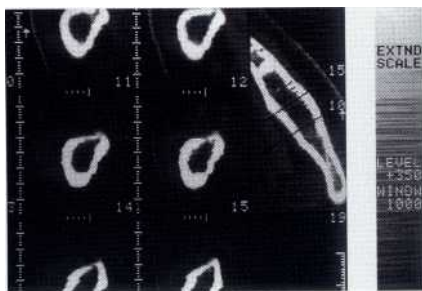
### RADIOGRAPHIC ANALYSIS

Proper radiographic analysis is needed to evaluate the amount of bone available in the area. CT scans (Fig. 16-7) disclose bone dimension and the contours of the residual ridge and guide proper angling of an implant at a given edentulous site. The sectional portion of the CT scan is especially important, because it gives an indication of buccal-lingual bone dimension, bone quality, and the location of vital structures.

The radiographic information, along with mounted models, allows coordination of implant position and angle.

### PSYCHOLOGIC CONSIDERATIONS

The issue of patient expectation must be addressed before implant placement.



*Fig. 16-7.* The precise dimension can be determined by computerized tomography scan showing the coronal evaluation and the sectional portion illustrating 1-mm slices.

**CLINICAL TIP.** Some patients have unusually high expectations about the esthetics and configurations of the final restoration. Be sure to consider this, or patients may not be satisfied with the final restoration despite its biologic success.

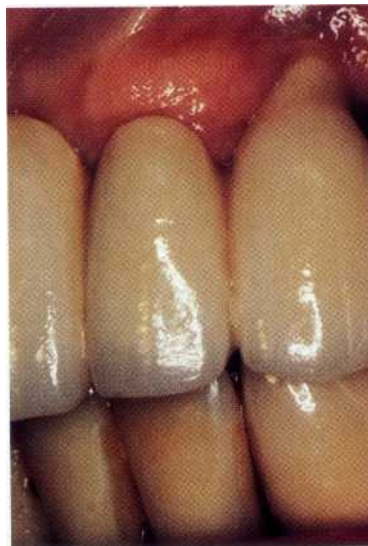A patient, for example, may expect a conventional crown and bridge prosthesis with no exposed metal in a clinical situation that is best managed with a hybrid prosthesis. In this case, it may be possible to hide all the metal and totally eliminate spaces. Patients must be informed that the professionals' ability to satisfy their concerns may be limited. Persistent unrealistic expectations warrant the use of alternate treatment plans.

### ABUTMENT SELECTION

The choice of abutment types is based on various requirements: visibility, accessibility, tissue architecture, angulation of the implant, interarch distance, tissue height, and tissue thickness.

#### Visibility

In areas of high visibility with thin tissue buccolingual, an abutment that allows porcelain to extend well below the soft tissue to the implant is needed (Fig. 16-8). This not only produces the best esthetic results but also compensates for future soft tissue recession.



*Fig. 16-8.* When very thin buccal tissues are displayed, as over this maxillary canine location, a castable abutment is used. If some recession takes place, no metal will be displayed. Also this type of abutment allows maximum control of the emergence profile.

**Accessibility**

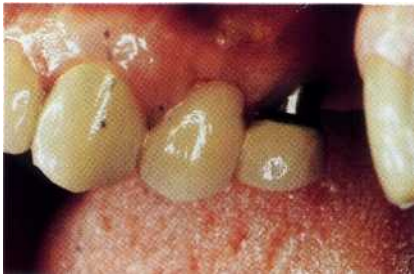Use of the cement retained prosthesis is warranted in posterior areas where accessibility with screwdrivers when inserting and retrieving the final prosthesis may be difficult.

**Tissue Architecture**

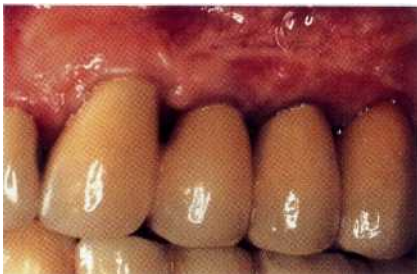If the tissue contours or levels are healthy but uneven and visible during function, the crown should follow the contours of the gingival tissue. Generally, this requires a preparable abutment or abutment post. This also helps preserve interproximal papillae, especially those adjacent to a natural tooth. Poor esthetic results occur when the unalterable flat margins of a prefabricated abutment do not conform with the gingival architecture (Fig. 16-9).

**CLINICAL TIP.** When uneven gingival architecture is present, better esthetics can be obtained by using a post-type abutment that can follow the gingival tissues (Fig. 16-10). Because this is a cement-retained prosthesis, the occlusal surface is covered entirely with porcelain (Fig. 16-11), producing a better esthetic result. Temporary cement allows retrievability of the restoration and access to the implant.

Temporary cement allows retrievability of the restoration and access to the implant.



*Fig. 16-9.* A poor esthetic restoration is the result of an abutment that cannot be adjusted to follow precise contours of the soft tissue.

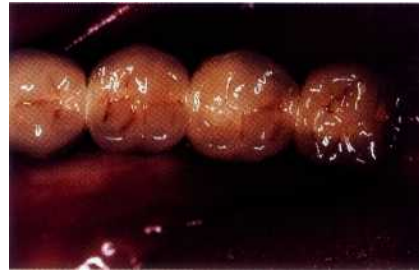

*Fig. 16-10.* A preparable abutment allows the final restoration to follow the contours of the gingiva.

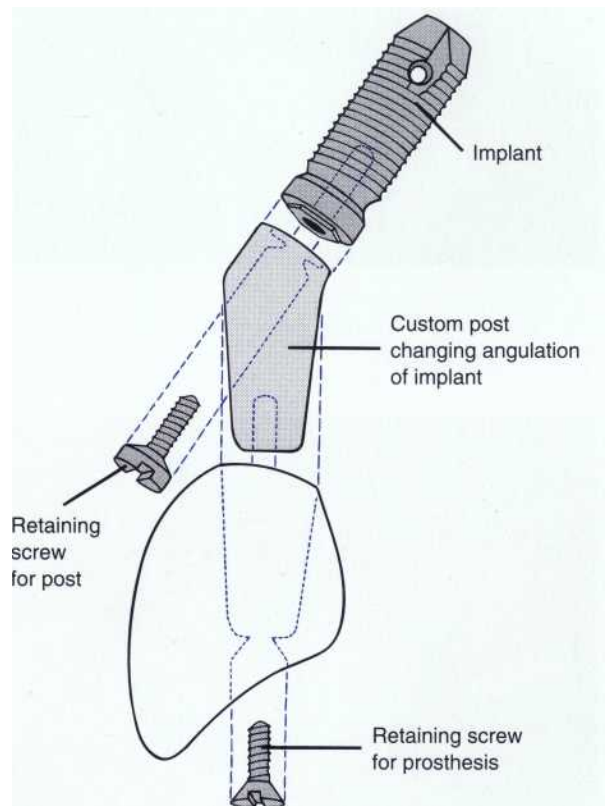
**Angle of the Implant**

Precise preplanning and the construction of surgical guide stents suggest the proper positioning of the implant. However, the clinical acceptability of this predetermined position is determined by the available bone. In the maxillary premolar regions, and sometimes in the maxillary anterior region, implants must be placed with a labial flare to be within the supporting bone. This, however, creates an unesthetic screw access opening in the facial aspect of the final screw retained restoration.

To compensate, a custom castable abutment can change the implant's angle (Fig. 16-12) so that it emerges

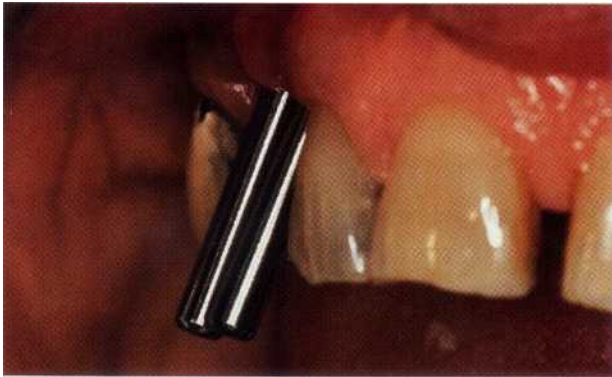

*Fig. 16-11.* Occlusal esthetics are preserved when using an abutment post, because the prosthesis is cemented, eliminating the screw access opening.

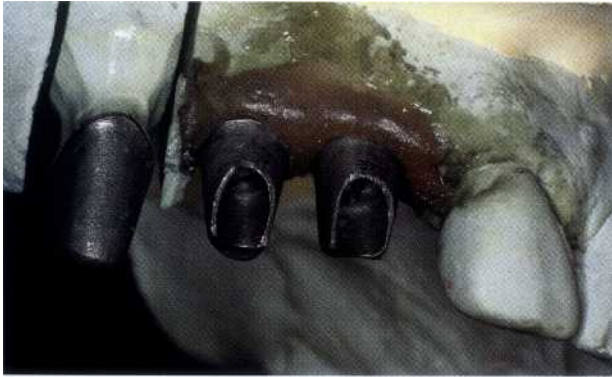

*Fig. 16-12.* A custom castable post is used to change angulation and create an esthetic prosthesis.

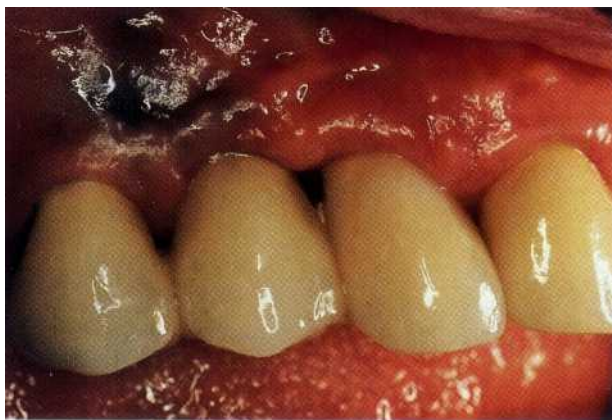
from the soft tissue in the correct position (Figs. 16-13 and 16-14). A prosthesis can be cemented over these castable abutments and extended below the soft tissue for an esthetic result (Fig. 16-15). Another option is the use of a preangled type abutment.



*Fig. 16-13. The residual ridge of this patient necessitated positioning implants with a buccal inclination.*



*Fig. 16-14. A custom post was fabricated to realign the buccally placed implants in a more palatal direction.*

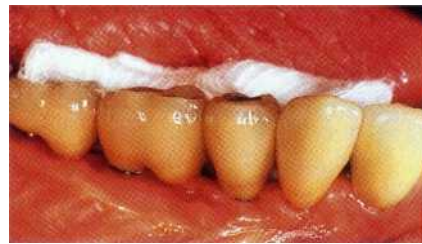


*Fig. 16-15. A final restoration over a custom post with the restorative material extending below the gingival margin.*

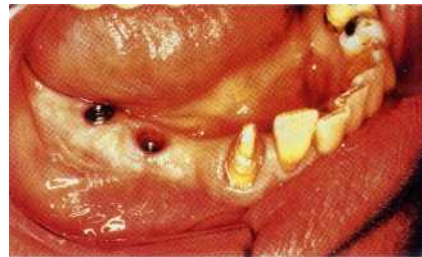
### Interarch Distance and Tissue Height

When minimal gingival height exists occlusal to the implant and the area is visible during function, the restoration must extend to the implant level by eliminating the second-stage abutment and using a castable abutment.<sup>1,6</sup> This allows successful esthetic management when as little as 2 mm of soft tissue height exists above the implant (Figs. 16-16 to 16-18).

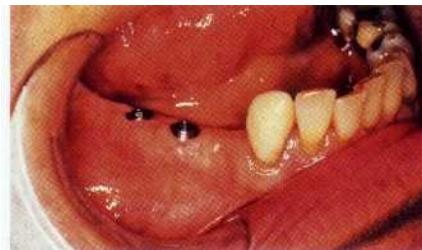
A comparison of the conventional abutment with that of the castable abutment (Figs. 16-19 and 16-20) shows that in this type of case the conventional design exhibits metal supragingivally. A comparison at the metal framework stage (Figs. 16-21 and 16-22) shows that the



*Fig. 16-16. This patient presented with minimal tissue height above the first premolar implant. Porcelain was extended down to the implant surface for maximum esthetics.*

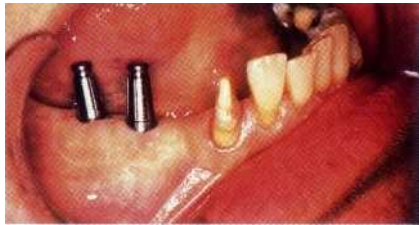

*Fig. 16-17. A minimal amount of soft tissue over the facial aspect at the first premolar implant site is noted.*

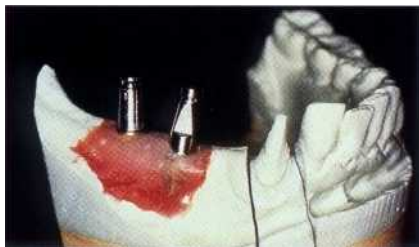

*Fig. 16-18. Placement of a standard type abutment, which is approximately at tissue height at the lingual aspect, will show metal at the facial.*

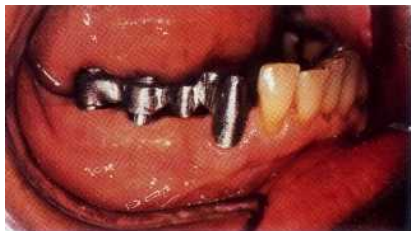conventional design exhibits a flat apical contour of the final restoration where the abutment and metal framework meet. A more natural flow develops when the castable abutment is used. On the master cast, a conventional abutment demonstrates restorations that are shorter than the adjacent teeth, with a flat apical contour



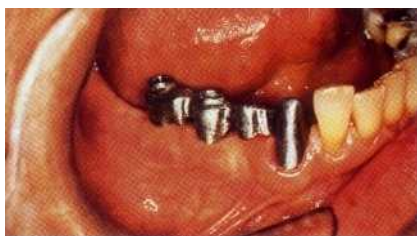*Fig. 16-19. An impression on the conventional abutment is made with a standard impression coping.*



*Fig. 16-20. On the side to be restored with a castable type abutment, an implant impression is made and a soft tissue model is constructed.*

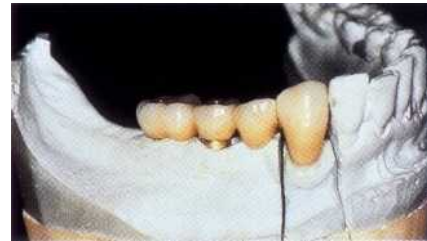

*Fig. 16-21. The metal framework on the conventional abutment is beginning to illustrate a flat contour at the apical portion of the casting.*

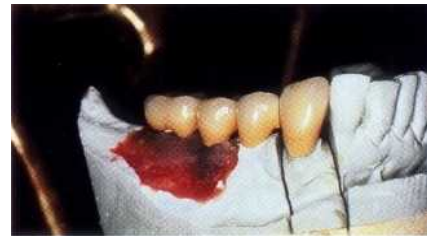

*Fig. 16-22. The casting made with the castable abutment is developing more toothlike contours.*

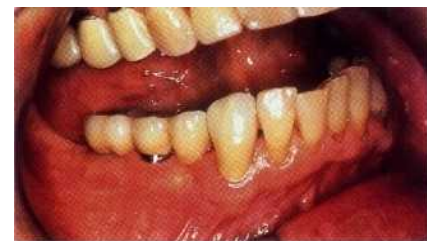and metal exposed above the soft tissue (Fig. 16-23). The UCLA-type abutment, however, permits porcelain extension below the soft tissue for a more natural toothlike form (Fig. 16-24). The final case exhibits the significant esthetic difference between the two systems (Figs. 16-25 and 16-26).



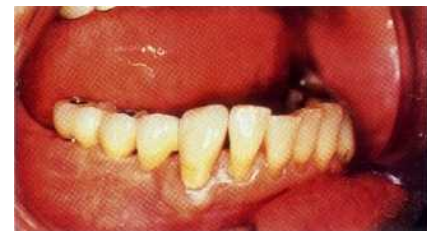*Fig. 16-23. On the master cast the final restoration on the standard abutment has a flat apical contour, is shorter than the adjacent teeth, and displays metal.*



*Fig. 16-24. The bridge with the castable abutment permits more natural toothlike form in the final restoration supported by the implant.*



*Fig. 16-25. As seen intraorally, the standard abutment is exposed supragingivally with a poor esthetic result.*



*Fig. 16-26. This bridge constructed with a castable abutment exhibits porcelain extending subgingivally for a more esthetic restoration.*

## IMPLANT POSITION AND ALIGNMENT

Osseointegrated implants are ideally positioned in the site previously occupied by the natural tooth. Implants placed in an interproximal position can cause considerable restorative difficulties in final crown contour and esthetics when crown and bridge type restorations are planned.

### *Considerations of the Interproximal Papilla*

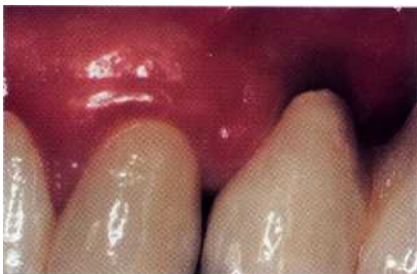Implant position affects interproximal tissue esthetics between the natural tooth and the implant restoration. The implant should be positioned so that a proper dimension of the interproximal papilla is maintained (Fig. 16-27), avoiding the dark, triangular space created when the soft tissue is lost.

The mesiodistal position of an implant is critical in the single tooth replacement case. Often the implant should be placed more mesially to preserve the interproximal papilla at the distal aspect of the natural tooth and to create a more natural soft tissue slope between the natural tooth and the restoration (Fig. 16-28). If the implant is placed centrally in the edentulous site, the esthetics may be compromised, because the papilla at the mesial aspect of the implant would be flattened, leaving a visible black triangular space anterior to the implant restoration.

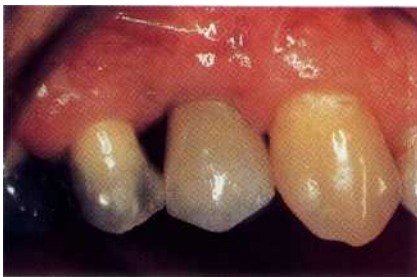The exact buccolingual position for the single tooth replacement is also critical. The restorative dentist and sur-

geon should predetermine whether a restoration will be screw or cement retained because of the ramifications upon the optimum positioning of the implant. The implant should be placed as buccally as possible to manage the emergence profile of the final restoration without creating a lip on the facial area of the crown (ridge lapping). Furthermore, use of a postlike construction in the final restoration better accomplishes this (Figs. 16-29 and 16-30).

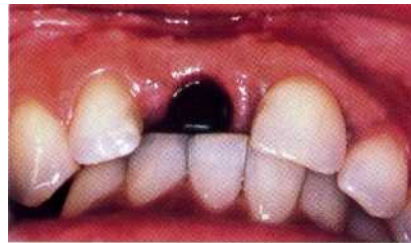However, a screw-retained prosthesis requires a more lingually placed implant, so the screw access opening will be in the cingulum area. If such a prosthesis is indicated and the patient has been edentulous for some time, rebuilding of the buccal aspect of the ridge with soft tissue augmentation may be necessary to create better facial esthetics. However, the final restoration in this case will generally have a buccal ridge-lapping extension in order to esthetically manage the crown at the gingival margin (Fig. 16-31).



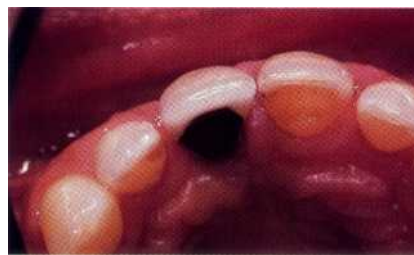**Fig. 16-27.** The implant was placed in such a manner as to support the papilla on the distal aspect of the canine.



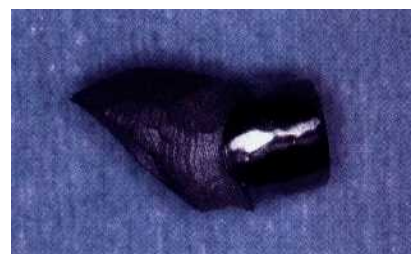**Fig. 16-28.** An implant placed in an extraction site allowed for preservation of the interproximal contours and gingival level at the canine-first premolar site.



**Fig. 16-29.** The implant in this case was restored with a custom post for precise final crown location.



**Fig. 16-30.** The final crown cemented on the custom post.



**Fig. 16-31.** Because of the implant position, overcontouring of the facial aspect of the crown is necessary to provide maximum esthetics.



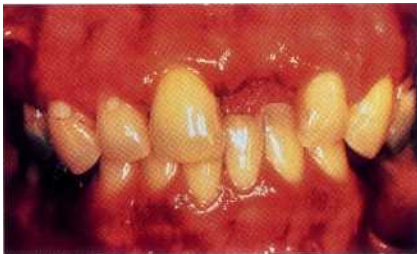**Anterior Diastema**

Tooth size and position are especially crucial in the maxillary anterior region. Ideally, the final restoration will simulate the natural tooth. The restored tooth should be normal sized with no component of the implant visible. Single-tooth replacement can easily maintain a preexisting diastemata. However, this restoration requires an implant with a built-in antirotational mechanism, such as a coronal hexagon elevation, to prevent rotation of the final crown.

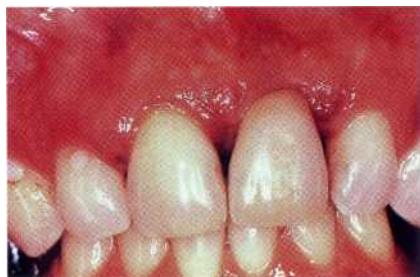**Clinical Case 1.** A 34-year-old female patient presented with a defective maxillary removable partial denture and maxillary anterior region diastema (Fig. 16-32). The edentulous space was larger than the adjacent teeth. The patient's medical history was noncontributory.

A single implant was precisely positioned in the edentulous space (Fig. 16-33). The correct buccolingual inclination ensures that the screw access will be confined to the cingulum area of the final restoration (Fig. 16-34).

**Clinical Case 2.** A 41-year-old female patient presented with an overretained primary canine in need of extraction (Fig. 16-35). The patient's medical history was noncontributory.

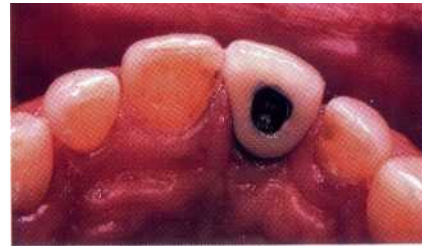


*Fig. 16-32. This patient presents with an existing maxillary removable partial denture. The edentulous space is larger than the adjacent central incisor. Traditional restoration of this area will be difficult with a conventional fixed bridge.*

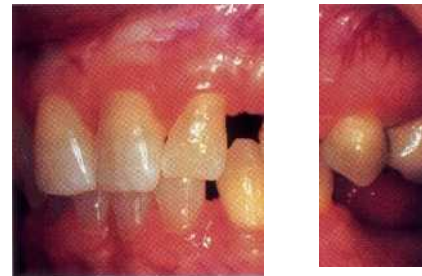

*Fig. 16-33. Restoration of this maxillary central incisor area with a single implant allowed maintenance of a distal diastema and an esthetic result (see also Fig. 16-34).*

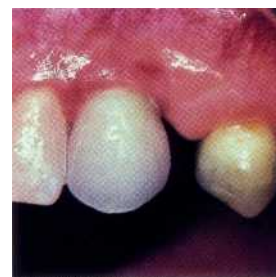Restorative options included an oversized tooth to completely fill the space or a normal-size tooth with symmetric mesial and distal diastemata. However, replacement with a normal-size tooth in mesial contact with the adjacent lateral incisor is esthetically preferable. In addition, this allows maintenance of the interproximal papilla between the natural tooth and the replacement canine. A distal diastema was created, which is not visible in normal function (Fig. 16-36). Precise positioning of the implant is especially crucial to an esthetic result in this type of case.



*Fig. 16-34. Palatal view of Fig. 16-33. An appropriate buccolingual positioning of this implant was chosen so that a screw-retained prosthesis could be constructed. Note that the screw access chamber is in the cingulum area of the tooth and the distal diastema is evident.*



*Fig. 16-35. A retained primary canine is to be extracted and replaced with an implant. Selecting the optimum location with the edentulous space is critical to obtain an esthetic result.*



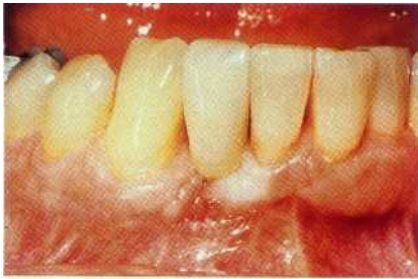*Fig. 16-36. The implant is placed in the mesial portion of the edentulous area to create a papilla between the canine and lateral incisor. A normal-size tooth was constructed and a distal diastema maintained.*

### Small Edentulous Space with Limited Bone

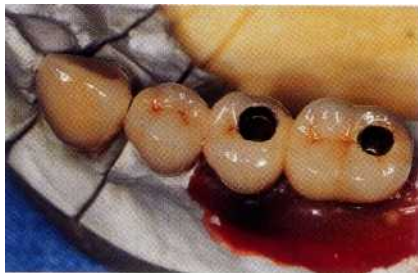When replacement tooth size or limited bone availability prevents placement of a standard-size implant, an implant of smaller diameter may be indicated. This type of implant can be used for replacing a single mandibular incisor tooth (Fig. 16-37) or a maxillary lateral incisor.

### Partially Edentulous Ridge

Implant positioning in the posterior regions often affects the esthetic outcome. When the patient presents with only a natural canine in a quadrant, strategic implant placement in the second premolar location will allow the more visible and esthetically important first premolar to be a pontic with an intact occlusal surface (Fig. 16-38). The screw access chamber and resultant occlusal restoration will now occur in the less visible second premolar. In addition, this allows the option of placing an interlock between the restoration and the natural tooth to provide for future removal of the restoration.



*Fig. 16-37.* To properly restore this mandibular right lateral incisor, a small diameter implant (Miniplant, 3i, Implant Innovations, Inc.) was placed so that proper dimension of the final restoration could be achieved.



*Fig. 16-38.* If possible, implants should not be placed in the first premolar region to allow maximum esthetics on this more visible area. In addition, this allows the technician more flexibility in constructing interlocks, if necessary, between the canine and first premolar position.

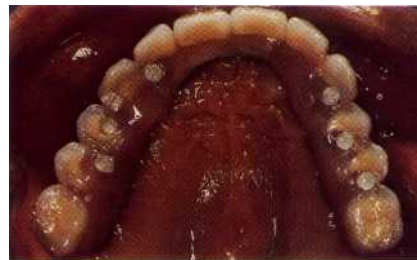### Totally Edentulous Maxilla

In the maxillary arch, implants are placed in the canine locations or posteriorly, if possible (Fig. 16-39). This also allows the restorative dentist flexibility in properly placing pontics for optimal lip support, phonetics, and esthetics. This is particularly necessary in the case of considerable resorption of the maxillary anterior region. In this instance, the final restoration can be placed near the anterior border of the residual maxillary ridge to provide proper lip support and optimal esthetics (Fig. 16-40).

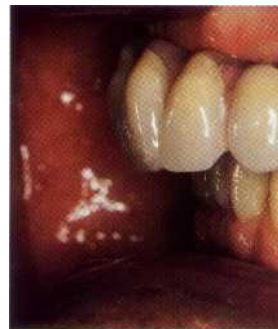Esthetically, implant-retained restorations in the maxillary anterior region may be complicated by the space needed for the restorative hardware and for proper oral hygiene. These considerations may affect speech as well as esthetics, especially in severely resorbed ridges. (See the section on soft tissue management in this chapter.)

### Totally Edentulous Mandible

In the mandibular arch, the type of prosthesis influences implant location. If severe ridge resorption has occurred and a hybrid-type prosthesis has been chosen, an implant must be placed in the symphysis area to properly support the final prosthesis. The restoration will have denture teeth and acrylic; therefore precise control of the location



*Fig. 16-39.* If possible, implants are not placed in the maxillary central and lateral incisor areas to provide maximum flexibility for pontics and for best esthetics.



*Fig. 16-40.* Note the placement of pontics anterior to the existing ridge. This allows proper lip support but would make restoration difficult if implants were placed in this area.

of the implant is not critical as long as the implants are angled properly so that the screw access opening is within the lingual aspect of the mandibular incisors.

However, placement of a conventional crown and bridge-type restoration and only minimal ridge resorption mandates placement of the implant precisely in a tooth location.

**CLINICAL TIP.** If bone dimension allows, place the implant in a canine or posterior tooth position rather than in a narrow lateral incisor location, which is difficult to restore with standard abutments (Fig. 16-41).

### *Angle of the Implant*

Limited bone availability often results in implant placement with a facial or buccal inclination (Fig. 16-42). If a screw retained final prosthesis is placed, the screw access opening will emerge through the facial or buccal aspect. The closeness of the metal of the screw access chamber to the occlusal surface may limit the technician's ability to esthetically manage the porcelain in this area. Composite resin coverings of the screw access opening are subject to marginal breakdown and staining. However, a custom telescopic post can change the angle of the implant so that it is confluent with the adjacent dentition. This permits placement of an esthetic restoration (Fig. 16-43).

### *Occlusal Height*

If the top of the implant is coronal to the cementoamel junction of the adjacent teeth, the final restoration will be shorter than normal (Fig. 16-44). Osseous surgery can reduce bone height so that the top of the implant can be several millimeters apical to the cementoamel junction of the adjacent teeth (Fig. 16-45). This allows the gingival margin on the abutment restoration to be level with the adjacent natural tooth. The apical-occlusal height of the implant should be determined before surgery, because

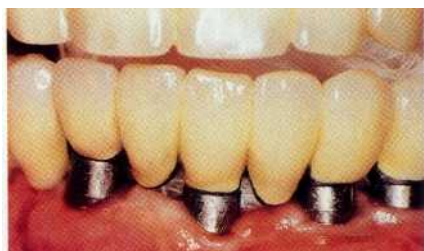

Fig. 16-41. Note the esthetic difficulty in restoring mandibular anterior teeth with crowns and standard implant abutments. The standard abutments are larger than the diameter of the mandibular incisors and therefore result in an unaesthetic outcome.

after osseointegration, alteration of implant position obviously is not possible.

### *Porcelain versus Acrylic Resin*

The choice of restorative material is influenced by the type of restoration needed. For example, a full-arch, hybrid-type

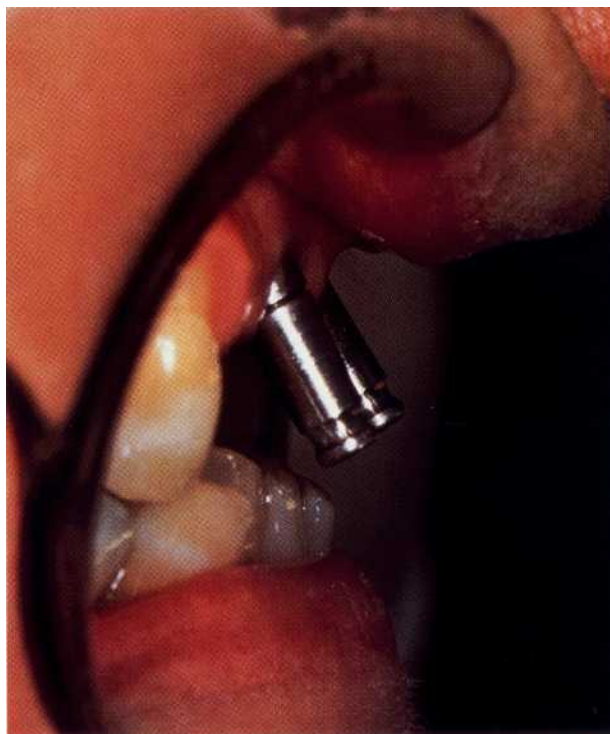

Fig. 16-42. Implants are placed with a labial flare in this primary anterior region because of the concavity of the facial aspect of the premaxilla.

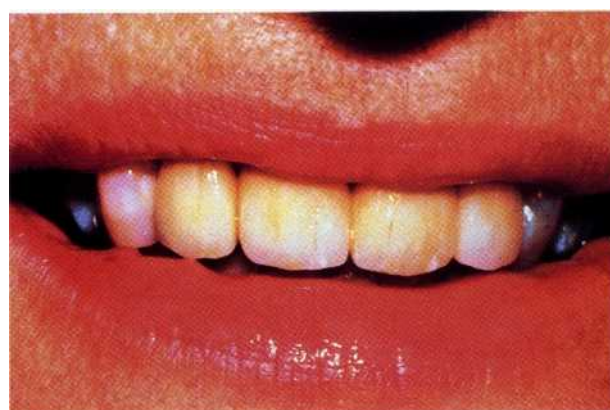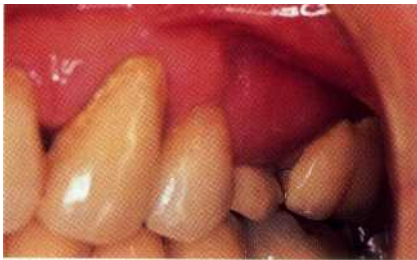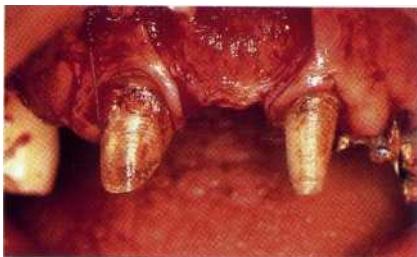


Fig. 16-43. Construction of custom posts and a superstructure that is cemented in place allows a very esthetic restoration of this difficult angulation problem.

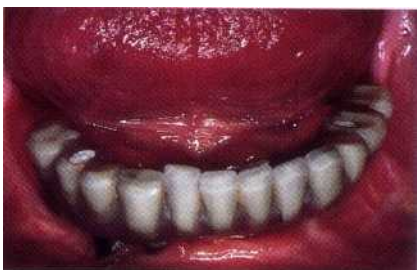restoration over a considerably resorbed residual ridge may require long span cantilevers, possible facial overcontouring to provide lip support, and large crown-to-root ratios. Because the implants are positioned in the anterior region, the length of the cantilever (as long as 10 to 20 mm) may create framework flexing. The stress relief of an acrylic resin occlusion would be advantageous in this case. However, in partially or fully edentulous patients with normal-size crowns and multiple implants placed in a widely distributed pattern without long cantilevers, porcelain is the material of choice. Porcelain, when compared with acrylic resin, provides great color stability and imparts a more natural translucency to the final restoration. It is more wear resistant than acrylic resin and more stable under heavy masticatory function (Fig. 16-46).



*Fig. 16-44. . . Because the implant and abutment were placed more occlusally than the adjacent teeth, it is more difficult to esthetically restore this area. Implants should be placed apical to the cemento enamel junction of the adjacent teeth.*



*Fig. 16-45. The bone at the implant site should be adjusted in a case such as this so that the coronal aspect of the implant is several millimeters apical to the cemento enamel junction of the adjacent teeth.*



*Fig. 16-46. This patient presents with severe wear of the occlusal aspect of the acrylic restoration.*

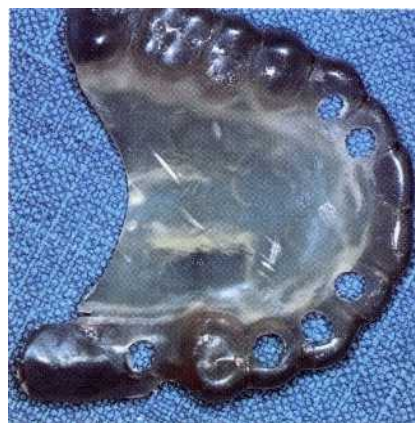### STENT CONSTRUCTION

After the completion of diagnostic workup and determination of implant type, implant location, and abutment type, a surgical stent is constructed to provide the surgeon with a guide during implant placement. The stent ensures proper positioning and angulation of the osseointegrated dental implants, thus coordinating radiographic analysis, clinical analysis, and model evaluation.

**CLINICAL TIP.** The key to an accurate surgical guide stent is a positive seat- This involves engaging the adjacent natural dentition or using the palate for positive seating of a maxillary surgical stent (Fig. 16-47). In the mandible, stent stabilization in the totally edentulous arch is more difficult and the stent usually is stabilized in the posterior areas, because the implants are often placed anterior to the mental foramen.

**CLINICAL TIP.** Carefully evaluate both the position and angle of the implant. Often the residual ridge is more lingual or palatal than the final teeth. To compensate for this in the maxilla, angle the implants buccally (Fig. 16-48). This allows the screw access opening to emerge from the occlusal aspect of the final restoration (Fig. 16-49). The predetermined angle may produce overangulation in the maxillary bone, which may cause the implant to be too close to the palatal crest or, in the mandible, may cause it to perforate through the lingual border. Therefore compromises between implant placement and ideal esthetics must be reached. Custom posts or preangled abutments may be necessary to compensate for less-than-ideal implant position.

Stents can be classified as either restricted position or variable position.



*Fig. 16-47. This stent illustrates the use of the palate as a stabilizing base for the surgical stent during placement procedures.*

*Restricted Position Stent*

If the surgeon and the restorative dentist, after clinical radiographic evaluation, are sure of the amount of bone at the implant location, construction is possible of a definitive stent that precisely indicates both location and angulation.

Generally, these stents guide implant location and angle because of the thickness of the acrylic resin or through the use of Pindex tubes. In many of these appliances, the palate serves as a definite stop for the stability of the guide stent, and a buccally placed flap is used to allow access to the bone.

*Stent from a Preexisting Removable Full Denture*

When an existing denture tooth position is adequate in the fully edentulous patient, the existing maxillary or mandibular dentures can be replicated to construct a guide stent.

Armamentarium

Basic dental setup:

- explorer
- mouth mirror
- periodontal probe
- high-speed handpiece
- low-speed handpiece

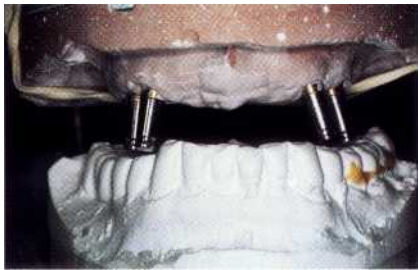
- Irreversible hydrocolloid impression material
- Impression trays
- Denture duplicator (Lang Dental Manufacturing Co., Inc.) (optional)
- #10 round bur
- 2-mm twist drill

Clinical Technique

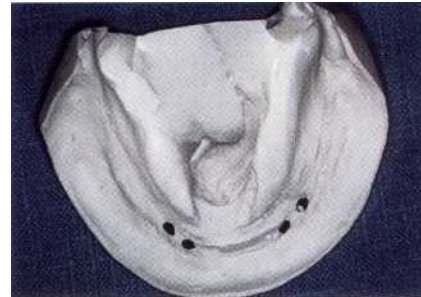1. Make an irreversible hydrocolloid impression and pour a study model.
2. Mark the desired implant locations on the model (Fig. 16-50).
3. Duplicate the denture in clear acrylic resin, either in the laboratory or chairside, using a denture replication flask (Fig. 16-51).

**CLINICAL TIP.** Clear acrylic resin permits visualization of the implant location as marked on the study model. This expedites precise positioning of the guide holes in the replicated denture stent.

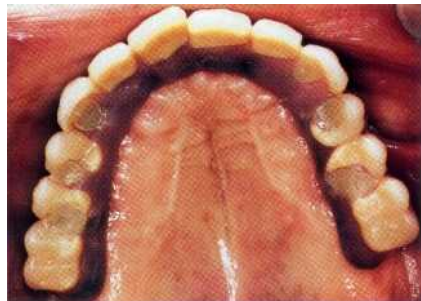4. Drill openings in the stent from the desired tooth position to the location marked on the model (Fig. 16-52). Place the holes with a #10 round bur to allow for the use of a 2-mm twist drill. This provides a location guide and an angulation guide, because



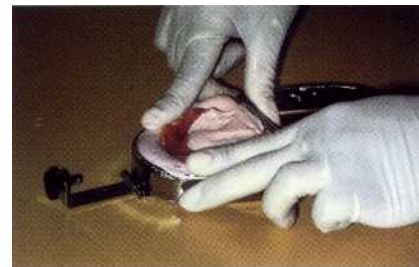*Fig. 16-49. Because of resorption of the maxillary ridge, implants had to be placed with a labial flare.*



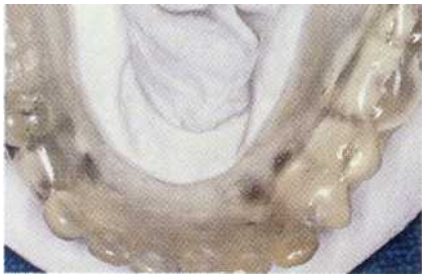*Fig. 16-50. Desired implant locations are marked on the cast after radiographic and clinical evaluation.*



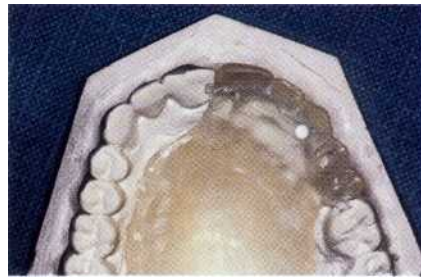*Fig. 16-49. Use of a surgical guide stent allows the final position of the screw access opening to be within the confines of the occlusal surface of the replacement teeth.*



*Fig. 16-51. Replication of the patient's existing denture in a denture replicating flask simplifies construction of a surgical guide stent.*



*Fig. 16-52. One can determine from the replicated denture the desired implant location. Holes will be drilled from the occlusal position of the tooth to the predetermined location of the ridge.*



*Fig. 16-53. The existing removable partial denture attachments provide a positive seat for precise placement of the stent at the time of surgery.*

the thickness of the replicated denture will guide the angulation of the surgeon's bur.

### Stent from Inadequate or Nonexistent Removable Full Denture

If the patient does not have an existing denture or the prosthesis does not have desirable tooth position, an occlusal rim must be fabricated first.

#### Armamentarium

Basic dental setup (see the section on stents from a preexisting removable full denture in this chapter)

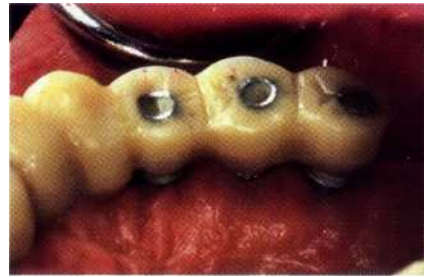#### Clinical Technique

1. Make an irreversible hydrocolloid impression and pour a study model.
2. Construct an occlusal rim with a preliminary tooth setup.
3. After the patient approves the esthetics of the tooth placement, duplicate the wax setup with a denture replicating flask to construct the guide stent.
4. Mark the model and drill holes in the stent in the same manner as for a preexisting denture. (See the section on stents from a preexisting removable full denture in this chapter.)

### Stent from a Removable Partial Denture

Partial dentures can be replicated in the same manner as preexisting dentures. (See the section on stents from a preexisting removable full denture in this chapter.)

**CLINICAL TIP.** If possible, try to capture the impression of any existing precision attachments in the surgical stent to provide a positive seat (Fig. 16-53).



*Fig. 16-54. In the transitional bridge phase it is evident that exact positioning was achieved by the use of the surgical guide stent.*

### Acrylic Buildup Technique

This type of stent is especially useful when the patient is partially or fully edentulous and the screw access openings must be placed in a specific location within the occlusal aspect of the final restoration (Fig. 16-54).

#### Armamentarium

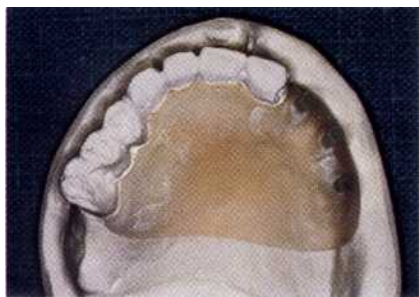- Basic dental setup (see the section on stents from a preexisting removable full denture in this chapter)
- Irreversible hydrocolloid
- 2-mm Pindex tubes (Whaledent)
- Clear orthodontic acrylic resin
- Cyanoacrylate cement

#### Clinical Technique

1. Make an irreversible hydrocolloid impression, and pour a study model.
2. Lute Pindex tubes to the model at the predetermined location and angle.

**CLINICAL TIP.** Hold the tubes in place by luting them to the model with cyanoacrylate.

3. **Construct a stent** using a salt-and-pepper technique of placing liquid acrylic monomer and sprinkling clear acrylic polymer power (Fig. 16-55).



*Fig. 16-55.* The surgical guide stent is fabricated with a palate and Pindex tubes to provide angulation guides during implant placement.

### Vacuum Form Technique

Vacuum form guide stents can be used if the patient has teeth both mesial and distal to the edentulous area.

#### Armamentarium

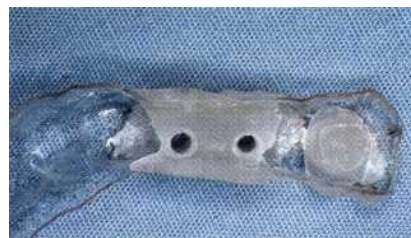
- Basic dental setup (see the section on stents from a preexisting removable full denture in this chapter)
- Irreversible hydrocolloid
- Vacuum forming unit (Buffalo Dental Mfg. Co., Inc.)
- Clear tray material (0.60 or 0.80 in) (Buffalo Dental Mfg. Co., Inc.)
- 2-mm Pindex tubes
- Clear orthodontic acrylic resin
- Cyanoacrylate cement

#### Clinical Technique

1. Make an irreversible hydrocolloid impression and pour a study model.
2. Place denture teeth in the edentulous area of the study model.
3. Vacuum form a stent in the usual manner. (See Chapter 11.)
4. Mark the implant location on the model.
5. Using the markings as a guide, place holes in the occlusal aspect of the vacuum-formed stent with the 2-mm twist drill.
6. Place the Pindex tubes (Whaledent, Inc.) in the openings drilled in the occlusal aspect of the vacuum-formed stent.
7. Angle the tubes in the stent to the predetermined position on the cast. Lute the tubes to the stent material with Cyanoacrylate and reinforce with a clear acrylic resin (Fig. 16-56).

### Provisional Fixed Bridge Technique

Provisional fixed bridges may be used as surgical guide stents. This requires that teeth adjacent to the implant site are treatment planned for a fixed prosthesis (Fig. 16-57).



*Fig. 16-56.* A vacuum formed surgical stent is used in combination with tubes to guide implant location between adjacent teeth.



*Fig. 16-57.* Temporary bridges are used as surgical guide stents, especially when maintaining hopeless or questionable teeth, during the osseointegration phase.

#### Armamentarium

- Basic dental setup (see the section on stents from a preexisting removable full denture in this chapter)

#### Clinical Technique

1. Prepare the abutment teeth and fabricate a provisional bridge to span the edentulous area where the implants will be placed.

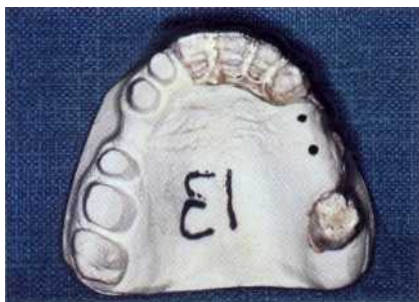**CLINICAL TIP.** Maintenance of hopeless teeth is acceptable during the osseointegration phase of treatment, if they will not affect implant location and the esthetic success of the final prosthesis.

They can serve as abutments to stabilize the provisional bridge, which can be used as a surgical stent during implant placement. They can also function as abutments for the provisional restoration during the integration phase of treatment.

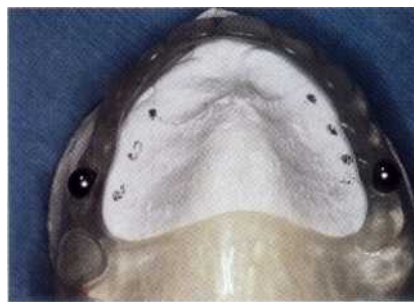2. With a #10 bur, place an opening in the pontic areas of the provisional bridge to act as a guide stent.
3. After surgery, seal these holes with acrylic resin.

### Variable Position Stent

Relief of the stent is warranted when the clinicians are unsure about the exact dimension, quality, and configuration



*Fig. 16-58.* Including the facial aspect of the teeth in the guide stent allows the surgeon flexibility in moving the location of the implant, while still remaining within the confines of a desired tooth location.



*Fig. 16-59.* This maxillary stent with radiographic marking balls has two functions; to provide a guide to exact placement of the implants at the time of surgery and to help the surgeon locate areas of maximum bone support as revealed on the radiograph.

of the bone, or if the surgeon feels there may be some reason for deviating from the predetermined location. This gives the surgeon a choice of acceptable implant locations while remaining within the dimension of the replacement tooth in the final restoration. However, it can be accomplished only with a removable-type stent. The variable position stent can be constructed from a replica of a preexisting full denture, an inadequate full denture, or a nonexistent denture, or a partial denture can be modified to become a variable position stent.

## Maxilla

### Armamentarium

Basic dental setup (see the section on stents from a preexisting removable full denture in this chapter)

### Clinical Technique

1. Partially construct the appropriate restricted position stent.
  - A. See the section on stents from a preexisting removable full denture in this chapter, steps 1 to 3.
  - B. See the section on **stents from inadequate or nonexistent removable full denture in this chapter, steps 1 to 3.**
  - C. **See the section on stents from a removable partial denture in this chapter, steps 1 to 3.**
  - D. **See the section** on vacuum form technique in this chapter, steps 1 to 3.
2. Cut away the occlusal and lingual aspect of the **teeth in the surgical area opening in the stent.** This allows the surgeon to place all sizes of drills, perform the tapping procedures, and possibly place the implant, with the surgical stent in place (Fig. 16-58).
3. In the maxillary arch, elevate the surgical flap buccally to allow maximum access and maneuverability

within the palatal aspect of the stent where the implants will be placed.

**CLINICAL TIP.** The facial aspect of the teeth in the stent serves as a guide to tooth location.

**CLINICAL-TIP.** Radiographic marking balls (3i, Implant Innovations, Inc.) placed in the stent determine its intracranial position on preoperative radiographs. This allows the surgeon to take advantage of the upward extensions of bone in the floor of the maxillary sinus, allowing placement of a longer implant (Fig. 16-59). The surgeon can take advantage of areas of foundation bone under the floor of the maxillary sinus.

## Mandible

### Armamentarium

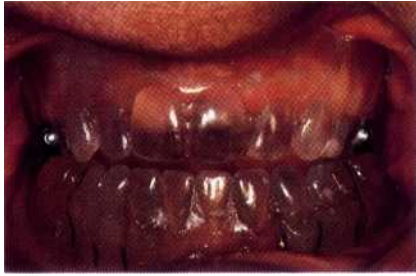Basic dental setup (see the section on stents from a preexisting removable full denture in this chapter)

### Clinical Technique

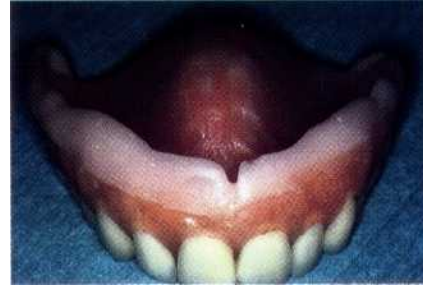
1. Make an irreversible hydrocolloid impression and pour a study model.
2. If teeth remain, replicate an existing partial denture or wax-up in a denture replicating flask. If the arch is edentulous, construct a clear occlusal rim or replicate a wax-up.
3. Cut away the entire lingual or facial portion of the mandibular teeth, leaving the facial or lingual outlines of the premolars and anterior teeth.

**CLINICAL TIP.** The facial or lingual aspect of **the teeth in the stent serves** as guide to tooth location (Fig. 16-60).





*Fig. 16-60. Maxillary and mandibular guide stents for this totally edentulous patient will permit precise positioning of the implants.*



*Fig. 16-61. The maxillary denture, which was relined for the patient, will be placed immediately at the time of stage 1 surgery. Note the thickness of the soft relining material to provide good cushioning and tissue adaptation.*

## ESTHETIC MANAGEMENT OF THE PATIENT IN TRANSITIONAL PHASES

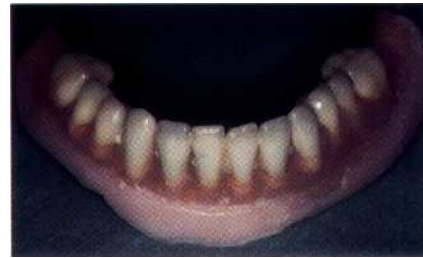### Stage 1

Following stage 1 surgery, patients often object to the lack of esthetics from not wearing their removable appliance for the initial healing period, as prescribed by some implant techniques. In the maxillary arch, it may be advantageous to place the denture immediately following surgery. Usually, a palatal incision is used and the tissue reflected buccally. The relined denture can act as a surgical compression stent to control bleeding and stabilize the flap postoperatively. The full denture should be adequately relieved in all surgical areas and soft relined immediately following suturing to ensure a pressure fit. A soft reline material provides the most comfort and avoids loading the implants through the soft tissue (Fig. 16-61).

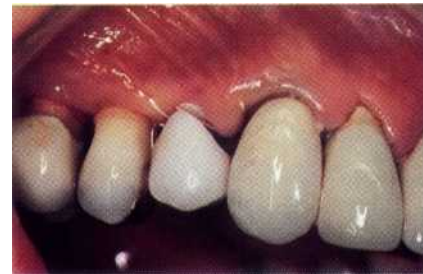In the mandibular arch, a similar procedure can be used, especially for vestibular deepening procedures (Fig. 16-62). Extension of soft reline material in the labial flange area provides a surface guide for tissue healing. However, when using either of these procedures, place the implants below the osseous crest so that they bear no load through the tissue during this phase.'

For single tooth replacements, a transitional acrylic resin removable denture can be placed. If implant placement is performed at the time of tooth extraction, space over the extraction site must be adequate so as to not load the implant (Fig. 16-63).<sup>1</sup> A transitional fixed restoration may also be bonded to the adjacent natural dentition or the replacement tooth may be luted onto orthodontic bands during the integration phase (Fig. 16-64).

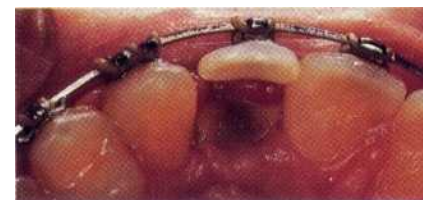Finally, wherever possible, hopeless teeth can be maintained to serve as transitional abutments during the integration phase of treatment, allowing the patient to have a fixed restoration during this time.



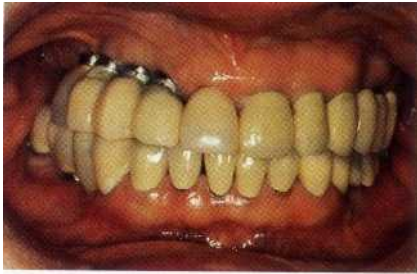*Fig. 16-62. The mandibular soft relining material is extended in the anterior area, where the vestibule has been extended.*



*Fig. 16-63. A transitional removable partial denture was placed immediately at the time of implant placement in the first premolar location.*



*Fig. 16-64. A single tooth implant in a patient undergoing orthodontic therapy allows the replacement tooth to be bonded to the orthodontic bands.*



*Fig. 16-65. A transitional fixed bridge fabricated following stage 2 surgery.*

### Stage 2

Provisional fixed bridgework has many advantages when used after stage 2 surgical procedures. It allows the restorative dentist to evaluate the esthetics, tooth position, lip support, pontic location, vertical dimension, and control of the gingival margin prior to constructing the final restoration. A provisional fixed bridge allows full maturation of the gingival tissues without the pressure of a removable appliance during healing. It provides the patient a degree of psychologic confidence by having an esthetically acceptable fixed appliance during the 2 months of soft tissue maturation following stage 2 surgery. In addition, oral hygiene procedures can be reinitiated at an earlier stage.

### After Stage 2 Healing

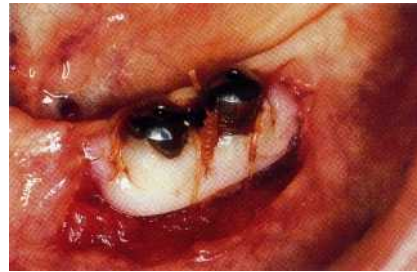The soft tissue around the abutments in the stage 2 post-operative period can recede considerably (Fig. 16-65). When healing is complete, the determination of abutment type and size is finalized. At this point, additional procedures can be performed, such as tissue recontouring or augmentation (see the section on soft tissue management in this chapter), evaluation of vertical dimension, placement of additional implants, or evaluation of tissue maturation after the extraction of hopeless teeth.

Provisional bridges at this time can either be cement retained, using temporary bridge heads on the standard abutments, or they can be screw retained with temporary cylinders (3i, Implant Innovations, Inc.), which provide long-term stability to the provisional prosthesis.

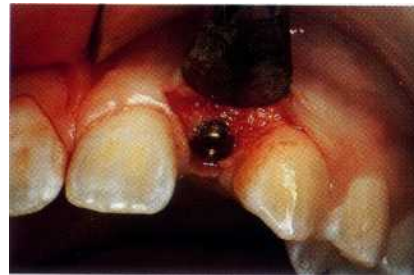**CLINICAL TIP.** Indexing the position of the implant at the time of placement with either an implant index coping or by taking an impression allows for placement of an appropriate abutment and provisional restoration at the time of stage 2 surgery.

## SOFT TISSUE MANAGEMENT

Tissue must not be inflamed, bleeding, or hyperplastic. In addition, an adequate zone of healthy attached gingiva is



*Fig. 16-66. Increasing the zone of attached gingiva around implants can be achieved by placing a gingival graft around transitional healing abutments at the time of stage 2 surgery.*

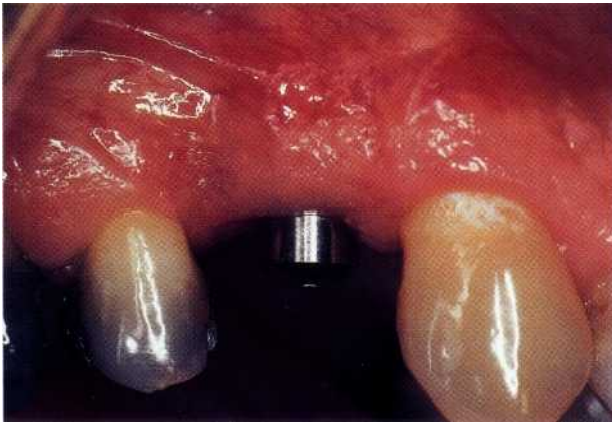


*Fig. 16-67. Incisions in the papilla areas during stage 1 and stage 2 surgery should be avoided to preserve the dimension of the interproximal papillae.*

necessary to maintain the level of the marginal tissue around the final restoration. This is particularly critical when subgingival margins are anticipated. Proper tissue type and health also prevents irritation from oral hygiene procedures and decreases the likelihood of marginal recession. Gingival grafting for tissue augmentation or to provide vestibular extension can be done either at the time of stage 2 surgery (Fig. 16-66) or after the tissue heals around the transitional healing abutments.

**CLINICAL TIP.** During stage I and 2 surgical procedures, the surgeon must avoid incision lines and reflection of papillary tissue around the natural dentition adjacent to an implant site (Fig. 16-67). This may interfere with surgical access; however, the resultant implant will appear more natural and will blend with the adjacent tooth form and contour. If the papilla next to a natural tooth is destroyed, the loss may be irreversible.

Papilla can be surgically created by removing the tissue directly over the facial aspect of the implant while leaving the mesial and distal tissues intact. In this procedure, implant placement must be deep enough in bone to maintain adequate tissue height above the implant for recontouring procedures. Unless sufficient facial tissue is present, the resultant gingival margin may be at a different level than the adjacent natural teeth.



*Fig. 16-68.* Although successful and properly placed, the final esthetics of this implant will be compromised by the flat contour of the gingival tissues at the implant site as well as by the height of the soft tissue relative to the adjacent natural teeth.

### Gingival Papilla

The key to successful tissue management in the partially edentulous patient is the maintenance of the interproximal profile of the papilla and the creation of a tissue flow that is similar to the natural dentition. The shape of the gingival tissues is particularly important in patients with high smile lines because of gingival display in the maxillary anterior and premolar regions.

### Gingival Recontouring

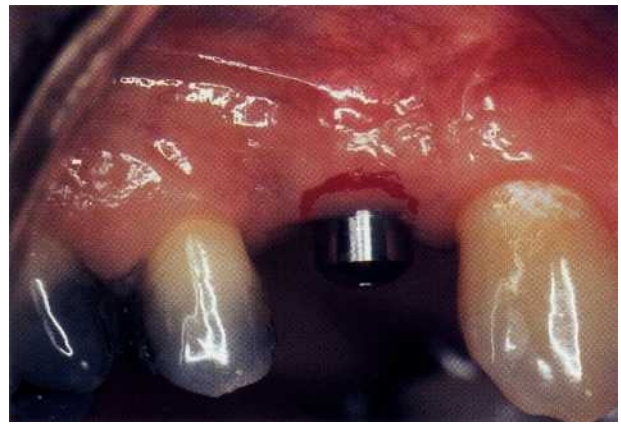The level and contour of the tissue in the implant area can differ from that of adjacent natural dentition (Fig. 16-68). The gingiva can be coronally positioned and without parabolic flow. Surgical correction is indicated.

#### Armamentarium

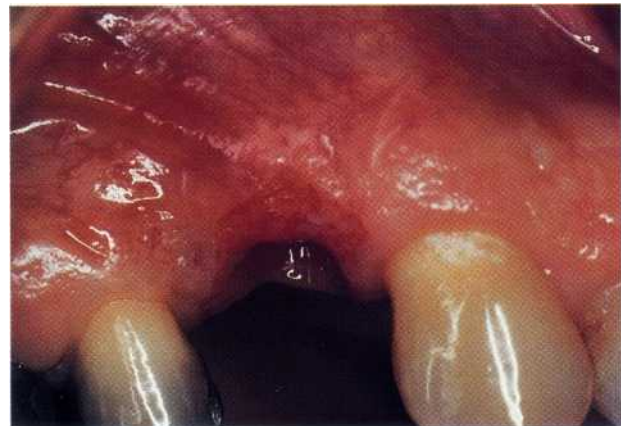- Basic dental setup (see the section on stents from a preexisting removable full denture in this chapter)
- Alcohol pen (Masel Orthodontics, Inc.)
- No. 15 scalpel blade

#### Clinical Technique

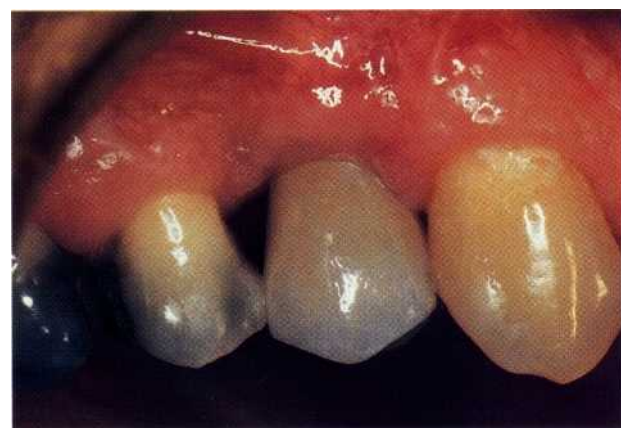1. Mark the desired gingival contour with an alcohol pen (Fig. 16-69).
2. Make a surgical incision with a No. 15 scalpel blade to create an even flow and blend of the soft tissue from the natural dentition through and including the implant site.
3. Healing occurs in 4 weeks. A natural flow of soft tissue should result and the interproximal papilla should remain intact (Fig. 16-70).
4. Fabricate the final restoration (Fig. 16-71).



*Fig. 16-69.* Using an alcohol pen, the location and the amount of planned tissue scalloping is marked.



*Fig. 16-70.* Scalloping of the soft tissue is achieved to produce an esthetic contour.



*Fig. 16-71.* Restoration illustrating the parabolic flow of the gingival contours. This cast ceramic crown is supported by an STR abutment (3i, Implant Innovations, Inc.).

## Gingival Augmentation

The buccal dimension of tissue over an implant site is an important aspect of the esthetic restoration, especially in the maxillary anterior and premolar regions.

### Armamentarium

- Periodontal surgical setup

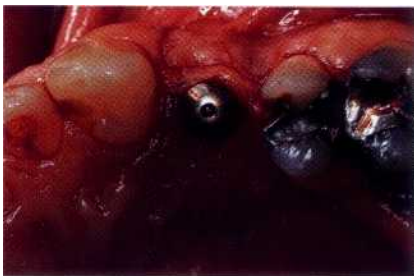
### Clinical Technique

1. Perform gingival augmentation procedures to enhance the dimension of the soft tissues at or following stage 2 surgery. An ideal donor site is connective tissue from under a palatal flap.
2. Place this tissue over the facial aspect of a temporary abutment (Fig. 16-72). This procedure will not only add tissue bulk but also provide good gingival stability, prevent recession, and allow for any necessary soft tissue recontouring.
3. Healing occurs in 6 weeks.

**CLINICAL TIP.** Considerable height changes occur in gingival tissue for at least 3 to 6 months following Stage 2 surgery. The placement of a fixed provisional appliance is advisable during this period of continued tissue shrinkage (Fig. 16-73). After stabilization of the soft tissue level, fabricate the proper prosthesis.

## Treatment of Severely Resorbed Edentulous Ridge

Severe tissue defects often create difficulties in proper positioning of the final restoration. This can result in limited support of the maxillary lip and improper contouring at the gingival margin of the final restoration. In addition, speech problems may accompany severely resorbed tissue and tissue height discrepancies. In the case of severe resorption in the region or a thin ridge, the emergence angle of the implant may not be ideal. This can result in anesthetic contours on the facial aspect of the restoration.

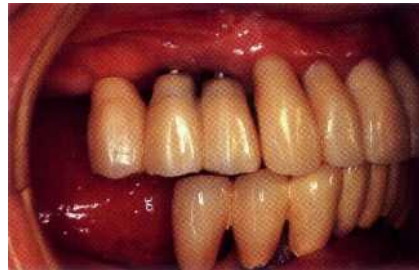

*Fig. 16-72.* Augmentation of the buccal tissues at the facial aspect of the temporary abutment allows construction of a normally shaped final restoration.

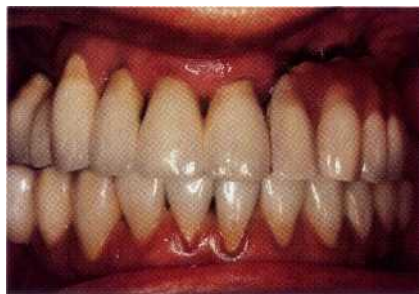When it is necessary to place an implant in a severely resorbed edentulous ridge next to the natural dentition, it is difficult to manage the tissue height discrepancy. Therefore to adequately restore this region, it may be necessary to use a conventional crown and bridge-type restoration on the natural teeth and a hybrid type appliance on the edentulous area (Fig. 16-74). Replacing teeth and lost alveolus ensures proper lip support, esthetics, and speech management. The restorative dentist must evaluate these possibilities in the preliminary workup phase. This allows esthetic restoration of the area, some type of facial cantilevering and ridge-lapping, and provides access for oral hygiene procedures.

## Coordination of Abutment Height to Soft Tissue Level

Esthetically, the ideal margin of the final restoration should be placed approximately 1 mm subgingivally. An appropriately sized abutment must be chosen to accom-



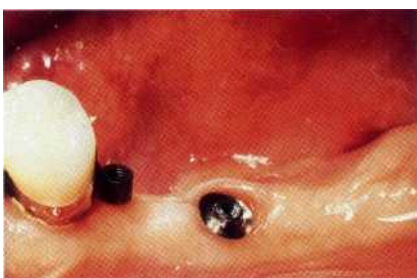*Fig. 16-73.* A provisional fixed bridge in the maxillary right quadrant is supported by osseointegration dental implants and temporary cylinders. Shrinkage in the soft tissues has taken place following stage 2 surgery. Now that the tissues are mature, the proper size abutment will be placed so that the margin of the final restoration can be brought to tissue level.



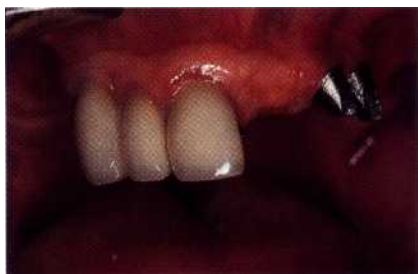*Fig. 16-74.* This patient has a unilateral hybrid prosthesis in the maxillary left quadrant to replace a large alveolar defect. It provides proper lip support, good esthetics, and speech control.

plish this. After maturation following stage 2 surgery, the soft tissue height must be measured. For example, if the clinician measures 4 mm of tissue height at the direct facial aspect, a 3-mm abutment is appropriate (Fig. 16-75). This allows the porcelain to extend approximately 1 mm subgingivally.

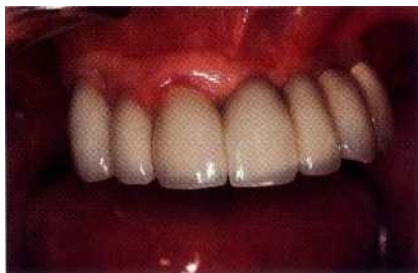**CLINICAL TIP.** Concern with soft tissue height coordination remains when custom posts are selected to correct angle discrepancies. A castable abutment can be used to construct the custom post (Fig. 16-76). The superstructure, or telescopic crown, should extend over the custom post and below the gingival margin in the area (Fig. 16-77).



*Fig. 16-75. Placing an abutment so that the coronal aspect is approximately 1 mm below the soft tissue level is ideal for an esthetic restoration.*



*Fig. 16-76. The buccal inclination of these maxillary implants is corrected with custom posts.*



*Fig. 16-77 The superstructure over the custom post extends subgingivally for proper esthetics.*

## *Adjustment of Abutment Post and Impressioning to Achieve Subgingival Margins*

### Armamentarium

- Basic dental setup (see the section on stents from preexisting removable full dentures in this chapter)
- Retraction cord (optional)
- Firm impression material (i.e., polyether or polyvinylsiloxane types)

### Clinical Technique

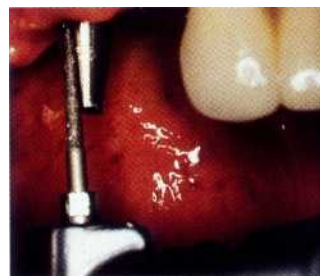1. After judging the amount of restorative material required at the occlusal level and after making determinations about angulation, mark the abutment and show where adjustments will be made.

**CLINICAL TIP.** Maintain a minimum of 5 mm of post to provide adequate retention for the final cement retained restoration.

2. Because extensive preparation in the mouth may create heat damage to the hard and soft tissues surrounding the implant, removal of the abutment posts from the mouth is recommended to make gross adjustments.
3. Return the abutment post to the mouth and, using copious irrigation, prepare a subgingival finish line that follows the gingival tissue (Fig. 16-78).
4. Place retraction cord, if necessary, and impress.

**CLINICAL Tip.** The retraction cord is usually not necessary when impressing the abutments because of the flexibility of the periimplant tissue.

5. At this point, treat the abutment as if it were a natural tooth, both in the impression and laboratory procedures.



*Fig. 16-78. The abutment post finishing line should be prepared intraorally, creating a finishing line that follows the gingival contours.*

## FABRICATION OF PROSTHESIS

It is beyond the scope of this chapter to discuss prosthetic fabrication in detail. The clinician must be well informed in implant techniques before attempting any technical procedures. However, for the sake of simplicity, implant restorations can be grouped into three broad categories.

### *Denture Type*

Overdenture construction is similar to conventional full denture construction over natural tooth roots.

#### **Armamentarium**

- Basic dental setup (see section on stent from a pre-existing removable full denture in this chapter)
- Irreversible hydrocolloid
- Tray acrylic for custom trays
- Border molding material
- Impression material

#### **Clinical Technique**

1. Following stage 2 surgery and healing, construct a denture in the usual manner, providing adequate relief over the overdenture abutment.
2. After approximately 2 to 3 weeks, the patient should be comfortable with the denture and the overdenture attachments can be cold cured into the denture.
3. When placing O-ring attachments, provide adequate relief in the corresponding internal aspect of the denture so that the denture contacts only the O-ring.

### *Cemented Type*

The fabrication of a prosthesis over a cemented type abutment is similar to that of a conventional fixed prosthesis.

#### **Armamentarium**

- Basic dental setup (see the section on stents from a preexisting removable full denture in this chapter)

#### **Clinical Technique**

1. After judging the amount of restorative material required at the occlusal level and after making determinations about angulation, mark the abutment to show where adjustments will be made.

**CLINICAL TIP.** Maintain a minimum of 5 mm of post to provide adequate retention for the final cement retained restoration.

2. The abutment post may be removed from the mouth for gross adjustment and then returned to the mouth or adjusted intraorally using high-speed rotary instrumentation and copious irrigation.
3. Make impressions and fabricate the prosthesis.

### *Screw Type*

The fabrication of a prosthesis over a screw-type abutment is unique to implants.

#### **Armamentarium**

- Basic dental setup (see the section on stents from a preexisting removable full denture in this chapter)
- Stock metallic trays
- Firm impression material (i.e., polyether or polyvinylsiloxane types)
- Impression copings
- Implant analogs

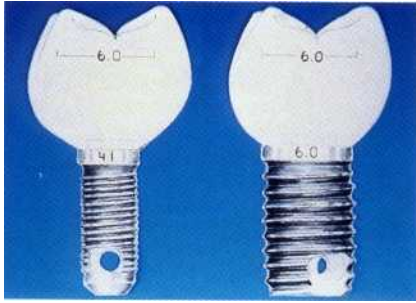
#### **Clinical Technique**

1. Remove the temporary screw from the abutments.
2. Verify the tightness of the abutments with an abutment driver.
3. Screw impression copings onto the abutments and verify that seating is complete.
4. Make an impression with firm impression material.
5. Remove the impression from the mouth.
6. Unscrew the impression copings from the abutments and attach them to the corresponding laboratory analog.
7. Reinsert the impression coping in the analog back into the appropriate position in the impression.
8. Paint stone in the area of the impression copings without using a vibrator and allow the stone to set before pouring the remainder of model.
9. After the initial pour has set, pour the remainder of the impression in the usual manner using a vibrator.
10. Fabricate the prosthesis.

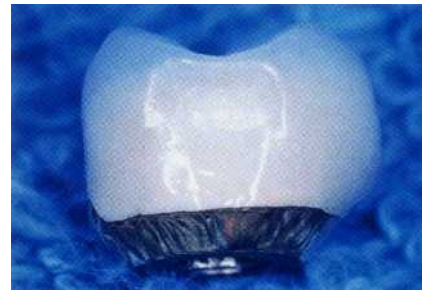## SOFT TISSUE EMERGENCE PROFILE

Teeth have a natural emergence from the root to the crown of the tooth that provides for a smooth transition in dimension as well as providing for soft tissue support. Implant dentistry has recently begun incorporating such principles into the fabrication of implant restorations.

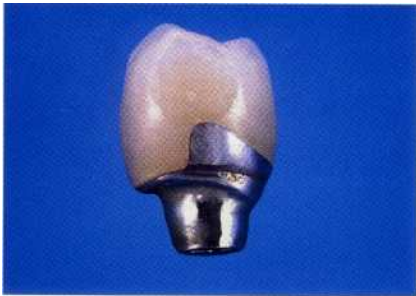The concept of emergence profile incorporates the understanding that soft tissue reacts best to smooth contours rather than sharp and abrupt changes in dimension. Using emergence profile components creates a crown, which will appear to emerge from within the soft tissue as



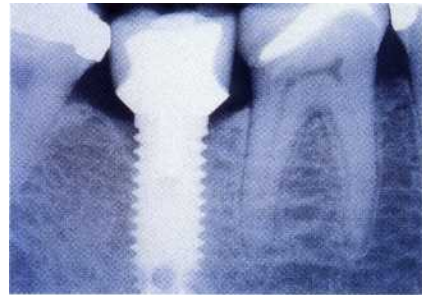
*Fig. 16-79.* The emergence angle decreases as the platform size increases.



*Fig. 16-81.* A crown fabricated for a 5-mm diameter implant showing gradual emergence from the implant platform.



*Fig. 16-80.* A clinical case showing a ridge-lapped pre-molar crown with severe emergence angle.



*Fig. 16-82.* A radiograph of the crown in Fig. 16-81.

opposed to resting on the soft tissue, as is the case with ridge-lapped restorations.

Emergence profile of the final restoration begins with the dimension of the supporting implant (Fig. 16-79). Wide-diameter implants and wide implant platforms create a softer and more gradual crown contour, which creates a softer transition in dimension from the implant to the crown. Ideally, the diameter of the implant will be similar to the tooth that it replaces. If too large or too small, the resulting emergence angle will be compromised (Fig 16-80). Additionally, if the implant is not placed properly in a coronal or apical direction, the emergence can also be compromised. It is recommended that the implant platform be located approximately 3 mm apical to a line drawn between the cemento-enamel junction of the adjacent teeth. This will usually provide enough space for the development of ideal emergence. However, this position needs to be altered if the implant diameter is significantly different than the diameter of the tooth for which it replaces. If an implant is placed that is significantly smaller than the tooth that it replaces, a more apical placement is necessary. Likewise, if the implant diameter is larger than the tooth that it is replacing, then a slightly more coronal position is recommended.

**CLINICAL TIP.** Ideal crown restorations require proper crown emergence profiles and the placement of properly sized implant platforms.

The development of an ideal crown emergence begins with the soft tissue. Healing abutments and definitive abutments have been developed which begin the process of recontouring the soft tissues at the time of stage 2 surgery. The placement of these specially contoured healing abutments at stage 2 surgery allows the soft tissues to heal and mature in a shape that can be incorporated into the final abutment or crown. The use of emergence profile concepts can provide for the fabrication of restorations that more closely resemble the natural dentition (Figs. 16-81 and 16-82).

## CONCLUSION

Close coordination between the surgeon and the restorative dentist in the preoperative phase will improve the quality of the final restoration. An esthetic approach to implant placement and restoration provides patients with stable, predictable fixed appliances that enhance the patient's quality of life both functionally and esthetically.

## REFERENCES

1. Branemark, P-I et al: Osseointegrated implants in the treatment of the edentulous jaw. Experience from a 10-year period, *Scan J Plast Reconstr Surg* 11(suppl 15):1, 1977.
2. Adell R et al: A 15-year study of osseointegrated implants in the treatment of the edentulous jaw, *J Oral Surg* 10:387, 1981.
3. Brandmark, P-I, Zarb GA, Albrektsson T *Tissue-integrated prosthesis*, Chicago, 1985, Quintessence Publishing.
4. Adell R: Clinical results of osseointegrated implants supporting fixed prosthesis in edentulous jaws, *J Prosthet Dent* 50:251,1983.
5. Lewis S, Beumer J, Hornburg W Moy P: The UCLA abutment, *Int J Oral Maxillofac Implants* 3:183, 1988.
6. Lewis S, Beumer J, Hornburg W Perri G: Single tooth implant supported restorations, *Int J Oral Maxillofac Implants* 3:25, 1988.
7. Lazzara R: Immediate implant placement into extraction sites: surgical and restorative advantages, *Int J Periodont Rest Dent* 9:333, 1989.
8. Adell R et al: Marginal tissue reactions at osseointegrated titanium fixtures, *Int J Oral Maxillofac Surg* 15:39, 1986.



انتشارات شایان نمودار



# PEDIATRIC DENTISTRY

Charles I. Citron

**T**HE MAJORITY OF ADULTS would not consider stainless steel crowns for their anterior teeth nor accept a partially edentulous smile for a period of 5 to 6 years. Dentistry should no longer subject children in their formative years to this fate.

The early loss of primary teeth may delay eruption of the permanent teeth if less than one half the root structure is formed on the succedaneous tooth.<sup>1</sup> If a child's central or lateral incisor is extracted at 3 years of age, the permanent teeth may not erupt until age 8 or 9.

Physical appearance and superficial attributes influence a child's impression of and reaction to others. In addition, a child who is perceived as attractive is also considered more socially adept than a child who is perceived as unattractive. This assumption is made by both acquainted and unacquainted preschool children.<sup>1</sup> Children as young as 3 years old are able to distinguish between attractive and unattractive peers. Children between the ages of 3 1/2 and 6 preferred attractive children for friends. Their judgments are similar to those of adults.<sup>1</sup>

Prematurely lost or congenitally missing teeth affect speech patterns. A child learning correct production of tongue tip sounds (t, d, s, sh, and ch), as well as the labial sounds of f and v, may be aided by an appliance that restores the maxillary anterior teeth.<sup>4,5</sup>

The primary dentition usually has interdental spacing in the anterior portion of the dental arch; a small percentage of the population has no spacing or exhibits crowding. It is imperative that the space in the anterior portion of the dental arch is preserved in children to ensure correct alignment of their permanent teeth.<sup>6</sup>

The need for restoration of the anterior primary dentition can be caused by two main factors: traumatic injuries or caries and developmental problems.

## TRAUMATIC INJURIES

The anterior primary teeth erupt between 6 and 9 months of age and exfoliate at about age 7. Treatment goals for injuries to primary teeth include the following:

1. Protecting the forming succedaneous tooth
2. Avoiding infection
3. Restoring normal form and function

Attainment of these goals often is not possible, and these goals do not always complement each other. Although it is possible to replant an avulsed primary tooth and restore normal function, this is contraindicated because the pressure of manipulation may damage the succedaneous tooth bud.<sup>7</sup> It may be possible to restore a fractured primary tooth, but a child of 2 years old may not cooperate sufficiently to complete the treatment. Any form of trauma to the primary tooth can directly affect the succedaneous tooth.

Maxillary central incisors are the most frequently traumatized tooth; accidents often occur when the child is between 6 months and 2 1/2 years of age. Children in this age group are gaining mobility and independence while lacking coordination and motor skills.<sup>8</sup> Traumatic injuries to primary teeth can be classified in a manner similar to the Ellis classifications of traumatic injuries to permanent teeth (Table 17-1).<sup>9</sup>

It is easier to treat a child when the parent's fears are first allayed.<sup>1</sup> The parent can help with the treatment by providing emotional support to the child. If the parent is too distraught, it is better to exclude him or her from the operatory.

After obtaining a thorough history of trauma,<sup>10</sup> medical history, and neurologic examination,<sup>11</sup> the traumatized area is cleaned and debrided so that the extent of the injury can be ascertained.



### Class I Traumatic Injuries

Class I injuries involve the enamel of the crown with little or no dentin involvement (Fig. 17-1). When the primary tooth is chipped or slightly fractured, it can be left untreated or smoothed and recontoured to prevent irritation to the soft tissue (Fig. 17-2). This will also create a more pleasing esthetic appearance (Fig. 17-3). A periapical radiograph should be taken to evaluate any changes, such as a root fracture.

### Class II Traumatic Injuries

Class II injuries involve both the enamel and dentin of the crown, but not the pulp (Fig. 17-4). These teeth

Table 17-1. Classification of traumatic injuries.

Class	Problem
I	Fracture of the crown into the enamel with little or no dentin involvement
II	Fracture of the crown into the dentin, but not involving the dental pulp
III	Fracture of the crown exposing the dental pulp
IV	Displacement of the tooth without fracture of the crown or root
V	Root fracture without loss of crown structure
VI	Traumatized tooth (vital or nonvital) that may or may not discolor




Fig. 17-1. Class I fracture of the enamel of a primary incisor.

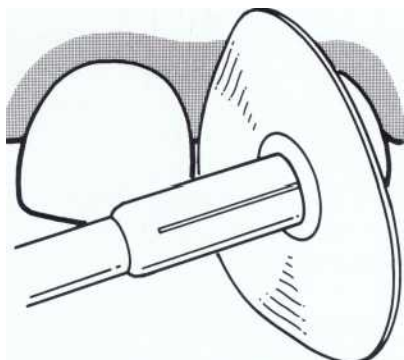


Fig. 17-2. The tooth can be smoothed and recontoured with a sandpaper disk or a fine diamond stone.

should be evaluated and restored by the dentist. The injured tooth may be examined clinically and radiographically to determine the extent of the damage.

#### Armamentarium

- Standard dental setup:
  - explorer
  - mouth mirror
  - periodontal probe
  - suitable anesthesia
  - rubber dam setup
  - high-speed handpiece burs, including a 12-fluted carbide bur
- Calcium hydroxide (e.g., Dycal, L.D. Caulk, Co.)
- Metacresylacetate (e.g., Cresatin, Schein, Inc.)
- Acid-etch gel
- Bonding agent of choice (see Chapter 3)
- Composite resin of choice (see Chapter 5)
- Teflon-coated composite resin placement instrument (e.g., Fleck's Instrument, Patterson, Inc.)
- Clear plastic crown forms (e.g., Crownforms, Caulk, Inc.)

#### Clinical Technique

1. Obtain a thorough medical history, neurologic evaluation, and history of trauma.
2. Perform a clinical examination, including a periapical radiograph.
3. Administer local anesthesia.
4. Place a rubber dam.
5. If the fracture is deep and close to the pulp chamber, a microscopic exposure may exist. Place metacresylacetate, a mild germicide and anodyne,<sup>12</sup> on the dentin for 5 minutes. If the fracture is small (about 1 min or less) and does not appear to be near




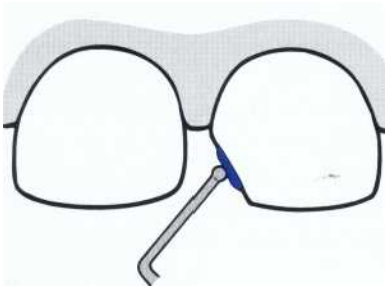
Fig. 17-3. The recontoured tooth.



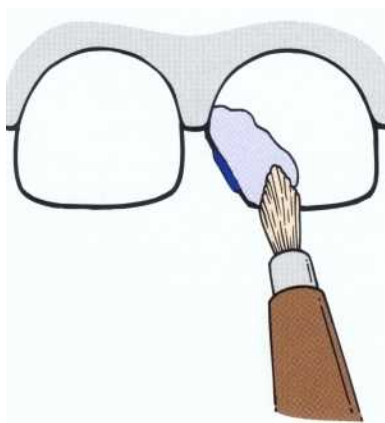
Fig. 17-4. A fracture involving the enamel and dentin of a primary incisor.

the pulp as seen on the radiograph, this step can be eliminated.

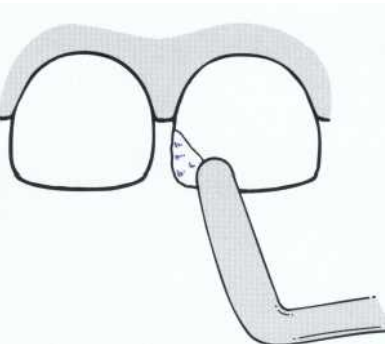
6. Apply calcium hydroxide to the dentin (Fig. 17-5) to promote the formation of secondary dentin.<sup>13</sup>
7. Acid etch the enamel for 30 to 45 seconds, rinse, and dry.
8. Apply bonding agent (Fig. 17-6). (See Chapter 3.)
9. Apply an acid-etch retained composite resin to the fractured portion of the tooth.
10. Place the composite resin with a Teflon-coated instrument in a manner similar to that of a Class II



*Fig. 17-5. Calcium hydroxide lining is placed on the dentin.*



*Fig. 17-6. The etched tooth with a layer of bonding agent applied.*



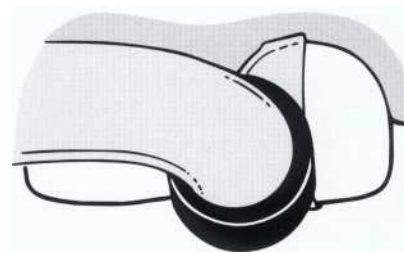
*Fig. 17-7. Placement of composite resin material.*

fracture of a permanent tooth (Fig. 17-7) but do not bevel the enamel. (See Chapter 5.)

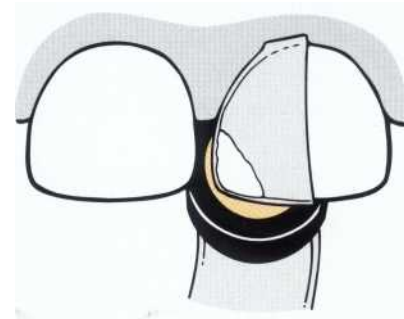
11. Use a crown form to hold the composite resin in place. Cure the resin both buccally (Fig. 17-8) and lingually (Fig. 17-9). For very large fractures, full coverage may be placed on the tooth. (See the section on crowns for primary teeth in this chapter.)
12. Shape and polish the restoration (Figs. 17-10 and 17-11).

### Class III Traumatic Injuries

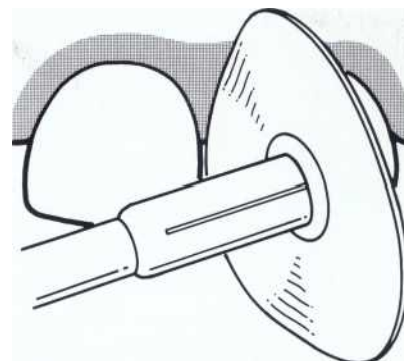
Class III injuries include the enamel, dentin, and pulp of the tooth. These injuries should be examined and treated as soon as possible because the chance of a successful



*Fig. 17-8. A fitted crown form is filled with composite resin, is placed, and is cured from the buccal direction.*



*Fig. 17-9. The tooth is then cured from the lingual direction.*



*Fig. 17-10. The restoration is contoured and polished.*



Fig. 17-11. The final restoration.

result decreases the longer the tooth is exposed to the oral environment.

If the pulp has been exposed for less than 24 hours and if the exposure is minimal, a pulpotomy should be performed. The roof of the pulp chamber is removed and the coronal pulp is extirpated with a spoon excavator. A vital healthy pulp will exhibit hemorrhage that can be controlled with pressure from a cotton pellet. If a tooth has been exposed for more than 24 hours, or if the exposure is large or if it is bleeding uncontrollably and can not be stopped with pressure, pulpal inflammation and degeneration are likely and a pulpectomy should be performed.

A complete pulpectomy should be performed if the pulp chamber is devoid of healthy tissue; this is evidenced by no hemorrhage from the root canal. Never perform a pulpotomy on a nonvital tooth."

#### Vital Primary Teeth: Pulpotomy

##### Armamentarium

Standard dental setup (see the section on Class II traumatic injuries)

Buckley's formocresol (19% formaldehyde, 35% creosol, and 46% glycerine (Sultan Chemists, Inc.)"

Zinc oxide and eugenol paste

Suitable restorative cement, such as polycarboxylate, zinc oxide cement (e.g., Duralon ESPE-Premier Sales Corp.) or eugenol paste, glass ionomer cement Keta-Cem, ESPE-Premier Sales Corp.)

Acid-etch gel

Bonding agent of choice (see Chapter 3)

Composite resin of choice (see Chapter 5)

##### Clinical Technique

1. Obtain a thorough medical history, neurologic evaluation, and history of trauma.
2. Perform a clinical examination, including a periapical radiograph.
3. Administer local anesthesia.
4. Place a rubber dam.
5. If the tooth is vital, perform a pulpotomy. Remove the coronal portion of the pulp tissue with a spoon excavator. Pulp capping for a primary tooth is contraindicated.
6. Control hemorrhage with a cotton pellet.

7. Place Buckley's formocresol on the pulp tissue for 5 minutes. This will fix the pulp in the coronal portion of the tooth, but vital tissue will remain in the apical one third.
8. Place a layer of zinc oxide and eugenol paste over the fixed pulp.
9. Place a base of polycarboxylate cement (Duralon) or glass ionomer cement.
10. Apply an acid-etch retained composite resin to the fractured portion of the tooth in a manner similar to that of a Class II fracture of a permanent tooth, but do not place a bevel (see Chapter 5) or place full coverage on the tooth (see the section on crowns for primary teeth in this chapter).

#### Nonvital Primary Teeth: Pulpectomy

A pulp that is exposed to the oral environment for any length of time may lose its vitality. A pulpectomy should be initiated in these cases. Endodontic therapy for a primary anterior tooth is not as exacting a procedure as for a permanent tooth.

##### ...Armamentarium

Standard dental setup (see the section on Class II traumatic injuries)

Paper points

Cotton pellets

Irrigating solution, such as chlorinated soda (Sultan Chemists, Inc.) or saline (Sultan Chemists, Inc.)

Germicidal agent, such as Buckley's formocresol (19% formaldehyde, 35% creosol, 46% glycerine (Sultan Chemists, Inc.) metacresylacetate (i.e., Cresatin, Henry Schein, Inc).

Endodontic files, reamers, headstoms and broaches

##### Clinical Technique

1. Obtain a thorough medical history, neurologic evaluation, and history of trauma.
2. Perform a clinical examination, including a periapical radiograph.
3. Administer local anesthesia.
4. Place a rubber dam.
5. Because it is difficult to obtain exact measurements, estimate the pulp length by the following:
  - A. Measuring the radiographic image
  - B. Ascertaining a tactile change in resistance during instrumentation

*CLINICAL TIP.* The newer model apex locators can be used to ascertain the length of the canals (Root 2X, J. Morita Corp.).

6. It is necessary only to debride the canals of necrotic material. Unlike the permanent dentition it is not necessary to shape the canals to accept a filling (Fig. 17-12).

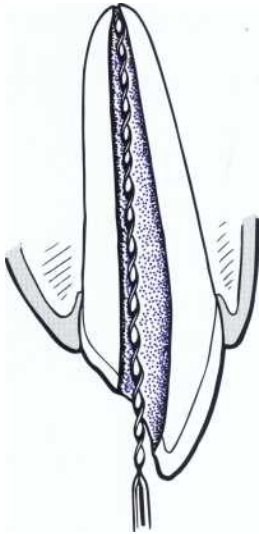


Fig. 17-12. A primary tooth with an endodontic instrument in place.

7. Clean the canals with a suitable irrigant.
8. Dry the canals with paper points and cotton pellets.
9. Place a germicidal agent in the canal. The medication is not as important as the actual debridement and irrigation.
10. Seal the access opening with a zinc oxide and eugenol type cement until the next visit (4 to 7 days).<sup>14</sup>
11. At the next visit, open the tooth.
12. Pass a lentulo spiral into the canal just short of the apex to fill the canal with a resorbable zinc oxide and eugenol paste. Alternatively, a pressure syringe can be used.

**CLINICAL TIP.** Avoid nonresorbable types of zinc oxide and eugenol (e.g., Intermediate Restorative Material (IRM), [L.D. Caulk/Dentsply](#)) with acrylic fibers.

**CLINICAL TIP.** An alternate approach involves a pressure syringe (Temp-Canal Kit, Pulpdent Corp.), which uses 18- to 30-gauge needles. Insert a special dense mixture of zinc oxide powder and eugenol (provided with the kit) into the needle hub and attach it to the syringe. Insert the needle to the appropriate length in the canal and inject the material. <sup>16</sup> Overfills act as a foreign substance, but are usually resorbed (Fig. 17-13).<sup>14</sup>

13. Place a full coverage restoration on the tooth (see the section on crowns for primary teeth in this chapter).

### Class IV Traumatic Injuries

Class IV injuries involve displacement of the tooth without fracture of the crown or root. They include intrusion injuries and buccolingual displacement of teeth.

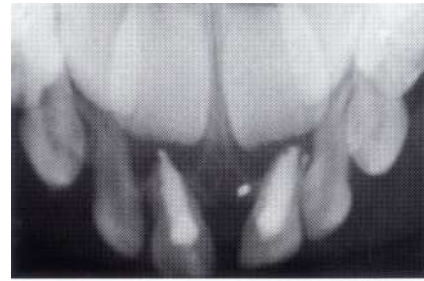


Fig. 17-13. Completed x-rays of primary incisors that were nonvital because of trauma and required pulpectomies.

**Intruded Teeth.** Intruded anterior teeth are one of the more common results of injuries to the primary dentition of the preschool child. The child's bone is soft, thus the force of a blow often can push the tooth into the maxilla. However, mandibular intrusions are rare because of the angle of blow required to cause them. The less severe the intrusion, the better the prognosis. If one half or less of the clinical crown is intruded, and no clinical or radiographic evidence of fracture exists, the tooth is left in place. It will probably reerupt within 3 to 4 weeks.'

**CLINICAL TIP.** Because a tooth may be totally intruded, it is common for the parent or dentist to assume the primary tooth has been avulsed. A diagnosis can be made only by *examining* a clear radiograph. Soft tissue swelling can also make a tooth appear more intruded than it actually is.

The primary concern involving intruded teeth is the proximity of the deciduous tooth to its successor. Only a thin layer of bone surrounds the crypt of the succedaneous tooth. If clinical judgment predicts that the intruded primary tooth will adversely affect the permanent tooth, the primary tooth should be extracted. This is determined by a radiograph that shows the primary tooth to be in direct proximity to its successor. The extent of damage to the permanent tooth depends on its stage of matrix formation and calcification at the time of injury. Trauma before the age of 3 (during matrix formation), often results in enamel hypoplasia (craterlike defects in the enamel). After the age of 3, the tooth is undergoing calcification and injury results in localized hypocalcification (chalky opaque spots)."

Most intruded teeth also have pulpal damage. However, pulp vitality testing is not dependable for a young child or a primary tooth, rather radiographs should be taken at 6-month intervals. Endodontic therapy should be instituted if periapical pathology is noted. Involved teeth must be followed carefully. If the intruded tooth does not begin to reerupt within 2 months, it should be extracted. Ankylosis may have resulted, which will effect the eruption pattern of the permanent incisor.

**Labially or Buccally Displaced Teeth.** Because the alveolar bone is soft, injury can result in labial or lingual displacement of the primary anterior tooth. If no radiographic evidence of root or bone fracture exists, the tooth can be slowly and carefully digitally moved to its normal position. The primary concern with a lingually displaced maxillary tooth is that occlusal interference is not created. It is imperative that occlusal interference is corrected or constant trauma to the teeth will result.

If primary anterior teeth are only slightly displaced, incidental muscle pressure from the tongue and lip will restore them to their correct position in the arch. They usually do not have to be splinted in place. If teeth exhibit more than 2 mm of mobility in any direction, a splint is necessary. The teeth can be etched and a thin layer of composite resin placed or a periodontal pack can be used. The splint is removed in 7 to 10 days.

### Splinting: Composite Resin

#### Armamentarium

Standard dental setup (see the section on Class II traumatic injuries in this chapter)

Acid-etch gel

0.018 orthodontic wire (Unitek/3M, Inc.); hollow-jawed pliers; wire cutters

Bonding agent of choice (see Chapter 3)

Composite resin of choice (see Chapter 5)

#### Clinical Technique

1. Obtain a thorough medical history, neurologic evaluation, and history of trauma.
2. Perform a clinical examination, including a periapical radiograph.
3. Pumice and dry the teeth.
4. Cut a sufficient amount of wire to splint from the maxillary right to maxillary left canine.
5. Contour the wire to conform to the arch.
6. Etch the teeth (primary teeth 30 to 45 seconds, permanent teeth 15 seconds), rinse, and dry.
7. Place liquid bonding agent on the teeth and cure.
8. Place the wire in the proper position.
9. Lute the wire to the teeth with composite resin.
10. Place composite resin over the wire.
11. Remove the splint in 7 to 10 days.

**Orthodontic Ligature.** As an alternative splinting procedure, orthodontic ligature wire can be twisted around **the adjacent teeth** and stabilized with auto-curing acrylic, using a brush-on technique. Acrylic is used because it is easier to remove than composite resin.

#### Armamentarium

Standard dental setup (see the section on class II traumatic injuries in this chapter)

Orthodontic ligature wire (0.008 in to 0.011 in) (Unitek/3M, Inc.)

Auto-curing acrylic (L.D. Caulk/Dentsply)

Brush

Matthew needle holder

Wire cutters

Acrylic burs for trimming

#### Clinical Technique

1. Obtain a thorough medical history, neurologic evaluation, and history of trauma.
2. Perform a clinical examination, including a periapical radiograph.
3. Pass the ligature wire around each tooth.
4. Using a Nealon technique, place acrylic over the wire to stabilize the teeth.
5. Adjust the occlusion to eliminate interferences.
6. Remove the splint in 7 to 10 days.

Instruct the parent to limit the child to a diet of soft foods for a few days and to prevent the child from incising food. Firm food should be cut into small, bite-size pieces.

**Avulsed Teeth.** If the primary anterior tooth is avulsed, no attempt should be made to replant it, because it can damage the succedaneous tooth and result in ankylosis. If the primary tooth is lost in an accident or must be subsequently extracted, it can be replaced with a prosthesis. (See the section on anterior fixed space maintainers in this chapter.)

### Class V Traumatic Injuries

Class V injuries consist of root fracture without loss of crown structure. This is an uncommon injury to the primary dentition because of the soft nature of the alveolar bone. If the radiograph reveals a root fracture of a primary incisor in the middle or coronal one third of the root, the tooth should be extracted. If the fracture is in the apical one third of the root, the tooth can be left in place and followed carefully for any clinical changes in the soft tissue, such as abscess formation, or for periapical radiolucencies or root resorption. Initially, the patient should be seen at 3 months and subsequently at 6-month intervals. Biologic repair of the root can occur by a number of different modalities":

1. Calcified tissue, similar to tooth structure, may form.
2. Interposition of connective tissue, causing the root surface to be covered by cementum.
3. Healing with interposition of bone and connective tissue, and healing with interposition of granulation tissue.

If granulation tissue forms in the fracture site, the prognosis is poor."

### Class VI Traumatic Injuries

Class VI injuries consist of either vital or nonvital teeth that have been traumatized. This trauma causes an immediate inflammatory reaction and may result in discoloration. Vasodilation, edema, an ingress of inflammatory cells, and displacement of odontoblasts follows. If the fibroblasts and odontoblasts regenerate, the pulp will heal. Overwhelming inflammation leads to infarction and pulpal necrosis." Vascular edema at the apical foramen occludes the apical vessels. If this occlusion continues, a slow generalized pulpitis leading to necrosis results.

Initial trauma will cause an escape of red blood cells from pulpal vessels into the dentin, with subsequent breakdown and bilirubin pigment formation. The tooth will become blue-gray in appearance (Fig. 17-14). This change may be reversible, but the injured tooth will retain some of the discoloration for an indefinite period.

A yellow opaque color appears with calcific degeneration. Secondary dentin is laid down, obliterating the pulp chamber and canal. This is a degenerative process of a non-inflammatory nature that takes place a few months after the injury.<sup>20</sup> Internal resorption is a result of odontoclastic activity. It can be seen radiographically within a few weeks or months of the injury. The tooth may appear translucent pink. Color is not an indication of the tooth's vitality.' Teeth can become nonvital at any time subsequent to traumatic injury or they may repair themselves. Initially, the patient should be seen at 3 months and subsequently at 6-month intervals. Changes in the soft tissue, periapical radiolucencies, and root resorption indicate devitalization.

If the parent is concerned about esthetics and the tooth remains vital, a thin veneer of composite resin can be applied. If the tooth is nonvital, it must be treated before restorative procedures (see the section on pulpectomy of nonvital primary teeth in this chapter).

**Armamentarium**

Standard dental setup (see the section on Class II traumatic injuries)

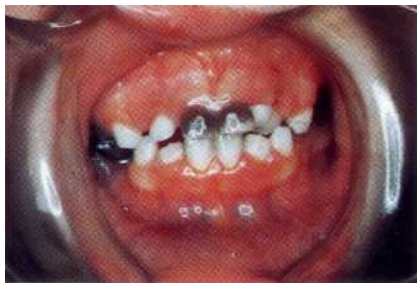

Fig. 17-14. Discoloration of primary teeth caused by blood pigments in the dentin.

- Acid-etch gel
- Bonding agent of choice (see Chapter 3)
- Composite resin of choice (see Chapter 5)

**Clinical Technique**

1. Obtain a thorough medical history, neurologic evaluation, and history of trauma.
2. Perform a clinical examination, including a periapical radiograph.
3. Remove a 0.5-mm layer of enamel from the labial portion of the teeth, etch, rinse, dry, and apply bonding agent.
4. Apply a layer of composite resin (microfilled) and a build up to cover the discolored tooth.
5. A composite resin crown can also be placed for a more esthetic result. (See the section on crowns for primary teeth in this chapter.)

### CARIES AND DEVELOPMENTAL DISTURBANCES

The morphology of the primary anterior dentition is unique and must be considered when restoring these teeth. The odontoblasts of primary teeth are active for less than half the time as the odontoblasts of the permanent teeth. Pulp chambers are larger and the enamel and dentin are half the thickness of the those of the permanent tooth.<sup>21</sup> This small crown size and large pulp chamber presents unique restorative problems.

The actual dimensions of the primary incisors offer little tooth structure for a permanent restoration.<sup>22</sup> The proportions may serve as a guide to the tooth structure present (Table 17-2). In many instances, however, the tooth is smaller and less hard tissue is available for preparation.

The mandibular anterior teeth are extremely difficult to restore. The slightest amount of decay results in a preparation close to the pulp.

Table 17-2. Average sizes of primary teeth.

		Maxillary incisors		Mandibular incisors	
		MAXILLARY INCISORS		MANDIBULAR INCISORS	
		CENTRAL	LATERAL	CENTRAL	LATERAL
LABIAL VIEW		1.5	1.4	1.4	1.4
		1.5	1.4	1.4	1.4
		M 2.4 D	M 2.0 D	M 1.7 D	M 1.7 D
		ENAMEL: 0.7(max.)		ENAMEL: 0.3(max.)	
PROXIMAL VIEW		2.0	1.9	1.4	1.4
		1.5	1.4	1.4	1.4
		M 2.0 D	M 1.9 D	M 1.0 D	M 1.0 D
		ENAMEL: 0.7(max.)		ENAMEL: 0.3(max.)	
		Li	La	Li	La

(From McBride WE: *Juvenile Dentistry*, ed 4, Philadelphia, Lea & Febiger, 1945.)

### Repair of Interproximal Caries

Restoration of primary incisors with interproximal decay requires an exacting technique. Prudent evaluation of both the tooth to be restored and the procedure to be used is advised. The lesions should be small compared with the total tooth size. A lock must be placed in the labial or lingual portion of the preparation, rather than in the proximal internal walls, where a danger of pulp exposure exists.<sup>23</sup> The small size of the mandibular incisors makes it almost impossible to use this procedure without exposing the pulp.

#### Armamentarium

- Standard dental setup (see the section on Class 11 traumatic injuries in this chapter)
- High-speed bur, such as inverted cone #33 $\frac{1}{2}$  or #34
- High-speed bur, such as pear-shaped bur #330 or #331
- Suitable liner material, such as calcium hydroxide (e.g., Dycal, [L.D. Caulk/Dentsply](#)) or glass ionomer cement (e.g., Keta-Cem, ESPE-Premier Sales Corp.)
- Polycarboxylate cement (e.g., Durelon, ESPE-Premier Sales Corp.)
- Acid-etch gel
- Bonding agent of choice (see Chapter 3)
- Composite resin of choice (see Chapter 5)
- Mylar strip and wooden wedge

#### Clinical Technique

1. Administer local anesthesia.
2. Place a rubber dam.
3. Remove interproximal caries with a small inverted cone bur #33 $\frac{1}{2}$  or #34 or pear-shaped bur #330 or #331.
4. Add a labial or lingual lock for retention (Fig. 17-15). If both mesial and distal decay exist, these locks can be connected (see Fig. 17-23). Remove the incisal angle if it is thin and undermined. If a small mechanical exposure occurs, perform a vital

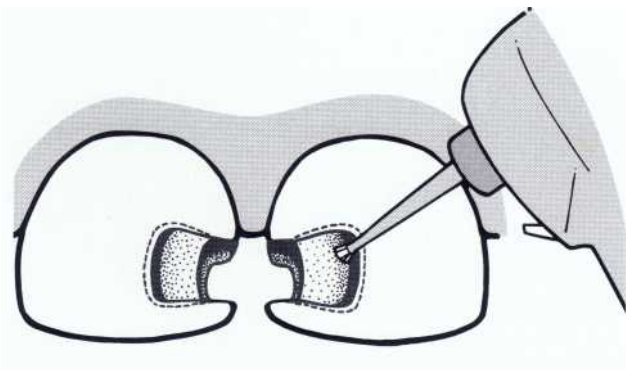


Fig. 17-15. Labial view of interproximal "through and through" decay requiring labial and lingual locks and peripheral undercuts for retention.

5. Place a liner of calcium hydroxide or glass ionomer cement on the dentin (Fig. 17-16; see also Fig. 17-24). If a pulpotomy is performed, place a poly carboxylate or glass ionomer cement over the zinc oxide and eugenol, which was placed during the pulpotomy procedure.

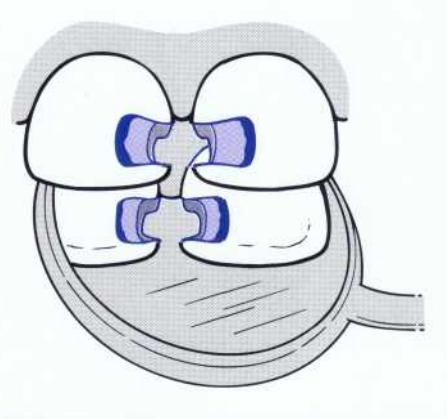


Fig. 17-16. Lingual view with a liner in place.

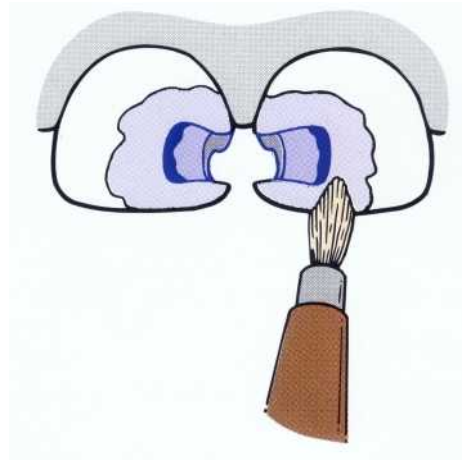


Fig. 17-17. Bonding agent is applied to etched enamel.

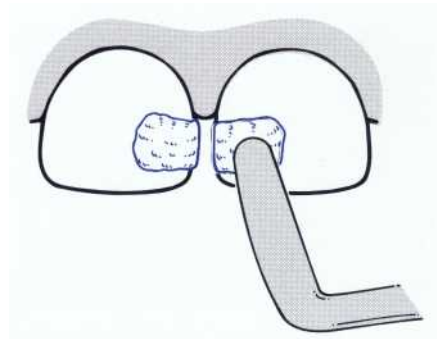


Fig. 17-18. Composite resin is placed.



6. Acid etch the enamel for 30 to 45 seconds, rinse, and dry.
7. Apply bonding agent (Fig. 17-17; see Fig. 17-25).
8. Depending on the restorative situation
  - A. If the dental arch exhibits interdental space between the anterior teeth, place a bonded composite resin (Fig. 17-18; see Fig. 17-25).
  - B. If no interdental space exists, place a wedge and a mylar strip to aid in shaping the composite resin (Fig. 17-19).

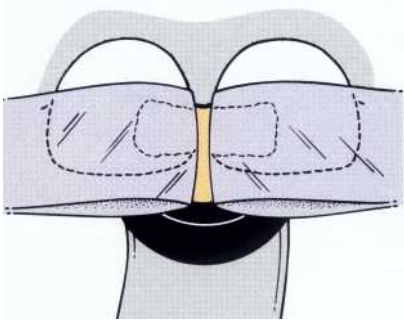


Fig. 17-19. Celluloid strips are used to stabilize the resin and the restoration is cured from the lingual direction.

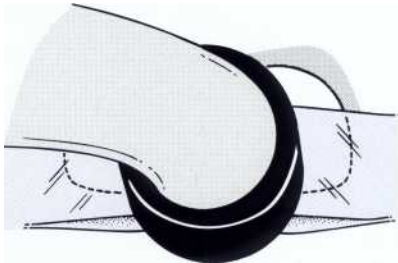


Fig. 17-20. The restoration is then light-cured from the labial direction.

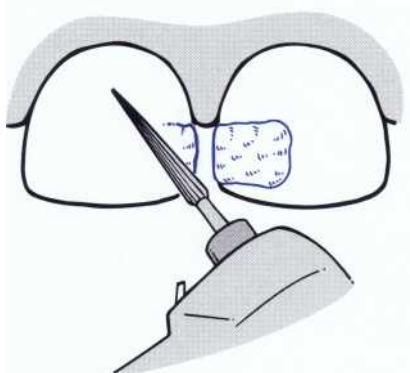


Fig. 17-21. The resin is trimmed with a 12-fluted bur and then polished.

- C. If the incisal angle is missing, a plastic crown form (e.g., Ion Crown Form, 3M, Inc.) may be used as an alternative to the mylar strip. Cut the form to fit the angle of the tooth and then



Fig. 17-22. The final restoration.

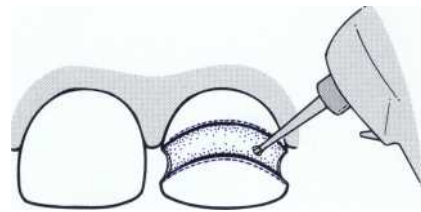


Fig. 17-23. Retentive locks can be interconnected when interproximal decay exists on both the mesial and distal surfaces.

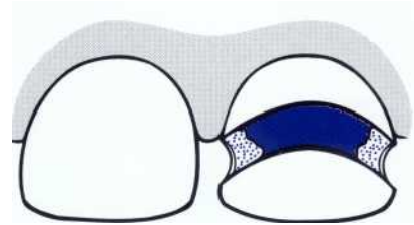


Fig. 17-24. Calcium hydroxide or glass ionomer liner is placed on dentin.

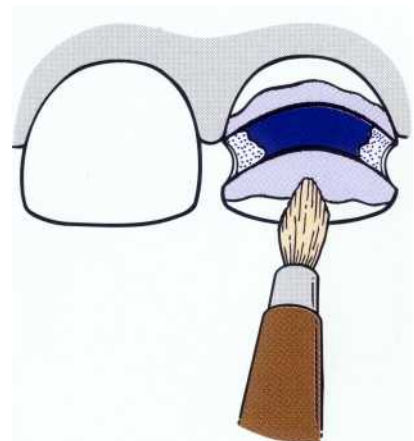


Fig. 17-25. Unfilled composite resin is applied to etched enamel.

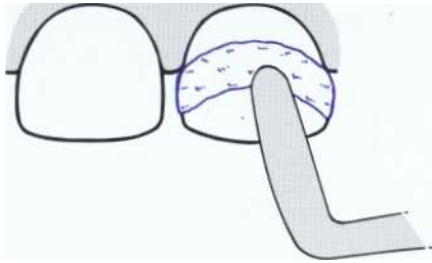


Fig. 17-26. Placement of composite resin.




Fig. 17-27. The restoration is light-cured from the labial direction.

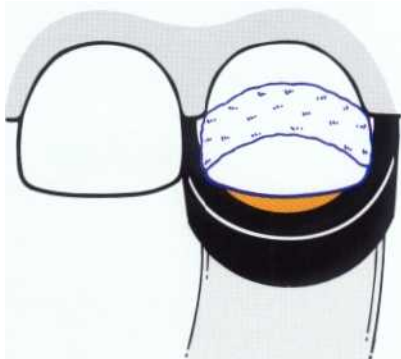


Fig. 17-28. The restoration is then light-cured from the lingual direction.

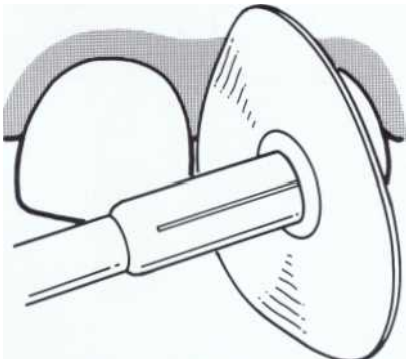


Fig. 17-29. The resin is trimmed and polished.



Fig. 17-30. The completed restoration.

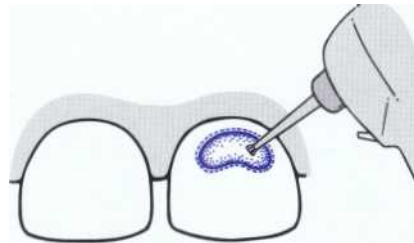


Fig. 17-31. An undercut is placed within the entire periphery of a Class V preparation.

fill it with a composite resin and bond it into place (Figs. 17-20 to 17-22; Figs. 17-27 to 17-30).

Composite resins need adequate enamel for bonding and may not be strong enough to withstand constant occlusion pressures. If the anterior tooth is malformed, fractured, discolored, or has extensive caries, full coverage is indicated.

### Repair of Buccal or Lingual Caries

The procedure for restoration of Class V caries on primary teeth is similar to that for permanent teeth. An undercut on the entire perimeter of the preparation ensures adequate retention of the composite resin.

#### Armamentarium

- Standard dental setup (see the section on Class II traumatic injuries in this chapter)
- High-speed bur, such as inverted cone #33I/1, or #34
- Suitable liner material, such as calcium hydroxide (e.g., Dycal, [L.D. Caulk/Dentsply](#)) or glass ionomer cement (e.g., Keta-Cem, ESPE-Premier Sales Corp.)
- Acid-etch gel
- Bonding agent of choice (see Chapter 3)
- Composite resin of choice (see Chapter 5)

#### Clinical Technique

1. Administer local anesthesia.
2. Place a rubber dam.
3. Remove buccal caries with a small inverted cone bur #33I/1 or #34.
4. Place an undercut within the entire perimeter of the preparation (Fig. 17-31). If a small mechanical



Fig. 17-32. A liner of calcium hydroxide or glass ionomer cement is placed on the dentin.

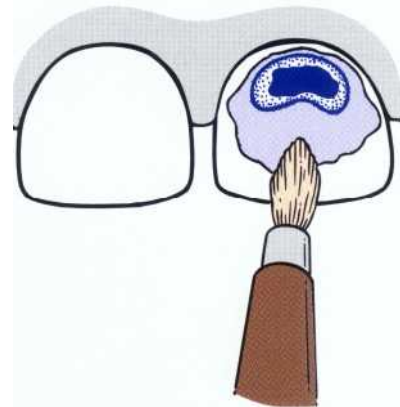


Fig. 17-33. Bonding agent is applied to etched enamel.

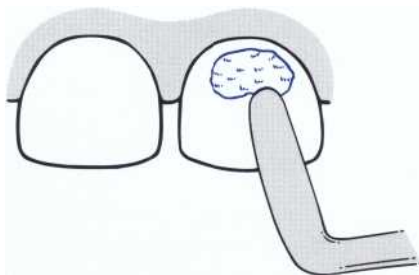


Fig. 17-34. Composite resin is placed in the restoration.

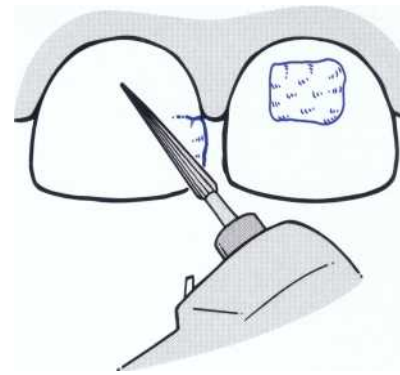


Fig. 17-35. The restoration is contoured.

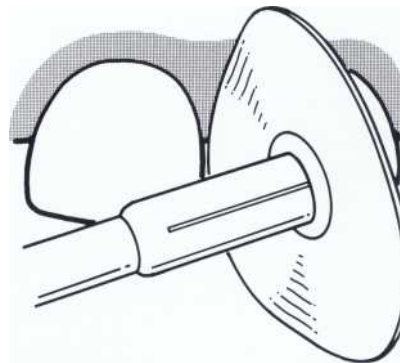


Fig. 17-36. The restoration is then polished.



Fig. 17-37. The final restoration.

exposure occurs, perform a vital formocresol pulpotomy (see the section on pulpotomy of vital primary teeth in this chapter). Pulp capping primary teeth is contraindicated.<sup>4</sup>

5. Place a liner of calcium hydroxide or glass ionomer cement on the dentin (Fig. 17-32). If a pulpotomy is performed, place a polycarboxylate or glass ionomer cement over the zinc oxide and eugenol, which was placed during the pulpotomy procedure.
6. Acid etch the enamel for 30 to 45 seconds, rinse, and dry.
7. Apply bonding agent (Fig. 17-33). (See Chapter 3.)
8. Place and light cure the composite resin (Fig. 17-34).
9. Finish the restoration (Figs. 17-35 to 17-37).

## COMPOMERS

Compomers are a new generation of restorative materials. They combine the chemistry, material properties, and working techniques of composite resins and glass ionomer cements. Glass ionomer cements bond to both dentin and enamel and release fluoride ions to prevent secondary decay. Composite resins have high wear resistance, polishability, and good strength. Compomers combine all these qualities in addition to forming strong bonds to dentin and enamel." Most restorations exhibited only cohesive, not adhesive, fractures. These materials are well suited for anterior primary restorations because their inherent bond strength allows for minimal tooth preparation. However, mechanical retention is still recommended.

## CROWNS FOR PRIMARY TEETH

A number of different types of crowns exist for use on primary teeth. All are relatively inexpensive, available in different sizes, and can be placed in one visit.

### *Stainless Steel Crowns*

Stainless steel crowns are manufactured for primary anterior maxillary teeth. They are strong, durable, and easily adapted to a prepared tooth; however, they are not esthetically acceptable. Early attempts at cosmetic resin filled windows have been unsuccessful.

### *Celluloid Strip Crowns*

Celluloid strip crowns are preformed plastic crown molds that are available in various sizes (e.g., Ion Crown Form, 3M, Inc.). They are used if the tooth is merely discolored and no occlusal interferences (e.g., an open bite) exist. They are packaged in a kit of four sizes of right and left maxillary central and lateral primary incisors. The advantages of celluloid strip crowns are the following:

1. Esthetic appearance.
  2. They require removal of only a small amount of tooth structure.
  3. Supplemental retention can be gained by bonding to the remaining enamel.
- The disadvantages are the following:
1. The restoration often has an insufficient bulk of material to withstand occlusal stress.
  2. They are manufactured only for the maxillary teeth and must be adapted to the mandibular anteriors.
  3. They are difficult to use in tight contact cases.

### Armamentarium

Standard dental setup (see the section on Class II traumatic injuries in this chapter)  
 High-speed bur, such as inverted cone #33<sup>1/2</sup> or #34  
 high-speed bur, such as pear-shaped bur #330 or #331  
 high-speed bur, such as fine tapered diamond stone or #699 or #700  
 carbide bur  
 Suitable liner material, such as calcium hydroxide (e.g., Dycal, [L.D. Caulk/Dentsply](#)) or glass ionomer cement (e.g., Ketac-Cem, ESPE-Premier Sales Corp.)  
 Celluloid strip crowns (e.g., Ion Crown Form, 3M, Inc.)  
 Acid-etch gel  
 Bonding agent of choice (see Chapter 3)  
 Composite resin of choice (see Chapter 5)

### Clinical Technique

1. Administer local anesthesia.
2. Place a rubber dam.

3. Remove interproximal caries with a small inverted cone bur #33<sup>1/2</sup> or #34 or pear-shaped bur #330 or #331.
4. Perform pulp therapy, if necessary. (See the sections on pulpotomy of vital primary teeth and pulpectomy of nonvital primary teeth in this chapter.)
5. If the tooth has been fractured, apply an adequate layer of calcium hydroxide.
6. Prepare the tooth using a fine-tapered diamond stone or #699 or #700 bur, for the labial and proximal areas. A pear-shaped diamond can be used to reduce the lingual area.
7. Reduce the tooth as follows (Fig. 17-38):
  - A. Mesial and distal, 1.0 mm
  - B. Buccal, 0.5 mm
  - C. Lingual, 0.5 mm
  - D. Incisal, 0.5 mm
8. Create a feather-edged finishing line slightly subgingivally.
9. Fit and adjust the crown cervically.
10. Protect the dentin with calcium hydroxide
11. Acid etch the enamel for 30 to 45 seconds, rinse, dry, and apply bonding agent.
12. Place an air vent in the incisolingual area and fill the crown with composite resin.
13. Seat the crown.
14. Stir the celluloid cover with a scalpel along the lingual surface to avoid damaging the smooth surface on the labial portion and remove the celluloid material.
15. Adjust the occlusion.
16. Finish and polish the composite resin.

### *Preformed Ceramo-Base Metal Crowns*

Preformed ceramo-base metal crowns<sup>25</sup> (e.g., Childers' Crown, Keller Laboratories, Inc.) are the restoration of choice if the tooth has lost significant structure from decay or trauma or if occlusal stresses are high. Developed by Dr. Logan Childers, they are manufactured in five sizes that fit on either the left or right primary maxillary incisors (Fig. 17-39). Only light and universal shades of porcelain are available. They are contoured to the correct shape by the dentist. Advantages of preformed ceramo-base metal crowns are as follows":

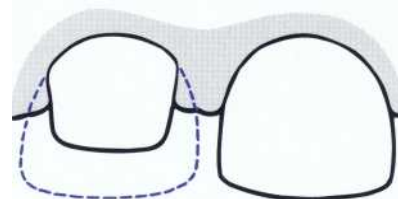

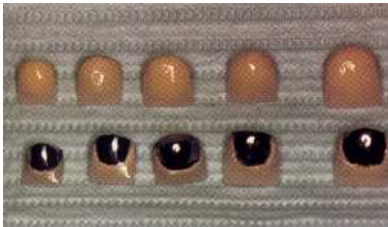Fig. 17-38. A typical crown preparation.

1. Excellent esthetics
  2. Strength
  3. Durability
- Disadvantages are the following<sup>26</sup>:
1. Require extensive tooth reduction
  2. Time consuming
  3. High cost
  4. Difficult to fit because of hardness and lack of pliability
  5. Risk of porcelain fracture during placement
  6. Possible risk of allergy to nickel
  7. Questionable adverse effects of beryllium (1.8%)

As with **the other crown techniques, the tooth** must be fit to the manufactured crown. The preparation is similar to that for celluloid crowns, but more tooth structure must be removed. Porcelain-fused-to-metal crowns do not "spring" and conform to the tooth as do posterior stainless steel crowns, thus a tight fit is not always achieved. Attempts at cervical contouring may fracture the porcelain; therefore marginal fit can be obtained only through proper tooth reduction.

#### Armamentarium

- Standard dental setup (see the section on Class II traumatic injuries)
- High-speed bur, such as inverted cone #33 $\frac{1}{2}$  or #34
- High-speed bur, such as pear-shaped bur #330 or #331
- High-speed bur, such as fine-tapered diamond stone or #699 or #700 carbide bur
- Suitable liner material, such as calcium hydroxide (e.g., Dycal, [L.D. Caulk/Dentsply](#)) or glass ionomer cement (e.g., Keta-Cem, ESPE-Premier Sales Corp.)
- Preformed ceramo-base metal crown kit (e.g., Childer's Crown, Keller Laboratories, Inc.)
- Suitable cementation medium, such as polycarboxylate cement (e.g., Durelon, ESPE-Premier Sales Corp.), zinc phosphate cement (e.g., Fleck's Cement, Mizzy, Inc.), or composite resin post and core material (e.g., Core Material, Henry Schein, Inc.)



*Fig. 17-39. Ceramo-base metal crowns (Childer's) are manufactured in five sizes in light and universal shades of porcelain.*

#### Clinical Technique

1. The initial preparation is identical to celluloid crowns (see steps 1 through 6 in the section on celluloid strip crowns).
2. This preparation requires greater reduction than for a celluloid crown. Reduce the tooth as follows:
  - A. Mesial and distal, 1.5 to 2.0 mm
  - B. Buccal, 1.0 mm
  - C. Lingual, 0.5 mm
  - D. Incisal, 2.0 mm
  - E. Occlusal, 2.0 mm
3. Create a feather-edged finishing line slightly subgingivally.
4. Select a suitable crown.
5. Fit the crown and adjust it cervically.
6. Contour and polish the crown with a porcelain finishing kit and diamond stones.
7. Cement the crown into place with a suitable luting agent.

#### *Stainless Steel Crowns with Esthetic Veneers*

Stainless steel crowns (Unitek, 3M, Inc.) have been veneered, using various laboratory processes, with composite resins and thermoplastics. These crowns (e.g., Nu-Smile, Whiter Biter, Kinder Krowns, Cheng) combine the durability of stainless steel with the esthetics of composite resin. They require a minimal amount of tooth reduction, can withstand occlusal forces, and are esthetically pleasing.<sup>27</sup>

In one study, by Waggoner and Cohen, the Whiter Biter II crown was significantly better at resisting shearing forces when compared with the others.<sup>28</sup> In another study by Baker, Moon, and Mourion, the Cheng crown was superior in resisting displacement than the others. All the newer crowns are clinically acceptable.

#### Armamentarium

- Basic dental setup
- High-speed burs similar to that for the celluloid strip crowns
- Suitable liner materials as that for celluloid strip crowns
- 114 pliers
- DeNovo crown crimping pliers
- Crown and bridge contouring scissors

#### Clinical Technique

1. Follow the technique for the celluloid strip crown to step 10 on p. 340.
2. The stainless steel crown can be cut and crimped on the lingual to aid in the final adaptation. Crimping or contouring these veneered crowns can cause some veneers to break; therefore this procedure is limited.

- Cement crowns into place with polycarboxylate or glass ionomer cement.

**CLINICAL TIP.** These crowns cannot be heat sterilized after unsuccessful try-in because of potential damage to the veneer material.

## Artglass Crowns

Preformed crowns constructed of Artglass material have recently been introduced to the profession. Artglass is a polyglass material designed as an alternative to porcelain. Artglass esthetics were noted to be as good as or better than porcelain fused to metal.<sup>29</sup>

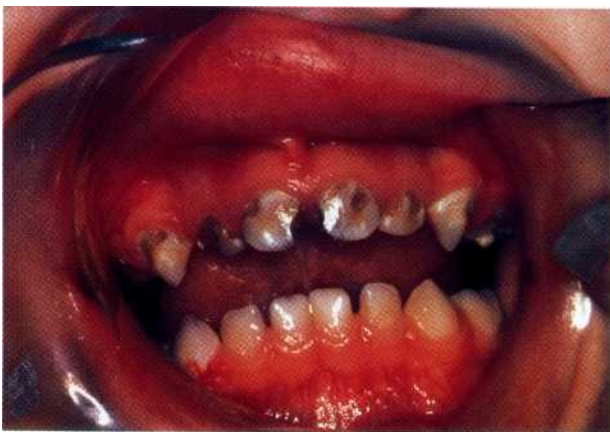The preparation of the teeth for these crowns is similar to the preformed ceramo-base metal crowns, but less tooth structure is removed. They have shown excellent results in recent applications.

## POST AND CORI

The ravages of decay are most commonly seen with nursing bottle caries. The complete coronal portion of the crown can be destroyed by caries (Fig. 17-40). In many instances, these teeth can be salvaged if the root structure is sound (Fig. 17-41).

### Armamentarium

- Standard dental setup (see the section on Class II traumatic injuries)
- High-speed bur, such as #699, #330, or #331
- Carbide bur
- Suitable post system (e.g., Flexi-Post, Essential Dental Systems, Inc.)
- Preformed ceramo-base metal crown kit (e.g., Childer's Crown, Keller Laboratories, Inc.)

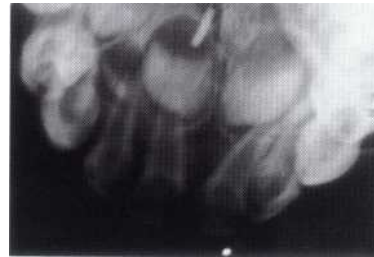

*Fig. 17-40.* Facial view of a patient with nursing bottle syndrome.

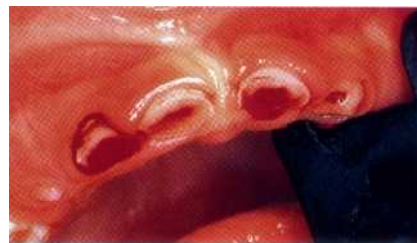- Suitable cementation medium, such as polycarboxylate cement (e.g., Durelon, ESPE-Premier Sales Corp.) or glass ionomer cement (e.g., Keta-Cem, ESPE-Premier Sales Corp.)

### Clinical Technique

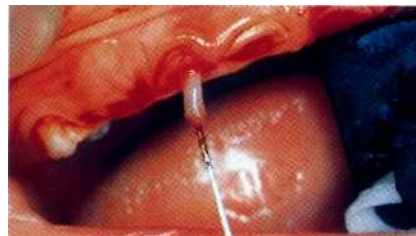1. Administer local anesthesia.
2. Place a rubber dam.
3. Remove all decay. Often only the root structure remains (Fig. 17-42).
4. Perform a complete pulpectomy (see the section on pulpectomy of nonvital primary teeth in this chapter) (Fig. 17-43).
5. Determine the length of the tooth radiographically.



*Fig. 17-41.* Radiograph of a patient with nursing bottle syndrome. The teeth are vital and sufficient root structure exists to salvage them.

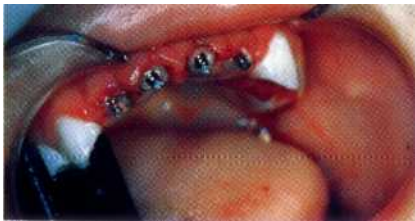

*Fig. 17-42.* Following the removal of all the decay, very little coronal tooth structure remains. Note that the deciduous molar was insufficiently erupted to allow for the placement of a rubber dam clamp.

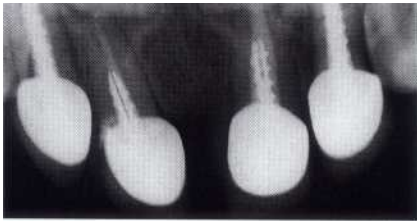


*Fig. 17-43.* Pulpectomies are performed on all the anterior teeth. Note that the pulps of the teeth were vital.

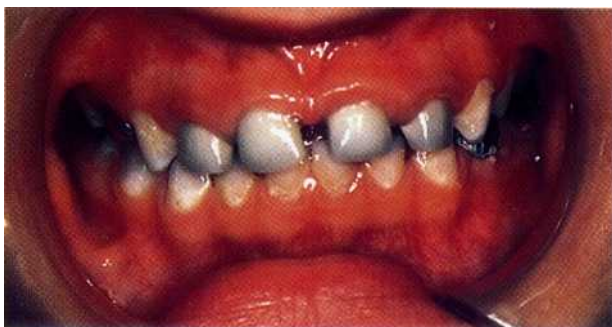6. Fit a stress-relieving post (e.g., Flexi-Post, Essential Dental Systems) to a depth of two thirds the length of the canal. Clinical experience has shown that non-stress-relieving brass screw posts are easily bent or broken and the chance of root fracture is high; thus these materials are not recommended.
7. The posts are held by friction and are not cemented.
8. Trim the post incisally, leaving 3 to 4 mm of material above the gingiva (Fig. 17-44).
9. Fit and cement a preformed ceramo-base metal crown (Figs. 17-45 to 17-47). (See the section on preformed ceramo-base metal crowns in this chapter.)



*Fig. 17-44. A second case showing the post trimmed incisally, leaving 3 to 4 mm of material above the gingiva.*



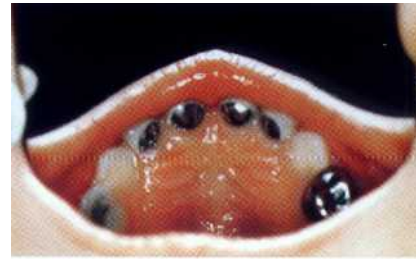*Fig. 17-45. Radiograph of the patient shown in Fig. 17-44 with nursing bottle syndrome whose teeth were restored with complete endodontics, preformed stress-relieving posts, and porcelain-fused-to-metal crowns.*



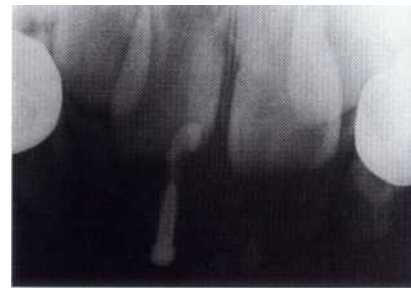*Fig. 17-46. Facial view of the patient shown in Fig. 17-44; the completed restorations.*

10. Follow up with a radiograph every 6 months to verify that no damage is occurring to the permanent tooth (i.e., as evidenced by a radiolucency).

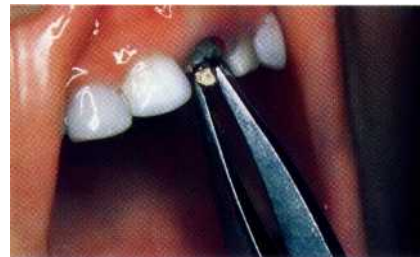These crowns can remain in place until just prior to the eruption of the maxillary permanent central incisors. This occurs when the mandibular permanent incisors have started to erupt or evidence of eruption of the maxillary permanent incisors is noted radiographically. The post has the potential of deflecting the succedaneous tooth as it erupts (Fig. 17-48). At this time, the crown is removed and the post is unscrewed (Fig. 17-49) or the entire tooth is extracted.



*Fig. 17-47. Occlusal view of the completed restorations.*



*Fig. 17-48. Before the eruption of the maxillary permanent central incisors, the post should be removed or the tooth extracted to prevent deflection of the succedaneous tooth as it erupts. Note that the root paste is being resorbed.*



*Fig. 17-49. The crown is removed and the post is unscrewed. Note the healthy appearance of the gingiva.*

**ANTERIOR FIXED SPACE MAINTAINERS**

Anterior teeth can be decayed to a point at which infection and resorption of the primary roots precludes endodontic therapy. Trauma and developmental disturbances can also cause early loss of the primary teeth. Anterior fixed space maintainers are the restoration of choice in this clinical situation (Figs. 17-50 and 17-51). Their advantages are the following:

1. Good esthetics
2. Restored function
3. Maintenance of space where necessary
4. Prevent supereruption of opposing dentition

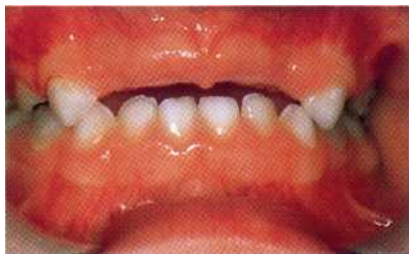Their disadvantages are the following:

1. Possible inadvertent orthodontic movement if improperly fabricated.
2. Require cementation of bands or crowns, which may affect posterior teeth by causing decalcification or decay if the cement washes out.

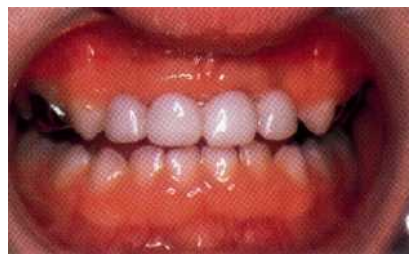*Bands versus Stainless Steel Crowns*

Bands are fitted on healthy first or second primary molars. Bands do not require the removal of tooth structure and are therefore preferable to stainless steel crowns. However, stainless steel crowns are indicated in the following situations:

1. Extensive decay is present
2. Band retention proves to be insufficient



The primary anterior teeth were removed because of nursing bottle syndrome.



A fixed space maintainer was fabricated to replace the primary central and lateral incisors.

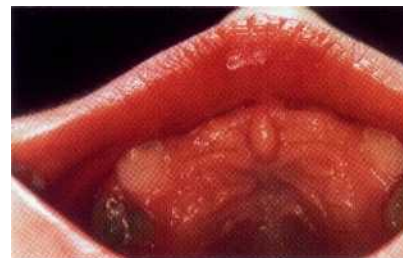
**CLINICAL TIP.** Crowns must be used bilaterally. This avoids the difficulties of stainless steel crown removal should the band component dislodge unilaterally.

**Armamentarium**

- Standard dental setup (see the section on Class II traumatic injuries in this chapter)
- A high-speed bur, such as #699, #330, or #331 carbide bur
- Dry angles (Dri-Aid, Lorvic Corp.)
- Stainless steel crowns or orthodontic bands
- Impression compound (Impression Compound, Kerr Manufacturing Co.)
- Irreversible hydrocolloid impression material (Jeltrate, [L.D. Caulk/Dentsply](#))
- Stone
- 0.036-in orthodontic wire (Unitek, 3M Inc.)
- Polycarboxylate cement (Durelon, ESPE-Premier Sales Corp.)

**Clinical Technique**

1. Fit the stainless steel crowns or bands on the maxillary primary first or second molars.
2. Capture the bands in a compound pick-up impression. Compound creates a firm seat to ensure proper transfer.
3. Obtain a counter irreversible hydrocolloid impression and a wax wafer bite registration.
4. Using sticky wax, lute the bands or crowns into place in the compound impression.
5. Pour the models.
6. If the primary teeth were extracted recently, or at the same visit (e.g., when general anesthesia is used), remove a few millimeters of stone from the corresponding portion of the cast. This compensates for the tissue shrinkage that occurs after healing.
7. Adapt a wire to the dental arch.
8. Add acrylic to the wire to form the missing teeth (Figs. 17-52 and 17-53).

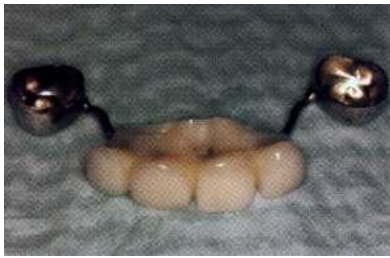

**FIGURE 17-52.** Occlusal view of an edentulous anterior maxilla requiring an anterior space maintainer.

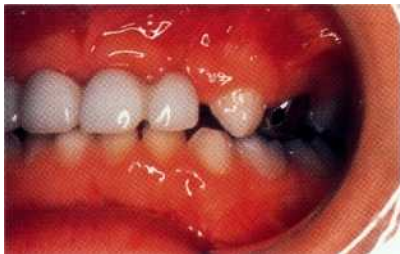

**CLINICAL TIP.** To eliminate restoration breakage, solder an open faced anterior stainless steel crown with the edges of the crown bent inward, or a solid direct bond pad with a mesh base and an eyelet tacked to the mesh for added retention. The retentive areas holding the teeth on the wire are usually stainless steel, not acrylic (Spacemaintainer Laboratories, Van Nuys)<sup>30</sup>

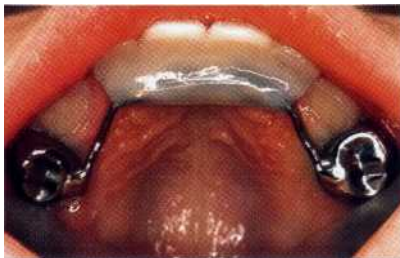9. Try-in the case by seating the crowns or bands into place. Then adjust the wire holding the replacement teeth so the pontics rest passively on the gingiva. During use this seat an additional 1 to 2 mm onto the ridge.
10. Isolate the teeth with a dry angle (e.g., Dri-Aids, Lorvic Corp.), dry the teeth with oil-free compressed air, and cement the appliance into place with a poly carboxylate cement (Figs. 17-54 and 17-55).



*Fig. 17-53. An anterior space maintainer is fabricated on the previously fitted stainless steel crowns.*



*Fig. 17-54. Three-quarter view of the fixed space maintainer in place.*



*Fig. 17-55. Occlusal view of the fixed space maintainer with acrylic teeth in place.*

Follow these restorations closely to check for eruption of the anterior teeth. Take maxillary and mandibular radiographs at 6-month intervals. When the mandibular permanent incisors are about to erupt or when evidence of eruption of the maxillary permanent central incisors is noted radiographically, remove the appliance. If the restoration is placed with bands, remove the entire appliance. If crowns are used, cut the wire, leaving the crowns as final restorations.

## REMOVABLE PROSTHETICS

Removable partial and complete dentures are necessary for children when fixed space maintainers are not adequate to replace teeth missing because of trauma and caries. Hereditary anomalies of tooth number also must be addressed. Anodontia (complete lack of teeth) or oligodontia (partial lack of teeth) is seen in ectodermal dysplasia and Down syndrome. Other diseases cause premature loss of teeth (e.g., histiocytosis X, Papillon-Lefevre syndrome, and hypophosphatasia). All of these conditions create the need for removable partial or complete dentures. The advantages of removable dentures are the following:

1. Good esthetics
2. Restored function

The disadvantages are the following:

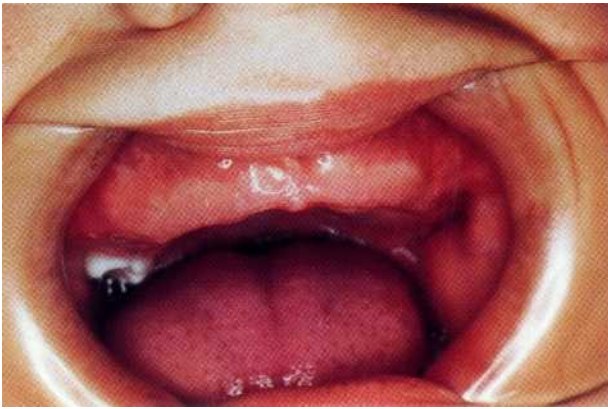
1. Require a mature and compliant patient
2. Easily lost

The concept that the denture must be changed every year is a fallacy. Essentially no interstitial growth occurs in the anterior portion of the mouth from the age of 3 until the permanent anterior teeth erupt. Only vertical growth occurs.

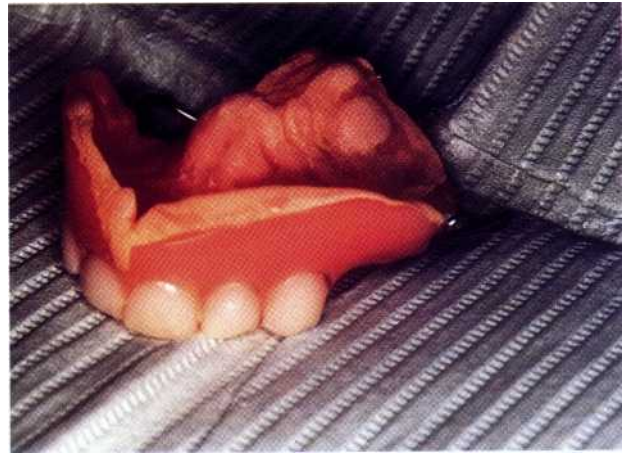
The dentures remain stable, with little adjustment needed in the years before the eruption of the permanent dentition; however, it is necessary to relines the dentures approximately every 12 or 18 months to accommodate vertical growth. With the eruption of the permanent teeth, a proliferation of alveolar bone occurs. It is impossible to cut holes in the denture for these teeth to fit. New dentures must be fabricated at this time.

### Armamentarium

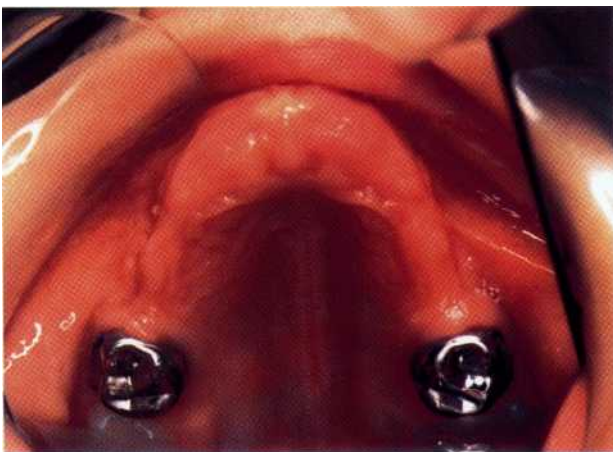
- Standard dental setup (see the section on Class II traumatic injuries in this chapter)
- Irreversible hydrocolloid impression material
- Impression compound (e.g., Impression Compound, Kerr Manufacturing Corp.)
- Acrylic custom tray material (e.g., Fastray, Bosworth Corp.)
- Impression material (e.g., Reprosil, [L.D. Caulk/Dentsply](#))



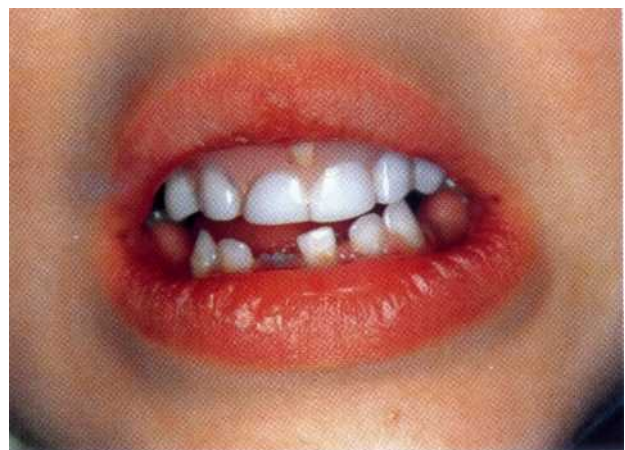*Fig. 17-56.* A patient with a loss of primary dentition, except for maxillary second primary molars, because of caries.



*Fig. 17-58.* A partial denture with full palatal coverage and labial flange to replace the missing anterior teeth.



*Fig. 17-57.* Occlusal view of the patient shown in Fig. 17-56.



*Fig. 17-59.* A patient who had been wearing the same partial denture for 4 years. Note that the mandibular anterior permanent teeth are erupting. Although the denture does not fit completely, it is still functional.

#### Clinical Technique

1. Make a preliminary irreversible hydrocolloid impression using stock trays.
2. Pour the impressions.
3. Fabricate custom trays.
4. Make muscle-trimmed impressions, as for adults.
5. Fabricate trays with wax occlusal rims on the master models.
6. If 1 or 2 teeth are present in the dental arch, it is not difficult to determine jaw relationships (Figs. 17-56 and 17-57). If no teeth are present, use the wax rim as a guide for proper orientation of the teeth. However, it is almost impossible to obtain a correct centric relationship from a child unless he or she is extremely cooperative.<sup>31</sup>
7. With the casts mounted on an articulator, arrange zero-degree plastic denture teeth with a flat occlusal

plane. Bambino Denture Teeth (OSE Dental Supplies and Equipment, Division Orthodontic Supply and Equipment Co., Inc.) can also be used.

8. If any primary teeth are present in the mouth, use them for retention by placing wrought wire clasps (Fig. 17-58).
9. Process and deliver the dentures to the patient.
10. Fit the dentures carefully. Children's vestibules are relatively shallow because they have no alveolar bone, only **basal bone**. In addition, follow the patient to determine when (and if) the denture must be replaced (Fig. 17-59).

Overlay complete or partial removable dentures can be fabricated over retained teeth or roots that are not specially prepared to accept copings.<sup>32</sup> These dentures can be

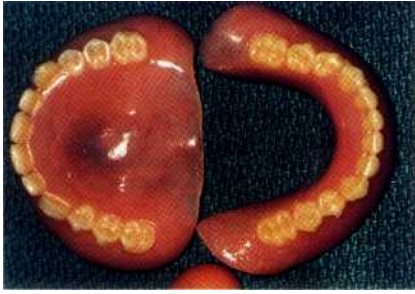


Fig. 17-60. A complete maxillary and mandibular denture for a patient with Papillon-Lefevre syndrome.

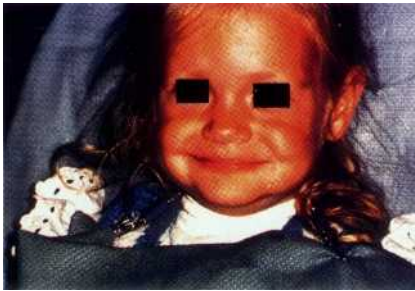

Fig. 17-61. The patient with the denture in place.

used in patients with cleidocranial dysostosis, ectodermal dysplasia, and cleft palate (Figs. 17-60 and 17-61).

## CONCLUSION

Esthetic restorations in the primary dentition are proper and necessary. With the many modalities available, children should have their mouths restored to proper form and function.

## REFERENCES

1. Morrees CF, Fanning EA, Gron AM: The consideration of dental development in serial extraction, *Angle Orthod* 33:44, 1963.
2. Styczynski LE, Langolis JH: The effects of familiarity on behavioral stereotypes associated with physical attractiveness in young children, *Child Dev* 48:1137, 1977.
3. Dion KK, Berscheid E: Physical attractiveness and peer perception among children, *Sociometry* 1:1, 1974.
4. Landis P, Fleming J: The interrelationship of speech therapy and prostheses for the handicapped child, *Dent Clin North Am* 3:725, 1974.
5. Reikman GA, Badrawy HG: Effects of premature loss of primary maxillary incisors on speech, *Pediatr Dent* 2:119, 1985.

6. Baume LK: Physiological tooth migration and its significance for the development of occlusion, *J Dent Res* 29:123, 1950.
7. Levine N: Injury to the primary dentition, *Dent Clin North Am* 26:461, 1982.
8. Schreiber CK: Effect of trauma on the anterior deciduous teeth, *Br Dent J* 106:340, 1959.
9. Ellis RG, Davies KW: *The classification and treatment of injuries to the teeth of children*, ed 5, Chicago, 1970, Year Book Medical Publishers.
10. Hill CJ: Oral trauma to the preschool child, *Dent Clin North Am* 28:177, 1984.
11. Croll TP et al: Rapid neurologic assessment and initial management for the patient with dental injuries, *J Am Dent Assoc* 100:530, 1980.
12. Citron CI: The clinical and histological evaluation of Cresatin with calcium hydroxide of the human dental pulp, *J Dent Child* July-Aug, 44(4):294, 1977.
13. Attalla MN, Nowjaim AA: Role of calcium hydroxide in the formation of reparative dentin, *J Can Dent Assoc* 35:268, 1969.
14. Camp JH: Pulptherapy for primary and young permanent teeth, *Dent Clin North Am* 28:4, 1984.
15. Ranly DM, Horn D: Assessment of systemic distribution and toxicity of formocresol following pulpotomy treatment, part two, *J Dent Child* 34:1, 1987.
16. Krakow AA, Berk H: Efficient endodontic procedures with the use of the pressure syringe, *Dent Clin North Am*, p 387, 1965.
17. Andreasen JO, Ravin JJ: Enamel changes in permanent teeth after trauma to their primary precursors, *Scand J Dent Res* 81:203, 1973.
18. Andreasen JO: *Traumatic injuries of the teeth*, St Louis, 1972, Mosby.
19. McDonald RE, Avery DR: *Dentistry for the child and adolescent*, ed 7, St Louis, 2000, Mosby.
20. Patterson SS, Mitchell DF: Calcific metamorphosis of the dental pulp, *Oral Surg* 20:94, 1965.
21. Schour I.: *Noyes' oral histology and embryology*, Philadelphia, 1962, Lea & Febiger.
22. Armum SS, Doyle MP: Dentin dimensions of primary teeth, *J Dent Children* 26:191, 1958.
23. McAvoy SA: Class III cavity preparation and composite resins, *Dent Clin North Am* 28:145, 1984.
24. Garcia-Godoy F, Rodriguez M, Barberia E: Dentin bond strength of fluoride-releasing materials, *Am J Dent* 9:80, 1996.
25. Childers L: Personal communication, 1989.
26. Christensen G: Esthetic pre-formed crowns, *Clin Res Assoc Newsl* 11:1, 1987.
27. Baker L, Moon P, Mourion A: Retention of esthetic veneers on primary stainless steel crowns, *J Dent Child* May-June, 63(3):185, 1996.
28. Waggoner W Cohen H: Failure strength of four veneered primary stainless steel crowns, *Pediatr Dent* 17:36, 1995.

29. Farah J, Powers J: *The dental advisor plus*, 7, 1997.
30. Jasmin JR, Groper JN: Fabrication of a more durable fixed anterior esthetic appliance, *J Dent Child* 51:124, 1984.
31. Johnson DL, Stratton RJ: *Fundamentals of removable prosthetics*, Chicago, 1980, Quintessence.
32. Schneidman E, Wilson S, Spuller RL: Complete overlay dentures for the pediatric patient: case reports, *Pediatr Dent* 10:222, 1988.



انتشارات شایان نمودار

## ESTHETICS AND PERIODONTICS

Edwin S. Rosenberg and James Torosian

**P**ERIODONTAL THERAPY plays an important role in esthetics, although the images invoked regarding conventional periodontal therapy (ugly spaces, gingival recession, tooth sensitivity) are anything but beautiful. The introduction of new surgical techniques and the adaptation of traditional periodontal procedures have led to a heightened esthetic awareness in periodontology. In addition, the recognition of the etiology and complicating factors underlying an esthetic periodontal problem is crucial. Often this identification alters or dictates the final treatment plan.

### PERIODONTAL ALVEOLAR BONE DEFECTS

#### Differential Diagnosis

Traditional periodontal pocket elimination therapy causes unesthetic results, including large interdental spaces and long clinical crowns. However, without adequate access to deep lesions, a healthy periodontal environment is unachievable. Several surgical solutions exist for this dilemma, depending on whether the defect is anteriorly or posteriorly located.

#### Treatment Options

**Retained Papilla.** The retained papilla technique is an ideal treatment alternative for periodontal defects. The procedure provides adequate access to deep anterior defects, allowing for thorough surgical debridement of the area while maintaining the position of the free gingival margin. This is accomplished by including the entire

interproximal tissue mass in the surgical flap. A straight-line incision is made in the palate and the papilla reflected buccally with the flap. After thorough debridement of the defect and the root surfaces (and grafting, palatal ramping, and regenerative procedures, when necessary), the flaps are sutured. By including the papillary tissues (as opposed to removing them as with conventional pocket elimination), interproximal tissue height is maintained and little or no apical shrinkage occurs. Thus the physiologic needs of the periodontium are satisfied along with the esthetic demands of the patient.

**Guided Tissue Regeneration.** The goal of guided tissue regeneration is pocket elimination through reformation of the periodontal connective tissue attachment. It is applicable to both anterior and posterior sextants. Exclusion of the rapidly proliferating epithelial tissues from the defect allows regeneration of the connective tissue attachment by cells of the periodontal ligament. This epithelial exclusion is achieved by placing a semipermeable membrane (e.g., Gore-Tex, Gore and Assoc. Corp.) between the periodontal defect and the flap, thus allowing nutrients to reach the flap while preventing the formation of a long junctional epithelium. The membrane is removed via a simple gingival flap procedure after 4 to 5 weeks and reveals a dense connective tissue fill of the defect that may or may not be accompanied with bone regeneration. Alveolar bone is not always necessary to achieve pocket closure, because the dense connective tissue attachment to the root surface can provide fill for the defect. Not all defects are amenable to this type of procedure (Class II furcation defects and deep, narrow three-walled defects offer the best prognosis), and the results are not completely predictable.



**Osseous Grafting.** Osseous grafting is another alternative for the treatment of deep angular defects. It is also applicable to both anterior and posterior sextants. The two primary types of materials used are decalcified freeze-dried cortical bone (DFDCB) and synthetic materials. With DFDCB, some regeneration is possible, whereas synthetic materials act as scaffolding to allow for osseous tissue ingrowth. The resultant pocket closure is via long junctional epithelial healing. Surgical access to the defects is gained via a flap designed to maintain the marginal tissues. Once the defects have been debrided, the graft material is placed into the defect. The flaps are replaced to cover the graft material (if primary closure is not achieved, exposed graft material may "fall out" of the defect). The result is clinical pocket closure with maintenance of the free gingival margin. There must be adequate bony wall structure to contain and support the material because it will not remain in place as a freestanding graft.

As with guided tissue regeneration, the results are not completely predictable. The criterion used to determine the appropriate procedure is the morphology of the alveolar defect. Guided tissue regeneration is best used in furcation involvements of mandibular molars, Class II buccal furcations of maxillary molars, and deep, narrow three-walled alveolar defects. Decreased predictability of results is seen with this procedure in two- and one-walled defects and in buccal and lingual dehiscences. Allogenic bone grafts are best utilized in Class II furcations, three-walled defects, and craters. Also, in **cases with interproximal craters** and root proximity, a bone graft would be indicated because of the ease of placement. As with the guided **tissue regeneration procedure, the success rate** decreases with two- and one-walled alveolar defects and with lingual and buccal plate defects.

Another factor to consider is the ability to achieve primary closure of the flap margins. This is of utmost importance with bone grafts, because the flap is needed for protection of the graft. Another factor is the need for a second surgical procedure with the Gore-Tex membrane; a minor flap procedure is needed to remove the membrane. All other factors being equal, a bone graft would be desirable in cases when a second stage would be a problem (e.g., difficult access, medical complications, patient cooperation).

The first procedure discussed above, the retained papillae technique, is used almost exclusively in the maxillary anterior sextant, and can be used in the presence or absence of alveolar bone defects. In addition, papillary retention in the flap does not preclude the use of guided tissue regeneration or bone grafts.

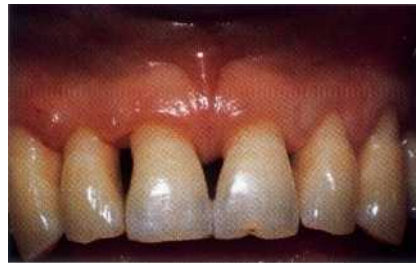The decision to use the retained papillae technique is, obviously, made before the time of the procedure. However, the final decision to use guided tissue regeneration, bone grafting, or neither is made during the procedure.

**Palatal or Lingual Ramping.** Another esthetic option in the posterior sextant is palatal or lingual ramping of alveolar defects without involvement of the buccal bone. Osteotomy is done to remove the palatal or lingual wall of a crater-type defect. This results in increased crown length on the palatal or lingual aspect of the teeth, with the gingival tissues angled palatally or lingually. The buccal height of tissue remains relatively intact because the buccal bone is spared.

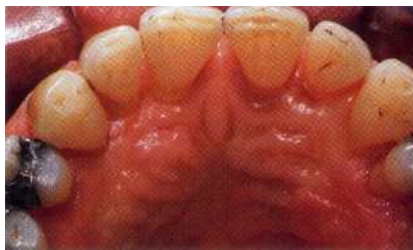**Open Debridement with Buccal Osteotomy.** Although the aforementioned procedures are designed to maintain buccal bone height, buccal osteotomy is sometimes necessary, such as in cases of a markedly uneven buccal bony profile. When this type of situation occurs, blending of the buccal alveolar crests is needed to ensure proper soft tissue healing and pocket closure. The patient must be made aware that despite best efforts to satisfy esthetic needs, physiologic demands may unfavorably affect the esthetics.

### *Clinical Case: Retained Papilla Technique*

A 52-year-old male presented with deep periodontal pocketing of the anterior maxillary teeth (Figs. 18-1 and 18-2). His medical history was noncontributory. Following initial periodontal therapy, a full-thickness flap procedure was performed using the retained papilla technique (Figs. 18-3 and 18-4). The interproximal tissues

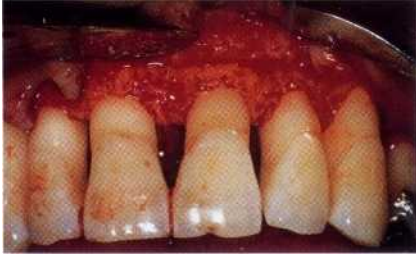

*Fig. 18-1. Facial view following initial therapy response in 52-year-old patient with deep periodontal pocketing.*

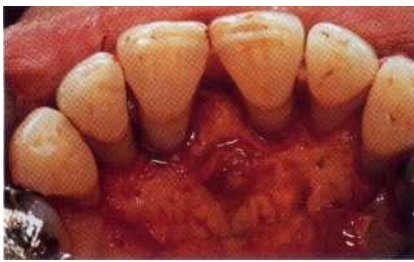

*Fig. 18-2. Palatal view of the patient shown in Fig. 18-1.*

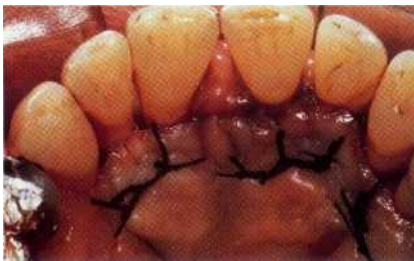were kept in the buccal flap. The papillae were reattached with sutures through the tissue, not over the interproximal space (Fig. 18-5). Healing resulted in pocket reduction with maintenance of the gingival margin (Fig. 18-6).



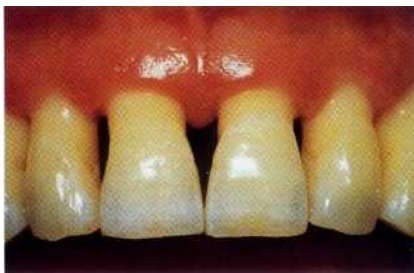*Fig. 18-3. A full-thickness flap was raised with complete retention of the papillae in the buccal flap.*



*Fig. 18-4. The osseous defects were exposed for thorough debridement.*



*Fig. 18-5. The flaps were repositioned and sutured in place.*

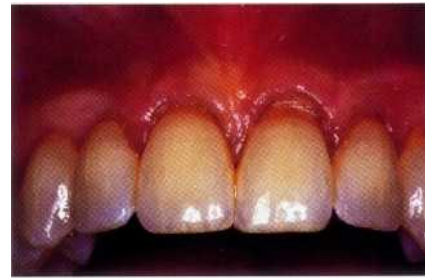

*Fig. 18-6. At 6 months after surgery, pocket elimination has been achieved along with maintenance of the original tissue height.*

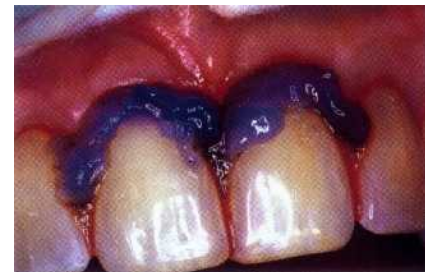### Clinical Case: Correction of Recession

A 38-year-old female patient presented with generalized facial recession in both arches. The defects seen on the maxillary central incisors were of particular concern because of the presence of a high smile line. The clinical examination revealed 2 to 3 mm of facial recession on both central incisors with a 5-mm zone of masticatory mucosa on both teeth (Fig. 18-7). In this particular case, gingival augmentation was not necessary, so a coronally positioned flap procedure was planned.

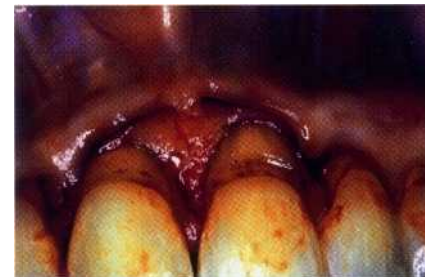
Before flap elevation, the cemento-enamel junction and exposed root dentin were etched for 30 seconds (Fig. 18-8) and rinsed thoroughly. A full-thickness mucoperiosteal flap was elevated on the facial aspect of the four incisors (Fig. 18-9) beyond the mucogingival junction.



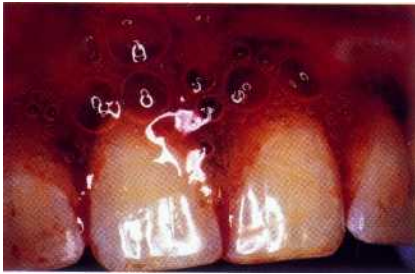*Fig. 18-7. This 38-year-old female had facial recession on both maxillary central incisors with an adequate zone of masticatory mucosa.*



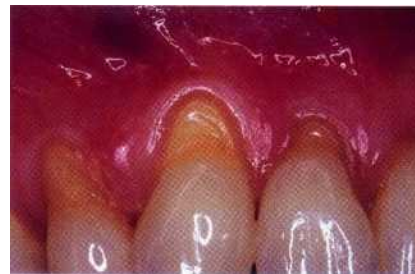*Fig. 18-8. The exposed root surfaces are etched with phosphoric acid gel for 30 seconds.*



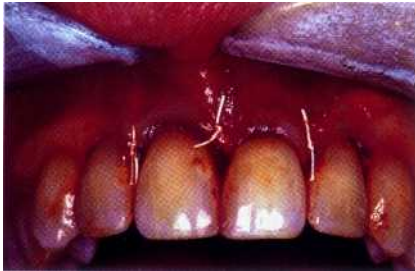*Fig. 18-9. A full-thickness flap is reflected to the mucogingival junction, with partial thickness dissection performed apical to the mucogingival junction to facilitate coronal positioning.*



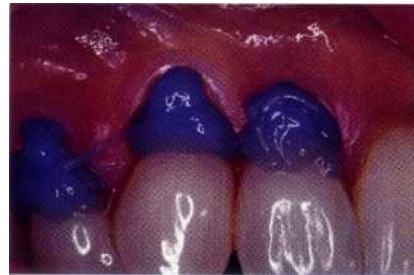*Fig. 18-10.* EMDOGAIN regenerative material is placed over the etched root surfaces.



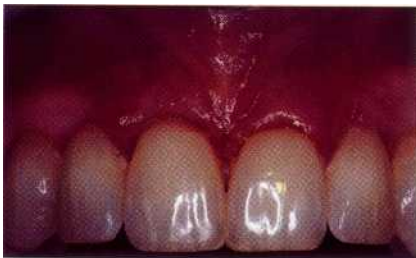*Fig. 18-14.* Generalized recession is noted with a lack of adequate masticatory mucosa in this 36-year-old female.



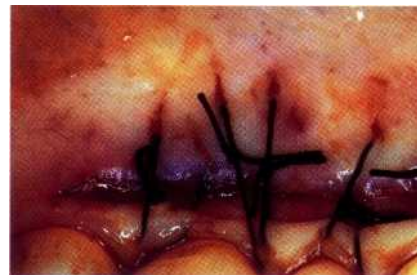*Fig. 18-11.* The flap is coronally positioned to the level of the cemento-enamel junction.



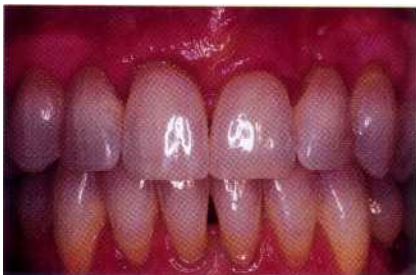*Fig. 18-15.* The exposed root surfaces are etched with phosphoric acid gel for 30 seconds.



*Fig. 18-12.* Patient in Fig. 18-7 seen 2 weeks postoperatively.



*Fig. 18-16.* A subepithelial connective tissue graft is harvested from the palate.



*Fig. 18-13.* An excellent result is seen after 4 weeks.

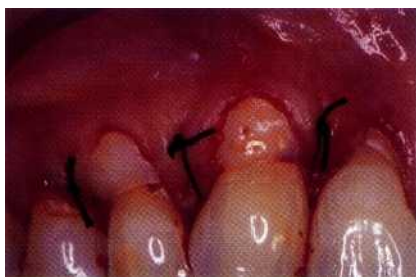The underlying periosteum was then scored to facilitate coronal positioning of the flap. The site was treated with EMDOGAIN regenerative material (Fig. 18-10) and the flap sutured in a coronal position to cover the exposed root surfaces (Fig. 18-11). The sutures were removed after 2 weeks (Fig. 18-12), with an excellent result noted by the fourth week (Fig. 18-13).

#### SUBEPITHELIAL CONNECTIVE TISSUE (SECT) GRAFT

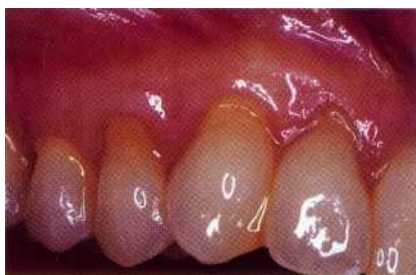#### Clinical Case: SECT Graft with Coronal Positioning of the Resulting Augmented Gingiva

A 38-year-old female patient presented with generalized facial recession in both arches. Teeth #5 through #7 demonstrated 3 to 5 mm of exposed root surface with an associated lack of masticatory mucosa (Fig. 18-14). A subepithelial connective tissue graft was planned to correct the lack of gingiva versus a free graft, because of the high lip line. The exposed root surfaces were etched with phosphoric acid for 30 seconds (Fig. 18-15), a facial flap elevated, and a subepithelial connective tissue graft placed (Figs. 18-16 and 18-17).

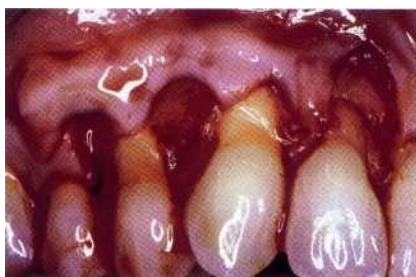




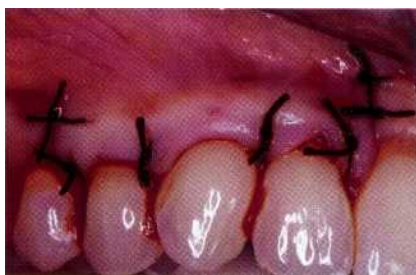*Fig. 18-17.* The connective tissue graft is placed under the full-thickness facial flap and sutured securely.



*Fig. 18-18.* Reconstruction of the facial gingiva has been achieved with excellent tissue color. However, residual recession is still noted.

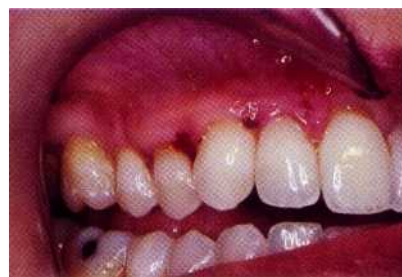

*Fig. 18-19.* A full-thickness flap is elevated and the periosteum scored apical to the mucogingival junction.



*Fig. 18-20.* The flap is coronally positioned to cover the exposed root surfaces.

Three months after the procedure, a satisfactory esthetic result was obtained with respect to the gingival augmentation aspect of the procedure, with the augmented zone of tissue exhibiting an excellent color



*Fig. 18-21.* Correction of the recession is seen at the 1-week postsurgical visit.

match. However, some residual recession remained (Fig. 18-18). A coronally positioned, split-thickness flap procedure was performed (Figs. 18-19 and 18-20), resulting in the desired root coverage (Fig. 18-21) as seen at the end of the first week.

## INADEQUATE TOOTH STRUCTURE FOR RESTORATION

### Differential Etiology

1. *Caries.* Many patients are unaware of subgingival caries, because the lesion is hidden under the gingiva and therefore they do not present for treatment until significant amounts of tooth structure have been destroyed.
2. *Trauma.* With traumatic injuries the patient is keenly aware of the problem. Teeth can be obliquely sheared, leaving margins below the alveolar crest. When the root fracture is horizontal or oblique, the longer the apical segment is, the better the prognosis. Vertical fracture usually requires extraction.

### Biologic Width

Proper margin placement of any type of restoration requires respect for the physiologic principle of biologic width: 1 mm of supracrestal connective tissue, 1 mm of junctional epithelium, and 1 to 2 mm of healthy sulcus. When a restoration is placed on a tooth in violation of this principle, a chronic inflammatory response occurs. The body is attempting to restore the dimensions required for periodontal health in the supracrestal attachment and sulcus. Histologically, crestal resorption is seen with apical migration of the connective tissue and functional epithelium. Clinically, gingival redness, swelling, bleeding, and discomfort are present. Even the most natural-looking restoration will fall short of the desired esthetic goals with such a gingival appearance. The inflammatory response will cease only when the biologic width has been reestablished, a process that may take years. This inflammation is not bacterial in origin and will not

respond to gingival curettage or antibiotic therapy. Attempting to subgingivally "bury" a restoration margin in the hope of avoiding further treatment will result only in failure.

### Treatment Options

**Surgical Crown Lengthening.** Surgical crown lengthening involves apical flap positioning with osteotomy around the involved tooth and the adjacent teeth. At least 3 to 4 mm of sound root structure must be exposed below the most apical extent of the proposed restoration. In addition, the alveolar crest of the adjacent teeth must be blended in with the involved tooth, otherwise an uneven, unesthetic gingival profile will result.

**Forced Eruption with Fiberotomy.** When osteotomy will result in extremely long clinical crowns and significantly weakened periodontal support (as with oblique fractures significantly apical to the alveolar crest), or when a surgical procedure is medically contraindicated, orthodontic forced eruption with a sulcular fiberotomy may be performed. Orthodontic force is applied to the involved tooth in an occlusal direction, while the supracrestal connective tissue fibers are severed via fiberotomy every 4 days. The fiberotomy prevents the tooth and alveolar bone from erupting as a unit, exposing sound tooth without changing the position of the alveolar crest or free gingival margin. The orthodontics will pull the root out of the bone, exposing the needed 3 to 4 mm of sound tooth structure, whereas the fiberotomy will prevent coronal reformation of the alveolar bone and maintain the free gingival margin at its original level. In addition to achieving the desired results, the crown-to-root ratio of the adjacent teeth remains intact and decreases for the involved tooth, thus improving the long-term periodontal prognosis.

#### Armamentarium

Standard dental setup:  
explorer  
mouth mirror  
periodontal probe  
high-speed handpiece

Orthodontic brackets (optional), stainless steel, or clear plastic edgewise brackets (Unitek, 3M, Inc.)  
0.036-inch orthodontic wire (Unitek, 3M, Inc.)  
0.036-inch orthodontic eyelet (Unitek, 3M, Inc.)  
0.20-inch rectangular arch wire

Crown and bridge cement, zinc phosphate (Flecks' Cement, Mizzy, Inc.) or polyvarboxylate cement (e.g., Durelon, ESPE-Premier Sates Corp.)

Medium- or heavy-gauge orthodontic elastic or thread (Unitek Corp.)

No. 15 surgical scalpel

### Clinical Technique

- I. Prepare a post preparation in the root.
2. Cement a 0.036-inch wire with an eyelet into the preparation with a zinc phosphate or polycarboxylate cement (Fig 18-22).
3. When using orthodontic brackets, etch the teeth to be bracketed and apply orthodontic bonding resin to the bracket pad. Place the bracket on the tooth (Fig. 18-23). When using bonded arch wire, bond a heavy gauge wire (0.030-inch to 0.040-inch) across the portion of the labial surface edges of the anterior teeth or occlusal surfaces of the posterior teeth.

**CLINICAL TIP.** A clear acrylic is the luting material of choice. Acrylic is strong enough to retain the wire under function and is easier to remove than composite resin.

For posterior amalgam restorations, prepare the occlusal slots as for intracoronat splints (see section on posterior A-splints in this chapter) and bond the wire in the slots. The arch wire must be positioned directly over the root to be extruded.

4. Adapt a heavy (0.020-inch) rectangular arch wire in the bracket slots and across the root to be erupted and position it directly over the root to be extruded (Fig. 18-24).

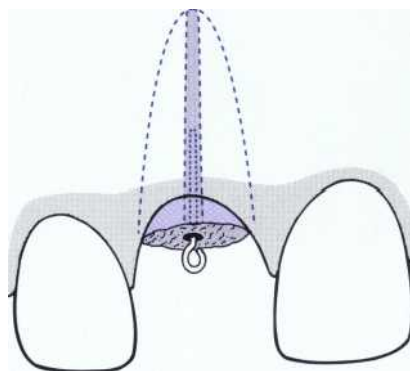


Fig. 18-22. Place a post preparation in the root and cement a 0.036-inch wire with an eyelet into the preparation with a zinc phosphate or polyvarboxylate cement.

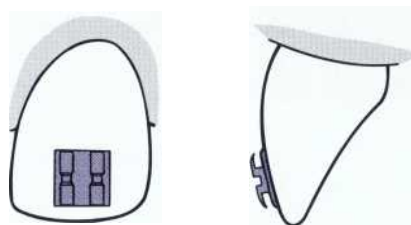


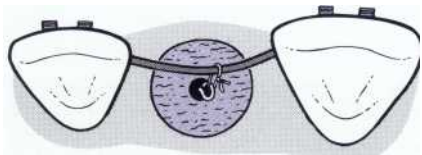
Fig. 18-23. Apply orthodontic bonding resin to the bracket pad and place the bracket on the tooth.

5. Thread a medium or heavy elastic through the eyelet and wrap it around the anchoring wire. Activate the elastic by pulling it taut and tying it (Fig. 18-25).
6. Perform an initial fiberotomy with a No. 15 scalpel blade.
  - A. Anesthetize the area.
  - B. Run the scalpel circumferentially in the sulcus around the root. This severs the supracrestal connective tissue fiber attachment.
7. Repeat the fiberotomy every 4 days to prevent the connective tissue fibers from reforming and to prevent coronal reformation of the alveolar bone. Generally eruption is accomplished at a rate of 0.5 mm to 1.0 mm per week. However, movement as slow as 1.0 mm per month is possible.
8. When the desired eruption is accomplished, stabilize the tooth for 2 to 3 months before fabricating the final restoration.

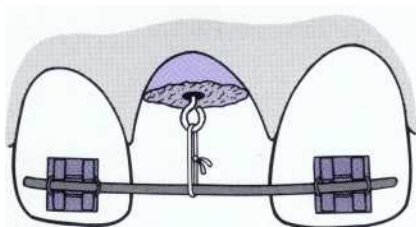
### Clinical Case: Surgical Crown Lengthening

A 42-year-old female presented with a provisional restoration from the maxillary right canine to the maxillary left canine. Her medical history was noncontributory. Although the restoration was physiologically acceptable, the varied heights of the restored teeth were esthetically unacceptable (Fig. 18-26). Surgical crown lengthening was performed to correct this situation.

A submarginal incision was made at the desired height of the gingival margin (Fig. 18-27) and a full-thickness flap reflected (Fig. 18-28). The disparity in the abutment crown length could be seen after reflection. Following the removal of some supporting bone a more

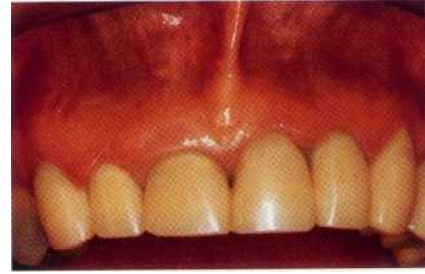

*Fig. 18-24.* The arch wire is positioned directly over the root to be extruded.

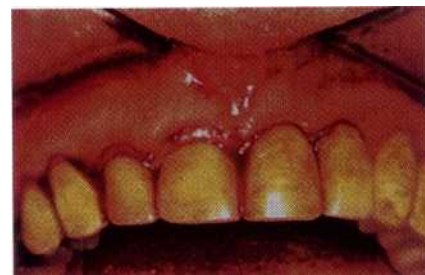

*Fig. 18-25.* Activate the elastic by pulling it taut and tying it.

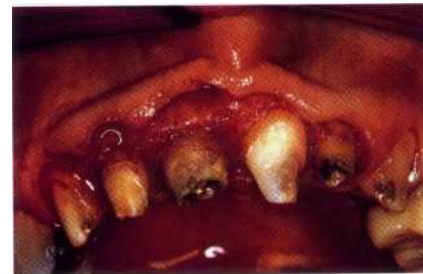symmetric appearance was achieved (Fig. 18-29). The flaps were apically positioned and sutured into place (Fig. 18-30). This symmetry is reflected by the gingival margins of the final restoration (Figs. 18-31 and 18-32).



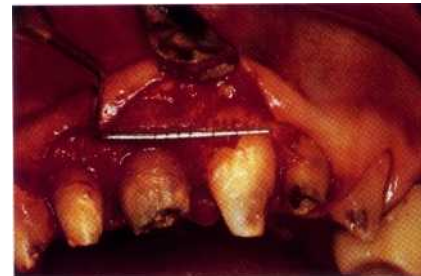
*Fig. 18-26.* An uneven free gingival margin is evident on the provisional restoration of this 36-year-old patient.



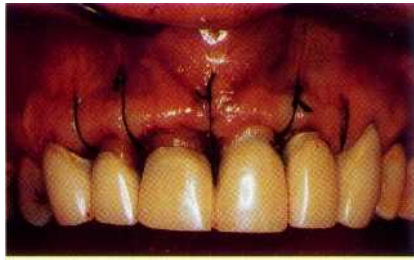*Fig. 18-27.* A submarginal incision was made to even the gingival margins.



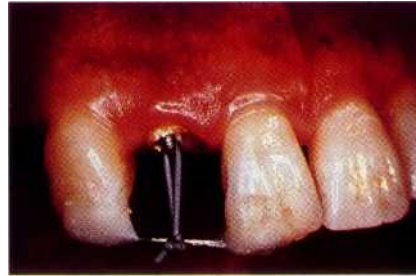*Fig. 18-28.* Full-thickness reflection revealed uneven alveolar crests on the abutment teeth.



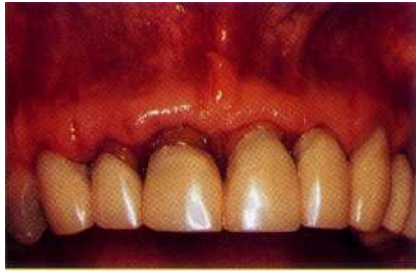*Fig. 18-29.* An osteotomy was performed to even the alveolar crests.



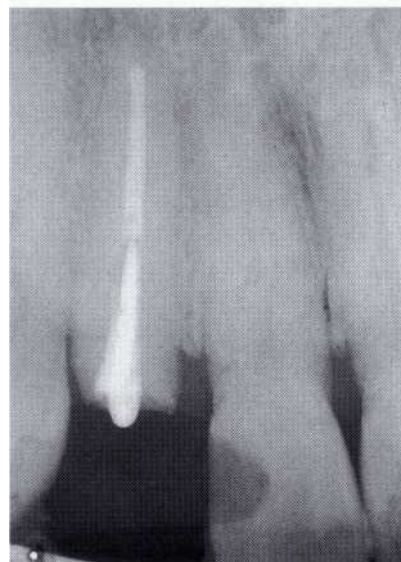*Fig. 18-30. The flaps were apically positioned and sutured into place.*



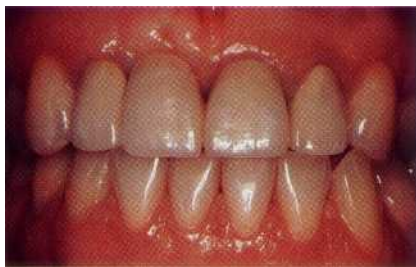*Fig. 18-33. The retained lateral incisor root posed a restorative problem. An eyelet post was cemented into the canal with activation to an incisal anchorage wire with elastic cord.*



*Fig. 18-31. The 3-week postoperative evaluation revealed an even free gingival margin.*



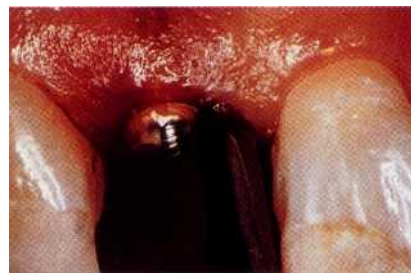*Fig. 18-34. Preeruption radiograph of the patient shown in Fig. 18-33.*



*Fig. 18-32. An esthetic restoration after 2 months of healing.*

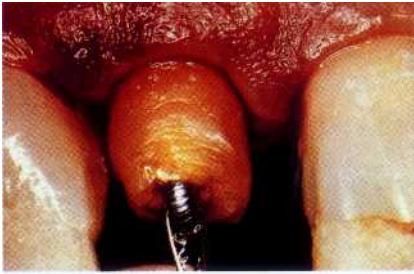### **Clinical Case: Forced Eruption with Fiberotomy**

A 57-year-old male presented with a maxillary right lateral incisor root that had fractured at the gingival margin as a result of cervical caries. His medical history was non-contributory. The patient desired a tooth replacement but did not wish to have the root extracted. A post preparation was made in the root, and a 0.036-inch wire with an eyelet was cemented into the preparation with zinc phosphate cement. A 0.040-inch orthodontic wire was bonded to the incisal edges of the canine and central incisor over the root to be erupted. This device was then engaged to the arch wire using a heavy elastic tie (Figs. 18-33 and 18-34). A sulcular fiberotomy was performed at the time of activation and every 4 days throughout the time of

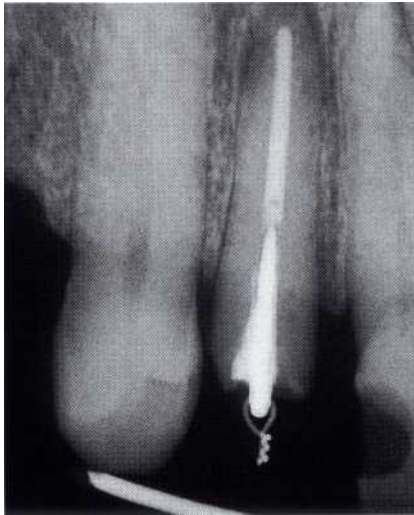

*Fig. 18-35. A sulcular fiberotomy was performed every 4 days.*

tooth movement (Fig. 18-35). The desired eruption was achieved within 3 weeks (Figs. 18-36 and 18-37), at which time a cast post and core was fabricated (Fig. 18-38) and a provisional restoration made. This technique produced an excellent esthetic result (Fig. 18-39).



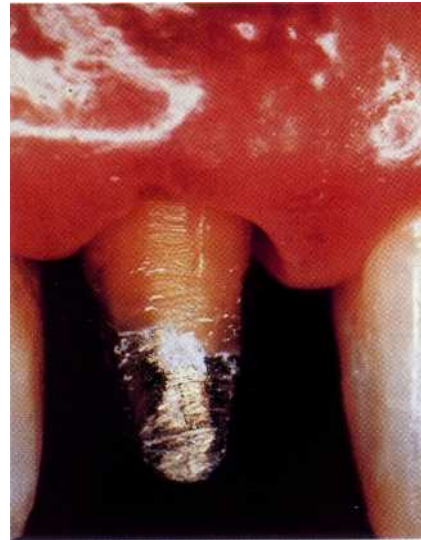*Fig. 18-36. Rapid eruption for 3 weeks exposed adequate root structure.*



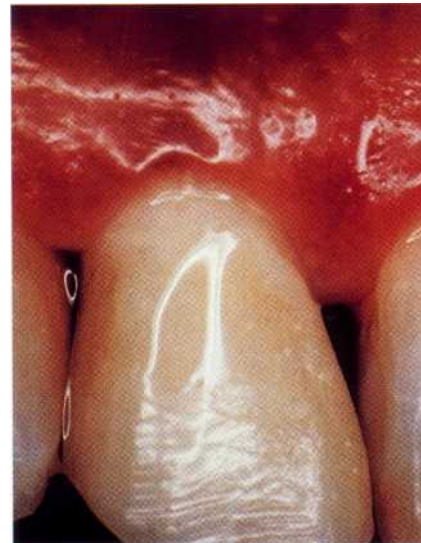
*Fig. 18-37. Postoperative radiograph of the patient shown in Fig. 18-36. Note the amount of eruption with maintenance of the coronal alveolar bone level.*

### **Clinical Case: Forced Eruption with Surgical Crown Lengthening**

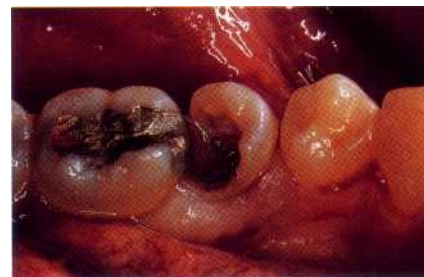
A 23-year-old male presented with subgingival caries on his mandibular right second premolar (Fig. 18-40). His medical history was noncontributory. After caries removal and endodontic therapy a 0.036-inch orthodontic wire was formed into a loop and cemented into the post preparation (Fig. 18-41). A straight 0.040-inch orthodontic wire was bonded from the mandibular right first premolar to an occlusal slot prepared in the amalgam of the mandibular right first molar. An elastic thread was used to pull the tooth occlusally (Fig. 18-42). Because the patient could come to the office only twice a month, repeated fibrotomy was not possible. As a result, the gingival margin and the underlying attachment moved coronally with the root (Fig. 18-43). After adequate eruption, apical positioning of the tissues was performed (Figs. 18-44 and



*Fig. 18-38. A post and core was fabricated.*



*Fig. 18-39. An esthetic final restoration was inserted.*



*Fig. 18-40. Subgingival caries can be seen on the distal aspect of the second premolar.*

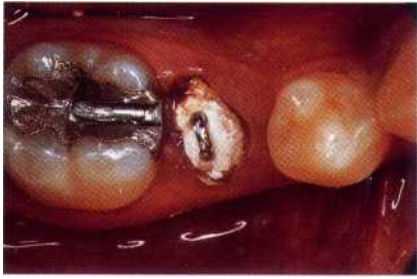

Fig. 18-41. After endodontic therapy was completed, an 0.036-inch eyelet was cemented into the canal.

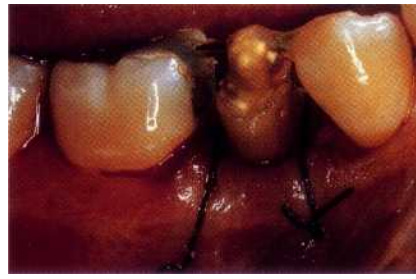

Fig. 18-45. The apically positioned gingiva is sutured into place.

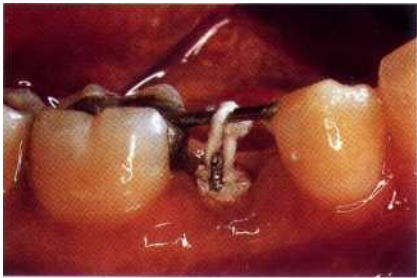


Fig. 18-42. An 0.040-inch straight wire was bonded directly over the root and activated with heavy elastic.

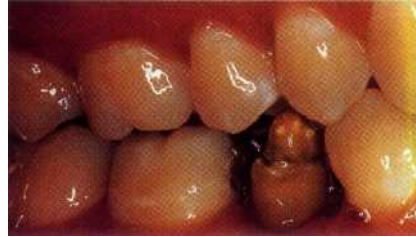

Fig. 18-46. Following healing, sound root structure is exposed while the free gingival margin is restored to a more esthetic level.

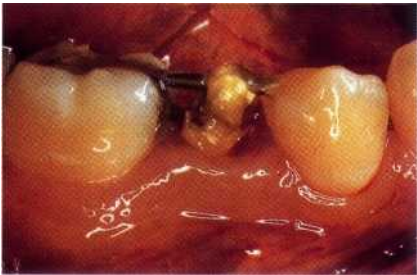

Fig. 18-43. Facial view 6 weeks after activation. Because a fibertomy was not feasible, the tooth and attachment apparatus had erupted 3 to 4 mm.

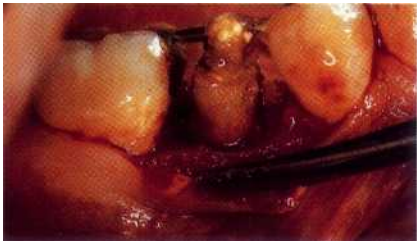

Fig. 18-44. Intraoperative view of the exposed flap.

18-45), resulting in adequate tooth structure and an even gingival margin (Fig. 18-46). Surgery without eruption would have resulted in an uneven gingival margin.

## RECESSION

### Differential Etiology

1. *Abrasion.* "Receding gums" will usually be diagnosed by a patient before presenting to the practitioner. The esthetic imbalance, particularly in the anterior sextants, is a common patient concern. Overzealous brushing (even with a soft nylon toothbrush) is the predominant cause of mechanically abraded gingiva. Less-frequent causes include the use of an abrasive dentifrice, iatrogenic flossing, electric rotary toothbrushes improperly used at the highest setting, and intraoral foreign object habits.
2. *Periodontitis.* Periodontitis and acute periodontal abscesses often destroy buccal attachment, resulting in recession.
3. *Trauma.* Intraoral trauma can result in severe defects, depending on the nature of the injury.
4. *Inadequacy of attached gingiva.* Inadequate gingiva may be caused by high frenal attachments, muscle pull, or scars.

### *Treatment Options*

**Free Gingival Grafts.** Gingival grafting techniques have been used for the past 25 years to cover exposed root surfaces. Although grafts have been one of the most predictable and successful procedures for augmenting the zone of attached gingiva, success in covering exposed root surfaces is less predictable and dependent on several factors:

1. The dimension of the root surface to be covered
2. The lateral probing depth
3. The position of the tooth in the arch

Grafts receive their primary nutrient supply from the underlying connective tissue of the recipient site, and donor tissue placed over the avascular root surface is fed solely by lateral circulation from the connective tissue bed. Because lateral circulation can maintain the viability of the donor tissue for only a limited distance, areas of narrow recession have better root coverage potential than deeper, wider areas of recession. Some areas that appear to be narrow actually have significant lateral probing depths and therefore have poorer root coverage potential than truly narrow areas.

**CLINICAL TIP.** Good results are obtained with widths of less than 2 mm and poor results with widths greater than 4 to 5 mm.

In addition, teeth that are prominent in the arch may have little or no buccal bone present with an underlying dehiscence presenting a major problem. Multiple procedures may be required for optimal results in these cases; however, performing multiple procedures does not guarantee total root coverage. In cases of very wide and deep recession, the purpose of multiple procedures is to achieve as much root coverage as possible. Tooth position and lateral bone support are two factors that could adversely affect the percentage of root coverage.

**CLINICAL TIP.** No formula can accurately predict how much root coverage can be achieved. Make sure the patient understands this before beginning treatment.

A choice must be made between using a free gingival graft and a pedicle graft, with free grafts being used in 90% to 95% of cases. When multiple roots are to be covered, the free gingival graft (with or without subepithelial placement of connective tissue) is the procedure of choice. When a single tooth is involved, the decision to use free gingival or pedicle grafting is based primarily on the preference of the surgeon. A consideration concerning the free gingival graft is the need for palatal involvement; when a patient's gag reflex is severe, a pedicle graft would be the procedure of choice, if the necessary conditions exist.

Free gingival grafting, the most commonly performed procedure, involves three steps:

1. Preparing the recipient site
2. Harvesting the donor tissue
3. Placing the graft

A well-vascularized connective tissue bed must be prepared around the graft site. If the goal is to augment the zone of attached gingiva, a submarginal incision can be made with apical dissection of the bed. This will maintain the existing free gingival margin, thus preventing possible postsurgical recession. However, if root coverage is desired, all marginal epithelium must be removed to create a connective tissue margin over which the graft is placed. Laterally the recipient site should extend a distance of at least one-half tooth in either direction to provide an adequate blood supply for the donor tissue.

Donor tissue is harvested from the palate. The anterior rugae must not be included in the graft, because they will be visible at the recipient site. A 1- to 2-mm zone of marginal tissue should be maintained around the donor site to prevent recession. A surgical template should be made for the recipient site and transferred to the palate, thus minimizing and customizing the amount of tissue removed. Once the graft is harvested, a hemostatic dressing is placed in the donor site and a clear acrylic surgical stent is inserted. The stent applies constant pressure for hemostasis and covers the raw palatal tissue during healing to increase patient comfort. The donor tissue is sutured firmly to the recipient bed. Surgical dressing is applied to protect the recipient site. Postoperatively, a chlorhexidine rinse may be used for 3 to 4 weeks until proper oral hygiene can be performed without damaging the grafted site. A minimum of 6 weeks of healing is required before resuming or beginning any prosthetic work.

**Lateral Pedicle Grafts.** Several factors must be considered when a pedicle graft is contemplated:

1. The amount of keratinized tissue adjacent to the recipient site
2. The existence of an adjacent edentulous ridge
3. The existence of frena that could cause excessive pull
4. The width of the recipient root surface

When using lateral pedicle grafts, a well-keratinized edentulous ridge or a wide zone of attached gingiva adjacent to the graft site is ideal. However, if the recipient area to be grafted is wide mesiodistally, excessive pull may occur on the donor tissue, causing strangulation and eventual failure. The lateral pedicle procedure involves bed preparation over the recipient root, partial thickness dissection of the donor tissue, and lateral positioning of the graft. The pedicle is sutured firmly and the donor area heals by granulation formation.

With the double papilla procedure, a variation of the lateral pedicle procedure, both adjacent papilla are split-thickness dissected and make up the pedicle. Again, the

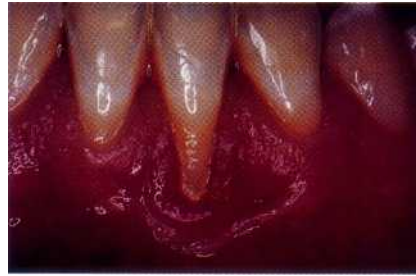
donor site heals by granulation formation. As was the case with free gingival grafts, surgical dressing is placed over the surgical site, although no surgical stent is needed because no palatal tissue is involved. Postoperative care is similar for all three procedures. As with free gingival grafts, a minimum of 6 weeks of healing is needed before prosthetic work can begin.

**Subepithelial Connective Tissue Graft.** The above procedures all involve placing a graft or flap over an exposed root surface, with root coverage predicated on whether or not the donor tissues adhere to the denuded root surface. A variation of the pedicle graft and flap techniques, the subepithelial connective tissue graft, involves the placement of a strip of connective tissue from the palate under a partial thickness flap.

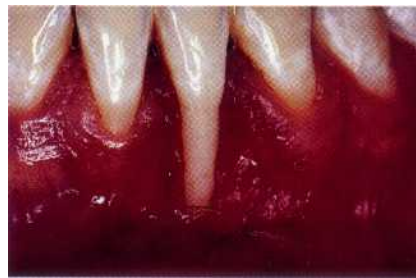
The recipient site is prepared with a split-thickness dissection, retaining all epithelium in the flap. An envelope procedure is performed on the palate to obtain the connective tissue. Two parallel horizontal incisions (the length of the site to be grafted) are made 3 mm apart near the palatal free gingival margin. Sharp dissection is performed vertically in the connective tissue to remove a strip of tissue similar in dimension to the graft site. The harvested donor tissue will be a "slab" of connective tissue with the 3-mm band of epithelium at one edge. This strip of connective tissue is then placed over the exposed root surfaces, and the flap positioned over the donor tissue and sutured firmly.

Advantages to this type of procedure include no denuded palatal donor site, increased patient comfort during healing, and the double blood supply to the free connective tissue, which is fed by the underlying periosteum and the connective tissue of the flap. In addition, the connective tissue contains the genetic information that dictates the type of epithelium that will form. Thus areas of the donor tissue that are not completely covered by the flap will form masticatory mucosa, aiding in healing and providing a much better blend of donor and recipient tissues.

**Prosthetic Gingiva.** When interdental spaces are a concern and no cosmetic prosthetic work is anticipated, artificial gingiva is an option. A border molded impression is made of the involved area. The laboratory fabricates a gingival veneer of pink denture acrylic, with the apical extent in the mucobuccal fold and the coronal extent restoring a normal free gingival margin appearance. Disadvantages to using this procedure include inaccurate color matching and instability of the prosthesis. Before embarking on this course of treatment, the patient should see pictures of inserted prostheses and understand their limitations. Only then should fabrication of artificial gingiva begin.



*Fig. 18-47. A severe dehiscence can be seen on the facial aspect of tooth #24 on this 24-year-old male resulting from a traumatic blow to the site.*



*Fig. 18-48. Preparation of the connective tissue bed for a free graft revealed 8 mm of exposed root surface with some loss of lateral alveolar bone.*

#### FREE GINGIVAL GRAFT PROCEDURE

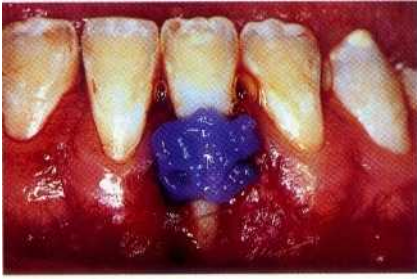##### *Clinical Case: Correction of an Isolated Area of Recession Resulting from Trauma*

A 24-year-old male patient presented with an isolated area of severe recession on the lower left central incisor resulting from a traumatic blow sustained during a basketball game. The tooth was monitored for 2 months after the traumatic injury to ensure no additional problems occurred. Ten weeks after the incident, tooth #24 presented with minimal clinical mobility and a vital pulp as determined by electric pulp test and cold tests.

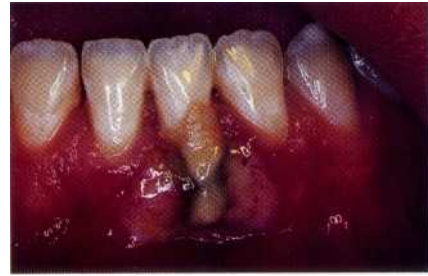Clinical examination revealed isolated 5-mm facial recession with lateral and apical probing depths of 3 to 4 mm (Fig. 18-47). Although loss of the overlying alveolus occurred on tooth #24, none of the adjacent teeth were affected, as demonstrated by minimal clinical probing depth (2 to 3 mm), lack of clinical mobility, and no radiographic evidence of bone loss. The planned procedure was to place a free gingival graft in conjunction with treating the area with EMDOGAIN regenerative material.

A trapezoidal connective tissue bed was prepared maintaining the gingival tissue attachment on the adjacent incisors (Fig. 18-48). The coronal root surface and

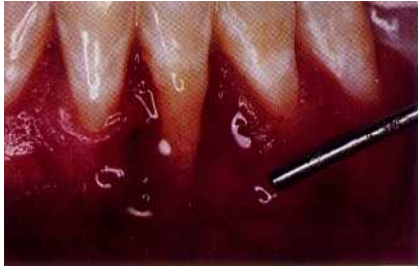




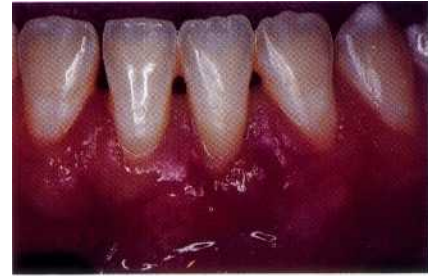*Fig. 18-49. The cementoenamel junction and root surface are acid etched.*



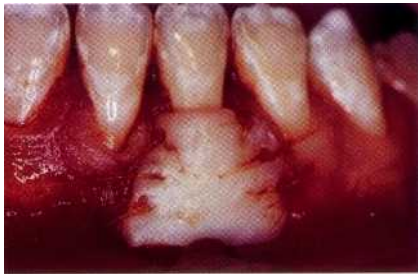*Fig. 18-52. At 1 week, the graft is well attached to the root surface, despite its appearance.*



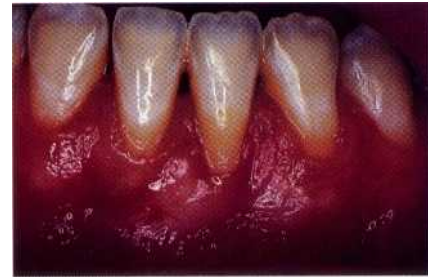*Fig. 18-50. EMDOGAIN regenerative material is applied to the root surface and alveolar defect.*



*Fig. 18-53. The 2-week postoperative visit.*



*Fig. 18-51. The free graft is affixed with "5-0" resorbable sutures.*



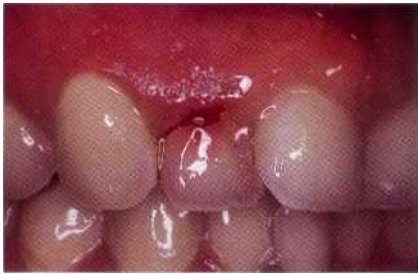*Fig. 18-54. Good root coverage is seen after 4 weeks.*

cementoenamel junction were etched with a phosphoric acid gel for 30 seconds (Fig. 18-49) and rinsed thoroughly without drying. EMDOGAIN regenerative material was then placed over the root and connective tissue bed (Fig. 18-50), and the graft sutured intimately with resorbable sutures (Fig. 18-51). After 1 week, it appeared as if the donor tissue overlying the dehiscenced root surface had sloughed; however, the tissue was stable and nonretractable (Fig. 18-52). At the 2-week postoperative visit, the graft surface had begun to mature (Fig. 18-53), with excellent results seen 4 weeks after surgery (Fig. 18-54).

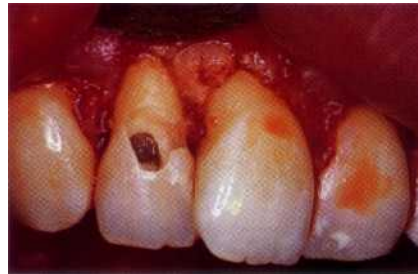#### ESTHETIC MANAGEMENT OF THE COMBINED LESION

##### Clinical Case: Treatment Of External Cervical Root Resorption and Altered Passive Eruption with Apically Positioned Flap and Surgical Crown Lengthening

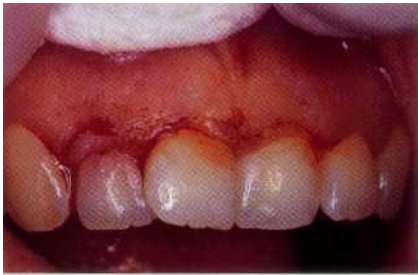A 26-year-old female patient presented with external cervical root resorption on her maxillary right lateral incisor. The clinical examination revealed inflammation of the facial gingiva of tooth #7 with associated bleeding and 5 to 6 mm pocketing. The gingival tissues on the adjacent teeth were within normal limits (Fig. 18-55). Additionally, the



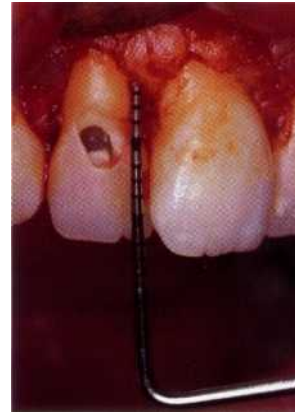*Fig. 18-55. This 26-year-old female presented with altered passive eruption and external cervical root resorption. Note the inflammation associated with the resorption lesion.*



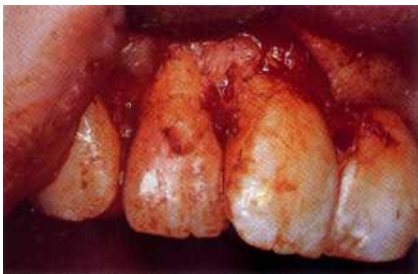*Fig. 18-58. After thorough debridement, violation of the biologic width was seen on the mesial of tooth #7.*



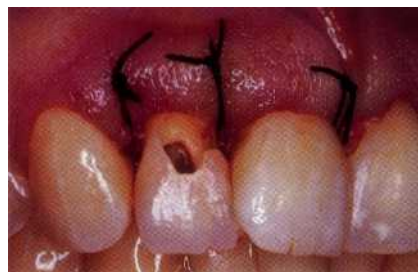*Submarginal incisions have been placed to facilitate apical positioning of the flap.*



*Fig. 18-59. The site after osteotomy to expose adequate root structure for restoration.*



*Fig. 18-57. Full-thickness flap elevation revealed a large resorptive lesion on the mesial aspect of #7 with a normal osseous crest on tooth #6 through tooth #9.*

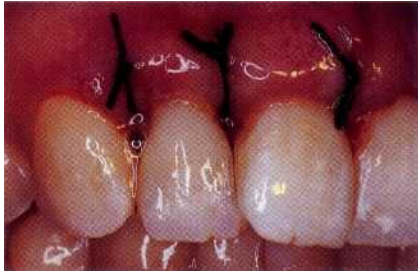

*Fig. 18-60. Apical positioning of the flap corrected the APE and exposed the resorptive lesion.*

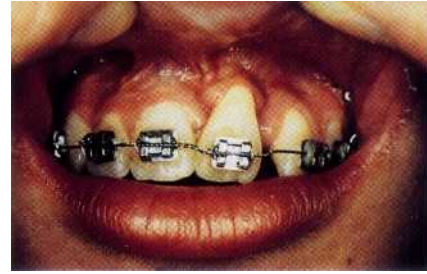free gingival margin on teeth #7 through #9 were in a coronal position consistent with altered passive eruption.

The planned surgical procedure was to apically position the facial gingiva and expose the resorptive lesion. An internally beveled incision was made in the facial gingiva of teeth #6 through #9, with submarginal placement on teeth #7 through #9 to coincide with the desired marginal position (Fig. 18-56). After reflection of the flap, the osseous crest was seen to have a normal relationship with the cemento-enamel junction of the involved teeth. A large, ovoid resorptive lesion was seen on the mesiofacial aspect of tooth #7, extending beyond the cemento-enamel junction and violating the pulp chamber (Fig.

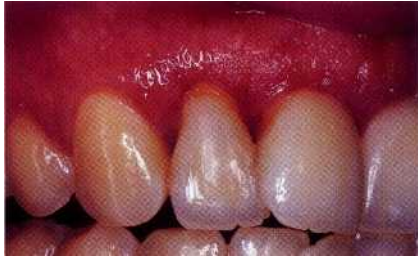18-57). After degranulation of the surgical site and removal of the resorptive tissue, it was determined that crown lengthening via osteotomy was necessary on the mesial line angle of tooth #7 because of violation of the biologic width (Fig. 18-58). Crestal bone was removed to expose 3 mm of uninvolved root surface (Fig. 18-59), and the facial flap was sutured apically (Fig. 18-60). A composite resin restoration was then placed to seal the re-



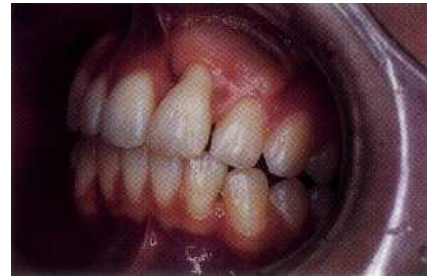*Fig. 18-61. A composite resin restoration was placed after suturing of the flap.*



*Fig. 18-63. The patient at age 13 before completion of orthodontic therapy. Note the facial prominence of tooth #9 as well as the lack of masticatory mucosa.*



*Fig. 18-62. Progress at 4 weeks postoperatively.*



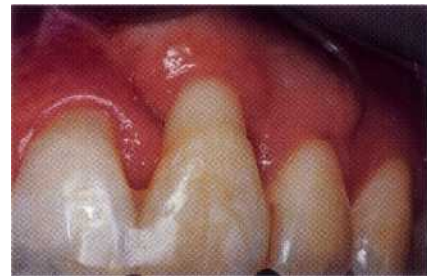*Fig. 18-64. A free gingival graft was placed apically on tooth #9 to reconstruct the masticatory mucosa; however, no root coverage was achieved.*

sorptive lesion (Fig. 18-61). An excellent result was noted 1 month after surgery (Fig. 18-62).

### ***Clinical Case: The Use of Guided Tissue Regeneration in Enhancing Anterior Esthetics***

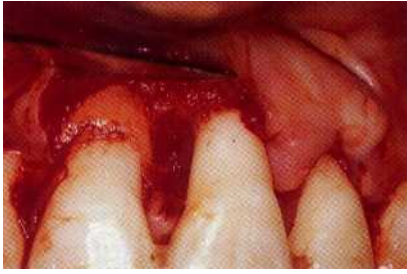A 20-year-old female presented with the chief complaint that the facial recession on her maxillary left central incisor had worsened over the past years. She requested something be done to stabilize the tooth and improve the esthetics.

A review of her past dental history revealed treatment for tooth #9. At age 9, she had a retained tooth #F removed along with a buccally positioned supernumerary incisor apical to #F, as well as exposure of tooth #9, which was horizontally impacted under the anterior nasal spine. Upon completion of orthodontic treatment, #9 was positioned well in the arch. However, because of the loss of adjacent bone (from the extractions and crown exposure) and original position of the tooth high in the labial mucobuccal fold, tooth #9 had no attached gingiva and a wide zone of facial recession extending beyond the facial line angles (Fig. 18-63). A free gingival graft was successfully placed to augment the zone of attached gingiva at age 14, although the esthetics remained unacceptable (Fig. 18-64). The area remained unchanged until the recent onset of progressive recession and mobility.

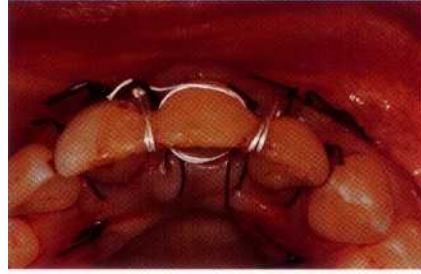


*Fig. 18-65. After 5 years, the patient presented with progressing recession and mobility on tooth #9, with a desire to treat the area functionally and esthetically.*

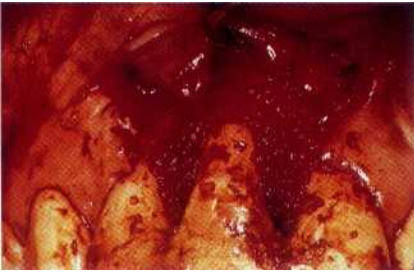The clinical examination at the time of treatment revealed 3 to 5 mm facial probing depth with bleeding upon probing and the detection of subgingival root calculus. Facial recession of 5 mm extended beyond both facial line angles (Fig. 18-65). Elevation of a full-thickness mucoperiosteal flap was performed in anticipation of coronal positioning; however, complete circumferential bone loss was noted extending apically to the midpalatal portion of the root (Fig. 18-66). A decalcified, freeze-dried bone allograft was placed into the defect (Fig. 18-67) and a wide Gore-Tex membrane affixed around the tooth (Fig. 18-68) in an attempt to regenerate the lost



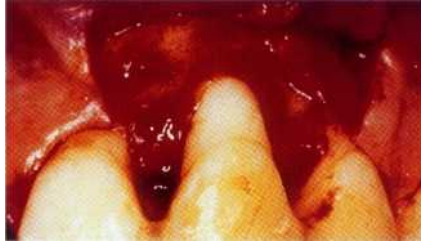*Fig. 18-66.* Elevation of a full-thickness flap revealed a 7- to 8-mm alveolar defect involving the entire circumference of the root.



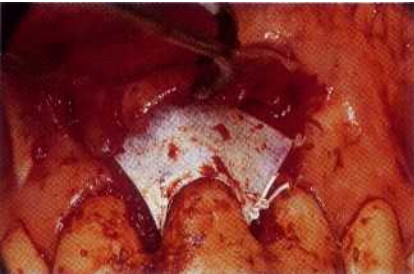*Fig. 18-70.* Supraincisal suspensory suturing was utilized to facilitate apical positioning and stabilize the flap.



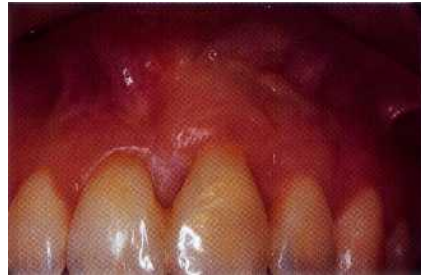*Fig. 18-67.* A decalcified, freeze-dried cortical bone allograft was placed into the defect.



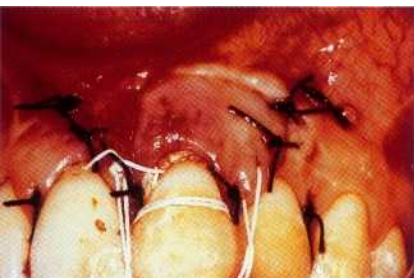
*Fig. 18-71.* After removal of the Gore-Tex membrane, a dense connective tissue fill is seen in the defect palatally and laterally.



*Fig. 18-68.* A wide Gore-Tex periodontal membrane was placed over the defect and bone graft.

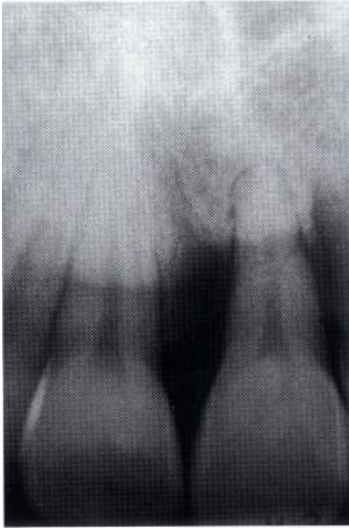

*Fig. 18-72.* The regenerated attachment allowed for the coronally positioned flap to heal in the proper position, as evidence by this 3-year follow-up view.

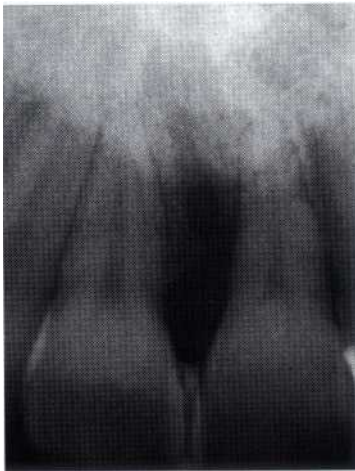

*Fig. 18-69.* The facial flap was coronally positioned as far as possible to cover the membrane. The underlying periosteum of the flap was scored apical to the mucogingival junction.

alveolar bone and provide the needed support for a coronally positioned flap. Vertical releasing incisions were placed laterally, the periosteum scored apical to the mucogingival junction, and the facial gingiva repositioned as coronally as possible (Figs. 18-69 and 18-70). The membrane was removed 3 1/2 months later, revealing a dense connective tissue fill of the entire palatal defect and along the lateral root surface (Fig. 18-71). The regenerated tissue provided the needed support and nourishment for the coronally positioned flap to heal and be maintained long term (Fig. 18-72). Evaluation of the pretreatment and 3-year posttreatment radiographs demonstrated excellent, sustained fill of the defect on tooth #8 (Figs. 18-73 and 18-74).



*Fig. 18-73. The preoperative radiograph reveals mesial and circumferential bone loss around tooth #9.*



*Fig. 18-74. Fill of the palatal and mesial defect is seen 2 years after regeneration.*

## EDENTULOUS RIDGE DEFORMITIES

### Differential Etiology

**Trauma.** Visible edentulous ridge defects and deformities are particularly challenging to treat both periodontally and prosthetically. The majority of these defects result from facial trauma sustained during motor vehicle accidents, contact sports, work-related accidents, and other mishaps. Violent avulsion of one or more teeth and surrounding buccal or lingual bone segments often occurs. Healing of such injuries results in collapse of the overlying soft tissue into the depression created by the bony loss, leading to a buccolingual or crestal concavity of the edentulous ridge. If the overlying mucosa and con-

nective tissue are also lost at the time of the injury, scarring of the vestibule and gingiva is a further complication.

**Periodontitis and Juvenile Periodontitis.** Other causes of edentulous ridge deformities include periodontitis and localized juvenile periodontitis (previously termed periodontosis). Periodontitis, a site-specific disease, often presents with severe involvement of one or two anterior teeth. A jagged bony topography can be associated with this severe loss of attachment. When these hopeless teeth are extracted, soft tissue healing mimics the alveolar profile, with resultant defects. With localized juvenile periodontitis, severe bone loss often occurs around the central incisors. If extraction is required, similar defects result. Usually, buccal defects result from loss of the buccal plate, whereas the apical extent of the defect is related to the amount of palatal bone loss.

### Classification

Edentulous ridge deformities are classified according to their dimensions:

1. *Buccolingual.* Buccolingual defects manifest as concavities on the buccal surface, brought about by loss of the buccal bone plate. Pontics placed in buccolingual defects appear unnaturally flat or thick.
2. *Occlusoapical.* Occlusoapical defects are the easiest to see because of an obvious discrepancy in the height of the gingival margin. In these cases, the pontics often are longer than the adjacent abutment teeth.
3. *Mesiodistal.* The mesiodistal dimension indicates the width of the area to be reconstructed and aids in determining the number of procedures necessary to correct the problem (a wide span may involve multiple procedures). It is not a true classification of a defect type.
4. *Atrophied papilla.* This defect involves loss of the papillae adjacent to an edentulous area. Usually caused by atrophy, this defect is not primarily traumatic or inflammatory in nature. These defects are highly visible and difficult to correct, and in many cases no change can be seen after multiple reconstructive attempts.

### Treatment Options

**Gingival Onlay Grafts.** The primary technique used to correct buccolingual and occlusoapical defects is the gingival onlay graft or soft tissue augmentation procedure, which is an adaptation of the free gingival graft technique to this special case. Thick palatal donor tissue is used to fill the defect (the minimum thickness is the depth of the defect). The donor tissue is then tightly sutured into the prepared defect site. If a provisional restoration or transitional removable appliance is present, the pontics overlying the

grafted site must be adjusted to allow 1 to 2 mm of clearance. This is necessary because the graft will swell during healing, and any excessive pressure can cause necrosis and failure. Once the graft has healed (approximately 6 to 8 weeks), a new provisional restoration can be made and an ovate pontic prepared to create the illusion of natural teeth emerging from their sockets.

**Connective Tissue Augmentation.** A subperiosteal tunnel can be created under the soft tissue of the defect and a connective tissue graft placed into the tunnel to "plump out" the defect. The connective tissue can be obtained from an area of the palate distant to the defect (free connective tissue augmentation) or adjacent to the defect (connective tissue roll augmentation). This technique attempts to correct the defect by internal augmentation. This procedure can be used for occlusoapical, buccolingual, and papillary defects. Pontics on provisional restorations must be adjusted to allow 1 to 2 mm of clearance over the surgical site during the 6- to 8-week healing period to compensate for postoperative tissue swelling.

**Synthetic Bone Grafts.** Synthetic bone graft material can also be placed under a ridge to "plump up" the defect. The graft material acts as scaffolding for connective tissue ingrowth and is not designed to regenerate the lost bone.

**Ovate Pontics.** Once the desired tissue reconstruction has been achieved, the area can be modified to allow for fabrication of ovate or bullet pontics. The advantage of this type of pontic design is that it creates the illusion of a natural tooth emerging from its socket and provides a more natural appearance to the adjacent "papillae." After adequate maturation of the grafted connective tissue (6 to 8 weeks), a round depression is placed into the augmented edentulous ridge crest with a round surgical diamond bur, the dimensions dependent on the tooth to be placed (e.g., a maxillary canine will require a larger preparation than a mandibular incisor). The provisional restoration is then relined so that acrylic material fills the depression and the area heals by epithelialization around the pontic.

The final prosthesis thus has apically tapered and rounded pontics that fit intimately into the tissue depression. This esthetic pontic design creates the appearance of a natural tooth emerging from a sulcus; the contours of the gingival aspects of the pontic are round without sharp or abrupt edges. Hygiene is easily performed by flossing under the pontic.

### Clinical Considerations

Some shrinkage is involved with these procedures, sometimes necessitating a second procedure. In the case of occlusoapical and buccolingual defects, several procedures may be needed before the desired result is achieved. The long-term esthetic results are usually well worth the sur-

gical time involved except for papillary reconstruction, which remains very unpredictable, and the patient should be made aware of the poor prognosis in these cases.

### Clinical Technique: Ovate Pontic

#### Armamentarium

- High-speed handpiece
- Round, coarse surgical diamond bur (#4)
- Indelible ink marker (e.g., Dr. Thompson's Sanitary Color Transfer Applicators, Great Plains Dental Products Co., Inc.)
- Self-cure acrylic
- Periodontal pack (e.g., Coe-Pack, Coe Laboratories, Inc.)

#### Clinical Technique

1. Anesthetize the area with 2% lidocaine with 1/50,000 epinephrine (unless medically contraindicated) for hemostasis.
2. Outline the pontic form in indelible marker. The preparation should be approximately 5 mm in diameter.
3. Using light strokes of the high-speed handpiece and copious irrigation, prepare the tissue to the desired depth. Ideally, the pontic preparation should be 5 mm in diameter and 2 to 3 mm deep at the center. The preparation should be parabolic (ovate), not cylindrical, in shape. Take extreme care not to exceed the boundaries of the indelible ink and not to damage or involve the adjacent papillae.
4. Once the depth and lateral dimensions have been achieved, apply pressure with sterile gauze until hemostasis is achieved.
5. Reline the pontic area of the provisional restoration with a self-curing acrylic. Intimate adaptations should be achieved between the relined pontic and the prepared tissue.

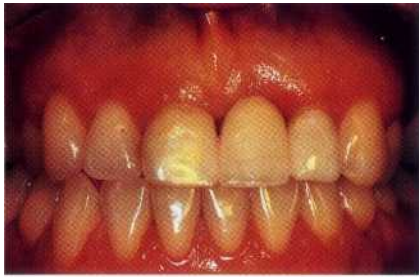**CLINICAL TIP.** A high polish must be placed on the relined surface to ensure optimal healing and minimize patient discomfort.

6. Recement the provisional restoration with temporary cement and place periodontal packing around the surgical site.
7. Epithelialization of the ovate preparation occurs in approximately 3 to 4 weeks. Completion of the final restoration can occur at that time. (See also Figs. 18-115 to 18-117 in this chapter.)

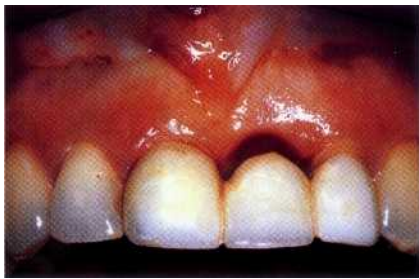**CLINICAL TIP.** The final restoration should lie passively on the tissue depression. Pressure may create an abscess with resultant necrosis.

### Clinical Case: Connective Tissue Augmentation and Gingivoplasty

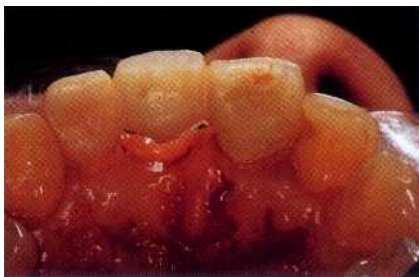A 37-year-old woman presented with a cupped occlusoapical ridge defect resulting from the extraction of the maxillary left central incisor after an endodontic perforation (Fig. 18-75). Her medical history was noncontributory. The pontic was reduced in apical height before proceeding with connective tissue augmentation of the edentulous ridge (Figs. 18-76 and 18-77). A partial-thickness palatal flap was reflected (Fig. 18-78) to allow harvesting of the underlying connective tissue, which was left as a pedicle. This connective tissue roll was placed over the edentulous bony ridge and under the connective tissue of the defect. The graft was sutured through to the



**Fig. 18-75.** A 3-unit provisional bridge was placed from the maxillary right central incisor to the left lateral incisor 3 months after removal of the left central incisor. Note the lack of an interproximal papilla adjacent to the pontic.

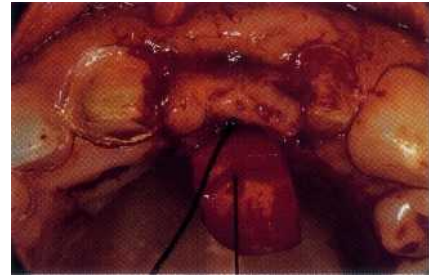


**Fig. 18-76.** The pontic is reduced in apical height before proceeding with connective tissue augmentation of the edentulous ridge.

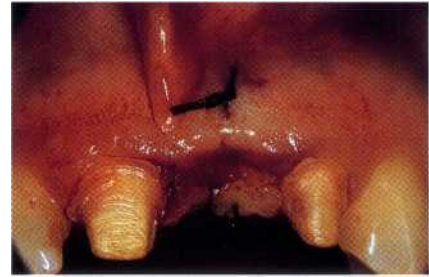

**Fig. 18-77.** Palatal view of the patient shown in Fig. 18-76.

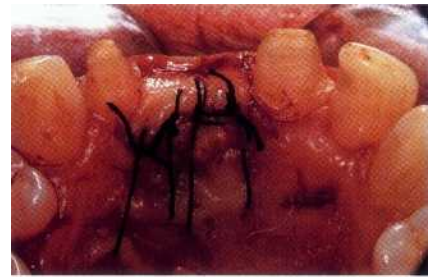
buccal mucosa for stability (Figs. 18-79 and 18-80), the provisional restoration was recemented (Fig. 18-81), and the area was allowed to heal (Fig. 18-82). After 12 weeks of healing, most of the defect resolved (Fig. 18-83) and a new provisional bridge was fabricated (Fig. 18-84). At



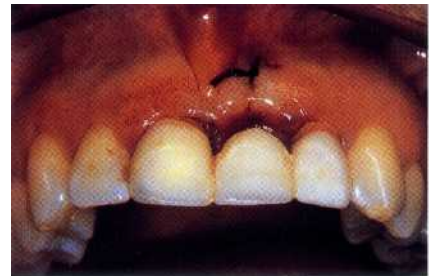**Fig. 18-78.** A partial thickness flap is reflected toward the palate.



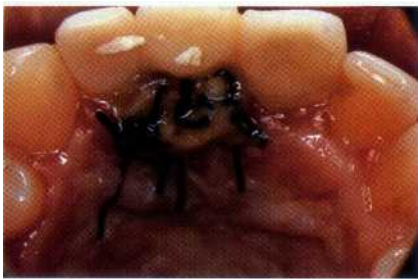**Fig. 18-79.** The connective tissue pedicle is sutured through to the buccal aspect.



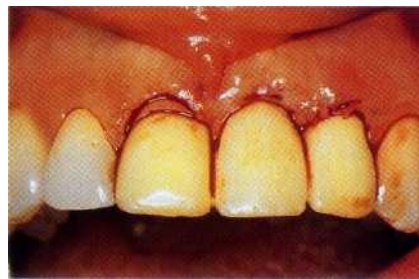**Fig. 18-80.** The palatal flap is sutured over the area.



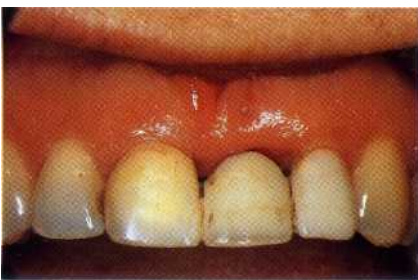**Fig. 18-81.** The provisional restoration is recemented.



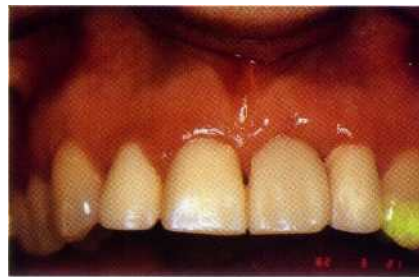*Fig. 18-82. Palatal view 10 days postoperatively.*



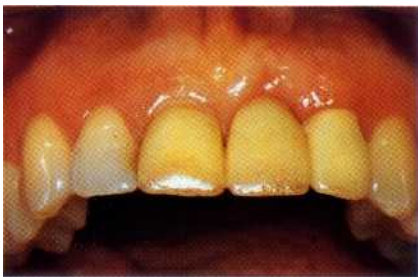*Fig. 18-86. A gingivoplasty, was performed to even the margins.*



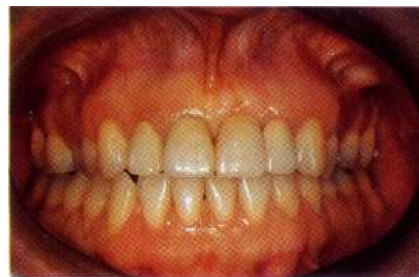*Fig. 18-83. Facial view after 3 months of healing.*



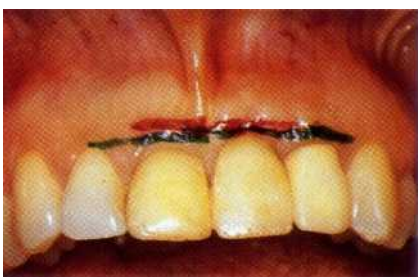*Fig. 18-87. Facial view after healing.*



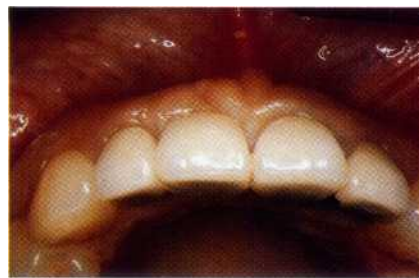*Fig. 18-84. A new provisional restoration was fabricated. Compare the interproximal papilla adjacent to the pontic with the preoperative view shown in Fig. 18-75.*



*Fig. 18-88. The final restoration was inserted after adequate healing.*



*Fig. 18-85. A discrepancy in the free gingival margins of the central incisors was noted.*

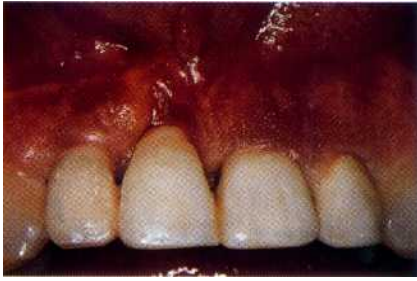

*Fig. 18-89. Note the buccolingual papilla profile.*

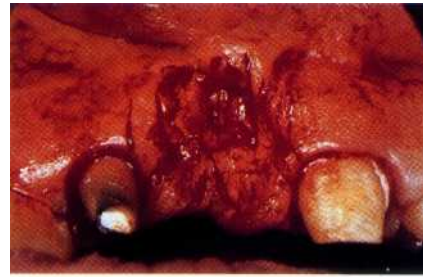that time it was noted that the central incisors had a slightly uneven gingival margin (Fig. 18-85). A simple gingivoplasty was performed to even the facial margins of the central incisors (Fig. 18-86). The patient was referred

for final restoration 4 weeks after this second surgery (Fig. 18-87) and the final restoration was fabricated (Figs. 18-88 and 18-89).

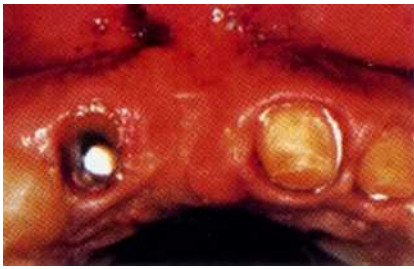



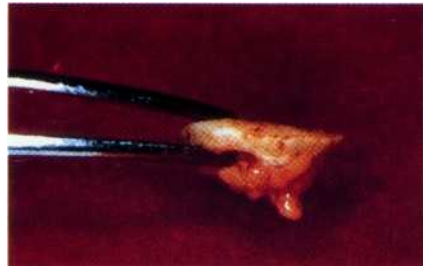*Fig. 18-90. Severe scarring and deformity of the maxillary anterior vestibule can be seen.*



*Fig. 18-92. The first surgical procedure addressed the buccolingual defect. The recipient bed preparation was done to conserve as much of the underlying connective tissue as possible.*



*Fig. 18-91. The patient shown in Fig. 18-90 without the provisional restoration.*

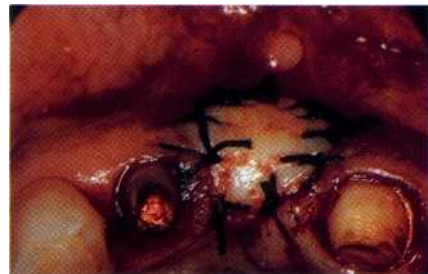

*Fig. 18-93. A thick palatal graft was harvested.*

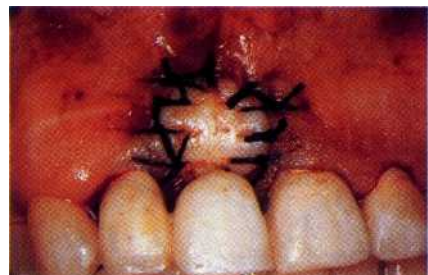### Clinical Case: Multiple Free Gingival Grafts and a Synthetic Bone Graft

A 33-year-old female was involved in an automobile accident, resulting in traumatic avulsion of the maxillary right central incisor (Fig. 18-90). Her medical history was noncontributory. The significant edentulous ridge defect required a multiple surgical approach (Fig. 18-91). First the buccolingual aspect was corrected by placing a thick free graft. Only the outer epithelial layer was removed at the recipient site to maintain as much of the connective tissue as possible (Fig. 18-92). By removing only the epithelial layer, all existing connective tissue at the recipient site was maintained. Removing some of the connective tissue during bed preparation would result in increasing the dimension of the defect to be grafted. For example, 4 mm thickness of tissue at the recipient site and a 5 mm defect warrant removal of the surface epithelium while maintaining the defect dimensions; however, removal of epithelium and 2 mm of connective tissue would increase the amount of defect to 7 mm.

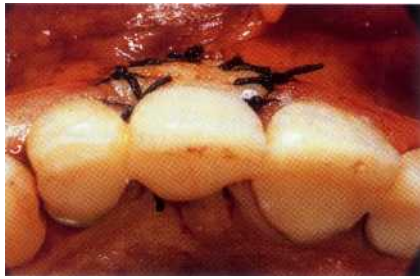The graft (Fig. 18-93) was placed in the recipient site (Fig. 18-94) and the pontic trimmed (Figs. 18-95 and 18-96) to avoid pressure necrosis. Healing was uneventful (Figs. 18-97 and 18-98). After 2 months, a second procedure was performed to correct the incisoapical defect (Fig. 18-99). The edentulous ridge was prepared (Fig. 18-100)



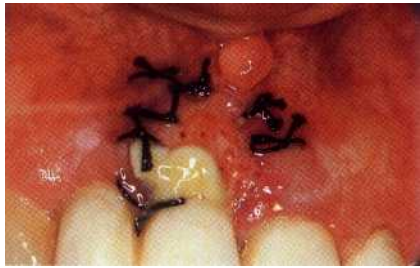
*Fig. 18-94. The graft is sutured in the recipient bed.*



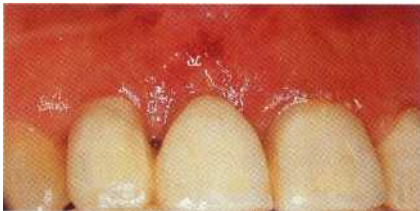*Fig. 18-95. The pontic is relieved and recemented.*



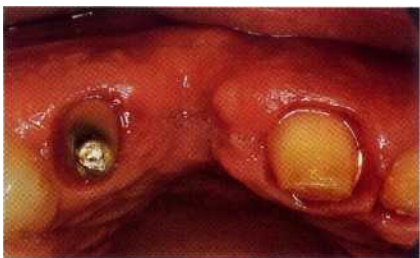
*Fig. 18-95. Palatal view of the patient shown in Fig. 18-94.*



*Fig. 18-97. The area 1 week postoperatively.*

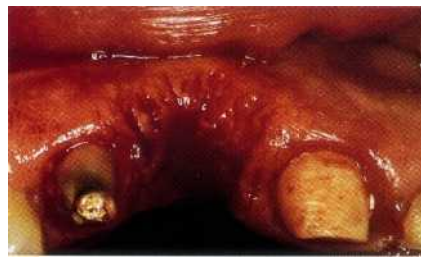


*Fig. 18-98. The area 6 weeks postoperatively.*

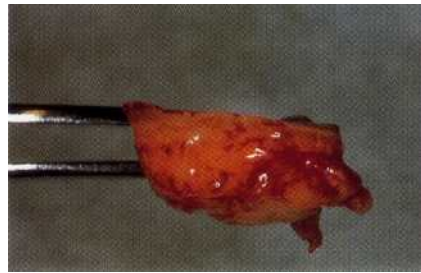


*Fig. 18-99. The second surgical phase addressed the incisopalatal defect. Palatal view of the site before bed preparation.*

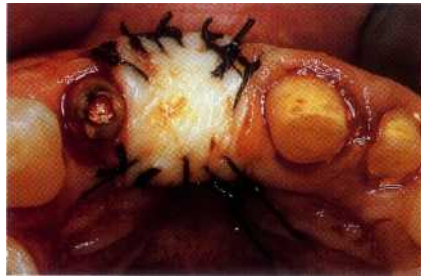
and a thick palatal graft, including the fatty tissues (Fig. 18-101), was sutured over the recipient site (Fig. 18-102). The graft was sutured in place and allowed to heal. After 8 weeks this area healed, but a slight depression remained (Fig. 18-103). To correct this incisopalatal defect, a full-



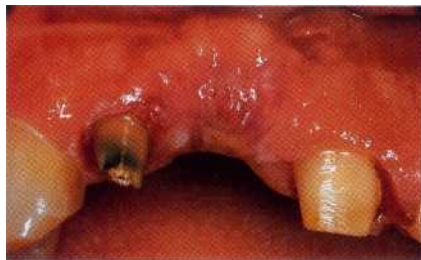*Fig. 18-100. The recipient bed is prepared.*



*Fig. 18-101. A thick piece of donor palatal tissue is removed.*

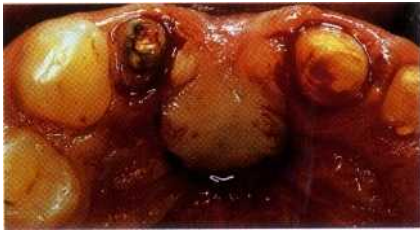

*Fig. 18-102. The graft is sutured intimately into the defect.*

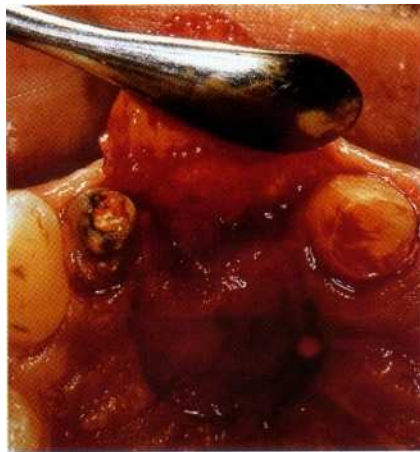

*Fig. 18-103. Despite good healing, some residual defect remained.*

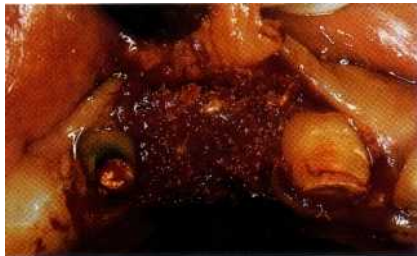thickness flap was reflected (Figs. 18-104 and 18-105) and a synthetic bone graft was placed (Fig. 18-106). The provisional restoration was recontoured and recemented in place (Fig. 18-107). A pleasing esthetic result was thus achieved (Figs. 18-108 and 18-109).



*Fig. 18-104.* A third procedure was performed. A full-thickness palatal flap was created.



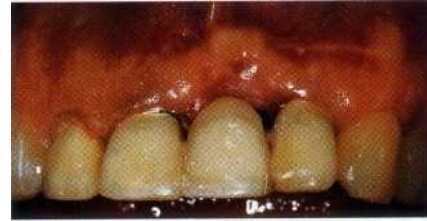
*Fig. 18-105.* The flap is reflected buccally.



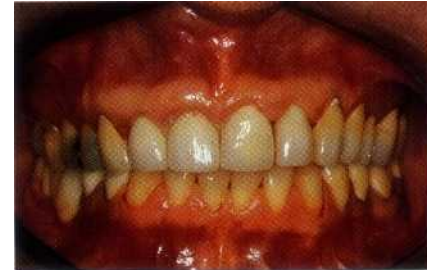*Fig. 18-106.* A synthetic bone graft is placed beneath the graft to correct the residual defect.

### Clinical Case: Papillary Reconstruction via Connective Tissue Augmentation

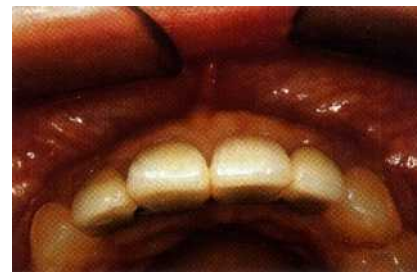A 22-year-old man presented with unesthetic replacement of both maxillary lateral incisors. His medical history was noncontributory. He was dissatisfied with the lack of papillae (Fig. 18-110). A connective tissue roll was used to "plump" the area (Fig. 18-111). The graft was taken from the palate directly behind the defect and sutured through the buccal mucosa for stability (Fig. 18-112). The pontic on the removable appliance was trimmed to prevent excessive pressure (Fig. 18-113). After healing, the ridge was



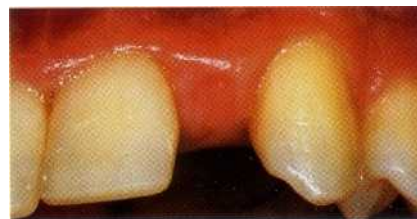
*Fig. 18-107.* The area is sutured and the provisional restoration is replaced.



*Fig. 18-108.* After restoration of proper buccolingual and incisopal dimensions apically and interproximally, a final restoration was inserted.

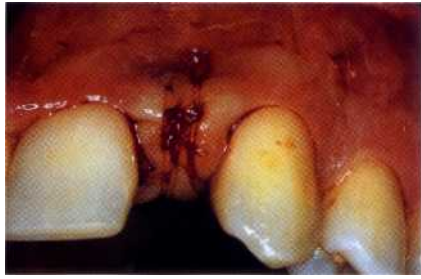

*Fig. 18-109.* Palatal view of the patient shown in Fig. 18-108.

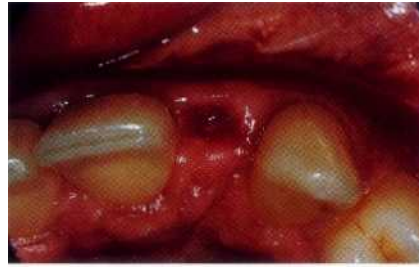

*Fig. 18-110.* This young male patient was dissatisfied with the lack of papillae around the missing lateral incisor.

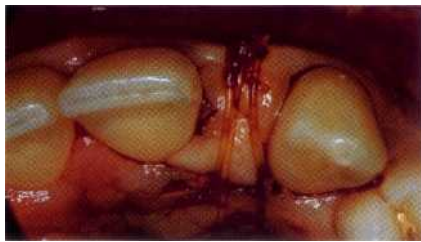
reprepared to accept an ovate pontic (Figs. 18-114 and 18-115). After 6 weeks the patient was referred for prosthetic restoration and an acid-etch retained fixed partial denture fabricated (Fig. 18-116). Although the entire papilla could not be reconstructed, the patient was satisfied with the results (Fig. 18-117).



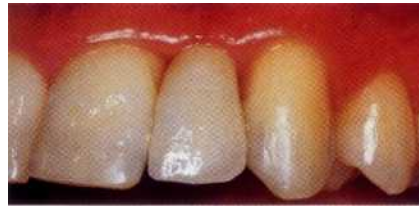*Fig. 18-111. A connective tissue roll was taken from the palate and sutured in place into a subperiosteal tunnel created under the edentulous ridge.*



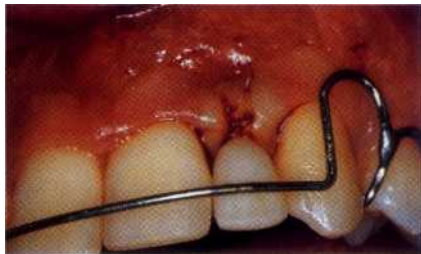*Fig. 18-115. Palatal view of the patient shown in Fig. 18-114.*



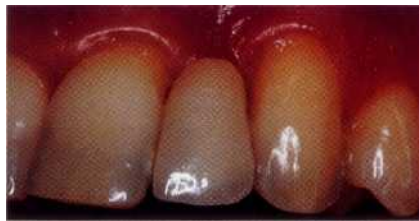*Fig. 18-112. Palatal view of the patient shown in Fig. 18-111.*



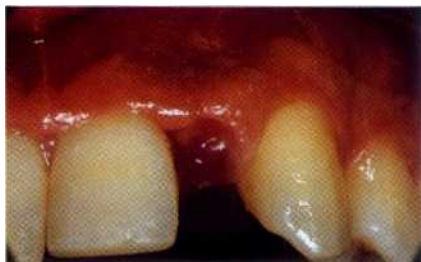*Fig. 18-116. Patient at 1 month after insertion of the Maryland bridge.*



*Fig. 18-113. The pontic on the removable appliance was trimmed to prevent excessive pressure.*



*Fig. 18-117. Although tissue has regressed in the apical region, the interproximal papilla remains stable.*



*Fig. 18-114. After healing, an ovate pontic preparation was performed into the augmented edentulous ridge to allow for fabrication of an ovate pontic on the Maryland bridge.*

## GINGIVAL OVERGROWTH

Patient dissatisfaction with the short appearance of the anterior teeth is commonplace. Identifying the underlying etiology is essential for proper treatment planning and prognosis.

### *Differential Etiology*

1. *Noninflammatory hyperplasia.* Noninflammatory hyperplasia is a common cause for both local and generalized gingival overgrowth. The best known cause is Dilantin hyperplasia. Several other frequently prescribed drugs may cause a similar response (e.g., nifedipine, cyclosporine, and Inderal). Such an underlying cause should be discovered during the medical history. The hyperplasia observed may be localized to a sextant or an arch or generalized in both

jaws. Another noninflammatory factor is irritation. This is seen with ill-fitting removable partial dentures or overhanging margins of restorations. In these situations, the overgrowth is seen only at the site of the irritation. An uncommon cause is genetic predisposition to gingival overgrowth. This will present as generalized buccal and lingual hyperplasia. These noninflammatory conditions are usually accompanied by an inflammatory component, because of the difficulty in performing proper oral hygiene.

2. *Inflammatory hyperplasia.* In some situations gingival hyperplasia is purely inflammatory. This is usually observed in chronic gingivitis or periodontitis with severe gingival involvement. Localized inflammatory hyperplasia is also seen adjacent to caries.
3. *Altered passive eruption.* Altered passive eruption has neither an inflammatory nor an extrinsic noninflammatory etiology. During normal eruption of the permanent dentition, the tooth erupts coronally while the gingiva migrates apically (passive eruption). When insufficient apical migration occurs, the gingival margin appears as gingival overgrowth. Clinically, this appears as short crowns with the free gingival margin in the middle one third of the enamel.

Histologically, two distinct presentations of altered passive eruption exist. In both cases, the free gingival margin is coronally positioned, but the position of the alveolar crest is different. In the first case, the alveolar crest is at its normal level of more than 1 mm apical to the cemento-enamel junction. In the second case, the alveolar crest is at or above the cemento-enamel junction. Although both cases are clinically identical, the histologic differences dictate different surgical approaches. The differentiation between the two histologic types can be made radiographically only when the alveolar bone can be definitely seen below the cemento-enamel junction. Otherwise, it is often impossible to predict the position of the buccal or lingual bone radiographically, and the need for ostectomy can be determined only after flap elevation.

### Treatment Options

**Plaque Control.** Plaque control is paramount in treating inflammatory hyperplasia. Oral hygiene instruction, scaling, and root planing or subgingival curettage should be performed before evaluating the need for surgical correction.

**CLINICAL TIP.** Often conservative, cause-related therapy will resolve infrabony hyperplasia.

If the hyperplasia persists, surgical reduction is indicated. The choice of surgical procedure (e.g., gingivectomy vs. apically positioned flap) is determined by any

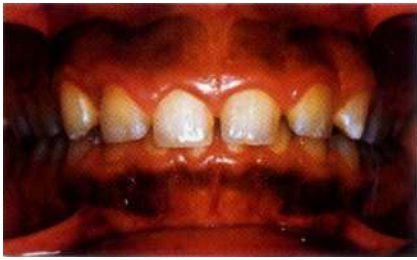underlying periodontal problems (e.g., pocketing, infrabony lesions).

**Gingivectomy or Gingivoplasty.** In cases of noninflammatory gingival hyperplasia, gingivectomy is usually indicated. With irritation-induced overgrowth, local reduction or excision is performed in conjunction with removal of the irritant. These patients usually respond well, without recurrence. With drug or genetically induced hyperplasia, gingivectomy is still the procedure of choice, although the frequency of recurrence must be considered. Changing the patient's medication often results in eliminating recurrences, although it will not reverse any existing hyperplasia. If change in medication is contraindicated, retreatment of recurrent problems must be evaluated on an individual basis. Recurrence is also common with genetically predisposed hyperplasia. The patient's functional and esthetic needs must be considered in deciding how often to perform surgical reduction.

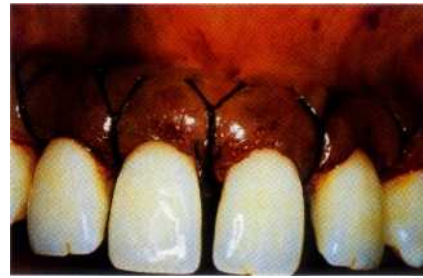**Apically Positioned Flap with or without Ostectomy.** Altered passive eruption is best treated with an apically positioned flap, which accomplishes two objectives: positions the gingival margin at a normal level and allows the evaluation of the alveolar crest. If the alveolar crest is correctly positioned, only apical positioning of the gingiva will be necessary. However, if the alveolar crest is at or above the cemento-enamel junction, ostectomy is required to first achieve a normal physiologic relationship between tooth and bone before apically positioning the soft tissue. The purpose of bone removal is to establish a new biologic width (see the section on inadequate tooth structure for restorations in this chapter), allowing the gingival margin to reform at an appropriate level. If a gingivectomy alone was performed in this situation, the gingiva would heal to its previous position, because the underlying bone dictates gingival margin position.

### Clinical Case: Full-Thickness Flap with Ostectomy

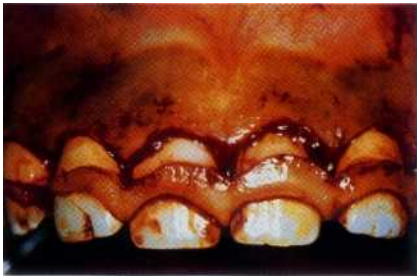A 17-year-old female presented for correction of the esthetics of her maxillary anterior teeth. Her medical history was noncontributory. She desired bonding to make the teeth larger and to close the spaces between them. Clinically, she had short teeth occlusogingivally and she exhibited multiple diastemata (Fig. 18-118). The diagnosis was altered passive eruption and a discrepancy between the tooth and arch size. The case demanded an integration of periodontal and restorative therapy. Restorative diastema closure would have resulted in unnaturally wide teeth with an apparently overexaggerated incisal edge. The anatomic crown was exposed with a full-thickness flap (Figs. 18-119 and 18-120). The alveolar crest was at the



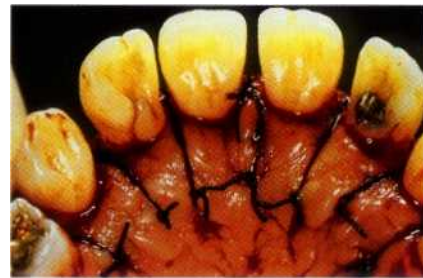*Fig. 18-118.* A 17-year-old female presented with altered passive eruption and a discrepancy between the tooth and arch size. She desired bonding to correct the unesthetic appearance of her teeth.



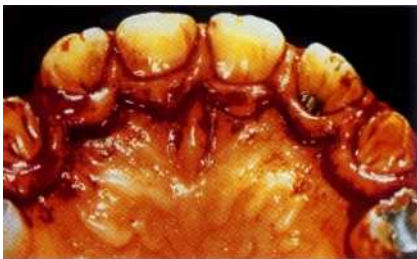*Fig. 18-122.* Minimal osteotomy was performed and the tissues sutured apically to reestablish the biologic width.



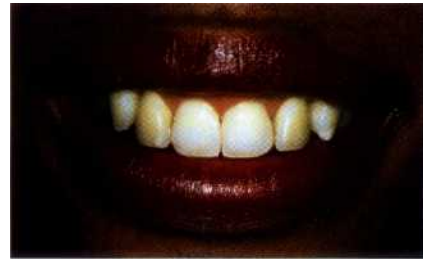*Fig. 18-119.* The first phase of treatment required exposure of the anatomic crowns. A submarginal incision was made on the buccal mucosa and the marginal collar of tissue was removed.



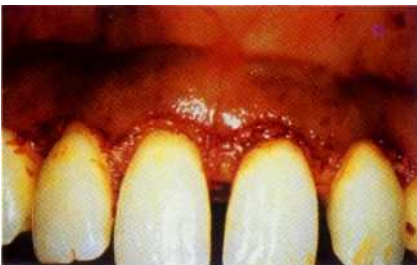*Fig. 18-123.* Palatal view of the patient shown in Fig. 18-122.



*Fig. 18-120.* An additional incision was made on the palatal aspect of the six maxillary anterior teeth.



*Fig. 18-124.* The teeth were ultimately restored using a microfilled composite resin.



*Fig. 18-121.* Reflection of the flap revealed the alveolar crest at the level of the cemento-enamel junction.

level of the cemento-enamel junction (Fig. 18-121), thus requiring osteotomy to allow for establishment of a proper biologic width (see the section on inadequate tooth structure for restorations in this chapter).

The tissue was apically repositioned and sutured into place (Figs. 18-122 and 18-123). After 3 months of healing, the patient was referred for restorative treatment. A microfilled composite resin was used to close the diastema. The increased crown length permitted fabrication of an esthetic restoration (Fig. 18-124).

## PATHOLOGIC MOBILITY

### Differential Etiology

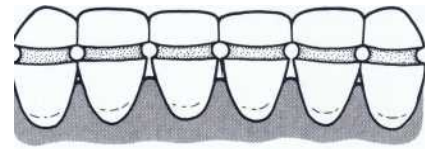
1. *Periodontitis.* Increased tooth mobility is a common problem of the adult periodontal patient. This results from the progressive loss of attachment.
2. *Occlusal trauma.* Occlusal trauma with or without a coexisting periodontal condition often causes tooth mobility. Occlusal trauma causes increased osteoclastic activity, which results in decreased alveolar bone volume and widening of the periodontal ligament with a resultant increase in tooth mobility. This is particularly evident when trauma is superimposed on periodontal inflammation.
3. *Postorthodontics.* Teeth sometimes have irreversibly increased mobility after orthodontic treatment. The mechanism for postorthodontic mobility is the same as that for occlusal trauma. It is impossible to predict this phenomenon, which occurs after "adult" orthodontics. If the patient is unaware of tooth mobility and mobility is not a symptom of untreated underlying disease and does not interfere with adequate function, no treatment is necessary.

### Treatment Options

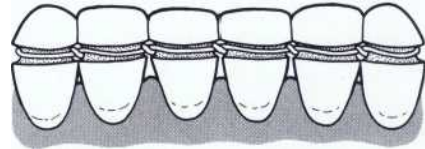
**Cast Porcelain-Fused-to-Metal Splinting.** The first choice of splints for treatment of pathologic mobility is cast porcelain-fused-to-metal, which would ideally satisfy both esthetic and functional demands. However, if financial limitations exist, intracoronal splinting is indicated.

**Intracoronal Splinting.** Intracoronal splinting involves preparing a channel in the occlusal surface of posterior teeth, or circumferentially in anterior teeth, to allow the placement of an anchoring wire. Composite resin is placed in the preparation to mask the wire and add strength. The advantage of these splints is the added reinforcement of the wire, coupled with the esthetics and reparability of the composite resins. The disadvantage is the irreversibility of the procedure (slot preparation), and the patient must be made fully aware of this before beginning. It is usually wise to have the patient examine photographs of these splints, because although the wire is hidden by composite resin, some shadowing may occur, making this esthetically unacceptable.

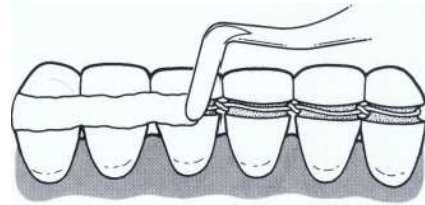
**CLINICAL TIP.** The use of clear nylon monofilament fishline (8-pound test) greatly reduces shadowing. Bury the knot carefully in composite resin, because this ligature tends to untie.



*Fig. 18-125.* Prepare a circumferential channel through the buccal and lingual surfaces of the involved teeth with a #1/2 or #1 high-speed round bur.



*Fig. 18-126.* Place a ligature wire through the channel around the involved teeth.



*Fig. 18-127.* The channel is restored with composite resin.

### Anterior A-splint

#### Armamentarium

Standard dental setup (see the section on forced eruption earlier this chapter)

- #1/2 or #1 high-speed round bur
- #33/2 high-speed inverted cone bur
- Monofilament fishline, 8-pound test or ligature wires
- Acid-etch gel
- Enamel/dentin bonding agent (see Chapter 3)
- Anterior composite resin (e.g., Silux, 3M, Inc.)

#### Clinical Technique

1. Prepare a circumferential channel through the buccal and lingual surfaces of the involved teeth with a #1/2 or #1 high-speed round bur (Fig. 18-125).
2. Place a slight undercut lingually and facially with a #33/2 high-speed inverted cone bur.
3. Place a ligature wire through the channel around the involved teeth (Fig. 18-126).
4. Acid etch the enamel margins.
5. Wash and dry the area.
6. Apply an appropriate bonding agent.
7. Restore with composite resin (Fig. 18-127).

## 8. Finish and polish (Fig. 18-128).

**Posterior A-splint**

## Armamentarium

The armamentarium is the same as that listed for anterior A-splints, plus the following:

- #330 or #245 inverted pear high-speed bur
- #35 or #37 inverted cone high-speed bur
- 0.026-inch or 0.036-inch orthodontic wire (Unitek, 3M, Inc.)

Posterior restorative material, such as posterior composite resin (e.g., P-50, 3M, Inc.; Herculite, Kerr, Inc.), or powder/liquid composite resin (e.g., Super-C, AMCO) or acrylic (e.g., clear orthodontic resin, Caulk, Inc.)

## Clinical Technique

1. Prepare a channel through the occlusal surface.
2. Place 0.036-inch orthodontic wire through the channel.
3. Acid etch the enamel margins.
4. Wash and dry the area.
5. Apply an appropriate bonding agent.
6. Restore with acrylic or composite resin.
7. Finish and polish.

**Extracoronary Splinting.** Extracoronary splinting is feasible only in the anterior sextants. Composite resin is placed over and between the crowns of the anterior teeth. Because this splint does not involve tooth preparation into dentin, it is reversible. However, it does have a greater tendency to fracture than intracoronary splinting. Should problems develop, conversion to a different kind of splint is possible.

## Armamentarium

- Standard dental setup (see the section on forced eruption in this chapter)
- Flame-shaped high-speed finishing bur
- Metal interproximal finishing strip (e.g., Lightening Strip, Moyco Industries, Inc.)
- Acid-etch gel
- Enamel/dentin bonding agent (see Chapter 3)
- Anterior composite resin (e.g., Silux, 3M, Inc.)

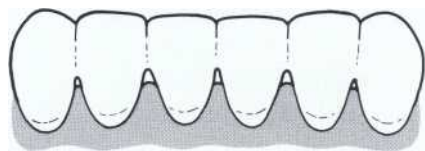


Fig. 18-128. The finished restoration.

## Clinical Technique

1. Acid etch the enamel margins.
2. Wash and dry the area.
3. Apply an appropriate bonding agent.
4. Place composite resin over and between the crowns of anterior teeth (some stripping may be necessary with crowded teeth).
5. Finish and polish.

**Clinical Consideration**

Both intracoronary and extracoronary procedures are intended as temporary stabilization. Frequently, they are used until a more permanent restoration can be made, or until stabilization occurs following surgery, orthodontics, or trauma.

**CLINICAL TIP.** When splints become long-term permanent restorations, it is imperative that the patient understands that frequent evaluation visits are required and that the splints will need repairs when they inevitably break.

Esthetic success can be achieved as long as the patient is aware of the maintenance involved and the limitations of these procedures.

**CONCLUSION**

Facial esthetics involves the interaction of many elements. The periodontium, which serves as a backdrop for the teeth, determines the environment in which any esthetic rehabilitation is seen. It is essential that periodontal procedures be considered an important part of any comprehensive esthetic treatment plan.

**BIBLIOGRAPHY**

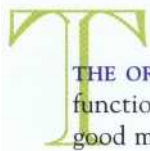- Abrams L: Augmentation of the deformed residual edentulous ridge for fixed prosthesis, *Compend Contin Educ Dent* 1:205, 1980.
- Allen EP: Use of mucogingival surgical procedures to enhance esthetics, *Dent Clin North Am* 32:307, 1988.
- Allen EP, Miller PD Jr: Coronal positioning of existing gingiva: short term results in the treatment of shallow marginal tissue recession, *J Periodont* 60:316, 1989.
- Becker BE, Becker W: Use of connective tissue autografts for treatment of mucogingival problems, *Int J Periodontics Restorative Dent* 6:88, 1986.
- Becker W, Becker BE, Berg L: Repair of intrabony defects as a result of open debridement procedures. Repair of 36 treated cases, *Int J Periodontics Restorative Dent* 6:8, 1986.



- Bernimoulin JP, Luscher B, Muhlemann: Coronally repositioned periodontal flap, *J Clin Periodont* 2:1, 1975.
- Clark JW, Weatherford TW Mann WV Jr: The wire ligature-acrylic splint, *J Periodont* 40:371, 1969.
- Cohen DW Ross SE: The double papillae positioned flap in periodontal therapy, *J Periodont* 39:65, 1968.
- deWaal H, Kon S, Ruben MP: The laterally positioned flap (review), *Dent Clin North Am* 32:267, 1988.
- Dorfman HS, Kennedy JE, Bird WC: Longitudinal evaluation of free autogenous gingival grafts: a four year report, *J Periodont* 53:349, 1982.
- Evans CA, Schaff HA: Acid etch technique adapted for splinting anterior teeth, *Am J Orthodont* 71:317, 1977.
- Evian CI, Com H, Rosenberg ES: Retained interdental papilla procedure for maintaining anterior esthetics, *Compend Contin Educ Dent* 16:58, 1985.
- Gray JL, Quattlebaum JB: Correction of localized alveolar ridge defects utilizing hydroxyapatite and a "tunnelling" approach: a case report, *Int J Periodontics Restorative Dent* 8:72, 1988.
- Grupe HE, Warren R: Repair of gingival defects by a sliding flap operation, *J Periodont* 27:92, 1956.
- Ingber J: Forced eruption: part II. A method of treating non-restorable teeth-periodontal and restorative considerations, *J Periodont* 47:203, 1976.
- Kozlovsky A, Tal H, Lieberman M: Forced eruption combined with gingival fiberotomy. A technique for clinical crown lengthening, *J Clin Periodont* 15:534, 1988.
- Langer B, Calagna L: The subepithelial connective tissue graft, *J Prosthet Dent* 44:363, 1980.
- Langer B, Langer L: Subepithelial connective tissue graft technique for root coverage, *J Periodontol* 56:715, 1985.
- Maynard JG Jr, Wilson RDK: Physiologic dimensions of the periodontium significant to the restorative dentist, *J Periodontol* 50:170, 1979.
- Mellonig JT et al: Clinical evaluation of freeze-dried bone allografts in periodontal osseous defects, *J Periodontol* 47:125, 1976.
- Mellonig JT: Decalcified freeze-dried bone allografts as an implant material in human periodontal defects, *Int J Periodontics Restorative Dent* 4:41, 1984.
- Miller CJ: The smile line as a guide to anterior esthetics, *Dent Clin North Am* 33:157, 1989.
- Miller PD Jr: Regenerative and reconstructive periodontal plastic surgery. Mucogingival surgery (review), *Dent Clin North Am* 32:287, 1988.
- Miller PD Jr, Binkley LH Jr: Root coverage and ridge augmentation in Class IV recession using a coronally positioned free gingival graft, *J Periodont* 57:360, 1986.
- Nelson SW: The sub-pedicle connective tissue graft. A bilaminar reconstructive procedure for the coverage of denuded root surfaces, *J Periodont* 58:95, 1987.
- Nevins M: Attached gingiva-mucogingival therapy and restorative dentistry, *Int J Periodontics Restorative Dent* 6:9, 1986.
- Ochsenbein C: A primer for osseous surgery, *Int J Periodontics Restorative Dent* 6:1, 1986.
- Ochsenbein C, Bohannon HM: The palatal approach to osseous surgery: part II. Clinical application, *J Periodont* 35:54, 1964.
- Pontoriero R et al: Guided tissue regeneration in the treatment of furcation defects in man, *J Clin Periodont* 14:618, 1987.
- Pontoriero R et al: Guided tissue regeneration in degree II furcation-involved mandibular molars. A clinical study, *J Clin Periodont* 15:247, 1988.
- Pontoriero R et al: Guided tissue regeneration in the treatment of furcation defects in mandibular molars. A clinical study of degree III involvements, *J Clin Periodont* 16:170, 1989.
- Pontoriero R, Celenza F Jr, Ricci G, Carnevale G: Rapid extrusion with fiber resection: a combined orthodontic-periodontic treatment modality, *Int J Periodontics Restorative Dent* 7:30, 1987.
- Raetzke PB: Covering localized areas of root exposure employing the "envelope" technique, *J Periodont* 56:397, 1985.
- Ross SE, Crosetti HW Gargiulo A, Cohen DW: The double papillae repositioned flap-and alternative. I. Fourteen years in retrospect, *Int J Periodontics Restorative Dent* 6:46, 1986.
- Saroff SA et al: Free soft tissue autografts: hemostasis and protection of the palatal donor site with a microfibrillar collagen preparation, *J Periodont* 53:681, 1980.
- Seibert JS: Reconstruction of deformed, partially edentulous ridges, using full thickness onlay grafts, *Compend Contin Educ Dent* 15:437, 1983.
- Sepe WW et al: Clinical evaluation of freeze-dried bone allografts in periodontal osseous defects. Part II, *J Periodont* 48:9, 1978.
- Steinberg AD: Office management of phenytoin-induced gingival overgrowth, *Compend Contin Educ Dent* 16:138, 1985.
- Sullivan HC, Atkins JH: The role of free gingival grafts in periodontal therapy, *Dent Clin North Am* 13:133, 1969.
- Takei H, Yamada H, Hau T Maxillary anterior esthetics. Preservation of the interdental papilla, *Dent Clin North Am* 33:263, 1989.
- Werbitt M: Decalcified freeze-dried bone allografts: a successful procedure in the reduction of intrabony defects, *Int J Periodontics Restorative Dent* 7:56, 1987.

# ESTHETICS AND ORTHODONTICS

Edward C. McNulty



**T**HE ORTHODONTIST, STRIVING for excellent form and function, not only aligns the dentition and provides for good masticatory function but also produces an esthetically pleasing result. Generalists and specialists in fields other than orthodontics should be capable of diagnosing the need for orthodontic intervention and be competent in performing simple orthodontic corrections. The orthodontist corrects complicated occlusal disharmonies, often using complex orthodontic mechanotherapy.

Before the introduction of more esthetic fixed appliances, patients (especially adults) often refused to accept full appliance mechanotherapy of even the shortest duration. The restorative dentist, limited by the patient's reticence to undergo prerestorative orthodontic correction, modified the treatment plan to accommodate the patient's wishes. This often compromised the success of the final restoration or placed its long-term stability in jeopardy.

## RATIONALE FOR ORTHODONTIC INTERVENTION

A treatment plan with a focus on esthetics must take into account whether orthodontic movements will enhance the success or stability of the final restorations. Diagnostic determinations should be based on the following principles:

1. Masticatory efficiency. Proper occlusion and the development of proper interdigitation allows for enhanced masticatory efficiency.

2. Periodontal protection. Correct axial inclination of the teeth dissipates the forces of mastication and lessens trauma to the periodontium.
3. Oral hygiene. Corrective alignment of a crowded dentition eliminates food impaction, improves self-cleansing during normal masticatory movements, and permits easier oral hygiene by the patient.
4. Temporomandibular joint protection. Proper occlusion, which permits a good functional relationship between the maxilla and mandible, mitigates strain of the masticatory muscles and the temporomandibular joint.
5. Speech improvement. Proper anatomic relationships between the teeth and the musculature of the orofacial complex enhances proper speech.
6. Esthetics. Orthodontic movement provides a dentition that is esthetically pleasing and takes into consideration the soft tissue profile of the patient.

## BASIC PREMISES FOR DIAGNOSTIC EVALUATION

Patients often have misconceptions regarding treatment results. The orthodontist should discuss probable results with the patient to build a diagnostic plan on a firm foundation of understanding.

1. There must be a clear pathway for tooth movement to take place when the patient is in maximal intercuspation. Interferences can be removed by selectively grinding the teeth when function or esthetics permits or by opening the vertical dimension of

occlusion through fixed or removable appliance therapy. If the latter is attempted, a thorough evaluation of the effects of altering vertical dimension must be considered.

2. Dentofacial harmony can only be evaluated on a personal, subjective basis. The clinician therefore should be prepared to discuss any profile or other facial changes expected to result from treatment with the patient before therapy begins. This is especially important when skeletal disharmonies will be altered by orthognathic surgery.
3. The treated occlusion must be stable. All orthodontic appliance therapy is planned with stability in mind. Overexpansion of the dental arch commonly results in relapse of crowding after retention is discontinued. Rotational discrepancies should be overcorrected because they also tend to relapse, as do closed bites and Class III malocclusions.
4. Orthodontic treatment has little effect on facial growth. This applies even to full-banded mechanotherapy performed by an orthodontist. The facial pattern exhibited by the patient should be accepted as the framework in which tooth movement must take place. In the mature adult, growth has ceased. Although it is possible to produce some orthognathic changes in the maturing maxilla and local changes in the alveolar arches and lips, facial changes are the result of growth and not treatment. Therefore the clinician should be well versed in predicting facial growth in the maturing patient or should refer the patient for an orthodontic consultation. Predictions are based on the current conditions of the face and dental arch presented by the patient, correlated with statistical probabilities. Race, gender, and familial tendencies are also important factors.
5. The mandibular dental arch provides the best starting point for diagnostic analysis and treatment planning, especially for fixed appliance mechanotherapy performed by an orthodontist. The mandibular arch usually shows only slight growth changes after 9 or 10 years of age and is less amenable to mechanotherapeutic changes than the maxilla. Treatment therefore must be planned so the maxilla will conform to the therapeutic result that can be achieved in the mandible. An exception to this premise is Angle Class III malocclusions in which limitations in the treatment of the maxilla take on primary diagnostic and treatment priorities.

Some clinical problems may be corrected using one of several treatment modalities. It is essential to identify and compare therapeutic alternatives during the diagnostic evaluation so the most appropriate procedure can be selected.

## DIAGNOSTIC EVALUATIONS

Malocclusions may result from skeletal, dental, or muscular disharmonies or from a combination of these components. The origin of the problem often dictates the treatment modality. The mandible and maxilla should be evaluated separately and in their relationship to each other during differential diagnosis. A general outline is provided here, but the clinician must examine each case on its own merits and design a treatment plan accordingly.

A patient with a therapeutic problem involving orthodontic principles beyond the scope of the clinician's knowledge should be referred to a specialist for a diagnostic opinion and, if needed, treatment. The orthodontist, in turn, must always consider whether restorative modalities may better serve a patient's needs than complicated orthodontic therapy.

Each case poses many questions and presents a set of different, self-limiting circumstances, making differential diagnosis easier for the astute clinician.

### *Assessment of the Skeletal Component*

Is the relationship of the bones of the face causing the malocclusion? Is a small mandible or a large maxilla causing the Class II or Class III protrusion, or is it caused by the dental or muscular component? Angle Class I bimaxillary protrusion is often seen in certain races (e.g., Australoid, Negroid, Mongoloid) and must be evaluated on racial norms and patient preference, not on the clinician's preconceived notion of an orthognathically ideal profile. The orthodontist should determine whether these skeletal disharmonies are mild enough to be masked by conventional orthodontic treatment or whether a surgical orthognathic approach should be undertaken. Many Class I bimaxillary protrusions can be treated orthodontically, but if a large overbite is present surgery may be indicated. Class II malocclusion has been successfully resolved orthodontically; however, the clinician must take care when treating patients with these malocclusions that the midface or chin does not become too prominent. As a general rule, Class III relationships that allow the teeth to come into edge-to-edge contact when the mandible is placed in its most retruded position can be successfully treated with conventional orthodontics, but the resulting soft tissue profile must again be considered in evaluating the case. More severe Class III relationships often require a combined orthognathic surgical approach.

### *Assessment of the Dental Component*

Spaces between the teeth or crowded teeth may be evidence of a poor tooth size to arch length ratio. The teeth may be too large or too small for the basal bone present. Other causes, such as early loss of primary teeth with re-

sultant mesial migration of the posterior teeth, must be ruled out. Are some teeth missing? Are teeth missing because of impaction or congenital absence of the suspect tooth? Are long-standing edentulous areas with resultant bite collapse evident? Has the periodontal integrity of the tooth been threatened by tipping or crowding?

**Assessment of the Muscular Component**

Are cuspal interferences causing deviation of the mandible laterally, anteriorly, or posteriorly during closure? Are these deviations caused by muscular imbalances, or are cuspal interferences causing the muscles to deflect the mandible on closure? Do any pernicious habits exert an undue influence on the dentition?

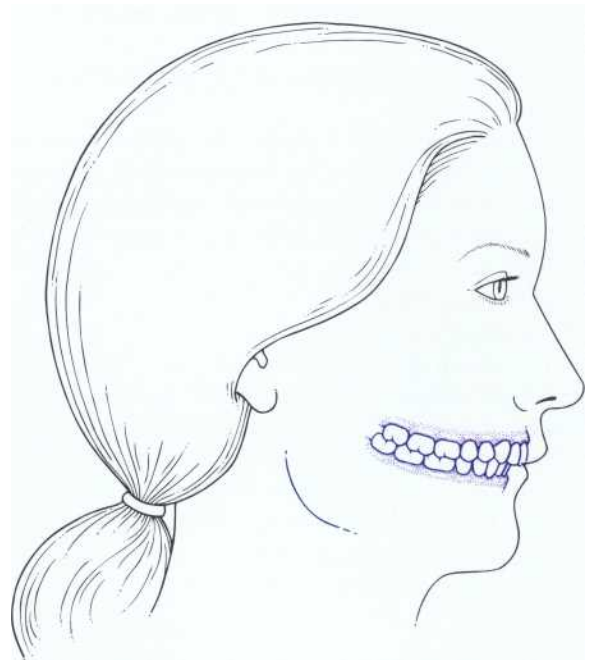
**Evaluation of the Mandibular Arch**

Do the present arch dimensions and any expected growth changes appear adequate to permit alignment of the teeth without expansion, or will space be required to properly align the teeth? Can any needed space be gained by interproximal reduction of enamel or are extractions necessary?

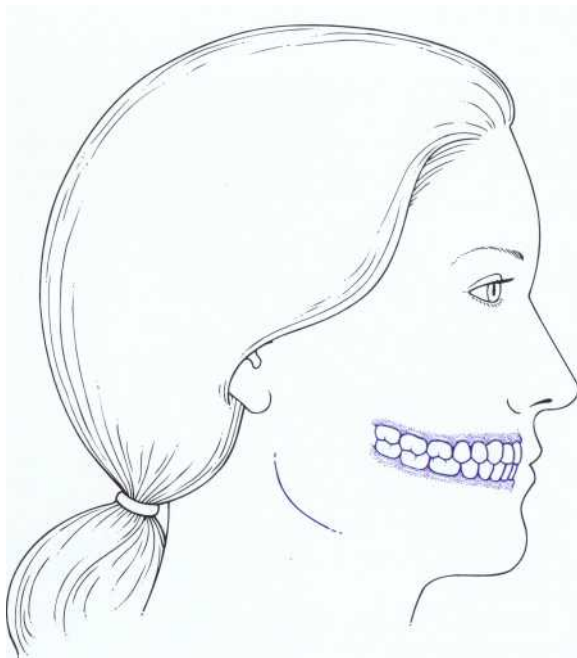
**Evaluation of the Maxillary Arch and Its Relation to the Mandibular Arch**

Are space requirements similar to those in the mandible? Using the mandibular molar position as a guide, does the

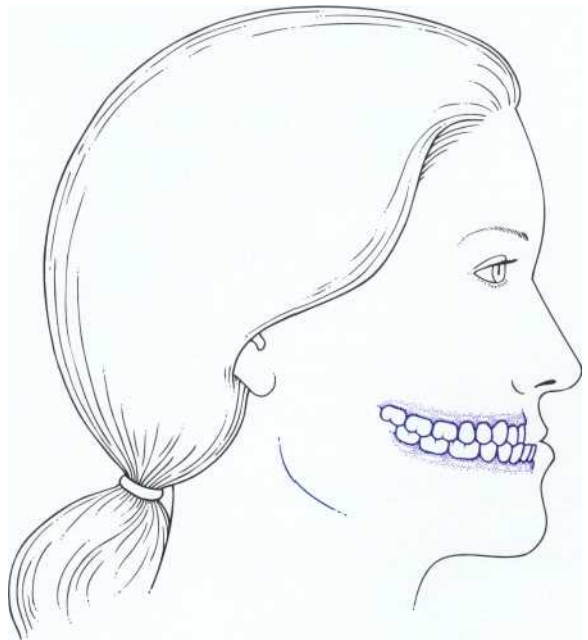
orthodontist need to move the maxillary molars to provide a Class I interdigitation (Figs. 19-1 to 19-3)? Using the mandibular incisors as a guide, what anteroposterior and vertical movements are required?



**Fig. 19-2.** Molar relationship in an Angle Class II malocclusion.



**Fig. 19-1.** Molar relationship in a normal Angle Class I occlusion.



**Fig. 19-3.** Molar relationship in an Angle Class III malocclusion.

## FUNDAMENTALS OF ORTHODONTICS-TYPES OF MOVEMENT

### *Types of Appliances*

1. Anterior ceramic or plastic brackets bonded to the facial/buccal surfaces of the teeth
2. Metal brackets bonded to the facial/buccal surfaces of the teeth
3. Lingual appliance-Specially designed metal brackets can be bonded to the lingual surfaces of teeth. Specially designed lingual arch wires must **be used and the biomechanics of treatment** must be analyzed to use this appliance.
4. Hawley appliance
5. Crozat appliance
6. Functional appliances (e.g., Andresen, Bimler, Frankel, Monobloc)-Removable appliances that fit over the occlusion and reposition the jaw to stimulate growth of the jaws to obtain the desired occlusion; some of the appliances have plastic flanges that fit in the labial vestibule and keep the buccal and orofacial musculature from contacting the teeth, thereby allowing some expansion of the jaws.

### *Types of Instruments*

1. Wire bending instruments-No. 139 pliers are used to bend heavier wires. Light wire pliers are used to bend light wires.
2. **Ligature cutters-Ligature cutters are used to tie and cut the ligature wire** (0.010-inch soft round wire).

## TREATMENT OF CLINICAL PROBLEMS-GENERAL CONSIDERATIONS

For the sake of simplicity, each type of malocclusion is discussed as a single entity. Often, however, the patient exhibits a combination of disharmonies. The final treatment plan must account for **all the** factors causing a malocclusion, allowing the orthodontist to select the most appropriate mechanotherapy to treat the particular case.

### *Placement of Edgewise Brackets*

#### Armamentarium

- Standard dental setup
  - Explorer
  - Mouth mirror
  - College pliers (nonlocking)
  - Low-speed dental handpiece
  - Periodontal staler (optional)

- Pumice
- 30% to 50% phosphoric acid (liquid or gel)
- Edgewise brackets (Unitek/3M, Inc.) (brackets are available in metal, plastic, or ceramic and in assorted sizes to fit either 0.018- or 0.022-inch wire)
- Orthodontic composite luting agent (e.g., Concise, 3M, Inc.)
- Bracket positioning gauge (e.g., Boone bracket positioning gauge, Unitek/3M, Inc.)
- Bracket removing pliers (e.g., ETM 345RT Unitek/3M, Inc.) (if necessary)

#### Clinical Technique

1. Pumice the appropriate teeth.
2. Select the appropriate brackets and position them on the bracket table to allow for easy access during bracket placement.
3. Mix **the orthodontic composite luting agent and apply it to the bracket according to the** manufacturer's recommendations.
4. Center the bracket on the tooth so that the edges are "square" with the long axis of the tooth. The incisal edge of the bracket should be 3.5 mm from the incisal edge of the tooth. A bracket positioning gauge ensures uniform placement of the brackets.

**CLINICAL TIP.** Place the brackets digitally or with nonlocking pliers. Do not use locking pliers because they may cause unintended movement of the bracket when the lock is released.

**CLINICAL TIP.** If a band is improperly placed, detach it with bracket removing pliers and remove any remaining resin with the chisel tip of the pliers or a periodontal staler. Repeat steps 1 to 4.

### *Placement of Orthodontic Bands*

#### Armamentarium

- Standard dental setup
  - Explorer
  - Mouth mirror
  - College pliers (nonlocking)
  - Low-speed dental handpiece
- Separating elastics (e.g., Alastik S Modules, Unitek 3M, Inc.)
- Band pusher (e.g., band seater and pusher 811-003, Unitek/3M, Inc.)
- Nylon molar seater (Unitek/3M, Inc.)
- Assorted orthodontic bands (Unitek/3M, Inc.)
- Buccal tubes (if necessary) (Unitek/3M, Inc.)
- Spot welder (if necessary)

- Zinc phosphate cement (e.g., Fleck's Cement, Mizzy, Inc.)

#### Clinical Technique

1. Place separating elastics one day before inserting orthodontic bands.
2. Remove the separating elastics.
3. Select the appropriate size band.
4. Place the band on the tooth seat with the band pusher.

**CLINICAL TIP.** Turn the head of the band pusher sideways and place it over the occlusal surface of the band. Apply thumb pressure to the band pusher until the band seats over the height of contour of the tooth.

5. Continue seating the band with the band seater.
6. After it is properly seated, adapt (swedge) the band to the cuspal and gingival anatomy with the band pusher.

**CLINICAL TIP.** Use the smallest band that fits the tooth. An ill-fitting band allows cement leakage, thus increasing the possibility of caries development.

7. Spot weld a buccal tube, if required. Place the tube parallel to the occlusal surface and as close to the gingiva as possible. Align the mesial edge of the tube with the middle of the mesial cusp of the tooth.
8. Apply cement to the entire internal surface of the band and completely seat the band as described in steps 4 and 5.

**CLINICAL TIP.** Carefully place cement to prevent voids from forming, especially at the gingival edge. Cement voids increase the likelihood of leakage and subsequent caries development.

**CLINICAL TIP.** Most minor tooth movement is accomplished in under six months. During extended treatment, remove the bands once a year to ensure that no caries development or cement leakage has occurred.

## GENERALIZED SPACING

### *Diagnosis*

Generalized spacing can be caused by the following:

1. Small teeth
2. A large tongue
3. Perverse sucking habits
4. A component of a more severe syndrome (i.e., a Class II, division 1 malocclusion)

5. A combination of one or more of the above

Generalized spacing is confirmed by measuring the size of the teeth on study models. Little can be done orthodontically for patients with generalized spacing. These conditions may be treated successfully with restorations by the general dentist.

If diastema are localized, the clinician should suspect sucking or tongue habits. A large tongue that is physiologically active usually has a scalloped edge because of constantly pushing against the teeth. Sucking habits can range from involvement of the thumb to several fingers turned in various positions when placed in the mouth. The fingers that are used in a sucking habit invariably are cleaner than their neighbors, and often exhibit a callus where the mandibular incisors contact them.

### *Treatment*

Elimination of pernicious habits is never easy but can be accomplished if the clinician is patient, persistent, and, most importantly, enlists the cooperation of the patient. The first step is to convince the patient that it is his or her responsibility to break the habit and that the doctor only offers assistance. It is helpful to encourage young patients to "give permission" for their parents to remind them that the habit exists. However, parents should not force the patient to stop. Start with small successes and build on them. It is essential to avoid discouraging the patient if small episodes of backsliding occur.

The plethora of devices used to break sucking habits speaks for their lack of singular success. They may be used, but should be considered adjuncts to the primary treatment previously described. Wearing cotton gloves is sometimes successful, as is the use of a bitter substance placed on the finger used during the habit. Success can often be obtained by asking the patient to wear an elastic bandage around the elbow during the times the patient is concentrating on breaking the habit (usually at bedtime and reading time and while watching television). The patient's parent should place the bandage so that no pressure occurs when the arm is extended. It should become tight when the elbow is bent. The resultant pressure on the elbow reminds the patient of the desire to stop the sucking habit. Frequent office visits reinforce patient progress. After the habit has been stopped, the spaces may correct by themselves or orthodontic closure may sometimes be necessary.

### *Diastema Closure Via Arch Contracture-Elastics*

In order to treat multiple **spacing with contraction of the maxillary arch, the orthodontist** must ensure that the mandibular antagonist does not interfere with movement.

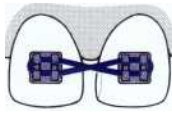


Fig. 19-4. A fixed appliance used to close a diastema involving the central incisors.



Fig. 19-5. A fixed appliance used to move a single tooth to close a diastema. Elastics are stretched from the tooth to be moved across multiple anterior teeth. Note the use of a stabilizing circumferential arch wire.




Fig. 19-6. A fixed appliance used to close multiple diastemata. Elastics are stretched from multiple teeth on either side of the midline. Note the use of a stabilizing arch wire.

#### Armamentarium

- Basic bracket and band placement setup. See the previous section on placement of orthodontic bands.
- 0.020-inch orthodontic elastic chord (Unitek/3M, Inc.)
- Orthodontic stress and tension gauge (Dontrix-Richmond, Unitek/3M, Inc.)

#### Clinical Technique

1. Place brackets on the labial surface of all teeth requiring diastema closure. See the previous section on placement of orthodontic bands.
2. Place bilateral brackets or bands on the three teeth immediately distal to the teeth requiring movement (anchor teeth).

**CLINICAL TIP.** Never wrap or tie an elastic band or cord around teeth that do not have brackets. An undetected elastic that has slipped under the gingiva will slowly work its way to the apex of the root, resulting in unintended loss of the tooth. Therefore elastics should be fastened only to teeth that have bonded brackets (Fig. 19-4).

3. Ligate the three left anchor teeth together with elastic chord to create an anchor unit.
4. Repeat step 3 for the three right anchor teeth.
5. If a single tooth must be moved laterally, accomplish this before arch contraction begins. To activate the movement, ligate the single tooth with elastic chord to the anchor unit toward which the tooth must be moved. The elastic should generate 1 ounce of force as measured by an orthodontic stress and tension gauge. However, an arch wire must be placed to guide this movement (Fig. 19-5).

NAME: \_\_\_\_\_ DATE: \_\_\_\_\_

ADDRESS: \_\_\_\_\_ PHONE: ( ) \_\_\_\_\_

CITY: \_\_\_\_\_ STATE: \_\_\_\_\_ ZIP \_\_\_\_\_

PATIENT NAME: \_\_\_\_\_

DATE NEEDED: \_\_\_\_\_ TIME NEEDED: \_\_\_\_\_

SPECIAL INSTRUCTIONS:

Please construct a maxillary and a mandibular Hawley appliance with a labial bow and circumferential clasps on the first molars. Slightly relieve the palatal and lingual acrylic to allow for the closing of multiple diastemata due to anterior flaring.

Thank you.

SIGNATURE:

LICENSE:

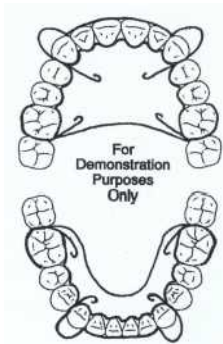


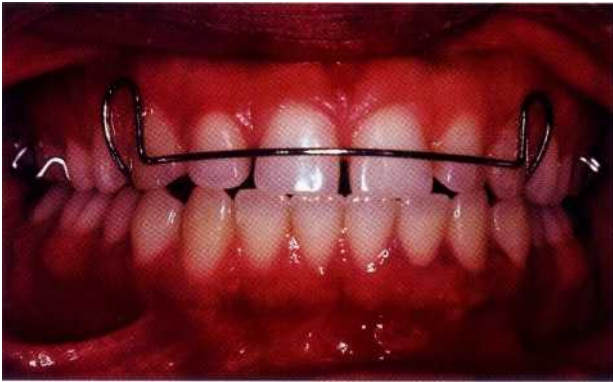Fig. 19-7. A sample prescription for the fabrication of maxillary and mandibular removable appliances for the correction of flared anterior teeth.

6. Ligate the left and right anchor units to each other using elastic chord. The elastic should generate 1 ounce of force as measured by an orthodontic stress and tension gauge (Fig. 19-6).
7. Additional therapy is discussed later in this chapter in the section on localized spacing of maxillary central incisors.

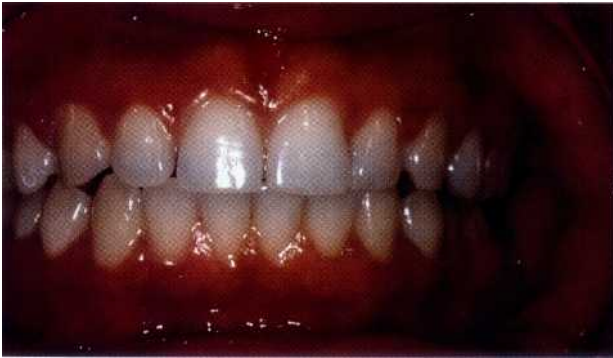### Multiple Diastema Closure-Removable Appliance

#### Armamentarium

- Irreversible hydrocolloid impression
- No. 139 pliers to activate Hawley appliance



*Fig. 19-8. Anterior view of a maxillary Hawley appliance inserted to reduce spacing between anterior teeth.*



*Fig. 19-9. Postoperative view showing the elimination of all the spaces between the maxillary anterior teeth.*

#### Clinical Technique

1. Make an irreversible hydrocolloid impression.
2. Send the models to an orthodontic laboratory for fabrication of a Hawley appliance (Fig. 19-7).
3. Activate the loops on the Hawley appliance to increase pressure on the labial area of the teeth to be moved, which will decrease the labial circumference in working relationship with the mandibular anterior teeth.
4. Be sure that the opposing arch or the palatal aspect of the appliance does not interfere with the proposed movement.
5. Adjust the appliance every 2 weeks.
6. Space closure occurs at a rate of 1 to 1.5 mm per month (Figs. 19-8 and 19-9).

### LOCALIZED SPACING- CLINICALLY ABSENT TEETH

#### Diagnosis

Causes of the clinical absence of teeth include the following:

1. Congenitally missing teeth
2. Unerupted teeth
3. Premature loss of permanent teeth
4. Perverse sucking habits
5. Supernumerary teeth that prevent normal eruption
6. A combination of the above

Overlong retention of primary teeth can cause ectopic impaction of the permanent successors. Congenitally missing lateral incisors are discussed later in this chapter in the section on localized spacing of maxillary central incisors. The diagnosis ultimately is confirmed by examination of the appropriate radiographs.

Prosthetic treatment sometimes is complicated by the mesiodistal drifting of teeth adjacent to the edentulous space. This drifting can occur through tipping or bodily movement. In the latter case the crown and the apex of the root move bodily through the bone with the long axis of the tooth remaining perpendicular to the occlusal plane. In the former case the crown tips mesially or distally ahead of the apex of the root. Radiographs confirm the type of movement that has occurred.

**CLINICAL TIP.** A tipped tooth always must be brought upright so that the crown is positioned over the apex. This provides a stable result.

Attempts to correct a mesiodistally drifted tooth with an abnormally proportioned restoration often create periodontal problems. Therefore teeth should be orthodontically uprighted before prosthetic treatment.

#### Treatment

Ectopic impaction should be treated by extraction of the primary teeth. If less than half of the root has formed, the permanent tooth usually is delayed in eruption. If more than half of the root is present and the tooth has failed to erupt despite the loss of the primary tooth, surgical exposure of the crown is required, often followed by mechanical orthodontic therapy to force eruption of the tooth.

Congenitally missing teeth are treated by prosthetic replacement. However, orthodontic intervention often is necessary if adjacent teeth have shifted mesiodistally.

#### Correction of a Migrated Anterior Tooth- Removable Appliance

##### Armamentarium

- Irreversible hydrocolloid impression
- No. 139 orthodontic pliers

##### Clinical Technique

1. Make an irreversible hydrocolloid impression.



2. Send the models to an orthodontic laboratory for fabrication of a Hawley appliance that includes up-righting springs imbedded in acrylic (Fig. 19-10).
3. Confirm that the labial arch wire lies passively against the teeth.
4. Activate the lingual springs against the interproximal surface of the tipped teeth.
5. Clinically evaluate the patient every 2 weeks.
6. Normal correction of a migrated tooth occurs at a rate of 1 to 1.5 mm per month (Figs. 19-11 to 19-14).

**Correction of a Migrated Anterior Tooth-Fixed Appliance**

Fixed appliances require that the generalist be absolutely familiar with all aspects of fixed orthodontic therapy. Fail-

NAME: \_\_\_\_\_ DATE: \_\_\_\_\_  
 ADDRESS: \_\_\_\_\_ PHONE: ( ) \_\_\_\_\_  
 CITY: \_\_\_\_\_ STATE: \_\_\_\_\_ ZIP \_\_\_\_\_  
 PATIENT NAME: \_\_\_\_\_  
 DATE NEEDED: \_\_\_\_\_ TIME NEEDED: \_\_\_\_\_  
 SPECIAL INSTRUCTIONS:

Please construct a maxillary Hawley appliance with a labial bow and circumferential clasps on the first molars. Add springs on the palate to move #6 distally and #8 mesially to gain space lost due to a congenitally missing #7.

Thank you.

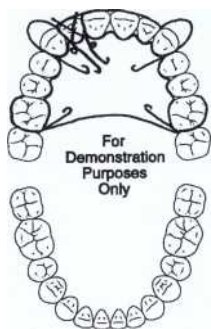
SIGNATURE:

LICENSE:

Fig. 19-10. A sample prescription for the fabrication of a maxillary removable appliance for the correction of teeth migration resulting from a congenitally missing lateral incisor.

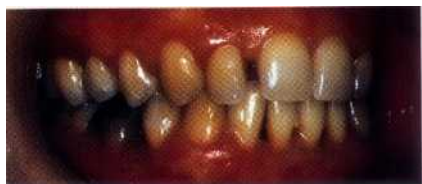

Fig. 19-11. Right labial view of a patient with spacing between the maxillary right lateral and central incisors.



ure to adhere to proper orthodontic technique can have adverse consequences.

**Armamentarium**

- Basic bracket and band placement setup. See the section on placement of orthodontic bands earlier in this chapter.
- 0.016-inch round orthodontic wire (Unitek/3M, Inc.)
- 0.022-inch × 0.018-inch rectangular wire (Unitek/3M, Inc.)



Fig. 19-12. Palatal view of a maxillary Hawley appliance designed with a labial arch wire and Adams clasps. Note also the auxiliary spring imbedded in the acrylic to move the maxillary, right lateral incisor mesially.

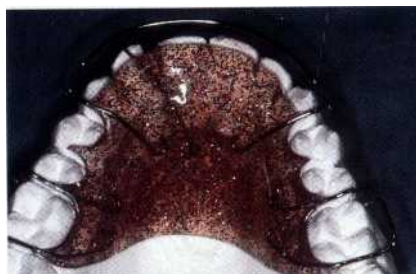

Fig. 19-13. Occlusal view of a Hawley appliance placed passively over a model of the maxillary arch. Note that the palatal auxiliary spring in the passive position lies in the middle of the right maxillary lateral incisor.

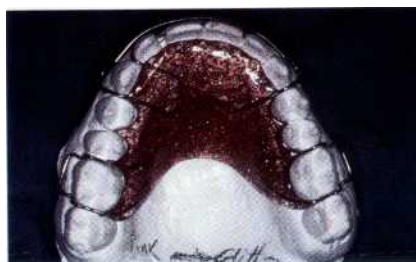

Fig. 19-14. Occlusal view of a Hawley appliance placed actively over a model of the maxillary arch. Note that the palatal auxiliary spring is engaged on the distal surface of the right maxillary lateral incisor.

- 0.010-inch diameter, 0.030-inch arbor diameter coil spring (Unitek/3M, Inc.)
- Orthodontic elastics (Unitek/3M, Inc.)
- Orthodontic stress and tension gauge (Dontrix-Richmond Orthodontic Stress and Tension Gauges, Unitek/3M, Inc.)

Clinical Technique

1. Acid etch the anterior teeth and premolars.
2. Apply the orthodontic bonding resin.
3. Place the orthodontic brackets. See the section on placement of orthodontic bands earlier in this chapter.


**CLINICAL TIP.** To ensure a satisfactory result, brackets must be placed perpendicular to the long axis of the tooth.

4. Construct an ideal arch wire to serve as a guide along which the teeth will be moved. Start with a thin (0.016-inch) round wire and finish with a 0.022-inch X 0.018-inch rectangular wire.

**CLINICAL TIP.** Coaxial wire delivers a more gentle force and provides a relatively painless start to the therapy.

**CLINICAL TIP.** To achieve a satisfactory result, the arch wire must follow an ideal arch form.

5. Activate the appliance with a coil spring or orthodontic elastics. Position the coil spring between the teeth; attach elastics from the tipped teeth distally to the end of the arch wire. The elastic should generate 1 ounce of force as measured by an orthodontic stress and tension gauge (Fig. 19-15).
6. Clinically evaluate the patient every 3 weeks.
7. Normal space closure occurs at the rate of 1 to 1.5 mm per month.



*Fig. 19-15. An example of a fixed appliance used to correct a migrated anterior tooth. Note that the elastics stretched over multiple anchors pulls the lateral incisor distally while a coil spring between the central incisors is used to upright and move the inclined right central incisor distally.*

### Correcting and Uprighting Migrated Premolars or Molars Removable Appliance

Armamentarium

- Irreversible hydrocolloid impression
- No. 139 orthodontic pliers

Clinical Technique

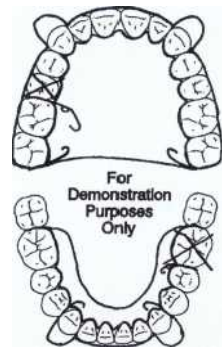
1. Make an irreversible hydrocolloid impression.
2. Send the models to an orthodontic laboratory for fabrication of a Hawley appliance that includes uprighting springs embedded in the acrylic (Fig. 19-16).
3. Activate the springs on the Hawley appliance while keeping the labial arch wire passive against the buccal surface of the mandibular teeth.
4. Clinically evaluate the patient every 2 to 3 weeks.
5. Normal uprighting occurs at a rate of 2 to 3 degrees per month.
6. Conically shaped teeth are much harder to upright with removable appliances because the spring tends to slip off the tooth. In these cases a fixed appliance should be used.

NAME: \_\_\_\_\_ DATE: \_\_\_\_\_  
 ADDRESS: \_\_\_\_\_ PHONE: ( ) \_\_\_\_\_  
 CITY: \_\_\_\_\_ STATE: \_\_\_\_\_ ZIP \_\_\_\_\_

PATIENT NAME: \_\_\_\_\_  
 DATE NEEDED: \_\_\_\_\_ TIME NEEDED: \_\_\_\_\_

**SPECIAL INSTRUCTIONS:**

Please construct a maxillary Hawley appliance with a circumferential labial bow and a coil spring from the lingual to upright #3 distally due to a missing #4. Also construct a mandibular Hawley appliance with a labial bow and a lingual spring to tip #20 mesially due to the loss of #19.



Thank you.

SIGNATURE: \_\_\_\_\_ LICENSE: \_\_\_\_\_

*Fig. 19-16. A sample prescription for the fabrication of maxillary and mandibular removable appliances for uprighting migrated teeth.*

### *Correcting and Uprighting Migrated Premolars or Molars-Fixed Appliance*

Fixed appliances require that the generalist be absolutely familiar with all aspects of fixed orthodontic therapy. Failure to adhere to proper orthodontic technique can have adverse consequences.

#### Armamentarium

- Basic bracket and band placement setup. See the section on placement of orthodontic bands earlier in this chapter.
- Premolar orthodontic bands with edgewise brackets (brackets may be bonded if the patient's esthetic concerns are paramount)
- Molar orthodontic bands with tubes
- Orthodontic zinc phosphate cement (Fleck's Cement, Mizzy, Inc.)
- 0.016-inch round orthodontic wire (Unitek/3M, Inc.)
- 0.022-inch X 0.018-inch rectangular orthodontic wire (Unitek/3M, Inc.)
- 0.010-inch diameter, 0.030-inch arbor diameter open coil spring (Unitek/3M, Inc.)

#### Clinical Technique

1. Fit the orthodontic bands to the teeth. See the section on placement of orthodontic bands earlier in this chapter.
2. Cement the bands into place. See the section on placement of orthodontic bands earlier in this chapter.

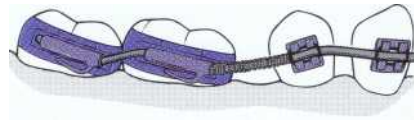
**CLINICAL TIP.** When uprighting premolar teeth, it is important to incorporate the first molar teeth in the appliance for stability of the dental arch.

**CLINICAL TIP.** To achieve a satisfactory result, the hand, **MUST** be properly phued.

3. If the goal is simple correction of lost space, construct the wire into an ideal arch form to serve as a guide along which the teeth will move (Fig. 19-17). If uprighting is required, include second order bends into the wire to create an uprighting action.

**CLINICAL TIP.** To ensure a satisfactory result, the arch wire must follow an ideal arch from

4. If the goal is simple correction of lost space, place a condensed (or activated) open coil spring. If uprighting is required, activate the wire with second order bends.
5. Clinically evaluate the patient every 2 weeks.



*Fig. 19-17. A fixed appliance used to upright and align migrated premolars and molars. The coil springs help to upright the molars and premolars while gaining space for future poetic placement and closing unwanted diastemata.*

6. Normal uprighting occurs at a rate of 3 to 5 degrees per month.

### *Correction of Anterior Flaring of Teeth-Removable Appliance*

#### Armamentarium

- Irreversible hydrocolloid
- No. 139 pliers (Unitek/3M, Inc.)

#### Clinical Technique

1. Make an irreversible hydrocolloid impression.
2. Send the models to an orthodontic laboratory for fabrication of a Hawley appliance.
3. Activate the labial arch wire to reduce the circumferences of the dental arch, thereby gently bringing the splayed teeth together.
4. Be sure that no occlusal interferences occur from the opposing arch as the teeth are brought together.
5. Clinically evaluate the patient every 2 weeks.
6. Normal correction of flaring occurs at a rate of 1 to 1.5 mm per month.

### *Correction of Anterior Flaring of Teeth-Fixed Appliance*

Fixed appliances require that the generalist be absolutely familiar with all aspects of fixed orthodontic therapy. Failure to adhere to proper orthodontic technique can have adverse consequences.

#### Armamentarium

- Basic bracket and band placement setup. See the section on placement of orthodontic bands earlier in this chapter.
- Bands for first molars
- Brackets for incisors, canines, and premolars (metal, ceramic, or plastic depending on the esthetic needs of the patient)
- Orthodontic zinc phosphate cement (Fleck's Cement, Mizzy, Inc.)

0.016-inch round orthodontic wire (Unitek/3M, Inc.)  
 0.022-inch X 0.018-inch rectangular orthodontic wire (Unitek/3M, Inc.)  
 0.010-inch diameter, 0.030-inch arbor diameter open coil spring (Unitek/3M, Inc.)  
 Orthodontic elastics  
 Orthodontic stress and tension gauge (Dontrix-Richmond Orthodontic Stress and Tension Gauges, Unitek/3M, Inc.)

#### Clinical Technique

1. Fit and cement the molar orthodontic bands. See the section on placement of orthodontic bands earlier in this chapter.
2. Acid etch the anterior teeth and premolars.
3. Apply the orthodontic bonding resin.
4. Place the orthodontic bonded brackets. See the section on placement of orthodontic bands earlier in this section.
5. Construct an ideal arch wire to serve as a guide along which the teeth will be moved. Start with a thin (0.016-inch) round wire and finish with a 0.022-inch X 0.018-inch rectangular wire.
6. Activate the appliance with orthodontic elastic cord or orthodontic elastics worn from hooks bent in the arch wire mesial to the brackets on canines to the end of the molar tubes. The elastic should generate 1 ounce of force as measured by an orthodontic stress and tension *eauee*.

**CLINICAL TIP.** Keep the book on the arch wire far enough mesial to the canine brackets to allow for continued closure of spaces. Also, build in bite-opening mechanics to open the bite if occlusal interferences are evident.

7. Clinically evaluate the patient every 3 weeks.
8. Normal space closure occurs at a rate of 1 to 2 mm per month unless the bite must be opened, in which case treatment time can increase by 3 to 6 months.

### LOCALIZED SPACING OF MAXILLARY CENTRAL INCISORS

Because of the great esthetic impact of localized spacing of the maxillary central incisors, this condition is described separately. The most common causes of this spacing are as follows:

1. Normal growth
2. Imperfect fusion of the midline
3. Enlarged labial frenum
4. Congenitally missing lateral incisors
5. Supernumerary teeth (mesiodens)
6. Anatomically small clinical crowns

### Differential Diagnosis

The space is localized between the central incisors.

**CLINICAL TIP.** Clinical examination of the frenum, along with lifting of the upper lip to note any blanching of the mucosa on the palate between the central incisors, will confirm an enlarged or malpositioned labial frenum.

Radiographic evidence will confirm a spade-shaped septum when the labial frenum is malpositioned. This radiologic characteristic also is seen in imperfect fusion of the midline, but in such cases no blanching of the frenum occurs when the lip is stretched. Supernumerary teeth and congenitally missing lateral incisors are confirmed with radiographs. Spacing as part of normal growth also can occur in patients with small bony bases and large teeth. The large crowns of the developing and unerupted lateral incisors and canines push the central incisor roots mesially toward each other, causing the central incisor crowns to erupt with a distal inclination and an accompanying diastema. Anatomically small teeth may be confirmed by measurement.

### Treatment

**Normal Growth.** If the spacing is determined to be part of normal growth, observe the patient until the lateral incisors and canines have erupted. In many instances the diastema closes during the normal eruption process. However, this type of diastema may also be evidence of possible future crowding of the permanent dentition.

**Imperfect Fusion of the Midline.** In the primary and mixed dentition, imperfect fusion of the midline becomes evident with the eruption of the permanent anterior teeth, including the canines, and should be treated in the permanent dentition stage. Treatment of imperfect fusion of the midline in the permanent dentition consists of moving the teeth together and retaining the positions.

### Diastema Closure-Removable Appliance

Simple closure of a maxillary midline diastema often creates spacing distally. For this reason, restorative dentistry may also be required to achieve proper esthetics (Figs. 19-18 and 19-19).

#### Armamentarium

Irreversible hydrocolloid impression  
 No. 139 pliers (Unitek/3M, Inc.)

#### Clinical Technique

1. Make an irreversible hydrocolloid impression.

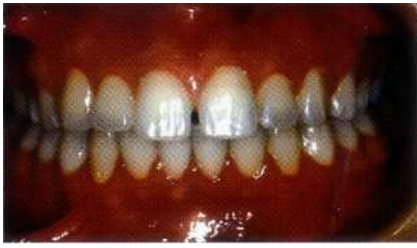

Fig. 19-18. Anterior view of a patient with a diastema between the maxillary central incisors.

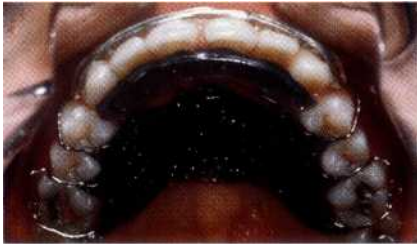

Fig. 19-19. Occlusal view of a maxillary Hawley appliance used to close the diastema for the patient shown in Figure 19-18.

2. Send the models to an orthodontic laboratory for fabrication of a Hawley appliance (Fig. 19-20).
3. Activate the springs on the Hawley appliance to bring the central incisors together while increasing pressure on the labial aspect to reduce the labial circumference in working relationship with the mandibular anterior teeth.
4. Be sure that no interference occurs in the working relationship with the mandibular anterior teeth.
5. Adjust the appliance every 2 weeks.
6. Space closure occurs at a rate of 1 to 2 mm per month.

### Diastema Closure-Fixed Appliance

Fixed appliances require that the generalist be absolutely familiar with all aspects of fixed orthodontic therapy. Failure to adhere to proper orthodontic **technique could have adverse consequences**. Because simple closure of a maxillary midline diastema often creates spacing distally, restorative dentistry may also be required to achieve proper esthetics.

#### Armamentarium

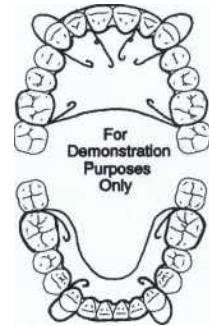
- Basic bracket and band placement setup. See the section on placement of orthodontic bands earlier in this chapter.
- Anterior edgewise orthodontic brackets (metal, ceramic, or plastic, depending on esthetic requirements)

NAME: \_\_\_\_\_ DATE: \_\_\_\_\_  
 ADDRESS: \_\_\_\_\_ PHONE: ( ) \_\_\_\_\_  
 CITY: \_\_\_\_\_ STATE: \_\_\_\_\_ ZIP \_\_\_\_\_  
 PATIENT NAME: \_\_\_\_\_  
 DATE NEEDED: \_\_\_\_\_ TIME NEEDED: \_\_\_\_\_

#### SPECIAL INSTRUCTIONS:

Please construct a maxillary Hawley appliance with a labial bow and circumferential clasps on the first molars. Please place lingual springs on the distal of both central incisors to close the diastema.

Also construct a mandibular Hawley appliance with a labial bow and circumferential clasps on the first molars to close anterior spaces. Slightly relieve the lingual acrylic to allow for the closing of the multiple diastemata.



Thank you.

SIGNATURE: \_\_\_\_\_ LICENSE: \_\_\_\_\_

Fig. 19-20. A sample prescription for the fabrication of maxillary and mandibular removable appliances for the closure of multiple diastemata.

- 0.016-inch round orthodontic wire (Unitek/3M, Inc.)
- 0.022-inch X 0.018-inch rectangular orthodontic wire (Unitek/3M, Inc.)
- Orthodontic elastics (Unitek/3M, Inc.)
- Orthodontic stress and tension gauge (Dontrix-Richmond Orthodontic Stress and Tension Gauges, Unitek/3M, Inc.)


#### Clinical Technique

1. Place the orthodontic brackets on the anterior teeth (Fig 19-21). See the section on placement of orthodontic bands earlier in this chapter.

**CLINICAL TIP.** To achieve a satisfactory result, the brackets must be placed perpendicular to the long axis of the tooth.

2. Construct an ideal arch wire to serve as a guide along which the teeth will be moved.

**CLINICAL TIP.** To achieve a satisfactory result, the arch wire must follow an ideal arch form.



*Fig. 19-21.* A fixed appliance used to close a diastema through activation of elastic stretched over multiple teeth and a stabilizing arch wire.

3. Activate the appliance with orthodontic elastics. The elastic should generate 1 ounce of force, as measured by an orthodontic stress and tension gauge.
4. Clinically evaluate the patient every 2 weeks.
5. Normal space closure occurs at a rate of 1 to 2 mm per month (Figs. 19-22 to 19-25).

### Diastema Closure-Retention

#### Armamentarium

- Irreversible hydrocolloid
- No. 128 pliers (Unitek/3M, Inc.)

#### Clinical Technique

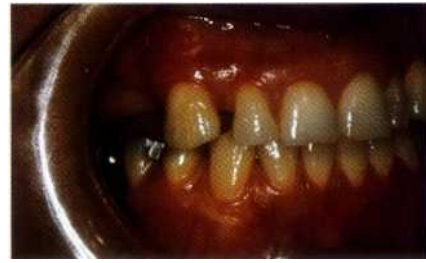1. Make an irreversible hydrocolloid impression.
2. Send the models to an orthodontic laboratory for fabrication of a Hawley appliance with a labial bow (Fig. 19-26).
3. Activate the labial bow to exert slight pressure on the labial surface of the teeth so as to retain the space closure. The patient must wear the appliance 24 hours a day for 3 months, then only at night for 3 to 6 months.
4. Clinically evaluate the patient in 3 weeks and then at 6-week intervals.
5. If the space starts to reopen, the patient must wear the appliance more often. Check to see if the mandibular anterior teeth are pushing against the maxillary anterior teeth during working movements. If so, expand treatment to the mandibular arch.

### Enlarged or Malpositioned Frenum

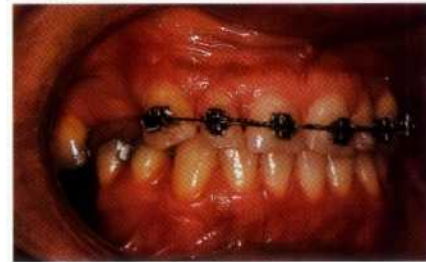Treatment and retention are identical to those described in the section on treatment of normal localized spacing of maxillary central incisors earlier in this chapter except that a frenectomy is necessary. A frenectomy is accomplished by using the following process.'

#### Armamentarium

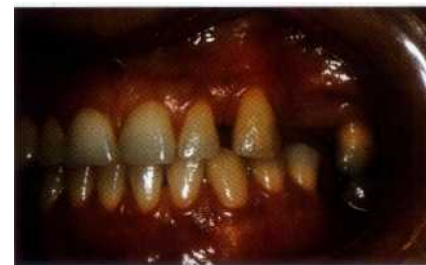- Standard dental setup
  - Explorer
  - Mouth mirror



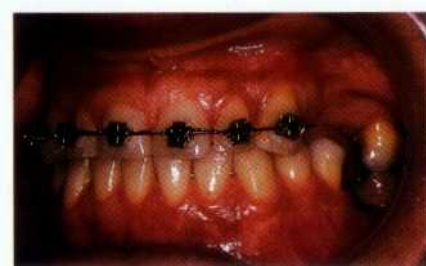*Fig. 19-22.* Right labial view of a patient showing a diastema between the right lateral and canine teeth.



*Fig. 19-23.* Right labial view of the patient shown in Figure 19-22. The diastema between the right lateral and canine teeth was eliminated using bonded brackets and a segmented arch wire.



*Fig. 19-24.* Left labial view showing a patient with a diastema between the left lateral and canine teeth.



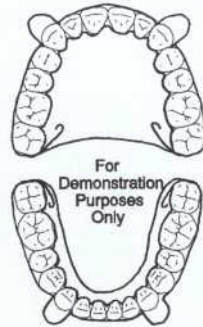*Fig. 19-25.* Left labial view of the patient shown in Figure 19-24. The diastema between the left lateral and canine teeth was eliminated using bonded brackets and a segmented arch wire.

NAME: \_\_\_\_\_ DATE: \_\_\_\_\_  
 ADDRESS: \_\_\_\_\_ PHONE: ( ) \_\_\_\_\_  
 CITY: \_\_\_\_\_ STATE: \_\_\_\_\_ ZIP: \_\_\_\_\_  
 PATIENT NAME: \_\_\_\_\_  
 DATE NEEDED: \_\_\_\_\_ TIME NEEDED: \_\_\_\_\_

**SPECIAL INSTRUCTION:**

Please construct a maxillary Hawley appliance and a mandibular Hawley appliance with labial bows and circumferential clasps on the first molars to retain the teeth following space closure.

Thank you.



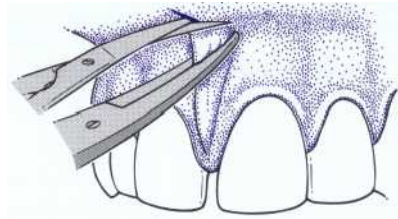
SIGNATURE: \_\_\_\_\_ LICENSE: \_\_\_\_\_

*Fig. 19-26. A sample prescription for the fabrication of maxillary and mandibular removable appliances to retain the position of the teeth after space closure.*

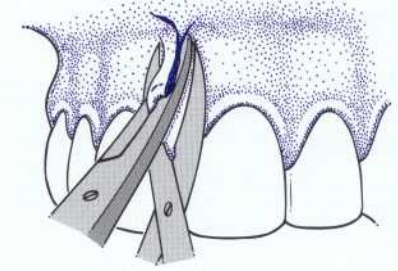
- Periodontal probe
- Suitable anesthesia
- Curved hemostat
- Periodontal tissue scissors
- No. 15 Bard-Parker knife
- Needle holder
- 4-0 black silk sutures
- Periodontal dressing (e.g., COE-pak, Coe Laboratories, Inc.)

**Clinical Technique**

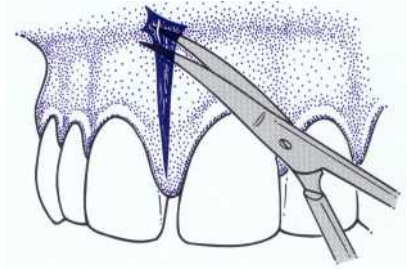
1. Obtain a proper medical history and presurgical evaluation.
2. Anesthetize the area.
3. Grasp the frenum with the curved hemostat.
4. Incise the upper margin of the frenum with a curved periodontal tissue scissors or a No. 15 Bard-Parker knife (Fig. 19-27).
5. Incise the lower margin of the frenum with a curved periodontal tissue scissors or a No. 15 Bard-Parker knife (Fig. 19-28).
6. Remove the incised wedge-shaped frenum.
7. If any mucosal tissue is under tension, place the curved periodontal tissue scissors beneath that tis-



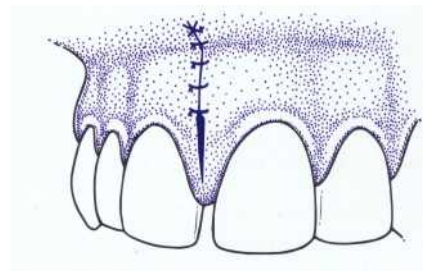
*Fig. 19-27. The upper margin of the frenum is incised with a curved periodontal tissue scissors or a No. 15 Bard-Parker knife.*



*Fig. 19-28. The lower margin of the frenum is incised with a curved periodontal tissue scissors or a No. 15 Bard-Parker knife.*



*Fig. 19-29. If any mucosal tissue is under tension, the curved periodontal tissue scissors is placed beneath that tissue and the fibers are released by blunt dissection.*



*Fig. 19-30. The incision is sutured with 4-0 black silk sutures.*

- sue and release the fibers by blunt dissection (Fig. 19-29).
8. Suture the incision with 4-0 black silk sutures (Fig. 19-30).

9. After achieving hemostasis, place a periodontal packing on the area.
10. Leave the packing and sutures in place for 1 week.

### Supernumerary Teeth

Supernumerary teeth (mesiodens) must be extracted. After removal of the supernumerary tooth in the primary and mixed dentition, normal tooth eruption may correct the situation. If spacing persists, use conventional orthodontic therapy. In the permanent dentition, conventional orthodontic therapy is required.

### Congenitally Missing Lateral Incisors

Congenitally missing permanent lateral incisors are not clinically evident in the primary dentition. If the condition is suspected from the family history, radiographs may be taken.

In the mixed dentition, congenitally missing lateral incisors can be clinically distinguished from other causes of localized spacing of the maxillary central incisors by overretention of the primary lateral incisors. Radiographs confirm the diagnosis.

In the permanent dentition, congenitally missing lateral incisors present the clinician with one of the greatest esthetic challenges. If the canines are slender, the spaces may be closed and the canines contoured to resemble the missing lateral incisors. This is often difficult because of the bulkiness of the canine. Several restorative approaches can be taken, dictated by the anatomic relationships present. Consultation and coordination of treatment objectives between the generalist and the orthodontic specialist are essential. The introduction of new esthetic materials has enhanced the resolution of these cases.

### Anatomically Small Teeth

Anatomically small teeth are best treated with esthetic restorative materials.

It is essential to observe the occlusion whenever treating patients with space problems. Occlusal interferences from the mandibular dentition may cause spacing or prevent attempts at space closure. Both arches must be treated to resolve these cases properly.

#### LABIOVERSION OF THE MAXILLARY INCISORS

Labioversion of the maxillary incisors is a type of malocclusion usually caused by adverse oral habits such as thumb or finger sucking. The generalist is likely to see these cases first, when palliative treatment of oral habits

might prevent the condition from fully developing and reversal may occur. Therefore early diagnosis and treatment or referral are essential. If serial extraction is selected, the clinician is committed to following the patient's treatment through the time of full eruption of the permanent dentition. The patient and the patient's parents should be advised of the extended nature of this type of correction and that treatment may include further fixed appliance therapy. However, such intervention usually tends to simplify and shorten the duration of active orthodontic appliance therapy if it is required.

### Diagnosis

Overjet of the maxillary anterior teeth often is combined with a Class I molar relationship. The amount of overbite varies, but a deep curve of Spee is common because the mandibular anterior teeth overerupt when their antagonists' forward position cannot provide a normal occlusal stop relationship. It is important not to confuse this with the case of a Class II, division I malocclusion in which the mandibular molars have moved mesially into a Class I position because of the early loss of the deciduous molars. Although the latter cases also show both overbite and overjet, the mandibular anterior teeth show extreme crowding as well.

### Treatment

In the primary dentition, palliative control of oral habits is indicated. See the section on generalized spacing earlier in the chapter.

In mixed dentition, the elimination of oral habits also is indicated. Removable appliance therapy may be successful at this time (see the section on correction of anterior flaring of teeth, removable appliance, earlier in this chapter). Selected serial extraction of the primary dentition may also influence the eruption pattern of the secondary teeth.

In the permanent dentition, full appliance mechanotherapy is used to open the bite and retract the anterior teeth (see the section on correction of anterior flaring of teeth, fixed appliance, earlier in this chapter). Oral habits also must be corrected for treatment to succeed.

#### LABIOLINGUALLY MALPOSITIONED TEETH

##### Differential Diagnosis

Teeth may be labiolingually malpositioned for a number of reasons.

**Normal Growth.** Often no other malocclusion occurs except for a lingually or labially displaced tooth. This



can be caused by overretained primary teeth or by the individual growth pattern of the patient. If a simple labiolingual displacement is involved, a removable Hawley appliance is used. If the teeth are rotated or tipped, fixed orthodontic appliance therapy is indicated.

**Crowded Teeth.** Crowded teeth usually result from teeth that are too large for the dental arch. Crowded teeth are discussed in the section on lateral disharmonies of the teeth and dental arch later in this chapter.

**Other Malocclusion.** Labiolingual malpositioning of anterior teeth is seen in Class II and Class III malocclusions and is discussed in the sections on Class II distocclusion and Class III mesiocclusion, respectively, later in this chapter.

**CLINICAL TIP.** Successful treatment of labiolingually malpositioned teeth requires adequate space within which to move the malpositioned tooth. If this space is not present, complete orthodontic therapy by a specialist is required.

### *Correction of Labially or Lingually Malpositioned Teeth-Removable Appliance*

#### Armamentarium

- Irreversible hydrocolloid impression
- No. 139 pliers (Unitek/3M, Inc.)

#### Clinical Technique

1. Make an irreversible hydrocolloid impression of the dentition.
2. Send the models to an orthodontic laboratory for fabrication of a Hawley appliance (Fig. 19-31).
3. If lingual movement is required, activate the labial arch wire (Figs. 19-32 and 19-33).
4. If labial movement is required, embed a finger spring in the palatal or lingual acrylic.
5. Normal movement occurs at a rate of 0.5 to 1 mm per month.

**CLINICAL TIP.** When labial movement is required, it is important to position the labial arch wire so that it does not inhibit movement of the tooth.

### *Correction of Labially or Lingually Malpositioned Teeth-Fixed Appliance*

Fixed appliances require that the generalist be absolutely familiar with all aspects of fixed orthodontic therapy. Failure to adhere to proper orthodontic technique could have adverse consequences.

#### Armamentarium

- Basic bracket and band placement setup. See the section on placement of orthodontic bands earlier in this chapter.
- Anterior edgewise orthodontic brackets (metal, ceramic, or plastic, depending on esthetic requirements)
- 0.016-inch round orthodontic wire (Unitek/3M, Inc.)
- 0.022-inch X 0.018-inch rectangular orthodontic wire (Unitek/3M, Inc.)
- 0.010-inch diameter, 0.030-inch arbor diameter coil spring (Unitek/3M, Inc.)
- Orthodontic elastics (Unitek/3M, Inc.)
- Orthodontic stress and tension gauge (Dontrix-Richmond Orthodontic Stress and Tension Gauges, Unitek/3M, Inc.)

#### Clinical Technique

1. Place anterior orthodontic bonding brackets, including at least three teeth beyond the tooth to be brought into alignment. See the section on placement of orthodontic bands earlier in this chapter.

NAME: \_\_\_\_\_ DATE: \_\_\_\_\_

ADDRESS: \_\_\_\_\_ PHONE: ( ) \_\_\_\_\_

CITY: \_\_\_\_\_ STATE: \_\_\_\_\_ ZIP \_\_\_\_\_

PATIENT NAME: \_\_\_\_\_

DATE NEEDED: \_\_\_\_\_ TIME NEEDED: \_\_\_\_\_

**SPECIAL INSTRUCTIONS:**

Please construct a maxillary Hawley appliance with a labial bow and circumferential clasps on the first molars to move #8 palatally into correct alignment. Relieve the palatal acrylic around #8 to allow for this movement.

Also, please construct a mandibular Hawley appliance with a labial bow and circumferential clasps on the first molars. A lingual spring on #23 to move it labially into alignment.

Thank you.

SIGNATURE: \_\_\_\_\_ LICENSE: \_\_\_\_\_

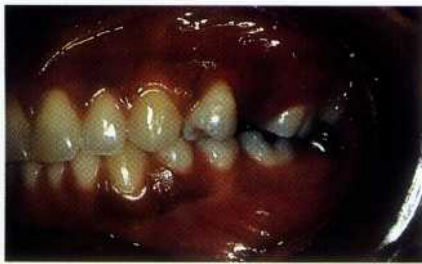

*Fig. 19-31. A sample prescription for the fabrication of maxillary and mandibular removable appliances to correct labially or lingually malpositioned teeth.*

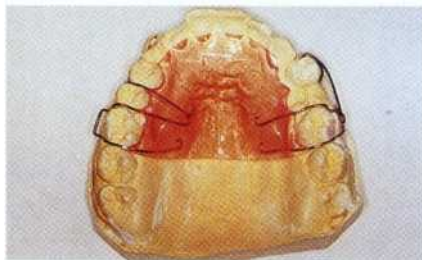

**CLINICAL TIP.** To ensure a satisfactory result, the brackets must be placed perpendicular to the long axis of the tooth.

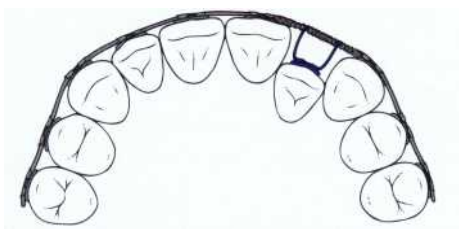
- Place a coil spring on the arch wire between the teeth adjacent to the malposed tooth or place elastics distally to the end of the arch if space is available to activate the appliance. The force on the tooth should be 1 ounce, as measured by an orthodontic stress and tension gauge (Fig. 19-34).
- Clinically evaluate the patient every 2 weeks.
- Normal movement occurs at a rate of 1 to 1.5 mm per month.



**Fig. 19-32.** Left buccal view of a patient with a crossbite of the maxillary first premolar.



**Fig. 19-33.** Occlusal view of a maxillary Hawley appliance with an Adams clasp and auxiliary springs soldered at the left. The Adams clasp is coming mesially to engage the first premolar to push it palatally to eliminate the crossbite.



**Fig. 19-34.** A fixed appliance to correct a lingually malposed tooth. A coil spring is used to move the tooth. Space is gained by interproximal reduction of enamel. Note that the stabilizing arch wire extends three teeth or more past the affected tooth.

## ROTATED TEETH

### Diagnosis

When spaces are present, the teeth often not only migrate mesiodistally but also may rotate. In addition, overretention of primary teeth may cause abnormal eruption patterns of the permanent tooth, causing abnormal rotational eruption.

### Treatment

In the primary and mixed dentition, early diagnosis of overretained primary teeth is imperative. Extraction of the offending tooth often leads to self-correction. Appliance therapy is not recommended at this time. In the permanent dentition, orthodontic correction is necessary.

### Rotated Teeth-Removable Appliance

#### Armamentarium

- Irreversible hydrocolloid impression
- No. 139 pliers (Unitek/3M, Inc.)

#### Clinical Technique

- Make an irreversible hydrocolloid impression of the dentition.
- Send the models to an orthodontic laboratory for fabrication of a Hawley appliance, which will include springs embedded in the lingual acrylic (Fig. 19-35).
- Activate the lingual springs of the Hawley appliance while maintaining positive labial pressure with the labial wire.
- Examine the patient every 2 to 3 weeks.
- Normal correction occurs at a rate of 2 to 3 degrees per month.

### Rotated Tooth-Fixed Appliance

Fixed appliances require that the generalist be absolutely familiar with all aspects of fixed orthodontic therapy. Failure to adhere to proper orthodontic technique could have adverse consequences.

#### Armamentarium

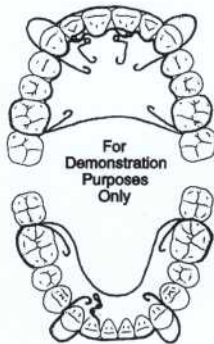
- Basic bracket and band placement setup. See the section on placement of orthodontic bands earlier in this chapter.
- Anterior edgewise orthodontic brackets (metal, ceramic, or plastic, depending on the esthetic requirements)
- 0.016-inch round orthodontic wire (Unitek/3M, Inc.)

NAME: \_\_\_\_\_ DATE: \_\_\_\_\_  
 ADDRESS: \_\_\_\_\_ PHONE: (\_\_\_\_) \_\_\_\_\_  
 CITY: \_\_\_\_\_ STATE: \_\_\_\_\_ ZIP \_\_\_\_\_

PATIENT NAME: \_\_\_\_\_  
 DATE NEEDED: \_\_\_\_\_ TIME NEEDED: \_\_\_\_\_

**SPECIAL INSTRUCTIONS:**

Please construct a maxillary Hawley appliance with a labial bow and circumferential clasps on the first molars with lingual springs to rotate #7 mesiolabially and #9 mesiolabially. Also, please construct a mandibular Hawley appliance with a labial bow and circumferential clasps on the first molars and a lingual spring on #26 to rotate it disto-labially.



Thank you.

SIGNATURE: \_\_\_\_\_ LICENSE: \_\_\_\_\_

*Fig. 19-35. A sample prescription for the fabrication of maxillary and mandibular removable appliances to correct rotated teeth.*

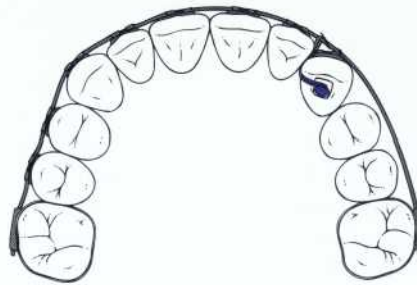
- 0.022-inch X 0.018-inch rectangular orthodontic wire (Unitek/3M, Inc.)
- 0.010-inch diameter, 0.030-inch arbor diameter coil spring (Unitek/3M, Inc.)
- Orthodontic elastics
- Orthodontic stress and tension gauge (Dontrix-Richmond Orthodontic Stress and Tension Gauges, Unitek/3M, Inc.)
- No. 128 pliers (Unitek/3M, Inc.)

**Clinical Technique**

1. Place the orthodontic brackets or bands on at least three teeth (or up to the first molar) on each side of the rotated tooth. **See the** section on placement of **orthodontic** bands earlier in this chapter.

**CLINICAL TIP.** To ensure a satisfactory result, the brackets must be placed perpendicular to the long axis of the tooth.

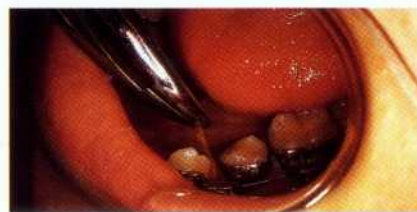2. Place a lingual button on the tooth to be rotated. See the section on placement of orthodontic bands earlier in this chapter. (Fig. 19-36).
3. Construct an ideal arch wire to serve as a guide for the rotation of the malposed tooth (Fig. 19-37).



*Fig. 19-36. A fixed appliance that is used to correct a rotated tooth. Note the use of elastic ligature attached to a lingual button to help rotate the tooth.*



*Fig. 19-37. Occlusal view of a mandibular arch wire with elastic "lig-o-ring" ligature placed on an arch wire before placement of the arch wires into the molar tubes.*



*Fig. 19-38. Occlusal view of a patient's left buccal area. The ligature is being stretched and attached to a button on the lingual side of a mesiolingually rotated second premolar.*

**CLINICAL TIP.** The arch wire must follow an ideal arch form, otherwise other teeth could migrate.

4. Activate the appliance with orthodontic elastics (Figs. 19-38 and 19-39).
5. **Clinically evaluate** the patient every 2 weeks.
6. Normal rotation occurs at a rate of 3 to 5 degrees per month.

**CLINICAL TIP.** Relapse is common after rotational correction of malpositioned teeth. Overcorrection is recommended to compensate for this relapse. Permanent retention can be achieved by bonding the lingual surface of the tooth to the adjacent teeth with a thin orthodontic wire embedded in composite resin.

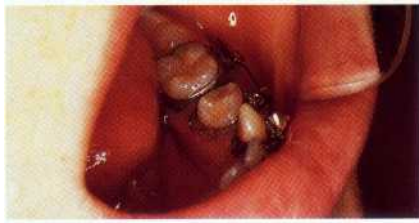

Fig. 19-39. Occlusal view of the left buccal area of the patient shown in Figure 19-38. The ligature is in place on the lingual side of the second premolar and rotation is taking place.

## EXTRUDED TEETH

### Diagnosis

An extrusion occurs when a tooth has overerupted past the normal plane of occlusion. It is most commonly seen in middle aged or older patients who have lost opposing teeth. Most cases also have periodontal involvement.

### Correction of Extruded Teeth-Removable Appliance

#### Armamentarium

- Irreversible hydrocolloid impression
- Orthodontic elastic (Unitek/3M, Inc.)
- No. 128 pliers (Unitek/3M, Inc.)

#### Clinical Technique

1. Make an irreversible hydrocolloid impression of the dentition.
2. Send the models to an orthodontic laboratory for fabrication of a Hawley appliance (Fig. 19-40).
3. The Hawley appliance should be modified with both a labial and a palatal hook.
4. After placement of the appliance, stretch the elastic over the labial and palatal hooks. This serves as a sling to intrude the tooth. Use the smallest elastic that will fit on the hooks.
5. Examine the patient every 2 weeks.
6. The normal rate of correction of extrusion is 0.10 to 0.25 mm per month.

### Correction of Extruded Teeth-Fixed Appliance

Fixed appliances require that the generalist be absolutely familiar with all aspects of fixed orthodontic therapy. Failure to adhere to proper orthodontic technique could have adverse consequences.

#### Armamentarium

- Basic bracket and band placement setup. See the section on placement of orthodontic bands earlier in this chapter.

NAME: \_\_\_\_\_ DATE: \_\_\_\_\_  
 ADDRESS: \_\_\_\_\_ PHONE: (\_\_\_\_) \_\_\_\_\_  
 CITY: \_\_\_\_\_ STATE: \_\_\_\_\_ ZIP \_\_\_\_\_

PATIENT NAME: \_\_\_\_\_

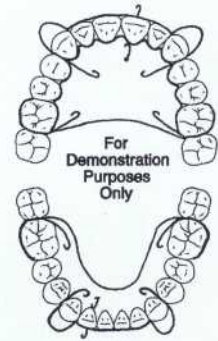
DATE NEEDED: \_\_\_\_\_ TIME NEEDED: \_\_\_\_\_

#### SPECIAL INSTRUCTIONS:

Please construct a maxillary Hawley appliance with a labial bow and circumferential clasps on the first molars. Solder hook on labial bow by tooth #9. Imbed a hook in the acrylic palatal to #9 so that an elastic can be placed to intrude the tooth.

Also construct a mandibular

Hawley appliance in a similar manner to allow for the intrusion of #26.



Thank you.

SIGNATURE: \_\_\_\_\_ LICENSE: \_\_\_\_\_

Fig. 19-40. A sample prescription for the fabrication of maxillary and mandibular removable appliances to intrude teeth.

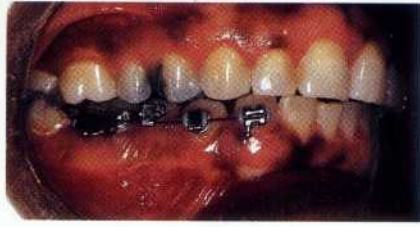- Anterior edgewise orthodontic brackets (metal, ceramic, or plastic, depending on the esthetic requirements)
- 0.016-inch round orthodontic wire (Unitek/3M, Inc.)
- 0.022-inch x 0.018-inch rectangular orthodontic wire (Unitek/3M, Inc.)
- Orthodontic elastics (Unitek/3M, Inc.)
- Orthodontic stress and tension gauge (Dontrix-Richmond Orthodontic Stress and Tension Gauges, Unitek/3M, Inc.)

#### Clinical Technique

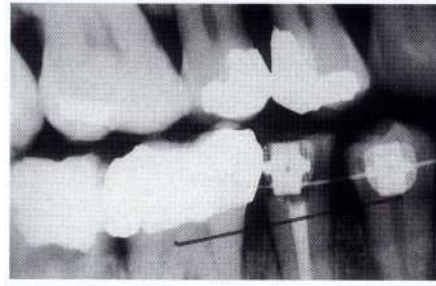
1. Place orthodontic bonded brackets on malposed tooth and on at least three teeth on each side of the tooth to be moved. See the section on placement of orthodontic bands earlier in this chapter.

**CLINICAL TIP.** It is important to place the brackets perpendicular to the long axis of the tooth and at the central part of the crown. Because the tooth requiring intrusion is at a different level than the adjacent teeth, the bracket must also be at the corresponding level. Upon the completion of therapy, all brackets will line up.

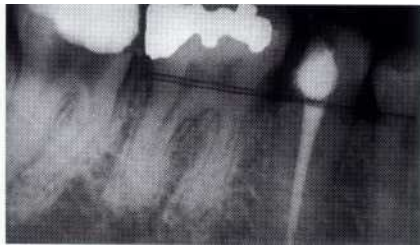




*Fig. 19-41. Right buccal view of a patient with a fixed segmented arch wire on the mandibular right canine through the first molar to elevate the crown of the mandibular right second premolar.*



*Fig. 19-43. Radiograph of the patient shown in Figure 19-41 showing elevation of the mandibular second premolar.*



*Fig. 19-42. Dental radiograph of the patient shown in Figure 19-41 at the beginning of treatment.*

2. Construct an ideal arch wire.

**CLINICAL TIP.** To ensure a satisfactory result, the arch wire must follow an ideal arch form.

3. Crimp and tie the labial arch wire to allow for ligation of the teeth.
4. The crimped arch wire will intrude the teeth as it returns to ideal form.
5. Clinically evaluate the patient every 2 weeks.
6. The normal rate of correction of extrusion is 0.25 to 0.50 mm per month.

### **INTRUDED TEETH**

Intrusion of teeth is caused by either ankylosis or trauma. Teeth intruded because of ankylosis are impossible to move orthodontically and often require prosthetic treatment to correct esthetic problems. Traumatically intruded teeth or teeth that require extrusion because of traumatic loss of the clinical crown can be extruded orthodontically. The principles discussed in the section on extruded teeth apply, except that the forces are reversed, as discussed under the section on crown lengthening procedures in Chapter 18 (Figs. 19-41 to 19-43).

### **SIMPLE ANTERIOR CROSSBITE**

#### *Diagnosis*

First molars are often in a Class I relationship with one or more of the maxillary anterior teeth inclined lingually. Simpler cases involving only one or two teeth can be treated by the generalist, but more complicated cases involving multiple teeth and an extreme lack of space should be referred to a specialist. These cases normally can be diagnosed on clinical examination, but space requirements are easier to determine when study models are used.

#### *Tongue Depressor Therapy*

When the patient is cooperative and only a single tooth is involved, the simplest solution is to use a tongue depressor to leverage the tooth into correct alignment.

#### Armamentarium

Tongue depressor

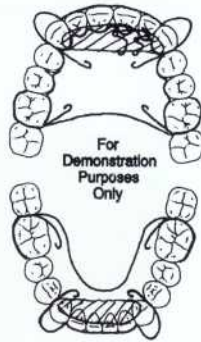
#### Clinical Technique

1. Instruct the patient to hold the tongue blade at a 45-degree angle against the lingual surface of the maxillary incisor.
2. Caution the patient not to impinge on the soft tissue of the palate with the tip of the blade while biting down.
3. Instruct the patient to execute this biting maneuver 50 times, twice a day, for 2 weeks. This usually is sufficient for the tooth to move labially into its correct position.

**CLINICAL TIP.** The tongue depressor technique works quickly provided enough space is available. However, because the patient experiences some pain, the technique usually is unsuccessful with sensitive patients or those with a low level of pain tolerance.

NAME: \_\_\_\_\_ DATE: \_\_\_\_\_  
 ADDRESS: \_\_\_\_\_ PHONE: ( ) \_\_\_\_\_  
 CITY: \_\_\_\_\_ STATE: \_\_\_\_\_ ZIP: \_\_\_\_\_  
 PATIENT NAME: \_\_\_\_\_  
 DATE NEEDED: \_\_\_\_\_ TIME NEEDED: \_\_\_\_\_  
 SPECIAL INSTRUCTION:

Please construct a maxillary Hawley appliance with a labial bow and circumferential clasps on the first molars. Place springs palatal to #9 and #10. Build an occlusal table palatal to #6 through #11 to open the bite to allow for the correction of the crossbite of #9 and #10. Also, construct a mandibular Hawley appliance with a labial bow and circumferential clasps on the first molars. Build up occlusal acrylic with a lingual inclination over the incisal edges of #22 through #27 to correct the crossbite.



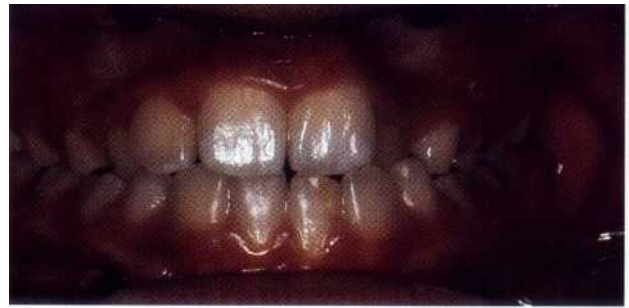Thank you.

SIGNATURE: \_\_\_\_\_ LICENSE: \_\_\_\_\_

**Fig. 1944.** A sample prescription for the fabrication of maxillary and mandibular removable appliances to correct an anterior crossbite.

### Appliance Therapy

An alternative to tongue depressor therapy is the use of a removable appliance. This is indicated when space is sufficient but the patient either cannot use or cannot tolerate tongue blade therapy or when several teeth are involved. A Hawley appliance with either an acrylic inclined plane or a finger spring to push the tooth into position is used. The finger spring appliance incorporates an occlusal plane to prevent the mandibular incisors from occluding. This type of appliance is used when a true crossbite relationship exists. The inclined plane appliance is used when the patient can incise in an edge-to-edge relationship when closing into the most retruded mandibular position but the mandible slips anterior into a bite of convenience during mastication. Sometimes, especially when space is insufficient, it is necessary to use full appliance therapy with Class III mechanics to correct the crossbite.



**Fig. 19-45.** Anterior view of a patient with a crossbite on the maxillary lateral incisor.

### Correction of Anterior Crossbite-Removable Appliance

#### Armamentarium

Irreversible hydrocolloid impression  
 No. 139 orthodontic pliers (Unitek/3M, Inc.)

#### Clinical Technique

1. Make an irreversible hydrocolloid impression.
2. Send the models to an orthodontic laboratory for fabrication of a Hawley appliance (Fig. 19-44).
3. Insert the Hawley appliance.
4. For the inclined plane appliance, adjust the acrylic so that the mandibular incisors are forced to occlude lingually and cannot position labially into a bite of convenience.
5. For the lingual finger spring appliance, adjust the spring so that the lingually tipped maxillary anterior teeth are pushed labially. The occlusal plane prevents the mandibular anterior teeth from occluding with the maxillary anterior teeth, which would inhibit therapeutic correction.
6. Clinically evaluate the patient every 2 weeks (Figs. 19-45 to 19-48).
7. Therapy usually is completed in 2 to 3 months.

### Correction of Anterior Crossbite-Fixed Appliance

Fixed appliances require that the generalist be absolutely familiar with all aspects of fixed orthodontic therapy. Failure to adhere to proper orthodontic technique could have adverse consequences.

#### Armamentarium

Basic bracket and band placement setup. See the section on placement of orthodontic bands earlier in this chapter.

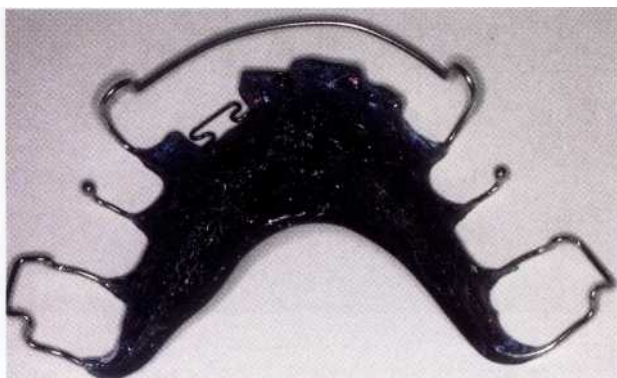

Fig. 19-46. Occlusal view of a Hawley appliance with an Adams clasp on the first molars and a palatal spring imbedded in the acrylic to move the lateral incisor out of crossbite.

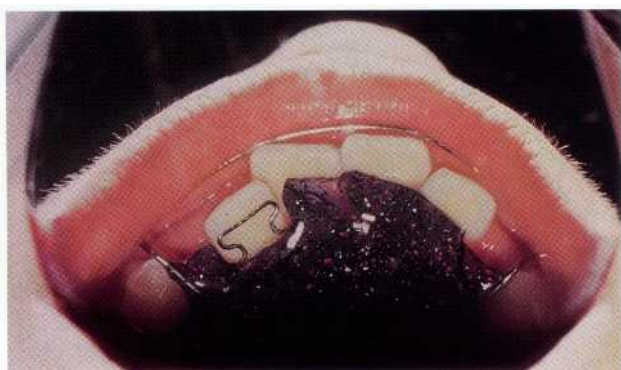

Fig. 19-47. Occlusal view of the patient shown in Figure 19-45 with the Hawley appliance engaged.

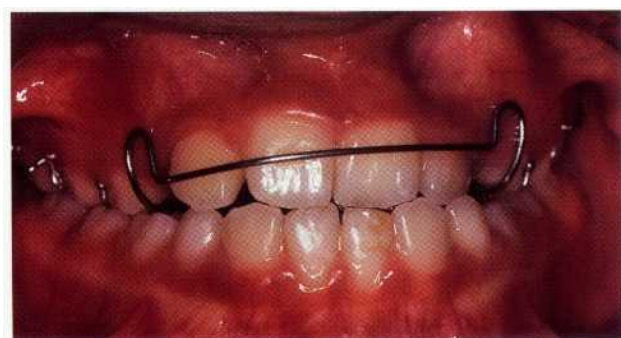


Fig. 19-48. Anterior view of the patient shown in Figure 19-45 with the appliance engaged.

- Anterior edgewise orthodontic brackets (metal, ceramic, or plastic, depending on the esthetic requirements)
- 0.016-inch round orthodontic wire (Unitek/3M, Inc.)

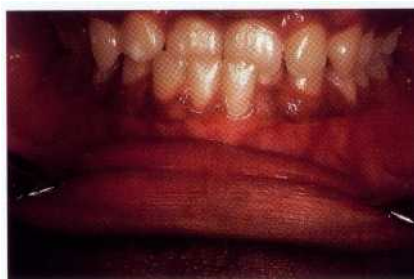
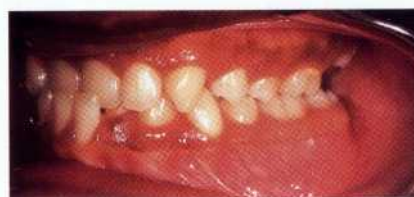
Fig. 19-49. Frontal view of a patient with an anterior crossbite involving the maxillary central incisors and the mandibular right lateral, right central, and left central incisors.



Left labial view of the patient shown in Figure 19-49.

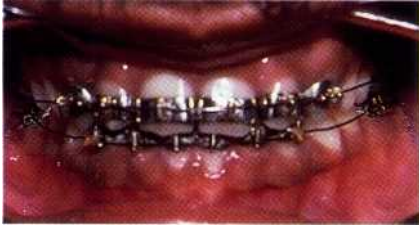- 0.022-inch X 0.018-inch rectangular orthodontic wire (Unitek/3M, Inc.)
- 0.010-inch diameter, 0.030-inch arbor diameter coil spring (Unitek/3M, Inc.) (optional)
- Orthodontic elastics (Unitek/3M, Inc.)
- Orthodontic stress and tension gauge (Dontrix-Richmond Orthodontic Stress and Tension Gauges, Unitek/3M, Inc.)

Clinical Technique

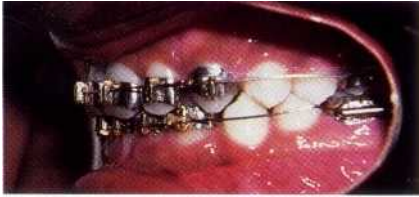1. Place anterior orthodontic brackets on all anterior teeth; place bands on the first molars. See the section on placement of orthodontic bands earlier in this chapter.

**CLINICAL TIP.** To ensure a satisfactory result, the brackets must be placed perpendicular to the long axis of the tooth.

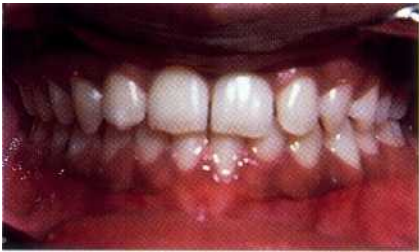2. Place bilateral Class III elastics from the mandibular canines to the maxillary first molars to move the mandibular anterior teeth lingually. In addition, bilateral coil springs may be placed between the maxillary canine and the first molar brackets if the maxillary anterior teeth must be moved labially. The elastic should generate 1 ounce of force as measured by an orthodontic stress and tension gauge.
3. Clinically evaluate the patient every 2 weeks.
4. Normal movement occurs at a rate of 1 to 1.5 mm per month (Figs. 19-49 to 19-54).



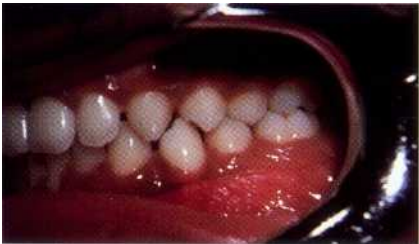*Fig. 19-51. Frontal view of the patient shown in Figure 19-49 with the fixed appliance in place. The first molars and all anterior teeth are banded. Ceramic, plastic, or even metal brackets could be substituted for bands if esthetics is a concern.*



*Fig. 19-52. Left labial view of the patient shown in Figure 19-51.*



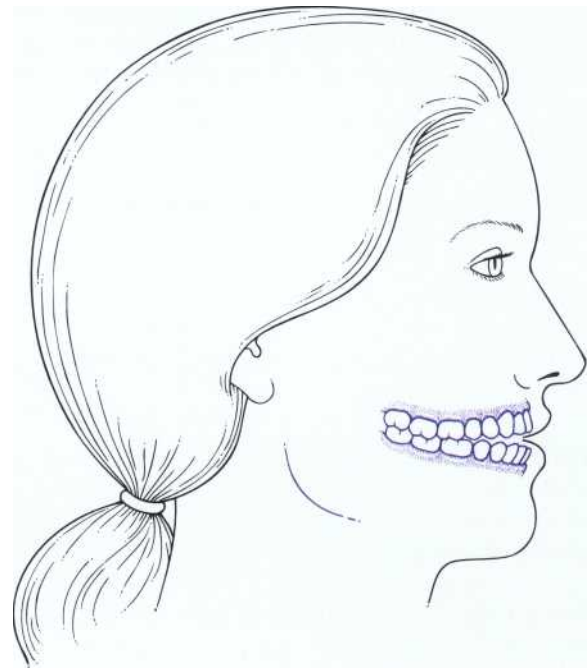
*fig 19-53. Frontal view after completion of orthodontic treatment.*



*Fig. 19-54. Left labial view after completion of orthodontic treatment.*

### ANTERIOR OPEN BITE

An open bite occurs when teeth of the opposing arches do not meet in a centric occlusion position (Fig. 19-55). This can occur with any type of molar relationship. Treatment often is complicated, and diagnosis usually requires clinical evaluation along with examination of study models



*Fig. 19-55. A patient with an anterior open bite.*

and cephalometric and panoramic radiographs. The generalist may wish to consult a specialist about these cases. Ankylosed teeth may require alternative treatments.

### Diagnosis

Deleterious habits, such as finger or tongue sucking, are the cause of anterior open bites in children. Constant biting on pencils or on the stem of a pipe can be the cause in adults. Sometimes the problem persists when the tongue fills the void. Gross osseous dysplasia, such as is seen in maxillary micrognathia, mandibular hypertrophy, or rickets, can give rise to an open bite, but this usually is a minor manifestation of the gross discrepancy.

### Treatment

Treatment requires elimination of the habit. See the section on generalized spacing earlier in this chapter. Conventional orthodontic fixed appliance therapy with vertical elastics may be necessary to close the bite. In extreme cases a surgical orthognathic approach may be indicated. It is important to provide adequate stabilization of the teeth after orthodontic therapy.

### POSTERIOR OPEN BITE

### Diagnosis

Tongue thrusting often is the suspected cause of a posterior open bite, but it is rarely the primary cause; it merely allows the problem to persist. Abnormal skeletal





development is the primary cause of a bilateral posterior open bite. Ankylosis of primary or permanent teeth may also be the cause of a localized posterior open bite.

### Treatment

The etiology of the open bite must be considered when planning treatment.

**Skeletal Cause.** A bilateral posterior open bite of skeletal origin must be treated with orthodontic mechanical therapy alone or combined with a surgical orthognathic approach.

**Muscular Cause.** Although the tongue is rarely the primary cause of a posterior open bite, an appropriate appliance often must be constructed to keep the tongue from interfering with bite closure.

**Dental Cause.** If the posterior open bite is caused by ankylosis of a primary tooth, radiographs must be taken to verify that a permanent tooth is present. If it is present, the primary tooth should be extracted and the permanent successor must be brought into position by an orthodontic specialist. If it is not present, alternative therapy includes attempting to rebuild the primary tooth to proper occlusion or extracting the tooth and constructing a fixed bridge. If a permanent tooth is ankylosed, it cannot be moved orthodontically. The ankylosed tooth must be restored to proper occlusion prosthetically. If the ankylosed tooth cannot be restored, it should be extracted and prosthetically replaced.

### EXCESSIVE OVERBITE

Excessive overbite can occur with all types of molar relationships. Dental factors are often the cause in Class I malocclusions, whereas skeletal factors are often combined with dental factors in Class II or Class III malocclusions. The generalist most commonly works with a specialist to diagnose these cases, with the orthodontist treating the more complicated types.

### Diagnosis

Cephalometric analysis is necessary to confirm whether the problem is skeletal or dental in nature.

### Treatment

In the primary dentition, eliminate occlusal interferences; otherwise, treatment is postponed until further growth has occurred.

In the mixed and permanent dentition, if a Class I molar relationship exists, use a bite plate to allow the first

molars to erupt and the curve of Spee to decrease. If a Class II molar relationship exists, extensive appliance therapy is indicated.

### CLOSED BITE

Usually seen in adults with any molar relationship, a closed bite is best diagnosed and treated through a team approach. Diagnosis often can be made clinically, but it is confirmed with study models and radiographic evidence.

### Diagnosis

In cases involving areas that have been edentulous for a long period, teeth commonly have tipped into a neighboring extraction site or supererupted from the opposing dental arch. A loss of arch length and posterior bite collapse, resulting in a closing or deepening of the bite, results in an exaggerated curve of Spec.

### Treatment

The bite is opened by orthodontic movement of tipped and intruded teeth in preparation for prosthetic rehabilitation. The removal of the orthodontic appliances should occur on the same day as preparation for fixed prosthetic replacements because the provisional restoration acts as a retainer.

### LATERAL DISHARMONIES OF THE TEETH AND DENTAL ARCHES

Lateral disharmonies of the teeth and dental arches appear in patients of all ages, without regard to anteroposterior molar relationships. Lateral disharmonies result in excess wearing of the cusps that normally maintain a functional occlusal relationship. Since cuspal wear is generally a function of time, the earlier the treatment is instituted, the more successful and stable the final result.

### Differential Diagnosis

Lateral disharmonies can involve one or multiple teeth and can be unilateral or bilateral. The generalist should have little difficulty diagnosing those of dental origin, whereas those of muscular and/or skeletal origin usually are diagnosed by a specialist. Study models will show cuspal wear, but a clinical examination is required to determine whether the disharmony is unilateral or bilateral and whether it is caused by a skeletal or muscular deviation from normal development.

**Skeletal Cause.** With a skeletal cause, there is a gross disharmony between the bony bases. Unilateral cross-

bites exhibit a deviation of the midline of the two jaws when the teeth are in occlusion.. Bilateral crossbites may have a normal midline relationship or may mimic a unilateral crossbite with a shifted midline. The difference is that this shift is one of convenience and occurs at the last moment of mandibular closure. If the mandible is placed in its most retruded position and slowly closed, the midline will be centered until just before occlusal contact is made.

**Muscular Cause.** Occlusal interference develops because of an aberrant muscular closing pattern.

**Dental Cause.** In this case the condition often is the result of lack of space in the dental arch. It usually involves tipped teeth and sometimes is accompanied by a muscular shift.

### Treatment

Treatment of these conditions can be handled by the experienced generalist, especially when dealing with the dental type. Those caused by skeletal or muscular deviations probably should be referred to a specialist for treatment.

**Skeletal Cause.** If the crossbite is slight, a maxillary lingual arch may be used to expand the maxilla or a Hawley appliance with an inclined plane may be used if only one or two teeth are involved (see the section on correction of anterior crossbites earlier in this chapter; modify the appliance to move involved buccal teeth.). In more severe cases, the treatment of choice would be a rapid palatal expansion appliance.

**Muscular Cause.** In the primary or mixed dentition, occlusal grinding often allows the proper closing pattern to resume. In the permanent dentition, occlusal grinding may allow for a proper closing pattern, but appliance therapy may be necessary.

**Dental Cause.** Space must be regained for the tooth or teeth to fit into the arch; this is accomplished by expanding the arch or by interproximal stripping.

The crossbite is eliminated by banding or bonding brackets onto the teeth in the opposing arches and having the patient wear through-the-bite elastics attached from buttons or hooks placed on the side of the tooth opposite the direction of desired tooth movement. If an anterior tooth is involved, a Hawley appliance with a finger spring to push the tooth labially and an occlusal plane to prevent the opposing arch from making contact during the time of movement may be used. See the section on correction of anterior crossbites earlier in this chapter.

### Correction of Posterior Crossbite: Palatal Expansion-Removable Appliance

A fixed appliance is the preferred method of palatal expansion because removable appliances tend to dislodge during therapy.

#### Armamentarium

- Irreversible hydrocolloid impression
- Adjustment instrument for palatal expansion device (supplied by laboratory)

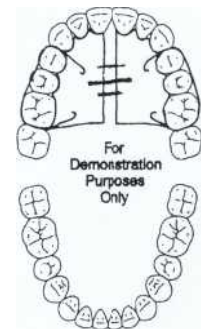
#### Clinical Technique

1. Make an irreversible hydrocolloid impression.
2. Send the models to an orthodontic laboratory for fabrication of a Hawley appliance modified with an expansion screw to expand the palate laterally (Fig. 19-56).
3. Insert the Hawley appliance.
4. Instruct the patient to adjust the palatal expansion device one-quarter turn twice daily.
5. Clinically evaluate the patient every 2 weeks.
6. Expansion occurs at a rate of 2 to 3 mm per month.
7. Once palatal expansion is complete, securely lock the expansion mechanism by applying autocured acrylic. Leave the appliance in place an additional

NAME: \_\_\_\_\_ DATE: \_\_\_\_\_  
 ADDRESS: \_\_\_\_\_ PHONE: (\_\_\_\_) \_\_\_\_\_  
 CITY: \_\_\_\_\_ STATE: \_\_\_\_\_ ZIP: \_\_\_\_\_  
 PATIENT NAME: \_\_\_\_\_  
 DATE NEEDED: \_\_\_\_\_ TIME NEEDED: \_\_\_\_\_  
 SPFCIAL INSTRUCTION: \_\_\_\_\_

Please construct a maxillary rapid palatal expansion appliance. Add labial wires to the bands on #3 and #5 and #12 and #14. Note that the bands placed on #3, #5, #12 and #14 were removed with the impression. -

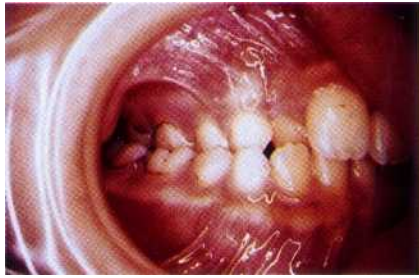Thank you.



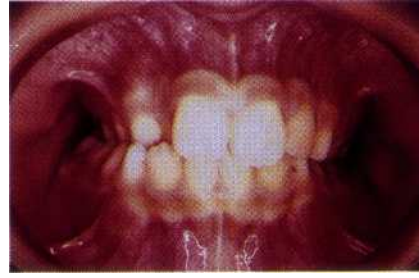SIGNATURE: \_\_\_\_\_

LICENSE: \_\_\_\_\_

Fig. 19-56. A sample prescription for the fabrication of a maxillary rapid palatal expansion appliance to correct a buccal crossbite involving all teeth distal to the canine.



*Fig. 19-57. Right lateral view of a patient with a buccal crossbite involving all the maxillary teeth distal to the right central incisor. Palatal crowding of the right lateral incisor also exists.*



*Fig. 19-58. Frontal view of the patient in Figure 19-57. There is a midline shift of the mandibular anterior teeth, which indicates that the maxilla is narrowed bilaterally and that the patient shifts to the right side into a "bite of convenience."*

6 to 8 weeks to allow for adequate healing and retention.

### Correction of Posterior Crossbite: Palatal Expansion-Fixed Appliance

Fixed appliances require that the generalist be absolutely familiar with all aspects of fixed orthodontic therapy. Failure to adhere to proper orthodontic technique could have adverse consequences.

#### Armamentarium

Basic bracket and band placement setup. See the section on placement of orthodontic bands earlier in this chapter.

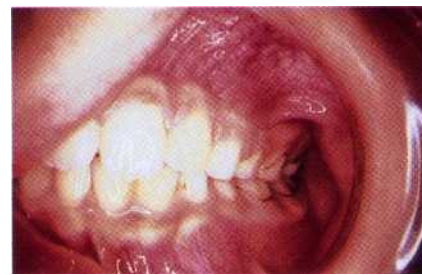Orthodontic bands (Unitek/3M, Inc.)

Irreversible hydrocolloid impression

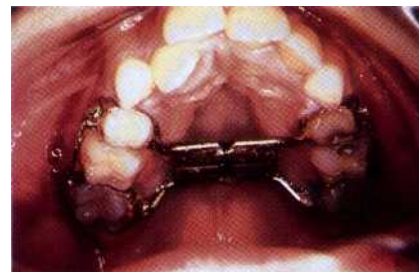Adjustment instrument for palatal expansion device (supplied by laboratory)

#### Clinical Technique

1. Fit the bands onto the maxillary first premolars (or first deciduous molars) and molars (see the section on placement of orthodontic bands earlier in this chapter). *Do not* cement the bands.
2. Make an irreversible hydrocolloid impression with the bands in place. If the bands do not come out with the impression they should be removed from the teeth and set into the impression before the impression is poured up with dental stone.
3. Send the models to an orthodontic laboratory for fabrication of the fixed rapid palatal expansion appliance.
4. Cement the appliance in place with zinc phosphate cement.
5. Instruct the patient to adjust the palatal expansion device one-quarter turn twice daily.
6. Clinically evaluate the patient every 2 weeks.

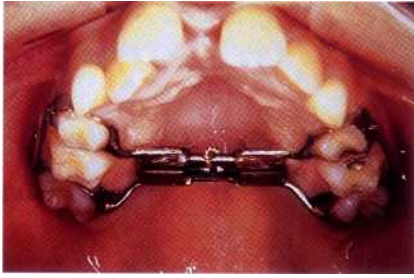

*Fig. 19-59. Left lateral view of the patient shown in Figure 19-57.*

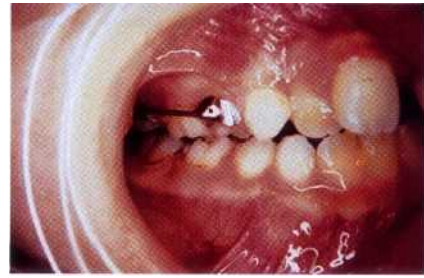

*Fig. 19-60. Occlusal view of a rapid palatal expansion appliance at the beginning of treatment.*

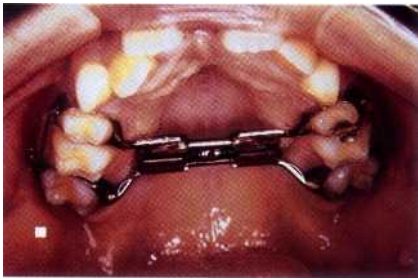7. Expansion occurs at a rate of 2 to 3 mm per month. Active expansion usually is complete in 4 to 6 weeks.
8. Once palatal expansion is complete, securely lock the expansion mechanism by applying autocured acrylic. Leave the appliance in place an additional 6 to 8 weeks to allow for adequate healing and retention (Figs. 19-57 to 19-67).



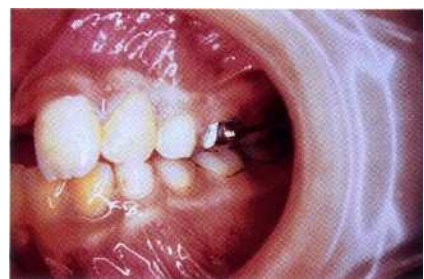*Fig. 19-61. Occlusal view of the rapid palatal expansion appliance during treatment. Note that the amount of space between the central incisors is less than the space between the halves of the open appliance because of the action of the transseptal fibers pulling the central incisors together.*



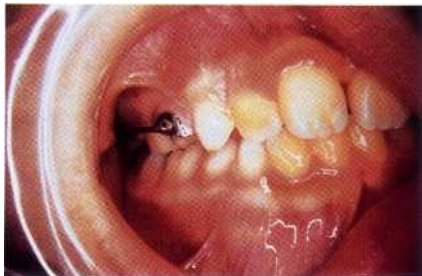
*Fig. 19-62. Right lateral view of the patient shown in Figure 19-61 at the end of palatal expansion.*



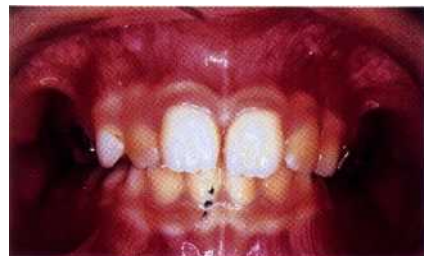*Fig. 19-63. Occlusal view of the patient shown in Figure 19-61 at the end of palatal expansion. The appliance is left passively in the mouth for 6 to 8 weeks while calcification of the increased arch width takes place.*



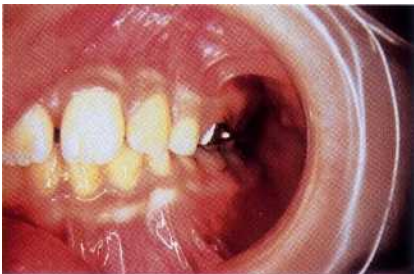*Fig. 19-64. Left lateral view of the patient shown in Figure 19-61 at the end of palatal expansion.*



*Fig. 19-65. Right lateral view of the patient shown in Figure 19-61 after completion of orthodontic treatment. Both the midline and the palatally crowded right lateral incisor have been corrected. The diastema between the central incisors closed without intervention as a result of the action of the transseptal fibers.*



*Fig. 19-66. Frontal view after completion of orthodontic treatment.*



*Fig. 19-67. Left lateral view after completion of orthodontic treatment.*

## CLASS II DISTOCLUSION

A normal relationship, or neutroclusion (Angle Class I), exists when the mesial buccal cusp of the maxillary molar occludes between the mesial and distal buccal cusps of the mandibular first molar (see Fig. 19-1). A Class II distoclusion occurs when the mandibular first molar occludes posterior to its normal relationship with the maxillary first molar (see Fig. 19-2). This is easily ascertained on clinical examination and is well documented on study models or cephalometric radiographs. Some simpler cases, especially in young patients, can be treated by a clinician who is well versed in orthodontic treatment procedures; however, referral to an orthodontist usually is indicated.

### *Differential Diagnosis*

**Skeletal Cause.** These distoclusions are caused by inherent growth patterns within the facial skeleton. Sometimes it is possible to mask these skeletal disharmonies with conventional orthodontic therapy. Occasionally orthognathic surgery is the treatment of choice. Clinically, these patients have a large overjet of the maxillary anterior teeth.

**Muscular Cause.** These distoclusions are caused by learned neuromuscular reflexes that can be altered in the primary and mixed dentition. The overjet usually is slight, and functional appliances are sometimes successful in correcting the malocclusion.

**Dental Cause.** These distoclusions involve mesial drifting of the teeth in the maxilla. Teeth often show edge-to-edge occlusion with severe crowding in the maxillary arch and distoclusion of the mandibular first molars.

### *Treatment*

**Skeletal Cause.** In the primary dentition, palliative treatment involves control of deleterious sucking habits and elimination of any tooth interferences that might inhibit mandibular growth. Judicious occlusal equilibration at an early age allows free anterior growth of the mandible if it has been forced distally because of occlusal interferences. Many appliances and techniques have been advocated for controlling sucking habits, but the most important factor is patient cooperation. No appliance can overcome a patient who is determined to continue a pernicious habit. See the section on **generalized spacing earlier** in this chapter.

Palliative treatment of distoclusion in a mixed dentition usually is beyond the scope of the generalist. However, the following procedures are normally undertaken by the orthodontist. If there is a good tooth size to arch

length ratio, headgear will allow growth of the mandible while keeping the maxilla in place. A functional appliance may also be used. Many of these patients require full appliance mechanotherapy. If there is an unfavorable tooth size to arch length ratio, the patient most likely will require the extraction of teeth and full appliance therapy. In the permanent dentition, comprehensive orthodontic therapy usually is necessary.

**Muscular Cause.** In the primary dentition, treatment involves elimination of cuspal interferences. This often can be accomplished by the generalist, and it allows the jaw to assume its normal occlusal position. If a patient requires treatment by an orthodontist, an Andresen or Frankel functional appliance could be used successfully at this stage of development.

The same therapeutic measures are used for treatment of distoclusion in the mixed dentition as in the primary dentition. Because the harmful habits are now longer standing, they are harder to correct.

In the permanent dentition, the distoclusion has commonly progressed to a locked-in bite, therefore full orthodontic appliance therapy is usually needed.

**Dental Cause.** Distoclusion is rarely seen in the primary dentition because there has not been time for mesial drifting of the teeth to take place.

In the mixed dentition of persistent thumb or finger suckers, all the teeth are tipped forward, with the distal cusp of the molar positioned more occlusally than the mesial cusp. Treatment, usually undertaken by the orthodontist, entails bringing the molars upright, which in turn, opens the bite and allows the anterior teeth to move distally. Head gear usually is used in the treatment of these cases.

Distoclusion in the permanent dentition is more difficult to treat because all growth potential has been lost. Often full orthodontic appliance therapy is necessary.

### *Special Considerations for Class II Malocclusions*

Certain situations can affect the prognosis of a Class II case and may require treatment by a specialist.

**Tooth Size to Alveolar Arch Length Ratio.** Large teeth may require therapeutic extractions, making the case more difficult to treat.

**Nasorespiratory Function.** Poor nasal breathing habits result in a narrow, underdeveloped palate, often rendering treatment and retention more difficult.

**Parental and Patient Interest in Treatment.** Enthusiastic cooperation is essential for good results.

## ANGLE CLASS III MESIOCLUSION

The **mandibular first molars** are mesial of their normal occlusal relationship in an Angle Class III malocclusion (see Fig. 19-3). Although true Class III cases represent only about 3% of the malocclusions seen in the United States, they are among the most difficult to treat. Referral to a specialist for diagnosis and therapy is indicated. When the cause is skeletal, it can be due to either a micromaxilla or mandibular hypertrophy. If the cause is functional in nature, tooth interferences cause the mandible to be moved forward of its normal position. This also is called an apparent or pseudo Class III occlusion. If the cause is dental in nature, linguoversion of the maxillary anterior teeth exists with a Class I molar relationship. See the section on correction of anterior cross-bites earlier in this chapter.

### Differential Diagnosis

A differential diagnosis requires cephalometric radiographs, study models, and clinical examination of the patient both at rest and during function.

**Skeletal (True Class III) Cause.** The characteristics of the skeletal or true Class III malocclusion follow.

**Profile.** The mandible is dominant and cannot be retruded (Fig. 19-68). This can be caused either by a large mandible or a small maxilla. The patient will have a

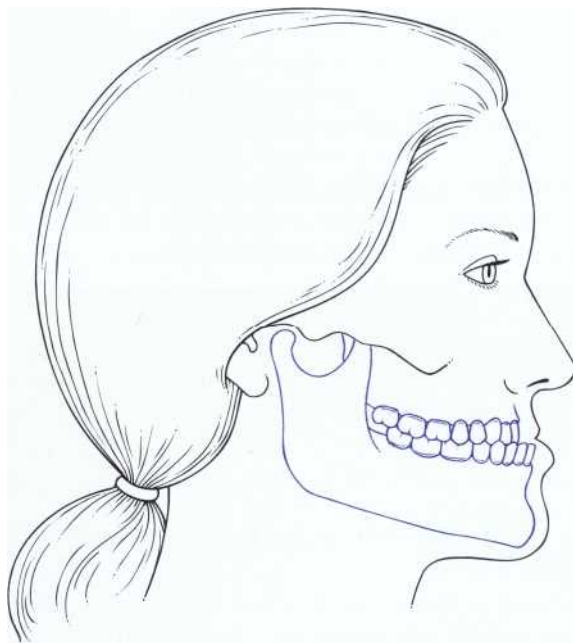


Fig. 19-68. Patient with a true Angle Class III skeletal relationship.

"dished in" appearance of the midface, especially in cases caused by a small maxilla.

**Mandibular Angle.** The mandibular angle is 130 to 140 degrees.

**Mandibular Incisal Angle.** The mandibular incisors often are crowded and in linguoversion.

**Mandibular Closing Pattern.** An even closing pattern occurs (not a "hit and slide" pattern because of cuspal prematurities).

**Molar Relationship.** The molars will always be in a Class III relationship, when the teeth are in centric relation, when they are together in maximum intercuspation, and when the mandible is in postural rest position.

**Dental (Pseudo Class III) Cause.** The characteristics of the dental or pseudo Class III malocclusion follow.

**Profile.** The mandible is in a Class I relationship posturally at rest but shows **the full Class III face when the teeth are** in occlusal contact.

**Mandibular Angle.** The mandibular angle is close to 120 degrees.

**Mandibular Incisal Angle.** The mandibular incisors are vertical or slightly in labioversion.

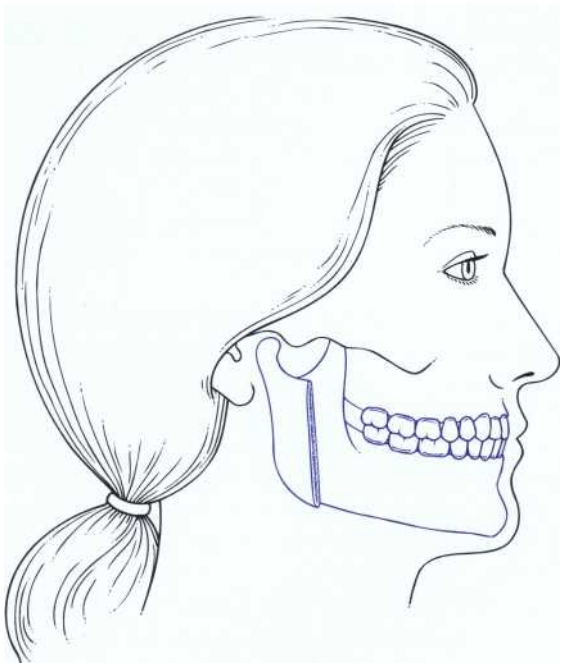
**Mandibular Closing Pattern.** When closing into maximal intercuspation, the mandible slides anteriorly because of cuspal interference.

**Molar Relationship.** The pseudo Class III relationship sometimes demonstrates molars in either a Class I or Class III alignment, with the mandible in maximum intercuspation and postural rest positions; therefore the clinician cannot rely solely on the molar position for the diagnosis. In some cases a shift from a Class I to a Class III relationship occurs on closing of the mandible.

### Treatment

The etiology of the malocclusion must be considered when planning treatment.

**Skeletal (True Class III) Cause.** Referral to a specialist is indicated in true Class III malocclusions. Active intervention with full appliance mechanotherapy often is delayed until the permanent teeth are present. It may be necessary to include a surgical orthognathic approach (Fig. 19-69).



*Fig. 19-69. Surgical correction of a true Angle Class III skeletal relationship.*

**Dental (Pseudo Class III) Cause.** In the primary or mixed dentition, it is sometimes possible to correct the bite by removing any tooth interferences. This could be accomplished in the primary or mixed dentition phase with a mandibular Hawley appliance that has an anterior inclined plane (see the section on correction of anterior crossbites earlier in this chapter, but modify the appliance to move the inclined plane in the opposite direction because the appliance is now on the mandible). Fixed orthodontic appliances may be used in some instances, with the use of Class III elastics to encourage a new closing pattern. In the permanent dentition, this is always treated with full appliances and often requires orthognathic surgery.

## BIMAXILLARY PROGNATHISM

In bimaxillary prognathism, the molars are in an Angle Class I relationship. Careful evaluation of the cephalometric radiograph and study models to determine the true nature of the problem is essential. The generalist should refer these difficult cases to a specialist.

### Differential Diagnosis

The three types of bimaxillary prognathism follow.

**Skeletal Bimaxillary Prognathism.** In these cases both the mandible and the maxilla are anterior to the

cranial base. Usually this is a hereditary growth pattern. It is a racial characteristic of the Australoid, Mongoloid, and Negroid races.

**Dental Bimaxillary Prognathism.** In these cases the maxillary and mandibular teeth are positioned anteriorly in their bony bases. This growth pattern seen in patients with large teeth.

**Combined Bimaxillary Prognathism.** In these cases the mandible, maxilla, and teeth are anteriorly positioned.

### Treatment

The etiology of the malocclusion must be considered when planning treatment.

**Skeletal Bimaxillary Prognathism.** Treatment planning is complicated in these cases because it is difficult to predict growth. Maxillary growth ceases at approximately 12 years of age, but mandibular growth continues into young adulthood. These patients are difficult to treat, despite extractions, using conventional orthodontic appliances. An orthognathic surgical approach is often indicated.

**Dental Bimaxillary Prognathism.** These patients are difficult to treat during growth. Treatment is not possible during the primary or early mixed dentition stages because all the first premolars have not yet erupted. These patients can be treated in the late mixed dentition stage once the first premolars have erupted because these teeth must be extracted. The teeth usually are mesially inclined on their bony bases, therefore treatment is successful in young adults with the extraction of four teeth and the use of conventional fixed appliance mechanotherapy.

**Combined Bimaxillary Prognathism.** Treatment of these patients consists of correcting both the skeletal and dental components of the prognathism (see above).

**CLINICAL TIP.** The clinician's personal esthetic preferences must not be imposed in cases of bimaxillary prognathism. Genetic and racial factors must be respected, and the wishes of the patient must be solicited and taken into consideration.

## GROSS FACIAL DEFORMITIES

Although a wide variety of facial dysplasias may be encountered in association with congenital deformities, only two are seen frequently enough to be discussed in this chapter. All gross facial deformities should be referred to specialists for treatment.

### *Mandibular Prognathism*

In this condition the mandible is proportionately too large for the rest of the face. It may be caused by mandibular hypertrophy, midface deficiency, or a combination of the two. Clinical examination is sufficient to diagnose the condition, but radiographs and study models are necessary to ascertain the cause and the preferred method of treatment. See the section on Angle Class III mesiocclusion earlier in this chapter.

### *Cleft Lip and Palate*

The diagnosis of cleft lip and palate is made at birth when the lip is involved. Cases involving only the hard or soft palate are discovered later and may be brought to the dentist for diagnosis. There are several popular approaches to treatment, and much research is being carried out at several centers that focus on this condition. Referral is indicated.

### RETENTION

Many orthodontic corrections are self-retaining, because the dentition has been aligned into a stable occlusion. Rotation, however, can be a particular problem, and retention is advised. Fixed lingual arches may be placed, or removable Hawley appliances or a positioner may be used, depending on the requirements of the case. Most cases are retained for 6 months to 1 year, but some cases need longer retention.

### CONCLUSION

The goal of the dentist is to provide a stable and maintainable occlusion. An occlusion that cannot be maintained and is unstable will fail.' If restorations can be

avoided by moving the teeth into a correct relationship, orthodontics is the method of choice.' Collaboration between the general dentist, the orthodontist, the periodontist, or any appropriate specialist is essential.'

Orthodontic treatment traditionally has been limited to correcting malocclusions in children or adolescents. Advances in esthetic appliance design have made page 5 esthetic orthodontic care feasible and common-

Removable appliances may be used in some cases, but fixed appliances offer more predictable and faster results.<sup>6</sup> With an enlightened introduction to modern orthodontic treatment, adults will happily accept it as part of their restorative plan.

Color figures courtesy of Joy Hudecz, D.D.S., Assistant Clinical Professor of Dentistry, and Malcolm E. Meistrell, Jr. D.D.S., Clinical Professor of Dentistry, Orthodontic Department, Columbia School of Dental and Oral Surgery, New York, NY.

### REFERENCES

1. Ward HL, Simring M: *Manual of clinical periodontology*, ed 2, St Louis, 1978, Mosby.
2. LaSota EP: Orthodontic considerations in prosthetic and restorative dentistry, *Dent Clin North Am* 32:447, 1988.
3. Dawson PE: *Evaluation, diagnosis, and treatment of occlusal problems*, St Louis, 1974, Mosby.
4. Baker IA, Stewart AV: Adult orthodontics services, *J Am Coll Dent* 57:16, 1990.
5. McNulty EC: Appliance selection, *Dent Clin North Am* 32:571, 1988.
6. DeAngelis V: Integration of orthodontics with prosthodontics and reconstructive dentistry, *J Mass Dent Soc* 30:130, 1981.





# ESTHETICS AND ORAL AND MAXILLOFACIAL SURGERY

Daniel Buchbinder

**T**HE MAXILLOFACIAL SURGEON can dramatically enhance facial esthetics through manipulation of the craniomaxillofacial skeleton and associated structures, as well as the soft tissue drape. The importance of recognition by the general practitioner of existing skeletal and soft tissues deformities beyond the dental arches and an awareness of the significant impact the correction will have on the patient's overall satisfaction and self-esteem should not be understated. For example, an edentulous patient with an overclosed vertical dimension and deep perioral furrows should not only be restored prosthetically but also should be offered a referral to an oral and maxillofacial surgeon for evaluation for laser-assisted skin resurfacing to enhance the perioral esthetics. Furthermore, the American Dental Association's definition of oral and maxillofacial surgery as "the specialty of dentistry which includes the diagnosis, surgical and adjunctive treatment of diseases, injuries, and defects involving both the functional and esthetic aspects of the hard and soft tissues of the oral and maxillofacial regions"<sup>1</sup> recognizes not only the functional but also the facial esthetic enhancement procedures that the contemporarily trained oral and maxillofacial surgeon can offer.

This chapter is not meant to cover the complete scope of oral and maxillofacial surgery, but rather to present selected surgical procedures and adjunctive measures that can improve the patient's overall dental and facial esthetic appearance. For a more comprehensive review, the reader should refer to a textbook on oral and maxillofacial surgery.

## INTRAORAL PROCEDURES TO IMPROVE ESTHETICS

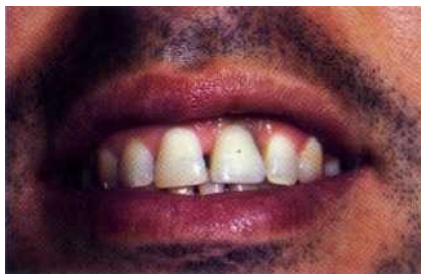### Gingivectomy

Gingival recontouring or laser-assisted sculpting of the gingiva is a relatively simple procedure that can significantly enhance the esthetics of a patient's restored smile. In cases of noninflammatory gingival hyperplasia, laser-assisted gingivectomy can be used to reshape the interdental papilla around an endosteal fixture to improve the emergence profile and enhance esthetics.<sup>2</sup> A more traditional gingivectomy procedure can be done to lengthen the clinical crowns of the anterior maxillary tooth or teeth.<sup>3</sup> (See Chapter 18.)

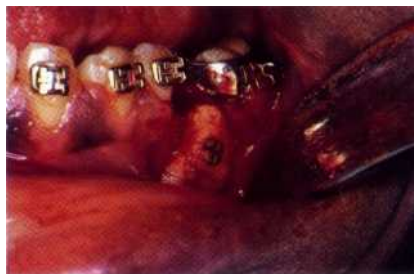### Dental Implants

The use of endosteal fixtures to retain implant-supported fixed or removable prostheses has gained wide acceptance over the past decade and has become part of the armamentarium of every practitioner.<sup>4,5</sup> Advances in implant designs and surface treatment have transformed the field of implant dentistry. It is now possible to provide cosmetically acceptable restorations using improved surgical techniques and judicious selection of appropriate hardware that can restore natural looking interdental papillae and soft tissue emergence profiles<sup>6</sup> (Fig. 20-1) (for a more detailed discussion of hardware and surgical procedures, see Chapters 16 and 21).





*Fig. 20-1. A single tooth replacement with good gingival contours and tissue emergence profile.*



*Fig. 20-2. Chin graft to the lateral alveolar ridge to augment the width and allow for implant placement. (Courtesy A. Montazem.)*

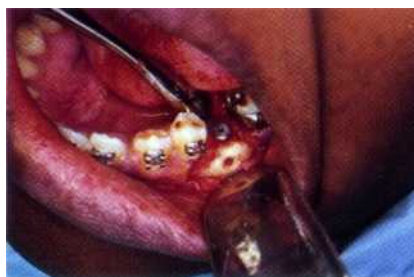### Bone Grafting

Minor bone grafts or bone substitutes can be used to augment a regional defect in the alveolus, such as a bony undercut or narrow ridge that may have resulted from buccal plate collapse after tooth extraction (Figs. 20-2 and 20-3) or from traumatic bony avulsion. After a period of consolidation of the graft, an endosteal titanium fixture can be placed. Bone grafts also can be placed within the maxillary sinus (sinus lift), enabling the dentist to restore implant fixtures distal to the maxillary canine/bicuspid area with a fixed splint' (Figs. 20-4 and 20-5). Larger grafts can restore the alveolar height of the complete maxillary or mandibular arches.

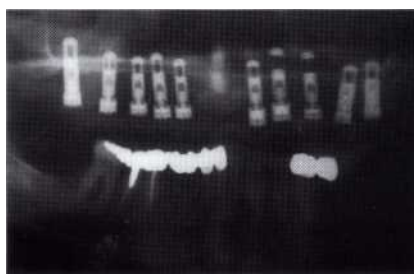
Bone grafts are classified as either autologous or homologous (allogenic). Autologous grafts are harvested from the patient and transplanted into the defect. Donor sites can be close to the surgical site (chin and maxillary tuberosity) or distant (calvarium, iliac crest or tibial plateau). The advantage of the intraoral source, aside from proximity, is the minimal morbidity associated with this type of graft harvest. Disadvantages include the paucity of marrow rich in osteoprogenitor cells and the limited amount of bone available for transplantation."

When the requirement for bone is more significant (e.g., for bilateral sinus augmentations or full-arch onlay grafting), the iliac crest is the preferred site for harvesting the large amounts of corticocancellous bone needed.<sup>9</sup> Almost 80 ml of bone can be harvested from the posterior iliac bone.<sup>10</sup> The tibial plateau is another good source of cancellous bone. Approximately 25 ml of bone can be harvested from this source. Although immediate sequelae, such as pain and gait disturbance, are common, long-term donor site morbidity is very rare. Calvarial bone grafts are mainly cortical in nature and are usually reserved for reconstruction of the midface, nasal, and orbital areas."

Homologous (allogenic) bone is obtained from human cadavers. The material is processed by human tissue banks to remove the antigenic and potentially infectious material (e.g., hepatitis, human immunodeficiency virus)

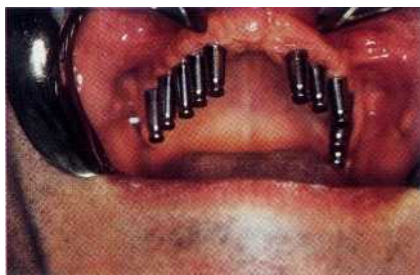

*Fig. 20-3. The patient in Fig. 20-2 after integration of the graft, showing removal of the buccal fixation screw and implant placement. (Courtesy A. Montazem.)*

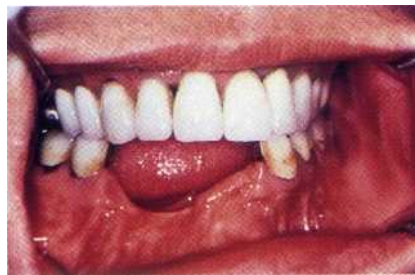

*Fig. 20-4. A panoramic radiograph showing implant fixtures placed after bilateral maxillary sinus lifts with cancellous bone graft from the iliac crest.*

and sterilized with ethylene oxide or gamma irradiation before packaging. Banked bone is available in lamellar strips, corticocancellous blocks, bone chips, and bone powder. The powder form also is available in a demineralized preparation. This process is believed to increase the concentration of an osseointegrative protein, bone morphogenic protein (BMP), which is present in the non-mineralized moiety." In general, allogenic bone grafts are used to restore small defects or to act as graft "expanders" when mixed with autologous bone harvested intraorally. The advantage of this type of grafting material is that it is



*Fig. 20-5. A frontal view of the patient in Fig. 20-4 after bilateral maxillary sinus grafts and implant placement.*



*Fig. 20-6. A traumatically induced regional defect of the mandibular alveolus. (Courtesy G. Urbani and ACE Surgical Supply Co.)*

readily available, thus eliminating the need for a surgical donor site and the associated morbidity. The major disadvantage is the risk of transmission of a disease for which no screening is currently done.

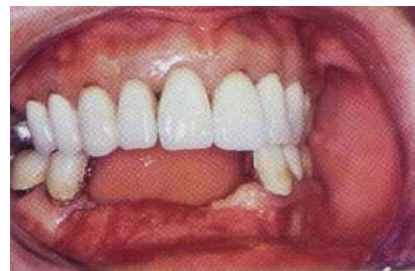Bone graft substitutes, such as resorbable or nonresorbable hydroxyapatite and other bioactive ceramic granules, also can fill minor contour defects and, to a lesser degree, expand autologous grafts.<sup>13</sup> Although these materials are considered osteophilic, they are not completely replaced by native bone and are not considered to produce good implantation sites. Again, the advantage of this material is that it is readily available. The disadvantage is that the material is replaced by bone only on its surface. It generally is not recommended for sinus lifts or significant ridge augmentation in preparation for implant placement.

### *Alveolar Distraction*

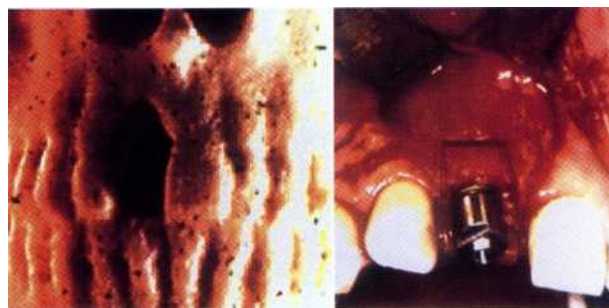
Alveolar bone distraction recently was introduced as an alternative to bone grafting for ridge augmentation of traumatically induced, limited alveolar defects (Figs. 20-6 and 20-7). Specially designed expansion devices are used to slowly "distract" an osteotomized bone segment to restore the lost alveolar height. Once this has been achieved and the regenerate has been allowed to consolidate, the distractors are replaced with endosteal fixtures that will osseointegrate and support a cosmetic prosthesis, which will then have a more acceptable crown to root (fixture) ratio.<sup>14</sup> A similar technique is now used to distract the anterior mandibular alveolus in patients with atrophic mandibles to create a more favorable site for the placement of endosteal fixtures." Changes in the design of alveolar distractors will allow these devices to play a dual role of distractor/implant fixture without having to change the hardware at the completion of the distraction (Figs. 20-8 and 20-9).

### *Skeletofacial Procedures*

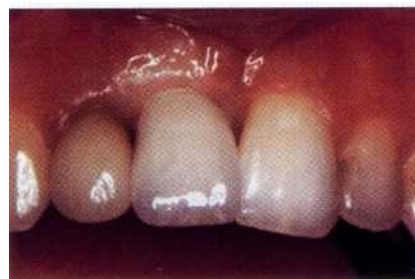Malalignment of the basal and tooth-supporting alveolar structures often results in facial "disharmony" and subop-



*Fig. 20-7. The patient in Fig. 20-6 with alveolar height restored using the osteodynamic alveolar distractor (ACE Surgical, Inc.). (Courtesy G. Urbani.)*



*Fig. 20-8. A, A three-dimensional model of a localized alveolar defect in the region of tooth #8. B, An intraoperative view of the defect after placement of Implantdistraktor (SIS Systems). (Courtesy H. Rainer.)*



*Fig. 20-9. Final restoration after completion of distraction and consolidation. (Courtesy H. Rainer.)*

timal function and appearance. Maxillary and mandibular osteotomies commonly are used to correct dentoskeletofacial deformities.

The first step in the evaluation of a patient suspected of having a dentoskeletofacial deformity is to obtain clinical and cephalometric radiographs. The lateral cephalogram can be traced manually or digitized and processed with treatment planning software and a personal computer (Figs. 20-10 and 20-11) (see also Chapter 24). Using the computerized approach, a digital photograph of the patient can be overlaid on the digitized cephalogram and manipulated to create a postoperative simulation that the patient can view. However, clinical results that do not reproduce the predicted simulation may lead to patient dissatisfaction, with possible legal implications (for a complete discussion, see Chapter 24). These software programs therefore include a disclaimer that states that the simulation must be viewed as an aid in visualizing the treatment result, which in no way "implies a guarantee of the surgical result."

Most dentoskeletofacial deformities are three dimensional. They must be evaluated and treated in the anteroposterior, vertical, and transverse planes.

Anteroposterior deformities include prognathism, or excessive growth of the jaw in a horizontal plane. Mandibular prognathism (Fig. 20-12), such as is seen in a Class III malocclusion, is more common than maxillary or bimaxillary (maxilla and mandible) prognathism. Retrognathism is an underdevelopment of the jaw in the horizontal plane (Fig. 20-13). Both the maxilla and mandible

may be affected (Fig. 20-14). Retrogenia is an underprojected chin, and prognia is an overprojected chin. These deformities are surgically corrected with maxillary or mandibular osteotomies. See the sections on maxillary surgery and mandibular surgery below.

Vertical deformities include vertical maxillary excess (VME), an excessive downward growth of the maxilla that results in a "gummy" smile and a "long face" with a narrow alar base and retrodisplaced mandible, caused by the counterclockwise mandibular rotation prompted by this excessive growth (Fig. 20-15). The lip to tooth ratio at rest is excessive (over 4 mm) and is accompanied by lip incompetence (the patient is unable to passively oppose the lips without straining the perioral musculature [orbicularis oris and mentalis]). When growth excess is limited

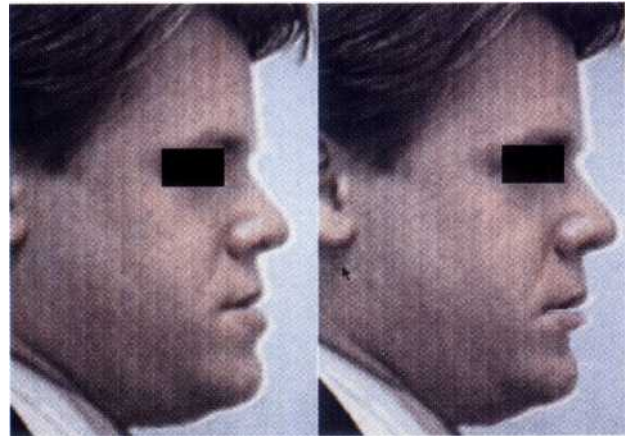


Fig. 20-11. A computerized prediction image.

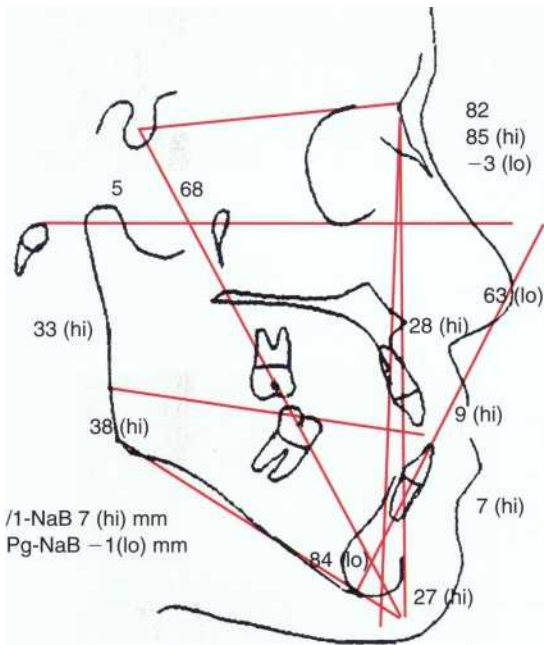


Fig. 20-10. A computerized cephalometric tracing and digital image overlay.

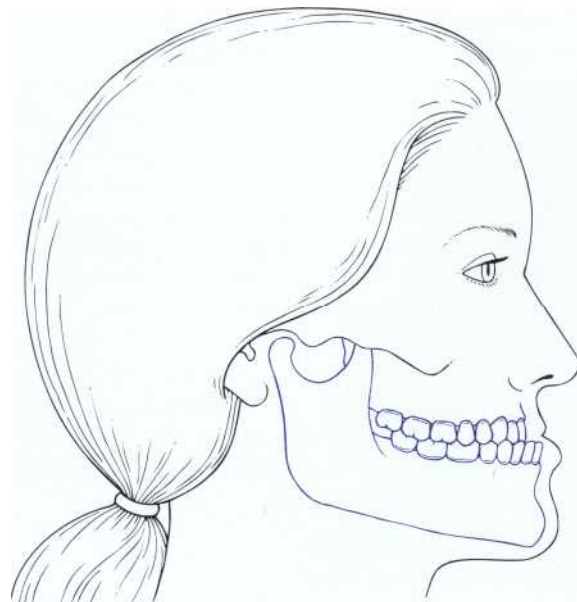
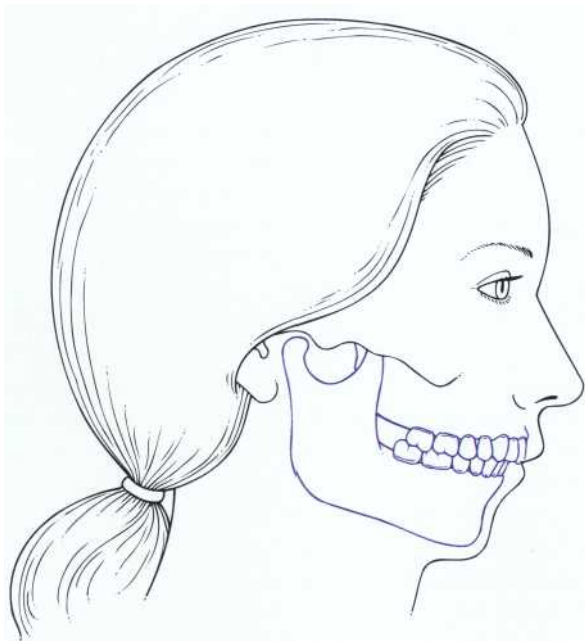
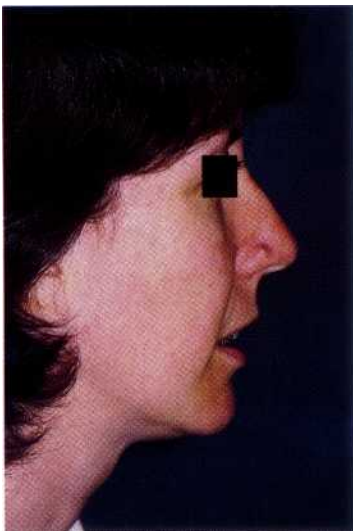

Fig. 20-12. Mandibular prognathism.

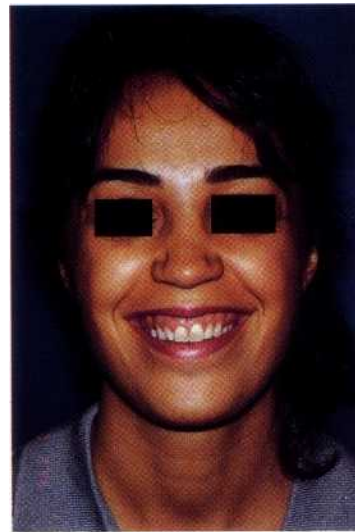to the posterior maxilla, an anterior open bite (apertognathia) will result, further accentuating the relative mandibular retrognathia (Figs. 20-16 and 20-17). Isolated anterior maxillary hyperplasia is rare and usually is caused by an overgrowth of the anterior alveolus in a patient with a severe mandibular retrognathia (Class 11, division I). Mandibular vertical excess usually is limited to the anterior mandible and can be corrected surgically by means of a horizontal osteotomy with the resection of a bony "wedge." Maxillary vertical excess is treated with a Le



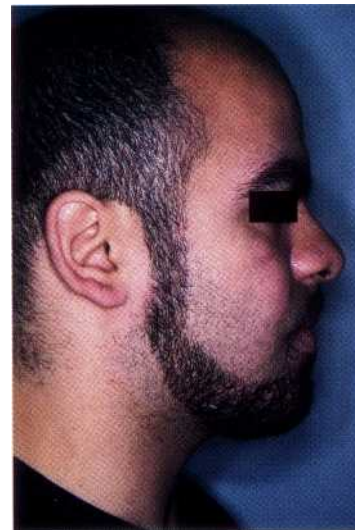*Fig. 20-13. Mandibular retrognathism.*



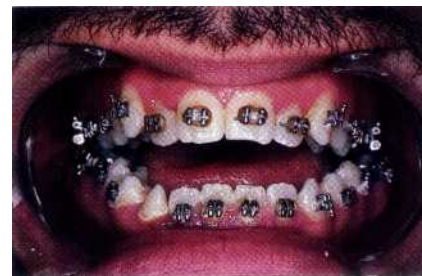*Fig. 20-14. Vertical maxillary excess combined with mild mandibular retrognathia.*



*Fig. 20-15. Full face view of a patient with vertical maxillary excess. Note "gummy" smile and narrow alar base.*



*Fig. 20-16. Lateral view of a patient with apertognathia (the result of posterior maxillary excess) and relative retrognathia (see Fig. 20-17).*



*Fig. 20-17. Frontal view of the patient in Fig. 20-16 showing significant open bite (apertognathia) with occlusal contacts limited to the second molars.*

Fort I osteotomy, removal of a wedge of bone, repositioning, and stabilization (Fig. 20-18). Maxillary vertical deficiency, another vertical deformity, is also corrected with a Le Fort I osteotomy. In this case, it requires the placement of a wedge of bone before the stabilization (fixation) of the maxilla (Fig. 20-18).

Transverse deformities usually result in a constricted arch form with overcrowding and tooth malalignment. The treatment goal is the expansion of the alveolar segment to correct the tooth/arch-length discrepancy. In the maxilla, a palatal expansion device can be used. Surgically assisted palatal expansion is based on the concept of distraction osteogenesis and relies on the creation of lateral maxillary wall and midpalatal osteotomies (Fig. 20-19). After a few days (the latency period), the ex-

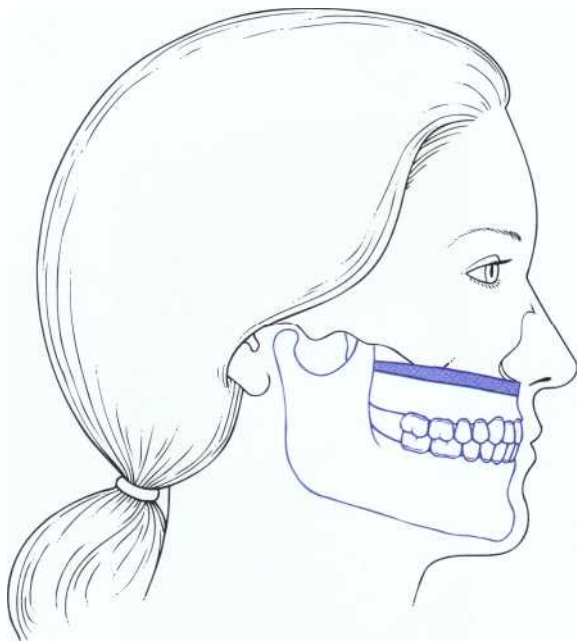


Fig. 20-18. A patient with maxillary vertical deficiency showing a Le Fort I osteotomy at a level immediately below the floor of the nose and placement of a wedge of bone.

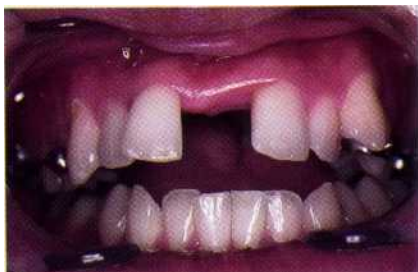

Fig. 20-19. A large diastema between the maxillary incisors after surgically assisted maxillary palatal expansion.

pander is activated and begins a controlled distraction of the callous at the osteotomy site. Once the expansion is complete, the regenerate bone is allowed to consolidate before the teeth can be moved into the neoalveolar segment. In cases in which the transverse deformity is not caused by a tooth/alveolar discrepancy and the orthodontist is unable to align the dental units over the alveolar segment, a multiple-segment Le Fort I osteotomy with interpositional bone grafting can be done to correct the transverse problem. A similar procedure can be performed to expand the mandibular arch with an internal bone/tooth-borne distraction device and a midline mandibular osteotomy to expand the mandibular alveolus." This device has now been approved for clinical use.

The deformities described above can involve both the maxilla and the mandible and may also be associated with facial asymmetries such as laterognathia or facial canting in cases of hemifacial atrophy or hypertrophy (congenital) or condylar hyperplasia (acquired). Temporomandibular joint pain and dysfunction and the resulting masticatory and swallowing difficulties often are associated with dentoskeletofacial deformities and should alert the practitioner to investigate for a malocclusion or jaw malposition. Recognition of the underlying condition and appropriate referral can increase the patient's confidence in the practitioner's ability to provide comprehensive care.

Once the workup has been completed and a problem list has been formulated, the surgeon selects the surgical procedures designed to correct the deformity and discusses the risks and benefits of each procedure with the patient. If the patient agrees with the proposed treatment, the general practitioner and orthodontist optimize the patient's dentition in preparation for the surgical procedure. Dental and periodontal diseases must be either eradicated or controlled before the surgery. The goal of preoperative orthodontics is to level and align the dental units over the alveolus. The fixed orthodontic appliances will also be used for maxillomandibular fixation at the time of surgery.

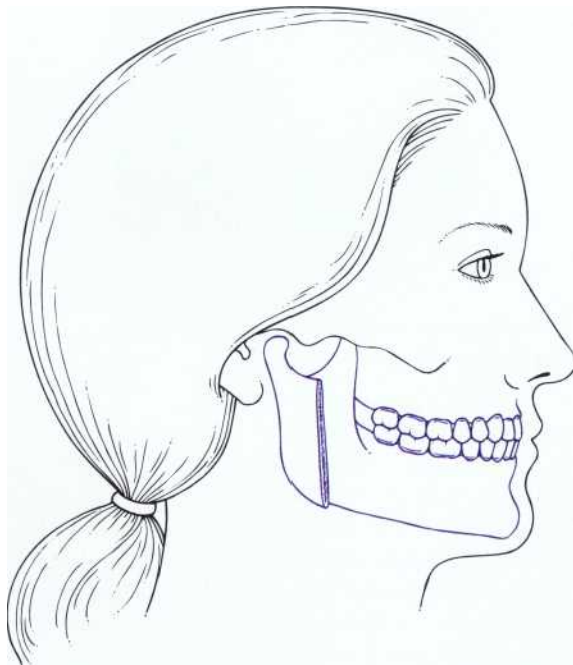
## SURGICAL PROCEDURES

### *Mandibular Surgery*

Most mandibular deformities are treated by surgery in the ramus or anterior mandible. The two most common ramal osteotomies are the sagittal (bilateral sagittal split ramus osteotomy, or BSSRO), first described by Obwegesser in 1946, and the vertical or subcondylar osteotomy (bilateral vertical ramus osteotomy, or BVRO)," originally described as an extraoral procedure, performed from a retromandibular, transfacial approach. Refinement of the instrumentation and introduction of a right-angled oscillating saw now allow an intraoral approach, which elimi-

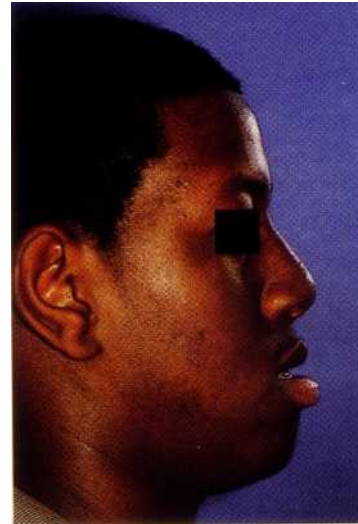
nates the facial scar. The ramus is sectioned vertically from the sigmoid notch to a point near the angle of the mandible. The cut remains posterior to the lingula to avoid injury to the inferior alveolar neurovascular bundle (Fig. 20-20). When performed bilaterally, this procedure allows repositioning of the distal (tooth-bearing) segment while preserving the condyle-fossa relationship of the proximal segments. Once the mandible has been placed in the desired position, as guided by the occlusion or by an acrylic surgical stent, maxillomandibular fixation is applied and maintained during the healing phase (4 to 6 weeks) to allow for bony union at the osteotomy sites (Figs. 20-21 and 20-22). This procedure is relatively quick, and the risk of injury to the inferior alveolar nerve is minimal. However, the procedure lacks versatility (it can only be used to correct prognathism) and has the obligatory postoperative period of maxillomandibular fixation." During that time the patient's diet is limited to fluids, and oral hygiene care is quite difficult.

The sagittal osteotomy, on the other hand is perhaps one of the most versatile facial osteotomies. It allows for the correction of prognathism, retrognathia, mandibular rotations, and small anterior open bite. This osteotomy is performed entirely intraorally. After dissection of the medial aspect of the ramus in a subperiosteal fashion, the neurovascular bundle is identified as it enters the lingula; it is retracted and protected. A horizontal corticotomy of the lingual cortex is then performed just above the level

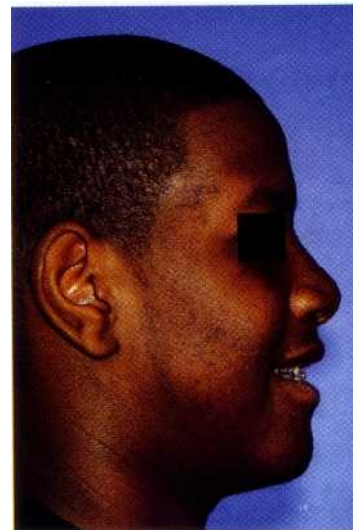

*Fig. 20-20. A vertical oblique osteotomy of the ramus allows the mandible to be pushed posteriorly while maintaining the condyles correctly in the articular fossae.*

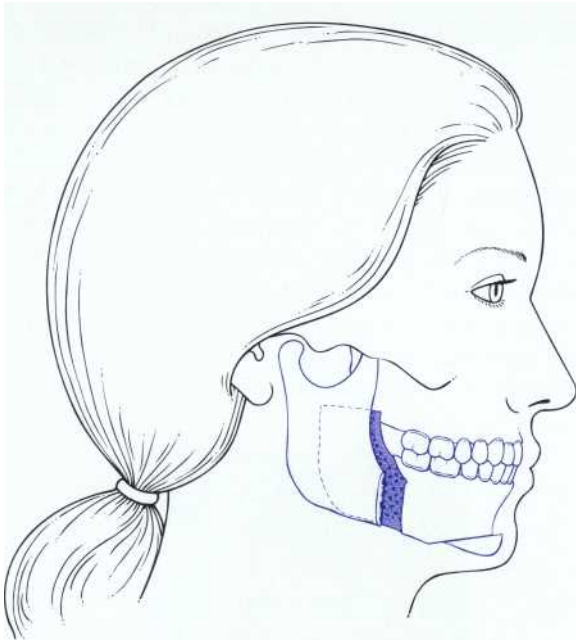
of the lingula. The bone cut extends from the level of the lingula to the anterior border of the ramus, where it is carried vertically just medial to the external ridge. It finally is connected to a vertical corticotomy of the buccal cortex of the mandible in the posterior body (Fig. 20-23).<sup>8</sup> Osteotomies and chisels are used to complete the osteotomy and separate the proximal ramal segment from the distal tooth-bearing segment. The sagittal nature of this osteotomy allows for a large surface area of bone-to-bone contact when the distal segment is moved to a more anterior position. The proximal segment remains in its preoperative position, maintaining the original



*Fig. 20-21. Preoperative lateral view of a patient with mandibular prognathism. (Courtesy A. Montazem.)*



*Fig. 20-22. The patient in Fig. 20-21 after undergoing bilateral vertical ramus osteotomies to correct the prognathism. (Courtesy A. Montazem.)*

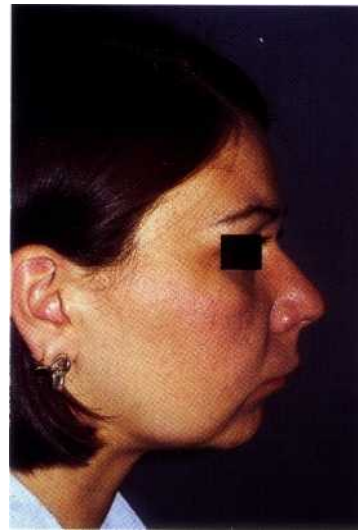

*Fig. 20-23. A sagittal split ramus osteotomy allows the surgeon the latitude of moving the mandible forward to correct a retrognathism or posteriorly to correct a prognathism while maintaining condylar position. Often a genioplasty is performed with this procedure.*

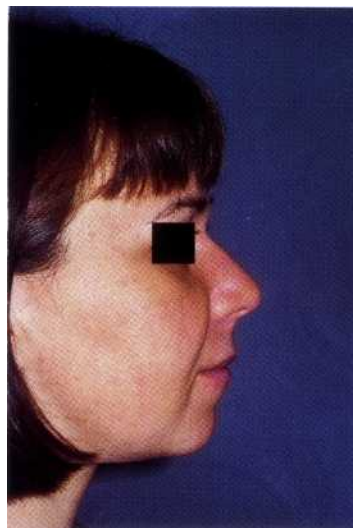condyle-fossa relationship (Figs. 20-24 and 20-25). During the healing phase the osteotomized segments can be maintained in their new position by maxillomandibular fixation, but this osteotomy design allows for the placement of fixation plates or screws (or both) that can maintain the position during the healing phase without maxillomandibular fixation (Fig. 20-26).

The internal fixation hardware usually is made of commercially pure titanium and is generally well tolerated by the body, rarely requiring retrieval once the osteotomies have healed. Occasionally loose hardware may cause a local reaction, necessitating removal. Some patients request that the hardware be removed after healing. Their concern about the long-term retention of a "foreign body" may not be evidence based, but it is nevertheless understandable. The recent introduction of bioresorbable screws and plates made of polylactide stereoisomers will obviate concerns about retained screw hardware because these devices are completely resorbed by hydrolysis and, to some extent, phagocytosis (Fig. 20-27).

The anterior horizontal mandibular osteotomy (AHMO), or genioplasty, can be used to advance, retrude, shorten, or lengthen the patient's chin (Figs. 20-28 and 20-29). The osteotomy is performed through an intraoral anterior degloving incision. It is important to avoid stripping the muscular attachments to the inferior border to prevent postoperative chin ptosis and the de-



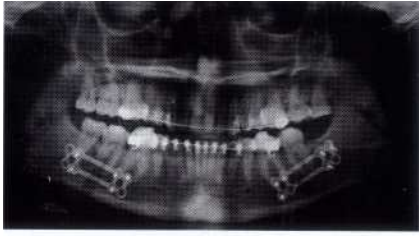
*Fig. 20-24. Preoperative lateral view of a patient with mandibular retrognathia.*



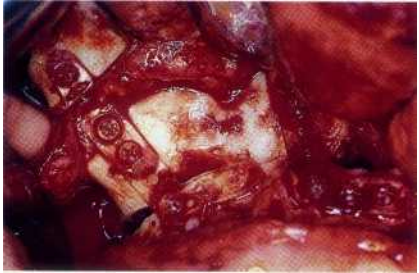
*Fig. 20-25. The patient in Fig. 20-24 after undergoing mandibular advancement with bilateral sagittal osteotomies to correct the retrognathia.*

velopment of the "witch's chin" deformity. The mental foraminae are identified bilaterally, and a bicortical osteotomy is performed below the apices of the incisors, ensuring adequate room for the placement of the fixation plates and extending below the mental foraminae as the cut is carried laterally.<sup>18</sup> The distal segment, with its blood supply derived from the lingual attachment of the geniohyoid and genioglossus muscles, is freed from the superior segment and can be repositioned anteriorly, posteriorly, or superiorly after the resection of a wedge from the proximal segment, and inferiorly with the placement of an interpositional graft. The segment is retained with a

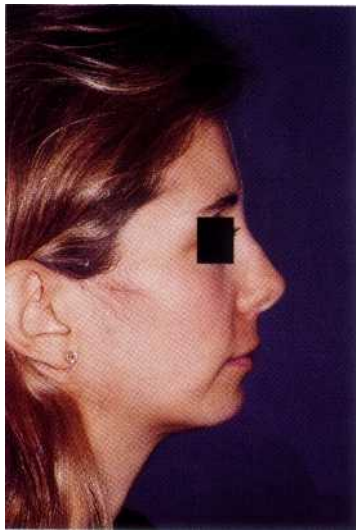



*Fig. 20-26. Radiograph showing titanium internal fixation hardware for the sagittal osteotomy.*

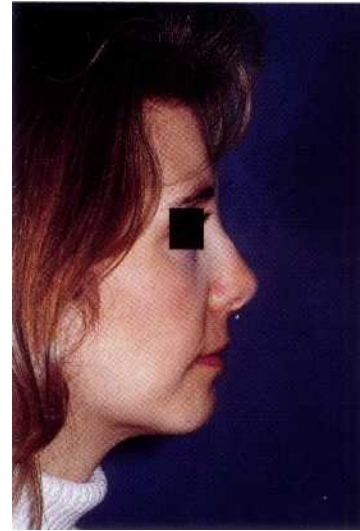


*Fig. 20-27. Intraoperative view of polylactide stereoisomer internal fixation hardware for a Le Fort I osteotomy.*

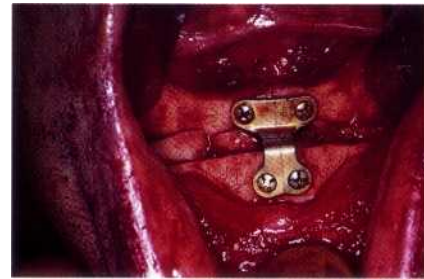


*Fig. 20-28. Lateral view of a patient with retrogenia.*

performed titanium plate and screws (Fig. 20-30). After closure of the mucosal incision, an external elastic dressing is placed to aid in the resuspension of the soft tissue and obliteration of the "dead space" to prevent hematoma formation that could result in a postoperative infection. As an alternative, an alloplast can be used to augment the patient's chin. See the section on facial implants later in this chapter.



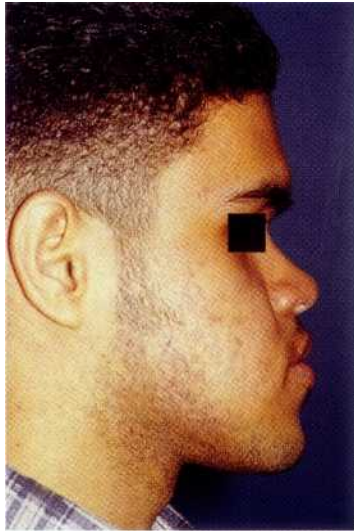*Fig. 20-29. The patient in Fig. 20-28 after advancement genioplasty (anterior horizontal mandibular osteotomy).*



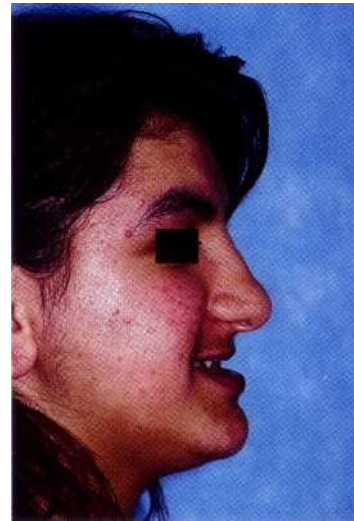*Fig. 20-30. Intraoperative view of an anterior mandibular osteotomy showing the use of interpositional bone grafting and prevent titanium fixation plate and screws. (Courtesy A. Montazem.)*

## Maxillary Surgery

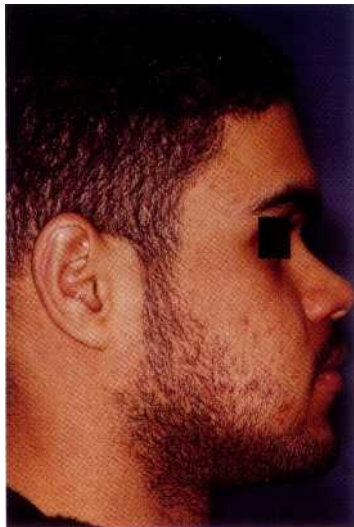The most common maxillary surgical procedure is the Le Fort I osteotomy. It can be performed as a single piece or divided into two or more segments to allow for the precise repositioning of each segment. A horizontal osteotomy is performed above the apices of the teeth and through the lateral wall of the maxilla and the lateral nasal walls. The pterygoid plates are then separated from the maxillary tuberosities. Finally, the nasal septum and vomer are separated from the maxilla, which is then downfractured. The maxilla can now be repositioned in a more anterior, posterior, superior, or inferior position. Vertical repositioning of the maxilla requires either a resection of a bony wedge for superior positioning or placement of an interpositional bone graft for inferior repositioning (Figs. 20-31 and 20-32). The osteotomized



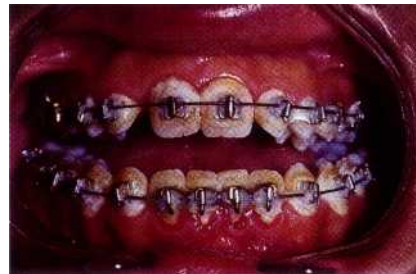*Fig. 20-31. Preoperative lateral view of a patient with maxillary deficiency and mandibular excess.*



*Fig. 20-33. Preoperative lateral view of a patient with maxillary hypoplasia, mandibular prognathism, and a large open bite.*



*Fig. 20-32. Postoperative view of the patient in Fig. 20-31 after bimaxillary osteotomy.*



*Fig. 20-34. Preoperative frontal view of the patient in Fig. 20-33.*

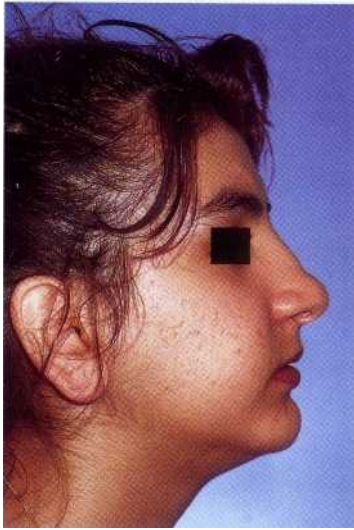segments are held in their new position by internal fixation devices made of titanium or a resorbable material' as described for the fixation of the sagittal osteotomy. When the maxilla is segmentalized, an occlusal acrylic splint is used to unitize and further stabilize the segments during the healing phase. Maxillomandibular fixation is not necessary. Light guiding elastics may be required early in the postoperative period to guide the new occlusion.

Modifications of the standard Le Fort I osteotomy include that in which the lateral osteotomy is carried on to the body of the zygoma before being tapered down in the

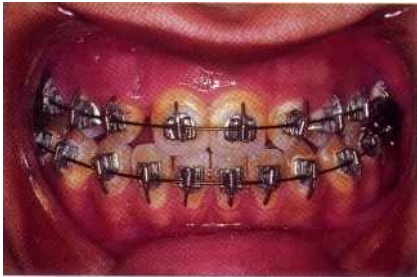area of the tuberosity to allow for the advancement of the malar complex. A quadrangular or high Le Fort I osteotomy can be performed where the lateral cut extends superiorly to the infraorbital rim area before tapering anteriorly to the base of the pyriform rim to avoid injury to the nasolacrimal duct and the resulting epiphora (excessive tearing).

### Bimaxillary Surgery

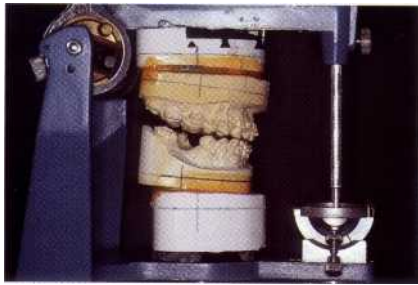
The correction of certain dentoskeletofacial deformities requires surgery on both the maxilla and the mandible's (Figs. 20-33 to 20-36). Vertical maxillary excess with mandibular retrognathia, maxillary deficiency with mandibular excess, and severe anterior open bite secondary to maxillary posterior excess are a few examples of deformities that require two-jaw surgery. The maxilla is osteotomized first and fixed in its final position with a prefabricated acrylic intermediate splint based on the "model



*Fig. 20-35. Postoperative lateral view of the patient in Fig. 20-33 after bimaxillary surgery.*



*Fig. 20-36. Postoperative frontal view of the patient in Fig. 20-33.*



*Fig. 20-37. "Model surgery" for planning bimaxillary surgery.*

surgery" (Fig. 20-37); the mandibular osteotomies are performed afterward. Bimaxillary surgery is more time-consuming and may result in additional blood loss. Autologous blood donation before surgery should be encouraged to prevent the need for a homologous (allogenic) transfusion in the rare instance when the blood loss would require a packed cell transfusion.

### *Postoperative Care*

Most orthognathic surgery, except for genioplasty, is performed as an inpatient hospital procedure with a stay of 1 or 2 days. The patient is discharged when able to tolerate a full fluid or soft diet that provides the proper caloric and nutritional requirements and when the patient can perform activities of daily living. A moderate amount of swelling in the immediate postoperative period is typical; this usually dissipates within the first week. The patient then is followed on a weekly basis until healing is complete (8 to 10 weeks). During that time the patient's diet is slowly advanced until a regular diet has been established, usually by the end of the seventh week. Physical therapy is instituted at 6 weeks to help the patient regain a good interincisal opening and function and to allow the orthodontist to complete the postoperative orthodontic phase. When maxillomandibular fixation is used and the patient is restricted to a liquid diet, a 10- to 15-pound weight loss early in the postoperative phase is expected. Sufficient caloric and nutritional intake is necessary to ensure an uneventful healing phase.

### *Adjunctive Procedures*

Soft tissue procedures that optimize the results of prosthetic and bony reconstructive procedures often are indicated. These procedures can be performed at the time of the orthognathic procedure, or they can be delayed until healing is complete and the surgeon is able to evaluate the effect of the skeletal surgery on the soft tissue drape.

## PERIORAL PROCEDURES

### *Lip Augmentation and Reduction*

Reduction of prominent lips is a relatively uncomplicated surgical procedure. A transverse, elliptic segment of mucosa and submucosal tissue is excised down to muscle. The anterior limit of the ellipse is placed behind the free border of the lip so that the scar remains inconspicuous. The excision must be uniform and symmetric to avoid any irregularities in the free border of the lip (Figs. 20-38 to 20-41).

Thin lips usually can be augmented either with submucosal injection of bovine-derived collagen or by placement of a strip of acellular dermis (Alloderm) through small incisions and submucosal tunneling.<sup>20,21</sup> The implant is fixed to the overlying tissue with a 5-0 plain gut suture. The results achieved from collagen injection can be expected to last 6 to 8 months; the Alloderm implant seems to offer a more "permanent" result, with over 50% of the volume in place after 1 year (Figs. 20-42 and 20-43).

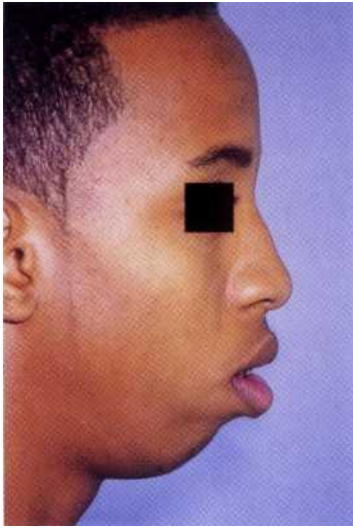

Fig. 20-38. Lateral view of a patient with macrocheilia.

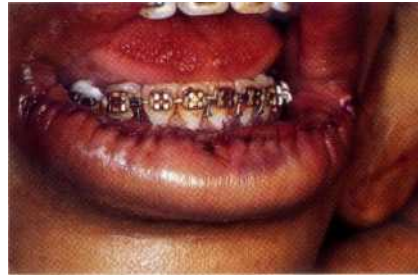

Fig. 20-41. The patient in Fig. 20-38 after excision of the mucosal wedge and primary closure. Note that the incision line does not extend beyond the free border of the lip.

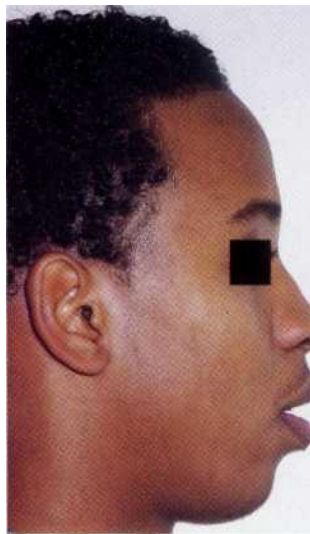

Fig. 20-39. Postoperative view of the patient in Fig. 20-38 after reduction cheiloplasty.

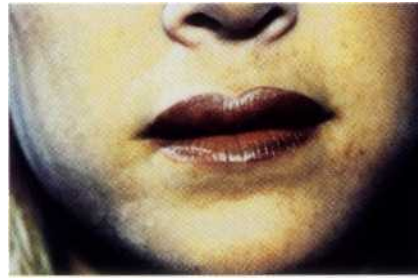

Fig. 20-42. Preoperative view of a patient desiring lip augmentation. (Courtesy B. Schwartz and the Lifecell Corp.)

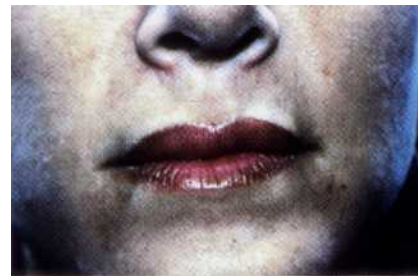

Fig. 20-43. Postoperative view of the patient in Fig. 20-42 after lip augmentation with Alloderm strips. (Courtesy B. Schwartz and the Lifecell Corp.)

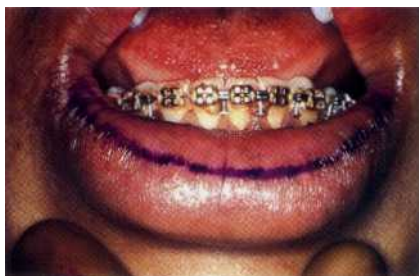
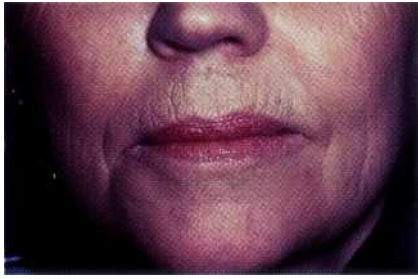
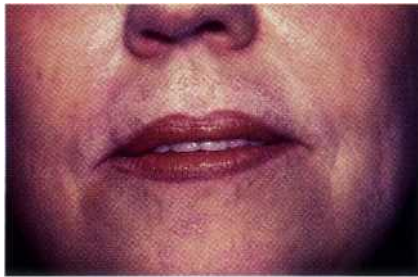Fig. 20-40. Outline of mucosal resection for reduction cheiloplasty for the patient in Fig. 20-38.

### Skin Resurfacing

The lips and perioral structures are common sites for age-related vertical wrinkles (rhytids) caused by loss of collagen. This condition is accentuated in "sun damaged" skin. Any treatment that reduces or eliminates these age-related perioral changes effectively enhances the result of the cosmetic dental reconstructive procedure (Figs. 20-44 and 20-45). Chemical peels, dermabrasion,<sup>22,23</sup> and laser-assisted skin resurfacing<sup>24</sup> are effective techniques for improving perioral wrinkling and hence esthetics. Face-lift procedures alone cannot address this problem.<sup>25</sup>



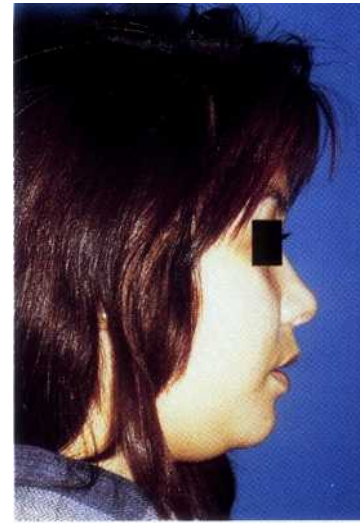
*Fig. 20-44. Preoperative view of a patient with deep perioral rhytids. (Courtesy S. Guttenberg.)*



*Fig. 20-45. Postoperative view of the patient in Fig. 20-44 after carbon dioxide perioral skin resurfacing. (Courtesy S. Guttenberg.)*

Chemical peeling using agents such as phenol (50% to 80%) or trichloroacetic acid (TCA) are applied to the affected skin and covered with an occlusive dressing for 48 hours. The chemical penetrates the epidermis and upper reticular layer of the dermis, resulting in a process very similar to a second-degree burn. The area begins healing in 48 hours, resulting in a consistent formation of a new, stratified collagen layer. This regenerative process is complete in 7 to 10 days, with some erythema lasting up to 6 weeks. A major problem with chemical peeling agents, especially phenol, is that skin bleaching results in sharp lines of demarcation between the treated and untreated areas. Because patients with a dark complexion are more prone to developing hyperpigmentation and discoloration, the patient's skin texture and tone must be carefully assessed before this type of treatment can be offered. Patients must be warned about the possibility of permanent color changes.

Dermabrasion is an inexpensive, very safe, and effective method of treating perioral rhytids and does not require highly specialized instrumentation. The epidermis and superficial dermis are abraded in a controlled fashion using abrasive wheels on an electric handpiece. As with the chemical peel, the partial thickness wound heals by the induction of collagen synthesis, upper dermal thickening and contracture, leading to a smoother skin surface.



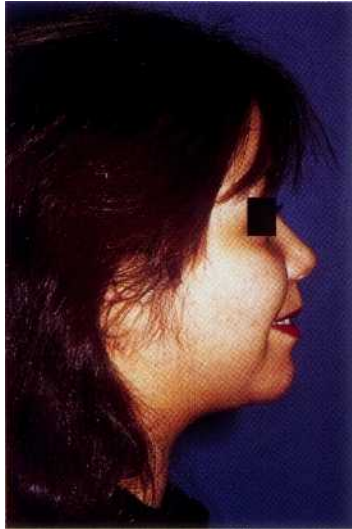*Fig. 20-46. Preoperative view of patient requiring a jaw and neck lift procedure.*

The success of all skin resurfacing procedures depends on the severity of the rhytids and the pigmentation of the skin. Hypopigmentation and hypertrophic scarring are some of the more common complications associated with skin resurfacing. Proper technique and meticulous postoperative wound care tend to minimize these complications.

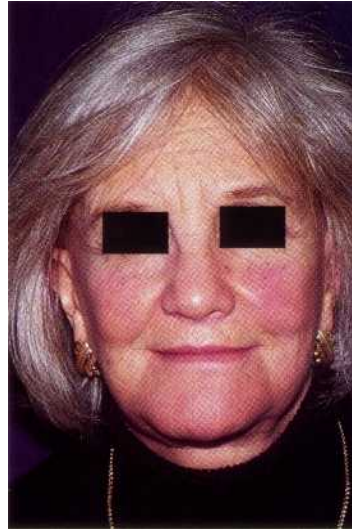Carbon dioxide (CO<sub>2</sub>) laser resurfacing has become an increasingly popular method of perioral skin resurfacing.<sup>26</sup> The epidermal cells absorb the laser beam and are heated, leading to vaporization. At the **level of the dermis, the conducted** heat produces a band of coagulation necrosis. The depth of the injury depends on the intensity of the beam and the duration of contact with the tissue. The introduction of high-energy, pulsed scanning CO<sub>2</sub> lasers with an ultra-short dwell time has enabled the surgeon to treat superficial wrinkles with minimal thermal injury to the underlying structures. The mechanism of healing is similar to that with other forms of skin resurfacing, with the added advantage that in patients with darker complexions, the CO<sub>2</sub> laser is more sparing of the melanocytes, resulting in a lower incidence of hyperpigmentation or hypopigmentation.

### *Submental Liposuction*

The patient population undergoing orthognathic procedures is becoming older and to a certain degree more discriminating. A desire for not only functional but also cosmetic facial improvement is often expressed. Esthetic neck surgery is by far the most common adjunctive procedure with orthognathic surgery (Figs. 20-46 and 20-47). Basically, two approaches can be used for cosmetic



*Fig. 20-47. Postoperative view of the patient in Fig. 20-46.*



*Fig. 20-45. Preoperative view of a patient requiring a "full" face-lift, including endoscopic brow and forehead lifts. (Courtesy P. Costantino.)*

improvement of the neck line. The first approach involves excision of submental fat with plication of the platysma muscles in the midline when indicated. This lipectomy can be performed with a suction-assisted method. A cannula hooked to a suction machine is introduced into the submental area through a small incision in the skin and used to "extract" the submental fat.<sup>27, 29</sup>

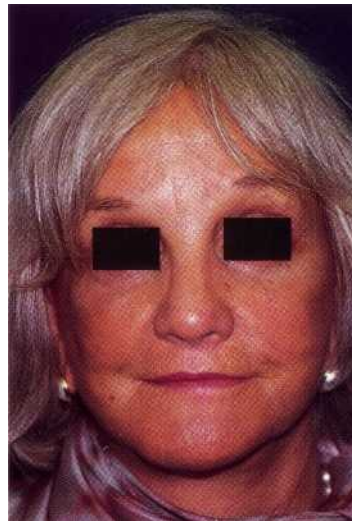As an alternative, a transfacial or transoral "open tipectomy" can be done. When performed in conjunction with a genioplasty, the surgeon can gain direct access to the submental fat through the intraoral mucosal incision by carrying the dissection underneath the anterior border of the mandible.<sup>30</sup> A submental transfacial approach is recommended when the surgeon is planning simultaneous resection of the redundant submental skin. Submental lipectomy can also be performed in conjunction with a rhytidoplasty-neck lift procedure.

After the neck recontouring procedure, the patient must wear a compressive dressing for several days to prevent formation of a seroma or hematoma and to ensure good tissue adaptation.

*Rhytidectomy (Face-lift)*

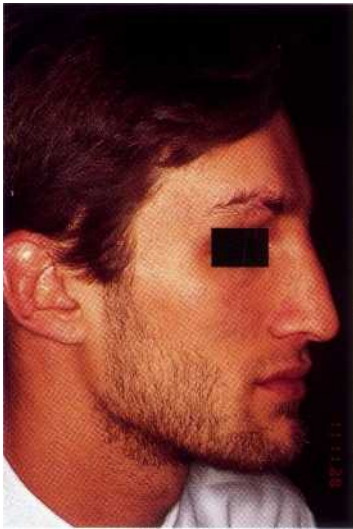Mandibular skeletal surgery may have either a positive or a negative impact on cervicofacial contours. When the planned mandibular procedure will accentuate a submental fullness, or jowls, elevation of the skin and restoration of the cervicomental contours and a well-defined jaw line will not only correct deformity but also enhance the result of the skeletal surgery (Figs. 20-48 and 20-49).

A skin incision is made in a natural skin crease immediately in front of the ear (preauricular).<sup>31,32</sup> The inci-

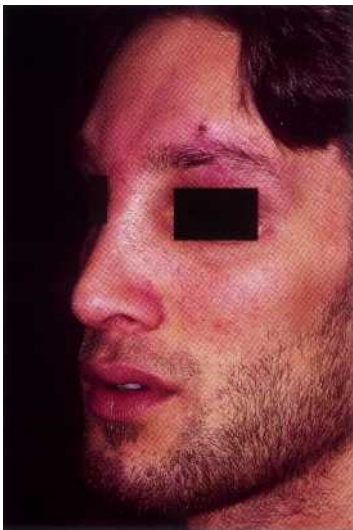

*Fig. 20-49. Postoperative view of the patient in Fig. 20-48. (Courtesy P. Costantino.)*

sion is carried behind the earlobe and into the hair-bearing area behind the ear (postauricular). After the skin flap is undermined, elevation of the preauricular component of the flap allows for the reduction of cheeks and jowls; elevation of the postauricular skin reduces the "sagging" in the neck and submental areas. After the excess skin has been excised, the skin is reapproximated using very fine nylon sutures. A pressure dressing is applied to aid in the adaptation of the tissues and to prevent hematoma formation. (For other indications for the face-lift procedure, see Chapter 23.)



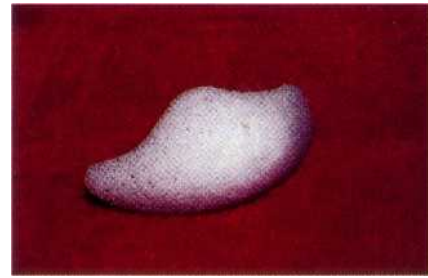
*Fig. 20-50. Preoperative view of a patient with a nasal ptotic (drooping) tip and dorsal hump. (Courtesy P. Costantino.)*



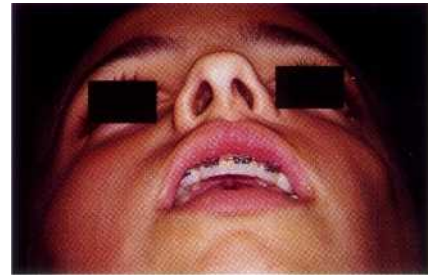*Fig. 20-51. Postoperative view of the patient in Fig. 20-50 after septorhinoplasty. (Courtesy P. Costantino.)*

### Rhinoplasty

Orthognathic surgery of the maxilla often results in minor changes in the width of the alar base or in the tip position.<sup>33</sup> For example, impaction of the maxilla in a patient with a wide alar base results in an even greater deformity after surgery unless simultaneous nasal surgery is performed, such as an alar base cinch suture, excision of skin from the alar base (weir), or tip procedures (Figs. 20-50 and 20-51).<sup>34</sup> Indications for simultaneous maxillary and nasal surgery include functional septal deviations, necessary correction of nasal tip and alar base position, and sig-



*Fig. 20-52. Porex (poly tetrafluoroethylene, or PTFE) malar implant.*



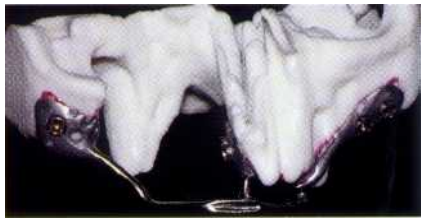*Fig. 20-53. Postoperative view of a patient with a left Porex malar implant for reconstruction of a defect caused by cancer surgery.*

nificant abnormality of the dorsum." Correction of subtle tip position and refined cartilage trimming should be performed as a secondary procedure once the healing from the skeletal surgery is complete. On the other hand, no contraindications exist for performing rhinoplastic procedures when performing isolated mandibular surgery with the use of internal fixation. Furthermore, the patient should be informed of the possible need for revision procedures to refine the surgical result.

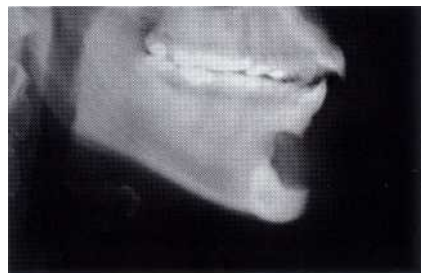
Cosmetic surgery of the periorbital area, including blepharoplasty, brow lift, and forehead lift, also has a significant impact on the result of skeletal jaw surgery (these procedures are discussed in Chapter 23).

### Facial Implants

Facial alloplastic implants have been used to augment the facial skeleton and, more specifically, the malar, mandibular angle, and chin regions (Figs. 20-52 and 20-53). These solid implants are available in a variety of preshaped sizes. They also are available in blocks that can be carved by the surgeon during surgery in cases of unilateral or asymmetric augmentations. In complex craniofacial cases, the data obtained from a computed tomography (CT) study of the patient can be used to custom fabricate the implant and construct a stereolithographic model, or a computer-assisted design (CAD) milling machine can be used (Fig. 20-54).



*Fig. 20-54.* Stereolithographic model used in the construction of a custom maxillary subperiosteal implant.



*Fig. 20-55.* Cephalogram/orthopantomogram showing resorption of the lateral mandibular cortex adjacent to a Silastic chin implant.

Alloplastic facial implants are made of Silastic, Proplast, or Medpore. Silastic or silicone implants are made of medical-grade polymer of dimethylpolysiloxane, a non carcinogenic, biocompatible material that induces very little inflammatory response when implanted subcutaneously. The principal drawback of solid Silastic is the rigidity and memory and nonporous state of this material. The lack of porosity prevents tissue ingrowth into the implant that would fix it to the surrounding tissue. Over time this can lead to migration of the implant, causing resorption of the underlying bone or extrusion of the implant (Fig. 20-55).<sup>36</sup>

Proplast is a highly porous material made of a teflon-fluorocarbon (PTFE) fiber base and, in the case of Proplast III, hydroxyapatite.<sup>37,38</sup> Earlier versions of the material contained first carbon (Proplast I) and then aluminum oxide (Proplast 11.) The advantage of hydroxyapatite is not only its osteoconductive properties and better tissue integration, but also that it eliminates the skin discoloration seen with the earlier material.

Medpore implants, manufactured from a high-density porous polyethylene, currently are the most popular and most widely used implants in facial augmentation. The large pore size (over 100  $\mu\text{m}$ ) and pore volume (in the 50% range) allows good tissue ingrowth. The firm nature of the material allows the surgeon to carve the implant with a scalpel during surgery without collapsing the

pore structure. As with all the above-mentioned materials, the major complication in alloplastic facial augmentation is infection. Inevitable contamination of the implants when placed via the intraoral route can lead to colonization of the implant and ultimately an infection that requires its removal. Impregnation of the implant in an antibiotic solution and postoperative administration of an oral antibiotic decrease the chance of infection.

Finally, small soft tissue irregularities can be corrected by subcutaneous placement of sheets of Alloderm. This material, made of homologous (allogenic) acellular dermis, is described earlier in the section on lip augmentation.

## REFERENCES

1. Commission on Dental Accreditation: American Dental Association accreditation standards for advanced specialty education programs in oral and maxillofacial surgery, Chicago, 1999, American Dental Association.
2. Russo J: Periodontal laser surgery, *Dent Today* 16:80, 1997.
3. Johnson RH: Lengthening clinical crowns, *J Am Dent Assoc* 121:473, 1990.
4. Eckert SE, Wollan PC: Retrospective review of 1170 endosseous implants placed in partially edentulous jaws, *J Prosthet Dent* 79:415, 1998.
5. Keller EE: Reconstruction of the severely atrophic edentulous mandible with endosseous implants: a 10-year longitudinal study, *J Oral Maxillofac Surg* 53:305, 1995.
6. Lyzak WA, Senn C: Anterior aesthetic considerations for the placement and restoration of nonsubmerged endosseous implants, *Pract Periodontics Aesthet Dent* 5:19, 1993.
7. Rioux K, Drangsholt M, Beirne OR: A review of survival rates for implants placed in grafted maxillary sinuses using meta-analysis, *Int J Oral Maxillofac Implants* 13:175, 1998.
8. Montezam A et al: Chin grafting in maxillofacial surgery: a quantitative analysis, Presented at the Fourteenth International Meeting of Oral and Maxillofacial Surgeons, Washington, DC, April 28, 1999.
9. Catone GA et al: Tibial autogenous cancellous bone as an alternative donor site in maxillofacial surgery: a preliminary report, *J Oral Maxillofac Surg* 50:1258, 1992.
10. Marx RE, Morales MJ: Morbidity from bone harvest in major jaw reconstruction: a randomized trial comparing the lateral anterior and posterior approaches to the ilium, *J Oral Maxillofac Surg* 46:196, 1988.
11. Harsha BC, Tuvey TA, Powers SK: Use of autogenous cranial bone grafts in maxillofacial surgery: a preliminary report, *J Oral Maxillofac Surg* 44:11, 1986.
12. Niederwanger M, Urist MR: Demineralized bone matrix supplied by bone banks for a carrier of recombinant human bone morphogenetic protein (rhBMP-2): a substitute for autogenic bone grafts, *J Oral Implantol* 22:210, 1996.



13. Tomasetti BJ, Munk LK, Zallen R: Treatment of trauma-related bony defects with nonresorbable hydroxyapatite, *Implant Soc* 5:10, 1995.
  14. Chin M, Toth BA: Distraction osteogenesis in maxillofacial surgery using internal devices: review of five cases, *J Oral Maxillofac Surg* 54:45, 1996.
  15. Unpublished data or data on file.
  16. Guerrero AC et al: Mandibular widening by intraoral distraction osteogenesis, *Br J Oral Maxillofac Surg* 35:383, 1997.
  17. Steinhauser EW. Historical development of orthognathic surgery, *J Craniomaxillofac Surg* 24:195, 1996.
  18. Bell WH, Proffit WR, White RP. Surgical correction of *dentofacial deformities*, Philadelphia, 1980, WB Saunders.
  19. Edwards RC, Kiely KD: Resorbable fixation of Le Fort I osteotomies, *J Craniomaxillofac Surg* 9:210, 1998.
  20. Tobin HA, Karas ND: Lip augmentation using an Allo-derm graft, *J Oral Maxillofac Surg* 56:722, 1998.
  21. Buttes S: Lip augmentation, *Dermatol Surg* 24:160, 1998.
  22. Branham GH, Thomas JR: Rejuvenation of the skin surface: chemical peel and dermabrasion, *Facial Plast Surg* 12:125, 1996.
  23. Baker TM: Dermabrasion as a complement to aesthetic surgery, *Clin Plast Surg* 25:81, 1998.
  24. Koch RJ: Laser skin resurfacing: what credentials are necessary? *Dermatol Surg* 24:595, 1998.
  25. Fulton JE: Simultaneous face lifting and skin resurfacing, *Plast Reconstr Surg* 102:2480, 1998.
  26. Weinstein C: Carbon dioxide laser resurfacing: long-term follow-up in 2123 patients, *Clin Plast Surg* 25:109, 1998.
  27. Knize DM: Limited incision submental lipectomy and platysmaplasty, *Plast Reconstr Surg* 101:473, 1998.
- Kovacs B et al: Submental liposuction in maxillofacial surgery, *Acta Stomatol Belg* 89:37, 1992.
- Pinto EB et al: Submental skin: morphohistological study of interest to liposuction, *Aesthetic Plast Surg* 21:388, 1997.
- Wider TM, Spiro SA, Wolfe SA: Simultaneous osseous genioplasty and meloplasty, *Plast Reconstr Surg* 99:1273, 1997.
- Becker FF: The preauricular portion of the rhytidectomy incision, *Arch Otolaryngol Head Neck Surg* 120:166, 1994.
- Stratigos AJ, Arndt KA, Dover JS: Advances in cutaneous aesthetic surgery, *JAMA* 280:1397, 1998.
- Schendel SA, Carlotti AE Jr: Nasal considerations in orthognathic surgery, *Am J Orthod Dentofacial Orthop* 100:197, 1991.
- Loh FC: A new technique of alar base cinching following maxillary osteotomy, *Int J Adult Orthodon Orthognath Surg* 8:33, 1993.
- Cottrell DA, Wolford LM: Factors influencing combined orthognathic and rhinoplastic surgery, *Int J Adult Orthodon Orthognath Surg* 8:265, 1993.
- Matarasso A, Elias AC, Elias RL: Labial incompetence: a marker for progressive bone resorption in Silastic chin augmentation, *Plast Reconstr Surg* 98:1007, 1996.
- Kent JN, Westfall RL, Carlton DM: Chin and zygomaticomaxillary augmentation with Proplast: long-term follow-up, *J Oral Surg* 39:912, 1981.
- Robiony M et al: Simultaneous malaroplasty with porous polyethylene implants and orthognathic surgery for correction of malar deficiency, *J Oral Maxillofac Surg* 56:734, 1998.



# ESTHETICS AND IMPLANT SURGERY

Enrique Lenchewski

ONE OF RESTORATIVE DENTISTRY'S loftiest goals has been the elimination of removable prosthetic devices in favor of fixed restorations that would enhance both function and esthetics, as well as the patient's self-esteem. The advent of osseointegrated implants in the past 20 years has significantly advanced these objectives. Other types of implants are still widely used, such as subperiosteal blades and other devices, but the indications for their use are declining.

## INDICATIONS AND CONTRAINDICATIONS

Significant changes have occurred since osseointegrated implants were introduced in the United States in 1982. Indications for their use range from **replacement of a single tooth** to full reconstruction of edentulous maxillary and mandibular ridges supported exclusively by implants. These implants have been used in irradiated bone with considerable success (see Figs. 21-7 to 21-10)'; they have been used for anchorage of orbital (see Fig. 21-29), auricular, and nasal prosthetic devices'; and they have been placed in mandibles reconstructed with bone harvested from distal parts of the patient's body, with predictably favorable results.<sup>3,4</sup>

## TYPES OF IMPLANTS

The blade implant was introduced in the 1960s,<sup>5-9</sup> and different varieties of endosteal types followed, as did the subperiosteal implant. However, a major leap forward in

the field occurred in 1982, when the Branemark root-form was introduced in North America (Fig. 21-1). The success rate of blade implants is significantly lower than the 85% to 97% success rate of root-form implants.<sup>10</sup> Because blade implants undergo a fibroosseous integration process, rather than osseointegration, failure of blade implants is preceded by inflammatory or infectious processes (or both) with significant loss of bone.

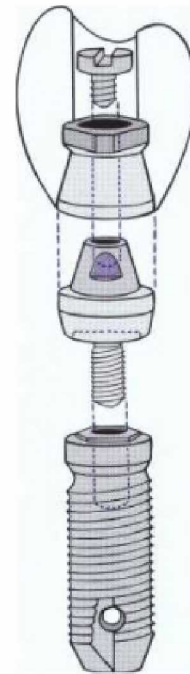


Fig. 21-1. Screw-retained prosthesis.

The blade implant, which has been popular for some time, allowed immediate prosthetic reconstruction. Its use was limited by anatomic structures that precluded placement of the implant and by poor quality bone.

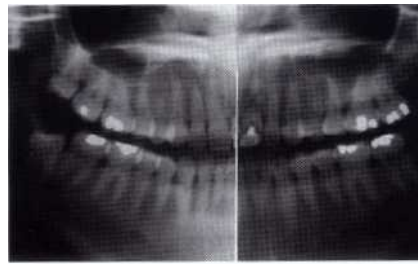
The subperiosteal implant filled a void in mandibular cases in which the presence of the inferior alveolar nerve did not allow placement of a blade-type implant. Use of subperiosteal implants in the maxillary arch was not as successful and is contraindicated. The two main categories of root-form devices are the screw type and the cylinder type. A previous type, the basket type (Core-Vent), currently is seldom used because of a poorer long-term prognosis as a result of recurrent prosthetic problems and esthetic liabilities when used in the anterior maxilla.<sup>1,12</sup>

Both main types of root-form implants have undergone progressive changes. They have been coated with hydroxyapatite and titanium plasma spray (TPS), their surfaces have been treated either by sandblasting or acid etching or both. Different manufacturers claim better rates of integration with their particular method. Current clinical studies appear to point to improved results using treated surfaces, particularly in type 4 bone or grafted areas." The means of attaching the prosthetic device include different locking mechanisms, such as hex-heads, morse-locks, and internal hexes.

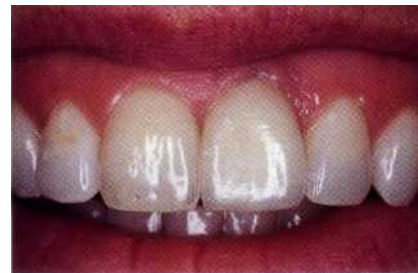One-stage implants (ITI and clones), which remain nonsubmerged from the time of initial placement, have eliminated the need for stage I surgery. An important consideration in deciding upon their use in the anterior area is the need to be very precise in their placement to avoid prosthetic problems. The use of a stent should be strongly considered.

Another significant improvement in the implant arsenal is the variety of widths now available, from the 3.25-mm microminimplant to the 6.5-mm wide implant. This variety of widths allows better esthetic results at the "cemento-enamel junction" ("CEJ") by duplicating the width of the tooth the implant replaces. In addition, manufacturers have increased the available widths of healing caps and abutments (EPS, 3i, Implant Innovations, Inc.; Frialit II, Friatec, Inc.) to guide tissue growth and ensure proper gingival papilla formation at the "CEJ" (Figs. 21-2 and 21-3). Additional lengths have been added (8, 8.5, 11.5, and 12 mm) that complement the initial lengths (7, 10, 13, 15, 18, and 20 mm), thus allowing greater choice in implant selection.

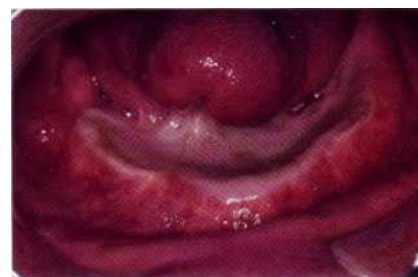The fairly recent introduction of the Frialit 11 implant, with its stepped-down shape, has modified the approach to implant placement in the anterior maxilla. This fact is important when immediate placement of the implant is considered. The true root-form shape of this fixture and its broad profile at the CEJ allow proper contouring of the gingiva and avoid the collapse of the alveolar bone, particularly in its buccal aspect. An additional benefit of this implant is the wider width at the



*Fig. 21-2. Preoperative Panorex radiograph of tooth #9, which requires extraction and a single tooth implant.*



*Fig. 21-3. Final restoration of tooth #9 using a cylinder-type implant and demonstrating proper papilla formation.*

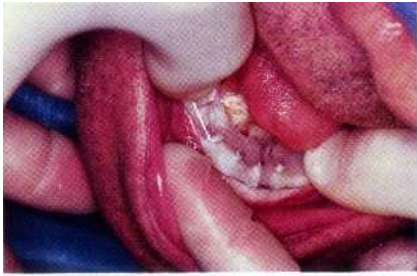

*Fig. 21-4. Preoperative view of the mandible after marginal resection for squamous cell carcinoma and skin graft reconstruction.*

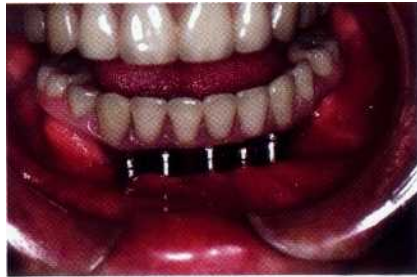CEJ (3.8 to 6.5 mm), which allows for better gingival esthetics.

## ABUTMENTS

The initial Branemark standard abutments, which had limited or compromised prosthetic applications from an esthetic point of view (Figs. 21-4 to 21-6), have given way to a wide assortment of abutments. These include the conical type, the UCLA type, prefabricated posts that are screw-in abutments, the CeraOne (Nobel Biocare AB), and a multitude of others to suit virtually every possible situation (see Chapter 16).



*Fig. 21-5. Surgical stent used as a guide for implant placement. (Courtesy Joseph Huryn.)*



*Fig. 21-6. Integrated implants with standard abutments, which create a "high water mark" prosthesis. (Courtesy Joseph Huryn.)*

Because most abutments require the use of healing caps, provisional restorations usually are deferred for a few weeks. When two-stage implants are used, the post screw-in abutment allows for construction of temporary restorations at the time of stage II surgery.

### IMPLANT ESTHETIC FUNDAMENTALS

Treatment is prosthetically, not surgically, driven. In most cases adequate preoperative planning allows for proper placement of implants. When inadequate bone precludes a proper esthetic result, a variety of grafting techniques may permit successful placement.

### PREOPERATIVE EVALUATION

As with any other invasive procedure, a thorough review of the patient's medical background is required. Factors that in the early days of osseointegrated implantology were considered limiting or as contraindications are no longer applicable; even patients with irradiated mandibles, cardiovascular compromise, or very advanced age can benefit from this modality of treatment."

Close consultation and communication with the treating physician are strongly suggested. Study models,

periapical or panoramic radiographs (or both) are mandatory. Computed tomography (CT) scans are helpful in properly assessing the height, width, and quality of the bone and in determining if retained roots are present. These scans also are invaluable for outlining the location of the inferior alveolar nerve and the true anatomic outline of the maxillary sinus. A CT scan can provide an accurate measurement of potential implant placement sites so that the dental surgeon can determine before surgery the longest and widest implant that can be used. The patient's oral hygiene should be thoroughly appraised and, if necessary, improved before stage I surgery.

The dental evaluation should also take into consideration the overall quality of the hard and soft tissue. The bone quantity and morphology at the implant site have been extensively discussed in the literature and are important when selecting the type and size of implant to be placed. Appraisal of the soft tissues also is critical. Any pathologic condition, such as hypertrophic ridges, hyperkeratotic areas, or mild periodontal disease, should be addressed before treatment. Any hard or soft tissue pathologic condition that could compromise implant placement or integration should be treated before stage I surgery.

### FACTORS THAT INFLUENCE IMPLANT PLACEMENT

A variety of clinical conditions could prevent ideal placement of the implant. Paramount in this issue is the appropriate quantity and quality of bone, as determined with preoperative radiographs. The condition of the postextraction bony ridge, the pattern of previous bone resorption, and the angulation of this bone, particularly in the anterior maxilla, should be considered during the planning stage to avoid esthetic calamities at the time of prosthetic restoration.

Similar care should be taken when the absent bone is a result of traumatic injuries or surgical ablation. Additional factors should be evaluated, such as the location of the inferior alveolar nerve, the width of the incisive canal, and the size and pneumatization of the maxillary sinuses. In the case of a single tooth implant, any rotations or movements of the adjacent teeth that may interfere with proper placement must also be considered.

If the patient's lip line is fairly high, extreme care should be taken in placing an anterior maxillary implant to avoid displaying metal or having to resort to subframes to achieve good esthetics. This situation, whether replacing one tooth with a single implant or using multiple implants, requires thorough preoperative evaluation. This includes a diagnostic wax-up to allow for precise placement of the implant or implants, including determination of the precise depth.

In the event of an unfavorable esthetic result, available grafting techniques might help alleviate the problem, but they obviously require additional surgery. Certain esthetic problems can be reduced by proper preparation of the site before implant placement. Newer techniques, including the use of bone distraction and forced eruption of the hopeless tooth before extraction (see the section on vertical deficiencies later in this chapter), can augment a ridge and improve the final esthetic result.

In high lip situations the placement of implants that are buccally oriented complicates the issue significantly. Strong consideration should be given to removal of the implant, followed by retreatment after proper healing."

Another factor that influences the placement of implants is the case that must be staged, with serial extraction and sequential elimination of pathologic conditions or diverse types of grafting. These situations should not adversely affect the final result if all steps are properly planned.

A variation of a staged case is the use of temporary implants (MTI-MP, Dentatus USA, Inc.) for provisionalization between first- and second-stage surgery (see Chapter 11). The use of temporary implants can be crucial when provisionalization is difficult; however it is vital that the temporary implants in no way influence the placement of the permanent restoration.

Clinical experience has shown that most multiple implant cases work better when they are overengineered; the old axiom 'the more the better' is undoubtedly true when planning extensive maxillary reconstruction'.

An exception to the "prosthetically driven implant placement rule" is the case that seems to have so many aggravating factors that a surgical solution appears impossible. In these cases the use of subframes may solve positional problems. It is advisable to place as many implants as practical or affordable to ensure a successful result. This placement allows for not only possible loss of one or more implants (particularly when working with poor quality bone) but also for the ability to submerge some implants if their utilization creates unacceptable esthetic results. Even these situations can be successfully treated when the case is properly planned.

### *Vertical Deficiencies*

One approach to vertical deficiency is grafting, preferably using autogenous bone or, as an alternative, allogeneic materials mixed with autogenous bone and membranes at the time of placement of the implant; the implant will protrude through the bony defect but will be covered by the grafting material and "tented" with the membrane.

Another useful approach is en bloc grafting of the area using autogenous bone harvested from the mentum or the retromolar area or, if conditions are appropriate,

from the iliac crest. In these situations soft tissue coverage is of paramount importance.

An additional technique is the forced eruption of the tooth (if present) using orthodontic wires to enable regrowth of 3 to 4 mm of the absent bone, followed by implant placement."

Alveolar bone distraction recently was introduced as an alternative to bone grafting for ridge augmentation of traumatically induced, limited alveolar defects (see Chapter 20).

### *Insufficient Interocclusal Space*

In some cases, the long absence of teeth in an arch produces significant overeruption in the opposite arch, to the extent that placement of implants is possible but their restoration is not. There are several ways to attempt to resolve this problem.

When the extrusion of teeth is manageable, endodontic and prosthetic means may solve the problems. In other situations, when teeth of the opposite arch virtually occlude with the gingiva of the arch in question, osteotomies may allow repositioning of the bony section and its teeth into a proper relationship in the arch, permitting placement of implants and reconstruction in the arch in question. Finally, the selection of abutments designed for minimal interocclusal space (e.g., a MirasCone [Nobel Biocare AB] abutment rather than an EstheticCone [Nobel Biocare AB] abutment) may change a marginal case into a successful case.

### *Cortical Bone Angulation*

Improper angulation of the bone, primarily in the anterior maxilla, presents significant problems. However, the use of segmental osteotomies borrowed from orthognathic surgery allows for an efficient and rather quick resolution.

In these cases the implant may be placed at the time of the osteotomy, provided that model surgery done in advance and in conjunction with all other diagnostic tools previously discussed virtually assures the dental surgeon of a proper placement.

## STENTS

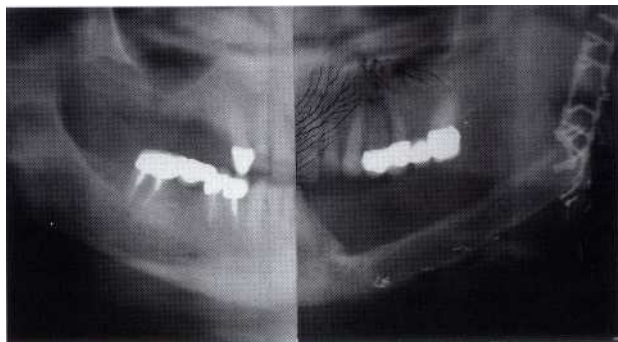
The use of surgical stents during the planning stage and stage I surgery ensures that placement will be quite accurate (Figs. 21-7 to 21-10). A multitude of stents are available that will serve in most situations, and any stent is better than no stent (see Chapter 16).

Stents also are convenient for determining the position of submerged implants during stage II surgery, especially when the mucosa is fairly thick. This is particularly true in maxillofacial reconstruction cases in which bone

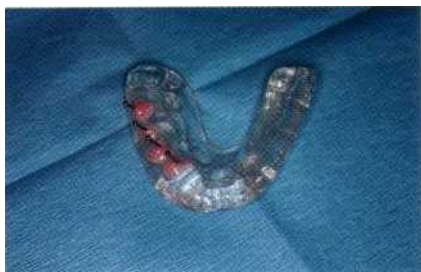has been grafted with accompanying soft tissues that are significantly thicker than attached gingiva.

### SURGICAL PROCEDURES AND COMPLICATIONS

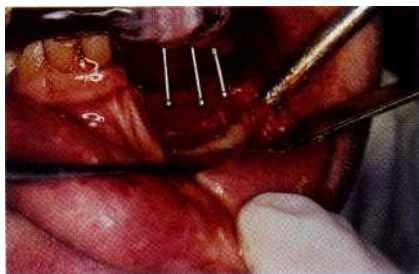The surgical aspect of implant placement has been simplified over the past few years, making the process fairly routine. Although many implant systems are available, requiring different armamentaria, sound surgical principles apply equally to all.



*Fig. 21-7. Postoperative Panorex radiograph (12 months later) of a patient with a hemimandibulectomy and reconstruction with microvascular free flap fibula, showing full bony consolidation.*



*Fig. 21-8. Surgical stent with movable pins to facilitate stage I and stage II surgery. (Courtesy Joseph Huryn.)*



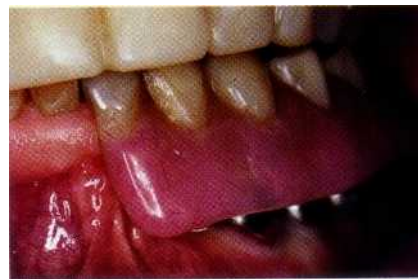*Fig. 21-9. Intraoperative view of properly aligned implants.*

Sterile or clean technique must be followed, with particular emphasis on avoiding contact with the implant before it is placed in the osteotomy site.<sup>19</sup> Pre mounted implant "carriers" have reduced this risk. Measures such as appropriate wound care and debridement, careful suturing technique, and taking care to avoid placing the soft tissues under tension greatly reduce postoperative complications. Postoperative care, including the uses of chlorhexidine mouthwashes and meticulous oral hygiene and the cessation or reduction of cigarette use, will contribute to a favorable postoperative course.<sup>20,21</sup> These hygiene issues, in addition to not wearing removable prostheses, are of paramount concern when nonsubmerged implants are used.<sup>17</sup> Specific postoperative instructions to the patient are obviously crucial in these particular situations."

Certain intraoperative complications can cause the dental surgeon to change the placement or position of the implant. Fracture of the buccal cortical plate when placing a threaded implant occurs with some frequency. This occurrence should not discourage implant placement if the bone is otherwise adequate and good implant stability is achieved." The fractured cortical plate can then be covered with grafting material and membrane.

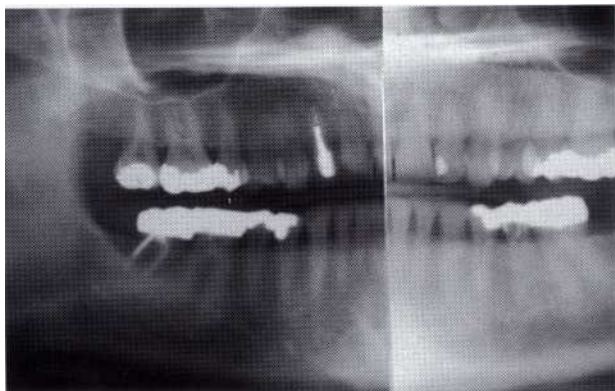
A more serious example is compression or direct penetration of the inferior alveolar canal by drilling equipment or the implant itself. This is an unfortunate event that is almost entirely preventable by proper preoperative treatment planning. In this case, immediate action is required, including an intraoperative or postoperative radiograph and the immediate removal of the implant.

Violation of the sinus membrane when drilling or placing the implant occurs with some frequency. In the absence of a pathologic condition of the sinus and with a stable implant in adequate bone, this situation does not compromise either the use of the implant or the clinical integrity of the antrum.<sup>17</sup> Displacement of the implant into the sinus also can occur; in this situation, retrieval of the implant is advisable.<sup>22</sup>

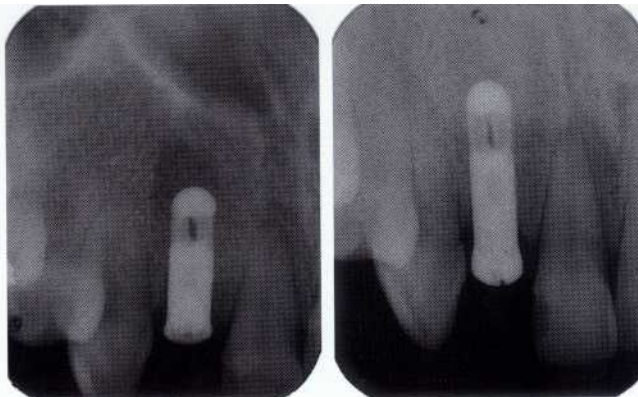


*Fig. 21-10. Completed case with hybrid prosthesis. (Courtesy Joseph Huryn.)*

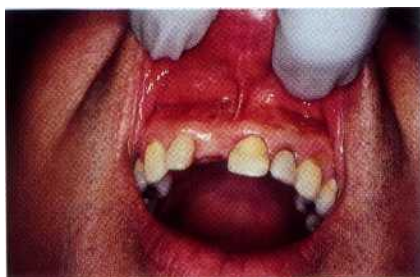



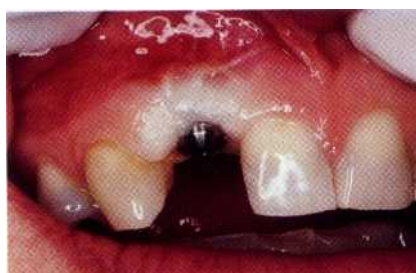*Fig. 21-11. Preextraction Panorex radiograph of tooth #7 with apical lesion.*



*Fig. 21-13. Radiographs of periapical lesion (left) and resolution of fistula (right), showing complete bone fill after periapical incision and drainage and apical debridement.*



*Fig. 21-12. A gingival fistula appeared 3 months after implant placement (6 weeks after extraction).*



*Fig. 21-14. Clinical presentation after stage II surgery.*

Other complications include impingement of the implant into the apical area of the adjacent tooth. The tooth in question may require endodontic therapy, an apicoectomy, or extraction. Evaluation of the individual implant (e.g., radiographic changes, pain, mobility) after solving the issue of the injured tooth determines if the implant is usable.<sup>23</sup>

Another complication is the infection of an implant from residual apical bacteria from the previously extracted tooth (Figs. 21-11 to 21-14). This can be treated with conventional antibiotics or even an apicoectomy-type procedure on the implant. Should the implant be rejected, a second implant can be placed after the area has healed completely.

Another common complication is the placement of implants that are too close to each other, the so-called kissing implants. Again, this is a problem that in most cases can be avoided by proper pretreatment evaluation and the use of a stent. In some cases inactivation of one implant may be required, especially if there is a problem of reverse angulation superimposed on extreme closeness.

The ultimate complication is lack of integration of the implant, which may manifest itself by pain, inflammation of the surrounding tissues, or even spontaneous

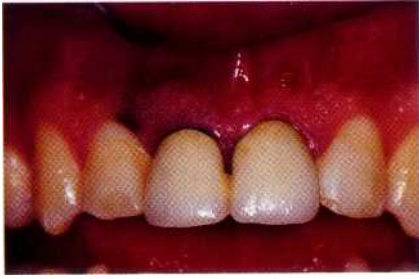protrusion or exfoliation of the fixture. In these cases the clinician must determine if any local or systemic causes would contraindicate a second attempt in the area.

#### ADVANCED PROCEDURES

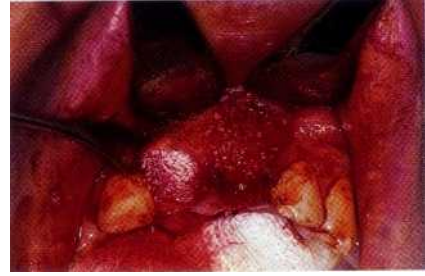
Advanced procedures in implantology can be divided into two categories: simple grafting or augmentation procedures performed to enable implant placement where bone or soft tissue is inadequate, and complex procedures associated with maxillofacial reconstruction and placement of implants in irradiated bone.

#### AUGMENTATION PROCEDURES

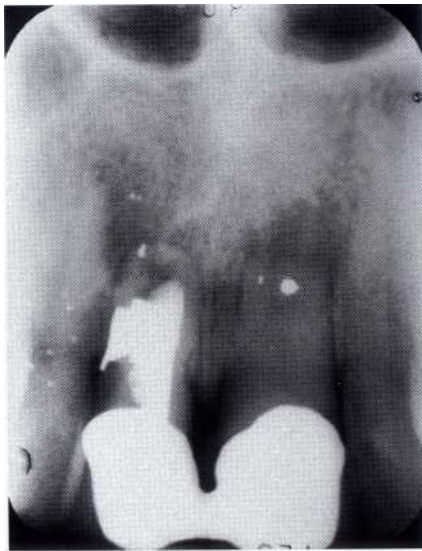Hard tissue procedures are the key to placement of fixtures. Soft tissue procedures are adjuvant processes that enhance esthetics but in general do not influence placement or survival of the implant. Hard tissue augmentation usually is performed before or during stage I surgery, whereas soft tissue procedures can be performed at any time.



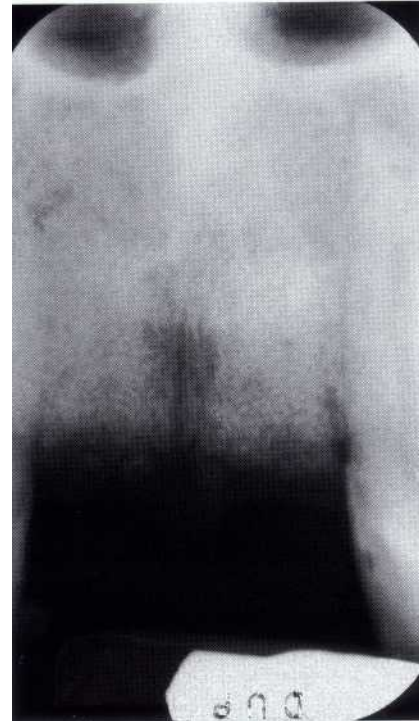
*Fig. 21-15. Preoperative clinical view of teeth #8 and #9. Both teeth had been traumatized 10 years earlier. (Courtesy Jorge Barrios.)*



*Fig. 21-17. Sockets and defects grafted with Bio-Oss. (Courtesy Jorge Barrios.)*



*Fig. 21-16. Radiographic appearance of teeth in Fig. 21-15. (Courtesy Jorge Barrios.)*

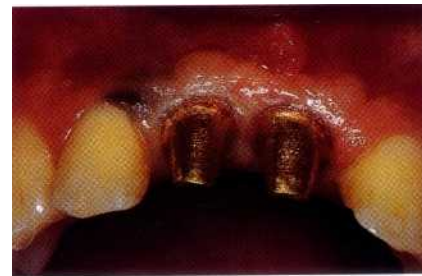

*Fig. 21-18. Postoperative radiograph taken 6 months later shows good bone consolidation. (Courtesy Jorge Barrios.)*

### *Hard Tissue Augmentation*

**Postextraction Bone Grafts.** One of the simplest augmentation procedures is the placement of a grafting material after an extraction. Once the tooth has been removed, the socket is thoroughly debrided of granulation tissue or any type of foreign bodies such as gutta-percha or cement. Once this has been accomplished, the dental surgeon can fill the socket or sockets with the grafting material of choice (e.g., Bio-Oss, Geistlich Pharma AG; Perioglass, Block Drug Corp.; freeze-dried bone) (Figs. 21-15 to 21-19).

In most cases primary closure of the wound will be difficult; the use of resorbable membranes (e.g., RESOLUT, WL Gore & Associates, Inc.; or lamellar bone) is quite useful and indicated. When this material shows proper consolidation, the implant or implants can be placed.



*Fig. 21-19. Clinical view of case in Fig. 21-18 with gold abutments in place. (Courtesy Jorge Barrios.)*

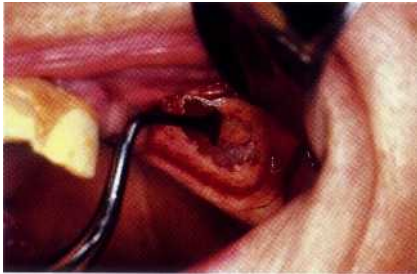


Obviously, these procedures are significant in the anterior maxilla to maintain the normal architecture of the alveolar ridge.

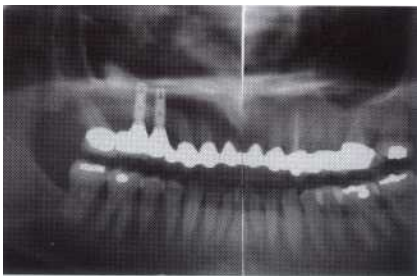
**Stage I Surgical Bone Grafts.** Grafting at stage I may be required when the cortical plate is fractured or when a section of the implant that must be in bone is partly exposed. In these cases the dental surgeon can use any of the allogeneic materials mentioned or autologous bone that can be harvested in the process of preparing the osteotomy sites or collected in bone traps attached to the suction system. This technique avoids the need to enter a separate area to harvest bone. The use of a barrier membrane is advisable.

**Sinus Lifts.** A novel procedure described approximately 20 years ago has become one of the staples of preimplant grafting for the posterior maxilla.<sup>24,25</sup> This is known as the sinus lift or sinus augmentation (Figs. 21-20 and 21-21). It is indicated when the height or width (or both) of posterior maxillary bone is inadequate.

This procedure can be performed as a separate surgical procedure before stage I implant placement (when there is less than 4 to 6 mm of bone) or at the time of implant placement. When performed for the placement of one implant, it is described as a minilift (Figs. 21-22 to 21-26) and is accomplished in conjunction with implant

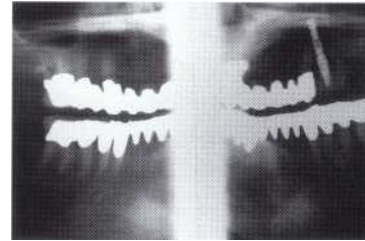


*Fig. 21-20. "Sinus lift" procedure showing sinus membrane fully retracted, with the lateral wall of the antrum now acting as the medial wall of the area to be grafted.*

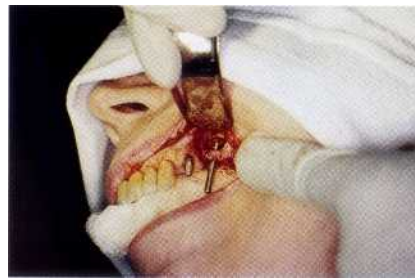

*Fig. 21-21. Panorex radiograph taken 2 years after grafting (15 months after placement of implants).*

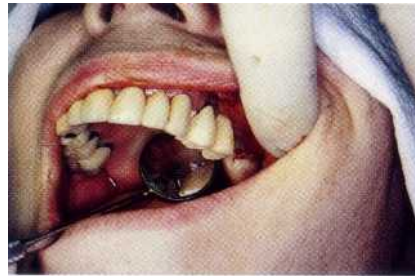placement. Proper treatment planning requires thorough radiographic evaluation of the sinus to rule out chronic disease. A CT scan is indicated in most cases. Grafting of infected sockets is not advisable.



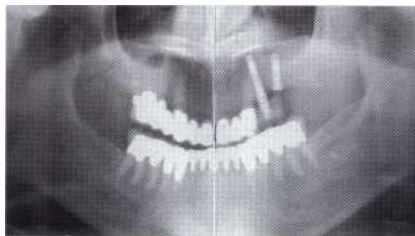
*Fig. 21-22. Panorex radiograph showing a solitary integrated implant and inadequate bone height for additional implants.*



*Fig. 21-23. Intraoperative view showing the antrum with the membrane reflected and the "direction indicator" in place.*



*Fig. 21-24. Immediate postoperative view with a provisional bridge in place.*



*Fig. 21-25. Panorex radiograph of well-integrated implant at the time of stage II surgery.*

The procedure involves the use of donor bone, either autologous bone from the cortical plate, iliac crest, chin, tuberosity, and mandibular retromolar area or bone mixed with materials such as Bio-Oss. The material is pushed up through an opening in the posterior maxilla and placed under the schneiderian membrane. The patient must be informed of possible sinus complications (sinus membrane perforation, as well as paresthesia of the infraorbital nerve as a result of aggressive dissection of the mucoperiosteal flap, which includes the infraorbital nerve as it exits the infraorbital canal).

The waiting time before placement of the implants varies from as little as 4 months (for autogenous bone) to 6 to 12 months. The rate of success after implant placement has been reported to be 75% to 90%.<sup>26,27</sup>

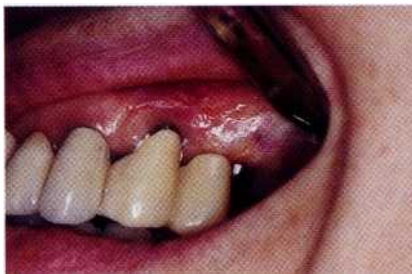**Ridge Augmentation.** A grafting procedure similar to the sinus lift can be performed in the posterior mandible particularly to increase the vertical height of bone over the mandibular nerve or to establish a more normal anatomic height of the mandible when excessive resorption of the posterior area has occurred.

### Soft Tissue Augmentation

**Vestibuloplasty.** A limited vestibuloplasty is indicated to remove hypermobile, pendulous tissue; this is an excellent procedure in the maxillary arch.<sup>28,29</sup> If the vestibule can be elevated to the proposed postoperative position without causing distortion of the vermilion border of the lip, sufficient mucosa exists to perform a limited vestibuloplasty. Implant surgery then can be performed under the best circumstances.

**Papilla Formation and Reconstruction Surgery.** The creation by surgical means of a proper papilla in the anterior maxilla has become an integral part of implant-supported prosthetic reconstruction (Figs. 21-27 and 21-28). The literature describes extensively different means of accomplishing this goal.<sup>30-32</sup>

Forced eruption of retained roots, when feasible, facilitates this. The use of wide implants in the anterior

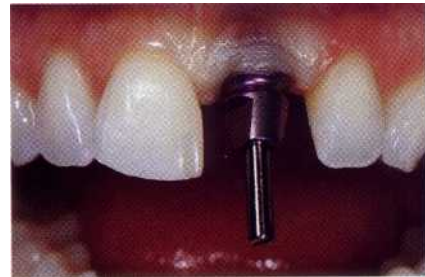

*Fig. 21-26. Clinical appearance of implant with healing abutment at the time of stage II surgery.*

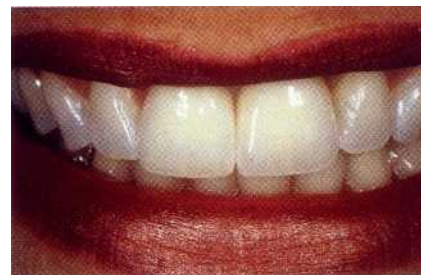maxilla, such as the Frialit 11, also helps in this respect. Stage II surgery, which displaces tissue from the palatal side of the socket and folds it under the buccal part of the flap to increase the height of the papilla, is a relatively simple procedure that also accomplishes this objective."

**Frenectomy.** Frenectomy, which is fairly simple and has been extensively described in the literature, is another adjunct in implant surgery designed to improve the final result of the prosthetic restoration, particularly when a diastema has been present in the area of the maxillary central incisors and a hypertrophic frenum exists.

**Gingivoplasty and Gingival Grafts.** Gingivoplasties and gingival grafts have been extensively described in the surgical and periodontal literature.<sup>33-35</sup> They are useful procedures intended to enhance principally the cosmetic results of anterior maxillary implant-supported restorations, to improve the thickness of the buccal tissues, to reconstruct interdental papillae, to correct gingival clefts, or to replace discolored or scarred gingiva in



*Fig. 21-27. Proper preoperative reconstruction and implant placement recreate the natural contours of the gingiva, including the papilla. (Implant and Restorative Dentistry David A. Garber, DMD and Maurice A. Salama, DMD, Goldstein, Garber, Salama, Gribble, L.L.C. Pinhas Adar, CDT, MDT Oral Design Center Atlanta, Inc.)*



*Fig. 21-28. Finished restoration of condition seen in Fig. 21-27 shows good contours and gingival tissue filling the papilla area. (Implant and Restorative Dentistry David A. Garber, DMD and Maurice A. Salama, DMD, Goldstein, Garber, Salama, & Gribble, L.L.C. Pinhas Adar, CDT, MDT Oral Design Center Atlanta, Inc.)*

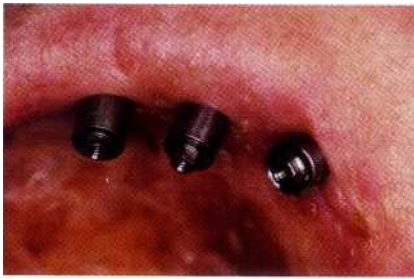

Fig. 21-29. Orbital implants 2 weeks after stage II with standard abutments in place.

areas where multiple procedures may have been previously performed around the natural teeth.

All these interventions may be performed before implant placement, concomitantly with placement, or at stage II surgery.

**Craniofacial Implants.** Specialized fixtures, including modified short implants (3 to 4 mm long) with a perforated ring at the level of their necks and sharp barbs in the perforations to provide additional anchorage in cortical bone, are used to anchor facial prostheses that replace ears, eyes, and noses (Fig. 21-29). Their uses are quite limited and require specialized training. They facilitate the task of the maxillofacial prosthodontist and provide significant esthetic and functional advantages over devices that must be held in place by conventional means, such as surgical cements. They also extend the life of the prosthesis. Use of conventional implants has allowed a full rehabilitation of patients who have suffered traumatic injuries or surgical ablations that result in considerable loss of hard or soft tissue substance.

## CONCLUSION

Implant surgery and implant-supported prosthetic reconstructions have evolved significantly since their introduction in the United States. The most significant advances have occurred in cosmetic reconstruction, driven by a demanding public and well-trained dental surgeons who combine oral surgical, periodontal, and cosmetic skills to achieve a superior esthetic result.

## REFERENCES

- Zlotolow I et al: Osseointegrated implants and functional prosthetic rehabilitation in microvascular fibula free flap reconstruction mandibles, *Am J Surg* 164(6):677 1992.
- Parel SM et al: Osseointegrated implants in maxillofacial prosthesis. II. Extraoral applications, *J Prosthet Dent* 55:600,1986.
- Hidalgo DA: Fibula free flap: a new method of mandible reconstruction, *Ann Plast Surg* 23:498, 1989.
- Hidalgo DA: Aesthetic improvements in free flap mandible reconstruction, *Plast Reconstr Surg* 88:574, 1991.
- Linkow LI: The endosteal blade-vent, *J Prosthet Dent* 30:611,1973.
- Linkow LI: Some variant designs of the subperiosteal implant, *Oral Implantol* 2:190, 1972.
- Linkow LI: The blade vent: the most promising tooth abutment, *Oral Implantol* 1:175, 1971.
- Linkow LI: Endosseous oral implantology: a 7-year progress report, *Dent Clin North Am* 14:185, 1970.
- Linkow LI: Reevaluation of mandibular unilateral subperiosteal implants: a 12-year report, *J Prosthet Dent* 1967 17:509, 1967.
- Albrektsson T et al: Osseointegrated titanium implants: requirements for ensuring a long lasting, direct bone-to-implant anchorage, *Acta Orthop Scand* 52:155, 1981.
- Takeshita F et al: Histologic study of failed hollow implants, *Int J Oral Maxillofac Implants* 1996 Mar-Apr; 11:245, 1996.
- Truhlar RS et al: The influence of bone quality on Periostest values of endosseous dental implants at stage 11 surgery, *J Oral Maxillofac Surg* 55(12 Supp15):55, 1997.
- Baker DA et al: Integration strength and speed of dual-etched Ti implants, Abstract presented at the Thirteenth Annual Meeting of the Academy of Osseointegration, Atlanta, March 6, 1998.
- Tanner T Treatment planning for dental implants: considerations, indications, and contraindications, *Dent Update* 24:253, 1997.
- Handelsman M: Treatment planning and surgical considerations for placement of wide body implants, *Compend Contin Educ Dent* 19:507, 1998.
- Weyant RJ, Burt BA: An assessment of survival rates and within-patient clustering of failures for endosseous oral implants, *J Dent Res* 72:2, 1993.
- Misch CE: *Contemporary implant dentistry*, ed 2, St Louis, 1998, Mosby.
- Garber D: Personal communication, December 1998.
- Scharf DR, Tarnow DP: Success rates of osseointegration for implants placed under sterile versus clean conditions, *J Periodontol* 64:954, 1993.
- Haas R et al: The relationship of smoking on peri-implant tissue: a retrospective study, *J Prosthet Dent* 76:592, 1996.
- Lindquist LW, Carlsson GE, Jemt T Association between marginal bone loss around osseointegrated mandibular implants and smoking habits: a 10-year follow-up study, *J Dent Res* 76:1667, 1997.

22. Ueda M, Kaneda T Maxillary sinusitis caused by dental implants: report of two cases, *J Oral Maxillofac Surg* 50:285, 1992.
23. Sussman HI: Implant pathology associated with loss of periapical seal of adjacent tooth: clinical report, *Implant Dent* 6:33, 1997.
24. Smiler DG, Holmes RE: Sinus lift procedure using porous hydroxyapatite: a preliminary clinical report, *J Oral Implantol* 13:239, 1987.
25. Smiler DG et al: Sinus lift grafts and endosseous implants: treatment of the atrophic posterior maxilla, *Dent Clin North Am* 36:151, 1992.
26. Tarnow DP, Emtiaz S, Classi A: Immediate loading of threaded implants at stage I surgery in edentulous arches: 10 consecutive case reports with 1- to 5-year data, *Int J Oral Maxillofac Implants* 12:319, 1997.
27. Scharf DR, Tarnow DP: The effect of crestal versus mucobuccal incisions on the success rate of implant osseointegration, *Int J Oral Maxillofac Implants* 8:187, 1993.
28. Wessberg GA, Schendel SA, Epker BN: Modified maxillary submucosal vestibuloplasty, *Int J Oral Surg* 9:74, 1980.
29. Hoelscher DC, Simons AM: The rationale for soft tissue grafting and vestibuloplasty in association with endosseous implants: a literature review, *J Mich Dent Assoc* 78(3):56, 1996.
- Salama H et al: Developing optimal peri-implant papillae within the esthetic zone: guided soft tissue augmentation, *J Esthet Dent* 7:125, 1995.
- Salama H et al: Treatment planning 2000: an esthetically oriented revision of the original implant protocol, *J Esthet Dent* 9:55, 1997.
- Reikie DF: Restoring gingival harmony around single tooth implants, *J Prosthet Dent* 74:47, 1995.
- Russo J: Periodontal laser surgery, *Dent Today* 16:80, 1997.
- Rosenquist B: A comparison of various methods of soft tissue management following the immediate placement of implants into extraction sockets, *Int J Oral Maxillofac Implants* 12:43, 1997.
- Davidoff SR: Late stage soft tissue modification for anatomically correct implant-supported restorations, *J Prosthet Dent* 76:334, 1996.
- Misch C: The maxillary anterior single tooth implant aesthetic-health compromise, *Int J Dent Symp* 3:4, 1995.
- Han TJ, Klokkevold PR, Takei HH: Strip gingival autograft used to correct mucogingival problems around implants, *Int J Periodontics Restorative Dent* 15:404, 1995.



انتشارات شایان نمودار

# ESTHETICS AND LASER SURGERY

Robert A. Strauss

**T**HE USE OF LASERS in dentistry has burgeoned at an astonishing rate over the past few years. Once relegated to use on soft tissue, now even hard tissue esthetic surgery can be done with lasers. Because of their many advantages, lasers are indicated for a wide variety of intraoral and extraoral esthetic procedures. To use them safely and successfully, however, a thorough understanding of their indications, contraindications, and safety parameters is imperative.

## HISTORY

The word laser is an acronym for light amplification by stimulated emission of radiation. The theory has its roots in several basic principles of physics first described by Einstein in 1917.<sup>1</sup> Amazingly, it was almost another 50 years before these principles were sufficiently understood and the technology could be converted into practical reality. The first laser to use visible light was developed by a physicist, Dr. Theodore Maiman, in 1960. Maiman used a ruby gemstone as the lasing medium, producing the red beam of intense light typically associated with lasers.<sup>2</sup> This was followed in 1961 by another crystal laser using a neodymium-doped crystal of yttrium, aluminum, and garnet (Nd:YAG). In 1964 physicists at Bell Laboratories produced a gaseous laser using carbon dioxide (CO<sub>2</sub>) as the lasing medium. That same year another gaseous laser that would prove important in dentistry, the argon laser, was invented.

Dental scientists investigating the effects of Maiman's ruby laser on the enamel of teeth found that it caused cracking and fissuring of enamel.<sup>3,4</sup> The studies

concluded that lasers had no place in dentistry, and few other studies were undertaken. In medicine, however, research and clinical use of lasers proliferated. In 1968 the CO<sub>2</sub> laser was used for the first time to perform soft tissue surgery. An increasing variety of laser wavelengths, as well as general and oral surgical indications, evolved. In the mid-1980s the expanded availability of different wavelengths and the improved understanding of laser physics and tissue interaction created a resurgence of interest in the use of lasers in dentistry for hard tissues such as enamel.<sup>5-8</sup>

Although a few wavelengths, such as that of the Nd:YAG laser, can be artificially manipulated for hard tissue use, their danger potential and lack of specificity for dental tissues make them less than ideal. Other lasers, such as the excited dimer (excimer) laser, which was studied extensively in the late 1980' and early 1990s, were shown to cause little damage to teeth but were plagued by problems of cost, size, and efficiency.<sup>9</sup> Not until 1997 did the U.S. Food and Drug Administration (FDA) finally approve a well-known laser, the erbium: YAG (Er:YAG) laser, for hard tissue use.<sup>10,11</sup> The efficiency, value, and indications for treatment with this dental laser have not yet been determined.

## BASIC CONCEPTS

Laser energy is unique in that laser light is coherent. This means that laser light has four distinct properties that distinguish it from regular light. Ideal laser light is monochromatic (composed of a single wavelength of light), collimated (the light waves run parallel to each other instead



of diverging), and *uniphasic* (the peaks and valleys of the waves are synchronous [Figs. 22-1 and 22-2]). It is also extremely *intense*. An important result of these four properties is that laser light can be targeted with great precision and is extremely powerful.

### Monochromatic Property

**Because lasers are monochromatic, each has a single frequency and wavelength and therefore a single "color."** Thus lasers often are defined by their visible color (e.g., red light or green light lasers), by their position in the electromagnetic spectrum (e.g., infrared, ultraviolet or x-ray lasers), or by the chemicals that create the light (e.g., CO, argon, or Nd:YAG lasers).

### Collimated Property

All laser beams are parallel, or collimated, unlike regular light. Because the laser beam does not diverge signifi-

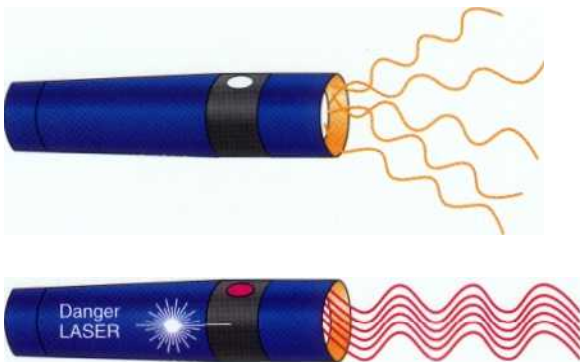


Fig. 22-1. Regular light, showing the different wavelengths present and the random spread of the beam. Laser demonstrating uniform, coherent light.

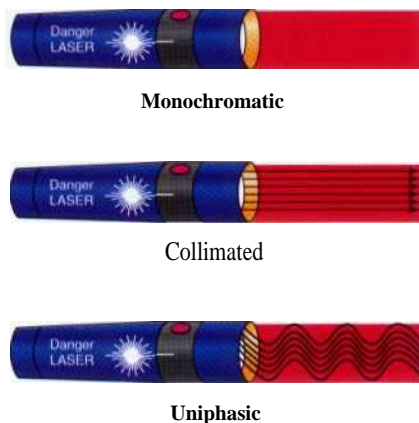


Fig. 22-2. Laser light, showing monochromatic wavelength, collimation, and uniformity of phase, which constitute coherent light.

cantly over distance, the source can **be positioned at great length from the target tissue** or can be very efficiently focused down to a small spot with a convex focusing lens.

### Uniphasic Property

The peaks and troughs of a laser light wave are directly in line (synchronous) with one another, making them uniphasic. All the peaks and troughs of the energy beam are stacked on top of each other.

### Intensity Property

Collimation, monochromaticity, and uniphasicity together produce a very intense and powerful flash or beam of light. The ability to efficiently focus the beam down to a small spot size (an effect of the collimation on a convex lens) produces an extremely powerful, condensed energy source.

Laser beams may reflect off, transmit through, scatter (break up) within, or be absorbed by organic target tissue. The first three conditions elicit no effect within the tissue, but when absorbed, a laser beam may produce several different results. The most important is the photothermal effect, or tremendous heat generation that occurs almost instantaneously within the tissue. In soft tissue this causes the intracellular water to boil or vaporize and literally explodes and disintegrates the cell. In hard tissues, similar effects may be seen in hydroxyapatite. Unlike other heat sources, however, the laser can be applied with incredible precision and with such speed that only microns of tissue can be removed at a time with very controlled and minimal damage to adjacent tissues and structures. Conversely, it sometimes is advantageous to have a lateral heat effect in tissue that results in thermal coagulation of adjacent blood vessels and a bloodless field. Lasers can be controlled to provide this as well.

The many lasers now available for medical and dental use differ in several aspects. The primary difference is the active medium, (i.e., the material that undergoes stimulated emission). The specific material used determines the wavelength of energy produced and therefore the clinical indications. Few materials in nature can undergo this process because the material must be capable of sustaining population inversion, an unnatural condition in which **most atoms are in a highly excited state**.

The ideal system **uses fiberoptic delivery of the laser beam to the target tissue**. These systems are flexible and precise, they allow for both contact and noncontact surgery, and they are capable of endoscopic delivery. Unfortunately, not all wavelengths (e.g., CO<sub>2</sub>) can be transmitted through the currently used quartz fiberoptic fibers. These other types of lasers use articulated arm delivery in which a series of hollow metal tubes connected by mirrored flexible joints or "knuckles" allow the beam to be

passed from the laser to the tissues. Although this is functional for superficial tissues, it is less than ideal for deeper tissues or areas of difficult access, such as the oral cavity. Some newer lasers use a hollow wave guide, a variation of the articulated arm. The hollow wave guide is a flexible metal tube internally lined with a mirrored surface or foil, which allows the beam to reflect down the guide to the tissues. Although not as flexible as a fiberoptic fiber and incapable of endoscopic delivery, this system has **dramatically improved the dentist's ability to provide convenient, precise delivery within the oral cavity.**

Some lasers produce a continuous beam of laser light as long as the machine is energized, whereas others can be pulsed. These very high power, short duration pulses of laser light minimize the time available for lateral tissue heating and damage.<sup>12</sup> Other lasers can be electronically enhanced to produce extremely fast, high-powered laser bursts ("superpulsed" or "ultrapulsed") for situations such as dermatologic skin surgery where lateral thermal damage produces scarring.

Selecting the appropriate laser for a given procedure usually is a simple matter of determining which laser wavelength is best absorbed by the target tissue while producing the least reflection, scatter, and transmission. Laser wavelengths that are absorbed by water (e.g., CO<sub>2</sub> and Er: YAG lasers) are appropriate for soft tissue surgery. Those well absorbed by hemoglobin are better suited for vascular tissues or lesions (e.g., argon, KTP:YAG, tunable dye, copper vapor lasers). Argon laser wavelengths are well absorbed by composite resin, and the Er:YAG laser wavelength, which is absorbed by both hydroxyapatite and water, allows for hard tissue use. Some lasers with wavelengths that are absorbed by a number of different tissues (i.e., chromophores) may be useful for a variety of tissue effects. In addition, some transmission may actually be desirable in certain cases to allow deeper penetration of tissues (e.g., when deep hemostasis is desired in vascular lesions). To allow for precise tissue effects and clinical uses, some devices can produce more than one wavelength (i.e., CO<sub>2</sub> and Er:YAG, KTP:YAG and Nd:YAG, and tunable dye), which allows the operator to select the desired tissue effect by varying the wavelength used. The choice of an appropriate wavelength involves a combination of known tissue effect and the operator's clinical experience."

### ADVANTAGES AND DISADVANTAGES

Many laser wavelengths either are absorbed by hemoglobin or constrict vascular wall collagen, allowing for bloodless surgery." This allows the dentist to work in a clean, dry environment unobstructed by bleeding. When used correctly, lasers also can remove precise and minimal amounts of tissue with minimal effect on adjacent tissues,

and they are ideal for detailed, exact tissue manipulation." Lasers have an effect on neural tissue that generally results in less pain after surgery compared with other types of treatment.<sup>16</sup> In fact, because of their great speed, some pulsed lasers may even be used for soft or hard tissue surgery without the need for local anesthesia." Minimal postoperative pain and absence of bleeding usually preclude the need for suturing, tissue closure, or coverage with splints or dressings except when cosmetic requirements dictate otherwise.

The elimination of lateral tissue damage is especially important in dentistry because of the proximity of such chemically diverse yet clinically vital structures as dental pulp, bone, tooth structure, and oral soft tissue. Lasers also make possible procedures such as perioral cosmetic skin resurfacing, in which even minimal adjacent dermal tissue damage would translate into inevitable and devastating scarring. Sealing of the lymphatic system during laser surgery and the minimal tissue trauma result in little or no postoperative edema in most cases.<sup>18</sup> Finally, because of the minimal tissue damage and the decrease in the number of myofibroblasts in laser-treated wounds compared with wounds made by scalpel or electrosurgical instruments, postoperative scarring and contracture are minimized, allowing dramatic surgery without the fear of significant postoperative cosmetic deformity or functional deficits.<sup>19</sup>

Disadvantages are few but important. The preeminent concern with lasers in dentistry is safety. Lasers require tremendous diligence to maintain a safe operative environment for both the patient and the dental team (see the section on laser safety later in this chapter). Other disadvantages include the generally high cost of purchasing and maintaining the laser, the loss of tactile sensation with noncontact lasers, the learning curve necessary to obtain uniform results, and the specificity of some laser wavelengths, necessitating the occasional need for more than one laser for a particular procedure. Finally, although healing after laser surgery generally is excellent, usually much better than with other instruments such as a scalpel or electrosurgical instrument, it also generally is slower because of the vascular sealing.<sup>20</sup>

### CLINICAL INDICATIONS

Hard tissue laser surgery was only recently approved by the FDA, therefore most current indications primarily involve soft tissue. Hard tissue uses such as bleaching with a CO<sub>2</sub> or argon laser or actual tooth preparation and modification procedures using the Er:YAG laser are becoming more popular, and it is certain that more hard tissue uses will evolve as these lasers gain clinical popularity and clinicians gain experience.

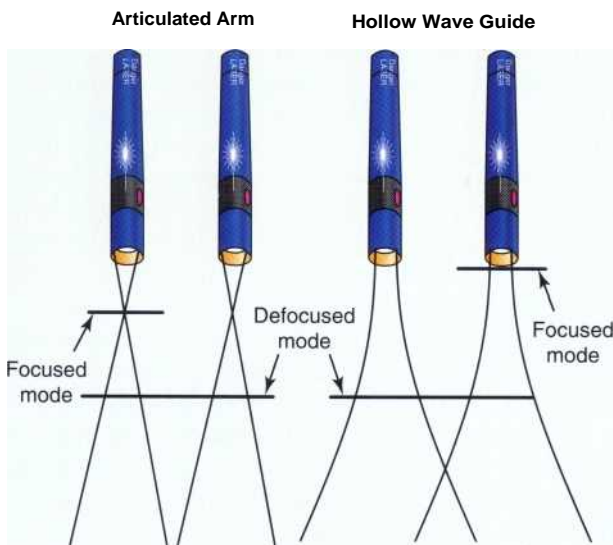


Fig. 22-3. Focused mode technique (for incision) and defocused mode technique (for vaporization). Note the different distances from target to laser for the hollow wave guide and the articulated arm.

Soft tissue procedures include excision of excess tissue, either normal or pathologic, and recontouring of tissue. There are few soft tissue surgeries in which the laser cannot be used and used advantageously. Teeth or bone intimately involved with the target tissue or lesion must be protected from the laser beam, which increases the difficulty of the procedure, but with reasonable precaution and care, this usually is not a problem. For example, a standard mucoperiosteal flap around the dentition can be created with a laser, but it is more easily and safely accomplished with a scalpel. Once the incision has been made, the rest of the surgery may well be enhanced by the use of lasers.

Despite the many different types of lasers available, the techniques for their use do not vary significantly. The three basic techniques are incision, vaporization, and hemostasis. The clinician should evaluate the lesion before surgery and determine which of these is most appropriate.

Incision is accomplished by placing the laser at its focal length (i.e., the smallest possible spot size) near the tissue or touching the tissue if a contact tip laser is used. This increases the density of the power and condenses the effect into a small area. This laser-target distance varies according to the delivery system and ranges from contact with a contact laser to 0.5 mm for a hollow wave guide to more than 1 cm for an articulated arm laser (Fig. 22-3).

Vaporization, also called ablation, allows the removal of large areas of very superficial tissue (e.g., removal of the surface mucosal epithelium) without affecting deeper structures. This is accomplished by defocusing, or backing the laser away from the target, to increase the spot size. De-

Box 22-1

SOFT TISSUE CLINICAL INDICATIONS FOR ESTHETIC DENTAL LASER SURGERY

- Frenectomy
- Gingivoplasty
- Tissue and papilla resculpting
- Gingivectomy
- Access gingivectomy
- Lesion removal
- Pigment and tattoo removal

focusing effectively lowers the density of the laser energy per unit area and causes the laser to act more superficially over a larger surface area. The target distance may vary dramatically depending on the type of delivery system, the available power, and the desired depth of penetration.

Most lasers are intrinsically hemostatic to a degree, depending on the laser's depth of penetration and whether hemoglobin or vascular collagen is the chromophore for a particular laser wavelength. The CO<sub>2</sub> laser generally seals vessels 500 μm or less in diameter, whereas the more hemoglobin-specific KTP : YAG, Nd : YAG, and argon lasers may provide deeper hemostasis. Even when another modality is used, the laser may be used to control hemorrhage. This is done by passing the laser over the surgical site somewhere between the focusing and defocusing distances to produce a hemostatic effect without causing significant tissue cutting or ablation.

The indications for the use of lasers in cosmetic dentistry are presented in Box 22-1. More than one wavelength may be suitable for a specific clinical situation, therefore proper wavelength selection is important. Because of the variety of manufacturers, wavelengths, machines, and clinical variations, there is no "cookbook" for laser surgery. Any clinician using lasers should receive appropriate instruction in that particular wavelength and device and should use known protocols along with individual clinical judgement.

The following sections give some examples of laser cosmetic dental procedures and the lasers most commonly used for that purpose, although other lasers may be used.

Gingivectomy for Tissue Hyperplasia

The laser (CO<sub>2</sub>, diode) is used to incise the location of the desired gingival margin in focused mode and then either to excise or ablate the superfluous hyperplastic tissues (Figs. 22-4 to 22-6). Care must be taken to protect the teeth from the laser beam by placing a thin instrument between the teeth and the gingiva. Additional



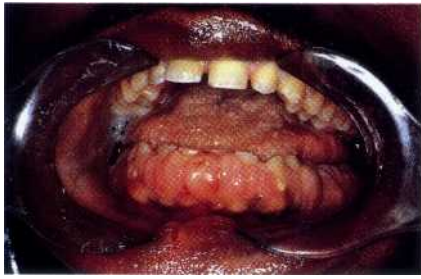

Fig. 22-4. Drug-induced gingival hyperplasia.

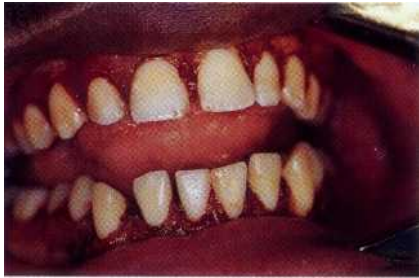

Fig. 22-5. Gingiva immediately after CO2 laser gingivectomy. Note the lack of bleeding and packing.

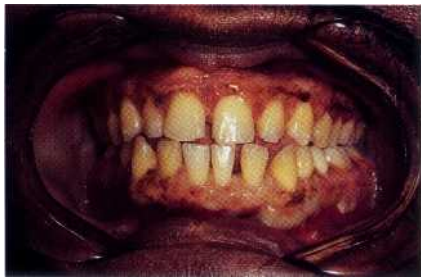

Fig. 22-6. Postoperative view 4 weeks later shows excellent healing.

tooth protection can be accomplished by covering the teeth with two curved instruments while lasing the papilla area. The advantages of this procedure include the lack of bleeding, a more precise control than is possible with electrosurgery, and the lack of need for a postoperative periodontal dressing.<sup>21</sup>

### *Gingival Cosmetic Resculpturing*

In cases involving asymmetry of gingival tissues or excessive gingival tissue in isolated areas, the laser (CO<sub>2</sub>, diode) can be used to precisely sculpt the tissues to ideal contour. This is also a useful technique when papillary hypertrophy has occurred after orthodontic therapy or when an unesthetic papilla requires recontouring (Figs. 22-7 to 22-9). The laser is used in the focused mode (or

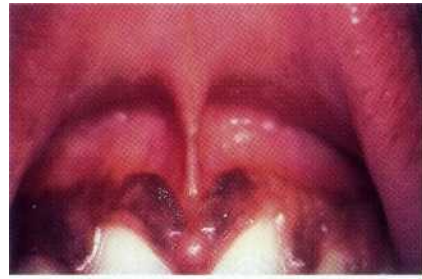

Fig. 22-7. Uncosmetic maxillary frenum and fibroma of the papilla. (Courtesy Alan Winner.)

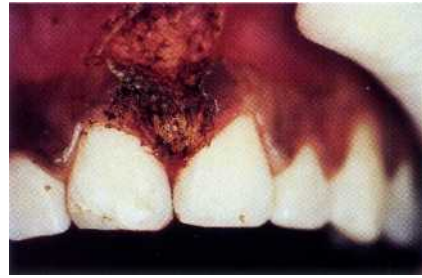

Fig. 22-8. View immediately after CO<sub>2</sub> laser vaporization of the frenum and removal of the oversized papilla. (Courtesy Alan Winner.)

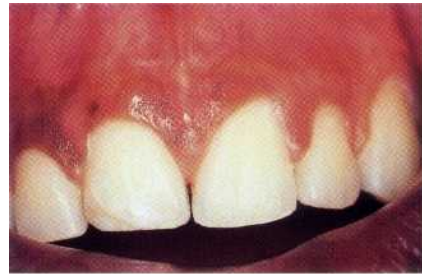

Fig. 22-9. Postoperative view 4 weeks later of patient in Fig. 22-7. (Courtesy Alan Winner.)

with a contact tip if it is the fiberoptic type) and usually is aimed vertically down the tooth surface toward the tissue to avoid contacting the tooth surface. Additional thickness removal may be accomplished by vaporization perpendicular to the tissue. A slow to medium pulsed mode (2 to 10 pulses per second) enhances precision and allows the dentist to slowly run along the gingival margin and vertically remove the amount of tissue needed to obtain a desirable contour.<sup>22</sup>

### *Access Gingivectomy*

The laser can be used to remove tissue when subgingival lesions cannot be reached for restoration. The procedure is similar to that for gingival recontouring, but care must be

taken to preserve the gingival attachment. Pocket depths should be measured before surgery to prevent impingement. The lack of bleeding makes immediate restoration and impressing possible (Figs. 22-10 to 22-12).

*Frenectomy*

Almost any dental laser (CO<sub>2</sub>, diode, argon, Nd:YAG) can easily and quickly remove either a lingual or labial frenum. The frenum can either be excised in continuous, focused mode (or with a contact tip) or ablated in continuous or pulsed, defocused mode. In any case, no closure is necessary, and healing generally is excellent. The lack of bleeding and elimination of sutures makes this an

ideal technique for children. Some lasers may also permit this procedure to be accomplished without local anesthesia, although most generally require a local anesthetic unless the frenum is small, in which case a topical anesthetic may suffice (Figs. 22-13 and 22-14).

*Removal of Benign Lesions*

The laser (CO<sub>2</sub>, diode, argon, Q-switched Nd:YAG) is an ideal tool for removal of cosmetically undesirable benign neoplastic or hamartomatous lesions. If a benign diagnosis has been confirmed, the laser may be used to excise the lesion in focused mode or to ablate it in defocused mode. Fibromas, mucoceles, granulomas, amalgam tattoos, and small lip, gingival, and tongue heman-

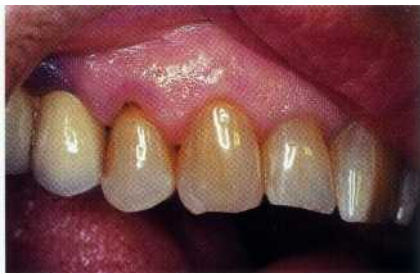

Fig. 22-10. Teeth with subgingival caries. (Courtesy Alan Winner.)

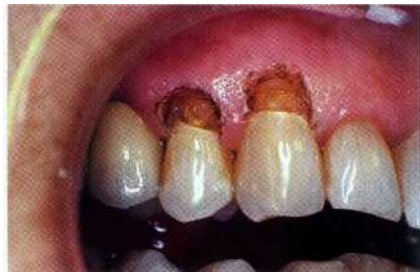

Fig. 22-11. CO<sub>2</sub> laser-assisted access gingivoplasty and recontouring to allow immediate placement of restorations in a bloodless field. (Courtesy Alan Winner.)

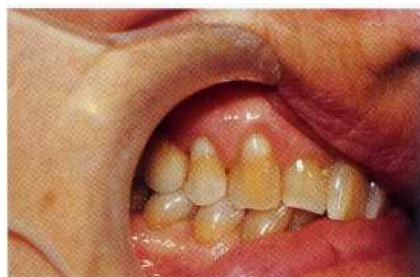

Fig. 22-12. Postoperative view 2 weeks later of patient in Fig. 22-11, after restoration. (Courtesy Alan Winner.)

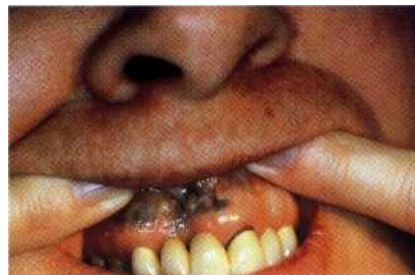

Fig. 22-13. Amalgam tattoo of maxillary gingiva.

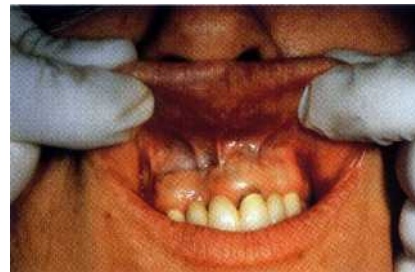

Fig. 22-14. Postoperative view of region shown in Fig. 22-13 after removal of tattoo with Q-switched Nd:YAG laser.

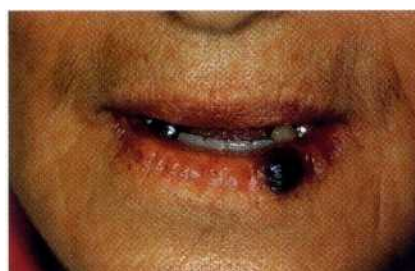
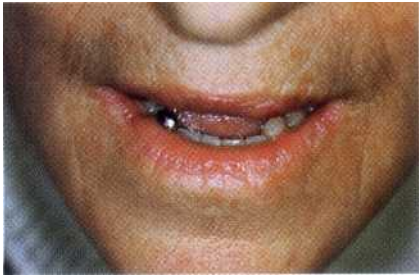
Fig. 22-15. Venous lake of lower lip (Courtesy John Sexton.)

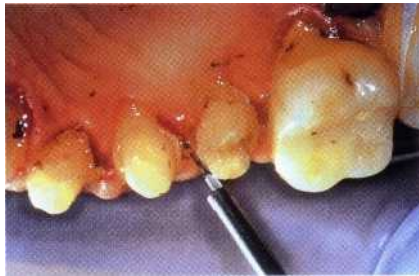
giomas and lymphangiomas can be managed in this manner (Figs. 22-13 to 22-16).<sup>23</sup>

### Gingival Troughing

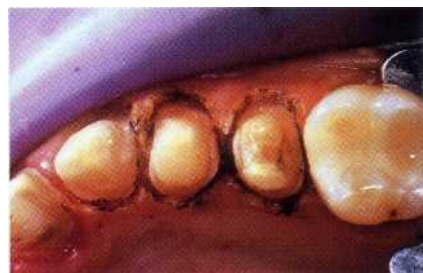The CO<sub>2</sub> and diode lasers are useful in bloodless gingival troughing before impressioning. This eliminates the need for retraction cords and vasoconstrictors. The laser tip is placed below the height of the gingival crevice, and the tissue is "ledged" to expose the margin of the preparation. This procedure is technique sensitive and must be done carefully to prevent inadvertent damage to the tooth (Figs. 22-17 and 22-18).



**Fig. 22-16.** Lip in Fig. 22-15 after ablation of lesion with argon laser. (Courtesy John Sexton.)



**Fig. 22-17.** Preoperative view of gingiva surrounding crown preparations. (Courtesy Premiere Laser Systems, Inc.)



**Fig. 22-18.** Gingival troughing before impression making using a diode laser and fiberoptic delivery. (Courtesy Premiere Laser Systems, Inc.)

### Cosmetic Skin Resurfacing

The Er: YAG laser and the CO<sub>2</sub> laser (using a high power, short pulse configuration such as "superpulsing") can selectively remove the surface epidermis and the papillary dermis of the skin while leaving the underlying reticular dermis and adnexal (epithelial-based) structures. This allows internal wound vertical migration of epithelium as opposed to the adjacent basal cell horizontal migration normally seen. **Because the result is rapid healing without scarring**, this technique can be used to "resurface" the skin. It can help remove the wrinkles around the lips commonly seen after prosthetic rehabilitation of an overdosed stoma and with chronic smoking, prolonged sun exposure, and aging skin. The procedure is performed by oral and maxillofacial surgeons and can be extended to include the entire perioral region or even the entire face.<sup>24,25</sup>

### Tooth Preparation

The Er:YAG and Excimer lasers can efficiently remove tooth structure without damage to adjacent structures or the dental pulp. Advantages of laser use include the elimination of local anesthesia in many cases and the quiet function of the laser compared to the sound of the dental handpiece. Disadvantages include the lack of long-term clinical studies, theoretical damage to the larger pulp in small children, and the difficulty in performing complex restorative procedures such as crown preparations. With time and experience, these disadvantages may become less problematic.<sup>26</sup>

### Tooth Etching

The laser (argon, CO<sub>2</sub>) may preclude the need for acid etching because the laser mechanically etches the tooth in **preparation for resin fillings**. The argon laser is so efficient that several millimeters can be etched in less than 10 seconds. In the future, diode lasers, which can cure resin in less than 1 second, undoubtedly will be used for this purpose once the problem of resin shrinkage is overcome.

### Dental Bleaching

The laser (argon, CO<sub>2</sub>) has been used in combination with chemical agents to perform rapid laser-enhanced cosmetic bleaching. This one-appointment procedure is fast and painless and appears to have a significant effect. Although at least one commercial unit is available for this purpose and although it appears to perform well clinically, there is little current scientific evidence in the literature to support its actual effectiveness. More research in this area should be forthcoming and will lead to increased and better clinical use (Figs. 22-19 to 22-20)<sup>27</sup> (see Chapter 24 for a complete discussion).

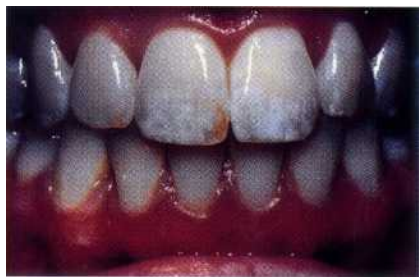

Fig. 22-19. Preoperative view of stained teeth. (Courtesy Premiere Laser Systems, Inc.)

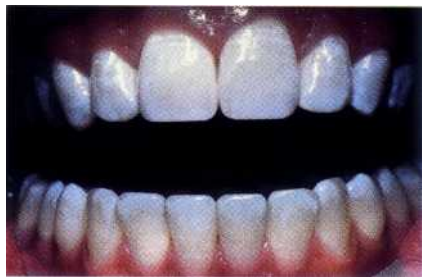

Fig. 22-20. Teeth in Fig. 22-19 after laser-activated bleaching with an argon laser. (Courtesy Premiere Laser Systems, Inc.)

### LASER SAFETY

Despite being outstanding surgical tools, lasers are inherently dangerous.<sup>27</sup> However, with proper caution and case selection, laser surgery should be as safe as any other modality.

Safety parameters vary to some extent based on differing absorption patterns. Each particular wavelength requires a different set of safety glasses to absorb that particular wavelength. One constant, however, is that all persons in the operatory, especially the patient, must wear appropriate eye protection with side shields.

Flammable items should be eliminated from the surgical field or thoroughly saturated with water to prevent them from igniting. Such items as gauze, cotton rolls, and cotton pellets are especially likely to be a problem if dry and touched by the laser beam. Flammable liquids or gases used for anesthesia or in the operatory should also be considered a danger and avoided. Cleaning agents and alcohol are common flammables. Although oxygen and nitrous oxide are not flammable, they do support combustion and if present in the surgical field could lead to a catastrophic event should something within the field catch fire. The current scientific literature should be consulted before these agents are used in conjunction with lasers.

Wet gauze should be placed in the mouth to protect adjacent tissues and teeth. A CO<sub>2</sub> laser needs only 1 watt-second (i.e., one watt of power in contact with the tooth for 1 second) to cause enamel damage.

A common byproduct of the photothermal laser effect is steam mixed with cellular and tissue debris. This smokelike material, the *laser plume*, contains intact biologic material, including some viral particles. It is vital for the surgical team to avoid surface contact or inhalation of the plume to prevent disease transmission. This can be avoided by using high-power smoke evacuators fitted with biologic filters and special laser masks that filter out smaller than usual particulate matter.

Because the laser can work at great distances from the target, it is important to take appropriate steps to prevent accidental lasing of unintended targets. This can be prevented by placing the laser in standby mode before removing the handpiece from the mouth using a covered foot pedal and having an assistant engage and disengage the laser for the dentist (in place of the dentist reaching over to put the machine in standby while it is still active).

Other safety rules exist, and it is important to consult the current scientific literature before using a laser.

### CONCLUSION

Laser use in cosmetic dentistry has many advantages. A thorough understanding of related physics, control parameters, indications and contraindications, and safety is essential. As more wavelengths become available, laser use for both hard and soft tissue cosmetic procedures will inevitably increase.

### REFERENCES

1. Einstein A: Zur Quanten Theorie der Strahlung, *Phys Zeit* 18:121, 1917.
2. Maiman TH: Stimulated optical radiation in ruby, *Nature* 187:493, 1960.
3. Stem RH, Sognnaes RF: Laser beam effect on dental hard tissues, *J Dent Res* 43:873, 1964.
4. Goldman L: Effect of laser beam impact on teeth, *J Am Dent Assoc* 70:601, 1965.
5. Myers TD, Myers WD: In vivo caries removal utilizing the YAG laser, *J Mich Dent Assoc* 67:66, 1985.
6. Keller V, Hibst R: Experimental studies of the application of the Er:YAG on dental hard substances. I, *Lasers Surg Med* 9:338, 1989.
7. Keller V, Hibst R: Experimental studies of the application of the Er:YAG on dental hard substances. II, *Lasers Surg Med* 9:345, 1989.
8. Featherstone JDB, Nelson DGA: Laser effects on dental hard tissues, *Adv Dent Res* 1:21, 1987.

9. Neev J et al: Scanning electron microscopy and thermal characteristics of dentin ablated by a short-pulse XeCl Excimer laser, *Lasers Surg Med* 13:353, 1993.
10. Cozean C et al: Dentistry for the 21st century: Erbium:YAG laser for teeth, *J Am Dent Assoc* 128:1080, 1997.
11. Keller U, Hibst R: Effects of Er:YAG laser in caries treatment: a clinical pilot study, *Lasers Surg Med* 20:32, 1997.
12. Strauss RA: Laser management of discrete lesions. In Catone G, Alling C, editors: *Laser applications in oral and maxillofacial surgery*, Philadelphia, 1997, WB Saunders.
13. Strauss RA: Laser management of discrete lesions. In Catone O, Alling C, editors: *Laser applications in oral and maxillofacial surgery*, Philadelphia, 1997, WB Saunders.
14. Gaspar L, Szabo G: Removal of benign oral tumors and tumorlike lesions by CO<sub>2</sub> laser application, *Lasers Surg Med* 9:33, 1989.
15. Pogrel MA, McCracken KJ, Daniels TE: Histologic evaluation of width of soft tissue necrosis adjacent to carbon dioxide laser incisions, *Oral Surg* 70:564, 1990.
16. Basu MF, Frame JW, Rhys-Evans PH: Wound healing following partial glossectomy using the CO<sub>2</sub> laser, diathermy, and scalpel: a histologic study in rats, *J Laryngol Otol* 102:322, 1988.
17. White JM, Goodis HE, Rose CL: Use of the pulsed Nd:YAG laser for intraoral soft tissue surgery, *Lasers Surg Med* 11:455, 1991.
18. Aranoff BL: CO<sub>2</sub> laser in surgical oncology. In Kaplan J, editor: *Laser surgery: Proceedings of the First and Second International Symposia on Laser Surgery*, Tel Aviv, OTPAZ, 191-216, 1978.
19. Fisher SE, Frame JW: The effects of the carbon dioxide laser on oral tissues, *Br J Oral Maxillofac Surg* 22:414, 1984.
20. Rhys-Evans PHR, Frame JW, Branddrick J: A review of carbon dioxide laser surgery in the oral cavity and pharynx, *J Laryngol Otol* 100:69, 1986.
21. Pick RM, Pecaro BC, Silberman CJ: The laser gingivectomy: the use of the CO<sub>2</sub> laser for the removal of phenytoin hyperplasia, *J Periodontol* 56:492, 1985.
22. Pick RM, Colvard MD: Current status of lasers in soft tissue dental surgery, *J Periodontol* 64:589, 1993.
23. Strauss RA: Laser management of discrete lesions. In Catone G, Alling C, editors: *Laser applications in oral and maxillofacial surgery*, Philadelphia, 1997, WB Saunders.
24. David L, Ruiz-Esparza J: Fast healing after laser skin resurfacing, *Dermatol Surg* 23:359, 1997.
25. Teikmeier O, Goldberg D: Skin resurfacing with the Erbium:YAG laser, *Dermatol Surg* 23:685, 1997.
26. Visuri SR, Walsh JT, Wigdor HA: Erbium laser ablation of dental hard tissue: effect of water cooling, *Lasers Surg Med* 18:294, 1996.
27. Garber-DA: Dentist-monitored bleaching: a discussion of combination and laser bleaching, *J Am Dent Assoc* 128(suppl):26S, 1997.



# ESTHETICS AND PLASTIC SURGERY

Gregory E. Rauscher

**T**HE USE OF COSMETIC plastic surgery to enhance self-image has spread from a small, privileged segment of society to mainstream America. Today people want their outward appearance to reflect their healthier lifestyles. Americans not only are more aware of the benefits of exercise, proper diet, and skin care, but they also are discovering that plastic surgery can improve the overall quality of their lives.

The American Society of Plastic Surgeons has defined cosmetic surgery as "that surgery which is done to revise or change the texture, configuration or relationship with contiguous structures of any feature of the human body which would be considered by the average prudent observer to be within the range of normal and acceptable variation for the age ethnic origin and, in addition which is performed for a condition which is judged by competent medical opinion to be without potential jeopardy to physical or mental health." The American Medical Association has accepted this definition.

The following sections briefly discuss various techniques for enhancing facial appearance. They vary from superficial adjustment of skin tone to facial skeletal alteration with implantation.

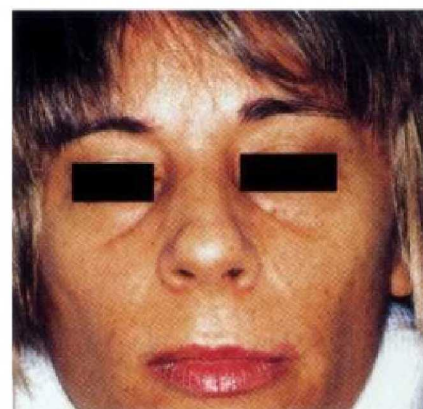## RHINOPLASTY

Rhinoplasty, or nose surgery, is one of the most commonly performed procedures in plastic surgery. Depending on the patient's needs, the nose can be reduced in size (Figs. 23-1 to 23-4), or the shape and size of the nasal tip, bridge, or nostrils can be altered (Figs. 23-5 to 23-8), or both procedures can be done. At the time of the surgical alteration,

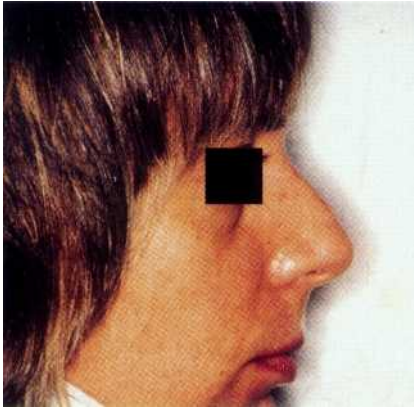
the relationship of the nose to the upper lip can be changed. Breathing problems may be relieved concurrently.

The best candidates for rhinoplasty are patients seeking reasonable improvement in their appearance. Several factors can prevent perfection, including individual healing properties, facial asymmetry, and unrealistic expectations. In most circumstances psychologically stable, healthy patients seeking natural results are good candidates. One in 10 patients who choose rhinoplasty requires a minor touch-up or revision.

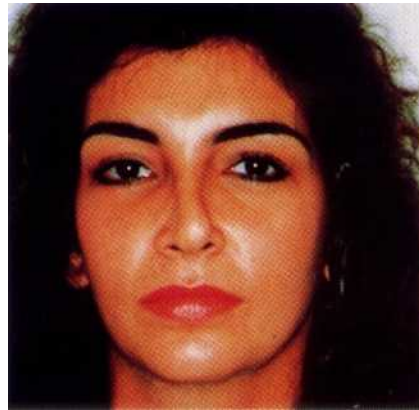Surgery often is performed in less than 2 hours, and a nasal splint usually is necessary for 1 week after surgery and at night for an additional 2 weeks. Most nasal surgery is performed on an outpatient basis. Surgical incisions are



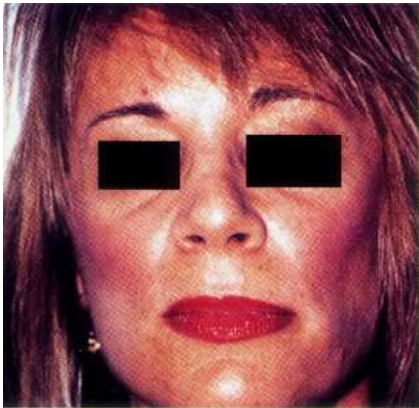
*Fig. 23-1. Preoperative frontal view of a female patient who is unhappy with a minor nasal bump and wide nasal bridge.*



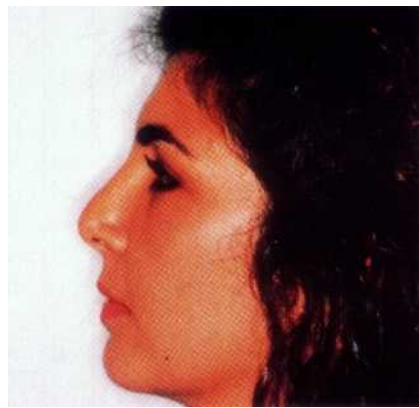*Fig. 23-2.* Preoperative lateral view of the patient in *Fig. 23-1.*



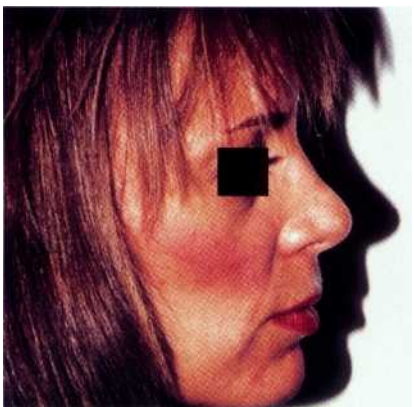*Fig. 23-5.* Preoperative frontal view of a 29-year-old female patient with a post-rhinoplasty nasal deformity.



*Fig. 23-3.* Postoperative frontal view of the patient in *Fig. 23-1* after conservative reduction of all nasal elements.



*Fig. 23-6.* Preoperative lateral view of the patient in *Fig. 23-5.*

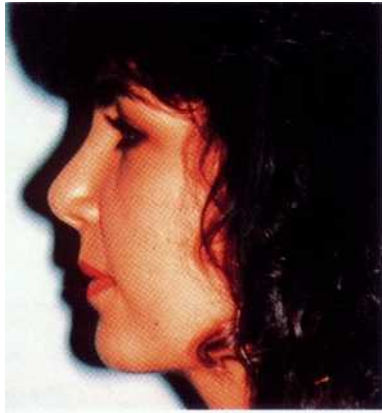

*Fig. 23-4.* Postoperative lateral view of the patient in *Fig. 23-1.*



*Fig. 23-7.* Postoperative frontal view of the patient in *Fig. 23-5* after augmentation of the nose with cartilage and bone.





Reprinted based on the patient.

Fig. 23.

necessary, but they usually are undetectable because they are placed internally in the nasal sill. In corrective nasal surgery the underlying cartilage and bone are sculpted. In some traumatic cases cartilage may be needed to support the tip or nasal bridge.

## RHYTIDECTOMY

Ideally, a rhytidectomy, or face-lift, smoothes loose skin on the face and neck. However, each patient has unique characteristics of skin texture and elasticity in addition to facial wrinkles and facial folds. Some adults have midface bone resorption, which produces a deep line or fold that runs from the ala of the nose to the angle of the mouth.

Other adults develop jowls, the loss of a well-defined jawline, which is a condition that may require removal of fat, muscle tightening, or both. Some candidates have loose skin, wrinkles, or excessive fat in the neck. Surgical treatment may require lifting of the neck, cheek, and forehead or a combination of procedures to achieve tightening and a fresher, firmer face (Figs. 23-9 and 23-10).

The best candidates for face-lift surgery usually are those whose cheek and neckline have begun to sag, whose skin has some remaining elasticity, and whose bone structure is good. The initial consultation may seem embarrassing, but honest discussion and communication are essential for the plastic surgeon to determine if the patient's expectations are realistic. The prior medical history is important, including previous operations and any medications taken. Smoking should be discontinued well in advance of surgery. Certain antiinflammatory drugs, aspirin, herbs, and alcohol should be avoided to reduce bruising and bleeding. Heredity, general health, and sun exposure, as well as the use of tobacco and alcohol, influence facial aging. All cosmetic procedures can turn back the clock; however, aging cannot be stopped.

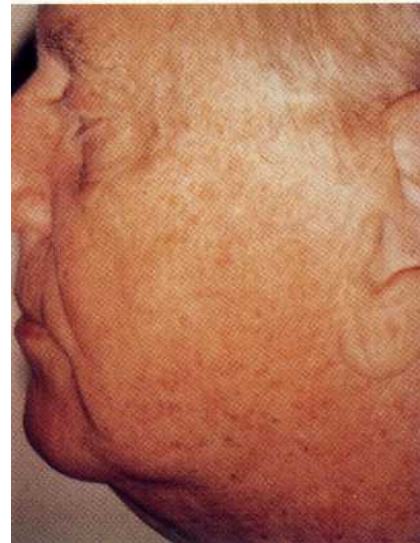

Fig. 23-9. Preoperative view of a male patient with a sagging neck.

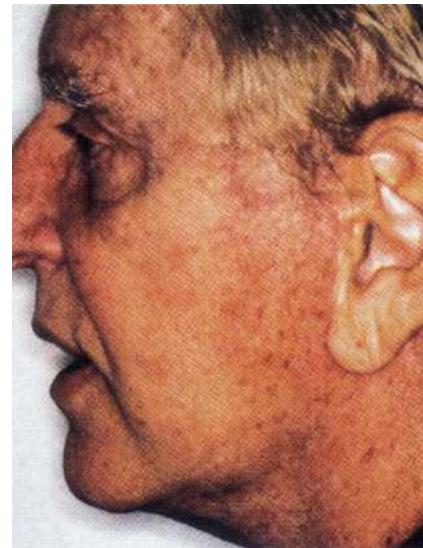
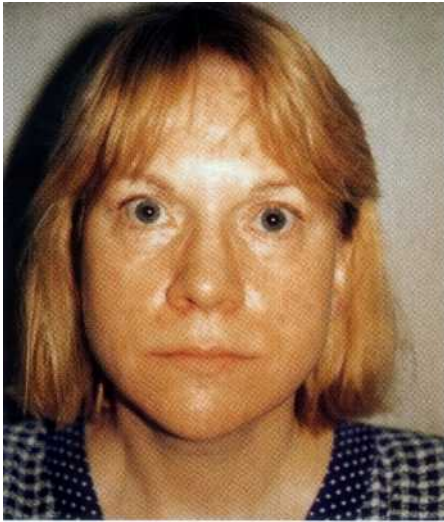
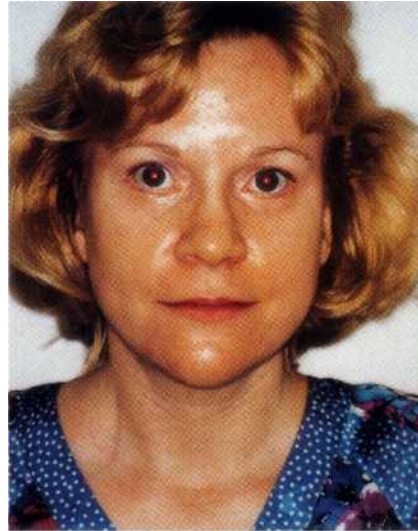Fig. 23-10. Postoperative view of the patient in Fig. 23-9 after a neck lift.

The results of face-lift surgery usually last 5 to 10 years. Face and neck skin can be improved with alternative treatments such as laser resurfacing, chemical peeling, liposuction, or augmentation of the cheek and chin. All treatments have some degree of risk. Minor or unexpected complications may occur, affecting the final result. Major complications are remotely possible but relatively rare.

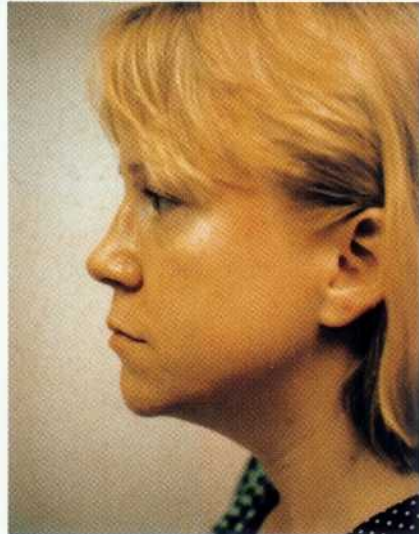



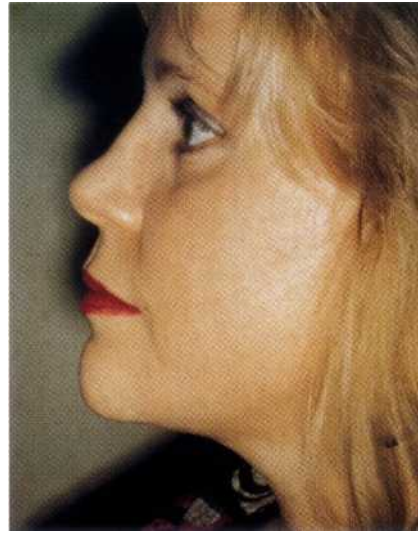*Fig. 23-11. Preoperative frontal view of a 45-year-old female patient with baggy eyelids and underdeveloped cheek bones who complained of looking tired.*



*Fig. 23-13. Postoperative frontal view of the patient in Fig. 23-11 after lower eyelid blepharoplasty and cheek augmentation.*



*Fig. 23-12. Preoperative lateral view of the patient in Fig. 23-11.*



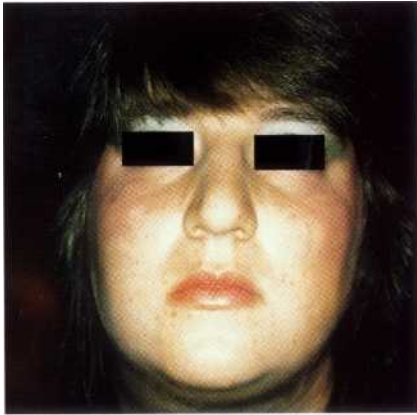
*Fig. 23-14. Postoperative lateral view of the patient in Fig. 23-11.*

### BLEPHAROPLASTY

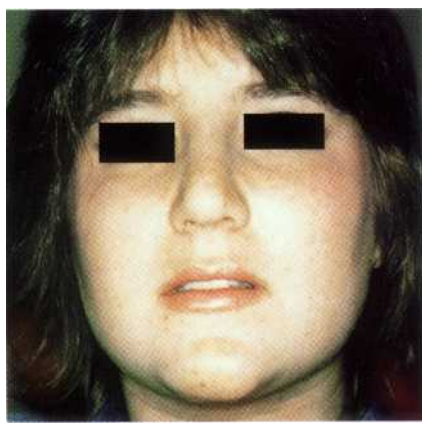Blepharoplasty (eyelid lift) is a procedure for removing excess skin and fat from the upper and lower eyelids. This can be done through the normal upper eyelid crease and lower eyelid lining, leaving minimal to no visible scar (Figs. 23-11 to 23-14). Recovery requires 1 week, and the results can last several years or may be permanent.

### FACIAL IMPLANTS

Facial implants can change the basic shape of the face by carefully building up a receding jaw, chin, or cheekbones. Implants may be made of natural or artificial materials. The results generally are permanent, and the procedure can be performed in less than 1 hour on an outpatient basis. Implant surgery often is combined with other plastic procedures (Figs. 23-15 and 23-16; also see Figs. 23-11 to 23-14).



-1 >. An 18-year-old female patient with an obtuse, ill-defined jawline and poor chin definition.



23-16. Postoperative view of the patient in Fig. 23-15 after combined chin augmentation, rhinoplasty, and liposuction of the neck.

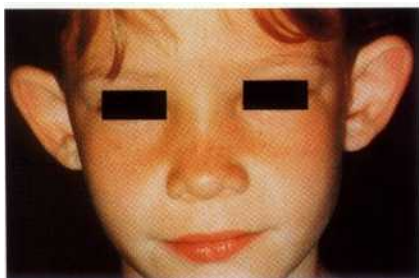
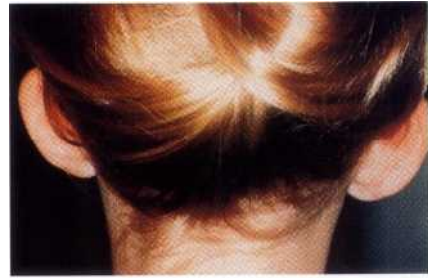
Fig. 23-17. Preoperative frontal view of a patient with prominent ears.

### OTOPLASTY

Otoplasty (ear surgery) is a procedure for repositioning prominent ears closer to the head (Figs. 23-17 to 23-20). Earlobe reduction also may be necessary to create a harmonious improvement. The results are permanent, and patients generally are back to school or work in 1 week.



Preoperative posterior view of the patient in Fig. 23-17.

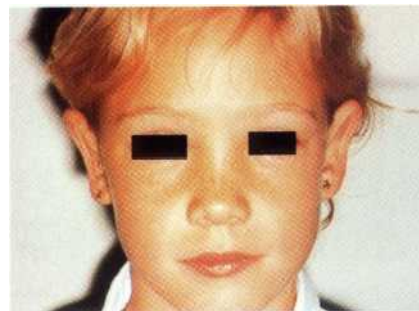

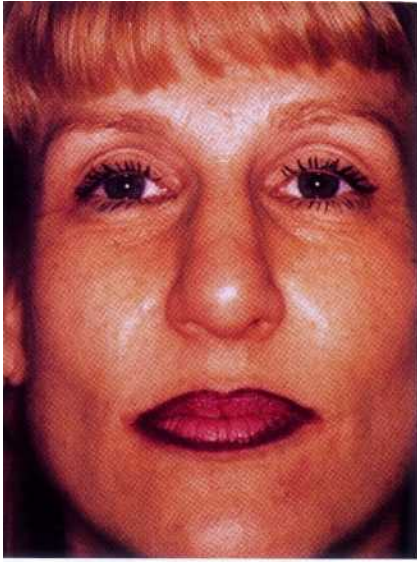Fig. 23-19. Postoperative frontal view of the patient in Fig. 23-17 after surgery to correct the prominent ears.



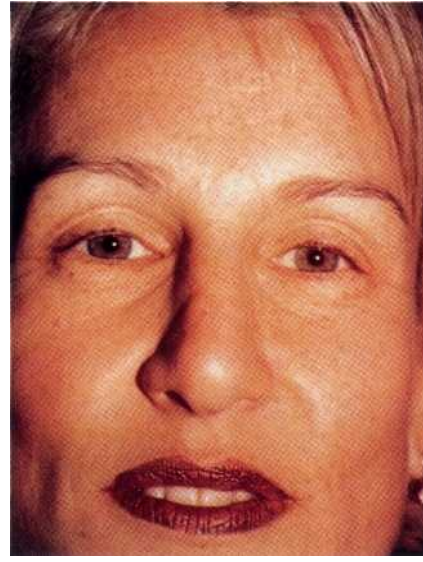Postoperative posterior view of the patient in Fig. 23-17.

### BROW LIFT

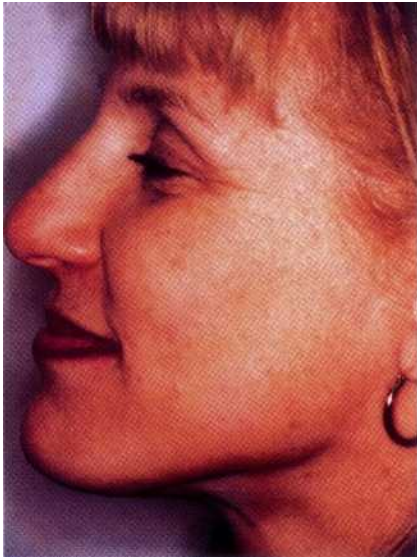Forehead or brow lifting procedures can minimize drooping eyebrows, reduce forehead furrows, and restore a youthful appearance to the upper third of the face. Depending on the degree of forehead elevation required, correction can be performed endoscopically (Figs. 23-21 to 23-24) through small incisions in the scalp or through a more extensive scalp incision. Recovery takes 1 week, and the results generally last 5 to 10 years.



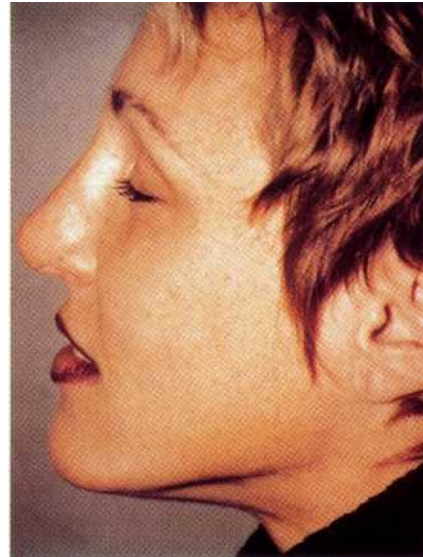*Fig. 23-21. Preoperative frontal view of a patient before elevation of the eyebrows and tip rhinoplasty.*



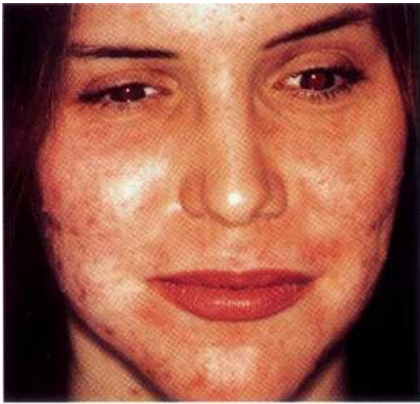*Fig. 23-23. Postoperative frontal view of the patient in Fig. 23-21 after endoscopic elevation of the eyebrows and nasal tip reduction.*



*Fig. 23-22. Preoperative lateral view of the patient in Fig. 23-21.*



*Fig. 23-24. Postoperative lateral view of the patient in Fig. 23-21.*



*Preoperative view of a 25-year-old female patient with severe active acne of the face.*



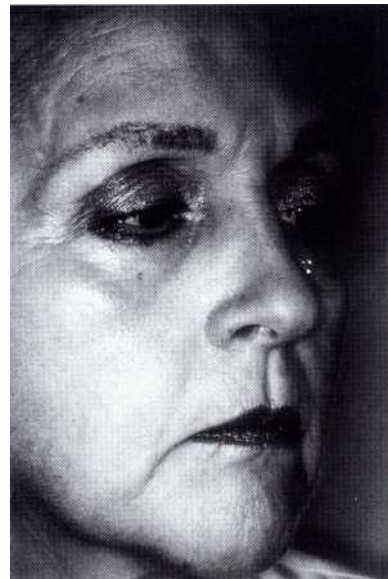
*Postoperative view of the patient in Fig. 23-25 after full face laser surgery.*

#### SKIN RESURFACING: CHEMICAL PEEL, DERMABRASION, AND LASER ABRASION

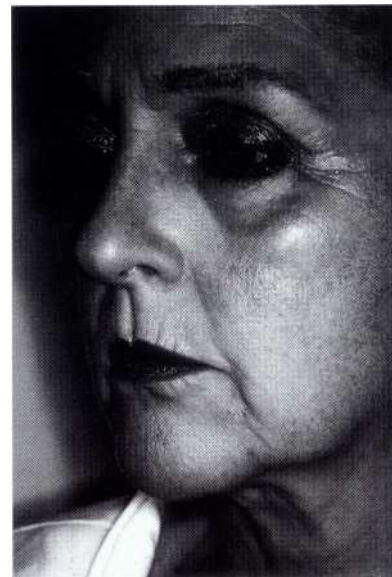Skin resurfacing and rejuvenation is a procedure that can be accomplished through chemical peeling, dermabrasion, or ablative laser resurfacing. Although all three techniques are used to remove wrinkles, sun-damaged facial skin, and acne scars, the results of each technique vary depending on the patient's skin texture and tone (Figs. 23-25 and 23-26). Temporary skin hyperpigmentation, whitehead formation (milia), and allergic skin flare-ups occasionally occur during the healing process.

#### COLLAGEN, ISOLAGEN, AND FAT INJECTIONS

Collagen, Isolagen, and fat injections are temporary and occasionally lasting measures to correct facial wrinkles and receding lips and to contour depressions. Collagen is




*Fig. 23-27. Right lateral view of a patient before injection of Isolagen into the cheek fold.*



*Fig. 23-28. Left lateral view of the patient in Fig. 23-27 before injection of Isolagen.*

a protein derived from cows. Injected cow protein dissipates over time under the skin. Isolagen is the patient's own collagen cloned from a skin biopsy from behind the patient's ear. The patient's own collagen (Isolagen) is grown from the skin biopsy in a laboratory and reintroduced into the patient for correction as needed (Figs. 23-27 to 23-30).

Fat injection works best on facial depression in thin, dry, light-skinned patients. Approximately 50% of the



*Fig. 23-29. Right lateral view of the patient in Fig. 23-27, 20 months after having received three Isolagen injections into the cheek fold.*



*Fig. 23-30. Left lateral view of the patient in Fig. 23-27, 20 months after Isolagen treatments.*

injected fat remains after injection. Isolagen and collagen are injected without anesthesia; successful fat injection requires intravenous sedation or general anesthesia. The duration of fat grafting results ranges from 6 months to permanent correction.

## BOTOX

Complete wrinkle removal is impractical, but temporary improvement can be obtained with Botox, a purified neurotoxin complex used since 1980 for blepharospasm (involuntary eyelid twitch). Botox binds to small nerve endings and, when injected into frown lines and crow's-feet, eliminates wrinkles for approximately 6 months. Botox can be used twice a year as the patient desires.

## COMPUTER IMAGING

Currently, computer imaging coupled with digital photography permits improved communication between the patient and plastic surgeon. Facial features and asymmetry can be visualized and intelligently discussed before surgery, and potential operative results can be simulated. Although the predictability of achieving an imaged result varies from patient to patient, the percentage of improvement can be presented. Visualization of varying facial changes can avoid an implied guarantee.

## CONCLUSION

Cosmetic facial surgery is becoming more popular. Every year thousands of men and woman undergo cosmetic plastic surgery and are pleased with the results. Reasons for choosing cosmetic plastic surgery are unique to the individual. Techniques for reducing noticeable signs of aging are available, and the continuing developments in and expansion of existing technology have resulted in improved and predictable surgical results.

Imperfections of the nose, ears, cheeks, and chin often are amenable to improvement with ever-advancing techniques and minimal scar surgery. Facial cosmetic surgery often is the first step a person takes to enhance the overall appearance. In many patients an improved appearance encourages the patient to take care of oneself and to maintain a new image through lifestyle modifications in diet, as well as skin, eye, and dental care.



انتشارات شایان نمودار

# ESTHETICS AND ADVANCED TECHNOLOGY

Kenneth W Aschheim

**A** **ADVANCES IN ELECTRONIC TECHNOLOGY** have influenced every aspect of our society including dentistry. New technologies are constantly introduced that will ultimately make current dental procedures obsolete. Incorporating these advances into an esthetic dental practice will enable the practitioner to offer a wider range of services and additional treatment options.

## TERMINOLOGY

The following glossary is provided to familiarize the average practitioner with the terminology common to current technology. In this section all italicized words contained within a definition are also separately defined.

**Active matrix display.** A type of *liquid crystal display* in which each *pixel* includes a transistor, thus creating an extremely bright screen'

**Advanced technology attachment (ATA).** A *disk drive* interface that enables communication between a *computer* and *hard disks*, removable drives, and CD-ROM

**Annotation.** The addition of explanatory text to an image

**ATA.** See *advanced technology attachment*

**Backwards compatibility.** The ability of newer *computer* models or *software* to perform all the tasks of the older models they replace

**Bandwidth.** The amount of data that can be sent between two electronic devices per second'

**Bundled software.** Software that is included with the purchase of hardware

**Byte.** The unit of measurement for the amount of *memory* in a *computer*

**Cache.** A small fast *memory* that sits between the larger slower main *memory* (RAM) and the CPU (see *primary cache* and *secondary cache*)

**CardBus.** Formerly known as "PC Card" or "PCMCIA Interface," it was developed by the Personal Computer Memory Card International Association as a standard developed for attaching devices to a notebook computers via a credit card-size device'

**CCD.** See *charged coupled device*

**CD-ROM.** See *compact disk read-only memory*

**CD-ROM drive.** A disk drive capable of reading CD-ROM

**Central processing unit (CPU).** The brain of the *computer*. It is synonymous with *microprocessor*. Because more than just the CPU determines what a computer understands, computers from two different manufacturers using the same CPU may not always be able to run the same *programs*

**Character generator.** A specialized device used to *annotate* (add text to) an image

**Charged coupled device (CCD).** An electronic *sensor* made up of millions of light-sensitive *sensors*, which "sees" an image. CCDs are often referred to as *solid state devices* to distinguish them from old-style vacuum tubes

**CIS.** See *computer imaging system* in the section on equipment categories in this chapter

**Command line interface.** A *program* that requires the user to type commands from a *keyboard* to direct the *computer* to perform a desired function (see also *graphical environment*)

**Compact disk read-only memory (CD-ROM).** An optical computer data storage medium using the same

- physical format as audio compact disk and capable of holding 640 megabytes of data`
- Compatibility. The ability of different computers from different manufacturers to run the same software. For example, a program written for an IBM brand PC will run on any IBM-compatible computer (i.e., Compaq, NEC, or Dell PC). However, a program written for an IBM computer will not run on an Apple Macintosh (see also CPU compatibility and software)
- Composite video signal. A single signal carrying all the video information from the *sensor* to the video controller (see also RGB signal)
- Computer. A major hardware component that can be instructed to do different tasks via software instructions called programs
- Computer-aided design and computer aided manufacturing (CAD/CAM). See computer-aided design and computer aided manufacturing (CAD/CAM) systems in the section on equipment categories in this chapter
- Computer imaging system (CIS). See computer imaging system in the section on equipment categories in this chapter
- Computer resolution. The sharpness of the image on a computer screen, usually defined by the number of dots that make up the image. Computer systems do not adhere to the *NTSC* standard and usually follow a standard which is unique to each brand of computer (see also *high-definition television*, *pixels*, *graphics* adaptor)
- Computer screen. See monitor
- Controller. A part of a computer, typically a separate circuit board, that allows the computer to use certain kinds of peripheral devices (see also video controller)
- CPU. See *central processing unit*
- CPU compatibility. The ability of a program to run on newer models of a computer. Because most programs are written under the Windows *interface*, compatibility is now more of a function of the *operating* system than the hardware
- Cursor. A small line, dot, or arrow that appears on the computer screen and marks the current working position on the screen. The position of the cursor can be changed by the user
- Digital camera. See Chapter 14
- Digital radiographic systems (DRS). See digital radiographic systems in the section on equipment categories in this chapter
- Digital video disk (DVD). An optical storage medium with improved capacity and bandwidth compared with a CD-ROM. The initial DVD drives are read only drives ("DVD-ROM") and store 4.7 Gb per side. However, double-sided (8.5 Gb total) and dual-layer double-sided disks will increase the capacity to 17Gb1
- Digital video disk random access memory (DVD-RAM). A multi-rewriteable DVD'
- Digital video disk recordable. A write-once recordable DVD disk
- Digitizer. A device capable of "reading" a photographic image and translating it into an electronic form that a computer can understand (see also graphics tablet)
- Disk. A thin, flat, circular disk covered on one or both sides with a ferrous material upon which information is magnetically stored (see also floppy disk, hard disk)
- Double *density*. A type of disk capable of holding twice the information as a regular disk
- DRS. See digital radiographic systems in the section on equipment categories in this chapter
- DVD. See digital video disk
- DVD-R. See digital video disk recordable
- DVD-RAM. See digital video disk random access memory
- E-mail. See *electronic* mail
- Electronic* mail. Messages that are transmitted from one computer to another, either through a computer network (especially the *Internet*) or directly via a modem
- FireWire. See *IEEE 1394*
- Floppy disk drive. A tape recorder-like device that is capable of retrieving (reading) and storing (writing) information onto a floppy disk (see also hard disk drive and optical disk drive)
- Floppy disk (or diskette). A round, flat, plastic *disk* encased in a protective soft cardboard or hard plastic shell. The *disk*, which is the thickness of a piece of paper, has an iron-oxide coating and is capable of magnetically storing information. Including the protective shell, *disks* usually measure 3.5 inches and can be up to  $\frac{1}{16}$  inch thick. In addition to different sizes, *disks* also have different storage capacities. The terms *single*, *double*, *high*, and *quad density* are used to describe the relative storage capacities of different types of *disks* (see also floppy disk drive and optical disk drive)
- Full-screen view. A graphic image that fills the entire viewing screen
- Gb. See gigabyte
- Gigabyte (Gb). Approximately 1 billion bytes
- Graphics adaptor. A circuit board containing the necessary electronics to enable a computer to display an image on a monitor. The graphics adaptor determines the maximum *resolution* of a particular computer. *Resolution* varies from between 320 X 200 pixels (*low resolution*) to more than 1920 X 1440 pixels (*high resolution*). For analog dental imaging, the computer's graphics adaptor is required to understand *NTSC* signals. Some newer digital dental imaging equipment bypasses the graphics adaptor completely and sends a digital signal directly to the computer via a serial port, USB port, *IEEE 1394* port, or a dedicated adaptor

- Graphical environment or graphical user interface (GUI). A program that enables the user to direct the computer to perform desired functions. The user "points" to small icons on the screen with a mouse (see also icons, command line interface)
- Graphics tablet (digitizer). A device for inputting information or manipulating images on the screen. It consists of a solid plastic board, a mouse-like device, or a pointing device called a stylus
- Hard copy. A printed page or photograph obtained from a computer, IIS, or CIS
- Hard disk. A metal coated disk encased in a hard disk drive that is capable of storing 2,000 to more than 60,000,000 times more data than a floppy disk (see also hard disk drive and optical disk drive)
- Hard disk drive (Winchester drive). One or more hard disks rotating about a central axle with associated read/write heads, electronics, and enclosure. Information is transferred to the computer via an ATA, IDE, or SCSI interface and is used to store data' (see also optical disk drive)
- Hardware. The actual equipment: the computer, the intraoral or digital camera, the monitor, or any components that interact with these devices. Hardware establishes the capabilities of a system, whereas the software determines how these capabilities are used
- HDTV. See high-definition television
- High-definition television (HDTV). A set of new higher resolution standards that has begun to replace NTSC and produce a more photograph-like image on a video screen. HDTV standards increase the maximum number of horizontal lines (currently 525) to more than 1000 (see also computer resolution and NTSC)
- High density. A type of floppy disk (see also floppy disk)
- Icon. A small picture on a computer screen that represents various functions the computer can perform
- IDE. See integrated drive electronics and advanced technology attachment (ATA)
- IEEE 1394. (formerly FireWire) A very high-speed communications protocol that can transfer large amounts of data between a computer and its peripherals and is especially suitable for video images'
- IIS. See intraoral imaging system in the section on equipment categories in this chapter
- Input. The information that is entered into a computer
- Integrated drive electronics. See advanced technology attachment (ATA)
- Interface. See user interface
- Internet. The world's largest interconnected computer network used for transmitting data consisting of e-mail, and other digital information (see also world wide web)
- Intraoral imaging system (IIS). See intraoral imaging system in the section on equipment categories in this chapter
- Jaz drive. A removable disk drive from Iomega Corp., which holds proprietary 1 or 2 Gb disk cartridges
- Keyboard. A typewriter-like device used to send (input) information to a computer
- Kilobyte. Approximately 1000 bytes
- Laser systems. See laser systems in the section on equipment categories in this chapter
- LCD. See liquid crystal display
- LED. See light-emitting diodes
- Level 1 cache. See primary cache.
- Level 2 cache. See secondary cache.
- Light-emitting diodes (LED). Specialized light bulbs (usually red), which draw very little power
- Liquid crystal display (LCD). A very thin electrooptical device used to display digits, characters, or images and serve as a replacement for cathode-ray tubes (CRT). Because of their light weight and low power consumption, they are ideal for use in battery-operated notebook computers or as "flat-screen" computer displays
- Macro lens. A close-up lens capable of sharply focusing on and magnifying a small object at very close range
- Main memory. The storage device used by a computer to hold the currently executing program and its working data
- Mb. See megabyte
- Megabyte (Mb). Approximately 1 million bytes
- Memory. See random access memory
- Microprocessor. See central processing unit (CPU)
- Modem. An acronym for modulating and demodulating device; used to transmit or receive computer or Internet information by converting data to an audio signal capable of being transmitted over telephone lines
- Monitor. A specialized television screen or liquid crystal display used to display computer text or graphics
- Mouse. A device usually attached by a wire to the computer (although some may be wireless), which is used to manipulate images on a screen
- Mouse pen. A pen-shaped mouse with a button on the side
- Multi-image view. Multiple images on the same screen
- National Television Standards Committee (NTSC). The Federal Communications Commission and the electronics industry have defined standards regarding how a video image may be displayed. NTSC resolution is described by the number of lines that make up the image. NTSC sets the maximum number of horizontal lines at 525, although, for technical reasons, rarely are more than 450 of these lines displayed. The number of vertical lines varies among manufacturers, from 250 to 400, depending on the quality of the television. The resolution of video cameras and video recorders is defined in the same way as television (see also high-definition television, computer resolution, pixels)
- Network. A combination of hardware and software that allows data communication between computers



- Non-graphical environment. See command line interface
- Operating system. The most basic software that loads first and enables the computer to work with other software. It performs such functions as scheduling tasks, allocating storage, communicating with peripheral devices and handling the user interface
- Optical disk drive. A very high-capacity plastic disk drive system capable of storing 200 to 10,000 times more data than a floppy disk. Like a hard disk, most are permanently attached to and cannot be removed from the computer
- Output. The information that is obtained from a computer
- Passive matrix display. A type of liquid crystal display that is a less bright screen than an active -matrix display
- PC Card. See CardBus
- PCMCIA Interface. See CardBus
- Picture elements. See pixels
- Pixels (picture elements). The smallest resolvable rectangular area of an image. A definition of resolution in a CIS based on the number of dots that make up the image. Although this unit is analogous to the lines on a television, the two units are not the same. No easy way exists to compare lines with dots. In addition, a number of other factors, such as the number of colors available, can affect the perceived resolution of a system. Thus the number of pixels alone cannot be the sole criteria for comparing the resolution of different systems (see also computer resolution and graphics adaptor)
- Primary cache (also called a Level 1). A small, fast cache memory inside or close to the CPU chip
- Processing unit. See central processing unit
- Program. See software
- Protocol. A set of rules governing the format of messages that are exchanged between computers
- Quad density. A type of floppy disk
- Radiographic image processing system (RIPS). **See radiographic image processing systems in** the section on equipment categories in this chapter
- RAM. See random access memory
- Random access memory (RAM). The electronic portion of the computer where currently used programs and data are stored. The size of the RAM is measured in kilobytes or megabytes. In general, the more powerful the program the more RAM is needed for it to run properly (see also byte, kilobyte, megabyte)
- Resolution. The sharpness of a picture (see also pixel)
- RGB signal. A signal divided into multiple frequencies of information. Separating information by color (usually red, green, and blue) allows for a higher fidelity picture. This is analogous to the way audio signals are separated into low (bass), medium (midrange), and high (treble) frequencies to obtain high-fidelity sound
- Scanner. A device that inputs an optical image and converts it into an electronic image represented as binary data. This can be used to create a computerized version of a photo or illustration'
- SCSI. See small computer system interface
- Secondary cache (also called Level 2 or L2 cache). A second cache memory that is usually external to the microprocessor and stores information taken from the main memory and sends it to the primary cache. It speeds up the transfer of data. New microprocessors are including the secondary cache on a second chip that is packaged together with the main CPU
- Sensor. An electronic device used to measure a physical quantity such as light, pressure, or loudness and convert it into an electronic signal that a computer understands. Optical sensors are able to "see" an object'
- Single density. A type of floppy disk (see also floppy disk)
- Small computer system interface (SCSI). A processor-independent standard for interfacing between a computer and intelligent devices including hard disks, floppy disks, CD-ROMs, printers, or scanners'
- Software. An electronic set of instructions, called a program, that tells the hardware exactly what to do and when to do it. Software is machine specific: a program written for an Apple Macintosh computer will not run on a Windows/Intel-based computer. The program is stored on a disk and is read (loaded) onto the computer's hard disk drive. The software often costs as much or more than the hardware because it is time consuming to write programs.
- Software compatibility. See compatibility
- Solid-state devices. See charged coupled device (COD)
- Stylus. A pointing device attached to a graphics tablet
- Tb. See terabyte
- Terabyte (Tb). Approximately 1 trillion bytes
- Transmission cable. The wire that transmits the image from the handpiece of an IIS to the CPU
- Universal serial bus (USB). A new communication protocol between a PC and external peripherals (e.g., keyboards, mice, monitors, printers, scanners, etc.) that uses inexpensive cable and is intended to replace current slower PC data connections (e.g., serial and parallel ports)'
- USB. See universal serial bus
- User interface. The method by which options from a program are selected (see also software)
- Video board. See graphics adaptor
- Video controller. See graphics adaptor
- Video head. The part of the handpiece of an IIS where the CCD is placed
- Winchester drive. See hard disk drive
- World-wide web (WWW). An Internet information retrieval system that originated from the CERN High-Energy Physics Laboratories in Geneva, Switzerland  
See world-wide web
- Zip drive. A removable disk drive from Iomega Corp., which holds a proprietary 100 or 250 Mb removable disk

EQUIPMENT CATEGORIES

Technologic trends in dentistry can be divided into two major categories: information systems and treatment systems.

Information Systems

Information systems, an outgrowth of the computer revolution, involves the accessing, storage, and manipulation of patient information. It is convenient to divide this category into six subcategories; however, new "multi-subcategory" devices are becoming available.

1. Intraoral imaging system (IIS). IISs consist of specialized intraoral cameras, controllers, and monitors designed to display on a screen, record, and print intraoral and limited extraoral images (Fig. 24-1).
2. Computer imaging system (CIS). CISs are extensions of IISs and allow for the modification of color, shape, and size of intraoral and extraoral images (Fig. 24-2).
3. Computer-aided design and computer-aided manufacturing (CAD/CAM) system. CAD/CAM systems are

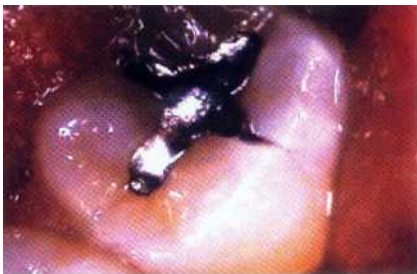

Fig. 24-1. An intraoral image.

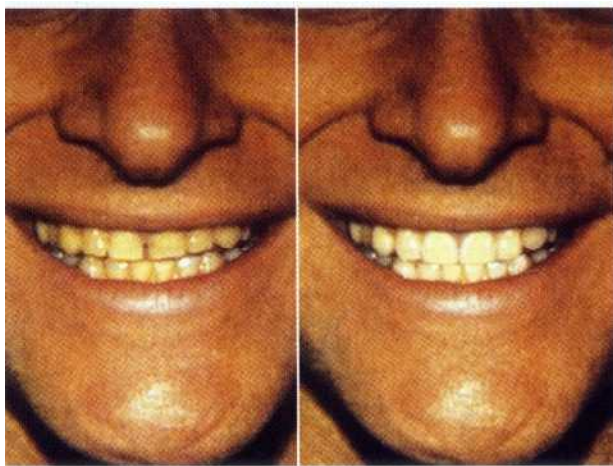


Fig. 24-2. A computer imaging system can modify the color, shape, and size of an intraoral image. (Courtesy McAndrews-Northern Dental Laboratory.)

- extensions of CISs. They create a modified intraoral image, which is used as an "electronic die" to fabricate a restoration (Fig. 24-3).
4. Digital radiographic system (DRS). DRSs consist of specialized sensors capable of recording, storing, displaying, and enhancing radiographic images (Fig. 24-4).
5. Radiographic image processing system (RIPS). RIPSs are capable of "reading" images from a radiographic film, manipulating or performing calculation on those images, and displaying the results on a monitor or a printout (Fig. 24-5).
6. Other systems. Other systems include those that use the computer to analyze oral nonimage information, such as centric occlusion analyses or periodontal pocket measurements (Fig. 24-6).

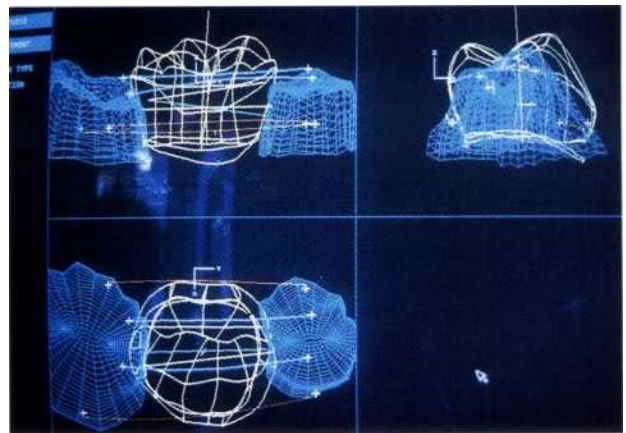


Fig. 24-3. A computer image of a CAD/CAM system calculating the shape of a crown restoration. (Duret system, courtesy Hennson International.)

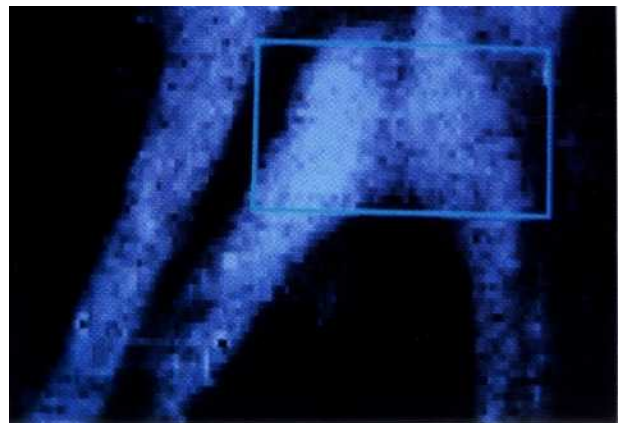


Fig. 24-4. A computer-enhanced digital radiographic image of a dental apex. (Courtesy Trophy U.S.A., Inc.)

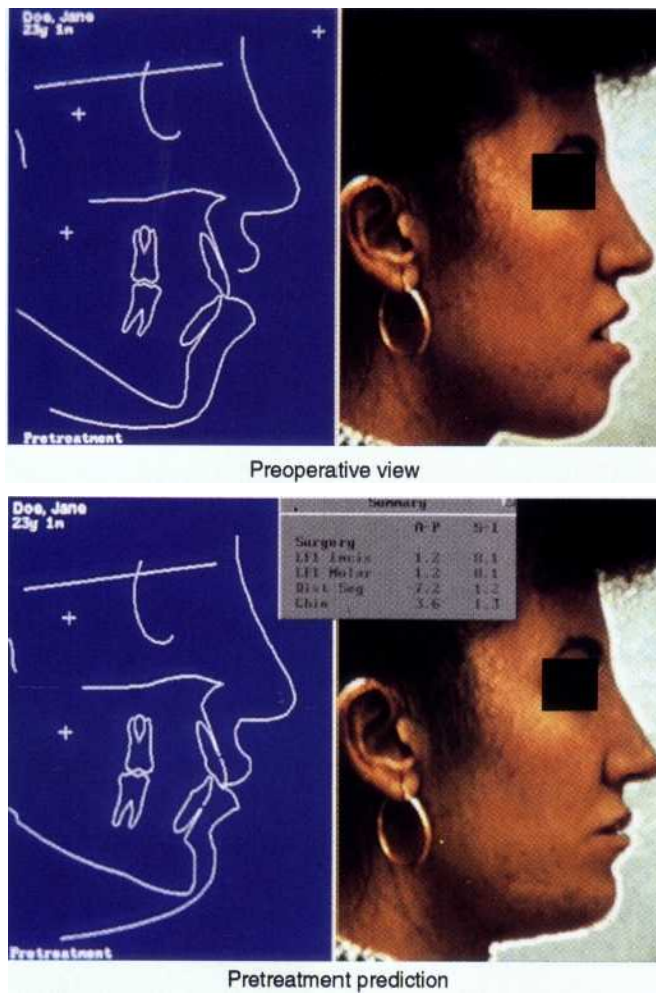


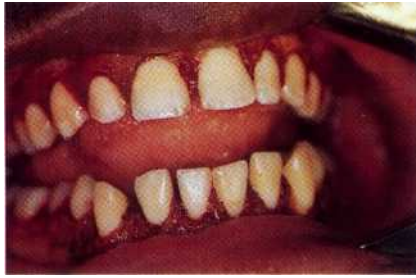Fig. 24-5. A color plot of a cephalometric tracing from a radiograph. (Courtesy Daniel Buchbinder.)



Fig. 24-6. A computerized periodontal probe. (Florida Probe, courtesy Computerized Probe, Inc.)



An air abrasion system. (MicroPrep table-top system, courtesy Lares Research.)



A laser gingivectomy. (Courtesy Robert A. Strauss.)

### Treatment Systems

Treatment systems involve new technologies for the treatment of intraoral hard and soft tissue diseases.

1. Air abrasion systems. Air abrasion systems (Fig. 24-7) use an air-propelled abrasive to remove tooth structure.
2. Laser systems. Laser systems (see Figs. 24-8 and 24-38) use high-energy coherent light to cut or manipulate hard and soft tissue.
3. Computer-regulated local anesthetic delivery systems. This system delivers a controlled amount of local anesthetic at a controlled rate and pressure.

### INTRAORAL IMAGING SYSTEMS

Intraoral imaging systems (IISs) were among the first electronic devices to be used in dentistry. Original IISs were modified gastroenterology endoscopes; however, newer models have been designed exclusively for dental use. IISs are primarily used to enhance clinical visualization by displaying intraoral images on a *monitor*. In addition, these systems can store, retrieve, and reproduce the images. They also are capable of limited image annotation. IISs as a category are slowly becoming integrated with CIS's systems. Digital technology and the integration of image storage and manipulation into dental management

programs will change IIS from an independent category to an "acquisition device" for CISs.

A new addition to this category is the digital camera (see Chapter 14). Many dentists use these consumer products in their practices to capture extraoral images of a patient. Some cameras have been specifically modified for dental use (e.g., Dynamix, SciCam, Inc.) and are equipped with macro *lenses* that allow limited intraoral capability.

### Advantages

1. Increased visibility. IISs provide an unparalleled view of the oral cavity, allowing the clinician to view areas that are otherwise difficult to see. Systems equipped with special *macro lenses* allow for visualization within endodontic canal systems and periodontal pockets.
2. Patient education and marketing. IISs allow patients to see their clinical situations on a monitor. This aids in the proper understanding of treatment options, which may lead to increased acceptance of proposed treatment plans. IISs can also produce prints of images.
3. *Medicolegal* documentation. All IISs can produce prints of images, which provide visual documentation for archival and legal purposes.
4. Evaluation of *treatment effectiveness*. IISs prints can provide serial documentation of the effectiveness of long-term treatments. Results of periodontal therapy, bleaching techniques, or patient home care, for example, can be compared with previous images.
5. Teledentistry. IISs create digital images that can be transmitted to other computers via a *modem* (see section on teledentistry in this chapter).

### Disadvantages

1. *Moderate to high cost*. The initial start-up costs of an IIS can range from \$3000 to more than \$10,000, depending on the single-operator versus multi-operator capabilities and options selected. Leasing may help to amortize the cost to a few hundred dollars each month.
2. *Complexity*. These systems have a considerable learning curve, although newer models have simplified *user interfaces*.
3. *Increased chair time*. These systems can increase the amount of time necessary to present simple cases. With experience, presentation time can be reduced. The initial viewing of a patient's oral condition can be delegated to an auxiliary employee.<sup>2</sup>
4. *Moderate resolution*. Early models, as well as current "budget" or "closeout" models, exhibit limited *resolution*. The *resolution* of most current models is good

- to excellent. The new HDTV standard has introduced resolution approaching photographic quality.
- Limited extraoral imaging. All IISs have been optimized for intraoral viewing. Most require the use of additional lenses or attachments for extraoral imaging. Early models produced a distorted "fish-eyed" appearance eliminated in current models. However, the image quality of a moderately priced digital camera or a CIS is still superior to an IIS.
  - Size. These systems traditionally required substantial operatory space. Early analog systems used a TV monitor and large image processing equipment. Newer digital systems are able to connect either directly to a computer or via a small processing unit, thus reducing the size. Moderately priced flat screen LCDs further reduce the amount of operatory space needed.
  - Evolving *technology*. Current systems may quickly become obsolete because of rapid advances in microelectronics. Increases in resolution, graphics capability, and storage capability, in addition to decreases in size and price, are inevitable. Newer digital systems will further reduce size and increase resolution.

## Components

Although *hardware* varies from system to system, all have certain common elements (Figs. 24-9 and 24-10).

- Input device*. Input is via a small camera mounted in a hand-held device shaped like a dental handpiece. The image is acquired through a front or side mounted lens coupled with a high-resolution CCD. The handpiece is also connected to a light source.
- Transmission cable. A transmission cable is the "wire" that transmits the image from the handpiece to the central processing unit. All cables function as "two-lane highways," transmitting a bright light from the processing unit to illuminate the image. The fiberoptic cable may degrade over time, especially if abused.
- Light source. Early IIS units required a xenon light source to produce the extremely bright light required by early CODs. These lights were expensive and needed to be switched on and off (pulsed) at a set rate to function, producing a stroboscopic flashing accompanied by an audible "clicking." Current CCD technology uses a cheaper continuously illuminating quartz bulb similar to those found in light-curing units.
- Display. Different sizes of high-resolution displays are available. These are usually *RGB* type video monitors with a higher resolution than the more common composite video monitors, which have resolutions similar to those of NTSC televisions found in the home. Flat-panel displays provide better image quality than *RGB* type monitors and require less space.
- Central processing unit. The central processing unit processes the image. Processing includes image freeze, color adjustment, graphics input, and text annotation. The image is "frozen" with a foot pedal, and some units also include a detachable *keyboard* for annotating the image.
- Video* storage unit. Image storage on these units is limited. Most interface with a computer, which stores the images.
- Video* output device. Video output devices provide a hard copy (printout) of the displayed image. Traditionally, the quality of the output was directly proportional to the cost of the output device. Currently, inexpensive inkjet printers using "photographic quality" paper can produce adequate results but have slow print speed. Dedicated photographic printers are more expensive but, because of their faster and crisper output, may be better suited for dental use. As the consumer market for "photo-

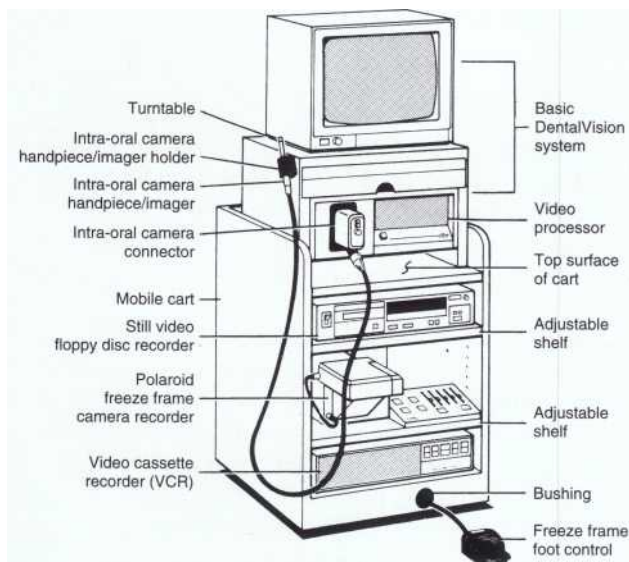


Fig. 24-9. A diagram of an intraoral imaging system (IIS).

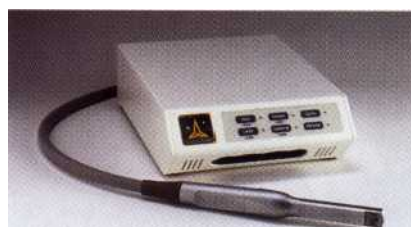

Fig. 24-10. An intraoral imaging system (IIS). (Courtesy Cygnus Imaging, Inc.)

graphic printers" expands, more inexpensive higher-resolution color graphics printers suitable for dental use will appear.

### Available Products

**CLINICAL TIP.** Products are continually updated and revised. Check with the manufacturer before purchasing to determine which options are still **available, what enhancements** have been made to the unit, and if limitations still exist. New products may have been introduced that make current products obsolete.

**CLINICAL TIP.** A great deal of time and effort is required to master the complexities of intraoral imaging systems. A dealer who can provide ample instruction and maintenance support is important. If a "bargain system" does not include servicing, the full capability of the system may never be realized.

### Clinical Procedure

Although the individual controls of different systems vary greatly, certain elements are common to all:

#### Armamentarium

##### Intraoral imaging system

#### Clinical Technique

1. Adjust the operatory lights for optimum viewing according to the manufacturer's recommendation.
2. Aim the camera at the desired image.
3. Freeze the image on the screen by activating the foot pedal.
4. Store the image (optional).
5. Print the image (optional).

## COMPUTER IMAGING SYSTEMS

The computer imaging system (CIS) has revolutionized diagnosis, treatment planning, and case presentation. Intraoral and extraoral images can be accessed, stored, and manipulated, creating "what-if" scenarios (Fig. 24-11). Patients see not only their current condition but also the possible results of various treatment plans. Most CISs perform the following tasks:

1. Magnify or shrink an image. CISs can alter the size of the entire image or an individual section of the image.
2. Crop an image. CISs can crop (isolate) sections of the image and remove extraneous information. This aids in focusing on problem areas.

3. Move an image. CISs can move a section of an image from one area to another. The possible results of proposed orthodontic treatment, for example, can be seen immediately.
4. Copy an image. CISs can duplicate images of individual teeth and move them to edentulous areas, enabling the patient to see the possible results of tooth replacement.
5. Change shading. The shade of any section of an image can be altered, allowing patients to see the possible results of bleaching, laminate veneer procedures, or other shade altering treatments.
6. Change the shape of an image. The shape of any section of an image can be altered to allow patients to see the possible results of porcelain laminate veneers, esthetic recontouring, or other procedures.
7. Store and retrieve image cutouts. CISs can save small sections of an image, retrieve them instantly, and add them to the appropriate position on the display screen. This creates a "library" of prosthetic parts. The dentist can, for example, instantly show a patient the effects of placing a pontic or wrought wire clasp.
8. Create a print of the altered image. Once a treatment goal has been established, a print of the image can be conveyed to the laboratory to aid in the fabrication of the final prosthesis. Some systems allow for immediate electronic telephone transmission of the image.
9. Take measurements directly from the screen. Most systems can take measurements of the image on the viewing screen. The measurements can be used when fabricating the restoration (Fig. 24-12).
10. Manipulate entire facial features. Some systems were first developed for plastic and cosmetic surgery and can predict the possible results of orthognathic and other maxillofacial surgical procedures.

### Advantages

CISs have the same advantages as IISs plus the following:

1. Create "what-if" scenarios. By allowing manipulation of the images, different treatment alternatives can be explored.

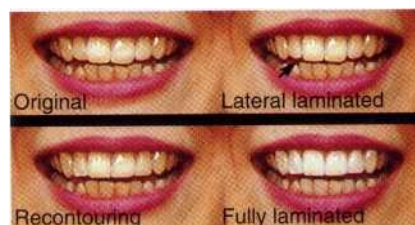
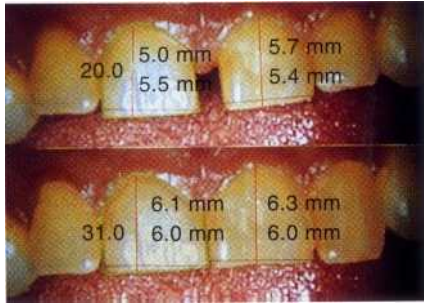


Fig. 24-11. Patients are shown "what-if" scenarios. (Courtesy McAndrews Northern Dental Laboratory.)



*Fig. 24-12.* Computer-generated superimposed measurements predict the final dimensions of the teeth after proposed diastema closure.

2. Decrease the chance of patient misunderstanding. Because the patient sees predicted treatment results, less chance of miscommunication exists (however, see the first item listed under "Disadvantages").
3. Convey the desired treatment goals to the dental laboratory. After the dentist and patient produce an acceptable treatment plan, the information can be conveyed to the dental laboratory. Some systems allow immediate transmission of the image directly to the laboratory over a standard telephone line.
4. Contain large capacity storage system. CISs have large capacity hard disks that can store thousands of images. This increases the ease and efficiency of information retrieval.
5. Accept images from multiple sources. All units can accept images obtained from an IIS.

### Disadvantages

CISs have the same disadvantages as IISs plus the following:

1. May inaccurately predict the final result. The major drawback of these systems is the possibility that the optimal results predicted on a preoperative computer simulation will not be achieved clinically.

**CLINICAL TIP.** The method by which images are manipulated is different from the way teeth are treated clinically. Emphasize to the patient that a predictive simulation may not be realized.

**CLINICAL TIP.** It is uncertain at this time if an inadequate clinical result after a favorable prediction by a computer simulation is a valid basis for litigation. (See medicolegal considerations in this chapter.)

2. May be redundant with intraoral imaging equipment. Some of the components found in these systems



*Fig. 24-13.* A digital camera modified for dental use. (Courtesy SciCam, Inc.)

may duplicate those found in intraoral imaging equipment. As the two technologies merge, most IISs will evolve CIS capabilities, while CISs will use IIS for image acquisition.

### Hardware Components

Initial CISs were sold as proprietary dedicated computers or standard computers preloaded with the CIS software. Current CISs run on Windows/Intel-based computers and most CIS manufacturers will either sell the software alone or bundled with a computer. All CISs are similar in terms of the hardware components they require. They all consist of the following:

1. Input device. Early CISs used bulky extraoral RGB video cameras. Current systems use a digital camera (Fig. 24-13) (see Chapter 14), an IIS, or a digital scanned image from a photograph.
2. Light source. Early CISs used extraoral RGB video cameras and they required large photographic studio lights to obtain proper color balance. Current systems use ambient light or a built-in xenon flash.
3. Video display. CISs are always attached to a computer and use a standard computer monitor or flat-screen display.
4. Video board. CISs use the standard high-resolution computer graphics adaptor built into computers. Many have additional NTSC inputs for analog IISs and video outputs to display images on a standard television monitor.
5. Central processing unit. Most CISs now run on a standard Windows/Intel-based computer. CIS manufacturers will specify minimum CPU and memory requirements. All systems can be controlled by a detachable keyboard.
6. Alternate input devices. All systems manipulate the image with a mouse, trackball, light pen, or other similar device.
7. Video storage unit. All systems use standard hard drives, zip drives, optical drives, or other similar computer-based storage devices. All recommend magnetic tape drives or similar devices for data backup.

8. Video output device. These devices are identical to those discussed for IISs.

## Software Components

A major difference among the different computer imaging systems is software. Early systems were written under a graphical environment called TrueVision Imaging Processing Software (TIPS). This was a very powerful program that allowed such extreme customization that it is virtually impossible to determine which systems use TIPS software and which used a different program.

Current systems use numerous Windows-based software products that have been modified for dental use. Because most software allows the importation of an image from almost any source, a user is not limited to a particular hardware/software combination. In fact, different hardware manufacturers often use similar or the same software to modify an image and may change the software that is included with their system as the new or improved software is introduced.

Software is the most critical part of a CIS system and evolves rapidly. It is important to evaluate the most current version of the software before purchasing a system. Most software have certain common elements (Fig. 24-14):

1. Graphical interface. All programs use a graphical interface, usually under the Microsoft Windows Operating System.
2. Multiple windows. This allows the viewing of multiple images.
3. Menu driven. All programs use a cascading menu system, usually under the Microsoft Windows Operating System.
4. Drawing tools. All use computer "tools" that allow the user to manipulate an image. They include the following:
  - A. Selection/highlighting tool. This tool aids in selecting the parts of the teeth upon which the dentist wishes to perform a function. The ease in which areas can be selected, usually the most frequent function performed, often determines the general ease of use of the entire software package.
  - B. Cut/copy/paste tools. These allow the removal, duplication or placement of "teeth."
  - C. Move/flip/rotate tools. These allow the movement and manipulation of highlighted "teeth."
  - D. Color tools. These allow the color manipulation of "teeth."
  - E. Other tools. These specialized tools perform numerous preprogrammed functions, such as "bleaching."
5. Annotation. This allows the insertion of text into the image.
6. "Stock image" libraries. Manufacturers include libraries of "ideal teeth" to simplify "pasting" an ideal

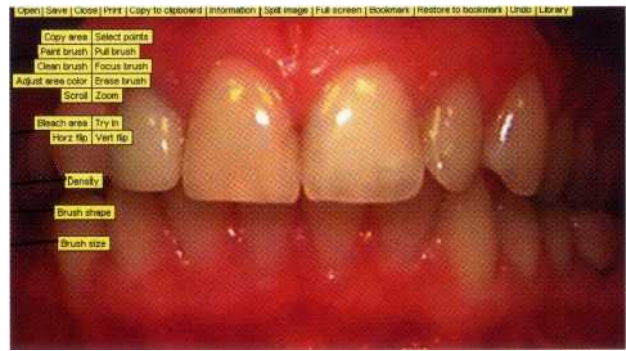

Fig. 24-14. A screen image from a computerized imaging system (CIS). (ImageFX, courtesy SeiCam, Inc.)

smile (see medicolegal considerations under clinical procedures-repair of missing teeth later in this chapter).

7. Specialized functions. Software developers are continually adding specialized functions that simplify image manipulation.

**CLINICAL TIP.** Products are continually updated and revised. Check with the manufacturer before purchasing to determine which options are still available, what enhancements have been made to the unit, and if limitations still exist. New products may have been introduced that make current products obsolete.

**CLINICAL TIP.** Mastering the complexities of computer imaging systems requires a great deal of time and effort. A dealer who can provide ample instruction and maintenance support is important. If a "bargain system" does not include servicing, the full capability of the system may never be realized.

## CLINICAL PROCEDURE

### Esthetic Dental Workup

Although system operation techniques vary greatly, the following are common to all.

#### Armamentarium

Extraoral camera and computer imaging software (e.g., ImageFX/Cosmetix Software and Dynamix Digital Camera with macro-lenses, SciCam, Inc.).

#### Clinical Technique

Because of the flexible nature of the software, many methods exist for achieving the same result. Personal experience with the system is required to understand which method will have the greatest predictive value of the outcome of a case.



1. Obtain an extraoral close-up image of the dentition using a digital camera (Fig. 24-15).

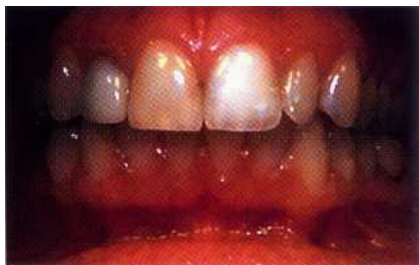**CLINICAL TIP.** If a digital camera is not available, either a patient-supplied photograph can be digitized using a flatbed scanner or the patient can be photographed using a standard film combined with Kodak PhotoCD digital processing. (See Chapter 14.)

2. After consulting with the patient, determine a proposed result.
3. Highlight the teeth using the highlighting tool (Fig. 24-16).
4. Select the correct amount of lightening of the highlighted image (Fig. 24-17).

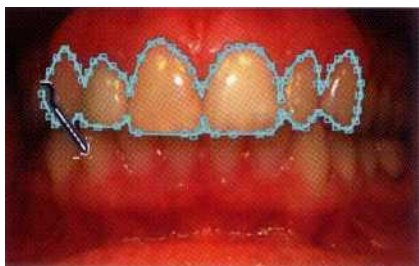
**CLINICAL TIP.** If an individual tooth requires additional lightening, it can be highlighted separately and individually lightened (Fig. 24-18).

5. Use the pull brush and the clean brush to reshape and lighten individual teeth (Fig. 24-19).
6. The results in steps 3 to 5 can also be accomplished by selecting an ideal tooth and pasting it over the tooth to be corrected (Fig. 24-20).

**CLINICAL TIP.** Bookmark (temporarily store an image change) and save work often to prevent accidental loss.



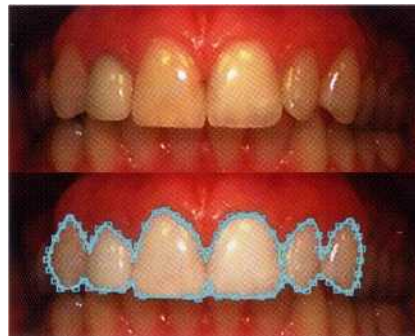
*Fig. 24-15. An extraoral close-up image of the patient's dentition is obtained.*



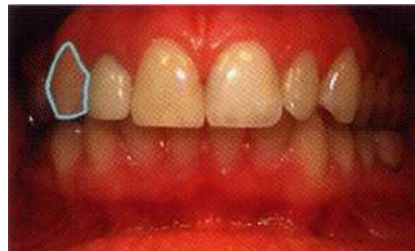*Fig. 24-16. The teeth are highlighted using the highlighting tool.*

7. After an acceptable result is obtained, save the image.

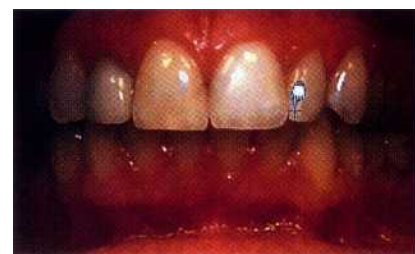**CLINICAL TIP.** Comparing the predicted postoperative image with the true postoperative image is instructive. Repeatedly performing this procedure enables practitioners to improve the predicative accuracy of their computer manipulations (Fig. 24-21).



*Fig. 24-17. The desired amount of lightening of the highlighted image is selected. A split-screen image aids in this determination.*



*Fig. 24-18. If the individual tooth needs additional lightening, such as the upper right canine, it can be highlighted separately and individually lightened.*



*Fig. 24-19. The pull brush and the clean brush are used to reshape and lighten individual teeth.*

## Repair of Missing Teeth

Armamentarium

Computer imaging system

Clinical Technique

1. Obtain an image and duplicate it on the *monitor* according to the manufacturer's recommendations (Fig. 24-22).
2. After consulting with the patient, determine a proposed result.
3. Highlight the segment of the image that will be duplicated.
4. Duplicate the highlighted image (Fig. 24-23).

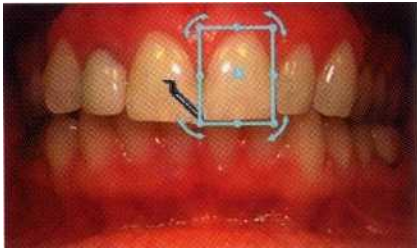


Fig. 24-20. Alternatively, sections of teeth can be highlighted, rotated, and pasted to obtain the proper esthetics.

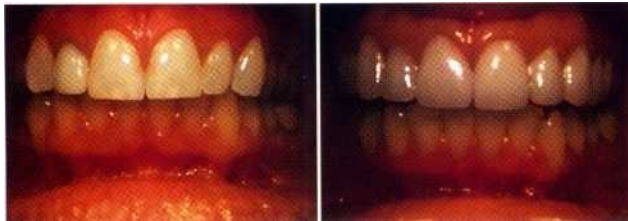

Fig. 24-21. A side-by-side comparison of computer-generated predicted results and an actual postoperative digital photograph. Despite a slight gingival asymmetry (easily correctable with a simple gingivectomy), the patient was extremely pleased and refused further treatment.

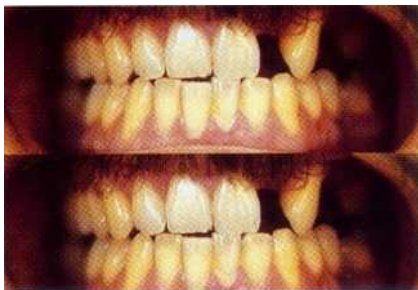


Fig. 24-22. A duplicated video image of the patient.

5. Select the correct orientation of the highlighted image (Fig. 24-24).
6. Move the image to **the proper position** (Fig. 24-25).
7. "Paste" the image into the new position.
8. Blend the colors as necessary.
9. Save the image.

### Medicolegal Consideration

The technique illustrated above was designed for simplicity; other methods would probably provide a more accurate prediction of the esthetic results. In the example,

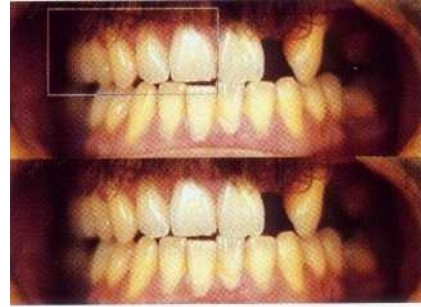


Fig. 24-23. The image segment to be duplicated is highlighted.

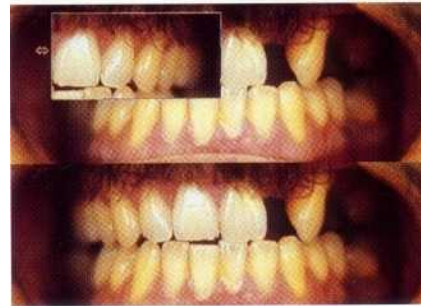


Fig. 24-24. The correct orientation of the highlighted image segment is selected.

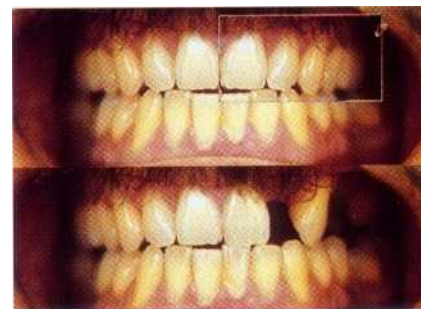


Fig. 24-25. The image segment is moved to the proper position.

the right arch (which was intact) was duplicated, inverted (a mirror image created), and superimposed on the left side where two teeth were missing. This does not take into account the relative position of any of the remaining teeth on the left side of the arch, which, fortunately in this case, were ideally positioned.

If, however, migration or tipping of the teeth in the left arch had occurred (although the computer simulation would have produced a perfect result), the actual treatment plan would require preprosthetic orthodontics to properly position the proposed abutment teeth. The manner in which the images are manipulated (duplicating the right side and superimposing it on the left side) is not the same manner in which the teeth are manipulated (preparing the teeth in their current position or in their postorthodontic position and then fabricating a fixed prosthesis). Thus it is important to attempt to simulate clinical technique as closely as possible (i.e., placing pontics in the edentulous areas of the left side, as with a conventional bridge, as *opposed to merely duplicating the right side*).

**CLINICAL TIP.** *Although the computer simulation may yield a mutually agreeable final result, only the dentist can determine if a treatment plan exists that can obtain these results. Because most of the techniques used by the computer to "rehabilitate" an arch are different from those used by a dentist to fabricate a prosthesis, a less desirable final result sometimes must be accepted. CIS can be extremely valuable in these cases because the dentist can simulate these limitations. This prevents unrealistic patient expectations and documents the possibility of less-than-optimal results.*

**CLINICAL TIP.** *Because various proposed final results may be contemplated, mark clearly and save each result before manipulating a new image.*

#### COMPUTER-AIDED DESIGN AND COMPUTER-AIDED MANUFACTURING (CAD/CAM) SYSTEMS

CAD/CAM systems have long promised to revolutionize dentistry. Many experimental in-office systems have been clinically evaluated, and a few have even enjoyed some degree of commercial success. Laboratory-based systems are beginning to penetrate the dental market. High-speed communication and overnight delivery services allow CAD/CAM laboratories to be located anywhere in the world. A typical CAD/CAM system can optically or mechanically "read" the preparation and then designs the restoration or it "reads" a "wax-up" of the final restoration. It then guides a micromilling machine to fabricate the prosthesis.

### *Advantages*

1. Eliminates impression making (some systems). Because some of these systems are optically based, an intra-oral camera replaces impression making by scanning the prepared tooth.
2. Dentist manufacturing of the restoration (some Systems). "Office-based" systems eliminate the need for a dental laboratory.
3. One-visit restoration (some systems). In-office based systems are able to fabricate the restoration in less than an hour.
4. *Alternative materials.* All CAD/CAM systems use milling technology; the dentist is not limited to castable materials.'

### *Disadvantages*

1. Expense. In-office systems are extremely expensive; however, most are leased and the cost of the actual restorations can be competitive with laboratory fees. The cost of restorations produced by laboratory-based systems are comparable to conventional restorations.
2. Introductory stage technology. Widespread use of these systems is a number of years away.
3. Multiple units limitations. Some systems are currently able to manufacture multiple-unit restorations. However, the use of a ceramic-based, multiple-unit framework is still in its infancy and has not been adequately reviewed in the literature.
4. Inability to characterize shades. Ceramic-based fabrication systems use monochromatic ceramic blocks that are available in only a limited number of shades. Some systems obviate this problem by fabricating a ceramic thimble, requiring a laboratory technician to add the outer layers of porcelain. Other systems simply require custom staining of the final restoration.
5. Inability to image in a wet environment. Optically based image acquisition systems are incapable of obtaining an accurate image in the presence of excessive saliva, water, or blood. Impression-based systems have similar considerations; however, hydrophilic impression materials are better able to overcome this limitation.
6. Incompatibility with other imaging systems. Because of the unique nature of these systems, none are compatible with currently available IISs and CISs.

### *Clinical Products*

**CLINICAL TIP.** *Systems are currently being modified and updated. It is therefore crucial to verify the current status of these products with the manufacturer before purchase.*

Celay System. (This product is made by Mikrona Technologies and distributed by Vident, Inc.) Although not a true CAD/CAM system (it does not use a computer), the Celay system has many features in common with them (Fig. 24-26). This system uses a small stylus attached to a digitizer (pantograph). A direct composite resin pattern can be fabricated intraorally or an indirect pattern can be fabricated on a model. A stylus is passed over the pattern, and the shape is transferred and milled into a porcelain blank using an "eight axis of freedom micro-milling machine" (Fig. 24-27).<sup>4</sup> This recording system is analogous to a key copying machine.<sup>1</sup> The milling machine is available for laboratory or in-office use and comes with eight different carving tools for it to fabricate inlays, onlays, veneers, and crown restorations.<sup>1</sup> Milling times vary from 8 to 10 minutes for a one-surface restoration to 20 minutes for a large onlay.<sup>4</sup> Although research has shown that profiling pressure can affect accuracy,<sup>6</sup> numerous studies confirm that the Celay system yields a clinically acceptable marginal fit.<sup>7,8,9</sup>



*Fig. 24-26.* Crown being fabricated by the Celay system. (Courtesy Vident, Inc.)



*Fig. 24-27.* A porcelain blank is milled into a porcelain restoration using an "eight axis of freedom micro-milling machine." (Courtesy Vident, Inc.)

The Cerec 11 System. (This product is made by Sirona Inc. and distributed by Patterson Dental Co.) The Cerec II, a computer-aided design and integrated milling machine, was introduced in the United States in 1996 (Fig. 24-28).<sup>10-12</sup> It designs and fabricates porcelain inlays, onlays, crowns, and veneers and allows immediate one-visit, esthetic restorations. A white, glare-free powder containing titanium oxide is placed on the tooth and a CCD sensor makes an infrared three-dimensional scan of the preparation in about 0.1 seconds at a resolution of 25  $\mu\text{m}$ .<sup>11,13</sup> A self-contained microprocessor displays the digitized image and the dentist designs the restoration. Preformed porcelain ingots, available in seventeen shades. (ProCAD, Ivoclar; VITA, Vivadent) are used by a digitally controlled six-axis micromilling machine to fabricate the prosthesis. Milling time is approximately 10 minutes for a simple restoration (Fig. 24-29). After fitting, the porcelain is custom stained, glazed, acid



*Fig. 24-28.* The Cerec II computer-controlled milling machine. (Courtesy Steve Ross.)



*Fig. 24-29.* A porcelain inlay being fabricated. (Courtesy Steve Ross.)

etched, silanated, and cemented with standard adhesive composite resin luting agents (Fig. 24-30) (see Appendix A).

**The Procera System.** (This product was manufactured by Nobel Biocare USA, Inc.) The original Procera system was designed to fabricate a titanium substructure core beneath a low fusing ceramic for use as a fixed partial denture.<sup>14</sup> The machine has since been modified to use a densely sintered high-purity alumina coping combined with a compatible veneering porcelain to create all-ceramic restorations (Fig. 24-31).<sup>15,18</sup>

The Procera system uses a conventional impression and stone model. After the die is properly ditched, it is **placed on the rotating platform of the Procera scanner.** A *stylus* then "reads" the shape into a computer in a manner similar to a key copying machine (pantographically).<sup>16,19</sup> The digital information (approximately 50,000 data points) is sent to a Procera Sandivik Dental Laboratory (Stockholm, Sweden) via a communication link. To account for sintering shrinkage, a model 20% larger than the original tooth is fabricated.<sup>19</sup> A high-strength aluminum oxide coping (600  $\mu\text{m}$ ) is manufactured by compacting the material against the enlarged model and **then milling the outer** shape. The ceramic coping is returned to the local dental laboratory via express mail<sup>19</sup> and an All-Ceram veneering porcelain is added by the local laboratory technician. The restoration is custom stained and glazed and then returned to the dentist. (See Chapter 8.)

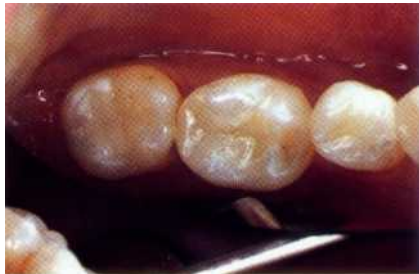

Fig. 24-30. The final restoration. (Courtesy Steve Ross.)



Fig. 24-31. The Procera system. (Courtesy Nobel Biocare USA, Inc.)

## DIGITAL RADIOGRAPHIC SYSTEMS

### Basic Theory

Xeroradiography, developed by Xerox, Inc., is a method of producing radiographic images without using conventional x-ray film. After exposure by a conventional x-ray source, an electronic *sensor* transfers the image to a specially treated glossy paper printer. This technology, now called digital radiography, uses either an intraoral CCD *sensor* (corded systems), which immediately displays the image or an intraoral flexible phosphorus *sensor* plate (cordless system) in which the reusable plate is subsequently processed (scanned) extraorally. All systems use a Windows/Intel-based system (desktop or notebook), a standard x-ray source, a *monitor* and a high-resolution printer.

All systems use digital technology that divides the images in discrete units (pixels). Current studies comparing DRS to film technology confirm an inferior resolution but clinically acceptable images.<sup>20,21</sup> In fact, even at current *resolutions* of 40 to 50  $\mu\text{m}$ , an accuracy of  $\pm 0.05$  mm for estimated root canal length compares favorably with the  $\pm 0.025$  mm obtained for film.<sup>21</sup> Other qualities of digital radiography such as dynamic range (the number of levels of grey) called *pixel* depth, linearity (how accurately light elements are mapped as light and dark elements are mapped as dark) and system noise (false information added or subtracted from the image because of electrical noise within the system) all fall within a clinically acceptable range.<sup>20,21</sup> Image enhancement technology (which can enhance caries detection) and more accurate *sensors* guarantee that this technology will ultimately replace film-based systems. Although all systems have high initial costs, the elimination of disposables (e.g., dental film, chemicals) results in an overall cost that compares favorably with conventional methods. DRSs offer the potential to transfer radiographic images over conventional telephone lines (teleradiology) to other practitioners or insurance companies.<sup>22</sup>

**CLINICAL TIP.** The medicolegal status of digital radiographs is still developing. All systems have some degree of security to verify the originality of a digital image; however, there have been few court cases to uphold their legal weight.

**CLINICAL TIP.** Bundled software can be as important a component of dental radiography as the image acquisition mechanism. Be certain that the software meets your office needs and is compatible with any dental management program currently owned.

## Corded Systems

A basic corded system replaces conventional film with a reusable *CCD sensor* attached to a Windows/Intel-based system via a port (Serial, CardBus, USB) (Fig. 24-32). The *sensor* is similar to those used in IIS and CIS but is optimized to the wavelengths used by x-ray units. Because they require no processing, they provide almost instantaneous image acquisition with a concurrent reduction in x-ray exposure of 60% to 80%. Although *sensors* are available in standard dental sizes, the *sensors* are much bulkier in width, and some dentists find the cord cumbersome.<sup>24</sup> In addition, high *sensor* cost limits the number of *sensors* an office may purchase.

**CLINICAL Tip.** Early sensors were less durable than current sensors. Be certain to obtain up-to-date sensors and consider warranty length when making purchasing decisions. A more expensive sensor with a higher durability and longer warranty period may ultimately be more inexpensive than a less durable, less costly sensor.

## Cordless Systems

Cordless systems use a reusable flexible phosphorus imaging plate identical in size, shape and width to conventional dental film (Fig. 24-33). After exposure, the phosphorus plate is placed in a high-speed laser scanner that



Fig. 24-32. A corded digital radiographic system. (Courtesy Schick Technology, Inc.)



Fig. 24-33. A cordless digital radiographic system. (Courtesy Dentsply, Inc.)

digitizes the image. As in corded systems, radiation exposure is reduced by 60% to 80%; however, cordless systems have the added advantage of handling techniques similar to those of conventional film. A major drawback of these systems is the additional time and space required for the laser scanner (1 to 3 min for image acquisition).

## Alternative Systems

An alternative to dedicated systems is the use of a flatbed or 35-mm scanner to input conventional film images. Studies have confirmed the variability of image quality<sup>25,26</sup>; however, the system is best used to transfer archived dental film into current digital systems. Most of the security verification systems built into current *software* do not consider a scanned image to be an "original," thereby creating medicolegal questions.

Research is currently underway for dental uses of tuned-aperture computed tomography (TACT). This system uses an x-ray source with a variable aperture size. These variations focus on different areas creating numerous tomography slices,<sup>27</sup> which can be computer image enhanced to produce three-dimensional images. Commercial products are currently being developed.<sup>27</sup>

## RADIOGRAPHIC IMAGE PROCESSING SYSTEMS

This broad category includes the *hardware* and *software* needed to process radiographic images. Although many DRSs have some image processing capabilities, radiographic image processing systems (RIPs) are dedicated systems designed to perform a specific type of function. Many RIPs have no image acquisition capability and some can acquire only nondigital images from conventional film-based radiographs. Some RIPs are able to "read" lateral and anterior facial films and perform cephalometric measurements (e.g., Dentofacial Planner, DFP, Inc.). Others "add-on" to computerized axial tomographic (CAT) x-ray machines designed for dental use. These RIPs (e.g., DentaScan, GE Medical Systems; SIM/Plant, Columbia Scientific Inc.) are designed for use in implant placement analysis.

## OTHER SYSTEMS

Evolving electronic technology has produced many other types of systems.

### Clinical Colorimeters

Advances in microelectronics and optical sensors have made electronic tooth shade selection possible. The



Fig. 24-34. ShadeEye-Ex Chroma Meter (Shofu Dental).




Fig. 24-36. The Probe One. (Courtesy American Technology, Inc.)



Fig. 24-35. The T-Scan II system. (Courtesy TekScan, Inc.).



Fig. 24-37. Dentistry on the Internet. (Courtesy Dental Domain, Inc.)

recently introduced ShadeEye-EX Chroma Meter (Shofu Dental Corp.) (Fig. 24-34) uses a special optical sensor and processor and has shown promise in vitro.<sup>28</sup> The colorimeter calculates the colors of the adjacent and contralateral teeth using Shofu's L\*A\*B\* color identification system. This information is sent to the lab technician, who then selects the proper Shofu Vintage Halo porcelains.

### Occlusal Analysis Systems

A computer peripheral device designed to attach to a standard PC, it locates occlusal prematurities and provides analyses from the point of initial tooth contact to the point of maximum intercuspation. The T-Scan II system (TekScan, Inc.) uses a special mylar sensor which allows analysis and recording of a patient's occlusion (Fig. 24-35). The dentist can subsequently verify that the appropriate occlusion has been duplicated in a prosthesis. Clinical studies have shown it to be a reliable method for the analysis and evaluation of occlusal contact distribution in maximum intercuspation.<sup>29</sup>

### Periodontal Recordkeeping

Electronic periodontal probing is a viable and accurate alternative to manual probing and charting, providing

measurements to the nearest tenth of a millimeter.<sup>30,31</sup> Current probe systems use a mechanical "sliding sleeve" probe (Probe One, American Dental Technologies Inc.) (Fig. 24-36) or constant pressure spring-loaded probe (Florida Probe, Computerized Probe, Inc.) (see Fig. 24-6). Both systems are able to integrate with numerous dental management systems.

### Periodontal Analysis

The Diamond Probe/Perio 2000 system (Diamond General Development Corp.) is designed to detect sulfide levels in the gingival sulcus. The manufacturer claims that volatile sulfur compounds (VSC), specifically hydrogen sulfide, have been identified as a byproduct of gram-negative bacteria associated with periodontal disease.<sup>32</sup>

## TELEDENTISTRY

The advent of telecommunications and the Internet also promises to transform dentistry. As more dental data becomes digitized, dentists will be able to transfer patient information to other dentists, dental laboratories, or insurance companies instantaneously."<sup>33</sup> The Internet and dental web sites are coming on-line to facilitate the exchange of images and data in real time anywhere in the world with no investment beyond a PC and Web browser software (e.g., <http://www.transcendonline.com>) (Fig. 24-37). Such sites allow the users to perform off-site stor-



Fig. 24-38. A dental laser system. (Courtesy American Technology, Inc.)

age of data, access to expert consultations, and imaging services. As these and other teledentistry technologies evolve, the crossing of interstate and international boundaries will require regulatory changes regarding licensure issues.<sup>36</sup>

## TREATMENT SYSTEMS

### Laser Technology

A laser (light activation by stimulated emission of radiation) is a device capable of producing an intense, highly focused monochromatic beam of light that, among other uses, can instantly vaporize living tissue (Fig. 24-38).

Lasers are classified according to their lasing medium.<sup>37</sup> The biologic effects of a laser are dependent on both the wavelength of light emitted and the absorption characteristic of the target tissue. The duration of exposure, power level, wave characteristics (a pulsed vs. a continuous wave) and intermediary absorption material (e.g., water) can also alter the amount of energy absorbed.<sup>37</sup>

The use of lasers in dentistry has been considered for more than 20 years.<sup>38-40</sup> The most common types used in dentistry today are the carbon dioxide (CO<sub>2</sub>) laser, the neodymium:yttrium-aluminum-garnet (Nd : YAG) laser, the erbidium yttrium-aluminum-garnet (Er:YAG) laser, the erbidium chromium-yttrium-scandium-gallium-garnet (Er,Cr:YSGG) laser, the Gallium Aluminum Arsenic (GaAlAs) solid state diode laser, and the Argon (Ar) laser.<sup>37</sup>

The unique wavelength of each type of laser makes it useful for specific purposes. Because the CO<sub>2</sub> laser's light is readily (approximately 98%) absorbed by water, it is mostly used in soft tissue surgery that is 75% to 90% water.<sup>37</sup> The Nd :YAG laser is also used on soft tissue; how-

ever, some scattering can occur, causing a greater depth of penetration into the soft tissue.<sup>41</sup> Argon emits a blue-green light that is readily absorbed by pigmented tissues such as hemoglobin and melanin but poorly absorbed by enamel and dentin.<sup>42,43</sup>

**Safety.** Despite early successes in medical laser use, routine dental use is still uncommon. Early studies on hard tissue use concluded that the energy levels needed to remove dental caries would cause irreversible pulpal necrosis.<sup>38 40</sup> Extensive hard and soft tissue damage also occurred when early lasers were used on gingival and mucosal tissues.<sup>38 4°</sup> Most laser delivery systems were too cumbersome for dental use. However, the advent of pulsed lasers and the better matching of laser wavelengths with target tissue characteristics have produced better and safer dental lasers.

Recent studies have shown that damage to soft tissue can be reduced by the substitution of a CO, Nd :YAG, Er:YAG, or Er,CT:YSGG laser for the previously used ruby laser.<sup>44,45</sup> For hard tissues the Er:YAG laser (Centauri Plus, Premier Laser Systems, Inc.) and a modified Er,Cr:YSGG laser using a water intermediary (Millennium, Biolase Technology) have shown to be safe on virgin tooth caries.<sup>46,49</sup> Although these lasers produce high energy levels, they are pulsed (turned on and off) at rates of 10 to 30 times per second and are less likely to cause damaging heat build-up because the tissue cools between pulses.<sup>50</sup> Dental lasers can be delivered via a fiberoptic cable to a dental handpiece, which allows for easy intraoral use.

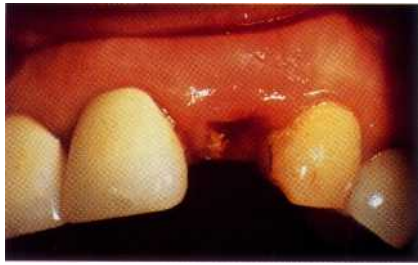
### Uses

**CLINICAL TIP.** Currently, the FDA has approved only the dental use of specific lasers for soft tissue procedures as well as specific lasers for hard tissue procedures (see below) "Lasers that are approved only for soft tissue use should not be used on hard tissue and vice versa. Contact the FDA, the ADA, or the manufacturer for the proper scope of approved uses.

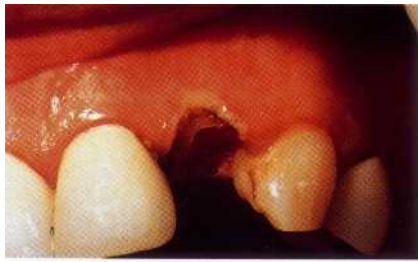The types of soft tissue procedures that can be performed using dental lasers are similar to those that can be performed using an electrosurgical unit. These procedures include gingivoplasty, gingivectomy, crown lengthening (Figs. 24-39 and 24-40), stage 11 implant surgery" (Figs. 24-41 and 24-42), frenectomy, subgingival curettage, biopsy, gingival troughing for crown and bridge procedures, and esthetic recontouring of gingival tissue. Lasers produce excellent hemostasis." (See Chapter 22.)

The use of dental lasers on hard tissue is relatively new. Early research on laser systems revealed that the Er:YAG (2.94  $\mu$ m) is absorbed by water and hydroxyapatite and therefore able to cut (ablate) dental hard tissue

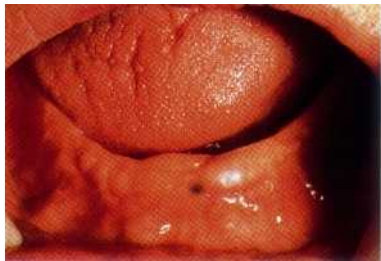




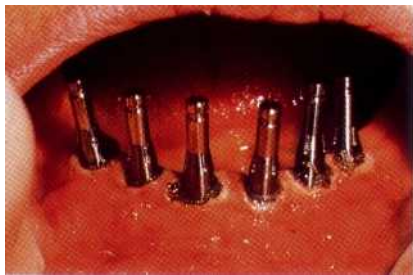*Fig. 24-39.* A preoperative view of a tooth requiring a periodontal crown lengthening procedure. (Courtesy American Dental Technology.)



*Fig. 24-40.* Immediate postoperative view of the crown lengthening procedure performed with a dental laser. (Courtesy American Dental Technology.)



*Fig. 24-41.* A preoperative view of a healed edentulous ridge with implants in place. (Courtesy American Dental Technology.)



*Fig. 24-42.* An edentulous ridge following stage II implant surgery using dental laser. (Courtesy American Dental Technology.)

effectively and efficiently.<sup>53-60</sup> In vivo studies show irreversible damage in 15% of the teeth tested when intrapulpal temperature rose more than 5.5° C.<sup>61</sup> This temperature change has become the benchmark for the maximum acceptable amount of heat rise before irreversible histologic damage to the pulpal tissues occurs.<sup>46,54,61,62</sup> Er: YAG lasers cause a temperature rise of less than 3° C; and the pulpal response is comparable to or less than that created by a high-speed handpiece.<sup>60,63-71</sup> Laboratory tests have shown that a pulsed Er:YAG laser can vaporize enamel with no detectable damage to the surrounding hard tissue.<sup>60</sup> Water spray has been shown to cool the tooth during ablation (laser cutting) and increase cutting efficiency.

An Er,Cr:YSGG laser recently was approved by the FDA. It is designed to heat water and cause microscopic "explosions."<sup>60</sup> These "explosions" (called the HydroKinetic Cutting System) remove small amounts of tooth structure. The manufacturer claims that this laser can be used on both hard and soft tissue.<sup>60</sup> Both the Er:YAG and the Er,Cr:YSGG lasers have received FDA approval for use on carious lesions on nonrestored teeth. A 1998 ADA Council on Scientific Affairs position paper expressed the need for additional safety and clinical application studies before a Seal of Acceptance Program would be created for this category of devices.<sup>53</sup> No currently marketed dental laser can cut complex fixed prosthetic restorations because of their slower cutting rate when compared with a conventional high-speed dental handpiece. Further study is needed regarding their use in the removal of old restoration because of concerns about heat conduction and the possible toxicity of the vapor formed by the debris (the laser plume).

The Argon laser has been cleared by the FDA for use in curing photo-activated composite resin."<sup>72</sup> The use of the Ar laser increases curing depth and the rate of cure. Further study is necessary to see how a rapid cure affects the composite resin, including the need to modify placement technique because of altered shrinkage.<sup>76</sup>

Additional uses of the laser include the photoactivation of a peroxide gel for tooth bleaching<sup>77</sup> and the laser etching of teeth. Studies comparing laser etch with acid etch have been mixed.<sup>78-84</sup> Lasers have also been advocated as an effective sterilant in endodontic therapy.<sup>85,86</sup>

#### Air Abrasion Systems

In 1951, the S.S. White company introduced Airdent, the first commercially available air-abrasion system. Although it had small commercial success (2000 units sold), the introduction of the high speed handpiece led to its demise.<sup>87,88</sup> Recent advances in the use of air abrasion units have made them an acceptable alternative to conventional high-speed dental handpiece for small carious lesions (see Fig. 24-7). In vivo canine studies have shown little differences in pulpal response between air abrasion and conventional high-speed turbines treated teeth, especially when higher pressures and smaller particles were



used.<sup>89</sup> The surrounding tissue also exhibited few adverse effects.<sup>89</sup>

All systems use compressed air and an abrasive powder to remove enamel and dentin. The powder, aluminum oxide, has an average size of 27 to 60 [Lm (93%) mixed with five other oxides (SiO<sub>2</sub>, Cr<sub>2</sub>O<sub>3</sub>, ZrO<sub>2</sub>, Fe<sub>2</sub>O<sub>3</sub>, and TiO<sub>2</sub>).<sup>87,88,90</sup> It is released in a high-pressure stream of compressed air at 40 to 60 psi. Like dental lasers, their use is limited to small carious lesions, although some reports in the literature relate their use to the removal of old restorations.<sup>87,88</sup> At least one study has shown higher-than-optimal air-borne mercury levels when air abrasion was used.<sup>91</sup> Questions also remain concerning airborne alumina oxide particles produced.<sup>92</sup> Although the tool has a much slower cutting rate than a conventional handpiece, the manufacturers claim that because many cases do not require anesthesia, overall time is saved.

Air abrasion has also been advocated as a tooth conditioner replacing phosphoric acid. However, air abrasion alone creates significantly lower composite-to-tooth bond strengths in dentin bonding when compared with acid-etch conditioning.<sup>93</sup> Air-abrasion, especially when combined with hydrofluoric acid application, creates a composite resin-to-porcelain bond strength comparable with the bond strength of a composite resin to a cured composite resin.<sup>96,97</sup>

### COMPUTER-REGULATED LOCAL ANESTHETIC DELIVERY SYSTEMS

A computer-regulated local anesthetic delivery systems (the Wand, Milestone Scientific) consists of two components, a sterile disposable handpiece and a computer-controlled drive unit. The computer-regulated system controls the flow rate and volume of anesthetic and adjusts it according to the amount of back pressure. Numerous studies have shown a significant decrease in discomfort compared with a conventional syringe.<sup>98,99</sup>

### CONCLUSION

Electronic and computer technologies are evolving at a rapid pace. The amount and types of digital diagnostic patient information are increasing every year. Business application standalone products (e.g., word processors, spreadsheets, databases) are being replaced with office suites (e.g., Microsoft Office, Microsoft, Inc.; Corel Office, Corel, Inc.; other all-in-one multi-application programs). In a similar manner, dental management programs (e.g., Dentrix, Dentrix Dental Systems; Computer Age Dentist, Computer Age Dentist, Inc.; Softdent, Dentsply, Inc.; Eaglesoft, Patterson Dental, Inc.) are also taking individual programs (e.g., IISs, DRSS, periodontal record keeping, etc.) and creating a central hub from which all digital information is accessed.

As dentistry continues to evolve into the digital era, new technologies will replace old. The photographic camera will be replaced with a digital camera, the x-ray film with a sensor, the high-speed dental handpiece with a laser or air-abrasion handpiece, and other diagnostic and treatment modalities with computer-controlled devices. Although these transformations are still incomplete, advances in technology are turning this vision into reality.

All digital photographs were obtained using a Dynamix digital camera and ImageFX/Cosmetix software (SciCam, Inc.).

### REFERENCES

1. FOLDOC on-line Computer Dictionary, 1993, 1998, Denis Howe. Available at <http://wombat.doc.ic.ac.uk/foldoc/index.htm> Accessed December 1998 to February 1999.
2. Christensen R: Clinical television, intra- and extraoral, *Clin Res Assoc Newsletter* 13:1, 1989.
3. Rekow D: Prosthesis by computer, *NY State Dent J* 54:4, 1988.
4. Trushkowsky R: Ceramic inlay fabrication with three-dimensional copy milling technology- Celay©, *Compendium* 19(11):1077, 1998.
5. Rekow D: Dental CAD-CAM systems, *J Am Dent Assoc* 122:43, 1991.
6. Seido T et al: A study on the grinding accuracy of a copy milling machine for dental use, *Bull Tokyo Dent Coll* 38:169, 1997.
7. Groten M, Girthofer S, Probst L: Marginal fit consistency of copy-milled all-ceramic crowns during fabrication by light and scanning electron microscopic analysis in vitro, *J Oral Rehabil* 24:871, 1997.
8. Moscovich H, Creugers NH: The novel use of extracted teeth as a dental restorative material-the "Natural Inlay," *J Dent* 26:21, 1998.
9. Kawai K et al: Marginal adaptability and fit of ceramic milled inlays, *J Am Dent Assoc* 126:1414, 1995.
10. Brandestini M et al: Computer machined ceramic inlays: in vitro marginal adaptation, *J Dent Res* 64:208, 1985 (abstract).
11. Moermann W et al: Marginal adaptation von adhesiven porzellaninlays in vivo, *SSO: Schweiz Monatsschr Zahnmed* 95:118, 1985.
12. Moermann W et al: Computer machined adhesive porcelain inlays: marginal adaptation after fatigue stress, *J Dent Res* 65:762, 1986 (abstract).
13. Moermann W Brandestini M: Method and apparatus for the fabrication of custom-shaped implants, US Patent No. 4,575,805, March 11, 1986.
14. Smedberg JI et al: Two-year follow-up study of Procera-ceramic fixed partial dentures, *Int J Prosthodont* 11:145, 1998.

15. Awliya W et al: Shear bond strength of a resin cement to densely sintered high-purity alumina with various surface conditions, *Acta Odontol Scand* 56:9, 1998.
16. Andersson M et al: Procera: a new way to achieve an all-ceramic crown, *Quintessence* 29:245, 1998.
17. Wagner WC, Chu TM: Biaxial flexural strength and indentation fracture toughness of three new dental core ceramics, *J Prosthet Dent* 76:140, 1996.
18. Persson M, Andersson M, Bergman B: The accuracy of a high-precision digitizer for CAD/CAM of crowns, *J Prosthet Dent* 74:223, 1995.
19. Andersson M et al: Procera: a new way to achieve an all-ceramic crown, *Quintessence Int* 29(5):285, 1998.
20. Analoui M: Evaluating quality of digital dental imaging: pixel size: how small is small enough? *Cont Esthetics Rest Prac* 1:6, 1997.
21. Cederberg RA et al: Endodontic working length assessment. Comparison of storage phosphor digital imaging and radiographic film, *Oral Surg Oral Med Oral Pathol Oral Radiol Endod* 85:325, 1998.
22. MacDonald R: Images and communication: a radiological perspective, *Ann R Australas, Coll Dent Surg* 12:60, 1994 (abstract).
23. Jones GA, Behrents RG, Bailey GP: Legal considerations for digitized images, *Gen Dent* May-Jun 1996, p 242.
24. Lackey AD: Advances in digital radiography: corded and cordless systems, *Prac Periodontics Aesthet Dent* 10:1021, 1998.
25. Shrout MK et al: 35-mm film scanner as an intraoral dental radiograph digitizer. ii: effects of brightness and contrast adjustments, *Oral Surg Oral Med Oral Pathol* 76:510, 1993.
26. Chen SK, Hollender L: Digitizing of radiographs with a flatbed scanner, *J Dent* 23:205, 1995.
27. Webber R: Tuned-aperture computed tomography dental applications, *Cont Esth Rest Prac* 2:60, 1998.
28. ShadeEye-Ex Chroma Meter, The New Standard in Color Matching, Shofu Inc.
29. Garrido Garcia VC, Garcia Cartagena A, Gonzalez Sequeros O: Evaluation of occlusal contacts in maximum intercuspation using the T-scan System, *J Oral Rehabil* 2:899, 1997.
30. Reddy MS, Palcanis KG, Geurs NC: A comparison of manual and controlled-force attachment-level measurements, *J Clin Periodontol* 24:920, 1997 (abstract).
31. Hefti AF: Periodontal probing, *Crit Rev Oral Biol Med* 8:336, 1997.
32. Diamond General's Summary Review of the Periodontal Literature, Diamond General Development Corp.
33. Antenucci EL: The dental information superhighway, *NY State Dent J* Oct 1995, p 54.
34. Hayakawa Y et al: Low-cost teleradiology for dentistry, *Quintessence Int* 27:175, 1996.
35. Eraso FE et al: Teledentistry: Protocols for the transmission of digitized radiographs of the temporomandibular joint, *J Telemed Telecare* 2:217, 1996 (abstract).
36. Silkas PM: Teledentistry: legal and regulatory issues explored, *J Am Dent Assoc* 128:1716, 1997.
37. Mattson JS, Blankenau R, Keene JJ: Use of an argon laser to treat drug-induced gingival overgrowth, *J Am Dent Assoc* 129:78, 1998.
38. Stern RH, Sognnaes RF: Laser beam effects on hard tissues, *J Dent Res* 43:873, 1964.
39. Sognnaes RF, Stern RH: Laser effects on resistance of human dental enamel to demineralization in vitro, *J South Cal Dent Assoc* 33:328, 1965.
40. Goldman L et al: Effects of laser beam impacts on teeth, *J Am Dent Assoc* 70:601, 1965.
41. Pick RM, Pecaro BC, Siberman CJ: The laser gingivectomy: the use of the CO<sub>2</sub> laser for the removal of phenytoin hyperplasia, *J Periodontol* 56:492, 1985.
42. Cohen RE, Ammons W: Lasers in periodontics: position paper, *J Periodontol* 67:826, 1996.
43. Kutsch VK, Blankenau RJ: Surgical applications of the argon laser. In Miserendino CJ, Pick RM, editors: *Lasers in dentistry*, Lombar Ill, 1995, Quintessence, p 129.
44. Meyers TD, Meyers WD: The use of laser debridement of incipient caries, *J Prosthet Dent* 53:6, 1985.
45. Meyers TD, Meyers WD: A review of lasers in dentistry, *II Dentista Moderno* 7:1, 1989.
46. Cozean C et al: Dentistry for the 21 st century, *J Am Dent Assoc* 128:1080, 1997.
47. Pelagalli JM: Using laser technology on hard tissue, *Dent Today* 16(6)44, 1997.
48. McCann D: FDA OKs laser for children, and tissue, *Am Dent Assoc News* 29:1, 1998.
49. Greider WA: A laser for hard and soft tissue application, *Dent Today* 17:68, 1998.
50. Meyers TD: What laser can do for dentistry and you, *Dent Manage* 29:26, 1989.
51. Russo J: Periodontal laser surgery, *Dent Today* 11:80, 1997.
52. Meyers TD, Meyers WD, Stone RM: First soft tissue study utilizing a pulsed Nd:YAG dental laser, *Northwest Dent* Mar-Apr, 1989.
53. ADA Council on Scientific Affairs Position Statement: revised October 30, 1998. Available at <http://www.ada.org/prac/position/lasers.htm>. Accessed January 12, 1999.
54. Visuri SR, Walsh JT Jr, Wigdor HA: Erbium laser ablation of dental hard tissue effect of water cooling, *Lasers Surg Med* 18:294, 1996.
55. Wigdor HA et al: Lasers in dentistry, *Lasers Surg Med* 16:103, 1995.
56. Hibst R, Keller U: Experimental studies of the application of the Er:YAG laser on dental hard substances. 1. Measurement of the ablation rate, *Lasers Surg Med* 93:38, 1989.
57. Walsh JT, Deutsch TE: Er:YAG laser ablation of tissue measurement of ablation rates, *Lasers Surg Med* 9:327, 1989.
58. Burkes EJ et al: Wet versus dry enamel ablation by Er:YAG laser, *J Prosthet Dent* 67:847, 1992.

59. Li Z, Code JE, Van De Merwe WP: ErYAG laser ablation of enamel and dentin of human teeth determination of ablation rates at various fluences and pulse repetition rates, *Lasers Surg Med* 12:625, 1992.
60. Paghdwala AF: Does the laser work on hard dental tissue? *J Am Dent Assoc* 12:279, 1991.
61. Zach L, Cohen G: Pulp response to externally applied heat, *Oral Surg Oral Med Oral Pathol* 19:515, 1965.
62. Powell GL, Whisenant BK, Morton TH: Carbon dioxide laser oral safety parameters for teeth, *Lasers Surg Med* 10:389, 1990.
63. Arcoria CJ, Cozean C: Hard-tissue effects using multiple wavelength lasers. In *Lasers in dentistry*, Bologna, Italy, Monduzzi (International Proceedings Division), 1995, p 131.
64. Paghdwala AF: Application of the Erbium:YAG laser on hard dental tissues measurement of the temperature changes and depths of cut. In *Laser Institute of America Proceedings* (International Congress on Applications of Lasers and Electro-Optics), Orlando, Fla, 1988, Laser Institute of America, 64:192, 1988.
65. Keller U, Hibst R: Tooth pulp reaction following Er:YAG laser application. In O'Brien SJ et al, editors: *Lasers in orthopedic, dental and veterinary medicine*, Bellingham, Wash, 1991, The International Society for Optical Engineering, p 127.
66. Abt E et al: The effect of the CO<sub>2</sub>, Nd:YAG and Er:YAG lasers on dentin and pulp tissues in dogs. In Anderson RR, editor: *Laser surgery advanced characterizations, therapeutics and systems III*, Bellingham, Wash, 1992, The International Society for Optical Engineering, p 464.
67. Sekine Y et al: Erbium:YAG laser application to cavity preparation light microscopic investigation of the tooth pulp. In *Laser in dentistry*. Bologna, Italy, Monduzzi (International Proceedings Division), 1995, p 167.
68. Sonntag K et al: Pulpal response to cavity preparation with the Er:YAG laser, *J Dent Res* 74:102, 1995 (abstract).
69. Keller U, Hibst R. Histological findings of pulpal changes after Er:YAG laser irradiation, *J Dent Res* 74:545, 1995 (abstract).
70. Raab W Heyeraas K, Davidson D: Preparation of dentine using ErYAG laser side effects on pulpal microcirculation and tissue pressure, *J Dent Res* 75:270, 1996.
71. Dostalova T et al: Dentin and pulp response to Erbium:YAG laser ablation: a preliminary evaluation of human teeth, *J Clin Laser Med Surg* 15(3):117, 1997.
72. Severin C, Maquin M: Argon ion laser beam as composite resin light curing agent. In Yamamoto H, Atsumi K, Kusakari H, editors: *Lasers in dentistry*, ed 1, Amsterdam, 1989, Excerpta Medica, p 241.
73. Kelsey WP III et al: Enhancement of physical properties of resin restorative materials by laser polymerization, *Lasers Surg Med* 9:623, 1989.
74. Blankenau RJ et al: Degree of composite resin polymerization with visible light and argon laser, *Am J Dent* 4:40, 1991.
75. Powell GL, Blankenau RJ: Effects of argon laser curing on dentin shear bond strengths, *J Gun Laser Med Surg* 14:111, 1996.
76. Bouschlicher MR et al: Effect of composite type, light intensity, configuration factor and laser polymerization on polymerization contraction forces, *Am J Dent* 10:88, 1997.
77. Rinaldi P, Rosenthal L: Utilizing plasma technology for rapid in-office whitening procedures, *Prac Perio Esth Fall supplement*, 1998, p 5.
78. Keller U, Hibst R: Effects of Er:YAG laser on enamel bonding of composite materials, *Proceedings of the International Society for Optical Engineering*, Bellingham, Wash, 1993, The International Society for Optical Engineering (SPIE), p 153.
79. Visuri SR et al: Shear strength of composite bonded to Er : YAG laser-prepared dentin, *J Dent Res* 75:599, 1995.
80. Kumazaki M. Results of etching with the Er:YAG laser. In *Proceedings of the Third International Congress on Lasers in Dentistry*, Salt Lake City, University of Utah Printing Service, 1993, p 141.
81. Hibst R, Keller U: Sealing quality of composites after Er:YAG laser enamel conditioning. The International Society for Optical Engineering (SPIE) Proceedings. Bellingham, Wash. The International Society for Optical Engineering, 1994, p 260.
82. Arcoria C, Cozean C: Oral tissue healing studies using multiple wavelength lasers. In *Lasers in dentistry*, Bologna, Italy, 1995, Monduzzi (International Proceedings Division), p 251.
83. Moritz A et al: Alternatives in enamel conditioning: a comparison of conventional and innovative methods, *J Clin Laser Med Surg* 14:133, 1996.
84. Corpas-Pastor L et al: Comparing the tensile strength of brackets adhered to laser-etched enamel vs. acid-etched enamel, *J Am Dent Assoc* 128:732, 1997.
85. Moritz A et al: Nd : YAG laser irradiation of infected root canal systems in combination with microbiological examinations, *J Am Dent Assoc* 128:1525, 1997.
86. Winn DW II: Laser use in endodontics, *Dent Today* 17:56, 1998.
87. Pitel ML: The resurgence of air abrasion into restorative dentistry, part 1, *Dent Today* 17:63, 1998.
88. Pitel ML: The resurgence of air abrasion into restorative dentistry, part 2, *Dent Today* 17:71, 1998.
89. Laurell KA et al: Histopathologic effects of kinetic cavity preparation for the removal of enamel and dentin: an in vivo animal study, *Oral Surg Oral Med Oral Pathol Oral Radiol Endod* 80:214, 1995.
90. Graeber JJ: New age operative dentistry: air abrasion, *Contemp Esth Rest Pract* May-Jun 1998, p 14.
91. Schiller B: Mercury vapor release during amalgam removal using high speed air abrasive instrumentation from two manufacturers: industrial hygiene study, Bloomfield Hills, Mich, 1997, Bert Schiller & Associates.

92. Christensen R: Air abrasion for caries removal (CA Status Report), Clin Res Assoc Newsletter 21:2, 1998.
93. Rinaudo PJ, Cochran MA, Moore BK: The effect of air abrasion on shear bond strength to dentin with dental adhesives, Oper Dent 22:254, 1997 (abstract).
94. Zyskind D et al: Effect of etching on leakage of sealants placed after air abrasion, Pediatr Dent 20:25, 1998 (abstract).
95. Nikaido T et al: Bond strengths of resin to enamel and dentin treated with low-pressure air abrasion, Oper Dent 21:218, 1996.
96. Olsen ME et al: Comparison of shear bond strength and surface structure between conventional acid etching and air-abrasion of human enamel, Am J Orthod Dentofacial Orthop 112:502, 1997 (abstract).
97. Kupiec KA, Barkmeier WW: Laboratory evaluation of surface treatments for composite repair, Oper Dent 21:59, 1996 (abstract).
98. Hochman M et al: Computerized local anesthetic delivery vs traditional syringe. Subjective pain response, NY State Dent J 63:24, 1997.
99. Brown CR. Computer-regulated anesthetic delivery, Prac Periodont Aesthet Dent 10:638, 1998.
100. Friedman MI: A 21st century computerized injection system for local pain control, Compend Comm Educ Dent 18:995, 1997.
101. Lackey AD: An advancement in the delivery of local anesthesia, Prac Periodont Aesthet Dent 10:1191, 1998.



SECTION FIVE

# ESTHETIC PRACTICE MANAGEMENT



انتشارات شایان نمودار

# ESTHETICS AND PSYCHOLOGY

Fred B. Abbott and Nellie Abbott

**R**ECENT ADVANCES IN DENTAL materials and procedures have greatly increased the ability to provide esthetic treatment. The wide array of available options increases the need for understanding the patient as a person and places greater emphasis on effective communication. Personality, motivations, desires, expectations, self-esteem ability to accept change, and willingness to cooperate are important factors for successful treatment.' An awareness of self theory and a broad application of psychological and sociologic principles can greatly enhance a dental practice that emphasizes esthetics.

## HISTORY OF PSYCHOLOGY AND DENTAL ESTHETICS

As early as 1872 White reminded the dental profession of the need to relate esthetic appearance to the laws of nature, that is, facial contours, age, and temperament.<sup>3</sup> White later attempted to apply this theory to tooth selection; temperamental forms of teeth were produced as "named sets."<sup>4</sup> The term *named sets* refers to the categorization of maxillary anterior teeth.

The search for teeth that would enhance personality and appearance continued. In 1895 a prominent American dentist and artist, J. Leon Williams, expressed concern that the teeth available for dentures did not look lifelike. He carried out extensive research on teeth shape and size. He adopted White's "named sets" idea and classified anterior maxillary teeth as square, ovoid, tapering, or a combination of these types. A newly emerging company (now called Dentsply International, Inc.) used his research to create a mold guide system and techniques

that made it possible for the first time for the dentist to select the size and form of teeth that would look best on the patient.' It was believed that Williams had discovered nature's law of the face-form-tooth-form harmony.<sup>6</sup>

M.M. House refined and expanded upon the work of Williams to include form and color harmony into denture esthetics.<sup>7</sup> The theories of Williams and House still serve as the frame of reference for tooth selection as taught in many dental schools today. A study by Brown failed to support Williams' and House's face-form-tooth-form theory.<sup>8</sup>

In 1937 House classified patients into four types based upon psychological assessment.' According to House,

1. The philosophic patient accepts his [or her] lot in life, copes with frustration, and is well organized with respect to time and habits.
2. The exacting individual is very methodical, accurate, demanding, and extremely precise in life's activities.
3. The indifferent patient is unconcerned, apathetic, and unmotivated.
4. The hysterical patient is emotionally unstable, highly excitable, and extremely apprehensive.

Although House's classification furnishes guidelines for diagnosing patients, the psychological assessment of a patient goes beyond simple categorization.

## "Dentogenic" Movement

In the 1950s the "dentogenic" movement became popular. *Dentogenics* was defined as the convergence of art, practice, and techniques that enabled a denture to add to a person's charm, character, dignity, and beauty in a fully expressive smile." As proponents of dentogenics, J.P.



Frush and R.D. Fisher placed great emphasis on projecting a denture wearer's personality, sex, and age. In collaboration with the Swissedent Foundation, they stressed the need to avoid the "denture look." They added to face-form and tooth-form the SPA *factor*: sex, personality, and age."

They hypothesized a personality spectrum ranging from vigorous to medium pleasing to delicate. Based on their experience, Frush and Fisher believed that about 15% of the population were the vigorous type. These individuals tended to be male. About 5% were delicate, and they tended to be female. The remaining 80% were the medium-pleasing type, composed of both sexes.

Tooth selections and characterizations for prostheses were partially guided by the perceived personality type." Frush and Fisher placed great emphasis on the need for sculpting the tooth and for selecting the color and position, to enhance the masculinity or femininity of the patient. They stressed the use of characterization to en-

hance age and gender." Enhancing age means to make someone appear more youthful; enhancing gender means to make a "rugged" masculine type appear more ruggedly masculine or a "delicate" feminine type appear more delicately feminine, for example.

Recent studies, however, do not support the belief that tooth shape and size have identifiable masculine or feminine characteristics." In a study of 300 diagnostic casts (equal numbers of male and female) judgments of gender were made by a layman, dental students, and dental faculty. The results showed an inverse relationship between correct judgment of the sex of the patient and the level of dental knowledge and experience of the judge." However, from an artistic perspective, the consummate delicacy of femininity and the ruggedness of masculinity remain as accepted guidelines reinforcing the dentogenic theory. The Swissedent Corporation still strongly adheres to incorporating personality, age, sex, and physiologic characteristics in the design of teeth (Fig. 25-1).

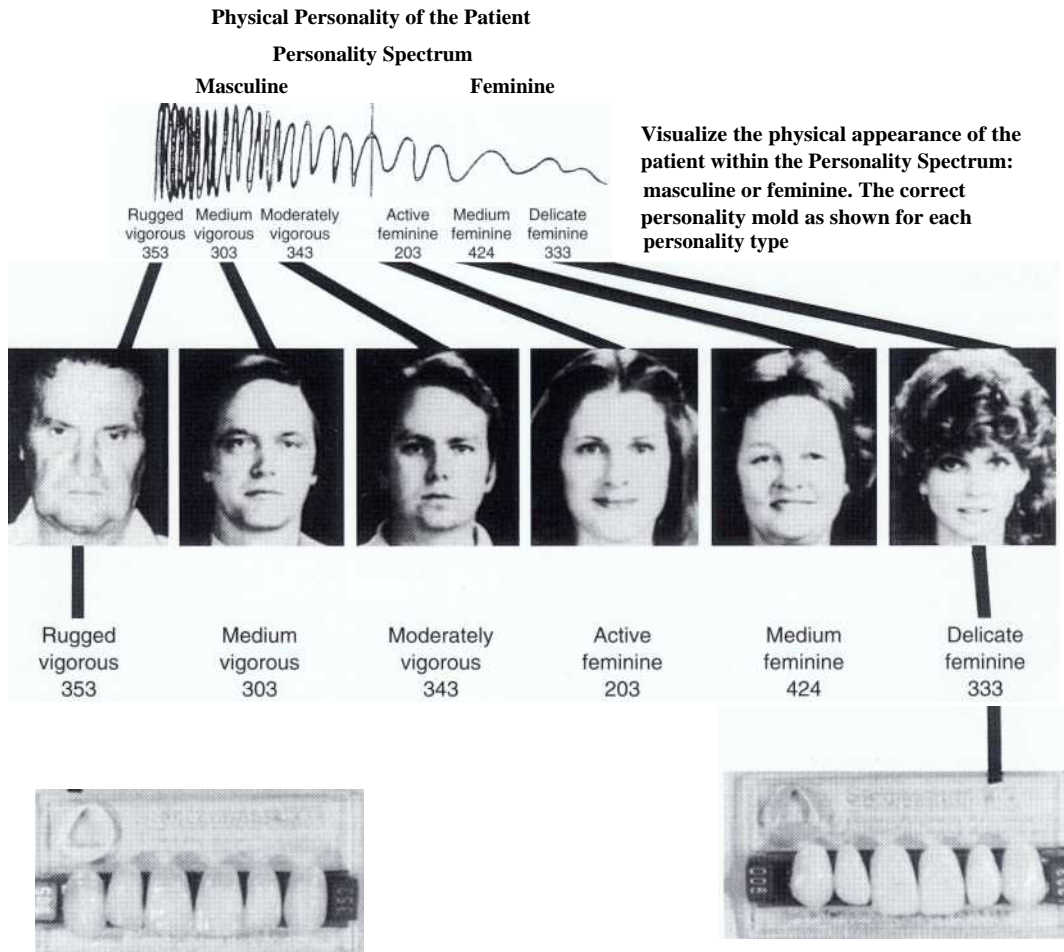


Fig. 25-1. Two of the sex and personality attributes (SPA) that influence, from an artistic perspective, the mold and shade selection of teeth. The two extremes are shown.



## THE CONCEPT OF SELF

### *Evolution of Self Theory*

Humankind has long sought to understand the causes of behavior and to create a sense of identity. The term *self-concept* has a twentieth-century origin. Most discussions of self before the twentieth century were embedded in philosophic and religious dogma.

A precursor to self theory goes back to antiquity. Synthesizing ideas from classical Greek medicine and astronomy, a theory of temperaments evolved that prevailed for many centuries. In essence, it stated that an individual's personality type was predetermined by physiology. In the mid 1800s the temperament theory of personality was still in vogue, although it had been modified somewhat. Three classifications of temperaments were believed to exist":

1. *Sanguine*. This type of personality radiated good humor and enthusiasm for life. It was believed to result from a predominance of blood over other body humors (fluids).
2. *Choleric*. This type of personality was irritable and found it difficult to establish a positive relationship. It was believed to result from a predominance of bile over other humors.
3. *Phlegmatic*. This type of personality was characterized by torpor and apathy. It was believed to result from a predominance of phlegma over other humors.

In the clinical situation it is common to find patients whose personalities fall into these categories. The sanguine personality is certainly easier to relate to; the other two may pose a challenge. The choleric type usually is harder to satisfy, and it may be difficult to obtain active involvement on the part of the phlegmatic type. The dentist must develop skill in recognizing personality types early in the data collection stage.

Near the turn of the century, William James postulated that the empiric self includes four components, which he classified in descending order of impact on self-esteem:

1. *Spiritual self*. By "spiritual," James meant thinking and feeling. This is the center around which all other aspects of the empiric self are clustered. He perceived it to be the source of interest, effort, attention, will, and choice. In other words, the spiritual self is a composite of intellectual, religious, and moral aspirations from which a sense of either moral superiority or inferiority or guilt could arise.
2. *Material self*. The material self refers to the clothing and material possessions that an individual views as an important part of himself. Many people define themselves by what they own rather than by what they do.
3. *Social self*. The social self refers to the various aspects of personality that are reflected in the individ-

Hats and groups to which one relates. These aspects are designed to serve social ends, such as gaining love and admiration or obtaining influence and power.

4. *Bodily self*. The bodily self was placed last in importance by James; others question this placement. This aspect refers to body image. Achieving an awareness of the self begins with experiencing one's body and feelings, often via the reactions of significant individuals. An individual who has a high degree of self-awareness is often perceived to be "more alive."

These four components interrelate in unique ways to constitute each person's view of his or her empiric self 15

The development of self theory was temporarily sidetracked by the ascendancy of behaviorism and its emphasis on the scientific method. During this period, psychology was directed to a rigorous study of only those aspects of **behavior that were observable** and measurable. However, around 1930 the focus shifted, and the importance of internal events was reintroduced into research and therapy. By the middle of the twentieth century the self concept was firmly established as an important construct in the study of human behavior.<sup>16-11</sup> Since then a massive amount of theorizing and experimenting has occurred in all components of self theory.

### *Self Theory: Relevant Constructs*

Self theory might be defined as that evolving constellation of self-referent constructs that are used to attain a more plausible and complete theoretical account of human conduct. Some of the relevant constructs or self theory are the following:

1. *Self-awareness*. Self-awareness has been defined as knowledge of one's own traits or qualities, insight into and understanding of one's own behavior and motives.
2. *Self-concept*. Many contemporary psychologists ascribe a key role to the self-concept as a factor in integrating personality, motivating behavior, and achieving mental health. Volumes have been written on this subject.<sup>9</sup> Essentially, self-concept is one's view of oneself, including feelings and perceptions about oneself.
3. *Self-image*. Self-image is the self that one thinks oneself to be. It is not a directly observed self-object but rather a complex concept of personality, character, status, body, and bodily appearance. It may differ greatly from objective fact.<sup>14</sup> A concept closely related to self-image is body image.
4. *Self-esteem or self-evaluation*. Self-evaluation is the process by which individuals examine their performance, capabilities, and attributes according to personal standards and values, which have been

internalized from society and significant others. These evaluations promote behavior consistent with self-knowledge. For example, an individual who firmly believes that he has unattractive or ugly teeth may develop speaking patterns or behavioral mannerisms that keep the teeth concealed. He may avoid pursuing certain vocations that, in his opinion, require a certain degree of attractiveness because of face-to-face contact with the public. The image a person has of himself may or may not coincide with reality. A person may be more or less attractive than conceptualized.

5. *Self-actualization.* The most recent development in self theory stresses the importance of a drive labeled "self-actualization." Abraham Maslow proposed that self-actualization results in a striving to develop one's capacities, understanding of self, and acceptance of self in accord with one's "inner nature."<sup>23,24</sup> Maslow looked to a more positive side of nature than many of his contemporaries. He believed that human nature was essentially good and, as personality unfolded through maturation, the creative powers manifested themselves ever more clearly. If people became neurotic or miserable, he felt that was caused by the environment. Humans became destructive or violent only when their inner nature was twisted or frustrated. Maslow assumed that basic needs, such as physiologic needs, safety, love, belonging, and esteem must be satisfied before self-actualization can be achieved (Fig. 25-2). Although it is well established that people who have not satisfied their basic physiologic needs are not likely to be interested in much else, the relative order of some

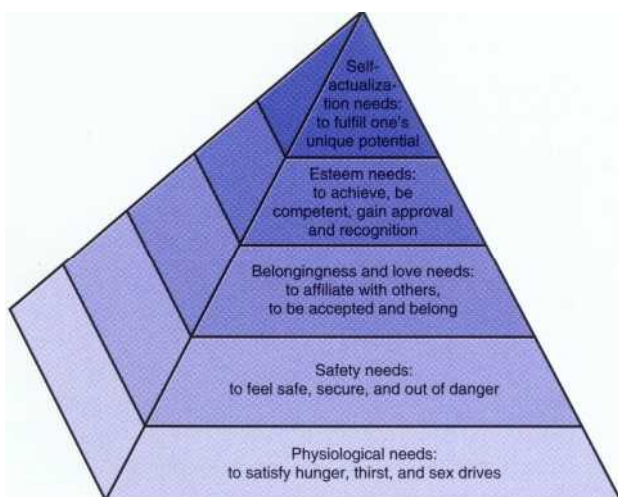


Fig. 25-2. Abraham Maslow's hierarchy of human needs. (Adapted from Rubin Z, McNeil EB: *Psychology of being human*, ed 4, New York, 1985, Harper & Row.)

of the other needs may vary from person to person. Also, several different needs may motivate behavior at any given time."

## PHYSICAL AND PHYSIOLOGIC INFLUENCES

### *Facial Appearance*

A study in 1921 highlighted the importance of facial appearance by proposing that the physical characteristics of individuals exert a profound influence over their associates.<sup>26</sup> However, researchers did not quickly adopt this concept. Some speculate that our society's emphasis upon egalitarianism may have contributed to this omission. In other words, the belief that a person's appearance ought not to make a difference in opportunities for development and success may have produced an "ostrich effect."<sup>27</sup>

It was not until the 1960s that studies of facial appearance began appearing in the literature. In the 1970s, research on the social psychology of facial appearance became more frequent. Although a vast number of studies have been reported, the quality of most of these studies is questionable.<sup>28</sup> However, a growing body of information is now accumulating on facial appearance. Facial attractiveness has an important impact upon an individual's life, a fact increasingly recognized by dentists and physicians.<sup>29</sup>

Few studies of facial appearance **have investigated in a scientific manner those dimensions of the face and teeth that are responsible** for a pleasant or an unpleasant face. In general, individuals in our society tend to reject the open bite facial types (either Class II or Class III) but more readily accept the deep bite facial type (Fig. 25-3)<sup>30,31</sup>

Regardless of the results of studies relating facial attractiveness to success in academics, careers, or interpersonal relationships, the personal testimonies of patients suggest that improved appearance is a goal worth pursuing, as the following case clearly demonstrates.

Mr. Z is a 49-year-old real estate agent. He originally presented with a dour, morose appearance and was somewhat argumentative. Over the years he had abraded his teeth through bruxism until they were no longer visible when he talked or smiled. Eating was no longer enjoyable because of the significant loss of vertical occluding dimension, which led to facial distortion when he chewed. He was embarrassed by his image. He hoped for a "quick fix" to his problem.

A transitional diagnostic acrylic splint was placed to determine his tolerance for a restored vertical occlusion. The attractive splint dramatically changed his appearance. Composite resin veneers further enhanced the esthetics (Figs. 25-4 to 25-6).

Over the next few weeks Mr. Z's personality gradually changed. He began to smile and appeared more relaxed. When questioned about this perceived change, he stated,

"You're absolutely right. You can't believe how good I feel inside. I want to smile at everybody. I can't pass a mirror without stopping to look at my new teeth. I can hardly wait to get my permanent restorations. Already I've started on a self-improvement program, losing a few pounds and toning up. Business has become a pleasure, and I feel more confident in social situations."

### The Mouth and Oral Cavity

The mouth has long played a prominent role in psychology theories (e.g., Freud incorporated the "oral" stage of development into psychoanalytic theory). Throughout life the mouth assumes a prominent role in our link with the outside world-nutritionally, sexually, and through verbal communication." When individuals first meet, the

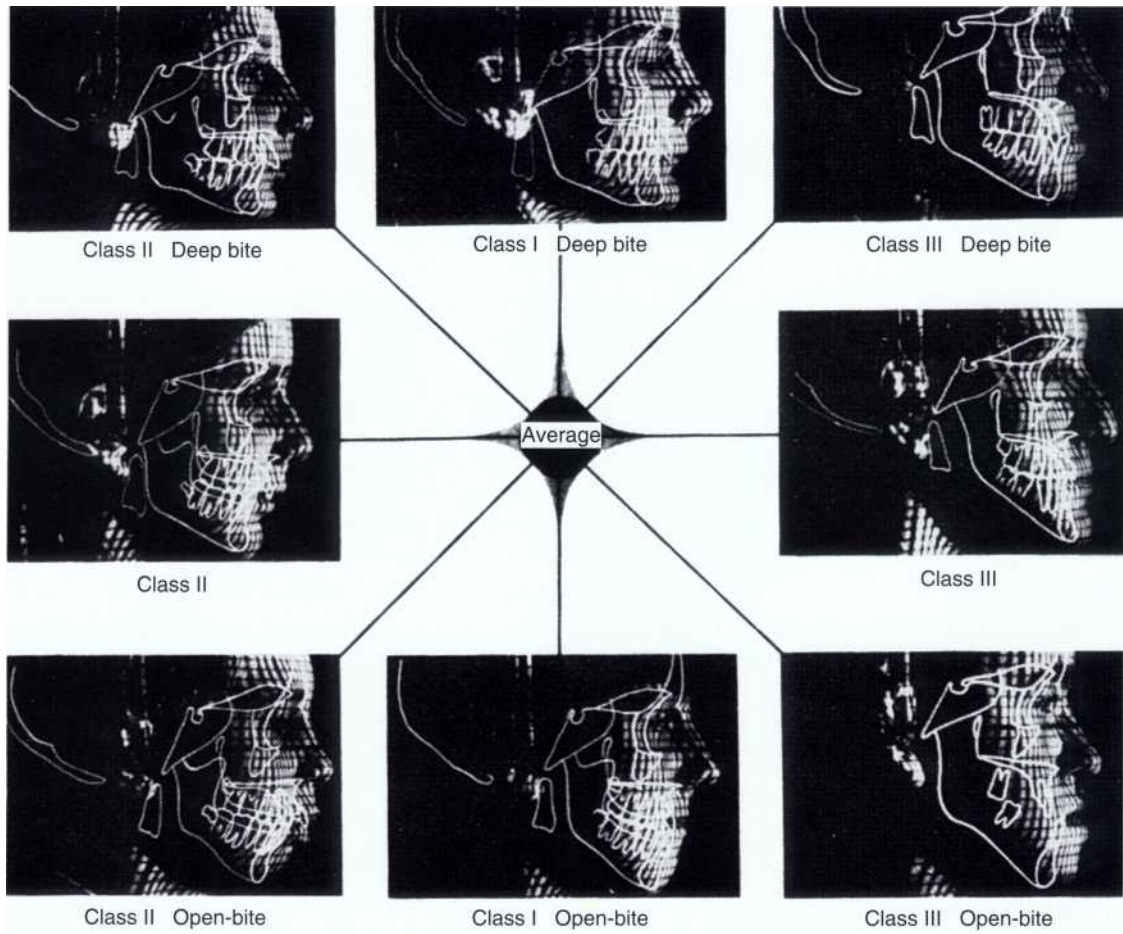


Fig. 25-3. Composite of four basic facial types and their combinations. (From Sassouni V. A classification of skeletal facial types, Am J Orthod 55:120, 1969.)

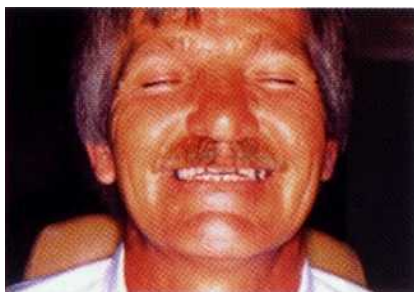
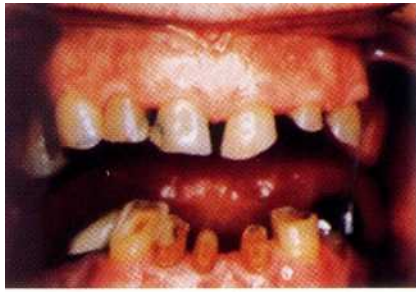
Fig. 25-4. Mr. Z before treatment.



Fig. 25-5. Mr. Z after restorations.



*Fig. 25-6. Pretreatment photograph that convinced a patient of the need for treatment.*

mouth is often the first body part noticed. Given the prominence of the mouth, it is surprising that more people do not show sufficient concern for the appearance of their teeth and mouth.

### Sex and Age

Many stereotypes regarding sex have changed over the years. Still, the sexes have major differences that must be considered in a dental practice. The dentist needs to be aware of how patients view their own sexuality and the degree to which they wish to emphasize their masculinity or femininity.

The dentist also must consider a person's age, both psychologic and chronologic. Through the use of veneers and bleaching, a more youthful appearance may be created. Although many people wish to appear more youthful, this is not universally true. As one woman so emphatically stated, "I am a little old lady and I want to look like one."

## PSYCHOLOGIC INFLUENCES

### Personality

An individual's personality is the result of many factors. The degree to which facial, and specifically oral, appearance contribute to personality is difficult to ascertain. We have referred to just a few of the many attempts to broadly classify personality. The individual dentist must choose an approach for determining personality. Because personality is the filter through which relationships take place, an accurate assessment of a patient's personality can be critical to the successful outcome of dental treatment.

### Measurement and Evaluation

A number of studies in the dental literature include personality variables in the assessment of patient satisfaction with their current dental condition," as well as with

treatments involving complete dentures," partial dentures,<sup>3s</sup> temporomandibular disorders and chronic pain,<sup>9</sup> orthognathic surgery,<sup>4°</sup> preprosthetic surgery,<sup>4'</sup> and orthodontics and prosthodontics.<sup>12</sup>

Many of these studies deal with captive audiences (e.g., veterans or patients at dental school clinics). Therefore the results are not extensively generalizable. Findings from one study sometimes conflicted with findings from another. No clear picture emerges. Very few studies have been done relating personality characteristics to esthetics, per se.

A variety of tools and techniques have been used to obtain information from patients. They include self-designed questionnaires, focused interviews, projective figure drawing, and standardized tests. Some specific tests that have been recommended include the Cattell 16 PF questionnaire (Form C)" and the Cornell Medical Index." Dentists considering using standardized psychologic tests should seek the assistance of a psychologist trained in measurement and evaluation.

A decision is needed regarding how psychologic information will be obtained and recorded.<sup>43</sup> Will it be an informal process based on an interview and observation of the patient, or will it be more formal? Will special forms be used to collect specific information? How will the forms be presented to patients in an effort to gain their cooperation? Who will interpret this information? How will this information be used?

### Motivations, Desires, and Expectations

A host of factors may bring patients to a dental office initially, as well as cause them to return. Motivations may include the following:

1. The desire to be better able to eat and enjoy food
2. The desire to improve speech patterns
3. The fear of losing teeth through decay or fracture
4. The desire to be free of pain and discomfort
5. The desire to have fresh breath
6. The desire to enhance appearance or self-image to compete more effectively for attention or advancement

Not all patients are motivated by self-actualization; however, some may be moved in that direction.

In some instances the patients' expectations are unachievable. Patients may have personality problems or interpersonal problems that they believe will be corrected or improved by the desired dental treatment. The dentist must be on guard for this problem and avoid getting into an unresolvable situation. The dentist should not promise more than can be delivered. The dentist should be sensitive to cues that the patients or those accompanying the patients reveal during the initial examination and interview process. The quintessential question that the practitioner must seek to answer is, What motivated these pa-

tients to seek dental treatment? If the patients are concerned primarily about appearance, what is the underlying motivation? If a particular problem has existed for a long time, what change in their lives caused them to seek help now?

The patients' motivations or concerns form a starting point for developing a proper treatment plan. When patients realize that the dentist is truly listening to their concerns, they will be more likely to also consider the dentist's limitations. For example, if the patient's primary concern is the ability to eat, the most appropriate treatment—to improve mastication—should be addressed first. To achieve that objective, a complete or partial denture may be required. Once that need is addressed, improved esthetics will be incorporated later in connection with the design.

Determining motivation, coupled with a fairly accurate personality assessment, is crucial to successful treatment planning and ultimately to patient satisfaction with the treatment.

**CLINICAL TIP.** Often it is input from sensitive staff members that provides insight into the patient's needs and desires. Patients often perceive the dentist as an authority figure and have difficulty expressing themselves to someone in that role.

Basic information should be obtained from the patient upon entry into the office. This usually is obtained by means of a form. Auxiliary personnel set the tone in the manner in which they request this information from the patient. Much can be learned from observations of how the person studies the form, from unanswered questions, and from conversations with significant others while filling out the form. Seeking clarification or using information from this form to initiate conversation may elicit valuable information that can illuminate the patient's personality and motivations. This can also help to determine whether the patient is able to articulate expectations in a clear manner.

## Developing a Trusting Relationship

**CLINICAL TIP.** Make a judgment regarding whether the patient can form a trusting relationship. When an individual is suspicious of every suggestion and asks an inordinate number of questions, it may indicate an inability to form a positive relationship.

At times, patients find it difficult to reveal all the relevant aspects of their lives. The dentist may need to gain patients' trust to enable them to open up and be forthright and honest. Roger's client-centered therapy" provides three qualities that help to engender trust<sup>44</sup>:

1. Accurate empathy involves the dentist's sensitivity to patients' feelings and an ability to communicate this awareness and acceptance of patients as unique individuals.
2. Nonpossessive warmth refers to the dentist's non-judgmental acceptance of the patient regardless of behavior. Patients should not be criticized for allowing their oral health to deteriorate.
3. Genuineness implies an openness and spontaneity on the part of the dentist.

## Decision-Making Ability

Efforts should be made very early to engage patients in decision making. To the extent possible, patients should be active participants in their treatment.

**CLINICAL TIP.** When the patient cannot make decisions, it is important to identify a "significant other" in the patient's life and include that person in the process.

## Cooperation and Follow-Through

Optimal oral health and a beautiful smile require cooperation from the patient, as well as persistence in maintenance activities. Some people are "starters" but not "finishers." Before initiating treatment, the dentist must adequately inform the patient of the need for follow-up care. Some reconstruction patients, for example, fail to accept responsibility for maintenance and end up losing all benefit of their extensive treatment.

## Abnormalities and Problem Patients

Occasionally, "troubled" or "difficult" patients with irrational perceptions of self seek treatment or esthetic alterations that are unrealistic. They may be narcissistic, depressed, paranoid, or have labile or hysterical personalities. Often these individuals are skillful at masking their condition, especially during the interview process.

Only by careful listening over a period of time can the patients' problems be identified. Patients may have unrealistic expectations or may be unable to internalize information provided by the dentist. These patients may be obsessed with perceived or minor flaws or may be unable to develop a trusting relationship.

Once a relationship has been established between a patient and a dentist, termination of that relationship must be handled very carefully to avoid a possible charge of abandonment (see Chapter 27). Treatment undertaken must be completed at least to the point where the patient is not left in a precarious position. Before terminating a relationship, the dentist must make every effort to correct the problem, improve communication, and gain cooperation. These efforts may not be successful.

If the patient's psychologic problems are severe, the dentist may determine that professional help is needed. Psychologic therapy does not fall within a dentist's scope of practice without training and certification in this field. However, the dentist must appreciate the delicate nature of making a referral to a mental health professional; the referral should be made with care, empathy, and tact.

Not all problems can be anticipated and prevented. The dentist must think about the type of problems faced in an esthetic dental practice and consider an approach to dealing with these problems. It is logical to believe that the following problems are likely to occur:

1. The patient has an unrealistic esthetic expectation that cannot be satisfied.
2. The patient expects that an esthetic improvement will remove or correct deep-seated psychologic problems.
3. The patient is not satisfied with results that are technically and esthetically correct—in other words, the "it's not me" phenomenon.
4. The patient is satisfied with the results, but family and friends are not.
5. The patient does not wish to have esthetics enhanced, and the dentist does.

In dealing with these problems the dentist must be explicit in what the proposed treatment can and cannot do. Active involvement of patients and family members in the treatment phase increases the chance of acceptance (e.g., have them select shades and shapes of teeth). Multiple joint esthetic evaluations may be required. The dentist and the patient may not agree on what is perceived as esthetically appropriate.

**CLINICAL TIP.** As long as no physiologic or ethical principles are violated, permit the patient to make the final esthetic determination.

Patients' views of their esthetic appearance are paramount, since dentists may be unaware of the extent to which patients have psychologically compensated for their esthetic shortcomings.

## CULTURAL INFLUENCES

Anthropologists have shown us that standards of beauty vary widely not only from society to society but also locally. Even in societies where it is fashionable to go naked, the face is extremely important. Malinowski has pointed out that the naked Trobriand Islanders of the Western Pacific devoted tremendous energy to the decoration and elaboration of the face."

The desire to alter the face is universal. In many primitive societies painful elaborations were undertaken

not only in pursuit of beauty but also for ritual significance. In Australia and New Guinea the native peoples celebrated the achievement of adulthood and maturity by having their two maxillary anterior teeth removed. This custom also prevailed in South Africa, where adults who still had all their teeth were considered ugly. In Borneo, teeth were blackened and holes were drilled through the labial surfaces of the six maxillary anterior teeth. Plugs of brass with outer ends shaped like stars were inserted. In the East Indies the mesial, distal, and incisal aspects of the teeth were filed off and shaped into points as part of the ceremony of marriage, puberty, or mourning. This custom prevails today among the pygmies of central Africa, specifically the Efe group.<sup>45</sup>

Within the United States today, many cultures exist. The practicing dentist should become aware of the various cultural groups represented in the patient population. In each community, certain ethnic groups have developed traditions of eating and self-care that have implications for dentistry. The dentist can become aware of these groups by subscribing to a local newspaper, becoming involved in community affairs, such as health fairs, and communicating with other health professionals who may be a part of the ethnic groups. It may be necessary to use or develop teaching materials geared specifically toward the customs and traditions of these groups.

## *Mores and Values*

Our mores and values have changed a great deal from those in vogue when the country was founded. At that point in history, plainness and austerity were the norm. Individuals who stressed beauty often were ostracized.

Gradually, our society has broadly accepted the idea that health and beauty occur simultaneously. Religious and psychologic barriers have been lowered. The "natural look" is popular. Styles have been modified to expose more of the body. Feeling good about oneself now is acceptable behavior. In fact, the pendulum has almost swung too far in the opposite direction. People who pay little attention to their personal appearance often instill confusion in others.

## SOCIOLOGIC INFLUENCES

A number of sociologic trends in our society are believed to contribute to the ability and willingness of individuals to seek out esthetic dentistry.

### *Affluence*

An increasing number of individuals are obtaining more discretionary income. Available funds, coupled with the newer emphasis on self-actualization and the freedom to

spend money on self, has led to an increase in the demand for self-improvement, including esthetic dentistry.

**CLINICAL TIP.** The patient's socioeconomic status can be misleading. Some patients who appear to be able to afford treatment may not value oral health or appearance enough to incur the expense. Other patients with limited resources are able to rearrange their priorities and mobilize resources. Therefore do not initially consider the patient's socioeconomic status, but rather present the ideal treatment as well as acceptable alternatives.

### Emphasis on Health, Wellness, and Fitness

After decades, and perhaps even centuries, of basing health care on a sickness model, the changes in recent years have been dramatic. Escalating health care costs, coupled with a national effort to curtail these increasing costs, have resulted in more emphasis on the prevention of illness, physical fitness, and health maintenance.

The dental profession has been at the forefront of this wellness movement. In the 1960s scientific evidence supported the efficacy of fluoridation. Dental disease was perceived to be preventable. Dentists were asked to change their clinical perspective from disease orientation to health orientation, and many did. As newer concepts have been accepted, chair time has been used increasingly for maintenance of health and esthetic dentistry.

### Media Influence

Possibly the greatest single factor responsible for increased esthetic awareness among the public is the media. Television, radio, and magazine reports and advertisements daily bombard our society with news of the newest advances in bleaching, bonding, veneering, crowns, implants, orthodontic therapy, and surgery.<sup>46</sup>

### Changed Attitudes Toward Medical and Dental Treatment

No longer willing to allow the physician or dentist to solely determine their needs and how to address those needs, many patients expect to be active participants in the analysis and planning phases of their care. They want to know what options are available and the pros and cons of each option.

Attitudes toward the cost of treatment are also slowly changing. Just as the expense of a college education is considered an investment, so is esthetic dentistry viewed as an investment by some individuals who are convinced that their success in life depends on appearance. Quality of life is becoming a value for the elderly.<sup>47</sup>

## CLINICAL PRACTICE

### Interaction Between Dentist and Patient

To some extent, psychologic bonding occurs **between the patient and the dentist**. Early in **the relationship it is** important to determine that a positive relationship can exist. The personalities of the patient and dentist must be compatible. The patient must have confidence in the dentist and believe that the dentist not only understands what the patient desires or needs but also has the creativity, knowledge, skill, and state-of-the-art equipment and materials to meet these needs. One dentist who had gone to great pains to design a modern office where all extraneous items were kept out of sight was surprised to learn that a patient believed he was not fully equipped. She was accustomed to traditional offices, in which the counters were filled with instruments and materials.

Following the diagnostic workup, the clinical information is integrated with the psychologic and sociologic information relevant to the patient. A detailed, written treatment plan is formulated. The plan sets forth the optimum treatment, as well as possible acceptable options. In other words, usually more than one way exists to achieve the treatment objectives. Choices must be made. Economics, as well as personality factors, influence which specific plan is selected.

**CLINICAL TIP.** Carefully structure the presentation of treatment options. If possible, schedule it at the close of the day when time is available for discussing and exploring alternatives. By learning specific treatment options along with the rationale for each, patients are able to recognize their active role in the treatment planning process.

The dentist should be prepared for some negative reactions to the comprehensive treatment plan. In **some instances the plan** can be overwhelming and even devastating. Patients who have ignored their oral health for years often have such great needs that they may say, "Why don't you just pull out all my teeth and give me some dentures?" They see that as the solution to their problem, not realizing that they are opening the door to a host of other problems. The dentist must be frank with the patient, explaining the many problems that they could face with dentures (e.g., problems with stability, pressure, potential inability to eat certain foods, and the need for relines). In addition, the dentist must point out the ethical and legal problem related to the extraction of teeth with adequate root structure.

Other patients may be more philosophic. They may say, "Well, this didn't happen overnight. **Let's get on with the treatment.**" **Sometimes their treatment can be** extended over time.

Still others may not wish to be too involved. They may claim to be "confused" by the various options. They

say, "Just tell me what I need to have done." In this decision-making role, the dentist must be guided by conscience and the Golden Rule, considering the options and arriving at the most permanent, most physiologic, and most esthetic treatment to address the need. The rationale should be explained to the patient and recorded in the chart. This approach assumes that the dentist is knowledgeable of state-of-the-art dentistry. (See the Clinical Tip in the section on decision-making ability in this chapter.)

A.G. Cheney suggests that the dentist avoid standardized treatment plans. To obtain greater patient acceptance, he believes that each treatment plan should be customized, based on an assessment of the patient's personality, needs, wants, and desires.<sup>48</sup> He utilizes the psychologic construct known as locus of control to help determine the individualized treatment plan for a given patient.

To the degree possible, the patient's needs, wants, and desires are incorporated into the treatment plan; however, both dental and physiologic limitations may prevent the dentist from fulfilling the patient's esthetic demands. For example, a patient may have a diastema that he wants closed. Treatment options include orthodontic treatment, crowns, composite resin restorations, or porcelain veneers. The treatment of choice is orthodontic treatment. The patient does not want this treatment, yet he insists that he does not want the anterior teeth to be larger than they are now. The dentist is faced with a dilemma. A provisional restoration could be placed to allow the patient to see whether he could accept it. Once the treatment plan has been agreed upon, the treatment phase should proceed as expeditiously as possible to reinforce the patient's motivation and to achieve the desired results. On the other hand, the patient's efforts to expedite the treatment should be resisted if this will compromise the desired results. This can be accomplished by explaining to the patient the specific steps required to achieve a plan of treatment (e.g., if a transitional removable partial denture is indicated, immediately placing a cast removable partial denture can result in poor function and esthetics).

**CLINICAL TIP.** Avoid shortcuts that will adversely affect quality, in spite of outside pressures.

### *Interaction Between the Dentist and Dental Laboratory Technician*

The relationship between the dentist and the technician is crucial to success. In addition to the knowledge and skill that each possesses, psychologic factors enter this relationship. Mutual respect for each other as individuals should exist, as well as a clear understanding of the role

that each plays in patient treatment. Dentists must seek out a technician with whom they can communicate, must set the tone for collaboration, and must provide for a two-way evaluation process that fosters progressive excellence. Both oral and written lines of communication must be kept open. Work authorization forms may need to be redesigned.

**CLINICAL TIP.** Whenever possible, visit the laboratory. It is helpful to know the laboratory personnel and be personally reassured of the quality of their work.

When the dentist and the technician collaborate on a difficult case and the results are pleasing, each gains satisfaction and the relationship is strengthened. Any gestures of staff appreciation should include the technicians, even if they are not on the premises of the dental practice.

Photographs give visual feedback to the technician, especially "before" and "after" views. They show color and texture dimensions that cannot be seen on the stone casts alone.

**CLINICAL TIP.** Send the technician photographs of completed cases. This type of evaluation serves as a motivator and may enhance the status of the technician in the eyes of co-workers.

Certain personality characteristics are needed for esthetic dentistry practice. The success of esthetic dentistry depends upon discipline and consistent adherence to procedures. Many newer esthetic materials are very technique sensitive.

## PRACTICE MANAGEMENT

The entire dental practice should take into consideration psychologic and sociologic principles. It should function as a well-integrated system.

### *Physical Environment*

An esthetic dental practice should operate in an attractive, neat, clean environment. The patient should be surrounded by pleasing colors and textures that complement each other and suggest that the treatment provided in this setting will be competent and esthetic. Colors, however, should be carefully selected and placed so that they do not interfere with tooth shade selection (muted colors are most desirable). Employing an interior decorator may be a worthwhile investment in creating the proper physical environment. If background music is played, it should be carefully selected to help create the mood for the office. Odors should be carefully monitored and controlled.



Care should be given to the selection and arrangement of furniture. Adequate space should be available in the reception area to provide a display area for teaching materials that highlight the esthetic nature of the practice (e.g., photographs, videotapes).

### Psychologic Environment

A greater use of technology in the practice mandates a greater need for the human touch. A sincere caring and concern should emanate from each member of the office staff toward the patient. Patients should be made to feel important. They should be treated with dignity and respect. Staff members should radiate concern for their comfort, privacy, and time. This is manifested in how patients are addressed, where conversations take place, and how the scheduling process is managed.

Scheduling appointments presupposes that the proper amount of time is budgeted and that necessary laboratory work has been completed. The patient should know what to expect and approximately how long it will take. Verifying appointments in advance and alerting patients to possible delays reinforce the value of the time that has been set aside specifically for them. Coordinating treatment between various specialties is another way to reduce stress for the patient and to ensure a more successful outcome.

### Personnel as an Extension of the Dentist

Although members of the dentist's staff have unique characteristics, a conscious effort should be made to select individuals who complement the dentist's practice philosophy. Just as the physical environment of the office is important, so is the appearance of each member of the team. Attention to small details such as hair, nails, uniforms, shoes, weight, and smoking will reap rewards. Above all, the staff members should have good oral health. Educating by example yields rewarding results.

Careful planning should go into patient communication. The burden of education must not rest entirely upon the dentist but rather should be shared, when appropriate, with other members of the team. Resources to facilitate understanding must be carefully selected. For example, a variety of teaching materials, ranging from three-dimensional models to photographic displays to brochures, booklets, and videotapes should be available. Informed consent implies patient understanding.

Critical points for communication are at consultation, diagnostic workup, presentation of the treatment plan, and initiation of treatment. Although technical terminology may be used, it should be translated into the layperson's language.

### Communication

Specific terms, such as "white teeth," may need to be clarified before the implementation of treatment. If the dentist has a bias against restorations that lie outside the parameters of the natural color of teeth, this must be made clear. A significant difference may exist between a patient's expectations and the dentist's philosophy or attitude. This point was illustrated when a dentist interacted with a patient who desired "white teeth." The patient was not swayed when the dentist explained that the shade the patient wanted was not natural. She replied, "I bleach my hair blond, put rouge on my cheeks, and mascara on my eyelids; I paint my lips red. These are not natural. So give me white teeth!"<sup>49</sup>

If the request or desire of the patient does not conflict with ethical codes and does not cause physiologic harm to the oral environment, then the dentist has freedom to cooperate. (See also the section on abnormalities and patient problems in this chapter.)

**CLINICAL TIP.** Upon initiation of treatment, verify with the patient the treatment plan. Clarify any misconceptions that have arisen between the time of the treatment conference and initiation of treatment.

Styles of communication vary widely. Some people communicate directly and honestly; others play games with their communication.<sup>50,51</sup> They may or may not be aware of this game playing. An understanding of transactional analysis therapy may facilitate true communication. This is not to say that the dentist should be a therapist, however. The objective is to get the patient to communicate as an adult and for the dentist not to be trapped into a "child" or "parent" communication style, but rather to also be able to communicate as an adult.

### Financial Considerations

Clinical treatment should be separated from the business aspects of the practice. In other health-related disciplines, treatment is not determined by the patient's ability to pay. Avoiding a discussion of fees at the time of treatment planning allows for a more objective discussion of options. Other than helping to decide the fee structure, the dentist should avoid getting involved in this aspect of the practice. This is not to say that the patient's decision will not be largely influenced by cost. However, cost may not be the most crucial consideration. Patients may be willing to invest more time and money than dentists have previously assumed. (See the section on affluence in this chapter.)

The team member responsible for the financial dealings must be psychologically strong and able to help the patient to view esthetic dentistry as an investment. Money

and time will be expended upon self-improvement, which has potential payoff in meeting some of the patient's goals and dreams, for example, to help get an advancement or better sell a proposal and win a contract. To accomplish this, the business manager must be aware of the patient's personality and socioeconomic status and relate to each patient in a manner consistent with the philosophy of the practice 52

### *Photography and Computer Technology*

Some patients who have become complacent about their deteriorating oral health are shocked when they see a photograph.<sup>53-55</sup> (See Chapter 14.) For example, Mrs. X exclaimed, "Is that me?" when she saw a picture (see Fig. 25-6) of her mouth; this helped to motivate her to pursue treatment. A fairly recent breakthrough in dental photography is the color video intraoral camera, which has the capacity to store images as well as to alter them to present different treatment options.<sup>55</sup> (See Chapter 24.)

### *Ethics, Quality Assurance, and Risk Management*

Clinical dental ethics focuses on decisions, both the decision-making process and the outcome, as they are reached in everyday practice. " Dentists are legally and morally obligated to the following:

1. Benefit the patient's health
2. Do no harm to the patient
3. Help the patient weigh the risks or harms of treatment against the anticipated result

Responsible treatment decisions must weigh the costs of the care against the anticipated benefits.

Although it is important to discern what a patient desires as a treatment outcome, desires may not always be consistent with treatment goals. For example, a patient may desire esthetic restorative dentistry for the maxillary anterior teeth without replacing mandibular posterior teeth. To provide the desired treatment would be unethical because it is doomed to failure. Continuous occlusal trauma of the mandibular anterior teeth will result. When a patient's cosmetic preferences compromise professional standards, the dentist faces a moral dilemma. Even if the patient is willing to take calculated risks, inappropriate treatment should not be undertaken. The dentist is not **legally** protected from charges of inappropriate treatment, even when the patient signs a release. (See Chapter 27.)

## CONCLUSION

The patient and the dentist each bring to the relationship unique personalities, values, expectations, and motiva-

tions, which have been shaped by their respective backgrounds. Dentists have the educational responsibility to learn about psychological and sociologic concepts and to incorporate them into their practice. If they assume this responsibility, the practice will be enriched.

Quality esthetic dentistry rendered to appreciative patients has lasting psychologic rewards for all involved.

The authors wish to recognize the editorial assistance of Marc B. Appelbaum, Morristown, NJ.

## REFERENCES

1. Abbott FB: Psychological assessment of the prosthodontic patient before treatment, *Dent Clin North Am* 28:361 1984.
2. Murrell GA: Esthetics and the edentulous patient, *J Am Dent Assoc* (special issue) No. 58E, 1987.
3. White JW: Aesthetic dentistry, *Dent Cosmos* 14:144, 1872.
4. White JW: Temperment in relation to teeth, *Dent Cosmos* 22:113, 1884.
5. Williams JL: A new classification of tooth forms with special reference to a new system of artificial teeth, *Dent Cosmos* 56:627, 1914.
6. Clapp GW: How the science of tooth form selection was made easy, *J Prosthet Dent* 5:596, 1955.
7. House MM: Full denture techniques. Notes of study Club No. 1. Unpublished notes on course given by MM House, 1937.
8. Brown F: Doctoral dissertation, Washington, DC, 1975, Howard University.
9. House MM, Loop FL: Form and color harmony in the dental art, Whittier, Calif, 1939, Monograph.
10. Frush JP, Fisher RD: Introduction to dentogenic restorations, *J Prosthet Dent* 5:586, 1955.
11. Frush JP, Fisher RD: How dentogenic. interprets the personality factor, *J Prosthet Dent* 6:441, 1956.
12. Frush JP, Fisher RD: How dentogenic restorations interpret the sex factor, *J Prosthet Dent* 6:160, 1956.
13. Abbott FB: Unpublished study, Philadelphia, 1986, Temple University.
14. English HB, English AC: A *comprehensive* dictionary of psychological and psychoanalytical terms, New York, 1958, David McKay Company.
15. James W: Principles of psychology, New York, 1890, Holt.
16. Lewin K: *Field* theory in social sciences, New York, 1951, Harper & Row.
17. Combs A, Snygg D: *Individual behavior: a perceptual approach*, New York, 1959, Harper & Row.
18. Rogers CR: *Client centered therapy*, Boston, 1951, Houghton Mifflin.
19. Bums RB: *The self concept: theory, measurement, development and behavior*, New York, 1979, Longman.

20. Fitts W et al: *The self concept and self actualization: studies on the self concept and rehabilitation*, Nashville, 1971, Dade Wallace Center.
21. Wegner D, Vallacher RR: *The self in social psychology*, New York, 1980, Oxford University Press.
22. Wylie R: *The self concept: a critical survey of pertinent research literature*, Lincoln, Nebr, 1961, University of Nebraska Press.
23. Maslow AH: *Motivation and personality*, New York, 1954, Harper & Row.
24. Maslow AH: *Toward a psychology of being*, Princeton, 1968, Van Nostrand.
25. Rubin Z, McNeil EB: *Psychology: being human*, ed 4, New York, 1985, Harper & Row.
26. Perrin F: Physical attractiveness and repulsiveness, *J Exp Psychol* 4:203, 1921.
27. Hatfield E, Sprecher S: *Mirror, mirror ... the importance of looks in everyday life*, Albany, NY, 1986, State University of New York Press.
28. Bull R, Rumsey N: *The social psychology of facial appearance*, New York, 1988, Springer Verlag.
29. Bersheid E, Gangestad S: The social psychological implications of facial physical attractiveness, *Clin Plast Surg* 9:289, 1982.
30. Sassouni V: A classification of skeletal facial types, *Am J Orthodont* 55:109, 1969.
31. Sassouni V, Sotereanos GC: *Diagnosis and treatment of dento-facial abnormalities*, Springfield, Ill, 1974, Charles C Thomas Publishers.
32. Ruel-Kellermann M: What are the psychosocial factors involved in motivating individuals to retain their teeth? *Int Dent J* 34:105, 1984.
33. Liggett J: *The human face*, New York, 1974, Stein & Day Publishing.
34. Bolender CL, Swoope CC, Smith DE: The Cornell Medical Index as a prognostic aid for complete denture patients, *J Prosthet Dent* 22:20, 1969.
35. Reeve P, Watson CJ, Stafford FD: The role of personality in the management of complete denture patients, *Br Dent J* 156:356, 1984.
36. Smith M: Measurement of personality traits and their relation to patient satisfaction with complete dentures, *J Prosthet Dent* 35:492, 1976.
37. Silverman S, Silverman SI, Silverman B, Garfinkel L: Self-image and its relation to denture acceptance, *J Prosthet Dent* 35:131, 1976.
38. Watson CL et al: The role of personality in the management of partial dentures, *J Oral Rehabil* 13:83, 1986.
39. Oakley ME et al: Dentists' ability to detect psychological problems in patients with temporomandibular disorders and chronic pain, *J Am Dent Assoc* 118:727, 1989.
40. Kiyak HA et al: Predicting psychologic response to orthognathic surgery, *J Oral Maxillofac Surg* 40:150, 1982.
41. Reeve P, Stafford GD, Hopkins R: The use of Carrell's personality profile in patients who have had preprosthetic surgery, *J Dent* 10:121, 1982.
42. Albino JE, Tedesco LA, Conny DJ: Patient perceptions of dental-facial esthetics: shared concerns in orthodontics and prosthodontics, *J Prosthet Dent* 52:9, 1984.
43. Warman E: Psychological aspects of the patient's history, *N Y J Dent* 46:52, 1976.
44. Mittelman JS: Getting through to your patients: psychological motivation, *Dent Clin North Am* 32:29, 1988.
45. Bailey RC: The Efe: archers of the rain forest, *National Geographic* 176:683, 1989.
46. Sheets CG: Modern dentistry and the esthetically aware patient, *J Am Dent Assoc (special issue)* 103-E, 1987.
47. Giddon DB: Psychologic aspects of prosthodontic treatment for geriatric patients, *J Prosthet Dent* 43:374, 1980.
48. Cheney HG: Effect of patient behavior and personality on treatment planning, *Dent Clin North Am* 21:531, 1977.
49. Ibsen R: *Advances in conservative porcelain bonded restorations*, Washington, DC, Cerinate Laboratories seminar, September 21, 1989.
50. Berne W. *Games people play*, New York, 1964, Grove Press.
51. Kotwal KR: Beyond classification of behavior types, *J Prosthet Dent* 52:874, 1984.
52. Goldstein RE: Survey of patient attitudes toward current esthetic procedures, *J Prosthet Dent* 52:775, 1984.
53. King M: Photos reinforce change in smile, *Dentist* 67:27, 1989.
54. Leinfelder KF, Isenberg BP, Essig ME: A new method for generating ceramic restorations: a CAD-CAM system, *J Am Dent Assoc* 118:703, 1989.
55. McCane D, Fisch S: Dental technology: knocking at high tech's door, *J Am Dent Assoc* 118:285, 1989.
56. Nash DA: Professional ethics and esthetic dentistry, *J Am Dent Assoc* 117:7E, 1988.
57. Siegler M, Bresnahan JF, Schiedermayer DL, Roberson P: Exploring the future of clinical dental ethics: a summary of the Odontographic Society of Chicago Centennial Symposium, *J Am Coll Dent* 56:13, 1989.
58. Simpson R, Hall D, Crabb L: Decision-making in dental practice, *J Am Coll Dent* 48:238, 1981.



# ESTHETICS AND DENTAL MARKETING

Phillip Bonner

**T**HE CONCEPT OF MARKETING elicits a variety of responses from dental professionals ranging from total opposition to enthusiastic acceptance and use of marketing techniques within the dental practice setting. All acknowledge, however, that the recent emphasis on marketing results from such factors as an increase in dental staffing, changing disease patterns, cost containment policies by business and government, and the rise of consumerism. These powerful factors, although sometimes cyclic in nature, will continue to affect the profession for some time. As a result, competition among dentists for patients, or for the discretionary income of consumers, has reached historically high levels. In a free market society, marketing is a logical by-product of increasing competition.

## HISTORY

Before 1977, when the U.S. Supreme Court ruling in *Bates v. State Bar of Arizona*<sup>1</sup> legalized advertising by attorneys, professional marketing essentially was limited to word-of-mouth patient referrals and fundamental in-office patient relations techniques. Active marketing by dentists was discouraged by organized dentistry, both nationally and at the local level. Soon after the Supreme Court ruling, however, dentistry and other health professions were required by law to allow advertising. The Federal Trade Commission (FTC) applied pressure to state dental boards and other dental organizations to change professional ethics standards and other rules that restricted or prohibited advertising. The FTC's position was that advertising

that was not false or misleading would stimulate competition and lower the cost of dental care for consumers. This ushered in a controversial era of conflict between dental professionals and organizations that felt that advertising was unprofessional and those in dentistry and government that felt that it was beneficial and acceptable.

Today, the furor over advertising in particular and marketing in general has abated, although strong differences of opinion remain. The marketing of dental services has become an accepted and integral part of the practice of dentistry for thousands of dentists. With the rapid advances in dental materials and techniques, particularly in the area of cosmetic dentistry, the role of marketing is likely to expand.

## WHAT IS MARKETING?

Marketing encompasses a variety of disciplines and techniques that are intended to motivate a targeted individual or group to take an action that is desired by the marketer. This action may be to purchase a product or service, to attend a specific event, to vote for a particular candidate, or to visit a dental office.

The two major disciplines within marketing are advertising and public relations. Advertising involves a marketing message that is made possible by direct payment from the advertiser to the specific advertising medium. Examples of advertising media are television, radio, magazines, and newspapers.

Advertising encompasses a variety of forms. Direct mail involves designing a marketing message that is



delivered to targeted recipients via the U.S. Postal Service or other delivery service. Another form of advertising, specialty advertising, involves the distribution of various specialty items, such as pens or calendars, with a marketing message imprinted on them.

Public relations involves the dissemination of information through a variety of channels without payment for the media space. For example, a dentist-marketer may write an article on some aspect of cosmetic dentistry that, because of its informational value, is published in a magazine. Although the article may contain information that is beneficial to the dentist's practice, the educational value of that information is sufficient to result in publication without payment for advertising space. As with advertising, there are many public relations techniques, including a variety of patient relations activities in the dental office. For the purposes of this chapter, the basic difference between the two disciplines is that direct payment for media space is required for advertising messages but not for public relations messages.

The 1977 Supreme Court decision focused on only one marketing technique—advertising. As a result of the controversy generated by this decision, many dentists equate marketing with advertising. However, there are many marketing methods in addition to advertising that can be used to reach a specific audience. Of particular relevance to dentists are two basic marketing approaches: external marketing and internal marketing. An understanding of these two approaches will aid in designing a marketing program that is in harmony with the individual dentist's philosophy.

### EXTERNAL AND INTERNAL MARKETING

Two basic goals of dental marketing are to attract new patients to the practice and to keep existing patients active within the practice. Marketing techniques designed to attract new patients to the practice can be categorized as external techniques; those designed to keep existing patients active and to motivate them to refer others to the practice are internal techniques.

#### *External Marketing*

External marketing techniques encompass any marketing activities designed to attract consumers into the dental office so that they can become active patients. A few examples of external marketing techniques that dentists can use are:

- Advertising (e.g., magazines, newspapers, radio, television, Yellow Pages, and direct mail)
- Community programs (e.g., health fairs and lectures to schools and civic groups)
- Dental article writing for newspapers or magazines

Communication with referral sources (e.g., health professionals, cosmetologists, and realtors)

#### *Internal Marketing*

Internal marketing techniques encompass any marketing or communication activities that take place within the practice setting or that are directed at active or inactive patients with the objective of retaining these patients in the practice and stimulating referrals. A few examples of internal marketing techniques that dentists can use are:

- Case presentations
- Office decor and design
- Staff-doctor-patient interaction (patient relations)
- Office newsletter, brochure, and educational aids
- "Patient friendly" management and clinical systems

### OBJECTIVES OF PROFESSIONAL MARKETING

One concern about the use of marketing is that it will tarnish the professional image of dentistry. To avoid this potential problem, it is imperative that dental personnel understand the true objectives of professional marketing. These are (1) consumer and patient education and (2) motivation of consumers and patients to seek and accept needed dental services and to take responsibility for their oral health. If these objectives are the focus of all marketing efforts by dentists, marketing will serve a beneficial function for both the public and the dental profession.

#### *Trends Affecting Marketing*

A number of major trends that affect our society have been identified.<sup>2</sup> Three have particular significance for dentists who wish to educate and motivate patients with marketing techniques.

**The Self-Help Movement.** People have become more concerned with helping themselves rather than relying on institutions. Self-help groups in a variety of specialized areas have materialized across the country, and self-help books routinely top the best-seller lists. The strong interest in physical fitness is one example of consumers assuming a more active role in their own health care. Dentists must understand this trend and refrain from dictating to the patient; dentists must work with patients to help them improve their oral health.

**Personal Attention.** People seek personal interaction to counter the current impersonal, highly technologic environment. If this need for individualized attention is not met by the dentist and staff, clinical expertise alone may not retain patients in an office they perceive as "unfriendly."

**The Age of Information.** The world's database is growing exponentially. People increasingly demand information about oral health. Much of this information is provided by sources outside the dental profession. Dentists and staff must also become a source of accurate information that the patient can personally use to improve oral health.

Marketing that is focused on education and motivation and that is based on these and related trends can be a powerful force. Marketing that educates the public about oral health satisfies society's need for information. Marketing that motivates people to participate with dental professionals in establishing and maintaining optimum oral health meets people's need for self-determination or self-help. When accomplished in an atmosphere of professional caring and concern for the needs of the individual, marketing becomes "high touch." Marketing as an educational and motivational process thus can become an ethical practice-building tool that enhances rather than tarnishes the image of dentistry.

### PRODUCT VERSUS SERVICE MARKETING

To properly focus marketing programs on education and motivation and to meet the needs and wants of individuals, it is important to distinguish between product marketing and service marketing.

Product marketing focuses on the actual products being sold. For example, in a television or magazine advertisement for an automobile, the focus of the visual, auditory, and written message is the particular car being marketed, including its most prominent features. In dentistry, product-focused marketing would emphasize the actual "product" being delivered to the patient, such as a crown, veneer, or composite resin restoration. Many dentists and staff, in their marketing materials and case presentations, focus on the actual restoration.

Service marketing focuses on the actual service being provided. The product being sold is secondary to the service and attendant benefits that the product provides. In the dental setting, the "services" and benefits of cosmetic dentistry might include: a more attractive smile, a better chance for career advancement, a better social life, and more self-confidence. The actual "product," the veneer or crown, is merely the vehicle for providing that service and achieving a benefit.

**CLINICAL TIP.** Dental marketing should be primarily service-focused marketing, because a service approach more clearly focuses on the patient's individual needs and wants and the ways in which treatment can meet those needs and wants.

In the world of marketing, perception is reality in the mind of the patient. If patients perceive that they have a need, then they definitely have that need, even if the dentist does not have the same perception. The public generally is not as interested in the product, or type of restoration, that is to be provided as they are in the benefits of treatment. These benefits must be tailored to individual needs and wants.

The correct focus can mean the difference between gaining patient acceptance of treatment and losing the patient's interest (and thus losing the patient). For example, a product-focused brochure, which simply lists the "products" available, forces the patient to take that information and somehow determine if these products meet his or her needs. In contrast, a service-focused approach does not demand extrapolation by the reader. It explains the benefits of cosmetic services in lay terms. It shows how cosmetic dentistry is the means to an end. It motivates the patient to accept treatment because such treatment is the answer to personal wants and needs.

The following excerpts are brief examples of product-focused and service-focused marketing statements.

*Product-focused brochure.* Our office is proud to provide the most advanced cosmetic dental technology. Ask Dr. Jones or our staff about the latest direct bonding procedures, tooth-colored crowns, porcelain veneers, and bleaching.

*Service-focused brochure.* Our office can give you a beautiful smile using the latest cosmetic dental technology. Ask Dr. Jones or our staff how we can work together to create an attractive smile that can help your career and your social life.

These are simple examples, but they illustrate the difference in approach between product and service marketing. The first example focuses on specific procedures and restorations, whereas the second example focuses on the patient's needs. Specific individual needs can be determined during patient interviews and in-office discussions and then can be addressed during the case presentation. Each staff member, as well as the dentist, should pay close attention to what patients say from the moment they come into the office. A great deal of information about individual needs and desires can be gained from patients' comments about their teeth and what they expect from the dental visits. See the sections on patient motivation profile and case presentation using the patient motivation profile later in this chapter.

### DESIGNING A MARKETING PROGRAM

The business community often uses a well-structured business plan. Such a plan sets short-term and long-term goals and provides a well-defined program for reaching those goals. Dental offices also should have an overall business

plan that incorporates a marketing plan. Before a cosmetic dentistry marketing plan appropriate for an individual dental office can be designed, basic market research must be undertaken. Market research will delineate:

1. The goals and objectives of the practice and its personnel
2. The profile of existing active patients
3. The profile of the surrounding community

### *Goals and Objectives of the Dental Practice*

The foundation of any marketing program is a clear understanding of goals and objectives. People perform at their best in an environment compatible with their needs and talents and when they are performing tasks they enjoy and believe in. If the dentist and staff do not have a clear conception of what they want the practice to be, it is impossible to design a marketing program that will help them achieve that image.

As the first task in designing a marketing program, the dentist and each staff member must write down their personal goals and the goals they seek for the practice. Do they want to provide only cosmetic dental services, or do they want to provide a range of general dental services, including cosmetic procedures? Do they want to focus only on the upper economic group of patients in the community or on a broader economic range? Do they want to focus on any particular age group of patients? Is the practice in an expansion or growth mode in terms of anticipating more personnel, or is the goal to maintain current patient load and practice size?

Many such questions should be addressed before a marketing plan is designed. After written answers have been provided by all personnel, a staff meeting should be held to discuss everyone's views and to arrive at a definitive mission statement that will govern the philosophy and direction of the practice.

### *Profile of Existing Active Patients*

After determining the practice direction, the types of patients already in the practice must be identified. The dentist and staff usually are surprised at how erroneous their perceptions are in this area. An assessment of existing patients may show that the practice philosophy and direction are not compatible with the majority of patients.

Dental practices take on "personalities" of their own, and ideally this personality coincides with the general characteristics of the patient base. If the office is not in tune with the majority of patients, this inevitably is reflected in the overall success of the practice. Similarly, if the existing patient base is out of tune with the true goals and objectives of the office personnel, the practice is misdirected, and stress and unhappiness can result.

No dental practice can be all things to all people. The most successful practices are those that first determine the type of patients they wish to treat and the guiding philosophy of the practice and then create an overall office environment that appeals to this type of patient. A patient assessment can help put the practice in perspective and guide the design of a marketing program.

**Conducting a Patient Assessment.** The dentist should compare the information in the office records with the following list, taken from a random sampling of 100 active patient records (certain data may require direct questioning of the patients if it is not included in the record).

1. Sex
2. Age
3. Marital status
4. Number of children
5. Education
6. Family income
7. Occupation
8. Frequency of dental visits
9. Driving time from work to dental office
10. Preferred times for dental visits
11. Types of dental procedures completed

Other questions may be added to answer individual practice questions. The objective of the assessment is to gain insight into the general characteristics of the active patient base. If this patient base is consistent with the practice's goals and objectives, a marketing program can be designed that will appeal to this type of patient both within and outside the practice. If the patient base is inconsistent with the practice ideals, serious thought must be given to slowly shifting the patient base in the desired direction.

### *Profile of the Surrounding Community*

Conducting a community profile can help both new and established dental practices focus properly for future growth. In today's mobile society, the makeup of a community can change dramatically in a few short years. A patient base acquired and courted over time often ceases to represent the predominant type of patient currently living in the community. Future practice growth may be generated by appealing to the typical community resident. This may require physical changes within the office.

**Conducting the Community Profile.** A number of companies offer demographic studies for a fee. The report furnishes a breakdown of the population by criteria such as age, sex, family income, travel time to work, ethnic groups, marital status, and other demographic characteristics. A community profile helps establish criteria for developing a marketing program that meets the needs and

expectations of the local population. Demographic data about the community can be compared to data obtained from the patient profiles to determine compatibility.

**CLINICAL TIP.** Some demographic studies rely on older Census information. Local organizations, such as the Chamber of Commerce and government agencies, can provide supporting data that can help fine-tune the community profile.

### *Elements of the Marketing Plan*

After preliminary market data have been collected and the practice's goals and objectives have been clarified, a definitive marketing plan should be designed. The following elements should be included in a marketing plan:

1. Goals and objectives
2. Target audience
3. Budget
4. Specific marketing techniques to be used
5. Time frame for implementation
6. Monitoring of results

The contents of the marketing plan should be decided in staff meetings specifically devoted to this purpose. After the plan has been designed, one or more staff members should be assigned the task of organizing and recording the plan in writing.

**Goals and Objectives.** The goals and objectives of the marketing plan are related to the goals and objectives of the practice as a whole, but they consist of the specific goals and objectives of the office's marketing program (i.e., exactly what is to be accomplished with the use of marketing techniques). Are you trying to attract a specific number of new patients each month? Are you trying to target a specific age category of patient, such as the elderly? Are you trying to increase the number of veneers placed per month by a specific amount? It is crucial to identify specific rather than general marketing goals and objectives.

**Target Audience.** The target audience most likely to satisfy the marketing goals must be identified. For example, if one goal is to add 20 new elderly patients to the practice each month, then individuals over the age of 55 would constitute the target audience. If the goal is to increase the number of veneers placed per month, the primary target audience might be women age 18 to 55. A secondary target audience might be men age 21 to 55. This does not mean that people older than 55 do not want veneers, or that men aren't interested in veneers; it simply means that it is more likely that women age 18 to 55 will make the decision to invest in veneers for cosmetic reasons. If the surrounding community is comprised predominantly of one demographic group, for example a

retirement community, the target audience must necessarily reflect that fact (or marketing to other communities may be necessary). Often a target market not normally considered "primary" requires a different marketing focus to motivate them to take action. The purpose of determining a target audience is to provide a tangible, well-defined "target" for the marketing efforts, a target with the highest likelihood of response.

**Budget.** Marketing plans are "budget driven." The techniques to be used and the size of the target market depend on available funds. A typical budget for marketing is 2% to 5% of gross practice revenues. Aggressive dental marketers budget 6% to 8% of revenues or more. A budget sufficient to accomplish the goals and objectives of the marketing plan must be allocated in the written plan and must be dispensed according to a time schedule as determined by the plan.

**Specific Marketing Techniques.** Within the confines of the plan's budget, specific marketing techniques should be selected that will best accomplish the marketing goals. Both internal and external marketing techniques can be used, depending on the marketing plan and the philosophy of the practice.

**Time Frame for Implementation.** A written marketing plan must contain a specific time frame for implementation. For example, if a direct mail campaign is budgeted and targeted for a specific number of patients within certain demographic parameters, a target date for implementation of the campaign should be included in the marketing plan. This date and any dates required for various steps involved in the campaign should be adhered to, with reports given by the responsible person at periodic staff meetings.

**Monitoring of Results.** Many dentists institute impressive marketing programs but fail to monitor the results of individual elements within the program. Monitoring systems that record results are imperative if the program is to be evaluated and improved. For example, if a Yellow Pages advertisement is used, the person answering the telephone for new patient appointments should ask the caller how he or she selected the office. All Yellow Pages respondents should be recorded, and the fees generated by these respondents logged as treatment proceeds. In this manner, the cost of the advertisement program can be weighed against the income generated.

**CLINICAL TIP.** If after a predetermined period of evaluation (perhaps 6 to 12 months) the advertisement does not generate sufficient fees, it should be changed or replaced with another marketing technique.



Continual monitoring of the marketing program is essential if the program is to optimize cost-effectiveness.

### SAMPLE MARKETING PLAN

Individual marketing plans for dental practices can be lengthy, or they can be concise to the point of being an outline. If the elements listed previously are addressed in enough detail to ensure implementation, the format and length of the plan are inconsequential. The following outline of a sample marketing plan includes both internal and external marketing techniques. This outline is intended as a guide for the development of an individually tailored plan for marketing cosmetic dental services, and as such its content is intentionally concise. Many of the indicated steps can be more detailed and can be intended to accomplish a broader goal. Actual dollar figures used are examples and are not intended as accurate estimates.

- I. Goals and objectives (based on a patient profile and community profile that showed a significant portion of the patient and community population to be families with children and both spouses working): To attract 20 new patients who need cosmetic bonding and veneering services per month. Average income goal per patient is \$500, for a total increase in income of \$10,000 per month derived from cosmetic services.
- II. Target Audience
  - A. Primary audience: women age 18 to 55
  - B. Secondary audience: men age 21 to 55
- III. Budget (based on current practice gross revenues of \$250,000 annually)
  - A. \$12,500 or 5% of annual gross revenues
- IV Marketing Techniques
  - A. Participation in two community health fairs to be held in the fall and spring at the local shopping mall. Exhibit table with color photograph album of cosmetic dental cases and display board with color photographs of cosmetic results and explanatory text. Table to be manned by Kathy and Sharon. Budget allocation for album development, table, and display board: \$750.
  - B. Civic lectures by Dr. Jones. Sharon will book one lecture every 2 months at the Rotary Club, Lion's Club, Men's Club, Garden Club, Chamber of Commerce meeting, and Businessmen's Club. Lecture plus slide presentation. Time of presentation: 20 to 30 minutes. Budget allocation for slide development: \$50.
  - C. Yellow Pages advertisement. One-quarter page black and white advertisement. Kathy to contact graphic artist for design and camera-ready

- art. Budget allocation for advertisement design and space in Yellow Pages directory: \$2000.
- D. Office brochure on cosmetic services and benefits available from our office. Brochure to be given to all active patients at their next visit; sent to new patients who make appointments by phone; and placed in local beauty shops and health clubs. Kathy to contact graphic artist and work with her on design. Sharon to work with printer to produce brochures. Budget allocation for design and production of initial print run of 5000 brochures: \$2750.
- E. Direct mail package to local residents, to include the office brochure and a cover letter explaining our cosmetic services and how they can benefit the reader. Sharon to write the letter, to be signed by Dr. Jones. Budget allocation for 1000 mailings: \$400.
- F. Four in-office color photograph albums of cosmetic cases for patient education. Kathy in charge of reproducing the photograph album used in the health fair exhibit. Budget allocation for four albums: \$160.
- G. Practice newsletter. Joanne in charge of writing quarterly newsletter, four pages, two colors. Content: dental education articles, with emphasis on cosmetic services available at our office. Joanne will send newsletter to all active patients, plus copies to all local beauty shops. Annual budget allocation for printing and mailing 2000 copies quarterly: \$3800.
- H. Development of office logo, business cards, stationery. Logo to reflect modern cosmetic-oriented dental practice. Kathy to work with graphic artist to develop logo. Each staff member to have business cards. Budget allocation for logo development and printing: \$1750.  
Total Budget Allocation: \$11,660  
Contingency fund: \$840

**CLINICAL TIP.** Contingency funds should be 5% to 10% of the total budget allocation.

### V Time Frame for Implementation

- A. Health fair exhibit materials ready by September 1.
- B. Slide presentation for civic lectures ready by September 1. Lectures booked every 2 months starting in October. Sharon will log each lecture appointment on office calendar and post on bulletin board.
- C. Kathy will meet with artist on August 1 to design Yellow Pages ad. First concept art due from artist on August 15. Final concept decision by

- September 1. Camera-ready art and copy due September 20. Kathy to meet with Yellow Pages representative on October 1.
- D. Kathy to meet with graphic artist on August 1 (same time as Yellow Pages meeting) to discuss concepts for office brochure. First concept art due from artist on August 20. Sharon will coordinate the written copy with her freelance writer friend. Final art and copy due September 28. Final art and copy to printer on October 5. Kathy to deliver to beauty shops and discuss with owners on October 15.
- E. Sharon will write direct mail letter by December 1 and get Dr. Jones' approval. Direct mail package mailed on January 10.
- E. Kathy will reproduce photograph albums and have them assembled and ready for office use by October 15.
- G. Target date for first issue of newsletter is January 1. Subsequent issues to be ready on April 1, July 1, October 1. Joanne will write newsletter, with the rest of the staff contributing, and have copy to the printer no later than two weeks prior to target dates. Joanne will set an editorial calendar and discuss at staff meeting on August 10, and at subsequent staff meetings prior to quarterly publication.
- H. Kathy will meet with graphic artist on November 15 to begin design of logo, business cards, and stationery. Initial concept review on December 5. Final art by December 20. Printing of cards and stationery completed by January 20.
- VI. Monitoring of Results
- A. Sharon will coordinate all monitoring activities. All new patients calling the office will be questioned about how they heard about the office. Answers will be recorded and categorized according to response. Direct mail response cards and newsletter response cards will be recorded. Response statistics will be evaluated quarterly and discussed at appropriate staff meetings.

## CASE PRESENTATION

Many marketing techniques can be used to build the cosmetic dental practice. Because each technique has advantages and disadvantages, the final choice depends on many factors. Each practice must decide which techniques are consistent with its philosophy and are appropriate for the goals and objectives of the practice.

One technique common to all practices is the individual patient case presentation. Many dentists do not

equate the case presentation with marketing. Some use a formal case presentation, which takes place in an area of the office specially designed for maximum patient comfort and communication. The case presentation follows a specific format, and every aspect of the presentation is planned to gain patient acceptance of treatment. Some dentists approach case presentation informally, with little preplanning and no prescribed format. However, case presentations, in whatever form they take, represent one of the most powerful types of internal marketing available to every dentist.

It is during the case presentation that the dentist and staff must educate the patient about his or her individual oral health needs and, most importantly, motivate the patient to accept and pay for needed treatment. If the patient leaves the case presentation without a firm commitment to treatment, that patient may be lost.

### Patient Motivation Profile

Use of the patient motivation profile can greatly improve the patient's motivation and inclination to accept treatment. Addressing these concerns may motivate a patient to undergo necessary treatment.

From the time a patient first enters or telephones the office, each staff member, as well as the dentist, should carefully monitor the importance to the patient of each of these four areas of concern':

1. Money
2. Romance
3. Self-preservation
4. Appearance

**CLINICAL TIP.** By classifying patients as closely as possible into one or more of the primary areas of concern (money, romance, self-preservation, and appearance), it becomes possible to target the case presentation to the individual, greatly improving the chances for patient Acceptance of treatment.

**Case Presentation Using the Patient Motivation Profile.** For example, an elderly gentleman presents with some missing teeth and one fractured tooth. The dentist, who has not taken the time to analyze the patient's motivating emotions, stresses the economic advantages of the treatment plan, emphasizing that it will save the patient money in the long run by preventing further deterioration of his oral health. The dentist takes this approach because currently the dentist's personal concerns center on money and achieving financial independence. The dentist assumes that the patient is thinking in the same terms, particularly because of his age and the need for financial security in his retirement years. The

dentist is surprised when the man shifts uncomfortably in the chair and says he will "think about it" and call later.

If the dentist, receptionist, or other staff members had noticed that during the initial office contact, the man did not mention money or financial concerns but did mention a magazine article he had read about "dental cripples" who had lost all their teeth, a clearer picture of the patient's emotional "trigger" would have been possible. When the man pointed out that his own mother had "pyorrhea" and had lost all her teeth and that he did not want to lose his teeth, too, this should have alerted the dentist to the fact that this person's emotional profile was "self-preservation," not money. Knowing this, the dentist would logically take another approach during the case presentation by explaining that treatment would prevent further tilting of the teeth adjacent to the missing spaces and would prevent the fractured tooth from breaking more extensively. The man's chewing would be more efficient, thus aiding in overall systemic health, and his entire mouth would be healthier. With proper home care, as instructed by the hygienist, the patient would significantly improve the likelihood of retaining his teeth for the rest of his life.

When the case presentation is keyed to the patient's motivation profile, the patient is far more likely to respond positively to the treatment plan. For the cosmetic dentist, the emotions associated with money, appearance, and romance can be targeted in a powerful way during case presentation. A more attractive smile can enhance one's career, thus providing the opportunity to make more money, and it can improve one's social life, thus meeting a patient's need to appear attractive or to find romance.

## MARKETING TECHNIQUES

Many marketing techniques can be used by dentists in a professional manner. The number of techniques available is limited only by the imagination of the marketer.

### *Referrals*

Referrals have been and remain the most effective marketing tool available. Special effort and a definitive plan should be devoted to stimulating referrals both from patients and from outside sources. Good outside referral sources include related health professionals, cosmetologists, realtors, and local businesspeople who meet the public and often are asked for recommendations about dentists and community services. Strong referral sources should be thanked in a noticeable way. A first- or second-time referral source may simply be sent a personalized thank you note. Those who continue to refer patients can be sent a special gift, such as flowers, concert tickets, or some other tasteful gift. With flowers, it is especially effective to send them directly to the referring individual's

place of business. Everyone in the referring person's office will see the flowers and notice who sent them, which expands the marketing effort.

### *Civic Lectures by Dentists and Staff*

An external public relations technique, the civic lecture is highly educational and benefits the entire profession, as well as the individual office. It is a strong marketing tool if the dentist or staff member is enthusiastic and a good speaker. Effective public speaking can be learned through practice.

### *Practice Newsletter*

A newsletter is an internal and external public relations technique. Its effectiveness can be diminished if a large number of dental offices in the area are using them. The content should be focused on services and benefits offered by the practice.

**CLINICAL TIP.** Avoid putting sections such as "Did You Know?" in a newsletter; this is mainly filler material for which the patient has little practical use.

A good idea before launching a newsletter is to survey a random sampling of perhaps 500 active patients by postcard, asking them if they would be interested in receiving a newsletter that educates them about cosmetic dental services and oral health. Base the decision to launch the newsletter on the strength of the response. It is important to adhere to a publication schedule and not to publish erratically. With any type of publication, consistency is important, because it gives the reader a sense of continuity and dependability. If patients come to expect a dental practice newsletter at a certain time, such as every quarter, it becomes part of their routine. This consistency reinforces the doctor's name in the minds of the patients and hopefully translates into consistency of office visits. From an in-office standpoint, if a fixed publication schedule is not established, the newsletter quickly becomes a task that "we'll get to when we can." This usually means that it will cease publication after a few erratically timed issues. A quarterly publishing schedule usually is sufficient and not too burdensome for the office staff.

### *Direct Mail*

An external advertising technique, direct mail can be expensive if not properly targeted.

**CLINICAL TIP.** Direct mail experts usually agree that a 1% response is strong, although this can vary according to how well the mailing is targeted.

The best results are obtained if target groups are clearly defined and the contents of the direct mail package are focused on the needs of that group. A response mechanism should be included, such as a reply card or a request to call the office for more information.

### *Yellow Pages Advertisement*

Yellow Pages advertisements are an external advertising technique. The results from these advertisements vary across the country. Dentists interested in this technique should try a test advertisement and monitor the results closely. The decision to renew should be based on results. As a general rule, larger advertisements work better, but it is important to determine the size of other advertisements that will run on the same page. In a page full of large advertisements, more graphic creativity is required if the advertisement is to stand out. The Yellow Pages representative or a graphic artist should be consulted about various graphic techniques that can improve the response.

### *In-Office Educational Materials*

An internal marketing technique, in-office educational materials such as educational brochures, photograph albums of cosmetic cases, and video or slide presentations are highly effective if combined with direct dentist-staff-patient interaction. Whenever possible, the dentist's own treatment results should be used in photograph albums. These aids represent an excellent opportunity for patient education.

### *Radio and Television Advertisements*

Although some large dental clinics have successfully used the external advertising technique of radio and television commercials, their effectiveness and feasibility for the average dental practice is questionable. Creation of an advertisement that maintains professionalism and generates new patients requires special talent, such as a professional advertising agency. This can be expensive.

## MARKETING ON THE INTERNET

The number of web sites on the Internet is exploding exponentially, covering virtually every type of business and profession. This "clutter" may give some dentists pause about investing time and money in designing and managing a web site that may simply become lost in a vast sea of sites. However, the number of people using the Internet on a daily basis is growing, and this phenomenon shows no sign of abating.

To help determine if a web site may be beneficial to the practice, the dentist should consider the following three factors:

1. The need for an ongoing financial commitment for designing and maintaining a web site. This amount can vary widely from a few hundred dollars a year to thousands of dollars, depending on a variety of factors.
2. The question of whether an additional method to reach potential new patients is actually needed in the marketing program, or does the practice already have all the new patients it can handle?
3. The added time necessary to coordinate the web site on a continuing basis. Even contracting with a web site management company requires you to provide content for the site.

A web site is probably not a practical marketing tool for every cosmetic dentistry practice, but with the number of people using the Internet increasing significantly, it can be surprising how many "hits" (visits) even a small site can generate. Cosmetic dentistry itself can provide graphically interesting content. Even in a small town consumers use the Internet, and they may see something on your site that prompts a visit to your office. As with any marketing technique, results vary from practice to practice. The results must be monitored to determine if it is worthwhile to continue maintaining the site.

**CLINICAL TIP.** Many web site management companies in the marketplace provide a range of services and pricing. Some dental supply companies also offer web site design and management services to dentists.

### *Web Site Content*

The content of a web site can be in the form of written information or graphic information (or both), including photographs, drawings, and video and audio information. It is best to begin with the "basics" rather than complex technologies such as video. Although it is tempting to consider a site that is "catchy" and full of "high tech" content, these complex graphics require more download time from the consumer. It can be very frustrating to wait for complex images to download when other forms of information could provide similar information more quickly.

From a marketing standpoint, the dentist should consider including the following content in the office web site:

1. The cosmetic dentistry services provided, including some "before and after" color photographs (discuss download time requirements for color photographs with the web manager)
2. Biographies and photographs of the dentist and staff
3. Facts about the practice (e.g., hours, location [map], philosophy)
4. Facts about cosmetic dentistry, including new technologies and techniques

The pertinent questions when developing content for a web site are:

1. Is this something a visitor to the site would really want to know if he or she is considering coming to our practice?
2. Will this information motivate a person to visit our office?

It is important to resist the temptation to load a site with "filler" material in an attempt to boost content.

### *Marketing the Web Site*

A major problem with many web sites is that potential visitors simply do not know it exists. Every web site has an "address," or URL (e.g., www.drjones.com), and people must know this address to visit the site. The web site URL should be displayed in the practice's Yellow Pages advertisement, on business cards and stationery, in any media advertising, on the fax cover sheet, and elsewhere. It should be displayed in the same manner and location as the office phone number and street address. The web manager can be consulted about the possibility of listing the site on the major search engines that serve as guides to web users.

**Getting Started.** A person in the office should be assigned to contact several web management companies to determine costs and the services provided. Also, the dental supplier should be contacted to see if web design services are provided as a value-added service to customers. Many small companies, even individual consultants, provide web design and management services, and their fees can be quite reasonable, depending on the level of technical service required.

After a web management company or consultant has been selected, the dentist's office is responsible for providing content for the site, which can be developed in

consultation with a web manager. Some individuals design their own web sites using books or online services for instruction, but this requires expertise and a time commitment that probably is not reasonable for most dentists. If possible, the web manager should monitor the number of visits the site receives so that it can be determined if the cost and time devoted to the site are reasonable in terms of the value received.

**Staff as Marketers.** A motivated, enthusiastic staff is one of the most powerful internal and external marketing tools a practice can use. Dentists should make a special effort to train the staff in proper telephone technique and patient interaction techniques. Each staff member should have a business card to distribute at outside functions. Regular staff meetings should be devoted to improving staff-patient relations.

### CONCLUSION

In the purest sense, marketing is education and motivation. As cosmetic dental technology continues to advance at a truly staggering rate, techniques for educating the public about the benefits of cosmetic dental services must keep pace with dentists' ability to deliver these services. The most successful dental practices are those that effectively educate patients about available dental services and motivate them to accept needed treatment.

### REFERENCES

1. *Bates v State Bar of Arizona*, 433 US 350, 1977.
2. Naisbitt J: *Megatrends*, New York, 1982, Warner Books.
3. Garn R: *The magic power of emotional appeal*, Englewood Cliffs, NJ, 1960, Prentice-Hall.



انتشارات شایان نمودار

# ESTHETICS AND DENTAL JURISPRUDENCE

Burton R. Pollack

## BRIEF HISTORY OF RISK MANAGEMENT

Until the mid-1970s the term *risk management* was not part of the dental lexicon. Today it is part of everyday conversation in dental circles. The health profession became interested in risk management during a medical malpractice crisis in the early 1970s. Hospitals could no longer afford the rapid rise in professional liability premiums. Many hospitals resorted to bearing their own litigation and liability loss costs through self-insurance. To decrease their exposure, hospitals adapted a system that was already being used for industrial risk management. The system instituted in-house programs to reduce liability by providing quality assurance in the provision of health care, identifying risk areas, changing hiring policies, reviewing patient complaints, studying incident reports, and purchasing insurance.

Reducing legal exposure in the hospital setting decreased the amount of money lost through legal actions. Eventually laws were enacted to require health facilities to institute formal programs in risk management. Some required periodic review of the credentials of physicians and dentists.

The concept of risk management spread from hospitals to physicians' and dentists' offices. Programs for dentists began in the late 1970s and early 1980s, when legal actions against dentists increased dramatically, settlements and jury awards escalated beyond expectations, and premiums rose to a level few could have anticipated. In addition, access to liability insurance in general and

malpractice insurance in particular became a problem for many practitioners.

## LOSS WITHOUT FAULT

In a study conducted by the author, 60% of several hundred malpractice claims were settled by the insurance company although no evidence of negligence on the part of the dentist existed. These cases could not be successfully defended because the defendant dentists' records were poor, they had no documentation that consent was obtained, or other office practices were sufficiently deficient to make it difficult to defend them. Thus the concept of loss without fault emerged.

## DENTAL RISK MANAGEMENT

Risk management adapted to dental practice appeared to be a reasonable means of controlling the worsening situation. The literature was flooded with risk management articles. Risk management presentations were included at most dental meetings. Insurance companies began risk management educational sessions, either as a benefit for insured dentists or so that they could qualify for premium discounts. Continuing dental education and risk management became inexorably linked. From the ashes of a profession threatened by litigation, there arose a program of office management that has raised the quality of dental care, provided dental practitioners with a sense of



security against legal claims, and created a profession that is more careful and caring than before.

### *Professional Responsibility*

To ensure a legally worry-free professional life, the dental practitioner has some new responsibilities, which include the following:

1. Knowing and obeying the laws that regulate dental practice and remaining informed about changes
  2. Continuing to become educated and remain knowledgeable about technical advances in the profession through membership in professional organizations, attending continuing dental education programs, subscribing to professional journals, and joining hospital staffs and the faculty of dental schools
  3. Being aware of areas of legal vulnerability in dental practice by reading appropriate literature, exchanging information with colleagues, and attending continuing dental education courses.
  4. Purchasing professional liability insurance
- CLINICAL TIP.** Purchase as much professional liability insurance as is affordable.
5. Carefully hiring, training, and supervising competent personnel
  6. Keeping proper records for each patient. See the discussion on keeping records in this chapter.
  7. Limiting care to areas of competence
  8. Making necessary and appropriate referrals
  9. Maintaining good interpersonal relationships with patients; showing care and ensuring that the staff does the same by monitoring what they say and how they relate to patients
  10. Being careful during treatments
  11. Obtaining proper consent before initiating treatment. See the section on consent in this chapter.
  12. Fastidiously documenting all actions. See the section on records in this chapter.
  13. Keeping patients informed about their oral health status and any problems that arise during treatment
  14. Carefully considering patients' responses if they were to be sued for nonpayment of fees. This is one of the major causes of malpractice suits.
  15. Taking careful health histories and updating them at appropriate intervals as determined by the prudent dentist
  16. Keeping patient records forever or as long as possible
  17. Never parting with an original record or radiograph unless ordered to do so by a court or an agency having subpoena powers
  18. Never altering a patient record after becoming aware that a malpractice suit is being contemplated or initiated by a patient or a patient's attorney

19. Notifying the insurance carrier at the earliest time after becoming aware that a patient intends or has threatened to sue or after becoming aware that an action taken during treatment could result in a malpractice suit—a provision in all professional liability policies

### *High-Risk Treatment Areas*

A study by the author regarding allegations brought against dentists revealed some interesting trends during the past decade of dental malpractice litigation.

#### Traditional Causes of Malpractice Suits

1. Extraction of the wrong tooth
2. Ill-fitting dentures
3. Bridges that have to be remade according to another dentist
4. Broken root tips left in the bone
5. Infections after extractions
6. Adverse outcomes caused by the administration of general anesthetics and intravenous sedatives

**Recent Causes of Malpractice Suits** Plaintiff attorneys have become sophisticated about dentistry since the proliferation of dental malpractice claims. New areas of dental vulnerability are constantly being discovered and include the following:

1. Failure to obtain informed consent
2. Failure to diagnose, refer, or treat (notably periodontal disease)
3. Faulty patient history taking, resulting in allergic responses, drug incompatibilities, paralysis, and in rare cases death
4. Problems associated with the temporomandibular joint
5. Implant failures
6. Treatment of a patient beyond the competence of the practitioner or that permitted by the dental practice act
7. Administration of wrong or inappropriate medication
8. Failure to inform the patient of an untoward event that occurred during treatment, such as a root tip fracture or an irretrievable broken instrument tip becoming lodged within a root canal
9. Failure to inform the patient of the consequences of refusal to follow professional advice
10. Abandonment of a patient by prematurely discontinuing care or not attending to the needs of a patient under treatment

Breaking a file in a root canal or fracturing a root tip may not constitute negligence; however, failure to inform the patient of the event is negligence. It may also be considered fraudulent concealment, thus falling within the statute of limitations for fraud, which does not begin to

run until the patient discovers or should have discovered the negligent act. This provides the patient considerably more time to enter suit against the dentist. In addition, fraudulent concealment may not be covered by malpractice insurance.

Oral and Iraxillofacial surgeons continue to be at the highest risk for malpractice in terms of the dollar amount of settlements and awards. However, the greatest numbers of suits are brought against generalists, with most being related to faulty crowns and bridges and failure to diagnose, treat, or refer the patient for periodontal disease conditions. Orthodontists have recently become targets of lawsuits because of bad results, periodontal and caries neglect, and root resorption. The practice of adult orthodontics has substantially increased the risks.

## LAW AND DENTAL PRACTICE

### Dentist-Patient Relationship: Brief Review of Contract Law

The relationship between a treating health professional and a patient has its foundation in contract law, which governs when the relationship begins and ends.

**When the Contract Begins.** The dentist-patient relationship begins when a dentist, in a professional capacity, expresses a professional opinion or recommends to a specific individual a course of health action on which the individual may rely. The locale in which the opinion is expressed or the recommendation made (whether it is in a parking lot, at a social event, or elsewhere) is inconsequential. Whether a fee was charged does not affect the relationship. Once the dentist-patient relationship begins, the rules of contract law apply.

The contract of care between a dentist and patient does not have to be in writing to be enforceable. However, when disputes arise, the written contract serves as evidence of its terms and that the parties reached an agreement. Except in the practice of orthodontics, written contracts in dentistry are rare.

**When the Contract Ends.** The dentist-patient relationship ends in the following circumstances:

1. The patient is cured.
2. The patient dies.
3. The dentist dies.
4. The patient voluntarily seeks the services of another provider.
5. The dentist unilaterally terminates the care.

**Abandonment.** One of the implied duties in the dentist-patient relationship is for the dentist to continue treatment until one of the previously mentioned five conditions occurs. When accepting a patient for care, the

dentist is agreeing not to abandon the patient. To unilaterally discontinue treatment and avoid liability for abandonment, the following generally accepted rules apply:

1. Dentists should not discontinue treatment when their patients' health may be compromised. This is a professional judgment, not a legal one.
2. Dentists should recommend that patients seek substitute care. It is best not to recommend another dentist or even to supply patients with a list from which to choose. To do so may create a link with the new dentist in future liability issues should the new dentist be accused of malpractice.
3. Dentists should inform patients that they will provide emergency care for a reasonable time during the period in which the patients are seeking care elsewhere. What constitutes "reasonable" depends on the availability of dentists in the community.
4. Dentists should inform their patients that they will cooperate with a new dentist by making copies of records, radiographs, reports, and other information available. Dentists should never send the original records or radiographs.
5. Dentists should inform patients that seeking care elsewhere is in the patients' best interest, not the dentists'.

Patients should first be informed orally regarding the previous guidelines and should then receive a signed receipt by certified mail that includes the same information. A dentist may refuse to accept a patient and may discontinue the care of a patient for any reason, without fear of abandonment, except for reasons of race, color, religion, or national origin. As a result of the enactment of the Americans with Disability Act (AWDA) of 1990, which declared a health practitioner's private office as a "place of public accommodation," a dentist who refuses to treat a patient solely because the patient has acquired immune deficiency syndrome (AIDS), is infected with the human immunodeficiency virus (HIV), or is disabled in any other way may be found guilty of discrimination and subjected to severe penalties (i.e., a large fine and possible restriction or loss of the license to practice). Although the AWDA makes it clear that federal, state, and local human rights agencies have jurisdiction over what a dentist does in the office (in relation to accepting or refusing patients), the appellate courts have yet to decide exactly what constitutes discrimination within the meaning of the law (e.g., wearing two pairs of gloves, restricting office hours, referring patients to special health facilities). However, until the courts decide, it is prudent not to treat patients who have AIDS or are infected with HIV any differently than uninfected patients.

### Express Terms in the Dentist-Patient Contract

Terms that are stated, orally or in writing, are called *express terms*. They usually include the service that is to be



provided by the dentist, the length of the treatment, and the payment arrangement. A dentist and patient may include any terms in the contract for care that are not illegal, provided the patient is not subjected to terms resulting from coercion, which places the patient in an unfair bargaining position. For example, if a patient chooses a practitioner who is reputed to have special skills in providing implants, but the practitioner refuses to provide the service unless the patient agrees not to sue the dentist for malpractice, the courts may look upon the agreement as an *adhesion* contract, which is unenforceable because it is against public policy.

### Implied Duties in the Dentist-Patient Contract

Implied duties are obligations that exist as a result of the dentist-patient relationship. These implied duties do not have to be explicitly stated or written to be legally enforceable.

**Dentist's Implied Duties.** The dentist automatically gives certain warranties to the patient, including the following:

1. The dentist uses knowledge and skill with reasonable care in the provision of services as measured against customary (acceptable) standards of other practitioners of the same school of practice in the community. The definition of community by the courts has undergone major changes. Previously, it was strictly defined as the local community in which the defendant dentist practiced. As communication and travel became more accessible, most courts changed the definition to mean a similar community. Some states further expanded the geographic community to include the entire state. Currently, a national trend is evolving to apply a national standard of care in judging board certified specialists. In some jurisdictions a national standard of care has been applied in judging generalists.
2. The dentist is properly licensed and registered and meets all other legal requirements to engage in the practice of dentistry.
3. The dentist employs competent personnel and ensures that they are properly supervised.
4. The dentist maintains a level of knowledge in keeping with current advances in the profession (e.g., participates in continuing dental education programs, subscribes to scientific journals, attends scientific meetings).
5. The dentist uses methods that are acceptable to at least a "respectable minority" of reasonable practitioners in the community (see entry #1). Court decisions are made on a case-by-case basis. No set number constitutes a "respectable minority."
6. The dentist does not use experimental procedures or drugs without the patient's knowledge and written consent. No clear definition explains what constitutes an experimental procedure or drug.
7. The dentist obtains the informed consent from the patient before beginning any examination or treatment. See the section on consent and informed consent in this chapter.
8. The dentist does not abandon the patient.
9. The dentist ensures that care is always available in emergency situations.
10. The dentist charges a reasonable fee for services based on community standards. "Reasonable" fees are determined by what other practitioners in the community charge. However, if a fee is stated, and the patient agrees to it, the agreement is binding regardless of the amount **of the fee**.
11. The dentist does not permit any person who is being supervised by the dentist to engage in unlawful acts.
12. The dentist keeps the patient informed about the progress of **the treatment**.
13. The dentist does not undertake any procedure for which the dentist is not qualified.
14. The dentist completes the care in a timely manner.
15. The dentist keeps accurate records of the examination and treatment of the patient.
16. The dentist maintains confidentiality.
17. The dentist informs the patient of any unusual occurrences during treatment.
18. The dentist requests consultations when appropriate and makes referrals for care when indicated.
19. The dentist complies with all laws regulating the practice of dentistry.
20. The dentist practices in a manner that is consistent with code of ethics of the profession.

**Patient's Implied Duties.** The patient also gives certain warranties to the dentist, including the following:

1. The patient keeps appointments.
2. The patient notifies the dentist (the office) in a timely manner if appointments cannot be kept.
3. The patient provides honest answers to health and history questions.
4. The patient informs the dentist if changes in health status occur.
5. The patient cooperates with the dentist in care (e.g., follows home hygiene instructions; a prescription medication schedule; diet and nutrition instructions; and instructions regarding alcohol, smoking, and drugs).
6. The patient pays reasonable fees in a timely manner. All of the mentioned stipulations, as well as additional issues, may be included in the contract of care be-

tween the dentist and patient, thus becoming part of the express agreement.

### *Breach of Terms*

In contract law, if one party breaches any of the terms, express or implied, the other party is relieved of the duty to perform. The courts have modified the rules as they apply to health care. For example, in the provision of orthodontic care for a minor, if the parent does not pay the fee as agreed, the dentist cannot remove the child's appliances and place the child's oral health at risk. The courts have declared that the dentist must resolve the conflict in **the courts, and the dentist cannot** hold the minor's health "hostage" to collect the fee from the delinquent parent.

**The courts treat breaches in contracts of health care as they do breaches in contract** law, with **the caveat** that a breach by a patient does not justify a "counter breach" by the dentist at a time when the patient's health may be adversely affected. For example, if a dentist and patient agree to a treatment plan involving ten individual crowns and the patient refuses to pay the agreed fee after two crown preparations have begun, the dentist must complete the treatment of those two crowns. However, at this point the dentist is not obligated to treat the remaining eight teeth; the dentist is expected to give the patient enough time to arrange for substitute care and to provide emergency care to the patient during that period.

### *Guarantees*

An important risk management caveat is to never guarantee the outcome of care. To do so is foolish because health care guarantees cannot be truthfully made. In some states, this is illegal. In many cases, guarantees lead to unrealistic expectations from the patient and eventual lawsuits. When a patient claims that a dentist breached a contract because a guaranteed result was not achieved, the suit may be subject to contract law. In contract law cases the patient does not have to produce an expert, whereas in malpractice law cases the testimony of an expert must support the patient's claim.

**CLINICAL TIP.** The considerations regarding guarantees should be strictly observed by dentists who practice cosmetic dentistry.

## STANDARDS OF CARE

The traditional standard to which dentists are held is undergoing a rapid change, as evidenced by some recent court decisions. Traditionally, dentists have been held to a customary standard that is established by the practice of rea-

sonable practitioners in the same community. This is known as the strict locality rule. Over the years, courts in many jurisdictions have substituted the words similar community for same community. In most states the standard applies to the entire state. Another modification involves acceptable standards rather than customary standards because the courts recognized that what is customary in a particular community may not be acceptable by any reasonable standard. The application of this legal concept is rare, but it has been used. The current trend is to apply a national standard of care to board-certified specialists. States that have adopted, by court decisions, a national standard for board-certified specialists include Alaska, Arizona, Colorado, Connecticut, Georgia, Iowa, Kansas, Louisiana, Maine, Massachusetts, Michigan, Minnesota, Missouri, Nevada, New Jersey, New Mexico, Ohio, Pennsylvania, South Carolina, and Wisconsin. One appellate department in New York has been added to the list. The effect is a two-tiered standard: one for board-certified specialists and another for other practitioners of the profession.

Based on court decisions and in the absence of legislation, dentists practicing cosmetic dentistry are held to the modified local standard of care-statewide. Unless a specialty group is formed for these dentists or courts apply a national standard for generalists, the current situation will prevail.

## CONSENT AND INFORMED CONSENT

### *Consent*

Examining or treating a patient without the patient's consent constitutes unauthorized touching (i.e., a trespass against the person) and makes the one who commits the act guilty of battery and liable to the patient in a civil suit. The trend in most courts today is to treat allegations of faulty consent as professional negligence. To support the theory, the courts have stated that to sustain an allegation of battery, it must be shown that an intent to harm was present in the commission of the act. This essential element can rarely be shown in cases brought against health practitioners. However, some courts have stated that if the dentist obtains no consent at all, a charge of battery may be appropriate. In the latter situation, the defendant dentist is at a distinct legal disadvantage and may not be covered by the professional liability insurance policy, may be subject to criminal action, and may be assessed punitive damages.

The fact that the act on which the suit is brought may have been necessary and beneficial to the patient does not affect liability. Similarly, liability is not altered if the act was gratuitous.

Only if a true emergency exists at the time the service is provided can the practitioner proceed at no risk

without the consent of the patient. Most jurisdictions state that an emergency exists when care must be rendered immediately to protect the life or health of the patient. When **these conditions are met** and time is of the essence, consent need not be obtained directly from the patient; the law implies consent. Most courts also consider two other factors: (1) whether consent would have been given if the patient was able to grant consent, and (2) whether a reasonable person in the same situation would have granted consent.

Consent may also be implied by the actions of the patient. For example: a patient enters a dentist's office, complains of a toothache, and asks to be examined. The dentist tells the patient that radiographs of the teeth will be taken. The patient allows the radiographs to be taken without objecting. Consent is implied by the action, or inaction, of the patient. The key elements are that (1) the patient was aware of the nature of the problem or the need for the treatment (examination) being provided, and (2) the patient made no objection when treatment began.

### Informed Consent

Treating a patient without consent is **different than treating a patient without informed** consent. As stated previously, treating without consent constitutes battery and may bring with it a criminal charge and punitive damages. Therefore it is better to obtain questionable consent than no consent at all.

For consent to be valid, it must be informed and obtained from a person who is deemed competent to grant it. The person must be an adult of sound mind. It is questionable whether a patient under the influence of alcohol or other drugs has the sufficient mental acuity to grant a valid consent. Should the patient appear to be under the influence of drugs or alcohol, consent and treatment should be postponed. A patient under stress, which most patients are, presents similar problems. If the patient appears apprehensive when faced with a surgical procedure, it is best to allow the patient to take the consent form home (if one is being used). If no form is **being used, allow the patient to delay the decision for a time, ideally overnight.**

Except in special circumstances not directly related to dental care, consent obtained from an adult with mental retardation is invalid. In some jurisdictions the parent of a mentally incompetent adult cannot grant a valid consent on behalf of the patient unless appointed guardian by the court. Other jurisdictions, such as New York, have ruled that the parent may grant consent to care without the need to be legally appointed as guardian.

Only the parent can grant valid consent for care of the minor. Consent given by siblings, grandparents, or any relatives other than the parents or legal guardians is

not valid. However, the parents may authorize another party to grant consent (e.g., the administrators of a resident school, a neighbor) during the parents' absence.

Either parent may grant a valid consent, even over the objection of the other parent. By common law a minor is anyone who has not reached the twenty-first birthday. The age has been reduced by statute to 18. In many jurisdictions, special statutes grant minors the right to consent to health care without the consent of the parent. In New York, as in most states, minors may consent to health care at 18, as **set by statute; in Alabama, the age is 14.**

By common law, minors may be emancipated and thus may consent to health care without the consent of the parent. Generally, a minor who is financially independent of parental support is emancipated. Many states such as New York have codified common law and may list the conditions under which a minor becomes emancipated. These conditions usually include marriage, pregnancy, or living outside the parent's home.

In some cases the courts have stated that a minor may grant a valid consent if the minor understands the nature of the treatment and the risks; this is known as the *mature minor rule*. The youngest age at which the rule has been applied is 14. In many jurisdictions a minor of any age may consent to care for treatment of venereal diseases, for sex-related advice and treatment, and for abortions without the consent of the parent. In many jurisdictions, disclosure of this information to the parent places the practitioner at legal risk of being charged with criminal action by the state and civil action by the child for breach of confidentiality.

Consent granted by a spouse is not valid. However, in emergency situations in which consent of the patient cannot be obtained, it is wise to obtain the assent of the spouse. Consent granted by an adult child for a parent or by a sibling for another sibling also is not valid.

Consent must be freely granted to be valid. Courts have declared consent invalid because to secure needed care, patients were required to consent to conditions not in their best interest. These types of consents are known as *adhesion contracts* and have been declared unenforceable by many courts. See the section on express terms in this chapter.

The **courts also look unfavorably on consents that contain exculpatory language (i.e., language that relieves the practitioner of liability** for negligence). An example is a consent that contains the following provision: "I accept this treatment with the understanding that I will hold the doctor harmless for any negligence in the performance of the treatment." The courts have stated in strong terms that exculpatory language in consents for health care is void as against public policy.

The trend in the courts and **the legislatures during the past 25 years** has been to demand that the health care provider disclose more information to the patient, thus

the concept of informed consent has been superimposed on the basic consent issue. Basic to the concept of informed consent is that the patient must be given, in understandable language, enough information about the proposed treatment to make an intelligent decision about whether to proceed with the proposed treatment and have an opportunity to ask questions and have them answered.

Both the courts and the legislatures in most jurisdictions have provided specific guidelines regarding the required elements of informed consent. In general, for consent to be valid and effective, the following conditions must be met:

1. The consent must be freely given.
2. The proposed treatment and its prognosis must be described.
3. The patient must be informed of the risks and benefits of the proposed treatment, including the prognosis if no treatment is provided.
4. Alternative treatment(s) to the one suggested, including their risks and benefits, must be described.
5. The patient must be given an opportunity to ask questions and have them answered.
6. All communication with the patient must be in language the patient understands.
7. The consent must be obtained from a person authorized to grant consent.

The element causing major problems for the courts and the practitioners concerns the amount of detail the practitioner should use when explaining the risks to the patient. Two different standards are applied by the courts. One holds the provider to the standard of what other doctors in the community tell their patients in the same or similar circumstances (the professional community standard). The other standard requires the dentist to provide the patient with sufficient information for the patient to make an intelligent decision about whether to proceed with the proposed treatment (the reasonable person standard). When the courts use the professional community standard, experts from the community must appear on behalf of the patient to inform the jury as to the standard exercised. When the reasonable person standard is used, no expert testimony is required. Also, when using the reasonable person standard, some courts apply the objective standard, which is, "Is the information provided sufficient for a reasonably intelligent person to make an intelligent choice?" Other courts apply the subjective standard, considering only what the patient was told, which is, "Was this person given enough information to make an intelligent decision?" New York has adopted the professional community standard for all health providers and requires expert testimony to establish the standard to which the defendant doctor is held.

In the reasonable person standard, the risks to be communicated to the patient are described as *material*. In the

professional community standard, they are described as *foreseeable*. Based on decisions of the courts, it appears that the more invasive the procedure or the greater the risk attached to it, the more detail regarding its risk the provider is required to disclose for the consent to be informed.

**CLINICAL TIP.** When properly executed, consent given over the telephone is acceptable to the courts. However, it must contain all the elements that constitute a valid consent and should be properly documented. When obtaining consent for a minor, the dentist should contact the parents or guardians of the minor and tell them that a third party is listening on an extension. The parents should be informed about the situation and the need for treatment, as well all the facts that are required to obtain a valid consent. After the consent is received, appropriate notes should be made on the patient's chart, which should then be signed by the person who obtained the consent and counter-signed by the listening third party.

Consent need not be in writing to be valid. However, in some jurisdictions written consent is required for surgical procedures. New York requires written consent for some surgical procedures (e.g., organ donation, acupuncture, abortion in minors).

The content of an oral consent can be challenged, as can whether the consent was actually obtained. The degree to which the doctor wishes to document that consent was obtained is a personal decision. In some situations a written, signed consent is appropriate, whereas in others an oral consent might suffice. It is advised that when the treatment is invasive or the risks are significant, the consent should be written regardless of whether local law requires that consent be written.

Recent court decisions have addressed the issue of who should obtain the consent to care. Options include the operating surgeon (the treating dentist), an associate, a hygienist, an assistant, or a receptionist (secretary). In a recent New York case the court referred to a case decided in Pennsylvania, stating that it was the only case on record in which a court was called on to decide whether the treating doctor or an office employee can obtain a valid consent from a patient. In the Pennsylvania case the dentist's wife, who was the dentist's assistant, obtained the consent of a patient. The court stated that it is the scope of the information that the patient had been given, rather than the identity of the person who relayed the information, that was important. In the opinion of the Pennsylvania court, the operating surgeon (in that case, the dentist) is not required to obtain the consent. In the New York case, the court followed the lead of the Pennsylvania court and stated that "a nurse (office employee), trained in obtaining informed consent to a particular procedure could act as an agent for the treating physician (dentist)."

Although the appellate courts of Pennsylvania and New York have ruled that an office worker may obtain the effective consent to care from a patient, dentists should keep in mind certain caveats before delegating the responsibility. The office worker should be trained in obtaining informed consent, and the degree of invasiveness and potential risks of the procedure should dictate who should answer questions asked by the patient about the procedure. Dentists who delegate the responsibility to obtain consent to someone else should be available to answer questions asked by the patient. (See Appendix D for samples of consent forms.)

## RECORDS

When a conflict arises between what a patient reports and the notes made by the dentist on the patient's record, the attorney for the patient (after reviewing the record) is likely to dissuade the patient from suing, provided the entries on the record and the entire record appear to be valid.

**CLINICAL TIP.** Properly maintained patient treatment records are the best defense against a claim of negligence when there has been no negligence. Records that are neat and legible and appear to be accurate representations of treatment can positively influence plaintiff attorneys, juries, and judges.

In many states, it is mandated by law, licensing agencies, or the state health department that records are to be kept of each patient. Rules also explain how long the practitioner is required to retain the records and what the record must contain. Dentists can contact the appropriate state agency or a local attorney to obtain this information.

Financial information should not be kept on the treatment record. The treatment record should be reserved for treatment and patient reactions to treatment. Financial information should be kept on separate sheets and placed within the folder. The presence of financial information on the treatment record may affect the outcome of a case. For example, if a juror believes the fees were excessive, it may influence the juror's decision on matters unrelated to the fees. In addition, any financial information appearing on the treatment record cannot be kept from the jury.

The following rules should be followed regarding patient treatment records:

1. The records should be legible, written in black ink or black ballpoint pen. Pencils should not be used.
2. No erasures should appear on the record.
3. Erroneous entries should not be blocked out so that they cannot be read. Instead, a single line should be drawn through the entry with a note stating, "error

in entry, see correction below." The correction should be dated at the time it is made.

4. Entries should be uniformly spaced on the form. The record should contain no unusual or irregular blank spaces.
5. On records in which more than one person is making entries, the entries should be signed or initialed. In addition to treatment information, the following should be included in every patient record:
  1. Documentation that consent to care was obtained before treatment was begun; documentation that all risks and benefits of the treatment were presented to the patient; documentation of any remarks made by the patient during the discussion
  2. Documentation of all cancellations, late arrivals, and changes of appointments
  3. Documentation of all requests for consultations with other health practitioners
  4. Documentation of the failure of a patient to comply with consultation or consultants' recommendations
  5. Careful documentation of all conversations held with other health practitioners relating to any consultation about or care of the patient
  6. Documentation that the patient was informed of any adverse occurrences or untoward events that took place during the course of treatment
  7. Documentation of instances in which the patient did not comply with home care instructions

Information obtained from the patient during the health history, conversations with the patient, or the course of treatment is confidential and should be carefully guarded.

Subjective evaluations, such as your opinion about the patient's mental health, should not be entered on the treatment record unless you are qualified and licensed to make such evaluations. In jurisdictions where the patient is entitled to a copy of the record, such notes may be counterproductive to the dentist. Notes about the patient's mental state or other personal evaluations should be made on a separate sheet.

If the practice of dentistry is discontinued, the local law should be checked to determine the requirements of how, where, and in what form the records must be retained.

**CLINICAL TIP.** Do not surrender the original records or x-rays to anyone unless ordered to do so by a court. Do not even surrender the original records to a specialist to whom you have referred a patient.

In one court case, failure of the defendant to produce the original radiographs was interpreted as an attempt to conceal information and resulted in a decision against the dentist. In addition, retaining the original records, including radiographs, is required by law in some states.

**CLINICAL TIP.** Never tamper with a record once legal action is suspected from a patient. This is fraud and may result in severe punishment by the courts.

### HEALTH HISTORY

Obtaining a patient's history verbally, with no written documentation of questions asked and answers given, is not a responsible office practice. Only a written history meets a "reasonable standard of care" in taking a patient's history.

Recent malpractice suits have involved failure to obtain an accurate health history. Some of the problems involved self-administered forms that required patients to check boxes or circle items to indicate "yes" or "no" as answers to various health questions. In a recent trial, conflicting testimony surrounded who actually made the check marks or circled the answers. Answers other than "yes" or "no" are possible for almost all questions (e.g., "I do not understand the question," "I am not certain of the answer.") To prevent these problems, the questionnaire should be designed with open-ended questions to which the patient writes a response. A handwriting analysis verifies the author of the answers.

The errors most commonly associated with medical problems are the following:

- I. Failure to discover a potential drug incompatibility
2. Failure to learn of a drug allergy or potential drug allergy
3. Failure to discover a medical condition that may result in serious injury to the patient as a result of dental treatment (e.g., rheumatic fever that caused valvular damage)

The errors most commonly associated with dental problems are the following:

1. Failure to discover that the patient had a history of problems associated with temporomandibular dysfunction
2. Failure to discover that the patient exhibited a reaction to the administration of a local anesthetic or other dental medications or drugs
3. Failure to discover problems associated with periodontal disease

Several other notable problems have surfaced in recent cases, such as discovering the identity of the person who completed the history form, reviewed the history forms, and discussed the history form with the patient. Appropriate notes should be made on the history forms and in the treatment record to prevent these problems.

Ideally, the treating dentist should take the history. However, if the responsibility of history taking is delegated to another person, the following rules should be heeded:

1. The person to whom the task is delegated should be specially trained in history taking.

2. The treating dentist should review the history with the patient. (It is important to document that the dentist reviewed the history with the patient.)

In offices with multiple practitioners in which more than one person may treat a patient, each practitioner should review the patient's health history before treatment begins. The same is true for consent. It is not sufficient to rely on the ability of others in the office, even another treating doctor or hygienist, to obtain an adequate health history or a valid consent. The rule is that the person who provides the care is responsible for ensuring that (1) the care provided is compatible with the health of the patient and (2) consent was obtained.

All history forms should include the following:

- I. The patient's name (which should be on the top of the form to prevent incorrect filing should the form become separated from the main record)
2. The patient's signature
3. The signature of the party completing the form if the person is not the patient
4. The signature of a witness to the patient's signature
5. The signature of the dentist who reviewed the form with the patient

The form and all signatures should be completed in black ink or with a black ballpoint pen supplied by the office. Not all copiers are capable of reproducing colors other than black. (See Appendix D for a sample health history form meeting all the requirements described.)

No law or fixed rule delineates how often the medical history should be updated; it is a professional judgment the dentist should make with each patient. For an apparently healthy teenager with uncomplicated dental problems, the dentist may decide to update the health history at every recall visit. For a geriatric patient with a history of diabetes, the dentist may decide to update the health history each month during an extended dental treatment process. Based on professional judgment, it may be sufficient to simply ask, "Has there been any change in your health since your last visit to the office?" If the dentist thinks that this is sufficient, it should be documented in the patient's record that the question was asked and the answer given by the patient.

**CLINICAL TIP.** The patient's medical and dental conditions should be monitored at intervals appropriate to the patient's age and medical and dental status.

When a formal update is required, the patient should be given a copy of the most recently completed self-administered history form for review. If the patient states that no changes have developed, this should be noted in the patient's record or on a form specially designed for that purpose. If the patient indicates that changes have occurred, it may be advisable to have the patient complete another history form and for the dentist to repeat

the entire history-taking process. (See Appendix D for sample copies of this and all office forms.)

In the field of cosmetic dentistry, a thorough evaluation of the patient's attitude toward dental care is essential. The practitioner should design suitable questions (that are presented orally or in writing) to determine the patient's perspective. The questions and responses should be accurately documented in the record. It may be important for the patient to demonstrate oral hygiene procedures. Questions designed to elicit the patient's attitude toward cosmetics in general and cosmetic dentistry in particular may be helpful for the cosmetic dentist. Forms alone are not enough for the dentist to properly and safely plan a treatment. A discussion and interview with the patient after the completion of the forms are essential.

Reviewing the completed forms, reading radiographs, evaluating consultant reports and test results, and reviewing the patient interview completes the health history and prepares the dentist to discuss the treatment plan and alternatives with the patient.

## STATUTE OF LIMITATIONS

The statute of limitations defines the time within which a lawsuit may be brought against an individual or any other form of legal entity. It is designed to prevent the threat of a suit from lasting forever. In addition, the statute takes into account fading memories and the unavailability of witnesses as a result of death or relocation. The statute prevents the execution of stale claims. If the statute has expired, the patient cannot maintain a suit.

Basic issues of the statute of limitations are the following:

1. When does the time begin?
2. Which events or conditions toll (delay) the running of the statute?
3. How long does the statute run?

No nationwide standard has been set for these issues. Therefore dentists who want to know the times related to a statute should consult a local attorney. Following are some generalizations about the statute of limitations as it applies to malpractice suits against dentists.

### Commencement

The statute of limitations usually begins when the act of negligence takes place, regardless of whether the patient is aware of the negligence at the time it occurs. States that follow this rule are called *occurrence states*. However, some states consider the statute of limitations to start when the patient discovers or should have discovered that an act of negligence caused an injury. States that follow this rule are called *discovery states*. Additional possibilities for the start of the statute of limitations include the following:

1. When the course of treatment in which the negligent act took place ends
2. When the dentist-patient relationship ends
3. When the patient discovers or should have discovered that a foreign object was erroneously left in the body

All states have some combination of the previously listed starting dates. For example, in New York the statute of limitations begins when the negligence takes place. However, exceptions exist for cases involving foreign objects and continuous treatment.

### Tolling

The statute of limitations is tolled during infancy and generally does not begin to run until the individual reaches majority (18 years of age). However, during the malpractice crises of the 1970s and 1980s, states enacted tort reform legislation in an attempt to control the growing number of malpractice suits. Some changes modified the tolling of the statute of limitations for infancy and placed a maximum on tolling years, regardless of when the individual reached adulthood.

Other factors that toll the statute of limitations are of little consequence to dentists, including the imprisonment of the plaintiff, mental incompetence, and the absence of the plaintiff from the jurisdiction of the court.

### Expiration

Even if the statute of limitations has run out, the patient may still file a suit against the dentist. It then becomes the dentist's burden, through an attorney, to answer the initial filing of the claim with an affirmative defense addressing the statute of limitations. Then the court will rule on whether the suit can continue.

The time in which suit may be brought is controlled by state law and varies between 1 and 5 years, with most states using a 2- to 3-year period. The time in which the statute begins and how long it runs create confusion and lack of uniformity. For example, in a state in which the statute does not begin to run until a patient discovers that a fractured root tip was left in the bone during an extraction, the statute may not begin to run until several years after treatment. In effect, the statute of limitations may be for an indefinite period. In another state in which the statute begins at the time of the incident (i.e., the breaking of the root tip), the statute begins to run without the knowledge of the patient and continues for the time set by local law.

## FRAUDULENT CONCEALMENT

Courts look unfavorably on dentists who withhold information from a patient about an act of negligence committed during the course of treatment. Many states have

enacted legislation on this issue. In those states the statute of limitations does not begin to run until the patient discovers or should have discovered the fraud, and the statute of limitations for alleged fraud is applied. Therefore even in an occurrence state with a fixed statutory limit, a dentist who withholds a fact from the patient may be charged with fraudulent concealment to extend the period in which the patient may bring suit.

**CLINICAL TIP.** When things go awry during the course of treatment, inform the patient. Document the event in the record, and document that the patient was informed. This fixes the time the statute will begin to run, offers time-related protection to the dentist in discovery states, and prevents tolling of the statute of limitations as a result of fraudulent concealment.

When the associate dentist is an independent contractor, the liability of the principal for the negligence of the independent contractor depends on the relationship between the two parties, the manner in which professional decisions are made, and the source of the patients. Decisions by the courts about liability are made on a case-by-case basis. However, the Internal Revenue Service has taken a firm position that although the parties may claim an independent contractor relationship, it may in fact be an employer-employee relationship for tax purposes. In addition, local and state agencies may have a stake in whether the arrangement in practice is a partnership or independent contractor relationship (e.g., the local labor department and its unemployment contributions and contributions to the workers compensation fund). Before entering into any relationship with another dentist, it is best to consult an attorney and an accountant.

**CLINICAL TIP.** The dentist should carefully select and monitor employees who may vicariously impart their negligence to others in the practice.

## FORMS AND RELEASES

The increase in paper work in the modern dental office has become oppressive to many dentists. The practice of dentistry has become more complex because of the expansion of services provided by the profession. New developments such as orthognathic surgery, the increased use of implants, new diagnostic procedures, the increased concern about temporomandibular joint problems, new public awareness about adult orthodontics, and the rapidly growing field of cosmetic dentistry have added to the complexity of modern dentistry. Further complicating dental practice is the emergence of third-party insurance programs and other forms of third-party payment programs. Dental offices must develop practice management defense in the form of risk management to counter events

in the legal arena. Complete and carefully designed record keeping systems are essential in all modern practices. Computers are almost as common and necessary as x-ray machines.

Dentists who practice risk management use a series of forms, including the ones that follow, to enable them to practice in a legally worry-free environment. (See Appendix D for samples of the following forms and additional office forms.)

1. *Release of information form.* To enable the dentist to obtain health information about the patient from other practitioners and health facilities, including hospitals
2. *Waiver of confidentiality form.* To permit the dentist to release information about the patient to insurance carriers, third-party payers, and other practitioners
3. *Informed consent form.* To document that the patient has agreed to the treatment; essential when the treatment is invasive or the risks are great
4. *Informed refusal form.* To document that the dentist has informed the patient of the consequences of not following the dentist's advice regarding recommended care, referrals, and specialty treatment; particularly useful when periodontal consultation or treatment is recommended and refused by the patient
5. *Permission to take photographs, slides, and videos form.* To allow the taking, use, and publication of photographs, slides, or videos; especially important in cosmetic dentistry
6. *Release of all claims form.* An essential form that must be signed before a fee is returned to a patient
7. *Permission for a previous dentist to forward copies of the patient's record form.* To allow a treating or consulting dentist to obtain the records of a patient sent by another treating or consulting dentist, physician, or hospital; contains a statement signed by the patient that permits the release of the records

## PROCEDURE FOR HANDLING A MALPRACTICE SUIT

The shock of a malpractice suit may result in various inappropriate responses. Among them is psychological denial, possibly causing a dentist to ignore the suit completely. Unfortunately, deadlines must be met. A dentist may want to phone the patient or contact the patient's lawyer. These are both improper because all professional liability insurance contracts contain a clause that requires the dentist to cooperate with the insurance company and to refrain from any activity that may compromise the suit. Payments made by the dentist to or for the patient, except for in cases of first aid, usually are prohibited by the terms of the policy and should not be made without previous approval by the insurance carrier.



Following are some guidelines for what *not* to do when faced with a malpractice suit:

1. The dentist should not respond to questions about the case or the treatment of the patient with anyone not known to be a representative of the insurance company or the dentist's attorney.
2. The dentist should not surrender original records to anyone except the dentist's attorney, the dentist's insurance company, or an official government agency having subpoena powers or unless required to do so by a court order signed by a judge. A receipt should be obtained if possible.
3. The dentist should not speak to a dentist who is known to have treated or currently treating the patient or wrote a report about the treatment the dentist performed.
4. The dentist should not alter or add any notes to the patient's treatment record.
5. The dentist should not lose any of the patient's records, radiographs, test results, or reports.
6. The dentist should not agree to see the patient, regardless of the reason. Once the patient elects to file suit, the dentist-patient relationship ends, and unfortunately the adversarial relationship begins. The dentist should notify his or her own attorney for advice when the patient requests a meeting.
7. The dentist should not make any entries on the patient's record about the lawsuit or any other matter relating to the suit, such as receipt of the summons, demand for records, or communications with the insurance company or attorney. All notes related to the case should be recorded on a separate sheet and labeled *confidential*.
8. The dentist should not tell anyone about current insurance coverage.
9. The dentist should not speak to colleagues about the case. All information about the case must remain confidential. The dentist's attorney is in charge and should decide all actions to be taken.
10. The dentist should not tell anyone about the suit.

Following are some guidelines for more appropriate steps to take when faced with a malpractice suit:

1. The dentist should remain calm.
2. The dentist should record the manner in which the suit was served (not on the patient's record, but on a separate sheet headed *confidential*).
3. The dentist should make a copy of all the papers that were included in the service.
4. The dentist should read the professional liability insurance policy to determine where the suit papers are to be sent. If the information is not present, the dentist should call the carrier.
5. The dentist should notify the insurance carrier of the suit by certified mail, return receipt requested, as soon as possible. The dentist should send the

- original of all papers included in the service of the suit, including the envelope, if it was sent through the mail (after making copies for the records).
6. The dentist should contact all insurance carriers if the carrier changed during the patient's treatment. The dentist should include a copy of all papers included in the service of the suit to each carrier (after making copies for the records).
7. The dentist should make a copy of all records and radiographs related to the care of the patient and secure the originals in a safe place.
8. The dentist should write a detailed narrative description of all treatment provided to the patient using the records to help. The sheet should be titled *confidential*. The dentist should include all that can be recalled about conversations held with the patient and statements made about the treatment. The narrative should be dated and signed and a copy sent to the insurance carrier. The original should be locked in a safe place.
9. The dentist should inform the office staff about the suit and caution them about speaking with anyone about the case or the patient.
10. The dentist should contact a personal attorney (if the dentist has one) to inform the attorney about the suit. If the dentist does not have a personal attorney, the dentist may consider retaining one. If the amount of the suit exceeds the limits of the dentist's policy, the dentist should retain an attorney to safeguard all his or her financial interests.

#### RISK MANAGEMENT IN COSMETIC DENTISTRY

Patient dissatisfaction with the results of care increases the risk of a patient filing a suit. An unsatisfactory result according to the patient is not always unsatisfactory according to the dentist. Too often patients fail to realize the limitations of dentistry, a scenario that is particularly true when cosmetic results are important. Therefore dentists who practice cosmetic dentistry are at greater risk than those who practice nonelective and noncosmetic procedures. Although all dentists practice some form of cosmetic dentistry, those who practice primarily cosmetic dentistry must meticulously adhere to risk management principles because of the increased risk of a suit.

Special precautions must be taken because subjective opinions about the outcome of care may determine whether a patient sues. The nature and content of the consent issued before care begins may determine whether the patient initiates a suit. Patient expectations must be realistic if a dentist wants to avoid problems when the care is completed. Predictable limitations in outcomes

must be incorporated into the consent form. Documentation is essential.

**CLINICAL TIP.** Keeping the patient informed during each step that affects the cosmetic result and continuing the involvement of the patient as the treatment progresses may decrease patient dissatisfaction.

Behavioral science plays a greater role in cosmetic dentistry than in most other fields of dental practice. Failure is measured in terms of litigation. When cosmetic dentists include in their treatment procedures the use of general anesthetics, intravenous sedatives, orthodontics, orthognathic surgery, or implants, they take on the added level of legal risk associated with those procedures.

Although risk management in cosmetic dentistry is no different from risk management in general dental practice, more emphasis should be placed in the following areas to avoid legal difficulties after treatment:

1. Record keeping must be meticulous.
2. Consent forms must be carefully constructed and executed.
3. The patient must be involved in all stages of treatment when the cosmetic result is a consideration.
4. Documentation rules must be carefully observed.
5. False and unrealistic hopes should not be fostered.
6. The patient must be kept informed.
7. Guarantees about outcome or patient satisfaction should not be made. The dentist and office personnel should not use words that imply a guarantee or patient satisfaction.

## CONCLUSION

During the past decade, services that fall within the dentist's scope of practice have dramatically expanded largely because of the improvements in restorative materials that have contributed to improved esthetics. Improved and expanded techniques have kept pace with the new materials. The use of implants and advances in orthognathic surgery have added to the armamentarium of the profession. The services available to patients, particularly in the field of cosmetic dentistry, have undoubtedly increased.

A concurrent increase in litigation has accompanied the expansion in services. The present legal environment has demonstrated that good professional care is not enough to prevent a lawsuit. Good records are part of good care. Patients are entitled to decide which procedures should be done and to have enough information to make an intelligent informed decision about them before the procedures are carried out. Documentation is essential in a lawsuit defense. Communication with patients to keep them informed about the care is essential. Because cosmetic dentistry is elective and evaluation of its results are rather subjective, special care must be taken to ensure that all legal preventive measures are followed when cosmetic dentistry is part of the treatment. Finally, good risk management is as important as good professional care. Without both, dentistry becomes a high-risk profession.





# CUSTOM STAINING

Kenneth W. Aschheim and Barry G. Dale

## FUNDAMENTALS OF CUSTOM STAINING

A fundamental understanding of hue, value, chroma, complementary hue, and the color wheel is essential before attempting custom staining (see Chapters 2 and 4).

### Dominant Hues

*Hue* is the name of the color. *Chroma* is the saturation or intensity of color (hue), therefore chroma can be present only when there is hue. *Value* is the relative whiteness or blackness of a color (hue). A light tooth has a high value; a dark tooth has a low value (for detailed definitions, see Chapter 2).

The dominant hue is the principle color of the "body" porcelain. Before custom staining is done, the dominant hue of a restoration must be determined. Shades are then altered from this baseline. The dominant shade is represented only in the middle one third of a tooth. The incisal edge usually is more translucent and the gingival one third more heavily stained.

**Known Shades.** If a standard shade is selected, a simple reference table can be used (Boxes A-1 and A-2).

**Unknown Shades.** Unknown shades should be evaluated under three different lighting situations or in the lighting situation most appropriate for the individual (see Chapter 2). Certain basic rules apply to the process of determining the dominant shade:

1. Avoid staring at a shade for a long period; the first glance usually is the most accurate.
2. The longer one stares at a shade, the grayer the shade appears to the eye.
3. Focus only on the middle one third of the tooth.

**CLINICAL TIP.** To aid in determining a shade, mask the incisal and gingival thirds of a tooth with white adhesive tape.

### Complementary Hues

The concept of complementary hues allows for certain clinically important modifications. Complementary hues are directly opposite one another on the color wheel (see Chapter 2).

1. When placed side by side, complementary hues appear to intensify each other. A green stain applied to the incisal edge of a red-dominant shade (e.g., Bioform B-65) intensifies the approximating dominant red hue.
2. When blended in equal amounts, complementary hues produce a neutral gray. If a red-dominant shade (e.g., Bioform B-65) is gradually overlapped with its complementary hue (green stain), a neutral gray eventually results. Other complementary pairs (violet-yellow and pink-green) produce similar results.
3. When complementary hues are blended in unequal proportions, the dominant hue will be reduced both in value (look grayer) and chroma (look less intense). When a red-dominant shade (i.e., Bioform B-65) is overlaid with a green stain (but not enough to completely neutralize the red), both the value and chroma of the red shade are reduced.

In dental stains a true red is difficult to achieve and seldom necessary, therefore pink is always substituted.



## BOX A-1

## DOMINANT HUE RANGE OF SELECTED BIOFORM PORCELAIN SHADES

B-51 Red-brown range	B-59 Yellow range	B-69 Red-gray range	B-91 Gray range
B-52 Yellow range	B-62 Red-gray range	B-77 Yellow range	B-92 Red-gray range
B-53 Red-brown range	B-63 Red-brown range	B-81 Red-gray range	B-93 Red-gray range
B-54 Red-brown range	B-65 Red-brown range	B-83 Red-brown range	B-94 Gray range
B-55 Yellow range	B-66 Red-gray range	B-84 Red-brown range	B-95 Gray range
B-56 Yellow range	B-67 Yellow range	B-85 Red-brown range	B-96 Gray range

Modified from the Trubyte Bioform Color Ordered Shade Guide, Vita Zahnfabrik, Bad Säckingen, Germany.

## BOX A-2

## DOMINANT HUE RANGE OF SELECTED VITA-LUMIN PORCELAIN SHADES

A-1 Orange range	B-1 Yellow range	C-1 Brown range	D-2 Orange range
A-2 Orange range	B-2 Yellow range	C-2 Brown range	D-3 Yellow range
A-3 Orange range	B-3 Yellow range	C-3 Brown range	D-4 Orange range
A-3.5 Orange range	B-4 Yellow range	C-4 Brown range	
A-4 Orange range			

## CHAIRSIDE STAINING

## Basic Principles

A few simple steps, meticulously adhered to, will produce optimal chairside staining results.

1. Apply chairside stains before glazing the ceramic.
2. Complete all anatomic and functional adjustment before applying stains.
3. Keep all brushes and instruments clean to avoid contamination.
4. Lay out the powders of the stains (the "feeder" supply) on the left side of a clean, dry, glazed porcelain palette.
5. Take care to avoid contaminating the "feeder" supply by accidentally mixing powders. Mix shades on the right side of the palette to avoid contamination.
6. Mix stains to a thick, toothpastelike consistency; this can be diluted later to the desired consistency.
7. If a feeder supply dries out, reconstitute it by adding the liquid medium.

**CLINICAL TIP.** Chairside stains should never be applied intraorally because an absolutely dry field is necessary.

## Applying Stains

## Armamentarium

## Basic staining setup

Stain kit (e.g., Ceramco Fine Grain Stain Kit, Ceramco, Inc.)  
 Glazing oven  
 Porcelain cleaning agent (e.g., Spar-Cling, Spartan Ceramic Studio) (if necessary)  
 Red sable brushes  
 Locking pliers or curved hemostat  
 Ceramic firing support  
 Shade guide

## Clinical Technique

1. Preheat the glazing oven to 1200° F (649° C).
2. Dilute the surface stains on the working side (right side) of the palette to a paintlike consistency to allow for easier transfer to the brush. The stain should neither drip nor run.
3. Wet a clean red sable brush with liquid medium, flick off the excess liquid, and draw the brush tip to a point.
4. Wash the crown with distilled water and thoroughly dry it with an oil-free air syringe or hair dryer.

**CLINICAL TIP.** If a restoration has been in the mouth for an extended period, bacteria may adhere to the porcelain surface. If bacteria are not completely removed, they can cause the porcelain to crack when it is heated in the glazing oven. Bacteria can be eliminated by soaking the restoration in a porcelain cleaning agent (e.g., Spar-Cling, Spartan Ceramic Studio).

5. Hold the restoration securely with locking pliers or a curved hemostat.

6. Apply the stain in a series of light dabbing motions

**CLINICAL TIP.** Do not overapply stain. You are looking for the effect of the stain, not the stain itself. Chroma can be controlled by avoiding excess powder in the mixture and by controlling the dispersion of the stain particles with the tip of the brush.

7. If the stain extends beyond the intended area, wipe the brush on a tissue until it is semidry and use the tip to absorb excess stain and medium.

**CLINICAL TIP.** Incorrect stains can be wiped off with a clean tissue, and new stain can be applied.

**CLINICAL TIP.** Two or three test stainings may be necessary before an acceptable result is obtained.

8. After the desired hue, value, and chroma have been obtained, place the restoration in front of the open door of the preheated glazing oven.
  9. Leave the restoration in place until the liquid medium has evaporated and a powdery film covers the stained surface.
  10. Place the restoration on a ceramic firing support.
  11. Gradually move the restoration into the oven.
  12. When the restoration is in place, close the oven door.
  13. Gradually increase the furnace temperature from 1200° F (649° C) to between 1650° and 1750° F (898° to 940° C) at a rate of 90° to 100° F (32° to 38° C) per minute. No vacuum is needed.
- CLINICAL TIP.** If high-temperature firing is undesirable (e.g., to avoid thermal stress in a fixed bridge), a lower temperature glaze or stain can be used. No vacuum is needed.
14. Upon completion, slowly remove the restoration from the furnace and allow it to bench cool.
  15. Evaluate the case intraorally.
  16. Repeat the above steps, if necessary. If necessary, the surface stain can be removed by gently grinding the restoration with a green stone.

## ADJUSTING HUE, CHROMA, AND VALUE

Shades should always be adjusted from lighter to darker. The converse can be accomplished only by applying a more opaque stain over the shade to be lightened. This rarely produces an esthetically satisfactory result.

## Adjusting Hue

In general, only minor adjustments to hue should be made with custom stains. Adjusting colors with complementary hues also decreases value. If major adjustments to hue are necessary, it is preferable to replace the porcelain with the proper shade.

### Armamentarium

Standard staining setup. See the section on applying stains earlier in this chapter.

### Clinical Technique

1. Determine the dominant hue of the existing restoration (the "original" hue) (e.g., Vita-Lumin D-2-orange) and the dominant hue to be achieved (the "desired" hue) (e.g., Vita-Lumin D-3-yellow).
2. Incrementally add sufficient amounts of the complementary hue to the appropriate areas of the restoration until the original hue is neutralized (e.g., the complementary hue of Vita Lumin D-2 is blue).
3. Apply the dominant hue of the desired hue (e.g., the dominant hue of Vita-Lumin D-3 is yellow) until the desired hue is obtained.

**CLINICAL TIP.** Steps 2 and 3 often can be combined into a single step. Because blue (step 2 above) and yellow (step 3 above) form green when mixed together, this procedure can be done in a single step if a properly proportioned green stain is used.

**CLINICAL TIP.** If the original hue contains no dominant hue (e.g., Bioform B-91), simply apply the desired stain.

4. After the desired result is obtained, fire and glaze the restoration. See the section on applying stains earlier in this chapter.

## Increasing Chroma

### Armamentarium

Standard staining setup. See the section on applying stains earlier in this chapter.

### Clinical Technique

1. Determine the dominant hue of the existing restoration (the "original" hue) (i.e., Vita-Lumin A-1-orange) and the dominant hue to be achieved (the "desired" hue) (i.e., Vita-Lumin A-4-orange).
2. Add the sufficient amount of dominant hue to the appropriate area of the restoration until the desired hue has been obtained (i.e., the dominant hue of Vita-Lumin A-1 is orange).

3. After the desired result has been obtained, fire and glaze the restoration. See the section on applying stains earlier in this chapter.

### Decreasing Chroma

#### Armamentarium

Standard staining setup. See the section on applying stains earlier in this chapter.

#### Clinical Technique

1. Determine the dominant hue of the existing restoration (the "original" hue) (i.e., Vita-Lumin A-4-orange) and the dominant hue to be achieved (the "desired" hue) (i.e., Vita-Lumin A-3.5-orange).
2. Apply the *complementary* hue to the original hue (i.e., the complementary hue of Vita-Lumin A-4 is blue) until the desired hue has been obtained.

**CLINICAL TIP.** Reducing chroma by applying the complementary hue also decreases value.

3. After the desired result has been obtained, fire and glaze the restoration. See the section on applying stains earlier in this chapter.

### Decreasing Value While Changing Hue

#### Armamentarium

Standard staining setup. See the section on applying stains earlier in this chapter.

#### Clinical Technique

1. Determine the dominant hue of the existing restoration (the "original" hue) (i.e., Bioform B-65-red-brown) and the dominant hue to be achieved, (the "desired" hue) (i.e., Bioform B-77-yellow).
2. Add a sufficient amount of the *complementary* hue to the appropriate area of the restoration until the original hue has been neutralized. This also lowers the value (e.g., the complementary hue of Bioform B-65 is green).

**CLINICAL TIP.** If overcorrection occurs, the complementary hue can be neutralized by adding a small amount of the original dominant hue. This also will reduce the value of the final restoration. Therefore it usually is better to remove all stain and start over.

3. Add the dominant hue (i.e., the dominant hue of Bioform B-77 is yellow) until the desired hue has been obtained.

4. After the desired result has been obtained, fire and glaze the restoration. See the section on applying stains earlier in this chapter.

### Decreasing Value Without Changing Hue

#### Armamentarium

Standard staining setup. See the section on applying stains earlier in this chapter.

#### Clinical Technique

1. Determine the dominant hue of the existing restoration (the "original" hue) (e.g., Bioform B-65-red-brown).
2. Add a sufficient amount of the *complementary* hue to the appropriate area of the restoration until the original hue has been neutralized. This also lowers the value (e.g., the complementary hue of Bioform B-65 is green).
3. Reapply the *dominant* hue of the original hue (i.e., the dominant hue of Bioform B-65 is red-brown), if necessary. Because this is applied over the previously neutralized hue, the "added gray" serves to reduce the value without changing the hue.
4. After the desired result has been obtained, fire and glaze the restoration. See the section on applying stains earlier in this chapter.

## ADJUSTING TRANSLUCENCY

Translucency is the ability of material to allow light transmission. The greater the amount of light transmitted, the greater the "real" translucency. In custom staining, an illusion of translucency can be created called "apparent" translucency.

### Increasing Real Translucency

Because real translucency is a quality of the material used, it is impossible to increase real translucency with surface stains.

### Decreasing Real Translucency

Decreasing real translucency is the same as increasing opacity. This usually is accomplished by applying a white stain. This opaque stain can be adjusted to more closely match the desired shade by applying other stains on top of the opaque layer.

### Increasing Apparent Translucency

Adjustments in translucency are most often required at the incisal edge of the tooth. Changes in apparent

translucency are accomplished by altering the amount of blue stain in the incisal area.

**CLINICAL TIP.** Variants of blue, such as blue-violet or blue-green, often must be used to adjust translucency because they contain complementary hues that neutralize excess amounts of yellow or pink, which may be visible in the incisal area.

#### Armamentarium

Standard staining setup. See the section on applying stains earlier in this chapter.

#### Clinical Technique

1. Examine the incisal area closely for excess pink, red, or yellow.
2. If pink or red is present, select a blue-green stain.
3. If yellow is present, select a blue-violet stain.
4. Apply the stain to the incisal area.

**CLINICAL TIP.** When placed side by side, complementary colors intensify each other. To further increase the apparent translucency, "rim" the incisal edge with yellow/orange (the complement of violet/blue) or white.

5. After the desired result has been obtained, fire and glaze the restoration. See the section on applying stains earlier in this chapter.

### Decreasing Apparent Translucency

A decrease in apparent translucency is accomplished by decreasing the amount of blue by applying its complementary hue, orange. In theory this also decreases value, but because the hues are so dilute, any perceivable change in value is unlikely.

**CLINICAL TIP.** Translucency alterations are subtle effects. Do not overapply the stain. Begin with very dilute amounts of orange and light applications.

### Adjusting the Incisal-Gingival Blend

Often the shade and translucency of a tooth are correct, but the proportion of body shade to incisal translucency is incorrect. The incisal area can be altered by changing the surface area of apparent translucency. If the incisal area must be lengthened, the appropriate amount of dominant body hue should be neutralized with the complementary hue. If the incisal area is too long, a stain should be blended to match the body shade.

**CLINICAL TIP.** If the dominant hue of the tooth is yellow and the blue incisal area is pronounced, the resultant hue in the incisal area that is being altered may have a greenish tint. If this is unesthetic, it can be neutralized with a small amount of violet stain.

## CHARACTERIZATION OF TEETH

Truly esthetic restorations often require the duplication of flaws that exist in adjacent teeth. As patients age, their dentition changes and they may wish to have these imperfections duplicated. Characterization is accomplished with the use of opaque white, brown-gray, and black stains. It sometimes is easier to use a sharp-edged instrument, a trimmed fine point brush, or a single bristle to apply these stains.

**CLINICAL TIP.** Characterization should be visible but not glaringly obvious. Some applications may be so subtle that one is barely aware of the effect.

Although variations in tooth characterization are limitless, certain types are quite common.

### Decalcification

Decalcified areas are common and easy to reproduce.

#### Armamentarium

- Standard staining setup. See the section on applying stains earlier in this chapter.

#### Clinical Technique

1. Mix the white stain to a moderately thick consistency.
2. Place the white stain with a brush or pointed instrument.

**CLINICAL TIP.** Vary the opacity within the opaque area to create a more realistic decalcification effect.

**CLINICAL TIP.** If additional areas of decalcification are required on the same tooth, differ the shapes and depths of opacity.

3. After the desired result has been obtained, fire and glaze the restoration. See the section on applying stains earlier in this chapter.

### Enamel Cracks and Checks

Enamel cracks are thin white lines that begin at the incisal edge and extend less than one third the length of the tooth. They generally occur in younger patients. Over time these cracks discolor, and they then are termed *enamel checks*. They range in shade from orange to brown,

sometimes with a grayish cast. Cracks and checks often cast a slight shadow along their length.

#### Armamentarium

- Standard staining setup. See the section on applying stains earlier in this chapter.

#### Clinical Technique

1. To create a crack, mix a white stain to a moderately thick consistency. For a check, use orange, brown, or gray stain.
2. Press a wetted brush against the porcelain palette to form a flat, "chisel" edge.
3. After picking up the stain, run the "chisel" edge of the brush from a point one third of the way up the tooth toward the incisal edge. This should be done in a single, fast, light stroke.

**CLINICAL TIP.** A sharp edge, a single bristle, or a pointed instrument may be used instead of a brush.

4. If the line is too thick or uneven, clean and "point" the brush, wipe it semidry, and run the point along the side of the "line" to remove excess stain.
5. After a line with the proper thickness has been created, clean the brush, reform the "chisel edge," and create a shadow effect by running a faint black line along one side of the white "crack."
6. After the desired result has been obtained, fire and glaze the restoration. See the section on applying stains earlier in this chapter.

#### *Stained Composite Resin or Silicate Restorations*

Old anterior restorations tend to be opaque and usually are discolored. In addition, they often exhibit marginal staining.

#### Armamentarium

- Standard staining setup. See the section on applying stains earlier in this chapter.

#### Clinical Technique

1. Determine the dominant hue of the restoration.

2. Mix a white stain to a moderately thick consistency to reduce the tendency of the material to run.
3. With a brush or instrument, create the simulated restoration with the white stain as a base and add gray, black, or other appropriate hues until the dominant hue of the restoration has been approximated.
4. Use orange or brown stain to precisely outline the restoration.

**CLINICAL TIP.** In younger patients with light translucent teeth, a hairline of black or gray stain may be used as an outline.

5. If discoloration is desired, use a brush to form an uneven halo of orange-brown-gray. The discoloration should not abut the outline, but should fade out in a narrow, uneven, feathery pattern.

**CLINICAL TIP.** Reflected undermining of teeth may be simulated by applying gray or brown stain, either individually or blended together in a semihalo effect on the incisal portion of the simulated restoration.

6. After the desired result has been obtained, fire and glaze the restoration. See the section on applying stains earlier in this chapter.

#### *Random Discolorations*

One type of characterization consists of slight intensifications of chroma in random areas of the tooth surface. This sometimes is accompanied by a slight change of hue. By varying the amount of medium used to dilute the stains, different degrees of discoloration can be produced.

#### *Pits and Fissures*

Characterization of pits and fissures is usually restricted to older patients. It is accomplished by applying thin orange or brown lines to the fissures, grooves, and pits. It is also possible to replicate worn enamel edges of mandibular anterior teeth by using an orange-brown or brown stain to mimic exposed dentin.





# NINETY-SECOND RUBBER DAM PLACEMENT

Barry G. Dale

**I**t is highly unlikely that a dentist would be faulted for routinely using a rubber dam. Few procedures in dentistry are more universally accepted. Ironically, the infrequency of rubber dam use demonstrates that few dental procedures are more universally rejected as well.'

This paradox is further complicated by the reasons given for the rejection of rubber dam placement as a routine part of the daily practice of dentistry. Those who shun the technique cite patient disapproval, inconvenience, lack of necessity, and additional time requirements as the rationale for rejection! Advocates hold diametrically opposing views, indicating patient preference, work simplification and convenience, necessity, and an overall time savings.<sup>1,3-5</sup>

The dental student's early experiences with rubber dam application often are negative because of a typical and expected lack of manual dexterity. The virtually total avoidance of rubber dam use, except during endodontic therapy, routinely begins immediately upon graduation.

A simplified technique, along with the average practitioner's naturally acquired manual adeptness, allows placement of the rubber dam in 90 seconds or less to be a quickly attainable reality. With a minimum of practice, placement time can be reduced even further. The average application time (isolating an average of 4.6 teeth) of five private practitioners who routinely used rubber dam was 50.7 seconds.'

## RUBBER DAM CLAMP SELECTION

Selection of a rubber dam clamp can be confusing because of the vast array of available clamp sizes and styles.

The basic assortment presented in Table B-1, however, can accommodate virtually every clinical situation.

### Armamentarium

- 6 X 6-inch rubber dam, medium gauge (e.g., Dental Dam, The Hygenic Corp.; Rubber Dam, Miles, Inc. Dental Products)
- 5 X 5-inch metal U-shaped rubber dam frame
- Rubber dam hole punch
- Rubber dam hole placement template or rubber stamp (e.g., from The Hygenic Corp.; Miles, Inc. Dental Products)
- Unwaxed regular dental floss (e.g., Johnson & Johnson)
- Rubber dam clamp assortment (see Table B-1)
- Rubber dam clamp forceps

### Clinical Technique

The approximate time required to perform each step is indicated at the end of the description.

1. Punch a double hole in the rubber dam at the point corresponding to the tooth to be clamped. For a single occlusal restoration, clamp only the tooth to be restored and skip to step 3. For a single multiple-surface tooth restoration or when restoring more than one tooth, clamp at least one tooth distal to the tooth to be restored, if possible. (3 seconds)

**CLINICAL TIP.** Punching a double-sized hole facilitates the placement of the rubber dam around the clamp (Fig. B-1).



Winged type	Wingless type	Indication
14A	W14A	Most adult molars
14	W14	Small adult molars, adult premolars, and primary molars
8A	W8A	More aggressive clamp for adult molars
1	W1	Mandibular anterior teeth
211	212	Maxillary and mandibular anterior teeth (Class V restorations)

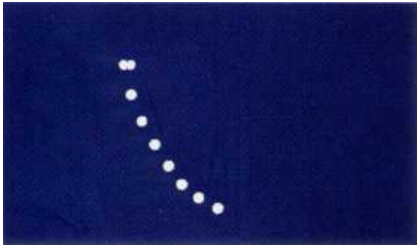


Fig. B-1. A double hole corresponding to the tooth to be clamped facilitates placement of the rubber dam.

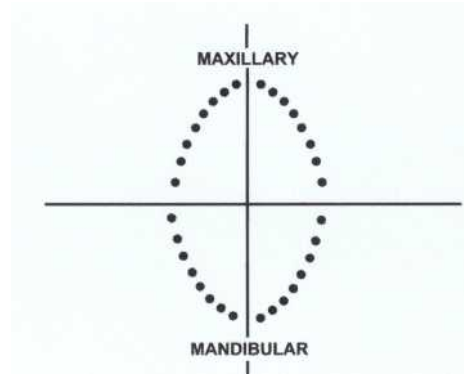


Fig. B-3. A rubber dam template aids in determining the proper position for the holes.

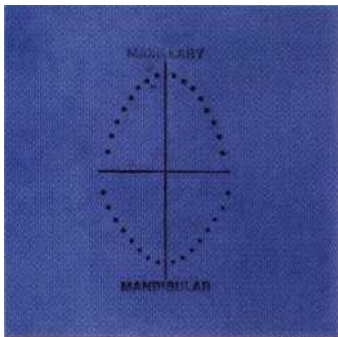
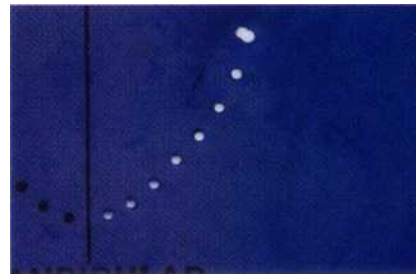

Fig. B-2. A rubber dam stamp aids in determining the proper position for the holes.




*Fig. B-4. Normally, floss and rubber dam material can easily be passed through the interproximal contact areas of the incisor teeth. Therefore extending isolation to include one central incisor facilitates placement of the rubber dam.*

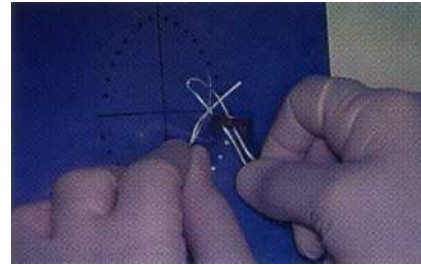
2. Punch single holes corresponding to the positions of the teeth to be isolated (see Fig. B-1). A rubber dam stamp (Fig. B-2) or rubber dam template (Fig. B-3) is helpful for properly positioning the holes. (7 seconds)

**CLINICAL TIP.** When isolating several teeth, always extend isolation to include one central incisor. This significantly increases the efficiency of rubber dam placement because the interproximal contact areas of the incisor teeth usually are not resistant to the passage of the rubber dam material (Fig. B-4).

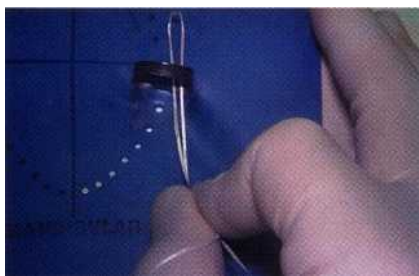3. Position the double hole in the rubber dam over the bow of the clamp. Push the bow through the hole (Fig. B-5). The open end of the clamp should face mesially. (5 seconds)
4. Tie dental floss to the bow of the rubber dam clamp. (5 seconds)




*Fig. B-5. The rubber dam clamp is positioned in the rubber dam with the open end of the clamp facing mesially.*



*Fig. B-7. Both ends of the floss are brought over the bow of the rubber dam clamp and through the loop of floss.*



*Fig. B-6. A loop of dental floss is placed under the bow of the rubber dam clamp.*



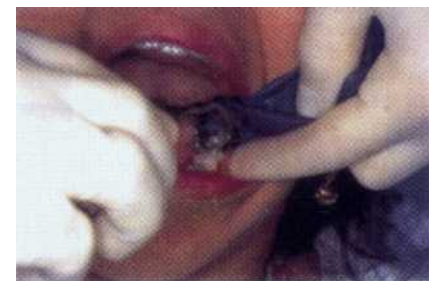*Fig. B-8. The floss is securely tightened in the center of the bow.*

**CLINICAL TIP.** The following ligation is easily placed and is more easily removed than a square knot:

1. Place a **loop of floss under the** bow of the rubber dam clamp (Fig. B-6).
2. Bring both free ends of the **floss** over the bow of the rubber dam clamp and through the loop of floss (Fig. B-7).
3. Tighten the floss securely in the center of the bow (Fig. B-8).

**CLINICAL TIP.** Do not ligate the clamp through the holes that often are found on the wings of the clamp. Ligation in this area complicates placement of the rubber dam.

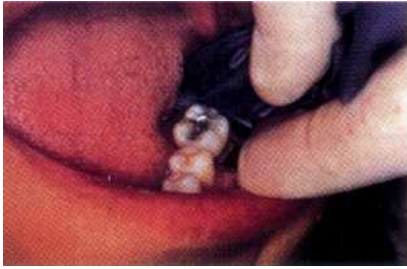5. Attach the rubber dam clamp to the rubber dam clamp forceps. Hold the forceps with the dominant hand (e.g., the right hand for right-handed dentists) and gather the rubber dam material with the other



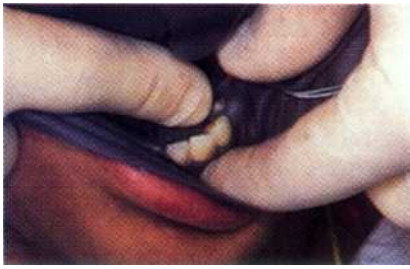*Fig. B-9. After the rubber dam clamp has been attached to the rubber dam clamp forceps, the forceps are held with the dominant hand (e.g., the right hand for right-handed dentists) and the rubber dam material is gathered with the other hand. The "teeth" of the rubber dam clamp should be readily visible.*

- hand so that the "teeth" of the rubber dam clamp are readily visible (Fig. B-9). (5 seconds)
6. Place the clamp on the appropriate tooth (Fig. B-10). (5 seconds)





*Fig. B-10. The rubber dam clamp is placed on the appropriate tooth.*



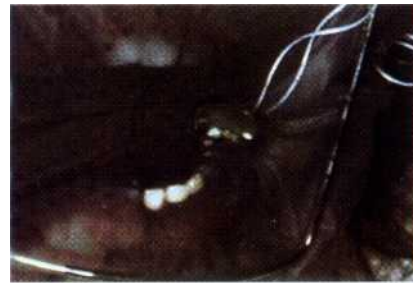*Fig. B-11. Typically at least one of the anterior interproximal contact areas will readily allow the passage of rubber dam material without the necessity of using dental floss. Often all three anterior teeth can be isolated with one quick maneuver.*

**CLINICAL TIP.** Mandibular *teeth:* If lingual anesthesia has been achieved along with mandibular block anesthesia, position the "teeth" of the rubber dam clamp onto the lingual surface of the tooth. Then gently slide the clamp onto the buccal surface. This sequence provides increased control of clamp placement in the area of the unanesthetized buccal gingiva. Maxillary *teeth:* If buccal anesthesia has been achieved, position the "teeth" of the rubber dam clamp onto the buccal surface of the tooth. Then gently slide the clamp onto the palatal surface. This sequence provides increased control of clamp placement in the area of the unanesthetized palatal gingiva.

7. For single tooth isolation, skip to step 8. For all other situations, position the most anterior three holes of the rubber dam over the corresponding anterior teeth. Attempt to slip the rubber dam through the interproximal contact areas of all three teeth in a single quick maneuver (Fig. B-11). Usually at least one of the anterior contact areas will permit easy passage of the dam material and often all three teeth can be isolated with one quick maneuver. Do not use dental floss at this time. (5 seconds)



*Fig. B-12. Modern rubber dam material can be stretched to the thinness of dental floss and still resist tearing while being "worked" through the interproximal contacts. This is the key to efficient rubber dam placement.*



*Fig. B-13. The rubber dam frame is positioned.*

**CLINICAL TIP.** The key to rapid placement of a rubber dam is the flexibility and tear resistance of modern rubber dam material. It can be stretched to the thinness of dental floss and used as such (Fig. B-12).

**CLINICAL TIP.** If a template or rubber dam stamp was not used, the holes may be properly spaced relative to one another, but the "arch" of holes may be improperly positioned within the square of rubber dam. Use of a 5 X 5-inch frame and a 6 X 6-inch rubber dam sheet may compensate for this error.

8. Position the rubber dam frame (Fig. B-13).  
(5 seconds)

**CLINICAL Tip.** This placement sequence allows for the positioning of the rubber dam frame as soon as possible. Once the frame is in place, rubber dam placement becomes significantly easier and more efficient because unobstructed visibility is assured and both hands are free.

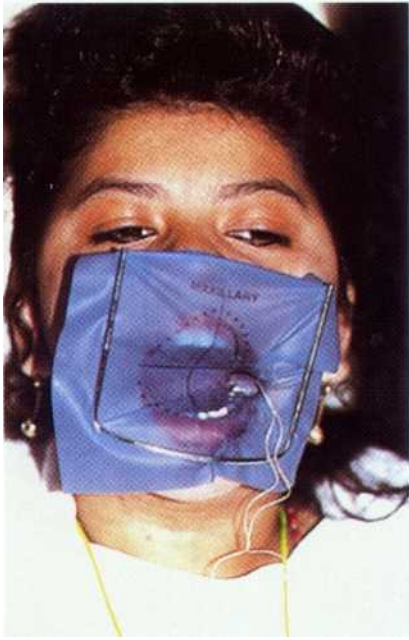

Fig. B-14. The rubber dam covers the patient's nose.

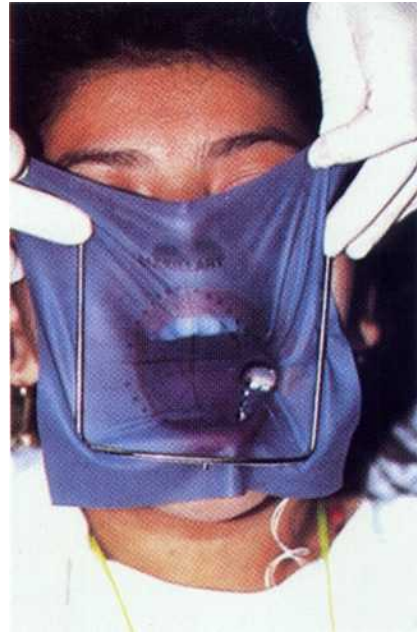

Fig. B-16. The rubber dam material is stretched over the nose.

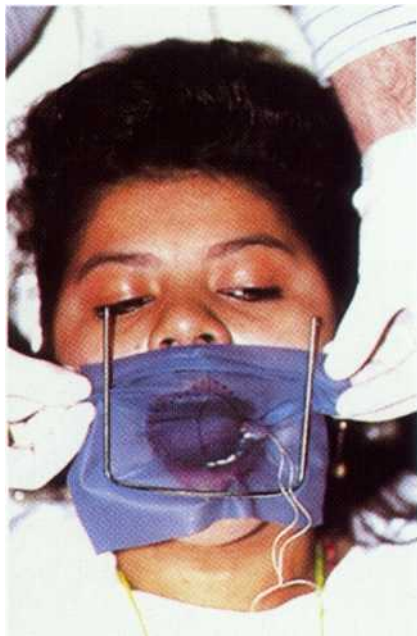

Fig. B-15. The rubber dam is released from the top retaining pins of the rubber dam frame.

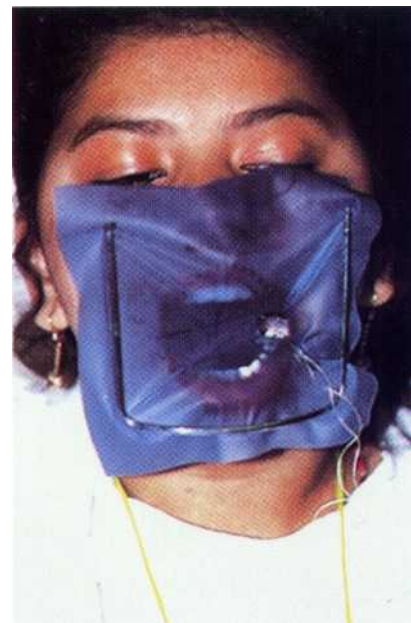

Fig. B-17. The rubber dam material is reattached to the rubber dam frame.

9. Fold any excess rubber dam material that contacts the nose under the top of the rubber dam frame (Fig. B-14). If the material still covers the nose, perform the following steps:

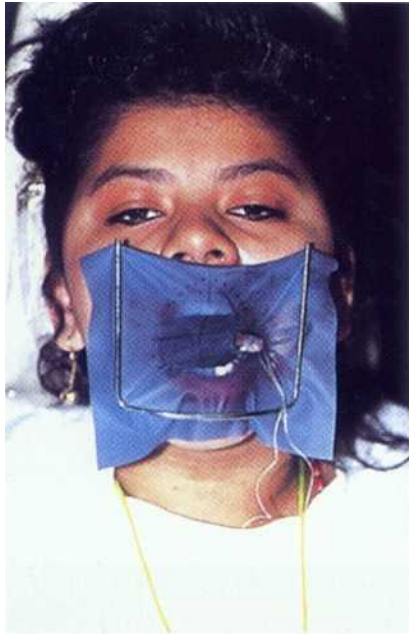A. Release the rubber dam material from the top right and left retaining pins (Fig. B-15).

B. Momentarily stretch an additional amount of rubber dam material over the nose (Fig. B-16) and reattach the rubber dam to the frame (Fig. B-17).

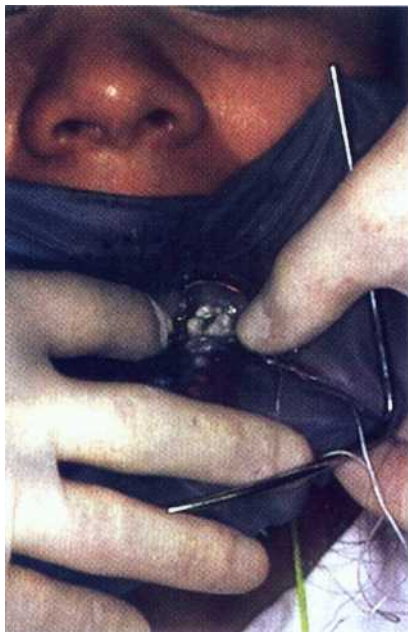C. Fold the excess rubber dam material under the top of the frame. The additional bulk of rubber

dam material will now remain in the proper position (Fig. B-18). (5 seconds)

10. Slip the rubber dam over the wings of the rubber dam clamp (Fig. B-19). (2 seconds)
11. Isolation for a single occlusal restoration is now complete. For all other restorations, attempt to position



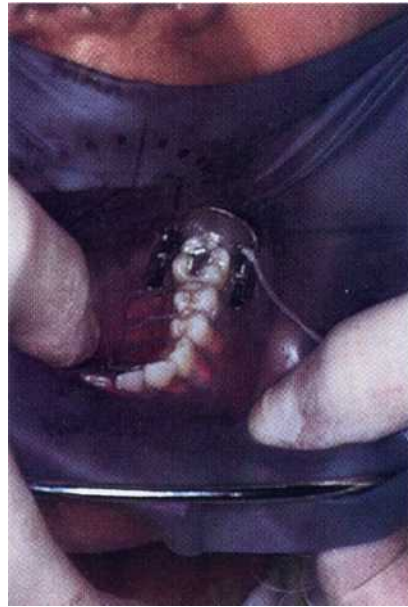*Fig. B-18.* The rubber dam material is folded under the top of the frame. The additional bulk of rubber dam material will now remain in place.



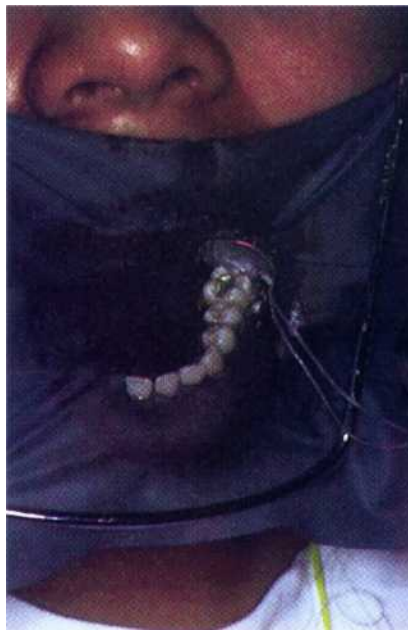*Fig. B-19.* The rubber dam is slipped over the wings of the rubber dam clamp.

the remaining rubber dam material through all of the remaining contact areas in a single quick maneuver. Do not use dental floss at this time. (3 seconds)

12. Forcefully attempt to pass the material through any individual resistant contact areas without using dental floss. Stretch the material until it is as thin as dental



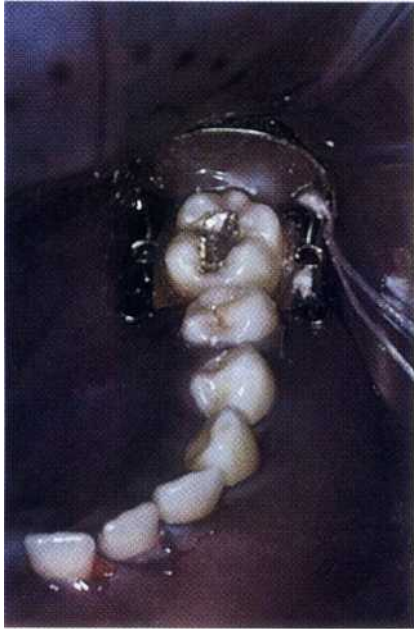
*Fig. B-20.* The rubber dam material is stretched to the thinness of dental floss and forcefully "worked," using a sawing motion, through the interproximal contact areas.



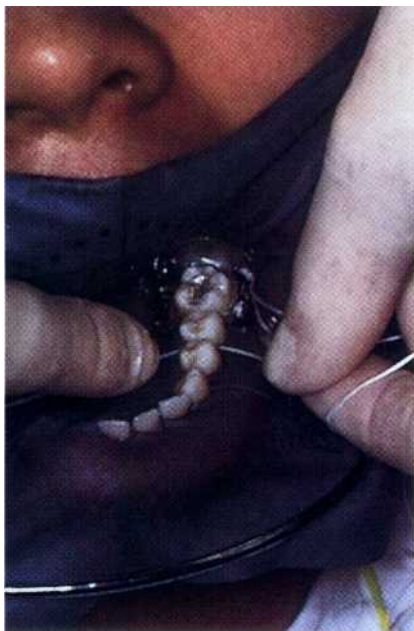*Fig. B-21.* Most interproximal contact areas have been negotiated without the use of dental floss.

floss (Fig. B-20) and use a sawing motion to work it through the interproximal contact area as if it were dental floss (Figs. B-21 and B-22). (10 seconds)

**CLINICAL TIP.** Avoiding the use of dental floss at this time is an important timesaving strategy.



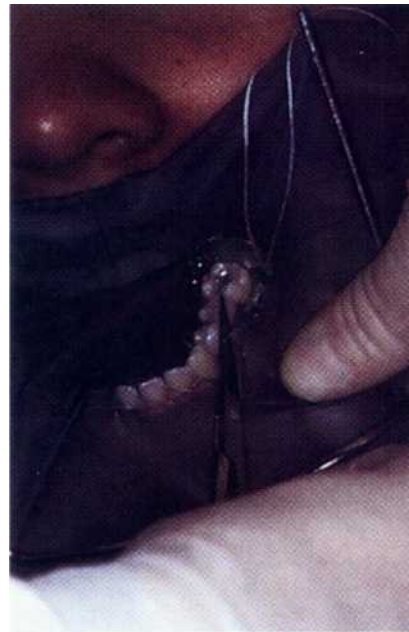*Fig. B-22.* In this case, placement through the contact area between the first and second premolars requires dental floss.



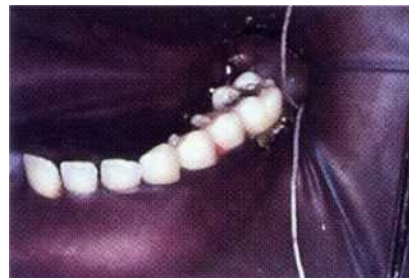*Fig. B-23.* Dental floss is used to position the rubber dam material between the premolars.

13. Use dental floss to position any remaining rubber dam material that could not be negotiated through the corresponding contact areas (Fig. B-23). (15 seconds)

14. Use scissors to cut any rubber dam material (Fig. B-24) that could not be negotiated through the corresponding contact area (Fig. B-25). (15 seconds)  
Total time: 90 seconds



*Fig. B-24.* The rubber dam material corresponding to any impenetrable interproximal contact areas can be cut.



*Fig. B-25.* Cutting the rubber dam material usually does not result in a clinically significant loss of isolation.

## RUBBER DAM INVERSION

It sometimes is necessary to invert the rubber dam into the gingival sulcus to achieve better isolation and visibility (Fig. B-26). This is easily accomplished in the following manner:

1. Stretch the rubber dam buccally so that it does not contact the cervical areas of the teeth.
2. Dry the teeth with compressed air (Fig. B-27).
3. Slowly release the tension on the rubber dam until it contacts the teeth. The dam usually will "self-invert" (Fig. B-28).
4. Any areas that do not self-invert can be properly positioned with a flat-ended plastic instrument (Fig. B-29).

## PATIENT REACTIONS TO RUBBER DAM USE

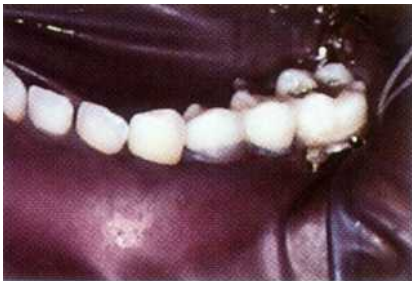In a preliminary study, patients were asked to indicate their reactions to the use of a rubber dam during operative procedures compared with similar procedures performed without a rubber dam. More than 87% preferred or were neutral about the use of a rubber dam. Rubber

dam use therefore may be a practice builder, especially when it is presented favorably.

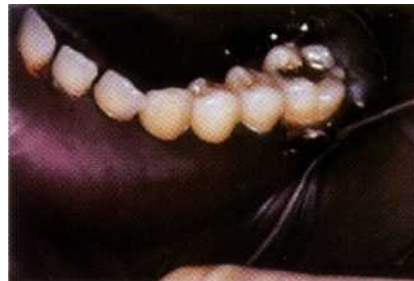The following introductory statements can further reinforce a positive patient response to rubber dam use:

1. The rubber dam prevents tooth structure, decay, debris, and restorative material from being swallowed.
2. The rubber dam prevents moisture contamination, which can adversely affect the properties and longevity of the medicaments and restorative materials.
3. By virtue of its elasticity, the rubber dam reduces the muscle fatigue associated with maintaining an open mouth posture.
4. The rubber dam allows the patient to breathe through both the mouth and the nose. The rubber dam is watertight only around the individual teeth.
5. The rubber dam merely "muffles" the patient's speech, as when a napkin is held to the mouth; verbal communication is still possible.

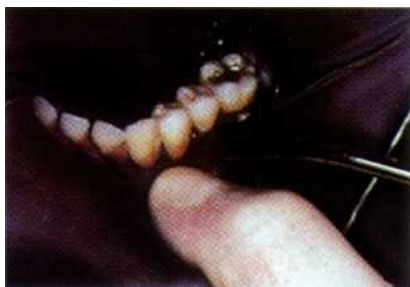**CLINICAL TIP.** The napkin analogy is particularly useful because it relates the rubber dam to a common, non-threatening, helpful object.



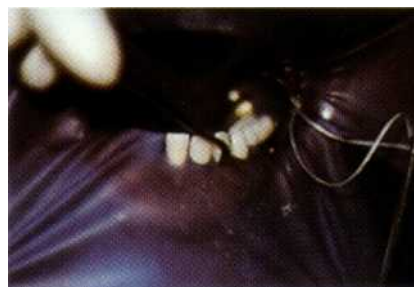*Fig. B-26.* The rubber dam material is not properly inverted around the first and second premolars.



*Fig. B-28.* When the rubber dam material is slowly released, it "self-inverts" into the gingival sulcus.



*Fig. B-27.* The rubber dam material is stretched away from the cervical area. A stream of air is directed at the cervical region of the first premolar until the area is dry.



*Fig. B-29.* A plastic instrument is used to invert the rubber dam material if the above sequence is not successful.





6. The rubber dam clamp should be referred to as a "ring." The sensation caused by clamp placement should be described as "tight and secure."

### REFERENCES

1. Going R, Sawinski V: Parameters related to use of rubber dam, *J Am Dent Assoc* 77:598, 1968.
2. Going R, Sawinski V: Frequency of use of the rubber dam: a survey, *J Am Dent Assoc* 75:158, 1967.
3. Stebner CM: Economy of sound fundamentals in operative dentistry, *J Am Dent Assoc* 49:294, 1954.
4. Ireland L: The rubber dam: its advantages and application, *Texas Dent J* 80:6, 1962.
5. Dale BG: Unpublished data.



انتشارات شایان نمودار



# SMILE ANALYSIS

Barry G. Dale and Kenneth W. Aschheim

## USING THE SMILE ANALYSIS

The smile analysis is an effective patient education and marketing aid. The analysis form can be filled out in the reception area or in the operatory before treatment, or it can be mailed to the patient along with an appointment

reminder. A "yes" or "unsure" response on the form indicates an area that requires further evaluation for possible treatment. When completed, the smile analysis form becomes part of the patient's permanent record.

## Smile Analysis

Patient Name: \_\_\_\_\_

Please look into a mirror and evaluate the following:

### Number

How many teeth are visible in a full smile (circle correct number)? 2 4 6 8 10 12

### Color

	yes	no	unsure		yes	no	unsure
Are your teeth:				too brown?	<input type="checkbox"/>	<input type="checkbox"/>	<input type="checkbox"/>
too yellow?	<input type="checkbox"/>	<input type="checkbox"/>	<input type="checkbox"/>	too uneven in color?	<input type="checkbox"/>	<input type="checkbox"/>	<input type="checkbox"/>
too dark?	<input type="checkbox"/>	<input type="checkbox"/>	<input type="checkbox"/>	too discolored?	<input type="checkbox"/>	<input type="checkbox"/>	<input type="checkbox"/>
too spotted?	<input type="checkbox"/>	<input type="checkbox"/>	<input type="checkbox"/>	too light	<input type="checkbox"/>	<input type="checkbox"/>	<input type="checkbox"/>
too grey	<input type="checkbox"/>	<input type="checkbox"/>	<input type="checkbox"/>	Do your teeth have unattractive fillings or restorations?	<input type="checkbox"/>	<input type="checkbox"/>	<input type="checkbox"/>

### Position

	yes	no	unsure
Are your teeth too crowded?	<input type="checkbox"/>	<input type="checkbox"/>	<input type="checkbox"/>
Do your teeth have spaces between them?	<input type="checkbox"/>	<input type="checkbox"/>	<input type="checkbox"/>
If your teeth have spaces between them how many spaces (circle correct number)?			
	1	2	3 4 5 6



<b>Size</b>					yes	no	unsure
Are your teeth:							
too long?					<input type="checkbox"/>	<input type="checkbox"/>	<input type="checkbox"/>
too wide?					<input type="checkbox"/>	<input type="checkbox"/>	<input type="checkbox"/>
too large?					<input type="checkbox"/>	<input type="checkbox"/>	<input type="checkbox"/>
Are your two upper center front teeth the same length or shorter than the two neighboring teeth?					yes	no	unsure
too short?					<input type="checkbox"/>	<input type="checkbox"/>	<input type="checkbox"/>
too narrow?					<input type="checkbox"/>	<input type="checkbox"/>	<input type="checkbox"/>
too small?					<input type="checkbox"/>	<input type="checkbox"/>	<input type="checkbox"/>

<b>Shape</b>					yes	no	unsure
Are your teeth unattractively shaped?					<input type="checkbox"/>	<input type="checkbox"/>	<input type="checkbox"/>
Are your teeth:	yes	no	unsure				
too square?	<input type="checkbox"/>	<input type="checkbox"/>	<input type="checkbox"/>	too rounded?	<input type="checkbox"/>	<input type="checkbox"/>	<input type="checkbox"/>
too irregular in shape?	<input type="checkbox"/>	<input type="checkbox"/>	<input type="checkbox"/>	Other?	<input type="checkbox"/>	<input type="checkbox"/>	<input type="checkbox"/>

<b>Gums</b>					yes	no	unsure
Do you show too much gum tissue (gummy smile)?					<input type="checkbox"/>	<input type="checkbox"/>	<input type="checkbox"/>
Are your gums red and/or swollen?					<input type="checkbox"/>	<input type="checkbox"/>	<input type="checkbox"/>
Does the shape of the gums surrounding the teeth appear unattractive?					<input type="checkbox"/>	<input type="checkbox"/>	<input type="checkbox"/>

Please list anything else about your smile that you wish to discuss:

---



---



---

Signature: \_\_\_\_\_ Date: \_\_\_\_\_


(Copyright 1992-2000 Barry G. Dale, D.M.D. and Kenneth W. Aschheim, D.D.S.)



# SAMPLE LEGAL FORMS

Copies of these forms may be downloaded from the following web site: [www.redwoodsgroup.com](http://www.redwoodsgroup.com). Those without access to the World Wide Web may call 800-237-9429 to request additional forms.

## Medical-Dental History



Patient's Name \_\_\_\_\_

DOB    /    /    SSN

The following information is essential for this office to provide dental care in a manner that is compatible with your general health. Your cooperation in providing accurate information is necessary to meet your dental needs safely and efficiently. Incorrect information can be dangerous to your health.

### Medical History

- Write the answer to each question in the space provided.
- If the question is not understood, you are not certain of the answer, or have any question, indicate so in the space, and discuss the matter with the doctor.
- All questions must be answered.
- Use black ink or ball point pen.

Name of Physician \_\_\_\_\_ Phone \_\_\_\_\_

Address \_\_\_\_\_

Date of Last Visit \_\_\_\_\_ Reason For Last Visit \_\_\_\_\_

1. Are you currently under the care of a physician? If yes, for what reason or condition? \_\_\_\_\_

2. Are you currently taking any medication? If yes, for what reason or condition? \_\_\_\_\_

### Have You Ever Had Or Been Treated For:

3. Rheumatic fever, rheumatic heart disease, heart murmur or congenital heart disease? \_\_\_\_\_

4. Heart trouble, heart attack, angina, heart surgery, a pacemaker, or irregular beats? \_\_\_\_\_

5. Stomach or intestinal disease? \_\_\_\_\_

6. Abnormal blood pressure, excessive bleeding, or anemia? \_\_\_\_\_

- 7. Breathing problems, asthma, tuberculosis, or hay fever? \_\_\_\_\_
- 8. Cancer, X-ray treatments, or chemotherapy? \_\_\_\_\_
- 9. Diabetes? \_\_\_\_\_
- 10. Hepatitis, jaundice, or liver disease? \_\_\_\_\_
- 11. Kidney problems or renal dialysis? \_\_\_\_\_
- 12. Venereal disease or AIDS? \_\_\_\_\_
- 13. A stroke, convulsions, or fainting spells? \_\_\_\_\_
- 14. Tumors or growths? \_\_\_\_\_
- 15. Arthritis or rheumatism? \_\_\_\_\_
- 16. Allergic reactions to medications? \_\_\_\_\_
- 17. Have you ever had a major operation? If yes, describe. \_\_\_\_\_
- 18. Have you ever had a serious injury to your head or neck? If yes, describe. \_\_\_\_\_
- 19. Are you on a special diet? If yes, for what reason and describe. \_\_\_\_\_
- 20. Do you smoke? If yes, describe type and quantity. \_\_\_\_\_
- 21. Have you consulted or been treated by a psychiatrist, psychologist or counselor? If yes, describe. \_\_\_\_\_
- 22. Are there any other problems about your health of which you are aware? \_\_\_\_\_
- 23. For women: are you pregnant? \_\_\_\_\_

*Dental History*

Date of your last visit to a dentist \_\_\_\_\_  
Reason for your last visit (or series of visits) \_\_\_\_\_  
Do you have any of your X-rays or dental records? \_\_\_\_\_

**In respect to any previous dental treatment have you:**

- 24. Ever fainted? \_\_\_\_\_
- 25. Had an allergic reaction? \_\_\_\_\_
- 26. Had abnormal bleeding? \_\_\_\_\_
- 27. Any other complications during or following dental treatment? If yes, describe. \_\_\_\_\_
- 28. Do your gums bleed on brushing or eating? \_\_\_\_\_
- 29. Does food catch between your teeth? \_\_\_\_\_
- 30. Have your teeth shifted, are there spaces between your teeth now where there were none, are your teeth flaring, or are some of your teeth becoming loose? \_\_\_\_\_



## History Updates

Date: \_\_\_\_\_

I have reviewed the attached MEDICAL HISTORY. My general health status and medication has changed as follows (if no change, write "NO CHANGE"):

\_\_\_\_\_

Person Completing The Update: Signature \_\_\_\_\_  
Print Name \_\_\_\_\_

If other than the patient, indicate relationship: \_\_\_\_\_

Update reviewed by Dr. \_\_\_\_\_

Date: \_\_\_\_\_

I have reviewed the attached MEDICAL HISTORY. My general health status and medication has changed as follows (if no change, write "NO CHANGE"):

\_\_\_\_\_

Person Completing The Update: Signature \_\_\_\_\_  
Print Name \_\_\_\_\_

If other than the patient, indicate relationship: \_\_\_\_\_

Update reviewed by Dr. \_\_\_\_\_

Date: \_\_\_\_\_

I have reviewed the attached MEDICAL HISTORY. My general health status and medication has changed as follows (if no change, write "NO CHANGE"):

\_\_\_\_\_

Person Completing The Update: Signature \_\_\_\_\_  
Print Name \_\_\_\_\_

If other than the patient, indicate relationship: \_\_\_\_\_

Update reviewed by Dr. \_\_\_\_\_

Date: \_\_\_\_\_

I have reviewed the attached MEDICAL HISTORY. My general health status and medication has changed as follows (If no change, write "NO CHANGE"):

\_\_\_\_\_

Person Completing The Update: Signature \_\_\_\_\_  
Print Name \_\_\_\_\_

If other than the patient, indicate relationship: \_\_\_\_\_

Update reviewed by Dr. \_\_\_\_\_

## Request for Release of Health Information

I, \_\_\_\_\_, hereby grant permission to  
(Print Name)

\_\_\_\_\_  
(Print Name of Doctor or Hospital)  
to release information related to my health history, status, and treatment, and copies of my health record, X-rays, and any test results to;

At \_\_\_\_\_

Signature \_\_\_\_\_ Date \_\_\_\_\_  
(If a minor, parent or guardian must sign)

© Budmor Enterprises Ltd. 1987  
All Rights Reserved

## Permission to Take Photographs, Slides, & Videos

I, (print name) \_\_\_\_\_, hereby  
authorize Dr. (print name) \_\_\_\_\_ to take photographs,  
slides, and/or videos of my face, jaws, and teeth.  
I understand that the photographs, slides, and/or videos will be used as a record of my care, and  
may be used for educational purposes in lectures, demonstrations, and professional publications.  
I further understand that if the photographs, slides, and/or videos are used in any publication,  
or as part of a demonstration, reasonable attempts will be made to conceal my identity.

\_\_\_\_\_  
Patient's Signature

\_\_\_\_\_  
If a Minor, Signature of Parent  
or Guardian

\_\_\_\_\_  
Witness Signature

\_\_\_\_\_  
Doctor's Signature

\_\_\_\_\_  
Date

© Budmor Enterprises Ltd. 1989  
All Rights Reserved  
FORM # 2013D



## Consent to Dental Treatment

I, (print name) \_\_\_\_\_ have been informed by Dr. (print name) \_\_\_\_\_, of the need to undergo dental treatment as presented to me on \_\_\_\_\_.

I have been fully informed about the details of the recommended treatment and alternatives, and agree to accept the treatment as recommended by the doctor.

I understand that as the treatment proceeds there may be need to change the treatment plan. If this occurs I expect to be informed before any change is instituted.

I further understand that individual reactions to treatment cannot be predicted, and that if I experience any unanticipated reactions during or following any treatment, I agree to report them to the office as soon as possible.

I have been told that the success of the recommended treatment depends upon my cooperation in keeping scheduled appointments, following home care instruction, including oral hygiene and dietary instructions, and reporting to the office any change in my health status as soon as possible.

I have discussed all of the above with the doctor, and all my questions have been answered.

I acknowledge that no guarantees or assurances have been given by anyone as to the results that may be obtained.

Following the explanation, the discussion, and the answers to my questions, I authorize the doctor to complete the treatment as described.

Patient's Signature	If a Minor, Signature of Parent or Guardian
Witness Signature	Doctor's Signature
Date	

## Consent for Orthodontic Treatment

I, (print name) \_\_\_\_\_, hereby authorize  
 Dr. (print name) \_\_\_\_\_ to complete orthodontic treatment  
 for my child (print name) \_\_\_\_\_

The procedure used in the provision of care has been fully explained to me, and I understand it.

I have been told that the success of the treatment depends upon several factors under my and my child's control, such as: following recommended oral hygiene procedures, diet and nutrition, home care advice, cooperate with maintaining the appliances, and keeping office appointments.

I understand that regular dental examinations by our family dentist are essential to the success of the orthodontic treatment. In addition, referrals to other dental specialists may be required e.g., an oral surgeon, a periodontist, etc.

I further understand that despite all estimates of the success of the treatment, there are many personal biologic factors that cannot be predicted in advance that may affect its success.

I have been informed that one of the complications of orthodontic treatment may be problems associated with the temporomandibular joint. This is the joint located in front of each ear and connects the lower jaw to the skull. If there is any discomfort in the joint during treatment I am to report it to the dentist as soon as possible. I understand that if this occurs further consultation and treatment may be necessary.

I understand that following completion of treatment my child may be required to use retaining devices to maintain the position of the corrected bite.

I have been informed that some grinding and reshaping of the teeth may be necessary to adjust the bite and correct the occlusion.

I have discussed all of the above with the doctor, all my questions have been answered, and I fully understand why the orthodontic treatment is necessary, its limitations, estimates of success, and the effect on my child's dental health for refusing to accept the recommended care.

I agree to report any change in my child's health, and any problem that my child has with the treatment or the appliances to the office as soon as possible.

Patient's Signature

If a Minor, Signature of Parent  
or Guardian

Witness Signature

Doctor's Signature

Date

# Authorization and Consent for Implants

authorize Dr. \_\_\_\_\_ hereby request and  
to provide me with oral implants.

The procedure has been fully explained to me, and I understand, that success with implants depend on the cooperation of the patient, and on the individual body response that cannot be accurately determined prior to the placement of implants.

I have been made aware of the following possible complications: improper occlusion, prosthetic and/or material failure, loss of permanent teeth, loss of prosthesis and/or the implant should dental disease develop due to improper home care, loss of the implant and/or prosthesis should systemic disease develop, and wear or breakage of the implant component and or the prosthesis. Other complications may occur that cannot be predicted at this time. Should any of the complications occur, I understand that there may be a need to surgically remove the implant and the use of alternative forms of treatment.

Specific complications related to my care may include:

I have been made aware that smoking and the excessive use of alcohol and sugar will have an adverse effect on my body's response, and may therefore affect the success of the implant, as will my cooperation in performing prescribed home care.

I understand that should the implant fail for any of the above reasons, I may require corrective surgery, and/or the modification of the restoration.

Alternative treatment plans have been fully explained to me along with possible outcomes and risks.

I understand that I am to return to the dental office at regular intervals for the purpose of examining the status of the implant and my oral health, and that a reasonable fee will be charged for such visits.

I hereby authorize the taking of photographs of my mouth and implants during the course of treatment, and that they may be used for educational purposes, with the understanding that reasonable efforts will be taken to hide my identity.

I acknowledge that no guarantees or assurances have been made to me concerning the results intended from the use of the implants.

I have been given this form to be taken home on \_\_\_\_\_ for review.

I have had the opportunity to discuss all of the above on \_\_\_\_\_ with

Dr. \_\_\_\_\_, and have had all my questions answered.

I certify that I fully understand all matters as described in this AUTHORIZATION AND CONSENT FOR IMPLANTS.

	Doctor	Patient
Date	Time	Witness

## Follow Up of Telephone Consent

I, (print name) \_\_\_\_\_, parent of  
(print name) \_\_\_\_\_, have been informed by  
telephone on (date) \_\_\_\_\_, of the need to have the  
following treatment performed on him/her:

\_\_\_\_\_  
\_\_\_\_\_  
\_\_\_\_\_  
\_\_\_\_\_  
\_\_\_\_\_

During the telephone conversation the service(s) were described, along with risks, benefits, and alternatives.

Following the receipt of the information on the telephone, and having all my questions answered, I authorized

Dr. (print name) \_\_\_\_\_ to perform the service(s) as listed above.

\_\_\_\_\_  
Signature of Parent or Guardian Date

## Release of All Claims

I, \_\_\_\_\_, as Releasor, being of lawful age, for the sole consideration of \_\_\_\_\_ dollars (\$ \_\_\_\_\_), paid to me, do hereby, and for my heirs, acquit and forever discharge Dr. \_\_\_\_\_, as Releasee, and his or her agents, associates, and employees from any and all claims, causes of actions, demands, damages, loss of services, expenses and compensation whatsoever, which I now have, or which may hereafter accrue on account of, or in any way may have been the result of treatment received now or in the past from the above named Releasee.

It is understood and agreed that this settlement is the compromise of a doubtful and disputed claim, and that the payment made is not to be construed as an admission of liability on the part of the party or parties hereby released, and that said Releasee denies liability therefor and intend merely to avoid litigation and buy their peace.

_____	_____
(Signature of Patient)	(Print Name)
_____	_____
(Signature of Doctor)	(Print Name)
_____	_____
(Signature of Witness)	(Print Name)
	_____
	Date



## Release from Liability Against Dental Advice

I, \_\_\_\_\_, the undersigned, being of lawful age, hereby release from liability Dr. \_\_\_\_\_, and his or her associates, employees, and agents from any injury I may currently, or in the future suffer as a result of my refusal to have the following service(s) or consultation(s) performed:

\_\_\_\_\_

\_\_\_\_\_

\_\_\_\_\_

The need for the service(s) or consultation(s) has been fully explained to me, along with the consequences of not having the service(s) or consultation(s) performed.

I have discussed the matter with the doctor, all my questions have been answered, and I fully understand why the recommendation has been made, and the effects of my refusal.

\_\_\_\_\_  
(Signature of Patient) (Print Name)

\_\_\_\_\_  
(Signature of Doctor) (Print Name)

\_\_\_\_\_  
(Signature of Witness) (Print Name)

\_\_\_\_\_  
Date

© Budmor Enterprises Ltd. 1989  
All Rights Reserved  
FORM # 2016



انتشارات شایان نمودار



# LIST OF MANUFACTURERS

- 3D MEDICAL, INC.**  
3 Canada Square East  
Wheaton, IL 60187-8483  
(830) 260-9455  
Fax: (630) 260-9086  
[3dmedical.com](http://3dmedical.com)
- 3IMPLANT INNOVATIONS, INC.**  
4555 Riverside Drive  
Palm Beach Gardens, FL 33410  
(800) 342-5454  
(561) 776-6700  
Fax: (561) 776-1272  
[ptscklen@implant.com](mailto:ptscklen@implant.com)
- 3M DENTAL PRODUCTS DIVISION**  
Bldg. 260-28-09  
3M Center  
St. Paul, MN 55144-1000  
(800) 634-2249  
(651) 575-5144  
Fax: (651) 733-5348  
[www.3m.com/dental](http://www.3m.com/dental)
- 3M MEDICA**  
Postfach 1462  
46322 Borken, Westfalen  
Germany  
49-02861-803-218  
Fax: 49-02861-803-250
- 3M UNITEK CORPORATION**  
2724 South Peck Road  
Monrovia, CA 91016  
(800) 423-4588  
(626) 445-7960  
Fax: (626) 574-4876
- 3RD DAY LTD., THE**  
2461 P Street  
Washington, D.C. 20007  
(202) 342-1695  
Fax: (202) 333-5772
- 800 SAFE MED**  
A Division of Unique Barrier  
Products, Inc.  
200 California Road, Suite 14  
Bronxville, NY 10708  
(800) 723-3633  
(914) 664-7607  
Fax: (914) 664-7607
- AALBA DENT, INC.**  
400 Watt Drive  
Cordelia, CA 94585  
(800) 227-1332  
(707) 864-3334  
Fax: (707) 864-2403
- AB DENTAL TRENDS**  
211 Grover Street  
Lynden, WA 98264  
(360) 354-4722  
Fax: (360) 354-7460
- ABIODENT, INC.**  
33 Cherry Hill Drive  
Danvers, MA 01923  
(800) 648-1802  
(978) 777-5386  
Fax: (978) 774-8411  
[abmd@abinmed.com](mailto:abmd@abinmed.com)
- ABRASIVE TECHNOLOGY, INC.**  
8400 Green Meadows Drive  
P.O. Box 6127  
Westerville, OH 43081  
(800) 964-8324  
(740) 548-4100  
Fax: (740) 548-7617  
[dschlitz@abrasive-tech.com](mailto:dschlitz@abrasive-tech.com)
- ACADEMY OF GENERAL DENTISTRY**  
211 East Chicago Avenue,  
Suite 1200  
Chicago, IL 60611  
(888) 243-3368  
(310) 440-4300  
Fax: (312) 440-0559  
[agdimpact@agd.org](mailto:agdimpact@agd.org)
- ACCELERATED SYSTEMS, INC.**  
4114 Herschel Street, Suite 101  
Jacksonville, FL 32210  
(800) 285-9001  
(904) 387-5546  
Fax: (904) 384-6991  
[hollandvh@aol.com](mailto:hollandvh@aol.com)
- AccoR, INC.**  
P.O. Box 21541  
Cleveland, OH 44121-0541  
(216) 381-2868  
Fax: (216) 381-2868
- ACLU BITE DENTAL SUPPLY, INC.**  
2 Industrial Park Drive  
Williamston, MI 48895  
(800) 248-2748  
(517) 655-5000  
Fax: (517) 655-7769  
[accubite2@aol.com](mailto:accubite2@aol.com)
- AGGU-BYTE, INC.**  
912 Killian Hill Road, Suite 100  
Lilburn, GA 30047  
(770) 923-3969  
Fax: (770) 564-8617
- ACLU-DENT RESEARCH & DEVELOPMENT COMPANY, INC.**  
85 Industrial Way, Suite F  
Buellton, CA 93427  
(800) 344-5457  
(805) 686-4672  
Fax: (805) 688-7928  
[accudent@impulse.net](mailto:accudent@impulse.net)
- ACLU-LINER PRODUCTS, INC.**  
14615 NE North Woodinville  
Way, Suite 203  
Woodinville, WA 98072  
(800) 458-6627  
(425) 482-1780  
Fax: (425) 482-2576  
[acculiner@seanel.com](mailto:acculiner@seanel.com)
- ACCUTRON, INC.**  
2020 West Melinda  
Phoenix, AZ 85027  
(800) 531-2221  
(602) 780-2020  
Fax: (602) 780-0444
- ACE SURGICAL SUPPLY CO.**  
1034 Pearl Street  
P.O. Box 1710  
Brockton, MA 02303  
(800) 441-3100  
(508) 588-3100  
Fax: (508) 583-3140  
[info@acesurgical.com](mailto:info@acesurgical.com)
- ACE SURGICAL SUPPLY CO.**  
Av. Sidonio Pais, N. 4-6, Pt 3-D  
Lisboa, Portugal 1050  
351-1-353-6641  
Fax: 351-1-353-6635
- A & D MEDICAL DIVISION**  
1555 McCandless Drive  
Milpitas, CA 95035  
(800) 728-3364  
(408) 263-5333  
Fax: (408) 263-0119  
[medical@andmedical.com](mailto:medical@andmedical.com)
- ADA**  
(See American Dental Association)
- ADCOA, INC.**  
2142 North Killingsworth  
Portland, OR 97217  
(800) 876-8276  
(503) 285-1534  
Fax: (503) 285-1590
- A-DEC, INC.**  
2601 Crestview Drive  
P.O. Box 111  
Newberg, OR 97132  
(800) 547-1883  
(503) 538-7478  
Fax: (503) 537-2702
- ADEX MEDICAL INC.**  
P.O. Box 97  
Temecula, CA 92590  
(800) 873-4776  
(909) 694-6004  
Fax: (909) 694-6018  
[able@adex.com](mailto:able@adex.com)
- ADIUM DENTAL PRODUCTS, INC.**  
3301 Olive Avenue  
Long Beach, CA 90807  
(800) 892-2144  
(562) 595-5693  
Fax: (562) 426-5509
- ADOLPH GASSER, INC.**  
5733 Geary Boulevard  
San Francisco, CA 9412,  
(800) 994-2773 ext. 199  
(415) 751-0145  
Fax: (415) 387-6566
- ADVANCED APPLICATIONS**  
10830 North Central Express  
Way, Suite 355  
Dallas, TX 75231  
(800) 466-5455  
(214) 346-0800  
Fax: (214) 346-0919  
[windent@windent.com](mailto:windent@windent.com)
- ADVANCED CLINICAL CONCEPTS**  
The Centrum Complex East  
Tower,  
8200 E. Belleview, Suite 440  
Englewood, CO 80111  
(800) 346-5204  
(303) 770-0801
- ADVANCED DENTAL CO. OF CANADA**  
Box 958  
5079 Victoria Avenue  
Niagara Falls, Ontario L2E 6V8  
Canada  
(800) 472-5409  
(905) 356-0848  
Fax: (905) 356-6330
- ADVANCED DENTAL TECHNOLOGIES**  
59575 South Gallup  
Littleton, CO 80120  
(800) 814-1992  
(303) 553-1476  
Fax: (303) 797-7325
- ADVANCED DENTAL TECHNOLOGY, INC.**  
107 West 100 South  
Tremonton, UT 84337  
(800) 471-2220  
(435) 257-5226  
Fax: (435) 257-4126
- ADVANCED PRODUCT DISTRIBUTORS, INC.**  
601A Lofstrand Lane  
Rockville, MD 20850  
(800) 421-1048  
(301) 279-2727  
Fax: (301) 279-0224  
[alanroth@adpinc.com](mailto:alanroth@adpinc.com)

This list was compiled by CRA, Provo, Utah. For updated information or any questions, please write or call at the following: CRA, 3707 N. Canyon Rd, Suite 6, Provo, Utah, 84604. Phone: 801-226-2121, Fax: 801-226-4726, E-mail [cra@cranews.com](mailto:cra@cranews.com).



- ADVANCED SURGICAL TECHNOLOGIES  
5644 Chipping Way  
Citrus, CA 95621  
(800) 966-7201  
(916) 852-5552  
Fax: (916) 852-5527  
[it@stsp.co.m](mailto:it@stsp.co.m)
- ADVANCED SYSTEMS  
7809 Redwood Road  
Plymouth, IN 46530  
(219) 936-6050  
Fax: (219) 936-6050
- ADVANTAGE INTERNATIONAL, INC.  
4 Side Hill Road  
Westport, CT 06880  
(203) 226-8442  
Fax: (203) 454-7605  
[www.advantageintl.qpp.co.m](http://www.advantageintl.qpp.co.m)
- ADVANTAGE NORTHWEST  
1777 S.E. Brookwood  
Hillsboro, OR 97123  
(503) 681-8991  
Fax: (503) 681-8991  
[advnw@aol.co.m](mailto:advnw@aol.co.m)
- ADVENTURE PRODUCTS  
(See Dr. Tungs Products)
- AD VICE ADVERTISING AGENCY  
P.O. Box 2631  
Capistrano Beach, CA 92624  
(800) 634-7467  
(714) 496-4874  
Fax: (714) 661-8364
- AEI Music NETWORK, INC./NOVATONE  
900 East Pine Street  
Seattle, WA 98122  
(800) 345-5000  
(206) 329-1400  
Fax: (206) 329-9952
- AERQ TECH DENTAL SYSTEMS, INC.  
7073 Elmsdale Drive  
San Jose, CA 95120  
(408) 268-8161
- AFFORDABLE DENTAL PRODUCTS  
3601 Hempstead Tpk., Suite 420  
Levittown, NY 11756  
(800) **666-9008**  
**(516) 796-6606**  
Fax: (516) 796-6616  
[fixdcay@aol.co.m](mailto:fixdcay@aol.co.m)
- AIREL  
2A des Grands Godets  
917, rue Marcel Paul  
F94500 Champigny-Sur-Marce  
011 33 1 48 82 22 22  
Fax: 011 33 1 48 82 46 13
- AIR/TAK, INC.  
637 West Main Street  
Worthington, PA 16262  
(724) 297-3416  
Fax: (724) 297-5189  
[airtak@airtak.com](mailto:airtak@airtak.com)
- AIR TECHNIQUES, INC.  
70 Cantigue Rock Road  
P.O. Box 870  
Hicksville, NY 11801  
(800) 247-8324  
(516) 433-7676  
Fax: (516) 433-7684  
[airchemo@aol.co.m](mailto:airchemo@aol.co.m)
- AIRTEK  
4087 Walden Avenue  
Lancaster, NY 14086  
(716) 685-4040  
Fax: (716) 685-1010
- AIR WISE, LTD.  
2460 West 26th Avenue, Suite 40C  
Denver, CO 80211  
(800) 574-2044  
(303) 477-0003  
Fax: (303) 477-0005
- AIT DENTAL INC.  
8920 Wilshire Boulevard, Suite 305  
Beverly Hills, CA 90211  
(800) 876-4620  
(310) 659-4820  
Fax: (310) 659-1594  
[akdental@earthlink.net](mailto:akdental@earthlink.net)
- ALADAN  
(See London International)
- ALAMO CITY DENTAL SUPPLY CO.  
6391 DeZavala Road, Suite 202  
San Antonio, TX 78249  
(800) 426-0464  
(210) 694-5700  
Fax: (210) 694-5701  
[samanach@express-news.net](mailto:samanach@express-news.net)
- ALASKA DENTAL SOCIETY  
3305 Artic Boulevard, Suite 102  
Anchorage, AK 99503  
(907) 563-3003  
Fax: (907) 563-3009  
[akdental@alaska.net](mailto:akdental@alaska.net)
- ALCIDE CORPORATION  
8561 154th Avenue NE  
Redmond, WA 98052  
(800) 543-2133  
(425) 882-2555  
Fax: (425) 861-0173
- ALDEN SCIENTIFIC, INC.  
550 Pleasant Street  
Winthrop, MA 02152  
(800) 742-1990  
(617) 846-1990  
Fax: (617) 846-8545
- ALFA MEDICAL EQUIPMENT  
59 Madison Avenue  
Hampstead, NY 11550  
(800) 762-1586  
(516) 489-3855  
Fax: **(516) 489-9364**  
[info@sterilizers.com](mailto:info@sterilizers.com)
- ALL DENTAL PRODX, LLC  
P.O. Box 441  
Gig Harbor, WA 98335  
(253) 265-8624  
Fax: **(253) 265-8639**  
[www.dentalprodx.com](http://www.dentalprodx.com)
- ALL DENTURE CLINIC  
271 South Downing  
Denver, CO 80209  
**(888) 474-7707**  
(303) 778-7707  
Fax: (303) 778-0731
- ALLEGIANCE HEALTHCARE  
1450 Waukegan Road  
McGaw Park, IL 60085  
(800) 635-6021  
(847) 689-8010  
Fax: (847) 473-5321
- ALLIANCE SUPPLY CORPORATION  
47733 Fremont Boulevard  
Fremont, CA 94538-6570  
(510) 659-1460  
Fax: (510) 683-9653  
[cleansed@cleansed.com](mailto:cleansed@cleansed.com)
- ALLIED DIAGNOSTIC IMAGING RESOURCES INC.  
5440-A Oakbrook Parkway  
Norcross, GA 30093  
(800) 262-9333  
(770) 448-0250  
Fax: (770) 448-0257  
[www.cpacimaging.com](http://www.cpacimaging.com)
- ALLIED PRODUCTS  
25 North Santa Anita Avenue  
Suite K  
Arcadia, CA 91006  
(818) 445-7832  
(303) 477-0003  
Fax: (818) 445-7832
- ALLPRO, INC.  
6930 West 116th Avenue, Suite 10  
Broomfield, CO 80020  
(800) 243-2285  
(303) 466-8911  
Fax: (303) 466-8965  
[allpro2@ibm.net](mailto:allpro2@ibm.net)
- ALLSEASONS ENVIRONMENTAL CONTROL, INC.  
41 Main Street  
Unionville, Ontario L3R 2E5  
Canada  
**(905) 475-9795**  
Fax: (905) 513-7650
- ALMORE INTERNATIONAL, INC.  
P.O. Box 25214  
Portland, OR 97298-0214  
**(800) 547-1511**  
**(503) 643-6633**  
Fax: (503) 643-9748  
[www.almore.co.m](http://www.almore.co.m)
- ALOE VERA OF AMERICA, INC.  
9660 Dilworth Road  
Dallas, TX 75243  
(214) 343-5700  
Fax: (214) 343-8322
- ALPHADENT  
3303 Harbor Boulevard, B-11  
Costa Mesa, CA 92626  
(800) 942-4884  
(714) 241-0211  
Fax: (714) 241-7349  
[adiinfo@alphadent.com](mailto:adiinfo@alphadent.com)
- ALPHADENTAL PRODUCTS CO.  
1920 North Clybourn  
Chicago, IL 60614  
(800) 835-0885  
(773) 327-9457  
Fax: (773) 404-8031  
[alphadenta@aol.com](mailto:alphadenta@aol.com)
- ALPHA HEALTHCARE  
(See Unident/Alpha Healthcare)
- ALPHA & OMEGA DENTAL PRODUCTS DEVELOPMENT, INC.  
110 Sitter Court  
Colorado Springs, CO 80911  
(800) 362-2722  
(719) 390-3249  
Fax: (719) 390-3249  
[mtnwinds@pcsys.net](mailto:mtnwinds@pcsys.net)
- ALPHA PROTECH, INC.  
903 West Center Street  
North Salt Lake City, UT 84054-2900  
(800) 749-1363  
(801) 298-3240  
Fax: (801) 298-3648  
[alphansi@aol.com](mailto:alphansi@aol.com)
- ALPHARMA  
One Executive Drive  
Fort Lee, NJ 07024  
(201) 947-7774  
Fax: (201) 947-4879
- ALPINE AIR INDUSTRIES  
9405 Brush Creek  
P.O. Box 2057  
Eagle, CO 81631  
(970) 328-6543  
Fax: (970) 328-4868
- ALPINE DENTAL COMPANY  
106 North Bryan Street  
Hicksville, OH 43526  
(419) 542-7748  
Fax: (419) 542-6534
- ALPINE INDUSTRIES  
310 T. Elmer Cox Drive  
Greeneville, TN 37745  
**(800) 989-2299**  
**(423) 638-7246**  
Fax: (423) 638-7561
- ALTO BOOKS/ADEPT INSTITUTE  
Publishers of the ADEPT Report  
P.O. Box 5433  
Santa Rosa, CA 95402-5433  
(707) 544-2586  
Fax: (707) 575-4033  
[altobooks@aol.com](mailto:altobooks@aol.com)
- ALZa CORPORATION  
950 Page Mill Road  
P.O. Box 10950  
Palo Alto, CA 94303-0802  
(800) 228-4748  
(415) 494-5000  
Fax: (415) 962-2488
- AMADAENT  
(See American Medical & Dental/Amadent)
- AMALGAMATED TECHNOLOGY, INC.  
29425 Chagrin Boulevard  
Pepper Pike, OH 44122  
(216) 765-0303  
Fax: (216) 765-0212  
[amalgamated@worldnet.att.net](mailto:amalgamated@worldnet.att.net)
- AMBIDERM OF AMERICA  
4206 West Charleston Avenue  
Las Vegas, NV 89107  
(800) 747-4568  
(702) 258-4510  
Fax: (702) 258-1663
- AMBU, INC.  
611 North Hammonds Ferry Road  
Linthicum, MD 21090  
(800) 262-8462  
(410) 636-1144  
Fax: (410) 636-9969  
[www.ambuusa.co.m](http://www.ambuusa.co.m)
- AMCo  
American Consolidated Mfg. Co.  
2 Union Hill Road  
West Conshohocken, PA 19428  
(800) 523-0740  
(610) 825-2630  
Fax: (610) 825-1958
- AMDENT CORPORATION  
P.O. Box 2807  
Waxahachie, TX 75168  
(800) 377-8799  
(972) 937-8799  
Fax: (972) 937-8888
- AMDRECOR  
5414 Antoine, Suite B  
Houston, TX 77091  
(800) 356-2938  
(713) 688-8357  
Fax: (713) 688-5636
- AMERICAN ACADEMY OF ORAL MEDICINE  
2910 Lightfoot Drive  
Baltimore, MD 21209  
(410) 602-8585
- AMERICAN ACADEMY OF ORAL PHARMACOLOGY  
24200 Chagrin Boulevard  
Cleveland, OH 44122  
(216) 292-0229  
[dsc@pacwv.edu](mailto:dsc@pacwv.edu)
- AMERICAN ACADEMY OF PEDIATRIC DENTISTRY  
211 East Chicago Avenue, Suite 700  
Chicago, IL 60611  
(312) 337-2169  
Fax: (312) 337-6329
- AMERICAN ACADEMY OF PERIODONTOLOGY  
737 North Michigan Avenue, Suite 800  
Chicago, IL 60611  
(312) 787-5518  
Fax: (312) 787-3670  
[dawn@perio.or.g](mailto:dawn@perio.or.g)
- AMERICAN ANALYTIC  
1314 South Grand, Suite 2112  
Spokane, WA 99202  
(509) 624-1090  
Fax: (509) 624-1290
- AMERICAN BANTEX CORPORATION  
1640 Rollins Road  
P.O. Box 4098  
Burlingame, CA 94010  
(800) 633-4839  
(415) 697-3545  
Fax: (415) 697-3596
- AMERICAN DENTAL ASSOCIATION (ADA)  
211 East Chicago Avenue  
Chicago, IL 60611  
(312) 440-2592  
Fax: (312) 440-2800  
[www.ada.or.g](http://www.ada.or.g)
- AMERICAN DENTAL HYGENICS  
(See Premier)
- AMERICAN DENTAL PRODUCTS, INC.  
22 West 246 Sunnyside Road  
Madinah, IL 60157-9705  
(800) 846-7120  
(630) 351-6284  
Fax: (630) 351-6284  
[amdentprod@aol.com](mailto:amdentprod@aol.com)
- AMERICAN DENTAL SUPPLY, INC.  
2600 William Penn Highway  
Easton, PA 18045-5224  
(800) 558-5925  
(610) 252-1464  
Fax: (610) 252-2822  
[contactads@aol.co.m](mailto:contactads@aol.co.m)
- AMERICAN DENTAL TECHNOLOGIES, INC.  
Corporate Center  
18860 West Ten Mile RD.  
Southfield, MI 48075  
(800) 359-1959  
(248) 395-3900  
Fax: (248) 395-3901
- AMERICAN DENTRONICS, INC.  
1350 East Flamingo Road, Suite 573  
Las Vegas, NV 89119  
(800) 774-7525  
(702) 386-8810  
Fax: (949) 363-0914  
[www.csonic@earthlink.net](mailto:www.csonic@earthlink.net)
- AMERICAN DIAMOND INSTRUMENTS  
36889 North Tom Darlington Drive, Suite B6-104  
Carefree, AZ 85377  
(800) 537-7474  
(602) 595-0261  
Fax: (602) 595-0251  
[ronadi@earthlink.net](mailto:ronadi@earthlink.net)



- AMERICAN DIVERSIFIED DENTAL SYSTEMS  
1440 S. State College Boulevard,  
Suite 3-H  
Anaheim, CA 92806  
(800) 637-2337  
(714) 991-1371  
Fax: (714) 991-9540
- AMERICAN EAGLE INSTRUMENTS, INC.  
2704 Palmer Street  
Missoula, MT 59802  
(800) 551-5172  
(406) 549-7451  
Fax: (406) 549-7452  
am-eagle@bigsky.net
- AMERICAN ELECTROMEDICS CORP.  
13 Columbia Drive, Suite 5  
Amherst, NH 03031  
(800) 227-8967  
(603) 880-6300  
Fax: (603) 880-8977
- AMERICAN LABORATORIES, INC.  
4410 South 102nd Street  
Omaha, NE 68127-1094  
(402) 339-2494  
Fax: (402) 339-0801  
alil2@worldnet.att.com
- AMERICAN LINEN  
3370 West 1820 South  
P.O. Box 25717  
Salt Lake City, UT 84104-4922  
(800) 339-1691  
(801) 973-7771  
Fax: (801) 973-7894  
[www.amlinen.com](http://www.amlinen.com)
- AMERICAN MEDICAL ASSOCIATION (AMA)  
515 North State Street  
Chicago, IL 60610  
(800) 621-8335  
(312) 464-5000  
Fax: (312) 464-5600  
[www.ama-assn.org](http://www.ama-assn.org)
- AMERICAN MEDICAL & DENTAL/AMADENT  
1236 Brace Road, Building B  
Cherry Hill, NJ 08034-3229  
(800) 289-6367  
(609) 429-8297  
Fax: (609) 429-2953  
[amadent@cybernet.com](http://amadent@cybernet.com)
- AMERICAN MEDICAL PUBLISHING CO., INC.  
P. O. Box 604885  
Bayside, NY 11360-4885  
(800) 263-3782  
(718) 263-3784  
Fax: (718) 263-3784
- AMERICAN ORTHODONTICS CORPORATION  
1714 Cambridge Avenue  
P.O. Box 1048  
Sheboygan, WI 53082-1048  
(800) 558-7687  
(920) 457-5051  
Fax: (920) 457-1485  
[amo@americanortho.com](mailto:amo@americanortho.com)
- AMERICAN SHIELD CO.  
1008 North Mills Avenue  
Orlando, FL 32801  
(407) 896-0373  
Fax: (407) 894-1872
- AMERICAN SOCIETY OF DENTISTRY FOR CHILDREN  
875 North Michigan Avenue,  
Suite 4040  
Chicago, IL 60611-1901  
(800) 637-2732  
(312) 943-1244  
Fax: (312) 943-5341  
asdckids@aol.com
- AMERICAN TOOTH INDUSTRIES  
Justi Division  
1200 Stellar Drive  
Oxnard, CA 93033-2404  
(800) 235-4639  
(805) 487-9868  
Fax: (805) 483-8482  
by @[americantooth.com](http://americantooth.com)
- AMERICARE HEALTH PRODUCTS  
1301 Enterprise Way  
Marion, IL 62959  
(888) 686-2443  
(618) 993-1875  
Fax: (618) 993-6592
- AMERICUS DENTAL LABS, INC.  
150-15 Hillside Avenue  
Jamaica, NY 11432  
**(888) 263-7428**  
**(718) 658-6658**  
Fax: (718) 558-1479
- AMINODERM LABORATORIES, INC  
610 North Hollywood Way  
Suite 203  
Burbank, CA 91505  
(800) 426-1681  
(818) 559-1314  
Fax: (818) 559-7368
- AMKAY MANUFACTURING CORP.  
73-51 Park Drive East  
Flushing, NY 11367  
(800) 325-3962  
(718) 575-1348  
Fax: (718) 575-1384
- AMMEX  
18642 72nd Avenue South  
Kent, WA 98032  
(800) 274-7354  
(425) 251-4000  
Fax: (425) 251-8656  
[www.ammex.com](http://www.ammex.com)
- AMTEL SYSTEMS CORPORATION  
Eaglepointe Industrial Center  
**55 Pottstown Pike, Suite 800**  
Chester Springs, PA 19425  
(800) 999-8903  
(610) 458-3320  
Fax: (610) 458-3321  
jacktaysman@compuserve.com
- ANACOMP, INC.  
100 Prestige Park Road  
East Hartford, CT 06108  
(860) 528-9876  
Fax: (860) 528-2095  
[www.anacomp.com/year2000](http://www.anacomp.com/year2000)
- ANALYTIC ENDODONTICS  
1717 West Collins Avenue  
Orange, CA 92649  
(800) 346-3636  
(714) 516-7979  
Fax: (714) 516-7911  
[messicks@syhronedental.com](mailto:messicks@syhronedental.com)
- ANCHOR CHEMICAL CO.  
777 Canterbury Road  
Westlake, OH 44145  
(800) 466-9925  
(216) 871-1660  
Fax: (216) 871-0665  
[www.anchorlube.com](http://www.anchorlube.com)
- ARDENT, INC. PUBLISHERS  
33263 North Cove  
Wildwood, IL 60030  
(847) 223-5077  
Fax: (847) 223-5077  
102254.525@compuserve.com
- ANDERSEN, H.W., PRODUCTS, INC.  
Health Science Park  
3202 Caroline Drive  
Haw River, NC 27258-8710  
(800) 523-1276  
(336) 376-3000  
Fax: (336) 376-8153  
[www.anpro.com](http://www.anpro.com)
- ANNALAN LABORATORY  
1215 Harris Avenue  
Union Beach, NJ 07735  
(800) 222-0495  
(732) 264-8950  
Fax: (732) 264-6340
- ANSELL GOLDEN NEEDLES  
P.O. Box 803  
Wilkesboro, NC 28697  
(800) 533-6808  
(910) 667-5102  
Fax: (910) 903-6023
- ANSELL PERRY  
1875 Harsh Avenue SE  
Massillon, OH 44646  
(800) 321-9752  
(303) 833-2811  
Fax: (303) 833-5991  
[sgromels@ansell.com.au](mailto:sgromels@ansell.com.au)
- ANTHOGRY  
164 Rue Des Trois-lac  
74700 Sallanches, France  
334-50-58-02-37  
Fax: 334-50-93-78-60
- APL  
7201 North Haven, Suite E 377  
Alta Loma, CA 91701  
(909) 989-4445  
Fax: (909) 944-3427  
[chiphy@juno.com](mailto:chiphy@juno.com)
- APO HEALTH COMPANY  
3590 Oceanside Road  
Oceanside, NY 11572  
(800) 365-2839  
(516) 594-0005  
Fax: (516) 763-5631  
[www.apohealth.com](http://www.apohealth.com)
- APOLLO DENTAL PRODUCTS  
245 West Dakota Avenue  
Clovis, CA 93612  
(800) 233-4151  
(209) 292-1444  
Fax: (209) 292-1555  
[www.apoldental.com](http://www.apoldental.com)
- A.P.S. TECHNOLOGIES  
3213 Dewitt Drive  
Los Angeles, CA 90068  
(888) 256-2515  
(213) 876-2447  
Fax: (213) 876-6452
- APTERYX  
554 White Pond Drive, Suite A  
Akron, OH 44320  
(330) 867-6077  
Fax: (330) 867-6077  
[www.apteryxware.com](http://www.apteryxware.com)
- AQUA-DENT  
A Division of Microtest Lab, Inc.  
3701 J. Street, Suite 207  
Sacramento, CA 95816  
(800) 713-3334  
(916) 452-9808  
Fax: (916) 452-5347
- ADUAGEN INTERNATIONAL, INC.  
International Sales Division  
154 East Ford Avenue  
Salt Lake City, UT 84115  
(800) 699-4336  
(801) 484-2777  
Fax: (801) 484-9383  
[www.aquagen.com](http://www.aquagen.com)
- AQUALIZER BY JUMAR CORP.  
PO. Box 5252  
Carefree, AZ 85377  
(800) 435-7863  
(602) 488-0881  
Fax: (602) 488-0940  
lesboblyn@aol.com
- ARCHER & WHITE SALES  
610 South Sherman, Suite 118  
Richardson, TX 75081  
(972) 669-0211  
Fax: (972) 669-0371
- ARCHTEK CORP.  
12105 West Cedar Drive  
Lakewood, CO 80228  
(800) 356-9026  
(303) 763-8900  
Fax: (303) 763-8071
- ARDENT INTERNATIONAL, INC.  
300 Executive Boulevard  
P.O. Box 1140  
Ossining, NY 10562  
(914) 923-1216  
Fax: (914) 923-3559
- ARGEN PRECIOUS METALS  
5855 Oberlin Drive  
San Diego, CA 92121  
(800) 255-5524  
(619) 455-7900  
Fax: (619) 626-8686
- ARICHELL TECHNOLOGIES INC.  
55 Border Street  
West Newton, MA 02165  
(888) 757-2500  
(617) 796-9001  
Fax: (617) 796-9005  
arichell@worldnet.att.net
- ARM & HAMMER DIVISION  
Church & Dwight Co. Inc.  
469 North Harrison Street  
Princeton, NJ 08540  
(800) 524-1328  
(609) 683-7015  
Fax: (609) 279-7611
- ARNICA, INC.  
3419 West MacArthur Boulevard  
Santa Ana, CA 92704  
(800) 545-8303  
(714) 966-2922  
Fax: (714) 673-0169
- ARROW PNEUMATICS, INC.  
500 North Oakwood Road  
Lake Zurich, IL 60047  
(708) 771-5010  
Fax: (708) 343-1907  
[www.arrowpneumatics.com](http://www.arrowpneumatics.com)
- ARTUS CORPORATION  
201 South Dean Street  
P.O. Box 511  
Englewood, NJ 07631  
(201) 568-1000  
Fax: (201) 568-8865
- ABDEN, LTD.  
Box 147  
Altrincham Cheshire  
England WA15 9EB  
44-161-980-8916  
Fax: 44-161-980-5330
- ASEPSIS INTERNATIONAL, INC.  
183 North Lakeshore Dr.  
Hypoluxo, FL 33462  
(800) 947-9949  
(561) 585-3737  
Fax: (716) 684-4692
- ASEPTICO, INC.  
19501-144th Avenue NE, Suite B-400  
Woodinville, WA 98072  
(800) 426-5913  
(425) 487-3157  
Fax: (425) 487-2608  
[www.aseptico.com](http://www.aseptico.com)
- ASEPTO SYSTEMS  
57 Ozone Avenue  
Venice, CA 90291  
(800) 347-3096  
(310) 396-9071  
Fax: (310) 396-7702  
[www.ddsnnet.com/asepto.html](http://www.ddsnnet.com/asepto.html)
- ASH  
(See Dentsply/ASH)
- ASHIKU DENTAL  
P.O. Box 886  
Ukiah, CA 95482  
(800) 783-9463  
(707) 466-6138
- ASHMAN DENTAL GROUP  
1275 North University Ave,  
Suite 11  
Provo, UT 84604  
(801) 373-6928  
Fax: (801) 377-2777  
ashman@netutah.net
- ASH TEMPLE LTD.  
31 Scarsdale Road  
Don Mills, Ontario M3B 2R2  
Canada  
(800) 268-6497  
(416) 449-2300  
Fax: (416) 449-5932  
email @ [ashtemple.com](mailto:ashtemple.com)
- AST MEDICAL INC.  
14550 Easter Avenue, Suite #1000  
Englewood, CO 80112  
(800) 566-9953  
(303) 766-3646  
Fax: (303) 766-3559
- ASKO, INC.  
1161 Executive Drive West  
Department HM 1292  
Richardson, TX 75081  
(800) 367-2444  
(972) 238-0794  
Fax: (972) 234-2706  
[www.askousa.com](http://www.askousa.com)
- A/S L. GOOF  
(See Flex Dental A/S)
- Assoc. OF DENTAL CONSULTANTS  
GROUP FOR ASEPSIS PROTECTION  
Westmount Medical Center  
100 South Cass Avenue  
Westmount, IL 60559  
(847) 564-2050  
Fax: (847) 564-1577  
berncole@ix.netcom.dot
- ASSOCIATED ENTERPRISES, INC.  
623 Charlie Hicks Road  
Jonesborough, TN 37659  
(423) 926-4488  
Fax: (423) 926-4488
- ASTRA TECH, INC.  
430 Bedford St., Suite 100  
Lexington, MA 02173  
(800) 531-3481  
(781) 861-7707  
Fax: (781) 891-7787  
ati1234@aol.com
- ASTRA PHARMACEUTICALS, LP  
50 Otis Street  
Westboro, MA 01581  
(800) 225-6333  
(508) 366-1100  
Fax: (508) 898-3570
- ASTRON DENTAL CORPORATION  
815 Oakwood Road, Unit G  
Lake Zurich, IL 60047  
(800) 323-4144  
(847) 726-8787  
Fax: (847) 726-8793  
[www.astron.com](http://www.astron.com)

ATHENA TECHNOLOGY, INC.  
984 North Amelia Avenue  
San Dimas, CA 91773  
(800) 253-1771  
(909) 394-1770  
Fax: (909) 394-1765

ATLANTIS MEDICAL TECHNOLOGY,  
INC.  
997 Eastwood Terrace  
Collierville, TN 38017  
(800) 346-2692  
(901) 853-1572  
Fax: (901) 853-3676  
[webmaster@atlantis-medical.com](mailto:webmaster@atlantis-medical.com)

ATRIX LABORATORIES, INC.  
2579 Midpoint Drive  
Fort Collins, CO 80525-4417  
(800) 652-5625  
(970) 482-5868  
Fax: (970) 482-9735  
[www.atrixlabs.com](http://www.atrixlabs.com)

ATTACHMENTS INTERNATIONAL, INC  
600 South Amphlett Boulevard  
San Mateo, CA 94402  
(800) 999-3003  
(650) 340-0393  
Fax: (650) 340-8423  
[www.attachments.com](http://www.attachments.com)

AUDRA, INC.  
21400 North Shore Drive  
Sturgis, MI 49091  
(800) 445-0170  
(616) 651-9106  
Fax: (616) 651-7611

AUKLAND MEDICAL PLASTICS, INC.  
PO. Box 5624  
Cary, NC 27512  
(800) 468-2363  
(919) 380-7000  
Fax: (919) 467-7981

ADSTENAL, INC.  
4101 West 51 st Street  
Chicago, IL 60632  
(800) 621-0381  
(773) 735-0600  
Fax: (773) 735-3940

AUTHENTIC PRODUCTS, INC.  
4415 Piedras West, Suite 160  
San Antonio, TX 78228  
(800) 683-1025  
(210) 735-1433  
Fax: (210) 735-2127

AUTRE PRODUCTS  
155 Sixth Street, Suite 4  
Chelsea, MA 02150-5686  
(800) 624-7672  
(617) 889-2386  
Fax: (617) 884-2262  
[joesautra@aol.com](mailto:joesautra@aol.com)

AN HEALTH PROMOTIONS  
PO. Box 1375  
La Jolla, CA 92038  
(800) 889-3343  
(619) 551-8105  
Fax: (619) 551-0621  
[avhpromo@aol.com](mailto:avhpromo@aol.com)

AVITAR TECHNOLOGIES INC.  
65 Dan Road  
Canton, MA 02021  
(800) 255-0511  
(781) 821-2440  
Fax: (781) 821-4458

AVTEK  
PO. Box 4406  
Glendale, CA 91202  
(800) 423-2868  
(818) 240-1028  
Fax: (818) 972-2115

AXIS DENTAL CORP.  
Capital Hills  
2928 West Story Road  
Irving, TX 75038  
(800) 355-5063  
(972) 273-2720  
Fax: (972) 257-3647  
[cusiserv@axisdental.com](mailto:cusiserv@axisdental.com)

BALDOR ELECTRIC COMPANY  
2520 West Barbary Place  
Denver, CO 80204  
(303) 623-0127  
Fax: (303) 595-3772  
[www.industry.net/baidor](http://www.industry.net/baidor)

BALLARD MEDICAL PRODUCTS  
12050 Lone Peak Parkway  
Draper, UT 84020  
(800) 528-5591  
(801) 572-6800  
Fax: (801) 572-6999

BANDITT DENTAL INSTRUMENT CO.  
82 Court Street  
P.O. Box 6841  
Freehold, NJ 07728  
(800) 222-0961  
(732) 462-5457  
upon request

BANTA HEALTHCARE, TIM BRAND  
570 Enterprise Drive  
P.O. Box 806  
Nennah, WI 54957  
(800) 521-1314  
(920) 751-4300  
Fax: (920) 751-4370

BANYAN INTERNATIONAL, CORP.  
2118 East Interstate 20  
PO. Box 1779  
Abilene, TX 79604  
(800) 351-4530  
(915) 677-1874  
Fax: (915) 677-1372  
[www.stalkit.com](http://www.stalkit.com)

BARNSTEAD/THERMOLYNE/HARVEY  
STERILIZERS  
2555 Kerper Boulevard  
PO. Box 797  
Dubuque, IA 52001  
(800) 553-0039  
(319) 556-2241  
Fax: (319) 556-0695  
[www.barnsteadthermolyne.com](http://www.barnsteadthermolyne.com)

BARRIER COMPLIANCE, INC.  
3039 South Harbor Boulevard  
Santa Ana, CA 92704  
(800) 367-5432  
(714) 556-8700  
Fax: (714) 556-8808

B.A.S.I.C. DENTAL IMPLANT SYS.  
U.S.A. Division  
3321 Columbia N.E.  
Albuquerque, NM 87107  
(888) 888-7564 (USA toll Free)  
(505) 884-1922  
Fax: (505) 884-1923  
[dentalimp@aol.com](mailto:dentalimp@aol.com)

BBJ CHEMICAL COMPOUNDS, INC.  
6802 Citicorp Boulevard, Suite 500  
Tampa, FL 33619  
(800) 889-2251  
(813) 622-8550  
Fax: (813) 623-4032  
[www.bbchem.com](http://www.bbchem.com)

B.C. DECKER INC. PUBLISHER  
4 Hughson Street South  
P.O. Box 620 LCD1  
Hamilton, Ontario L8N 3K7  
Canada  
(800) 568-7281  
(905) 522-7017  
Fax: (905) 522-7839  
[info@bcdecker.com](mailto:info@bcdecker.com)

BEAVERS DENTAL  
Division of Sybron Canada Ltd.  
PO. Box 900  
Morrisburg, Ontario K0C 1X0  
Canada  
(888) 567-2877  
(613) 543-3791  
Fax: (613) 543-2525

BECK, E.A., & CO.  
657 West 19th Street  
RO. Box 10859  
Costa Mesa, CA 92627-0258  
(800) 854-0153  
(714) 645-4072  
Fax: (714) 645-4085  
[abeck@aol.com](mailto:abeck@aol.com)

BECTON DICKINSON & CO.  
1 Becton Drive  
Franklin Lakes, NJ 07417  
(888) 237-2762  
(201) 847-6800  
Fax: (201) 847-6475

BEEHIVE ENVIROTECH  
PO. Box 179  
Vernal, UT 84078  
(888) 246-5760  
(435) 789-0122  
Fax: (435) 789-1948

BEGO USA  
1088 Main Street  
Pawtucket, RI 02860  
(800) 342-2346  
(401) 723-1630  
Fax: (401) 723-6510  
BegoUSA @ [aol.com](mailto:aol.com)

BELLE DE ST. CLAIRE, INC.  
1717 West Collins Avenue  
Orange, CA 92867  
(800) 322-6666  
(714) 516-7400  
Fax: (714) 516-7906

BELL INTERNATIONAL, INC  
31 Edwards Court  
Burlingame, CA 94010  
(800) 523-6640  
(650) 348-2055  
Fax: (650) 348-3937

BENCHMARK COMMERCIAL INC.  
466 Lawndale Drive, Suite D  
Salt Lake City, UT 84115  
(800) 645-5545  
(801) 463-3901  
Fax: (801) 463-3908  
[benchmark@burgoyne.com](mailto:benchmark@burgoyne.com)

BERGMAN COMPANIES, THE  
13745 Seminole Drive  
Chino, CA 91710  
(909) 627-3651  
Fax: (909) 627-5425

BEST FRIEND PRODUCTS  
385 Pinewood Circle  
Athens, GA 30606  
(706) 549-0302  
Fax: (706) 549-0302  
[rikimari@mindspring.com](mailto:rikimari@mindspring.com)

BEST GLOVE MANUFACTURING CO.  
Edison Street  
Menlo, GA 30731-0008  
(800) 241-0323  
(706) 862-2302  
Fax: (706) 862-6000  
[www.bestglove.com](http://www.bestglove.com)

BETA DIAMOND PRODUCTS, INC.  
P.O. Box 2069  
Yorba Linda, CA 92885-1269  
(714) 777-7144  
Fax: (714) 693-9351

BEUTLICH PHARMACEUTICALS  
1541 Shields Drive  
Waukegan, IL 60085  
(800) 238-8542  
(847) 473-1100  
Fax: (847) 473-1122  
[www.beutlich.com](http://www.beutlich.com)

B & H PHOTO/VIDEO/PRO AUDIO  
420 Ninth Avenue  
New York, NY 10011  
(800) 947-9950  
(212) 444-6600  
Fax: (212) 239-7770  
[www.bhphotovideo.com](http://www.bhphotovideo.com)

BICON DENTAL IMPLANTS  
1153 Centre Street  
Boston, MA 02130-3492  
(800) 882-4266  
(617) 524-4443  
Fax: (617) 524-0096  
[bicon@bicon.com](mailto:bicon@bicon.com)

BIEN AIR SA  
Langgasse 60  
Case Postale 6008  
CH-2500 Bienne 6  
Switzerland  
(800) 433 2436  
41-32-342-41-31  
Fax: 41-32-342-41-91  
[bienaire.ch](mailto:bienaire.ch)

BIEN AIR USA INC.  
19600 Fairchild Road, Suite 25C  
Irvine, CA 92612  
(800) 433-2436  
(714) 477-6050  
Fax: (714) 477-6051  
[amatee@msn.com](mailto:amatee@msn.com)

BIO-CIDE INTERNATIONAL, INC.  
2845 Broce Drive  
PO. Box 722170  
Norman, OK 73070-8644  
(800) 323-1398  
(405) 329-5556  
Fax: (405) 329-2681  
[bio-cide@telepath.com](mailto:bio-cide@telepath.com)

BIOCOMP  
4526 Telephone Road, Suite 204  
Ventura, CA 93003  
(805) 644-4892  
Fax: (805) 644-4893

BIOCOSMETICS S.L.  
c/Arco de la Frontera, 15  
28023 Madrid  
Spain  
34-91-3571583  
Fax: 34-91-3570499

BIODENT  
32 Champlain  
Monte Saint-Hilaire  
Quebec, J3H 3R5  
Canada,  
(800) 211-1200  
(514) 536-3329  
Fax: (514) 536-3532  
[biodent.com](mailto:biodent.com)

BIG FLEX INTERNATIONAL, INC.  
1001 North Federal Highway,  
3rd Floor  
Hallandale, FL 33009  
(800) 755-4588  
(954) 457-2655  
Fax: (954) 457-2688

BIOHORIZONS IMPLANT SYSTEMS,  
INC.  
1 Perimeter Park South,  
Suite 230 South  
Birmingham, AL 35243  
(888) 246-8338  
(205) 871-1345  
Fax: (205) 870-0304

BIOLASE TECHNOLOGY, INC.  
981 Calle Amanecer  
San Clemente, CA 92673  
(800) 699-9462  
(949) 361-1200  
Fax: (949) 361-0204

BIO-MEDICAUDENTAL CORP.  
2143 Davcor Street Southeast  
Salem, OR 97302  
(800) 444-1765  
(503) 399-1765  
Fax: (503) 364-1934

BIOPLANT, INC.  
20 North Main Street  
South Norwalk, CT 06854  
(800) 432-4487  
(203) 899-0466  
Fax: (203) 899-0278

BIO-PROBE, INC.  
P.O. Box 608010  
Orlando, FL 32860-8010  
(800) 282-9670  
(407) 290-9670  
Fax: (407) 299-4149  
[bpinfo@bioprobe.com](mailto:bpinfo@bioprobe.com)

BIORA, INC.  
415 North LaSalle Street, Suite 615  
Chicago, IL 60610-4530  
(888) 246-7287  
(312) 832-1414  
Fax: (312) 832-1429  
[amandasamuels@biora.com](mailto:amandasamuels@biora.com)

BIORESEARCH, INC.  
4113 North Port Washington  
Road  
Milwaukee, WI 53212  
(800) 251-2315  
(414) 332-3003  
Fax: (414) 332-5317  
[biores@execpc.com](mailto:biores@execpc.com)

BIOSHIELD TECHNOLOGIES, INC.  
4405 International Boulevard,  
Suite B109  
Norcross, GA 30093  
(770) 925-3432  
Fax: (770) 921-3637/1065

BIOTECH INC.  
652 East Main Street  
Zeeland, MI 49464  
(616) 772-2133  
Fax: (616) 772-4320  
[hasorenson@aol.com](mailto:hasorenson@aol.com)

BIO-TEK INDUSTRIES, INC.  
1380 West Marietta Street NW  
RO. Box 93746  
Atlanta, GA 30318  
(800) 843-7687  
(404) 799-2050  
Fax: (404) 799-2058

BIOTROL INTERNATIONAL  
650 South Taylor Avenue,  
Suite 20  
Louisville, CO 80027-3032  
(800) 822-8550  
(303) 673-0341  
Fax: (303) 673-0346  
[Biontrol@aol.com](mailto:Biontrol@aol.com)

- BIOTHONIX**  
3235 Fairfield Avenue South  
Saint Petersburg, FL 33712  
(800) 899-9220  
(813) 321-0828  
Fax: (813) 321-1561  
[www.biothonix.com](http://www.biothonix.com)
- BIOWARE, INC.**  
2 Bala Plaza, Suite 300  
Bala Cynwyd, PA 19004  
(800) 225-3780  
(610) 664-2200  
Fax: (215) 878-6441  
[www.saveyoursmile.com](http://www.saveyoursmile.com)
- BISCO DENTAL PRODUCTS**  
1100 West Irving Park Road  
Schaumburg, Illinois 60193  
(800) 247-3368  
(847) 534-6000  
Fax: (847) 534-6111
- BLAZER CORP.**  
114 East 32nd Street, Room 904  
New York, NY 10016  
(212) 532-1166  
Fax: (212) 684-4103  
contact @ [blazercorp.com](mailto:blazercorp.com)
- BLEVINS, MACK ENTERPRISES**  
819 Southeast Madison Boulevard  
Bartlesville, OK 74006  
(800) 654-7311  
(918) 335-3989  
Fax: (918) 335-3551  
propickl @ [aol.com](mailto:aol.com)
- BLOCK DRUG COMPANY**  
Oral Health Care Division  
105 Academy Street  
Jersey City, NJ 07302  
(800) 365-6500  
(201) 434-3000  
Fax: (201) 434-4990  
george-clark @ [blockdrug.com](mailto:blockdrug.com)
- BLOSSER, J.L., INC.**  
22 North Main Street  
Liberty, MO 64068  
(800) 200-3594  
(816) 781-3206  
Fax: (816) 781-0164
- BLUE BOOK-OTC & FIX REFERENCE, THE**  
American Academy of Oral Pharmacology  
24200 Chagrin Boulevard Department 258  
Cleveland, OH 44122  
(216) 292-0229  
dcs @ [po.cwru.edu](mailto:po.cwru.edu)
- BLUE DOLPHIN PRODUCTS**  
15900 Concord Circle, Unit 1  
Morgan Hill, CA 95037  
(800) 448-8855  
(408) 776-0433  
Fax: (408) 776-0145  
ptc @ [nesscon.com](mailto:nesscon.com)
- BLUE MESA GROUP, THE**  
1726 North Orchard  
Chicago, IL 60614  
(800) 258-6372  
(312) 943-5858  
Fax: (312) 664-9344  
vepet@flash.net
- BLUME IMAGING INC.**  
24953 Paseo de Valencia  
Suite 11c  
Laguna Hills, CA 92653  
(949) 830-1395  
Fax: (949) 830-7237
- BOBAB PUBLISHING**  
304 Newbury Street, Suite 169  
Boston, MA 02115  
(617) 249-2022  
Fax: (617) 249-2023  
[www.bobab.com](http://www.bobab.com)
- BOECKELER INSTRUMENTS, INC.**  
4650 S. Butterfield Drive  
Tucson, AZ 85744-3403  
(800) 552-2262  
(520) 745-0001  
Fax: (520) 745-0004  
[admin@boeckeler.com](mailto:admin@boeckeler.com)
- BOND POND**  
East 12308 Broadway  
Spokane, WA 99216  
(800) 391-2663  
(509) 928-5112  
Fax: (509) 927-3789
- BON MANGE, INC.**  
P.O. Box 74992  
Davis, CA 95616  
(800) 553-1224  
(530) 666-9771  
Fax: (530) 668-9263  
monjay @ pacbel I. net
- Bosco**  
(See W. Bosco)
- BOSWORTH, HARRY J., CO.**  
7227 North Hamlin Avenue  
Skokie, IL 60076-3999  
(800) 323-4352  
(847) 679-3400  
Fax: (847) 679-2080  
bosworth C @ ais.net
- BRAHLER PRODUCTS, INC.**  
2301 Ponderosa  
Lawrence, KS 66046  
(785) 843-0932  
Fax: (785) 832-0932
- BRANSON ULTRASONICS CORP.**  
41 Eagle Road  
Danbury, CT 06813-1961  
(800) 637-8582  
(203) 796-0400  
Fax: (203) 796-2240
- BRASSELER U.S.A.**  
800 King George Boulevard  
Savannah, GA 31419-9598  
(800) 841-4522  
(912) 925-8525  
Fax: (912) 927-8671  
[brasseler@aol.com](mailto:brasseler@aol.com)
- BRAUN AKTIENGESELLSCHAFT**  
Frankfurter Str. 145  
61476 Kronberg  
Germany  
49-06173-30-2100  
Fax: 49-06173-30-2875
- BRAUN, B. MEDICAL INC.**  
824 12th Avenue  
Bethlehem, PA 18018  
(800) 359-2439  
(610) 691-6785  
Fax: (610) 691-1785  
[www.burronoem.com](http://www.burronoem.com)
- BRAUN, INC.**  
400 Unicorn Park Drive  
Woburn, MA 01801  
(800) 272-8611  
(781) 939-8317  
Fax: (781) 939-8900
- BREAKTHROUGH SYSTEMS**  
1294 Rockrimmon Road  
Stamford, CT 06903  
(203) 324-6171  
Fax: (203) 348-5392
- BREATHAID**  
1015 Fair Street  
Camden, South Carolina 29020  
(888) 733-7374  
(803) 432-3571  
Fax: (803) 432-2625
- BREATH ASURE, INC.**  
26025 Mureau Road  
Calabasas, CA 91302  
(800) 548-8686  
(818) 878-0011  
Fax: (818) 878-0055  
ARAISSEN @ [Breathasure.com](mailto:Breathasure.com)
- BREATHLESS NORTHERN, INC.**  
7805 Ludwig Castle Way  
Piano, TX 75025  
(800) 501-2946  
(972) 208-1559  
Fax: (972) 208-1559
- BREVET, INC.**  
16661 Jamboree Road  
Irvine, CA 92606  
(949) 474-7000  
Fax: (949) 474-7044  
sales @ [brevet.com](mailto:brevet.com)
- BREWER CO., THE**  
13901 Main Street  
Menomonee Falls, WI 53051  
(800) 558-8777  
(414) 251-9530  
Fax: (414) 251-1786
- BRIDGER BID MEDICAL**  
2430 North 7th Avenue, Suite 4  
Bozeman, MT 59715  
(888) 300-7833  
(406) 586-7666  
Fax: (406) 586-5665
- BRIGHT INNOVATIONS INC.**  
3309 Fillmore Street  
Marina District  
San Francisco, CA 94123  
(415) 922-3220  
Fax: (415) 775-4867
- BRIMMS COMPANIES**  
425 Fillmore Avenue  
Tonawanda, NY 14150  
(800) 828-7669  
(716) 694-7100  
Fax: (716) 694-0462
- BRINECELL, INC.**  
2109 West 2300 South  
Salt Lake City, UT 84119  
(800) 973-4603  
(801) 973-6400  
Fax: (801) 973-6463  
[brinecell@cyber-west.com](mailto:brinecell@cyber-west.com)
- BROOKSTONE**  
1655 Bassford Drive  
Mexico, MO 65265-1382  
(800) 846-3000  
(573) 581-7777  
Fax: (573) 581-7361  
[www.brookstoneonline.com](http://www.brookstoneonline.com)
- BROWN METALS CO.**  
4225 East Airport Drive  
Ontario, CA 91761  
(800) 992-5015  
(909) 390-3199  
Fax: (909) 390-3182  
[www.brownmetals.com](http://www.brownmetals.com)
- BRULIN CORPORATION, THE**  
2920 Dr. Andrew J. Brown Avenue  
P.O. Box 270  
Indianapolis, IN 46206  
(800) 776-7149  
(317) 923-3211  
Fax: (317) 925-4596  
[www.brulin.com](http://www.brulin.com)
- BTG USA**  
2200 Renaissance Boulevard  
Renaissance Business Park  
Gulph Mills, PA 19406  
(610) 278-1660  
Fax: (610) 278-1605
- BUCKY PRODUCTS, INC.**  
3653 Woodland Park Avenue  
North  
P.O. Box 31970  
Seattle, WA 98103  
(800) 692-8259  
(206) 545-8790  
Fax: (206) 545-0729  
david @ [bucky.com](mailto:bucky.com)
- BUD HAM CONSULTING**  
2697 South Macon Court  
Aurora, CO 80014  
(303) 745-7205  
Fax: (303) 369-9925  
budham @ [IRM.com](mailto:IRM.com)
- BUFFALO DENTAL MFG. CO., INC.**  
99 Lafayette Drive  
Syosset, NY 11791  
(800) 828-0203  
(516) 496-7200  
Fax: (516) 496-7751  
@ [psinet.com](mailto:psinet.com)
- BURLEY HANDPIECE REPAIR**  
3969 Williams Street  
Clarkston GA, 30021  
(800) 847-9068  
(404) 292-9066  
[www.lubricator.com](http://www.lubricator.com)
- BUSINESS OF IMPLANT DENTISTRY, THE**  
11601 Wilshire Blvd., Suite 500  
Los Angeles, CA 90025  
(310) 575-4843  
(310) 456-1534  
tbid@pacifnet.net
- BUTLER, JOHN O., COMPANY**  
4635 West Foster Avenue  
Chicago, IL 60630  
(800) 528-8537  
(773) 777-4000  
Fax: (773) 777-5101  
[www.jbutler.com](http://www.jbutler.com)
- CAESY EDUCATION SYSTEMS**  
A Division of Advanced Learning Technology  
200 Southeast Park Plaza  
Drive, Suite 1001  
Vancouver, WA 98684  
(800) 505-4430  
(360) 892-1298  
Fax: (360) 892-1747  
caesyrl @ [aol.com](mailto:aol.com)  
[www.caesy.com](http://www.caesy.com)
- CALCITEK**  
(See Sulzer Calcitek Inc.)
- CALIBER DENTAL TECHNOLOGY, INC.**  
1815 West 1st Avenue, Suite 134-13  
Mesa, AZ 88202  
(800) 456-2014  
(602) 655-0333  
Fax: (602) 655-0390
- CALTECH INDUSTRIES, INC.**  
2420 Schuette Drive  
Midland, MI 48642  
(800) 234-7700  
(517) 496-3110  
Fax: (517) 496-0212  
info @ [caltechind.com](mailto:caltechind.com)
- CAMBIARE, LTD.**  
4401-A US 220 North  
Summerfield, NC 27358  
(800) 752-4679  
(336) 643-9200  
Fax: (336) 643-9465
- CAMERON-MILLER, INC.**  
3949 South Racine  
Chicago, IL 60609  
(800) 621-0142  
(773) 523-6360  
Fax: (773) 523-9495
- CAM-VAC, INC.**  
572 A-#2 ReactorWay  
Reno, NV 89502  
(800) 327-4401  
(702) 856-4400  
Fax: (702) 856-4401  
Cam Vac nc @ [aol.com](mailto:aol.com)
- CANADIAN DENTAL SUPPLY**  
(See Patterson Dental Canada)
- CARETEK PROTECTIVE PRODUCTS**  
Division of Caretek Resources  
6355 East Nassau Court  
P.O. Box 260051  
Highlands Ranch, CO 80126  
(800) 545-7587  
(303) 470-1947  
Fax: (303) 470-1661  
mail @ [caretek.com](mailto:caretek.com)
- CARLISLE LABORATORIES, INC.**  
100 Banks Avenue  
Rockville Centre, NY 11570  
(800) 448-7323  
(516) 832-8771  
Fax: (516) 832-8770  
[www.darbydental.com](http://www.darbydental.com)
- CARL ZEISS, INC.**  
One Zeiss Drive  
Thornwood, NY 10594  
(800) 442-4020  
(914) 747-1800  
Fax: (914) 681-7418
- CARMEL DENTAL COMPANY**  
147 West Carmel Drive, Suite 105  
Carmel, IN 46032  
(317) 846-6616
- CASTAGNOLD PRODUCTS**  
10440 South DeAnza Boulevard  
Suite D2  
Cupertino, CA 95014  
(800) 334-9513  
(408) 446-9513  
Fax: (408) 446-9571  
thebox @ [hest.com](mailto:hest.com)
- CATSKILL MOUNTAIN PHOTOS**  
2565 Route 212  
Woodstock, NY 12498  
(800) 404-9696  
(914) 679-4899  
Fax: (914) 679-4899  
[www.catskillphotos.com](http://www.catskillphotos.com)
- CAULK**  
(See Dentsply/Caulk)
- CBI (CHARLES BRUNGART, INC.)**  
3625 North Andrews Avenue  
Oakland Park, FL 33309  
(800) 654-5705  
(954) 561-8597  
Fax: (954) 563-1124
- C.C.S. INC.**  
5 Oxford St. West  
London Ontario  
N6H 1R1 Canada  
(519) 672-2220  
Fax (519) 672-8557  
billeo @ colorado.net

**C & C SYSTEMS, INC**  
 P.O. Box 4244  
 Greenwich, CT 06830  
 (800) 836-3660  
 (914) 939-2393  
 Fax: (914) 939-9291  
[pjpmatchris@earthlink.net](mailto:pjpmatchris@earthlink.net)

**CDO SMART MOVE, CORP.**  
 540 Ravine Court  
 Wycoff, NJ 07481  
 (800) 933-9282  
 (201) 612-3420  
 Fax: (201) 670-1225  
[cdgsm@worldnet.att.net](mailto:cdgsm@worldnet.att.net)

**CEDETA DENTAL INTERNATIONAL, INC.**  
 Landmark Square, 18 Knight St.  
 Norwalk, CT 06851  
 (800) 350-8232  
 (203) 855-8610  
 Fax: (203) 855-8789  
[cedetadental@snet.net](mailto:cedetadental@snet.net)

**C.E.I.A. USA LTD**  
 9177 Dutton Drive  
 Twinsburg, OH 44087  
 (330) 405-3190  
 Fax: (330) 405-3196  
[www.ceia-usa.com](http://www.ceia-usa.com)

**C.E.J. DENTAL**  
 32332 Camino Capistrano  
 Suite 101  
 San Juan Capistrano, CA 92675  
 (714) 493-2449  
 Fax: (714) 493-2492

**CENTER FOR ORAL BIOLOGY**  
 Karolinska Institute  
 Box 4064  
 S-14104 Huddinge  
 Sweden  
 46-8-746-0238  
 Fax: 46-8-779-3166

**CENTRIX, INC**  
 770 River Road  
 Shelton, CT 06484-5458  
 (800) 235-5862  
 (203) 929-5582  
 Fax: (203) 929-6804  
[ceo@centrixdental.com](mailto:ceo@centrixdental.com)

**CERADEN SINGAPORE PTE. LTD.**  
 Bilk 9008 #02-35  
 Tampines Street 93  
 Singapore 528843  
 65-7878781  
 Fax: 65-7865458  
[ceraden@mbox4.singnet.com.sg](mailto:ceraden@mbox4.singnet.com.sg)

**CERAMATIC INSTRUMENT AB**  
 Mystastigen 4, S-436 51  
 Hovas  
 Sweden  
 46-31-68-59-00  
 Fax: 46-31-68-59-00

**CERAMCO**  
 (See Dentsply Ceramco, Inc.)

**CERAMED DENTAL, L.L.C**  
 12860 West Cedar Drive  
 Lakewood, CO 80228  
 (800) 426-7836  
 (303) 985-0800  
 Fax: (303) 989-5669  
[www.ceramed.com](http://www.ceramed.com)

**CERAMIC ENGINEERING ASSOCIATION**  
 3700 East Marion Street  
 Seattle, WA 98122  
 (206) 543-2032 (message)  
 Fax: (206) 543-3100  
[wscott@u.washington.edu](mailto:wscott@u.washington.edu)

**CERAPRESS**  
 Hauptstrasse 42  
 Aschau, 84544  
 Germany  
 49-086 38-881124  
 Fax: 49-086-38 881125

**CETYLITE INDUSTRIES, INC.**  
 9051 River Road  
 P.O. Box 90006  
 Pennsauken, NJ 08110  
 (800) 257-7740  
 (609) 665-6111  
 Fax: (609) 665-5408  
[cetylite@aol.com](mailto:cetylite@aol.com)

**CHAIRSIDE GUIDE, INC.**  
 7846 South Logan Street  
 Littleton, CO 80122  
 (303) 798-2790  
 Fax: (303) 798-2790

**CHALLENGE PRODUCTS, INC.**  
 1100 Bluff Drive  
 Osage Beach, MO 65065  
 (800) 322-9800  
 (573) 348-2227  
 Fax: (573) 348-2228  
[gaiste@challengeproducts.com](mailto:gaiste@challengeproducts.com)

**CHAMELEON DENTAL PRODUCTS, INC.**  
 200 North 6th Street  
 Kansas City, KS 66101  
 (800) 366-0001  
 (913) 281-5552  
 Fax: (913) 621-7012  
[myrominc@aol.com](mailto:myrominc@aol.com)

**CHAMPION DENTAL PRODUCTS, INC.**  
 984 North Amelia Place  
 San Dimas, CA 91773  
 (800) 722-1032  
 (909) 394-1770  
 Fax: (909) 394-1765  
[championdental@worldnet.att.net](mailto:championdental@worldnet.att.net)

**CHARLES DEVELOPMENT CO. & TEXTBOOK PUBLISHERS**  
 P.O. Box 23620  
 Oakland Park, FL 33307-3620  
 (954) 772-4571

**CHASTAIN DENTAL GROUP**  
 607 South Missouri Avenue  
 Lakeland, FL 33815  
 (941) 688-9001  
 Fax: (941) 686-6732

**CHATSWORTH LATEX, INC.**  
 9421 Winnetka Avenue, Unit M  
 Chatsworth, CA 91311  
 (888) 674-5683  
 (818) 773-6696  
 Fax: (818) 773-8002

**CHEESEBROUGH PONDS USA**  
 Unilever Home and Personal  
 Care USA Business Unit  
 33 Bendict Place  
 Greenwich, CT 06830  
 (800) 636-8233  
 (203) 661-2000  
 Fax: (203) 625-1968

**CHEMBRITE**  
 15 South Jeremy Street  
 Salt Lake City, UT 84104  
 (800) 748-5153  
 (801) 595-1800  
 Fax: (801) 533-9210

**CHEMICHL INC.**  
 16149 Redmond Way, Suite  
 #178  
 Redmond, WA 98052  
 (425) 836-7713  
 Fax: (425) 836-8225  
[chemichl@aol.com](mailto:chemichl@aol.com)

**CHEMLINK LABORATORIES, LLC**  
 1590 North Roberts Rd. NW  
 Suite 111  
 Kennesaw, GA 30144  
 (800) 775-1288  
 (770) 499-8008  
 Fax: (770) 421-1984  
[cevalker@chemlinklabs.com](mailto:cevalker@chemlinklabs.com)

**CHIDE, R., INC.**  
 4531 North Dixie Highway  
 Boca Raton, FL 33431  
 (800) 645-2628  
 (561) 338-8866  
 Fax: (561) 338-5668  
[chigepep@aol.com](mailto:chigepep@aol.com)

**CHILD KEYPPERS INTERNATIONAL**  
 221 19th Avenue North  
 Lake Worth, FL 33466  
 (407) 586-6695  
 Fax: (407) 585-4372

**CHISWICK TRADING, INC.**  
 33 Union Avenue  
 Sudbury, MA 01776-2267  
 (800) 225-8708  
 (508) 443-9592  
 Fax: (508) 443-8091

**CHS GROUP, INC., THE**  
 43357 Business Park Drive,  
 Suite 102  
 Temecula, CA 92590  
 (888) 699-6166  
 (909) 699-6166  
 Fax: (909) 699-6163

**CLASSIC PRACTICE RESOURCES**  
 7885 Jefferson Highway  
 Baton Rouge, LA 70809  
 (800) 928-9289  
 (504) 928-0799  
 Fax: (504) 923-2499

**CLEAN ESD PRODUCTS, INC.**  
 47733 Fremont Boulevard  
 Fremont, CA 94538-6570  
 (510) 659-1803  
 Fax: (510) 683-9653  
[cleansed@cleansed.com](mailto:cleansed@cleansed.com)

**CLESTRA CLEANROOM, INC.**  
 7000 Performance Drive  
 North Syracuse, NY 13212-3448  
 (800) 253-7872  
 (315) 452-5200  
 Fax: (315) 452-5252

**CLINICAL RESEARCH DENTAL SUPPLIES & SERVICES INCORPORATED**  
 P.O. Box 28040  
 London, Ontario N6H 5E1  
 Canada  
 (800) 265-3444  
 (519) 641-3066  
 Fax: (800) 719-3292

**CLINICAL TECHNOLOGIES, INC.**  
 11383 East Jenan Drive  
 Scottsdale, AZ 85259  
 (800) 204-9937  
 (602) 391-1400  
 Fax: (602) 860-2321  
[teklube@aol.com](mailto:teklube@aol.com)

**CLINICIANS CHOICE DENTAL PRODUCTS, INC.**  
 1535 North Routledge Park  
 London, ON N1S 1\_6  
 Canada  
 (800) 265-3444  
 (519) 641-3066  
 Fax: (800) 719-3292

**CLINICOVERS**  
 (See Pro-Safe)

**CMP INDUSTRIES**  
 413 North Pearl Street  
 Albany, NY 12207  
 (800) 833-2343  
 (518) 434-3147  
 Fax: (518) 434-1288

**COASTAL CONNECTIONS**  
 2205 Autumn Drive  
 Kinston, NC 28501  
 (252) 523-1185  
 Fax: (252) 527-0738

**COAST FEDERAL SUPPLY**  
 P.O. Box 1785  
 Mango, FL 33550  
 (800) 992-8988  
 (813) 621-2177  
 Fax: (813) 978-8169

**COAXCO**  
 (See CPI International)

**COBS DENTAL SYSTEMS**  
 6400 Carmel Road, Suite 102  
 Charlotte, NC 28226  
 (800) 541-8108  
 (704) 541-7200  
 Fax: (704) 541-7587  
[www.cobbdental.com](http://www.cobbdental.com)

**COLGATE ORAL PHARMACEUTICALS**  
 One Colgate Way  
 Canton, MA 02021  
 (800) 225-3756  
 (781) 821-2880  
 Fax: (781) 828-7330

**COLLAGENEX PHARMACEUTICAL, INC**  
 301 South State Street  
 Newtown, PA 18940  
 (215) 579-7388  
 Fax: (215) 579-8577  
[margy@collagenex.com](mailto:margy@collagenex.com)

**COLLIMATED HOLES, INC.**  
 460 Division Street  
 Campbell, CA 95008  
 (408) 374-5080  
 Fax: (408) 374-0670  
[chi2000@pacbell.net](mailto:chi2000@pacbell.net)  
[www.collimatedholes.com](http://www.collimatedholes.com)

**COLLIS CURVE, INC.**  
 610 California Road  
 Brownsville, TX 78521  
 (800) 945-6665  
 (956) 546-1426

**COLONIAL SURGICAL SUPPLY**  
 1812 North Vermont Avenue  
 Los Angeles, CA 90027  
 (800) 252-2425  
 (310) 284-8010  
 Fax: (310) 284-8010

**COLORADO BIOMEDICAL, INC.**  
 6851 Highway 73  
 Evergreen, CO 80439  
 (800) 962-2272  
 (303) 674-5447  
 Fax: (303) 674-1296  
[info@Coloradobio.com](mailto:info@Coloradobio.com)

**COLTENE AG**  
 Feldwiesenstrasse 20  
 CH-9450  
 Altstätten, Switzerland  
 41-71-7575300  
 Fax: 41-71-7575301  
[office@coltene-whaledent.ch](mailto:office@coltene-whaledent.ch)

**COLTENE/WHALEDENT**  
 750 Corporate Drive  
 Mahwah, NJ 07430  
 (800) 221-3046  
 (201) 512-8000  
 Fax: (201) 529-2103  
[www.coltenewhaledent.com](http://www.coltenewhaledent.com)

**COLUMBIA DENTOFORM CORPORATION**  
 34-24 Hunters Point Avenue  
 Long Island City, NY 11101  
 (800) 688-0662  
 (718) 482-1569  
 Fax: (718) 482-1585

**COLUMBIA SCIENTIFIC, INC.**  
 8940-K Old Annapolis Road  
 Columbia, MD 21045  
 (888) 327-8202  
 (410) 964-3110  
 Fax: (410) 964-2513  
[www.csi7.com](http://www.csi7.com)

**COLWELL SYSTEMS**  
 201 Kenyon Road  
 Champaign, IL 61820  
 (800) 637-1140  
 (217) 351-5400  
 Fax: (800) 843-3676

**COMFORT ACRYLICS, INC.**  
 2103 Northeast 272nd Avenue  
 Camas, WA 98607  
 (800) 748-2566  
 (360) 834-9218  
 Fax: (360) 834-4403  
[www.comfortacrylics.com](http://www.comfortacrylics.com)

**COM-PAC INTERNATIONAL**  
 800 Industrial Park Road  
 PO. Box 2707  
 Carbondale, IL 62902  
 (800) 824-0817  
 (618) 529-2421  
 Fax: (618) 529-2234  
[www.midwest.net/cp.web](http://www.midwest.net/cp.web)

**COMPRESSOR TECH**  
 (See DENTL Equipment Compressors)

**COMPUTER AGE DENTIST, INC.**  
 11300 W. Olympic Boulevard,  
 Suite 600  
 (800) 426-8927  
 (310) 479-3456  
 Fax: (310) 479-0363  
[cadinfo@computeragedentist.com](mailto:cadinfo@computeragedentist.com)

**COMPUTERIZED PROBE, INC.**  
 2821 Northwest 57th Street  
 Oklahoma City, OK 73112  
 (800) 460-2772  
 (405) 843-9741  
 Fax: (405) 842-5158  
[flprobe.CAD@ionet.net](mailto:flprobe.CAD@ionet.net)

**COMTRAD INDUSTRIES**  
 2820 Waterford Lake Drive,  
 Suite 102  
 Middlethian, VA 23113  
 (800) 992-2966

**CONAIR CORPORATION**  
 1 Cummings Point Road  
 Stamford, CT 06904  
 (800) 633-6363  
 (732) 389-4500  
 Fax: (732) 389-4998  
[janmark-inc@manmouth.com](mailto:janmark-inc@manmouth.com)

**CONCEPTS INTERNATIONAL, INC.**  
 111 Smith Hines Road, Suite H  
 Greenville, SC 29607  
 (800) 627-9729  
 (864) 987-9200  
 Fax: (864) 987-9400  
[info@conceptsintl.com](mailto:info@conceptsintl.com)

**CONFI-DENTAL PRODUCTS CO.**  
 416 South Taylor Avenue  
 Louisville, CO 80027  
 (800) 383-5158  
 (303) 665-7535  
 Fax: (303) 666-4320



CONNAY SAFETY PRODUCTS CO.  
3202 Latham Drive  
P.O. Box 44190  
Madison, WI 53744-4190  
(800) 356-9100  
(608) 271-3300  
Fax: (608) 271-3322  
safety @ [connay.co](mailto:connay.co)

CONTINENTAL CARBIDE CORP.  
5659 West 63rd Avenue  
Arvada, CO 80003  
(303) 422-2775  
Fax: (303) 422-2775

CONTINUING EDUCATION UPDATE  
65 Prospect Street  
Stamford, CT 06901-1634  
(203) 348-4646  
Fax: (203) 358-0678  
[ceudent@aol.com](mailto:ceudent@aol.com)

COOKE & ASSOCIATES, INC.  
7602 Old Galveston Road  
P.O. Box 34626  
Houston, TX 77234-4626  
(800) 231-3058  
(713) 941-8455  
Fax: (713) 943-8797  
[www.cooke.co](http://www.cooke.co)

COOLEY & COOLEY, LTD.  
8550 Westland West Boulevard  
Houston, TX 77041  
(800) 215-4487  
(281) 897-0009  
Fax: (281) 897-8040  
[www.copalite.co](http://www.copalite.co)

CORE-VENT BIOENGINEERING  
27030 Malibu Hills Road  
Calabasas Hills, CA 91301  
(800) 877-9994  
(818) 878-7818  
Fax: (818) 878-7848

COSMEDENT, INC.  
5419 North Sheridan Road  
Chicago, IL 60640  
(800) 621-6729  
(773) 989-6844  
Fax: (773) 989-1826  
[cosmedent@cosmedent.co](mailto:cosmedent@cosmedent.co)

COTTRELL, LTD.  
7399 South Tucson Way  
Englewood, CO 80112-9957  
(800) 843-3343  
(303) 799-9401  
Fax: (303) 799-9408

COURTNEY DENTAL  
723 Parkhurst Lane  
Lexington, SC 29072  
(803) 359-5539  
Fax: (803) 356-5623

CPI INTERNATIONAL  
Physical Address:  
6730 McEwan Road  
Lake Oswego, OR 97035  
Mail to:  
PO. Box 99  
Newberg, OR 97132  
(BOO) 637-0001  
(503) 620-2100  
Fax: (503) 691-2443

CPR PROMPT CO.  
Health & Safety Products Division  
4543 Taylor Lane  
Warrensville, OH 44128  
(600) 391-4277  
(216) 765-1234  
Fax: (216) 765-0278  
[www.cprprompt.co](http://www.cprprompt.co)

CRANIOMETRICS, INC.  
1445 City Avenue  
Wynne Wood, PA 19096  
(610) 642-4042  
Fax: (610) 642-9056

CRC INC.  
3930 Hillyard Street  
Eugene, OR 97405  
(800) 345-3169  
(541) 345-3169  
Fax: (541) 334-4656  
[wigg@continet.com](http://wigg@continet.com)

CREATIVE BIOMOLECULES  
45 South Street  
Hopkinton, MA 01748  
(508) 782-9202  
Fax: (508) 787-1541

CREATIVE MARKETING CONCEPTS, INC.  
1110 Camino Del Mar, Suite F  
Del Mar, CA 92014  
(800) 827-9202  
(619) 481-9575  
Fax: (619) 350-7810  
cmci@gte.net

CRESCENT DENTAL MFG., CO.  
7750 West 47th Street  
Lyons, IL 60534-1826  
(800) 323-8952  
(708) 447-8050  
Fax: (708) 447-8190  
[resdent@ix.netcom.co](mailto:resdent@ix.netcom.co)

CREST ULTRASONICS CORP.  
Scotch Road  
PO. Box 7266  
Trenton, NJ 08628  
(800) 273-7822  
(609) 883-4000  
Fax: (609) 530-0923

CROSSTEX INTERNATIONAL  
Cross Country Paper Products  
10 Ranick Road  
P.O. Box 13188  
Hauppauge, NY 11788  
(800) 223-2497  
(516) 582-6777  
Fax: (516) 582-1726  
[www.crosstex.co](http://www.crosstex.co)

CROWN & BRIDGE UPDATE  
2370 Sunset Point Road  
Clearwater, FL 33765-1423  
(800) 235-2515  
(813) 797-9011  
Fax: (813) 797-6993  
[Strupow@aol.co](mailto:Strupow@aol.co)

CROWN DELTA CORP. [magneit@ICLI.com](mailto:magneit@ICLI.com)  
1550 Front Street  
Yorktown Heights, NY 10598  
(914) 245-8910  
Fax: (914) 245-8912

CRYSTAL MARK DENTAL DIVISION  
SYSTEMS, INC.  
613 Justin Avenue  
Glendale, CA 91201-2396  
(888) 264-4337  
(818) 240-7596  
Fax: (818) 247-3574  
[crystal@wavenet.com](mailto:crystal@wavenet.com)

CT FIBEROPTICS, INC.  
64 Field Road  
Somers, CT 06071  
(660) 763-4341  
Fax: (860) 763-3055  
ctfo@compsol.net

CURTIS DENTAL LAB  
850 1 Street #C  
Sparks, NV 89431  
(702) 358-1788  
Fax: (703) 358-8706

CUSTOM ULTRASONICS  
144 Railroad Drive  
Lylyland, PA 18974  
(215) 364-1477  
Fax: (215) 364-7674

CUTTING EDGE TECHNOLOGIES  
L.L.C.  
205 Washington Avenue  
Endicott, NY 13760  
(800) 478-5616  
(607) 757-0664  
Fax: (607) 757-0256

CUT-TROL/ICHTHYS ENTERPRISES  
4059 Bay Front Road  
P.O. Box 50700  
Mobile, AL 36605-0700  
(800) 288-8765  
(334) 478-4177  
Fax: (334) 478-5288  
[fmichthys@funo.co](mailto:fmichthys@funo.co)

CYBERDENT INC.  
68 Leveroni Court, Suite 1  
Novato, CA 94949  
(415) 883-0484  
Fax: (415) 883-3037

CYGNUS IMAGING, INCORPORATED  
8240 East Gelding Drive,  
Scottsdale, AZ 85260  
(800) 626-2664  
(602) 905-1500  
Fax: (602) 905-1129  
[cygimage@cris.com](mailto:cygimage@cris.com)

**D**  
DAIDO CORP.  
Precision Engineered Products  
615 Pierce Street  
PO. Box 6739  
Somerset, NJ 08875-6739  
(800) 880-1278  
(908) 805-1900  
Fax: (908) 805-0122

DAISY DENTAL  
1106 5th Street  
Redding, CA 96002  
(800) 633-2479  
(530) 221-0528  
(888) 633-2479  
Fax: (530) 222-3356

DANESS DENTAL DISTRIBUTORS,  
INC.  
205 Lexow Avenue  
P.O. Box 468  
Nyack, New York 10960  
(914) 358-3331  
Fax: (914) 358-4030

DANVILLE ENGINEERING  
2021 Omega Road  
San Ramon, CA 94583  
(800) 827-7940  
(925) 838-7940  
Fax: (925) 838-0944  
[www.daneng.co](http://www.daneng.co)

DARBY DENTAL LABS  
865 Merrick Avenue  
Westbury, NY 11590  
(800) 826-6050  
(516) 683-1800  
Fax: (516) 832-7904  
[www.darbygroup.com](http://www.darbygroup.com)

DARBY INSTITUTIONAL SALES  
865 Merrick Avenue  
Westbury, NY 11590  
(800) 344-3397  
(516) 683-1800  
Fax: (800) 417-0416  
[www.darbygroup.com](http://www.darbygroup.com)

DARBY INTERNATIONAL  
865 Merrick Avenue  
Westbury, NY 11590  
(516) 683-1800 x 2263  
Fax: (516) 832-7904  
[www.darbygroup.com](http://www.darbygroup.com)

DARWAY, INC.  
20 North San Mateo Drive,  
Suite 10  
San Mateo, CA 94401  
(650) 548-9261  
Fax: (650) 548-9262  
[palodent@darway.co](mailto:palodent@darway.co)

DASH MEDICAL GLOVES, INC.  
10180 South 54th Street  
Franklin, WI 53132  
(800) 523-2055  
(414) 421-2229  
Fax: (414) 421-4106  
[dashmed@msd.co](mailto:dashmed@msd.co)

DAVID'S DENTAL LABORATORY  
3918 Seneca Street  
West Seneca, NY 14224-3462  
(800) 628-3384  
(716) 674-2770  
Fax: (716) 674-2771

DAVIS, FA., COMPANY/PUBLISHERS  
1915 Arch Street  
Philadelphia, PA 19103  
(800) 323-3555  
(215) 440-3001  
Fax: (215) 440-3016  
[orders@fadavis.com](mailto:orders@fadavis.com)

D.B.I. AMERICAN CORPORATION  
8194 Woodland Center  
Boulevard  
Tampa, FL 33614  
(800) 884-3507  
(813) 886-0494  
Fax: (813) 888-5921  
dbiamerica@worldnet.att.net

DCI INTERNATIONAL  
305 North Springbrook  
P.O. Box 228  
Newberg, OR 97132  
(800) 624-2793  
(503) 538-8343  
Fax: (503) 538-9302

DDS CO.  
3118 Westwood Drive  
PO. Box 608  
Rocklin, CA 95677  
(916) 784-3537  
Fax: (916) 781-7886

DEDECO INTERNATIONAL, INC.  
Route 97  
Long Eddy, NY 12760  
(800) 431-3022  
(914) 887-4840  
Fax: (914) 887-5281

DEEP TRADING  
(See Oolitt)

DEFEND HEALTHCARE PRODUCTS  
A Division of Carl Parker  
Association, Inc.  
275 Oser Avenue  
Hauppauge, NY 11788  
(800) 275-0020  
(516) 434-7760  
Fax: (516) 434-7750

DEGUSSA CORPORATION  
Dental Division  
3950 South Clinton Avenue  
South Plainfield, NJ 07080  
(800) 221-0168  
(908) 754-6300  
Fax: (908) 754-6440

DELAR CORPORATION  
PO. Box 226  
Lake Oswego, OR 97034  
(800) 669-7499  
(503) 635-6820  
Fax: (503) 635-2978

DELIDENT, LTD.  
19 Keren Kayemet Street  
49372 Petach Tikva  
Israel  
972-3-921-1492  
Fax: 972-3-923-1649  
[delinter.net.i](mailto:delinter.net.i)

DELTA DENTAL OF RHODE ISLAND  
10 Charles Street  
Providence, RI 02904-2208  
(800) 843-3582  
(401) 752-6000  
Fax: (401) 752-6060

DEMETRONKERR  
21 Commerce Drive  
Danbury, CT 06810-4131  
(800) 932-7634  
(203) 748-0030  
Fax: (203) 791-8284

DENBUR, INC.  
P.O. Box 3473  
Oak Brook, IL 60522-3473  
(800) 992-1399  
(630) 986-9667  
Fax: (630) 986-9688

DENERICA DENTAL CORP.  
313 Oswalt Avenue  
Batavia, IL 60510  
(800) 336-7422  
(630) 761-0680  
Fax: (630) 761-9663  
[denerica@aol.com](mailto:denerica@aol.com)

DENLINE  
301 Oak  
Quincy, IL 62301  
(800) 336-5463  
(217) 228-9272  
Fax: (217) 228-8825

DEN-MAT CORP.  
2727 Skyway Drive  
P.O. Box 1729  
Santa Maria, CA 93456  
(800) 433-6628  
(605) 922-8491  
Fax: (805) 922-6933  
[info@denmat.co](mailto:info@denmat.co)

DENOVO  
5130 Commerce Drive  
P.O. Box 548  
Baldwin Park, CA 91706-0548  
(800) 854-7949  
(626) 939-5000  
Fax: (626) 939-5020  
[www.denovodental.com](http://www.denovodental.com)

DENPAC/5 STAR  
60 Church Street, Building 4  
Yalesville, CT 06492  
(800) 526-4656  
(203) 269-0734  
Fax: (203) 269-0752

DEN-SERV: CO/DENTAL DYNAMICS  
411 Lakewood Circle, Suite  
C201  
Colorado Springs, CO 80910  
(800) 788-9174  
(719) 597-9070  
Fax: (719) 570-4499

DENTACO PRODUCTS  
73 East Merrick Road  
Freeport, NY 11520  
(800) 925-8696  
(516) 868-8641  
Fax: (516) 868-1309

DENTAIRVAC, INC.  
4710 Prairie Dunes Drive  
Austin, TX 78747  
(800) 294-0834  
(409) 242-3021  
Fax: (409) 242-3024  
[dentairvac@aol.com](mailto:dentairvac@aol.com)

DENTAL ANCHOR SYSTEMS  
179-9 Route 46 West, Suite 112  
Rockaway, NJ 07866  
(800) 397-4433  
(201) 328-0018  
Fax: (201) 328-0288

DENTAL ARTS LABORATORIES, INC.  
241 Northeast Perry  
Peoria, IL 61651  
(800) 322-2213  
(309) 674-8191  
Fax: (309) 674-8174

DENTAL CONCEPTS, INC.  
100 Clearbrook Road  
Elmsford, NY 10523  
(800) 592-6661  
(914) 592-1860  
Fax: (914) 592-4922

DENTAL DISPOSABLES  
INTERNATIONAL  
P.O. Box 308  
Marlboro, NJ 07746  
(800) 825-5727  
(732) 462-1508  
Fax: (732) 780-8865  
[staff@dentaldisposables.com](mailto:staff@dentaldisposables.com)

DENTALEz GROUP  
101 Lindenwood Drive  
Valleybrook Corporate Center,  
Suite 225  
Malvern, PA 19355  
(800) 293-5206  
(610) 725-8004  
Fax: (610) 725-9898

DENTAL HEALTH PRODUCTS, INC.  
4011 Creek Road  
P.O. Box 355  
Youngstown, NY 14174  
(800) 828-6868  
(716) 754-2696  
Fax: (716) 754-4352

DENTAL HEALTH STORE, INC.  
3604 Forest Drive  
Alexandria, VA 22302  
(703) 931-4242  
Fax: (703) 998-7460

DENTAL HEALTHWAY, INC.  
7000 Highway 2 East  
Minot, ND 58701-9364  
(800) 345-1143  
(701) 852-1711  
Fax: (701) 837-9729

DENTAL HERB COMPANY  
78 Main Street, Suite 311  
Northampton, MA 01060  
(800) 747-4372  
(413) 582-0600  
Fax: (413) 582-0699  
[dhco@javanet.com](mailto:dhco@javanet.com)

DENTAL INVISIONS, INC.  
246 N. Dixie Boulevard  
Delray Beach, FL 33444  
(800) 322-7207  
(561) 279-0130  
Fax: (561) 279-9495  
[gpage3@worldnet.att.net](mailto:gpage3@worldnet.att.net)

DENTAL LOGICS, INC.  
20 E 11th Ave  
Conshohocken, PA 19428  
(800) 778-0075  
(610) 566-5703  
Fax: (610) 566-0605  
[pbk@concentric.net](mailto:pbk@concentric.net)

DENTAL MATERIALS GROUP, LTD.  
275 Oser Avenue  
R.O. BOX 12084  
Hauppauge, NY 11788  
(516) 434-7760  
Fax: (516) 434-7750

DENTAL NETWORK OF AMERICA,  
INC.  
Two TransAm Plaza Drive  
Suite 500  
Oakbrook Terrace, IL 60181  
(800) 323-6840  
(630) 691-1133  
Fax: (630) 495-0575

DENTAL OPTICS MANUFACTURING,  
INC.  
203 Long Beach Road  
Island Park, NY 11558  
(800) 423-7688  
(516) 889-5857  
Fax: (516) 889-5874

DENTAL PREFERRED  
2201 South Oneida Street  
Green Bay, WI 54304  
(800) 948-4048  
(414) 494-1678  
Fax: (414) 494-3386

DENTAL PRODUCTS REPORT (DPR)  
Two Northfield Plaza, Suite 300  
Northfield, IL 60093-1219  
(800) 323-3337  
(847) 441-3700  
Fax: (847) 441-3702  
[dpr@medac.com](mailto:dpr@medac.com)

DENTAL PROSTHETIC SERVICES,  
INC.  
1150 Old Marion Road NE  
Cedar Rapids, IA 52406  
(800) 332-3341  
(319) 393-1990  
Fax: (319) 393-8455

DENTAL RECORD, THE  
Division of the Wisconsin Dental  
Association Professional Ser-  
vices, Incorporated  
111 East Wisconsin Avenue,  
Suite 1300  
Milwaukee, WI, 53202  
(600) 243-4675  
(414) 276-3954  
Fax: (414) 276-2186  
[wdatdr@tcccom.net](mailto:wdatdr@tcccom.net)

DENTAL RESOURCES, INC.  
530 River Street South  
Delano, MN 55328  
(800) 328-1276  
(612) 972-3801  
Fax: (612) 972-3807  
[dentresources@onrampine.net](mailto:dentresources@onrampine.net)

DENTAL SERVICES/DENTAL  
DYNAMICS  
(See Den-Serv-Co)

DENTAL SERVICES GROUP (DSG)  
Sentage Corporation  
5775 Wayzata Boulevard,  
Suite 670  
Minneapolis, MN 55416  
(800) 765-3004  
(612) 541-9622  
Fax: (612) 541-1358  
[corporate@dentalservices.net](mailto:corporate@dentalservices.net)

DENTAL SPECIALTY MFG. CO.  
3013 Mangum Dairy Road  
Monroe, NC 28112  
(704) 764-3424

DENTAL STORE, THE  
1061 South Roselle Road  
Schaumburg, IL 60193-3900  
(847) 301-0400  
Fax: (847) 301-0120  
[www.dentalstore.com](http://www.dentalstore.com)

DENTAL SUPPLY SPECIALTIES  
(See Infection Control Products)

DENTAL SURGEON  
24, Dubnor Street  
Tel Aviv, 64957; Israel  
03 262 2550  
Fax: 03 696 2550

DENTAL TECHNICIANS SUPPLY  
6385 West 52nd Avenue,  
Suite 6  
Arvada, CO 60002  
(800) 828-3393  
(303) 467-2003  
Fax: (303) 467-2008  
DTS@RMI.NET

DENTAL TECHNICIANS SUPPLY  
8301 NW, 100-1st Terrace,  
Suite 1  
Kansas City, MO 64153  
(800) 247-2385  
(816) 891-8387  
Fax: (816) 891-8385  
[dtskc@aol.com](mailto:dtskc@aol.com)

DENTAL TOOLS  
2525 Bay Area Boulevard,  
Suite 170  
Houston, TX 77058  
(281) 488-3434  
Fax: (281) 488-8350  
[Jellies@hikbox.com](mailto:Jellies@hikbox.com)  
[www.dentaltools.com](http://www.dentaltools.com)

DENTAL TRENDS  
21818 Falvel Road  
Spring, TX 77388  
(888) 353-3327  
(281) 353-3327  
Fax: (281) 353-7115

DENTAL VENTURES OF AMERICA,  
INC.  
217 Lewis Court  
Corona, CA 91720  
(800) 228-6696  
(909) 270-0606  
Fax: (909) 270-0636  
[www.dentalventures.com](http://www.dentalventures.com)

DENTAL VIDEO SUPPLY OF  
ST. LOUIS  
262 Cleate Court  
Ballwin, MO 63021  
(800) 785-3471  
(314) 230-6336  
Fax: (314) 230-6336

DENTAL WELL INSTRUMENTS  
1920 Palm Beach Lakes Boule-  
vard,  
Suite 104  
West Palm Beach, FL 33409  
(561) 684-2282  
Fax: (561) 626-3752

DENTAMERICA  
P.O. Box 3200  
Industry, CA 91744  
(626) 912-1388  
Fax: (626) 913-0510

DENTAPEDIC  
10220 Timberwood Circle  
Louisville KY 40223  
(800) 500-0518  
(502) 244-4673  
Fax: (502) 896-4096

DENTAPOPS  
11230 Gold Express Drive,  
Suite 310-119  
Gold River, CA 95670  
(SOD) 959-8517  
(916) 635-1960  
Fax: (916) 858-1250

DENTAPURE  
1234 South Wasson Lane  
P.O. Box 617  
Riverfalls, WI 54022  
(800) 972-3543  
(218) 739-2222  
Fax: (218) 736-3241  
[dentapur@prairietech.com](mailto:dentapur@prairietech.com)

DENTASYS, INC.  
P.O. Box 6660  
4910 B. South 31st Street  
Arlington, VA 22206  
(703) 820-4841  
Fax: (703) 820-2735  
[dentasys@aol.com](mailto:dentasys@aol.com)

DENTA-SYSTEMS  
15870 Franklin Trail  
Prior Lake, MN 55372  
(800) 535-4370  
(612) 440-1212  
Fax: (612) 447-1051

DENTATUS USA, LTD.  
192 Lexington Avenue, Suite  
901  
New York, NY 10016  
(800) 323-3136  
(212) 481-1010  
Fax: (212) 532-9026

DENTAURUM, INC.  
10 Pheasant Run  
Newtown, PA 18940  
(800) 523-3946  
(215) 968-2858  
Fax: (215) 968-0809  
[admin@dentaurum.com](mailto:admin@dentaurum.com)

DENTA-VISION, INC.  
571 Bloomfield Avenue  
Verona, NJ 07044  
(973) 857-8538  
Fax: (973) 746-2934

DENTco RESEARCH &  
DEVELOPMENT CORP.  
7-11 South Broadway  
White Plains, NY 10601  
(800) 454-9244  
(914) 682-6600  
Fax: (914) 948-1711

DENTE@ COMPANY  
31 Industrial Avenue  
Mahwah, NJ 07430  
(800) 828-8944  
(201) 529-2019  
Fax: (201) 529-1349

DENTECH CORPORATION  
529 West Front Street  
Sumas, WA 98295  
(800) 826-5004  
(360) 988-7911  
Fax: (360) 988-7906

DENTECO INC.  
74 Highland Street  
Worcester, MA 01609  
(888) 640-3344  
(508) 755-0804  
Fax: (508) 756-9013  
[Dr.audette@denteco.com](mailto:Dr.audette@denteco.com)

DENTICATOR INTERNATIONAL, INC.  
8400 Carbide Court  
Sacramento, CA 95828  
(800) 227-3321  
(916) 682-1660  
Fax: (916) 682-2339

DENTIFax/DI-Eoul  
17 Old Route 9  
Wappingers Falls, NY 12590-  
4036  
(914) 297-1014  
Fax: (914) 297-1626  
[dentifax@aol.com](mailto:dentifax@aol.com)

DENTIST PREFERRED, INC.  
113 Floral Vale Boulevard,  
Suite 10  
Yardley, PA 19067  
(800) 997-7694  
(215) 504-9388  
Fax: (215) 504-9366

DENTIVAC Loop  
5228 North Lombard Street  
Portland, OR 97203  
(800) 854-5667  
(503) 289-7043  
Fax: (503) 289-1425

DENT-MED CO.  
5050 Country Drive  
Okemos, MI 48864  
(517) 349-3212  
Fax (517) 339-2990

DENTO-PROFILE SCALE CO.  
40 Country Club Court  
Fond Du Lac, WI 54935  
(800) 336-8610  
(920) 922-5446  
Fax: (920) 922-2500  
[popp@fdl.net](mailto:popp@fdl.net)

DENTOP SYSTEMS, LTD  
Hamelacha Street 22  
P.O. Box 11388  
Rosh Ha'ayin 48901  
Israel

DENTRADE INTERNATIONAL  
P.O. Box 15-B  
San Francisco, CA 94115  
(415) 929-1774  
Fax: (415) 929-1321

DENTRIX DENTAL SYSTEMS INC.  
732 East Utah Valley Drive,  
Suite 500  
American Fork, UT 84003  
(800) 336-8749  
(801) 763-9300  
Fax: (801) 763-9336  
[info@dentrix.com](mailto:info@dentrix.com)

DENTRONIX, INC.  
101 Steamwhistle Drive  
Ivlyland, PA 18974  
(800) 523-5944  
(215) 322-4220  
Fax: (215) 364-8607

DENTSPLY CAULK  
38 West Clarke Avenue  
P.O. Box 359  
Milford, DE 19963-0359  
(800) 532-2855  
(302) 422-4511  
Fax: (302) 422-3480  
[www.aulk.com](http://www.aulk.com)

DENTSPLY CERAMCO, INC.  
Six Terri Lane  
Burlington, NJ 08016  
(800) 487-0100  
(609) 386-8900  
Fax: (609) 386-8282  
[mtking@ceramco.com](mailto:mtking@ceramco.com)

DENTSPLY DETREY GMBH  
DeTrey-Str. 1  
D-78467 Konstanz  
Germany  
49-7531 583-0  
Fax: 49-7531 583 1 04  
[aeg@dentplyde](mailto:aeg@dentplyde)

DENTSPLY/GENDEX DENTAL  
DIVISION  
4379 South Howell Avenue,  
Suite 2  
Milwaukee, WI 53207  
(800) 769-2909  
(414) 769-2888  
Fax: (414) 769-2868  
[www.gandexray.com](http://www.gandexray.com)

- DENTSPLY IMPLANT  
(See Paragon Implant)
- DENTSPLY INTERNATIONAL  
570 West College Avenue  
P.O. Box 872  
York, PA 17404-0872  
(800) 877-0020  
(717) 845-7511  
Fax: (717) 849-4376
- DENTSPLY MAILLEFER N.A.  
5001 E. 68th St.  
Suite 500  
Tulsa, Oklahoma 74136  
(800) 924-7393  
(918) 493-6598  
Fax: (918) 493-6599  
www.maillefer.com.
- DENTSPLY/MIDWEST DENTAL PRODUCTS  
Division of Dentsply International  
901 West Oakton Street  
Des Plaines, IL 60018-1884  
(800) 800-7202  
(847) 640-4800  
Fax: (847) 640-4854  
www.midwestdental.com
- DENTSPLY/IMPL TECHNOLOGIES  
A Division of Dentsply International, Inc.  
9400 King Street  
Franklin Park, IL 60131-2116  
(800) 621-6421  
(847) 678-7555  
Fax: (847) 678-7585
- DENTSPLY NEW IMAGE  
2283 Cosmos Court  
Carlsbad, CA 92093  
(800) 634-7349  
(760) 930-9900  
Fax: (760) 930-9999
- DENTSPLY PREVENTIVE CARE  
1301 Smile Way  
P.O. Box 7807  
York, PA 17404-0807  
(800) 989-8825  
(717) 767-8524  
Fax: (717) 767-8252  
RltPaschke@usa.net
- DENTSPLY/RINN DIVISION  
1212 Abbott Drive  
Elgin, IL 60123-1819  
(800) 323-0970  
(847) 742-1115  
Fax: (847) 742-1122  
aleigh@rinncorp.com
- DENTSPLY/TRUBYTE  
570 West College Avenue  
P.O. Box 872  
York, PA 17405-0872  
(800) 877-0020  
(717) 845-7511  
Fax: (717) 845-7514  
www.trubyte.com
- DENTSPLY TULSA DENTAL PRODUCTS  
5001 East 68th Street, Suite 500  
Tulsa, OK 74136  
(800) 924-7393  
(918) 493-6598  
Fax: (918) 493-6599  
www.tulsadental.com
- DENT-X  
250 Clearbrook Road  
Elmsford, NY 10523  
(800) 225-1702  
(914) 592-6665  
Fax: (914) 592-6148  
www.dentx.com
- DENT-ZAR co.  
6362 Hollywood Boulevard,  
Suite 214  
Los Angeles, CA 90028  
(800) 444-1241  
(213) 465-3621  
Fax: (213) 465-2994
- DEPLAQUE, INC.  
P.O. Box 255  
Victor, NY 14564  
(716) 924-3190  
Fax: (716) 924-3190  
www.DePlaquine.com
- DESIGN 2000, LLC.  
Pillo Beans Dental Division  
4730 East Indian School Road  
Suite 120  
Phoenix, AZ 85018  
(602) 230-5237  
Fax: (602) 840-8321
- DESIGNER CARE co., LTD.  
548 5th Ave  
Neche, ND 58265  
(800) 848-6335  
(701) 886-7778  
Fax: (701) 886-7588
- DESIGNS FOR VISION, INC.  
760 Koehler Avenue  
Ronkonkoma, NY 11779  
(800) 345-4009  
(516) 585-3300  
Fax: (516) 585-3404
- DETAx GMBH & Co. KG  
P. O. Box 10 02 25  
D-76256 Ettlingen  
Germany  
49-07243 510-0  
Fax: 49-07243-510-143  
Denax@t-online.de
- DEXIDE, INCORPORATED  
7509 Flagstone Drive  
P. O. Box 185789  
Ft. Worth, TX 76118-6995  
(800) 645-3378  
(817) 589-1454  
Fax: (817) 589-3783  
www.dexide.com
- DIAGRAM  
Via Mascagni,  
Forli Italy 67-1-47100  
39 543 782078  
Fax: 39 543 782378  
f.mercuriali@fo-nettuno.it
- DIAL CORP., THE  
Dial Technical & Admin. Center  
15701 North Scottsdale Road  
Scottsdale, AZ 85254-2199  
(800) 253-3425  
(602) 754-3425  
Fax: (602) 754-1098
- DIAL CORP., THE  
Headquarters Office  
15501 North Dial Boulevard  
Scottsdale, AZ 85260-1619  
(800) 253-3425  
(602) 754-7199  
Fax: (602) 754-1098  
jrussell@dialcorp.com
- DIAMOND DENTAL STUDIO  
13760 West 67th Circle  
Arvada, CO 80004  
(303) 431-5111
- DIAMOND TECHNOLOGIES co.  
304 Whittington Parkway, Suite 107  
Louisville, KY 40222-4193  
(800) 454-9763  
(502) 425-4800  
Fax: (502) 425-3131
- DIGIDEAL, INC.  
Washington Mutual Building  
West  
601 Main Street, Suite 812  
Spokane, WA 99201  
(509) 747-8887  
Fax: (509) 623-2500
- DIGIDENT  
8190 Royal Palm Boulevard,  
Suite 205  
Coral Springs, FL 33065  
(800) 741-7966  
(954) 753-9938  
Fax: (954) 753-9794  
draubl701@aol.com
- DIGITAL Doc, INC.  
101 E. Natoma, Ste. A  
Folsom, CA 95630  
(800) 518-1102  
(916) 985-8170  
Fax: (916) 605-8167
- DINE, LESTER A., INC.  
351 Hiatt Drive  
Palm Beach Gardens, FL 33418  
(800) 624-9103  
(561) 624-9100  
Fax: (561) 624-9103  
dinecorp@emi.net
- DIOPICS MEDICAL PRODUCTS, INC.  
51 Zaca Lane, Suite 150  
San Luis Obispo, CA 93401  
(800) 959-9040  
(805) 781-3300  
Fax: (805) 781-3322
- Discus DENTAL CANADA, INC.  
1985 Landsdowne Street West  
Rural Route #3  
Peterborough, Ontario K9J 6X4  
Canada  
(800) 363-4568  
(705) 740-9466  
Fax: (705) 740-2773  
grega@discusdental.com
- Discus DENTAL, INC.  
8550 Higuera Street  
Culver City, CA 90232  
(800) 422-9448  
(310) 845-8200  
Fax: (310) 845-1537  
www.discusdental.com
- DISPOMED, INC.  
P. O. Box 97  
Temecula, CA 92593  
(800) 873-4776  
(909) 694-6004  
Fax: (909) 694-6018  
able@ardex.com
- DISTAR, INC.  
3748 Eubank Boulevard NE  
Albuquerque, NM 87111  
(800) 477-6673  
(505) 299-9172  
Fax: (505) 299-9164  
distar@distar.com
- DIVERSIFIED CHEMICAL PRODUCTS  
30 Germany Dr.  
Williamsburg, DE 19804  
(800) 320-0084  
(302) 656-5293  
Fax: (302) 656-1530
- DIVERSIFIED DENTAL SALES  
2110-G Northeast Cornell Road  
Hillsboro, OR 97124  
(800) 764-2766  
(503) 693-4695  
Fax: (503) 693-3594  
pcheney@juno.com
- Dix PREVENTIVE PRODUCTS, INC.  
145 East 15th Street  
New York, NY 10003  
(212) 254-7563  
Fax: (212) 979-7152  
dixppi@worldnet.att.net
- D.J. ENTERPRISES  
1490 Commercial, Suite 202  
Astoria, OR 97103  
(503) 325-0722  
Fax: (503) 325-1795
- (DMD) DENTAUMEDICAL  
DIAGNOSTIC SYSTEMS, INC.  
200 North Westlake Boulevard  
Suite 202  
Westlake Village, CA 91362  
(800) 399-0999  
(805) 381-2700  
Fax: (805) 374-1966  
dmdcorp@ix.netcom.com
- DMD TECHNICS, INC.  
507 Washington Avenue  
Kenilworth, NJ 07033  
(908) 272-3010  
Fax: (908) 654-7961  
technetx@home.com
- DMG-HAMBURG  
Elbgastr. 248  
D-22547 Hamburg, Germany  
49-40-84006-0  
Fax: 49-40-84006-222  
info@dmg-hamburg.de
- DNTLWORKS EQUIPMENT  
CORPORATION  
11504 E. Hinsdale Circle, Unit B  
Englewood, CO 80112  
(800) 847-0694  
(303) 693-1410  
Fax: (303) 693-6189  
dntlworks@aol.com
- Do-HICKEY INTERNATIONAL, INC.  
1106 Millidge Road  
Augusta, GA 30904  
(706) 739-0071  
Fax: (706) 739-0820  
judhickey@aol.com
- DOK REMOUNT ARTICULATORS  
131 Chesterfield Road  
Box 573  
Bogart, GA 30622  
(800) 828-6521  
(706) 369-0417  
Fax: (706) 549-8611
- DOLAN-JENNER INDUSTRIES, INC.  
678 Andover Street  
Lawrence, MA 01843  
(800) 833-4237  
(978) 681-8000  
Fax: (978) 682-2500  
www.dolan-jenner.com
- DONAGAN OPTICAL co., INC.  
15549 West 108th Street  
P.O. Box 14308  
Lenexa, KS 66285-4308  
(888) 492-2503  
(913) 492-2500  
Fax: (913) 492-2503  
magnify@swbell.net
- D-O SCIENTIFIC PRODUCTS, INC.  
1711 Pine Street  
Philadelphia, PA 19103  
(215) 735-9469
- DOVE SYSTEMS, INC.  
1735 East Baysshore Road,  
Suite 6A  
Redwood City, CA 94063  
(650) 306-0194  
Fax: (650) 306-0207
- DRAGON BREATH PRODUCTIONS  
122 Calistoga Road #136  
Santa Rosa, CA 95404  
(707) 539-3279  
Fax: (707) 544-7041  
nokandy@aol.com
- DRAKE PRECISION DENTAL  
LABORATORY, INC.  
2400 Crown Point Executive  
Drive, Suite 200  
Charlotte NC 28227  
(800) 476-2771  
(704) 845-2401  
Fax: (704) 845-2289  
www.drakelab.com
- DR. EDWIN I. LEVIN  
Dental Surgeon  
42 Harley Street  
London, England W1 N 1 AB  
011 44 0171 935 6202  
Fax: 0 11 44 0181 292 2662  
eddylevin@dentalurgeon.  
demon.co.uk
- DREIR PHARMACEUTICALS, INC.  
8479 East San Daniel Drive  
Scottsdale, AZ 85258  
(800) 541-4044  
(602) 607-3584  
Fax: (602) 607-0731
- DR. HOFF GMBH & Co. KG  
Bayernstrasse 9  
D-30855 Langenhagen  
Germany  
49 511 78 9924  
Fax: 49 511 74 1130
- DRIDENT  
826 Pipestone  
Columbus, OH 43235  
(800) 540-7377  
(614) 433-7367  
Fax: (614) 433-7223  
drident@aol.com
- DR. JOHNS CANDIES  
2242 Cardiff Court Northeast  
Grand Rapids, MI 49505  
(888) 375-6462  
(616) 454-3707  
Fax: (616) 459-3378  
www.drjohns.com
- D & R MINER DENTAL  
1743 Elm Road  
Concord, CA 94519  
(925) 376-5802  
Fax: (925) 674-8431
- DROSMAN DENTAL  
16500 Ventura Boulevard, Suite 205  
Encino, CA 91436  
(818) 783-5157  
Fax: (818) 783-0306
- DR. TUNG'S PRODUCTS  
6160 Lusk Boulevard, Suite C/lot  
San Diego, CA 92121  
(800) 960-7144  
(619) 587-0061  
Fax: (619) 587-8818  
drtungs@hawaii.rr.com
- DRY INVENTION AB  
Gotgalani  
75315 Uppsala  
Sweden  
46 18 502608  
Fax: 46 18 502490
- DR. YOUNG'S SOFTWARE  
5500 Cottonwood Lane  
Salt Lake City, UT 84117  
(800) 421-1044  
(801) 278-0802

DST PUBLISHING  
(See Blue Book OTC & FIX Reference, The)

D & S VIDEO WAREHOUSE  
11367 Pyrites Way, Suite G  
Gold River, CA 95670  
(888) 700-0715  
(916) 852-7283  
Fax: (916) 852-9468  
[www.dsvw-dental.com](http://www.dsvw-dental.com)

DUKANE CANADA CORP.  
461 Manitou Drive  
Kitchener, Ontario N2C 1 L5  
Canada  
(519) 748-5357  
Fax: (519) 748-9221

DUMEX-ALPHARMA A/S  
37 Prags Boulevard  
DK 2300  
Copenhagen S  
Denmark  
4531 544500  
Fax: 45 31 95 0504

DUMEX LIMITED  
Tring Business Center  
Upper Icknield Way, Tring  
Hertfordshire HP234JX  
England  
44-2-890-090  
Fax: 44-2-890-899

DU-MORE, INC.  
1751 South 1st Street  
P.O. Box 1167  
Rogers, AR 72757  
(800) 643-3447  
(501) 631-1088  
Fax: (501) 631-1934

DURR DENTAL  
D-74321 Bietigheim-Bissingen  
R.O. Box 1264  
West Germany  
49-07142-705-0  
Fax: 49-07142-61365  
[www.durr.de](http://www.durr.de)

DYNA-DENTAL SYSTEMS  
903 South Rural Road, Suite  
238  
Phoenix, AZ 85281  
(800) 785-5595  
(602) 368-0500  
Fax: (602) 368-0363  
[www.ionicbrush.com](http://www.ionicbrush.com)

DYNA FLEX, LTD.  
10246 Bach Boulevard  
St. Louis, MO 63132  
(800) 489-4020  
(314) 426-4020  
Fax: (314) 429-7575  
[www.dynaflex.com](http://www.dynaflex.com)

DYNAMIC DENTAL INNOVATIONS  
627 Southwest Topeka Boulevard  
Topeka, KS 66603  
(800) 418-2278  
(785) 234-3660  
Fax: (785) 838-9435  
[DDI3@juno.com](mailto:DDI3@juno.com)

DYNAMIC DENTAL SYSTEMS  
2481 Hilton Drive, Suite 8  
(888) 837-1837  
(707) 534-0487  
Fax: (707) 534-0883

DYNAREX CORPORATION  
One International Boulevard  
Brewster, NY 10509  
(800) 431-2786  
(914) 279-9600  
Fax: (914) 279-9601

DYNATRONICS CORP.  
7030 Park Centre Drive  
Salt Lake City, UT 84121  
(800) 874-6251  
(801) 568-7000  
Fax: (801) 568-7711  
[www.dynatronics.com](http://www.dynatronics.com)

## E

E.A. BECK & COMPANY  
657 West 19th Street  
P.O. Box 10859  
Costa Mesa, CA 92627-0258  
(800) 854-0153  
(949) 645-4072  
Fax: upon request  
[eabackco@aol.com](mailto:eabackco@aol.com)

EAGLESOFT, INC.  
2202 Althoff Drive  
P.O. Box 1267  
Effingham, IL 62401  
(800) 294-8504  
(217) 347-5964  
Fax: (217) 342-6950  
[www.eaglesoft.net](http://www.eaglesoft.net)

EARTHPower INC.  
175 Rock Road  
Glen Rock, NJ 07452  
(201) 445-7068  
Fax: (201) 493-1126  
[buckey@earthpower.com](mailto:buckey@earthpower.com)

**F.A.S.F. MEDICAL SUPPLIES**  
743 Gold Hill Place, Suite 123  
Woodland Park, CO 80866  
(800) 800-5914  
(719) 742-3437  
Fax: (719) 742-3449

EASTMAN KODAK CO.  
Dental Division  
343 State Street  
Rochester, NY 14650-1122  
(800) 933-8031  
Fax: (800) 374-1871  
[www.kodak.com/go/dental](http://www.kodak.com/go/dental)

EASY-ART CORP.  
9200 Park Lane  
Franklin Park, IL 60131  
(800) 455-3700  
(847) 455-1095

EASY TRAY, INC.  
2209 North 56th  
Seattle, WA 98103-6203  
(800) 726-1628  
(206) 545-7971  
Fax: (206) 545-8011

E.C. MOORE CO., NC.  
13325 Leonard Street  
P.O. Box 353  
Dearborn, MI 48121  
(800) 331-3548  
(313) 581-7878  
Fax: (313) 581-8348

ECOLAB PROFESSIONAL PRODUCTS  
DIVISION  
370 Wabasha Street N/12  
St. Paul, MN 55102-1390  
(800) 332-6522  
(612) 293-2966  
Fax: (612) 293-2959

ECONO SYSTEMS  
2946-N Chainbridge Road  
Oakton, VA 22144  
(703) 281-2111  
Fax: (703) 281-0973

E & D  
(See Kerr)

EDGE DENTAL INC.  
P.O. Box 4332  
13606 West Bayshore Road  
Traverse City, MI 49685-4332  
(800) 873-6070  
(616) 946-6070  
Fax: (616) 922-2274  
[edge@nbhs.com](mailto:edge@nbhs.com)

EDGE SYSTEMS CORPORATION  
2321 East 28th Street, Suite  
404  
Signal Hill, CA 90806  
(800) 603-4996  
(562) 988-1175  
Fax: (562) 988-1195  
[smokesafe@aol.com](mailto:smokesafe@aol.com)

EDROY PRODUCTS CO., INC.  
245 North Midland Avenue  
P.O. Box 998  
Nyack, NY 10960  
(914) 358-6600  
Fax: (914) 358-4098

E. E. SYSTEMS, INC.  
P.O. Box 1591  
Vienna, VA 22180  
(800) 527-2076  
(703) 242-2258  
Fax: (703) 356-1602

E FOR M  
(See Marquette Medical Systems Division)

EFOS, INC.  
(See Dentsply/Caulk)

ELECTRONIC IMAGES  
(See Digident)

ELECTRONIC WAVEFORM LAB, INC.  
16168 Beach Boulevard, Suite  
232  
Huntington Beach, CA 92647  
(800) 874-9283  
(714) 843-0463  
Fax: (714) 843-1992  
[www.h-wave.com](http://www.h-wave.com)

ELECTED THERAPY ASSOCIATION  
P.O. Box 33189  
Tulsa, OK 74153  
(918) 663-0297  
Fax: (918) 663-0298  
[electro@electrotherapy.com](http://electro@electrotherapy.com)

ELLMAN INTERNATIONAL, INC.  
1135 Railroad Avenue  
Hewlett, NY 11557  
(800) 835-5355  
(516) 569-1482  
Fax: (516) 569-0054  
[www.eliman.com](http://www.eliman.com)

EMERGING INFECTIOUS DISEASES  
Public Health Service  
Center for Disease Control  
1600 Clifton Road (MSC12)  
Atlanta, GA 30333  
(404) 639-3967  
Fax: (404) 639-3075  
[www.cdc.gov](http://www.cdc.gov)

EMERGING TECHNOLOGIES GROUP,  
THE  
824 U.S. Highway 1, Suite 370  
North Palm Beach, FL 33408  
(561) 627-5560  
Fax: (561) 627-4214  
[kruman001@aol.com](mailto:kruman001@aol.com)

EMERY DENTAL, INC.  
2510 12th St. S.E.  
Salem, OR 97302  
(800) 637-6611  
(503) 378-0523  
Fax: (503) 378-0687

EMF CORP.  
239 Cherry Street  
Ithaca, NY 14850  
(800) 456-7070  
(607) 272-3320  
Fax: (607) 272-3369

EMS AMERICA  
Electro Medical Systems, Corp.  
670 International Parkway,  
Suite 100  
Richardson, TX 75081  
(800) 367-0367  
(972) 690-8382  
Fax: (972) 690-8981  
[emsusa@ix.netcom.com](mailto:emsusa@ix.netcom.com)

EMS DEUTSCHLAND GMBH  
Electro Medical Systems  
Schatzbogen 86  
81829 Munchen  
Germany  
49-89 42 71 61 0  
Fax: 49-89 42 71 61 60  
[emsde@t-online.de](mailto:emsde@t-online.de)

EMS SWITZERLAND  
Electromedical System SA  
Rue Vuarpilliere 31  
CH - 1260 Nyon  
Switzerland  
01141229944700  
Fax: 01141-22-9944701  
[ems@iprlink.ch](mailto:ems@iprlink.ch)

ENAMELON, INC.  
7 Cedarbrook Drive  
Cranberry, NJ 08512  
(888) 432-3535  
(609) 395-6900  
Fax: (513) 825-5601  
[anz@ny.frbid.com](mailto:anz@ny.frbid.com)

ENDo TECHNICAL  
Division of Biolase Technology  
981 Calle Amanecer  
San Clemente, CA 92673  
(800) 699-9462  
(949) 361-1200  
Fax: (949) 361-0204

ENFRESH PRODUCTS, INC.  
500 Sugar Mill Road, Suite  
170A  
Atlanta, GA 30350  
(678) 461-4442  
Fax: (678) 461-4457  
[www.enfresh.com](http://www.enfresh.com)

ENGELHARD-CLAL/BAKER DENTAL  
700 Blair Road  
Carteret, NJ 07008  
(800) 631-5599  
(732) 205-5800  
Fax: (732) 205-7453

ENGINEERED SYSTEMS & DESIGNS  
119 A Sandy Drive  
Newark, DE 19713  
(800) 328-0516  
(302) 456-0446  
Fax: (302) 456-0441  
[esd@esdinc.com](mailto:esd@esdinc.com)

ENGLER ENGINEERING  
CORPORATION  
1099 East 47th Street  
Hialeah, FL 33013  
(800) 445-8581  
(305) 688-8581  
Fax: (305) 685-7671  
[info@engler-engineering.com](mailto:info@engler-engineering.com)

ENVIRO-AMERICAN, INC.  
1300 West Main  
Oklahoma City, OK 73106  
(800) 729-2048  
(405) 236-4255  
Fax: (405) 236-4261  
[enviro@oklahoma.net](mailto:enviro@oklahoma.net)

ENVIROTECH ENTERPRISES, INC.  
Glove Division  
2555 North Jackrabbit Avenue  
Tucson, AZ 85745-1206  
(888) 577-1199 x119  
(520) 884-4977  
Fax: (520) 882-9763

ENVISION INTERNATIONAL  
(See Knowledge Systems International)

ENZYME SOLUTIONS, INC.  
3211 Falling Creek Road S.W.  
P.O. Box 3888  
Hickory, NC 28603  
(800) 523-1323  
(704) 328-3600  
Fax: (704) 328-3655

EQUIDENT LAB  
206 Madison Avenue  
Lakewood, NJ 08701  
(800) 729-1864  
(732) 363-3838  
Fax: (732) 905-8125

ERGO I.M.  
P.O. Box 1716  
Aspen, CO 81612  
(888) 374-6426  
(970) 925-3104  
Fax: (970) 925-3104

ERGONOMIC PRODUCTS LLC.  
767 Main Road, Suite 1  
Westport, MA 02790  
Mailing address  
P.O. Box 3411  
Westport, MA 02791  
(800) 275-2547  
(508) 636-3600  
Fax: (508) 636-3830  
[besidesign@desergo.com](mailto:besidesign@desergo.com)

ERICKSEN, BENT, & ASSOCIATES  
3941 Park Drive, Suite 20-317  
El Dorado Hills, CA 95762  
(916) 933-5117  
Fax: (916) 933-0973  
[www.bent-ericksen.com](http://www.bent-ericksen.com)

ESC MEDICAL SYSTEMS  
22011 30th Avenue S.E.  
Bothell, WA 98021  
(800) 548-1482  
(425) 483-4142  
Fax: (425) 483-6844  
[www.escmed.com](http://www.escmed.com)

ESMA, INC.  
450 West Taft Drive  
South Holland, IL 60473  
(800) 276-2466  
(708) 331-1855  
Fax: (708) 331-8919

ESPE AMERICA, INC.  
1710 Romano Drive  
P.O. Box 111  
Norristown, PA 19404  
(800) 344-8235  
(610) 277-3800  
Fax: (610) 239-2398  
[info.espeusa.com](mailto:info.espeusa.com)

ESPE DENTAL AG  
82229 Seefeld  
Oberbay  
Germany  
49-8152-700-0  
Fax: 49-8152-700-680  
[www.espe.de](http://www.espe.de)

ESSENTIAL DENTAL SYSTEMS  
89 Leuning Street  
South Hackensack, NJ 07606  
(800) 223-5394  
(201) 487-9090  
Fax: (201) 487-5120  
[eds@nipeline.com](mailto:eds@nipeline.com)



- ETM CORP.  
1717 West Collins Ave.  
Orange, CA 92867  
(800) 854-1741  
(714) 516-7400  
Fax: (714) 516-7543
- EUGENEICS  
3531 Lake Shore Drive  
Longmont, CO 80503  
(303) 776-7281  
Fax: (303) 776-6042
- EVELYN CO., INC, THE  
5436-K South Mingo Road  
P.O. Box 35265  
Tulsa, OK 74146  
(800) 221-0518  
(918) 665-3952  
Fax: (918) 665-6027
- EVIDENT DENTAL CO., LTD.  
57 Wellington Crt, Wellington  
Rd  
London, England NW8 9TO  
44-171-722-0072  
Fax: 44-171-722-0976  
[helpdesk@evident.co.uk](mailto:helpdesk@evident.co.uk)
- EXACTA DENTAL PRODUCTS  
1940 Thunderbird Street  
Troy, MI 48084  
(800) 474-7665  
(248) 269-9380  
Fax: (248) 269-9395
- EXPERDENT  
Vancouver Office  
Suite 218-4940 #3 Road  
Richmond, SC V6X 3A5  
Canada  
(604) 278-5059  
Fax: (604) 278-1406
- EXTRACTION SYSTEMS, INC.  
10 Forge Park  
Franklin, MA 02038  
(800) 992-0281  
(508) 553-3900  
Fax: (508) 553-3901
- E-Z FLEX/FLUID MOTION BIOTECH  
Audobon Business & Technology Center  
3960 Broadway  
New York, NY 10032  
(800) 522-6500  
(212) 342-7017  
Fax: (212) 342-7019  
[www.EZFLEX.com](http://www.EZFLEX.com)
- E-Z FLOSS  
P.O. Box 2292  
Palm Springs, CA 92263  
(800) 227-0208  
(760) 325-1888  
Fax: (760) 325-0290
- E-Z JECT SYRINGE  
81 Casa Buena Drive, Suite 4  
Corte Madera, CA 94925  
(800) 323-7922  
(415) 459-0191  
Fax: (415) 924-7263
- FACE-IT, INC.  
445 Coloma Street  
Sausalito, CA 94965  
(415) 331-0757  
Fax: (415) 331-0195  
[faceit@well.com](mailto:faceit@well.com)
- FAIRFAX DENTAL, INC.  
2601 South Bayshore Drive  
Suite 875  
Miami, FL 33133-5460  
(800) 233-2305  
(305) 859-7233  
Fax: (305) 859-7433
- FANTASTIC FINISHES  
5 North Morgantown Street  
Fairchance, PA 15436-1180  
(800) 564-9015  
(412) 564-9010  
Fax: (412) 564-1778
- FARRAN REPORT, THE  
10850 South 48th Street  
Phoenix, AZ 85044  
(602) 598-9757  
Fax: (602) 598-3450  
[hfarrandds@worldnet.att.net](mailto:hfarrandds@worldnet.att.net)
- FELIX DENTAL Co.  
7143 ILA Lane  
Brighton, MI 48116  
(800) 453-3549  
(810) 227-3644  
Fax: (810) 227-0601
- FIBERCOR  
Division of Minntech Corp.  
14605 28th Avenue North  
Minneapolis, MN 55447  
(800) 328-3340  
(612) 553-3364  
Fax: (612) 553-3387  
[jnidetz@minntech.com](mailto:jnidetz@minntech.com)
- FILHOL DENTAL  
Castlefekre, County  
Cork, Ireland  
353-23-48589  
Fax: 353-23-48093  
[filhol@indigo.ie](mailto:filhol@indigo.ie)
- FILHOL DENTAL USA  
1219 B. Greenwood Road  
Baltimore, MD 21208  
(800) 910-2050  
(410) 484-6303  
Fax: (410) 484-6354  
[filhol@indigo.ie](mailto:filhol@indigo.ie)
- FILMORE INDUSTRIAL  
COOPERATIVE, INC.  
90 North Main Street  
Fillmore, UT 84631  
(800) 743-9669  
(435) 743-7508  
Fax: (435) 743-7311  
[dop@filmore-coop.com](mailto:dop@filmore-coop.com)
- FILMTECH, INC./BRIXTON  
581 McDonald Avenue  
Brooklyn, NY 11218  
(718) 438-8900
- FIRST MEDICA INC.  
3704-C Boren Drive  
Greensboro, NC 27407  
(800) 777-7072  
(336) 292-8877  
Fax: (336) 292-1322
- FISCHER INDUSTRIES, INC.  
2630 Kaneville Court  
Geneva, IL 60134  
(800) 356-5911  
(630) 232-2803  
Fax: (630) 232-2875  
[fischerind.com](mailto:fischerind.com)
- FISHER-SCIENTIFIC  
Corporate Headquarters  
2000 Parkland  
Pittsburg, PA 15275  
(800) 766-7000  
(412) 490-8300  
Fax: (412) 490-8304  
[www.fisherf.com](http://www.fisherf.com)
- FLAIR NEWCASTLE  
344 Churchmans Road  
P.O. Box 667  
New Castle, DE 19720  
(302) 328-1345  
Fax: (302) 328-4833
- FLATLAND DENTAL PRODUCTS  
496 "B" Street  
San Rafael, CA 94901  
(415) 457-5790  
Fax: (415) 457-5790
- FLEX DENTAL A/S  
Usseroed Moelle  
DK-2970 Hoersholm  
Denmark  
011 45 70 205511  
Fax: 011 45 70 205510
- FLORIDA PROBE CORPORATION  
3700 NW 91st St.  
C-100  
Gainesville, FL 32606  
(800) 460-2772  
(352) 372-1142  
Fax: (352) 372-0257  
[www.floridaprobe.com](http://www.floridaprobe.com)
- FLOSS & Go, INC.  
5304 West Century Boulevard  
Los Angeles, CA 90045  
(310) 215-0756  
Fax: (310) 215-0756
- FLOSSCOCORP.  
(See Inven Corporation)
- FLOW X-RAY  
420 Hempstead  
West Hempstead, NY 11552  
(800) 356-9729  
(516) 485-7000  
Fax: (516) 485-7012  
[billw71262@aol.com](mailto:billw71262@aol.com)
- FOXITE CO., INC.  
31 Industrial Avenue  
Mahwah, NJ 07430  
(800) 828-8944  
(201) 529-2019  
Fax: (201) 529-1349
- FOEEN TONING DEVICE  
1613 Chapman Drive  
Waukesha, WI 53186  
(414) 547-3036
- FOREMOST DENTAL MFG. INC.  
(See Zenith/DMG)
- FOREST MEDICAL PRODUCTS, INC.  
5289 N.E. Elam Young Parkway,  
Suite E-800  
Hillsboro, OR 97124  
(800) 423-3555  
(503) 640-3012  
Fax: (503) 640-4008
- FRANK HILLSON CO.  
P.O. Box 2231  
Cupertino, CA 95015-2231  
(408) 446-9660  
Fax: (408) 777-1030
- FRESH BREATH INSTITUTE  
2389 Ringing Boulevard,  
Suite C  
Sarasota, FL 34237  
(888) 324-8378  
(941) 957-4855  
Fax: (941) 957-3310  
[mmsdds@aol.com](mailto:mmsdds@aol.com)
- FRESH-CONCEPTS DIRECT, INC.  
P.O. Box 953  
Elk Grove Village, IL 60009  
(800) 537-3745  
(847) 439-0930  
Fax: (847) 439-0501  
[freshconcepts@juno.COM](mailto:freshconcepts@juno.COM)
- FRINK DENTAL  
(See Meer/Frink Dental Supply  
Company)
- FRONT EDGE TECHNOLOGY, INC.  
13455 Brooks Drive, Suite A  
Baldwin Park, CA 91706  
(626) 856-8979  
Fax: (626) 851-1369  
[rogerfet@earthlink.net](mailto:rogerfet@earthlink.net)
- FT DENTAL MANUFACTURING, CO.  
1120 Monument Place  
P.O. Box 1329  
New Castle, CA 95658  
(800) 248-8779  
(916) 645-8779  
Fax: (916) 645-8979
- FUJINON, INC.  
10 High Point Drive  
Wayne, NJ 07470  
(800) 385-4666  
(201) 633-5600  
Fax: (201) 633-8818
- FUNCTIONS & FACES FOUNDATION  
3616 Far West Boulevard  
Suite 101-218  
Austin, TX 78731-3074  
(512) 345-0311  
Fax: (512) 345-6798
- FUTURE DENTISTRY  
(See Sio-Probe Inc.)
- G**
- GAC INTERNATIONAL, INC.  
185 Oval Drive  
Central Islip, NY 11722-1402  
(800) 645-5530  
(516) 582-5700  
Fax: (516) 582-5704  
[info@gacintl.com](mailto:info@gacintl.com)
- GARGOYLES PERFORMANCE  
EYEWEAR  
5866 South 194th  
Kent, WA 98032  
(800) 834-1973  
(253) 872-6100  
Fax: (253) 437-0001  
[www.gargoylesinc.com](http://www.gargoylesinc.com)
- GARRISON DENTAL SOLUTIONS  
LLC  
110 Dewitt Lane  
Spring Lake, MI 49456  
(888) 437-0032  
(616) 842-2244  
Fax: (616) 842-2430
- GC AMERICA, INC.  
3737 West 127th Street  
Alsip, IL 60803  
(800) 323-3386  
(708) 597-0900  
Fax: (708) 371-5148  
[www.gcdental.co.jp](http://www.gcdental.co.jp)
- GC CORPORATION  
76-1, Hasunuma-cho  
Itabashi-Ku  
Tokyo 174, Japan  
03-3-558-5181  
Fax: 03-3-966-1470  
[info@mail.gcdental.co.jp](mailto:info@mail.gcdental.co.jp)
- GC EUROPE  
Research Park  
Interleuvenlaan #13  
3001 Leuven  
Belgium  
32-16-39-80-50  
Fax: 32-16-40-02-14  
[www.gchelgium.be](http://www.gchelgium.be)
- GEBAUER CO.  
9410 Saint Catherine Avenue  
Cleveland, OH 44104  
(800) 321-9348  
(216) 271-5252  
Fax: (216) 271-5335  
[75461.176@compuserve.com](mailto:75461.176@compuserve.com)
- GELMAN SCIENCES  
600 South Wagner Rd.  
Ann Arbor, MI 48103-9019  
(313) 913-6143 (direct line)  
Fax: (313) 913-6475
- GEMCO  
1009 Second Avenue  
P.O. Box 432  
Sheldon, IA 51201  
(800) 831-8580  
(712) 324-4928  
Fax: (712) 324-5210  
[www.inmax.com/standaia](http://www.inmax.com/standaia)
- GENERAL DENTAL PRODUCTS, INC.  
201 Ogden Avenue  
Ely, NV 89301-1888  
(702) 289-4461  
Fax: (702) 289-6152
- GENERAL SCIENTIFIC CORPORATION  
77 Enterprise Drive  
Ann Arbor, MI 48103  
(800) 959-0153  
(734) 996-9200  
Fax: (734) 662-0520  
[sales@surgitel.com](mailto:sales@surgitel.com)
- GENT-L-KLEEN PRODUCTS, INC.  
3445 Board Road  
York, PA 17402  
(800) 233-9382  
(717) 767-6881  
Fax: (717) 767-6888  
[www.gent-l-kleen.com](http://www.gent-l-kleen.com)
- GEORGE GOLDIE & ASSOCIATES  
155 Normandy Court  
San Carlos, California 94070-1542  
(888) 411-DPEA  
(650) 595-0431  
Fax: (650) 595-0431  
[gga@slip.net](mailto:gga@slip.net)
- GERI INC.  
P.O. Box 9086  
North St. Paul, MN 55109  
(612) 681-9388  
Fax: (612) 681-9388
- GERITREX CORPORATION  
2 East Sandford Boulevard  
Mount Vernon, NY 10550-4510  
(800) 736-3437  
(914) 668-4003  
Fax: (914) 668-4047  
[geritrex@aol.com](mailto:geritrex@aol.com)
- GERM FREE WATER  
P.O. Box 146  
Saint Elizabeth, MO 65075  
(573) 493-2201  
Fax: (573) 493-2488
- GERMIPHENE CORP.  
P.O. Box 1748  
Brantford, Ontario N3T 5V7  
Canada  
(800) 265-9931  
(519) 759-7100  
Fax: (519) 759-1625
- GILCOM TECHNOLOGY, INC.  
10115 East Mill Plain Boulevard  
Vancouver, WA 98664  
(360) 256-7455  
Fax: (360) 892-5533
- GILL MECHANICAL Co.  
P.O. Box 24628  
Eugene, OR 97402  
(541) 686-1606  
Fax: (541) 342-1193
- GINGI-PAK  
4825 Calle Alto  
P.O. Box 240  
Camarillo, CA 93011-0240  
(800) 437-1514  
(805) 484-1051  
Fax: (805) 484-5076

GLASSPAN, INC.  
101 J.R. Thomas Drive  
Exton, PA 19341  
(800) 280-7726  
(610) 363-7573  
Fax: (610) 363-6391  
[dripscharf@aol.com](mailto:dripscharf@aol.com)

GLASTECH, INC.  
9501 Stonebridge Drive  
Austin, TX 78758  
(888) 452-7832  
(512) 833-5757  
Fax: (512) 973-9333

GLENROE TECHNOLOGIES  
1912 44th Avenue East  
Bradenton, FL 34203  
(800) 237-4060  
(941) 748-0857  
Fax: (941) 748-1350  
[glenroe@worldnet.att.net](mailto:glenroe@worldnet.att.net)

GLENWOOD & WESTERN  
PHARMACEUTICAL  
Division of Glenwood  
82 North Summit Street  
Tenafly, NJ 07670  
(800) 237-9083  
(201) 569-0050  
Fax: (201) 567-4443

GLIDEWELL LABORATORIES  
4141 MacArthur Boulevard  
Newport Beach, CA 92660  
(800) 854-7256  
(714) 440-2600  
Fax: (714) 440-2799  
[glide@ix.netcom.com](mailto:glide@ix.netcom.com)

GLOBAL DENTAL PRODUCTS CO.,  
INC.  
P.O. Box 537  
North Bellmore, NY 11710  
(516) 221-8844  
Fax: (516) 785-7885  
[globaldent@aol.com](mailto:globaldent@aol.com)

GLOBAL INTERNATIONAL (USA) LTD  
776 South Military Trail  
Deerfield Beach, FL 33442  
(954) 570-9999  
Fax: (954) 570-9990

GLOBAL SURGICAL CORP.  
3585 Tree Court  
Industrial Boulevard  
St. Louis, MO 63122  
(800) 861-3585  
(314) 861-3388  
Fax: (314) 861-2969  
[global@globalsurgical.com](mailto:global@globalsurgical.com)

GMX INTERNATIONAL  
13771 Roswell Avenue  
Chino, CA 91710  
(909) 627-5700  
Fax: (909) 627-4411

GNATHOS DENTAL PRODUCTS, INC.  
PO. Box 655  
Weston, MA 02493  
(800) 325-0285  
(781) 237-6029  
Fax: (781) 237-1168

Go,lo INDUSTRIES  
3783 State Road  
P.O. Box 991  
Cuyahoga Falls, OH 44223  
(800) 321-9647  
(330) 920-8100  
Fax: (330) 920-8119  
[www.purell.com](http://www.purell.com)

GOLDEN NEEDLE  
(See Ansell Golden Needle)

GOLDMAN'S PRODUCTS, INC.  
950 North Rand Road, Suite  
201  
Wauconda, IL 60084  
**(888) 223-3682**  
(847) 526-1166  
Fax: (847) 526-1363  
[www.goldmandental.com](http://www.goldmandental.com)

GOLDSMITH & REVERE  
242 South Dean Street  
Englewood, NJ 07631  
(800) 662-6383  
(201) 894-5500  
Fax: (201) 894-0213

GOLD STANDARD MULTIMEDIA INC.  
3825 Henderson Boulevard,  
Suite 200  
Tampa, FL 33629  
(800) 375-0943  
(813) 287-1775  
Fax: (813) 287-1810  
[www.gsm.com](http://www.gsm.com)

GORE, W.L., & ASSOC., INC.  
3750 West Kiltie Lane  
P.O. Box 900  
Flagstaff, AZ 86002-0900  
(800) 437-8181  
(520) 526-3030  
Fax: (520) 774-3525  
[jbmartinez@wlgore.com](mailto:jbmartinez@wlgore.com)

G.P. DENTAL PRODUCTS, INC.  
5701 Broad Street  
Greendale, WI 53129  
(800) 236-7677  
(414) 421-6595  
Fax: (414) 421-7657  
[rpppp9@idt.net](mailto:rpppp9@idt.net)

GRAMM TECHNOLOGY, INC.  
3016 PS Business Center  
Woodbridge, VA 22192  
(800) 752-8846  
(703) 878-3658  
Fax: (703) 730-0272

GREAT LAKES ORTHODONTIC  
PRODUCTS  
199 Fire Tower Drive  
Tonawanda, NY 14150  
(800) 828-7626  
(716) 695-6251  
Fax: (716) 695-0810  
[www.greatlakesortho.com](http://www.greatlakesortho.com)

GREAT PLAINS MEDIA  
1047 North 204th Avenue  
Elkhorn, NE 68022  
(402) 289-0808  
Fax: (402) 289-4054

GREENO ORGANIZATION  
5754 East Dayton, Suite 104  
Fresno, CA 93727  
(800) 452-5046  
(209) 348-9250  
Fax: (209) 348-9391

GRESKO PRODUCTS, INC.  
13391 Murphy Road  
PO. Box 865  
Stafford, TX 77477  
(800) 527-3250  
(281) 261-1811  
Fax: (281) 499-6515  
[Gresco@PDO.NET](mailto:Gresco@PDO.NET)

GUARD AID  
PO. Box 6272  
Carmel, CA 93921  
(800) 225-4002  
(408) 384-8020

GUARDIAN CONTROL SYSTEMS  
Division of Professional Dental  
Maintenance  
9124 North Cave Creek Road  
Phoenix, AZ 85020  
(602) 861-0613  
Fax: (602) 861-0835

GUTHRIE LATEX, INC.  
7400 North Oracle Road, Suite  
330  
Tucson, AZ 85704  
(800) 336-2535  
(520) 742-3087  
Fax: (520) 575-0511

HABITEK INTERNATIONAL DBA U.S.  
MEDICAL SYSTEMS INC  
515 Congress Avenue, Suite  
2520  
Austin, TX 78701  
(800) 460-0440  
(512) 494-8444  
Fax: (512) 494-8445  
[www.miraclegrip.com](http://www.miraclegrip.com)

HAGER & WERKEN GMBH &  
Co. KG  
Pulvenweg 10  
D-47051 Duisburg,  
Postfach 10 0654  
D-47006 Duisberg  
Germany  
0203-99-269-0  
Fax: 0203-299283

HAGER WORLDWIDE, INC.  
Worldwide Dental Division  
& Bull Frog Motor Repair  
1280 Automobile Bvd. Ste. A  
**Clearwater, FL 33762**  
(800) 328-2335  
(813) 573-1422  
Fax: (813) 541-3496  
[www.hagerworldwide.com](http://www.hagerworldwide.com)

HALL, FRANK M., JR. &  
ASSOCIATES  
46 Heritage Drive  
San Rafael, CA 94901-8308  
(415) 455-9212  
Fax: (415) 455-0298  
[closehalld@aol.com](mailto:closehalld@aol.com)

HALL SURGICAL  
11311 Concept Boulevard  
Largo, FL 33773  
(800) 925-4255  
(813) 392-6464  
Fax: (813) 399-5358

H.A.L. PRODUCTS  
Dental Products Division  
1457 Eastwind Circle  
Westlake Village, CA 91361  
(800) 395-7222  
(805) 497-2222  
Fax: (805) 495-2900  
[dralder@gte.net](mailto:dralder@gte.net)

HAMPTON RESEARCH &  
ENGINEERING, INC.  
2670 West Interstate 40  
Oklahoma City, OK 73108  
(800) 800-6369  
(405) 232-5103  
Fax: (405) 232-5104

HANDLER MFG. CO., INC.  
612 North Avenue, East  
P.O. Box 520  
Westfield, NJ 07090  
(800) 274-2635  
(908) 233-7796  
Fax: (908) 233-7340  
[handent@aol.com](mailto:handent@aol.com)

HANDPIECE PARTS & PRODUCTS  
707 West Angus Avenue  
Orange, CA 92868  
(800) 368-3684  
(714) 997-4331  
Fax: (714) 997-5440  
[antnyd123@aol.com](mailto:antnyd123@aol.com)

HANKISON INTERNATIONAL  
1000 Philadelphia Street  
Canonsburg, PA 15317  
(724) 745-1555  
Fax: (724) 745-6040  
[inquiry@hankisonintl.com](mailto:inquiry@hankisonintl.com)

HARMONY-O-PRESS  
c/o Dr. Gary C. Hunt  
85 Braemar Drive  
Hillsborough, CA 94010  
(415) 343-7010  
Fax: (415) 343-0704  
[GC.Hunt@ix.netcom.com](mailto:GC.Hunt@ix.netcom.com)

HARRY J. BOSWORTH  
(See Bosworth, Harry J.)

HARTZELL, G., & SON  
2372 Stanwell Circle  
P.O. Box 5988  
Concord, CA 94520  
(800) 950-2206  
(925) 798-2206  
Fax: (925) 798-2053

HAWE-NEOS DENTAL  
CH-6934  
Bioggio, Switzerland  
0041-91-604-62-73  
Fax: 0041-91-604-63-18  
[Salesadmin@hawe.ch](mailto:Salesadmin@hawe.ch)

HAYDEN, INC  
P.O. Box 6  
Oradell, NJ 07649  
(201) 265-1492  
Fax: (201) 265-1525

HAYS & MEADE INC., DBA SNORE  
GUARD  
12011 Huebner, Suite 214  
San Antonio, TX 78230  
(800) 680-9361  
(210) 641-6655  
Fax: (210) 641-6629  
[snore@connecti.com](mailto:snore@connecti.com)

HCLS, INC.  
45150 Polaris Court  
Plymouth MI 48170  
(800) 829-4257  
(313) 414-3400  
Fax: (313) 414-3421  
[www.hclsinc.com](http://www.hclsinc.com)

HDK/MARKLINE BUSINESS  
PRODUCTS  
P.O. Box 171  
Belmont, MA 02478  
(800) 343-8572  
(781) 891-8954  
Fax: (781) 899-1833

HEALEX PRODUCTS, INC.  
243 Elmwood Ave  
Providence, RI 02907  
(800) 622-6780  
(401) 781-3223  
Fax: (401) 781-9854

HEALTHDENT INTERNATIONAL, INC.  
118D Kirkland Circle  
Oswego, IL 60543  
(800) 845-5172  
(630) 851-0088  
Fax: (630) 851-8899

HEALTHFIRST CORP  
22316 70th Avenue, West,  
Unit A  
Mountlake Terrace, WA 98043  
(800) 331-1984  
(425) 771-5733  
Fax: (425) 775-2374  
[anordby@healthfirstcorp.com](mailto:anordby@healthfirstcorp.com)

HEALTH SCIENCE PRODUCTS, INC.  
1000 11th Court West  
Birmingham, AL 35204-1800  
(800) 237-5794  
(205) 251-0500  
Fax: (205) 251-0419  
[www.hsipinc.com](http://www.hsipinc.com)

HEALTH SONICS CORP.  
6262 Patterson Pass Road,  
Unit A  
Livermore, CA 94550  
(800) 342-3096  
(925) 455-7899  
Fax: (925) 373-8733  
[www.healthsonics.com](http://www.healthsonics.com)

HEALTH-TECH SYSTEMS, INC.  
275 Oser Avenue  
Hauppauge, NY 11788-3637  
(800) 288-7691  
(516) 434-3111  
Fax: (516) 434-7750  
[www.healthtechinc.com](http://www.healthtechinc.com)

HENRY SCHEIN, CORPORATE  
135 Duryea Road  
Melville, NY 11747  
(800) 372-4346 Reno, NV Of-  
fice  
(800) 582-2702 New York Office  
(516) 843-5500  
Fax: (516) 843-5665

HENRY SCHEIN DENTINA GMBH  
MEX-STROMEYER-STR. 170  
C-D  
Konstanz, Germany 78467  
4975-31-9920  
Fax: 4975-31-992270

HERAEUS KULZER DENTAL LAB  
DIVISION  
(See J.F. Jelenko & Co.)

HERAEUS KULZER GMBH  
Philipp-Reis-Strasse 8/13  
D-61273 Wehrheim 1  
Germany  
49 6081 959 310  
Fax: 49 6081 959 3 04

HERAEUS KULZER, INC.  
Dental Product Division  
4315 South Lafayette Boulevard  
South Bend, IN 46614  
(800) 343-5336  
(219) 291-0661  
Fax: (219) 299-6616

HERITAGE COMMUNICATIONS  
11469 Lippelman Road  
Cincinnati, OH 45246  
(513) 771-2230  
Fax: (513) 771-5241

HERRCO  
320 Noxon Road  
Poughkeepsie, NY 12603  
(800) 522-3678  
(914) 486-0150  
Fax: (914) 485-7476  
[www.herrco.com](http://www.herrco.com)

HGM MEDICAL LASERS  
Distributed by Advanced Laser  
Systems  
3959 West 1820 South  
Salt Lake City, UT 84104  
(800) 447-0234  
(801) 972-0500  
Fax: (801) 972-4884

RIGA MANUFACTURING, LTD.  
660 Clyde Avenue  
PO. Box 91160  
West Vancouver, B.C. V7V 3N6  
Canada  
(604) 922-5261  
Fax: (604) 925-9173

HIGH IMPACT MARKETING  
1880 Willow Park Way  
Monument, CO 80132  
(888) 764-5347  
(719) 488-0808  
Fax: (719) 488-0805  
[drfit@hswellnet.com](mailto:drfit@hswellnet.com)

HIGH Q DENTAL  
6302 East Aster Drive  
Scottsdale, AZ 85254  
**(800) 775-3433**  
(602) 905-0664  
Fax: (602) 905-0794  
[hqdm@aol.com](mailto:hqdm@aol.com)

HIT, INC.  
1700 Pine Avenue  
**Niagara Falls, NY 14301**  
(800) 472-5409  
(716) 285-0644  
Fax: (905) 356-6330  
[www.hitinc.com](http://www.hitinc.com)

Ho DENTAL CO., INC.  
2780 State Street, Suite 7  
**Santa Barbara, CA 93105**  
(800) 706-1133 ext. 1818  
(805) 898-9748  
Fax: (805) 898-9898

HOECHST MARION ROUSSEL  
10236 Marion Park Drive  
P.O. Box 9627  
Kansas City, MO 64137  
Zip: 64134  
(800) 362-7466  
(816) 966-4000  
Fax: (816) 966-3860

HOLLOWAY DELIVERY SYSTEMS  
410 South Wells  
P.O. Box 427  
Edna, TX 77957  
(512) 782-3282  
Fax: (512) 782-3517

HOLMES & ASSOCIATES  
(See American Analytic)

HOLMES DENTAL CO.  
50 South Penn Street  
P.O. Box 243  
Hatboro, PA 19040  
(800) 322-5577  
(215) 675-2877  
Fax: (215) 675-7147  
[ssagge@aol.com](mailto:ssagge@aol.com)

HOOKER SALES CO., INC.  
2610 South Street  
R.O. Box 491333  
**Leesburg, FL 34749-1333**  
(800) 359-5180  
(352) 728-1123  
Fax: (352) 728-2600

HOPE PHARMACEUTICALS  
7626 East Greenway Road,  
Suite 101  
Scottsdale, AZ 85260  
(800) 755-9595  
(602) 607-1970  
Fax: (602) 607-1971

HORIZON CO., THE  
P.O. Box 1109  
Orange Park, FL 32073  
(800) 778-2855  
(904) 272-9983  
Fax: (904) 272-9985

HPC INNOVATIONS, INC.  
2502 Silverside Road, Suite 7  
Wilmington, DE 19810  
(800) 472-9400  
(302) 477-1155  
Fax: (302) 477-1152  
[dentalhpc@aol.com](mailto:dentalhpc@aol.com)

HU-FRIEDY MFG. CO., INC.  
3232 North Rockwell Street  
Chicago, IL 60618-5982  
(800) 483-7433  
(773) 975-6100  
Fax: (773) 975-1683  
[www.hufriedy.com](http://www.hufriedy.com)

HU-FRIEDY MFG. CO., INC.  
Zweigniederlassung Deutsch-  
land  
Rudolf-Diesel-Str. Nr. 8  
Postfach 1380  
D-69171 Leimen  
Germany  
49 6224 97000  
Fax: 49 6224 9700 97  
[quetin@aol.com](mailto:quetin@aol.com)

HUKUBA DENTAL CORP.  
914-1 Nazukari  
Nagareyama-City, Chiba  
270-01, Japan  
81-471-45-3516  
Fax: 81-471-45-3546

HUNTER RESEARCH LABORATORIES  
INC.  
1015 S. Gaylord Street, Suite  
2918  
Denver, CO 80209  
(888) 764-5463  
Fax: (303) 727-5746

HUNTINGTON LAB  
(See Ecolab Professional Prod-  
ucts Division)

HURD DENTAL LABORATORY, INC.  
413 1/2 North 20th Avenue  
Yakima, WA 96902  
(509) 452-8229

HVS LABORATORIES, INC.  
3427 Exchange Avenue  
Naples, FL 34104  
(800) 521-7721  
(941) 643-4636  
Fax: (941) 643-7370  
[www.hvslabs.com](http://www.hvslabs.com)

H.W. ANDERSON  
(See Anderson, H.W.)

HYDRo FLOSS, INC.  
404 Business Center Drive  
Birmingham, AL 35244  
(800) 322-7955  
(205) 733-1352  
Fax: (205) 733-8170  
[hydrofloss@aol.com](mailto:hydrofloss@aol.com)

HYGENIC CORP., THE  
(For dental vision see  
Coltene/Whaledent)

IBA DENTAL PRODUCTS COMPANY  
1749 Green Meadow Lane  
Orlando, FL 32825  
(800) 240-5677  
(407) 273-0860  
Fax: (407) 381-2742  
[www.dentalproducts.com](http://www.dentalproducts.com)

ICB BRUSH COMPANY  
420 Cezanne Drive  
Osprey, FL 34229  
(888) 827-8745  
(941) 966-3038  
Fax: (941) 497-3491  
[icbrushco@aol](mailto:icbrushco@aol)

I. C. PUBLICATIONS  
1150 East Nicholls Road  
Fruit Heights, UT 84037  
(801) 292-8008  
Fax: (801) 544-2146

IDD INTERNATIONAL DENTAL  
DISTRIBUTORS, INC.  
P.O. Box 311  
Kings Park, NY 11754  
(516) 544-4313  
Fax: (516) 544-6123  
[iddusa@worldnet.att.net](mailto:iddusa@worldnet.att.net)

IDDS INC.  
Int'l Dental Design Specialists  
Inc.  
629 Ninth Street  
Imperial Beach, CA 91932  
(888) 537-3749  
(619) 628-8125  
Fax: (619) 628-8129

IDEA DEVELOPMENT  
(See Swing lock)

IDENTALLOY COUNCIL  
76 Cranbrook Road, Suite 307  
Hunt Valley, MD 21030  
(888) 577-2634  
(410) 683-4856  
Fax: (410) 683-6281

IDENTOFLEX A.G.  
Postfach 440  
CH-9470 BUCHS  
Switzerland  
41 41 780 44 01  
Fax: 41 41 780 27 44  
[u.hubler@bitsmart.com](mailto:u.hubler@bitsmart.com)

I.E.A. (ISHIYAku EURD/AMERICA,  
INC., PUBLISHING)  
(See Medico Dental Media Inter-  
ter'l Inc.)

IMAGE FIX SOFTWARE SOLUTIONS  
INC.  
15047 Marine Drive, Suite 201  
White Rock, BC  
Canada V4B-1C5  
(888) 535-8861  
(604) 531-2521  
Fax: (604) 535-7320  
[tdrees@imgfx.com](mailto:tdrees@imgfx.com)

IMPEX-WORLDWIDE, INC.  
7651 Tecumseh Road East,  
Suite 206  
Windsor, Ontario N8T 3H1  
Canada  
(800) 265-6277  
(519) 974-4820  
Fax: (519) 974-6121  
[wnhimpex@ican.net](mailto:wnhimpex@ican.net)

IMTEC CORPORATION  
2401 North Commerce  
P.O. Box 1562  
Ardmore, OK 73402  
(800) 879-9799  
(580) 223-4456  
Fax: (580) 223-4561  
[imtecc@brightok.net](mailto:imtecc@brightok.net)

INDISPERSE DISTRIBUTOR, U.S.A.  
23224 14th Place West  
Bothell, WA 98021  
(800) 755-7720  
(206) 367-1002  
Fax: (206) 363-9983

IN DISPOSABLES, INC.  
P.O. Box 425  
**Stratford, CT 06497**  
(800) 269-4568  
(203) 696-2485  
Fax: (203) 384-1932  
[hecklee@connix.com](mailto:hecklee@connix.com)

INDUS RESOURCES, INC.  
507 N. Lake Street  
Mundelein, IL 60060  
(888) 463-8799  
(847) 367-8995  
Fax: (847) 367-8722  
[indus99@aol.com](mailto:indus99@aol.com)

INDUSTRIAL SPECIALTIES, INC.  
2741 West Oxford, Unit 6  
Englewood, CO 80110  
(303) 781-8486  
Fax: (303) 761-7939

INFALLIBLE ENTERPRISES INC.  
1233 Mt. Pisgah Downs  
Austell, Georgia 30001  
(770) 739-5484

INFECTION CONTROL PRODUCTS  
P.O. Box 5367  
De Pere, WI 54115  
(800) 353-9595  
(920) 435-3070  
Fax: (920) 435-3640

INFECTION CONTROL SERVICES,  
INC.  
115 Tillicum Street  
Renton, WA 98055  
(206) 271-5394

INFECTION CONTROL SYSTEMS,  
INC.  
3095 Kerner Boulevard, Unit G  
**San Rafael, CA 94901**  
(800) 835-3003  
(415) 459-0367  
Fax: (415) 459-0553  
[sschatz@unident.unimed.com](mailto:sschatz@unident.unimed.com)

INFECTION CONTROL TECHNOLOGY  
1610 South 800 West Rear  
P.O. Box 870403  
Woods Cross, UT 84087  
(800) 551-0735  
(801) 292-8008  
Fax: (801) 292-8052

INFORMATION PRESENTATION  
SYSTEMS, INC.  
1555 Williams Drive, Suite 110  
Marietta, GA 30066  
(800) 849-2489  
(770) 919-2260  
Fax: (770) 919-2188

INFOSOFT, INC.  
7939 Honeygo Boulevard,  
Suite 212  
Baltimore, MD 21236  
(800) 433-2409  
(410) 931-6926  
Fax: (410) 931-4109

INLAND DENTAL DISTRIBUTORS  
10569 111th Street  
Edmonton, Alberta T5H 3E8  
Canada  
(800) 661-6569  
(403) 420-6901  
Fax: (403) 425-2241

INNOVADENT TECHNOLOGIES, LTD.  
2189 King Road  
King City, Ontario  
Canada L7B 1G7  
Canada  
(800) 574-9186  
(905) 833-2374  
Fax: (905) 833-0708

INNOVATIVE PRACTICE SOLUTIONS  
127 W. Worthington Avenue,  
Suite 200  
Charlotte, NC 28203  
(704) 342-4900  
Fax: (704) 342-4995  
[www.phomolycom](http://www.phomolycom)

INSIGHT IMAGING  
(See Dentsply New Image)

INSPIRED IDEAS  
2220 Eastman Avenue, Suite  
105  
Ventura, CA 93003  
(888) 867-7479  
Fax: (805) 676-1175

INSTAGUARD  
12974 Pearl Road  
Strongsville, Ohio 44136  
(440) 238-4972  
Fax: (440) 238-4972

INSTRUMENTARIUM IMAGING  
300 West Edgerton Avenue  
Milwaukee, WI 53207  
(800) 558-6120  
**(414) 747-1030**  
Fax: (414) 481-8665  
[info@ilmaging.com](mailto:info@ilmaging.com)

INSTRUMENT WORLD  
1780 Balboa Drive, Suite F  
Idaho Falls, ID 83404  
**(800) 832-1777**  
(208) 529-3669  
Fax: (208) 529-5255  
[inworld@ida.net](mailto:inworld@ida.net)

INTEGRA DYNAMICS, INC.  
20 Bedwood Road Northeast  
Calgary, Alberta T3K 2K4  
**Canada**  
(800) 791-8117  
(403) 275-5554  
Fax: (403) 275-5928  
103266.73@compuserve

INTEGRA LIFE SCIENCES  
105 Morgan Lane  
Plainsboro, NJ 08536  
(800) 762-1574  
(609) 275-0500  
Fax: (609) 799-3297

INTEGRATED DENTAL  
TECHNOLOGIES  
(See PracticeWorks)

INTERDENT, INC.  
8554 Hayden Place  
Culver City, CA 90232  
(800) 556-7606  
(310) 845-3160  
Fax: (310) 845-1512

INTERNATIONAL DENTAL  
CONSULTANTS  
500 Birch Road  
Malverne, NY 11565  
(816) 593-3806  
Fax: (516) 887-6036

INTERNATIONAL IMAGING  
ELECTRONICS  
881 Remington Boulevard  
Bolingbrook, IL 60440  
(800) 323-6316  
**(630) 378-4800**  
Fax: (630) 378-1800

INTERPLAK  
527 Industrial Way West  
Eatontown, NJ 07724  
(800) 633-6363  
(732) 389-4500  
Fax: (732) 389-4998  
[csimpson@lanmarkgrp.com](mailto:csimpson@lanmarkgrp.com)

INTERPORE  
(See Steri-Oss)

INTRATECH DENTAL PRODUCTS  
P.O. Box 56025  
Dallas, TX 75356-0225  
(800) 443-3536  
(972) 986-5568  
Fax: (972) 790-9480  
[www.intratechdental.com](http://www.intratechdental.com)

ISLAND POLY/FoodD HANDLER  
514 Grand Boulevard  
Westbury, NY 11590  
(800) 338-4433  
(516) 338-4433  
Fax: (516) 338-4405

ISOLYSER co., INC.  
650 Engineering Drive  
Norcross, GA 30092  
(800) 777-7977  
(770) 582-6363  
Fax: (770) 582-6360

ISO-VAC INDUSTRIES  
6 Roosevelt Avenue  
Port Jefferson Station, NY  
11776  
(800) 741-2963  
(516) 928-3994  
Fax: (516) 928-6911

ITL DENTAL  
Implant Technologies Limited  
2922 Daimler Street, Suite 101  
Santa Ana, CA 92705  
(800) 277-0073  
(949) 223-8950  
Fax: (949) 223-8960  
[sales@itldental.com](mailto:sales@itldental.com)

IVOCLAR AGNIVADENT  
Bendererstrasse 2  
FL-9494  
Schaan, Liechtenstein  
41-75-235-3535  
Fax: 41-75-235-3608  
[marketing@ivoclar.com](mailto:marketing@ivoclar.com)

IVOCLAR DENTAL DEUTSCHE  
GMBH  
Postfach 1152  
D-73471 Ellwangen  
Germany  
49-79-61-88-90  
Fax: 49-79-61-63-26  
[marketing@ivoclar.com](mailto:marketing@ivoclar.com)

IVOCLAR NORTH AMERICA, INC.  
175 Pineview Drive  
Amherst, NY 14228  
(800) 533-6825  
(716) 691-0010  
Fax: (716) 691-2285  
[www.ivoclar.com](http://www.ivoclar.com)

IVOCLAR-VIVADENT-WILLIAMS  
(See Ivoclar North America,  
Inc.)

IVOCLAR-VIVADENT CANADA  
23 Hannover Drive, Suite 3  
Saint Catharines, Ontario,  
Canada L2W 1A3  
(800) 263-8182 in Canada  
(800) 533-6825 in USA  
(905) 988-5400  
Fax: (905) 988-5411

JADA  
211 East Chicago Avenue  
20th Floor  
Chicago, IL 60611  
(312) 440-2785  
Fax: (312) 440-3538  
[www.adajournal.com](http://www.adajournal.com)

JAVA CROWN, INC.  
6111 FM 1960 West, Suite 215  
Houston, TX 77069  
(800) 322-5282  
(281) 583-9373  
Fax: (281) 583-7154

JAYTEC, INC.  
520 West 9th  
Winfield, KS 67156  
(316) 221-2460  
Fax: (316) 221-0135

J.B. DENTAL SUPPLY Co.  
15525 S.E. For-Mor Court  
Clackamas, OR 97015  
(800) 777-0577  
(503) 650-5255  
Fax: (503) 650-7462

JENERIC/PENTRON DEUTSCHLAND  
GMBH  
Raiffeisenstr. 18  
Postfach 1155, 72125  
Kusterdingen  
Tubingen Germany  
0130-833535  
49-7071-93980  
Fax: 49-7071-939898

JENERIC/PENTRON, INC.  
53 North Plains Industrial Road  
P.O. Box 724  
Wallingford, CT 06492-0724  
(800) 551-0283  
(203) 265-7397  
Fax: (203) 284-0240  
[info@jeneric.com](mailto:info@jeneric.com)

JENNIFER DE ST. GEORGES &  
ASSOC., INC.  
P.O. Box 35640  
Monte Serano, CA 95030  
(800) 366-7004  
(408) 354-4144  
Fax: (408) 354-1931

JENSEN INDUSTRIES, INC.  
50 Stillman Road  
North Haven, CT 06473  
(800) 243-2000  
(203) 239-2090  
Fax: (203) 234-7176  
[www.jensenindustries.com](http://www.jensenindustries.com)

J.F. JELENKO & Co., KULZER LAB  
PRODUCTS  
Corporate Division  
99 Business Park Drive  
Armonk, NY 10504  
(800) 431-1785  
(914) 273-8600  
Fax: (914) 273-9379  
[www.jelenko.com](http://www.jelenko.com)

JLB SARL SPECIALTIES DENTAIRES  
69440 St. Maurice Sur Dargare  
Lyon, France  
047881 2965  
Fax: 04 78 81 23 51

J. MORITA USA, INC.  
9 Mason  
Irvine, CA 92618  
(800) 752-9729  
(949) 581-9600  
Fax: (949) 581-8811  
[www.imorita.com](http://www.imorita.com)

JOCARE INTERNATIONAL  
134 East Andrews Drive  
Atlanta, GA 30305  
(404) 869-7711  
Fax: (404) 869-7755

JOHNSON & JOHNSON PERSONAL  
PRODUCTS  
Professional Oral Health  
199 Grandview Road  
Skillman, NJ 08558-9418  
(800) 224-6513  
(908) 874-1000  
Fax: (908) 874-2546  
[www.jnj.com](http://www.jnj.com)

JOHNSON & JOHNSON MEDICAL,  
INC.  
2500 Arbrook Boulevard  
RO. Box 90130  
Arlington, TX 76014  
(800) 433-5170  
(817) 465-3141  
Fax: (817) 784-5400

JOHNSON-PROMIDENT, INC.  
242 North Main Street  
New City, NY 10956  
(914) 634-3997  
Fax: (914) 634-4898  
[promident@aol.com](mailto:promident@aol.com)

JONES MEDICAL INDUSTRIES, INC.  
1945 Craig Road  
St. Louis, MO 63146  
(800) 525-8466  
(314) 576-6100  
Fax: (314) 469-5749

JORDAN  
Haavard Martinsens vei 30  
0978 Oslo, Norway  
47-22-78-80-00  
Fax: 47-22-78-80-50

JORDEL INTERNATIONAL  
2828 North Camden Place  
Boise, ID 83704  
(800) 743-3179  
(208) 377-8029  
Fax: (208) 377-8120

JORDCO, INC.  
595 NW 167th Avenue  
Beaverton, OR 97006  
(800) 752-2812  
(503) 531-3904  
Fax: (503) 531-3757  
[info@jordco.com](mailto:info@jordco.com)

JOURNAL OF DENTAL RESEARCH  
American Association of Dental  
Research  
1619 Duke Street  
Alexandria, VA 22314  
(703) 548-0066  
Fax: (703) 548-1883  
[www.iadr.com](http://www.iadr.com)

JOURNAL OF PRACTICAL HYGIENE  
Montage Media Corporation  
1000 Wyckoff Ave.  
Mahwah, NJ 07430-9794  
(800) 899-5350  
(201) 891-3200  
Fax: (201) 891-2626  
[www.montagemedia.com](http://www.montagemedia.com)

JOYCE TOMER CONSULTING  
6 London Circle North  
Rehoboth Beach, Delaware  
19971  
(302) 226-9960  
Fax: (302) 226-9956  
[jbtomer@dmv.com](mailto:jbtomer@dmv.com)

JS DENTAL MFG., INC.  
196 North Salem Road  
P.O. Box 904  
Ridgefield, CT 06877  
(800) 284-3368  
(203) 438-8832  
Fax: (203) 431-8485  
[info@jsdental.com](mailto:info@jsdental.com)

JUN-AIR U.S.A., INC.  
1350 Abbott Court  
Buffalo Grove, IL 60089  
(800) 458-6247  
(847) 215-9444  
Fax: (847) 215-9449  
[jaspertorp@jun-air.com](mailto:jaspertorp@jun-air.com)

## K

KAESER COMPRESSORS  
PO. Box 946  
Fredricksburg, VA 22404  
(540) 898-5500  
Fax: (540) 898-5520  
[kaeser2@erols.com](mailto:kaeser2@erols.com)

KAUFMAN DENTAL MFG., INC.  
2435 South West Timberline  
Drive  
P.O. Box 219056  
Portland, OR 97225  
(800) 228-0532  
(503) 292-9642  
Fax: (503) 297-5936  
[kdm@teleport.com](mailto:kdm@teleport.com)

KAYO AMERICA CORPORATION  
340 East Main Street  
Lake Zurich, IL 60047  
(888) 528-6872  
(847) 550-6800  
Fax: (847) 550-6825

KAYCOR INTERNATIONAL, LTD.  
3611 Commercial Avenue  
Northbrook, IL 60062  
(800) 323-4612  
(847) 564-4334  
Fax: (847) 564-9040

KAY-SEE DENTAL MFG. GO.  
124 East Missouri Avenue  
Kansas City, MO 64106-1294  
(800) 842-8844  
(816) 842-2817  
Fax: (816) 842-3402  
[info@kay-seedental.com](mailto:info@kay-seedental.com)

Kcomp  
4860 San Fernando Road  
Glendale, CA 91204  
(800) 747-6633  
(818) 500-7222  
Fax: (818) 500-1859

KEELER INSTRUMENTS, INC.  
456 Parkway  
Broomall, PA 19008  
(800) 523-5620  
(610) 353-4350  
Fax: (610) 353-7814  
[keeler@keelerusa.com](mailto:keeler@keelerusa.com)

KEITH ILLUMINATION CORP.  
61963 West Road  
P.O. Box 908  
La Grande, OR 97850  
(800) 433-9698  
(541) 963-3616  
Fax: (541) 963-9406

KELLER LABORATORIES, INC.  
10966 Gravols Industrial Court  
St. Louis, MO 63128  
(800) 325-3056  
(314) 919-4000  
Fax: (314) 919-4015

KEMPER DENTAL SYSTEMS  
1525 W. 12th Street  
Brooklyn, NY 11204  
(718) 837-3090  
Fax: (718) 837-0093

KEM PUBLISHING  
5735 Cake  
Las Vegas, NV 89102  
(702) 227-8656

KENDALL/SHERW000-DAVIS &  
GECK  
15 Hampshire Street  
Mansfield, MA 02048  
(800) 355-7030  
(314) 241-5700  
Fax: (314) 241-8705

KENT DENTAL, LTD.  
Medcare House/Centurion  
House  
Gillingham Business Park  
Gillingham, Kent, ME8 0SB  
England  
44-1634-878787  
Fax: 44-1634-878788

KENTZLER-KASCHNER DENTAL  
GMBH  
MOHlgraben 36  
Ellwangen/Jagst D-73479  
Germany  
49-79 61 9073-0  
Fax: 49-79 6152-031

KERR CORPORATION  
1717 West Collins Avenue  
Orange, CA 92667  
(800) 537-7123  
(718) 516a400  
Fax: (714) 516-7633  
[www.kerrdental.com](http://www.kerrdental.com)

KERR GMBH  
Liststrasse 28  
Postfach 21 08 48  
76158 Karlsruhe  
Germany  
49 721 955 670  
Fax: 49 721 955 6751

KERSTEN MANUFACTURING/RESE  
ARCH & DEVELOPMENT  
2767 Quail Valley Road  
Solvang, CA 93463-9614  
(805) 688-9786  
Fax: (805) 688-1339

KEYSTONE INDUSTRIES  
Keystone/Mizzy/Tri-Dynamics  
616 Hollywood Avenue  
Cherry Hill, NJ 08002  
(800) 333-3131  
(609) 663-4700  
Fax: (609) 663-0381  
[nkeystone@aol.com](mailto:nkeystone@aol.com)

KHS POLYMER TECHNOLOGIES  
124 East Missouri Avenue  
Kansas City, MO 64106  
(800) 475-4547  
(816) 842-9775  
Fax: (816) 842-3402

KILCULLEN-CLAYDON MEDICAL INC.  
P.O. Box 52  
South Port, CT 06490  
(888) 356-3611  
(203) 333-4377  
[www.latexsolutions.com](http://www.latexsolutions.com)

KILGORE INTERNATIONAL, INC.  
P. O. Box 98  
Coldwater, MI 49036  
(800) 892-9999  
(517) 279-9000  
Fax: (517) 278-2956  
[kilgoreew@orion.branch-co.lib.mi.us](mailto:kilgoreew@orion.branch-co.lib.mi.us)

KIMBERLY-CLARK  
1400 Holcomb Bridge Road  
Roswell, GA 30076  
(800) 742-1996  
(770) 587-8000  
Fax: (770) 587-7277

KINETIC INSTRUMENTS, INC.  
Berkshire Boulevard  
Bethel, CT 06801  
(800) 233-2346  
(203) 743-0080  
Fax: (203) 790-1227  
[docken@cyburban.com](mailto:docken@cyburban.com)

KINGSWOOD LABORATORIES, INC.  
10375 Hague Road  
Indianapolis, IN 46256  
(800) 968-7772  
(317) 849-9513  
Fax: (317) 849-9514  
[service@kingswood-labs.com](mailto:service@kingswood-labs.com)

Kis PRODUCTS, INC.  
2717 East Oakland Park Boule-  
vard  
Fort Lauderdale, FL 33306  
(954) 566-5225  
Fax: (954) 973-6417

KISCO  
232 North Seneca  
Wichita, KS 67203  
(800) 325-8649  
(316) 262-1456  
Fax: (316) 262-0013

KKO LABS  
Support & Supply Div.  
4435 North First Street,  
Suite 109  
Livermore, CA 94550  
(800) 794-8142  
(925) 373-8808  
Fax: (925) 371-6017

KLEEN PEN, INC.  
P.O. BOX 2128  
Tucker, GA 30085  
(888) 553-3695  
(770) 527-8300  
Fax: (404) 250-4333  
[www.kleenpen.com](http://www.kleenpen.com)

KLH MEDICAL, INC.  
(See Totalmed)

KNOLL BIOPRODUCTS CO., INC.  
P.O. Box 2736  
Santa Fe, NM 87504  
(505) 983-4066  
Fax: (505) 989-8660

KNOWELL THERAPEUTIC  
TECHNOLOGIES  
4800 Dundas Street West, Suite  
105  
Toronto, Ontario, Canada M9A  
1B1  
(800) 463-2999  
(416) 233-3777  
Fax: (416) 233-7698

KNOWLEDGE SYSTEMS  
INTERNATIONAL INC.  
334 Greyhound Pass West  
Carmel, IN 46032  
(800) 434-6444  
(317) 580-0665  
Fax: (317) 580-0663

KORTEAMINTERNATIONAL, INC.  
777 Palomar Avenue  
Sunnyvale, CA 94086  
(800) 763-1688  
(408) 733-7888  
Fax: (408) 733-9888  
[www.korteam.com](http://www.korteam.com)

KOWA AMERICAN CORP.  
342 Madison Avenue, Suite 710  
New York, NY 10173  
(800) 221-2076  
(212) 972-4600  
Fax: (212) 972-4625

KREATIV, INC.  
9025 Balboa Avenue  
San Diego, CA 92123  
(800) 573-2848  
(619) 514-4235  
Fax: (619) 514-8850  
[kreativ541@aol.com](mailto:kreativ541@aol.com)

KRISALEX PRODUCTS, LLC  
101 Queens Drive South  
Little Silver, NJ 07739  
(800) 597-7245  
(732) 758-6538  
Fax: (732) 389-3104  
[drhqb@krisalex.com](mailto:drhqb@krisalex.com)

KROMOPAN USA, INC.  
1265 Rand Road  
Des Plaines, IL 60016  
(800) 841-7398  
(847) 298-1259  
Fax: (847) 298-0349

KULZER  
(See Heraeus Kulzer)

KUPCO INTERNATIONAL  
P.O. Box 654  
Hanson, MA 02341  
(617) 294-7865  
Fax: (617) 294-7865

KURARAY COMPANY, LTD.  
Dental Material Department  
1-12-39, Umeda,  
Kita-ku, Osaka 530-8611 Japan  
81-6-348-2603  
Fax: 81-6-348-2552

KUSHIONINTERNATIONAL SYSTEMS,  
INC.  
84 High Street, Suite 204  
Medford, MA 02155  
(617) 395-2000 LASCO  
Fax: (617) 396-5477

## L

LAB ONE  
971 Norfolk Square  
Norfolk, VA 23502  
(888) 448-7889  
(757) 455-8686  
Fax: (757) 455-8363

LABORAORRE PERIODONTAL S.A.  
Au Capital De 843-000F  
Saint Andre-B.P. 30  
Chareurey du Fadu  
France 29520  
33-298-81-84-04  
Fax: 33-298-73-23-87

LABORATORY IMPLANT SYSTEMS,  
INC.  
367 Metzgar Street  
Half Moon Bay, CA 94019  
(800) 932-6427  
(650) 726-7704  
Fax: (650) 726-7704  
[curtnames@earthlink.net](mailto:curtnames@earthlink.net)

LAB SAFETY SUPPLY  
P.O. Box 1368  
Janesville, WI 53547-1368  
(800) 356-0783  
(608) 754-2345  
Fax: (608) 754-1806  
[www.labsafety.com](http://www.labsafety.com)

LACLEDE RESEARCH LABS  
2030 East University Drive  
Rancho Dominguez, CA 90220  
(800) 922-5856  
(310) 605-4280  
Fax: (310) 605-4288  
[www.laclede.com](http://www.laclede.com)

LACTONA CORPORATION  
P.O. Box 2787  
50 Ash Circle  
Warminster, PA 18974  
(888) 522-8662  
(215) 682-7100  
Fax: (215) 682-7689

LA-MAN CORP.  
700 Glades Court  
Port Orange, FL 32127  
(800) 348-2463  
(407) 521-7477  
Fax: (407) 521-2126  
[info@laman.com](mailto:info@laman.com)

LANCER ORTHODONTICS/DENTAL  
253 Pawnee Street  
San Marcos, CA 92069  
(800) 854-2896  
(619) 744-5585  
Fax: (619) 744-5724  
[lancerortho@mindspring.com](mailto:lancerortho@mindspring.com)

LANG DENTAL MFG. CO., INC.  
175 Messner Drive  
P.O. Box 969  
Wheeling, IL 60090  
(800) 222-5264  
(847) 215-6622  
Fax: (847) 215-6678  
[langdental@aol.com](mailto:langdental@aol.com)

LAREs RESEARCH, INC.  
295 Lockheed Avenue  
Chico, CA 95973  
(800) 347-3289  
(530) 345-1767  
Fax: (530) 345-1870  
[www.laresdental.com](http://www.laresdental.com)

DIAMOND PRODUCTS, INC.  
P.O. Box 4657  
Chatsworth, CA 91313  
(800) 621-4726  
(818) 882-2423  
Fax: (818) 882-3550  
[jascodiamond.com/dental](mailto:jascodiamond.com/dental)

LASERLYTE  
2201 Amapola Court  
Torrance, CA 90503  
(800) 255-9133  
(310) 450-8551  
Fax: (310) 392-1754  
[lyte@laserlyte.com](mailto:lyte@laserlyte.com)

LASERMED, INC.  
3675 West 1987 South  
Salt Lake City, UT 84104  
(800) 903-2873  
(801) 974-9468  
Fax: (801) 974-9443  
[sales@lasermed.com](mailto:sales@lasermed.com)

LAWHORN INNOVATIONS  
218 East Front Street, Suite 302  
Missoula, MT 59802  
(406) 543-3777  
Fax: (406) 543-6205

LEACH & DILLON  
161 Comstock Parkway  
Cranston, RI 02921  
(800) 535-2633  
(401) 464-5850  
Fax: (401) 464-5862  
[jeachdillon@WORldnet.att.net](mailto:jeachdillon@WORldnet.att.net)

LEE PHARMACEUTICALS  
1434 Santa Anita Avenue  
P.O. Box 3836  
South El Monte, CA 91733  
(800) 950-5337 LOCHEMCO  
(626) 442-3141  
Fax: (626) 443-1561  
[leeexpress.com](http://www.leeexpress.com)

LE-HAN DENTAL & MEDICAL, INC.  
414 Patrick Place  
Burlington, Ontario Canada  
L7L 5Z3  
(800) 388-5194  
(905) 631-8199  
Fax: (905) 631-0467  
[lehan@idirect.com](mailto:lehan@idirect.com)

LENTY SALES, INC.  
P.O. Box 786  
Long Lake, MN 55356  
(800) 635-3689  
(612) 473-5775  
Fax: (612) 473-4179

LEXI-COMP, INC.  
1100 Terex Road  
Hudson, OH 44236  
(800) 837-5394  
(330) 650-6506  
Fax: (330) 656-4307  
[Brad@Lexi.com](mailto:Brad@Lexi.com)

LIFECORE BIOMEDICAL, INC.  
Oral Restorative Division  
3515 Lyman Boulevard  
Chaska, MN 55318-3051  
(800) 752-2663  
(612) 368-4300  
Fax: (612) 368-3411

LIFE-LIKE COSMETIC SOLUTIONS  
OF HARBOR DENTAL BLEACHING  
727 Bond Avenue  
Santa Barbara, CA 93103  
(800) 543-3545  
(805) 568-0775  
Fax: (805) 962-9773  
[life-like@aol.com](mailto:life-like@aol.com)

LIGHTSPEED TECHNOLOGY, INC.  
15600 San Pedro, Suite 304  
San Antonio, TX 78232  
(800) 817-3636  
(210) 495-4942  
Fax: (210) 495-4945  
[senias3@aol.com](mailto:senias3@aol.com)

LIGHT-TECH, INC.  
8900 West Josephine Road  
Sebring, FL 33872  
(800) 462-5542  
(941) 385-6000  
Fax: (941) 382-6000  
[www.light-tech.com](http://www.light-tech.com)

LIGHTWAVE HEALTH SYSTEMS, INC.  
(See Miragen)

LINK ERGONOMICS CORP.  
3149 California Boulevard  
R.O. Box 2877  
Napa, CA 94558  
(800) 424-5465  
(707) 255-4822  
Fax: (707) 255-7191

LL DENTAL  
P.O. Box 2123  
McKenzie Bridge, OR 97413  
(888) 723-2123  
(541) 822-3839  
Fax: (541) 822-3851

L-M-DENTAL  
PB 729  
Fin-20361  
Turku, Finland  
358-2-274-0100  
Fax: 358-2-274-0117  
[info@lmdental.com](mailto:info@lmdental.com)

DENTAL  
101 Copperwood Way, Suite L  
Oceanside, CA 92057  
(800) 882-1788  
(760) 630-4848  
Fax: (760) 630-1818  
[lochenco@earthlink.net](mailto:lochenco@earthlink.net)

LOMBART INSTRUMENT  
5358 Robin Hood Road  
Norfolk, VA 23513  
(800) 446-8092  
(757) 853-8888  
Fax: (757) 855-1232  
[www.lombartusa.com](http://www.lombartusa.com)

LONE STAR TECHNOLOGIES  
155 Post Road East, Suite 5  
Westport, CT 06880  
(800) 526-4911  
(908) 575-1976  
Fax: (908) 575-1981

LORD'S DENTAL STUDIO, INC.  
501 Packerland Drive  
Green Bay, WI 54307-9048  
(800) 821-0859  
(920) 499-0411  
Fax: (920) 499-9833  
[lords@lordsdental.com](mailto:lords@lordsdental.com)

LORICH MANUFACTURING  
CORPORATION  
200 South 16th Street  
P.O. Box 654  
Herrin, IL 62948  
(618) 942-2874  
Fax: (618) 942-2874

LOTUS BRANDS, INC.  
P.O. Box 325  
Twin Lakes, WI 53181  
(800) 824-6396  
(414) 889-8561  
Fax: (414) 889-8591  
[Ekotec@lotuspress.com](mailto:Ekotec@lotuspress.com)

L & R MANUFACTURING CO.  
577 Elm Street  
P.O. Box 607  
Kearny, NJ 07032-0607  
(800) 572-5326  
(201) 991-5330  
Fax: (201) 991-5870  
[jrsnics@erals.com](mailto:jrsnics@erals.com)

LUBRICLAVE, INC.  
2190 Southeast 17th Street,  
Suite 210  
Ft. Lauderdale, FL 33316  
(800) 736-3574  
(954) 523-2976  
Fax: (954) 523-5467

LUCKMAN CORPORATION  
1930 Old York Road  
Abington, PA 19001  
(215) 659-1664  
Fax: (215) 659-5506

LuMACHEM  
3677 West 1987 South  
Salt Lake City, UT 84104  
(888) 944-8391  
(801) 886-3047  
Fax: (801) 974-9443

LUME  
3027 Larimer Street, Suite 102  
Denver, CO 80205  
(800) 554-5863  
(302) 297-0910  
Fax: (302) 297-0938

LUSTRECORP, INC.  
4780 Okemos Road  
Okemos, MI 48864  
(877) 477-6749  
(517) 349-0002  
Fax: (517) 349-4325

LYTE OPTRONICS  
2201 Amapola Court  
Torreca, CA 90501  
(800) 255-9133  
(310) 782-0220  
Fax: (310) 782-0662  
[lyte@lytelaser.com](mailto:lyte@lytelaser.com)

MACAN ENGINEERING & MFG., CO.  
1564 North Damen  
Chicago, IL 60622  
(773) 772-2000  
Fax: (773) 772-2003

MACINTYRE PUBLISHING  
41 Temescal Terrace  
San Francisco, CA 94118  
(415) 831-0602  
Fax: (415) 831-3805  
[macintyram@aol.com](mailto:macintyram@aol.com)

MACKIE X-RAY  
264 Roger Williams Avenue  
Rumford, RI 02916  
(800) 293-9496  
(401) 438-0301  
Fax: (401) 438-0305  
[mac@mackiexray.com](mailto:mac@mackiexray.com)

- MACROCHEM CORP.**  
110 Hartwell Avenue, Suite 2  
Lexington, MA 02421  
(781) 862-4003  
Fax: (781) 862-4338
- MADA EQUIPMENT CO., INC.**  
60 Commerce Road  
Carlstadt, NJ 07072  
(800) 332-6232  
(201) 460-0454  
Fax: (201) 460-3509
- MAGIC SAFETY PRODUCTS**  
4301 B New Brunswick Avenue  
South Plainfield, NJ 07080  
(800) 719-9800  
(732) 968-0008  
Fax: (732) 752-4914  
[hellomike@net.com](mailto:hellomike@net.com)
- MAJESTIC DRUG CO., INC.**  
711 East 134th Street  
Bronx, NY 10454  
(800) 238-0220  
(718) 292-1310  
Fax: (718) 292-2835  
[majestic.drug@worldnet.att.net](mailto:majestic.drug@worldnet.att.net)
- MAJOR PHARMACEUTICAL CORP.**  
31778 Enterprise Drive  
Lironia, MI 48150  
(800) 616-2471  
Fax: (800) 696-9101
- MALAYTEX USA INC.**  
140 Dodd Court  
American Canyon, CA 94589  
(707) 553-6190  
Fax: (707) 553-6191  
[Malaytex@compuserve.com](mailto:Malaytex@compuserve.com)
- MANAGEMENT ALLIANCE, THE**  
135 N.W. 33rd Street, Unit B2  
Newport, OR 97365  
(541) 574-6787  
Fax: (541) 574-6787
- MANLOE LABS, INC.**  
6320 South Sandhill Road,  
Suite 10  
Las Vegas, NV 89120  
(800) 777-4876  
(702) 433-7154  
Fax: (702) 433-7192
- MANNATECHINC**  
7676 South Lakeridge Drive  
Seattle, WA 98178-3133  
(800) 844-9772  
(206) 772-7424  
Fax: (206) 772-8396  
[brendar@connectexpress.com](mailto:brendar@connectexpress.com)
- MAR-A-MAP DENTAL INC**  
1281 Kimmerling Road, Suite 5  
Gardnerville, NV 89410  
(800) 445-6719  
(702) 265-1313  
Fax: (702) 265-1315
- MARE PUBLISHING & DISTRIBUTION**  
Department 101  
PO. Box 230311  
Brooklyn, NY 11223  
(718) 256-7928  
Fax: (718) 339-3010
- MARILLION LABS**  
PO. Box 1667  
Tustin, CA 92781  
(714) 633-9760  
Fax: (714) 633-0907
- MARKET MASTERS INC./DIRECT  
DENTAL SERVICE (DDS)**  
4790 South Hagadom Road  
Suite 134-C  
East Lansing, MI 48823  
(800) 342-5337  
(517) 333-3223  
Fax: (517) 333-3838  
[dds5@ix.netcom.com](mailto:dds5@ix.netcom.com)
- MARKET TECHNOLOGIES**  
4516 Valleydale Road  
Birmingham, AL 35242  
(800) 767-6765  
(205) 991-5374  
Fax: (205) 991-5396  
[martech@zebra.net](mailto:martech@zebra.net)
- MARQUETTE MEDICAL SYSTEMS  
DIVISION**  
625 Alaska Avenue  
Torrance, CA 90503  
(800) 443-3676  
(310) 320-8334  
Fax: (310) 618-8315  
[www.mel.com](http://www.mel.com)
- MARSIN INTERNATIONAL**  
6800 Lindberch Boulevard  
Philadelphia, PA 19142  
(800) 468-4886  
(215) 365-6100  
Fax: (215) 365-6108  
[greenlind@nmi.com](mailto:greenlind@nmi.com)
- MARTIN Fox co.**  
10372 Forest Brook  
St. Louis, MO 63146  
(314) 567-1833  
Fax: (314) 569-0893
- MASEL, INC.**  
2701 Bertram Road  
Bristol, PA 19007-6892  
(800) 423-8227  
(215) 785-1600  
Fax: (215) 785-1680  
[sales@masel.com](mailto:sales@masel.com)
- MASTER DENTAL, INC.**  
205 Colony Drive North  
Saginaw, MI 48603-7166  
(517) 792-4431  
Fax: (517) 792-4387
- MASTERSONICS, INC.**  
(See Advanced Systems)
- MATECH, INC.**  
13010 San Fernando Road  
Sylmar, CA 91342  
(800) 292-6620  
(818) 367-2472  
Fax: (818) 367-7059
- MAXWELL, P.J., GO., INC.**  
1817 18th Avenue  
Rockford, IL 61104  
(815) 399-1180  
Fax: (815) 398-1047
- MAYER LABORATORIES, INC.**  
646 Kennedy Street, Building C  
Oakland, CA 94606  
(510) 437-8989  
Fax: (510) 536-9912
- MAY PELL CHEMICAL  
DEVELOPMENT COMPANY**  
211 East South Street  
Davison, MI 48423-1699  
(810) 653-1830  
Fax: (810) 658-7990
- MCCLEAY DENTAL**  
(See Emery Dental)
- MCCLELLAN MARKETING**  
1128 South Daniel Way  
San Jose, CA 95128  
(800) 597-2583  
(408) 248-4062  
Fax: (408) 985-5227
- MQHENRY LABORATORIES, INC.**  
710 N. 5th St.  
Copperas Cove, TX 76522  
(800) 746-5486  
(254) 547-9373  
Fax: (254) 547-2553  
[dray@n.link.com](mailto:dray@n.link.com)
- M-DEC**  
16604 Southeast 17th Place  
Bellevue, WA 98008  
(800) 321-6332  
(425) 747-5424  
Fax: (425) 746-6332  
[mdec@halcyon.com](http://mdec@halcyon.com)
- M-D PRODUCTS**  
(See Reflex Technologies)
- MDS MATRIX**  
145 Mid County Drive  
Orchard Park, NY 14127  
(800) 847-1000  
(716) 662-6650  
Fax: (716) 662-7130  
[matrix@matrixmedical.com](mailto:matrix@matrixmedical.com)
- MDS PRODUCTS, INC.**  
American Diversified  
Dental Systems  
1440 South State College Blvd.,  
Suite 3H  
Anaheim, CA 92806  
(800) 637-2337  
(714) 490-0114  
Fax: (714) 991-9540
- MDT**  
(See Barnstead/Thermolyne/  
Harvey Sterilizers)
- MED-A-MARK, MESSAGE-ON-HOLD  
COMPANY**  
1150 West Eighth Street,  
Suite 201  
Cincinnati, OH 45203  
(800) 848-2024  
(513) 381-4653  
Fax: (513) 381-8427  
[Med-A-Mark@aol.com](mailto:Med-A-Mark@aol.com)
- MEDESCO ATTACHMENT &  
IMPLANTS**  
23461 South Pointe Drive, Suite  
155  
Laguna Hill, CA 92653  
(800) 633-3726  
(949) 588-8834  
Fax: (949) 588-9844
- VED ET AL DEVELOPMENT**  
8539 Monroe Road, Suite 19  
Charlotte, NC 28212  
(800) 863-0717  
(704) 532-2882  
Fax: (704) 532-1082  
[medetal@freeweb.com](http://medetal@freeweb.com)
- MEDICAL AIR Vac CORP.**  
2506 Ticheli Road  
Monroe, LA 71202  
(888) 360-0334  
(318) 361-0334  
Fax: (318) 325-8000
- MEDICAL DISCOVERIES INC.**  
2985 North 935 East, Suite 9  
Layton, UT 84041  
(801) 771 0523  
Fax: (801) 771-0527  
[www.mdi-p.com](http://www.mdi-p.com)
- MEDICAL DYNAMICS, INC.**  
99 Inverness Drive East  
Englewood, CO 80112  
(800) 525-1294  
(303) 790-2990  
Fax: (303) 799-1378
- MEDICAL I.D. SYSTEMS, INC.**  
3954 44th Street Southeast  
Grand Rapids, MI 49512-3942  
(800) 262-2399  
(616) 698-0535  
Fax: (616) 698-0603  
[medidrx@aol.com](mailto:medidrx@aol.com)
- MEDICAL INNOVATIONS, INC.**  
8040 South 1450 West  
West Jordan, UT 84088  
(800) 826-5650  
(801) 255-4677  
Fax: (801) 568-9239  
[minnovations@msn.com](http://minnovations@msn.com)
- MEDICAL LETTER, INC., THE**  
1000 Main Street  
New Rochelle, NY 10801  
(800) 211-2769  
(914) 235-0500  
Fax: (914) 576-3377
- MEDICAL POLYMERS TECH.**  
(See Habitek Int'l DBA U.S.  
Medical Systems Inc.)
- MEDICAL SCIENCE SYSTEMS**  
3100 North West Street, Suite A  
Flagstaff, AZ 86004  
(888) 677-1778  
(520) 556-0305  
Fax: (520) 677-2778
- MEDICANIX**  
30 Nurney Street  
Stamford, CT 06902  
(203) 324-3711
- MEDICODE, INC.**  
5225 Willey Post Way, Suite 500  
Salt Lake City, UT 84116  
(800) 999-4614  
(801) 536-1000  
Fax: (801) 536-1009  
[www.medicode.com](http://www.medicode.com)
- MEDICO DENTAL MEDIA  
INTERNATIONAL, INC.**  
PO. Box 434  
Pacific, MO 63069  
(888) 677-6364  
(314) 271-6364  
Fax: (314) 257-6364  
[cs@mdmii.com](mailto:cs@mdmii.com)
- MEDIDENTA INTERNATIONAL, INC.**  
39-23 62nd Street  
PO. Box 409  
Woodside, NY 11377  
(800) 221-0750  
(718) 672-4670  
Fax: (718) 565-6208  
[medidenta@medidenta.com](mailto:medidenta@medidenta.com)
- MEDIMARK/INTREPID ENTERPRISES,  
INC.**  
1154 Park Avenue, Suite 200  
St. Paul, MN 55115  
(888) 752-4243  
(612) 723-8502  
Fax: (651) 653-9421  
[medimark@hotmail.com](mailto:medimark@hotmail.com)
- MEDPAC, INC.**  
PO. Box 165  
Bedford Hills, NY 10506  
(800) 829-2221  
(914) 234-1212  
Fax: (914) 234-6166
- MEER DENTAL**  
7277 North Haggerty Road  
Canton, MI 48187  
(800) 235-6337  
(313) 454-0300  
Fax: (313) 454-1044
- MELALEUCA, INC.**  
3910 South Yellowstone High-  
way  
Idaho Falls, ID 83402-6003  
(800) 282-3000  
(208) 522-0700  
Fax: (208) 528-2090
- MERCK & CO.**  
PO. Box 4  
HM 302  
West Point, PA 19486-0004  
(800) 637-2579  
(215) 652-5000  
Fax: (215) 328-2409
- MEREDETH COMMUNICATIONS, INC.**  
Corporate Office  
3639 Black Hawk Drive, Suite 1  
New Port Richey, IL 34652  
(800) 660-0409  
(727) 846-1600  
Fax: (727) 846-7396
- MERITECH, INC.**  
8250 South Akron Street,  
Suite 202  
Englewood, CO 80112  
(800) 932-7707  
(303) 790-4670  
Fax: (303) 790-4859  
[www.cleantech@meritech.com](http://www.cleantech@meritech.com)
- METRE% RESEARCH CORPORATION**  
1717 West Collins  
Orange, CA 92867  
(800) 841-1428  
(714) 516-7400  
Fax: (714) 516-7904  
[metre@spynet.com](mailto:metre@spynet.com)
- METRO WEST I PHYSICIANS &  
SURGEON**  
61 Lincoln Street, Suite 212  
Framingham, MA 01702  
(508) 875-9787  
Fax: (508) 872-3476
- METTLER ELECTRONICS CORP.**  
1333 South Claudina Street  
Anaheim, CA 92805  
(800) 854-9305  
(714) 533-2221  
Fax: (714) 635-7539  
[Mettler.customer@juno.com](mailto:Mettler.customer@juno.com)
- MEXPO INTERNATIONAL, INC.**  
2671 McCone Avenue  
Hayward, CA 94545  
(800) 838-8299  
(510) 293-6800  
Fax: (510) 293-9056  
[mexpoglove@aol.com](mailto:mexpoglove@aol.com)
- MEYER SUPERDENTA GMBH**  
Im Grohenstuck  
65396 Wallut  
Gewerbegebiet, Germany  
49-6123-9772-0  
Fax: 49-6123-9772-2
- MICRO ASEPTIC PRODUCTS, INC.**  
(See Kerr Corp)
- MICROBE% ASEPTICS, INC.**  
67 Lesmill Road  
North York, Ontario M3B 2T8  
Canada  
(416) 391-1700  
Fax: (416) 391-2516
- MICROBRUSH CORP.**  
1376 Cheyenne Avenue  
Grafton, WI 53024  
(414) 375-4011  
Fax: (414) 375-2777  
[www.microbrush.com](http://www.microbrush.com)
- MICROCOPY**  
3120 Moon Station Road  
PO. Box 2017  
Kennesaw, GA 30144  
(800) 235-1863  
(770) 425-5715  
Fax: (770) 423-4996

MICRODENTAL LABORATORIES  
6665 Amador Plaza Road  
Dublin, CA 94568  
(800) 229-0936  
(510) 829-3611  
Fax: (510) 829-0685  
[info@microdental.com](mailto:info@microdental.com)

MICROFLEX MEDICAL CORP.  
P.O. Box 32000  
Reno, NV 89533-2000  
(800) 876-6866  
(702) 746-6600  
Fax: (800) 876-6632  
[microflex@aol.com](http://microflex@aol.com)

MICRO MOTORS, INC.  
151 East Columbine Avenue  
Santa Ana, CA 92707  
(800) 562-6204  
(714) 546-4045  
Fax: (714) 546-1109

MICRON DENTAL MANUFACTURING, INC.  
2704 Palmer  
Missoula, MT 59802  
(800) 720-6293  
(406) 542-8537  
Fax: (406) 549-7452

MICR-O-REG  
40-49 74th Street  
Jackson Heights, NY 11373  
(718) 429-7555

MICRO SELECT  
6665 Amador Plaza Road  
Dublin, CA 94568  
(800) 840-2650  
(925) 829-3611  
FAX: (925) 551-0110  
[www.microdental.com](http://www.microdental.com)

MICROSTAR CORPORATION  
4220 Steven Reynolds Boulevard,  
Suite 19  
Norcross, GA 30093  
(800) 313-6427  
(770) 935-4466  
Fax: (770) 935-4460  
[www.microstarcorp.com](http://www.microstarcorp.com)

MICRO SURFACE CORP.  
465 East Briscoe Drive  
P.O. Box 788  
Morris, NJ 08045-0788  
(800) 248-4221  
(815) 942-4221  
Fax: (815) 942-4265  
[www.microsurface.com](http://www.microsurface.com)

MICROTECH LABORATORIES CORPORATION  
3305 Caldwell Lane  
DelValle, TX 78617  
(800) 339-8321  
(512) 247-4511  
Fax: (512) 247-3676  
[bankriver@aol.com](mailto:bankriver@aol.com)

MICRO-VAC, INC.  
4132 East Speedway Boulevard  
Tucson, AZ 85712  
(800) 729-1020  
(520) 325-2968  
Fax: (520) 327-6659

MICRYLIUM LABORATORIES CANADA  
4590 Dufferin Street  
Toronto, Ontario, M3H 585  
Canada  
(800) 489-8868  
(416) 667-7040  
Fax: (416) 223-5892  
[greenteam@micrylium.com](mailto:greenteam@micrylium.com)

MICRYLIUM LABORATORIES USA  
1755 West University Drive,  
Suite 118  
Tempe, AZ 85281  
(800) 489-8868  
(602) 736-1773  
Fax: (602) 736-1481  
[greenteam@micrylium.com](mailto:greenteam@micrylium.com)

MIDMARK CORP.  
60 Vista Drive  
Versailles, OH 45380  
(800) 643-6275  
(937) 526-3662  
Fax: (937) 526-5542

MIDWEST  
(See Dentsply/Midwest)

MIELE PROFESSIONAL  
Professional Products Group  
22D Worlds Fair Drive  
Somerset, NJ 08873  
(800) 843-7231  
(732) 560-0899  
Fax: (732) 560-9649  
[www.mieleusa.com](http://www.mieleusa.com)

MIKRONA TECHNOLOGIE AG  
Wigartestrasse 8  
CH-8957, Spreitenbach Switzerland  
41-56-401-18-56  
Fax: 41-56-401-58-18  
[mikrona@swissonline.ch](http://mikrona@swissonline.ch)

MILESTONE SCIENTIFIC  
151 South Pfingsten Road  
Deerfield, IL 60015  
(800) 862-1125  
(847) 272-3207  
Fax: (847) 559-1065

MILLER, E. LYNN, & ASSOCIATES  
1002 Locust Street  
Columbia, MO 65201  
(800) 677-0222  
(314) 443-2434  
Fax: (573) 443-7224

MILLIPORE CORPORATION  
Corporate Headquarters  
80 Ashby Road  
Bedford, MA 01730  
(800) 645-5476  
(781) 275-9200  
Fax: (781) 533-3143  
[www.millipore.com](http://www.millipore.com)

MILTEX INSTRUMENT CO., INC.  
6 Ohio Drive  
CB 5006  
Lake Success, NY 11042-0006  
(800) 645-8000  
(516) 775-7100  
Fax: (516) 775-7185

MINI DENT IMPLANT CENTERS  
MANAGEMENT, INC.  
30 Central Park South, Suite 14B  
New York, NY 10019  
(212) 753-2619  
Fax: (212) 753-9064

MINNTECH CORPORATION  
14605 28th Avenue North  
Minneapolis, MN 55447  
(800) 328-3340  
(612) 553-3300  
Fax: (612) 553-3387

MION INTERNATIONAL CORP.  
100 Center Street  
P.O. Box 363  
Winslow, IN 47598-0363  
(800) 759-6466  
(812) 789-5350  
Fax: (812) 789-2618

MIOX CORPORATION  
5500 Midway Park Place N.E.  
Albuquerque, NM 87109  
(888) 646-9426  
(505) 343-0090  
Fax: (505) 343-0093  
[miox@rt66.com](mailto:miox@rt66.com)

MIRAGEN INC.  
16632 Milliken Avenue  
Irvine, CA 92606  
(800) 647-2436  
(949) 454-1441  
Fax: (949) 454-1557  
[miragen@aol.com](mailto:miragen@aol.com)

MITER, INC.  
P.O. Box 1133  
Warsaw, IN 46581-1133  
(800) 325-8566  
(219) 267-6662  
Fax: (219) 267-6157

MJR EXOUISITE IMPORTS, INC.  
370 Mulberry Drive, Suite B  
San Marcos, CA 92069  
(760) 591-9541  
Fax: (760) 591-9547

M & M INNOVATIONS, INC.  
4 Carteret Road  
Brunswick, GA 31525  
(800) 688-3384  
(912) 265-7110  
Fax: (912) 262-9080

MODERN EQUIPMENT CO.  
3718 Cedar Avenue  
Minneapolis, MN 55407  
(612) 721-1634  
Fax: (612) 721-2648

MOELSTER INTERNATIONAL AS  
Snorer Senter  
P.O. Box 503  
N-6901 Fiore, Norway  
(47) 5-7741010  
Fax: (47) 5-7749090  
[muelster@sf.telia.n](mailto:muelster@sf.telia.n)

MOGO, INC.  
801 North Cass Avenue, Suite 100  
Westmont, IL 60559  
(800) 944-6646  
(630) 323-2478  
Fax: (630) 323-6240  
[www.mogo.com](http://www.mogo.com)

MOLECUCARE, INC.  
P.O. Box 266  
Centerbrook, CT 06409  
(800) 966-9853  
(860) 399-4656  
Fax: (860) 399-5886  
[info@molecucare.com](mailto:info@molecucare.com)

MOLTEN MEDICAL CORPORATION  
8-17 . 2 Chome Daido  
Tennoji-Ku  
Osaka, Japan 543  
81 6 771 3503  
Fax: 81 6 771 3380  
[ji085@mb.infoweb.or.jp/jackey](mailto:ji085@mb.infoweb.or.jp/jackey)

MONARCH LEARNING SYSTEMS  
675 Pine Avenue  
Pacific Grove, CA 93950  
(831) 649-1055  
Fax: (831) 649-0567  
[www.montereynet.com](http://www.montereynet.com)

MOORE MEDICAL CORP.  
389 John Downey Drive  
P.O. Box 2620  
New Britain, CT 06050-2620  
(800) 234-1464  
(860) 826-3600  
Fax: (860) 826-3653

MOOSEHORN  
RO. Box 24701  
Little Rock, AK 72221  
(888) 686-6866  
Fax: (501) 686-8655  
[warrenCatherine@Exchange.UAMS.Edu](mailto:warrenCatherine@Exchange.UAMS.Edu)

MORACK, INC.  
9132 Windsor Drive  
Palos Hills, IL 60465  
(800) 837-9696  
(708) 598-0580  
Fax: (708) 598-9203

MORESCHINI DENTAL  
1000 West 6th Street  
Pueblo, CO 81003  
(719) 542-7420

MOSBY-YEAR BOOK, INC.  
11830 Westline Industrial Drive  
St. Louis, MO 63146  
(800) 426-4545  
(314) 872-8370  
Fax: (314) 453-4379  
[www.mosby.com](http://www.mosby.com)

MOTLOID, Co., THE  
300 North Elizabeth Street  
Chicago, IL 60607  
(800) 662-5021  
(312) 226-2454  
Fax: (312) 226-2480  
[motloid@aol.com](mailto:motloid@aol.com)

MOUNTAIN STATES SUPPLY, INC.  
184 West 3300 South  
Salt Lake City, UT 84115  
(801) 484-8885  
Fax: (801) 484-6954

MOUNTAINVILLE HOUSE CALLS  
P.O. Box 331148  
Fort Worth, TX 76163-1148  
(800) 460-7282  
(817) 370-7215  
Fax: (817) 370-7179

Moyno TECH  
(See Union Broach)

MPL TECHNOLOGIES  
(See Dentsply/MPL)

MTI PRECISION PRODUCTS  
175 Oberlin North Avenue  
P.O. Box 221  
Lakewood, NJ 08701  
(800) 367-9290  
(732) 905-7440  
Fax: (732) 905-7445

MUGGU DENTAL STUDIO  
7101 North Green Bay Avenue  
Milwaukee, WI 53209  
(800) 439-4401  
(414) 351-4401  
Fax: (414) 351-1227

MURDOCK LABORATORIES INC.  
132 Primrose Road  
Burlingame, CA 94010  
(800) 439-2497  
(650) 579-1352  
Fax: (650) 579-1351  
[murdock@purebrush.com](mailto:murdock@purebrush.com)

MURDOCK MADUS SCHWABE  
PROFESSIONAL PRODUCTS, INC.  
10 Mountain Springs Parkway  
Springville, Utah 84663  
(800) 766-3303  
(801) 489-1500  
Fax: (801) 489-1700  
[www.mnwn.naturesway.com](http://www.mnwn.naturesway.com)

MXR, INC.  
(See Mackie X-Ray)

MYCO MEDICAL SUPPLIES, INC.  
101 Rose Valley Woods Drive  
Cary, NC 27513  
(800) 454-6926  
(919) 678-0680  
Fax: (919) 677-1445  
[sales@mycomedical.com](mailto:sales@mycomedical.com)

MYOENT CORPORATION  
275 Oser Avenue  
Hauppauge, NY 11788  
(800) 275-0020  
(516) 434-3190  
Fax: (516) 434-7750  
[mrieders@mydent.com](mailto:mrieders@mydent.com)

MYOFUNCTIONAL RESEARCH CO.  
P.O. Box 15835  
San Diego, CA 92175-5835  
(888) 666-2807  
(619) 583-2807  
Fax: (619) 582-4824  
[www.myofresearch.com](http://www.myofresearch.com)

Myo-TRONICS RESEARCH, INC.  
15425 53rd Avenue South  
Tukwila, WA 98188  
(800) 426-0316  
(206) 243-4214  
Fax: (206) 243-3625  
[www.myo-tronics.com](http://www.myo-tronics.com)

NAE-TECH CO.  
11305 Georges Mill Road  
P.O. Box 337  
Lovettsville, VA 20180  
(540) 822-4412  
Fax: (540) 822-4412

NATIONAL BAG Co., INC.  
2233 Old Mill Road  
Hudson, OH 44236  
(800) 247-6000  
(330) 425-2600  
Fax: (330) 425-9800

NATIONAL DATA CORPORATION  
National Data Plaza  
Atlanta, GA 30329  
(800) 356-1711  
(404) 728-2000  
Fax: (404) 728-2059  
[www.ndc.com](http://www.ndc.com)

NATIONAL SALES COORDINATOR  
3995 Goya Drive  
Pensacola, FL 32504  
(850) 494-1121  
Fax: (850) 433-6972

NATURAL ARTS DENTAL LAB, INC.  
11803 Warfield  
San Antonio, TX 78216  
(800) 322-6235  
(210) 349-1004  
Fax: (210) 349-3880

NATURAL DENTIST, THE  
Woodstock Natural Products  
140 Sylvan Ave.  
Englewood Cliffs, NJ 07632  
(800) 615-6895  
(201) 944-0123  
Fax: (201) 944-1717  
[natdent@worldnet.att.net](mailto:natdent@worldnet.att.net)

NATURAL WHITE, INC.  
15449 Yonge Street, Suite 206  
Aurora, Ontario L4G 1 P3  
Canada  
(905) 841-9229  
Fax: (905) 841-4312

NATUS  
(See Shape Rite Inc.)

- NDC DENTAL**  
12240 Merriman Road  
P.O. Box 3331  
Livonia, MI 48150  
(800) 521-4970  
(734) 261-0440  
Fax: (800) 232-4975
- ND LASS, INC.**  
3379 Shore Parkway  
Brooklyn, NY 11235  
(718) 646-7998  
Fax: (718) 591-5420
- NDL LAB**  
(See Regent Labs Inc.)
- NEEDLE EATER MARKETING CO.**  
SPS Medical Equipment  
Company  
450 West 1st Avenue  
Roselle, NJ 07203  
(800) 978-8006  
(908) 245-0007  
Fax: (908) 245-1139
- NEOLOD/DENTEX, INC.**  
5101 South Keeler Avenue  
Chicago, IL 60632  
(800) 628-7336  
(773) 735-3349  
Fax: (773) 735-3935
- NEOPTX**  
2205 152nd Avenue Northeast  
**Redmond, WA 98052**  
(800) 344-2020  
(425) 644-2420  
Fax: (425) 644-6107
- NETM COMMUNICATIONS, INC.**  
502 Main Street, Suite 232  
Carbondale, CO 81623  
(970) 963-3183  
Fax: (970) 963-3122  
[www.afdd.com](http://www.afdd.com)
- NETWORK INTERNATIONAL**  
1720 East Garry Avenue, Suite  
109  
Santa Ana, CA 92705  
(714) 863-7133  
Fax: (714) 863-7135
- NEVIN LABORATORIES, INC.**  
5000 South Halsted Street  
Chicago, IL 60609  
(800) 544-5337  
(773) 624-4330  
Fax: (773) 624-7337
- NEWARK WIRE CLOTH CO.**  
351 Verona Avenue  
Newark, NJ 07104  
(800) 221-0392  
(973) 483-7700  
Fax: (973) 483-6315  
[www.newarkwire.com](http://www.newarkwire.com)
- NEWAYS, INC.**  
150 East 400 North  
Salem, UT 84653  
(801) 423-2800  
Fax: (801) 423-7433
- NEW CENTURY SEMINARS**  
3430 Dodge-Inn Plaza  
Dubuque, IA 52004  
(800) 999-9551 ext. 986  
(319) 556-8388  
Fax: (319) 557-1809
- NEW IMAGE INDUSTRIES, INC.**  
(See Dentsply New Image)
- NEW ORLEANS MEDICAL  
MARKETING LL**  
4848 Coliseum, Suite 202  
New Orleans, LA 70115  
(504) 362-8000  
Fax: (504) 362-8063
- NEW WEST DENTAL CERAMICS**  
2184 McCulloch Boulevard  
Lake Havasu City, AZ 86403  
(800) 321-1614  
(502) 453-7522  
Fax: (502) 453-6517
- NEY DENTAL INTERNATIONAL**  
65 Dudleytown Road  
Bloomfield, CT 06002  
(800) 243-1942  
(860) 242-6188  
Fax: (860) 769-5050  
[neyinfo@neydental.com](http://neyinfo@neydental.com)
- NIKKEN, INC.**  
10393 South 1300 West  
South Jordan, UT 84095  
(888) 280-0983  
(801) 254-1400  
Fax: (801) 280-0983
- NIKON, INC.**  
1300 Walt Whitman Road  
Melville, NY 11747-3064  
(800) 645-6687  
(516) 547-4200  
Fax: (516) 547-0299  
[www.nikonusa.com](http://www.nikonusa.com)
- NMT**  
P.O. 2000  
3430 CA  
Nieuwegein, The Netherlands  
31 306077-6276  
Fax: 31 306048994  
[nmt@nmt.nl](mailto:nmt@nmt.nl)
- NOBEL BIOCARE USA, INC.**  
777 Oakmont Lane, Suite 100  
Westmont, IL 60559  
(800) 891-9191  
(630) 654-9100  
Fax: (630) 654-1833
- NOBILJUM**  
413 North Pearl Street  
P.O. Box 350  
Albany, NY 12207  
(BOO) 833-2343  
(518) 434-3147  
Fax: (518) 434-1288
- NOM MEDICAL TECHNOLOGIES**  
6155 Pontiac Trail  
PO. Box 159  
South Lyon, MI 48178  
(800) 521-9746  
(734) 769-5565  
Fax: (734) 769-1708
- NOLA SPECIALTIES**  
P.O. Box 24129  
Hilton Head Island, SC 29925  
(800) 346-6652  
(843) 342-5553  
Fax: (843) 342-5554
- NOROENT MANUFACTURING, INC.**  
1374 Jarvis Avenue  
Elk Grove Village, IL 60007  
(800) 966-7336  
(847) 437-4780  
Fax: (847) 437-4786
- NORDISKA DENTAL AS**  
P.O. Box 1082  
Framtidsg.1  
Angelholm, Sweden S-251-09  
46-431-443360  
Fax: 46-431-443399
- NRGRN COMPANY**  
5400 South Delaware Street  
Littleton, CO 80120-1663  
(303) 794-2611  
Fax: (303) 795-9487  
[www.usa.norgren.com](http://www.usa.norgren.com)
- NORTH AMERICAN MARKETING,  
INC./KLEBR Vu-ANTI-FOG**  
3005 North 4th East  
Idaho Falls, ID 83401  
(208) 524-4949  
Fax: (208) 524-5280  
[kz750@srv.net](mailto:kz750@srv.net)
- NORTH BAY/BIO SCIENCE, INC.**  
13606 S. West Bay Shore Drive  
PO. Box 4319  
Traverse City, MI 49684  
(800) 289-7786  
(616) 922-2211  
Fax: (616) 922-2274  
[northbay@nbbs.com](http://northbay@nbbs.com)
- NORTHSTAR DENTAL, INC.**  
406 Main Street  
P.O. Box 49  
Ogdensburg, WI 54962  
(800) 722-4192  
(920) 244-7435  
Fax: (920) 244-7432
- NORTHWEST DENTAL, INC.**  
2225 North Vancouver Avenue  
Portland, OR 97227  
(800) 346-5709  
(503) 335-3385  
Fax: (503) 335-3387
- NORTHWEST DENTAL SUPPLY**  
590 Clearwater, Suite C  
Postfalls, ID 83854  
(800) 842-2787  
(208) 777-8511  
Fax: (208) 777-8592  
[ndsidental@aol.com](mailto:ndsidental@aol.com)
- NOVAPLEX INC.**  
2255 Cumberland Parkway  
Building 400  
Atlanta, GA 30339  
(800) 426-5271  
(770) 435-6445  
Fax: (770) 435-6601  
[novaplex@mindspring.com](mailto:novaplex@mindspring.com)
- NOVATEC MEDICAL PRODUCTS, INC.**  
305 Mayerling Drive  
Houston, TX 77024  
(713) 266-1976  
Fax: (713) 266-1976
- NOVEN PHARMACEUTICALS**  
11960 Southwest 144th Street  
Miami, FL 33186  
(888) 556-6836  
(305) 253-5099  
Fax: (305) 251-4682
- NSK AMERICA CORPORATION**  
700 B Cooper Court  
Schaumburg, IL 60173  
(847) 843-7664  
Fax: (847) 843-7622
- NT COMPANY**  
(See Tycom Dental)
- NUCLEAR ASSOCIATES**  
Unit of Innovision  
**100 Voice Road**  
Carle Place, NY 11514-1593  
(888) 466-8257  
(516) 741-6360  
Fax: (516) 741-5414
- Nu-LITE RETRACTOR, INC.**  
108-18 72nd Avenue, Suite 6  
Forest Hills, NY 11375  
(718) 886-3461  
Fax: (212) 688-6433
- NULITE SYSTEMS INTERNATIONAL  
PTY., LTD.**  
**7142 Leighton Place**  
P.O. Box 388  
Hornsby, NSW 2077  
Australia  
**61-2-9482-1888**  
Fax: 61-2-9482-1875  
[www.nulite.com.au/nsi/](http://www.nulite.com.au/nsi/)
- NURSERY NEEDS BY SANITOV, INC.**  
P.O. Box 2167  
Nursery Lane  
Fitchburg, MA 01420  
(800) 726-4869  
(978) 345-7571  
Fax: (978) 342-5887
- Nu SKIN INTERNATIONAL, INC.**  
One Nu Skin Plaza  
75 West Center  
Provo, UT 84601  
(801) 345-1000  
Fax: (801) 345-2799
- NUSOURCE INTERNATIONAL, INC.**  
3605 Greathill Road  
Crystal Lake, IL 60012  
(815) 477-9844  
Fax: (815) 477-9845
- O**
- OBTURA CORP.**  
1727 Larkin Williams Road  
Fenton, MO 63026  
(800) 344-1321  
(314) 343-8733  
Fax: (314) 343-5794
- "O" COMPANY, INC.**  
600 Paisano Street Northeast,  
Suite A  
Albuquerque, NM 87123  
(800) 228-0477  
(505) 293-0025  
Fax: (505) 293-0447
- ODONTOS PUBLISHING**  
34696 Vine Street  
Eastlake, OH 44095  
(800) 203-6936  
(440) 684-0800  
Fax: (440) 684-0804  
[www.dentaldigest.com](http://www.dentaldigest.com)
- OHLENDORF ORTHODONTIC  
LABORATORIES, INC.**  
2840 Clark Avenue  
PO. Box 7212  
St. Louis, MO 63103  
(800) 325-8921  
(314) 533-3440  
Fax: (314) 533-7331  
[ohlendorf@dds.dx.com](http://ohlendorf@dds.dx.com)
- OIS/SC ORTHODONTICS**  
3890 Park Central Boulevard  
North  
Pompano Beach, FL 33064  
(800) 441-7700  
(305) 978-3545  
Fax: (305) 979-5856
- OLSON LABORATORIES, INC.**  
P.O. Box 171  
Port Washington, WI 53074  
(414) 284-9755  
Fax: (414) 284-7448
- OMEGA PUBLICATIONS**  
3553 Wheeler Road  
Augusta, GA 30909  
(800) 521-8913  
(706) 738-8070  
Fax: (706) 733-0543  
[www.implantbook.com](http://www.implantbook.com)
- OMNIGENE DIAGNOSTICS, INC.**  
3361 Belvedere Road, Suite E  
West Palm Beach, FL 33406  
(561) 712-9096  
Fax: (561) 712-0919
- OMNI PRODUCTS**  
1500 North Florida Mango  
Road, Suite 1-3  
West Palm Beach, FL 33409  
(800) 445-3386  
(561) 689-1140  
Fax: (561) 689-1159
- ON-GARD SYSTEMS**  
**815 Tek Drive**  
Crystal Lake, IL 60014  
(800) 323-2220  
(815) 455-4700  
Fax: (815) 455-5599
- OOLITT ADVANTAGE**  
2906 Whittington Place  
P.O. Box 273653  
Tampa, FL 33618  
(813) 931-0390  
Fax: (813) 931-0390  
[oolitt@aol.com](mailto:oolitt@aol.com)
- OP-D-OP INC.**  
8559 Washington Boulevard  
Roseville, CA 95678  
(916) 783-5741  
Fax: (916) 783-5765  
[opdop2@quicknet.com](mailto:opdop2@quicknet.com)
- OPEN TEXT INC**  
38777 West 6th Mile Road,  
Suite 101  
Lovina, MI 48152  
**(800) 559-5955**  
(734) 542-5955  
Fax: (734) 542-1805  
[www.ontime.com](http://www.ontime.com)
- OPTICARE/MED-REP, INC.**  
33631 Calle Miramar  
San Juan Capistrano, CA 92675  
(949) 493-6202  
Fax: (949) 493-6202  
opticareet@FLN.com
- OPTIVA CORPORATION**  
3222 Southeast 30th  
Bellevue, WA 98005  
(800) 957-9310  
(425) 957-0970  
Fax: (425) 401-4826  
[thomas.hassell@optiva.com](mailto:thomas.hassell@optiva.com)
- ORACHEM PHARMACEUTICALS**  
9990 Global Road  
Philadelphia, PA 19115  
(800) 523-0191  
(215) 677-2700  
Fax: (215) 677-7736
- ORA FLOW, INC.**  
PO Box 219  
Plainview, NY 11803-0219  
(516) 669-8954  
Fax: (516) 587-9435
- ORAGARD PRODUCTS GROUP**  
245-M #115 Mt. Herman Road  
Scotts Valley, CA 95066  
(408) 429-9077  
Fax: (408) 429-6663
- ORAL-B LABORATORIES**  
600 Clipper Drive  
Belmont, CA 94002-4119  
(800) 446-7252  
(650) 598-5000  
Fax: (650) 591-3396  
[www.oralb.com](http://www.oralb.com)
- ORALGIENE USA, INC.**  
8460 Higuera Street  
Culver City, CA 90230  
(800) 368-6725  
(310) 204-7888  
Fax: (310) 204-7893



- ORAL HEALTH U.S.A., INC.  
255 Old New Brunswick Road,  
Suite 30  
Piscataway, NJ 08854  
(800) 533-5069  
(732) 981-9440  
Fax: (732) 981-9440
- ORAL-VISION  
(See Cygnus Imaging Incorporated)
- ORAMAX DENTAL PRODUCTS, INC.  
48 Merrick Road  
Rockville Center, NY 11570-4708  
(800) 672-6229  
(516) 536-1303  
Fax: (516) 536-1305  
[oramax@li.net](mailto:oramax@li.net)
- ORANGE-SOL GROUP  
P.O. Box 306  
Chandler, AZ 85244  
(800) 877-7771  
(602) 497-8822  
Fax: (602) 497-0444
- ORASCOPTIG RESEARCH  
5225-3 Verona Road  
P.O. Box 44451  
Madison, WI 53744-4451  
(800) 369-3698  
(608) 278-0111  
Fax: (608) 278-0101  
[vision@arascoptic.com](mailto:vision@arascoptic.com)
- ORATEC CORPORATION  
12181 Balls Ford Road  
Manassas, VA 20109-2449  
(800) 368-3529  
(703) 257-4141  
Fax: (703) 257-1714  
[oratec@msn.com](mailto:oratec@msn.com)
- ORIEL INSTRUMENTS  
150 Long Beach Boulevard  
PO. Box 872  
Stratford, CT 06497-0872  
(203) 377-8282  
Fax: (203) 378-2457  
[res-sales@oriel.com](mailto:res-sales@oriel.com)
- ORMCO  
1717 West Collins Ave.  
Orange, CA 92867  
(800) 854-1741  
(714) 516-7400  
Fax: (714) 516-7543
- ORTHODONTIC STORE, THE  
18904 Premiere Court  
Gaithersburg, MD 20879  
(800) 553-2166  
(301) 963-1536  
Fax: (301) 963-4406
- ORTHOTRAC/OMSYSTEMS, INC.  
3120 Crossing Park  
Norcross, GA 30071  
(800) 358-0112  
(770) 447-6766  
Fax: (770) 448-9587  
[jhawks@orthotrac.com](mailto:jhawks@orthotrac.com)
- ORTHOTRONICS, INC.  
29 North Main Street  
Gloversville, NY 12078-3093  
(800) 800-1410  
(518) 725-2455  
Fax: (518) 725-9522  
[www.orthotronics.com](http://www.orthotronics.com)
- ORTHOVITA  
45 Great Valley Parkway  
Malverne, PA 19355  
(800) 342-5454  
(610) 640-1775  
Fax: (610) 640-1714  
[www.orthovita.com](http://www.orthovita.com)
- ORYAN INDUSTRIES, INC.  
12711 Northeast 95th Street  
P.O. Box 8978  
Vancouver, WA 98668-8978  
(800) 426-4311  
(360) 892-0447  
Fax: (360) 892-6742  
[oryan@pacifier.com](mailto:oryan@pacifier.com)
- OSADA, INC.  
8436 West Third Street, Suite  
695  
Los Angeles, CA 90048  
(800) 426-7232  
(213) 651-0711  
Fax: (213) 651-4691
- OSHA  
D.C. Dept. of Employment Services  
950 Upshur Street, N.W.  
2nd Floor  
Washington, DC 20011  
**(202) 576-6339**  
Fax: (202) 576-7579
- O-So ATTACHMENT SYSTEMS/SCODENCO, INC.  
7405 East 31st Place  
P.O. Box 2426  
Tulsa, OK 74145  
(800) 274-1050  
(918) 627-6795  
Fax: (918) 627-6796
- OSTEOHEALTH COMPANY  
One Luitpold Drive  
Shirley, New York 11967  
(800) 874-2334  
(516) 924-4000  
Fax: (516) 924-1731
- OSTEOMED  
3750 Realty Road  
Dallas, TX 75244  
(800) 456-7779  
(972) 241-3401  
Fax: (972) 241-3507
- OXYFRESH WORLDWIDE, INC.  
East 12928 Indiana Avenue  
P.O. Box 3723  
Spokane, WA 99220  
(800) 333-7374  
(509) 924-4999  
Fax: (509) 924-5285
- P**
- PACE IMPLANTS  
110 Timbercove Circle South  
Longwood, FL 32779  
(800) 482-5744  
(407) 788-7977  
Fax: (407) 788-7977
- PACIFIC ABRASIVES, INC.  
16824 198th Avenue Northeast  
Woodinville, WA 98072  
(800) 999-5255  
(425) 788-7433  
Fax: (425) 788-7473  
[www.aa.net/pac](http://www.aa.net/pac)
- PACIFIC RIM DENTAL  
173 Shady Lane  
P.O. Box 2147  
Stateline, NV 89449  
(800) 298-9074  
(702) 588-0884  
Fax: (702) 588-0557  
[www.pacrimdental.com](http://www.pacrimdental.com)
- PAGODA INTERNATIONAL  
Eight Sunny's Way  
Newtown Square, PA 19703  
(610) 356-4582  
Fax: (610) 356-7334
- PAIN RESOURCE CENTER, INC.  
P.O. Box 2836  
Durham, NC 27715  
(800) 542-7246  
(919) 286-9180  
Fax: (919) 286-4506
- PALISADES DENTAL  
(See Glenwood & Western Pharmaceuticals)
- PALMERO HEALTH CARE  
120 Goodwin Place  
Stratford, CT 06497  
(800) 344-6424  
(203) 377-6424  
Fax: (203) 377-8988
- PALM TREE SYSTEMS  
P.O. Box 850  
Severna Park, MD 21246  
(800) 346-4510  
(410) 544-1800  
Fax: (410) 544-7359  
[sabins@severmapark.com](mailto:sabins@severmapark.com)
- PANORAMIC CORPORATION  
4321 Goshen Road  
Ft. Wayne, IN 46818  
(800) 654-2027  
(219) 489-2291  
Fax: (219) 489-5683  
[sales@panacorp.com](mailto:sales@panacorp.com)
- PARAGON IMPLANT  
15821 Ventura Boulevard, Suite  
420  
Encino, CA 91436  
(800) 877-9991  
(818) 783-1517  
Fax: (818) 789-3928
- PARAGON INTERNATIONAL  
4410 Naussau Drive  
Wichita Falls, TX 76308  
(800) 919-0077  
(940) 691-0424  
Fax: (940) 691-0433  
[paragon@wv.quik.com](mailto:paragon@wv.quik.com)
- PARK DENTAL RESEARCH CORP.  
19 West 34th Street, Suite 301  
New York, NY 10001  
(800) 243-7372  
(212) 736-3765  
Fax: (212) 268-6845
- PARKELL  
155 Schmitt Boulevard  
P.O. Box 376  
Farmingdale, NY 11735  
(800) 243-7446  
(516) 249-1134  
Fax: (516) 249-1242  
**parkell@pb.net**
- PARKER TAYLOR  
2345 North Woodruff  
Idaho Falls, ID 83401  
(800) 274-7999  
(208) 523-5180  
Fax: (208) 523-5386
- PAR LTD.  
Box 147 Altrincham  
Cheshire, England  
WA15 9EB  
44-161-980-8916  
Fax: 44-161-980-5330
- PASCAL COMPANY, INC.  
2929 Northeast Northrup Way  
P.O. Box 1478  
Bellevue, WA 98009-1478  
(800) 426-8051  
(425) 827-4694  
Fax: (425) 827-6893  
[pascal dental@pascal dental.com](mailto:pascal dental@pascal dental.com)
- PASSAP AMERICA, INC.  
2200 Winter Springs Boulevard,  
Suite 106-350  
Oviedo, FL 32765  
(800) 727-5648  
(407) 359-5454  
Fax: (407) 359-9455  
[www.passapamerica.com](http://www.passapamerica.com)
- PATIENT SAFETY PRODUCTS  
364 Argyle Road  
Brooklyn, NY 11218  
(800) 457-5699  
(718) 287-6453  
Fax: (718) 940-9897
- PATTERSON DENTAL CANADA  
6300 A Ciscout Road  
Mississauga  
Ontario, CANADA  
L4V 1H3  
(800) 268-0944  
(905) 677-7711  
Fax: (905) 677-2940
- PATTERSON DENTAL SUPPLY, INC.  
Corporate Offices  
1031 Mendota Heights Road  
St. Paul, MN 55120  
(800) 328-5536  
(612) 686-1600  
Fax: (612) 686-0288  
[www.pattersondental.com](http://www.pattersondental.com)
- PC LEMPERT AB  
P.O. Box 3032  
S-25003,  
Helsingborg, Sweden  
46-42-12-1530  
Fax: 46-42-21-3302
- PEAK ENTERPRISES, INC.  
962 South Tamiami Trail, Suite  
202  
Sarasota, FL 34236  
(941) 373-0046  
Fax: (941) 373-0048
- PEARCE-TURK DENTAL LAB  
201 North Emporia  
PO. Box 760  
Wichita, KS 67201  
(800) 835-2776  
(316) 263-0284  
Fax: (316) 263-5869
- PEARSON DENTAL SUPPLY  
13161 Telfair Avenue  
Sylmar, CA 91342  
(800) 535-4535  
(818) 362-2600  
Fax: (818) 833-7700  
[www.pearson-dental.com](http://www.pearson-dental.com)
- PEERLESS INTERNATIONAL, INC.  
P.O. Box 789  
438 Deposit Street (Rt. 123)  
S. Easton, MA 02375  
(800) 527-2025  
(508) 230-2174  
Fax: (508) 230-2177
- PEGASUS DENTAL SUPPLIES, LTD.  
BOX 147  
Altrincham  
Cheshire, England  
WA15 9EB  
44-161-980-8916  
Fax: 44-161-980-5330
- PELTON & CRANE  
11727 Fruehauf Drive  
P.O. BOX 7800  
Charlotte, NC 28241  
(800) 659-6560  
(704) 588-2126  
Fax: (800) 659-7255
- PENCAR, M., & ASSOCIATES  
137-75 Geranium Avenue  
Flushing, NY 11355  
(800) 788-5781  
(718) 939-7031  
Fax: (718) 359-5782
- PENTAPURE, INC.  
150 Marie Ave. East  
West St. Paul, MN 55118-4002  
(651) 450-4913  
Fax: (651) 450-5182
- PERFECT PRESENT CO., THE  
P.O. Box 423  
Gladwyne, PA 19035  
(888) 850-1001  
(610) 642-7634  
Fax: (610) 642-7634  
<http://members.aol.com/perfectpres/index.html>
- PERIOGIENE  
3188 Airway Avenue #K2  
Costa Mesa, CA 92626  
(800) 368-5776  
(714) 662-3300  
Fax: (888) 368-4787  
[woodall@webaccess.net](mailto:woodall@webaccess.net)
- PERIO-MONITOR SYSTEMS  
c/o Dr. Lawrence Snow  
372 Central Park West  
New York, NY 10025  
(212) 663-8270  
Fax: (212) 663-2270
- PERIO REPORTS  
P.O. Box 30367  
Flagstaff, AZ 86003-0367  
(800) 374-4290  
(520) 526-2523  
Fax: (520) 526-0852
- PERIOSCOPE ENTERPRISES, INC.  
686 CatalinaWay  
Los Altos, CA 94022  
(650) 949-5449  
Fax: (650) 949-5449
- PERLINK USA, INC.  
321 Ellis Street  
New Britain, CT 06051  
(800) 874-0120  
(860) 223-8882  
Fax: (860) 223-5941  
R-Kahwar@Worldnet.att.net
- PERSON & COVEY, INC.  
616 Allen Avenue  
P.O. Box 25018  
Glendale, CA 91221-5018  
(800) 423-2341  
(818) 240-1030  
Fax: (818) 547-9821
- PFINGST & Co., INC.  
105 Snyder Road  
P.O. Box 377  
South Plainfield, NJ 07080-0377  
(908) 561-6400  
Fax: (908) 561-3213
- PFIZER, INC.  
Consumer Health Care Group  
235 East 42nd Street  
New York, NY 10017-5755  
(800) 533-4535  
(212) 573-3312  
Fax: (212) 573-3894  
[www.pfizer.com](http://www.pfizer.com)
- PHARMASCIENCE LABORATORIES, INC.  
175 Rano Street  
Buffalo, NY 14207  
(800) 207-4477  
(716) 871-9376  
Fax: (716) 871-3415  
[dgdavis@pharmascience.com](mailto:dgdavis@pharmascience.com)

- PHB, INC.  
N 48862  
US Highway 53  
Osseo, WI 54758  
(800) 553-1440  
(715) 597-3935  
Fax: (715) 597-3802  
[info@phblnc.com](mailto:info@phblnc.com)
- PHOTOMED INTERNATIONAL  
15500 Erwin Street, Suite 1021  
Van Nuys, CA 91411  
(800) 998-7765  
(818) 908-5369  
Fax: (818) 908-5370  
photomed@earthlink.net
- PIBL  
1321 North Vermont Avenue,  
Suite A  
Los Angeles, CA 90027  
(800) 255-4425  
(213) 663-8906  
Fax: (626) 744-9884
- PILLG-BEANS  
(See Design 2000)
- PINNACLE PRODUCTS, INC.  
21401 Hemlock Avenue  
Lakeville, MN 55044-8489  
(800) 878-3902  
(612) 469-2445  
Fax: (612) 469-5482
- PLAK SMACKER, INC.  
4105 Indus Way  
Riverside, CA 92503  
(800) 228-9021  
(909) 734-3333  
Fax: (909) 734-4750  
www.pe.net/~plaky
- PLANDENT AB  
Box 134  
127 23 Skarholmen  
Sweden  
46-8-97-9730  
Fax: 46-8-88-5597
- PLANMECA, INC.  
362 Balm Court  
Wood Dale, IL 60191-1273  
(630) 595-7077  
Fax: (630) 595-7135
- PLASTIDONICS, INC.  
1032 South Linden Road  
Flint, MI 48532  
(810) 733-8211  
Fax: (810) 230-2523
- PLATINUM INTERACTIVE EDUCATION  
SYSTEMS, LTD.  
34250 Hazlewood Avenue #26  
Abbotsford, B.C. V2S 7L4  
Canada  
(800) 853-0898  
(604) 556-0467  
Fax: (604) 556-0487  
[www.the-professor.ca](http://www.the-professor.ca)
- PLS & SMILE VISION  
125 Walnut Street  
Watertown, MA 02172  
(800) 634-3480  
(617) 923-9616  
Fax: (617) 924-8163  
prolab@shore.net
- PM GLOVES, INC.  
13808 Magnolia Avenue  
Chino, CA 91710  
(800) 788-9486  
(909) 465-9188  
Fax: (909) 465-0028  
[alin1688@cnai.com](mailto:alin1688@cnai.com)
- POLAROID CORPORATION  
575 Technology Square, 4th  
Floor  
Cambridge, MA 02139  
(800) 343-5000  
(617) 386-2000  
Fax: (617) 386-6266
- POLLARD DENTAL PRODUCTS  
755 Lakefield Road, Unit K  
WestLake Village, CA 91361  
(800) 235-1849  
(805) 495-5222  
Fax: (805) 379-3273  
[email@pollard-dental.com](mailto:email@pollard-dental.com)
- POLTECO, INC.  
23595 Cabot Blvd. Ste. #110  
Hayward, CA 94545  
(800) 830-4849  
(510) 887-8122  
Fax: (510) 887-8418
- POLYDENTIA SA  
Strada Cantonale  
CH-6805 Mezzovico  
Switzerland  
41-91-946-2948  
Fax: 41-91-946-3203  
[info@polydentia.com](mailto:info@polydentia.com)
- POLYGENEX INTERNATIONAL, INC.  
PO. Box 4468  
Cary, NC 27519-4468  
(919) 380-8100  
Fax: (919) 380-8115
- POLY-MED MEDICAL SUPPLY  
801 11th Street  
Lakeport, CA 95453  
(800) 432-9633  
(707) 263-7734  
Fax: (707) 263-7722
- POLY OPTICS  
18 Harvard Terrace  
West Orange, NJ 07052  
(973) 669-3799  
Fax: (973) 669-3799
- PORTER INSTRUMENT CO., INC.  
245 Township Line Road  
P.O. Box 907  
Hatfield, PA 19440-0907  
(215) 723-4000  
Fax: (215) 723-5106  
picodentals@enter.net
- PORT-GH** DENTAL LABORATORIES  
150A Liverpool Street  
Sydney, Australia 2010  
61-2-9360-6605  
61-2-9361-3228
- POSCA BROTHERS' LABORATORY,  
INC.  
641 West Willow Street  
Long Beach, CA 90806  
(800) 338-1811  
(562) 427-1811  
Fax: (562) 595-5821
- POWEREX  
150 Production Drive  
Harrison, OH 45030  
(888) 769-7979  
(513) 367-3121  
Fax: (513) 367-3125
- POWER PRODUCTS, INC.  
101 North Clayview Drive,  
Suite D  
Liberty, MO 64068  
(800) 831-7245  
(816) 792-0865  
Fax: (816) 792-2400  
[ppi@gpi.com](mailto:ppi@gpi.com)
- POWERS DENTAL & MEDICAL TECH.  
1855 Waldorf Northwest  
Grand Rapids, MI 49544  
(888) 825-8392  
(616) 791-4733  
Fax: (616) 791-1055
- PRACTICAL CLINICAL COURSES,  
INC.  
3707 North Canyon Road,  
Suite 3D  
Provo, UT 84604  
(800) 223-6569  
(801) 226-6569  
Fax: (801) 226-8637
- PRACTICE OUTLOOK, INC.  
11070 North 24th Avenue,  
Suite 101  
Phoenix, AZ 85029-4751  
(800) 247-6173  
(602) 861-9972  
Fax: (602) 943-5866  
[hotline@practiceoutlook.com](mailto:hotline@practiceoutlook.com)
- PRACTICEWORKS  
A Zila Company  
11291 Sunrise Park Drive  
Rancho Cordova, CA 95742  
(800) 800-9511  
(916) 638-1945  
Fax: (916) 638-8218  
[www.practiceworks.com](http://www.practiceworks.com)
- PRACTICON, INC.  
1112 Bugg Parkway  
Greenville, NC 27834  
(800) 959-9505  
(919) 752-5183  
Fax: (919) 752-2439  
[ccr@practicidental.com](mailto:ccr@practicidental.com)
- PRD CONSULT, LTD.  
(See Pacific Rim Dental)
- PREAT CORPORATION  
1120 7th Avenue  
San Mateo, CA 94402  
(800) 232-7732  
(650) 342-5700  
Fax: (650) 342-5233
- PRECISE DENTAL DEVICES  
P.O. Box 890245  
Houston, TX 77289-0245  
(888) 453-9017  
(409) 938-3064  
Fax: (409) 938-3069  
precisedd@kni.net
- PREMIER DENTAL PRODUCTS, CO.  
3600 Horizon Drive  
P.O. Box 61574  
King of Prussia, PA 19406-0974  
(888) 773-6872  
(610) 239-6000  
Fax: (610) 239-6171  
[www.premusa.com](http://www.premusa.com)
- PREMIER LASER SYSTEMS, INC.  
3 Morgan  
Irvine, CA 92618  
(800) 544-8044  
(949) 859-0656  
Fax: (949) 951-7218  
[www.premierlaser.com](http://www.premierlaser.com)
- PREMIER MARKETING  
INTERNATIONAL, INC.  
209 East Washington Street  
Burlington, WI 53105  
(800) 771-8366  
(414) 767-9050  
Fax: (414) 767-9055
- PREP TECHNOLOGY CORP.  
43204 Christy Street  
Fremont, CA 94538  
(510) 440-8800  
Fax: (510) 440-8797  
[www.preptechnology.com](http://www.preptechnology.com)
- PREVENTECH  
1207 Crews Road, Suite C  
Matthews, NC 28105  
(800) 474-8681  
(704) 849-2416  
Fax: (704) 849-2417
- PREVENTION HEALTH PRODUCTS  
293 Route 100  
Mill Pond Offices, Suite 209  
Somers, NY 10589  
(800) 858-6668  
(914) 277-8899  
Fax: (914) 277-8935
- PREVENTION LABORATORIES  
1 South Vine  
Harrisburg, IL, 62946  
(800) 473-1205  
(618) 252-6922  
Fax: (618) 252-2846
- PREVENTIVE CARE, INC.  
915 Blue Gentian Road, Suite 1  
Eagan, MN 55121  
(800) 998-2002  
(612) 452-3648  
Fax: (612) 452-3877  
preventive.care@internetmci.com
- PREVENTIVE DENTAL  
1 Elkay Drive, Suite 5  
Chester, NY 10918  
(800) 448-5089  
(914) 469-4868  
Fax: (914) 469-4854
- PREVEST, INC.  
23420 Lakeland Boulevard  
Cleveland, OH 44132  
(S00) 526-1725  
(216) 731-6800  
Fax: (216) 731-6806  
[www.prevest.com](http://www.prevest.com)
- PRICE BUSTERS  
401 East Lake Street  
Wayzata, MN 55391  
(800) 813-6435  
(612) 476-0940  
Fax: (612) 476-0624
- PRIDE INSTITUTE  
300 Drakes Landing, Suite 200  
Greenbrae, CA 94904  
(800) 925-2600  
(415) 461-5200  
Fax: (415) 461-5275  
[www.prideinstitute.com](http://www.prideinstitute.com)
- PRIMA BOOKS AB  
Sputvagen 11  
SE-772 32 Grangesberg  
Sweden  
0240-23660  
Fax: 0240-23037
- PRINCETON PMC  
(See Wisdom Oral Care)
- PRISM TECHNOLOGIES  
6952 Fair Grounds Parkway  
San Antonio, TX 78238  
(800) 432-8722  
(210) 520-8051  
Fax: (210) 520-8039
- PROCTER & GAMBLE  
2 Procter & Gamble Plaza  
Cincinnati, OH 45202  
(800) 447-4865  
Fax: (513) 983-2163  
[pgdental@hms-partners.com](mailto:pgdental@hms-partners.com)
- PRODENT-X INT'L  
13915 Northwest 3rd Court  
Vancouver, WA 98685  
(800) 252-5863  
(360) 576-4444  
Fax: (360) 576-9828
- PRO-DENTEC  
633 Lawrence Street  
P.O. Box 3889  
Batesville, AR 72501  
(800) 228-5595  
(870) 698-2300  
Fax: (870) 793-5554
- PRODONTA SA MICRO-MEGA  
ExpORT  
Rue de la Mairie 3  
P.O. Box 6209  
1211 Geneva 6, Switzerland  
41-22-735-8760  
Fax: 41-22-786-3887  
[prodonta@worldcom.ch](http://prodonta@worldcom.ch)
- PRODUCTIONS WEST  
511 North Webster Street  
Naperville, IL 60563  
(630) 357-4703
- PRODUCTIVITY TRAINING CORP.  
15900 Concord Circle, Unit 1  
Morgan Hill, CA 95037  
(800) 448-8855  
(408) 776-0433  
Fax: (408) 776-0145  
[ptc@nesson.com](mailto:ptc@nesson.com)
- PROFESSIONAL DENTAL SUPPLIES  
DTY LTD  
Unit 3/8 Nicole Close  
N1# Bayswater  
Victoria, Australia 3153  
61-3-9761-6615  
Fax: 61-3-9730-1073
- PROFESSIONAL DENTAL SUPPLY  
(See Exacta Dental Products)
- PROFESSIONAL DEVELOPMENT  
CORP.  
30003 Southfield Road  
Southfield, MI 48076  
(800) 964-0964  
(248) 646-2273  
Fax: (248) 646-2434
- PROFESSIONAL DISPOSABLES, INC.  
Two Nice-Pak Park  
Orangeburg, NY 10962-1376  
(800) 444-6725  
(914) 365-1700  
Fax: (914) 398-3024  
[www.pripdi.com](http://www.pripdi.com)
- PROFESSIONAL DISTRIBUTION  
SYSTEMS, INC.  
250 International Parkway,  
Suite 200  
Heathrow, FL 32746  
(888) 737-7225  
(407) 829-2000  
Fax: (407) 829-2222
- PROFESSIONAL MANUFACTURING  
CORP.  
475 Brook Avenue  
Deer Park, NY 11729  
(516) 586-2440  
Fax: (516) 586-2443
- PROFESSIONAL POSITIONERS, INC.  
2525 Three Mile Road  
Racine, WI 53404-1328  
(800) 742-6640  
(414) 639-8617  
Fax: (414) 639-0190  
[prolab@exacpc.com](mailto:prolab@exacpc.com)
- PROFESSIONAL QUALITY AIR  
SYSTEMS  
3655-A Old Court Road, Suite 9  
Pikesville, MD 21208  
(410) 484-2583  
Fax: (410) 484-6606

- PROFESSIONAL RESULTS, INC.  
17 Phaedra  
Laguna Niguel, CA 92677  
(800) 350-3705  
(949) 249-3705  
Fax: (949) 249-2705
- PROFESSIONAL STERILE SYSTEMS  
P.O. Box 1480  
Lawrenceville, GA 30046  
(800) 886-7257  
(770) 962-2425  
Fax: (770) 962-2391
- PROFESSIONAL SUCCESS INSTITUTE  
North Scottsdale Family Dental  
9070 E Desert Cove, Suite 105  
Scottsdale, AZ 85260  
(602) 483-8822  
Fax: (602) 614-1122
- PROFITFINDER  
401 East Lake Street  
Wayzata, MN 55391-1610  
(800) 443-5095  
(612) 476-0362  
Fax: (612) 476-0624  
[www.profitfinder.com](http://www.profitfinder.com)
- PROFRESHINTERNATIONAL CORP.  
1801 Pine Street  
Philadelphia, PA 19103  
(800) 210-2110  
(215) 985-4985  
Fax: (215) 629-1347  
[profreshl@aol.com](mailto:profreshl@aol.com)
- PROMA, INC.  
751 East Kingshill Place  
Carson, CA 90746  
(800) 447-4624  
(310) 327-0035  
Fax: (310) 327-4601
- PRO ORTHODONTIC LABORATORY  
2525 Three Mile Road  
Racine, WI 53404-1328  
(800) 742-6640  
(414) 639-8617  
Fax: (414) 639-0190
- PROPHY PATCH, U.S.A.  
2713 Prince Circle  
Tuscaloosa, AL 35401  
(800) 344-3862  
(205) 758-5982  
Fax: (205) 348-9062
- PROPHY PERFECT, INC.  
1605 South Farwell  
Eau Claire, WI 54701  
(800) 776-3948  
(715) 838-0813  
Fax: (715) 836-7622
- PRO-SAFE PROFESSIONAL LINENS,  
INC.  
1240 Pitkin Avenue  
Grand Junction, CO 81501  
(888) 881-4497  
(970) 245-7870  
Fax: (970) 244-2955  
[prosafe@gj.net](mailto:prosafe@gj.net)
- PROSTHODONTICS INTERMEDICA  
Institute for Facial Esthetics  
467 Pennsylvania Avenue,  
Suite 201  
Fort Washington, PA 19034  
(800) 748-3265  
(215) 646-6334  
Fax: (215) 643-1149  
[piteam@aol.com](mailto:piteam@aol.com)
- PROTECH PROFESSIONAL PROD.,  
INC.  
6421 Congress Avenue, Suite  
102  
Boca Raton, FL 33487  
(800) 872-8898  
**(561) 241-0400**  
Fax: (561) 241-2858  
[protech@ix.netcom.com](mailto:protech@ix.netcom.com)
- PRO-TEX INTERNATIONAL INC.  
5038 Salida Boulevard  
P.O. Box 1038  
Salida, CA 95368-1038  
(209) 545-1691  
Fax: (209) 545-3533
- PROVIDENCE DENTAL PRODUCTS  
10020 Main Street, Suite 387  
Bellevue, WA 98004  
(253) 735-6050  
Fax upon request
- PROVISION DENTAL SYSTEMS INC.  
203 Bryant St. Suite 3  
Palo Alto, California 94301-1404  
**(888) 883-3947**  
(650) 322-3005  
Fax: (650) 322-2313
- PSI DENTAL MATERIALS  
1241 Appian Way  
P.O. Box 464300  
Lawrenceville, GA 30042-0300  
(800) 443-5459  
(770) 995-1615  
Fax: (770) 277-9010  
[psidental@aol.com](mailto:psidental@aol.com)
- PULPDENT CORPORATION  
80 Oakland Street  
PO. Box 780  
Watertown, MA 02471-0780  
(800) 343-4342  
(617) 926-6666  
Fax: (617) 926-6262  
[pulpdent@worldnet.att.net](mailto:pulpdent@worldnet.att.net)
- PULSE INNOVATIONS, INC.  
P.O. Box 520  
King City, Ontario L7B 1A7  
Canada  
(905) 833-5122  
Fax: (905) 833-5439
- PURE ALLOY LABORATORIES, INC.  
3035 47th Street  
Boulder, CO 80301  
(800) 950-1399  
(303) 443-1399  
Fax: (303) 448-9928
- PURE BRUSH  
(See Murdock Laboratories)
- PURE COMPANY  
2045 Preisker Lane  
Santa Maria, CA 93454  
(888) 922-1497  
(805) 922-1497  
Fax: (805) 922-2870
- PUREMAX  
237 Old River Road  
Wilkes-Barre, PA 18702  
(800) 877-5359  
(717) 821-0494  
Fax: (717) 823-0453
- PYMDENT NOMINEES  
(See Victory Mouthguards)
- PYRAMID, INC.  
P.O. Box 200  
Newton, IA 50208  
(515) 792-2405  
Fax: (515) 792-2478  
[pyramid@netins.net](mailto:pyramid@netins.net)
- Q & B FOODS  
15547 First Street  
Iwindale, CA 91706  
(800) 423-4505  
(626) 334-8090  
Fax: (626) 969-1587
- QUALITY ASPIRATORS  
P.O. Box 382120  
Duncanville, TX 75138-2120  
(800) 858-2121  
(972) 298-2669  
Fax: (972) 298-6592  
[qa@onramp.net](mailto:qa@onramp.net)
- QUALITY LATEX PRODUCTS, INC.  
P.O. Box 3273  
Terre Haute, IN 47803  
(800) 292-3273  
(812) 235-2122
- QUALITY SYSTEMS, INC.  
17822 East 17th Street, Suite  
210  
Tustin, CA 92780  
(800) 888-7955  
(714) 731-7171  
Fax: (714) 731-9494  
[www.qsiii.com](http://www.qsiii.com)
- QUANTUM COMMUNICATIONS  
INTERNATIONAL  
4165 Silverton Road NE  
Salem, OR 97305  
(800) 995-2666  
(503) 588-3144  
Fax: (503) 531-0763
- QUANTUM LABS, INC.  
9851 13th Avenue North  
Minneapolis, MN 55441  
(800) 328-8213  
(612) 545-1984  
Fax: (612) 545-7613  
[gloves@quantumlabs.com](mailto:gloves@quantumlabs.com)
- QUEST CAPITAL PARTNERS INC.  
9850 Federal Blvd. #97  
Denver, CO 80221  
(303) 465-2457  
Fax: (303) 465-4140
- QUINTESSENCE PUBLISHING co.,  
INC.  
551 North Kimberly Drive  
Carol Stream, IL 60188-1881  
(800) 621-0387  
(630) 682-3223  
Fax: (630) 682-3288  
[quinpub@aol.com](mailto:quinpub@aol.com)
- RADIX CORP.  
922 Benton Drive  
Iowa City, IA 52246  
(319) 354-3042
- RAINTREE Esslx  
1069 S. Jefferson Davis Park-  
way  
New Orleans, LA 70125  
(800) 883-8733  
(504) 488-0080  
Fax: (504) 488-2429
- RAMVAC CORP.  
3100 First Avenue  
Spearfish, SD 57783  
(800) 572-6822  
(605) 642-4614  
Fax: (605) 642-3776  
[ramvac@ramvac.com](mailto:ramvac@ramvac.com)
- RAND, J.R., CORP.  
100-South East Jeffryn Boule-  
vard  
Deer Park, NY 11729  
(800) 526-7111  
(516) 253-0101  
Fax: (516) 253-0505
- RAY DENTAL LAB, INC.  
807 7th Street  
P.O. BOX 8132  
Rapid City, SD 57709  
(605) 348-5620  
[rdllnc@uno.com](http://rdllnc@uno.com)
- RAYTHEON COMMERCIAL LAUNDRY  
LLC  
Shepherd Street  
P.O. Box 990  
Ripon, WI 54971-0990  
(920) 748-3121  
Fax: (920) 748-4429
- RAZZANO & ASSOCIATES  
P.O. Box 669605  
Marietta, GA 30066-0111  
(770) 591-1555  
Fax: (770) 591-1705  
[mrazzurano@aol.com](mailto:mrazzurano@aol.com)
- R & C PROBRANOS  
1655 Valley Rd.  
Wayne, NJ 07470  
(800) 677-9218  
(973) 633-3600  
Fax: **(973) 633-4816**
- REBEC  
18921 Dellwood Drive  
Edmonds, WA 98026  
(800) 569-1088  
(425) 776-0723  
Fax: (800) 964-1412  
[rebecsys@cmc.net](mailto:rebecsys@cmc.net)
- RECIGNO LABORATORIES, INC.  
519 Davisville Road  
Willow Grove, PA 19090  
(800) 523-2304  
(215) 659-7755  
Fax: (215) 657-1505
- RECKITT & COLMAN, INC.  
1655 Valley Rd.  
Wayne, NJ 07470  
(800) 333-3899  
(973) 633-3600  
Fax: (760) 781-3330
- RECD-DENT INTERNATIONAL co.,  
LTD.  
4F, No. 5, Pa De Street  
Su Lin Town  
Taipei Hsien  
Taiwan ROC  
886-2-26877227  
Fax: 88-2-26851390
- RECSEI LABORATORIES  
330 South Kellogg  
Building M  
Goleta, CA 93117  
(805) 964-2912
- REDDI-PRODUCTS co.  
5250 Merrick Road  
Massapequa, NY 11758  
(516) 541-0900  
Fax: (516) 541-0913
- REDWOOD DENTAL SUPPLY  
23920 Walling Road  
Geyserville, CA 95441  
(707) 433-7141  
Fax: (707) 894-5586
- REFLEX TECHNOLOGY  
12565 Palm Rd. Suite B  
Miami, FL 33181-2611  
(800) 330-7846  
(305) 891-8367  
Fax: (305) 895-9095  
[www.dec.res.com](http://www.dec.res.com)
- REXAM MEDICAL SYSTEMS  
Regementsvagen 5  
S-852 38, Sundsvall,  
Sweden  
46-60-15-8045  
Fax: 46-60-61-0808  
[market@regam.se](mailto:market@regam.se)
- REGENCY DIAMOND COMPANY  
P.O. Box 19948  
Houston, TX 77224  
(713) 783-9200  
Fax: (713) 789-8899
- REGENT LABS, INC.  
700 West Hillsboro Boulevard,  
Building 2, Suite 206  
Deerfield Beach, FL 33441  
(800) 872-1525  
(954) 426-4403  
Fax: (954) 426-8535
- REGENT MEDICAL  
A division of London Interna-  
tional Group, Inc.  
3585 Engineering Drive, Suite  
200  
Norcross, Georgia 30092  
(800) 843-8497  
(770) 582-2222  
Fax: (770) 582-2228  
[info@regentmedical.com](mailto:info@regentmedical.com)
- REGENT MEDICAL ENGLAND  
London International House  
Turnford Place  
Brombourne Herts EN 10 6LN  
England  
44-1992-451111  
Fax: 44-1992-450742  
[www.regentmedical.co.uk](http://www.regentmedical.co.uk)
- REINFORCED POLYMERS, INC.  
4047 Okeechobee Blvd.  
Suite 219-220  
West Palm Beach, FL 33409  
(561) 640-7600  
Fax: (561) 881-7589
- RELATIONSHIP FACTORI, THE  
520 Cathedral Parkway  
New York, NY 10025-2072  
(888) 809-8997  
(212) 749-0600  
Fax: (212) 222-4248  
[Mansky@fnet.net](mailto:Mansky@fnet.net)
- RELIANCE ORTHODONTIC  
PRODUCTS  
P.O. Box 678  
Itasca, IL 60143  
(800) 323-4348  
(630) 773-4009  
Fax: (630) 250-7704  
[www.paulgropl.com](http://www.paulgropl.com)
- REMEDENT USA, INC.  
1220 Birch Way  
Escondido CA 92027  
(800) 871-7426  
(760) 781-3333  
Fax: (760) 781-3330  
[www.remedent.com](http://www.remedent.com)
- REM PUBLISHING  
5735 Oakle Street  
Las Vegas, NV 89102  
(702) 227-8656
- RESEARCH INFORMATION SERVICES  
One Raleigh Road  
Marshfield, MA 02050  
(800) 235-6646 ext. 615  
(781) 834-6199  
Fax: (781) 834-6199
- RESTORATIVE TECHNICS DIVISION  
73 Dalton Road, Suite B  
Holliston, MA 01746  
(508) 429-7225  
Fax: (508) 429-7306
- REXAM MEDICAL PACKAGING, INC.  
1919 South Butterfield  
Mundelein, IL 60060  
(847) 918-4293  
Fax: (847) 918-4600  
[mark\\_heiss@rexam.com](mailto:mark_heiss@rexam.com)
- REXAM MEDICAL PACKAGING LTD  
Moresby Parks, Whitehaven  
Cumbria CA28 8YD  
England  
**44-1946-66444**  
Fax: 44-1946-66445

- RGP DENTAL  
22 Burnside Street  
Bristol, RI 02809  
(800) 522-9695  
(401) 254-9695  
Fax: (401) 254-0157  
[www.rgp dental.com](http://www.rgp dental.com)
- RIBBOND, INC.  
1402 Third Avenue, Suite 1030  
Seattle, WA 98101-2118  
(800) 624-4554  
(206) 340-8870  
Fax: (206) 382-9354  
[ribbond@ribbond.com](mailto:ribbond@ribbond.com)
- RICHLUND SALES  
75695 Highway 1053  
Kentwood, LA 70444  
(504) 229-4922  
Fax: (504) 229-4956  
[www.dentalwash.com](http://www.dentalwash.com)
- RICHMOND DENTAL CO.  
1100 Hawthorne Lane  
P.O. Box 34276  
Charlotte, NC 28234-9912  
(800) 277-0377  
(704) 376-0380  
Fax: (704) 342-1892  
[DMC.mkt@worldnet.att.net](mailto:DMC.mkt@worldnet.att.net)
- RMO, INC.  
P.O. Box 17085  
Department 394  
Denver, CO 80291-0394  
(800) 525-6375  
(303) 592-8200  
Fax: (303) 592-8209
- ROBELL RESEARCH, INC.  
635 Madison Avenue  
New York, NY 10022  
(800) 550-6510  
(212) 755-6577  
Fax: (212) 755-3263
- ROCKY MOUNTAIN ORTHODONTICS  
P.O. Box 17085  
Denver, CO 80217-0085  
(800) 525-6375  
(303) 592-8200  
Fax: (303) 592-8209
- RODE, CHAS W., INC.  
R.O. Box 1238  
San Clemente, CA 92674-1238  
(714) 492-3524  
Fax: (714) 492-2378
- ROEKO GMBH + Co.  
Raiffeisenstr. 30 (PLZ 89129)  
P.O. Box 1150  
D-89122 Langenau  
Germany  
49-7345-8050  
Fax: 49-7345-805201
- ROEKO USA, INC.  
835 Meridian Street  
Durate, CA 91010  
(626) 256-0411  
Fax: (626) 256-0422
- RONVIG A/S  
Gl. Vejlevej 57-59  
DK-8721 Daugaard  
Denmark  
45-75-89-57-11  
Fax: 45-75-89-57-44  
[export@ronvig.com](mailto:export@ronvig.com)
- RONVIG DENTAL PRODUCTS, INC.  
5283 Cribari Heights  
San Jose, CA 95135  
(800) 270-9566  
(408) 366-2044  
Fax: (408) 270-9904  
[export@ronvig.com](mailto:export@ronvig.com)
- ROSCO LABORATORIES  
52 Harbor View Avenue  
Stamford, CT 06902  
(800) 767-2669  
(203) 708-8900  
Fax: (203) 708-8919  
[www.rosco.co.uk](http://www.rosco.co.uk)
- Ross ORTHODONTIC  
880 Eastgate Drive  
P.O. Box 882  
Midlothian, TX 76065  
(800) 247-4109  
(972) 775-8757  
Fax: (972) 775-8758  
[rossortho@worldnet.att.net](mailto:rossortho@worldnet.att.net)
- ROTH INTERNATIONAL, LTD.  
669 West Ohio Street  
Chicago, IL 60610  
(800) 445-0572  
(312) 733-1478  
Fax: (312) 733-7398  
[www.rothendo.com](http://www.rothendo.com)
- ROWENTA, INC.  
**196 Boston Avenue**  
Medford, MA 02155  
(781) 396-0600  
Fax: (781) 396-1313
- ROWLAND CO., THE  
1675 Broadway  
New York, NY 10019  
(212) 527-8800  
Fax: (212) 527-8989
- RowPAR PHARMACEUTICALS, INC.  
7720 East Evans, Suite 208  
Scottsdale, AZ 85260  
(800) 643-3337  
(602) 948-6997  
Fax: (602) 948-5918  
[rowparl@worldnet.att.net](mailto:rowparl@worldnet.att.net)
- ROXBURY, INC.  
**(See Jordan International)**
- ROYAL DENTAL MANUFACTURING  
INC.  
12414 Highway 99, Unit 29  
Everett, WA 98204  
(800) 275-0988  
(425) 743-0988  
Fax: (425) 743-3588
- ROYDENT DENTAL PRODUCTS, INC.  
1010 West Hamlin Road  
Rochester Hills, MI 48309  
(800) 992-7767  
(248) 652-2500  
Fax: (248) 652-2505  
[www.roydent.com](http://www.roydent.com)
- RUTHAL INDUSTRIES, LTD.  
31 Industrial Avenue  
Mahwah, NJ 07430  
(800) 445-6640  
(516) 493-0200  
Fax: (516) 543-0777
- FIX HONING MACHINE  
CORPORATION  
1301 East Fifth Street  
Mishawaka, IN 46544  
(800) 346-6464  
(219) 259-1606  
Fax: (219) 259-9163  
[fxhoning@datacruz.com](mailto:fxhoning@datacruz.com)
- SABRA- THE DENTAL PRODUCTS  
GROUP  
7642 North Kolmar  
Skokie, IL 60076-3744  
(800) 537-2272  
(847) 675-8718  
Fax: (847) 675-8722  
[hdape@ol.com](mailto:hdape@ol.com)
- SAFECO DENTAL SUPPLY CO.  
527 South Jefferson Street  
Chicago, IL 60607  
(800) 621-2178  
(312) 922-8118  
Fax: (312) 922-5577
- SAFELINK  
2986 Johnson Ferry Road,  
Suite C-201  
Marietta, GA 30062  
(800) 330-6003  
(770) 518-8790  
Fax: (770) 518-7929
- SAFESKIN CORPORATION  
Del Mar Corporate Plaza  
12671 High Bluff Drive  
San Diego, CA 92130  
(800) 462-9993  
(619) 794-8111  
Fax: (619) 250-2378
- SAFETY SYRINGES, INC.  
1715 South Freeman  
Oceanside, CA 92054  
(760) 439-5582  
Fax: (760) 439-5301  
[candreaaron@safetysyringes.com](mailto:candreaaron@safetysyringes.com)
- SAFWARE INC.  
9475 Lottsford Road, Suite 150  
Largo, MD 20774  
(888) 331-6707  
(301) 925-1234  
Fax: (301) 925-2060  
[patrick649@aol.com](mailto:patrick649@aol.com)
- SAFE-WAVE PRODUCTS, INC.  
460 Sovereign Court  
Ballwin, MO 63011-4432  
(800) 767-8477  
(314) 230-3660  
Fax: (314) 527-9005
- SALVIN DENTAL SPECIALTIES  
500-H Clanton Road  
Charlotte, NC 28217  
(800) **535-6566**  
(704) 522-9960  
Fax: (704) 522-9961  
[www.salvin.com](http://www.salvin.com)
- SANDIKA PHARMACEUTICALS, PVT  
LTD.  
40 DDA SFS Flats Niti Bagh  
Khel Gaon Marg  
New Delhi 110049  
India  
91-11-686-8177  
Fax: 91-11-651-9620  
[drugs@del2vsninet.in](mailto:drugs@del2vsninet.in)
- SANTA BARBARA MEDCO, INC.  
6483 Calle Real, Suite C  
GOLleta, CA 93117  
(800) 346-3326  
(805) 683-1486  
Fax: (805) 683-4864  
[sbmedco@silcom.com](mailto:sbmedco@silcom.com)
- SARGON DENTAL IMPLANTS  
260 South Beverly Drive, 2nd  
Floor  
Beverly Hills, CA 90212  
(800) 641-2905  
(310) 777-0391  
Fax: (310) 777-0410
- SATELEC  
Z.I. Du Phar  
BP 216  
33708 Merignac, Cedex  
France  
33 556 340607  
Fax: 33 556 349292
- SAVAGE LABORATORIES  
60 Baylis Road  
Melville, NY 11747  
(800) 231-0206  
(516) 454-7677  
Fax: (516) 454-0732  
[www.fougera.com](http://www.fougera.com)
- SAV-A LIFE SYSTEMS, INC.  
550 Frontage Road, Suite 2620  
Northfield, IL 60093  
(800) 933-5885  
(847) 441-5290  
Fax: (847) 441-5293
- SAVOGRAN  
259 Lenox Street  
P.O. Box 130  
Norwood, MA 02062  
(800) 225-9872  
(617) 762-5400  
Fax: (617) 762-1095
- SCANDINAVIA NATURAL HEALTH &  
BEAUTY PRODUCTS, INC.  
13 North 7th Street  
Perkasie, PA 18944  
(800) 288-2844  
(215) 453-2505  
Fax: (215) 453-2508  
[HEALTH@SALIX.com](http://HEALTH@SALIX.com)
- SCHEIN  
(See Henry Schein)
- SCHICK TECHNOLOGIES  
31-00 47th Avenue  
Long Island City, NY 11101  
(888) 472-4425  
(718) 937-5765  
Fax: (718) 937-5962  
[www.schicktech.com](http://www.schicktech.com)
- SCHUTZ-DENTAL GMBH  
Dieselstr.5-6  
D-61191 Roszbach  
Germany  
49-6-003-8140  
Fax: 49-6-003-814-906
- SCHWED, CHARLES B. CO., INC.  
124-02 Metropolitan Avenue  
Kew Gardens, NY 11415  
(800) 847-4073  
(718) 441-0526  
Fax: (718) 441-4507
- SCICAN  
Division of Lux & Zwinger-  
berger Ltd.  
1440 Don Mills Road  
Toronto, Ontario M3B 3P9  
Canada  
(800) 667-7733  
(416) 445-1600  
Fax: (416) 445-2727
- SCICAN, INC. (U.S.A.)  
2002 Smallman Street  
Pittsburgh, PA 15222  
(800) 572-1211  
(412) 281-6780  
Fax: (412) 281-6841  
[www.scican.com](http://www.scican.com)
- SCIENTIFIC PHARMACEUTICALS  
3221 Producer Way  
Pomona, CA 91768  
(800) 634-3047  
(909) 595-9922  
Fax: (909) 595-0331  
[scipfarm@msn.com](mailto:scipfarm@msn.com)
- SCIENTIFIC SERVICES, INC.  
131 West Lacy Street  
Chester, SC 29706  
(803) 385-2135  
Fax: (803) 385-2137
- SCITECH DENTAL INC.  
562 1st Avenue South, Suite  
700  
Seattle, WA 98104  
(800) 524-6984  
(206) 382-0880  
Fax: (206) 382-0823  
[www.scitechdental.com](http://www.scitechdental.com)
- SCM MEDICAL  
P.O. Box 3855  
Cherry Hill, NJ 08034  
(800) 338-2707  
(609) 810-0670  
Fax: (609) 810-0775
- SCORE INTERNATIONAL, INC.  
411 Central Park Drive  
Sanford, FL 32771  
(800) 726-7365  
(407) 322-3230  
Fax: (407) 330-0919  
[www.score-ez.com](http://www.score-ez.com)
- SCOTT ALL-SPORTS, INC.  
120 Professional Drive  
West Monroe, LA 71291  
(318) 322-1500  
Fax: (318) 322-9714
- SCRIB130N  
511 SW Tenth Avenue, Suite  
914  
Portland, Oregon 97205  
(800) 364-2922  
(503) 223-4775  
Fax: (503) 243-2777
- S.D.I. LABORATORIES, INC.  
10350 Dearlove Road, **Suite D**  
Glenview, IL 60025  
(800) 227-8507  
(847) 803-1880  
Fax: (847) 803-1885  
[sdillabs@uss.net](mailto:sdillabs@uss.net)
- SEAMOUNT RESEARCH  
11615 Highway 99 South,  
Suite B104  
Everett, WA 98204  
(800) 794-6522  
(425) 353-9203
- SELTZER INSTITUTE  
49 Prospect Hill Road  
Harvard, MA 01451  
(800) 229-8967  
(978) 456-9191  
Fax: (978) 456-9055  
[sseltzer@hightecheducation.com](mailto:sseltzer@hightecheducation.com)
- SENTRY MEDICAL PRODUCTS, INC.  
R.O. Box 12117  
Green Bay, WI 54307-2117  
(800) 603-1224  
(920) 337-0201  
Fax: (920) 337-0436
- SEPTODONT, INC. (CONFI-DENTAL)  
245 C. Quigley Boulevard  
New Castle, DE 19720  
(800) 872-8305  
(302) 328-1102  
Fax: (302) 328-5653
- SF DENTAL SUPPLY  
(See Dental Preferred)
- SHAFFER LABORATORIES  
1058 North Allen Avenue  
Pasadena, CA 91104  
(800) 231-6725  
(626) 798-8644  
Fax: (626) 798-0628

- SHAKLEE CORPORATION  
444 Market Street  
San Francisco, CA 94111  
(800) 742-5533  
(415) 954-3000  
Fax: (415) 954-2412
- SHAPE RITE INC.  
9850 South 300 West  
Sandy, UT 84070  
(888) 742-7374  
(801) 562-3600  
Fax: (801) 562-3611
- SHARPS COMPLIANCE INC.  
PO. Box 35495  
Houston, TX 77235-5495  
(800) 772-5657  
(713) 772-9660  
Fax: (713) 432-0555
- SHIELD GLOVES MFR. (M) SDN BHD  
87, 2nd floor, Jalan SS15/4C  
47500 Subang Jaya  
Selangor Darul  
Ehsan, Malaysia  
60-03-734-2982  
Fax: 60-03-733-4479  
[lian@tm.net.my](mailto:lian@tm.net.my)
- SHOFU DENTAL CORPORATION  
4025 Bohannon Drive  
Menlo Park, CA 94025-1096  
(800) 827-4638  
(650) 324-0085  
Fax: (650) 323-3180  
[info@shofu.com](mailto:info@shofu.com)
- SHOFU DENTAL CORP. LAB DIVISION  
10200 S.W. Nimbus Ave. Suite G2  
Portland, OR 97223-4339  
(800) 893-0833  
(503) 639-6313  
Fax: (503) 639-3630  
[jabdiv@shofu.com](mailto:jabdiv@shofu.com)
- SHOFU DENTAL GMBH  
Am Bruell 17  
40878 Ratingen  
Germany  
49-2102-86-64-10  
Fax: 49-2102-86-64-64  
[sdghh@aol.com](mailto:sdghh@aol.com)
- SHOWERFLOSS, INC.  
30930 Persimmon Place  
Estero, FL 33928  
(800) 959-3567  
(941) 947-2855  
Fax: (941) 947-2855  
[www.showerfloss.com](http://www.showerfloss.com)
- SHYWAR DENTAL SUPPLIES  
2995 Kingston Road  
Scarborough, Ontario M1M 1P1  
Canada  
(416) 265-1400  
Fax: (416) 785-7301
- SIDEKICK, INC.  
7221 West 79th  
Overland Park, KS 66204  
(800) 972-5515  
(913) 385-1411  
Fax: (913) 385-1433  
105341.3622@compuserve.com
- SIEMENS/PELTON & CRANE  
(See Pelton Crane)  
(See Sirona Dental Systems)
- SIGNALCOM SYSTEMS, INC.  
10 Rollins Road  
Millbrae, CA 94030  
(800) 733-7266  
(650) 692-1056  
Fax: (650) 692-9703  
[signalcomsystems.com](http://signalcomsystems.com)
- SILMET USA CORP.  
18968 NE 4th Court  
Miami, FL 33179  
(800) 228-4390  
(305) 651-7003  
Fax: (305) 770-0651
- SIMPLER IMPLANTS, INC.  
2370 Maple Street  
Vancouver, BC V6J 3T6  
Canada  
(BOO) 565-3559  
(604) 736-9890  
Fax: (604) 736-9747  
[simpler@intouch.bc.ca](mailto:simpler@intouch.bc.ca)
- SIMPLIFIED SYSTEMS, INC.  
4014 Chase Avenue, Suite PH  
Miami Beach, FL 33140  
(800) 888-0900  
(305) 672-7676  
Fax: (305) 531-5339
- SINTEQ DENTAL, INC.  
350 Concord Lane  
P.O. Box 129  
East Wakefield, NH 03830  
(800) 233-2162  
(603) 522-3397  
Fax: (603) 522-8624  
[sintec@worldpath.net](mailto:sintec@worldpath.net)
- SIPCO  
7236 Wilson Avenue  
Delta, BC V4G 1H3  
Canada  
(800) 565-3070  
(604) 940-9922  
Fax: (604) 940-9334
- SIRONA USA, INC.  
1200-A Westinghouse Boulevard  
Charlotte, NC 28217  
(800) 659-5977  
(704) 587-0453  
Fax: (704) 587-9394  
[www.sirona.de](http://www.sirona.de)
- SKIN + CORP. & MANUFACTURING Industrieweg 4  
2712 LB Zoetermeer  
The Netherlands  
31-79-342-1841  
Fax: 31-79-342-6371
- SKY-VISION  
2103 East Southern  
Tempe, AZ 85282  
(602) 491-1313  
Fax: (602) 491-1926
- S.L. McCLALLAN CO., INC.  
Rural Road 2, Box 201  
Eureka, IL 61530  
(309) 467-6138  
Fax: (309) 467-6138 (call first)
- SMARTPRACTICE  
3400 East McDowell  
P.O. Box 29222  
Phoenix, AZ 85008-7899  
(800) 522-0800  
(602) 225-9090  
Fax: (602) 225-0599
- SMITH COMPANIES DENTAL PRODUCTS  
4368 Enterprise Street  
Fremont, CA 94538-6305  
(800) 336-3263  
(510) 490-8999  
Fax: (510) 659-1855  
[info@smithdental.com](mailto:info@smithdental.com)
- SMITHKLINE BEECHAM  
100 Beecham Drive  
Pittsburgh, PA 15205  
(800) 245-1040  
(412) 928-1000  
Fax: (412) 928-1030
- SNORE GUARD  
(Hays & Meade Inc., DBA)  
  
SNOREX, INC.  
P.O. Box 20388  
Reno, NV 89515  
(800) 276-6739  
(510) 713-6797  
Fax: (510) 793-3582
- SOFT-CORE SYSTEM INC  
5424 Rufe Snow Drive, Suite 102  
N. Richland Hills, TX 76180  
(888) 462-8878  
(817) 427-2640  
Fax: (817) 427-2655
- SOFTECH, INC.  
28104 Orchard Lake Road,  
Suite 100  
Farmington Hills, MI 48334-3759  
(800) 233-4998  
(248) 855-6130  
Fax: (248) 855-1688  
[www.dentech-net.com](http://www.dentech-net.com)
- SOLO VAC  
922 East Edison  
PO. Box 127  
Sunnyside, WA 96944  
(888) 838-7818  
(509) 837-7818  
Fax: (509) 837-7415
- SONEX INTERNATIONAL CORP.  
Route 22,  
P.O. Box 533  
Brewster, NY 10509-0533  
(800) 633-7858  
(914) 279-7048  
Fax: (914) 279-8474
- SONIC SYSTEMS, INC.  
109 Pheasant Run  
Newtown, PA 18940  
(800) 447-6642  
(215) 968-3833  
Fax: (215) 579-1791
- SONIX IV CORPORATION  
17622 Metzler Lane  
Huntington Beach, CA 92647  
(BOO) 878-2769  
(714) 842-7622  
Fax: (714) 843-1867  
[sales@sonixiv.com](mailto:sales@sonixiv.com)
- SONY MEDICAL SYSTEMS  
Corporate Headquarters  
1 Sony Drive  
Park Ridge, NJ 07656  
(800) 535-7669  
(201) 930-1000  
Fax: (201) 358-4977  
[medical@mail.sel.sony.com](mailto:medical@mail.sel.sony.com)
- SOREDEX INC.  
200 Beach Airport Road  
Conroe, TX 77301  
(800) 235-8854  
(409) 760-3198  
Fax: (409) 760-3184  
[www.soredexusa.com](http://www.soredexusa.com)
- SOURCE DENTAL IMAGE  
(See Image F/X Software Solutions)
- SOUTH EAST INSTRUMENTS CORPORATION  
3706 Northwest 97th Boulevard  
Gainesville, FL 32606  
(BOO) 648-9445  
(352) 332-0125  
Fax: (352) 332-0186  
[seimed95@msn.com](mailto:seimed95@msn.com)
- SOUTHERN DENTAL ASSOCIATION  
P.O. Box 36972  
Birmingham, AL 35236  
(205) 985-9488  
Fax: (205) 733-1006
- SOUTHERN DENTAL INDUSTRIES, INC.  
246 1st Street, Suite 204  
San Francisco, CA 94105  
(800) 228-5166  
(415) 975-8060  
Fax: (415) 975-8065  
[sdiaus@sprynet.com](mailto:sdiaus@sprynet.com)
- SOUTHERN DENTAL INDUSTRIES, LTD.  
5-9 Brundson Street, Bayswater  
PO. Box 314  
Victoria, Australia 3153  
(800) 228-5166 (US)  
61-3-9729-9088  
Fax: 61-3-9720-2435
- SOUTHERN PACIFIC COAST CORP.  
PO. Box 4223  
Diamond Bar, CA 91765  
(626) 913-2779  
Fax: (626) 913-2358
- SOUTHLAND DISTRIBUTION & SALES  
3822 Commercial Court,  
Suite C  
Augusta, GA 30907  
(800) 880-0240  
(706) 868-0105  
Fax: (706) 650-7468  
[sdssouthland@mindspring.com](mailto:sdssouthland@mindspring.com)
- SOUTHWEST DENTAL PRODUCTS  
Two Cielo Center, Suite 300  
1250 Capital of Texas Hwy  
Austin, TX 78746  
(800) 580-2950  
(512) 329-2950  
Fax: (512) 263-1387
- SPARTAN CHEMICAL CO., INC.  
P.O. Box 110  
1110 Spartan Drive  
Maumee, OH 43537-0110  
(800) 537-8990  
(419) 897-5551  
Fax: (419) 897-9862
- SPARTAN U.S.A., INC.  
1727 Larkin Williams Road  
Fenton, MO 63026  
(800) 325-9027  
(314) 343-8300  
Fax: (314) 343-5794
- SPECIAL METALS CORPORATION  
2310 South Industrial Highway  
Ann Arbor, MI 48104  
(734) 665-0669  
Fax: (734) 665-7349
- SPECIAL PRODUCTS, INC.  
102 Western Court  
Santa Cruz, CA 95060  
(800) 538-6836  
(408) 425-0240  
Fax: (408) 425-8565  
[www.betterendo.com](http://www.betterendo.com)
- SPECTRAVU/ITC  
11501 Dublin Boulevard  
Dublin, CA 94568  
(BOO) 480-1129  
(925) 556-9550  
Fax: (925) 566-9554
- SPEED QUEEN CO.  
(See Raytheon Commercial Laundry LLC)
- SPENCER MEAD  
865 Merrick Avenue  
Westbury, NY 11590  
(800) 645-2310  
(516) 683-1800  
Fax: (516) 832-7904  
[www.darbygroup.com](http://www.darbygroup.com)
- SPINTECH, INC.  
(See Milestone)
- SPORICIDIN INTERNATIONAL  
5901 Montrose Road  
Rockville, MD 20852  
(800) 424-3733  
(301) 231-7700  
Fax: (301) 231-8165  
[info@sporicidin.com](mailto:info@sporicidin.com)
- SPRING HEALTH PRODUCTS  
705 General Washington Avenue  
Suite 701  
Norristown, PA 19403  
(800) 800-1680  
(610) 630-9171  
Fax: (610) 630-9730
- SPS MEDICAL  
6789 West Henrietta Road  
Rush, NY 14543  
(800) 722-1529  
(716) 359-0130  
Fax: (716) 359-0167
- SPS MEDICAL EQUIPMENT CO.  
(See Needle Eater Marketing Co.)
- SQUIGLE, INC.  
105 Forrest Avenue  
P.O. Box 813  
Narberth, PA 19072  
(610) 645-5556  
Fax: (610) 896-3840
- S.S. WHITE BURS, INC.  
1145 Towbin Avenue  
Lakewood, NJ 08701  
(800) 535-2877  
(732) 905-1100  
Fax: (732) 905-0987  
[staff@sswhiteburs.com](mailto:staff@sswhiteburs.com)
- STAHLER, WESTON SCIENTIFIC  
350 Heritage Avenue  
Portsmouth, NH 03801  
(800) 423-7188  
(603) 427-0662  
Fax: (603) 427-0881  
[stahler@nh.ultranet.com](mailto:stahler@nh.ultranet.com)
- STAR  
(See DentalEZ Dental Group)
- STARDENTINTERNATIONAL  
(See Interdent Inc.)
- STAR X-RAY CO., INC.  
63 Renick Drive  
Amityville, NY 11701  
(800) 374-2163  
(516) 842-3010  
Fax: (516) 842-5910
- STEINMAN SERVICES, INC.  
237 North Main Street  
Edwardsville, IL 62025  
(800) 692-0818  
(618) 692-0818  
Fax: (618) 692-0819  
[deta@lw.edwpub.com](mailto:deta@lw.edwpub.com)
- STELLI CONCEPT  
708 N. Dearborn St.  
Chicago, IL 60610  
(312) 642-3447  
Fax: (312) 642-1803  
p.pierre@interaccess.com

STEPAC L.A., LTD.  
Tefen Industrial Park  
Building 12  
Tefen, W. Galilee 24959  
Israel  
(888) 277-1470  
972-4-987-2131  
Fax: 972-4-987-2946  
[stepac@doryanet.co.il](mailto:stepac@doryanet.co.il)

STEPFLOW  
(See ITL Dental)

STEPPING STONES TO SUCCESS  
18 Club Manor Drive  
Pueblo, CO 81008  
(800) 548-2164  
(719) 545-0511  
Fax: (719) 545-3020  
[stepston@rmii.net](mailto:stepston@rmii.net)

STERAc LIMITED  
Century House  
Market Street  
Swavesey, Cambridge  
UK CB4 5QG  
44 1954 206400  
Fax: 44 123 811258

STEM-DENT CORPORATION  
1330-13 Lincoln Avenue  
Lincoln Towers  
Holbrook, NY 11741  
(800) 346-3368  
(516) 737-4646  
Fax: (516) 737-0036

STERILE DENTAL SYSTEMS, INC.  
7817 National Service Road,  
Suite 508  
Greensboro, NC 27409  
(800) 531-5883  
(910) 665-0504  
Fax: (910) 665-0212

STERILEX CORPORATION, THE  
1415 South Rolling Road  
Box 2-12  
Baltimore, MD 21227  
(800) 511-1659  
(410) 455-5500  
Fax: (410) 581-8864  
[tube.dok@aol.com](mailto:tube.dok@aol.com)

STERILIZATION CASSETTE  
SYSTEMS, INC.  
435 East Main Street, Suite A-6  
Greenwood, IN 46143  
(888) 625-4497  
(317) 865-8950  
Fax: (317) 865-8945  
[ops@sterilecassette.com](mailto:ops@sterilecassette.com)

STERILURE INTERNATIONAL, LTD.  
7127 East Becker Lane, Suite  
77  
Scottsdale, AZ 85254  
(800) 884-9760  
(602) 991-8349  
Fax: (602) 991-8137

STERIOSS, INC.  
22895 Eastpark Drive  
**Yorba Linda, CA 92887**  
(800) 322-5001  
(714) 282-4800  
Fax: (714) 998-9236  
[www.sterioss.com](http://www.sterioss.com)

STERIS CORPORATION  
5960 Heisley Road  
Mentor, OH 44060-1834  
(800) 444-9009  
(440) 354-2600  
Fax: (440) 350-7077

STERI-SHIELD PRODUCTS, INC.  
340 South Kellogg #G  
Goleta, CA 93117  
(800) 699-7220  
(805) 692-4972  
Fax: (805) 692-4992

STERNGLD IMPLAMED  
23 Frank Mossberg Drive  
P.O. Box 2967  
Attleboro, MA 02703-0967  
(800) 243-9942  
(508) 226-5660  
Fax: (508) 226-5473  
[sternglid@liac.com](mailto:sternglid@liac.com)

STER-O-LIZER MFG. CORP.  
2109 West 2300 South  
Salt Lake City, UT 84119  
(800) 973-6400  
(801) 973-6400  
Fax: (801) 973-6463  
[brinecell@cyber-west.com](mailto:brinecell@cyber-west.com)

STEUART LABORATORIES  
237 2nd Avenue NW  
P.O. Box 297  
Harmony, MN 55939  
(800) 210-9665  
(507) 886-2661  
Fax: (507) 886-2762  
[steuart@means.net](mailto:steuart@means.net)

STEVENSON DENTAL RESEARCH  
4510 Donlon Road  
P.O. Box 399  
Somis, CA 93066  
(800) 638-2721  
(805) 386-4469  
Fax: (805) 386-4472

STEVENS SKIN SOFTENER, INC.  
4401 South 500 West  
Murray, UT 84123  
(800) 678-7546  
(801) 262-4973  
Fax: (801) 264-1002

STONEGATE PUBLISHING  
552 South Trimble Road  
Mansfield, OH 44906  
(419) 756-3144  
Fax: (419) 774-9671  
[teeth@richnet.net](mailto:teeth@richnet.net)

STOOR & JACOBS, LTD. &  
ASSOCIATES  
1895 North Trekkell Road  
Casa Grande, AZ 85222  
(520) 836-8776  
Fax: (520) 426-9060

STRAUMANN COMPANY, THE  
Reservoir Place  
1601 Trapelo Road  
Waltham MA 02451  
(800) 448-8168  
(781) 890-0001  
Fax: (781) 890-6464  
[ii@straumann.com](mailto:ii@straumann.com)

STRAUSS DIAMOND INSTRUMENT,  
INC.  
63 Richmondville Avenue  
Westport, CT 06880  
(800) 982-9641  
(203) 221-1332  
Fax: (203) 226-0105

STRONG DENTAL PRODUCTS  
2725 Hidden Hills Way  
Corona, CA 91720  
(800) 648-9729  
(909) 371-5185  
Fax: (909) 371-1468  
[www.strongproducts.com](http://www.strongproducts.com)

SUCCESS DYNAMIC INC.  
11 Vanad Drive  
Roslyn, NY 11576-2538  
(516) 482-5959  
Fax: (516) 626-1340

SULCABRUSH, INC.  
4600 Wittmer Industrial Estates,  
Suite 2  
Niagara Falls, NY 14305  
(800) 387-8777  
(416) 665-0716  
Fax: (416) 665-0893  
[ira@better.net](mailto:ira@better.net)

SULLIVAN-SCHNEIN DENTAL  
PRODUCTS, INC.  
10920 West Lincoln Avenue  
West Allis, WI 53227  
(BOO) 558-5200  
(414) 321-8881  
Fax: (414) 321-5163

SULTAN CHEMISTS, INC.  
85 West Forest Avenue  
Englewood, NJ 07631  
(800) 637-8582  
(201) 871-1232  
Fax: (201) 871-0321  
[www.sultaniti.com](http://www.sultaniti.com)

SULTAN DENTAL PRODUCTS, INC.  
242 South Dean Street  
Englewood, NJ 07631  
(800) 238-6739  
(201) 894-5500  
Fax: (201) 894-1539  
[www.sultandental.com](http://www.sultandental.com)

SULZER CALCITEK, INC.  
2320 Faraday Avenue  
Carlsbad, CA 92008-7216  
(800) 854-7019  
(760) 431-9515  
Fax: (760) 431-9753

SUNBEAM-OSTER  
1501 Woodfield Road, Suite  
400 N  
Schaumburg, IL 60173  
(800) 528-7713  
(708) 995-8900  
Fax: (708) 995-8950

SUN MEDICAL CO., LTD.  
571-2 Furutaka-Cho  
Moriyama, Shiga  
524-0044 Japan  
81 77 582 9981  
Fax: 81 77 582 9984  
[sun-medical@suzuki.nifty.ne.jp](mailto:sun-medical@suzuki.nifty.ne.jp)

SUPER TOOTH PRODUCTS, INC.  
2629 Louisiana Avenue South  
Minneapolis, MN 55426  
(800) 522-7883  
(612) 926-5324  
Fax: (612) 926-6331

SURE BITE, INC.  
10611 East 74th Street South  
Tulsa, OK 74133  
(800) 834-6220  
(918) 252-2301  
Fax: (918) 252-2301

SUPER DENTAL MFG. CO., INC.  
P.O. Box 1329  
632 Cedar Street  
Chico, CA 95927  
(800) 368-8376  
(530) 893-8376  
Fax: (530) 893-0473  
[suter@dcs-chico.com](mailto:suter@dcs-chico.com)

SUZANNE BOSWELL  
PRESENTATIONS  
3767 Forest Lane, Suite 124-  
470  
Dallas, TX 75244-7100  
(972) 243-2086  
Fax: (972) 406-8738  
[BoswellPresentations.com](http://BoswellPresentations.com)

SWEETTOOTH PUBLISHING CO.  
18160 U.S. Highway 281 North,  
Suite 104  
San Antonio, TX 78232  
(210) 490-7100  
Fax: (210) 490-7100

SWING LOCK  
P.O. Box 187  
Milford, Texas 76670  
(214) 361-8263  
Fax: (972) 493-3907

SYNAPSE DENTAL INFORMATION  
SYSTEMS  
R.O. Box 882  
Perrysburg, OH 43551  
(419) 874-5419

SYNCA  
337 Marion  
Le Gardeur, Quebec  
Canada J5Z 4W8  
(800) 667-9622  
(450) 582-1093  
Fax: (450) 654-1414  
[synca@synca.com](mailto:synca@synca.com)

SYTAR SYSTEMS, INC.  
495 North University Avenue  
Suite 100  
Provo, UT 84601  
(800) 877-9827  
(406) 672-9827  
Fax: (801) 377-9684  
[sytar@aol.com](mailto:sytar@aol.com)

**T**  
T-4 PRODUCTS  
P.O. Box 3778  
Missoula, MT 59806  
(800) 409-9137  
(406) 721-4163  
Fax: (406) 721-1892  
[tp.k1@aol.com](mailto:tp.k1@aol.com)

TAGG INDUSTRIES  
23210 Dell-ago  
Laguna Hills, CA 92653  
(800) 548-3514  
(949) 770-9029  
Fax: (949) 770-3016

TAK SYSTEMS  
P.O. Box 939  
East Wareham, MA 02538  
(800) 333-9631  
(508) 295-9630  
Fax: (508) 291-3240  
[tak@capecod.net](mailto:tak@capecod.net)

TALLADIUM, INC.  
25031 Anza Drive  
Valencia, CA 91355  
(800) 221-6449  
(805) 295-0900  
Fax: (805) 295-0895  
[talladium@earthlink.net](mailto:talladium@earthlink.net)

TANAKA DENTAL PRODUCTS  
5135 Golf Road  
Skokie, IL 60077  
(800) 325-5266  
(847) 679-1610  
Fax: (847) 674-5761

TARA CROWN, INC.  
441 Stuart Street  
Boston, MA 02116  
(800) 523-8272  
(617) 236-4469  
Fax: (617) 236-4469

TAUB, GEORGE, PRODUCTS  
277 New York Avenue  
Jersey City, NJ 07307  
(800) 828-2634  
(201) 798-5353  
Fax: (201) 659-7186

T.C. DENTAL PRODUCTS INC.  
939 Fairway Drive  
Walnut, CA 91789  
(888) 779-8500  
(909) 839-0868  
Fax: (909) 839-0766

TECH CHEM, INC.  
P.O. Box 100  
Arcola, MO 65603-0100  
(800) 852-5641  
(417) 424-3292  
Fax: (417) 424-3294  
[techchem@mocom.net](mailto:techchem@mocom.net)

TECHNICRAFT INDUSTRIES, INC.  
Plaza Terrace Office Building  
445 East 2nd South, Suite 308  
Salt Lake City, UT 84111  
(801) 363-8537  
Fax: (801) 363-8537

TECNOL  
6316 Airport Freeway  
Fort Worth, TX 76117  
(800) 826-5763  
(817) 831-4700  
Fax: (817) 831-2462

TEGNET INTERNATIONAL INC.  
Suite 321 Medical-Dental Bldg.  
650 West 41 st Avenue  
Vancouver, British Columbia  
Canada V5Z 2M9  
(604) 266-8910  
Fax: (604) 266-6329

TEK DENTAL  
26985 Brighton Lane  
Lake Forrest, CA 92630  
(888) 835-3368  
(949) 770-5140  
Fax: (949) 770-2657  
[www.tekdental.com](http://www.tekdental.com)

TEKSCAN, INC.  
307 West First Street  
South Boston, MA 02127-1309  
(800) 248-3669  
(617) 464-4500  
Fax: (617) 464-4266  
[marketing@tekscan.com](mailto:marketing@tekscan.com)

TELEDYNE WATER PIK  
1730 East Prospect Road  
Fort Collins, CO 80553-0001  
(800) 525-2020  
(970) 484-1352  
Fax: (970) 221-8715  
[www.waterpik.com](http://www.waterpik.com)

TEMREX CORPORATION  
P.O. Box 182  
112 Albany Avenue  
Freeport, NY 11520  
(800) 645-1226  
(516) 868-6221  
Fax: (516) 868-5700  
[temrex@centuryinter.net](mailto:temrex@centuryinter.net)

SENSOR CORPORATION  
100 Everett Avenue, Suite 10  
**Chelsea, MA 02150**  
(800) 872-5267  
(617) 884-7744  
Fax: (617) 889-2785

TEPE ORAL HYGIENE PRODUCTS  
Knackstengatan 2  
S-21376  
Malmo, Sweden  
46-40-22-84-70  
Fax: 46-40-94-43-04

TESS CORPORATION  
1226 International Drive  
Eau Claire, WI 54701  
(800) 762-1765  
(715) 832-7271  
Fax: (715) 832-0093

- TETRAHEDRON, INC.  
P.O. Box 2033  
Sandpoint, ID 83864  
(800) 336-9266  
(208) 265-2573  
Fax: (208) 265-2775  
[tetra@tetrahedron.org](mailto:tetra@tetrahedron.org)
- TEXAS INSTITUTE FOR ADVANCED DENTAL STUDIES  
P.O. Box 1044  
Refugio, TX 78377-0956  
(800) 866-3054  
(512) 526-4698  
Fax: (512) 526-4699  
[jimrainey@msn.com](mailto:jimrainey@msn.com)
- TEXELL PRODUCTS CO.  
1400 Triple Peak Drive  
Canyon Lake, TX 78133  
(830) 964-4121
- THERA-TECH  
4918 Leary Avenue NW  
Seattle, WA 98107  
(800) 221-0180  
(206) 781-1776  
Fax: (206) 781-1643
- THIERMAN PRODUCTS, INC.  
P.O. Box 83371  
Portland, OR 97283  
(503) 286-1158  
Fax: (503) 285-7541
- THM BIOMEDICAL, INC./COSMED  
325 South Lake Avenue, Suite 608  
Duluth, MN 55802  
(800) 327-6895  
(218) 720-3628  
Fax: (218) 720-3715
- THOMPSON DENTAL MFG. CO.  
1201 South 6th West  
Missoula, MT 59806  
(800) 622-4222  
(406) 728-0000  
Fax: (406) 728-4885  
[ident@tdent.com](mailto:ident@tdent.com)
- THORNTON INTERNATIONAL INC.  
149 Water Street  
Norwalk, CT 06854  
(800) 445-3567  
(203) 831-8244  
Fax: (203) 831-8266  
[tbhorn@earthlink.net](mailto:tbhorn@earthlink.net)
- TIDI PRODUCTS  
(See Banta Health Care, Tidi Brand)
- TILLOTSON HEALTHCARE CORP.  
360 Route 101  
Bedford, NH 03110  
(800) 445-6830  
(603) 472-6600  
Fax: (603) 472-5151  
[cornetta@thcnet.attmail.com](mailto:cornetta@thcnet.attmail.com)
- TITANIUM PRO OPTICS  
23224 94th Avenue South  
P.O. Box 6055  
Kent, WA 98064  
(253) 852-6037  
Fax: (253) 852-5940  
[aknaus@aol.com](mailto:aknaus@aol.com)
- T K ENTERPRISES, INC.  
PO. Box 7554  
Menlo Park, CA 94026  
(650) 854-9276  
Fax: (650) 854-8011  
[retgard@aol.com](mailto:retgard@aol.com)
- TMC, INC.  
7875 Trans Canada Highway  
Ville St. Laurent, Quebec  
H4S 1 L3 Canada  
(514) 333-6407  
Fax: (514) 322-6915
- TMD HANDLE CO.  
609 Navigator Court  
Carlsbad, CA 92009  
(760) 431-5355  
Fax: (760) 431-5355
- TMJ CLINIC, PC., THE  
Medical Building, Suite 810  
833 S.W. 11th Avenue  
Portland, OR 97205  
(503) 241-7353  
Fax: (503) 525-2966
- TODAY'S DENTAL/THE FARRAN REPORT  
10850 South 48th Street  
Phoenix, AZ 85044  
(602) 893-1223  
Fax: (602) 496-9363
- TOKUYAMA AMERICA, INC.  
1875 South Grant Street,  
Suite 570  
San Mateo, CA 94402  
(800) 275-2867  
(650) 571-8872  
Fax: (650) 571-8037
- TONGUE CLEANER CO.  
PO. Box 1070  
Capitola, CA 95010  
(408) 662-9500  
Fax: (408) 662-3910  
[www.tonguecleaner.com](http://www.tonguecleaner.com)
- TONY RISO COMPANY, INC.  
17070 Collins Avenue, Suite 263  
Miami, FL 33160  
(305) 940-3043  
Fax: (305) 940-6383
- TOTALMED  
18108 Point Lookout Drive,  
Suite A  
Nassau Bay, TX 77058  
(800) 328-8884  
(281) 333-1888  
Fax: (281) 333-1818  
[hking@neosoft.com](mailto:hking@neosoft.com)
- TP ORTHODONTICS, INC.  
100 Center Plaza  
P.O. Box 73  
La Porte, IN 46350-9672  
(800) 348-8856  
(219) 785-2591  
Fax: (219) 324-3029  
[portho@tportho.com](mailto:portho@tportho.com)
- TRADEMARK MEDICAL  
1053 Headquarters Park  
Fenton, MO 63026  
(800) 325-9044  
(314) 349-3270  
Fax: (314) 349-3294  
[trademark@worldnet.att.net](mailto:trademark@worldnet.att.net)
- TREX TROPHY  
37 Apple Ridge Road  
Danbury, CT 06810  
(800) 667-1780 -  
(203) 207-4545  
Fax: (203) 207-4546  
[www.trexmedical.com](http://www.trexmedical.com)
- TRIANGLE FURNITURE SYSTEMS, INC.  
330 Aime-Vincent Street  
Vandrevuil, Quebec J7V 5V5  
Canada  
(450) 424-4040  
Fax: (450) 424-4040
- TRIDENT DENTAL, INC.  
Route 2 Box 251-A  
Hendersonville, NC 28792  
(704) 685-2660  
Fax: (704) 685-2661
- TRI HAWK CORPORATION  
150 Highland  
Massena, NY 13662-3205  
(800) 874-4295  
(315) 764-7664  
Fax: (315) 764-8128  
[www.trihawk.com](http://www.trihawk.com)
- TRIPALAY DENTAL LAB, INC.  
600 Grant Avenue  
PO. Box 613  
York, NE 68467  
(800) 252-0232  
(402) 362-5588  
Fax: (402) 362-6409  
[tripalay@navix.net](mailto:tripalay@navix.net)
- TRIUMPH PHARMACEUTICALS, INC.  
4933 North Tamiami Trail  
Naples, FL 34103  
(800) 492-7040  
(941) 430-0695  
Fax: (941) 430-0694  
[www.tpihealth.com](http://www.tpihealth.com)
- TROLLPLAST, INC.  
P.O. Box 1703  
New Milford, CT 06776  
(800) 537-8765  
(203) 775-4342  
Fax: (203) 775-8385
- TRONEX HEALTHCARE INDUSTRIES  
One Tronex Centre  
3 Luger Road  
Denville, NJ 07834  
(800) 833-1181  
(973) 627-3800  
Fax: (973) 625-7630  
[tronex.intl@worldnet.att.net](mailto:tronex.intl@worldnet.att.net)
- T & S DENTAL & PLASTICS COMPANY, INC.  
P.O. Box 264  
Myerstown, PA 17067-0264  
(800) 835-5103  
(717) 866-7571  
Fax: (717) 866-5129  
[staff@tsdental.com](mailto:staff@tsdental.com)
- TULSA  
(See Dentsply Tulsa)
- TUTTNAUER USA CO., LTD.  
33 Comac Loop  
Equi-Park  
Ronkonkoma, NY 11779  
(800) 624-5836  
(516) 737-4850  
Fax: (516) 737-0720  
[www.tuttinauer.com](http://www.tuttinauer.com)
- TYcom DENTAL  
17862 Fitch  
Irvine, CA 92614  
(800) 288-6484  
(714) 955-0800  
Fax: (714) 955-0874
- ULTRACAM  
1301 Water Ridge Drive  
Lewisville, TX 75057-6022  
(800) 945-8474  
(972) 353-6500  
Fax: (972) 353-6685
- ULTRACLENZ  
70 Finnell Drive, Suite 14  
Weymouth, MA 02188  
(800) 931-8911  
(781) 331-7877  
Fax: (781) 335-8016  
[www.ultracenz.com](http://www.ultracenz.com)
- ULTRADENT PRODUCTS, INC.  
505 West 10200 South  
South Jordan, UT 84095  
(800) 552-5512  
(801) 572-4200  
Fax: (801) 572-0600  
[www.ultradent.com](http://www.ultradent.com)
- ULTRASONIC SCALER INSERTS, INC.  
11897 Beckett Fall Road  
Florissant, MO 63033-7412  
(800) 338-8634  
(314) 653-0760  
Fax: (314) 653-0641  
[usisitm@aol.com](mailto:usisitm@aol.com)
- ULTRASONIC SERVICES, INC. (USI)  
PO. Box 2009  
Bellaire, TX 77402-2009  
(800) 874-5332  
(713) 665-4949  
Fax: (713) 665-4984  
[www.usiultrasonic.com](http://www.usiultrasonic.com)
- ULTRAVENA INDUSTRIES, LTD.  
2201 South Oneida Street  
Green Bay, WI 54304  
(800) 738-7483  
(920) 494-8935  
Fax: (920) 494-8576
- UNIDENT  
4701 Innovation Drive,  
Suite CB-102  
Lincoln, NE 68521  
(402) 441-3070  
Fax: (402) 476-3660  
[www.unident.com](http://www.unident.com)
- UNIDENT/ALPHA HEALTHCARE INC.  
4660 Main Street, Suite 100  
Springfield, OR 97478  
(800) 283-0004  
(541) 726-9111  
Fax: (541) 726-8825
- UNIDENT SA  
34 AV. Eugene-Pittard  
CH-1206 Geneva  
Switzerland  
41-22-839-79-00  
Fax: 41-22-839-79-10  
[unident@hyg.ch](mailto:unident@hyg.ch)
- UNION BROACH  
Division of Moyco Technologies  
589 Davies Drive  
York, PA 17482  
(800) 221-1344  
(717) 840-9335  
Fax: (717) 840-9347  
[www.moycotech.com/~moyco](http://www.moycotech.com/~moyco)
- UNION CARBIDE CORPORATION  
P.O. Box 670  
Bound Brook, NJ 08805  
(908) 563-5815  
Fax: (908) 563-6074
- UNITED COMMUNICATIONS, INC.  
4520 South 36th Street  
Omaha, NE 68107-1329  
(800) 228-3400  
(402) 734-5211  
Fax: (402) 734-6815
- UNITED SERVICE  
5669 147th Street North  
Hugo, MN 55038  
(800) 328-9689  
(612) 429-8660  
Fax: (612) 429-1096
- UNIVERSAL DENTAL ARTS  
2460 West 26th Avenue,  
Suite 40-C  
Denver, CO 80211  
(800) 574-2044  
(303) 477-0003  
Fax: (303) 477-0005
- UNIVERSAL DENTAL CO.  
108-A Park Drive  
PO. Box 447  
Montgomeryville, PA 18936-0447  
(800) 523-2559  
(215) 540-0800  
Fax: (215) 523-7550
- UNIVERSAL DENTAL IMPLEMENTS  
Oak Tree Business Center  
906-B Oak Tree Road  
South Plainfield, NJ 07080  
(908) 754-8882  
Fax: (908) 754-5588
- UNIVERSAL IMPLANT SYSTEMS, INC  
4400 Jenner Street, Northwest,  
Suite 200  
Washington, DC 20015  
(800) 327-8879  
(202) 244-9200  
Fax: (202) 244-3277
- UP-RAD CORPORATION  
P.O. Box 289  
Leonardtown, MD 20650  
(800) 327-8879  
(847) 644-1410  
Fax: (847) 844-1413
- U.S. DENTAL CORPORATION  
6420 Highway 93 South  
P.O. Box 724  
Lakeside, MT 59922  
(800) 603 8118  
(406) 857-3711  
Fax: (406) 857 3712  
[usdental@digisys.net](mailto:usdental@digisys.net)
- U.S. DENTAL PETRA BRUCKS GMBH  
Schmidner Str 24A  
70732 Stuttgart  
Germany  
49-711-560609  
Fax: 49-711-560157  
[usdental@t-online.de](mailto:usdental@t-online.de)
- U.S. DENTEK  
1460 Cader Lane Suite A  
Petaluma, CA 94954  
(800) 433-6835  
(707) 762-4646  
Fax: (707) 762-2534  
[www.usdentek.com](http://www.usdentek.com)
- U.S. MEDICAL SYSTEMS  
(See Habitek Int'l DBA U.S. Medical Systems Inc.)
- U.S. PHARMACOEPIA  
12601 Twinbrook Parkway  
Rockville, MD 20852  
(800) 227-8772  
(301) 881-0666  
Fax: (301) 816-8148  
[www.usp.org](http://www.usp.org)
- U.S. SH17AL CORPORATION  
2001 South Barrington Avenue,  
Suite 222  
Los Angeles, CA 90025  
(310) 444-1422  
Fax: (310) 444-1455
- U.V.D.I  
28220 Industry Drive  
Valencia, CA 91355  
(805) 295-8140  
Fax: (805) 295-8350
- VACUDENT  
381 West Center Street  
P.O. Box 477  
Pleasant Grove, UT 84062  
(800) 453-8474  
(801) 785-3534  
Fax: (801) 785-8049
- VA MEDICAL CENTER  
National Media Development  
Center (142 A)  
50 Irving Street Northwest  
Washington, D.C. 20422  
(202) 745-8458  
Fax: (202) 745-8395

- VANCOUVER DENTAL CERAMICS LTD  
3291 Dunbar Street  
Vancouver B.C.  
Canada V6S 2L38  
(604) 228-9200  
Fax: (604) 228-9201
- VANIMAN MANUFACTURING CO.  
140 North Brandon  
P.O. Box 74  
Fallbrook, CA 92028  
(800) 826-4626  
(760) 723-1498  
Fax: (760) 723-6990  
[sales@vaniman.com](mailto:sales@vaniman.com)
- VAN R DENTAL PRODUCTS, INC.  
600 East Hueneme Road  
Oxnard, CA 93033-8600  
(800) 833-8267  
(805) 488-1122  
Fax: (805) 488-2266  
[www.vanr.com](http://www.vanr.com)
- VELOPEX INTERNATIONAL INC.  
136 Main Street  
Catawissa, PA 17820  
(888) 835-6739  
(717) 356-2614  
Fax: (717) 356-2613  
[velopez@sunlink.net](mailto:velopez@sunlink.net)
- VERIDIEN CORPORATION  
11800 28th Street North  
St. Petersburg, FL 33716  
(800) 345-5444  
(813) 572-5500  
Fax: (813) 572-5708  
[veridien@gte.net](mailto:veridien@gte.net)
- VFS SYSTEMS PATIENT VIEW  
523 Remington Street  
Fort Collins, CO 80524  
(970) 482-6891  
Fax: (970) 484-5555
- VISON FIBER OPTICS CORP.  
90 Secor Lane  
Pelham Manor, NY 10803  
(914) 738-5006  
Fax: (914) 738-6920
- VICTORY MOUTHGUARDS  
Suite 304, Pymble Corporate  
Centre  
20 Bridge Street  
Pymble, NSW 2073  
Australia  
612 9488 7555  
Fax: 612 9488 7317  
[www.sportsdentistry.com.au](http://www.sportsdentistry.com.au)  
[bdorney@sportsdentistry.com.au](mailto:bdorney@sportsdentistry.com.au)
- VIDENT  
3150 East Birch Street  
PO. Box 2340  
Brea, CA 92821  
(800) 828-3839  
(714) 961-6200  
Fax: (714) 961-6299  
[www.vident.com](http://www.vident.com)
- VIDEO DENTAL CONCEPTS  
1095 Mason Avenue  
Daytona Beach, FL 32117  
(800) 323-2690  
(904) 254-5099  
Fax: (904) 254-7981  
[www.videdental.com](http://www.videdental.com)
- VIKING ENGINEERING COMPANY  
111 East Fayett  
P.O. Box 68  
Pittsfield, IL 62363  
(217) 285-4021  
Fax: (217) 285-2459
- VI. R. ENGINEERING, INC.  
5580 Calle Real  
Santa Barbara, CA 93111  
(805) 964-0553  
Fax: (805) 964-9588  
[vidalasilcom.com](http://vidalasilcom.com)
- VISION ENGINEERING, INC.  
745 West Taft Avenue  
Orange, CA 92865  
(714) 974-6966  
Fax: (714) 974-7266
- VISION MEDICAL & DENTAL  
8235 Ridgeview Drive  
Ben Lomond, CA 95005  
(408) 336-3345  
Fax: (415) 883-5050
- VISUAL HORIZONS  
180 Metro Park  
Rochester, NY 14623-2666  
(800) 424-1011  
(716) 424-5300  
Fax: (716) 424-5313  
[www.visualhorizons.ca](http://www.visualhorizons.ca)
- VISUAL SOLUTIONS  
Advance Learning Technologies  
200 SE Park Plaza Drive, Suite  
1001  
Vancouver, WA 98684  
(800) 691-9026  
(360) 892-1298  
Fax: (360) 892-1747
- VITA-STAT MEDICAL SERVICES, INC.  
P.O. Box 97013  
Redmond, WA 98073-9713  
(800) 338-9684  
(206) 867-7357  
Fax: (206) 883-9115  
[www.space-labs.com/health.htm](http://www.space-labs.com/health.htm)
- Voco GMBH  
Aston-Plettner-Strasse 1-3  
HR B 1260  
27457 Cuxhaven  
Germany  
49-47-21-719-0  
Fax: 49-47-21-719-109  
[info@voco.de](mailto:info@voco.de)
- VORTEX WATER TECHNOLOGIES,  
INC.  
1097 Iron Springs Road,  
Prescott, AZ 86301  
(520) 717-7250  
Fax: (520) 717-7247  
[vortex@northlink.com](http://vortex@northlink.com)
- WALL STREET CAMERA  
82 Wall Street  
New York, NY 10005  
(800) 221-4090  
(212) 344-0011  
Fax: (212) 425-5999  
[alik@inch.com](mailto:alik@inch.com)
- WARNER-LAMBERT COMPANY  
201 Tabor Road  
Morris Plains, NJ 07950  
(800) 547-8374  
(201) 540-6749  
Fax: (201) 540-4400  
[hoyliac@mps.wl.com](http://hoyliac@mps.wl.com)
- WASHINGTON SCIENTIFIC CAMERA  
CO., INC.  
615 Wood Avenue  
Sumner, WA 98390  
(253) 863-2854  
Fax: (253) 863-2854  
[wscpr@aol.com](http://wscpr@aol.com)
- WASHINGTON TRADING CO.  
One Cypress Knee Trail  
Kitty Hawk, NC 27949  
(800) 253-2460  
(252) 261-6181  
Fax: (252) 261-0408  
[darcjon@intexpath.com](http://darcjon@intexpath.com)
- W. Bosco, INC.  
8620 Sorenson Avenue, Suite 7  
Santa Fe Springs, CA 90670  
(562) 464-1189  
Fax: (562) 464-1190
- WEBSTER ASSOCIATES, INC.  
6450 South Quebec Street,  
Suite 528  
Englewood, CO 80111  
(800) 627-4875  
(303) 773-8989  
Fax: (303) 773-8993
- WELCH ALLYN DENTAL PRODUCTS  
4619 Jordan Road  
P.O. Box 187  
Skanateles Falls, NY 13153  
(800) 867-3832  
(315) 685-9514  
Fax: (315) 685-7905  
[dental@mail.welchallyn.com](mailto:dental@mail.welchallyn.com)
- WESTDENT  
3680 Charter Park Drive,  
Suite B  
San Jose, CA 95136  
(800) 848-4880  
(408) 266-1160  
Fax: (408) 266-0706
- WESTERN MD, INC./CROWN  
SEATING  
313 Corey Way  
South San Francisco, CA 94080  
(650) 869-4177  
Fax: (650) 869-4179  
[www.america.rmxcl.com](http://www.america.rmxcl.com)
- WESTERN PHASE CHANGE CORP.  
15931 North 80th Street  
Scottsdale, AZ 85260  
(800) 332-4322  
(602) 951-4322  
Fax: (602) 951-0501
- WESTONE LABORATORIES, INC.  
P.O. Box 15100  
Colorado Springs, CO 80935  
(800) 660-8848  
(719) 540-9333  
Fax: (719) 540-9183  
[westone@earthlink.com](mailto:westone@earthlink.com)
- WESTONE PRODUCTS, LTD.  
8 Hampstead Gate  
1A Frognal  
London, NW3 6AL  
England  
44-171-431-9001  
Fax: 44-171-431-9002  
[westone@digital-pipe.com](http://westone@digital-pipe.com)
- WEST TEO INDUSTRIES, INC.  
124 East 400 South  
Heber Valley, UT 84032  
(800) 341-6164  
(801) 654-5929  
Fax: (801) 654-5929
- WHATMAN BALSTON, INC.  
260 Neck Road  
Haverhill, MA 01835  
(800) 343-4048  
(508) 374-7400  
Fax: (508) 374-7070
- W \$, H DENTALWERK BURMOOS  
GMBH  
Ignaz-Glaser-Strasse 53  
A-5111 Burmoos  
Austria  
43-6274-6236-0  
Fax: 43-6274-6236-55  
[www.wndent.com](http://www.wndent.com)
- WHIP MIX CORPORATION  
361 Farmington Avenue  
PO. Box 17183  
Louisville, KY 40217  
(800) 626-5651  
(502) 637-1451  
Fax: (502) 634-4512  
[www.whipmix.com](http://www.whipmix.com)
- WHITE BITE, INC.  
136 Northeast Street  
Exeter, CA 93221  
(800) 231-9665  
(209) 592-3311  
Fax: (209) 592-3319
- WHITE GAPS  
423 West Wheatland Road  
Suite 103  
Duncanville, TX 75116  
(800) 456-2272  
(972) 572-9707  
Fax: (972) 572-9779
- WHITELEY INDUSTRIES PTY, LTD.  
Level 1  
23 Berry Street  
North Sidney NSW  
Australia, 2060  
61-2-9929-9155  
Fax: 61-2-9929-9077  
[whiteley@worldnet.com.au](mailto:whiteley@worldnet.com.au)
- WHITE SHIELD, INC.  
5723 109 A Street  
Edmonton, AB, T6H 3C4  
Canada  
(403) 448-1246  
Fax: (403) 448-1433  
[whtshd@telvsplnt.net](mailto:whtshd@telvsplnt.net)
- WHITMORE MEDICAL  
1211 South Industrial Parkway  
Provo, UT 84601  
(801) 374-2556  
Fax: (801) 374-2606
- WIC, INC.  
PO. Box 383  
Williamston, MI 48895-0383  
(888) 636-8729  
(517) 655-7735  
Fax: (517) 655-7790
- WILKERSON CORPORATION  
1201 West Mansfield Avenue  
Englewood, CO 80110  
(303) 761-7601  
Fax: (303) 783-2300
- WILSON SAFETY  
205 Washington Street  
Reading, PA 19601  
(800) 345-4112  
(610) 376-6161  
Fax: (610) 371-7725
- WISDOM ORAL CARE  
Division of Milestone Scientific  
151 South Pffingsten Road  
Deerfield, IL 60015  
(800) 628-4798  
(847) 272-2040  
Fax: (847) 272-2584
- WOLVERINE DENTAL LAB  
20937 John R. Street  
Hazel Park, MI 48030  
(248) 543-1400  
Fax: (248) 543-1400
- WOODSIDE BIOMEDICAL, INC  
1915 Aston Avenue, Suite 102  
Carlsbad, CA 92008  
(800) 469-1518  
(760) 804-6900  
Fax: (760) 804-6925
- WOODWARD LABORATORIES, INC.  
11132 Winners Circle, Suite 100  
Los Alamitos, CA 90720  
(800) 780-6999  
(562) 598-0800  
Fax: (562) 598-0010  
[wlabinfo@ix.netcom.com](mailto:wlabinfo@ix.netcom.com)
- WORLD HEALTHCARE SYSTEMS,  
INC.  
3025 McHenry Avenue, Suite N  
Modesto, CA 95350-1449  
(209) 527-0101  
Fax: (209) 524-9922  
[mlipsey@sonnet.com](mailto:mlipsey@sonnet.com)
- WORLD HEALTHCARE SYSTEMS,  
INC. RU.  
Pushkarev Per. H.8, Apt. 49  
Moscow, Russia 103045  
(800) 208 7616  
Fax: 095 956 2715  
[healthcomd32@glas.apc.or.jp](mailto:healthcomd32@glas.apc.or.jp)
- WORLD HEALTHCARE SYSTEMS,  
INC. UK  
21 Gagarin Street, Apt. 44  
Simferopol33026  
Ukraine  
38 06 52 224735
- Wow! LABORATORIES, INC.  
18430 Bandilier Circle  
Fountain Valley, CA 92708-7011  
(714) 378-6067  
Fax: (714) 378-6017
- W.T. FARLEY, INC.  
4450 Shopping Lane  
Simi Valley, CA 93063  
(600) 327-5397  
(805) 526-4991  
Fax: (805) 581-2071  
[www.wtfarley.com](http://www.wtfarley.com)
- WYETH-AYERST LABORATORIES,  
INC.  
PO. BOX 7447  
Philadelphia, PA 19101-7447  
(800) 999-9384  
(610) 902-7112  
Fax: (610) 964-5999
- WYKLE RESEARCH, INC.  
2222 Hot Springs Road  
Carson City, NV 89706  
(800) 859-6641  
(702) 887-7500  
Fax: (702) 882-7952  
[wykle-direct@compuserve.com](mailto:wykle-direct@compuserve.com)
- X-RITE, INC.  
3100 44th Street, Southwest  
Grandville, MI 49418  
(616) 534-7663  
Fax: (616) 534-9212  
[www.x-rite.com](http://www.x-rite.com)
- XTRITIUM LABORATORIES  
415 W. Pershing Rd.  
Chicago, IL 60609  
(800) 587-3721  
(773) 268-5800  
Fax: (773) 924-6002
- YARTER-TEK CORP.  
Dental Products Division  
2315 Eudora  
Denver, CO 80207  
(800) 326-4501  
(303) 320-4500  
Fax: (303) 320-1215  
[yartertek-phil@compuserve.com](mailto:yartertek-phil@compuserve.com)



APPENDIX E LIST OF MANUFACTURERS

YATES S. BIRD  
300 North Elizabeth Street  
Chicago, IL 60607  
(800) 662-5021  
(312) 226-2412  
Fax: (312) 226-2480  
motloid @ [aol.com](mailto:aol.com)

YOUNG DENTAL MANUFACTURING  
13705 Shoreline Court East  
Earth City, MID 63045  
(800) 325-1881  
(314) 344-0010  
Fax: (314) 344-0021  
[info@youngdental.com](mailto:info@youngdental.com)

ZANDER FILTER SYSTEMS, INC.  
5201-D Brook Hollow Parkway  
Norcross, GA 30071  
(800) 543-0851  
(770) 446-3614  
Fax: (770) 263-0856  
[zanderusa@aol.com](mailto:zanderusa@aol.com)

ZEISS, CARL  
(See Carl Zeiss)

ZENITH/DMG  
242 South Dean  
Englewood, NJ 07631  
(800) 662-6383  
(201) 894-5500  
Fax: (201) 894-0213

ZEST ANCHORS, INC.  
2061 Wineridge Place, Suite  
100  
Escondido, CA 92029  
(800) 262-2310  
(760) 743-7744  
Fax: (760) 743-7975  
zest @ [ix-netcom.com](mailto:ix-netcom.com)

ZEZA, INC.  
5400 South University Drive  
Suite 103  
Davie, FL 33328  
(800) 527-8937  
(954) 680-2566  
Fax: (954) 680-9275

ZILA, INC  
5227 North 7th Street  
Phoenix, AZ 85014-2817  
(800) 922-7887  
(602) 266-6700  
Fax: (602) 234-2264  
[www.zila.com](http://www.zila.com)

ZIMMERMAN ENTERPRISES  
13133 130th Lane N.E.  
Kirkland, WA 98034  
(206) 823-5097  
Fax: (206) 823-5097

ZIRC DENTAL CO., INC.  
3918 Hwy 55 SE  
Buffalo, MN 55313  
(800) 328-3899  
(612) 682-6636  
Fax: (612) 682-6604  
zinc-dental-  
mfg @ worldnet.att.net

ZOLL-DENTAL  
1866 Johns Drive  
Glenview, IL 60025  
(800) 239-2904  
(847) 729-2904  
Fax: (847) 729-2447  
zman03l O68 @ [aol.com](mailto:aol.com)

Z TRAINING APPLIANCE  
7606 McHenry Avenue  
Crystal Lake, IL 60014  
(815) 459-7800  
Fax: (815) 459-7850



انتشارات شایان نمودار

# INDEX

## A

Abandonment, 511

Abrasion

- anterior veneers and, 101
- composite resin inlays and onlays and, 106
- gingival recession from, 358
- mechanical, for staining, 255

Absorption in color perception, 27

Abutments, implant, 430-431

- coordinating to soft tissue level, 324-325
- post for, adjustment of, to achieve subgingival margins, 325
- selection of, 308-311
- types of, 305-306

Accessibility in abutment selection, 309

Acid etching

- composite resin and, 71-72
- nonvital tooth bleaching and, 260
- porcelain-bonded restorations and, 152

Acid/abrasion technique for staining, 255-256

Acrylic buildup technique for stent construction, 318, 319

Acrylic resin(s), 199-243

- implant and, 315-316
- in provisional restorations
  - auto-cured resin in, 201
  - basic concepts of, 199-200
  - cementation of, 219
  - chemistry of, 201
  - clinical cases on, 221-223
  - clinical technique for, 209-211
  - color correction of, 218
  - for coronally debilitated teeth, 214

Acrylic resin(s)-cont'd

in provisional restorations-cont'd

- direct preparation of, 207-208
- for edentulous spaces, 215
- Ellman press-form system for, 209
- finishing of, 217-218
- impression technique for, 207-208
- indirect technique for, 212-213, 216-217
- indirect/direct technique for, 208-209
- intraoral technique for, 216
- laboratory prescription of, 220
- laboratory-produced shell and relin technique for, 213-214
- light-cured resin in, 201
- modular transitional implants and, 220, 220-221
- plastic matrix technique for, 209
- polishing of, 217-218
- polycarbonate crowns and, 201, 203t, 204-206
- preformed crowns and crown forms and, 201, 203, 203t
- properties of, 202t
- remargination and, 217
- requirements for, 200-201
- shade characterization of, 218
- vacuum former unit and, **211-212**
- for removable prosthesis(es), 227-243**
  - custom laboratory services for, 240-241
  - dental composition for, 237-239
  - denture esthetics limitations and, 241-243
  - evaluating existing esthetics for, 229-232
  - fee presentation for, 237
  - first appointment for, 228-229
  - mold selection for, 234-237

Page numbers in italics indicate illustrations; page numbers followed by *t* indicate tables.



- Acrylic resin(s)-cont'd  
 for removable prosthesis (es)-cont'd  
 presentation of prognosis for, 232  
 setting teeth in, information needed by technician for, 239  
 shade selection for, 232-234  
 tooth selection techniques for, 232-237  
 wax try-in of, 239-240
- Acrylic veneer crown, repair of, color modifiers for, 61-62
- Active matrix display, definition of, 459
- Adhesion contracts, 514
- Adhesion fixed partial dentures, 186-187
- Adhesive bonding of adhesive resin bonded cast restorations, 196-197
- Adhesive resin bonded cast restorations, 185-197  
 bonding of, 195-197  
 chemical bonding of, 186-187  
 cingulum and, 187  
 esthetic try-in of, 194-195  
 gingival chamfer for, 187  
 history of, 185-186  
 impressions for, 193-194  
 interocclusal clearance in, 187  
 maximal enamel coverage in, 187  
 occlusal rests and, 187  
 path of insertion of, 188  
 philosophy of, 185-186  
 preparation of, for final cementation, 195  
 principles of, 186-189  
 provisional, 188  
 retention grooves in, 187-188  
 reversibility of, 188  
 tooth mobility and, 189  
 tooth preparation for, 189-195  
 anterior, 189-190, 191  
 miscellaneous, 192-193  
 posterior, 190-192  
 unit size in, 188
- Adhesive resin systems, 186-187
- Adhesive systems for bonded cast restorations, etch systems versus, 188-189
- Advanced Photo System (APS), 274-275  
 cameras in, 276
- Affluence, influence on health, 492-493
- Age  
 cultural bias on, 35-36  
 psychology and, 490  
 tooth form for ceramometal restorations and, 127
- Air abrasion systems, 465, 478-479
- Alert composite resin kit, 92
- All-ceramic restorations, 137-147  
 biocompatibility and, 140  
 Dicor for, 137, 138
- All-ceramic restorations-cont'd  
 die preparation for, 144, 145  
 electroforming of, 139-141  
 Empress, 137-138  
 ideal preparation requirements for, 141  
 impressions for, 142-144  
 In-Ceram, 138-139  
 light absorption and, 139-140  
 luting of, 147  
 margin placement control in, 140-141  
 placement of, 144-147  
 porcelain jacket crowns as, 137  
 Procera AllCeram, 139  
 properties of, 147t  
 provisional, 144-147  
 refraction and, 139-140  
 technique for, 141-144  
 try-in of, 144-147
- Alloys, ceramometal, 115-119
- Alveolar bone defects, 349-352  
 clinical cases on, 350-352  
 differential diagnosis of, 349  
 guided tissue regeneration for, 349  
 lingual ramping for, 350  
 open debridement with buccal osteotomy for, 350  
 osseous grafting for, 350  
 palatal ramping for, 350  
 retained papilla technique for, 349
- Alveolar canal, inferior, compression/penetration of, complicating implant, 433
- Alveolar distraction in oral and maxillofacial surgery, 413
- Amalgam, staining from, 251-252
- Amelogenesis imperfecta, tooth discoloration in, 252
- Analgesia, nitrous oxide, for electrosurgery, 294
- Anemia, sickle cell, tooth discoloration in, 252
- Anesthetic delivery systems, computer-regulated, 465, 479
- Annotation, definition of, 459
- Anterior fixed space maintainer, in child, 344-345
- Anterior veneers, 101-105
- Apertognathia, 415
- Aperture of camera, 272
- Appliance(s)  
 fixed  
 for anterior crossbite, 399-400, 400-401  
 in anterior flaring teeth correction, 388-389  
 for diastema closure, 390-391  
 for extruded teeth, 397-398  
 for malpositioned teeth, 394-395  
 in migrated anterior tooth correction, 386-387  
 in migrated premolar/molar correction and uprighting, 388

- Appliance (s)-cont'd  
 fixed-cont'd  
   for posterior crossbite, 404, 404-405  
   for rotated teeth, 395-396, 3969-397  
 in orthodontics, types of, 382  
 removable  
   for anterior crossbite, 399  
   in anterior flaring teeth correction, 388  
   for diastema closure, 389-390  
   for extruded teeth, 397  
   for malpositioned teeth, 394  
   in migrated anterior tooth correction, 385-386  
   in migrated premolar/molar correction and upright-  
     ing, 387  
   in multiple diastema closure, 384-385  
   for posterior crossbite, 403-404  
   for rotated teeth, 395
- Argon laser, 477, 478  
 bleaching assisted by, 257
- Artglass, 98
- Artglass crown for primary tooth, 342
- Artistic biases on tooth form, 32
- Atrophied papilla, 365
- Augmentation  
   of hard tissue, for implants, 435-437  
   of ridge for implants, 437  
   of sinus for implants, 436-437  
   of soft **tissues for implants, 437-438**
- Authorization for implants, form for, 550**
- Auto-cured resin, for provisional restorations, 201**
- Avulsed teeth in child, 334**
- B**
- Backwards compatibility, definition of, 459
- Bacteria, chromogenic, tooth discoloration from, 252
- Bands, orthodontic, placement of, 382-383
- Bandwidth, definition of, 459
- Base metal alloys, 115
- Bases for composite resins, 74-75
- Bates v. State Bar of Arizona*, 499
- BelleGlass HP, 98-99
- Bellows system for photography, 276
- Benign lesion removal, laser in, 446-447
- Bevel in ceramometal restorations, 122-123  
   placement of, 130-131
- Bimaxillary prognathism, 408
- Bimaxillary surgery, 420-421
- Biocompatibility, all-ceramic restorations and, 140
- Bioglass polymer, 98t, 100
- bis-GMA resin  
   brands and manufacturers of, 204t  
   color modifiers and, 54
- bis-GMA resin-cont'd  
   development of, 69  
   properties of, 202t
- Bite; *see also* Crossbite; Overbite  
 closed, 402  
 open  
   anterior, 401  
   posterior, 401-402
- Bleaching of tooth/teeth; *see also* **Stained teeth**  
**acid abrasion and, 255-256**  
**custom tray fabrication for, 257**  
**general considerations on, 253-254**  
**history of, 247**  
**home**  
   dentist-prescribed, 257-259  
   over-the-counter unsupervised, 259  
 hydrochloric acid **and, 254-255**  
**laser in, 447, 448**  
**laser-assisted, 257**  
**nonvital, 259-263**  
**office, 256-257**  
**power, 256-257**  
 treatment modalities for, **253-263**
- Blepharoplasty, 454**
- Blue color modifier, indications for, 54, 55**
- Bodily self, 487
- Bonding  
   of adhesive resin bonded cast restorations, 195-197  
     adhesive, 196-197  
     Panavia, 195-196  
   dentin, polymerization shrinkage and, 73-74  
   enamel, 72  
   enamel-dentin, 72
- Bonding agent(s), 41-52  
   application of, 45-46  
   cleaning cavity preparation for, 45  
   clinical procedures for, 46-51  
   dentin-enamel, 72  
   as desensitizers, 51  
   etching tooth surface for, 45  
   historic perspective on, 41  
   ideal characteristics of, 42  
   indications for, 42-43  
   metal, 63t  
   multicomponent, 43  
     clinical technique for, 46-49  
   selection of, 42  
   single component, 43  
     clinical technique for, 49-51
- Bone  
   cortical, angulation of, implant placement  
     and, 432

- Bone-cont'd**  
 grafts of  
   in oral and maxillofacial surgery, 412-413  
   postextraction, implants and, 435-436  
   stage I surgical, implants and, 436  
   synthetic, for edentulous ridge deformities, 366  
     clinical case on, 368-370, 369-371
- Botox injections, 458
- Brackets, orthodontic, edgewise, placement of, 382
- Breach of terms, 513
- Bridge; *see also* Denture(s)  
 adhesive resin bonded, 185-197; *see also* Adhesive resin bonded cast restorations
- Brow lift, 455, 456
- Buccal osteotomy for alveolar bone defects, 350
- Buccolingual edentulous ridge deformity, 365
- Bundled software, definition of, 459
- Butt joint  
 facial, in ceramometal restorations, 123  
 indications for, 122t
- Byte, definition of, 459
- C**
- Cache  
 definition of, 459  
 primary, definition of, 462  
 secondary, definition of, 462
- CAD/CAM; *see* Computer-aided design and computer-aided manufacturing (CAD/CAM)
- CAD/CAM machining of porcelain-bonded restorations, 153
- Calcium hydroxide  
 as liner for composite resin restorations, 74  
 nonvital tooth bleaching and, 260
- Camera system, 269-270, 278-280  
 components of, 271-274  
 digital, 275, 276
- Canine  
 face of, alteration of, 34  
 law of face and, 34
- Carbamide peroxide as bleaching agent, 257
- Carbon dioxide laser, 441, 477  
 in skin resurfacing, 423
- CardBus, definition of, 459
- Caries  
 in child, 335-339  
   buccal, repair of, 338-339  
   interproximal, repair of, 336-338  
   lingual, repair of, 338-339  
 inadequate tooth structure from, 353  
 recurrent, around ceramometal margins, repair of  
   cervical addition in, 64-66  
   glass ionomer cement in, 66-68
- Case presentation, photography for, 270
- Cast perforated fixed partial dentures, 185-186
- Cast restorations, adhesive resin bonded, 185-197; *see also* Adhesive resin bonded cast restorations
- Cavity preparation for bonding to dentin, 45
- Celay system, 473
- Celluloid strip crown for primary tooth, 340
- Celluloid strip crowns, 206
- Cement(s)  
 glass ionomer, in ceramometal margin repair, 66-68  
 luting, composite resin, for porcelain-bonded restorations, 152-153
- Cementation  
 of acrylic resin provisional restorations, 218  
 of ceramometal restorations, 134  
 final, of fixed partial denture, preparation for, 195  
 of porcelain laminate veneers, 171-174, 174-175
- Cement-retained prosthesis, 306
- Central processing unit (CPU)  
 in computer imaging system, 468  
 definition of, 459  
 in intraoral imaging system, 466
- Ceramic optimized polymer, 98t, 100-101
- Ceramic type IV gold alloys, 116-117t, 119
- Ceramics, dental, composition of, 114t
- Ceramometal alloys, 115-119  
 base metal, 115  
 ceramic type IV gold, 116-117t, 119  
 cobalt-based, 116-117t, 118  
 gold noble, 115, 116-117t, 117  
 gold-palladium, 116-117t, 118  
 high-palladium, 116-117t, 118  
 nickel-chromium, 116-117t, 118  
**palladium-silver, 116-117t, 118**  
**precious, 115**  
**properties of, 116-117t**  
**titanium, 116-117t, 119**  
**white noble, 116-117t, 117**
- Ceramometal margins, repair of  
 cervical addition in, 64-66  
 color modifiers in, 64-68  
 glass ionomer cement in, 66-68
- Ceramometal restorations  
 basic considerations in, 119-126  
 bevel placement and, 130-131  
 cementation of, 134  
 chemistry of, 113-115  
 chroma and, 127-129  
 dental illusions and, 130-131  
 diagnostic models for, 119  
 diastemata and, 129  
**die trimming of, 132**  
**finishing lines for, 120-123**

- Ceramometal restorations-cont'd  
 framework considerations for, 124-125  
 hue and, 127-129  
 impression considerations for, 123-124, 131  
 malaligned teeth and, 129-134  
 medicolegal considerations on, 119  
 periodontal considerations on, 119  
 photography for, 119  
 pontic design for, 125-126  
 porcelain try-in and, 133  
 preparation of, 132  
 protruded teeth and, 129-130  
 provisional, 120  
 shade selection for, 132-133  
 soft tissue models for, 132-133  
 tissue management and, 131  
 tooth form and, 126-127  
 tooth reduction for, 120, 130  
 try-in of castings for, 132  
 value and, 127-129  
 work authorization for, 132
- Cerec 11 system, 473-474
- Ceromer, 98t, 100-101
- Cervical addition in ceramometal margin repair, 64-66
- Cervical root resorption, external, bleaching and, 259-260
- Chairside repairs, anterior veneers for, 102
- Chairside staining, 526-527
- Chamfer, gingival, in adhesive resin bonded cast restorations, 187
- Chamfer preparation  
 in ceramometal restorations, 121  
 in porcelain-bonded restorations, 156, 157
- Character generator, definition of, 459
- Charged coupled device, definition of, 459
- Chemical bonding of fixed partial dentures, 186-187
- Chemical peeling of skin, 423, 457
- Children  
 dentistry for, 329-347; see also Pediatric dentistry  
 periodontitis in, edentulous ridge deformities from, 365
- Chlorophyll in dental plaque, tooth discoloration from, 252
- Choleric personality, 487
- Chroma, 28  
 ceramometal restorations and, 127-129  
 decreasing, 528  
 definition of, 525  
 increasing, 527-528
- Chromogenic bacteria, tooth discoloration from, 252
- Clearfil CR Inlay, 98t, 99
- Cleft lip and palate, 409
- Clinical colorimeters, 475-476
- Clip bar, retained prosthesis and, 303
- Closed bite, 402
- Cobalt-based alloys, 116-117t, 118
- Coefficient of multiplication in mold selection for acrylic resin removable prosthesis, 235
- Collagen injections, 457
- Collimated property of laser light, 442
- Color  
 of all-ceramic restorations, 146-147  
 change in, in porcelain laminate veneers  
 major, 159-165  
 minimal or no, 156-158  
 depth of, 31  
 matching of, porcelain-bonded restorations and, 154  
 opacity and, 30-31  
 principles of, 27-31  
 of tooth/teeth in acrylic resin provisional restorations, 218  
 translucency and, 31
- Color modifier(s), 53-68  
 in acrylic veneer crown repair, 61-62  
 in ceramometal margin repair, 64-68  
 chemistry of, 53-54  
 class III restorations and, 56-58  
 class IV restorations and, 56-58  
 diastema closures and, 58-59  
 direct labial veneers and, 59-61  
 general considerations on, 54  
 history of, 53  
 indications for, 54-56  
 in porcelain repairs, 63-64  
 visual effects of, 54t
- Color relationship, 28-31
- Color wheel, 28, 29
- Colorimeters, clinical, 475-476
- Coltene Inlay System, 98t, 99-100
- Command line interface, definition of, 459
- Commencement of statute of limitations, 518
- Communication(s)  
 laboratory, 36  
 photography in, 270-271  
 on porcelain-bonded restorations, 168-169  
 in practice management, 495
- Community service, photography for, 271
- Compact disk read-only memory, definition of, 459-460
- Compatibility, definition of, 460
- Complementary hues, 29, 525
- Compomers, 71  
 in pediatric dentistry, 339
- Composite resin(s), 69-111  
 acid etching in, 71-72  
 bases for, 74-75  
 basic chemistry of, 70  
 clinical cases with, 91, 91-92

- Composite resin(s)-cont'd  
 in enamel bonding, 72  
 in enamel-dentin bonding, 72  
 finishing of, 75-76  
 future of, 111  
 history of, 69-70  
 hybrid, 70  
 indirect technique for, 97-111  
   anterior veneers and, 101-105  
   basic concepts of, 97  
   chemistry of, 97  
   posterior inlays and onlays and, 106-108, 108-110  
 layering procedure for, 79-80  
 liners for, 74-75  
 matrix use for establishing occlusal anatomy with, 91, 91-92  
 microfilled, 70  
 multiple-step buildup technique with  
   in class II restorations, 80-82  
   in class IV restorations, 86-88  
   in class V restorations, 89-90  
 packable, new, 92-93  
 particle size of, 70-71  
 polishing of, 76  
 polyacid-modified, 71  
 polymerization shrinkage and, 72-73  
 in postorthodontic therapy, 91  
 restorations with  
   class I, 76-78  
   class II, 78-82  
     posterior, 91, 92  
   class III, 82-86  
     placing restorative material in, 84-86  
     type 1, 84-85  
     type 2, 85  
     type 3, 85-86  
   class IV, 86-88  
   class V, 88-90  
     stained, in tooth characterization, 530  
 shrinkage of, 78-70  
 single-step buildup technique with  
   in class IV restorations, 86  
   in class V restorations, 88-89  
 for splint in child, 334  
 types of systems of, 98-101
- Composite resin luting cements for porcelain-bonded restorations, 152-153
- Composite resin veneers, labial, color modifiers for, 59-61
- Composite video signal, definition of, 460
- Computer, definition of, 460
- Computer imaging in plastic surgery, 458
- Computer imaging system (CIS), 463, 467-469  
 advantages of, 467-468  
 definition of, 460  
 disadvantages of, 468  
 hardware components of, 468-469  
 software components of, 469
- Computer resolution, definition of, 460
- Computer technology in practice management, 496
- Computer-aided design and computer-aided manufacturing (CAD/CAM), 463  
 definition of, 460  
 systems for, 472-474  
   advantages of, 472  
   clinical products in, 473-474  
   disadvantages of, 472
- Computer-regulated local anesthetic delivery system, 465, 479
- Concealment, fraudulent, 518-519
- Cones, functions of, 28
- Connective tissue  
 augmentation of  
   for edentulous ridge deformities, 366  
     clinical case on, 367-368, 367-369  
   papillary reconstruction via, clinical case on, 371, 371-372  
   subepithelial, graft of, 352-353  
     for gingival recession, 360
- Consent, 513-514  
 for dental treatment, form for, 548  
 for implants, form for, 550  
 informed, 514-516  
 for orthodontic treatment, form for, 549  
 telephone, follow up form for, 551
- Contact(s)  
 devices for forming, composite resin and, 80  
 proximal  
   porcelain laminate veneers and, 156  
   tight, composite resin and, 80
- Contract  
 adhesion, 514  
 dentist-patient, 511-513
- Contract law, 511
- Controller, definition of, 460
- Cooperation, psychology and, 491
- Cores in pediatric dentistry, 342-343
- Cortical bone angulation, implant placement for, 432
- Cortical plate, buccal, fracture of, complicating implant, 433
- Cosmetic dentistry, risk management in, 520-521
- Cost of porcelain-bonded restorations, 153
- CPU (central processing unit), definition of, 459
- CPU compatibility, definition of, 460



- Craniofacial implants, 438
- Creep, 115
- Cristobal, 98t, 100
- Crossbite  
 posterior, correction of, 403-404, 403-405  
 simple anterior, 398-400, 399-401
- Crown(s)  
 acrylic veneer, repair of, color modifiers in, 61-62  
 artglass, for primary tooth, 342  
 celluloid strip, 206  
   for primary tooth, 340  
 metal, modified, 206-207  
 polycarbonate, 201, 203t, 204-206  
 porcelain jacket, 137  
 preformed acrylic, 201, 203, 203t  
 preformed ceramo-base metal, for primary tooth, 340-341  
 for primary teeth, 340-342  
 stainless steel  
   with esthetic veneers for primary tooth, 341-342  
   for primary tooth, 340, 344  
 surgical, lengthening of  
   in combined lesion management, clinical case on, 361-363  
   for inadequate tooth structure, 354  
   clinical case on, 355, 355-356
- Crown and bridge type implant, 304-305
- Cultural biases on tooth form, 31-36  
 age and, 35-36  
 gender and, 36
- Cultural influences on psychology, 492
- Curing, incremental, 78-79
- Current for electrosurgery, types of, 290
- Cursor, definition of, 460
- Cusp(s)  
 shrinkage of, in class 11 restorations, 79-80  
 strengthening of, composite resin in, 80
- Custom laboratory services, on acrylic resin removable prostheses, 240-241
- D
- Data back in photography, 277
- Debridement, open, with buccal ostectomy in periodontics, 350
- Decalcification in tooth characterization, 529
- Decision-making ability, psychology and, 491
- Dental arches, teeth and, lateral disharmonies of, 402-405
- Dental bimaxillary prognathism, 408
- Dental causes  
 of Angle Class III mesiocclusion, 407  
 treatment of, 408
- Dental causes-cont'd  
 of class 11 distocclusion, 406  
 of lateral disharmonies of teeth and dental arches, 403  
 of malocclusions, 380-381
- Dental illusions, creation of, for ceramometal restorations, 128-129
- Dental practice, goals and objectives of, 502
- Dental treatment  
 changed attitudes toward, 493  
 consent form for, 548
- Dentin, bonding to; *see also* Bonding agent(s)  
 polymerization shrinkage and, 73-74  
 theory and practice of, 43-45
- Dentin bonding agents, 41-52; *see also* Bonding agent(s)
- Dentinogenesis imperfecta, tooth discoloration in, 252
- Dentist  
 interaction of  
   with dental laboratory technician, 494  
   with patient, 493-494  
 personnel as extension of, 495
- Dentistry, pediatric, 329-347; *see also* Pediatric dentistry
- Dentogenic movement, 485-486
- Denture(s)  
 esthetics of, limitations of, in acrylic resin removable prostheses, 241-243  
 full, removable, stent construction from, 317-318  
 partial  
   fixed  
     adhesion, 186-187  
     cast perforated, 185-186  
     etched cast resin bonded, 186  
     multiple-unit metal-free, 110, 110-111  
     removable, stent construction from, 318
- Dermabrasion, 423, 457**
- Desensitizers, dentin bonding agents as, 51
- Desires, psychology and, 490-491
- Developmental disturbances in child, 335-339
- Devitrification, 114
- Diagnostic models for ceramometal restorations, 119
- Diastema  
 anterior, implant position and alignment and, 313  
 ceramometal restorations and, 129  
 closure of  
   color modifiers for, 58-59  
   fixed appliance in, 390-391  
   removable appliance in, 389-390  
   retention after, 391, 392  
   via arch contracture, 383-384  
 multiple, closure of, 384-385  
 porcelain laminate veneers and, 158  
 preparing proximal chamfer finishing lines for, 162



- Dicor restorations, 137, 138
- Die  
 preparation of  
   for all-ceramic restorations, 144, 145  
   for ceramometal restorations, 132  
 trimming of, for ceramometal restorations, 132
- Digital cameras, 275, 276
- Digital radiographic system(s), 463  
 alternative, 475  
 basic theory of, 474  
 corded, 475  
 cordless, 475  
 definition of, 460
- Digital video disk, definition of, 460
- Digital video disk random access memory, definition of, 460
- Digital video disk recordable, definition of, 460
- Digitizer, definition of, 460
- Direct castings, porcelain laminate veneers and, 153
- Disk, definition of, 460
- Display in intraoral imaging system, 466
- Distoclusion, class 11, 406
- Documentation, treatment, photography for, 270
- Dominant hues, 525, 526t
- Double cord retraction for impressions for all-ceramic restorations, 142-144
- Double density, definition of, 460
- Durability of porcelain laminate veneers, 153
- Duties, implied, in dentist-patient contract, 512-513
- DX settings, 273
- E
- Ectopic eruption, electrosurgery for, 293
- Edentulous ridge  
 deformities of, 365-371, 367-372  
 classification of, 365  
 clinical considerations on, 366  
 connective tissue augmentation for, 366  
   clinical case on, 367-368, 367-369  
 differential etiology of, 365  
 gingival onlay grafts for, 365-366  
 gingivoplasty for, clinical case on, 367-368, 367-369  
 multiple free gingival grafts for, clinical case on, 368-370, 369-371  
 ovate pontics for, 366  
 synthetic bone graft for  
   clinical case on, 368-370, 369-371  
 synthetic bone grafts for, 366  
   clinical case on, 368-370, 369-371  
 treatment options for, 365-366  
 partially, implant position/alignment and, 314  
 severely resorbed, treatment of, 324
- Edentulous spaces  
 provisional restorations for, 215  
 small, with limited bone, implant position/alignment and, 314
- Education, photography for, 271
- Elastics in diastema closure, 383-384
- Elastomeric impression materials for ceramometal restorations, 123-124
- Electroforming of all-ceramic restoration, 139-141
- Electronic mail, definition of, 460
- Electrosurgery  
 advantages of, 294  
 basic concepts of, 289-292  
 clinical applications of, 294-297  
 clinical cases of, 297-298  
 conceptions/misconceptions about, 289  
 contraindications to, 294  
 current types for, 290  
 diagnosis and, 292-294  
 equipment for, 291-292  
 history of, 289  
 indications for, 292-293  
 lateral heat in, 290-291  
 mechanism of action of, 289-290  
 nitrous oxide analgesia for, 294  
 research applicable to, 291  
 treatment planning and, 292-294
- Ellman press-form system, 209
- Empress restorations, 137-138
- Enamel  
 cracks and checks in, in tooth characterization, 529-530  
 maximal coverage of, in adhesive resin bonded cast restorations, 187
- Endodontic therapy  
 bleaching and, 261  
 staining from, 250-251
- Endodontically treated teeth, provisional restorations for, 214
- Environment  
 physical, in practice management, 494-495  
 psychologic, in practice management, 495
- Environmental staining, extrinsic, 249, 249-250
- Erbium:YAG laser, 441, 477-478
- Eruption  
 ectopic, electrosurgery for, 293  
 forced, for inadequate tooth structure, 354-355  
   clinical case on, 356-358  
   surgical crown lengthening with, clinical case on, 357-358  
 passive  
   altered  
     gingival overgrowth from, 373

- Eruption-cont'd  
 passive-cont'd  
 altered-cont'd  
 treatment of, clinical case on, 361-363  
 incomplete, electrosurgery for, 293
- Erythroblastosis fetalis, tooth discoloration in, 252
- Esthetics  
 advanced technology in, 459-479; *see also* Technology  
 color and, 27-31  
 electrosurgery and, 289-298; *see also* Electrosurgery  
 fundamentals of, 27-36  
 historical perspective on, 23-24  
 implant prosthetics and, 301-327; *see also* Implant  
 prosthesis  
 implant surgery and, 429-438  
 laser surgery and, 441-448; *see also* Laser surgery  
 light and shadow and, 27  
 oral and maxillofacial surgery and, 411-426; *see also*  
 Oral and maxillofacial surgery  
 oral photography and, 269-287; *see also* Photography  
 orthodontics and, 379-409; *see also* Orthodontics  
 periodontics and, 349-376; *see also* Periodontics  
 plastic surgery and, 451-458; *see also* Plastic surgery  
 psychology and, 485-496; *see also* Psychology  
 in United States, 25-26
- Etch **systems for bonded cast restorations, adhesive systems versus**, 188-189
- Etched cast resin bonded fixed partial dentures, 186
- Etching  
*acid*; *see* Acid etching  
 for bonding to dentin, 43-44, 45
- Ethics in practice management, 496
- Ethyl methacrylate, brands and manufacturers of, 204t
- Evaluation, psychology and, 490
- Expectations, psychology and, 490-491
- Expiration of statute of limitations, 518
- Exposure in photography, 273
- Extruded teeth, 397-398
- F
- Fabrication alternatives, anterior veneers as, 102
- Fabrication of posterior inlays and onlays  
 direct/indirect technique of, 106  
 indirect technique of, 107
- Face  
 appearance of, psychology and, 488-489  
 of canine, alteration of, 34  
 of incisors, alteration of, 34  
 of tooth, 32-33  
 law of, 32-33  
 canines and, 34
- Face-lift, 424, 453
- Facial access to class III composite resin restorations, 85
- Facial bevels in ceramometal restorations, 122-123
- Facial deformities, gross, 408-409
- Facial implants, 425-426, 454, 455
- Fat injections, 457-458
- Feldspar in dental porcelains, 113t, 152
- Feminine qualities in tooth form, 31, 36
- Fiberotomy for inadequate tooth structure, 354-355  
 clinical case on, 356-358
- Film, 277-278  
 digitalizing, methods of, 275-276  
 DX settings of, 273  
 speed of, 272-273
- Financial considerations in practice management, 495-496
- Finishing  
 of acrylic resin provisional restorations, 217-218  
 of ceramometal restorations, 120-123  
 bevel types in, 122-123  
 chamfer preparation in, 121  
 full shoulder preparation *in*, 121, 122  
 full shoulder with bevel preparation in, 121, 122  
 knife-edged preparation in, 121  
 composite resin and, 75-76  
 of porcelain laminate veneers, 175-178  
 proximal chamfer preparation for, 156, 157
- Finishing lines  
 gingival, in porcelain-bonded restorations, 158  
 proximal chamfer, in porcelain-bonded restorations, 156, 157
- Fissures in tooth characterization, 530
- Fitness, influence on, 493
- Flap  
 apically positioned  
 for combined periodontal lesion, 361-363  
 for gingival overgrowth, 373  
 full-thickness, with ostectomy, for gingival overgrowth, 373-374
- Flash in photography, 276-277
- Floppy disk, definition of, 460
- Floppy disk drive, definition of, 460
- Fluorosis, 249
- Focal length of lens, 272
- Focus of camera, 272
- Follow-through, psychology and, 491
- Form(s)  
 artistic biases on, 32  
 cultural biases on, 31-32  
 perception of, 31  
 principles of, 31-32  
 in risk management, 519
- Fracture  
 of buccal cortical plate complicating implant, 433

- Fracture-cont'd  
of porcelain  
with exposed metal, repair of, color modifiers in, 63-64  
with no exposed metal, repair of, color modifiers in, 63
- Fragility of porcelain-bonded restorations, 153
- Framework for ceramometal restorations, 124-125
- Fraudulent concealment, 518-519
- Frenectomy  
for implants, 437  
laser for, 446
- Frenum, enlarged/malpositioned, 391-393
- F-stop, 272
- Full arch bridge implant, 304-305
- Full coverage restorations  
all-ceramic, 137-147; *see also* All-ceramic restorations  
ceramometal, 113-134; *see also* Ceramometal restorations
- Full shoulder preparation, in ceramometal restorations, 121, 122  
with bevel and facial butt joint preparation, 123
- Full-screen view, definition of, 460
- Fully rectified current for electrosurgery, 290, 291  
filtered, 290, 291
- G
- Galvanoceramics, 139-141
- Gender  
cultural bias on, 36  
tooth form for ceramometal restorations and, 126-127
- Genioplasty, 418-419
- Gigabyte, definition of, 460
- Gingiva  
attached, inadequacy of, recession from, 358  
augmented, subepithelial connective tissue graft and, 352-353  
cosmetic resculpturing of, laser in, 445  
electrosurgery of, 293  
free, grafting of  
for edentulous ridge deformities, clinical case on, 368-370, 369-371  
for recession, 359  
procedure for, 360-361  
grafts of, for implants, 437-438  
hyperplasia of  
inflammatory, 373  
noninflammatory, 372-373  
overgrowth of, 372-374  
clinical case on, 373-374  
differential etiology of, 372-373  
treatment options for, 373
- Gingiva-cont'd  
prosthetic, for recession, 360  
recession of, 358-360  
recontouring of, for implants, 323  
troughing of, laser for, 447
- Gingival chamfer in adhesive resin bonded cast restorations, 187
- Gingival finishing lines in porcelain-bonded restorations, 158
- Gingival **margins alignment of, tooth form for ceramometal restorations and**, 127
- Gingival onlay grafts for edentulous ridge deformities, 365-366
- Gingivectomy, 411  
access, laser in, 445-446  
for gingival overgrowth, 373  
laser in, 444-445
- Gingivoplasty  
for edentulous ridge deformities, clinical case on, 367-368, 367-369  
for gingival overgrowth, 373  
for implants, 437-438
- Glass ionomer cement in ceramometal margin repair, 66-68
- Glass ionomers, light cured, as liner for composite resin restorations, 75
- Gold noble alloys, 115, 116-117, 117
- Golden proportion for tooth form, 31-32, 235
- Gold-palladium alloys, 116-117, 118
- Grafting  
bone  
in oral and maxillofacial surgery, 412-413  
postextraction, implants and, 435-436  
stage I surgical, implants and, 436  
synthetic, for edentulous ridge deformities, 366  
clinical case on, 368-370, 369-371  
gingival  
free  
for edentulous ridge deformities, clinical case on, 368-370, 369-371  
for recession, 359  
procedure for, 360-361  
for implants, 437-438  
onlay, for edentulous ridge deformities, 365-366  
lateral pedicle, for gingival recession, 359-360  
osseous, in periodontics, 349-350  
subepithelial connective tissue, 352-353  
for gingival recession, 360
- Graphical environment, definition of, 461
- Graphical user interface, definition of, 461

- Graphics adaptor, definition of, 460  
 Graphics tablet, definition of, 461  
 Gray color modifier, indications for, 54, 55  
 Grit blasting of implant surfaces, 303  
 Guide tooth, 34  
 Guided tissue regeneration  
   in enhancing anterior esthetics, clinical case on, 363-364, 363-365  
   in periodontics, 349  
     clinical case on, 351-352
- H**
- Hard copy, definition of, 461  
 Hard disk, definition of, 461  
 Hard disk drive, definition of, 461  
 Hard tissue augmentation for implants, 435-437  
 Hardware  
   in computer imaging system, 468-469  
   definition of, 461  
 Hawley appliance  
   for anterior crossbite, 399, 400  
   for diastema closure, 389-390, 390  
   for diastema retention, 391  
   for extruded teeth, 397  
   for flaring of teeth, 388  
   for malpositioned teeth, 394  
   for migrated anterior tooth, 386  
   for migrated premolars or molars, 387  
   for posterior crossbite, 403  
   for rotated teeth, 395, 396  
 Health history, 517-518  
 Health information, request for release of, form for, 547  
 Heat, lateral, in electrosurgery, 290-291  
 High density, definition of, 461  
 High-definition television, definition of, 461  
 High-palladium alloys, 116-117t, 118  
 History  
   health, 517-518  
   patient, form for, 543-545  
   update, 546  
 Hue(s), 28  
   adjusting, 527  
   ceramometal restorations and, 127-129  
   changing, decreasing value while, 528  
   complementary, 29, 525  
   definition of, 525  
   dominant, 525, 526t  
   primary, 28  
   secondary, 28  
 Hue relationship, 28-31  
 Hue sensitivity, 29
- Hybrid composite resin  
   Clearfil CR Inlay as, 98t, 99  
   Coltene Inlay System as, 98t, 99-100  
   True Vitality as, 98t, 101  
 Hydrochloric acid for staining, 254-255  
 Hydrogen peroxide as bleaching agent  
   for nonvital tooth, 259-260  
   for vital teeth, 256  
 Hydroxyapatite for dental implant coating, 302  
 Hygiene, oral, orthodontics for, 379  
 Hypersensitivity, nickel, 118
- I**
- Icon, definition of, 461  
 IEEE1394, definition of, 461  
 Illumination, principle of, 32  
 Illusion(s), 32  
   control of, using principles of perception in, 32-36  
   creation of, for ceramometal restorations, 128-129  
 Implant(s)  
   Alloderm, in lip augmentation, 421, 422  
   consent form for, 550  
   craniofacial, 438  
   facial, 425-426, 454, 455  
   **modular transitional, 220, 220-221**  
   **in oral and maxillofacial surgery, 411, 412**  
   **osseointegrated**, temporization of, 215-216  
 Implant prosthesis, 301-327  
   abutments for, 430-431  
     selection of, 308-311  
       accessibility in, 309  
       angle of implant in, 309-310  
       interarch distance in, 310-311  
       tissue architecture in, 309  
       tissue height in, 310-311  
       visibility in, 308  
   types of, 305-306  
   acceptance of, 302  
   advanced procedures for, 434  
   augmentation procedures for, 434-438  
     hard tissue, 435-437  
     soft tissue, 437-438  
   blade, 429-430  
   cement-retained, 306  
   complications of, 433-434  
   contraindications for, 429  
   crown and bridge type, 304-305  
   esthetic fundamentals for, 421  
   fabrication of, 326  
   hybrid type of, 305  
   indications for, 429

- Implant prosthesis-cont'd  
 kissing, 434  
 lack of integration of, 434  
 materials for, 302-303  
 mounted model analysis of, 307-308  
 overdenture-retained, 303-304  
 placement of, factors influencing, 431-432  
 position and alignment of, 312-316  
   angle of implant and, 315  
   anterior diastema and, 313  
   interproximal papilla and, 312  
   occlusal height and, 315, 316  
   partially edentulous ridge and, 314  
   porcelain versus acrylic resin and, 315-316  
   small edentulous space with limited bone and,  
     314  
   totally edentulous mandible and, 314-315  
   totally edentulous maxilla and, 314  
 preoperative evaluation for, 431  
 preoperative planning for, 307-308  
 psychologic considerations on, 308  
 radiographic analysis of, 308  
 root-form, 429, 430  
 screw-retained, 305-306  
 soft tissue emergence profile and, 326-327  
 soft tissue management for, 322-325  
 stent construction and, 316-320  
 stents and, 432-433  
 subperiosteal, 430  
 surface modifications for, 302-303  
 terminology of, 302  
 transitional phases in, esthetic management of,  
   321-322  
 types of, 303-305, 429-430  
 UCLA-type retained, 306
- Impressions  
 for acrylic resin provisional restorations, 207-208  
 for adhesive resin bonded cast restorations, 193-194  
 for all-ceramic restorations, 142-144  
 for ceramometal restorations, 123-124, 131  
 for implants, adjustment of, to achieve subgingival  
   margins, 325  
 for porcelain-bonded restorations, 166
- In-Ceram restorations, 138-139  
 In-Ceram Spinell restorations, 139
- Incisor(s)  
 face of, alteration of, 34  
 lateral, congenitally missing, 393  
 maxillary  
   central  
     localized spacing of, 389-393  
     trauma to, in child, 333
- Incisor(s)-cont'd  
 maxillary-cont'd  
   labioversion of, 393  
   preparation of, for porcelain-bonded restorations, 158
- Infection complicating implant, 434
- Infiltration ceramic restorations, 138-139
- Inflammation, pulp, after class II restorations, 78
- Information  
 age of, dental marketing and, 501  
 health, request for release of, form for, 547
- Information systems, 463, 463-464
- Informed consent, 514-516
- Injections  
 Botox, 458  
 collagen, 457  
 fat, 457-458  
 Isolagen, 457, 458
- Inlays  
 porcelain, posterior, 178-181  
 posterior, composite resin, 106-108
- Input, definition of, 461
- Input device  
 in computer imaging system, 468  
 in intraoral imaging system, 466
- Insurance, photography for, 271
- Intensity property of laser light, 442-443
- Internet  
 definition of, 461  
 marketing on, 507-508
- Interocclusal clearance in adhesive resin bonded cast  
 restorations, 187
- Interocclusal space, insufficient, implant placement for, 432
- Intraoral imaging system, 463  
 clinical procedure with, 467  
 products available in, 467
- Intraoral imaging system (IIS), 465-467  
 advantages of, 465  
 components of, 466-467  
 definition of, 461  
 disadvantages of, 465-466
- Intruded teeth in child, 333
- Isobutyl methacrylate  
 brands and manufacturers of, 204t  
 properties of, 202t
- Isolagen injections, 457, 458
- J
- Jaz drive, definition of, 461
- Jurisprudence, dental, 509-521; *see also* Legal issues
- K
- Kaolin in dental porcelains, 113t  
 Kevlar, 213

- Keyboard, definition of, 461  
 Kilobyte, definition of, 461  
 Knife-edges finishing line, in ceramometal restorations, 121
- L**
- Labial depth, reduction of, for porcelain-bonded restorations, 158  
 Labial veneers, color modifiers for, 59-61  
 Labiolingually malpositioned teeth, 393-395  
 Labioversion of maxillary incisors, 393  
 Laboratory communication(s), 36  
   photography in, 270-271  
   on porcelain-bonded restorations, 168-169  
 Laboratory services, custom, on acrylic resin removable prostheses, 240-241  
 Laboratory technician, dental, interaction of dentist with, 494  
 Laser, bleaching assisted by, 257  
 Laser light, properties of, 441-443  
 Laser surgery, 441-448  
   access gingivectomy in, 445-446  
   advantages of, 443  
   basic concepts of, 441-443  
   for benign lesion removal, 446-447  
   clinical indications for, **443-447**  
   **in dental bleaching, 447, 448**  
   **disadvantages of, 443**  
   **frenectomy in, 446**  
   gingival cosmetic resculpturing in, 445  
   gingival troughing in, 447  
   gingivectomy in, for tissue hyperplasia, 444-445  
   history of, 441  
   safety of, 448  
   for **skin resurfacing, 423, 447, 457**  
   for tooth etching, 447  
   for tooth preparation, 447  
 Laser systems, 465  
 Laser technology, 477-479  
 Lateral disharmonies of teeth and dental arches, 402-405  
   differential diagnosis of, 402-403  
   treatment of, 403-404, 404-405
- Law**  
   dental practice and, 511-513; see also Legal issues of face, 32-33  
 Le Fort I osteotomy, 419-420  
 Legal forms, 543-553  
 Legal issues  
   breach of terms and, 513  
   with ceramometal restorations, 119  
   with computer imaging systems, 471-472  
   consent as, 513-514
- Legal issues-cont'd**  
   dentist-practice relationship and, 511  
   forms/releases as, 519  
   fraudulent concealment as, 518-519  
   guarantees as, 513  
   health history as, 517-518  
   informed consent as, 514-516  
   loss without fault and, 509  
   with photography, 271  
   records as, 516-517  
   risk management and, 509-511  
   standards of care in, 513  
   statute of limitations as, 518
- Lens of camera, 272  
   macro, 276  
 Lester Dine camera, 279, 280  
 Lester Dine Instant Model 4 camera, 280  
 Leucite-reinforced prefabricated ceramic inserts, 93  
 Ligature, orthodontic, for traumatized teeth in child, 334
- Light**  
   absorption of, all-ceramic restorations and, 139-140  
   natural vs. unidirectional, 27  
   point, 273  
   resins activated by, 93  
   ring, 273  
   shadow and, 27
- Light source**  
   in computer imaging system, 468  
   film exposure and, 273  
   in intraoral imaging system, 466
- Light-cured glass ionomers as liners for composite resin restorations, 75  
 Light-cured resin, for provisional restorations, 201  
 Light-emitting diodes, definition of, 461  
 Line, principle of, 32, 34-35  
 Liners for composite resins, 74-75  
 Lingual access to class III composite resin restorations, 84-85  
 Lingual ramping for alveolar bone defects, 350
- Lip**  
   augmentation and reduction of, 421, 422  
   cleft, 409
- Liquid crystal display, definition of, 461  
 Local anesthetic delivery systems, computer-regulated, 465, 479  
 Luting cements, composite resin, for porcelain-bonded restorations, 152-153  
 Luting of all-ceramic restorations, 147
- M**
- Macro lens**  
   definition of, 461  
   for photography, 276

- Magnification in photography, 274
- Main memory, definition of, 461
- Malocclusion(s); *see also* Bite
- Angle Class III mesiocclusion and, 407-408
  - class II, 406
  - class II distocclusion and, 406
  - labiolingually malpositioned teeth and, 393-395
- Malpractice suits
- procedure for handling, 519-520
  - recent causes of, 510-511
  - traditional causes of, 510
- Mandible
- edentulous, implant position/alignment and, 314-315
  - stent construction and, 320
  - surgery on, 416-419
- Mandibular angle in Angle Class III mesiocclusion, 407
- Mandibular arch
- orthodontics and, 381
  - relation of maxillary arch to, 381
- Mandibular closing pattern in Angle Class III mesiocclusion, 407
- Mandibular incisal angle in Angle Class III mesiocclusion, 407
- Mandibular prognathism, 409
- Mandibular vertical excess, 415
- Manufacturers, list of, 555-581
- Marginal bevels of composite resin restorations, 75
- Margins
- of all-ceramic restorations, placement of, control of, 140-141
  - of **porcelain laminate veneers, integrity of, 153**
  - subgingival, adjusting abutment post and impressioning to achieve, 325**
- Marketing, dental, 499-508**
- case presentation in, 505-506**
  - civic lectures by dentists and staff in, 506
  - community profile in, 502-503
  - definition of, 499-500
  - direct mail in, 506-507
  - external, 500
  - history of, 499
  - in-office educational materials in, 507
  - internal, 500
  - on Internet, 507-508
  - marketing plan in, 503-505
  - objectives of, 500-501
  - patient profile in, 502
  - photography for, 271
  - practice goals and objectives in, 502
  - practice newsletter in, 506
  - product versus service, 501
  - program for, designing, 501-504
  - radio advertisements in, 507
- Marketing, dental-cont'd
- referrals in, 506
  - techniques of, 506-507
  - television advertisements in, 507
  - trends affecting, 500-501
  - yellow pages advertisement in, 507
- Masculine qualities in tooth form, 31, 36
- Masticatory efficiency, orthodontics for, 379
- Material self, 487
- Matrix in establishing occlusal anatomy, 91, 91-92
- Mature minor rule, 514
- Maxilla
- edentulous, implant position/alignment and, 314
  - rehabilitation of, acrylic resin provisional restorations in, 221-222
  - stent construction and, 320
  - surgery on, 419-420
- Maxillary arch
- orthodontics and, 381
  - relation of mandibular arch to, 381
- Maxillary incisors
- central
    - localized spacing of, 389-393
      - anatomically small teeth and, 393
      - congenitally missing lateral incisors and, 393
      - diastema closure and, 389-391, 390-392
      - differential diagnosis of, 389
      - frenum enlargement/malposition and, 391-393
      - supernumerary teeth and, 393
      - treatment of, 389
    - trauma to, in child, 333
  - labioversion of, 393
- Maxillary vertical deficiency, 416
- Le Fort I osteotomy for, 415-416
- Maxillary vertical excess, 415-416
- Measurement, psychology and, 490
- Media influence, 493
- Medical treatment, changed attitudes toward, 493
- Medicolegal considerations; *see* Legal issues
- Megabyte, definition of, 461
- Memory, main, definition of, 461
- Mesiodistal edentulous ridge deformity, 365
- Metal, exposed, fractured porcelain with, repair of, color modifiers in, 63-64
- Metal crown, modified, 206-207
- Metallic pigment in dental porcelains, 113t
- Metamerism, 29-30
- Methyl methacrylate, brands and manufacturers of, 204t
- Microfill resin, 98t, 101
- Minolta Maxxum camera, 279
- Mirrors for photography, 277

- Mobility, tooth  
 adhesive resin bonded cast restorations and, 189  
 pathologic, 375-376
- Model(s)  
 demonstration, porcelain laminate veneers and, 156  
 refractory, porcelain laminate veneer and, 153
- Modem, definition of, 461
- Modular Transitional Implant and Prosthetic System (MTI-MP), 220, 220-221  
 clinical case on, 223
- Molars  
 migrated, correction and uprighting of  
 fixed appliance in, 388  
 removable appliance in, 387  
 relationship of, in Angle Class III mesiocclusion, 407
- Monitor, definition of, 461
- Monochromatic property of laser light, 442
- Mores, 492
- Motivation(s)  
 class II distocclusion and, 406  
 psychology and, 490-491
- Mounted model analysis of implants, 307-308
- Mouse, definition of, 461
- Mouse pen, definition of, 461
- Mouth, psychology and, 489-490
- Multi-image view, definition of, 461
- Multiple-step buildup technique for composite restorations  
 class II, 80-82  
 class IV, 86-88  
 class V 89-90
- Muscles  
 class II distocclusion and, 406  
 lateral disharmonies of teeth and dental arches and, 403  
 orthodontics and, 381
- N
- Nasorespiratory function, class II distocclusion and, 406
- National Television Standards Committee, definition of, 461
- Nd:YAG laser, 441, 477
- Network, definition of, 461
- Nickel hypersensitivity, 118
- Nickel-chromium alloys, 116-117t, 118
- Nikon 120-mm Medical Nikkor camera, 278-279
- Nitrous oxide analgesia for electrosurgery, 294
- Nose surgery, 451-453
- O
- Occlusal adjustments for all-ceramic restorations, 145-146
- Occlusal analysis systems, 476
- Occlusal anatomy, establishing, matrix use for, 91, 91-92
- Occlusal wear of composite resins, 78
- Occlusoapical edentulous ridge deformity, 365
- Onlays  
 porcelain, posterior, 178-181  
 posterior, composite resin, 106-108, 108-110
- Opacity, 30-31
- Opaquers, 53-68  
 chemistry of, 54  
 history of, 53
- Open bite  
 anterior, 401  
 posterior, 401-402
- Operating system, definition of, 462
- Optical disk drive, definition of, 462
- Oral and maxillofacial surgery, 411-426  
 adjunctive procedures in, 421  
 alveolar distraction in, 413  
 bimaxillary, 420-421  
 bone grafting in, 412-413  
 dental implants in, 411, 412  
 facial implants in, 425-426  
 gingivectomy in, 411  
 intraoral procedures in, 411-416  
 lip augmentation and reduction in, 421, 422  
 mandibular, 416-419  
 maxillary, 419-420  
 perioral procedures in, 421-426  
 postoperative care in, 421  
 procedures in, 416-421  
 rhinoplasty in, 425  
 rhytidectomy in, 424  
 skeletofacial procedures in, 413-416  
 skin resurfacing in, 422-423  
 submental liposuction in, 423-424
- Oral cavity, psychology and, 489-490
- Oral hygiene, orthodontics for, 379
- O-ring, retained prosthesis and, 303-304
- Orthodontic ligature for traumatized teeth in child, 334
- Orthodontics, 379-409  
 Angle Class III mesiocclusion and, 407-408  
 bimaxillary prognathism and, 408  
 class II distocclusion and, 406  
 for clinical problems, 382-383  
 closed bite and, 402  
 composite restorations after, 91  
 consent form for, 549  
 dental component assessment for, 380-381  
 diagnostic evaluations for, 379-381  
 excessive overbite and, 402  
 extruded teeth and, 397-398  
 fundamentals of, 382



## Orthodontics-cont'd

- general considerations on, 382-383
  - gross facial deformities and, 408-409
  - intruded teeth and, 398
  - labiolingually malpositioned teeth and, 393-395
  - labioversion of maxillary incisors and, 393
  - lateral disharmonies of teeth and dental arches and, 402-405
  - mandibular arch evaluation for, 381**
  - maxillary arch evaluation for, 381**
  - mobility after, 375**
  - movement types in, 382
  - muscular component assessment for, 381
  - open bite and
    - anterior, 401
    - posterior, 401-402
  - rationale for, 379
  - retention and, 409
  - rotated teeth and, 395-396, 396-397
  - simple anterior crossbite and, 398-400, 399-401
  - skeletal component assessment for, 380
  - spacing in
    - generalized, 383-385
    - localized, 385-393
- Osseointegrated implants, 301-327, 429-438; *see also* Implant prosthesis; Implant(s)
- Osseointegrated implants, temporization of, 215-216
- Osseous grafting in periodontics, 349-350
- Ostectomy
  - buccal, for alveolar bone defects, 350
  - for gingival overgrowth, 373
- Osteotomy (ies)
  - anterior horizontal mandibular, 418-419
  - Le Fort 1, 419-420
  - ramal, 416-417
  - sagittal, 417-418
  - vertical oblique, 417
- Otoplasty, 455
- Output, definition of, 462
- Ovate pontics, 126
  - for edentulous ridge deformities, 366
- Overbite, 393
  - excessive, 402
- Overdenture-retained prosthesis, 303-304
- Overjet of maxillary anterior teeth, 393

## P

- Paint **simulation for porcelain laminate veneers, 154-155**
- Palatal ramping for alveolar bone defects, 350
- Palate
  - cleft, 409

## Palate-cont'd

- expansion of, for posterior crossbite, 403-404, 403-405
- Palladium-silver alloys, 116-117, 118
- Panavia, 186, 187
- Panavia bonding of adhesive resin bonded cast restorations, 195-196
- Papilla
  - atrophied, 365
  - formation of, for implants, 437
  - gingival, implants and, 323
  - hypertrophied, electrosurgery for, 293
  - interproximal, implant position and alignment and, 312
  - malpositioned, electrosurgery for, 293
  - reconstruction of, via connective tissue augmentation, clinical case on, 371, 371-372
  - retained, in periodontics, 349
    - clinical case on, 350-351
- Parallax, dental photography and, 269, 270
- Partially rectified current for electrosurgery, 290**
- Passive matrix display, definition of, 462**
- Patient**
  - interaction of dentist with, 493-494
  - records of, photography for, 270
- Pediatric dentistry, 329-347
  - anterior fixed space maintainers in, 344-345
  - caries in, 335-339
  - compomers in, 339
  - developmental disturbances in, 335-339
  - post and cores in, 342-343
  - removable prosthetics in, 345-347
  - traumatic injuries in, 329-335
    - class I, 330
    - class II, 330-331, 330-332
    - class III, 331-333
    - class IV, 333-334
    - class V, 334
    - class VI, 335
- Pedicle graft, lateral, for gingival recession, 359-360
- Perception, principles of, to control illusion, 32-36
- Periodontal analysis, electronic, 476
- Periodontal protection, orthodontics for, 379
- Periodontal record keeping, electronic, 476
- Periodontics, 349-376
  - alveolar bone defects and, 349-352
  - ceramometal restorations and, 119
  - combined lesion in, esthetic management of, 361-364, 362-365
  - edentulous ridge deformities in, 365-371, 367-372
  - gingival overgrowth and, 372-374
  - guided tissue regeneration in, 349
    - clinical case on, 351-352

- Periodontics-cont'd**  
 inadequate tooth structure for restoration in, 353-358  
   biologic width and, 353-354  
   clinical cases on, 355-358  
   differential etiology of, 353  
   treatment options for, 354-355  
 lingual ramping in, 350  
 open debridement with buccal osteotomy in, 350  
 osseous grafting in, 350  
 palatal ramping in, 350  
 pathologic mobility and, 375-376  
 recession in, 358-360  
 retained papilla technique in, 349  
   clinical case on, 350-351  
   subepithelial connective tissue graft in, 352-353
- Periodontitis**  
 edentulous ridge deformities from, 365  
 gingival recession from, 358  
 pathologic mobility from, 375
- Perioral procedures, 421-426**
- Permission to take photographs, slides, & videos, form for, 547**
- Personal attention, dental marketing and, 500**
- Personality**  
 psychology and, 490  
 tooth form for ceramometal restorations and, 126-127
- Personality types, 487**
- Phenylketonuria, tooth discoloration in, 252**
- Phlegmatic personality, 487**
- Photo CD system, 275**
- Photography, 269-287**  
 Advanced Photo System for, 274-275  
 armamentarium for, 276-278  
 bellows system in, 276  
 cameras in, 269-270, 278-280  
   components of, 271-274  
   digital, 275, 276  
 for case presentation, 270  
 ceramometal restorations and, 119  
 for community service, 271  
 composition in, 274  
 data back in, 277  
 depth of field in, 273-274  
 digital cameras in, 275, 276  
 for education, 271  
 exposure in, 273  
 extraoral technique and, 285-286  
 film for, 277-278  
 film speed and, 272-273  
 flash in, 276-277  
 history of, 269-270  
 for insurance, 271
- Photography-cont'd**  
 intraoral technique and, 280-285  
   for buccal view, 283-284  
   for incisal quadrant view, 285  
   for lateral view, 285  
   for lingual view, 284  
   for mandibular occlusal view, 282-283  
   for maxillary occlusal view, 282  
   for occlusal quadrant view, 285  
 in laboratory communication, 270-271  
 light source for, 273  
 macro lens in, 276  
 magnification in, 274  
 for marketing, 271  
 for medicolegal concerns, 271  
 mirrors and, 277  
 for patient records, 270  
 permission for, form for, 547  
 photo CD system in, 275  
 porcelain laminate veneers and, 156  
 in practice management, 496  
 principles of, 271-275  
 in quality control, 270  
 retractors and, 277  
 technical errors in, 286, 287t  
 in treatment documentation, 270  
 uses of, 270-271
- Photo-oxidation, ultraviolet, 249**
- Pigment, metallic, in dental porcelains, 113t**
- Pink color modifier, indications for, 56**
- Pits in tooth characterization, 530**
- Pixels, definition of, 462**
- Plaque**  
 control of, for gingival overgrowth, 373  
 tooth discoloration from, 252
- Plastic surgery, 451-458**  
 blepharoplasty as, 454  
 Botox in, 458  
 brow lift as, 455, 456  
 collagen injections in, 457  
 computer imaging in, 458  
 facial implants in, 454, 455  
 fat injections in, 457-458  
 Isolagen injections in, 457, 458  
 otoplasty as, 455  
 rhinoplasty as, 451-453  
 rhytidectomy as, 453  
 skin resurfacing in, 457
- Platinum foil backing for porcelain laminate veneer, 153**
- Point light, 273**
- Polaroid Macro 5 camera, 280**

- Polishing  
of acrylic resin provisional restorations, 217-218  
of composite resins, 76  
of porcelain laminate veneers, 175-178
- Polyacid-modified resin composites, 71
- Polycarbonate crowns, 201, 203t, 204-206
- Polyethyl methacrylate, properties of, 202t
- Polyethylene Riber, 213
- Polyglass composite, 98
- Polymer, ceramic optimized, 98t, 100-101
- Polymer rigid organic matrix material (PRIMM), 92
- Polymer-ceramic composite  
Belle-Glass HP as, 98-99  
Sculpture as, 98t, 100
- Polymerization shrinkage  
composite resins and, 72-73, 92  
indirect technique and, 97  
dentin bonding and, 73-74
- Polymethyl methacrylate, properties of, 202t
- Polyvinyl methacrylate, properties of, 202t
- Pontic(s)  
ovate, for edentulous ridge deformities, 366  
for provisional restorations for edentulous spaces, 215  
bonded, for adhesive resin bonded cast restorations, 185  
for ceramometal restorations, design of, 125-126
- Porcelain(s)  
ceramometal, 113-134; see also Ceramometal restorations  
coefficient of thermal expansion of, 114, 114-115  
fractured  
with exposed metal, color modifiers in, 63-64  
with no exposed metal, color modifiers in, 63  
implant and, 315-316  
ingredients of, 113t, 115t  
inlays and onlays of, posterior, 178-181  
low-fusing, 114  
repairs of, color modifiers in, 63-64  
shades of, dominant hue range of, 526t  
staining of, custom, 525-530; see also Staining, custom
- Porcelain jacket crown, 137
- Porcelain laminate veneer(s), 151-178  
advantages of, 153  
cementation of, 171-174, 174-175  
characterization of, 168-169  
chemistry of, 152-153  
clinical case studies on, 181-182  
computer imaging and, 156  
contraindications for, 154  
custom staining of, 171  
development of, 151-152  
diagnostic aids for, 154-156  
disadvantages of, 153-154
- Porcelain laminate veneer(s)-cont'd  
finishing of, 175-178  
history of, 151  
impressioning for, 166  
indications for, 154  
laboratory communications and, 168-169  
laboratory technique for, 153  
patient education on, 156  
polishing of, 175-178  
provisional restorations with, 166-168  
tooth preparation for, 156-165  
diastemata in, 158  
gingival finishing lines in, 158  
incisal preparation in, 158  
labial depth reduction in, 158  
with major color change, 159-165  
with minimal or no color change, 156-158  
proximal contact area in, 156  
proximal finishing lines in, 156, 157  
proximal subcontact area in, 157, 157-158  
static versus dynamic area of visibility in, 156  
treatment planning aids **for, 154-156**  
**try-in** of, 169-171  
wax and paint simulation for, 154-155
- Posts in pediatric dentistry, 342-343
- Potassium-sodium aluminosilicate glasses in ceramometal porcelains, 113
- Practice management, 483-521  
communication in, 495  
computer technology in, 496  
dental marketing in, 499-508; see also Marketing, dental  
ethics in, 496  
financial considerations in, 495-496  
personnel as extension of dentist in, 495  
photography in, 496  
physical environment in, 494-495  
psychologic environment in, 495  
psychology and, 485-496; see also Psychology  
quality assurance in, 496  
risk management in, 496
- Precious alloys, 115
- Pre-eruption trauma, staining from, 251
- Preformed ceramo-base metal crown for primary tooth, 340-341
- Premolars  
celluloid strip crowns for, 206  
migrated, correction and uprighting of  
fixed appliance in, 388  
removable appliance in, 387  
polycarbonate crowns for, 201, 203t, 204-206
- Primary cache, definition of, 462

- Primary tooth/teeth  
 avulsed, 334  
 crowns for, 340-342  
 displaced, labially/buccally, 334  
 intruded, 333  
 orthodontic ligature for, 334  
 pulpectomy on, 332-333  
 pulpotomy on, 332  
 splinting of, 334
- Procera AllCeram restorations, 139
- Procera system, 474
- Profile in Angle Class III mesiocclusion, 407
- Profile photography, 286
- Prognathism  
 bimaxillary, 408  
 mandibular, 409, 414  
 bilateral vertical ramus osteotomies for, 417
- Prosthesis  
 acrylic resin; see Acrylic resin entries  
 implant, 301-327; see also Implant prosthesis  
 removable in child, 345-347
- Protective base in nonvital tooth bleaching, 260-261
- Protocol, definition of, 462
- Provisional fixed bridge technique for stent construction, 319
- Provisional restorations  
 acrylic resin for, 199-224; see also Acrylic resin(s), provisional restoration with  
 adhesive resin bonded cast, 188  
 all-ceramic, 144-147  
 auto-cured resin in, 201  
 ceramometal, 120  
 for coronally debilitated teeth, 214  
 for edentulous spaces, 215  
 implant retained, provisional components for, 216t  
 light-cured resin in, 201  
 porcelain-bonded, 166-168
- Proximal contacts, tight, composite resin and, 80
- Psychology  
 abnormalities and, 491-492  
 affluence and, 492-493  
 age and, 490  
 clinical practice and, 493-494  
 cooperation and, 491  
 cultural influences on, 492  
 decision-making ability and, 491  
 desires and, 490-491  
 developing trusting relationship and, 491  
 evaluation and, 490  
 expectations and, 490-491  
 facial appearance and, 488-489  
 follow-through and, 491  
 history of dental esthetics and, 485-486
- Psychology-cont'd  
 influences on, 490-492  
 measurement and, 490  
 mores and, 492  
 motivations and, 490-491  
 mouth and, 489-490  
 oral cavity and, 489-490  
 personality and, 490  
 physical influences and, 488-490  
 physiologic influences and, 488-490  
 problem patients and, 491-492  
 self concept and, 487-488  
 sex and, 490  
 sociologic influences on, 492-493  
 values and, 492
- Pulp  
 inflammation of, after class II restorations, 78  
 staining related to, 250
- Pulpectomy in child, 332-333
- Pulpotomy in child, 332
- Q
- Quality assurance in practice management, 496
- Quality control photography in, 270
- Quartz in dental porcelains, 113t
- R
- Radiographic image processing system, 463, 464, 475  
 definition of, 462
- Ramal osteotomies, 416-417
- Random access memory, definition of, 462
- Records  
 legal aspects of, 516-517  
 patient, photography for, 270
- Red color modifier, indications for, 56
- Reflection in color perception, 27
- Refraction, all-ceramic restorations and, 139-140
- Refractory model, porcelain laminate veneer and, 153
- Related tooth, 34
- Relationship  
 dentist-patient, 511  
 trusting, developing, 491
- Release(s)  
 of all claims, form for, 552  
 from liability against dental advice, form for, 553  
 in risk management, 519
- Reline technique for provisional restorations, 213-214  
 clinical case on, 222, 223
- Removers, crown, 203t
- Resin(s)  
 acrylic, 199-243; see also Acrylic resin(s)

- Resin(s)-cont'd  
 light-activated, 93  
 bis-GMA  
 color modifiers and, 54  
 development of, 69  
 composite, 69-111; see also Composite resin
- Resin-modified glass ionomer, 71
- Resolution, definition of, 462
- Restoration(s)  
 adhesive resin bonded cast, 185-197; see also Adhesive resin bonded cast restorations  
 ceramometal, 113-134; see also Ceramometal restorations  
 class 111, color modifiers and, 56-58  
 class IV, color modifiers and, 56-58  
 composite resin  
 class I, 76-78  
 class II, 78-82  
 posterior, 91, 92  
 class III, 82-86  
 class IV, 86-88  
 class V 88-90  
 full coverage  
 all-ceramic, 137-147; see also All-ceramic restorations  
 ceramometal, 113-134; see also Ceramometal restorations  
 porcelain-bonded, 151-178; see also Porcelain laminate veneer(s)
- Retained papilla technique in periodontics, 349  
 clinical case on, 350-351
- Retention grooves, 79
- Retention grooves in adhesive resin bonded cast restorations, 187-188
- Retractors for photography, 277
- Retrogenia, 414
- Retrognathia, 414, 415  
 mandibular, sagittal osteotomy for, 418
- RGB signal, definition of, 462
- Rhinoplasty, 425, 451-453
- Rhytidectomy, 424, 453
- Rhytids, skin resurfacing for, 422-423
- Ridge lap pontic, 125, 126  
 modified, 125-126, 126
- Ring light, 273
- Risk management  
 in cosmetic dentistry, 520-521  
 dental, 509-511  
 forms/releases in, 519  
 high-risk treatment areas and, 510-511  
 history of, 509  
 in practice management, 496  
 professional responsibility in, 510
- Rods, functions of, 28
- Root resorption, cervical  
 external, bleaching and, 259-260  
 treatment of, clinical case on, 361-363
- Rotated teeth, 395-396, 396-397
- Rubber dam  
 inversion of, 538  
 patient reactions to, 538-539  
 placement of, ninety-second, 531-539  
 armamentarium for, 531  
 clamp selection in, 531, 532t  
 clinical technique for, 531-537
- S
- Safety of lasers, 448, 477
- Sagittal osteotomy, 417-418
- Sanguine personality, 487
- Sanitary pontic, 125, 126
- Scanner, definition of, 462
- Screw-retained prosthesis, 305-306
- Sculpture, 98t, 100
- Secondary cache, definition of, 462
- Self, concept of, 487-488
- Self theory  
 evolution of, 487  
 relevant constructs in, 487-488
- Self-actualization, definition of, 488
- Self-awareness, definition of, 487
- Self-concept, definition of, 487
- Self-esteem, definition of, 487-488
- Self-evaluation, definition of, 487-488
- Self-help movement, dental marketing and, 500
- Self-image, definition of, 487
- Sensitivity  
 after composite resin restoration, 78-80  
 hue, 29
- Sensor, definition of, 462
- Sex, psychology and, 490
- Shade(s)  
 porcelain, dominant hue range of, 526t  
 of tooth/teeth  
 in acrylic resin provisional restorations, 218  
 laboratory communications on, in porcelain-bonded restorations, 168  
 selection of  
 for acrylic resin removable prosthesis, 232-234  
 for ceramometal restorations, 132-133
- Shadow, light and, 27
- Shell, laboratory produced, for provisional restorations, 213-214  
 clinical case on, 222, 223
- Shutter of camera, 271-272
- Sickle cell anemia, tooth discoloration in, 252



- Shane coupling agents  
for porcelain-bonded restorations, 152
- Silicate restorations, stained, in tooth characterization, 530
- Silver amalgam, staining from, 251-252
- Single density, definition of, 462
- Single lens reflex (SLR) camera system, 269-270, 276
- Single-step buildup technique for composite restorations  
class IV, 86  
class V 88-89
- Sinus lift procedure, implants and, 436-437
- Sinus membrane, violation of, complicating implant, 433
- Skeletal bimaxillary prognathism, 408
- Skeletal causes  
of Angle Class III mesiocclusion, 407  
of class II distocclusion, 406  
of lateral disharmonies of teeth and dental arches, 402-403  
of malocclusions, 380
- Skeletofacial procedures in oral and maxillofacial surgery, 413-416
- Skin resurfacing, 422-423, 457  
cosmetic, laser in, 447, 457
- Small computer system interface, definition of, 462
- Small span bridge implant, 304
- Smile analysis, 541-542
- Social self, 487
- Sociologic influences on psychology, 492-493
- Soft tissue(s)  
compatibility of porcelain laminate veneers with, 153  
emergence profile of, implants and, 326-327  
level of, coordinating abutment height to, 324-325  
management of, for implants, 322-325
- Soft tissue models for ceramometal restorations, 132-133
- Software  
bundled, definition of, 459  
in computer imaging system, 469  
definition of, 462
- Solitaire, 93
- Space maintainer, fixed, in child, 344-345
- Spacing in orthodontics  
generalized, 383-385  
localized, 385-393  
anterior flaring of teeth and, 388-389  
with clinically absent teeth, 385-389  
of maxillary central incisors, 389-393  
migrated anterior tooth and, 385-387  
migrated molars and, 387-388  
migrated premolars and, **387-388**
- Sparking current for electrosurgery, 290**
- Spectrum, 27**
- Speech improvement, orthodontics for, 379**
- Spiritual self, 487**
- Splint Bars, 213-214**
- Splinting**  
cast porcelain-fused-to-metal, for pathologic mobility, 375  
extracoronaral, for pathologic mobility, 376  
intracoronaral, for pathologic mobility, 375-376  
of traumatized teeth in child, 334
- Stained teeth  
anterior veneers and, 102  
from tetracycline, 247-249
- Staining  
chairside, 526-527  
custom, 525-530  
characterization of teeth in, 529-530  
chroma adjustment in, 527-528  
fundamentals of, 525, 526t  
hue adjustment in, 527, 528  
translucency adjustment in, 528-529  
value adjustment in, 528  
of porcelain laminate veneers, custom, 171
- Stainless steel crown for primary tooth, 340, 344  
with esthetic veneers, 341-342
- Standards of care, 513
- Statute of limitations, 518
- Stein pontic, 126
- Stent(s)  
construction of  
acrylic buildup technique for, 318, 319  
implant and, 316-320  
from inadequate or nonexistent removable full denture, 318  
mandibular, 320  
maxillary, 320  
from preexisting removable full denture, 317-318  
provisional fixed bridge technique for, 319  
from removable partial denture, 318  
vacuum form technique for, 319  
in implant placement, 432-433  
restricted position, 317  
variable position, 319-320
- Stylus, definition of, 462
- Subcontact area, proximal in porcelain-bonded restorations, 157, 157-158
- Subepithelial connective tissue graft, 352-353  
for gingival recession, 360
- Sulfethemoglobin, tooth discoloration from, 252
- Super Bond, **187**
- Supernumerary teeth, 393
- Supragingival margins of onlay preparations, 106
- SureFil, 92

- T
- Targis, 98t, 100-101
- Technician, dental laboratory, interaction of dentist with, 494
- Technology, 459-479  
 clinical procedure with, 469-472  
 for esthetic dental workup, 469-470  
 for repair of missing teeth, 471  
 computer, in practice management, 496  
 digital radiographic systems and, 474-475  
 equipment categories in, 463-465  
 information systems and, 463, 463-464  
 intraoral imaging systems and, 465-467  
 medicolegal considerations on, 471-472  
 radiographic image processing systems and, 475  
 treatment systems and, 465, 477-479
- Teeth; see Tooth (teeth)
- Teledentistry, 476-477
- Television, high-definition, definition of, 461
- Temperament types, 487
- Temporomandibular joint protection, orthodontics for, 379
- Terabyte, definition of, 462
- Tetracycline staining, 247-249  
 appearance of, 248  
 mechanism of, 247-248  
 treatment of, 248-249
- Thalassemia, tooth discoloration in, 252
- Thermal expansion, porcelain coefficient of, 114, 114-115
- Thermocatalytic technique of tooth bleaching, 256
- Thermophotocatalytic technique of tooth bleaching, 256
- Through-and-through class III composite resin restorations, 85-86
- Time, porcelain-bonded restorations and, 153
- Tissue(s)  
 architecture of, in abutment selection, 309  
 connective  
 augmentation of  
 for edentulous ridge deformities, 366  
 clinical case on, 367-368, 367-369  
 papillary reconstruction via, clinical case on, 371, 371-372  
 subepithelial, graft of, 352-353  
 guided regeneration of  
 in enhancing anterior esthetics, clinical case on, 363-364, 363-365  
 in **periodontics**, 349  
 clinical case on, 351-352  
 height of, in abutment selection, 310-311  
 management of, ceramometal restorations and, 131
- Tissue (s)-cont'd  
 soft  
 compatibility of porcelain laminate veneers with, 153  
 level of, coordinating abutment height to, 324-325  
 management of, for implants, 322-325
- Titanium alloys, 116-117t, 119
- Titanium plasma sprayed implants, 302
- Tolling of statute of limitations, 518
- Tongue depressor therapy for simple anterior crossbite, 398
- Tooth (teeth)  
 adjacent to implant, impingement on apical area of, 434  
 anatomically small, 393  
 anterior  
 flaring of, correction of  
 fixed appliance in, 388-389  
 removable appliance in, 388  
 migrated, correction of  
 fixed appliance in, 386-387  
 removable appliance in, 385-386  
 area of visibility of, static versus dynamic, porcelain laminate veneers and, 156  
 bleaching of, 247-263; see also Bleaching of tooth/teeth  
 characterization of, in custom staining, 529-530  
 clinically absent, 385-389  
 anterior flaring of teeth and, correction of  
 fixed appliance in, 388-389  
 removable appliance in, 388  
 migrated anterior tooth and, correction of  
 fixed appliance in, 386-387  
 removable appliance in, 385-386  
 migrated premolars/molars and, correction and up-righting of  
 fixed appliance in, 388  
 removable appliance in, 387  
 color of, in acrylic resin provisional restorations, 218  
 coronally debilitated, provisional restorations for, 214  
 crowded, 394  
 and **dental arches**, **lateral disharmonies** of, 402-405  
 discoloration of, types of, 247-253  
 endodontically treated, provisional restorations for, 214  
 eruption of  
 ectopic, electrosurgery for, 293  
 forced, for inadequate tooth structure, 354-355  
 clinical case on, 356-358  
 surgical crown lengthening with, clinical case on, 357-358

- Tooth (teeth)-cont'd**
- eruption of-cont'd
    - passive
      - altered
        - gingival overgrowth from, 373
        - treatment of, clinical case on, 361-363
      - incomplete, electrosurgery for, 293
    - etching of, laser in, 447
    - extruded, 397-398
    - form of, for ceramometal restorations, 126-127
    - guide, 34
    - intruded, 398
    - labiolingually malpositioned, 393-395
    - malaligned, ceramometal restorations and, 129-134
    - missing, repair of, computer imaging system in, 471
    - mobility of
      - adhesive resin bonded cast restorations and, 189
      - pathologic, 375-376
    - older, 35
    - preparation of
      - for adhesive resin bonded cast restorations, 189-195
        - anterior, 189-190, 191
        - miscellaneous, 192-193
        - posterior, 190-192
      - laser in, 447
      - for porcelain laminate veneers, 156-165
        - with major color change, 159-165
        - with minimal or no color change, 156-158
        - static versus dynamic area of visibility in, 156
    - primary
      - avulsed, 334
      - crowns for, 340-342
      - displaced, labial ly/buccally, 334
      - intruded, 333
      - orthodontic ligature for, 334
      - pulpectomy on, 332-333
      - pulpotomy on, 332
      - splinting of, 334
    - protruded, ceramometal restorations and, 129-130
    - reduction of
      - for ceramometal restorations, 120, 130**
      - minimal, for porcelain laminate veneers, 153**
    - related, 34
    - rotated, 395-396, 396-397
    - selection of, for acrylic resin removable prosthesis, 232-237
    - setting of, in acrylic resin removable prosthesis, information needed by technician for, 239
    - shade of
      - in acrylic resin provisional restorations, 218
      - laboratory communications on, in porcelain-bonded restorations, 168
      - selection of, for ceramometal restorations, 132-133
  - Tooth (teeth)-cont'd**
    - shape of, laboratory communications on, in porcelain-bonded restorations, 168
    - stained, anterior veneers and, 102
    - structure of, inadequate for restoration in periodontics, 353-358
    - supernumerary, 393
    - texture of, laboratory communications on, in porcelain-bonded restorations, 168
    - younger, 35-36
  - Translucency, 31
    - adjusting, 528-529
  - Transmission cable
    - definition of, 462
    - in intraoral imaging system, 466
  - Trauma
    - in child, 329-335; *see also* Pediatric dentistry, traumatic injuries in
    - edentulous ridge deformities from, 365
    - gingival recession from, 358
      - free gingival graft for, 360-361
    - inadequate tooth structure from, 353
    - occlusal, pathologic mobility from, 375
    - pre-eruption, staining from, 251
  - Treatment
    - dental
      - changed attitudes toward, 493
      - consent form for, 548
      - documentation of, photography for, 270
    - orthodontic
      - composite restorations after, 91
      - consent form for, 549
  - Trubyte Tooth Indicator, 235
  - True Vitality, 98t, 101
  - Trusting relationship, developing, 491
  - Try-in
    - of all-ceramic restorations, 144-147
    - of castings for ceramometal restorations, 132
    - esthetic, of adhesive resin bonded cast restorations, 194-195
    - porcelain, for ceramometal restorations, 133
    - of porcelain-bonded restorations, 169-171
    - wax, of acrylic resin removable prosthesis, 239-240
- U**
- UCLA-type retained prosthesis, 306
  - Ultraviolet photo-oxidation, 249
  - Uniphasic property of laser light, 442
  - Universal serial bus, definition of, 462/462
  - User interface, definition of, 462
- V**
- Vacuum form technique for stent construction, 319



- Vacuum former unit, 211-212
- Value(s), 492  
of color, 28  
ceramometal restorations and, 127-129  
decreasing, 528  
definition of, 525
- Vectris, 101
- Veneer(s)  
acrylic, crowns of, repair of, color modifiers for, 61-62  
anterior, 101-105  
esthetic, stainless steel crowns with, for primary  
tooth, 341-342  
labial, color modifiers for, 59-61  
porcelain laminate, 151-178; see also Porcelain laminate veneer(s)
- Vertical deficiencies, implant placement for, 432
- Vertical maxillary excess, 414, 415  
bimaxillary surgery for, 420-421
- Vertical oblique osteotomy, 417
- Vestibuloplasty for implants, 437
- Video board in computer imaging system, 468
- Video display in computer imaging system, 468
- Video head, definition of, 462
- Video output device  
in computer imaging system, 469  
in intraoral imaging system, 466-467
- Video storage unit  
in computer imaging system, 468  
in intraoral imaging system, 466
- Vinyl ethyl methacrylate, brands and manufacturers of, 204t
- Violet color modifier, indications for, 54, 55
- Visibility in abutment selection, 308
- Visio-Gem, 98t, 101
- Vitrification, 114
- W
- Wax simulation for porcelain laminate veneers, 154-155
- Web site in marketing, 507-508
- Wellness, influence on, 493
- White color modifier, indications for, 54, 55
- White noble alloys, 116-117t, 117
- White spot lesions, 251, 251-252
- "Witch's chin" deformity, 418
- Work authorization for ceramometal restorations, 132
- World-wide web, definition of, 462
- Wrinkles, skin resurfacing for, 422-423
- X
- Xeroradiography, 474
- Y
- Yashica Dental Eye III camera, 279
- Yellow color modifier, indications for, 54, 55
- Yellow-brown modifier, indications for, 54, 55
- Z
- Zip drive, definition of, 462



انتشارات شایان نمودار