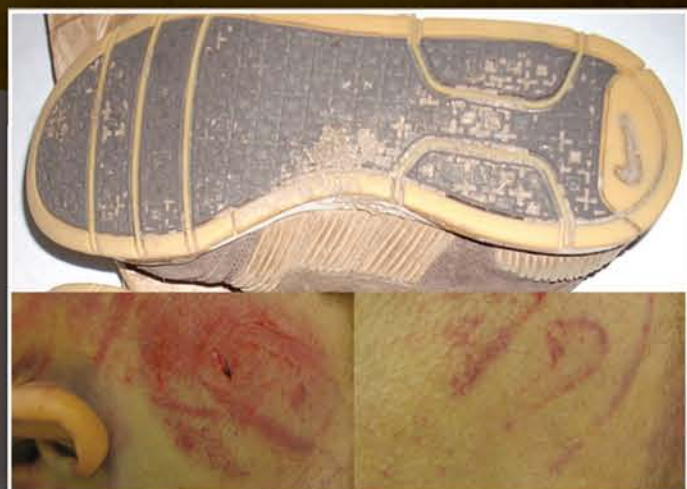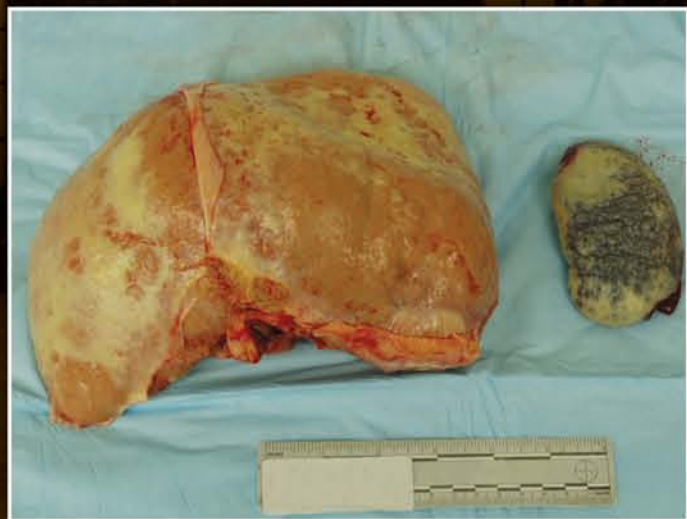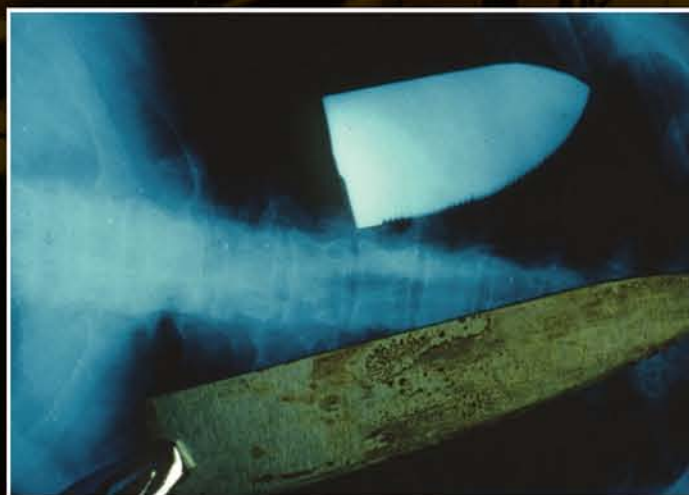


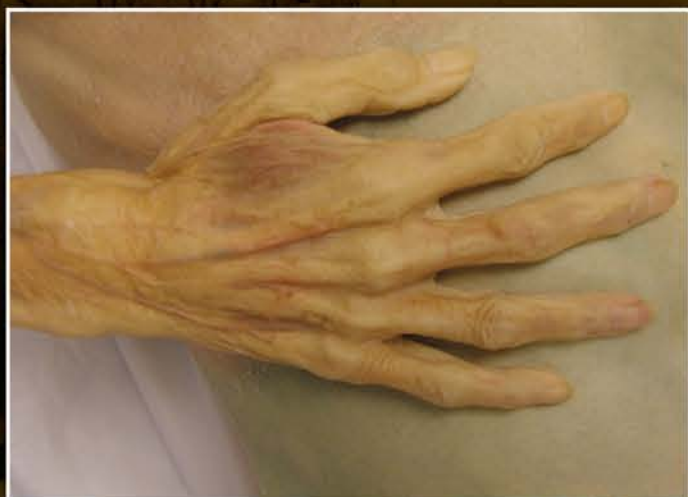# Color Atlas of Forensic Medicine and Pathology



Edited by  
**Charles A. Catanese**

 CRC Press  
Taylor & Francis Group

**Color Atlas of  
Forensic Medicine  
and Pathology**



# **Color Atlas of Forensic Medicine and Pathology**

**Edited by**

**Charles A. Catanese**



**CRC Press**

Taylor & Francis Group

Boca Raton London New York

---

CRC Press is an imprint of the  
Taylor & Francis Group, an **informa** business

Contributor Gina Marie Santucci retains copyright of photo of New York City skyline used on the dedication page and the photo of the morgue used on the back cover.

CRC Press  
Taylor & Francis Group  
6000 Broken Sound Parkway NW, Suite 300  
Boca Raton, FL 33487-2742

© 2010 by Taylor and Francis Group, LLC  
CRC Press is an imprint of Taylor & Francis Group, an Informa business

No claim to original U.S. Government works

Printed in the United States of America on acid-free paper  
10 9 8 7 6 5 4 3 2 1

International Standard Book Number: 978-1-4200-4320-4 (Hardback)

This book contains information obtained from authentic and highly regarded sources. Reasonable efforts have been made to publish reliable data and information, but the author and publisher cannot assume responsibility for the validity of all materials or the consequences of their use. The authors and publishers have attempted to trace the copyright holders of all material reproduced in this publication and apologize to copyright holders if permission to publish in this form has not been obtained. If any copyright material has not been acknowledged please write and let us know so we may rectify in any future reprint.

Except as permitted under U.S. Copyright Law, no part of this book may be reprinted, reproduced, transmitted, or utilized in any form by any electronic, mechanical, or other means, now known or hereafter invented, including photocopying, microfilming, and recording, or in any information storage or retrieval system, without written permission from the publishers.

For permission to photocopy or use material electronically from this work, please access [www.copyright.com](http://www.copyright.com) (<http://www.copyright.com/>) or contact the Copyright Clearance Center, Inc. (CCC), 222 Rosewood Drive, Danvers, MA 01923, 978-750-8400. CCC is a not-for-profit organization that provides licenses and registration for a variety of users. For organizations that have been granted a photocopy license by the CCC, a separate system of payment has been arranged.

**Trademark Notice:** Product or corporate names may be trademarks or registered trademarks, and are used only for identification and explanation without intent to infringe.

---

**Library of Congress Cataloging-in-Publication Data**

---

Color atlas of forensic medicine and pathology / editor, Charles Catanese.

p. ; cm.

Includes index.

ISBN 978-1-4200-4320-4 (hardcover : alk. paper)

1. Forensic pathology--Atlases. 2. Autopsy--Atlases. I. Catanese, Charles. II. Title.

[DNLM: 1. Forensic Pathology--Atlases. 2. Pathology, Clinical--Atlases. W 617 C7186 2010]

RA1063.4.C65 2010

614'.10222--dc22

2009029826

---

Visit the Taylor & Francis Web site at  
<http://www.taylorandfrancis.com>

and the CRC Press Web site at  
<http://www.crcpress.com>

---

# Dedicated

---

*â is book is dedicated to the members of service who lost their lives as a result of the 9/11 attacks, and further dedicated to all those who suffered a loss associated with the aftermath.*





---

# Table of Contents

---

|  |             |
|--|-------------|
| <b>Preface</b>   | <b>ix</b>   |
| <b>Acknowledgments</b>   | <b>xi</b>   |
| <b>Editor</b>  | <b>xiii</b> |
| <b>Contributors</b>  | <b>xv</b>   |
| <b>Research Assistants and Photo Imaging Contributors</b>        | <b>xvii</b> |
| <b>1 Sudden Natural Death in a Forensic Setting</b>              | <b>1</b>    |
| CHARLES A. CATANESE AND AMY V. RAPKIEWICZ                        |             |
| <b>2 Therapeutic Interventions, Complications, and Accidents</b> | <b>57</b>   |
| MICHAEL J. CAPLAN AND CHARLES A. CATANESE                        |             |
| <b>3 Substance Abuse and Poisoning</b>                           | <b>85</b>   |
| CHARLES A. CATANESE AND LAURA M. LABAY                           |             |
| <b>4 Postmortem Change and Time of Death</b>                     | <b>111</b>  |
| CHARLES A. CATANESE, BRUCE LEVY, AND GERARD CATANESE             |             |
| <b>5 Pediatric Forensic Pathology</b>                            | <b>147</b>  |
| MICHAEL J. CAPLAN AND CHARLES A. CATANESE                        |             |
| <b>6 Blunt-Force Injuries</b>                                    | <b>189</b>  |
| CHARLES A. CATANESE AND JONATHAN LUCAS                           |             |
| <b>7 Sharp-Force Injuries</b>                                    | <b>239</b>  |
| CHARLES A. CATANESE  |             |
| <b>8 Gunshot Wounds</b>  | <b>283</b>  |
| CHARLES A. CATANESE, THOMAS GILSON, AND THOMAS ANDREW            |             |
| <b>9 Burns</b>   | <b>353</b>  |
| CHARLES A. CATANESE AND GERARD CATANESE                          |             |
| <b>10 Asphyxia</b>   | <b>373</b>  |
| CHARLES A. CATANESE AND BARBARA K. BOLLINGER                     |             |
| <b>Index</b>   | <b>399</b>  |





---

# Preface

---

While death investigation, and what we have come to understand as “forensic pathology,” has been practiced in one way or another back to antiquity, official designation of forensic pathology as a subspecialty by the American Board of Pathology dates back only to 1956. The subspecialty comprises a small band of trainees in pathology and at any given time there are only 400 to 500 full-time practitioners of the specialty in the United States.

Furthermore, as a recognized subspecialty, forensic pathology is young enough that each of its full-time practitioners can trace his or her roots back to one of the six individuals who sat for that original examination back in 1956. For many of the authors of this volume,

that family tree goes from Lester Adelson through Charles Hirsch and ultimately to us. We acknowledge and are proud of the fact that we stand on the shoulders of giants.

Our collective experiences as trainees and staff at the Office of the Chief Medical Examiner in New York City under the tutelage of Dr. Charles S. Hirsch has made us the forensic pathologists we are today. Our mentor’s emphasis on precision and accuracy in description of findings, translation of these descriptions into language easily understood by a broad range of end users, and the public health importance of our work has left an indelible imprint that we desire to pass on to others. It is our hope that this atlas reflects these qualities.

With sincerest gratitude,

**Thomas Andrew**

*Fellowship Class of 1992*

**Michael J. Caplan**

**Gerard Catanese**

**Bruce Levy**

*Fellowship Class of 1993*

**Thomas Gilson**

**Charles A. Catanese**

*Fellowship Class of 1995*

**Barbara K. Bollinger**

**Jonathan Lucas**

*Fellowship Class of 2000*



---

# Acknowledgments

---

I would first like to thank my parents, S. John Catanese and Helen J. Amendola, and my grandparents, with a special thanks to my grandfather, Anthony J. Amendola, who taught me a strong work ethic and instilled a driving force to succeed while helping others. I would also like to thank my older brother, Anthony Catanese, MD, who first excited my interest in pursuing a career in medicine.

I would like to thank my judo sensei, Hank Kraff, who taught me how to defend myself, the nature of competition, and the value of pursuing an education.

I would like to thank my analytical chemistry professor at St. John's University, Richard E. Cover, PhD, whose kind nature and brilliant thought first excited my interest in the field of forensics.

I am grateful to Edward Laski, MD, PhD, who instilled in me an interest and understanding of psychiatry during medical school at SUNY Downstate, which led me to further understand different motivations leading to death.

I would like to thank Alistair Cunningham, MD, Dominick DiMaio, MD, Thomas Athanassiades, MD, Martin J. Salwen, MD, and Theresa DiMaio, MD, who taught me autopsy pathology during medical school and residency training at Downstate Medical Center/Kings County Hospital in Brooklyn, NY.

My fellowship training in forensic pathology was by Charles S. Hirsch, MD, at the New York City Office of the Chief Medical Examiner. My gratitude goes to Dr. Hirsch again for being such a great teacher and mentor.

I would also like to thank Maria Luz Alandy, MD, Joaquin Gutierrez Jr., MD, Thomas Andrew, MD, Gerard Catanese, MD, Kari Reiber, MD, Vernon Armbrustmacher MD, and Joseph Veress, MD for their patience in teaching and mentoring me as a junior attending in the New York City Medical Examiner system.

Thanks to Charles V. Wetli, MD, and Stewart Dawson, MD, who taught me many important concepts about forensic medicine while I worked for several years giving locums coverage at the Suffolk County (New York) Medical Examiner's Office.

I would like to thank all the NYC Medical Examiners, and the New York City Office of the Chief Medical Examiner for giving me access to many high quality academic images. More specifically, I thank Corinne Ambrosi, MD, Vernon Armbrustmacher, MD, Barbara Bollinger, MD, Stephen deRoux, MD, Thomas Gilson, MD, James Gill, MD, Lara Goldfeder, MD, Beverly Leffers, MD and Kristen Roman, MD.

I would also like to thank the Photography Department, the interns and clerical staff who assisted on this work over several years, and without whose help this publication would not have happened.

I would like to thank the Brooklyn District Attorney's Office and the New York City Police Department for always following through and maintaining the highest standard of work and professionalism in a harsh environment. Included in this is a special thanks to the Brooklyn North and South Homicide Divisions, with a very special thanks to Louis Savarese, Detective First Class, retired, and Terence Murnane, Detective First Class, retired.

Finally, I would like to thank the Orange County Executive, Edward Diana; the Orange County Commissioner of Health, Jean Hudson, MD; and the Orange County Deputy Commissioner of Health, Chris Dunleavy, for giving me the opportunity to serve the public and for helping me establish Orange County's first medical examiner system.

My sincerest thanks to all of you,

**Charles A. Catanese**



---

# Editor

---

**Charles A. Catanese, MD** completed his medical school education at SUNY Downstate and his residency training at State University Hospital—Kings County Hospital complex in Brooklyn, New York. He is board certified by the American Board of Pathology in Anatomic Pathology and Forensic Pathology. Following his forensic pathology fellowship training in New York City, he was employed as a full time medical examiner in the Brooklyn office of New York City for more than 10 years. He has performed in excess of 4000 autopsies, including more than 400 homicides, and has supervised many more. As educational coordinator of Brooklyn, he accumulated many academic images demonstrating a wide variety and

spectrum of presentation for many forensic topics. The Brooklyn Office is the busiest of the five boroughs and New York City has the largest medical examiner's system in the country. Dr. Catanese has also worked as a private consultant for many years and has provided locums coverage in the States of New Hampshire, New Jersey, Tennessee, Rhode Island, Vermont, and New York. He also worked through several disasters including TWA Flight 800, AA Flight 587 and more than 9 months on the World Trade Center fatalities. He is currently the Chief Medical Examiner of Orange County New York, where he established and converted that office from a preexisting coroner system.



---

# Contributors

---

**Thomas Andrew, MD**

Chief Medical Examiner  
State of New Hampshire  
Concord, New Hampshire

**Barbara K. Bollinger, MD**

Deputy Chief Medical Examiner  
Orange County, New York

**Michael J. Caplan, MD**

Pediatric and Forensic Pathologist  
Mercy Hospital-Cadillac  
Cadillac, Michigan  
and

Department of Pathology and Laboratory Management  
Medical University of South Carolina  
Charleston, South Carolina

**Gerard Catanese, MD**

Deputy Medical Examiner  
Nassau County, New York  
East Meadow, New York

**Thomas Gilson, MD**

Chief Medical Examiner  
State of Rhode Island  
Providence, Rhode Island

**Laura M. Labay, PhD**

Forensic Toxicologist  
National Medical Services Laboratory  
Willow Grove, Pennsylvania

**Bruce Levy, MD**

Chief Medical Examiner  
President and CEO Forensic Medical  
State of Tennessee  
Nashville, Tennessee

**Jonathan Lucas, MD**

Deputy Medical Examiner  
San Diego County, California  
and  
Associate Clinical Professor  
Department of Pathology  
University of California at San Diego  
San Diego, California

**Amy V. Rapkiewicz, MD**

Director of Autopsy Service  
Director, Anatomic Pathology  
New York University/Bellevue Hospital  
New York, New York





---

# Research Assistants and Photo Imaging Contributors

---

**Vanessa Cannone**

Autopsy/Research Assistant  
Orange County, New York

**Jim Carlson**

Department of Forensic Imagery and Radiology  
New York City Office of the Chief Medical Examiner  
New York, New York

**Patrick Horan**

Autopsy/Research Assistant  
Orange County, New York

**Salwa Jwayyed**

New York City Police Department  
New York, New York

**Jaclyn McCarthy**

Autopsy/Research Assistant  
Orange County, New York

**Jennifer McMahon**

Medical Investigator  
Orange County, New York

**Tarin Romich, MPH**

Osteopathic Medical Student  
New York College of Osteopathic Medicine  
Old Westbury, New York

**Gina Marie Santucci**

Department of Forensic Imagery  
New York City Office of the Chief Medical Examiner  
New York, New York



---

# Sudden Natural Death in a Forensic Setting

# 1

CHARLES CATANESE AND AMY V. RAPKIEWICZ

---

## Introduction

---

This chapter offers a brief overview of some common and some not so common natural deaths that typically may occur in a medical examiner system. Also demonstrated are examples that may alter appearance of tissue such as formaldehyde fixation and variation due to different types of photographic imagery. There are also examples of normal organs in both a fresh and formaldehyde fixed state that can be used by the reader to compare with diseased organs.

Deaths under this category are often unexpected and sometimes unwitnessed. There is often a suspicion of foul play. Families may say, "But Doctor, he was in fine health. I saw him an hour ago. It cannot be natural. Somebody must have harmed him," etc. Because of the sudden, often unexpected nature of these deaths, it is best to do an autopsy to clarify exactly what happened. This decision to autopsy depends on many factors, including the decedent's age, medical history, family wishes, decedent's wishes (wills, etc.), religious beliefs, circumstance at time of death, resources of a particular system, etc. As one becomes less certain of the cause of death, the level of suspicion will increase. At some point, the decision to autopsy becomes obvious and absolutely necessary. This decision is based on experience, knowledge, and sound judgment. Not infrequently, seemingly natural deaths can have unnatural or traumatic previous circumstances; therefore, when uncertain, an autopsy is best performed. In many medical examiner systems, the majority of deaths end up being certified as natural.

Sudden death is defined in different ways. It may indicate a death that occurs within 24 hours of the onset of symptoms. It may also indicate the death occurred within 1 hour or even within seconds. There are not many diseases that can cause death within minutes of the onset of symptoms. Natural death means the manner of death is exclusively or 100% natural. If there is a 1% component of another manner of death, it is no longer natural. If there are multiple components of different manners of death commingled in a case investigation, the following rule will apply: a homicide overrides all, then an accident, then a therapeutic complication. A suicide requires the establishment of intent to do harm to oneself. For example, someone with end-stage

metastatic liver cancer ingests 100 acetaminophen tablets to commit suicide. In the process of waiting to die, he decides to walk to a store. On the way, he trips in a pothole, falls in the street, strikes his head, and has an expanding subdural hemorrhage. While he is lying there waiting for EMS, a stolen car fleeing the scene of a robbery runs him over, lacerates his heart in half, and he dies within seconds. The manner of death in the case would be homicide. The death occurred as a result of being run over by a car during an illegal act. A lacerated heart is universally fatal regardless of the other violent and natural processes. The death certificate should include only the trauma from the car. If the trauma from the car was not lethal by itself, one may add "other finding" to part two of the cause of death, but the manner would remain homicide.

## Heart Disease

Heart disease leading to ventricular irritability to create a lethal arrhythmia is the most significant cause of death in this category. The most common arrhythmia leading to sudden cardiac death is ventricular fibrillation. Ventricular tachyarrhythmias are most commonly seen within 12 hours of a myocardial infarction. Critical coronary atherosclerosis and hypertension are by far the leading causes of these processes. Some diseases that contribute to atherosclerosis and arteriosclerosis formation include hyperlipidemia, high blood pressure, diabetes mellitus, obesity, cigarette smoking, stress, and sedentary life style.

Having 75% or greater blockage in any of the epicardial vessels is considered critical stenosis and is consistent with being alive one second and having loss of consciousness leading to death the next. Hypertensive cardiovascular disease is usually essential in origin from an intrinsic abnormality of sodium metabolism. Other significant causes of hypertension include many types of kidney disease including adult polycystic kidney disease and renal artery stenosis. Hypertension may be sporadic and missed on routine doctor appointments. High blood pressure is also associated with small-vessel coronary artery disease, as is diabetes mellitus, which is a reasonable cause of death by itself. Once people reach a pivotal point of myocardial irritability and go

into ventricular fibrillation they usually have approximately 15 seconds of consciousness left. Prior to losing consciousness, decedents may reach up to chest or neck and mention a fluttering sensation in the chest. They may have pressure, pain, or no expectation of what is to come. Ventricular irritability associated with coronary artery ischemia is due to lack of oxygen and nutrients reaching the conducting system of the heart. If the heart is not cardioverted back to a normal rhythm within 4–6 minutes, there is usually irreversible brain damage.

Another major cause of ventricular irritability leading to fatal arrhythmia is hypertension. Concentric left ventricular hypertrophy usually defined at autopsy as having a left ventricular wall thickness greater than 1.5 cm for most average-sized adults is a known risk factor for sudden cardiac death. Left ventricular thickness is best measured approximately 2 cm below the mitral valve annulus and excludes trabeculations and papillary muscles. As the disease process causing cardiac hypertrophy advances, heart failure may ensue with chamber dilatation. Although the overall heart size is enlarged, the left ventricle wall thickness may be less than 1.4 cm. Although hypertensive disease is the major risk factor for the development of left ventricular hypertrophy, other risk factors include aortic stenosis, either congenital or acquired. The hearts of patients with hypertensive or arteriosclerotic cardiovascular disease typically show evidence of prior infarction and interstitial fibrosis. Both findings also predispose to myocardial irritability and fatal (tachy)arrhythmias.

Complications other than tachyarrhythmia and pump failure of myocardial infarctions can result in sudden cardiac death; the most common include the myocardial rupture syndromes including ventricular wall and papillary wall rupture. Typically, these insults occur approximately 1 week following a myocardial infarction, the point at which there is removal of necrotic myocytes by macrophages. Hemopericardium with ensuing cardiac tamponade can occur following ventricular free wall rupture; this scenario is rapidly fatal in most cases, causing decreased venous return to the heart with jugular venous distention.

In young patients, particularly athletes, hypertrophic cardiomyopathy is not an uncommon cause of sudden death. These patients can be asymptomatic prior to the sudden event or may have past episodes of palpitations or syncope. Typically, macroscopic heart evaluation shows cardiac hypertrophy with significant asymmetry of the subaortic septal region, which poses as an outflow obstruction. Microscopic sections from this region show variable degrees of myocyte disarray, fibrosis, myocyte hypertrophy, and small-vessel disease. The disease is due to an autosomal dominant mutation in the cardiac

sarcomere apparatus, most commonly the myosin heavy chain, but many mutations have been described.

Arrhythmogenic right ventricular cardiomyopathy can present with sudden unexpected death. At autopsy, the right ventricle is thinned, with microscopic evaluation showing significant transmural infiltration by fibrofatty tissue.

Myocarditis due to a variety of causes including viral, bacterial, fungal, parasitic, autoimmune, and hypersensitivity can present as sudden death. The degree of activity, myonecrosis, and the location of the inflammation (i.e., conduction system involvement) are important in determining the significance of the infiltrates. Notably, eosinophils are seen quite commonly in hypersensitivity myocarditis and can be a clue to the underlying etiology.

Dilated cardiomyopathy is common, and has many etiologies that include idiopathic arteriosclerotic disease, hypertensive cardiovascular disease, alcoholism, elevated catecholamines, myocarditis, postpartum, doxorubicin, endocrinopathies, and genetic diseases. The heart typically is enlarged with a globoid configuration. The microscopic analysis shows interstitial fibrosis.

Rare infiltrative cardiac disease such as amyloidosis, hemochromatosis, primary or metastatic tumors, and sarcoidosis can result in sudden death. Microscopic evaluation in these cases is necessary, with particular attention to nodal tissues.

*S. aureus* is the most common organism found in infective endocarditis (IE). *S. aureus* endocarditis is associated with the highest mortality and risk of embolism. Increasing age, periannular abscess, heart failure, and absence of surgical therapy were identified in multivariate analysis as independent poor prognostic factors for increased mortality in patients with *S. aureus* IE. Other risk factors for the development of IE include congenital or acquired anatomic valve abnormalities such as stenosis. Impaired cardiac conductivity and function with heart failure not infrequently develops in patients with multiple septic myocardial emboli and infarcts due to IE, particularly with paravalvular abscess formation. According to a recent study of a cohort of 606 cases of infective endocarditis, 99 cases have embolization, of which 32 cases involve the central nervous system (CNS) with significantly higher mortality (65%) than those without CNS emboli.

Recently, genetic abnormalities have been found to underlie many of the intrinsic abnormalities of conducting systems including Wolff–Parkinson–White syndrome (WPW) and long Q-T syndrome. Sudden death in WPW is thought to occur as a result of an induction of ventricular tachycardia via an atrioventricular re-entry pathway. Long-QT syndrome can also present

with sudden death. Investigations are ongoing around the association of sudden infant death syndrome with long-QT syndrome. Recent data is suggesting that a genetic basis for the arrhythmogenic disease with the identification of the long-QT genes.

Sudden death related to cardiac valve pathology other than endocarditis is relatively uncommon, as valve replacement surgery has become a standard therapy. Patients with aortic stenosis, especially when acutely symptomatic, can experience sudden cardiac death. Most cases of aortic stenosis are caused by either rheumatic heart disease or valve calcification, which can occur on trileaflet or congenitally (uni)bicuspid valves. The mechanism for death in severe aortic stenosis (valve area <1cm<sup>2</sup>) appears to be through left ventricular hypertrophy and subsequent myocardial instability. In rare instances of severe aortic valve calcification, the deposits can erode the region and involve the conduction system. Mitral valve prolapse has long been associated with sudden cardiac death. The underlying etiology is not well understood, but seems to most frequently involve a severe valve deformity with a redundant, thickened, myxomatous mitral valve and ventricular arrhythmias such as ventricular fibrillation. On histologic sectioning, the mitral valve will show deposition of acid mucopolysaccharides.

Coronary artery anomalies are not uncommon but only certain anomalies result in ischemia such as anomalous origin of a coronary artery from the opposite sinus (ACAOS), anomalous left coronary artery from the pulmonary artery (ALCAPA), ostial atresia/stenosis, and coronary artery fistulas. Left-sided ACAOS can result in acute takeoff angles with an increased risk of sudden death during or shortly after exercise. Besides the acute angle take off, there maybe ridge like defect at the coronary ostia further decreasing blood flow in times of accelerated heart rates with increased oxygen demand. Myocardial tunneling is another anomalous coronary artery distribution that maybe associated with increased arrhythmogenic potential. There is debate about the significance of this anomaly. Some still believe it may be significant when a large portion of the epicardial coronary artery dips deeply into the left ventricle wall for a considerable distance, during times of rapid muscle contraction.

### Vascular Disease

Causes of sudden death associated with vascular disease include those that lead to occlusion, narrowing, or rupture of a blood vessel. Atherosclerotic aneurysms can rupture, leading to rapid loss of consciousness and death. These aneurysms can occur just about anywhere, but are by far most common in the abdominal

aorta. Most abdominal aortic aneurysms occur below the renal artery. The risk of rupture increases with the size of the aneurism, smoking history, and hypertension. The annual risk of rupture over 7 cm in size is 33%. Retroperitoneal rupture is typically associated with hematoma formation, whereas rupture into the abdominal cavity can be rapidly fatal, with hemoperitoneum and shock. Patients who have a ruptured aortic aneurysm and reach the hospital have a 50% mortality rate, with the overall mortality rate greater than 85%.

Aortic dissection is characterized by an intimal tear followed by a dissection of blood within the wall of the aorta, most commonly the tunica media. Rupture of this dissecting aortic hematoma may lead to hemothoraces, hemopericardium, or fatal arrhythmia. Aortic dissection is a major cause of sudden death, mostly in patients over 50 years of age with the underlying risk factor being essential hypertension. However, pregnant women and patients with connective-tissue diseases such as Marfan's syndrome also make up a significant affected patient population. Aortic dissection can also occur following accidental or iatrogenic trauma to the aortic intima. In younger patients and those with connective tissue disease, microscopy may reveal cystic medial degeneration of the aortic media.

Most spontaneous subarachnoid hemorrhages (SAH) (90%) are caused by ruptured intracranial saccular (berry) aneurysms. SAH occurs at a peak age of 55–60 years. Rupture of an intracranial aneurysm is believed to account for 0.4 to 0.6% of all deaths. SAH is associated with a greater than 50% mortality rate. Some hospital-based studies suggest that approximately 10% of patients with aneurysmal SAH die prior to reaching the hospital, 25% die within 24 hours of SAH onset, and about 45% die within 30 days. It is not unusual to perform forensic autopsies where death was almost instantaneous and outside of a hospital. The mechanism of death in such cases is cardiac arrhythmia, which is described in greater depth later. Most intracranial aneurysms (approximately 85%) are located in the anterior circulation, predominately on the circle of Willis. Risk factors for both SAH and intracranial aneurysms are similar and include hypertension, cigarette smoking, and alcohol consumption. Atherosclerosis is an independent risk factor for the development of intracranial aneurysms. The natural history of subarachnoid hemorrhage shows that rupture often occurs when they reach a size over 7 mm. Rupture of an aneurysm releases blood directly into the cerebrospinal fluid (CSF) under arterial pressure. The blood spreads quickly within the CSF, rapidly increasing intracranial pressure. A major symptom associated with SAH includes patients describing the worst headache of one's life. Increased intracranial

pressure is associated with the Cushing's triad (hypertension, bradycardia, and abnormal respiration). SAH is associated with cerebral edema and subsequent herniation. Tonsillar and central transtentorial herniation is associated with compression of cardiovascular and respiratory centers in the medulla and as such is rapidly fatal. Other less common causes of subarachnoid hemorrhages include angiomas and arteriovenous malformations. Ruptured berry aneurysms are the most common natural cause of SAH, whereas trauma is the most common overall cause. Ruptured berry aneurysms are a leading cause of sudden death in women during sexual activity, whereas for men it is heart disease.

Cerebrovascular accidents (episodes), which include ischemic or intracerebral hemorrhage, can lead to sudden death. I recommend not using the term "accident" because there is nothing accidental about this process and its use often adds confusion in forensic proceedings. The terms "stroke" or "event" as an alternative is less confusing to nonmedical personnel. Thromboembolic events can underlie ischemic cerebral events and are associated with heart disease, valvular pathology, or carotid artery disease. Hypertension is a major risk factor for intraparenchymal hemorrhage and may lead to increased intracranial pressure, herniation, and death.

The greatest percentage of thrombi resulting in pulmonary embolism is thought to originate in the deep veins of the lower extremities. Deep-venous thrombosis can also occur in the pelvis or other locations. Fragments of blood clot may break off and embolize to the pulmonary arteries. An occlusion greater than 50 to 75% of the large pulmonary vessels results in a rise of the pulmonary artery pressure greater than 40 mmHg. This rise of pulmonary arterial pressure is accompanied by an increase in right ventricular diastolic, right atrial, and systemic venous pressures, with a decrease in cardiac output resulting in sudden death. Patients who have multiple small pulmonary emboli or in situ thrombus formation over time may present with increasing shortness of breath and right-sided heart failure. Because the lungs have dual circulation, infarctions are less common unless there is significant underlying natural disease with decreased cardiac function.

Various types of vasculitis or blood vessel inflammation can cause wall thickening, thrombosis, dissection, and rupture. Mesenteric thrombosis may be associated with polyarteritis nodosum and other autoimmune conditions.

### Other Causes of Sudden Death

Rare undiagnosed brain tumors may present with sudden death. Infiltration or edema formation into the key respiratory/cardiac centers of the brain with

possible herniation are two mechanisms. Early or late stage malignancies may sometimes metastasize to the heart and interfere with the conducting system, causing a fatal arrhythmia. Other causes of sudden death in patients with malignancies include cardiovascular events such as acute myocardial infarction, therapeutic complications (i.e., anaphylaxis), and metabolic derangements. Rare causes of sudden death in patients with tumors or malignancies include erosion of large vessels or visci with fatal hemorrhage. A colloid cyst of the third ventricle may lead to sudden death and is usually associated with premortem postural headaches. In certain positions, the cyst will act like a ball valve and suddenly block the flow of cerebral spinal fluid, resulting in acute obstructive hydrocephalus. One may be fine standing but develop symptoms when he or she lies down. This buildup of cerebral spinal fluid pressure can cause a fatal arrhythmia. Bacterial pneumonia with the combination of hypoxia and bacterial toxins and end products can cause sudden death.

Status asthmaticus and sudden asphyxic asthma are life-threatening forms of asthma. These cases are not unusual in a forensic setting. Status asthmaticus is defined as an acute attack of respiratory failure due to airway inflammation, edema, and mucous plugging. Sudden asphyxic asthma is due to bronchospasm rather than airway inflammation. Viral infections and other causes have been implicated as precipitants of these potentially fatal complications. Grossly in both cases, the lungs may appear so much hyperaerated that at times rib indentations will show. Thick mucus plugs may obstruct the upper airways. Sudden death in asthmatic patients is thought to be secondary to fatal arrhythmia, occurring as a consequence of global hypoxia and right heart failure.

There is a condition known as sudden unexpected death in epilepsy (SUDEP). The mechanism is unclear but this phenomenon occurs in up to 18% of patients with epilepsy, presumably in those with subtherapeutic levels of anticonvulsants. Autonomic dysfunction has been proposed as a mechanism. Other mechanisms for death in patients with epilepsy include accidental/traumatic incidents such as drowning and choking that occur during a seizure. Hypoxia as a result of respiratory compromise can result in ischemic cardiac events. This may be part of the final mechanism of death in epileptic patients experiencing status epilepticus. Another interesting point to remember is that there is often very rapid rigor mortis formation in deaths directly following static epilepticus due to substantial adenosine triphosphate (ATP) depletion associated with prolonged muscle contractions from prolonged convulsions. Usually there are few pathologic findings that explain the sudden death

in epileptic patients. Autopsy findings may include bite marks to the tongue with hemorrhage or a voided urinary bladder. There may be no finding at all. These are nonspecific findings and seizure activity may also occur prior to many other nonepilepsy-related deaths.

Fatal anaphylaxis can result from exposure to insect stings, foods, latex, drugs, chemicals, and exercise. This mast cell-mediated systemic reaction results in severe angioedema and bronchoconstriction of the upper respiratory tract along with hypotension resulting in respiratory and circulatory collapse. Death caused by anaphylaxis is primarily due to airway obstruction when laryngeal edema fills the rich lymphatic supply of the epiglottic folds. Increased mast cell tryptase levels in the patient's serum can be detected that peaks approximately 15 to 60 minutes after the onset of anaphylaxis and then declines with a half-life of about 2 hours.

The mortality for gastrointestinal bleeding (GI) in the case of ruptured esophageal varices most commonly encountered in patients with portal hypertension is high. Intra-aortic balloon pumps are lifesaving procedures but only if the patient presents in a timely fashion. Other causes of fatal upper gastrointestinal bleeding include stomach and duodenal ulcers; in this scenario the source is arterial as opposed to venous in esophageal varices. Fatal lower gastrointestinal bleeding can be seen in patients with angiodysplasia, diverticulitis, and carcinoma; however, this scenario is less common than upper GI bleeding.

Mostly complications of morbid obesity are thought to underlie the association with sudden death. Hypertension, left ventricular hypertrophy, and

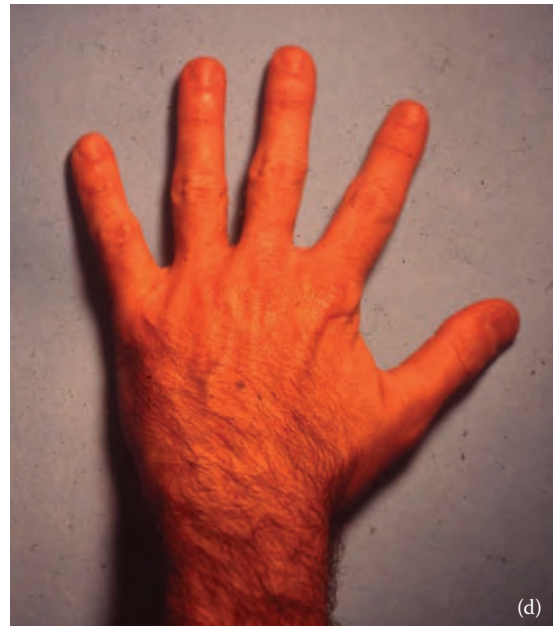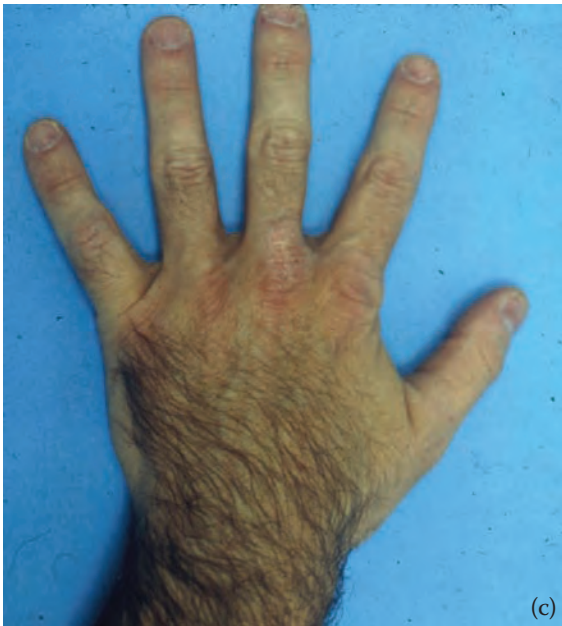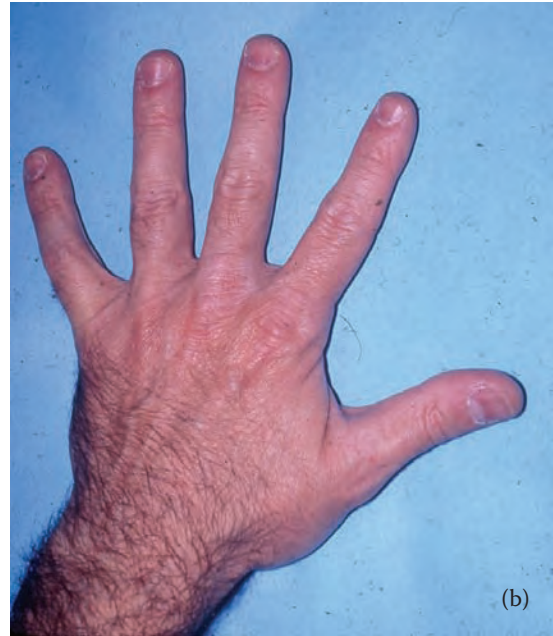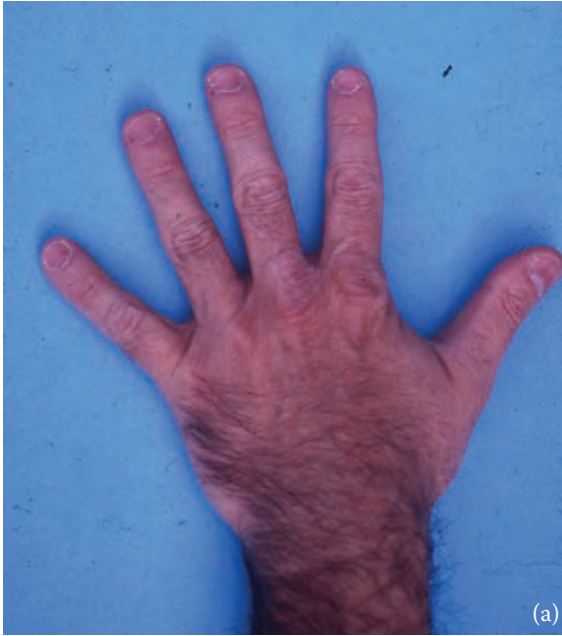cardiomegaly are all independent risk factors for sudden death. Postural asphyxia may occur as a result of obesity. Morbid obesity is a reasonable cause of death by itself due to stress on the heart. An individual who is three times the expected body weight has roughly three times the vasculature with three times the blood volume to pump. In times of other stress, this can have devastating consequences on the heart, with death by arrhythmia.

Waterhouse–Friderichsen syndrome was first described as occurring in patients with meningococemia and is characterized by severe bacteremia and bilateral adrenal hemorrhages. This combination results in overwhelming shock and, if untreated, sudden death can occur. Organisms other than *N. meningitidis*, such as *E. Coli*, have been reported to produce this syndrome.

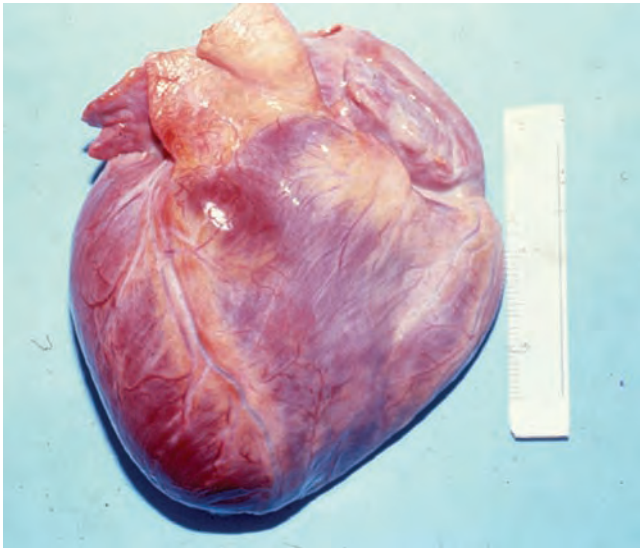
Multiorgan failure and death can be seen in sickle cell anemia patients with an acute crisis. Precipitants may include infection, dehydration, hypoxia, physical exertion, vaso-occlusion, or fat embolus following bone infarction. This acute hemolytic sickling crisis results in severe hypoxemia with end organ failure. Patients with sickle cell anemia have auto-infracted spleens and are much more susceptible to encapsulated organisms such as pneumococcal bacteria. Even patients with sickle cell trait may develop crisis in times of great physical exertion with dehydration, such as basic training in the army or boot camp.

Natural disease processes may weaken the body, making fatal traumatic injury more likely. Osteoporosis from aging, Cushing syndrome, steroid use, and other natural disease processes will make bones more fragile and allow fractures to occur more easily.

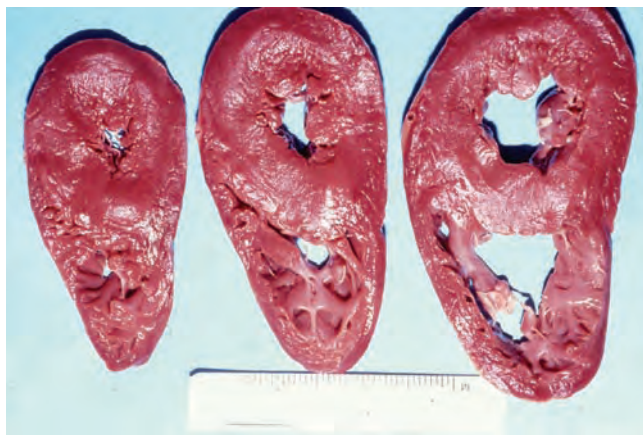
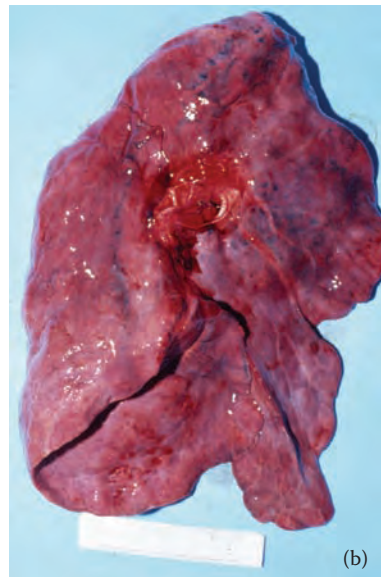
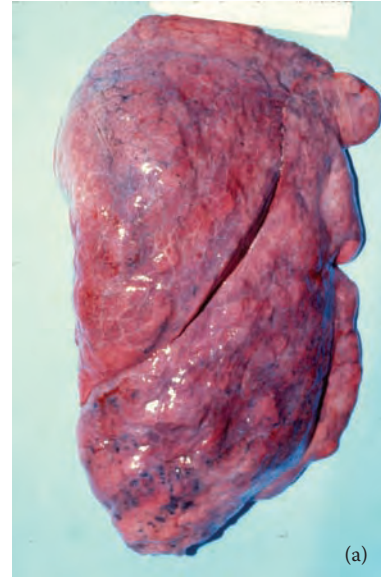




When examining photographic evidence it may be important to have knowledge of the type of camera, film, and lighting used when documenting different disease states. These four photos demonstrate different types of lighting causing variation in picture color. Figure (a) was taken in overcast sunlight, (b) with camera flash, (c) under fluorescent light, and (d) with a Tungsten filament regular light bulb. If your opinion is that a photographic image is not interpretable, it is perfectly acceptable to say that you cannot render an opinion based on this two-dimensional image.

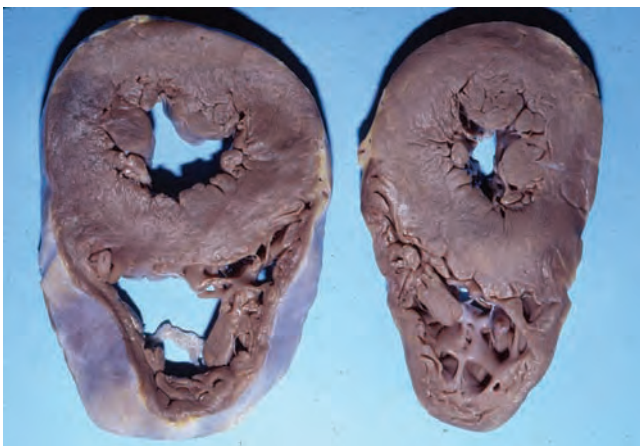

Normal fresh heart.

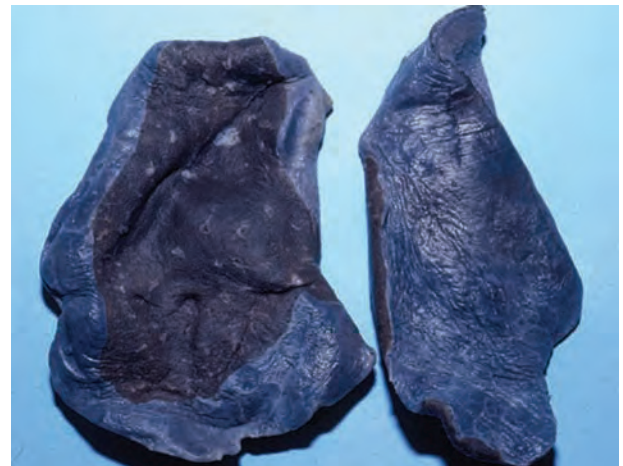

Sections of a normal fresh heart showing right and left ventricle.

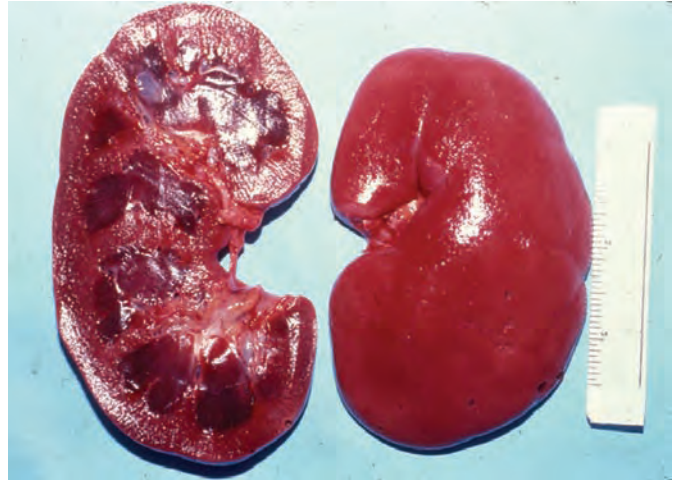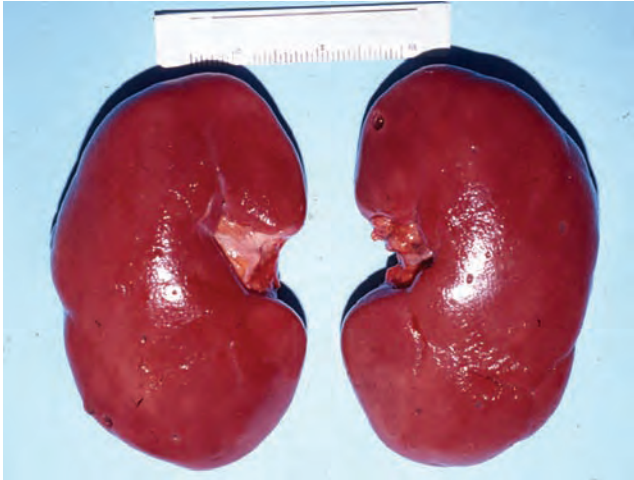
Normal fresh left lung (a) demonstrating two lobes. Right lungs (b) have three lobes.



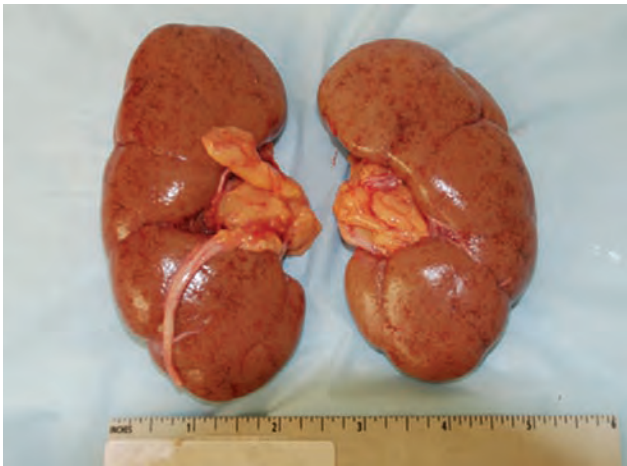Sections of normal right and left ventricle after formaldehyde fixation.



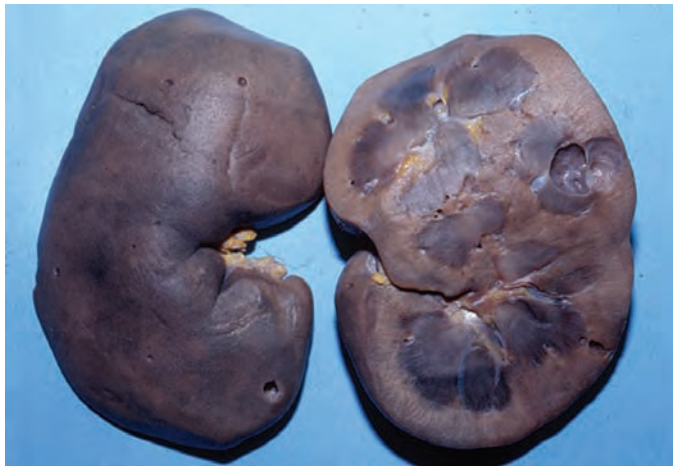Normal lung fixed in formaldehyde.



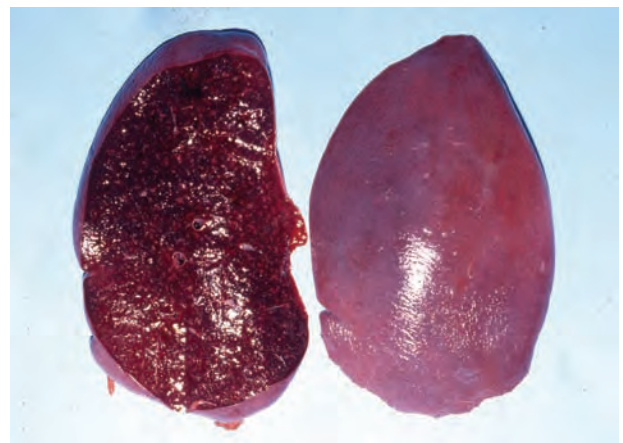
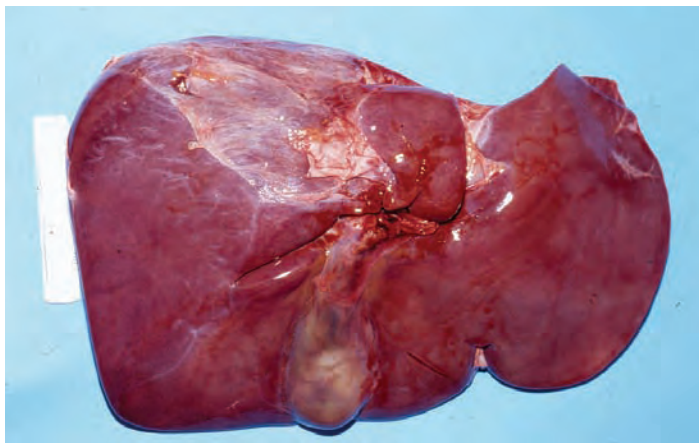
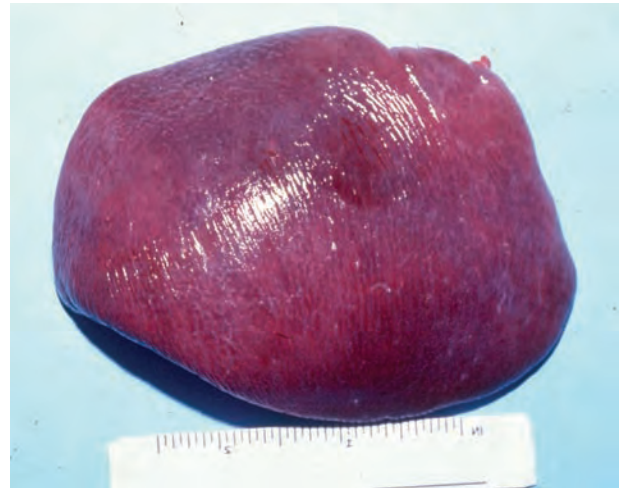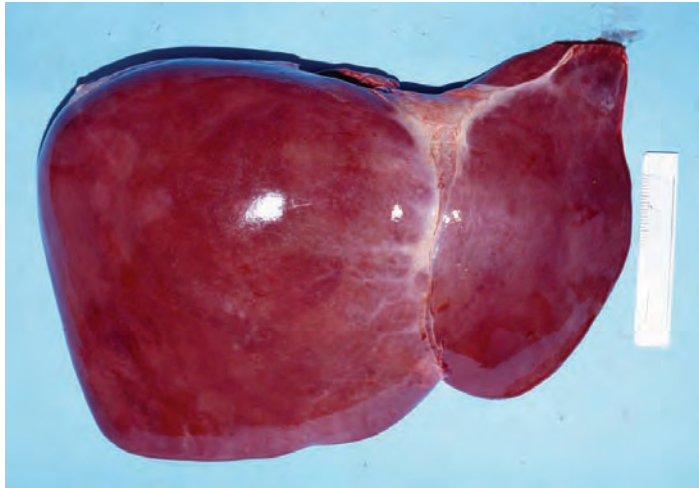
Normal fresh kidneys.



Non-fixed fresh kidneys. Note the pale discoloration resulting from fatal blood loss prior to death due to a gunshot wound.

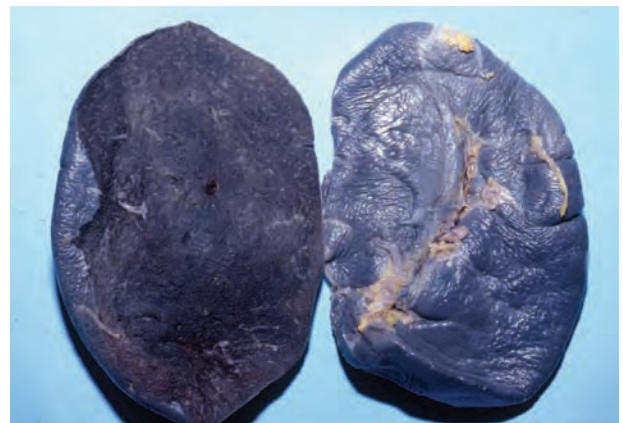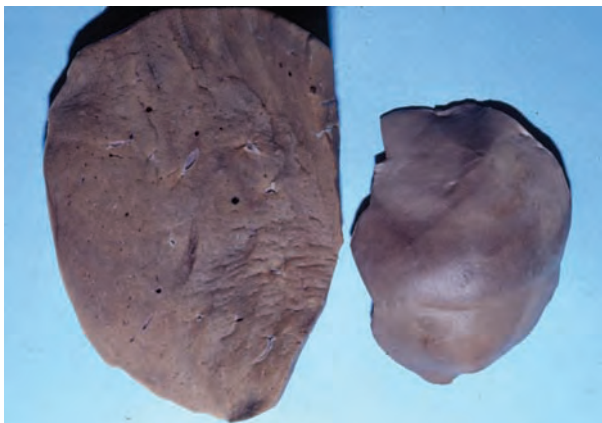


Normal kidney fixed in formaldehyde.



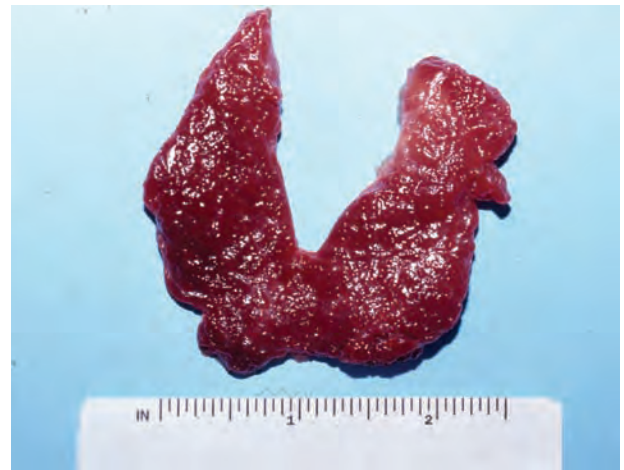
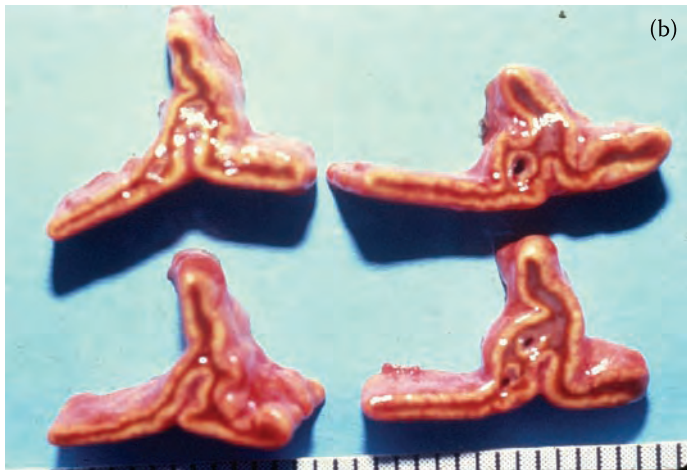
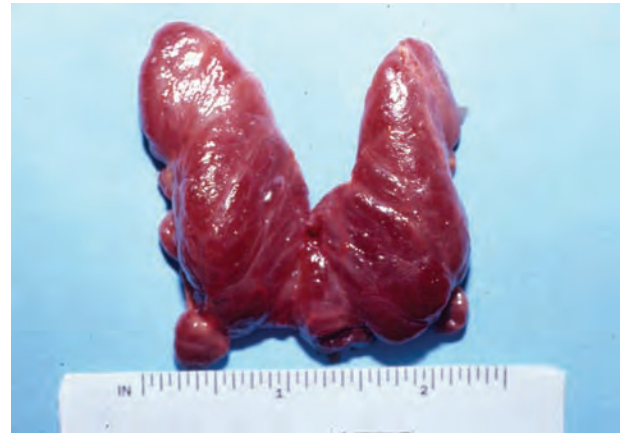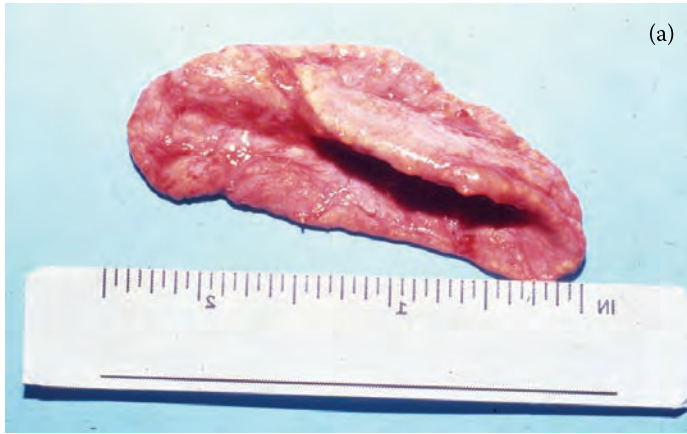Normal fresh liver.

Normal fresh spleen.



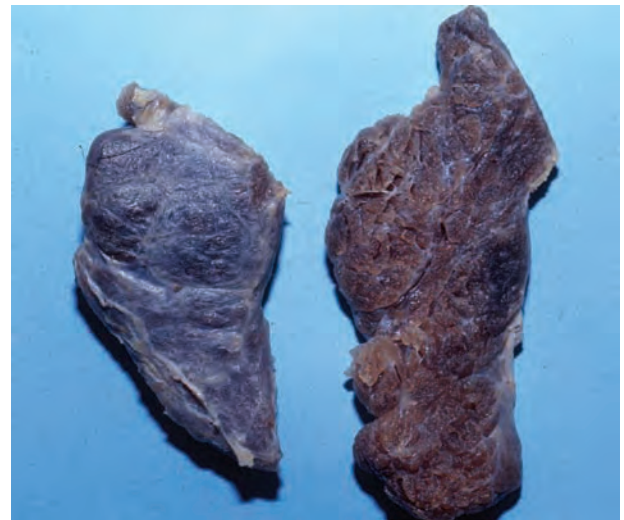
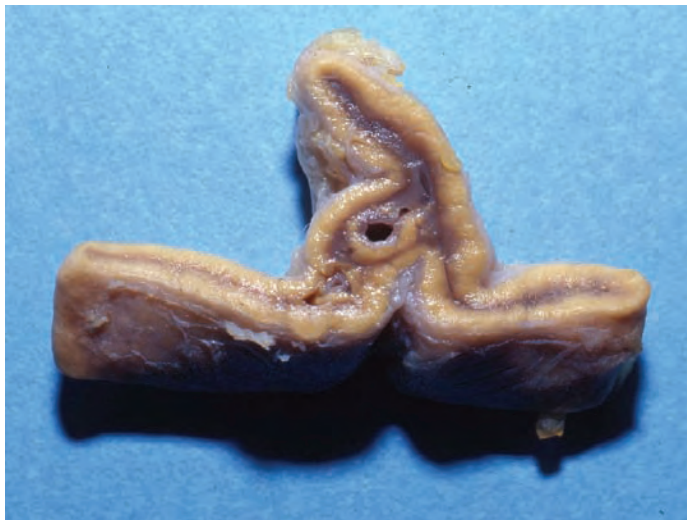Normal liver fixed in formaldehyde.

Normal spleen fixed in formaldehyde.



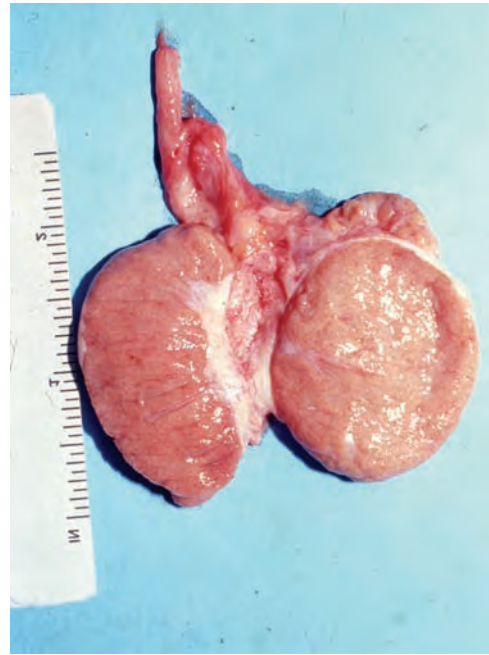
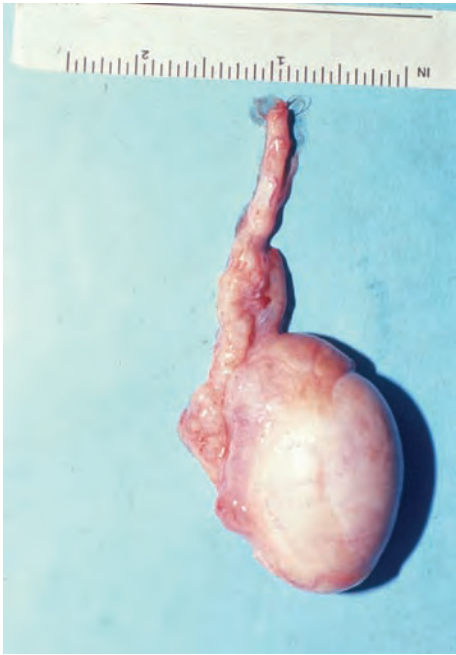Normal fresh adrenal gland intact (a) and sectioned (b).

Normal fresh thyroid gland.

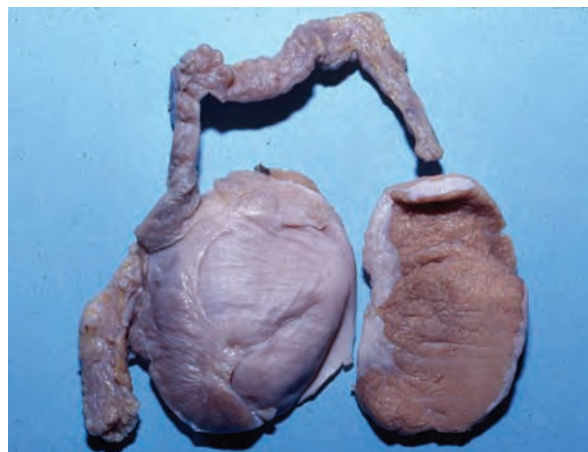

Normal adrenal gland section fixed in formaldehyde.

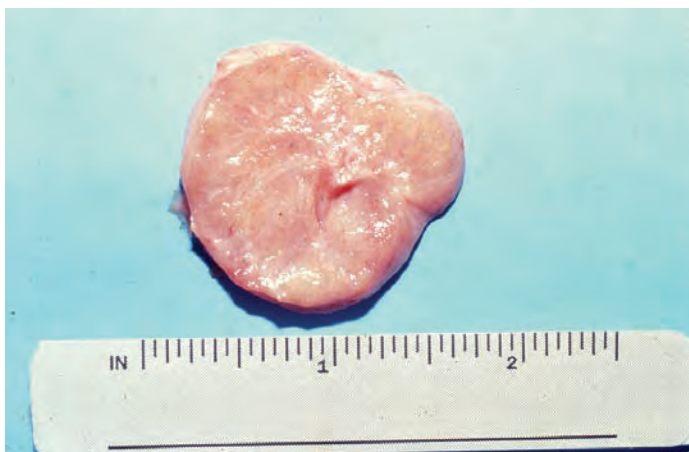
Normal thyroid fixed in formaldehyde.



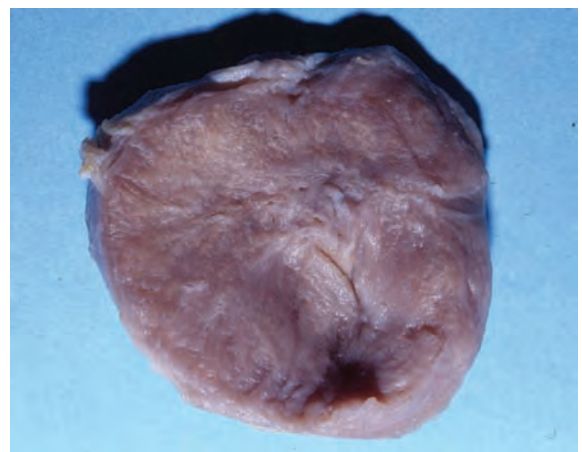
Normal fresh testes.



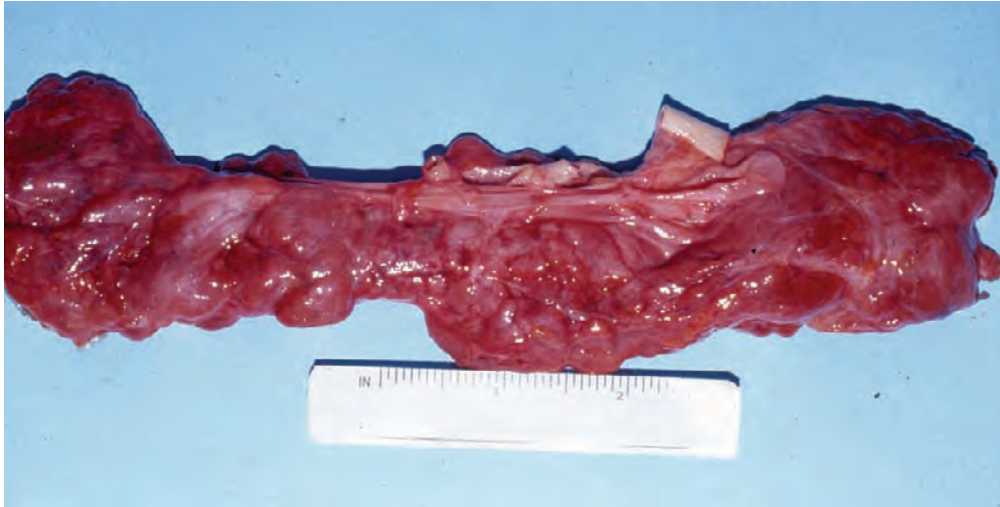Normal testes fixed in formaldehyde.



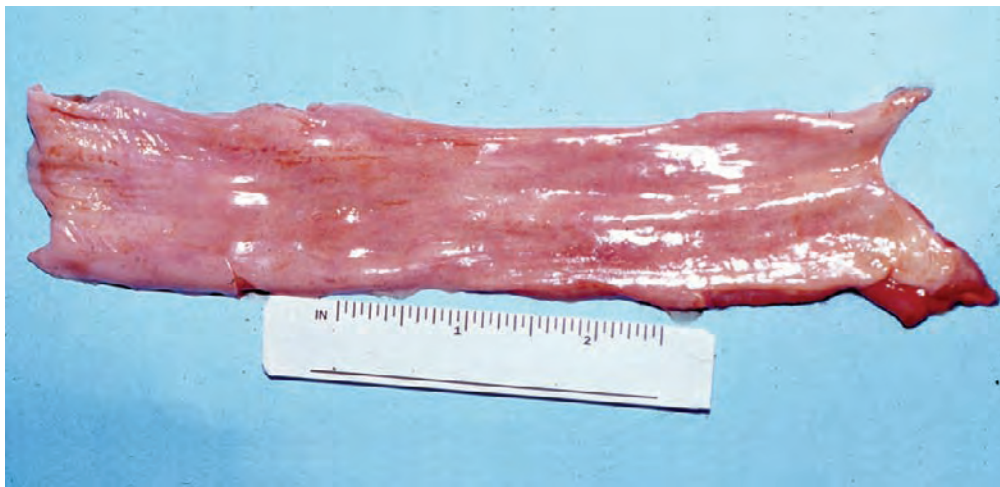Normal fresh prostate.



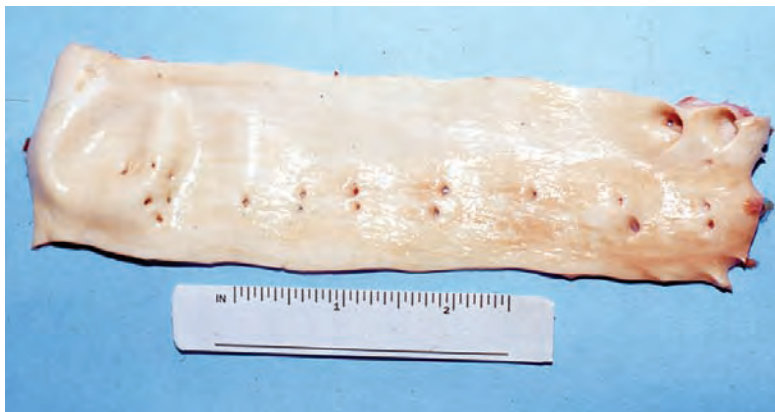
Normal prostate fixed in formaldehyde.



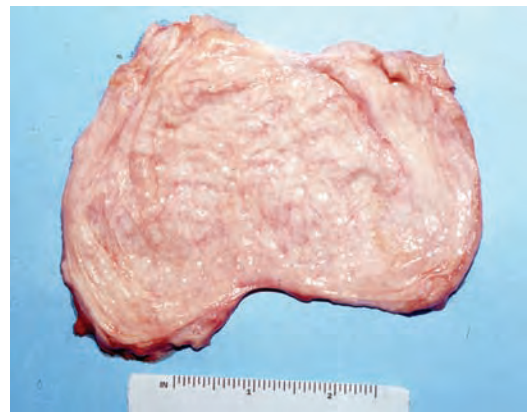Normal fresh pancreas.



Normal fresh esophagus.



Aorta with slight atherosclerosis. Note the fatty streaks on the intimal surface.



Normal fresh bladder.

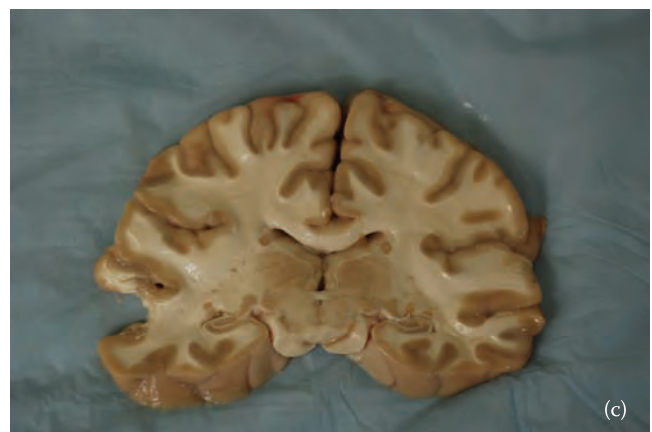
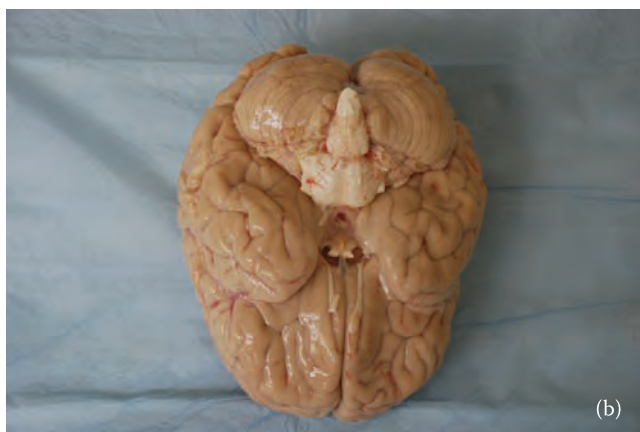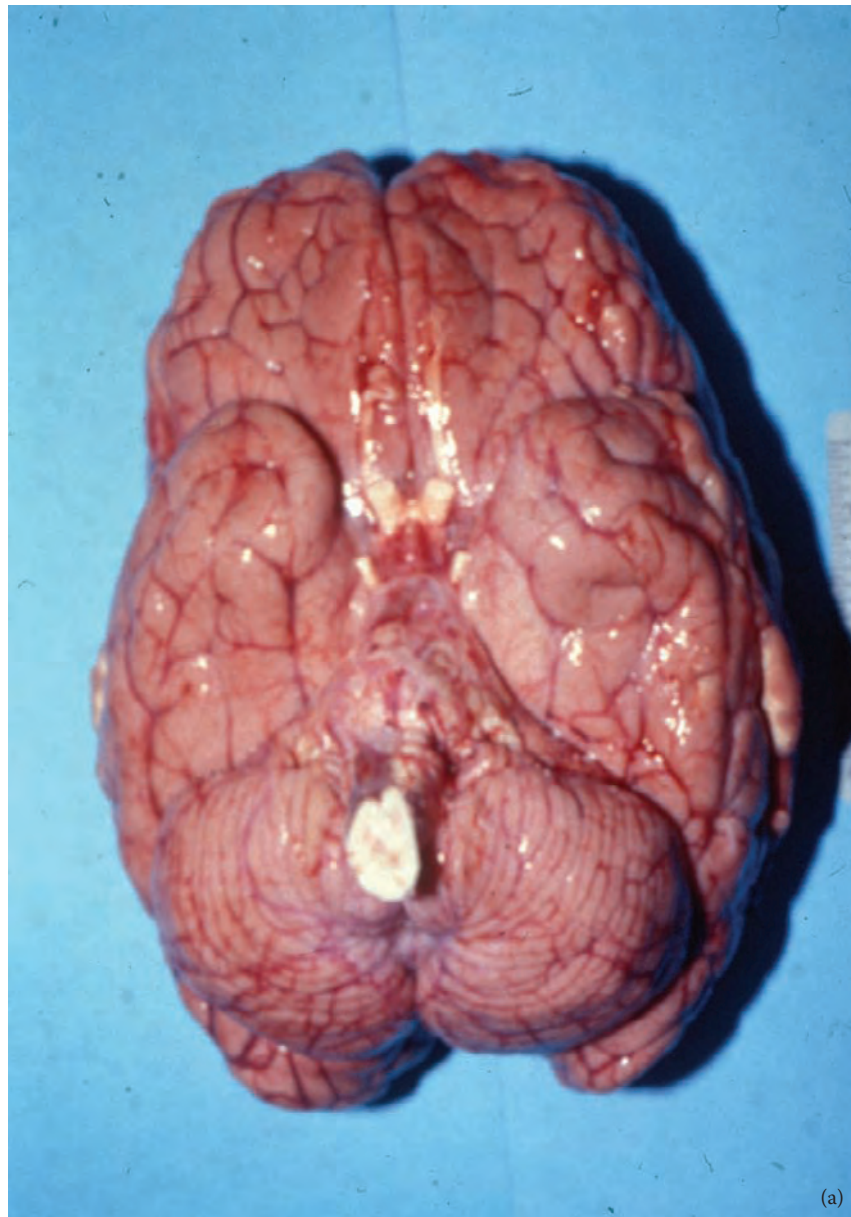

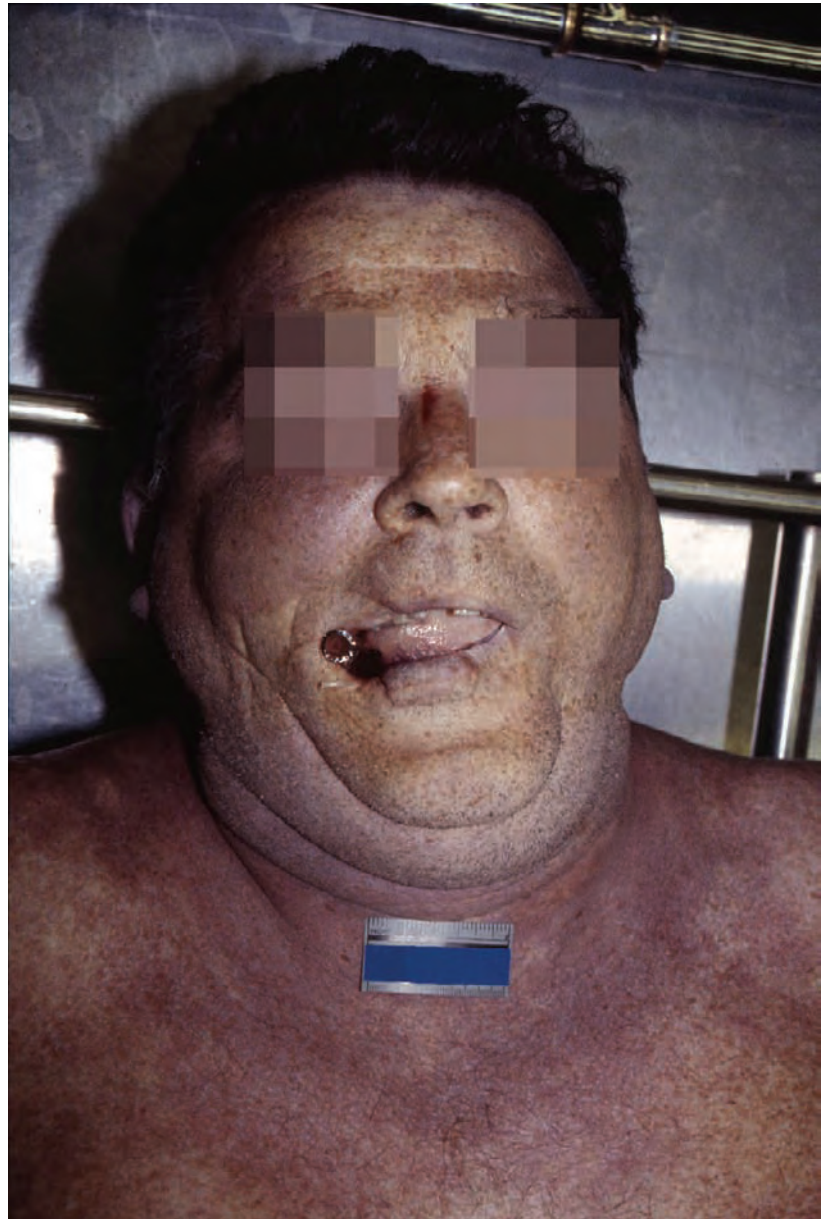
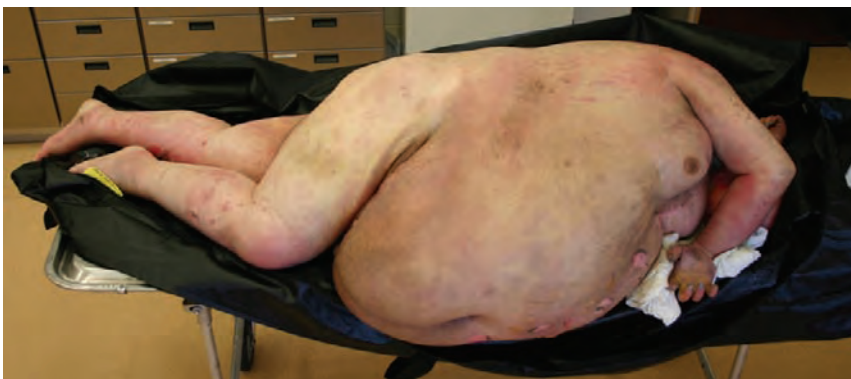Figure (a) demonstrates congestion of fresh brain. Note the slight pink color. Figures (b) and (c) demonstrate fresh brain in an individual who exsanguinated from a ruptured aortic aneurysm. Note the pale discoloration due to blood loss.

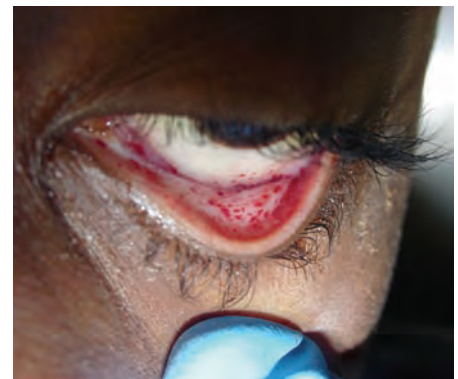



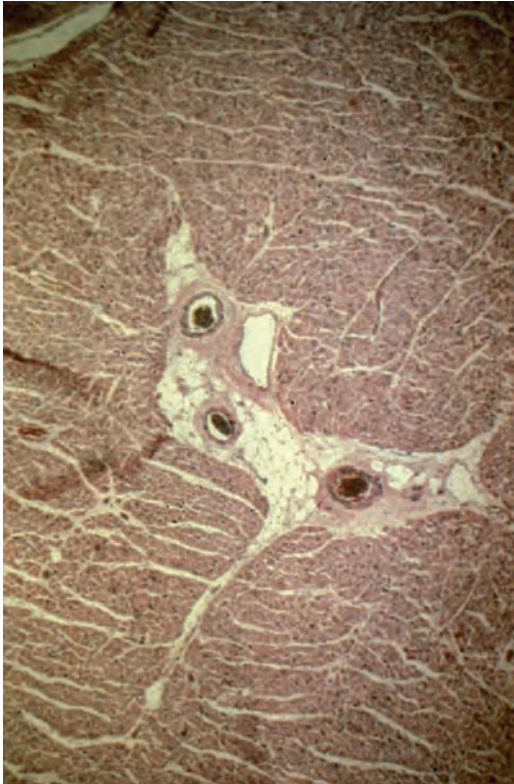
This figure depicts a decedent with an endotracheal tube in the right side of his mouth. It also demonstrates the "purple head sign," a common finding in victims of sudden death, particularly cardiac death. The explanation for this finding is not known in entirety but is attributed to uncontrolled terminal sympathetic nervous system discharges, which open free capillary sphincters and produce a gush of capillary blood.



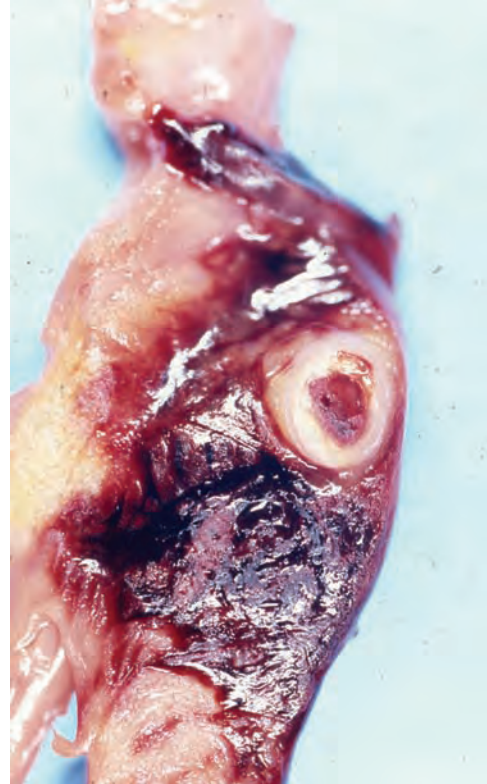Morbid obesity. This is a legitimate cause of death and can stand alone on a death certificate.



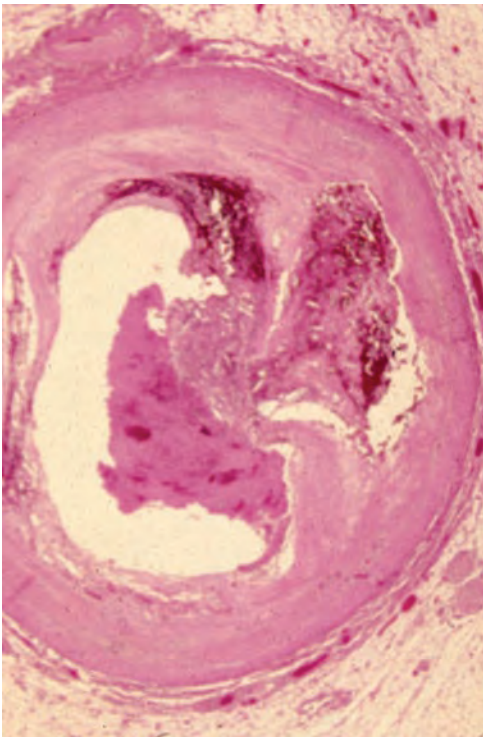
Petechiae associated with heart disease and resuscitation.



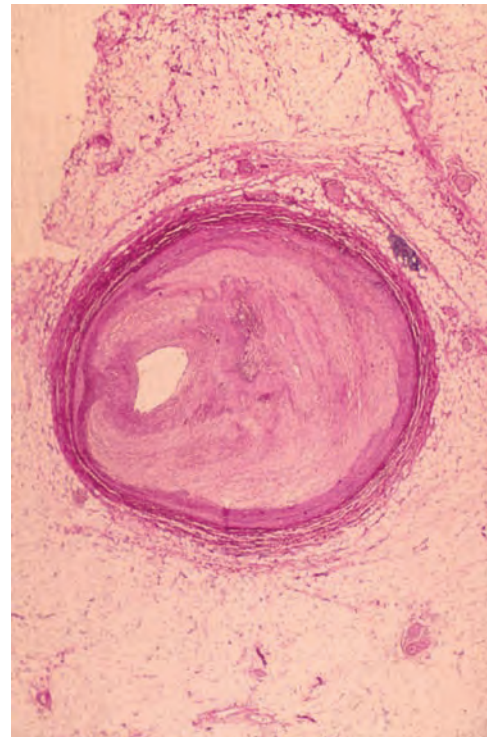
Low-power magnified view of small coronary arteries with thrombosis.



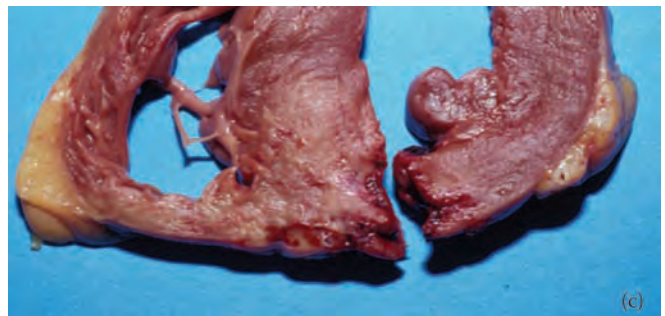
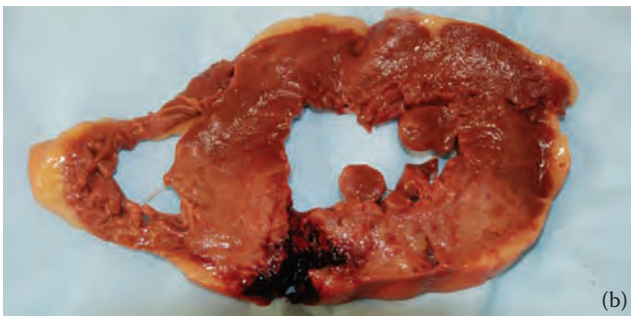
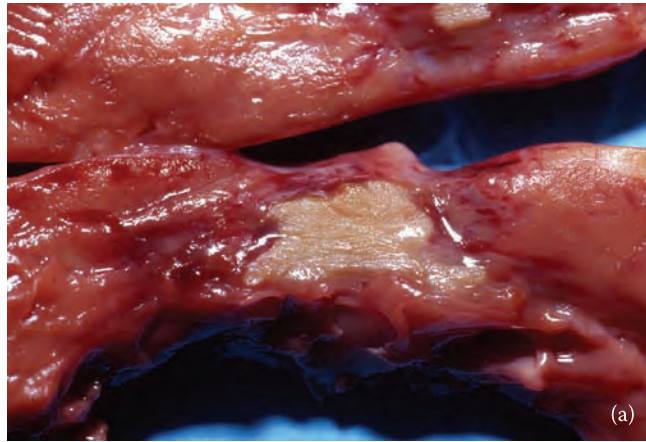
Epicardial vessel with complete occlusion by organizing thrombus. Note the adjacent epicardial hemorrhage.



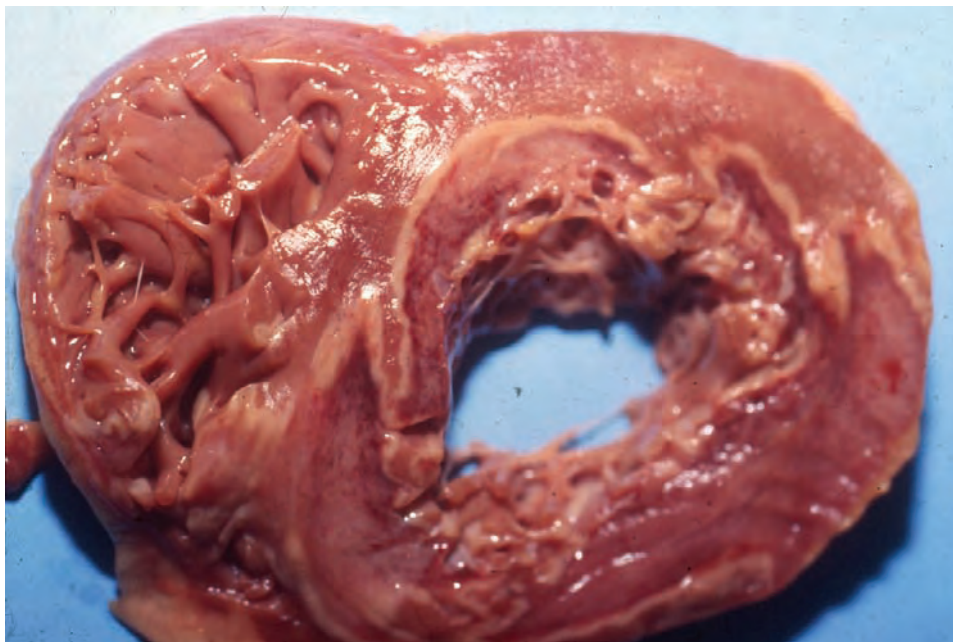Coronary artery with a ruptured atherosclerotic plaque and thrombus formation.



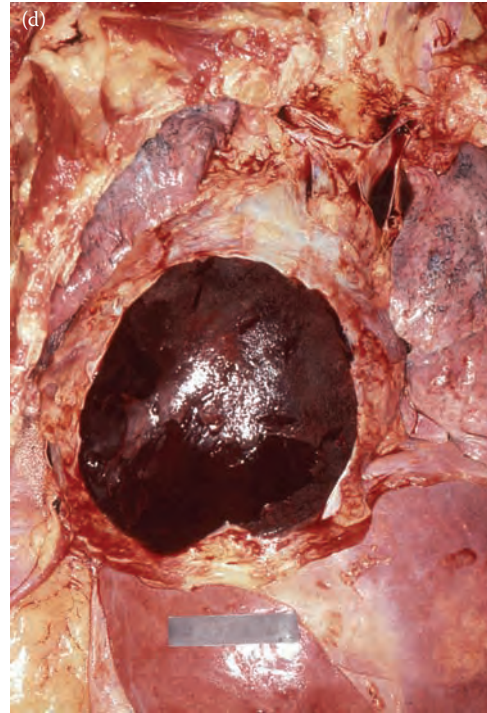
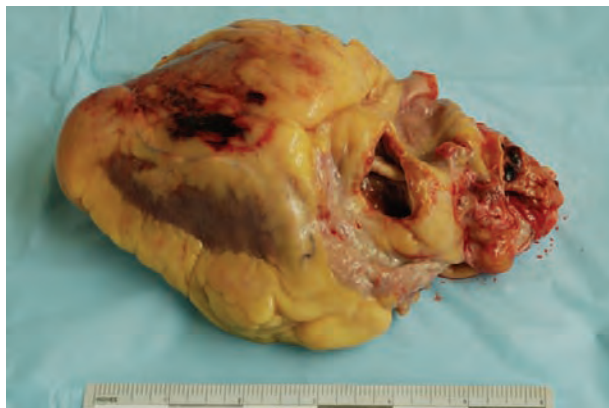
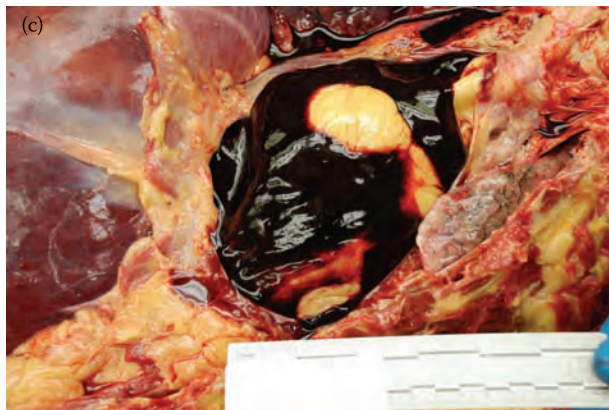
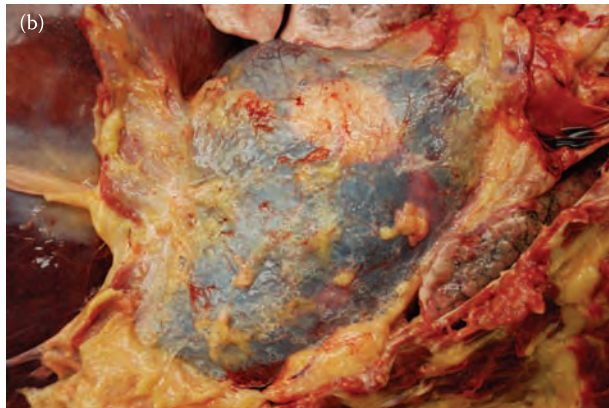
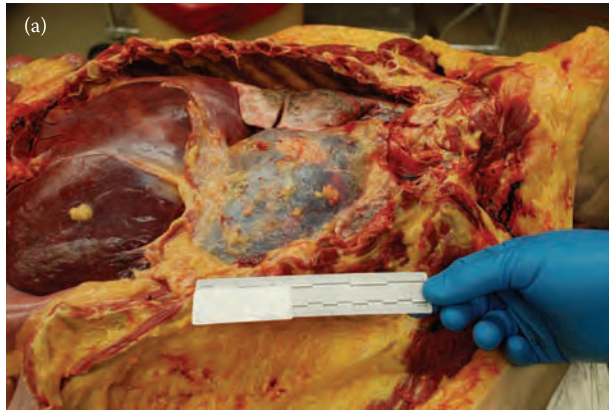Marked coronary atherosclerosis in an epicardial vessel.



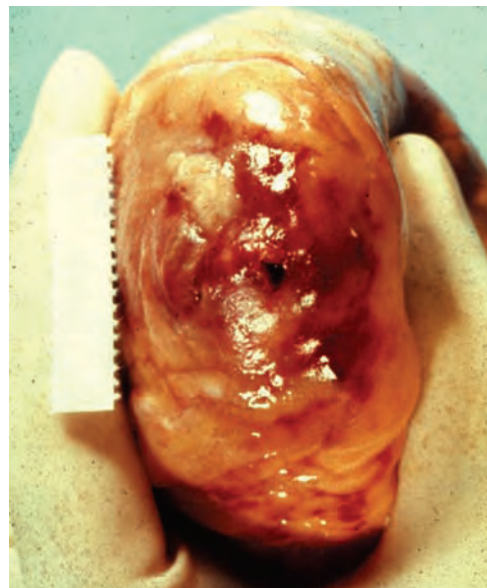
An acute myocardial infarction. Note the yellow discoloration due to necrosis. This infarction is approximately 3 to 6 days old. In Figure (b) and (c), there is a transmural acute myocardial infarction with rupture.



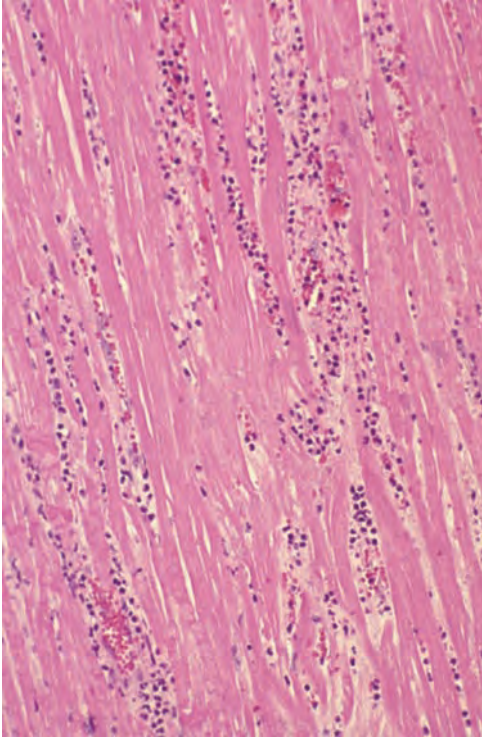
Acute myocardial infarction.



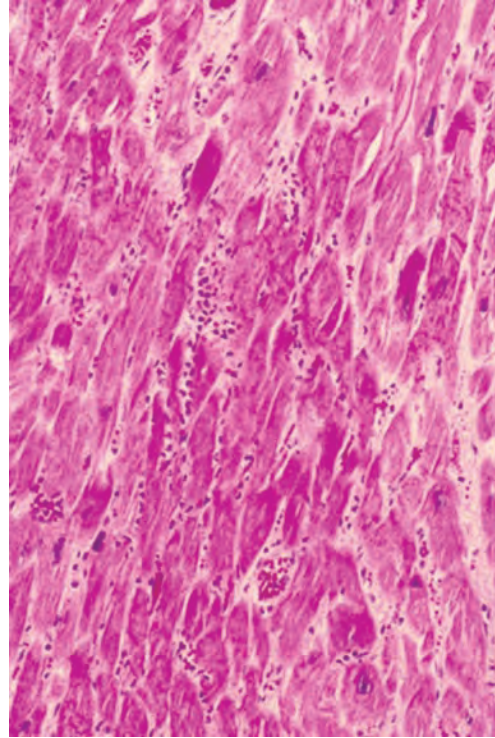
View of the thoracic cavity looking downward at the heart during autopsy (a) and (b). Note the purple discoloration of the pericardial sac due to underlying accumulation of blood. Note the two different examples with large blood clot encasing the heart after the pericardial sac was removed (c) and (d). This demonstrates a cardiac tamponade following an acute ruptured myocardial infarction.



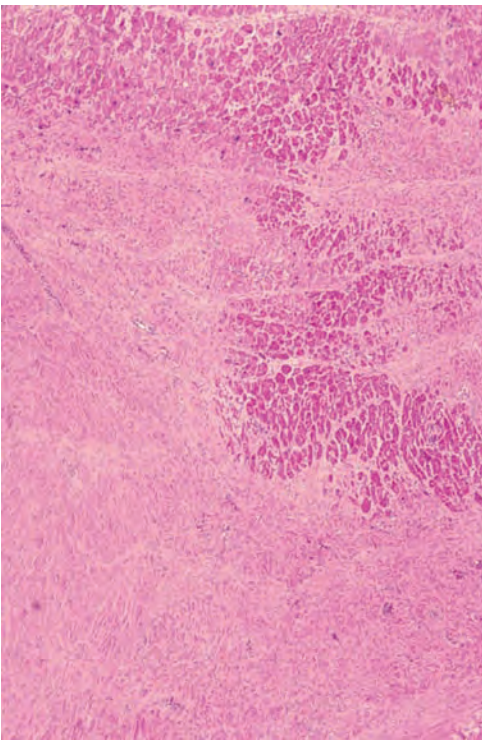
Two examples of hearts demonstrating acute ruptured myocardial infarction. Note the adjacent hemorrhage and perforation site. This resulted in cardiac tamponade and sudden death.



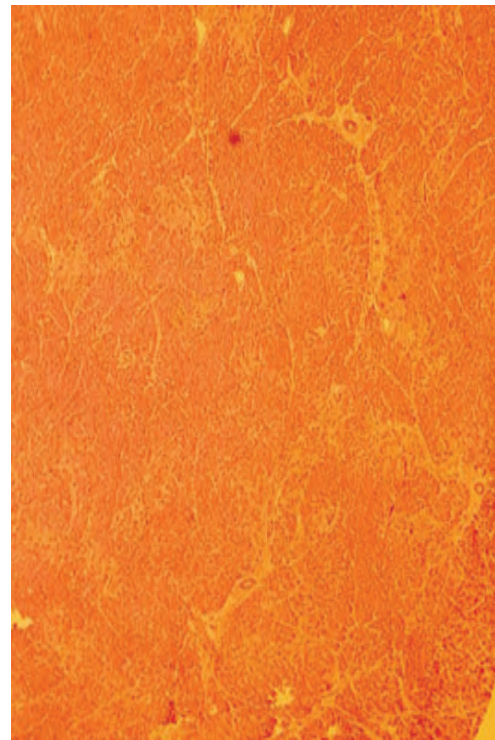
This microscopic section of heart muscle reveals an acute myocardial infarction with hemorrhage, polymorphonuclear cell infiltrates, and myocardial necrosis.



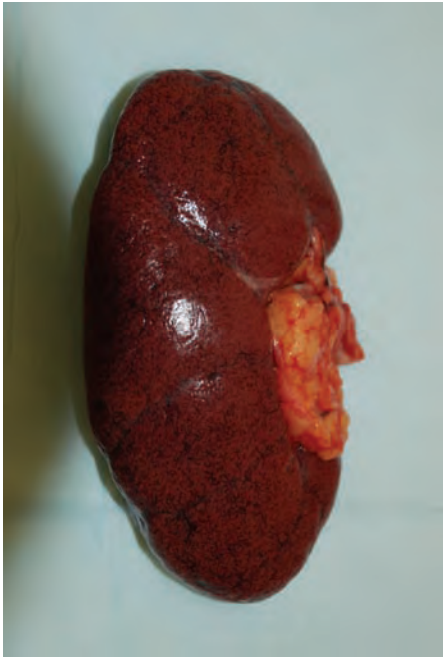
This acute myocardial infarction demonstrates coagulative necrosis with contraction bands. There are also polymorphonuclear cell infiltrates.



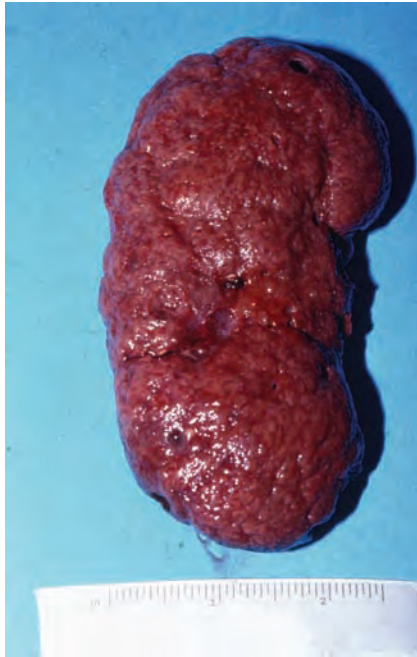This histopathologic section of myocardium reveals an old infarction with fibrosis.



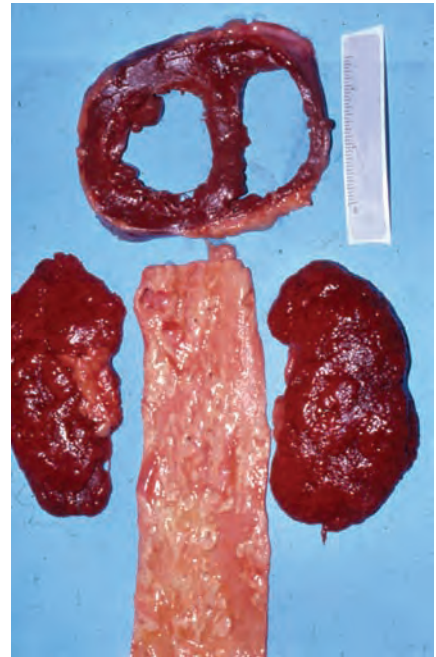
This low-power view of heart muscle reveals patchy areas of fibrosis consisting of healed hypoperfusion infarctions secondary to a remote trauma with severe shock. Also note the perivascular fibrosis.



Early to moderate nephro-arteriosclerosis.

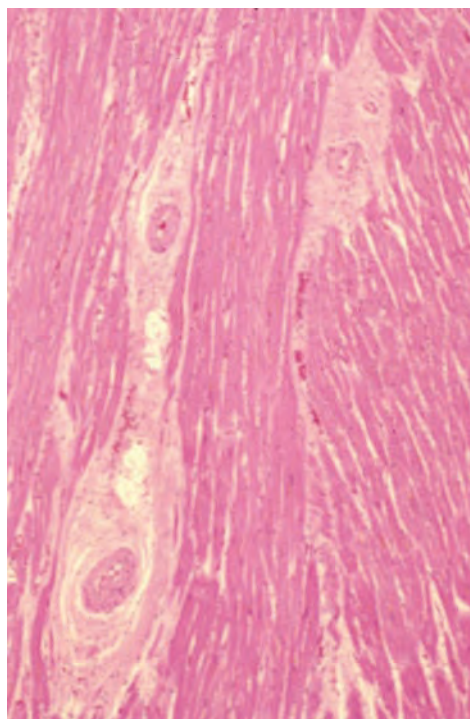
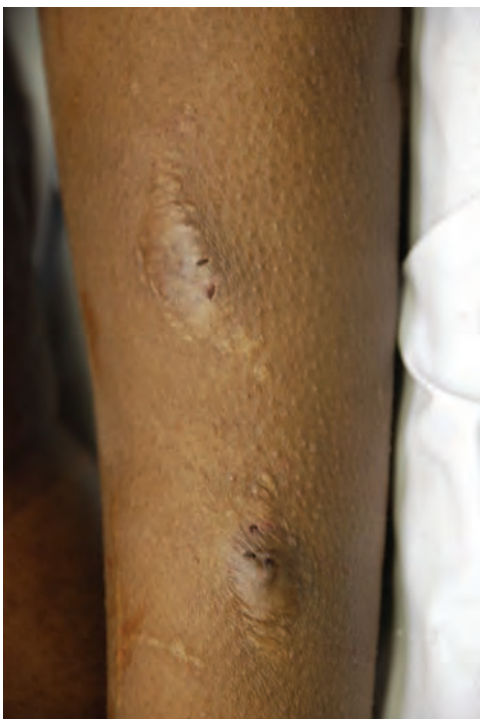

Moderate to marked nephro-arteriosclerosis.

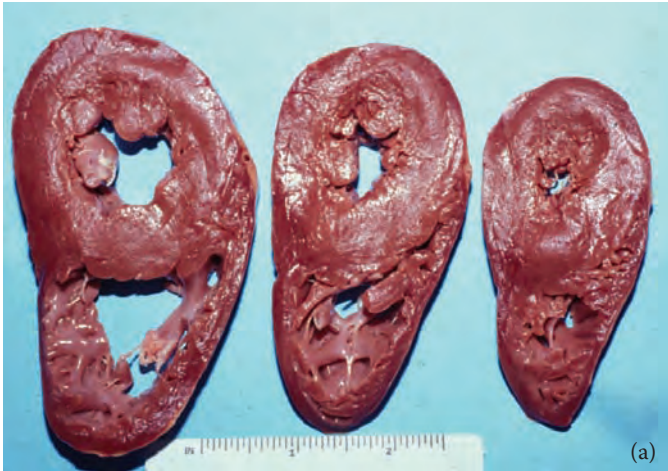


Nephro-arteriosclerosis associated with hypertensive cardiovascular disease. Note the cardiac hypertrophy and biventricular dilatation in this failing heart. There is also moderate atherosclerosis of the aorta. Note the markedly granular subcapsular kidney surfaces and cortical scarring also associated with this process.

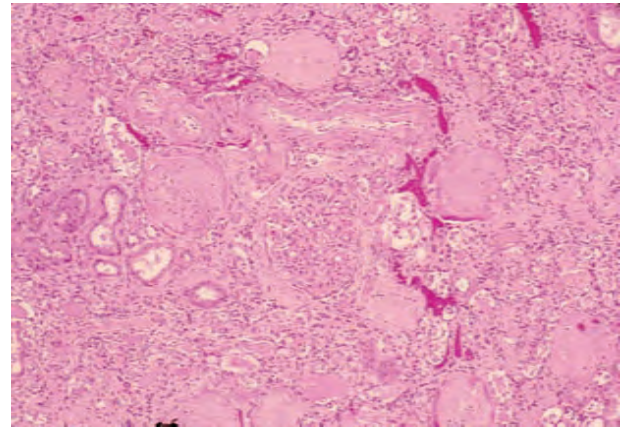
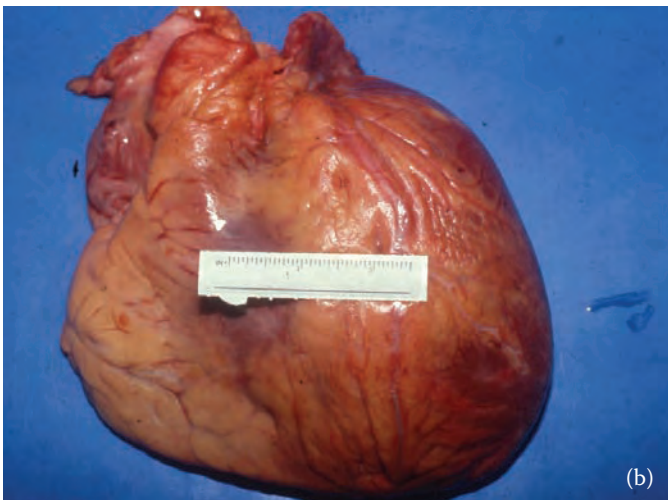
Arteriovenous hemodialysis grafts for treatment of chronic renal failure due to hypertensive cardiovascular disease.



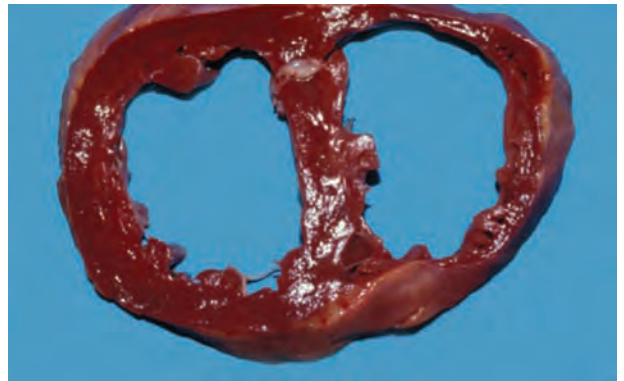
This microscopic image of myocardium reveals significant perivascular fibrosis and small vessel disease in a patient who had a long history of hypertensive cardiovascular disease and diabetes mellitus.



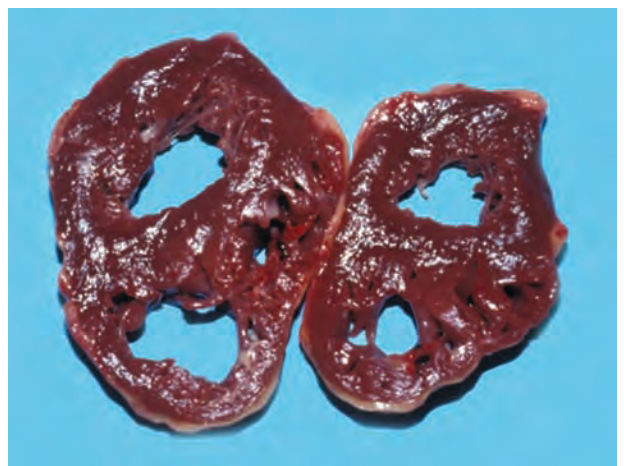
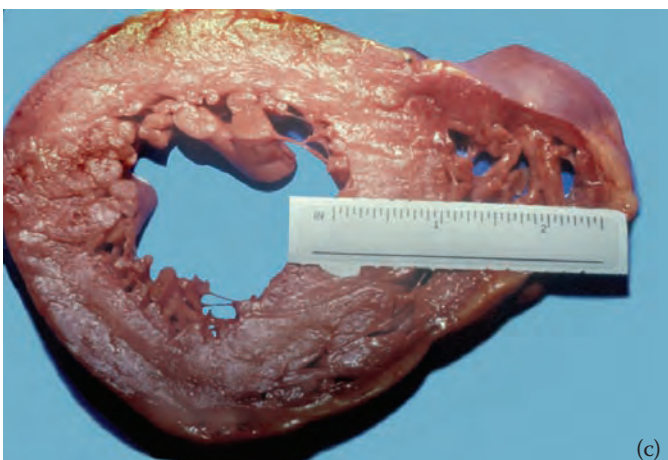Normal cross sections of heart (a). Compare this image to the ones below. Figure (b) shows a markedly enlarged heart due to hypertensive cardiovascular disease. This heart is diffusely enlarged and shows cardiac hypertrophy. Figure (c) is a markedly hypertrophied heart with extreme concentric left ventricle hypertrophy. This individual had severe hypertension.



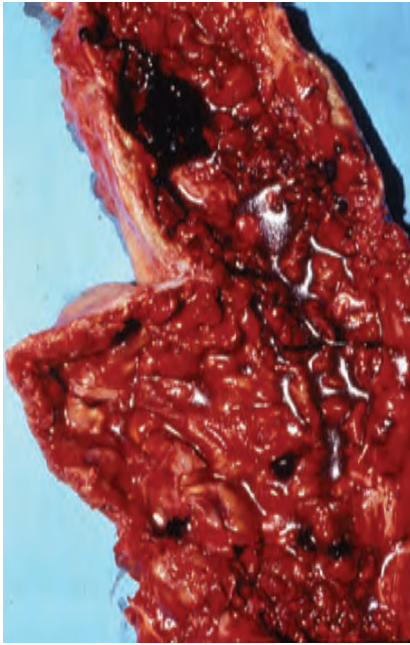This is a microscopic section of kidney showing fibrosis, arteriosclerosis, and nephrosclerosis due to hypertensive cardiovascular disease.



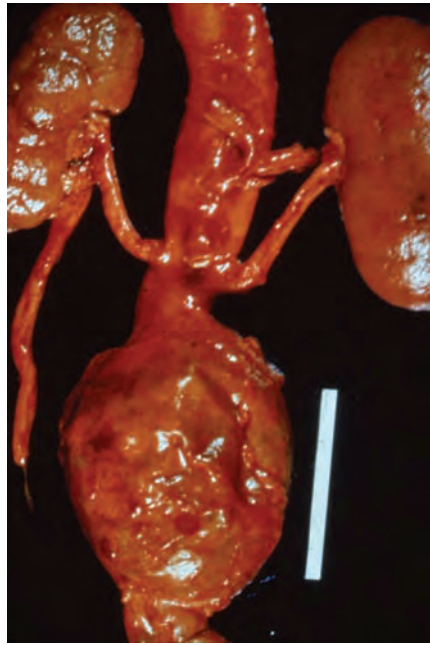
The right and left ventricles show marked dilatation. This individual died of a peripartum cardiomyopathy. A dilated cardiomyopathy or end stage hypertensive cardiovascular disease with cardiac failure will appear the same grossly.



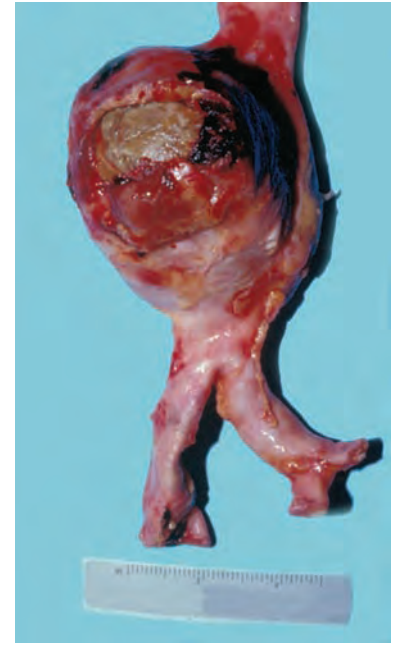The sections of these ventricles reveal marked right ventricle hypertrophy. This individual had end-stage primary pulmonary fibrosis with cor pulmonale and cardiac failure.



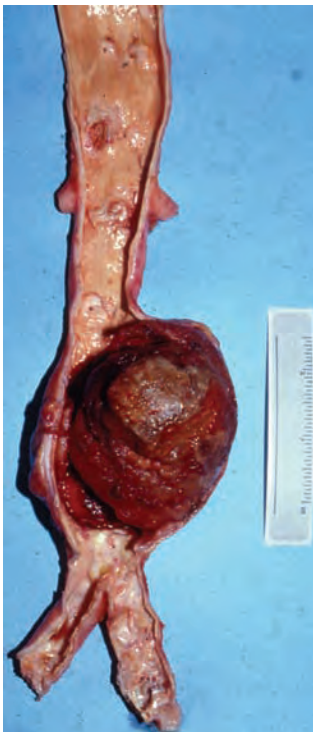
The intimal lining of an aorta with marked atherosclerosis in a decedent with a longstanding history of smoking, diabetes, high cholesterol, and high blood pressure.



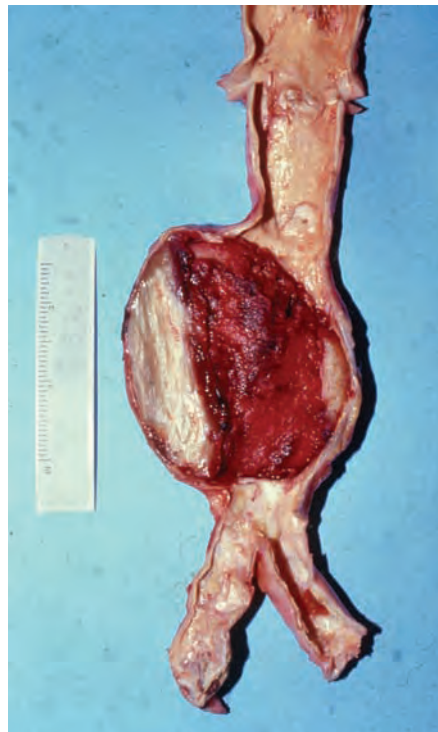
Abdominal aortic aneurysm shown in its typical location inferior to the renal arteries and above the iliac bifurcation.



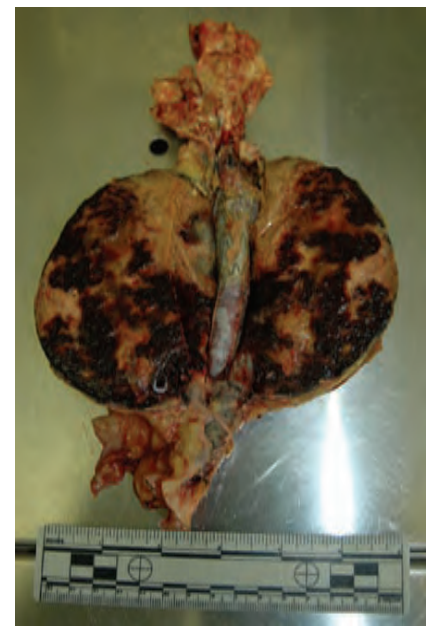
An abdominal atherosclerotic aneurysm with a rupture at its anterior aspect and visible thrombosis.



This abdominal aortic aneurysm that has been opened to remove half of the vessel wall and show the underlying intimal surface with moderate atherosclerosis except for the region of the aneurysm, which has marked atherosclerosis and a large overlying thrombus.

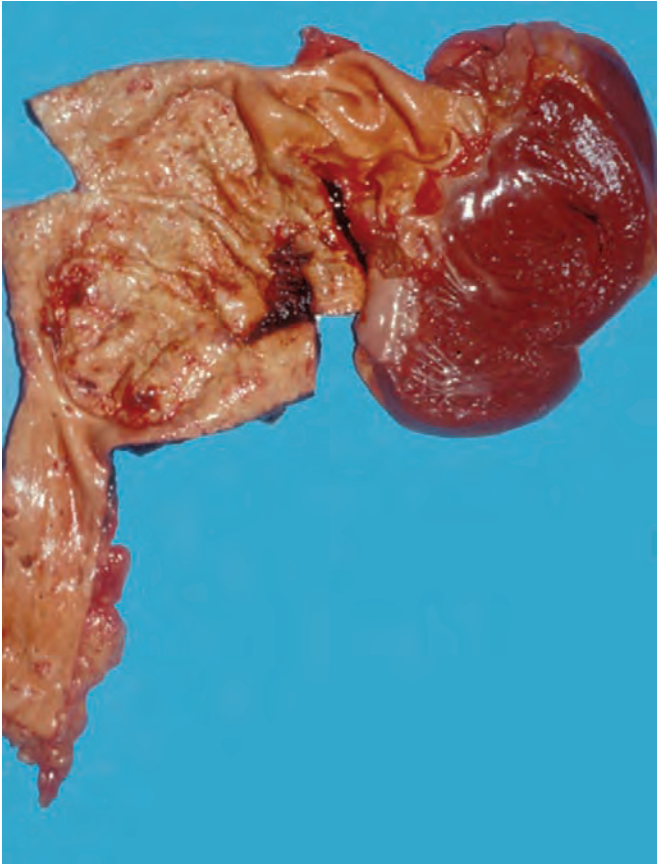


This abdominal aortic aneurysm has been cross sectioned to show the partial obstruction of the aneurysm by organizing thrombosis. The lumen is demonstrated by fresh red blood clot at its surface and the thrombus is demonstrated by the light grey regions adjacent to the right and left wall.

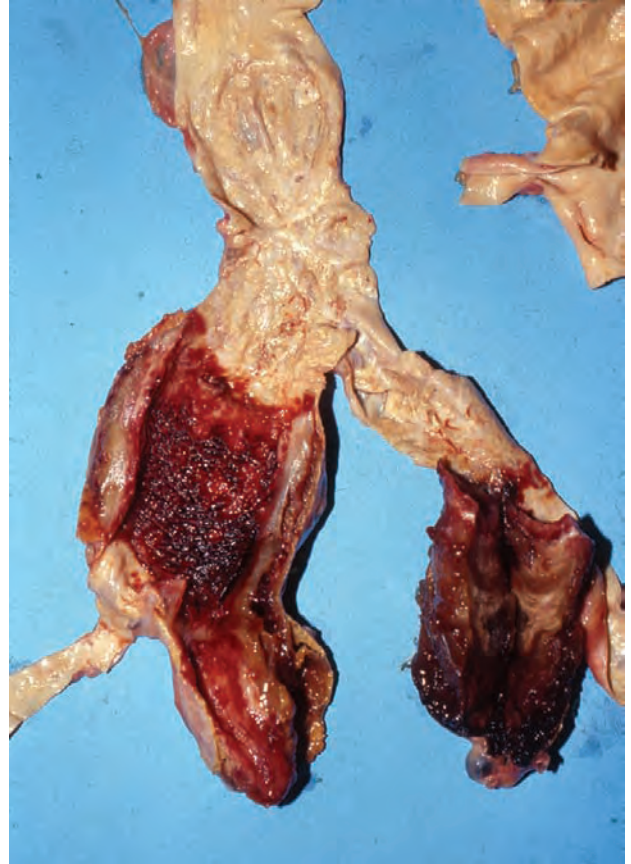


Abdominal aortic aneurysm with vascular graft repair.

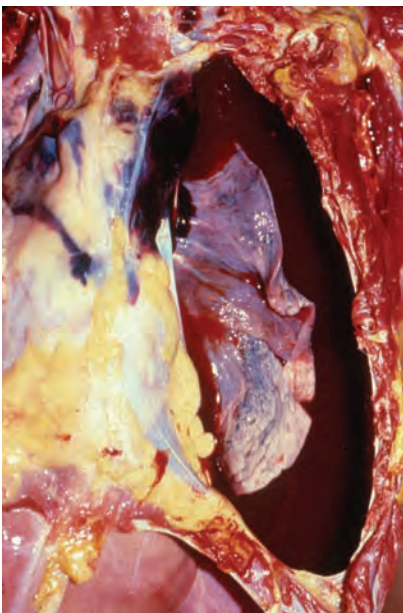




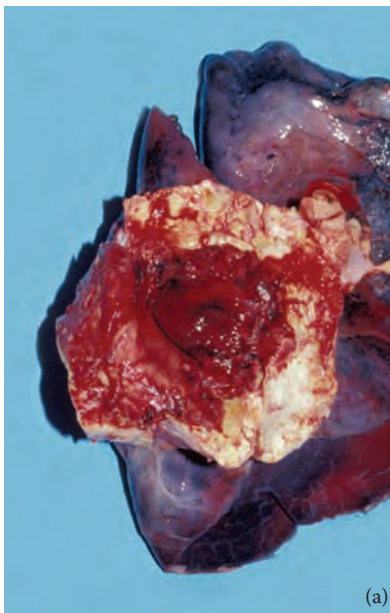
Thoracic aortic atherosclerotic aneurysm. This is not the typical location for such an aneurysm. Also note the aneurysm begins distal to the root of the aorta.



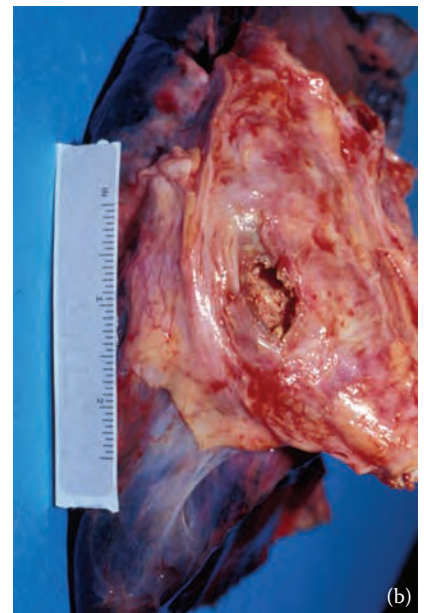
This demonstrates a decedent who had multiple atherosclerotic aneurysms including both iliac arteries.



Hemothorax from a ruptured thoracic atherosclerotic aneurysm.

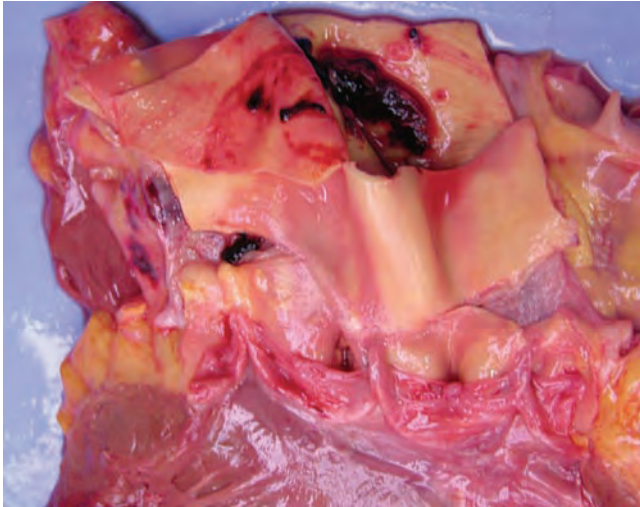


(a)

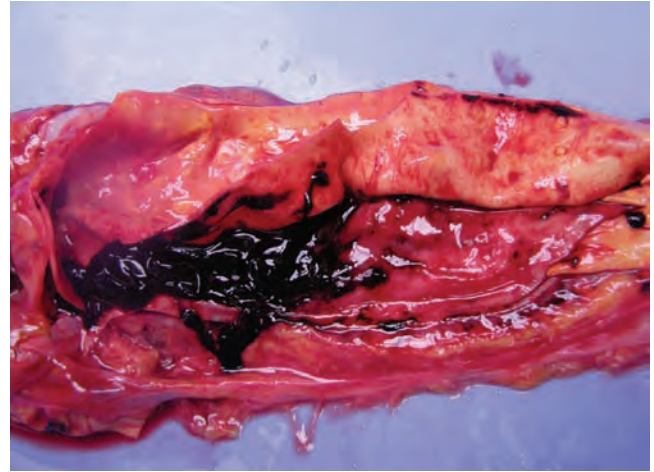


(b)

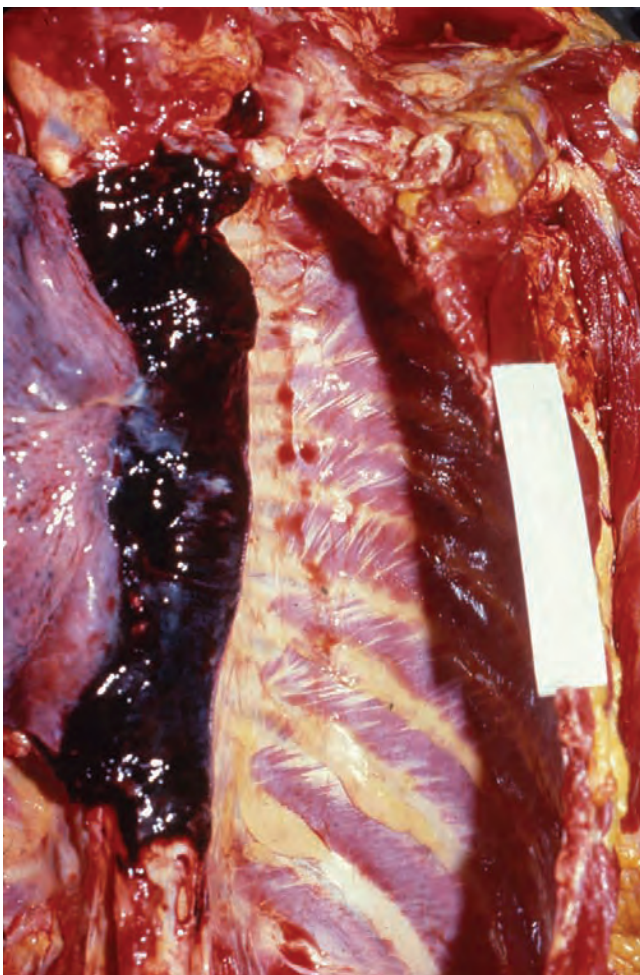
Thoracic atherosclerotic aortic aneurysm adherent to lung with rupture into the lung parenchyma causing massive hemoptysis. Note that Figure (b) demonstrates the rupture site with adherent blood clot removed.



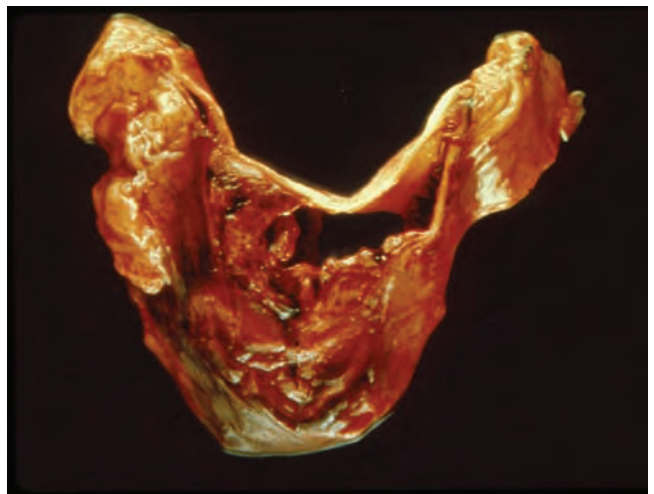
Intimal tear of the ascending aorta with dissection. Note blood tracking through the separated media.



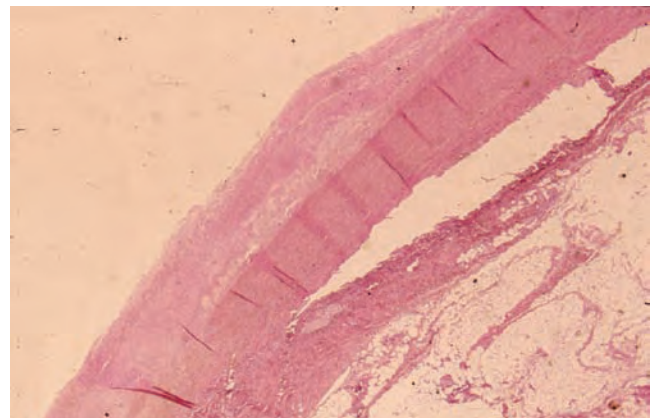
Aortic dissection with exposed separated media with blood clot in a person with Marfan's syndrome.



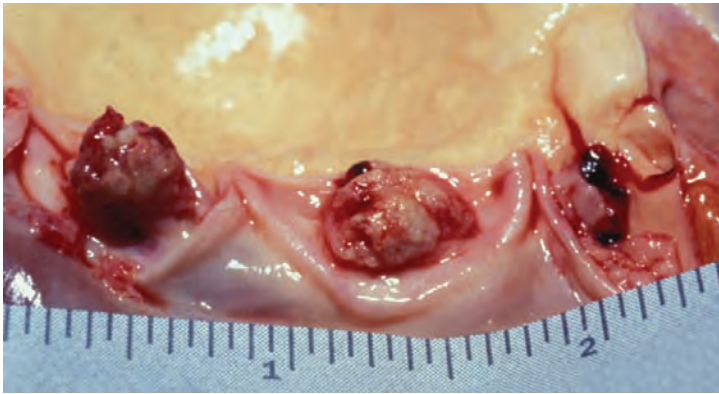An in situ aortic dissection. Note the hemorrhage extending from the root of the aorta down the paravertebral region shown by dark red hemorrhagic discoloration. This decedent had severe hypertensive cardiovascular disease.



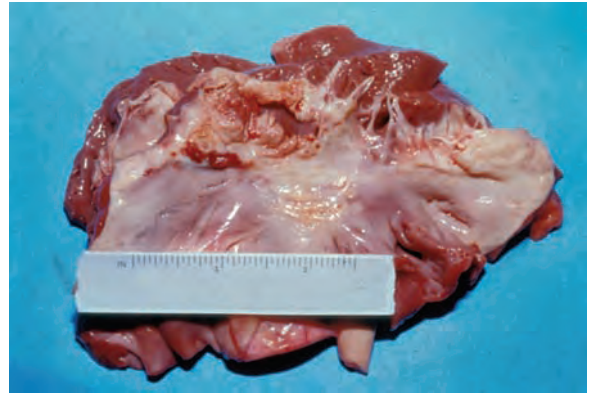
Cross section of aorta revealing a double-barrel lumen. The superior aspect of this figure shows an opened aorta with the exposed lumen. Directly inferior to this is the separated media and adventitia with a second lumen that is partially thrombosed.



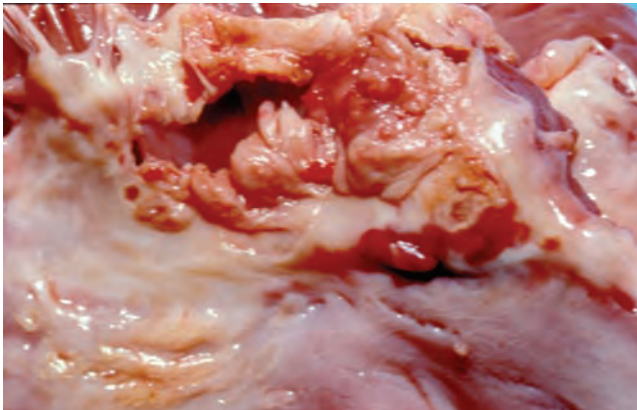
Microscopic view of an aortic dissection.



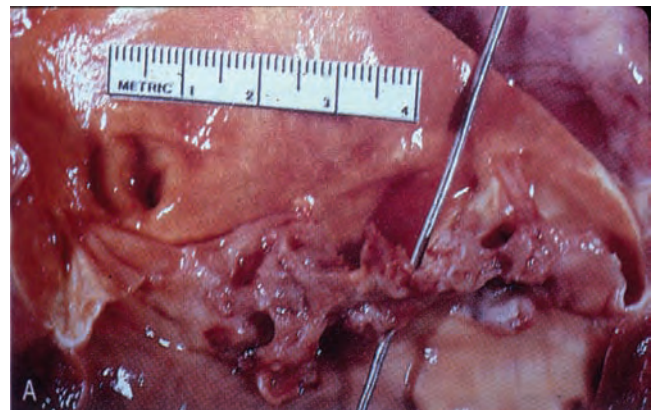
This endocardial surface shows large nonbacterial thrombotic endocarditis associated with a hypercoagulable state from metastatic adenocarcinoma. Special stains were negative for microorganisms.



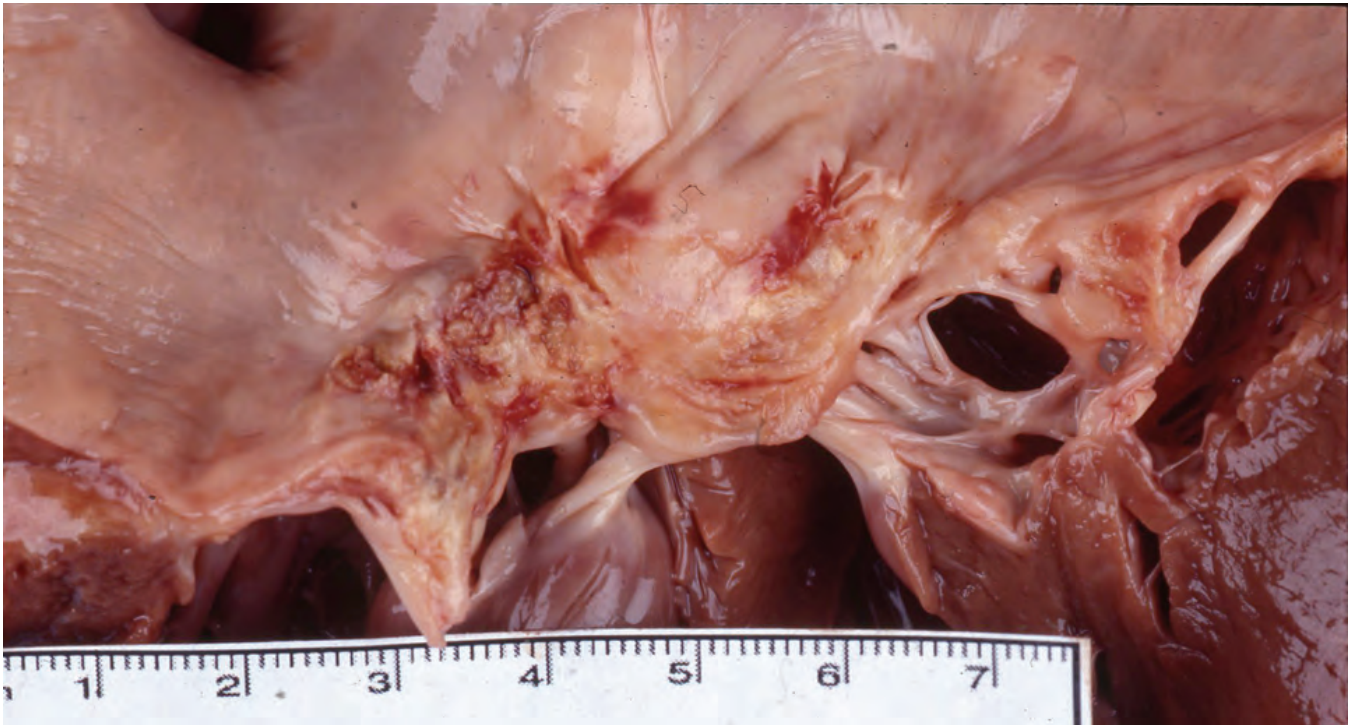This perforated mitral valve is secondary to acute bacterial endocarditis. This individual first went to the emergency room approximately a day and a half before with the complaint of fever and chest pain. He was sent home with antibiotics and later returned with severe pulmonary edema and died shortly after.



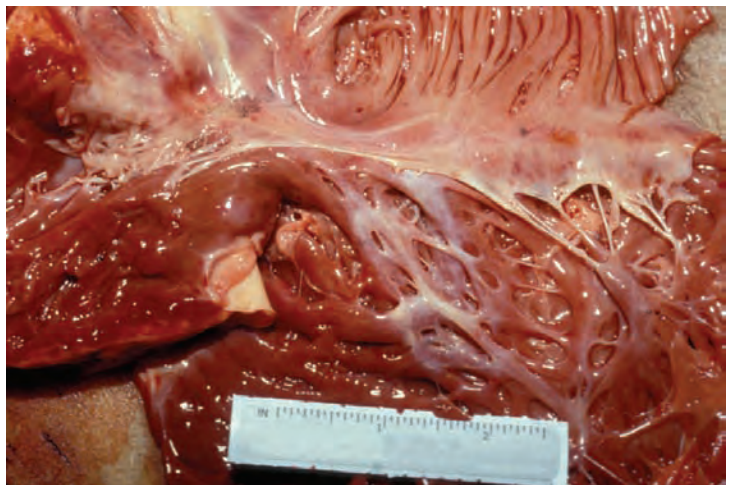
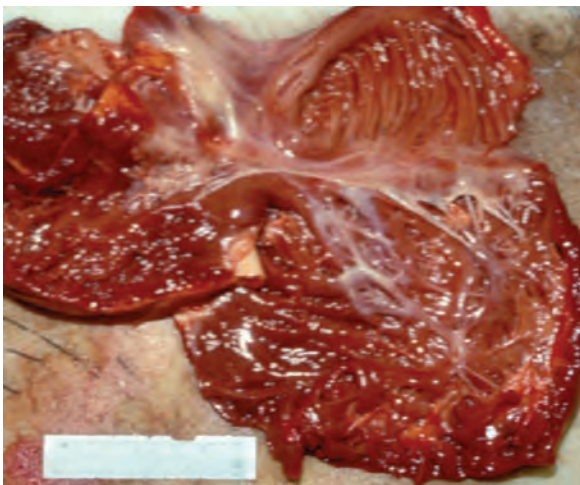Close-up view of an acute infectious endocarditis with valve perforation. Gram stain revealed numerous gram positive organisms.



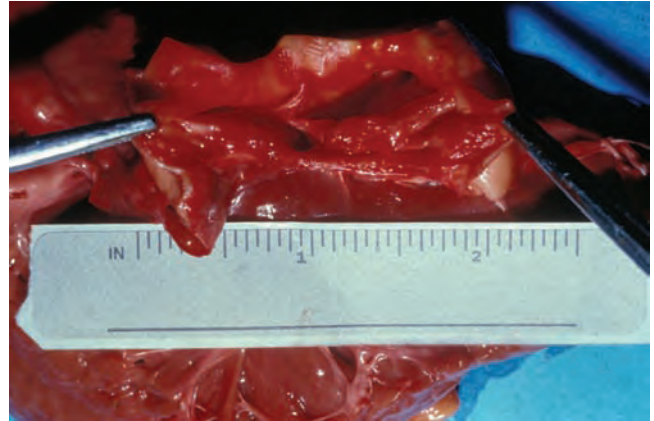
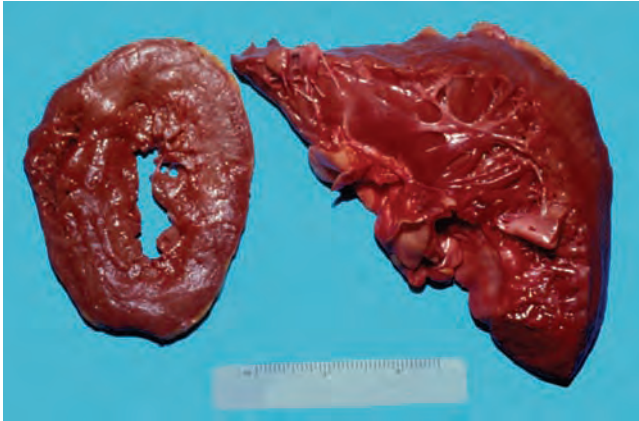
Acute infectious endocarditis with valve leaflet perforation.



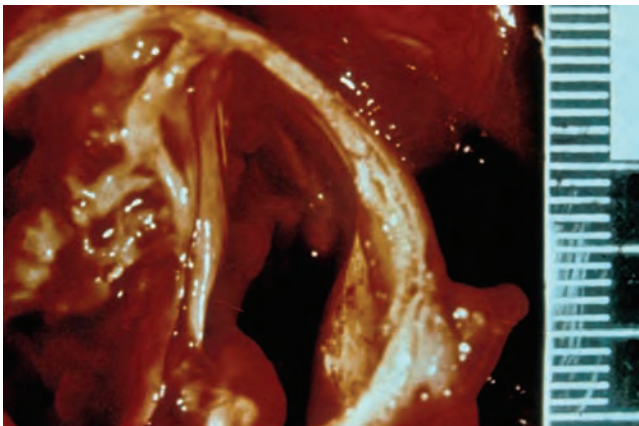
Remote cardiac valve damage from rheumatic fever.



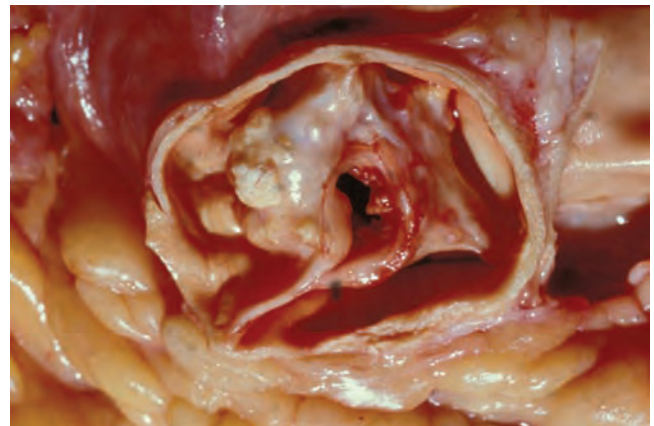
These figures are views of a remotely damaged tricuspid valve secondary to chronic intravenous drug abuse and past endocarditis. Note the fibrosis of the adjacent endocardium secondary to regurgitative turbulent blood flow. The decedent was known to have a longstanding cardiac murmur.



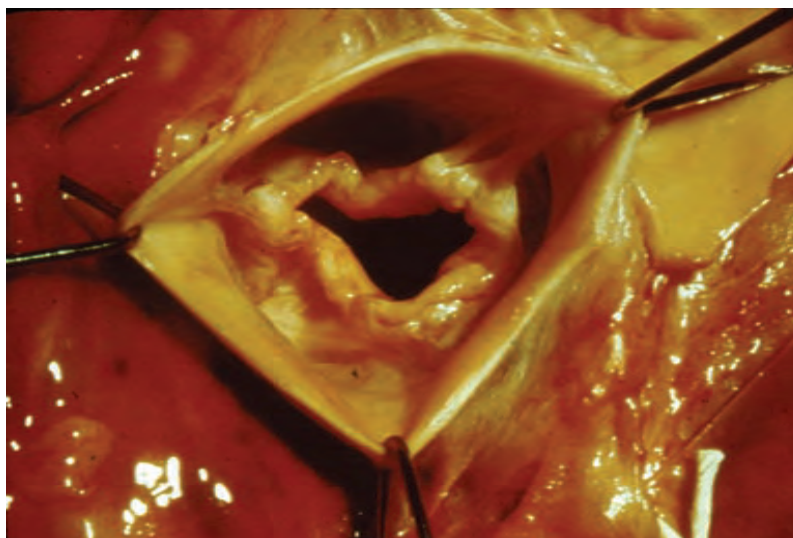
These figures show a markedly hypertrophied heart with concentric left ventricle hypertrophy and a congenital subaortic band causing marked aortic stenosis and sudden cardiac death at age 42 years. The decedent had decided years earlier not to have a valve replacement.



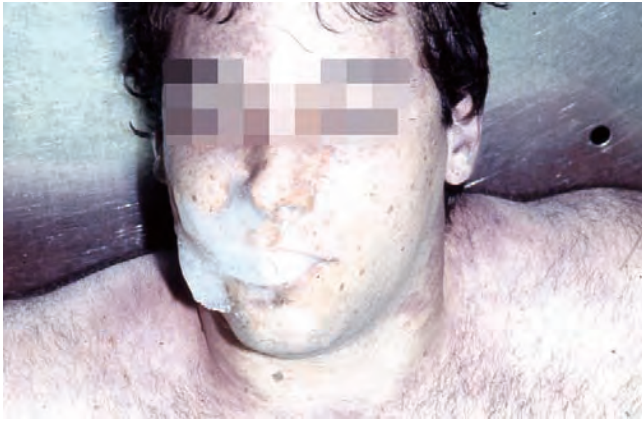Bicuspid aortic valve. With advancing age and atherosclerosis, these valves may become markedly stenotic and increase one's risk for sudden cardiac death.



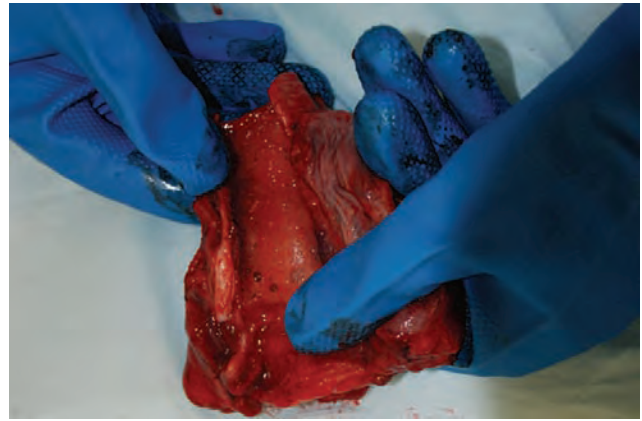
Markedly stenotic bicuspid aortic valve from an older individual with a longstanding history of atherosclerotic cardiovascular disease.



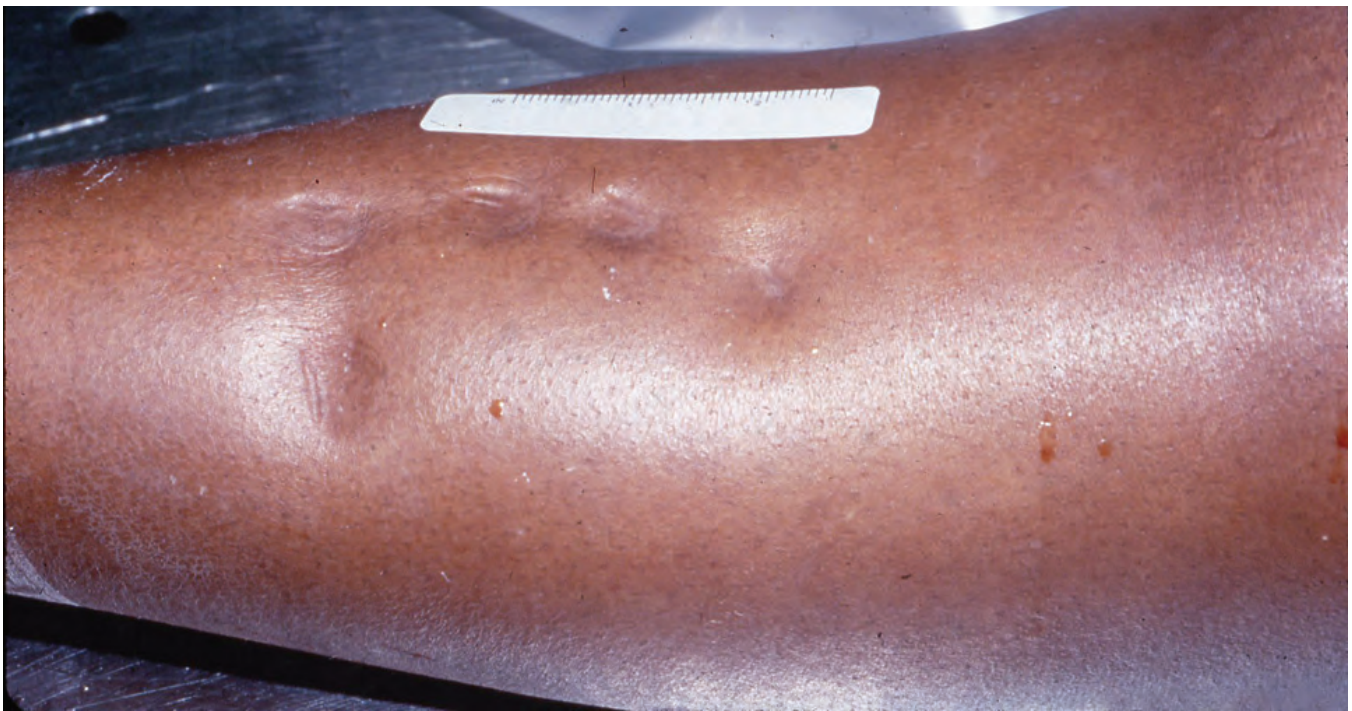Severely stenotic and insufficient aortic valve associated with childhood rheumatic fever. Correction of aortic stenosis will decrease the risk of sudden cardiac death.



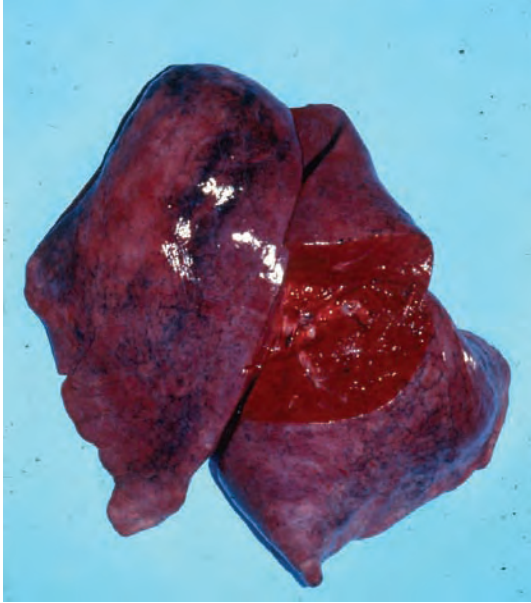
A fulminant pulmonary edema with foam extending from the mouth and nose due to congestive heart failure.



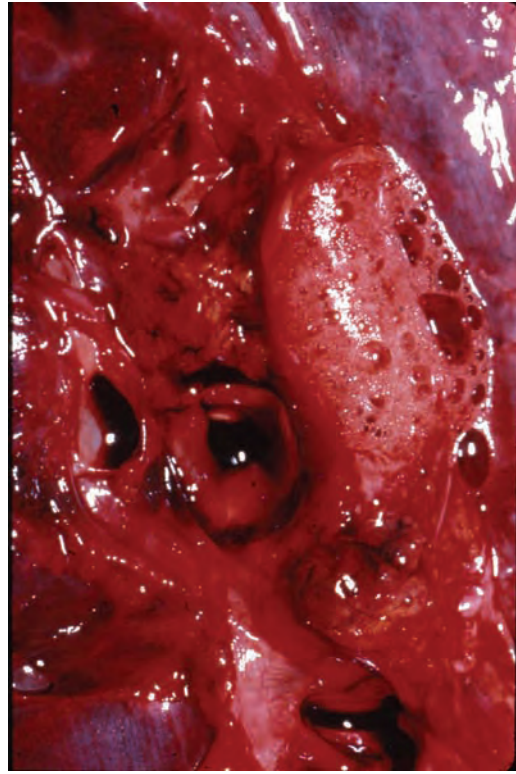
Note the frothy fluid from pulmonary edema extending into the laryngeal airway.



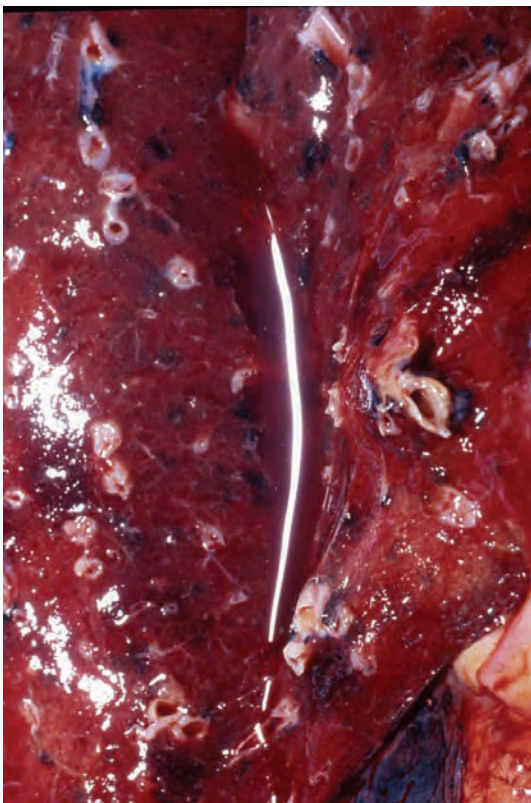
Pitting edema of the leg due to congestive heart failure.



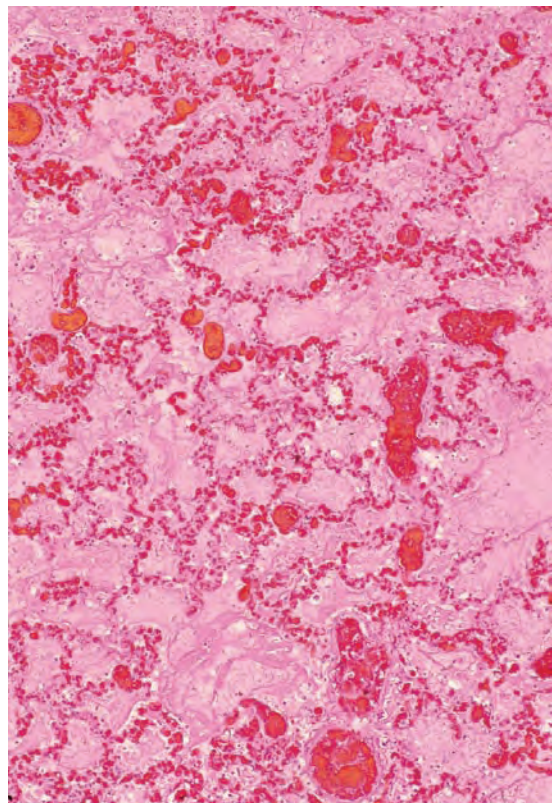
Lung with marked congestion and edema. Note the diffuse purple discoloration.



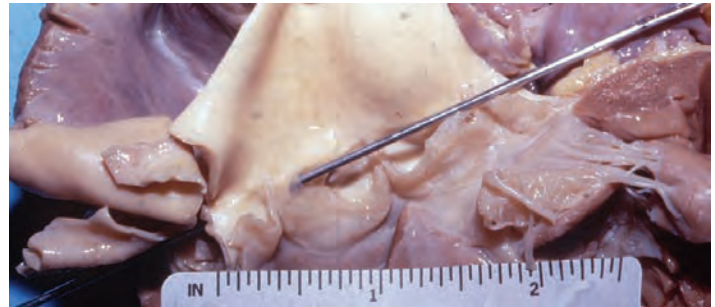
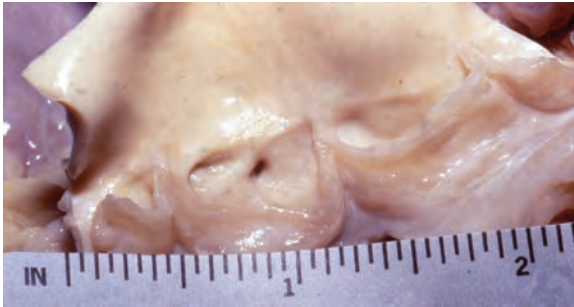Marked pink to red frothy fluid extending from the cut parenchyma of a lung due to fulminant pulmonary edema.



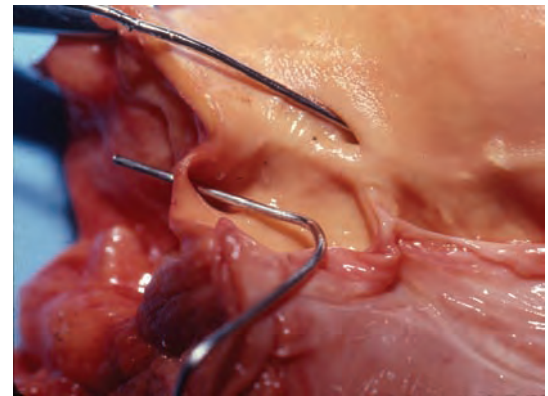
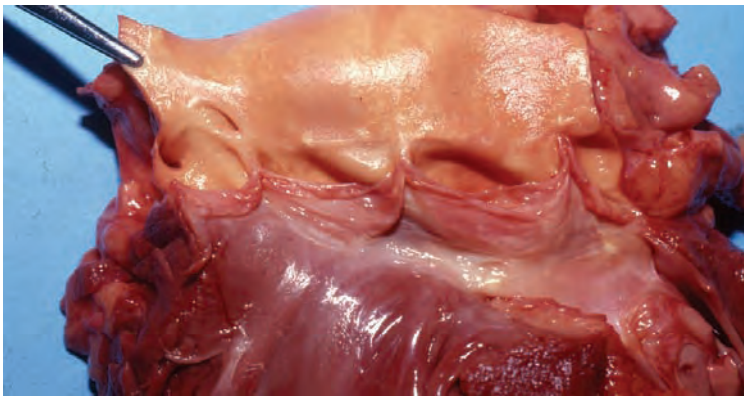
Cut section of a lung with pulmonary edema.



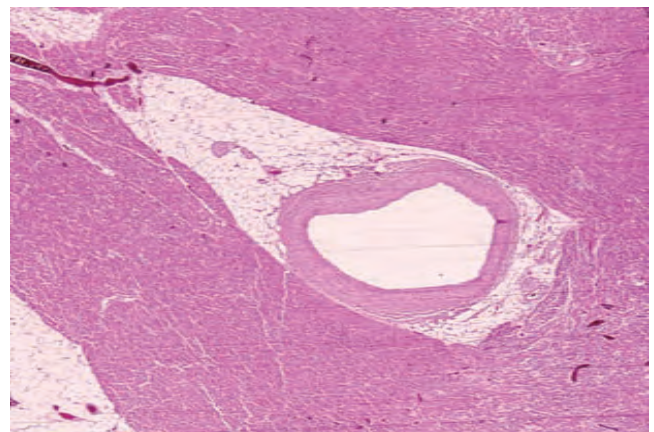
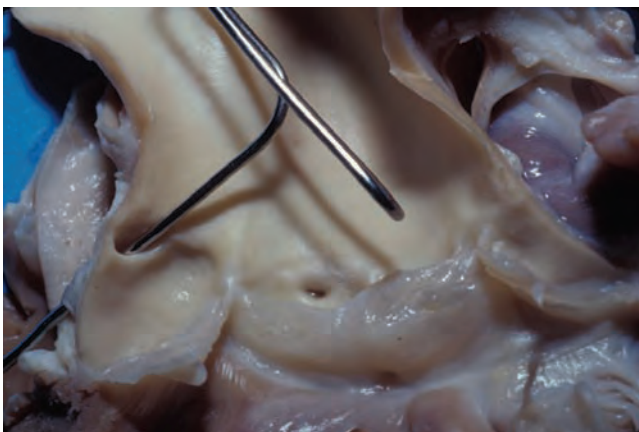
Microscopic view of lung with acute fulminant pulmonary edema.



These two figures demonstrate a coronary artery anomaly with acute angle takeoff and luminal narrowing in a 15-year-old who died suddenly during a basketball game. There was no history of blunt impacts to the chest during the game. There was no past history of syncopal episodes or chest discomfort.



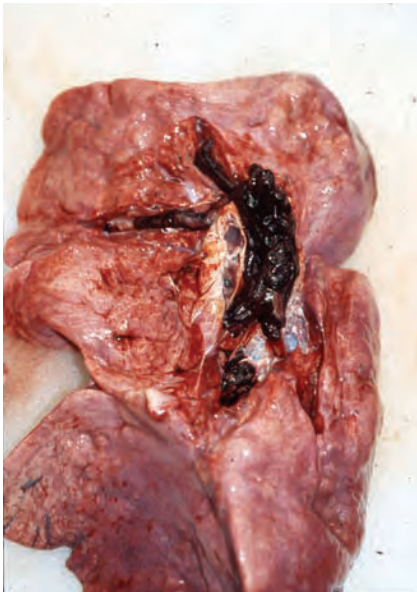
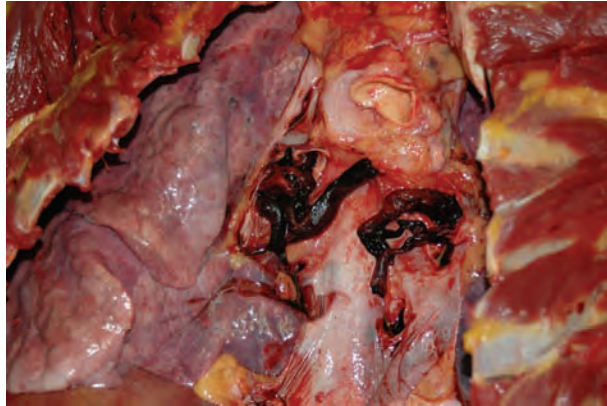
A coronary artery anomaly with acute angle takeoff and luminal narrowing. This individual died a sudden cardiac death shortly after exertion.



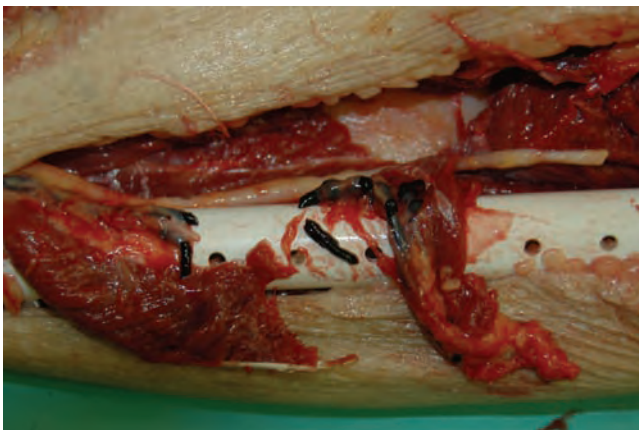This coronary anomaly reveals a bicuspid aortic valve with superior displacement of one of the coronary ostia. This child died of trauma sustained in a motor vehicle accident and this finding was incidental.

This low-power histopathologic view demonstrates "myocardial tunneling" where the left anterior descending coronary artery dipped deeply into the left ventricle wall.

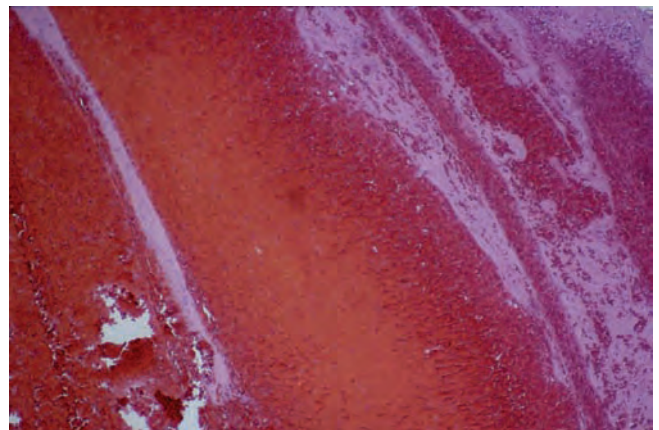




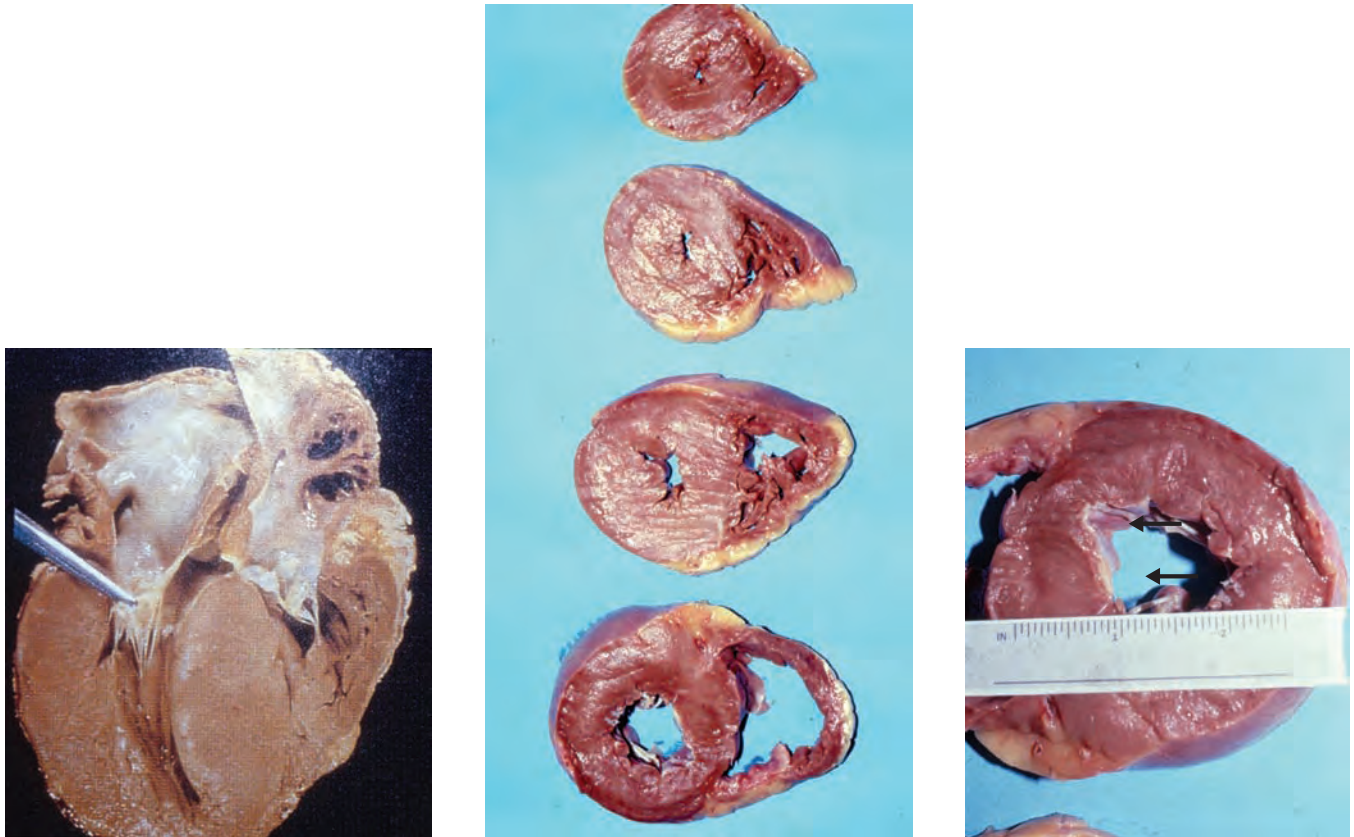
Pulmonary thromboembolus in an obese woman who was on birth control pills and smoked cigarettes.



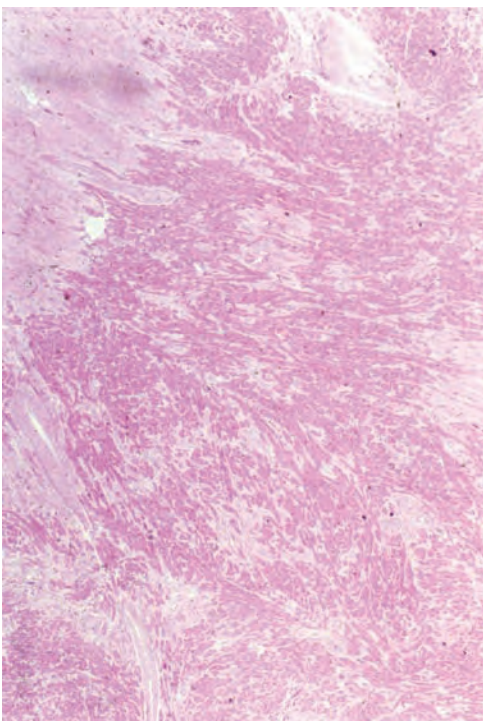
Incision of the lower leg with dissection of the gastrocnemius muscle demonstrating multiple deep venous thrombi in an individual who underwent organ donation with removal of bone and soft tissue from each leg. Note the plastic tubing left by the organ donor network.



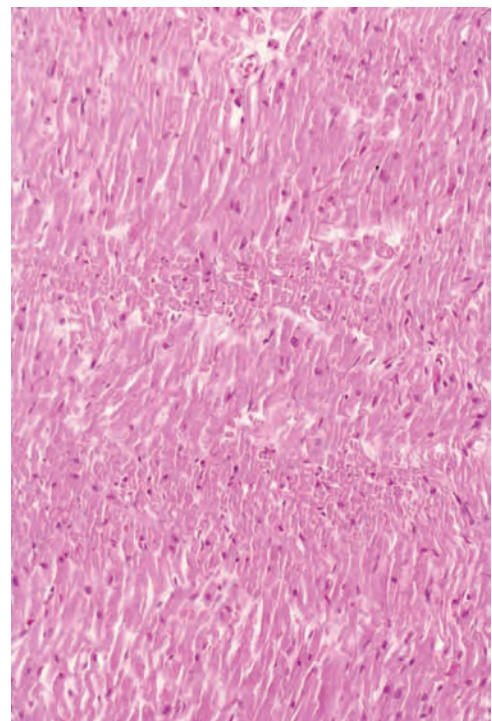
Microscopic view of a pulmonary thromboembolus. Note the laminated alternating lighter fibrin bands referred to as the lines of Zahn.



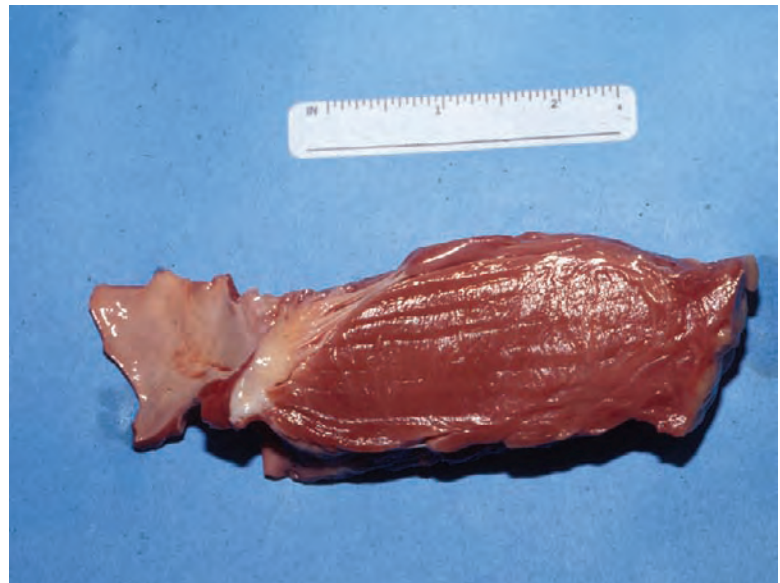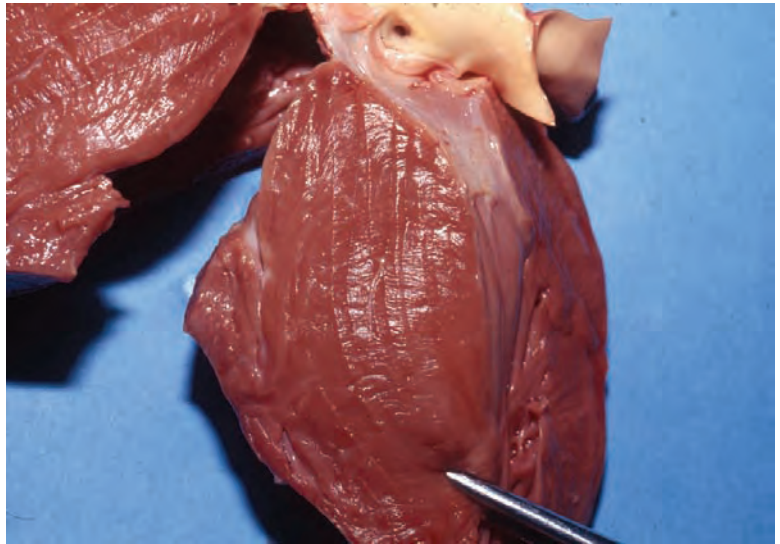
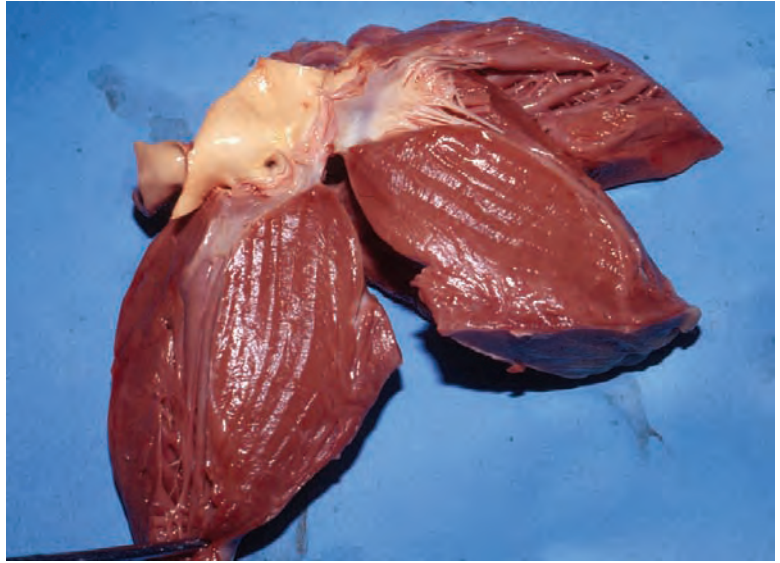These are different views of two hearts with the classical variant of hypertrophic cardiomyopathy. Note the large degree of asymmetric left ventricle hypertrophy.



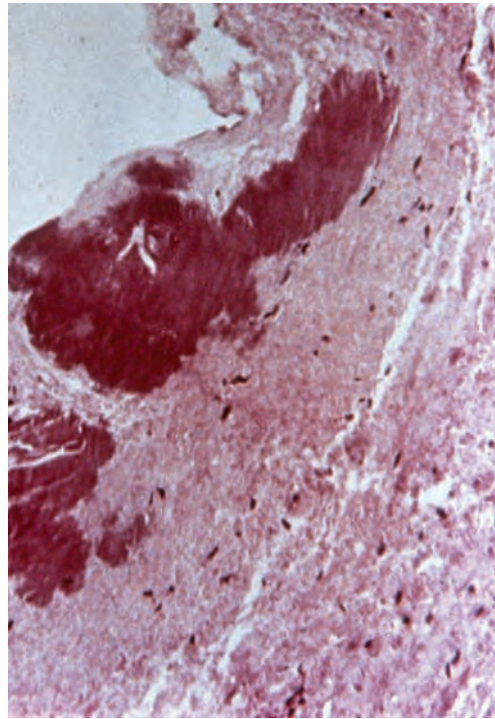
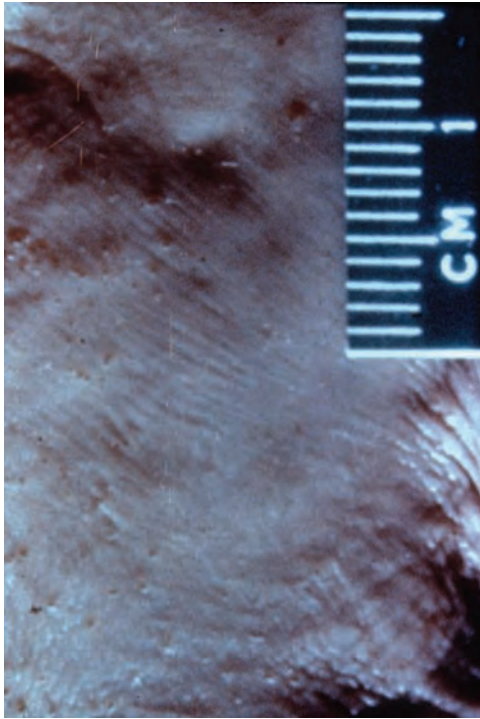
Hypertrophic cardiomyopathy with myocyte fiber disarray and fibrosis.



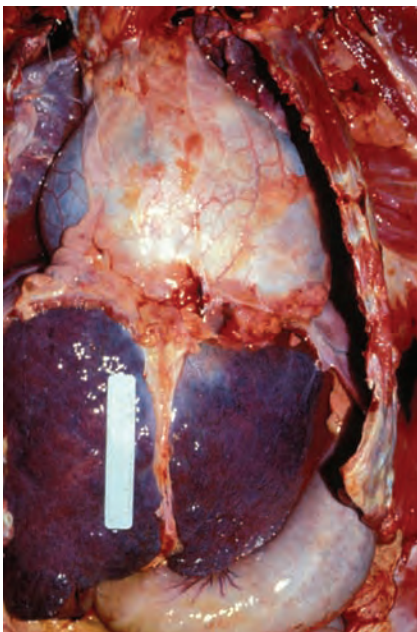
Hypertrophic cardiomyopathy with myocyte fiber bundle disorganization.



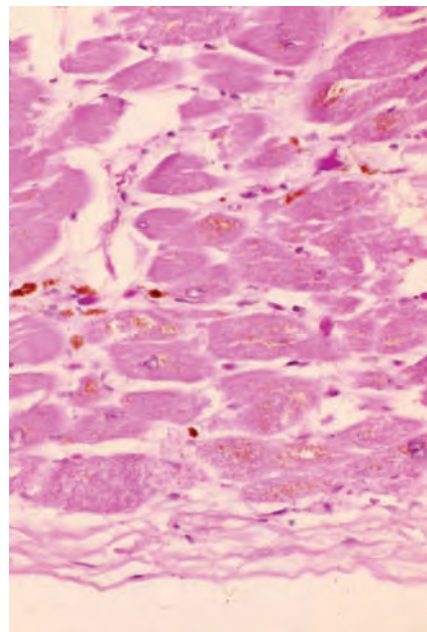
Hypertrophic cardiomyopathy. Note the marked septal hypertrophy with asymmetry.



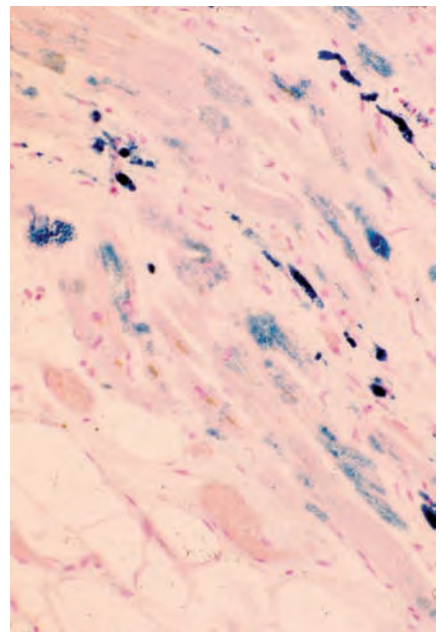
Note the waxy pink myocardial discoloration in this individual with amyloidosis.



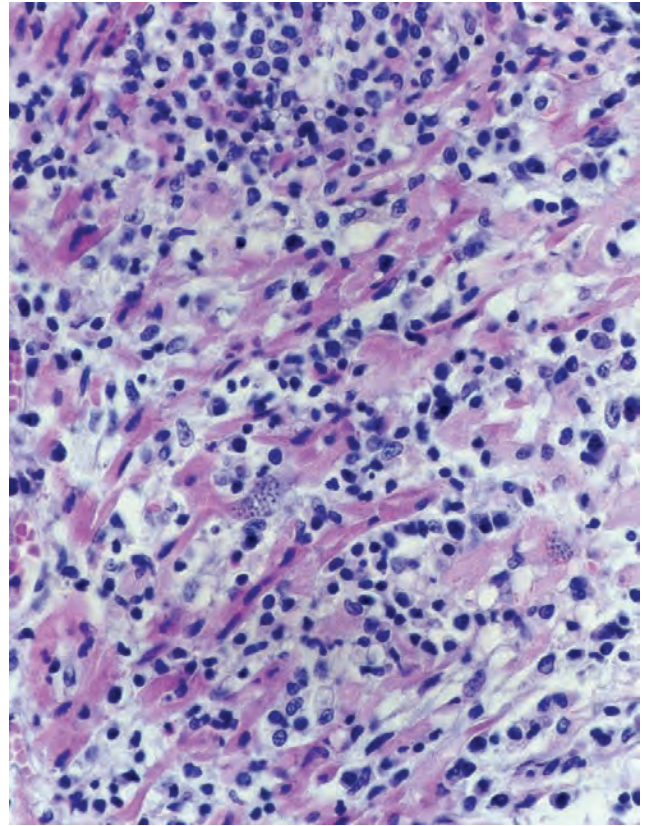
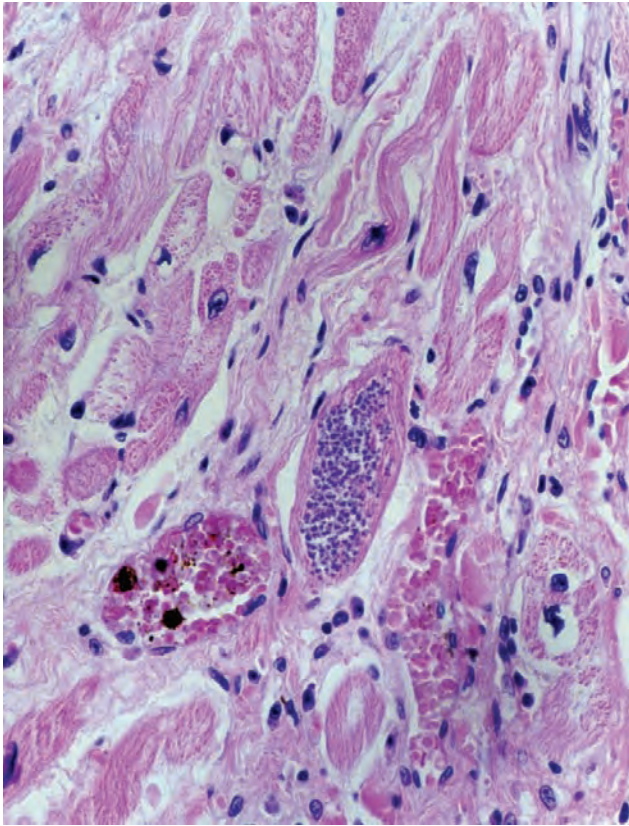
This decedent's pericardial sac was full of several hundred cc's of yellow-pink fluid. The gradual buildup of this fluid over a long period was due to advanced secondary hemochromatosis.



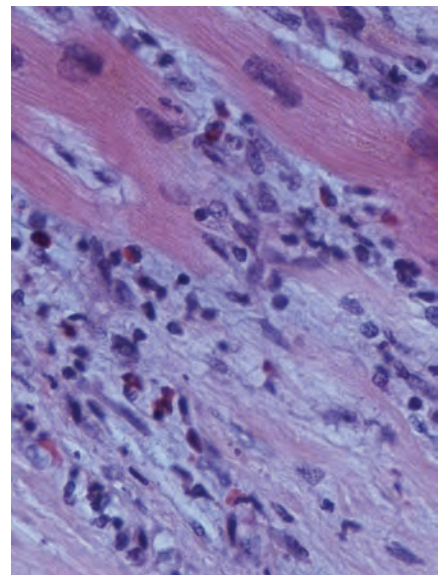
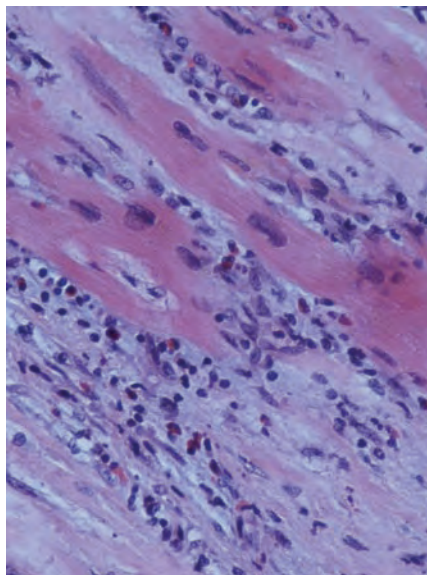
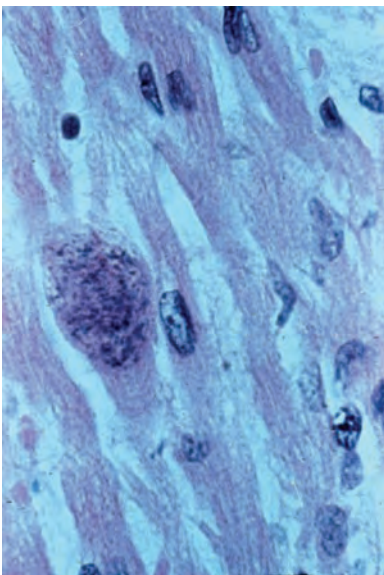
Microscopic section of heart showing iron deposition from secondary hemochromatosis associated with blood transfusions for treatment of beta-thalassemia major.



Microscopic section of heart with Prussian blue staining of iron deposits in the heart of the same individual with secondary hemochromatosis.

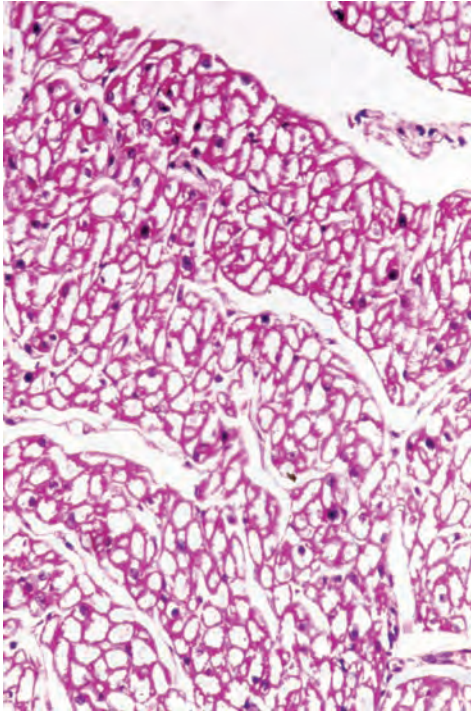


These microscopic myocardial views demonstrate Chagas' disease. Note the extensive chronic inflammation.

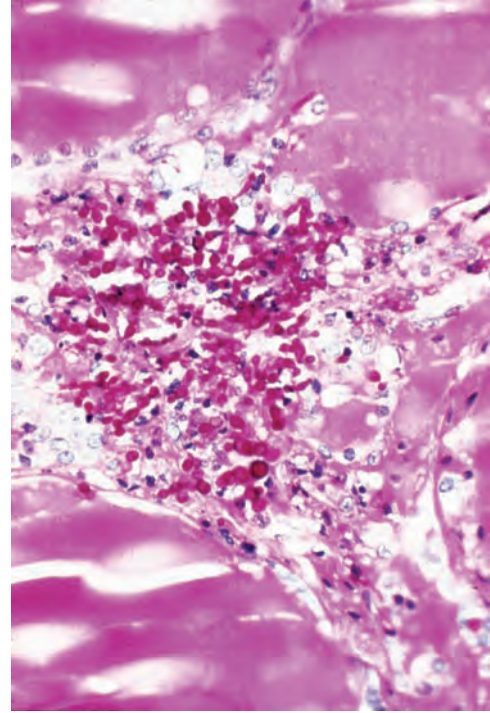


Myocarditis secondary to toxoplasmosis in an individual with acquired immunodeficiency syndrome.

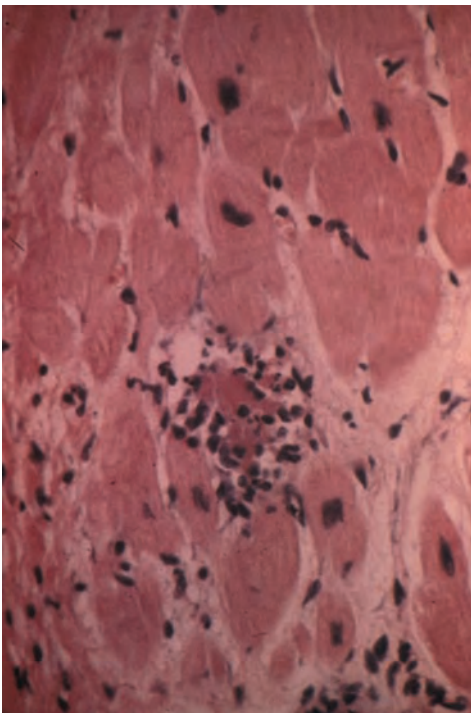
Eosinophilic myocarditis associated with a hypersensitivity drug reaction.



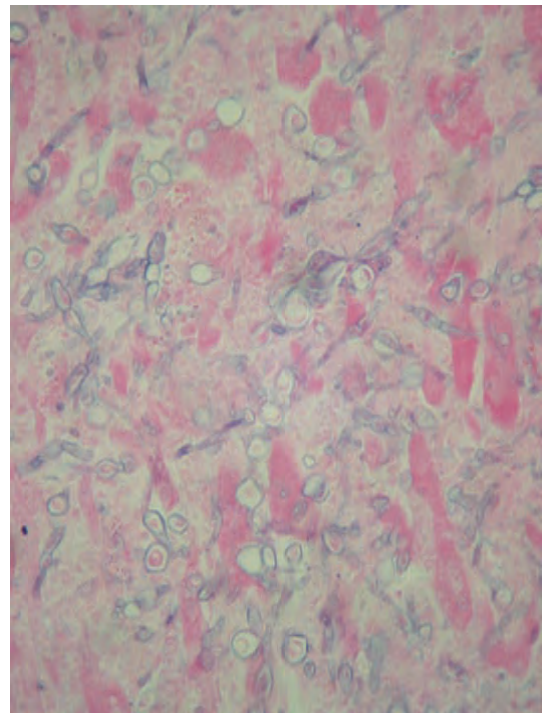
Microscopic view of myocardium in an individual who died of Pompe's disease. Note the many artifactual empty vacuoles following processing leading to glycogen loss.



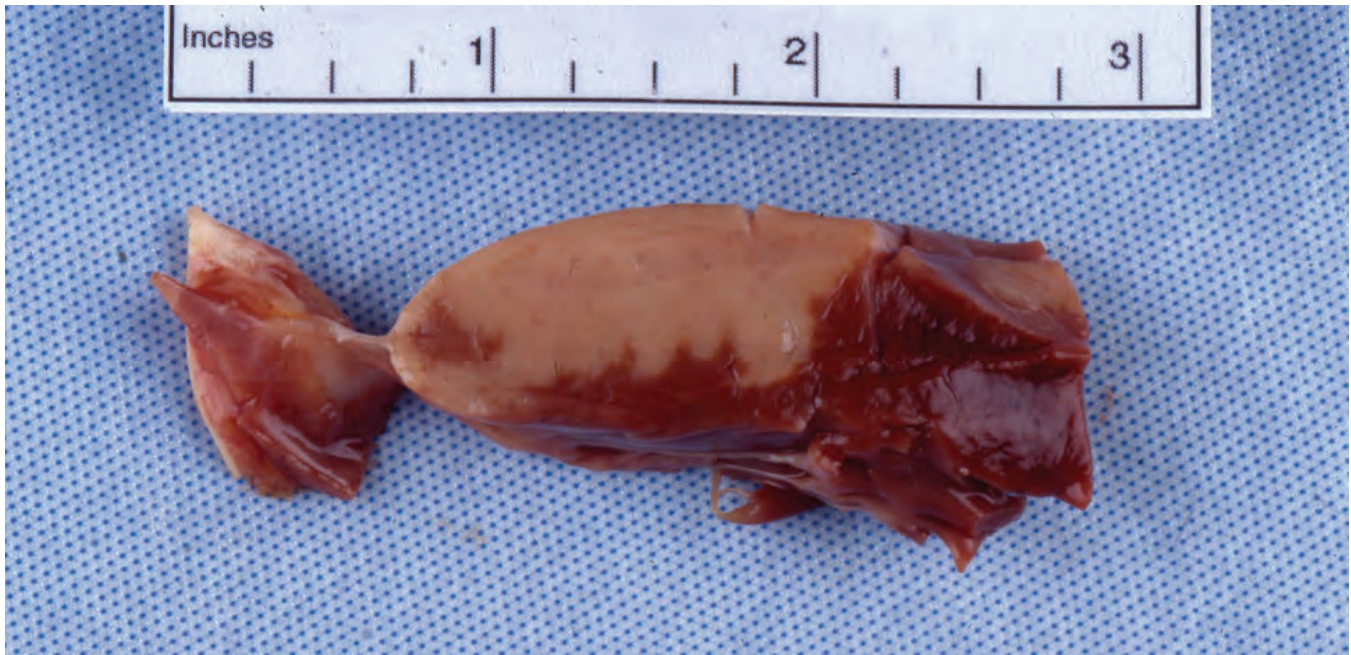This candidal myocarditis was found in an individual with acquired immunodeficiency syndrome.



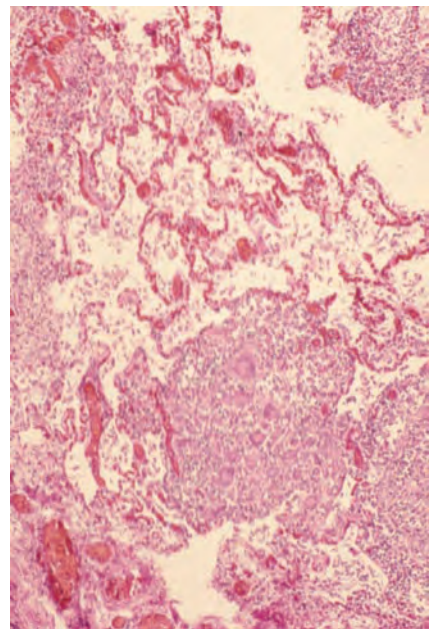
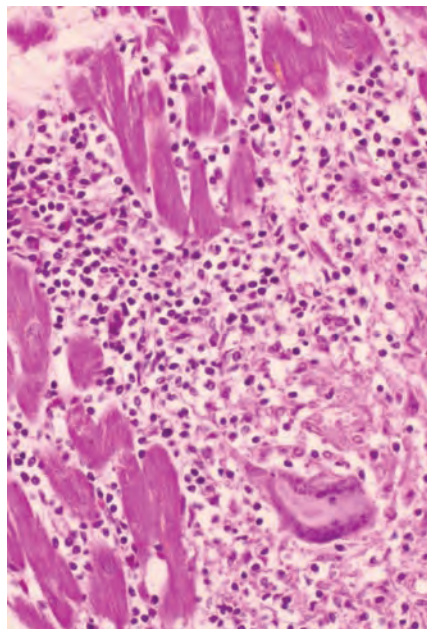
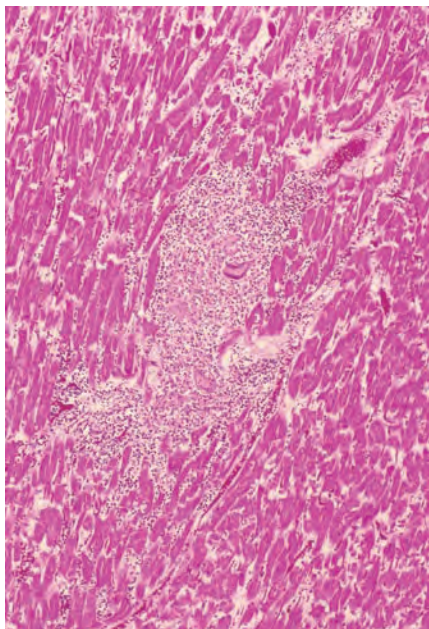
This focal viral myocarditis demonstrates myocardial necrosis with inflammation made up predominately of lymphocytes.



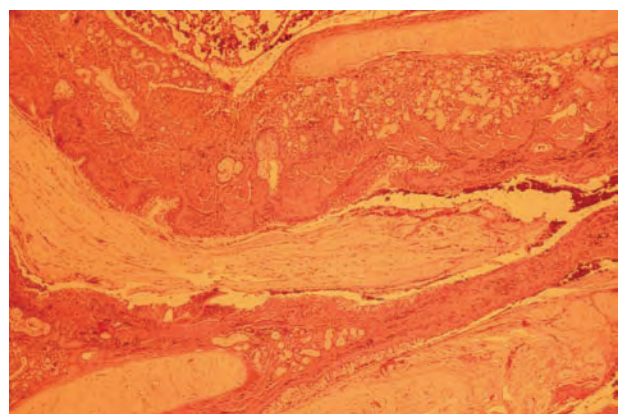
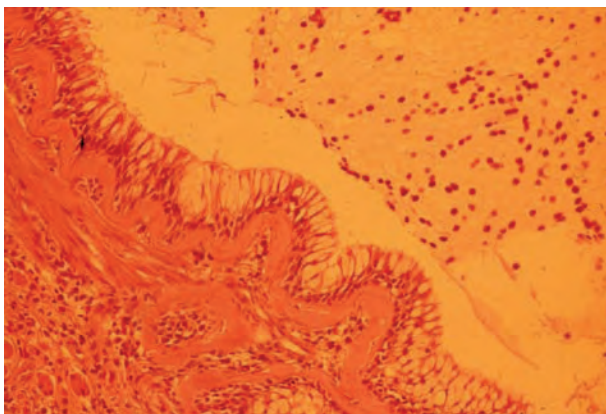
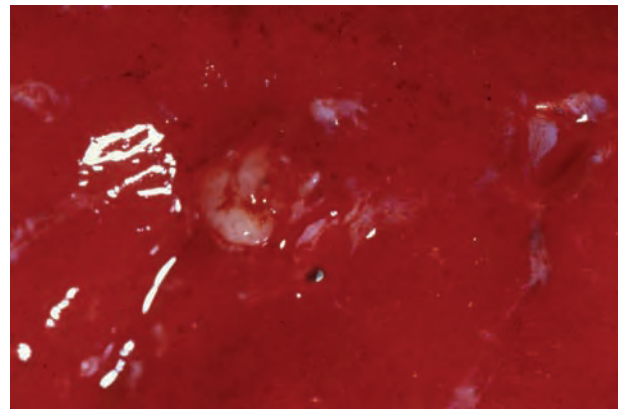
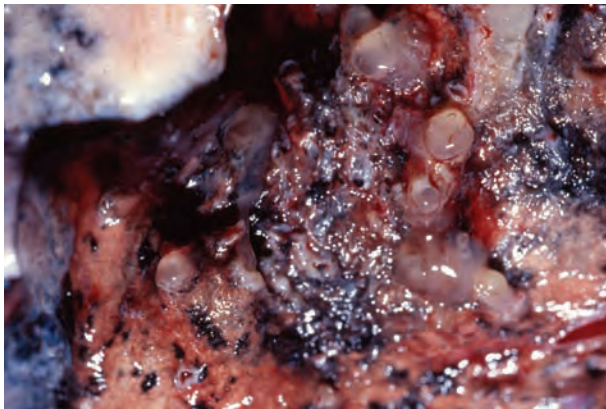
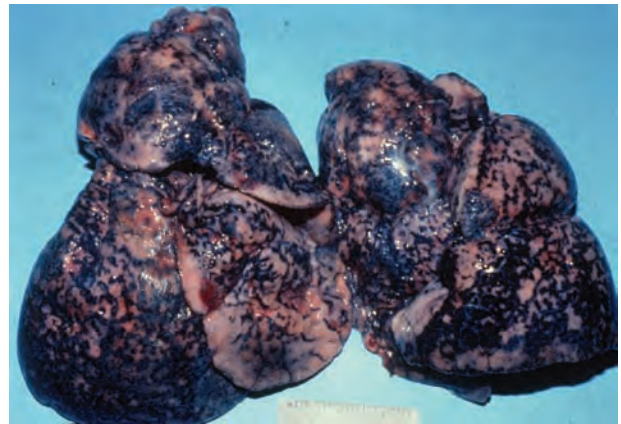
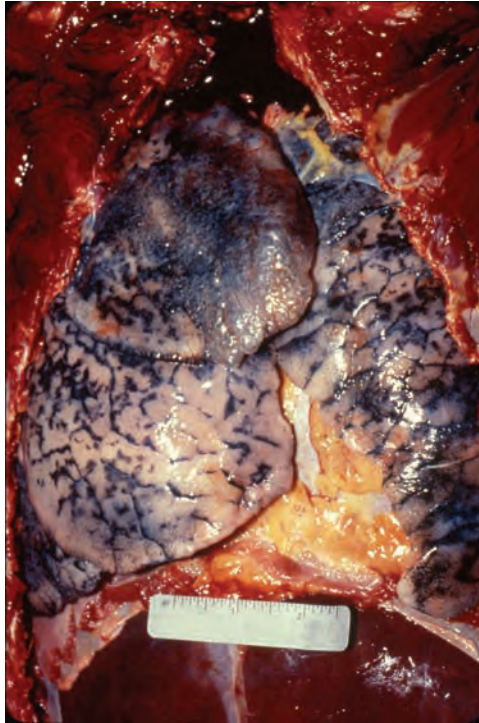
Aspergillosis myocarditis from an immunocompromised individual who underwent a recent bone marrow transplant.



Macroscopic section of myocardium from an individual who died of cardiac sarcoidosis.

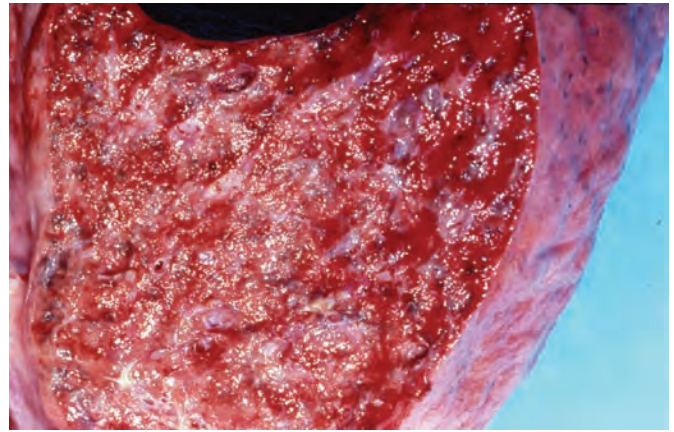
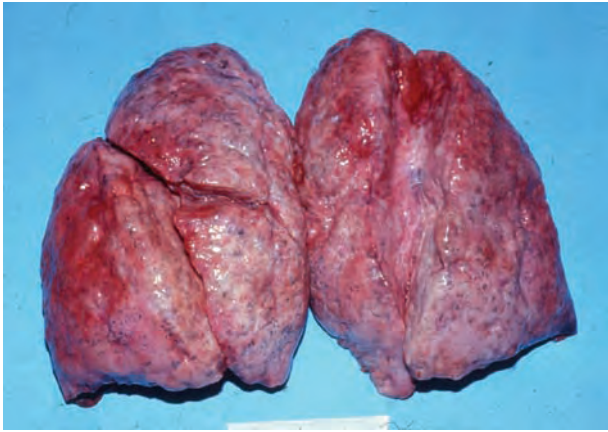


Sarcoidosis. Note the noncaseating granulomas consisting of chronic inflammation, epithelioid cells, lymphocytes, and giant cells found throughout the body. These views demonstrate examples from the heart and lungs.

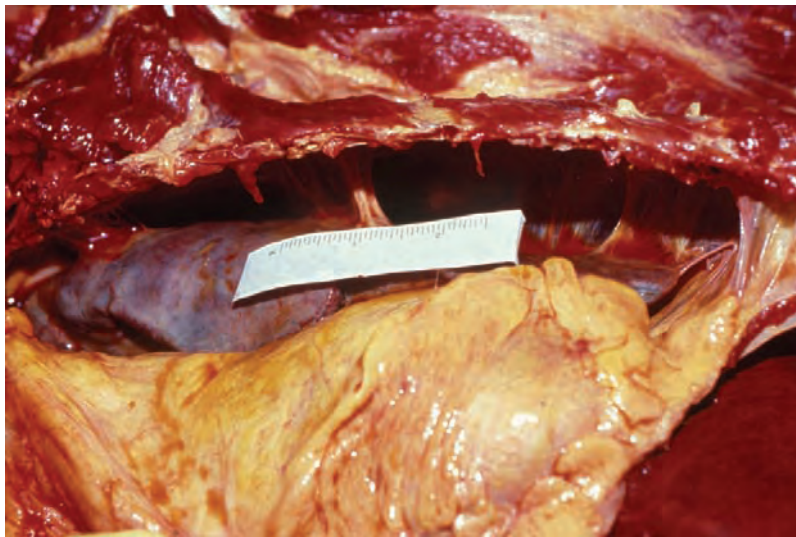


These figures demonstrate acute and chronic bronchial asthma. Note the lungs within the thoracic cavity are hyperaerated and expand to overlie the pericardial sac. Upon removal of the lung, they appear markedly hyperaerated. If these lungs were placed in a water bath they would float almost entirely on the surface. Cut section through the parenchyma reveals thick copious mucoid secretions within the bronchial distribution. Microscopic section reveals increased amounts of goblet cells and smooth muscle. There is a large mucous plug within the airway with numerous eosinophils. The parenchyma also has numerous inflammatory cells, predominantly eosinophils.

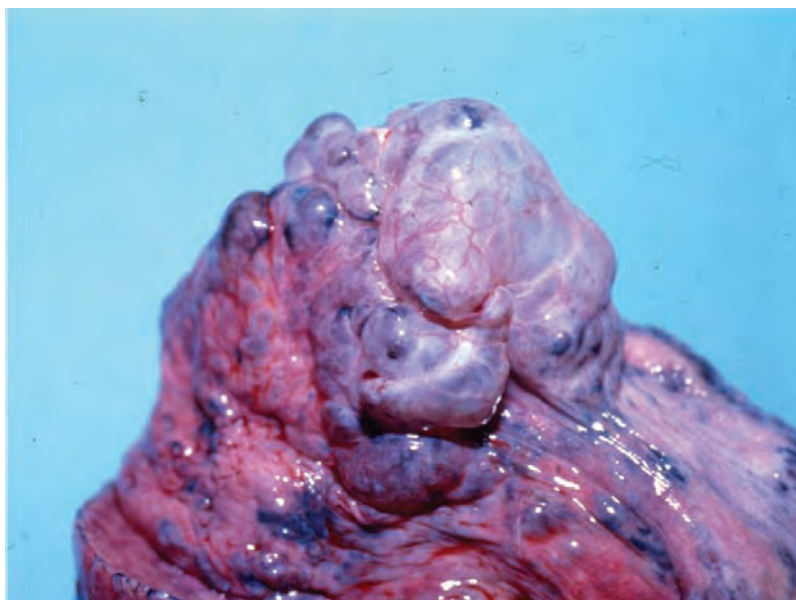



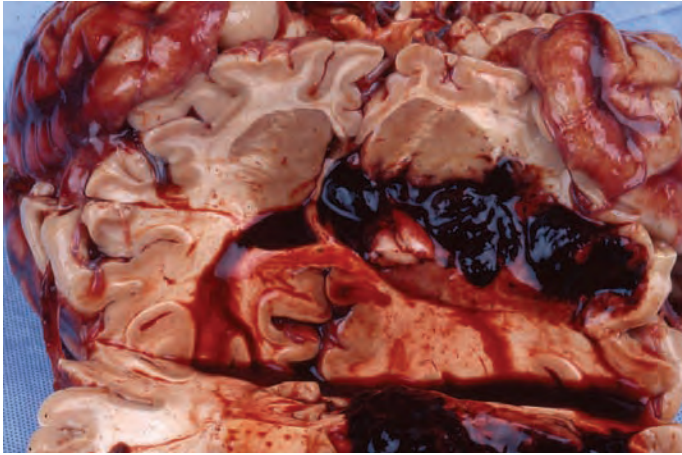
Chronic obstructive pulmonary disease (COPD) with hyperaeration and emphysematous change.



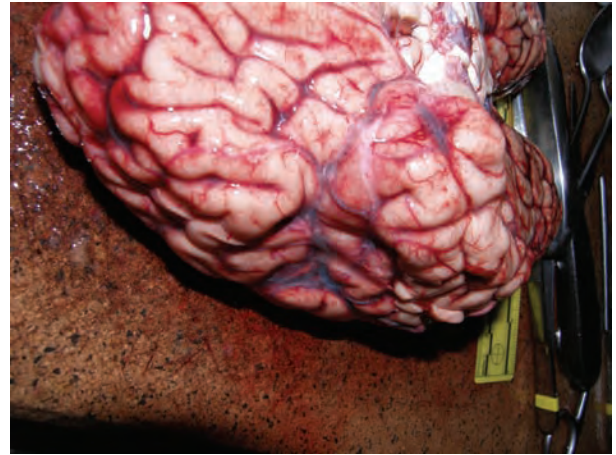
Pleural adhesions most likely due to past bouts of pneumonia.



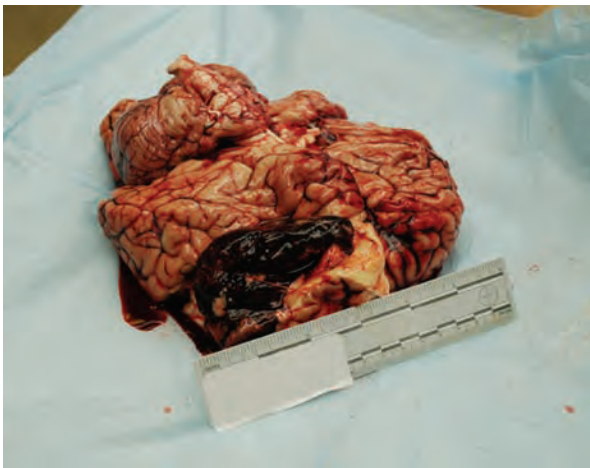
Bolus emphysema in a person with COPD. These bullae may occasionally rupture and cause a pneumothorax.



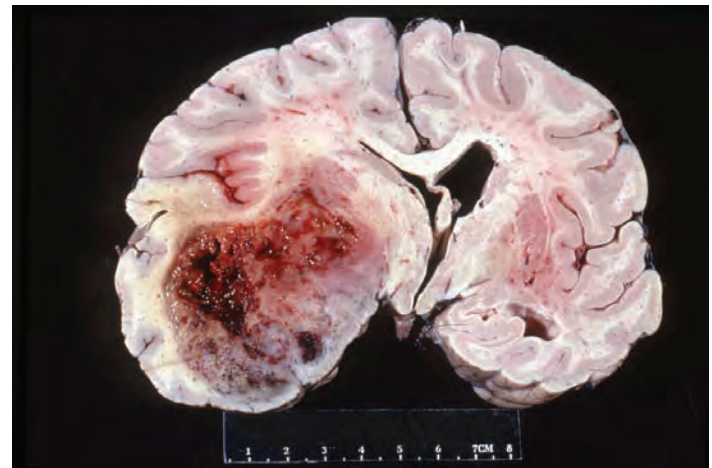
Hypertensive intracerebral hemorrhage. Mostly caused by rupture of a small intraparenchymal vessel.



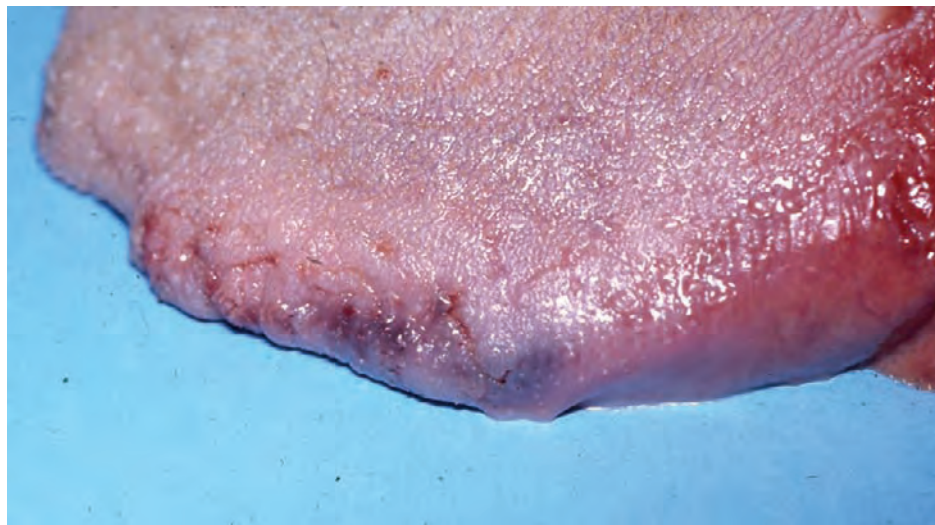
Old healed stroke. Note the indentation of the cerebral hemisphere.



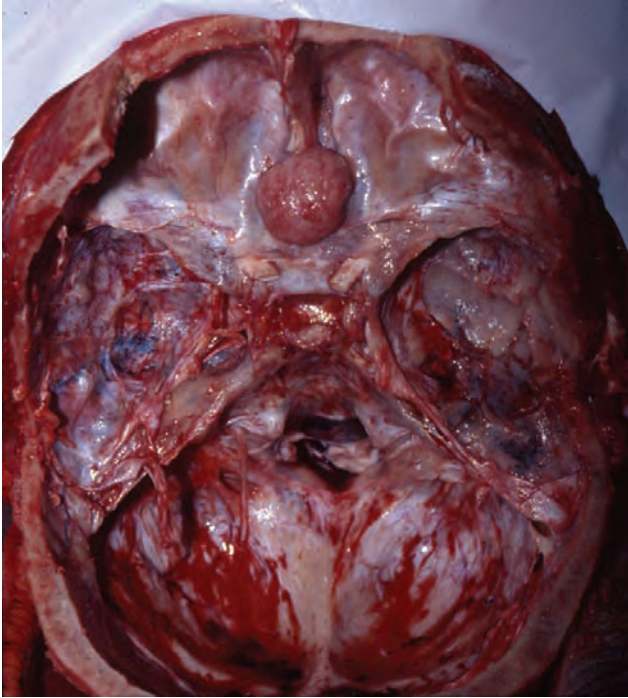Intracerebral hemorrhage due to ruptured A-V malformation.



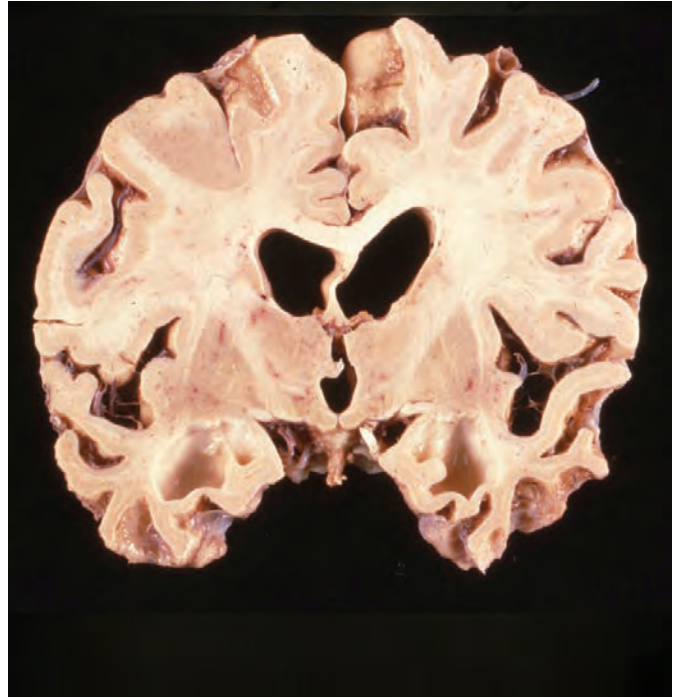
Astrocytoma causing significant compression of the surrounding structures.



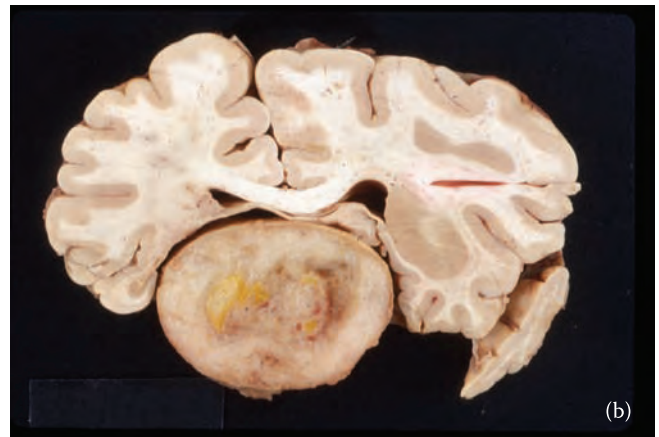
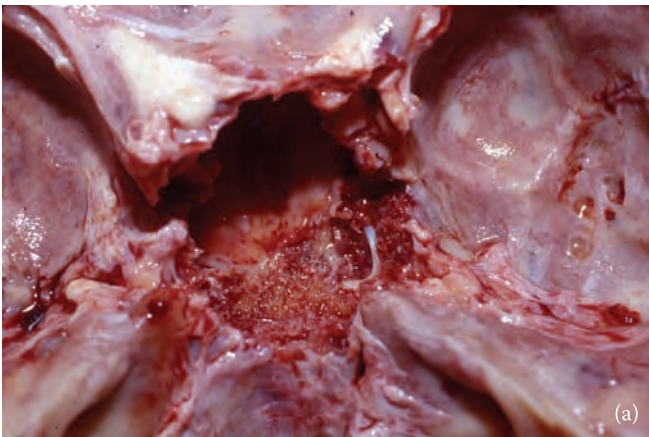Bite marks to tongue with hemorrhage from an individual who died of epilepsy. This was the only finding at autopsy.



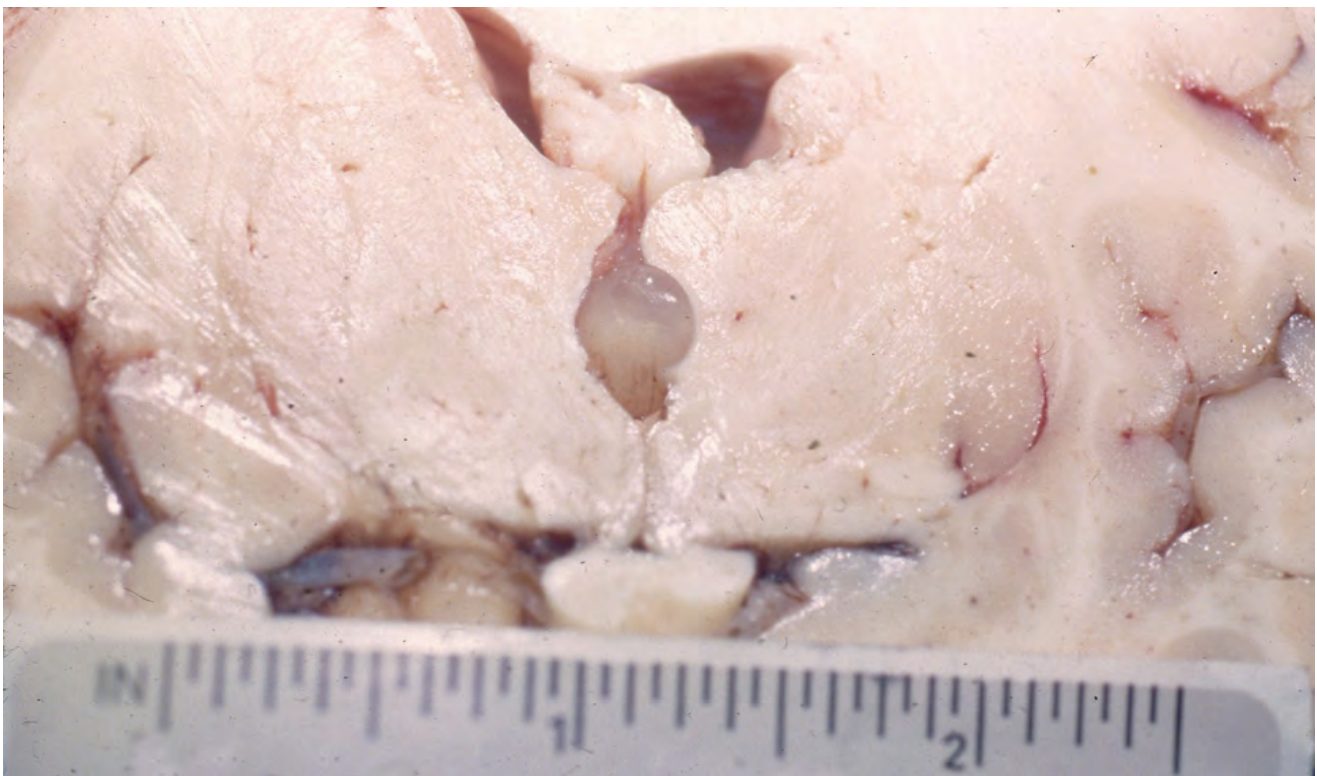
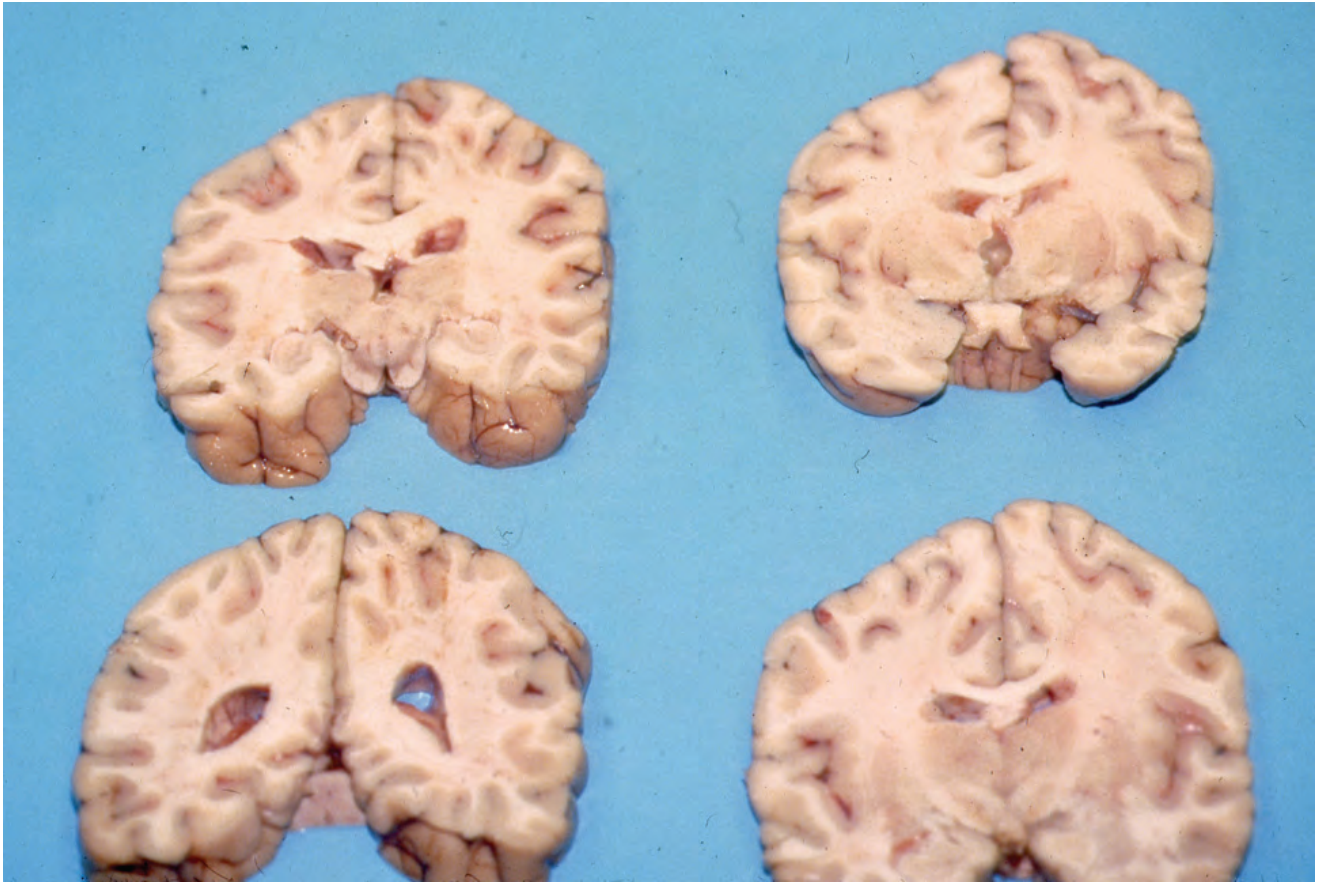
Anterior cranial fossa meningioma.



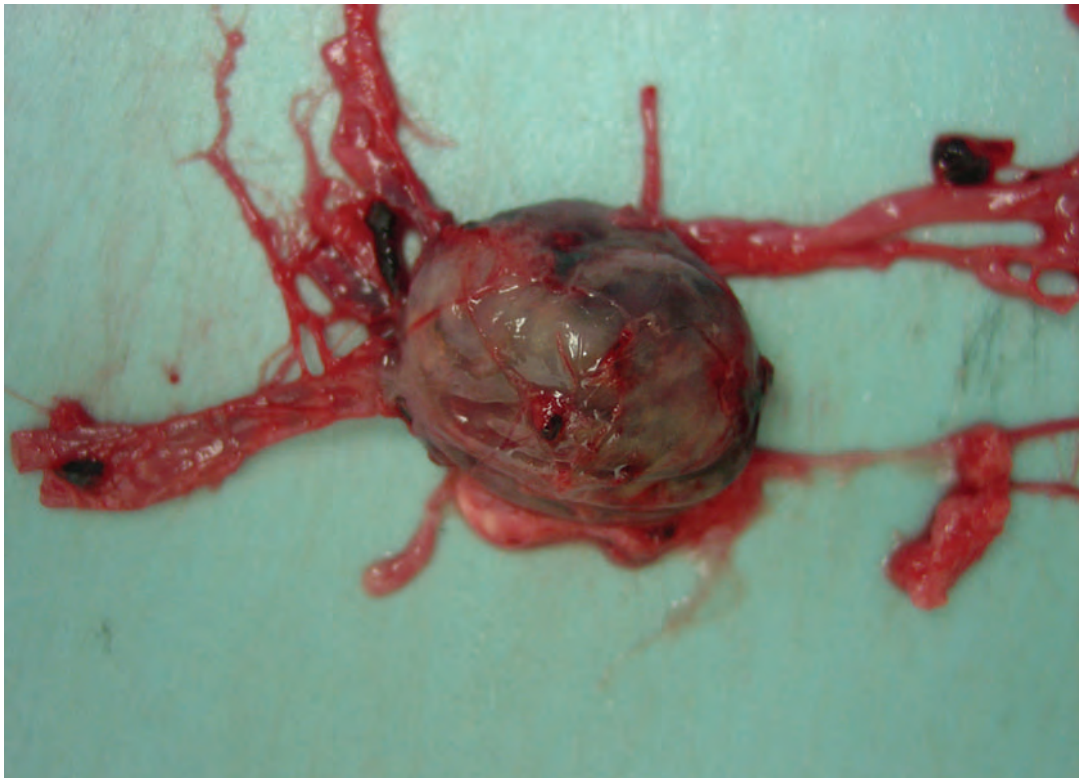
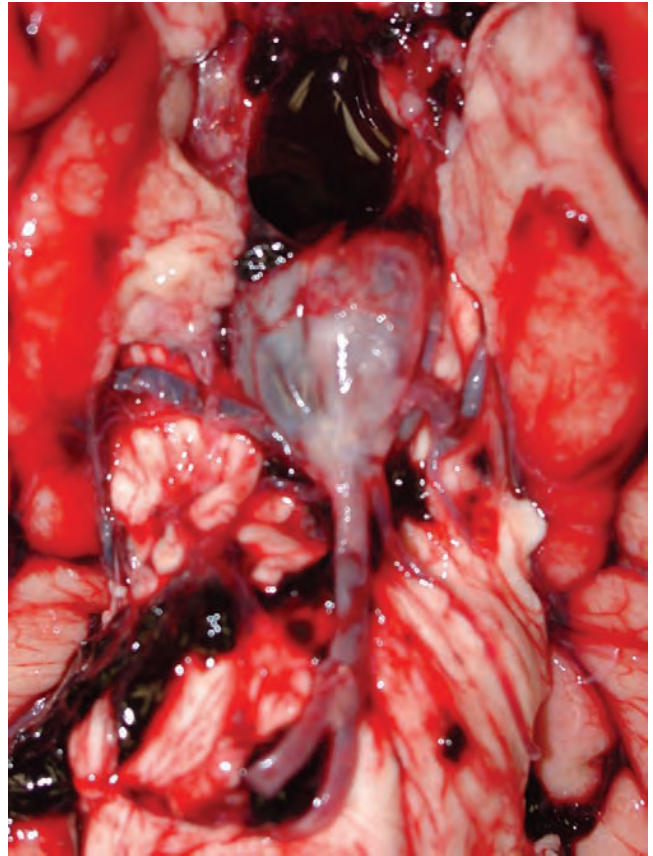
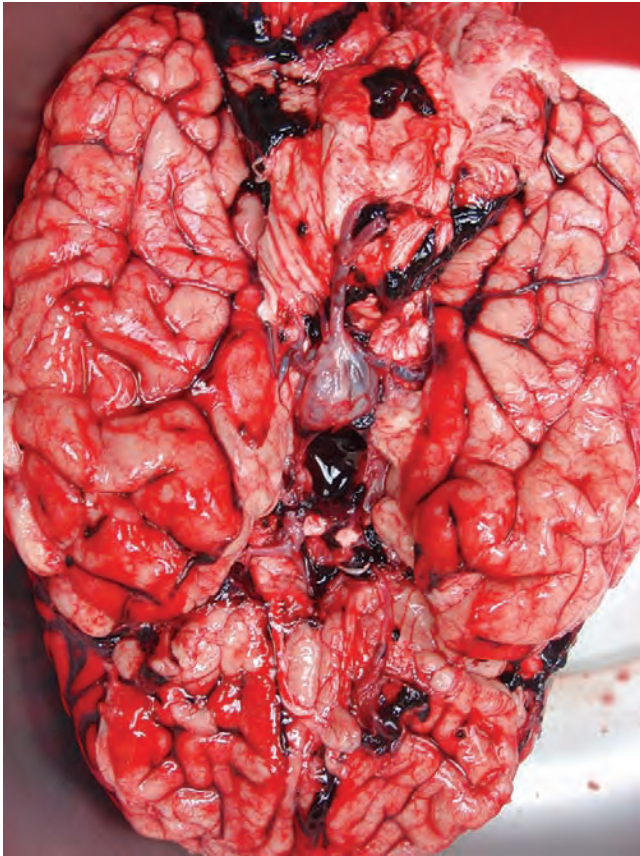
Pick's disease. Note the asymmetric atrophy of the frontal, temporal, and parietal lobes. This form of chronic dementia occurs far less frequently than Alzheimer's disease.



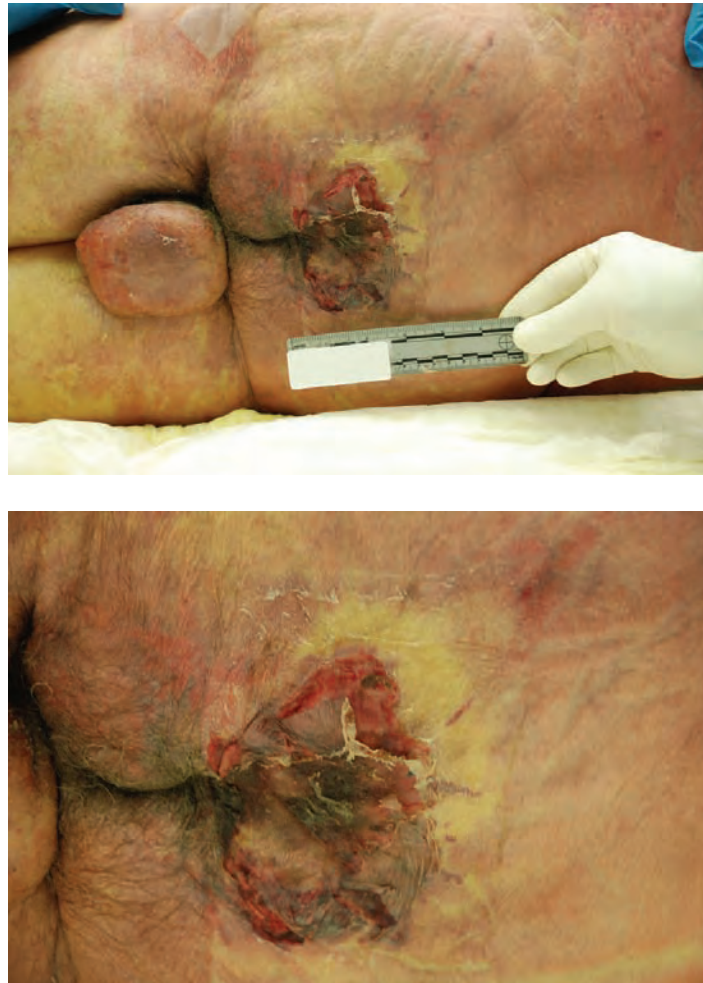Two separate cases of pituitary adenoma. Figure (a) depicts a large erosion into the sella turcica and (b) demonstrates a large adenoma viewed on a cross section of a cut formaldehyde-fixed brain. These adenomas may vary largely in size.



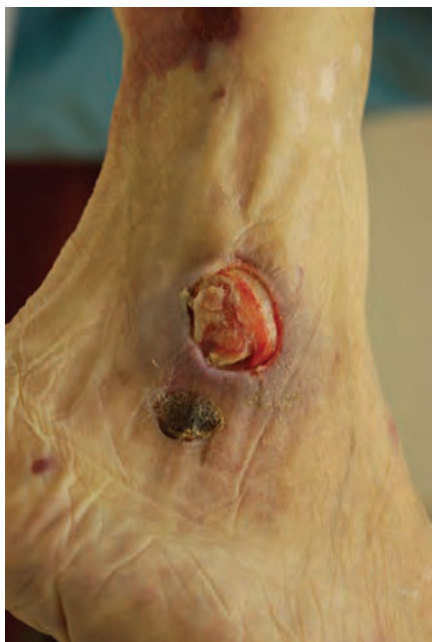Colloid cyst of the third ventricle. This decedent had a history of severe headache with postural changes. This may be associated with sudden cardiac death following a buildup of cerebrospinal fluid pressures associated with central nervous system cardiac center disruption and fatal arrhythmia.



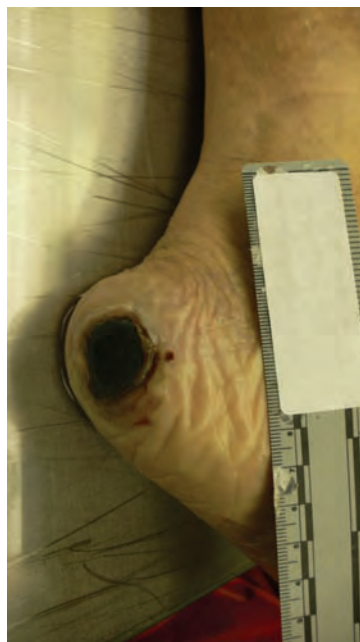Sudden death associated with ruptured saccular cerebral artery aneurysm with subarachnoid hemorrhage. These are examples of giant berry aneurysms, which are greater than 2.5 centimeters in greatest dimension. Small saccular aneurysms may rupture the same way. The jolt of increased pressure from arterial blood through the subarachnoid space at the base of the brain may disrupt the cardiac centers, causing fatal arrhythmia.



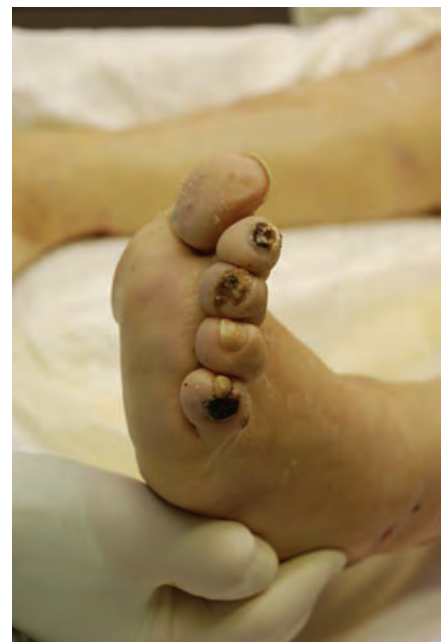Decubital ulceration or pressure sore. This is often associated with poor patient care.

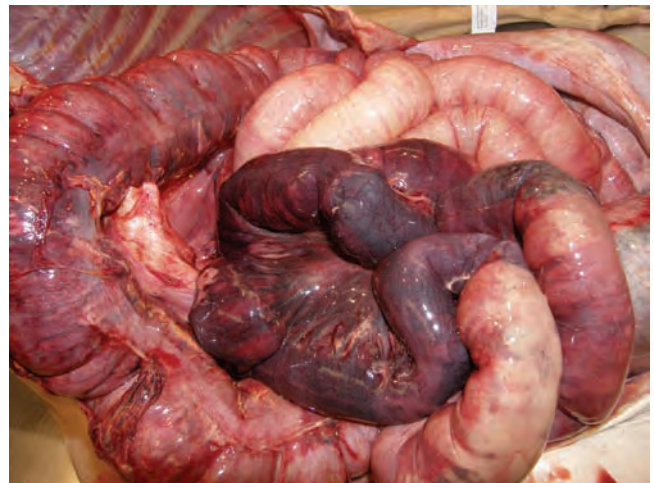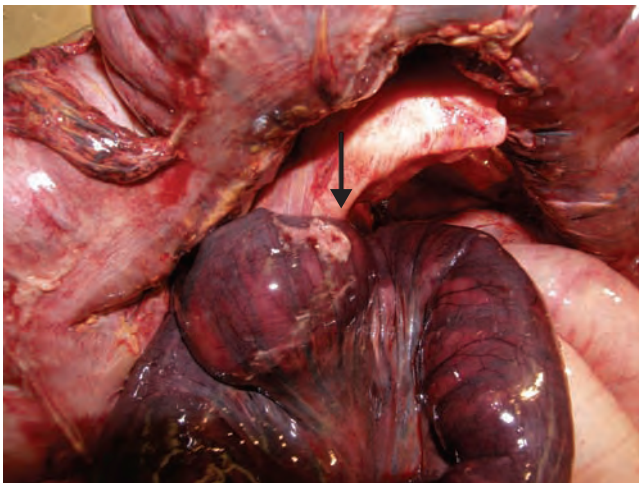
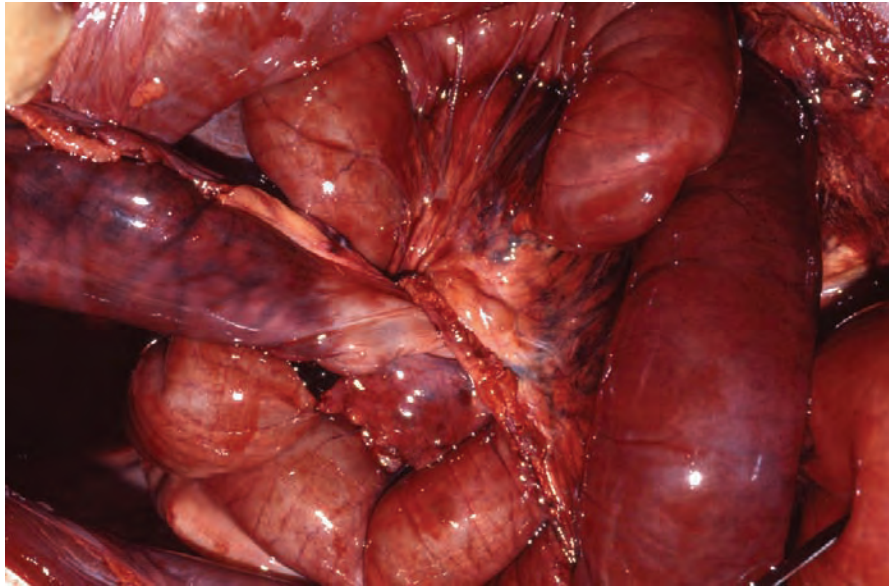


Healing ankle ulceration associated with peripheral vascular disease.

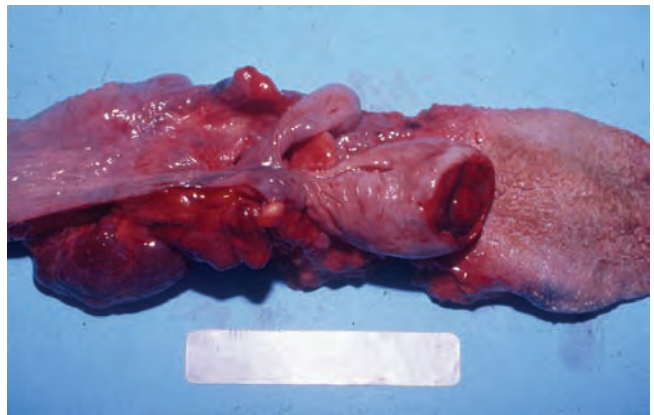
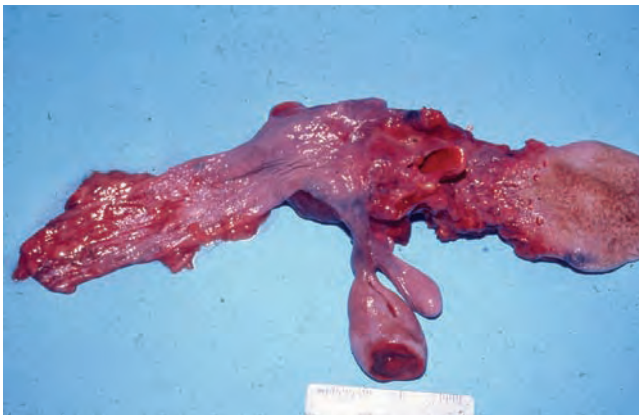

Dry gangrene associated with peripheral vascular disease due to long-term diabetes mellitus.

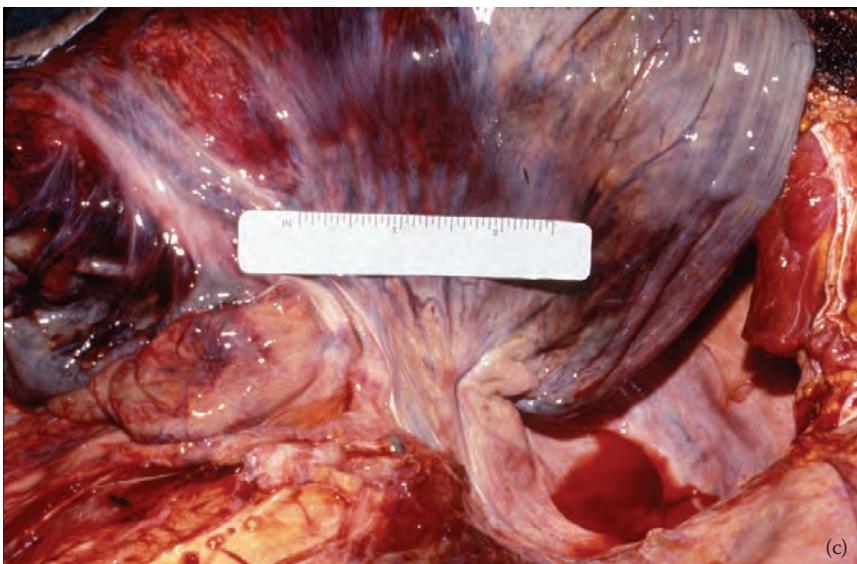
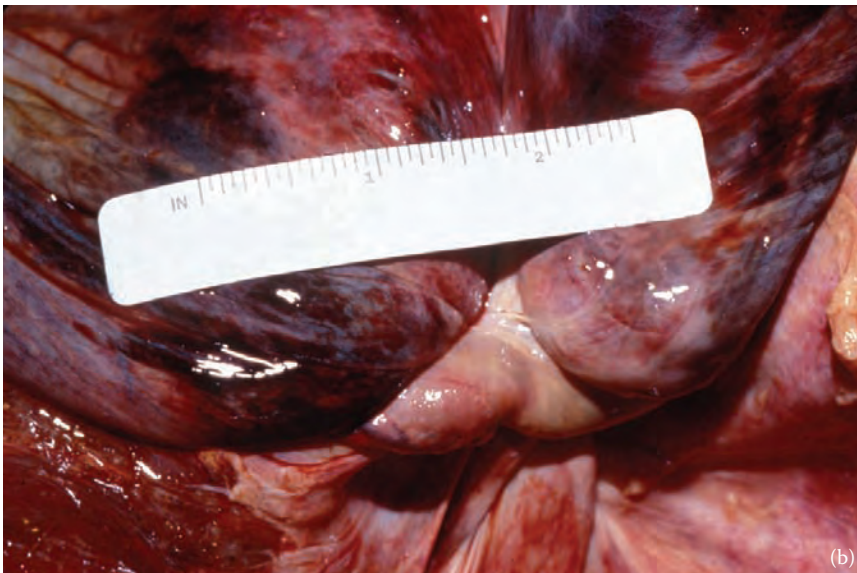
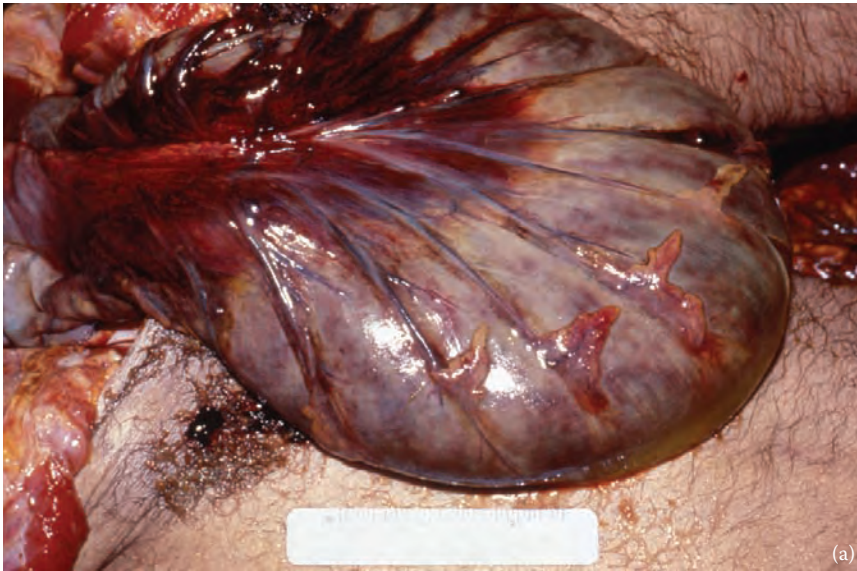



Ischemic bowel due to small intestine volvulus with vascular compromise. The arrow indicates purulent exudate at the serosal surface.

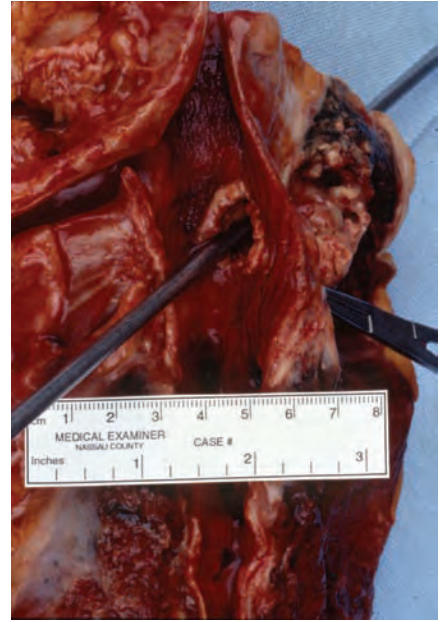
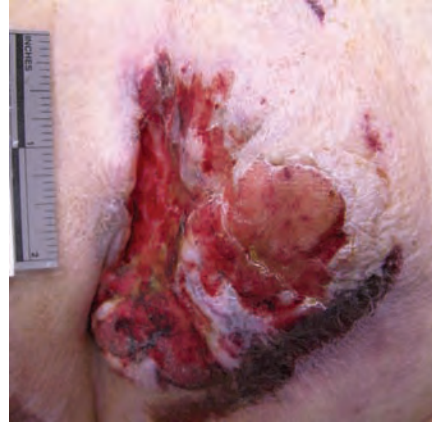
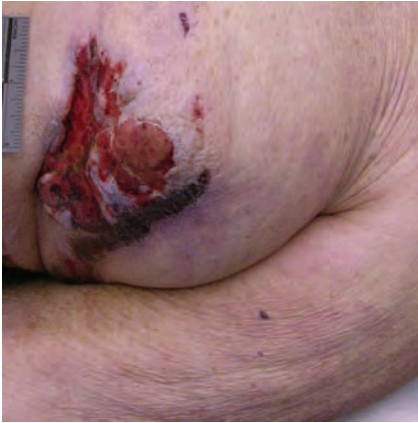
This decedent had a longstanding history of difficulty swallowing. She was seen to gesture as though she could not breathe and then collapsed. Autopsy revealed a large benign esophageal polyp that obstructed the upper airway. Note the ulceration at the tip of the polyp from constant rubbing. During this last episode she was unable to clear the obstruction.



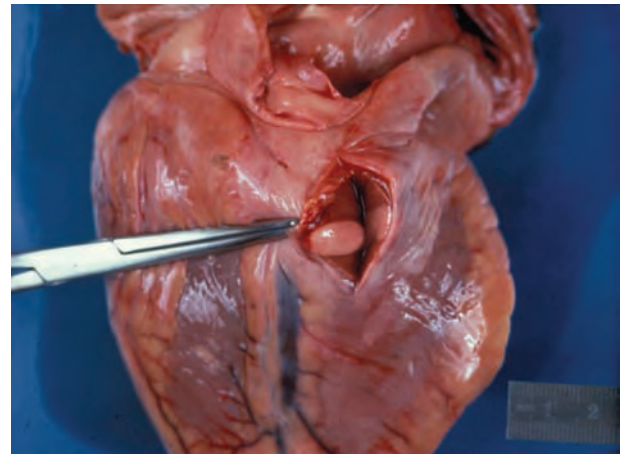
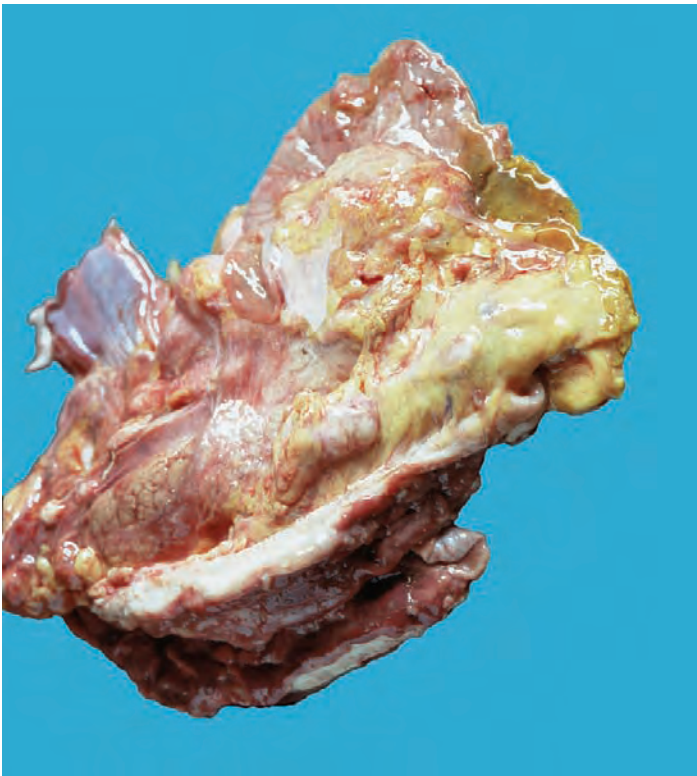
Cecal volvulus. Note the red discoloration of the serosal surface. Figure (a) demonstrates cecal enlargement due to obstruction, (b) demonstrates the cecal volvulus with rotation and obstruction, and (c) demonstrates this region untwisted.





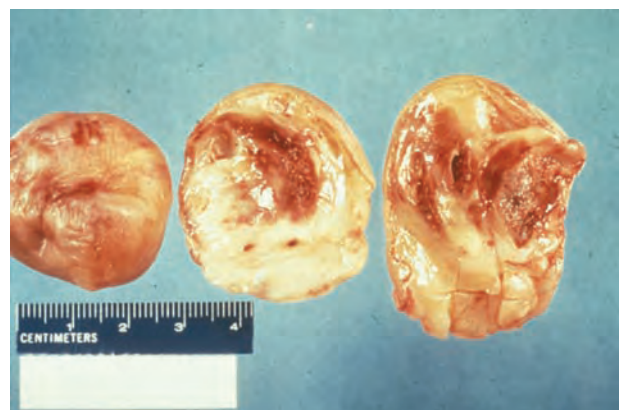
This individual never sought medical attention for her breast carcinoma and died at home.

Bronchogenic carcinoma with erosion through the airway.

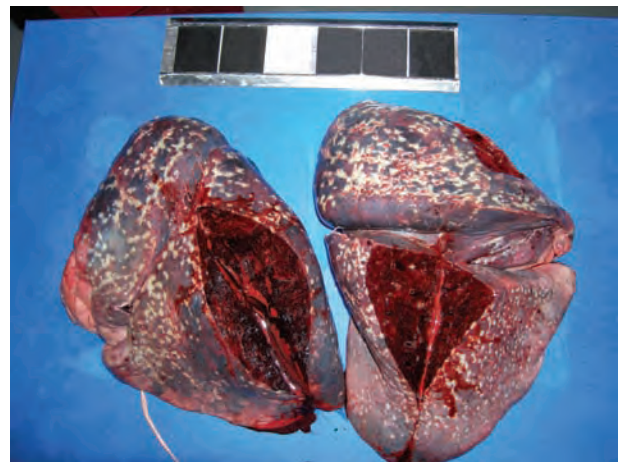
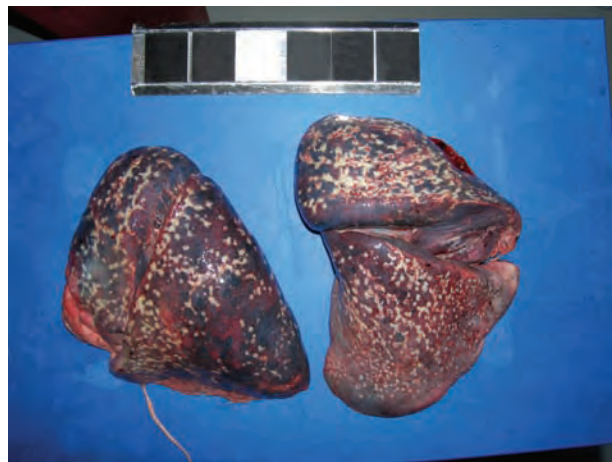
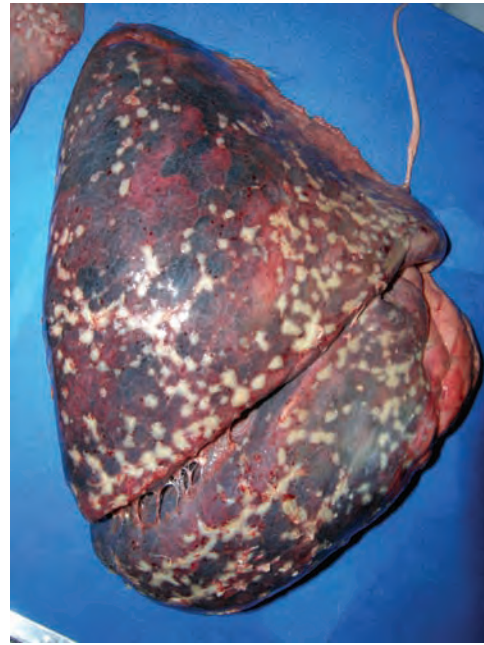
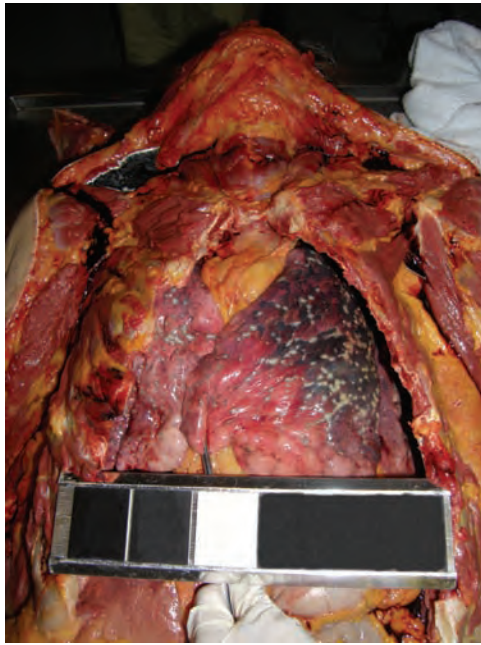Metastatic bronchogenic carcinoma of the lung. Note the metastatic nodule in the heart muscle causing fatal arrhythmia.

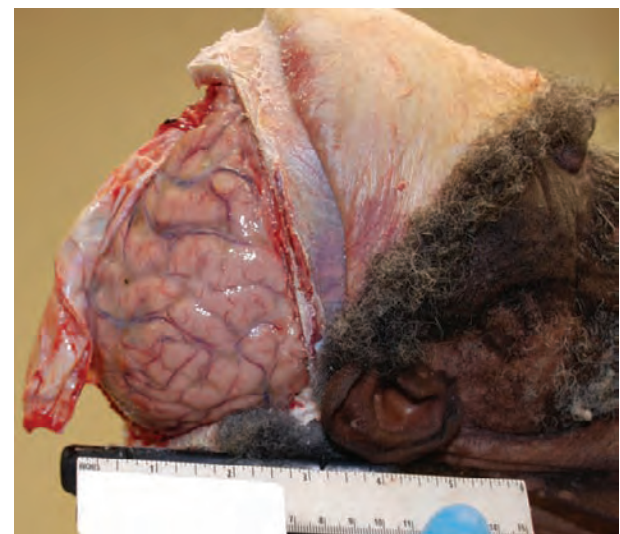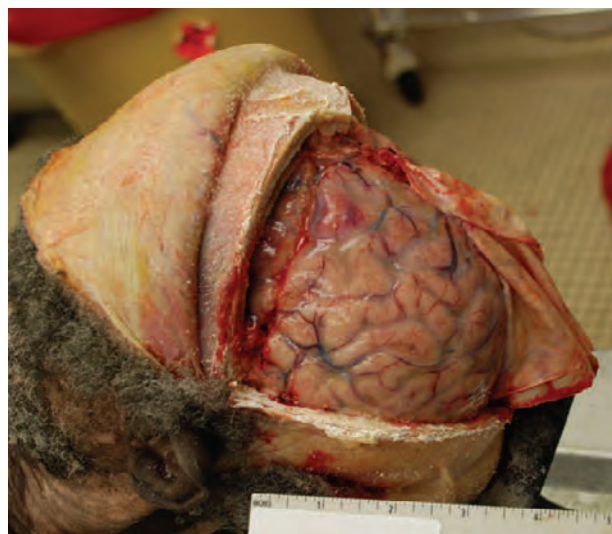
This individual never sought medical attention for his gastric cancer and died at home.



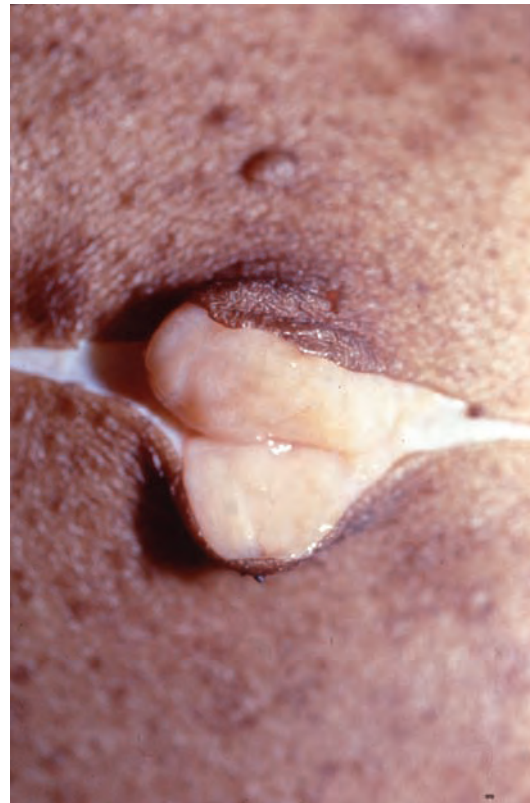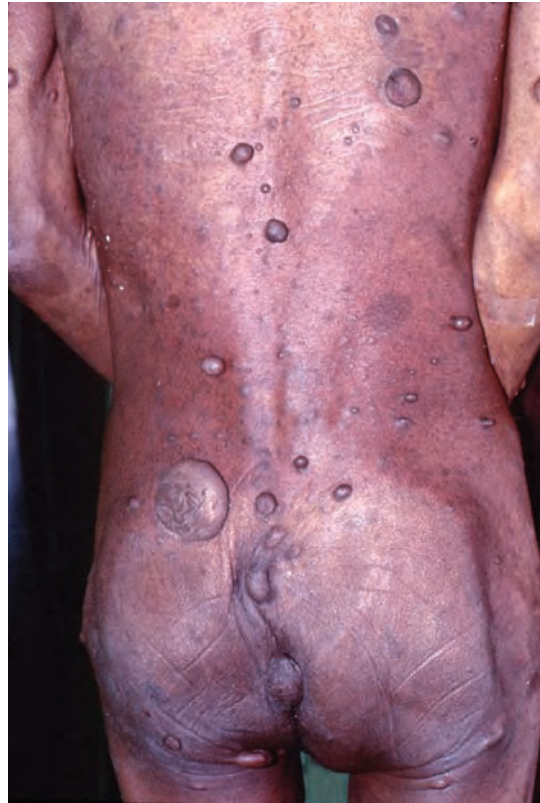Primary rhabdomyosarcoma of the heart.



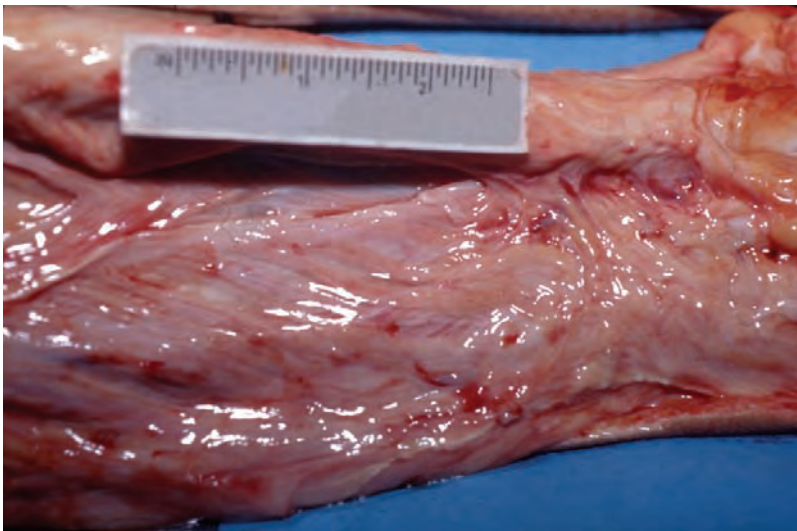
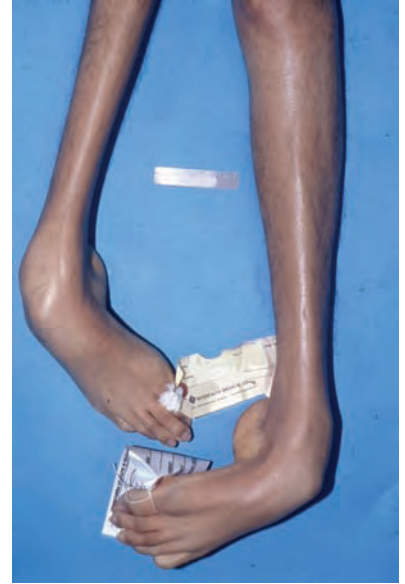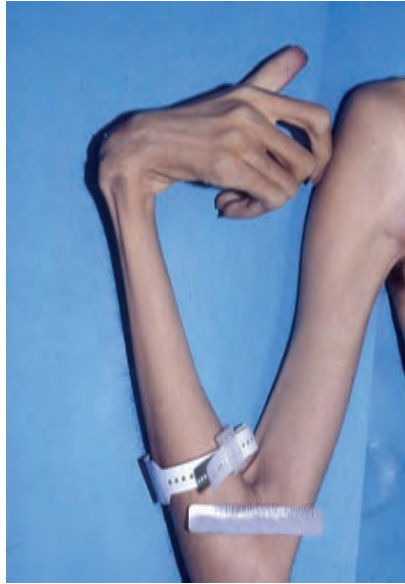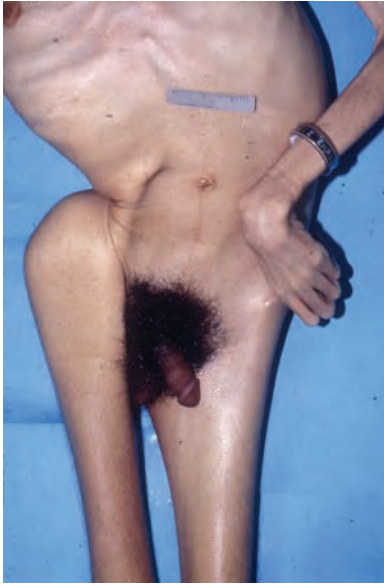Multiple healed granulomas most likely from a past fungal infection.



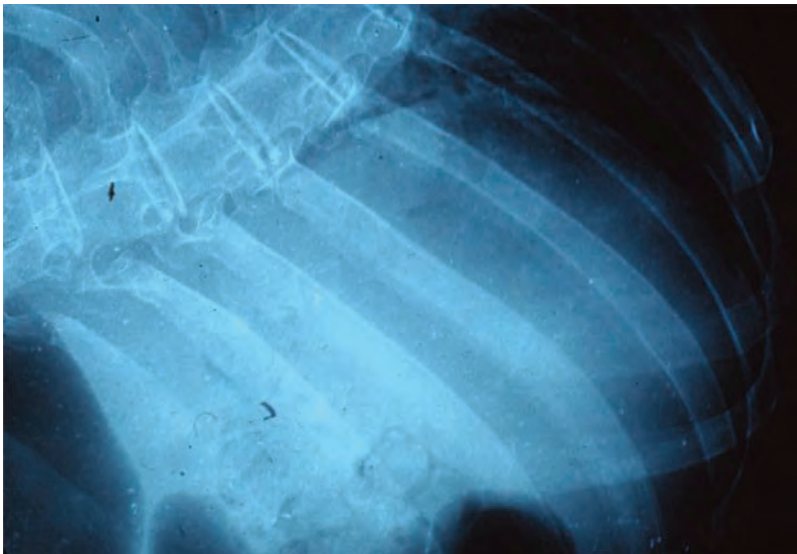
Cryptococcal meningitis in an individual with AIDS caused by intravenous drug use.

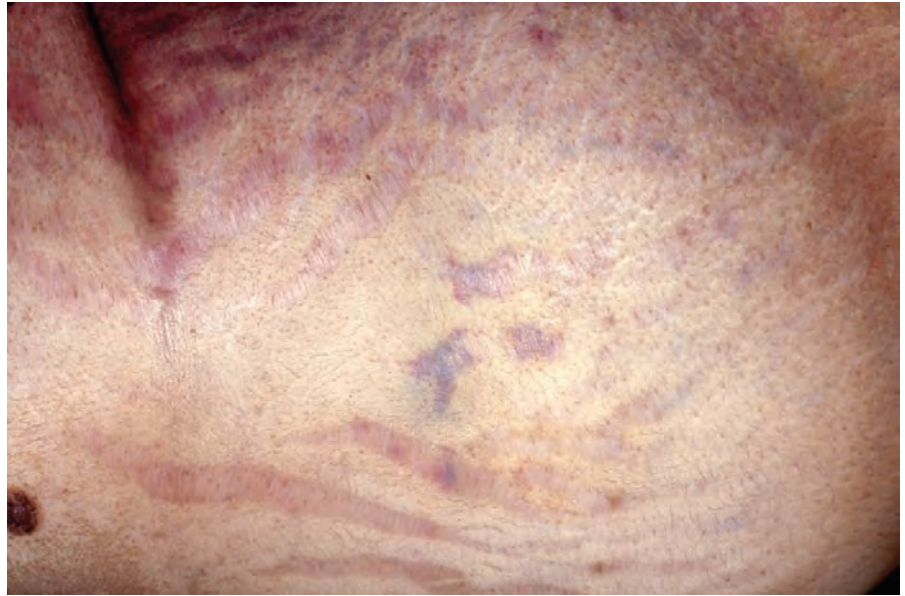
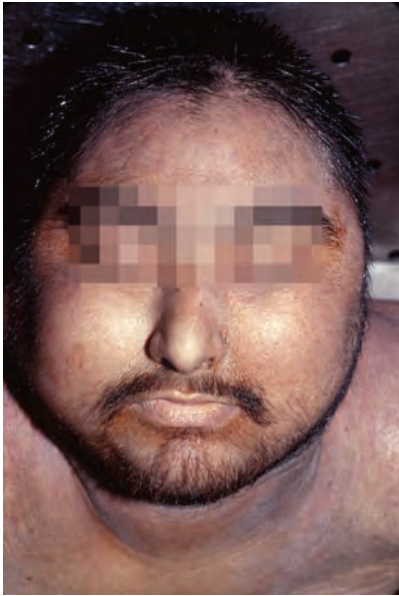

Neurofibromatosis type 1. Note the numerous neurofibromas at the surface of the body. These tumors may be found throughout the body. Death may occur by tumor growth leading to damage of adjacent structures such as the gastrointestinal track with obstruction, central nervous system with compression, renal artery with hypertension, etc.

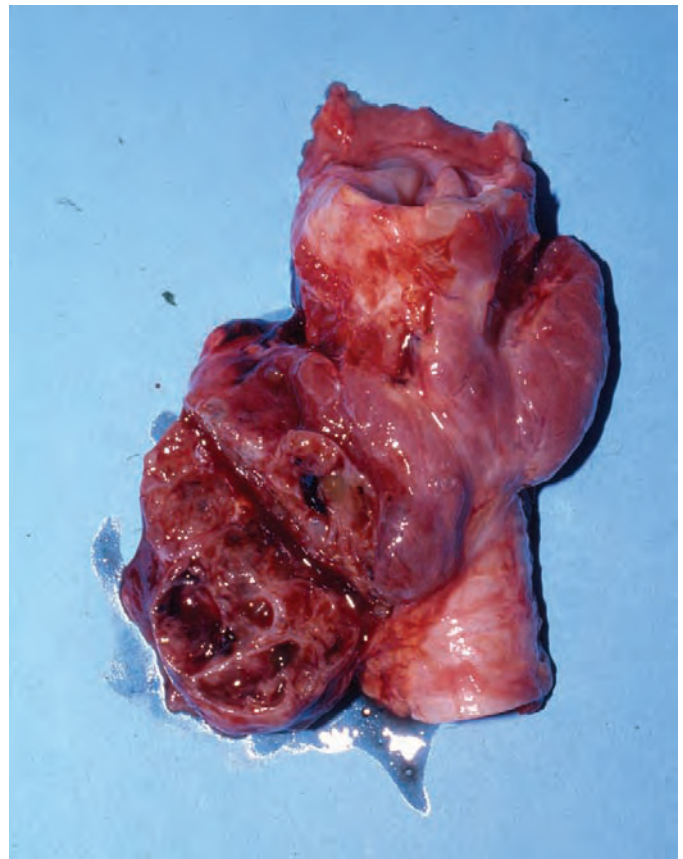
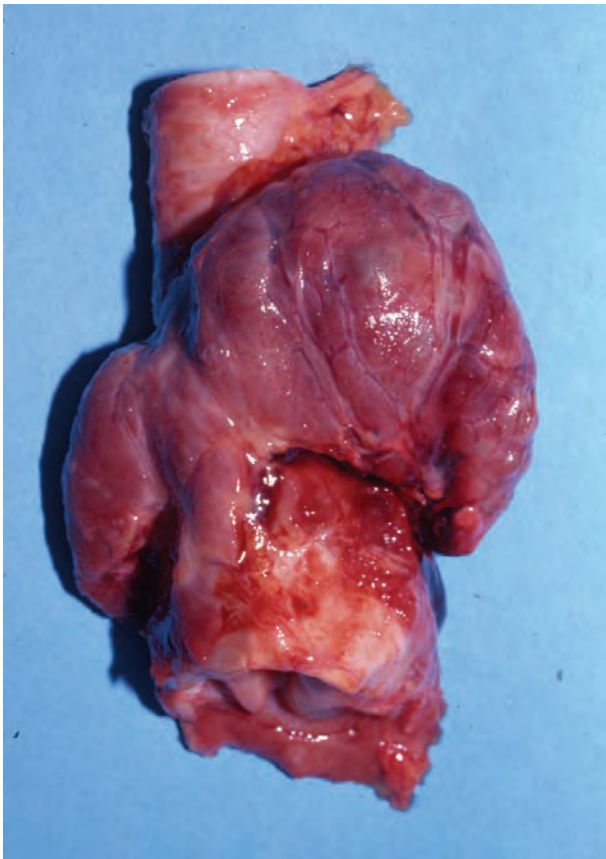


This decedent had Duchenne's muscular dystrophy and was bedridden for many years. He developed severe osteoporosis. While being removed from bed one day by a new caregiver, he sustained bilateral femur fractures and died shortly after.

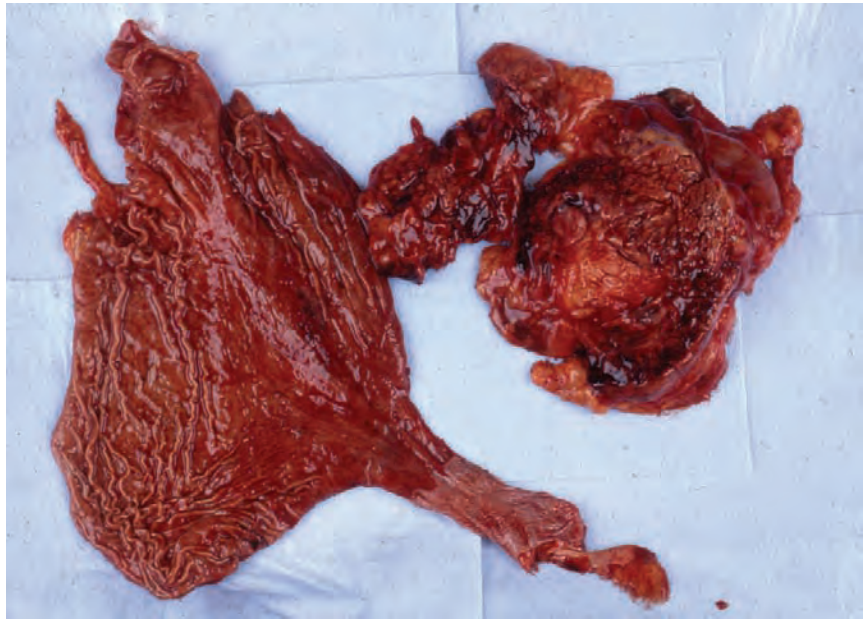
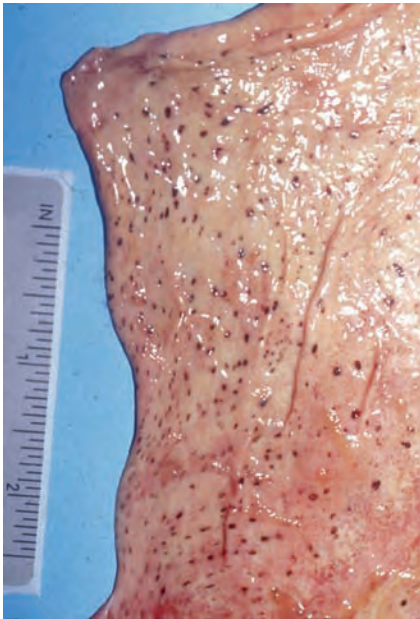




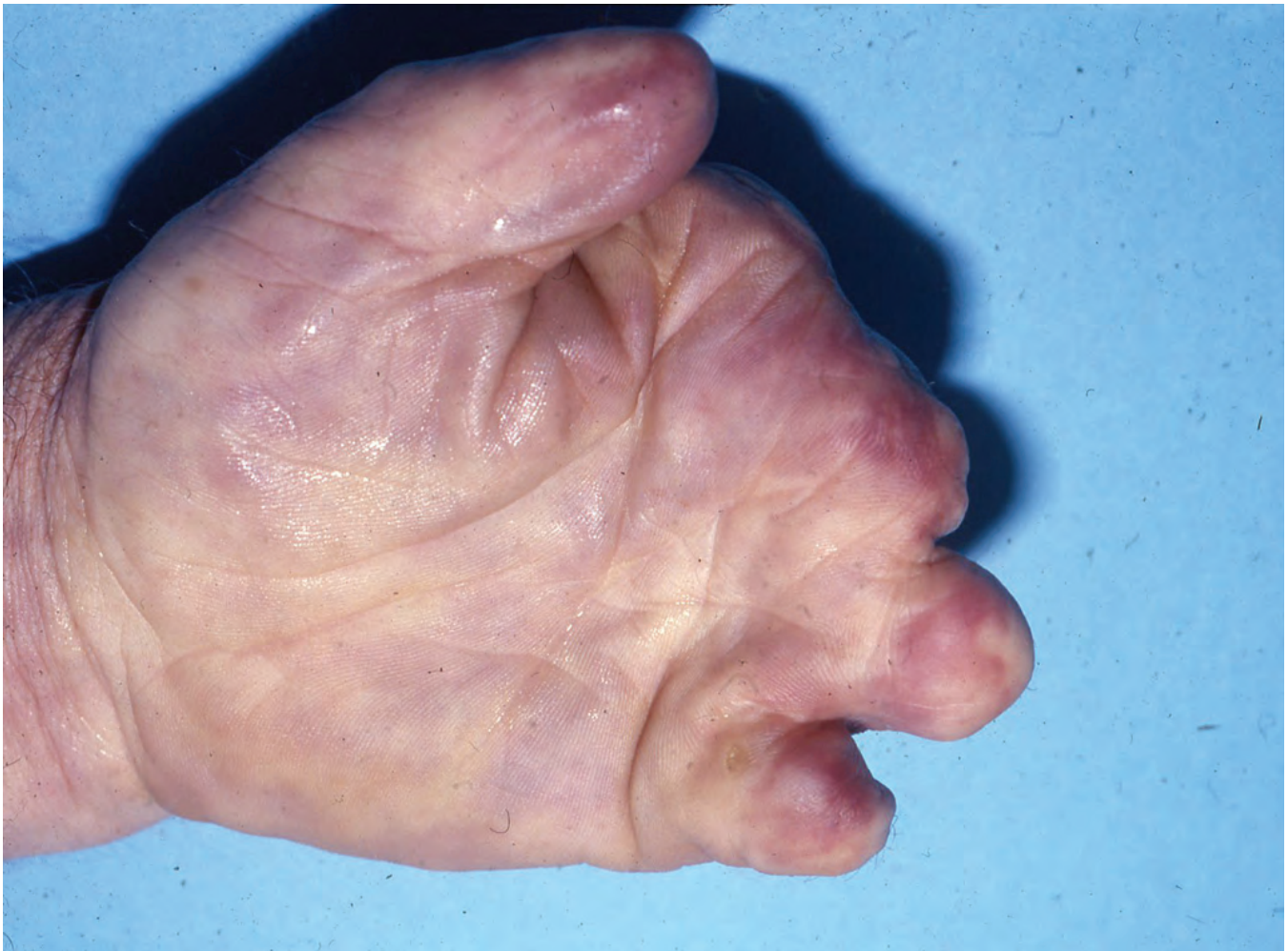Cushing's syndrome due to hypercortisolism. Note the "moon face," "truncal obesity" and purple striae at the lower abdomen. This syndrome is also associated with glucose intolerance. From a forensic standpoint and interpreting injuries, it is important to know this is associated with osteoporosis, increased bruisability, and poor healing.



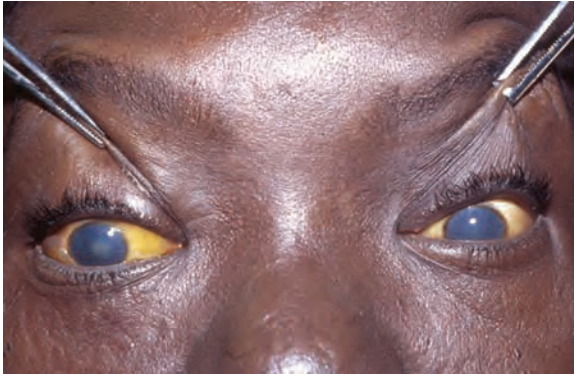
Goiter with hyperthyroidism may lead to thyrotoxicosis and sudden cardiac death due to tachyarrhythmia.



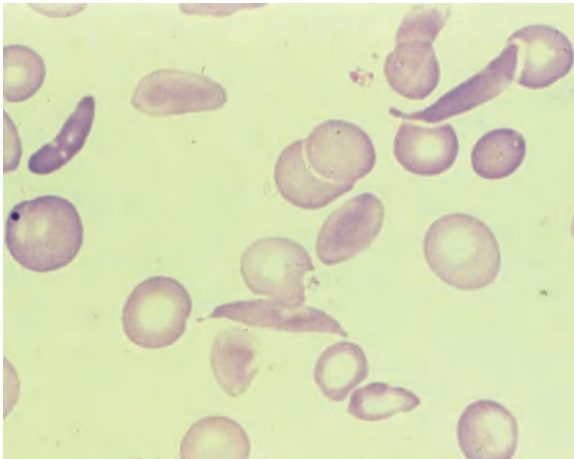
This portion of gastric mucosa reveals multiple small areas of hemorrhage in an individual with hypothermia. "Leopard skinning" of the gastric mucosa and acute pancreatitis are often seen with cases of marked hypothermia followed by short-term survival.



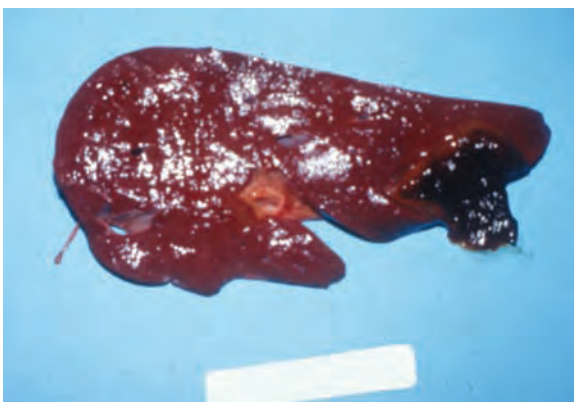
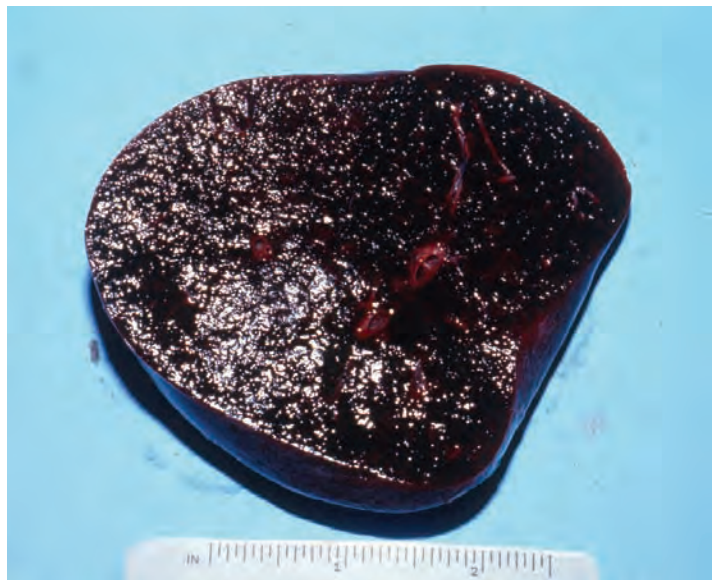
This individual had his fingers and toes amputated years before following extensive hypothermic injury with frostbite.



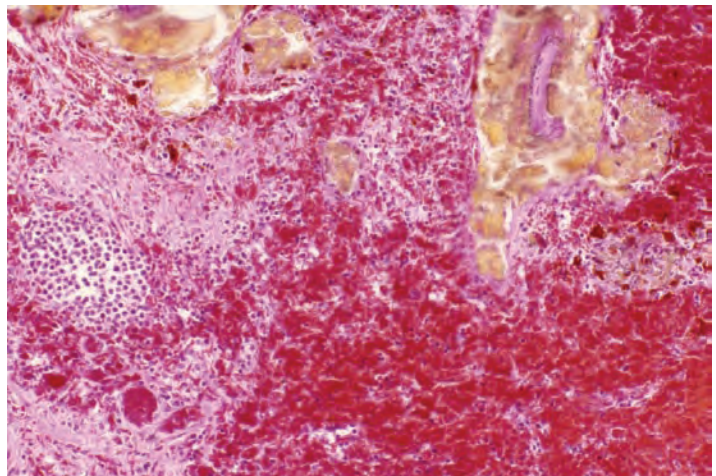
Jaundice due to hemolysis associated with sickle cell crisis.



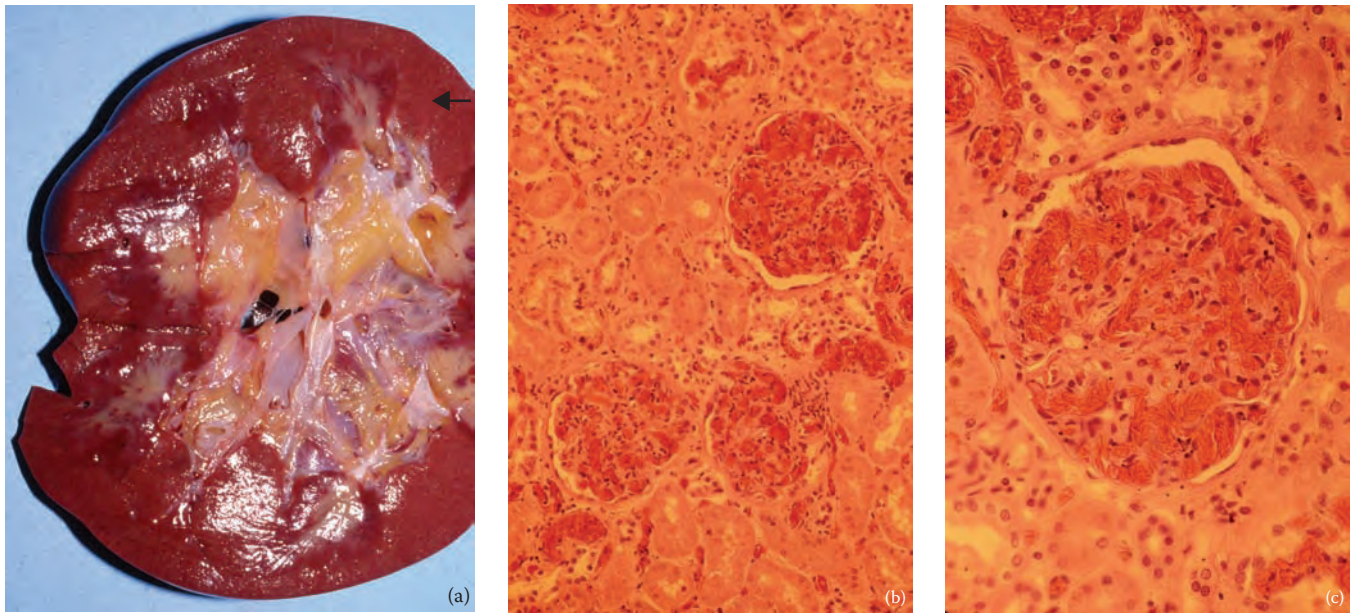
Sickle cell anemia. Peripheral blood smear showing sickled cells.



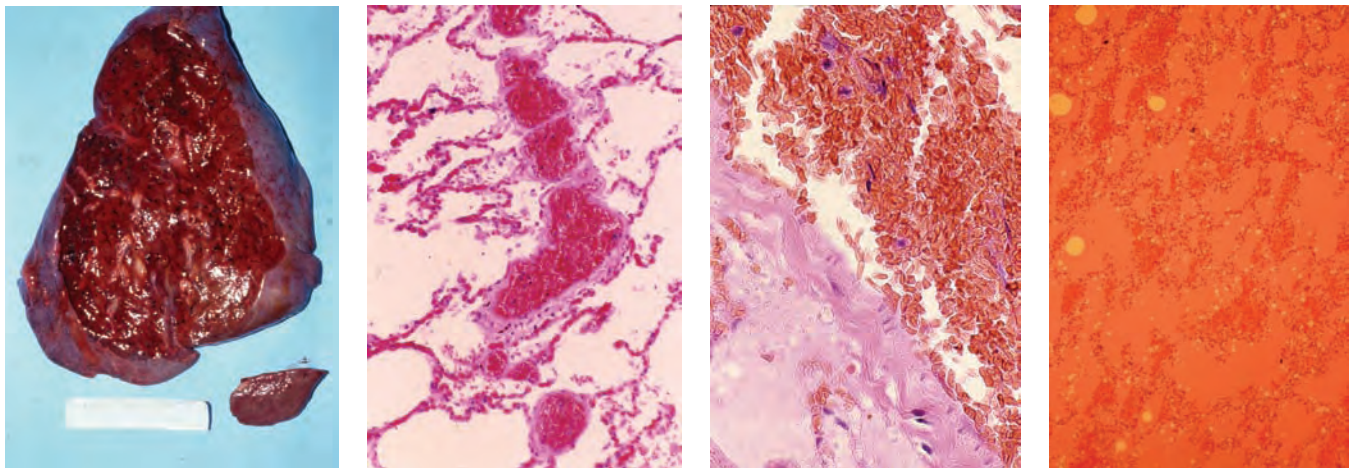
Sickle cell crisis. Note the dark red-black sludge within the gall bladder from hemolysis.



Autoinfarction of spleens from adult individuals with sickle cell anemia. These spleens are typically shrunken and firm. Note the histopathology sections with marked congestion, fibrosis and Gamna-Gandy bodies from iron pigments with calcium salts.

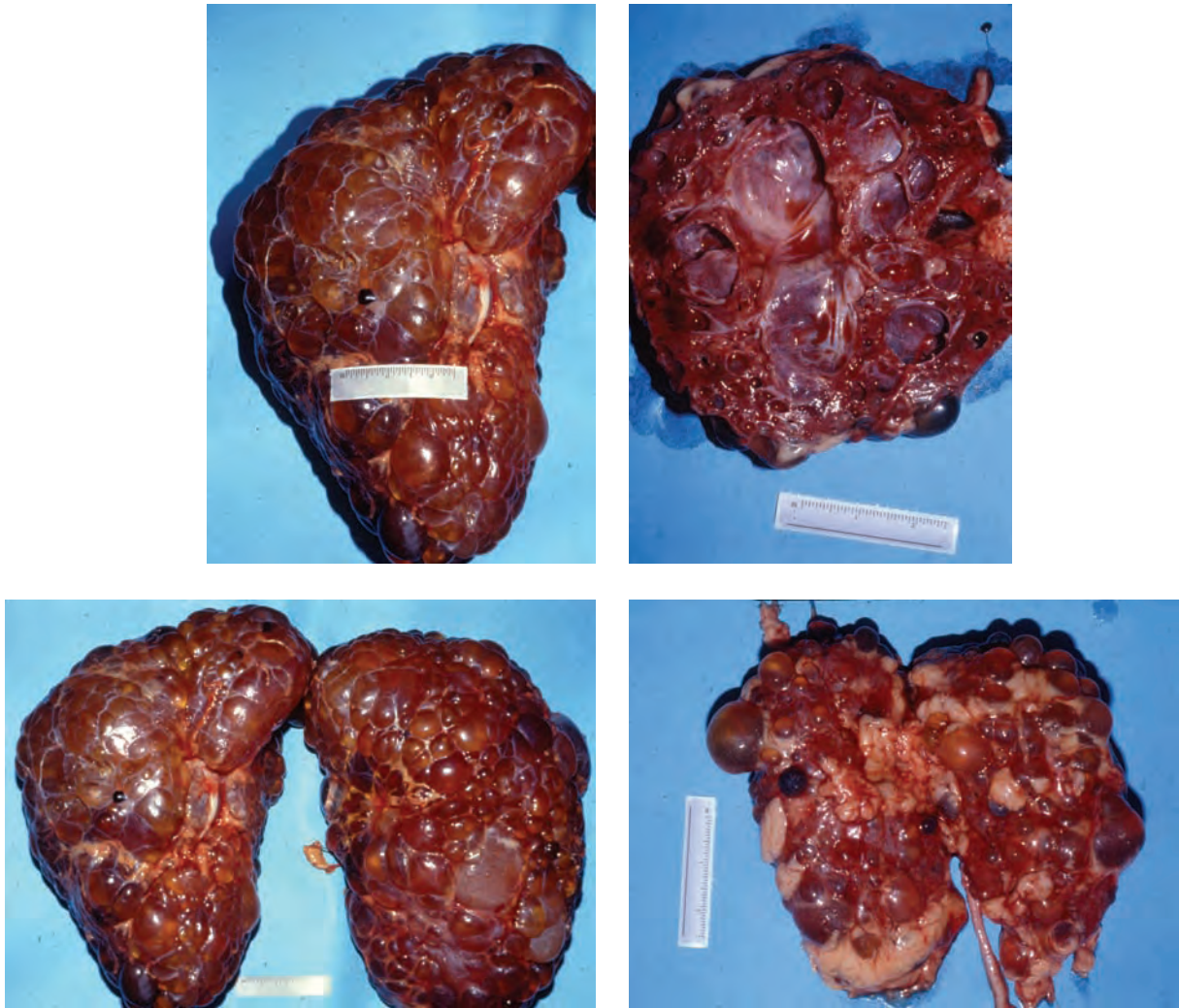


Sickle cell anemia with crisis. Kidney with papillary necrosis (a) and congestion (b) and (c).

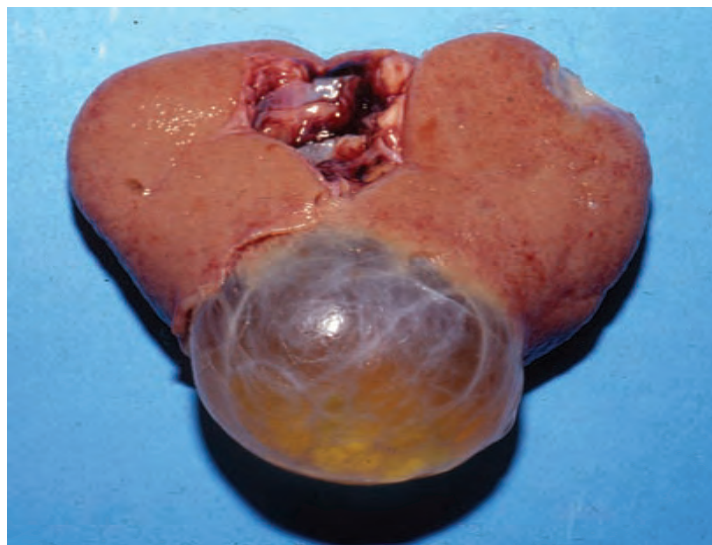


Sickle cell anemia with crisis. Lung with marked congestion and pulmonary edema.

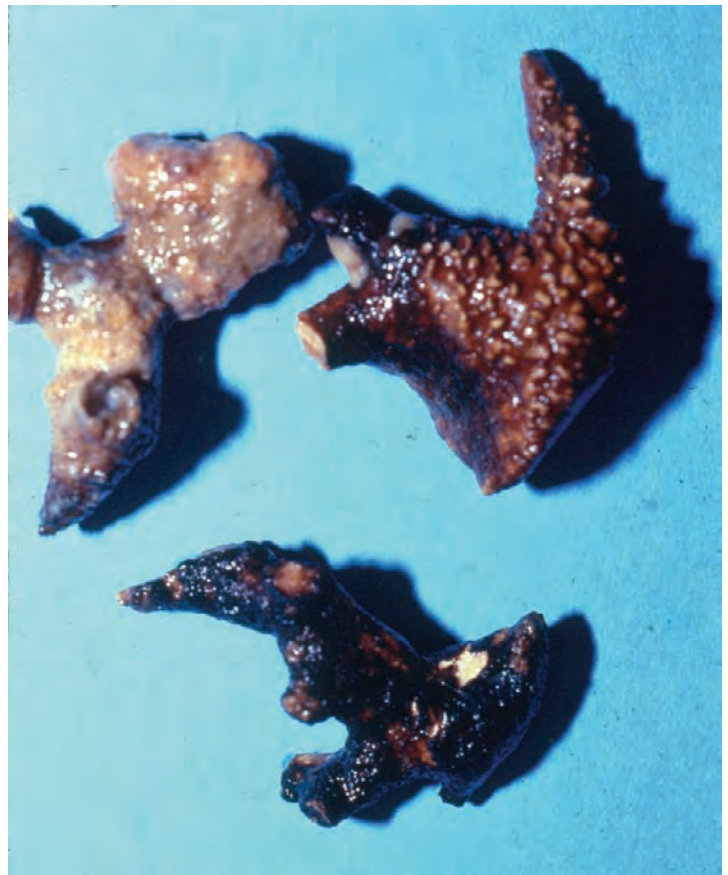
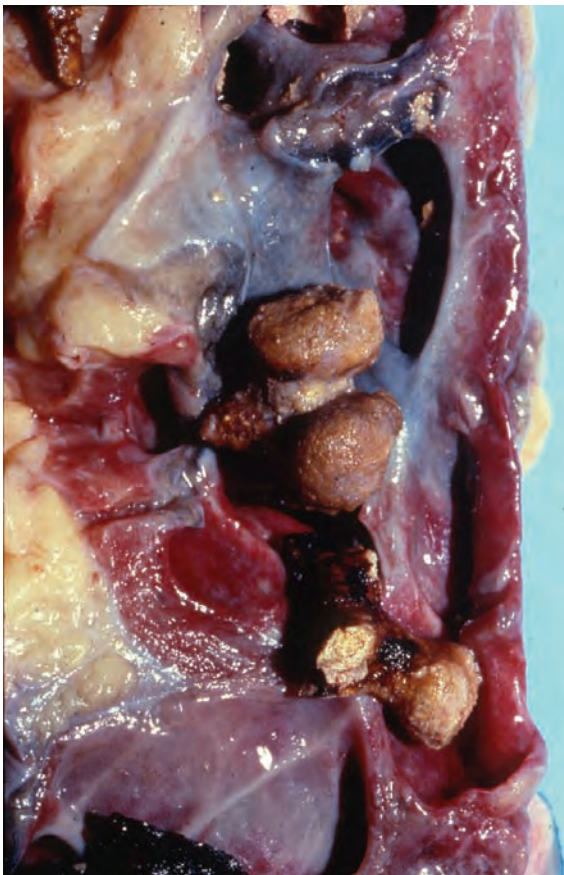
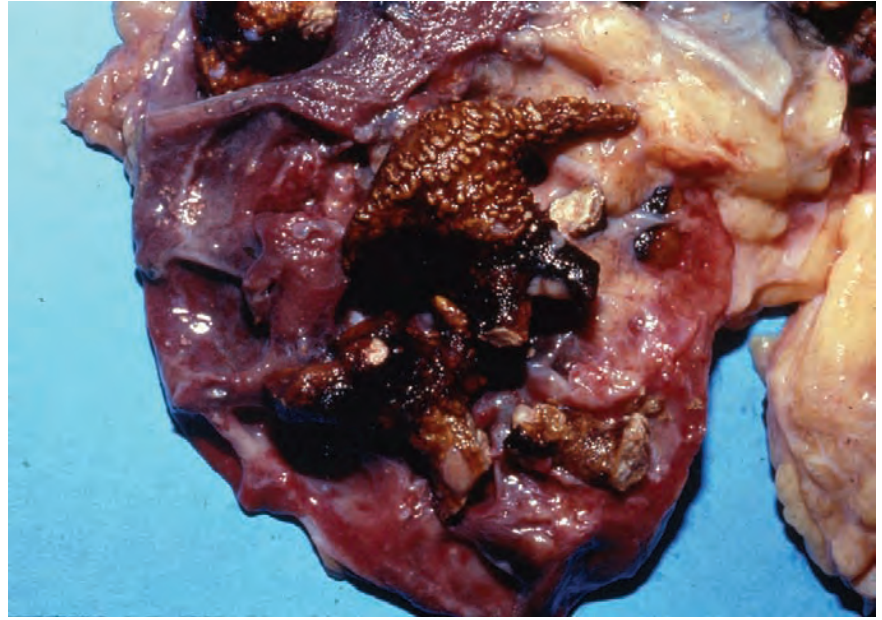
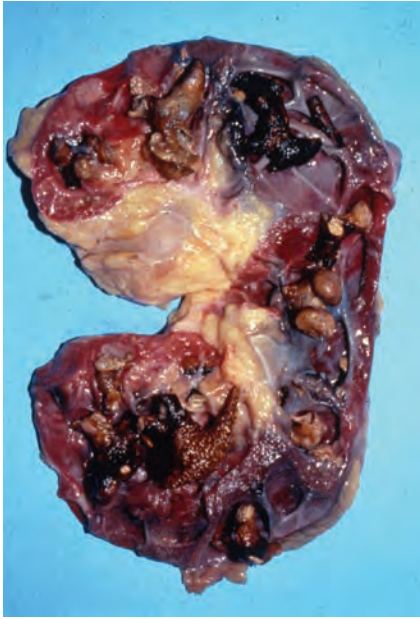



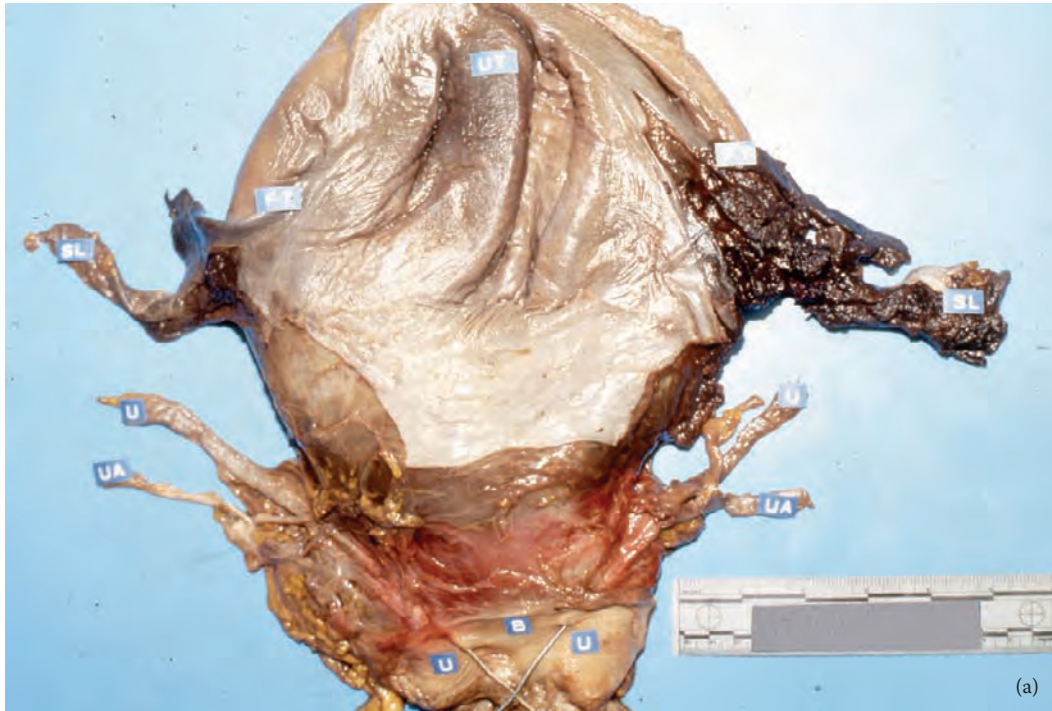
Adult polycystic kidney disease. This autosomal dominant disorder is another significant cause of hypertension. These kidneys weighed over 3000 grams each. There is also an association with cysts in other organs and intracranial berry aneurysms.



Simple benign cyst.



Chronic pyelonephritis with “stag horn calculi” associated with urea splitting bacterial infection such as proteus or staphylococci causing magnesium ammonium phosphate salt precipitation. It is also important to know that acute obstructive urolithiasis with urosepsis can be rapidly fatal.



This is a postpartum death involving a 30-year-old nurse. This woman was known to be colonized by group A beta-hemolytic streptococcus (*Streptococcus pyogenes*). Approximately 8 hours following an uneventful delivery, she began to complain of back and pelvic pain. Within 4 hours she was in full-blown shock and was refractory to resuscitative measures. Death was pronounced approximately 14 hours following her delivery. Figure (a) depicts the gravid uterus and confluent brown-black discoloration of the left adnexa, which proved microscopically to show areas of necrosis with numerous clusters of bacterial cocci and scant neutrophilic infiltrates. Postmortem cultures of multiple organs, including lungs, liver, spleen, uterus, and peritoneal fluid, all grew group A beta-hemolytic streptococcus. This "toxic shock like" death due to group A streptococcus has given rise to the term "flesh-eating bacteria."

---

# Therapeutic Interventions, Complications, and Accidents

# 2

MICHAEL J. CAPLAN AND CHARLES A. CATANESE

---

The evaluation of deaths related to complications of diagnostic and therapeutic procedures has traditionally been a problematic area for forensic pathologists and death investigators. The reasons for this are multiple: (1) these deaths often blur the boundaries dividing medicolegal and hospital death investigation; (2) many forensic pathologists do not feel comfortable approaching the often complex and highly technical issues present today in modern medicine; and (3) at least some forensic pathologists believe that these types of death belong more appropriately within the domain of the hospital autopsy. Despite this ongoing controversy, most forensic pathologists and death investigators will, at some point during their careers, be forced to handle these types of deaths.

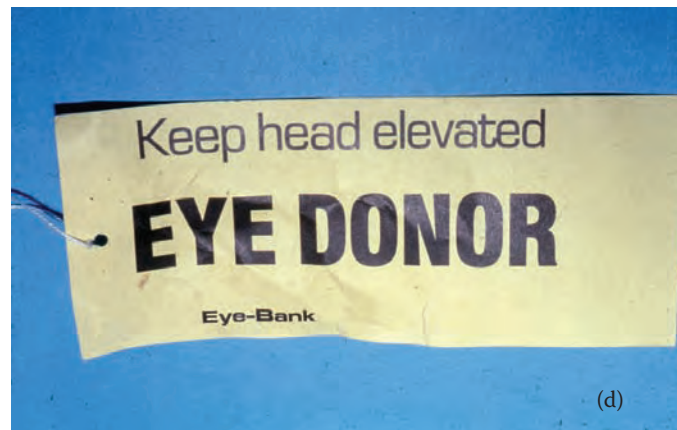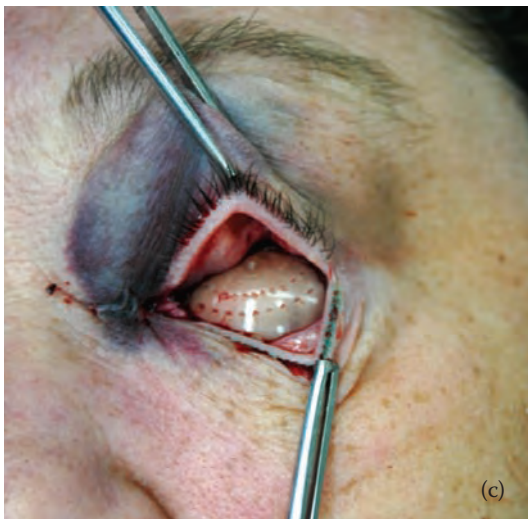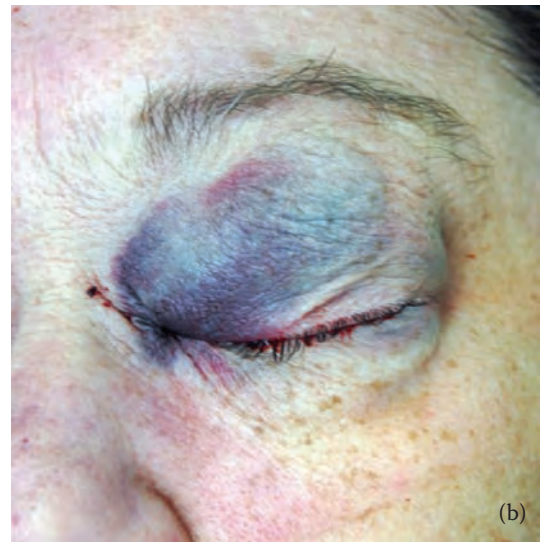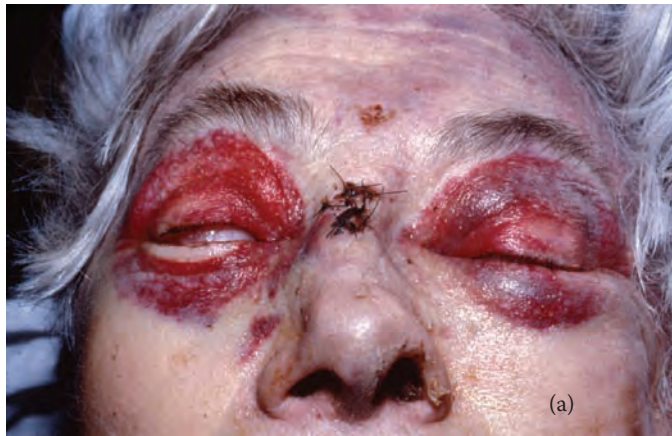If a patient dies either during or sometime following a diagnostic and therapeutic procedure, the first question in the diagnostic algorithm or decision tree becomes: Was the death in any way related to the procedure or was the procedure simply an artifact, with the death attributable to some underlying natural disease process or injury? For example, if a 65-year-old man who has stubbornly refused surgical intervention of a known 8-cm-diameter abdominal aortic aneurysm suddenly collapses and manages to make it to the operating room but dies before repair can be attempted, the “intraoperative death” is simply an artifact of modern medical resuscitation and transport technologies. In such a case, the medical intervention or procedure played no part in the death, and the cause of death would be worded as “ruptured abdominal aortic aneurysm due to atherosclerotic cardiovascular disease, manner: natural.” On the other hand, if an otherwise healthy individual underwent an elective procedure, for example, a bunionectomy, and died on the operating table, to ascribe the death to “hallux valgus” would be as ridiculous as it was erroneous. It is for cases like this that the concept of therapeutic complication merits consideration for a place in manner-of-death certification.

Once it is determined that the death was related somehow to the procedure, the next question in the algorithm becomes: Was the death a result of a known or predictable (albeit rare or unusual) complication of a properly performed diagnostic procedure or appropriately administered therapy, or did it ensue from a

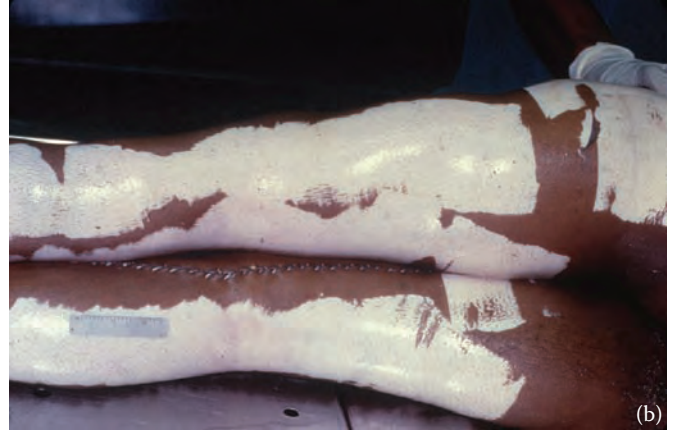
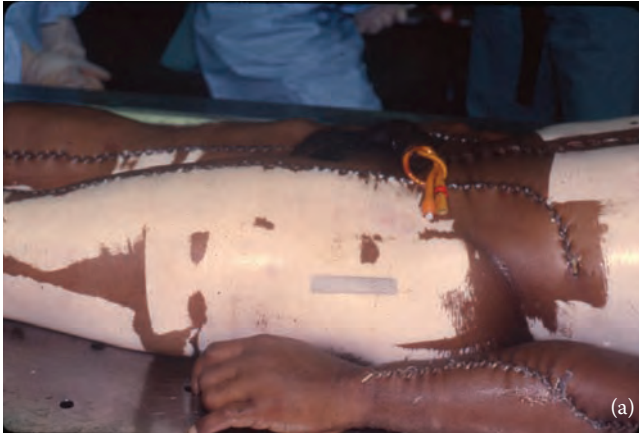procedural error? When the former scenario exists, the term *therapeutic complication* is preferred, because that is a neutral designation as opposed to the term “therapeutic misadventure,” which is inflammatory and prejudicial. When the latter situation is present, the manner of death is most accurately designated *accident*. Many examples of legitimate therapeutic complications exist. In the case of a 64-year-old man who sustained a non-ST (non-Q wave) segment elevation myocardial infarct, and who was treated with the antiplatelet drug eptifibatide (Integrilin), a platelet glycoprotein IIb-IIIa antagonist, he suffered intractable pulmonary hemorrhage and ultimately succumbed to respiratory failure. Pulmonary hemorrhage has been a recently reported complication of eptifibatide therapy. No error was committed in this case; rather, the decedent experienced an unusual yet known (documented) complication of appropriate therapy for his non-ST elevation MI. Therefore, the cause of death would be worded as: “Complications of pulmonary hemorrhage following eptifibatide (Integrilin) treatment for non-ST (non-Q wave) segment elevation myocardial infarct (due to atherosclerotic heart disease)” and the manner, therapeutic complication. On the other hand, if a middle-aged woman underwent a surveillance colonoscopy and presented days later with peritoneal signs and was found to have *E. coli* bacteremia and sepsis due to peritonitis resulting from inadvertent perforation of the colon during the procedure, the death certificate would read: “*E. coli* sepsis due to peritonitis due to colonic perforation complicating surveillance colonoscopy.” However, because this complication is not an accepted sequela of an appropriately performed diagnostic or therapeutic procedure, but rather, an unintentional error, the manner of death in this case is most accurately deemed accident. Admittedly, there are cases that fall within the murky zone between natural and therapeutic complication and between therapeutic complication and accident. In such cases, all that one can do is exercise one’s best objective clinical judgment. It is important to recognize and remember that death certificates are not immutable documents that are “written in stone”; rather, they can be amended should more accurate information regarding the circumstances of death become available at a later time.

While the concept of therapeutic complication is an invaluable tool in the assessment of these types of deaths, the practical applicability of the term to the death certificate has enjoyed less success. Only two known jurisdictions—Cuyahoga County, Ohio, and New York City—include “therapeutic complication” as a choice in the manner of death on the death certificate. Therefore, when a death fits the criteria for therapeutic

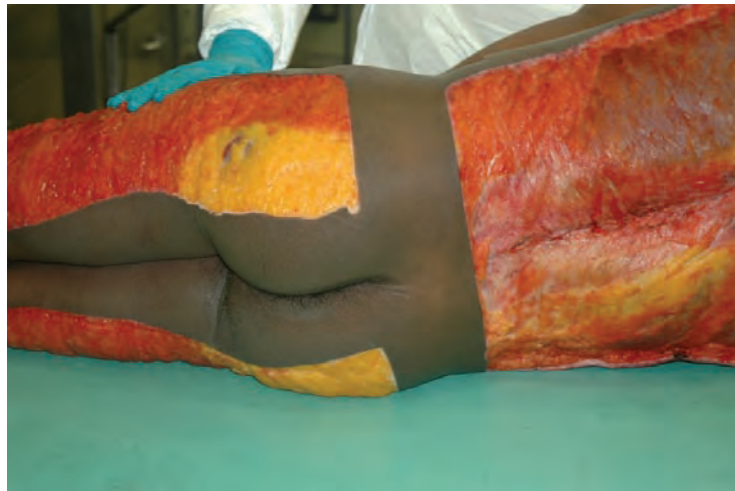complication as the manner, but the particular jurisdiction does not include it on the death certificate, then the manner defaults to natural. One other option is to list “therapeutic complication” in parentheses after “natural,” but this probably is not common practice. Thus, for the indefinite future, forensic pathologists will be resigned to using the term as a conceptual tool in the evaluation of these most challenging deaths.



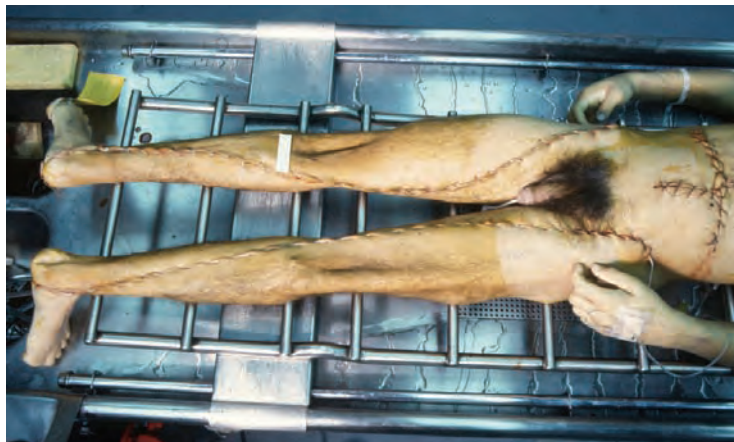These figures show one of many possible artifacts associated with organ donation that may be mistaken for injuries. Note (a) the hemorrhagic discoloration around each eye (periorbital) and (c) the plastic insert in the opened eye following tissue removal. Medical record review and clinician interview revealed that these periorbital hemorrhages were not present at the time of admission.



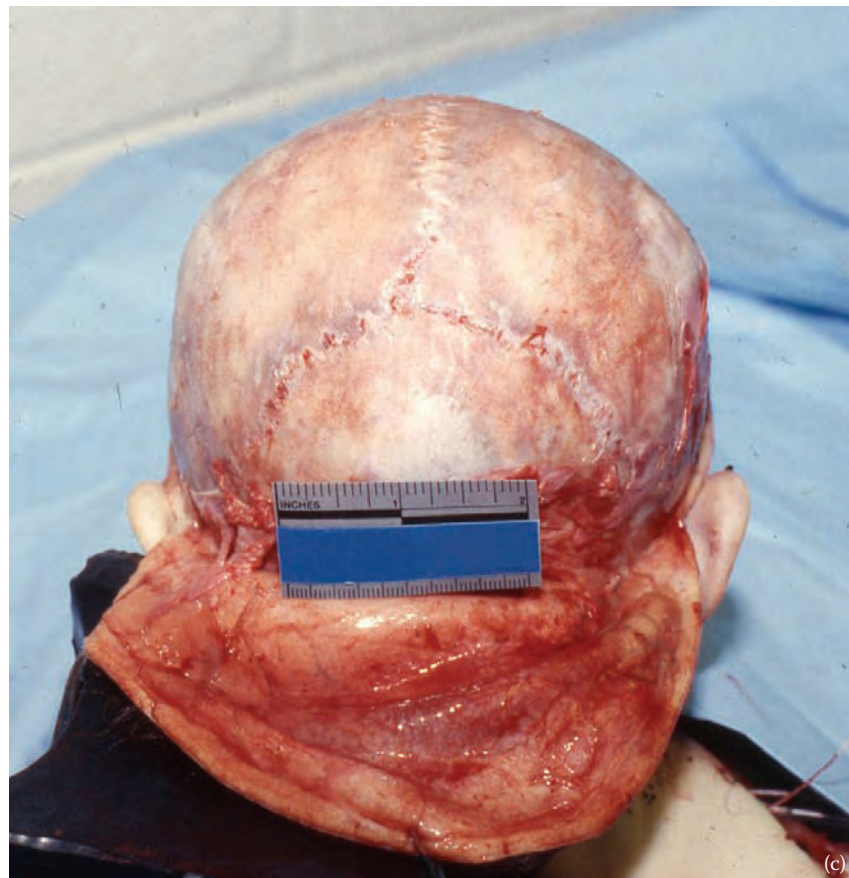
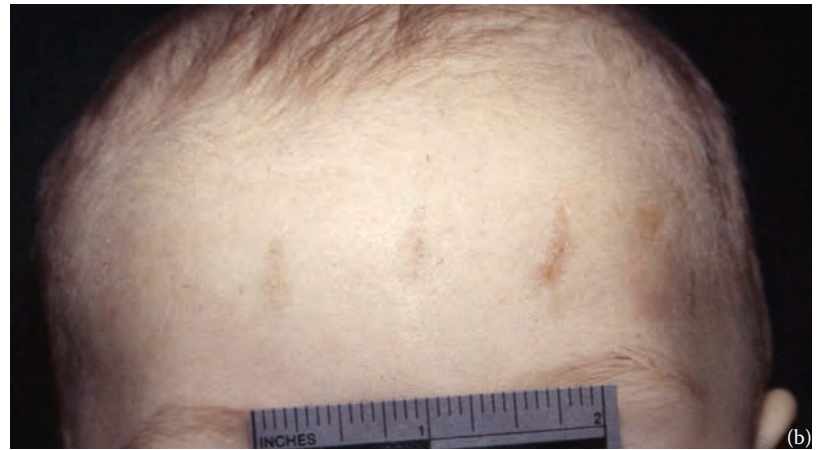
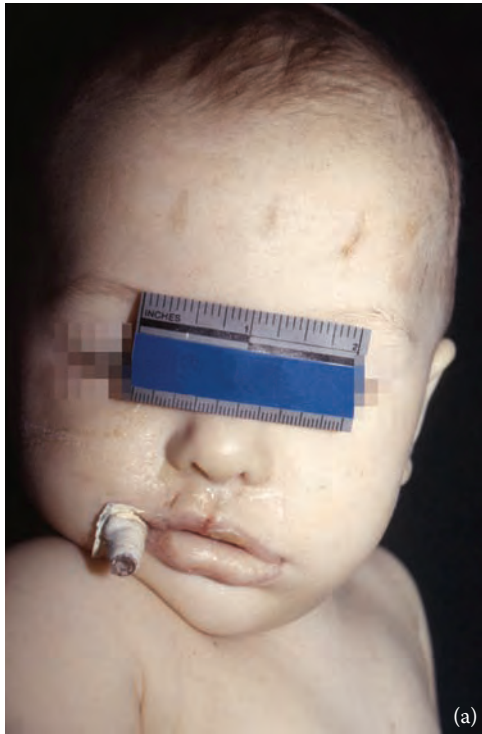Tissue procurement of superficial skin.



Postmortem tissue procurement and full thickness skin.

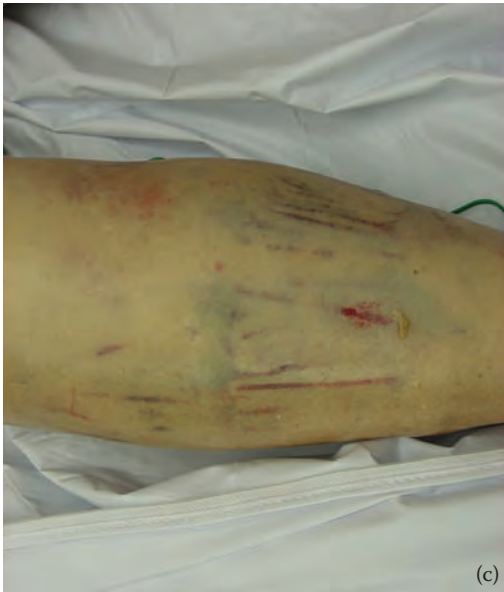
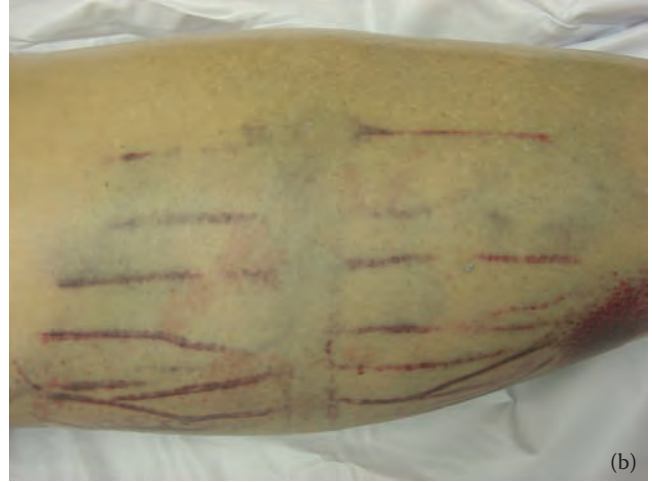
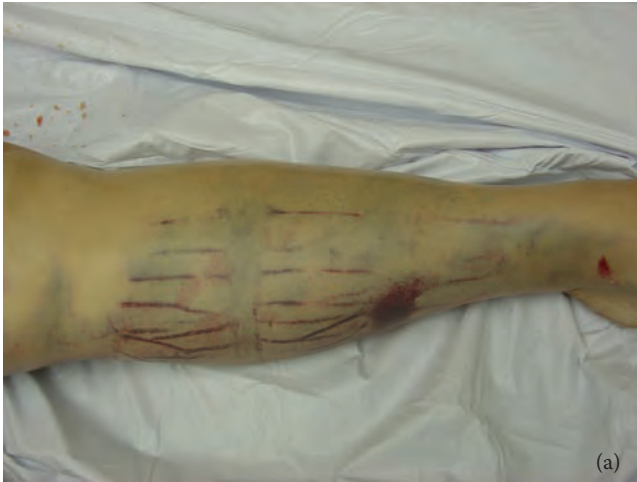
Sutured incisions following long bone, soft tissue, and saphenous veins removal for postmortem tissue procurement.

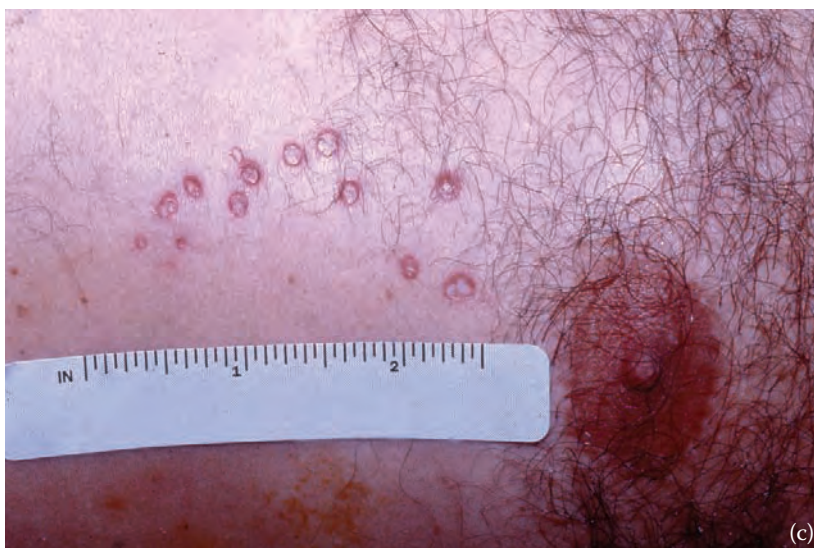
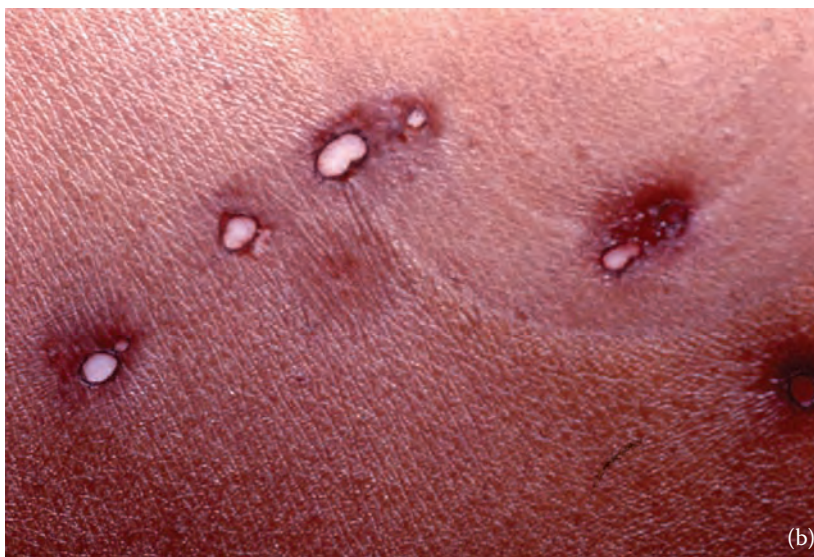
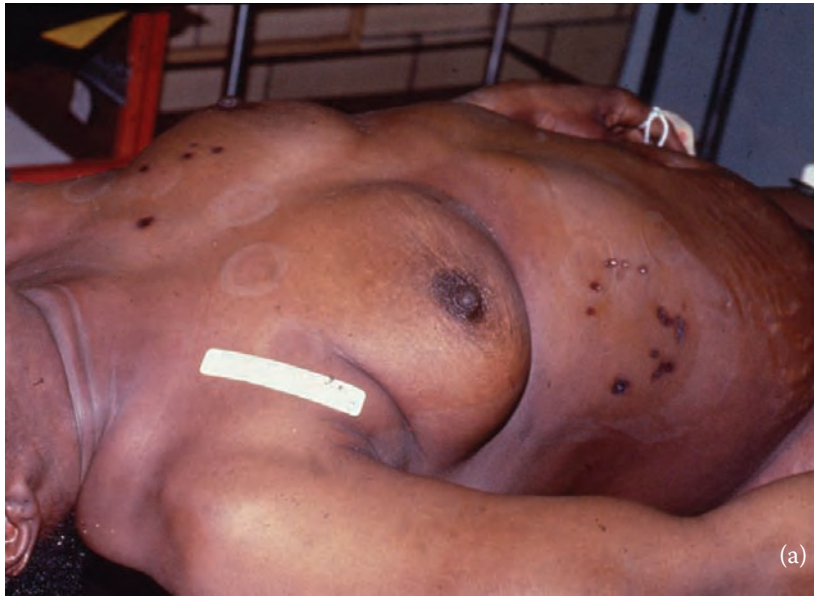Figures (a) and (b) show ill-defined, parallel, vertically oriented gray-brown marks on the forehead. These are artifacts of transport. The child's head was stabilized with a strap while flown by helicopter from an outside hospital to a tertiary pediatric center. Figure (c) shows reflected scalp and well-defined sagittal and lambdoid sutures without features of subgaleal contusions or skull fractures.

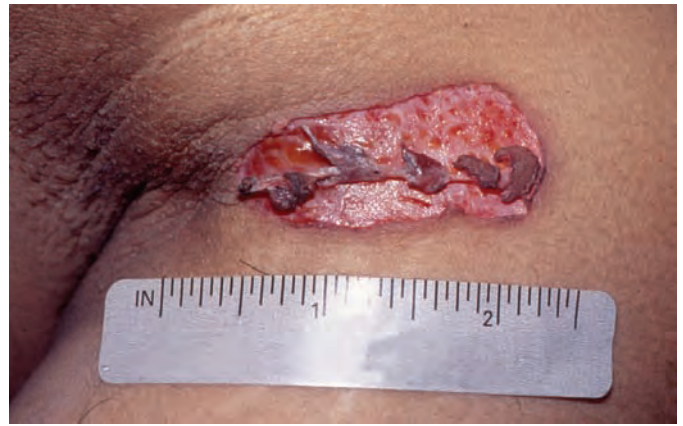
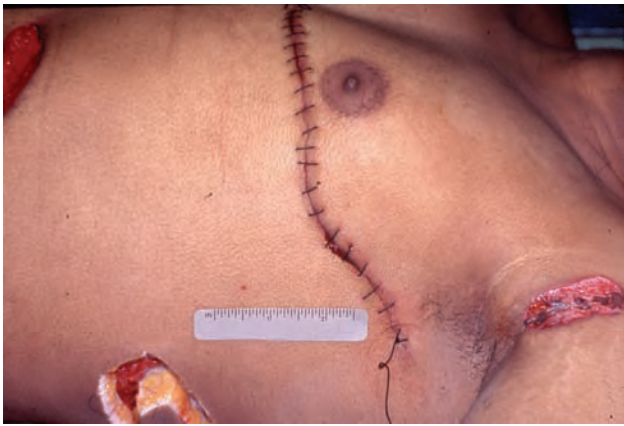
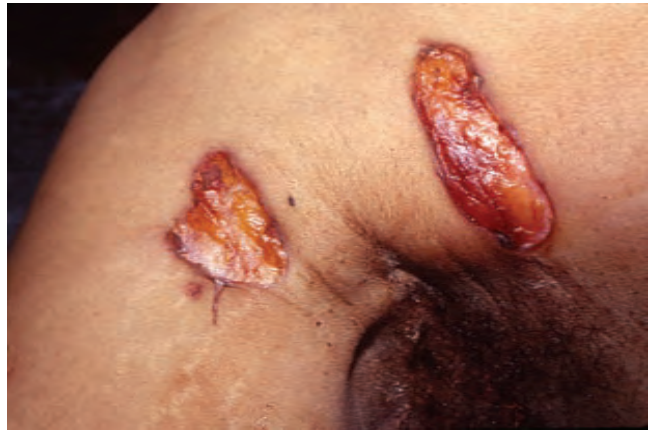
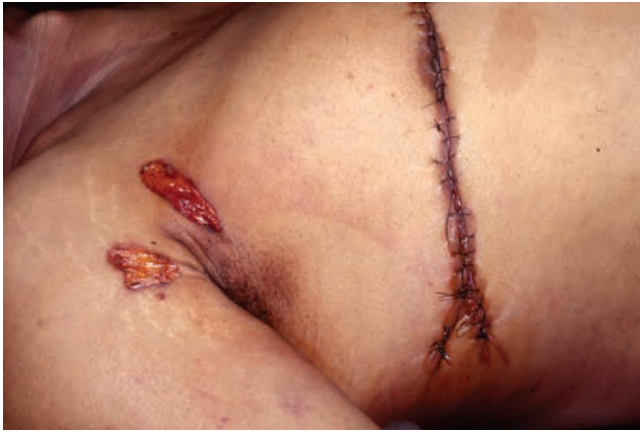
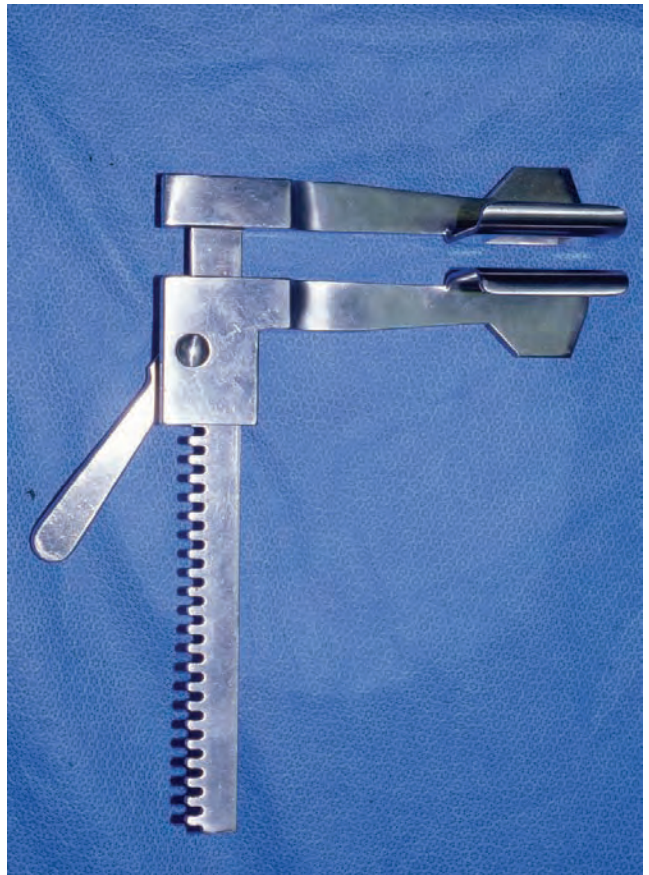
This individual was ejected from a car during a collision. She was taken to the hospital in an unconscious state and remained so until her death. There was initial speculation that she was struck by another motor vehicle due to the "tire-like" patterns on her legs (a–c). Further investigation revealed these injuries were not present at the time of arrival to the emergency department. She survived in the hospital for approximately 2 days. There was a pelvic fracture with blood seeping into the legs, extensive generalized edema, and disseminated intravascular coagulation (b). Pressure boots were placed to decrease the risk of deep venous thrombosis (d). This pattern of ecchymosis was caused by the pressure boots in conjunction with the complications of the injuries.

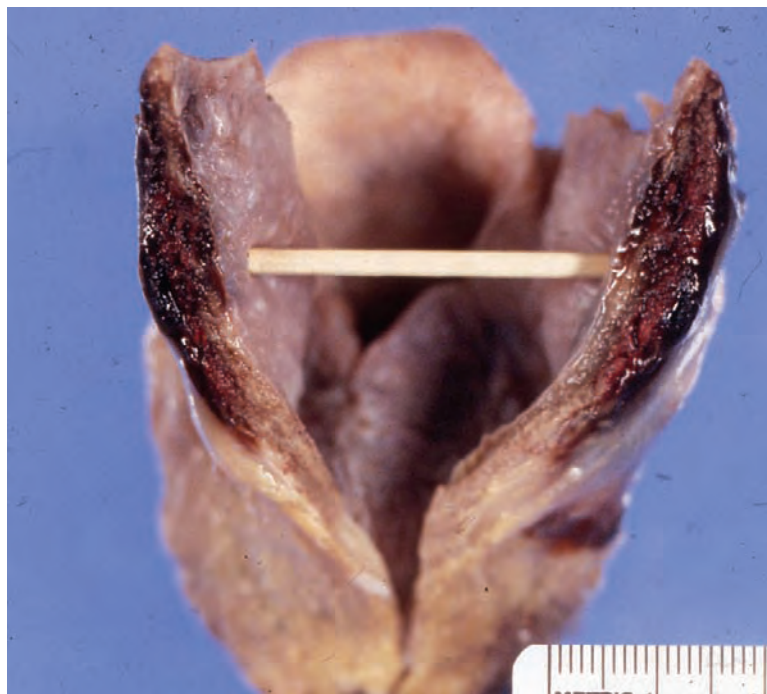
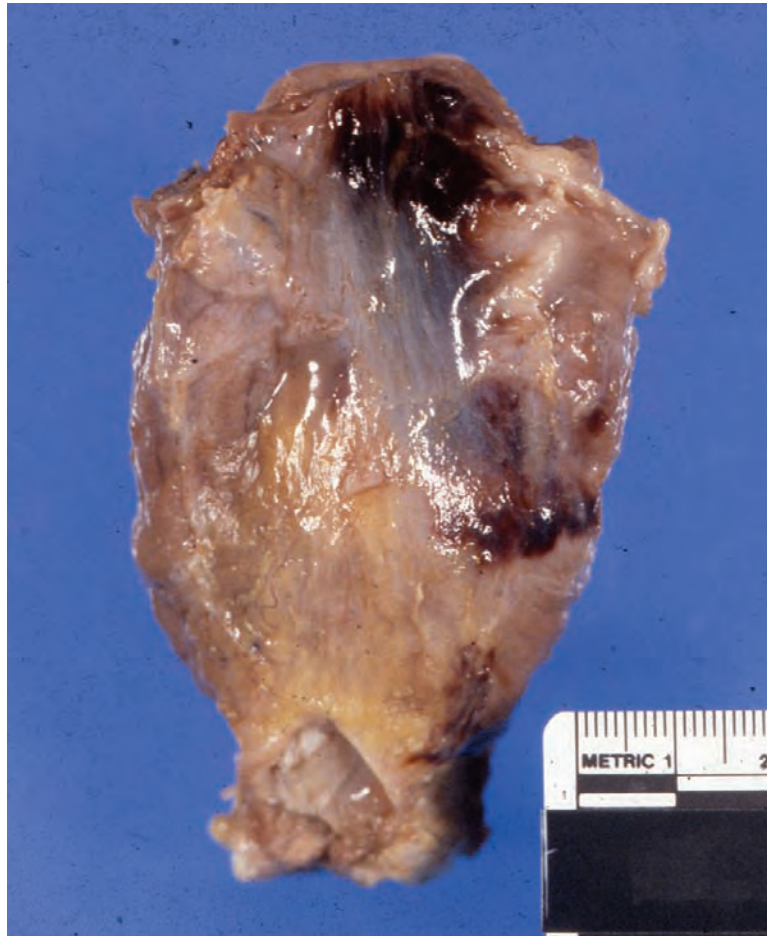

Figures (a), (b), and (c) show electrical burns caused by defibrillation with damaged cardioversion paddles during attempted resuscitation.

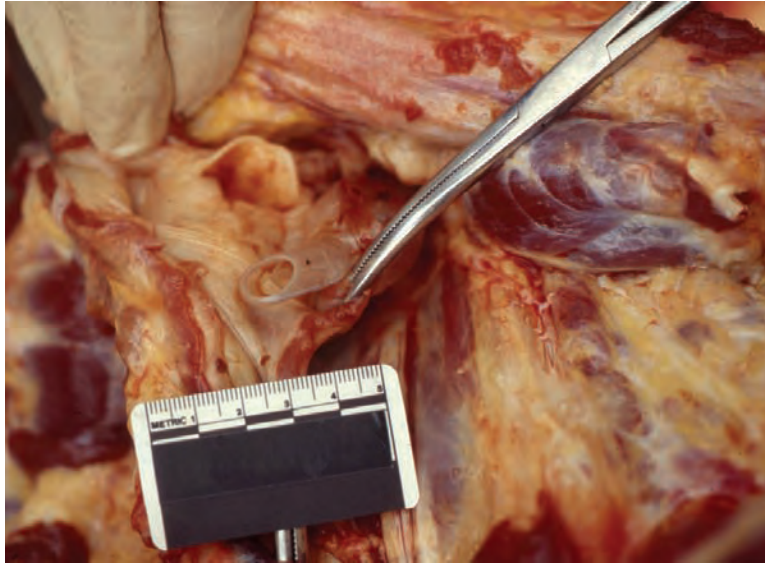


These figures show perimortem injuries to the anterior chest, axillary regions, and the anterior aspects of the upper arms associated with incorrect placement of a rib splitter during a thoracotomy.

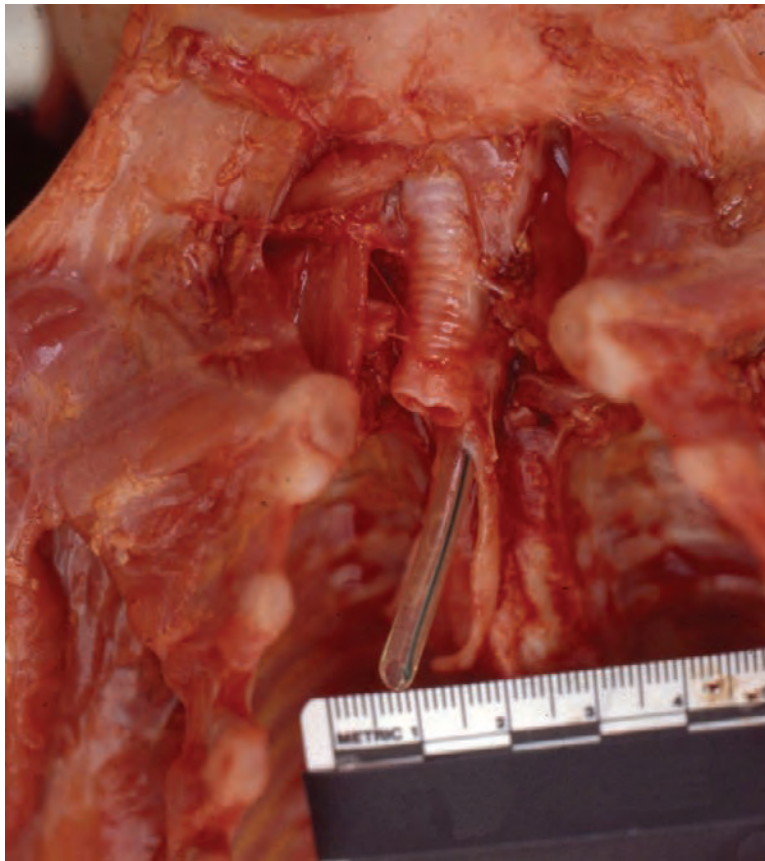




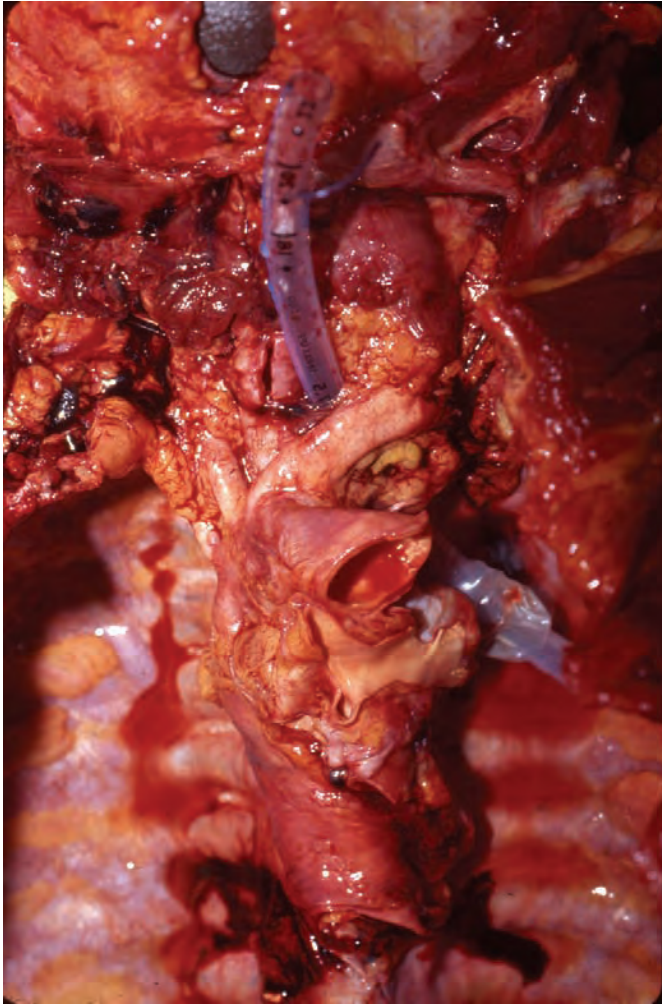
These figures demonstrate the posterior pharyngeal/esophageal cut surface with intramural hemorrhage. This is an artifact encountered frequently during resuscitative measures. The rich esophageal venous plexus tends to be a very hemorrhagic area following intubation.



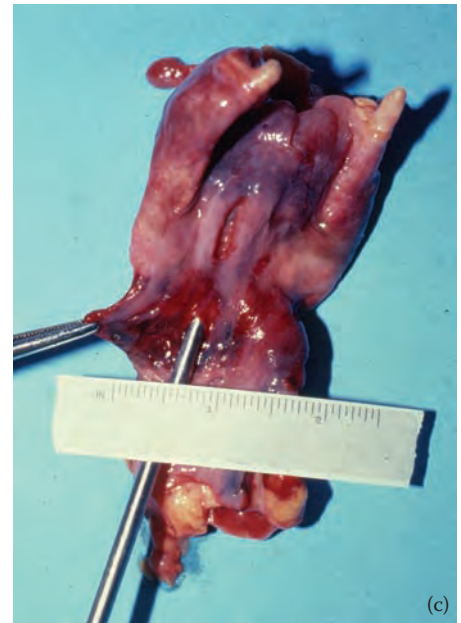
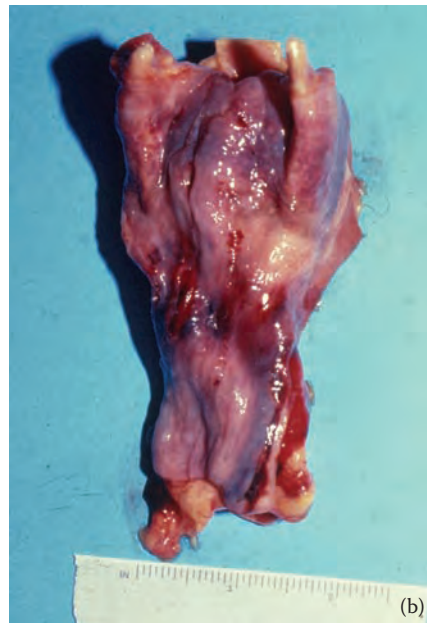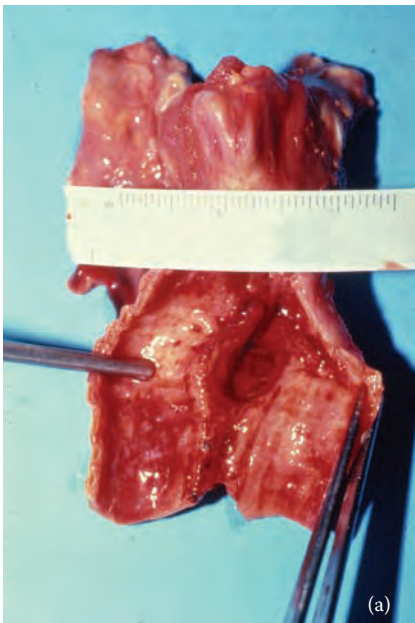
This demonstrates an esophageal intubation with the tip of the endotracheal tube protruding from the esophageal lumen. The epiglottis can be seen slightly behind the endotracheal tube, confirming an esophageal intubation.



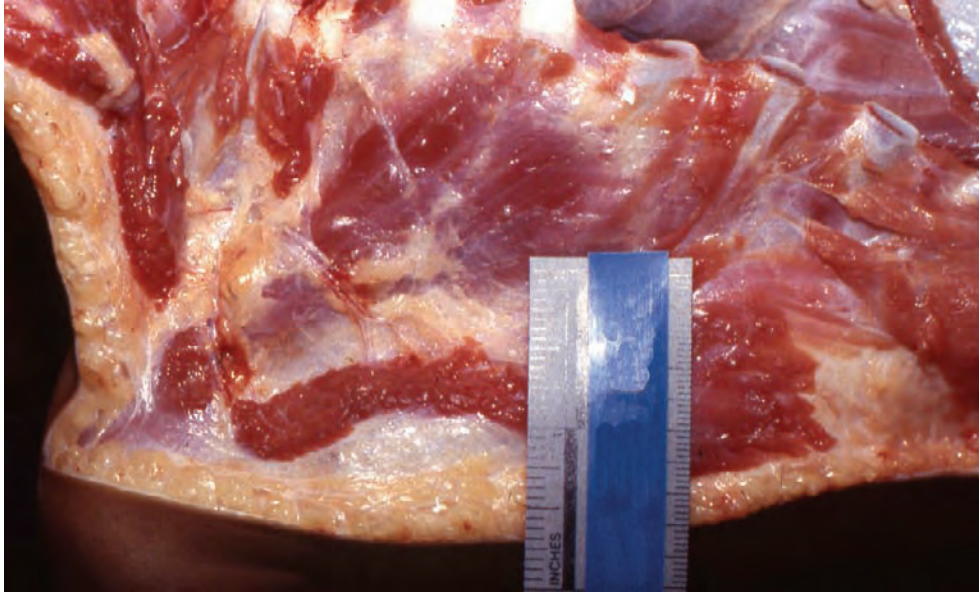
This autopsy involved an infant who succumbed to sudden infant death syndrome (SIDS). The close-up photograph depicts an esophageal intubation, with the endotracheal tube clearly within the esophageal lumen and the concentric tracheal rings visible slightly anterior to and (anatomically) to the right of the tube. Esophageal intubation is not an uncommon finding associated with resuscitation and usually plays no substantial contributory role in the death; however, it should always be documented as part of a complete autopsy and may, in some situations, be a quality control measure for Emergency Medical Services (EMS) personnel and paramedics. Esophageal intubations during an elective procedure, on the other hand, are very important and potentially causal or contributory to the death.



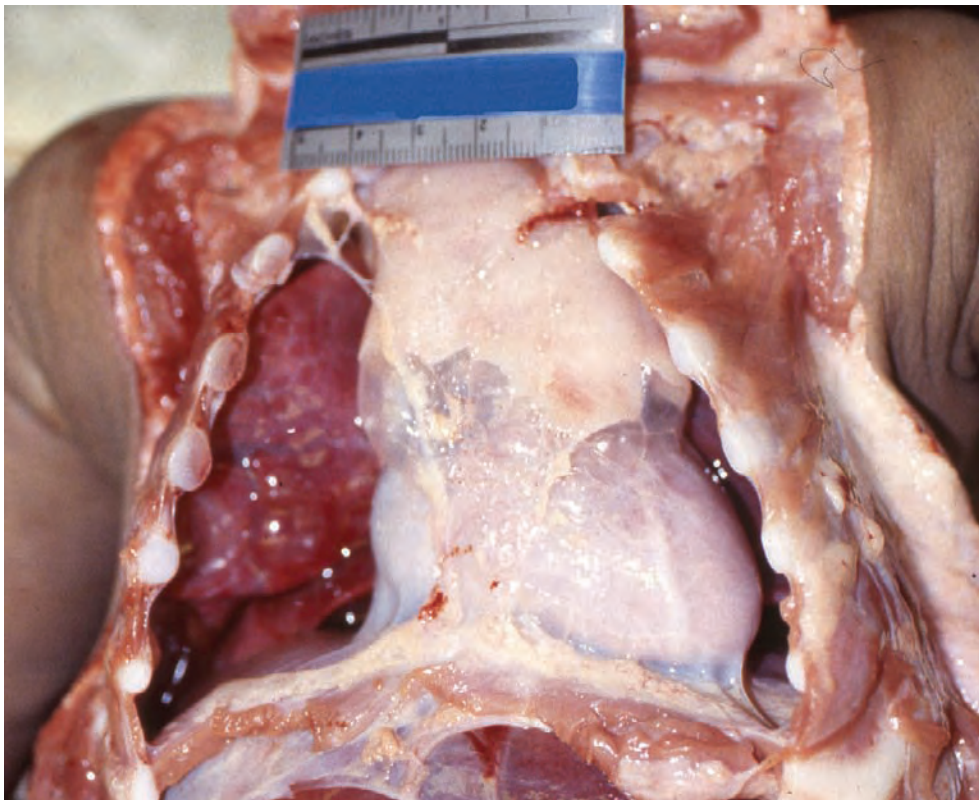
This endotracheal tube was inserted through the trachea and paratracheal soft tissues into the thoracic cavity during resuscitation.



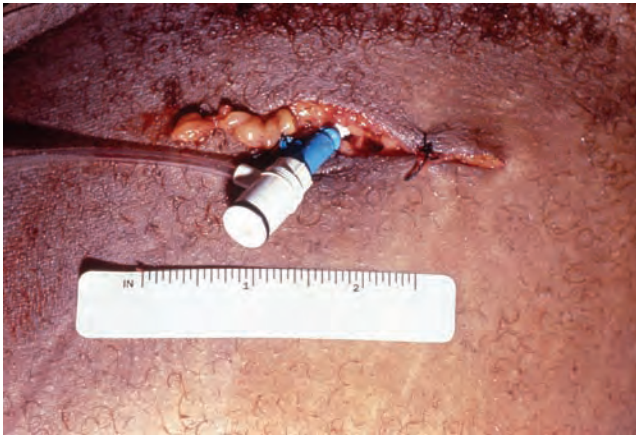A tracheostomy tube was inserted through the posterior aspect of the trachea (a) into the esophagus (b) (traumatic tracheoesophageal fistula). Note the perforations on the posterior surface of the trachea (a) and the anterior aspect of the esophagus (b).



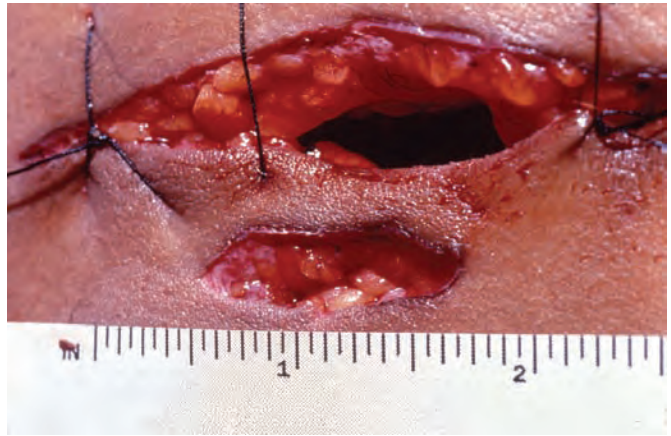This is a view of the chest wall of an 18-month-old toddler with a history of tracheomalacia and subaortic stenosis who required a tracheostomy. During a bout of crying, the tracheostomy tube became dislodged, and after nurses attempted to reposition it, the baby rapidly developed subcutaneous emphysema, followed by bilateral tension pneumothoraces. Autopsy demonstrated marked subcutaneous emphysema, including periorbital swelling. The tube had been removed before the autopsy, precluding assessment of its placement. This particular view demonstrates air bubbles within the subcutaneous fat. It is important that all tubes remain in the body for objective postmortem (autopsy) evaluation of their placement.



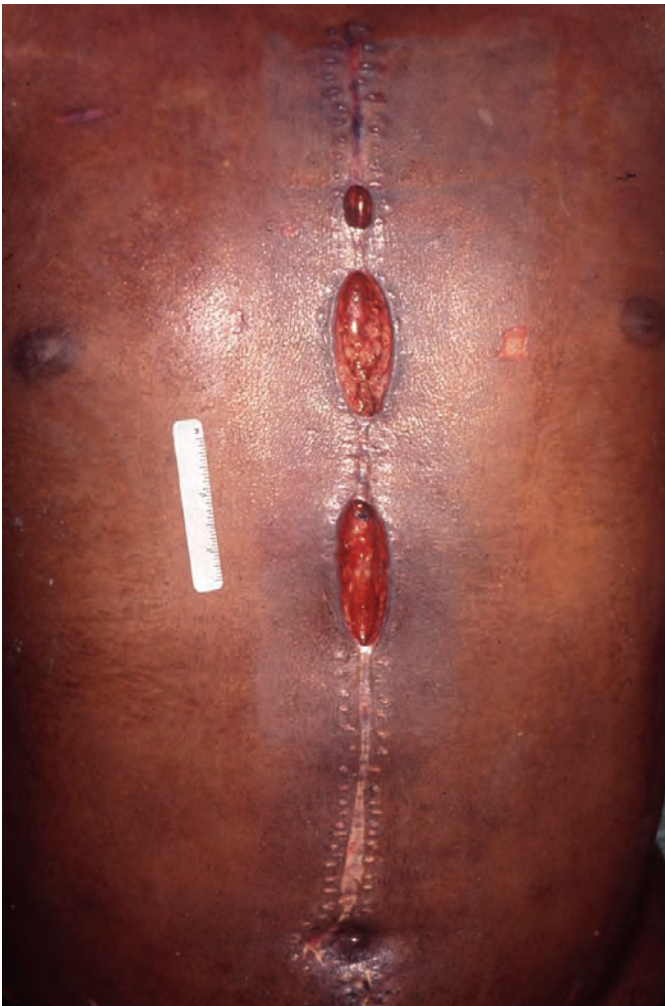Subcutaneous emphysema. Anterior chest with air bubbles throughout the mediastinal soft tissues. This may be commonly observed with vigorous resuscitation or trauma. Palpation of these regions often reveals crepitus.



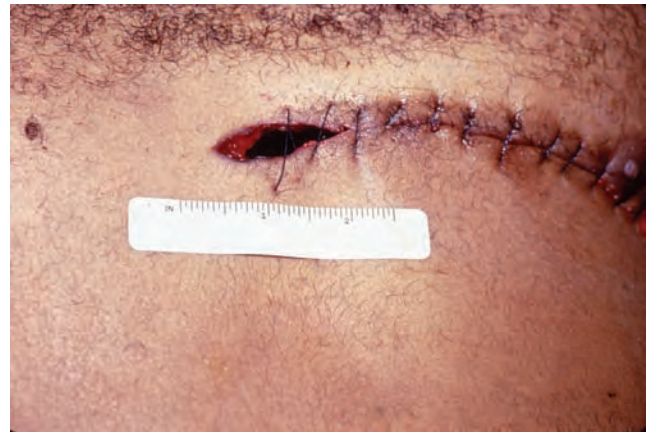One must be careful while examining injuries altered by therapeutic intervention. This picture demonstrates a catheter placed into an injured blood vessel through a stab wound.



This demonstrates a stab wound adjacent to a sutured chest tube incision. This may make injury interpretation more challenging.



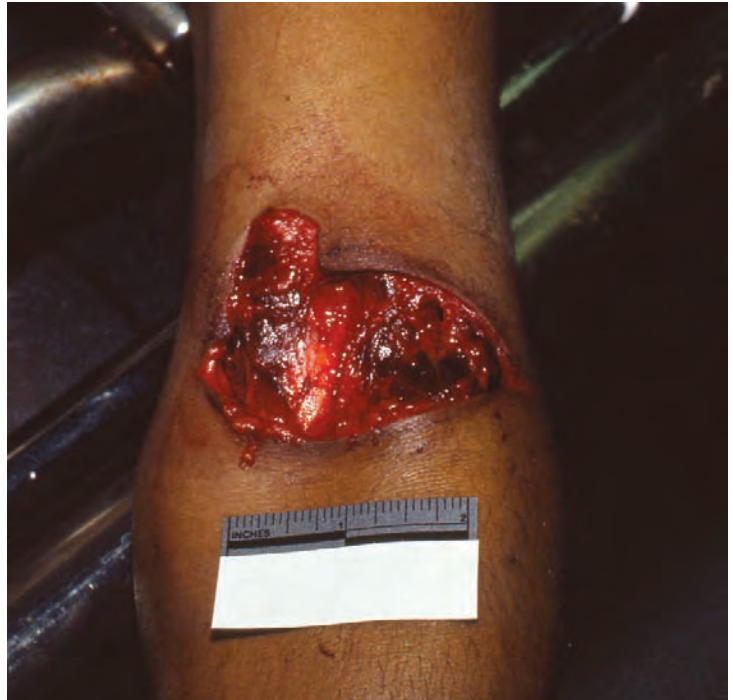Healing infected incision. This individual died of septic complications of his initial trauma. Had it not been for this trauma, the infection that took his life would not have occurred. The manner of death in this case was ruled accidental.



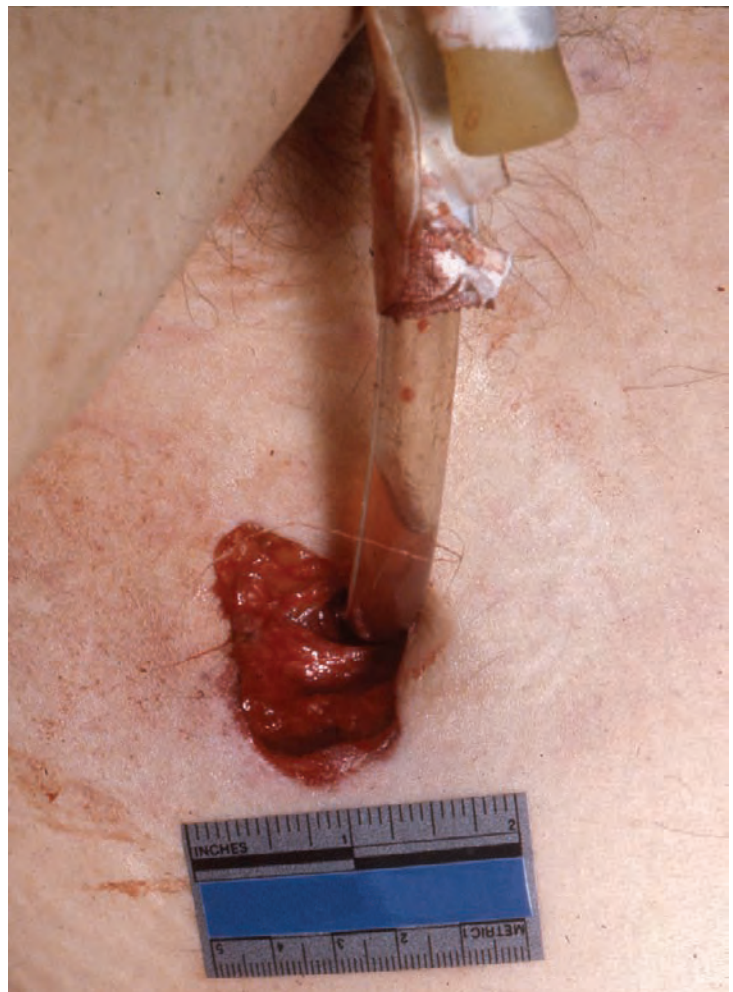This demonstrates a stab wound that the clinicians converted along one side (edge) into a thoracotomy incision. If at all possible, this should never be done, because it makes injury interpretation much more difficult.

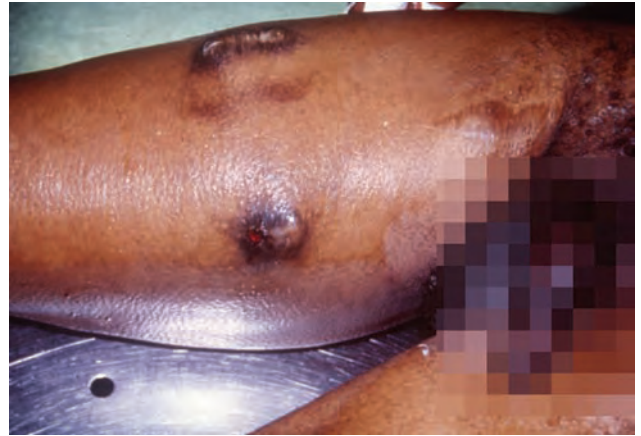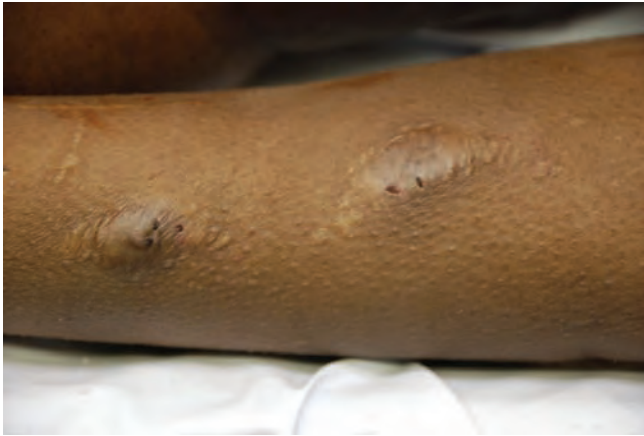


This is a “cutdown site” used for vascular access by a hospital emergency department (ED) physician, created by a transverse incision within the antecubital fossa. This decedent had also sustained stab and incised wounds in other parts of the body. Again, this illustrates the importance of having a complete medical record and discussions with the treating ED physicians or trauma surgeons to properly differentiate between therapeutic interventions and injuries sustained before such therapeutic interventions.

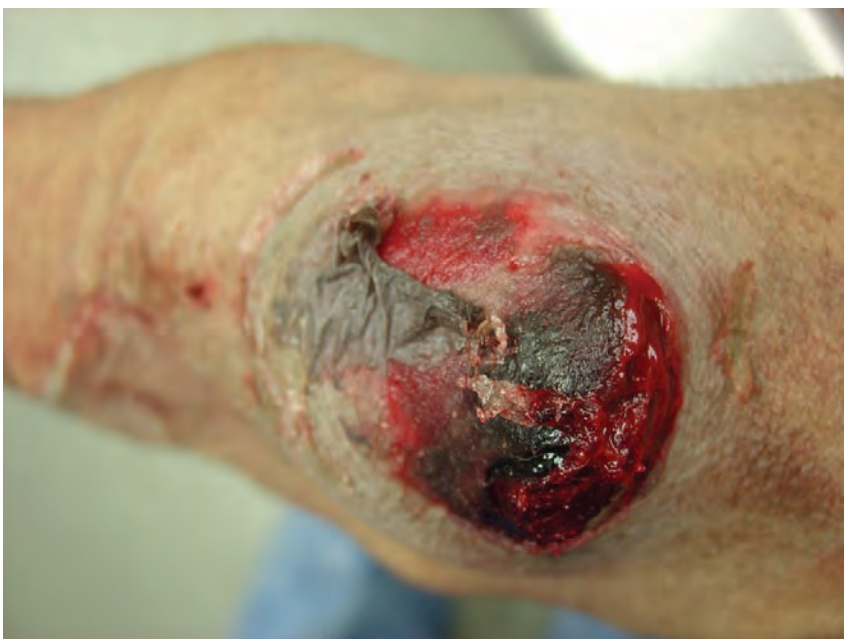
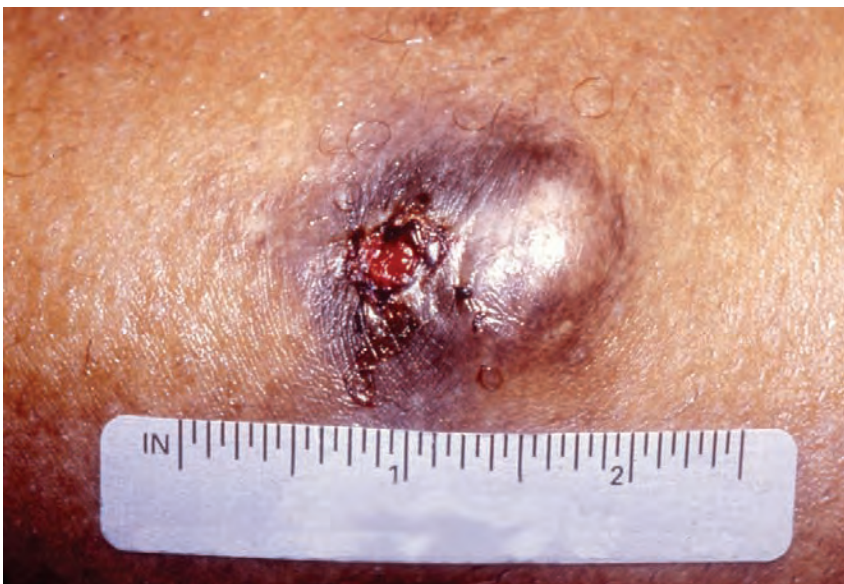
This chest tube was inserted through a previously existing perforation. Notice, however, that along the left margin of this perforation (from the 7–11 o'clock positions), there is a distinct abrasion. Further investigation established that the chest tube was inserted through a previously sustained entrance gunshot wound, thus explaining the abraded margin of this perforation.

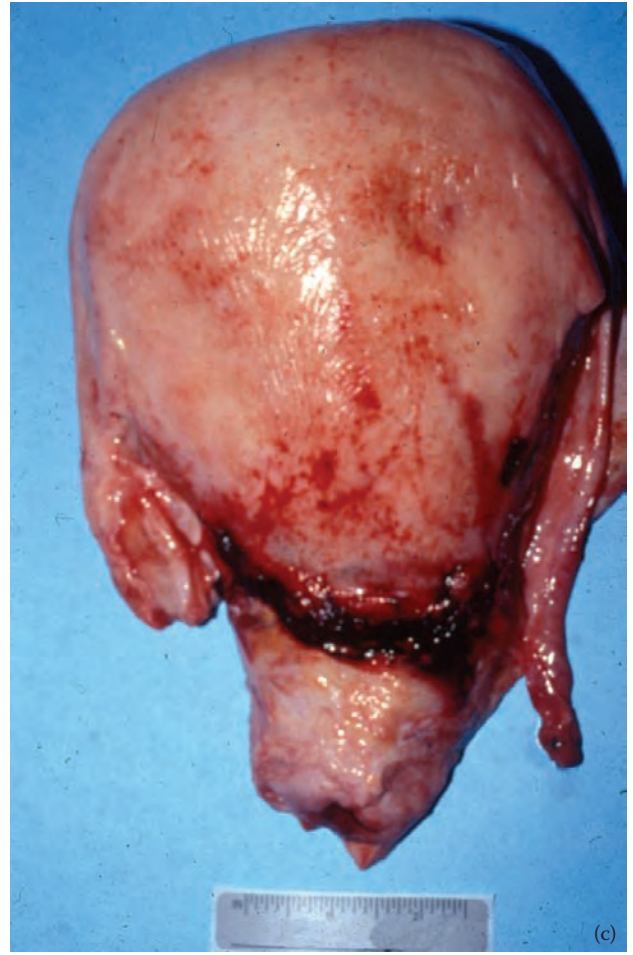
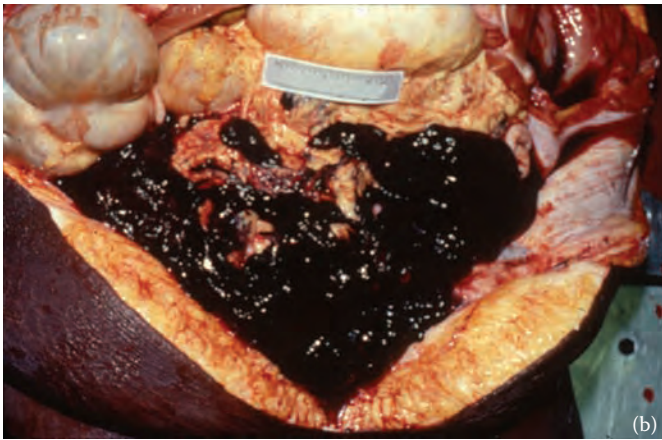
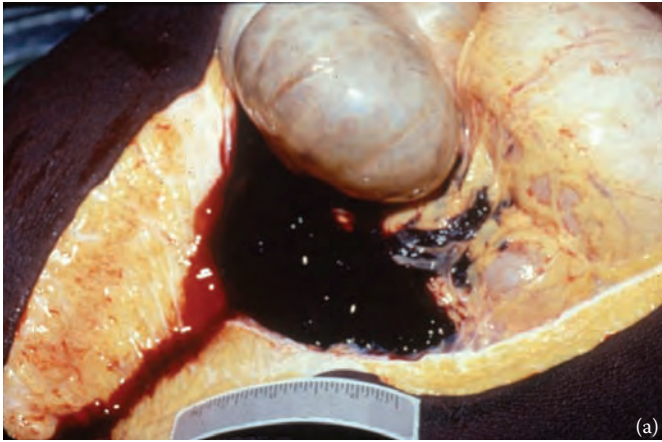




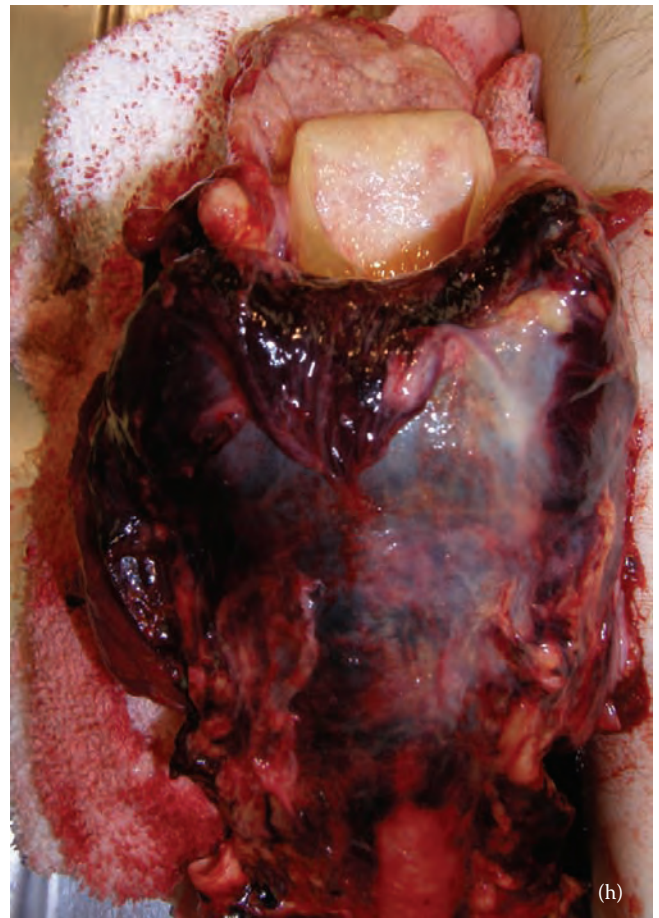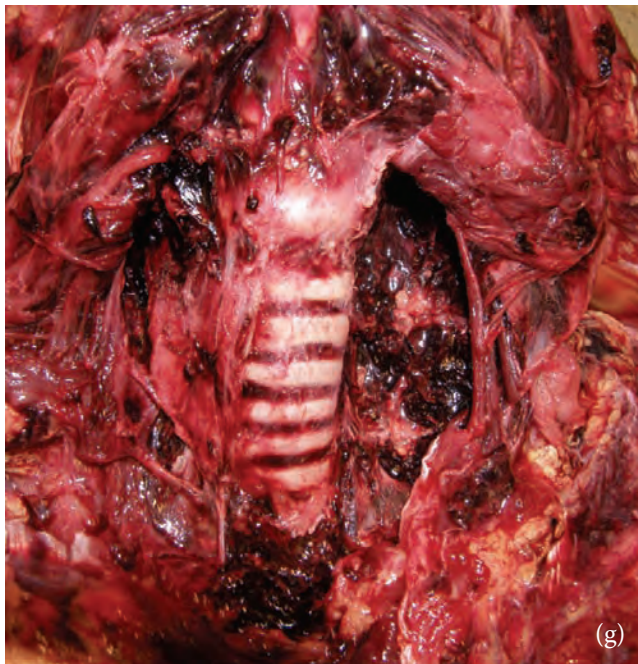
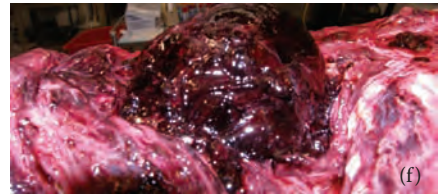
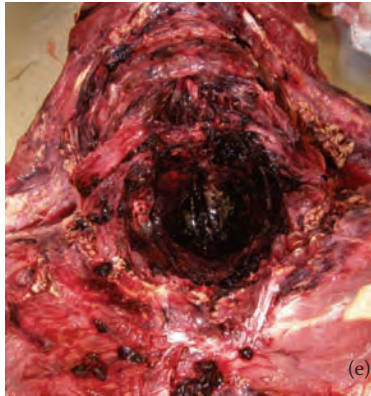
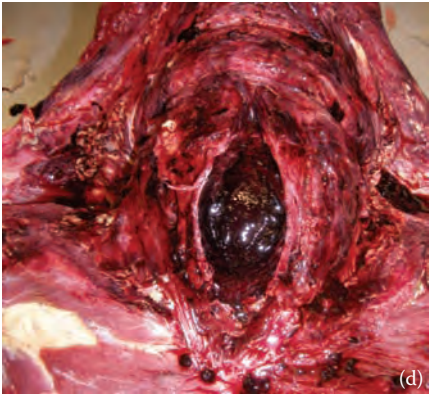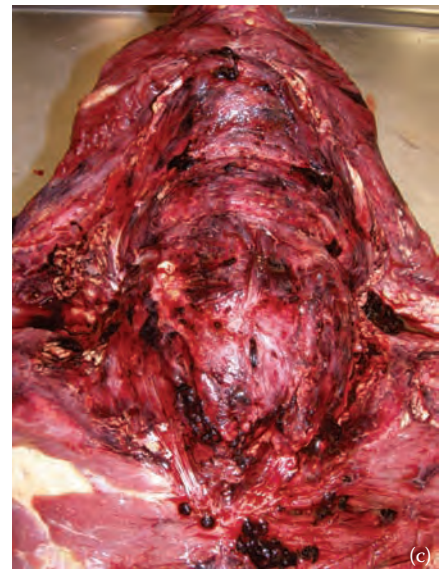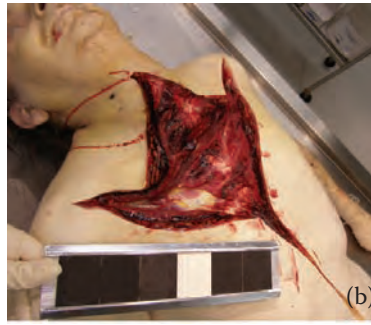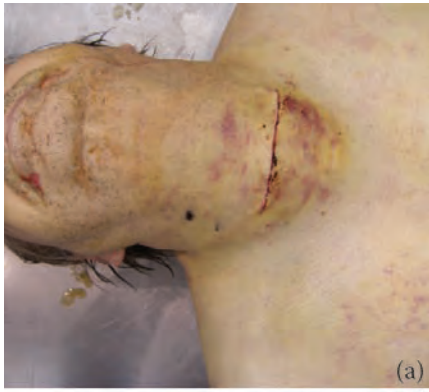Arteriovenous hemodialysis grafts with healing needle puncture marks.



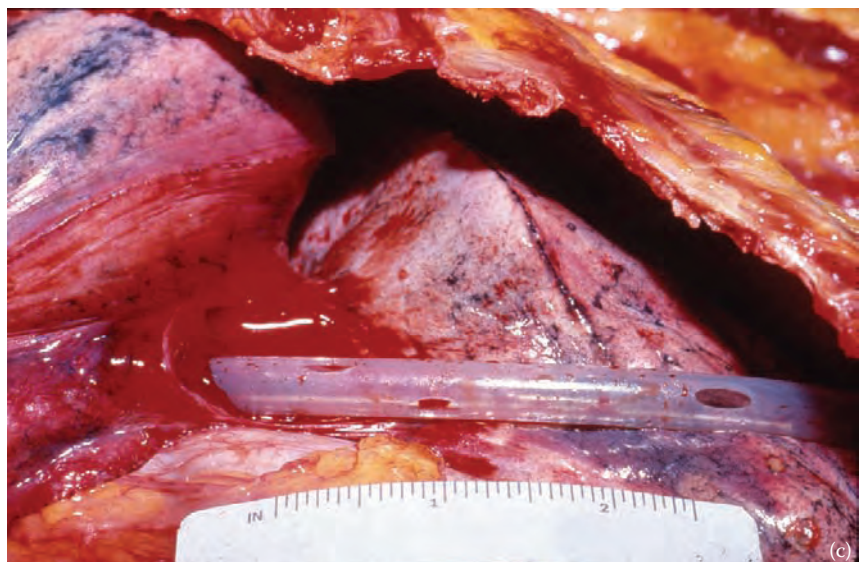
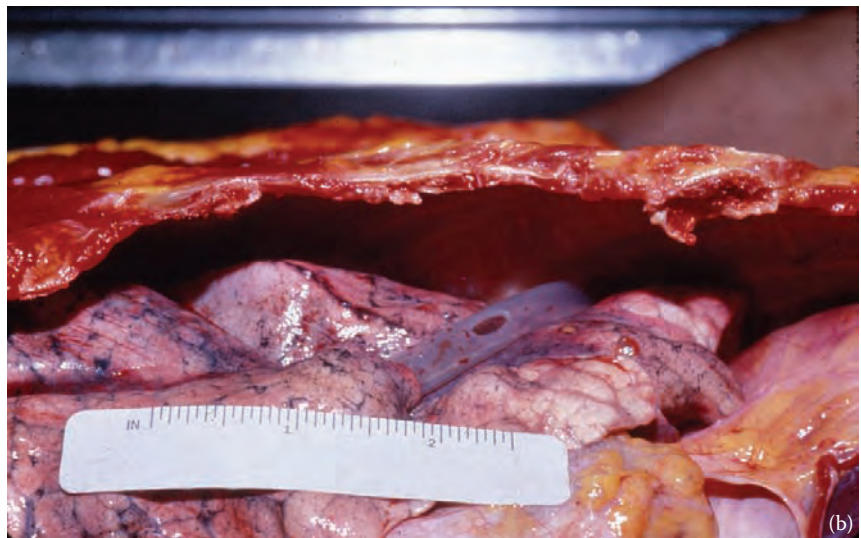
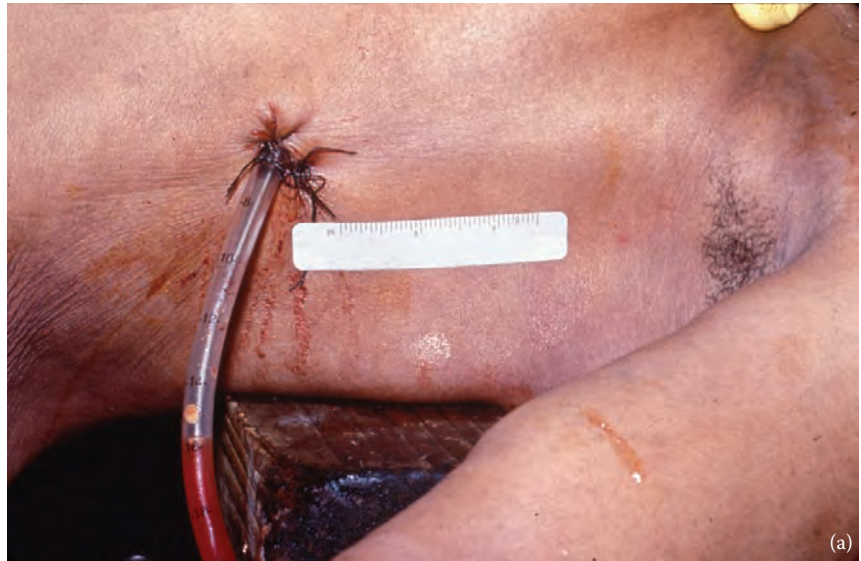These individuals exsanguinated in their residences following ruptures of their infected arteriovenous dialysis grafts.



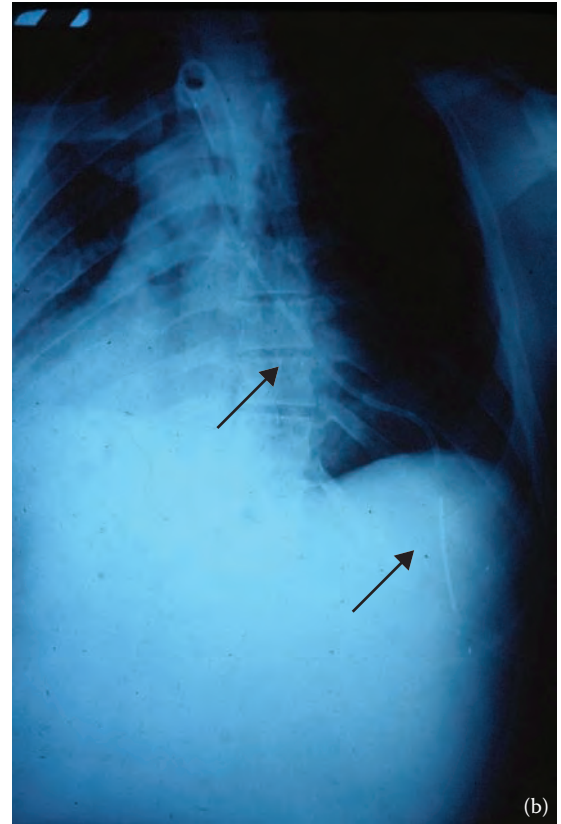
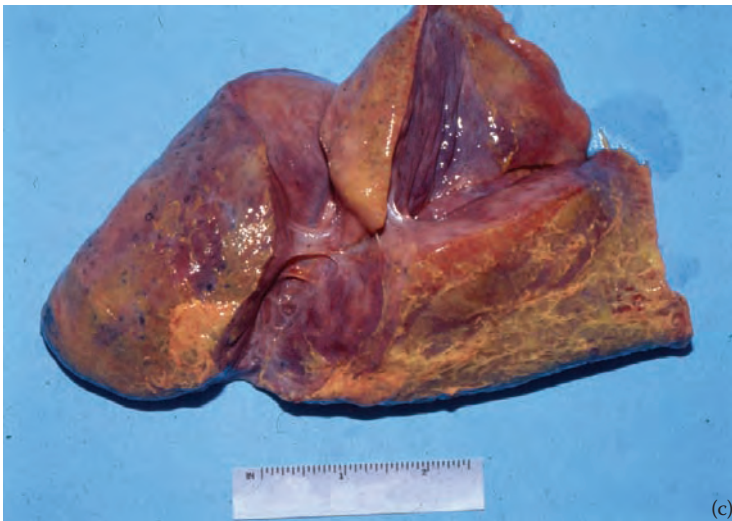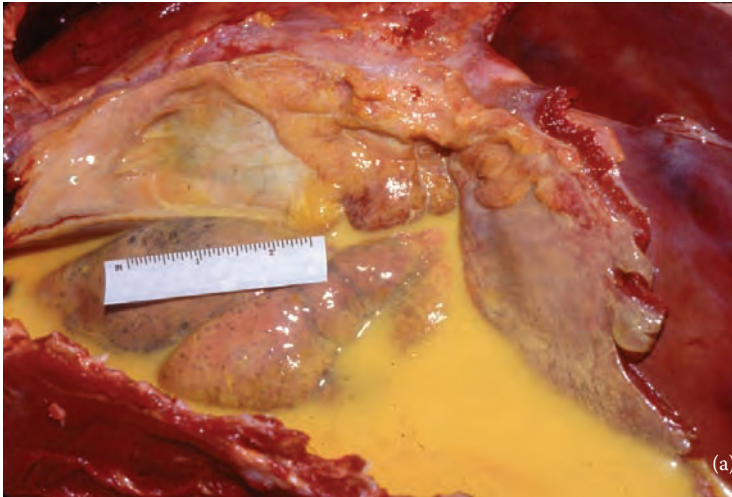
This woman underwent (a) Cesarean section (c) for an otherwise unremarkable term pregnancy hours before going into hemorrhagic shock while in the recovery room. Autopsy disclosed a large hemoperitoneum with clotted blood extending from a bleeding abdominal wall vein (a) and (b).



These figures show an individual who died of hemorrhagic complications following (a) a thyroidectomy. A large accumulation of clotted blood collapsed his airway while he was sedated at home. He was found unresponsive lying on a sofa. Note the hemorrhage and larger blood clot in the anterior neck and chest.



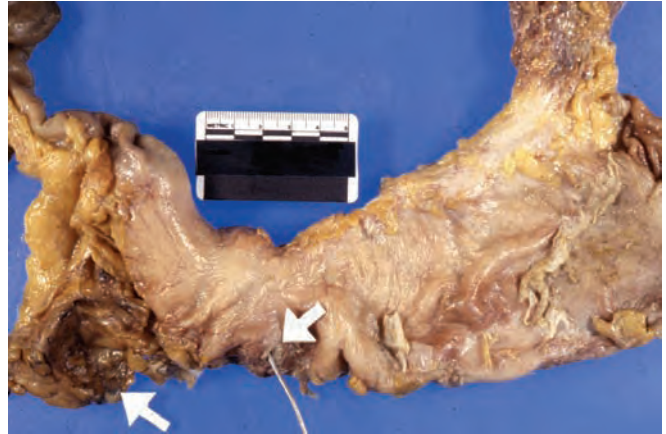These figures show a patient who was admitted in cardiac arrest following an acute asthma attack. Chest tube placement was inserted through the lung parenchyma during resuscitation. Approximately 150 mL of liquid blood were recovered from the left hemithorax, indicating that this injury was perimortem and iatrogenic.



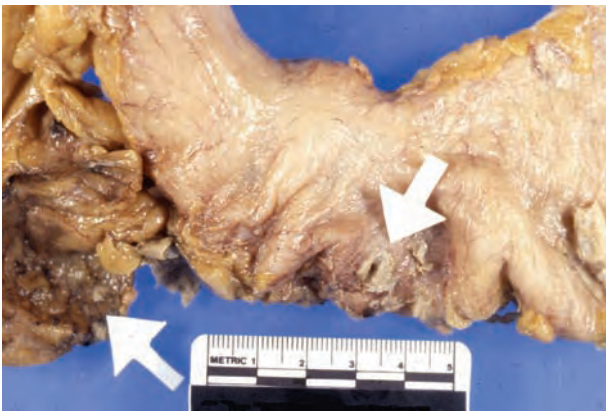This individual underwent placement of a nasogastric tube that perforated the esophagus and entered the right thoracic cavity (hemithorax). The injury went unnoticed for many hours. The decedent was fed through the nasogastric tube, which is demonstrated by the accumulation of yellow fluid within the thoracic cavity. Autopsy revealed a fibrinous pleuritis and an early pneumonia.



Percutaneous endoscopic gastrostomy feeding tube.



Panoramic view illustrating the anterior gastric wall, with a probe through the previous PEG site, also demarcated by an arrow, and the other arrow demonstrating greater omentum with fibrinous exudate. Similarly appearing exudate can also be seen on the anterior surface of the gastric body and fundus.

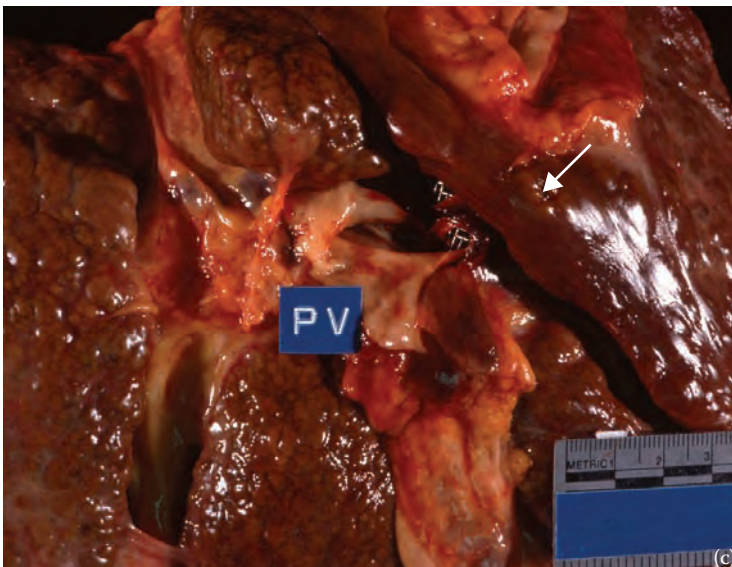
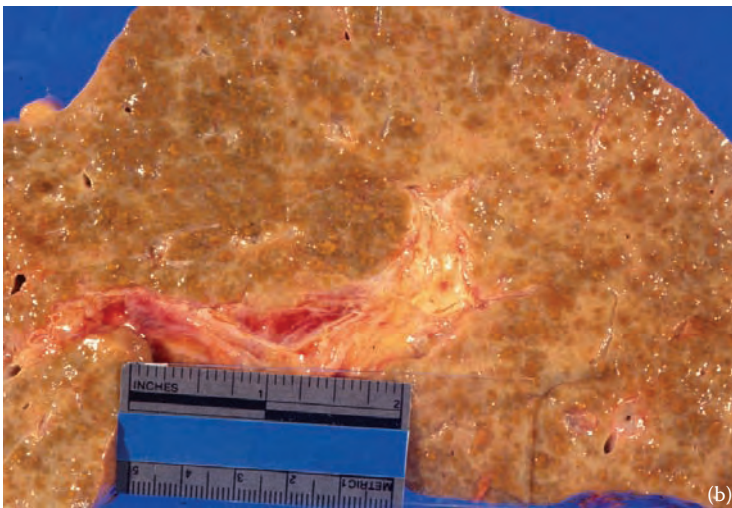
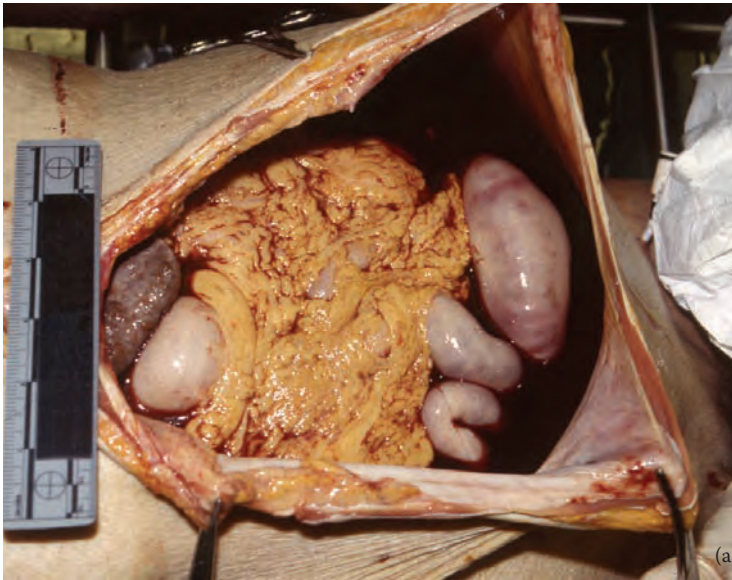


This is a close-up anterior view of the stomach, demonstrating the previous PEG site through the anterior gastric wall, as well fibrinous exudate on the surface of the greater omentum, with both features demarcated by arrows.



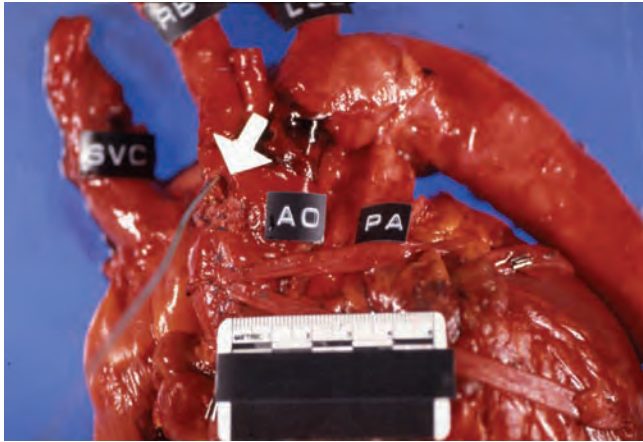
This depicts the parietal peritoneum with a gray, shaggy, fibrinous exudate.

This case involved an elderly woman with a history of dementia who could no longer live independently and was made a ward of the state. She was hospitalized for long-term intermediate care. She had undergone percutaneous endoscopic gastrostomy (PEG) tube insertion due to insufficient oral intake (a). She underwent a tube replacement for leakage. Later that evening, she experienced acute onset of abdominal pain that was complicated by increasing abdominal distension, green discoloration of the abdominal wall site, and purulent drainage from the tube site. The remainder of her course was characterized by respiratory distress, aspiration of gastric contents, hypotension, and tachypnea, culminating in systemic inflammatory response syndrome with lactic acidosis, multisystem organ failure, and hemodynamic instability, refractory to aggressive resuscitative measures. Autopsy revealed intraperitoneal placement of the gastrostomy tube with intraperitoneal administration of enteral feedings and a collection of approximately 700 mL of turbid peritoneal fluid with extensive fibrinous adhesions. Microscopic examination confirmed an exuberant fibrinous exudate with scattered clusters of bacterial cocci and yeast, as well as birefringent material. The cause of death was certified as complications of peritonitis following intraperitoneal placement of gastrostomy tube during tube change, following percutaneous endoscopic gastrostomy insertion for insufficient oral intake related to atherosclerotic cerebral vascular disease and dementia. The manner of death was certified as accident.

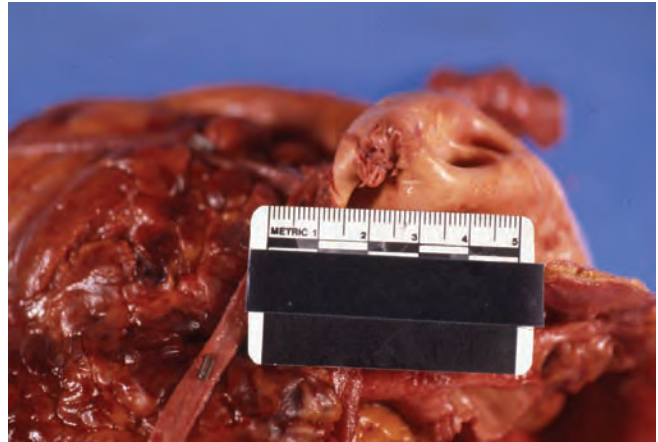


This was a middle-aged woman with primary biliary cirrhosis who underwent a transjugular intrahepatic portosystemic shunt (TIPS) for decompression of high portal venous pressure (portal hypertension). The picture (a) depicts a large hemoperitoneum, with greater omentum, stomach, and intestines floating on top of a pool of blood. There was advanced end-stage cirrhosis (b), with confluent scar enveloping and entrapping regenerative parenchymal nodules. Liver diseases such as this are associated with an increased risk of hemorrhagic complications due to coagulopathy and portal hypertension. This fatal hemorrhage resulted from laceration of a portal vein branch occurring during stent placement (c).

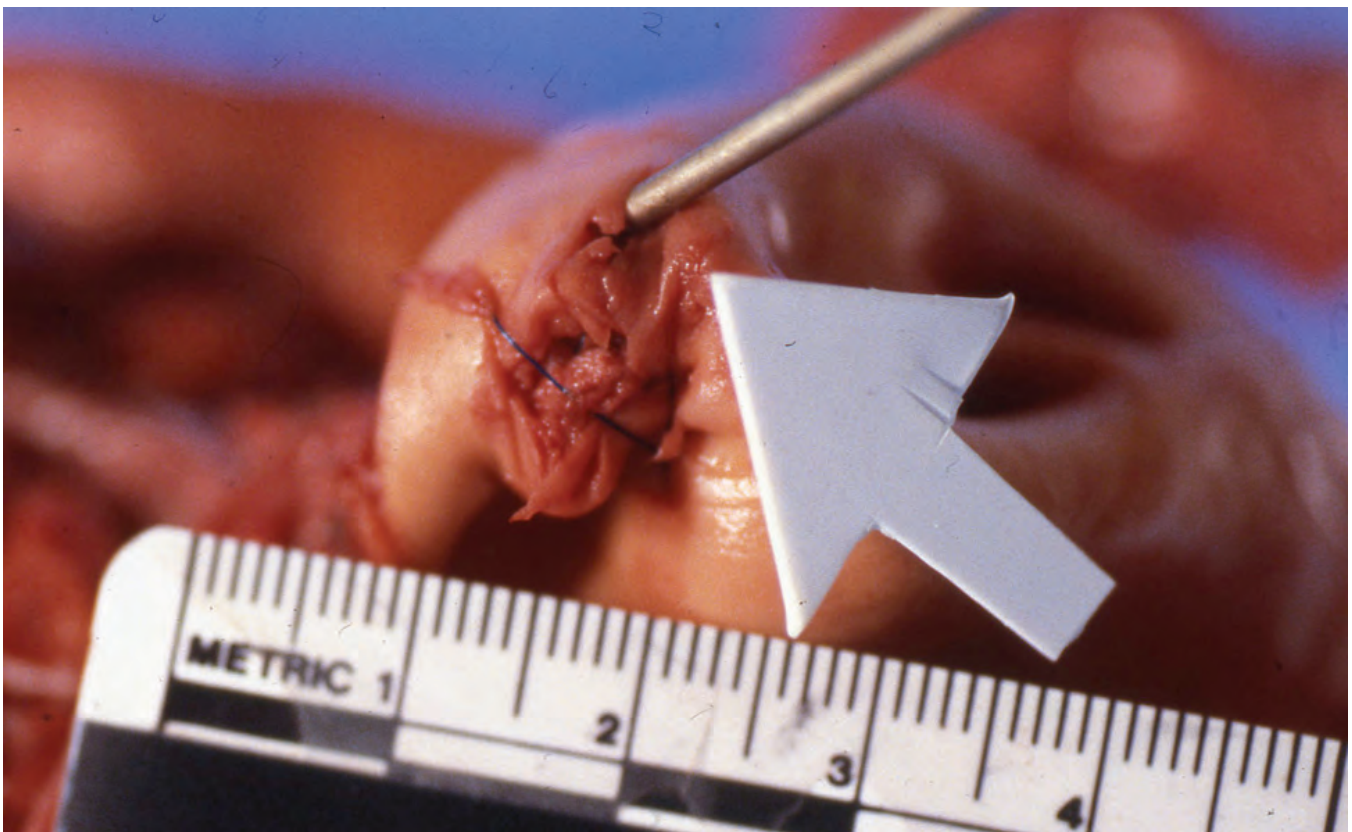



Note the probe inserted through the perforation site, which is also demonstrated with the arrow.

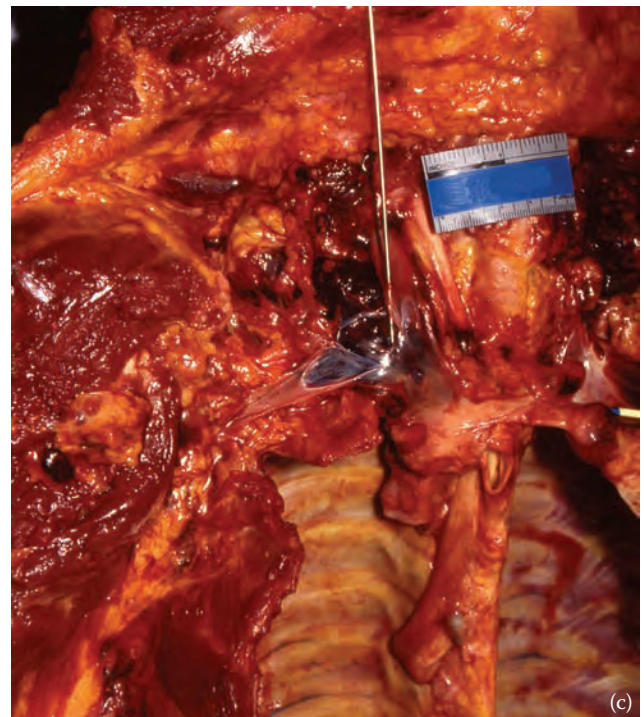
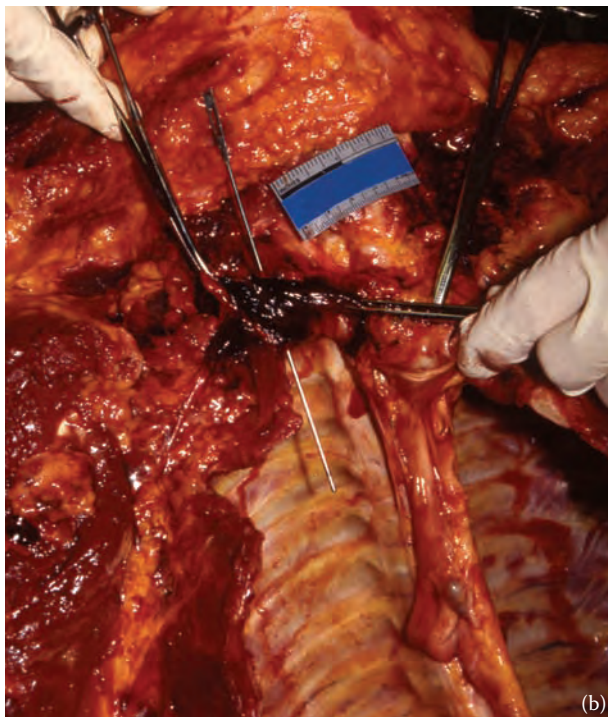
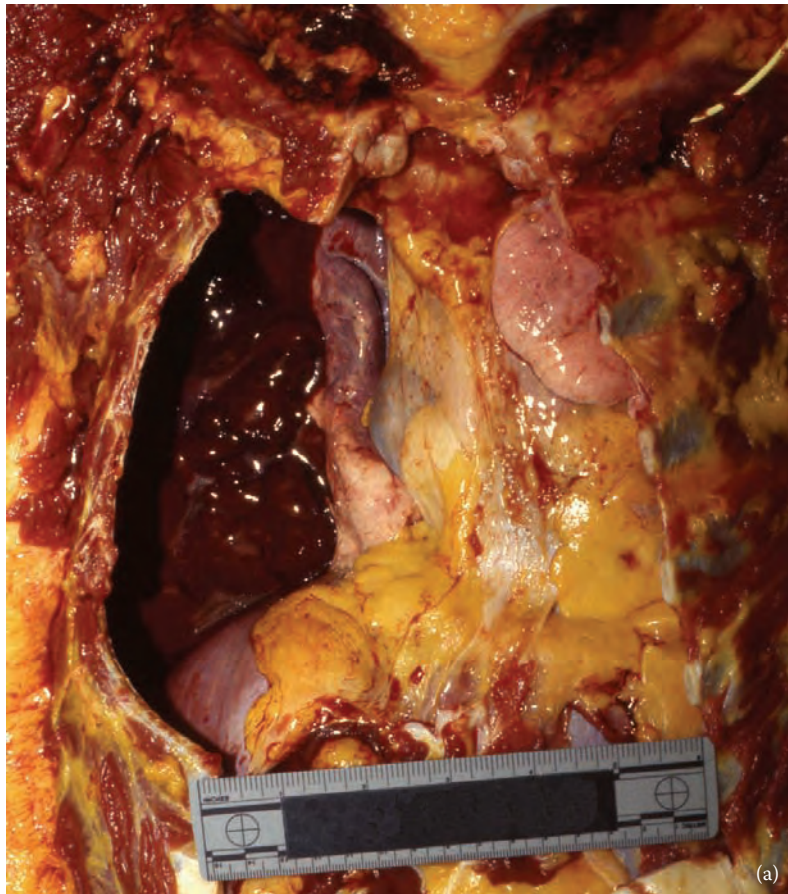


This image demonstrates the sutured cannulation site as well as one of the bypass grafts.

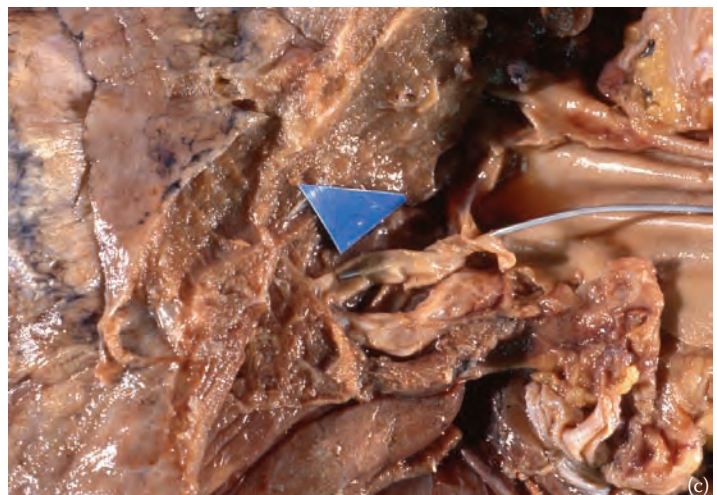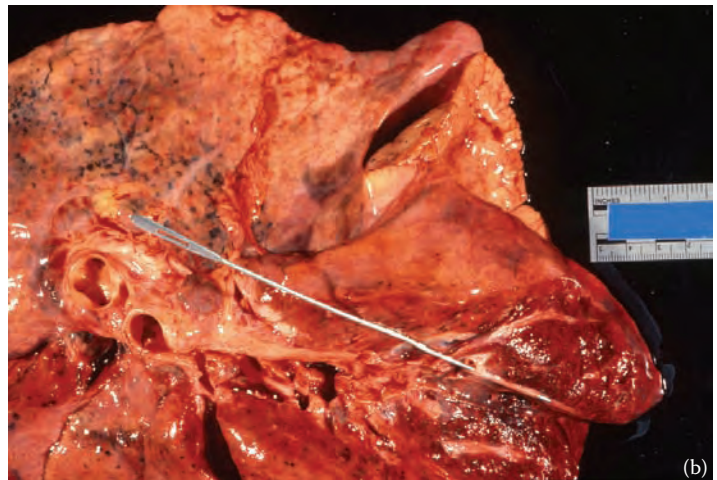

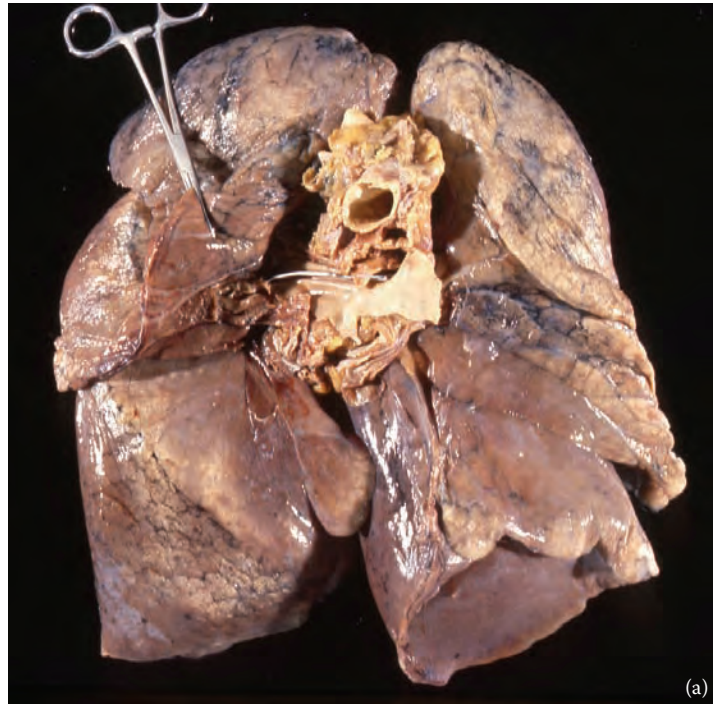
Close-up of perforation site demonstrated by probe and arrow.

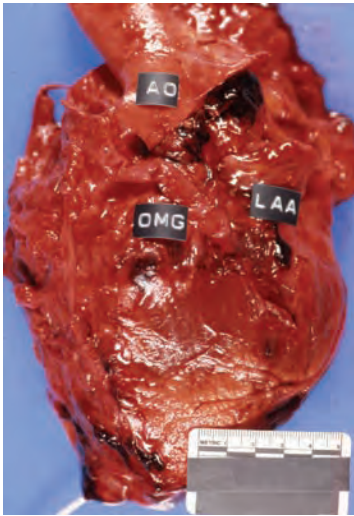
This case involved a patient who underwent six-vessel coronary artery bypass grafting that was followed by intractable postoperative hemorrhage. The pericardial and left pleural drainage exceeded 1 liter within the first postoperative hour. The patient became hypotensive, requiring emergent re-exploration that was refractory to resuscitative efforts. Autopsy revealed an approximately 3-mm perforation of the ascending aorta, immediately above and distal to a sutured aortic cardiopulmonary bypass cannulation site, with residual bilateral hemothoraces. (left: 1,100 mL and right: 450 mL). The cause of death was certified as intractable hemorrhage with perforation at the aortic cannulation site complicating coronary artery bypass grafting for atherosclerotic coronary artery disease. Hypertensive heart disease was listed as a contributory cause (heart weight: 690 grams and body weight: 120 kgs). The manner of death was certified as therapeutic complication.



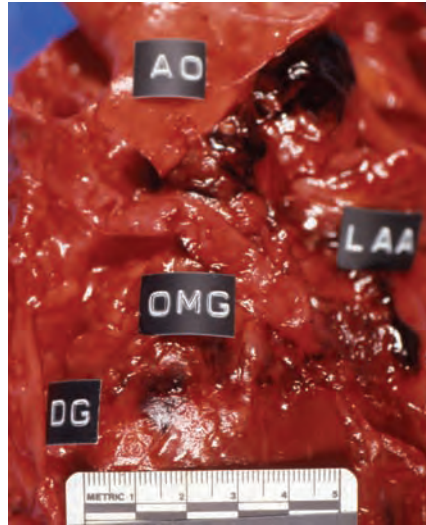
Right hemothorax (a) due to perforation of right internal jugular vein complicating catheter insertion. Note the probe (b) and (c) demonstrating the perforation through the right internal jugular vein and the hemorrhage within the anterior overlying soft tissues.



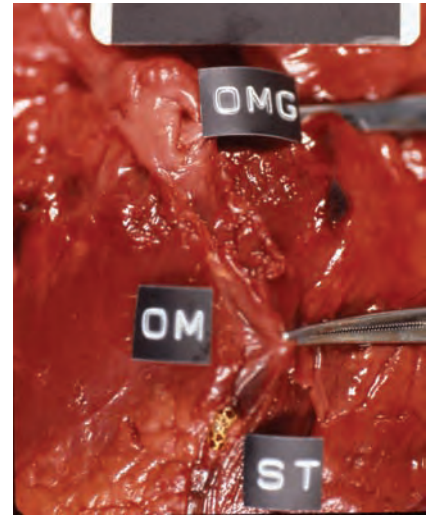
This case involved complications of a transbronchial biopsy in an individual who was HIV-positive and was slightly thrombocytopenic (platelet count: approximately 75,000/uL). The procedure was followed by extensive pulmonary hemorrhage, which culminated in respiratory compromise and death. Figure (a) demonstrates a Swan-Ganz catheter within the pulmonary arterial system. Figures (b) and (c) is a close-up view with a probe through a perforation of one of the large branches of the right main pulmonary artery with the arrow head demarcating the tip of the probe.



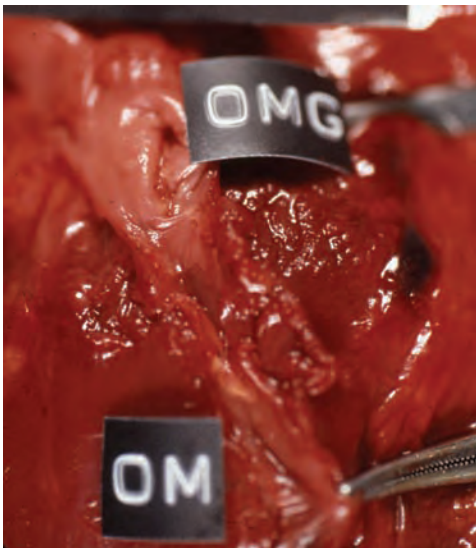Heart with labels illustrating the aorta (AO), obtuse marginal graft (OMG), and left atrial appendage (LAA).



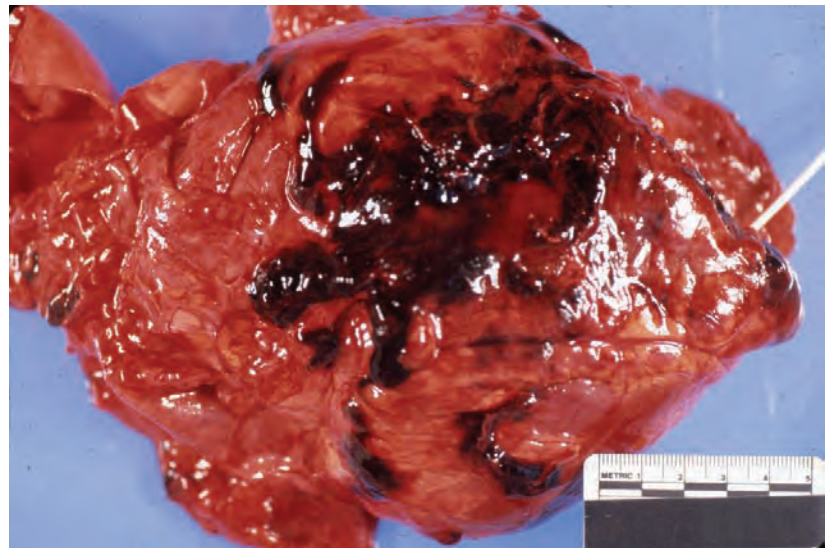
Close-up view of grafts.



This image demonstrates the relationship of obtuse marginal graft and native obtuse marginal vessel, as well as a stent protruding through the lacerated native obtuse marginal artery.

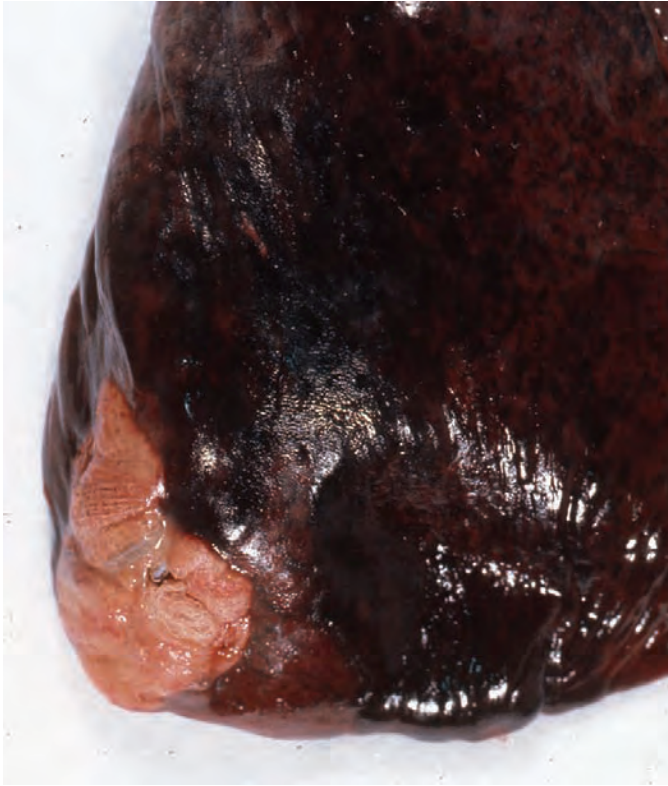


Close-up view of the junction between the obtuse marginal graft and the native obtuse marginal artery demonstrating the irregularity in the arterial wall.

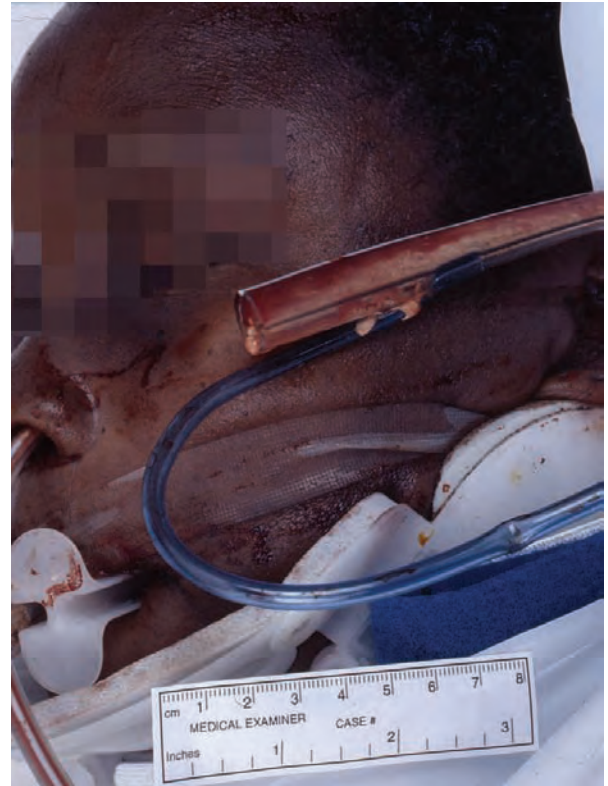

Posterior view of heart demonstrating confluent epicardial hemorrhage associated with this procedure.

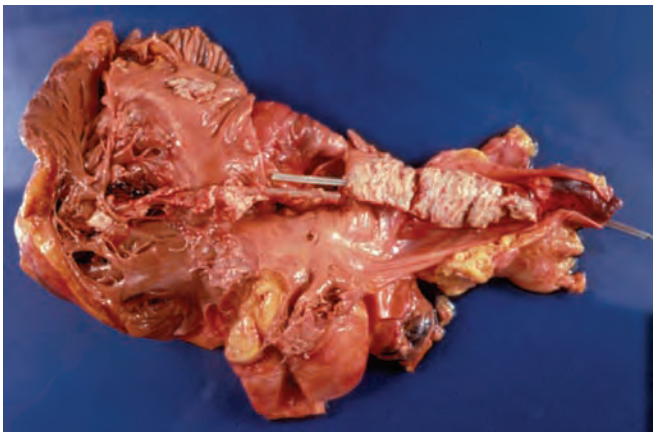
These pictures demonstrate a complication of coronary artery bypass grafting. In this case, a stent perforated the native obtuse marginal branch of the left circumflex artery immediately distal to the anastomosis between the graft and native vessel.



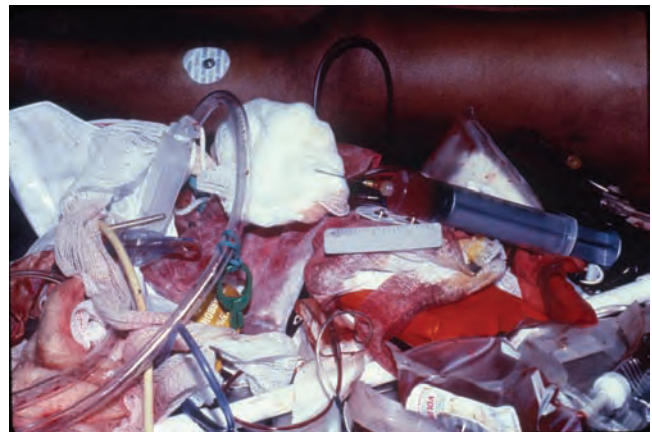This depicts the lower lobe of the left lung with congestion and pneumonia. Note at the inferolateral aspect of the left lower lobe is a fragment of gauze that was inadvertently left behind during another operation months earlier. The gauze is adherent to the surface with overlying adhesions and adjacent purulent exudate.



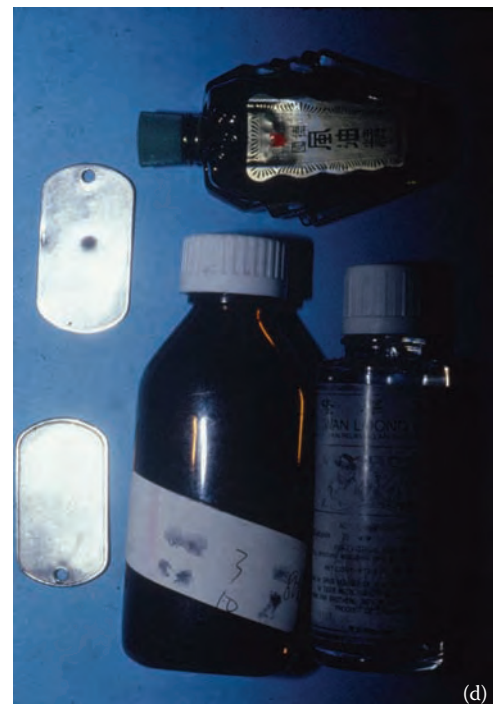
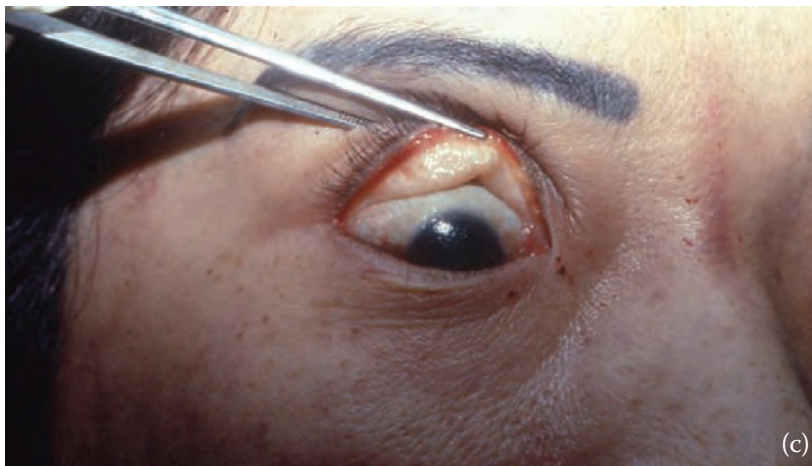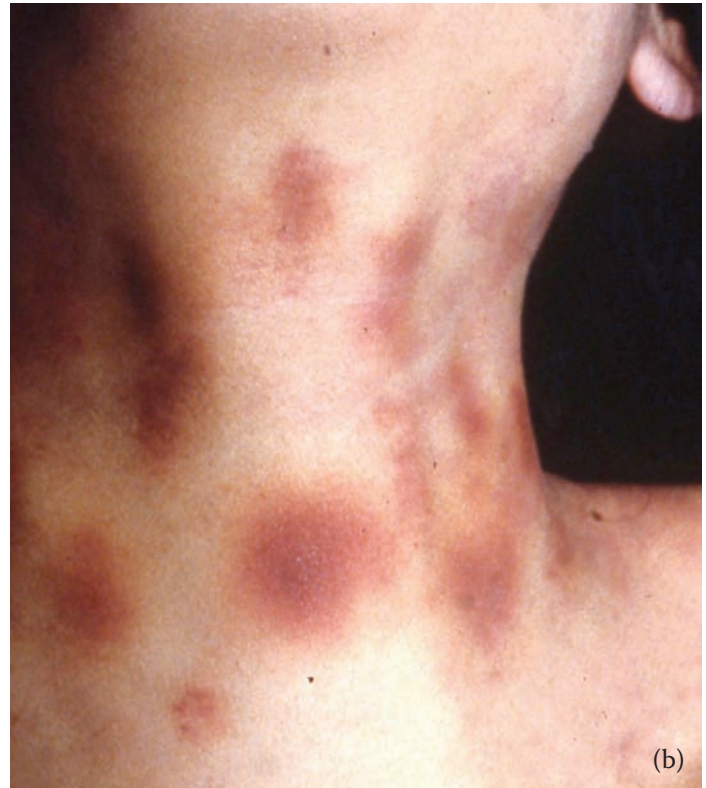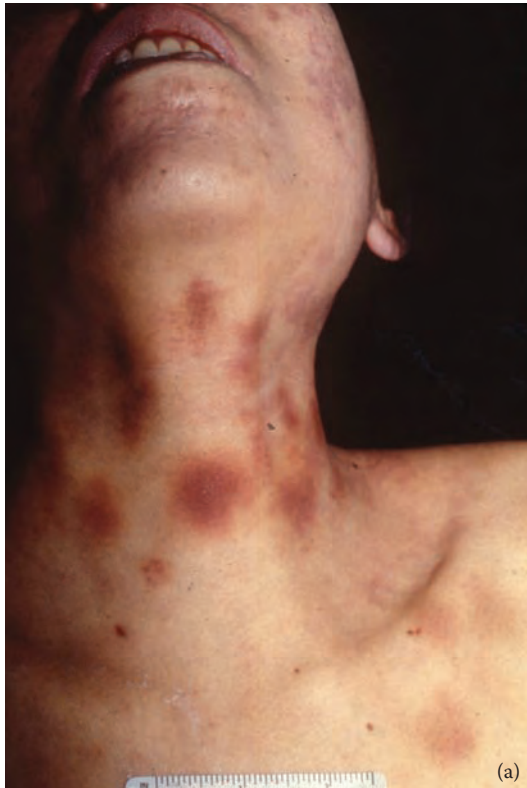This individual was in a motor vehicle accident and sustained a skull fracture involving the cribriform plate. A nasogastric tube was inserted that inadvertently penetrated the cranium. The tube was placed on intermittent suction. Aspirated brain matter is visible at the end of the tube.



This demonstrates a large gray-tan thrombus encasing a pacemaker lead extending from the heart.



In busy trauma centers, the body is sometimes received with multiple instruments used for resuscitative efforts. This photograph was taken after the body bag was opened at the morgue. It is always important to be careful of sharps that have been inadvertently left behind.



This Vietnamese woman died of Takayasu arteritis that was complicated by a ruptured aortic aneurysm. She was treated at home by her grandmother with Southeast Asian folklore remedies, including coining, which involves rubbing of hot oils and medicine onto skin (d). Note the unusual location of the coin marks at her neck (a) and (b). At first this was mistaken for manual strangulation. There were no internal neck injuries and no scleral or conjunctival hemorrhages (c).



---

# Substance Abuse and Poisoning

# 3

CHARLES A. CATANESE AND LAURA M. LABAY

---

## Introduction

---

The term substance abuse is most simply defined as the excessive use of one or numerous drugs. In general, most people typically have some level of access to several types of drugs, including legitimately prescribed medications, and on average, will benefit from their appropriate use. However, the term substance abuse can be applied to a variety of situations or circumstances. For example, one person may intentionally be abusing a multitude of substances including illicit drugs, prescribed medications, and over-the-counter remedies (i.e., supplements, herbals, diet aids, etc.). This is in direct contrast to another individual who may be taking only a single medication, but deliberately using it in a manner that is not consistent with normal therapeutic use. It stands to reason that when individuals begin to abuse one or more substances, and use them in an uncontrolled manner without the appropriate oversight, that they place themselves in a potentially harmful or lethal situation.

In a forensic or medicolegal setting it often becomes a matter of necessity to interpret drug findings and render an opinion regarding the toxicological, physiological, and pathological impact the drugs may have had upon an individual. To this end, it is important to evaluate and consider a host of factors. These factors are not always straightforward or quantifiable, but nevertheless include the drug's inherent physical and chemical properties, the dosage of the drug used, the frequency of the drug intake, the route of drug administration, the concentration of drug and drug metabolite found, the person's tolerance level to the drug and any medical conditions or disease states the person may have experienced.

It is important to recognize that for a particular drug to ultimately produce a toxic or lethal effect, it must be present in an individual at a sufficient concentration for a sufficient length of time. However, while references and other texts are available that help to classify drug concentrations as "therapeutic," "toxic," or "lethal," interpretation is often not so simple. For example, postmortem methadone concentrations are often challenging to interpret because the range of blood concentrations detected in people enrolled in narcotic maintenance programs may overlap the blood concentrations found in overdose or lethal situations.

Also, some drugs, depending on their physical and chemical properties and their concentrations in the body, will exert their most toxic or lethal effects in an acute manner, while others will take a longer period of time to act. In general, deaths associated with substance abuse may be related to acute or chronic complications. *Acute substance abuse* indicates that the death was related to direct toxic effects of the drug shortly after administration. In a *delayed overdose*, the drug produces damage to the body over hours or days following acute intoxication, with complications that may include coma, sepsis, brain swelling, and herniation. This process may evolve over days with the drug(s) metabolized from the body. The underlying process that set off this sequence of events is the acute intoxication.

Depending on the type of drug and its half-life there may be no or minimal amounts of drug left in the blood or other tissues at the time of death. However, the possibility exists that the drug or its metabolite(s) could still be detected and identified in the urine. In these circumstances, it is important to take into account that urine is really a pooled specimen collected in the bladder over a period of time and that a quantitative result represents only the average drug-urine concentration over the period of time that the urine was produced. Therefore, this type of specimen does not accurately reflect the blood-drug concentration at any single point in time. Rather, a positive finding of a drug or drug metabolite in urine indicates prior exposure only to that particular drug and in this regard it is relevant to consider other information (e.g., case history, medical records, anatomical findings, etc.) as well.

If a decedent suffered trauma while intoxicated and developed an *epidural* or *subdural hemorrhage*, you would expect to find the drug present in these samples even after many days. *Chronic sequela* associated with substance abuse include complications of infections such as HIV disease, hepatitis, hepatic cirrhosis, and endocarditis. Injection of ground-up oral medications may lead to pulmonary failure, with multiple foreign body granulomas and fibrosis demonstrated on histopathologic section. There are many other complications, including Wernicke's-Korsakoff's encephalopathy, alcoholic cardiomyopathy, and hardening of the arteries due to cocaine use.



*Intravenous drug abuse* may present with many different features. If the drugs are injected acutely in the same vein during binges, they appear as multiple fresh needle marks in a row. These are called “track marks” because they resemble a pattern of railroad ties being laid down one after another. It may be possible to detect the parent drug by excising the immediate area surrounding the injection site and submitting this section for toxicological analysis. If several injection sites are observed and a decision is made to submit more than one for testing, make certain to package the specimens in separate containers, identify the sites from which each was taken, and note their age and appearance. Alternatively, the syringe or other drug paraphernalia such as vials, pipes, or spoons, if available, can also be submitted for analysis. This is a good option if, for whatever reason, limited biological specimens exist. Once the nonbiological contents of the items are identified, directed toxicological analysis on the biological specimens can then proceed. If this is done, it is important that the items be packaged in individual containers, away from biological specimens, so that contamination does not occur.

Injecting drugs into blood vessels can lead to the introduction of many types of infections. Sharing of needles may cause transmission of the hepatitis virus or the human immunodeficiency virus. Various types of bacteria can also be introduced during injection, leading to vasculitis, cellulitis, pneumonia, and endocarditis. Acute intravenous fatalities, such as those caused when individuals inject themselves, are usually classified as *accident*. If one can demonstrate the drug was given to the individual in order to purposefully cause his or her death, the manner would be classified as *homicide*. Also, if another individual injects the drug into the decedent’s arm the manner of death should be homicide.

As the vein is chronically abused, it will scar and develop a chronic track mark. Chronic track marks appear as linear scars that traverse the path of underlying veins. Histological sections from these regions often show polarizable debris from impurities found in past-injected drugs. If a chronic intravenous drug abuser consistently rotates the injection sites from one vein to another chronic track marks will not develop.

*Skin-popping* refers to drugs, such as heroin, injected into the subcutaneous tissues. This usually indicates a long history of drug abuse with destruction of the previously accessible peripheral veins. This may appear as fresh needle marks, usually at the surface of the thighs, or in other places without an underlying vein. These sites often get infected and lead to cellulitis, abscess formation, and scarring.

Another route of drug administration includes *inhalation*. Inhalation (i.e., snorting) of drugs may lead

to mucosal reddening from direct irritation. Crack pipes may become very hot during use and burn the drug abuser’s mouth and lips. Sometimes histopathology sections of the lungs reveal numerous pigment-laden macrophages from constant inhalation of smoke and debris from inhaled burning drugs such as crack. *Chronic snorting* of drugs may lead to a perforated nasal septum.

Keep in mind, it is not only the illicit drugs such as cocaine or heroin that can be inhaled; an individual may choose to *crush* and “snort” a tablet or pill as well. In some instances, residue may be observed in the nasal or oral cavity, and these areas can be swabbed and the parent drug identified through analytical testing. Individuals may also choose to inhale or “huff” commercial products such as gases, fuels, aerosols, solvents, or propellants as a means of abuse. This may be accomplished by breathing in the fumes from a rag that has been soaked in the material or by placing a bag containing the fumes over the nose and mouth. In some cases, the inhalation may take place directly from the item (i.e., aerosol can, glue bottle), as well. Users have died from hypoxia, pneumonia, cardiac failure, and aspiration of vomit. If the latter situation is relevant to the case, it is important to inform the toxicology lab of this, as most routine toxicology screens do not include these substances in the scope of their analysis. For these cases, lung tissue or tracheal air, in addition to the routine biological samples, can be collected as well.

Transdermal drug delivery systems introduce medications into the general circulation through a slow diffusion process, and may be considered a desirable alternative to taking oral medications or using substances that require repeated injection. In addition, the transdermal systems, perhaps most importantly, help to minimize the extreme blood spikes and trough levels that may be experienced with orally administered medications. Instead, blood–drug concentrations are maintained at more consistent concentrations.

Examples of commonly encountered medications delivered through transdermal systems include nicotine, hormones (i.e., contraceptives) and the potent narcotic analgesic fentanyl. However, similar to any medication, these patch-style systems may be subject to abuse. For instance, a person may make the decision to apply a multiple number of patches to the body, or through manual or chemical means remove the drug from the drug reservoir or from the adhesive matrix. It is also not uncommon for a person to chew or even swallow them. In these cases, remnants of patches may be observed in the oral cavity or the gastric contents. Other signs of this type of abuse would be if a person presented with patches applied in a manner not consistent with normal therapeutic use. For these cases, document the number of patches found on the body, their locations, any writing

or markings on the patches and any other descriptive features. Make an attempt to ascertain if all the patches represent a single acute application or if some of the patches may be from remote use.

In these types of death situations where patch use is known or suspected (i.e., old adhesive markings are noted on the body) it is important to make certain that specimens are not collected in proximity to a vein or artery that is in the immediate vicinity of a patch or patch marking. As a specific example, following the death of an individual wearing a fentanyl patch, some drug may still be present in the depot beneath the patch. If a blood specimen is collected from an area immediately beneath or near the location of the patch, the concentration of fentanyl may not accurately reflect the circulating concentration at or around the time of death.

Similar to the patch, suppositories represent another type of drug delivery system. Suppositories contain medicated material for insertion into a bodily passage or cavity such as the rectum. Once the suppository, typically a solid substance, is inserted, it will begin to dissolve over time and subsequently will deliver the medication into the body. Substance abuse using this route of administration is relatively rare.

## Substance Abuse

---

### Acute and Chronic Alcoholism

Death occurring from acute alcoholism is usually classified as *natural*, although this may not always be the case. A young adult at a party trying to impress friends may attempt to guzzle a liter of whisky. This is more than enough alcohol at one time to kill most adults. In this case, the manner of death would be accident. Sometimes depressed people with an acute triggering event, tell their family that they are going to “drink themselves to death.” After several days of drinking large quantities of alcohol, they die. If you can establish the intent to do harm, the manner of death would be *suicide*. If someone at a party drinks alcohol from a funnel and a hose, by pouring the alcohol themselves, and then dies, the manner of death would be accident. If someone holds the hose and pours the alcohol for them, the manner of death should be homicide.

The deaths of individuals with a history of chronic alcoholism, including varying degrees of liver disease, intoxications, and withdrawal, are mostly certified as natural. Chronic alcoholics who stop drinking abruptly may get the “shakes” and eventually experience seizures leading to death. Withdrawal of many other drugs without other underlying natural disease will not typically cause death.

It is very difficult to give an opinion about individuals’ state of mind or behavior while they were drinking or using any drug, for that matter. One has no way to know their true thought processes unless their behavior was witnessed or somehow clearly documented. Chronic alcoholics, with a high degree of tolerance, may be able to achieve a high blood alcohol level and not show visible signs or symptoms consistent with intoxication. Some alcoholics become aggressive, loud, and agitated while others become subdued and complacent.

It is important to obtain blood samples with care in cases where there is suspected alcohol use, and trauma played a role in the person’s death. If one obtains a blood sample only from the pericardial sac or chest cavity, where other visceral lacerations may exist, contamination with gastric contents or other bodily fluids is a likely possibility. In turn, the measured blood alcohol level may be markedly increased as compared with the actual circulating blood concentration at and around the time of death.

As a more specific example relating to alcohol, when death is a consequence of multiple traumatic injuries there is the possibility that significant damage to the internal organs occurred. These organs include, but are not necessarily limited to, the stomach, small intestine, and liver. If those organs, now damaged, contained unabsorbed alcohol, a blood specimen collected from the chest area may readily become contaminated. As a result, the concentration of alcohol determined may not accurately reflect the circulating concentration at and around the time of the fatal event. Instead, ideally, for postmortem alcohol analysis and to mitigate some of these issues, an alternative specimen type should be harvested. These specimen types would include a vitreous specimen, a urine specimen, or blood collected from a peripheral site such as the femoral vein. This is because, in those cases where the heart blood may have become contaminated due to events such as trauma, the alternative specimen can be used to help provide an interpretable alcohol concentration.

Alternative specimens, such as vitreous fluid, are vital to collect, especially when alcohol is suspected or involved. It is important to recognize that alcohol may form postmortem, and analytical testing cannot make the distinction between this type of alcohol and alcohol that was present prior to death. Indeed, an alcohol finding may represent a combination of these two circumstances. To prevent or minimize postmortem formation once blood is collected, it should be placed into an appropriate type of specimen collection container, one that contains preservatives that help to inhibit microbial growth. If the postmortem formation of alcohol is a concern, such as in a case where marked decomposition has

occurred, a positive alcohol finding may be confirmed in the vitreous fluid, a specimen type that is more resistant to microbial growth.

### Post-Mortem Redistribution

Besides contending only with the issue of contamination as caused by trauma, drugs and their metabolites may also be subject to postmortem redistribution. Postmortem redistribution is the movement of drugs among tissues, organs, and bodily fluids after death. The rate and extent of this movement varies according to several factors, including the nature of the drug, and the time interval between death and the postmortem collection time of specimens. Within the torso, the major organs constitute potential drug pools, and the gastrointestinal tract might contain considerable quantities of unabsorbed drug. Therefore, central blood is subject to redistribution from these local organs. In general, redistribution into central vessels is greater than redistribution into peripheral vessels and this is why it is preferred that final quantitative amounts be determined from a peripheral blood source. Therefore, while central blood pools are acceptable for screening purposes, it is always better to get a peripheral blood sample for quantitative confirmation work, if possible.

### Cocaine

Cocaine, a Schedule II controlled substance, is found in the leaves of a South American shrub called *Erythroxylon coca* and is one of the most potent of the naturally occurring central nervous system (CNS) stimulants. First isolated in 1855, it has been used medicinally as a local anesthetic. However, because of its high potential for abuse, the use of cocaine for clinical situations has become severely limited. When cocaine is taken for illicit reasons it is either taken as the water-soluble hydrochloride salt by nasal insufflation ("snorting"), intravenous injection, or as the free-base ("crack") by smoking. Regardless of the chemical form or route of administration, once cocaine is administered it is rapidly absorbed and distributed throughout the body. Once inside the body, the dosage form of cocaine cannot be distinguished and analytical determinations are reported as the free-base form.

Cocaine is rapidly biotransformed in the body to a few major metabolites and products including benzoylecgonine, ecgonine methyl ester, ethylecgonine, and ecgonine. These metabolites are all pharmacologically inactive. Small amounts of an active metabolite, norcocaine, may also be produced. However, this product

is rarely detected in blood. Cocaethylene is a pharmacologically active substance formed in the liver when cocaine and ethanol are co-ingested. The most predominant cocaine product detected in the majority of biological specimens is benzoylecgonine. Elimination on half-lives are approximately 4.5 hours for benzoylecgonine and approximately 0.8 hours for cocaine.

Effects displayed by an individual under the influence of cocaine may include dilated pupils, increased blood pressure, increased pulse rate, and increased sense of strength or invincibility. It is believed that cocaine is toxic to the cardiovascular system causing thrombosis, myocardial infarction, tachycardia, or fibrillation that may occur in cases of acute and chronic abuse.

### Heroin

Heroin is a Schedule I controlled substance and a synthetic derivative of morphine. It is made by first extracting morphine from opium and then chemically treating the morphine with acetic anhydride, sodium chloride, and hydrochloric acid.

Once heroin is taken into the body, most frequently by injection, smoking, or inhalation, it is rapidly deacetylated to 6-monoacetylmorphine (6-MAM), a product that is then hydrolyzed at somewhat of a slower rate than morphine. Unlike the heroin, which has little affinity for the opiate receptors in brain tissue, both 6-MAM and morphine are pharmacologically active. Because 6-MAM is a specific product of heroin, if it is found to be present in a biological specimen, it can be concluded that the individual either used or was exposed to heroin at some point prior to death. However, due in part to the short half-life of 6-MAM, morphine is most often the predominant species detected in biological specimens. Therefore, in cases where heroin is suspected to be the lethal agent and morphine is found in the blood but 6-MAM is not, it may be of benefit to test an alternate specimen type such as urine for the presence of this heroin specific marker as well.

The primary toxic manifestations of heroin use may last for approximately 4 to 6 hours and include the same effects most commonly associated with other opioids. Some of the more common effects include drowsiness, loss of coordination, decreased blood pressure, decreased pulse and respiration, mental clouding, sedation, and sweating. At sufficiently high levels, the user may slip into a coma and may ultimately stop breathing.

### Lysergic acid diethylamide (LSD)

LSD, a Schedule I semisynthetic controlled substance, is manufactured from the main precursor chemicals

lysergic acid, lysergic acid amide and ergotamine tartrate. LSD is normally taken by placing a “dot” laced with the material on the tongue. The LSD is then dissolved by the saliva and readily absorbed through the mucous membranes. This method of ingestion allows for its effects to be rapidly felt. Other means of ingestion include mixing the LSD with liquids or adding it to sugar cubes. However, the drug cannot be taken into the body by smoking, as pyrolysis destroys the LSD.

LSD is generally classified as a hallucinogen or psychedelic drug, and may produce both auditory and visual illusions. Approximately 30 to 60 minutes after ingestion, the user will experience the initial effects which, in general, may last for about 8 to 12 hours. Physiological effects are primarily sympathomimetic and may include mydriasis, hyperthermia, seizures, panic, and paranoid reactions. Flashback reactions, a brief recurrence of the LSD experience, are not uncommon in the experienced user, and may occur for weeks, months, or years after the last usage.

Death due to the pharmacological effects of LSD is rare, with most deaths occurring as a result of LSD-induced suicide and accidental trauma.

## Marijuana

Marijuana, a Schedule I controlled substance, is a complex mixture of several products obtained from various parts of the *Cannabis sativa* plant, and is the most widely used illicit substance in the United States and the rest of the world. More than 400 chemical substances are found in marijuana. Sixty of these substances are called cannabinoids and are responsible for the psychoactive properties of the plant. The most relevant cannabinoid is tetrahydrocannabinol (THC), as it is the primary psychoactive ingredient in marijuana.

One of the most notable features of this drug is its long half-life, with some metabolic components exceeding 50 hours. This is because the drug is a highly lipid soluble and may undergo significant enterohepatic recirculation. In fact, the redistribution of THC from tissue to blood has been shown to be the rate-limiting step in its metabolism. In the body, THC is metabolized to two major metabolites, 11-hydroxy-THC (11-OH-THC) and tetrahydrocyclohexanecarboxylic acid (THCC). The former metabolite is pharmacologically active, while the later is devoid of any pharmacological activity.

Marijuana is most frequently smoked, although it can be ingested as well. THC rapidly leaves the blood, even during a smoking period, and falls to below detectable levels within several hours. The most common physical effects are acceleration of heart rate, a moderate increase in blood pressure, a slight decrease in body temperature, reddening of the eyes, and a dryness of the mouth. The

psychological effects of marijuana use include a pleasant feeling of well-being and euphoria, distortion of time, reduced ability to concentrate and memorize, and impaired short-term memory. Individuals under the influence of marijuana may have difficulties in tracking movement and demonstrate an inability to appropriately respond to stimuli. In general, this condition may persist for hours after the feelings of intoxication have dissipated, leaving users with a false sense of security concerning their abilities to safely operate a motor vehicle or machinery.

Death strictly due to the pharmacological effects of marijuana is not well documented, with most deaths occurring as a result of accidental trauma.

## Methamphetamine

Methamphetamine is a Schedule II controlled substance with a very high potential for addiction and abuse. There are two different chemical forms or isomers of methamphetamine, each producing effects that differ in scope and magnitude. The l-isomer of methamphetamine may be found in over-the-counter nasal inhalers and is used for its vasoconstrictive properties. Compared with d-methamphetamine, it is a weak central nervous system stimulant. In contrast, the d-isomer may represent the licit or illicit forms of methamphetamine. In terms of legitimate or legal use, methamphetamine may be prescribed for a limited number of medical conditions such as weight loss, narcolepsy, and attention deficit disorder. However, because other less addictive and dangerous substances that do not quickly result in patient tolerance to the drug are also available, it is not that frequently prescribed.

Methamphetamine in the body undergoes demethylation to its primary active metabolite amphetamine; in most cases both methamphetamine and amphetamine will be detected. Analytical methods that differentiate the isomers of methamphetamine (and amphetamine) exist and may be employed if warranted.

People who abuse methamphetamine experience certain sequelae of such drug use. In general, the effects of methamphetamine can be broken down into three main stages. The first stage is the “high,” where blood concentrations are at their greatest and people are feeling the stimulant effects of methamphetamine. The second stage is the “tweaking” period, where blood levels are on the decline and it is this period where people crave the drug and may behave in an aggressive and violent manner. The third stage is the “crash,” where people feel exhausted and drained. High doses of methamphetamine can elicit restlessness, confusion, hallucinations, circulatory collapse, and convulsions.

## Methadone

Methadone is a Schedule II controlled substance that is often prescribed during the process of narcotic detoxification, narcotic maintenance, and treatment programs, and to control severe and chronic pain. As compared with morphine, it produces less sedation and euphoria, but cessation of its use may result in withdrawal symptoms—not as severe as those seen with morphine, but longer in duration. Methadone works by decreasing the withdrawal symptoms felt by the narcotic abuser and, when a person attempts to reuse, the desired effects of the illicit drug are minimized.

In the body, methadone is metabolized to EDDP (2-ethylidene-1,5-dimethyl-3,3-diphenylpyrrolidine) and EMDP (2-ethyl-5-methyl-3,3-diphenylpyrrolidine). These metabolites do not possess any pharmacological activity and do not accumulate to an appreciable extent in plasma during therapy.

Methadone overdose is characterized by stupor, lethargy, pupillary constriction, hypotension, coma, respiratory collapse, and death.

## 3,4-Methylenedioxymethamphetamine (MDMA)

MDMA is a synthetic sympathomimetic compound with mixed stimulant, psychotropic, and hallucinogenic activities. It was used briefly as an adjunct to psychotherapy, but because of widespread abuse it has now been reclassified as a Schedule I controlled substance. The synthesis of MDMA is both complex and time-consuming. As a direct result, the final product may contain a variety of impurities that may be toxic in their own right. Also, drug manufacturers may add an illicit substance or a stimulant in an attempt to enhance the effects of the MDMA. The drug is available in tablet and powder form and it may be injected, inhaled, or ingested. Tablets of MDMA come in a litany of colors and shapes, and may be imprinted with a variety of images including things such as peace symbols, cartoon characters, butterflies, and angels.

In the body, MDMA is metabolized to many other compounds, but the main metabolite is a demethylated product called methylenedioxyamphetamine (MDA).

The effects of MDMA are related to the dose. A lower-level dose (approximately 50 mg) may result in feelings of enhanced creativity, while mid-level doses (approximately 100 mg) may make the user feel open to improved communication and empathy. The ability of the user to undergo self-exploration and analysis is achieved with the doses typically greater than 125 mg. In general, the psychological effects are much more pronounced than the physical effects. Abusers of the drug have been reported to experience longlasting neurobehavioral

disorders following cessation of its use. Symptoms of MDMA toxicity include visual hallucinations, confusion, hypotension, agitation, coma, and death.

## Phencyclidine (PCP)

PCP is a Schedule II controlled substance that was developed and marketed in the 1950s for use as an intravenous anesthetic. However, it was discontinued for medicinal use in 1965 as patients frequently would become agitated, delusional, and irrational, and experience the distortion of sights and sounds. In the early 1960s, PCP gained a reputation as a drug that produced certain desired feelings such as detachment and dissociation, but also caused the user to sometimes experience unwanted reactions (i.e., bad trips).

At low doses, PCP may cause changes in body awareness and produce psychological effects of euphoria, an alteration of time and space, confusion, bizarre behavior, and panic. Physical effects produced by PCP include impaired motor skills, shallow breathing, sweating, blank staring, speech disturbance, and an inability to regulate body temperature. At high doses, PCP may result in hallucinations, seizures, coma, and death. Because PCP has sedative-like effects, interactions with other central nervous system depressants, such as alcohol and benzodiazepines, may also lead to a life-threatening situation. In general, chronic PCP users may repeatedly use the drug for days at a time and during this period go without food or sleep. There appears to be no relation between plasma levels of phencyclidine and the degree of intoxication that a person may experience.

## Oxycodone

Oxycodone is a Schedule II controlled semisynthetic narcotic analgesic derived from thebaine. It is used to control pain associated with such ailments as bursitis, injuries, simple fractures, and neuralgia, and is often found in combination with other drugs such as acetaminophen and aspirin. The addiction liability of oxycodone is about the same as for morphine.

Oxymorphone is a pharmacologically active metabolite of oxycodone that may be seen in blood in very low concentrations. Of interest is that oxymorphone may be prescribed as a parent drug and has a greater analgesic potency than morphine.

In overdose, oxycodone can produce stupor, coma, muscle flaccidity, severe respiratory depression, hypotension, and cardiac arrest. However, sustained-release preparations appear to produce adverse reactions, up to and including death, at lower-level concentrations, especially in combination with other central nervous

system depressants, depending on use pattern and route of administration.

## Poisons

---

### Arsenic

Arsenic is a metalloid that is present in all parts of the environment and, for example, may be found in water, soil, and sediment. In broad terms, there are two main forms of arsenic—organic and inorganic. Organic arsenic is present in food, with crustaceans and fish being some of the richest sources. These organic forms of arsenic (arsenobentaine and arsenocholine) are considered to be relatively nontoxic and will be rapidly excreted unchanged in the urine. Inorganic arsenic occurs in two oxidation states: a trivalent form (arsenite) and a pentavalent form (arsenate), with the trivalent form being more toxic than the pentavalent form, which undergoes metabolism to monomethylarsonic acid (MMA) and dimethylarsenic acid (DMA). MMA and DMA are then excreted in the urine.

Arsenic inactivates up to 200 enzymes, most notably those involved in cellular energy pathways, and DNA replication and repair. Unbound arsenic also exerts its toxicity by generating reactive oxygen intermediates that cause lipid peroxidation and DNA damage. Inorganic arsenic binds thiol or sulfhydryl groups in tissue proteins of the liver, lungs, kidney, spleen, gastrointestinal mucosa, and keratin-rich tissues such as the skin, hair, and nails.

The lethal dose of arsenic in acute poisoning ranges from 100 mg to 300 mg. Severe acute arsenic intoxication produces several well-described symptoms. Bloody vomit and diarrhea may occur within 1 to 4 hours of ingestion. Gastrointestinal volume loss is compounded by profound capillary permeability produced by arsenic's interruption of cellular energy metabolism. Cerebral edema, microhemorrhage, encephalopathy, and seizures may also arise from loss of capillary integrity. The rate-corrected QT interval (QT<sub>c</sub>) prolongation and tachyarrhythmias may develop.

Subacute arsenic toxicity involves predominately the neurologic and cardiovascular systems. Within days to weeks after ingestion, many untreated or undiagnosed patients describe debilitating peripheral neuropathy characterized by excruciating pain and severe motor weakness. Persistent QT<sub>c</sub> prolongation and the accompanying risk of *torsades de pointes*, a specific type of cardiac arrhythmia, occur among patients with clinically significant body burdens of arsenic.

Chronic arsenic toxicity presents itself following months or years of exposure. Some hallmark features of this type of toxicity not described above include

hyperpigmentation of the skin, hyperkeratosis of the hands and feet and the appearance of Mee's lines in the fingernails.

It is important to note that death may occur in all of the above situations (e.g., acute, subacute, and chronic) if the person is exposed to a sufficiently high dose of arsenic.

### Carbon Monoxide

Carbon Monoxide (CO) is an odorless, colorless gas without taste that forms as the result of the incomplete combustion of carbon-containing material. Motor vehicles, appliances, and heaters that use carbon-based fuels are major sources of exposure. However, it is important to note that natural sources of carbon monoxide also exist. These sources include fire, gases emitted from mines, marine algae, and human metabolism. Carbon monoxide is endogenously produced when hemoglobin, the molecule responsible for oxygen transport, and other heme-containing substances are degraded or broken down. Because of this, endogenous levels of CO, analytically measured as carboxyhemoglobin, are typically less than 1%. It is important to note that CO levels within the body may vary depending on several other factors as well. For example, because cigarette smoke contains CO, a smoker may exhibit carboxyhemoglobin levels as high as 8% saturation.

A person becomes exposed to CO via inhalation with the ultimate biological saturation level dependent upon several factors including CO concentration, duration of exposure and the activity level of the individual. Carbon monoxide poisoning produces hypoxia by two main mechanisms of action. First, CO binds to hemoglobin with an affinity that is greater than 200 times that of oxygen and therefore, by occupying the oxygen binding sites of hemoglobin, CO directly decreases the oxygen-carrying capacity of blood. Second, when CO binds to hemoglobin, the hemoglobin undergoes a change in its configuration so that oxygen release from the hemoglobin is hindered. Early signs of CO poisoning include headache, nausea, and vomiting. As the CO poisoning progresses, the person may experience impaired mental function, an inability to concentrate, and personality changes. Finally, the individual may develop seizures, coma, and death. Classic pathological signs that are most often associated with CO poisoning, although rarely observed, include cherry red skin and retinal hemorrhages.

### Cyanide

Cyanide is a potent, rapidly acting lethal poison, and death may occur within minutes following its ingestion.

Common sources of cyanide include industrial manufacturing byproducts, plants, fruit pits, chemicals, and combustion products of certain plastics. Because of the latter, cyanide may play a role in the hypoxic events from fires.

Cyanide exerts its effects by disrupting electron transport at the cytochrome c oxidase step and this in turn adversely impacts the production of adenosine triphosphate (ATP). This break in the oxidative phosphorylation process stops the Krebs's cycle, and ultimately causes a metabolic acidosis as both pyruvic and lactic acid begin to accumulate.

The signs and symptoms of toxicity are dependent upon several factors. These factors include the form of the cyanide (e.g., gas versus solid), the route of exposure (e.g., inhalation versus ingestion), the duration and the extent of the exposure. The minimum lethal dose in an adult has been estimated to be 100 mg for hydrocyanic acid and 200 mg for potassium cyanide.

Cyanide produces a range of symptoms including dizziness, weakness, motor impairment, and mental impairment. These symptoms may progress toward slowed respiration, lactic acidosis, seizures, coma, and death.

It is important to recognize that blood concentrations of cyanide can increase or decrease during storage depending on the length of time, the temperature, and the presence of cyanogenic bacteria.

### Ethylene Glycol

Ethylene Glycol is a nonvolatile liquid that is a common ingredient of automotive products such as antifreeze, de-icers, and coolants. It can also be found in some preservatives and as a glycerin substitute.

Following ingestion, ethylene glycol is rapidly absorbed, and manifestations of toxicity may be noted within approximately 30 minutes. Ethylene glycol is metabolized in the liver to several toxic metabolites including glycoaldehyde, glycolic acid, glyoxylic acid, and oxalic acid, and it is these metabolites that then may elicit central nervous system, cardiopulmonary, and renal dysfunction as well as produce a severe metabolic acidosis. The magnitude of the toxicity is dependent upon dose and the onset and success of treatment.

The effects of an ethylene glycol exposure are typically described in three main stages. In the first stage (0.5 to 12 hours post ingestion), neurological symptoms that include signs consistent with ethanol intoxication are manifested. Coma, convulsions, and possibly death may result in this stage. The second stage (12 to 24 hours post-ingestion) is often characterized by cardiopulmonary disturbances including tachycardia, tachypnea,

and hypertension. In severe ingestions, congestive heart failure, pulmonary edema, and circulatory collapse may be seen. The end stage of ethylene glycol toxicity is renal failure (24 to 72 hours post-ingestion).

### Methanol

Methanol is a type of alcohol that is extremely versatile, and so can be found as a component in industrial solvents, fuels, and antifreeze preparations, and as a denaturant for ethanol. Methanol may be introduced into the body through multiple routes of administration including inhalation and ingestion. Once in the body, methanol is first metabolized to formaldehyde and then to formic acid. Interestingly, although formaldehyde is considered a toxic substance, it has on average a half-life of only several minutes and it is the formic acid that ultimately produces the hallmark features of methanol toxicity, including metabolic acidosis and the loss of visual acuity. Methanol poisoning can be treated by the administration of ethanol, because both methanol and ethanol share a common metabolic pathway. In essence, the ethanol competes for binding to the alcohol dehydrogenase enzyme and indirectly limits the formation of formic acid. Acute methanol exposure may produce severe signs and symptoms of toxicity, including nausea, abdominal pain, and lethargy. In some cases, the poisoning will progress to where the person experiences an anion gap metabolic acidosis leading to coma, seizure, and respiratory collapse. It is important to recognize that methanol may be a component found in embalming fluids and, because of this, tissues or other samples that have come into contact with this type of material may test positive for the presence of methanol.

### Poison Hemlock

Poison hemlock (*Conium Maculatum*) is a biennial member of the carrot family that grows wild throughout the United States, especially along roadsides. Socrates is thought to have died from ingestion of poison hemlock. Its toxicity is from several simple piperidine alkaloids including coniine, gamma-coniceine, conhydrine, N-methylconiine, and pseudoconhydrine. Coniine and gamma-coniceine are thought to have the most significant contribution to the toxic effects, which are similar to nicotine poisoning.

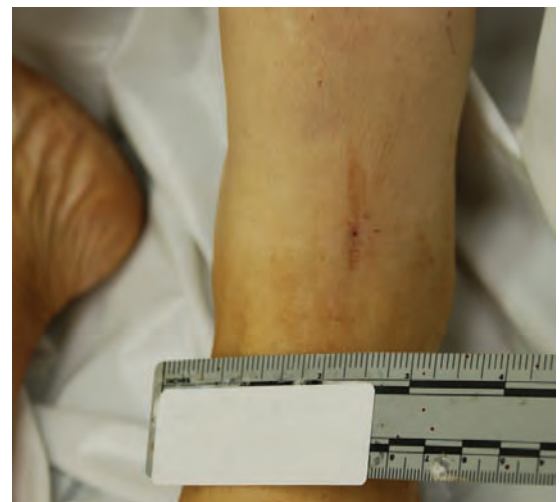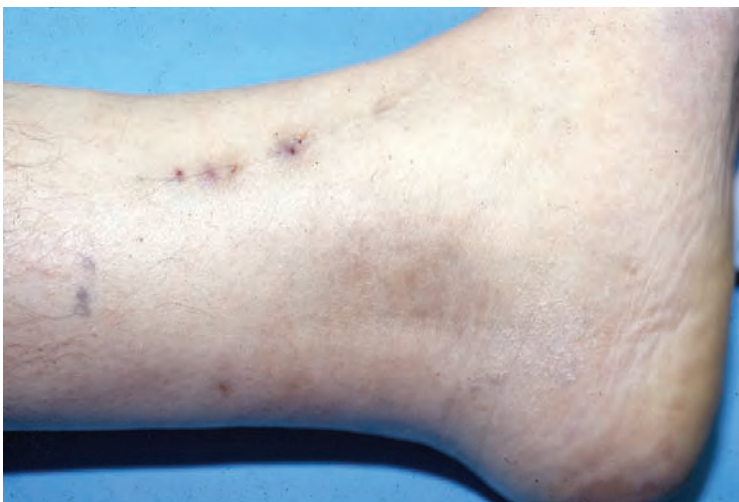
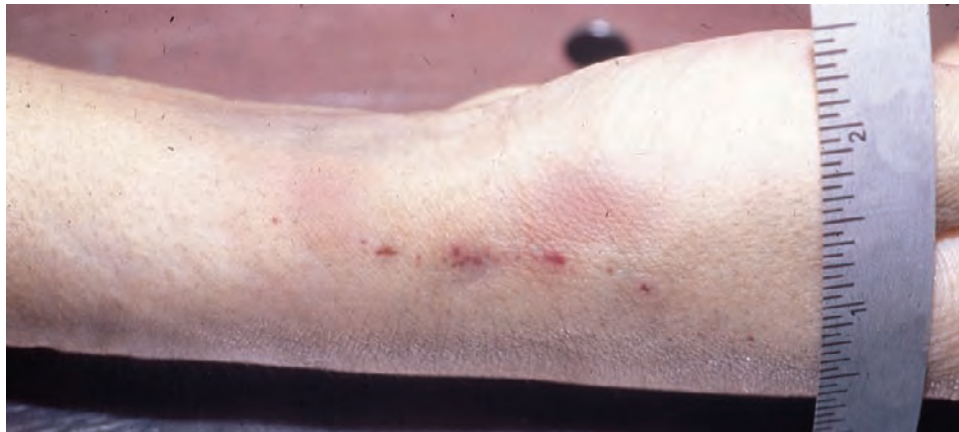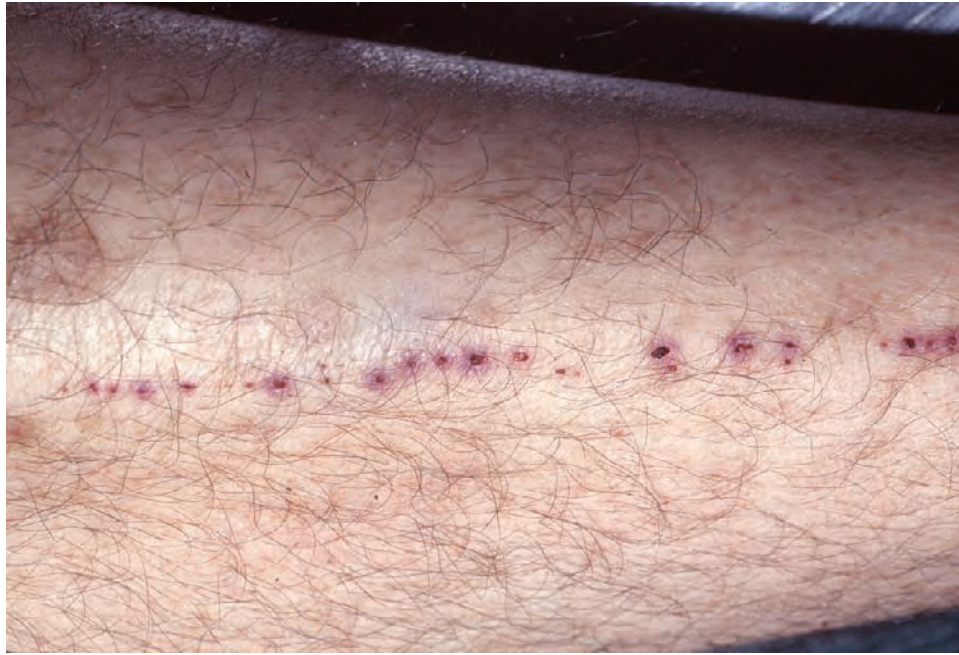
### Thallium

Thallium is a metal that was once used in rodenticides, insecticides, and depilatories, but was banned from residential use in the 1970s. Today, it is used in the

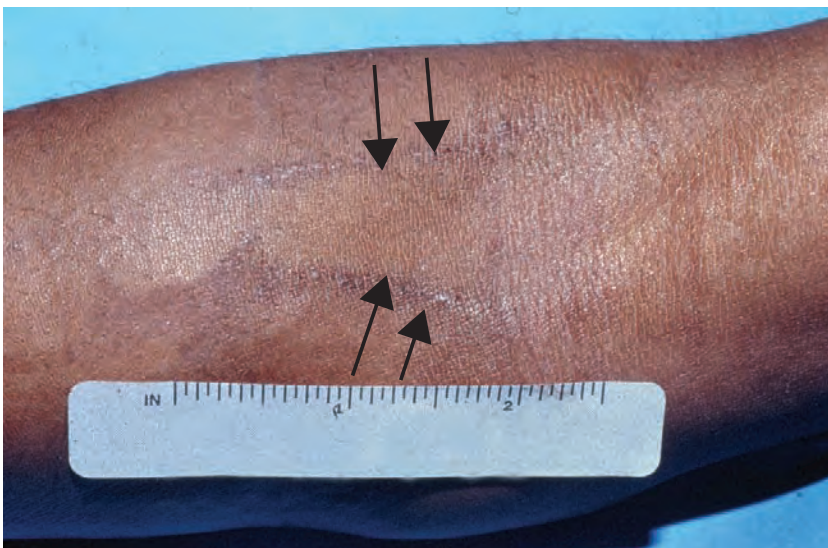
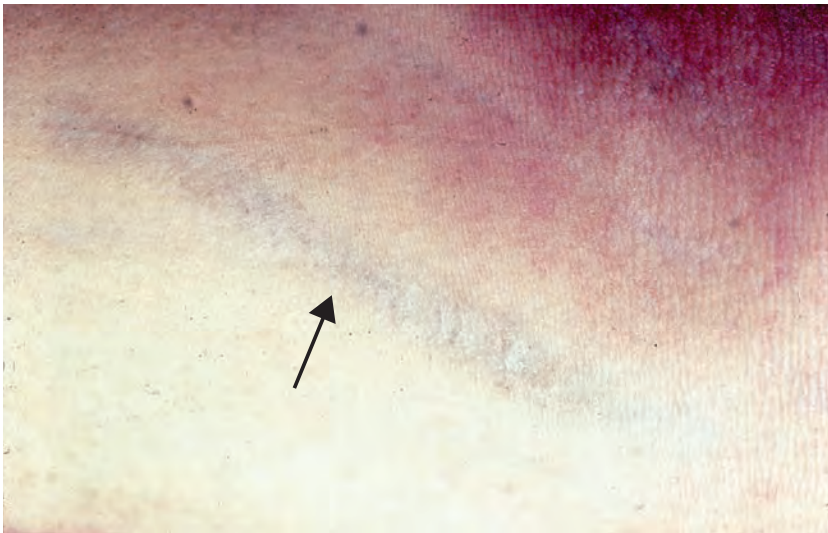
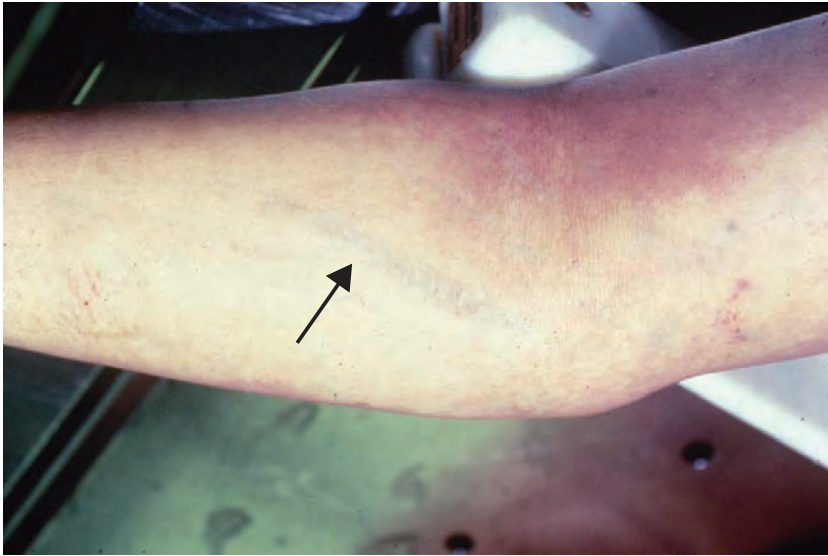
semiconductor industry and may be found in switches and electronic devices. Thallium is readily absorbed from the gastrointestinal tract and may be detected in most of the body's tissues and fluids, including blood, brain, liver, kidney, spleen, bone, hair, and urine. The half-life of thallium in the blood is approximately 2 to 4 days, with one of the hallmark symptoms of this type of

poisoning, alopecia or loss of hair, occurring after about 1 to 3 weeks. Symptoms of acute exposure include severe gastrointestinal distress, tingling of the hands and feet, paralysis, and respiratory failure. In people being chronically exposed, additional signs and symptoms include paralysis, hepatic and renal issues, and respiratory failure.

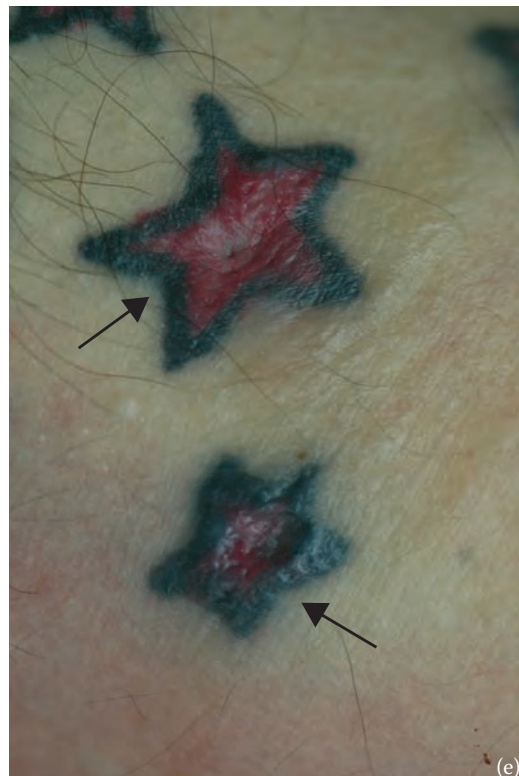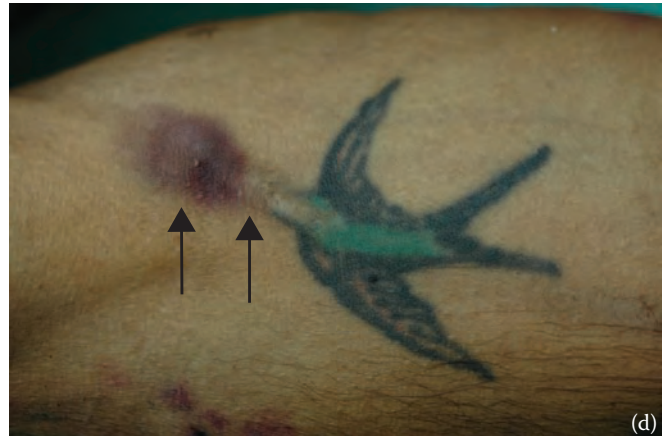

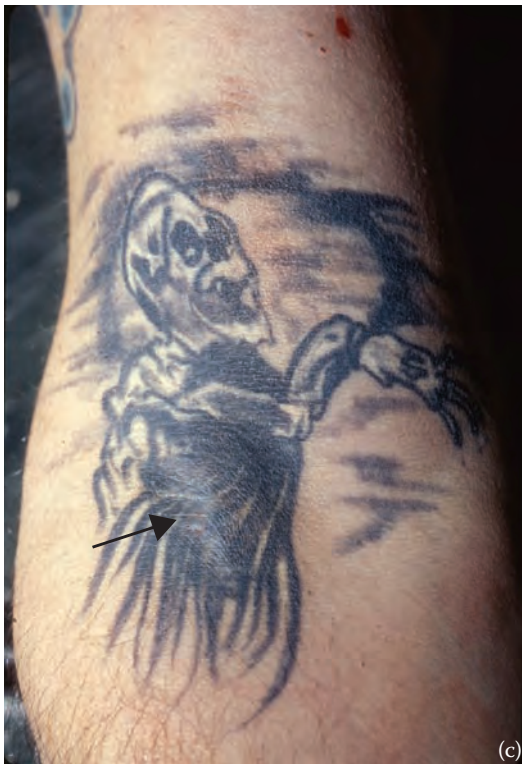
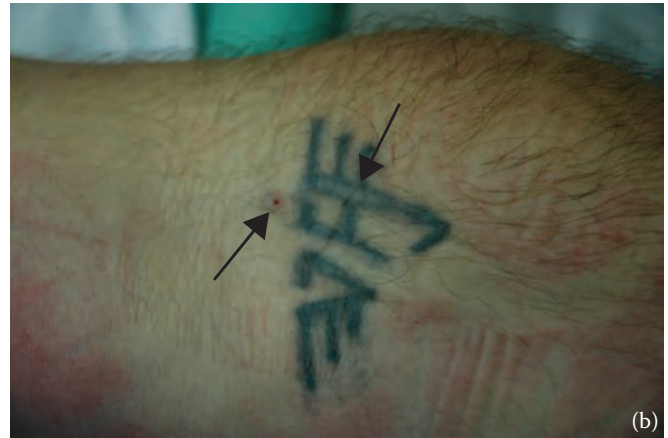
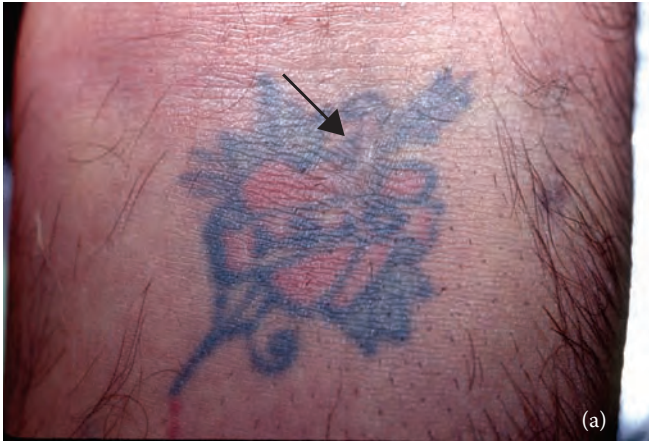
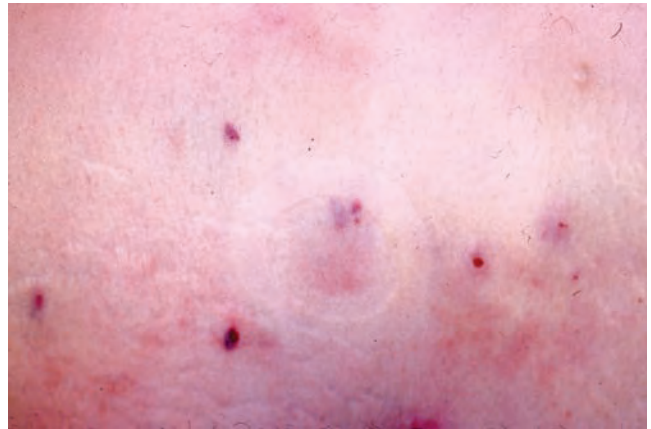
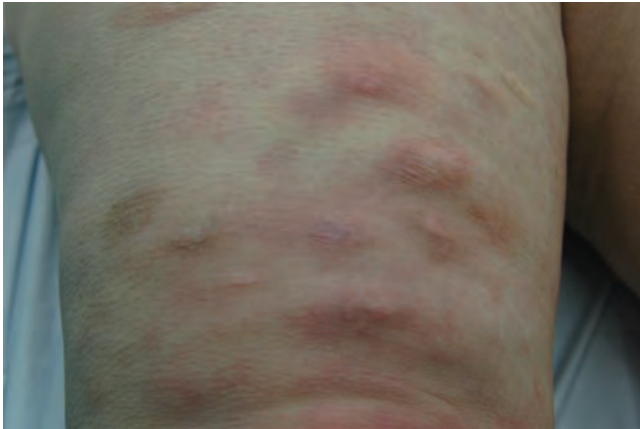Acute track marks. Multiple fresh needle mark injection sites that traverse the path of underlying veins. Incision of these regions will often reveal underlying hemorrhage. Toxicological testing of underlying injection site tissue may reveal the parent compounds, such as heroine.



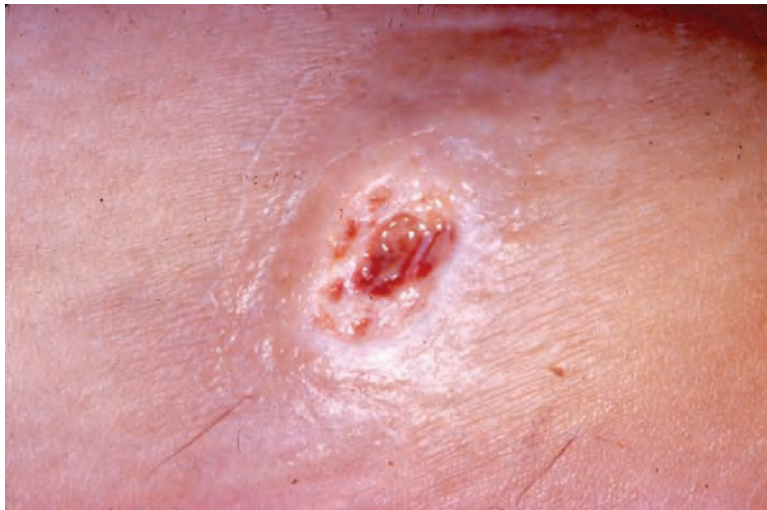Chronic track marks. Linear scars that traverse the path of underlying veins. Microscopic sections may demonstrate inorganic debris in sub-adjacent soft tissues.



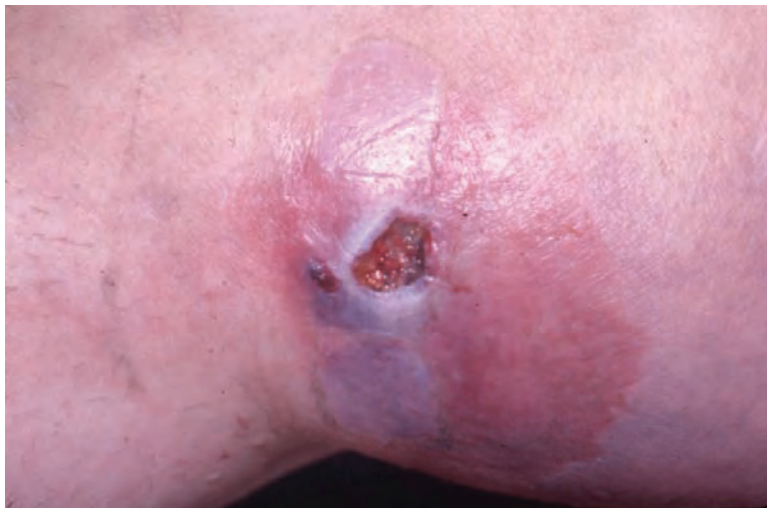Tattoos are sometimes used to disguise intravenous drug abuse. These figures show examples of track marks in tattoos. Note the fresh injection site at the tip of the bird beak (d) and the healing injection sites at the stars (e), as well as other chronic linear track marks. Also note the fresh needle mark to the left of the tattoo (b) due to documented therapeutic intervention.



Fresh "skin popping" lesions. When drug abusers exhaust peripheral vein access they may start injecting drugs subcutaneously.

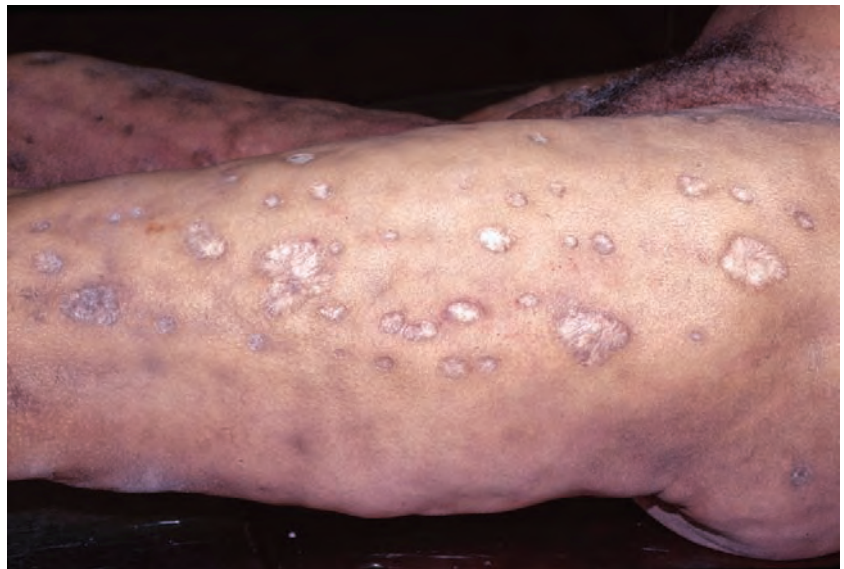
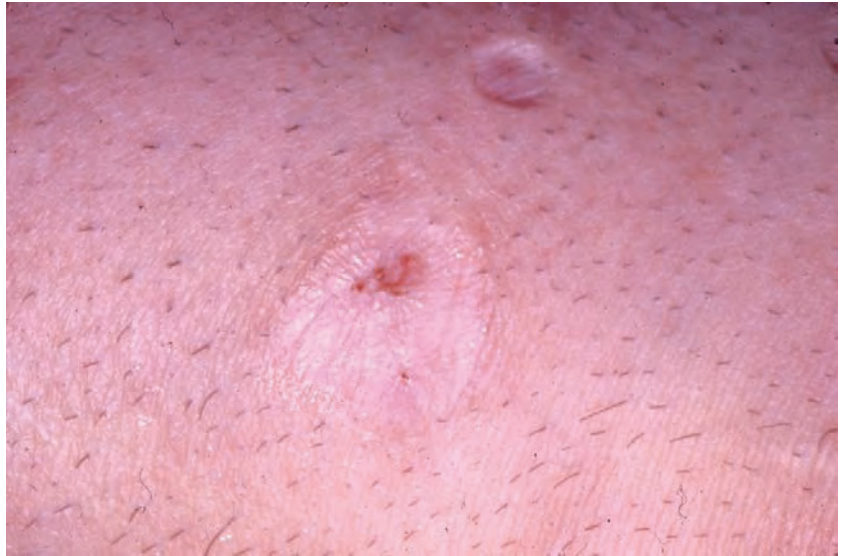
Recent healing infected skin popping lesion with adjacent cellulitis. It is common for these lesions to become infected due to the nonsterile nature of the injection equipment.

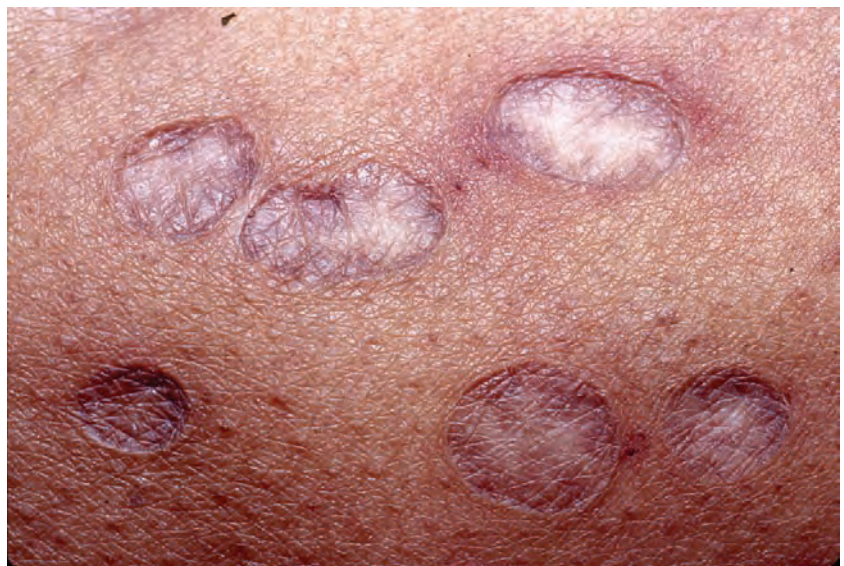

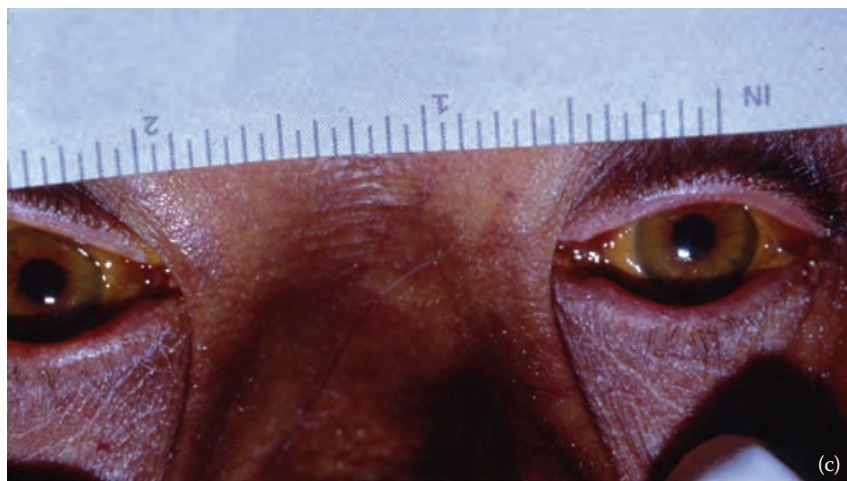
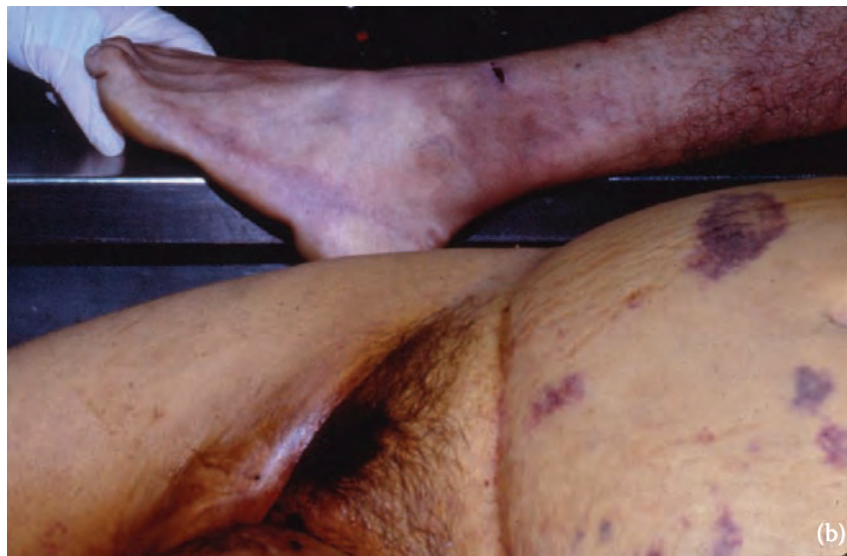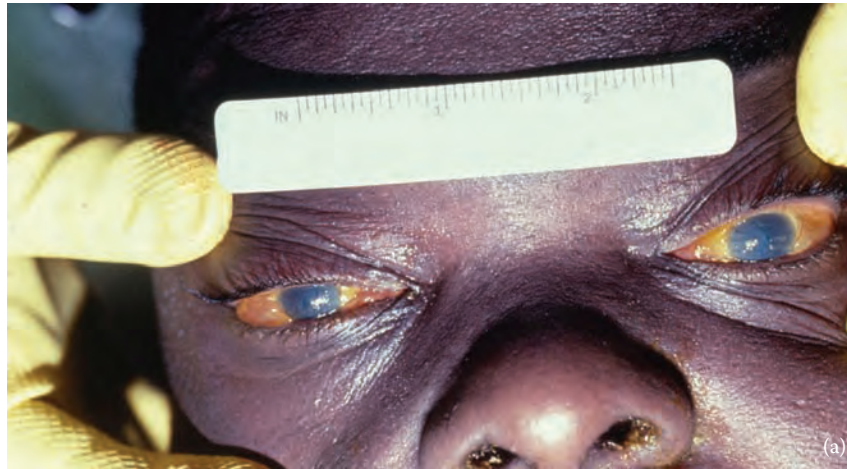
Recent healing infected skin popping lesion.

Healed and almost completely healed skin popping lesions. Note the lower wound has almost complete replacement by scar except for the central healing defect.

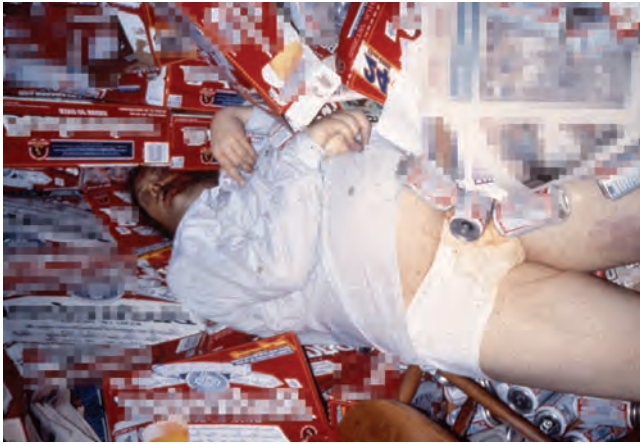

Remote old healed skin popping lesions.

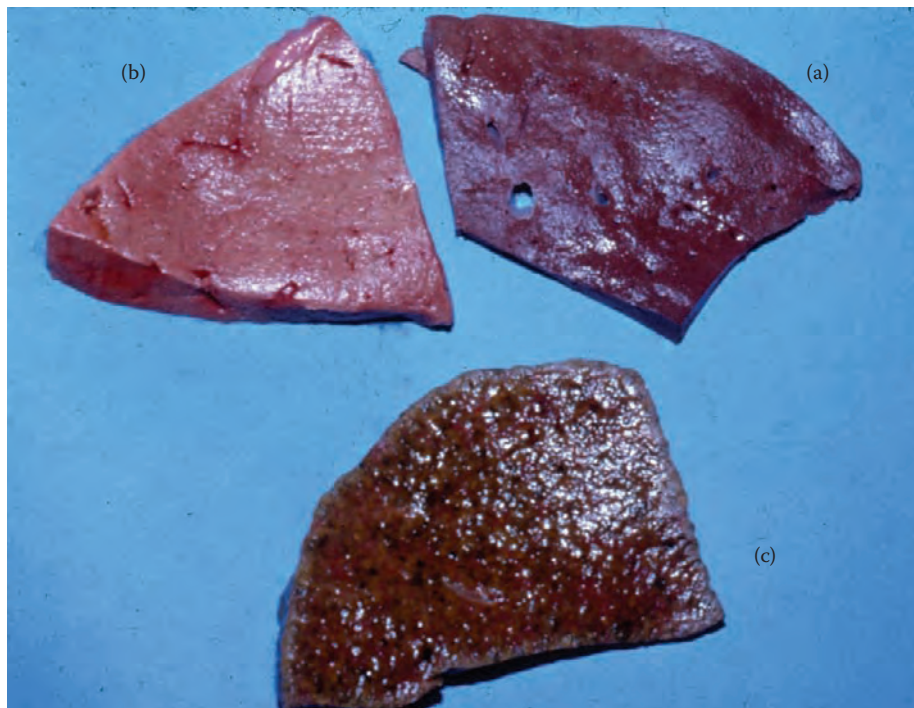
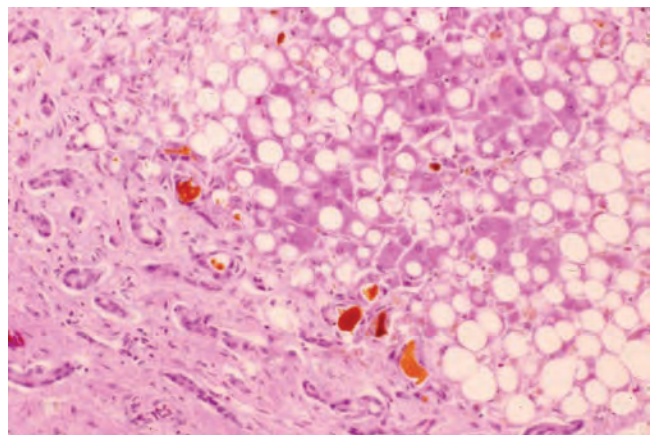
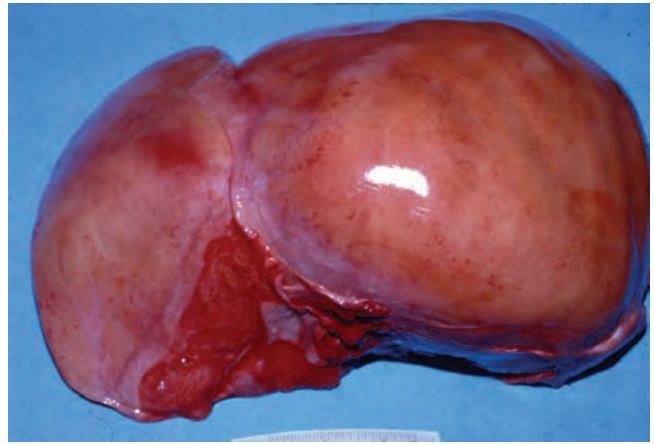




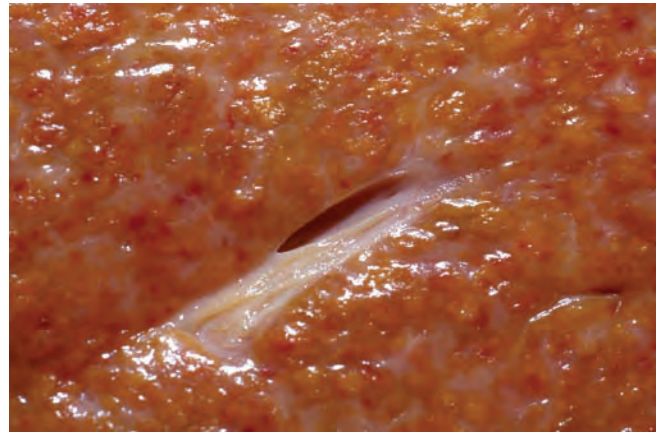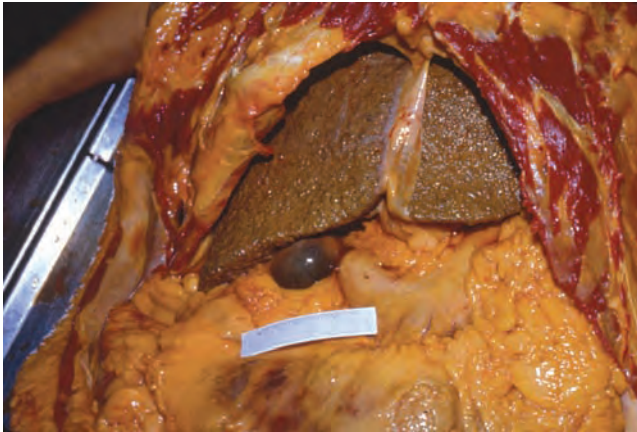
Examples of jaundice following hepatic failure due to hepatic cirrhosis as the result of chronic alcoholism; and viral hepatitis caused by chronic intravenous drug abuse. Note the yellow discoloration in the sclera and skin (a) and (c). Figure (b) demonstrates a comparison to a nonjaundiced individual. Also note the patchy areas of ecchymosis due to coagulopathy associated with the liver disease.



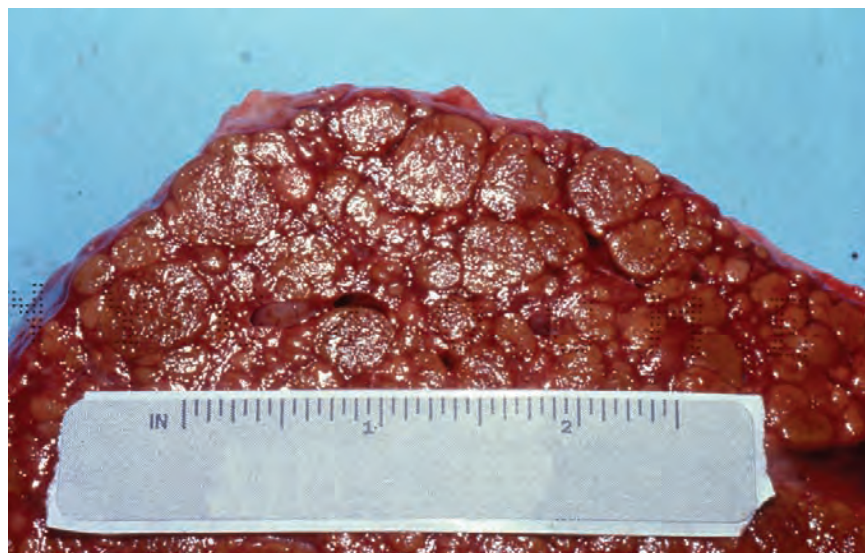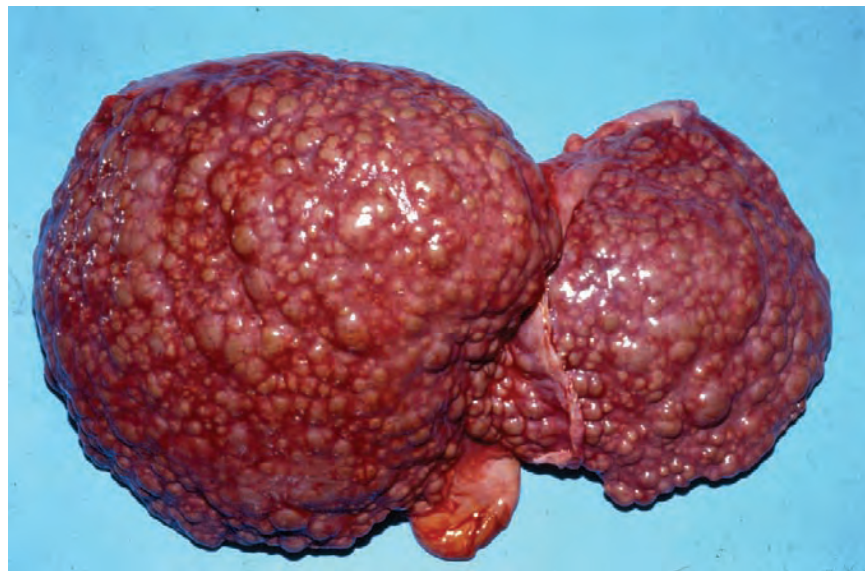
Marked hepatic steatosis due to acute alcoholism.



This image demonstrates cut portions of liver. Normal liver is brown (a); the yellow section demonstrates marked steatosis or fatty liver (b). The green section demonstrates micronodular cirrhosis due to chronic alcoholism with inspissated bile (c). The bile imparts this green discoloration.

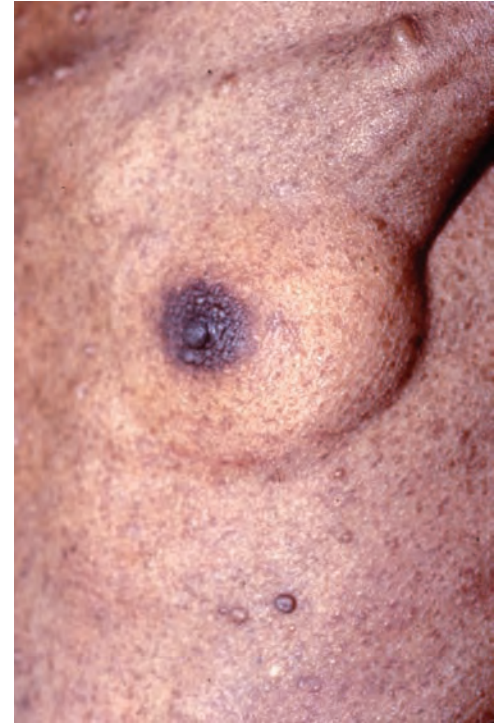
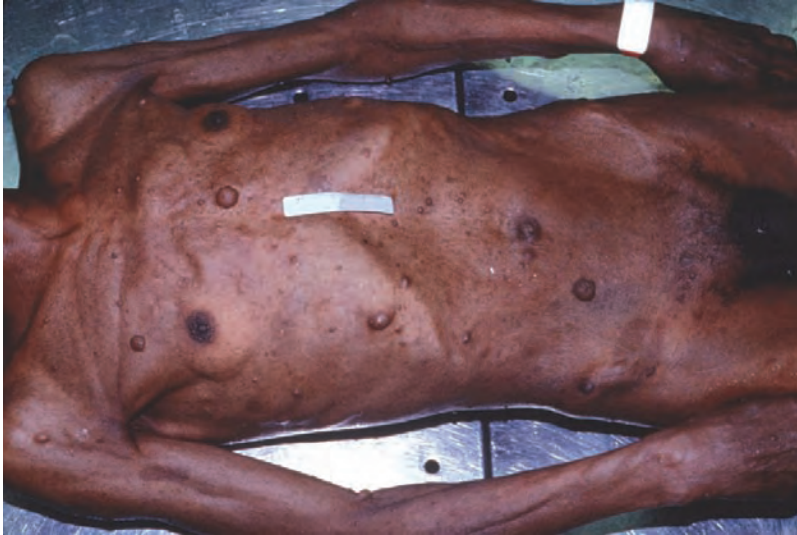
Micronodular hepatic cirrhosis with steatosis due to chronic alcoholism.

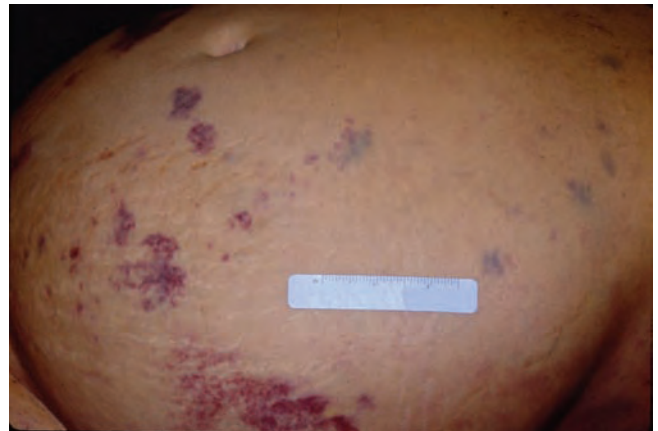
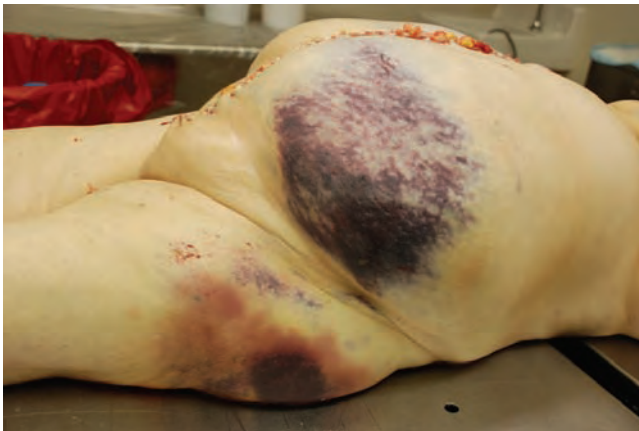

Macronodular hepatic cirrhosis due to hepatitis B infection as a result of chronic intravenous drug abuse.

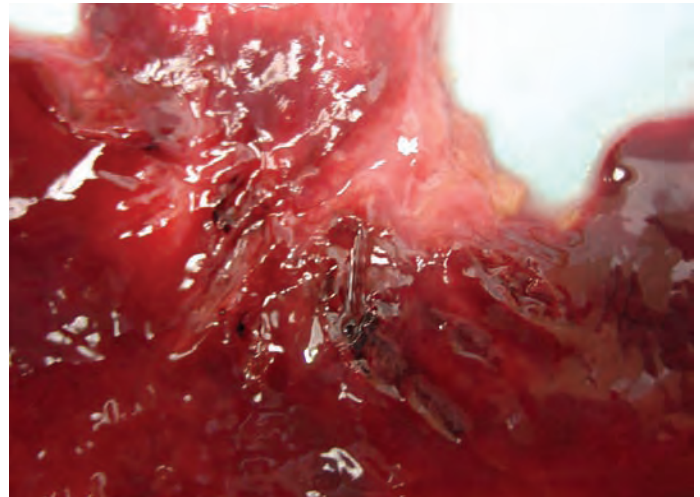
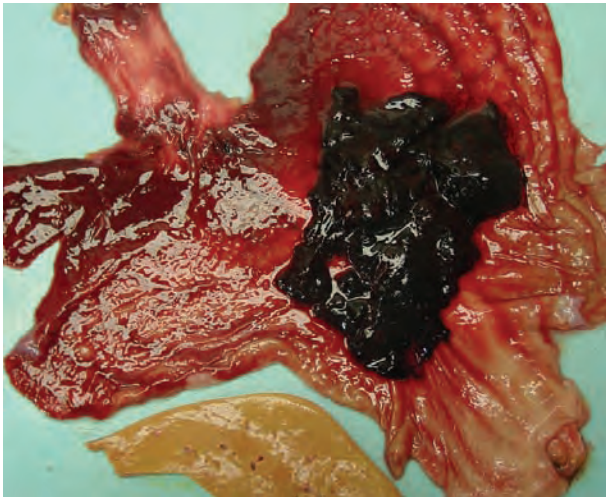




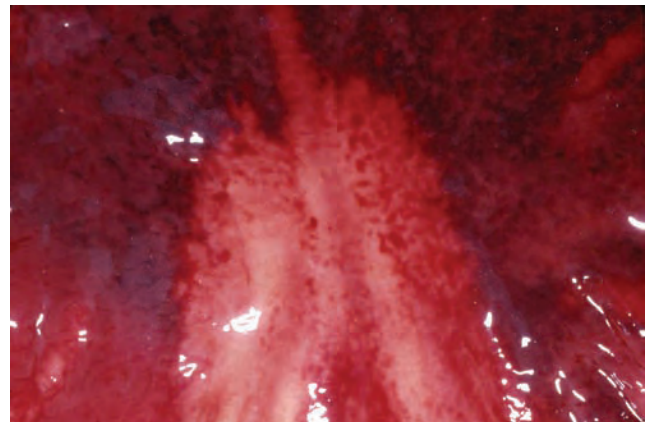
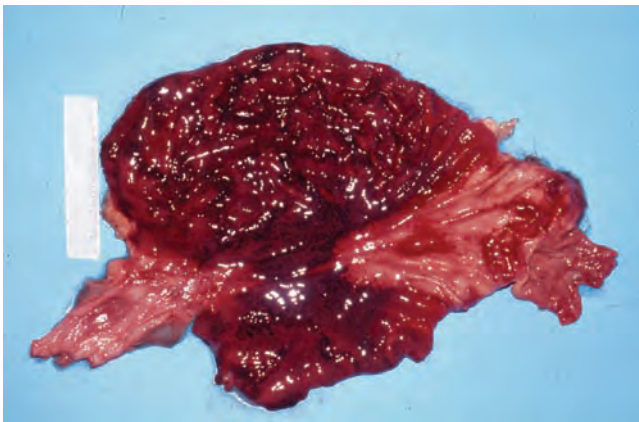
Chronic alcoholic with hepatic cirrhosis and gynecomastia. This individual also had neurofibromatosis, which is demonstrated by the multiple subcutaneous nodules.



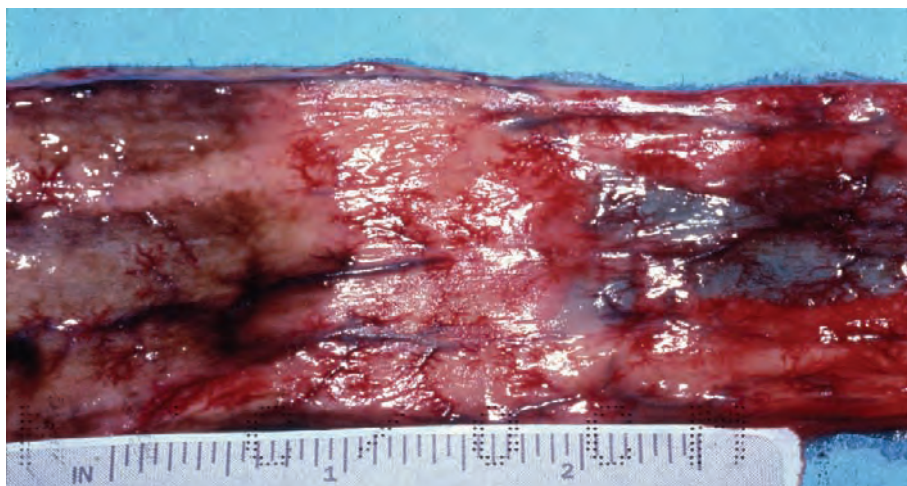Chronic alcoholic with hepatic cirrhosis and coagulopathy. Note the multiple areas of ecchymosis and contusion caused by minimal blunt force trauma.



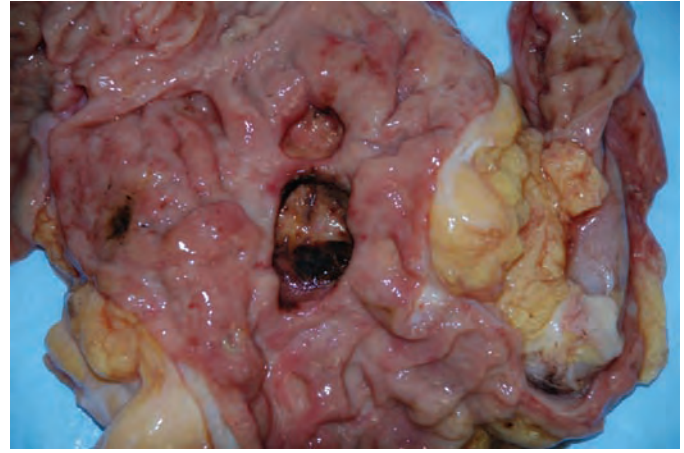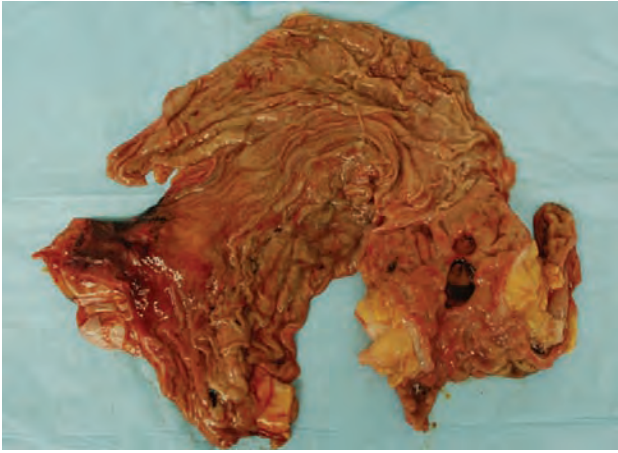
Gastrointestinal hemorrhage due to Mallory-Weiss tears in a chronic alcoholic. Note the laceration of the gastroesophageal junction leading to death from gastrointestinal hemorrhage following multiple episodes of vomiting.



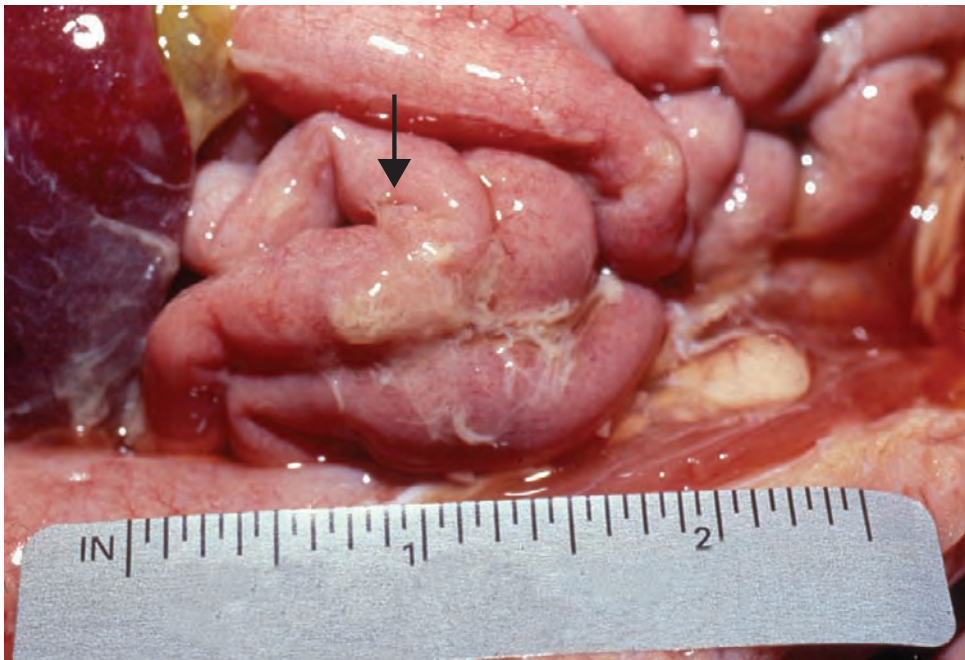
Acute gastritis associated with chronic alcoholism. Note the red discoloration of the mucosa.



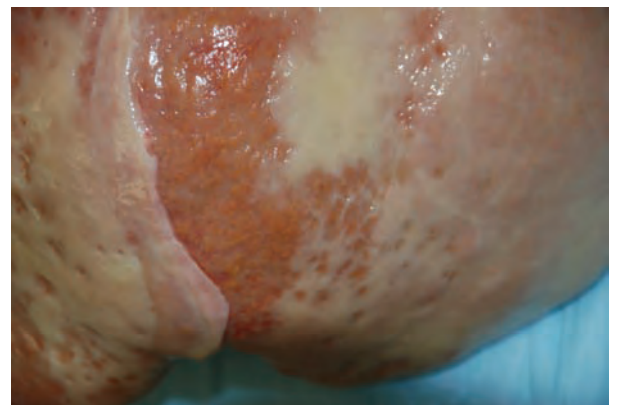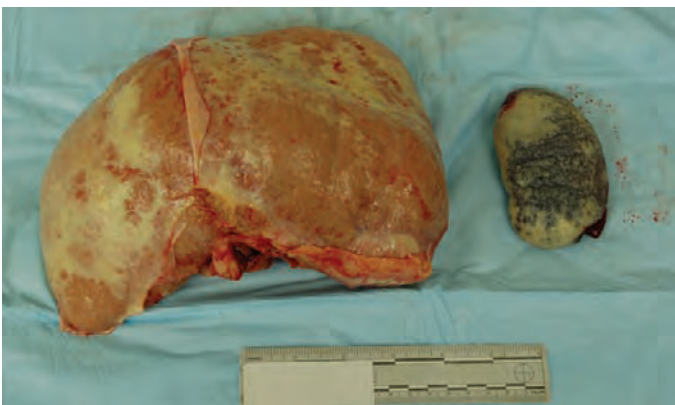
Esophageal varices due to hepatic cirrhosis and increased portal hypertension. Note the dilated red to brown submucosal veins that may rupture and possibly cause exsanguination.



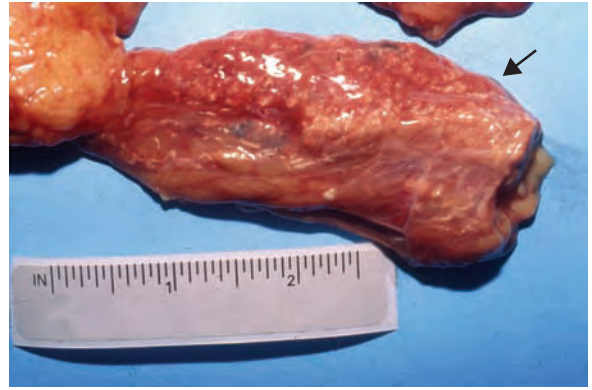
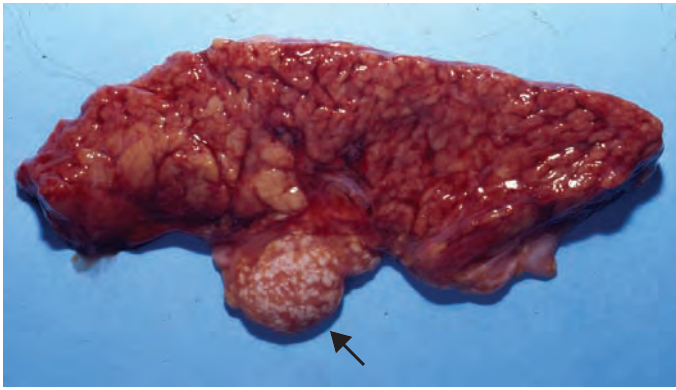
Bleeding peptic ulcers in a chronic alcoholic with gastrointestinal hemorrhage and hepatic cirrhosis.



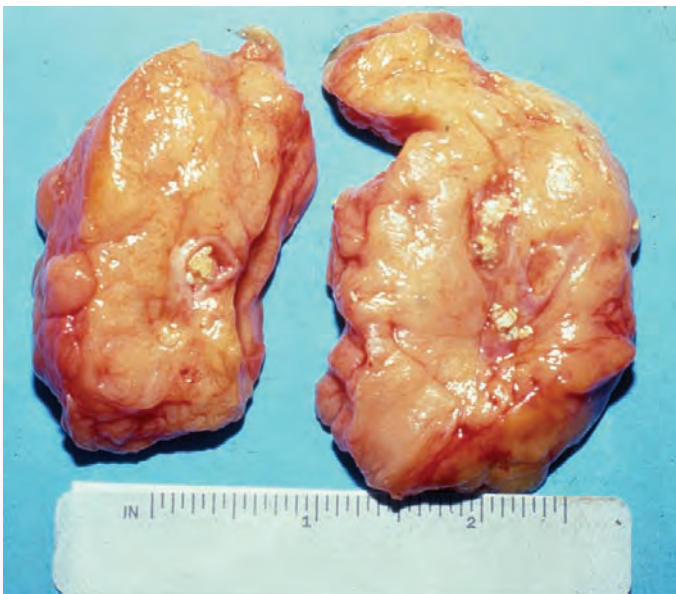
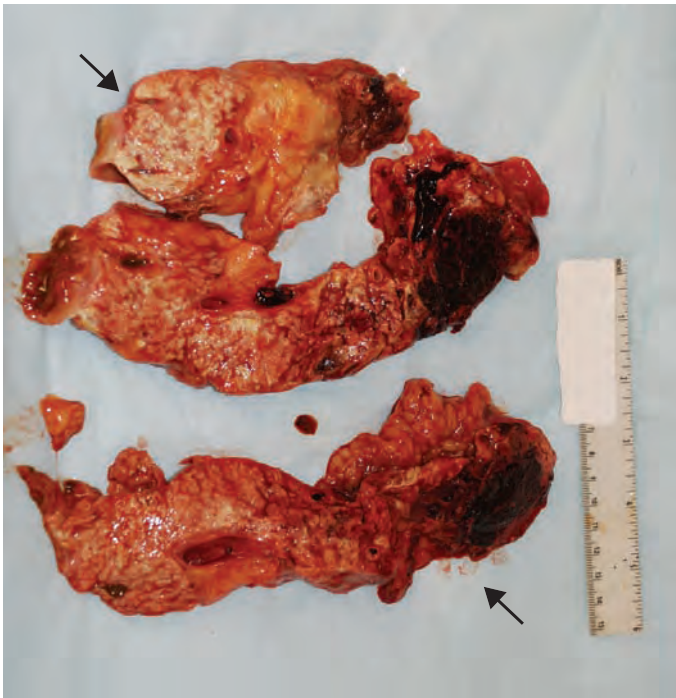
Acute peritonitis in a chronic alcoholic. Note the purulent exudate at the intestinal surface.



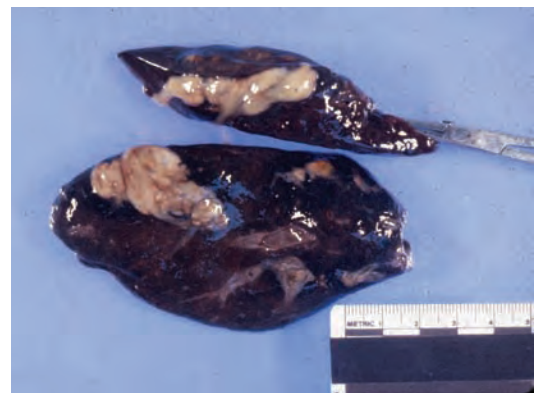
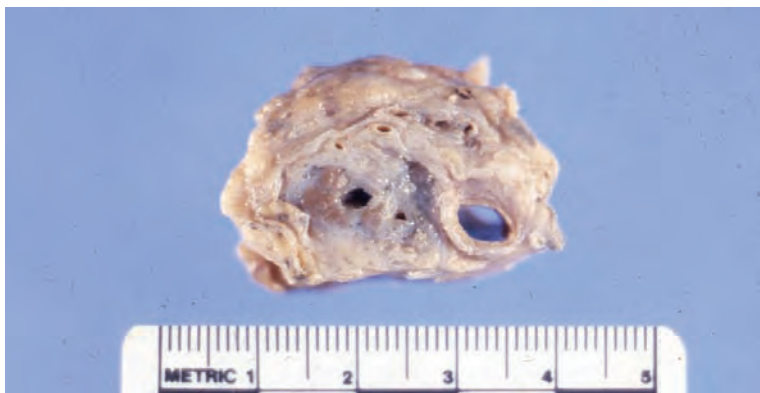
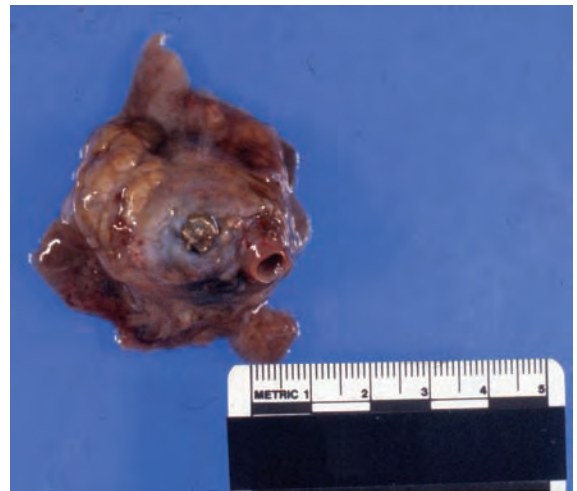
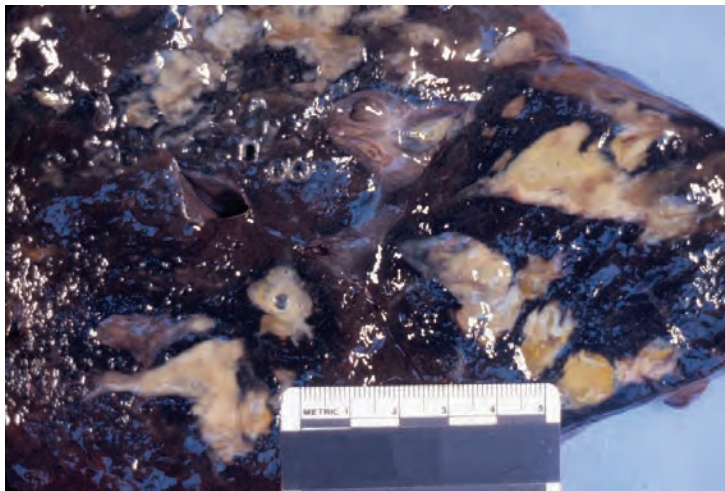
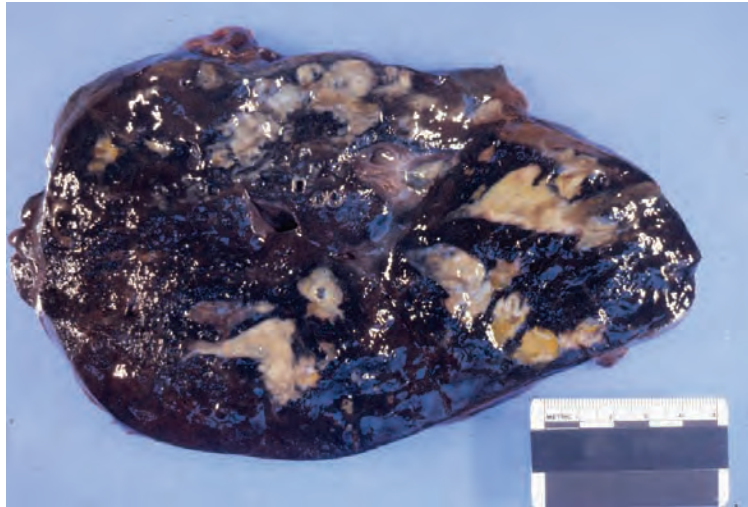
Hyaloseritis. Old healed peritonitis with fibrosis at the surface of the liver and spleen in a chronic alcoholic.



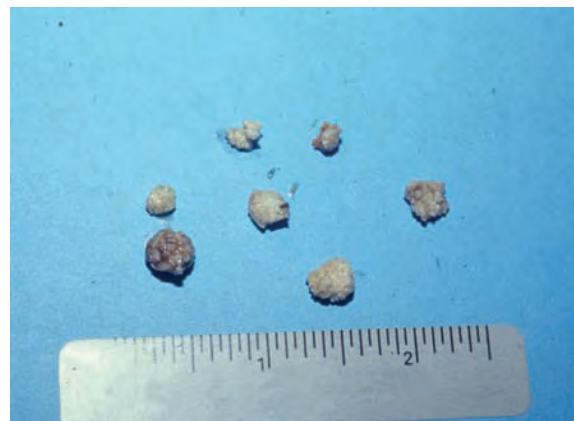
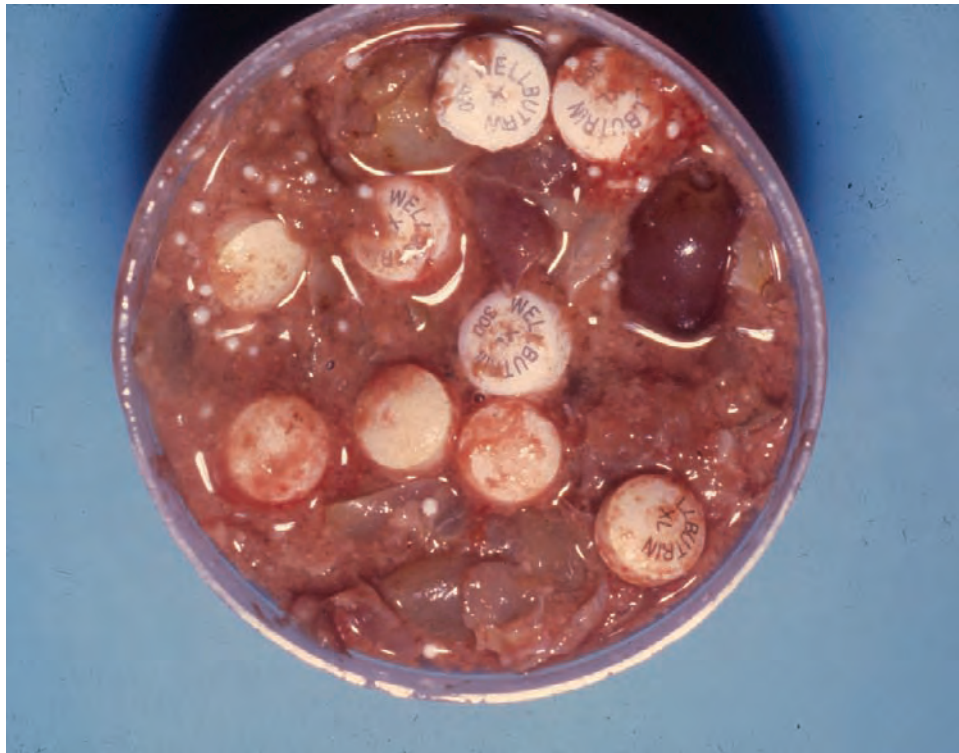
Acute pancreatitis due to chronic alcoholism. Note the white flecks due to fat necrosis and areas of hemorrhage.



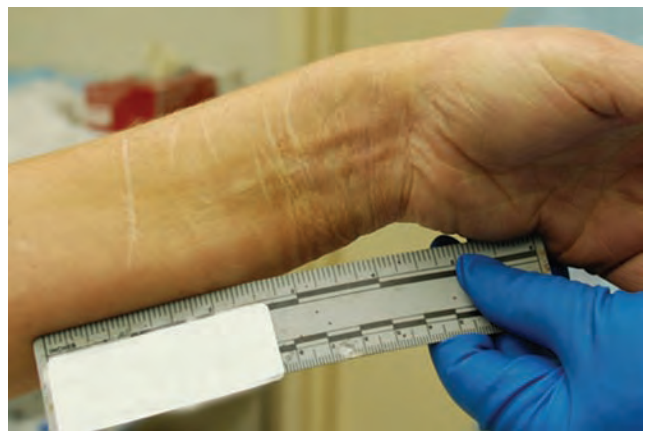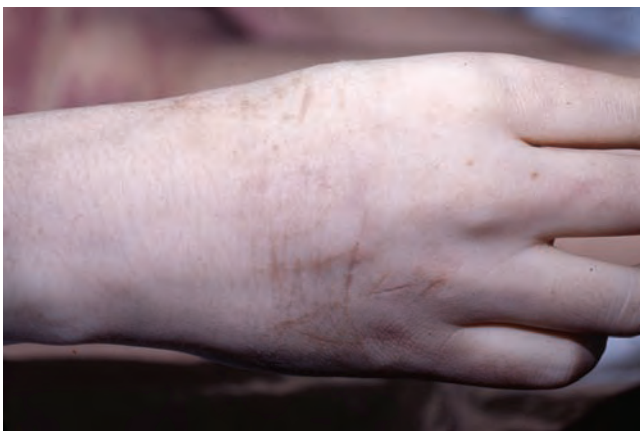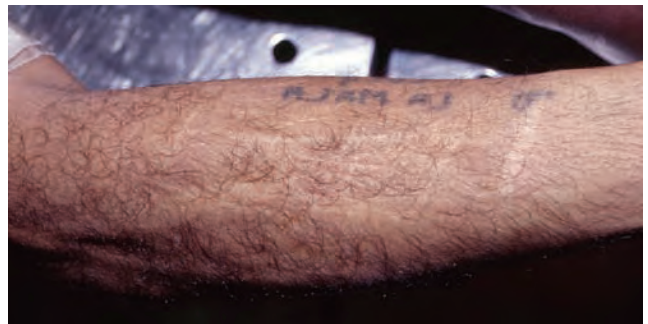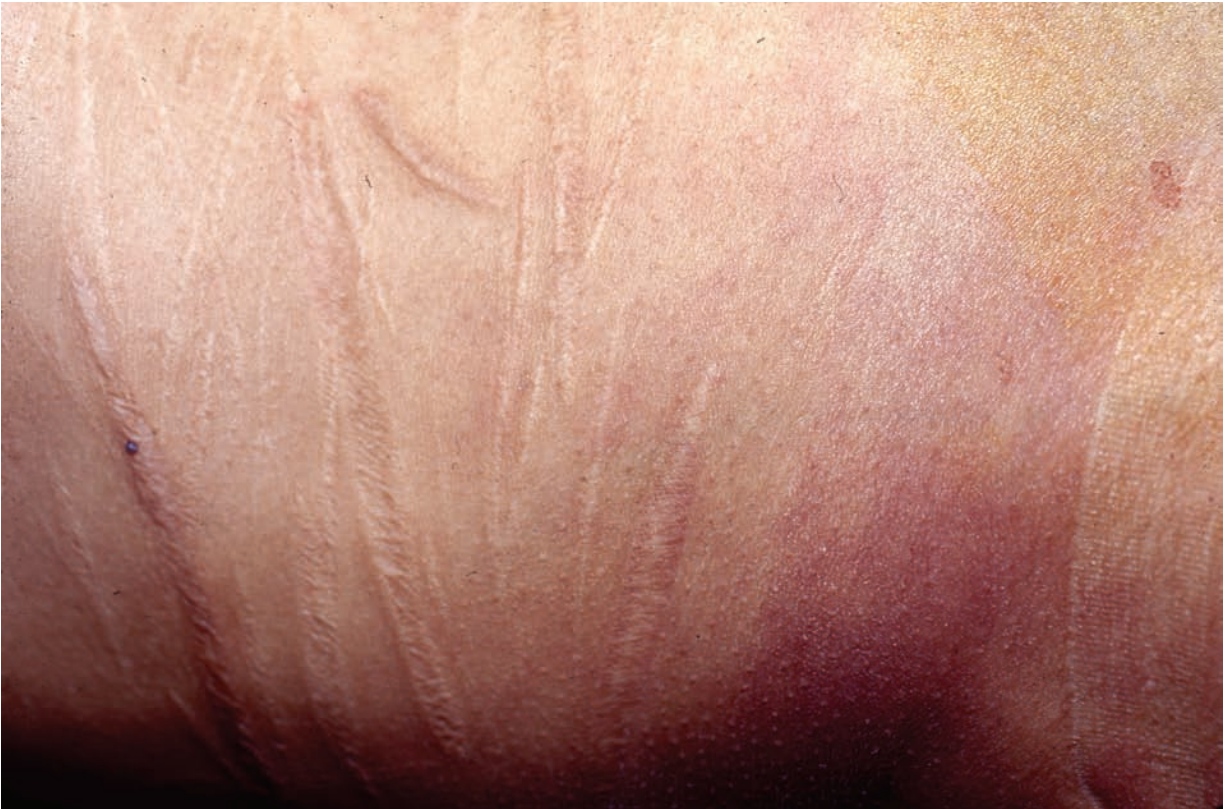Fatty metamorphosis or atrophy of the pancreas with duct concretions in a chronic alcoholic.



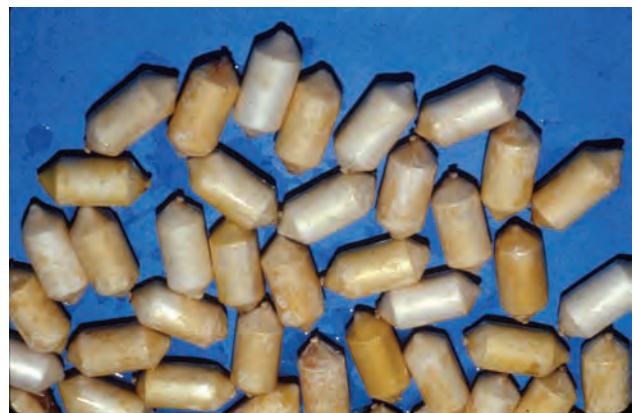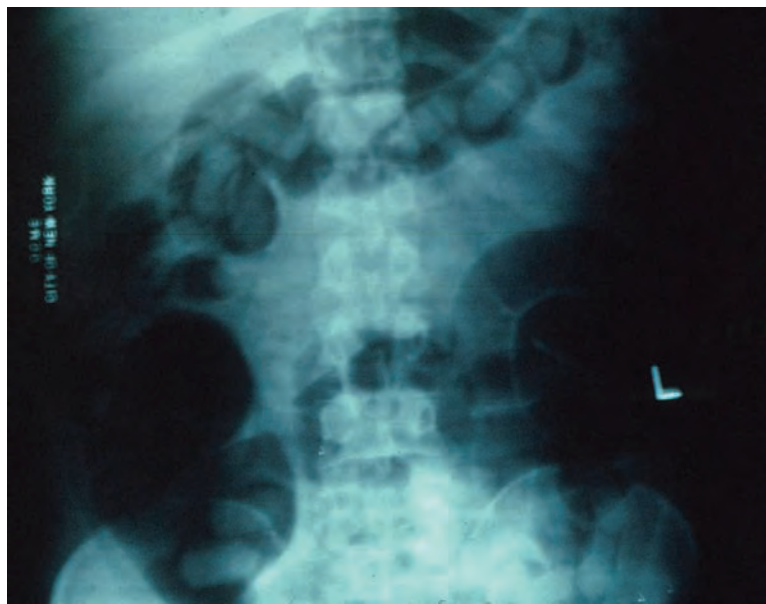
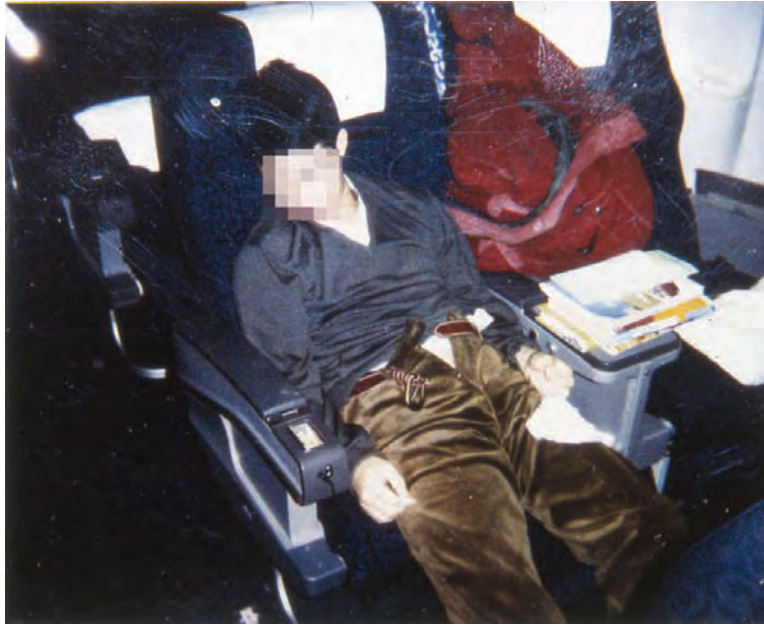Pyogenic liver abscesses. This decedent had a history of chronic alcoholism with chronic pancreatitis and recent abdominal pain of unknown etiology. This photo depicts multiple geographic, creamy yellow-white collections of purulent material within the liver parenchyma that microscopically proved to be dense collections of neutrophils, karyorrhectic nuclear debris, and masses of faintly basophilic, fine filamentous bacteria. Samples of the abscesses were submitted to the microbiology laboratory but the best that they could do was anaerobic gram negative rods. Candidates included bacteroides, prevotella, and fusobacterium. Actinomyces would have been a consideration but they are gram positive. Pyogenic liver abscesses, while relatively rare, are known complications of chronic alcoholism and pancreatitis.



Suicidal overdoses demonstrating intact and fragmented granular pieces of partially digested pills. Note the containers with the granular white flecks at the bottom that indicate pill fragments.

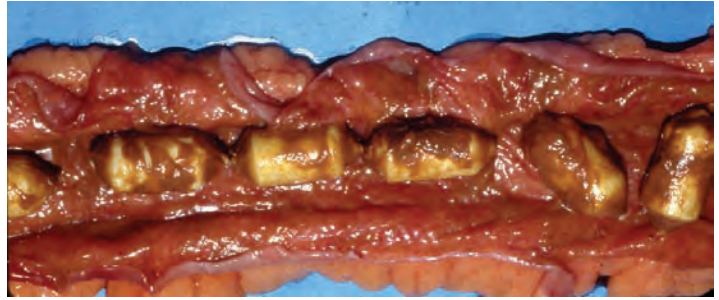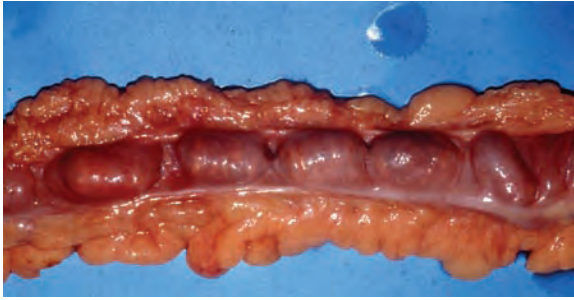


Note the multiple scars demonstrating destructive behavior associated with drug abuse, mental illness, and suicide.

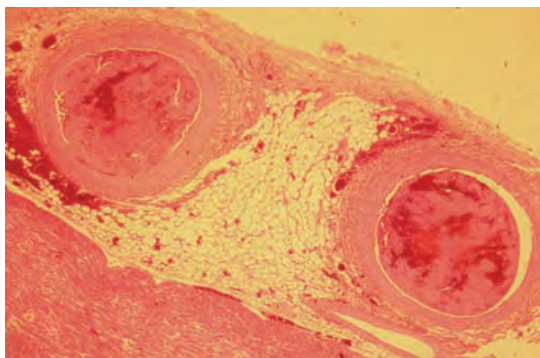
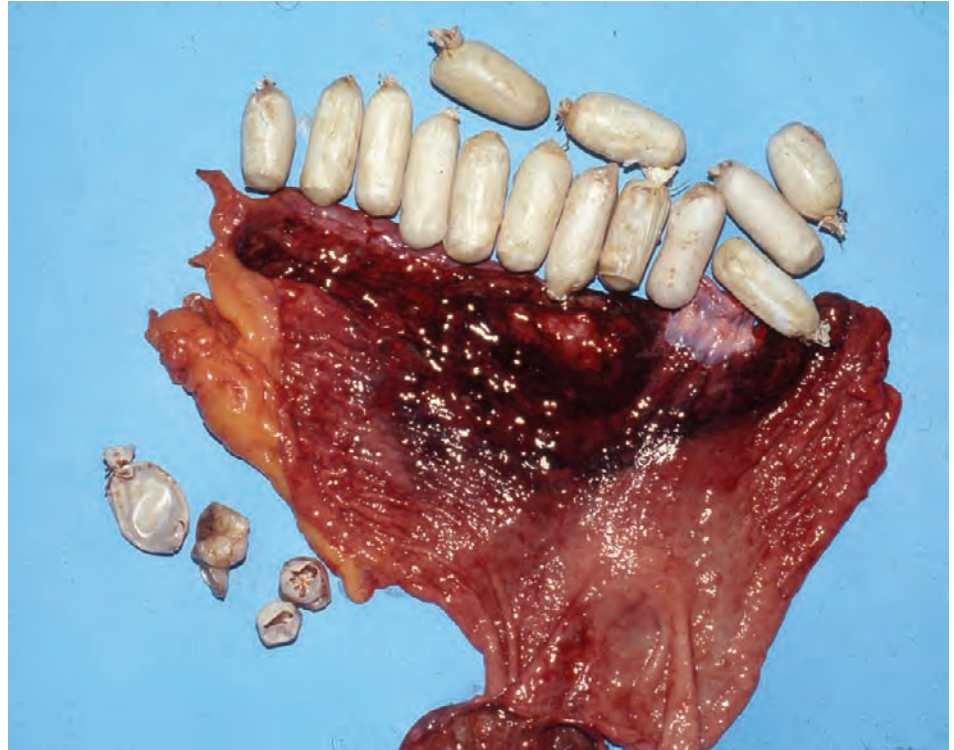

Acting as a “mule,” this person ingested multiple packets of drugs to smuggle them into the country. One of the packets ruptured and the individual died of a drug overdose before the plane landed. Note the typical x-ray findings demonstrating these packets within the gastrointestinal tract.

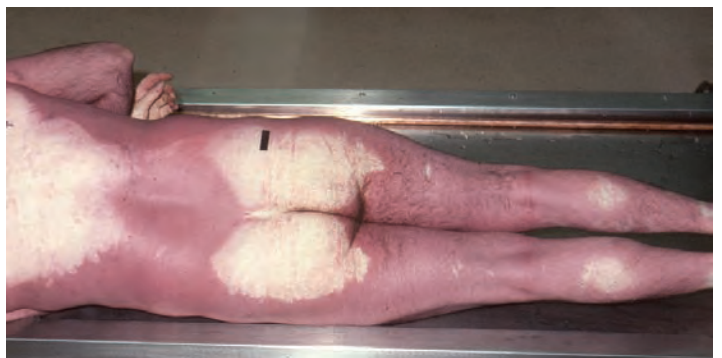



Packets of drugs discovered at autopsy in individuals who died in hotels next to an airport. Note the broken packets demonstrated at the bottom of the last picture.



Epicardial vessels with slight atherosclerosis and occluding thrombosis associated with acute cocaine intoxication.



Carbon monoxide poisoning with cherry red lividity.

---

# Postmortem Change and Time of Death

# 4

CHARLES A. CATANESE, BRUCE LEVY,  
AND GERARD CATANESE

---

## Introduction

---

In most jurisdictions the time of death is legally defined as the time that the person is declared or recognized to be dead. Thus, a decomposed body or skeletonized remains, clearly deceased for significant periods of time, may have an official time of death that is days, weeks, months, or even years after the actual death of the individual. However, being able to estimate the actual time of death (or the postmortem interval) can be critically important in criminal investigations, civil litigation, or settlement of the deceased's estate.

The concept of a "window of death" was developed to help answer these questions. This window can be initially bracketed by the time that the person was last known to be alive and the time he or she was declared dead. Forensic science can then apply a variety of observations and tests in an attempt to narrow that window as much as is scientifically and medically possible. Accurate interpretation of postmortem change is crucial in helping to establish the actual time of death.

Postmortem changes can be subdivided into several categories. These categories include early postmortem changes, decomposition, and skeletonization. Each has characteristics that can overlap with advancing time and are variable depending on environmental conditions and the physiologic state of the body at the time of death. The activity of insects and animals will also create artifacts that can lead to misinterpretation of the postmortem interval. Interpreting postmortem changes is not an exact science, and without a witness, one can only estimate a time period in which the death was most likely to have occurred.

## Early Postmortem Changes

---

Generally considered to occur or evolve within the initial 24 hours after death, these consist of algor mortis, livor mortis, and rigor mortis.

### Algor Mortis

The cooling of the body after death. After death the body will gradually cool until it equilibrates with the ambient

temperature. Under standard climate controlled conditions, with average humidity and a room temperature of about 72° F, the body generally loses about 2° F per hour for the first 12 hours and then approximately 1° F per hour for the next 12 to 18 hours. If the ambient temperature is greater than the body temperature, algor mortis occurs in reverse and the body temperature rises until it reaches the ambient temperature.

The above calculations apply only at or near room temperature and will become variable as the ambient temperature changes. As a general rule, the rate of temperature change in a body is proportional to the difference between the temperature of the body and its environment. In other words, if the ambient temperature is below 72° F, the rate of heat loss will be increased from the numbers above. The reverse would be true for temperatures greater than 72° F. Moving air will cool faster than still air, and wet bodies will cool faster than dry bodies. Bodies found in stagnant water, flowing water, or those found buried in the ground will cool at different rates from those in the air and from each other. When the body and environment are at the same temperature, they have reached steady state and estimates of time of death based on temperature are limited to a minimum period of time.

Many other variables can influence algor mortis. In general, an elevated body temperature at the time of death will give the appearance of a shorter postmortem interval based on a measurement of the body temperature. A lower body temperature will have the reverse effect. Things that affect body temperature include infection, strokes, seizures, thyroid disease, and many other natural diseases. Whether or not the person was involved in strenuous physical activity prior to death (such as a violent struggle) will increase body temperature. Many other factors, including the age of the person, his or her overall health, and many drugs or medications can also have an effect on the calculation of postmortem interval based on this and other observations.

It is important to make certain there is consistency in how the body temperature is obtained. First, these calculations are based on a core body temperature, meaning either taking a rectal temperature or, more ideally, introducing a thermometer into the abdominal cavity beneath the liver to measure core temperature. Temperature readings on

the surface of the body, including axillary, oral, or ear temperature are unacceptable for determining a postmortem interval. The thermometer must be kept in place long enough for the body temperature to equilibrate.

### Livor Mortis

The settling of blood under the effects of gravity after death. It can first be appreciated as early as 20 minutes after death in very light-skinned individuals. The color of the livor will deepen to a purple color over the first 8 to 12 hours after death. During this period the livor is typically blanching, meaning that pressure on an area of livor will cause the color to briefly leave the area, resulting in a pale mark. After about 12 hours the livor will become fixed and no longer blanch under pressure. As with algor mortis, temperature will influence the rate at which livor becomes fixed, with increased temperatures shortening the time for livor to become fixed and decreased temperatures lengthening the fixation time. In some cases, livor mortis advances to cause small visible hemorrhages in the skin known as Tardieu spots, which should be distinguished from petechiae.

The medical condition of the person and the cause of the death can also create changes in livor mortis. People who are anemic (low blood count) or sustain an injury resulting in significant loss of blood might have very faint or even absent livor mortis. It can also be difficult to appreciate livor in dark-skinned individuals.

When evaluating livor mortis, it is important to note its location, intensity, whether it is blanching or fixed, and if it is appropriate for the position of the body. If livor is inappropriate for position, you can conclude that the person was moved at some point after the onset of livor. You can also evaluate livor for its color. For example, people who die as a result of carbon monoxide or cyanide poisoning will have a bright “cherry red” color to their livor mortis. People who die in a cold environment might also have a similar red color to their livor.

### Rigor Mortis

The stiffening of the body after death. It is the result of a physiochemical process within the muscles of the body that does not cause actual contraction of the muscles. Under typical conditions, rigor will first be appreciated within 30 minutes to 2 hours after death. It will progress to a maximum intensity over the first 12 hours and remain at a maximum until about 24 hours after death. It will then “pass” from the body between 24 and 36 hours after death, after which the body will remain flaccid.

As with algor mortis and livor mortis, many variables will affect the rate of development and passing of rigor mortis. In general, increased environmental or body temperatures will speed the rate of development and passing of rigor mortis. Lower environmental or body temperatures will have the reverse effect. People at the extremes of age (children and the elderly) will have different rates of appreciation of rigor mortis due to the decreased muscle mass in these age groups.

When evaluating rigor mortis, it is important to note its location and intensity and whether it is appropriate for the position of the body. If rigor is inappropriate for position you can conclude that the person was moved at some point after the onset of rigor.

## Decomposition

---

As time advances, decomposition gradually increases. Decomposition can be subdivided into two basic categories, putrefaction and mummification. While they can be seen in isolation, careful observation will typically reveal features of both processes simultaneously.

### Putrefaction

Decomposition that occurs due to the actions of bacteria. The bacteria typically break down the body from the inside out, causing many of the changes we associate with a person who has been deceased for a longer period of time. However, when there is penetrating trauma that breaks the surface of the body, bacteria from the environment can gain access and hasten putrefaction. These changes include darkening and slipping of the skin, the production of a foul-smelling gas, with bloating of the body and marbling of blood vessels. A dark colored bloody-appearing purge fluid will come from the nose and mouth and should not be confused with blood related to trauma.

This process is extremely environmentally dependent. As with the early postmortem changes, warmer temperatures accelerate this process and cooler temperatures slow it down, with many of the same factors playing a role. A body placed in a dark dumpster in the hot summer sun for half a day can reach a state of putrefaction equivalent to a body left at room temperature for several days or one in the winter cold for greater than a week. In the case of fire fatalities, charring will preserve the body and decelerate this process. A frozen body that has thawed will putrefy at a markedly accelerated rate due to spaces left by frozen ice crystals.

## Mummification

Mummification occurs in a dry environment, typically such dry outside environments as a desert, or in heated indoor environments during the winter months when the relative humidity is low. Initially, there is a darkening and hardening of the skin. This will progress to produce flaking of the surface of the skin that can give extremities the appearance of a log, thus the term “tree barking.” As with putrefaction, the skin will begin to split and eventually the skin and soft tissues under the skin are also lost.

## Skeletonization

Both putrefaction and mummification eventually lead to skeletonization of the body. The loss of soft tissue progresses at a variable rate, depending on the environmental conditions and access of the body to a variety of animals and insects. The face and ends of the extremities are the first areas where bone is exposed, and the pelvic soft tissues are the last to be lost. While this process is usually measured in months, work performed at the Anthropologic Research Facility at the University of Tennessee in Knoxville has demonstrated that complete skeletonization of a person can occur within days under appropriate conditions.

## Autolysis

Autolysis associated with decomposition occurs after cell death and is due to the actions of digestive and catalytic enzymes released from cells in the body. This term, “self-destruction,” is advanced in certain organs, especially the intestinal tract and pancreas, due to their rich enzyme content. This is important to note because autolysis can mimic certain disease processes at the time of gross examination. Maceration of stillborns who were dead inside a uterus for days is a type of autolysis associated with moist sterile environments, appears as a red discoloration with skin slippage, and is not to be confused with trauma or disease.

## Adipocere

A process that is rarely seen outside of exhumation cases. It is a chemical change that occurs in the fatty tissues of the body exposed to wet conditions. Adipocere takes many months to develop, and once it forms is extremely persistent, stopping the typical loss of soft tissue and skeletonization of the body.

## Other Factors in Evaluating Postmortem Interval

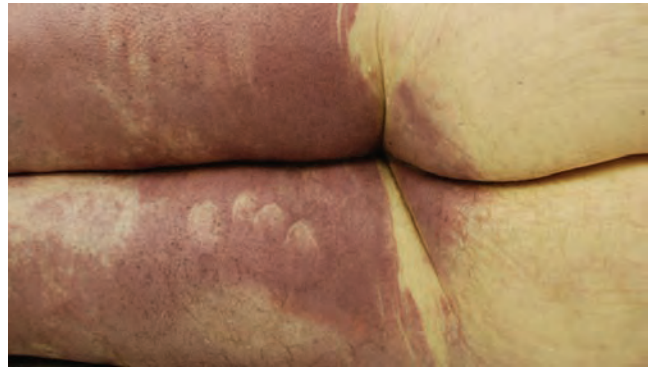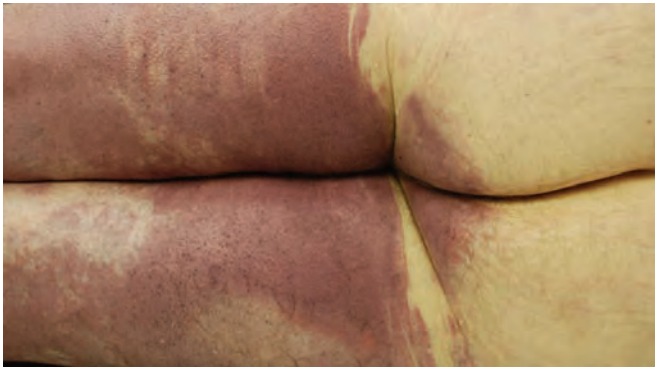---

When a deceased body has been exposed to insect or animal activity, we can make observations that might assist in the determination of the post-mortem interval. Maggots (the larval stage of blowflies) can be collected from the body and examined by an entomologist. You need to collect two sets of specimens. One set should be kept alive while the other set is killed. The entomologist will determine the exact species of fly from the matured living specimens and the likely time of death from the killed specimens. In persons who have been deceased for a prolonged period of time (months to years), an evaluation of the type and age of plants growing up through the body might also provide useful information.

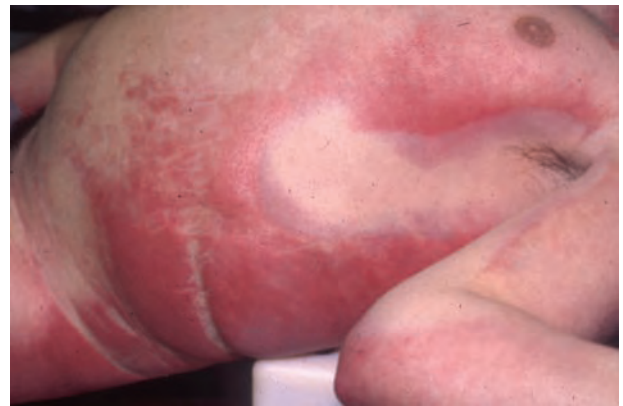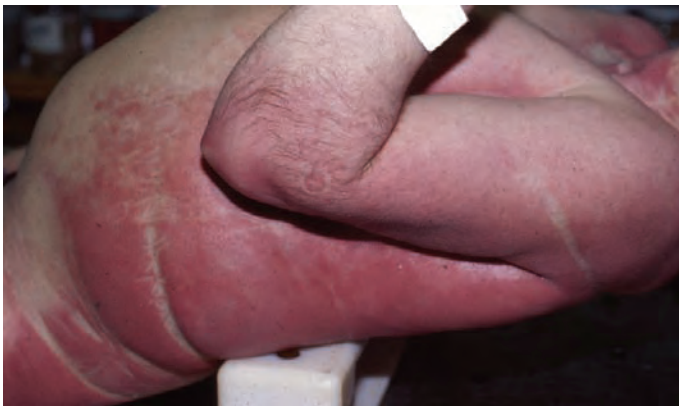Examination of the stomach and intestinal contents can also provide clues to help us in the determination of time of death. Our bodies digest food at a fairly predictable rate, depending on the quantity and types of foods consumed. Higher caloric content foods, such as fats, are digested slower than less complex foods. Larger meals remain in the stomach for a longer period of time. The rate of stomach emptying can be accelerated or slowed by natural disease, drugs, alcohol, or emotional stress. The description of the quantity, type, and condition of food in the stomach is part of the routine autopsy. This can be combined with information about that person’s recent consumption of food obtained during the investigation to estimate the time from the eating of that meal until the time of death. Even without information about the last meal consumed, the stomach contents might provide clues as to when death occurred based on the types of food in the stomach.

Finally, markers found at the scene of death might provide the best information regarding the date or time of death of the individual. Observations regarding uncollected mail or newspapers, information from the telephone company about the last time the phone was used, dated sales receipts, or a noted change in habitual behavior might assist with determining the date of death. The clothing the person is wearing or the status of lighting in the home might provide clues regarding the time of the day or night that death occurred.

In conclusion, determining the postmortem interval can be difficult. Start with a broad window of death (last-known-alive to found-dead). Then use as many of the above elements as are available to attempt to narrow that window as much as possible. It is important to remember that there is variability of these observations and calculations, so keep an open mind and be willing to reevaluate your opinion based on new information as it becomes available.

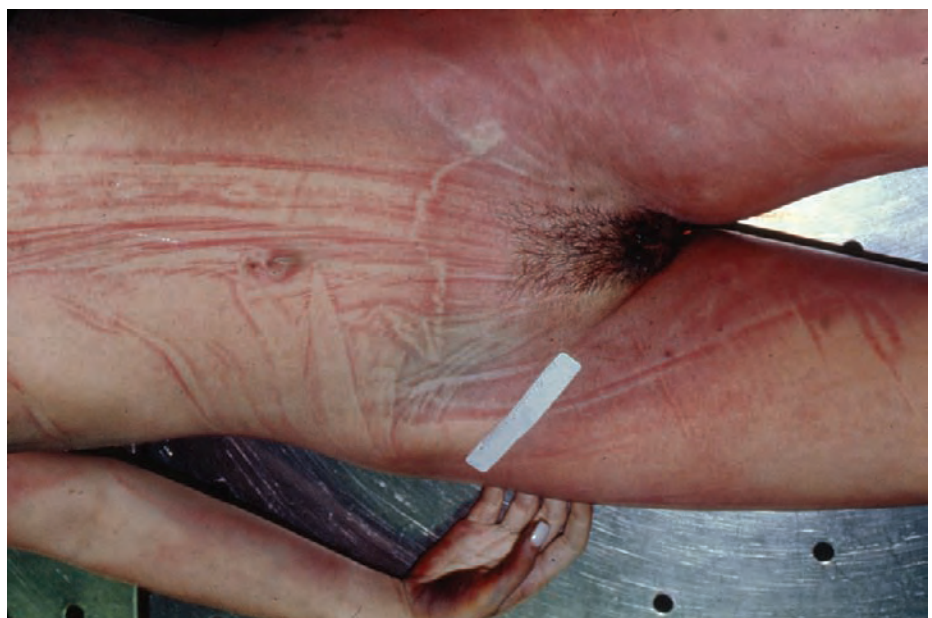

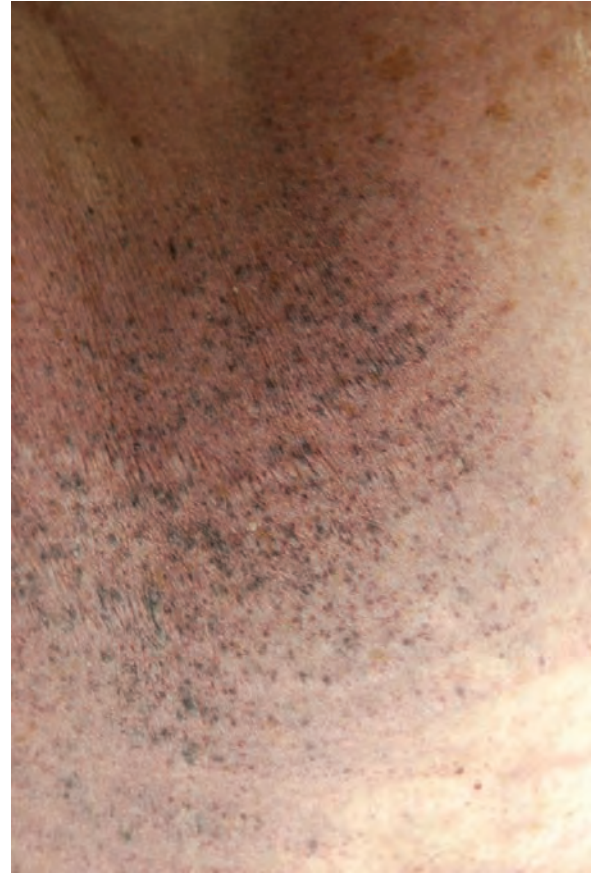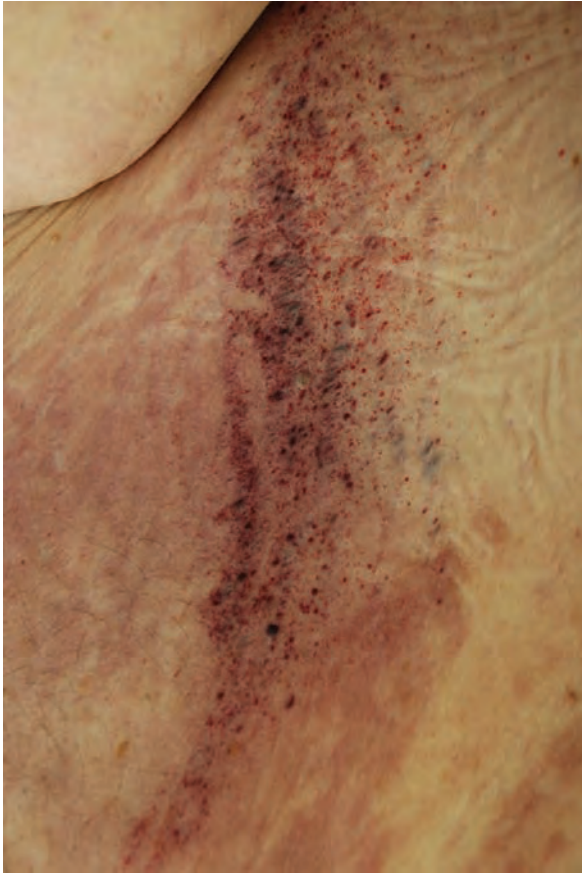
Blanching lividity. Note the finger marks caused by pressing the blood away from the skin surface at the posteromedial aspect of the right thigh.



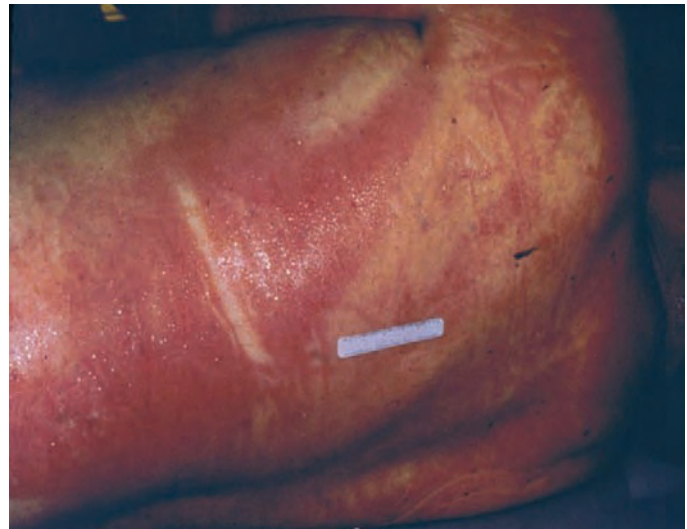Fixed lividity at the lateral and posterior torso. Note the absence of lividity underlying the pressure region exerted by the arm against the weight of the chest. This child was discovered lying on his left side. This body was stored in a cold refrigerator for many hours prior to being autopsied.

This individual was placed in the morgue on her back the day before this examination. Note the fixed anterior lividity with partial sparing over with pressure points caused by lying on a wrinkled bedspread in her home for many hours prior to being discovered. Also note the early putrefaction consisting of slight green discoloration of the lower right abdomen.

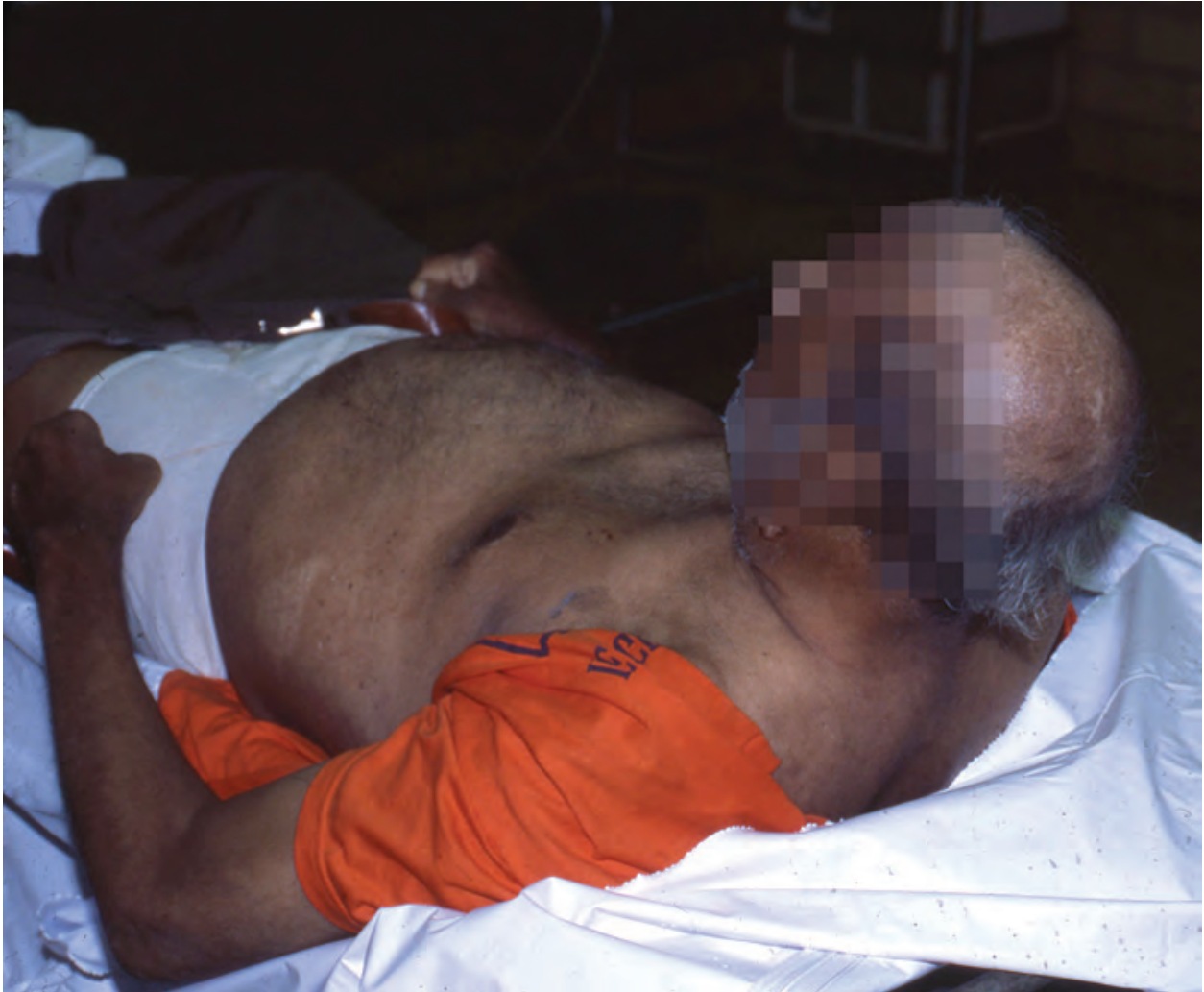



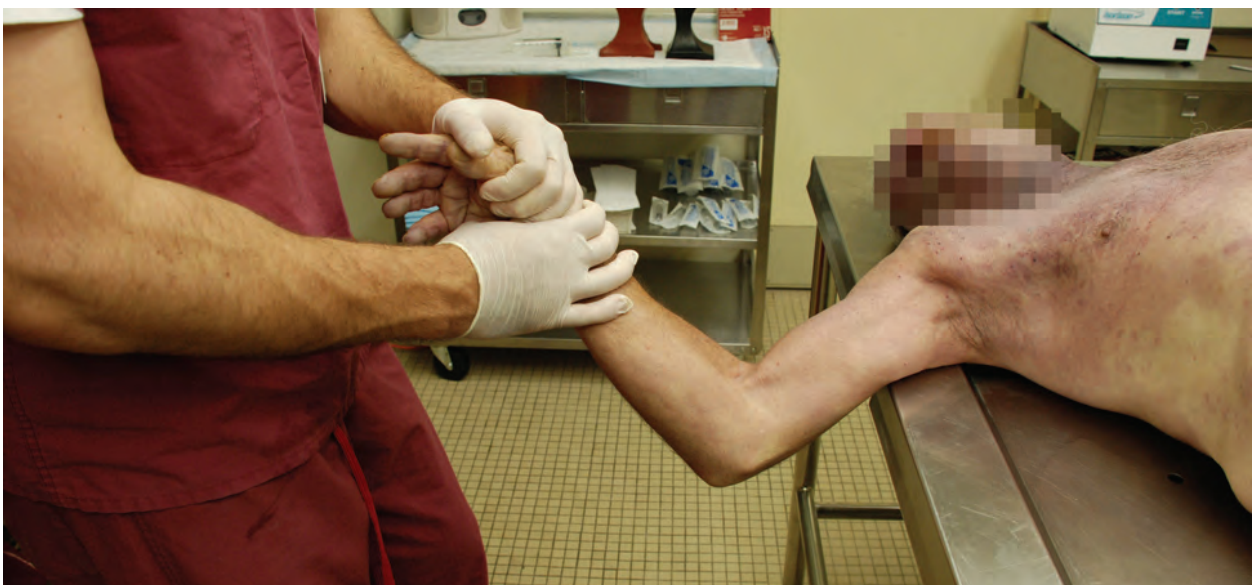Marked fixed lividity with dark purple spots known as "tardieu spots." Also note the vague chain pattern. It is not unusual for objects such as this to leave postmortem imprints.



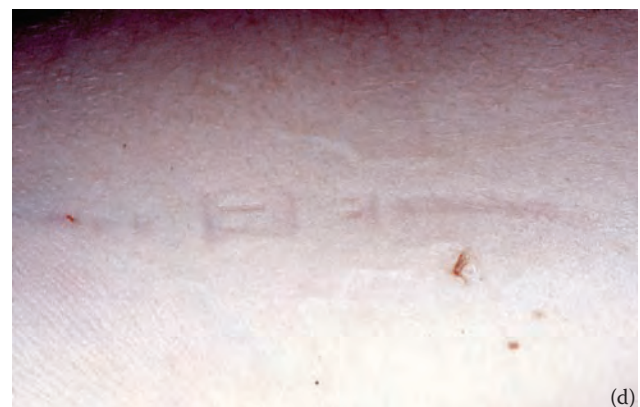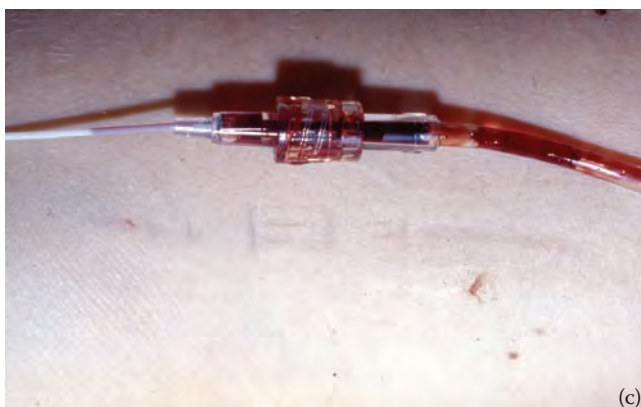
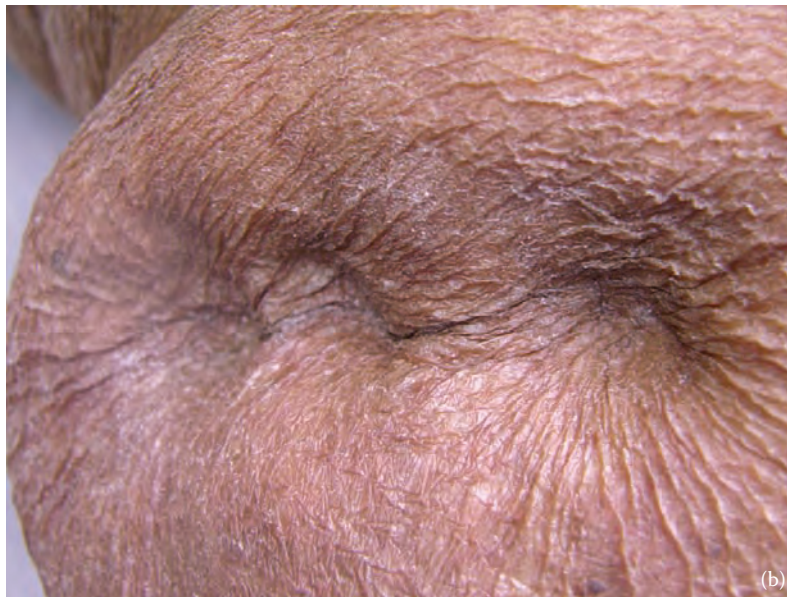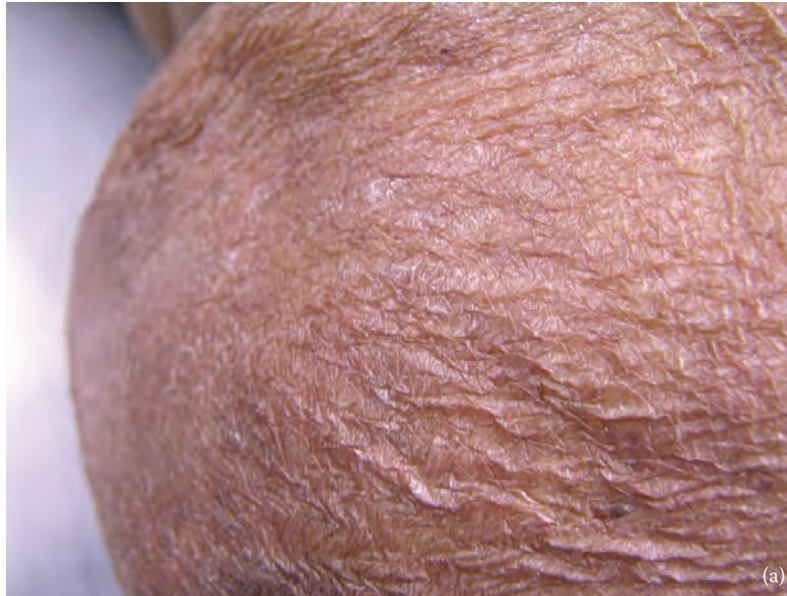In carbon monoxide poisoning, the color of the livor mortis is more of a bright red instead of the typical red-purple color. This change can also be seen in cases of cyanide poisoning or in decedents who have died in cold environments. Note that the color differences are very subtle and it may not be possible to make a determination from visual inspection alone.



The decedent was found lying on his back with his head elevated on top of several pillows. He was in full rigor mortis at the scene and maintained this position through his arrival into the morgue.

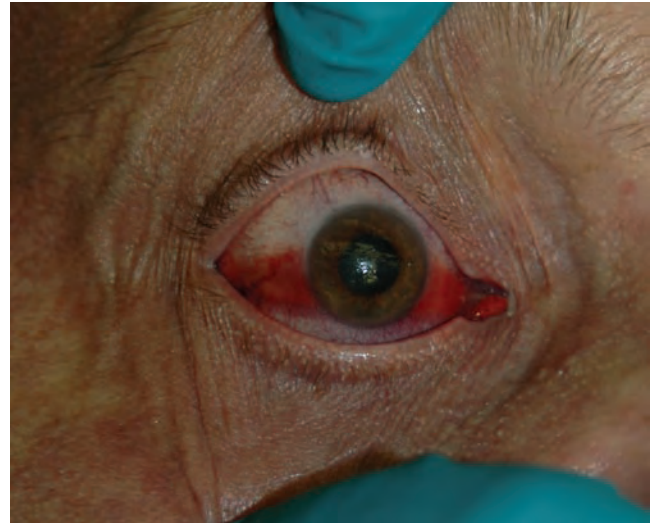
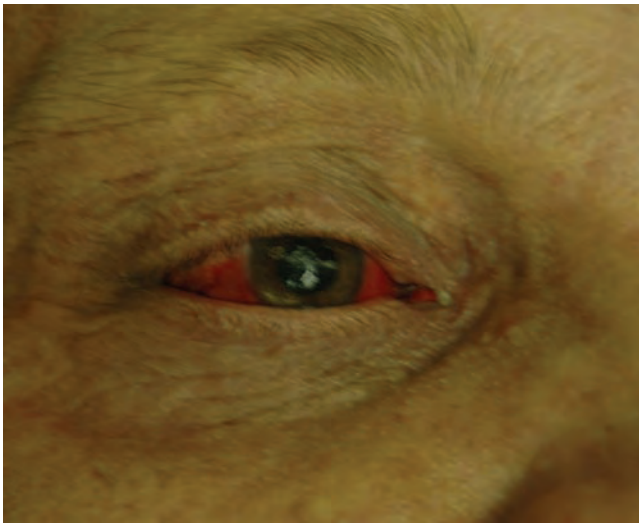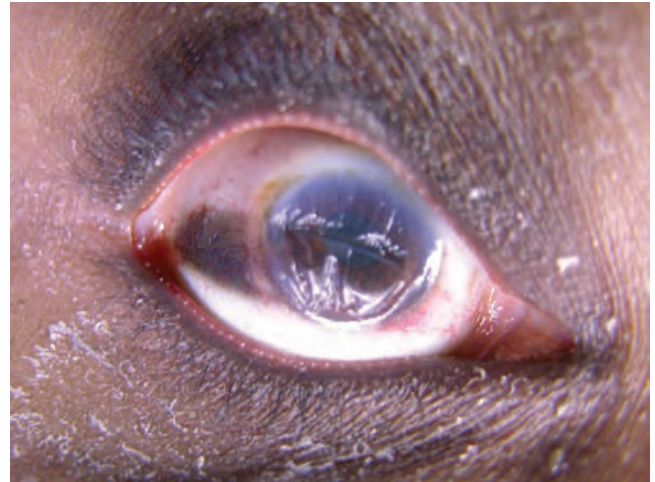
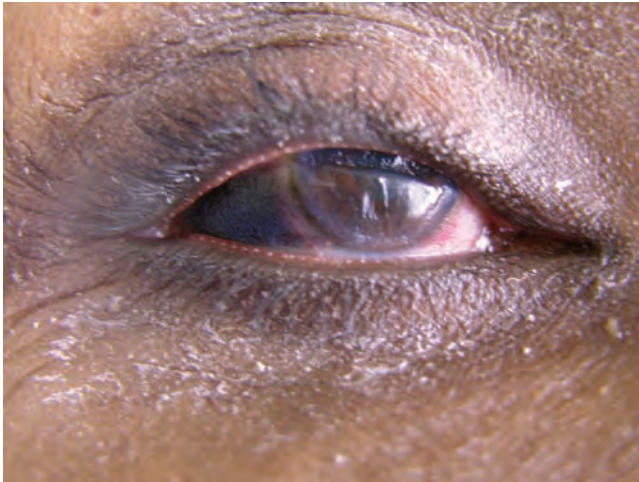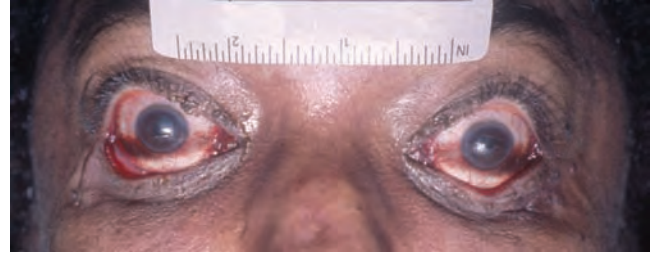
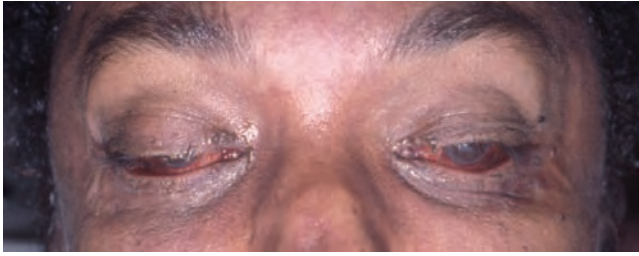


Full rigor mortis. Note the morgue technician pulling tightly on this decedent's arm, which is stuck in a bent position.



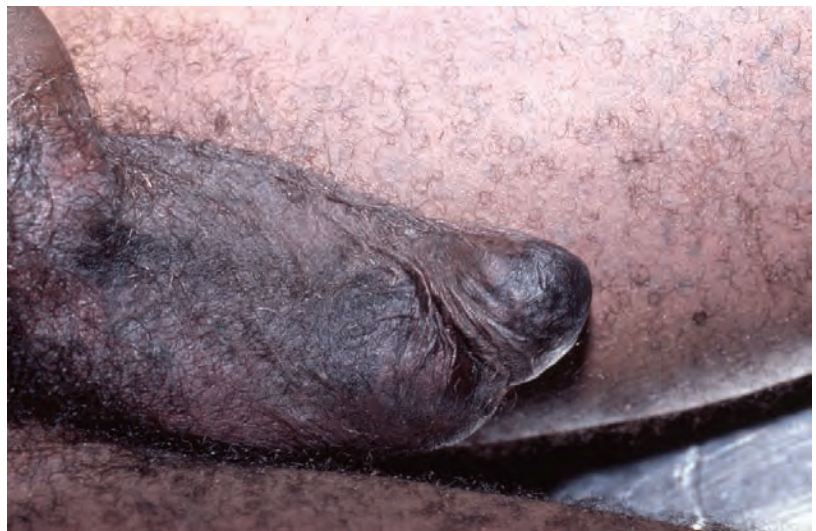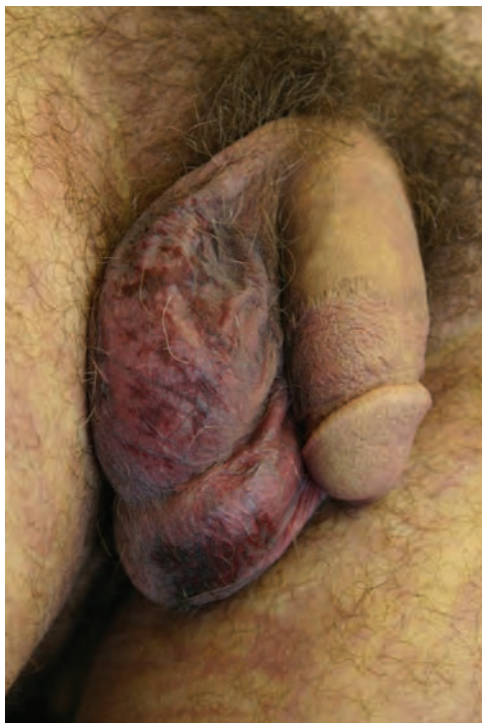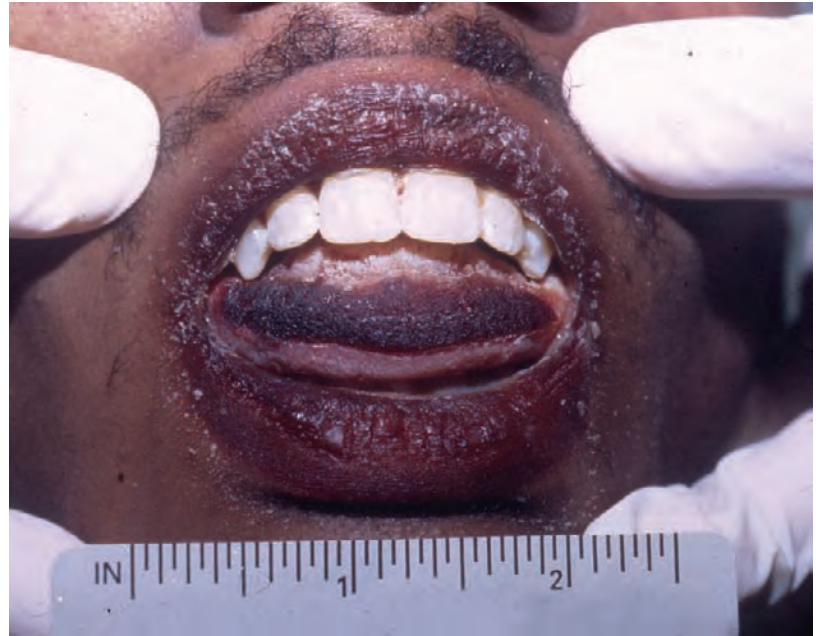Congeaing of fat. Adipose tissue at very cold temperatures will demonstrate increased viscosity. This might be mistaken for poor skin elasticity due to dehydration, which may or may not be present with congealing of fat. Note figure (b) shows indentations that have been retained following pressure exerted by fingers.



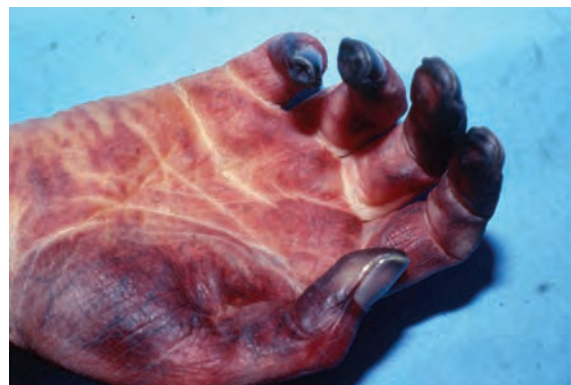
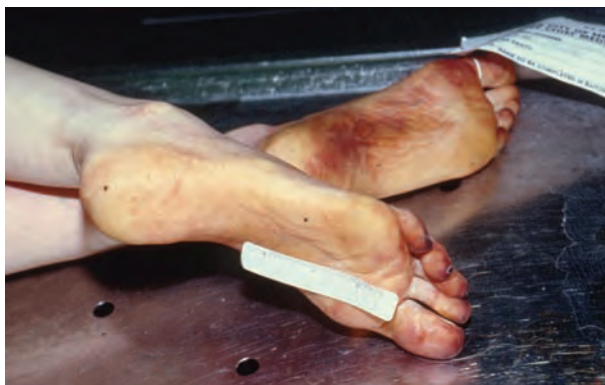
These are examples of "tache noire," which is a dark discoloration of a portion of sclera exposed to air. This is due to drying and is usually brown to red. This postmortem change may be misinterpreted as hemorrhage associated with strangulation.

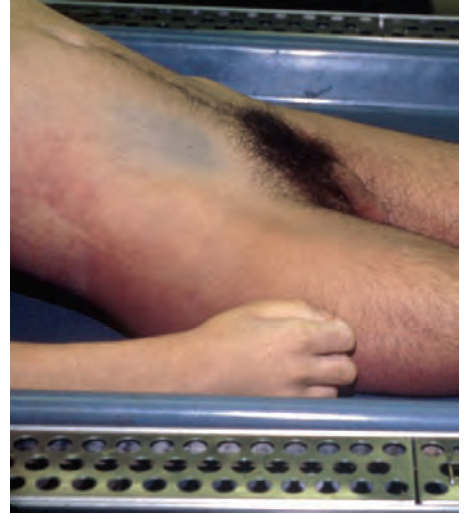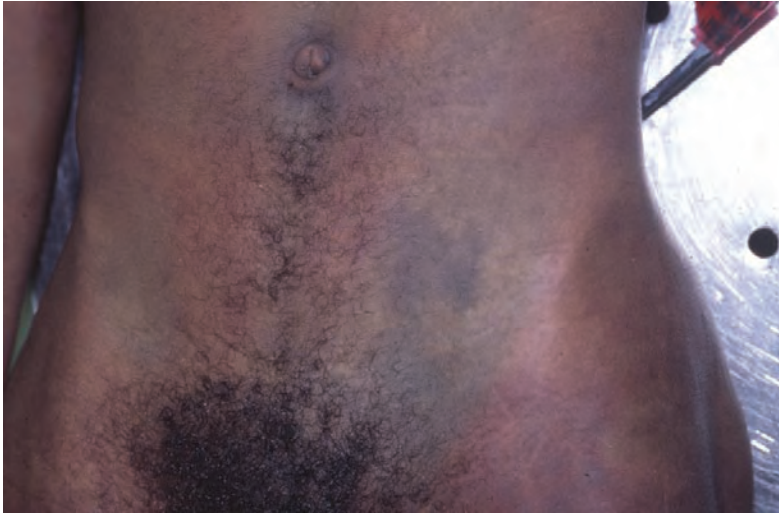
This drying of the lips and tongue with dark discoloration is due to postmortem drying associated with mucosal exposure to air. This may be misinterpreted as an antemortem finding resulting from ingestion of caustic substances. The process of suicidal hanging caused the individual's tongue to stick out and become dry and dark.



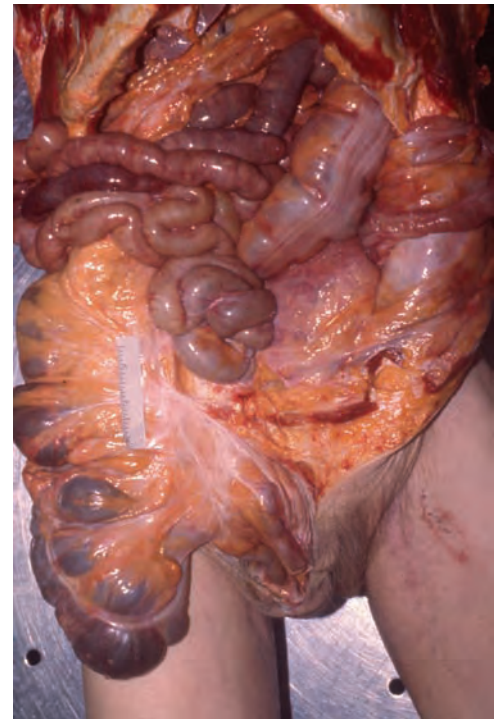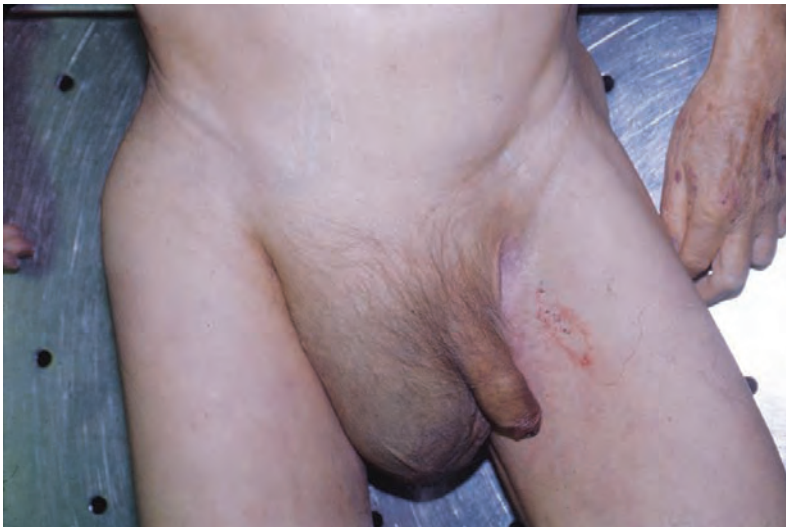This is also postmortem drying with dark discoloration of the scrotum and shaft of the penis. This may also be mistaken for an antemortem injury such as an abrasion. If there is doubt, one may make an incision to document underlying hemorrhage.



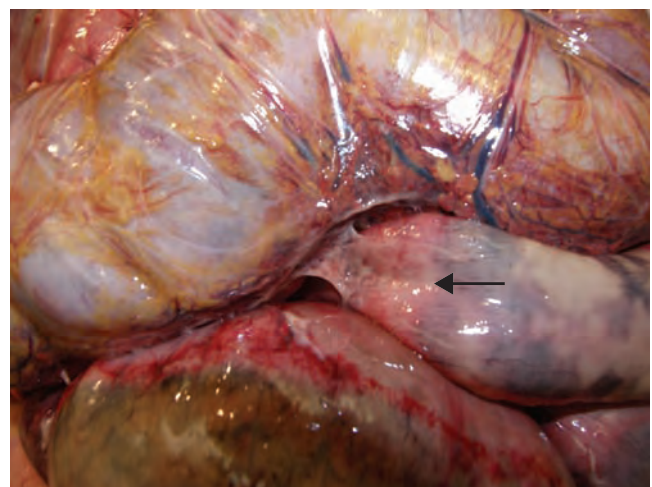
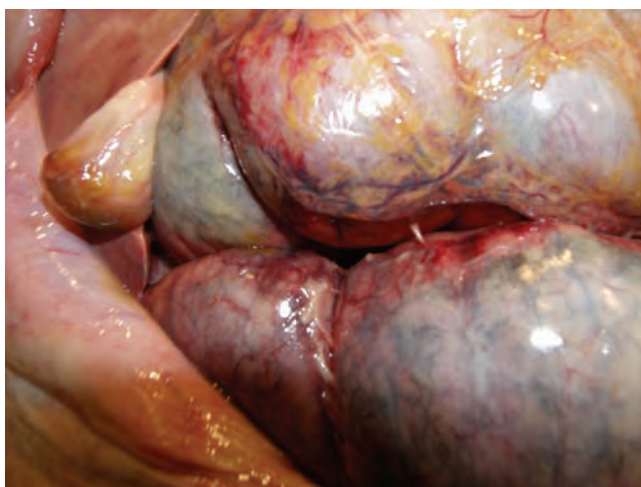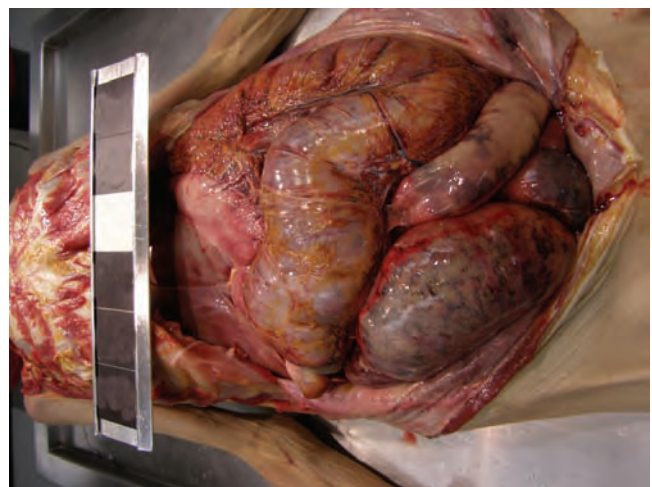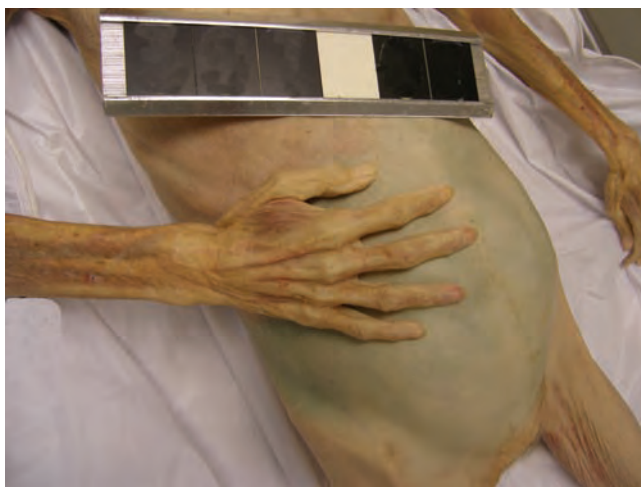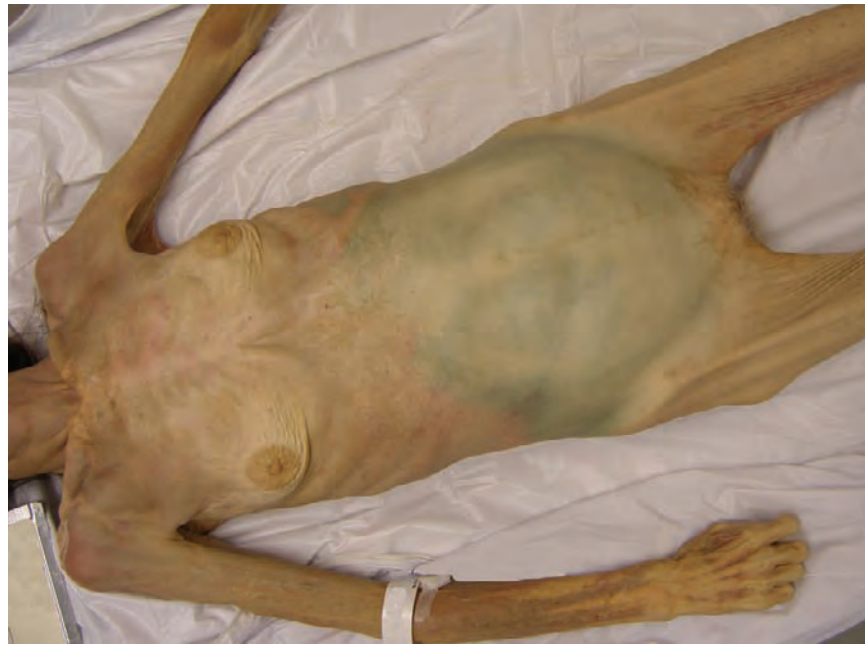This is early mummification with drying of the hands and feet. Note the dark discoloration of the fingers with indentation from dehydration. Portions of the body with larger surface areas relative to underlying tissue mass will mummify more rapidly.



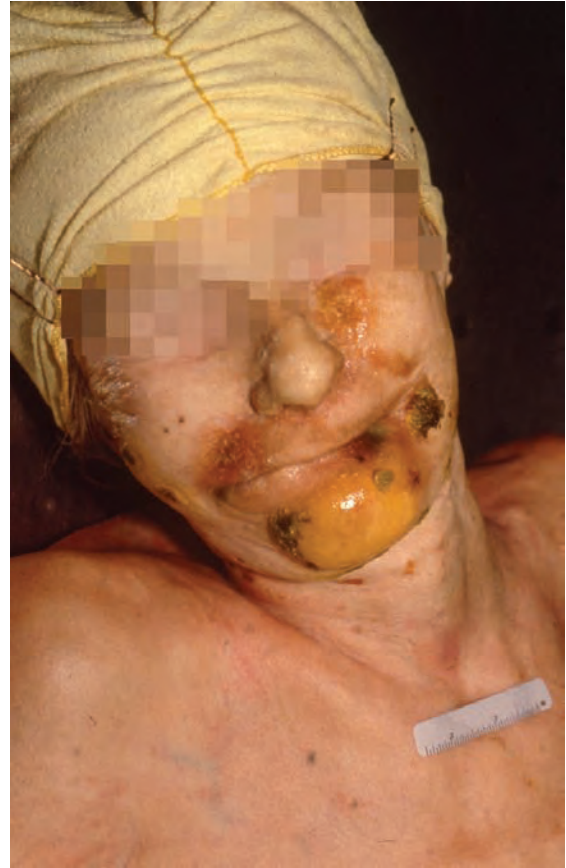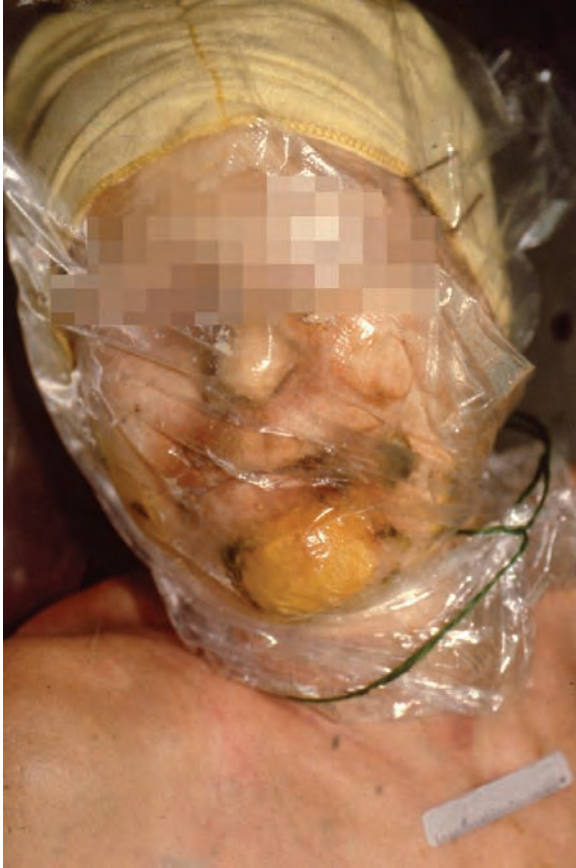Early putrefactive change with green-brown discoloration of the lower abdomen. The first place for this to occur is typically the lower left abdomen above the cecal region.



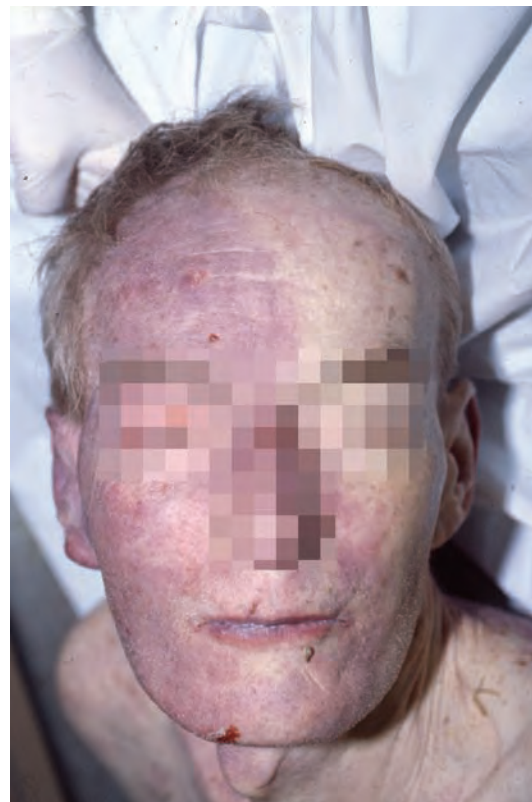This large hernia demonstrates early decomposition with slight green discoloration of the scrotum due to a portion of the large intestine extending into the scrotal sac.



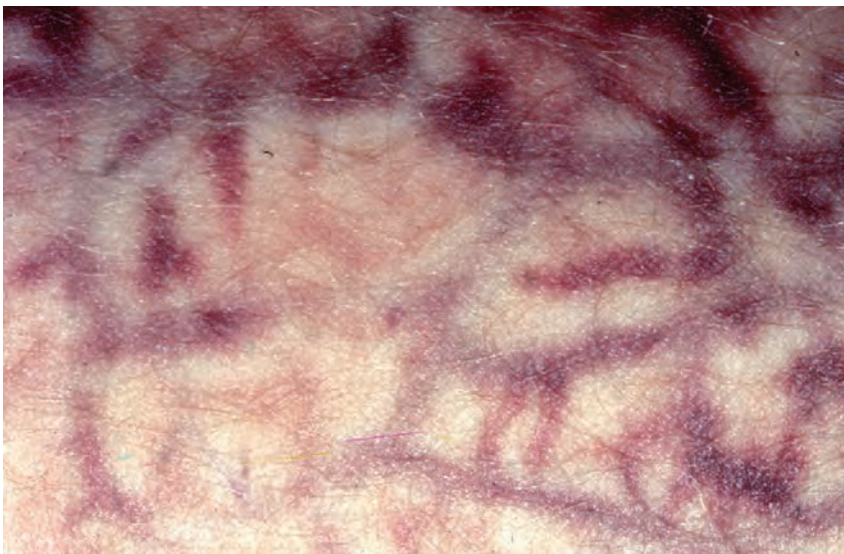
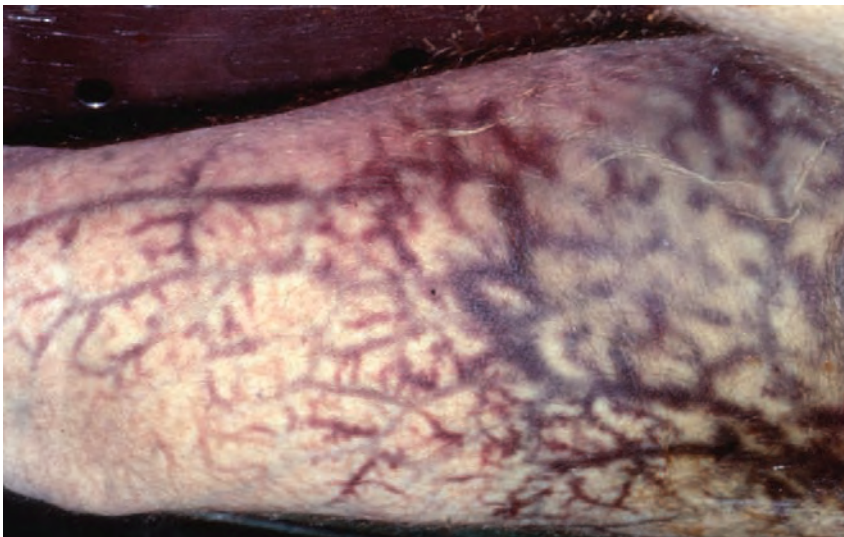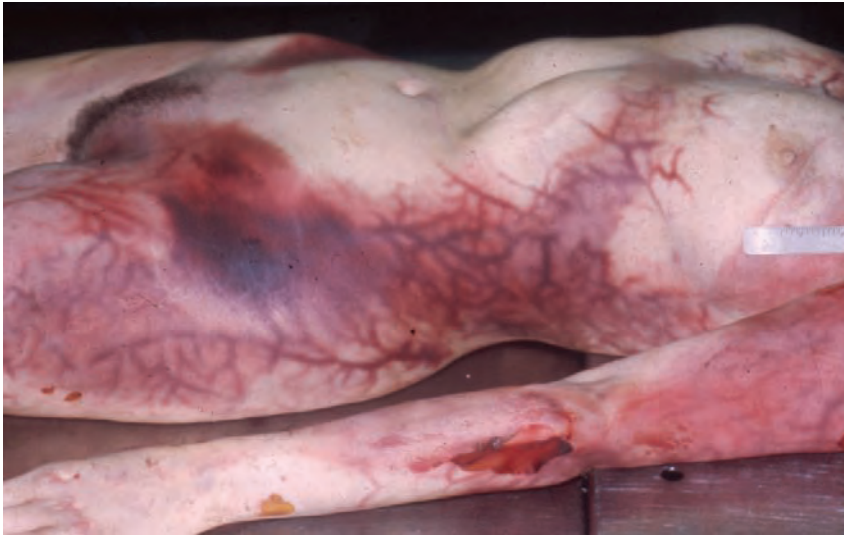Disproportionate advancing putrefactive change of the abdomen due to acute peritonitis. Note the green discoloration of the abdomen and the absence of green discoloration elsewhere. The presence of infection with bacteria caused this regionally accelerated process. Note the parulent exudate at the surface of the intestines, indicated by the arrow.



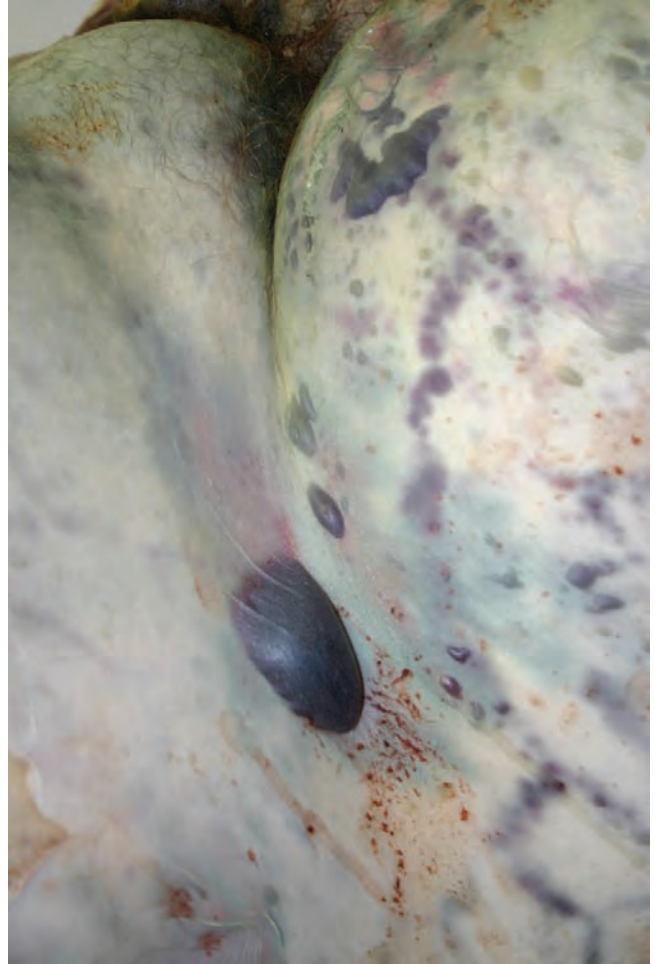
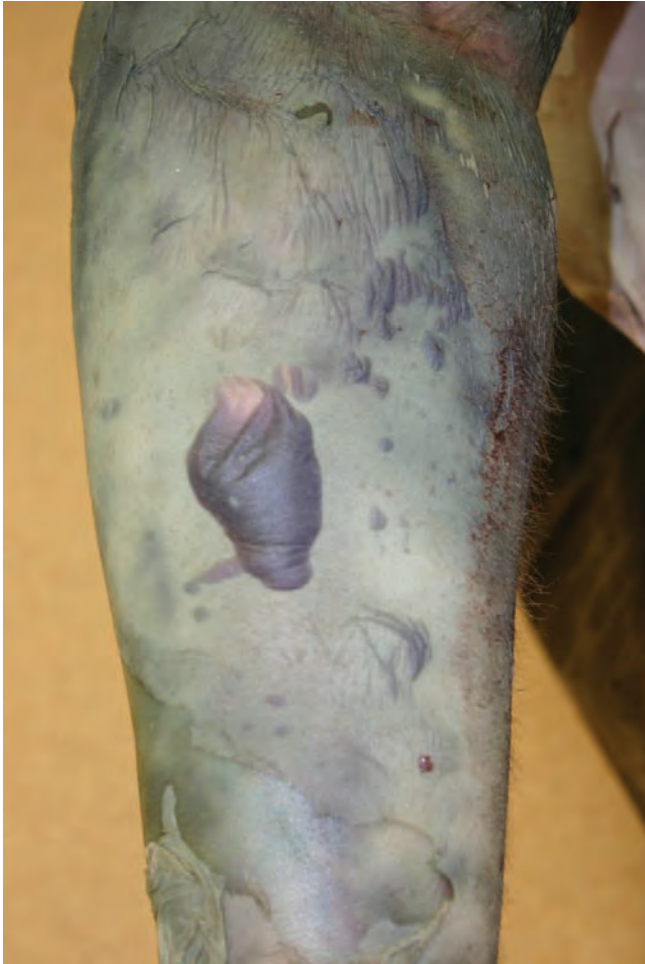This individual committed suicide by ingesting excess prescription medication and placing a loosely fixed plastic bag over the head. The moisture collecting at the face covered by plastic during breathing helped to create an environment where mold and mildew could form at the chin and face.



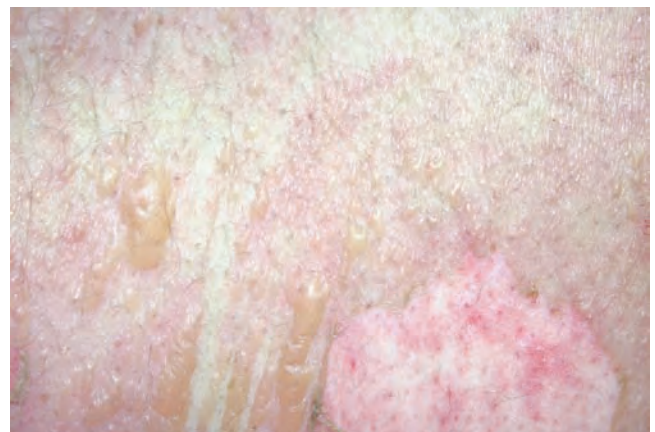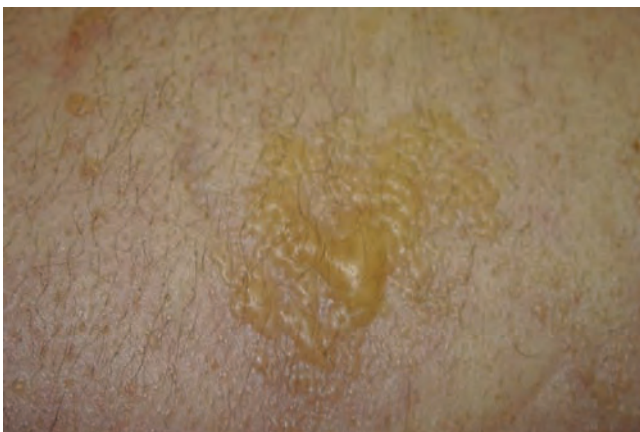Postmortem hot water burns of the face in this individual, who was found partially submerged in the warm water of a bathtub. He suffered a cardiac event while taking a shower. It requires less heat to cause thermal damage to a dead body than to a living body. Note the sharply demarcated red region indicating his nose and mouth were below the hot water.



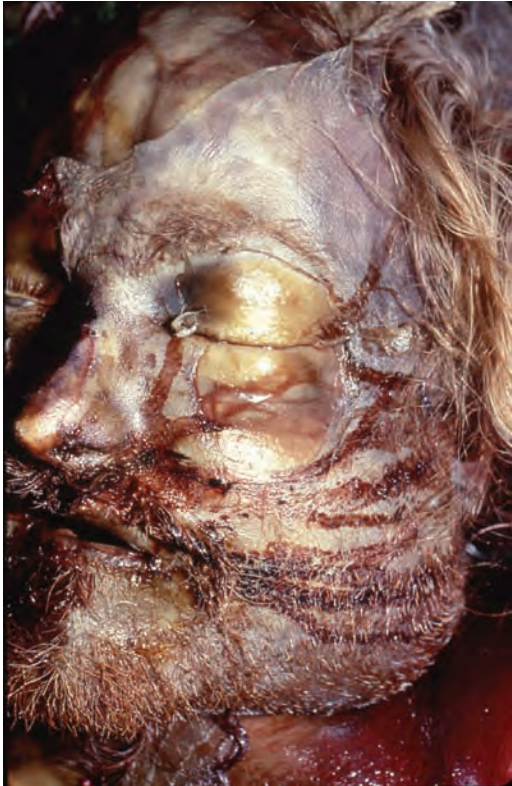Marbling. This early presentation of putrefaction is predominantly caused by bacteria tracking through the superficial blood vessels causing pigment changes in blood and vessel walls as microorganisms digest the body.



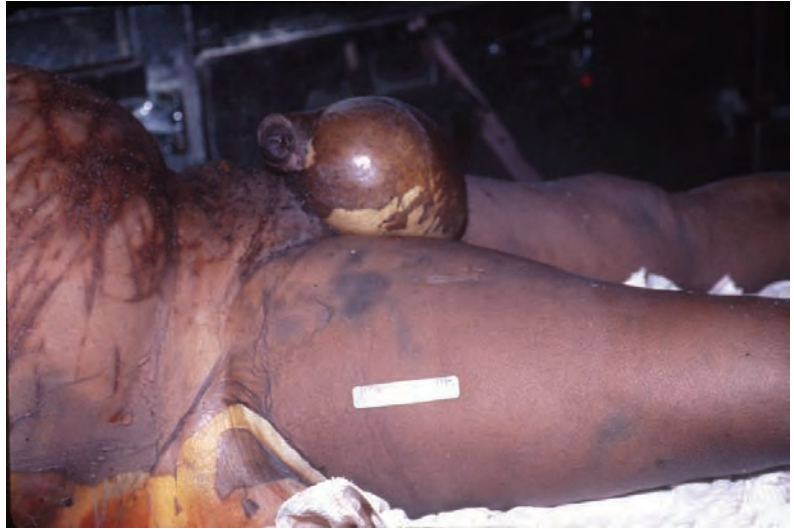Early to moderate putrefactive change with green-brown fluid-filled blisters. Such blisters may be mistaken for second degree thermal burns or aggressive antemortem bacterial skin infections.



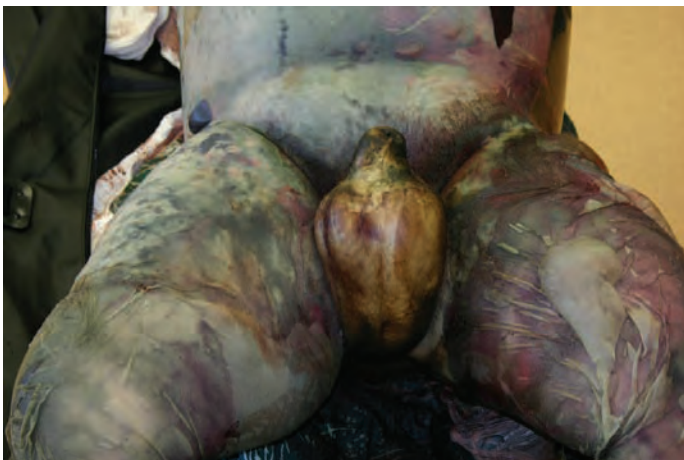Early putrefactive change with clear yellow fluid-filled blister formation. The rupture of these blisters would appear as skin slippage.



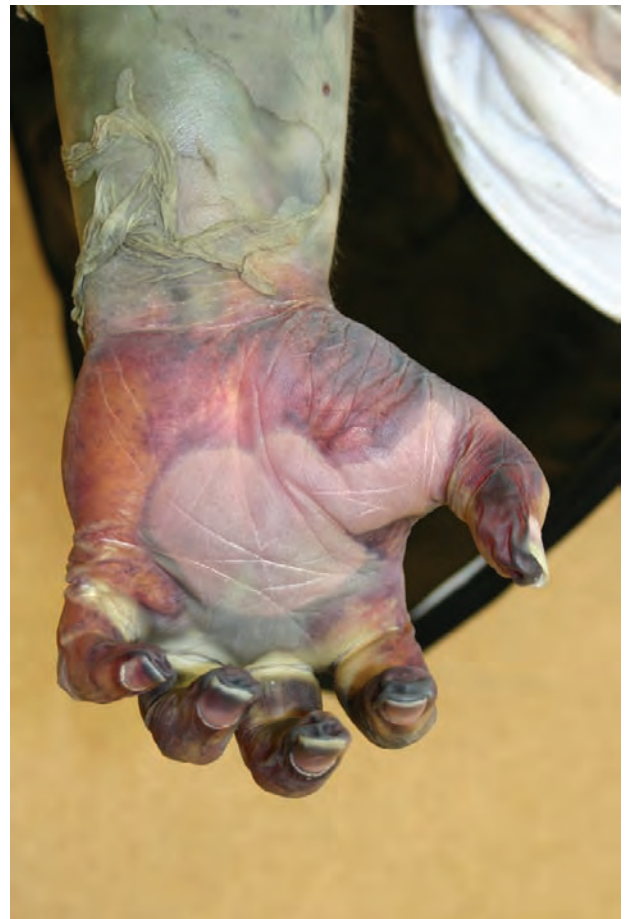Putrefaction with "purging." Note the red to brown fluid gurgling from the mouth and nose. This can sometimes be mistaken for an upper gastrointestinal hemorrhage.



Putrefactive change with bloating and expansion of the scrotum due to gas accumulation.

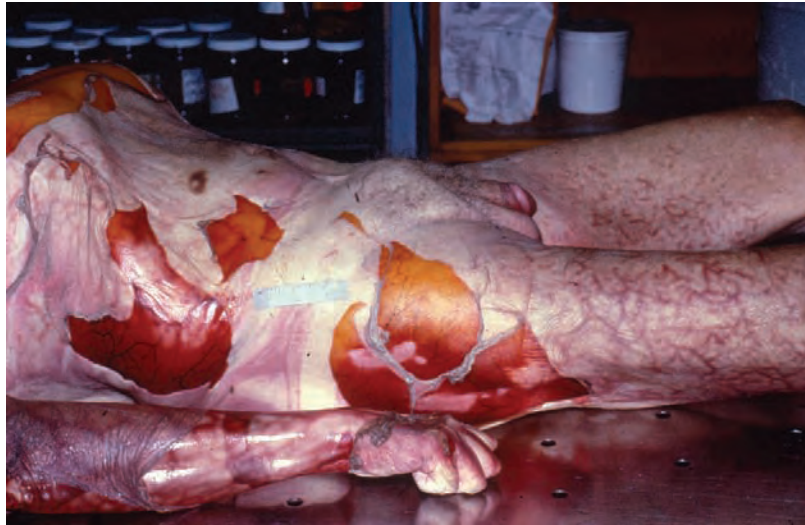

Green-brown-red discoloration with fluid-filled blister formation and skin slippage, scrotal enlargement from gas formation due to metabolism of proliferating microorganisms.

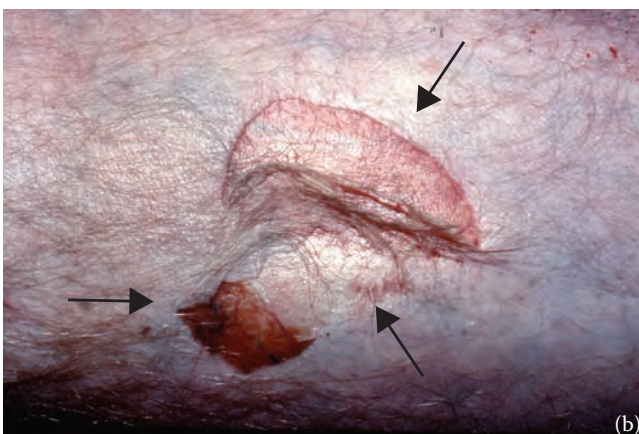
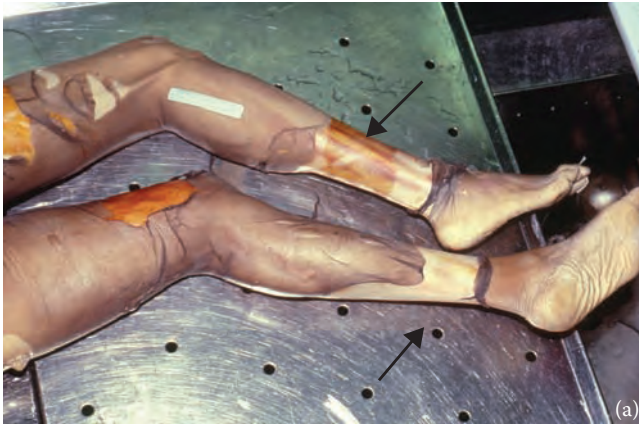


There is mummification of the fingertips with an expanded gas-filled blister and green to brown putrefied fluid in its inferior aspect.

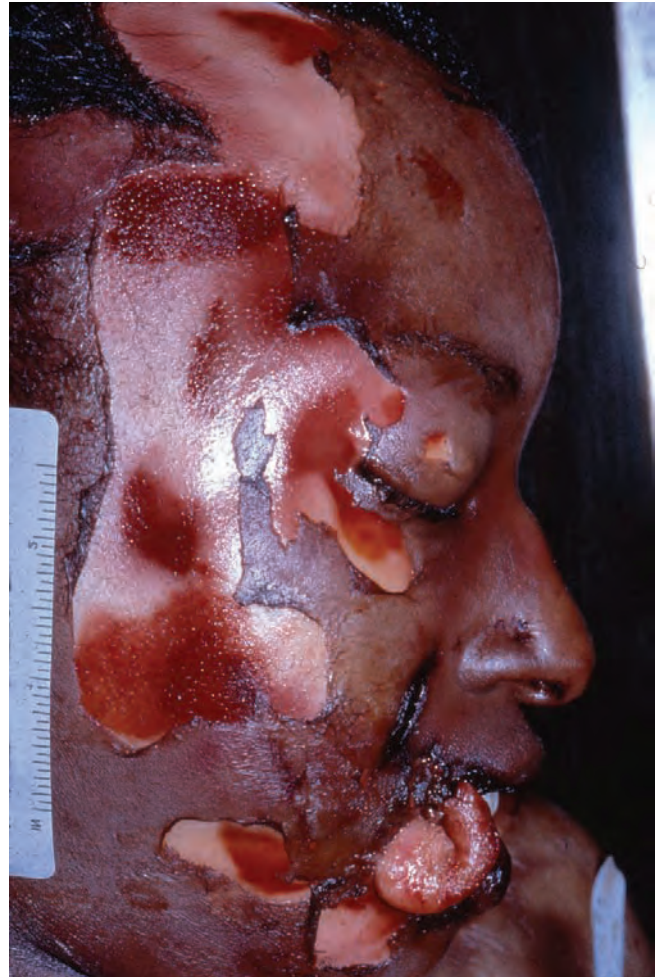



Marbling and skin slippage; early to moderate putrefaction.



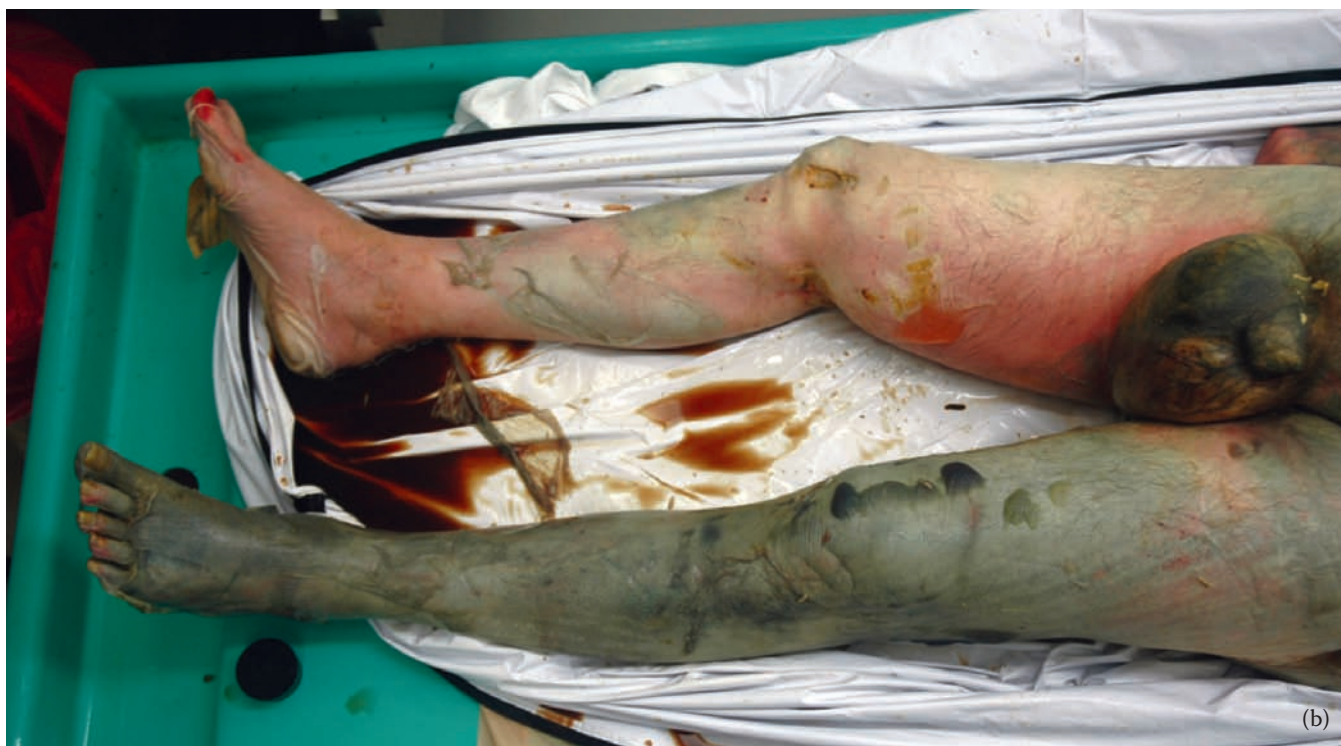These images, (a) and (b), demonstrate skin slippage that occurred at different times. Note the regions of underlying dermis that are dry and dark, indicating older regions of skin slippage. Also note the other adjacent regions, which are moist, pale, and less dark, indicating shorter duration of underlying dermis exposure to air. This darker discoloration is due to more drying and longer exposure to the air.



Decomposing homicide victim with multiple decomposing blunt impact injuries. The combination of postmortem change with injuries may make interpretation challenging. Note the red to brown abraded contusions at the individual's face and head, with skin slippage and darker discoloration.

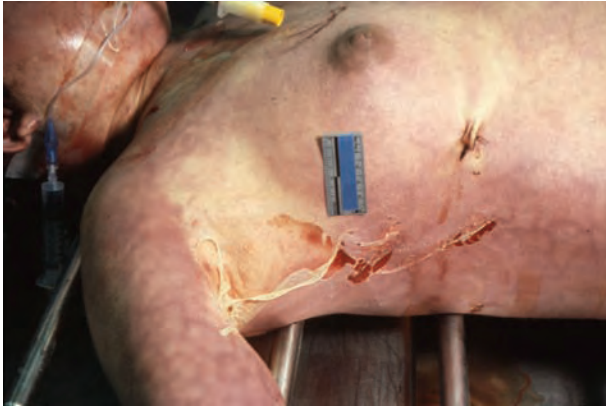


(a)

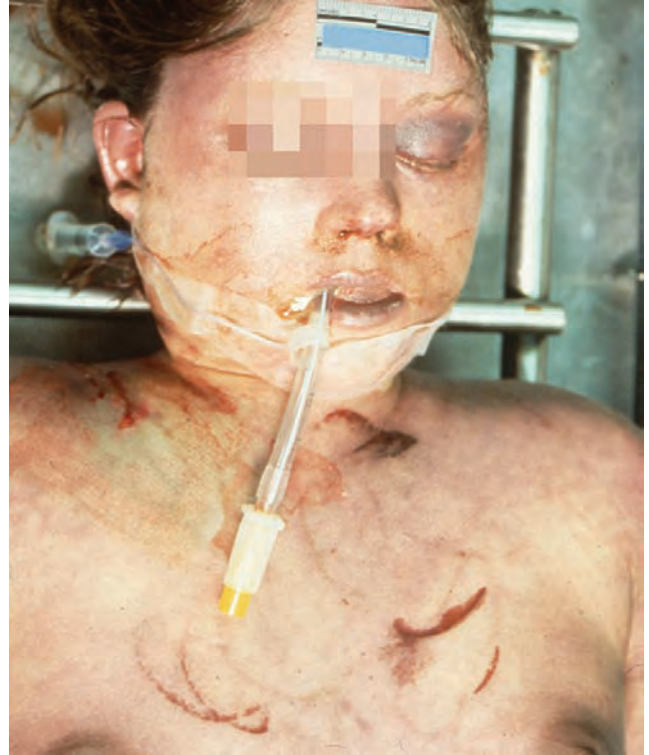

(b)

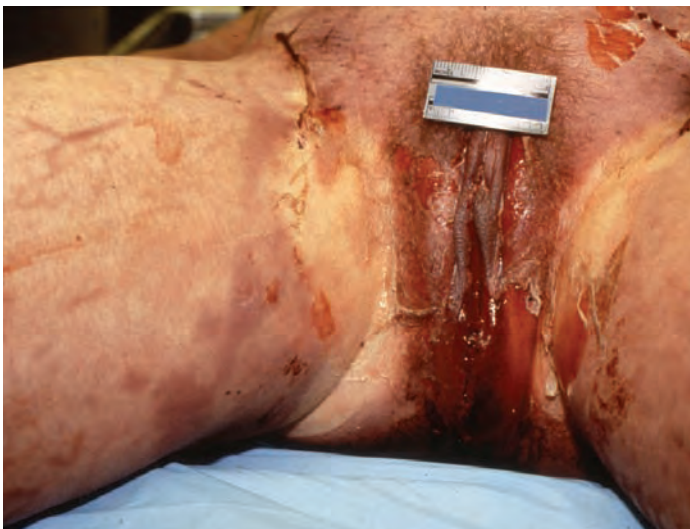This individual was found lying on his left side with a mild to moderate degree of putrefaction. Note the puddle of purged fluid underneath his upper trunk and head (a). Also note the greater decomposition with green discoloration in the regions of dependent lividity where the body contacted the warm floor. Purged fluid such as this is often misinterpreted as the result of traumatic injury.



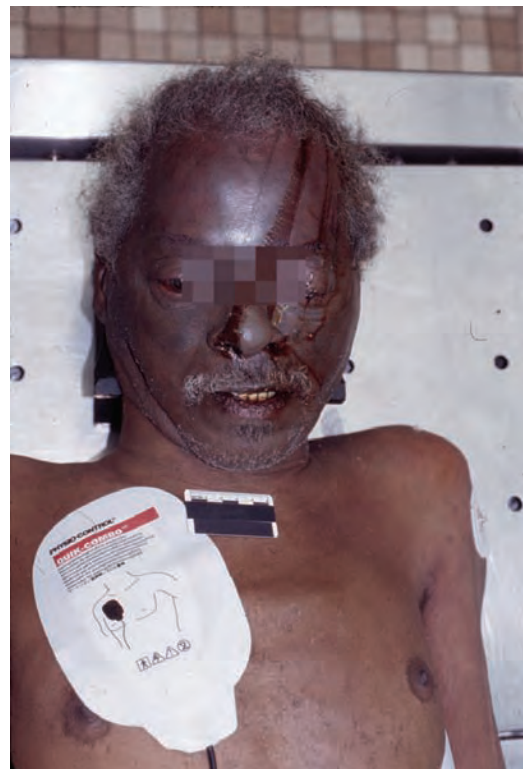Accelerated putrefaction due to bacterial sepsis at the time of death. This picture depicts the left side of the patient's body with extensive skin slippage as well as green discoloration within the left infraclavicular area. Additionally, an endotracheal tube can be seen protruding from the mouth and taped to the side of her face. Such a depiction might lead one to conclude that overzealous paramedics had worked on a decedent who was decomposing. Marbling is also visible on the lateral and anterior aspects of the left arm. What this case really illustrates is the rapidity with which bacteria, already present within the blood stream at the time of death, can disseminate and propagate throughout the blood system, leading to accelerated postmortem putrefactive change.



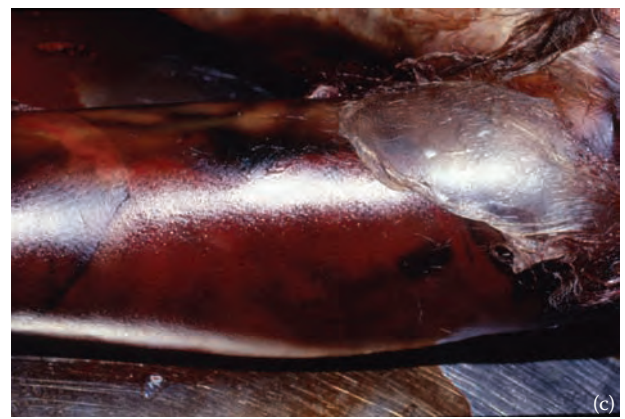
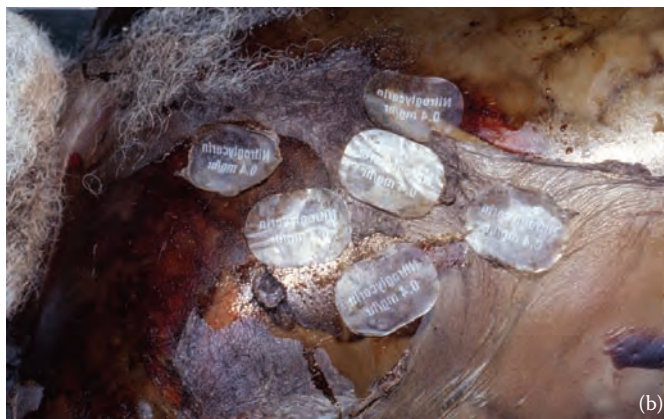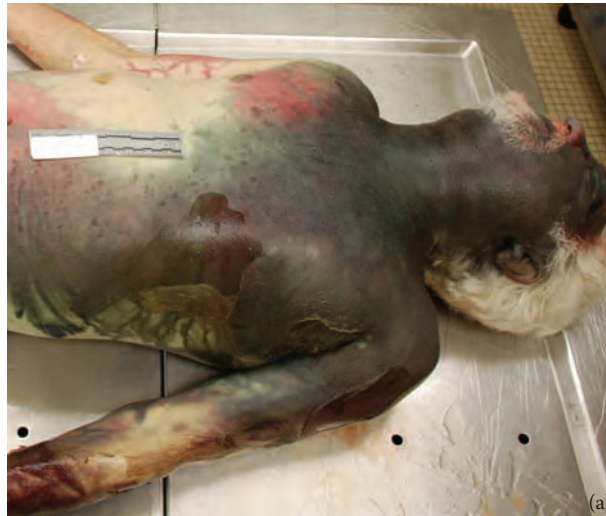Same case with front view of patient's face, also illustrating green discoloration around right infraclavicular puncture site and defibrillator marks.



This is the same case, demonstrating skin sloughage and exudation of hemolytic fluid from the external genital region.



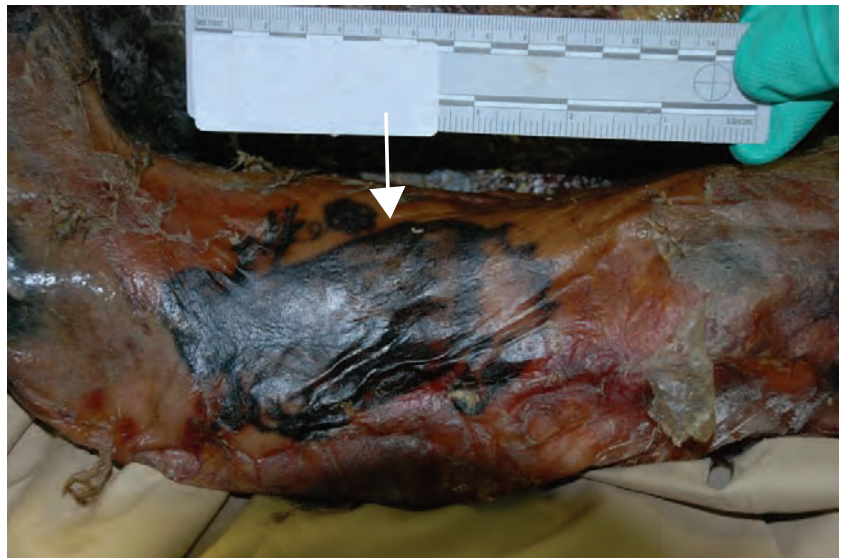
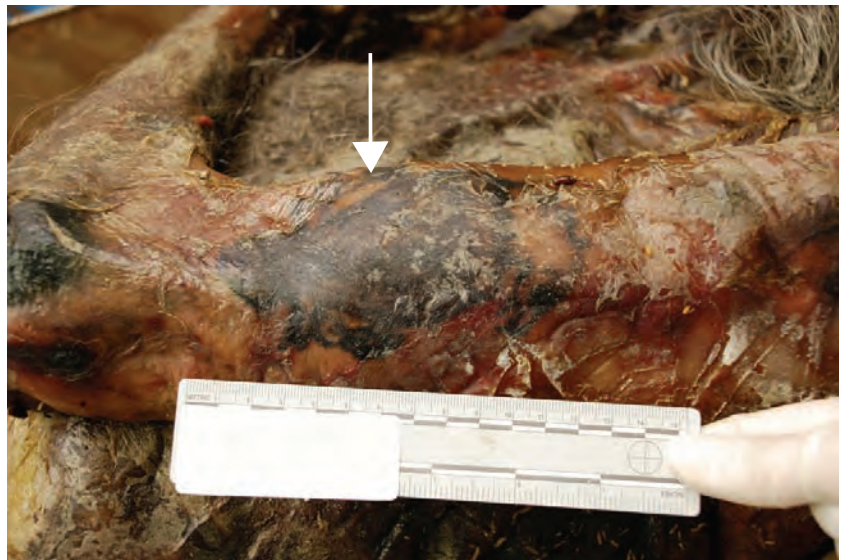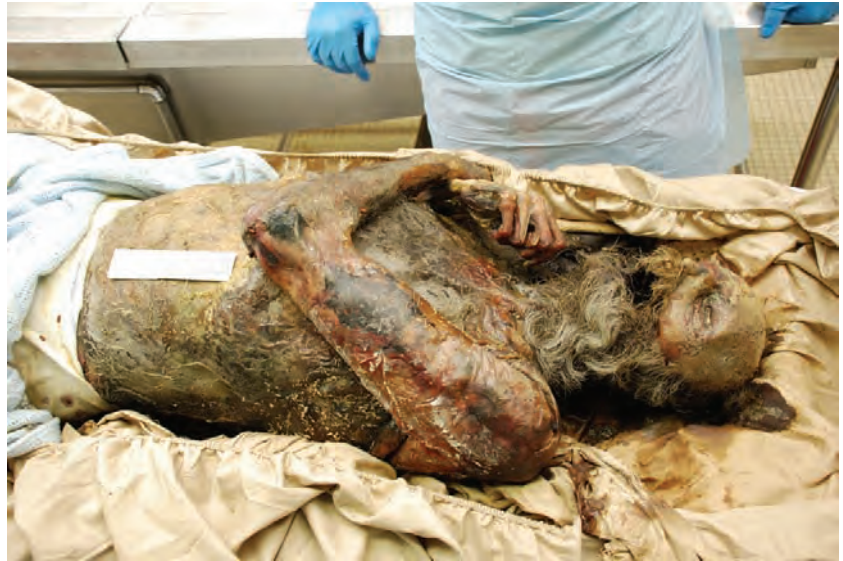Another case depicting a decedent with dark red-brown discoloration due to postmortem putrefactive change that was accelerated by the probable bacteremic state at the time of death.



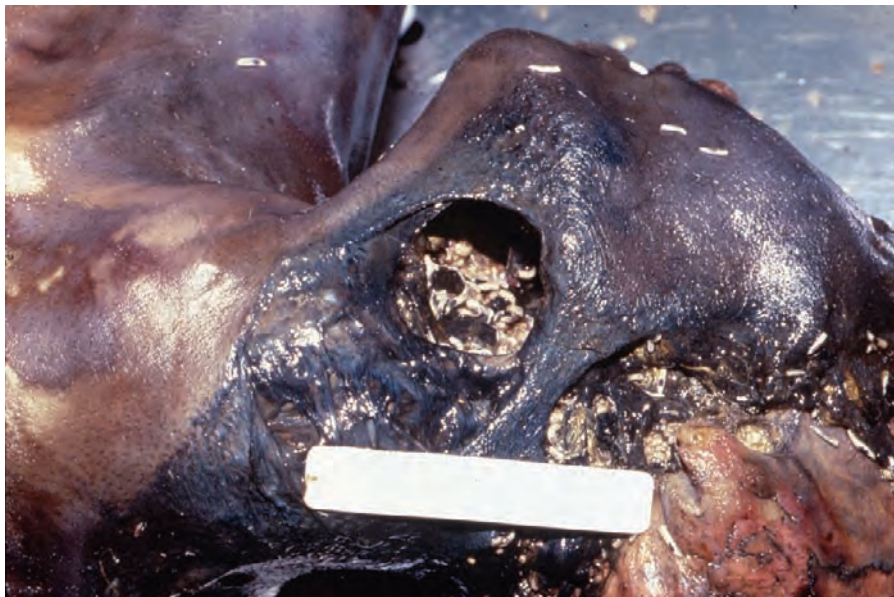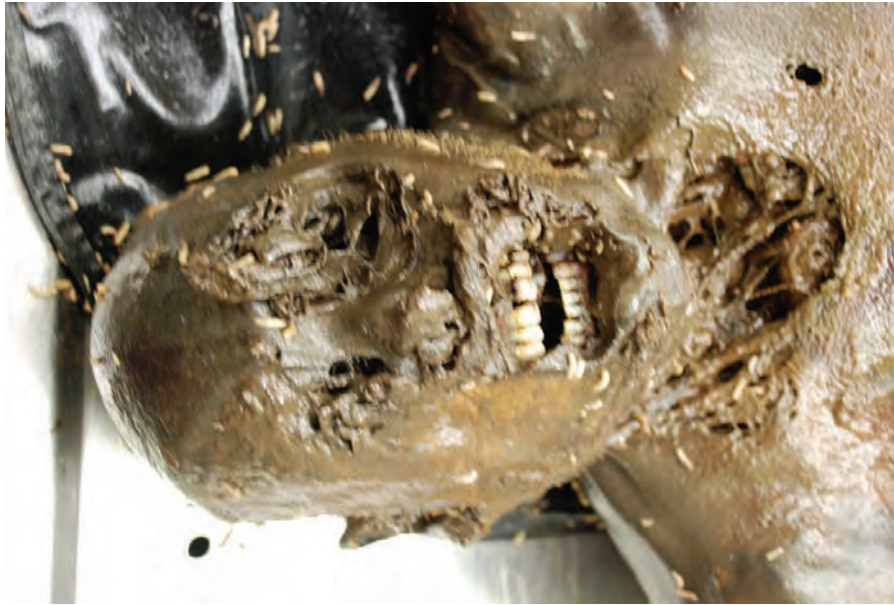Skin slippage with confluent red to brown discoloration, moderate putrefaction. Note figure (b) shows multiple nitroglycerin patches in an individual with known significant heart disease.



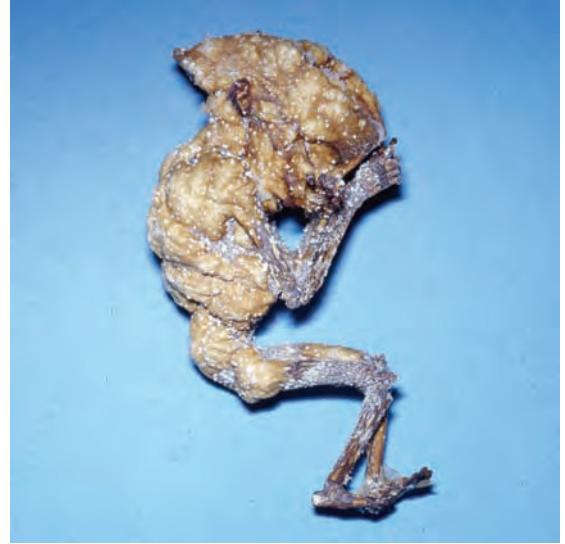
Moderate to marked putrefaction with dark brown discoloration and early mummification.



Moderate to marked putrefaction. Identification may sometimes be challenging with advancing decomposition. This individual had a tattoo on his left arm that was initially difficult to view due to putrefactive change. Cleaning of this area with removal of the superficial layers of skin made visualization and thus identification much easier.



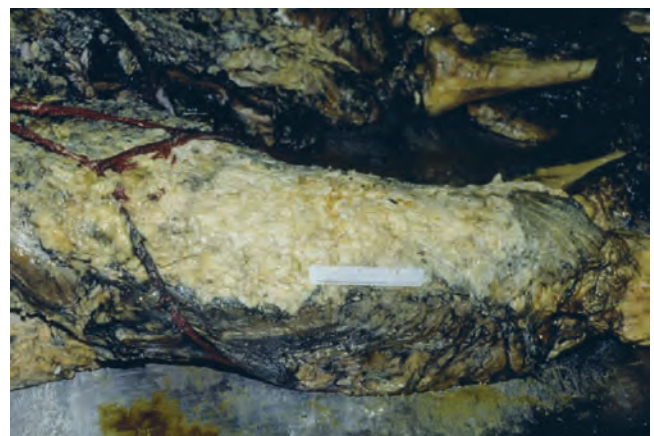
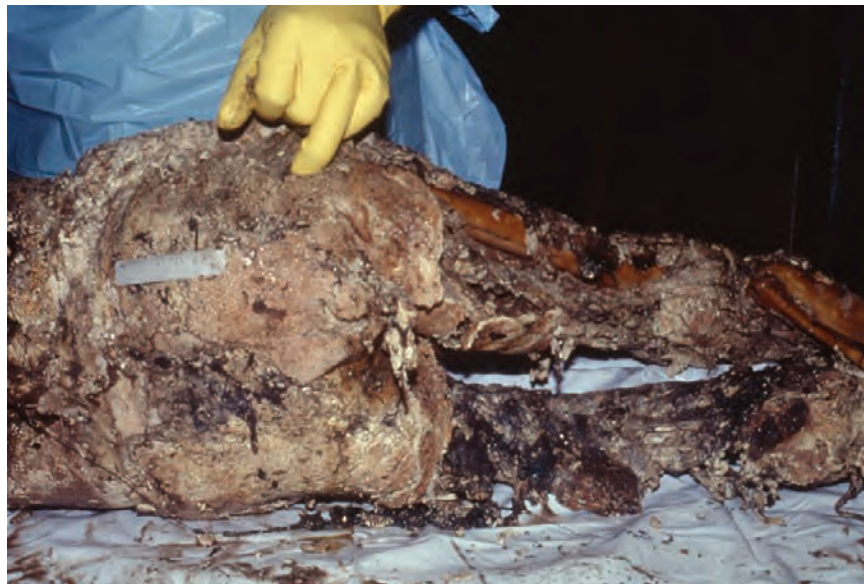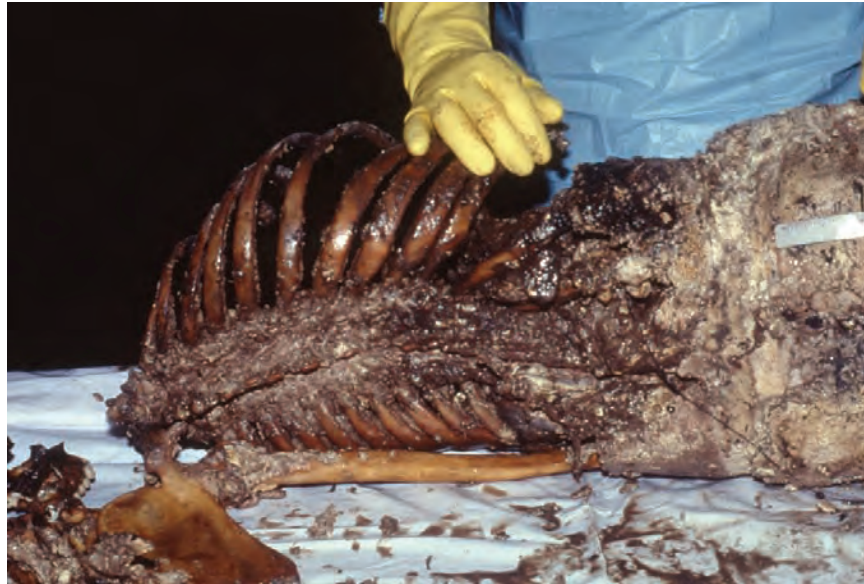Marked putrefactive change with dark brown discoloration and maggot feeding. Note the small circular perforations caused by maggots tunneling through skin and soft tissue.



Mummified fetuses retrieved from dried-out formaldehyde containers found within an abandoned building that once housed a doctor's office that closed more than 30 years earlier.



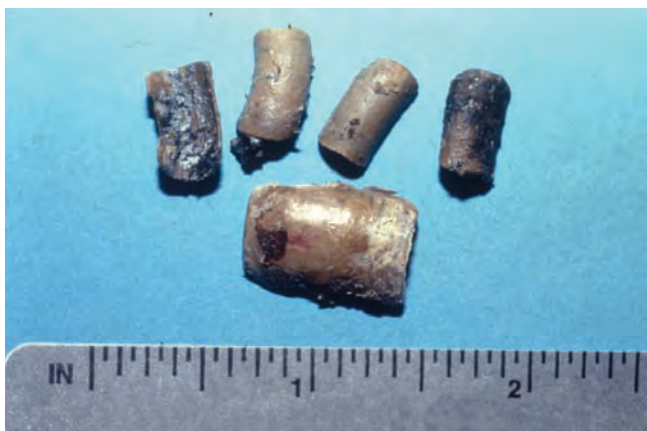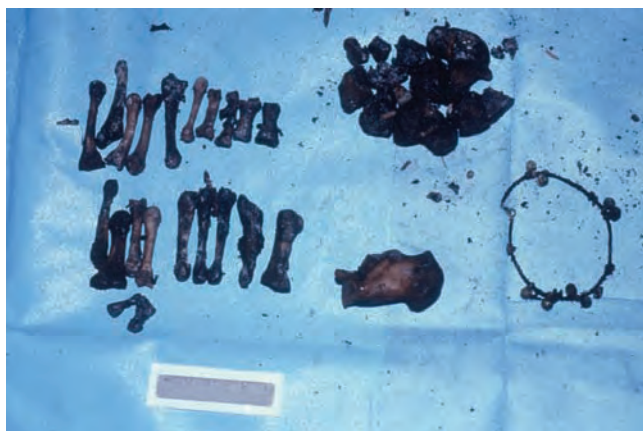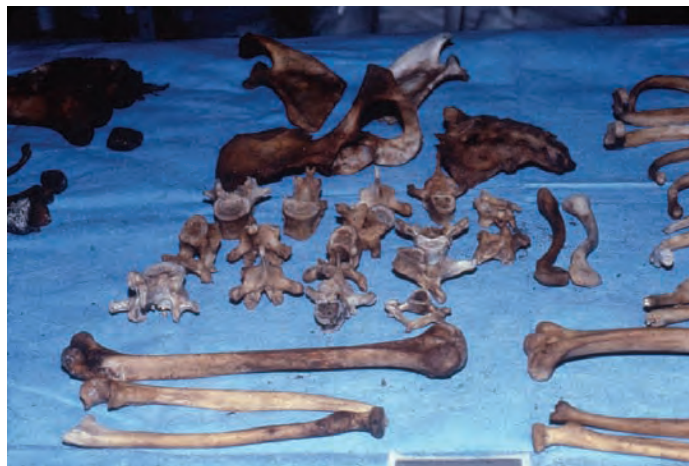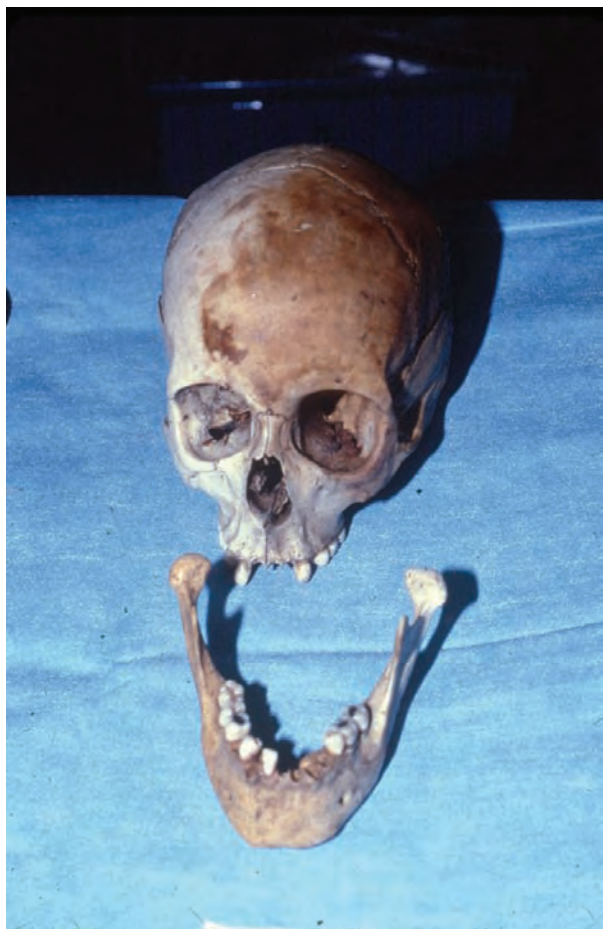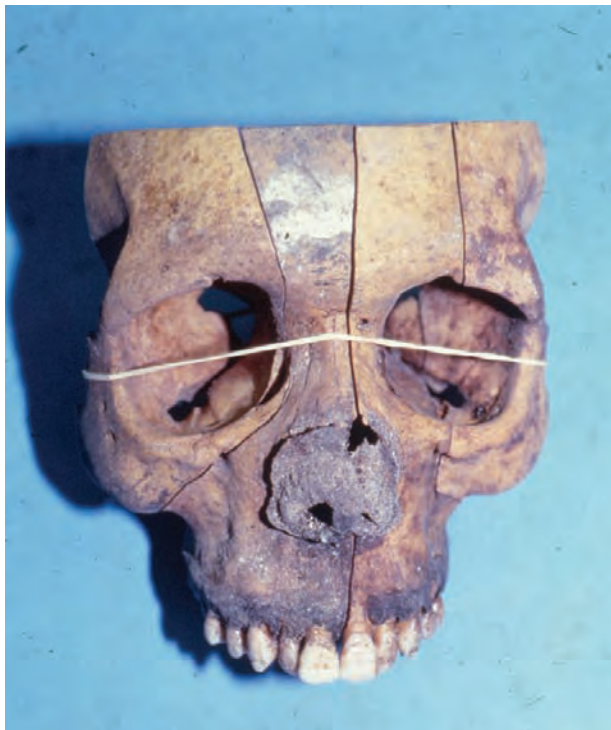Advanced decomposition with mummification of the entire body. Note the dry dark leathery appearance of the skin.



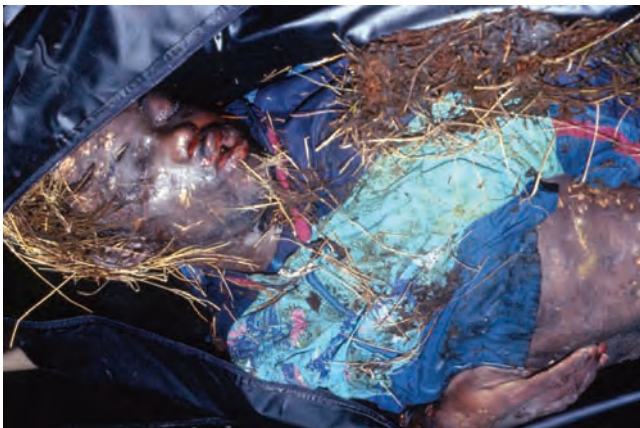Adipocere is a decomposition process seen with immersions or damp, warm environments. The neutral fats are converted to oleic, palmitic, and stearic acids. Note the white/tan-colored adipocere, which has a waxy feel. In some areas you can see a light sheen of oil on the surface. Once formed, adipocere is resistant to further decomposition.



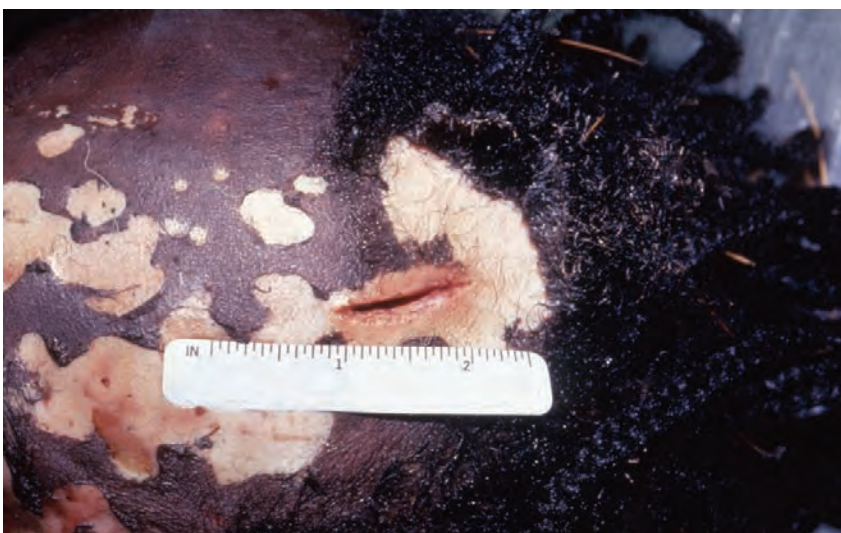Skull found tucked under the bottom of a stairwell in the basement of a brownstone in Brooklyn, New York. Note the dried skin at the nose. There was resin and perforation of the cribriform plate. This was the historical remains of an Egyptian mummy skull that was most likely used in religious ceremonies. There were also commingled chicken bones, feathers, and wax.



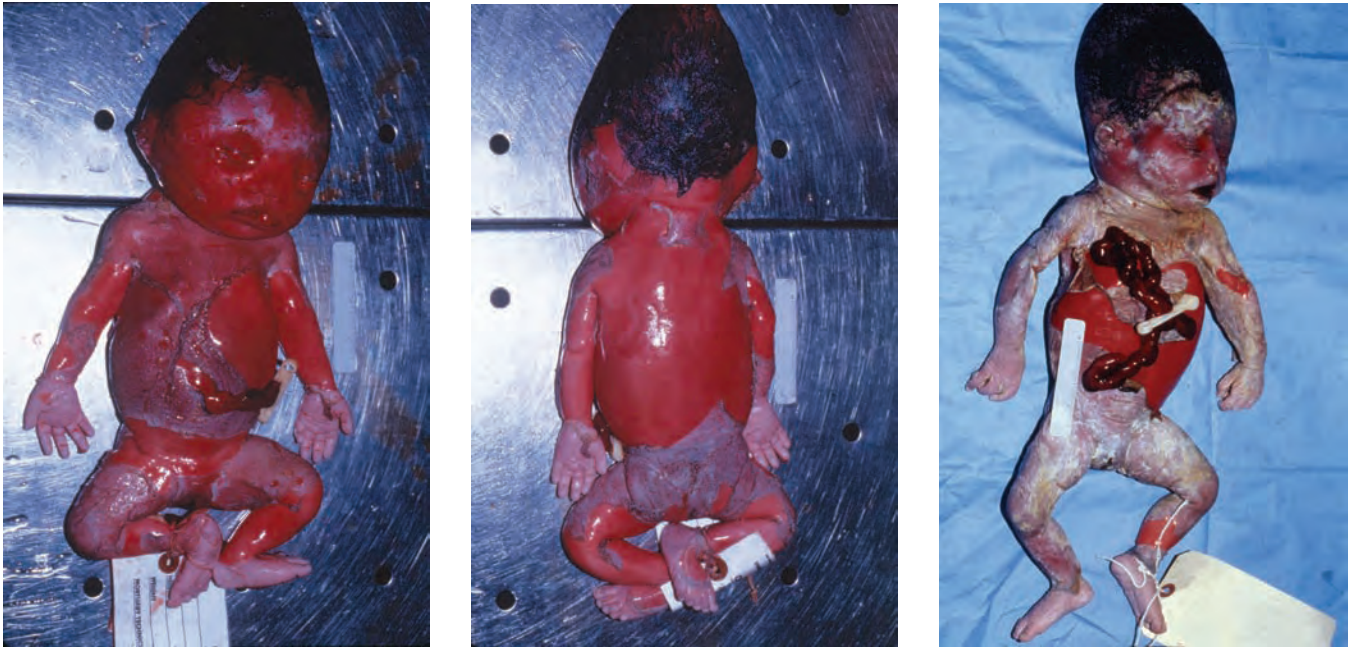
Advanced decomposition with skeletonization from a body dumped in a wooded area approximately 1 year earlier. The last image demonstrates five toenails from inside a shoe.



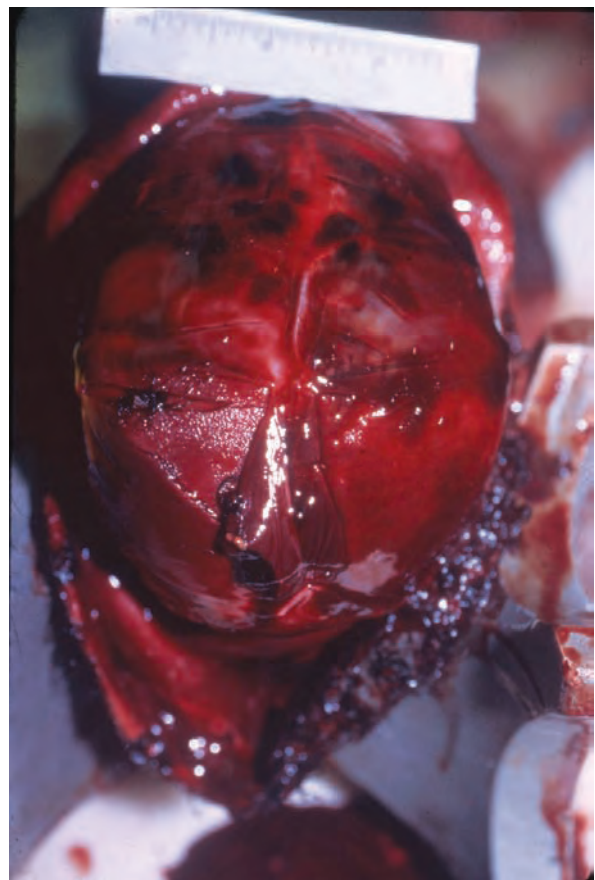
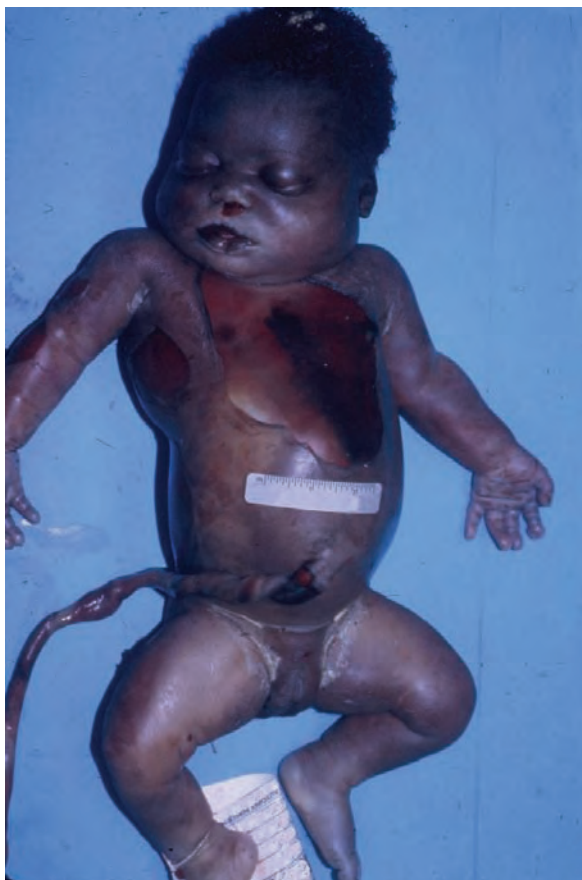This frozen individual was murdered approximately 1 month prior to being found. His body was in a slight state of putrefaction due to preservation by the freezing winter temperature. Once the body thawed out for autopsy, putrefaction advanced at a markedly accelerated rate.



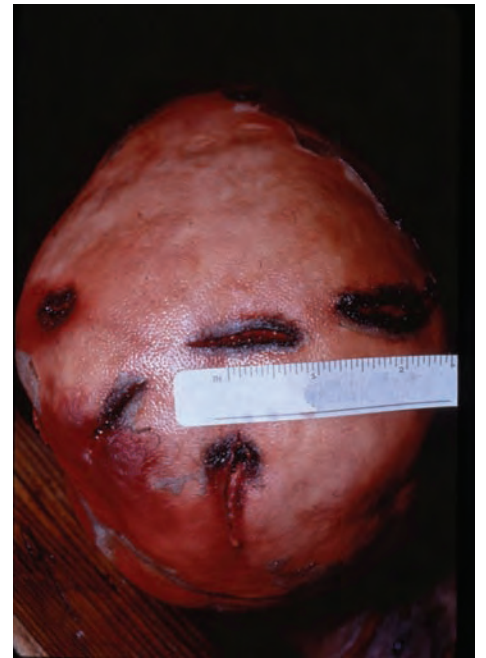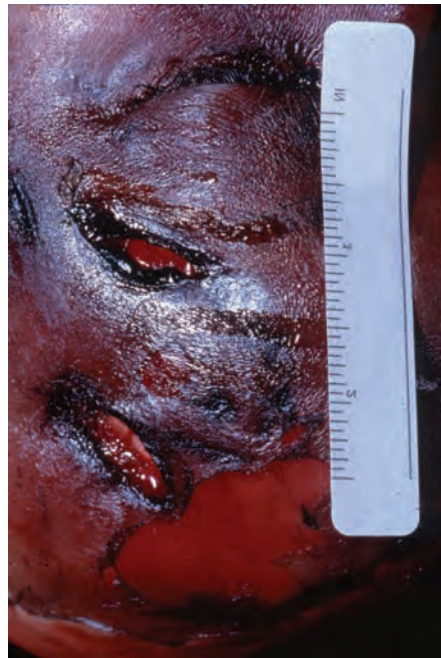
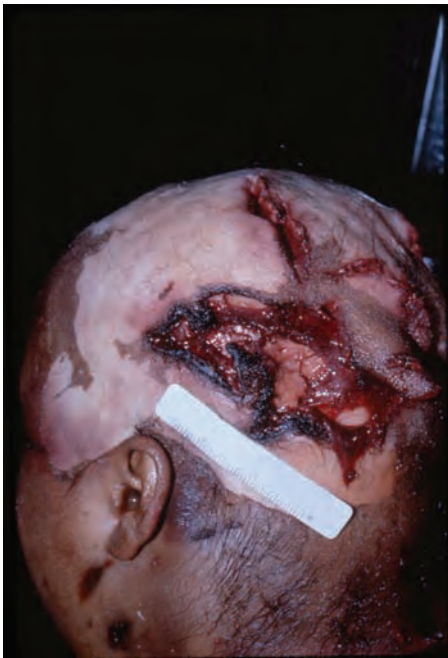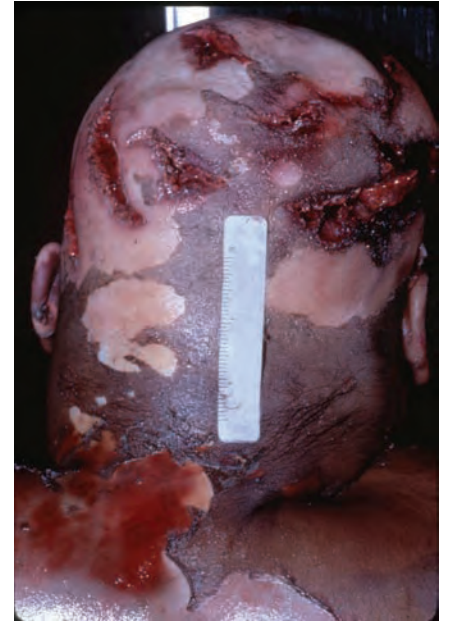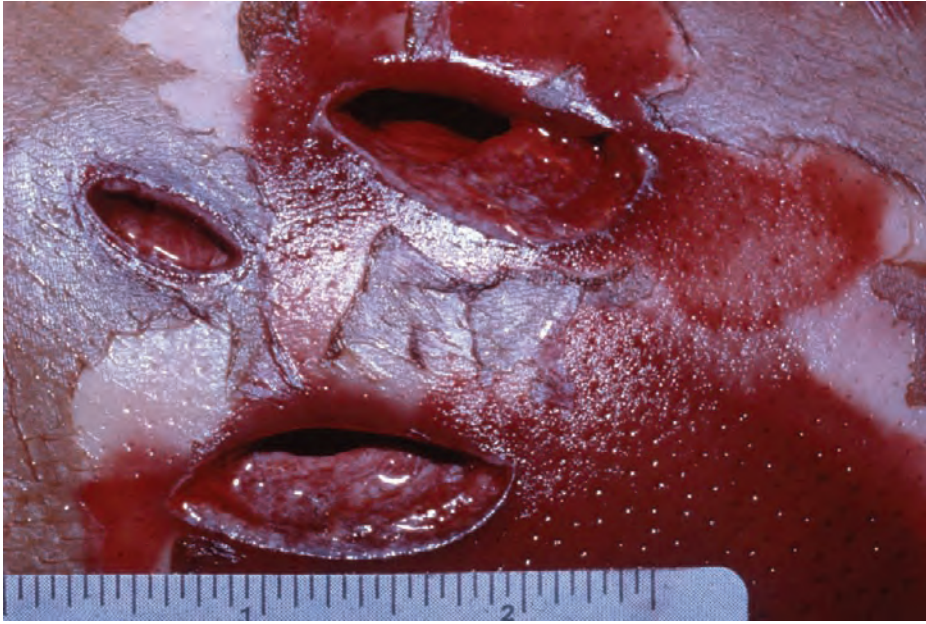Photograph taken at time of autopsy. Note the advancing putrefaction with skin slippage. Also note the scalp laceration.



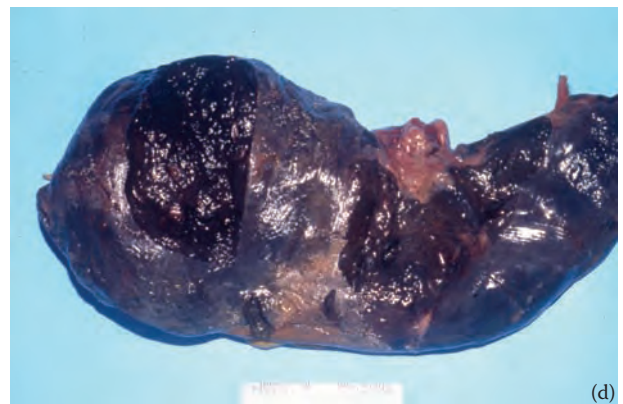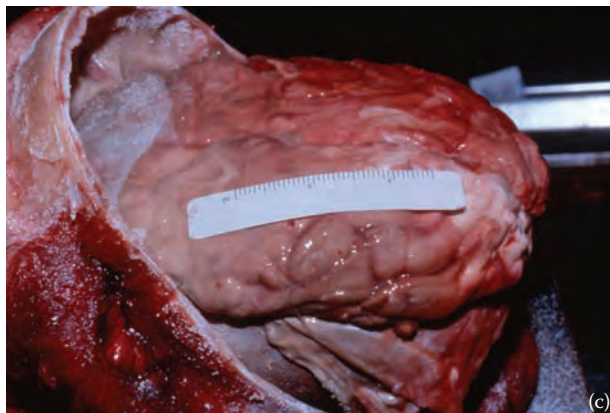
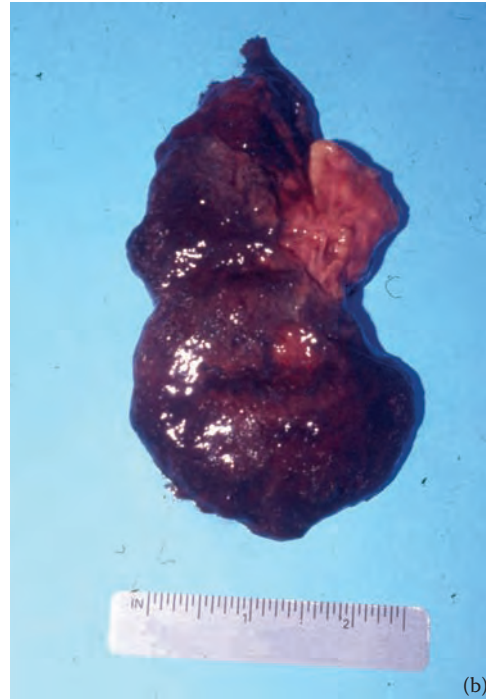
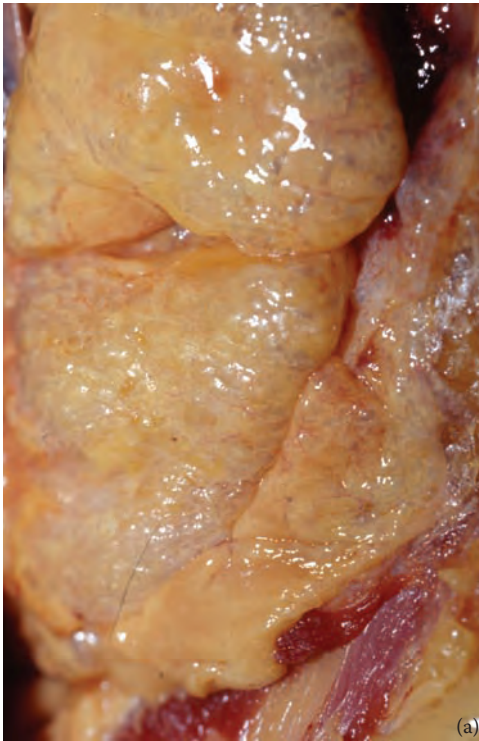Macerated stillborns with red to brown discoloration. This type of decomposition is autolysis. The womb is normally a sterile environment and there should not be putrefaction unless there is an infection such as chorioamnionitis.



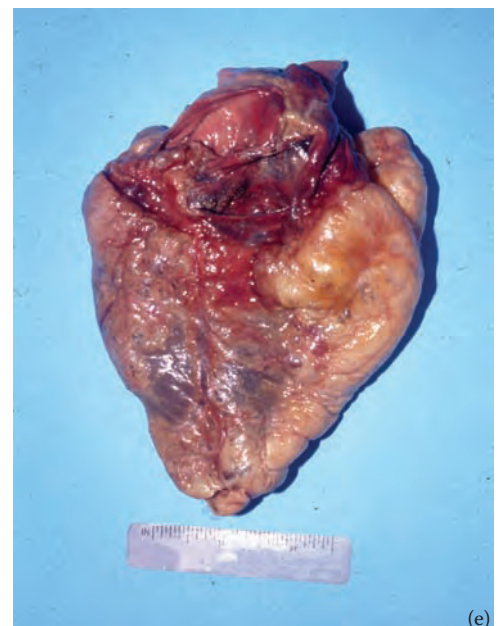
This child was discovered in the back of a garbage truck after being crushed by the trash compactor. The child was commingled with rotting food. Note the green discoloration of the skin due to putrefaction. Note the skull fracture with hemorrhage and dark discoloration due to putrefaction.

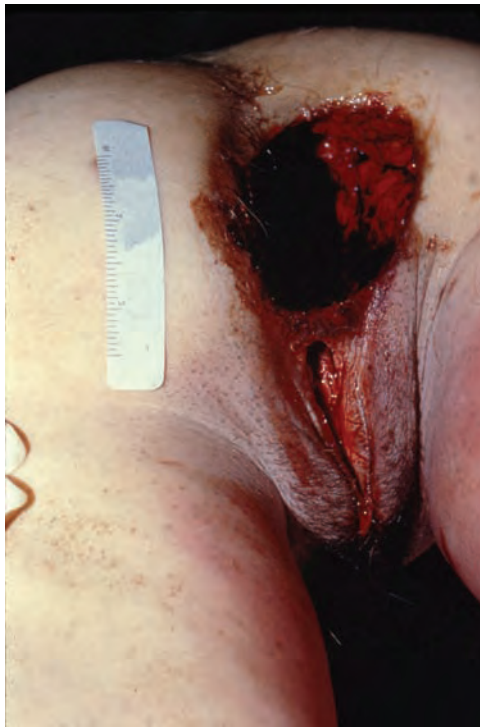
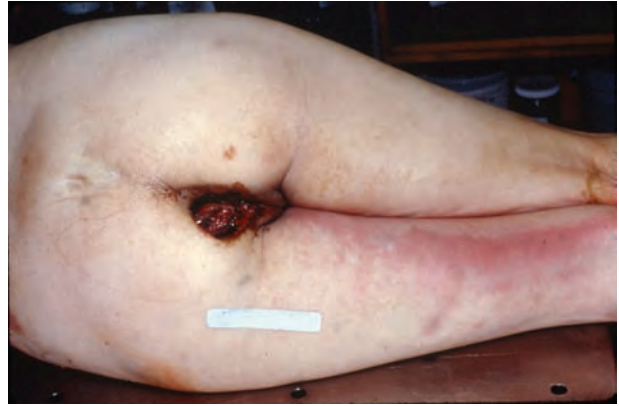
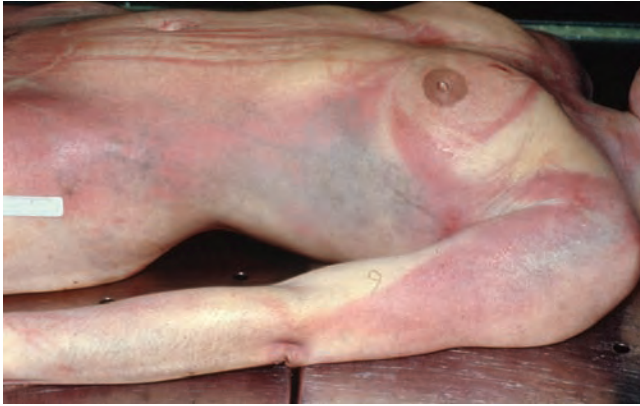These slides show antemortem injuries that have been obscured by postmortem change. These individuals had multiple stab wounds and lacerations. Note the wound margins are dark and irregular due to drying. This may make wound interpretation challenging and at some point impossible. Also, animals and insects will often more readily feed from injured areas with exposed soft tissue and blood, further obscuring these findings.

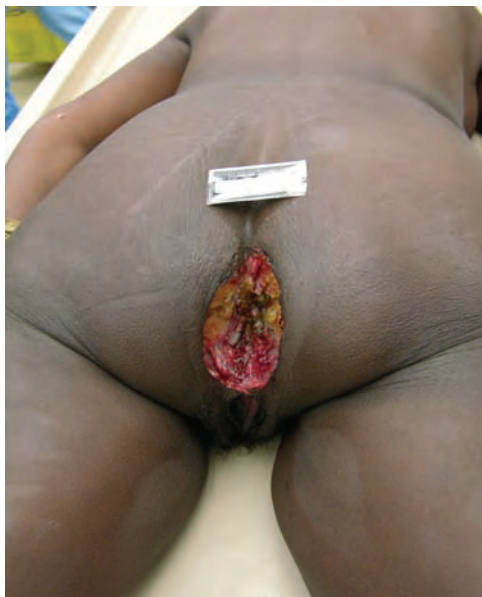

These are examples of moderate putrefactive changes of internal organs with softening, dehydration, shrinkage, and partial loss of architecture. In (a) note the crepitant adipose tissue due to expanding cavities of gas from proliferating microorganism metabolism. Also note in (c) the gray discoloration of the brain with partial loss of architecture. As central nervous system putrefaction advances, the brain will develop into a liquid, oatmeal-like consistency with few or more recognizable structures. Figure (d) is of a putrefying liver and (e) is of a putrefying heart.

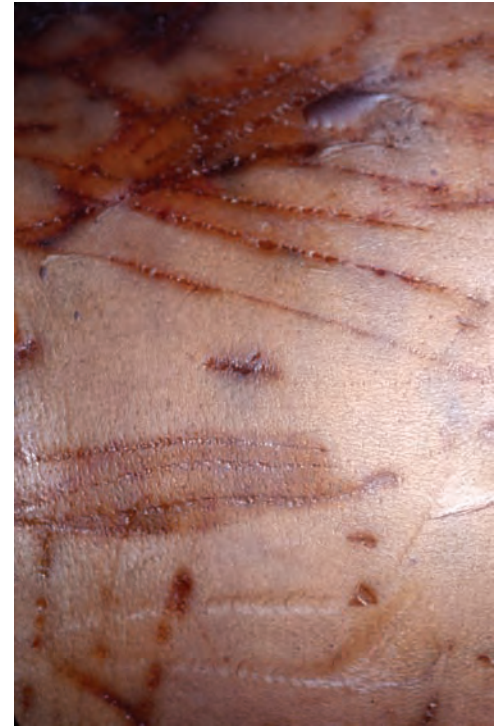
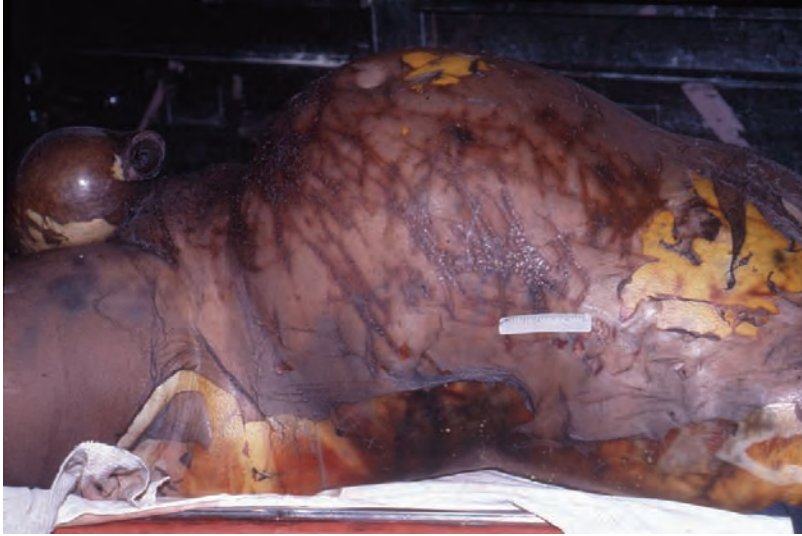


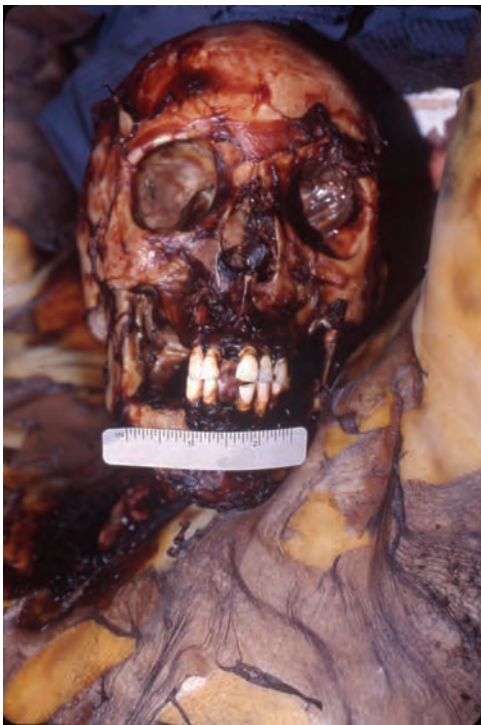Note the fixed anterior lividity. The decedent was lying prone on a bed with a wrinkled comforter. Postmortem dog feeding occurred around the anus. Autopsy revealed the absence of large portions of intestines. Note that the torn clothing has dog hairs and blood staining. This case was first suspicious for homicidal violence. Large amounts of blood had drained from the body to the bedding, which was further spread about by the dog.



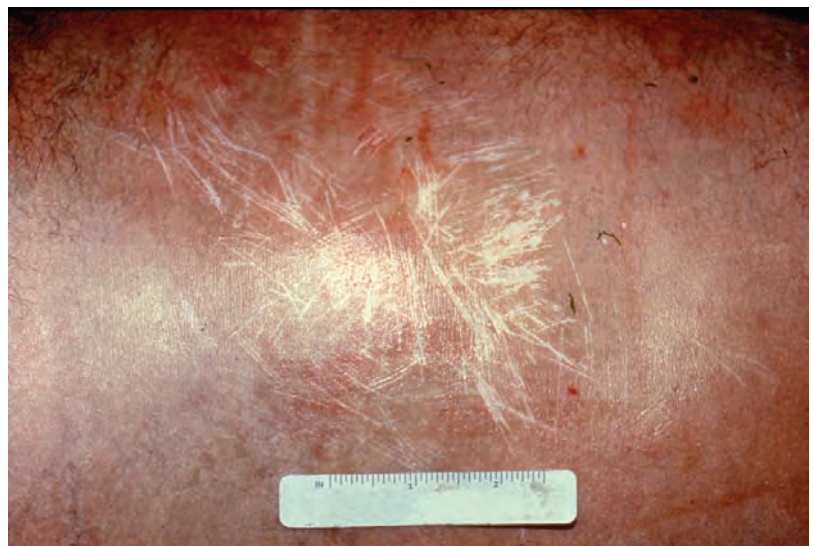This is another example of postmortem dog feeding, which often initially involves the face, genitals, anus, and areas of wounds.



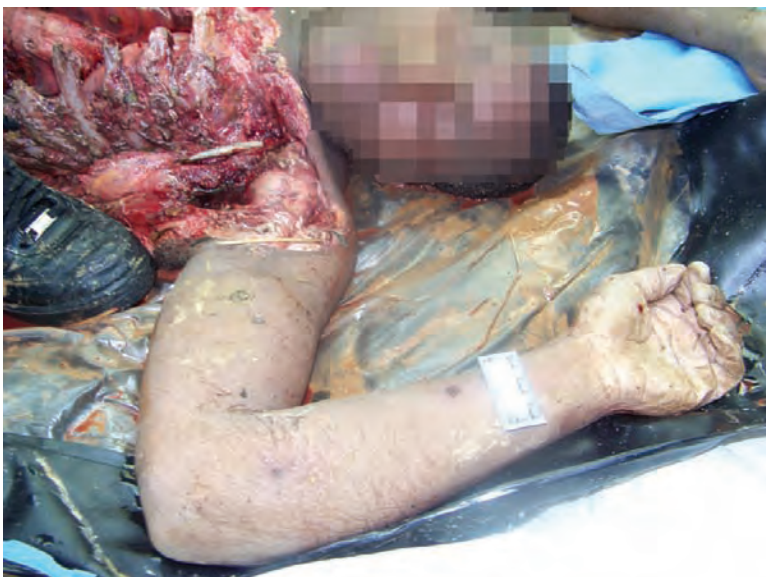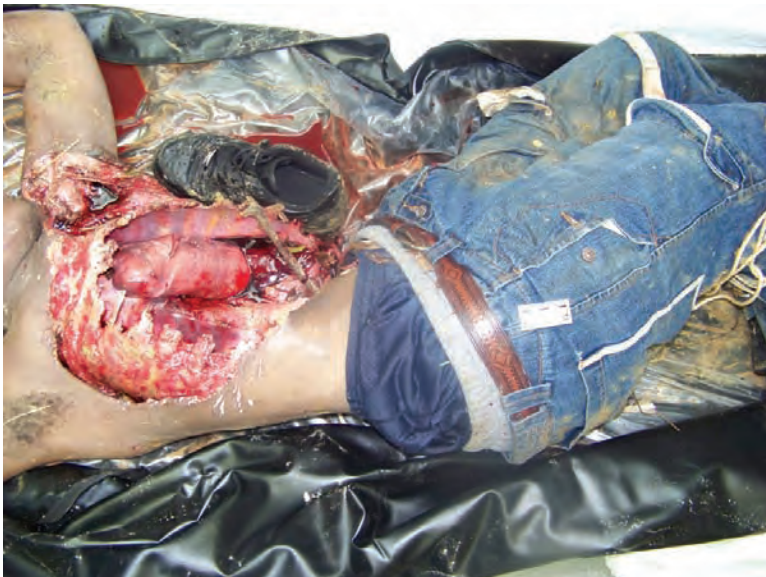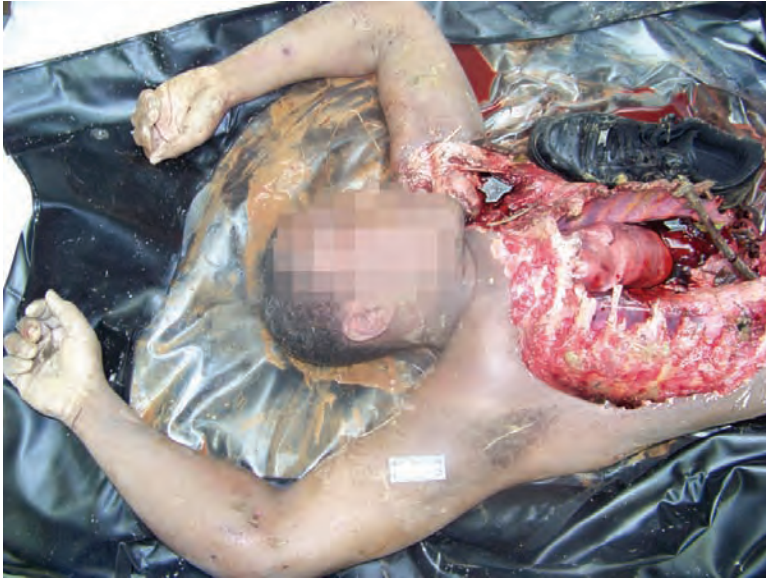Postmortem animal feeding with dog claw abrasions.



Postmortem feeding by the decedent's dog.

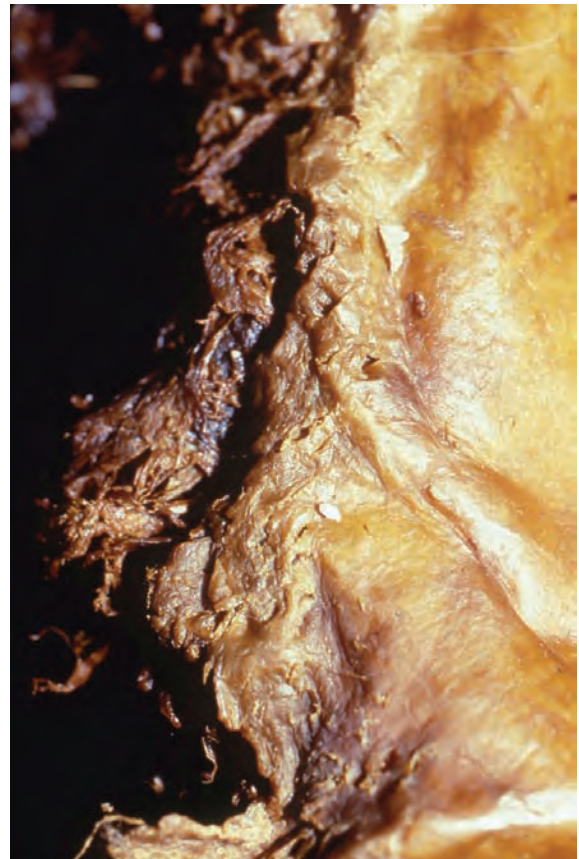
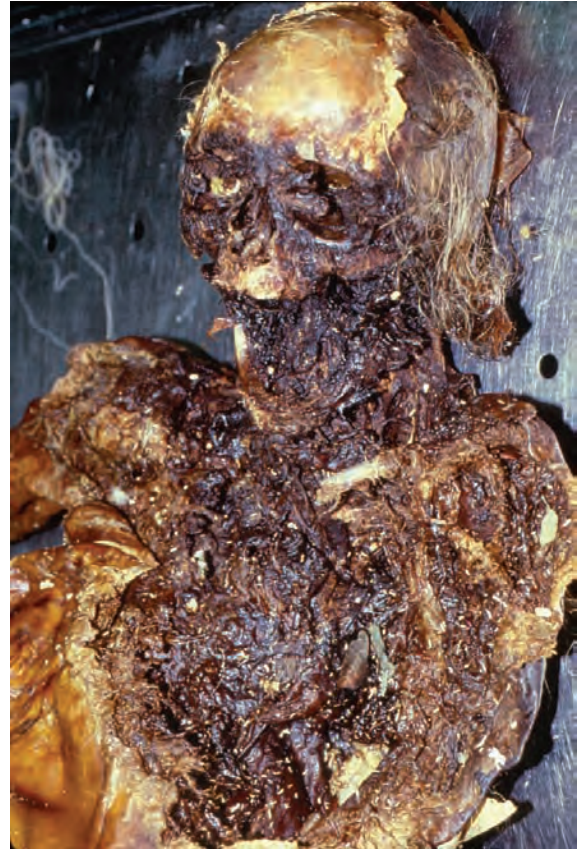
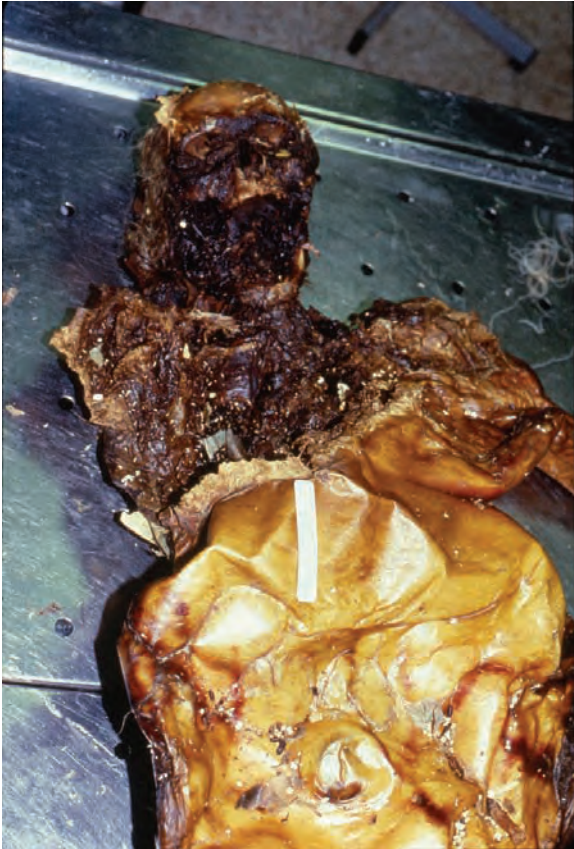

Postmortem anemic superficial linear abrasions from a body retrieved from the Hudson River. This region of the body was noted to be scraping against a rocky surface just prior to retrieval from the water.



Larger carnivore activity is common in rural and suburban areas. In many cases, there may be activity from several different animals in the same environment. In this case, the damage appears to mostly be from the canine family (likely wild) with evidence of tearing of the skin and ribs. There is no obvious vital reaction, indicating the damage occurred postmortem. In these cases, one must consider whether the postmortem activity has obscured injuries sustained during life.

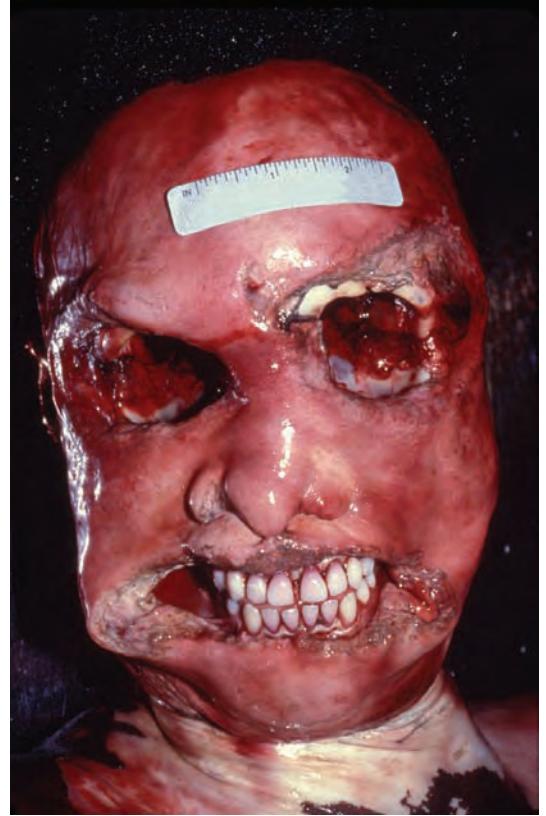
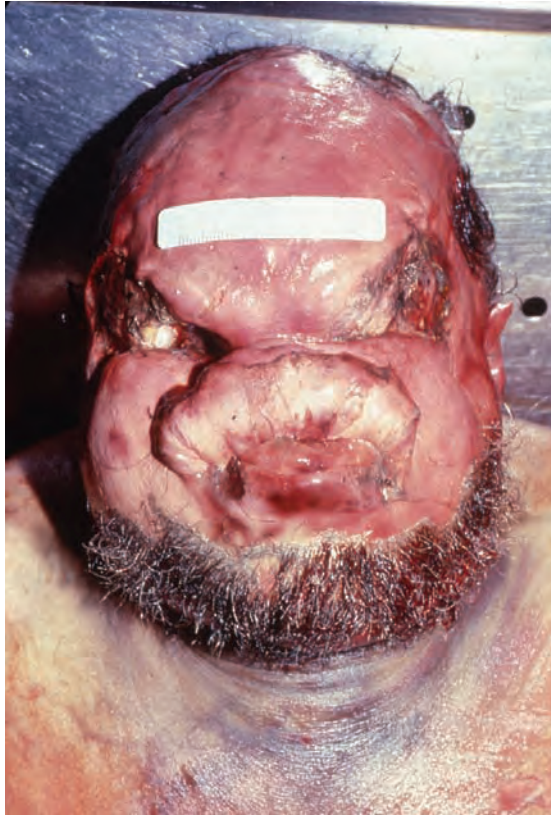


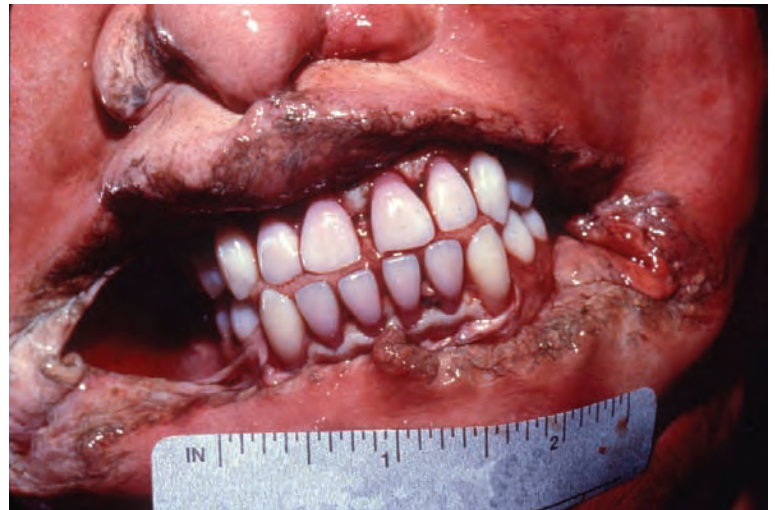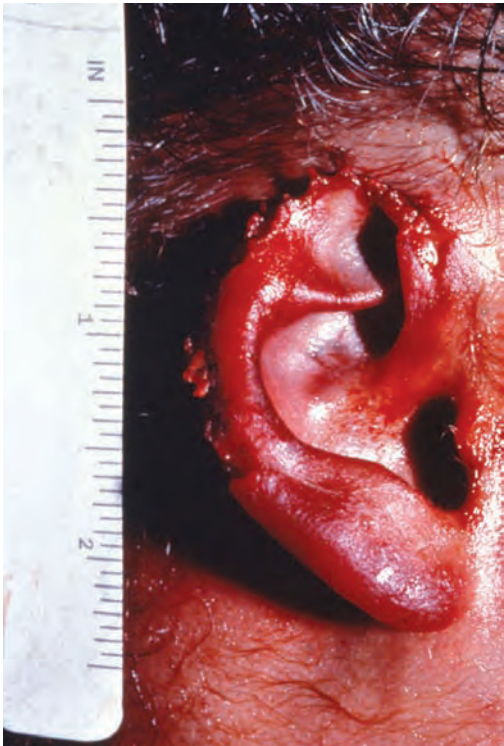Advanced decomposition with mummification and animal feeding by the decedent's cats. Note the margin with claw marks and a scalloped border from feeding. One arm, a larger portion of the chest and most of the internal organs were absent.



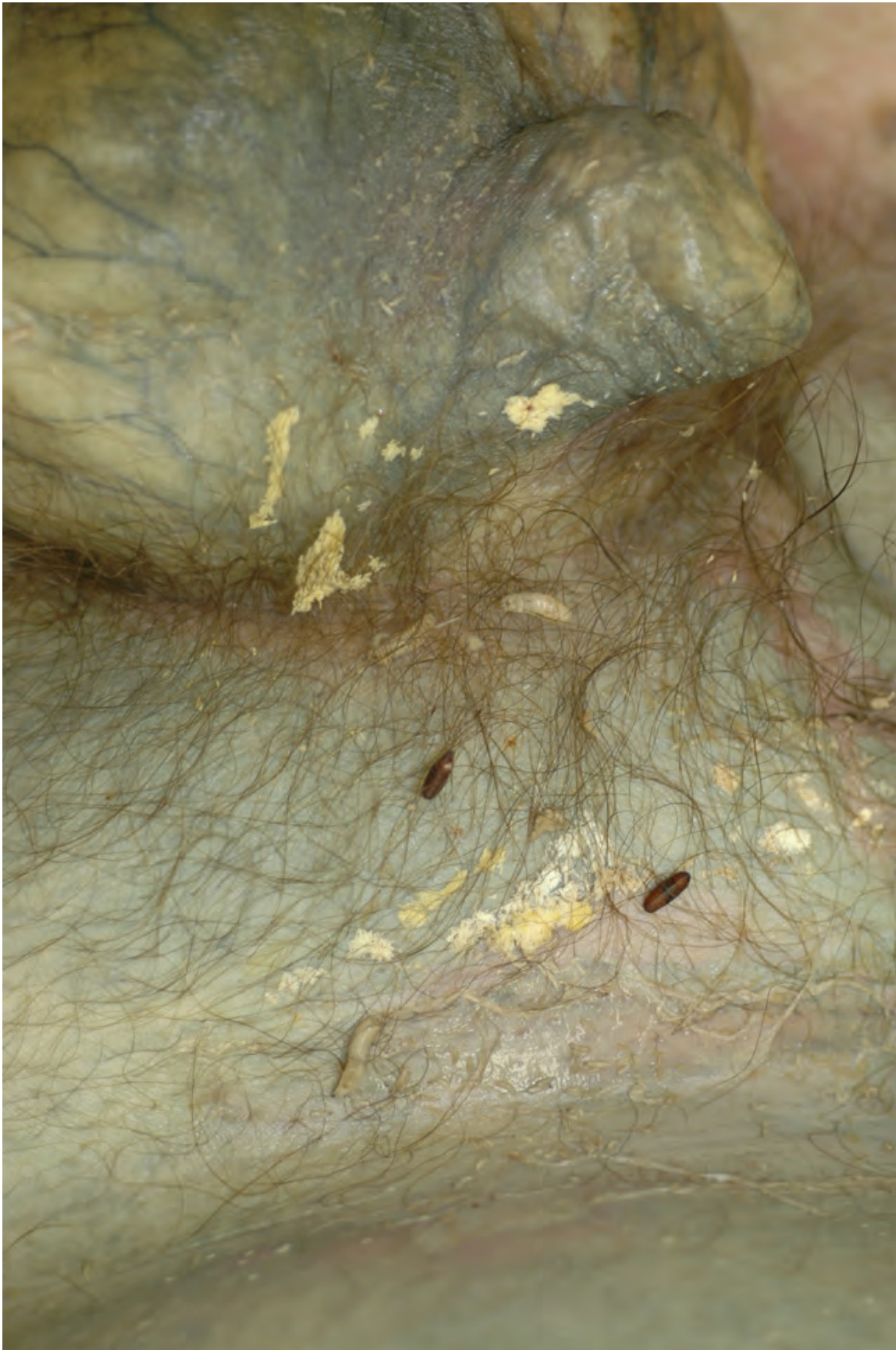In this case the carnivore activity was caused by domestic pigs.



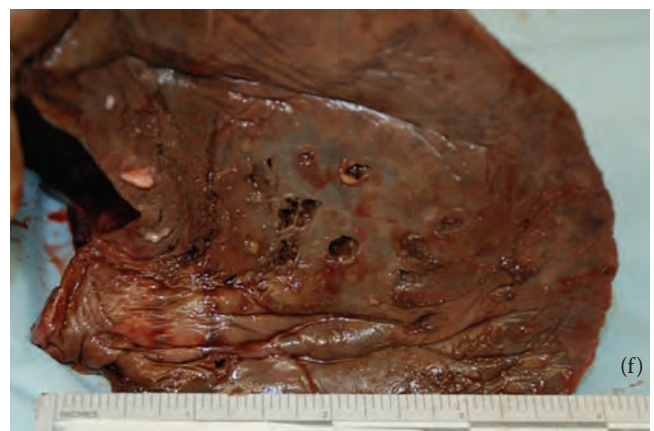
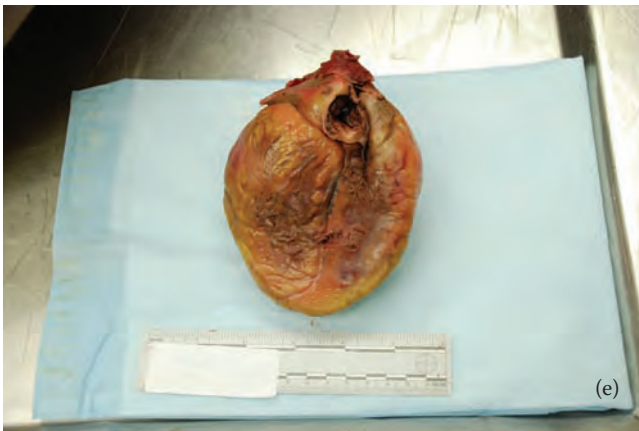
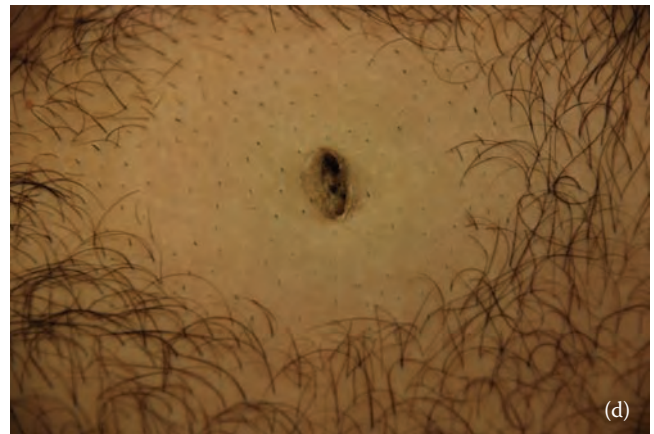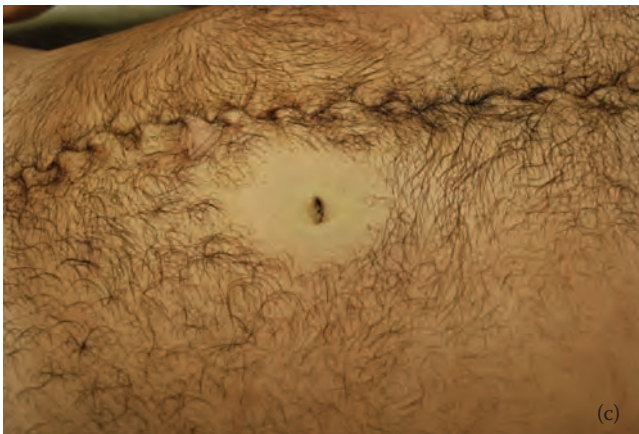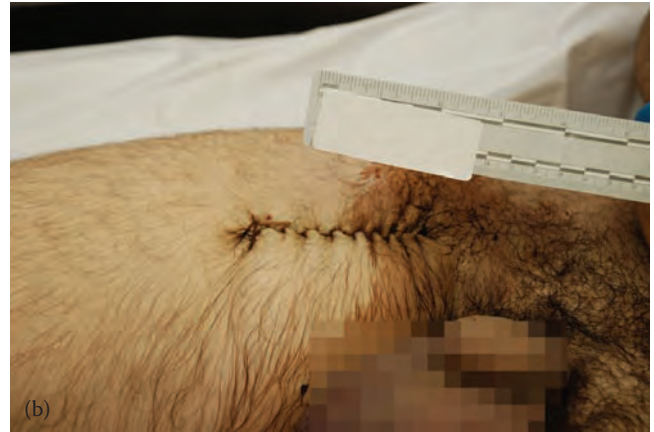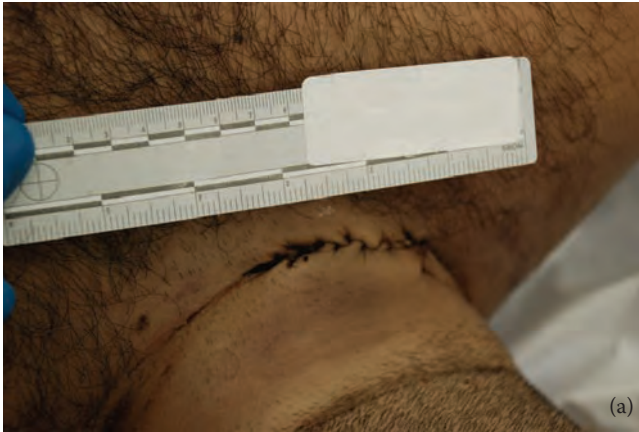Postmortem feeding from fish and crustaceans found on these bodies retrieved from the ocean.



Postmortem feeding of the ear due to mice and rats.



Note the varying stages of blowfly development. Eggs have an appearance similar to grated cheese or sawdust. When the eggs hatch, maggots develop and are shown in this picture in varying sizes as small, white, and wormlike. The dark brown pupa cases from hatching flies are also apparent. This entire cycle is accelerated in hotter temperatures.



Embalmed body. Figures (a) and (b) demonstrate sutured incisions made by funeral directors to gain access for blood removal with addition of embalming fluid. Figures (c)–(f) demonstrate multiple “trocar” (a metal rod used to infuse embalming fluid) puncture marks through the body’s surface and organs. These may be misinterpreted as injuries.

## Introduction

Pediatric forensic pathology is the name for the unofficial and poorly defined subspecialty of forensic pathology that focuses on the evaluation of sudden, unexpected, unexplained or traumatic deaths in children, infants, neonates, and even fetuses. By definition, therefore, this discipline requires specialized knowledge of and familiarity with the various stages in growth and development that occur during childhood, infancy, and intrauterine life, along with the differential vulnerabilities of these periods to various insults, and finally, the unique patterns of injury that characterize these different periods.

Perhaps one of the most illustrative examples of this concept is the assessment of nonaccidental or inflicted head trauma in infants and very young children. An understanding of this type of injury would not be possible without being thoroughly acquainted with the following concepts: (1) the elasticity of the infant's scalp, such that it could potentially sustain a serious blunt impact without necessarily manifesting the impact in the form of a subgaleal contusion; (2) the thin, pliable, unilaminar quality that renders the skull less susceptible to fracture but also allows it to transmit forces to the underlying brain more readily; (3) the broad, shallow skull base in infants, which facilitates rotational movement of the brain and lowers the threshold for diffuse axonal injury; (4) the incompletely myelinated infant brain, with a gray- and white-matter water content substantially higher than that of an adult, imparting a consistency of unset gelatin and making the brain more vulnerable to shearing forces; and (5) the top-heavy calvarium and the weak, underdeveloped neck muscles that fail to effectively dampen the oscillations that are initiated when rotational movement of the brain begins. It is the interface of pediatric and forensic pathology that allows the most complete and comprehensive understanding of these concepts to occur; however, very few individuals actually have such expertise in both fields. As a result, forensic pathologists may have to rely on pediatric pathologists and neuropathologists when they are evaluating difficult, complex, or problematic cases involving deaths in the pediatric population.

Of the many scenarios encountered by the pediatric forensic pathologist, none is as enigmatic as the seemingly

healthy infant who is found unresponsive after being put to sleep sometime earlier by a parent, sibling, or other caretaker, either in a crib, a child or adult bed, a couch, or some other location, often in a prone (face-down) position, and with soft bedding, pillows, and clothing. Sudden infant death syndrome (SIDS), a term that was coined in the early 1960s to remove the stigma of an unforeseeable and unpreventable death of an infant from that baby's parents, has now come full circle and runs the risk of being used as a "wastebasket" term for any infant death that is not obviously explainable by a disease or injury. The time-honored external and internal autopsy findings of froth (pulmonary edema) at the nares, intrathoracic (thymic, epicardial, or visceral pleural) petechiae, moderately congested organs, and an empty urinary bladder, while characteristic, are in no way specific for or pathognomonic of SIDS, and have been observed in a wide variety of other types of deaths. Forensic pathologists and pediatricians are just beginning to gain some appreciation of the myriad of factors involved in achieving respiratory control, arousal, and autoresuscitation.

Even in this modern age of molecular medicine, SIDS remains largely an unexplored entity. Thus, the forensic pathologist probably makes the greatest contribution in this area by identifying which deaths do not lie within the spectrum of SIDS. To do this effectively demands a carefully conducted medicolegal death investigation, a meticulously performed autopsy, and the use of ancillary studies, including postmortem toxicology, microbiology, chemistry, radiography, and metabolic screening. Only after all of these studies have been completed and integrated with the autopsy, scene, and anamnestic findings can the pathologist make an opinion about the cause and manner of death.

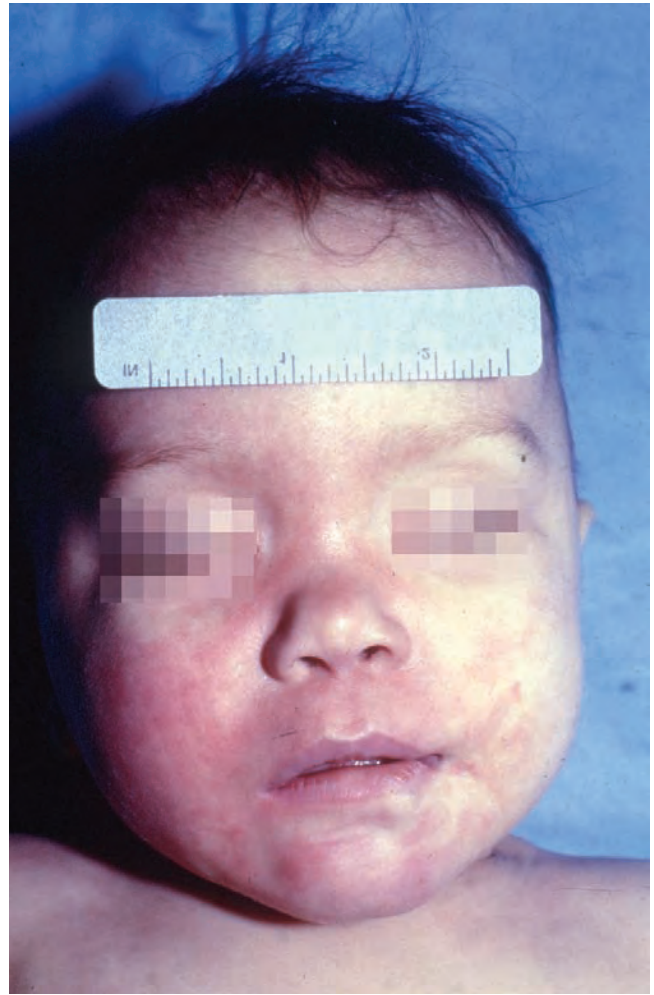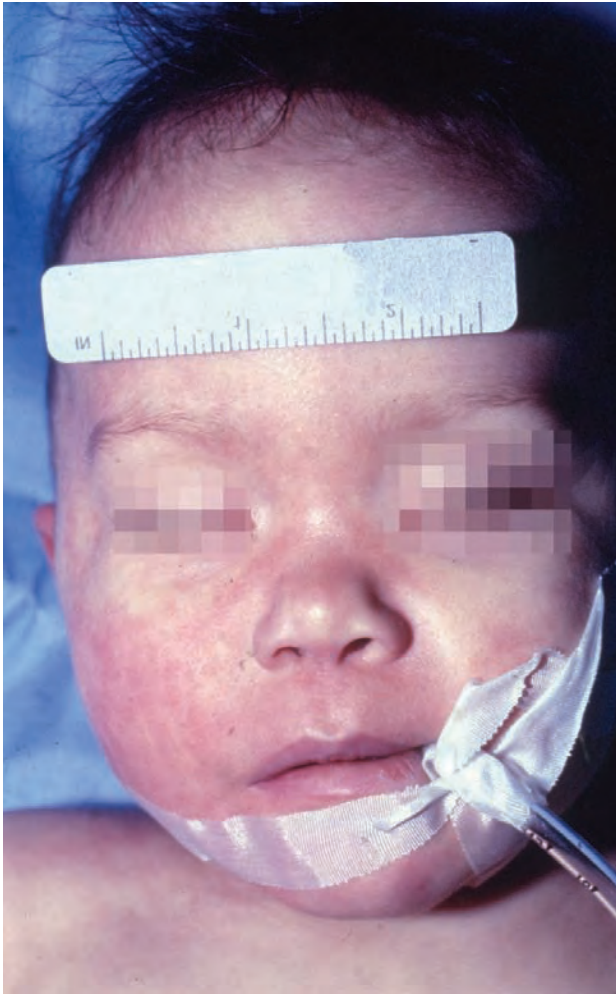Other situations necessitating specific pediatric forensic expertise include the assessment of sudden unexplained deaths in otherwise healthy children, either during sleep or while awake, at rest or following exertion; sudden deaths in infants or children who have undergone operations for congenital heart disease; unexpected or unexplained deaths during or following diagnostic or therapeutic procedures; complex child abuse cases involving a multiplicity of injuries separated over space and time; deaths from genetic diseases that might mimic child abuse, such as osteogenesis imperfecta; and

unexplained deaths following apparent minor trauma. In all of these scenarios, knowledge of the specific disease processes or related therapies is required in order to achieve the most complete understanding of the circumstances that culminated in the infant's or child's death. Other types of deaths affecting infants and children that are similar to those involving adults are typically fatal injuries sustained in motor vehicle crashes, either as occupants or pedestrians, although the considerable disparity in height, weight, and center of gravity often produces patterns of injury in infants and children that are distinctly different from those in adults.

Fatal child abuse presents primarily in two forms: (1) as the culmination of a repetitive pattern of inflicted injury, creating wounds of varying ages, in different parts of the body (what has been coined "the battered child syndrome"); and (2) as an impulse act by a caretaker who, following an act of urinating, defecating, or vomiting by the infant or child, lacks the self-control to prevent anger

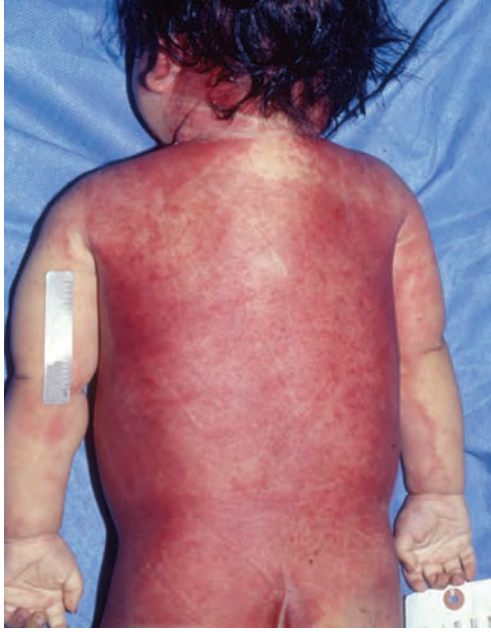and frustration from translating into physical violence. The pediatric forensic pathologist must know what studies are necessary to perform in order to document not only what did happen, but to exclude all of the other reasonable possibilities that undoubtedly will be introduced by the defense in the adjudication of the case.

In some ways, the pediatric forensic pathologist often walks a diagnostic tightrope—deciding between SIDS and smothering, between inflicted closed-head injury and spontaneous intracranial hemorrhage, or between preeclampsia and maternal blunt trauma precipitating placental abruption. Toward that end, it is equally important to be aware of the limitations of a particular case and not offer opinions beyond what the circumstances and pathologic evidence allow. In some situations, "undetermined," while unsatisfying, is at the same time the fairest and most reasonable ruling until additional information is obtained that allows a more definitive ruling.

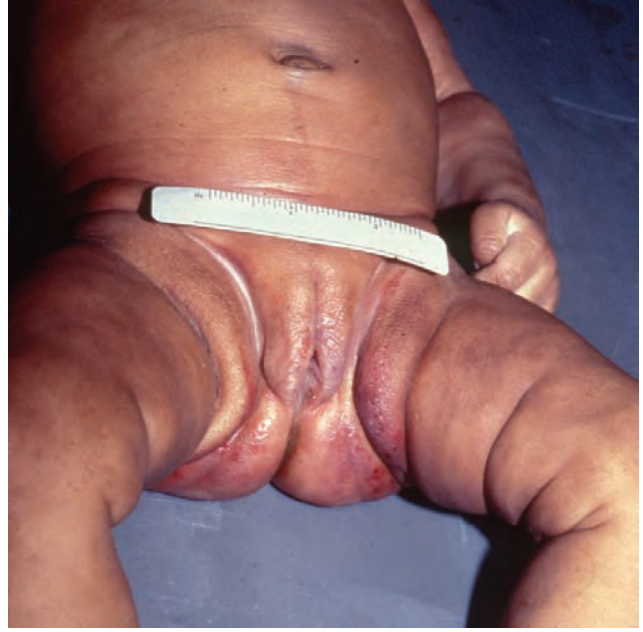

This child was brought to the emergency room and vigorously resuscitated. Note the marks left on the face as a result of endotracheal intubation and application of tape. It is important to document such findings and not confuse them with possible signs of child abuse, such as faint abrasions or contusions due to smothering. It is very important for clinicians to leave all tubes in place for postmortem (autopsy) confirmation of their placement.

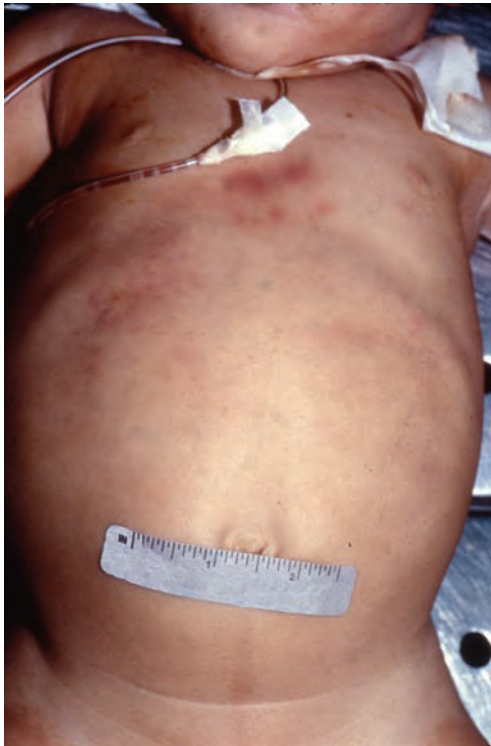



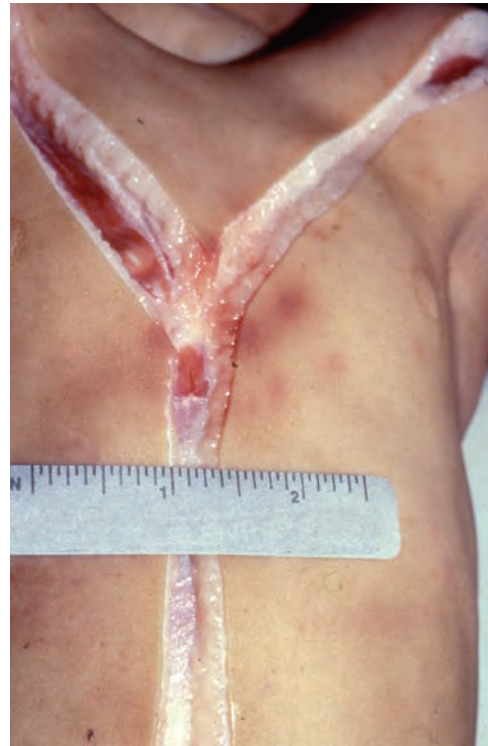Posterior lividity, which may be mistaken for injuries such as contusions related to child abuse.



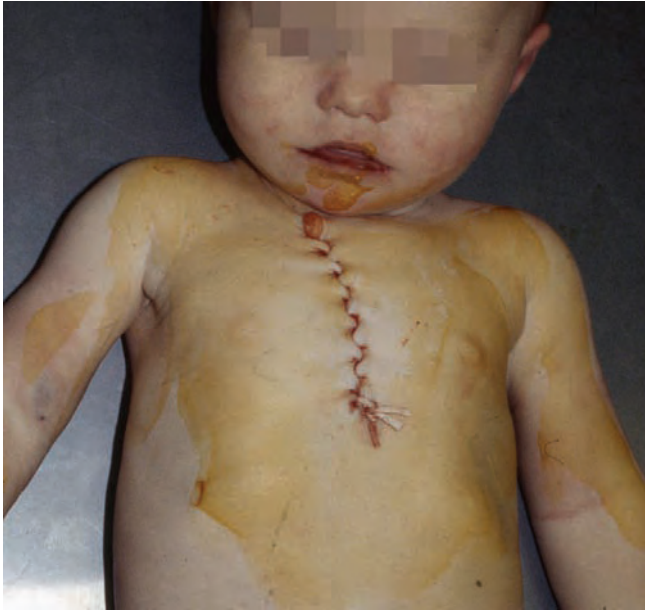Diaper rash. Note the red cutaneous eruptions. These indicate some degree of neglect.



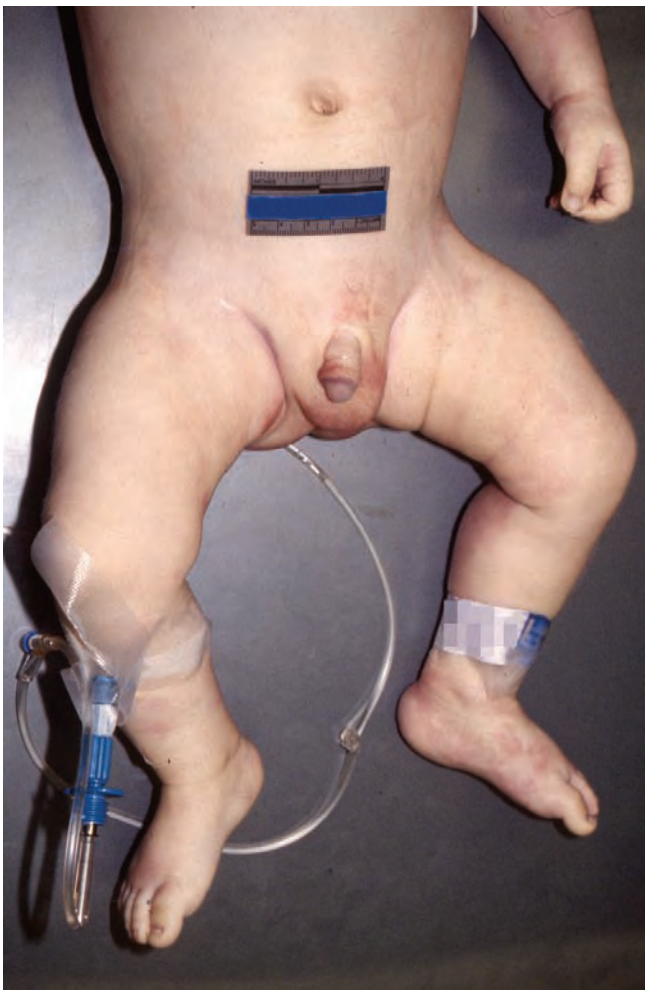Child abuse case with resuscitative efforts and perimortem sternal contusions due to chest compressions. Note other small contusions at the lateral aspect of the upper abdomen and lower chest. These were inflicted while the child was grabbed and flung about violently during the assault.



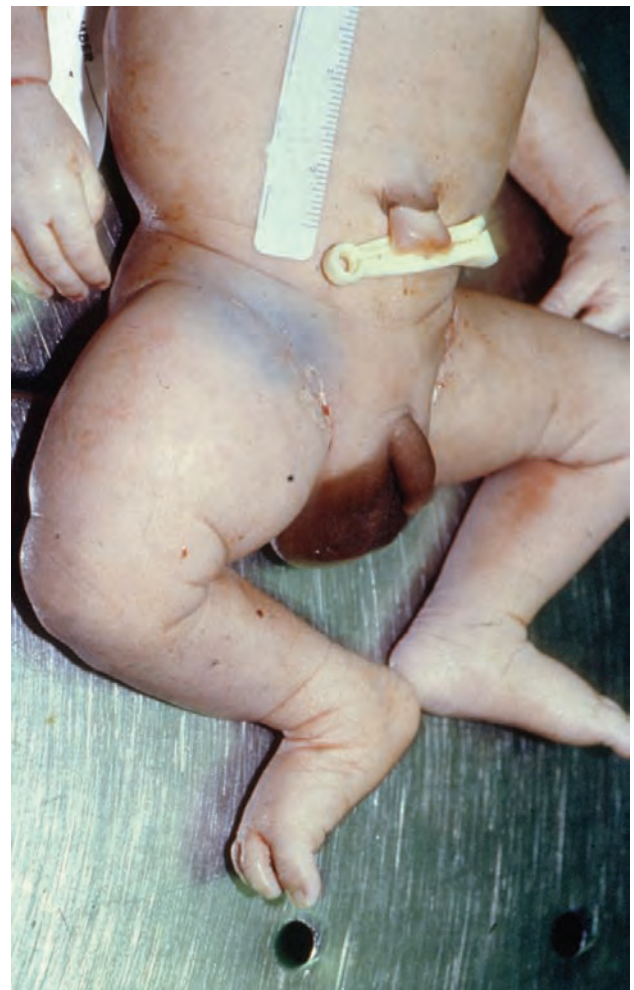The same case showing perimortem contusions to the middle aspect of the chest due to resuscitation. Note the small amounts of subcutaneous hemorrhage overlying the sternum. Note the other segment of the "Y"-shaped incision is devoid of hemorrhage.



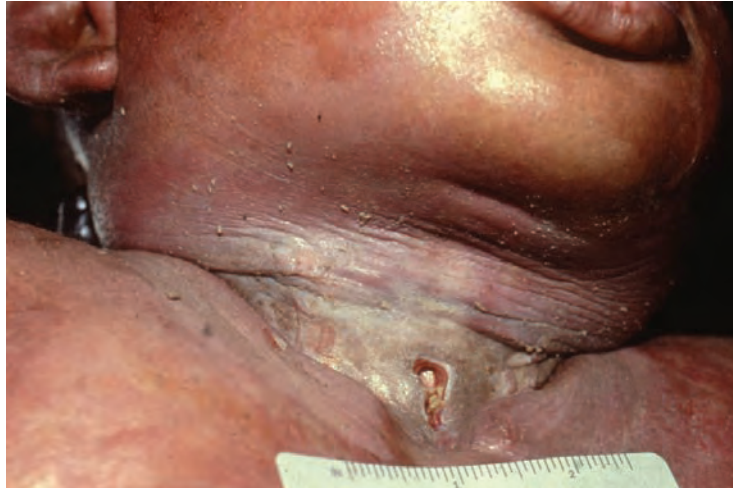This case involved an infant who was found unresponsive in her crib. The case was referred to the medical examiner's office for autopsy. However, as the external examination was about to begin, this sutured midline incision was encountered. Further inquiries revealed that the emergency department physician had authorized postmortem procurement of the infant's heart for heart valves. When this was discovered, the organ procurement agency was contacted, and released the heart to the medical examiner's office. The heart was found to have an anomalous origin of the left coronary artery from the right sinus of Valsalva, a rare yet documented cause of sudden death in both adults and infants. The issue of organ procurement remains a controversial and at times problematic one for the forensic pathologist. Consistently reliable methods for evaluating the coronary ostia have not been established in many tissue procurement agencies for the retrieval of hearts.



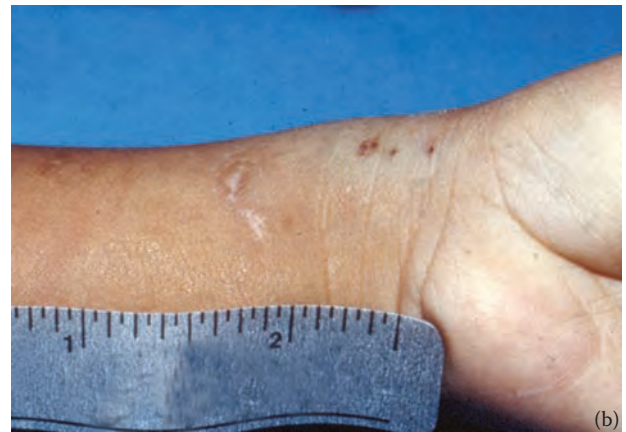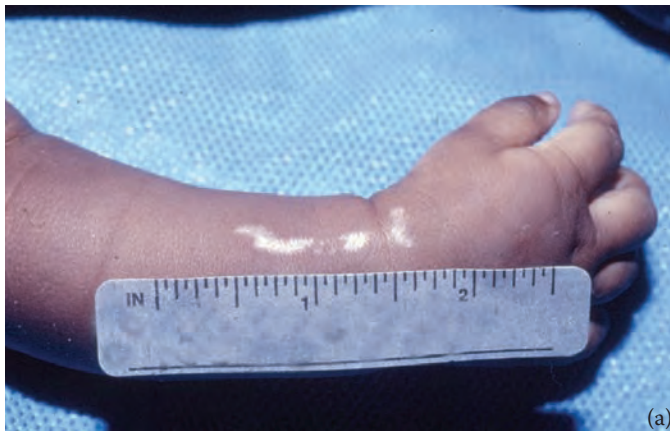
View of lower trunk, external genitalia, and lower extremities depicting a right-sided intraosseous catheter. This is a common mode of resuscitation in infants with extremely small, often collapsed blood vessels.



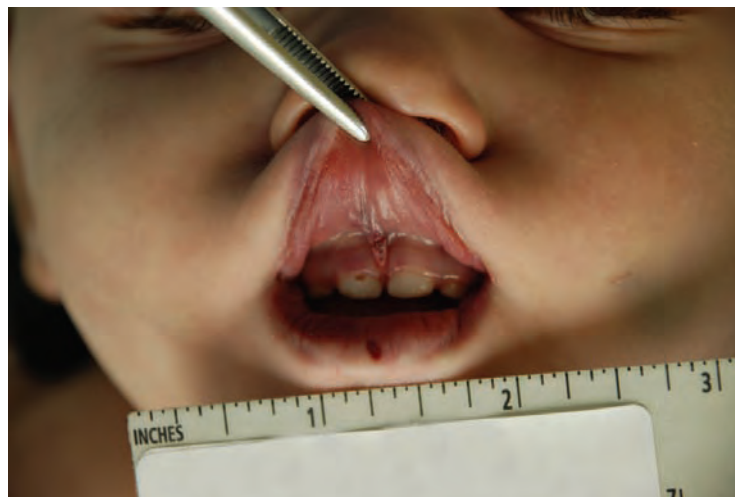Hemorrhage with swelling of the thigh due to a misplaced femoral line.



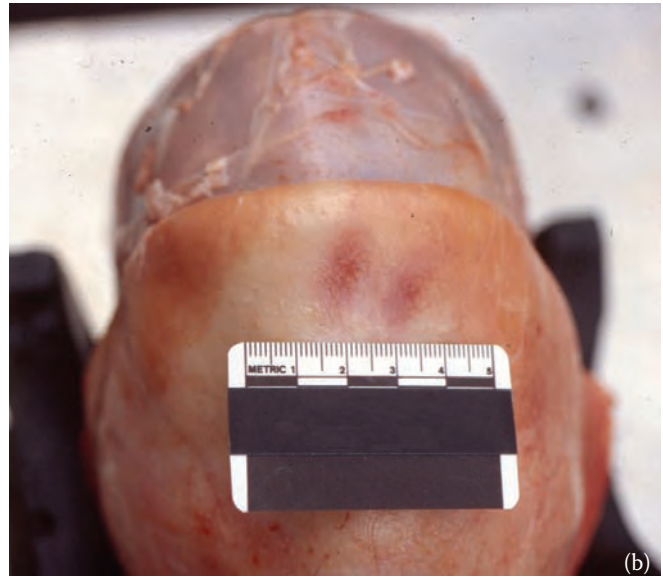
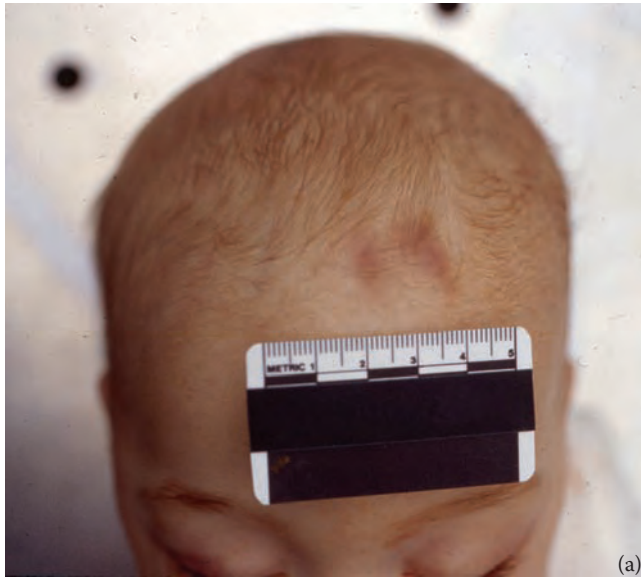Healing infected tracheotomy incision.



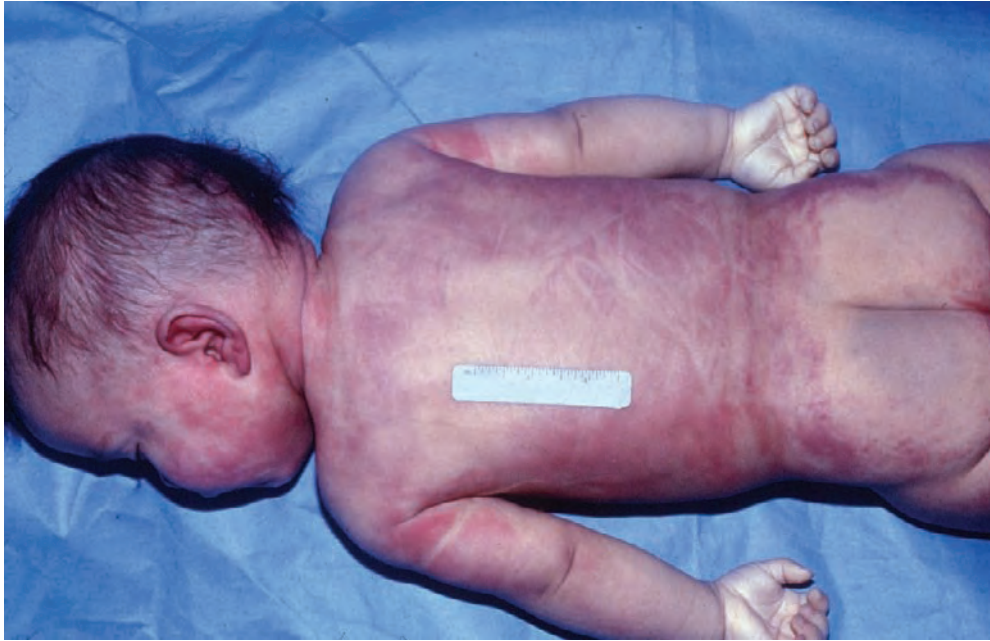Scars to each wrist due to past therapy. Note image (b) has fresh needle marks as well. Therapeutic procedures should not be mistaken for injuries.



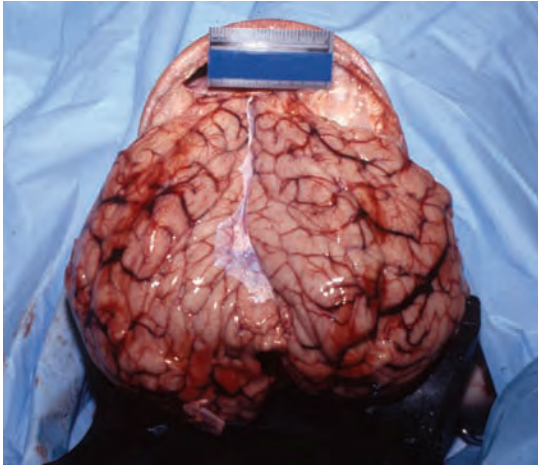
Small tear of the upper frenulum due to vigorous resuscitative efforts by an untrained person. Note the small bruise to the left side of the face, which had been caused by a fall several days earlier. The first phase of resuscitation was captured on a department store video camera when this child became lifeless following a seizure.



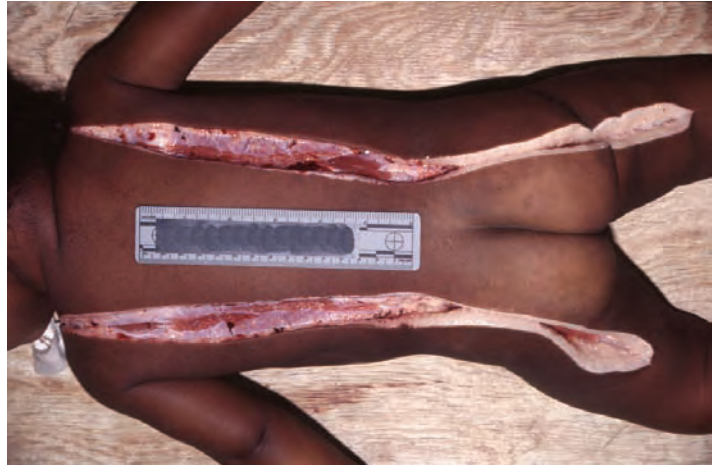
This case involved an infant who suffered an asphyxial death. He was found with his head compressed (wedged) between an adult bed and a wall. He was pulseless, apneic, and asystolic, and despite resuscitative efforts could not be revived; (b) depicts the frontal and temporal regions of the scalp with two ill-defined contusions within the frontal subgaleal region; (c) shows the relationship between the mattress and the wall. The mattress was separated from the wall by at least several inches, allowing the infant to fall into this space and become compressed; (d) is a view looking toward the floor, where the infant was found lying wedged between the wall and the mattress.



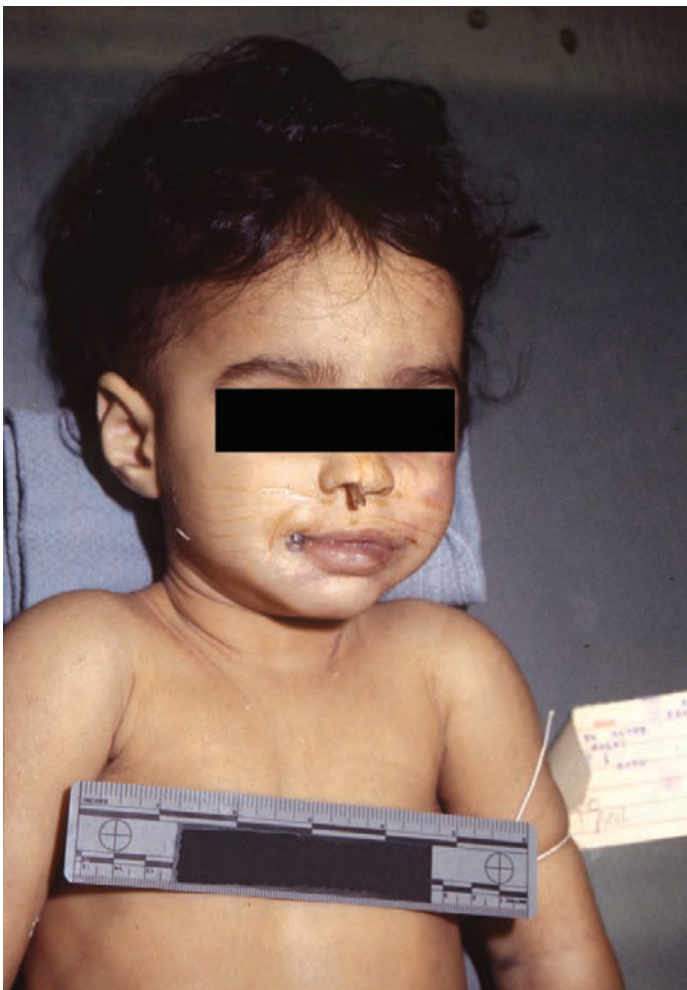This child was brought to the Emergency Department (ED) by parents who spoke a foreign language. The child was reported to be found dead in a crib. The ED physicians believed that this death could be a result of SIDS but there was no initial scene investigation. Note the posterior patchy red lividity. There is also a faint Mongolian-type birthmark within the left gluteal region. Further scene investigation by the Medical Examiner's office and police department revealed that the child had actually slid between the crib railing and mattress, suffering an asphyxial death. There were no marks on the child's body at autopsy. The mattress was from another crib and was slightly smaller, allowing the child to slide between the railing and mattress. Note the doll demonstrating how the child was found at the scene.



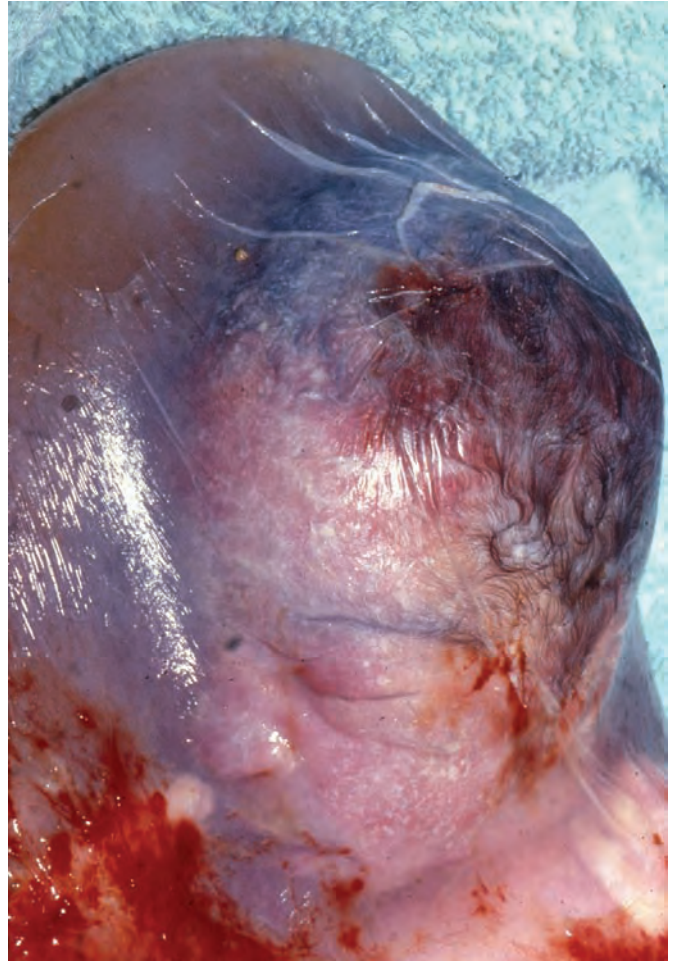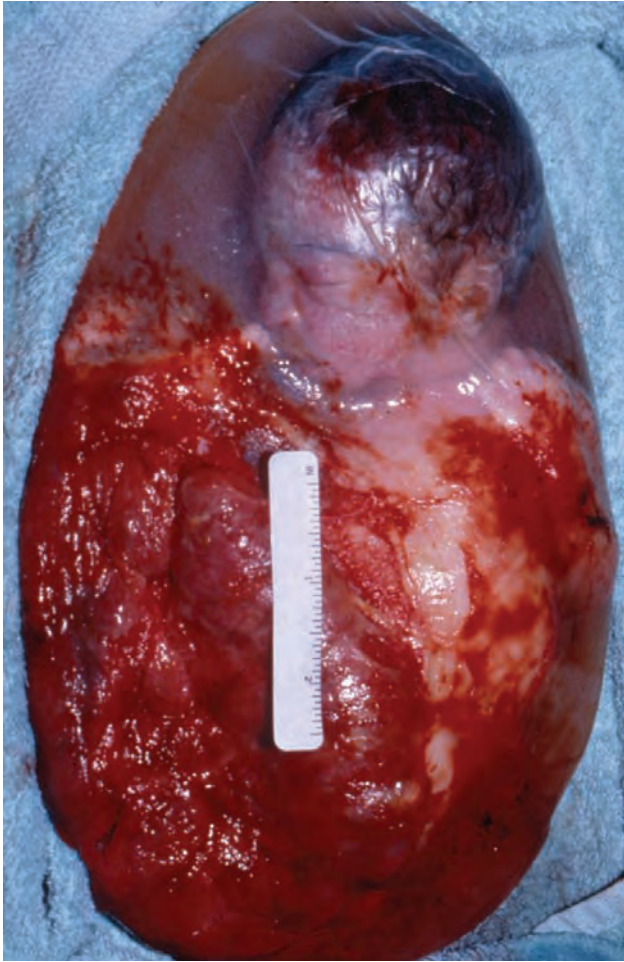
This image demonstrates brain swelling with flattening of gyri and obliteration of sulci due to hypoxic-ischemic brain injury. This 7-month-old female infant was found unresponsive in a car seat that fell off of an adult bed, with her chin tightly opposed to her chest, satisfying the criteria for positional asphyxia. She survived for several days and was ultimately declared brain dead. No other injuries were identified upon autopsy examination.



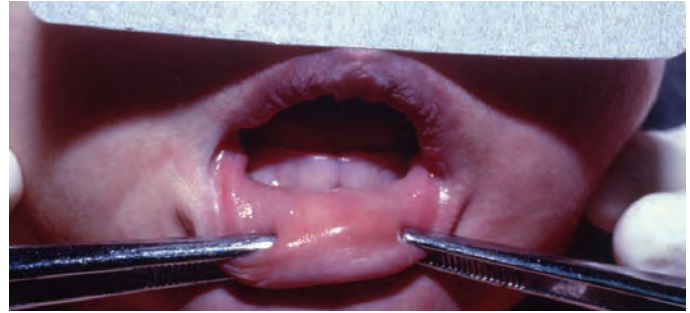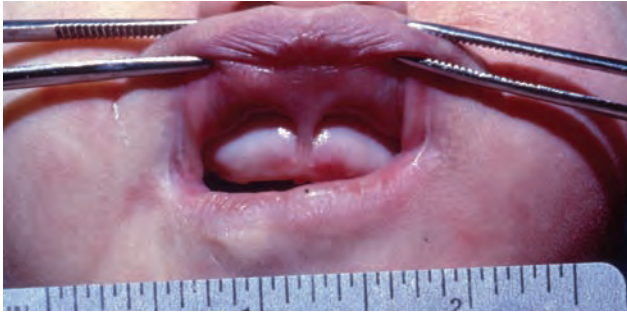This 9-month-old child with a history of asthma was found unresponsive in her crib. Autopsy demonstrated multiple mucous plugs within the medium-sized airways, along with well-defined pathologic features of chronic asthma. No injuries were found. Death was certified as complications of bronchial asthma. Although unusual in a child this young, asthma can indeed be fatal. These bilateral vertical incisions made at the time of autopsy failed to demonstrate contusions.



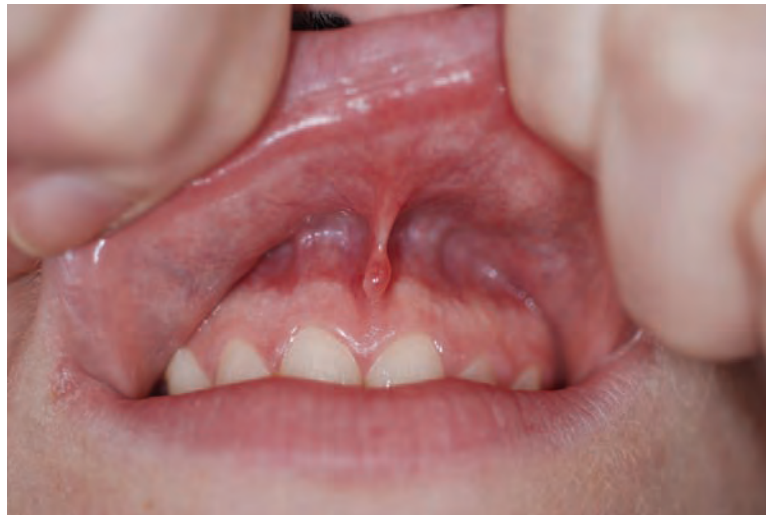This was the body of a completely healthy female infant. Her mother, who had left her unattended for an unknown period of time with her 18-month-old brother, found her submerged in a bathtub. The mother reportedly left them both in the tub without water and claimed the brother had to have turned on the faucets. When police attempted to reconstruct the scene, the older brother was unable to turn the faucets. Although the cause of death in this case was certified as drowning and the manner homicide, the mother was released on probation.



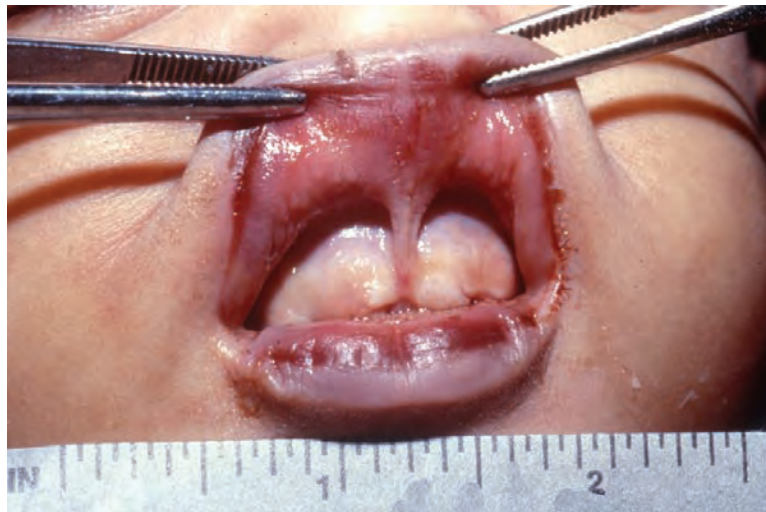This normally developed neonate was delivered with the placenta enclosed in an intact amniotic sac. The baby died of asphyxia and the manner of death was certified as natural. The child was delivered at home and the young mother did not have medical knowledge to know that the membranes had to be immediately opened following delivery. She noted the child to be moving within this placental unit.



It is important to examine the frenulum and mouth region internally and externally in infants to rule out possible findings associated with smothering. Both of these cases show no injuries.

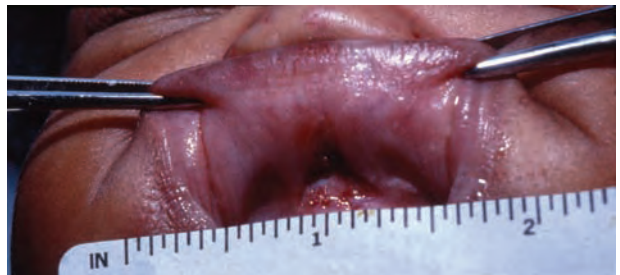
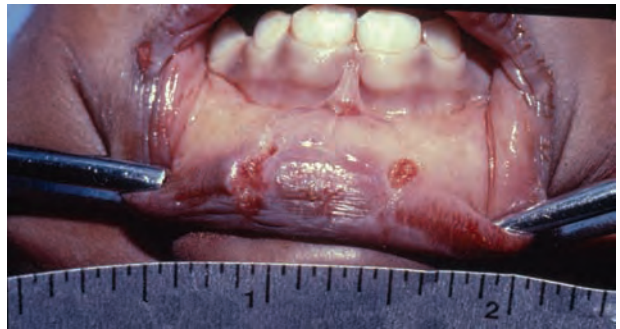
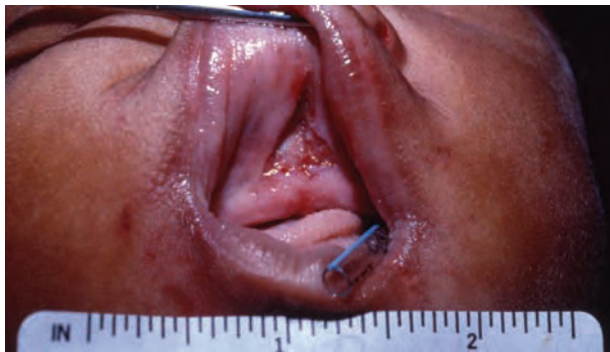
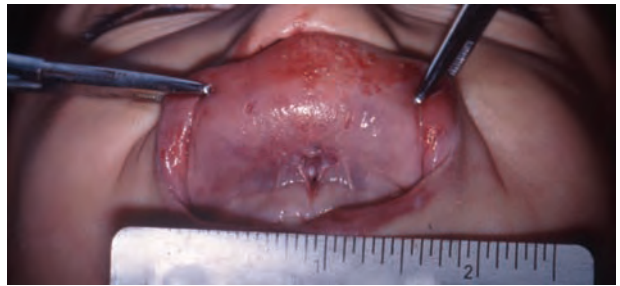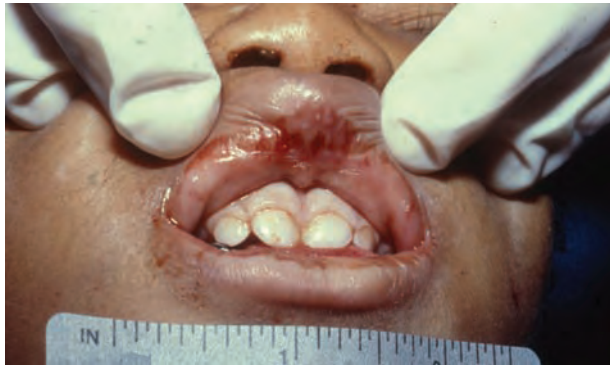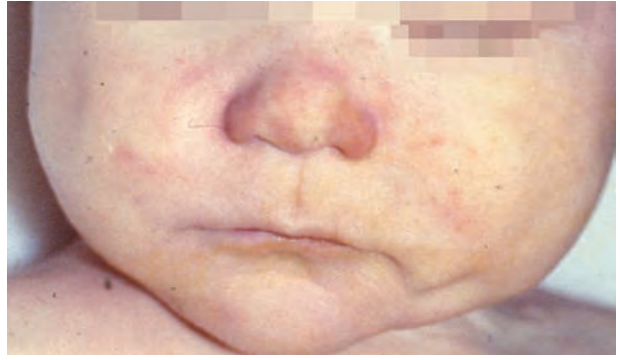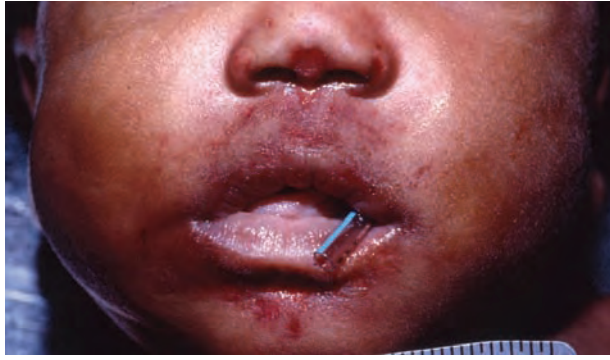Healed frenulum laceration. This individual fell as a small child and accidentally struck her face on a kitchen cabinet.

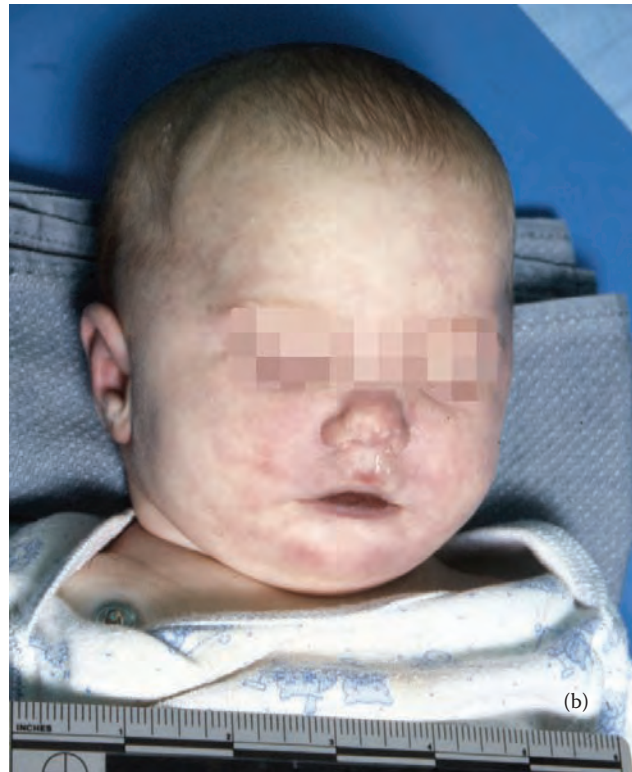
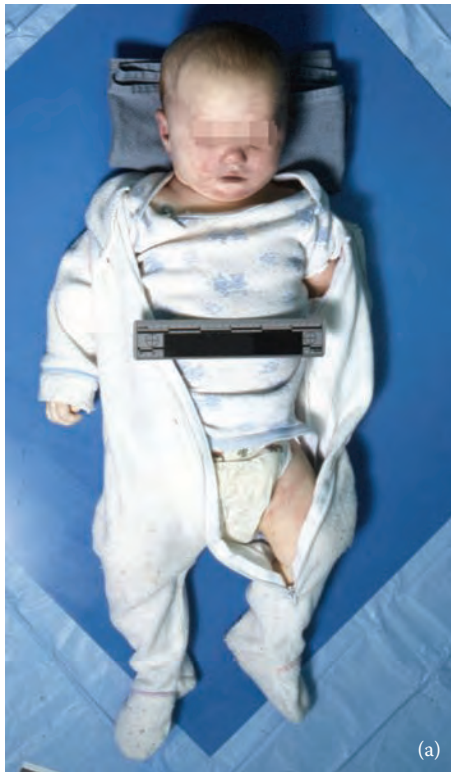
Intact frenulum with postmortem drying of the lips. This does not indicate child abuse.

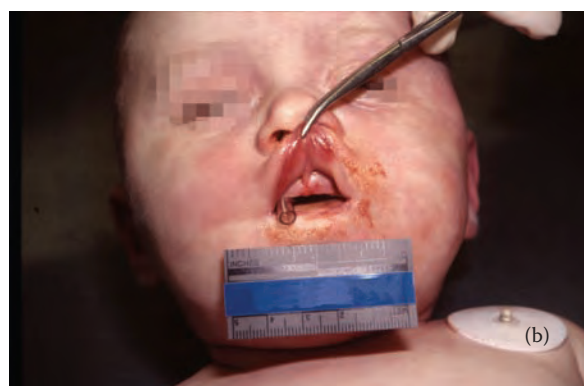
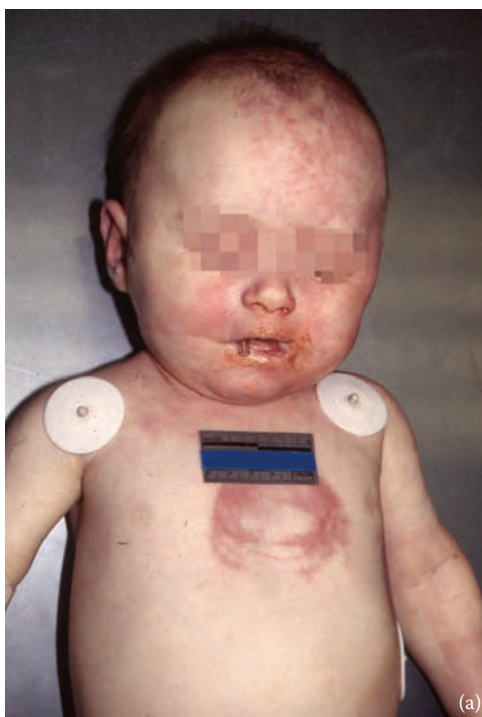


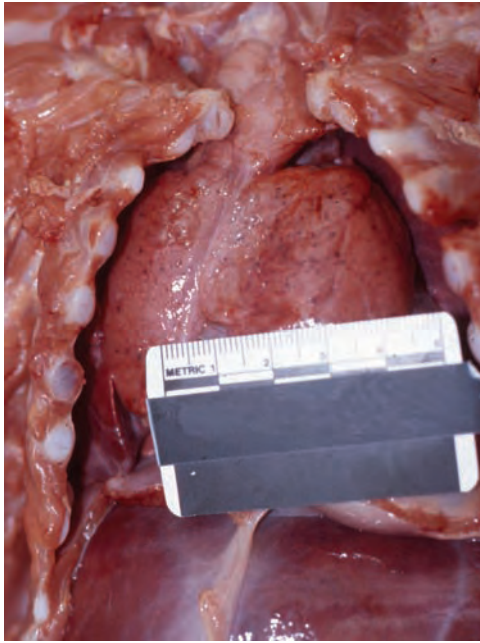
These children have varying degrees of abrasions to their face with trauma to the lips and torn frenula. All are cases of homicidal smothering. It is important to also realize that a homicidal smothering may occur without leaving marks of any kind.



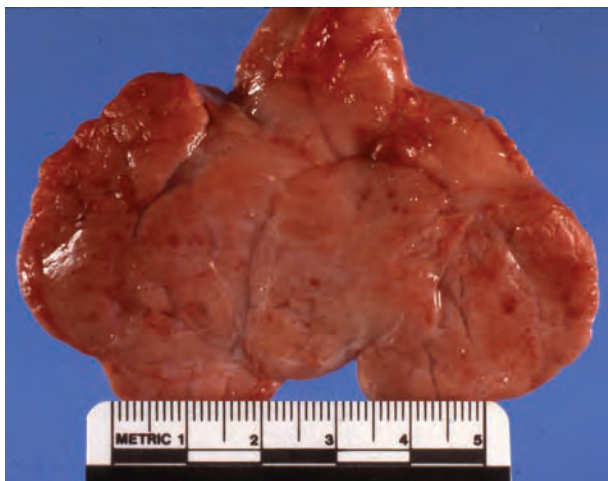These images demonstrate a case involving a several-month-old infant who was found unresponsive in her crib. She had no known previous illnesses. If possible, it is always important to photograph infants in their original clothing, which allows for more accurate reconstruction of the terminal events (i.e., stains of blood-tinged fluid.) View (a) demonstrates clear fluid emanating from the left nostril with a faintly frothy quality, probably indicative of pulmonary edema, which is a common finding in victims of SIDS, particularly when attempts are made to resuscitate. The elastic nature of infants' lungs and the vigorous resuscitation efforts collectively contribute to the formation of this edema fluid, which is often blood-tinged due to rupture of small capillaries. Oftentimes, the blood-tinged fluid is misinterpreted by police personnel as being suspicious of foul play. It is important for pathologists and emergency medical services (EMS) personnel to educate people with nonmedical backgrounds regarding the distinction between blood-tinged edema fluid and actual clotted blood.



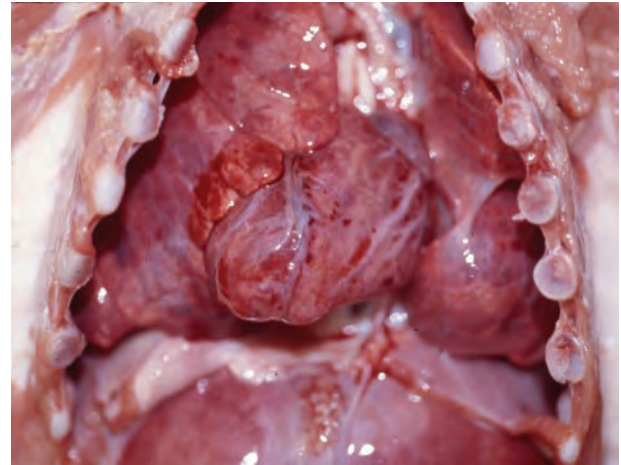
This case involved sudden death in an otherwise healthy infant. Notice the confluent burns and abrasions on his left anterior chest wall, extending to the midline (a). These marks are indicative of defibrillation attempts from resuscitation. Additional therapeutic interventions can be seen, including an endotracheal tube, along with electrocardiogram (ECG) electro pads. Notice also the blotchy red discoloration of the forehead and face (left side slightly greater than right). While one might be tempted to conclude that this is livor mortis, it is important to realize that vigorous resuscitative efforts may also alter the patterns of vascular congestion; in the same case, (b) demonstrates an intact upper frenulum with dried blood-tinged secretion around the left side of the mouth and no trauma.



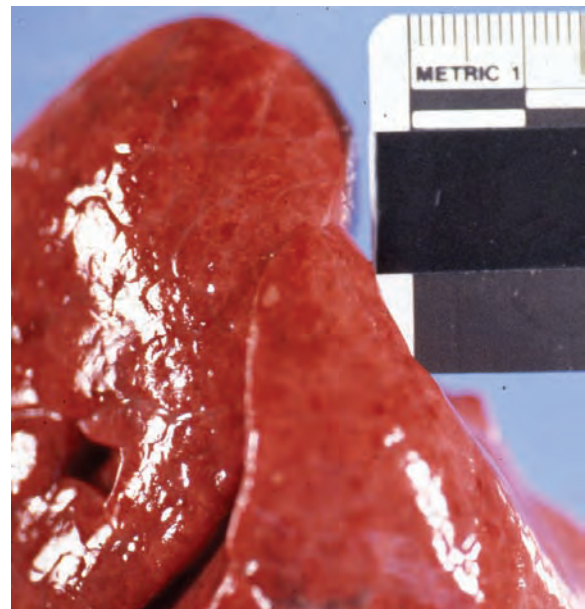
This infant was found unresponsive in his crib and could not be resuscitated. Maternal history was significant only for group B streptococcal infection. This picture depicts prominent petechiae on the anterior capsular surface of the thymus. Petechiae involving the thymic, visceral pleural, and epicardial surfaces are extremely common findings in sudden infant deaths, including deaths that have been ascribed to SIDS (up to ~85 % of SIDS fatalities). The precise mechanism underlying the formation of petechiae remains elusive, but is believed to be related to the negative pressure created by terminal gasping in infants. However, it is well known that these petechiae are not in any way specific or pathognomonic for SIDS and may be found in deaths due to many other causes, including definable natural disease conditions, accidental injuries, and inflicted injuries (homicides). In this case, the petechiae, which appear as pinpoint hemorrhages, are particularly striking.

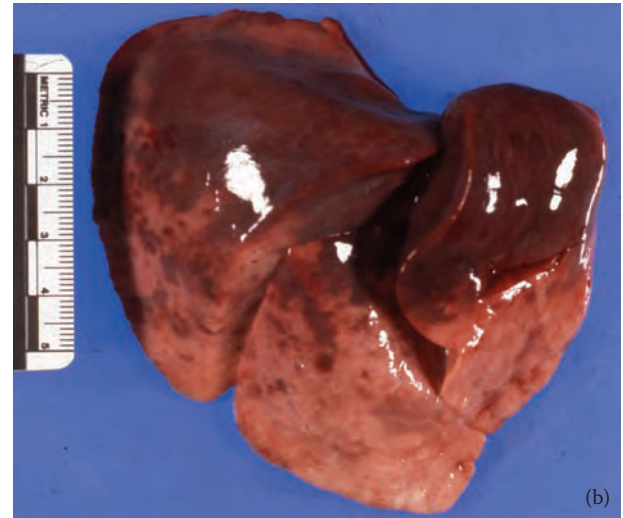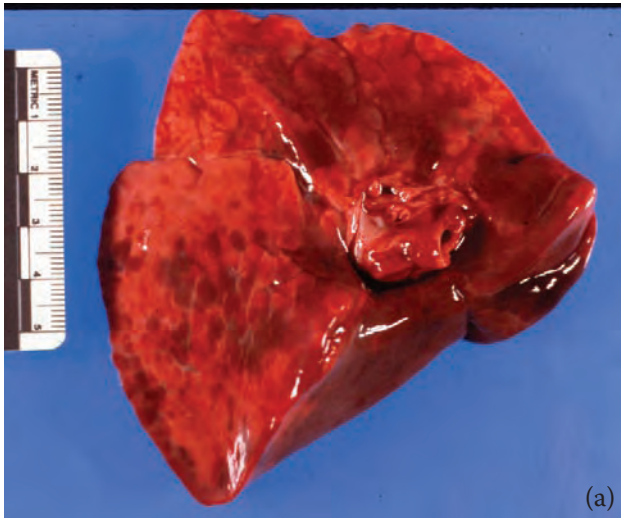


This case involved an infant who was born prematurely at 35 weeks gestation and was found prone in a bassinet with his face between a "covered" adult-sized pillow and the corner of the bassinet. The findings of this case were not sufficient to render a diagnosis of mechanical asphyxia, but asphyxia was of sufficient concern to denote the cause of death as sudden unexplained death in infancy and the manner undetermined. This picture shows sparse, inconspicuous visceral pleural and thymic petechiae, which were the only gross findings at autopsy.

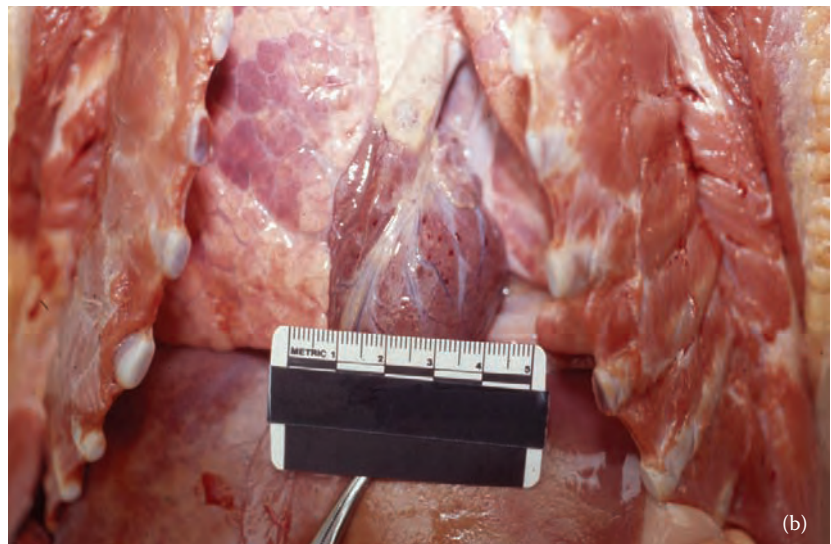
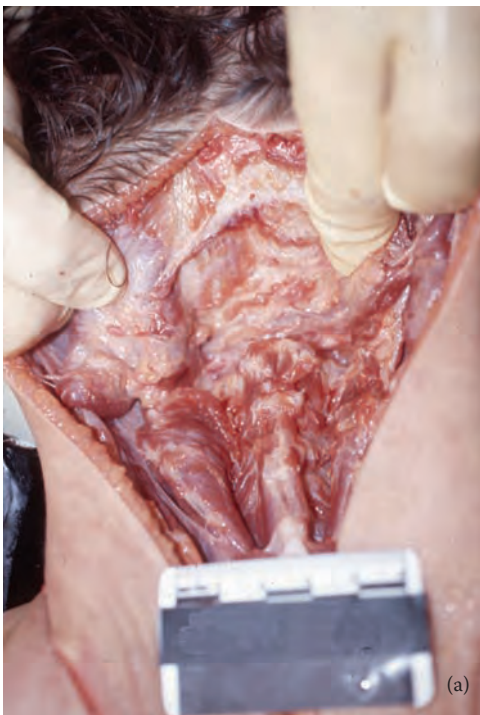

This is a view of the thoracic contents of an infant who was found unresponsive while sharing a bed with his mother while in a supine position. She called 911 and paramedics arrived to find him apneic and pulseless. He could not be resuscitated. Pertinent history included prematurity, maternal group B streptococcal infection, and a recent upper respiratory infection. The only significant findings at autopsy were a moderately cellular mononuclear leptomenigeal exudate consistent with a viral meningoencephalitis. However, there was no significant brain swelling. This fatality occurred in the early to mid-1990s, and the death was ascribed to SIDS. If a similar case were encountered today, bedsharing in an adult bed would probably be listed as a risk factor in part two of the cause of death statement and the manner of death would be undetermined. This picture depicts prominent petechiae on the anterior epicardial surface of the heart.

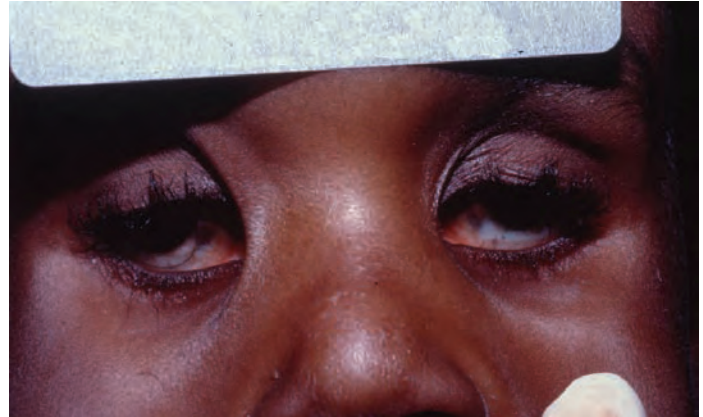
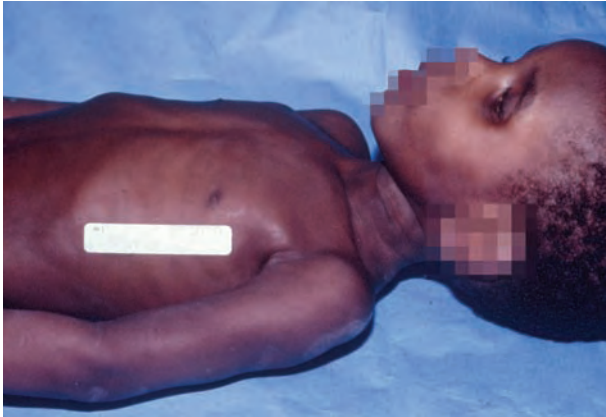


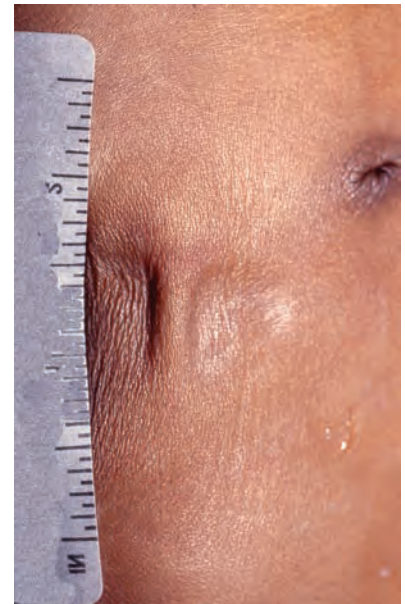
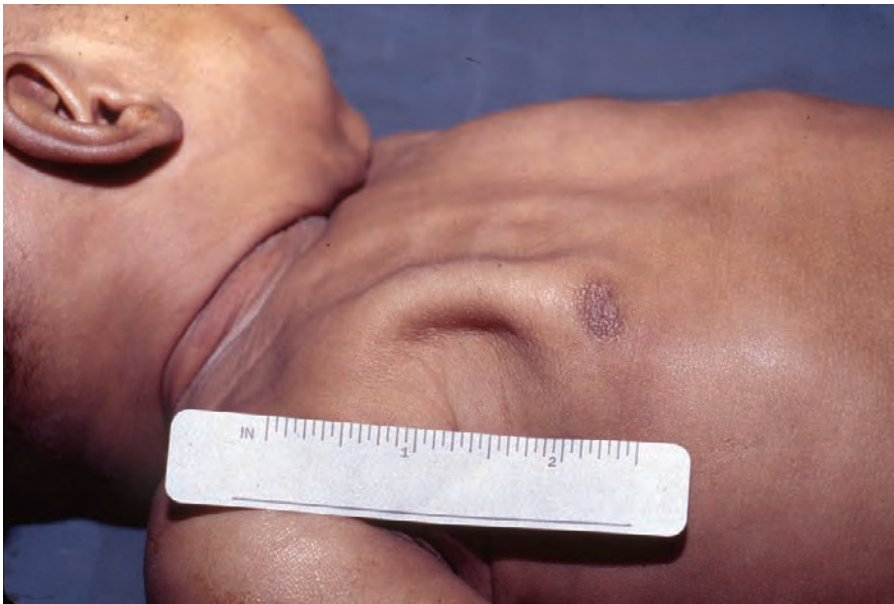View of the mediastinal surface of the left lung (a) demonstrates confluent subpleural hemorrhages within the lower lobe, likely an artifact of vigorous cardiopulmonary resuscitation (CPR). Note the way the hemorrhages conform to anatomic boundaries, similar to what is observed in aspiration of blood; (b) demonstrates the costal surface of the lung, with blotchy subpleural hemorrhages, some slightly larger than petechiae. Note also the confluent congestion within the posterior aspects of the lung, most likely a result of postmortem hypostasis, or settling of blood due to gravity.



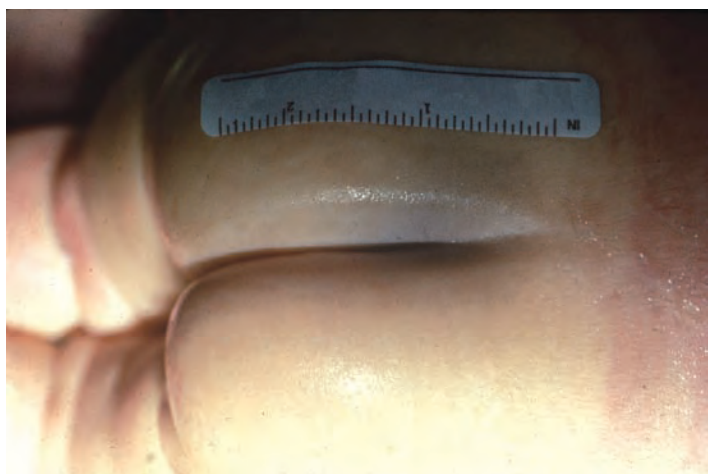
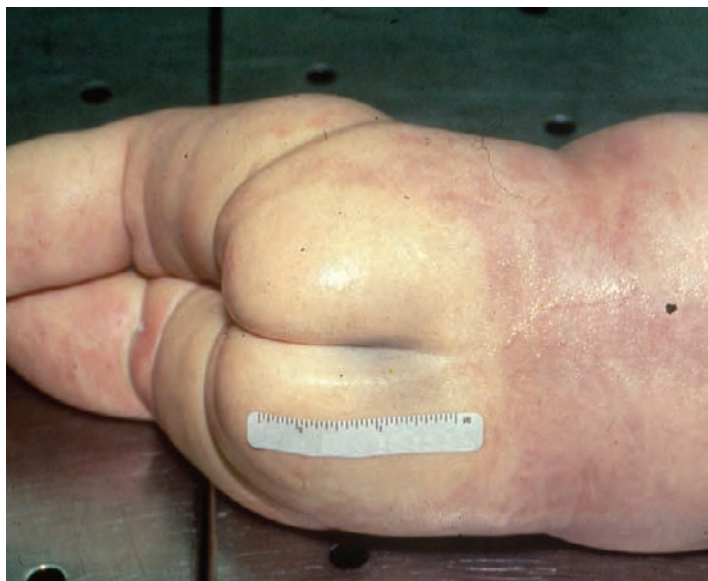
This was a case involving the enigmatic death of a 2-year-old child who was previously completely healthy. She had finished a course of amoxicillin for otitis media 3 days prior to her death. On the day before her death, she apparently fell off a "teeter-totter" and struck her head on the ground, which was a muddy, grassy surface, but she never lost consciousness and experienced no mental status changes. She could not be aroused from an afternoon nap and could not be resuscitated by pediatric life support protocol. The gross autopsy findings were unrevealing, including absence of injuries of scalp, skull, and brain. The only finding in addition to thymic, epicardial, and visceral pleural petechiae (b) was fibromuscular hyperplasia of the atrioventricular (AV) nodal artery, which was discovered by an expert cardiac pathologist who consulted on the case. This picture depicts a posterior neck dissection (a), demonstrating soft tissues and skeletal muscles that are entirely free of injury. In this case, anterior neck dissection was negative for injuries as well; (b) depicts prominent epicardial petechiae on the anterior surface of the heart. This case illustrates that the findings of intrathoracic petechiae are not confined to infants but can also be seen in young children.



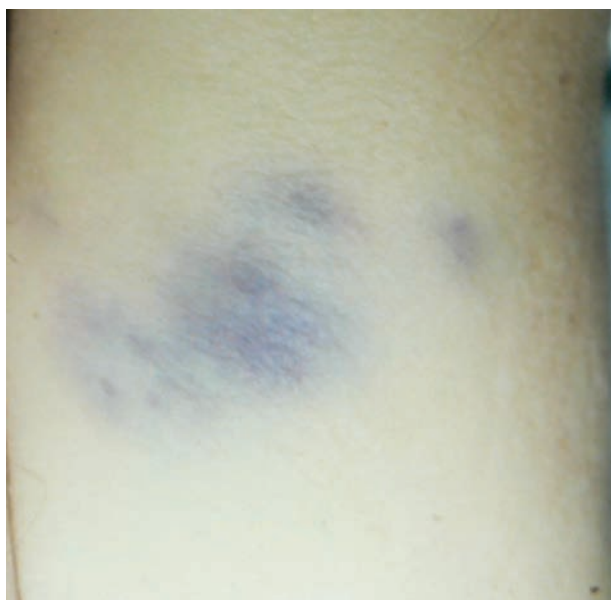This child died of complications of dehydration following a prolonged viral gastroenteritis. Note the sunken eyes.



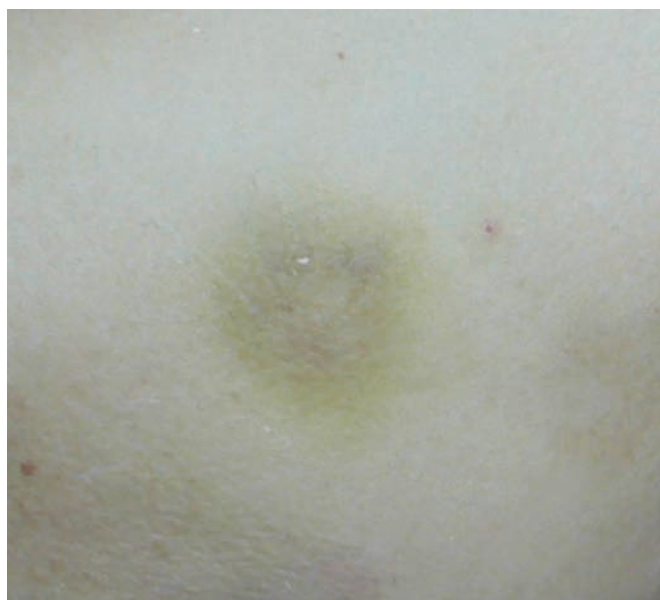Poor skin elasticity (turgor) is demonstrated in these infants who were refrigerated in the morgue overnight. These infants were shown not to be dehydrated by vitreous analyte determination and antemortem hospital chemistry testing. The poor skin elasticity in these cases is due to the congealing of fat as a result of postmortem refrigeration.



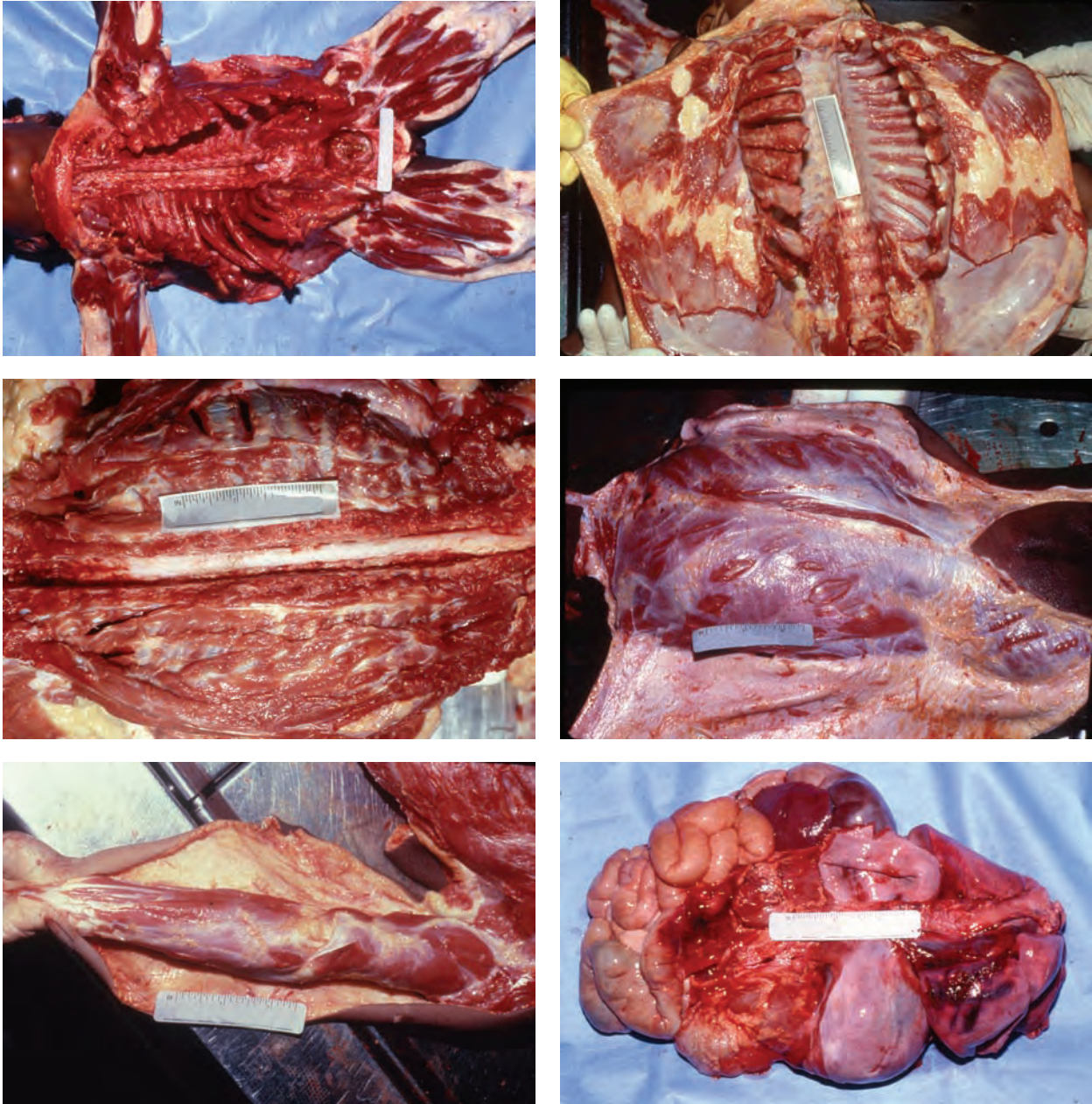
Mongolian spot. This is a birthmark and is sometimes mistaken for a contusion. During the time of autopsy it is easy to differentiate between the two by making an incision and documenting the presence or absence of underlying hemorrhage. The author has had at least one case where a contusion was demonstrated subjacent to a Mongolian spot.



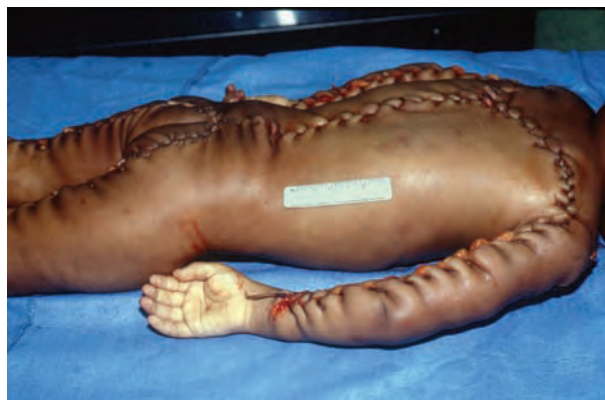Recent contusion.



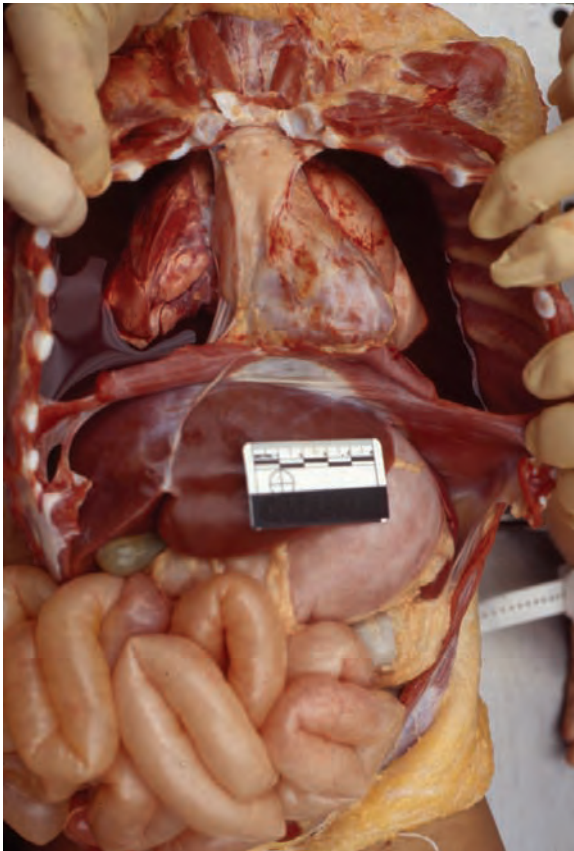
Old contusion.



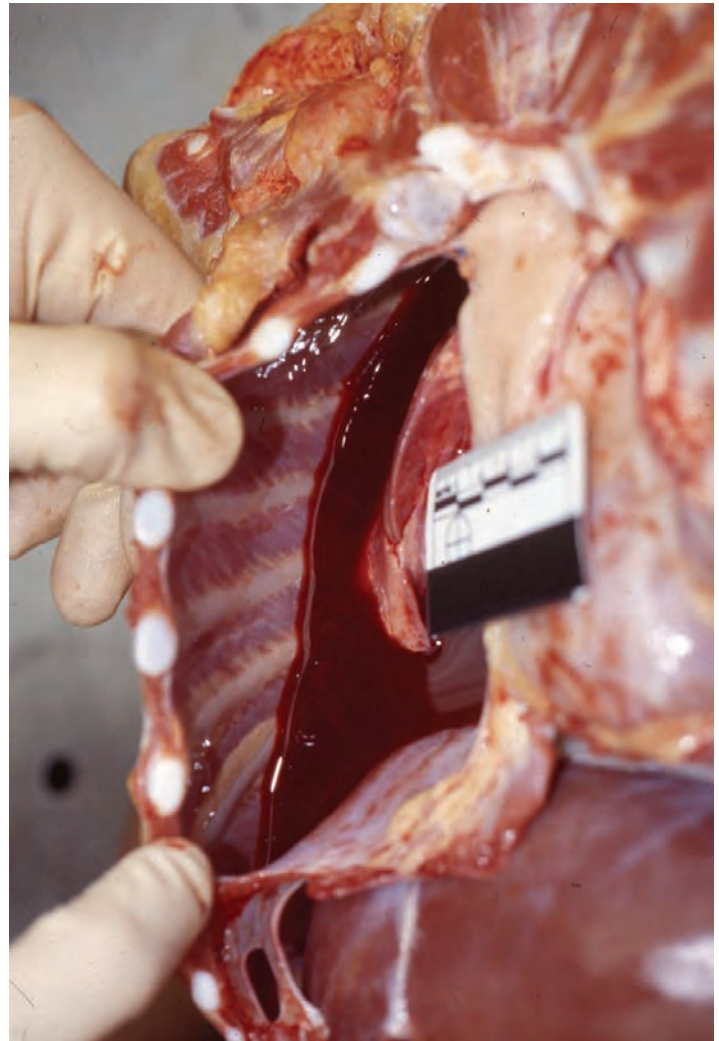
While performing autopsies on suspected child abuse cases it is important to be very thorough and it is recommended to incise the extremities and back to further document deep contusions, particularly in darker-skinned children. When examining the rib cage it is important to strip the pleural surface, separate each rib and evaluate each one separately. It is also good practice to do a posterior neck and back dissection while examining each rib as well.



This figure demonstrates how the body is sutured prior to funeral home release.



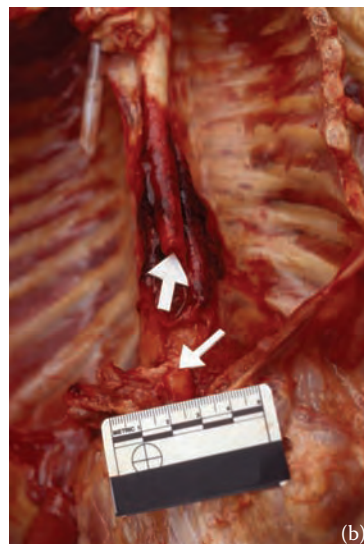
This 2-year-old child was brought to the ED by his mother's boyfriend after he was found unresponsive. The only observed external injury was a small faint contusion to the child's forehead. Autopsy revealed a fracture of the lumbar spine with a transected descending thoracic aorta and an old healed fractured clavicle. This picture demonstrates bilateral hemothoraces.



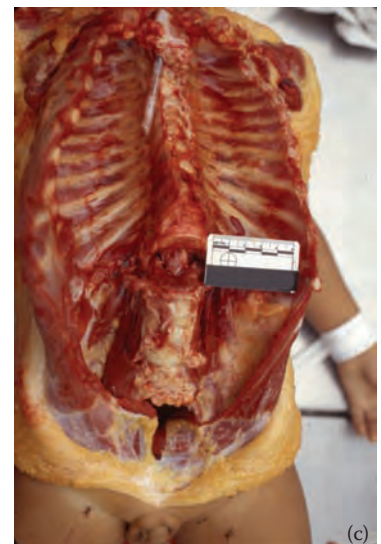
Right hemothorax due to aortic transection.



(a)



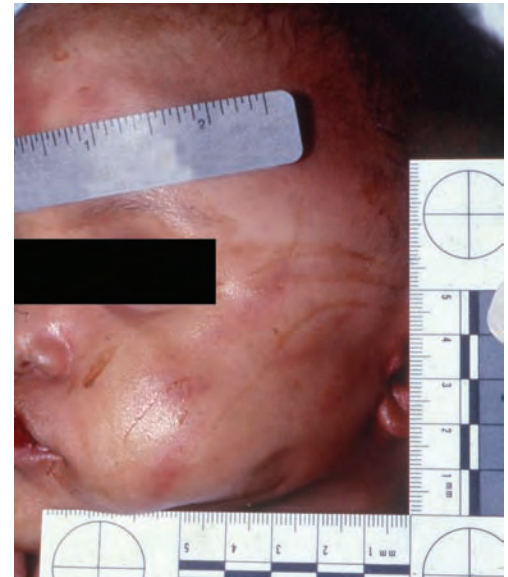
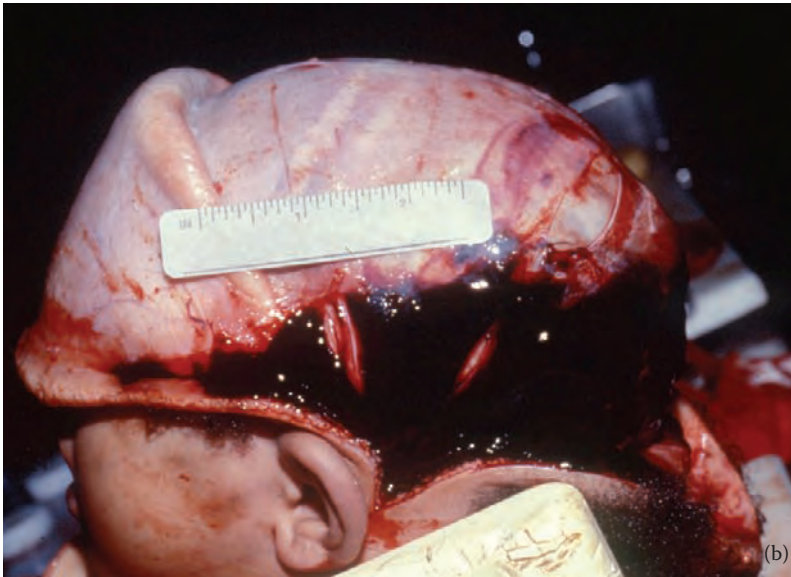
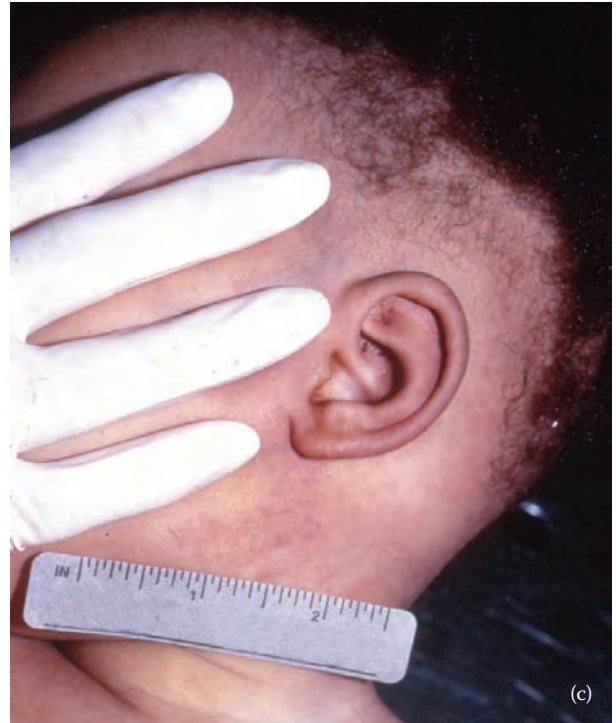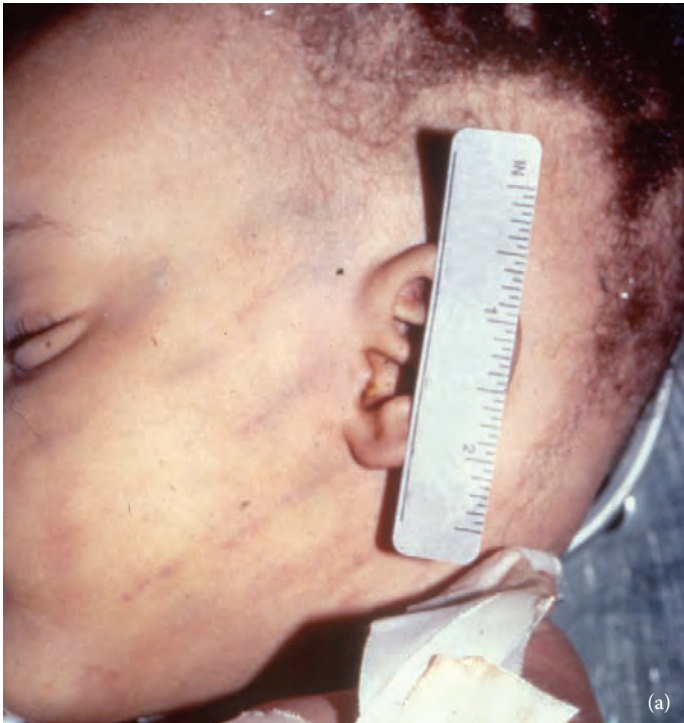(b)



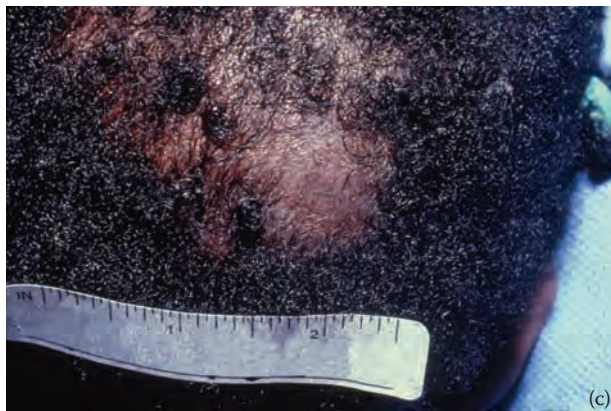
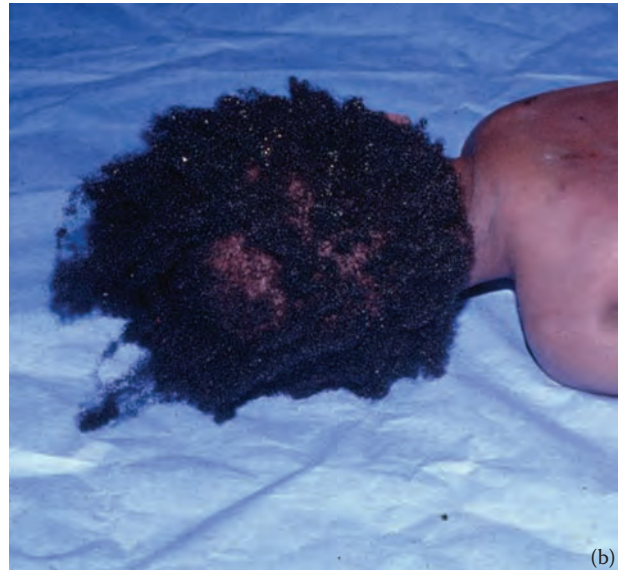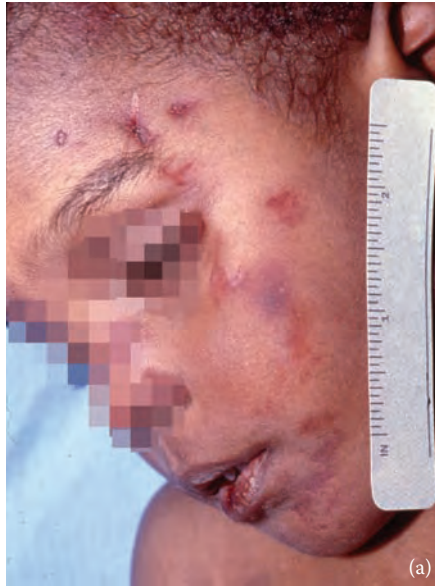(c)

Image (a) demonstrates the volume of blood collected from the bilateral hemothoraces (approximately 165 mL in total). In a case such as this, the mechanisms of death are probably multifactorial, including not only blood loss but also a component of spinal cord or sympathetic nervous system dysfunction; (b) depicts transected free ends of lacerated descending thoracic aorta, marked with arrows; (c) is a panoramic view of lumbar fracture, which resembles a "hinge" at L1-L2.

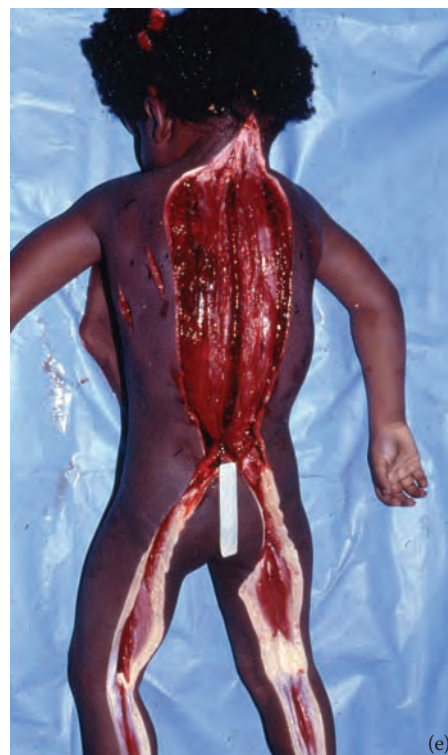
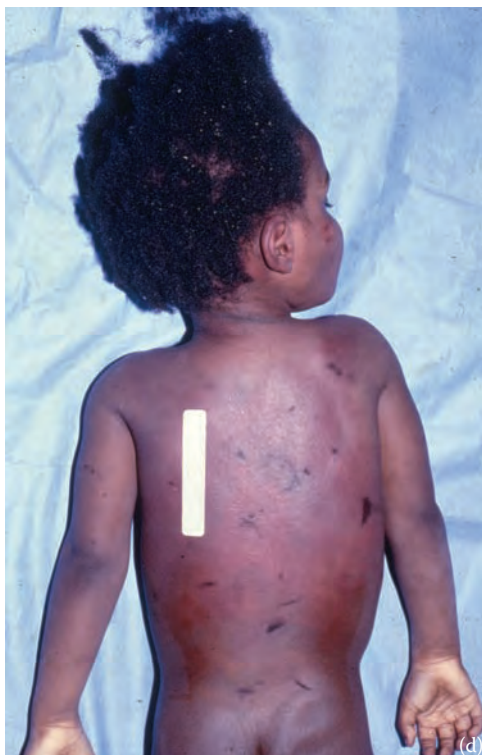


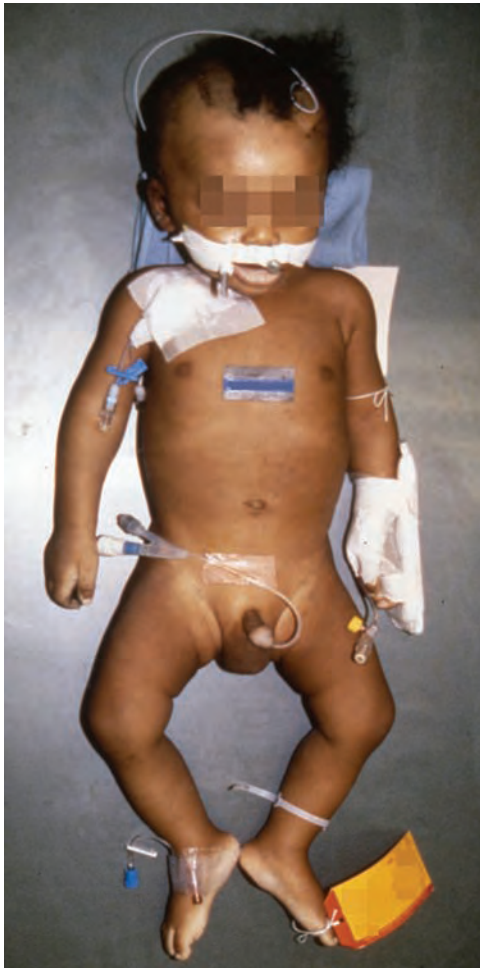This child died from multiple blunt force injuries. (a) Note the hand pattern with parallel contusions across the child's face. The contusions are more obvious when depicted following the intermastoid incision and scalp reflection (b). Note the excessive dark red blood clot at the inferior portion of the side of the head. Also note that this is not as visible when viewed from the external skin surface. Deep contusions may be difficult to see when viewed only from the external surface of the body; (c) demonstrates the same child approximately 2 days after autopsy. Note that the characteristics of the facial bruises have changed slightly due to the extended postmortem interval.

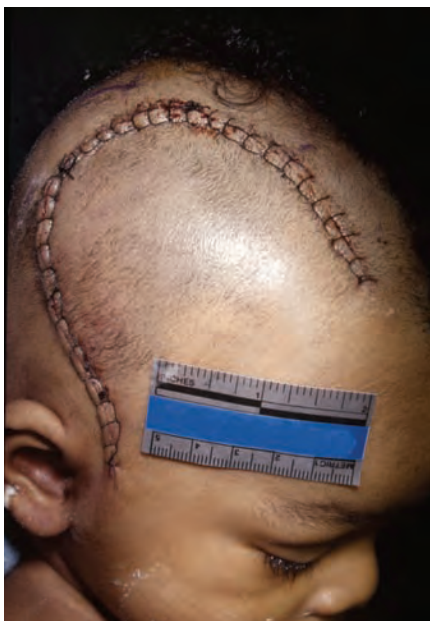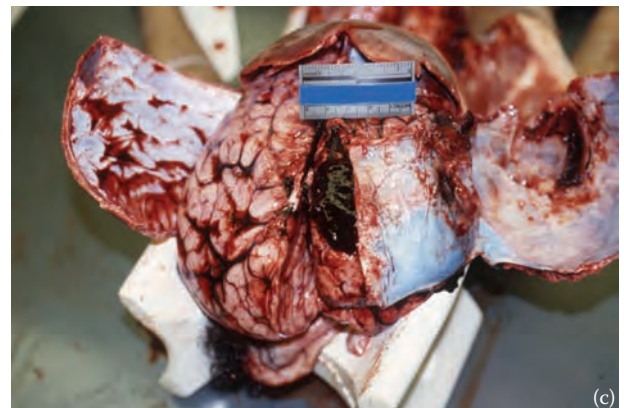
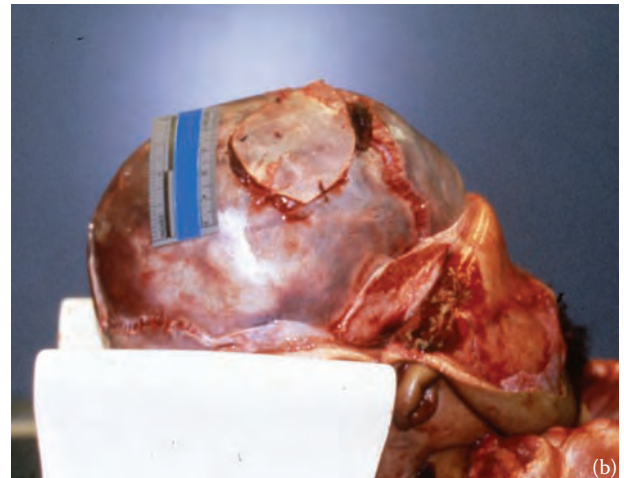

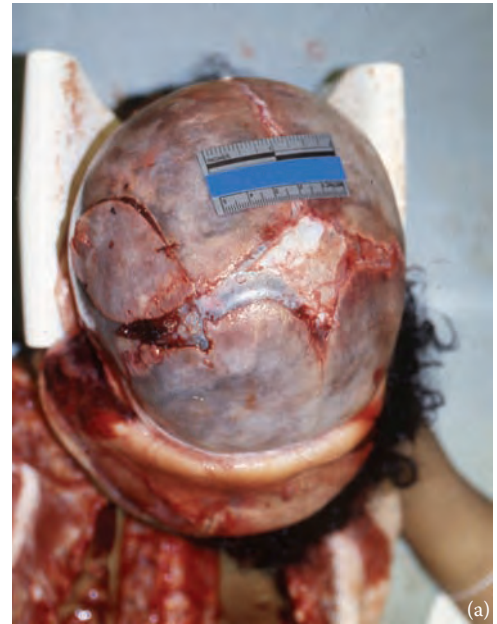
This child sustained multiple blunt force injuries to his head, back, and extremities (a–b). The child's hair was traumatically pulled from his scalp (c). Note the multiple angulated red to brown abraded contusions on the child's back (d), consistent with a belt buckle strike. Also note, following incision of the back and extremities during autopsy (e), the large degree of red bruising within the subcutaneous soft tissues of the back. Note the pale yellow subcutaneous tissue within the posterior compartments of the lower extremities, which are atraumatic and without hemorrhage.



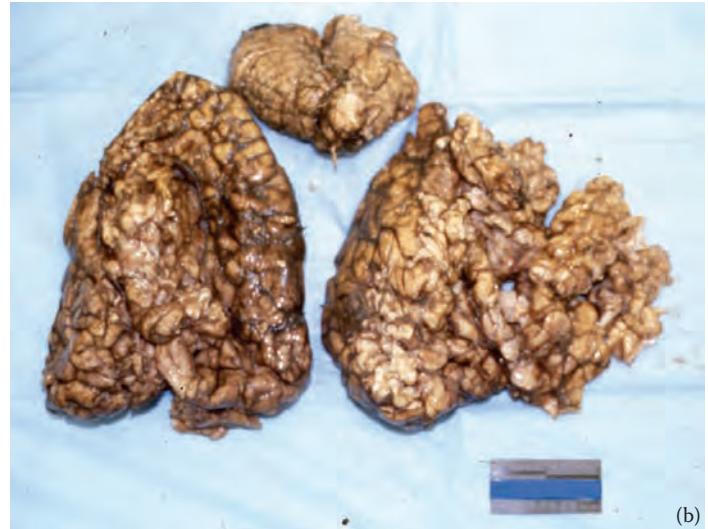



Note the multiple therapeutic interventions documented at autopsy. This documentation is important to help prevent misinterpretation of therapeutic intervention as injuries.

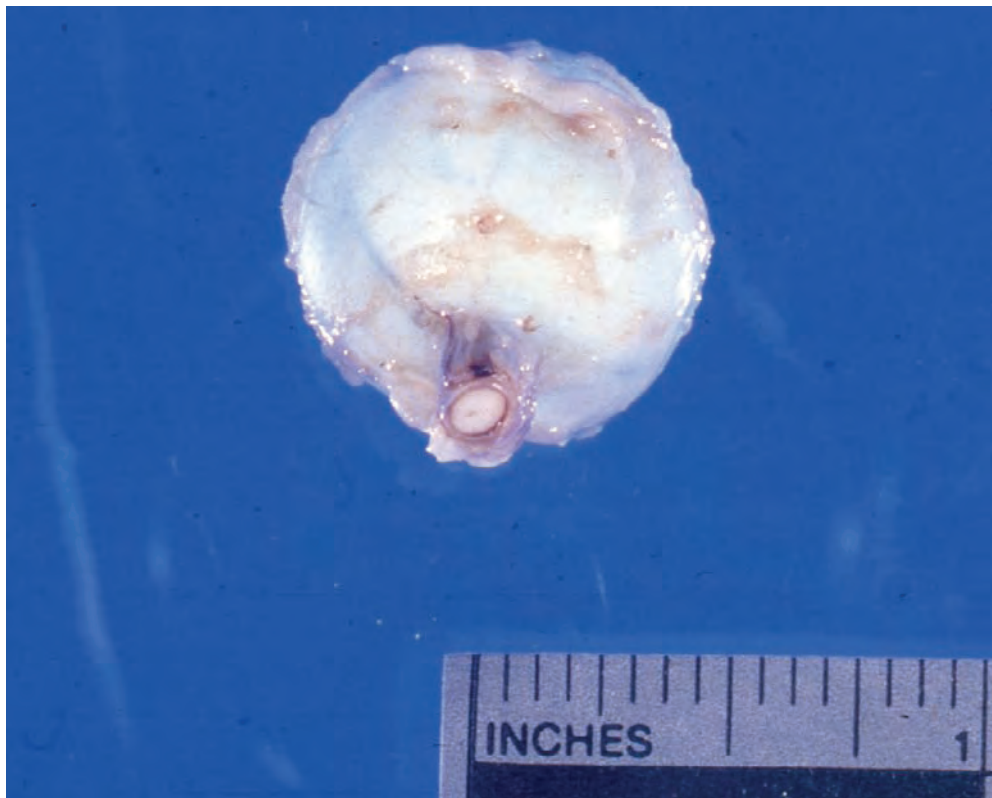

This case demonstrates a sutured right-sided scalp incision as part of a craniotomy for evacuation of a right-sided subdural hematoma.

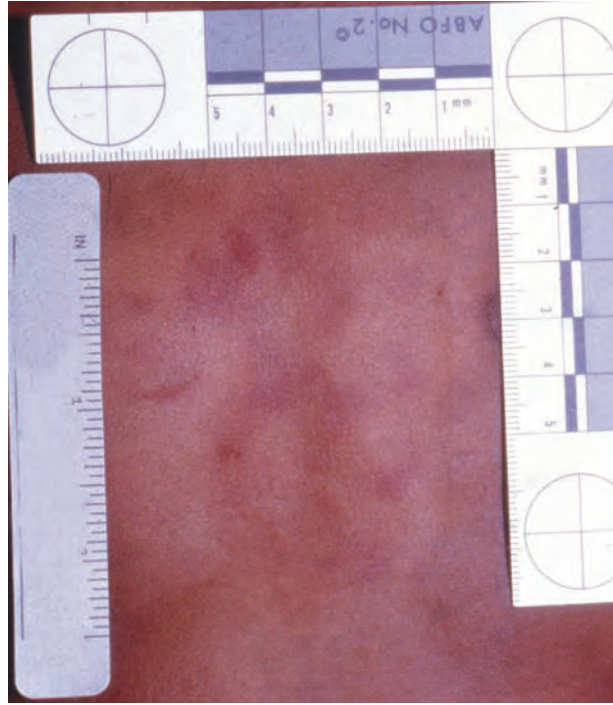
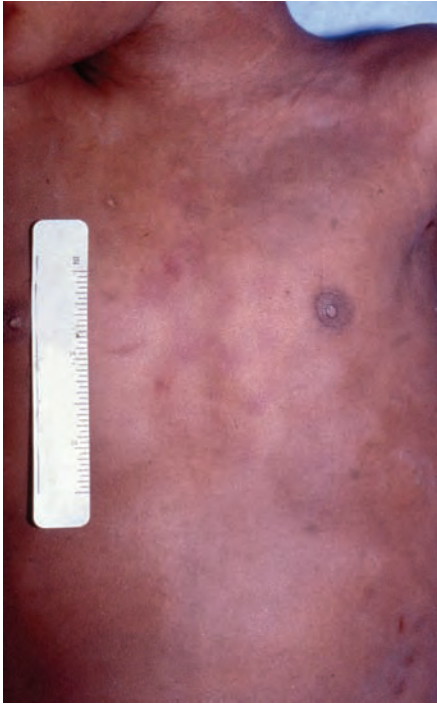
Superior view of the calvarium (a) illustrating marked widening of the coronal suture (diastasis) due to brain swelling, along with a right-sided craniotomy window; (b) right side of face and skull, including craniotomy window. Marked diastasis of the coronal suture is also seen; (c) residual right-sided subdural hemorrhage and marked brain swelling, characterized by complete flattening of gyri and effacement of sulci on the cerebral convexity of the left cerebral hemisphere. The inner surface of the left vertex dural leaf is blood-stained.



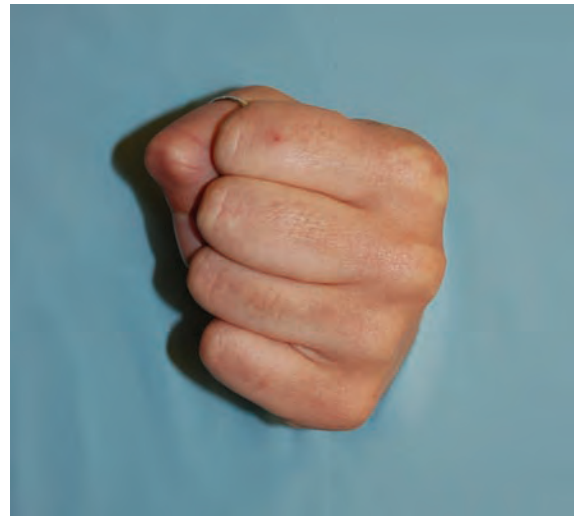Formaldehyde-fixed portion of dura mater from an approximately 4-month-old infant with a history of tetralogy of Fallot who was found unresponsive by his mother's boyfriend. The boyfriend claimed that he had fallen approximately 3 feet from a couch onto a carpeted floor. Such explanations are often incompatible with the spectrum of injuries observed at autopsy. In this case, the adherent, thin-layered, clotted subdural blood indicates a duration of approximately 3–4 days following the injury, which correlates with the survival period of this infant after being found unresponsive. (b) Illustrates the fixed, markedly friable, fragmented brain attributable to marked hypoxic-ischemic injury, and is therefore a nonspecific finding, as it can be seen within the setting of hypoxic-ischemic brain injury of any cause.



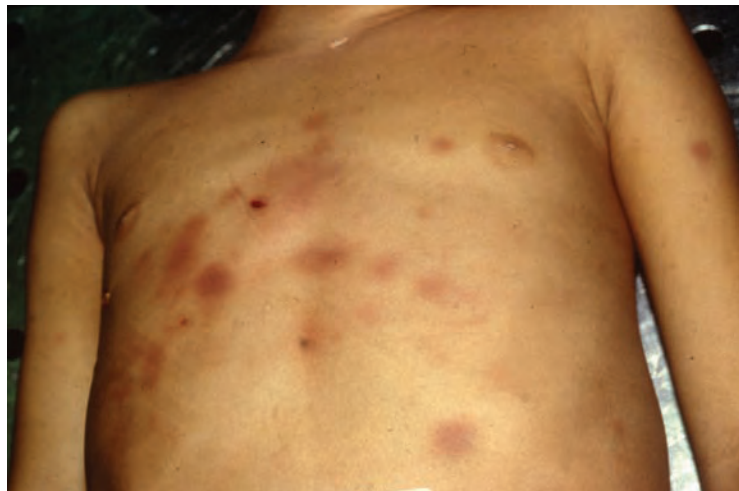Cross-section of the optic nerve in an infant found to have unilateral subdural hematoma and brain swelling, who underwent evacuation of the subdural hematoma. The infant never regained consciousness and was declared brain dead approximately 3 days following the surgery. Optic nerve sheath hemorrhage is correlated with retinal hemorrhages, although it is not specific for inflicted injury, and may be seen in conditions of sepsis, hemorrhagic diathesis, and other rare natural conditions.

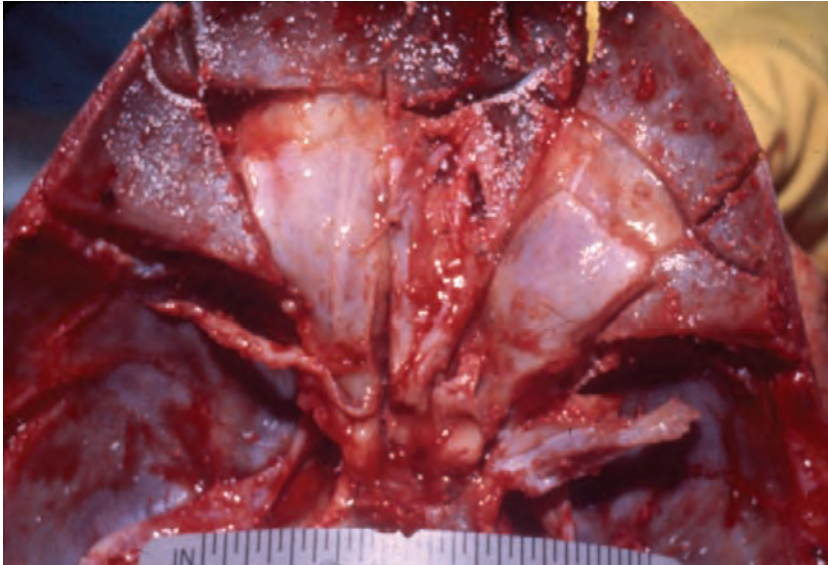


Note the vague pattern contusion of a fist on the anterior chest in this child-abuse fatality. This child died of multiple blunt impact injuries and was discovered dead at the scene in full rigor. No resuscitation was performed.

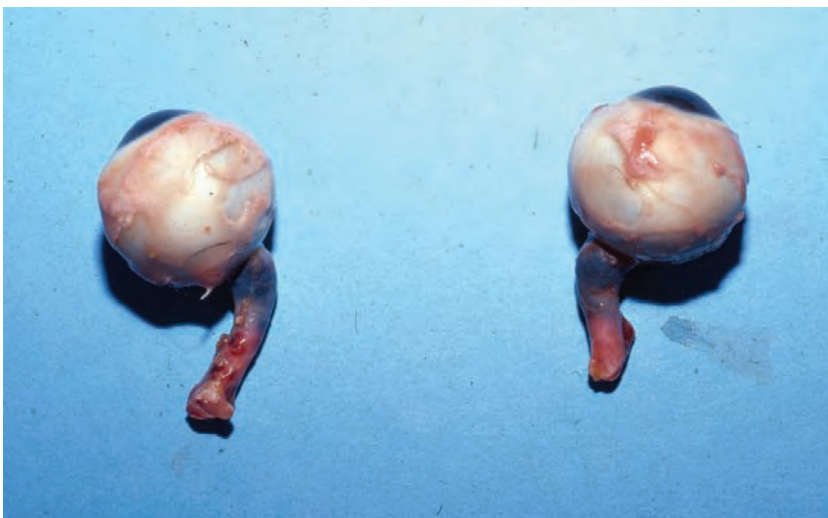
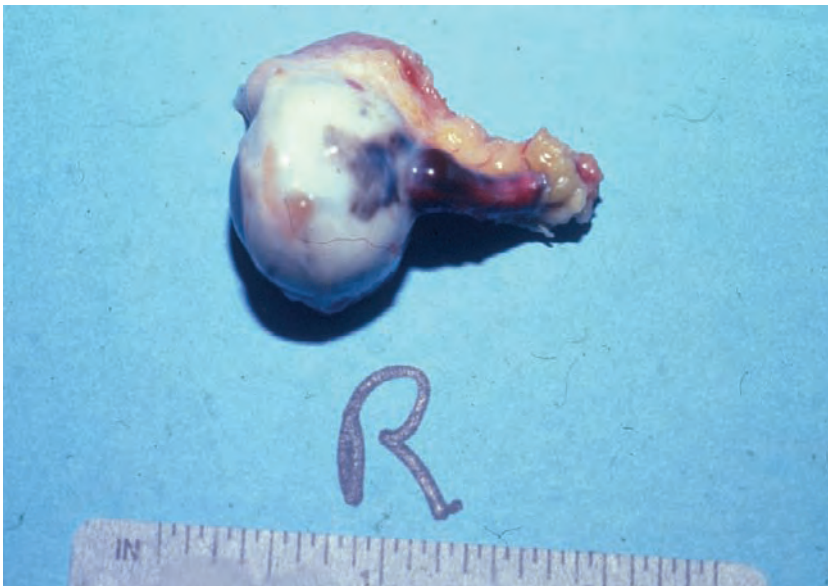

Antemortem contusions associated with child abuse combined with superimposed perimortem contusions associated with resuscitation. The resuscitative injuries overlie the sternum.

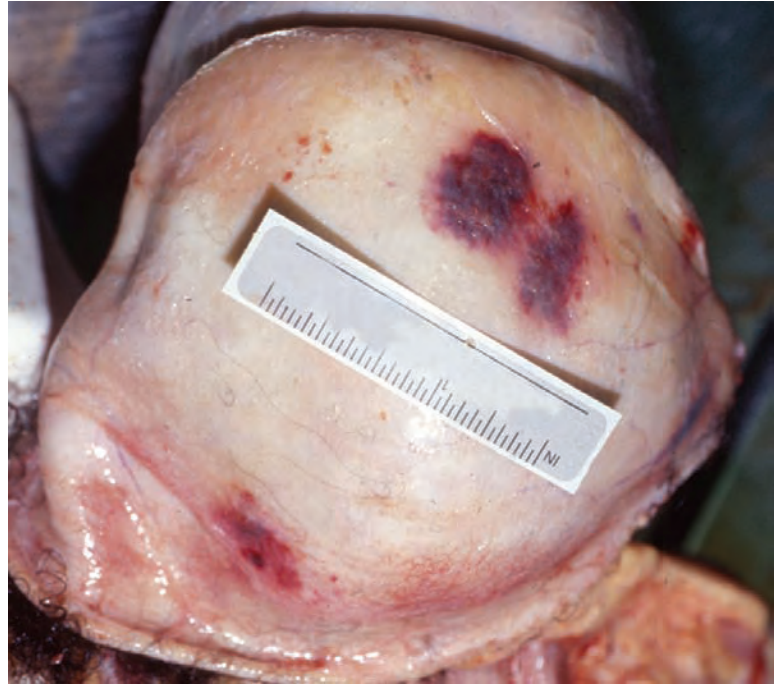
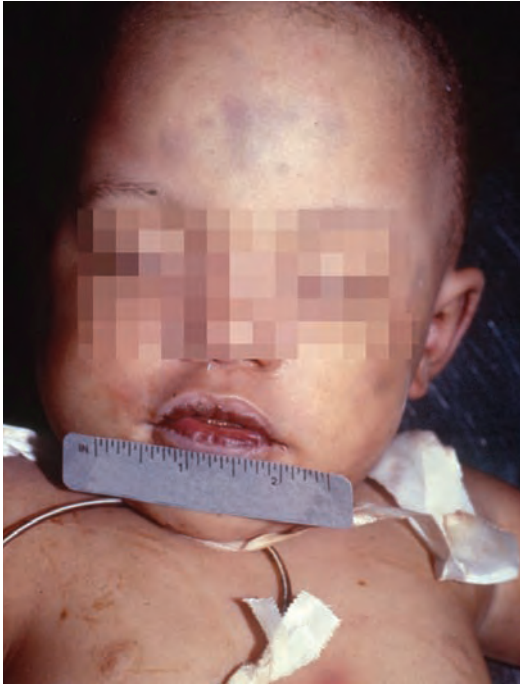


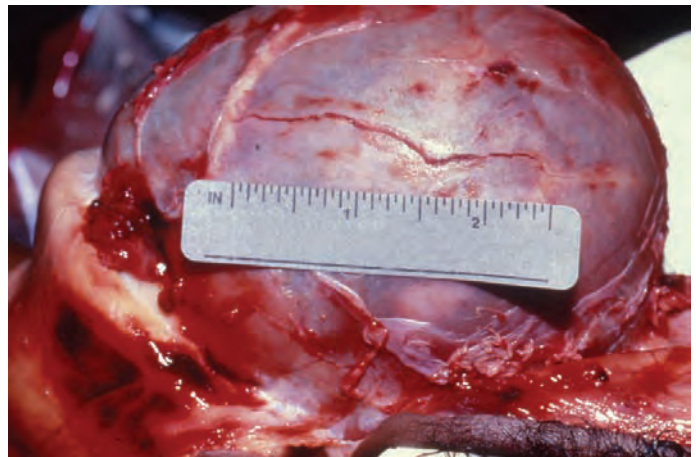
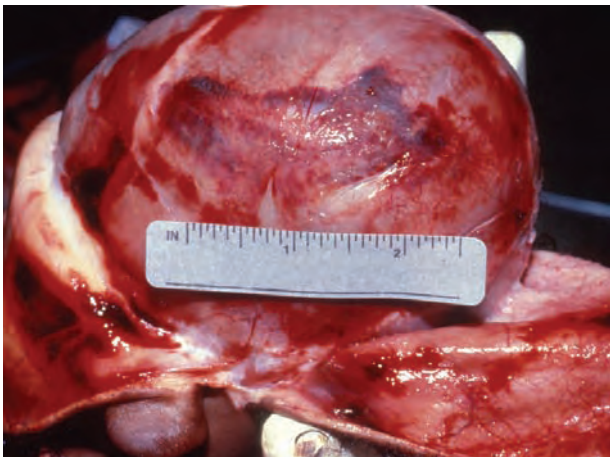
This demonstrates saw cuts through the floor of the anterior cranial fossa (orbital plate of the frontal bone) prior to removal of the eye with its attached optic nerve.



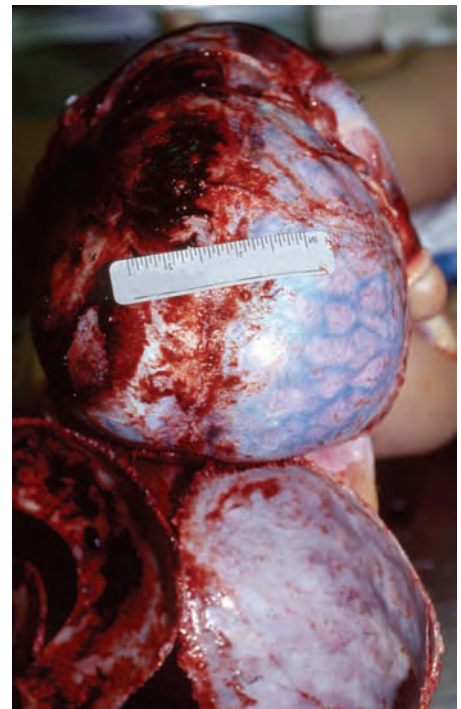
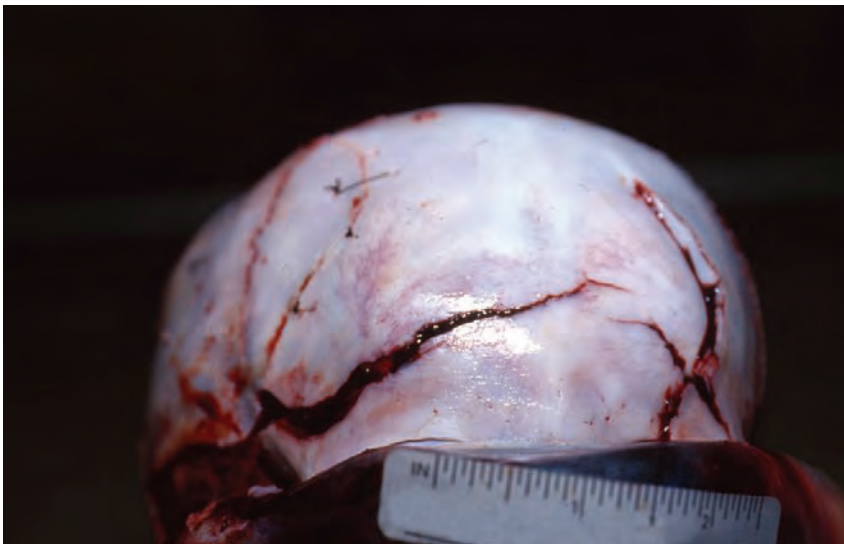
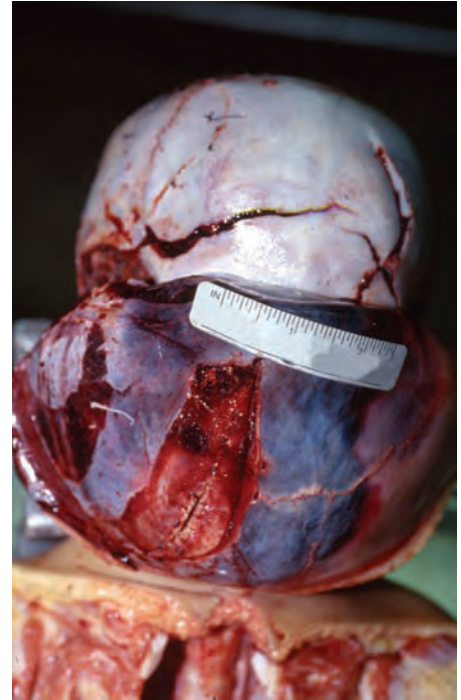
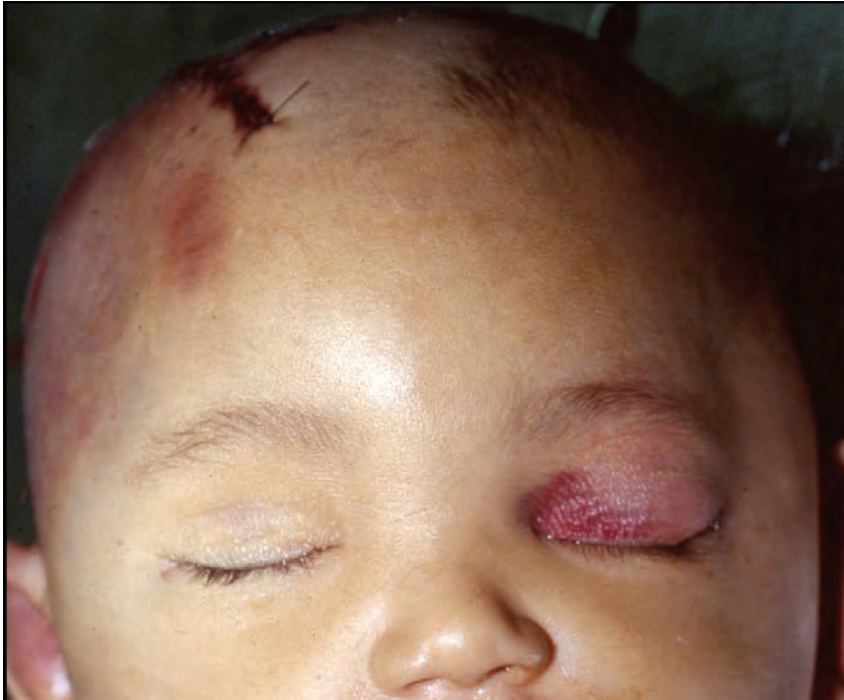Note the optic nerve sheath hemorrhages. Both of these images demonstrate optic nerve sheath hemorrhages in small children who died from shaken-impact syndrome. Histopathology revealed retinal hemorrhages. There was no evidence of natural disease including coagulopathic syndromes or connective tissue disorders.



The first image of this child-abuse case demonstrates vague contusions on the child's forehead. Reflection of the scalp shows much more prominent soft tissue (subgaleal) hemorrhage.



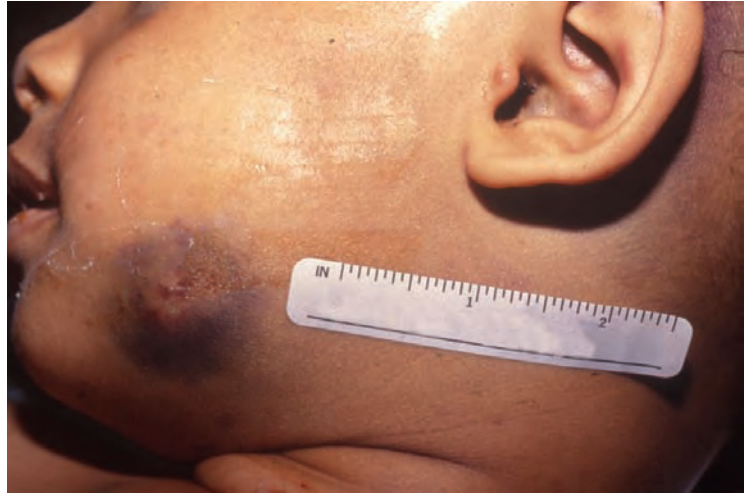
Child abuse case with reflected scalp demonstrating contusions and underlying linear skull fracture.



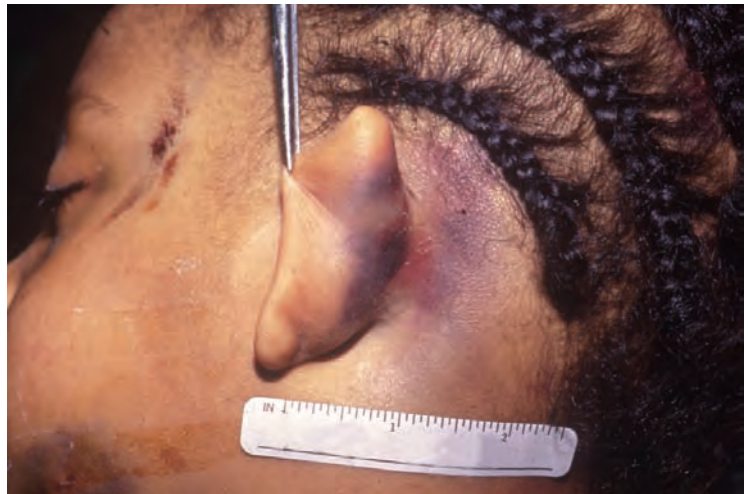This child was visiting his grandfather with his parents from another country. The grandfather's apartment was not made "child-safe" prior to the visit. The toddler was standing and rocking a large old wooden television back and forth on a stand that was missing several screws. The television toppled over and crushed the child's head. Note the fracture pattern to the skull indicating a crush-type injury. Also note the photograph demonstrating the top of the skull reflected with underlying dura mater still overlying the brain with epidural hemorrhage. The fractures involved the temporal, frontal, and parietal bones and there was severe brain injury with brain swelling and herniation.



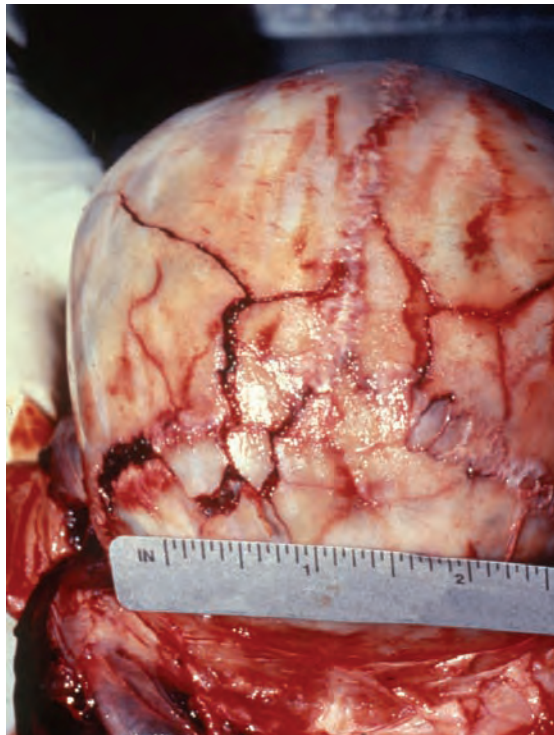
Note the large contusion to the side of the child's face from being punched.

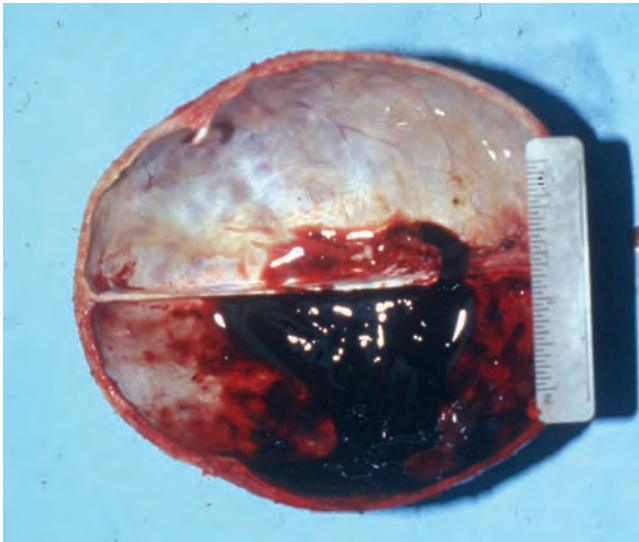


This child was the victim of an assault and suffered a skull fracture with brain injury that caused his death. Note the area of hemorrhage to the mastoid portion of the scalp demonstrating "battle sign."

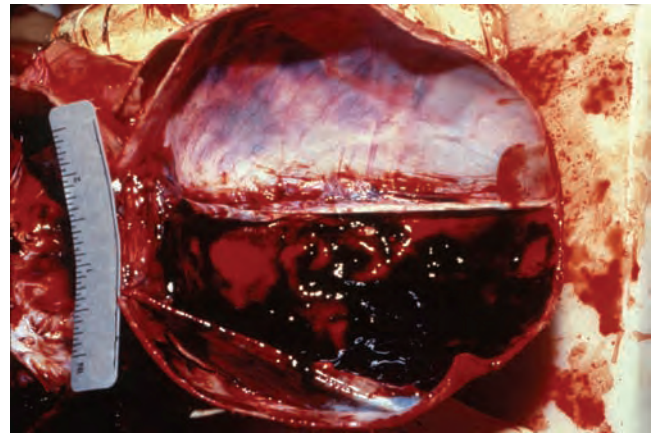


Child abuse case with comminuted skull fracture. This was most likely produced by flinging the child in a downward trajectory, and striking the child's head against a hard countertop. A fracture of this nature would take tremendous force to produce.

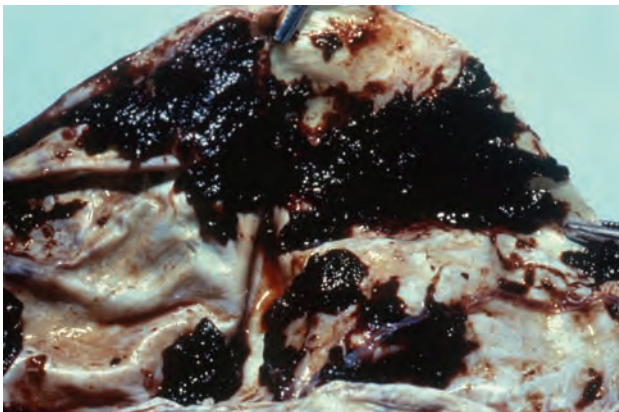




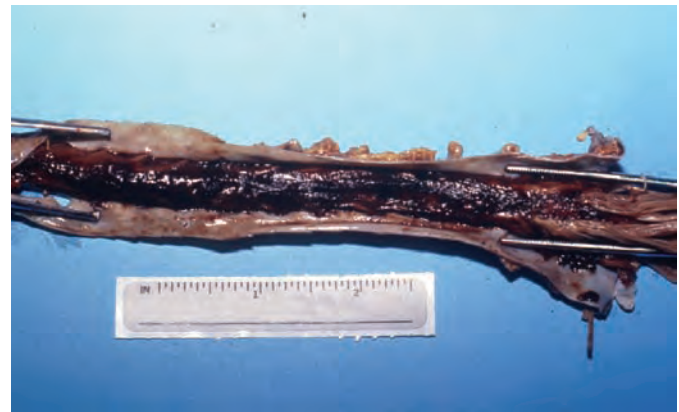This demonstrates the top portion of the skull (calvarium) removed during autopsy with the dura mater still attached and clotted, partially adherent, subdural hemorrhage. Clotted adherent red-black subdural hemorrhage indicates an injury age of approximately 2-4 days.



This is the top portion of the skull with adherent clotted subdural hemorrhage involving the left vertex dura (overlying the left cerebral hemisphere) with portions of dura mater separated at the posterior temporal-parietal-occipital regions, adjacent to sites of skull fracture.

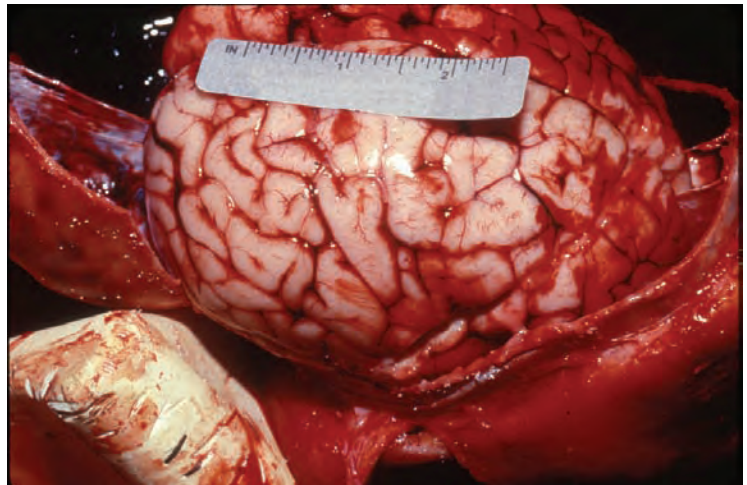
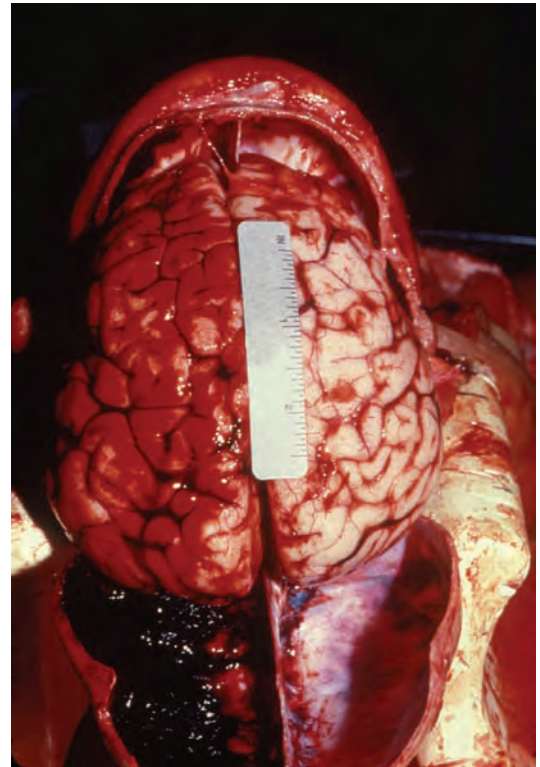


Portion of formaldehyde-fixed dura mater saved for further neuropathologic evaluation. Note the adherent clotted, black-brown subdural hemorrhage.

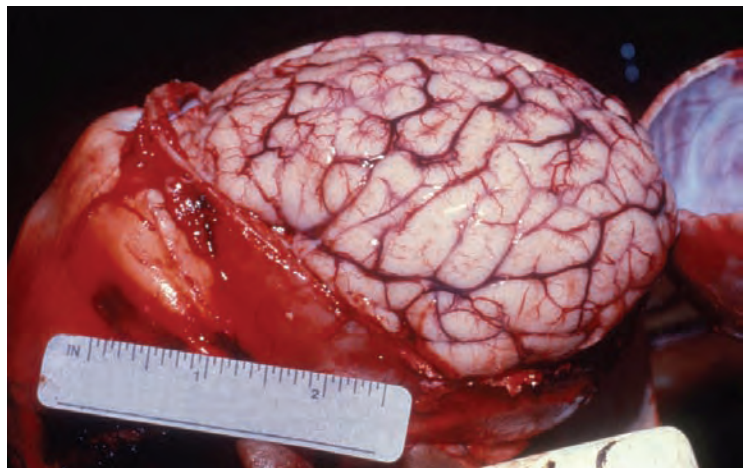

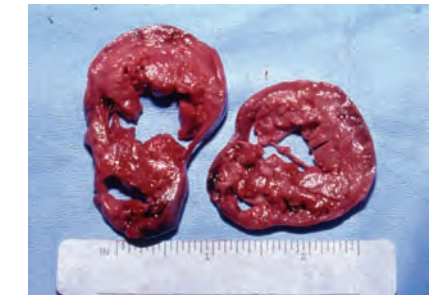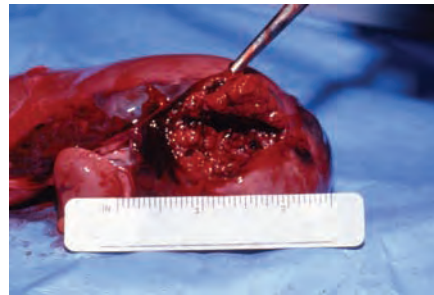
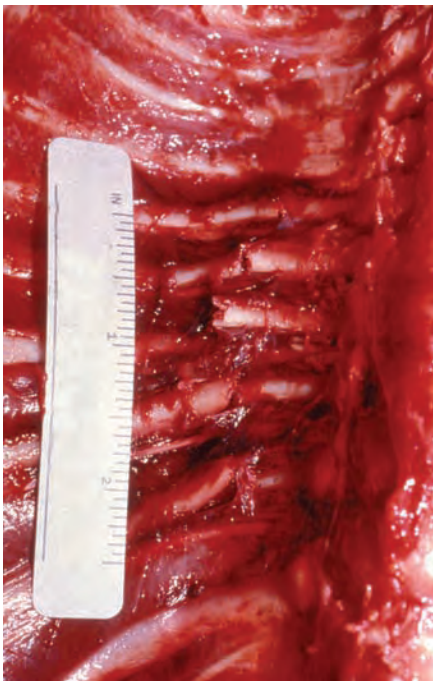
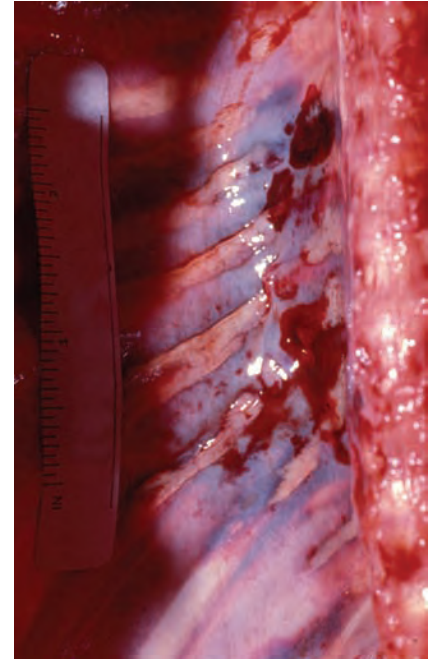
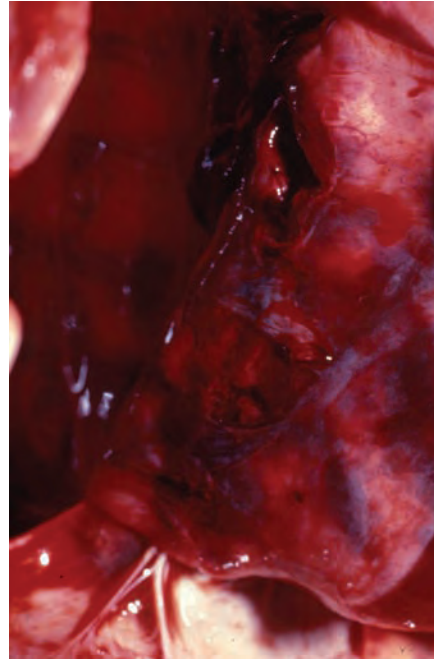
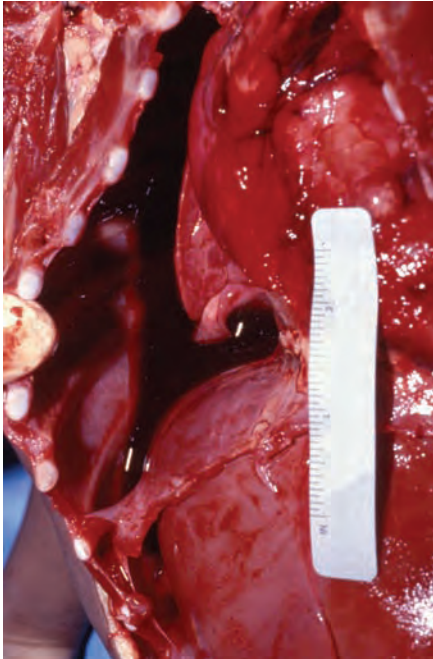
Formaldehyde-fixed portion of spinal cord removed with the dura mater demonstrating subdural hemorrhage. It is important to remove the cervical spinal cord as carefully as possible during the autopsy process in order to avoid potentially troubling postmortem artifact.

This shows the top portion of the skull (calvarium) being unroofed during the autopsy process for removal of the brain. Note that the dura mater is still adherent to the inner aspect of the skull (endocalvarial surface). There is a large left-sided adherent clotted subdural hemorrhage. There is diffuse cerebral swelling with flattening of the gyral configuration and obliteration of the sulci. There is patchy subarachnoid hemorrhage, which is greatest over the left cerebral hemisphere.

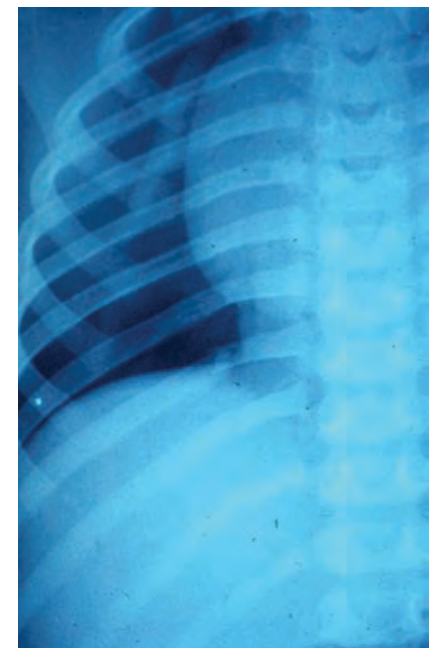

Close-up views of brain swelling with flattening of gyri and obliteration of sulci in a child who survived several days following blunt force trauma due to homicidal violence.

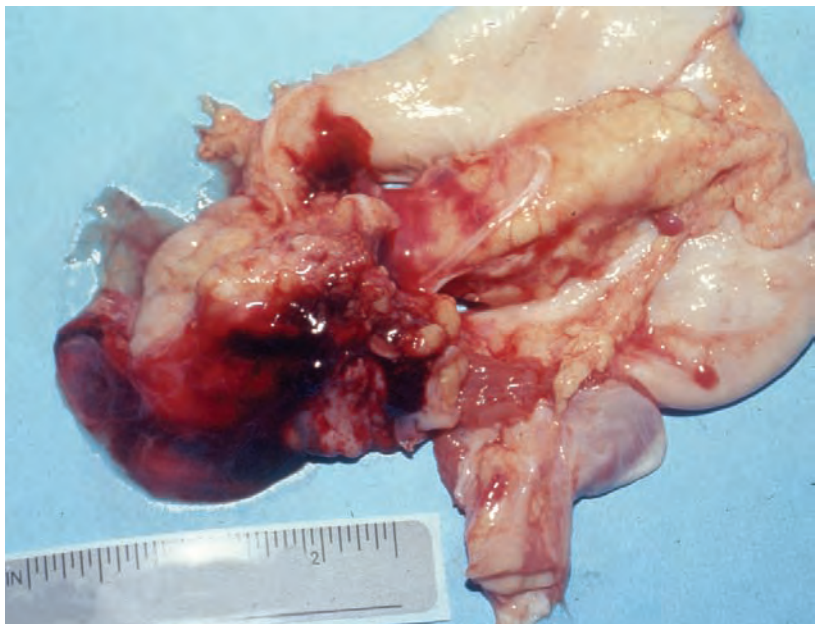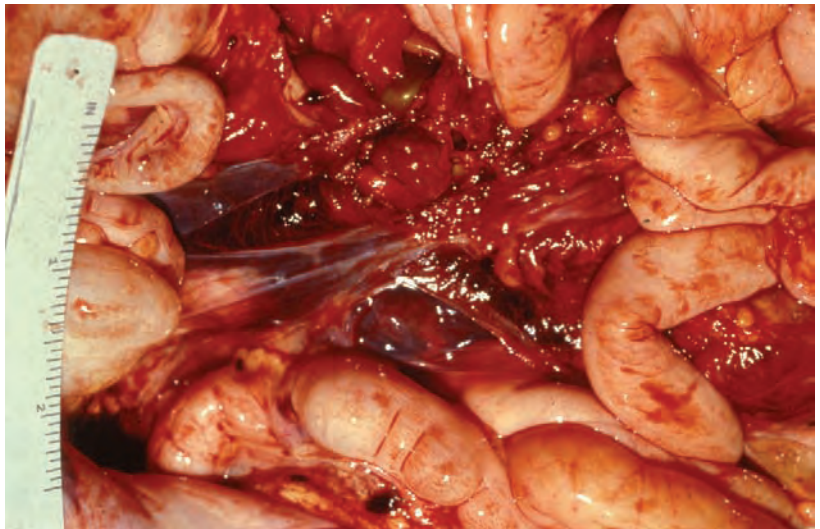
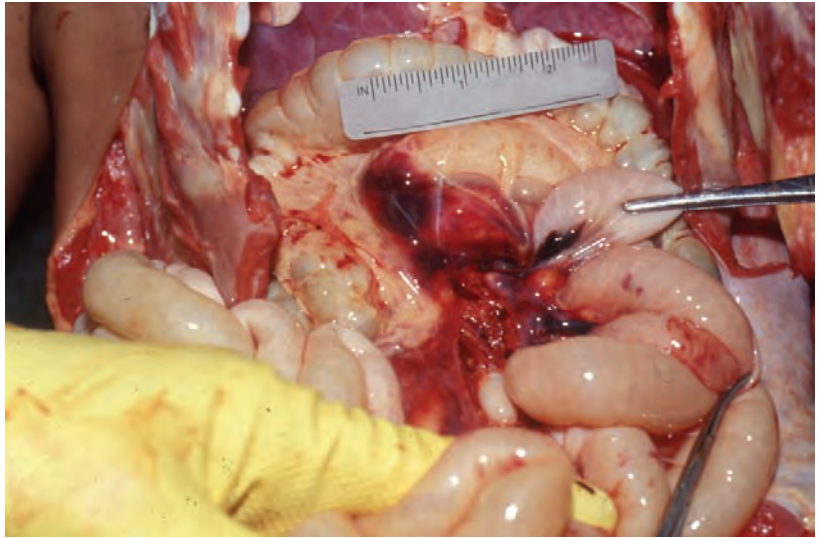




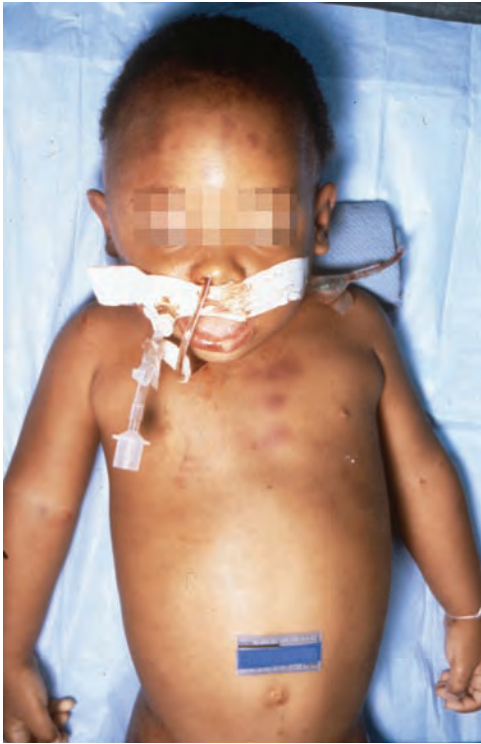This child sustained multiple posterior rib fractures after being stomped by an adult while lying face-down on the floor. The fractured segments of the ribs penetrated the posterior aspect of the right lung, producing extensive pulmonary and intrathoracic hemorrhage. There were also large lacerations to the posterior aspect of the liver and heart.



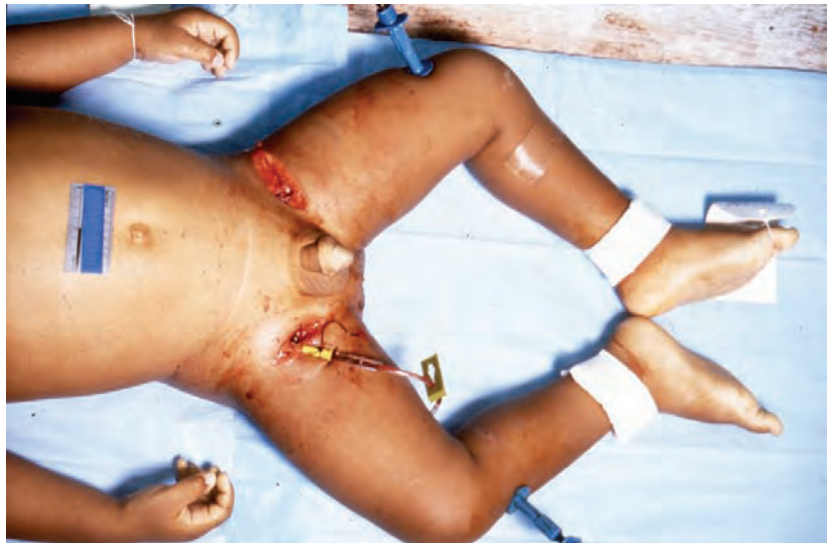X-ray showing multiple recent rib fractures.



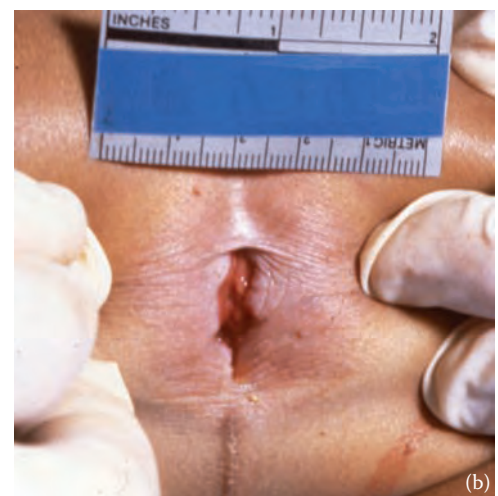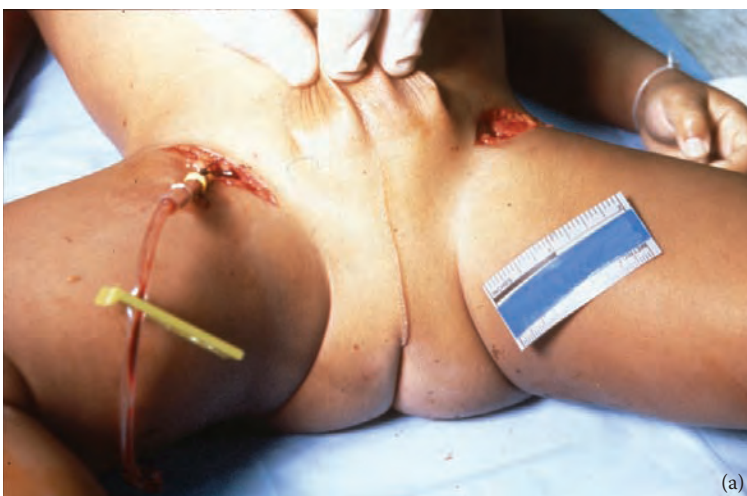These images demonstrate multiple lacerations involving the mesentery, mesocolon, and peripancreatic soft tissues following blunt abdominal impacts associated with homicidal violence.



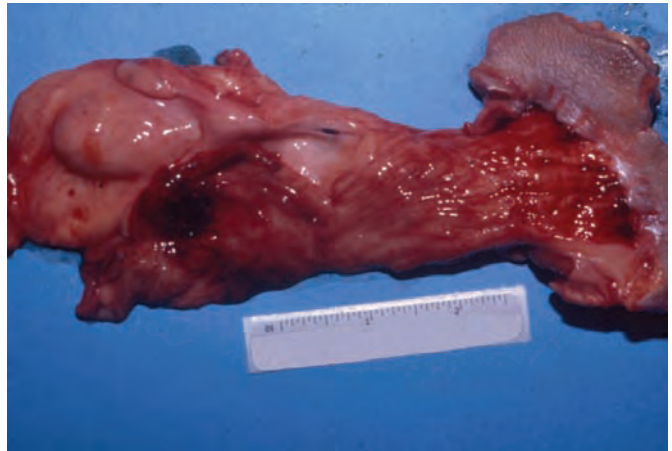
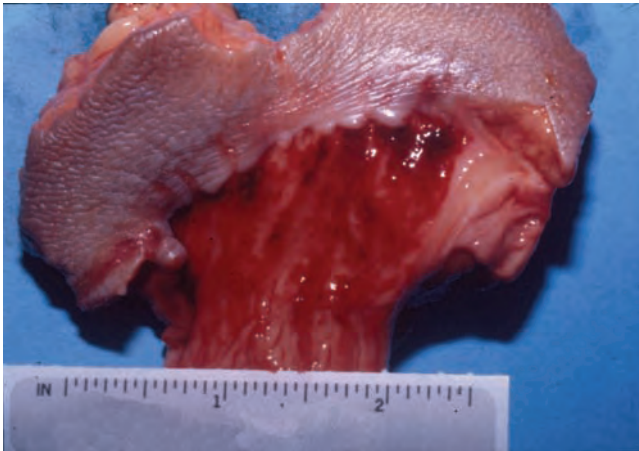
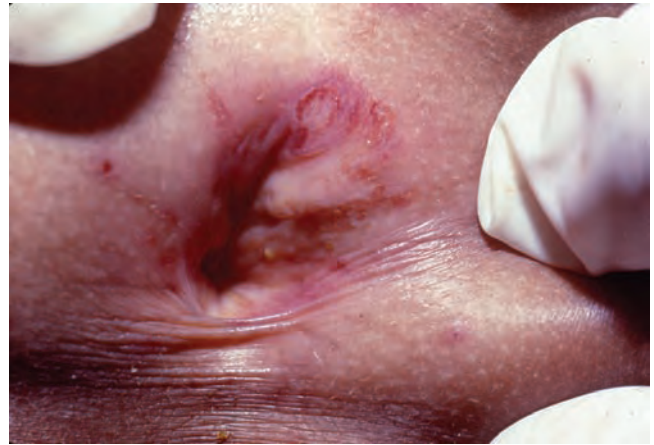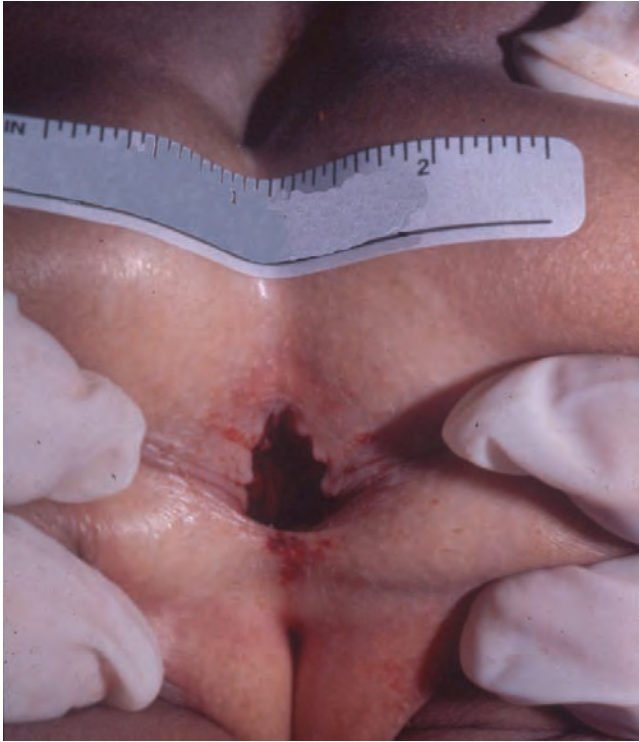This 2-year-old child was found by a caretaker unresponsive in the bathtub. An autopsy revealed confluent subgaleal contusions, essentially spanning from ear to ear, along with brain swelling, although the skull was intact. Death was attributed to blunt impacts to the head with brain swelling. A component of drowning cannot be ruled out in this case. The defendant, a casual acquaintance of the mother, was convicted of second-degree murder and sentenced. Note the bilateral intraosseous catheters, used while attempting to resuscitate this child even though he was slightly over 2 years old. This image depicts the face and anterior trunk of a child with patchy contusions involving the forehead and the left paramedian aspect of the anterior chest wall. Multiple therapeutic interventions are also present. As stated previously, differentiating between the effects of therapy and antecedent injury can be problematic, and the two processes may coexist.



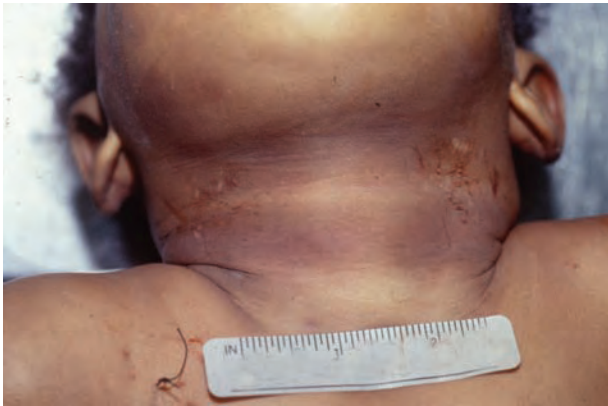This depicts lower trunk and lower extremities of child, with multiple therapeutic interventions including transverse cutdown sites within both groins, bilateral intraosseous catheters, and a right groin catheter.



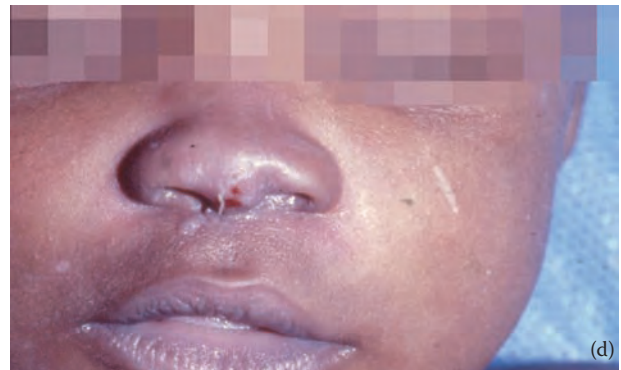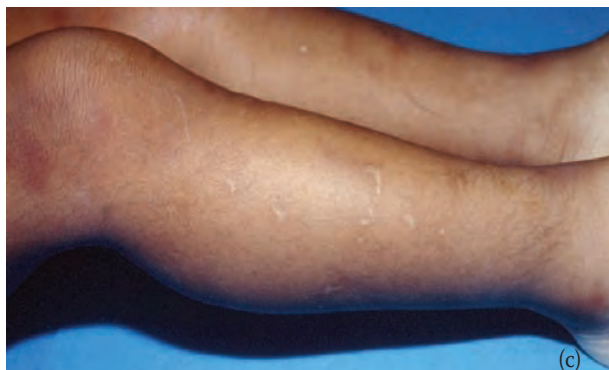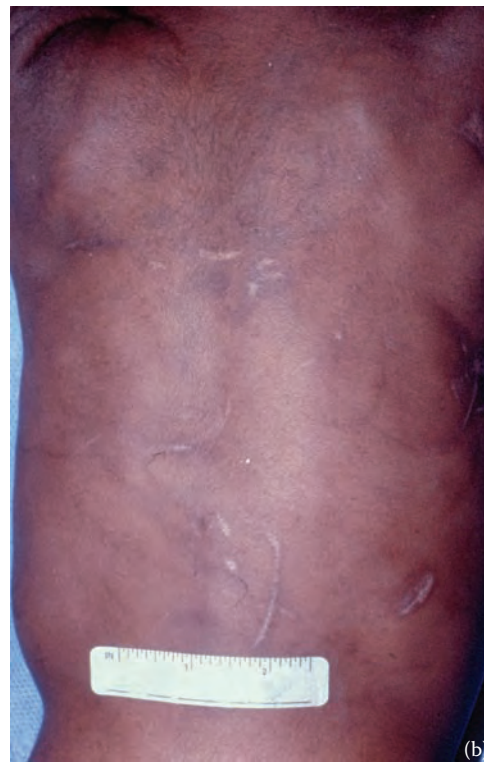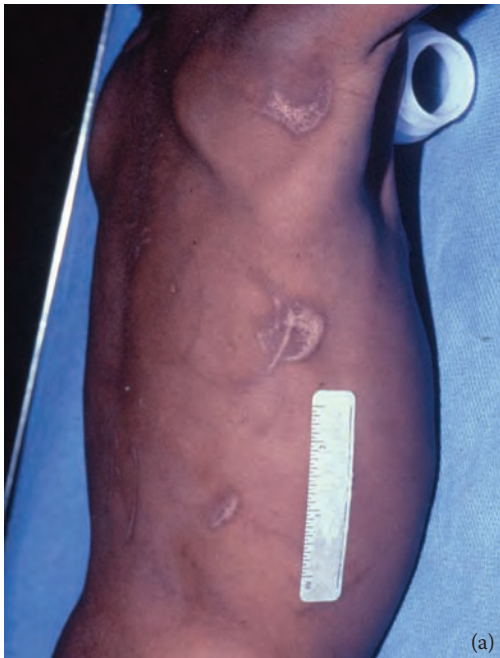This image shows the perineal area of this child (a). No injuries are detected. (b) depicts the child's anus. No injuries are demonstrated. In cases such as these, it is good practice to document photographically the presence or absence of injuries, as the multiplicity of injuries may be one of the determining factors in the ultimate sentencing. Sometimes external examination may be difficult and mucosal folds may be misinterpreted as lacerations. If there is any question as to the nature of a possible lesion or injury, we recommend removing the region en bloc, opening the anorectal segment and photographing it for documentation.



These images demonstrate sexual abuse in a young child. Note the abrasions and lacerations around the anal region. En bloc dissection of this region with the anal-rectal segment of the intestine removed. Note the internal lacerations near the anal border and the intestinal hemorrhage



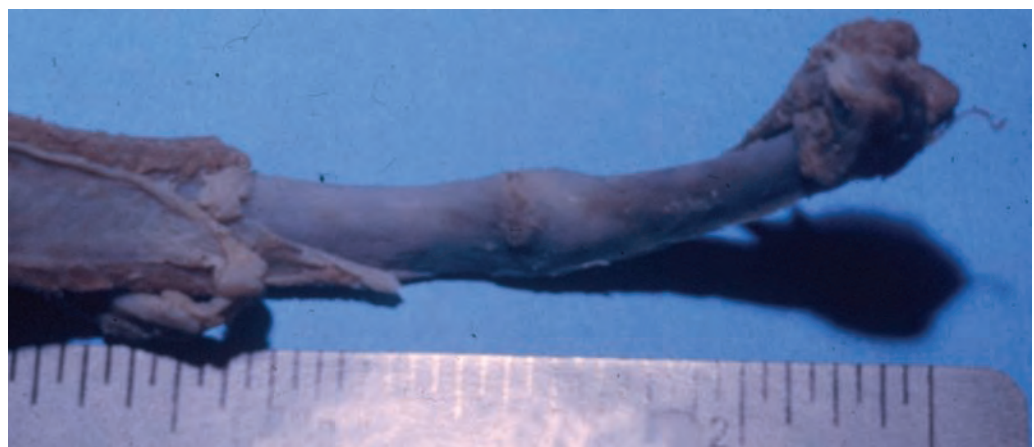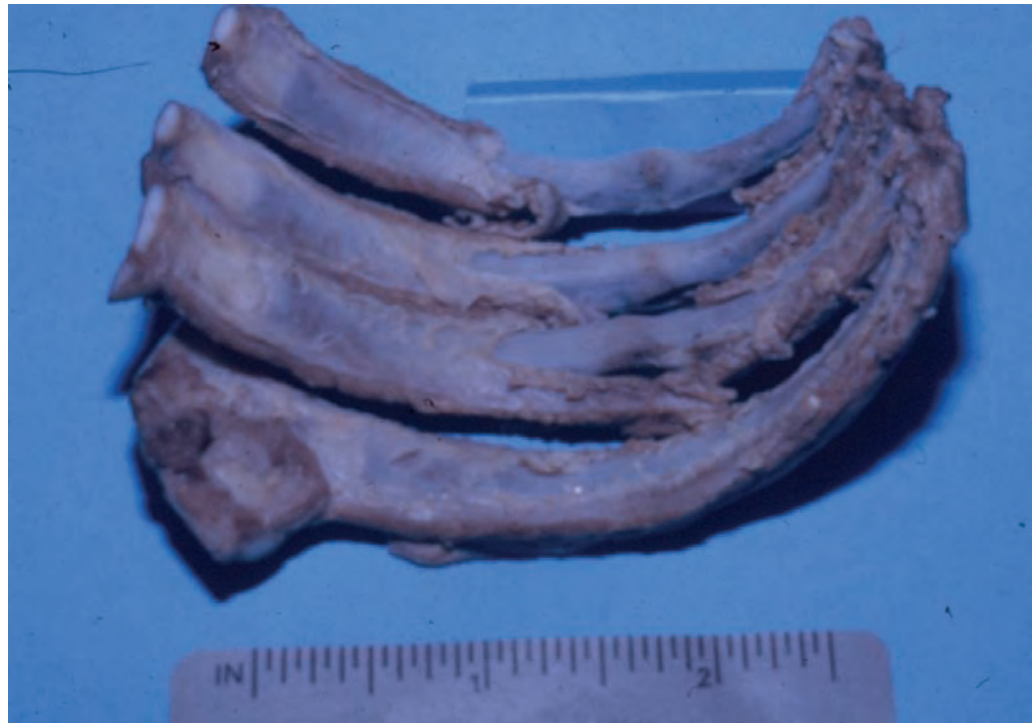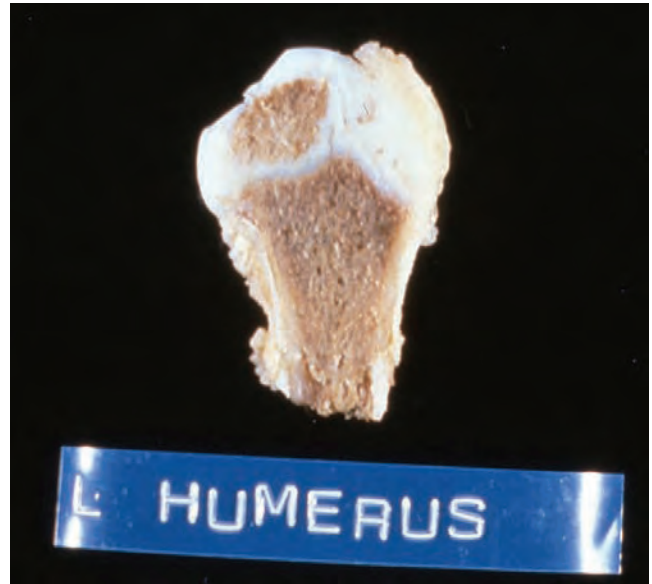Superficial, healing, criss-crossed, linear abrasions due to rubbing of Velcro jacket patches on each side of this child's neck. This indicates rough handling. This child was later killed by multiple blunt impact injuries during an assault. Note the suture and fresh needle marks at the right chest from a removed subclavian line.



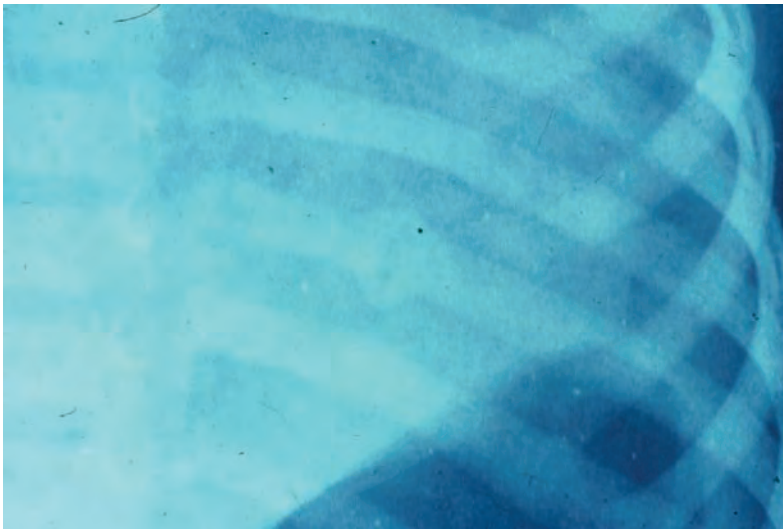
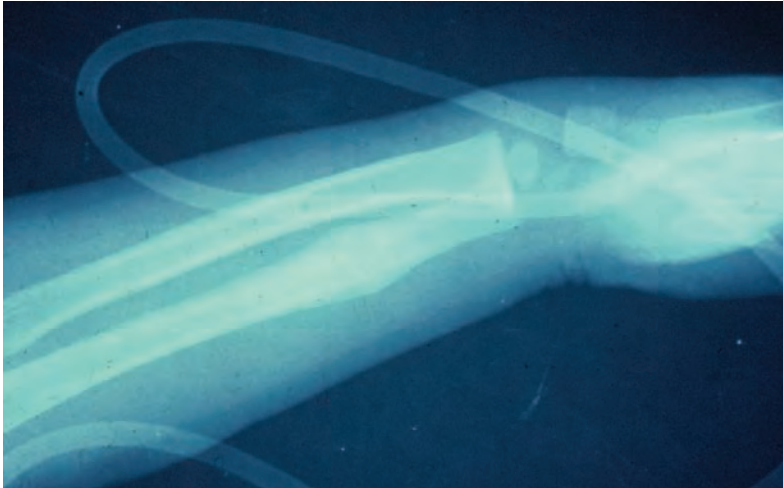
These are multiple scars, many of which were associated with chronic child abuse. When evaluating old injuries, it is important to take into context the child's age and developmental status. A child who is able to run and jump about may fall and sustain blunt-impact injuries. Sometimes it may be difficult, if not impossible, to formulate the nature of such old injuries without history or witnesses. (a) and (b) images are associated with abuse; (c) and (d) represent healed scars from accidental injuries. Note the healing injury at the nose associated with a nasogastric tube and therapy.



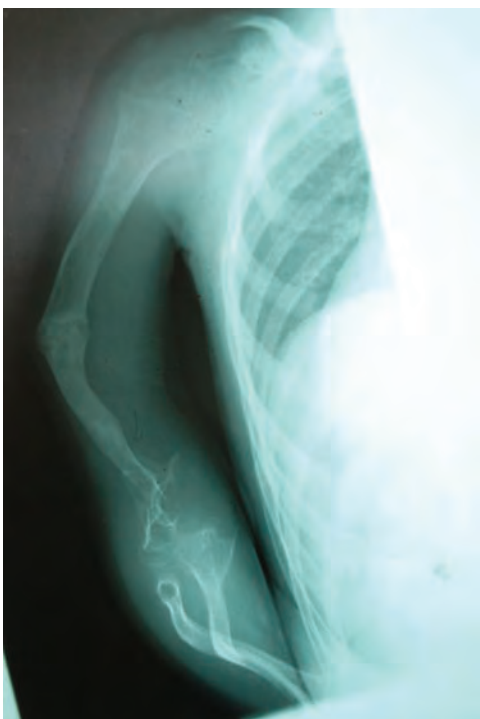
This demonstrates a coronal section of a humerus. Microscopic sections of long bones may be sampled in cases involving a suspicious death of an infant or young child in order to identify transmetaphyseal fractures in situations in which shearing forces have been applied (i.e., violent shaking). Unlike the case in more obvious fractures with extensive visible hemorrhage, these fractures (alternatively referred to as "bucket handle" or "corner" fractures on radiologic plain films, depending upon the view), may sometimes be more readily documented with microscopic examination.



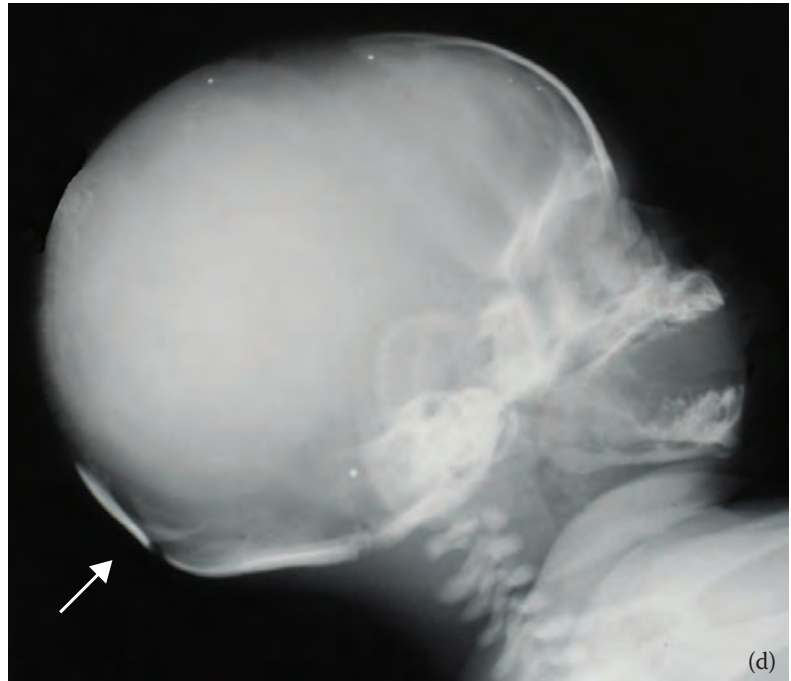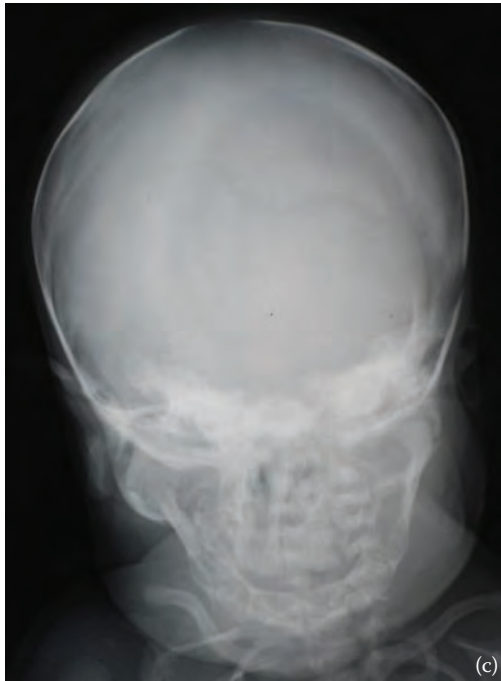
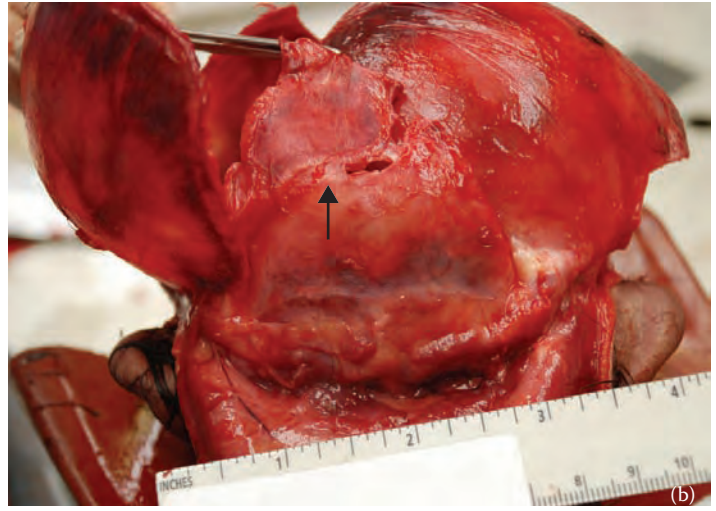
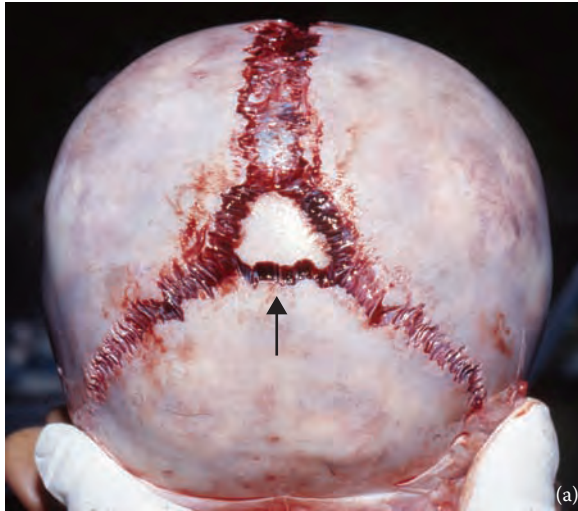
Old healed rib fractures from a case of battered child syndrome.



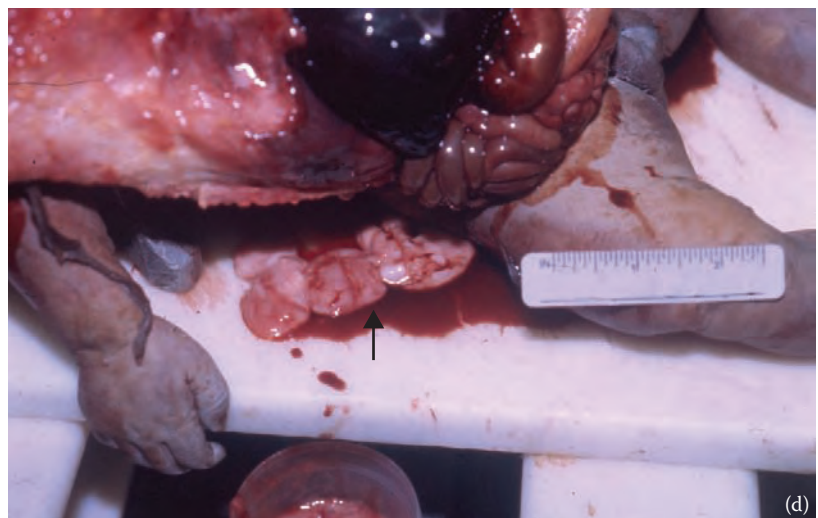
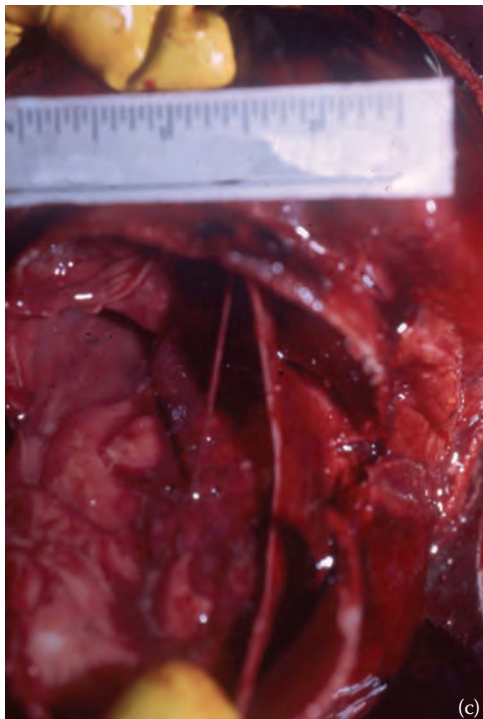
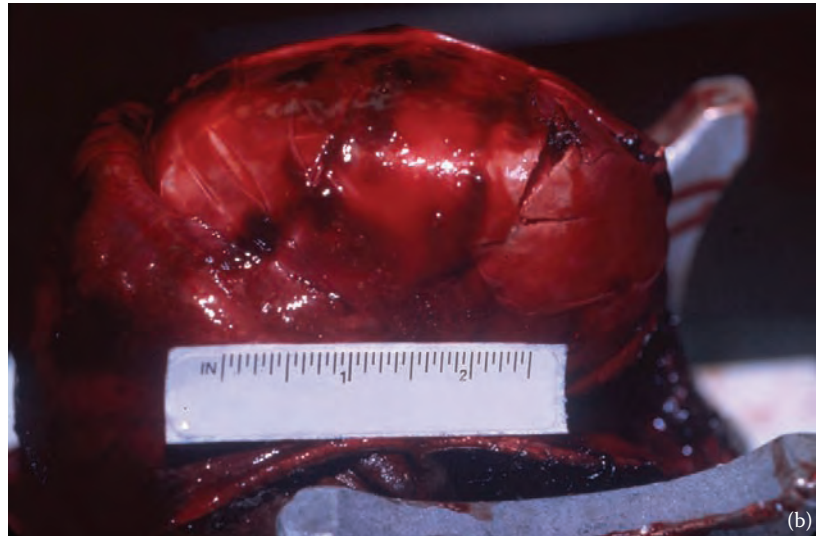
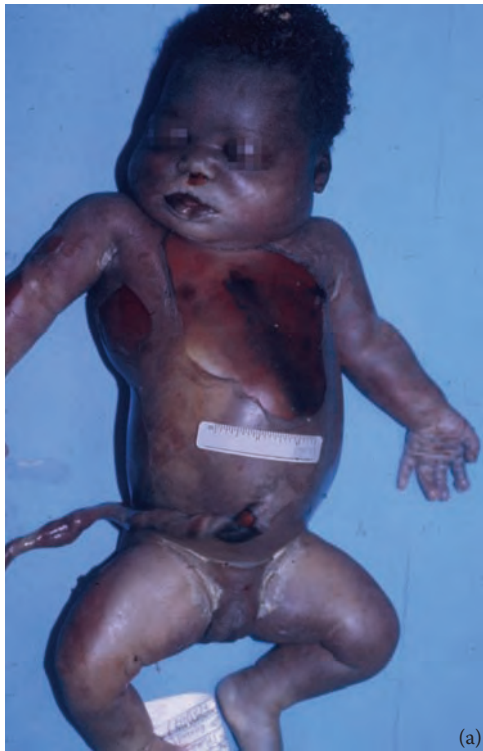These x-rays demonstrate healing fractures.



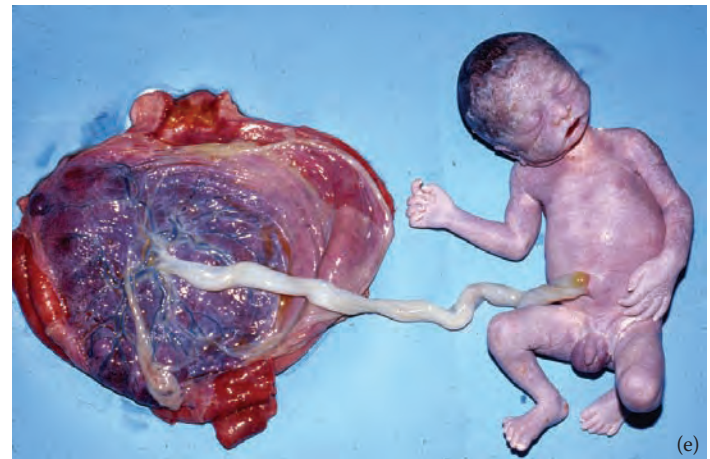
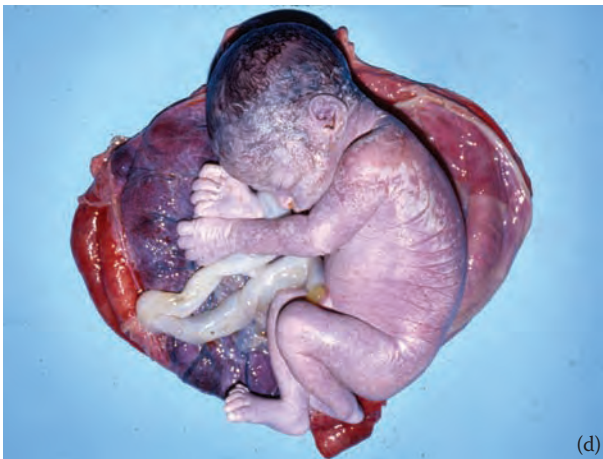
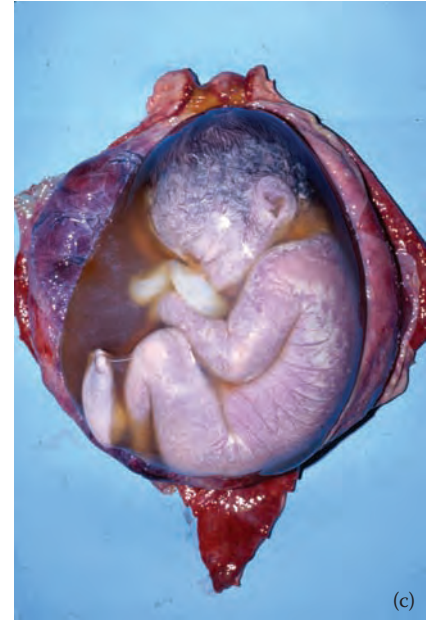
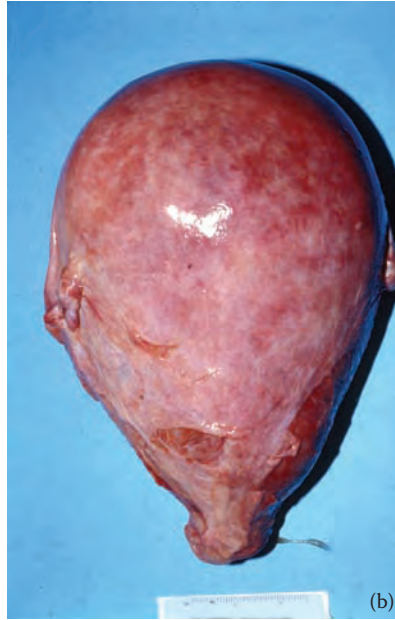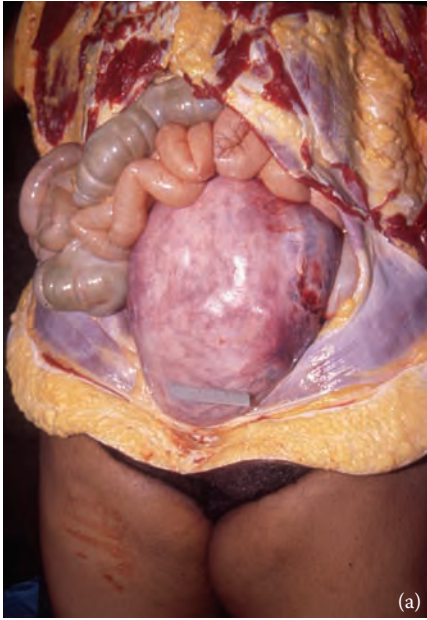
Osteogenesis imperfecta with multiple fractures. This may or may not indicate child abuse. Fractures may occur with very little force.



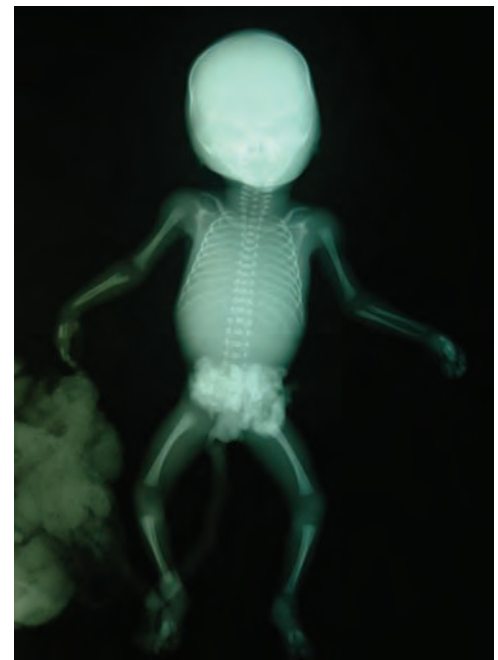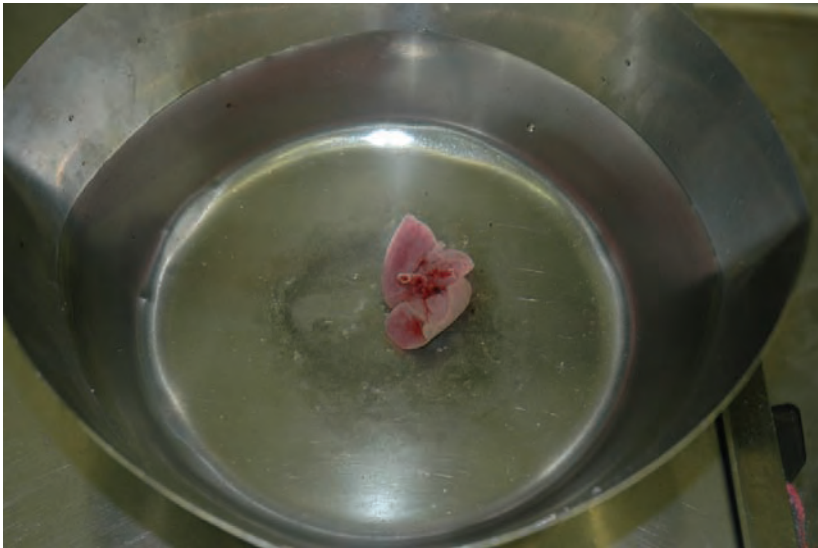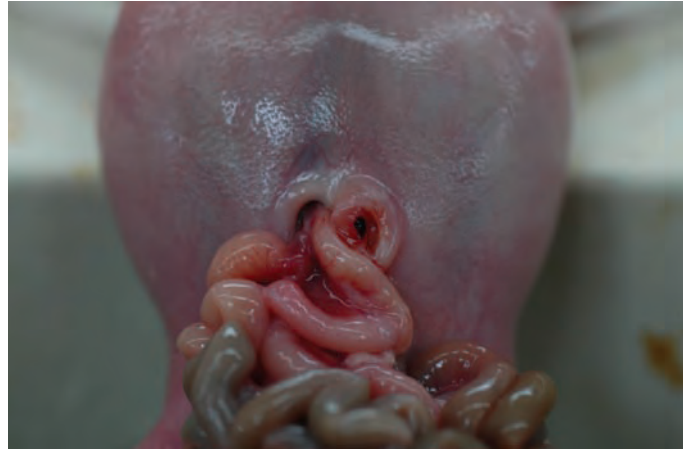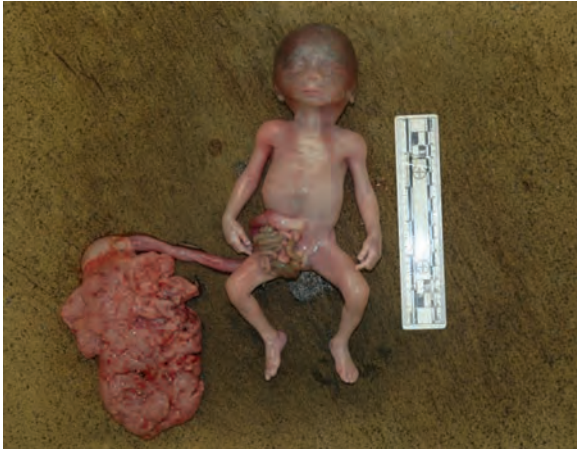Inca bone skull anomaly. In both of these cases it was mistaken for a skull fracture. The x-rays at the bottom correspond to (b).



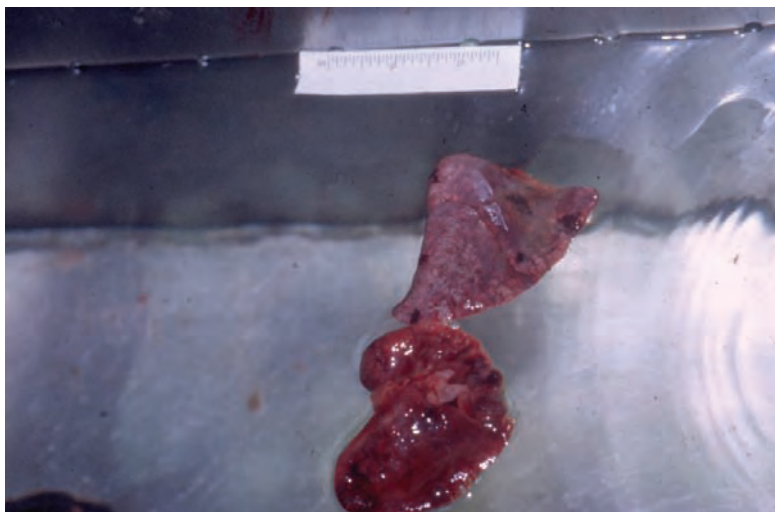
This child was retrieved from the back of a garbage truck partially tied within a torn plastic bag following compression by a trash compactor. Note the confluent hemorrhage to the scalp and the largely empty cranial vault. This child was mildly to moderately decomposed with bloating and separation of tissue planes. The brain material was squeezed from the cranium through the neck following compression of the head by the compactor. When the initial Y-shaped autopsy incision was made to the skin of the trunk, brain material leaked from the chest region (d). The child's body was found mixed with decomposing food material. Note the green discoloration from putrefaction.



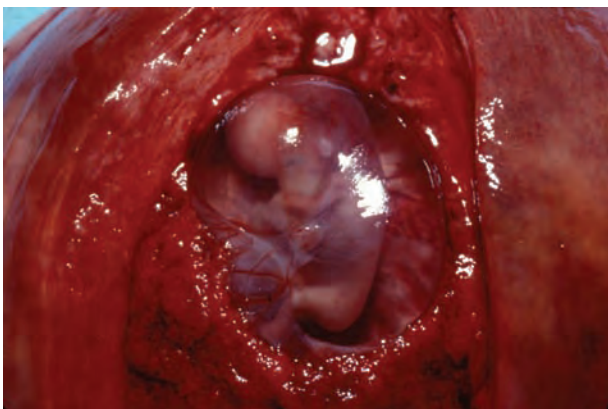
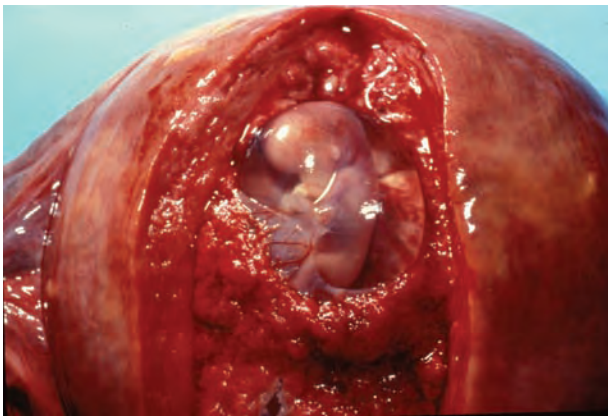
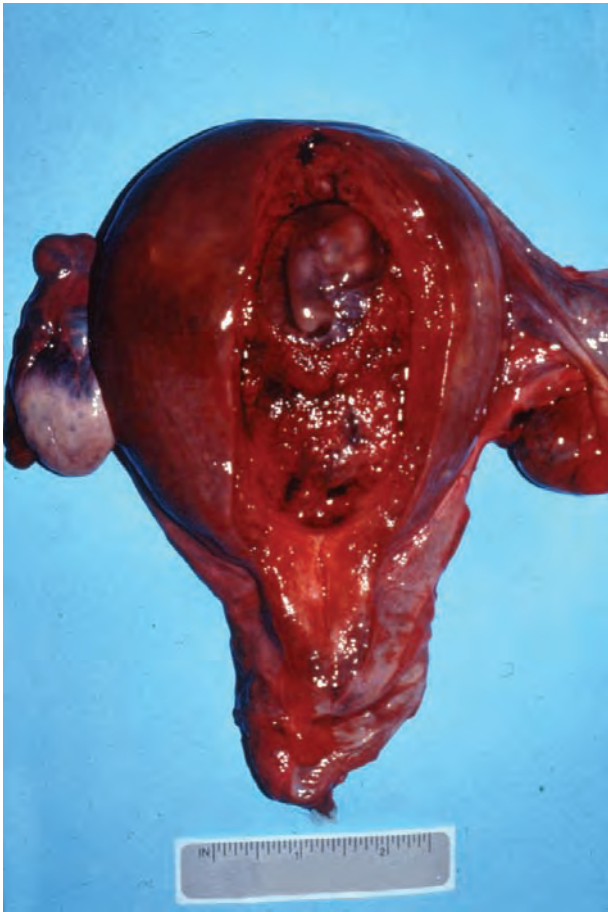Late-second-trimester pregnancy demonstrating the uterus (a), placenta (b), and fetus (c).



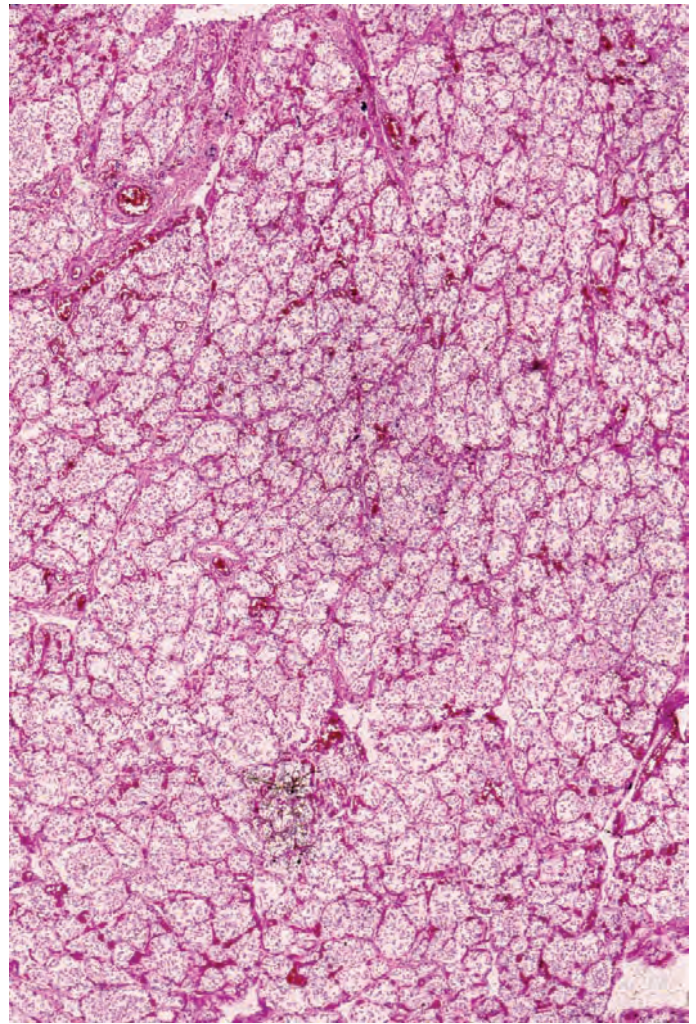
Second trimester stillborn with omphalocele, illegally aborted following administration of drugs given by a nonmedical practitioner. Note the x-ray and the sunken lungs at the bottom of the water container indicating no breaths were taken.



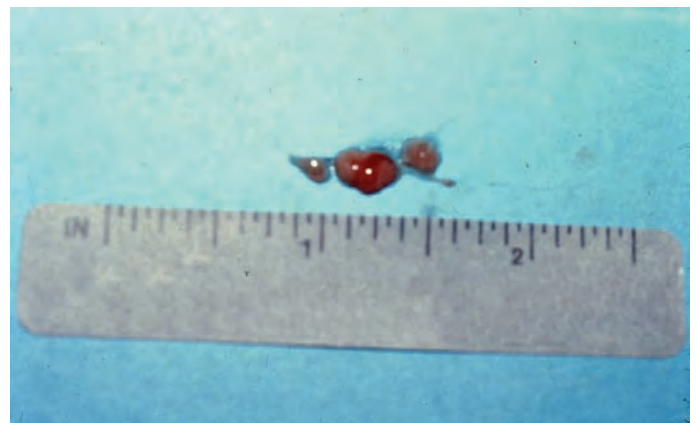
Lungs from a live birth that were expanded with air. Note how they float on top of this water bath. Admittedly, the "flotation test" to confirm independent respiration is far from foolproof and is subject to a number of artifacts and exceptions, thus limiting its utility in resolving the question of live birth versus stillbirth.



First-trimester pregnancy.



Brown fat.



Early first-trimester pregnancy.

## Introduction

---

These are injuries produced when the body is struck with, or strikes, a blunt object. A blunt surface produces injuries by scraping, tearing, shearing, or crushing. This is in contrast to a sharp force injury, which cuts and separates the tissue as it penetrates. What injuries result from trauma are a balance of the amount of force, the area over which it is applied, and the duration of force. In general, the greater the force, smaller the area, or shorter the duration over which the force is applied, the greater the injury will be.

Blunt objects have a relatively large surface area in contrast to sharp objects, where the cutting edge has a relatively small surface area. It takes much less force to penetrate the skin with an ice pick than with the end of a baseball bat. Examples of blunt objects are fists, shoes, pipes, bricks, bats, hammers, roadways, sidewalks, cars, trains, airplanes, walls, etc. Types of blunt-force injuries include *abrasions*, *contusions* and *lacerations*. These may occur separately but are often present at the same time. As an example, an injury maybe described as an abraded contusion with central laceration. *Fractures* are breaks in the bone as a result of blunt force. *Avulsions* are splits in the soft tissue or soft tissue planes with or without a laceration as a result of shearing forces.

## Abrasions

Abrasions are simply scrapes. They are produced as the body contacts a surface and rubs across it with sufficient force. The distance of travel can be very short (falling and scraping your knee) or very long (being dragged under a car). It is often possible to determine the direction of impact. Layers of skin are scraped away and bead up at the margin where the contact to the wound last occurred. Fragments of skin beading up at the inferior wound margin indicate a downward impact. Antemortem abrasions or those that occur during life are typically red to brown and will eventually form a scab with dried blood. Postmortem abrasions are yellow in non-lividity-dependent areas. In general, one needs a beating heart with blood pressure to produce hemorrhage and a red to brown discoloration. A postmortem scrape in a lividity-dependent region will appear red

and may be difficult to differentiate from an antemortem injury.

This is important in certain cases. Lawyers will argue different ways to create reasonable doubt. For example, some may argue that an injury occurred during resuscitative efforts in the hospital, or the body was dropped from the stretcher in the morgue. Some other arguments may include: he was dead already when the second car hit him, the other perpetrator shot the body after he was dead, the child had no injuries before entering the hospital, etc.

Abrasions may also change character with increasing time. For example, initial examination of a body retrieved from water may reveal no or much less obvious injuries due to the moisture from the water at the skin's surface. As the body is stored in the morgue overnight and allowed to dry, the abrasions will darken and may become much more apparent.

## Contusions

Contusions are simply bruises. These are produced following an impact where the soft tissues and blood vessels, underneath or within the skin, are torn and produce hemorrhage. Grabbing an arm tightly can produce bruising with minimal impact and greater crushing force. One needs a beating heart and blood pressure to produce a contusion. A postmortem impact may accumulate blood due to lividity in a gravity-dependent area. This type of postmortem artifact may be difficult to differentiate from an antemortem injury.

One must exercise great care when dating contusions at the time of autopsy with gross findings alone. One must account for skin color, whether the contusion is deep or superficial, the presence of hematoma, etc. Bruises go through various color changes with advancing time as the body reacts to repair the injury. This depends on the size of the injury, the physiologic state of the individual, including his or her immune and coagulation systems, the vascular efficiency adjacent to the damaged tissue, etc. Color changes range from light blue-red to dark purple then green to yellow-brown as time progresses. Inaccurate interpretations of dating contusions grossly can create significant problems in court. If one sees a variability with color ranges demonstrating



some bruises as red-purple and others as yellow-brown, it is reasonable to say that some injuries are older than others. It is much more accurate to use histopathology to date the injuries using established time ranges for advancing inflammation and healing. Random sections of injuries should be taken including the wound margins. The first several hours reveal hemorrhage with no inflammation. This is followed by iron deposition as a result of hemoglobin breakdown. Estimation of injury dating should be given in ranges.

Bruises can also change appearance as the postmortem time interval increases. A contusion will become more obvious as blood settles away from the impact site. The surrounding tissue will become paler and the contusion will be more pronounced, as in a supine body with anterior contusions in full livor. Bleeding associated with a contusion does not settle away from the impact site as lividity forms, because it is spread throughout the soft tissues and cannot drain within the vessels. Also, during vigorous emergency room resuscitation, the head and upper trunk may become congested. As lividity settles to the back of the head, injuries to the face become more prominent. Clinicians may sometimes miss these subtle contusions.

It is also important to realize that deep contusions may not be visible at external exam and may be visualized only after incisions are made. Clinicians should realize this and create a medical record that is as accurate as possible. If one documents that no bruises are present to regions of the body, yet they are found on autopsy, this may potentially weaken the case in court. The autopsy remains the most accurate way to demonstrate these findings.

## Lacerations

Lacerations are tears of the skin, soft tissues, or internal organs or vessels as a result of an impact, overstretching, or crushing-type forces. These injuries are characterized by irregular margins, often with a marginal abrasion, with tissue bridging by fibrous strands and small blood vessels. If the laceration is large and gaping, tissue bridging may not be present due to the strands' being pulled apart. Skin lacerations tend to occur more often over hard surfaces, such as the scalp, knees, elbows, etc. The direction of the impact can be determined by the presence of soft tissue undermining. The underlying soft tissue adjacent to the laceration may form a pocket of separation extending in the direction of impact. A downward impact will produce undermining at the inferior aspect. These directions should be described with reference to standard anatomic planes.

## Motor Vehicle Injuries

Motor vehicles include any motorized means of carrying or transporting someone. These include trucks, buses, cars, motorcycles, mopeds, snow mobiles, etc. It is always important to be as accurate as possible, including the *type of vehicle* on the death certificate for vital records. The type of vehicle is obviously important when evaluating injuries.

It is important to recognize various patterns that might help *differentiate drivers from passengers*. In high-speed collisions with unrestrained occupants, people may be ejected from the vehicle. If criminal or civil charges are filed, the living driver may indicate that the dead passenger was driving.

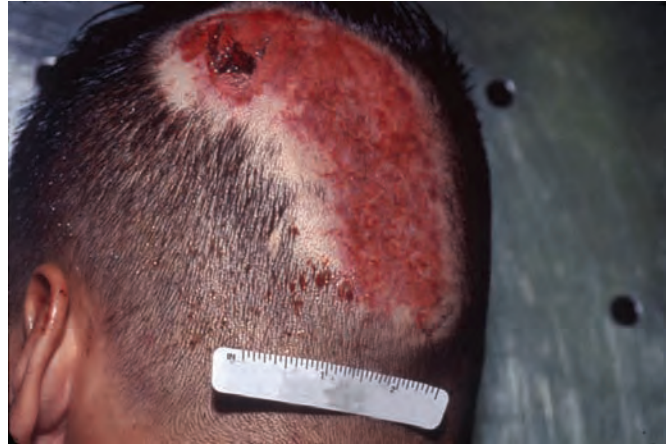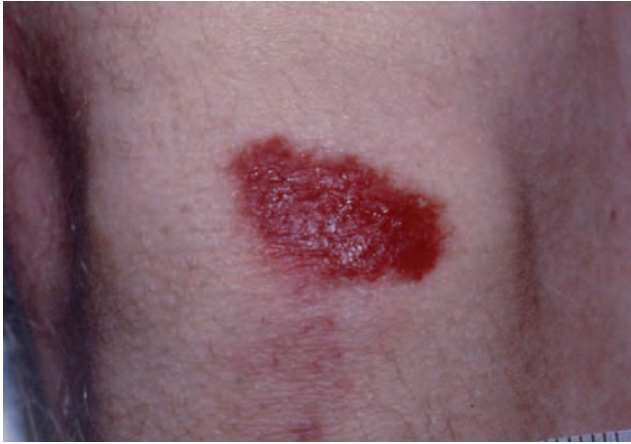One should look for steering wheel impact marks to the chest, seatbelt-related abraded contusions, and pattern injuries associated with impacts to the windshield, dashboard, or vehicle roof. *Front and back windshields* are often made of laminated glass and fracture with elongated curves or splinters. *Side windows* are often made of tempered glass and fracture into small cubes. Seatbelt-patterned injuries or side impact dicing pattern injuries to the right or left side of the head will help formulate opinions about an individual's seating position. Dicing injuries to the left side of the head of an individual found next to a car with a broken left side window is evidence that he or she was the driver. One could also collect DNA samples from these regions and compare it with ejected occupants. Those not wearing seatbelts are much more likely to be ejected from the vehicle, especially in a roll-over accident. Those who are ejected may impact other objects (such as a tree or pole) or may sustain crush injuries due to the vehicle's rolling over them.

Pedestrian clothing and impact sites to the body can reveal many clues with evidence about the circumstances of a collision. Questions one should ask include: Was the pedestrian standing or lying in the street? Was the individual run over or run under by the vehicle? Was more than one vehicle involved? Impact sites may reveal different front grill or tire pattern injuries. With standing pedestrian impacts, one should measure the distance between the impact site and the bottom of the foot or shoe the pedestrian was wearing at the time of the incident. It may be necessary to incise this region to visualize it better. It is good practice to include the measuring stick in the picture. This may give insight into whether the vehicle was braking before the impact occurred. As a driver jams on the brakes, the front end of a car will go downward. Fractures may occur to weight-bearing legs. Fracture patterns may be difficult to interpret when the bone is splintered and fractured into many pieces. Generally speaking, as a force passes through a bone, the fracture pattern

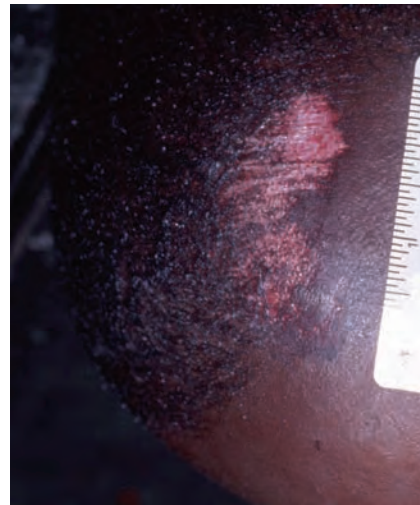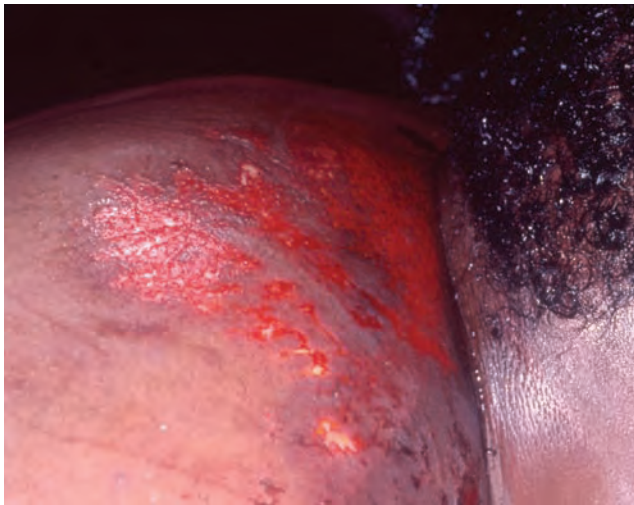
extends outward from the impact site similar to a skull fracture from an entrance gunshot wound producing internal beveling. With posterior standing impact, one might find stretch marks at the inguinal region opposite the impact site. This is caused by hyperextension of the hip and leg in an anterior direction.

Slow-moving vehicles tend to run over people. Fast-moving vehicles tend to run under people, meaning after being struck, the victim is tossed onto and over the hood. Flaps of skin may be torn away as a tire passes over a body. The clothing may yield significant

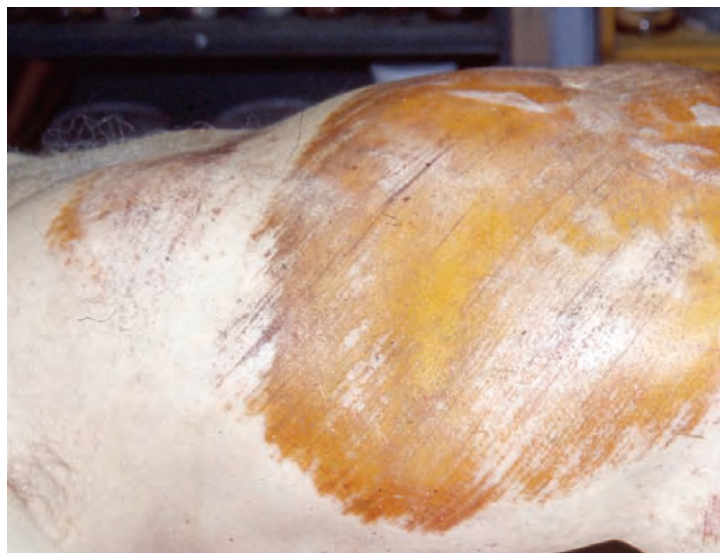evidence such as paint fragments. The car may have fragments of blood and hair that can be used for DNA analysis. This can be useful when there are multiple pedestrians and cars involved in collisions. Many pedestrian collisions involve children, who are sometimes impulsive and careless and may run out into oncoming traffic; the elderly, may not be quick enough to get out of the way; or individuals who have psychological histories, such as the homeless, or intoxicated individuals, who may think it's not that dangerous to cross a busy freeway.



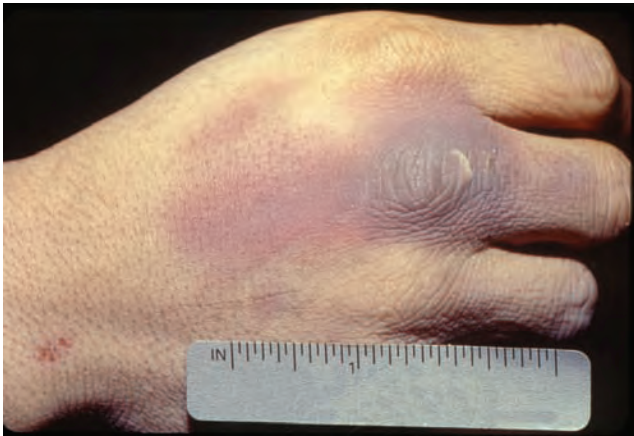Recent antemortem abrasions.



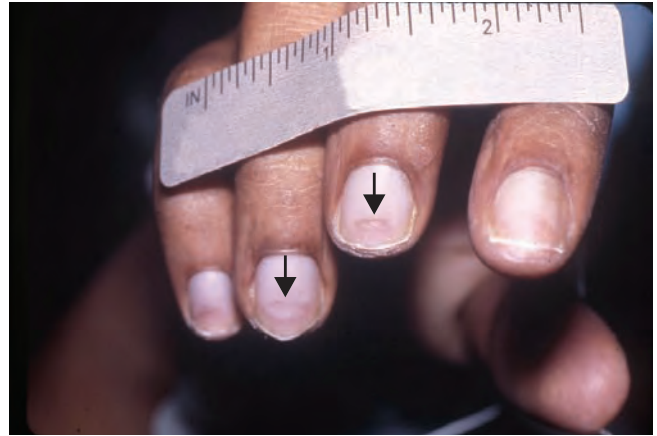
Recent deep antemortem abrasions.



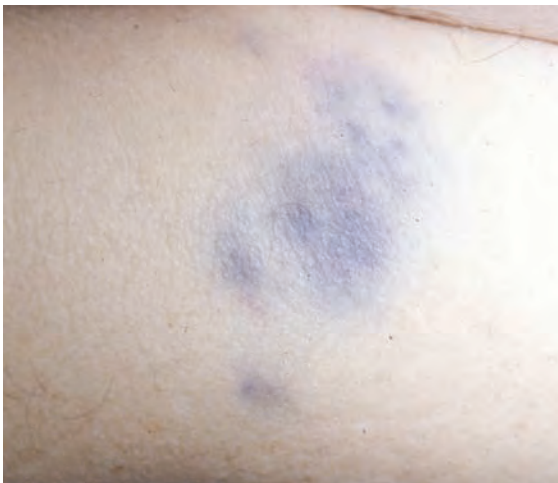Large yellow anemic postmortem abrasion.



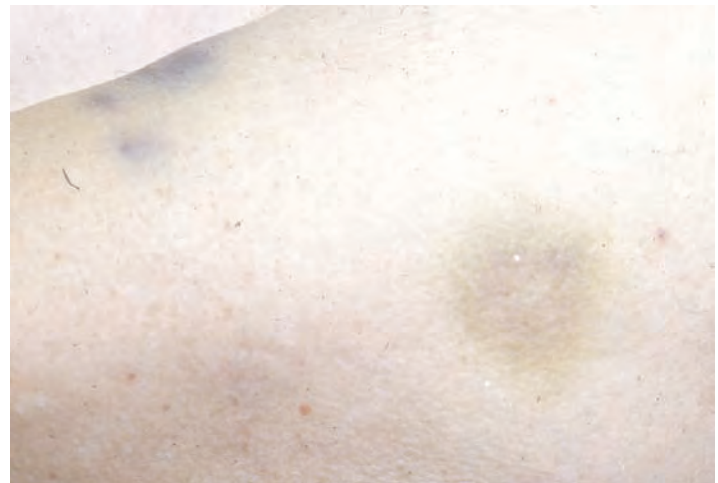Recent contusion of the left hand associated with a fist fight. This individual punched the attacker before being murdered.



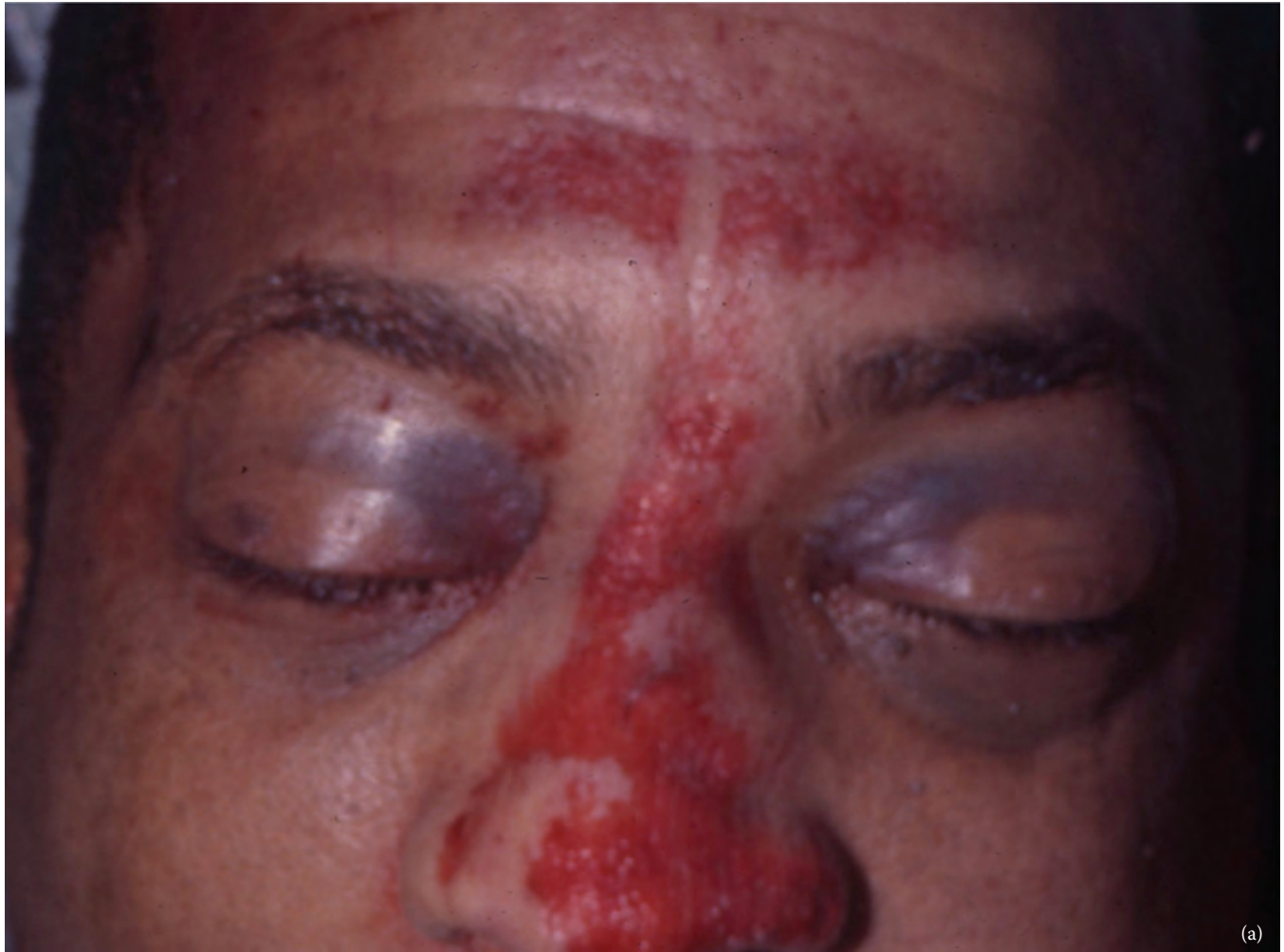Damaged fingernails with nail bed contusions. Blunt-force injury during struggle.



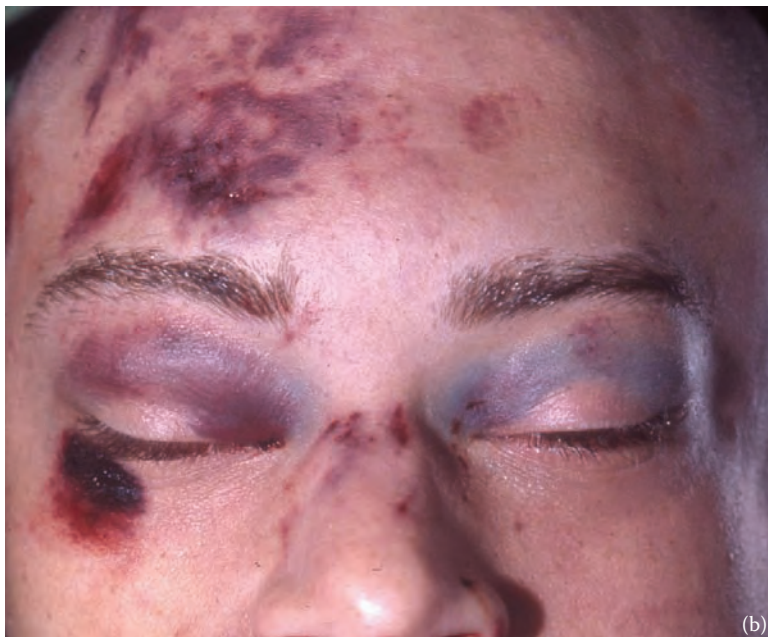Recent purple contusion of arm.



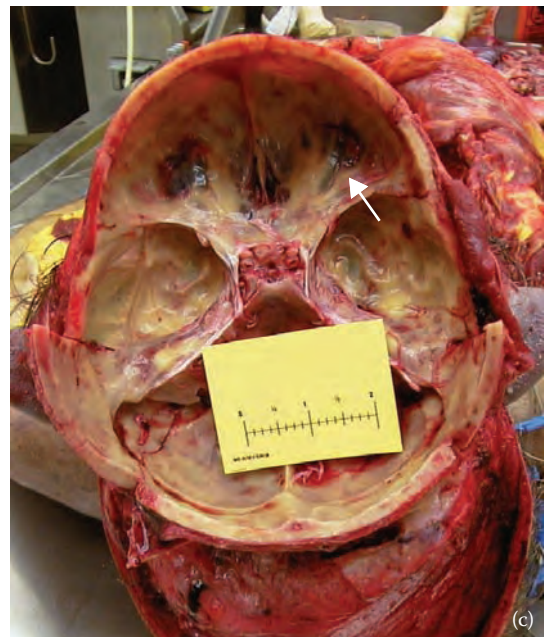Older yellow-brown contusion.



(a)

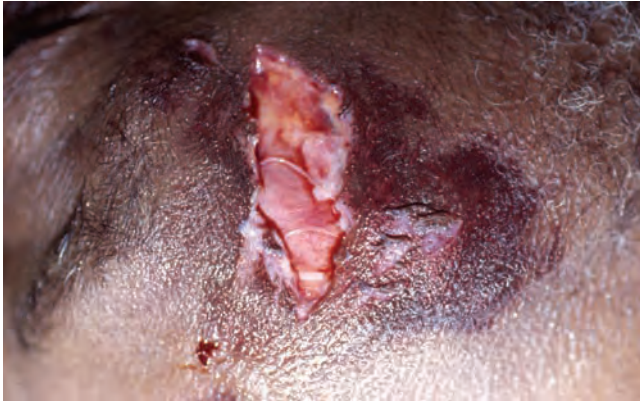

(b)

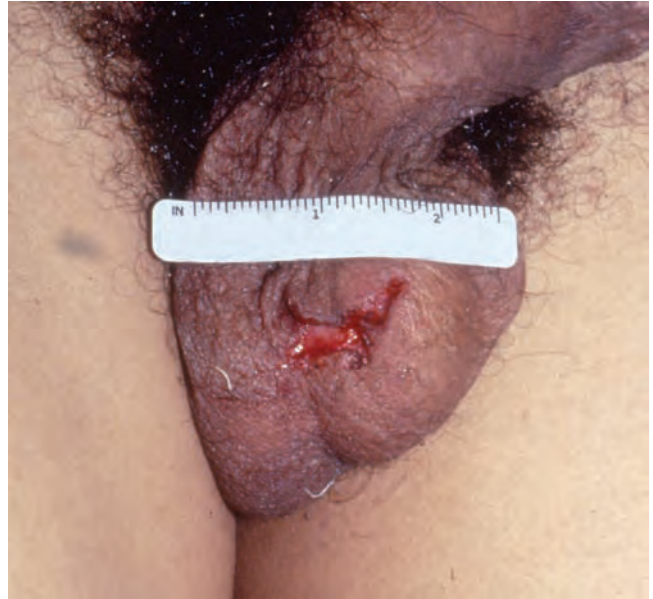

(c)

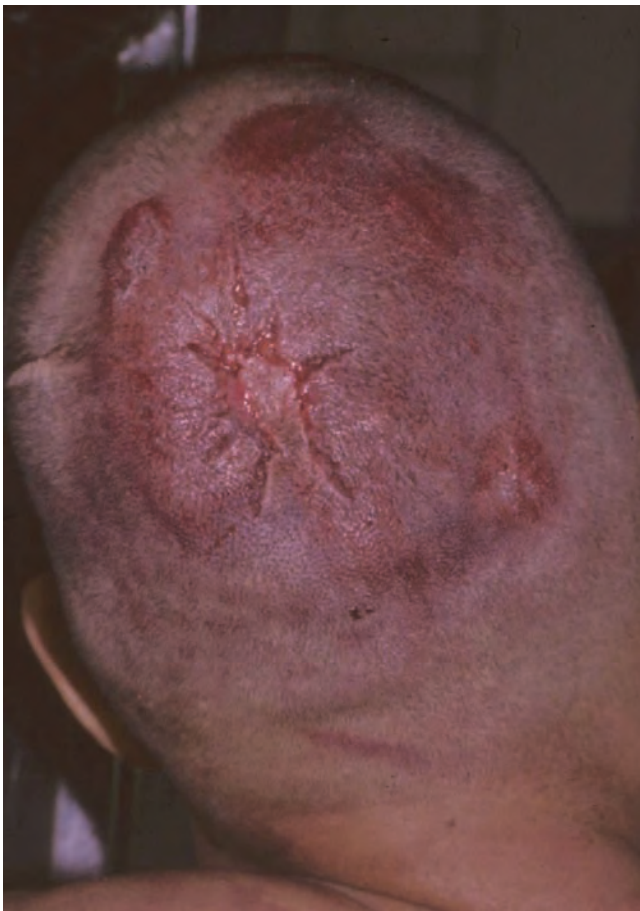Multiple abrasions and contusions of face. Note the bilateral periorbital ecchymosis associated with fracture of the anterior cranial fossa. This is also known as "raccoon eyes." A similar injury is Battle's sign, hemorrhage behind the ear, also a sign of basilar skull fractures. Figure (c) demonstrates a basilar skull fracture.



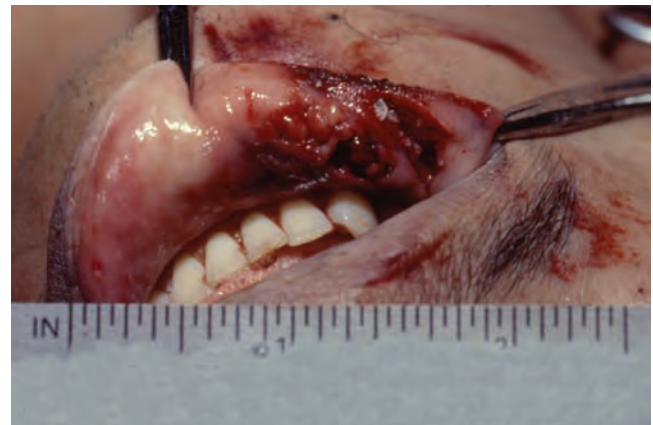Recent laceration with adjacent abrasion. Note the irregular margin at the point of skin separation due to the skin's ripping or tearing apart.



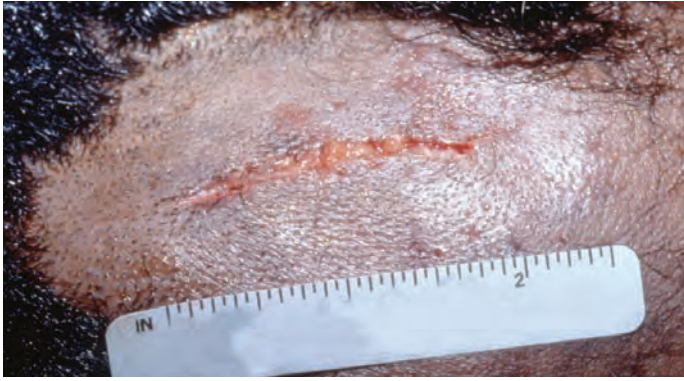
Recent laceration of scrotum.



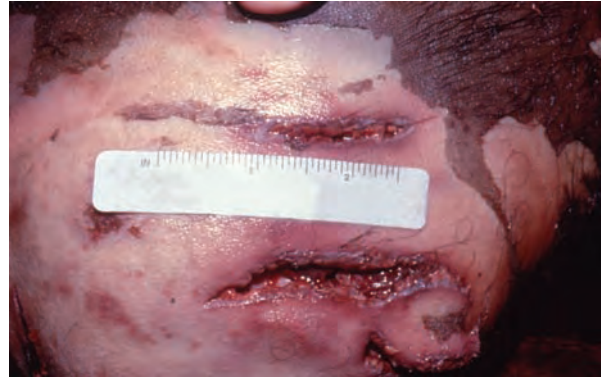Large recent abraded contusion at the back of the head with a stellate laceration. This individual was intoxicated at a party on a rooftop. He was taking a group photograph and while backing up accidentally fell three stories to the pavement below. He had a comminuted skull fracture.



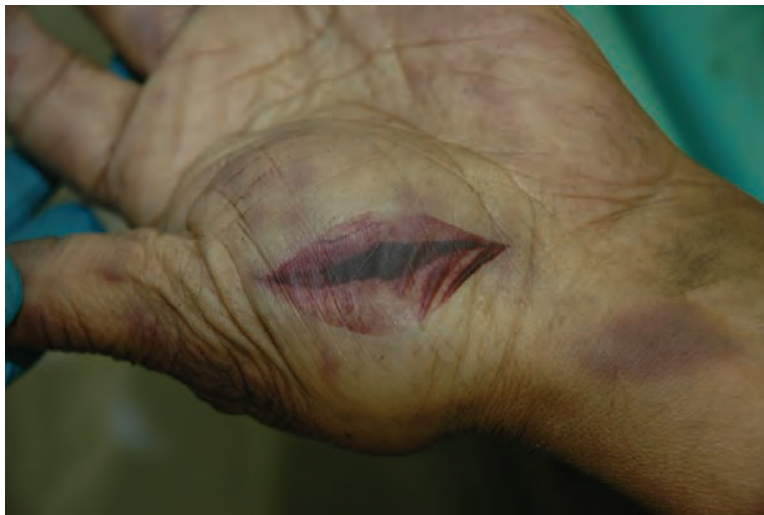These are multiple recent lacerations and contusions at the inner aspect of the mouth following multiple blunt impacts to this individual's face with a fist.



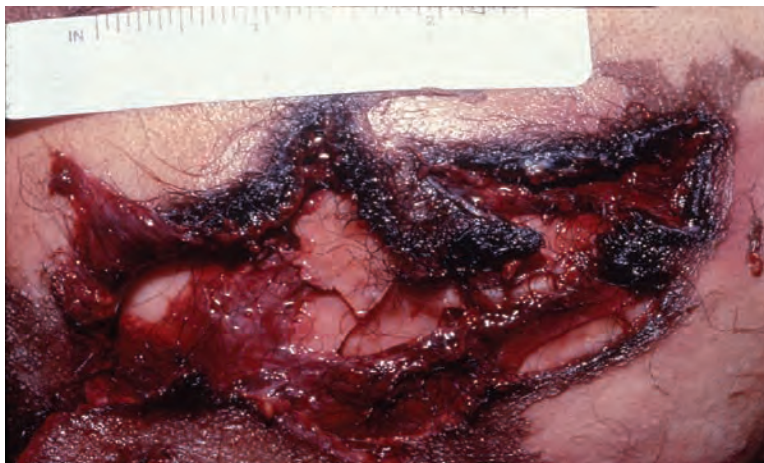This is a postmortem anemic laceration in an individual who was stabbed to death in an apartment and later thrown out of a window.



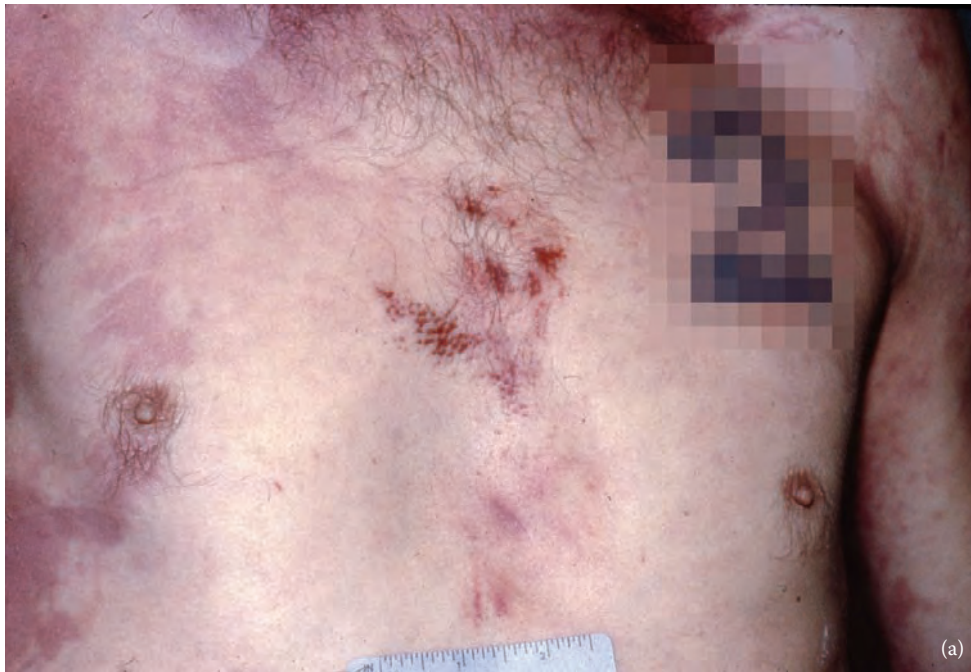This decomposing body has skin slippage with separation of scalp hair. Note the scalp lacerations with slight to moderate decomposition.



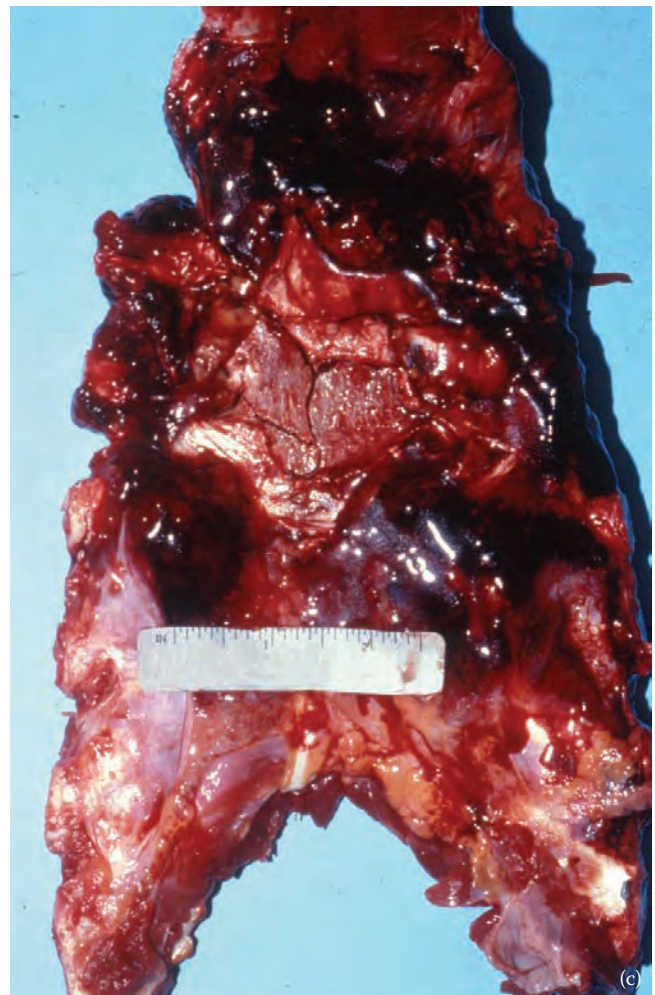
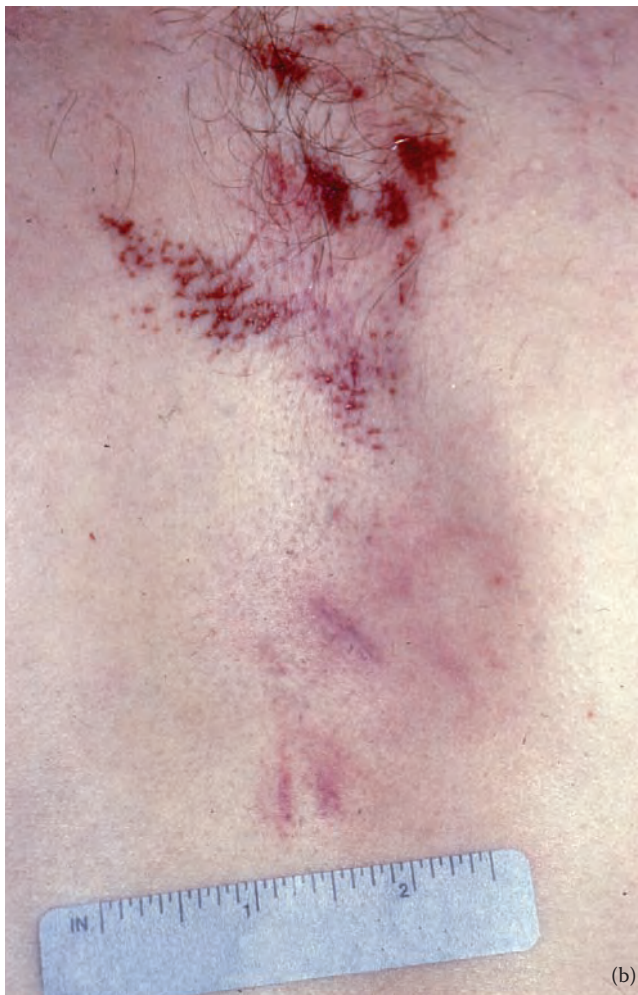This individual was struck by a train. Note the soft tissue avulsion underneath the intact thick skin.



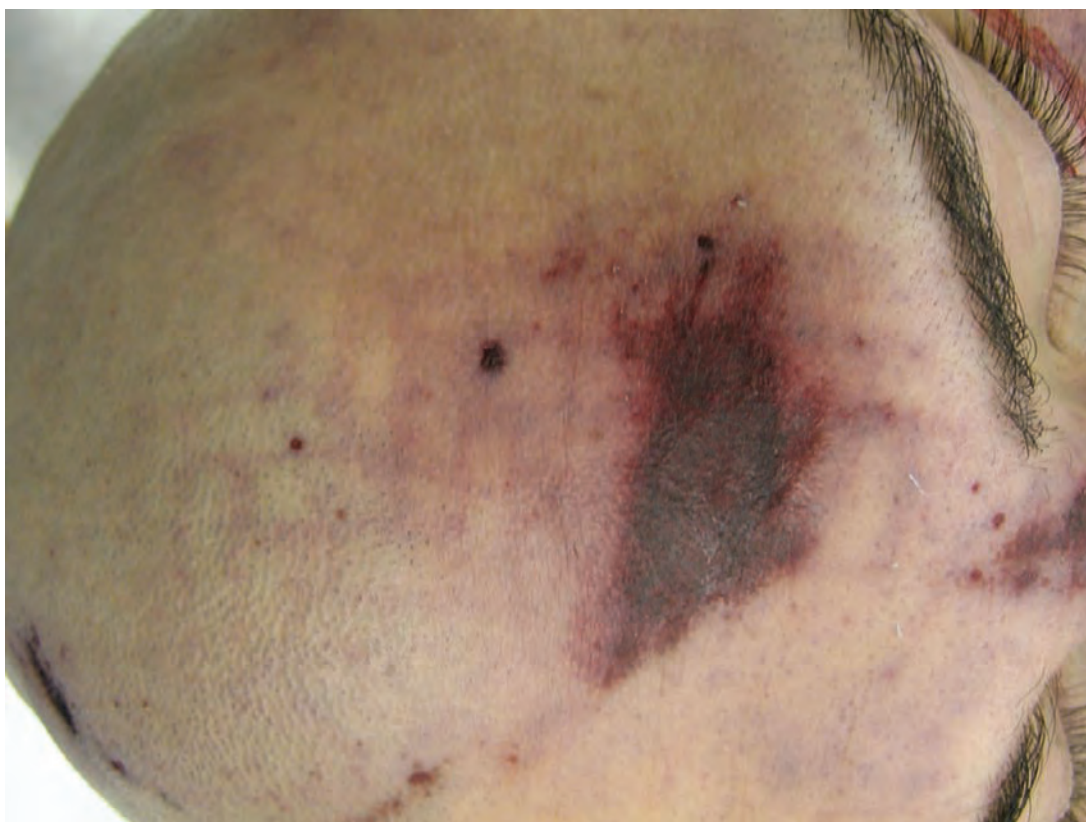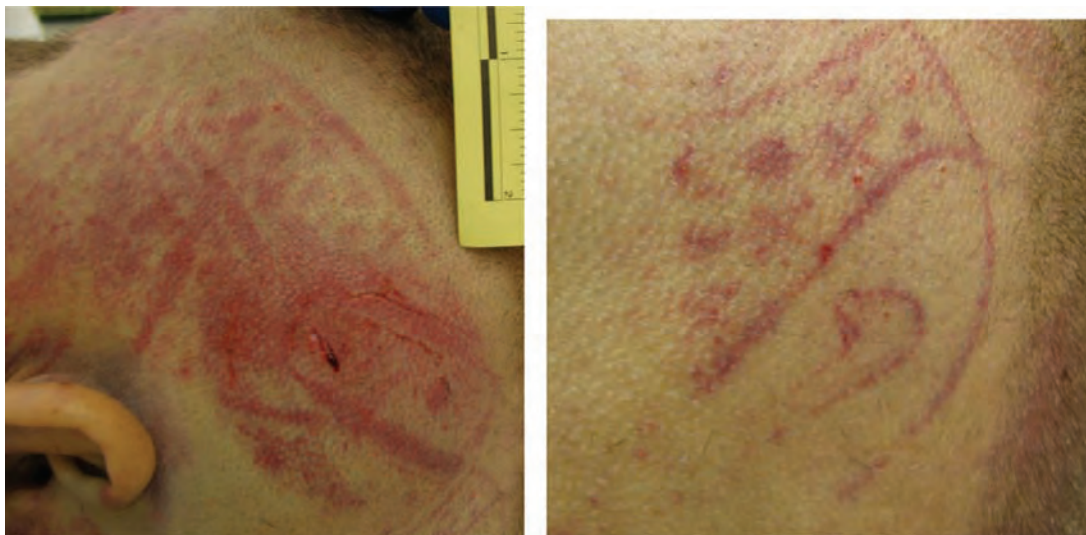
This individual died of multiple homicidal blunt- and sharp-force injuries. These are scalp lacerations in an individual with moderate decomposition. Note the extensive drying of the wound margins with clotted blood and fragments of hair. Also note the separation of the scalp from the skull with sub adjacent fractures.



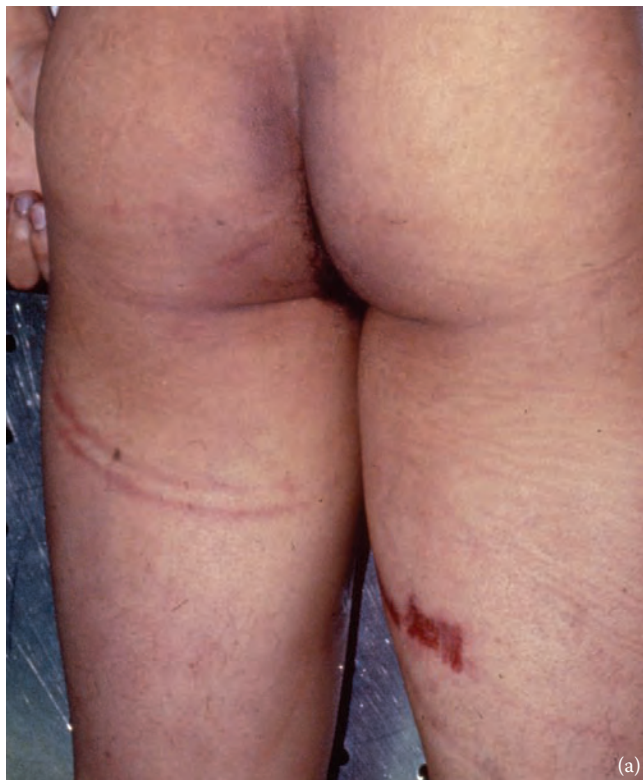Note the recent abraded contusion to the middle aspect of the chest (a). This individual had multiple layers of clothing and was reportedly stomped on by an individual with heavy boots following assaults with other weapons. The abraded contusion to the middle aspect of his chest forms a rough outline of a boot (b). The multiple layers of clothing prevented a more discernable defined boot pattern. The individual had a fractured sternum and a cardiac contusion (c).



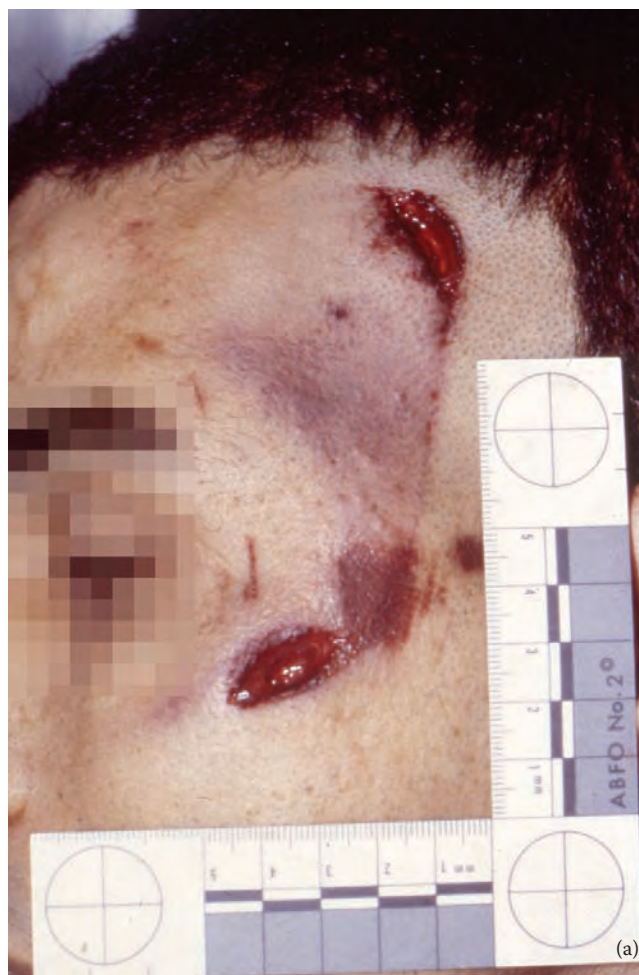



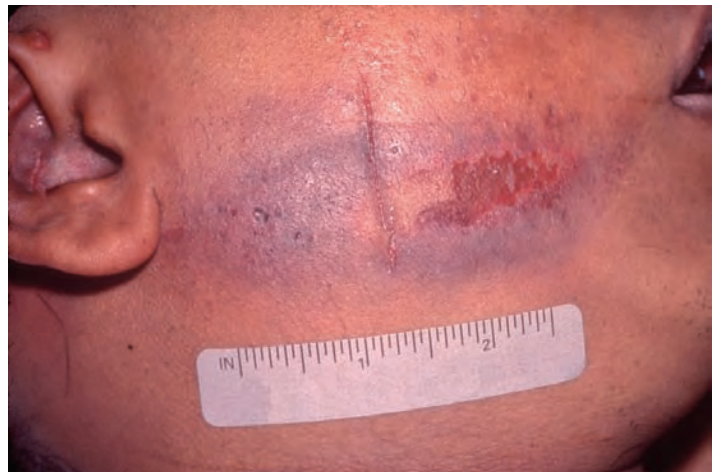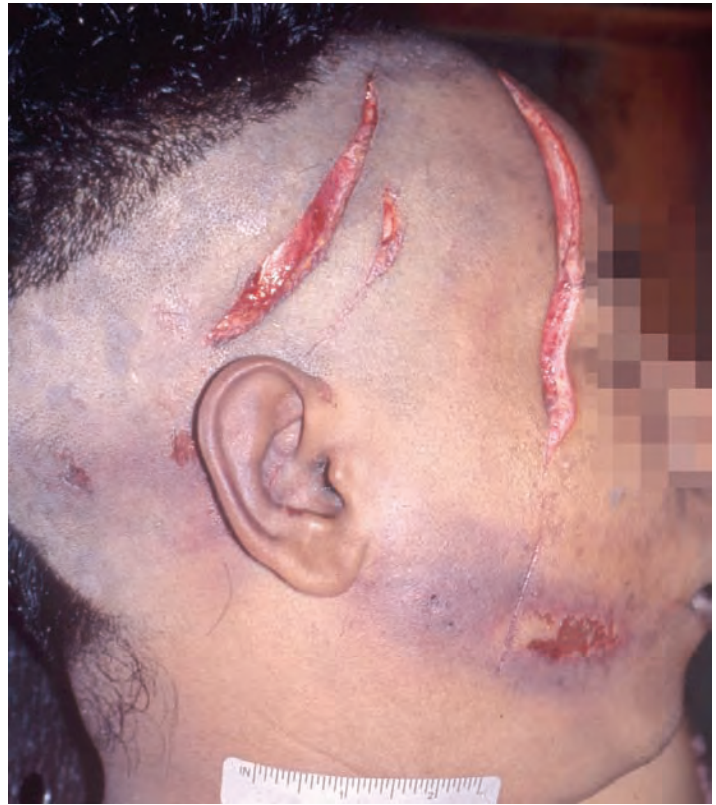Pattern injuries associated with impacts from the bottom of a shoe while being stomped and kicked.



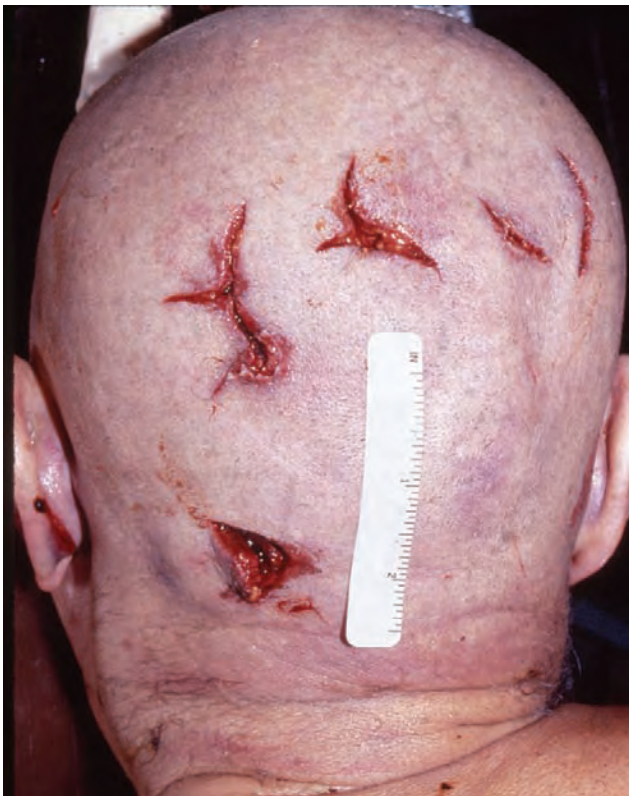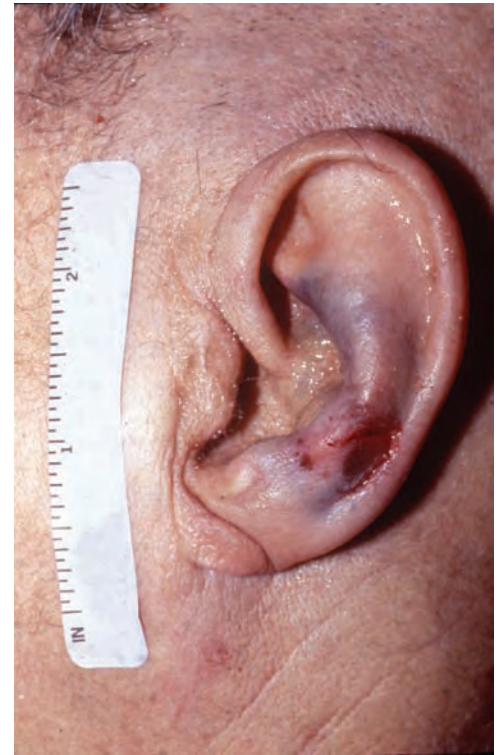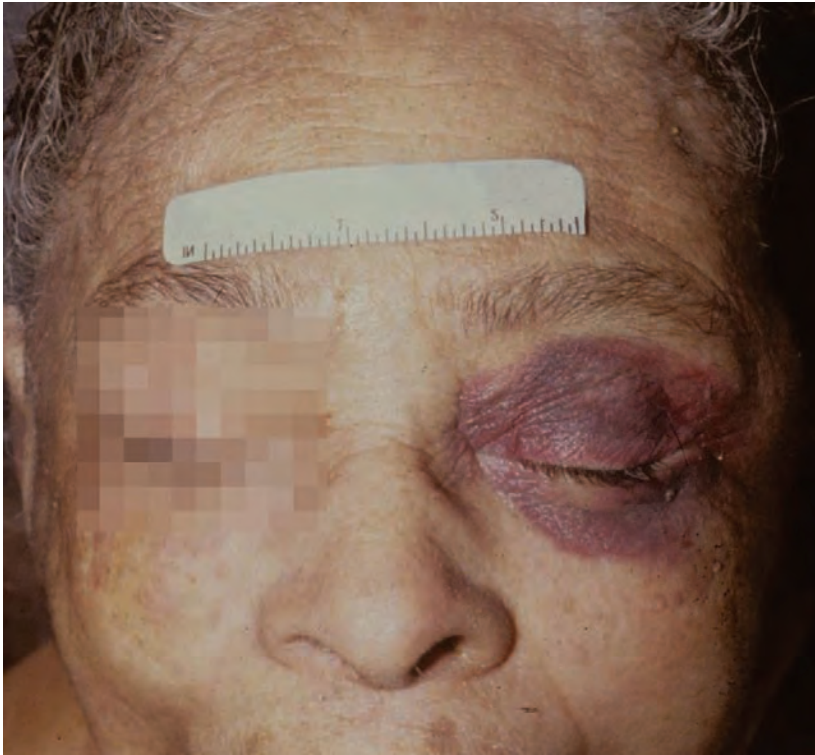This individual was assaulted with fists and a metal pipe or rod. Note the parallel linear contusions at the posterior aspect of the left thigh (a). Depression of the soft tissues contacting the rod causes stretching at each margin with blood vessel injury and parallel linear bruises.



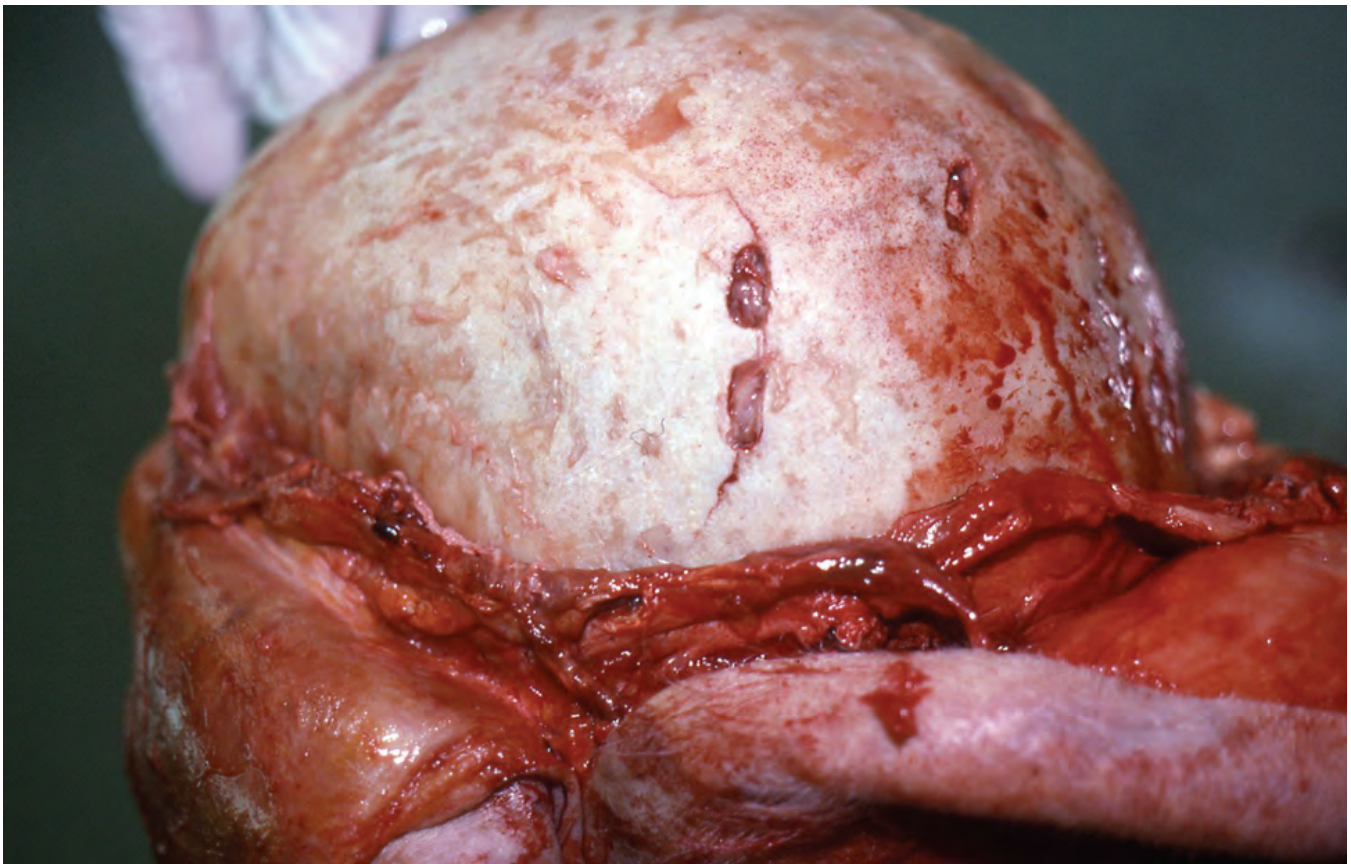
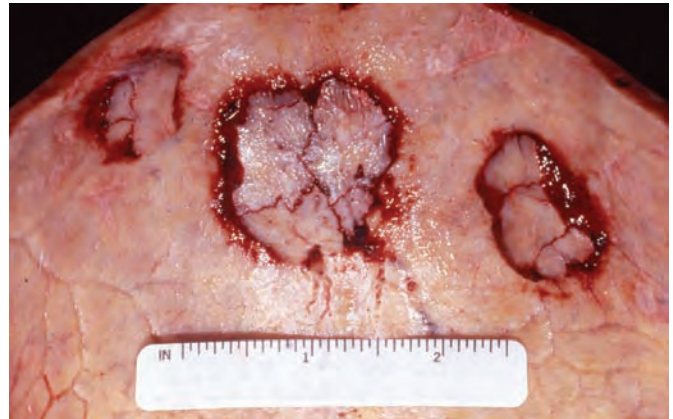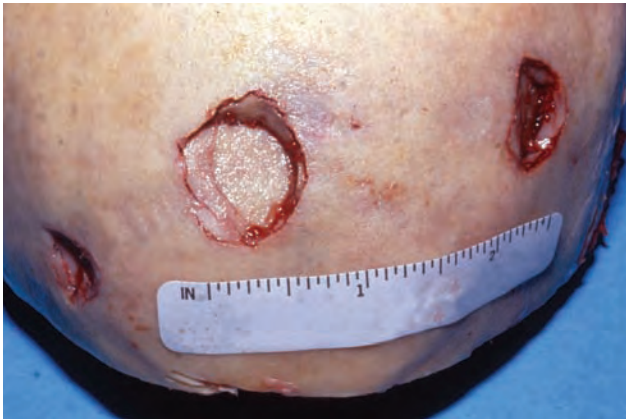This individual was struck multiple times with a putter golf club. Note the pattern injury at the forehead and face, with the shaft of the club extending at the inferior aspect.



This individual was assaulted by multiple people with bottles and a baseball bat. These abraded contusions at his face and head are characteristic of a baseball bat impact. Note the oval contusion with sparing of the central aspect with overlying abrasion. Also note the abraded central region.

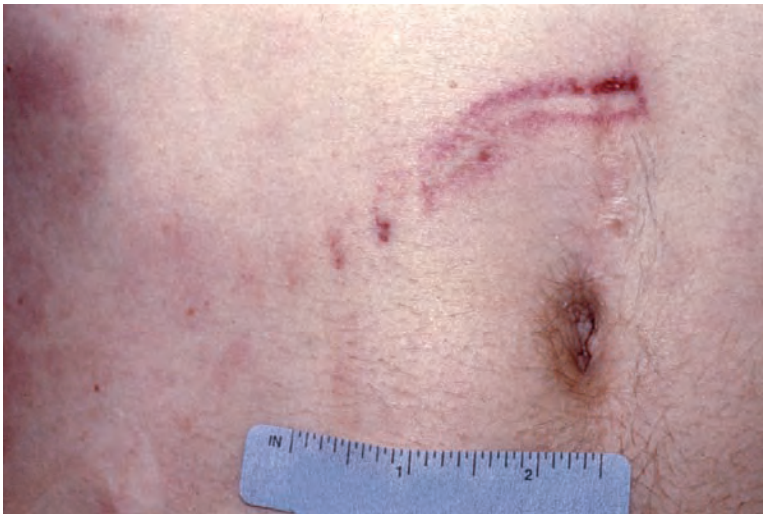
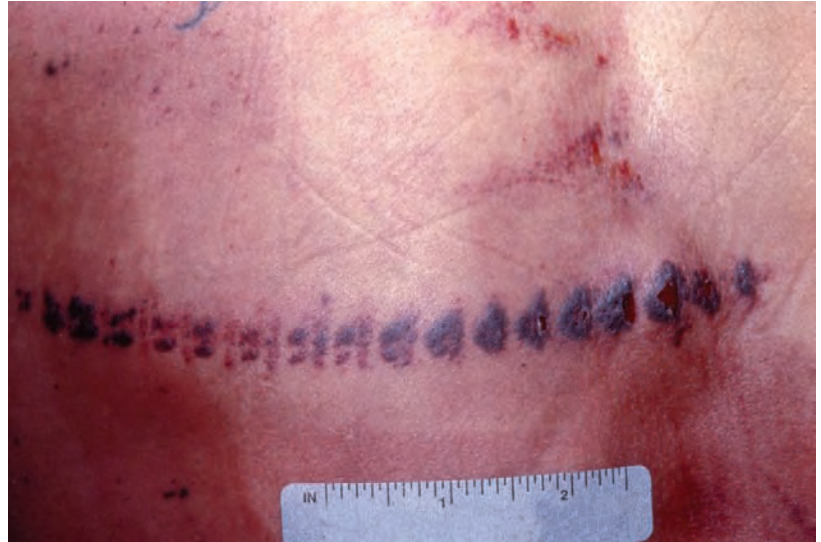
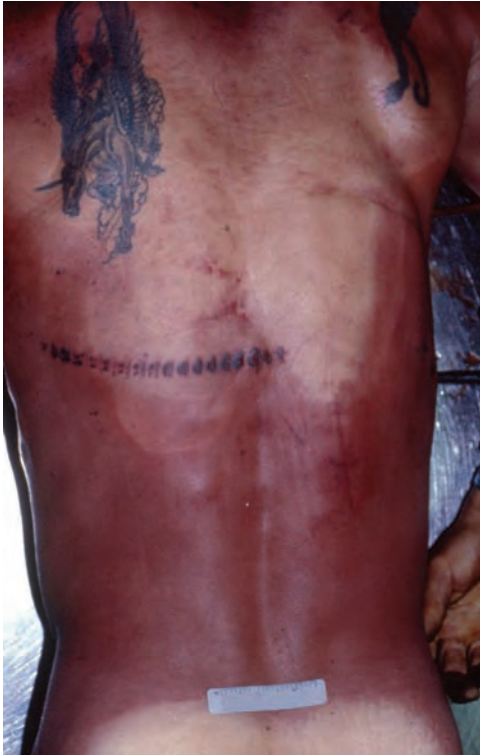
This elderly woman had a history of an unsteady gait associated with Parkinson's disease and remote stroke. She was found in her apartment with several impact injuries to her scalp. It was initially thought by investigators that she had fallen several times and possibly suffered a heart attack. Further examination of her scalp revealed more lacerations and impacts that were initially not observed at the scene due to poor lighting and dried blood matted in her scalp hair. These scalp lacerations were produced by being struck with a hammer head.



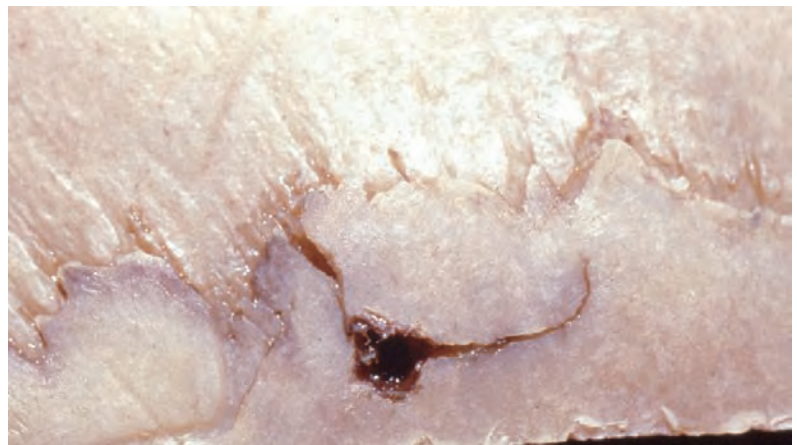
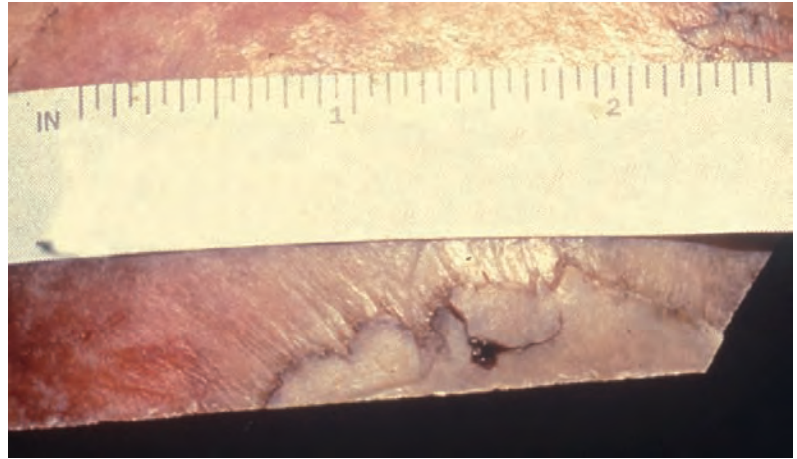
Depressed skull fractures due to multiple impacts with the head and claw of a hammer. Standard household hammer heads have a diameter of  $\frac{3}{4}$  to 1 inch, and the injuries on the skull tend to reflect this.



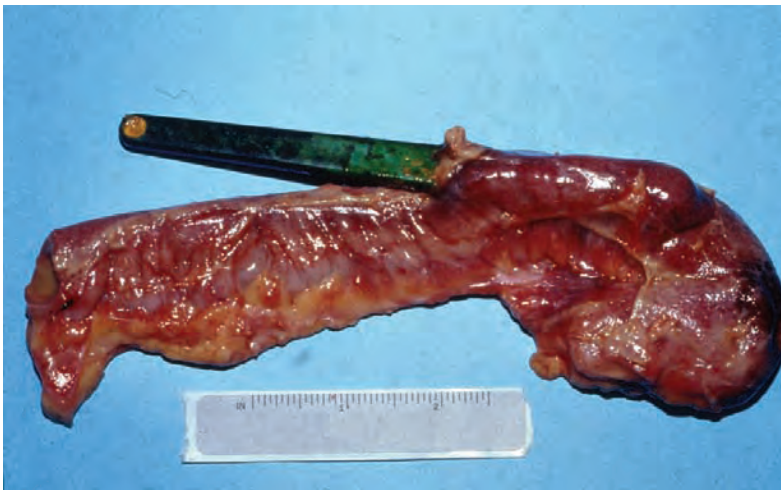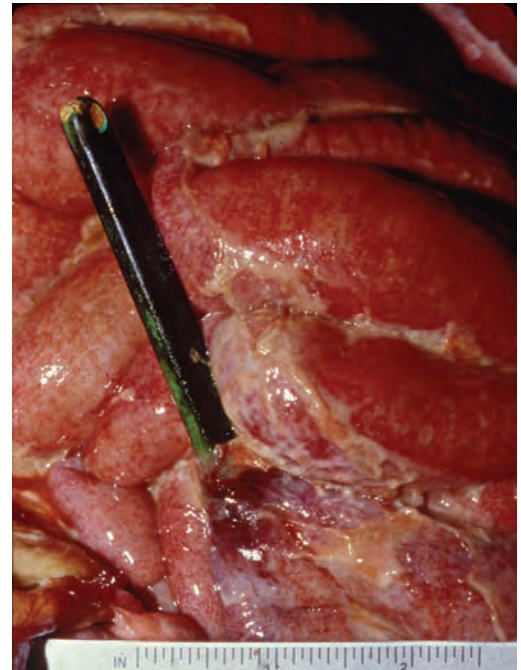
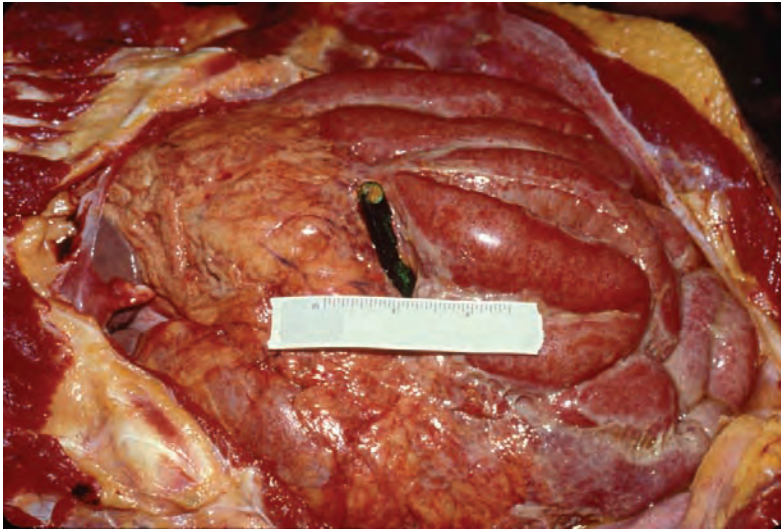


This individual was assaulted by multiple people including one with a bicycle chain. These injuries are characteristic for bicycle chain impacts.

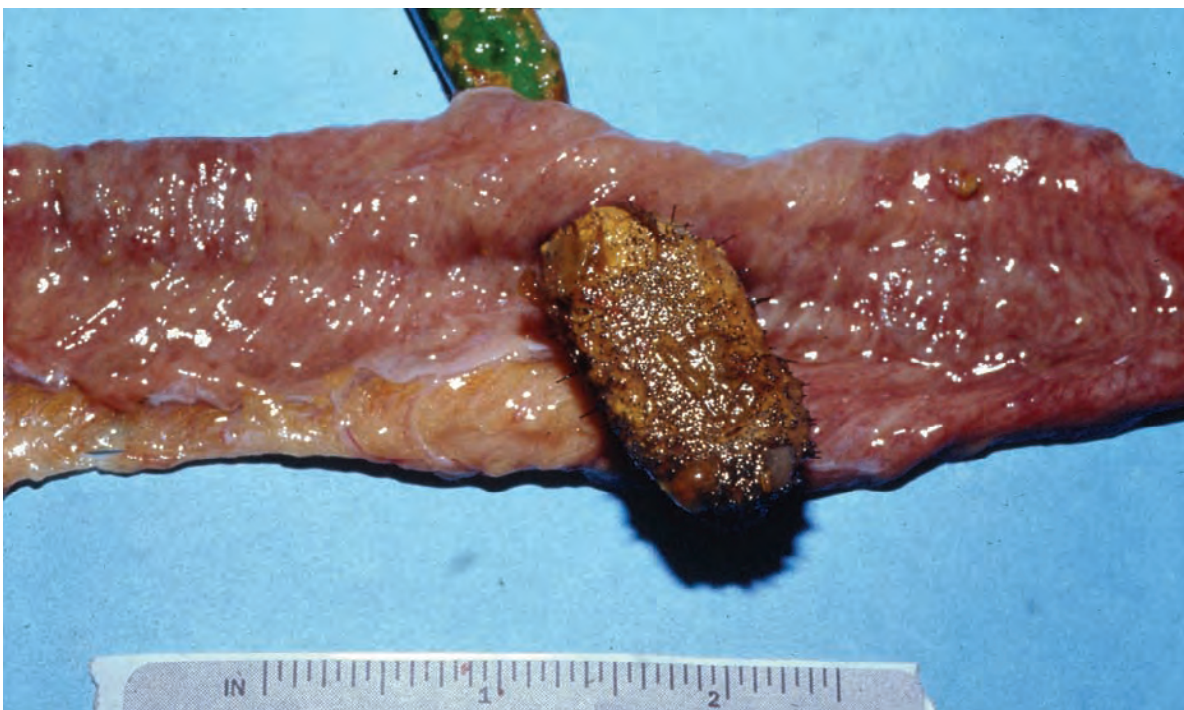




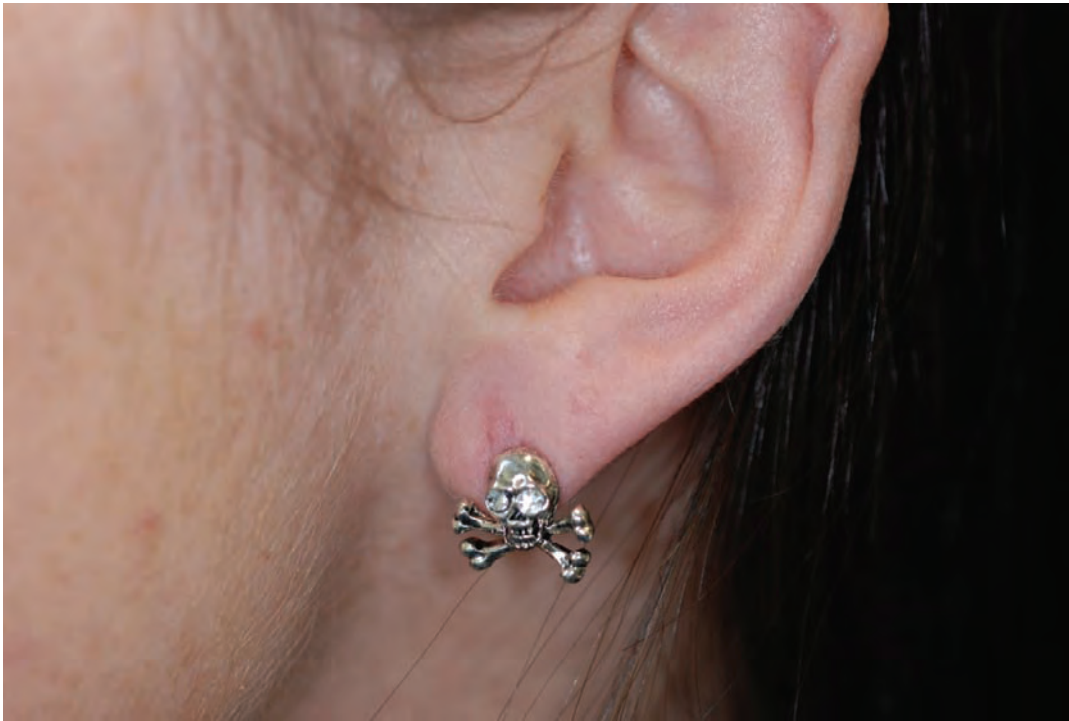This individual was found naked from the waist down in an abandoned pipe yard. She had multiple defects to her scalp with exposed bone and extensive maggot and animal feeding. Careful inspection of the skull revealed a 1/4" linear fracture of the superior temporal bone with a 1/16" roughly square indentation. Further investigation of the scene revealed a board with a nail at the other side of the yard. Further testing confirmed this was the murder weapon.



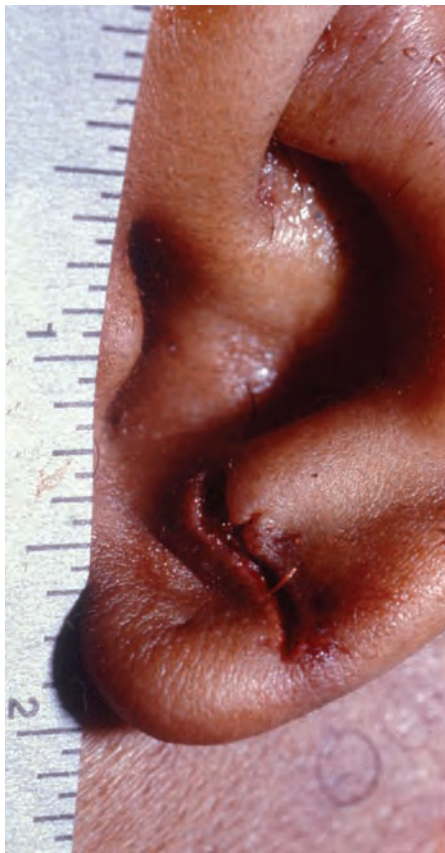This psych patient had a history of swallowing miscellaneous objects. The blunt side of this toothbrush, in conjunction with peristalsis, eroded through the intestinal wall. This person died of peritonitis with septic complications.



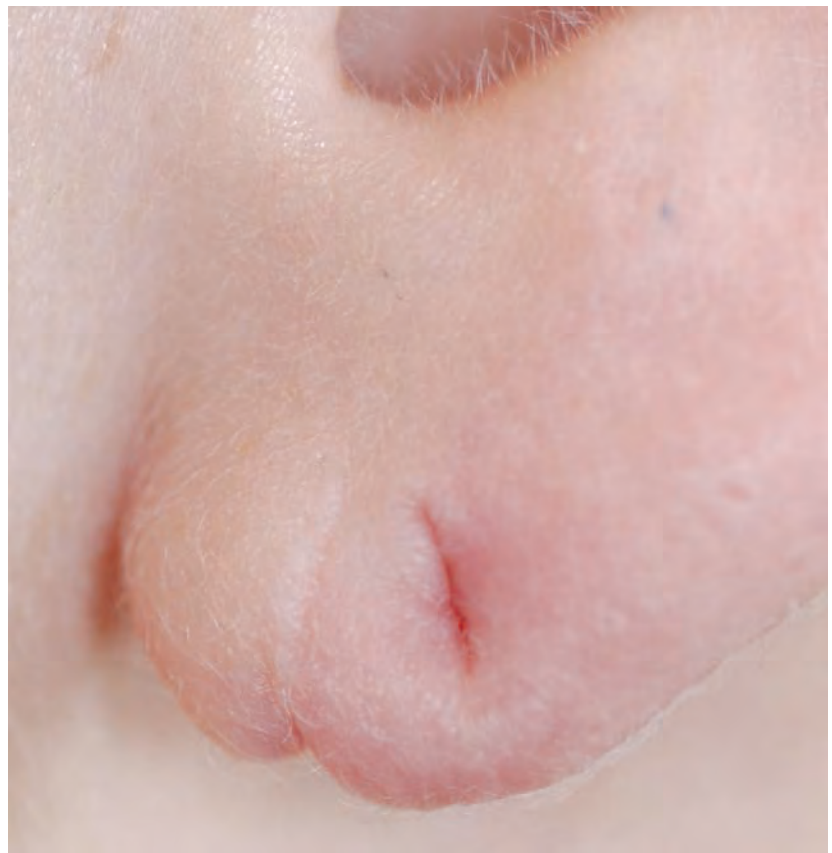



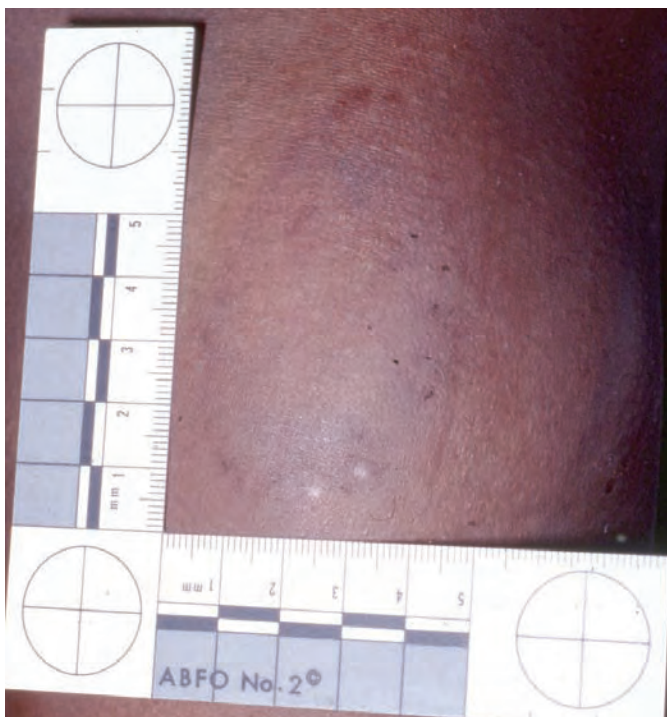
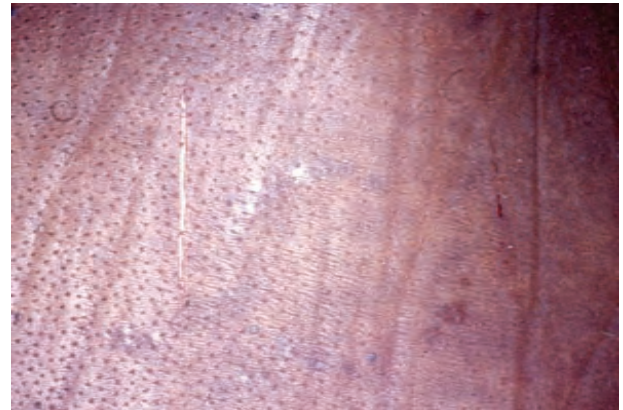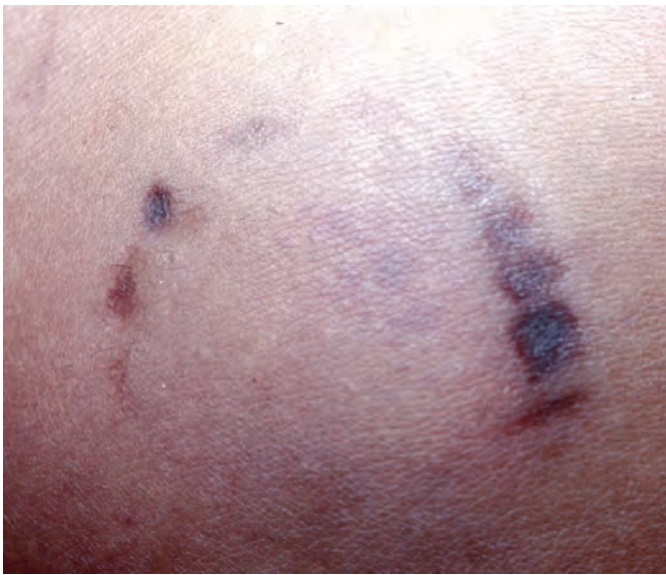
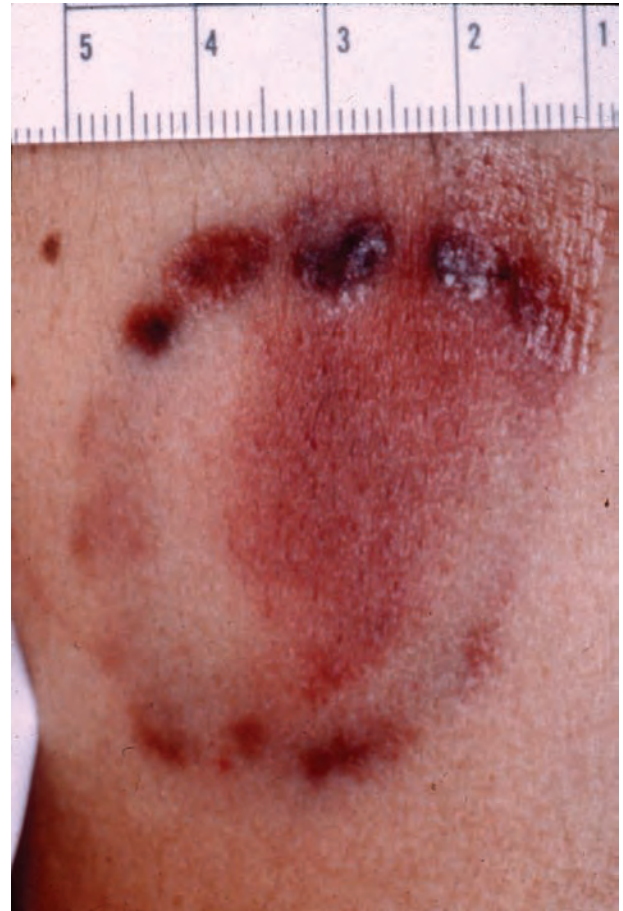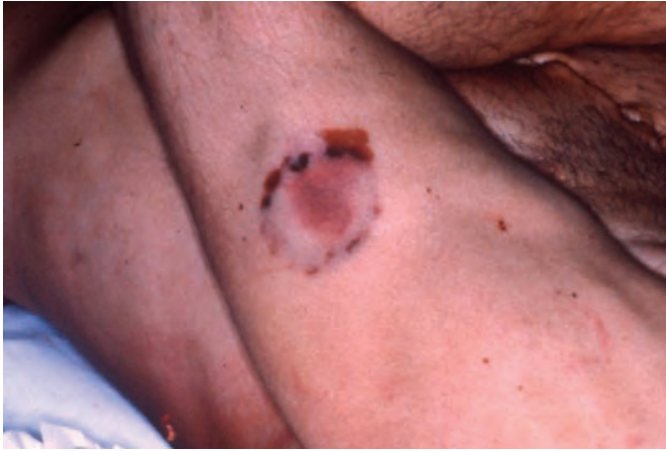Pierced ear lobe with sociopathic pirate earring.



This is a homicide case where the individual had her earring torn from her ear lobe during the assault.



Note the slit elongation of the piercing site from wearing very heavy earrings. Also note the healed linear scar to the left due to a traumatic tearing of the earring from the ear lobe with complete separation and nonplastic-surgical repair.



These are various examples of recent bite marks with different placement of the mouth while exerting pressure and different degrees of force applied. Note some patterns are very vague and others are extremely prominent. The typical example of a bite mark reveals a circular pattern with a central region of contusion. It is good practice to consult a forensic dentist as soon as possible whenever a bite mark is suspected. The injury should not be cleaned until swabs are taken to detect oral DNA left behind from the perpetrator. As time goes on with drying and decomposition, the injury may yield less valuable information for dental comparison and DNA analysis.

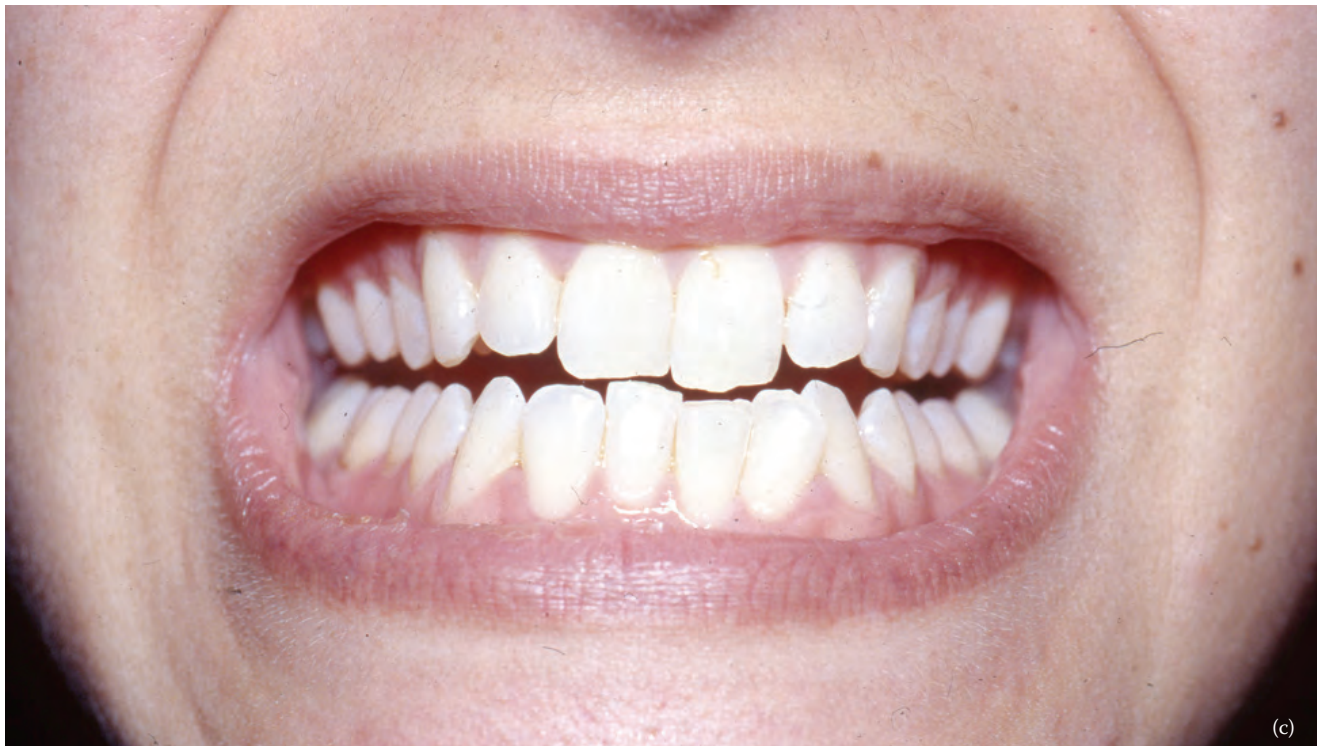
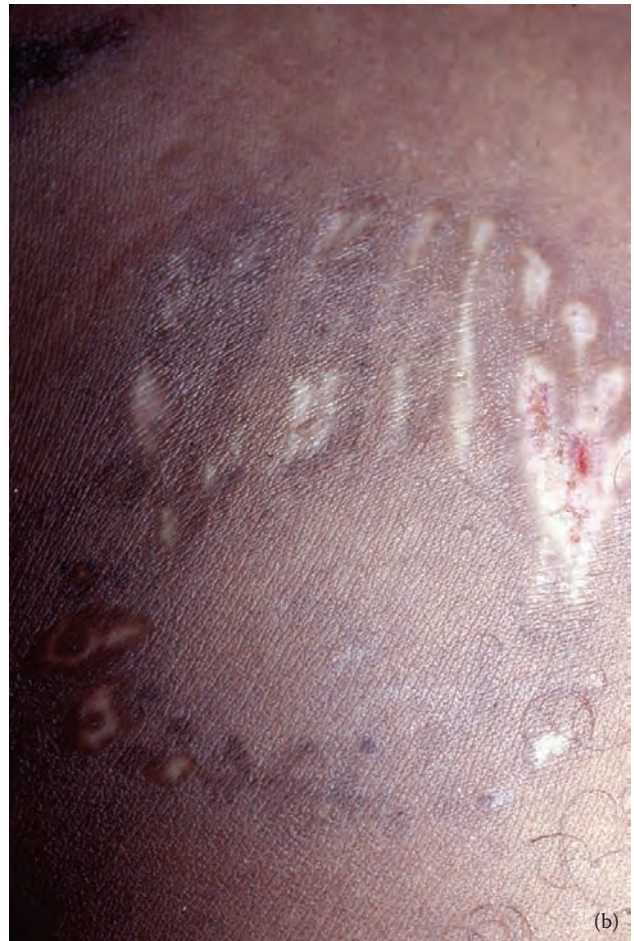
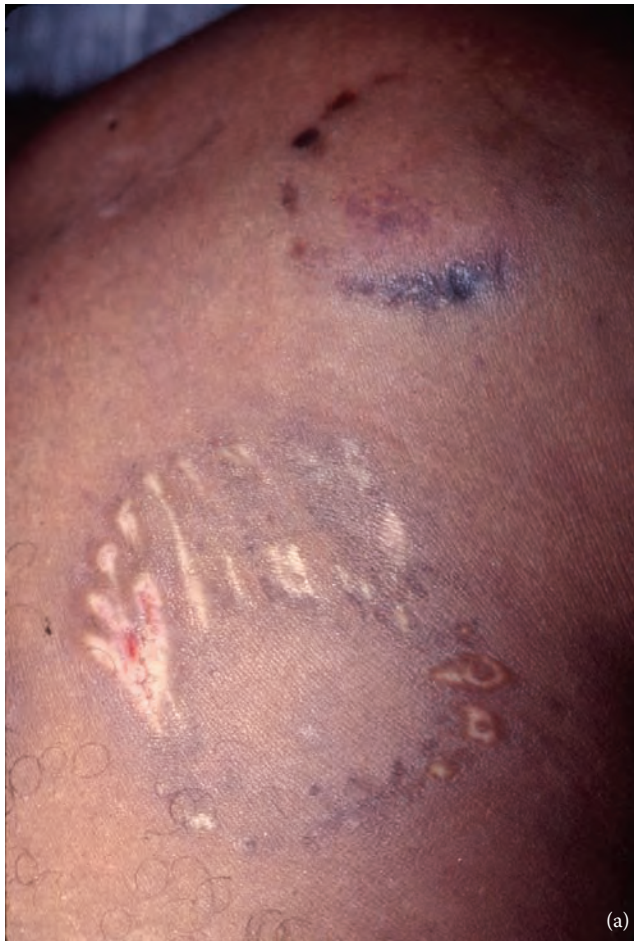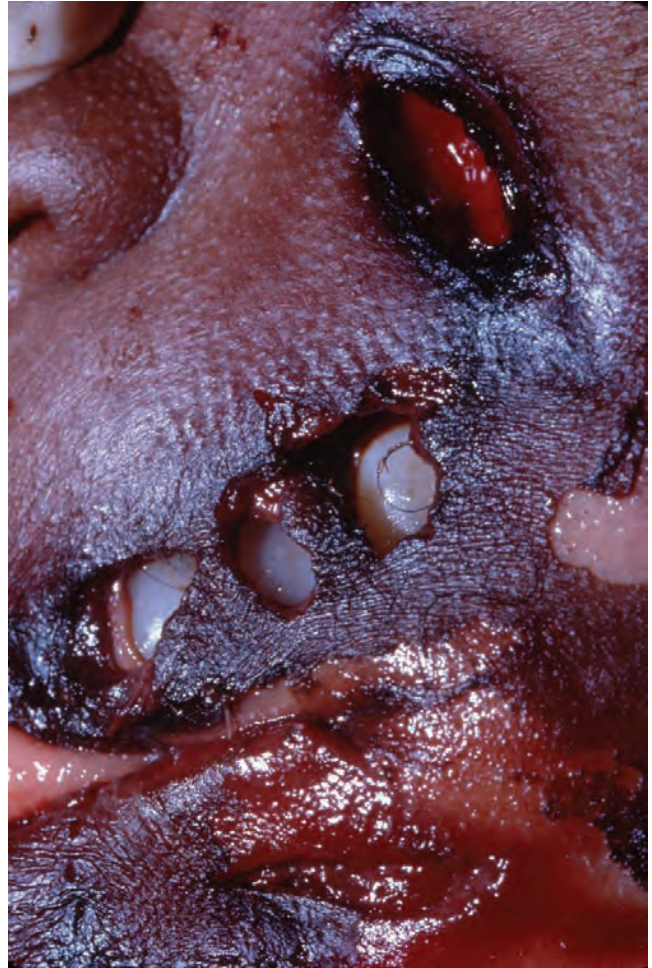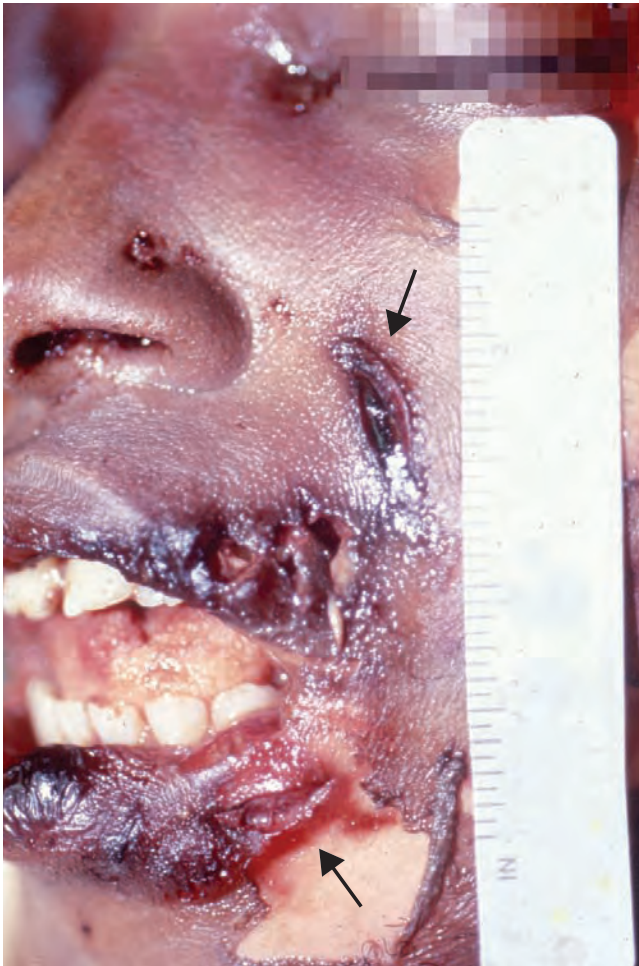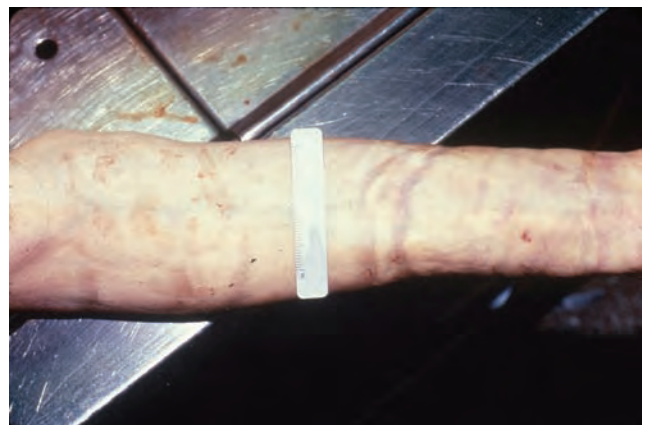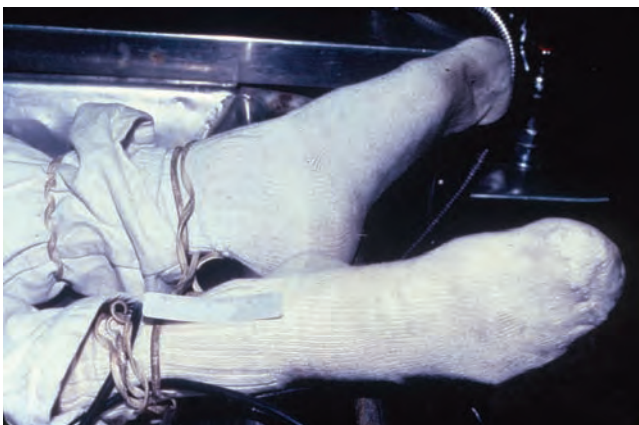Image (a) demonstrates both a recent and a healed bite mark. The old bite mark is largely healed with hypo-pigmented deep abrasions from teeth dragging across the epidermal surface.

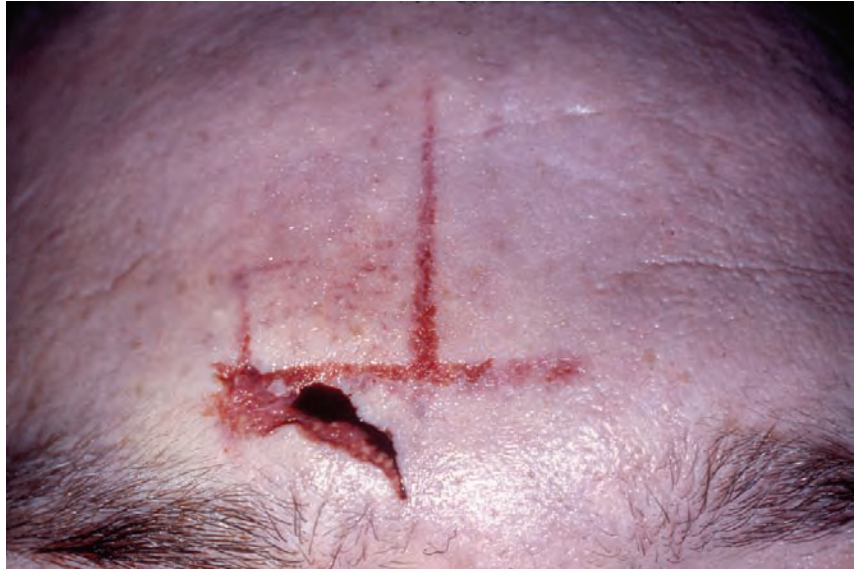

This individual and her roommate were found in their apartment with multiple blunt- and sharp-force injuries. Note the roughly semicircular lacerations at the superior and inferior aspect of the cheek, with the deeper lacerations of the lip revealing exposed underlying teeth. There was a large cylindrical storefront padlock within a tube sock found at the scene. There were multiple other pattern injuries to the decedent's body consistent with these roughly circular impacts.

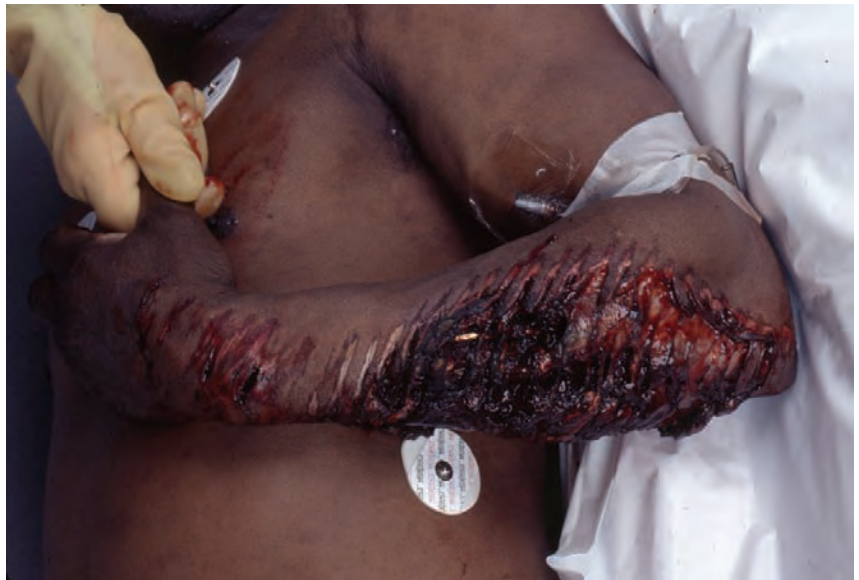

Note the furrow indentations associated with extremities bound by rope and cord prior to the victim's being stabbed to death.

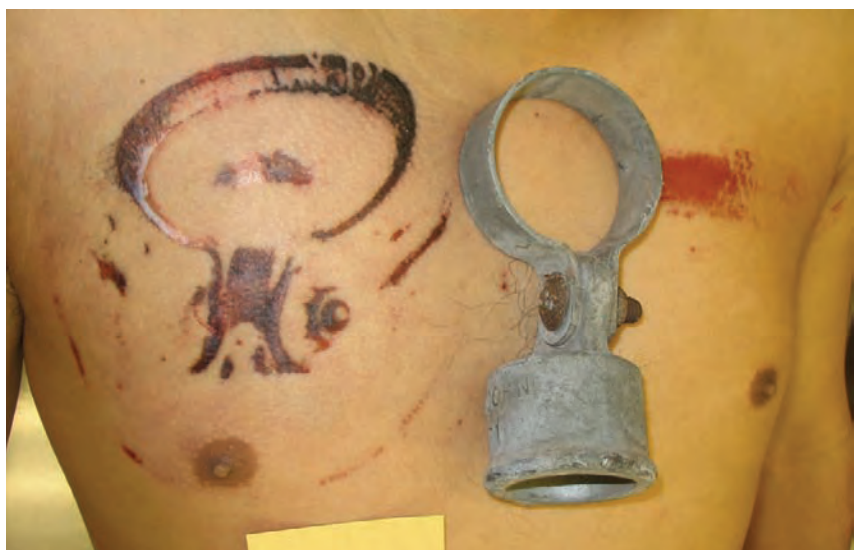
This individual suffered a witnessed fatal cardiac event while standing. While falling to the ground he sustained this pattern injury by striking his head on a radiator.



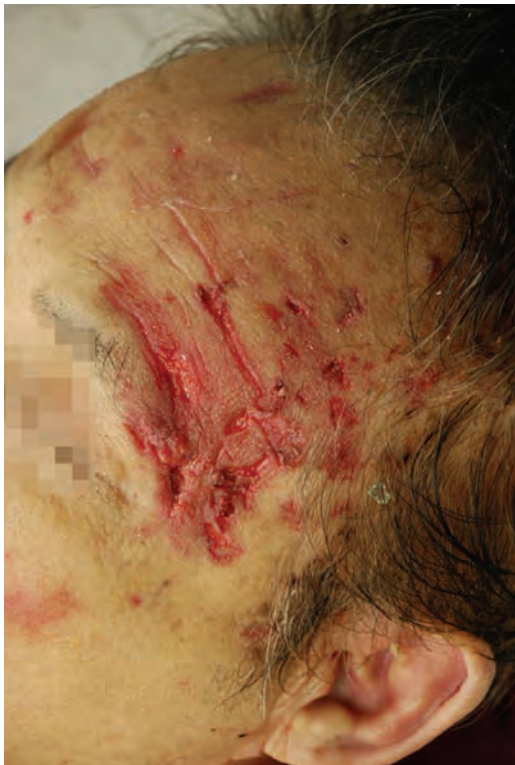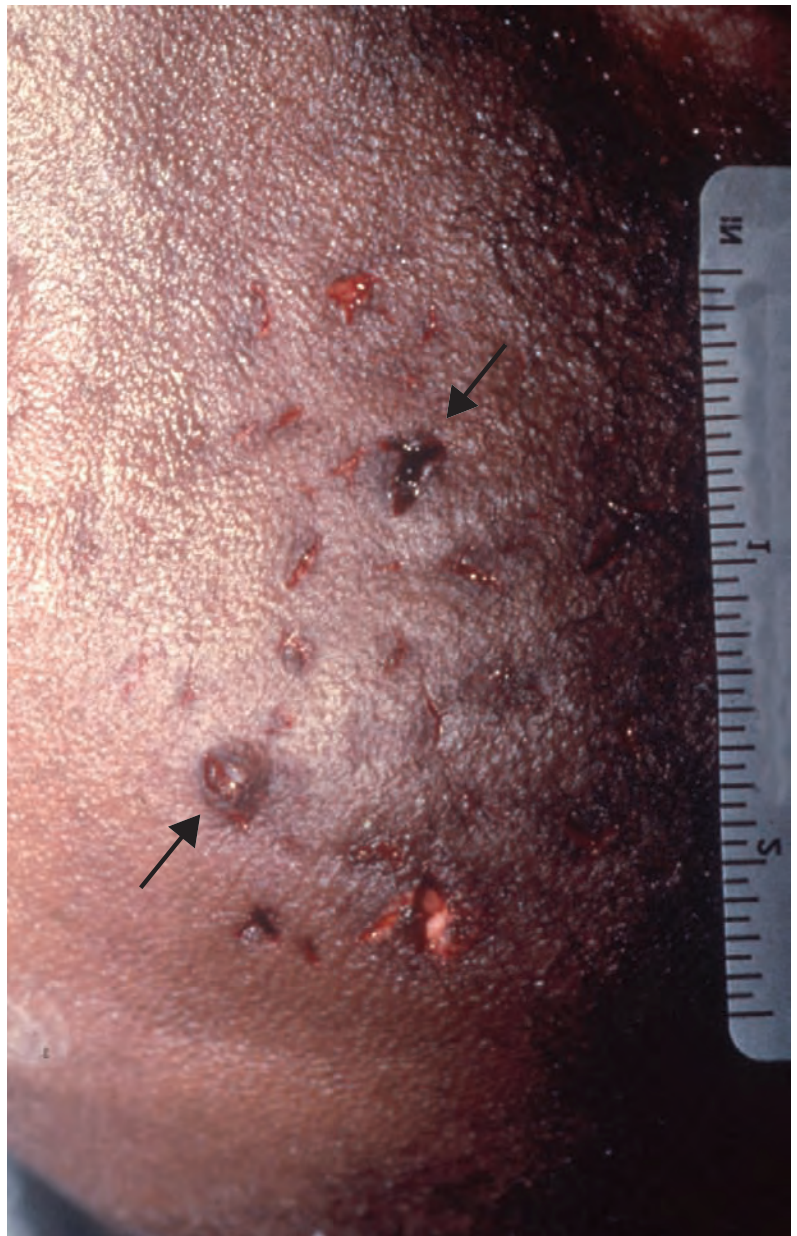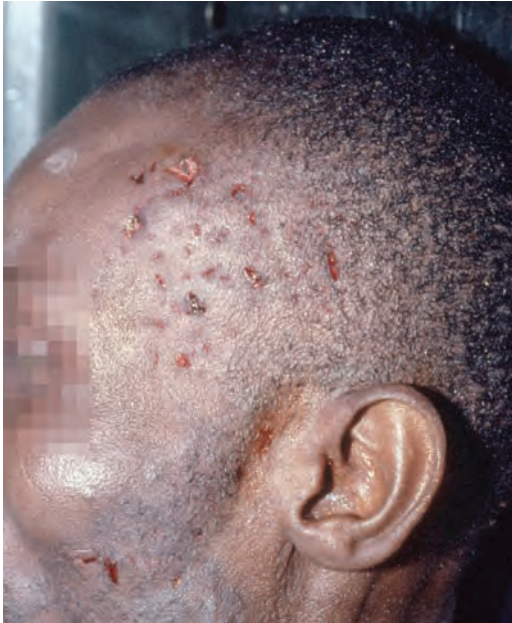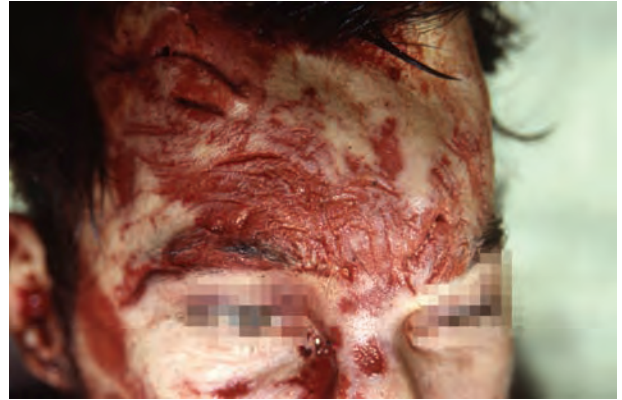This individual suffered a fatal cardiac event while riding on an escalator. He was found lying at the bottom of the escalator. Note the pattern injury to his arm from the continued rubbing of escalator treads.



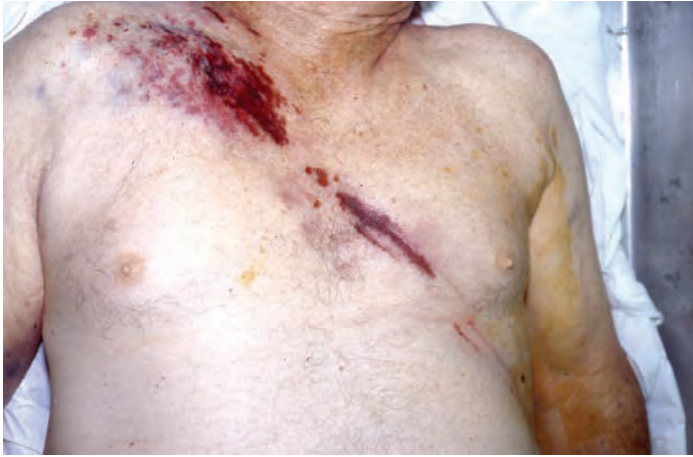This individual impacted a fence at a high rate of speed, leaving a pattern injury from the top of the fencepost's contacting his chest.



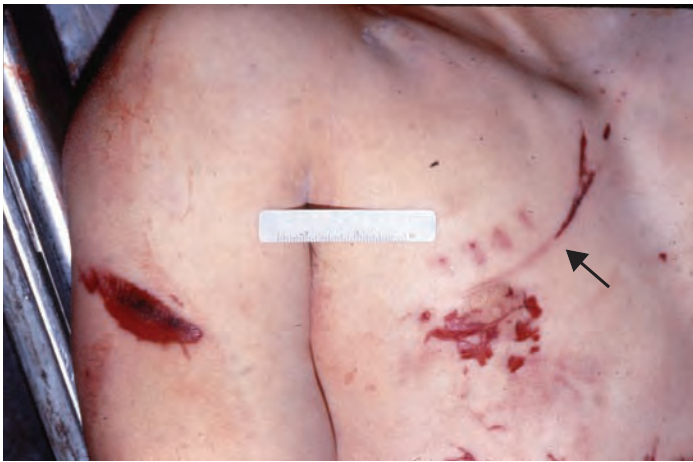This individual was an unrestrained passenger in a motor vehicle during a head-on collision. His face went through the front windshield. He sustained multiple curvilinear lacerations and sharp-force injuries from broken glass and impact with the car roof. This type of pattern is consistent with a front windshield impact.



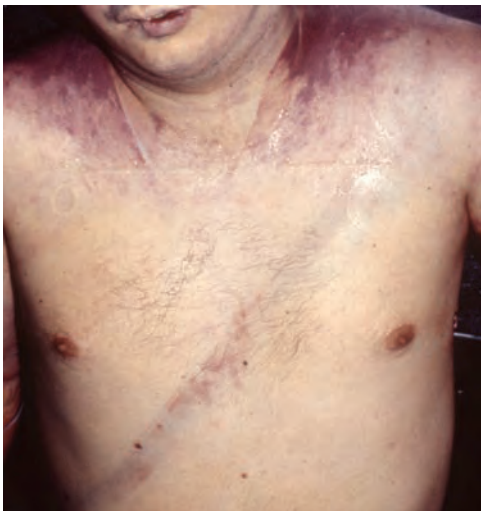Note the dicing type injuries to the scalp with cubed fragments of glass embedded in the injuries. This type of injury is consistent with an impact and fracture of tempered glass, which is present in many side windows. These individuals were passengers with left-door-window head impact.



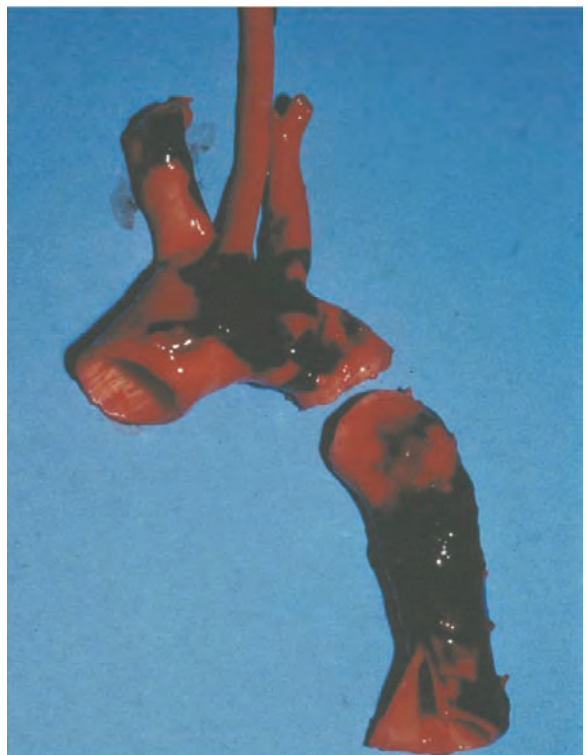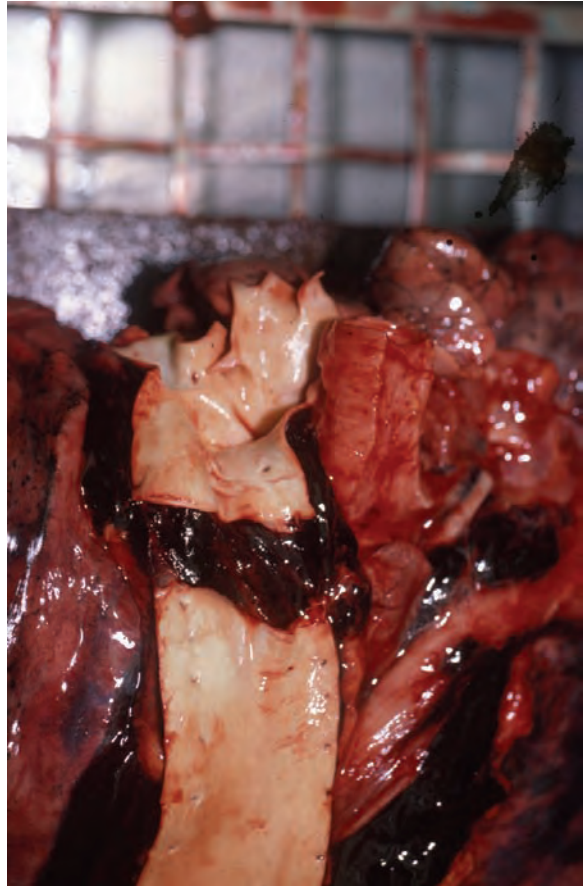
This individual was the passenger in a front seat collision. Note the abraded contusion from his seat belt.



Note the abraded contusion at the chest and arm of this individual from a steering wheel impact. He was the driver of this car in a multiple-fatality vehicular accident.



This was the driver of a car in a motor vehicle accident. Note the abraded contusion from the seat belt.



These demonstrate a transection of the aorta in the proximal descending region just distal to the ductus ligatosum. This is a common location of laceration.

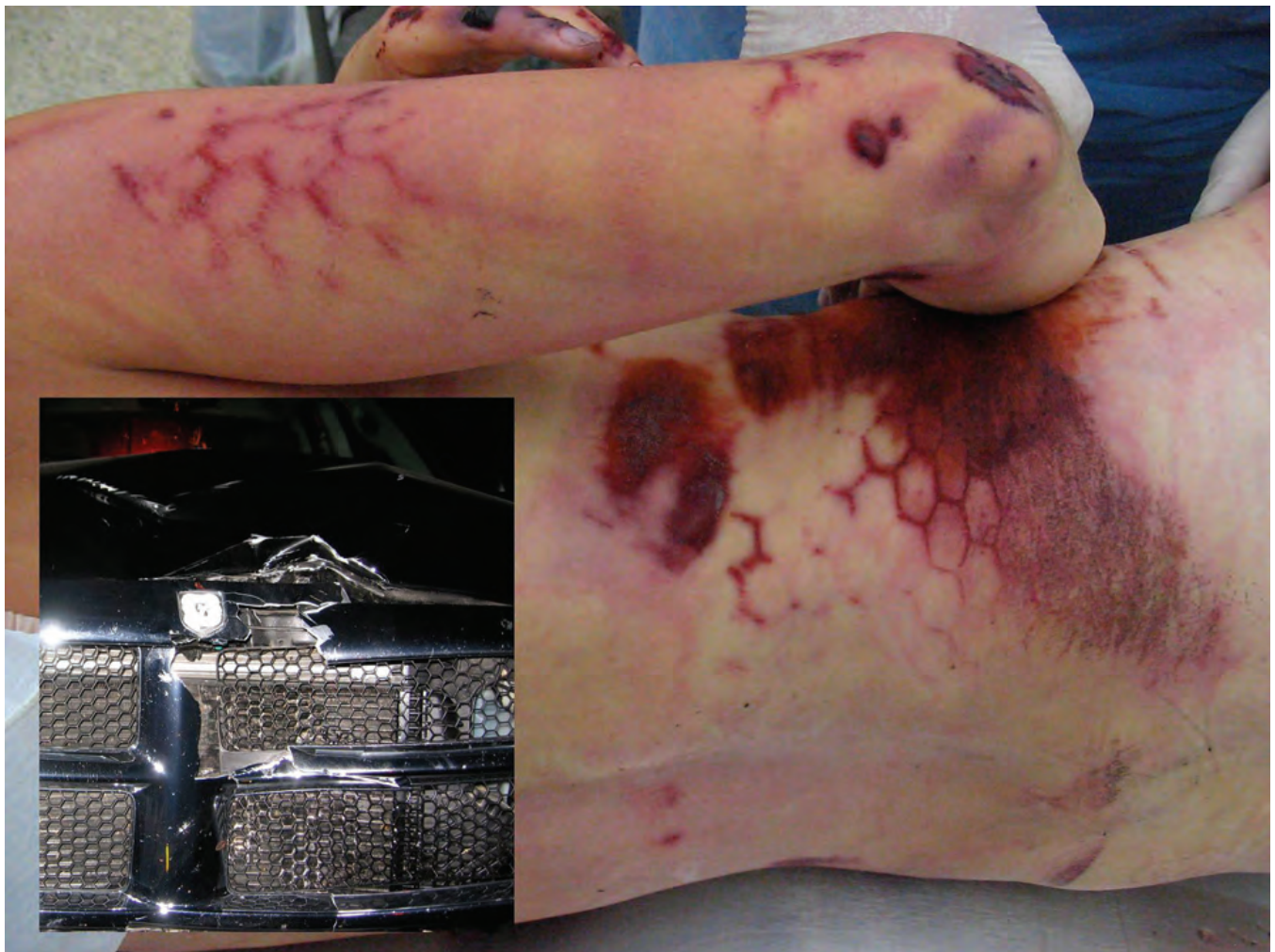
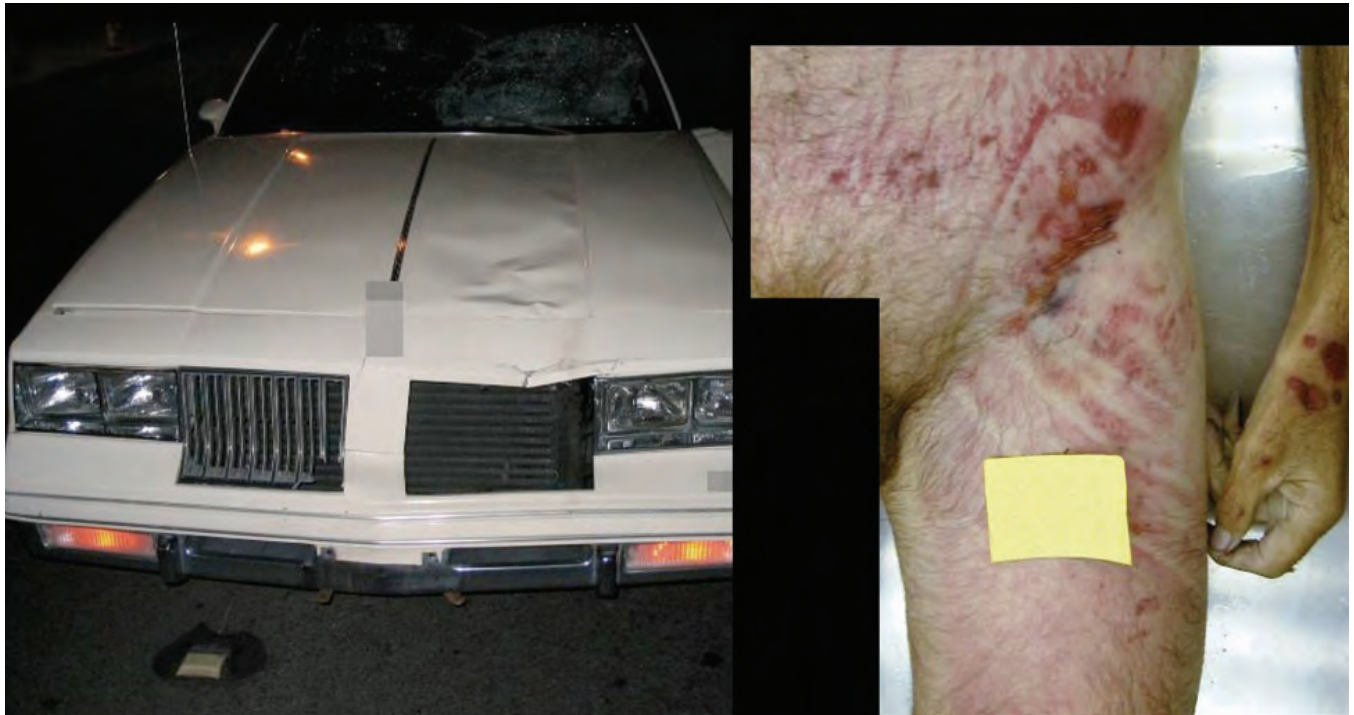
This photograph demonstrates an individual who was struck at a high rate of speed and hit the pavement with great force. Note the exposed comminuted skull fracture with brain material.




These pictures of a car show an impact from a pedestrian who was struck and run under. Note the fragment of scalp with hair embedded in the top part of the windshield and adjacent car roof. The driver of this car initially fled the scene.

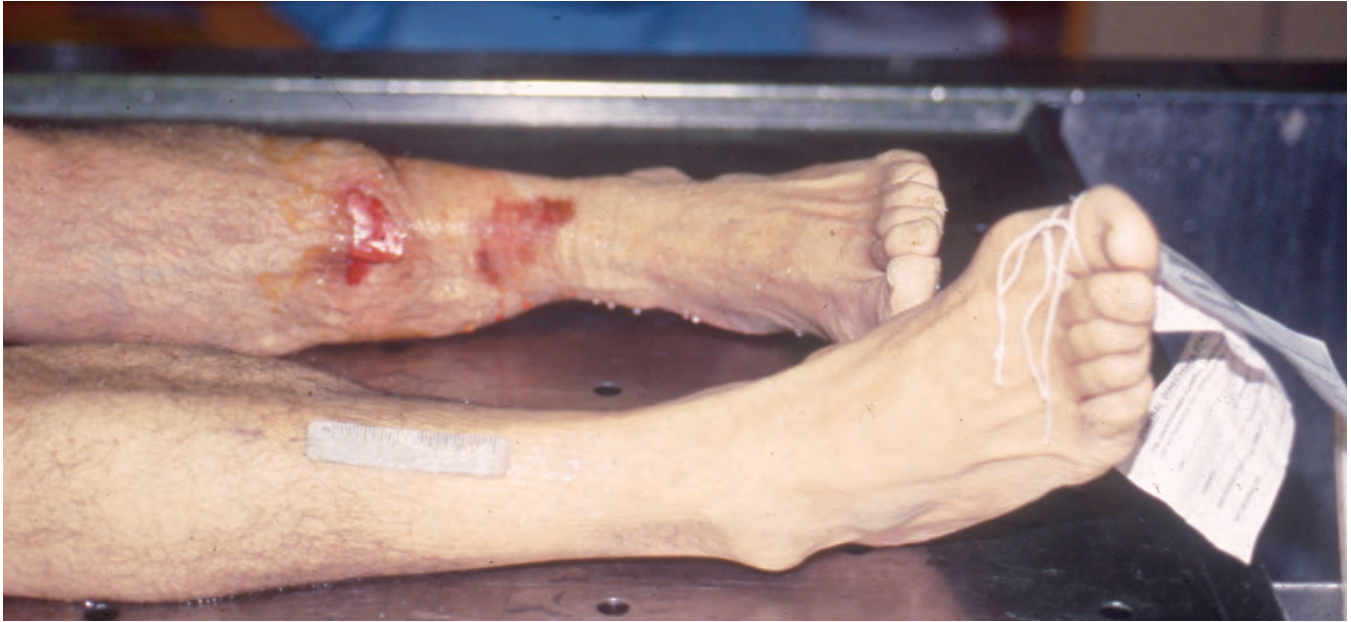



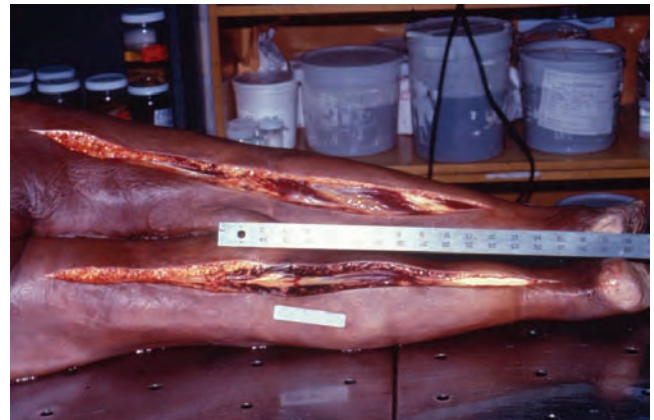
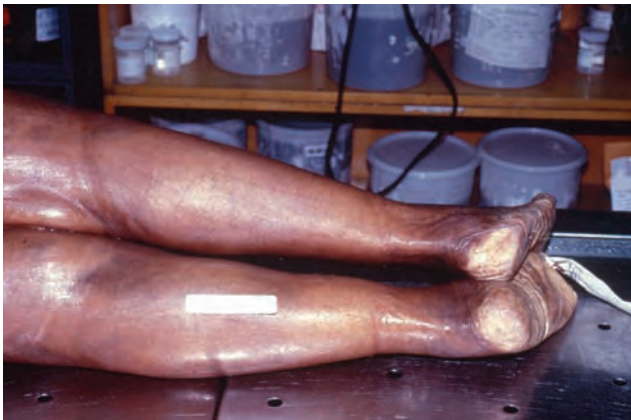Pedestrians struck by cars with grill pattern injuries.



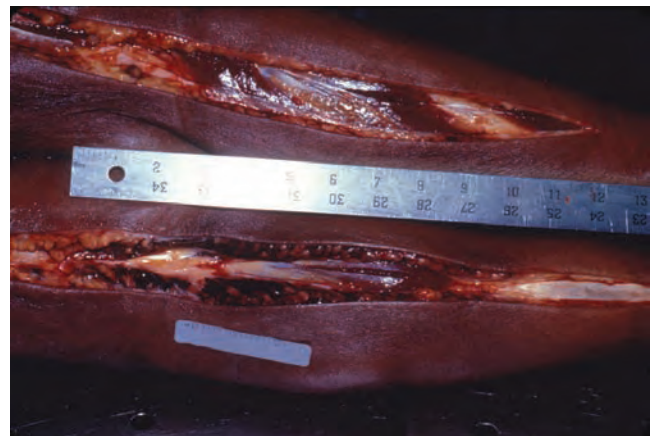
Motor vehicle accident with decapitation.

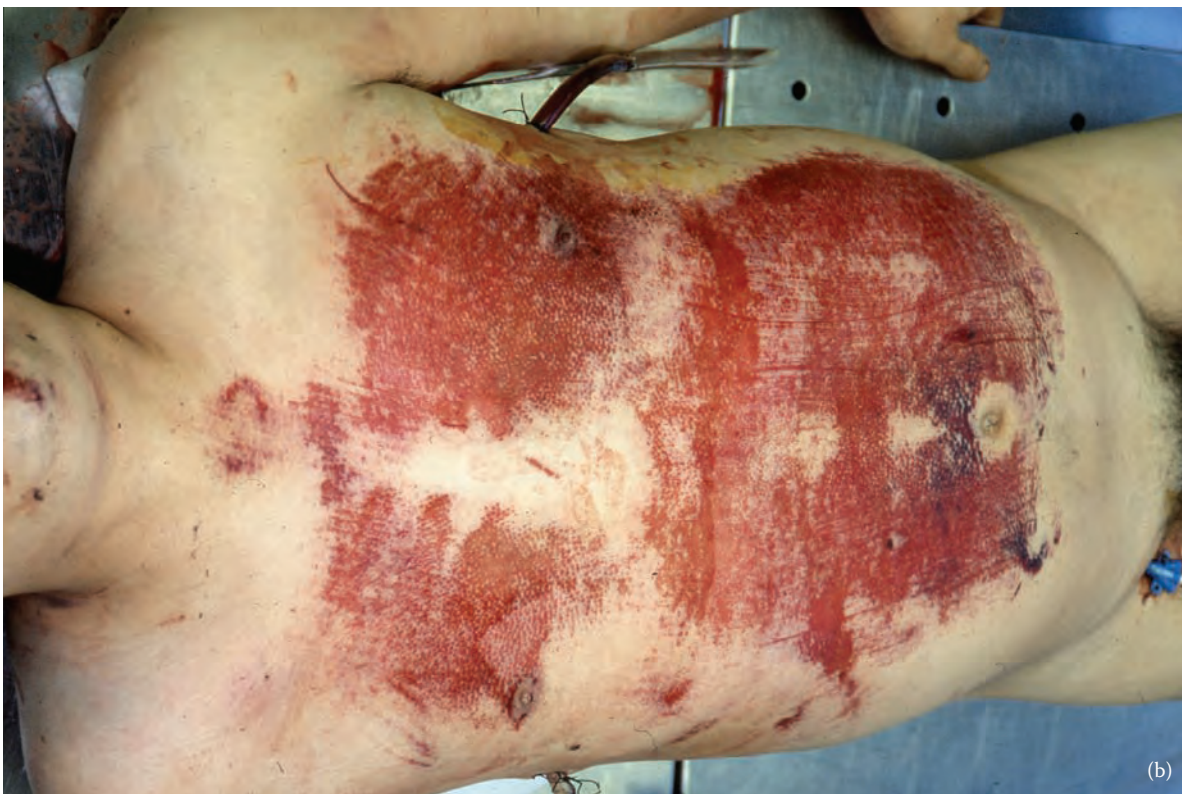

This is another pedestrian who was struck by a car. Note the tibial fracture at the weight-bearing left leg.

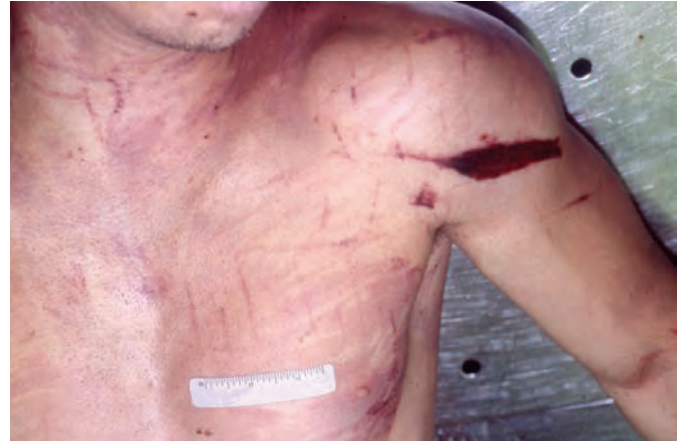
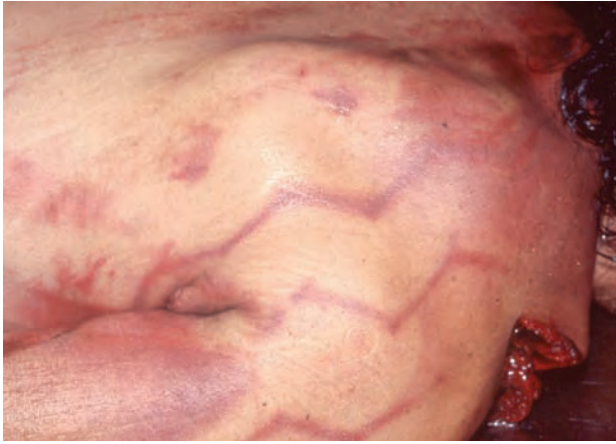
This individual was a pedestrian who was struck from behind by a car. Due to her dark skin, the contusions are not obvious from external examination alone. Incision of the posterior aspects of her leg reveal hemorrhage due to the bumper impact. It is good practice to photograph these impact sites with a ruler to demonstrate the distance from the decedent's heels. This can be matched to a particular car and to whether the driver applied brakes before striking this pedestrian. The front of the motor vehicle will go downward when the braking occurs.

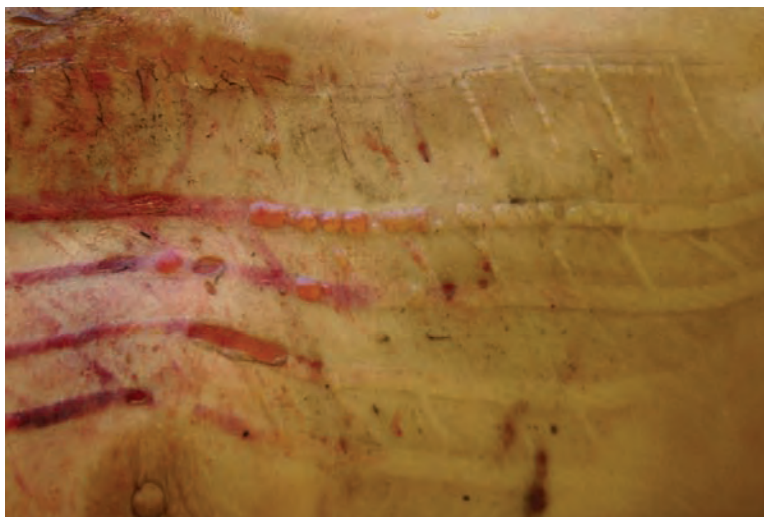




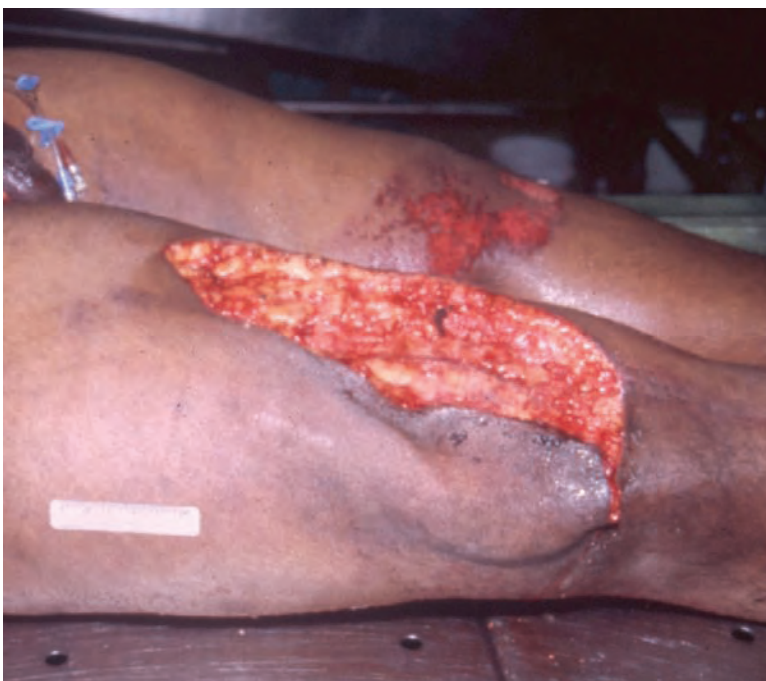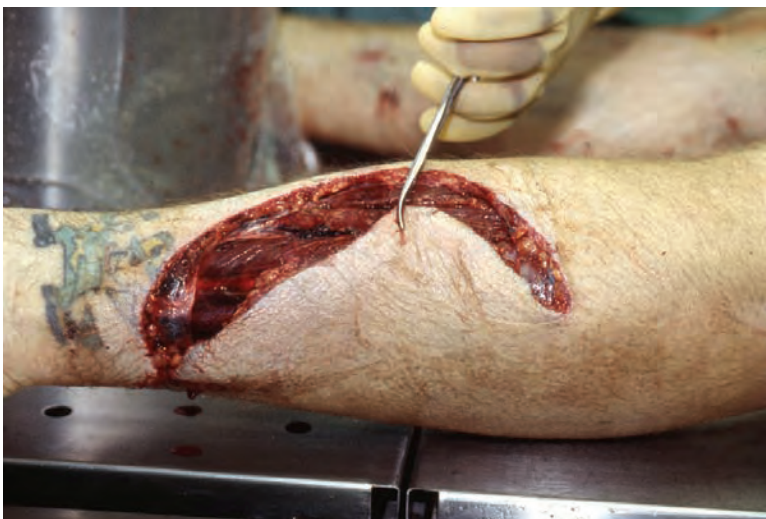These individuals were both struck by cars and dragged across the pavement. (a) shows yellow anemic abrasions that occurred after the first impact, where the decedent sustained extensive central nervous system injury and a transected aorta. He was thrown into another lane of traffic and dragged by another car. The anemic nature of this injury and yellow discoloration suggests decreased blood perfusion. The injury in (b) shows red to brown discoloration, which is significant for vital reaction in an individual who had an intact beating heart with blood pressure.



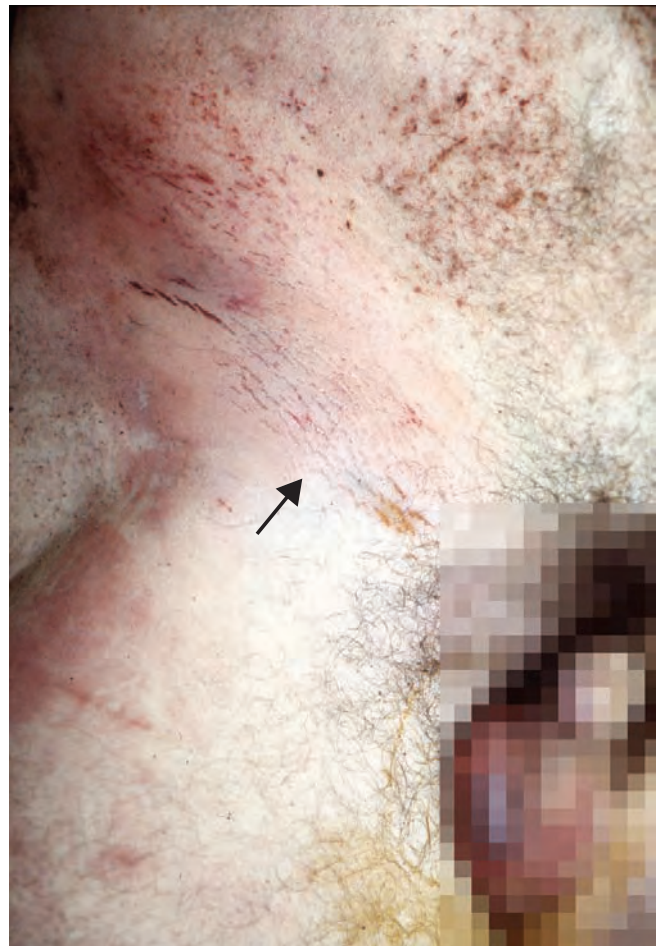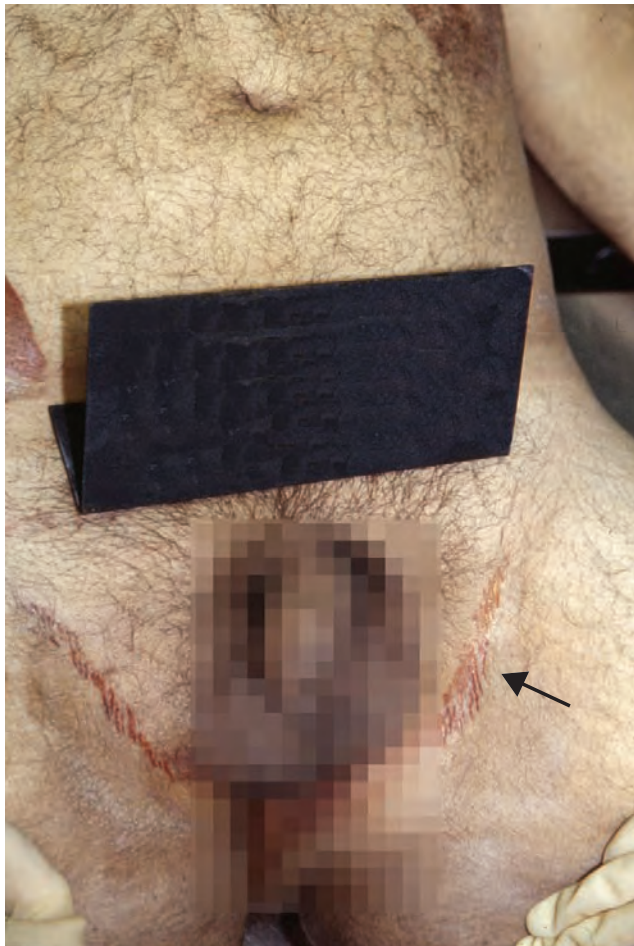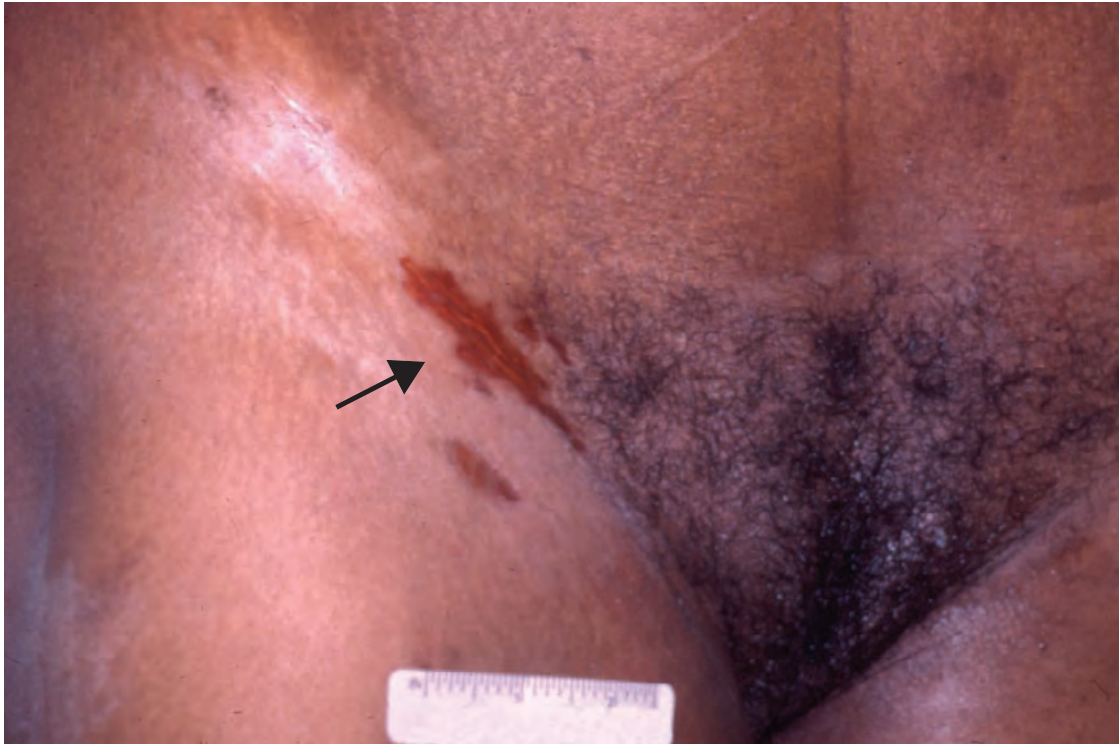These are multiple examples of tire imprints from people who were run over by cars. In one case, the individual was thrown into another lane of traffic after being struck. The second car denied hitting the individual, but his tire pattern was a perfect match and there was forensic evidence found on the under surface of his car.



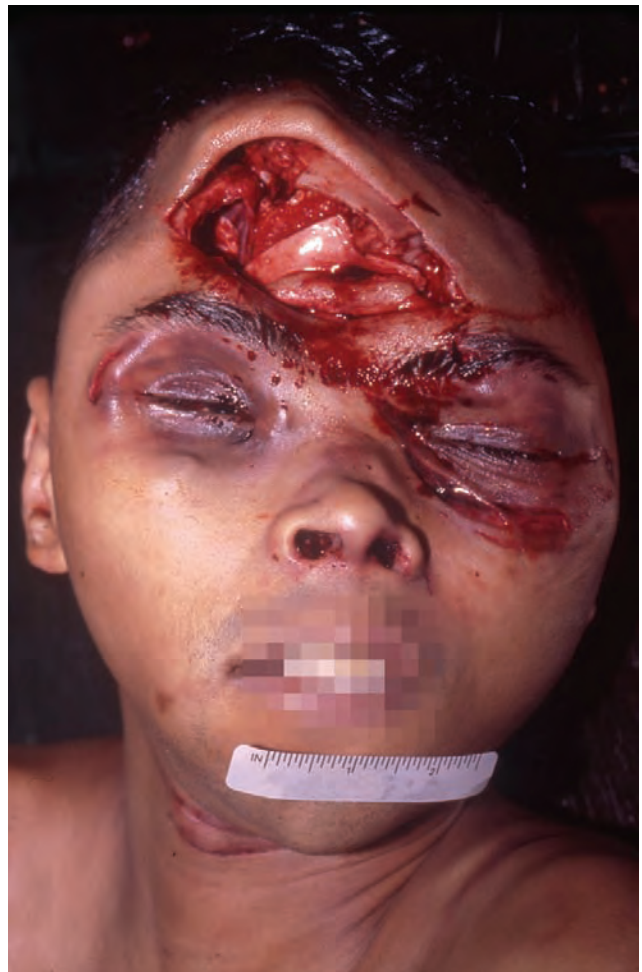Individual trapped under a car with tire imprint to chest.



These individuals were run over by a motor vehicle while lying on the ground. Note the flap of skin being torn away from the thigh as the tire rolled over the leg.

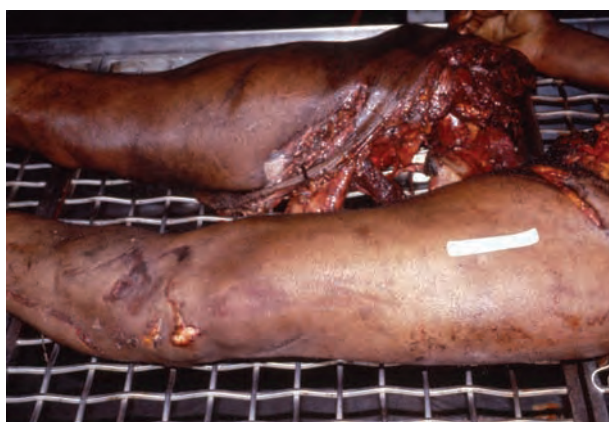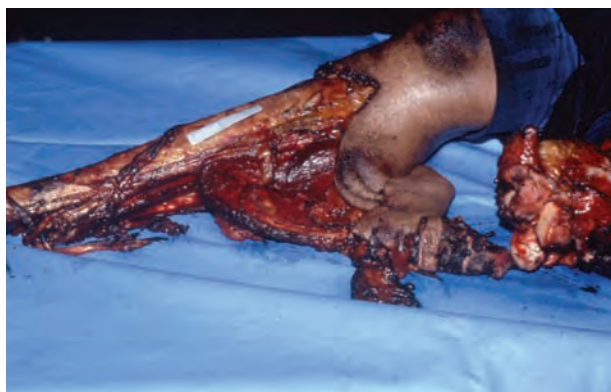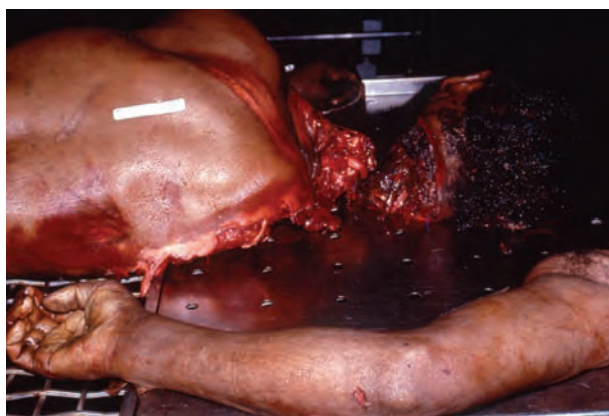
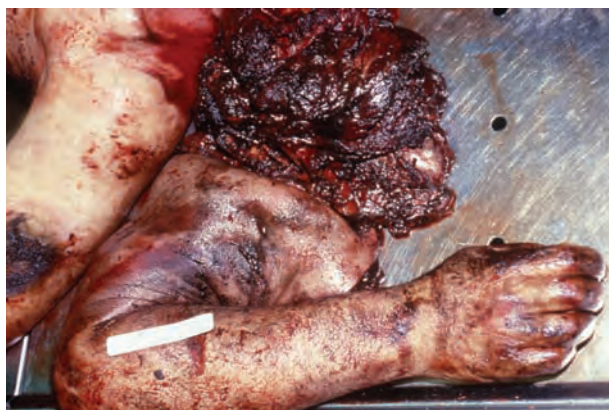


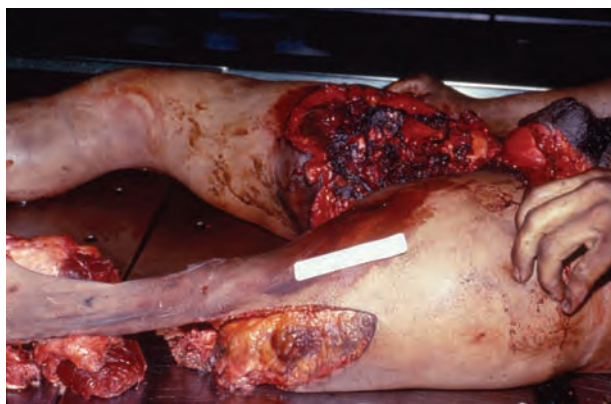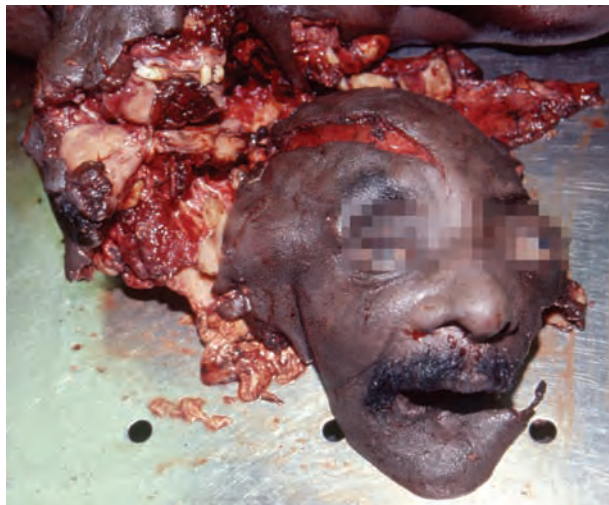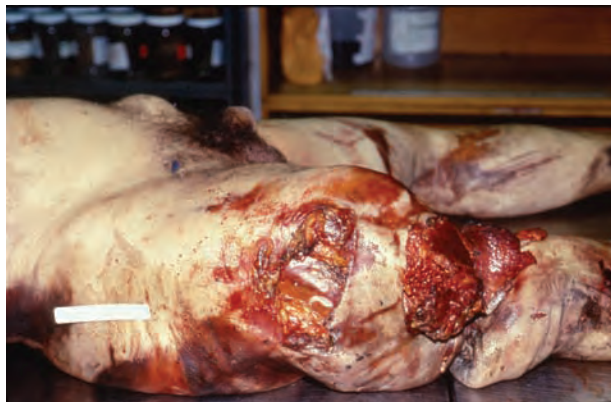These individuals were struck from behind by a car. Note the inguinal stretch marks caused by hyperextension of the hips and legs at the time of impact.



This fractured motorcycle helmet shows blood clot and brain material from an individual who fractured his skull after striking a pole.

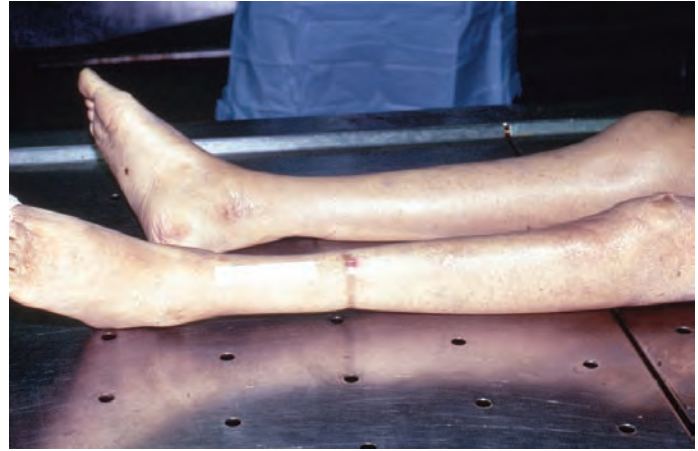



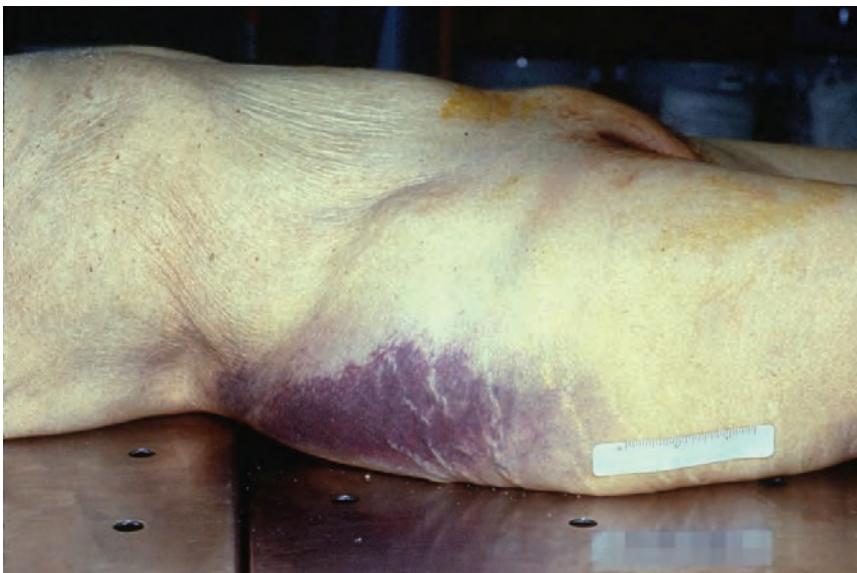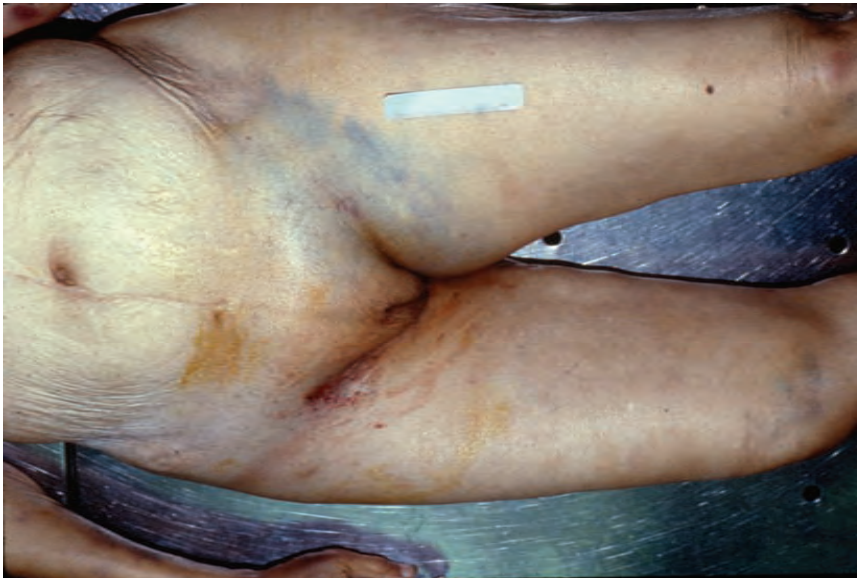
These figures demonstrate various subway fatalities where individuals were run over by trains. Note the separated body portions with extensive crush injury and axle grease from the train wheels.



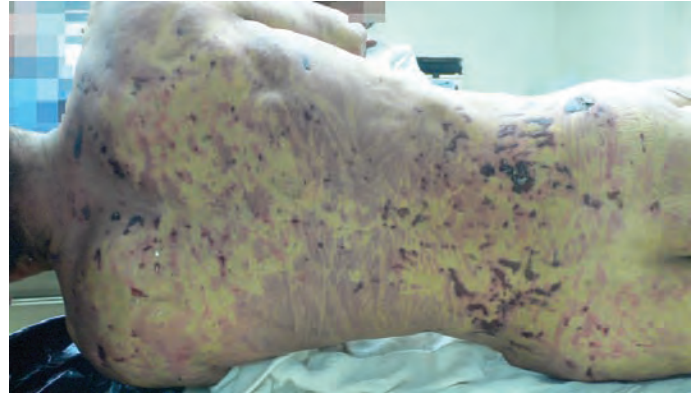This individual fell from the top of her steps and sustained multiple blunt-impact injuries including a femur fracture and a skull fracture. Note the slipper at the top steps.



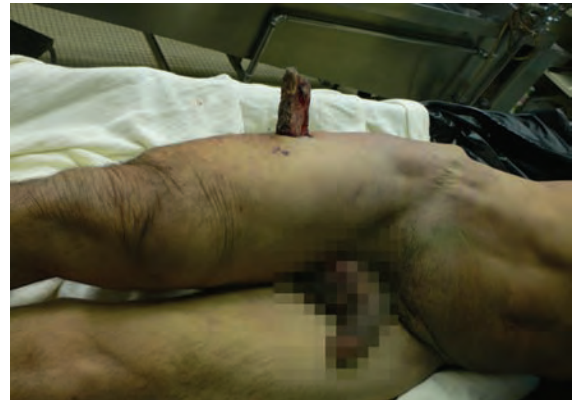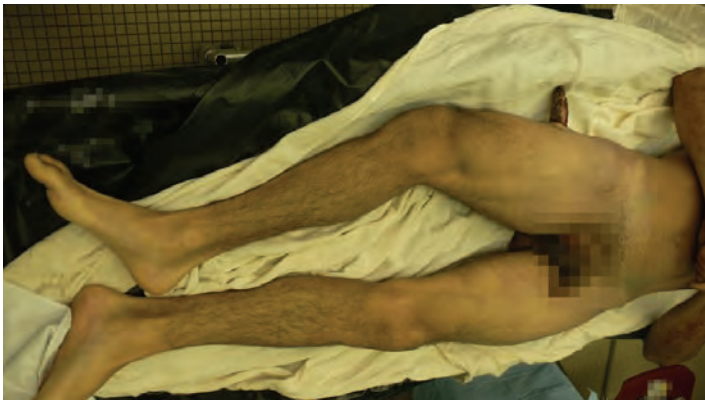This individual has a femur fracture. Note that the fractured leg is shorter and the foot is laterally rotated.



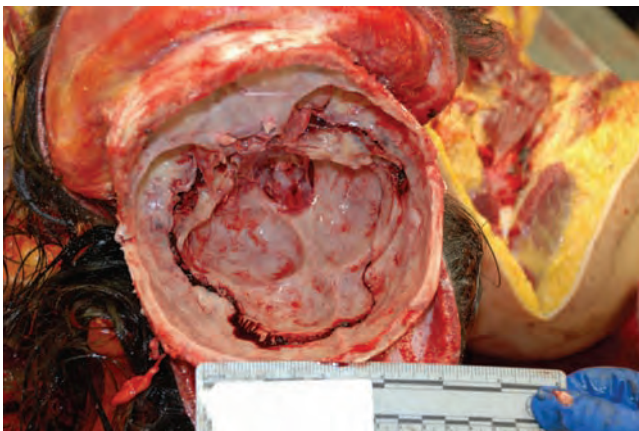
People with significant osteoporosis may fracture bones with little force. These two pictures demonstrate large areas of contusion and ecchymosis following a femur fracture secondary to a standing height fall.



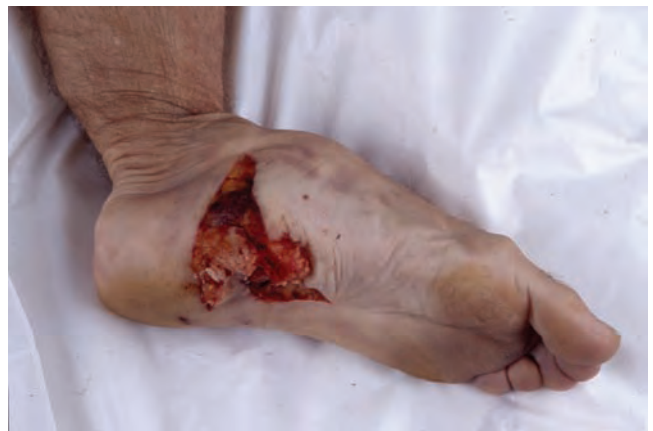Angulated irregular abrasions of back due to striking a gravel bed with great force.



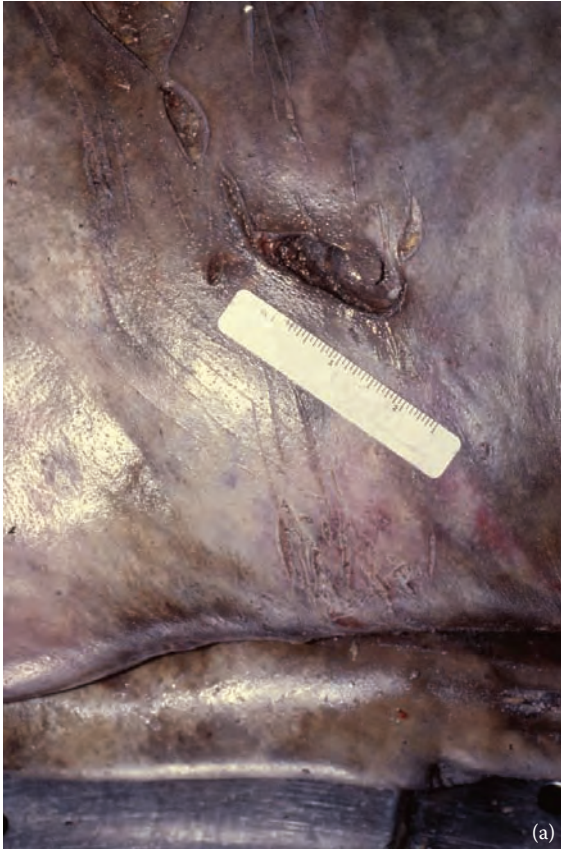This decedent jumped from a great height and fractured his right femur. Note the fractured bone protruding from the thigh. Also note the shortening of the right leg with lateral rotation.



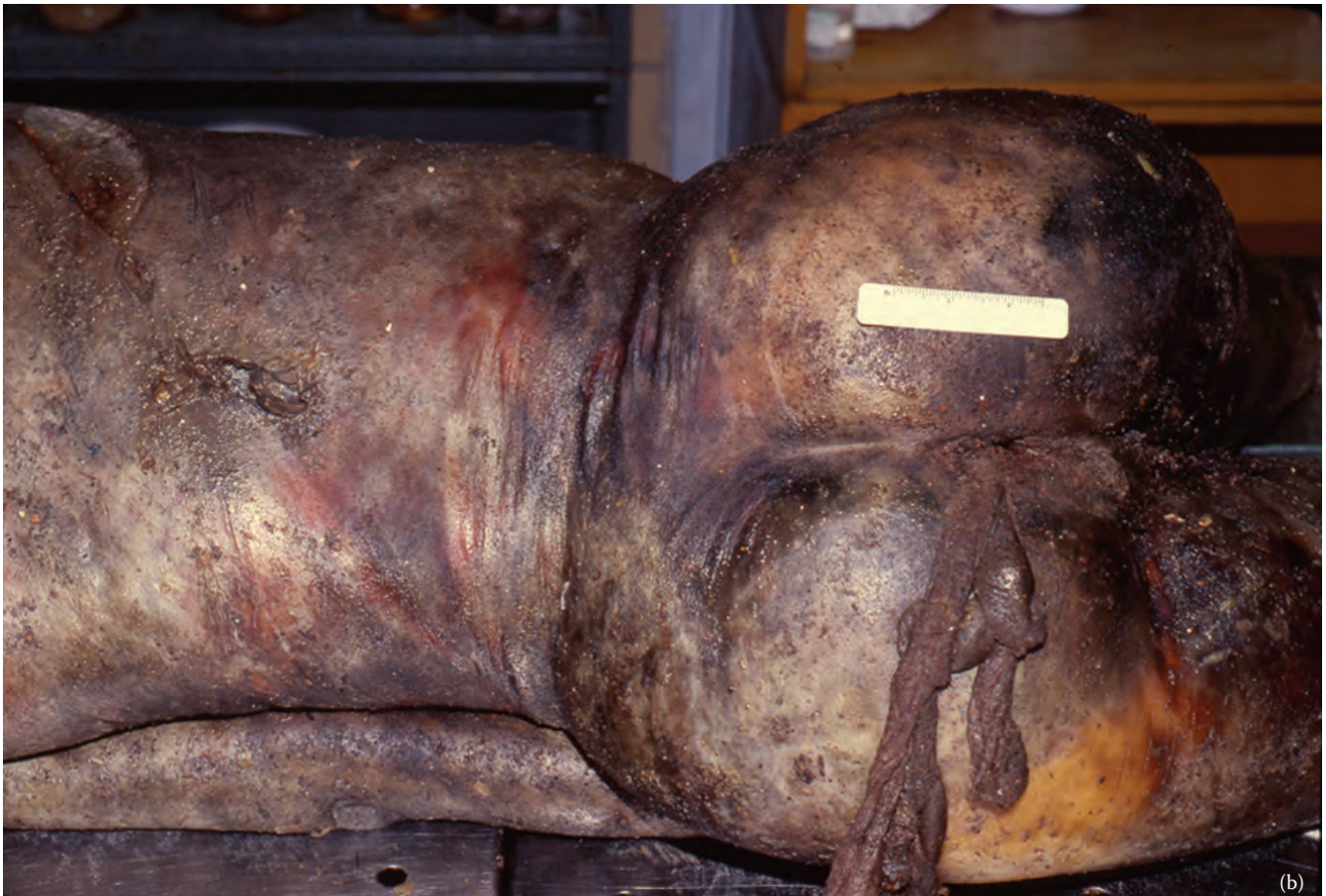Ring fracture. This usually occurs following a fall with initial impact to the feet or buttocks.

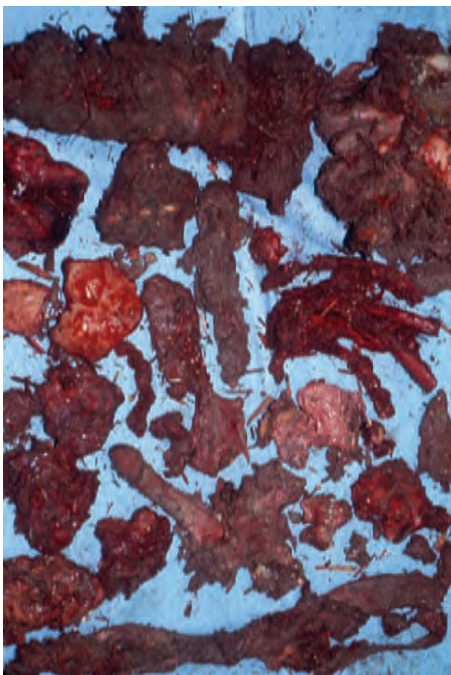
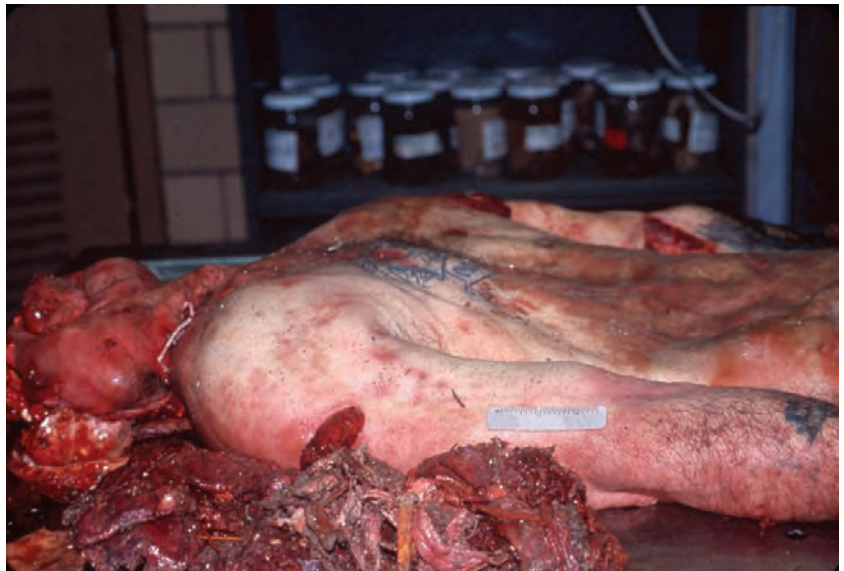
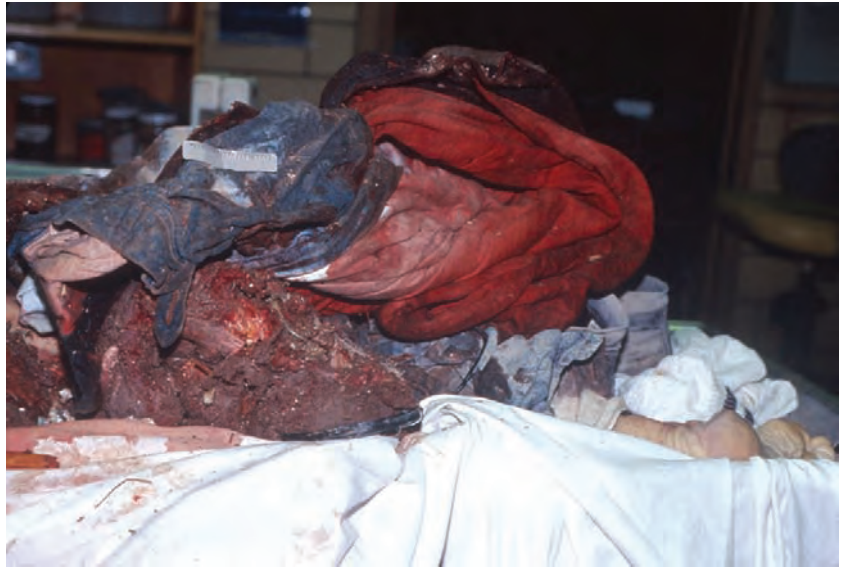
The decedent fell from a great height and landed on his feet. The fractured tibia was forced through the bottom of the foot upon impact.

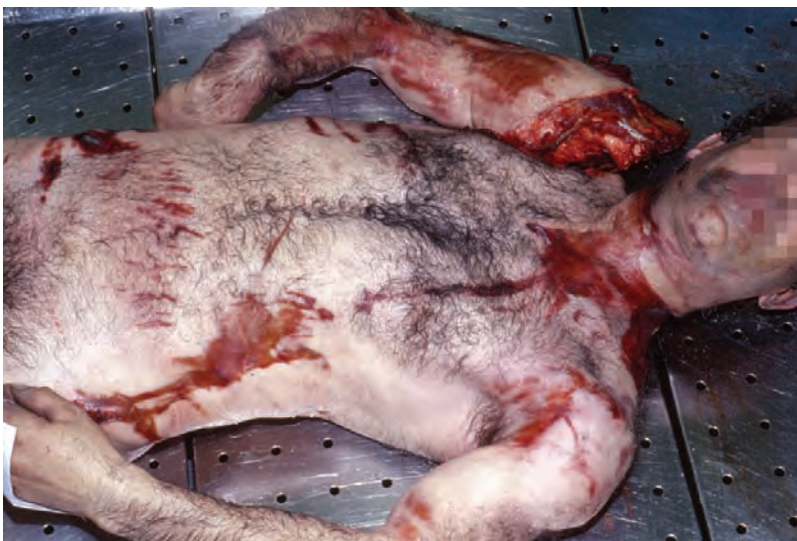
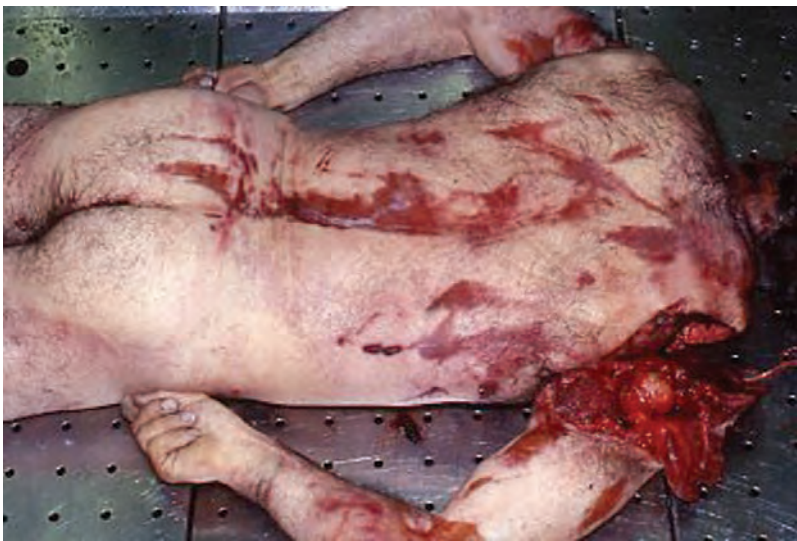
This individual was placed in a garbage dumpster and left to decompose. The trash compactor in the truck was engaged before the body was observed. Note the garbage truck shovel laceration to the back (a). Also note the intestines forced from the anus following compactor compression (b).

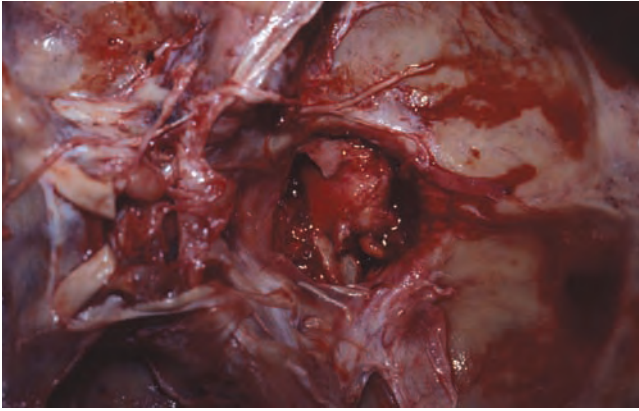




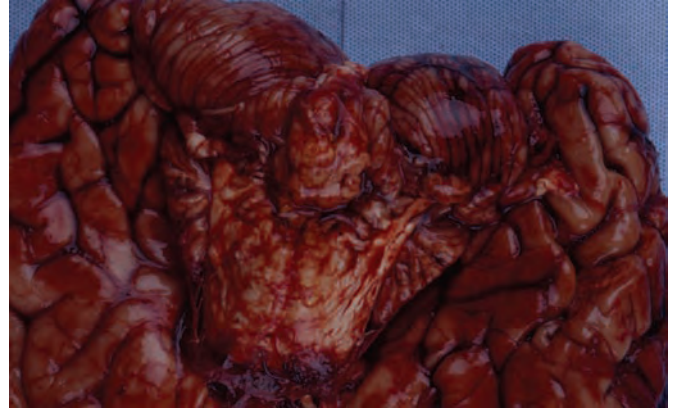
This individual was shot in the head, processed through a trash compactor, and left to decompose. Note the flattening of the body with extensive blunt-force injury and fragmentation.



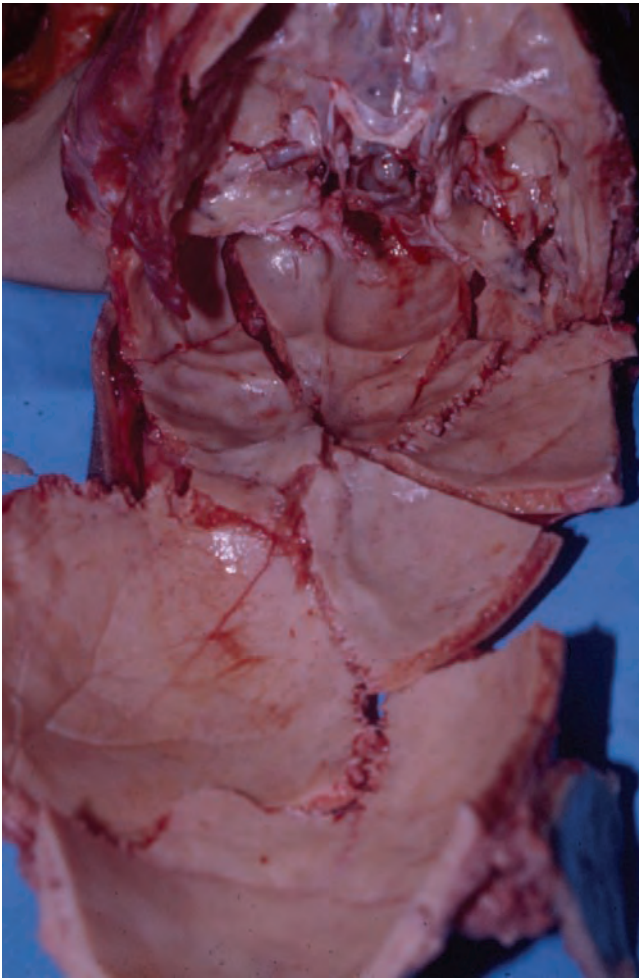
This individual slipped into a terrain leveler and sustained multiple abrasions, with blunt- and sharp-force injuries including extensive fractures and internal lacerations.



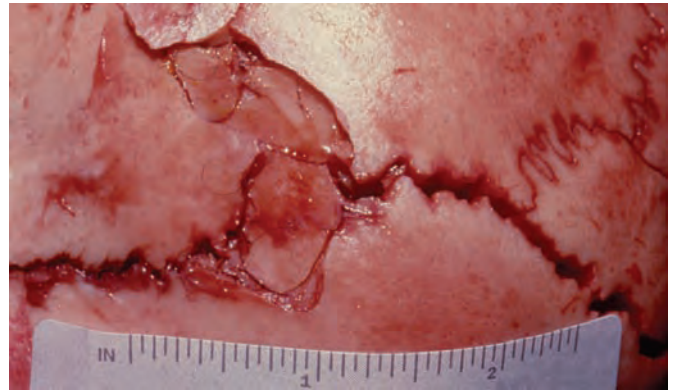This individual had a severe blunt impact to his face that caused the atlanto-occipital ligaments to stretch and dislocate. This caused brainstem and upper cervical spinal cord injury resulting in asystole and apnea.



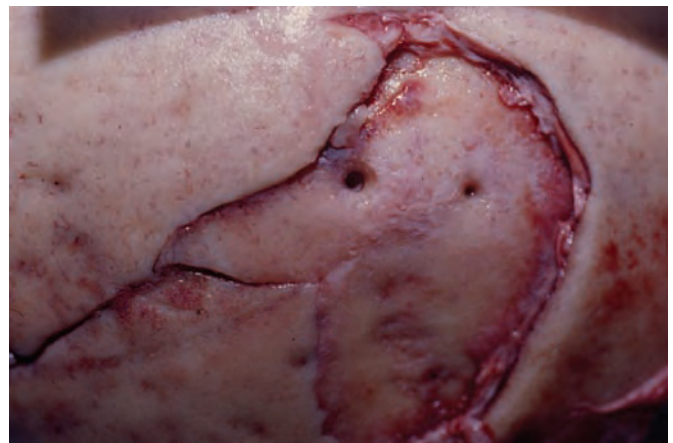
This picture of the base of the brain shows a medullary pontine laceration with extensive subarachnoid hemorrhage.



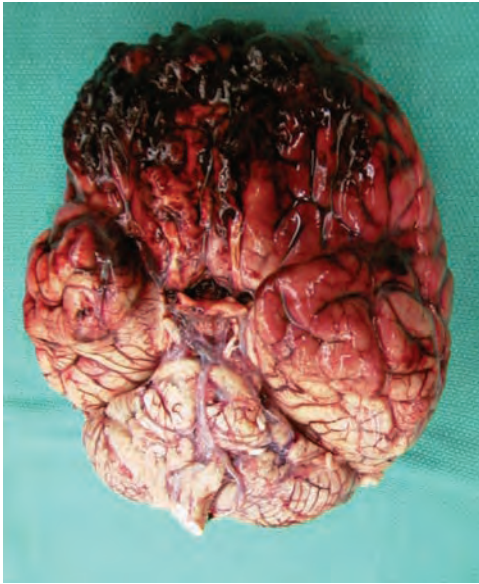Comminuted skull fracture where the bone is broken into separate pieces.



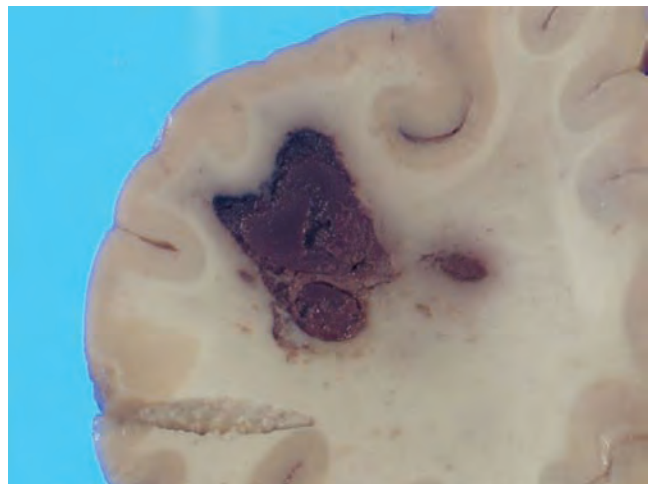
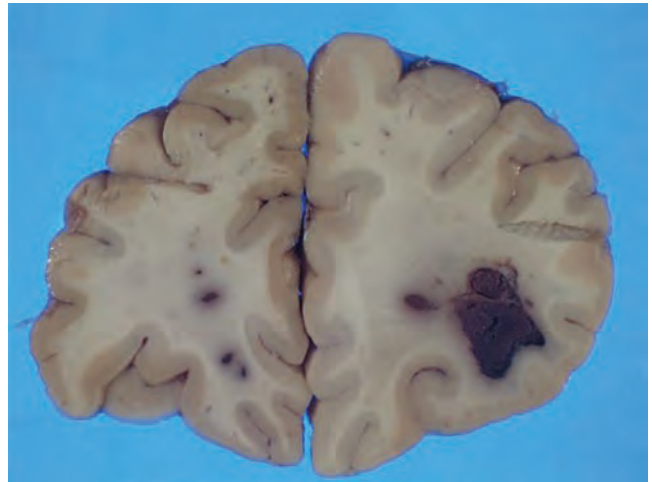
Diastatic skull fracture showing the fracture site passes through a cranial suture.



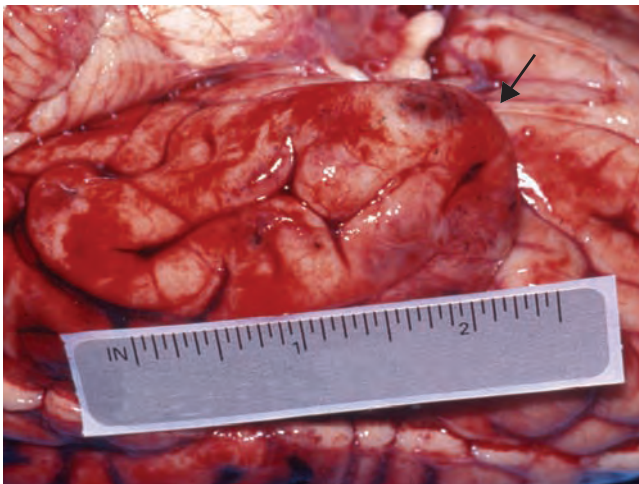
Healing skull fracture.



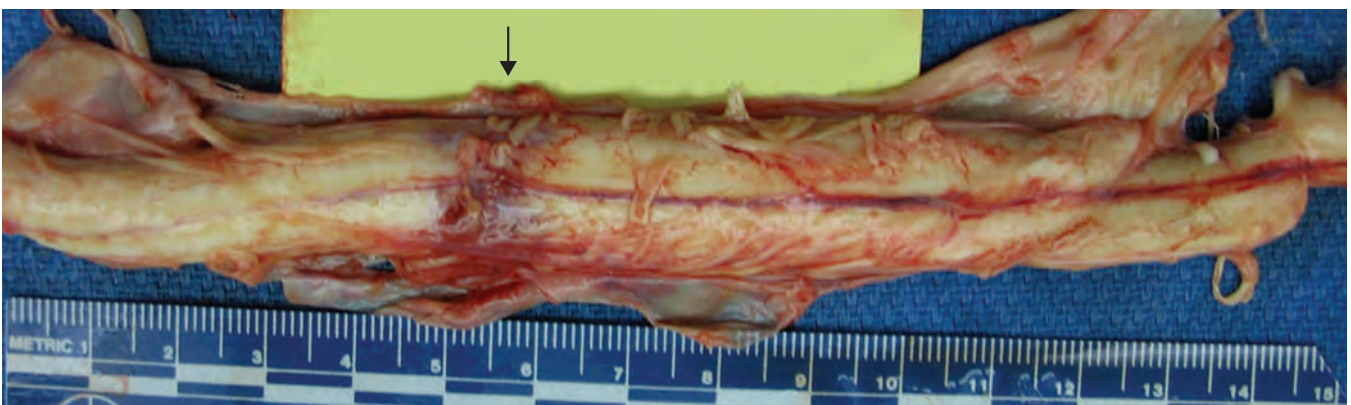
Frontal and temporal contusional hematomas associated with a falling impact to the back of the head in an individual with liver disease.



These images demonstrate gliding cortical contusions that typically occur near the white and gray matter junction following blunt-force head trauma.

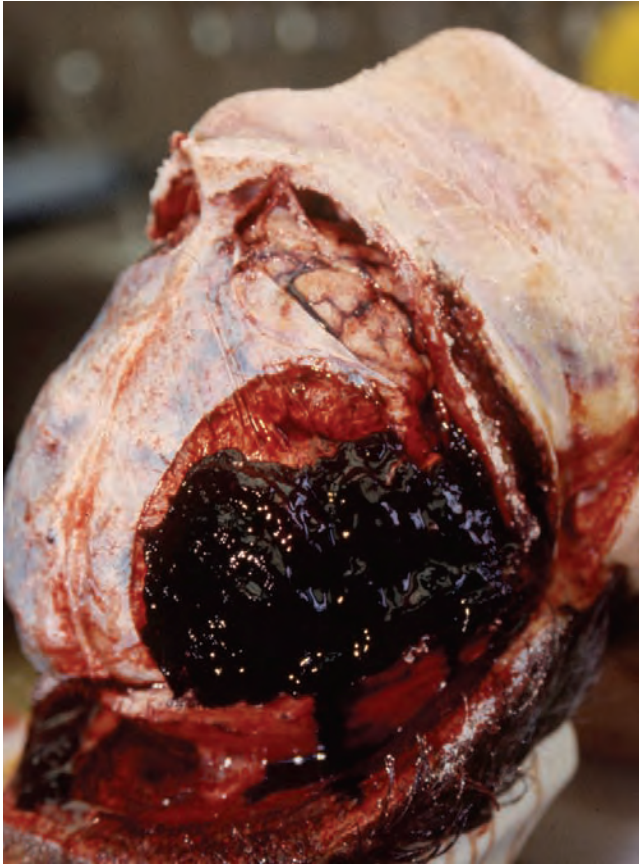

Temporal lobe with multiple splinter-type hemorrhages demonstrating typical cerebrocortical contusions.

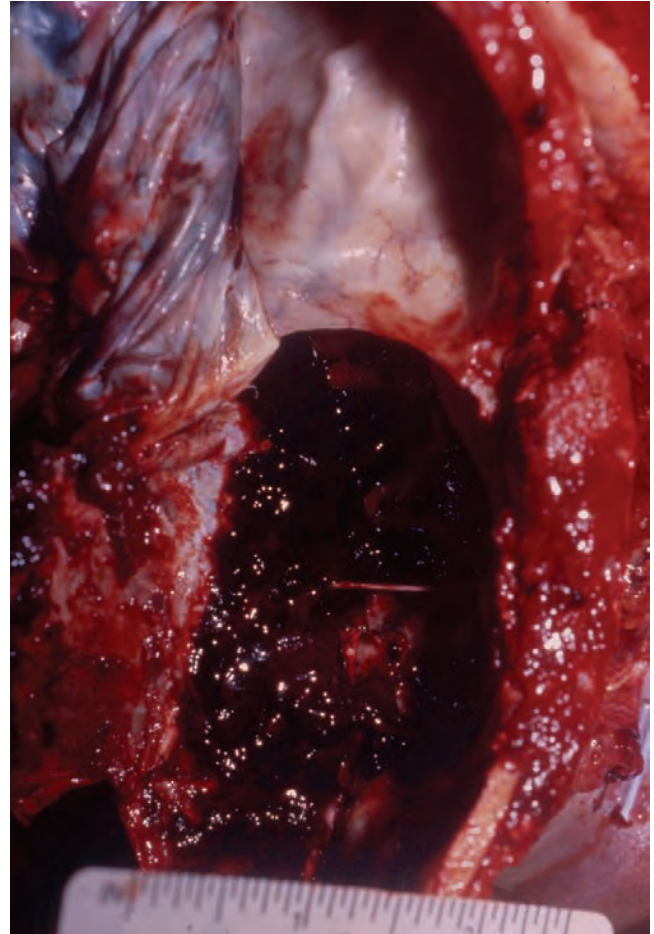


Spinal cord with a region of purple discoloration and softening demonstrating a spinal cord contusion.

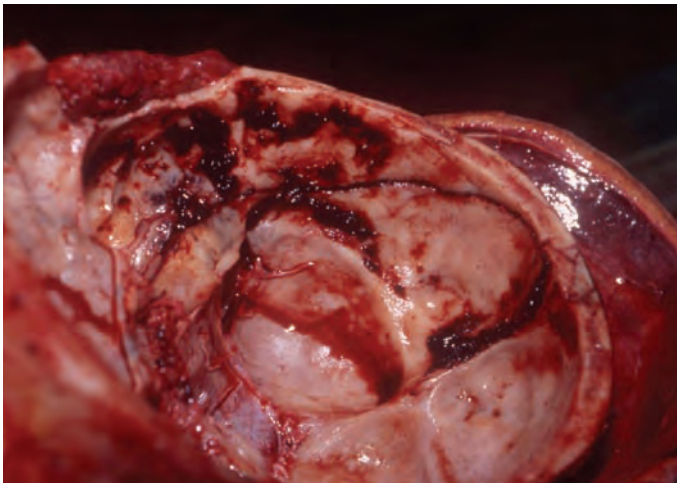




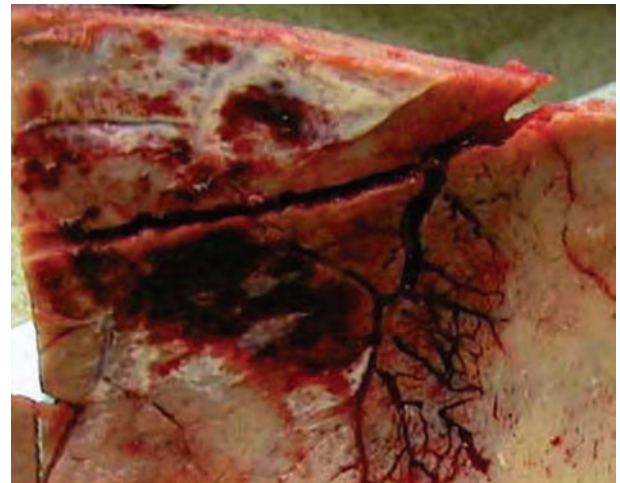Epidural hemorrhage in an individual with a temporal bone fracture and middle meningeal artery laceration. Note the clotted blood at the surface of the dura mater.

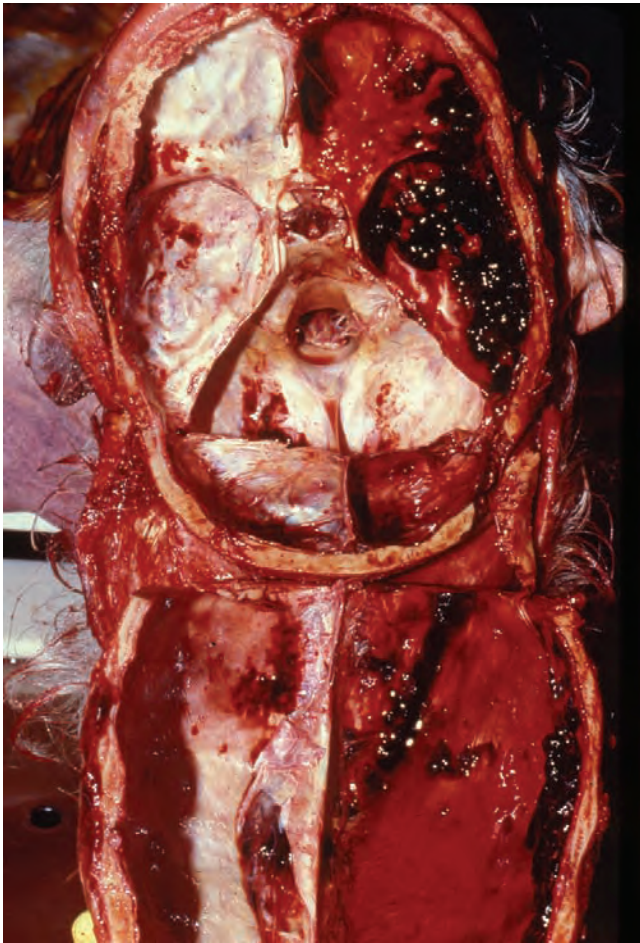


Epidural hemorrhage.

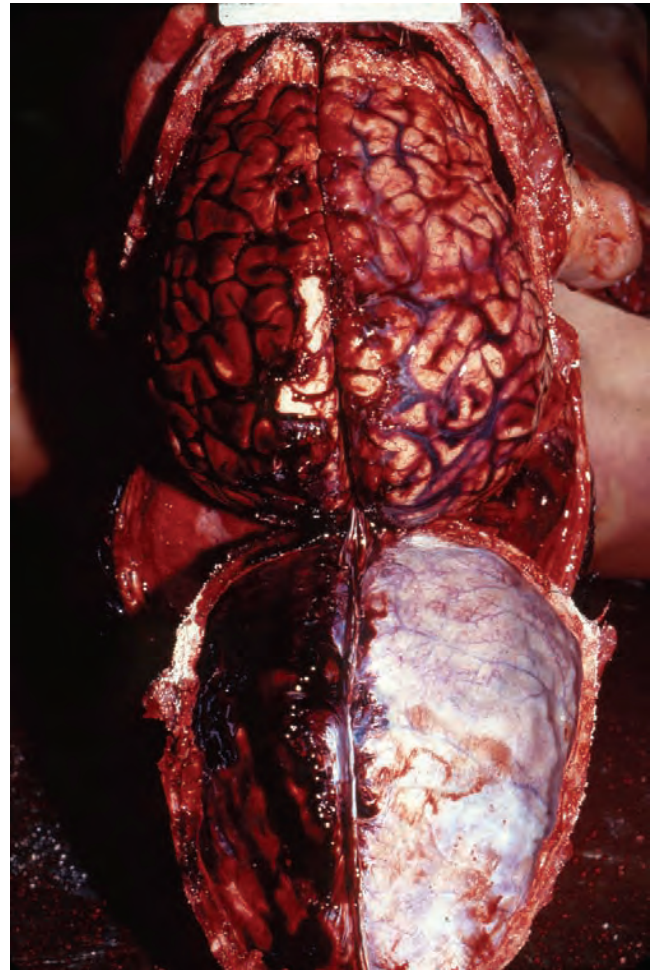


This shows the dura mater stripped from the inner aspect of the calvarium. Note the clotted adherent epidural hemorrhage within the temporal region of the skull.

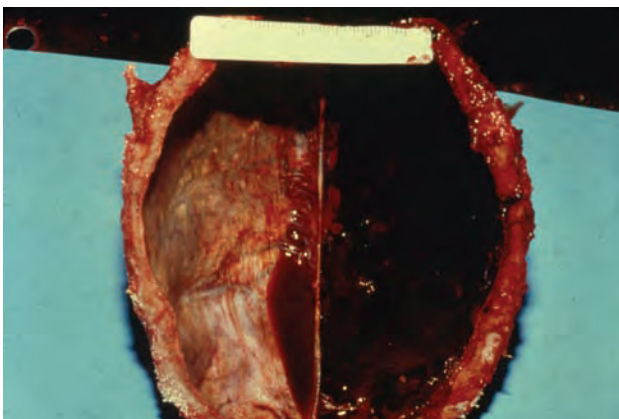




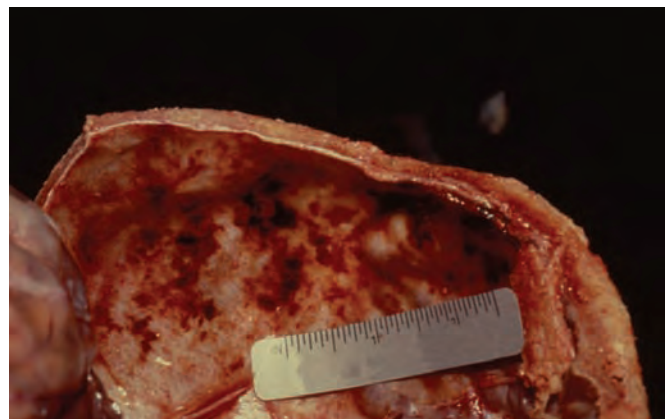
Acute right subdural hemorrhage.

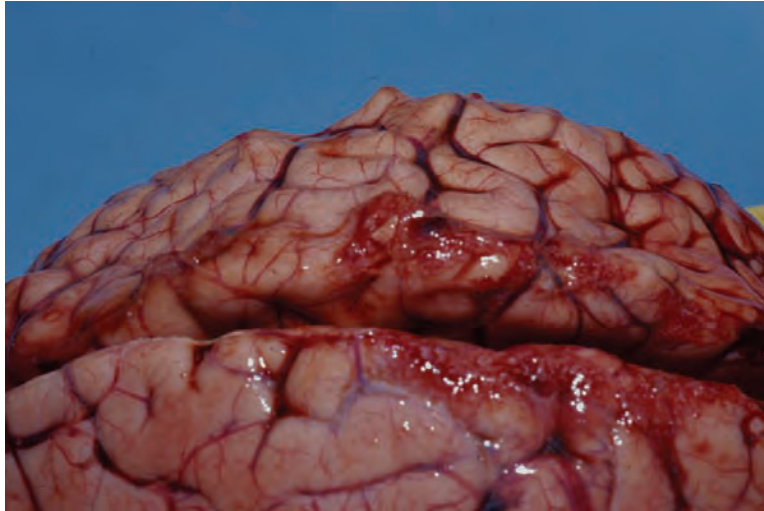

Left subdural hemorrhage that is slightly older with clotted adherent blood.

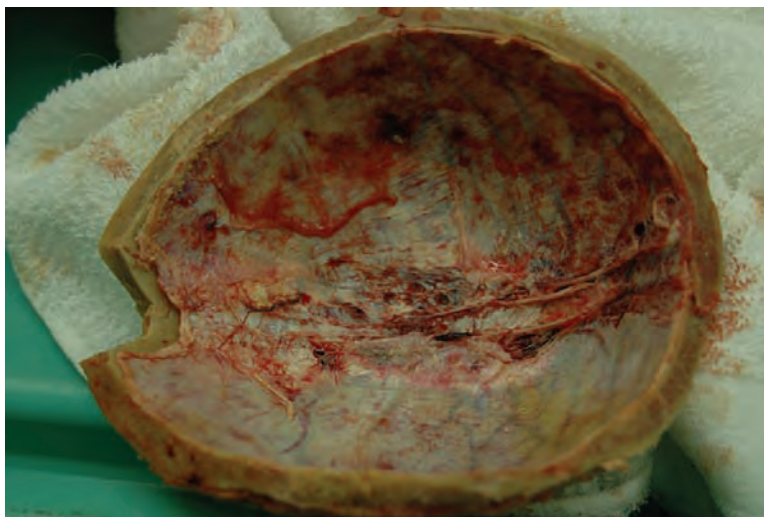


This demonstrates an older, clotted, red, adherent, subdural hemorrhage with portions of rust discoloration and membrane formation.

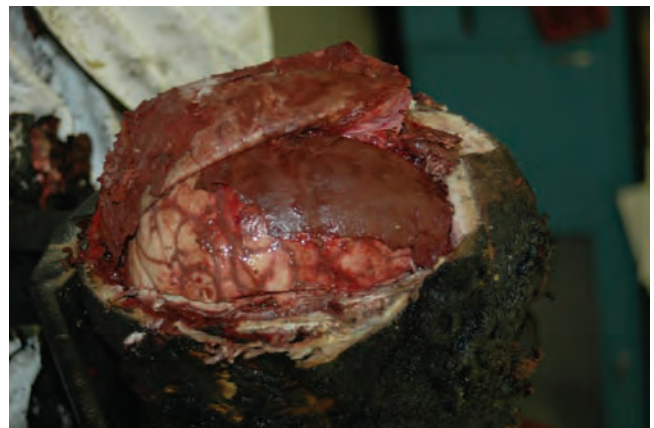
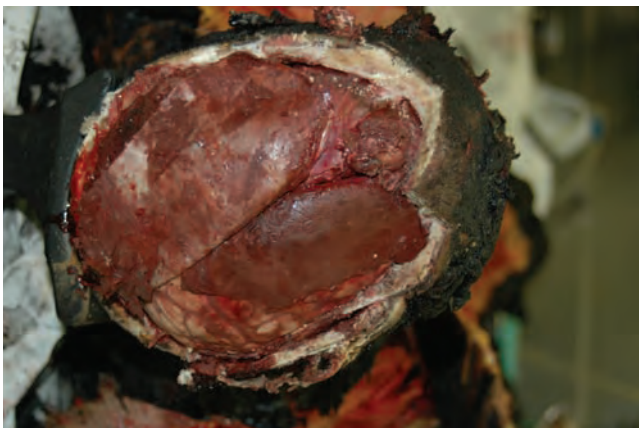




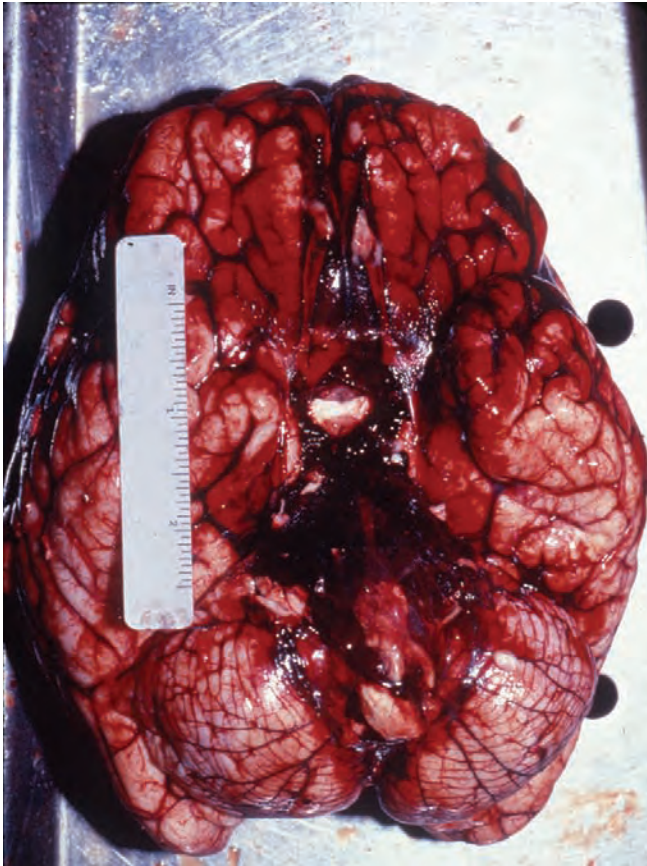
This cerebral cortex demonstrates an irregular flattened surface caused by a chronic subdural hematoma. In contrast, a chronic epidural hematoma generally leaves a flattened and less irregular cerebral cortex deformation.



Old subdural hemorrhage with clear to rust-colored membrane formation. Note the membrane separation with beading up away from the midline caused by scraping a scalpel blade along the subdural surface.

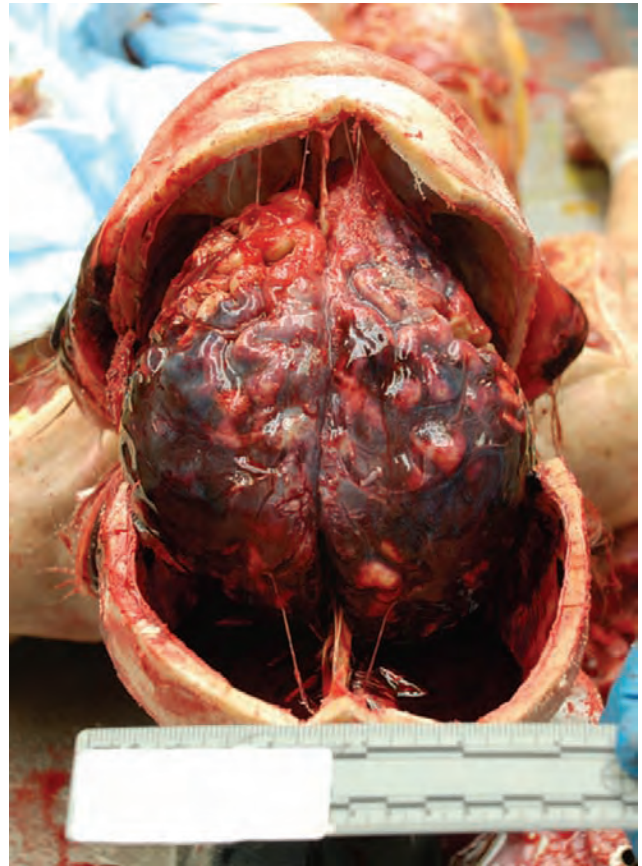

Large antemortem subdural hemorrhage altered by excessive heat due to fire.

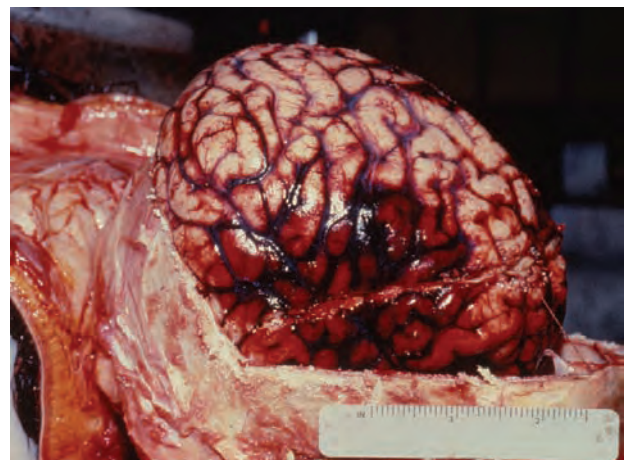
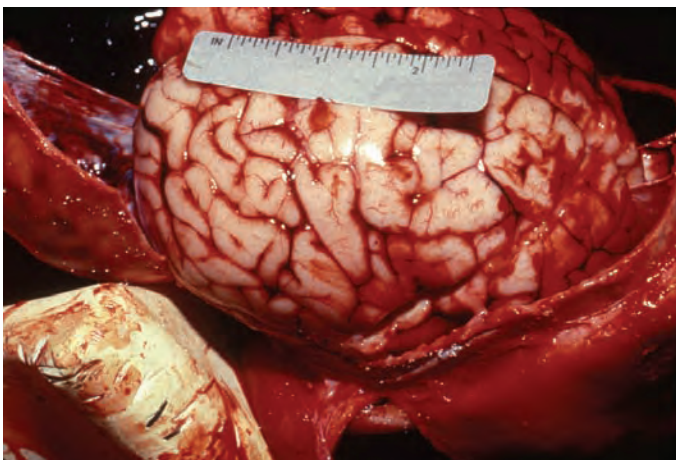


This brain demonstrates multifocal subarachnoid hemorrhage with subarachnoid hematoma at the base of the brain. This hemorrhage occurred following a blunt impact to the face causing hyperextension and rotation of the head with laceration of the right vertebral artery.

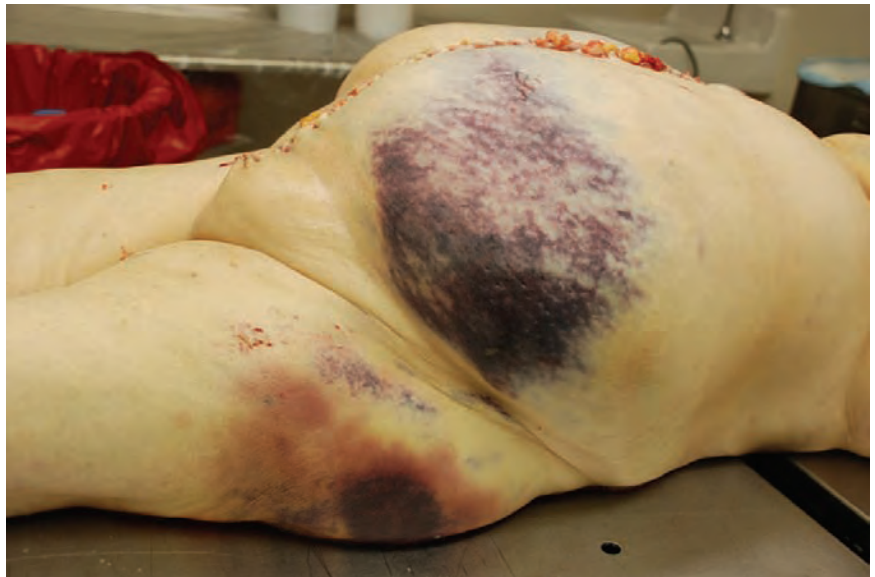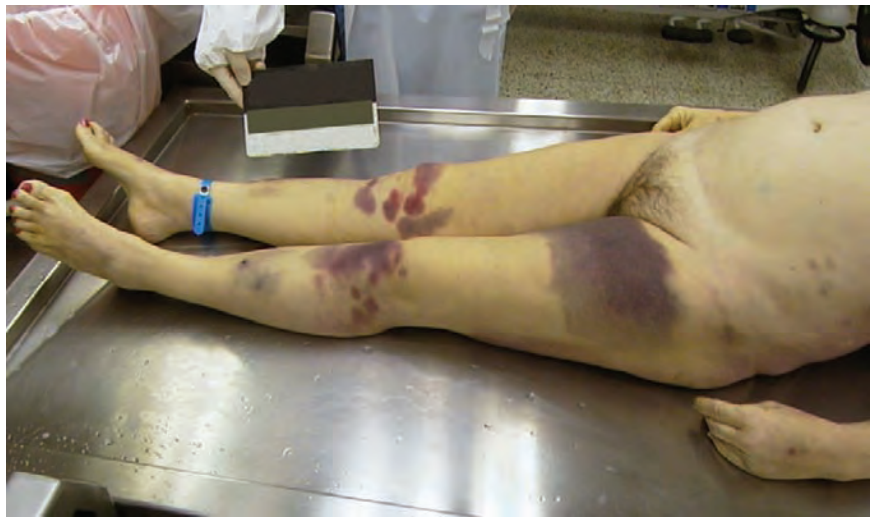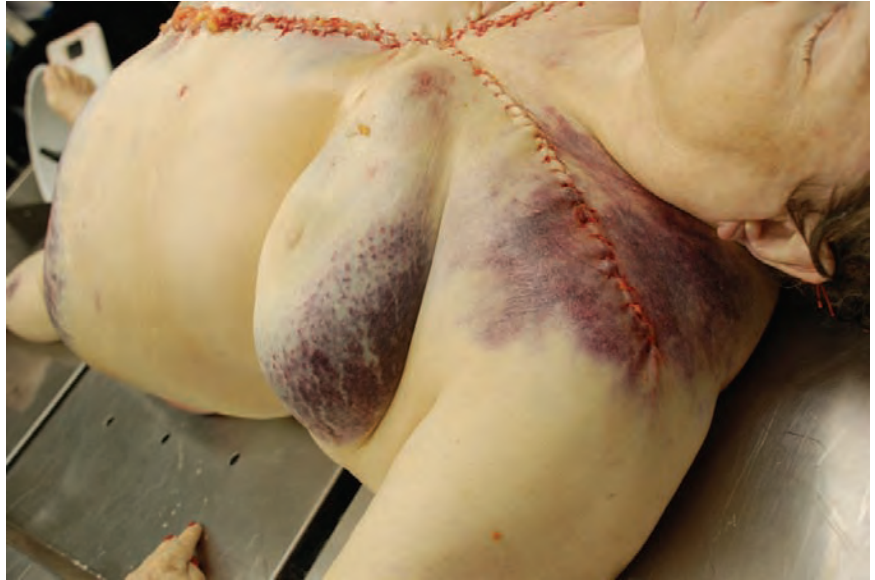Source: Kindleburger D, Gilmore K, Catanese C., Armbrustmacher V. Subarachnoid hemorrhage due to internal carotid artery laceration following blunt impact to face with hyperextension and rotation of neck: A case report and review of the literature. *Journal of Forensic Science* 48:1366–1368, 2003.



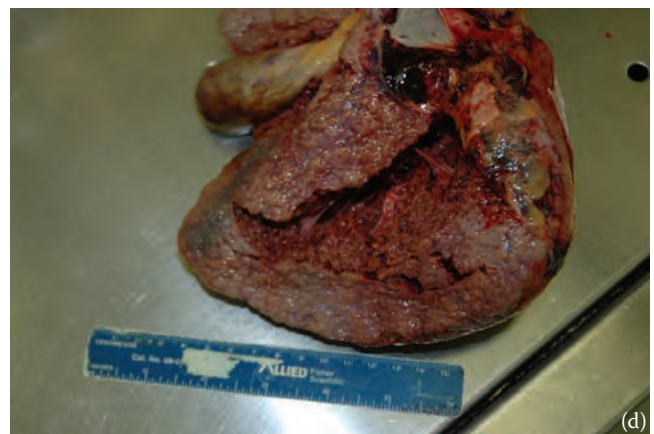
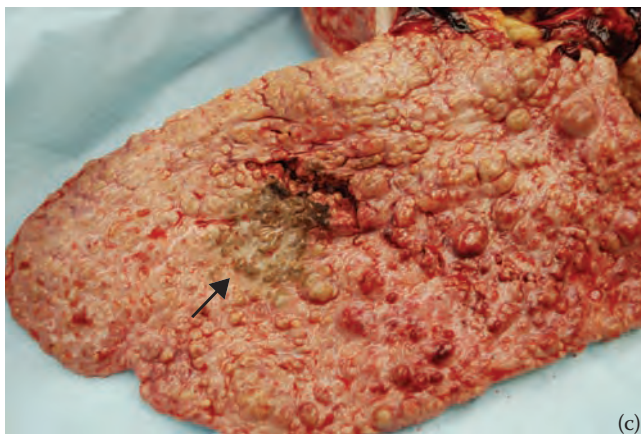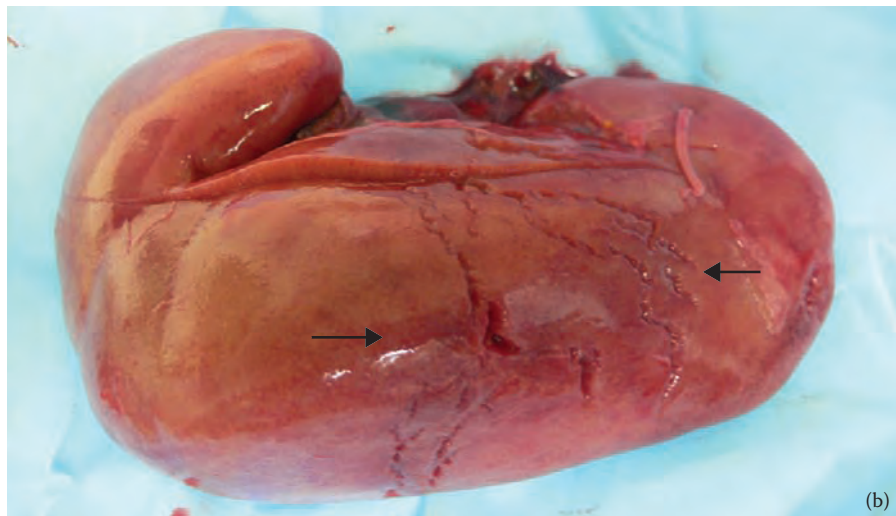
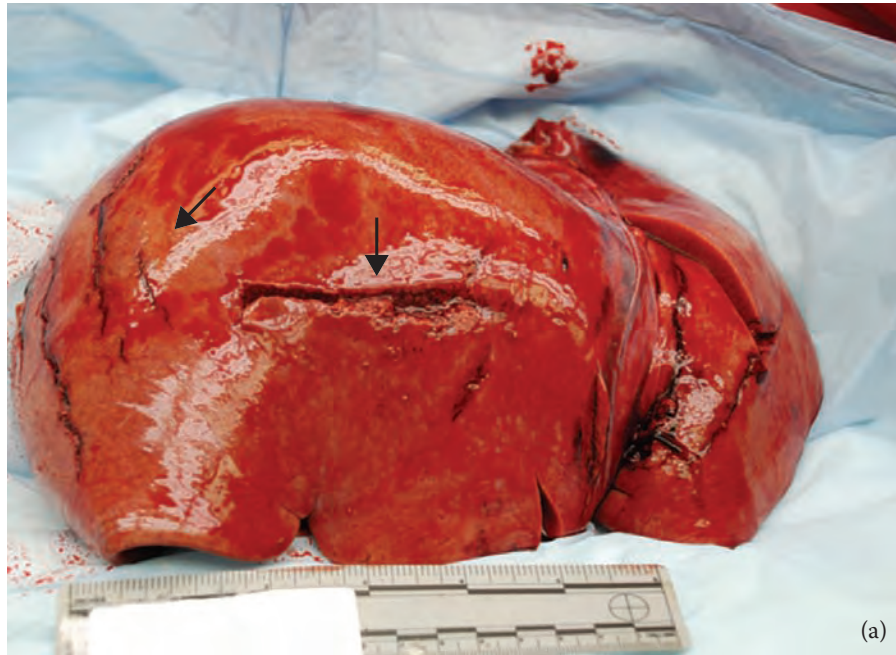
This demonstrates a large subarachnoid hemorrhage in an individual who died several days following a traumatic head injury.



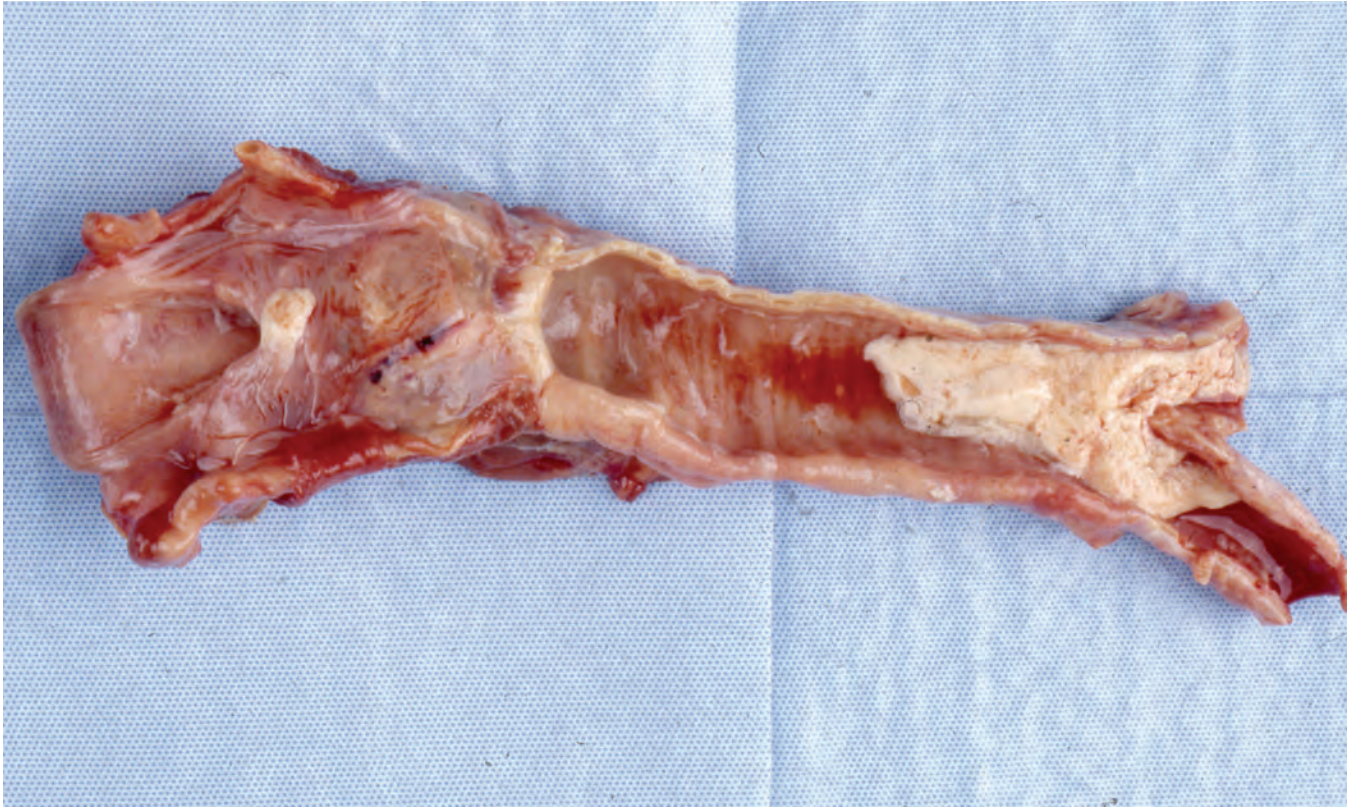These brains are diffusely swollen with flattened gyral configuration and sulci obliteration. These individuals lived from several hours to several days after the initial insult.



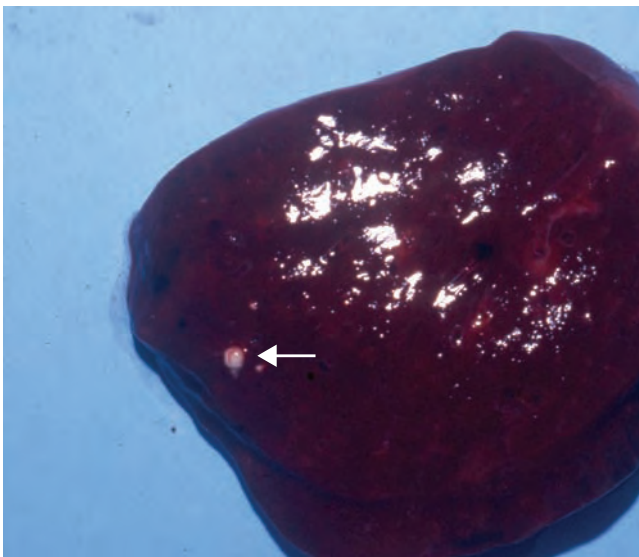
Note the large areas of contusion with ecchymosis following minimal trauma in these individuals with chronic alcoholism, hepatic cirrhosis, and coagulopathy.



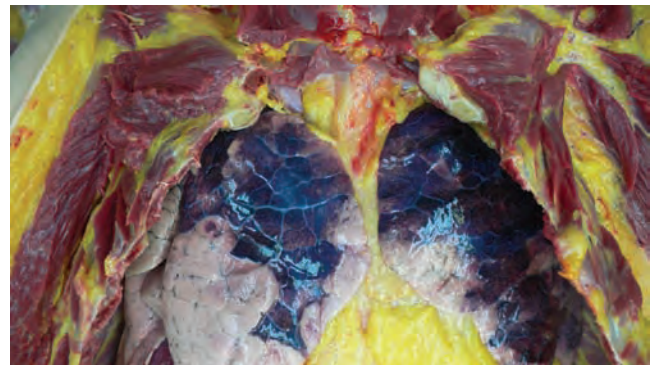
Lacerations of liver and kidney due to blunt-force trauma. Note that (c) and (d) have hepatic cirrhosis, which is less commonly associated with laceration due to fibrosis. A normal liver is the most common organ in the peritoneal cavity to lacerate (a) in association with blunt-force trauma.



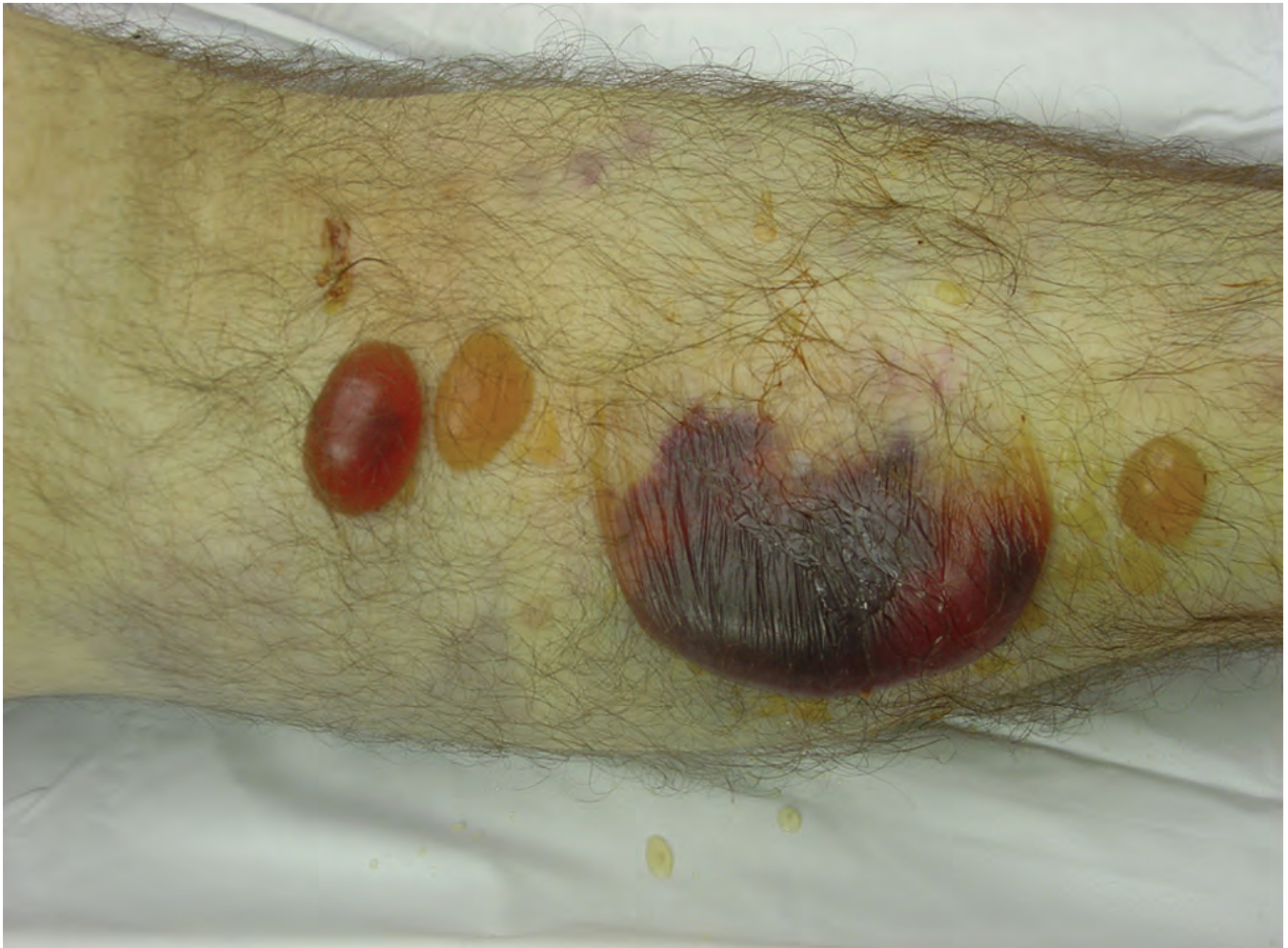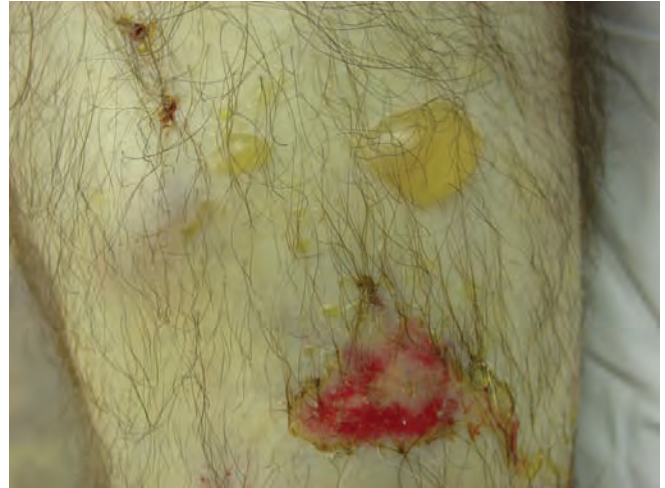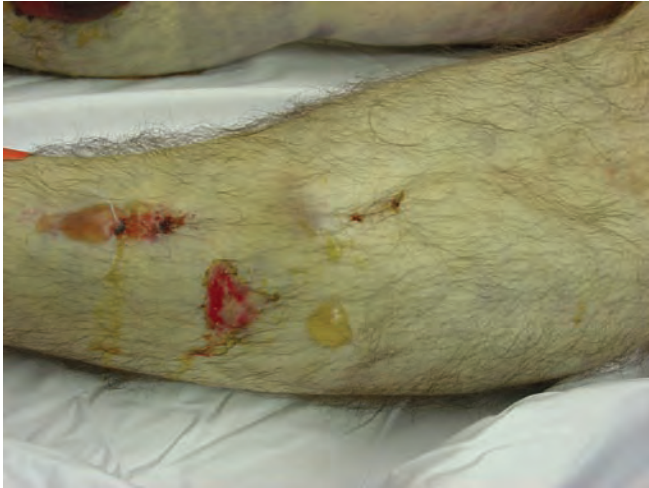This opened airway demonstrates a large piece of aspirated brain in an individual who was resuscitated following extensive blunt-force head trauma with comminuted skull fracture and communicating lacerations extending into the oral cavity. When Emergency Services arrived, the decedent was found in agonal respirations.



This cut section of lung demonstrates a small white to gray fragment in the parenchyma at the lower lateral aspect. Microscopic examination of this revealed intravascular embolic cerebellar tissue. This individual sustained a comminuted skull fracture with multiple central nervous system lacerations. He was vigorously resuscitated several times over the course of several hours. Brain tissue embolized through damaged blood vessels at the base of the brain.



Note the patchy red to purple discoloration indicating aspiration of blood in an individual with a gunshot wound to the head, lacerations extending to the oral pharynx and residual respiratory effort before death.



This is another pedestrian who was struck by a car and survived approximately 2 days in the hospital. Note the tibial fracture with adjacent abrasions and broken skin. There is also blister formation confined to this region associated with sepsis following infection associated with this trauma.





---

# Sharp-Force Injuries

# 7

CHARLES A. CATANESE

---

## Introduction

---

Sharp-force injuries are defined as injuries produced by an instrument with a thin edge or point. Examples of these instruments include a knife, razor, box cutter, scalpel, sharp-edged piece of metal, broken glass bottle, broken glass window, scissor, ice pick, fork, propeller, screw driver, saw blade, axe, machete, arrow, nail, pick-axe, spiked fence post, meat cleaver, etc.

A *stab wound* is typically made by a knife blade and is defined as having a greater depth of penetration than surface dimension. An *incised wound* is a slicing-type injury where the surface dimension is greater than the depth of penetration.

Accurate, concise, and organized wound documentation is important, as with all other injuries. Each injury should have a documented location on the body, including a description of adjacent abrasions or contusions, wound dimensions, depth of penetration, and direction of penetration into the body. All injured structures should be documented, including the amount of hemorrhage both in the wound track and within body cavities. In cases where there are multiple injuries, it is acceptable to group them with ranges. It is good practice to take overall photographs of the body before and after cleaning; as well as close-up photographs of each wound.

Important aspects concerning interpretation of injury involve pattern recognition. Familiarization with this will allow opinion formulation concerning correlation of a particular instrument to a particular wound. One example involved the arrest of several suspects with different concealed weapons. The police may approach you to render an opinion about what type of weapon produced injuries so they can focus their early investigation. In one actual case, each suspect had a different instrument in his or her pocket, including a flat-edged pocket knife, a box cutter, a screw driver, and a slightly bent serrated table knife. The injuries to the decedent's body consisted of slit-like perforations with multiple adjacent parallel linear abrasions. This pattern injury is consistent with a serrated knife. Many of the images in this chapter are designed to help with pattern recognition.

## Location and Direction of Injury

This should be given with reference to a particular body position, usually standard anatomic planes. Each wound should be documented by location on the body's surface, and measured from vertical and horizontal planes of reference. An example of this would be from below the top of the head or above the feet, and to the right or left of the midline. Standard anatomic planes are demonstrated with the body in an upright position with the head tilted slightly upward, the legs together, the arms at the sides, and palms facing forward. The head is superior and the feet inferior, medial is toward the midline and lateral away from the midline. The anterior or front of the body includes the face, chest, and the palms. The posterior part of the body includes the back, buttocks, etc. The direction of the wound into or through the body should be given with reference to three planes when possible, front-back, right-left, and up-down. This is important because it allows one to correlate the injuries to possible assault descriptions and help discredit or substantiate statements.

## Wound Dimension

This should be documented separately for each sharp-force injury, unless there are many that can be grouped together and described in ranges. Example: There are twenty 1-inch to 2-inch, by up to 1/4-inch, stab wounds within a 5-inch × 7-inch region at the middle aspect of the right chest, which is centered 13 inches below the top of the head and 4 inches to the right of the midline.

It is good practice to document the injury as it exists on the body and then again when in a relaxed state. The important aspect is to document the wound dimension in ranges that most closely reflect the actual dimensions of the knife blade or instrument. A stab wound can be put into a relaxed state by pressing the surrounding skin toward the wound and releasing the surrounding tension, or by placing tape over the perforation site to approximate the margins. It is also acceptable to cut a square around the surrounding skin to release the tension. The skin and underlying tissues are elastic, with

different degrees of tension. This can make the surface dimension of the wound length and width slightly variable depending on location and orientation of the body. Cut marks through bone and cartilage may reflect accurate weapon dimension with tool marks and should be retained in formaldehyde.

This same concept applies for the depth of penetration, as well. Dimensions should be given in a range to account for changes in body position when examined on the autopsy table compared with the body position when the injuries were inflicted. Variables that may change this parameter while the assault is taking place include deep breaths or exhales, flexion, extension, rotation, the force used to inflict the injury, the location on the body including underlying bone or soft tissue, etc.

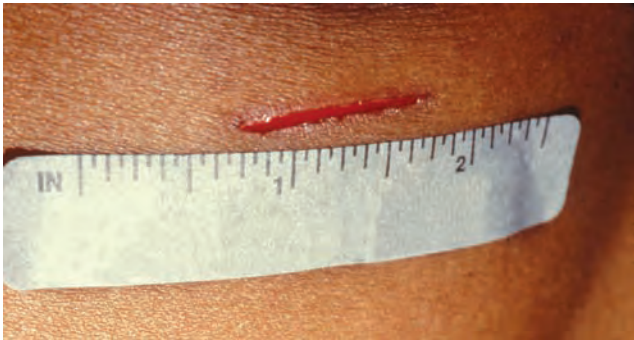### **Adjacent Abrasions and Contusions**

These may indicate body contact from the knife handle, lower part of the knife blade, or the knife hilt. This is important information in formulating an opinion as to how much force was needed to produce the injury. If the knife blade penetrates a bone and there are hilt marks adjacent to the perforation site, one can extrapolate that the knife must have been stuck into the body with great force.

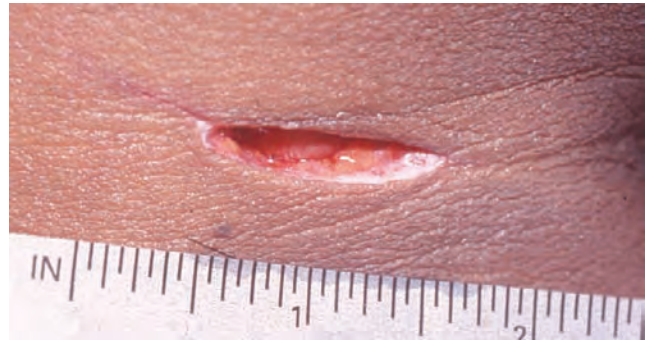
### **Injured Organs or Structures**

This information helps to allow interpretation of how functional one might be after an assault. The number and extent of internal injuries give insight into the nature of the assault and perpetrator.

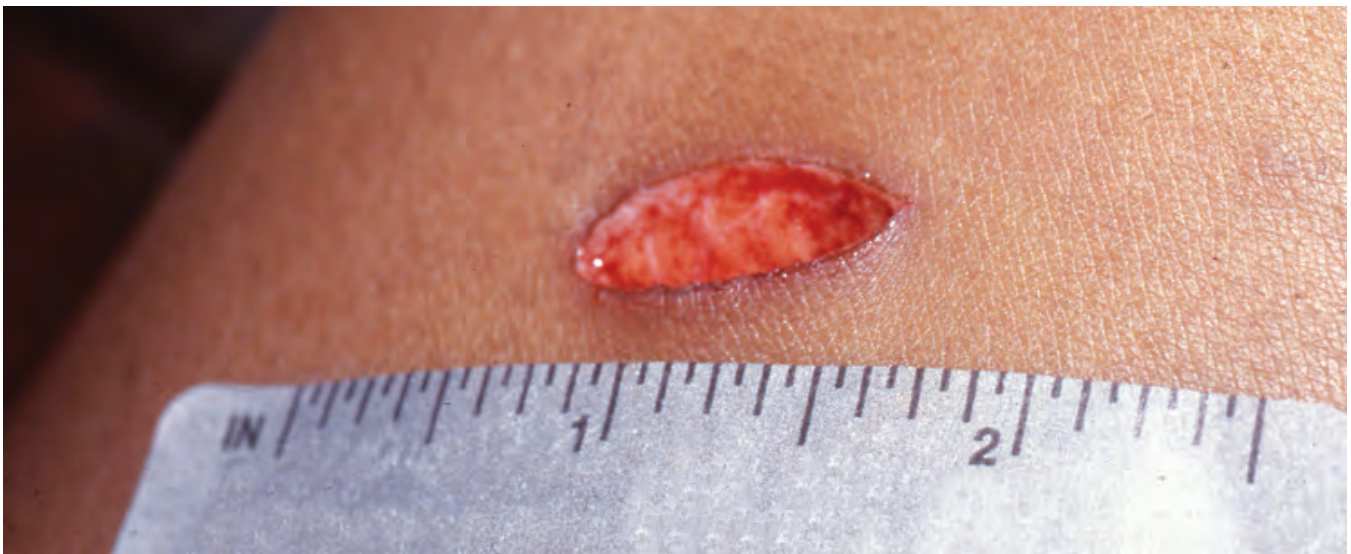For instance, "I stabbed him in the neck and he continued to chase me so I stabbed him again in the chest and abdomen." If the neck wound injured the spinal cord, you know the statement is false because the victim would no longer have voluntary movement to part of the body, as with a tendon or peripheral nerve's being cut. Also, depending on the structures damaged, the rate of blood loss may be quite variable. This would help define how fast the individual would lose blood, and what the individual might be capable of doing after the injury, and for how long. Questions like this may often come up in trial. A transected aorta would incapacitate someone more rapidly than a transected brachial (arm) artery, which would be more rapid than a transected cephalic (superficial) vein. Someone with a stab wound to the heart will often lose consciousness within minutes but still be capable of running away, defending themselves, or continuing an assault, particularly if the heart does not go into a lethal arrhythmia. It is possible for someone to get stabbed in the heart, run several blocks and shoot several people before dying.



Stab wound consisting of a flat slit-like perforation with minimal surrounding skin tension.



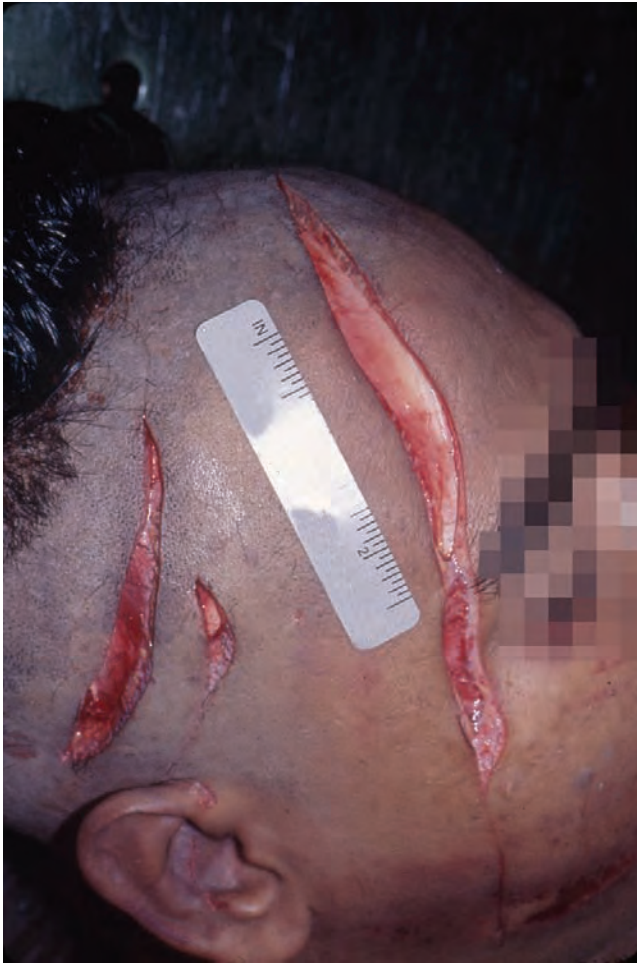Stab wound with moderate surrounding skin tension. Note the separation of the wound margins.



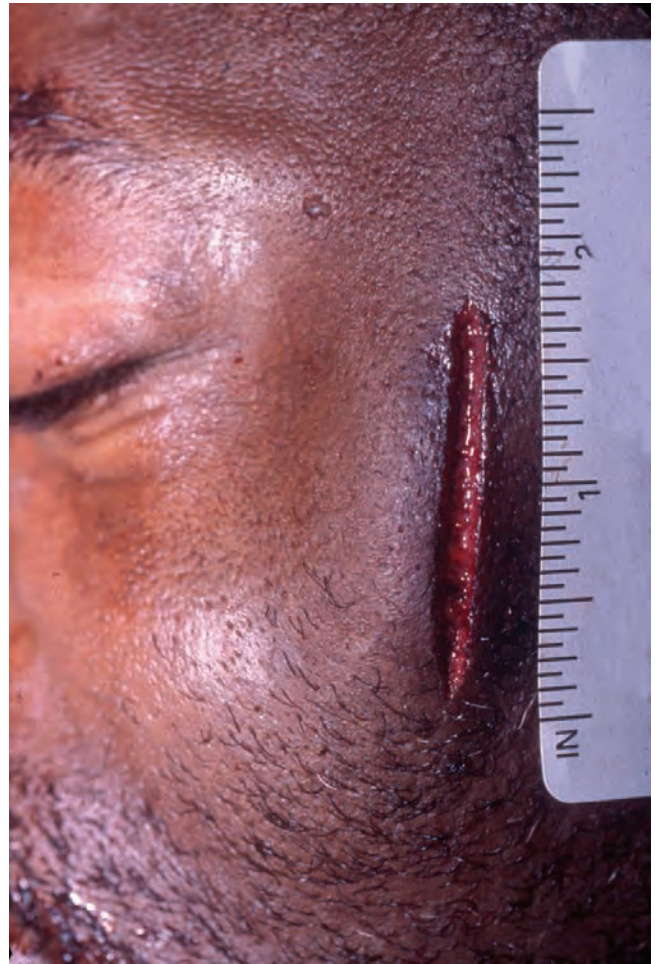Gaping stab wound consisting of an oval perforation caused by significant surrounding skin tension.



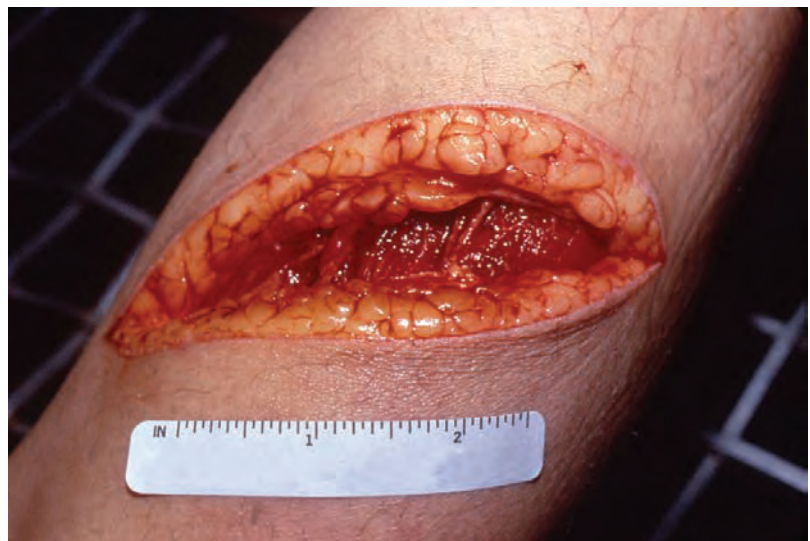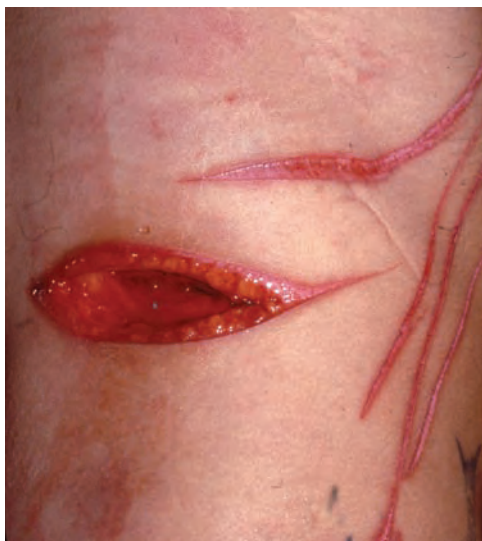A non-serrated knife blade similar to the one used to inflict these wounds. It is important to take the surrounding skin tension into account when estimating the size and type of weapon used.



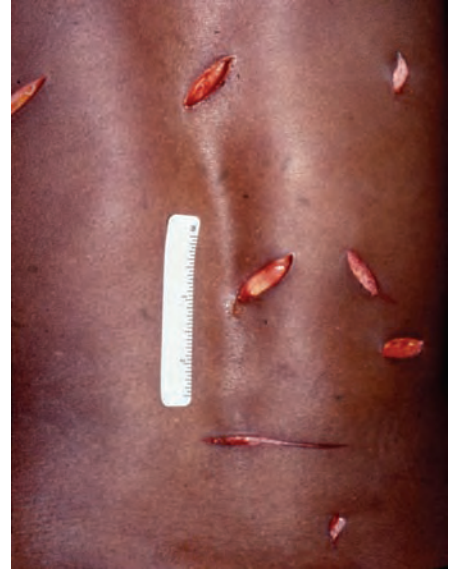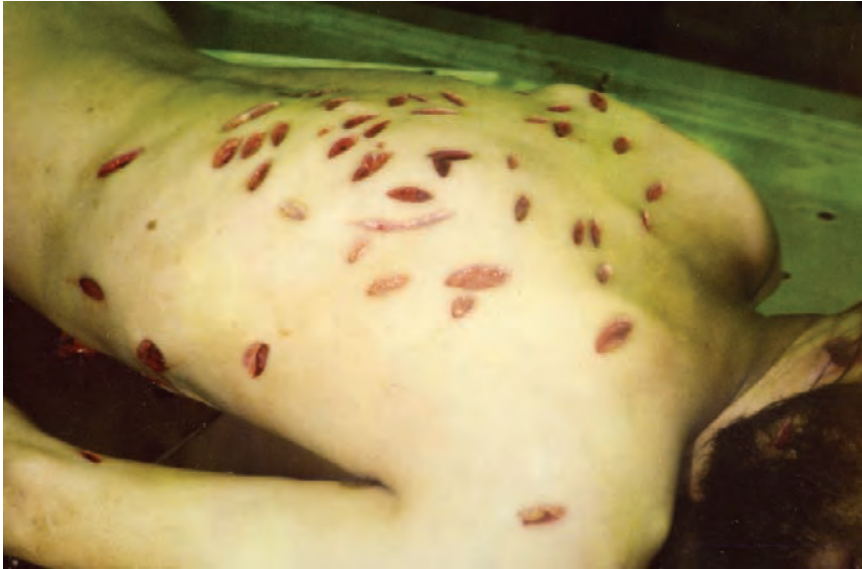Incised wounds produced by a broken bottle.



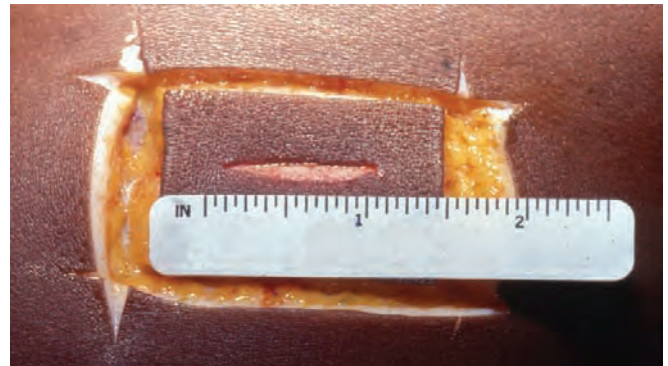
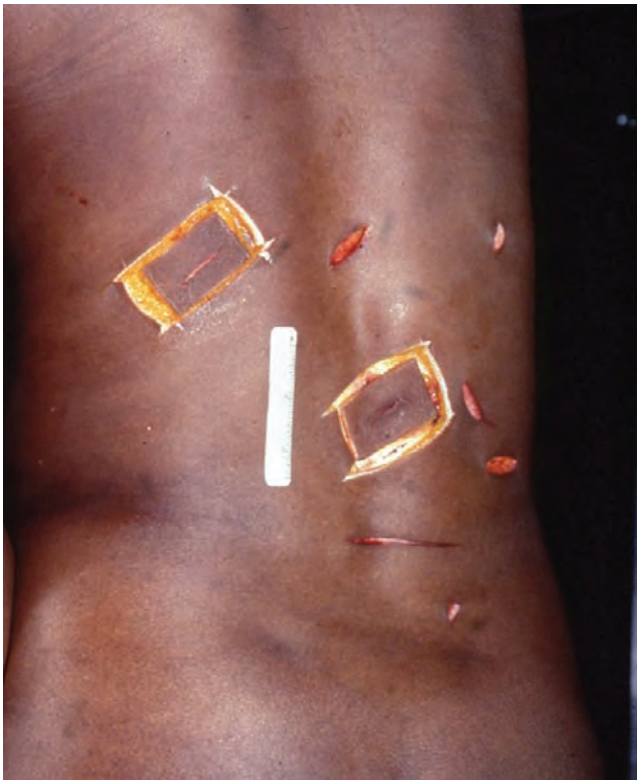Incised wound to the face produced by a knife.



Incised wounds produced by a box cutter.

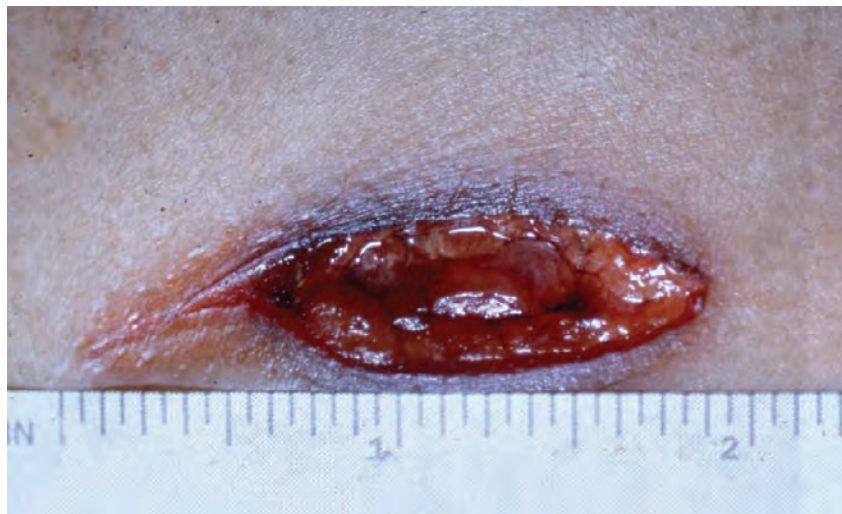
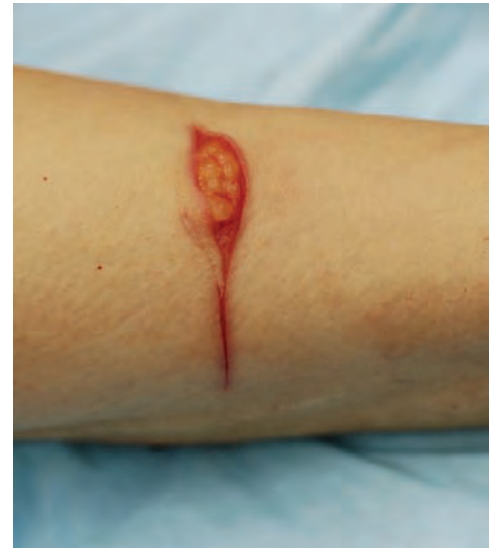
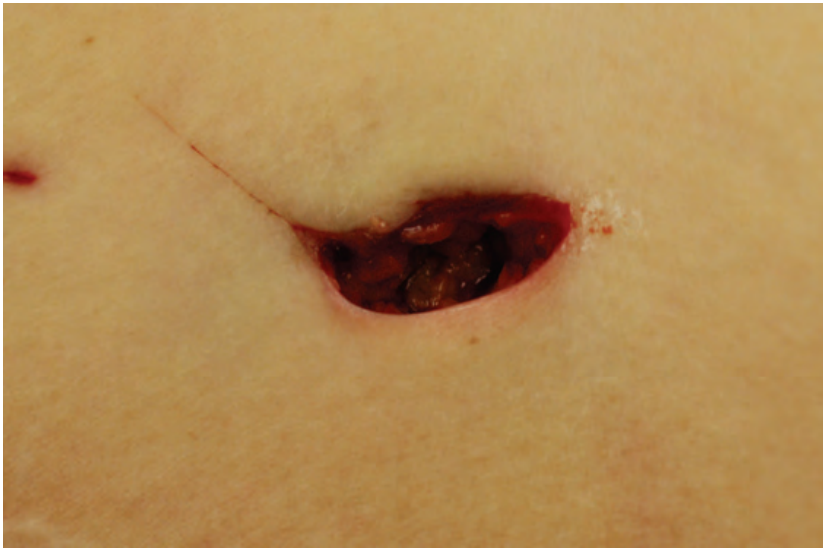
These are multiple stab wounds to the back. Note the varying dimensions and gaping nature due to the varying degrees of skin tension from underlying tissue planes in different locations.

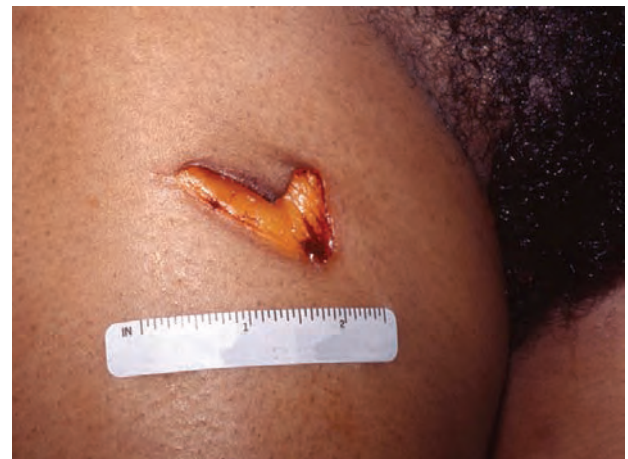
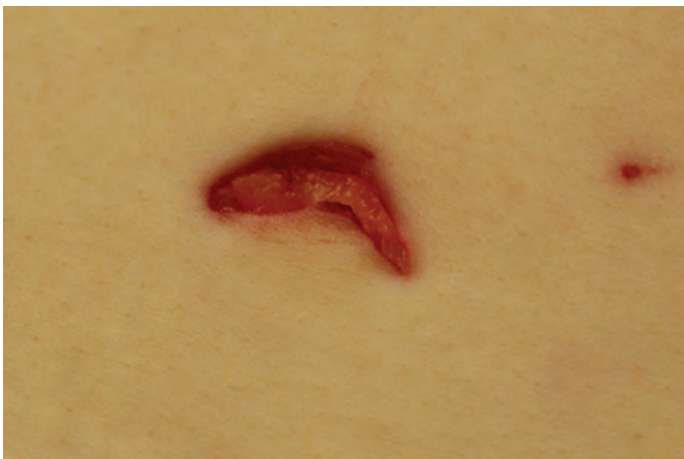
This is a close-up of one of the wounds that were cut into a relaxed state and measured. Note the sharp end at the left aspect and the blunt end at the right aspect.

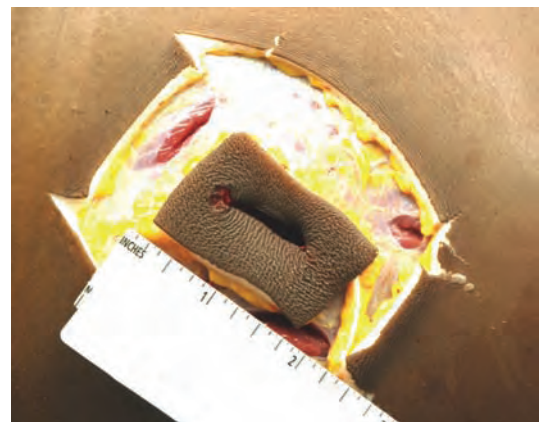
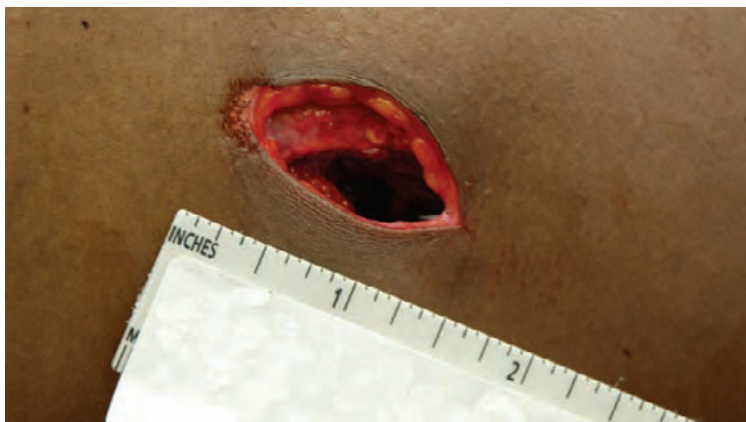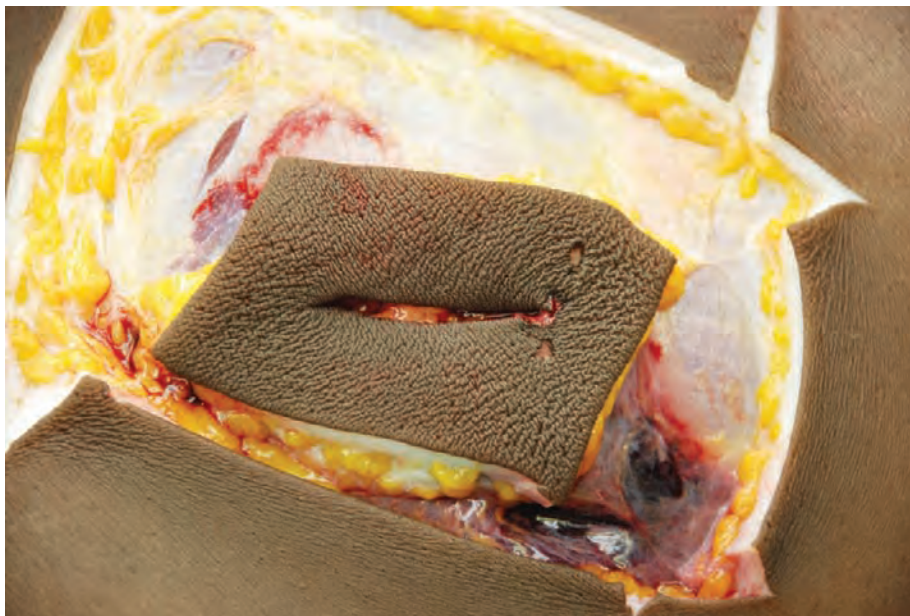
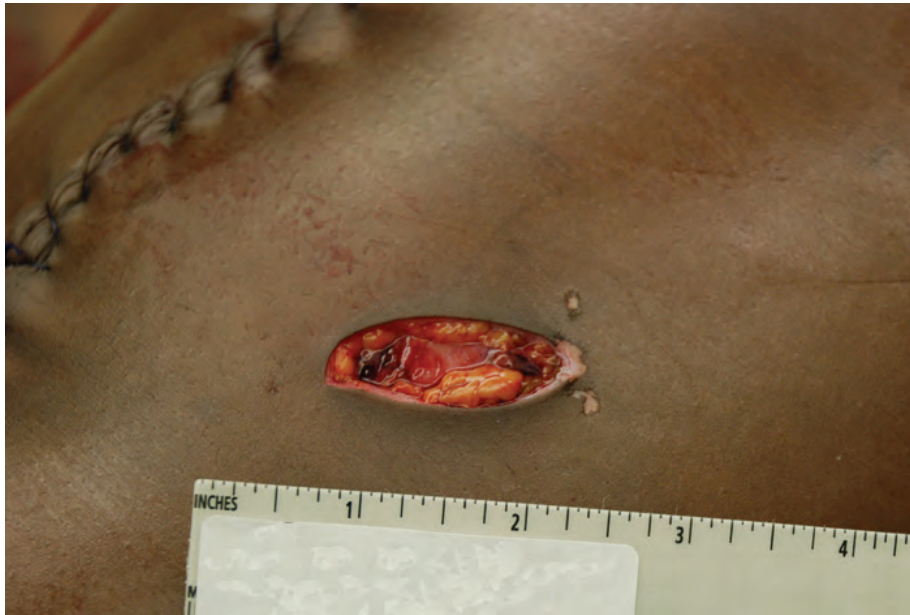Several of these wounds were chosen based on estimation that they were more reflective of the actual knife blade size. These wounds were then cut into a relaxed state and re-measured to help estimate the actual size of the knife blade.



Stab wounds to body with slight drying of the margins and a “linear extension” from one end due to the sharp part of the knife blade being dragged through the wound and across the body surface, changing the dimension of the injury.

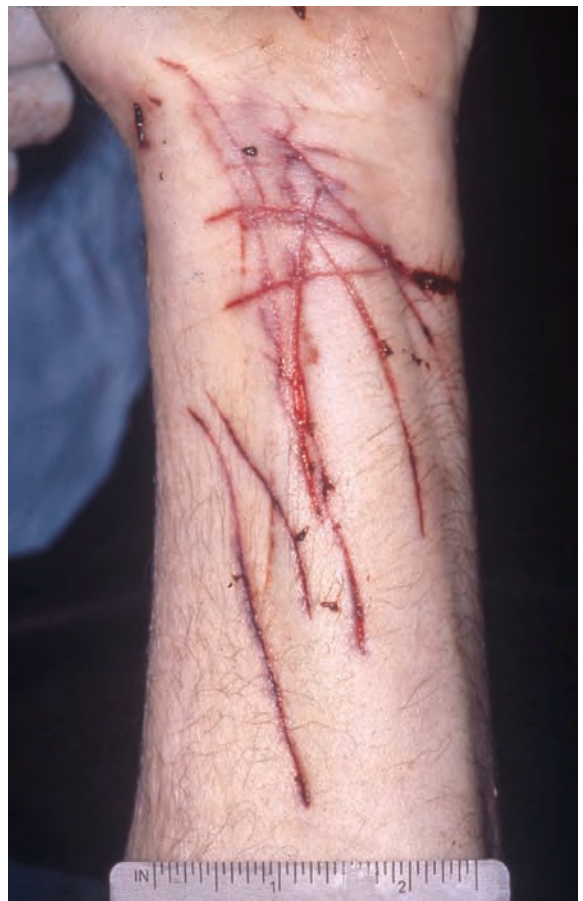
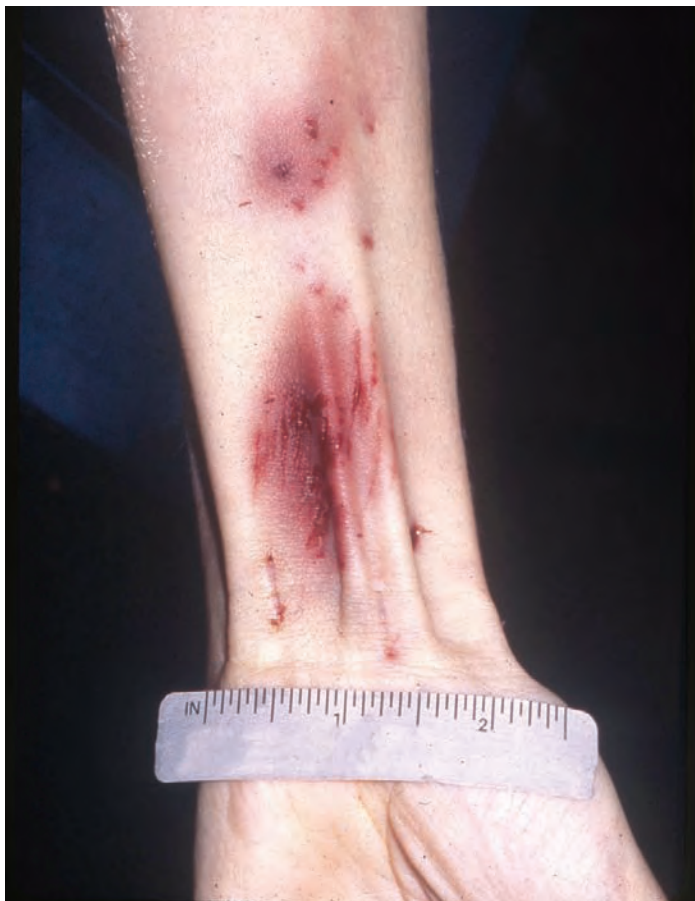
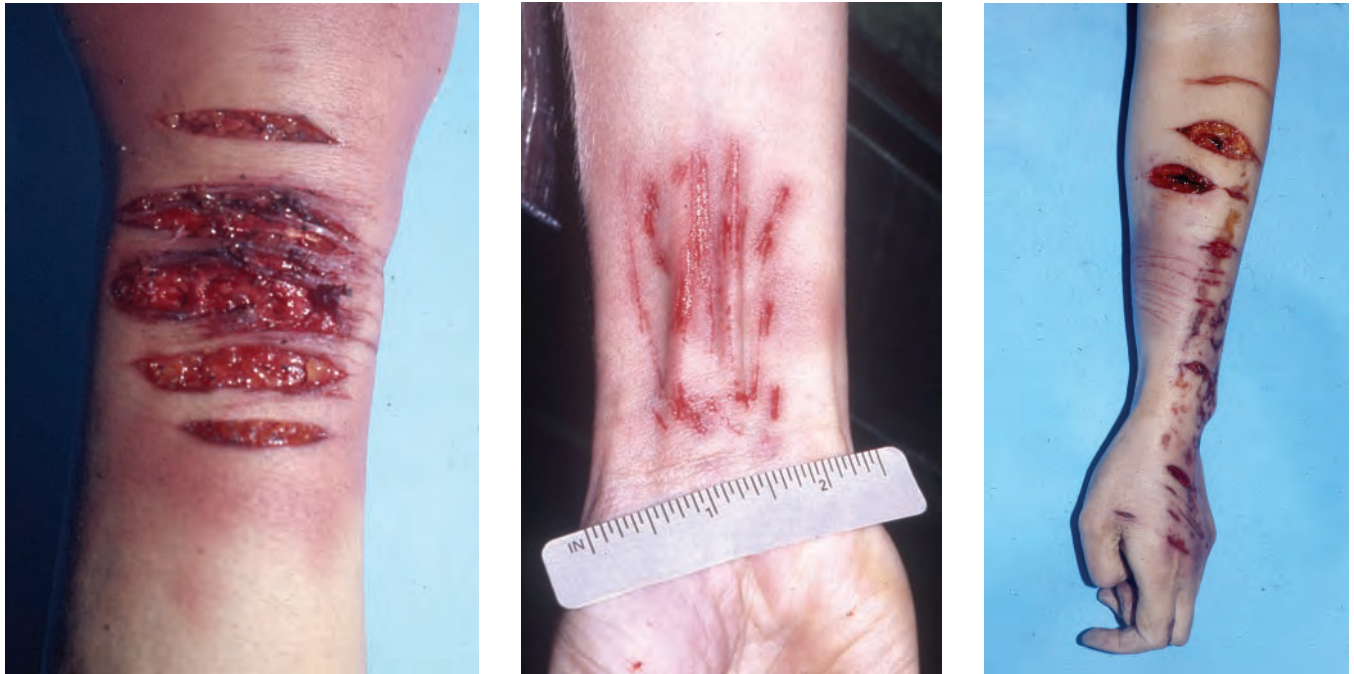These two images demonstrate a “swallowtail”-type injury where the knife was inserted into the body in one direction, turned and then removed in another direction, producing two angulated cuts. This type of injury may be produced by the movement of the perpetrator, victim, or both.

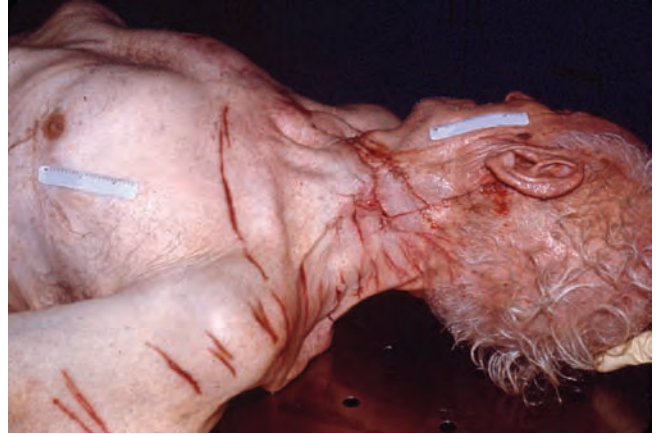
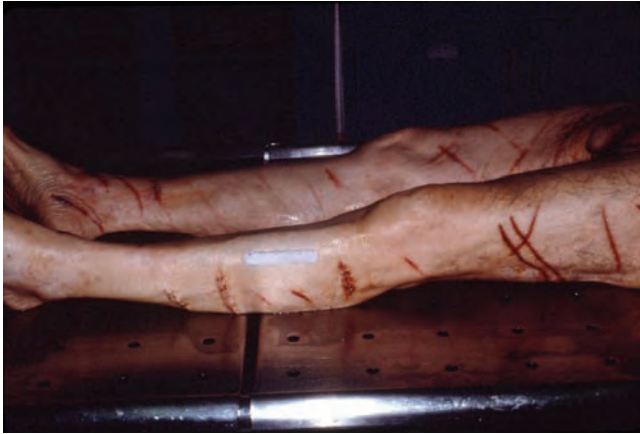
These stab wounds demonstrate adjacent abrasions from the hilt of the knife contacting the skin with great force.

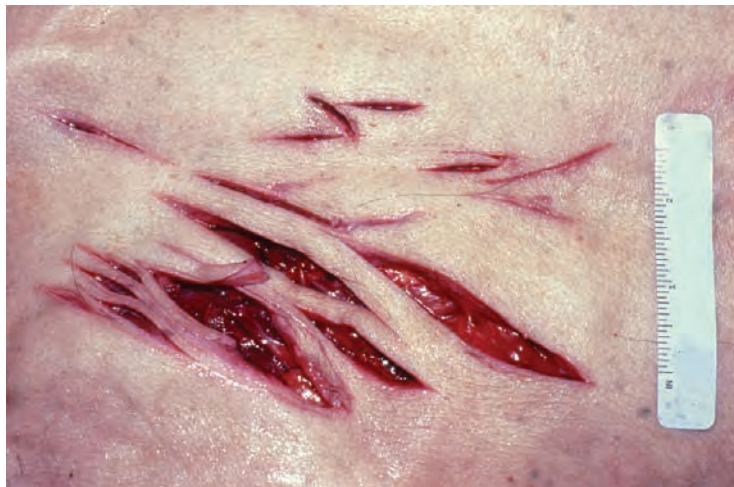



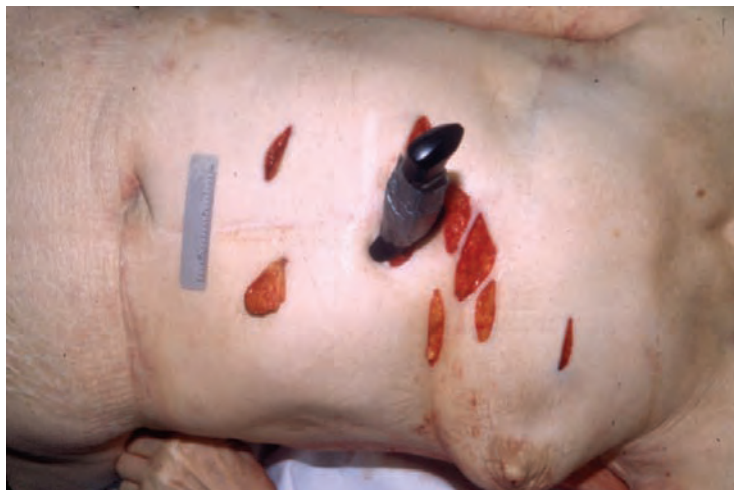Multiple self-inflicted linear abrasions and incised wounds to the arms and wrists demonstrating hesitation marks in individuals who committed suicide with other lethal injuries.



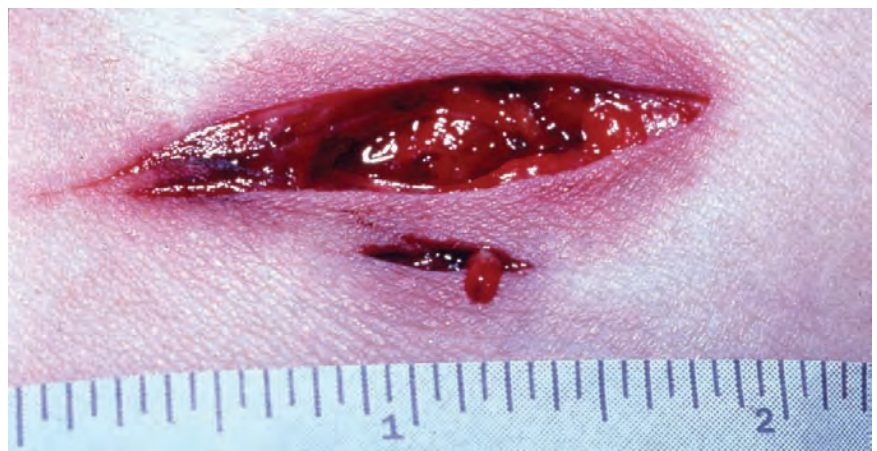
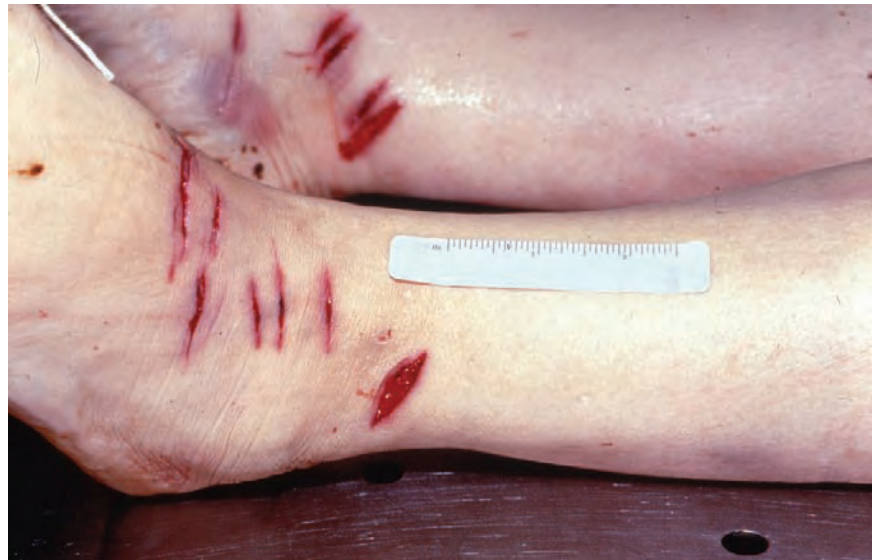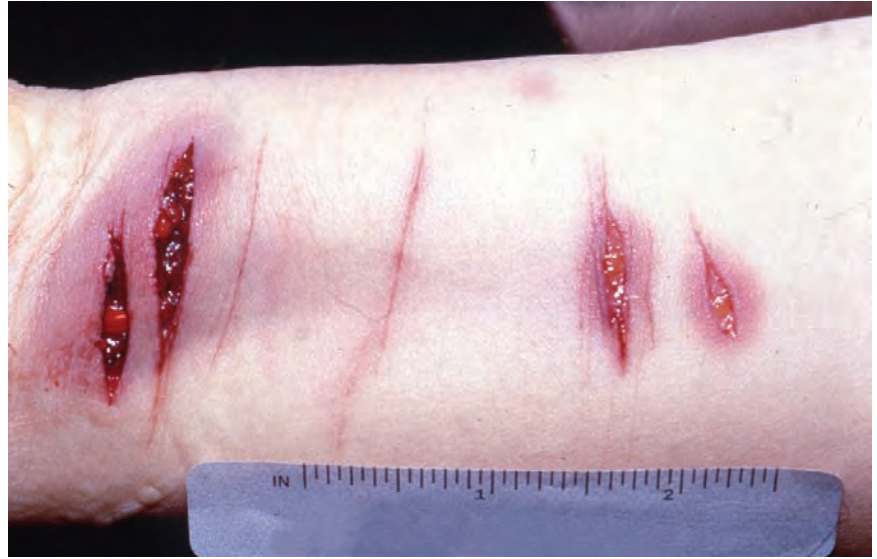Multiple linear incised wounds in an individual who lived for several hours. He died of a heart attack associated with the stress and blood loss from the self-inflicted injuries. The manner of death in this case was classified as suicide. The cause of death was listed as both multiple incised wounds and heart disease.



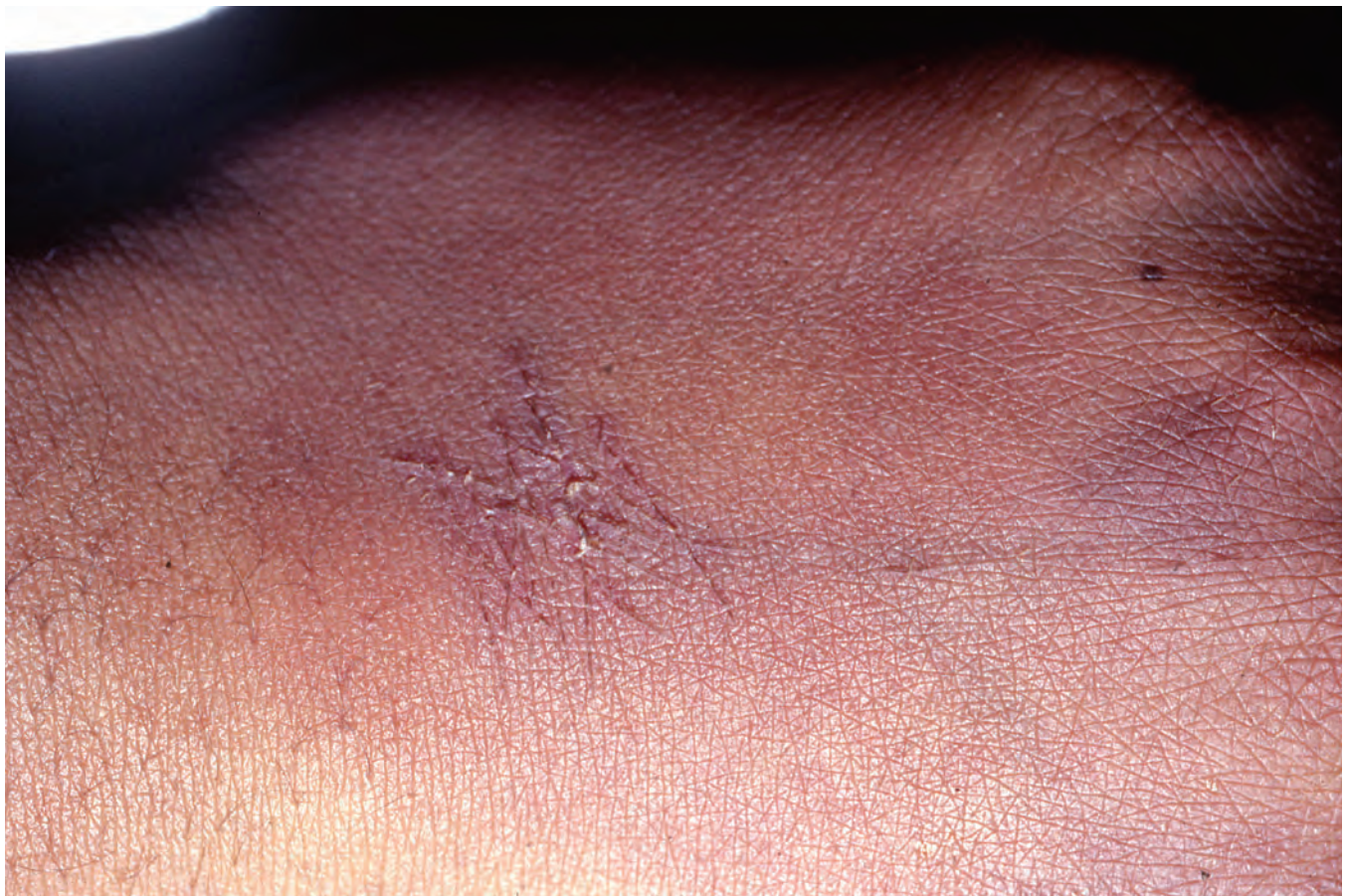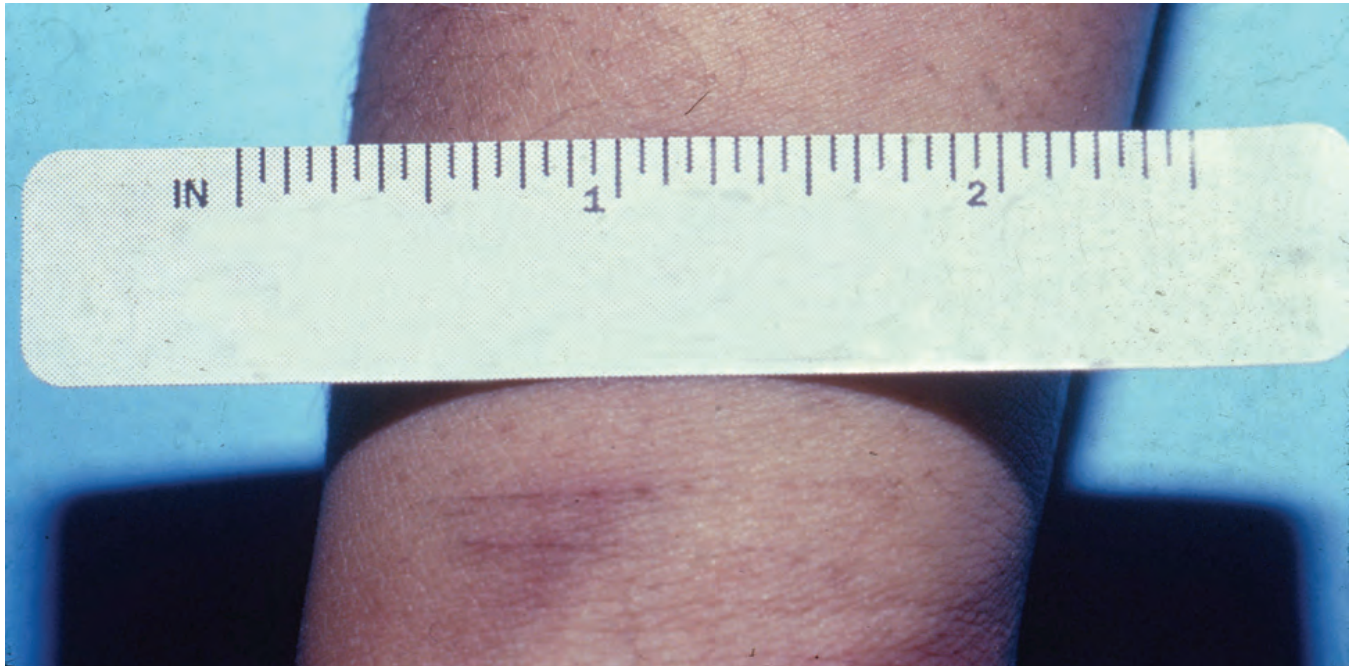
Multiple self-inflicted sharp-force injuries including stab and incised wounds. Note the tightly clustered orientation of these injuries, which is common in suicides.



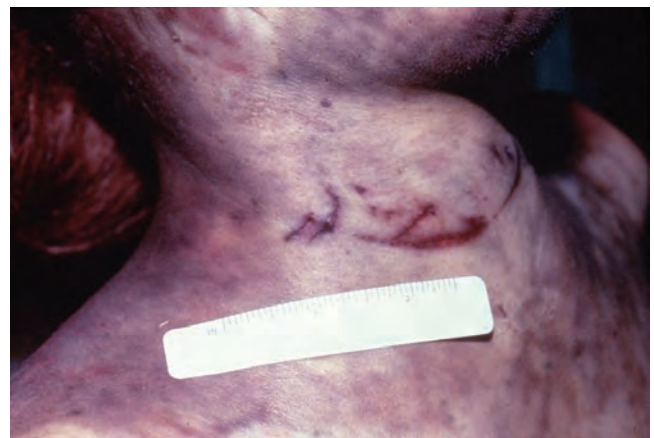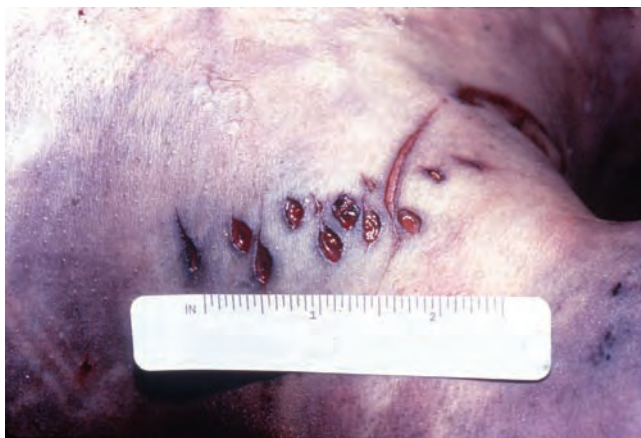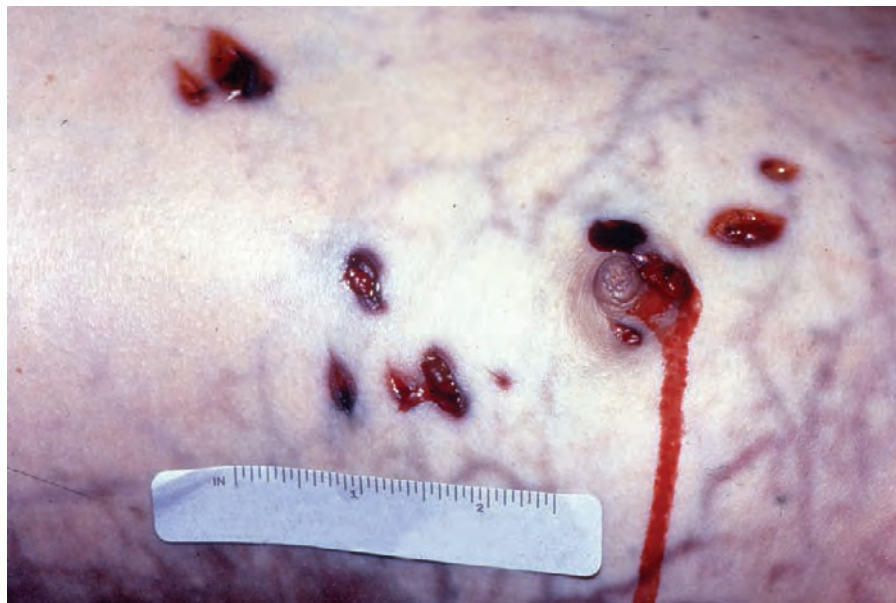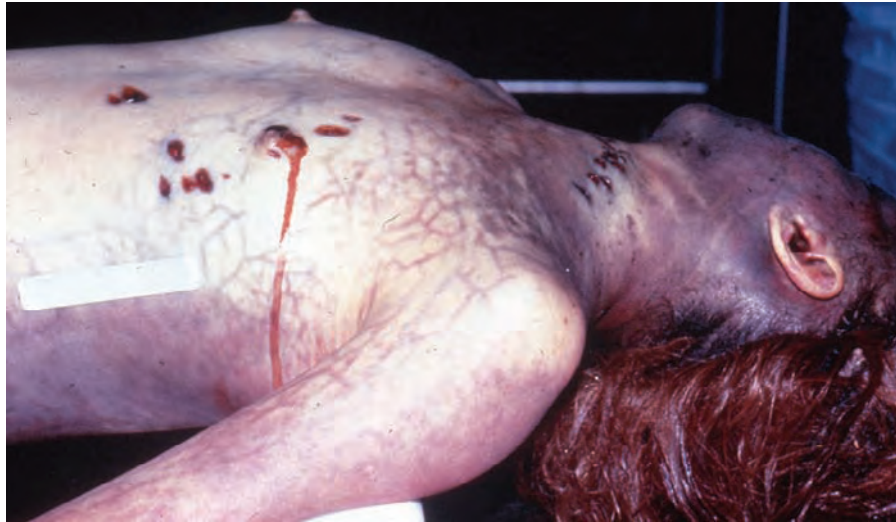Multiple self-inflicted stab wounds. This individual was found with her hands surrounding the knife handle in a moderate state of rigor mortis.



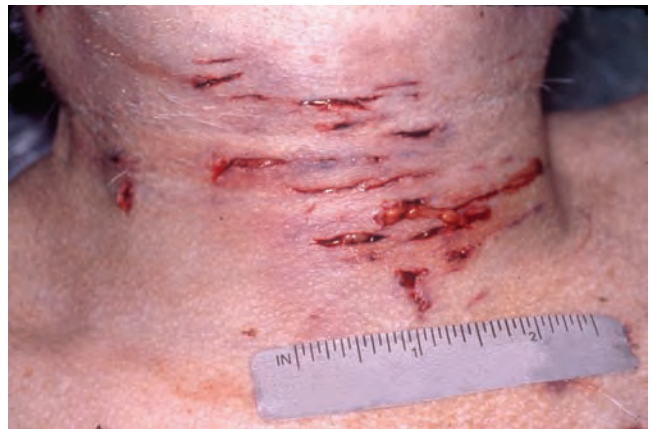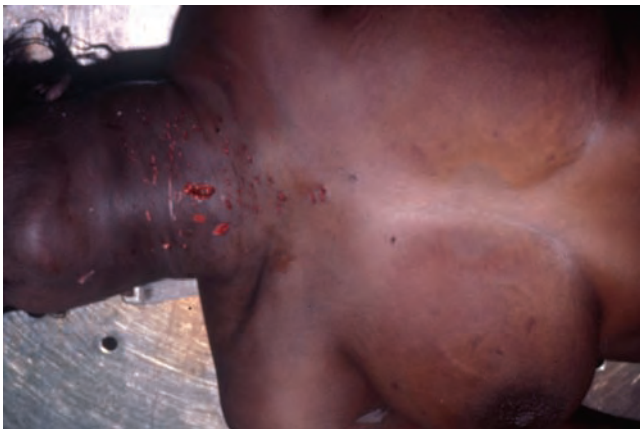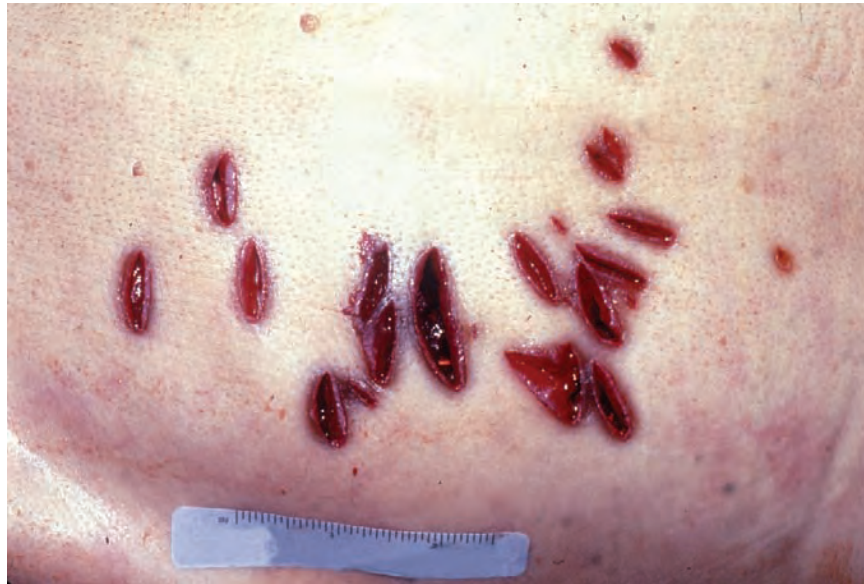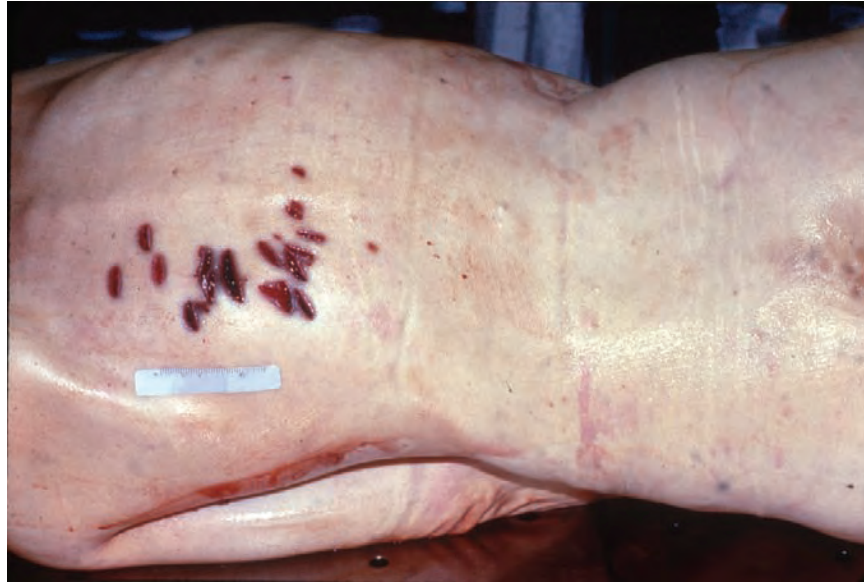
This individual was found with multiple clustered linear abrasions, incised wounds, and stab wounds to the wrists, arms, and ankles. She first attempted suicide by ingesting large quantities of acetaminophen, then inflicted the above sharp-force injuries. Note the erythema around the wounds, indicating vital reaction. There was blood noted all over the apartment. The individual later jumped out a window and died from blunt-impact injuries. The wounds shown are hesitation wounds.



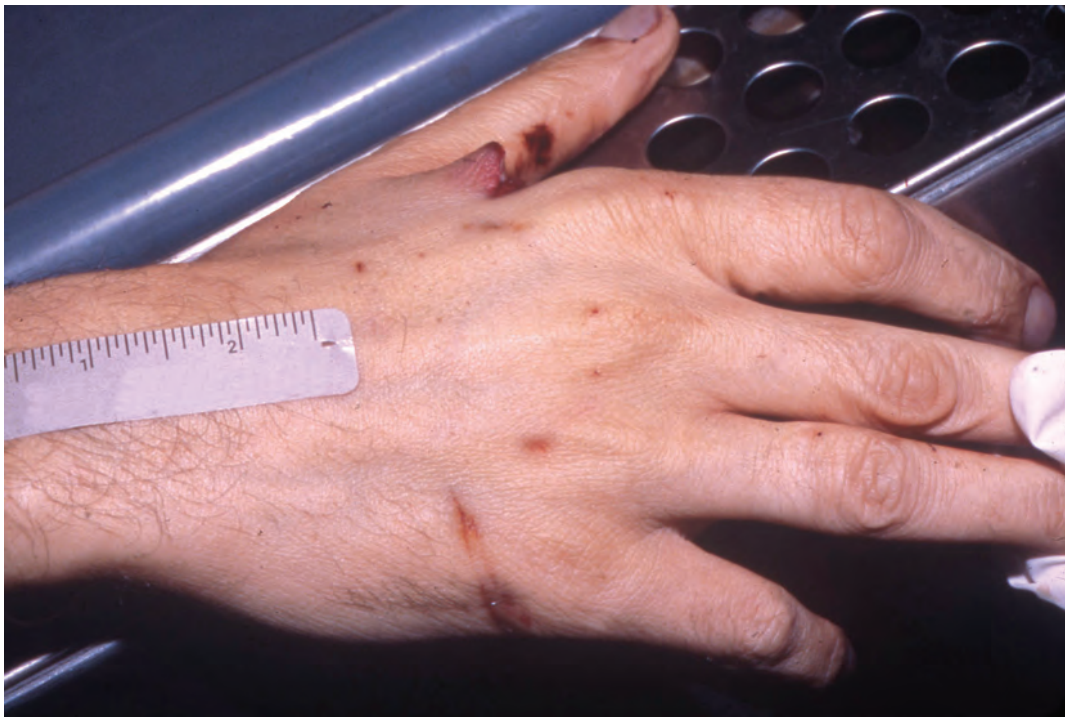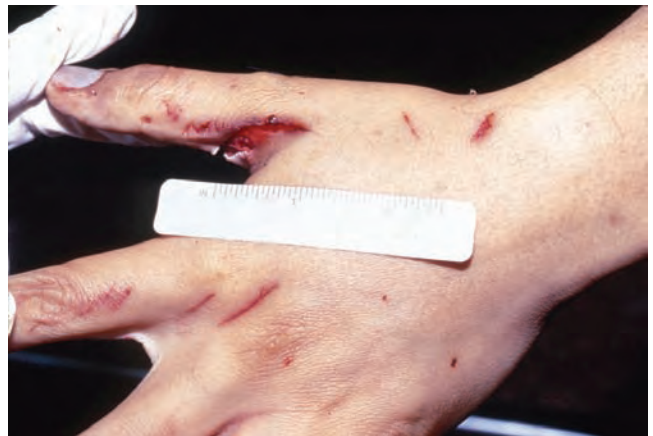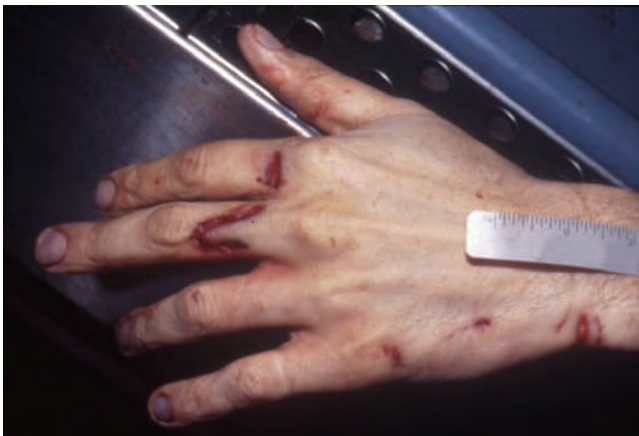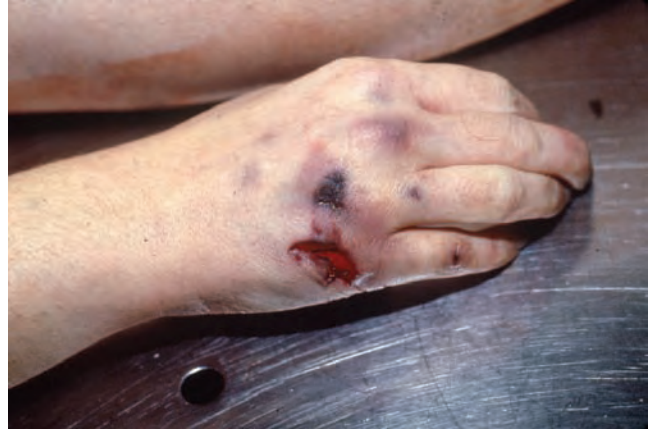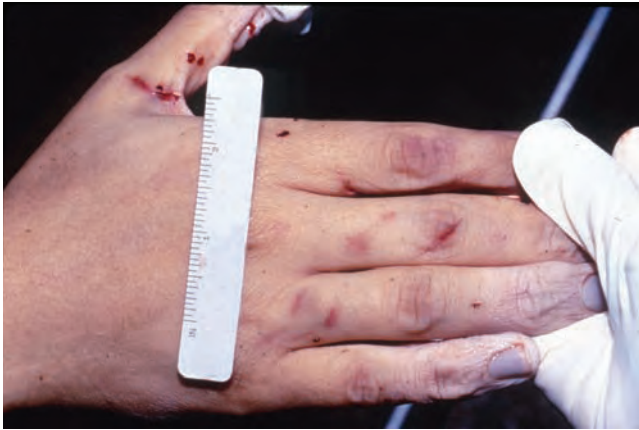Superficial linear abrasions caused by dragging a knife blade across the wrist and hand prior to committing suicide by hanging.



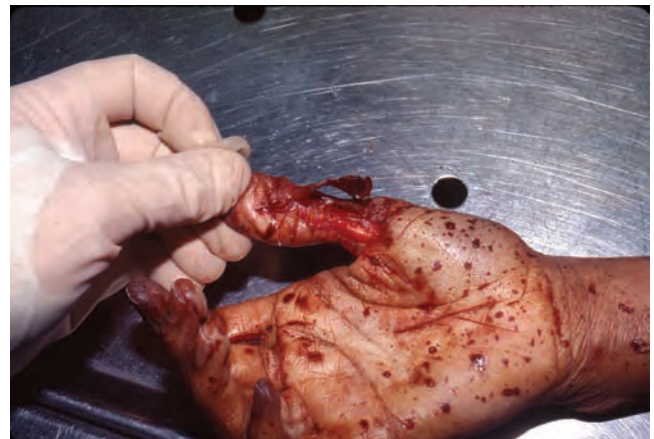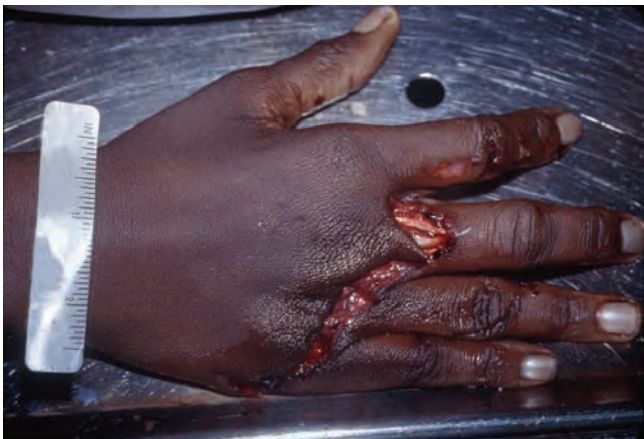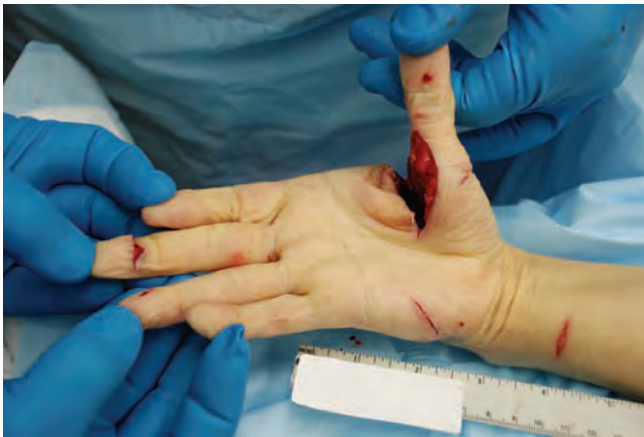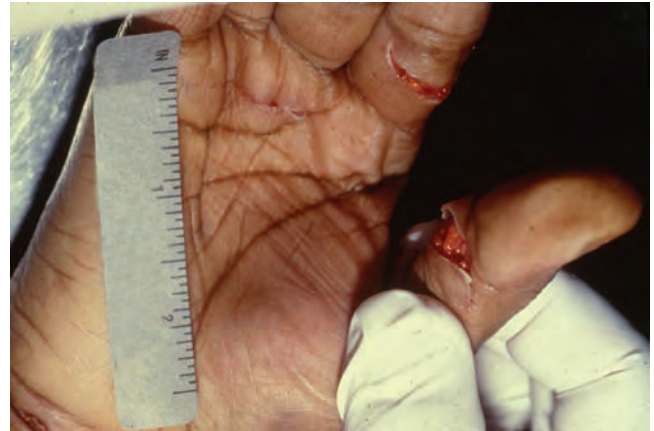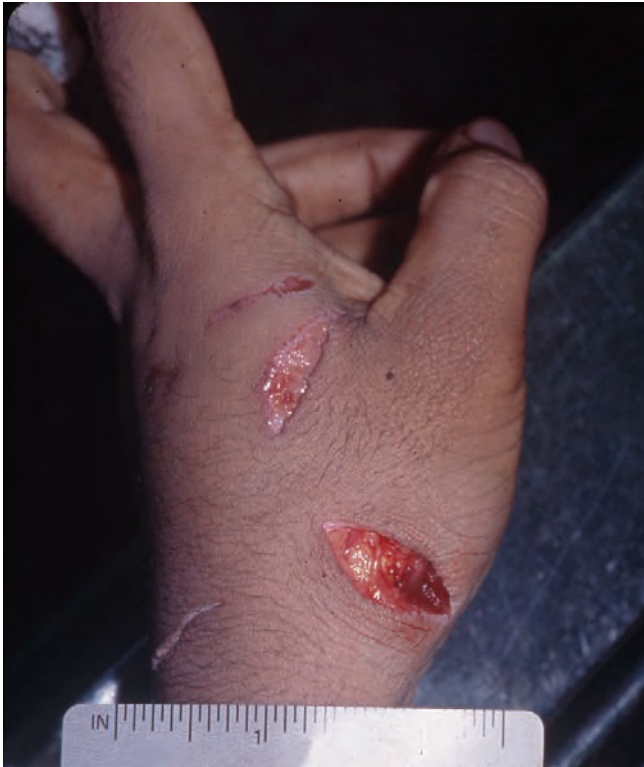Multiple clustered self-inflicted incised and stab wounds located on each side of the neck and chest in an individual who committed suicide. Most of these stab wounds were very superficial in depth of penetration and can be described as hesitation marks. Three of these stab wounds to the chest entered the thoracic cavity and penetrated the heart and lung, causing death. Note the slight degree of decomposition with wound margin drying.



Multiple clustered homicidal stab wounds in individuals who were also bound during a sexual assault. Note the location of the multiple stab wounds to the middle aspect of the individual's back, making it virtually impossible for them to have been self-inflicted.

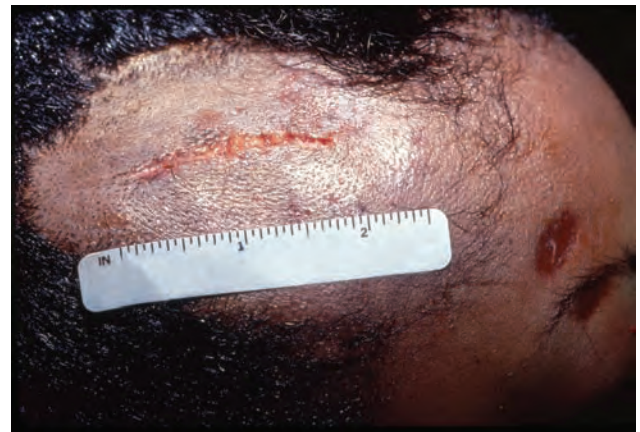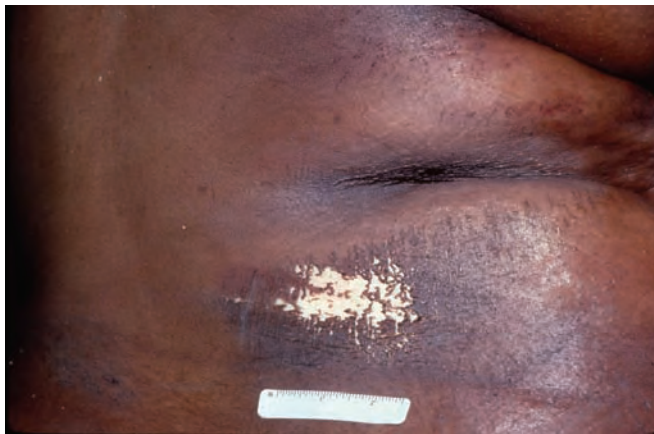
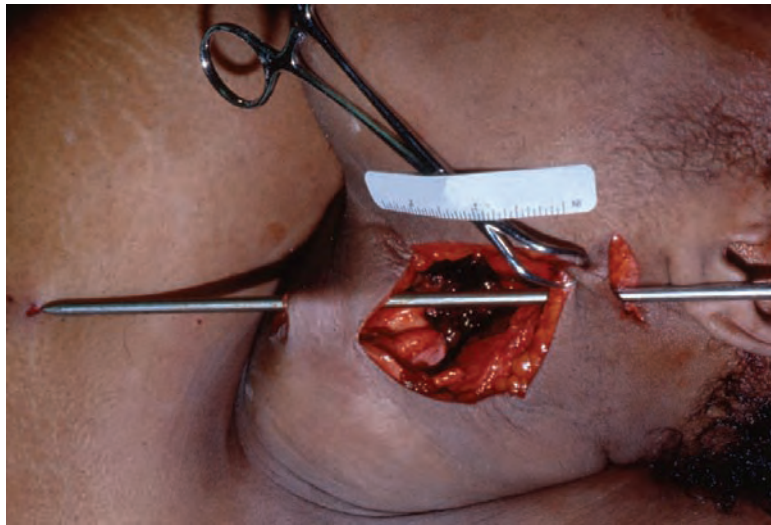

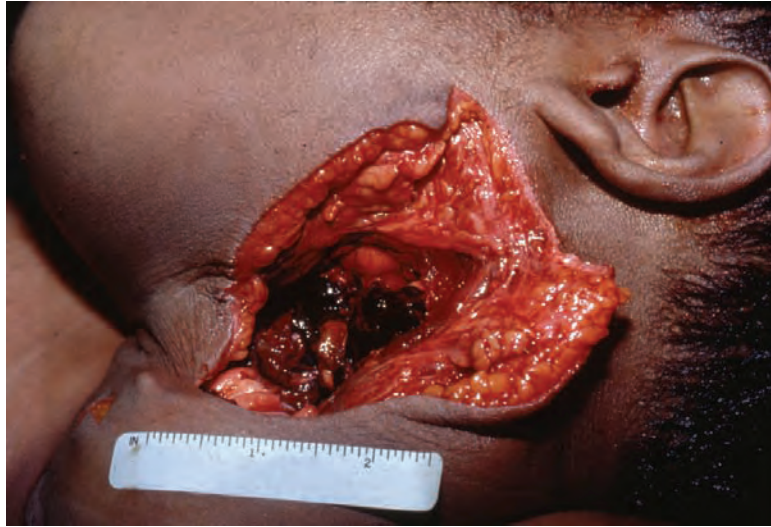
These are multiple examples of defensive-type wounds from individuals who were attempting to ward off an assault from a knife-wielding attacker. Note the multiple linear abrasions, incised wounds, and stab wounds to the hands. Several of these injuries show cut marks between the thumb and fingers, due to the individual's attempting to grab the knife blade.

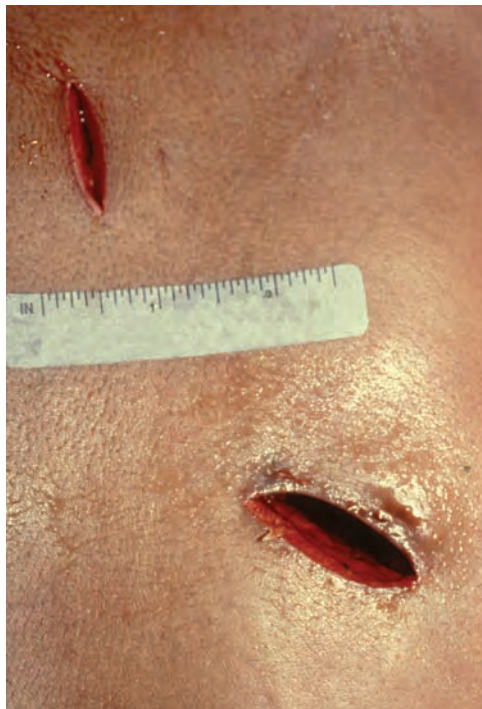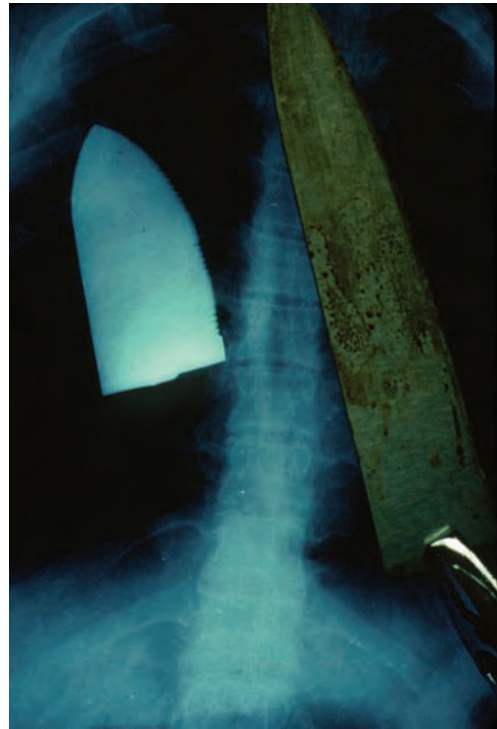
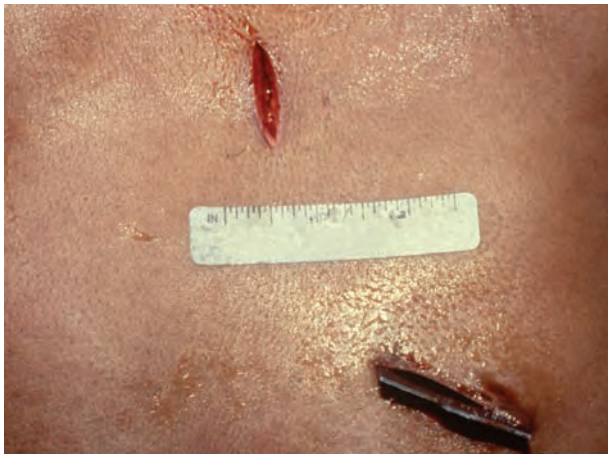
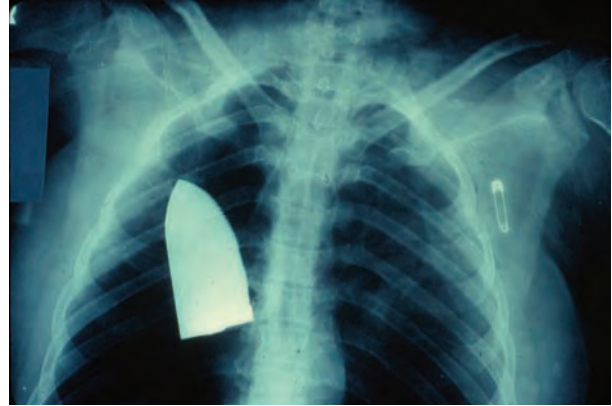

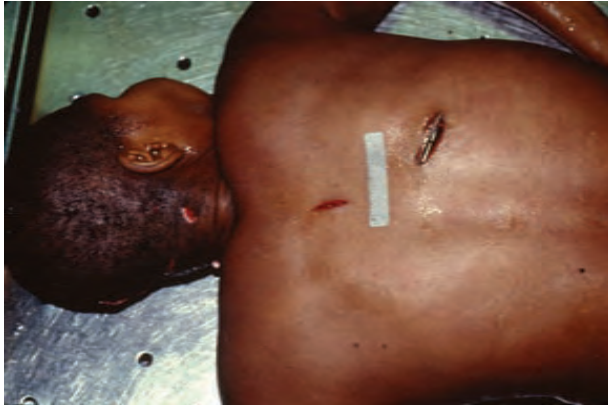
Other examples of wounds consistent with being inflicted while an individual is fending off an attack.

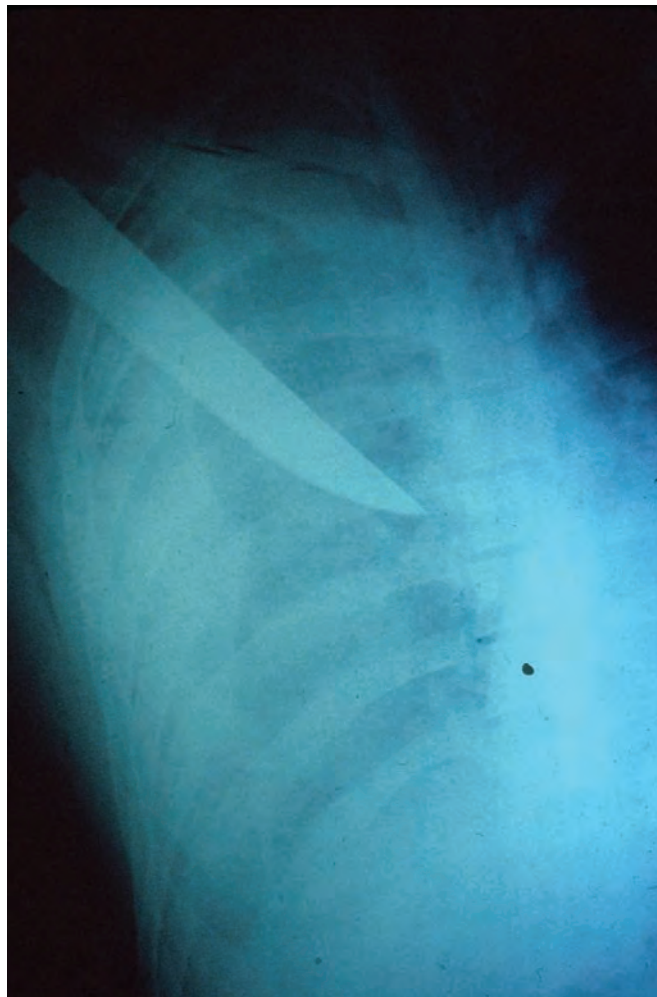
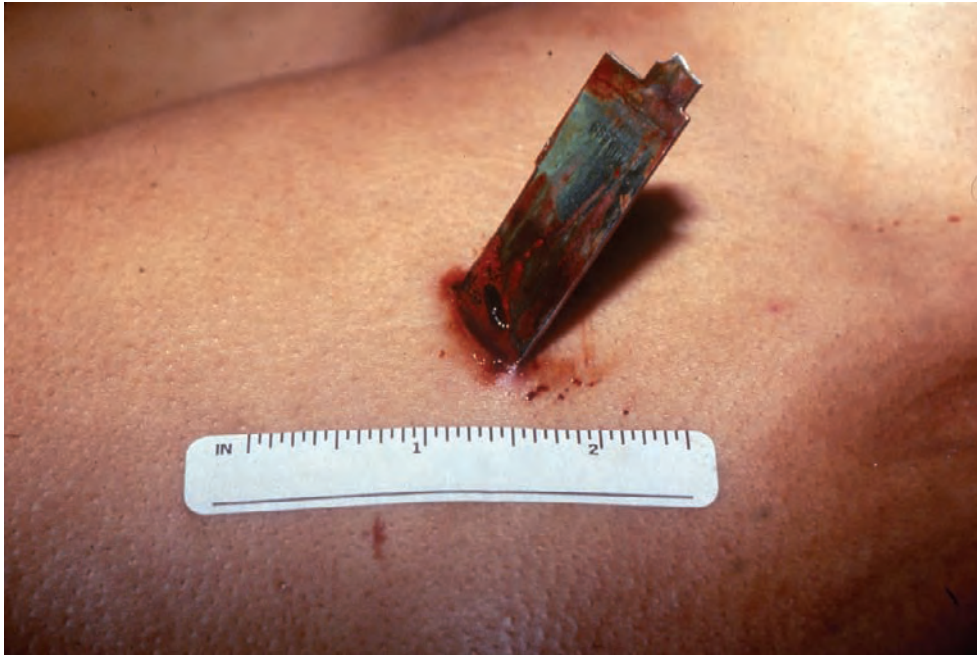



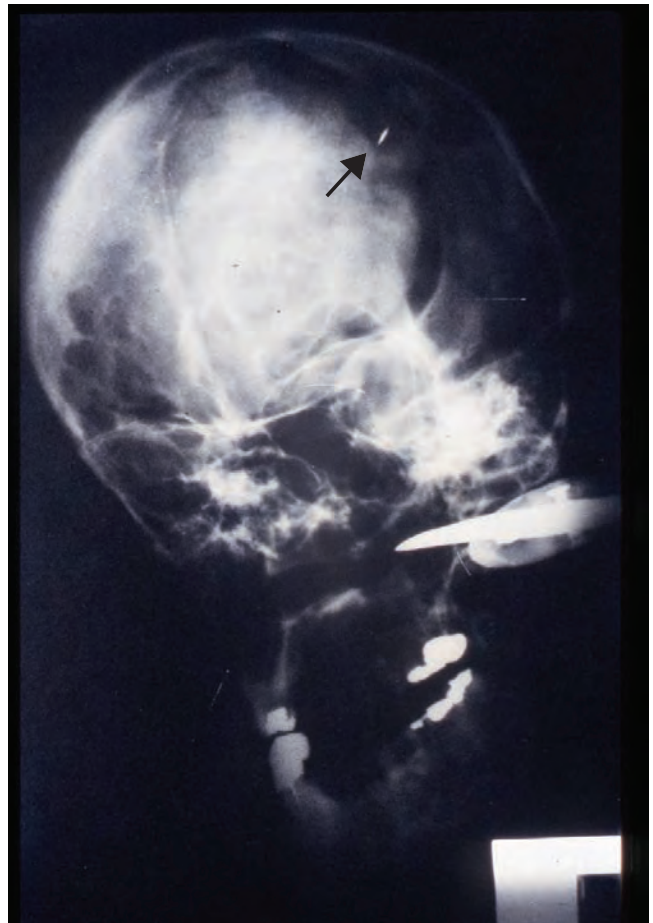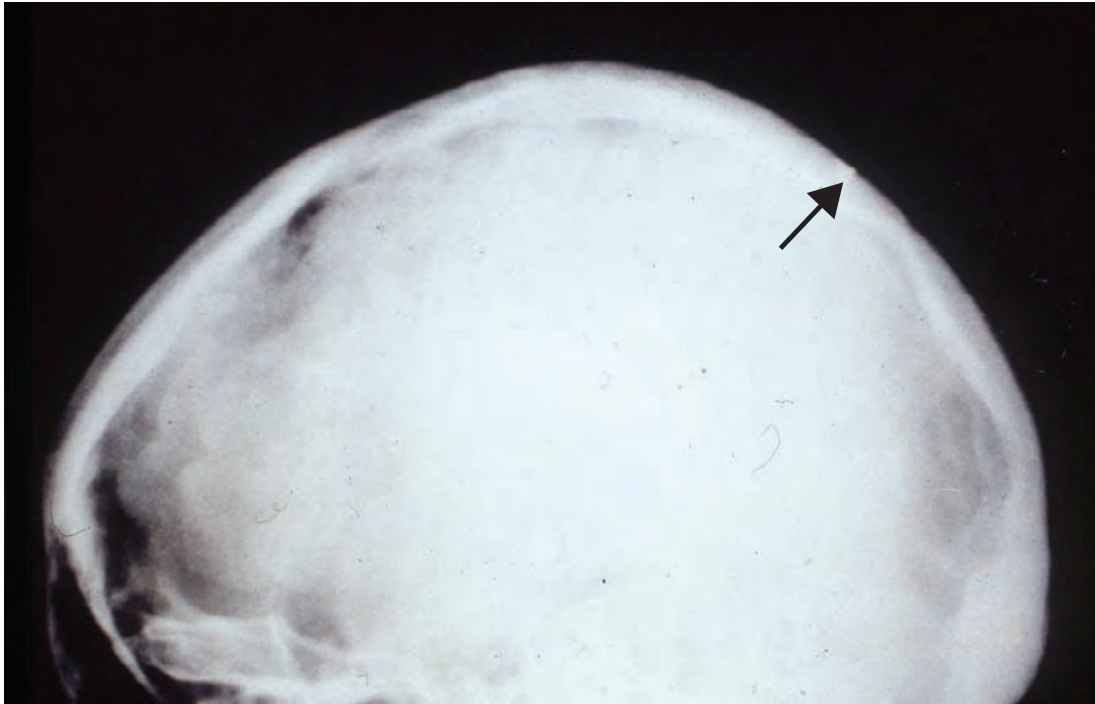
This individual was stabbed in the neck and then thrown from a window. The perpetrator described the injuries as being self-inflicted by the decedent who cut herself and then jumped out a window. The window ledge and outside wall were smeared with blood, which was easily visible from below. During autopsy, approximation of the margins revealed a stab wound just below the left ear from a knife blade that exited through her neck and stuck in her right shoulder. There was also an anemic abrasion to her back and an anemic laceration to the scalp, indicating the decedent had lost much of her blood volume and did not have a beating heart with blood pressure enough to produce hemorrhage from the injuries sustained when striking the ground.



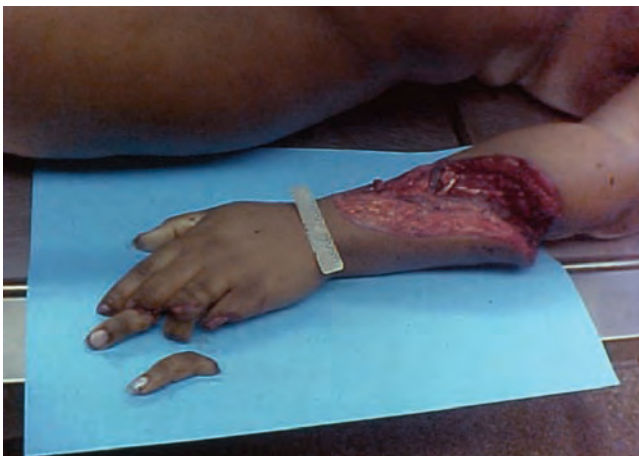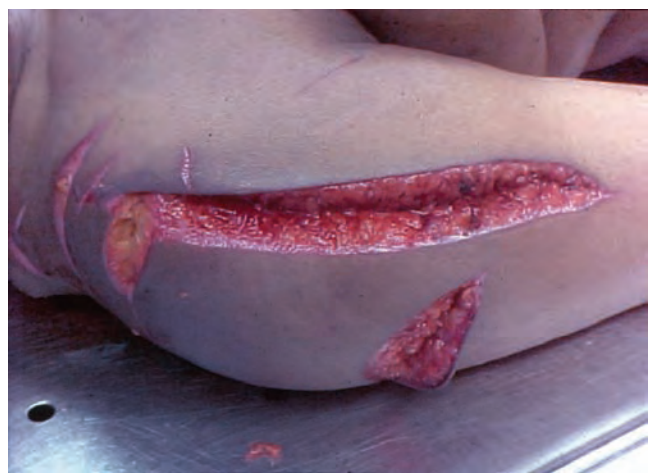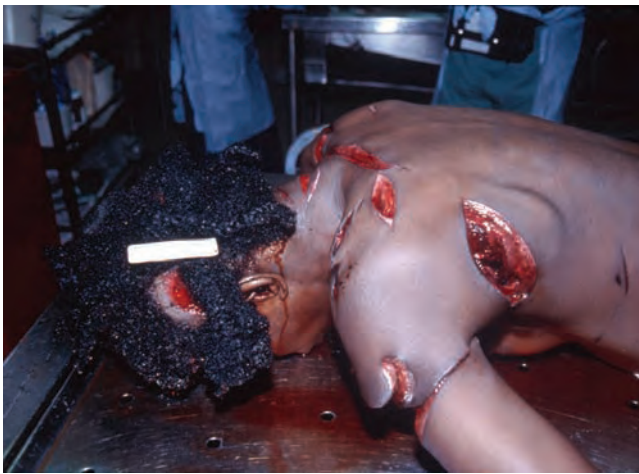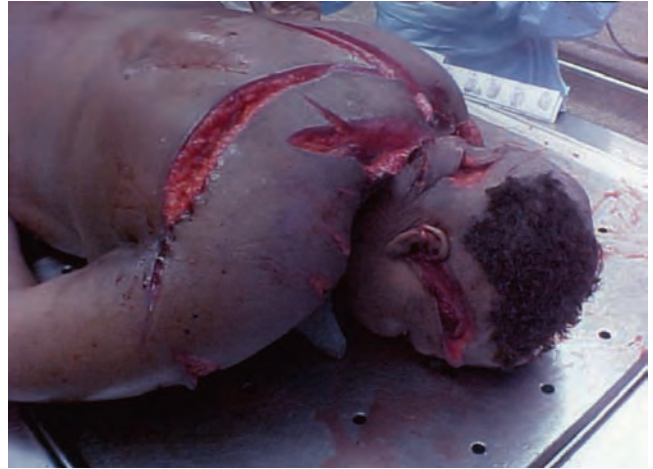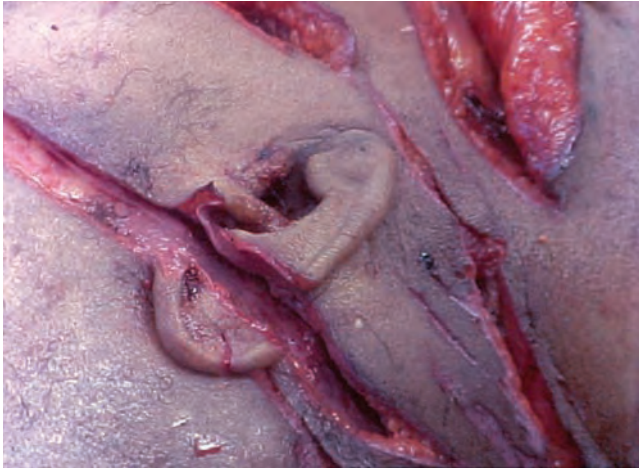
Note the two stab wounds to the left back and the broken knife blade extending from one of the wound tracks. Note the close-up view of the back, demonstrating the knife within the wound track and then with the knife removed. Note the change in the wound dimension after the knife was removed. This demonstrates the elastic nature of skin and the possible challenges of correlating a weapon to a particular wound dimension. Also note the x-ray, which demonstrates the knife blade within the body. Note the dimension of the actual knife blade compared with the dimension of the blade image on the x-ray. This is due to the angle in which the x-rays contacted the knife blade in the thoracic cavity. Weapon.



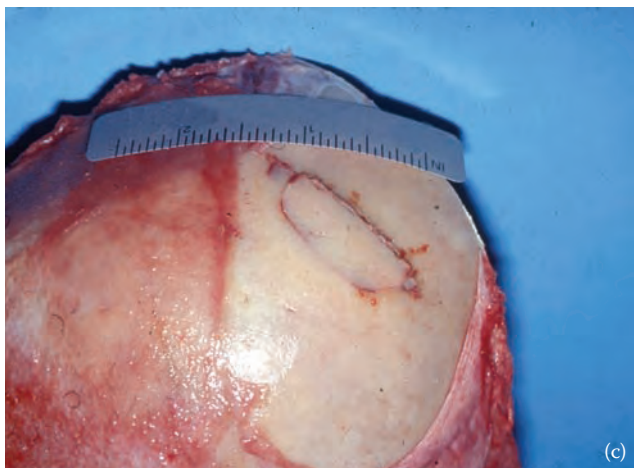
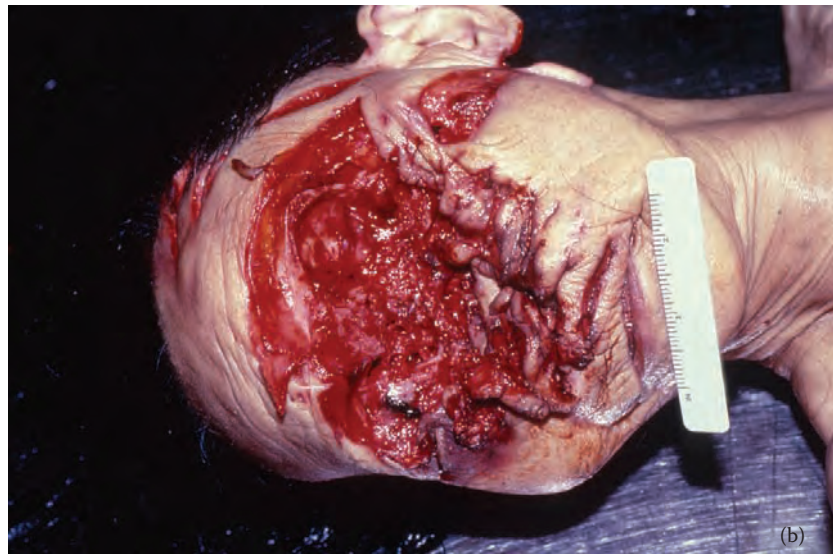
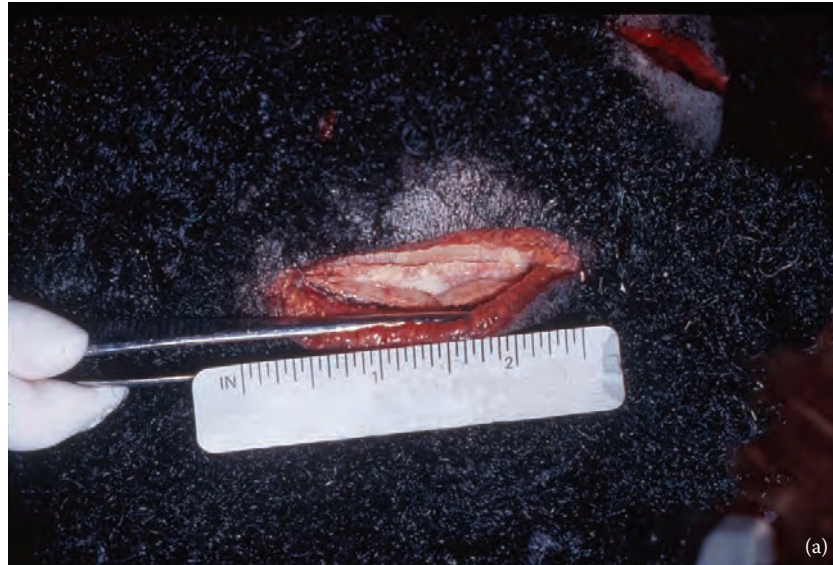Broken knife blade left in body following a homicidal assault. This knife was stuck into this individual with great force and the blade got stuck in a bone. When the perpetrator attempted to remove it, the handle broke off and the knife blade was left behind.



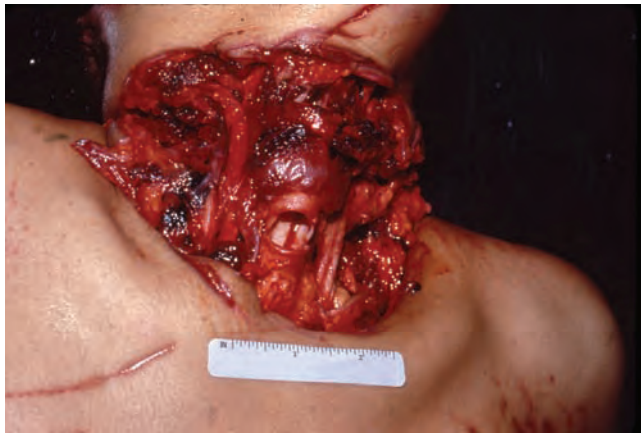
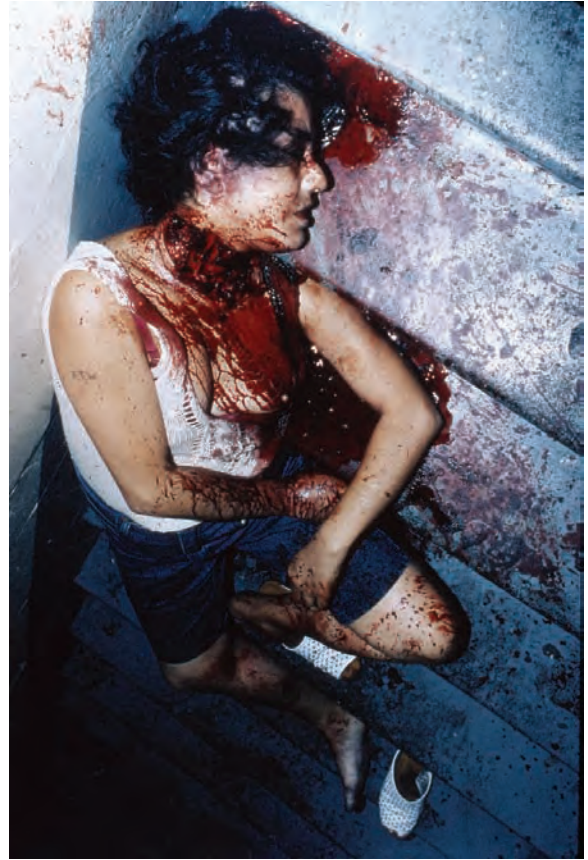This individual was stabbed more than 75 times by a scorned lover. The tip of the knife blade broke off in the skull during this violent assault. Note the small radio-dense fragment depicted in these skull x-rays. This reinforces the notion that it is good practice to x-ray all sharp-force homicidal violence cases. A fragmented portion of knife blade can later be matched to a suspect's knife.



These individuals were attacked multiple times with machetes. Note the long gaping hack marks, several of which cut into and through bone. Most often, this degree of violent rage indicates the victim and the perpetrator had a relationship.

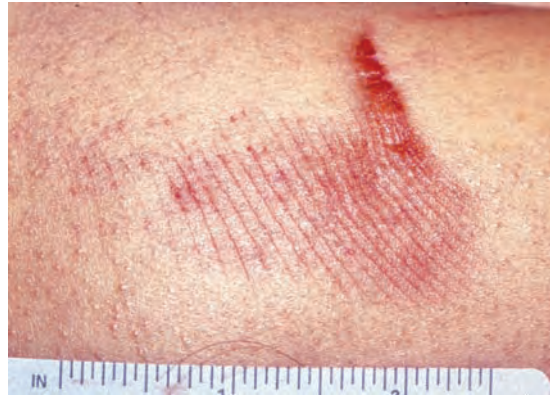
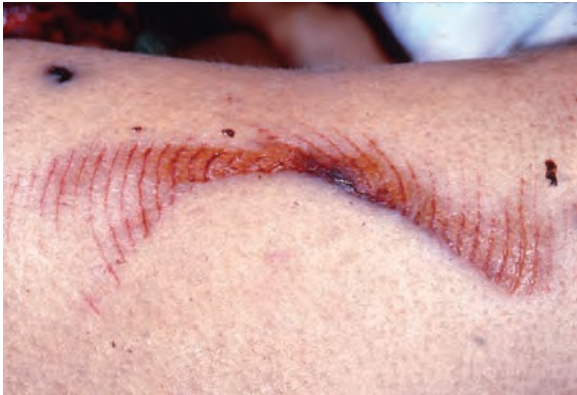
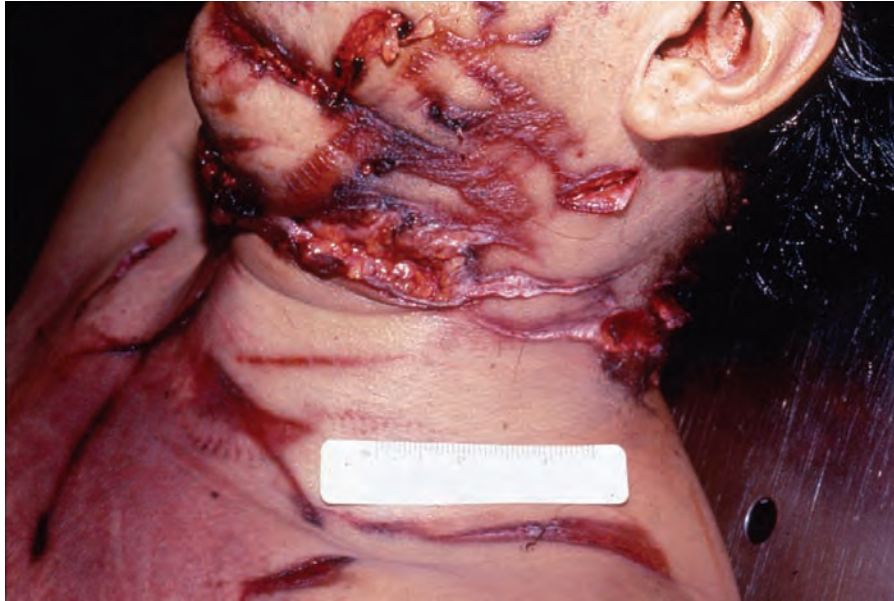
Chopping-type sharp-force injuries produced by an axe. Image (b) shows an individual whose eyes were chopped out by another person with a long history of psychosis. These types of assaults are not common. He reportedly did this because she kept staring at him.



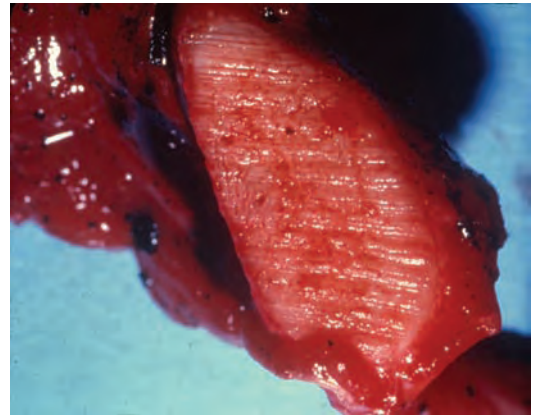
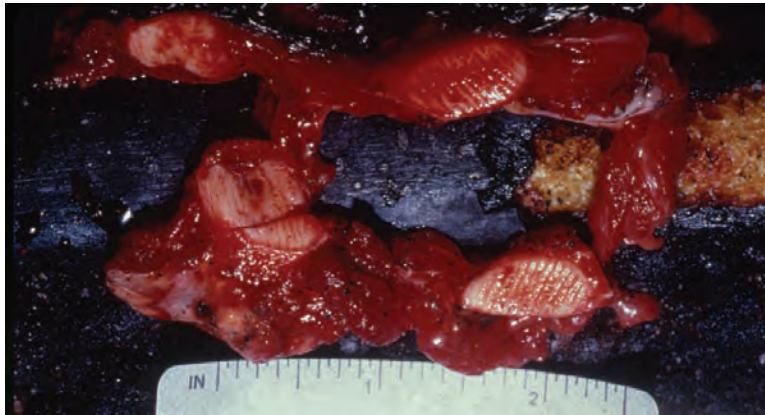
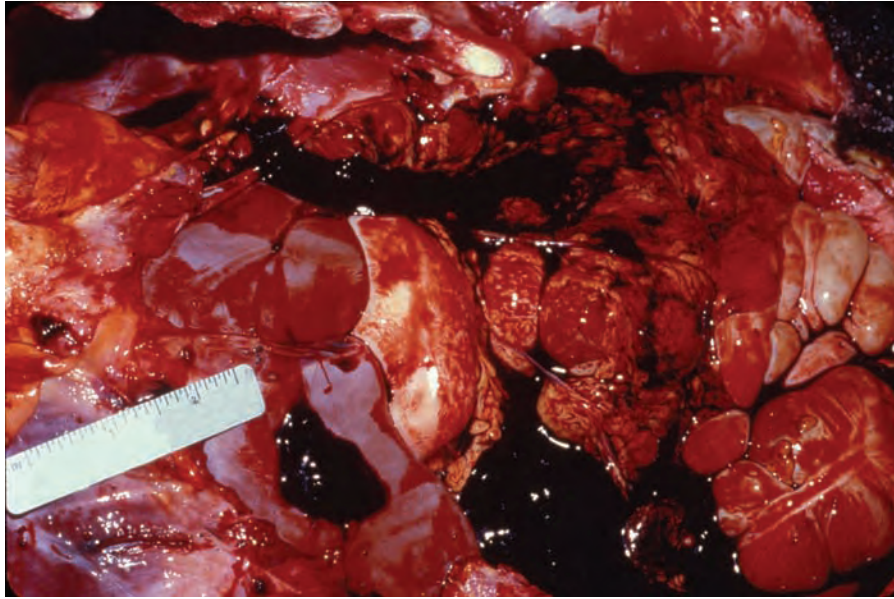
This individual was chased up several flights of stairs in an apartment complex and was cut multiple times with a box cutter similar to the one shown here. Note the blood splatter pattern on the steps. Also note that the individual was almost decapitated. This was reportedly over a dispute concerning gang-related drug dealing territory.





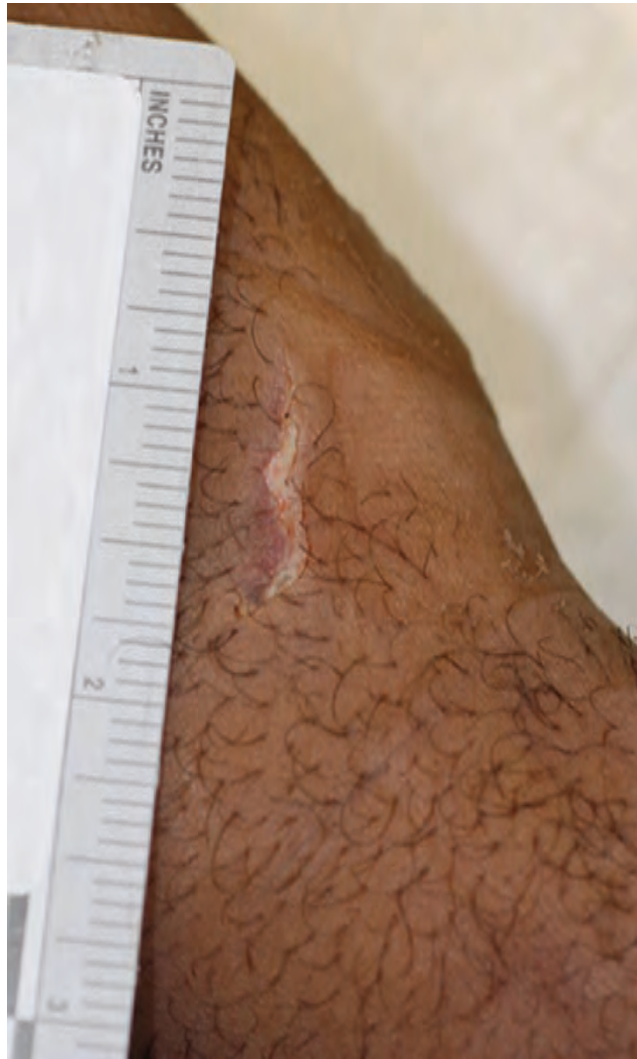This individual had multiple stab wounds with adjacent abrasions consisting of multiple superficial linear parallel lines. This is a typical pattern found following a serrated knife attack. The absence of these marks does not preclude the use of a serrated knife. If a serrated knife is stuck directly into a body and not dragged across the surface, there will be no parallel linear abrasions.



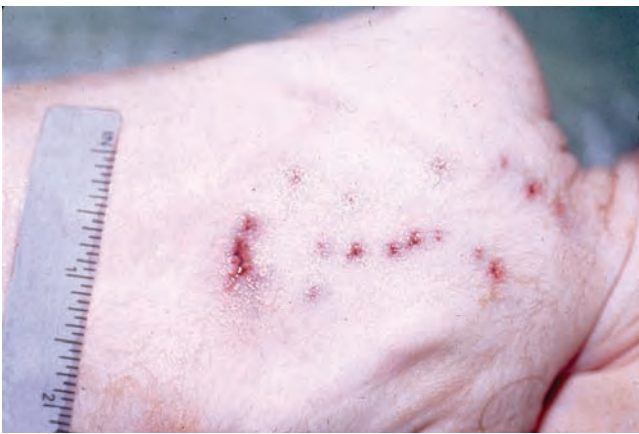
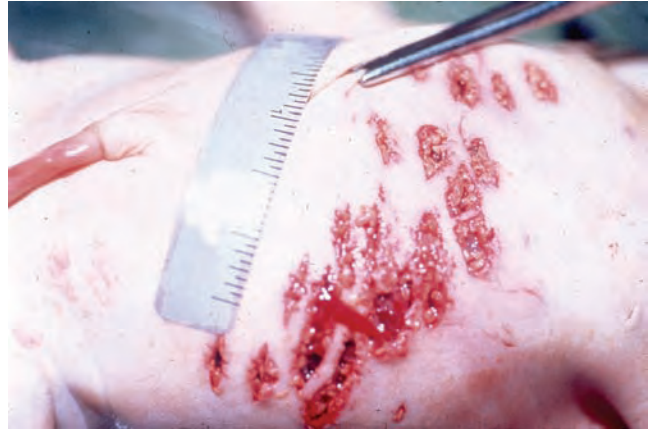
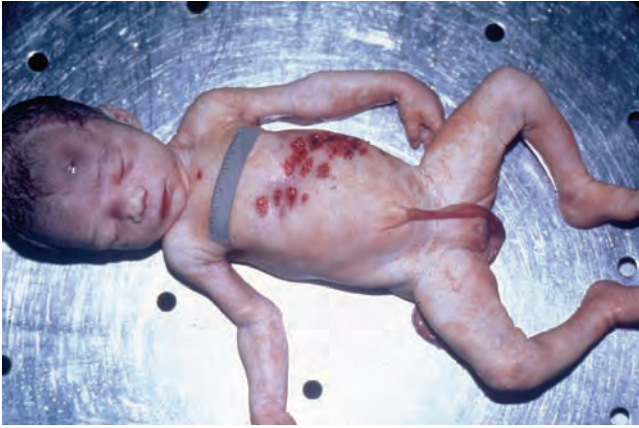
This individual was stabbed multiple times with a Ginsu-type knife. His dwelling was then set on fire and he sustained extensive thermal burns with charring of the skin. Note the costal cartilages with tool markings forming an imprint of the knife blade. Image on lower right demonstrates a knife similar to the one used in the attack.

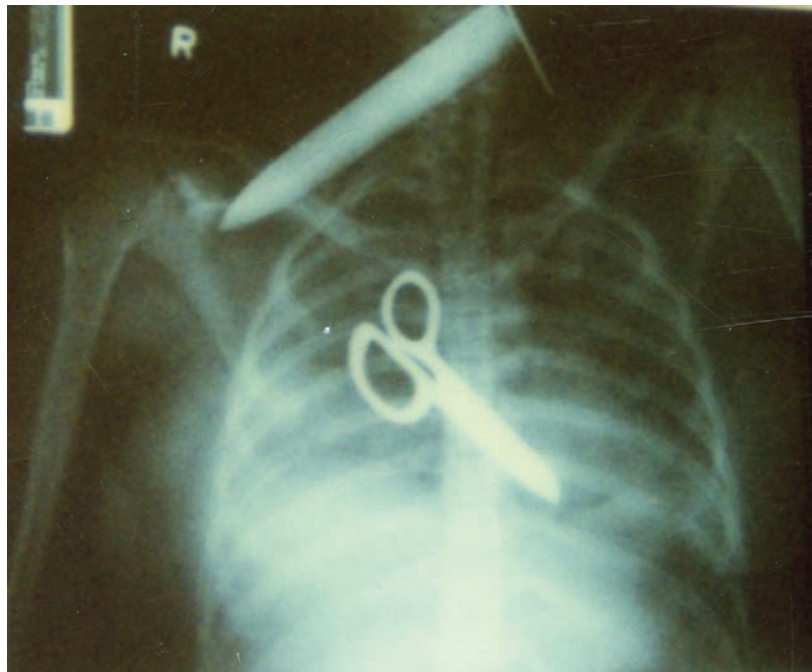




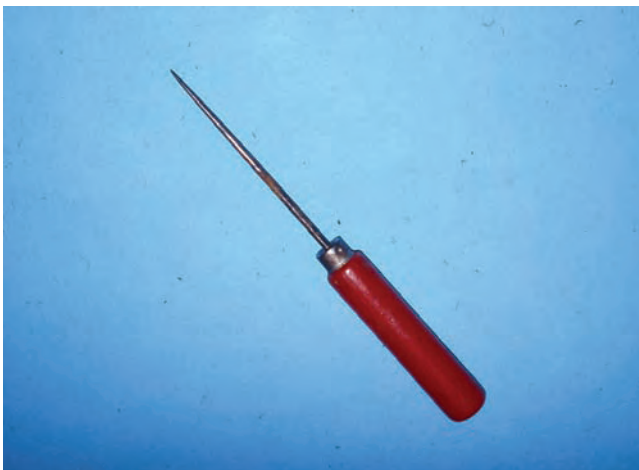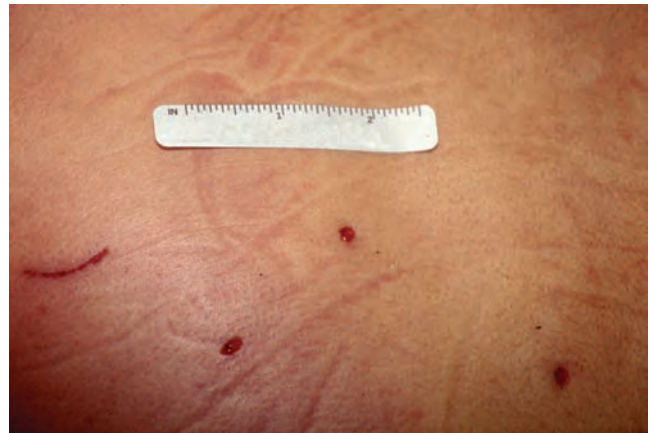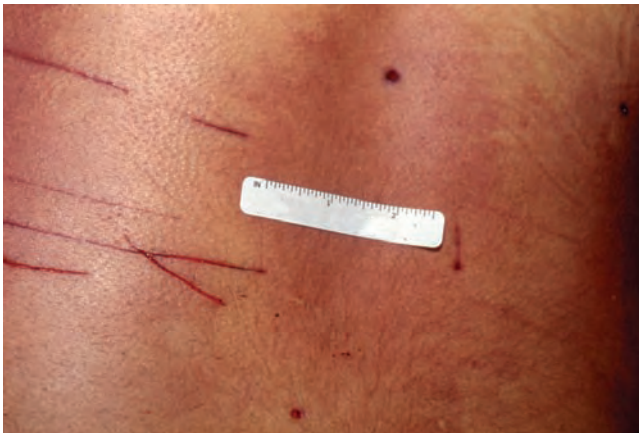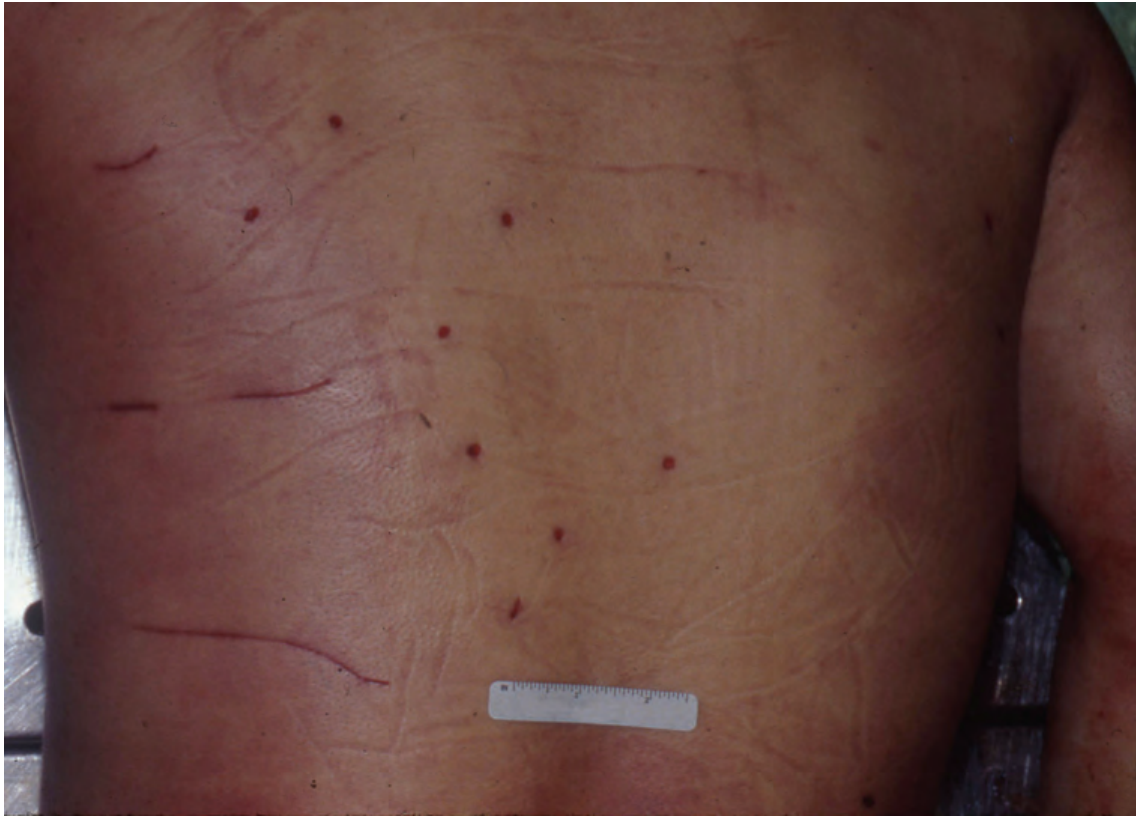Note this irregular incised wound with curved sharp margins produced by a knife similar to the one depicted in the previous figure.



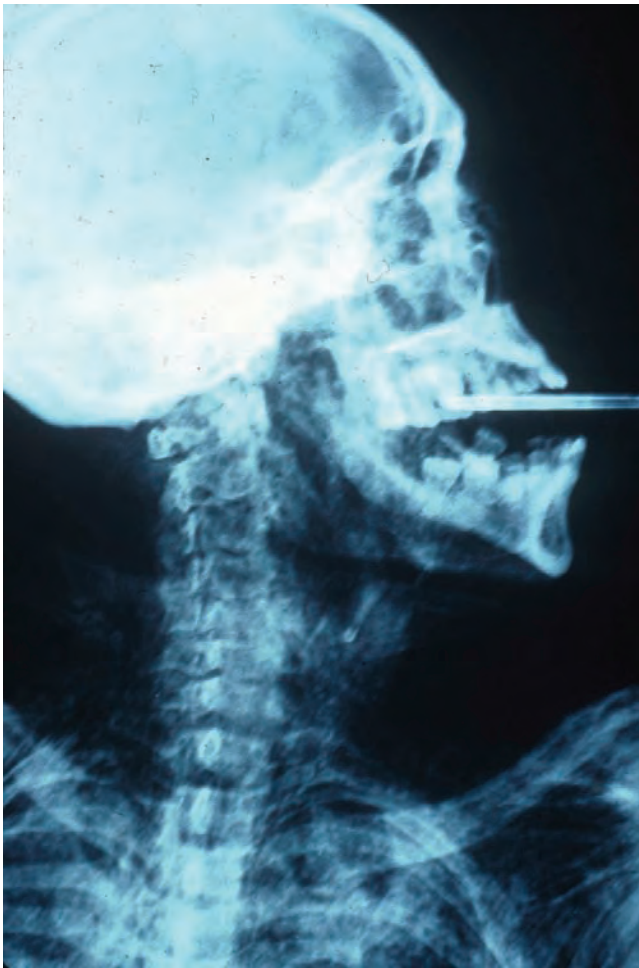
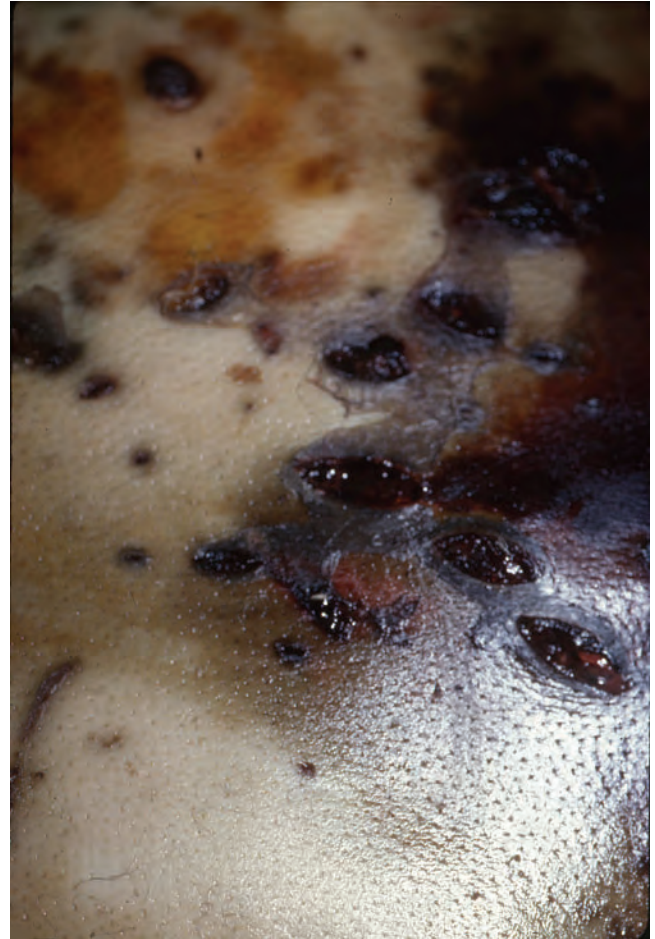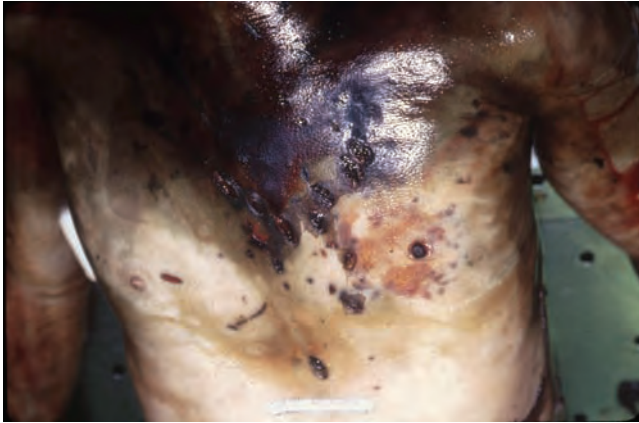
This child was stabbed multiple times with a pair of scissors. Note that the entrance defects to the anterior trunk have a slightly widened angulated character consistent with being inflicted by a pair of scissors. The posterior trunk demonstrates the pointed end of the scissor perforating the entire body.



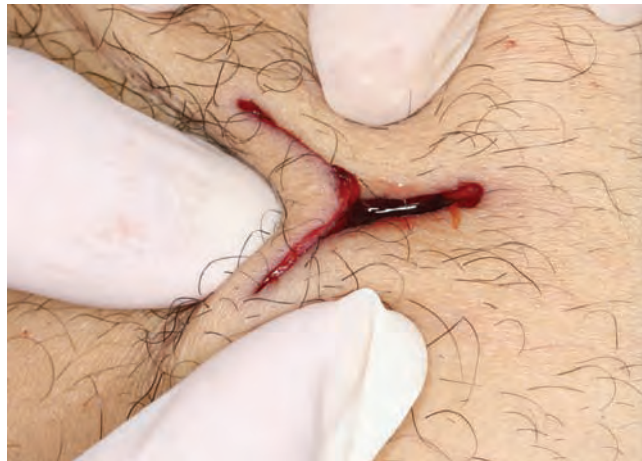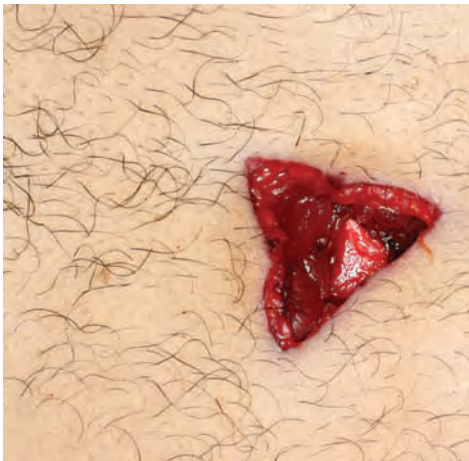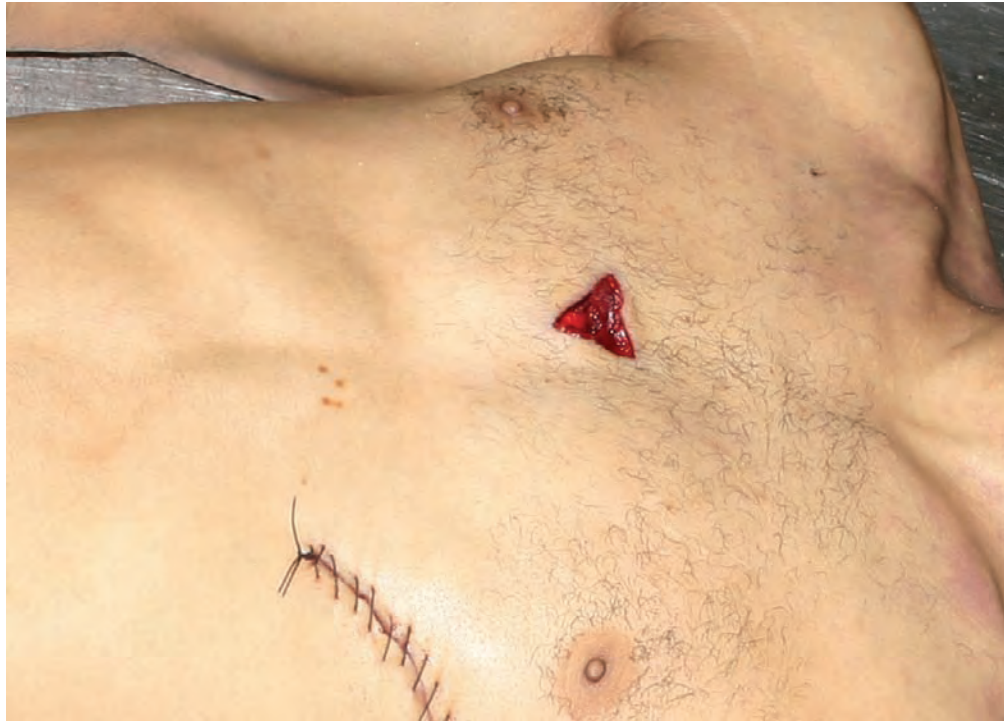This image shows an x-ray of an adult who was stabbed with a pair of scissors that were left in the wound.



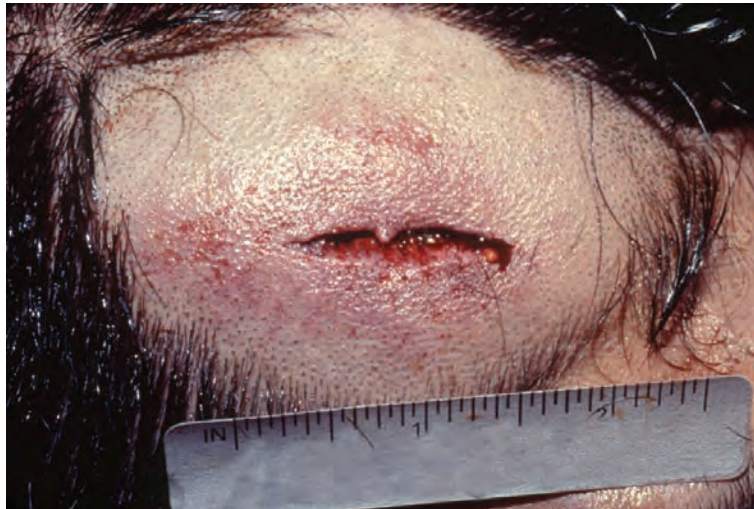This individual was stabbed more than 75 times with an ice pick. Note the linear abrasions extending in different angles across the back as the tip of the ice pick was dragged across the skin's surface. The small dimension of these perforation wounds would take more time to lose significant blood compared with a typical knife blade. Generally speaking, the larger the wound, the faster the blood flow in an extravascular region. There was evidence of a violent struggle over a long period of time in this case.



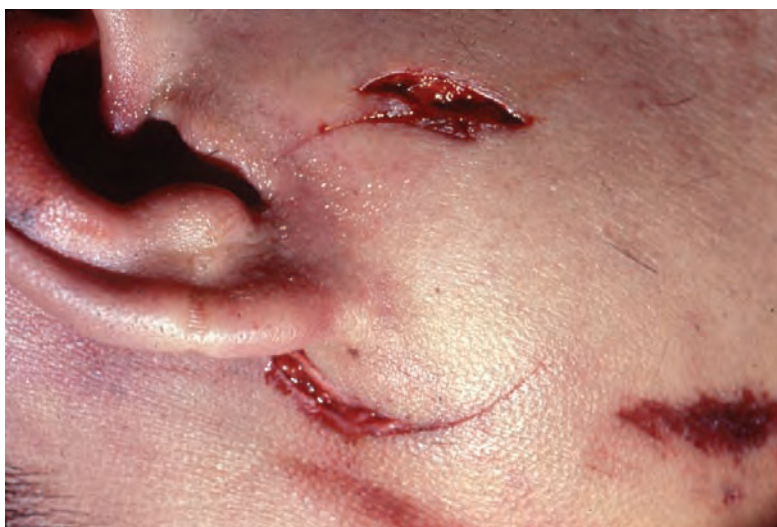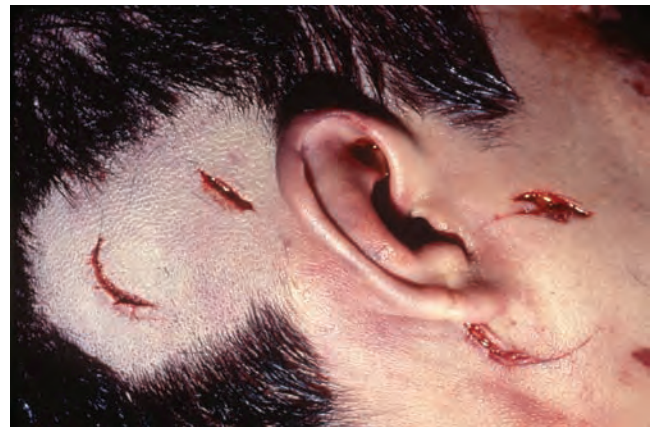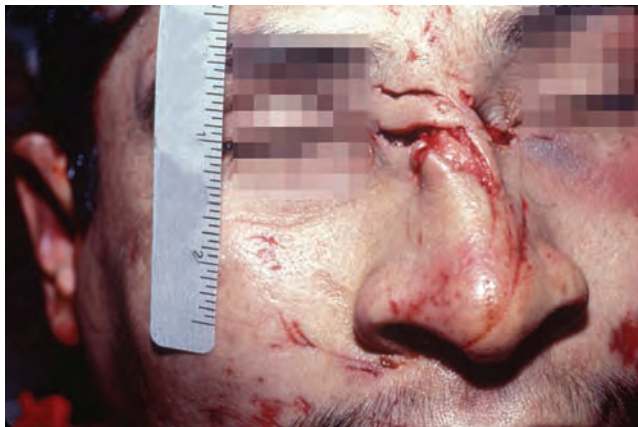This individual was found within a crack house, in a mild to moderate state of decomposition. He sustained multiple stab wounds and puncture-type wounds to his body that were produced by broken pieces of antenna used as crack pipes. One of these antennas was jammed down his throat. He also sustained multiple blunt-impact injuries with rib fractures and other broken bones from being stomped. Note the drying and slight distortion of the wound margins due to decomposition.



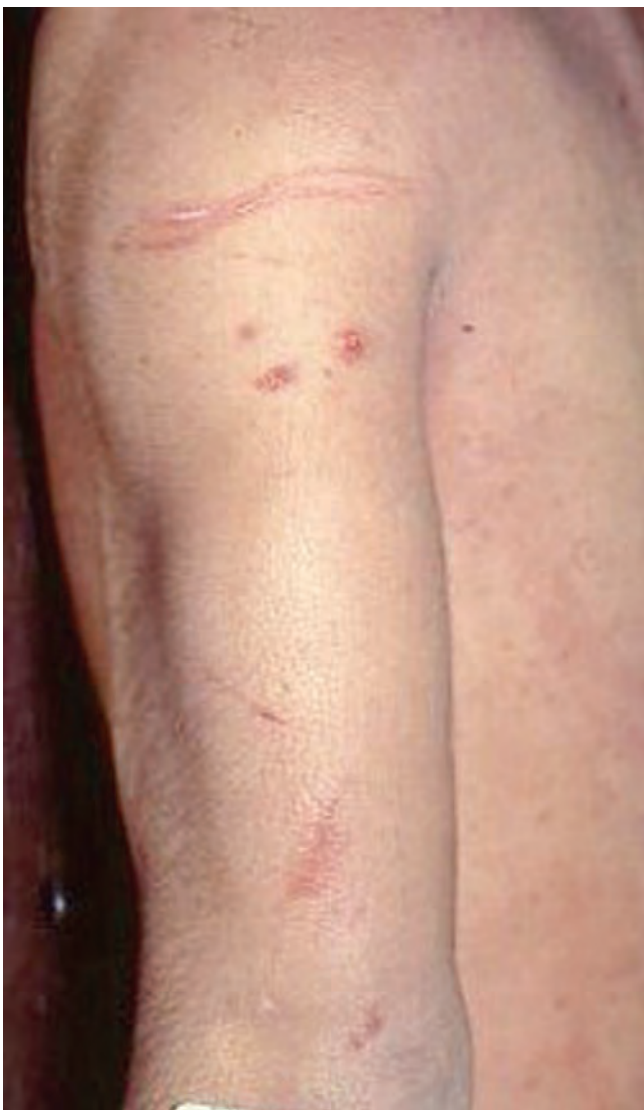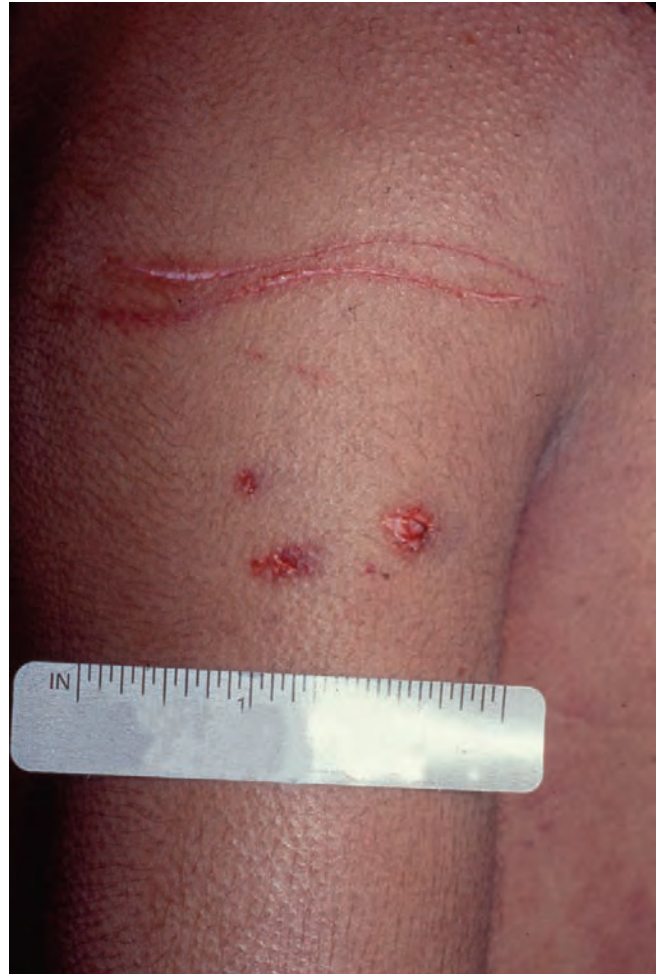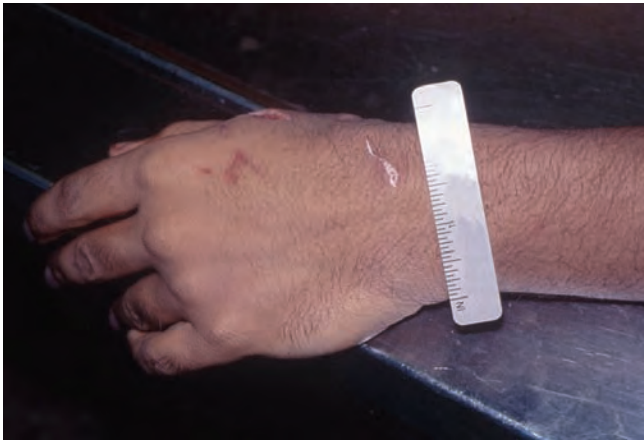This individual was shot with a hunting arrow. The entrance wound is to the medial aspect of the right chest and the exit wound was to the right back. Note the comparison of the injury to the arrow head.



This individual was struck with a bottle that produced a minimal abrasion with a greater underlying contusion and a central laceration. Note the slightly irregular margins at the laceration site due to this blunt impact. The surrounding scalp hair was shaved to demonstrate the injury in greater detail. The presence of the scalp hair at the time this injury was inflicted also served to cushion the impact site.

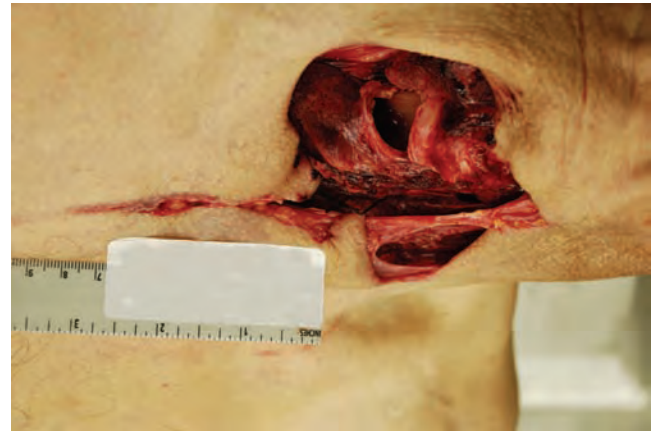
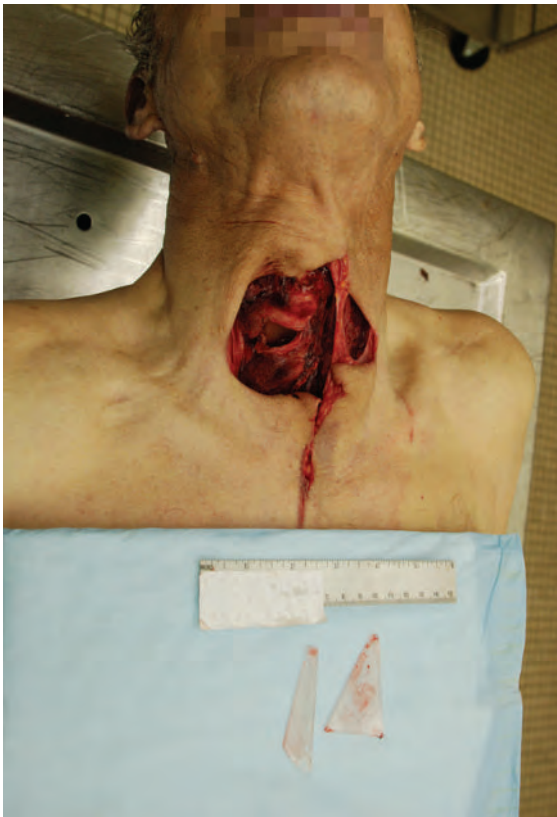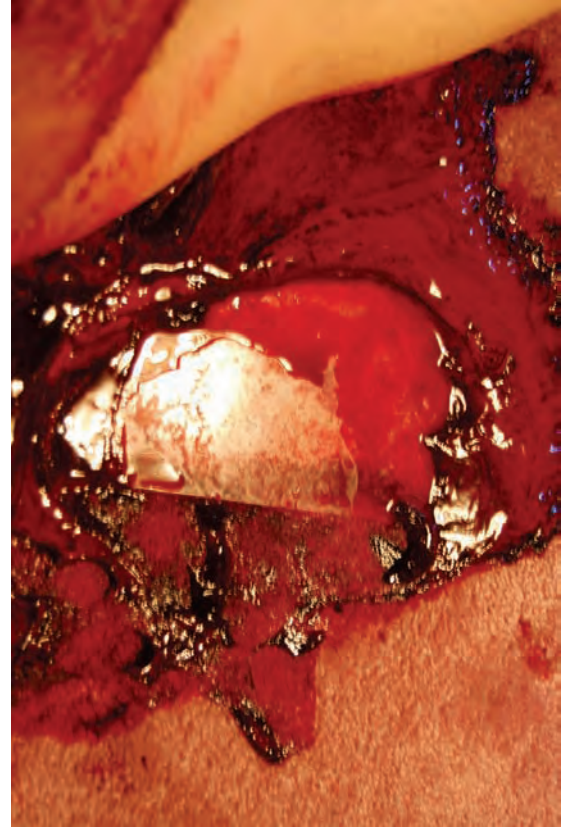

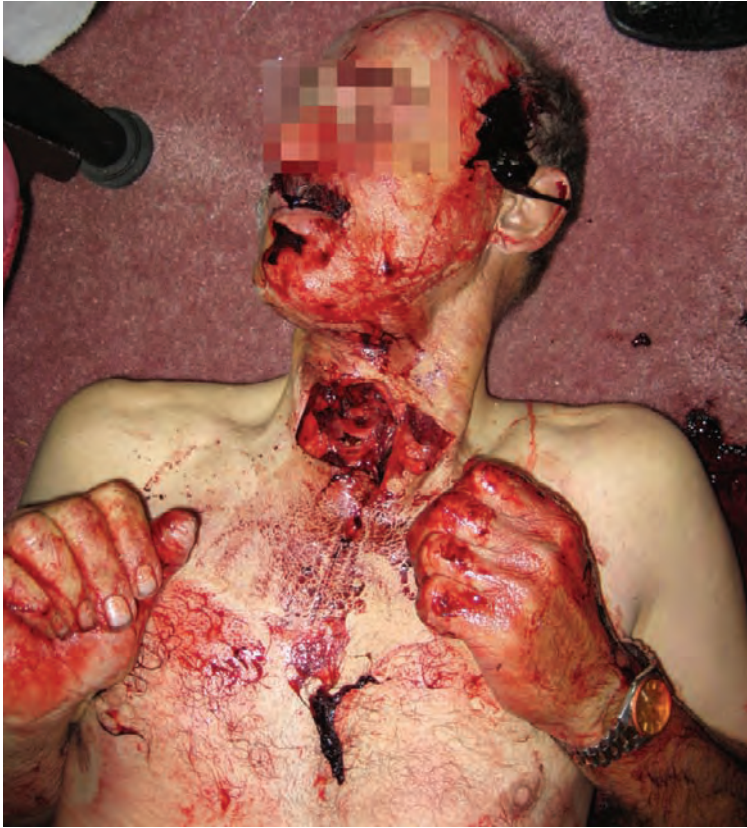
This is the same individual, who was then cut multiple times with the sharp broken glass end of the bottle, producing a partial transection to the carotid artery and exsanguination.

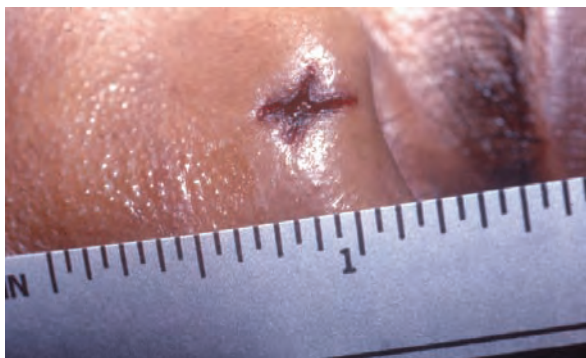
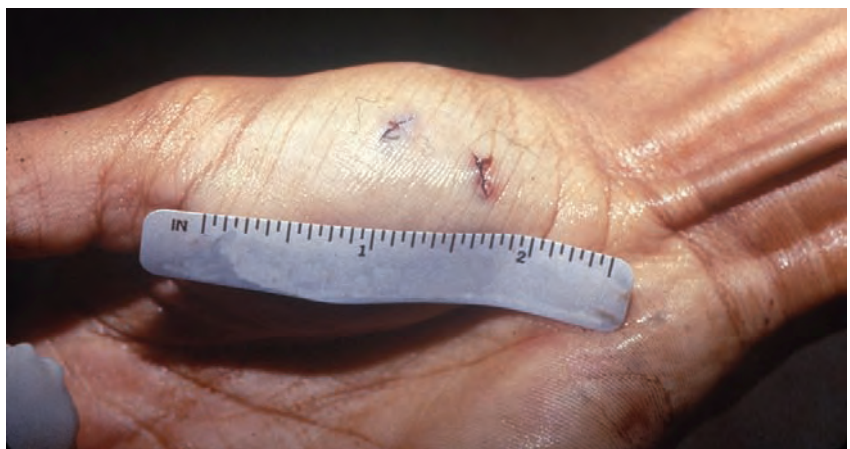
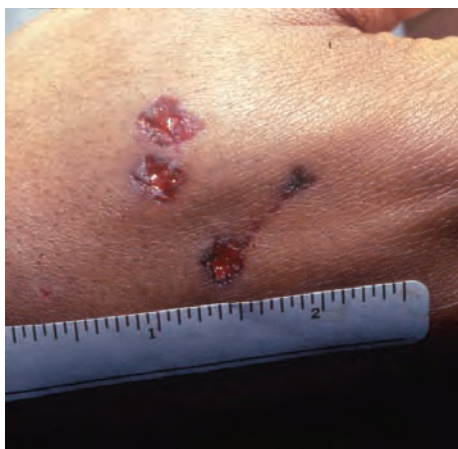
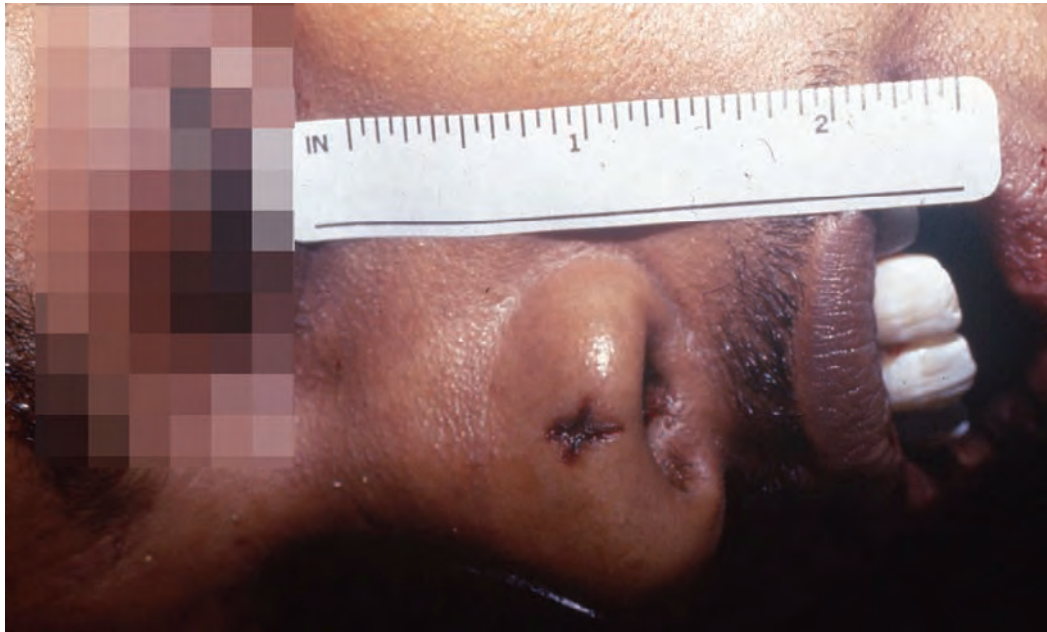The individual had multiple curvilinear parallel abrasions and other superficial abrasions caused by a bottle top and broken glass scraping across the body surface during the assault. This initial argument began over which rival baseball team was better.

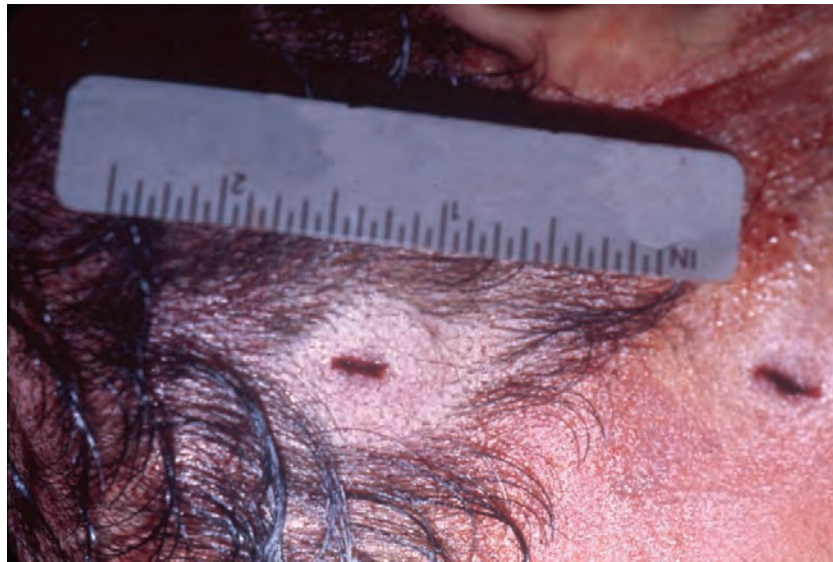
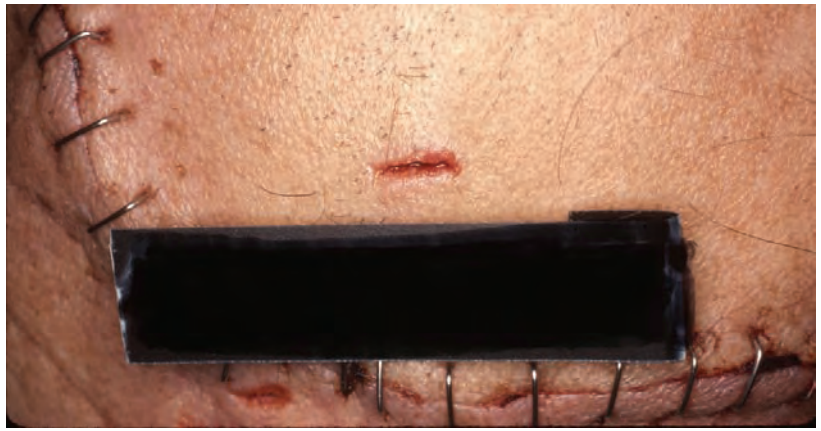
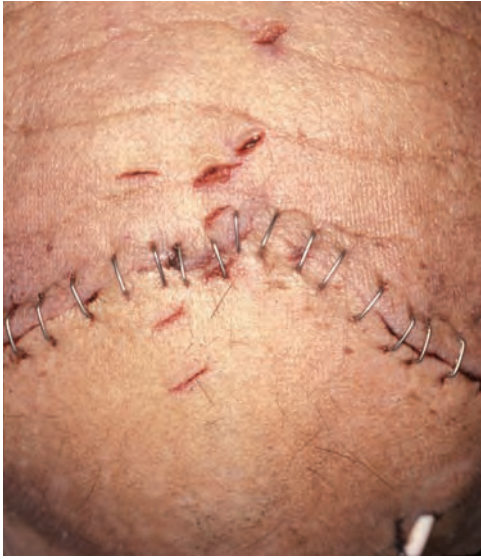


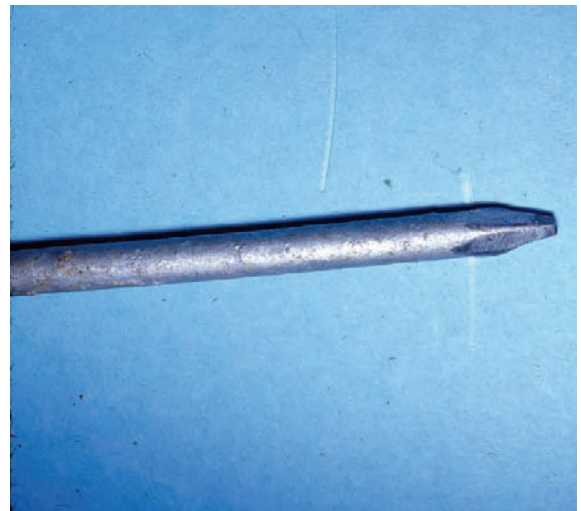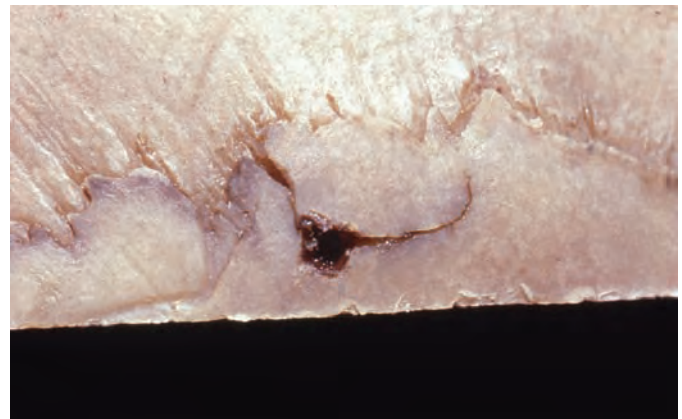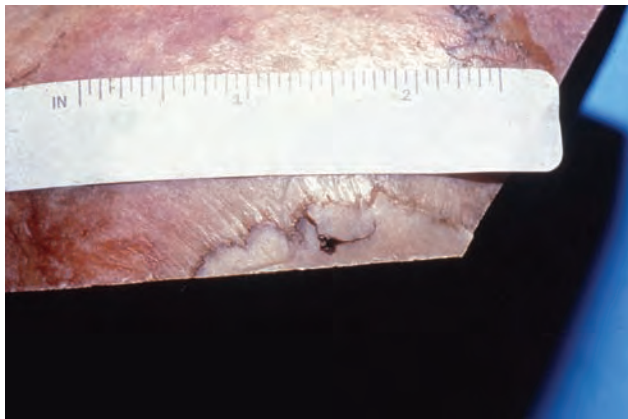
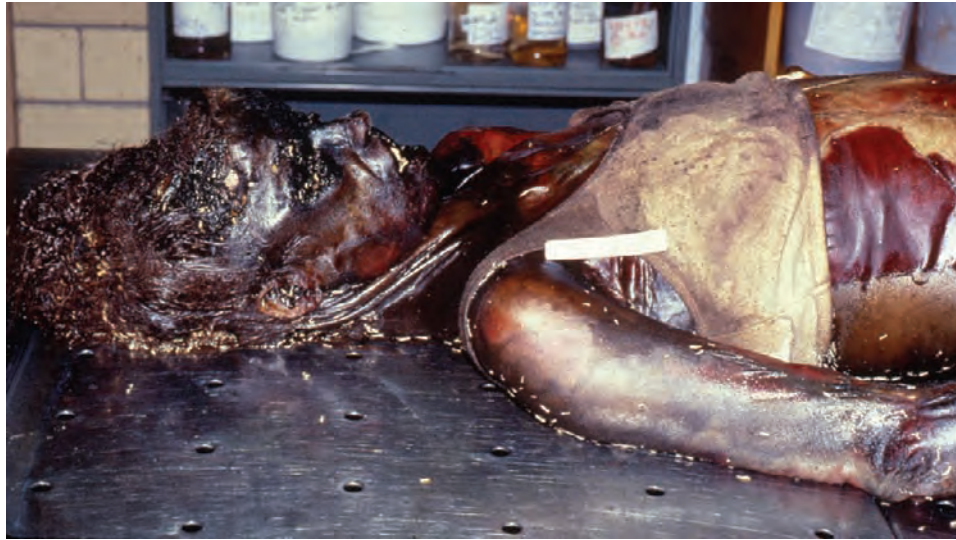Suicide by multiple sharp-force injuries with broken glass taken from an empty picture frame.



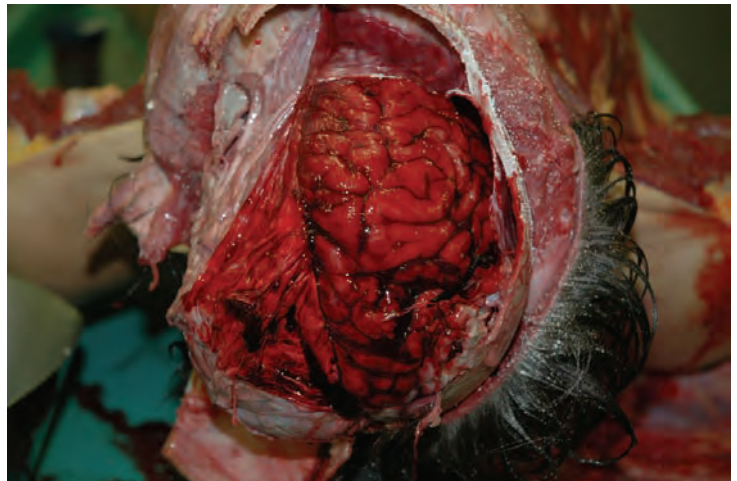
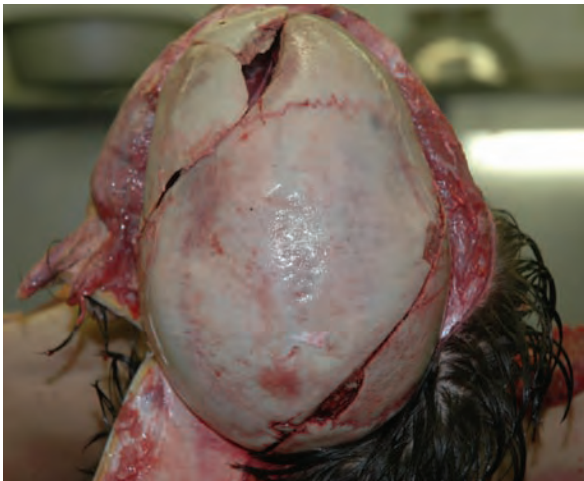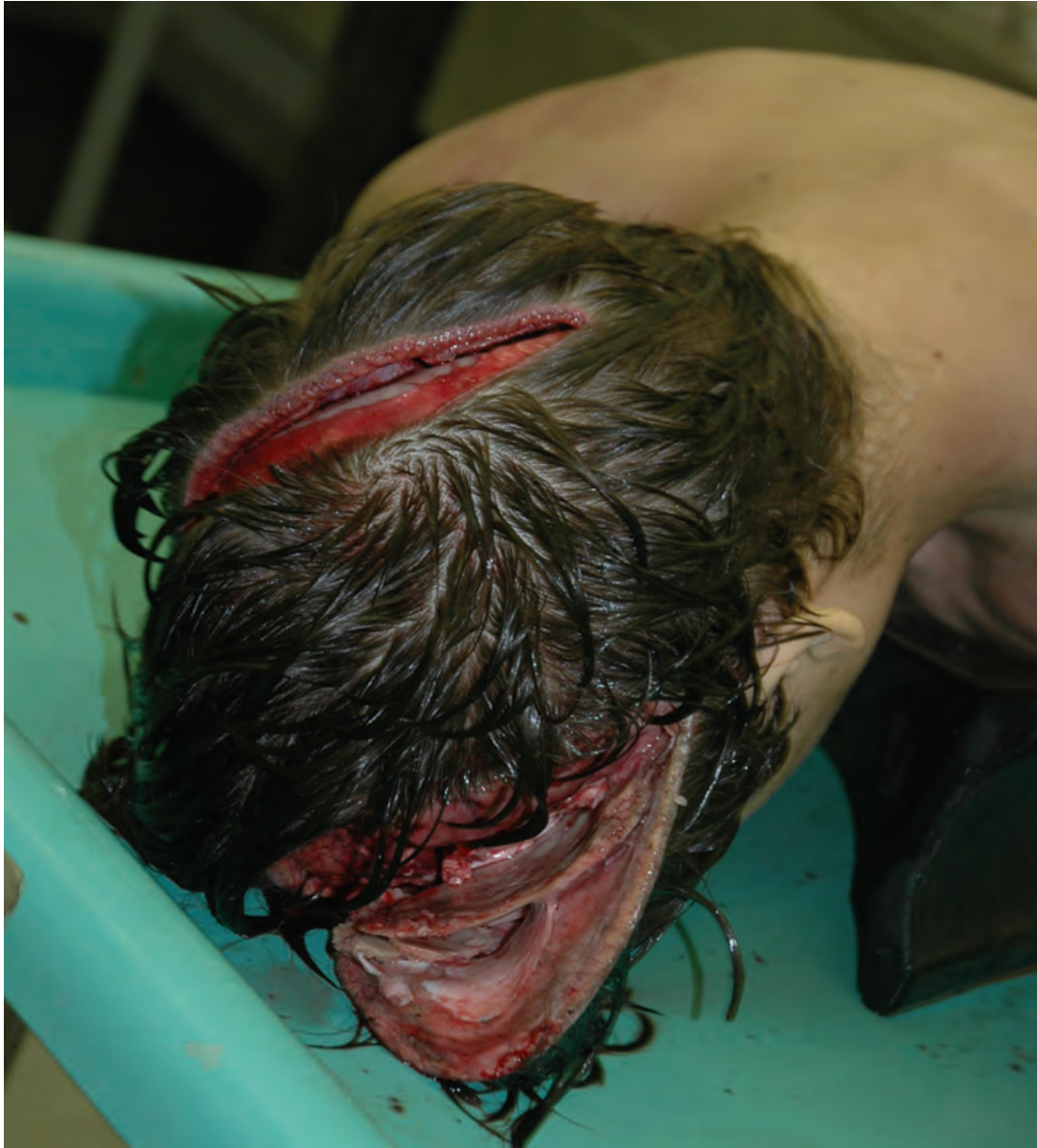These are multiple examples of puncture wounds caused by a Phillips-head screwdriver, demonstrating the range of presentation of this type of injury.



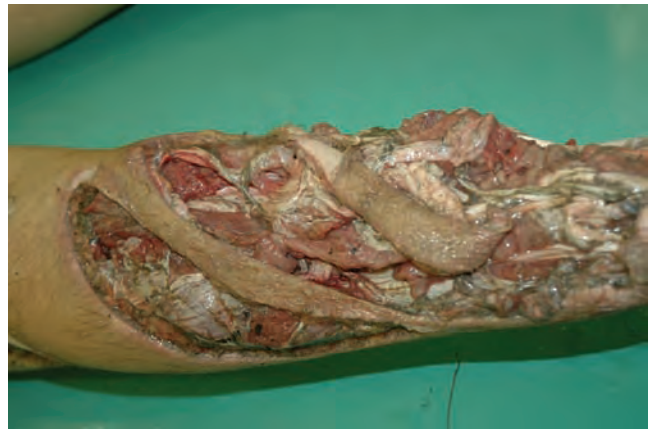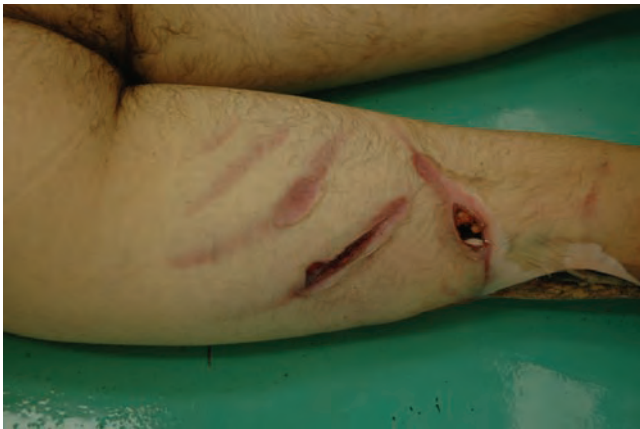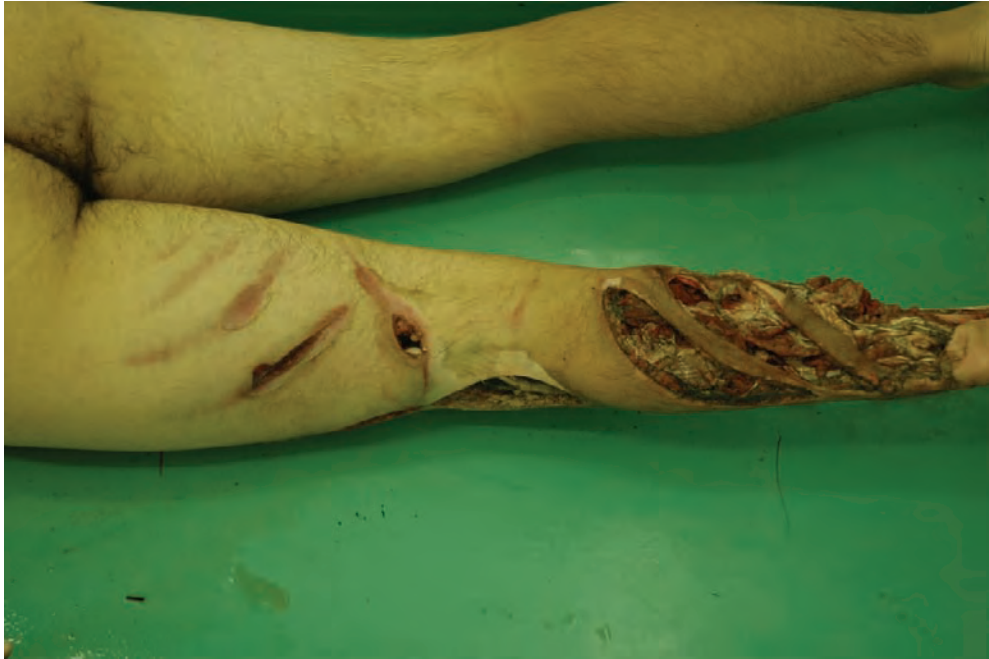These are multiple examples of flat-head screwdriver puncture wounds.



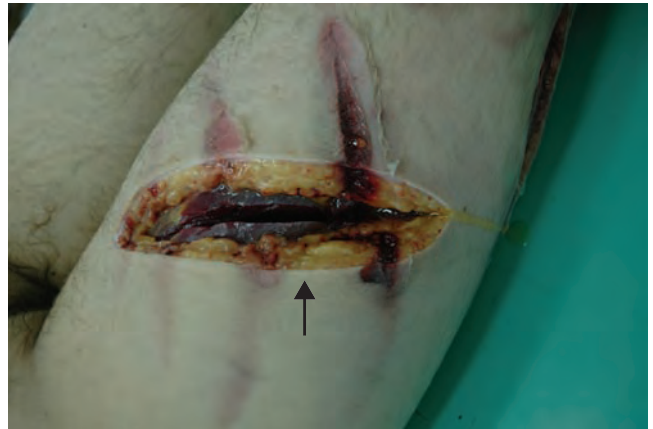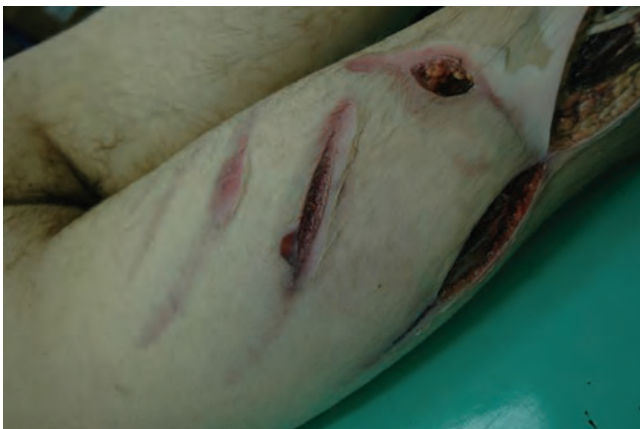This approximately 30-year-old woman was found naked from the waist down in a construction yard. She had moderate decompositional changes with insect and animal feeding. She had multiple defects to her scalp and face with numerous maggots tracking through the underlying soft tissue. The soft tissues in this region were darkly discolored throughout. It becomes more difficult to interpret soft-tissue injuries as decomposition progresses. Careful examination of the underlying bone in such cases may often yield valuable information. Note the approximately 1/4" linear skull fracture with a 1/16" roughly square indentation at the superior right temporal bone. Further examination of the scene revealed a bloodstained board with a nail at the opposite side of the construction site.



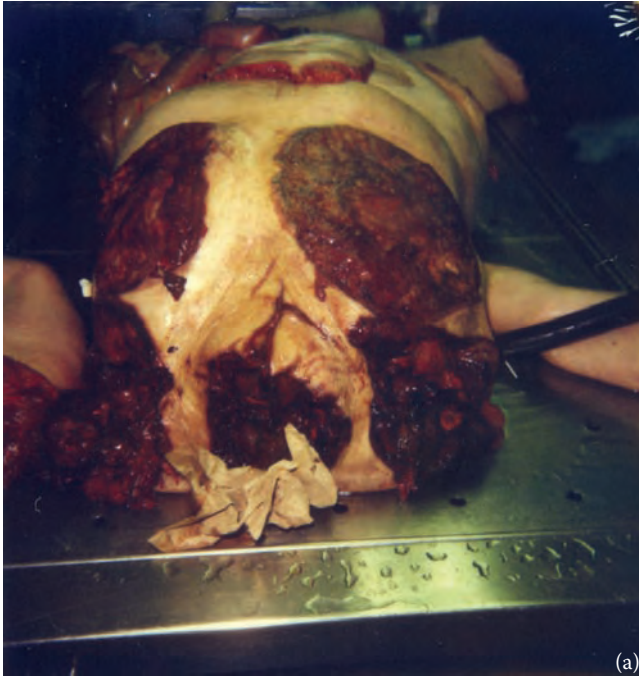
Antemortem boat propeller injuries. Note the presence of wound track hemorrhage and the parallel slicing-type injuries.



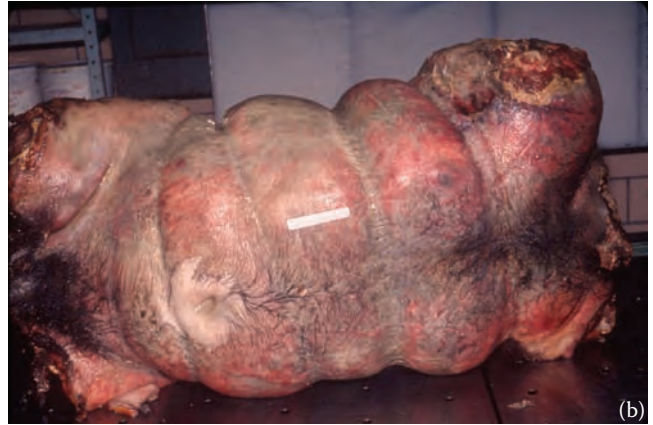
Injuries produced by a boat propeller.



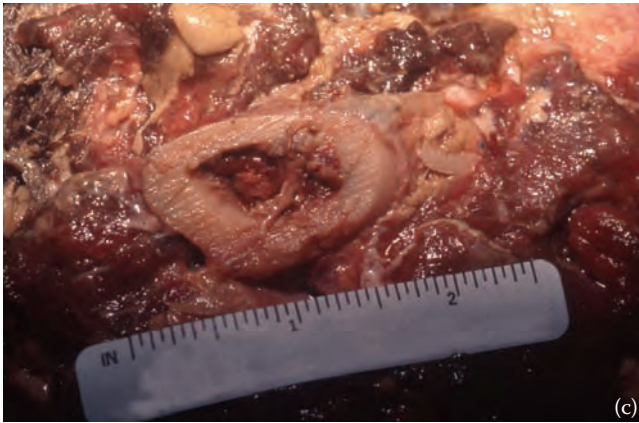
Injuries produced by a boat propeller. Note the hemorrhage at the autopsy incision (lower right), demonstrating the individual was alive when these injuries occurred. Note the range of injury presentation, including superficial abrasion to deep slicing-type wounds with extensive soft-tissue damage.



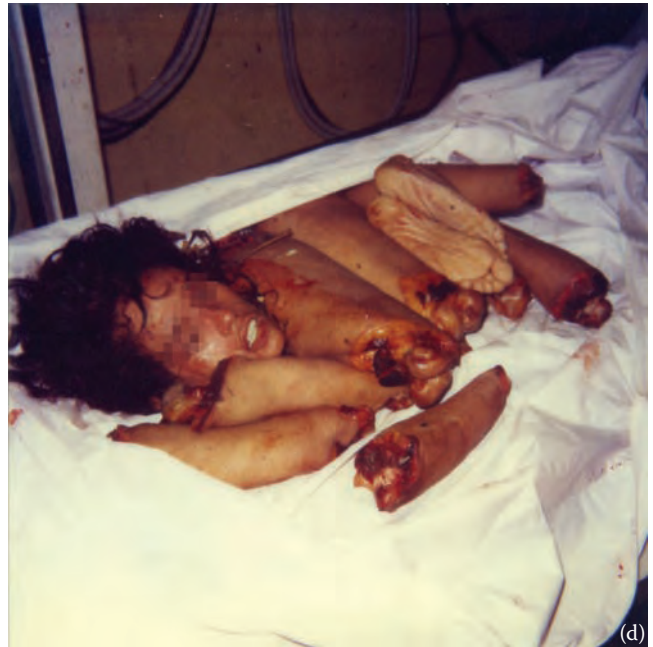(a)



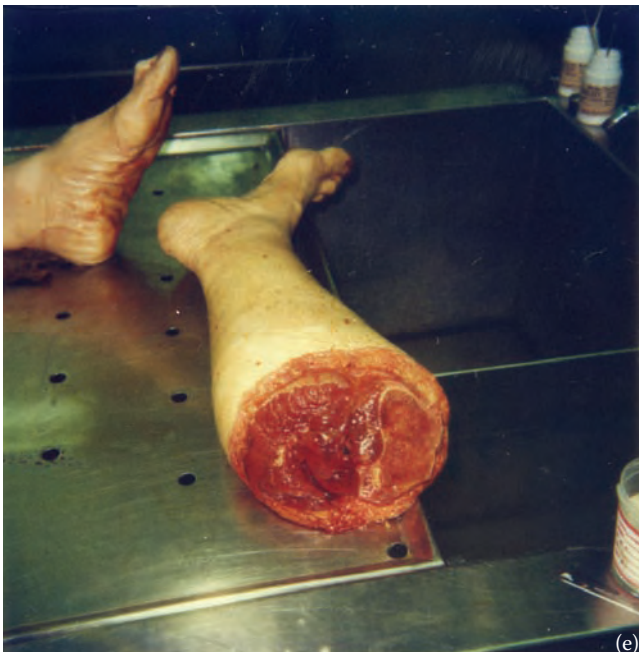
(b)



(c)



(d)

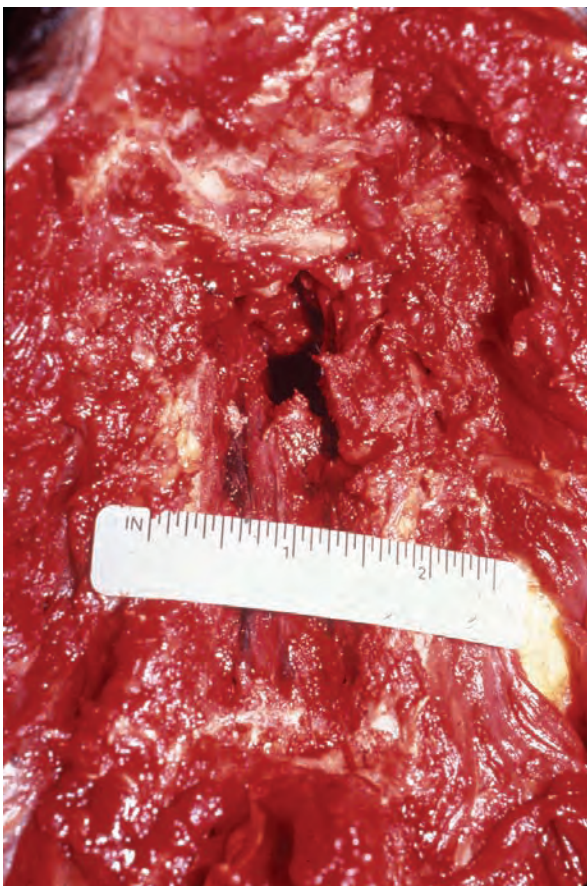
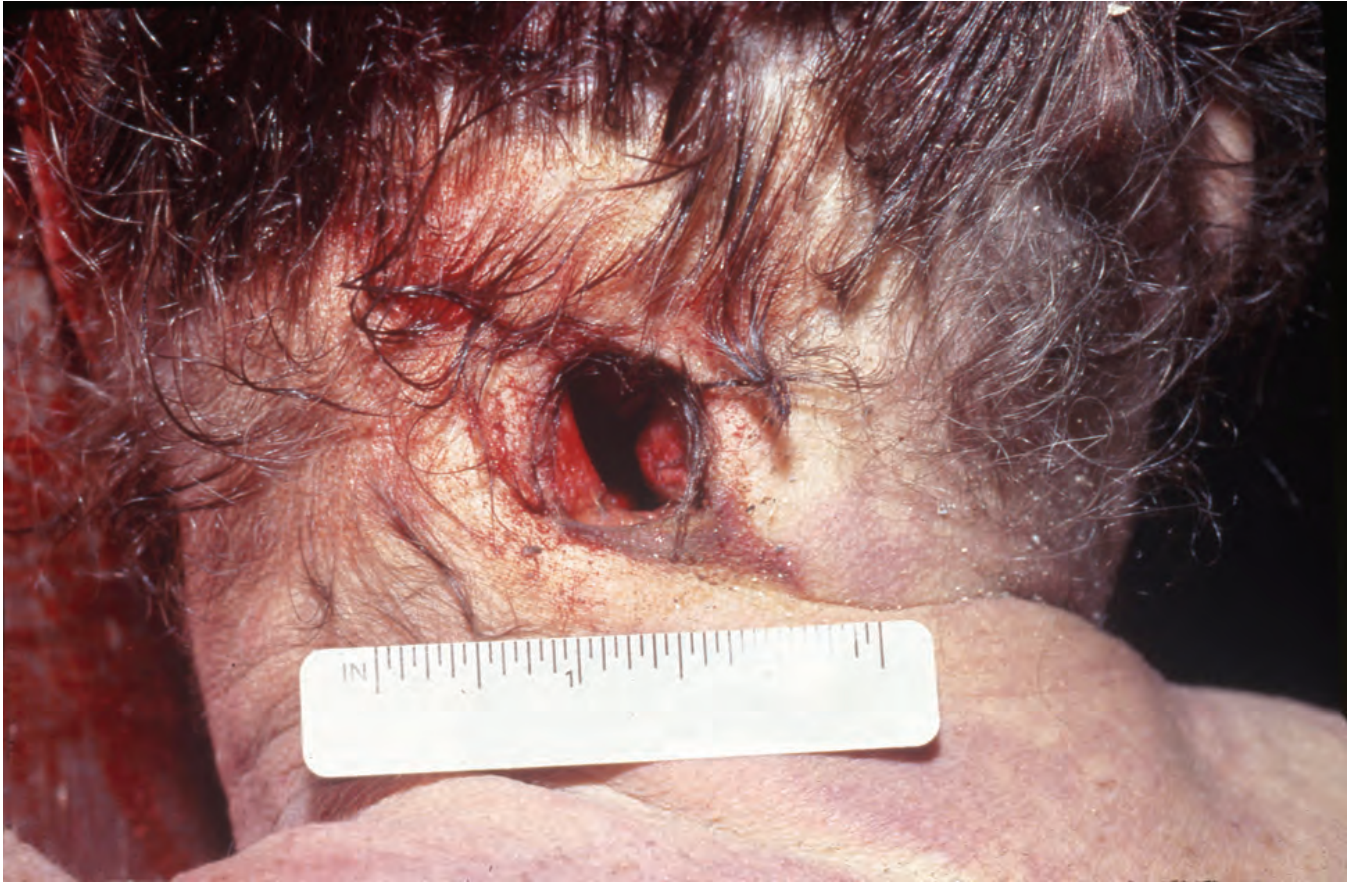

(e)



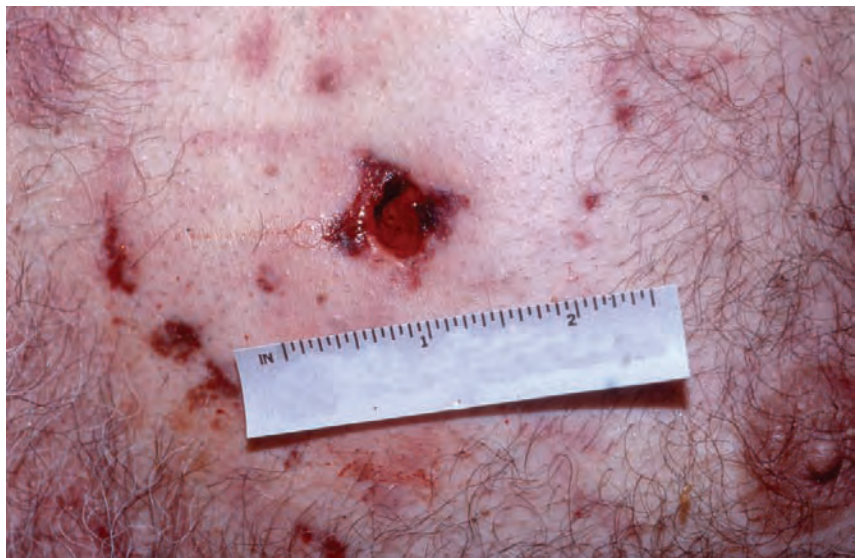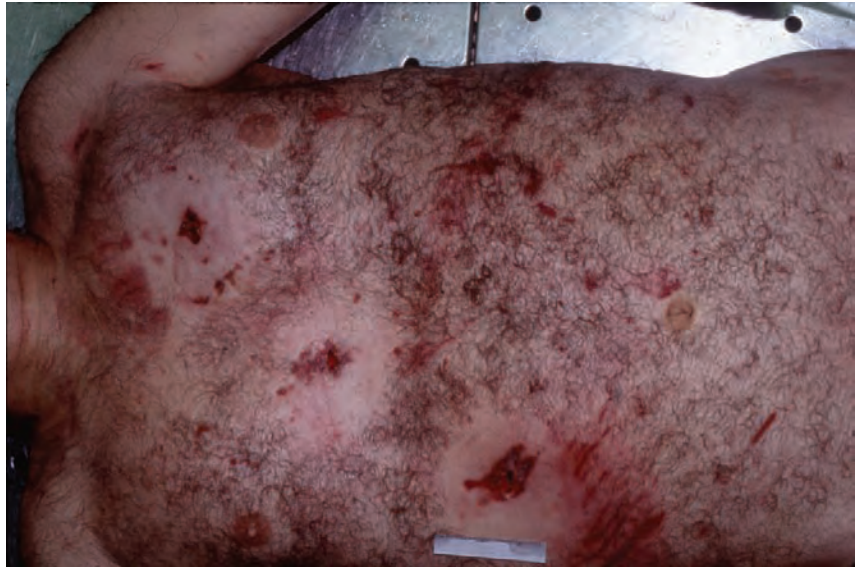(f)

These are examples of dismembered bodies with saw cut marks through bone. It is important to save these portions of bone for possible later tool mark comparison with saw blades used during the dismemberment. Note image (a), where sexual mutilation was performed, with the breasts cut from the body. Also note image (d) of this young individual, who was cut into multiple pieces and neatly stacked on a rooftop.

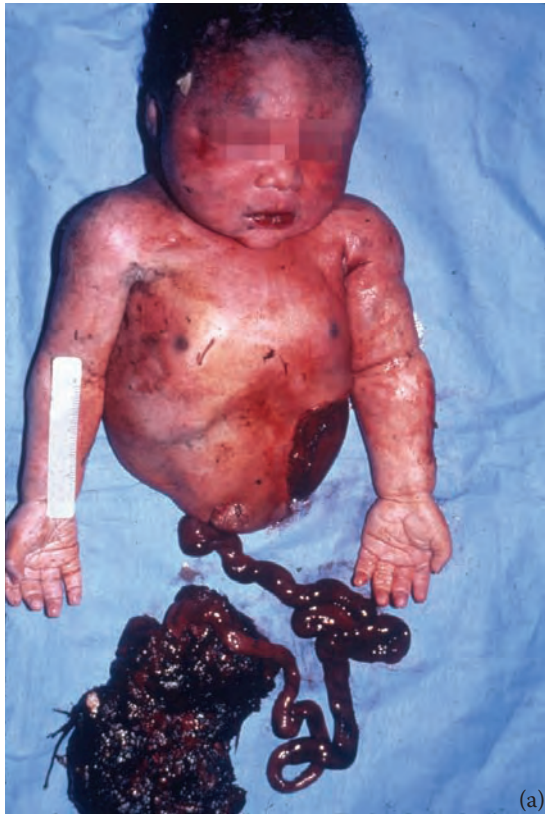

This individual was killed by being struck in the back of the neck with a pickaxe. Note the abraded margin and the perforation matching the roughly squared dimension of the pickaxe. This dispute was reportedly over not receiving back pay after complete work.

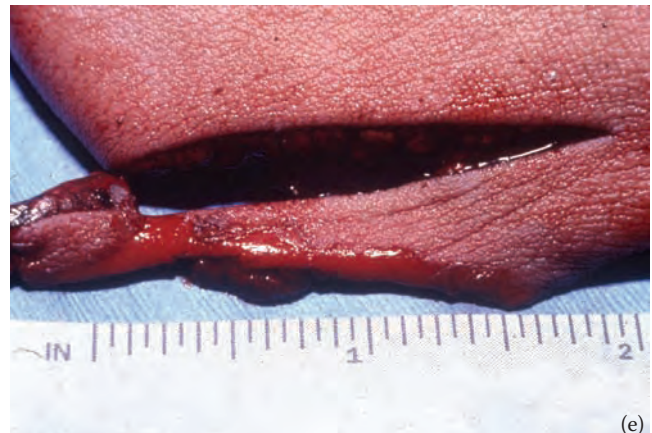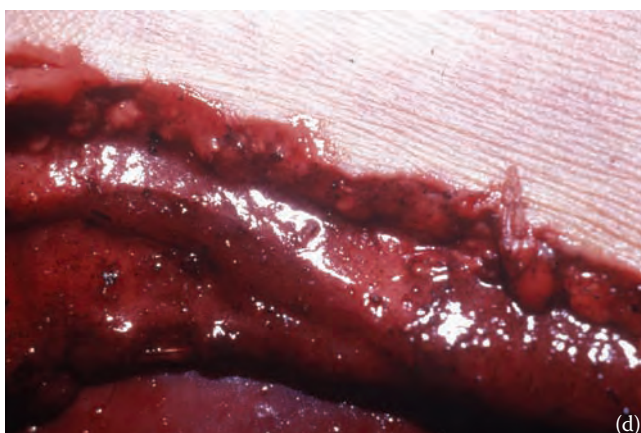

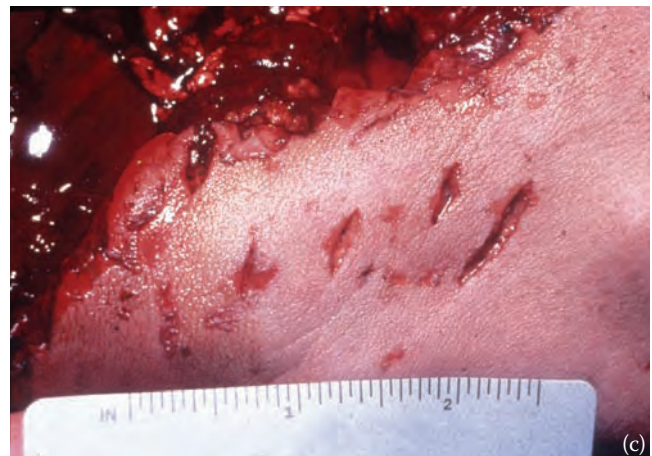
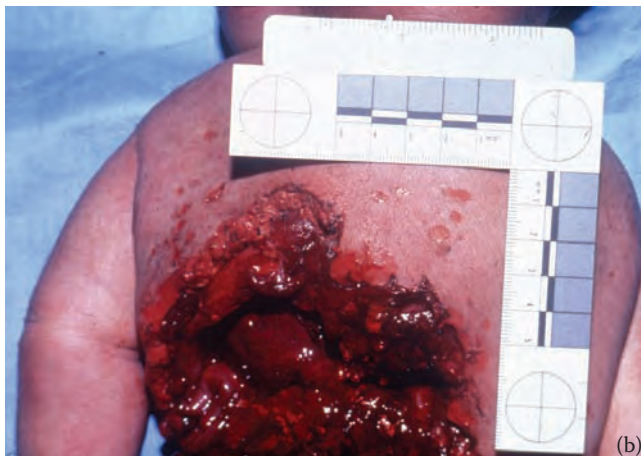

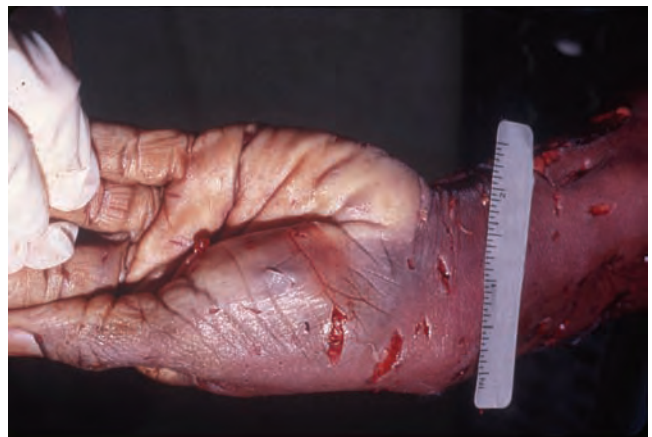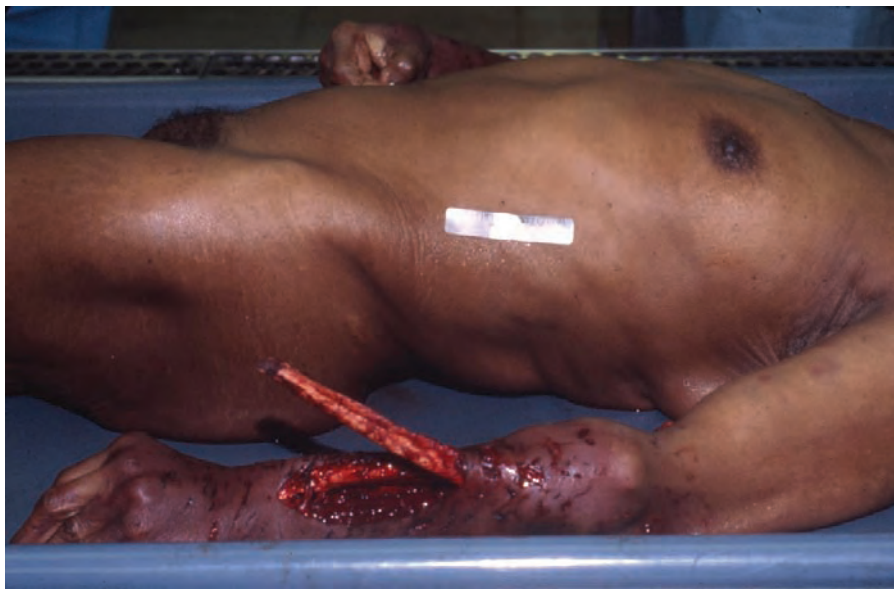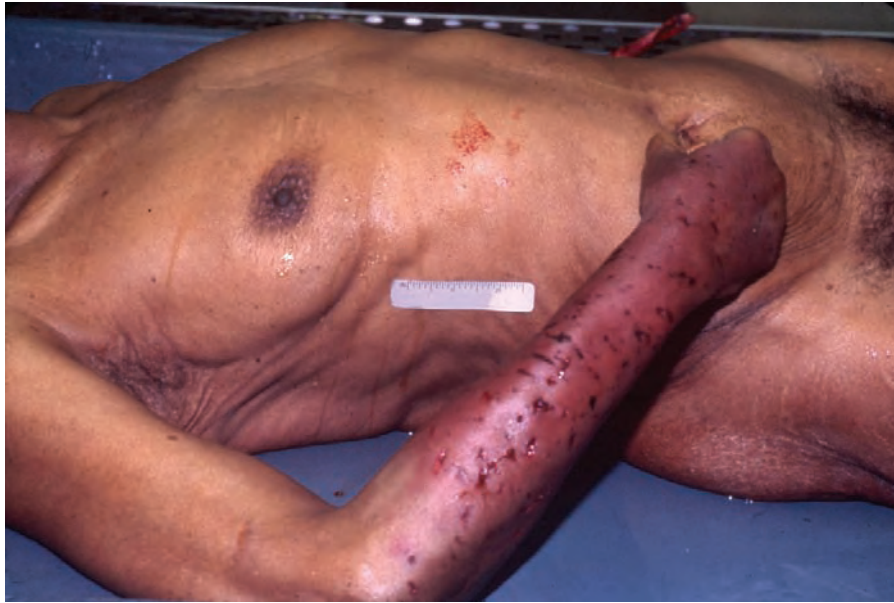This individual committed suicide by jumping out of a window and landing on top of a spiked metal fence similar to the one shown in image (c). The hair surrounding these injuries was shaved to demonstrate the nature of the wound in greater detail. Note the pointed circular perforation site leading into a square abrasion, which was perfectly consistent with the fence spike that penetrated his chest.

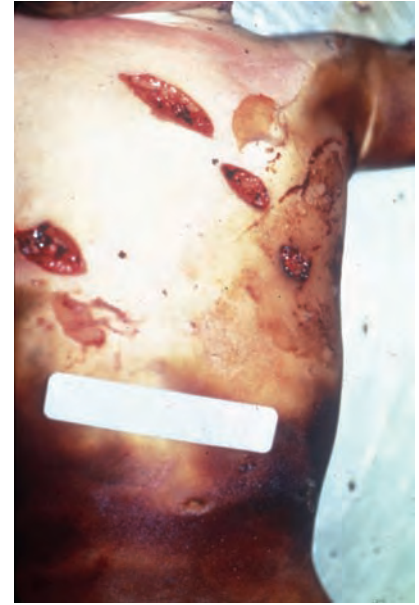
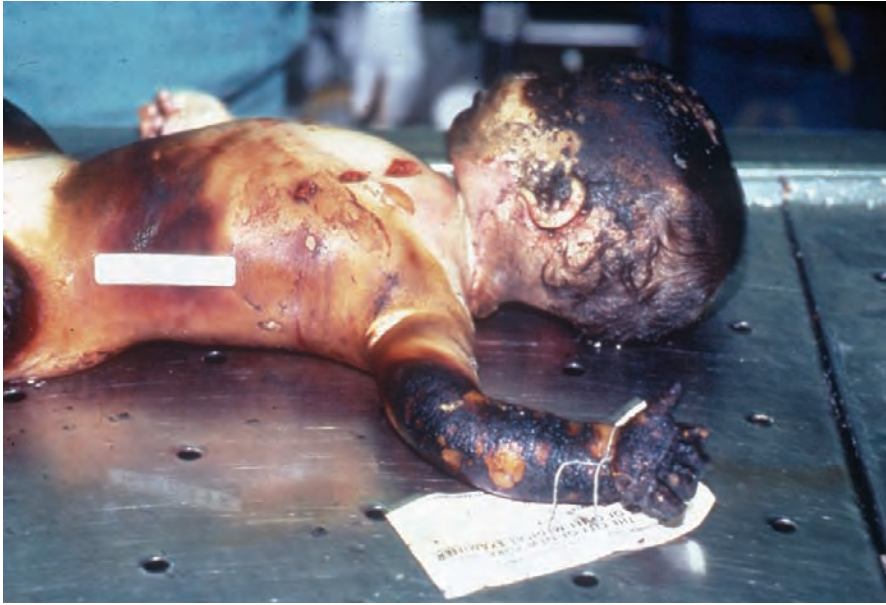
This infant was found partially eaten by dogs in a building courtyard. Note the irregular nature of the wounds to the back (b–d), demonstrating a scalloped border produced by teeth and claws. Other injuries to the child’s body were inconsistent with animal feeding and more likely were produced by a sharp instrument such as a knife. Note the sharp wound margins in image (e). Dogs may eat a decomposing body when they are left to starve, or they may kill living individuals, more often without eating them. It has been my experience that it is rare for a domesticated dog to eat an individual unless it is coaxed into it by exposing the hungry dog to initiate feeding activity. The dog should always be examined including the gastrointestinal contents. In one such case, neatly cut strips of soft tissue were found within the dog’s stomach that were fed to the dog by the perpetrator to initiate more feeding activity.

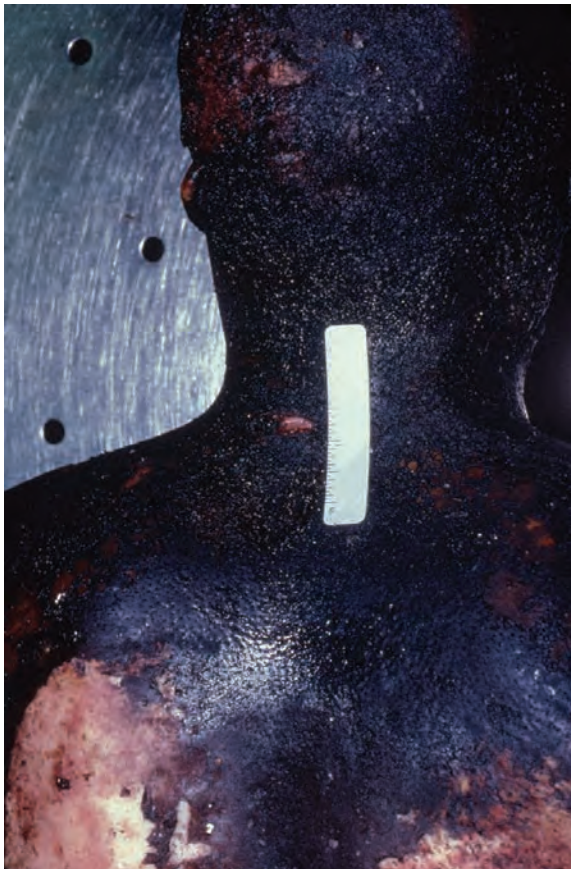



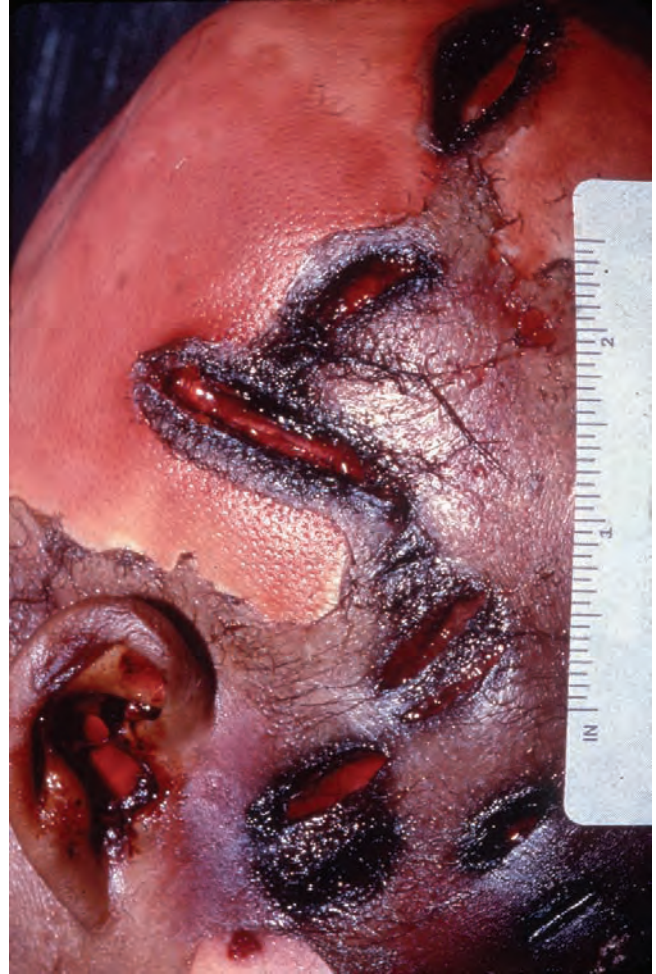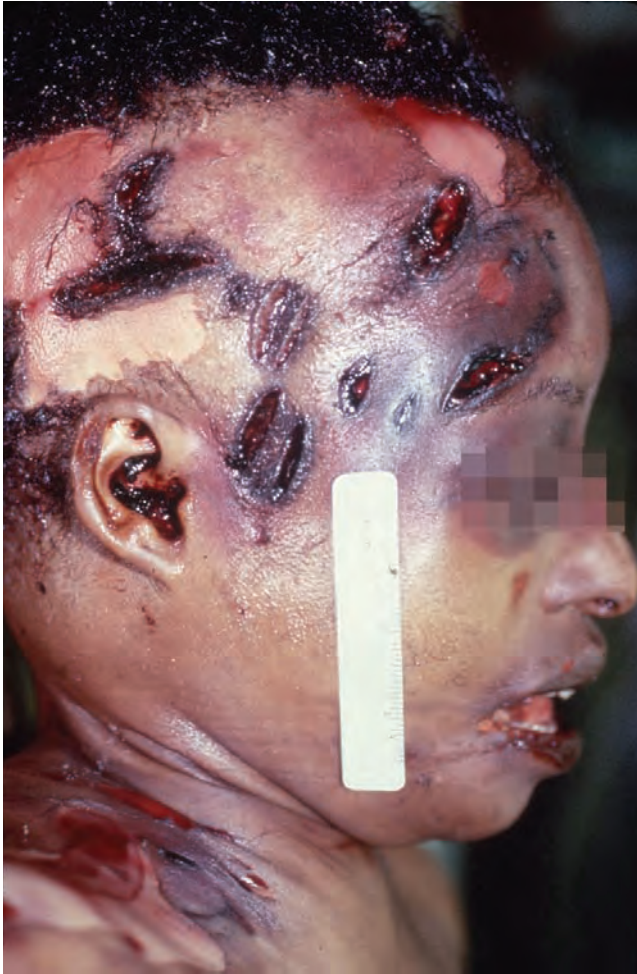These are multiple puncture marks and lacerations with extensive adjacent hemorrhage due to an antemortem dog attack by a pit bull. This individual died as a result of blood loss.



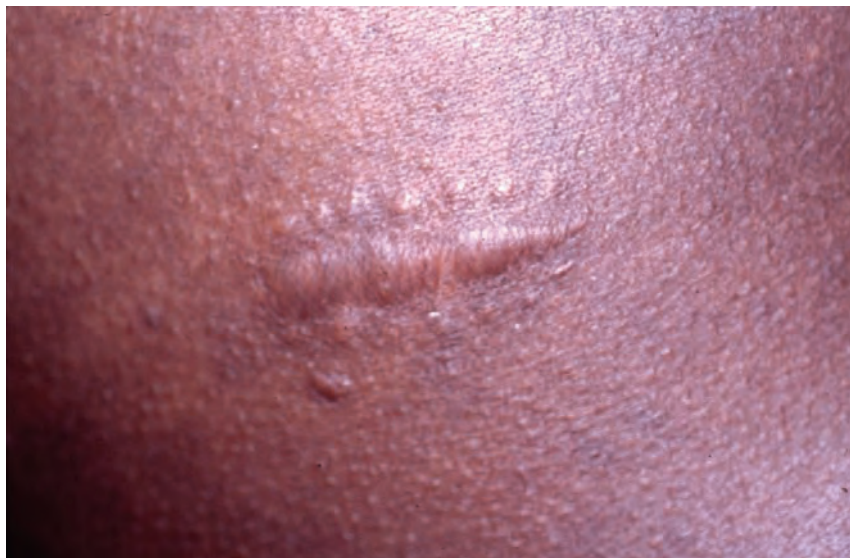This perpetrator killed his family by inflicting multiple stab wounds and then setting their house on fire. Note the relationship between environmental factors such as heat and the change in wound characteristic. This is demonstrated to a greater degree in the following figures.



This individual was stabbed multiple times and his apartment was set on fire to conceal evidence of the crime. Note the charring of the skin with the sharply margined defect, which was from a stab wound. Internal examination revealed extensive hemorrhage throughout and surrounding the wound track. Sometimes the surface interpretation of such injuries can be challenging. Thermal damage may cause cracking of the skin, which may be misinterpreted as antemortem sharp- or blunt-force injuries.



This individual sustained multiple blunt- and sharp-force injuries due to homicidal violence. She was found many hours after the assault during a hot summer month. Note the putrefactive changes with skin slippage and green to brown discoloration. Also note the wound margins are dry and dark. Some of these wounds could obviously be classified as lacerations or stab wounds and others could not be classified due to distortion by decomposition.



Healed stab wound.

---

# Gunshot Wounds

# 8

CHARLES A. CATANESE, THOMAS GILSON,  
AND THOMAS ANDREW

---

## Introduction

---

The evaluation of gunshot wounds is an area of importance in forensic medicine. Analysis of gunshot wounds should involve:

- Differentiation of wounds of entrance from exit
- Range of fire estimation for entrance wounds
- Determination of trajectory through the body
- Recovery of evidence (e.g. ballistics)

Whenever possible, clothing worn by a gunshot wound victim should also be examined.

## Entrance and Exit Differentiation

---

### Entrance Gunshot Wounds

Most entrance wounds appear as circular perforations with a margin of abrasion, a collar of abraded skin, and the entrance defect. The margin of abrasion is produced by stretching with eventual tearing of the skin surface as the bullet enters the body. It is the most reliable feature in identifying entrance gunshot wounds. Exit gunshot wounds lack this feature, as the undersurface of the skin is stretched outward when a bullet exits the body. The margin of abrasion may provide useful preliminary information regarding trajectory of a bullet through the body. When the bullet enters the body perpendicular to the surface, the margin of abrasion is symmetric. As the bullet enters the body on an angle, the margin will be elongated on the side where the bullet first contacts the skin. The trajectory is confirmed by subsequent internal examination.

### Exit Gunshot Wounds

These types of wounds typically appear as slit-like or irregular perforations without margins of abrasion. An exception to this is a shored or supported exit, which occurs when a bullet exits from the body where the skin is firmly supported. This might occur as a bullet exits when an individual is leaning against a wall, lying on the sidewalk, or even wearing tight-fitting clothing. These

wounds generally have a round appearance and may have superficial abrasion around the defect. Unlike the true abrasion margin of an entrance wound, the shored exit abrasion tends to lack any significant depth and is often very irregular.

### Atypical Gunshot Wounds

These are entrance wounds characterized by an irregular appearance. They may have irregular or obscure margins of abrasion. The skin adjacent to the entrance wound may show irregular abrasions or lacerations. Sometimes these perforations may appear as irregular tears. Ricochet bullets, or bullets that pass through intermediate targets, often produce atypical entrance wounds. Sometimes the jacket and the slug may separate and produce two separate irregular entrance wounds. Bullets may strike surfaces such as concrete and fragment into pieces, causing multiple irregular defects from impacts of both twisted metal and rock fragments. Fragments from upholstery, chrome, plastic, etc. may be found at the wound surface or even within the wound track. This atypical appearance may also be seen in certain areas of the body where the skin is thicker (palms and soles) or the skin contour is irregular (face). Atypical wounds may be difficult to interpret, particularly in perforating gunshot wounds where the bullet passes through soft tissue only. Fracture characteristics of bone (especially flat bones such as the skull) and lead fragmentation patterns may give great insight into establishing direction of fire.

### Range of Fire Estimation

---

In estimating range of fire, an attempt is made to determine the distance from the end of the barrel of the gun to an entrance wound at the time the weapon is discharged. This is most reliably estimated by observing the wound and trying to re-create an observed pattern by test firing the weapon. Because the weapon is often not available, estimates based on the physical characteristics of the wound are frequently employed.

An understanding of ammunition aids in understanding range of fire estimation. The ammunition

placed into a firearm is a cartridge. A cartridge consists of a bullet, which rests atop a casing containing gunpowder. A primer located at the base of the cartridge ignites the powder. The primer is itself ignited by the mechanical action of the hammer of the firearm, when the hammer strikes the base of the cartridge. The bullet is the portion of the cartridge that exits the barrel. It is propelled by the burning gunpowder. In general, there is some residual gunpowder that does not burn. In addition to the bullet, burned and unburned gunpowder exits the barrel when a weapon is discharged. This forms the basis of range of fire and estimation.

Range of fire can be divided into three major categories. These include *close range*, *intermediate range*, and *distant range*. As noted, range of fire is best estimated by the use of test firings employing the known weapon with similar ammunition. Lacking these ideal conditions, estimates can be made on the basic wound characteristics as described next. Even when test firings can be performed it is worth remembering that the wounding characteristics of skin are not identical to gunpowder residue deposition on a test-firing cloth.

### Close Range of Fire

This is characterized by the presence of *soot* on the adjacent skin surface or within the wound track. Soot is burned gunpowder residue with a dark powdery appearance. It is critical to remember that soot can be wiped from the body's surface, so gunshot wounds need to be examined prior to any washing, whenever possible. The presence of soot indicates the end of the barrel of the gun was held within approximately 6 to 8 inches from the body's surface. Different guns may have different ranges. The closer the end of the barrel is to the body, the denser the soot deposition. As this distance increases, the soot deposition becomes sparser. Soot may be present with stippling (see intermediate range of fire), but this is more accurately still considered close range of fire. When the end of the barrel is very close to the body, there may also be searing of the adjacent skin from burning gunpowder and flame that extends from the end of the barrel. Soot can be filtered away through intermediate targets such as clothing, car doors, walls, etc. This pattern becomes more dispersed as the distance becomes greater.

Within the close-range-of-fire category are contact gunshot wounds where the end of the barrel touches the body. These may be further subdivided into *tight contact* and *loose contact*. Some classify wounds where the barrel is very close to the body as *near contact*. The term "close contact" is redundant, potentially confusing, and best avoided.

### Tight Contact Gunshot Wounds

These are produced when the barrel of the gun is held tightly against the body's surface. Most of the soot will be deposited within the wound track and may not be apparent until autopsy examination. Small amounts of soot may be present at the wound margins. Depending on the body region, type of gun, type of ammunition, and force with which the gun is pressed against the body, the wound may appear different. There are often abrasions adjacent to the gunshot wound. These are associated with the muzzle of the gun rubbing against the body's surface as the gun is discharged. These may take the form of a semicircular rim or a complete imprint pattern of the entire muzzle. When the gun is held tightly to the body, particularly over a bony surface such as the skull, there may be multiple radiating linear lacerations. These lacerations may be small or large and are more commonly associated with larger-caliber bullets. Approximation of the laceration margins reveals a central circular perforation typical of an entrance wound with abraded margins. Observation of the muscle under a tight contact wound may reveal a pink discoloration owing to the introduction of combustion products into the wound track such as nitrites and especially carbon monoxide binding with myoglobin.

### Loose Contact and Near Contact

When a gun is held less tightly against the body, soot may escape more readily to the skin's surface. If the gun is discharged at an angle to the body's surface, the pattern of soot dispersion will extend over a greater surface area in the direction of fire. A partial muzzle imprint may be observed. In near contact wounds, the soot is deposited in a dense, relatively small area around the entrance and searing of the skin may be observed as noted above.

### Intermediate Range of Fire

This range of fire is characterized by the presence of *stippling* defects around the entrance wound. These are small, (approximately 1/16 inch) red to brown, punctuate abrasions of the skin's surface. Stippling indicates the end of the barrel of the gun was held approximately 18 to 24 inches away from the body's surface. These defects are produced primarily by fragments of unburned gunpowder that exit the barrel with the bullet. These fragments strike the body with greater force than soot and produce permanent defects. Such defects cannot be wiped away from the body's surface. The appearance of stippling may vary depending on the type of gunpowder used in the cartridge, (e.g., ball, disk, or flake).

The term *stippling* applies to the defects in the body's surface. This pattern will become more dispersed as the distance from the weapon to the body's surface increases. Like soot, stippling can be dampened or completely filtered by clothing or other intermediate targets. Powder residue found on intermediate targets at this range of fire is characterized by small, separate, gunpowder fragments.

Soot or stippling defects may be present on an outstretched hand but not surrounding the entrance wound. For this reason, close examination of the upper extremities in gunshot wound cases may be helpful. Range of fire is estimated in the same way and the distance between the weapon and the entrance wound can be approximated by factoring in the distance from the wound to the upper-extremity findings.

Occasional "pseudostippling" may be seen around an entrance wound. This phenomenon is generally seen when a bullet passes through an intermediate target and fragments of the intermediate target strike the skin's surface (causing abrasions) around the entrance wound. As noted, such entrance defects tend to be irregular and the adjacent stippling defects exhibit wider size variation than true stippling, where the abrading gunpowder tends to produce abrasions of relatively uniform size.

### Distant Range of Fire

This range of fire is characterized by the absence of gunpowder residue around an entrance gunshot wound without an intermediate target between the end of the barrel and the wound. This indicates the end of the barrel of the gun was held more than approximately 18 to 24 inches away from the body's surface. Some experts prefer to call this intermediate range, especially when the possibility of an intermediate target cannot be excluded.

### Trajectory Determination

---

The path a bullet takes through the body may have substantial medicolegal significance. In some cases, the trajectory can be easily determined by careful dissection. In other cases, (e.g., multiple gunshot fatalities), full delineation of wound tracks may be harder to accomplish as a result of extensive internal injury. Surgical intervention may also obscure wound tracks in part. It is also worth remembering that a wound sustained in a certain body position may look slightly out of alignment with the body lying supine on the autopsy table. Superficial wounds can pose difficulties in trajectory determination as entry and exit wounds may not be easily identified. These include graze and tangential gunshot wounds.

### Graze-Type Gunshot Wounds

These are produced when the bullet contacts the skin superficially at a very narrow angle, producing an elongated superficial oval abrasion. One may determine direction of fire by a semicircular margin of abrasion at the entrance side and a more irregular margin at the exit side.

### Tangential Gunshot Wounds

These are produced when the bullet strikes the skin superficially at a narrow angle and creates lacerations of the underlying subcutaneous tissue and overlying skin. Direction of fire may be established by the presence of a semicircular margin of abrasion at the entrance side. Also, the laceration of the skin overlying the wound track produces tears with skin tag formation. These tags will extend outward on angles. The tips of these lacerations, at their most medial aspects (e.g. within the wound track), point toward the side from which the bullet entered the body.

### Gunshot Wounds in Bone

Gunshot injuries of bone may be helpful in trajectory determination, especially in the skull and, less frequently, other flat bones. When a bullet passes through the skull, it creates a cone-shaped beveled defect. The entry point has crisp margins and the exit point is larger and represents the wider portion of the cone. Bullets entering the skull produce internal beveling and those exiting the skull produce external beveling. A tangential bullet strike of the skull may cause the bullet to fragment and result in complex beveling if a portion enters the cranial cavity and a portion shears off and remains outside the surface. In such cases, the bony defect created may exhibit internal and external beveling. Such defects are referred to as "keyhole" defects, as their appearance may resemble a keyhole.

### High-Velocity Gunshot Wounds

Trajectory delineation in high-velocity gunshot wounds is similar to low-velocity injury, however, the extent of injury is far more significant and exit wounds are often dramatically large. Hunting ammunition used at high velocity will fragment more in the body than low-velocity bullets, creating a characteristic x-ray picture called a "lead snowstorm."

### Evidence Recovery

---

Bullets retained in the body must be recovered at autopsy. Rifled firearms leave characteristic markings



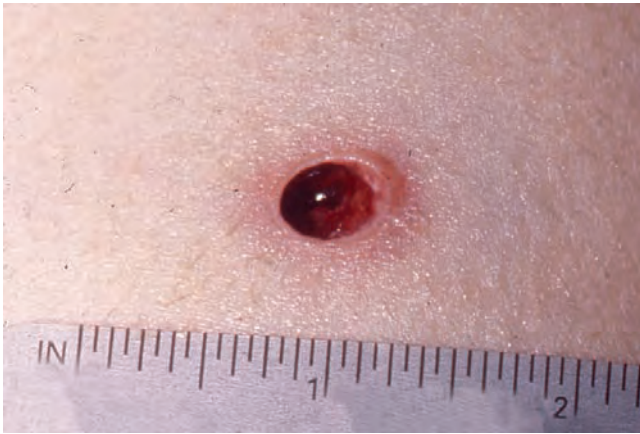on bullets that can be used for identification of a firearm by comparison with projectiles known to have been fired from that weapon. Care must be taken during dissection to avoid or minimize the creation of any additional marks on the bullet that might obscure the rifling marks. This also applies to any identifying marks inscribed place directly on the bullet after recovery. These identifying marks should be inscribed on the base of the bullet. Older bullets should be recovered at the time of autopsy. These may be enclosed in fibrous capsules at the site of lodgment and often have a dull gray appearance as a result of oxidation. Rifling marks may still be present and useful for ballistic comparison.

### Shotgun Wounds

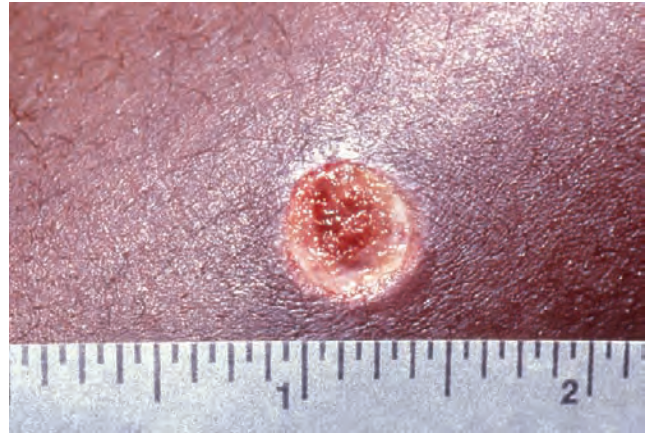---

Because of differences in construction and ammunition, shotguns merit special consideration. Shotguns can be used to fire a single projectile (slug) or several pellets (shot). Shot size can vary (buckshot versus birdshot). Slugs behave essentially as single projectiles. The shotgun cartridge (or shell), contains some additional components (e.g., wadding, filler material) that might produce injuries that can be used in range of fire estimation. Soot and stippling remain

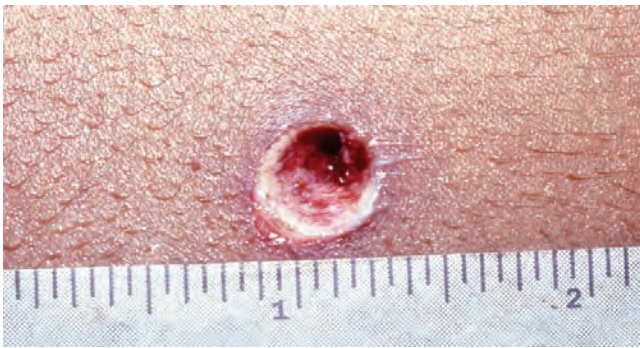useful in close- and intermediate-range determinations. The wounds produced by shotgun shells containing shot look different from conventional bullet wounds. Soot, stippling, wadding, and other components can be used for range of fire estimation, but the behavior of the pellet cluster over distance provides additional information regarding range of fire. When the shot exits the barrel, it travels initially as a tightly grouped cluster. Striking the skin, the tight cluster produces a round defect. The grouping opens up over distance with the first noticeable change in wound appearance occurring at about 3 feet. A single defect is still observed but the margins now take on a scalloped appearance. With further distance (and more pellet dispersal), wounds now consist of a central defect with scattered satellite defects surrounding them. These satellite defects increase in number with greater distance, until the central defect is lost entirely and pellets maintaining sufficient velocity strike the skin's surface individually. The dispersal pattern of pellets is not predictable once an intermediate surface intervenes. It is not possible to evaluate these wounds for range estimations and, for similar reasons; estimates of range of fire by x-ray examination are unreliable. As with other firearms, test firings are the most reliable means for range of fire approximations.



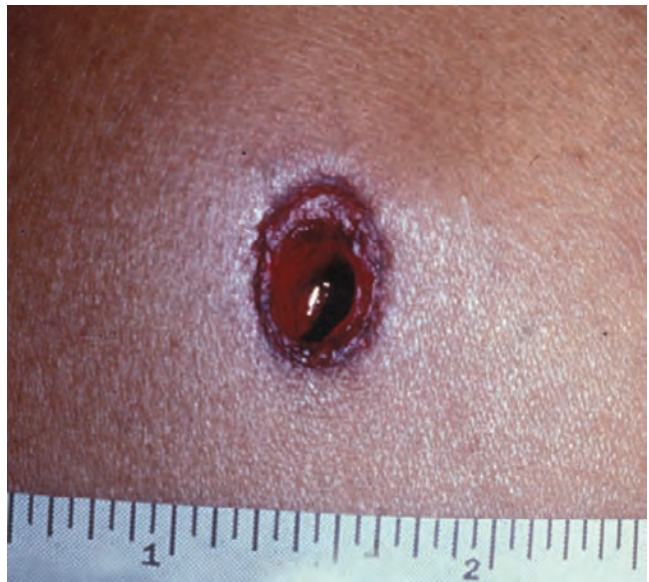Distant entrance gunshot wound. This bullet struck the body nose end first, roughly perpendicular to the surface. Note the thin and roughly symmetric margin of abrasion surrounding the slightly oval perforation.



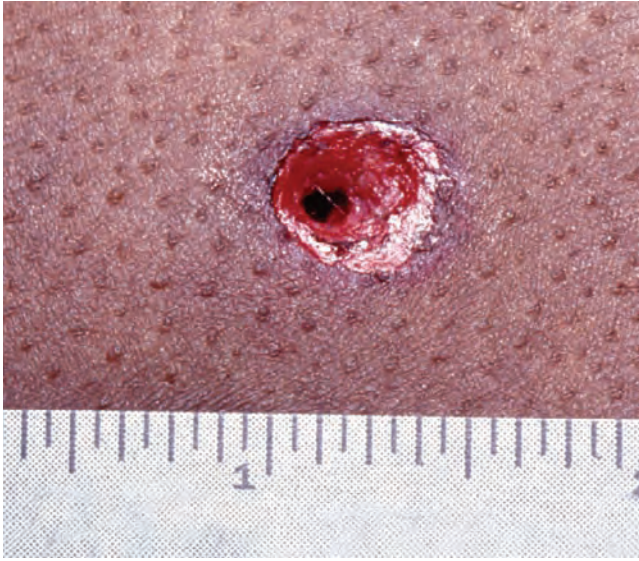
Distant entrance gunshot wound in a darker-skinned individual. Note the slightly asymmetric margin of abrasion, which is greatest at its inferior aspect. This indicates the bullet struck the body nose first, and at a slight upward trajectory. These directions are stated *relative to the body*.



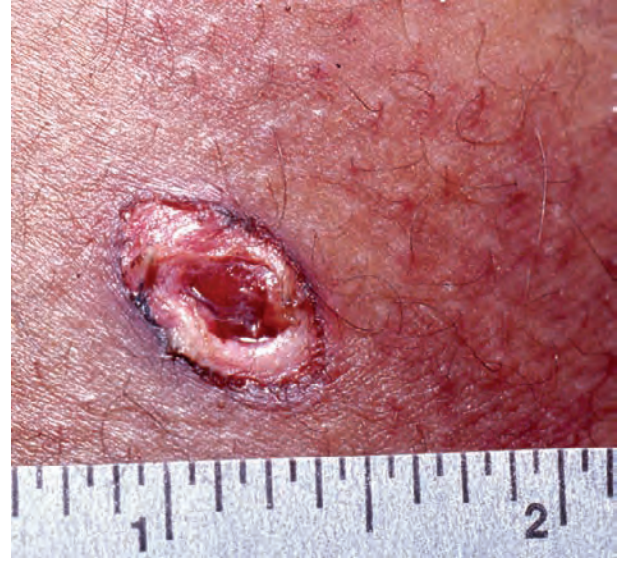Distant entrance gunshot wound with slightly asymmetric margin of abrasion, which is greatest at the right inferior aspect. This usually indicates the bullet struck the body nose first, almost perpendicular and at a slightly upward and right-to-left trajectory. These directions are stated *relative to the body*.



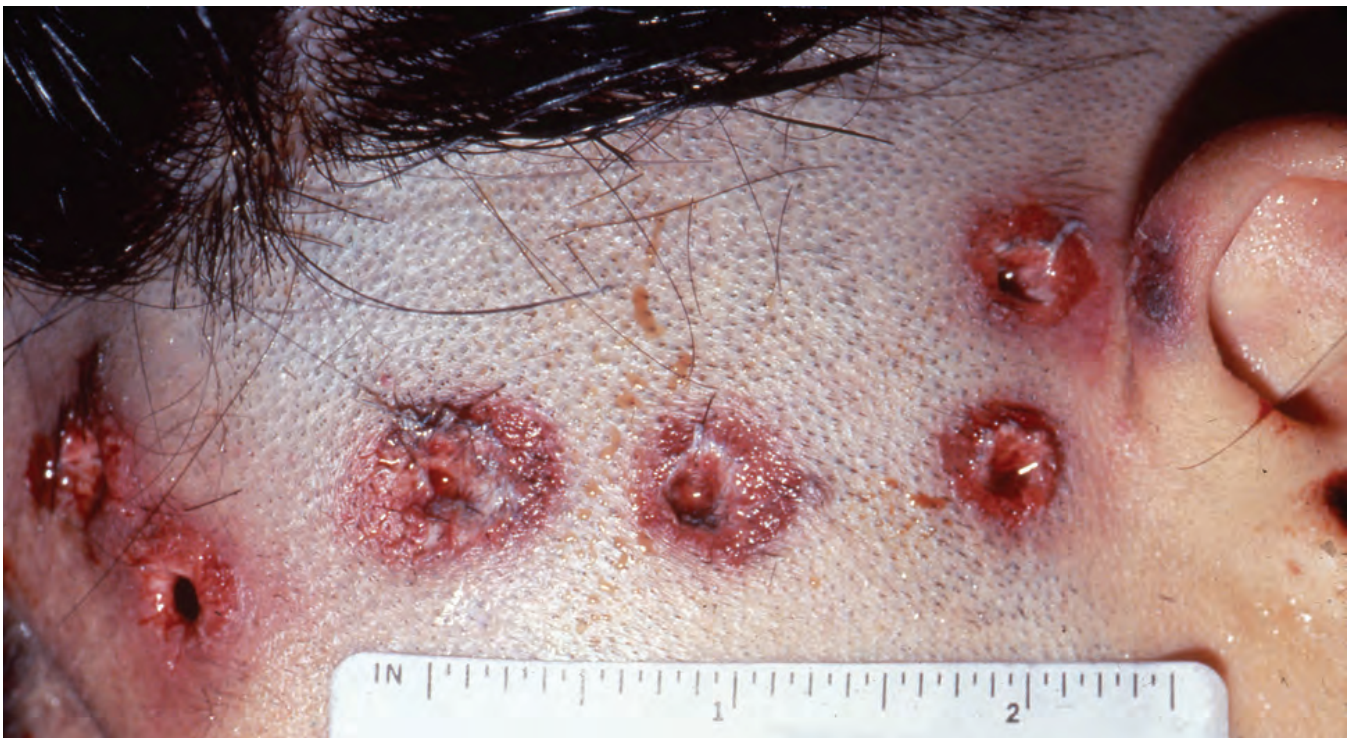Distant entrance gunshot wound with slightly asymmetric margin of abrasion greatest on its superior and left aspect. This usually indicates that the bullet struck the body nose first, almost perpendicular and at a slightly downward, left-to-right trajectory. These directions are stated *relative to the body*.



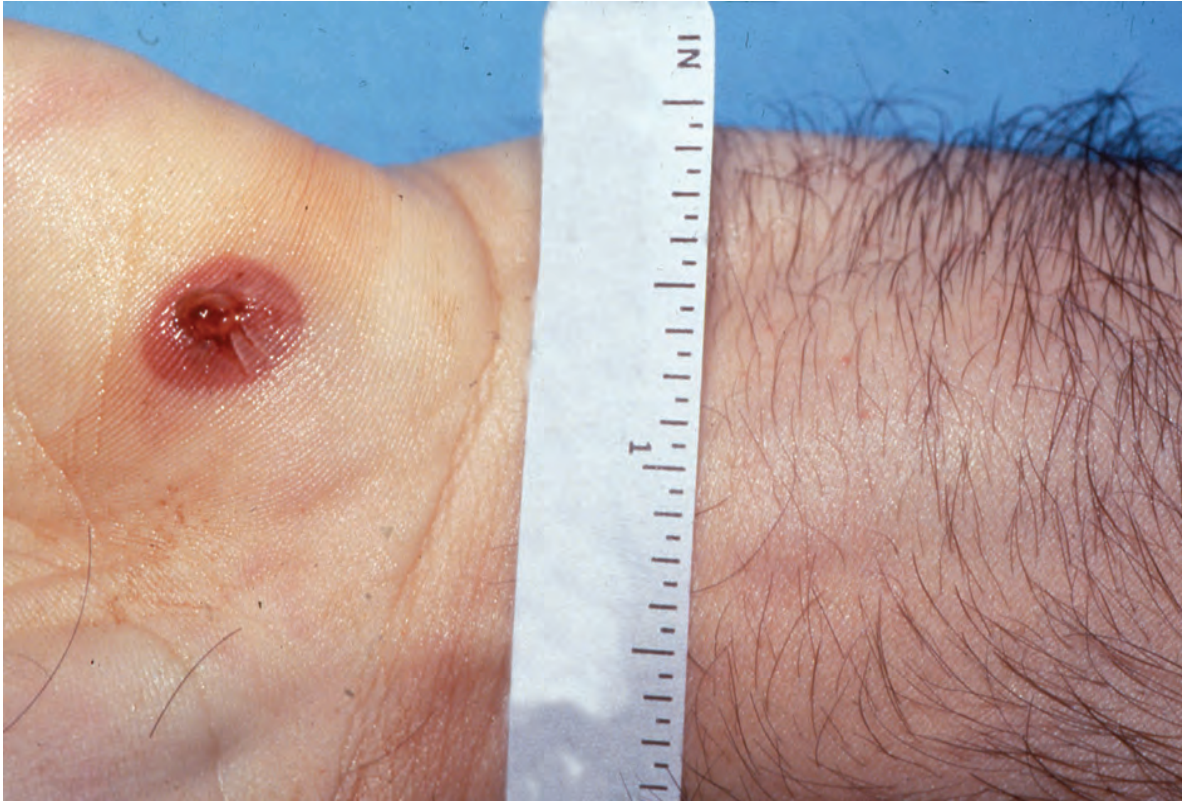Distant entrance gunshot wound with slightly irregular, widened margin of abrasion, which is greatest at the right lateral aspects. This indicates the bullet struck the body from a slightly inferior and right-to-left trajectory. The slightly irregular nature of the margin of abrasion may sometimes be seen, as the bullet perforates clothing first.



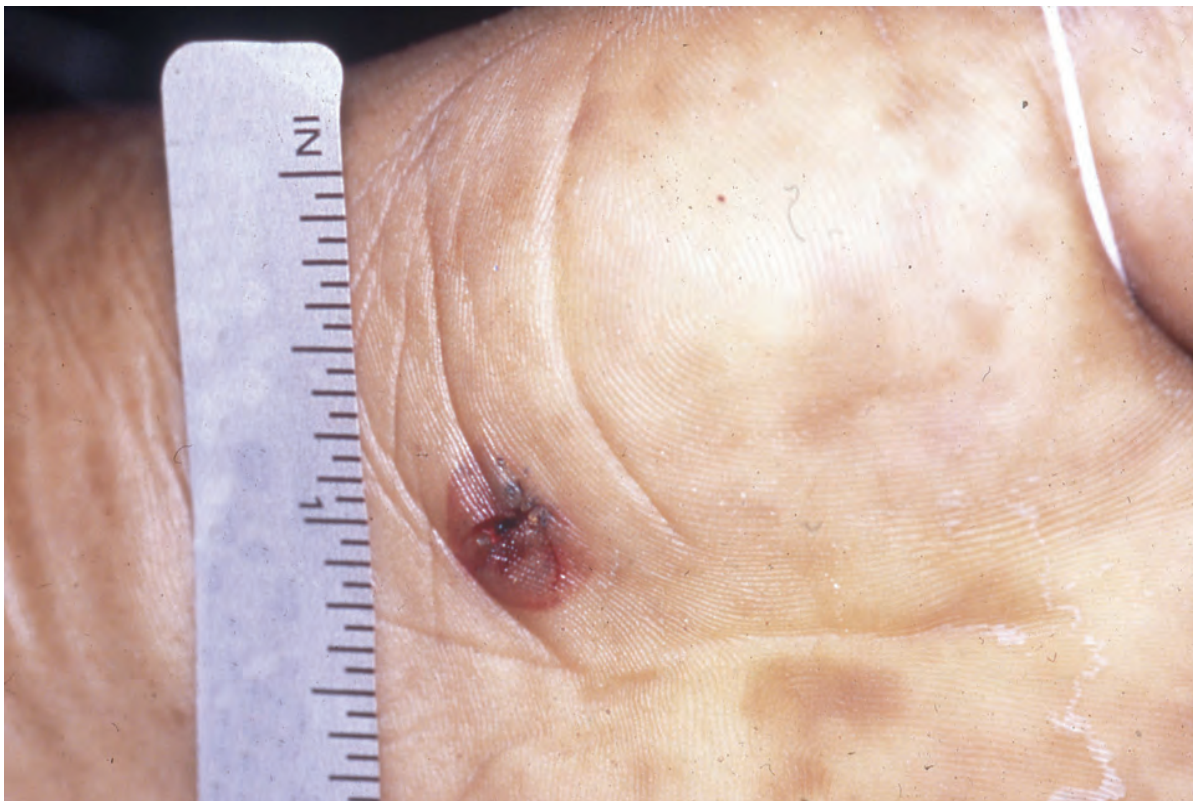Distant entrance gunshot wound that is slight stretched into an oval due to skin tension. Note the slightly asymmetric margin of abrasion, which is greatest at the 9 o'clock through 12 o'clock position, indicating the bullet struck the body with a slightly downward and left-to-right trajectory.



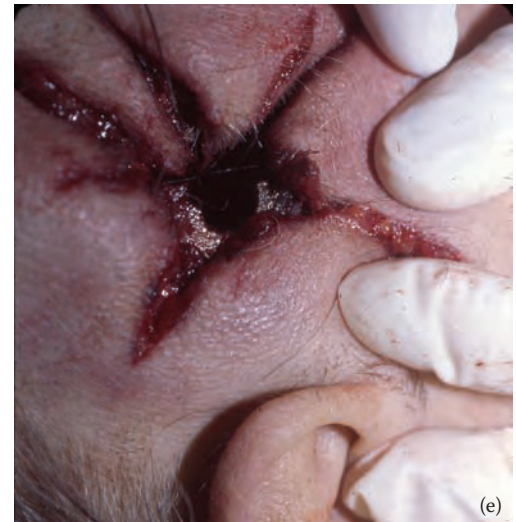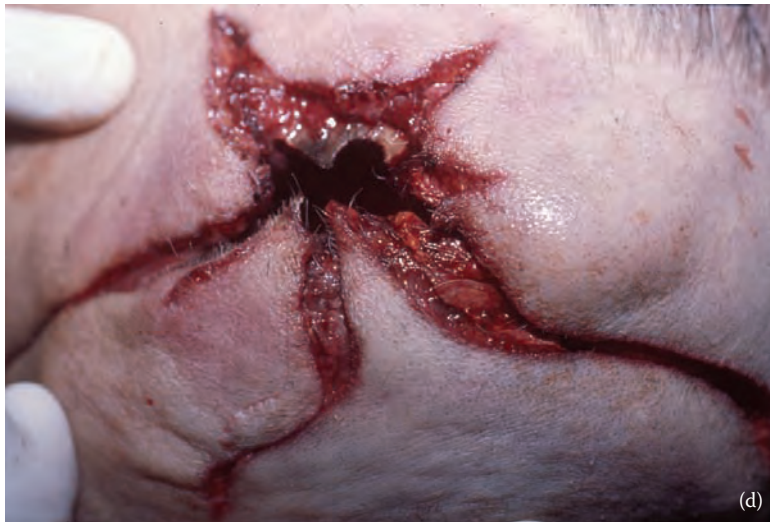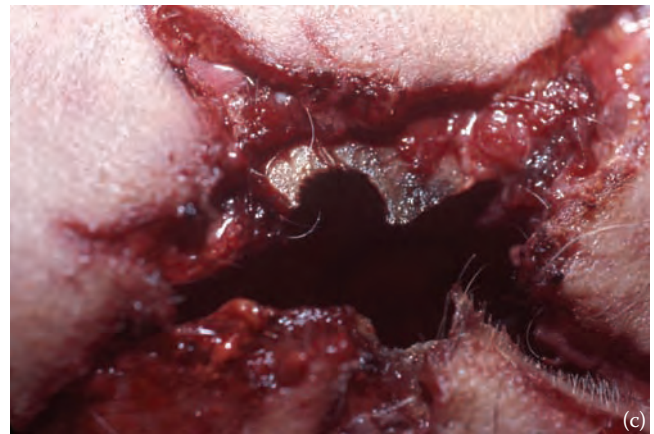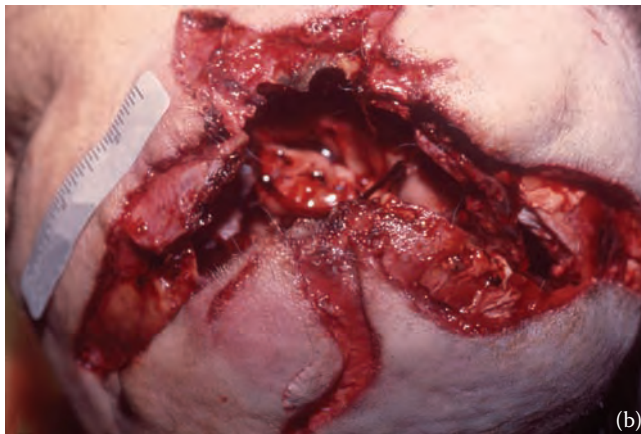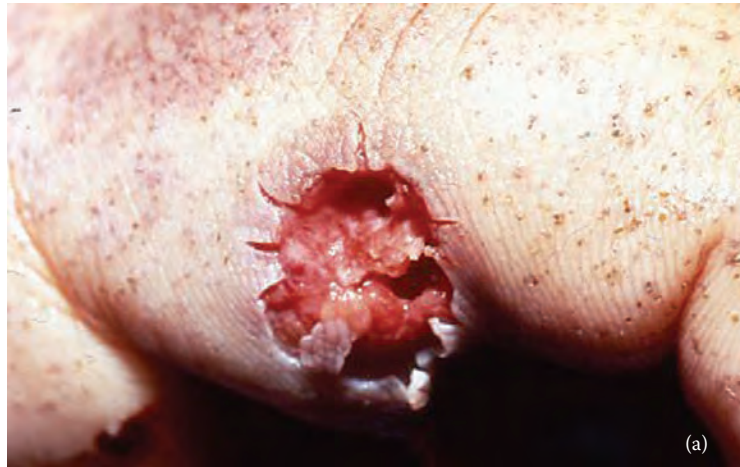There are six separate clustered entrance gunshot wounds to this individual's head. Note the abrasion to the posterior ear helix caused by a bullet. Shaving the hair is recommended for external examination of such gunshot wounds.



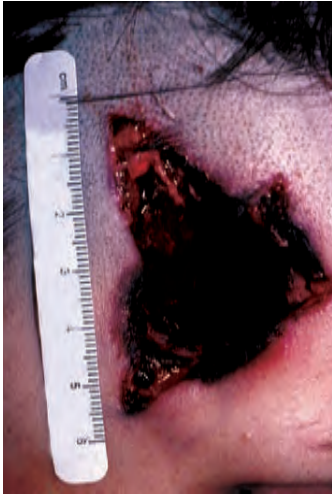
Distant entrance gunshot wound to the palm of the hand through thick skin.



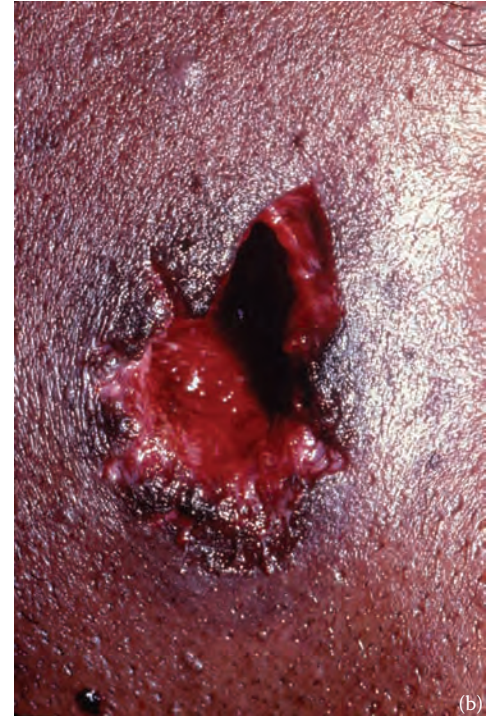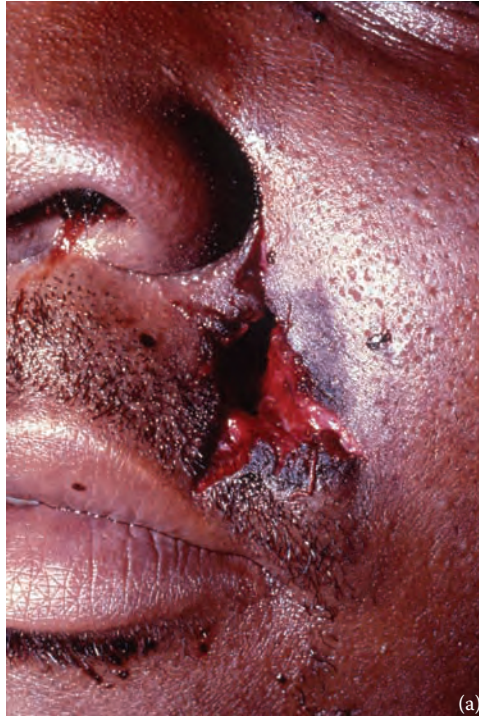Distant entrance gunshot wound through the thick skin of the sole of the foot. This bullet first perforated the bottom of a shoe and a sock before entering the body.



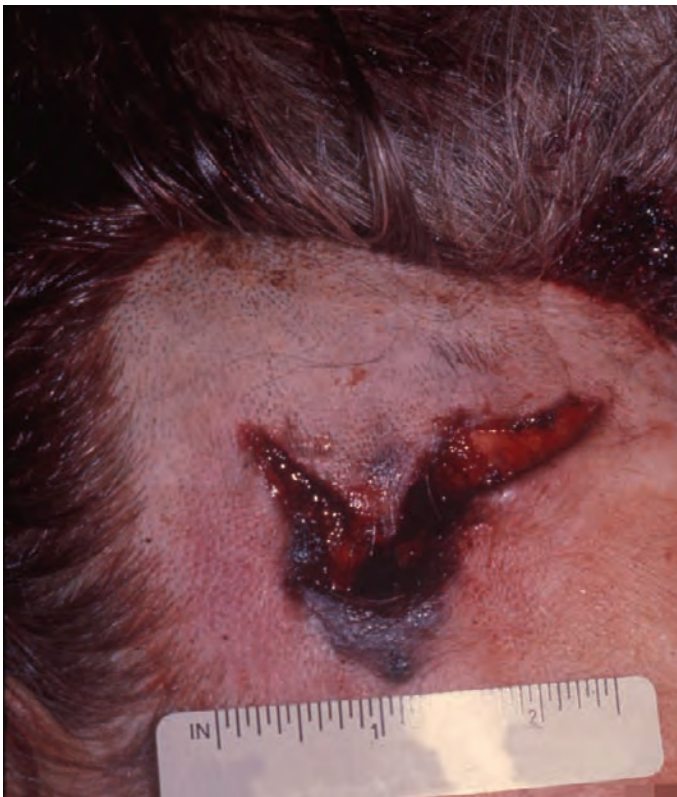Entrance gunshot wound with surrounding stippling defects indicating intermediate range of fire. This gunshot wound (a) to the thick skin of the palm of the hand reveals typical small radiating lacerations without prominent margin of abrasion. These characteristics are typical for gunshot wounds of the palms of the hand and soles of the feet. These images (b–e) represent the same contact gunshot wound with varying degrees of tension surrounding the wound's surface. Note that with approximation of the margins (d–e) the wound forms a roughly circular perforation with margin of abrasion typical of an entrance gunshot wound. Also note the copious amounts of soot within the wound track and at the underlying bone surface. Such large radiating linear lacerations are usually associated with higher-caliber guns and tight contact of the gun muzzle on the body surface with underlying bone close to the skin. The expanding gases from burning gunpowder forced into the wound track causes such lacerations.



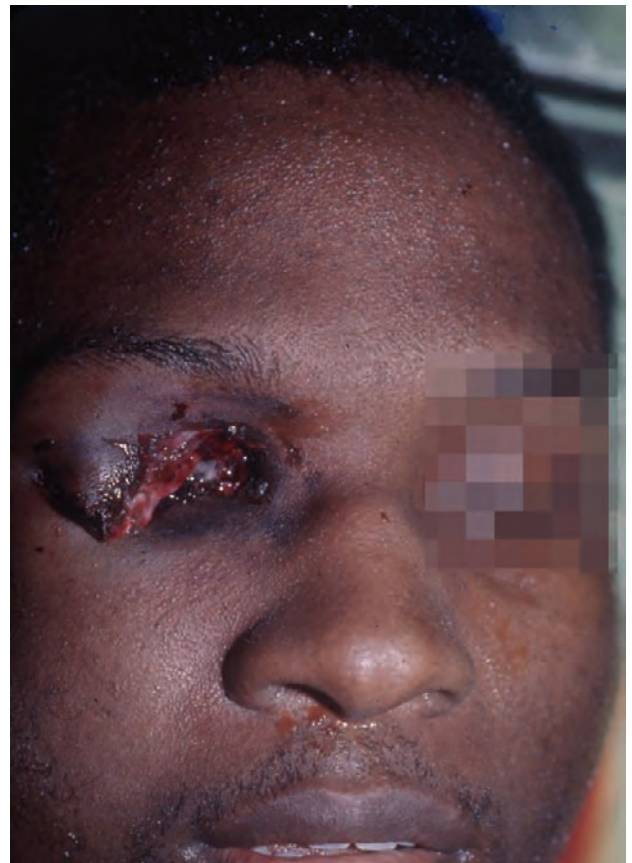Contact gunshot wound to the scalp with radiating lacerations and soot deposition within the wound track and at the wound margins. These lacerations are caused by burning gunpowder, with expanding gases forced into the wound track and causing the overlying skin to lacerate.



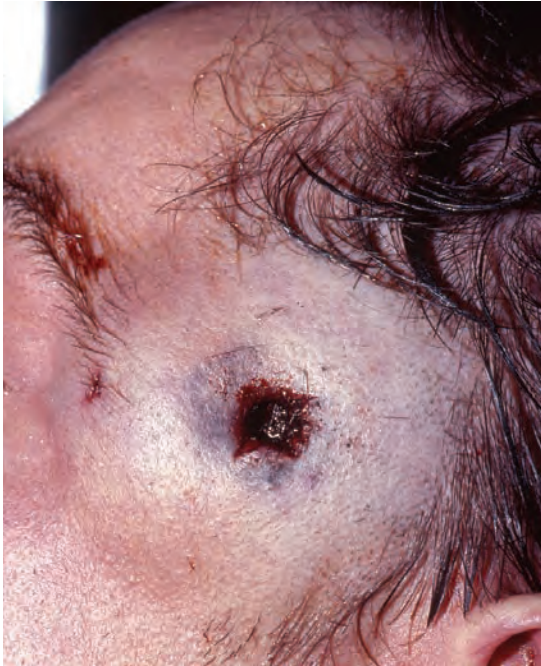Contact gunshot wound to the face (a). Note the stellate lacerations radiating from the perforation site with soot deposition; (b) a close-up view with a different orientation.



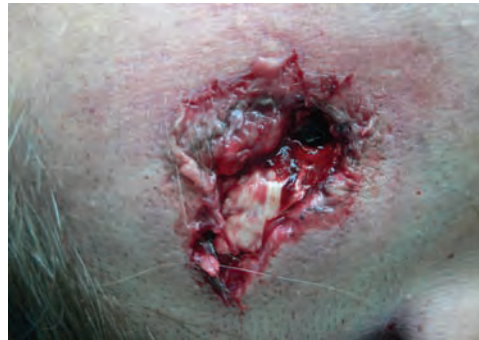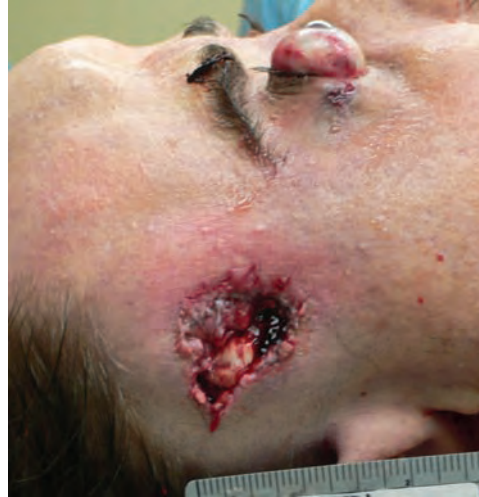Contact gunshot wound to the right temporal region. Note the larger lacerations extending from the perforation site with adjacent soot deposition.



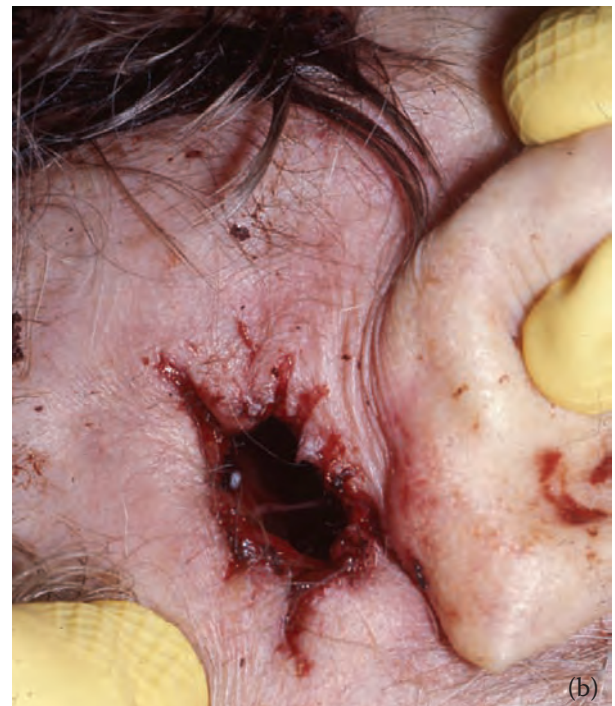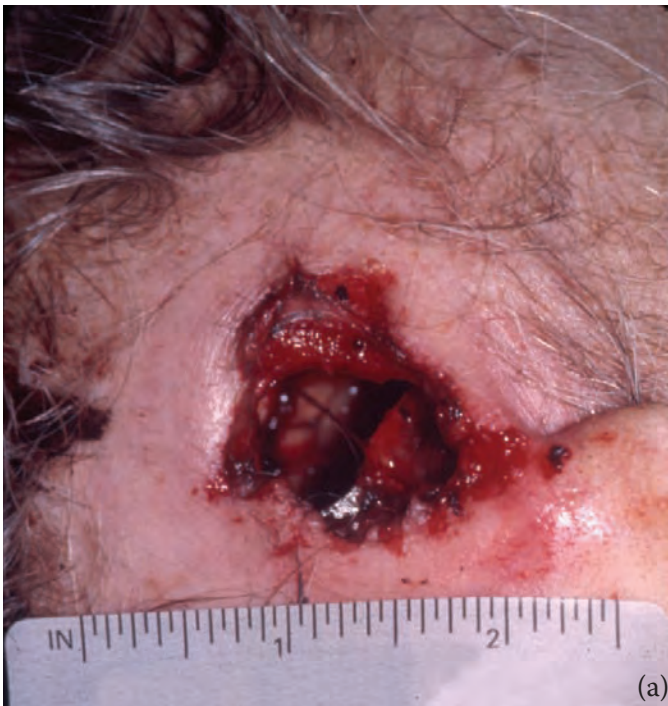Contact gunshot wound to the eye. Note the lacerations of the eyelid and eye globe with soot deposition at the adjacent skin and within the wound track.



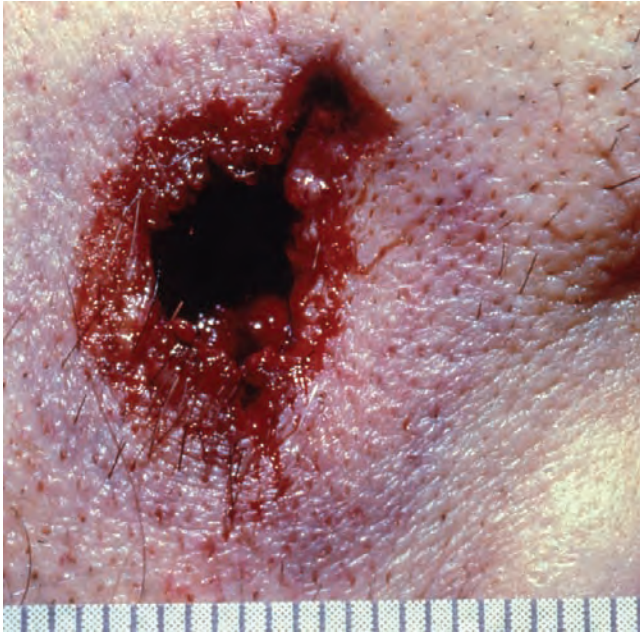
Contact gunshot wound to the temple. Note the small radiating lacerations from the perforation site. Note the presence of soot within the wound track and adjacent skin.



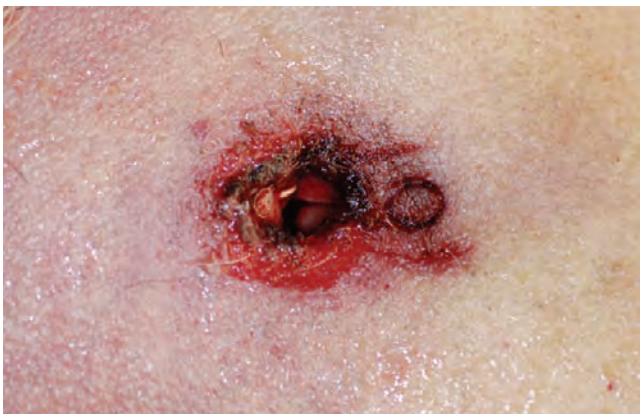Note this tight contact gunshot wound to the right temporal region with lacerated borders and soot deposition. A .357 Magnum caused a comminuted skull fracture with head deformity and the eye protruding from the socket.



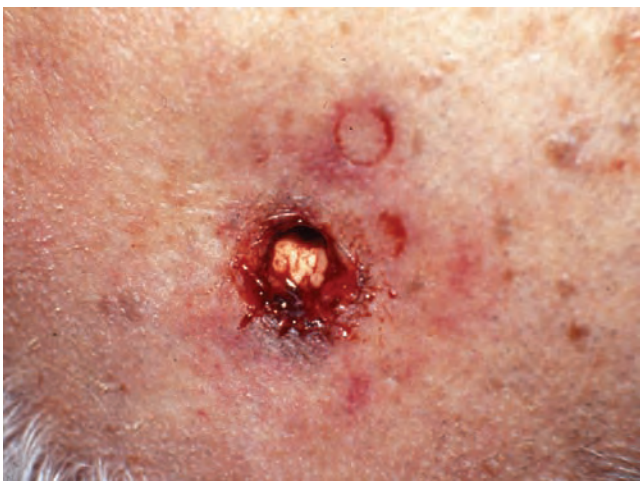Contact gunshot wound to the scalp. (a) Note the small radiating lacerations with soot deposition. (b) Note the same wound after cleaning. The tension surrounding the wound is relieved by pressing the surrounding skin inward toward the perforation. This will approximate the wound margins and reveal a roughly circular perforation with margin of abrasion characteristic for an entrance gunshot wound. Note that even after cleaning, small amounts of soot are still present at the wound margins. Further cleaning might eliminate this gunpowder residue as well. In many cases, such as this one, it is essential to photograph the body before cleaning.



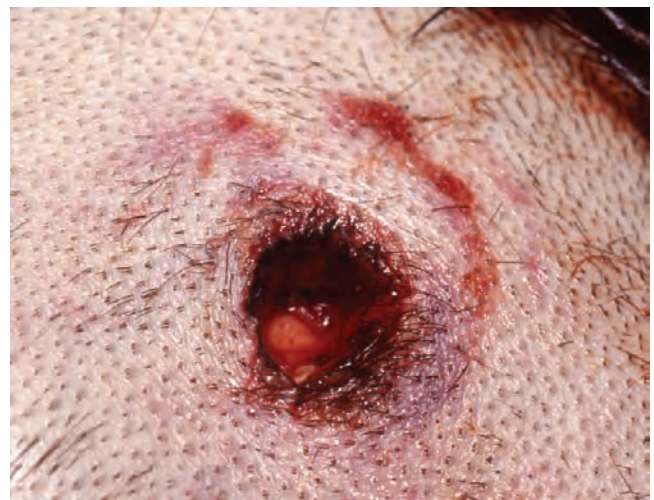Contact entrance gunshot wound to the temple. Note the abraded imprint of the eyepiece portion of the gun at the superior aspect. The perforation site has a margin of abrasion. There is no obvious soot at the surface of the adjacent skin, but there were copious amounts of soot within the wound track. Note the pink to red discoloration surrounding the perforation due to nitrates and carbon monoxide released from burning gunpowder. These components may sometimes cause this discoloration when reacting with the underlying muscle. In this case, it is more obviously due to the decedent's light skin color.



Contact gunshot wound with muzzle imprint.

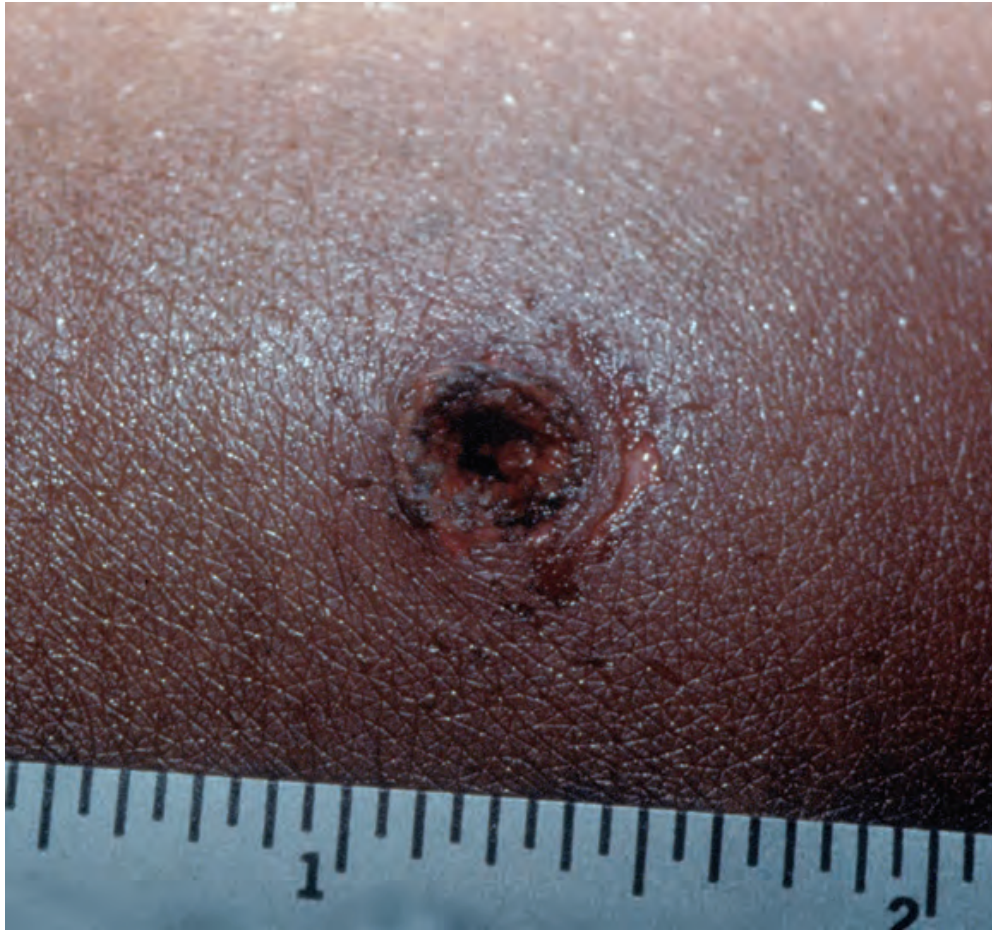


Contact gunshot wound. Note the adjacent abrasion to the perforation site due to contact with a revolver ejector rod when the gun was discharged. There are also small amounts of soot visible at the wound margins and more within the wound track.

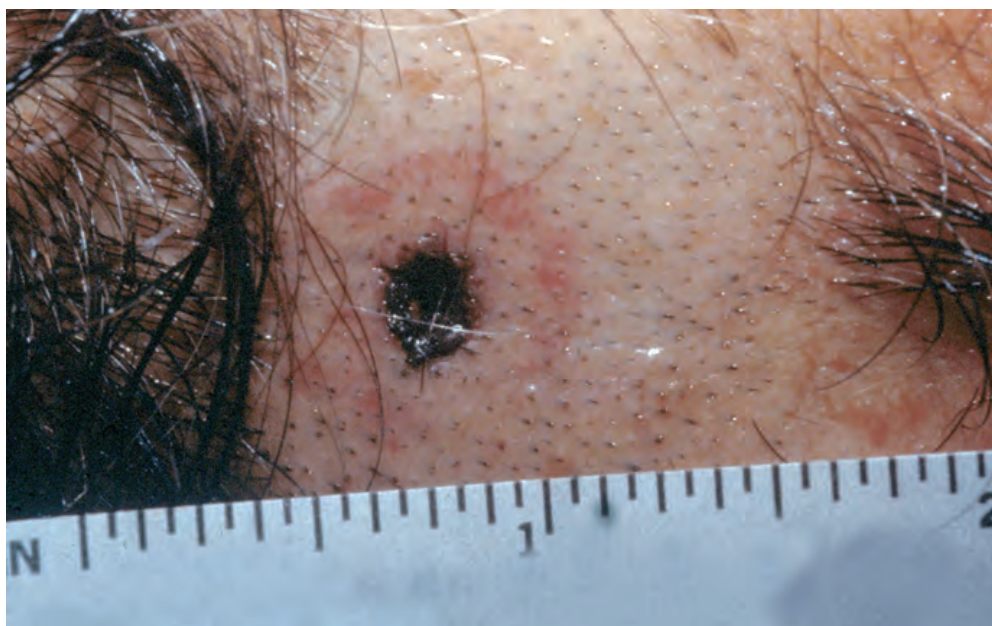

Contact gunshot wound to the scalp with an abrasion at the superior left aspect due to the gun muzzle. There is visible soot within the wound track. Sometimes it may be difficult to visualize the presence of gunpowder residue on thick, dark, scalp hair.

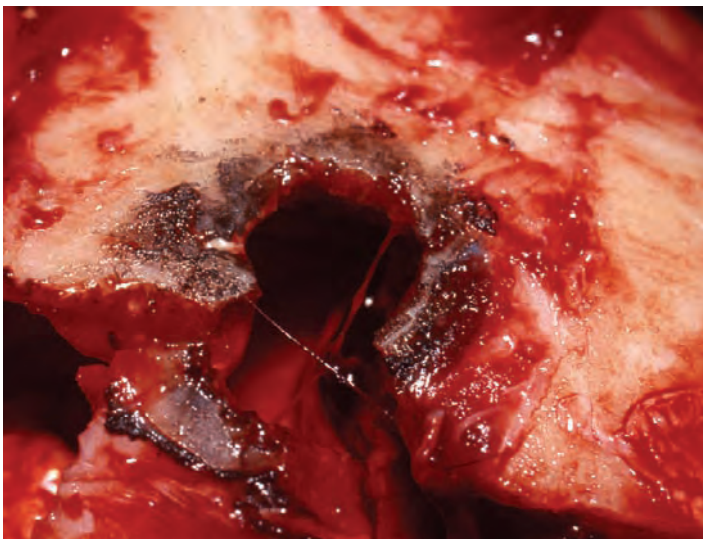
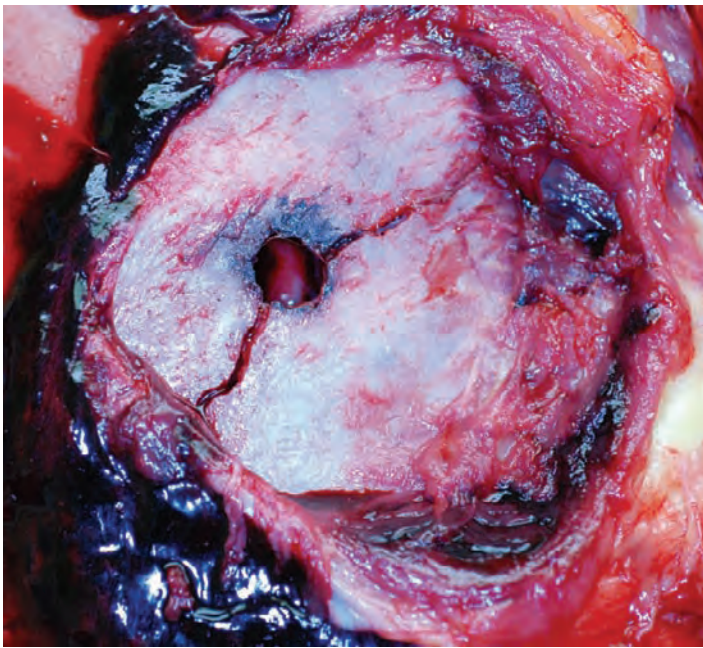
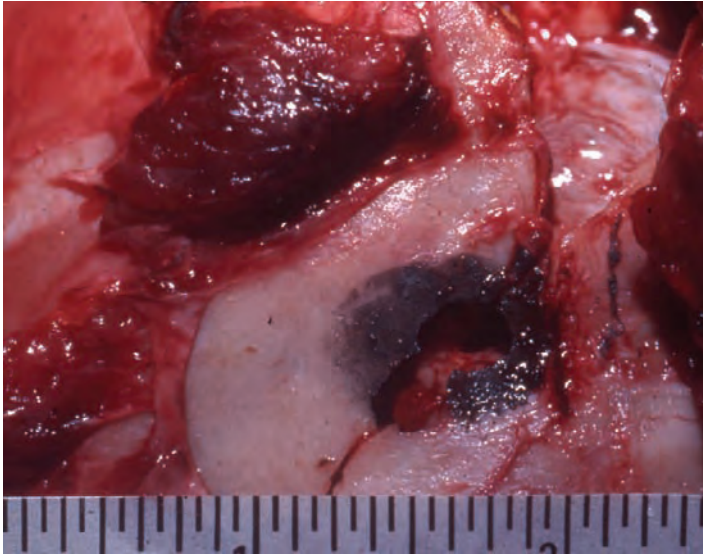




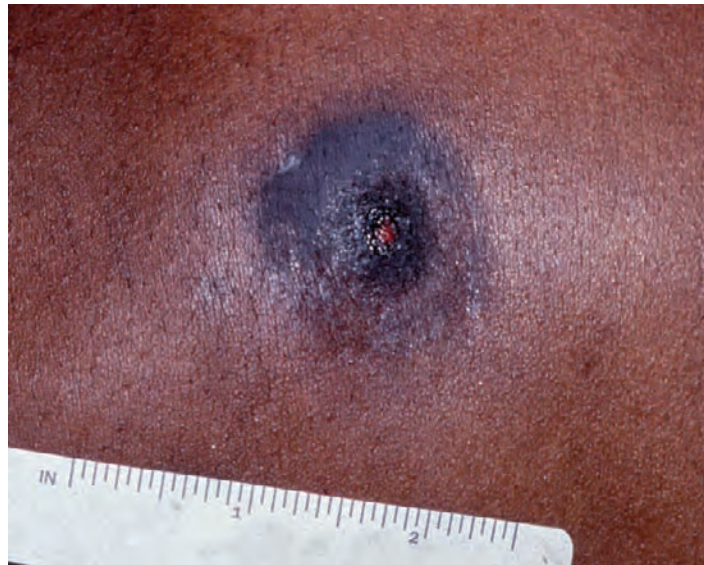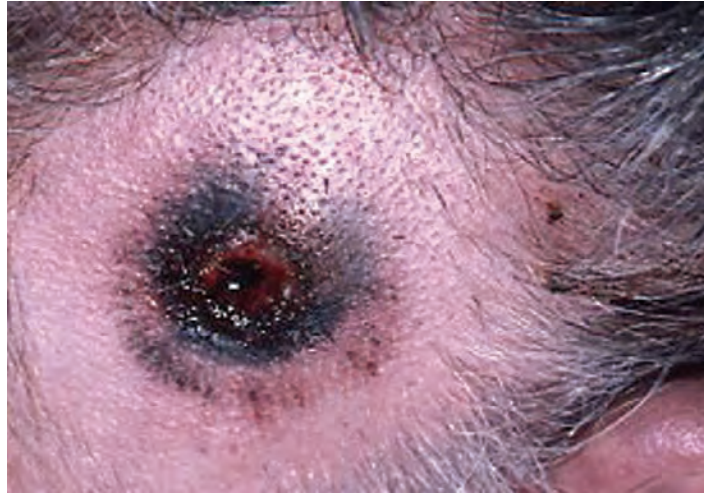
Contact gunshot wound. Note the soot at the margin of the perforation site. Note the surrounding abrasion from a partial muzzle imprint.



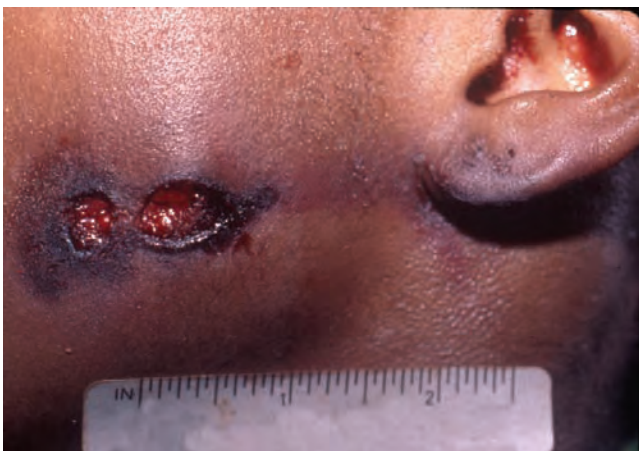
Contact gunshot wound to the right temporal scalp. Note the soot deposition surrounding the margin and the red discoloration of the adjacent skin.



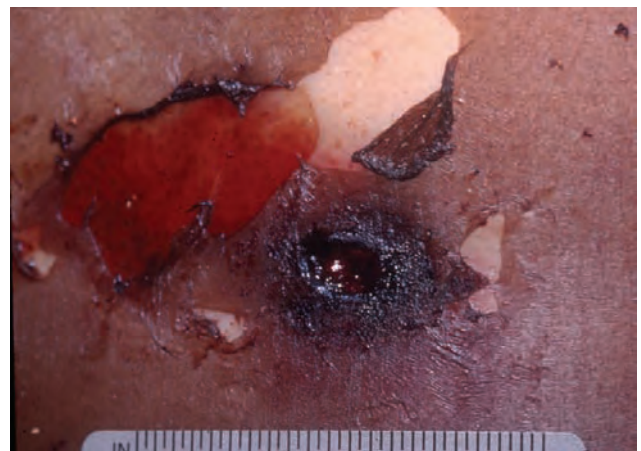Underlying soot deposition within the wound track on the outer surface of the exposed skull. This is typically seen with a tight contact gunshot wound where soot is forced into the wound track.



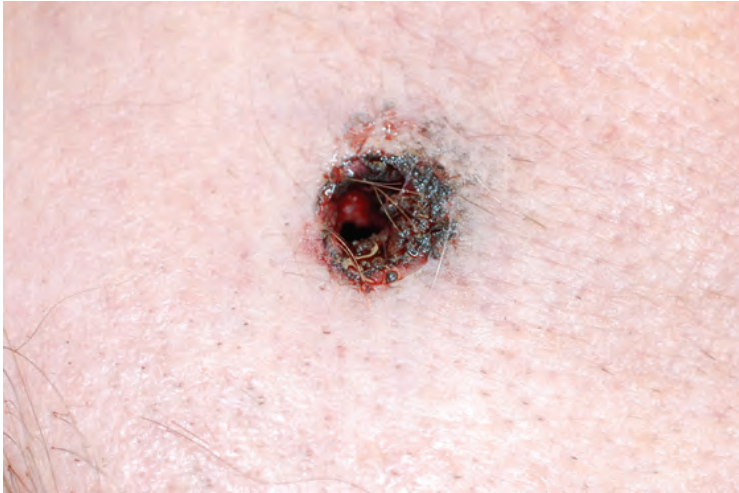
Close-range gunshot wounds with soot deposition.



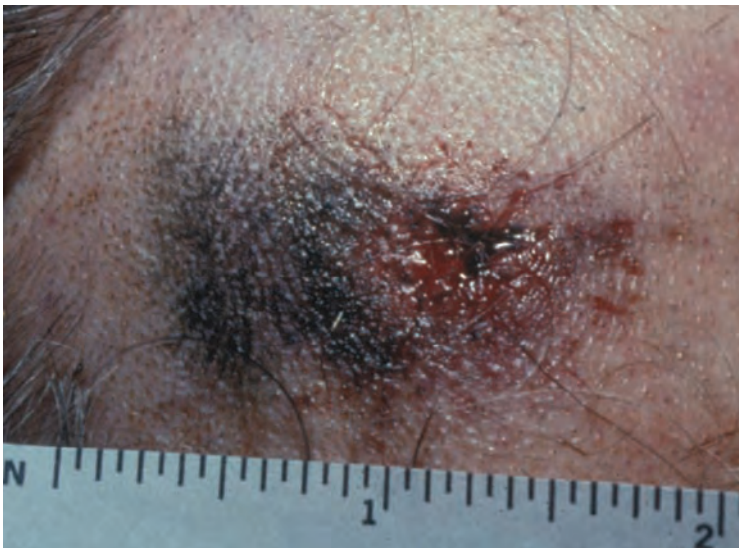
Note the entrance wound is to the left where soot is visible at the adjacent skin.



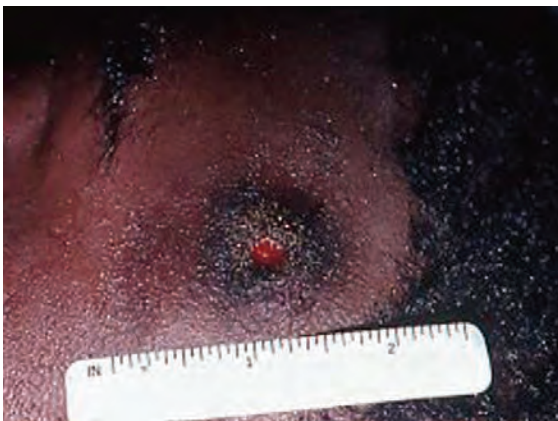Close-range gunshot wound to a body with early decompositional changes. Note the soot deposition surrounding the perforation site. These early putrefactive changes consist of skin slippage and discoloration.



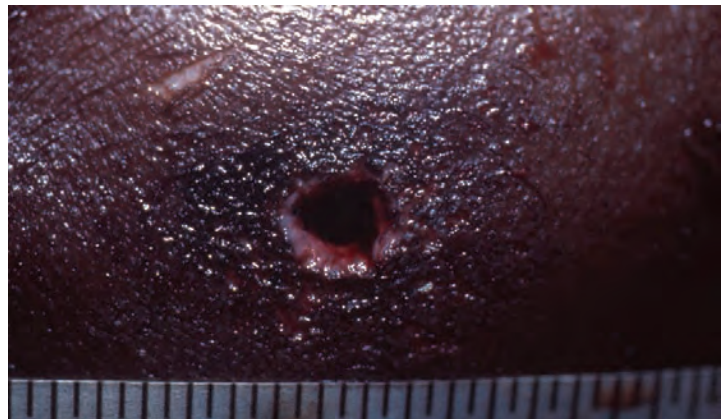
Loose contact with more soot extending to the right side of the perforation.



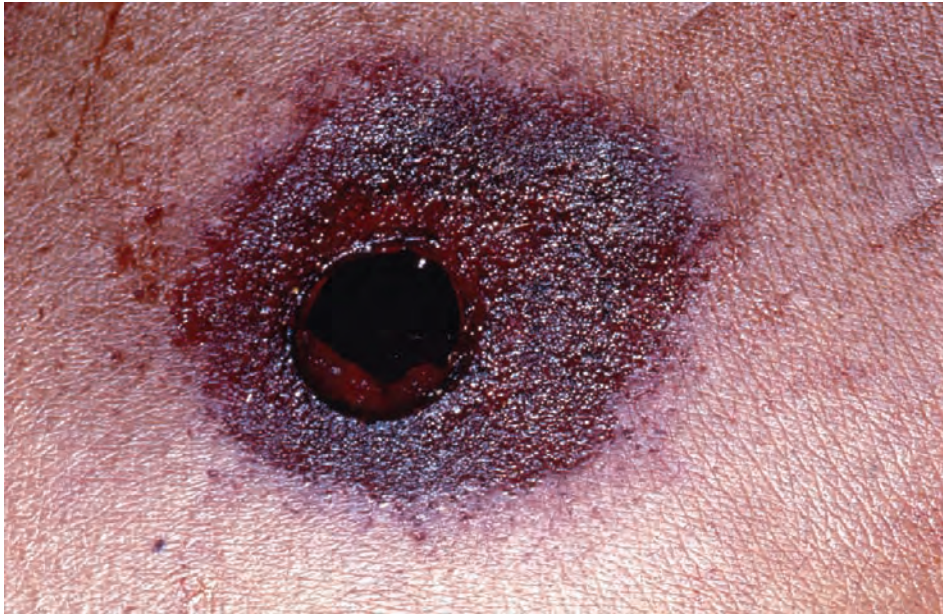Loose contact with the muzzle more tightly applied at the right aspect. Note the greater soot deposition to the left of the perforation.



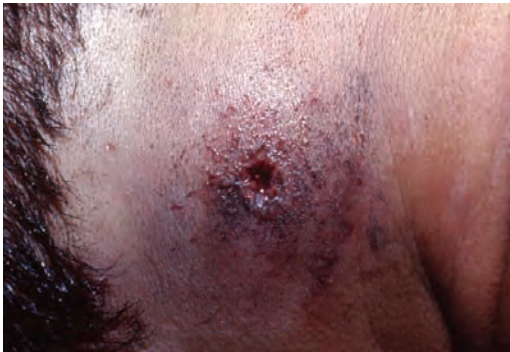Close-range gunshot wound with soot deposition.



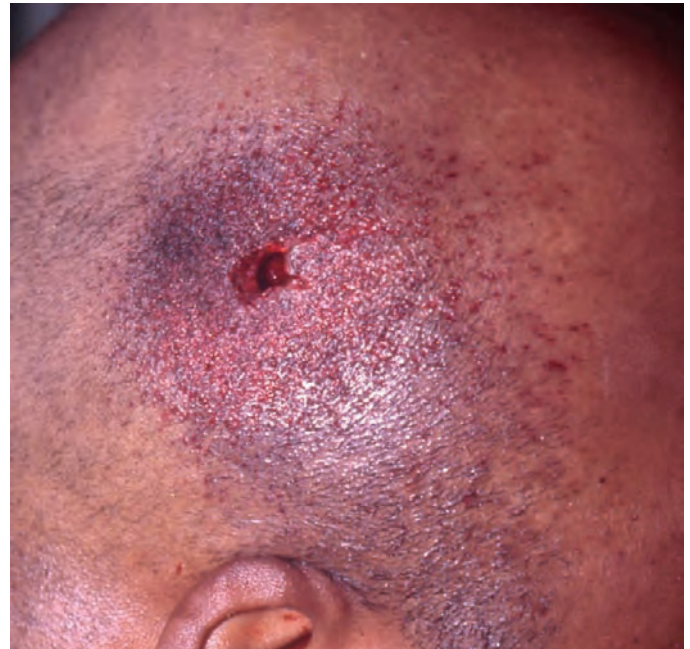Close-range gunshot wound in a very dark-skinned individual. Note the gunpowder residue surrounding the entrance gunshot wound.



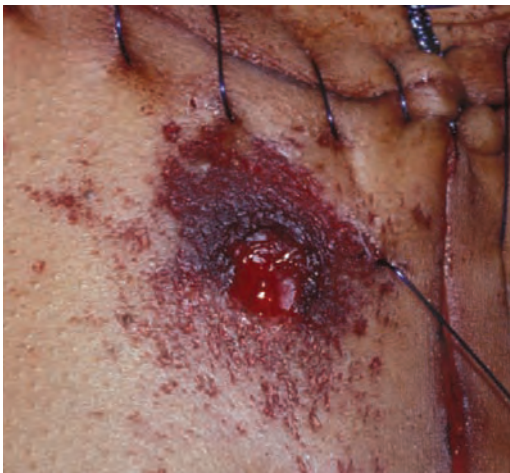Close-range gunshot wound with a muzzle flare burn and soot encircling the perforation site.



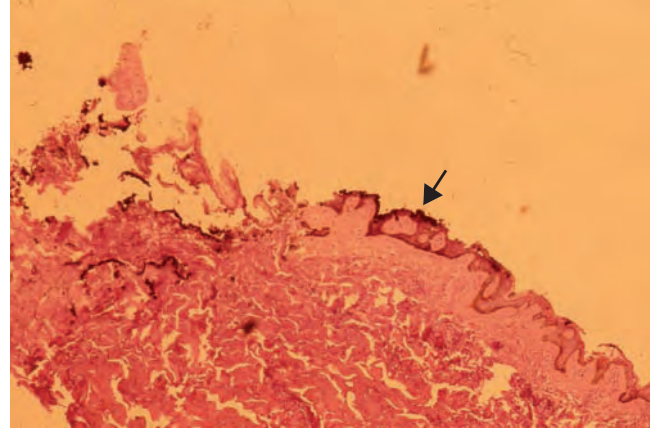
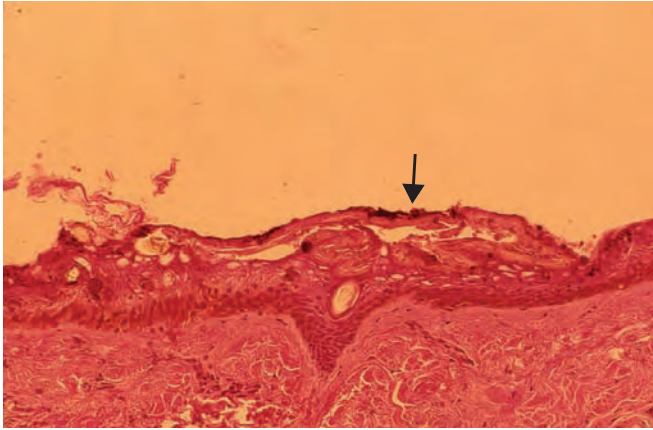
Close-range gunshot wound with sparse soot deposition surrounding the perforation site with adjacent superficial skin erosions due to muzzle flare.



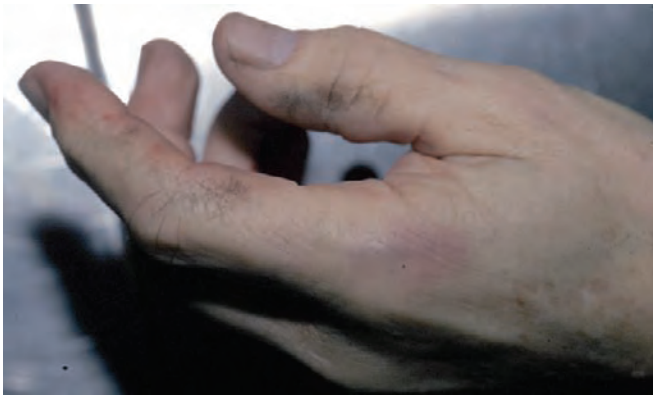Close-range gunshot wound to the scalp with sparse soot deposition, adjacent burning of the scalp due to muzzle flare, and closely packed stippling defects.



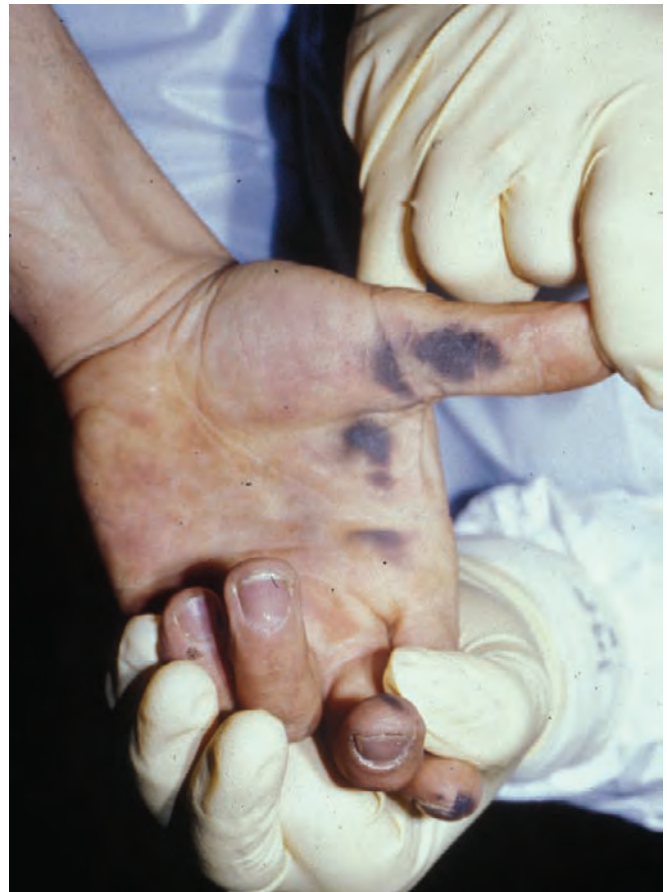Close-range gunshot wound with soot deposition, superficial skin erosions from muzzle flare with tightly compacted stippling-type defects.



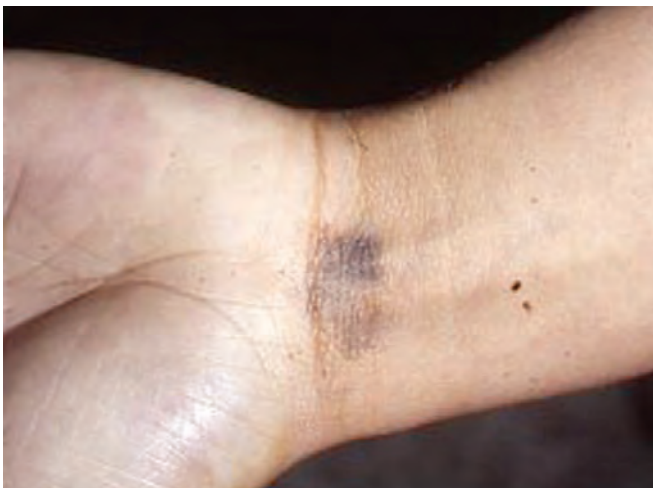These demonstrate histopathology sections of skin with soot deposition at its surface. The soot appears as a black film on the skin's surface; unburned powder particles may also be visible.



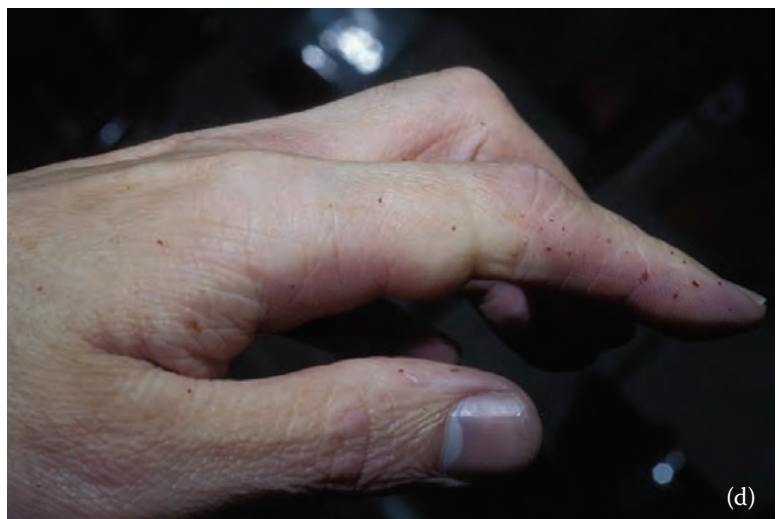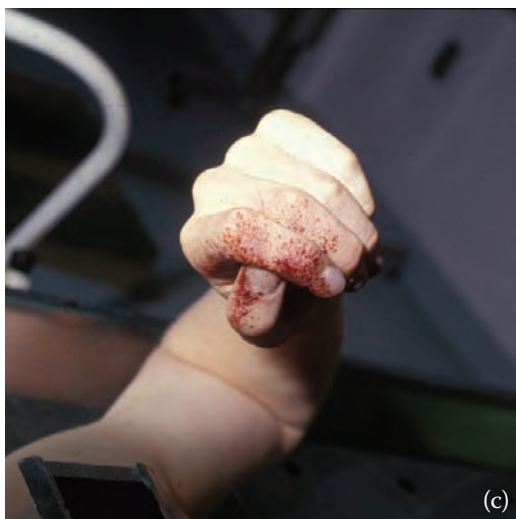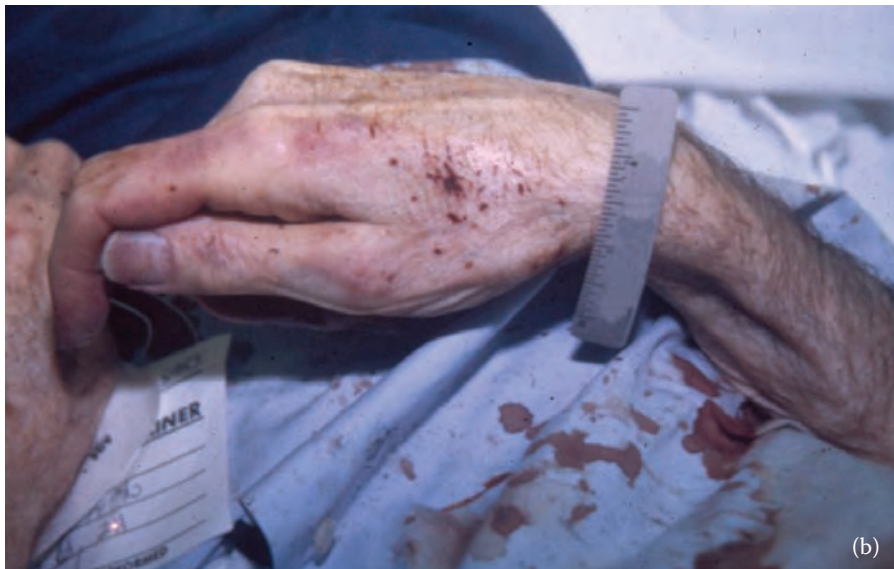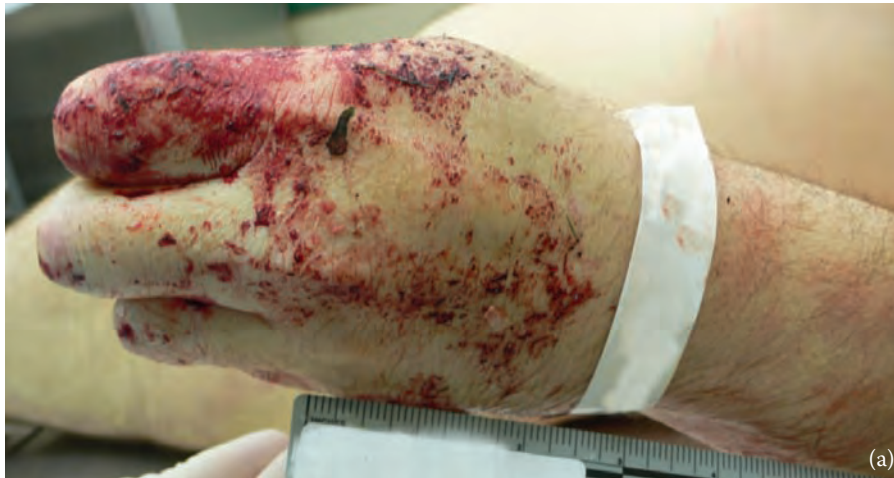Gunpowder residue at the fingers due to firing a handgun. This individual died from a self-inflicted gunshot wound to the head. The amount of gunpowder residue following discharge of a firearm may be quite variable and sometimes not very obvious.



This pattern of soot was caused by holding a revolving cylinder while discharging the weapon.



Soot may also be deposited as it exits from the muzzle of the gun or from cylinder gap in revolver type handguns.

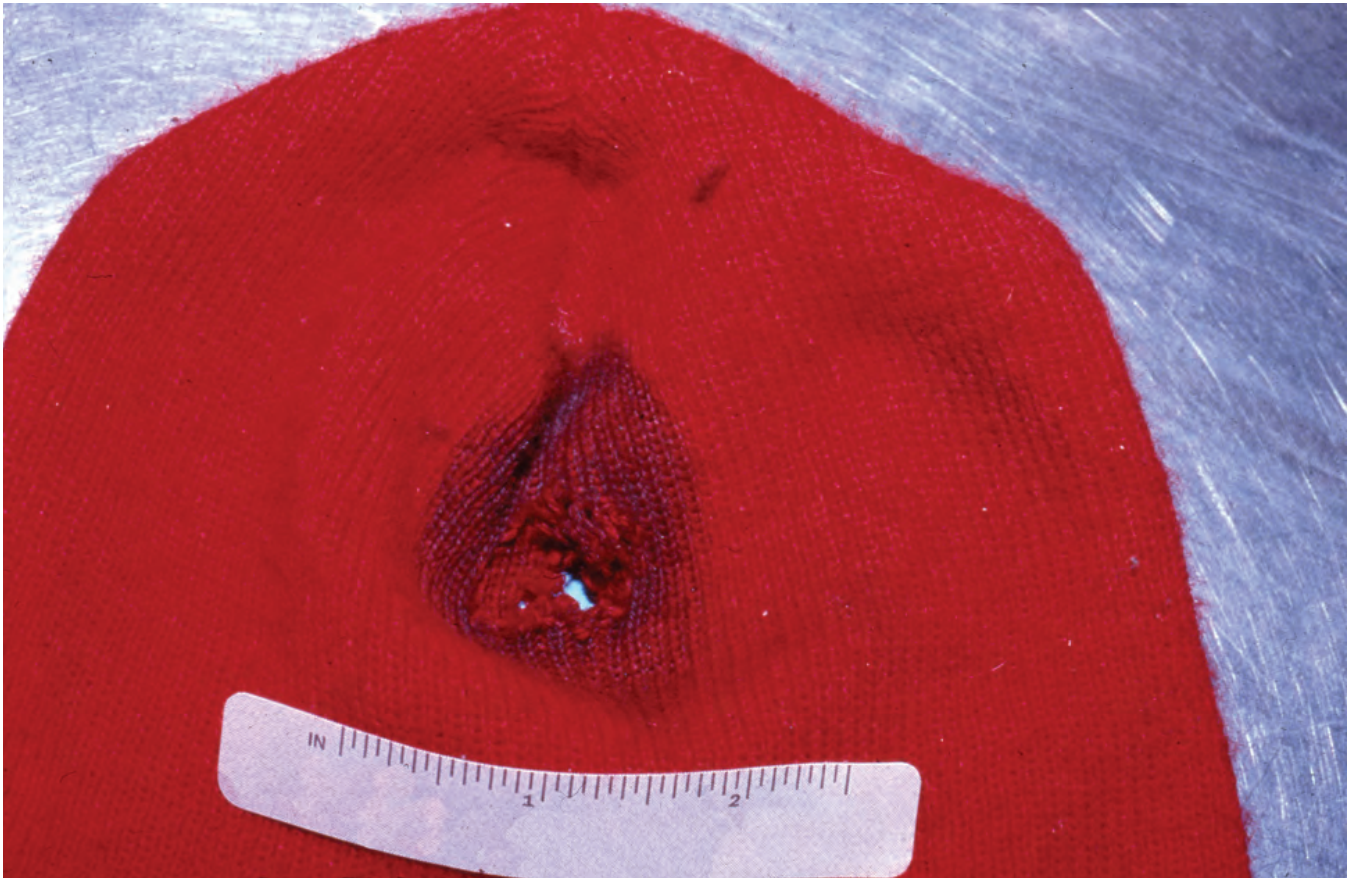


Note the "blowback" blood spatter pattern on the hands of these individuals who died from self-inflicted gunshot wounds to the head. Note that in (a) the spatter pattern is partially obscured by subsequent contact deposit of blood. Also note in (d) the extent of spatter may be minimal.

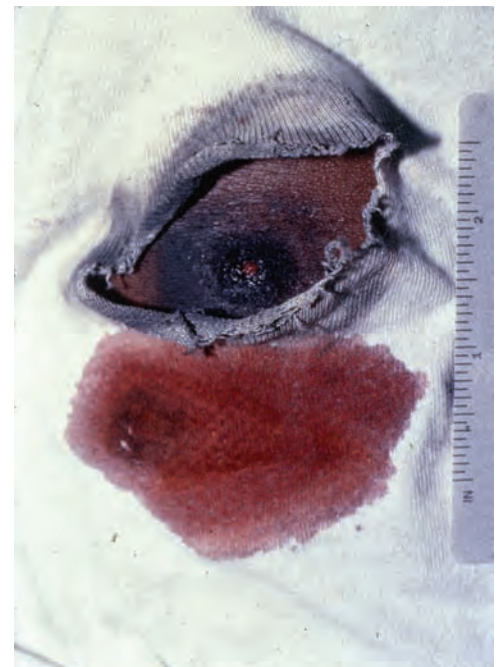
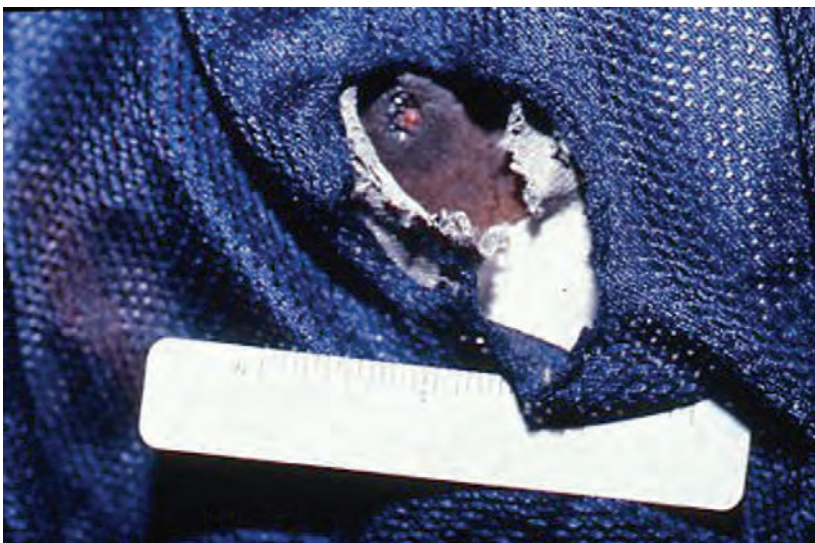

All of these are articles of clothing demonstrate close-range gunshot perforations with soot deposition. It is always important to inspect the decedent's clothing. Multiple layers of heavy clothing may filter gunpowder residue from the body surface. It is also important to distinguish bullet wipe from soot deposition. Bullet wipe is a small, encircling, gray discoloration around the perforation site of the clothing due to lubricants and residue from within the barrel of the gun that adhere to the bullet surface as it passes through the barrel. Unlike soot, bullet wipe is not useful in range of fire estimations.





Clothing with soot indicating close range of fire. The individual wearing the hat had long curly black hair and there was no appreciable soot noted at the scalp.




Note the large tear in the clothing from this contact wound and the minimal amount of adjacent external hemorrhage. This is an antemortem injury with more than a liter of blood observed in the thoracic cavity during autopsy.




(a)



(b)



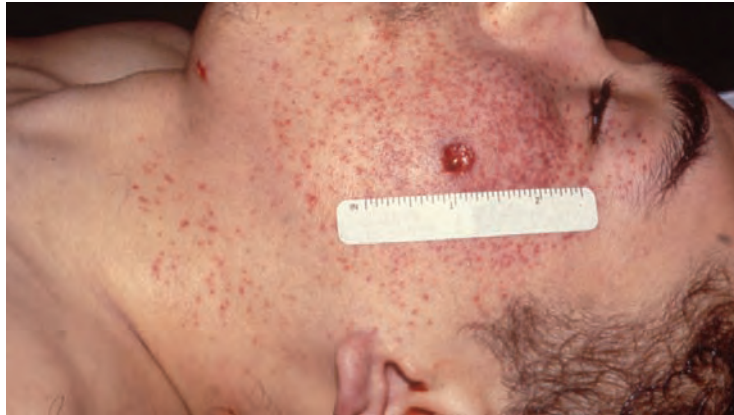(c)



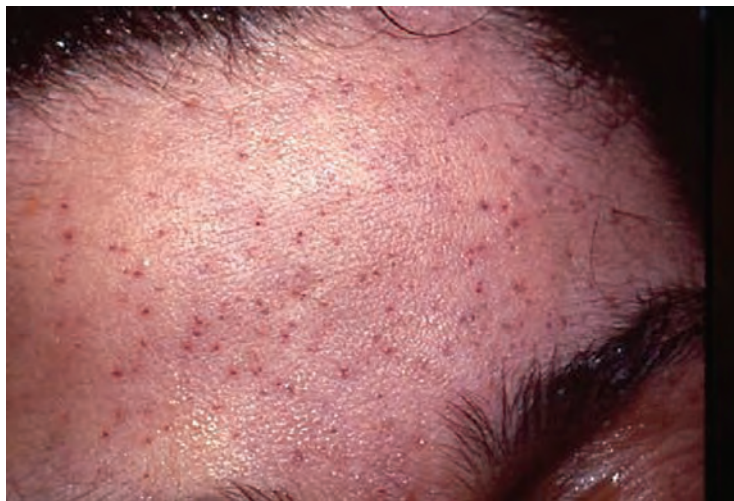(d)

This entrance gunshot defect is surrounded by dark clotted blood. The dark discoloration of blood, particularly on dark clothing, may make it difficult to observe soot. This is a distant gunshot wound (d).

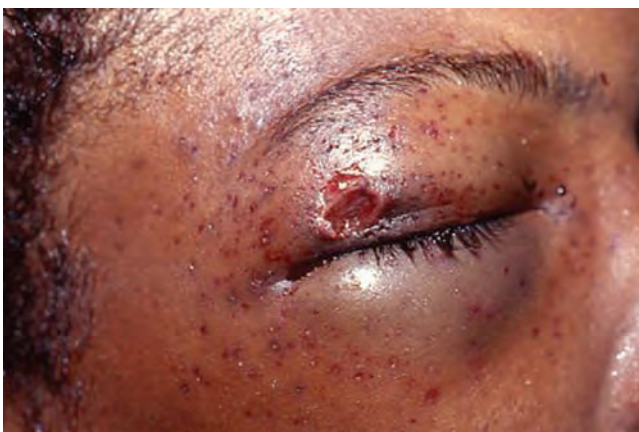Bullet wipe. This individual had his shirt tucked in, creating folds in the cloth. Note the dark discoloration around the perforation site with the right aspect separated several inches from the site of bullet entry. By refolding the fabric and approximating the margins we can simulate how the individual actually wore his shirt (a-c).



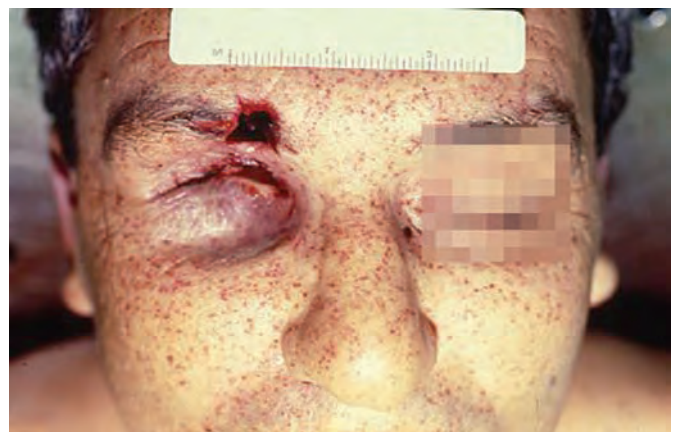Intermediate range of fire. Tightly packed stippling defects surrounding this entrance gunshot wound to the cheek. There is no apparent soot deposition.



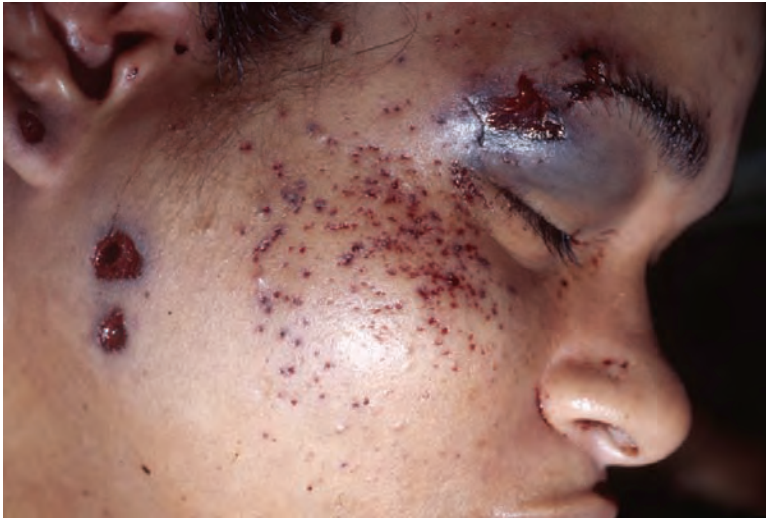Multiple stippling defects to this individual's forehead indicating intermediate range of fire.



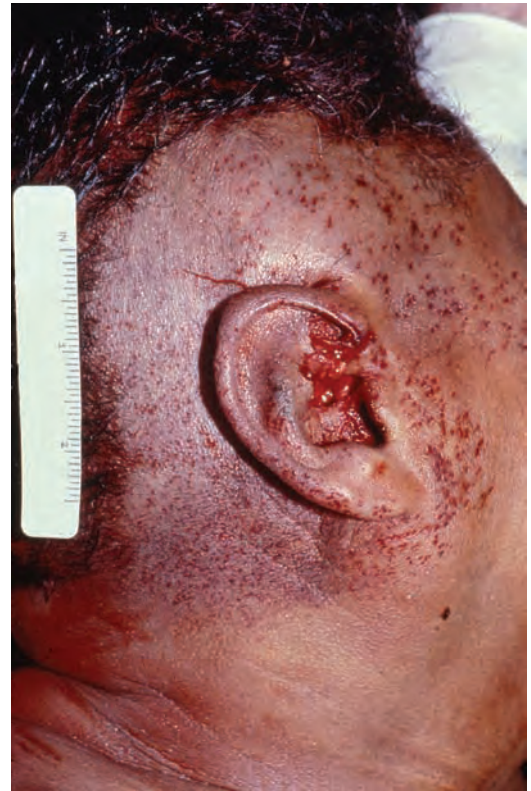Intermediate range of fire with stippling defects. Stippling defects represent abrasions that, unlike soot, cannot be wiped away.



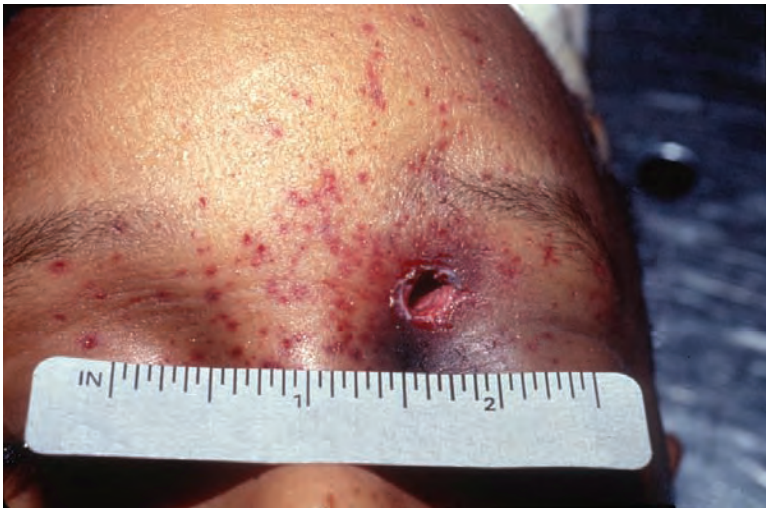Intermediate range entrance gunshot wound to the eyebrow with stippling defects across the face. Note the irregular nature of the wound due to the location of the gunshot wound through the eyebrow ridge, with the underlying frontal bone closely subadjacent to the skin surface.



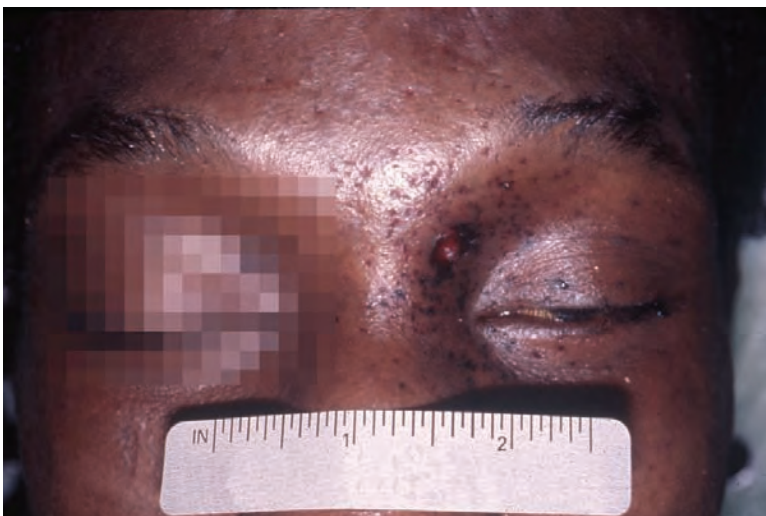Intermediate range of fire.



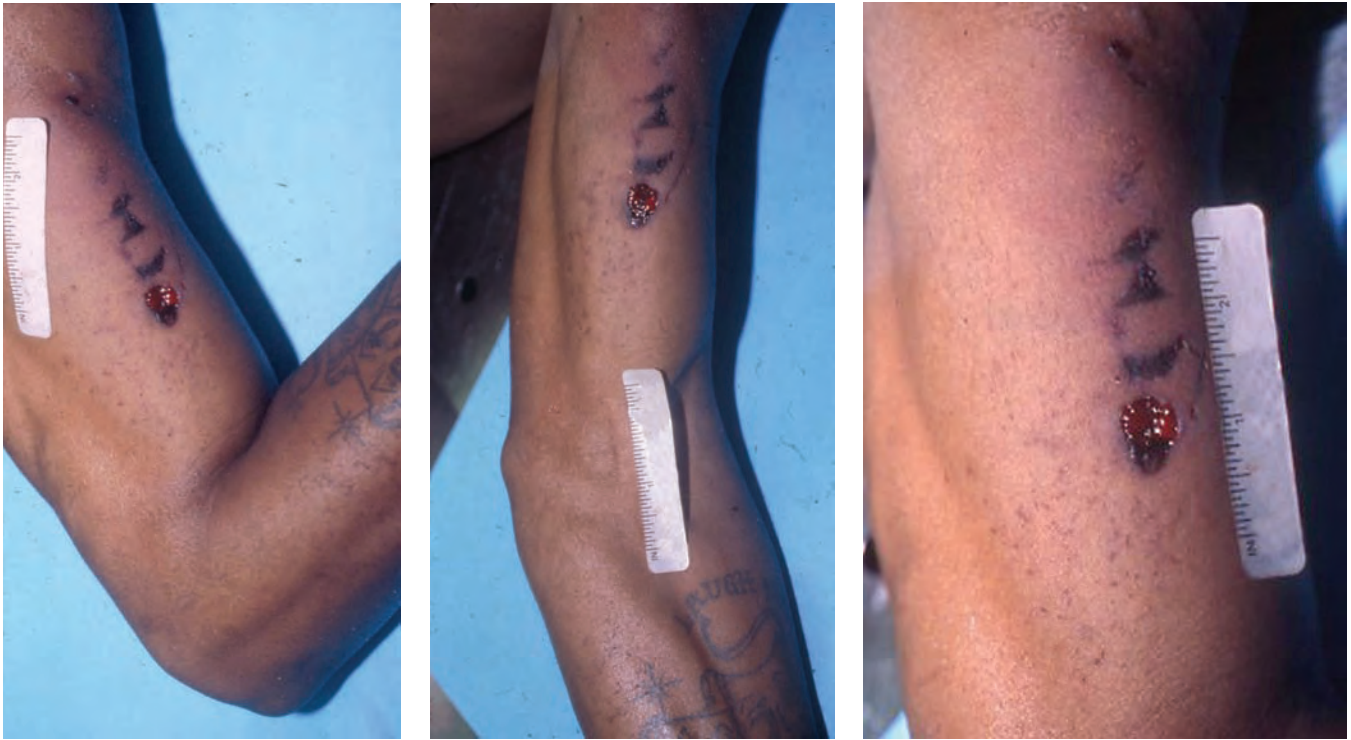Intermediate-range entrance gunshot wound with stippling defects. The scalp is partially shaved. Note the decreased number of defects in the shaved area as a result of hair dampening the effect. The weapon was a sawed-off 30/30 hunting rifle that was reportedly discharged approximately 15 inches away from the decedent's head.



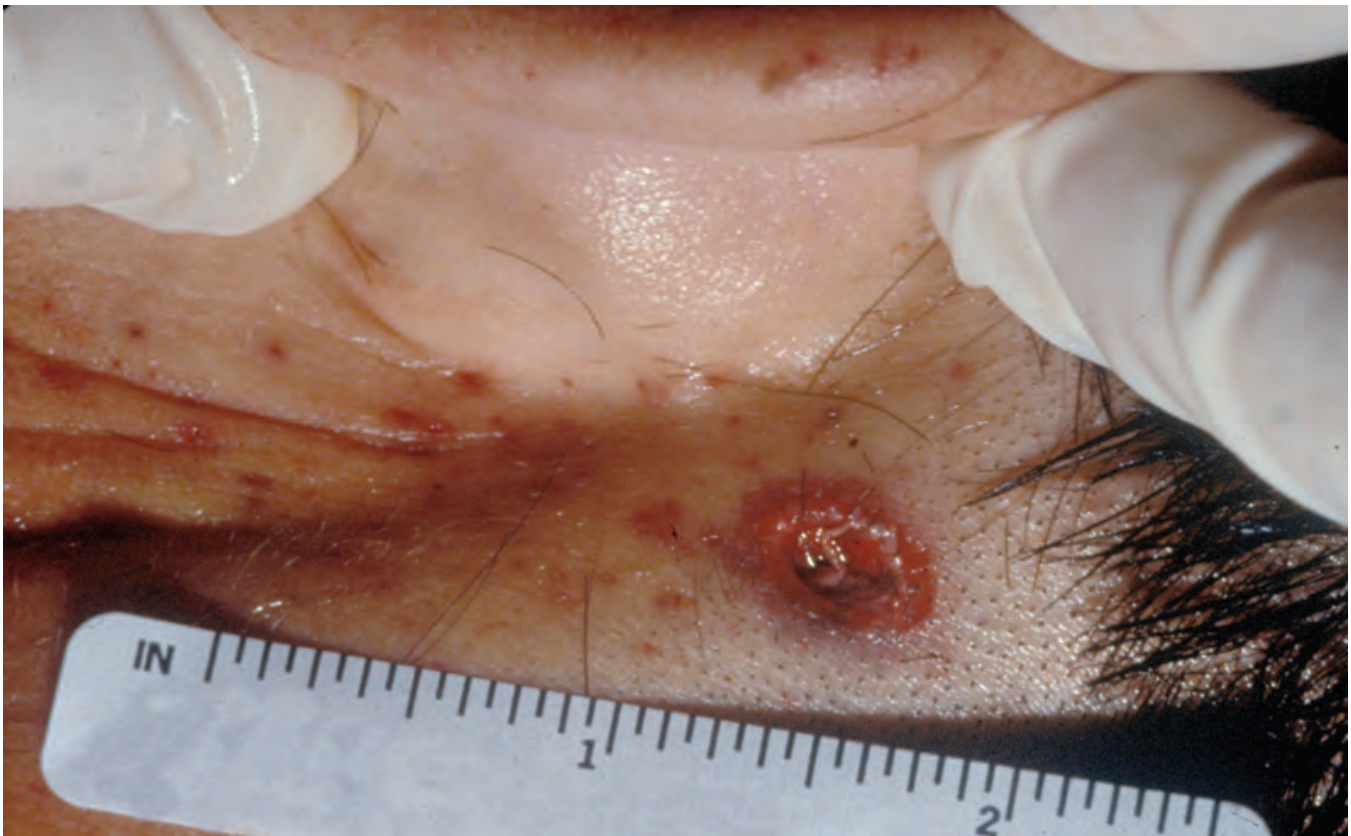Entrance gunshot wound with stippling defects indicating intermediate range of fire.



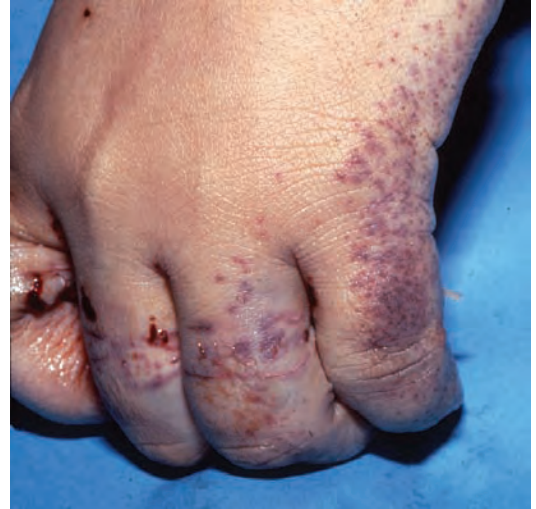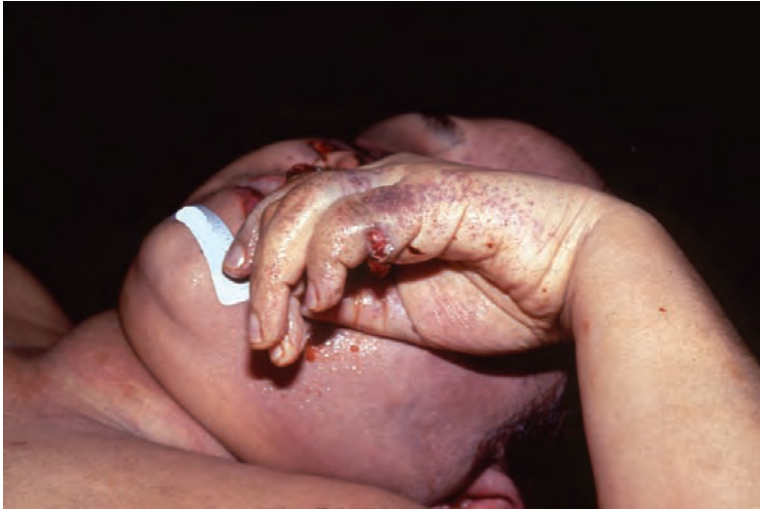Intermediate-range gunshot wound with stippling in a dark-skinned individual.



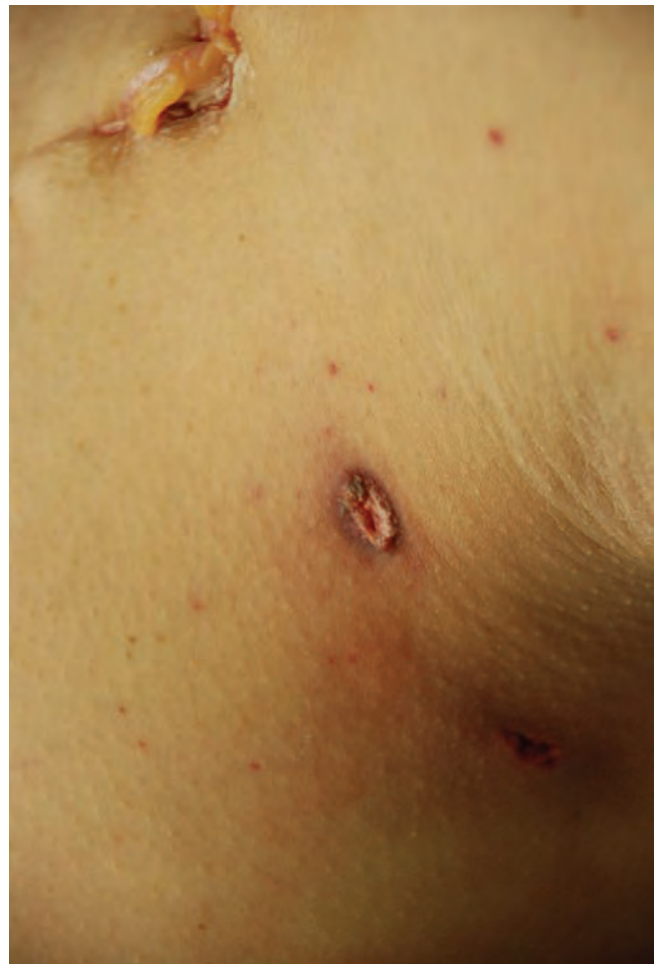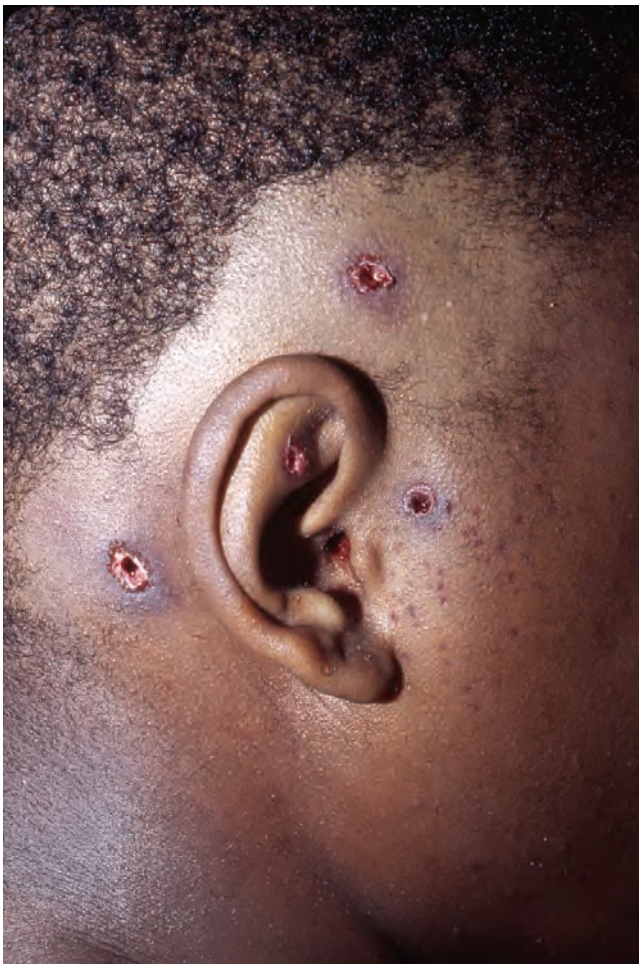Intermediate-range gunshot wound. Note the sparse stippling defects along the bicep and forearm with sparing of the antecubital fossa region. This indicates the decedent had his arm bent when he was shot.



This individual had stippling defects involving the posterior portion of his lateral outer ear and temporal scalp. Note the sparing of the posterior medial ear.

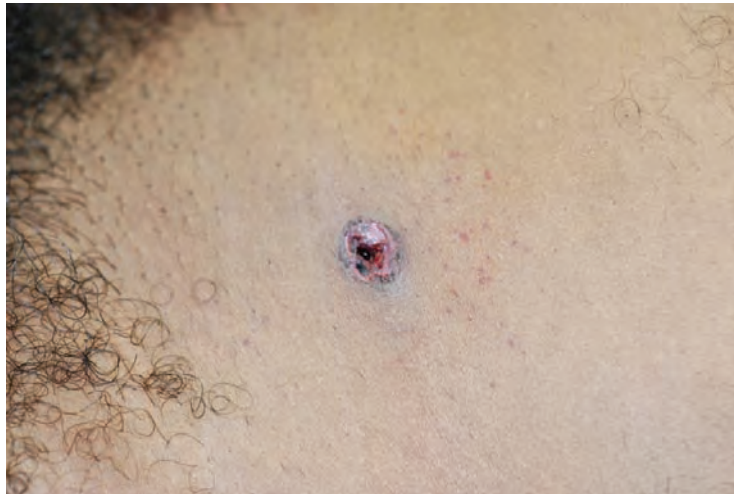
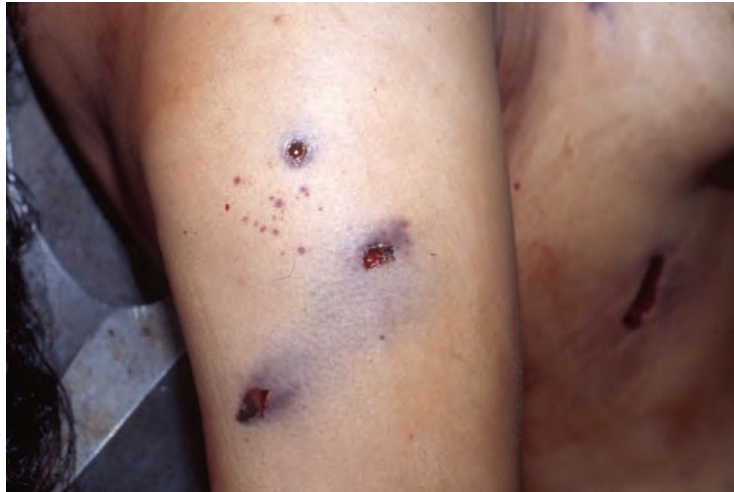
Stippling defects with soot deposition on the side of an outstretched hand, indicating intermediate to close range of fire.

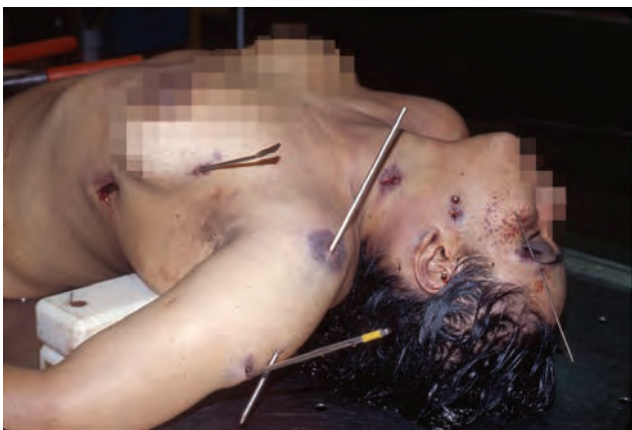

Multiple-entrance gunshot wounds. Note the sparse stippling defects indicating intermediate range of fire at the skin anterior to the ear. The farther away a gun is discharged from the body, the more spread out the stippling defects become.

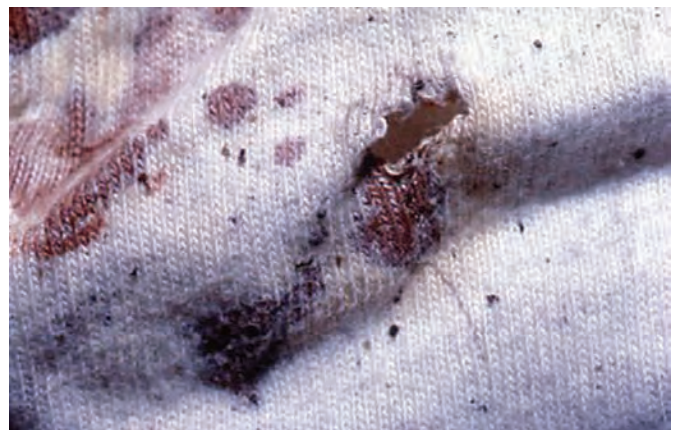
Intermediate range of fire. Note the sparse stippling defect surrounding the bullet perforation site.



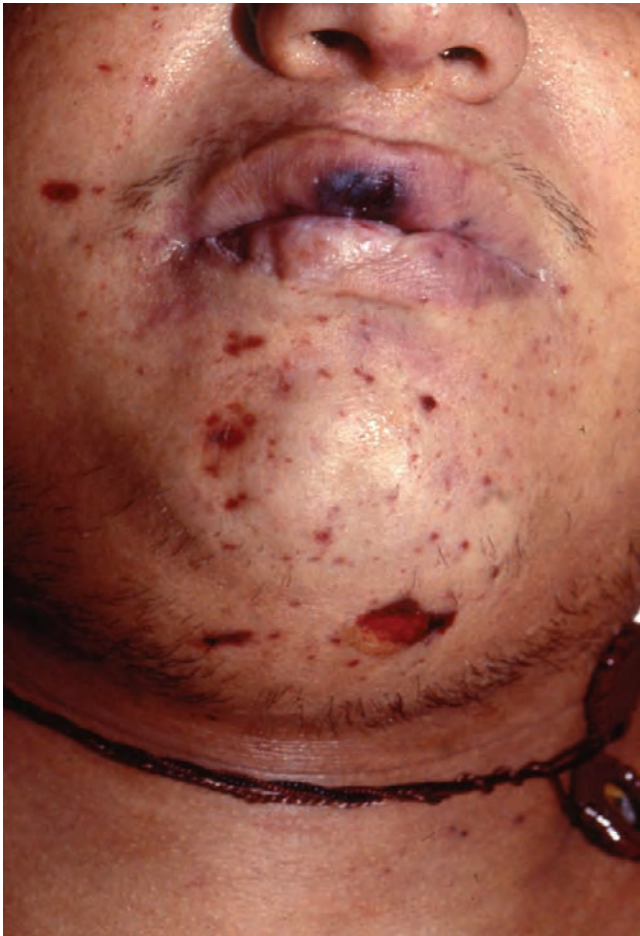
A few sparse stippling defects indicating intermediate range of fire. Note the contusion surrounding the perforating gunshot wound at the arm. This dark discoloration should not be confused with gunpowder residue.



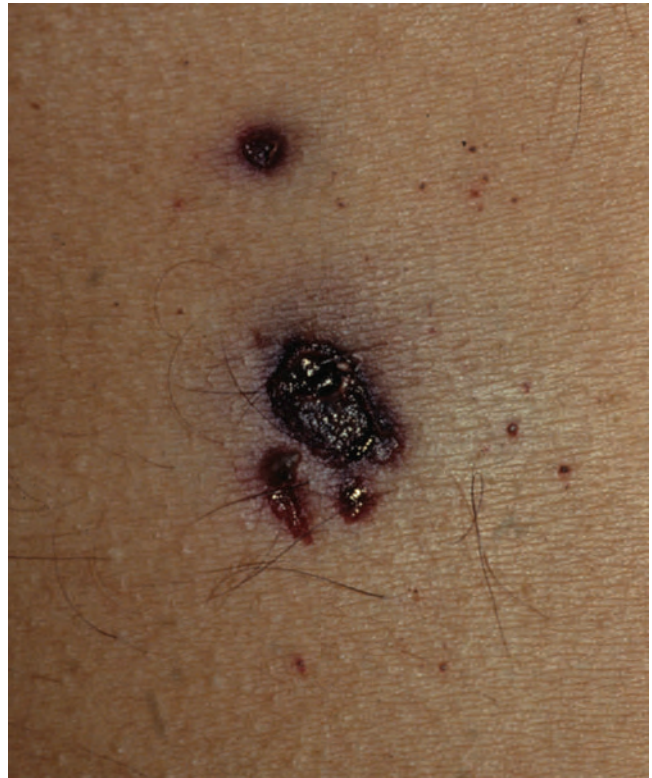
Note the multiple gunshot wounds to this individual in varying directions. She was shot multiple times while jumping in different directions in an attempt to run away. Note the contusion to her left shoulder and the stippling defects to her face. It is important to realize that the direction of fire may vary greatly.



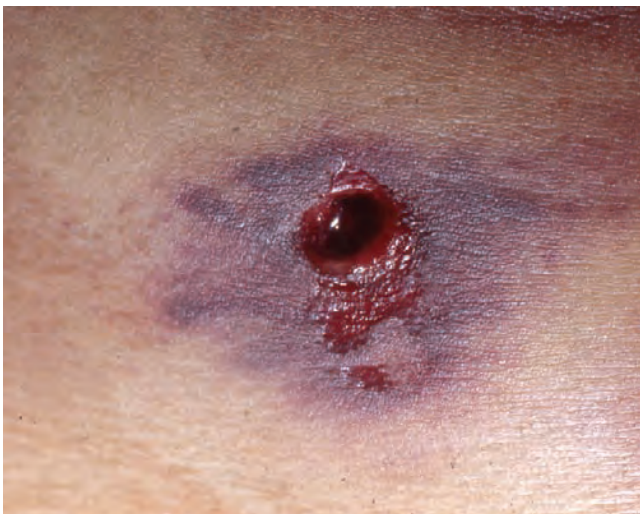Gunshot wound perforation of clothing with multiple gunpowder residue flecks at the surrounding surface. The underlying entrance gunshot wound still revealed a sparse stippling pattern consistent with intermediate range of fire.



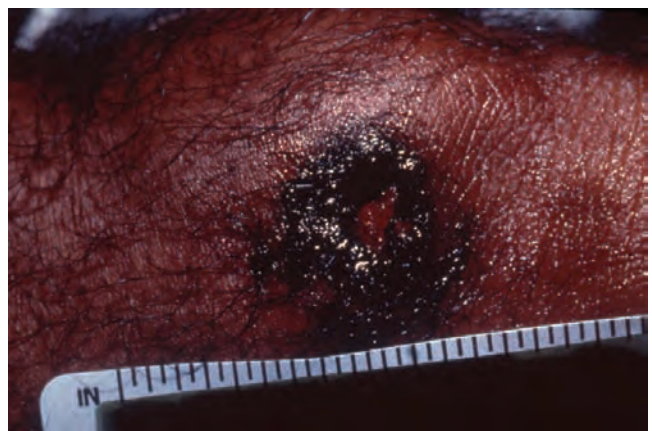
Distant gunshot wound with pseudostippling to this individual's face caused by fragmented debris as the bullet passed through a car window.



Distant gunshot wound with pseudostippling. Note the large size variation in the abrasions to the gunshot wound. True stippling defects are more uniform in size.

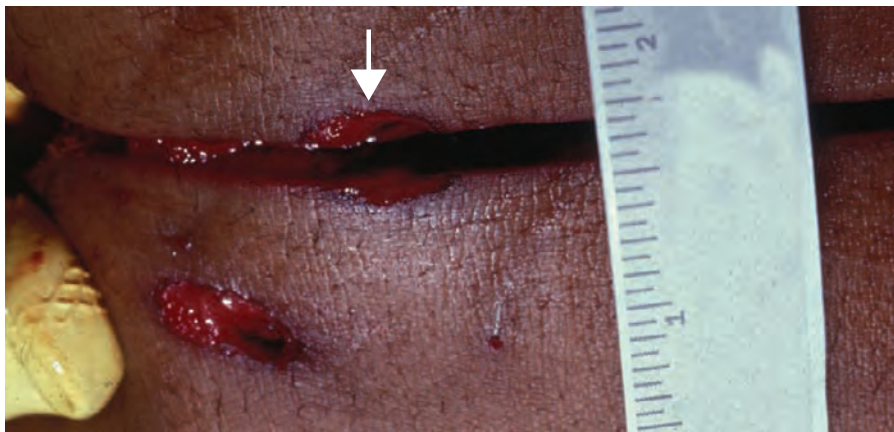
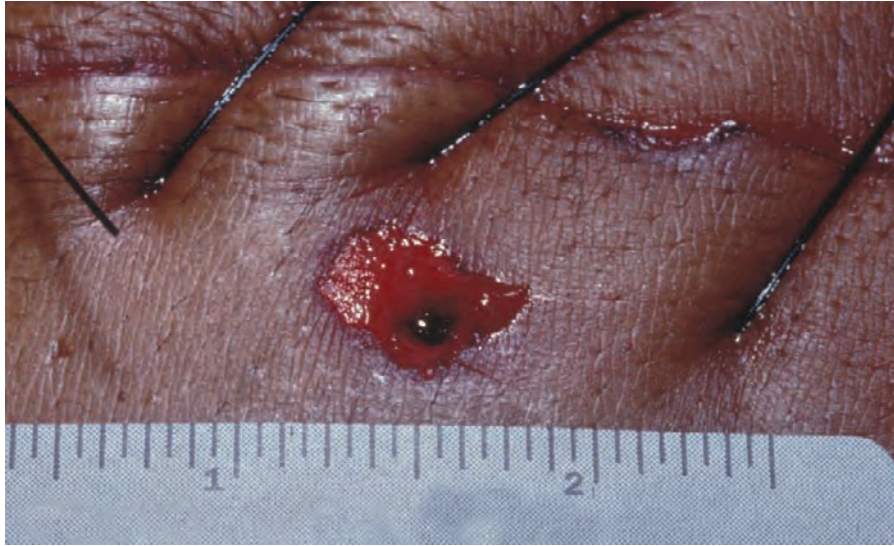


Atypical distant-entrance gunshot wound with surrounding contusion.

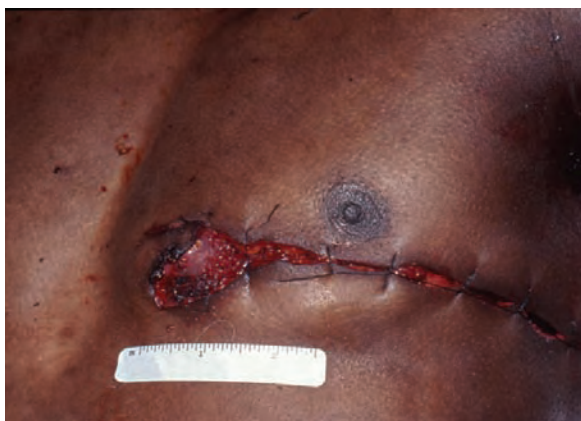

Distant-entrance gunshot wound with surrounding clotted blood. In this case, histopathology of the adjacent skin demonstrated no dark particles consistent with gunpowder residue. It may be challenging to visualize soot when it is mixed with dried blood. Dried clotted blood has a shinier character than gunpowder residue, which has a duller appearance. It may be challenging to interpret range of fire when both dried blood and soot are present simultaneously. If there is any question concerning the presence of soot, we recommend microscopic examination to help clarify this point.

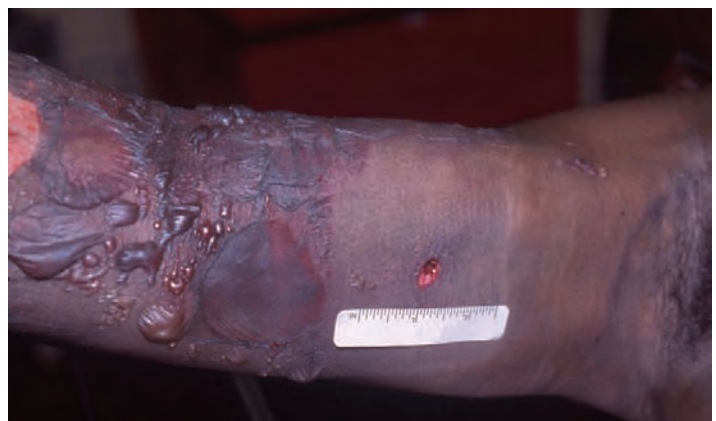



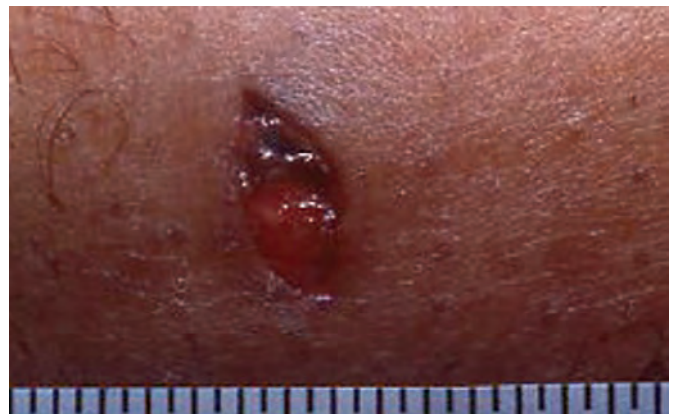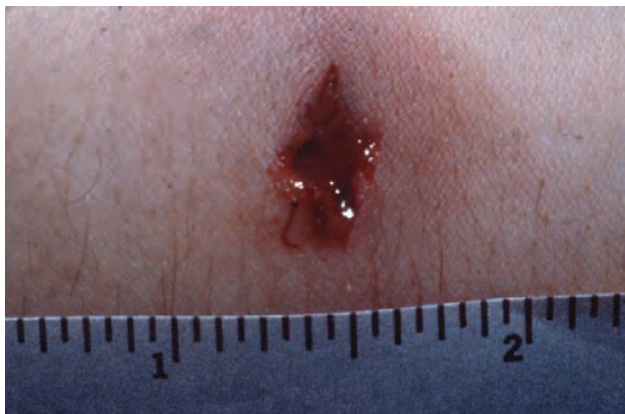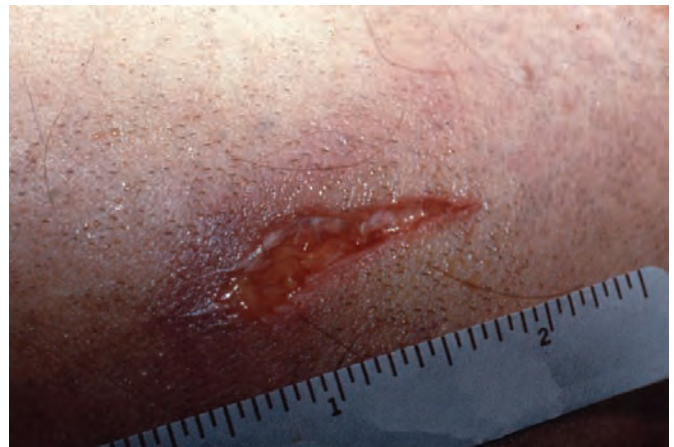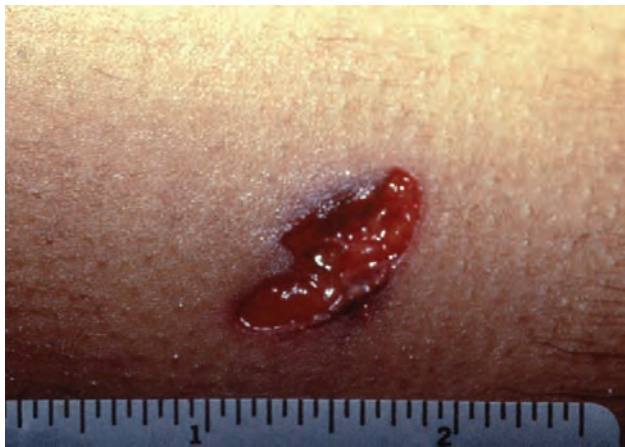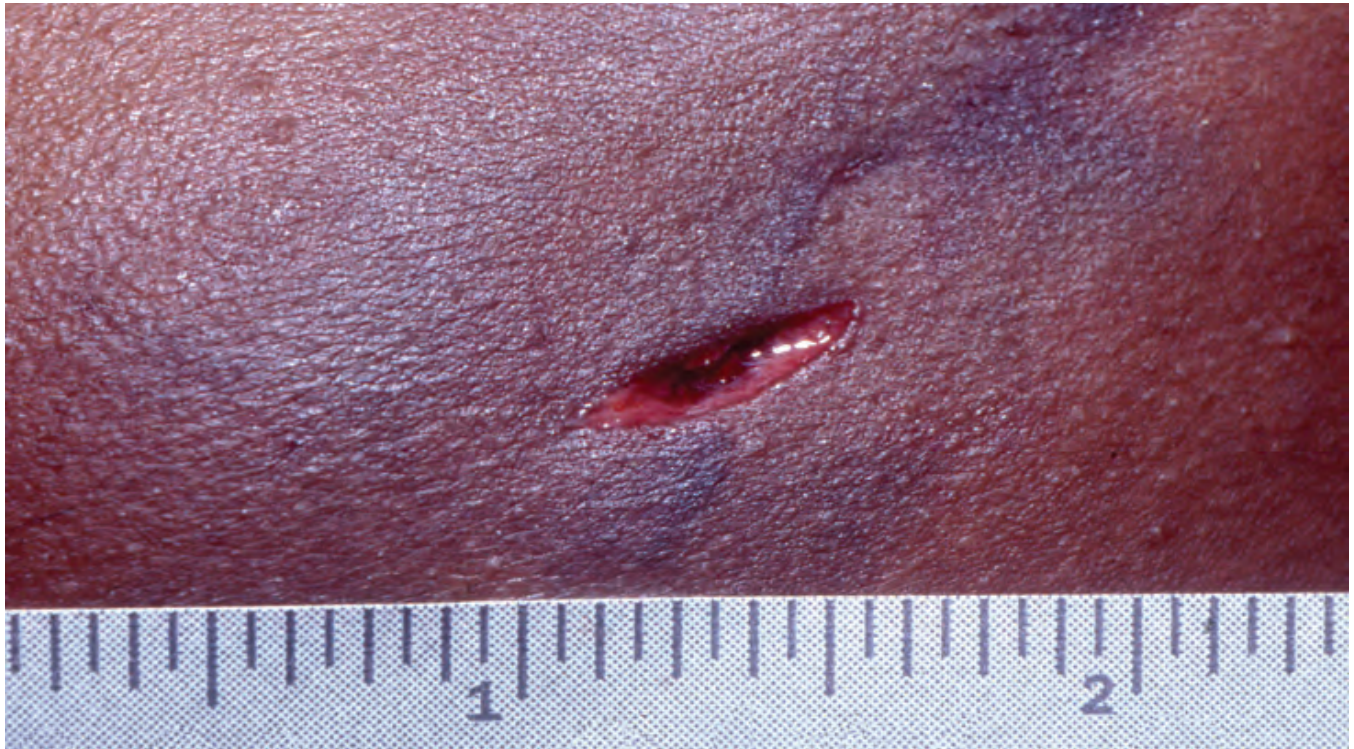Thoracotomy incision through entrance gunshot wound. One should never cut through the wound during resuscitative efforts. No one would argue the importance of saving the individual's life. Cutting next to the wound will not affect the chances for survival. Cutting through the wound may make wound interpretation very difficult and hinder criminal proceedings. Note one gunshot wound was cut through and hidden in the suture line. The defect becomes more obvious with suture removal.



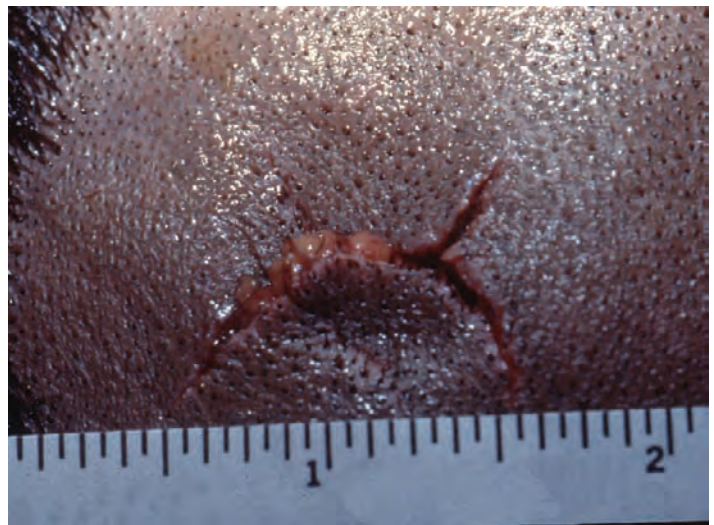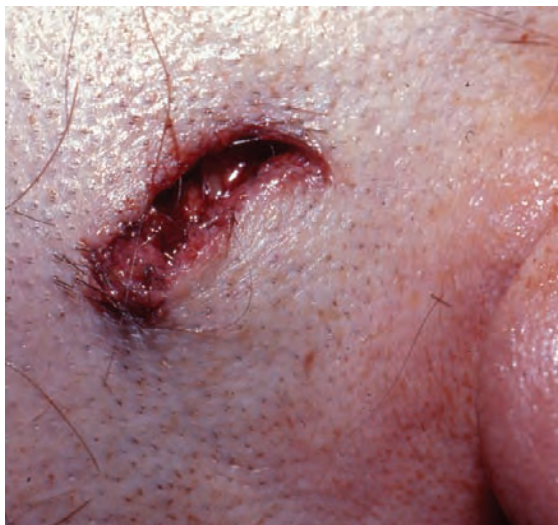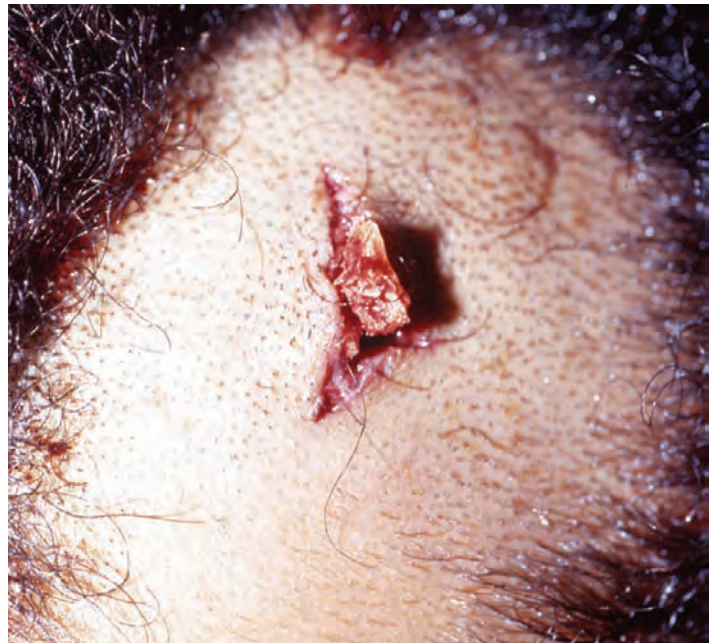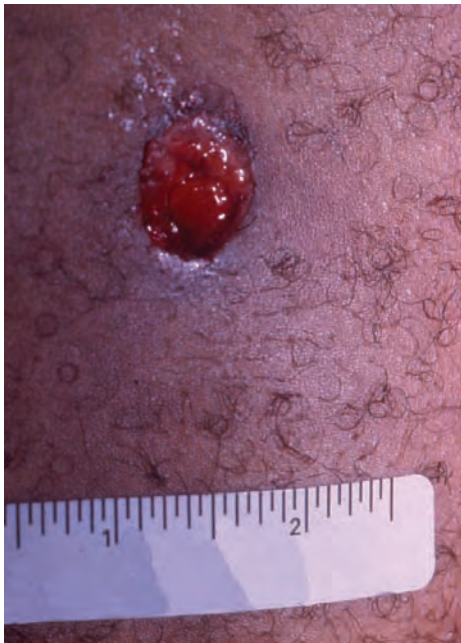
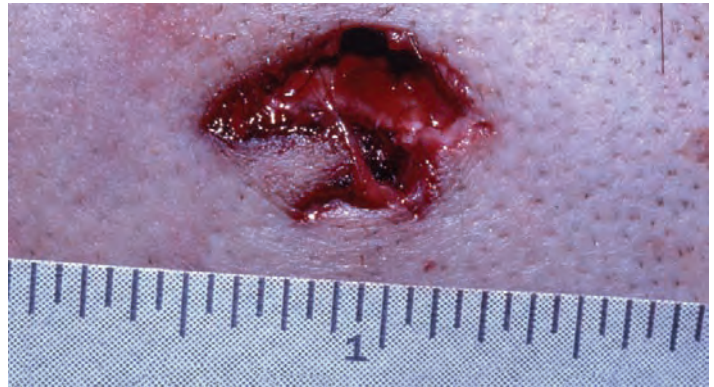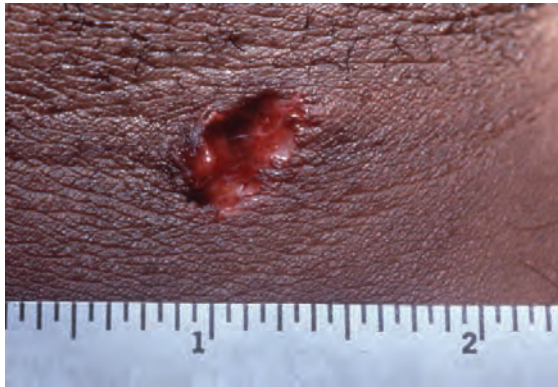
Note the large gunshot wound at the medial aspect of this thoracotomy incision.



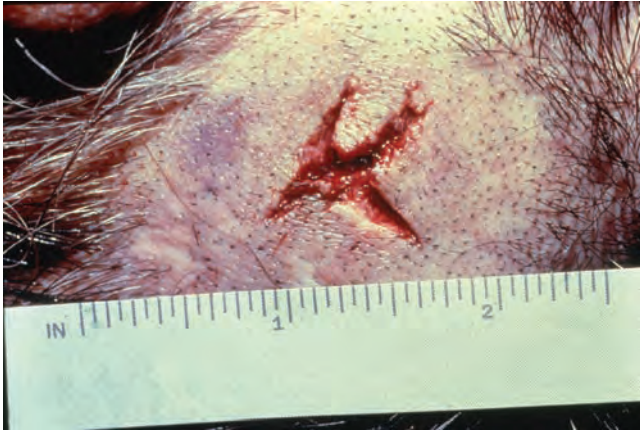
This is a gunshot wound that is several days old. This person died of septic complications. Note the adjacent wound infection distal to the GSW site.



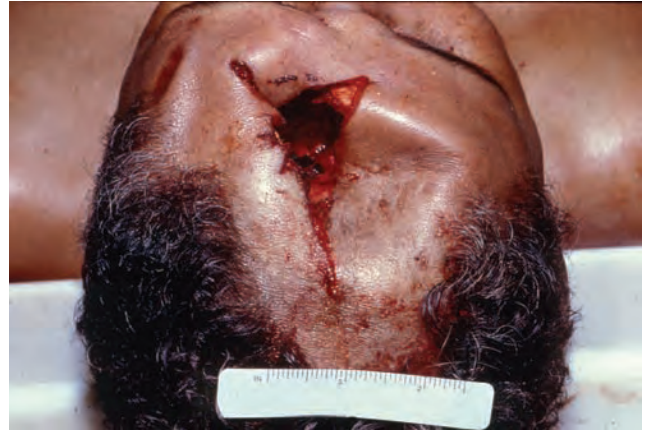Exit gunshot wounds. Note the typical, often irregular, slit-like defects without margins of abrasion. The appearance is generally more irregular and less round than the entrance wound.



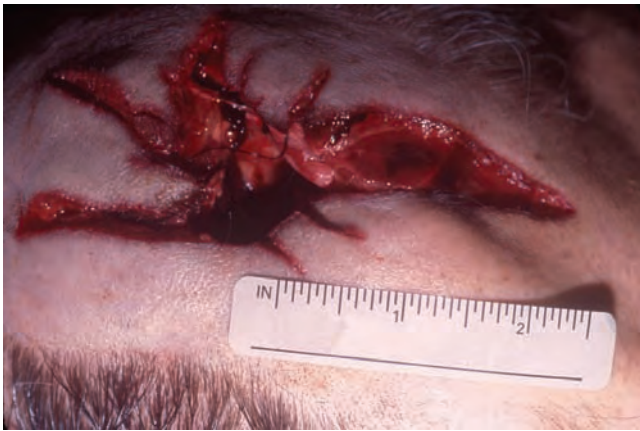Exit gunshot wounds.



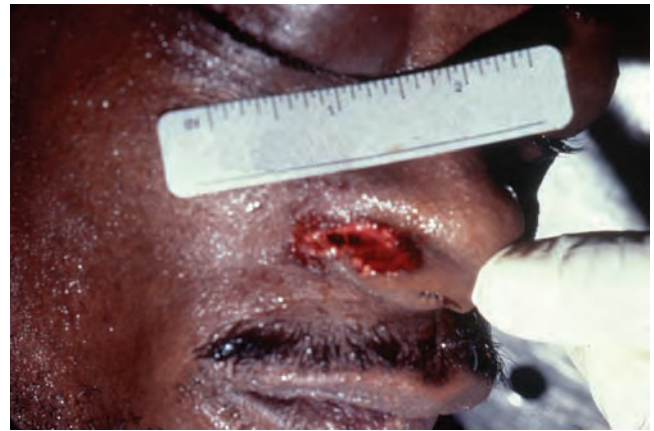Exit wound with lacerated margins.



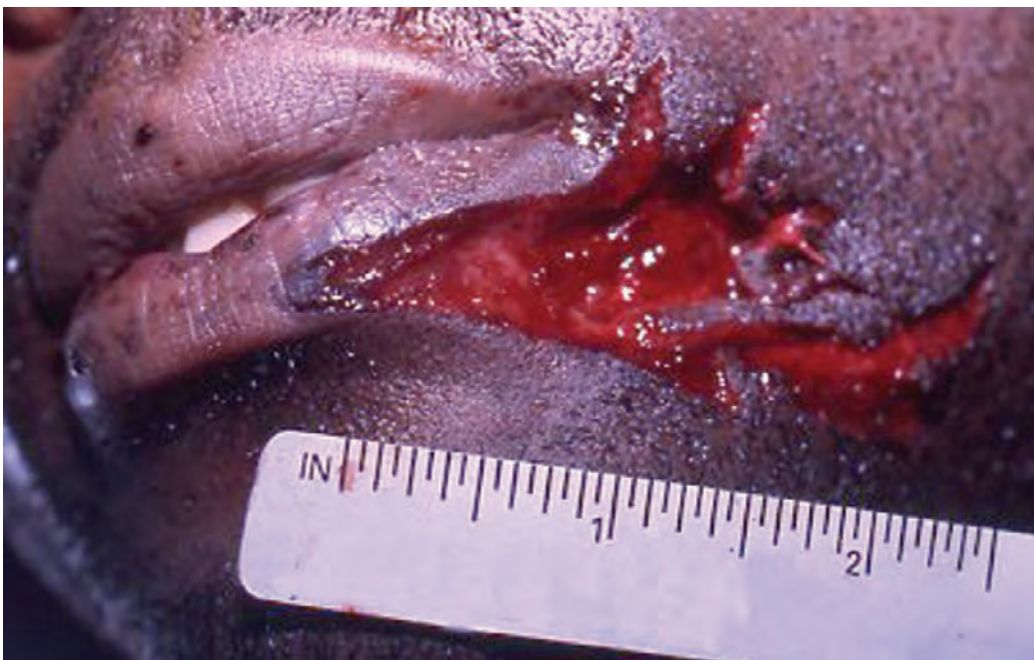
Exit wound from a sawed-off 30/30 hunting rifle.



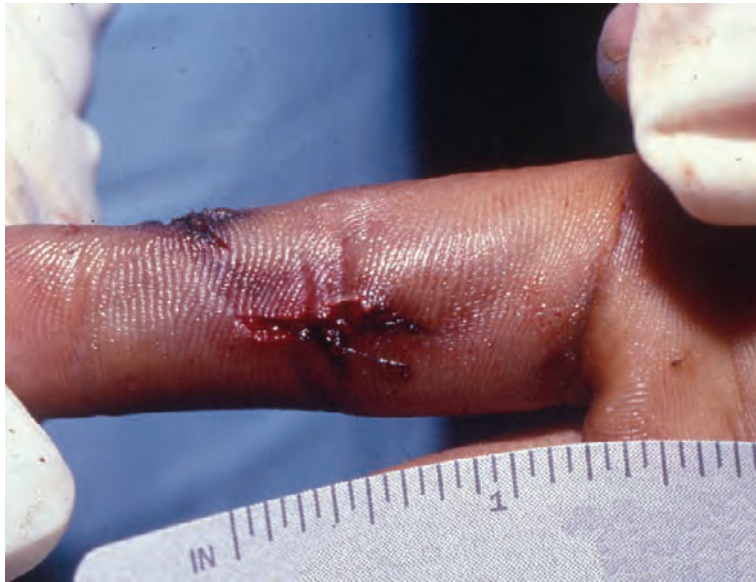Exit wound from a handgun. It is not typical to get such a large laceration from a medium-caliber bullet that already perforated the skull.



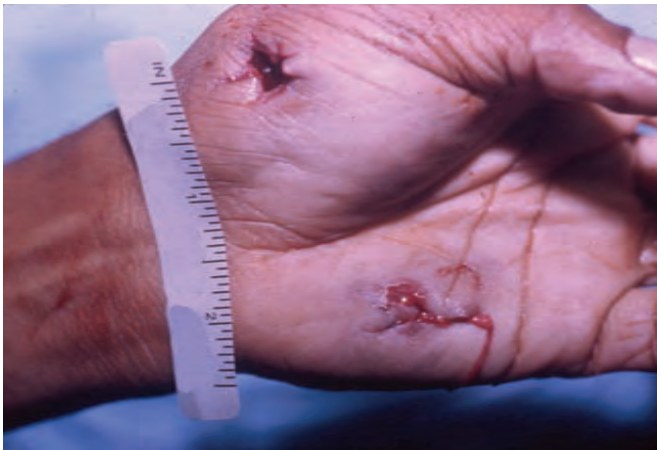Exit gunshot wound through the right nares.



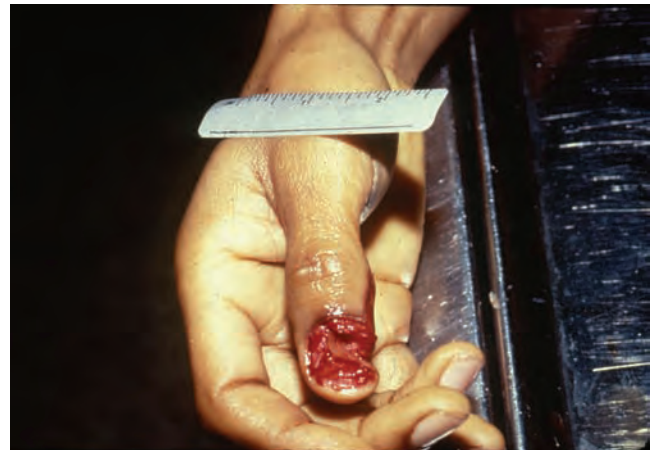Exit gunshot wound to the lower face caused by a bullet that was markedly deformed by striking underlying bone before exiting.



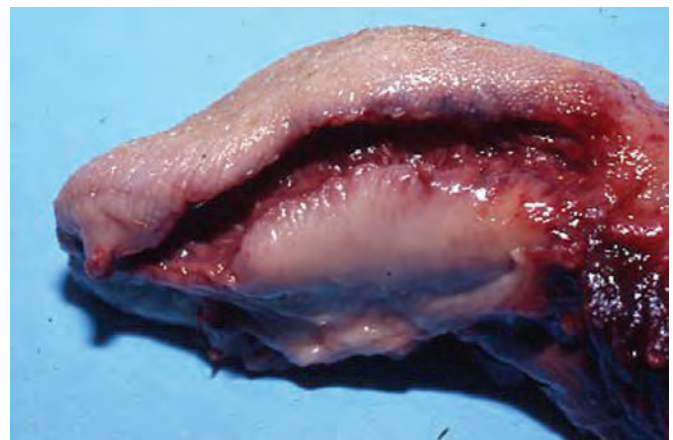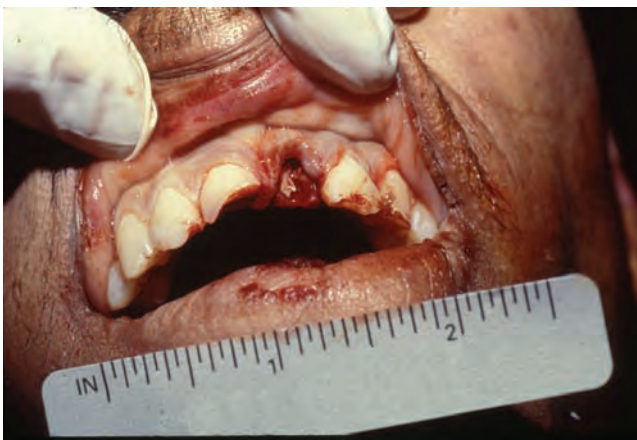Exit gunshot wound through the finger.



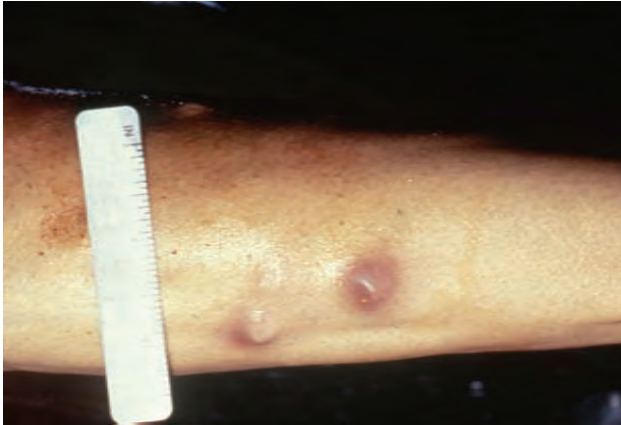
Exit gunshot wounds through the palm of the hand.



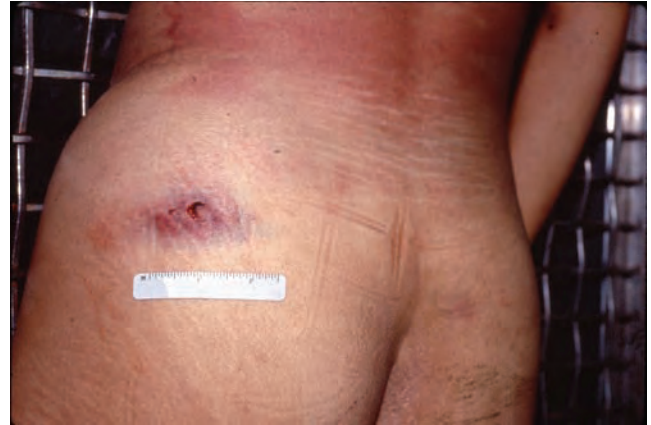
Exit gunshot wound through the thumbnail bed.



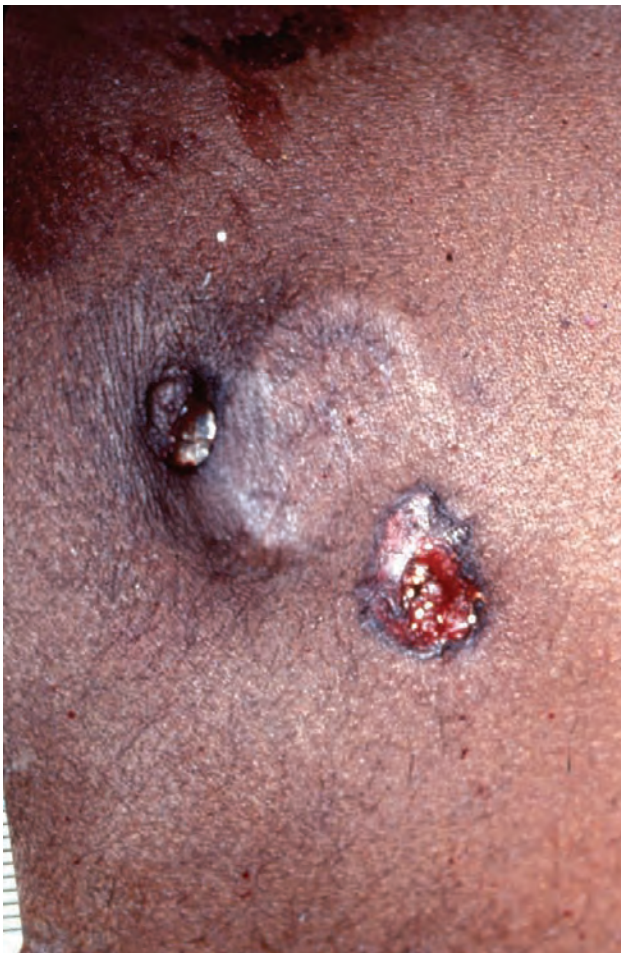This individual was shot in the lower back while leaning forward. The bullet perforated the structures of the thoracic cavity and neck, producing a grazing-type gunshot wound to the tongue. The bullet then knocked out the individual's front tooth before exiting the body from the open mouth.



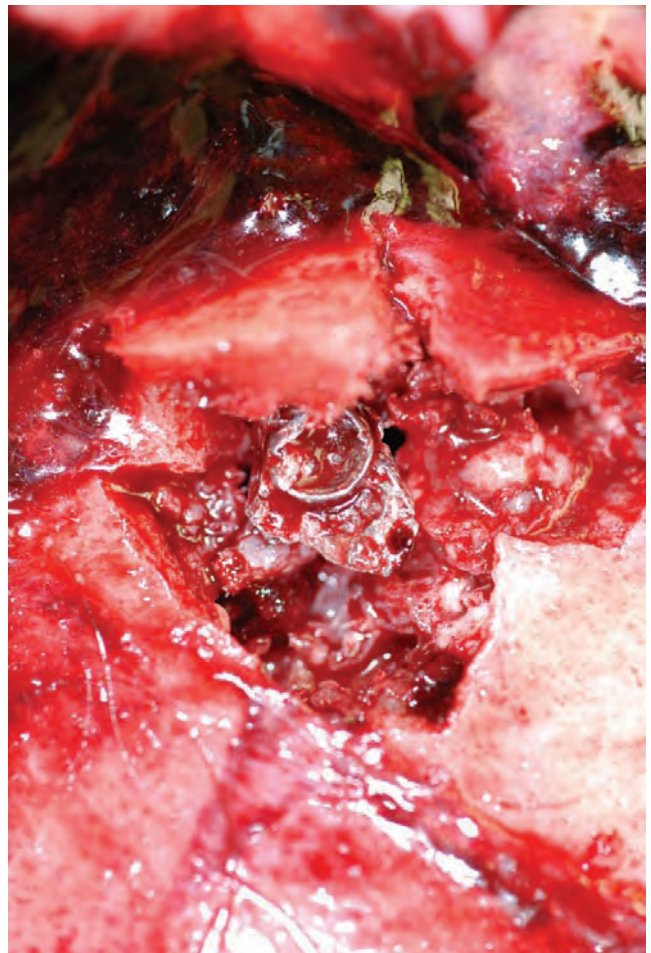
Note the lumps directly underneath the skin's surface. These are caused by bullets just beneath the surface of the skin that did not have enough kinetic energy to exit the body.



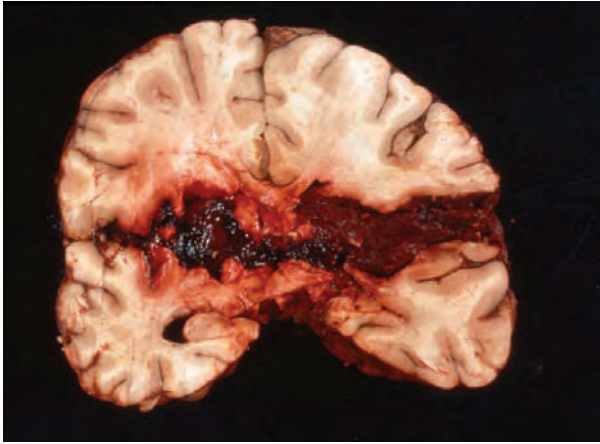
A bullet was retrieved just beneath the surface of the skin within this area of contusion.



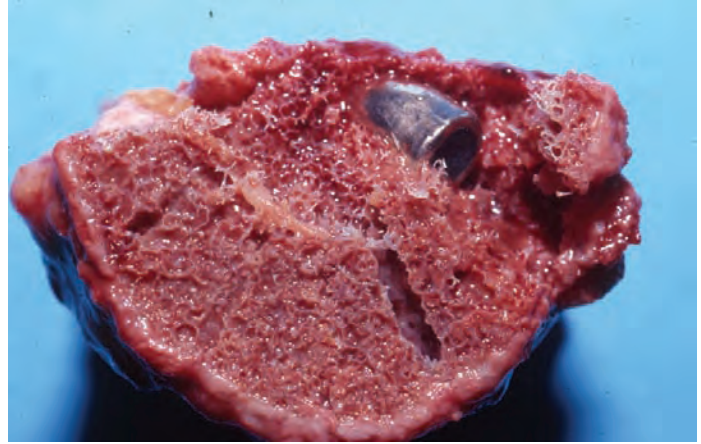
There is a large deformed gray metal slug just underneath the surface of the skin that is partially visible underneath the broken skin.



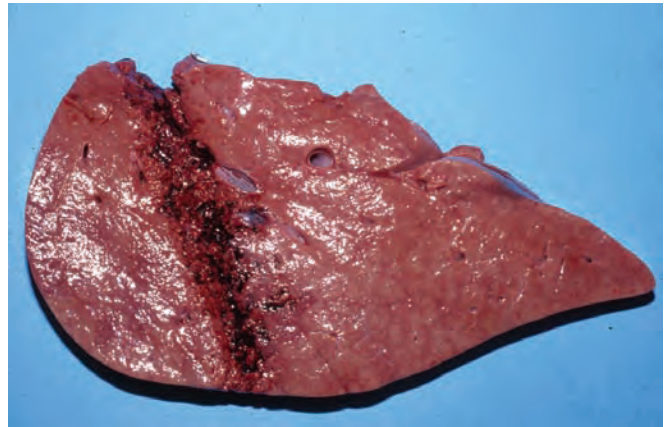
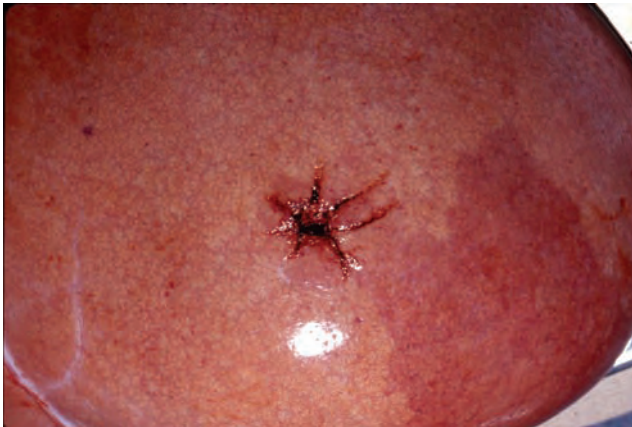
Bullet retrieved from skull fracture directly underneath the skin's surface.



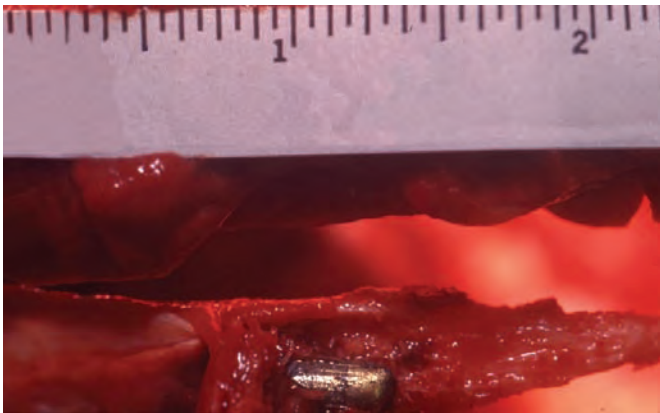
This image demonstrates a hemorrhagic pulpified wound track through the cerebral hemispheres caused by a medium-caliber handgun bullet.



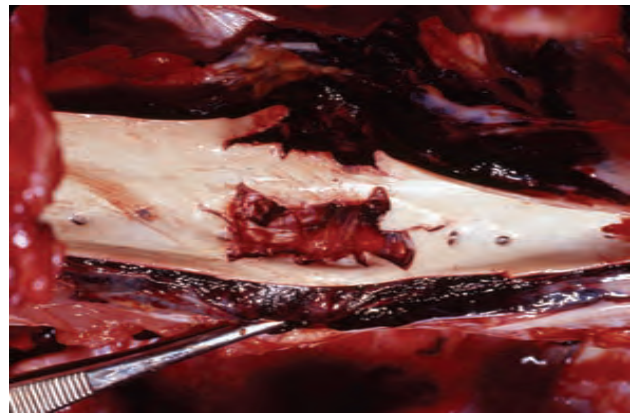
This bullet was retrieved within this portion of thoracic vertebra. It is important to carefully remove such bullets encased in bone, so as not to destroy ballistic markings on the sides of the bullet.



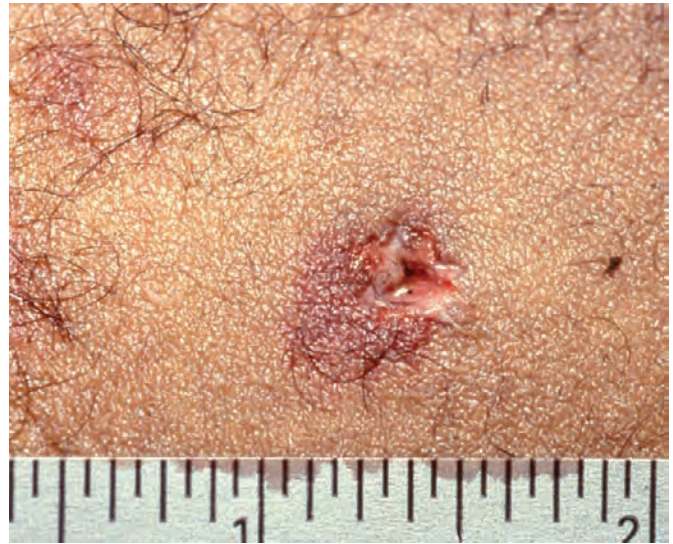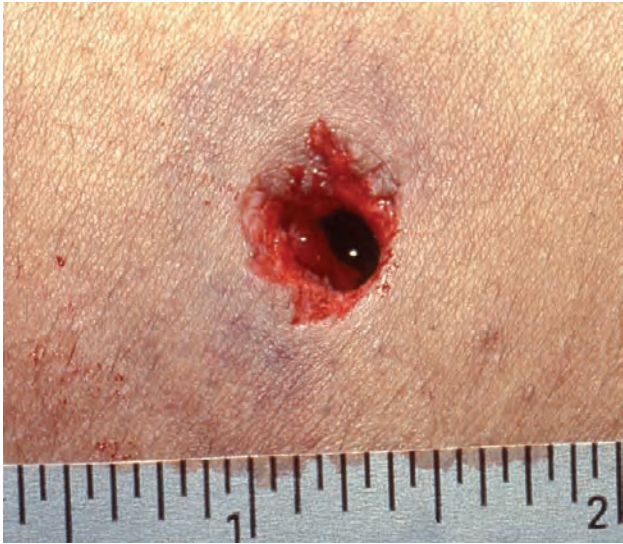These figures demonstrate a wound track through the liver caused by a medium-caliber handgun.



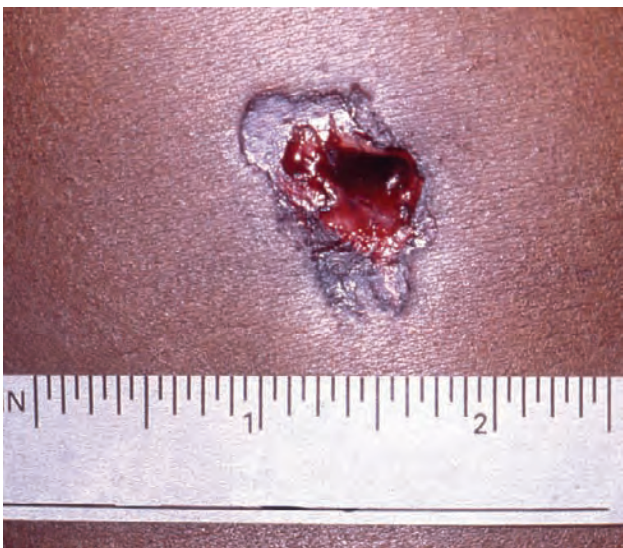
This individual had been shot several weeks earlier with a .22 caliber handgun. One of his ribs fractured while removing the breastplate during autopsy and a bullet was retrieved from within the medullary cavity.



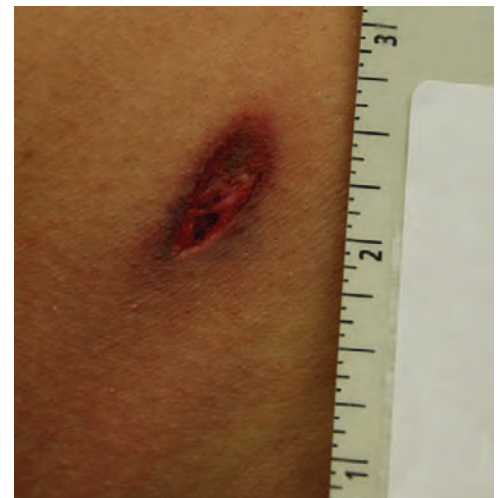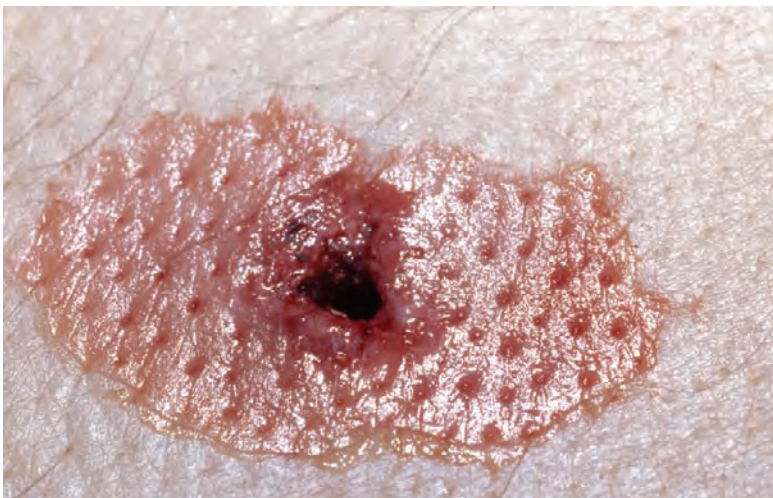A wound track through the aorta with adjacent surrounding hemorrhage. This wound was caused by a medium-caliber weapon.



Shored exits. These wounds were produced by bullets exiting the body where the skin's surface is supported (e.g., by a firm surface or tight clothing).



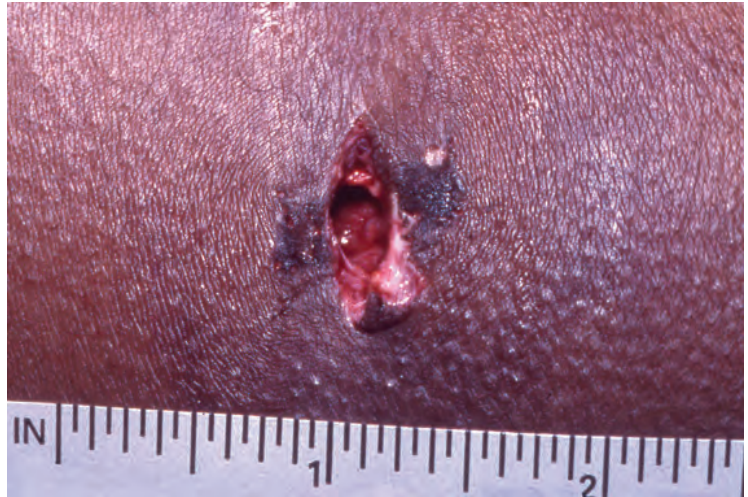Atypical entrance gunshot wound caused by a bullet that was deformed by passing through an intermediate target. Note the large irregular abrasion caused by the deformed edges of the bullet's striking the skin surface.



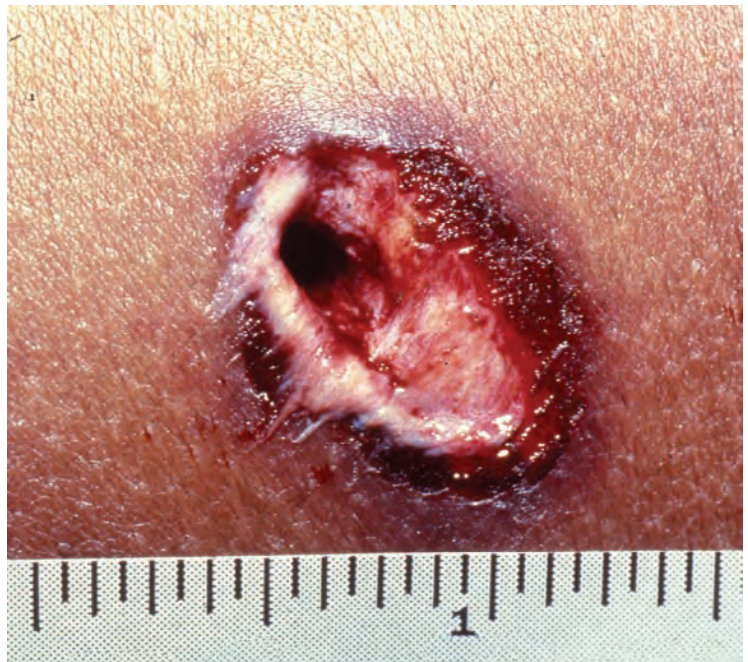
Shored exit wounds.



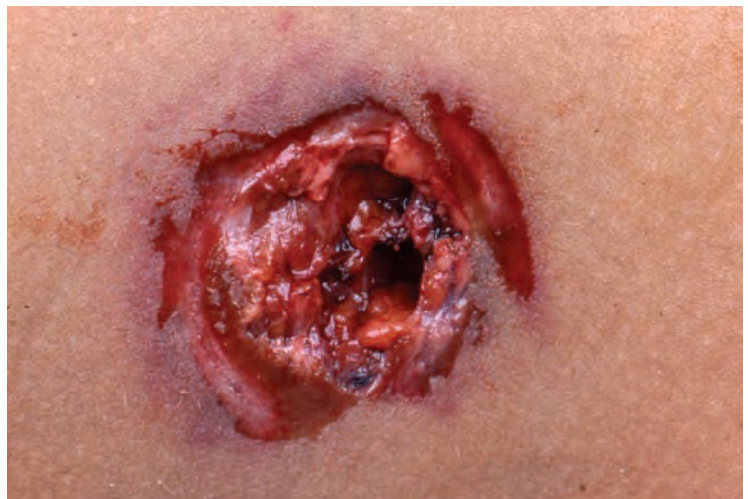Irregular exit gunshot wound with adjacent abrasion due to its location on the body through a region of folded skin.

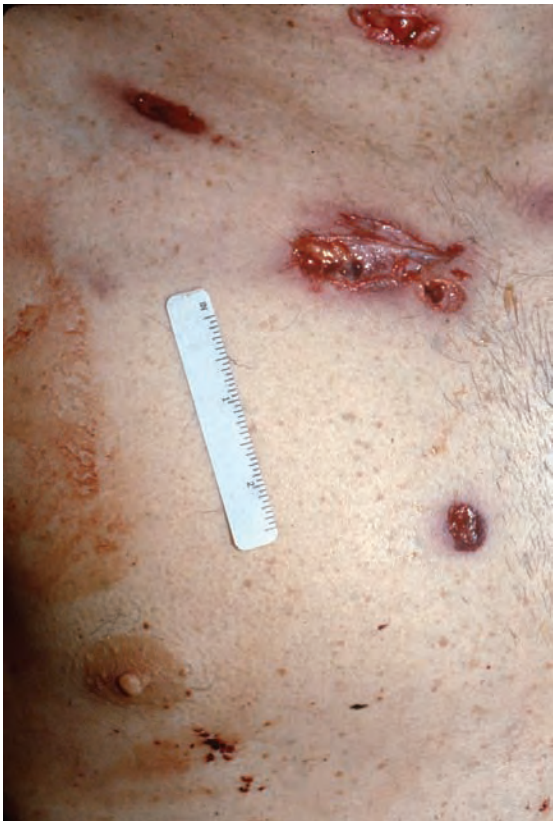
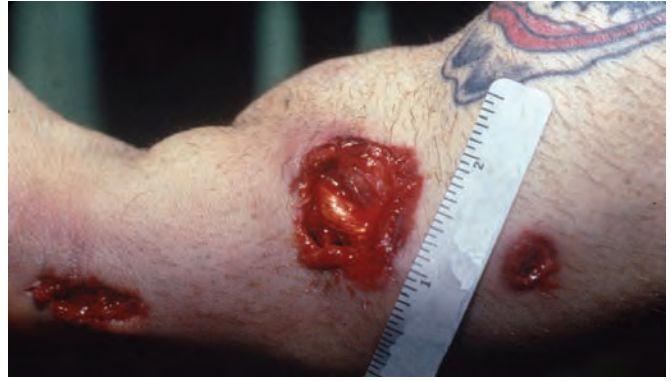
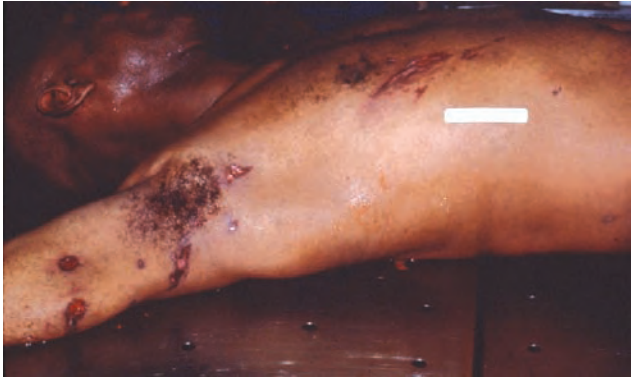This distant-entrance gunshot wound has slight oval shape with an irregular margin of abrasion that is greatest at its inferior right aspect. This wound was produced by a ricochet bullet that first struck a brick wall. Part of the bullet had an irregular scratched surface. Also, this bullet most likely struck the body sideways.

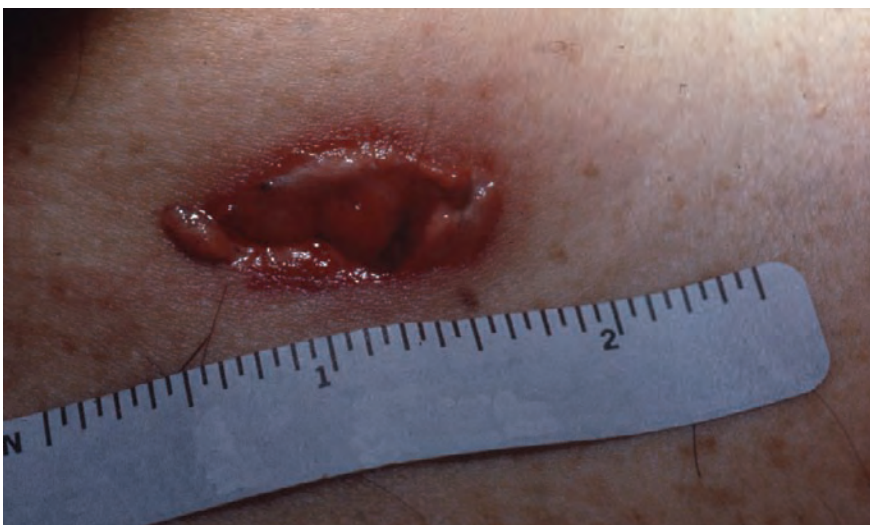
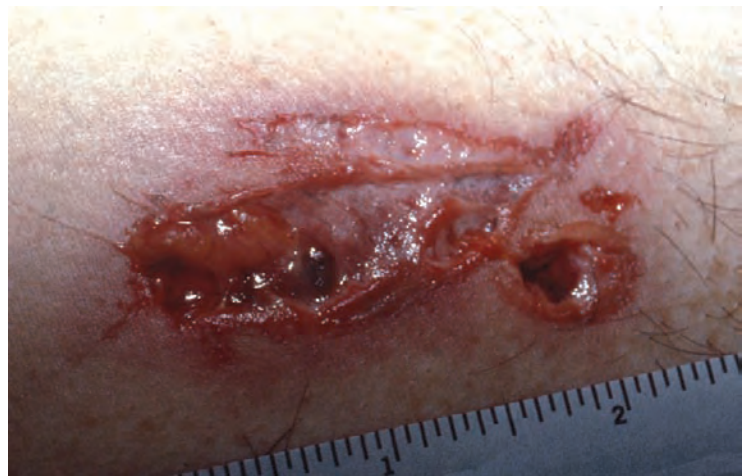
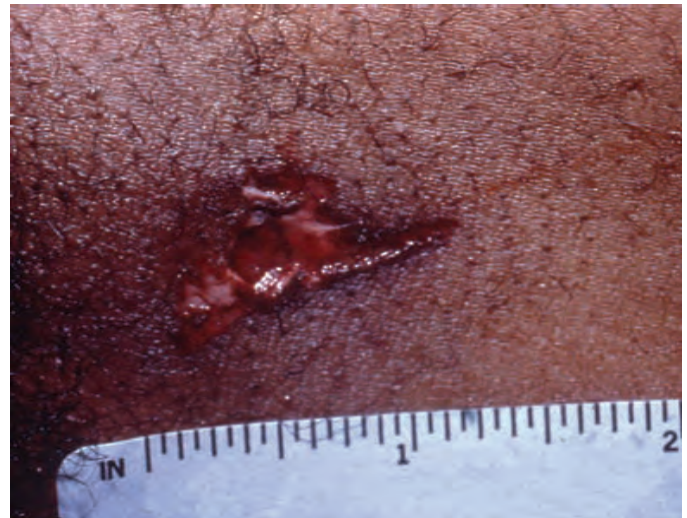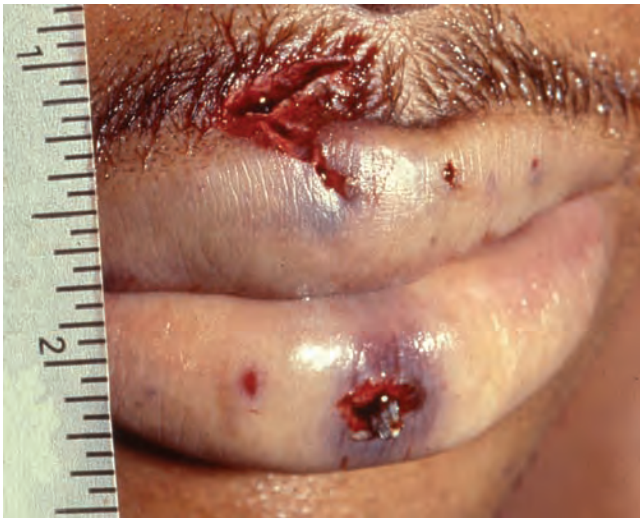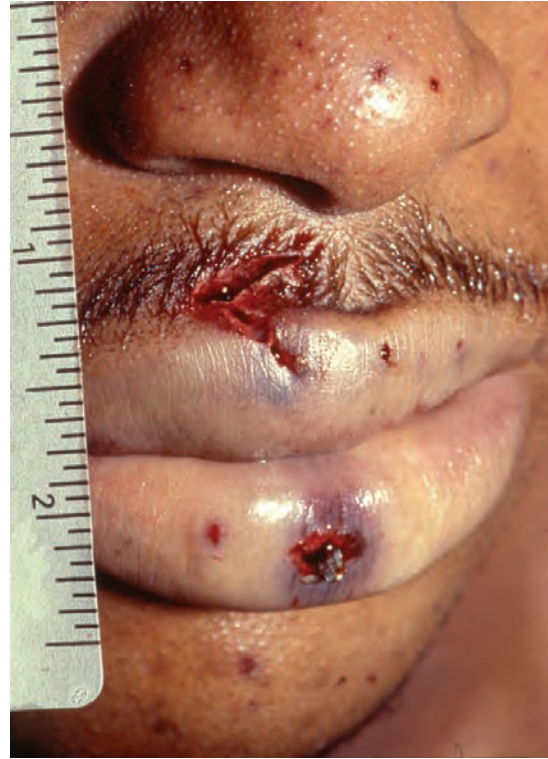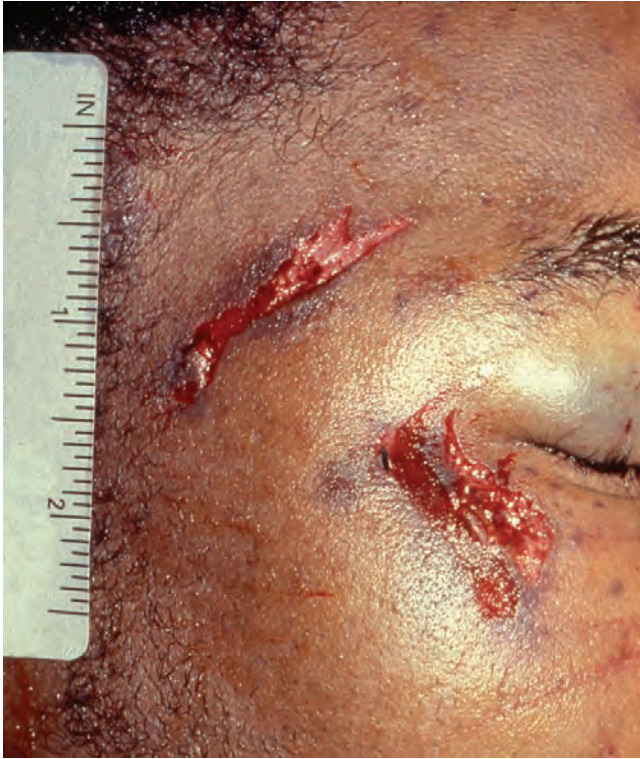Atypical gunshot wound. This is a re-entry gunshot wound produced from a bullet that was markedly deformed from striking a bone in another part of the body. Note the irregular nature of the perforation with the irregular adjacent abrasions.



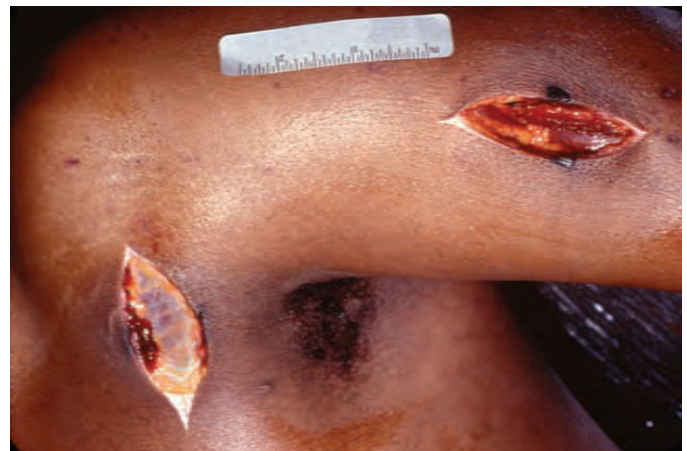

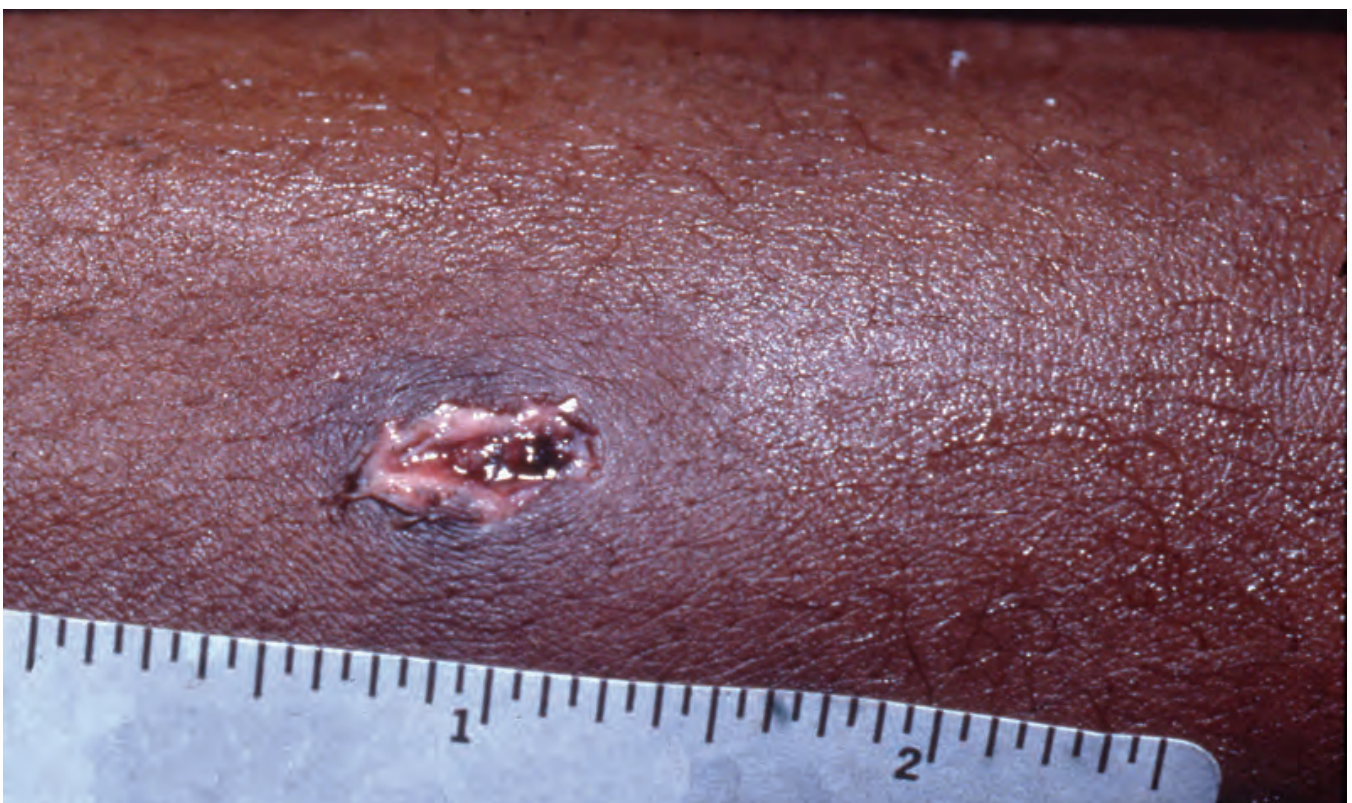
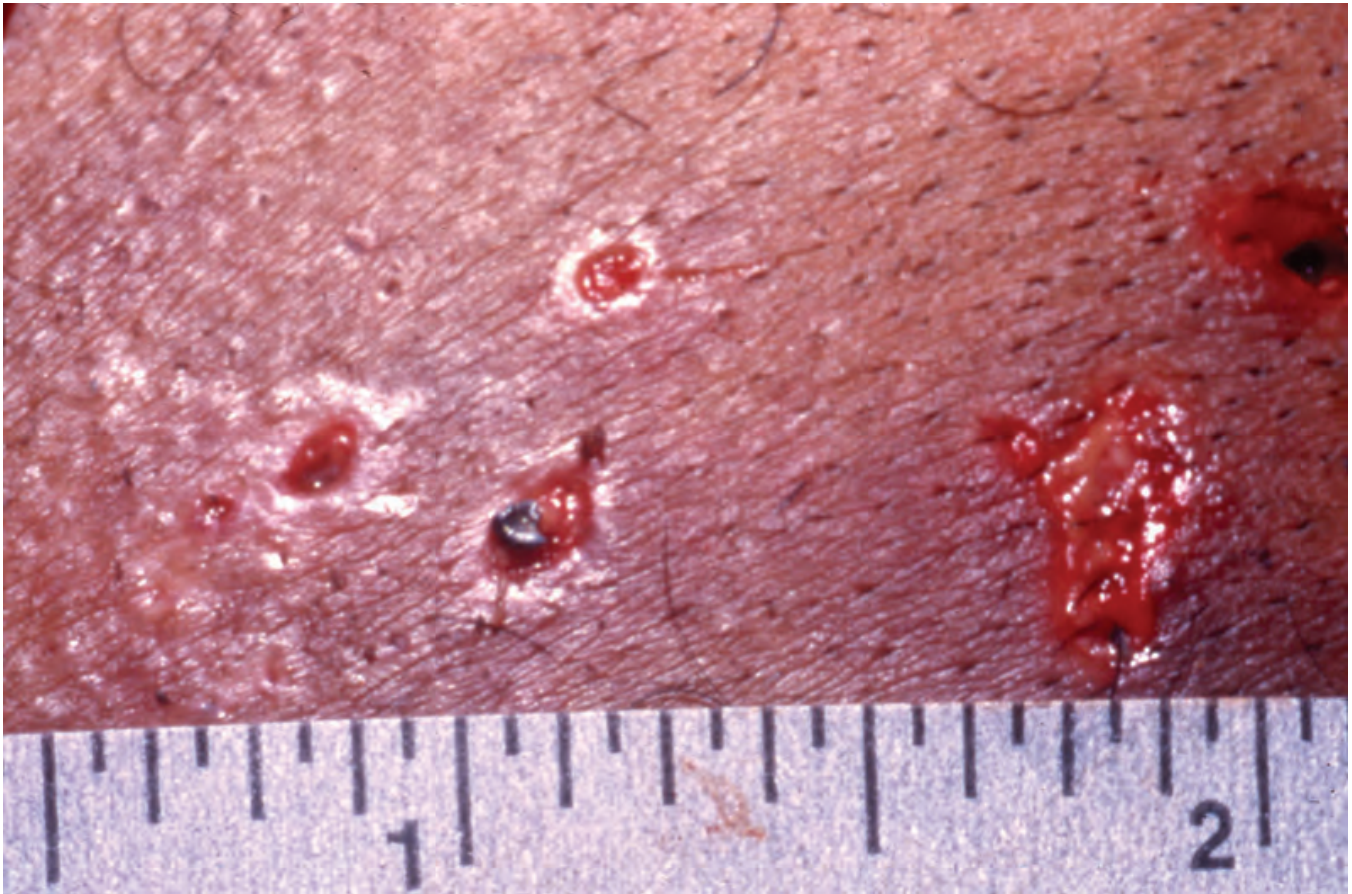
Atypical gunshot wounds from deformed and fragmented bullets that passed through an intermediate target, such as a car door and window, before entering and exiting the body. Note the markedly irregular nature of these injuries.



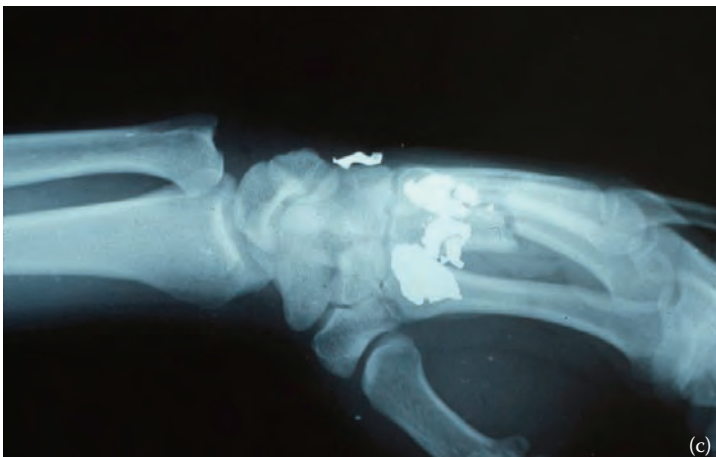
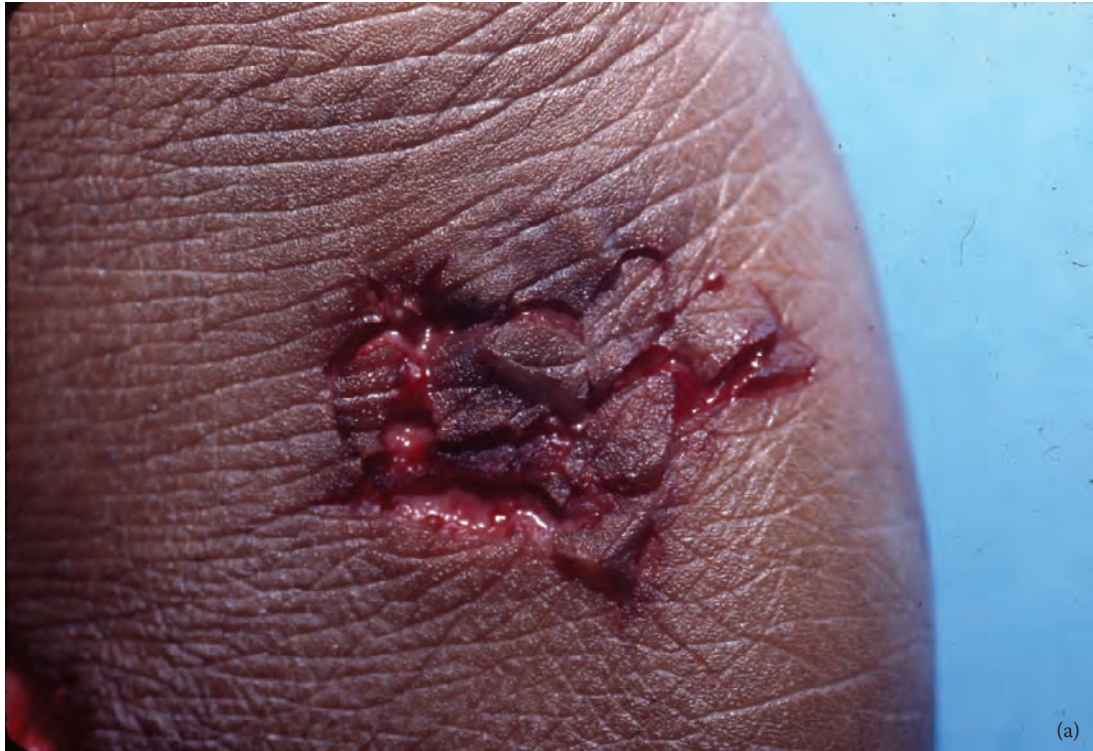

Multiple atypical entrance gunshot wounds produced by fragmented pieces of lead caused by .22 caliber nonjacketed bullets that struck concrete and fragmented before striking an individual who was lying on the sidewalk. Note the irregular nature of these injuries with superficial fragmented pieces of lead observed in several of the wound tracks.





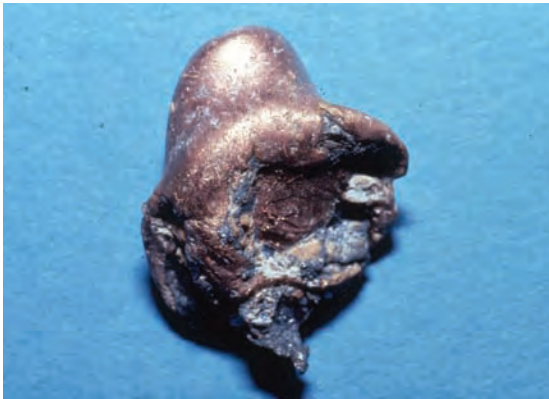

Several atypical injuries produced by fragmented nonjacketed lead bullets. The individual survived in the hospital for days. Note the healing margins and fragments of lead being pushed from the underlying soft tissue.



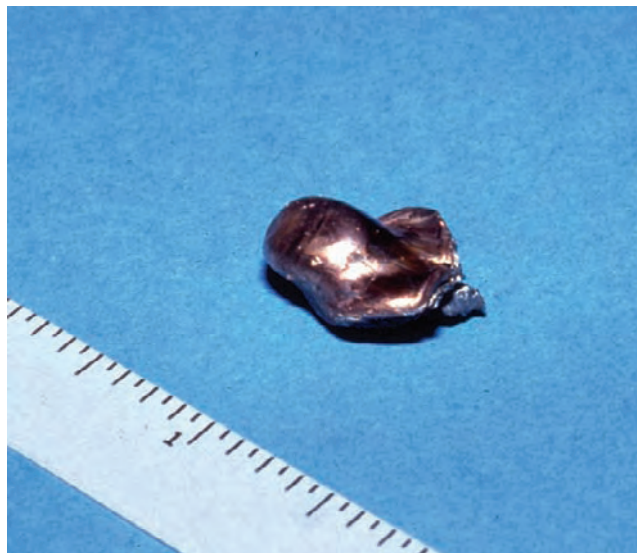
This child was shot multiple times. One of the bullets struck another object, fragmented, and produced this atypical entrance wound to his wrist (a). There were fragments of bullets retrieved from the decedent's jacket corresponding to this location (b). X-ray (c) shows multiple fragments of deformed metal retrieved just underneath the skin surface adjacent to the bones of the hand. The last image (d) shows all the bullet fragments retrieved from this individual's hand and wrist. There were no other wounds to this region of the body.



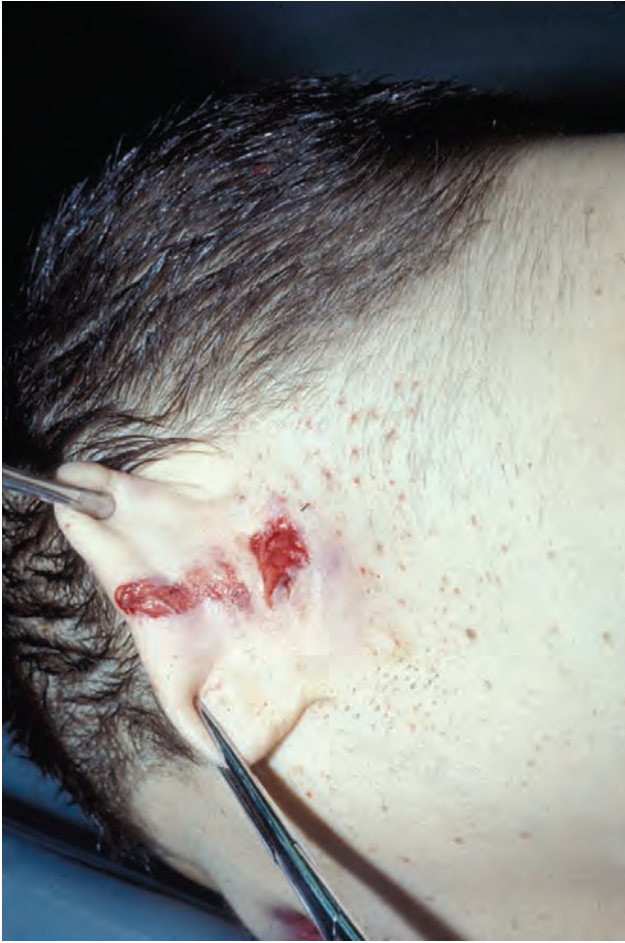This ricochet bullet was retrieved within the abdomen of an individual with a perforated iliac artery. The bullet perforated the individual's shirt and did not strike bone while passing through the body.



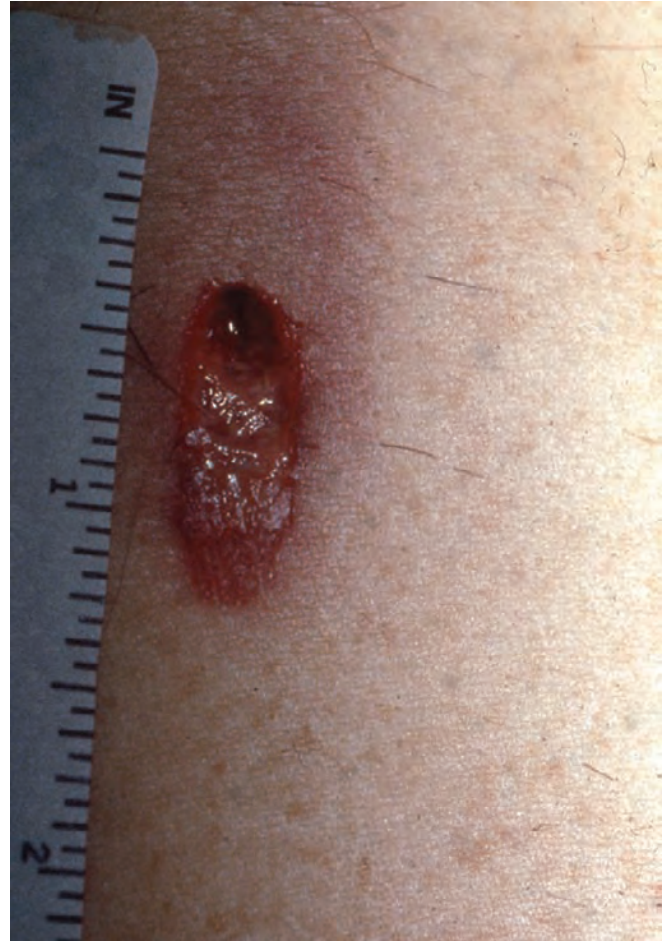This bullet struck the ground, fragmented portions of tile, and became markedly deformed before ricocheting upward and striking the body of an individual already lying on the ground. The resulting gunshot wound was markedly atypical, producing irregular injuries to the body surface.



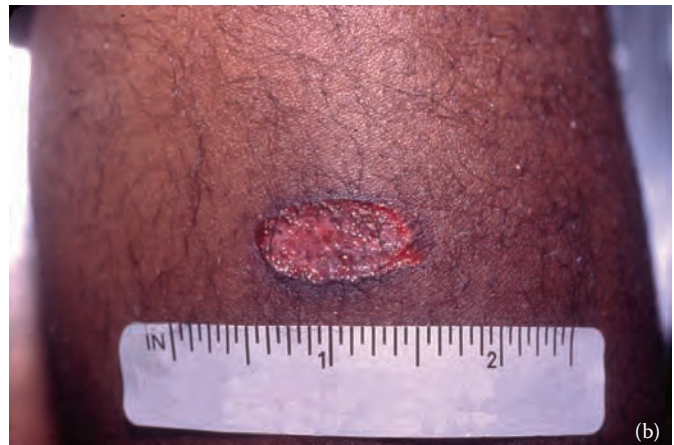
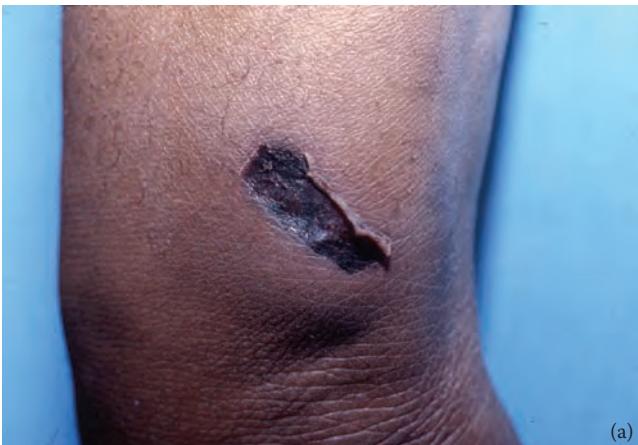
This deformed bullet was retrieved from an individual after it ricocheted off an intermediate target.



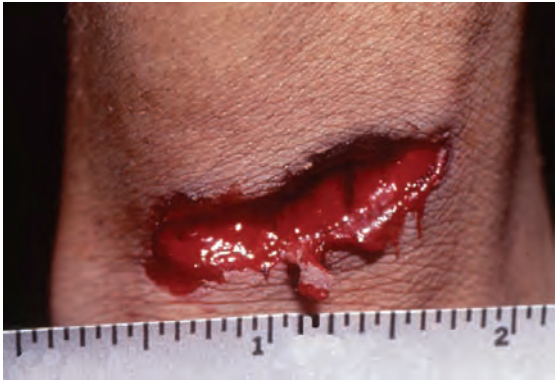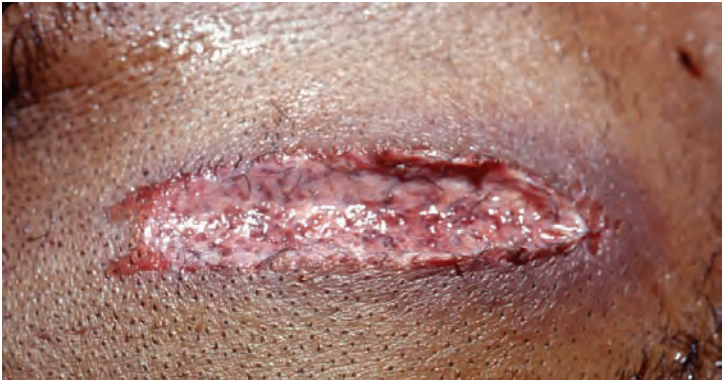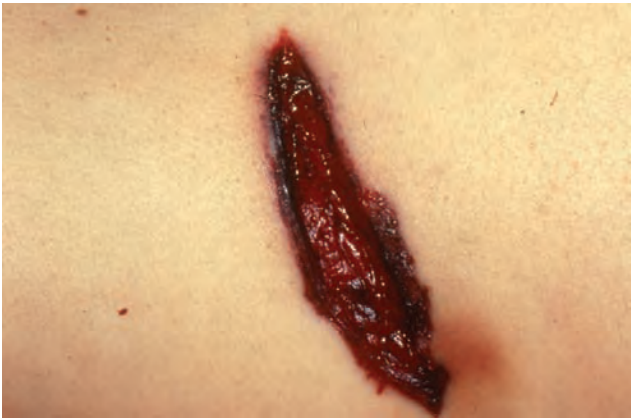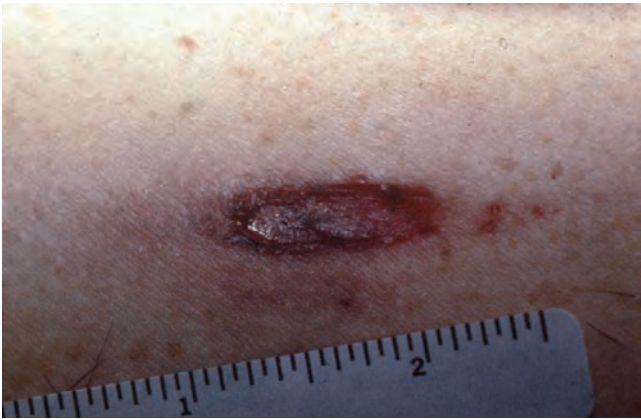
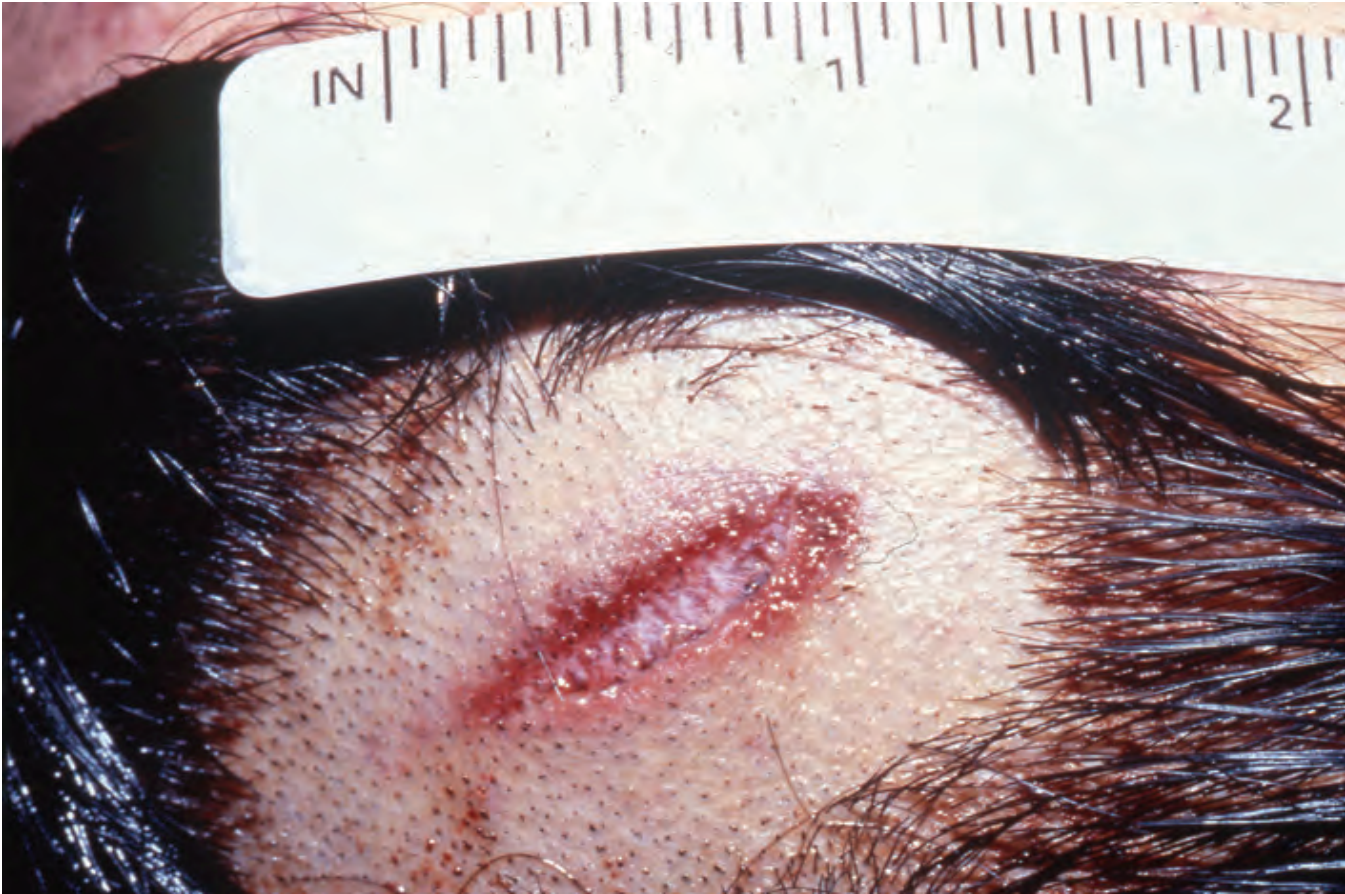
Intermediate-entrance gunshot wound with stippling. Note the irregular natural of the wound due to the location on the body. The bullet entered between the cartilage of the ear at a skin fold between the ear and the scalp. Note the elongated abrasion at the posterior ear due to the bullet's grazing the skin before entering the body.



Distant-entrance gunshot wound with an asymmetric margin of abrasion. This indicates that the bullet grazed the body at an upward trajectory before perforating the skin.

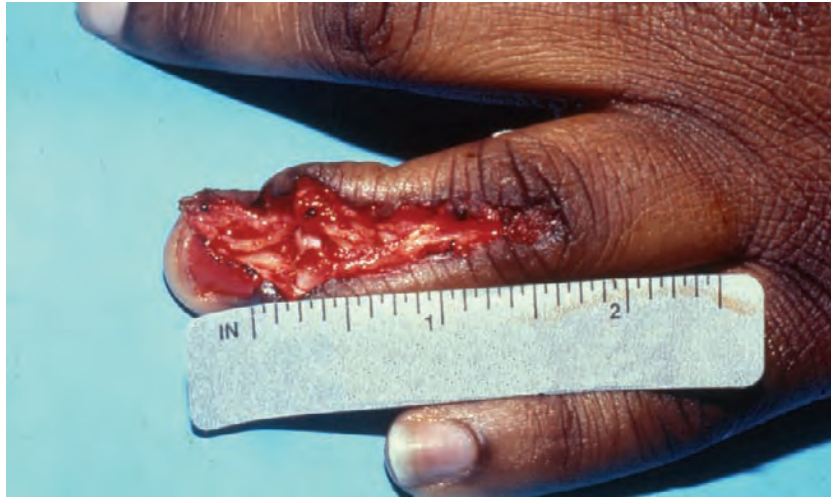

Graze gunshot wounds; (a) is more atypical.

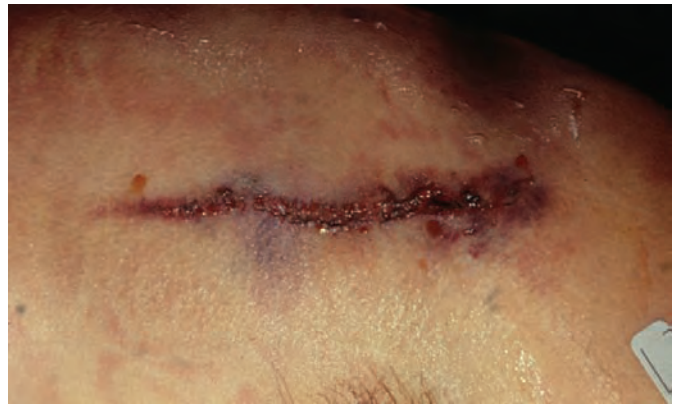
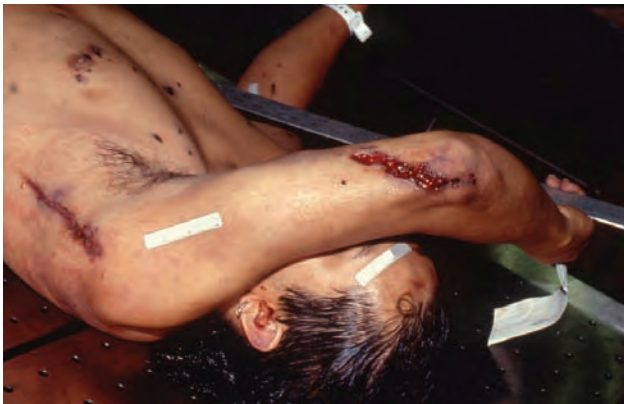
Graze gunshot wounds.

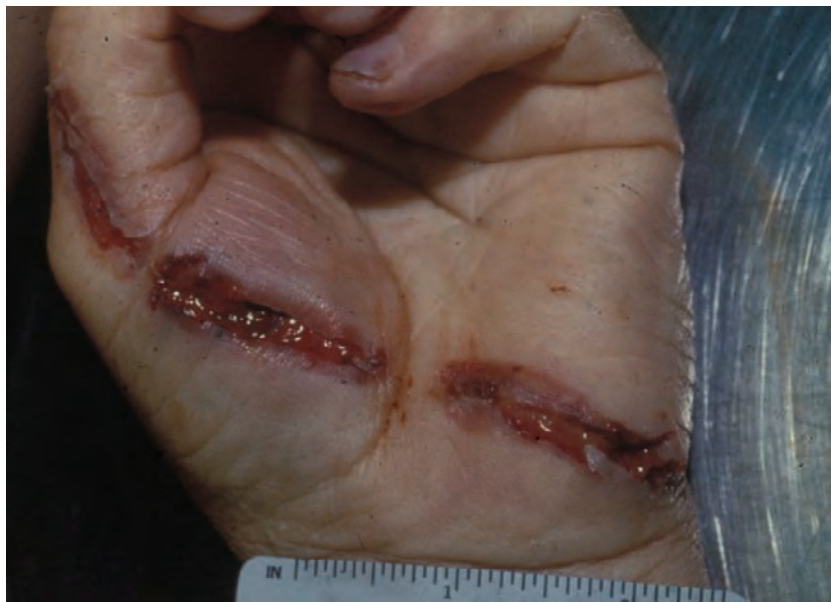



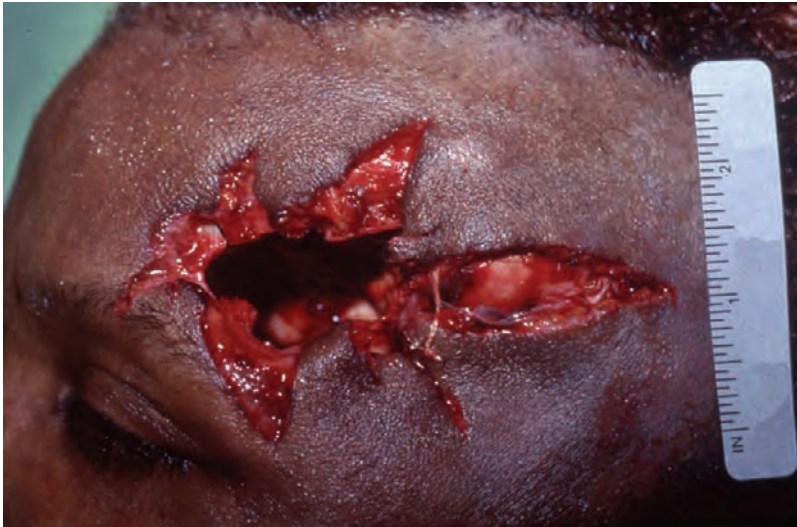Tangential gunshot wound with a trajectory from the middle to distal aspect of the finger. Note the semicircular entrance defect at the right side of this wound overlying the proximal middle phalange.



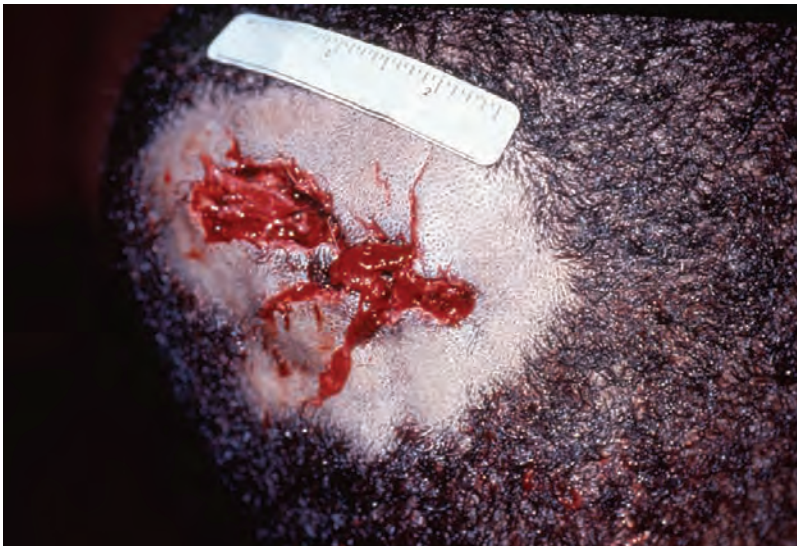Tangential gunshot wounds to the arm and trunk. Note the skin tag formation at the wound margin produced as the bullet perforated underneath the skin's surface.



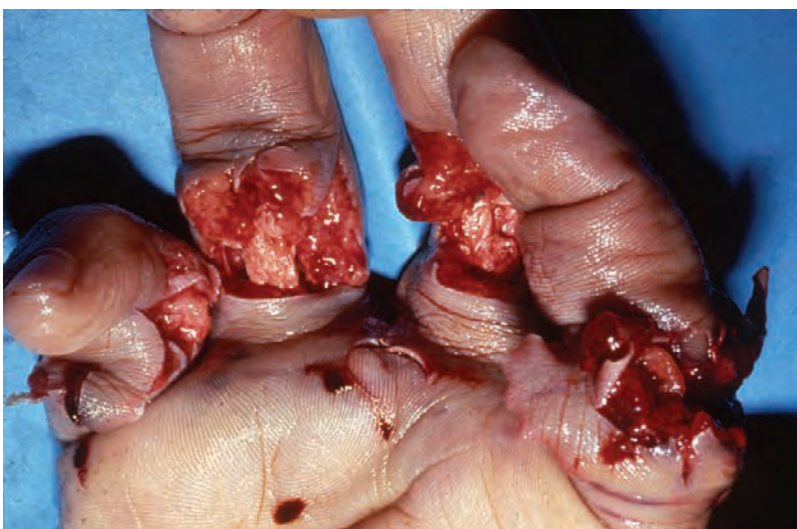
Tangential gunshot wound with skin tag formation. The direction of fire is from left to right.



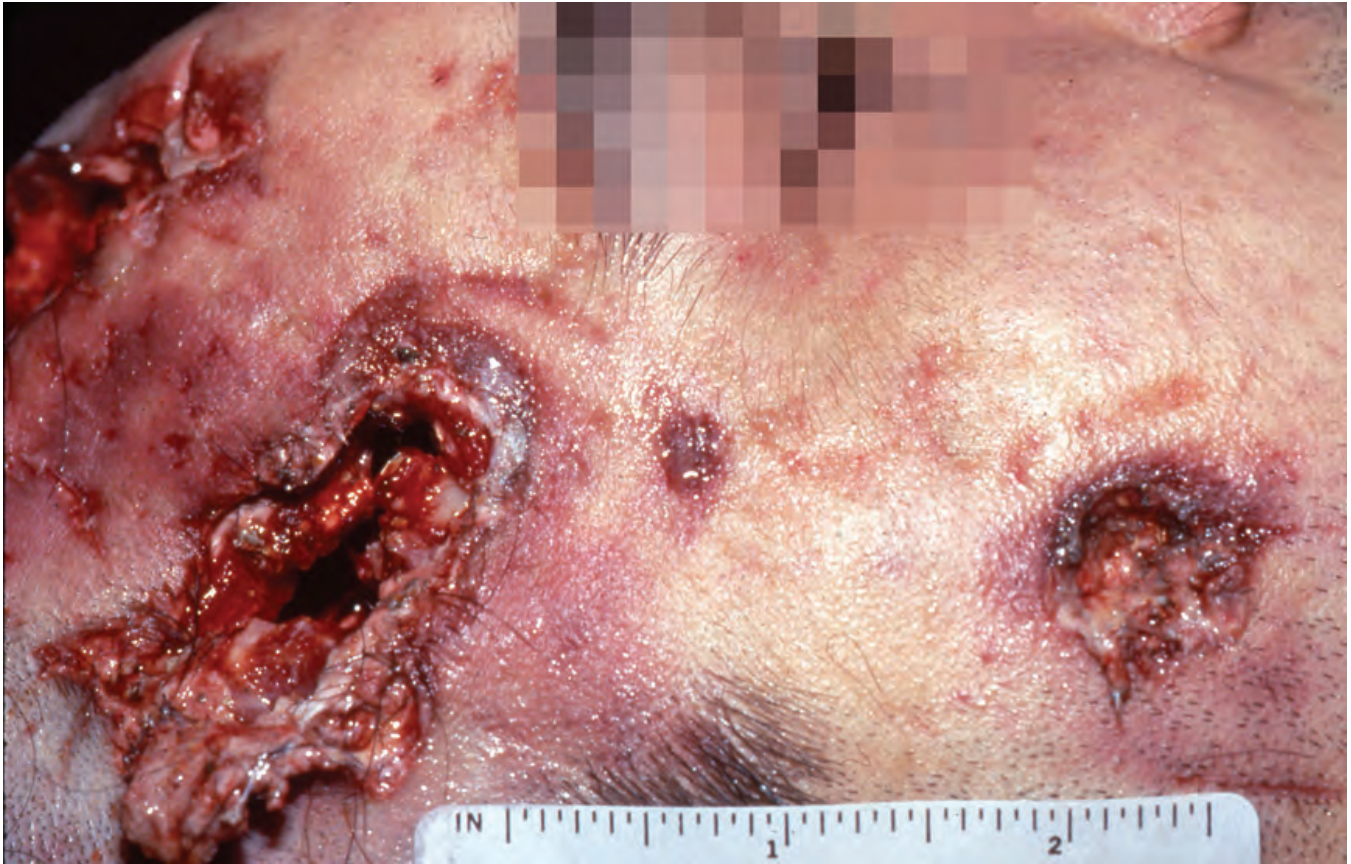Distant tangential gunshot wound. Tangential gunshot wounds are produced when the bullet strikes the body at a narrow angle, producing skin tag formation. Usually the bullet exits the body leaving an open wound through the skin's surface, connecting the path of entrance and exit perforations. These wounds are deeper than graze gunshot wounds. This wound is associated with bullet fragmentation and partial exit, which may occur when the bullet strikes the body at a surface directly adjacent to underlying bone. This is an example with bullet fragmentation, partial exit, and underlying keyhole deformity of the skull. Note the entrance side of this wound is at the anterior aspect. There is a semicircular margin of abrasion leading into this laceration. The direction of fire is from left to right.



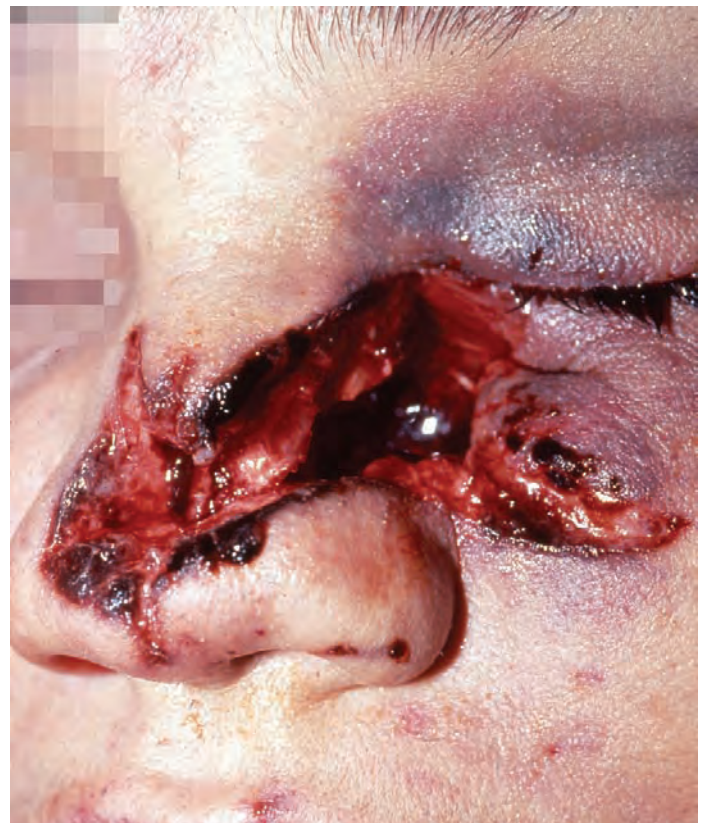Tangential gunshot wound of the scalp. The direction of fire is from right to left. Note the skin tag formation pointing away from the semicircular entrance site at the right side of the wound.



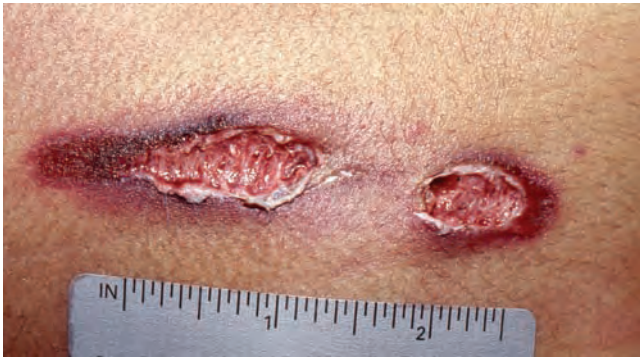Note the tangential gunshot wound through the palmar surfaces of the fingers.



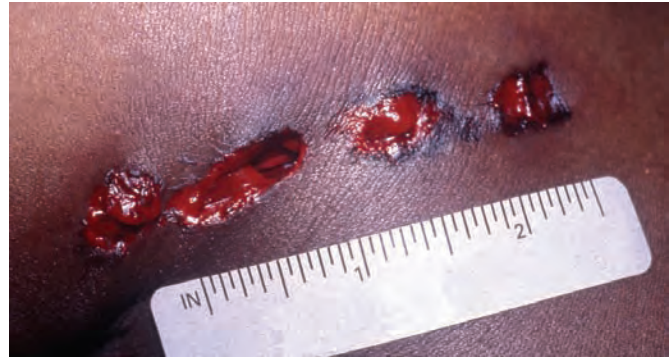
Tangential gunshot wound to the forehead. Part of this bullet entered the cranium and a portion of the bullet exited the body. There was an underlying keyhole deformity to the skull.



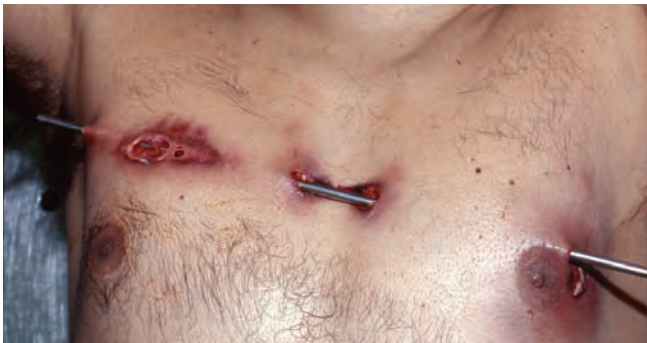After this bullet perforated the fingers it produced a tangential gunshot wound to the nose before entering the body at the face.



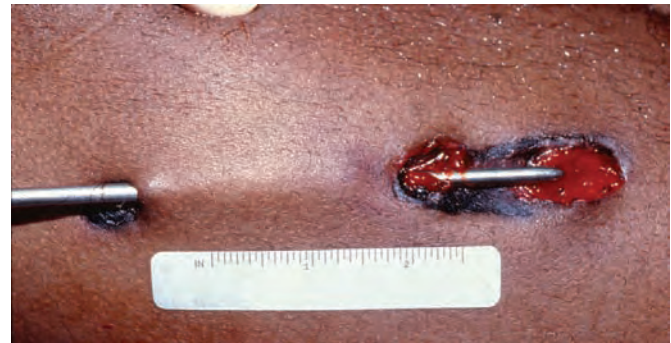
This demonstrates an entrance and exit gunshot wound that passed superficially beneath the skin surface. The direction of fire is right to left. Note that the perforation at the right side has a more uniform oval shape with a more symmetric margin of abrasion. The exit component to this wound is more irregular.



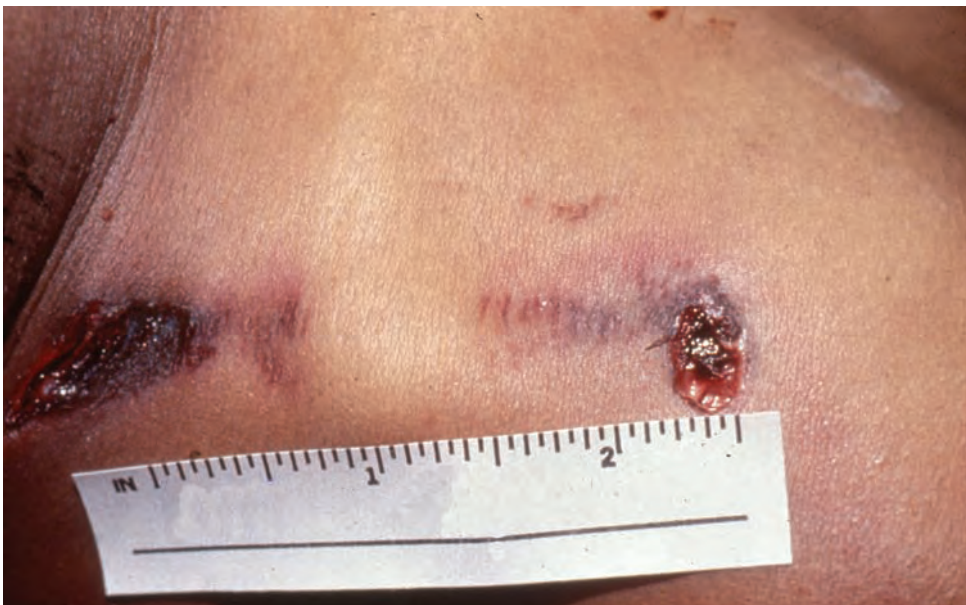This gunshot wound produced multiple tears and perforations to the surface of the skin as the bullet passed close to the underlying surface. Such injuries often occur in regions of the body where skin folds on itself, such as the inguinal, gluteal, and axillary regions.



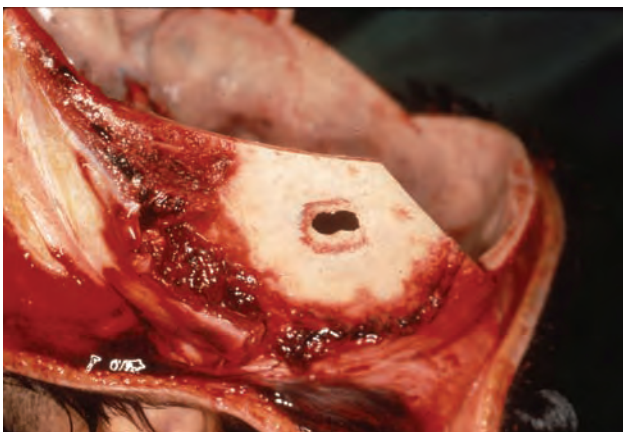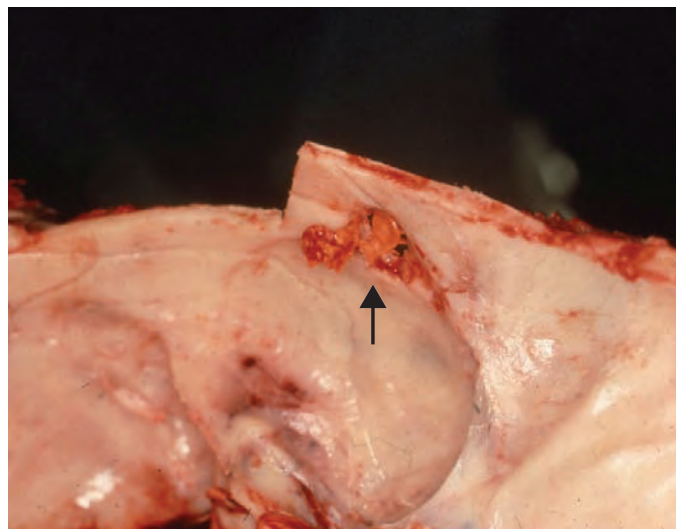

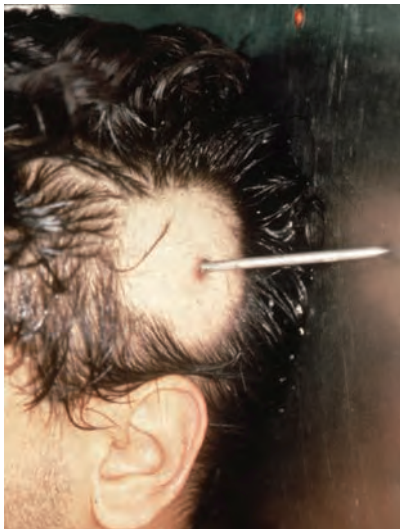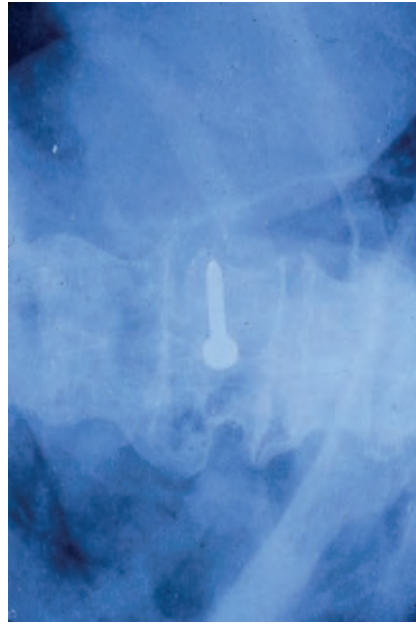
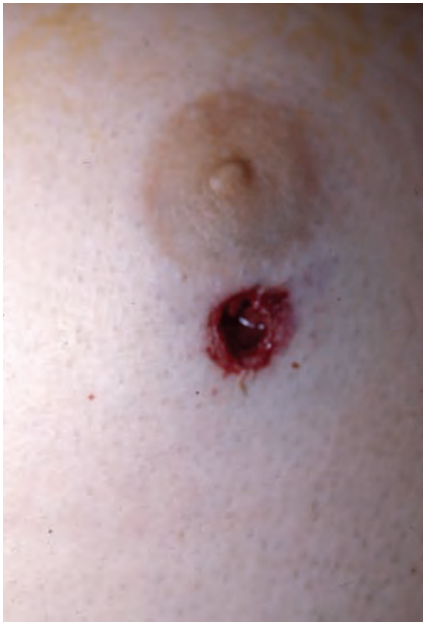This single gunshot wound passed through the superficial soft tissues of the chest, producing multiple perforations and tears to the surface. Note the irregular nature of the torn skin and irregular abrasions at the exit reentry site.



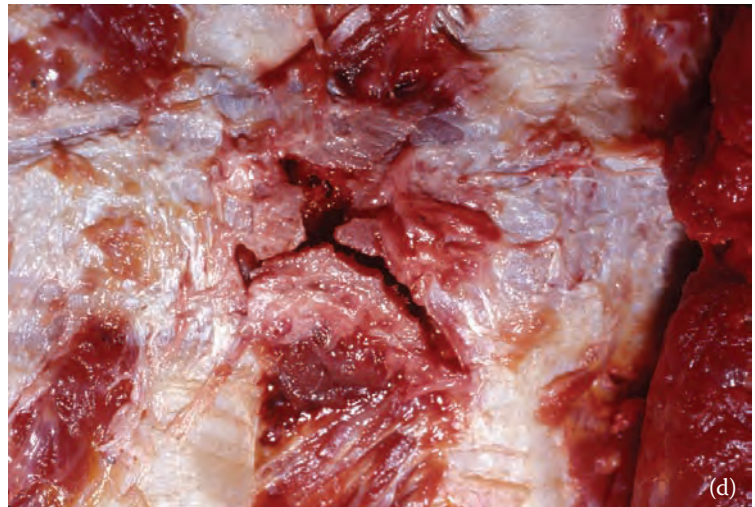
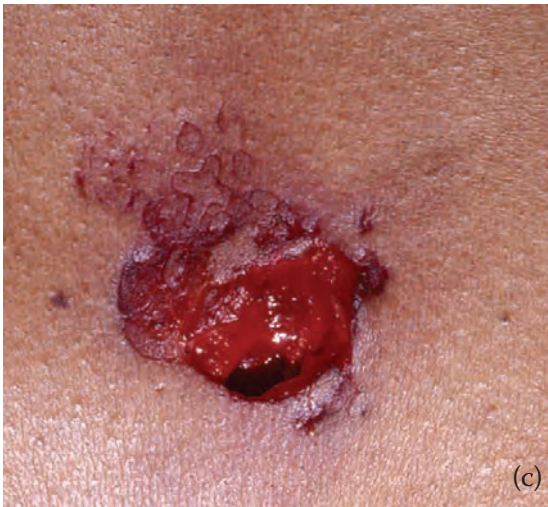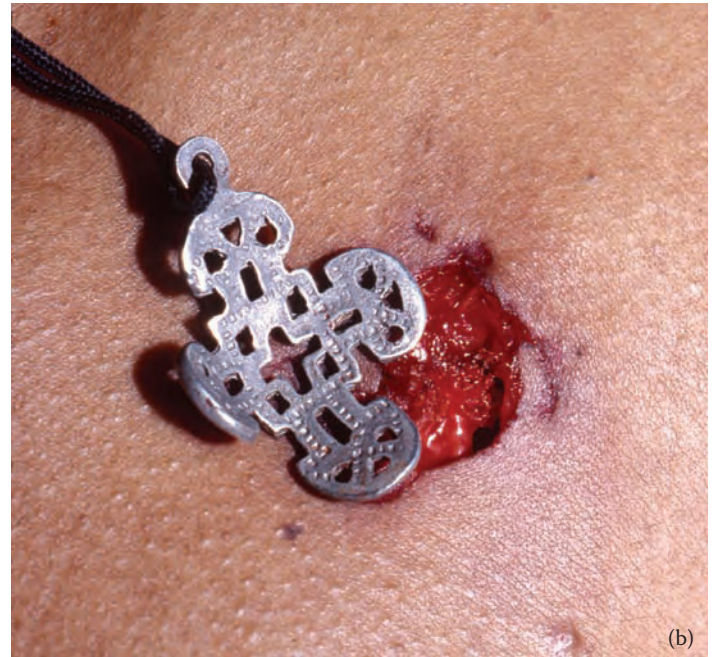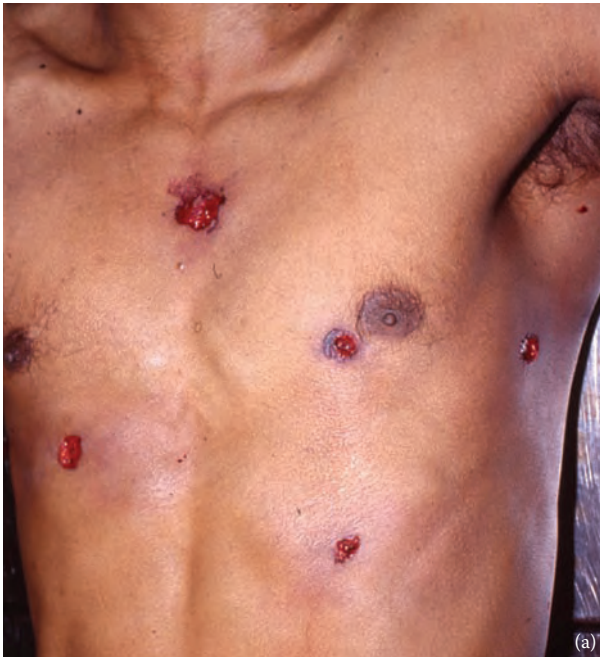This is another example of an entry-exit-reentry wound where the bullet passed close to the underlying skin surface. Note the larger irregular abrasions connecting the exit and re-entry sites. Also note the dark discoloration due to drying.



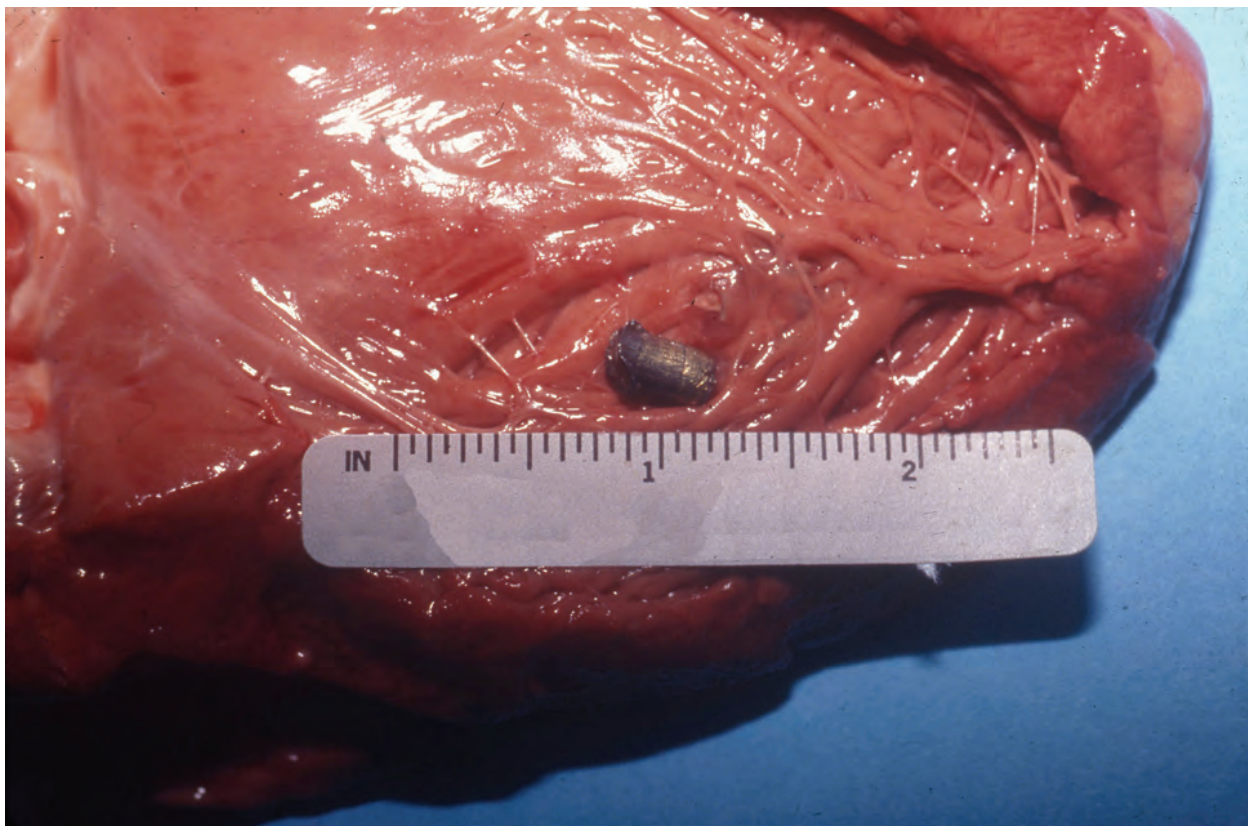
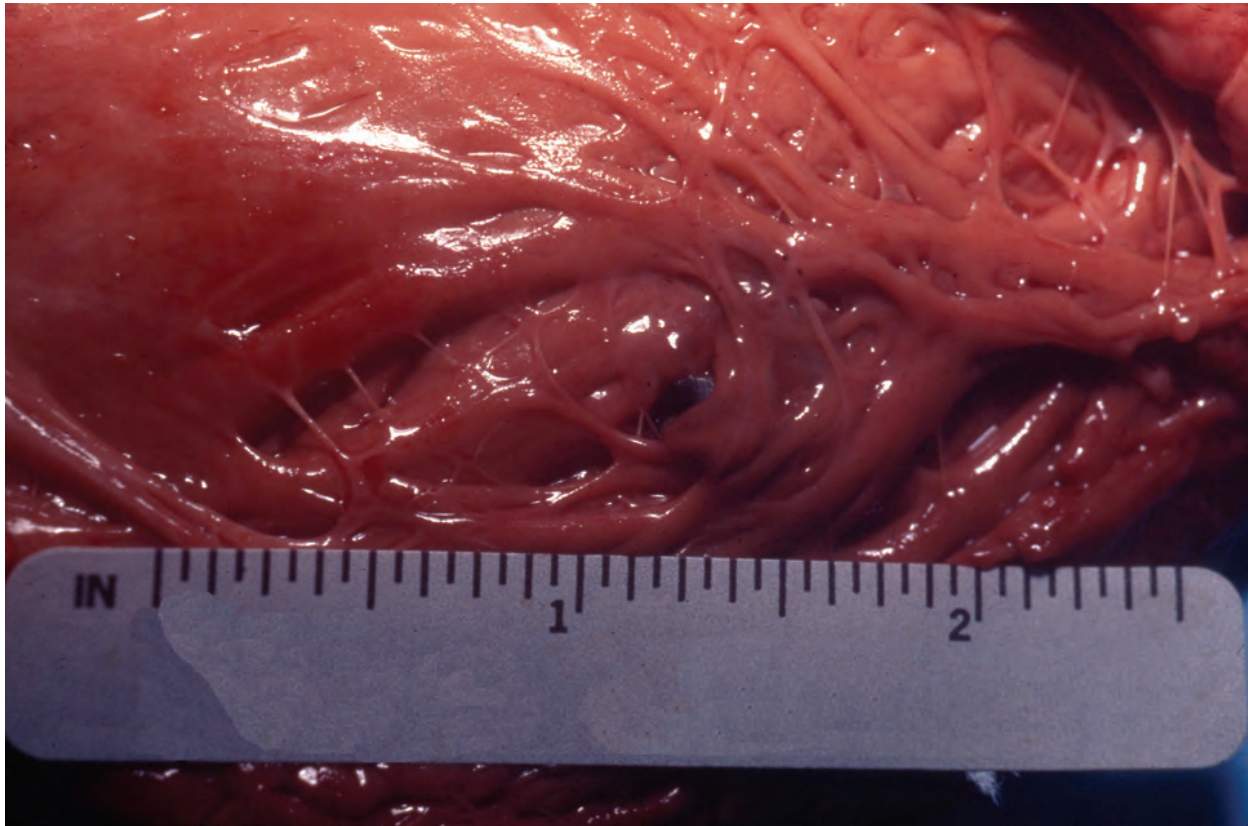
This is an entrance and exit gunshot wound where the bullet passed very close to the under surface of the skin.



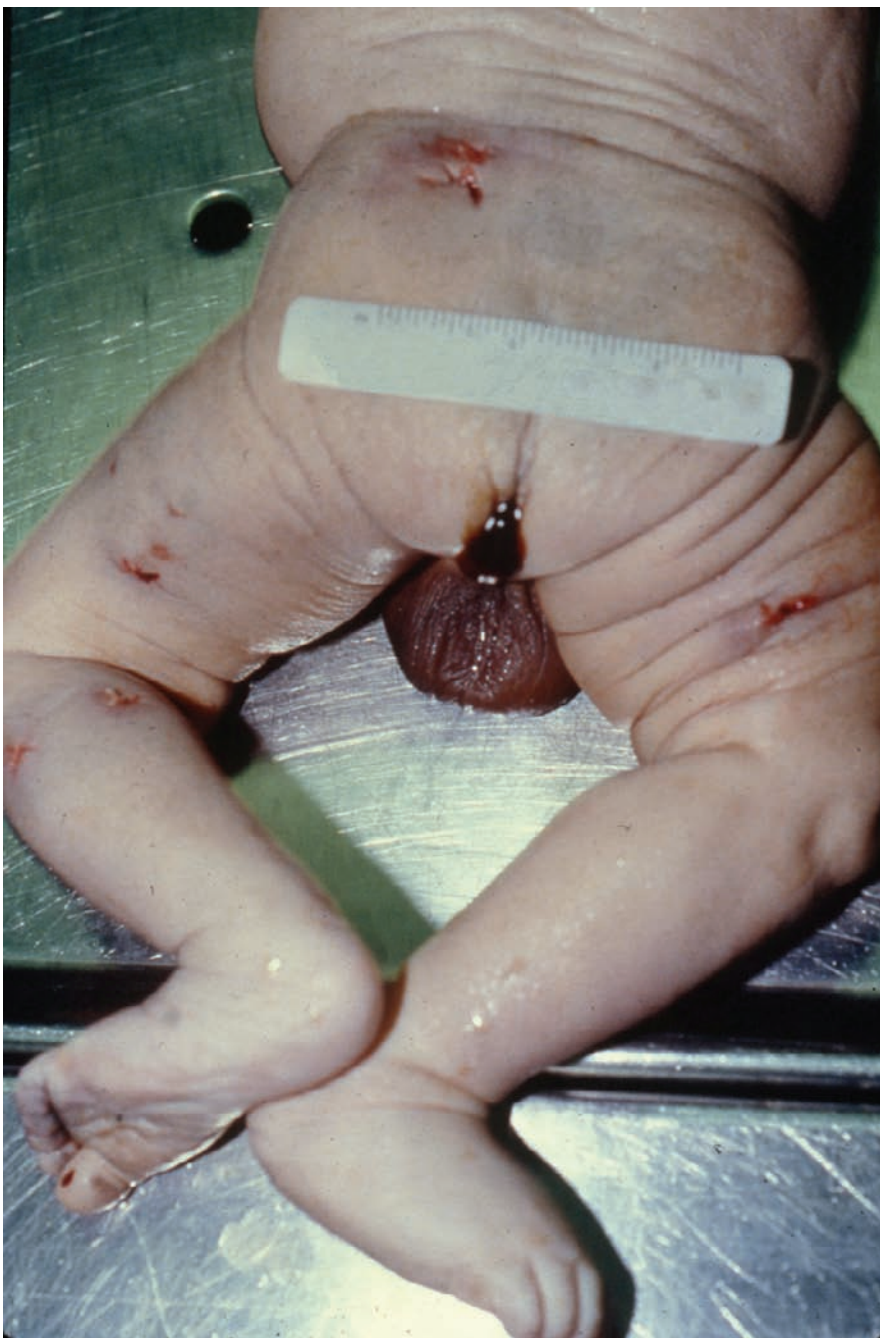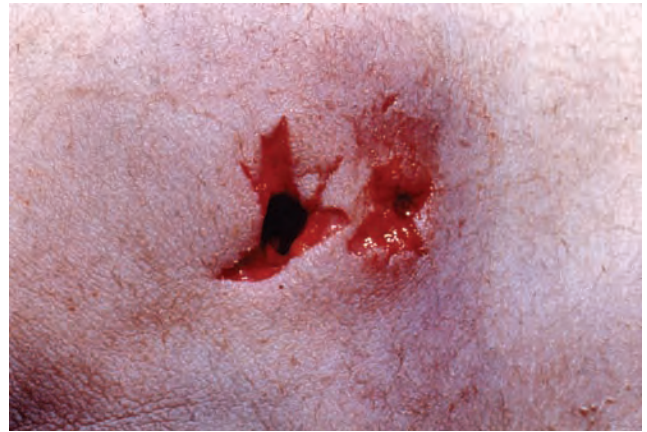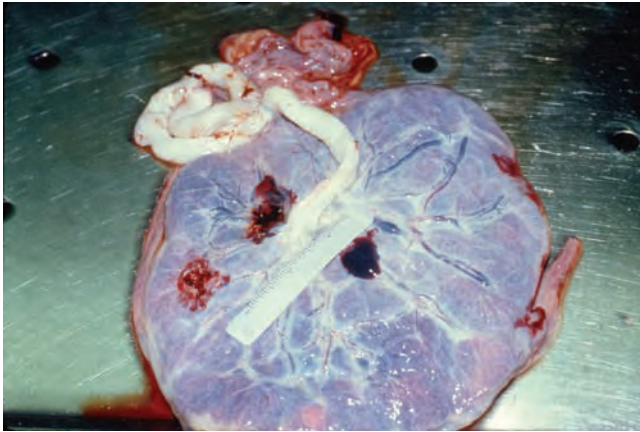
These images show different examples of nailgun wounds. Both of these cases were suicides. Both nailguns were similar to the one shown in the last image, which used gunpowder-loaded cartridges. Both entrance wounds consisted of circular perforations with symmetric margins of abrasion indistinguishable from typical entrance gunshot wounds. Note the orange plastic ejected into the entrance perforation of the temporal skull that is used in some nail guns to hold and steady the nail prior to discharge.



This individual was shot multiple times. Note the exit gunshot wound to the superior aspect of his middle chest (a). He was wearing a medallion on a string that was struck by the bullet as it exited the body, producing an imprint on the skin surface. The chest surface was most likely pressing against another object when the bullet exited. Figure (b) illustrating the medallion actually demonstrates it facing the wrong way. The medallion should be oriented with the inward curvature facing the chest. This was at first erroneously thought to be an entrance gunshot wound. Among other points arguing this to be an exit wound was the sternum fracture with bone splinters pointing in an outward anterior direction(d).



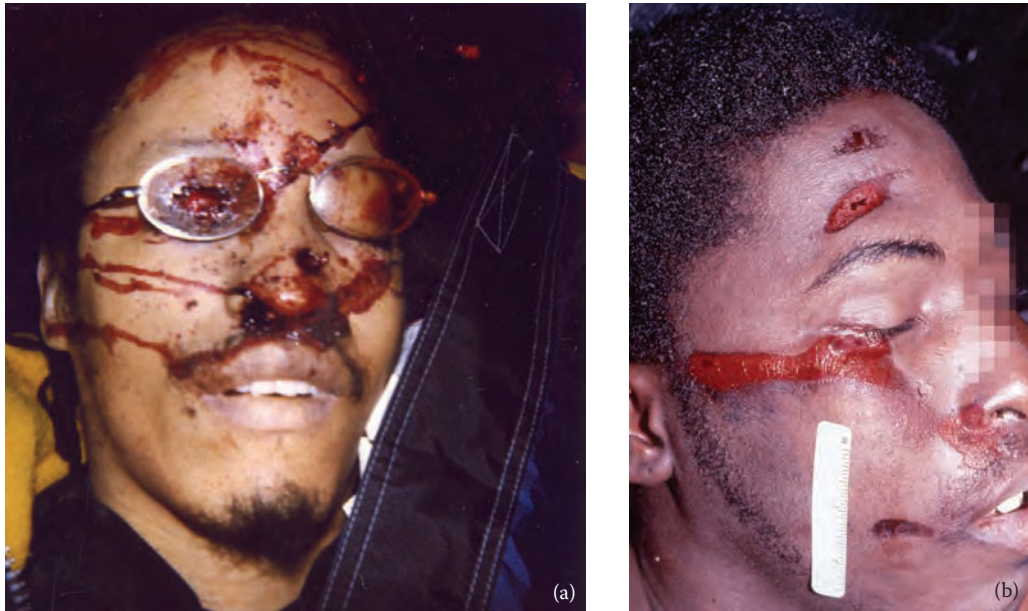This individual was shot multiple times and survived in the hospital for approximately 2 weeks. One of the bullets entered the lung parenchyma and embolized to the heart, where it got wedged in papillary muscles of the left ventricle. He developed bronchopneumonia and his lung wound reopened, causing hemorrhage and death.



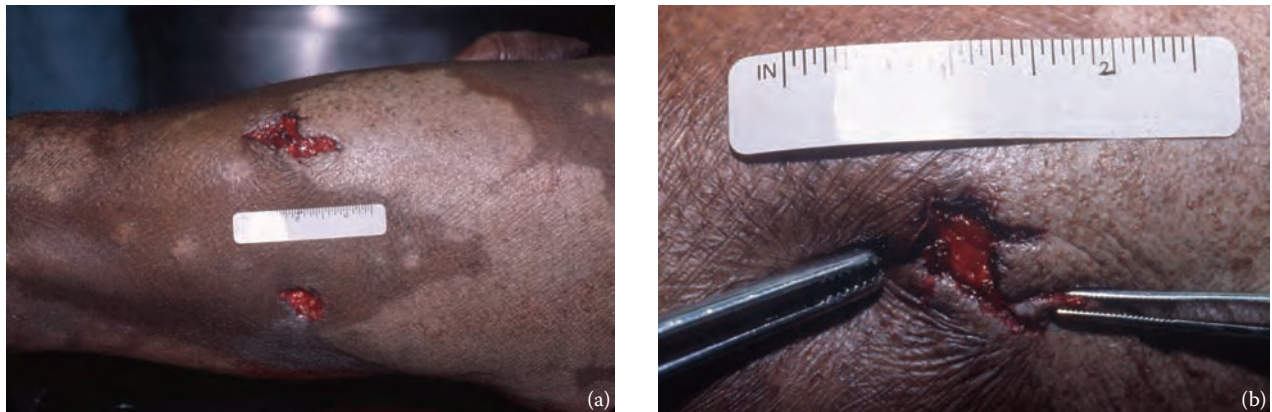
An otherwise healthy, full-term pregnant woman was shot multiple times in the abdomen. There were multiple perforating gunshot wounds to her fetus that were atypical due to the intermediate targets, including the mother, uteroplacental unit, and amniotic fluid. All the fetal wounds appeared as irregular lacerations with irregular abrasions. Direction of fire could not be determined.

*Source for upper right and lower figures: Catanese C. and Gilmore K. A case report and brief analysis of fetal gunshot wound characteristics. Journal of Forensic Science 47:1067-069; 2002. Reprinted with permission from ASTM International.*

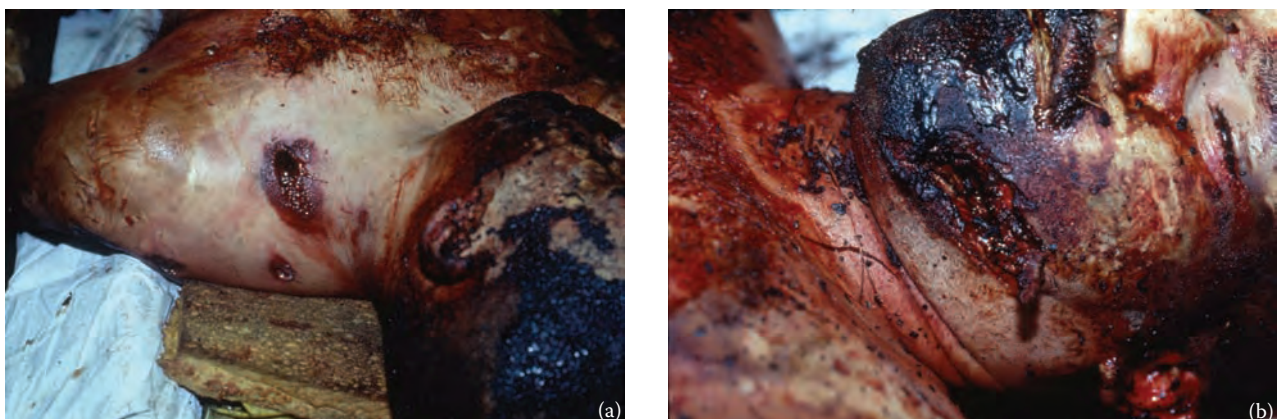




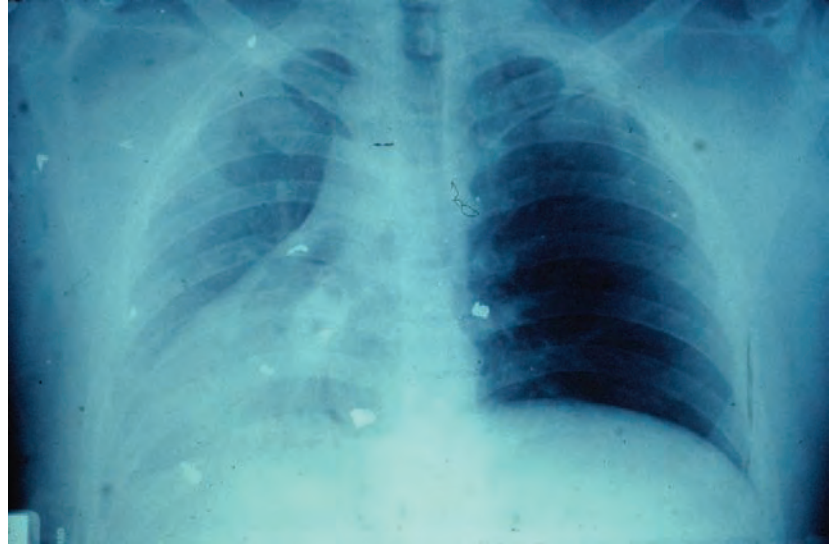
This individual was shot in the face while wearing eyeglasses. Note the irregular nature of the entrance gunshot wound just beneath the eye (a) and the elongated abrasion extending across the cheek to the decedent's ear (b), corresponding to the eyeglass frame.



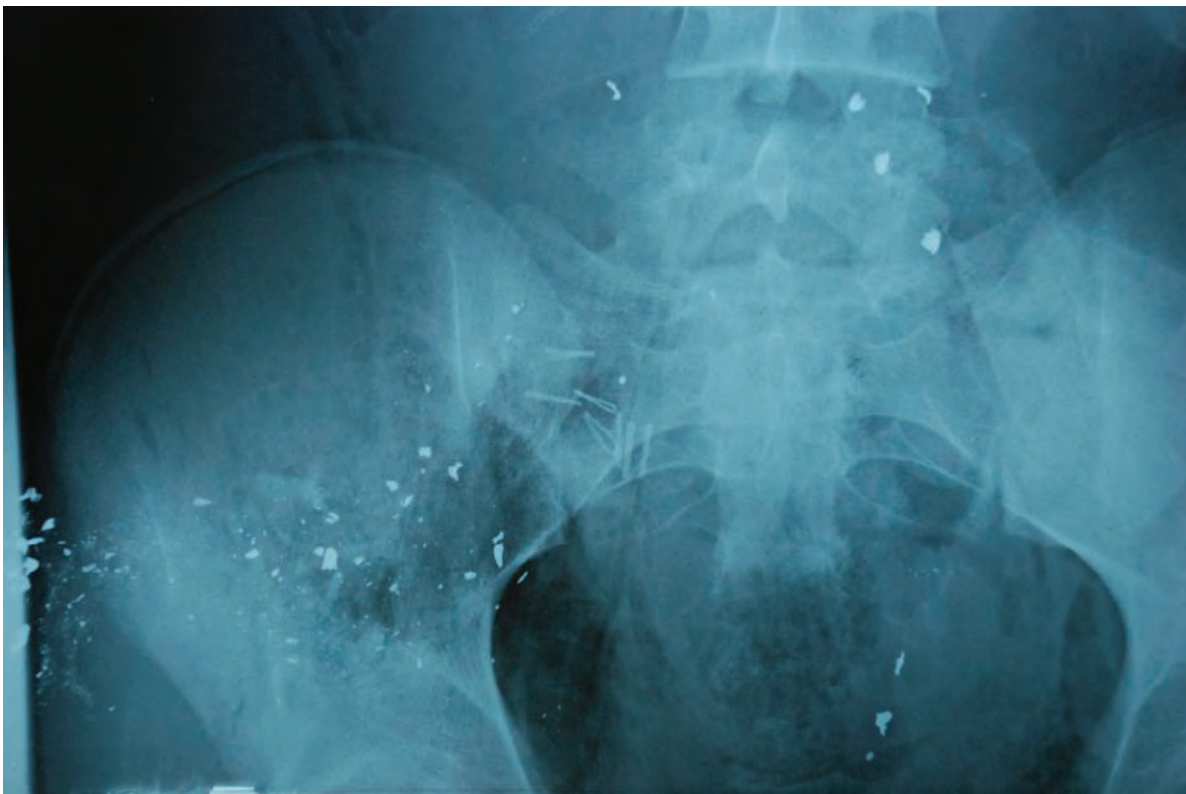This individual was shot multiple times and had psoriatic skin disease. Note the irregular nature of this entrance gunshot wound through one of the plaques (a). The skin had small radiating lacerations and decreased abrasion similar to what is sometimes seen with gunshot wounds through thick skin found on the palms of the hands or soles of the feet (b).



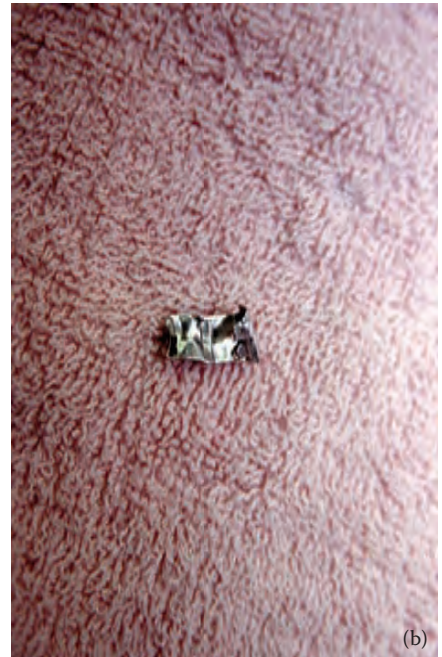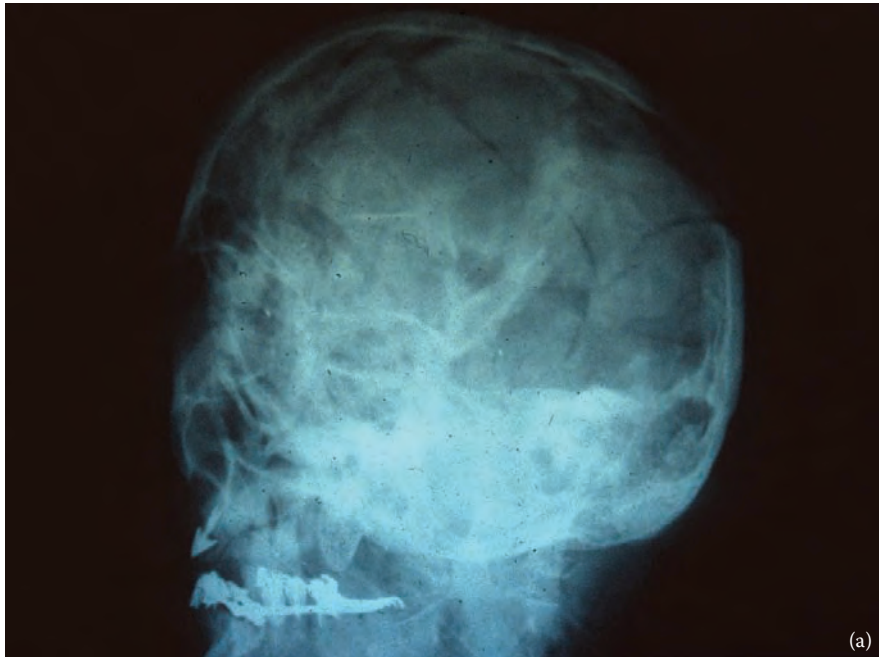These are gunshot wounds to an individual who was set on fire to destroy evidence after being shot in his residence. His carbon monoxide blood level was negligible. Note the change in character of these injuries due to thermal effect. These thermal burns are postmortem.



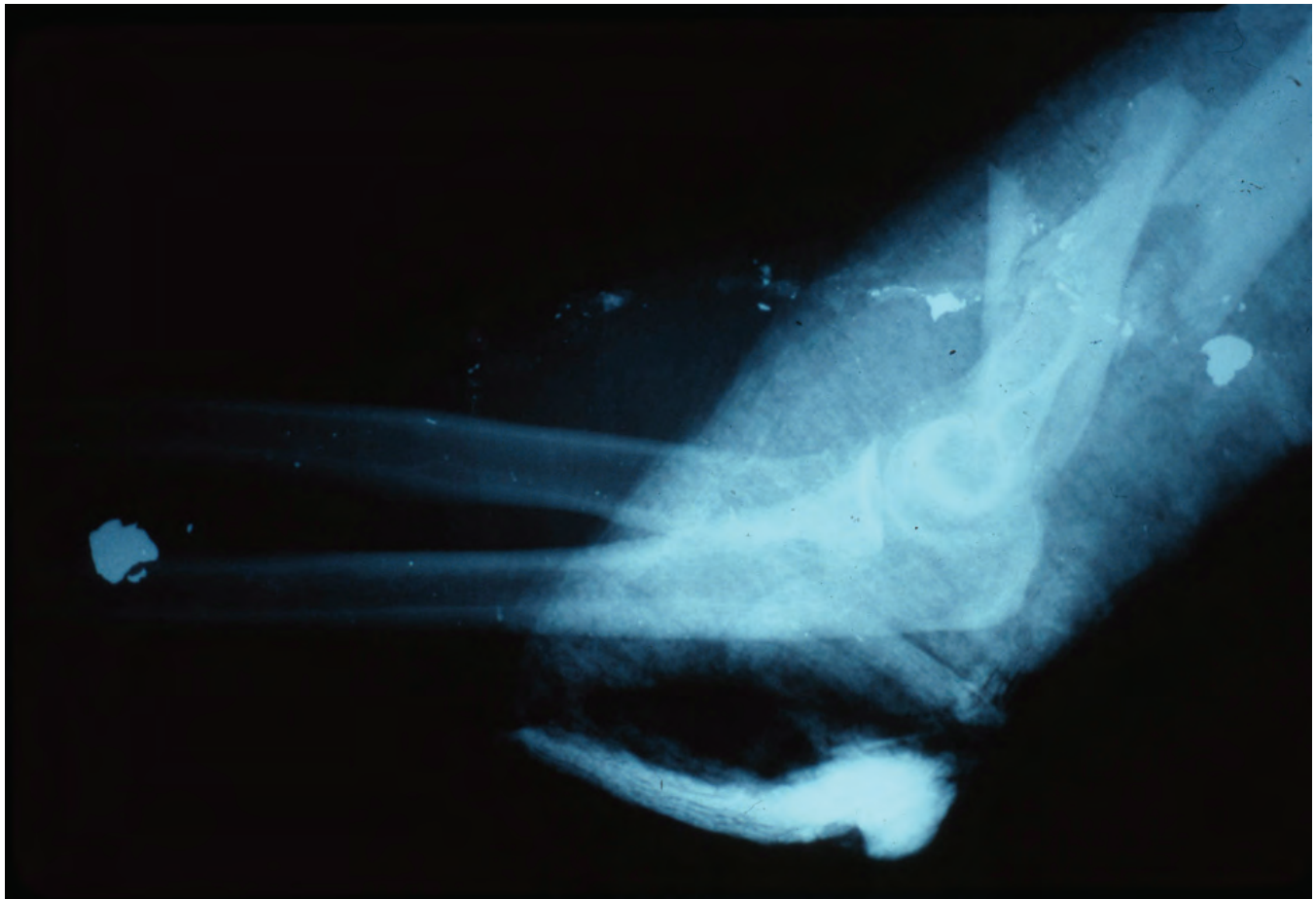This individual was shot multiple times where the bullet struck bones and fragmented into multiple pieces. It is important to keep track of which bullets are associated with which gunshot wounds. There may be three different shooters and only one of the bullet wounds lethal. Linking the lethal bullet to a particular shooter may have different legal implications.




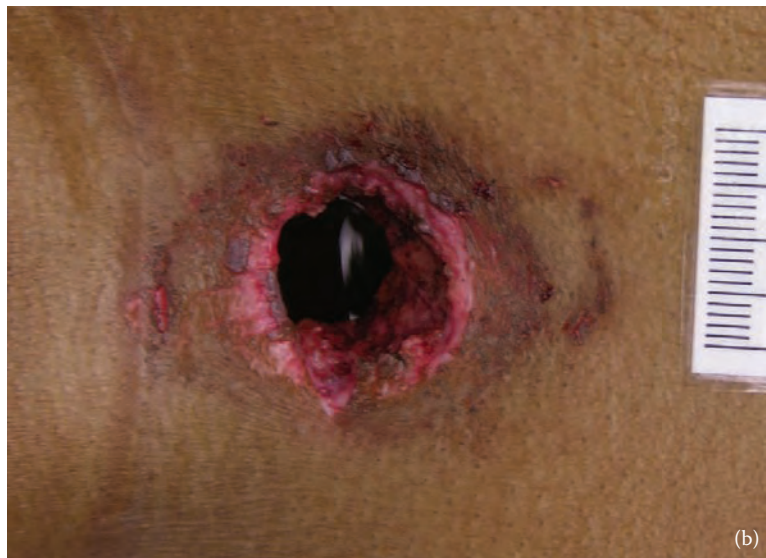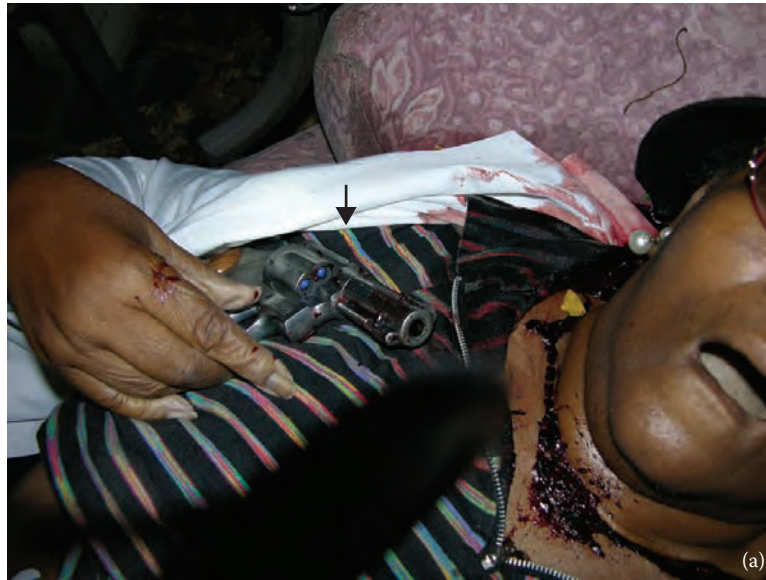
This individual was shot in the abdomen with a hunting rifle. Note the snowstorm effect of bullet lead fragmentation depicted on this x-ray.



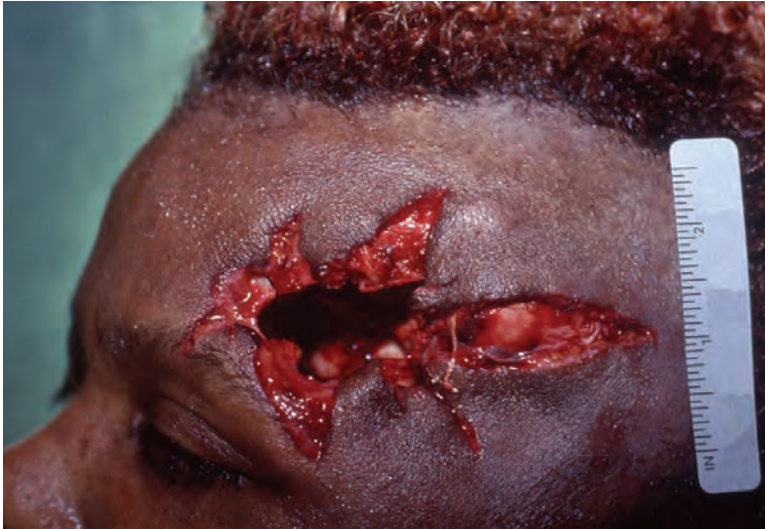This individual (a) was shot with an aluminum-jacketed bullet. This fragment of aluminum (b) was retrieved within the wound track. Aluminum, being a relatively less dense metal, may not be apparent on x-ray, particularly when it is lying over a dense thick bone.



Note from this x-ray that one can tell the direction of travel. The bullet struck the humerus, fragmented into pieces, and then left a trail of metal fragments as it passed through the soft tissues before coming to rest.



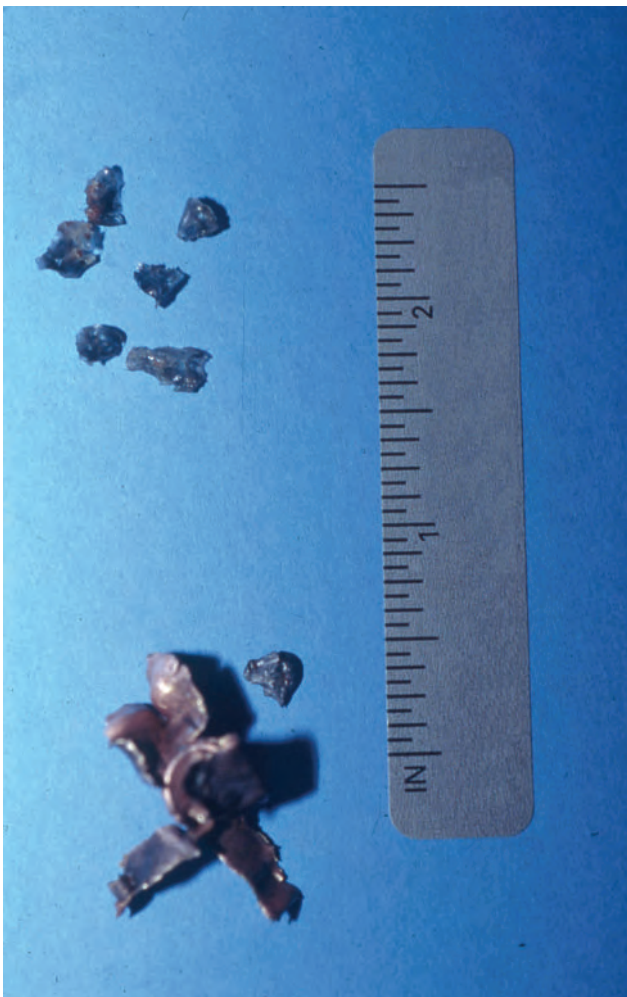This is a contact gunshot wound to the chest with visible muzzle imprint abrasion (b). Note the blue-tipped Teflon plug Glazer safety ammunition visible within the revolver chamber (a). Note the yellow metal jacket, Teflon plug, and multiple lead pellets seen on x-ray (c), and demonstrated after removal from the body (d).



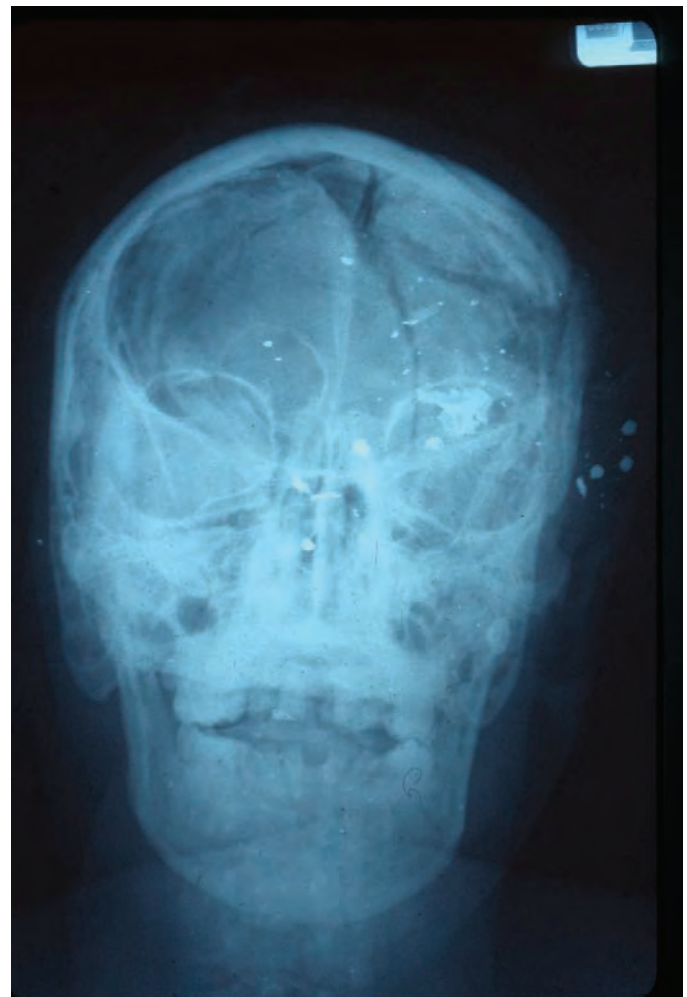Tangential distant gunshot wound produced by Mag-safe ammunition (prefragmented).



This diagram shows a comparison of the components of Mag-safe ammunition and Glaser safety slug.



This x-ray is taken from an individual shot with Mag-safe ammunition. Note the metal jacket, gray to blue epoxy fragments, and gray metal pellets.

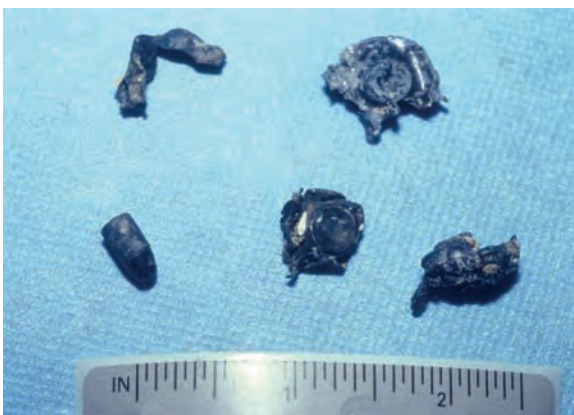
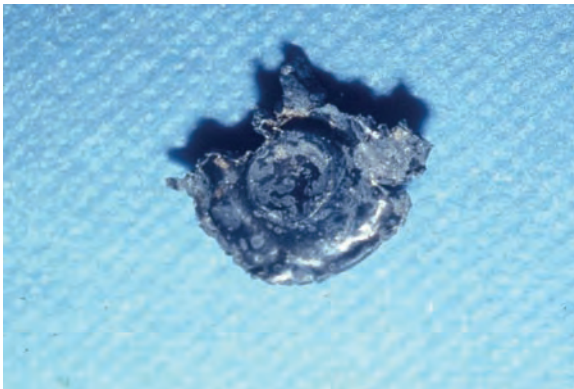




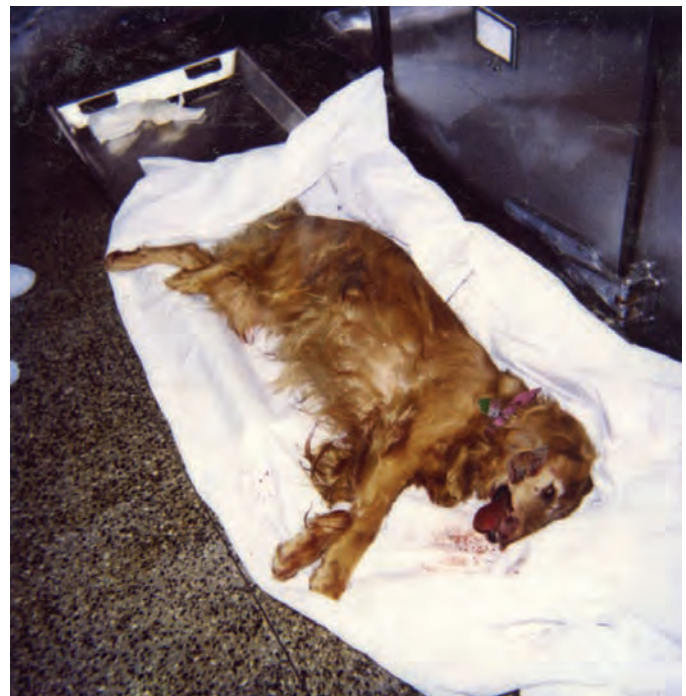This demonstrates a bullet retrieved from an individual who was shot approximately 1 day prior to autopsy. Note the shiny surface of the bullet, signifying no significant oxidation.



This demonstrates a bullet retrieved from an individual who was shot over a year before. This bullet remained in his body until it was retrieved during autopsy after somebody else shot and killed him. Note the dull oxidized surface on this old bullet.

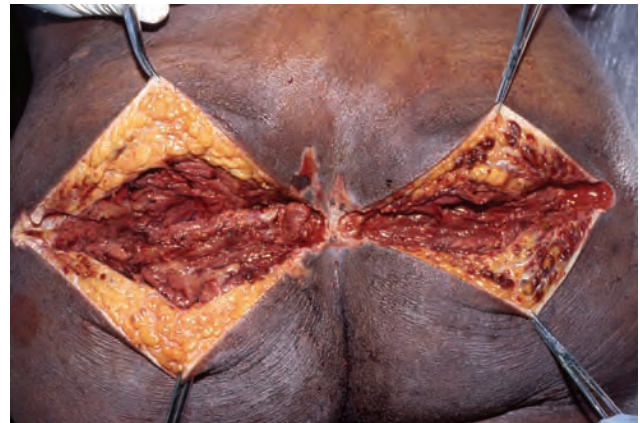
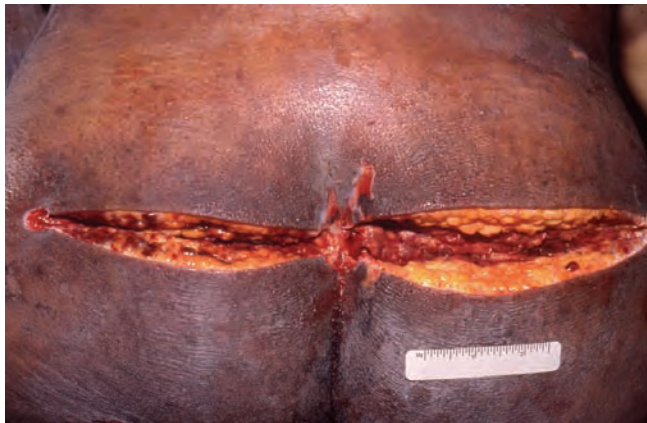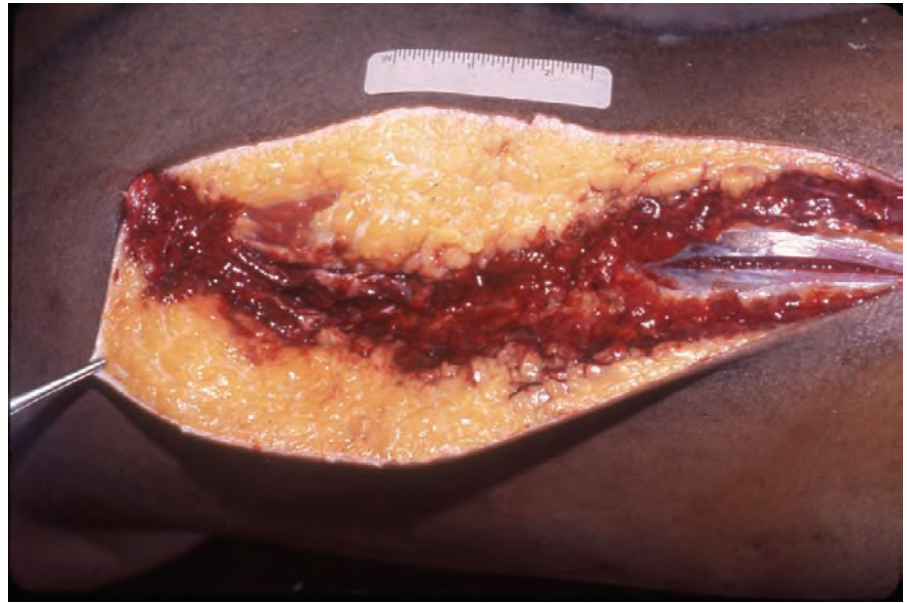


These are multiple weathered fragments of bullet retrieved from underneath and within the body of a partially skeletonized individual who was shot and thrown down a well shaft several years earlier. Note the irregular weathering marks at the surface of the bullets due to erosion.

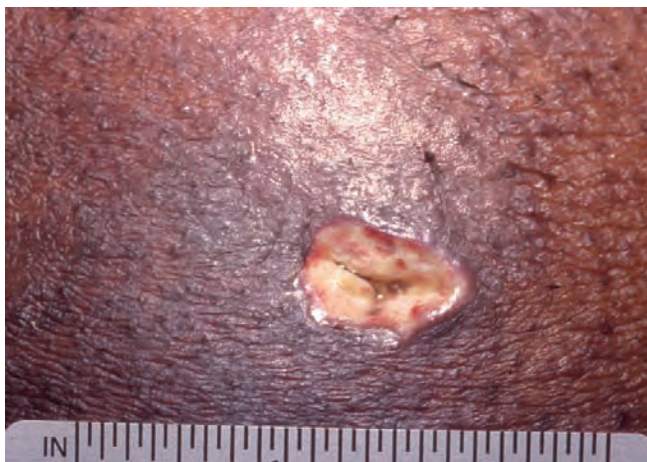


The homicide victim who owned this dog died of multiple perforating gunshot wounds. The dog sustained penetrating gunshot wounds during the attack and was autopsied to retrieve ballistic evidence.

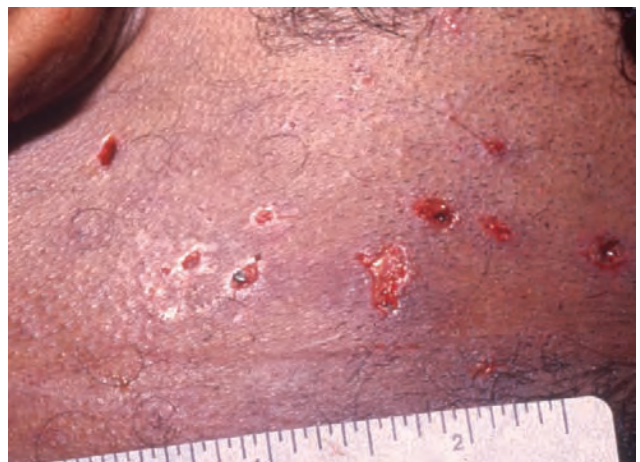This is a recent gunshot wound to an individual who was shot through the subcutaneous and fatty tissues of the gluteal region and thigh. Note the curvature of the wound track. This demonstrates how wound tracks may change when the body is laid on a flat autopsy table. One must keep this in mind when formulating bullet trajectories with reference to standard anatomic planes. This information may later be used as a reference to help explain possible body positions during the actual shooting. Interpreting wound track directions can become complicated when there are multiple gunshot wounds in proximity, particularly when the individual was shot while curled up in a fetal position and then later examined while spread out on an autopsy table. Directions should be stated with reference to standard anatomic planes.



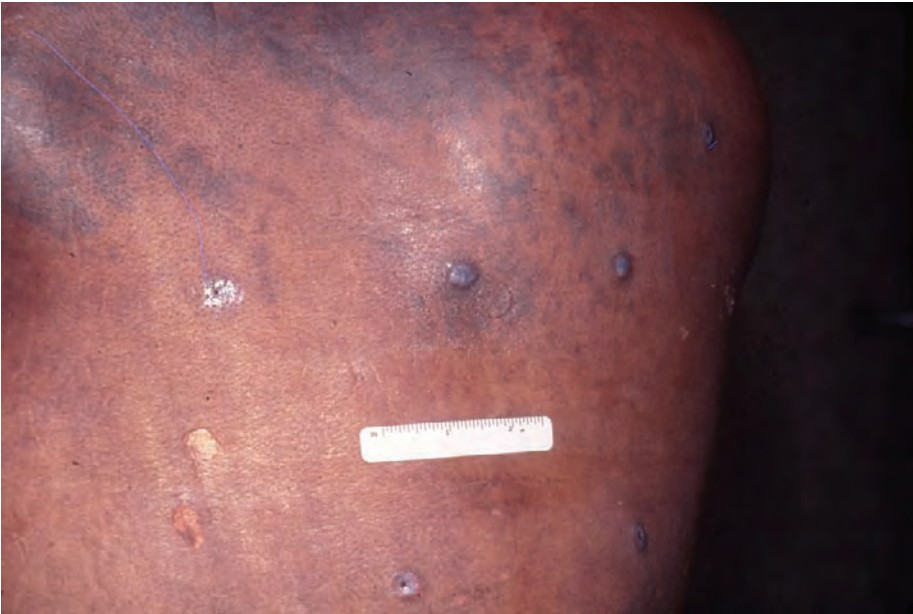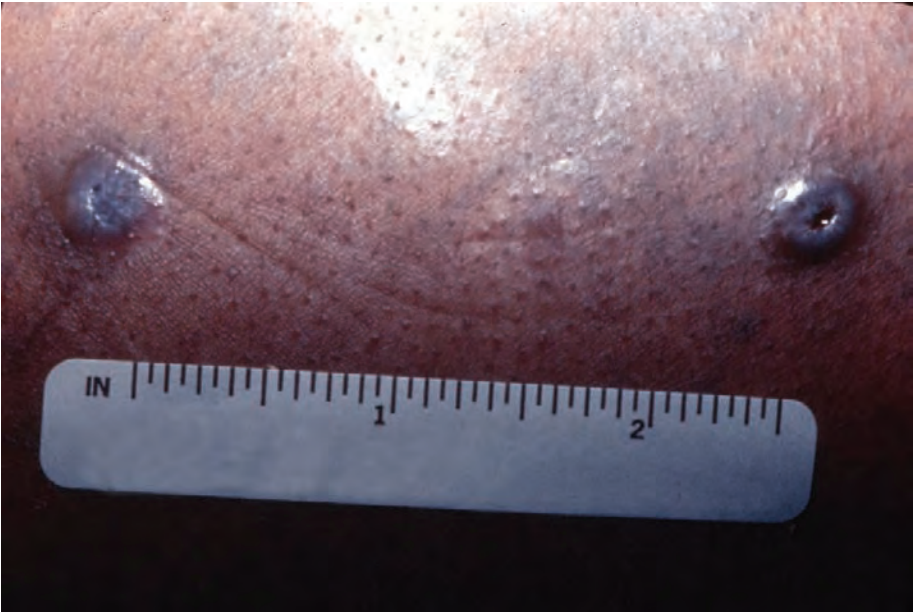
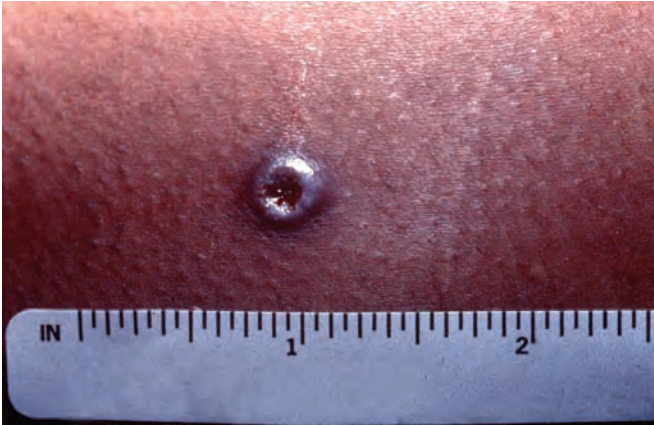
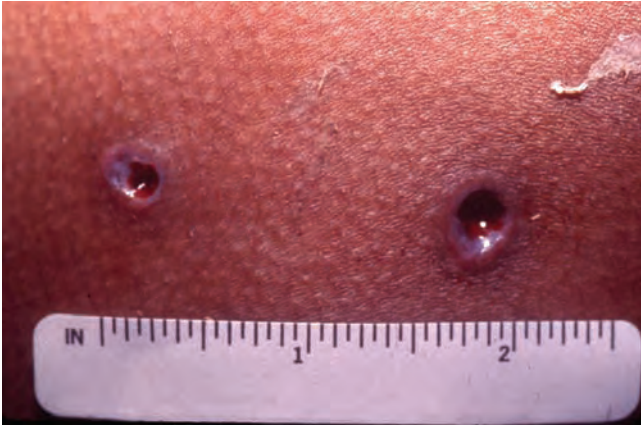
This is a healing wound track through the subcutaneous and fatty tissues of the gluteal region. Note the dull granular nature due to healing and the presence of granulation tissue.



This is a healing gunshot wound that is approximately a week old.

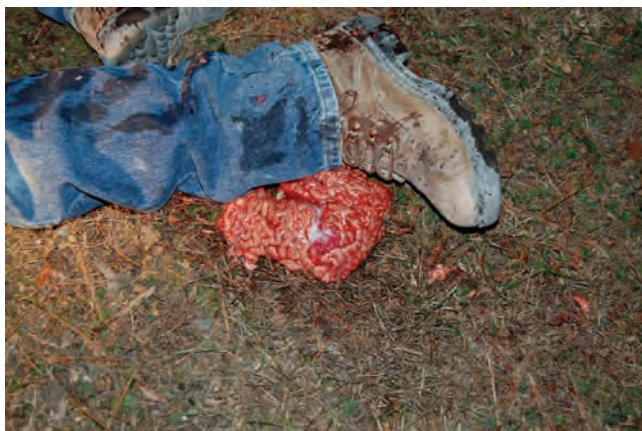
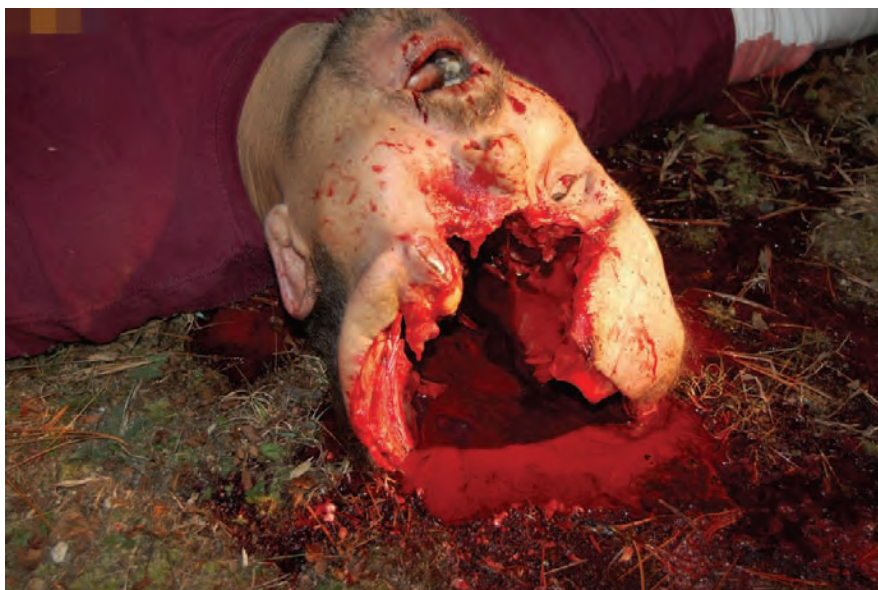
Atypical healing gunshot wounds with fragmented pieces of lead.

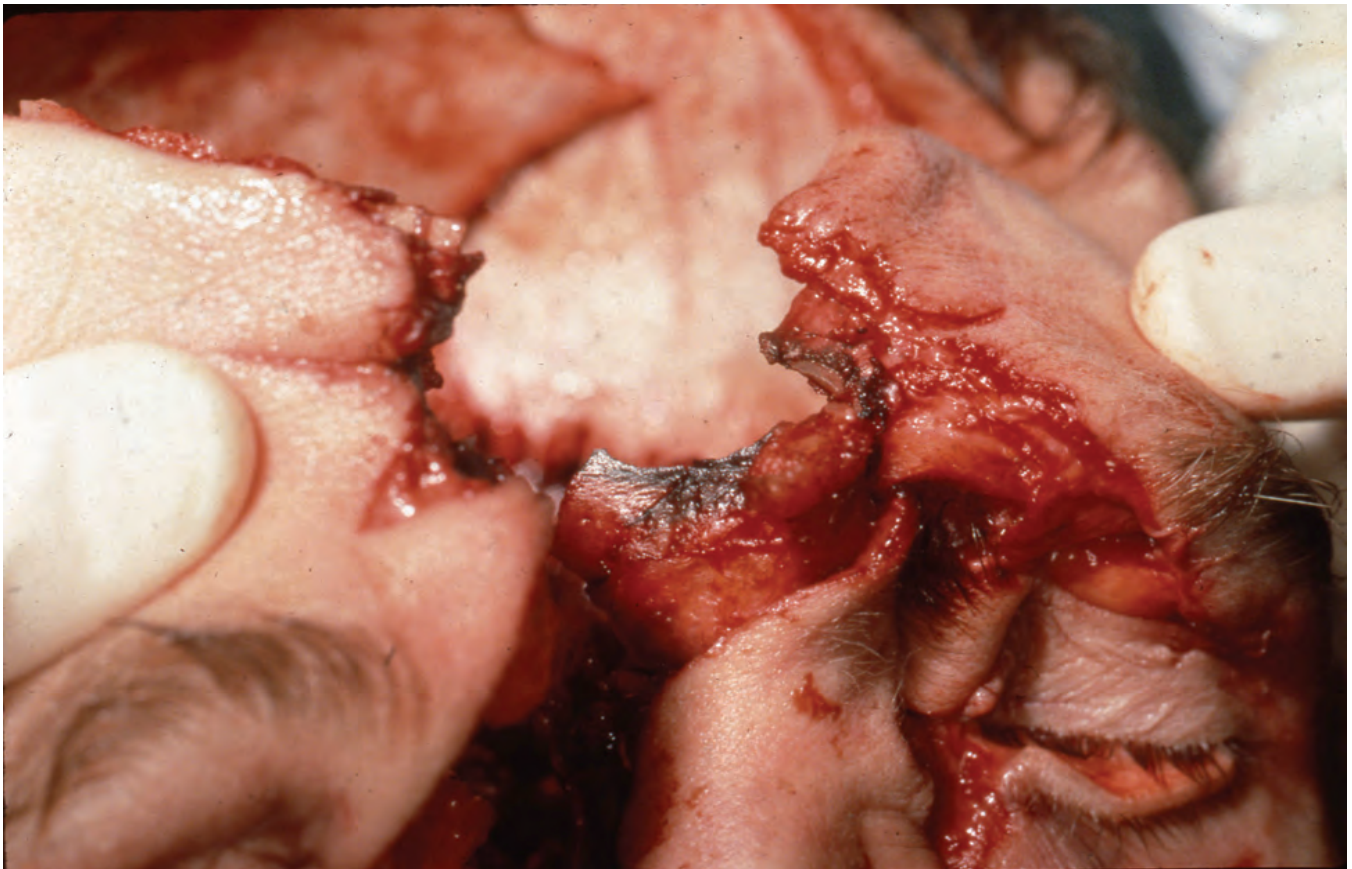
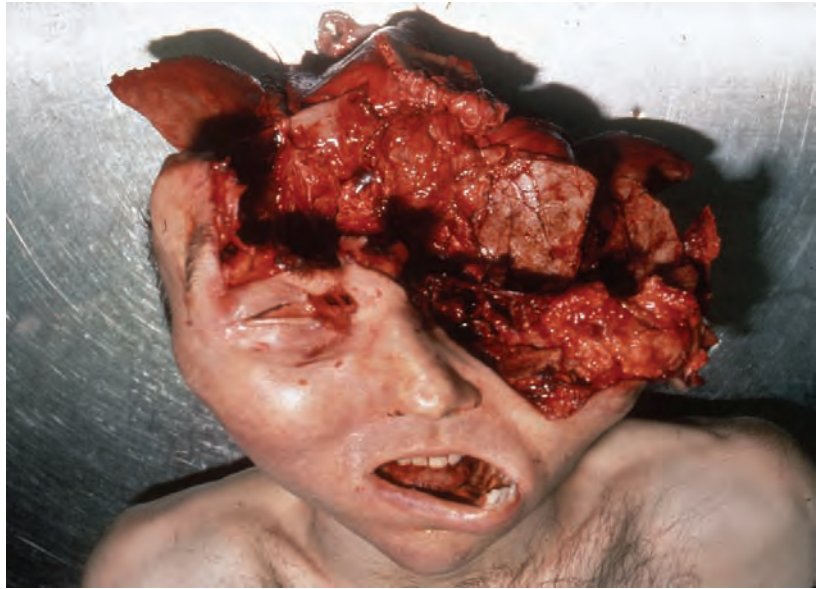
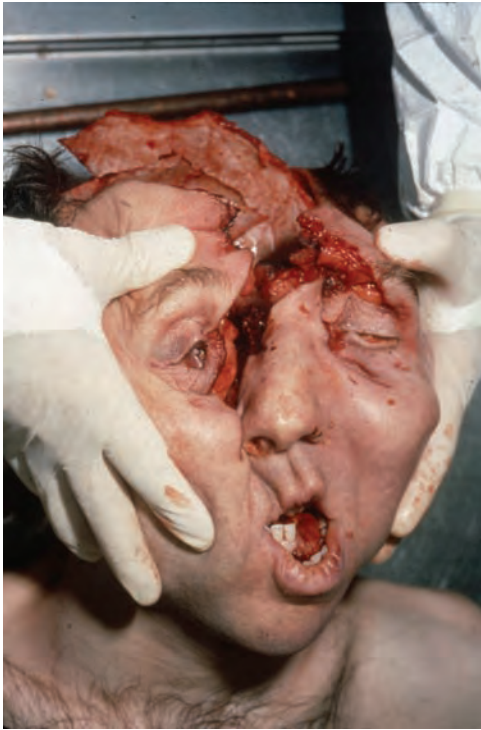Varying stages of healing gunshot wounds.



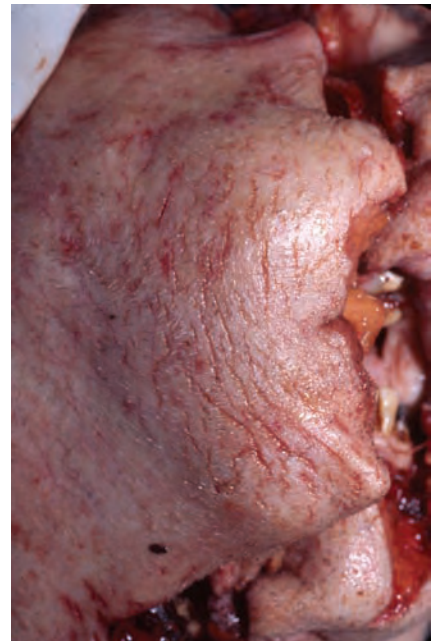
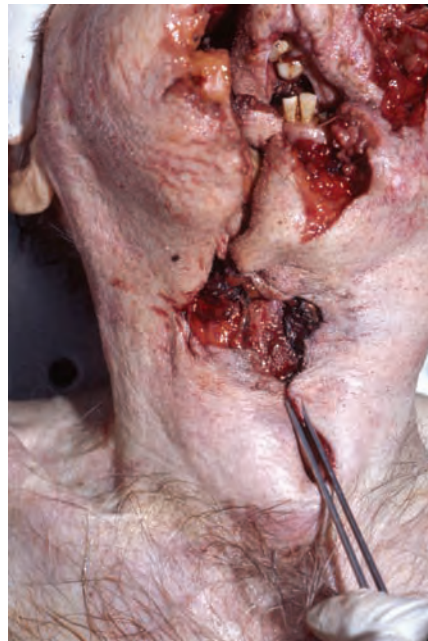
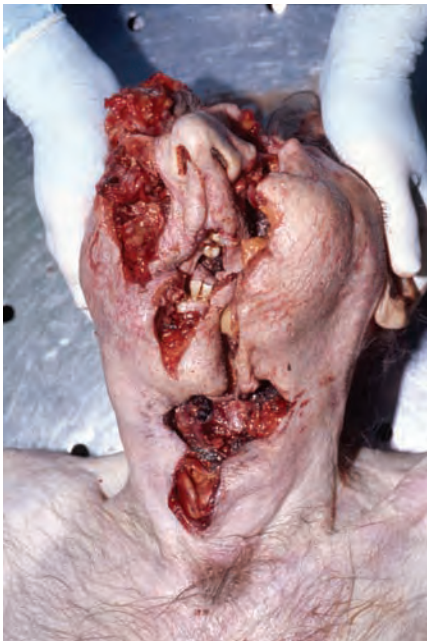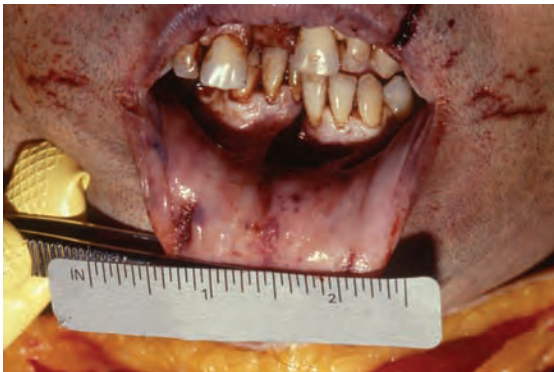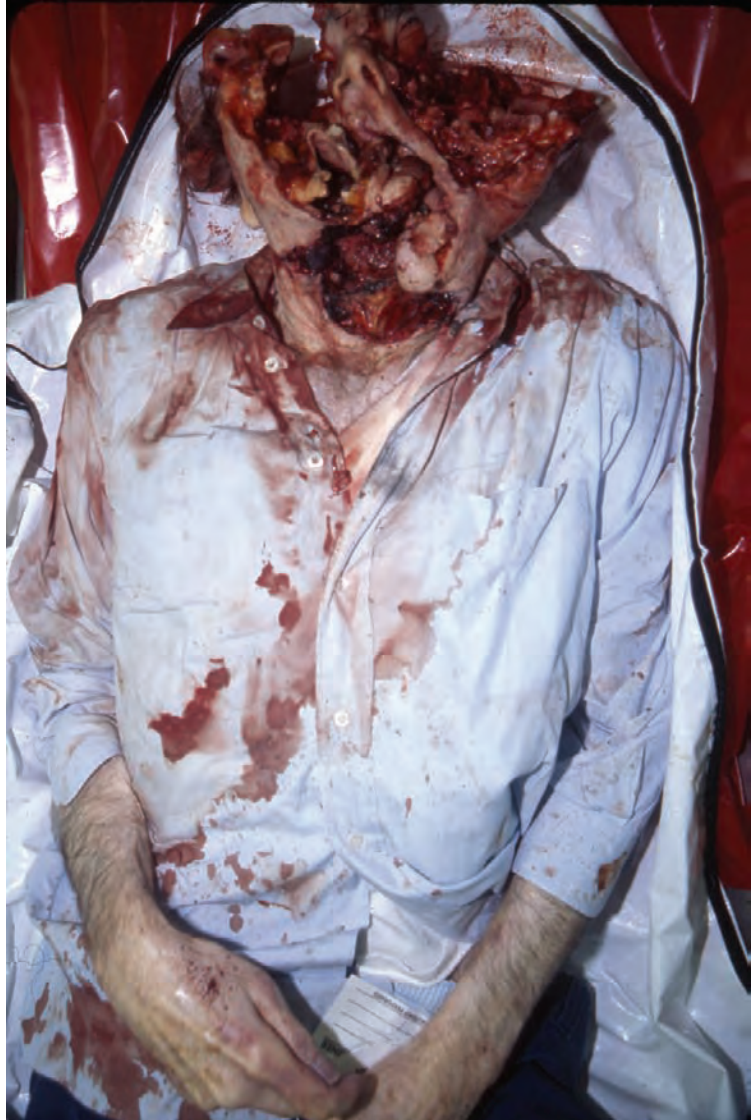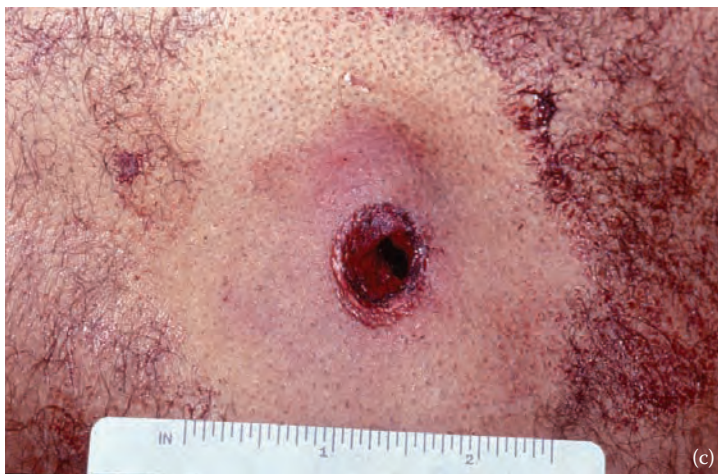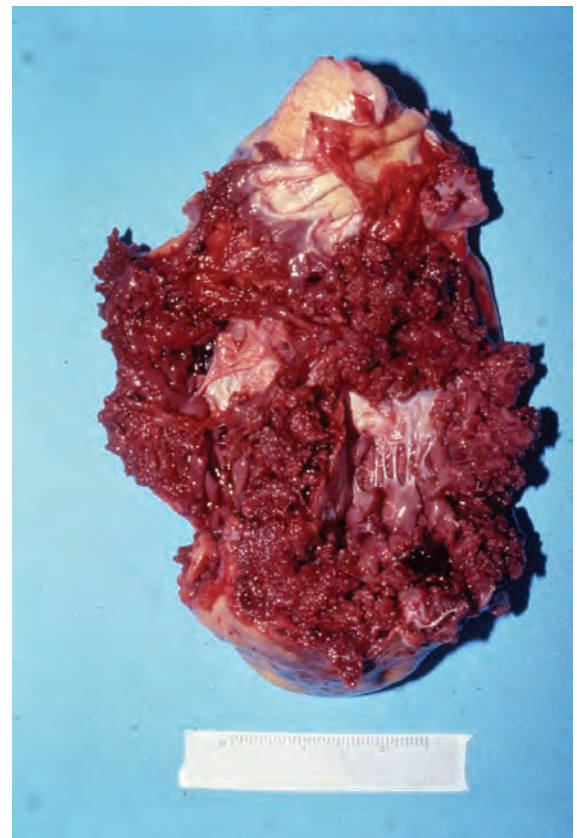
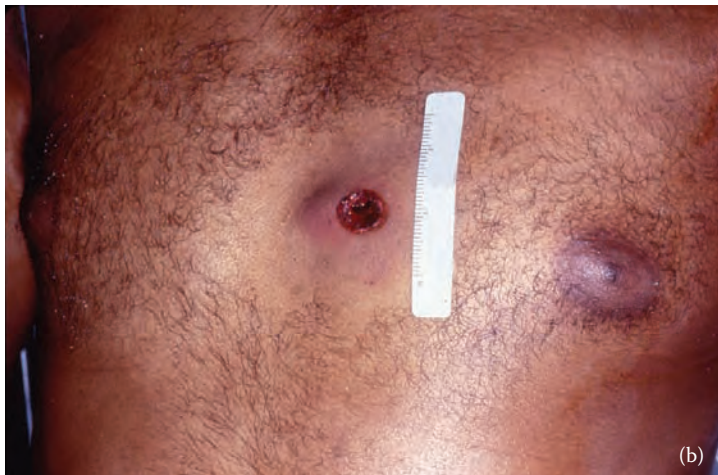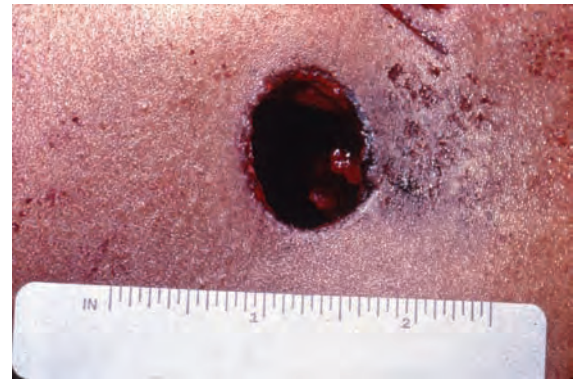
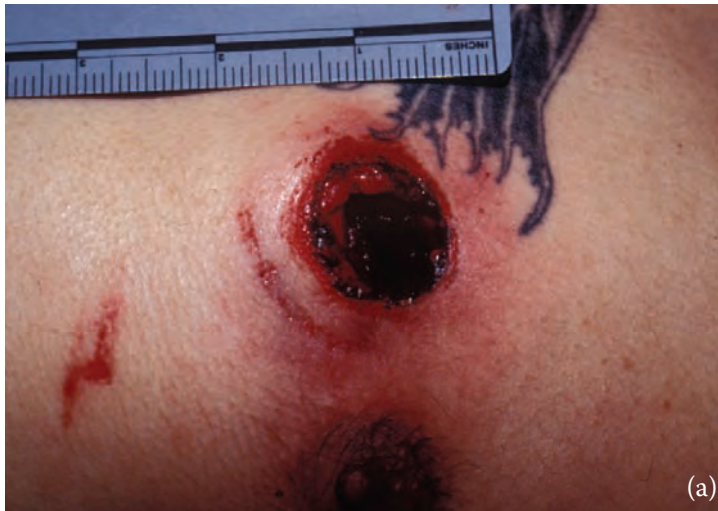This case involves a suicidal tight-contact intraoral .44-caliber rifle wound with extensive fractures and lacerations to the head. Note the gaping injury at the top of the head with the empty cranial vault. The brain was ejected almost entirely intact due to expanding muzzle gases.



This individual died from a self-inflicted contact 16-gauge buckshot shotgun wound to his forehead. His cerebral hemispheres were ejected from the cranium almost completely intact and were discovered behind the body. Note reconstruction of this wound produces an obvious circular perforation with soot at the individual's forehead. Initially, at the scene investigation, it was thought to have been an intraoral shotgun wound, many of which are associated with stretching and lacerations of the lips and mouth region.

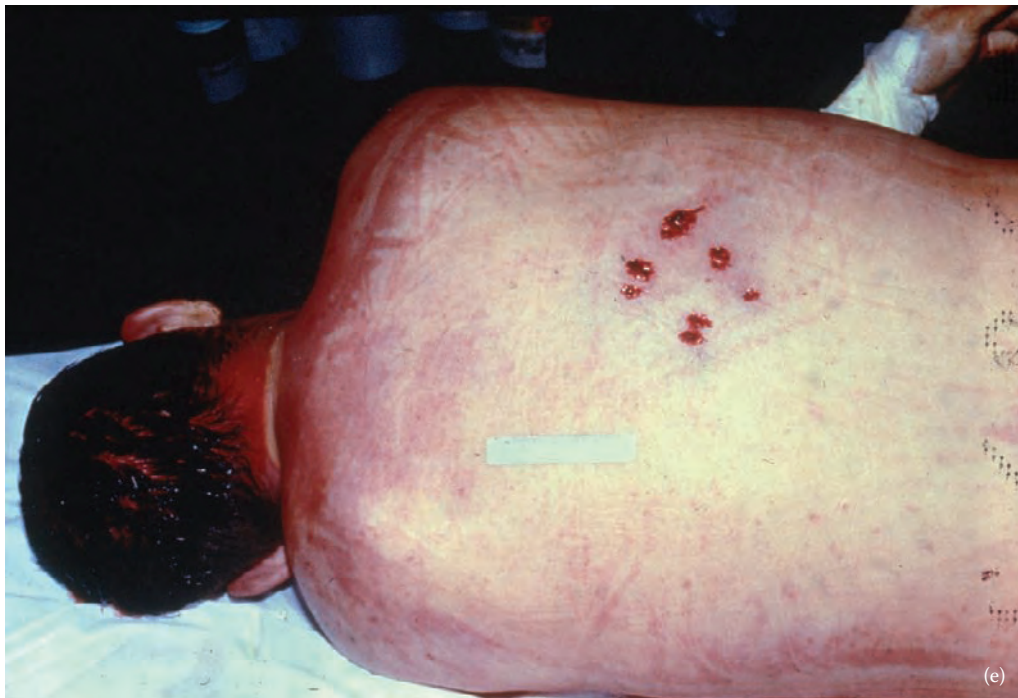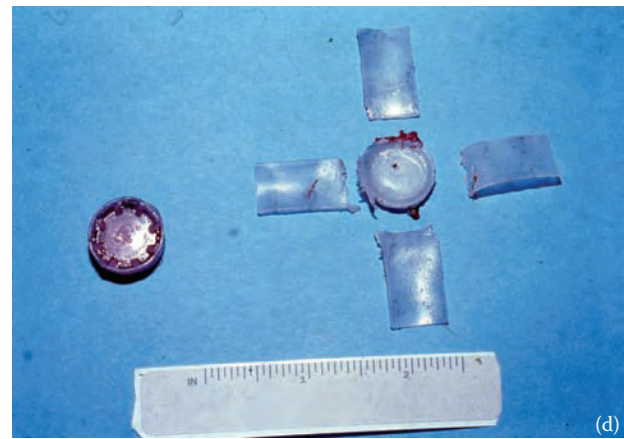
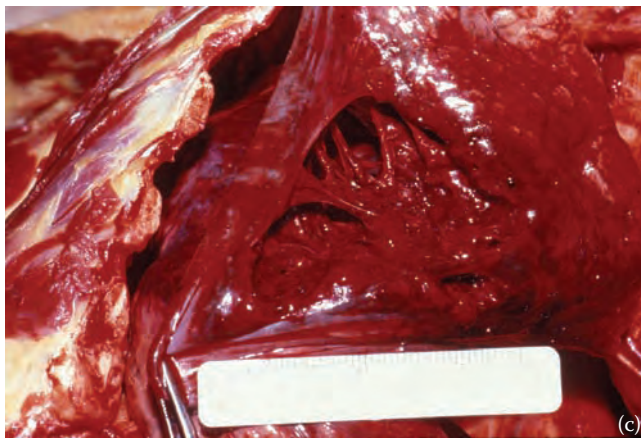
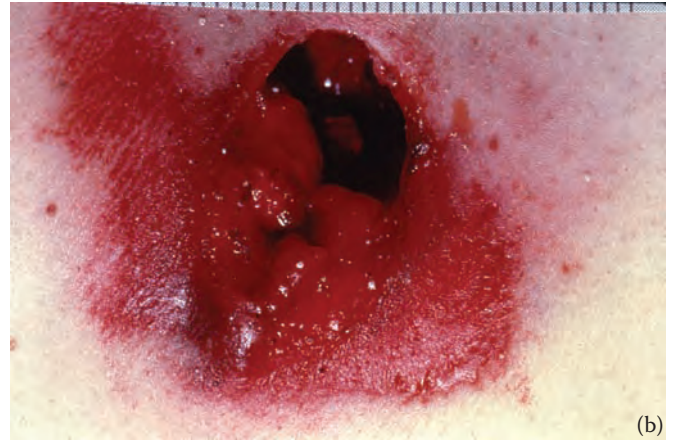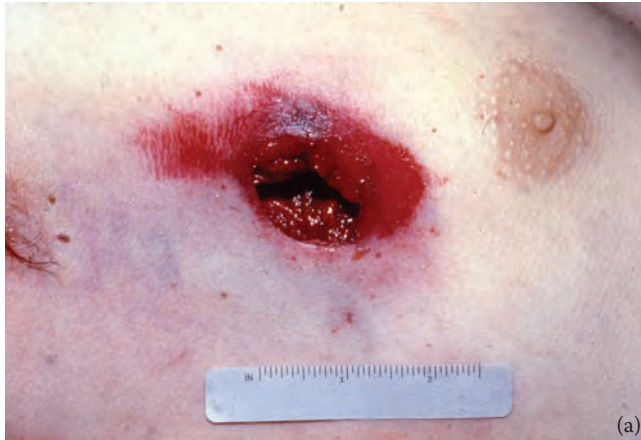This individual died of a self-inflicted, contact, 12-gauge shotgun wound to the superior aspect of his neck underneath his chin. Note approximation of the wound margins produces a roughly circular perforation with soot. There were extensive lacerations to the face and head. Note the extensive stretch marks at the decedent's face. Note the blood spatter pattern and gunpowder residue on the hand.



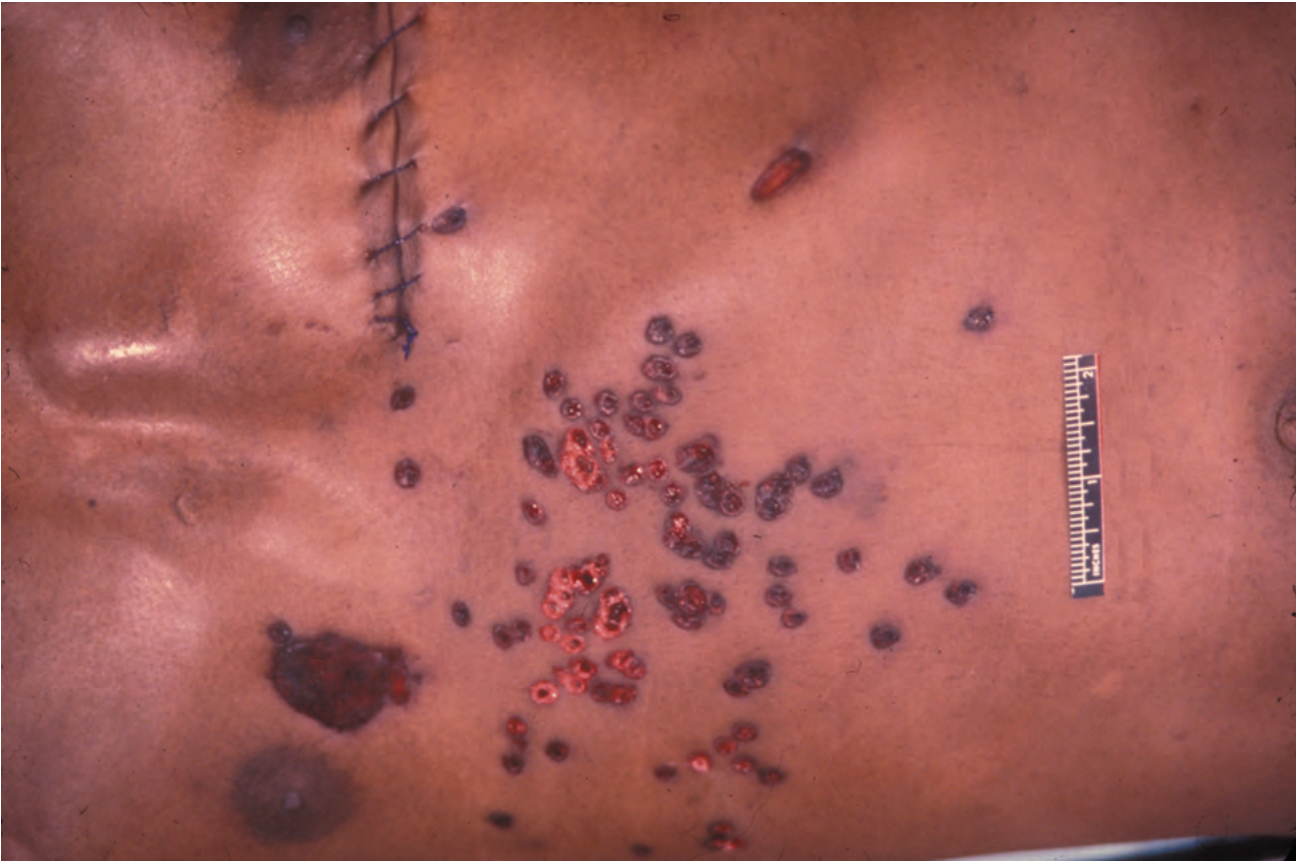
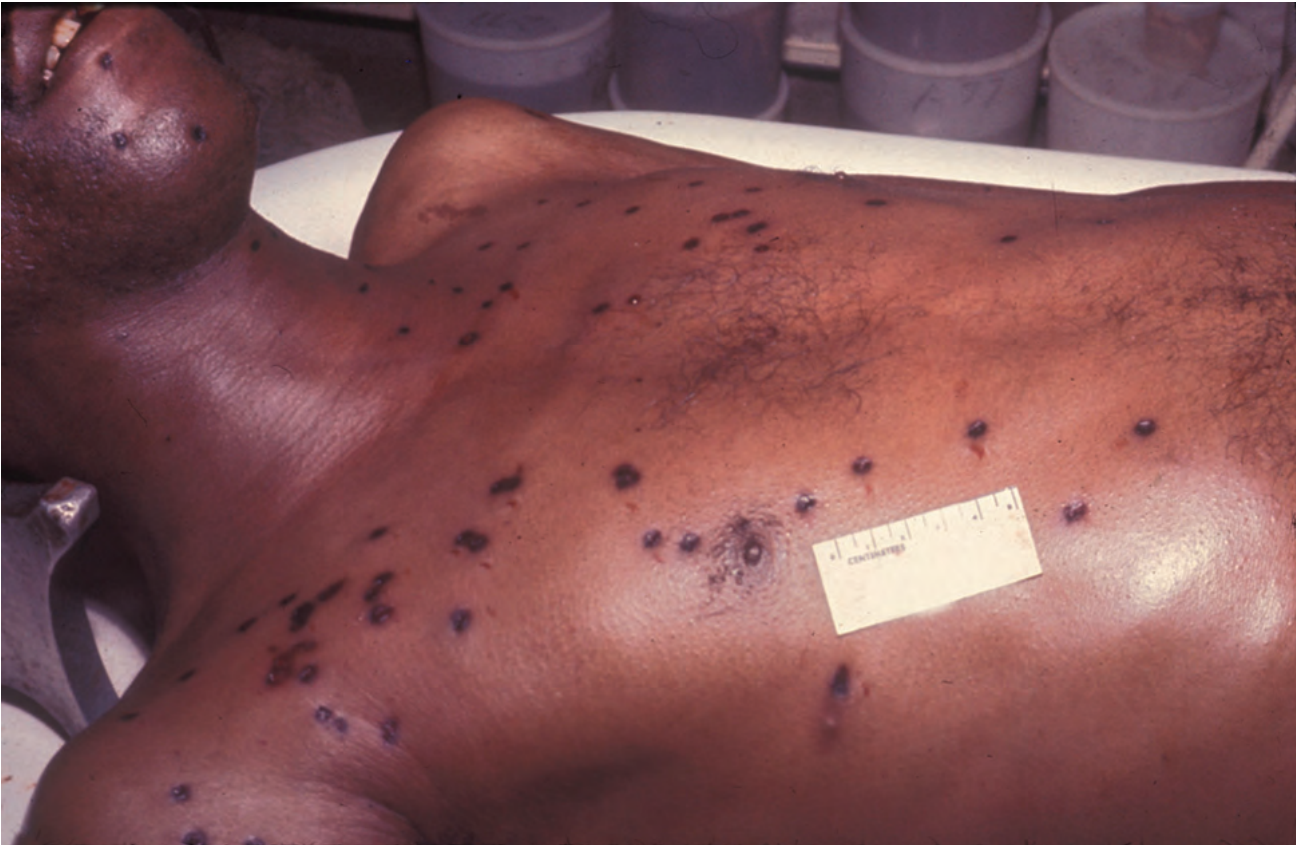
These are contact shotgun wounds to the chest. Note the roughly symmetric margin of abrasion with small amounts of soot. More soot was observed within the wound track. Note in (a) another encircling abraded ring corresponding to where the muzzle contacted the body when the gun was discharged. Note in (b–c) there is an encircling vague pink discoloration from carbon monoxide and nitrites in the burning gunpowder that reacted with the underlying muscle and blood, producing this red discoloration.

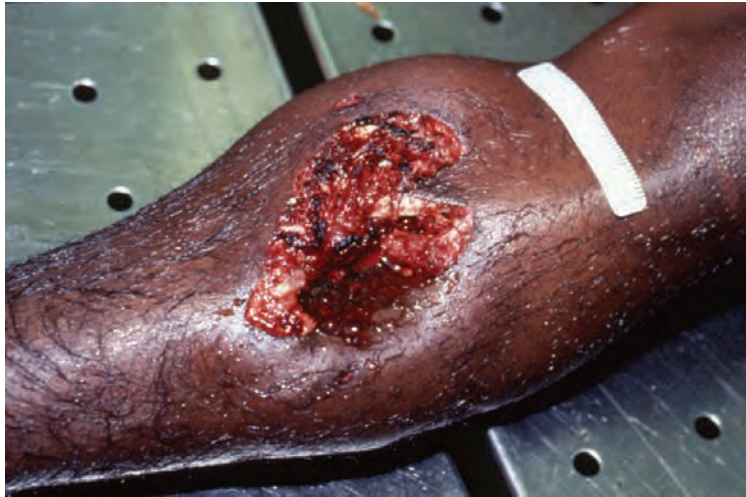This is another example of a shotgun-slug wound. Note the extensive fragmentation and laceration to the heart. The last image shows the deformed lead shotgun slug with wadding retrieved from the wound track.



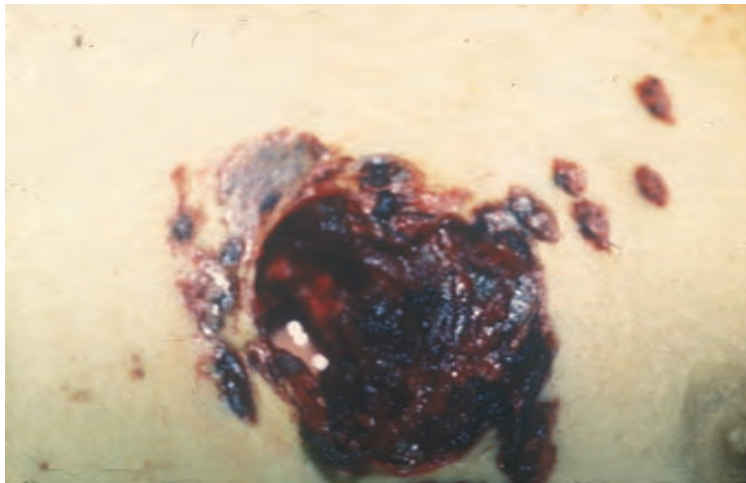
This is a .12-gauge shotgun wound through clothing showing few stippling defects and a larger abrasion adjacent to the entrance defect (a and b). The power piston was retrieved within the wound track (d). Note the abrasions adjacent to the entrance wound due to power piston impact (b). There was extensive fragmentation of the lung (c). Note the multiple exit buckshot-pellet wounds to the decedent's back (e).



Distant birdshot-shotgun wounds.



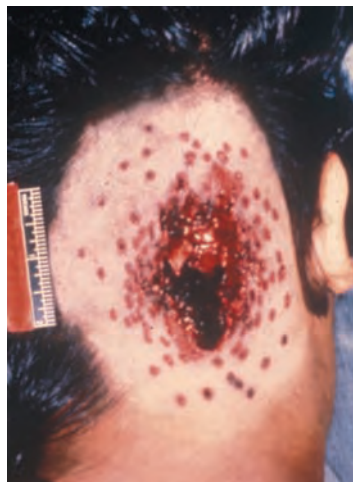This birdshot-shotgun wound to the forearm is estimated at a range of approximately 3 to 4 feet.



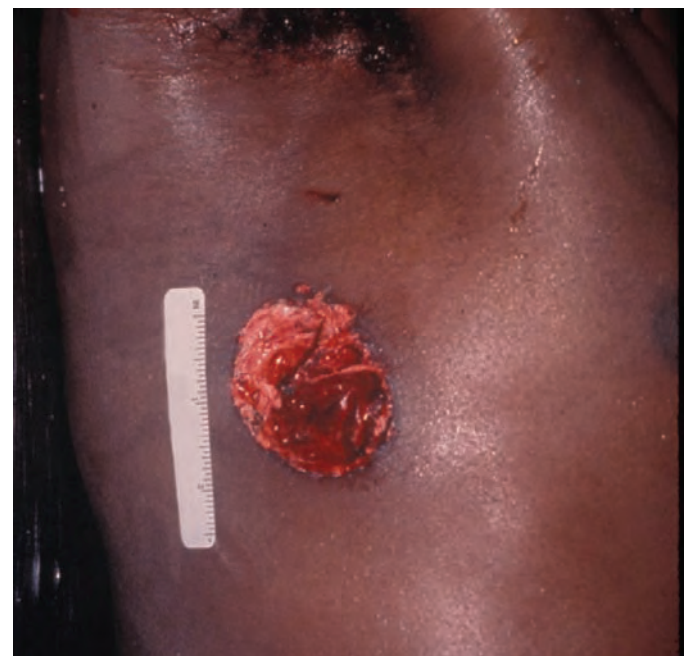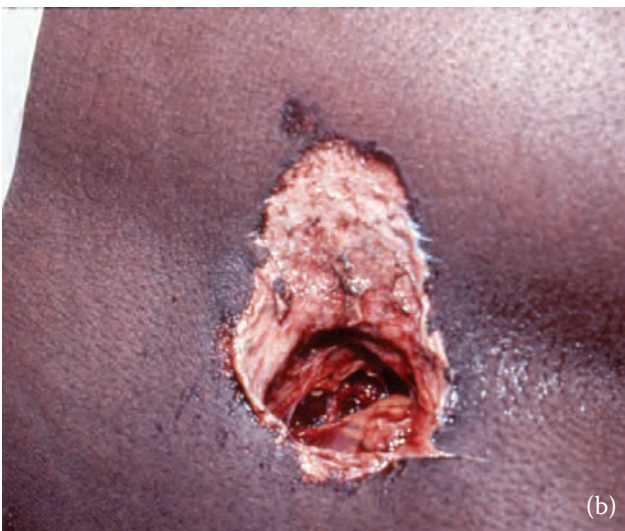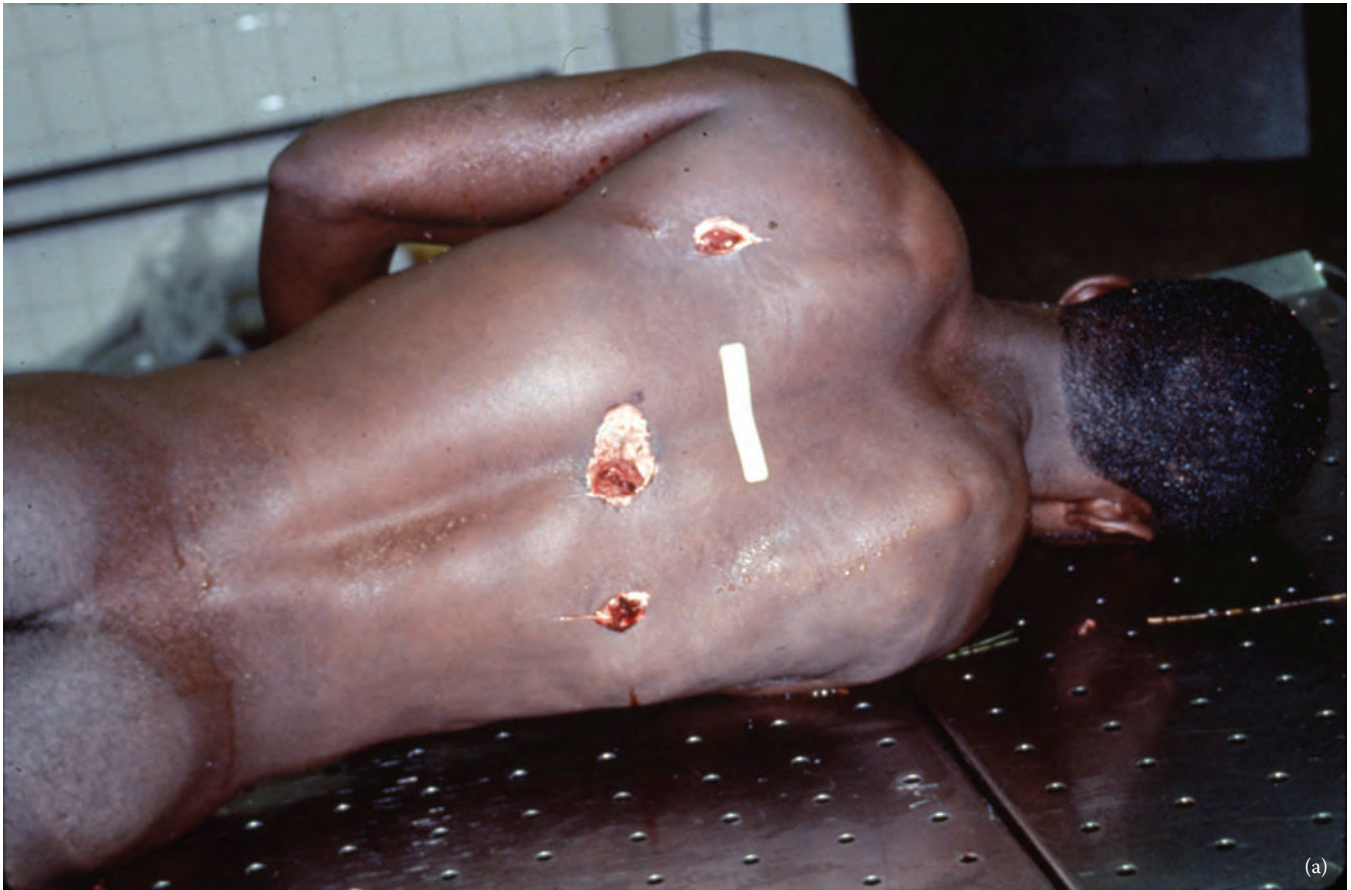Birdshot shotgun wound with an estimated range of fire of 4 to 5 feet.



Birdshot shotgun wound with an estimated range of fire of 6 to 8 feet.



Birdshot with power piston type cup from a shotgun shell.



This individual was shot multiple times with shotgun slugs. Note the large circular perforations with margins of abrasions typical for entrance handgun wounds (a). Note the elongated margin of abrasion at the middle wound (b), indicating the slug struck the body on an angle, traveling in a left-to-right direction.

Entrance shotgun wound with an estimated range of fire of 3 to 4 feet based on the scalloped appearance of the wound margins.

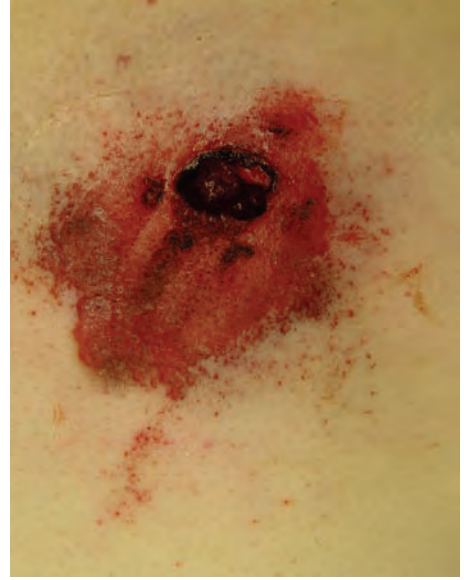




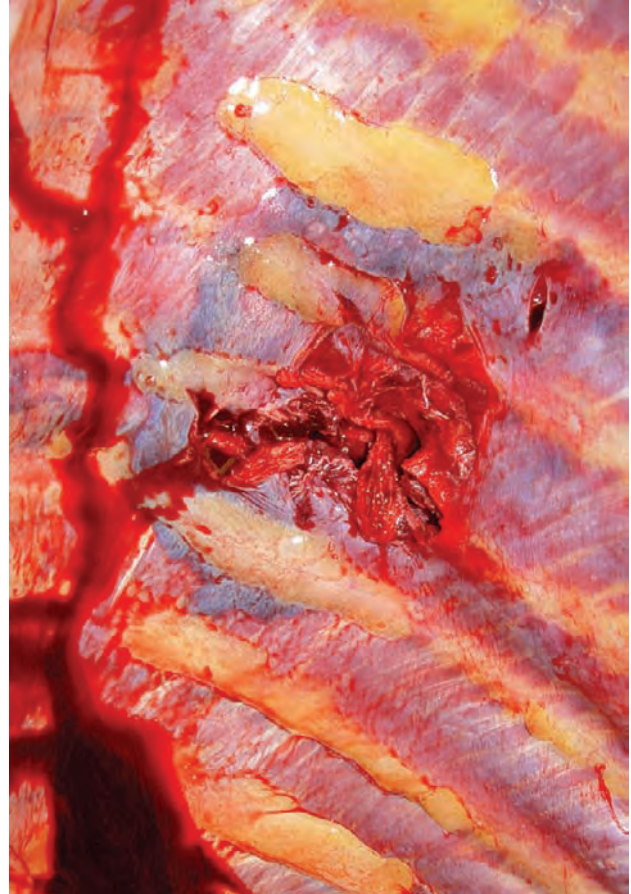
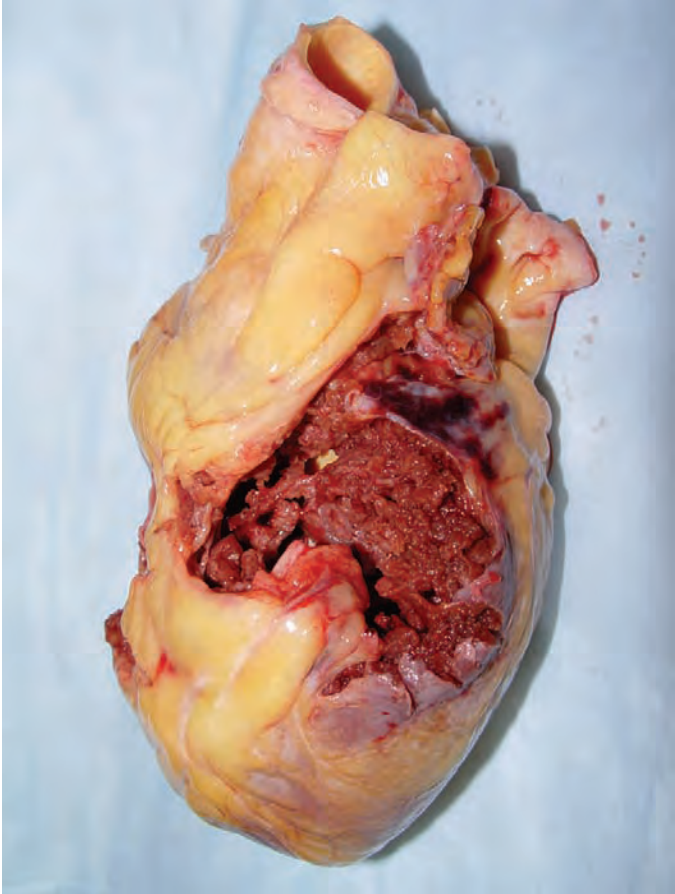
Mini-14 Ruger rifle.



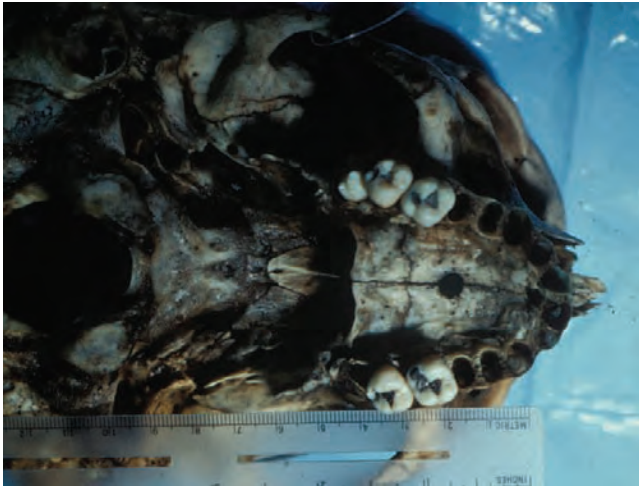Flash suppressor.



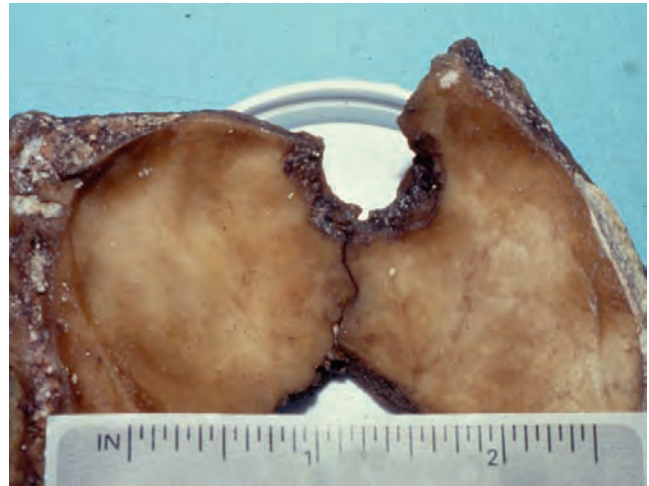
Contact Ruger mini-14 gunshot wound with a .223 bullet. Note the flash suppressor burns with soot deposition.



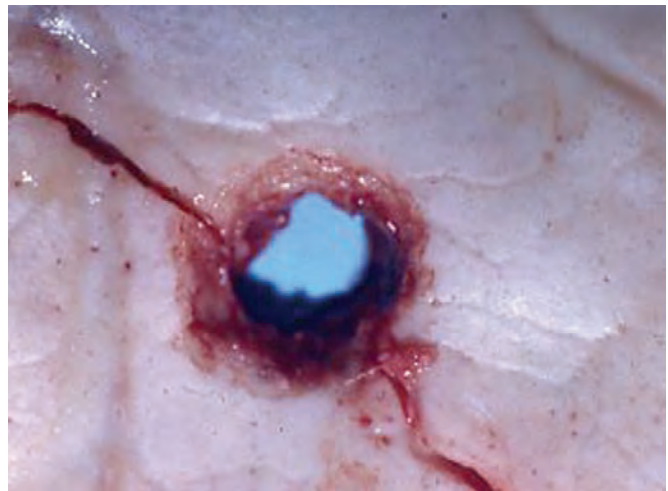
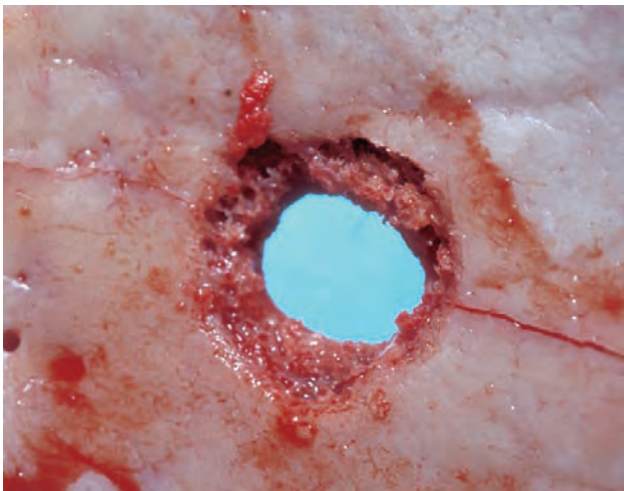
Internal injuries caused by a .223-caliber high-velocity military bullet.



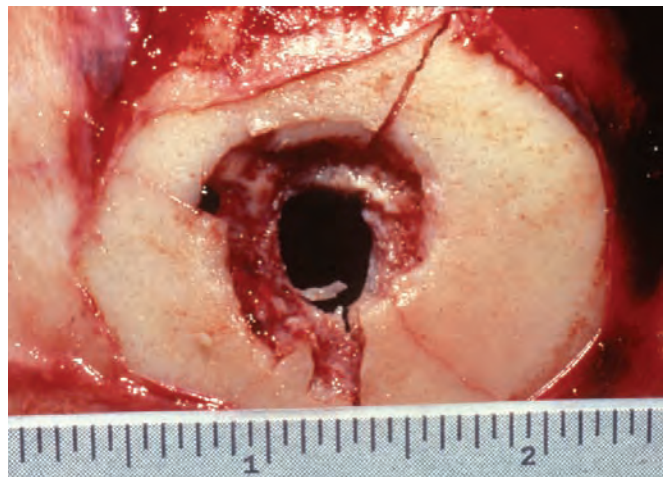
Entrance gunshot wound to the roof of the mouth in the skeletonized remains of this individual with a history of depression. The remains were found with a handgun.



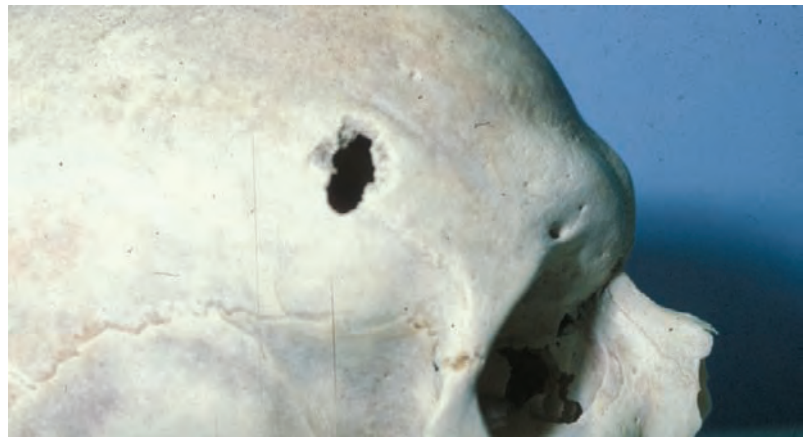
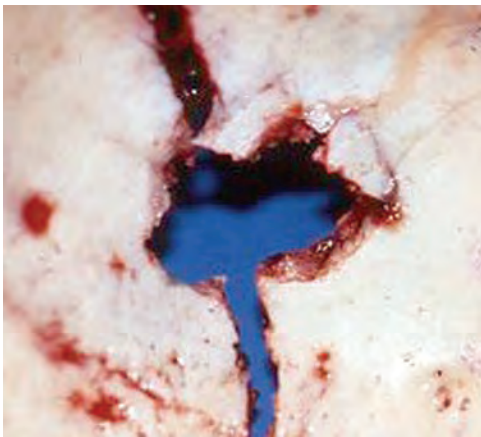
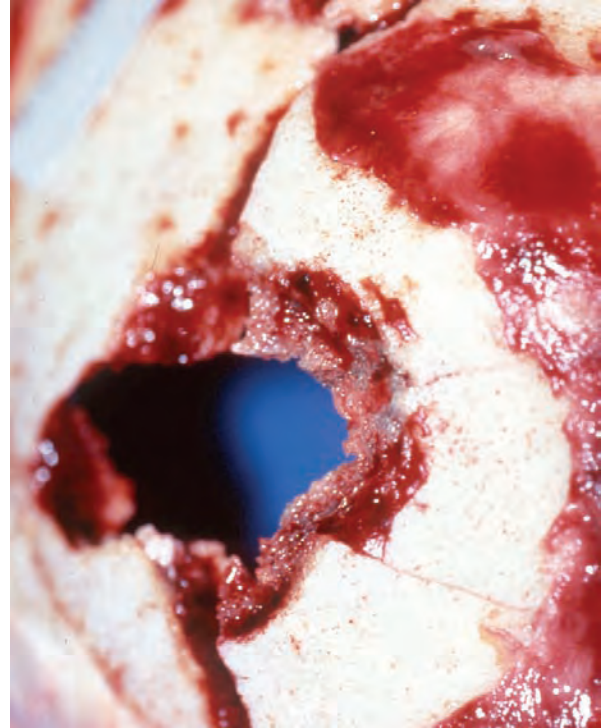
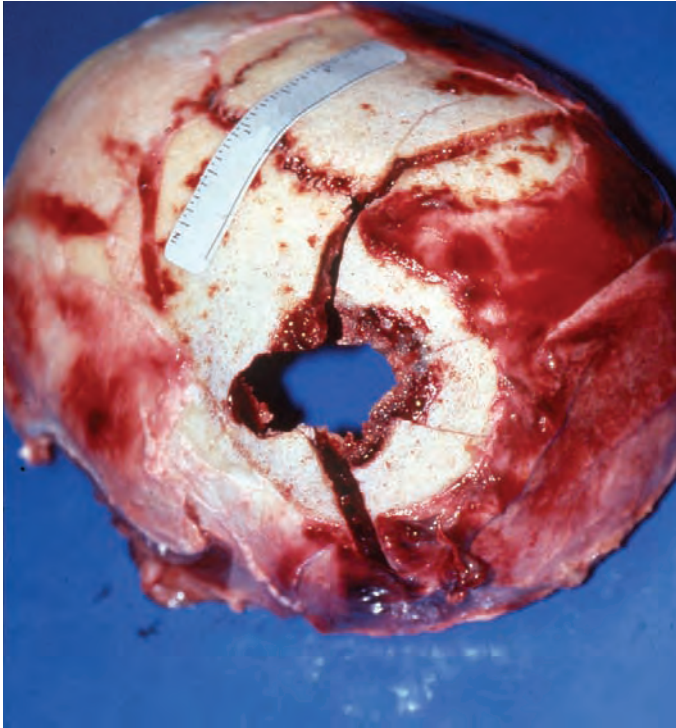
This is the inner aspect of a fractured portion of skull with a roughly circular perforation and internal beveling visible at the inner aspect of the skull indicating this to be an entrance gunshot wound.



Entrance gunshot wounds to the head demonstrating internal beveling of the inner calvaria.



Exit gunshot wound through the skull. This image demonstrates the surface of the skull with external beveling typical for an exit gunshot wound.



These defects at the external surface of these skulls were produced by an entrance tangential gunshot wound. This demonstrates a keyhole deformity with both internal and external beveling. The bullet typically strikes the bone tangentially, producing internal beveling at the entrance side. Then it will often fragment and partially exit the body. The exit side will have external beveling.

## Introduction

---

Burns may occur following exposure to heat (thermal burns), electricity, chemicals, or radiation.

*First-degree burns* are the most superficial and involve the epidermis. They appear as a red discoloration of the skin. An example of this would be sunburn without blister formation. *Second-degree burns* have deeper penetration of injury involving the epidermis and dermis causing blister formation. An example of this may occur when one touches a hot pot on a stove and pulls the hand away quickly. *Third-degree burns* are full thickness, involving the epidermis, dermis, and subcutaneous layer, and appear as collapsed blisters with skin sloughing and red-to-brown discoloration. *Fourth-degree burns* have even deeper penetration of damage, often with charring and exposed underlying tissue including bone. The bones may be fractured from intense heat and the internal organs may have a firm, discolored, and shrunken appearance.

Burns following exposure to heat are *thermal burns*, which may occur following contact with hot liquid or fire. Children may be scalded while left unattended in a bath tub. They may inadvertently hit the hot water knob to increase hot water flow. They may jump into a bath tub full of very hot water, scalding their feet. One must exercise great care in evaluating these cases as they may be a result of abuse or neglect. A child with both feet scalded with scarring around a shoe pattern is more likely the result of abuse or neglect. A child who is waiting to take a bath will not usually have shoes on and will most likely step one foot into the tub at a time. The burns will be on one foot but not usually both. Both feet scalded at once may indicate dunking into hot water as punishment.

If an individual dies and is placed in a tub full of hot water after death, the body will develop thermal injury more readily than if a living body was placed in the same water. A living body can counteract heat injury by vasodilation and circulating the heat to the body's core away from the surface, thus providing some protection to the skin. A dead body left in warm water will quickly develop postmortem thermal burns that appear as skin slippage. Decomposition may also present with skin slippage and blister formation. An individual may sustain full thickness

burns to greater than half of his or her body and still be conscious without immediate death. Death often occurs later due to electrolyte imbalances or infection.

Also, mortality increases with age. Second- to third-degree thermal burns to half the body's surface would much more likely kill a senior citizen than a child. Second-degree burns are more painful than third- or fourth-degree burns due to less damage to nerve endings.

Antemortem burns may be characterized by fluid-filled-blister formation. To have fluid-filled blisters in a nondecomposing body in a nongravity-dependent area not adjacent to an area with more extensive burns with contracted tissue, one needs a blood pressure and a beating heart. Antemortem blisters also typically have a red base with surrounding erythema. This concept remains controversial in some jurisdictions. Also, a dead body from a house fire will decompose at a much slower rate than a dead body not exposed to smoke and intense heat. Smoke and heat serve as preservatives. Low heat will accelerate the putrefication process. Radiant heat in a dry environment will quickly cause tissue to become firm and dehydrated, often with hair still present. This depends on the amount of heat and humidity and the duration of exposure. Also, intense heat may produce postmortem artifacts that may be misinterpreted as antemortem injury, such as an epidural hemorrhage. Epidural hemorrhage may be postmortem and is caused by heat-related contracture of the dura mater forcing blood from adjacent vessels into the epidural space. Subdural hemorrhages do not occur in this manner and are antemortem injuries.

Thermal burns sustained by fire may be accompanied by smoke inhalation. In general, most fatalities from house fires are caused by smoke inhalation. Decedents dying directly in house fires usually have mostly postmortem burns. Fire fatalities that occur outside in an open space often do not have associated significant smoke inhalation because the smoke rises rapidly and is not inhaled. In the case of a flash fire, inhaled super-heated gases damage the upper airways, including the laryngeal mucosa, and causing death from reflexive closure of the airway at the level of the vocal cords with asphyxia and eventual fatal arrhythmia. The effects of smoke inhalation are often reflected by the amount of carbon monoxide present in the blood. This depends on the nature of the burning material.

There are often other significant poisons associated with burning materials that can rapidly contribute to death, such as hydrogen cyanide. A fire victim does not need a lethal level of carbon monoxide to die of smoke inhalation. Carbon monoxide is produced from incomplete combustion of organic fuels. Carbon monoxide, in the absence of smoke, is a colorless, odorless gas that reversibly binds the hemoglobin molecule approximately 200 times greater than oxygen, resulting in hypoxia and possible death. Levels of carbon monoxide that exceed 50% saturation are considered life threatening, but may cause death with levels less than 26% saturation. Carbon monoxide levels of greater than 80% are possible. These levels need to be correlated with the physiologic disease state of the individual's body, including heart disease, for example. Someone with marked coronary-artery atherosclerosis would often require much less carbon monoxide exposure to produce death than a young healthy individual with slight atherosclerosis. Cigarette smokers may reach carbon monoxide levels of 10%. Carbon monoxide levels of 15–30% are associated with dizziness, nausea, and headache. Cherry-red lividity first becomes apparent at levels of 30–35%. The half-life for carboxyhemoglobin elimination in a resting adult at sea level is generally 4 to 5 hours. This may be reduced to 80 minutes following administration of pure oxygen, and may be further reduced to 24 minutes by using oxygen at 3 atmospheres of pressure. Primary elimination of unchanged carbon monoxide occurs by pulmonary excretion. Also, if there is more than one fatality without obvious cause, one should consider carbon monoxide poisoning.

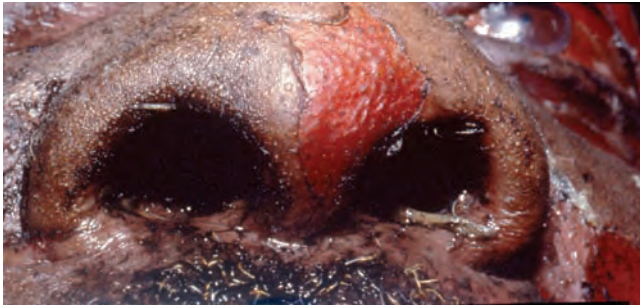*Electrical burns* may be due to low- or high-voltage exposure. The electrical current may be direct or alternating in nature. Alternating current is more likely to cause a fatal cardiac arrhythmia than direct current. High voltage is generally defined as greater than 1000 volts for alternating current and greater than 1500 volts for direct current. High-voltage burns are usually associated with extensive obvious injury. Low voltage is generally defined as being less than 1000 volts for alternating current and less than 1500 volts for direct current. Low-voltage burns may present with no visible marks to the body's surface at all. The degree of injury depends on many factors, including the duration of exposure and the amount of heat generated.

Electrical burns may also occur as a result of a lightning strike. Lightning bolts occur with an enormous short-term release of electricity, often producing minimal injuries. Lightning strikes may also produce a fern-like red pattern at the skin's surface. Patterns similar to this may be observed in high-voltage electrocution. These types of electrical discharges present with different autopsy findings. The mechanism of death is

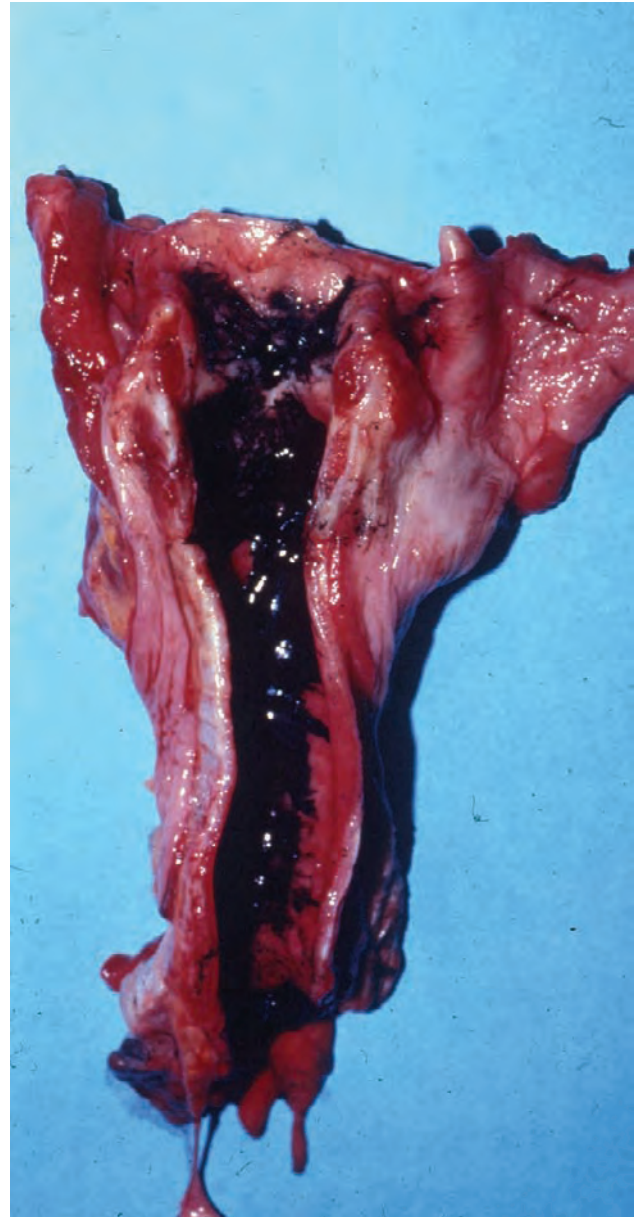
usually arrhythmia and more likely to occur if the current passes directly through the heart. Death may also occur due to asphyxia if there is interference with the central nervous system's respiratory centers or paralysis of the chest muscles. To complete an electrical circuit one needs an entrance and exit point for electricity to pass through the body. An otherwise healthy individual may be found lying barefoot and on a damp floor next to a power tool with a frayed electrical cord. This is why adequate scene investigation is crucial. It is also important to keep the electrical device as evidence to be tested, and to prevent any other fatalities. There may or may not be burns to the body's surface at autopsy.

*Chemical burns* are due to exposures to caustic substances. These burns most often involve injury to the skin or mucosa, leaving red discoloration or sloughing of the superficial layers. More extensive injuries may involve damage to the underlying tissue including bone. This depends on the strength and nature of the caustic substance, which include acids, bases, and other chemicals that can damage the body. Individuals may die acutely following chemical burns from many different mechanisms including hemorrhage, infection, dehydration, or they may die many years following such injuries. For instance, if an individual attempts to commit suicide by ingesting lye 20 years earlier and later develops esophageal cancer as a result of these burns, the manner of death would be suicide. Children may accidentally drink caustic substances, leading to gastrointestinal perforation that may lead to adhesion and gastrointestinal obstruction many years later. In this case, the manner of death would be accidental. It is always very important to find out the initial event that starts the ball rolling in the sequence of events that eventually leads to an individual's demise.

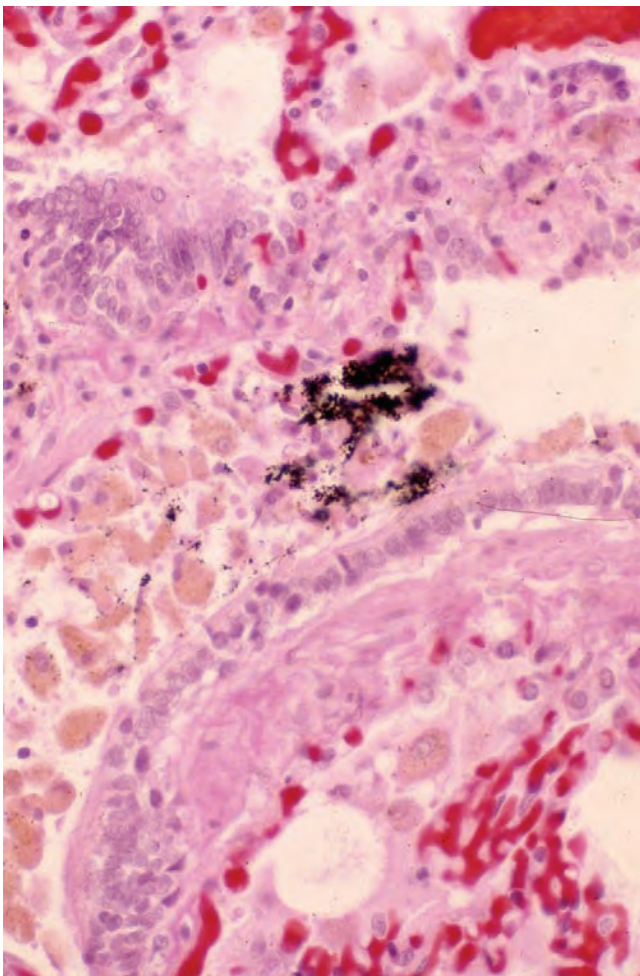
*Radiation* is defined as energy distributed as waves or particles across the electromagnetic spectrum. This includes electric, radio, radar, microwaves, infrared, visible light (lasers), ultraviolet light, x-rays, gamma rays, and cosmic radiation. Waves are characterized as having long wavelengths and low frequencies, whereas particles have short wavelengths and high frequencies. The types of biological effects vary greatly depending on the type of radiation, duration of exposure, and intermediate barriers. Acute exposure to skin may range from erythema to overt necrosis with eventual epidermal atrophy and dermal fibrosis. Biological effects include cataracts, burns to the retina and skin, necrosis, fibrosis, and cancer. Generally speaking proliferating cells are affected more substantially with acute exposure as indicated by damage to the gastrointestinal and hematopoietic systems with increased risks of infection, nausea, vomiting, diarrhea, and hemorrhage. Damage to DNA may eventually lead to many different forms of cancer.



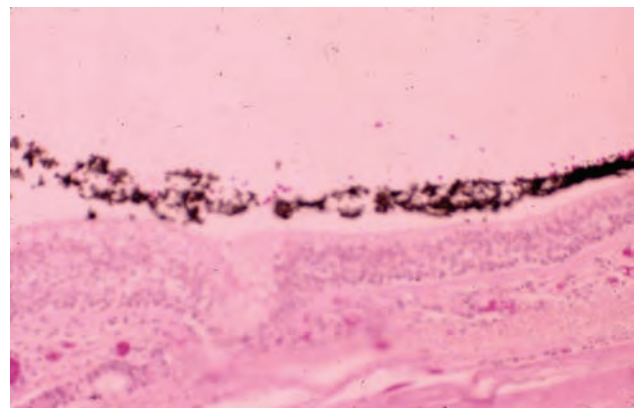
Soot within the nares due to smoke inhalation.



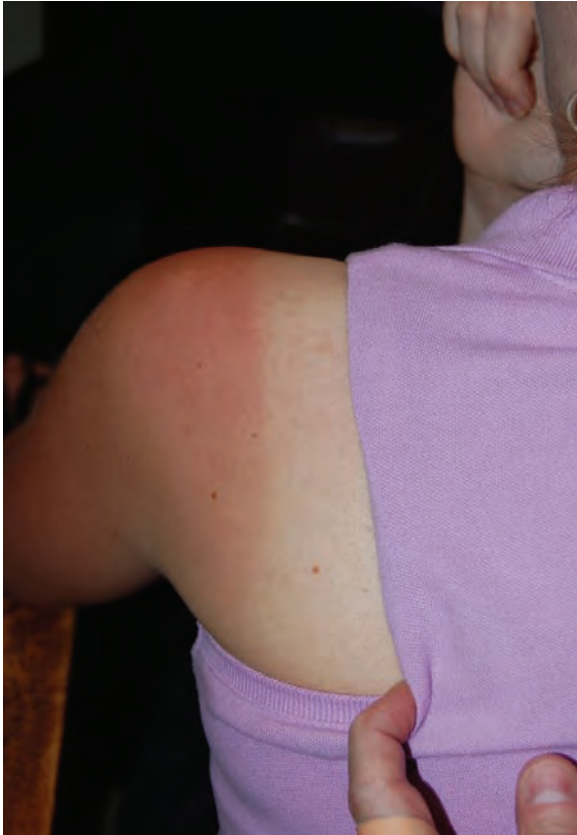Smoke inhalation with soot deposition on the airway mucosa of the larynx and trachea.



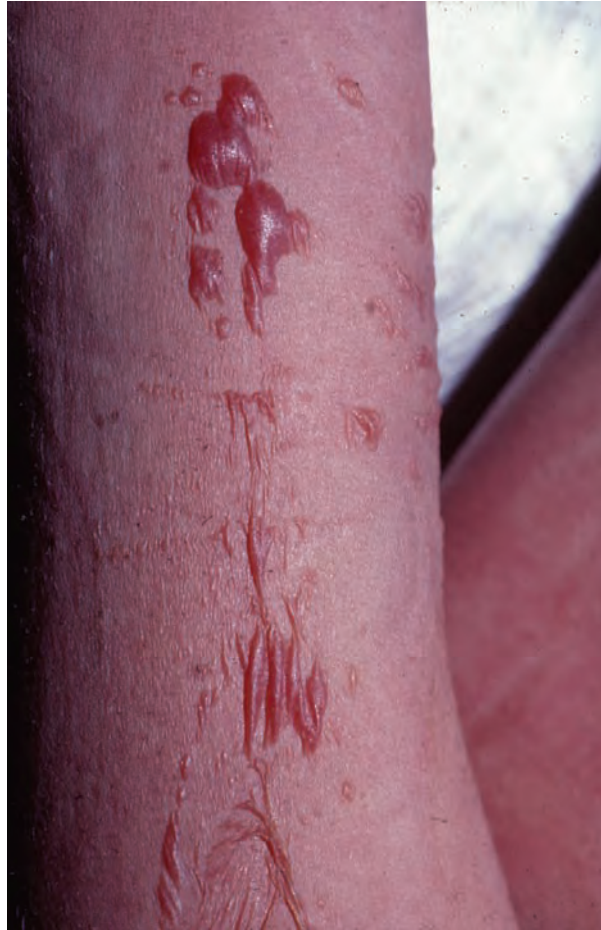Microscopic view of lung with soot deposition in the distal bronchi.



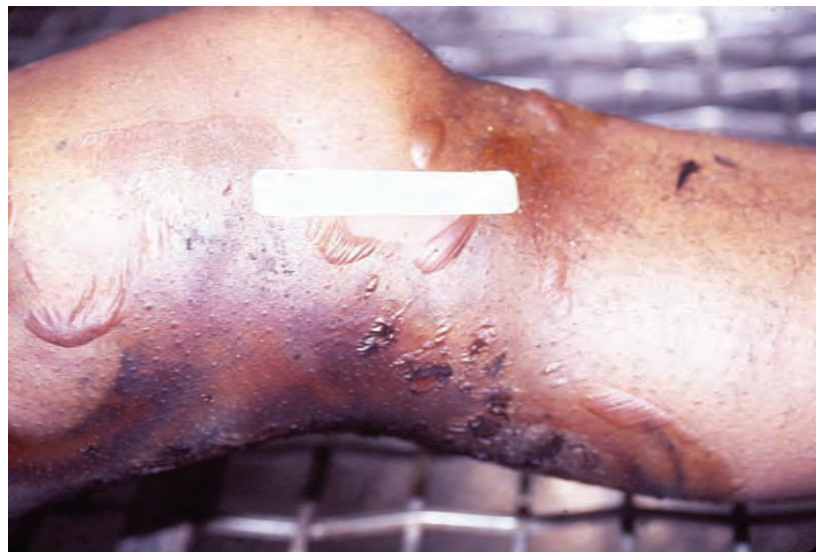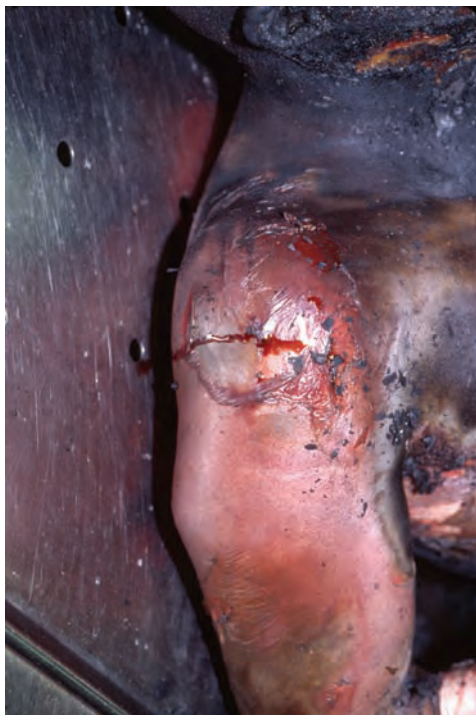Microscopic view of airway with soot deposition at the surface of respiratory epithelium.



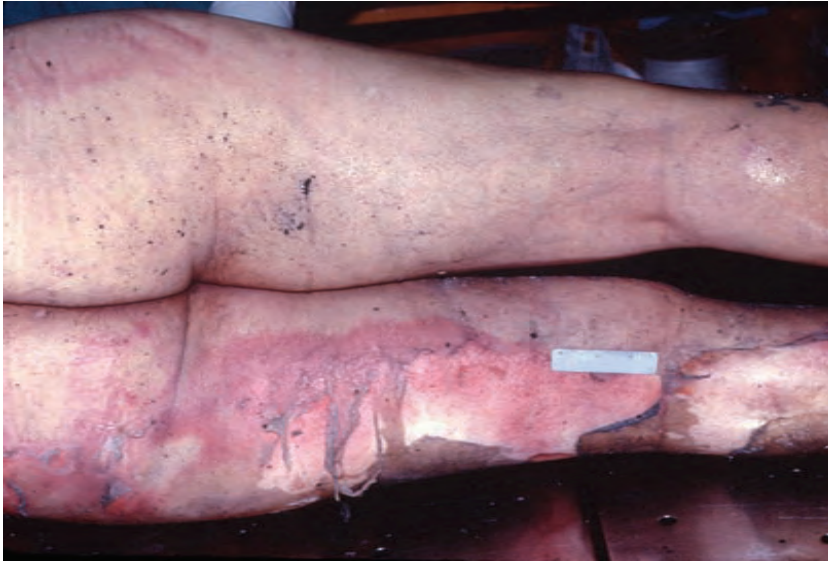First-degree burn characterized by red discoloration with injury limited to the epidermis.



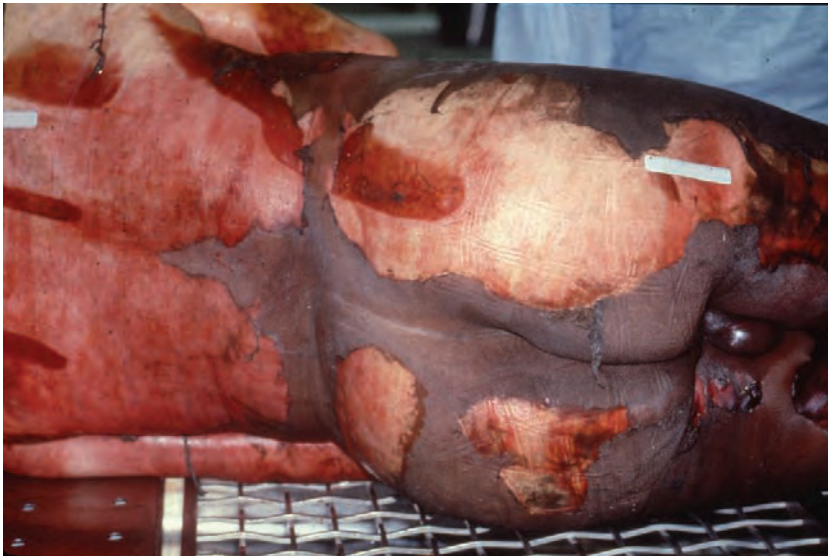Second-degree thermal burns characterized by fluid-filled-blister formation. Second-degree burns include damage to both the epidermis and dermis and are often more painful than third-degree burns due to less destruction of nerve endings.



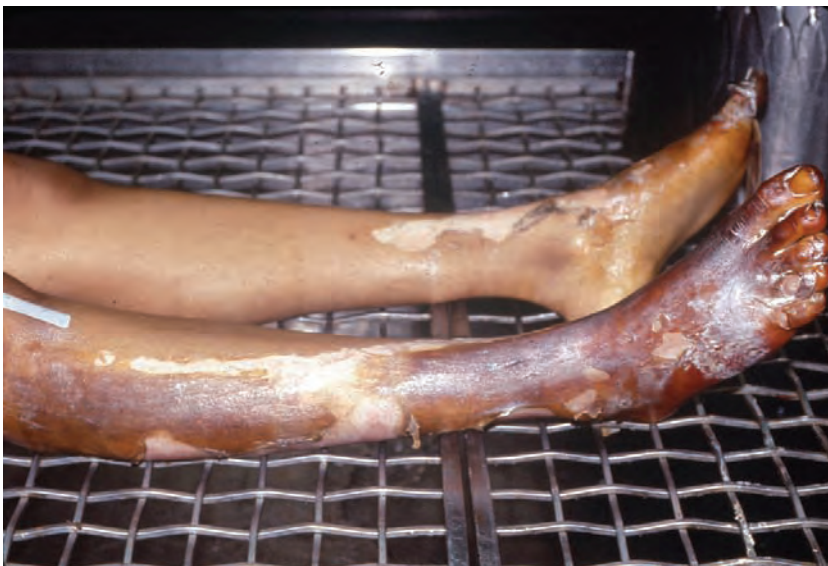Second- to third-degree thermal burns. These areas demonstrate fluid-filled-blister formations that were interpreted as antemortem. To have fluid-filled-blister formation associated with thermal injury, one usually needs to have a blood pressure. Fluid-filled blisters generally do not occur due to putrefaction in burn victims due to the preservative effects of fire and smoke. Postmortem blister formation may occur in gravity-dependent regions without significant thermal damage or adjacent to regions with soft-tissue heat-related contractures. Also, postmortem blisters lack vital reaction.



First- to third-degree thermal burns involving the posterior aspect of the left thigh and gluteal region. The right leg is without thermal burns. First-degree thermal burns in this picture are characterized by the red discoloration without blister formation or skin slippage. Note the areas of collapsed blister formation, which are consistent with a postmortem burn. Sometimes it is difficult to interpret antemortem burns if continued heat causes fluid-filled blisters to collapse and fluid to evaporate. Most fire fatalities succumb from smoke inhalation before extensive burns occur.



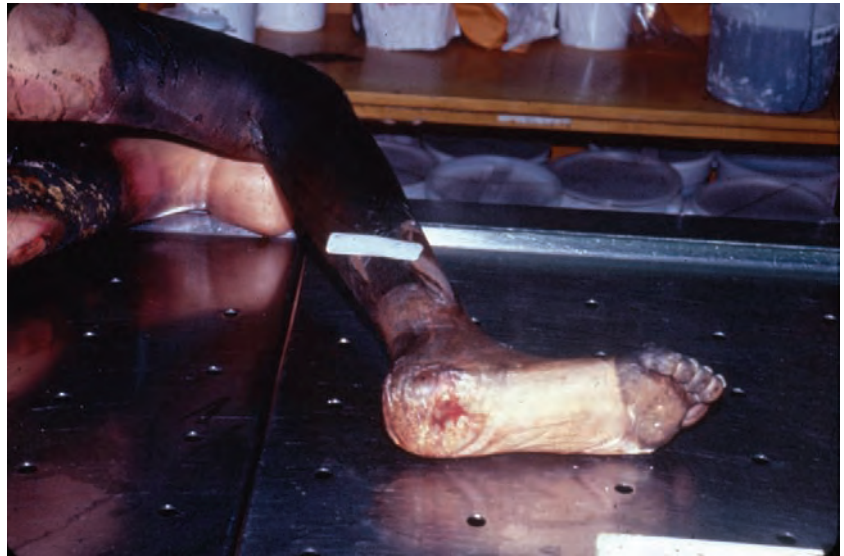Postmortem second- to third-degree thermal burn with skin slippage and collapsed blister formation.



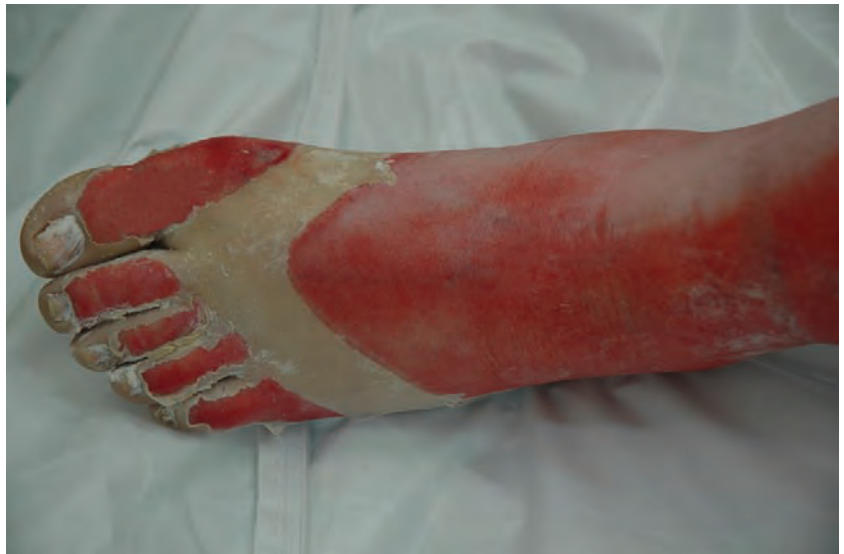Full-thickness or third-degree burns in an individual who lived hours after being shot in the head and having his or her residence set on fire to destroy evidence. Full thickness refers to involvement of the epidermis, dermis, and subcutaneous layers. These are often less painful than second-degree burns due to more complete damage of nerve endings in the latter.



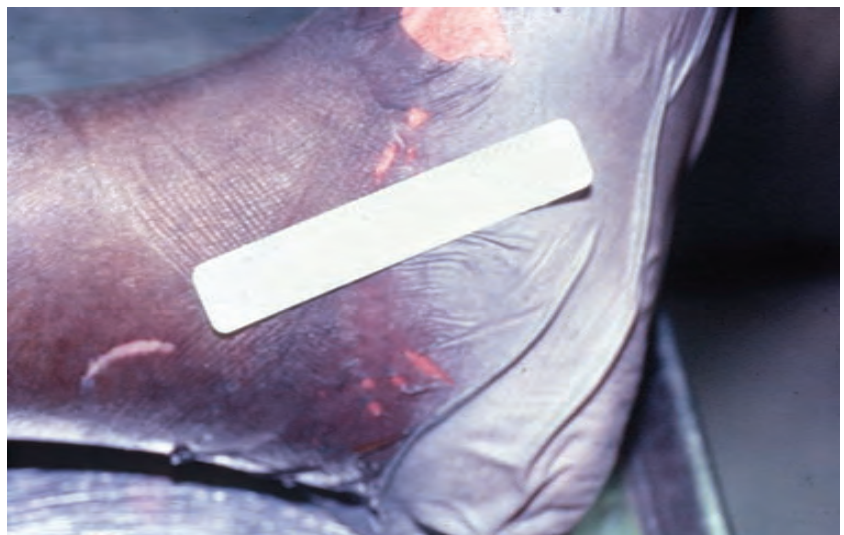
Note the sparing of thermal injury at the bottom of the decedent's foot due to protection by a shoe.

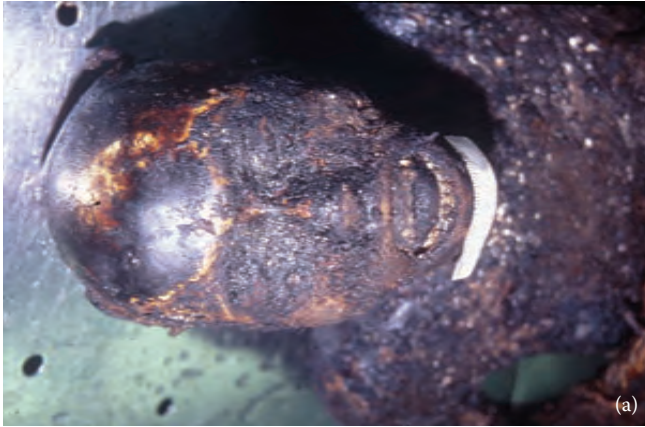

Antemortem third-degree burns. This is self-immolation of an individual who was wearing sandals. Note the lack of thermal injury in the region protected by the shoe strap.



This image demonstrates postmortem second- to third-degree thermal burns to the sole of this foot. Note the wrinkled thick skin demonstrating skin slippage. There was minimal underlying fluid accumulation or blister formation.

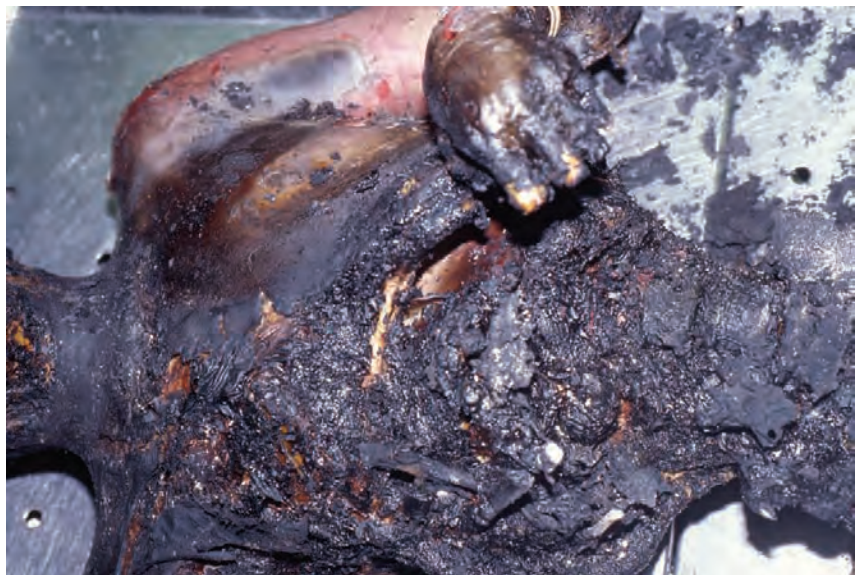




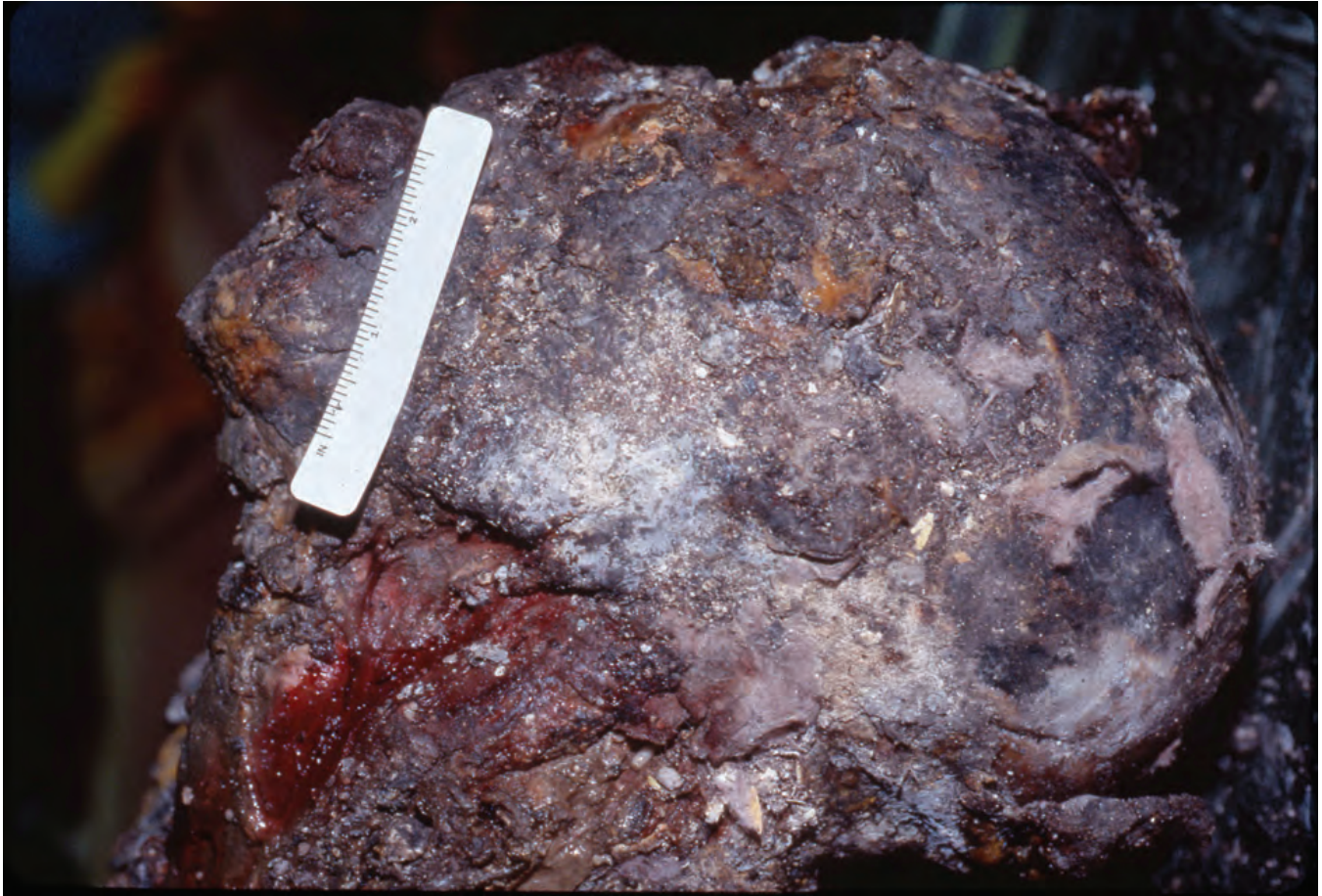Postmortem fourth-degree thermal burns with extensive charring and exposed muscle and bone. Note the pugilistic stance of the body with arms raised (b). Also note the postmortem skeletal fractures due to extensive heat (c).



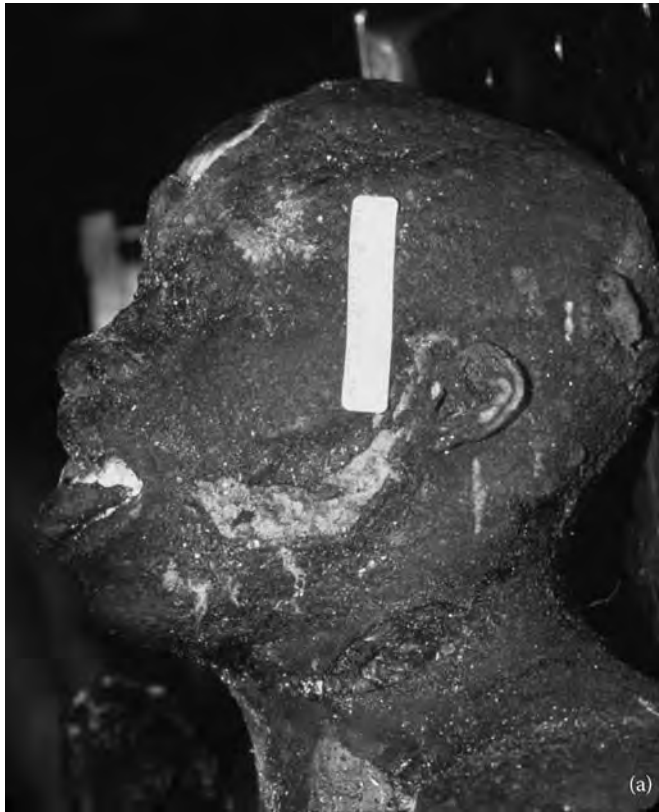

This individual was wheeled out of a building in a shopping cart and set on fire. Note the postmortem cracking of the skin due to heat exposure. This is indicated by the exposed yellow subcutaneous tissue with no hemorrhage. There were extensive fourth-degree thermal burns to the entire body.



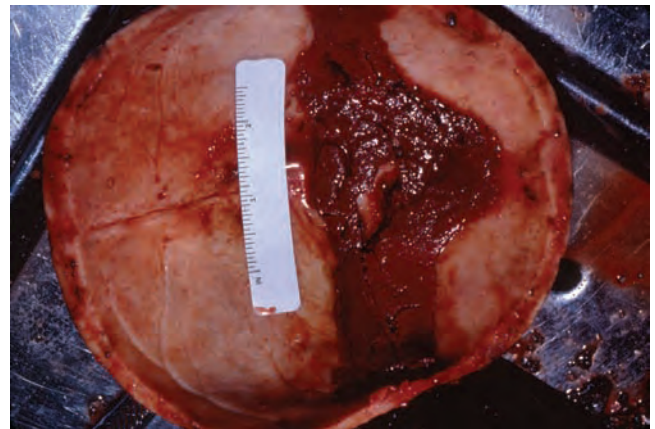
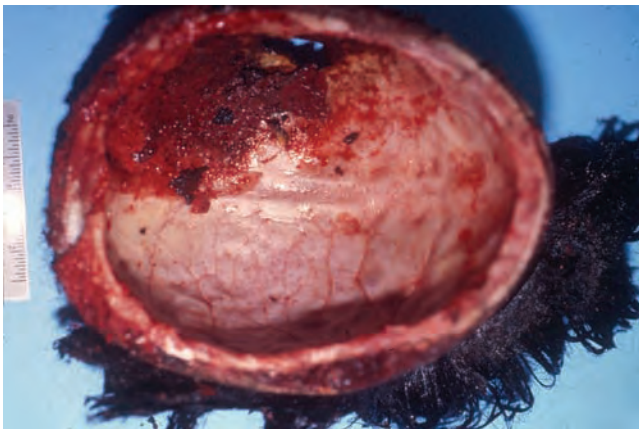
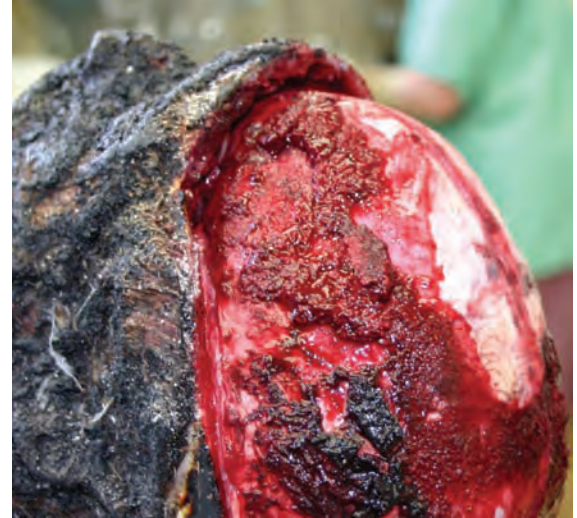Extensive third- to fourth-degree thermal burns with partial skeletal fragmentation due to the wick effect, which refers to a self-perpetuating, low-intensity flame following ignition of certain materials contacting the body, where the skin is cracked from heat and the underlying fatty tissue is rendered into oil that is absorbed into the charred clothing, producing a wick. This low-level heat can produce extensive destruction to a body over hours.



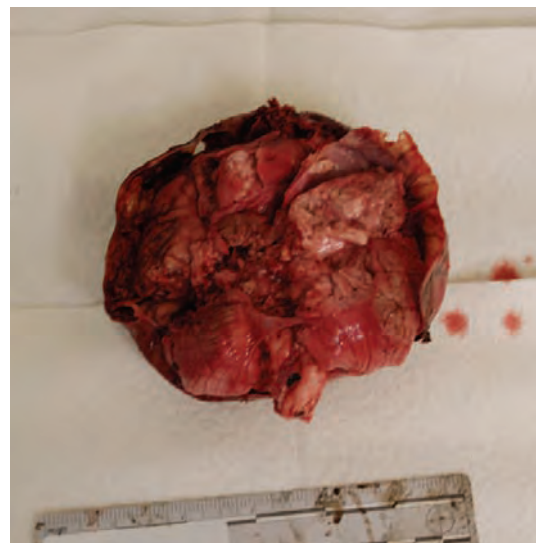
This is a rare finding of decomposition after extensive thermal injury and exposure to smoke. The decedent was involved in a fatal fire and the body was not discovered for several days after being soaked in water following fire extinguishing. Note the microorganisms and mold growing at the body surface shown by the gray-white discoloration. Putrefactive changes were markedly inhibited due to the effects of exposure to smoke and heat.



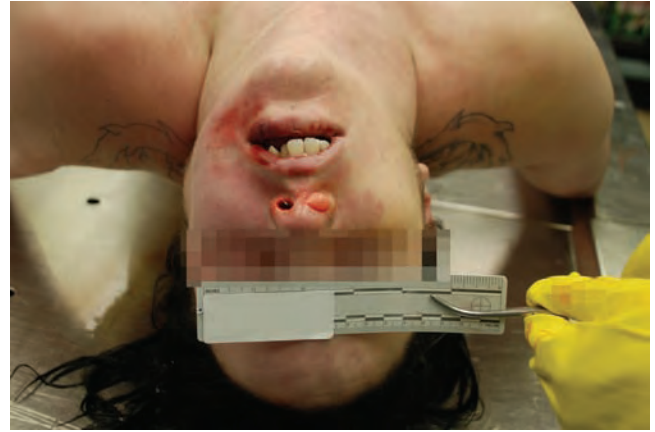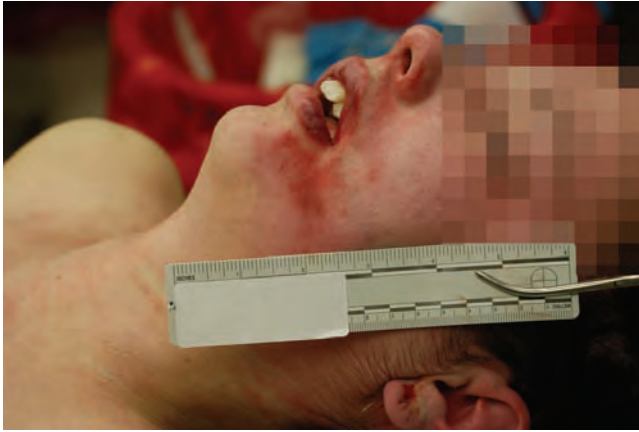These are all examples of homicides where apartments or houses were set on fire to destroy evidence. Figures (b–d) are examples of antemortem stab wounds that have been altered by postmortem thermal burns. Note that the margins are relatively sharp and do not appear as though the skin has cracked secondary to heat exposure. Upon internal examination, these injuries become much more apparent with hemorrhage and blood accumulation. Note in (a) areas of cracked skin with exposed yellow subcutaneous tissue without hemorrhage, which is indicative of postmortem thermal injuries. Note the wound at the upper aspect of the lateral left neck with hemorrhage due to an antemortem stab wound.



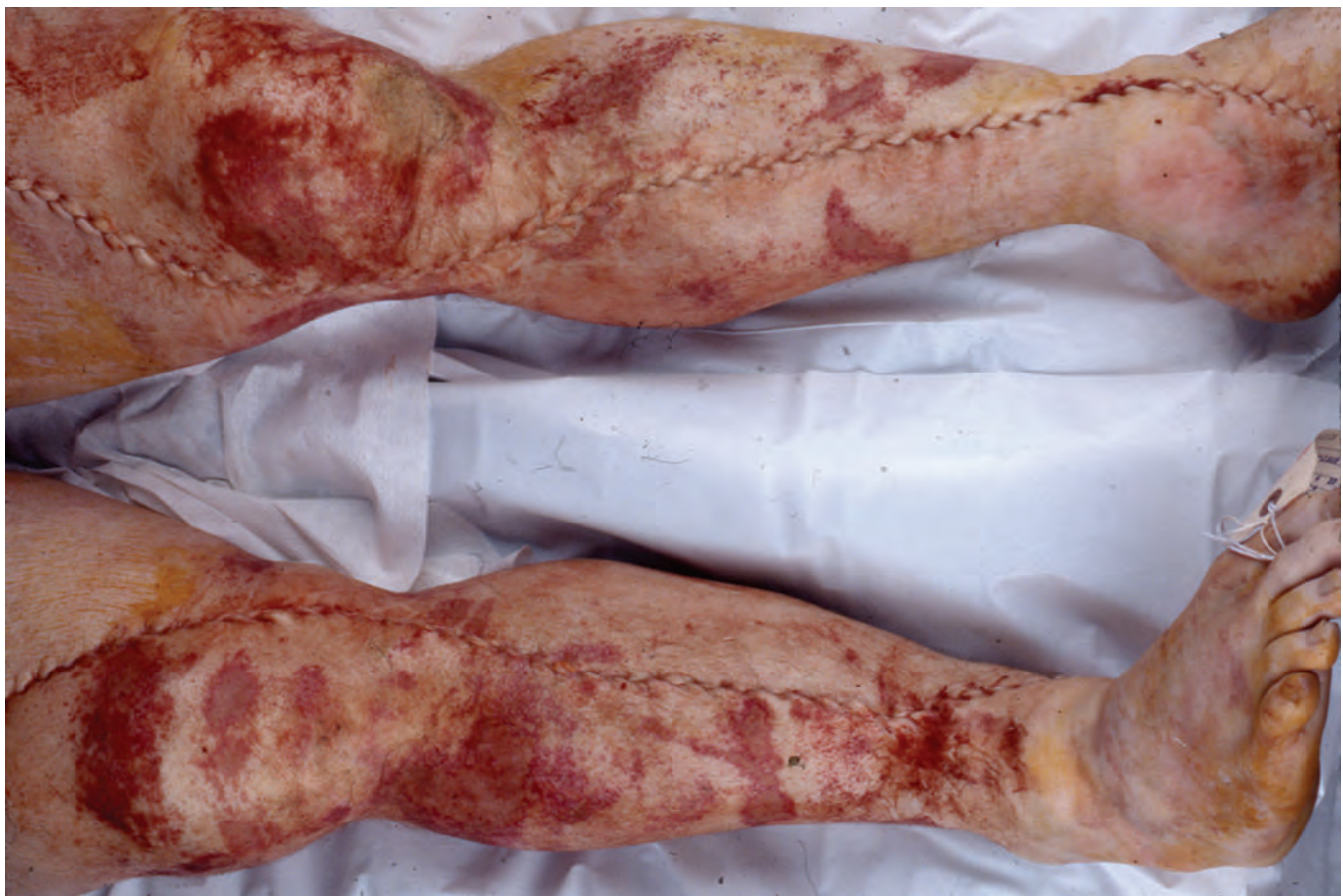These figures demonstrate postmortem epidural hemorrhage. These can sometimes be misinterpreted as antemortem blunt force trauma. With exposure to flames, the brain and dura mater may contract, and blood may be forced from the small vessels at the inner aspect of the cranial bone and through the dural sinuses, producing epidural blood accumulation that will coagulate with heat.



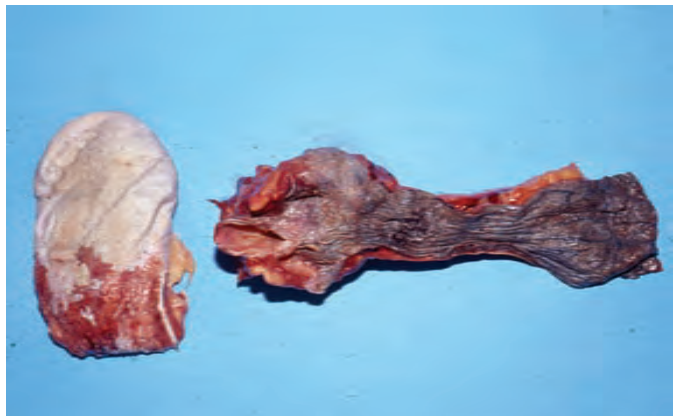
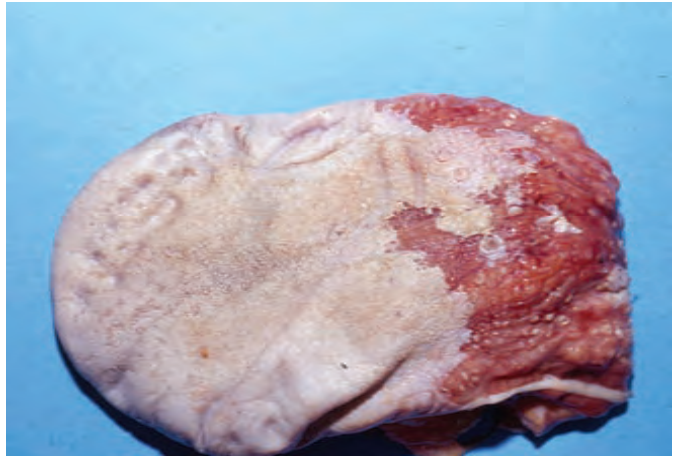
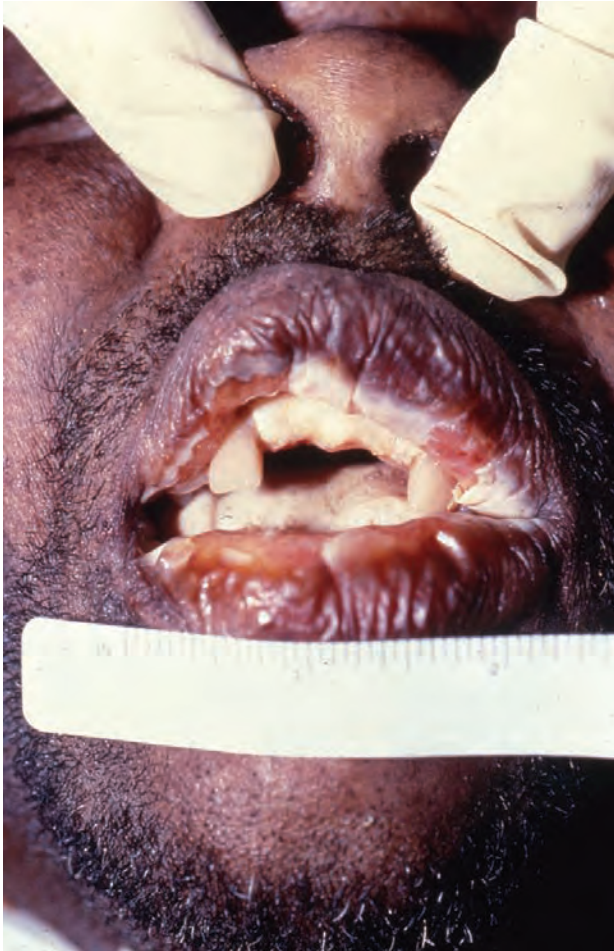Extensive postmortem thermal injury with brain shrinkage. Organs exposed to extensive heat will decrease in size largely due to dehydration.



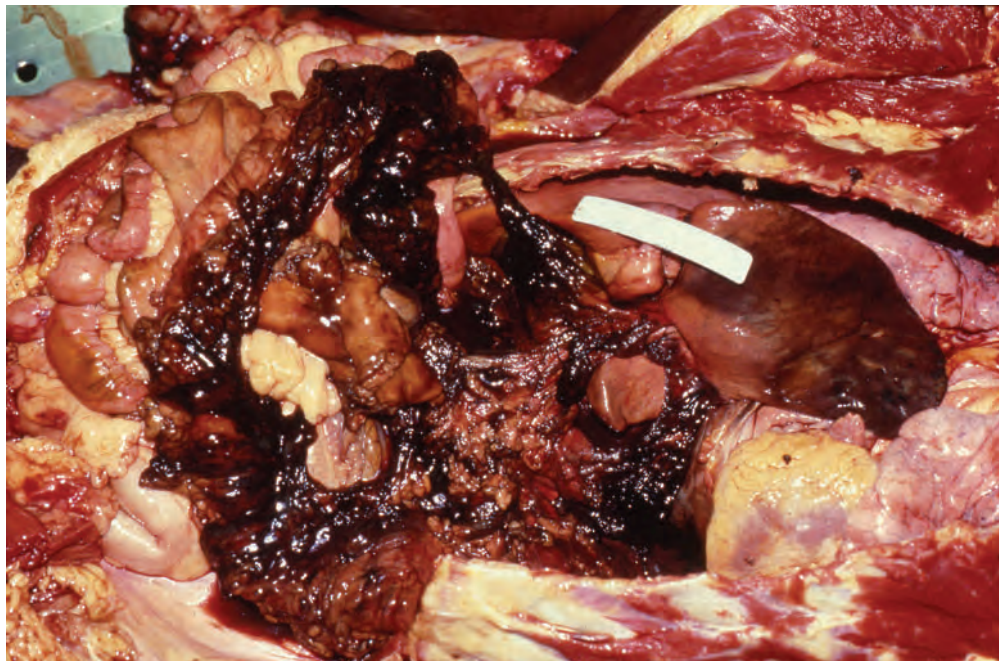
This individual died of an overdose and was found with dried vomitus on her face. Note the red discoloration caused by gastric acids producing burns to her face.



Chemical skin burns caused by spilling sulfuric acid. The sutured linear incisions are due to organ donation with retrieval of bone and soft tissues.

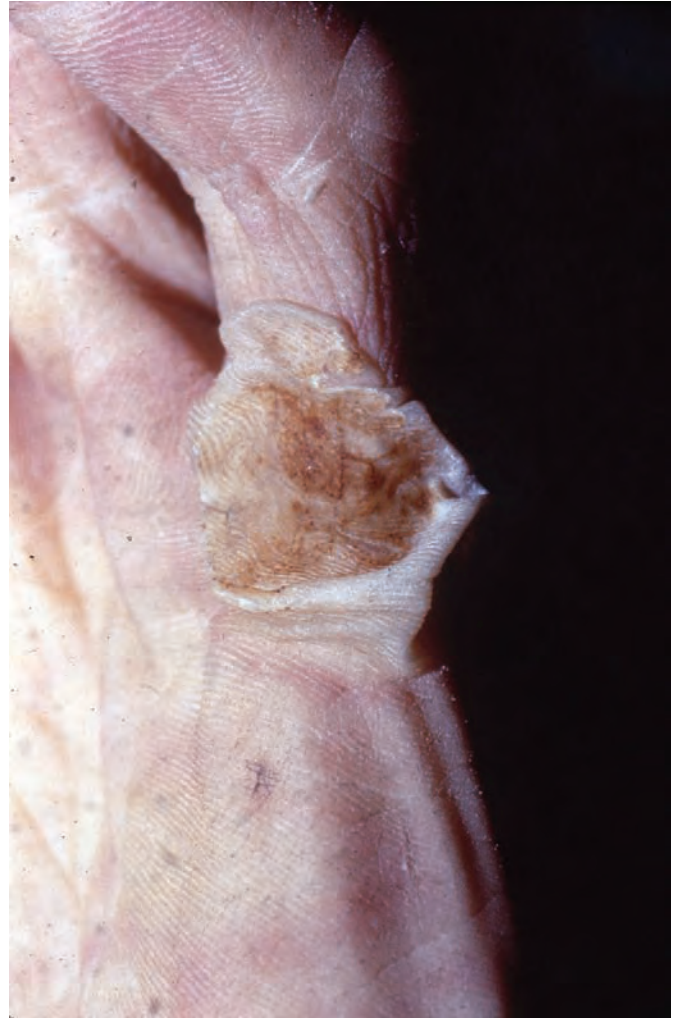
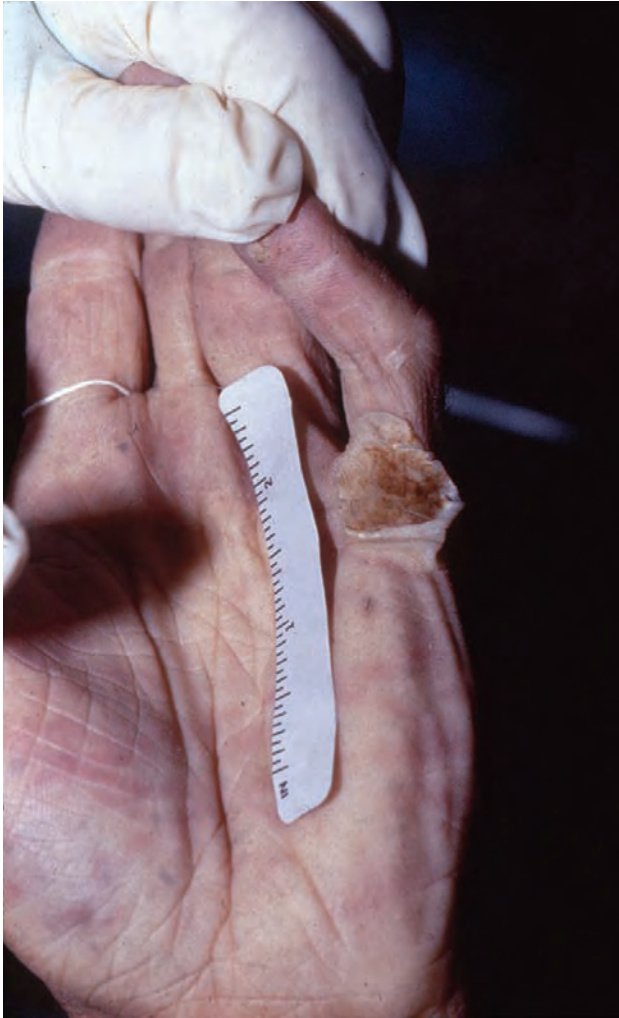
This individual drank a mixture of lye, kerosene and other caustic chemicals. Note the white discoloration from chemical burns at the lips, mouth, tongue, and esophagus.

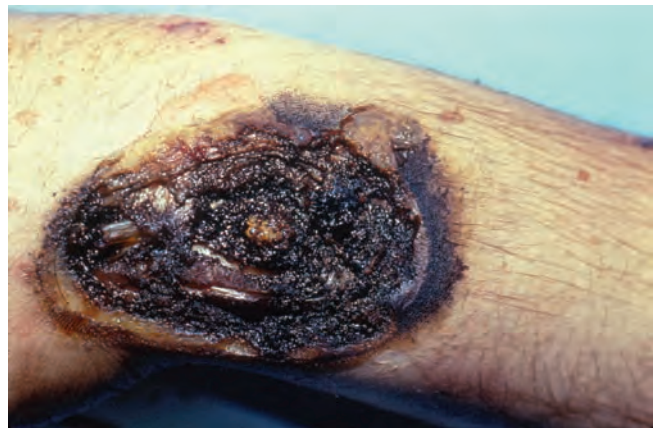
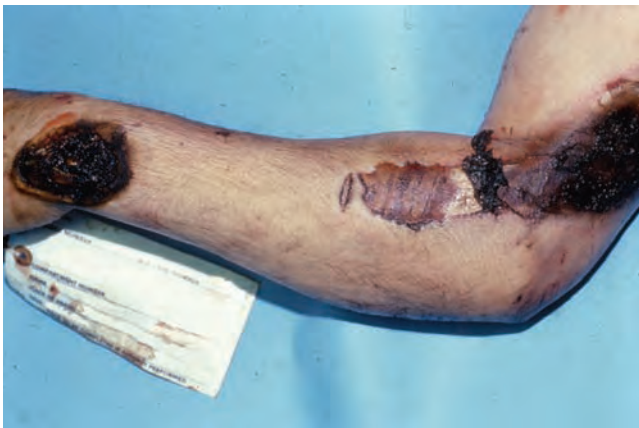
Note the red to brown discoloration in the abdominal cavity following gastric perforation and leakage of the caustic chemicals into the peritoneal cavity.

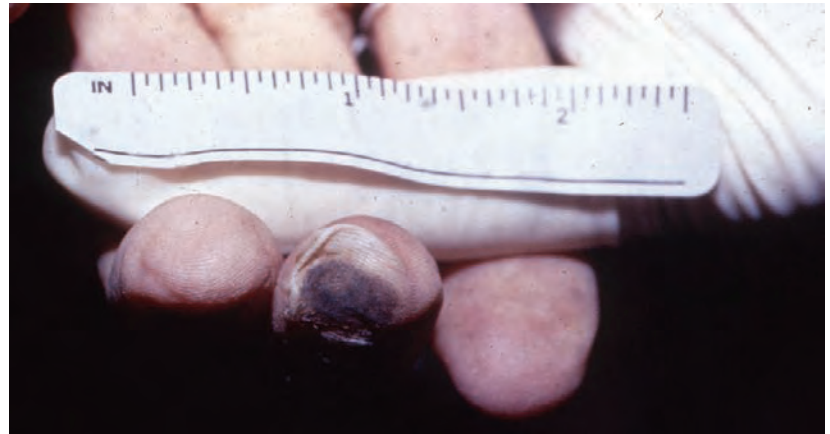
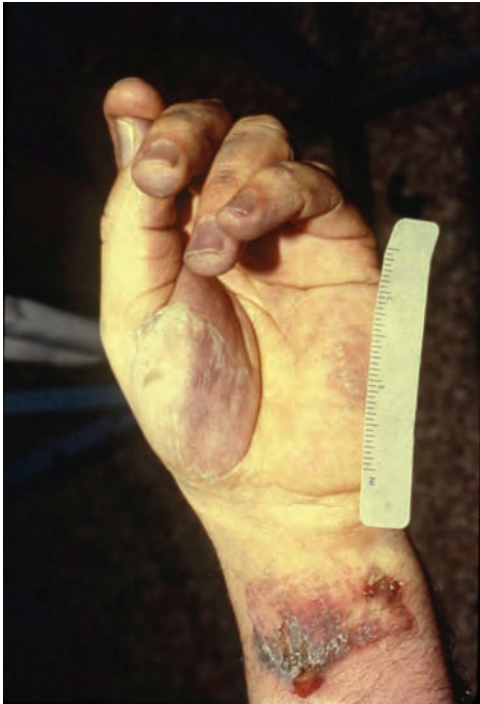


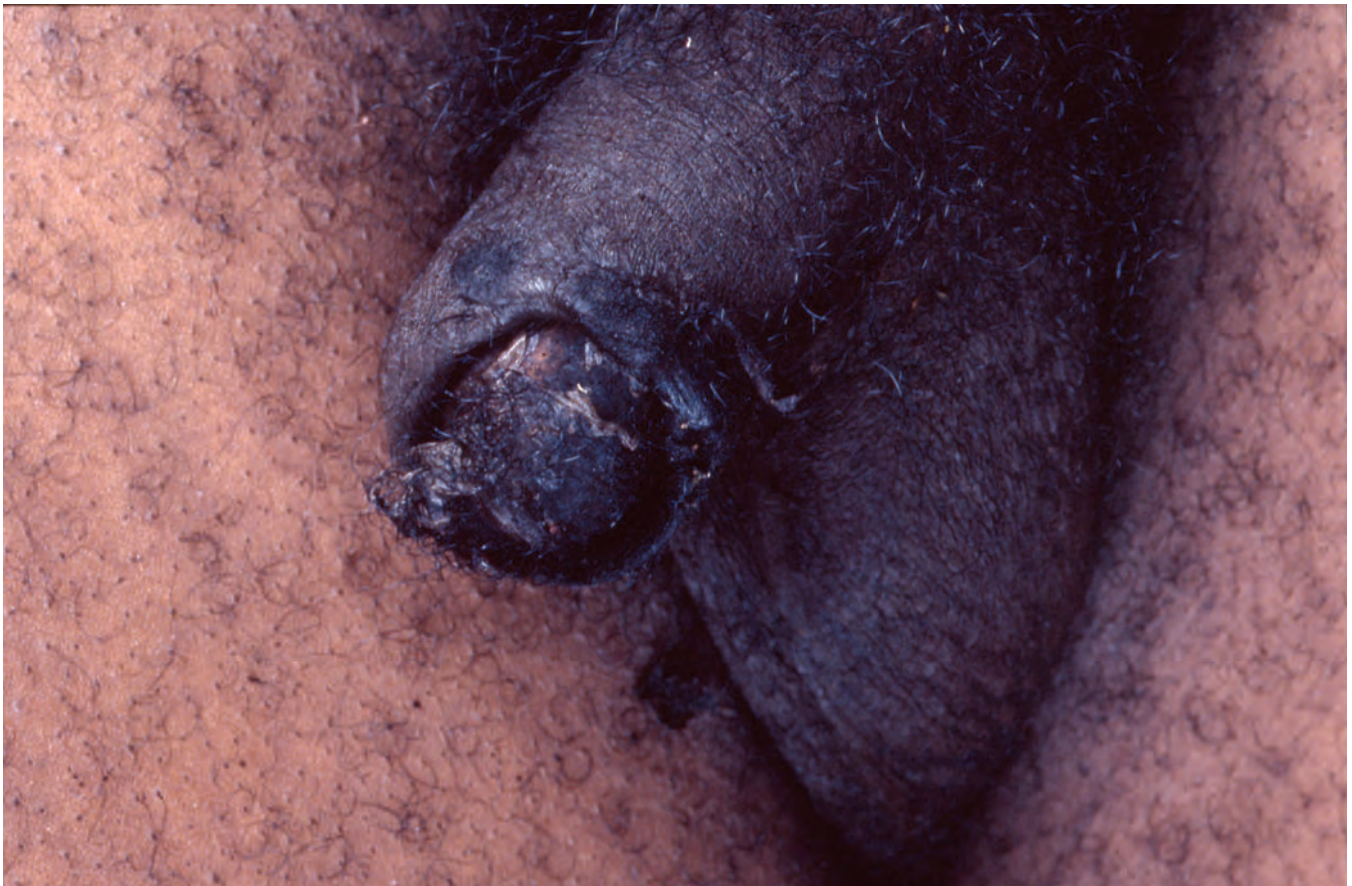Electrical burn on the hand of this individual who reached into a ceiling and grabbed a live wire. He was standing on an aluminum ladder wearing shorts. His leg contacting the ladder completed the circuit through his heart, producing a fatal arrhythmia.



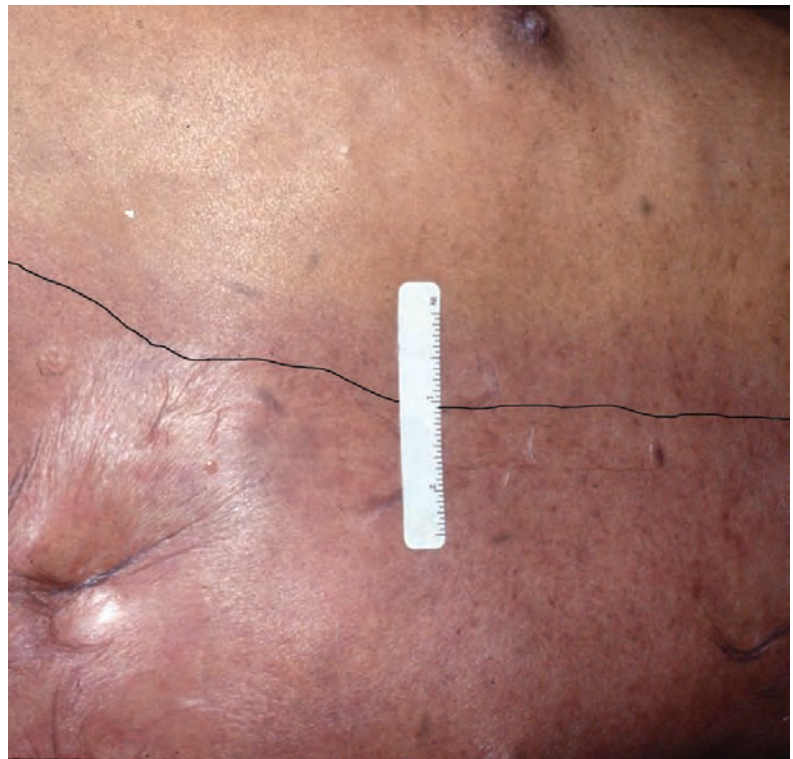
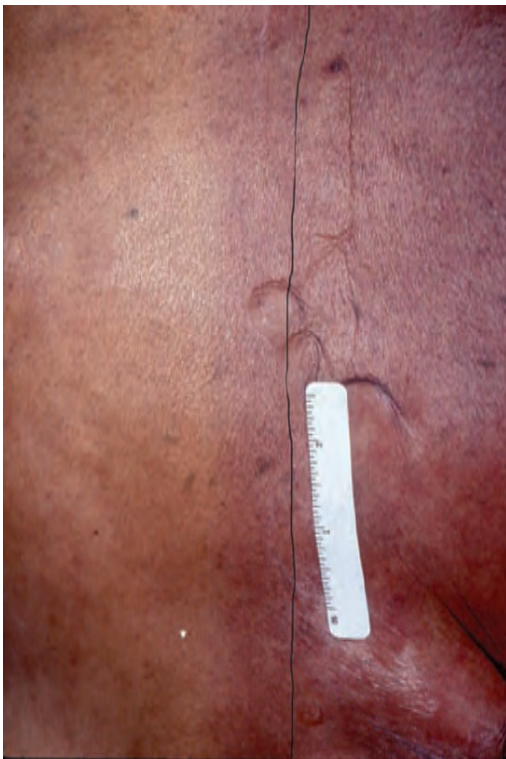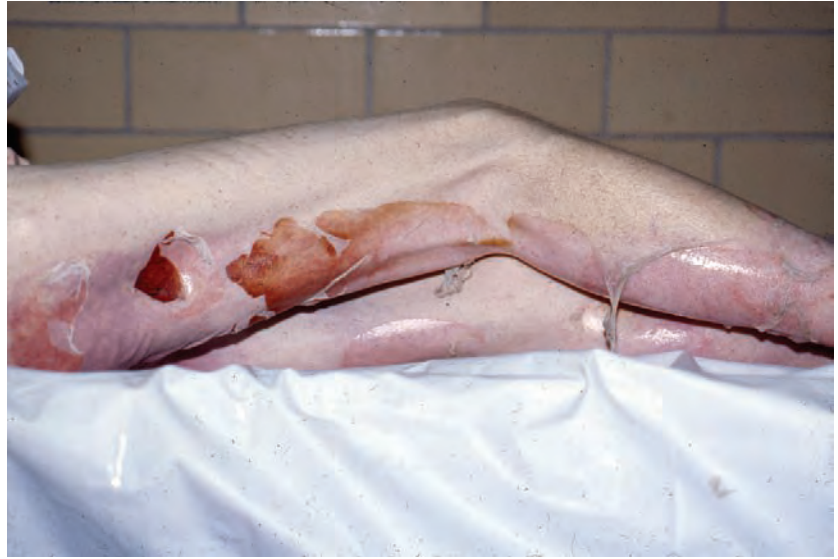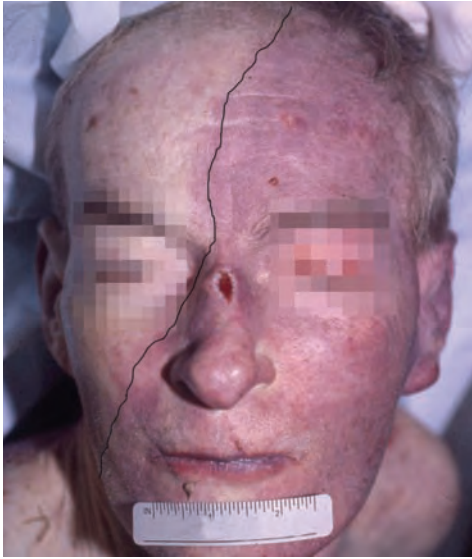This individual fell from a subway platform onto the third rail and sustained these electrical burns.



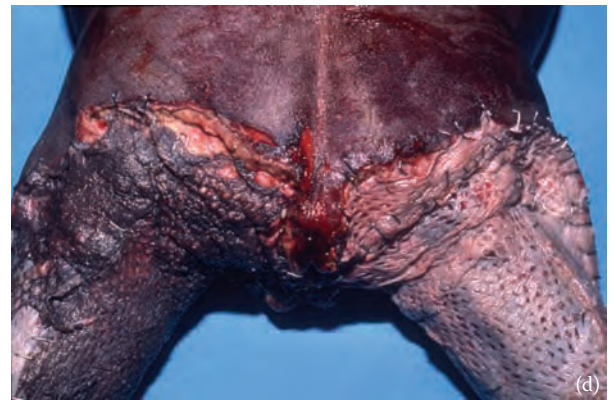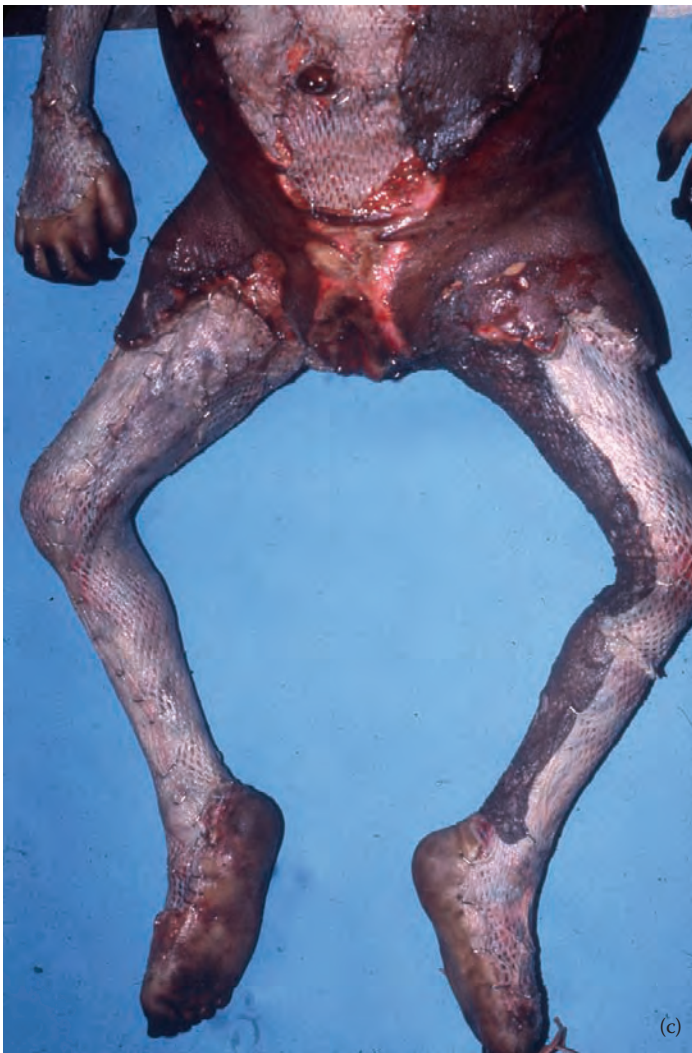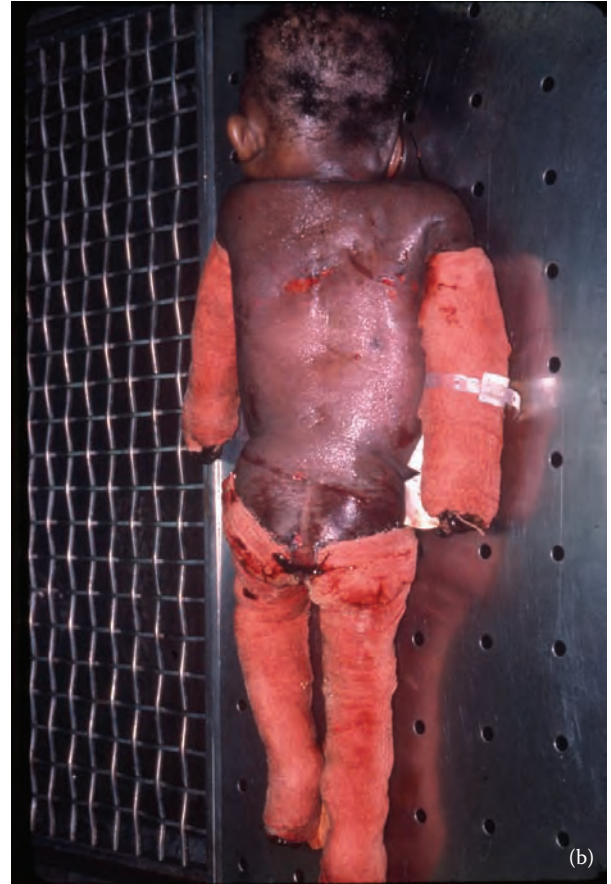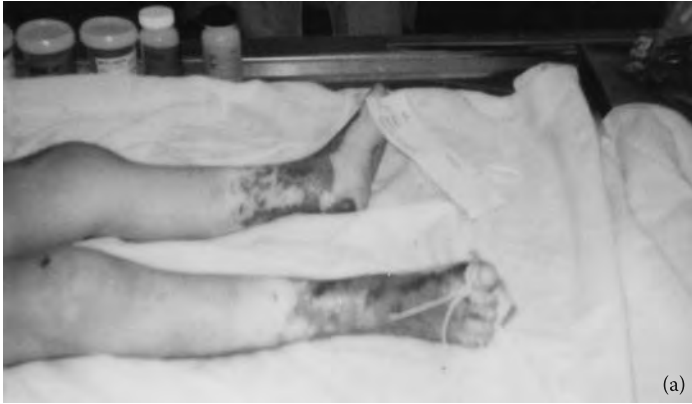These are examples of second- to third-degree electrical burns caused by inadvertently contacting live wires at construction sites. These individuals died as a result of a fatal cardiac arrhythmia. They fell to the ground lifeless within about 15 to 20 seconds after contact.



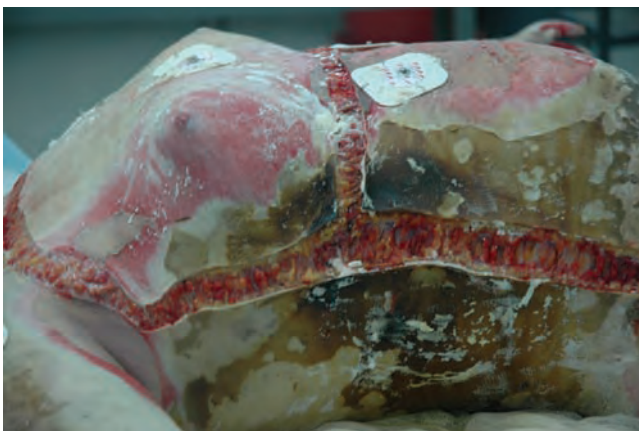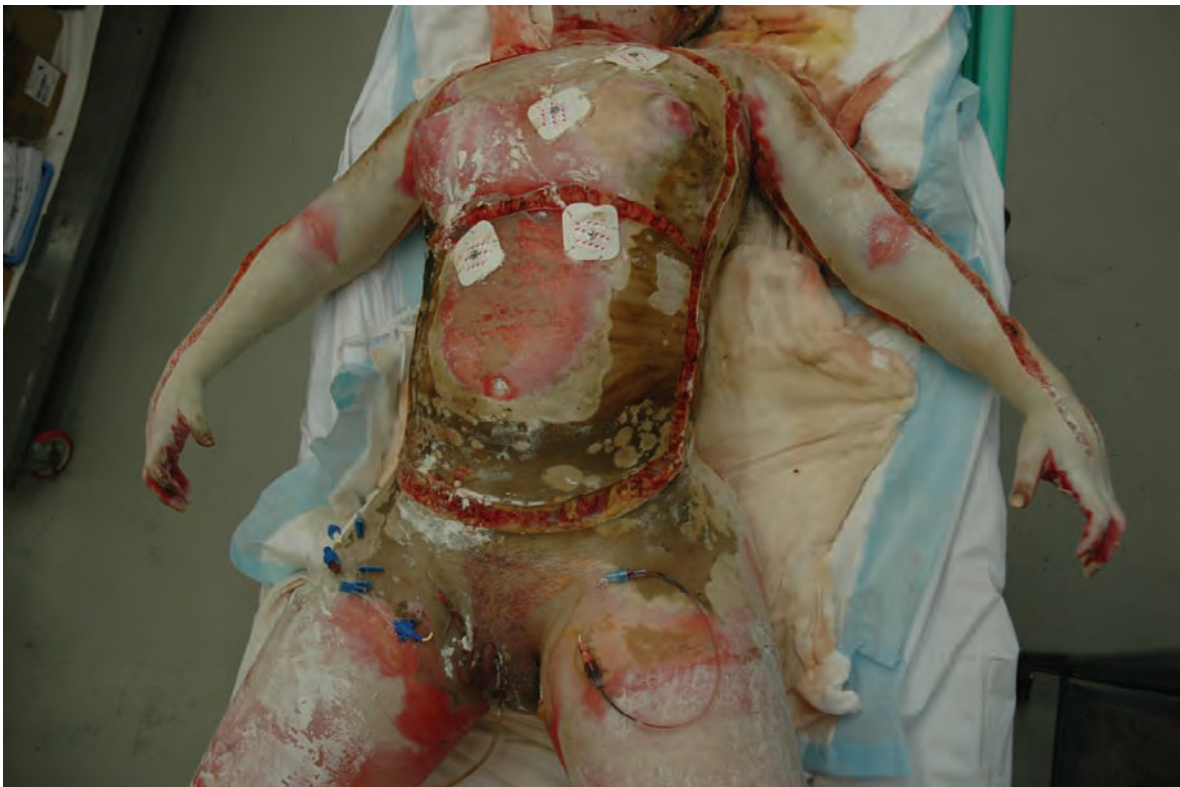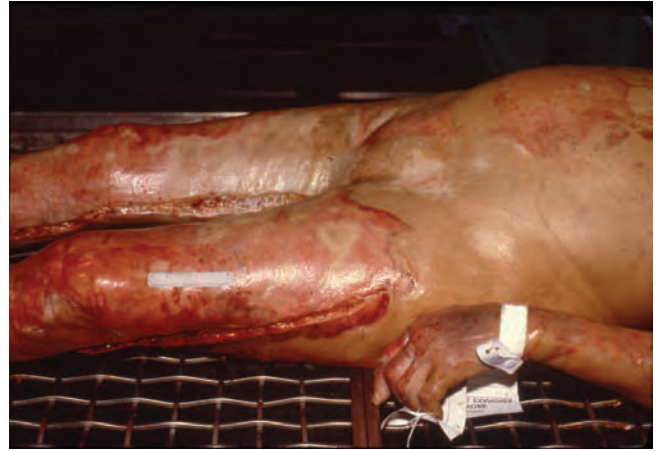
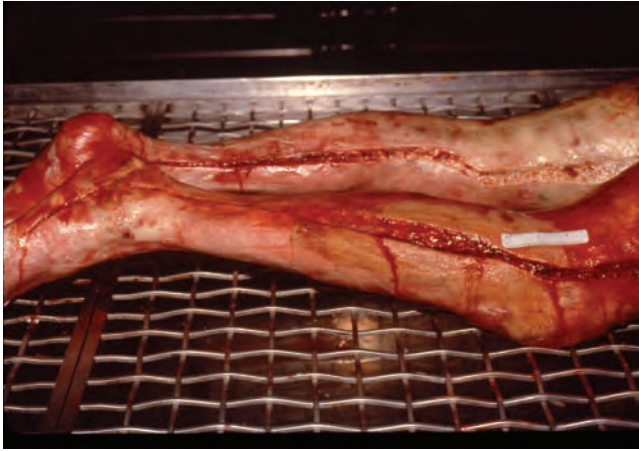
This individual was found lying next to an electrified subway rail with his pants down, and an electrical burn to his penis. He was lying in a puddle of urine and was markedly intoxicated at the time of his death.



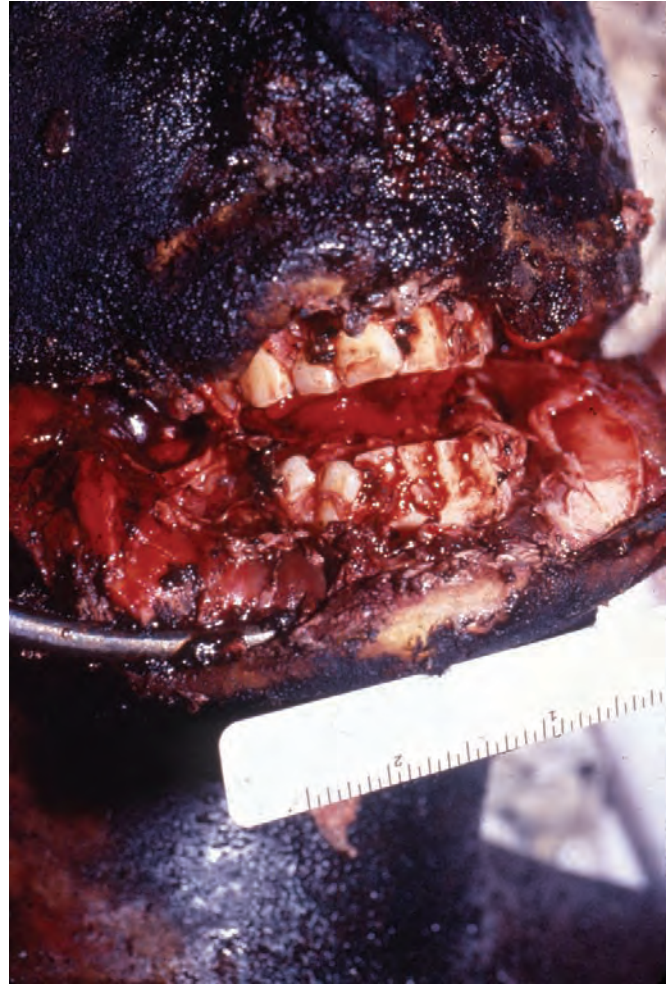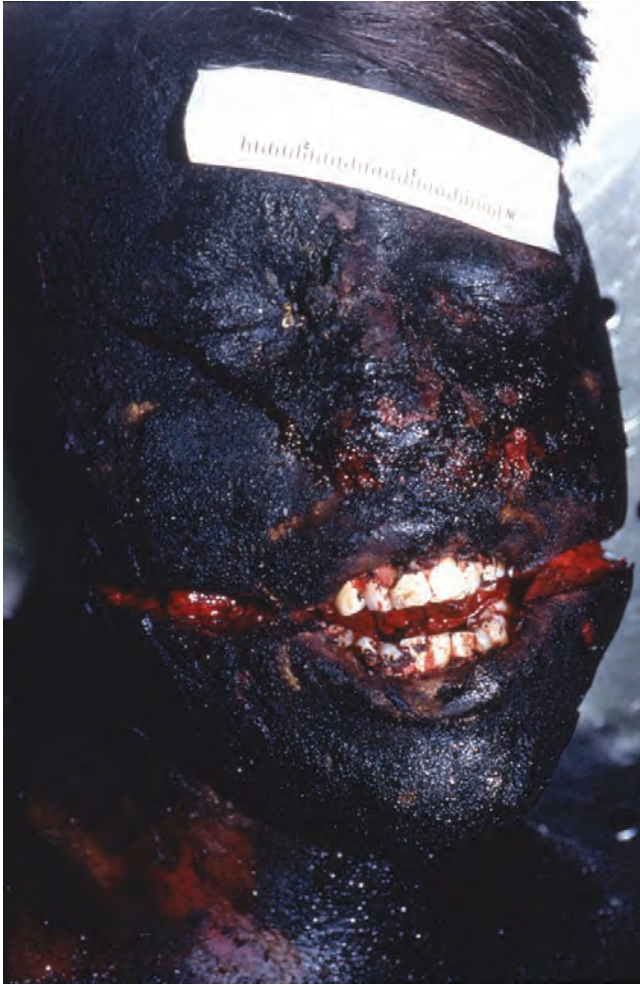These individuals died of heart disease while taking a bath. These are examples of second- to third-degree postmortem burns due to being submerged in warm to hot water. Postmortem burns occur with less heat than antemortem burns. Note the red discoloration with skin slippage and a sharply demarcated border defining the submerged and unsubmerged areas. To help the viewer distinguish between these regions we placed a line adjacent to this demarcation. Individuals who drown in bathtubs have some contributing factor dictating why they could not keep their head above the water. They maybe neurologically compromised or intoxicated. People with seizures may accidentally drown.



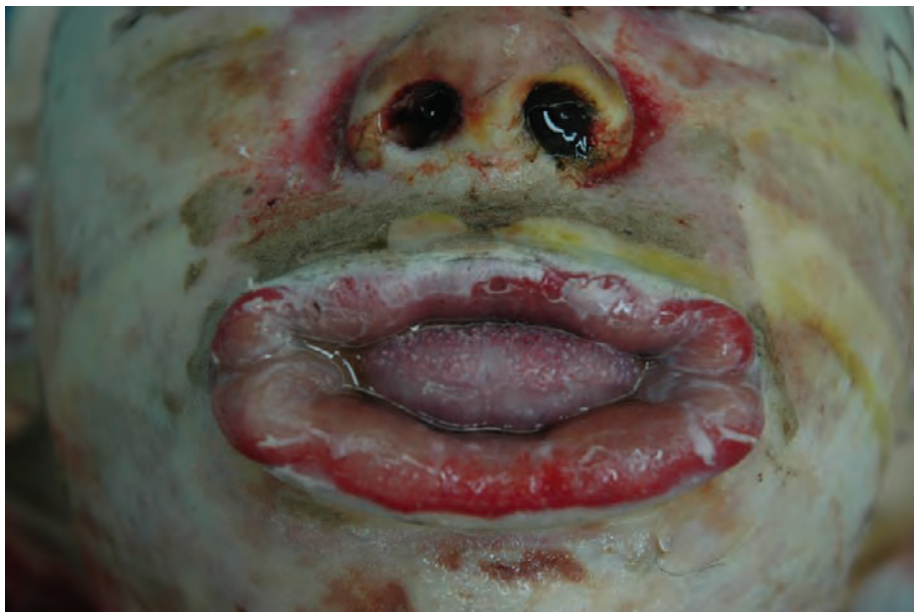Child abuse cases with homicidal scalding. Image (a) demonstrates second- to third-degree burns to both feet and ankles from repeatedly being dunked in hot water. Images (b–d) show skin grafting with therapeutic intervention in a child with fourth-degree burns who was left sitting in scalding water.



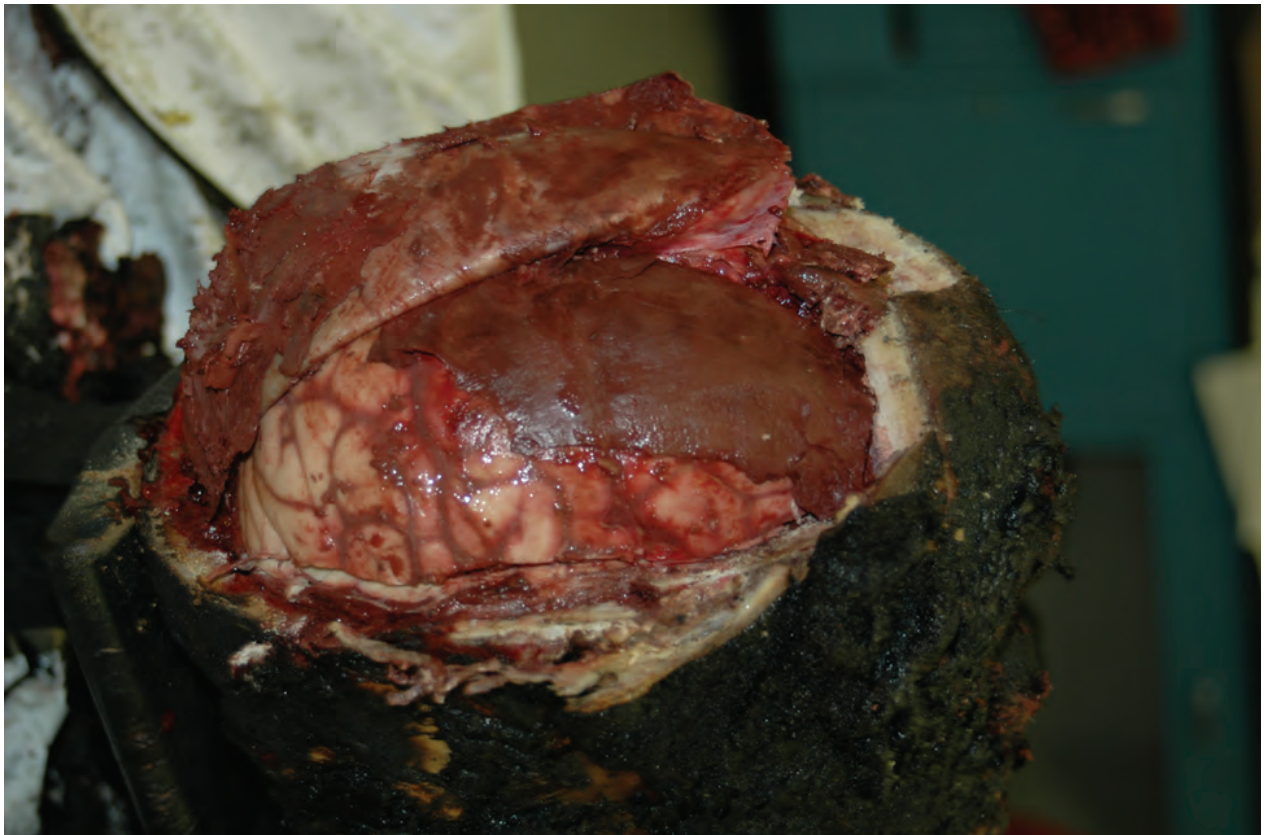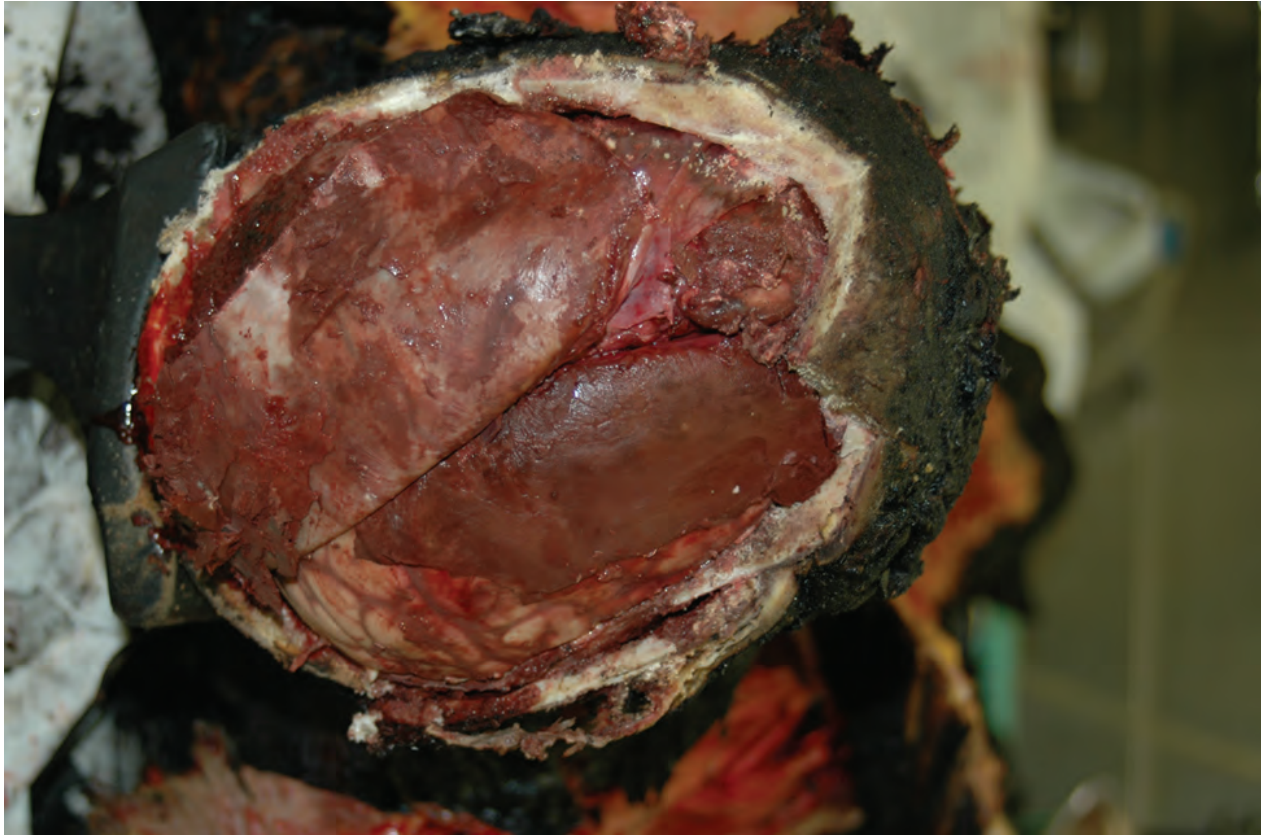
These are fasciotomy incisions made by physicians for medical therapy to relieve pressure in extremities.



Identifications may be very challenging in fire fatalities. These cases may require dental analysis for identification. Incisions may be made in the face to access the teeth. Funerals in such cases are closed casket due to the severe extensive nature of the injuries.



Swelling of the tongue due to inhaling super heated gases in an individual who survived for 1 day.



This individual crashed an airplane and sustained extensive blunt force trauma. These images demonstrate an antemortem subdural hematoma altered by extensive postmortem thermal injuries.

This is a general term used to describe decreased oxygen uptake or use, together with decreased carbon dioxide elimination.

**Airway obstruction** may occur by smothering, neck compression, foreign body aspiration, excess secretions or swelling of the airway, etc. *Smothering* is defined as external occlusion of the mouth and/or nose which prevents air exchange. Children may *aspirate foreign bodies* such as peanuts, hotdogs, popcorn, watch batteries, coins, etc. Adults who aspirate food are invariably neurologically compromised or intoxicated. Airway obstruction due to *excess mucus or swelling* as with asthma or anaphylaxis can produce asphyxia. Also various body positions may produce airway obstruction (*positional asphyxia*) as with occupants of motor vehicles trapped after collisions or intoxicated people passing out and sliding into awkward positions that prevent chest expansion and air exchange.

Autopsy findings associated with *smothering* may be very subtle or non-existent. Findings may include abrasions around the nose and/or mouth that *cannot* be explained by other means (i.e., resuscitative efforts). Great force is applied to the mouth and lips which may cause tears to the frenulum of the lip, the mucous membrane that connects the inside of the lip to the corresponding gum. Smothering may occur with the use of hands or by placing an object over a face, such as a pillow.

Depending on the degree of force applied and the structures compressed, there may or may not be petechiae present on the skin of the face, mucous membranes or eyes. Arguably, the greater the disparity in size between the perpetrator and the victim (i.e., adult and child), the less likely there will be a demonstrable injury due to the overpowering relative nature of this type of struggle. It is important that in cases of suspected smothering, experienced police interrogators and medical investigators perform the interviews. In cases where autopsy findings are very subtle, well-documented descriptions of the circumstances with specific details are extremely important.

**Chemicals** can produce asphyxia. *Inert gases* like methane or carbon dioxide will displace oxygen from the air and produce asphyxia by depletion or replacement of oxygen. Various *poisons* such as carbon monoxide or cyanide interfere with oxygen uptake and utilization, respectively.

**Chest compression** can produce asphyxia by *preventing air flow* into the lungs.

**Neck compression** as with *hanging and strangulation* can also produce asphyxia by obstruction of various neck structures including the airway, venous circulation and arterial circulation.

Interpretation of autopsy findings with respect to *hanging vs. strangulation* can be challenging. Each subheading below will describe the presenting classic and most common features, and then elaborate on less common features. It is important to realize that there is overlap between how the two present; depending on how the act is carried out, they may appear very similar. In establishing the manner of death, one should consider all aspects of the case including the past medical history (i.e., depression, end stage cancer, etc.), scene investigation and autopsy findings.

**Hanging** refers to ligature compression of the neck mitigated by the gravitational forces of the hanging head, causing partial or complete obstruction of the neck structures including blood vessels and the airway.

In a typical non-judicial suicidal hanging an individual places a ligature with a slip knot encircling the superior aspect of his or her neck. He or she secures the other end of the rope to a fixed support and allows the entire or partial body weight to pull downward, occluding the neck structures until loss of consciousness and death. In this case there should be furrow pattern that matches the overlying ligature which forms an inverted “v” mark or indentation, extending upward at the superior aspect of the neck and head. With the entire body weight pulling downward, all of the neck structures are (i.e., arterial, venous, and airway) are usually occluded at the same time and one would not expect to find petechiae in the face or eyes. There are typically no hemorrhages or fractures of the neck structures or other injuries to the body indicating a struggle. The cervical vertebrae are rarely fractured in suicidal hangings. When the body hangs for longer periods of time the furrow indentation becomes more prominent. Individuals cut down shortly after this act may have little or no furrow mark. This depends on the type of ligature used. A wide soft ligature will leave less of a mark than a narrow, more resistant ligature. If the body is left to hang for days, decomposition with stretching may eventually lead to the head being pulled away from the body.



In the case of a judicial hanging, the body is dropped from a height to produce sufficient force to fracture the upper cervical vertebrae resulting in spinal cord injury with cardiac and respiratory saturation.

An individual hanging in a sitting or lying position may have partial occlusion of the neck structures before loss of consciousness ensues. In situations where the body is adjacent to another structure, the individual may partially pull his or her body up and down, causing varying degrees of pressure–release before loss of consciousness. This will produce a similar effect to what is seen in strangulation. In these circumstances, the up and down motion of pressure release will obstruct different neck structures at different intervals. Venous circulation requires the least amount of pressure for occlusion, as compared to the arterial system and the airway. When venous circulation is obstructed without the arterial circulation, the higher pressure arterial blood beats through the capillary beds rupturing small blood vessels producing petechiae. As this process continues the hemorrhage size increases and may become confluent. These are most obvious within the sclera and conjunctivae. These movements may also produce hemorrhages or fractures to the neck structures including the airway cartilages and hyoid bone. These findings are more characteristic for strangulation, but may be seen in hangings.

Though unusual, people have been known to tie their hands behind their backs during the process of hanging themselves. The individual may have tried to complete this act several times in the past but the will to survive overpowered the will to end life. The tied hands are usually loosely tangled and not tightly tied. This will give the individual enough time to prevent himself from stopping the process. There are usually no other signs of a struggle or defensive type injuries.

With a free hanging and total body weight suspension, an otherwise healthy individual, using a slip knot, would be expected to lose consciousness within 15 to 20 seconds, and suffer irreversible brain damage within 4 to 6 minutes.

Hanging is usually suicidal, but may be accidental or homicidal.

**Strangulation** may be by ligature or manual. A *ligature* is something flexible that can encircle the neck, like a cord, belt or piece of clothing, etc. *Manual* strangulation refers to the use of one's hands leading to compression and blockage of the neck structures.

Manual strangulation is usually characterized by multiple irregular, angulated, abraded contusions around the neck. The marks may be curvilinear, corresponding to fingernail prints. These external marks

can be somewhat variable and can range from a few to many.

Ligature strangulation is usually characterized by a horizontal furrow or mark pattern around the neck. The extent of these injuries depends on the type of ligature, how broad and soft it is, and the amount of struggle, etc.

The act of strangulation is often a very physically dominating, often non-premeditated, way of killing somebody. This act takes time and comes with the risk of injury to all those involved. The individual strangled is usually smaller and of weaker strength. Often a sexual component to the assault exists and a rape kit should be performed in all cases of suspected strangulation. Petechiae are usually present in the face and eyes. There are usually hemorrhages in the strap muscles of the neck, and there may be fractures of the laryngeal cartilages and/or hyoid bone. These fractures are more common in older victims because the cartilages are more calcified, brittle and less elastic. Older people may also have osteoporosis. Younger victims or children tend to have more flexible upper airways that often will stretch or collapse rather than fracture. Depending on how great the struggle, the amount of force used, and the type of neck compression, there may or may not be petechiae and/or hemorrhages above the ligature or region of neck compression. The presence of petechiae formation is more likely when there is a pressure–release component associated with a struggle or if less variable force is applied and if the ligature is wide with a large surface area. The presence of petechiae is less common when the force is very strong, consistent, and applied with a small surface area ligature. The latter example is more similar in nature to a hanging. Victims of strangulation often have defensive type injuries including other abrasions and contusions to their body.

It is possible to ligature strangle yourself; it is not possible to manually strangle yourself. If one is able to apply enough force to lose consciousness manually, revival occurs after the pressure is released. Continued force is necessary for death to ensue.

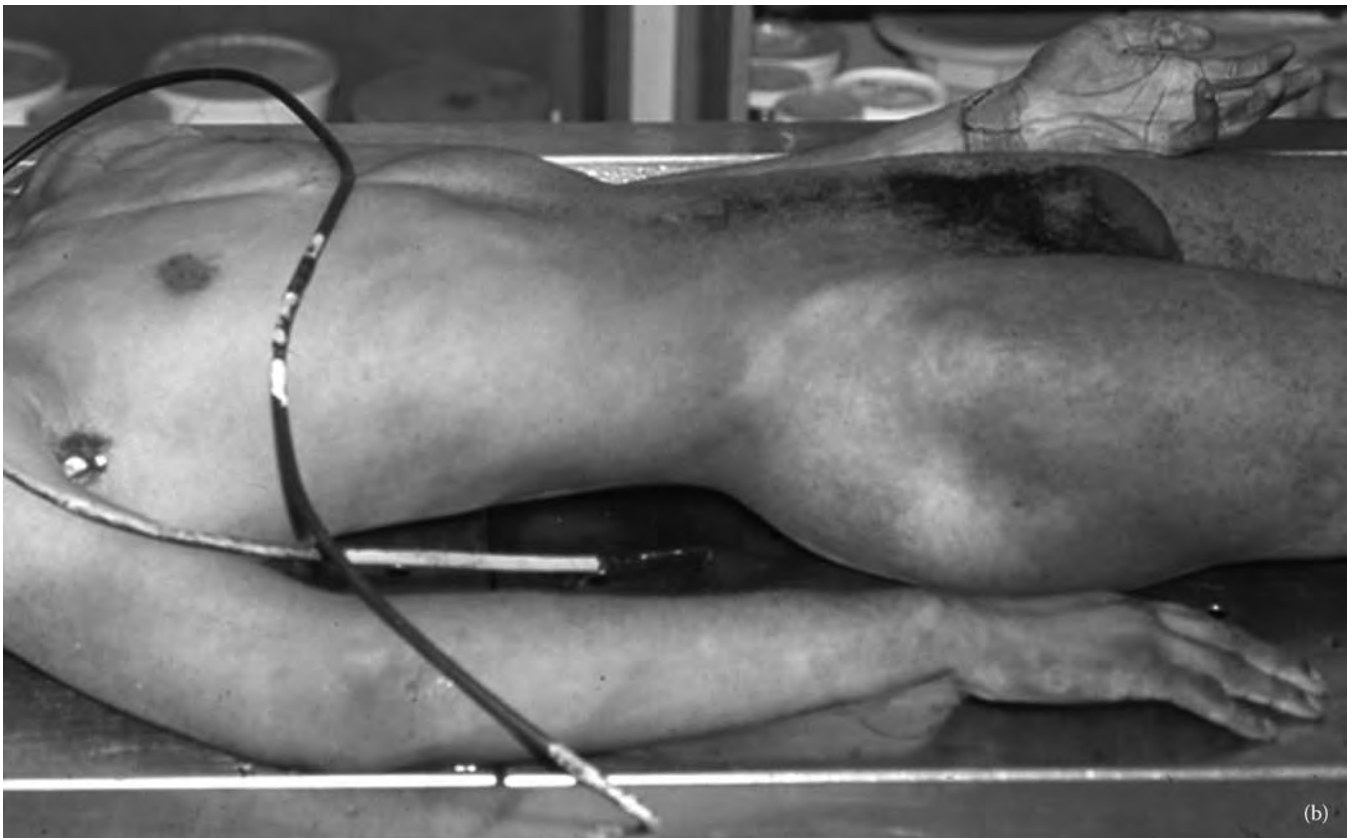
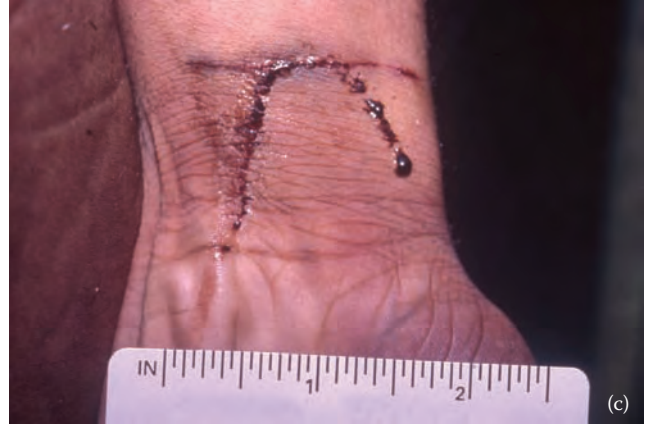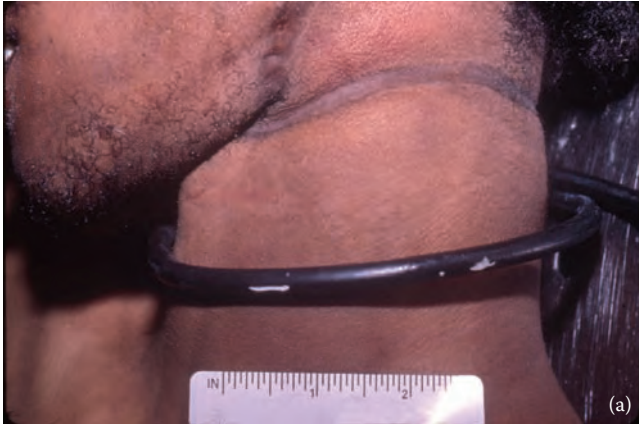Someone murdered by ligature strangulation may die within a similar time frame as someone hanged; however, the time frame is usually longer. If there are multiple petechiae with hemorrhages and fractures of the neck structures, whether ligature or manual, the time frame may be much longer. This latter example usually indicates pressure–release, pressure–release over several minutes until loss of consciousness, and then continued pressure for several more minutes until death occurs. If an individual is released shortly following loss of consciousness, revival may follow.

Proper autopsy technique dictates that the *brain and visceral organs be removed prior to a layered neck*

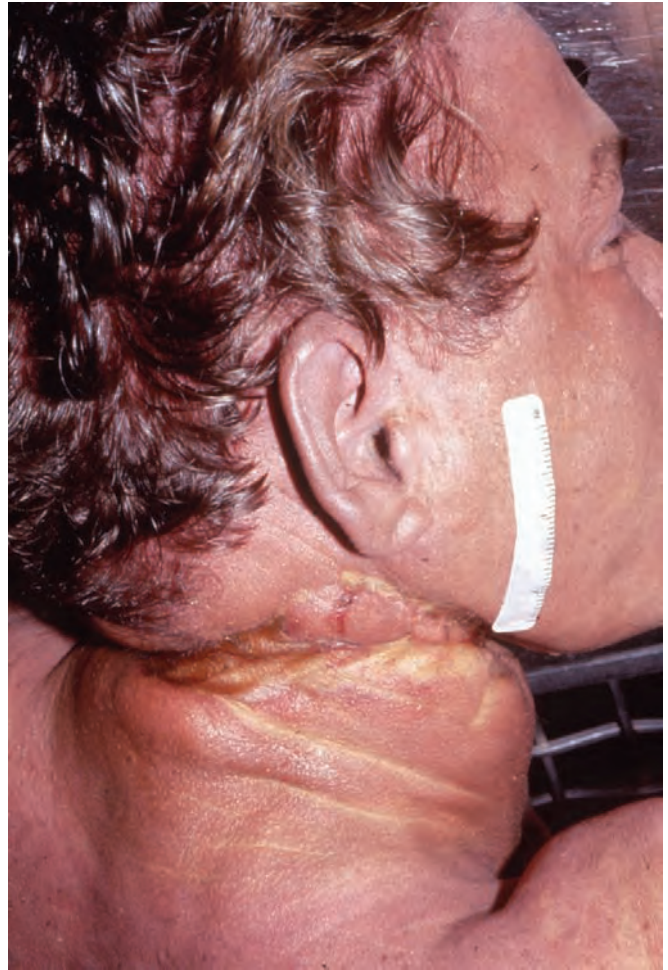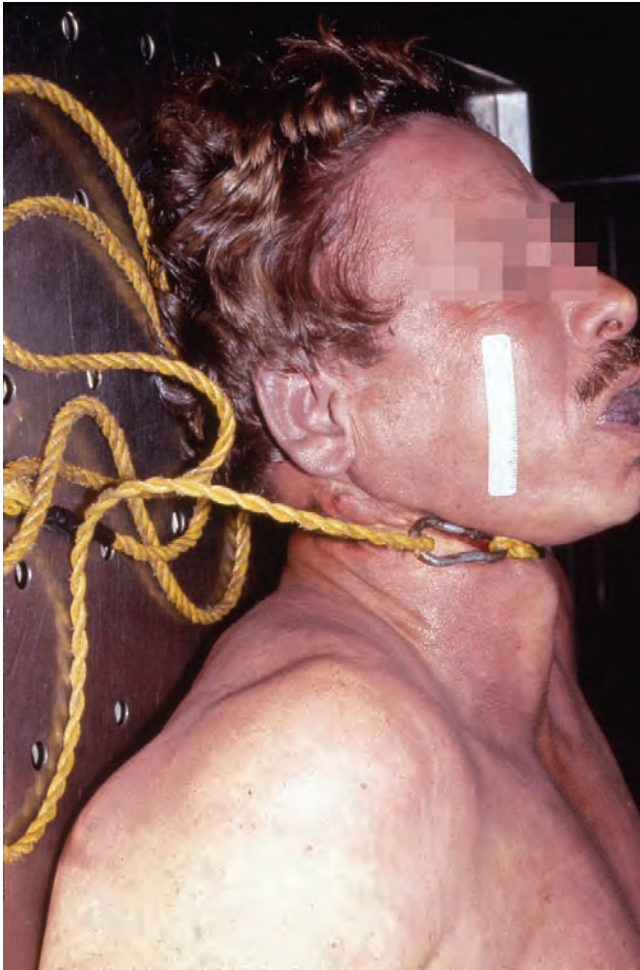*dissection* being performed. Photographs of the neck dissection in layers are recommended.

**Drowning** occurs when water is inhaled, filling up the alveolar spaces and preventing gas exchange. The manner of death will vary depending on how the individual came to be in the water. If the event is not witnessed the manner often remains undetermined. Water in the lungs (pulmonary edema) and the paranasal sinus is often present. The degree of pulmonary edema may vary in a fraction of the cases due to the

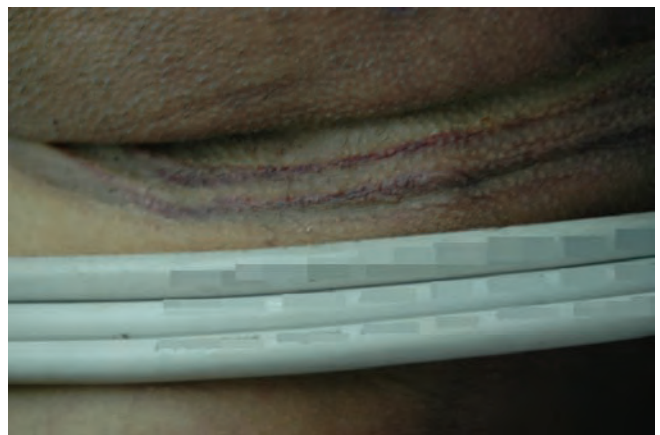
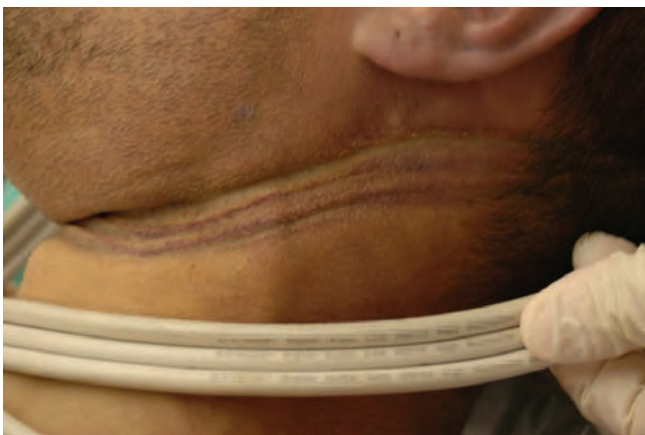heart beating after respirations cease. As the heart beats, before eventual asystole, some of the fluid in the lungs will be absorbed. An adult may drown in a big pool or ocean but not in a small pool or bathtub unless *neurologically compromised or intoxicated*. Homicide victims are sometimes placed in a water-filled *bathtub* to wash away evidence. The story given may be, "I found him in the tub, and he must have drowned." Common sense would dictate that an individual does not need to move very much to get his head above the water.



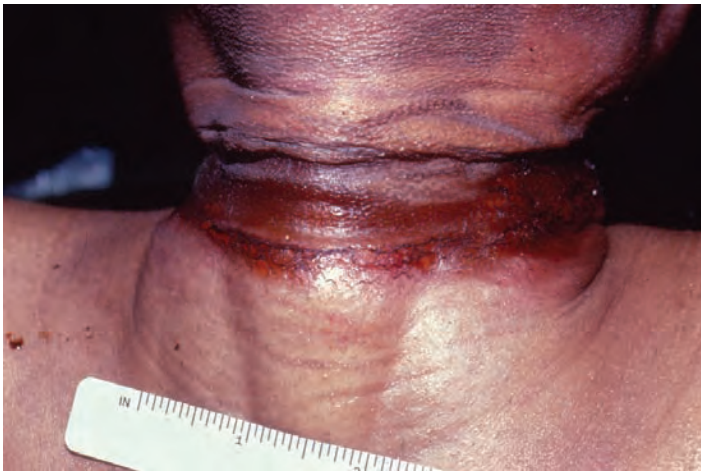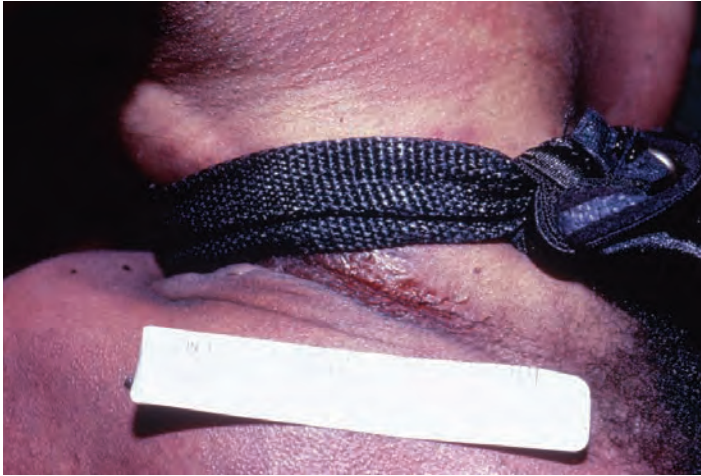Suicidal hanging. Note the black cord (a) that matches the underlying furrow pattern at the superior aspect of the neck with upward extension at the left side of the face. Also note that the individual's lividity becomes more apparent and is fixed at the level of the upper thigh extending down to the feet (b). This fixed lividity pattern is appropriate for an individual who remained in an upright position for many hours after death. If his lividity was fixed posteriorly and not inferior, this would indicate prior scene alteration. There were hesitation marks at the wrist with blood seeping downward due to gravity (c).



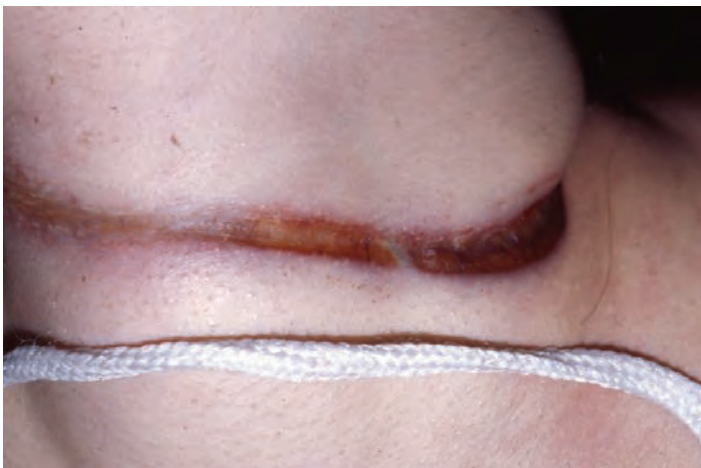Suicidal hanging with matching rope and furrow pattern circling superior aspect of the neck forming a slight inverted "V" pattern behind the right ear.



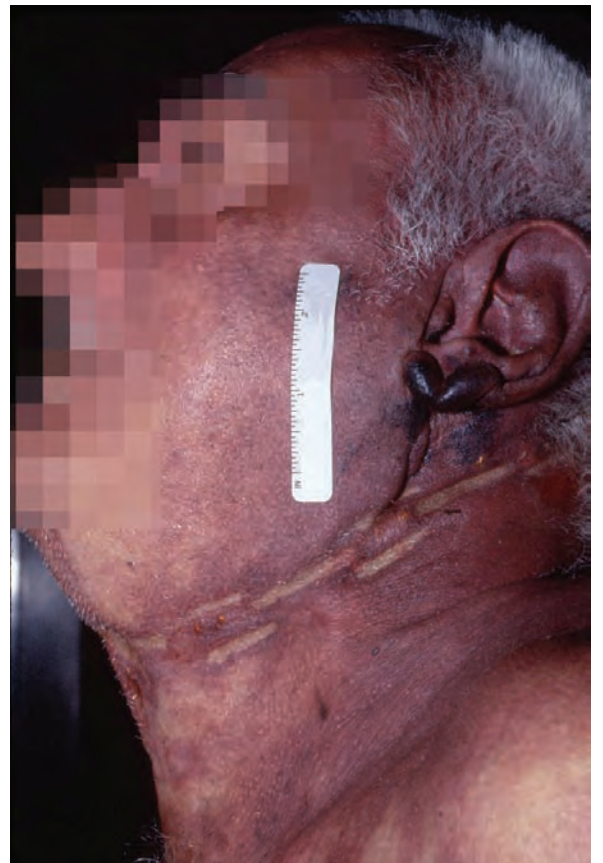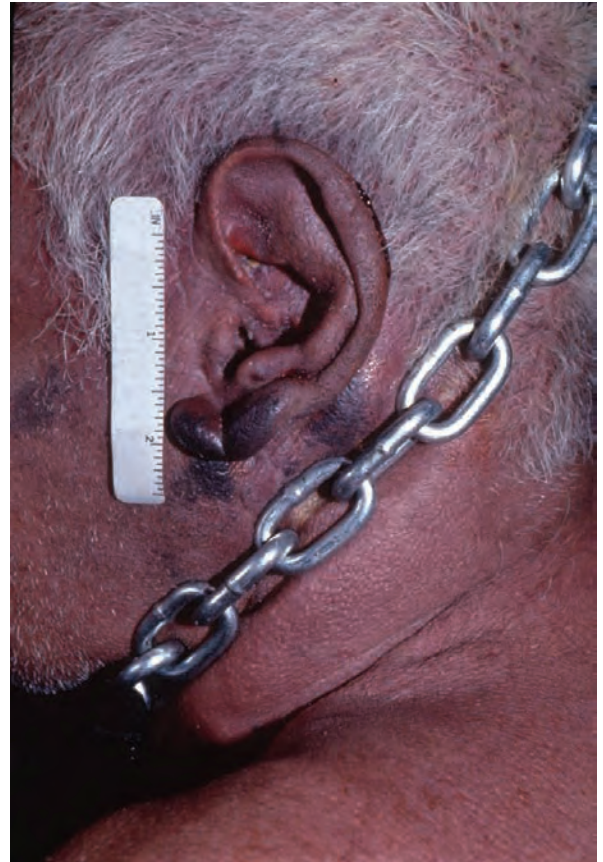
Suicidal hanging with computer cord.



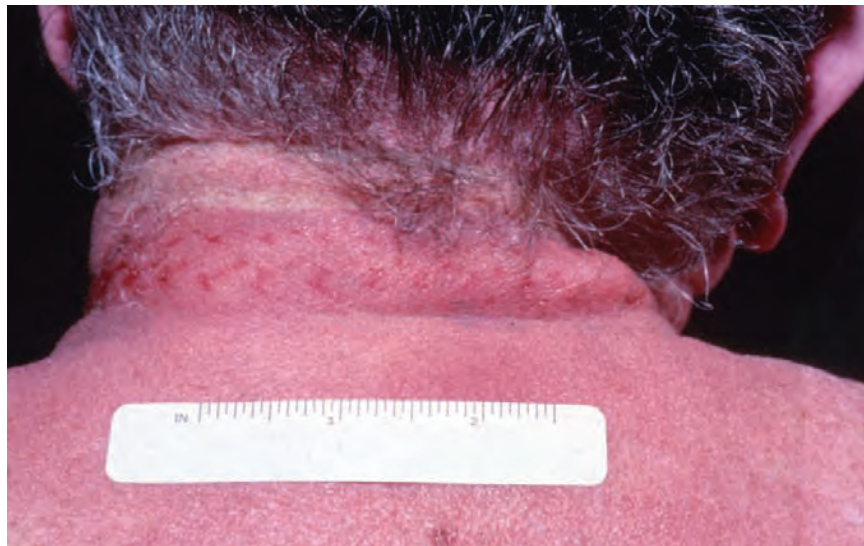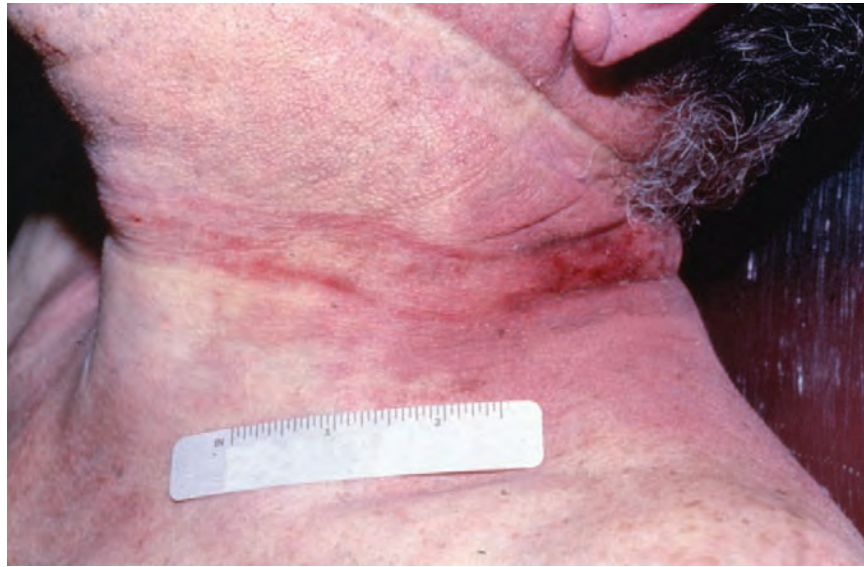Suicidal hanging with nylon bag strap.



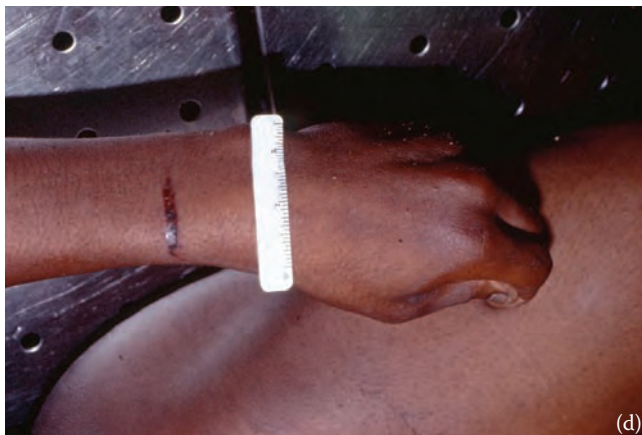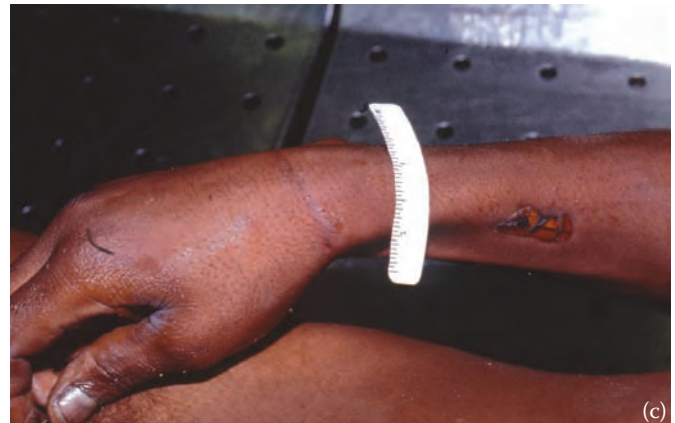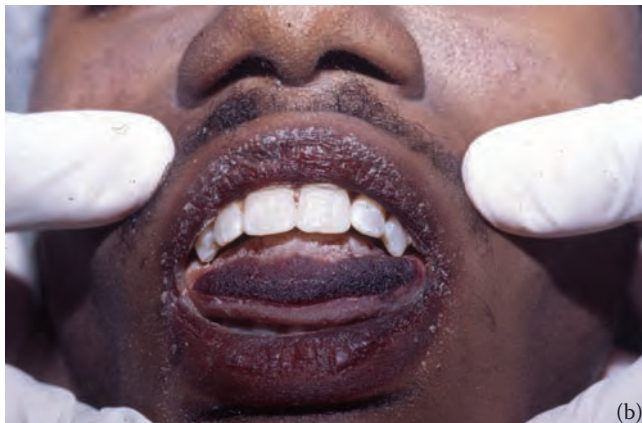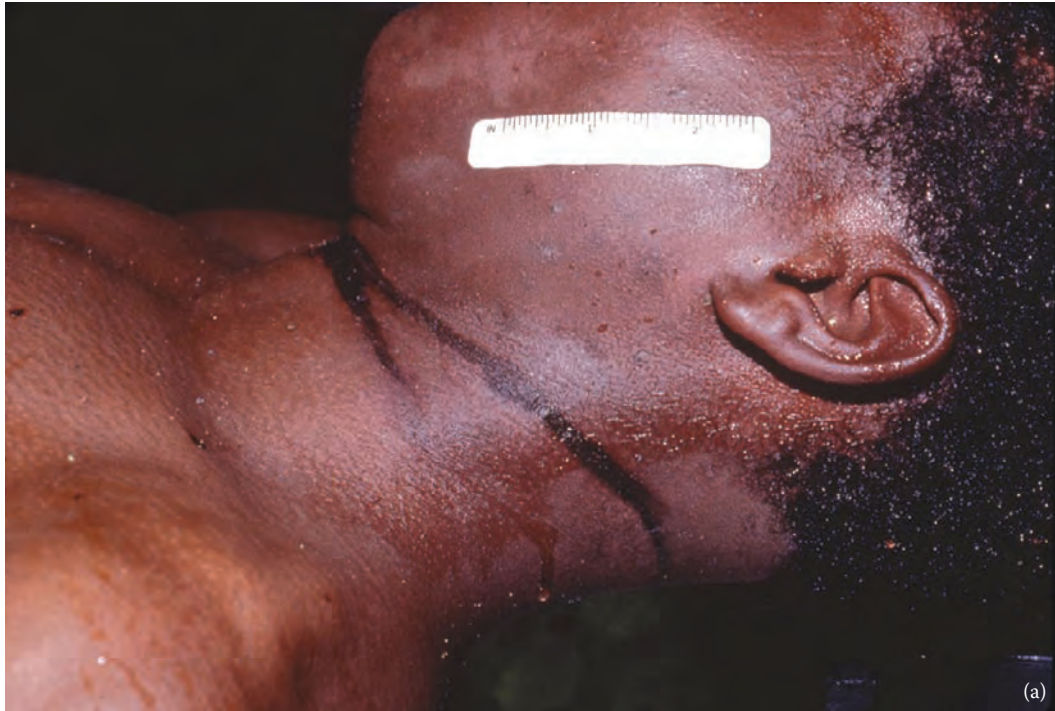Accidental hanging in an individual with Alzheimer's dementia who enjoyed whirling around in circles while sitting on a desk chair. The person was left unattended for a short period of time by chronic care nursing staff, and got tangled in the cord from a window blind. This furrow pattern matches a blind cord as a ligature.



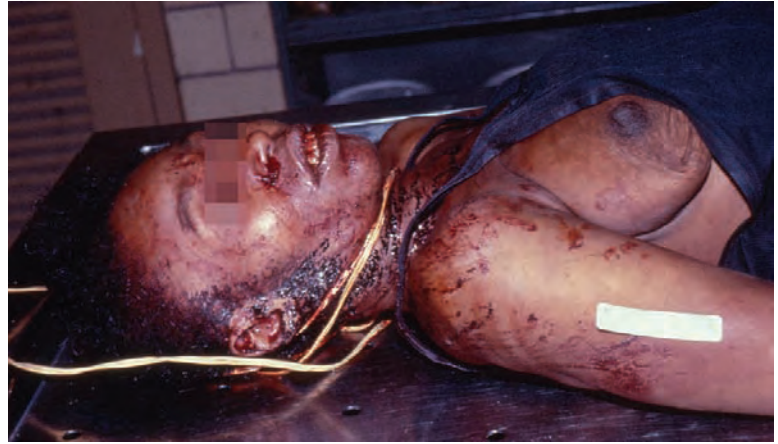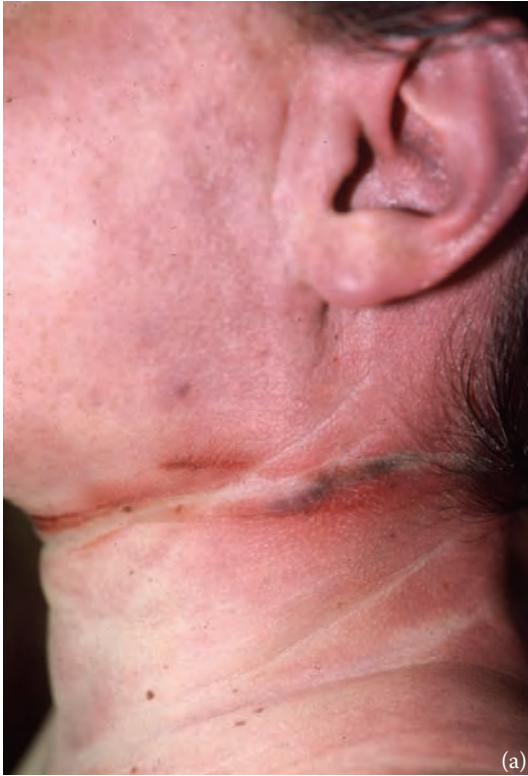Suicidal hanging with chain.



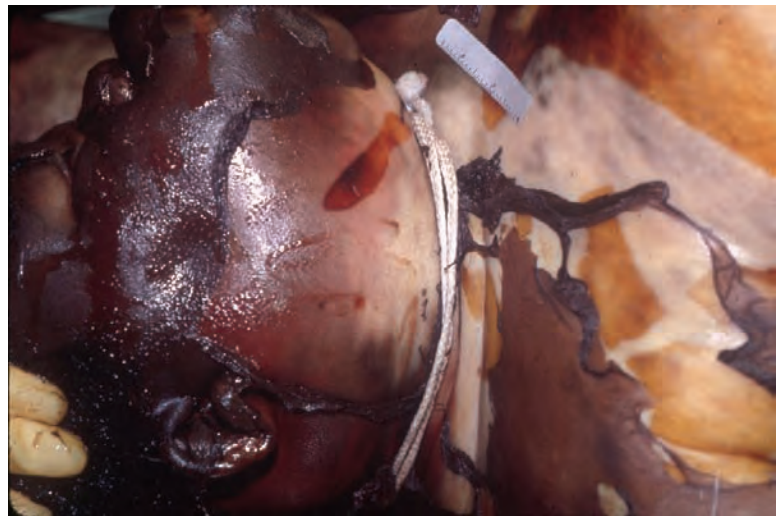
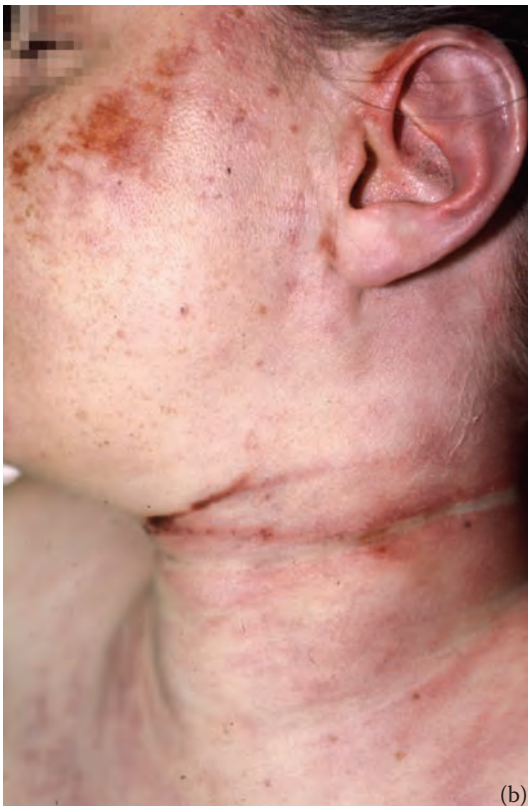Suicidal hanging by braided belt. Note the matching skin pattern.



Suicidal hanging with earphone cord (a). This individual also took part of the cord and loosely wrapped his hands behind his back so he would not be able to reach up and prevent the hanging from being successful. This is not very unusual for people to hang themselves and loosely tie their hands in this fashion. Note the force of the ligature caused the tongue to protrude from his mouth (b). Also note the dark postmortem drying of the mucosa exposed to air.



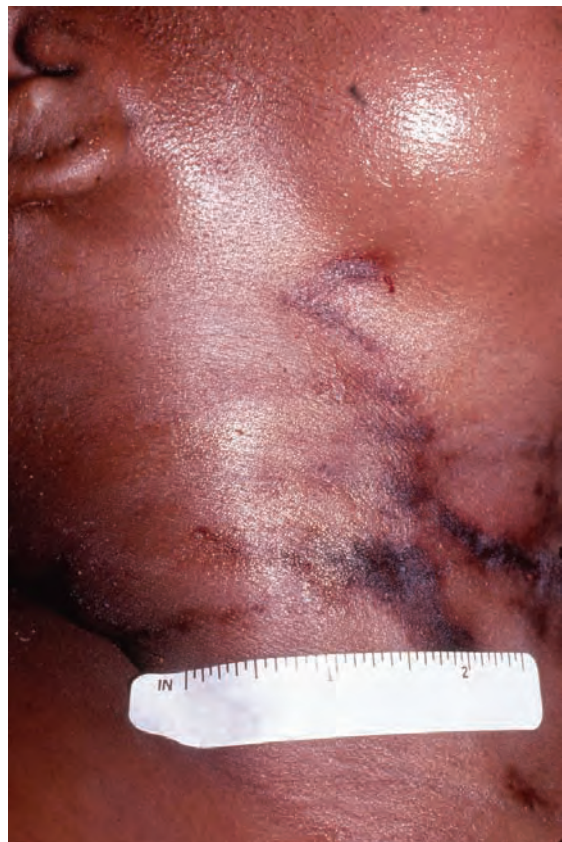
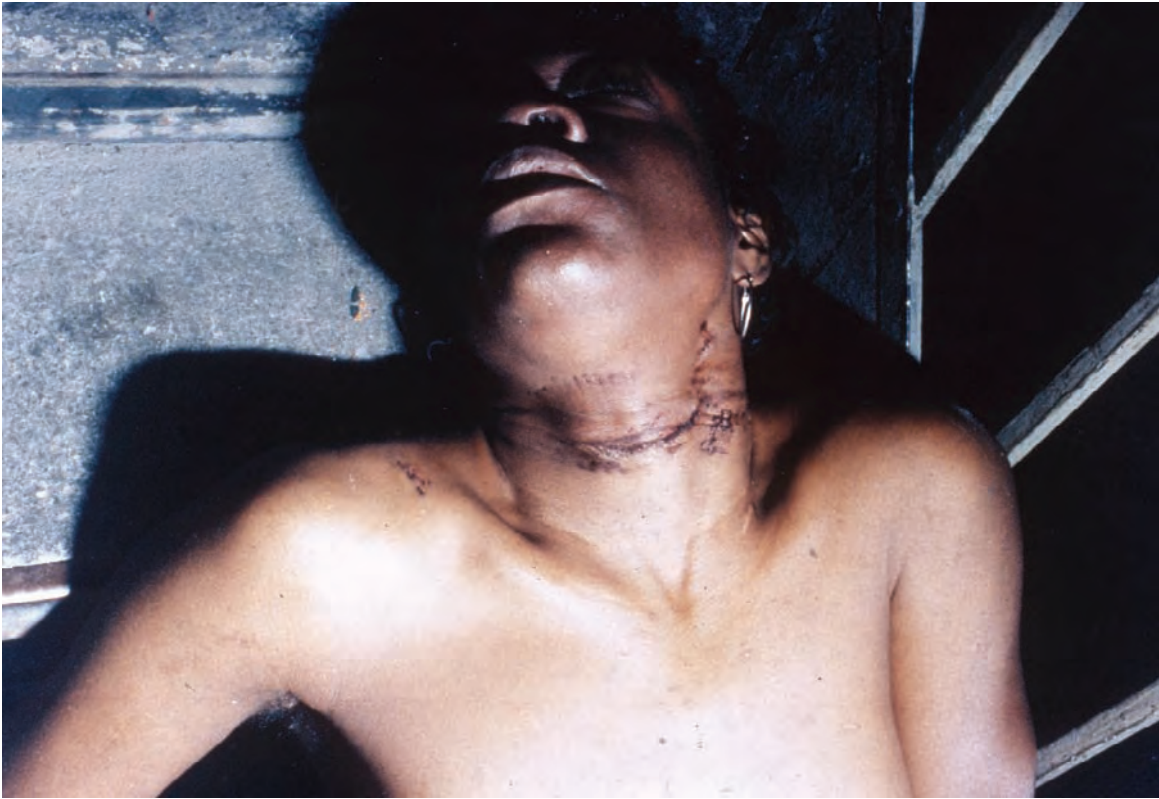Homicidal ligature strangulation in a prostitute who had large amounts of cocaine and heroin in her system. Her fingers were also noted to be crushed by a pair of pliers during the assault.



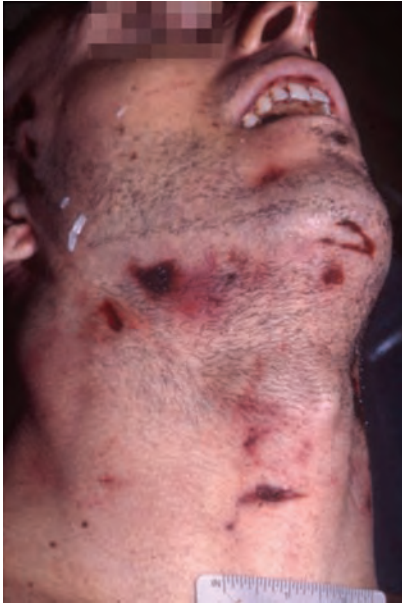This is a suicidal ligature strangulation in an individual with a longstanding history of depression who was found in a locked secured apartment with a suicide note. Note the cord is tied tightly around his neck. There is also a moderate state of putrefactive change with skin slippage, bloating, and purging.

Homicidal ligature strangulations with horizontal cord marks surrounding the necks. Note the other injuries to the decedent's face in (b), including abrasions. Both of these victims were also sexually assaulted.

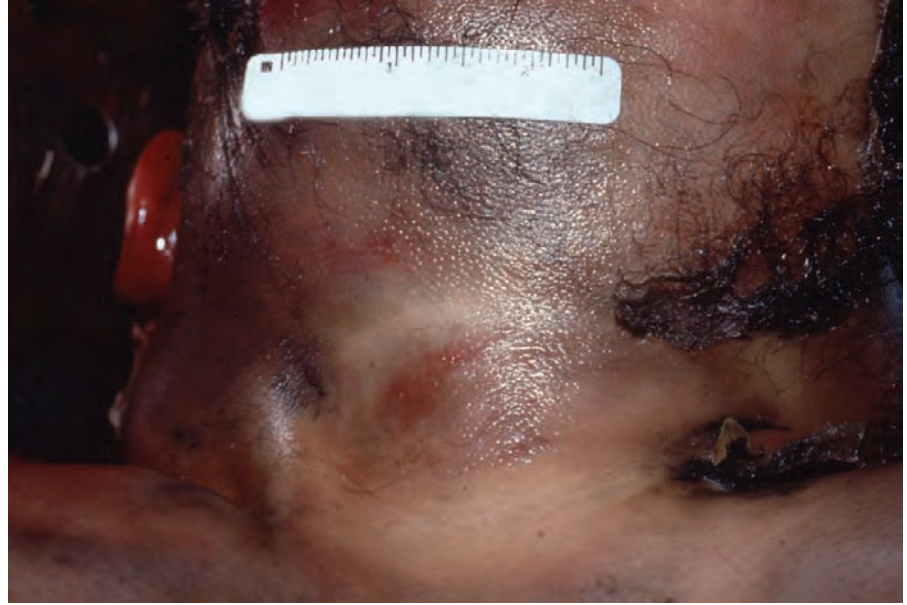




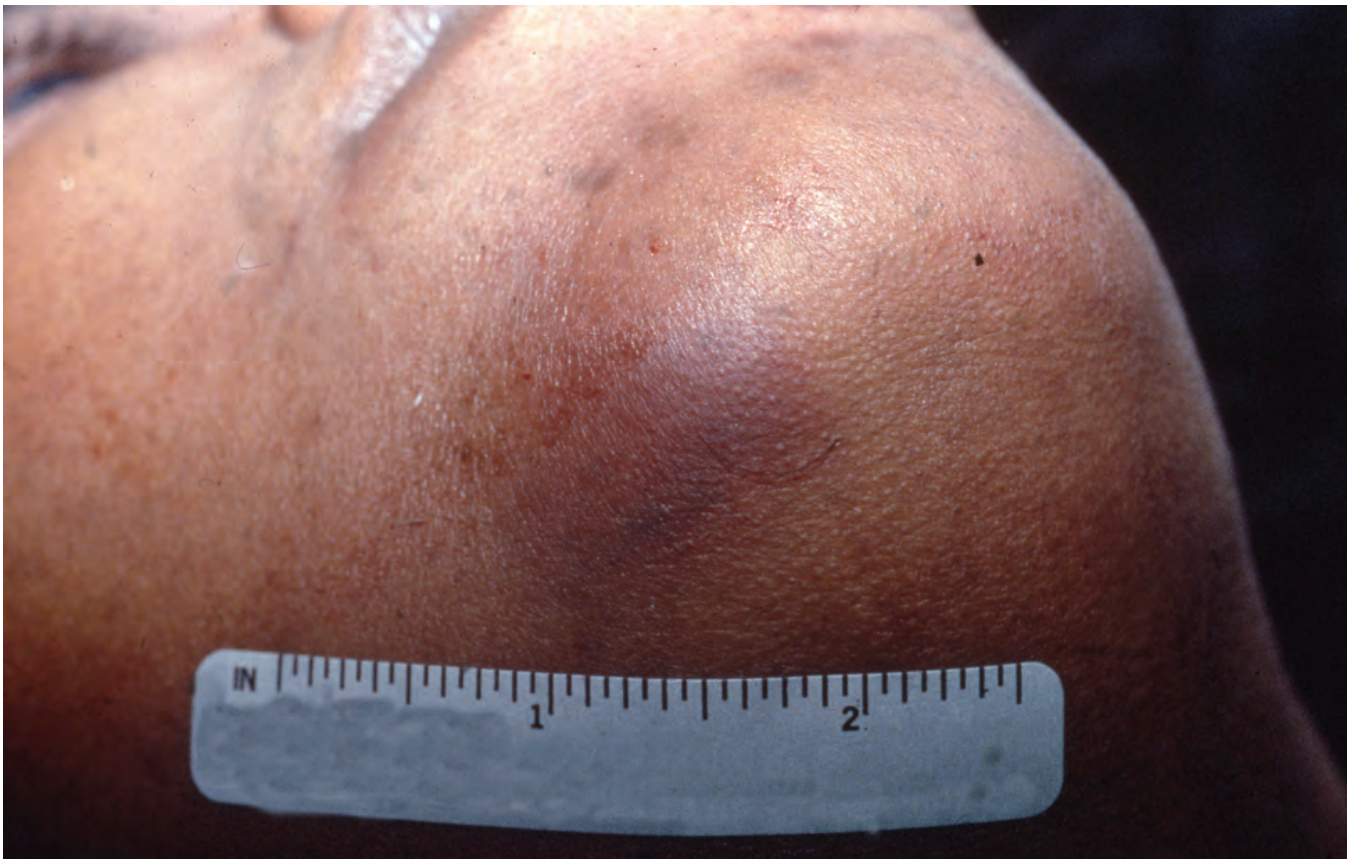
Manual strangulation. Note the multiple irregular abraded contusions surrounding the neck. There were multiple areas of strap muscle hemorrhage and a fractured hyoid bone. She was sexually assaulted and left in a stairwell. There were multiple petechiae with areas of hemorrhage in the sclerae and conjunctivae of each eye. The constellation of these findings are typical for a homicidal manual strangulation.



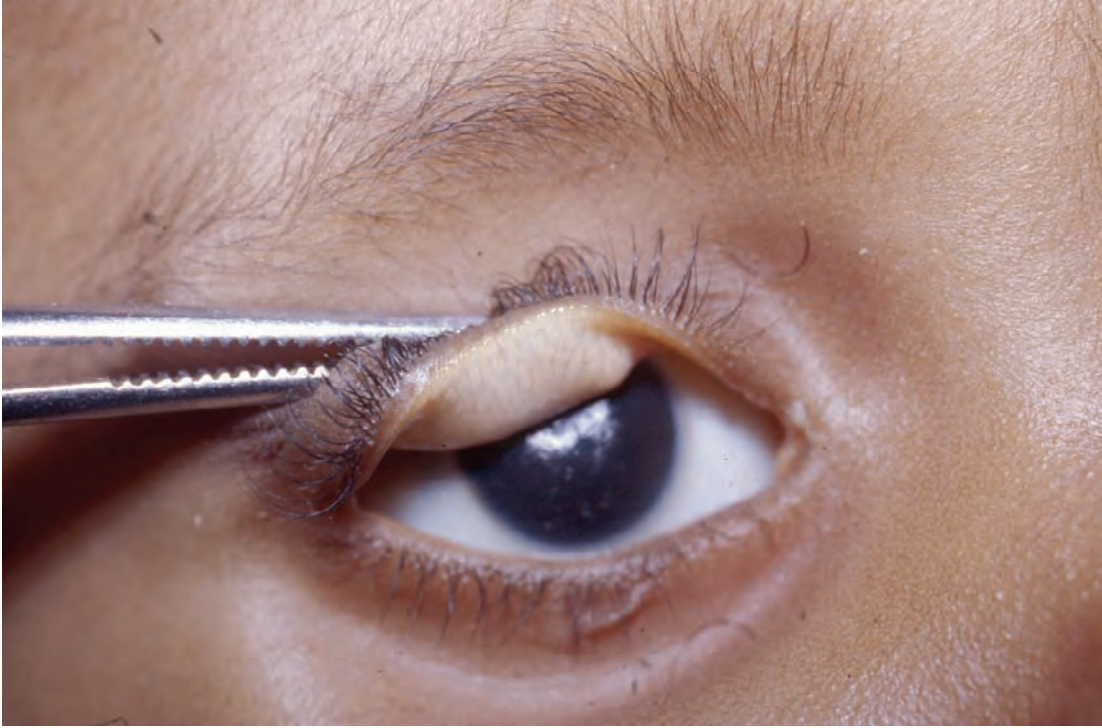Manual strangulation. Note the abraded contusions to the anterior neck.



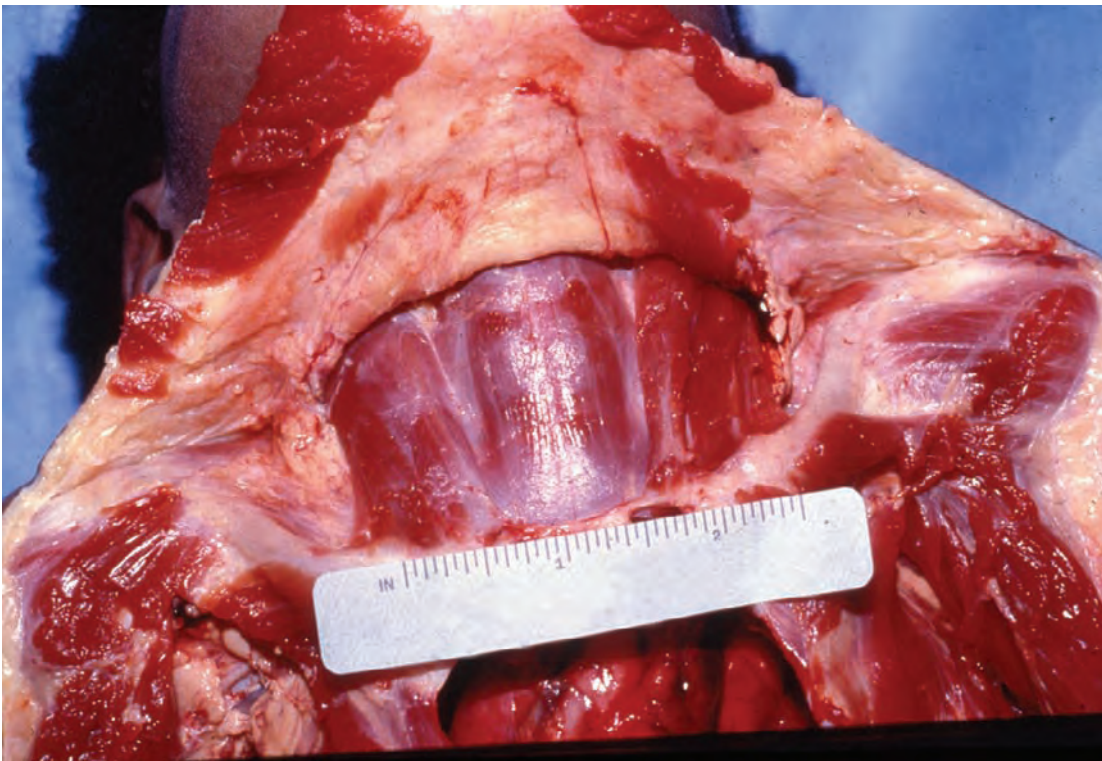
Manual strangulation. There is early decomposition with skin slippage. There are vague abrasions and superficial contusions at the neck. As decomposition progresses it may become more difficult to interpret these findings.



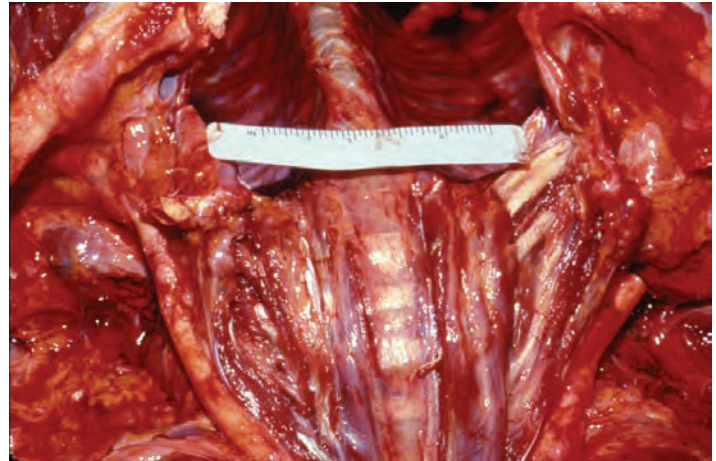
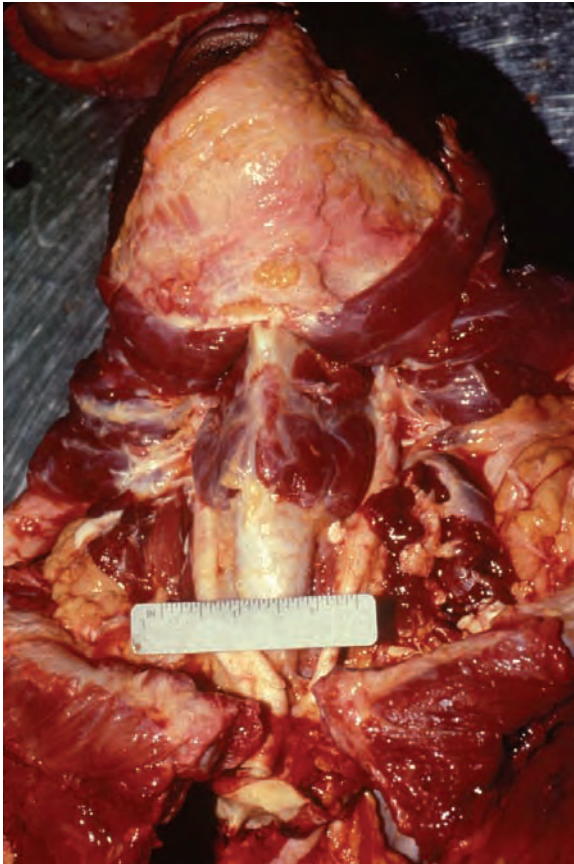
This individual was punched in the face and then yoked from behind during a sexual assault. There were no visible external injuries to the neck except this contusion at the border of the right chin. Careful internal examination after the brain and visceral organs had been removed revealed areas of hemorrhage within the anterior strap muscles and posterior paraspinal muscles. There were also petechiae with hemorrhage of the sclera and conjunctivae. This individual was found face down and the eye hemorrhages were originally thought by some to be associated with postmortem lividity. The perpetrator was caught after bragging about the assault.



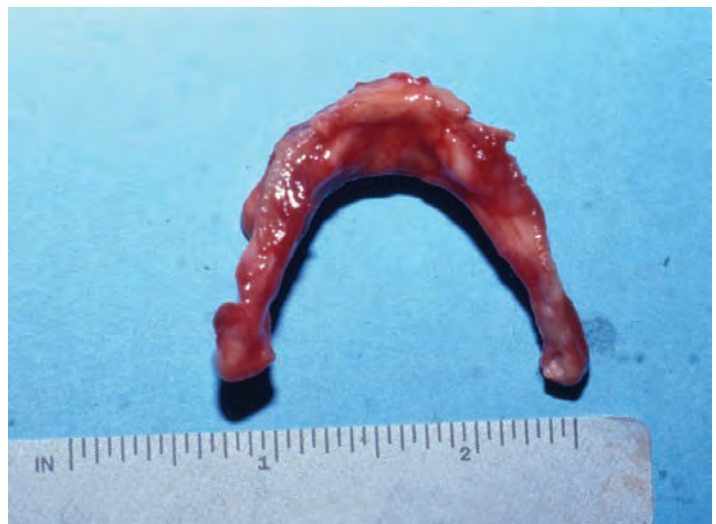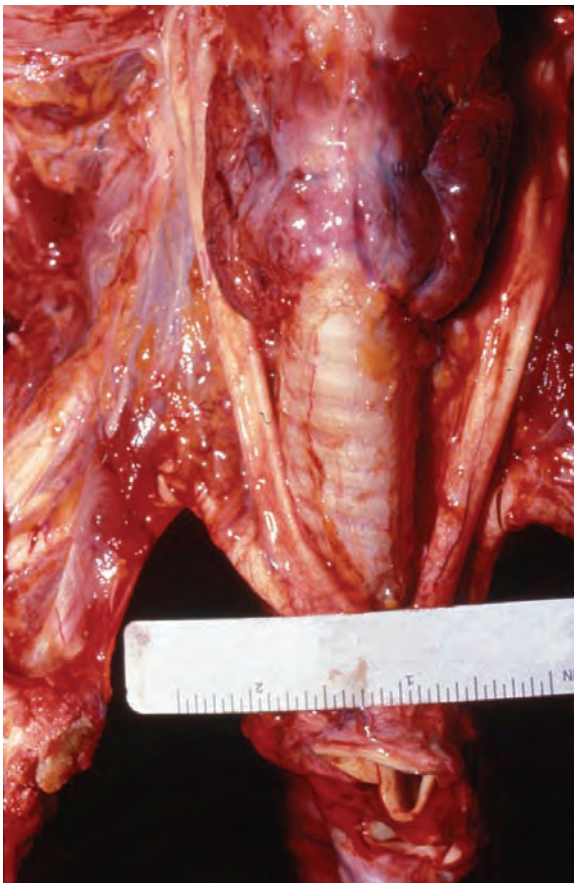This image demonstrates an eye from a person who hanged him or herself. Note there are no petechiae or scleral/conjunctival hemorrhages. The decedent's weight pulling down on the ligature produced a significant enough force to obstruct the entire blood supply to the head. Therefore, there was no pressure-release mechanism, leading to capillary rupture and hemorrhage. The absence of scleral or conjunctivae hemorrhages is more typical in hanging fatalities.



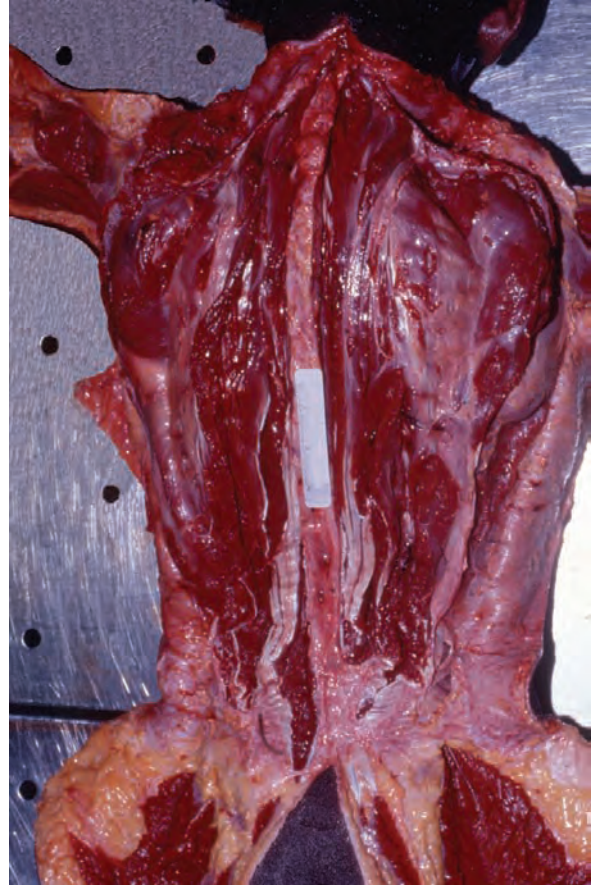
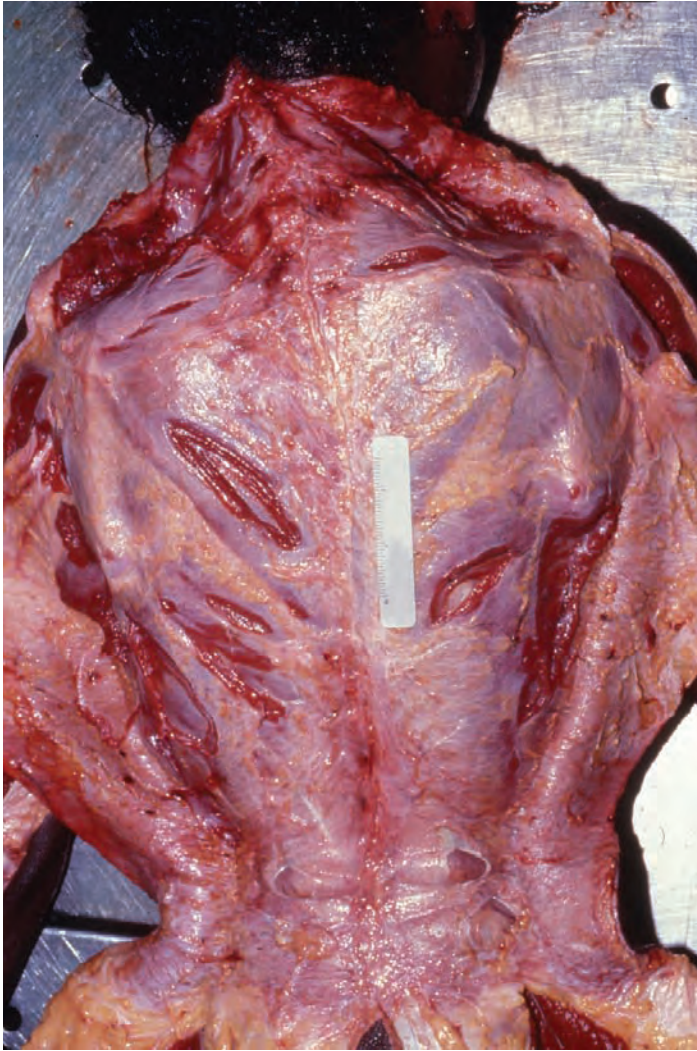Anterior neck dissection after the visceral organs and brain have been removed. Part of the undersurface of the platysma muscle is visible at the top of this image adjacent to the yellow subcutaneous tissue of the neck. The anterior strap muscles are visible directly above the label and are free of antemortem injury. There were no hemorrhages or fractures of the remaining neck structures. The absence of these injuries is common in hanging fatalities.



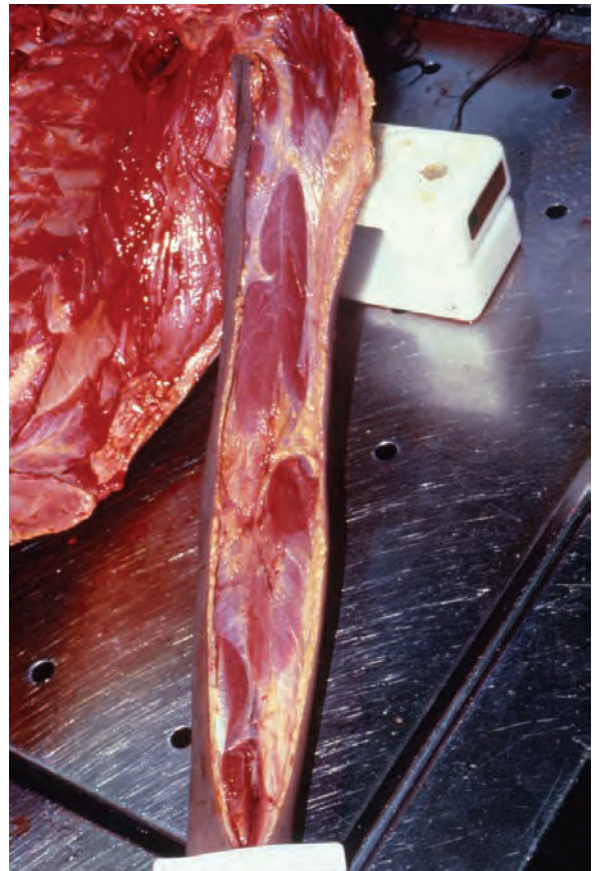
These figures demonstrate anterior neck dissections with no hemorrhages. The absence of hemorrhage is typical for most hangings.

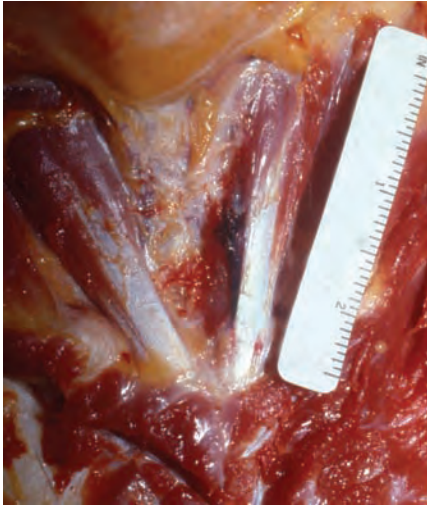


This demonstrates a normal hyoid bone with no fractures or contusions.

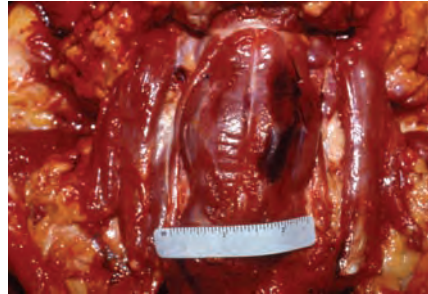


Some cases may require further evaluation including a posterior neck and back dissection. This case involved a 12-year-old African American child who was strangled. Dissection should be done in a layer-by-layer fashion until the surface of bone is exposed. It is important to dissect the arms as well, which may demonstrate contusions from being held during a struggle. There were no hemorrhages found in this case. It is often more difficult to externally visualize contusions in darker-skinned individuals.

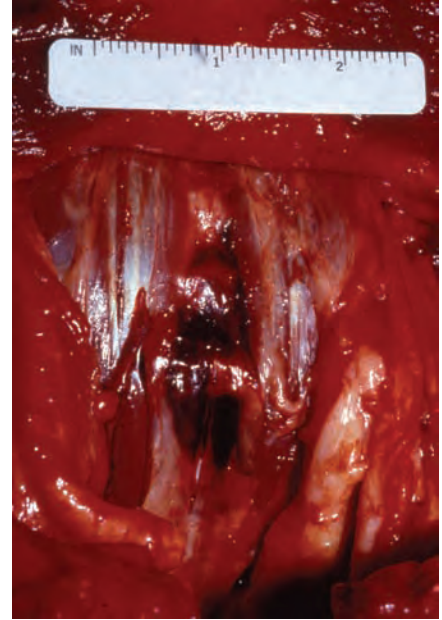




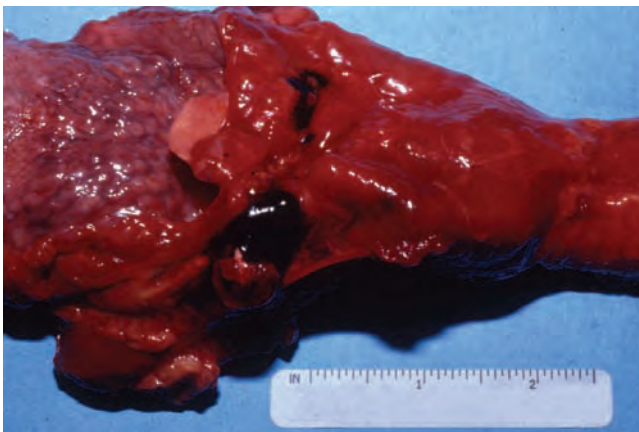
Strangulation. Hemorrhage of the medial left sternocleidomastoid muscle.



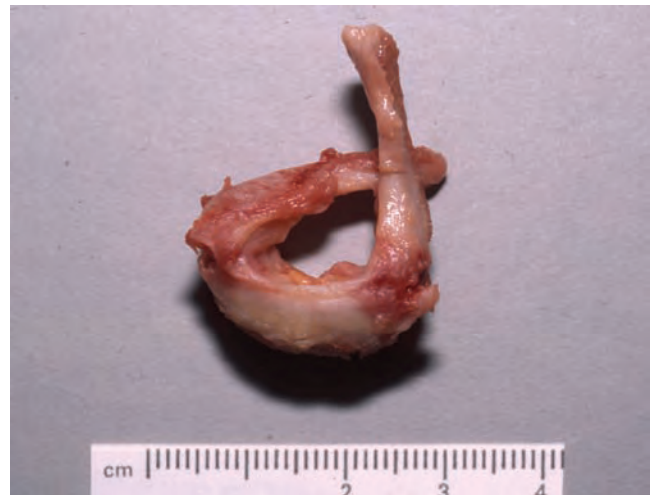Strangulation. Note the large hemorrhage to the anterior neck structures including the left sternohyoid muscle.



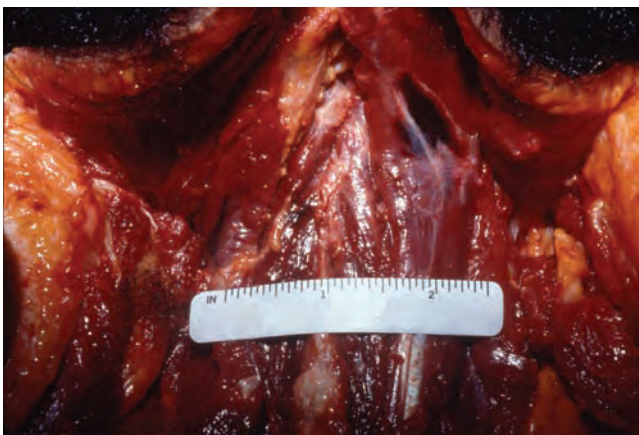
Strangulation. Note the hemorrhage in the anterior neck structures.



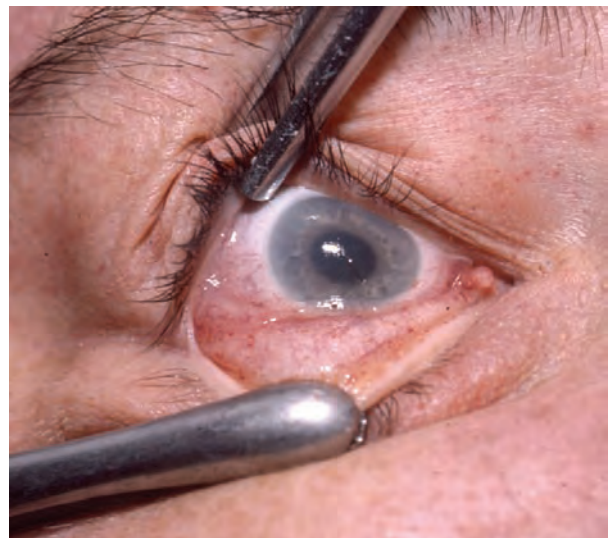
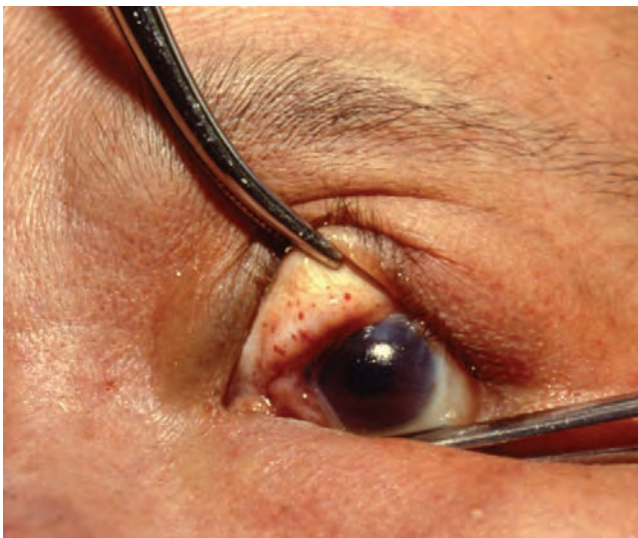
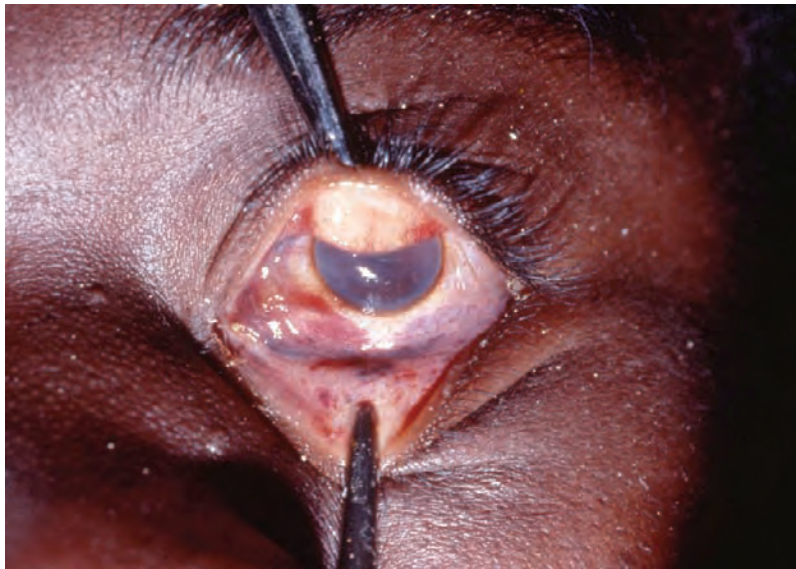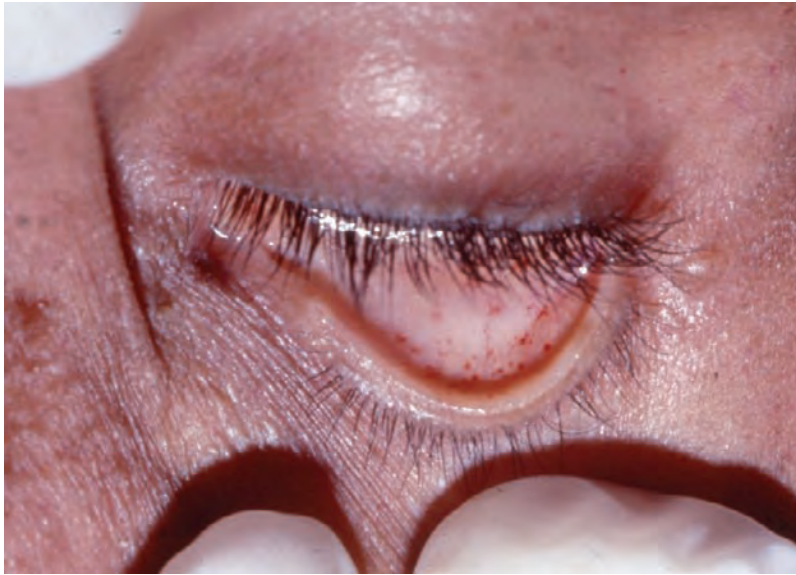
Strangulation. Note the hemorrhage overlying the left superior horn of the thyroid cartilage. The underlying cartilage was fractured.



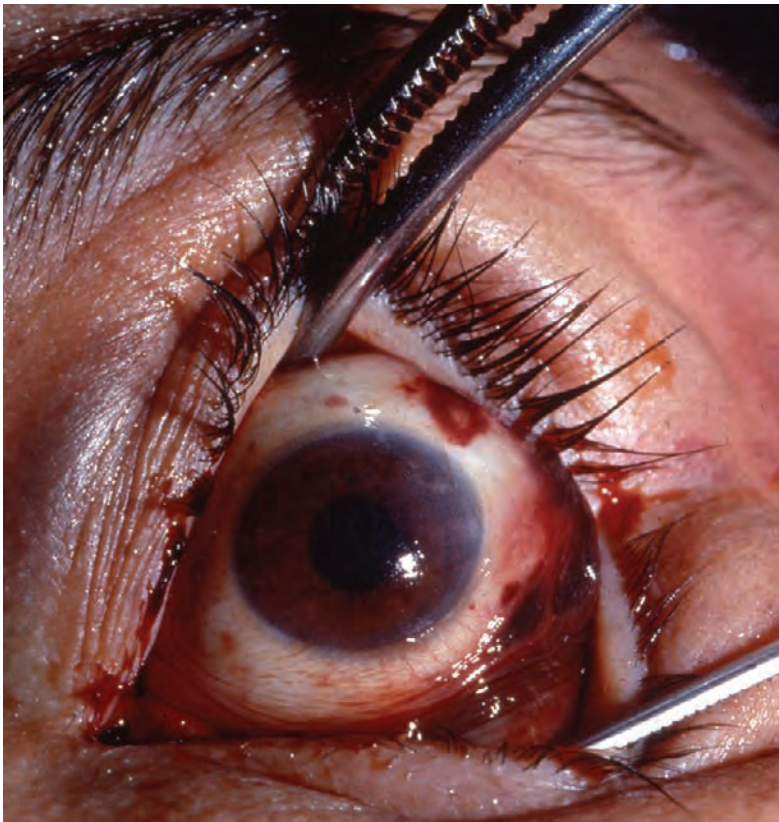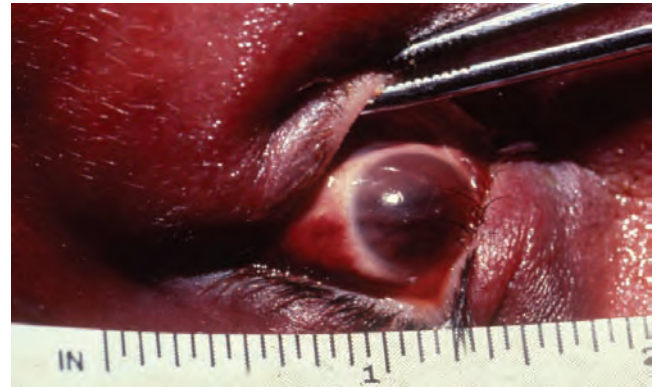
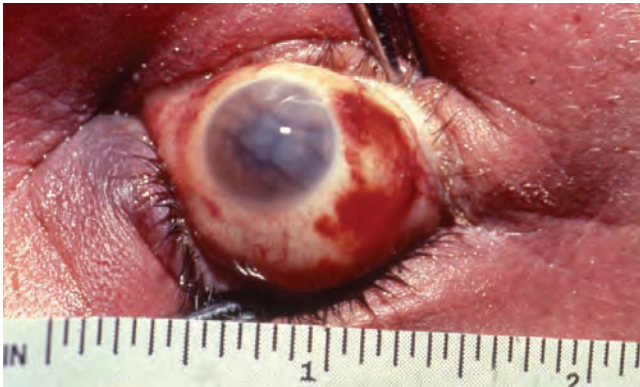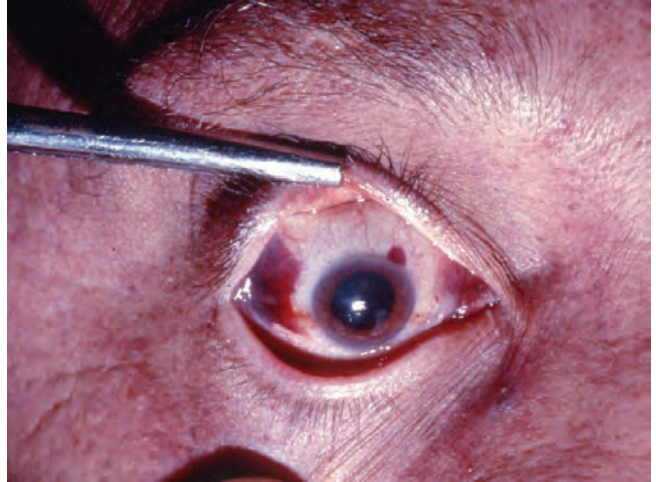
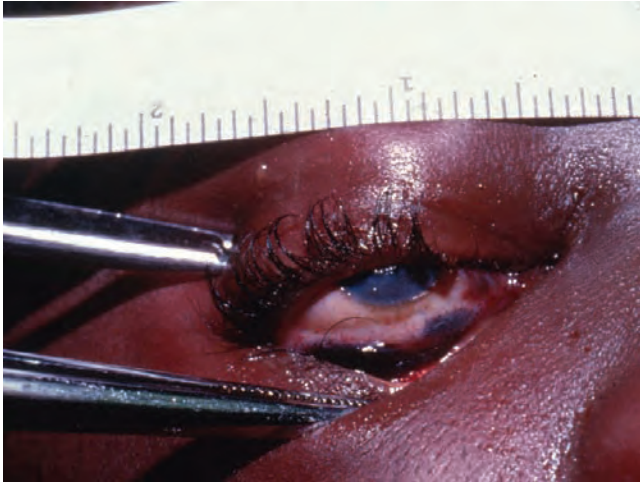Note the fractures of this hyoid bone with vague hemorrhages in a decedent with slight to moderate decomposition. Fractures of the hyoid bone are often found in association with homicidal strangulation. The presence of a hyoid bone fracture does not indicate that the case must be a strangulation and the absence of fractures to the hyoid bone does not indicate the decedent was not strangled. Fractures can occur as a result of a blunt impact as well.



Strangulation. Posterior neck dissection with hemorrhage to the superior aspect of the semispinalis capitis muscle.

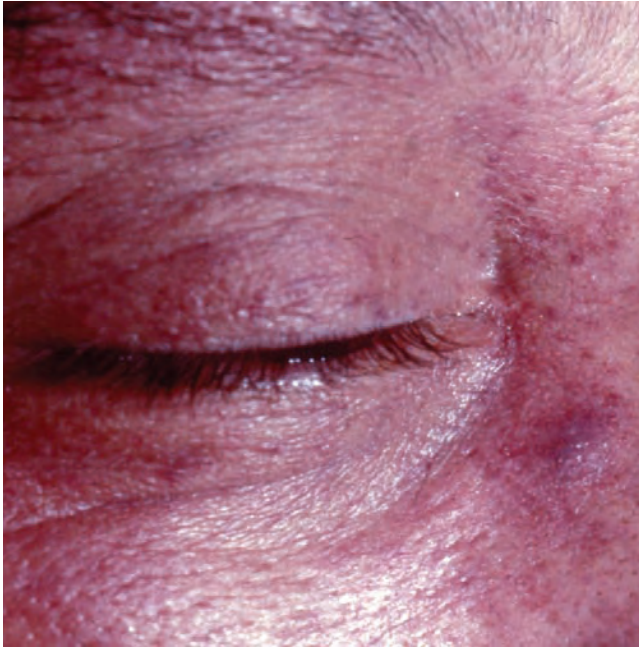


Cases of strangulation demonstrating petechial hemorrhages of the sclera and conjunctivae.

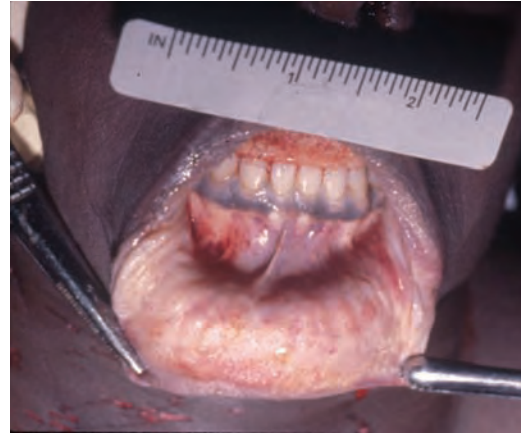

These demonstrate a range of scleral and conjunctival hemorrhages. As varied degrees of neck pressure continue after petechiae formation these hemorrhages progressively become larger and possibly confluent until death ensues.

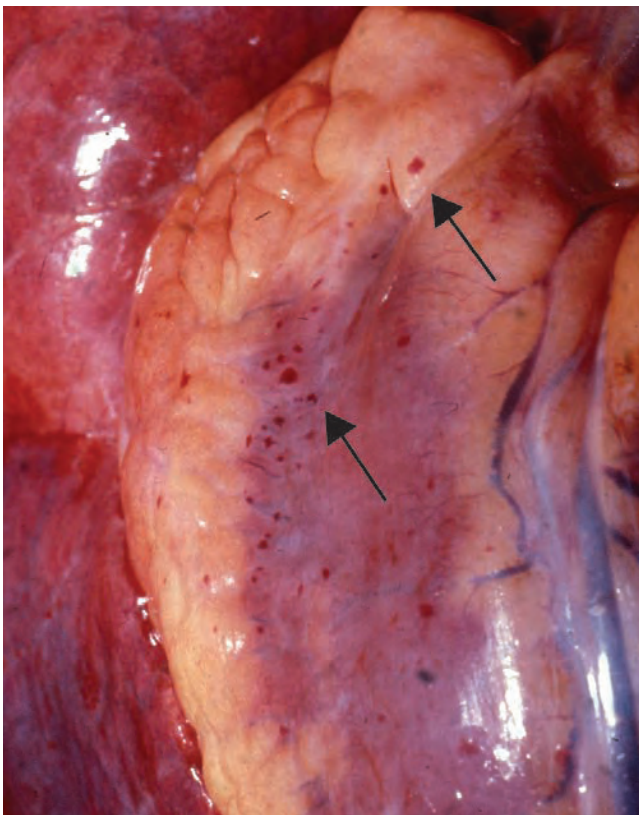




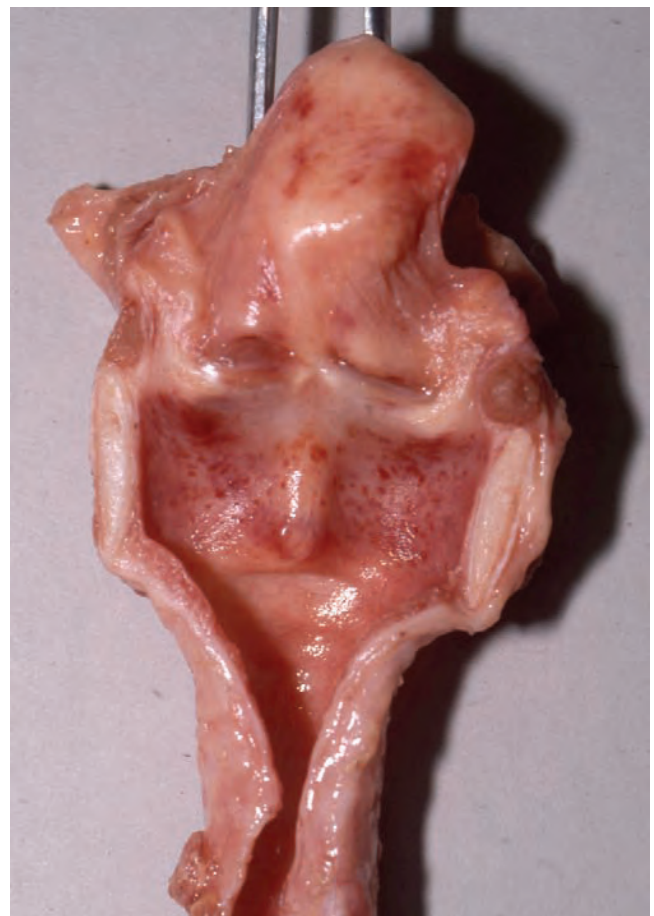Petechial hemorrhages of the face.



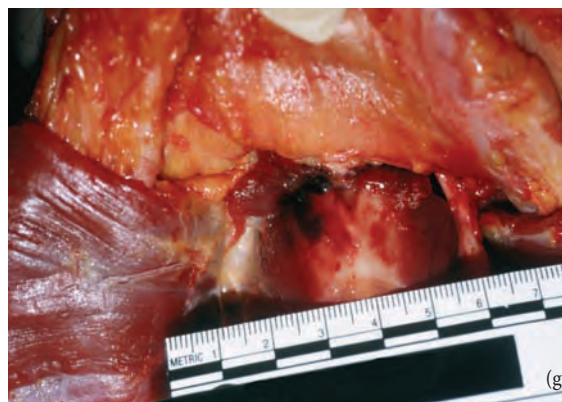
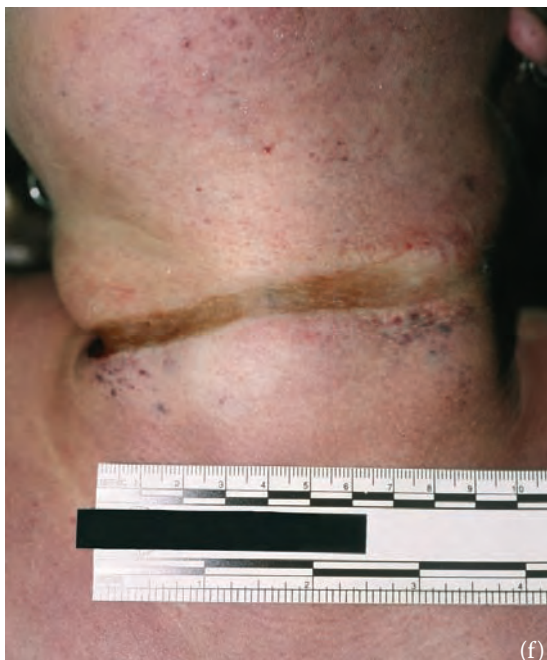
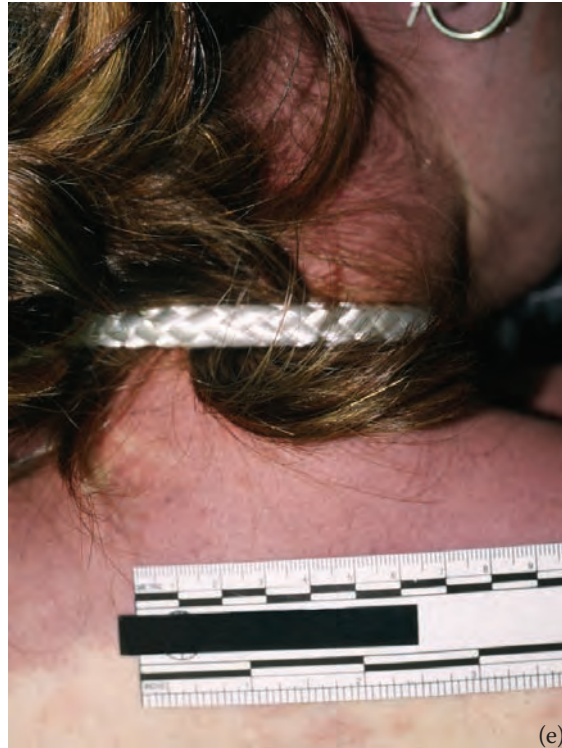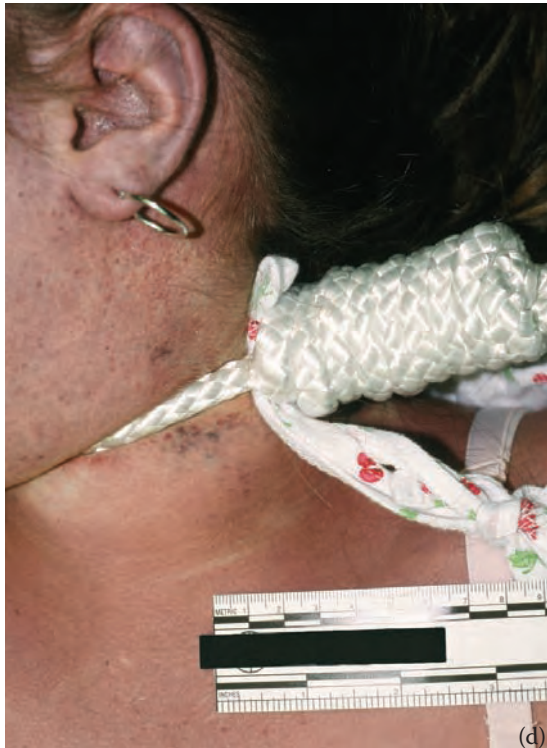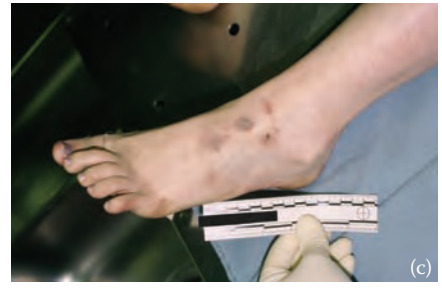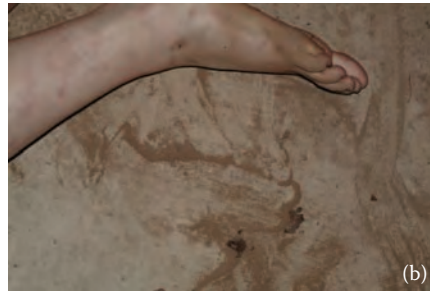Strangulation. Petechial hemorrhages within the mucosal surface of the mouth.



Petechial hemorrhages at the surface of the heart associated with asphyxia due to chest compression.

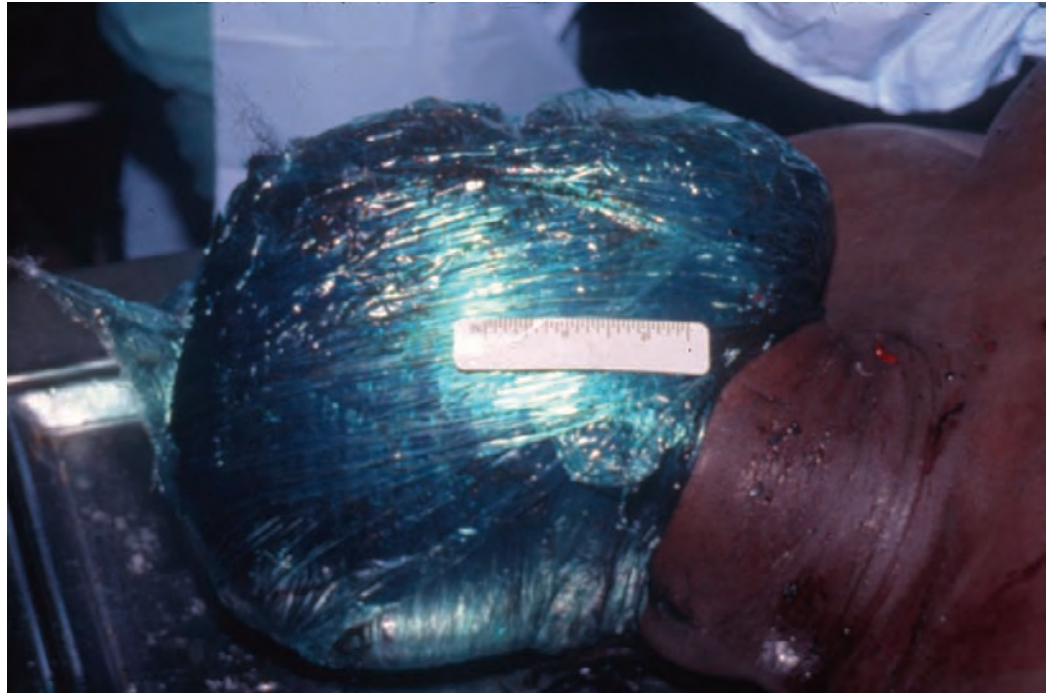

Strangulation. Petechial hemorrhages within the mucosa of the tracheal and laryngeal cartilage.

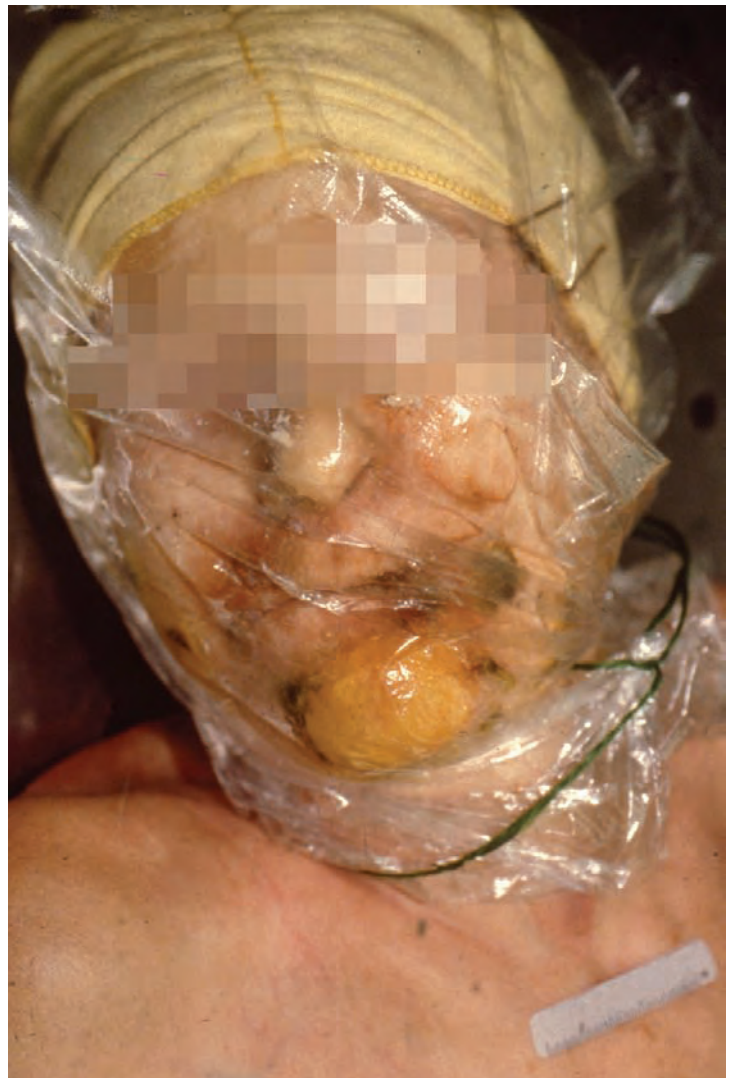

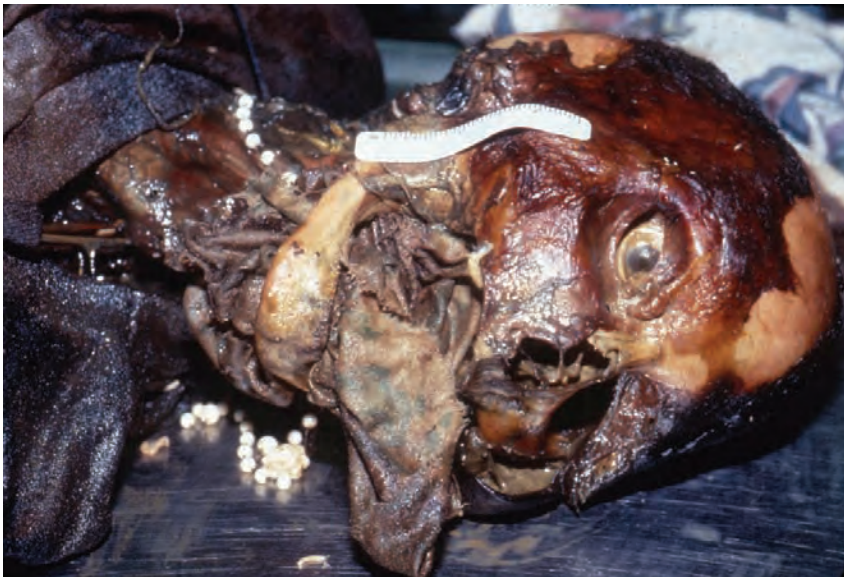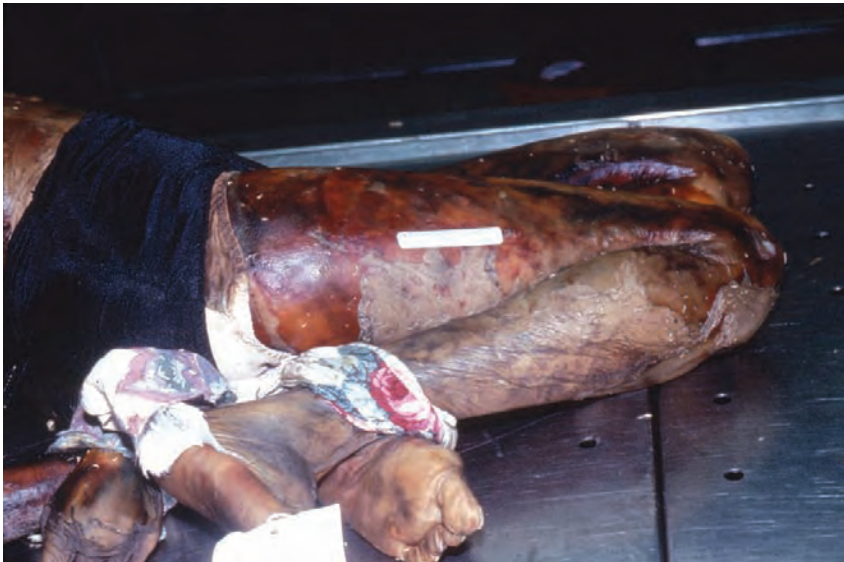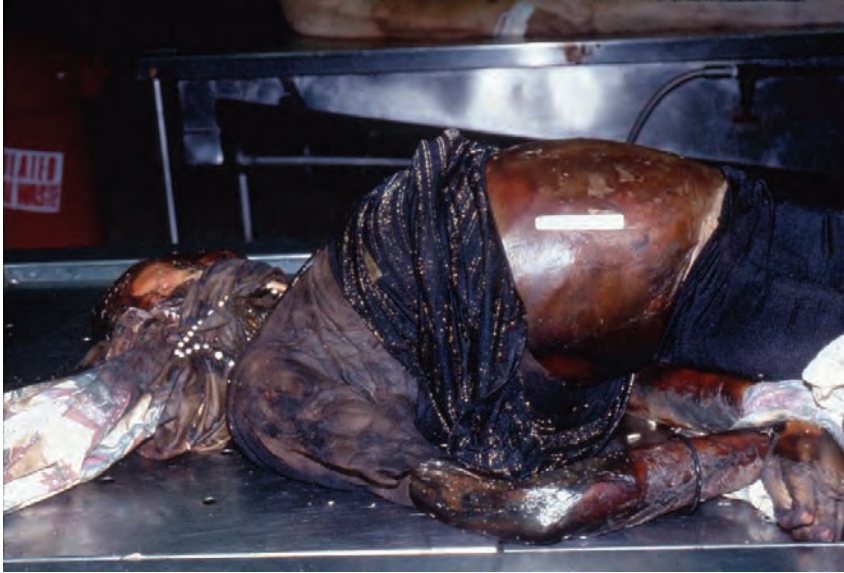This individual was strangled and then hanged in an attempt to stage a suicide and cover up this crime. Note the injuries to the back of the decedent's feet during a struggle and the haphazard scuff marks to the floor surrounding the body (b-c). Also note the decedent's hair and clothing stuck under the noose (d-e). There are also injuries with hemorrhage to the neck structures. These findings are completely inconsistent with a suicidal hanging.

This individual was abducted, bound, and had multiple superficial stab wounds associated with a sexual assault. Her head was wrapped in multiple layers of plastic that covered her mouth and nose.

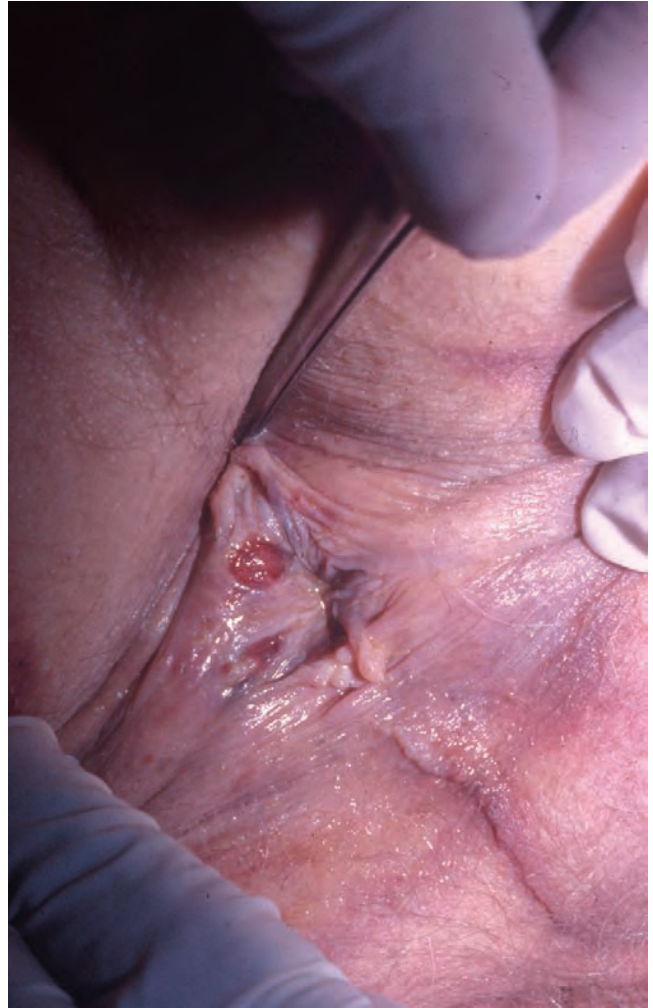
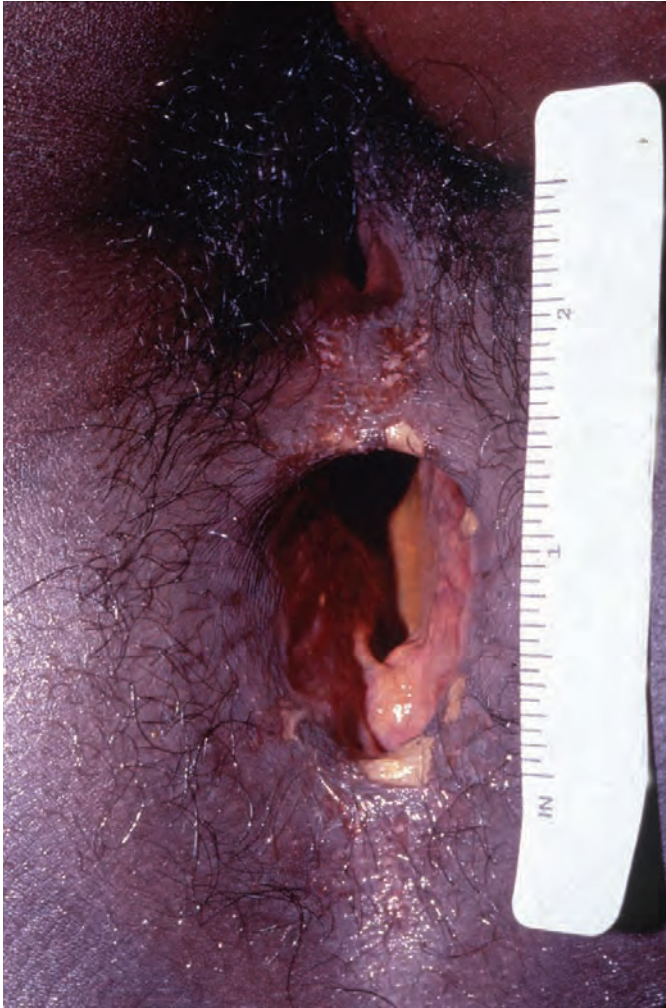
This individual committed suicide by taking multiple pills and tying a plastic bag tightly over her head. It is the author's experience that it is better to pend these cases for toxicology.



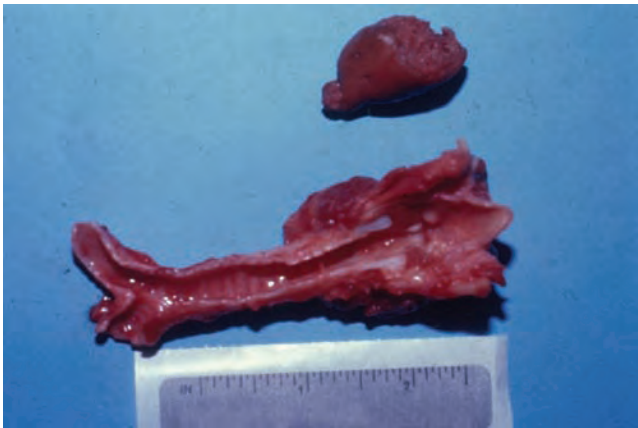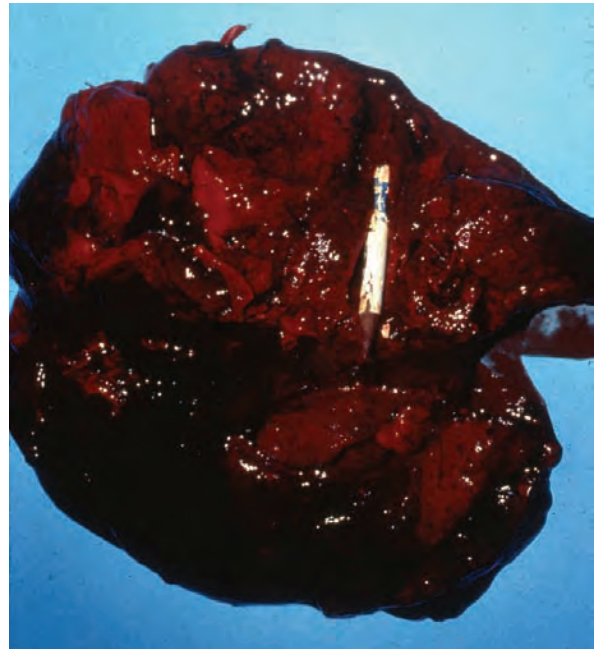

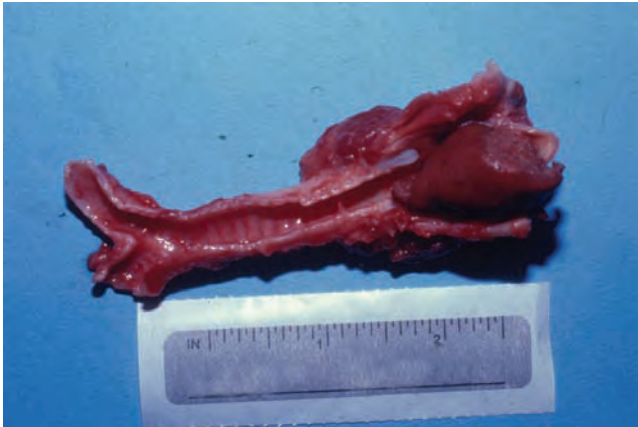
Homicidal asphyxia due to airway obstruction. This individual was found in a moderate to marked state of decomposition within her apartment. She was reportedly dealing drugs and was found tied up with a piece of cloth stuck down her mouth and throat.

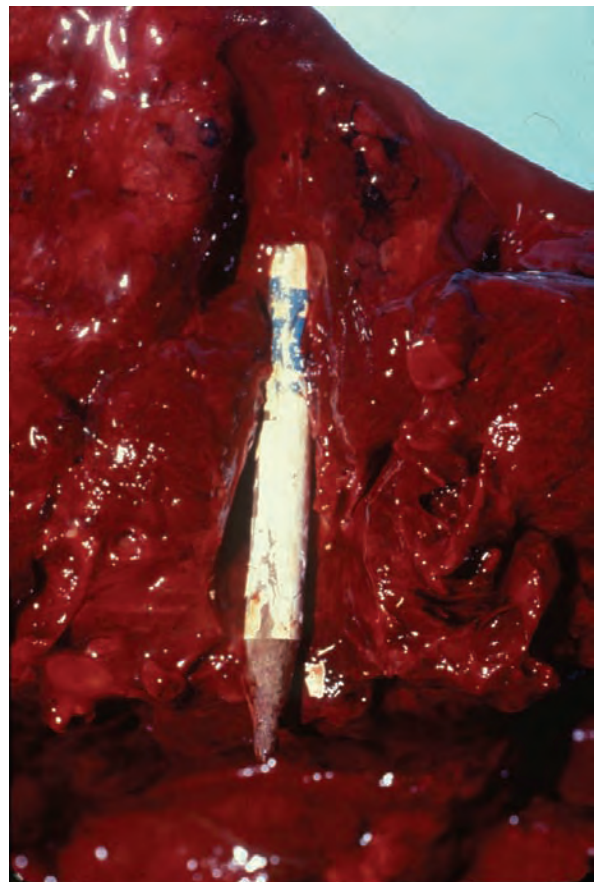


Anal trauma with abrasions and lacerations due to sexual assault during strangulation. One should always assume strangulation victims have been sexually assaulted. A rape kit should always be performed in these cases.

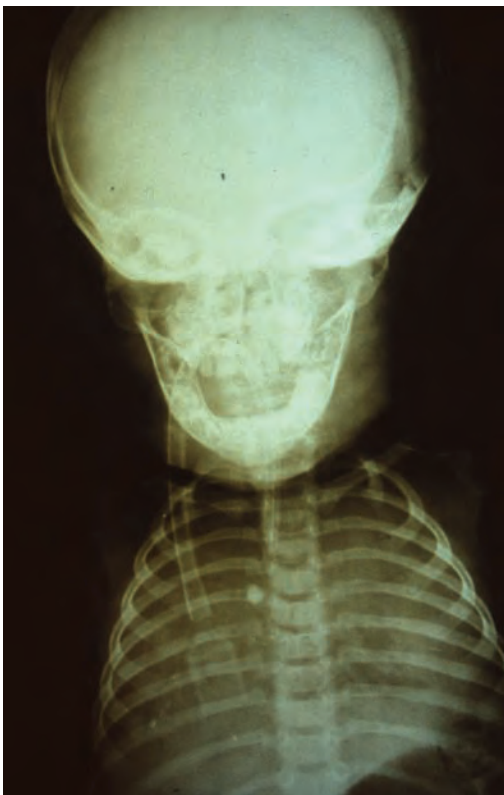



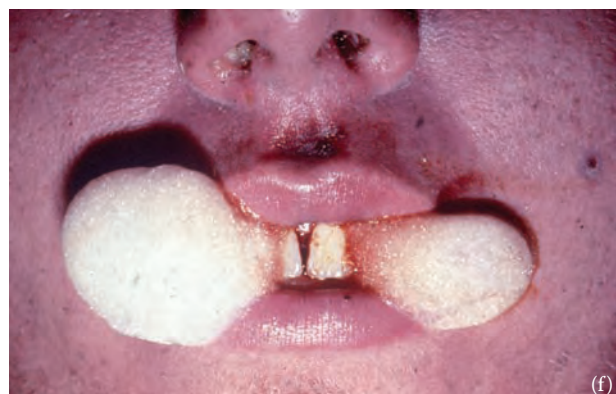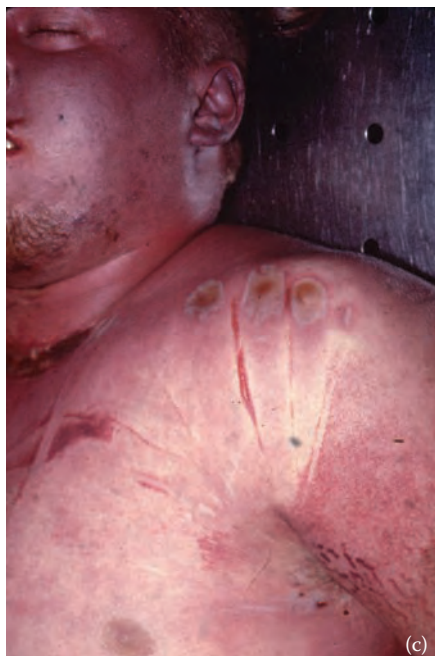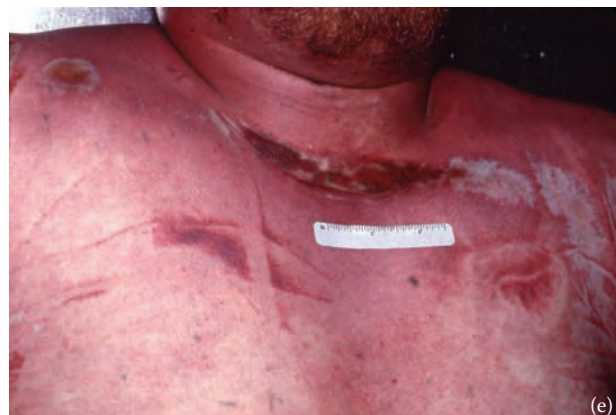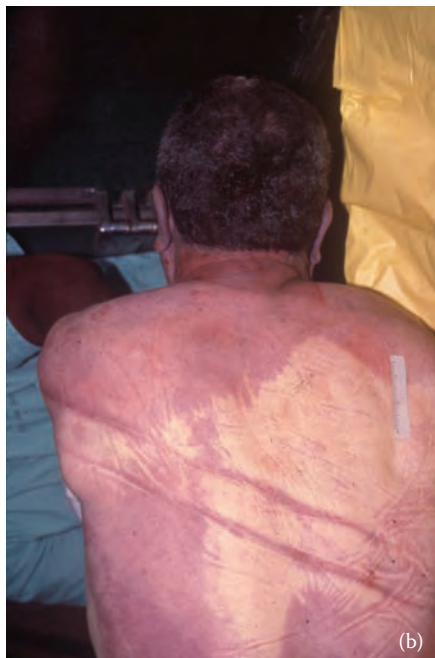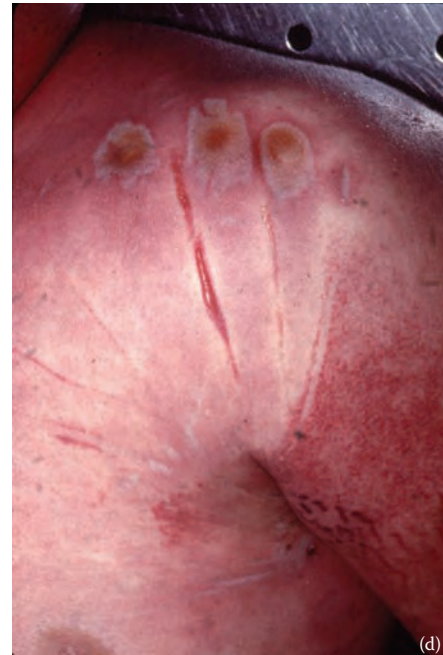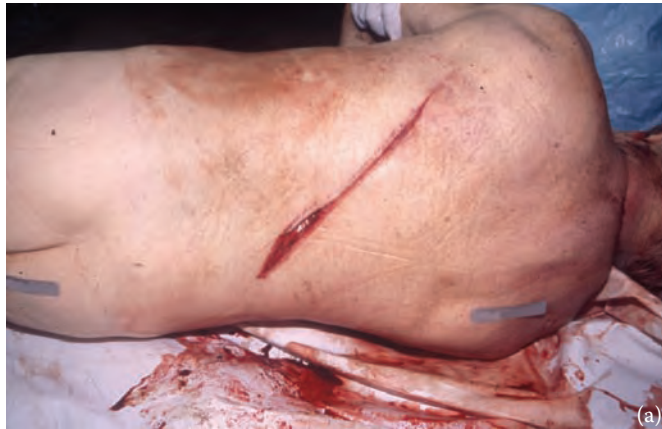This is an airway from a 2-1/2 year-old who was fed a hot dog by her older sibling. The large size of the hot dog piece caused it to get wedged in her throat, leading to asphyxia.



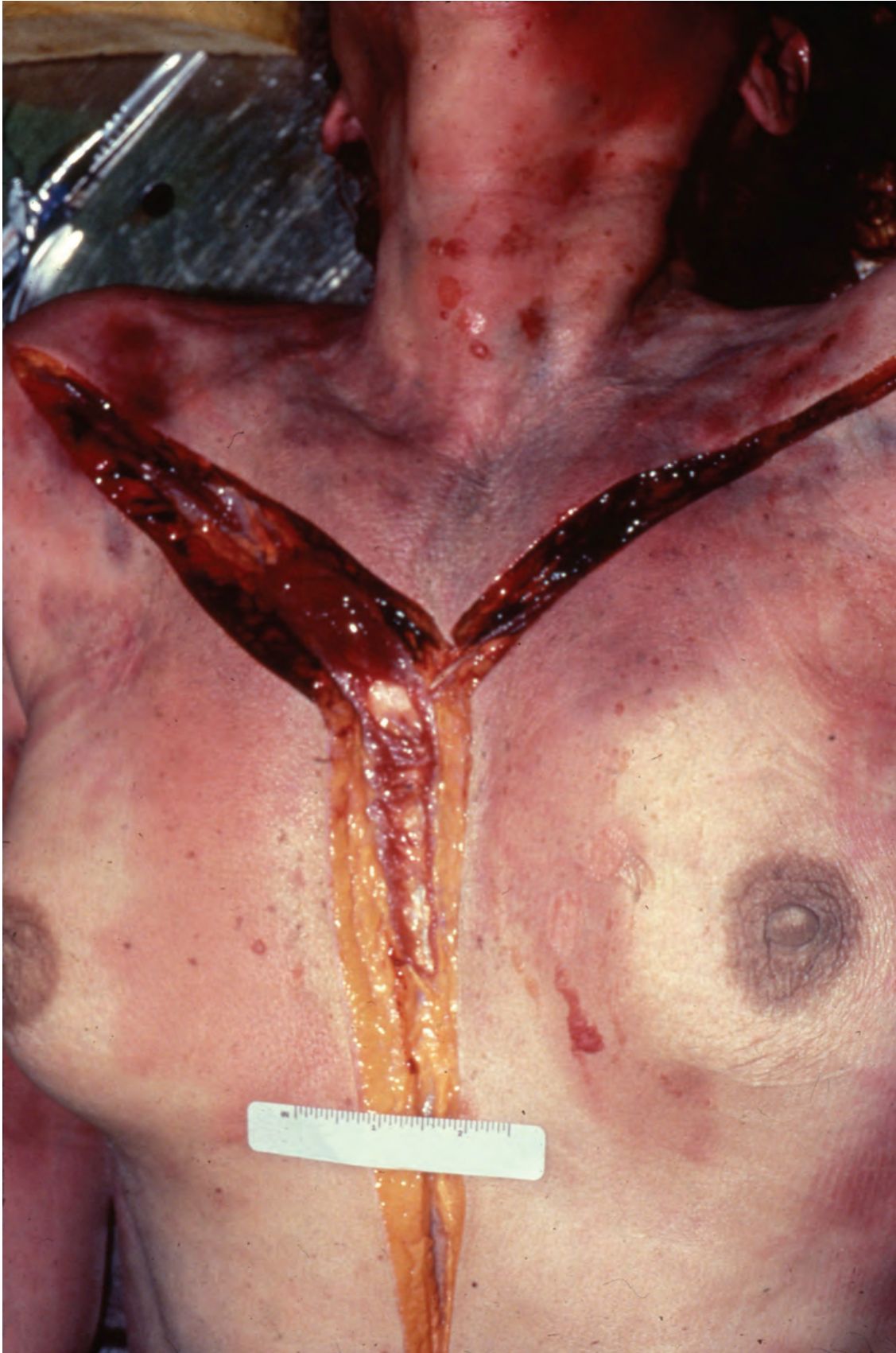
This individual had a pencil in his mouth when he collapsed at work. The pencil was inhaled and wedged in the right mainstem bronchus.



This child was found to have a pebble wedged within her right mainstem bronchus, as evident on this radiograph.



These individuals were trapped in machines that caused chest compression and inability to breathe. One was stuck in a box folding machine, another trapped under a car and another stuck under a single-person elevator lift. Note the imprint of the individual's hand (d) while he was struggling to escape, with the blister formation between these finger marks. Also note the pulmonary edema demonstrated by froth coming out of the mouth (f). This individual also had numerous petechial hemorrhages of the upper trunk, face, eyes, and visceral organs including the heart.



Homicidal asphyxia due to compression of chest and neck. Note the extensive hemorrhage at the superior chest visible at the superior aspect of the Y-shaped incision during autopsy. The lower aspect of this incision is yellow, anemic, and postmortem. This individual was punched, strangled and then the perpetrator sat on her chest during the assault.





Positional asphyxia. These individuals were markedly intoxicated and passed out in positions that prevented them from breathing, thus obstructing blood circulation.



# Index

## A

Abrasions, 194, 224, 227  
Accidental head trauma due to falling  
television, 173  
Acute alcoholism with hepatic steatosis,  
100  
Acute and chronic bronchial asthma, 37  
Acute and chronic pancreatitis in a chronic  
alcoholic, 105  
Acute and chronic track marks hidden by  
tattoos, 96  
Acute and healed peritonitis in a chronic  
alcoholic, 104  
Acute peritonitis, 121  
Acute, chronic and healing skin popping  
lesions, 97, 98  
Adenosine triphosphate (ATP), 4, 92  
Adipocere, 113, 133  
Adult polycystic kidney disease, 54  
Airway obstruction  
hotdog, 395  
pebble, 395  
pencil, 395  
Altered homicidal stab wound with  
postmortem blunt force trauma,  
254  
Amyloidosis, cardiac, 33  
Anterior neck dissection, 161  
Aortic dissection, 3, 23  
Aortic stenosis, 68  
Artifacts of therapy, 59, 61, 65  
Asphyxia  
accidental, pediatrics, 153, 154  
Cloth gag, 393  
due to un-ruptured placental  
membranes, 156  
Aspiration of brain, 236  
Asthma, pediatrics, 155  
Astrocytoma, 39  
Atherosclerosis  
aortic with aneurysm, 21  
coronary artery, 15  
Atypical entrance gunshot wound with  
contusion, 309  
Atypical gunshot wounds, 318, 319  
ATP, *see* Adenosine triphosphate  
Autopsy dissection, suspected child abuse,  
164  
Avulsions, 189

## B

Bite marks, 207, 208  
Blanching lividity, 114

Blunt-force injuries, 189–237  
Bloating, 125, 185  
Blood aspiration, 236  
Blowfly activity, 145  
Boat propeller injuries, 274, 275  
Brain  
embolism, 236  
shrinkage due to thermal injury, 363  
swelling, 179  
Breast carcinoma, 46  
Bronchogenic carcinoma, 46  
Brown fat microscopy, 188  
Bucket handle or corner fractures,  
pediatrics, 182  
Bullet wipe, 301, 303  
Bullets  
subadjacent to skin, 304  
new, old and weathered, 339  
Bumper impacts to legs, 216  
Burns, 353–372  
thermal, 353  
third-degree, 353

## C

Carbon monoxide (CO), 91  
poisoning with cherry red lividity, 110  
Cardiac tamponade, 17  
Central nervous system (CNS), 2, 88  
contusions, 217  
Cardiopulmonary resuscitation (CPR), 161  
Cerebral artery aneurysm, 42  
Cerebrospinal fluid (CSF), 3  
Cesarean section, abdominal wall  
hemorrhage, 72  
Chagas' disease, 34  
Chemical burns, 354  
Chest compression with asphyxia, 373  
Chest tube, 69, 70, 74  
Child abuse, 150, 170, 174, 181, 369  
Chopping type injuries with axe, 259  
Chronic  
alcoholism with micronodular cirrhosis,  
100  
obstructive pulmonary disease (COPD),  
38  
pyelonephritis with urolithiasis, 55  
track marks, 95  
Close range gunshot wounds, 296, 297, 298  
Coining, Asian folklore remedy, 83  
Colloid cyst of third ventricle, 41  
Congealing of fat, 117, 162  
Conjunctival petechiae, heart disease and  
resuscitation, 14  
Contact gunshot wounds, 291, 292, 293,  
294

Contusions, 193, 194, 195  
and ecchymosis with coagulopathy, 234  
old and recent, 163  
Cor pulmonale, 20  
Coronary artery  
anomalies, 29  
bypass grafting with hemorrhage, 78  
stent placement with hemorrhage, 81  
thrombosis, 15  
due to acute cocaine intoxication, 110  
Crushing  
by terrain leveler, 227  
by trash compactor, 185  
Cushing's syndrome, 50  
Cutdown site, 70

## D

Decapitation, 215  
Decubital ulceration, 43  
Defensive type wounds, 252  
Dehydration, pediatrics, 162  
Diaper rash, 150  
Dilated cardiomyopathy, 2, 20  
Dimethylarsenic acid (DMA), 91  
Dismembered bodies with saw, 276  
Dog feeding, 139, 140, 279  
Drowning, pediatrics, 155  
Drug packing, 109, 110  
Drying artifact, 119  
Duchenne's muscular dystrophy, 49

## E

Early mummification, 119  
Early putrefication, 123  
Electrical burns, 354  
Embalmed body, 146  
Emergency department (ED), 70, 154  
Emphysema, pulmonary, 38  
Endocarditis, 24, 25  
Entrance gunshot wound, 290, 305, 351  
through thick skin, 289  
with clotted blood, 309  
Epidural hemorrhage, 230, 363  
Epilepsy, 4, 39  
Escalator injury, 210  
Esophageal polyp, 44  
Esophageal varices due to hepatic cirrhosis,  
103  
Exit gunshot wounds, 283, 311, 312, 313, 314

## F

Fasciotomy incisions, 370  
Fetal gunshot wounds, 333

Fibromuscular hyperplasia of AV nodal artery, 161  
 First degree burn, 353, 356  
 Fixed lividity, 115  
 Flesh eating bacteria, group a beta-hemolytic streptococcus, 56  
 Fourth degree thermal burns, 360  
 Frenulum  
   healed laceration, 157  
   normal with dried blood, tinged secretions, 159  
   postmortem drying, 157  
   resuscitative laceration, 152  
 Fresh track marks, 94  
 Frozen body, 135

## G

Gastric cancer, 46  
 Gastritis due to chronic alcoholism, 103  
 Gastrointestinal (GI) bleeding, 5  
 Gastrostomy feeding tube, 76  
 Glazer safety ammunition, 337  
 Graze type gunshot wounds, 314, 324  
 Gunpowder residue  
   soot deposition on hands, 299  
   soot on clothing, 301  
 Gunshot skull fractures, 315  
 Gunshot wound  
   “blowback” blood spatter, 300  
   therapeutic alteration, 70  
   through eye glasses, 334  
   to dog, 339  
   with medallion imprint, 331  
   with septic complication, 310  
   with burns, 334  
 Gynecomastia due to hepatic cirrhosis, 102

## H

Healed gunshot wounds, 340  
 Healed stab wound, 282  
 Healing atypical gunshot wounds, 321  
 Healing skeletal fractures, 183  
 Hemochromatosis, cardiac, 33  
 Hemodialysis, arteriovenous graphs, 19  
 Hepatic cirrhosis  
   with coagulopathy, 102  
   with jaundice, 99  
 Homicidal sharp force injury, 196, 282  
 Hunting arrow injury, 267  
 Hyperextension injuries to pedestrians  
   stuck by car from behind, 220  
 Hypertensive cardiovascular disease, 19, 20, 23  
 Hyperthyroidism with goiter, 50  
 Hypertrophic cardiomyopathy, 31  
 Hypostasis, pediatrics, 161  
 Hypothermia, 51

## I

Identification following extensive thermal injury, 371

Impact injuries  
   to fence post, 210  
   to front windshield, 211  
   to gravel, 224  
   to side windshield, 211  
 Impaled on fence post, 278  
 Inca bone, 184  
 Incised wounds, 242  
 Infant crushed in trash compactor, 185  
 Infective endocarditis (IE), 2  
 Injury  
   caused by baseball bat, 200  
   caused by bicycle chain, 203  
   caused by gold putter, 199  
   caused by hammer, 201  
   caused by metal lock, 209  
   caused by nail through board, 204  
   caused by pipe, 199  
   caused by swallowed toothbrush, 205  
   due to broken bottle, 242  
   produced by tires, 218  
   due to dog attack, 280  
   to bound extremities, 209  
   to ear lobes, 206

Intermediate range of fire, 304, 305, 307  
 Internal injuries caused by gunshot wounds, 350  
 Internal lacerations, 227  
 Internal organs and putrefication, 138  
 Intra-cerebral hemorrhage, 39  
 Intubation complications, 65

## J

Jugular vein catheter placement with hemorrhage, 79

## L

lacerations, 195, 201, 209, 225  
 ligature strangulation  
   homicidal, 381  
   suicidal, 380, 381  
 linear extensions and “swallow-tail” injury, 244  
 lividity and contusions, pediatrics, 150  
 Lysergic acid diethylamide (LSD), 88

## M

3,4-Methylenedioxyamphetamine (MDMA), 90  
 Maceration, 136  
 Machete injuries, 258  
 Macronodular cirrhosis due to viral hepatitis, 101  
 Mag-safe ammunition, 338  
 Mallory-Weiss tears due to chronic alcoholism, 103  
 Manual strangulation, 382, 383  
 Marbling, 123, 126, 128  
 Marked decomposition with skeletonization, 134  
 Marked putrefication, 131

Meningioma, 40  
 Meningitis, cryptococcal, 47  
 Mini-14 ruger rifle, 350  
 Moderate putrefication, 126  
 Mold and mildew formation, 122  
 Mongolian spot, 163  
 Monomethylarsonic acid (MMA), 91  
 Morbid obesity, 14  
 Motor vehicle impact damage, 211  
 Motorcycle collision, 221  
 Mummification, 132, 142  
 Myocardial infarction, acute, 16, 17, 18  
 Myocarditis  
   aspergillosis, 35  
   candidal, 35  
   eosinophilic, 34  
   toxoplasmosis, 34  
   viral, 35

## N

Nail guns, 330  
 Nasogastric tube  
   aspiration of brain, 82  
   misplacement of, 82  
 Neck dissection, 384, 386, 387  
 Neonate putrefication, 136  
 Neurofibromatosis, 48  
 Normal, fresh, and fixed organs, 7–12

## O

Omphalocele, 187  
 Organ procurement, heart, 151  
 Osteogenesis imperfecta, 183  
 Osteoporosis, 5, 49, 223

## P

PCP, see Phencyclidine  
 Pacemaker lead with thrombus, 82  
 Pattern injuries caused by car grills, 214  
 Peptic ulcer disease in a chronic alcoholic, 104  
 Periorbital ecchymosis “raccoon eyes,” 194  
 Peripartum cardiomyopathy, 20  
 Peripheral vascular disease, 43  
 Petechial hemorrhages  
   of airway, 390  
   of face, 390  
   of heart, 390  
 Phencyclidine (PCP), 90  
 Photographic imagery, 1  
 Pick’s disease, 40  
 Pickaxe injury, 277  
 Pituitary adenoma, 40  
 Plastic bag, asphyxia, 392  
 Pleural adhesions, 38  
 Pompe’s disease, heart, 35  
 Portal vein stent placement with hemorrhage, 77  
 Positional asphyxia, 373, 398  
 Posterior neck and back dissection, 386

- Postmortem  
 abrasions, 140  
 eating by fish and crustaceans, 144  
 feeding by domestic pigs, 143  
 feeding by domesticated cat, 142  
 feeding by mice and rats, 144  
 water burns, 122
- Pregnancy  
 first trimester, 188  
 late second trimester, 186
- Pseudostippling, 309
- Pulmonary edema, 28, 159
- Pulmonary thrombo-embolus, 30
- Puncture wounds with nail through board, 273
- Purple head sign, 14
- Putrefactive  
 blister formation, 124  
 purging, 125
- Putrefication  
 following sepsis, 128  
 with thermal injury, 356
- Pyogenic liver abscess with chronic pancreatitis due to chronic alcoholism, 106
- R**
- Radiator impact head injury, 210
- Renal cyst, simple benign, 54
- Resuscitation artifact, pediatrics, 149, 150, 161, 170
- Rhabdomyosarcoma, 46
- Ricochet bullets, 323
- Rigor mortis, 112
- S**
- SAH, see Subarachnoid hemorrhages
- Sarcoidosis, 36
- Scalding injury, child abuse, 369
- Scars  
 demonstrating past suicide attempts and destructive behavior, 108  
 interpretation, pediatrics, 181
- Scleral and conjunctivae hemorrhages, 389
- Scleral and conjunctivae petechiae, 388
- Seat belt injuries, 212
- Second-degree burn, 353, 356
- Second- to third-degree burn, 367
- Septic complications of blunt force trauma, 69
- Serrated and Ginsu knife injuries, 262, 263
- Sexual assault with strangulation, 394
- Sharp force injury  
 by box cutter, 242  
 with broken glass from picture frame, 270
- Sharps, improper disposal, 82
- Shoe pattern injuries, 198
- Shored exit gunshot wounds, 317
- Shotgun wounds, 344, 345, 346, 349
- Sickle cell disease, 52, 53
- Skeletal fractures due to falls from great height, 224
- Skin  
 elasticity (turgor), postmortem, 162  
 slippage, 135
- Skull fractures, 213  
 postmortem thermal, 372
- Small vessel disease, 19
- Smoke inhalation, 355
- Smothering, homicidal, pediatrics, 158
- Stab wounds, 241  
 altered by decomposition, 282  
 altered by fire, 281  
 therapeutic alteration, 69  
 with flat head screwdriver, 272  
 with hilt marks, 245  
 with ice pick, 265  
 with knife and broken antenna, 266  
 with knife blade stuck in body, 257  
 with Phillips screwdriver, 271  
 with scissors, 264  
 with skin tension, 241  
 with thermal injury, 362
- Steering wheel impact injury, 212
- Stillborn, second trimester, 187
- Stomping injury, 177, 198, 266
- Strangulation staged as a suicidal hanging, 391
- Subarachnoid hemorrhage, 3, 228
- Subdural hematoma, antemortem thermal injury, 372
- Subdural hemorrhage, 231
- Subway train injuries, 222
- Sudden infant death syndrome (SIDS), 66, 147, 154, 159, 160
- Suicide  
 hanging, 376, 377, 378, 379, 380  
 overdoses by ingestion of drugs, 107  
 sharp force injury, 246, 247  
 Superficial gunshot wounds, 329  
 tracks, acute and healing, 320
- T**
- Tetrahydrocannabinol (THC), 89
- Tache noire, 118
- Tangential gunshot wounds, 326, 327, 328, 338
- Tardieu spots, 115
- Thymic and visceral petechiae, pediatrics, 160
- Thyroidectomy hemorrhage, 73
- Tissue procurement, 60
- Tongue and mouth swelling due to heat injury, 371
- Transbronchial lung biopsy with hemorrhage, 80
- Transjugular intrahepatic portosystemic shunt (TIPS), 77
- V**
- Volvulus  
 cecal, 45  
 small intestine, 44
- W**
- Water, postmortem burns, 122
- Wick effect, 360
- Wolff–Parkinson–White syndrome (WPW), 2





## Color Atlas of Forensic Medicine and Pathology

New York City has the largest medical examiner's office in the United States, and the Brooklyn division is the busiest of the five boroughs. Charles A. Catanese received his Forensic Pathology fellowship training in New York, and then worked full time as a Medical Examiner in the Brooklyn office for more than 10 years. He has personally performed more than 4000 autopsies, including over 400 homicides. Dr. Catanese has worked through several disasters, including TWA Flight 800, AA Flight 587, and more than nine months on the World Trade Center fatalities. He is currently the Chief Medical Examiner of Orange County, New York. Drawing on his wealth of knowledge and experience in solving some of the most difficult cases a forensic examiner could encounter, he assembles hundreds of images from his own work experience to present the *Color Atlas of Forensic Medicine and Pathology*.

Featuring twice the number of images as any other forensic pathology atlas, the book is filled with high-resolution photos that demonstrate postmortem changes of the human body and the different types of patterns produced in deaths caused by

- Natural causes
- Diagnostic or therapeutic procedures
- Substance abuse
- Poisoning
- Child abuse
- Firearms
- Blunt instruments
- Sharp instruments
- Burns
- Asphyxia

This easy-to-read atlas, created for medical and non-medical personnel, covers basic and advanced forensic concepts that relate to all manners of deaths. The carefully worded, unambiguous text describing each photo and the side-by-side comparisons of similar, yet different, pathologies make this remarkable atlas a powerful teaching tool for all those who must confront and solve the mystery of human demise. A fully searchable DVD version is also available.

4320X

 **CRC Press**  
Taylor & Francis Group  
an **informa** business  
[www.crcpress.com](http://www.crcpress.com)

6000 Broken Sound Parkway, NW  
Suite 300, Boca Raton, FL 33487  
270 Madison Avenue  
New York, NY 10016  
2 Park Square, Milton Park  
Abingdon, Oxon OX14 4RN, UK



[www.crcpress.com](http://www.crcpress.com)