

Minimally Invasive Gynecology

An Evidence Based
Approach

Geraldo Gastal Gomes-da-Silveira
Gustavo Py Gomes da Silveira
Suzana Arenhart Pessini
Editors

 Springer

EXTRAS ONLINE

Minimally Invasive Gynecology

Geraldo Gastal Gomes-da-Silveira
Gustavo Py Gomes da Silveira
Suzana Arenhart Pessini
Editors

Minimally Invasive Gynecology

An Evidence Based Approach

 Springer

Editors

Geraldo Gastal Gomes-da-Silveira
CliniOnco
Porto Alegre, Rio Grande do Sul
Brazil

Gustavo Py Gomes da Silveira
UFCSPA
Porto Alegre, Rio Grande do Sul
Brazil

Suzana Arenhart Pessini
Universidade Federal do Rio Grande do
Sul (UFRGS) and Universidade Federal
de Ciências da Saúde de Porto Alegre
(UFCSPA),
Porto Alegre, Rio Grande do Sul
Brazil

ISBN 978-3-319-72591-8 ISBN 978-3-319-72592-5 (eBook)
<https://doi.org/10.1007/978-3-319-72592-5>

Library of Congress Control Number: 2018936522

© Springer International Publishing AG, part of Springer Nature 2018

This work is subject to copyright. All rights are reserved by the Publisher, whether the whole or part of the material is concerned, specifically the rights of translation, reprinting, reuse of illustrations, recitation, broadcasting, reproduction on microfilms or in any other physical way, and transmission or information storage and retrieval, electronic adaptation, computer software, or by similar or dissimilar methodology now known or hereafter developed.

The use of general descriptive names, registered names, trademarks, service marks, etc. in this publication does not imply, even in the absence of a specific statement, that such names are exempt from the relevant protective laws and regulations and therefore free for general use.

The publisher, the authors and the editors are safe to assume that the advice and information in this book are believed to be true and accurate at the date of publication. Neither the publisher nor the authors or the editors give a warranty, express or implied, with respect to the material contained herein or for any errors or omissions that may have been made. The publisher remains neutral with regard to jurisdictional claims in published maps and institutional affiliations.

Printed on acid-free paper

This Springer imprint is published by the registered company Springer International Publishing AG part of Springer Nature
The registered company address is: Gewerbestrasse 11, 6330 Cham, Switzerland

Preface

The purpose of this book is to present some of the most important topics in the minimally invasive gynecology by the greatest authors worldwide.

It was a careful work to make this dream team of the current minimally invasive gynecology. Each author was invited based on his or her personal experience and international status in the specific theme of the chapter, without relationship with the country, continent, or medical society.

We believe in this formula, based on the contributor's authority, to build a solid scientific manuscript, free of any other interests or purposes.

The result looks amazing: a very interesting book, friendly to read and rich in content.

We would like to thank so much our colleagues from Europe, the United States, and South America who spend time and energy to allow us to deliver to gynecologists around the world this exclusive and unique book in minimally invasive gynecology area.

We hope to contribute with deep scientific content that could be helpful to everybody in the minimally invasive gynecology field, from fellows to experienced gynecologists.

Porto Alegre, Rio Grande do Sul, Brazil Geraldo Gastal Gomes-da-Silveira
Porto Alegre, Rio Grande do Sul, Brazil Gustavo Py Gomes da Silveira
Porto Alegre, Rio Grande do Sul, Brazil Suzana Arenhart Pessini

Contents

1	Minimally Invasive Gynecology: A Therapeutic (R)evolution! . . .	1
	Geraldo Gastal Gomes-da-Silveira	
2	Laparoscopic Hysterectomy: The Big Cutoff in Laparoscopic Surgery Development	5
	Harry Reich	
3	Robotics in Gynecology	17
	Arnold P. Advincula and Obianuju Sandra Madueke-Laveaux	
4	Single-Port Surgery.	31
	Kevin J. E. Stepp and Dina A. Bastawros	
Part I Anatomy and Surgical Routes		
5	Anatomical Landmarks in Deep Endometriosis Surgery	45
	Marcello Ceccaroni, Giovanni Roviglione, Daniele Mautone, and Roberto Clarizia	
6	Nerve-Sparing Routes in Radical Pelvic Surgery	61
	Nucelio L. B. M. Lemos, Reitan Ribeiro, Gustavo Leme Fernandes, Mauricio S. Abrão, and Renato Moretti-Marques	
Part II Endometriosis		
7	Patient Language in Endometriosis Surgery	79
	William Kondo, Nicolas Bourdel, Monica Tessmann Zomer, and Michel Canis	
8	Endometriosis: From Diagnosis to Surgical Management	91
	Mateus Moreira Santos Rosin and Mauricio Simões Abrão	
9	Surgical Treatment of Deep Endometriosis	105
	Rodrigo Fernandes, Karolina Afors, and Arnaud Wattiez	
10	Endometrioma and Ovarian Reserve: A Surgical Approach	121
	María-Angeles Martínez-Zamora, Gemma Casals, Sara Peralta, and Francisco Carmona	

Part III General Gynecologic Procedures

- 11 Vaginal Hysterectomy, Salpingectomy, and Adnexectomy** 131
Iwona Gabriel and Rosanne Kho
- 12 Minimally Invasive Myomectomy** 137
Kirsten J. Sasaki and Charles E. Miller
- 13 Salpingectomy in Benign Hysterectomy** 149
Meritxell Gràcia, Jordina Munrós, Mariona Rius,
and Francisco Carmona
- 14 Ovarian Cysts: Preoperative Evaluation
and Laparoscopic Approach** 157
William Kondo, Monica Tessmann Zomer, Nicolas Bourdel,
and Michel Canis
- 15 Laparoscopic Cerclage** 175
Geraldo Gastal Gomes-da-Silveira, Suzana Arenhart Pessini,
and Gustavo Py Gomes da Silveira
- 16 Cesarean Scar Defects: Hysteroscopic Treatment
of Isthmocele in Menstrual Disorders and Infertility** 181
Carlo Tantini, Gersia Araújo Viana, and Giampietro Gubbini

Part IV Uro-gynecology

- 17 Minimally Invasive Approach in Urogynecology:
An Evidence-Based Approach** 195
Tatiana Pfiffer Favero and Kaven Baessler
- 18 Urinary Incontinence: Minimally Invasive Techniques
and Evidence-Based Results.** 217
Hemikaa Devakumar and G. Willy Davila

Part V Onco-gynecology

- 19 Radical Wide Local Resection in Vulvar Cancer** 231
Alejandro Soderini and Alejandro Aragona
- 20 Classification of Radical Hysterectomy** 237
Denis Querleu
- 21 Laparoscopic Operative Staging in Cervical Cancer** 247
Christhardt Köhler and Giovanni Favero
- 22 Laparoscopic-Vaginal Radical Hysterectomy** 257
Denis Querleu and Eric Leblanc
- 23 Laparoscopic and Robotic Radical Hysterectomy** 265
Farr Nezhat, Maria Andrikopoulou, and Ashley Bartalot
- 24 Robotic Radical Hysterectomy: Surgical Technique** 275
Antonio Gil-Moreno and Javier F. Magrina

25	Paraaortic Laparoscopic Node Dissections	283
	Eric Leblanc, Fabrice Narducci, Delphine Hudry, Lucie Bresson, Arnaud Wattiez, Audrey Tsunoda, and Denis Querleu	
26	Transperitoneal Para-aortic Lymphadenectomy: Surgical Technique, Results, Challenges, and Complications	297
	Audrey Tiekou Tsunoda, Carlos Eduardo Mattos da Cunha Andrade, Bruno Roberto Braga Azevedo, José Clemente Linhares, and Reitan Ribeiro	
27	Radical Vaginal Trachelectomy	305
	Suzana Arenhart Pessini, Gustavo Py Gomes da Silveira, and Denis Querleu	
28	Laparoscopic Radical Trachelectomy Vaginal-Assisted Nerve Sparing: Description of the Surgical Technique and Early Results in a Reference Oncology Brazilian Center	311
	Marcelo de Andrade Vieira, Geórgia Fontes Cintra, Ricardo dos Reis, and Carlos Eduardo Mattos da Cunha Andrade	
29	Laparoscopic Surgery in Endometrial Carcinoma	321
	Natalia R. Gomez-Hidalgo and Pedro T. Ramirez	
30	Ovarian Cancer: Current Applications of Minimally Invasive Techniques	333
	Giovanni Favero, Christhardt Köhler, Alexandre Silva e Silva, and Jesus Paula Carvalho	
31	Sentinel Node in Gynecological Cancer	345
	Cecilia Escayola Vilanova and Denis Querleu	
 Part VI Complications		
32	Complications of Laparoscopy	363
	Jamal Mourad, Stephanie Henderson, and Javier Magrina	
	Index	375

Contributors

Mauricio Simões Abrão, M.D., Ph.D. Department of Obstetrics and Gynecology, University of São Paulo Medical School, São Paulo, SP, Brazil

Arnold P. Advincula, M.D. Department of Obstetrics and Gynecology, Division of Gynecologic Specialty Surgery, Columbia University Medical Center/New York-Presbyterian Hospital, New York, NY, USA

Karolina Afors ICESP, University of São Paulo, São Paulo, Brazil

Carlos Eduardo Mattos da Cunha Andrade, M.D., M.Sc. Gynecologic Oncology Department, Hospital de Câncer de Barretos, Barretos, SP, Brazil

Maria Andrikopoulou, M.D. Winthrop University Hospital, Mineola, NY, USA

Alejandro Aragona, M.D. University of Buenos Aires, Buenos Aires, Argentina

Oncologic Hospital of Buenos Aires “Marie Curie”, Buenos Aires, Argentina

Bruno Roberto Braga de Azevedo, M.D. Instituto de Hematologia e Oncologia do Paraná and Hospital São Vicente, Curitiba, PR, Brazil

Kaven Baessler, M.D. Franziskus und St. Joseph Krankenhäuser, Beckenbodenzentrum, Berlin, Germany

Ashley Bartalot, M.D. Winthrop University Hospital, Mineola, NY, USA

Dina A. Bastawros, M.D. Urogynecology and Minimally Invasive Gynecologic Surgery, Advanced Surgical Specialties for Women, Carolinas Healthcare System, Charlotte, NC, USA

Department of Obstetrics and Gynecology, Mercy Medical Plaza, Charlotte, NC, USA

Nicolas Bourdel Department of Gynecologic Surgery, CHU Estaing, Clermont-Ferrand, France

Lucie Bresson, M.D. Department of gynecologic oncology, Centre Oscar Lambret, Lille, France

Michel Canis Department of Gynecologic Surgery, CHU Estaing, Clermont-Ferrand, France

Francisco Carmona, M.D., Ph.D. Department of Gynecology, Institut Clínic of Gynecology, Obstetrics and Neonatology, Hospital Clínic of Barcelona, Barcelona, Spain

Jesus Paula Carvalho, M.D., Ph.D. Department of Gynecology, Instituto do Câncer do Estado de São Paulo (ICESP), Faculdade de Medicina da Universidade de São Paulo, São Paulo, SP, Brazil

Gemma Casals, M.D., Ph.D. Department of Gynecology, Institut Clínic of Gynecology, Obstetrics and Neonatology, Hospital Clínic of Barcelona, Barcelona, Spain

Marcello Ceccaroni, M.D., Ph.D. Department of Gynecology and Obstetrics, Gynecologic Oncology and Minimally-Invasive Pelvic Surgery, International School of Surgical Anatomy, “Sacred Heart” Hospital, Negrar (Verona), Italy

Cecilia Escayola, M.D. Hospital Pilar Quiron Salud, Barcelona, Spain

Geórgia Fontes Cintra Gynecologic Oncology Department, Hospital de Câncer de Barretos, Barretos, SP, Brazil

Roberto Clarizia, M.D., Ph.D. Department of Gynecology and Obstetrics, Gynecologic Oncology and Minimally-Invasive Pelvic Surgery, International School of Surgical Anatomy, “Sacred Heart” Hospital, Negrar (Verona), Italy

G. Willy Davila Section of Urogynecology and Reconstructive Pelvic Surgery, Cleveland Clinic Florida, Weston, FL, USA

Hemikaa Devakumar Section of Urogynecology and Reconstructive Pelvic Surgery, Cleveland Clinic Florida, Weston, FL, USA

Giovanni Favero, M.D. Department of Advanced Operative and Oncologic Gynecology, Asklepios Hospital, Hamburg, Germany

Department of Gynecology, Instituto do Câncer do Estado de São Paulo (ICESP), Faculdade de Medicina da Universidade de São Paulo, São Paulo, SP, Brazil

Gustavo Leme Fernandes, M.D., Ph.D. Gynecology Oncology Division, Department of Obstetrics and Gynecology, Central Hospital of Irmandade da Santa Casa de Misericórdia de São Paulo, São Paulo, SP, Brazil

Rodrigo Fernandes ICESP, University of São Paulo, São Paulo, Brazil

Iwona Gabriel, M.D. Department of Obstetrics and Gynecology, Medical University of Silesia, Bytom, Poland

Antonio Gil-Moreno, M.D., Ph.D. Unit of Gynecologic Oncology, Department of Obstetrics and Gynecology, Hospital Materno-Infantil Vall d’Hebron, Barcelona, Spain

Geraldo Gastal Gomes-da-Silveira CliniOnco, Porto Alegre, Rio Grande do Sul, Brazil

Natalia R. Gomez-Hidalgo Department of Surgery, Memorial Sloan Kettering Cancer Center, New York, NY, USA

Meritxell Gràcia, M.D. Gynecology Department, Institut Clínic de Ginecologia, Obstetrícia i Neonatologia, Hospital Clínic de Barcelona, Barcelona, Spain

Giampietro Gubbini, M.D. Clinica Madre Fortunata Toniolo, Bologna, Italy

Stephanie Henderson The Women's Center, Banner University Medical Center Phoenix, University of Arizona College of Medicine—Phoenix, Phoenix, AZ, USA

Delphine Hudry Department of Gynecologic Oncology, Centre Oscar Lambret, Lille, France

Rosanne Kho, M.D. Department of Obstetrics and Gynecology, Women's Health Institute, Cleveland Clinic, Cleveland, OH, USA

Christhardt Köhler, M.D., Ph.D. Department of Advanced Operative and Oncologic Gynecology, Asklepios Hospital, Hamburg, Germany

William Kondo Department of Gynecology, Sugisawa Medical Center, Curitiba, PR, Brazil

Department of Gynecology, Vita Batel Hospital, Curitiba, PR, Brazil

Eric Leblanc, M.D. Department of Gynaecologic Oncology, Oscar Lambret Center, Lille, France

Nucelio L.B.M. Lemos, M.D., Ph.D. Department of Obstetrics and Gynecology, University of Toronto, Women's College Hospital, Toronto, ON, Canada

José Clemente Linhares, M.D., M.Sc. Breast and Gynecologic Oncology Department, Instituto de Oncologia do Paraná, Erasto Gaertner Hospital, Curitiba, PR, Brazil

Obianuju Sandra Madueke-Laveaux, M.D. Department of Obstetrics and Gynecology, Division of Gynecologic Specialty Surgery, Columbia University Medical Center/New York-Presbyterian Hospital, New York, NY, USA

Javier F. Magrina, M.D. Department of Obstetrics and Gynecology, Mayo Clinic Arizona, Phoenix, AZ, USA

María-Angeles Martínez-Zamora, M.D., Ph.D. Department of Gynecology, Institut Clínic of Gynecology, Obstetrics and Neonatology, Hospital Clínic of Barcelona, Barcelona, Spain

Charles E. Miller, M.D. The Advanced Gynecologic Surgery Institute, Naperville, IL, USA

Department of Obstetrics and Gynecology, Lutheran General Hospital, Naperville, IL, USA

Renato Moretti-Marques, M.D., Ph.D. Oncology Department, Hospital Israelita Albert Einstein, São Paulo, SP, Brazil

Jamal Mourad The Women's Center, Banner University Medical Center Phoenix, University of Arizona College of Medicine—Phoenix, Phoenix, AZ, USA

Jordina Munrós, M.D. Gynecology Department, Institut Clínic de Ginecologia, Obstetrícia i Neonatologia, Hospital Clínic de Barcelona, Barcelona, Spain

Fabrice Narducci, M.D. Department of gynecologic oncology, Centre Oscar Lambret, Lille, France

Farr Nezhat, M.D., FCOG, FACS Weill Cornell Medical College, Cornell University, Ithaca, NY, USA

Department of Obstetrics, Gynecology and Reproductive, Medicine School of Medicine, Stony Brook University, Stony Brook, NY, USA

Minimally Invasive Gynecologic Surgery and Robotics, Winthrop University Hospital, Mineola, NY, USA

Sara Peralta, M.D. Department of Gynecology, Institut Clínic de Gynecology, Obstetrics and Neonatology, Hospital Clínic of Barcelona, Barcelona, Spain

Suzana Arenhart Pessini, M.D., Ph.D. Universidade Federal do Rio Grande do Sul (UFRGS) and Universidade Federal de Ciências da Saúde de Porto Alegre (UFCSPA), Porto Alegre, RS, Brazil

Tatiana Pfiffer, M.D. Abteilung für Gynäkologie, Helios Mariahilf Klinik, Hamburg, Germany

Daniele Mautone, M.D. Department of Gynecology and Obstetrics, Gynecologic Oncology and Minimally-Invasive Pelvic Surgery, International School of Surgical Anatomy, "Sacred Heart" Hospital, Negrar (Verona), Italy

Denis Querleu, M.D. Department of Surgery, Institut Bergonié, Bordeaux, France

Pedro T. Ramirez Department of Gynecology Oncology and Reproductive Medicine, The University of Texas MD Anderson Cancer Center, Houston, TX, USA

Harry Reich, M.D., F.A.C.O.G., F.R.C.O.G. Advanced Laparoscopic Surgery, Columbia Presbyterian Medical Center, New York, NY, USA

Ricardo dos Reis Gynecologic Oncology Department, Hospital de Câncer de Barretos, Barretos, SP, Brazil

Reitan Ribeiro, M.D. Gynecologic Oncology Department, Hospital Erasto Gaertner, Instituto de Oncologia do Paraná, and Hospital Marcelino Champagnat, Curitiba, PR, Brazil

Surgical Oncology Department, Erasto Gaertner Hospital, Curitiba, PR, Brazil

Mariona Rius, M.D. Gynecology Department, Institut Clínic de Ginecologia, Obstetrícia i Neonatologia, Hospital Clínic de Barcelona, Barcelona, Spain

Mateus Moreira Santos Rosin Department of Obstetrics and Gynecology, University of São Paulo Medical School, São Paulo, SP, Brazil

Giovanni Roviglione, M.D. Department of Gynecology and Obstetrics, Gynecologic Oncology and Minimally-Invasive Pelvic Surgery, International School of Surgical Anatomy, “Sacred Heart” Hospital, Negrar (Verona), Italy

Kirsten J. Sasaki, M.D. The Advanced Gynecologic Surgery Institute, Naperville, IL, USA

Department of Obstetrics and Gynecology, Lutheran General Hospital, Naperville, IL, USA

Alexandre Silva e Silva, M.D. Department of Gynecology, Instituto do Câncer do Estado de São Paulo (ICESP), Faculdade de Medicina da Universidade de São Paulo, São Paulo, SP, Brazil

Gustavo Py Gomes da Silveira, M.D., Ph.D. Federal do Rio Grande do Sul (UFRGS) and Universidade Federal de Ciências da Saúde de Porto Alegre (UFCSPA), Porto Alegre, RS, Brazil

Alejandro Soderini, M.D., Ph.D. University of Buenos Aires, Buenos Aires, Argentina

Oncologic Hospital of Buenos Aires “Marie Curie”, Buenos Aires, Argentina

Kevin J.E. Stepp, M.D. Urogynecology and Minimally Invasive Gynecologic Surgery, Advanced Surgical Specialties for Women, Carolinas Healthcare System, Charlotte, NC, USA

Department of Obstetrics and Gynecology, University of North Carolina-Chapel Hill, Charlotte, NC, USA

Mercy Medical Plaza, Charlotte, NC, USA

Department of Obstetrics and Gynecology, Mercy Medical Plaza, Charlotte, NC, USA

Carlo Tantini, M.D. Centro de Pesquisa e Assistência em Reprodução Humana (CEPARH), Salvador, BA, Brazil

CENAFERT/INSEMINA, Centro de Medicina Reprodutiva, Salvador, BA, Brazil

Audrey Tsunoda, M.D. Department of gynecologic oncology, Hospital Israelita Albert Einstein Curitiba, São Paulo, Brasil

Audrey T. Tsunoda, M.D., Ph.D. Gynecologic Oncology Department, Hospital Erasto Gaertner, Instituto de Oncologia do Paraná, Universidade Positivo and Hospital Marcelino Champagnat, Curitiba, PR, Brazil

Gersia Araújo Viana, M.D. CENAFERT/INSEMINA, Centro de Medicina Reprodutiva, Salvador, BA, Brazil

Marcelo de Andrade Vieira Gynecologic Oncology Department, Hospital de Câncer de Barretos, Barretos, SP, Brazil

Arnaud Wattiez, M.D., Ph.D University of Strasbourg - France, Head of Gynecology department Latifa Hospital, Dubai, UAE
University of Strasbourg, Strasbourg, France

Monica Tessmann Zomer Department of Gynecology, Sugisawa Medical Center, Curitiba, PR, Brazil

Department of Gynecology, Vita Batel Hospital, Curitiba, PR, Brazil



Minimally Invasive Gynecology: A Therapeutic (R)evolution!

1

Geraldo Gastal Gomes-da-Silveira

A treatment with the same effectiveness, fewer morbidity, faster recovery times, lower infection rates, less bleeding, an earlier return to work and social life, better cosmetic results, and lower costs: Welcome to minimally invasive gynecology!

Gynecology and Minimally Invasive Approaches: The Beginning

Historically, gynecological surgery has used the vaginal route as a minimally invasive operation approach for hysterectomies, most prolapses and urinary incontinence. Gynecologists are familiar with minimally invasive concepts because the vaginal route represents the natural route to perform these procedures.

The first laparoscopic hysterectomy was performed in 1988 by Harry Reich. This historic operation broke previous paradigms about gynecology and popularized the new way of thinking about gynecological operations. In the last 25 years, laparoscopic development has been responsible for many advances in minimally invasive surgery.

G. G. Gomes-da-Silveira
CliniOnco, Porto Alegre, Rio Grande do Sul, Brazil
e-mail: gggomesdasilveira@terra.com.br

In the development of laparoscopic surgery, the first few years were difficult because of the lack of reliably-powered equipment and adequate video technology. Some of the initial problems that occurred were regarding operation time, bleeding, urinary tract and intestinal lesions, and a high conversion rate. The absence of laparoscopic surgery standards was a crucial factor in the initial challenges in this field. There were only a few skillful and innovative surgeons who were able to perform these complex procedures with good results. As an example of the progression in this field, the technique used for the laparoscopic hysterectomy was only standardized after the introduction of a specific uterine manipulator designed for this surgery. At this time, new horizons began to appear for laparoscopic surgeons around the world. Besides the surgical techniques, it is very important that surgical devices continue to be researched and refined according to new scientific evidence published. As the equipment advances, this will allow more procedures to be performed using minimally invasive approaches.

The Minimally Invasive Concept

The minimally invasive concept describes a less invasive technique to perform any kind of surgical procedure. It does not necessarily mean a

small procedure, but instead it results in fewer morbidity relative to the size of the surgical access point, dissection, and specimen extraction.

Confusion can occur between the minimally invasive term and conservative gynecological surgery or fertility-sparing procedures. For example, the surgery techniques used to treat a stage 1 ovarian cancer with unilateral salpingo-oophorectomy by laparotomy or a laparotomic radical trachelectomy are conservative and fertility-sparing surgeries, but they are not minimally invasive surgeries.

The benefits linked to minimally invasive procedures are: less bleeding, lowered post-operative pain and infection rates, shorter hospital stay, rapid recovery, and return to familiar, social, and professional life.

Development of the Laparoscopic Technique: From Skills to Cultural Changing

Development of advanced laparoscopic surgery followed the universal learning curve, which is different to the personal learning curve. At the beginning, laparoscopic techniques for most procedures were not standardized as surgeons were in the learning process. The second step in this learning curve was to demand better quality video equipment, improved power sources, and ergonomic instruments. The third step involved the more personal process. Surgeons experienced in complex laparoscopic surgeries began teaching inexperienced surgeons. And in the final step of the learning curve, many procedures began to follow the minimally invasive approach as more scientific evidence supported the use of minimally invasive surgeries in a number of different fields, specifically cancer, reconstruction, and infection diseases.

Nowadays, laparoscopic advances in techniques as well as in equipment (video and surgical devices) have resulted in many surgeries becoming safer, with less bleeding and the use of nerve-sparing techniques. What the surgeon sees by using the modern video apparatus could be of

a much better quality compared to that seen in open surgery. With advanced surgical skills and good equipment, unbelievable pelvic nerve and vascular dissections are possible today using laparoscopy.

Despite the many advantages of minimally invasive procedures compared to laparotomic access, it has been challenging to disseminate these techniques and encourage most surgeons around the world to adopt them systematically. Reasons for this include the long learning curve and lack of adequate instrumental and surgical equipment. Many surgeons, after successful graduation in minimally invasive gynecology, return to their hospital/institution and do not progress further in the surgical process. Why is it difficult to popularize the minimally invasive culture?

In many institutions, the culture of traditional surgery remains very strong at all levels—from leadership to the surgical team. This culture can only be changed when the institutional culture changes and this change is dependent on information, education, scientific progress, systemic thinking, training, team empathy, and leadership support. The minimally invasive concept should spread to all levels in the institution, as one unit with the same goal.

The Participation of Scientific Societies

During the development of minimally invasive gynecology, the work of scientific societies (e.g., AAGL-American Association of Gynecologic Laparoscopists, Advancing Minimally Invasive Gynecology Worldwide in the USA and ESGE-European Society for Gynaecological Endoscopy in Europe) was crucial to the scientific and technical evolution of this concept, as well as to attract more surgeons to this area. As opposed to the majority of scientific innovations, minimally invasive gynecology (specifically laparoscopic surgery) did not originate from public universities and traditional schools of medicine. It originated from a parallel researching field developed by private institutions and societies.

During this time, public institutions reinvented vaginal surgery. It became more powerful and more standardized, with new morcellation and cancer surgery techniques, as well as urethral slings in urinary stress/incontinence procedures. In this friendly competition between laparoscopic and vaginal surgery, both techniques improved and became more useful and safer. This was good for surgeons and patients.

For Hospitals

Another important benefit of the minimally invasive culture is the lowered demand on hospital beds. Currently, most hospitals have 100 % occupancy of inpatient beds. This is the main problem in admission of new surgical patients. With minimally invasive gynecology, the shorter hospital-

ization period allows for increased capacity of the institution. In addition to this, many surgeries (e.g., hysterectomy), when performed by minimally invasive techniques, can be performed in the outpatient setting.

Conclusion

With the full use of minimally invasive techniques, changing institutional cultures with all staff working together towards one goal, everybody wins: surgeons, hospitals, health-care systems, and, most importantly, the patients. Patients will receive the highest level of treatment resulting in minimal peri-operative morbidity and faster recovery. Gynecology has been improved with the addition of the minimally invasive concept.

There is no doubt—the minimally invasive concept is a therapeutic revolution!



Laparoscopic Hysterectomy: The Big Cutoff in Laparoscopic Surgery Development

Harry Reich

Laparoscopic Hysterectomy: Historical Perspective

Laparoscopic hysterectomy, defined as the laparoscopic ligation of the uterine vessels, is a substitute for abdominal hysterectomy, with more attention to ureteral identification and cuff suspension. Laparoscopic hysterectomy (LH) is rarely indicated for the treatment of abnormal uterine bleeding (AUB) from a normal-sized uterus with no other associated pathologies! Most of these cases can be done vaginally without the use of a laparoscope [1].

Background

LH did not occur by accident. The necessary skills were acquired before this well-known event. And they occurred before video cameras were available. For a right-handed surgeon standing on the patient's left side, left-handed skills were required as they were necessary while the surgeon's right hand held the laparoscope.

Laparoscopic hysterectomy evolved from my commitment in the late 1970s and early 1980s to minimize abdominal incisions in all cases by a combination of vaginal and laparoscopic surgery.

This choice was facilitated by my discovery in 1976 that bipolar desiccation of the infundibulopelvic ligament effectively controlled bleeding from the ovarian blood supply. For the next 10 years, I used the laparoscope to help start or finish vaginal hysterectomies, essentially doing what is called an LAVH today. After 1980, I did less than 20 laparotomies over the next 25 years.

I started my private practice in 1976, and vaginal surgery was my major area of interest. That year, I was the consultant for an infertility clinic that had over 100 active patients who had never been laparoscoped. During residency training, I did a diagnostic laparoscopy for infertility and, when indicated, laparotomy surgery usually 2 months later for excision of ovarian endometriosis and separation of tubal adhesions. Before that year was out, I realized that many of these operations could be done at the time of diagnostic laparoscopy. The cul-de-sac was considered "no man's land" in the late 1970s, and pain from there was treated by presacral neurectomy.

In 1983 I began photodocumenting all of my operations using an Olympus OM2 camera with CLEF light source system, after a visit to Bob Hunt during Boston Marathon week. (I bought my own equipment.) I used the laparoscope as a part of a total vaginal hysterectomy (TVH) before 1980, whenever uncomfortable with an exclusively vaginal approach. Thus, by 1988, I had done many laparoscopic oophorectomies and lysis of adhesions procedures with TVH. Today these cases would be called LAVH [2–4].

H. Reich, M.D., F.A.C.O.G., F.R.C.O.G.
Advanced Laparoscopic Surgery, Columbia
Presbyterian Medical Center, New York, NY, USA

I consider 1976–1980 to be my learning curve years, as I prepared myself to be a successful laparoscopic surgeon. By 1985, I was competent to do almost all gynecologic operations laparoscopically or vaginally, including oncology. That summer I spent 2 days in Clermont-Ferrand, France, with Professor Bruhat and his team to give me confidence to continue on the path that I was on, as no one was doing these surgeries in the USA. In 1985 I presented laparoscopic treatment of pelvic abscess at ACOG and both laparoscopic endometrioma excision and laparoscopic electrosurgical oophorectomy at AAGL. I began teaching these techniques soon thereafter as they were considered original and taught an advanced laparoscopic course at AAGL for the next 20 years. One year earlier, Ron Levine presented laparoscopic oophorectomy using endoloop sutures after visiting Kurt Semm in Kiel, Germany. Ron then put together the first US free-standing laparoscopic surgery course in April 1986 in Louisville and invited me as part of the faculty, along with Semm, Hulka, and Hasson. Kurt Semm told me “you learn to suture, you be king” in his broken English. He did not like my use of electrosurgery.

Again, please realize that these operations were done with the operating surgeon visualizing the operative field with his right eye while holding the laparoscope with the right hand, with minimal assistance before 1986. Throughout the rest of the 1980s, I operated using my eye and with a beam splitter to the video monitor so my assistant surgical technician and my students could see. In the 1990s I switched to the more conventional video observation techniques but held the camera in my right hand. I rarely used a doctor assistant, so nurses or anesthetists held the camera when I sutured. Most of these techniques have disappeared with the questionable new technology of today.

First Laparoscopic Hysterectomy

The first laparoscopic hysterectomy recorded in the literature was done in January 1988. This was called a laparoscopic hysterectomy as the major

blood supply to the uterus was secured laparoscopically. The only difference between this operation and total laparoscopic hysterectomy (TLH) is that the vaginal cuff was closed vaginally [5–8].

The case involved a 14-week-size symptomatic fibroid uterus. A 3 mm and a 5 mm lower quadrant trocar were used. I dissected, desiccated, and divided the left infundibulopelvic ligament and the right utero-ovarian ligament. I exposed the ureter and uterine vessels on each side. I decided to ligate the uterine vessels using bipolar desiccation instead of completing the operation from below vaginally, as was my usual custom. The uterine artery and vein on each side had been skeletonized. Each ureter had been exposed to demonstrate their distance from the area of the bipolar desiccation energy. An ammeter was used to monitor current flow to determine the end point of the bipolar desiccation process. In that operation I opened the vagina anteriorly and posteriorly before going vaginally to complete the procedure. Operation time was 3 h. All instruments used were reusable including the trocars.

Development of Total Laparoscopic Hysterectomy (TLH) Concept

Soon thereafter in 1988, the next problem was tackled: TLH. It was cumbersome and time-consuming for the surgeon to change from operating laparoscopically to a vaginal position and back again. And I did not like a position change with the patient asleep. I decided that the laparoscopic view was so good that the vagina could be opened circumferentially in most cases laparoscopically. I used a CO₂ laser through the operating channel of the operating laparoscope or cutting current electrosurgery to open the cervicovaginal junction posteriorly over sponge forceps and anteriorly over a narrow Deaver and then connect the two incisions. The uterosacral ligaments work divided. The major problem, of course, was loss of pneumoperitoneum. We went through 2 years using wet packs, balloon catheters, and surgical gloves filled with air or fluid to

maintain pneumoperitoneum during cuff suturing. It was always a struggle.

In December 1990 at a meeting in London, England, I met Professor Gerhard Buess from Germany who was suturing the rectum through a large anoscope manufactured by Richard Wolf GmbH, Knittlingen, Germany. This instrument was what I needed to be able to maintain pneumoperitoneum during the culdotomy incision of laparoscopic hysterectomy and to suture repair the vaginal cuff afterward. Richard Wolf GmbH, Knittlingen, Germany modified it for me. The concept was simple: the instrument had to be made longer than an anoscope and be approximately 4 cm in diameter. (There was too much leakage at 3.5 cm diameter in most women.) When applied to the cervix, the surgeon could see the junction of the anterior and the posterior vagina with the cervix. The posterior rim is longer than the anterior so that the posterior fornix can be entered first. Thereafter the anterior fornix is entered, and the lateral vagina on each side is pushed upward and outward away from the ureters to complete the incision on each side without losing pneumoperitoneum. The tube is reinserted into the vagina after the uterus is out to maintain pneumoperitoneum during cuff closure. I believe that the uterosacral ligaments must be divided to successfully perform a laparoscopic hysterectomy, and I use them for prophylactic cuff suspension during cuff repair at the end of the operation. This vaginal delineator device remains available in the Wolf catalog today. I believe most of the vaginal delineators that are now available on the market are modifications of this original idea that was developed in the early 1990s [7–9].

Realize that the opening of this tube is large enough that it doesn't hug the cervix, thus avoiding the prolapse problems common with the intrafascial hysterectomy-type procedure done with the Koh Cup. Intrafascial hysterectomy leaves the uterosacral ligaments attached to the pericervical ring doing nothing to correct persistent prolapse problems. Most gyns using the Koh Cup do an intrafascial hysterectomy often avoiding cutting of the uterosacral ligaments.

I do not do intrafascial hysterectomy.

Please realize that the Richardson abdominal hysterectomy technique published in 1929 in

Surg Obstet Gynecol was written in response to the problems created by supracervical hysterectomy. **The major changes in technique introduced were extrafascial removal of the entire uterus with anchoring of the anterior and posterior vaginal cuff at the corners to the uterosacral ligaments.**

So why do some practitioners promote supracervical and intrafascial hysterectomy? I don't know! Culdotomy proximal to the uterosacral ligament insertion site preserving level 1 support will promote future pelvic organ prolapse surgery, as will supracervical hysterectomy! Culdotomy proximal to the uterosacral ligament insertion site preserving level 1 support is more like a supracervical hysterectomy than a TLH.

I have always emphasized that laparoscopic hysterectomy is a substitute for abdominal hysterectomy and not for vaginal hysterectomy. Since 1987, no patient was denied a vaginal or laparoscopic approach to hysterectomy except when advanced cancer was suspected. Uterine size and extent of endometriosis were not considered contraindications; rather they were the reasons to do a laparoscopic approach. Less than 15% of my hysterectomy patients had surgical castration, as I believe in ovarian function preservation.

The concept of laparoscopic hysterectomy was presented to US Surgical Corporation, Norwalk, Connecticut, in January 1988, soon after it was done. The company swiftly adopted the concept that surgeons would much rather use techniques other than electricity to ligate the uterine arteries. The development of a laparoscopic clip followed by a laparoscopic stapler was in the works in 1988 because of this presentation of laparoscopic hysterectomy to this small group in Norwalk, Connecticut.

Unfortunately, big business goes into new fields for big business. Clinical trials were not necessary for the clip applicator because of the huge demand for it from general surgeons using make-shift instrumentation. The same was true for the EndoGIA, a great device for general surgery but with few gynecologic applications. So LAVH was born.

LAVH is not LH. It is an expensive vaginal hysterectomy. Gynecologists were encouraged to

use the EndoGIA device to do the easy upper pedicle part of a vaginal hysterectomy. Hospital administrators soon calculated that the cost of laparoscopic hysterectomy was exorbitant. Expensive disposable trocars followed by multiple firings of a stapling device cost more than the reimbursement from the managed care or other insurers at that time. Unlike cholecystectomy where the surgeon could operate using a disposable clip device with one or two firings from a single instrument, laparoscopic hysterectomy required at least four firings of a surgical stapler. The operation cost too much. And remuneration from insurance companies for laparoscopic skills was poor. This, I believe, destroyed the option of having a laparoscopic hysterectomy operation for most women in the USA. The rest of the world rarely took to staples, and laparoscopic hysterectomy thrived there.

EndoGIA

The EndoGIA was released in the late 1990s. I did the first TLH using the EndoGIA stapler. Through much of 1991, I used the EndoGIA for laparoscopic hysterectomy, always after ureteral dissection. Ureteral dissection was done in some cases after application of the GIA, and its broad distal tip was too close to the ureter for comfort. Ok, so I went from bipolar desiccation to the EndoGIA stapler. What was next? The acceptance level of laparoscopic hysterectomy had not improved. Hospitals did not want to pay for the expensive disposable instruments used by gynecology in contrast to their attitude toward general surgery operations.

At that time I felt that the best way to progress was to go back to a technique that we all knew from laparotomy, i.e., suture ligation of the uterine vessels. While I had only a 30-year experience with bipolar desiccation of large vessels, suture has been around for centuries. When one looks at the evolution of laparoscopic hysterectomy and laparoscopic surgery in general, one of the major obstacles to adoption was the perception that too much expensive gimmickry was used. The simple solution was to use sutures for

ligation for the major vessels, similar to what was done during major laparotomy surgery. I believe that suture ligation of the uterine and ovarian vessels is the safest technique near the ureter. Adhesions from the living tissue distal to a tie still bother me as they may be more prevalent than after bipolar desiccation.

Suture

More about suturing. Kurt Semm in 1986 encouraged me to learn how to suture. For that I thank him very much. I think that he was right: the ability to suture defines a laparoscopic surgeon. In the early days, 1986–1988, I used a small Keith needle and a slipknot like Kurt and Liselotte Mettler. The persistence of Courtenay Clarke led to me adopting his knot pusher to do extracorporeal ties by 1989. Soon thereafter, I developed my technique to get large curved needles into the peritoneal cavity using a 5 mm trocar, and from then on, I felt that I could operate as well or better than most laparotomy surgeons [10].

Why ligate the uterine arteries with suture instead of bipolar? If suture is used, suture can be removed if a ureter problem is suspected afterward during routine cystoscopy at surgery. Unless the surgeon is absolutely sure that the uterine arteries are a reasonable distance away from the ureters, suture is the best technique. Of course this means that the surgeon has to have some suturing skill. I've learned over the years that most general surgeons think it's very easy to suture from their right side from 3 o'clock to 6 o'clock or 6 o'clock to 9 o'clock but have difficulty suturing from 9 o'clock to 12 o'clock. This makes no sense. If the surgeon grasps the suture with his left hand instead of his right hand, it should be easy to accomplish suturing from 9 o'clock to 12 o'clock by rotating the wrist in a backhand motion.

So we have three events with laparoscopic hysterectomy evolution. First, the discovery that bipolar desiccation was possible for large vessel hemostasis made the operation possible. Next is the industry's recognition that staples could be used. Disposable staples brought them into the

ball game. Finally, the safest technique is suture. Usually, what you see is what you get with suture with no danger of energy spread. In most cases where the vessels are isolated and separated from the ureter, bipolar desiccation works fine. Most gynecologists will not dissect the ureter. Thus I believe that when the gynecologist sees the pulsation of the uterine artery, it's much safer to use the technique of ligation of the uterine vessels with suture and at the end of operation check the ureters by cystoscopy after indigo carmine dye IV push to be sure that dye flows out of the ureteral orifices. If it does not, it is simple to look back with the laparoscope and undo the suture to release a potential ureteral injury [11, 12].

A final look at suture is warranted but it will never happen. Industry seems to forever work on new modifications of bipolar electrosurgery, usually at the expense of a reduction in surgical expertise. Regarding the large uterus, it seems to me to make more sense to selectively ligate the skeletonized uterine artery and let the veins drain; the result will be at least one unit of blood saved.

As we know then and today, TLH and related procedures can be done with reusable instrumentation. In fact most of the procedures that have been developed over the last 20 years in laparoscopic surgery can be done using reusable instrumentation available in most ORs. This knowledge really helps when teaching the technique around the world, as most countries where I introduced TLH (Chile, Spain, Australia, Italy, Russia, Ireland) had no disposable instrumentation. Now the whole world uses disposable instrumentation manufactured in the USA, Mexico, or China.

Finally, please realize that publication of laparoscopic gynecological operations was very difficult in the 1980s as few of the pioneers were in academic positions. Laparoscopic hysterectomy was unpublished in 1988 and before. This has been a major struggle. In fact, many papers of substance on laparoscopic surgery in the early 1990s were in a journal that never got Index Medicus acceptance: *Gynaecological Endoscopy*. This travesty in our system prevented over a decade of great work from many pioneers in lap-

aroscopic surgery to be rarely quoted. I remember, with bitterness, my struggles to get bipolar oophorectomy and cul-de-sac dissection for deep fibrotic endometriosis published in the 1980s, despite teaching these techniques to the professors. My paper on laparoscopic treatment of ovarian cancer received harsh reaction in 1988 in the USA but not in Europe [13, 14].

Technique

Total Laparoscopic Hysterectomy Technique (TLH)

My technique for a TLH is described, since other types of laparoscopic hysterectomy are simply modifications of this more extensive procedure. These steps are designed to prevent complications. Very little has changed in this technique since its publication in 1993, except for the incorporation of cystoscopy. In the original paper, TLH is a substitute for abdominal hysterectomy and not for vaginal hysterectomy. In the original paper, laparoscopic vaginal vault closure with vertical uterosacral ligament suspension was described. Uterine vessel ligation was also described. Curved needles were used, pulled thru the 5 mm incision using my technique.

The patient is counseled extensively regarding currently available options appropriate to her individual clinical situation. It is clearly not acceptable to advocate hysterectomy without detailing the risks and benefits of other intermediary procedures, such as myomectomy and/or excision of endometriosis with uterine preservation. Whereas conversion to laparotomy when the surgeon becomes uncomfortable with the laparoscopic approach has never been considered a complication, conversion rates should be monitored to safeguard the consumer's right to have this procedure performed by a competent laparoscopic surgeon. Surgeons who do more than 25% of their hysterectomies with an abdominal incision should not tout their ability and degree of expertise with a laparoscopic approach to their patients. Perhaps, conversion to laparotomy should be considered a complication!

Preoperative Preparation

The patient is optimized medically for coexistent problems. Patients are encouraged to hydrate on clear liquids the day before surgery. Fleet enema to evacuate the lower bowel is encouraged. Lower abdominal, pubic, and perineal hair is not shaved. All laparoscopic procedures are done using general endotracheal anesthesia with orogastric tube suction to minimize bowel distension. The patient's arms are placed at her side, and shoulder braces at the acromioclavicular joint are positioned. Trendelenburg position up to 40° is available. I use one dose of prophylactic antibiotics after induction of anesthesia.

Incisions

Three laparoscopic puncture sites including the umbilicus are used. Pneumoperitoneum to 25–30 mmHg is obtained before primary umbilical trocar insertion and reduced to 15 mm afterward. The lower quadrant trocar sleeves are placed under direct laparoscopic vision lateral to the rectus abdominis muscles and just beside the anterior superior iliac spines in patients with large fibroids. The left lower quadrant puncture is my major portal for operative manipulation as I stand on the patient's left and hold the camera in my right hand. Reduction in wound morbidity and scar integrity as well as cosmesis are enhanced using 5 mm sites. The use of 12 mm incisions when a 5 mm one will suffice is not an advance in minimally invasive surgery.

Vaginal Preparation

Every year, new innovations for uterine and vaginal manipulation appear. The Valtchev uterine manipulator (Conkin Surgical Instruments, Toronto, Canada) has been around for more than 25 years and allows anterior, posterior, and lateral manipulation of the uterus and permits the surgeon to visualize the posterior cervix and vagina. Newer devices are currently available developed by Pelosi, Wattiez, Hourcabie, Koninckx, Zepeda,

Koh, McCartney, Donnez, and myself. I still use the Valtchev and the Wolf tube.

Exploration

The upper abdomen is inspected, and the appendix is identified. Endometriosis is excised before starting TLH. Bleeding is controlled with microbipolar forceps.

Retroperitoneal Dissection

The peritoneum is opened early with scissors in front of the round ligament to allow CO₂ from the pneumoperitoneum to distend the retroperitoneum. The tip of the laparoscope is then used to perform “optical dissection” of the retroperitoneal space by pushing it into the loosely distended areolar tissue parallel to the uterus to identify the uterine vessels, ureter, or both. The uterine artery is often ligated at this time, especially in large-uterus patients.

Ureteral Dissection (Optional)

The ureter is identified medially, superiorly, or laterally (pararectal space). Stents are not used as they may cause hematuria and ureteric spasm. The laparoscopic surgeon should dissect (skeletonize) either the ureter, the uterine vessels, or both during a laparoscopic hysterectomy.

Bladder Mobilization

The round ligaments are divided at their midportion, and scissors or a spoon electrode is used to divide the vesicouterine peritoneal fold starting at the left side and continuing across the midline to the right round ligament. The upper junction of the vesicouterine fold is identified as a white line firmly attached to the uterus, with 2–3 cm between it and the bladder dome. The initial incision is made below the white line while lifting the bladder. The bladder is mobilized off the

uterus and upper vagina using scissors or bluntly until the anterior vagina is identified. The tendinous attachments of the bladder in this area may be desiccated or dissected.

Upper Uterine Blood Supply

When oophorectomy is indicated or desired, the peritoneum is opened on each side of the infundibulopelvic ligament with scissors and a 2/0 Vicryl free ligature passed through the window created and tied extracorporeally using the Clarke-Reich knot pusher. This maneuver helps develop suturing skills. The broad ligament is divided lateral to the utero-ovarian artery anastomosis using scissors or cutting current electrosurgery. I rarely desiccate the infundibulopelvic ligament as it results in too much smoke early in the operation.

When ovarian preservation is desired, the utero-ovarian ligament and fallopian tube are compressed and coagulated until desiccated with bipolar forceps, at 25–35 W cutting current, and then divided. Alternatively, the utero-ovarian ligament and fallopian tube pedicles are suture-ligated adjacent to the uterus with 2/0 Vicryl, using a free ligature passed through a window created around the ligament.

If the ovary is to be preserved and the uterus large, the utero-ovarian ligament/round ligament/fallopian tube junction may be divided with a 30 or 45 mm GIA-type stapler. This may be timesaving for this portion of the procedure, thus justifying its increased cost. Many complications are related to the use of staplers [23*]. Whereas it decreases operative time, it also increases the risk for postoperative hemorrhage and injury to the ureter. Ligation or coagulation of the vascular pedicles is safer.

Uterine Vessel Ligation

The uterine vessels may be ligated at their origin, at the site where they cross the ureter, where they join the uterus, or on the side of the uterus. Most surgeons use bipolar desiccation to ligate these

vessels, but this author prefers suture because it can be removed if ureteral compromise is suggested at cystoscopy [11, 12].

In most cases, the uterine vessels are suture ligated as they ascend the sides of the uterus. The broad ligament is skeletonized to the uterine vessels. Each uterine vessel pedicle is suture-ligated with 0 Vicryl on a CTB-1 blunt needle (Ethicon JB260) (27"), as a blunt needle reduces surrounding venous bleeding. The needles are introduced into the peritoneal cavity by pulling them through a 5 mm incision. A short, rotary movement of the needle holder brings the needle around the uterine vessel pedicle. This motion is backhand if done with the left hand from the patient's left side and forward motion if using the right hand from the right side. In some cases, the vessels can be skeletonized completely and a 2-0 Vicryl free suture ligature passed around the artery. Sutures are tied extracorporeally using a Clarke-Reich knot pusher [10].

In large-uterus cases, selective ligation of the uterine artery without its adjacent vein is done to give the uterus a chance to return its blood supply to the general circulation. It also results in a less voluminous uterus for morcellation.

Division of Cervicovaginal Attachments and Circumferential Culdotomy

The cardinal ligaments on each side are divided. Bipolar forceps coagulate the uterosacral ligaments. The vagina is entered posteriorly over the uterine manipulator near the cervicovaginal junction. A 4 cm diameter reusable vaginal delineator tube (R. Wolf) is placed in the vagina to prevent loss of pneumoperitoneum and to outline the cervicovaginal junction circumferentially as it is incised using the CO₂ laser with the delineator as a backstop or electrosurgery to complete the circumferential culdotomy. The uterus is morcellated, if necessary, and pulled out of the vagina.

I know that the term colpotomy is often used in gynecology literature when describing the technique of total laparoscopic hysterectomy, but it is wrong! Colpotomy is translated as incision to

the vagina (colpos = vagina; tomy = incision in Greek).

Colpotomy is an incision made vaginally. If the incision is made laparoscopically, it is called a culdotomy. The other name is totally industry driven.

The term “culdotomy” was first used in 1985–1986 as the procedure done to remove ovaries and fibroids. The term “circumferential culdotomy” was first introduced in 1989–1990 to describe the incision made to separate the vagina from the cervix during hysterectomy. I don’t recall anyone using the term circumferential *colpotomy*, until used by industry to name a cervical cup for the hysterectomy incision.

Culdotomy is an incision through the cul-de-sac peritoneum, the rectovaginal fascia, and finally the vaginal wall. This incision is made after the rectum has been reflected off the posterior vagina and cervix and is facilitated by using a vaginal delineator to outline the vagina and tamponade blood supply.

Colpotomy is a vaginal incision made in the vagina and through the vagina and is usually accompanied by at least 100 cc of bleeding, differentiating it from the nearly bloodless culdotomy.

Morcellation (Laparoscopic and Vaginal)

Morcellation can be done laparoscopically or vaginally. Vaginal morcellation is done with a #10 blade on a long knife handle to make a circumferential incision into the uterus while pulling outward on the cervix and using the cervix as a fulcrum. The myometrium is incised circumferentially parallel to the axis of the uterine cavity with the scalpel’s tip always inside the myomatous tissue and pointed centrally, away from the surrounding vagina.

Morcellation through anterior abdominal wall sites is done when vaginal access is limited or supracervical hysterectomy requested. Reusable electromechanical morcellators are not used. Using claw forceps or a tenaculum to grasp the fibroid and pull it into contact with the skin incision, morcellation is done with a #10 blade on a

long knife handle fibroid using a coring technique until the myoma can be pulled out through the trocar incision. With practice these instruments can often be inserted through a stretched 5 mm incision without an accompanying trocar.

Laparoscopic Vaginal Vault Closure with Vertical Uterosacral Ligament Suspension [15]

The vaginal delineator tube is placed back into the vagina for closure of the vaginal cuff, occluding it to maintain pneumoperitoneum. The uterosacral ligaments are identified by bipolar desiccation markings or with the aid of a rectal probe. The first suture is complicated as it brings the uterosacral and cardinal ligaments as well as the rectovaginal fascia together. This single suture is tied extracorporeally bringing the uterosacral ligaments, cardinal ligaments, and posterior vaginal fascia together across the midline. It provides excellent support to the vaginal cuff apex, elevating it and its endopelvic fascia superiorly and posteriorly toward the hollow of the sacrum. The rest of the vagina and overlying pubocervicovesicular fascia are closed vertically with one or two 0 Vicryl interrupted sutures. I have used this same technique since 1990.

Some suggestions for cuff closure to reduce dehiscence:

- Vertical closure.
- Hemostasis with microbipolar forceps before closure.
- Interrupted well-spaced sutures, for good drainage. Avoid continuous barbed suture!
- Apply sutures through the fascia and not the vagina.
- Sutures are for support, not hemostasis.
- Cuff closure sutures are for the fascia, not the vaginal epithelium.
- Cuff division with electrosurgery and harmonic is much more destructive than the CO₂ laser.
- Harmonic may be over 200°C. Do not use!
- Use low-voltage cutting current. Avoid coagulation current.

Cystoscopy [11, 12]

I introduced cystoscopy to LH in 1990, because I could. (Unlike most gynecologists, I had cystoscopy privileges.). Cystoscopy is done after vaginal closure to check for ureteral patency in most cases, after intravenous administration of indigo carmine dye. This is necessary when the ureter is identified but not dissected and especially necessary when the ureter has not been identified. Blue dye should be visualized through both ureteral orifices. The bladder wall should also be inspected for suture and thermal defects.

Underwater Examination

At the close of each operation, an underwater examination is used to detect bleeding from vessels and viscera tamponaded during the procedure by the increased intraperitoneal pressure of the CO₂ pneumoperitoneum. The CO₂ pneumoperitoneum is displaced with 2–4 L of Ringer's lactate solution, and the peritoneal cavity is vigorously irrigated and suctioned until the effluent is clear of blood products. Any further bleeding is controlled underwater using microbipolar forceps to coagulate through the electrolyte solution, and 1–2 L of lactated Ringer's solution is left in the peritoneal cavity. I have never electively used a drain either vaginally or abdominally. Interrupted vertically placed laparoscopically sutures encourage drainage, but despite the fluid left in the peritoneal cavity, little vaginal drainage is observed.

Skin Closure

The vertical intraumbilical incision is closed with a single 4-0 Vicryl suture opposing deep fascia and skin dermis, with the knot buried beneath the fascia. This prevents the suture from acting like a wick transmitting bacteria into the soft tissue or peritoneal cavity. The lower quadrant 5 mm incisions are loosely approximated with a Javid vascular clamp (V. Mueller, McGaw Park, IL) and covered with Collodion (AMEND, Irvington, NJ) to allow drainage of excess Ringer's lactate solution.

Conclusion

Laparoscopic hysterectomy was first performed in January 1988. The sine qua non for laparoscopic hysterectomy is the laparoscopic ligation of the uterine vessels. Although hysterectomy is not the most difficult laparoscopic procedure, it can be long and tedious because four very well-defined vascular pedicles must be ligated. In 1988 no one was thinking about doing hysterectomy by laparoscopy. The major centers in the world doing laparoscopic surgery were in Clermont-Ferrand, France; Kiel, Germany; and Kingston, Pennsylvania. I acknowledge that Kurt Semm, Maurice Bruhat, and Hubert Manhes were great influences because they also knew no boundaries. However, most of my thinking was original.

It took 5 years for laparoscopic cholecystectomy to be universally adopted. Laparoscopic hysterectomy has been available for the last 25 years with sporadic acceptance. In our specialty IVF took off and laparoscopic surgery didn't. Just look at the remuneration. Abdominal hysterectomy remains the preferred method of treatment based on training and economics, and this poses an ethical dilemma. Are we offering the best choices to our patients? We as specialists need to answer this question. Why would physicians take time to learn a new technique if they are going to be poorly reimbursed for time spent? The type of laparoscopic hysterectomy is usually defined by the extent of laparoscopic dissection performed during the procedure. The recently published Cochrane review of the surgical approach to hysterectomy uses the description of different techniques detailed by Reich and Roberts, which is based on the definitions published by Garry et al. [16, 17].

Recent papers by Clayton and the Cochrane database reviewed evidence-based hysterectomy studies and concluded that vaginal hysterectomy (VH) is preferable to abdominal hysterectomy (AH). There is no evidence to support the use of LH if VH can be done safely. Compared to AH, LH is associated with less blood loss, shorter hospital stay, and speedier return to normal activities, but it

takes longer and costs more, and urinary tract injuries are more likely. They emphasize that vaginal hysterectomy should be the preferred route when applicable. Laparoscopic hysterectomy should be considered as an alternative to abdominal hysterectomy [18–20].

Most of us agree that the minimal access route offers significant patient benefits over open surgery. Previous exclusion criteria (malignancy, uterine size greater than 12 weeks, hysterectomy performed primarily for prolapse, hysterectomy performed in conjunction with the resection of deep infiltrating endometriosis including rectal resections) are considered to be indications for TLH at many centers today. Actually, there have not been significant technological advances for TLH. Newer-generation cutting and sealing devices are just expensive bipolar devices, disposable, and designed to make more money for the industry. Advanced uterine manipulation devices are no better than the reusable Valtchev mobilizer from Toronto, Canada.

I believe that most hysterectomies can be done using a laparoscopic approach. It is certain that if the problem is bleeding, especially from a large fibroid uterus, it can be solved by TLH, and the woman will be very pleased. Why are there so few laparoscopic hysterectomies done today? Most gynecologists today are not trained to do laparoscopic surgery. **Unfortunately they are not trained to do vaginal surgery, either.** The truth of the matter is that the low payments for gynecological surgery make it much more cost-effective to stay in the office and to avoid surgery if possible. The major problem for LH from its birth to the present remains inappropriate reimbursement for the work and extra training involved in developing the appropriate expertise.

Laparoscopic hysterectomy is clearly beneficial for patients in whom vaginal surgery is contraindicated or can't be done. When indications for the vaginal approach are equivocal, laparoscopy can be used to determine if vaginal hysterectomy is possible. With this philosophy, patients avoid an abdominal incision

with resultant decrease in length of hospital stay and recuperation time. The laparoscopic surgeon should be aware of the risks and how to minimize them and, when they occur, how to repair them laparoscopically.

References

1. Reich H. Hysterectomy as treatment for dysfunctional uterine bleeding. In: Smith SK, editor. *Bailliere's clinical obstetrics and gynecology. Dysfunctional uterine bleeding*, vol. 13. London: Bailliere Tindall (Harcourt Health Sciences); 1999. p. 251–69.
2. Reich H, McGlynn F. Laparoscopic oophorectomy and salpingo-oophorectomy in the treatment of benign tuboovarian disease. *J Reprod Med*. 1986;31:609.
3. Reich H. Laparoscopic oophorectomy and salpingo-oophorectomy in the treatment of benign tuboovarian disease. *Int J Fertil*. 1987;32:233–6.
4. Reich H. Laparoscopic oophorectomy without ligature or morcellation. *Contemp Ob Gyn*. 1989;34(3):34.
5. Reich H, DeCaprio J, McGlynn F. Laparoscopic hysterectomy. *J Gynecol Surg*. 1989;5:213–6.
6. Reich H. Laparoscopic hysterectomy. *Surgical laparoscopy & endoscopy*, vol. 2. New York: Raven Press; 1992. p. 85–8.
7. Reich H, McGlynn F, Sekel L. Total laparoscopic hysterectomy. *Gynaecol Endosc*. 1993;2:59–63.
8. Garry R, Reich H. *Laparoscopic hysterectomy*. Oxford, England: Blackwell Scientific Publications Ltd; 1993 (Textbook).
9. Reich H. The role of laparoscopy in hysterectomy. In: Rock JA, Faro S, Gant NF, Horowitz IR, Murphy A, editors. *Advances in obstetrics and gynecology*, vol. 1. St. Louis, MO: Mosby Year Book; 1994. p. 29–54.
10. Reich H, Clarke HC, Sekel L. A simple method for ligating in operative laparoscopy with straight and curved needles. *Obstet Gynecol*. 1992;79:143–7.
11. Ribeiro S, Reich H, Rosenberg J. The value of intraoperative cystoscopy at the time of laparoscopic hysterectomy. *Hum Reprod*. 1999;14:1727–9.
12. Reich H. Letters to the editor. Ureteral injuries after laparoscopic hysterectomy. *Hum Reprod*. 2000;15:733–4.
13. Reich H, McGlynn F, Wilkie W. Laparoscopic management of stage I ovarian cancer. *J Reprod Med*. 1990;35:601–5.
14. Reich H, McGlynn F, Wilkie W. Laparoscopic management of stage I ovarian cancer: a case report. *Obstet Gynecol Surv*. 1990;45:772–4.
15. Reich H, Orbuch I, Seckin T. Reich modification of the McCall Culdoplasty to prevent and/or repair prolapse during total laparoscopic hysterectomy. In: Jain N, editor. *Complete manual & atlas of laparoscopic suturing*. New Delhi, India: Jay Pee Brothers; 2006. p. 78–82.

16. Garry R, Reich H, Liu CY. Laparoscopic hysterectomy- definitions and indications. *Gynaecol Endosc.* 1994;3:1–3.
17. Reich H, Roberts L. Laparoscopic hysterectomy in current gynecological practice. *Rev Gynaecol Prac.* 2003;3:32–40 (Elsevier).
18. Clayton RD. Hysterectomy: best practice and research. *Clin Obstet Gynecol.* 2006;20:1–15.
19. Johnson N, Barlow D, Lethaby A, et al. Surgical approach to hysterectomy for benign gynaecological disease. *Cochrane Database Syst Rev.* 2005;1:CD003677.
20. Johnson N, Barlow D, Lethaby A. Methods of hysterectomy: systematic review and meta-analysis of randomized controlled trials. *BMJ.* 2005;330:1478–81.



Arnold P. Advincula
and Obianuju Sandra Madueke-Laveaux

Introduction

Minimally invasive surgery (MIS) has revolutionized women's healthcare. A woman with advanced abdominopelvic disease who would have been subject to a laparotomy with 6–8 weeks of convalescence is able to undergo an outpatient surgery and be *back on her feet* in less than 2 weeks.

Although unarguably the least invasive route of surgery, the vaginal route is not always feasible, for example, in cases of deeply infiltrating endometriosis and complex hysterectomies. It is in these clinical scenarios that laparoscopy is the minimally invasive route of choice.

Conventional laparoscopy is an excellent route of minimally invasive surgery. It was introduced by internists and urologists in the early 1900s, and by the 1960s and 1970s, gynecologists took the lead in its advancement. After painstakingly overcoming the challenge of reforming the deeply engrained surgical thinking that “large problems required large incisions,” the so-called laparoscopic revolution was a success, and by the 1990s, laparoscopy was incorporated into surgical thinking [1].

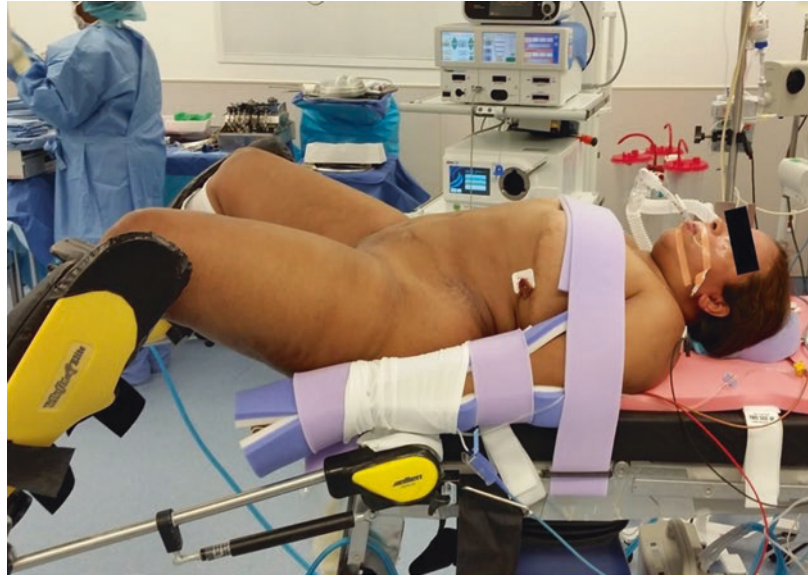Since its introduction into gynecology, laparoscopy has evolved from its use in a limited range of minor surgical procedures (diagnostic laparoscopies and tubal ligations) to being used for major and complex surgeries [2]. With its increased use in complex surgical procedures, the limitations of laparoscopic surgery became more evident. Some of these limitations include the counterintuitive hand movements, two-dimensional visualization, and limited range of motion encountered with the instruments [3]. With the advent of computer-enhanced technology and with these limitations in mind, robotic-assisted laparoscopic surgery was developed.

The first robotic gynecology procedures were performed in 1998, and in 2005 the US Food and Drug Administration approved the first robotic device for gynecologic surgery—the da Vinci Surgical System (Intuitive Surgical Inc., Sunnyvale, CA) [4, 5]. Robotic laparoscopy features improved precision and dexterity with

Electronic supplementary material The online version of this chapter (https://doi.org/10.1007/978-3-319-72592-5_3) contains supplementary material, which is available to authorized users.

A. P. Advincula, M.D. (✉)
O. S. Madueke-Laveaux, M.D.
Department of Obstetrics and Gynecology, Division
of Gynecologic Specialty Surgery, Columbia
University Medical Center/New York-Presbyterian
Hospital, New York, NY, USA
e-mail: aa3530@cumc.columbia.edu
osm2108@cumc.columbia.edu

Fig. 3.1 Modified low dorsal lithotomy position



wristed instruments, three-dimensional imaging, and improved ergonomics for surgeon comfort. It also offers a shorter learning curve when compared to conventional laparoscopy, enabling surgeons to overcome the limitations of conventional laparoscopy while offering minimally invasive options to patients [6, 7]. Some limitations of robotic laparoscopy include the absence of haptic (tactile) feedback and the cost, the latter of which is a point of major controversy and debate [8].

Basic Robotic Setup

At our institution, the basic setup for all robotic procedures is as follows:

1. Patient positioning

- (a) Patients are placed in modified dorsal lithotomy position using Allen Yellofins stirrups (Allen Medical Systems, Acton, Massachusetts). Extreme joint flexion, extension, and abduction are avoided to prevent nerve compression injuries.
- (b) A standard motorized operating room table with maximum tilt of at least 30° is used.
- (c) Anti-skid: the Pink Pad (Pigazzi Positioning System) is used to secure the

patient while in steep Trendelenburg (Fig. 3.1).

2. Port placement

- (a) Port placement may vary based on:
 - Number of robotic arms used for the surgery
 - Generation of da Vinci robot used—Si vs. Xi (Figs. 3.2 and 3.3)

3. Robot docking

- (a) We perform either left- or right-side docking of the da Vinci Si robot in order to allow unobstructed access to the perineum (Fig. 3.4).

4. Uterine manipulator

- (a) Although any of the standard uterine manipulators are effective, we use the Advincula Arch for non-hysterectomy procedures and the Advincula Delineator or the Advincula Arch with the Koh-Efficient system (Cooper Surgical, Trumbull, CT) for hysterectomies (Fig. 3.5).

Deeply Infiltrating Endometriosis

Endometriosis is a chronic disease that affects women worldwide. The true prevalence is not known because the diagnosis is established at

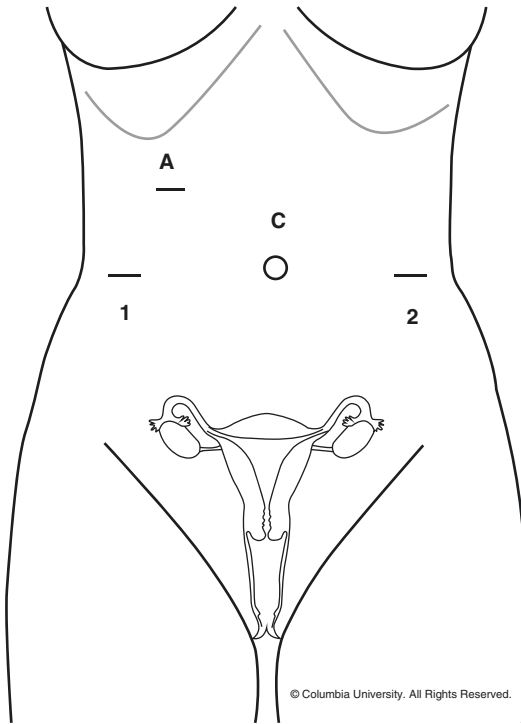


Fig. 3.2 Three-arm robotic port placement (da Vinci Si). (A) 5 mm accessory port. (C) 12 mm camera port. (1) 8 mm robotic port, Monopolar Hot Shears; (2) 8 mm robotic port, Gyrus PK Dissector

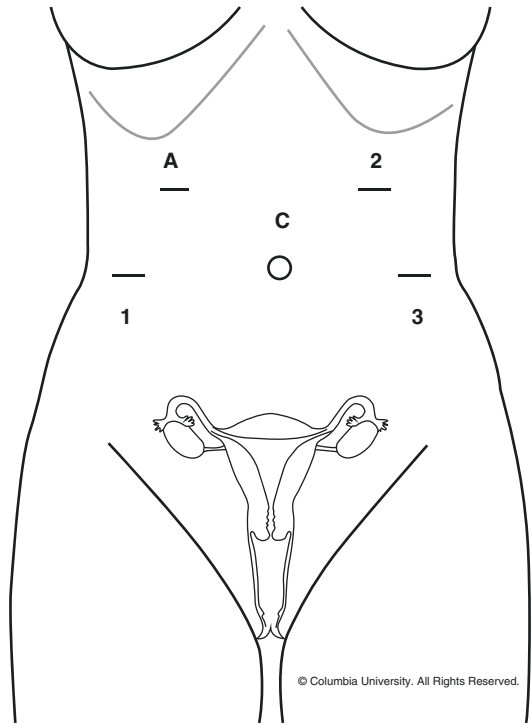


Fig. 3.3 Four-arm robotic port placement (da Vinci Si). (A) 5 mm accessory port. (C) 12 mm camera port. (1) 8 mm robotic port. (2) 8 mm robotic port. (3) 8 mm robotic port. Note the difference in location of the two and three arms compared to the three-arm setup

laparoscopy. It is however estimated to have a prevalence of 10% among women of reproductive age [9]. The clinical presentation of endometriosis ranges from a complete lack of symptoms to severe and debilitating chronic pelvic pain and infertility.

Deeply infiltrating endometriosis (DIE) is a severe form of endometriosis, which is defined as lesions extending greater than 5 mm underneath the peritoneum [10]. DIE lesions can occur in various locations (rectovaginal septum, rectum, sigmoid, bladder, vagina). The predominant symptom in patients with DIE is pain, and the severity of the pain tends to correlate with the depth of infiltrative disease [11, 12]. The classic presentation of women with deeply infiltrating disease includes a history of dysmenorrhea, dyschezia, and dyspareunia. In addition to this, some women present with subfertility, heavy menstrual bleeding, and abdominal bloating [7]. Use of transrectal/transvaginal ultrasound, CT colonography,

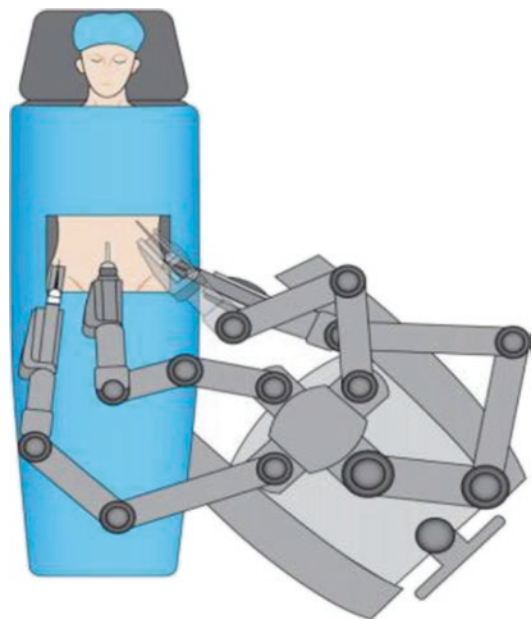
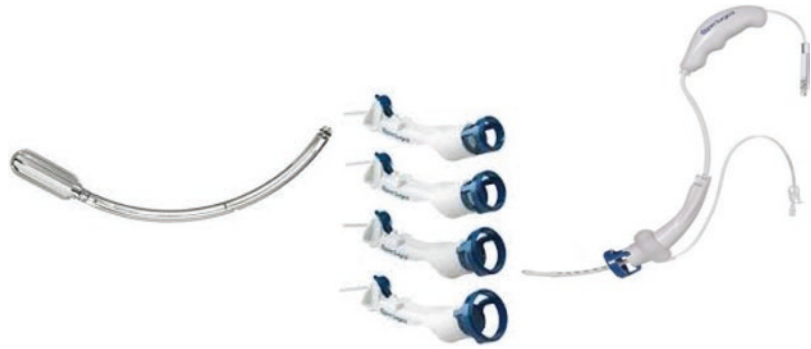

Fig. 3.4 Left-side docking of the da Vinci SI robot

Fig. 3.5 (a) Advincula Arch. (b) Koh-Efficient system. (c) Advincula Delineator



and MRI can aid with diagnosis. However, the gold standard is laparoscopy with histologic confirmation [13].

Surgical resection of deeply infiltrating endometriosis (DIE) is performed when conservative management with hormonal therapy fails to control pain and also to improve fertility outcomes [14]. Resection of endometriosis can range from shaving of superficial lesions to total hysterectomy with or without bilateral salpingo-oophorectomy. When surrounding organs are involved with disease, portions of these organs are resected to ensure complete excision of endometriotic lesions.

Surgery for DIE poses a unique challenge to the gynecologist and is probably one of the most suited surgeries for robotic assistance. However, the role of robotics in endometriosis surgery is controversial, and to date no randomized controlled trials have been performed to evaluate its use over conventional laparoscopy. The available literature consists of mostly case reports and retrospective studies that suggest a role for robotics in advanced-stage endometriosis [14–16]. In 2014, a retrospective cohort study by Siesto et al. evaluated the feasibility of robotic surgery for management of DIE. In this series, 19 bowel resections, 23 removals of rectovaginal septum nodules, and 5 bladder resections were performed. Posterior vaginal resections were performed in 12 cases. No intraoperative complications or conversions to laparotomy occurred, and one anastomotic leak was recorded [15]. Pellegrino et al. followed suit in 2015, evaluating the feasibility of robotic laparoscopy for management of DIE involving the rectovaginal septum (RVS). They reported complete nodule debulking with clear

margins using a shaving technique in 25 patients, with a median operative time of 174 min (range, 75–300 min), blood loss of 0 mL, and good long-term outcomes with a median follow-up time of 22 months (range, 6–50 months) [16]. Neme et al. reported on the feasibility of robotic-assisted laparoscopic colorectal resection for severe endometriosis. In their study, ten women with colorectal endometriosis underwent robotic surgery and were evaluated based on short-term complications, clinical outcomes, long-term follow-up, pain relief, recurrence rate, and fertility outcomes. Eight women underwent extensive ureterolysis, seven had ovarian cystectomies, nine had either unilateral or bilateral uterosacral ligament resection, and all women underwent torus and segmental colorectal resections. The mean operative time was 157 min and mean hospital stay was 3 days. Of the six patients with preoperative infertility, four women conceived naturally (67%) and two underwent in vitro fertilization (33%) [17].

Increased operating time is a critical factor for which robotic laparoscopy receives criticism. A retrospective review by Magrina et al. performed to determine perioperative outcomes and factors impacting operating time, length of hospital stay, and complications included 493 patients undergoing surgery for stage III or IV endometriosis (robotic laparoscopy; $n = 331$ |conventional laparoscopy; $n = 162$). They found that blood loss, number of procedures per patient, and robotics were significantly associated with increased operating time. Similarly, a 2014 retrospective cohort study by Nezhat et al. compared perioperative outcomes in robotic-assisted laparoscopy (RAL; $n = 32$) to conventional laparoscopy (CLS;

$n = 86$) for stage III or IV endometriosis. The main outcome measures were extent of surgery, estimated blood loss, operating room time, intraoperative and postoperative complications, and length of hospital stay. With the exception of higher operating room times in the RAL group (250.50 min versus 173.50 min [$P < 0.0005$]), no other significant differences were found between the groups [18].

Despite the controversy surrounding the role of robotics in endometriosis and the lack of level I evidence to support its use, an increasing number of fertility specialists advocate the use of robotics for reproductive surgery, acknowledging the time and effort required to achieve and maintain proficiency in the “anti-ergonomic” environment of conventional laparoscopy and recognizing that the use of robotic technology “minimizes aptitudinal restrictions to the adoption of advanced laparoscopy” [19].

Ultimately, the proverbial jury is still out on the role of robotics in endometriosis surgery. Randomized controlled trials need to be conducted evaluating this topic. Based on the available literature, it is reasonable to conclude that robotic-assisted laparoscopy is a safe, feasible, and effective route for surgical management of deeply infiltrating endometriosis.

Stage IV Endometriosis Case Card

Please refer to the basic robotic setup above. We use a four-arm robotic setup for DIE resection (Fig. 3.3).

Below is a list of instruments we use specifically for resection of DIE:

1. Robotic instruments: Monopolar Hot Shears (Arm 1), Gyrus PK Dissector (Arm 2), +/- Long Tip Forceps or ProGrasp Forceps (Arm 3), Mega Needle Driver (Arm 1)
2. EEA sizers
3. Fornix presenter: for resection of lesions invading the posterior vaginal wall
4. 2-0 V-Loc™ barbed suture (Medtronic, Minneapolis, MN): used if colpotomy is required for complete resection

See video of robotic-assisted laparoscopic resection of RVE nodule.

Myomectomy

Uterine fibroids are the most common solid pelvic tumor in women and the leading indication for hysterectomy in the United States [20]. By age 50, 70% of white women and 80% of black women have fibroids [21]. Although largely asymptomatic, abnormal uterine bleeding (AUB) with resultant anemia and bulk symptoms are the most common complaints of women with fibroid uteri. Uterine fibroids are also associated with reproductive dysfunction [22].

The diagnosis of uterine fibroids is made based on a combination of physical exam and imaging studies: transvaginal ultrasound, saline infusion sonography, and MRI. When medical management (hormonal therapy) fails in patients with AUB and when patients have bulk predominant symptoms with a desire to preserve fertility, the only option for surgical management is a myomectomy [23]. In addition some fertility patients require myomectomy to optimize the uterine cavity and potentially improve fertility outcomes.

The route of myomectomy—laparotomy, laparoscopy, robotic, or hysteroscopy—depends on the location, size, and number of the uterine fibroids and, to a certain extent, the indication for the myomectomy. In some cases multiple routes need to be employed for optimal results, and sometimes these procedures have to be staged.

In the past, laparotomy was the surgical route of choice for fibroid removal. This surgery was associated with long hospital stays, high rates of blood transfusions, postoperative pain, and long recovery periods. As minimally invasive surgery gained popularity, laparoscopic myomectomy (LM) became more commonly performed and accepted by many as the “gold standard” approach for myomectomy [24]. Many studies comparing laparoscopic myomectomy to the abdominal approach showed a decrease in blood loss, less postoperative pain, shorter hospital stay, and quicker recovery with laparoscopy [25–27].

Unfortunately, myomectomy via conventional laparoscopy is technically challenging, limiting the performance of this surgery to select groups of highly specialized laparoscopic surgeons. Some of the major challenges with conventional LM include enucleation of the fibroid along the correct plane and a multilayered hysterotomy closure [28]. The obvious concern with the latter is the potential risk for uterine rupture. Accordingly, several cases of uterine rupture in the second and third trimesters of pregnancy after laparoscopic myomectomy led to recommendations for more strict selection criteria that excluded patients with fibroids >5 cm, multiple fibroids, and deep intramural fibroids [29].

Robotic-assisted laparoscopic myomectomy (RALM) was developed to overcome the difficulties of conventional laparoscopy as well as to offer minimally invasive options to a broader patient pool. In 2004, Advincula et al. reported the first case series of 35 women, introducing the use of the da Vinci robot for RALM [30]. Since this report, multiple retrospective studies have verified the safety, feasibility, and efficacy of RALM.

With regard to its comparison to the traditional abdominal myomectomy (AM), RALM has been found to be associated with less blood loss, shorter hospital stay, quicker recovery time, fewer complications, and higher costs [31]. In a case control study by Ascher-Walsh et al., RALM was associated with less drop in hematocrit concentration on postoperative day 1, less number of days to regular diet, decreased length of hospital stay, less febrile morbidity, and longer operating times [32]. Similarly, Hanafi et al. found shorter hospital stay, less blood loss, and increased operative time with RALM as compared to AM [33]. Nash et al., in a comparative analysis of surgical outcomes and costs between RALM and AM, found that RALM patients required less IV hydromorphone and had shorter hospital stays and equivalent clinical outcomes compared to AM patients. In addition, a correlation between increased specimen size and decreased operative efficiency of RALM was observed [23]. Retrospective cohort studies by Mansour et al. and Sangha et al. echo similar conclusions [34, 35].

The review of the literature provides sufficient evidence in favor of RALM over AM. However, as we begin to review the available data comparing RALM to conventional LM, it is clear that although the available evidence strongly suggests a role for RALM, more comparative studies need to be conducted.

In 2013 Pundir et al. completed a meta-analysis and systematic review comparing RALM to abdominal and laparoscopic myomectomy. Ten observational studies were reviewed; seven compared RALM to AM, four compared RALM to LM, and one study compared RLM to AM and LM (this was included in both groups). In the comparison between RALM and AM, estimated blood loss, blood transfusion, and length of hospital stay were significantly lower, risk of complication was similar, and operating time and costs were significantly higher with RALM. When compared to LM, blood transfusion risk and costs were higher with RALM, and no significant differences were noted in estimated blood loss, operating time, length of hospital stay, and complications. The authors therefore concluded that based on operative outcome, RALM showed significant **short-term** benefits when compared to AM but no benefit when compared to LM [36].

Barakat et al. compared surgical outcomes of RALM to AM and conventional LM; RALM was associated with decreased blood loss and length of hospital stay compared to LM and AM. Interestingly in this study, significantly heavier fibroids were removed in the robotic compared to the laparoscopic group (223 vs. 96 g); the average weight in the AM group was 263 g [37]. Bedient et al. in their 81-patient retrospective study comparing RALM to LM concluded that short-term surgical outcomes were comparable between both groups. Gargiulo et al. also found similar operative outcomes between RALM and LM patient groups. In this study, the RALM group had longer operative times (191 vs. 115 min) and significantly greater blood loss; however, barbed suture was used in the LM group, and as acknowledged by the authors, this likely had an effect on the observed differences. In 2009 Nezhat et al. performed a retrospective matched control study comparing RALM to LM.

They concluded that in the hands of skilled laparoscopists, RALM offered no major advantage and that further studies were needed to assess the “utility of RALM for general gynecologic surgeons.”

In 2015, Gargiulo and Nezhat co-authored a book chapter, “Robot-assisted Myomectomy: Broadening the Laparoscopist’s Armamentarium.” In this chapter, they acknowledge that the technical demand in performing conventional LM explains why it is underutilized, in spite of the strong evidence to suggest laparoscopy over laparotomy for myomectomy. This acknowledgment prefaced the conclusion that despite the lack of level-I evidence to support the role of robotic surgery for myomectomies, adapting this technology can raise the threshold for AM [38].

A majority of the studies evaluating RALM do not discuss long-term outcomes. The 2013 meta-analysis discussed earlier [35] reported an uncertainty about long-term benefits such as recurrence, fertility, and obstetric outcomes. In our literature review, we came across a handful of retrospective studies reporting pregnancy outcomes after RALM. One such study by Pitter et al. included a cohort of 872 women who underwent RALM between October 2005 and November 2010 at 3 centers. Of the 872 women, 107 conceived resulting in 127 pregnancies and 92 deliveries through 2011. The mean age at myomectomy was 34.8 ± 4.5 year, and the average number of myomas removed was 3.9 ± 3.2 with a mean size of 7.5 ± 3.0 cm and mean weight of 191.7 ± 145 g. Preterm delivery rates were higher with greater number of fibroids removed and anterior location of the largest incision. Overall the pregnancy outcomes in this study were comparable to those reported in the literature for conventional LM. Cela et al. had similar outcomes in a review of 48 patients who underwent RALM between the years 2007 and 2011. The average patient age was 35 years, and seven women (13%) became pregnant after RALM with eight pregnancies. Six deliveries were via cesarean section, one was spontaneous, and the last was ongoing at the time of the report. There were no spontaneous abortions or uterine ruptures [39]. Following suit, Yeon Kang et al. in 2016 reported their outcomes

in 100 women who underwent RALM for deep intramural fibroids (FIGO 2–5). The average number of fibroids was 3.8 ± 3.5 with mean size of 7.5 ± 2.1 cm. All patients recovered without major complications, and 75% of those pursuing pregnancy conceived [40].

Pitter et al. published the first paper on symptom recurrence after RALM in March 2015. In this retrospective survey of 426 women undergoing RALM for symptom relief or infertility across 3 practice sites, 62.9% reported being symptom-free after 3 years, and 80% of symptom-free women who had undergone RALM to improve fertility outcomes conceived after 3 years. The mean time to pregnancy was 7.9 ± 9.4 months. Overall, pregnancy rates improved, and symptom recurrence increased with time from surgery [41].

After this exhaustive review of the available data on RALM, it is fair to conclude that robotic surgery is a game changer for minimally invasive management of uterine fibroids. However, there is not enough evidence to support its superiority over conventional laparoscopy. Larger and ideally prospective studies are needed. Furthermore, future studies comparing these two modalities should be performed by surgeons who are skilled in both techniques and beyond their learning curves [42].

At our institution a majority of the myomectomies are performed robotically. We are careful in our selection of RALM candidates with a goal of ensuring a successful procedure and minimizing the risk of conversion. The factors we consider when selecting candidates for RALM include location, size, and number of fibroids, patient’s body habitus, and relative size of uterus to length of patient’s torso. A preoperative MRI is a critical part of the preoperative evaluation. It serves as a map of the fibroids and rules out the presence of adenomyosis. Although RALM is performed by four high-volume providers with slightly different patient selection criteria and thresholds for robotic candidacy, in general, we do not offer robotic surgery to patients with >15 myomas and with a single myoma >12 – 15 cm and when the uterus is more than 2 finger breadths above the umbilicus.

Myomectomy Case Card

Please refer to the basic robotic setup above. We use a four-arm robotic setup for RALM (Fig. 3.3).

Below is a list of instruments we use specifically for RALM:

1. Robotic instruments: Monopolar Hot Shears (Arm 1), Gyrus PK Dissector (Arm 2), Endowrist Tenaculum (Arm 3), Mega Needle Driver (Arm 1)
2. Uterine manipulator (Advincula Arch)
3. ALLY Uterine Positioning System (Cooper Surgical, Trumbull, CT)
4. Cytotec/vasopressin (20 U in 50 cc of saline) administered via 7 in. 22 gauge spinal needle
5. Interceed (Johnson & Johnson, New Brunswick, NJ)
6. 2-0 V-Loc™ barbed suture (Medtronic, Minneapolis, MN)

See video of RALM.

Hysterectomy

Hysterectomy continues to be the most common major surgical procedure performed by gynecologists in the United States. Data from 2000 to 2004 suggests that greater than 600,000 procedures were performed annually with approximately two-thirds being performed abdominally for benign indications [43]. It is well documented that minimally invasive hysterectomy via a vaginal or laparoscopic approach is associated with less blood loss, decreased length of hospital stay, shorter recovery periods, and overall decreased morbidity when compared to abdominal hysterectomy [44–47]. The long-term advantage of minimally invasive hysterectomy has also been evaluated. Nieboer et al. conducted a randomized controlled trial evaluating quality of life after laparoscopic and abdominal hysterectomy. Of the 59 women randomized, 27 underwent LH and 32 underwent AH. After 4 years the patients were given a quality of life questionnaire with an overall response rate of 83%. Patients who had LH had higher scores (50.4 point difference) mostly

with questions addressing physical role functioning, social role functioning, and vitality [48].

A recent American College of Obstetricians and Gynecologists (ACOG) committee opinion released in 2015 reaffirmed a 2009 statement endorsing vaginal approach as the preferred route for benign hysterectomy due to its lower complication rates and well-documented advantages [49, 50]. LH is recommended as an alternative approach when vaginal route is not feasible by both ACOG and AAGL [51]. It is clear that the primary goal with these recommendations is to avoid the morbidity of laparotomy whenever feasible. In the midst of these recommendations, the role of robotic surgery has not been clearly delineated. This is because there is a dearth of evidence in the available literature to prove the role or advantage of robotic-assisted laparoscopic hysterectomy over vaginal or laparoscopic routes. Accordingly, ACOG recommends “randomized controlled trials or comparably rigorous non-randomized prospective trials *be performed* to determine which patients are likely to benefit from robot-assisted surgery and to establish the potential risks” [49].

Since the approval of robotic surgery for gynecologic procedures, many observational studies and only four randomized controlled trials comparing robotic-assisted laparoscopic hysterectomy (RALH) to conventional laparoscopic hysterectomy (LH) have been conducted. From 2010 to 2014, six systematic reviews and meta-analyses comparing RALH to LH in both benign and malignant gynecologic diseases were published. These reviews, which included mostly observational studies, showed superiority of RALH over traditional AH. However, the results of the comparison between RALH and conventional LH were generally mixed [57]. The meta-analysis by Scandola et al. comparing RALH to conventional LH found that RALH was associated with shorter length of hospital stay, less postoperative complications (OR, 0.69; 95% CI –0.68 to –0.17), and fewer conversions to laparotomy (OR, 0.5; 95% CI 0.31–0.79) [52]. These results were in contrast to the 2014 Cochrane review, which found limited evidence to support the safety and efficacy of RALH compared with

conventional LH or AH for gynecologic cancers [53]. The analysis by Gala et al. revealed superiority of RALH over AH but conflicting data when comparing RALH to LH. However, they found that the proficiency plateau seemed lower for RALH than for LH. In this study, the authors go on to conclude that the specific method of minimally invasive surgery should be based on the patient presentation, surgeon ability, and equipment availability [54].

In 2016 a systematic review and meta-analysis of the previously mentioned RCTs was published in the *Journal of Minimally Invasive Gynecology*. The most recent of the four RCTs by Lonnerfors et al. primarily compared hospital costs between RALH and traditional minimally invasive hysterectomy (vaginal and laparoscopic). The study included 122 women with benign disease and uterine size ≤ 16 weeks. The women were randomized into two arms: RALH and MIS hysterectomy. The designated surgeon decided the route of MIS hysterectomy with vaginal hysterectomy as the first choice. The 122 women were randomized equally to each arm resulting in 61 robotic cases and 61 MIS cases (25 vaginal, 36 laparoscopic). The average cost of vaginal hysterectomy was \$4579 compared to \$7059 for conventional LH, and the per protocol subanalysis comparing conventional LH to RALH showed similar costs (\$7059 vs. \$7016) when the robot was a pre-existing investment. In addition the secondary outcome, which evaluated short-term complications, demonstrated less blood loss and fewer postoperative complications with RALH. The authors concluded that based on hospital costs, RALH should not be performed in lieu of vaginal hysterectomy. Although the study was underpowered for comparing conventional LH to RALH due to the surprisingly high rate of vaginal hysterectomies, this study is probably one of the very few that suggest relatively similar hospital costs for conventional LH and RALH [55]. Martinez-Maestre et al. in their quasi-randomized prospective controlled trial comparing total surgical time, conversion to laparotomy, blood loss, hospital stay, and complication between RALH and conventional LH found that RALH had shorter operating times (154.63 ± 36.57 vs. 185.65 ± 42.98 min;

$P = 0.0001$) and less reduction in hemoglobin and hematocrit and no differences in complications and conversion rates. An important fact in this study is that the surgeons were “confronting themselves with a relatively new procedure in both study arms,” thus leading to the authors’ conclusion that robotic assistance can facilitate surgery during the learning curve period [56]. The last two RCTs by Paraiso et al. and Sarlos et al. compared operative outcomes between RALH and conventional LH and demonstrated longer operating times with RALH and no other clinical or statistically significant differences between the two routes [57, 58].

In the meta-analysis which included the sum of all women in the RCTs (326 total participants), the primary outcome evaluated was perioperative complications, and the secondary outcomes were length of hospital stay, skin-to-skin operating time, conversion to alternative surgical approach, blood loss, cost, and patient experience measures (post-operative pain and quality of life). In summary, this analysis found no statistically significant or clinically meaningful difference between RALH and LH. Three of the seven secondary outcomes (cost, pain, and quality of life) were inconsistently reported and could not undergo formal pooling for analysis. In addition, “significant heterogeneity” of the results from the other four secondary outcomes made it difficult to make generalizable inferences. A limitation of this study, as acknowledged by the authors, is the increased risk of type II error (not identifying a difference when one truly exists) due to the small number of trials reviewed. Nevertheless, the authors conclude that based on their analysis, no clear significant improvement in outcomes for RALH compared to conventional LH exists and recommend that more targeted research needs to be performed to highlight the advantages of robotic surgery in a selected patient population [59].

In our practice, minimally invasive approach to hysterectomy is the absolute gold standard. Our surgeons are skilled in vaginal, laparoscopic, and robotic techniques for hysterectomy. Although each of our surgeons has a unique practice style and different comfort levels with each route of surgery, in general RALH is reserved for

patients with more complex pathology including uterine size >18–20 weeks, advanced stage endometriosis, and surgical history concerning for severe adhesive disease. As a large tertiary referral center, a significant proportion of the hysterectomies that we perform fall under the category of complex hysterectomy.

Hysterectomy Case Card

Please refer to the basic robotic setup above. We use a three-arm or four-arm robotic setup for RALH (Figs. 3.2 and 3.3).

Below is a list of instruments we use specifically for RALH:

1. Robotic instruments: Monopolar Hot Shears (Arm 1), Gyrus PK Dissector (Arm 2), Mega Needle Driver (Arm 1), and +/- ProGrasp Forceps (Arm 3)
2. Uterine manipulator (Advincula Arch/Koh-Efficient system or Advincula Delineator) (Cooper Surgical, Trumbull, CT)
3. +/- EEA sizer
4. 2-0 V-Loc™ barbed suture (Medtronic, Minneapolis, MN)

Sacrocolpopexy

Pelvic organ prolapse (POP) is a common condition faced by women worldwide. A commonly referenced statistic is that a woman has an 11.1% lifetime risk of surgery for either incontinence or pelvic organ prolapse by the age of 80 years [60, 61]. In 2009 Wu et al. published a forecasting study in which they predicted that by 2050, ~44 million women would be affected by a form of pelvic floor disorder [62]. The mainstay of treatment for POP is surgery, and with its increasing prevalence, surgical interventions for POP have become more commonly performed by gynecologists.

In 1962, Lane introduced the sacrocolpopexy (SC) as a technique for surgical management of apical prolapse [63]. Today it represents the gold

standard in prolapse surgery proving superiority over a variety of vaginal procedures—sacrospinous ligament fixation, uterosacral ligament suspension, and vaginal mesh kits. The clear drawbacks of sacrocolpopexy, which was first described and performed via laparotomy (as compared to the vaginal POP procedures), include longer operating time, longer convalescence, and increased cost of the abdominal approach [64]. In an effort to overcome these drawbacks, a laparoscopic approach to SC was described and adopted.

Laparoscopic sacrocolpopexy (LSC) has been shown in many studies to be associated with shorter hospital stays and less blood loss when compared to the abdominal approach (ASC); the data on operating time has been conflicting. Coolen et al. evaluated surgery-related morbidity in 85 patients with post-hysterectomy vaginal vault prolapse undergoing LSC versus ASC. The results of this study showed significantly less blood loss (77 mL±182 versus 192 mL±126; $P < 0.001$) and shorter hospital stay (2.4 versus 4.2 days) in the LSC group. Although there was no statistically significant difference in the complication rates between both groups ($p = 0.121$), the authors reported more severe complications in the ASC group [65]. Hsiao et al. reported similar findings and in addition noted significantly longer operating times in the LSC group (219.9 versus 185.2 min; $P = 0.045$) [66]. Freeman et al. conducted a randomized controlled trial (RCT) primarily comparing point C on the POP-Q at 1 year following LSC versus ASC in women referred with symptomatic post-hysterectomy vaginal vault prolapse (at least 1 cm above or beyond the hymen). They reported a C of -6.63 cm in the ASC group and -6.67 cm in the LSC group. The subjective outcomes at 1 year showed that 90% of the ASC group and 80% of the LSC group were “much better.” LSC was also found to be associated with decreased blood loss and shorter length of hospital stay. The trial ultimately concluded that LSC is clinically equivalent to ASC for management of POP [67, 68]. In spite of the clear and well-documented benefits of LSC over ASC, its global adoption by urogy-

necologists has been limited due to its marked learning curve [69]. As a result, when the da Vinci Surgical System received approval for use in gynecologic surgery (2005), a proposal was made by some urogynecologists for robotic-assisted sacrocolpopexy (RASC).

When compared to ASC, RASC offers the advantage of a minimally invasive procedure without the challenges of conventional laparoscopy [70]. Interestingly, Collins et al. reported that women undergoing RASC did not recover more quickly or have less pain control than those undergoing ASC. These findings were admittedly surprising considering the abundance of quality evidence to support the benefits of minimally invasive surgery over abdominal approach [71].

With regard to cost differences, Elliot et al. performed a cost minimization analysis between RASC and ASC in a retrospective cohort of patients undergoing SC from 2006 to 2010. The analysis showed a 4.2% decrease in cost with RASC as compared to ASC [72]. Hoyte et al. reported similar findings with slightly less cost of RASC (\$6668 versus 7804; $P = 0.002$) but increased operating time (212 versus 166 min) when compared to ASC [73].

Since the introduction of RASC, two randomized trials have been performed comparing LSC to RASC. Paraiso et al. compared operating times (primary outcome) and surgical outcomes including postoperative pain, complications, costs, and postoperative subjective and objective cure rates (secondary outcomes). The study outcomes demonstrated less operative time (162 ± 47 min vs. 221 ± 47 min; $P < 0.001$), decreased costs (\$14,342 vs. \$16,278), and less pain with LSC compared to RASC [74]. Anger et al. reported similar findings of less time (178 ± 49.8 min vs. 202.8 ± 46.1 min), decreased costs (\$11,573 vs. \$19,616), and less pain with LSC [75]. In both studies no other significant differences were noted.

An interesting caveat to consider with the result of these studies is that the minimum number of RASC performed by the participating surgeons in the study by Anger et al. ranged from 10 to 50 (no report on LSC numbers), and in the Paraiso et al. trial, 1 surgeon had performed 400–500 LSCs and

10 RASCs, while the other had performed 100 LSCs and 10 RASCs. Although a definite conclusion cannot be made about the impact of the stark difference in surgical experience with the LSC versus RASC on the study outcomes, it is reasonable to infer that the observed differences in the operative outcomes including patient postoperative pain, length of surgery, and complications were impacted by the surgeons' limited experience in robotic versus laparoscopic surgery.

To conclude, there is still no consensus on the role of robotic technology in performing sacrocolpopexy. The available literature is inconclusive about its advantages over LSC. In a 2015 meta-analysis comparing LSC to RASC, the authors concluded that despite the widespread performance of RASC, its advantages in terms of complications and anatomical outcomes remain unclear [76]. A more recent 2016 meta-analysis also comparing LSC to RASC acknowledged the advantages of robotic surgery in terms of its ability to “boost surgical capacities” but cautioned about the high cost of robotic surgery and the need to negotiate lower costs [77].

At our institution we perform sacrocolpopexies via the laparoscopic and robotic approach. The approach of choice is based on surgeon and patient preference.

Sacrocolpopexy Case Card

Please refer to the basic robotic setup above. We use a three-arm or four-arm robotic setup for RASC (Figs. 3.2 and 3.3).

Below is a list of instruments we use specifically for RASC:

1. Robotic instruments: Monopolar Hot Shears (Arm 1), Gyrus PK Dissector (Arm 2), Mega Suture Cut Needle Driver (Arm 1), and \pm Long Tip Forceps (Arm 3)
2. Uterine manipulator (Advincula Arch/Koh colpotomizer or Advincula Delineator) (Cooper Surgical, Trumbull, CT)
3. Vaginal manipulator
4. 0 Polysorb suture

Conclusion

The paucity of level I evidence in the literature addressing robotic surgery underlies the inability to clearly identify and delineate the role of robotics in benign gynecology. The available data, although mostly of low-to-moderate quality, generally share consensus on a few issues:

- Robotic surgery has a role in benign gynecology. However, the specifics of this role are unclear.
- Robotic surgery offers an advantage over abdominal surgery as a minimally invasive route of surgery.
- Robotic surgery offers a safe and feasible minimally invasive surgical approach to the management of benign disease.
- Robotic surgery is costly and it is unclear if the cost is worth its benefits.
- The superiority of robotic surgery over laparoscopy has not been proven.
- Robotic surgery should not be performed when vaginal surgery is a feasible option.

Our stance is that a minimally invasive approach to surgery is the absolute standard of care. Vaginal, laparoscopic, and robotic surgery should be offered and performed over abdominal surgery at all times. The route of minimally invasive surgery undertaken should be based on the patient's preference, the surgeon's surgical expertise, and the option that is felt to ensure the most successful outcome.

References

1. Litynski GS. Endoscopic surgery: the history, the pioneers. *World J Surg.* 1999;23(8):745–53.
2. William W. Hurd, MD, MSc, MPH; Chief Editor: Michel E. Rivlin, MD. Gynecologic laparoscopy. Medscape. Available at <http://emedicine.medscape.com/article/265201-overview#showall>. Accessed 16 Apr 2016.
3. Rosero EB, Kho KA, Joshi GP, Giesecke M, Schaffer JI. Comparison of robotic and laparoscopic hysterectomy for benign gynecologic disease. *Obstet Gynecol Surv.* 2014;69(1):18–9.
4. Falcone T, Goldberg JM, Margossian H, Stevens L. Robotic-assisted laparoscopic microsurgical tubal anastomosis: a human pilot study. *Fertil Steril.* 2000;73:1040–2.
5. Diaz-Arrastia C, Jurnalov C, Gomez G, Townsend C Jr. Laparoscopic hysterectomy using a computer-enhanced surgical robot. *Surg Endosc.* 2002;16:1271–3.
6. Soto E, Lo Y, Friedman K, Soto C, Nezhat F, Chuang L, Gretz H. Total laparoscopic hysterectomy versus da Vinci robotic hysterectomy: is using the robot beneficial? *J Gynecol Oncol.* 2011;22(4):253–9.
7. Kumari S, Rupa B, Sanjay M, Sinha R. Robotic surgery in gynecology. *J Minim Access Surg.* 2015;11(1):50–9.
8. Advincula AP, Song A. The role of robotic surgery in gynecology. *Curr Opin Obstet Gynecol.* 2007;19(4):331–6.
9. Eskenazi B, Warner ML. Epidemiology of endometriosis. *Obstet Gynecol Clin N Am.* 1997;24(2):235–58.
10. Cornillie FJ, Oosterlynck D, Lauweryns JM, Koninckx PR. Deeply infiltrating pelvic endometriosis: histology and clinical significance. *Fertil Steril.* 1990;53(6):978–83.
11. Fauconnier A, Chapron C, Dubuisson J-B, Vieira M, Dousset B, Bréart G. Relation between pain symptoms and the anatomic location of deep infiltrating endometriosis. *Fertil Steril.* 2002;78(4):719–26.
12. Fauconnier A, Chapron C. Endometriosis and pelvic pain: epidemiological evidence of the relationship and implications. *Hum Reprod Update.* 2005;11(6):595–606.
13. Hsu AL, Khachikyan I, Stratton P. Invasive and non-invasive methods for the diagnosis of endometriosis. *Clin Obstet Gynecol.* 2010;53(2):413–9. <https://doi.org/10.1097/GRF.0b013e3181db7ce8>.
14. Practice Committee of the American Society for Reproductive Medicine. Endometriosis and infertility: a committee opinion. *Fertil Steril.* 2012;98(3):591, 598.
15. G S, Ieda N, Rosati R, Vitobello D. Robotic surgery for deep endometriosis: a paradigm shift. *Int J Med Robot.* 2014;10(2):140–6.
16. Pellegrino A, Damiani GR, Trio C, Faccioli P, Croce P, Tagliabue F, Dainese E. Robotic shaving technique in 25 patients affected by deep infiltrating endometriosis of the rectovaginal space. *J Minim Invasive Gynecol.* 2015;22(7):1287–92.
17. Neme RM, Schraibman V, Okazaki S, Maccapani G, Chen WJ, Domit CD, Kaufmann OG, Advincula AP. Deep infiltrating colorectal endometriosis treated with robotic-assisted rectosigmoidectomy. *JLS.* 2013;17(2):227–34.
18. Nezhat FR, Sirota I. Perioperative outcomes of robotic assisted laparoscopic surgery versus conventional laparoscopy surgery for advanced-stage endometriosis. *JLS.* 2014;18(4)
19. Gargiulo AR. Computer-assisted reproductive surgery: why it matters to reproductive endocrinology and infertility subspecialists. *Fertil Steril.* 2014;102(4):911–21.

20. Management of uterine fibroids. Summary, Evidence Report/ Technology Assessment: Number 34. AHRQ Publication No. 01-E051, 2001. Agency for Healthcare Research and Quality, Rockville, MD, USA.
21. Baird DD, Dunson DB, Hill MC, Cousins D, Schectman JM. High cumulative incidence of uterine leiomyoma in black and white women: ultrasound evidence. *Am J Obstet Gynecol.* 2003;188:100–7.
22. Stewart EA. Uterine fibroids. *Lancet.* 2001;357:293–8.
23. Nash K, Feinglass J, Zei C, Lu G, Mengesha B, Lewicky-Gaupp C, Lin A. Robotic-assisted laparoscopic myomectomy versus abdominal myomectomy: a comparative analysis of surgical outcomes and costs. *Arch Gynecol Obstet.* 2012;285:435–40.
24. Herrmann A, De Wilde RL. Laparoscopic myomectomy – the gold standard. *Gynecol Minim Invasive Ther.* 2014;3(2):31–8.
25. Holzer A, Jirecek ST, Illievich UM, Huber J, Wenzl RJ. Laparoscopic versus open myomectomy: a double-blind study to evaluate postoperative pain. *Anesth Analg.* 2006;102(5):1480–4.
26. Mais V, Ajossa S, Guerriero S, et al. Laparoscopic versus abdominal myomectomy: a prospective, randomized trial to evaluate benefits in early outcome. *Am J Obstet Gynecol.* 1996;174:654–8.
27. Jin C, Hu Y, Chen XC, et al. Laparoscopic versus open myomectomy – a meta-analysis of randomized controlled trials. *Eur J Obstet Gynecol Reprod Biol.* 2009;145:14–21.
28. Pluchino N, Litta P, Freschi L, et al. Comparison of the initial surgical experience with robotic and laparoscopic myomectomy. *Int J Med Robot.* 2014;10:208–12.
29. Parker WH, Iacampo K, Long T. Uterine rupture after laparoscopic removal of a pedunculated myoma. *J Minim Invasive Gynecol.* 2007;14(3):362–4.
30. Advincula AP, Song A, Burke W, et al. Preliminary experience with robot-assisted laparoscopic myomectomy. *J Am Assoc Gynecol Laparosc.* 2004;11:511–8.
31. Advincula AP, Xu X, Goudeau S, Ransom SB. Robot-assisted laparoscopic myomectomy versus abdominal myomectomy: a comparison of short-term surgical outcomes and immediate costs. *J Minim Invasive Gynecol.* 2007;14:698–705.
32. Ascher-Walsh CJ, Capes TL. Robot-assisted laparoscopic myomectomy is an improvement over laparotomy in women with a limited number of myomas. *J Minim Invasive Gynecol.* 2010;17:306–10.
33. Hanafi MM, Hsu Y-S, Fomo AN. Comparative study between robotic laparoscopic myomectomy and abdominal myomectomy and factors affecting short-term surgical outcomes. *J Reprod Med Endocrinol.* 2010;7:258.
34. Mansour FW, Kives S, Urbach DR, Lefebvre G. Robotically assisted laparoscopic myomectomy: a Canadian experience. *J Obstet Gynaecol Can.* 2012;34:353–8.
35. Sangha R, Eisenstein D, George A, Munkarah A, Wegienka G. Comparison of surgical outcomes for robotic assisted laparoscopic myomectomy compared to abdominal myomectomy. *J Minim Invasive Gynecol.* 2010;17(Suppl):S108.
36. Pundir J, Pundir V, Walavalkar R, Omanwa K, Lancaster G, Kayani S. Robotic-assisted laparoscopic vs abdominal and laparoscopic myomectomy: systematic review and meta-analysis. *J Minim Invasive Gynecol.* 2013;20(3):335–45.
37. Barakat EE, Bedaiwy MA, Zimberg S, Nutter B, Nosseir M, Falcone T. Robotic-assisted, laparoscopic, and abdominal myomectomy: a comparison of surgical outcomes. *Obstet Gynecol.* 2011;117:256–65.
38. Gargiulo AR, Nezhat C. Robot-assisted myomectomy: broadening the Laparoscopists’s armamentarium. In: Tinelli AA, Malvasi A, editors. *Uterine myoma, myomectomy and minimally invasive treatments.* Basel, Switzerland: Springer International Publishing; 2015. p. 193. https://doi.org/10.1007/978-3-319-10305-1_13.
39. Cela V, Freschi L, Simi G, Tana R, Russo N, Artini PG, Pluchino N. Fertility and endocrine outcome after robot-assisted laparoscopic myomectomy (RALM). *Gynecol Endocrinol.* 2013;29(1):79–82.
40. Kang SY, Jeung I-C, Chung Y-J, Kim H-K, Lee CR, Mansukhani TS, Kim M-R. Robot-assisted laparoscopic myomectomy for deep intramural myomas. *Int J Med Robot.* 2016. <https://doi.org/10.1002/rcs.1742>.
41. Pitter MC, Srouji SS, Gargiulo AR, et al. Fertility and symptom relief following robot-assisted laparoscopic myomectomy. *Obstet Gynecol Int.* 2015; Article ID 967568, 9 pages. doi:<https://doi.org/10.1155/2015/967568>.
42. Quaas AM, Einarsson JI, Srouji S, Gargiulo AR. Robotic myomectomy: a review of indications and techniques. *Rev Obstet Gynecol.* 2010;3(4):185–91.
43. Whiteman M, Hillis S, Jamieson D, et al. Inpatient hysterectomy surveillance in the United States, 2000–2004. *Am J Obstet Gynecol.* 2008;198(1):34.e1–7. <https://doi.org/10.1016/j.ajog.2007.05.039>.
44. Olsson JH, Ellstrom M, Hahlin M. A randomised prospective trial comparing laparoscopic and abdominal hysterectomy. *Br J Obstet Gynaecol.* 1996;103:345–50.
45. Garry R, Fountain J, Mason S, Napp V, Brown J, Hawe J, et al. The eVALuate study: two parallel randomised trials, one comparing laparoscopic with abdominal hysterectomy, the other comparing laparoscopic with vaginal hysterectomy. *BMJ.* 2004. <https://doi.org/10.1136/bmj.37984.623889.F6>.
46. Jacoby VL, Autry A, Jacobson G, Domush R, Nakagawa S, Jacoby A. Nationwide use of laparoscopic hysterectomy compared with abdominal and vaginal approaches. *Obstet Gynecol.* 2009;114(5):1041–8.
47. Govern JM, Rosemeyer CJ, Barter JF, Steren AJ. Comparison of robotic, laparoscopic, and abdominal myomectomy in a community hospital. *JSLs.* 2013;17(1):116–20. <https://doi.org/10.4293/108680812X13517013317473>.
48. Nieboer TE, Hendriks JCM, Bongers MY, Vierhout ME, Kluivers KB. Quality of life after laparoscopic

- and abdominal hysterectomy: a randomized controlled trial. *Obstet Gynecol.* 2012;119(1):85–91.
49. American College of Obstetricians and Gynecologists. ACOG Committee Opinion no. 628: robotic surgery in gynecology. *Obstet Gynecol.* 2015;125:760–7.
 50. American College of Obstetricians and Gynecologists. ACOG Committee Opinion no. 444: choosing the route of hysterectomy for benign disease. *Obstet Gynecol.* 2009;114:1156–8.
 51. AAGL Advancing Minimally Invasive Gynecology Worldwide. AAGL position statement: route of hysterectomy to treat benign uterine disease. *J Minim Invasive Gynecol.* 2011;18:1–3.
 52. Scandola M, Grespan L, Vicentini M, Fiorini P. Robot-assisted laparoscopic hysterectomy vs traditional laparoscopic hysterectomy: five metaanalyses. *J Minim Invasive Gynecol.* 2011;18:705–15.
 53. Liu H, Lawrie TA, Lu D, Song H, Wang L, Shi G. Robot-assisted surgery in gynaecology. *Cochrane Database Syst Rev.* 2014;12:CD011422.
 54. Gala RB, Margulies R, Steinberg A, et al. Systematic review of robotic surgery in gynecology: robotic techniques compared with laparoscopy and laparotomy. *J Minim Invasive Gynecol.* 2014;21:353–61.
 55. Lönnerfors C, Reynisson P, Persson J. A randomized trial comparing vaginal and laparoscopic hysterectomy vs robot-assisted hysterectomy. *J Minim Invasive Gynecol.* 2015;22:78–86.
 56. Martínez-Maestre MA, Gambadauro P, González-Cejudo C, Torrejón R. Total laparoscopic hysterectomy with and without robotic assistance: a prospective controlled study. *Surg Innov.* 2014;21:250–5.
 57. Paraiso MF, Ridgeway B, Park AJ, et al. A randomized trial comparing conventional and robotically assisted total laparoscopic hysterectomy. *Am J Obstet Gynecol.* 2013;208:368.e1–7.
 58. Sarlos D, Kots L, Stevanovic N, von Felten S, Schär G. Robotic compared with conventional laparoscopic hysterectomy: a randomized controlled trial. *Obstet Gynecol.* 2012;120:604–11.
 59. Albright BB, Witte T, Tofte AN, Chou J, Black JD, Desai VB, Erekson EA. Robotic versus laparoscopic hysterectomy for benign disease: a systematic review and meta-analysis of randomized trials. *J Minim Invasive Gynecol.* 2016;23(1):18–27.
 60. Olsen AL, Smith VJ, Bergstrom JO, Colling JC, Clark AL. Epidemiology of surgically managed pelvic organ prolapse and urinary incontinence. *Obstet Gynecol.* 1997;89(4):501–6.
 61. Fialkow MF, Newton KM, Lentz GM, Weiss NS. Lifetime risk of surgical management for pelvic organ prolapse or urinary incontinence. *Int Urogynecol J Pelvic Floor Dysfunct.* 2008;19(3):437–40.
 62. Wu JM, Hundley AF, Fulton RG, Myers ER. Forecasting the prevalence of pelvic floor disorders in U.S. women: 2010 to 2050. *Obstet Gynecol.* 2009;114:1278–83.
 63. Lane FE. Modified technique of sacral colpopexy. *Am J Obstet Gynecol.* 1982;142:933.
 64. Maher C, Feiner B, Baessler K, Schmid C. Surgical management of pelvic organ prolapse in women. *Cochrane Database Syst Rev.* 2013:CD004014.
 65. Coolen AL, van Oudheusden AM, van Eijndhoven HW, et al. A comparison of complications between open abdominal sacrocolpopexy and laparoscopic sacrocolpopexy for the treatment of vault prolapse. *Obstet Gynecol Int.* 2013;2013:528636.
 66. Hsiao KC, Latchamsetty K, Govier FE, Kozlowski P, Kobashi KC. Comparison of laparoscopic and abdominal sacrocolpopexy for the treatment of vaginal vault prolapse. *J Endourol.* 2007;21:926–30.
 67. Freeman RM, Pantazis K, Thomson A, et al. A randomised controlled trial of abdominal versus laparoscopic sacrocolpopexy for the treatment of post-hysterectomy vaginal vault prolapse: LAS study. *Int Urogynecol J.* 2013;24(3):377–84.
 68. Costantini E, Mearini L, Lazzeri M, Bini V, Nunzi E, di Biase M, Porena M. Laparoscopic versus abdominal sacrocolpopexy: a randomized controlled trial. *J Urol.* 2016;196(1):159–65.
 69. Yohannes P, Rotariua P, Pintoa P, Smitha A, Leea B. Comparison of robotic versus laparoscopic skills: is there a difference in the learning curve? *Urology.* 2002;60(1):39–45.
 70. Geller EJ, Siddiqui NY, Wu JM, et al. Short-term outcomes of robotic sacrocolpopexy compared with abdominal sacrocolpopexy. *Obstet Gynecol.* 2008;112(6):1201–6.
 71. De Gouveia M, Claydon LS, Whitlow B, Artahona MAD. Laparoscopic versus open sacrocolpopexy for treatment of prolapse of the apical segment of the vagina: a systematic review and meta-analysis. *Int Urogynecol J.* 2016;27(1):3–17.
 72. Elliott CS, Hsieh MH, Sokol ER, Comiter CV, Payne CK, Chen B. Robot-assisted versus open sacrocolpopexy: a cost-minimization analysis. *J Urol.* 2012;187:638–43.
 73. Hoyte L, Rabbanifard R, Mezzich J, Bassaly R, Downes K. Cost analysis of open versus robotic-assisted sacrocolpopexy. *Female Pelvic Med Reconstr Surg.* 2012;18:335–9.
 74. Paraiso MF, Jelovsek JE, Frick A, Chen CC, Barber MD. Laparoscopic compared with robotic sacrocolpopexy for vaginal prolapse: a randomized controlled trial. *Obstet Gynecol.* 2011;118(5):1005–13.
 75. Anger JT, Mueller ER, Tarnay C, Smith B, Stroupe K, Rosenman A, Brubaker L, Bresee C, Kenton K. Robotic compared with laparoscopic sacrocolpopexy: a randomized controlled trial. *Obstet Gynecol.* 2014;123(1):5–12.
 76. Ke P, Zhang Y, Wanga Y, Wangd Y, Xua H. A systematic review and meta-analysis of conventional laparoscopic sacrocolpopexy versus robot-assisted laparoscopic sacrocolpopexy. *Int J Gynecol Obstet.* 2016;132(3):284–91.
 77. Callewaert G, Bosteels J, Housmans S, Verguts J, Van Cleynenbreugel B, Van der Aa F, De Ridder D, Vergote I, Deprest J. Laparoscopic versus robotic-assisted sacrocolpopexy for pelvic organ prolapse: a systematic review. *Gynecol Surg.* 2016;13(2):115–23.



Single-Port Surgery

4

Kevin J. E. Stepp and Dina A. Bastawros

Introduction

Conventional laparoscopy is the preferred approach for many, if not most, major gynecologic procedures that require abdominal access. Conventional laparoscopic instrumentation and access devices as well as robotic-assisted laparoscopic instrumentation are improving rapidly. Whether conventional or robotic laparoscopy is considered, we prefer to minimize the size and number of ports. Many surgical procedures are customarily performed via 3–5 ports through small incisions in the abdominal wall. Each additional port carries a small but not negligible risk for port site complications [1]. These risks

include bleeding, infection, injury to nearby organs, soft tissue trauma, herniation, and decreased cosmesis [2, 3].

Single-port laparoscopy was first described in gynecology when Wheless et al. performed tubal ligation [4]. The first major single-port laparoscopy was described by Pelosi et al. with laparoscopic-assisted vaginal hysterectomy [5]. With new instrumentation and better visualization, gynecologists began re-exploring single-port laparoscopy again in 2007.

To this day, authors around the world use multiple terms to describe laparoscopy carried out via a single port. However, in 2010, a multispecialty international consortium recommended the name laparo-endoscopic single-site surgery (LESS) [6]. LESS is meant to recognize and include subtle differences in technique such as using a single port with or without multiple channels or using multiple ports through a single skin incision.

A consortium of LESS experts developed a standardized and reproducible technique using *Core Principles* to perform LESS surgery in gynecology (Table 4.1) [7]. This chapter will cover the basic concepts that are easily understood, replicated, and useful for beginning and advanced LESS surgeons. Challenges unique to the LESS surgical approach include an in-line view, instrument crowding, and lack of triangulation. Understanding the principles and techniques described here will help the surgeon proceed efficiently, avoid external and internal clashing, and prevent frustration.

K. J. E. Stepp, M.D. (✉)

Urogynecology and Minimally Invasive Gynecologic Surgery, Advanced Surgical Specialties for Women, Carolinas Healthcare System, Charlotte, NC, USA

Department of Obstetrics and Gynecology, University of North Carolina-Chapel Hill, Charlotte, NC, USA

Mercy Medical Plaza, Charlotte, NC, USA

Department of Obstetrics and Gynecology, Mercy Medical Plaza, Charlotte, NC, USA
e-mail: kevin.stepp@carolinashealthcare.org

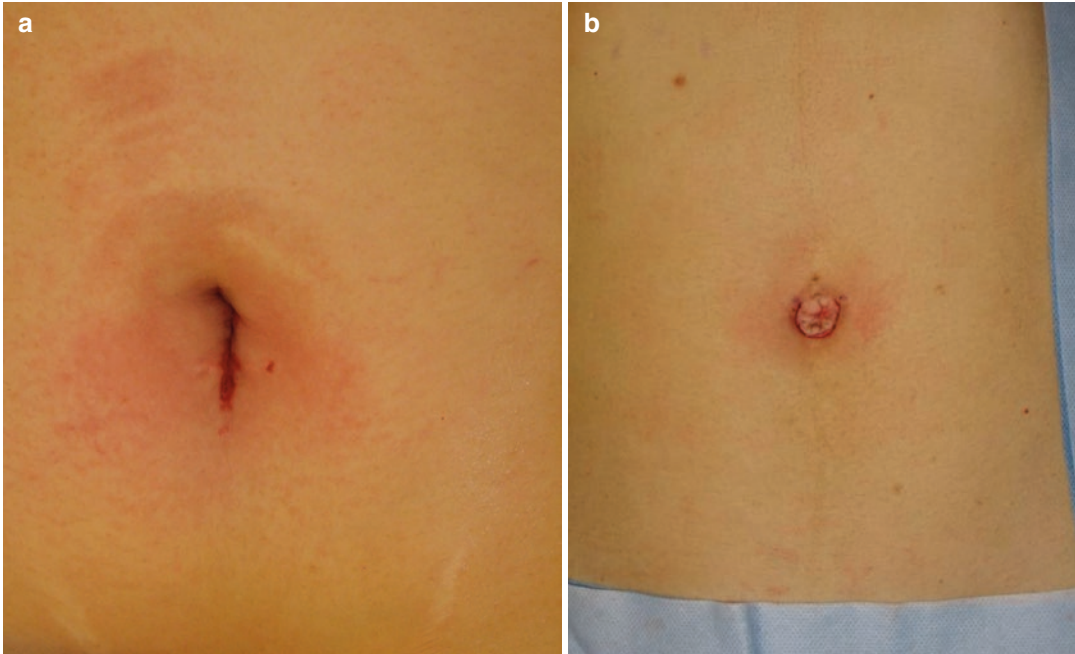
D. A. Bastawros, M.D.

Urogynecology and Minimally Invasive Gynecologic Surgery, Advanced Surgical Specialties for Women, Carolinas Healthcare System, Charlotte, NC, USA

Department of Obstetrics and Gynecology, Mercy Medical Plaza, Charlotte, NC, USA
e-mail: dina.bastawros@carolinashealthcare.org

Table 4.1 Core principles for LESS

1.	Always retract in such a way that the handle of the instrument moves laterally, away from the camera and central area above the umbilicus. This prevents extracorporeal clashing of instruments
2.	Plan the procedure and choose instrumentation and techniques that minimize the need for instrument exchanges. Devices that are multifunctional are strongly encouraged
3.	Use a uterine manipulator. For hysterectomy, we suggest one with a colpotomizer or ring to delineate the vaginal fornix
4.	If significant difficulty is encountered at any time during the procedure, an additional port can always be considered

**Fig. 4.1** Incision options. Top, vertical skin incision before (left) and after (right). Bottom, omega incision before (left) and after (right)

Ports and Gaining Access

One of the benefits of LESS is the incision is concealed at the base of the umbilicus, rendering a virtually scarless result. Various access devices and techniques have been described for peritoneal access. Regardless of the method used, the skin incision should be created to provide a cosmetically appealing result. The umbilicus itself is a scar that differs from person to person. In many patients, a vertical skin incision is preferable. However, the omega incision first described by pediatric surgeons in 1986 can provide additional space for specimen removal while maintaining

excellent cosmesis [8, 9] (Fig. 4.1). It has been postulated by some that an omega umbilical incision may carry an increased risk of infection. However, a retrospective study in gynecology compared vertical and circumferential umbilical incisions in 120 patients that underwent a LESS procedure and did not find a difference in rates of infection [10]. Special care should be taken to ensure careful reconstruction of the umbilicus for the best cosmetic result. If the umbilical stalk is detached from the fascia, it should be reattached to the fascia where it was previously attached [11]. Limiting the size of the incision may exert unnecessary tension on the skin edges that could

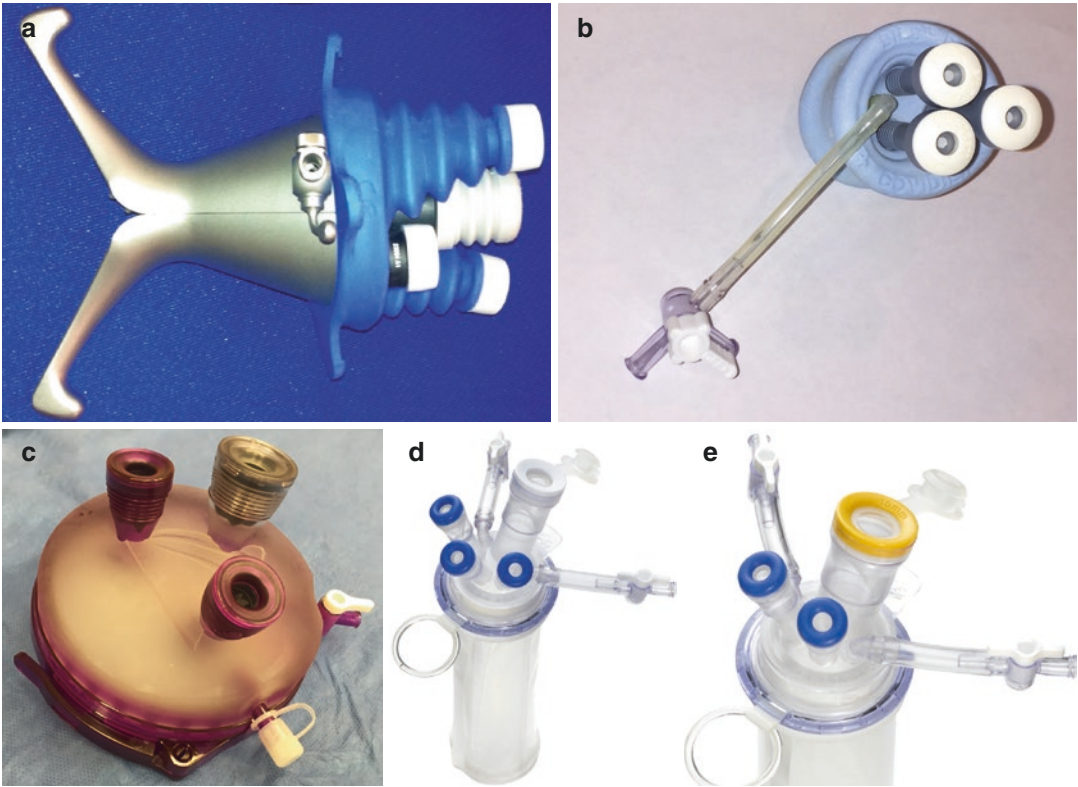


Fig. 4.2 LESS ports. (a) The X-CONE™ (Storz Endoscopy, Tuttlingen, Germany). (b) AnchorPort® SIL Kit device (Surgiquest Inc., Orange, CT). (c) SILS™ Port (Covidien, Norwalk, CT). (d) GelPoint™ (Applied

Medical, Rancho Santa Margarita, CA). (e) TriPort Plus™ (Advanced Surgical Concepts, Wicklow, Ireland). (f) TriPort 15™ (Advanced Surgical Concepts, Wicklow, Ireland)

lead to pressure necrosis. Although this condition usually heals well, this risk should be considered while making the skin incision and selecting the appropriate port for each patient.

The majority of commercially available LESS ports have two attachments that can be used for insufflation, outflow, smoke evacuation, or an additional insufflation port as necessary (Fig. 4.2). There are several patented port systems currently cleared by the US Food and Drug Administration for LESS, which will be discussed next.

The AirSeal port (SurgiQuest, Inc., Orange, Connecticut, USA) creates pneumoperitoneum by creating an air seal, which results from flow of air around the port at a higher pressure than what the pneumoperitoneum creates. One of the biggest advantages of this system is that the constant air circulation reduces smoke accumulation [12].

The GelPoint system (Applied Medical Resources Corp., Rancho Santa Margarita, California, USA) is comprised of a wound retractor that is placed in the incision. Next, a 10 cm gel cap is placed over the outer ring of the retractor. This cap is made of a gel interface that allows the surgeon to pass many instruments through this interface with the provided cannulas and decrease instrument crowding. The biggest disadvantage of this system is the potential for a gas leak if the gel interface has a large slit [12].

Covidien (Mansfield, Massachusetts, USA) developed a system called the SILS Port. It can accommodate up to three instruments through a single fascial incision up to 2 cm in length. The port is made of an elastic polymer. An advantage of this system is that each instrument has its own dedicated channel. Ports with dedicated channels

provide less rubbing or unintended crossing of the instruments at the level of the fascia. A disadvantage is that the port requires a slightly larger incision 2.0–2.5 cm). Ports that utilize a single fascial incision maximize space for additional instruments.

TriPort by Advanced Surgical Concepts, Ltd., (Bray, County Wicklow, Ireland) comes in two configurations. Each has a retraction sleeve with two or three 5 mm ports and one 12 mm or 15 mm port. This system is very advantageous because it can be used on varying abdominal wall lengths, up to 10 cm. If the retraction sleeve is damaged, loss of pneumoperitoneum may result [12].

Karl Storz GmbH & Co. KG (Tuttlingen, Germany) developed the X-CONE and ENDOCONE; however, it is not currently approved by the US FDA for use in the United States.

Surgeons also successfully use noncommercial ports constructed from retractors, gloves, and other materials readily available in any operating room [13].

When necessary, conversion to two-port or multiport conventional laparoscopy should not be considered a complication.

Set Up and Instrumentation

The majority of gynecologic LESS surgical procedures can be performed using conventional straight instrumentation available in all operating rooms. Some surgeons use specialized articulating and curved instruments specifically designed for LESS surgery to help overcome the lack of triangulation. However, there is generally a learning curve associated with these devices.

An articulating camera has some significant advantages over conventional laparoscopes in LESS surgery and is preferred by most experts. However, bariatric length or longer, 30° or 45° laparoscopes can also be used in LESS surgery with the techniques and principles described here. Conventional laparoscopes have a light




Fig. 4.3 Laparoscope options. (a) 30° or 45° laparoscope for LESS with 90° light cord adaptor (inset). (b) Articulating laparoscope (EndoEye™ (Olympus Surgical & Industrial America Inc., Center Valley, PA))

cable perpendicular to the scope, which can exacerbate external crowding and clashing, an obstacle already inherent to LESS procedures. In contrast, articulating cameras are designed with a single cord, which includes the light source in the same axis as the scope to help minimize external crowding (Fig. 4.3b). If a non-articulating laparoscope is used, we recommend using a 90° adaptor to minimize interference from the light cord (Fig. 4.3a and inset).

During LESS procedures, uterine manipulation is essential. A uterine manipulator can provide another means to retract the uterus. Common manipulators include systems such as the RUMI with KOH Colpotomizer (CooperSurgical, Trumbull, Connecticut, USA) and the VCare uterine manipulator (ConMed Corporation,

Utica, New York USA). Both of these systems come with different sizes of colpotomy cups in order to help displace the ureters laterally and delineate the cervicovaginal junction [14].

Candidate Selection

There is no set criterion that defines the ideal patient for a LESS procedure. Fader and Escobar [15] studied outcomes and found no differences in groups stratified based on BMI, comorbidities, or previous surgeries. It has been suggested, however, that patients with a BMI greater than 28 kg/m² may pose a surgical challenge due to thicker abdominal walls or large amount of intraperitoneal fat [16]. Additionally, patients who've had prior surgeries may represent a challenge due to pelvic adhesions. Therefore, Chern et al. suggest that patients who are not ideal candidates for this procedure include those with high BMI, greater than two prior laparotomies, malignancy, or who do not have a native umbilicus [16]. Although the techniques described here work well for complex surgical cases, we strongly recommend surgeons first become familiar with the technique for simple procedures with benign indications. As with any surgical approach, complicating factors, such as endometriosis, large fibroid uteri, malignancy, and significant adhesions, represent an additional layer of complexity and are not addressed here. We recommended those cases be reserved for experienced LESS surgeons.

Key Steps

There are a few key steps and principles for an efficient LESS procedure. We present a simplified and efficient technique that is useful in all gynecologic procedures. This technique when strictly followed will eliminate extraneous or duplicative movements. Together with the Core Principles in Table 4.1, this technique will maximize space between instruments and avoid

extracorporeal and intracorporeal clashing and crossing. The instructions that follow assume the primary surgeon is on the patient's left side. This process could be reversed if the surgeon is standing on the opposite side.

Step 1: Orientation of the Port and Camera Placement

The surgeon should choose the port so that the advantages and disadvantages of the specific port are well suited to the complexity of the case. Once securely placed in the peritoneal cavity, the port should be oriented as in Fig. 4.4. The channels or valves should be oriented so that the laparoscope can be placed through the most cephalad channel. This allows the camera to be lowered externally toward the chest wall while elevating the internal end of the laparoscope toward the anterior abdominal wall. Then, use the articulation or angle of the scope to position the camera low and laterally (Fig. 4.5). Externally, this positions the assistant's hand and the external aspect of the camera away from the umbilicus to allow space for other instruments and permit the primary surgeon to operate directly above the umbilical port without external clashing. The greater the angle of the laparoscope (30°, 45°, or flexible), the easier it is to get the camera away from the operative field and avoid clashing.

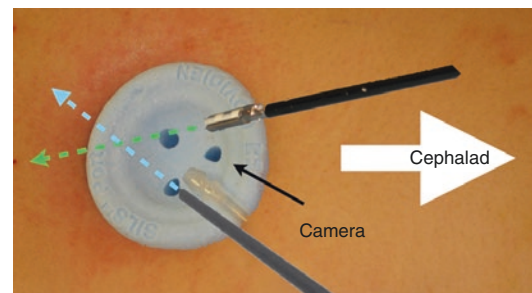


Fig. 4.4 Port orientation and camera placement. The laparoscope is placed through the cephalad channel, valve, or cannula

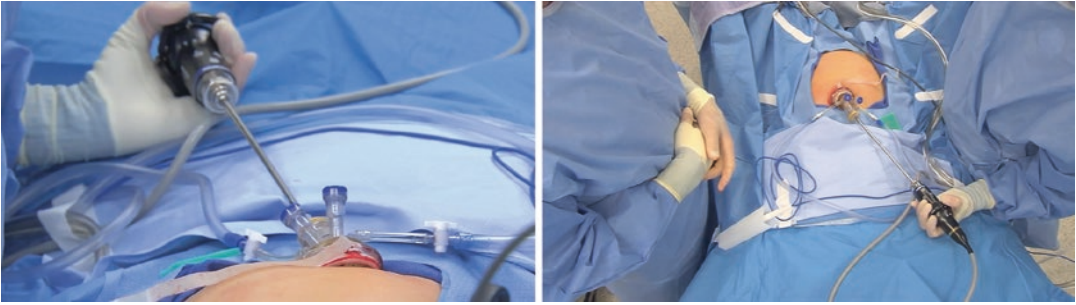


Fig. 4.5 Camera placement. The camera should be placed first prior to any additional instruments. Use the articulation or angle of the scope to position the camera and light cord low and lateral

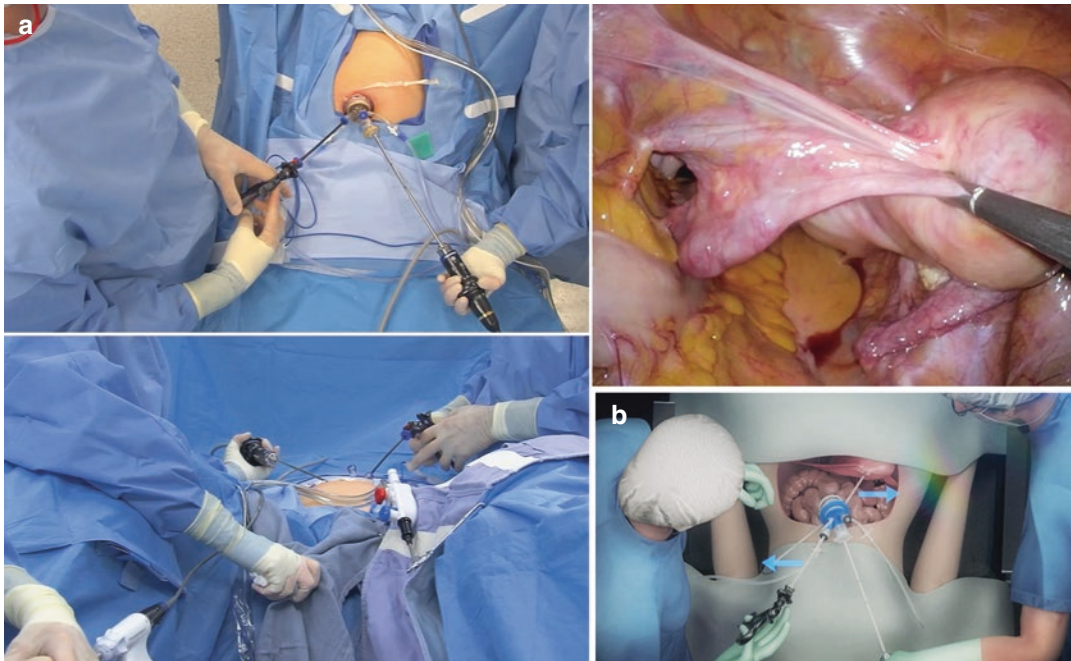


Fig. 4.6 (a and b) Insertion of the assistant grasper. Always retract so that the handle moves laterally, away from the midline

Step 2: Insert the Assistant Instrument

According to the Core Principles, all retraction by any assistant grasper should be performed by lateral retraction of the handle away from midline. Always retract in such a way that the handle of the instrument moves laterally, away from the camera and central area above the umbilicus. This means that the tissue is actually being retracted across the pelvis toward the contralateral side. This max-

imizes room for the laparoscope and other instruments externally preventing extracorporeal clashing of instruments. For example, to retract a uterus to the right, an assistant grasper instrument is inserted through the left port channel and controlled by moving the handle laterally to deviate the uterus to the right (Fig. 4.6). If the instrument was inadvertently inserted through the right port channel and then the uterus is retracted toward the right (internally), the instrument handle would move toward the central area above the

umbilicus—thus limiting space externally and causing clashing. Therefore, it is very important to place the assistant instrument through the port on the side in the direction of the lateral retraction so that the port channel and instrument move laterally, away from midline.

Step 3: Insert the Operating Electrosurgical Instrument

The operating instrument will be inserted through the right channel (Fig. 4.7). It will enter the internal operative field through the center and usually be directed straight toward the surgical target. In the event that the instrument handles interfere with each other or the camera, the handles should be positioned opposite of each other (Fig. 4.7).

Early in the learning curve, we believe the simplest option is to set up and expose the surgical target in a systematic way and then insert the primary operative instrument (scissors, bipolar vessel sealer, etc.). In this way, the assistant grasper can be applied and maintain good expo-

sure without movement of the assistant hand. Then the surgeon can focus on the dominant/operative hand. Until the surgeon is experienced with LESS, it is easy to get frustrated with retraction across the table or clashing when both hands are moving simultaneously. Therefore simpler procedures that can be accomplished in a straightforward routine process with little variation are most suited for learning a LESS approach. As the surgeon becomes more experienced, more complex procedures become easily feasible.

Specimen Extraction

One potential advantage of the LESS technique is for specimen extraction. Specimens can be more easily removed through the slightly larger skin incision (15–25 mm versus 12–15 mm for standard open laparoscopy). Extracorporeal morcellation can be accomplished through the larger incision. Some ports include a wound protector. These ports have a removable portion of the port that reveals a wound protector that facilitates easy

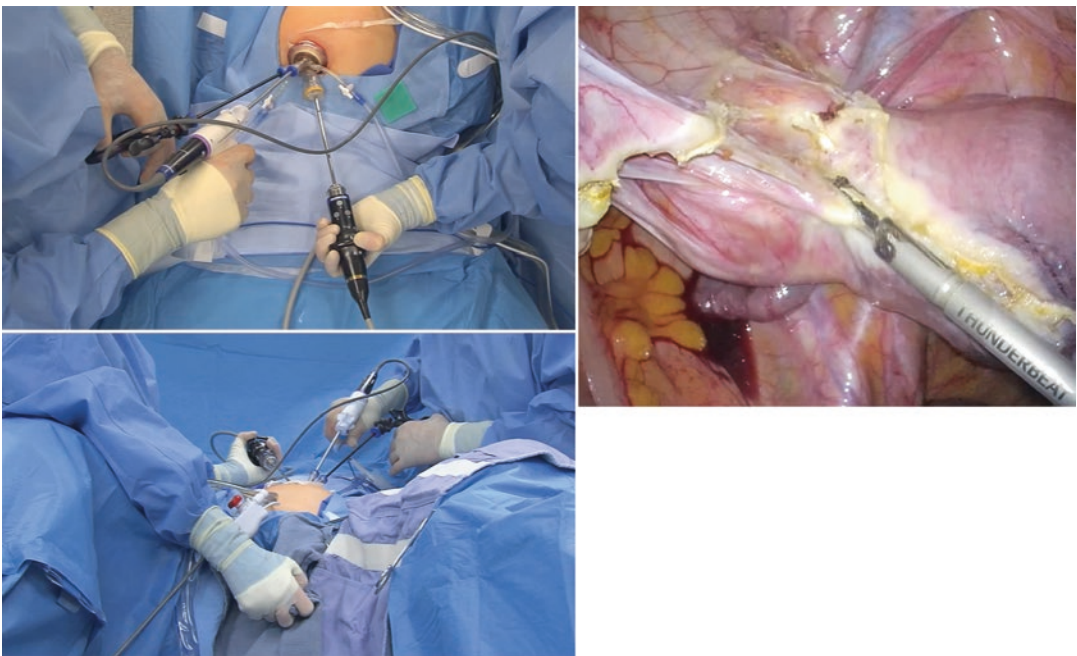


Fig. 4.7 External instrument position. External view showing setup and instrument positions without clashing. Note handles of the bipolar device and assistant grasper are facing opposite directions

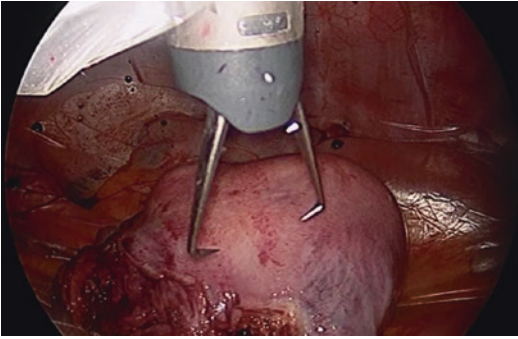


Fig. 4.8 Contained morcellation in a bag. Internal view of the uterus and morcellator contained within a pseudo-pneumoperitoneum

extraction of specimens and allows easy replacement of the port, such as TriPort (Advanced Surgical Concepts, Wicklow, Ireland) and GelPoint (Applied Medical, Rancho Santa Margarita, California, USA). Because the camera and instruments enter through a single-port site, completely contained intracorporeal morcellation can be performed by inserting a large surgical bag through the port and then creating a pseudo-pneumoperitoneum directly within the bag. Purpose-built commercially available morcellation bags are under development. The camera, mechanical morcellator, and an assistant grasper can be inserted through the port and into the bag to perform the morcellation within a contained system. Any small pieces would remain in the bag. This would minimize or eliminate the risk of potential spread of benign or malignant tissue (Fig. 4.8).

Suturing

Laparoscopic suturing requires the most skill. Therefore, we recommend traditional suturing be considered only by those experienced with LESS. If laparoscopic suturing is necessary, we strongly suggest utilizing suturing assist devices such as the Endostitch (Covidien, Norwalk, Connecticut, USA), barbed suture, or Laparo-Ty (Ethicon Endo Surgery, INC. Cincinnati, Ohio, USA). In the case of a total hysterectomy, the authors suggest closing the vaginal cuff from a vaginal approach until the surgeon is experienced with LESS.

Challenges and Risks Specific to LESS

With the advent of LESS technique, instruments and ports have been developed to streamline the technique. However, many technical challenges still remain. When working within a small incision no larger than 3 cm, instrument crowding will always be an issue. Because of this, range of motion is restricted. To overcome this challenge, the surgeon may cross instruments; however, this may lead to counterintuitive motions.

LESS also leads to loss of triangulation due to the instruments and the camera all working within a small incision. This is a very important factor in order to safely perform laparoscopy. The basic surgical technique of traction-countertraction is best achieved with triangulation [17]. The best strategy to maintain the triangulation is to keep all instruments except the primary operating one away from the “target” zone. This zone is defined as the midline area that extends into the axial direction and in the highest plane above the abdominal wall [14]. This may be overcome by using instruments that already have a curve, therefore reducing the need for the surgeon to cross arms. Karl Storz and Olympus have manufactured curved instrumentation for LESS [12].

Another challenge with LESS is the learning curve. As with any new technique, new skill sets must be obtained. With LESS, a very high skill level is warranted, therefore potentially prolonging the learning curve and making it a difficult one. It is very important that surgeons adopting LESS be highly skilled and adept at conventional laparoscopy.

As with any laparoscopic technique, it is imperative that surgeons have thorough knowledge of electrosurgery to avoid electrosurgical complications. Surgeons should be aware of the different types of electrosurgical complications. There may be a theoretical increased risk of capacitive coupling when performing LESS. Working with instruments in close quarters may predispose them to insulation damage. Therefore, we recommend meticulous inspection of the instruments. Disposable electrosurgical

instruments may have decreased risk of insulation damage and thus lower risk of direct coupling. We believe good technique should mitigate these risks.

Summary of Available Evidence

The feasibility of LESS in most laparoscopic procedures is demonstrated in multiple case reports and series in the medical literature. Several studies have addressed the potential advantages and disadvantages of LESS compared to conventional laparoscopy.

One of the first studies was performed by White et al. [18] in urologic patients. They looked at a series of eight patients in 2007–2008 who had undergone single-port retroperitoneal surgery and compared retrospectively to patients who had undergone retroperitoneal surgery with traditional laparoscopy. Based on their findings, they found no significant difference between the two groups, except that the LESS cohort had significantly decreased pain.

Most studies currently available comparing LESS hysterectomy to conventional laparoscopy have median uterine weights less than 300 g. However, Song et al. [19–21] demonstrated that LESS hysterectomy is also a safe and feasible option when removing a uterus weighing 500 g or more. Increasing uterine weight was associated with longer operative times and blood loss but was not associated with an increased need to convert to traditional laparoscopy [19–21]. With few exceptions, currently available studies demonstrate comparable operative times between LESS and standard laparoscopic technique. Escobar et al. [2, 3] examined the learning curve for LESS and found similar results when compared to published conventional laparoscopic learning curves.

There are few randomized trials. A recent meta-analysis of six randomized controlled trials by Song et al. [19–21] found no significant difference between any of their primary outcome measures including perioperative complications, conversion rates, postoperative pain, and cosmesis. Their conclusions were consistent with

other studies with the exception of their assessment of cosmetic preferences. LESS may represent a superior alternative to traditional laparoscopy with respect to cosmetic results. At least three randomized controlled trials to date have shown superior patient satisfaction with LESS cosmetic results [19–23].

Another meta-analysis by Yang et al. [24] reviewed six randomized control trials and 12 retrospective studies, with a combined total of 3725 patients. This systematic review demonstrated that single-incision laparoscopy, compared to conventional laparoscopy, had higher procedure failure rates (3.59%), longer operative times, but shorter hospital course and faster return to bowel function. Additionally, this review showed no statistically significant differences in perioperative complications, postoperative pain, blood loss, or uterine weights. The higher failure rate of single-incision laparoscopy was due to the necessity of additional ports.

In 2015, Angioni et al. published a prospective case-control study exploring the perioperative outcomes between patients who underwent single-incision laparoscopic supracervical hysterectomy and conventional laparoscopic supracervical hysterectomy. The outcomes of this study demonstrated that patients in the single-incision group had longer operative times, shorter hospital course, decreased pain, and higher cosmetic satisfaction than the conventional laparoscopy group. These findings agree with the findings by Chen et al. [25] discussed earlier in this chapter. Additionally, a retrospective study by Yim et al. [26] studied the surgical outcomes and postoperative pain in patients undergoing hysterectomy either via single-port incision or conventional four-port laparoscopy. This study demonstrated a statistically significant difference in many parameters, including less intraoperative blood loss, shorter hospital stays, and faster recovery. Song et al. [19–21] performed a randomized controlled trial where they compared cosmetic satisfaction from LESS versus traditional laparoscopy and found that the LESS group had higher satisfaction rates.

Robotic LESS

LESS is also being introduced to the da Vinci (Intuitive Surgical, Sunnyvale, California, USA) robotic surgical sphere. Traditional robotic surgery has greatly improved postoperative pain while decreasing hospital stay and necessary analgesia when compared to open laparotomy. Escobar et al. [27] published a case report detailing an initial technique for robotic-assisted LESS. Since that time, a specialized robotic single-site platform with specific instrumentation has been introduced. Additional robotic LESS platforms are also being investigated.

Robotic-assisted LESS provides the advantage of enabling more rotational degrees of freedom, thereby reducing instrument crowding. It also enables triangulation, which is important to decrease the technical challenges associated with LESS. Additionally, this approach is also more ergonomically friendly [27].

Conclusion

LESS is a rapidly maturing minimally invasive modality that offers patients many benefits, including better cosmesis. As industries continue to develop newer technologies and instrumentation, the learning curve associated with this technique should decrease. It will be important for future residents, fellows, and practicing physicians to maintain a high level of dexterity in conventional laparoscopy prior to embarking on this modality. LESS still comes with technical challenges; however, as technology continues to advance, these should decrease. Studies have shown that LESS has favorable outcomes with patients and, therefore with continued study efforts, should be attainable for the majority of gynecologic surgeons.

References

1. Tracy CR, Raman JD, Cadeddu JA, Rane A. Laparoendoscopic single-site surgery in urology: where have we been and where are we heading? *Nat Clin Pract Urol*. 2008;5:561–8.
2. Escobar PF, Starks DC, Fader AN, et al. Single-port risk-reducing salpingo-oophorectomy with and with-

- out hysterectomy: surgical outcomes and learning curve analysis. *Gynecol Oncol*. 2010a;119:43–7.
3. Escobar PF, Starks DC, Fader AN, et al. Laparoendoscopic single-site and natural orifice surgery in gynecology. *Fertil Steril*. 2010b;94:2497–502.
4. Wheelless CR Jr. Elimination of second incision in laparoscopic sterilization. *Obstet Gynecol*. 1972;39:134–6.
5. Pelosi MA, Pelosi MA III. Laparoscopic hysterectomy with bilateral salpingo-oophorectomy using a single umbilical puncture. *N J Med*. 1991;88:721–6.
6. Gill IS, Advincula AP, Aron M. Consensus statement of the consortium for laparoendoscopic single-site surgery. *Surg Endosc*. 2010;24(4):762–8.
7. Stepp KJ, et al. An AAGL Task Force consensus statement: a standardized approach to LESS hysterectomy. American Association of Gynecologic Laparoscopists 43rd Annual Clinical Meeting, Vancouver, BC. November 16–21, 2014.
8. Hong SH, Seo SI, Kim JC, Hwang TK. Cosmetic circumumbilical incision for extraction of specimen after laparoscopic radical prostatectomy. *J Endourol*. 2006;20(7):519–21.
9. Huang CK, Houng JY, Chiang CJ, et al. Single incision transumbilical laparoscopic Roux-en-Y gastric bypass: a first case report. *Obes Surg*. 2009;19:1711–5.
10. Kane S, Stepp KJ. Circumumbilical (Omega) incision for laparoendoscopic single-site surgery. Oral Presentation: Society Gynecologic Surgeons Annual Clinical Meeting, San Antonio, TX, April 2011.
11. Angioni S, Pontis A, Pisanu A, et al. Single-port access subtotal laparoscopic hysterectomy: a prospective case-control study. *J Minim Invasive*. 2015;22:809–12.
12. Uppal S, Frumaovitz M, Escobar P. Laparoendoscopic single-site surgery in gynecology: review of literature and available technology. *J Minim Invasive*. 2011;18:12–23.
13. Lee YY, Kim TJ, Kim CJ, et al. Single-port access laparoscopic-assisted vaginal hysterectomy: a novel method with a wound retractor and a glove. *J Minim Invasive Gynecol*. 2009;16(4):450–3.
14. Sobolewski C, Yeung PP, Hart S. Laparoendoscopic single-site surgery in gynecology. *Obstet Gynecol Clin N Am*. 2011;11:741–55.
15. Fader AN, Escobar PF. Laparoendoscopic single-site surgery (LESS) in gynecologic oncology: technique and initial report. *Gynecol Oncol*. 2009;114:157–61.
16. Chern BSM, Lakhota S, Kho CK, et al. Single incision laparoscopic surgery in gynecology: evolution, current trends, and future perspectives. *Gynecol Minim Invasive Ther*. 2012;1:9–18.
17. Boruta DM. Laparoendoscopic single-site surgery in gynecologic oncology: an update. *Gynecol Oncol*. 2016;141:616–23.
18. White W, Goel R, Kaouk J. Single port laparoscopic retroperitoneal surgery: initial operative experience and comparative outcomes. *Urology*. 2009;73:1279–82.

19. Song T, Cho J, Kim TJ, Kim IR, et al. Cosmetic outcomes of laparoendoscopic single-site hysterectomy compared with multi-port surgery: randomized controlled trial. *J Minim Invasive Gynecol.* 2013a;20(4):460–7.
20. Song T, Lee Y, Kim ML, et al. Single-port access total laparoscopic hysterectomy for large uterus. *Gynecol Obstet Investig.* 2013b;75:16–20.
21. Song T, Kim ML, Jung YW, et al. Laparoendoscopic single-site versus conventional laparoscopic gynecologic surgery: a meta-analysis of randomized controlled trials. *Am J Obstet Gynecol.* 2013c;209:317.e1–9.
22. Fagotti A, Bottoni C, Vizzielli G, et al. Post operative pain after conventional laparoscopy and laparoendoscopic single site surgery (LESS) for benign adnexal disease: a randomized trial. *Fertil Steril.* 2011;96(1):255–9.
23. Yoo EH, Shim E. Single-port access compared with three-port laparoscopic adnexal surgery in a randomized controlled trial. *J Int Med Res.* 2013;41(3):673–80.
24. Yang L, Gao J, Zeng L, et al. Systematic review and meta-analysis of single-port versus conventional laparoscopic hysterectomy. *Int J Gynecol Obstet.* 2016;133:9–16.
25. Chen YJ, Wang PH, Ocampo EJ, et al. Single-port compared with conventional laparoscopic-assisted vaginal hysterectomy: a randomized controlled trial. *Obstet Gynecol.* 2011;117:906–12.
26. Yim GW, Jung YW, Paek J, et al. Transumbilical single port versus conventional total laparoscopic hysterectomy: surgical outcomes. *Am J Obstet Gynecol.* 2010;203:26.e1–6.
27. Escobar PF, Fader AN, Paraiso MF, et al. Robotic-assisted laparoendoscopic single-site surgery in gynecology: initial report and technique. *J Minim Invasive.* 2009;16:589–91.

Part I

Anatomy and Surgical Routes



Anatomical Landmarks in Deep Endometriosis Surgery

5

Marcello Ceccaroni, Giovanni Roviglione,
Daniele Mautone, and Roberto Clarizia

Introduction

Deep endometriosis (DE) represents a chronic inflammatory disease, affecting pelvic viscera and peritoneal and retroperitoneal structures and completely distorting their normal aspect and reciprocal relationships by a mechanism of progressive infiltration and retraction. One of the main objectives of its surgical treatment, together with reducing pelvic pain and improving fertility, is the restoration of normal pelvic anatomy. For this reason, surgeons must have a deep knowledge of pelvic anatomy, in order to reassess a grossly distorted surgical field. Thus, pelvic anatomical landmarks represent essential points of reference to start procedures such as mobilization of the pelvic viscera, wide peritoneal resections, or the identification of further anatomical structures to be preserved, such as parasympathetic and orthosympathetic pelvic neural fibers in nerve-sparing procedures.

This chapter has the objective to illustrate all the pelvic parietal or visceral retro- or peritoneal landmarks useful to perform a radical, safe and anatomical surgical eradication of DE.

M. Ceccaroni, M.D., Ph.D. (✉) • G. Roviglione, M.D.
D. Mautone, M.D. • R. Clarizia, M.D., Ph.D.
Department of Gynecology and Obstetrics,
Gynecologic Oncology and Minimally-Invasive
Pelvic Surgery, International School of Surgical
Anatomy, “Sacred Heart” Hospital,
Negrar (Verona), Italy

Pelvis: Limits and Parietal Landmarks

The pelvis is a cone-shaped cavity, continuing cranially with the abdominal cavity and closed caudally by the pelvic floor, represented by the levator ani muscle [1, 2]. The latter represents the caudad limit of pelvic spaces, to which dissection has to be performed during the development of retroperitoneal structures, in order to obtain the best identification and mobilization of surgical landmarks such as the ureter, pelvic nerves, and parametria. The levator ani muscle is constituted by three parts (Fig. 5.1):

1. The pubo-coccygeus muscle
2. The ilio-coccygeus muscle
3. The ischio-coccygeus muscle

Laterally to these muscles, the pelvic cavity is closed by the obturator muscle (divided by the so-called “white line” by the ilio-coccygeus muscle) and dorso-laterally by the piriformis muscle. All these muscles are covered cranially by a thick and strictly adherent fibrotic structure, called *parietal pelvic fascia* which really represents the surgical landmark till which the dissection of retroperitoneal spaces has to be conducted [1, 2].

The pelvic cavity has also bone limits, which represent useful anatomical landmarks for dissection maneuvers in course of eradication of severe DE.

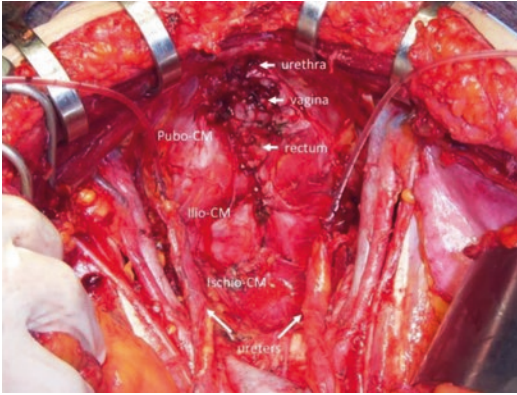


Fig. 5.1 Cranio-caudad view, after total pelvic exenteration, of the levator ani muscle with its three components: pubo-coccygeus muscle (pubo-CM), ilio-coccygeus muscle (ilio-CM), ischio-coccygeus muscle (ischio-CM)

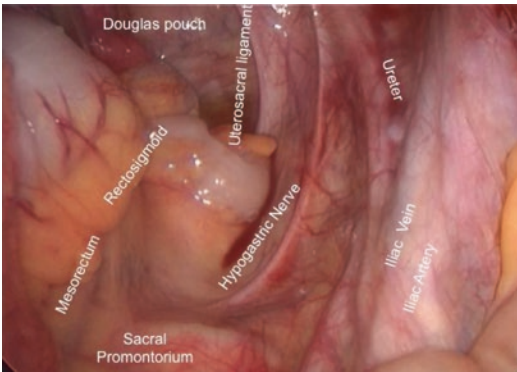


Fig. 5.2 Laparoscopic view of the sacral promontorium and of the transperitoneal profiles of the right ureter, iliac vessels, right hypogastric nerve in its relationships with the utero-sacral ligament and mesorectum

Dorsally, the sacral promontorium is the starting point for the opening steps of the retroperitoneum in order to face DE affecting the pelvic posterior compartment (“torus uterinus”, Douglas’ pouch, posterior broad ligaments, utero-sacral and recto-vaginal ligaments, lateral rectal ligaments, also called *rectal stalks*, recto-vaginal septum, pelvic ureter, ortho- and parasympathetic components of pelvic innervation) (Fig. 5.2).

The junction of L5–S1 vertebrae constitutes an anterior arch which defines the limits between abdominal and pelvic cavities. Caudally to the sacral promontorium, the sacral bone (formed by the fusion of S1–S2–S3–S4–S5 vertebrae) forms

a concavity closed downward by the coccyx. The sacral bone is covered by the regional part of the parietal pelvic fascia, called *pre-sacral fascia*; this structure is a crucial anatomical landmark which has to be respected during the posterior dissection of the recto-sigmoid for the preparation of the surgical field in case of eradication of DE with bowel infiltration. In fact, the dissection has to be conducted along the surface of this fascia, between this and the visceral rectal fascia (the *fascia propria recti*), paying attention not to interrupt it, for the risk of creating vascular lesions to the middle sacral vein or artery and to the numerous artero-venous pre-sacral anastomoses which are covered by the presacral fascia.

The same pre-sacral fascia extends laterally to cover the sacral plexus and the sacral roots S1, S2, S3, S4, and S5, which lie on the ventral surface of the piriformis muscle. In this area, the major concern of surgical dissection is the preservation of the parietal fascia in order not to damage the parasympathetic system of the sacral roots; however, in cases of DE infiltrating or compressing the visceral fascia of the sacral roots, the parietal fascia has to be removed in order to totally eradicate the disease [3].

In some wide extensive infiltration pattern, the visceral fascia might be itself infiltrated with the need of resection, and some evidence exists that fascial infiltration reflects disease severity in patients with colorectal endometriosis. Its removal affects intra-operative morbidity and may lead to a higher rate of voiding dysfunction [4].

The ventral border of the pelvis is closed by the two ischiopubic branches (Fig. 5.3), connected medially at the level of the pubis by the pubic ligament. These bone landmarks are to be identified especially in the treatment of DE infiltrating the anterior compartment or in cases where a complete mobilization of the bladder is required (e.g., to obtain a tension free suture in case of extended cystectomy for large bladder nodules or in case of ureteral reimplantation).

In these cases, the bladder is mobilized starting by the anterior abdominal wall, identifying medially the urachus and laterally the profile of the obliterated artery. The umbilical (or obliterated) artery is the first anterior parietal branch of

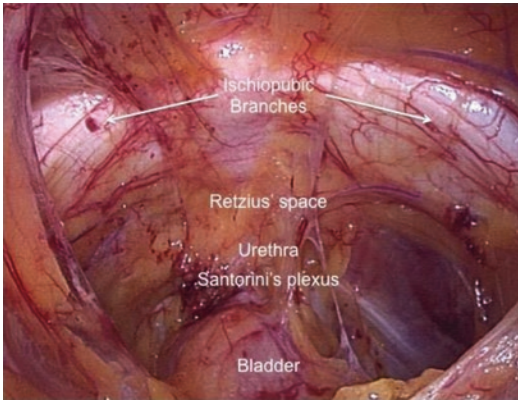


Fig. 5.3 Laparoscopic view of the retropubic (Retzius') space, looking in detail at the ischiopubic branches and at Santorini's retropubic venous plexus

division of the hypogastric artery (i.e., internal iliac artery); it crosses the retroperitoneum below the broad ligament, and after originating the uterine artery and the superior vesical artery, it reaches the anterior abdominal wall, in the context of the para-vesical space, at the level of the ischiopubic branch, thus directing itself to the umbilicus. This artery (also considered as a ligament) represents a useful anatomical landmark for the opening of the para-vesical space: this space may be divided in medial or lateral with respect to the umbilical artery, thus having the medial or lateral para-vesical space, respectively. The procedure of mobilization of the bladder thus starts from the incision of the abdominal peritoneum medial to the umbilical artery toward the urachus (at the midline), which may be sectioned cranially to the vesical dome (thus avoiding damage to the bladder) permitting to caudally develop the retro-pubic space (so-called Retzius' space) until the Santorini's venous retropubic and paraurethral plexus. This venous system represents the median caudad anatomical landmark for the mobilization of the bladder and is not to be damaged for the possibility of severe bleedings. In some cases, instead, the bladder needs further lateral mobilization, and this may be obtained by the opening and dissection of the lateral para-vesical space lateral to the obliterated artery.

Finally, the round ligament is another landmark of the retro-inguinal area of the anterior

abdominal wall, which may serve as reference for dissection but may also be retracted and infiltrated by DE. This ligament originates from the uterine horn and reaches the abdominal orifice of the inguinal ligament where it enters. This structure is vascularized by the so-called Sampson's artery, one of the three terminal branches of the uterine artery (together with the branch for the uterine fundus and the one for the salpinx). It can be sectioned in order to better mobilize the uterus in cases of anterior adenomyosis extensively infiltrating the vesico-uterine fold; moreover it may be sectioned and removed in cases of its nodular infiltration.

Peritoneal Surfaces: Vesico-uterine Fold, Broad Ligament, Douglas' Pouch, Utero-sacral Ligaments

The peritoneum is a serous membrane, covering the internal abdominal wall and all the pelvic viscera (except for the ovary) and ligaments by which are connected and among which it forms pouches and folds [1, 2].

Schematically, the peritoneum forms three anatomical landmarks which have great importance in the treatment of DE.

1. Vesico-uterine fold: it is the peritoneal fold covering the Halban's pre-cervical fascia, reflecting on the anterior face of the cervix and the vesical couple (Fig. 5.4). It is often infiltrated by the adenomyosis growth expanding ventro-caudally by the anterior isthmic

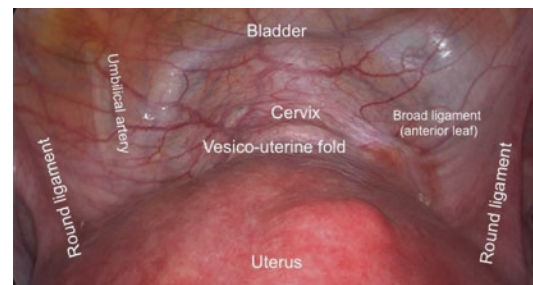


Fig. 5.4 Laparoscopic view of the vesico-uterine fold, the anterior leaf of the broad ligament, and the transperitoneal profile of the umbilical (obliterated) artery

wall of the uterus, infiltrating the vesico-cervical and vesico-vaginal septum.

2. Rectouterine fold (Douglas' pouch): it is the posterior reflection of the peritoneum, lying in a caudo-cranial level at least 1.5–2 cm caudad to the corresponding level of reflection of the vesico-uterine fold. It covers the retro-cervical area (the so-called *torus uterinus*, point of convergence of both utero-sacral ligaments on the posterior face of the cervix), blending over the anterior face of the rectum at least 8 cm from the anal margin (Fig. 5.5). Laterally, the rectouterine pouch confines with the utero-sacral ligaments, caudally with the recto-vaginal septum.
3. Broad ligament: it is the peritoneal sheet covering the lateral *uterine wing*, tended by the round ligament, the salpinx, and the utero-ovarian ligament. It can be divided into two compartments: the *anterior leaf*, ventral to the round ligament and continuing with the peritoneum covering the vesico-uterine fold and the bladder dome, and the *posterior leaf*, covering the salpinx until the ampulla and the utero-ovarian ligament and confining medially with the profile of the utero-sacral ligaments [5].

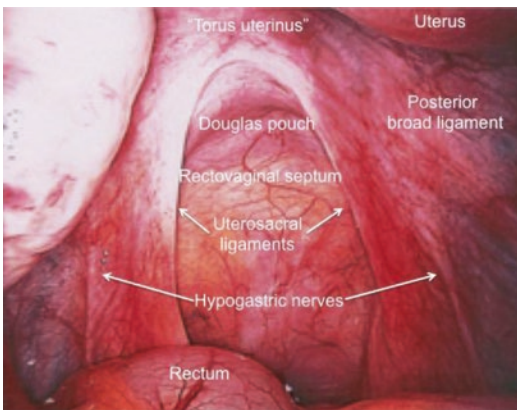


Fig. 5.5 Laparoscopic image of the recto-uterine (Douglas') fold, utero-sacral ligaments, posterior leaf of the broad ligament, and hypogastric nerves

Pelvic Spaces (Retzius', Bogros', Lateral and Medial Paravesical, Vesico-uterine, Lateral and Medial Para-rectal, Recto-vaginal, Retro-rectal)

Retropubic (Retzius' Space)

The retropubic space (Fig. 5.3) is a median pelvic space extending between the posterior face of the pubic bone and the ischio-pubic branches and the vesical dome [6]. It is very useful for the surgical approaches for bladder endometriosis especially in case of full-thickness infiltration of the bladder wall. In these cases, in order to obtain a tension-free suture, a good mobilization of the bladder is needed. Thus, starting by the section of the urachus along the midline of the anterior abdominal wall (Fig. 5.6), above the cranial limit of the vesical dome, it is possible to achieve a partial mobilization of the dome, which may be improved if the dissection, initially conducted on a median plane, is extended laterally by the dissection of the medial paravesical spaces. In cases of lateral infiltration of the bladder, also the lateral para-vesical spaces

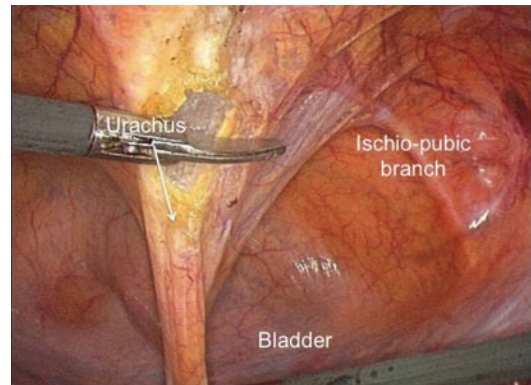


Fig. 5.6 Laparoscopic image of the urachus, sectioned during the initial step of development of the retropubic space, in its relationship with the bladder dome and the ischio-pubic branches

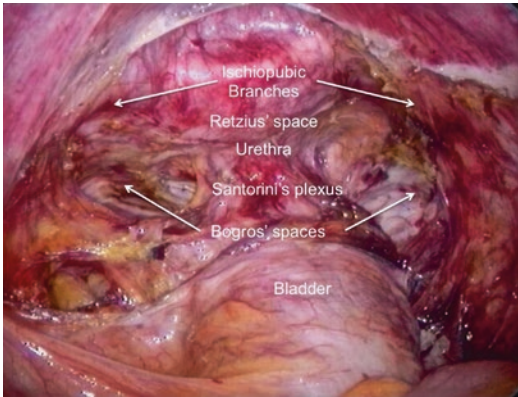


Fig. 5.7 Laparoscopic view of Bogros' spaces, Retzius' space, and the ischio-pubic branches after complete mobilization of the bladder

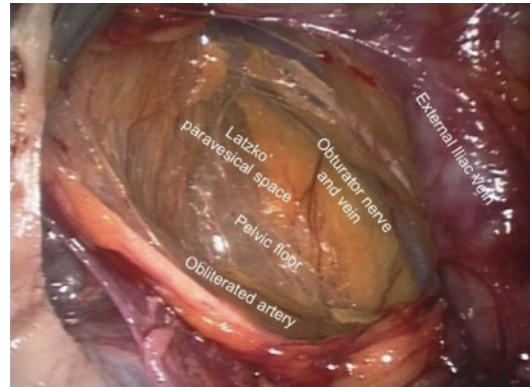


Fig. 5.8 Laparoscopic view of the lateral para-vesical space during lateral mobilization of the bladder for vesical endometriosis

need to be developed. The caudad limit of this spaces is bilaterally represented medially and caudally by the Santorini's venous plexus and laterally by the pelvic floor of the medial para-vesical spaces. The lateral limit of the Retzius' space is given by the umbilical pre-vesical fascia (also called Charpy's fascia), ventral part of the genito-sacral fascia, which continues medially with the vesico-cervical fascia [7].

Bogros' Space

The retro-inguinal space (or Bogros' space) is the extraperitoneal bilateral space situated laterally to the lateral para-vesical spaces (PVS), deep to the inguinal ligament (Fig. 5.7). It is ventrally limited by the fascia transversalis, dorsally by the parietal peritoneum, and laterally by the iliac fascia [6].

Lateral Para-vesical Space

Para-vesical space (PVS) development gives bilaterally initial access to the anterolateral compartment of the pelvis for the lateral approach to the

bladder in course of eradication of DE or reconstructive procedures such as ureteral/bladder resection and/or ureteroneocystostomy (Fig. 5.8).

It can be divided into a medial PVS and a lateral PVS with respect to the obliterated umbilical artery and the umbilical pre-vesical fascia, which, respectively, represent its lateral and medial limits [8–10].

The anatomical limits of the PVS in each side are as follows:

- Laterally: parietal pelvic fascia (PPF), external iliac vein/artery, and retro-inguinal Bogros' space
- Medially: the obliterated umbilical artery and the umbilical pre-vesical fascia
- Ventrally: Bogros' retro-inguinal space and ischio-pubic branches
- Dorsally: Mackenrodt's cardinal ligament (lateral parametrium) with uterine artery and vein
- Cranially: round ligament and peritoneum of the anterior leaf of the broad ligament
- Caudally: pelvic floor, i.e., ilio-coccygeus muscle covered by the PPF and its attachment to the obturator muscle arcus tendineus fasciae pelvis and arcus tendineus levator ani (ATFP and ATLA)

Opening and Development of Lateral Para-vesical Space

After coagulation and transection of the round ligament at the level of pelvic wall (and lateral and ventral traction of the lateral part of its cut portion), the anterior and posterior peritoneal layers of the broad ligament are bluntly opened with a craniocaudad and dorso-ventral dissection, and the ureter is identified. After subsequent dissection, more ventrally, the obliterated umbilical artery is identified, following its course up to the anterior abdominal wall. The lateral para-vesical space is then developed by a gentle medial traction of umbilical artery together with the lateral umbilical ligament fascial sheet, bluntly developing the cellular tissue between umbilical artery and external iliac vessels.

This space is developed up to the level of the pelvic floor until the parietal endopelvic fascia covering the levator ani muscles, thus consenting the identification of the internal obturator and coccygeal muscle [11–13].

Lateral Para-rectal Space

The lateral para-rectal space (PRS), also known as Latzko's space, is the retroperitoneal avascular area usually dissected between the mesoureter and the pelvic wall by opening up the space between the internal iliac artery (lateral) and the ureter (medial).

Its anatomical limits are as follows:

- Medial: visceral endopelvic rectal fascia (fascia propria recti), lateral ligaments of the rectum (*rectal wings, rectal pillars*), and the ureter
- Lateral: parietal pelvic fascia (PPF), inferior hypogastric plexus with pelvic splanchnic nerves, internal iliac artery, and piriformis muscle
- Dorsal: pre-sacral fascia and sacral bone
- Ventral: Mackenrodt's cardinal ligament and paracervix (cranial and caudad ligaments of lateral parametrium)
- Caudad: pelvic floor, i.e., ischio-coccygeal muscle, branches of the pubo-rectal and pubo-coccygeal muscle

Cranial: round ligament and peritoneum of the posterior leaf of the broad ligament [3]

The mesoureter is the connective tissue bundle that emerges between medial (Okabayashi's) and lateral (Latzko's) para-rectal spaces, and it is also named as ureteral leaf or ureteral blatt. At this level, two visceral pelvic fasciae are fused, and between them the ureter, the hypogastric nerve, and the ureteral branches of the hypogastric vessels are contained. This leaf envelops the ureter up to its bladder entry, for about 4 cm, and contains vascular and nervous elements as well as smooth muscular sub-peritoneal cells.

The opening of the Latzko's space is a peculiar key-step during a lateral and posterior parametrectomy of DE, giving full access to the internal iliac (hypogastric) vessels branches, especially the uterine artery, but also the visceral pelvic innervation such as the pelvic splanchnic nerves and the pelvic plexus [3, 11–13] (Figs. 5.9 and 5.10).

Opening and Development of Lateral Latzko's Para-rectal Space

After the identification of the course of the ureter at the level of the pelvic brim, the peritoneum is coagulated, incised, and opened. Then, starting from the level of iliac vessels bifurcation, the

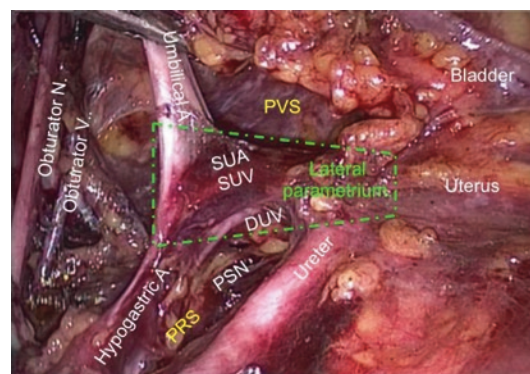


Fig. 5.9 Laparoscopic view of left lateral parametrium, looking in detail at the superficial uterine artery (SUA) and vein (SUV), the deep uterine vein (DUV), and the pelvic splanchnic nerves (PSN), after the development of the para-rectal space (PRS) and para-vesical space. Laterally, the obturator nerve and vein are exposed, in the obturator fossa

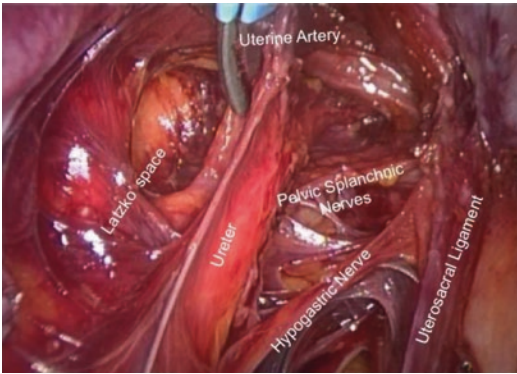


Fig. 5.10 Laparoscopic view of the left posterior parametrium with the hypogastric nerve, the pelvic splanchnic nerves, and the utero-sacral ligament

right *lateral Latzko's para-rectal space* is developed. This space is opened by blunt dissection (in a craniocaudal and dorsoventral direction) of the areolar tissue between the mesoureter and pelvic wall by developing the space between the internal iliac artery (lateral) and the ureter (pulled medially together with the mesoureter), up to the level of the parietal endopelvic fascia covering the pelvic floor. This step allows the identification of the dorsal portions of coccygeal and piriformis muscles and the internal iliac lymph nodes.

The identification of the so-called hypogastric fascia consisted by pre-sacral parietal pelvic fascia covering the muscles and pierced by the parasympathetic pelvic splanchnic nerves originating at this level from sacral roots S2–S4 and directed to join their fibers with inferior hypogastric plexus (or pelvic plexus) crossing the paracervix.

This fascial sheet is then pierced and bluntly developed with medio-lateral dissection, and the pelvic splanchnic nerves are completely identified and exposed, in order to preserve their fibers during the lateral and posterior nerve-sparing parametrectomy.

In these procedures the blunt opening of pelvic spaces is considered the key-step, allowing the identification of surgical landmarks and a better exposure of parametrial ligaments.

At the end of surgical steps, together with the opening of the medial Okabayashi's para-vesical

and pararectal spaces, four retroperitoneal avascular spaces are opened in each hemi-pelvis consenting the exposition and separation of lymph nodal tissues from the visceral and parametrial compartment. Parametrial tissues appear divided from each side in the three following portions:

- Anterior parametrium: consisted by cranial and caudal layers of vesico-uterine ligaments
- Lateral parametrium: represented by the cardinal ligament, also called Mackenrodt's ligament (cranial), and the paracervix together with the paracolpia (caudal)
- Posterior parametrium: consisted by uterosacral ligament (cranial) and recto-vaginal and lateral rectal ligaments (caudal) [3, 11–13]

Medial Para-vesical Space

The medial PVS, as previously exposed, represents the part of the PVS medial to the obliterated artery, confining medially with the bladder and the cervico-vesical fascia, laterally with the umbilical artery and the umbilical pre-vesical fascia, and caudally and ventrally with the levator ani muscle. It is useful as it gives access to the lateral board of the bladder, when there is no need to perform an excessive mobilization of the vesical couple. Moreover, it gives easy access to the anterior parametrium, in case of ureteral resection for infiltration by DE (Fig. 5.11).

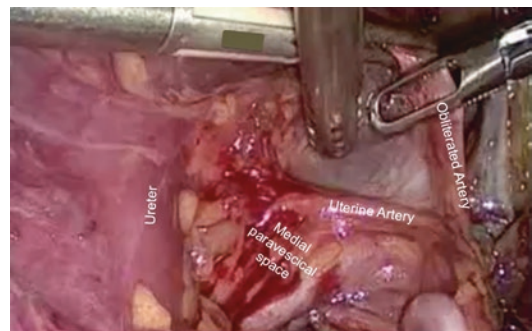


Fig. 5.11 Laparoscopic image of the medial para-vesical space, medial to the obliterated artery, which is developed for the medial approach to the bladder in case of vesical endometriosis

Medial Para-rectal Space

The medial (Okabayashi's) PRS is half of the para-rectal space confined laterally by the ureter and the mesoureter and medially by the rectum [14]. Ventrally it continues with the lateral parametrium and dorsally with the sacrum and the retro-rectal space. The utility of the dissection of this space is due to the medial isolation of the ureter, giving access to the posterior parametrium. In particular, lateralizing the ureter and the mesoureter with the hypogastric nerve in its contest, the opening of this space permits to isolate and skeletonize the utero-sacral and recto-vaginal ligaments, thus removing the endometriotic infiltration with a nerve-sparing technique. The knowledge of the medial para-rectal space is also important in case of extensive isolation of the ureter (or in case of ureterolysis) when there is the need to perform a lateral parametrectomy or propedeutical to the ureteral mobilization and section in course of major ureteral surgery with ureteral resection and ureteroneocystostomy (with or without the Psoas Hitch procedure) [3, 10–13] (Fig. 5.12).

Retro-rectal Space

The laterocaudal dissection of the para-rectal space toward the sacral bone's concavity gives access to the retro-rectal space, opening the so-called *holy plane* of Heald on the midline. Dissection is bluntly performed in a cranio-caudal

and medio-lateral direction up to the level of the recto-sacral fascia (also called the Waldeyer's fascia). This fascia is then resected in the course of eradication of DE with rectal resection. During this surgical step, the thin and loose pre-sacral visceral pelvic fascia between the pre-rectal and para-rectal space is bluntly mobilized and pulled laterally. This lateral part, surrounded by the superior hypogastric plexus, at the level of the sacral bone at the promontorium courses bilaterally by the hypogastric nerves and the anterior branches of the lumbo-sacral sympathetic trunk's chain. During this step, sacral roots S2–S4 and pelvic splanchnic nerves are identified bilaterally [15].

The dissection of the retro-rectal plane is developed in an avascular way, bluntly separating the peri-rectal fascia from the presacral fascia down to the coccyx. The pre-sacral parietal fascia covers medially the middle sacral vein (which directly drains into the vena cava), the middle sacral artery (originating from the aorta), and numerous pre-sacral artero-venous anastomoses; for this reason, caution has to be given not to incise this fascia in order not to create lesions on these vessels and produce important bleedings (Fig. 5.13).

Recto-vaginal Septum (RVS)

The RVS extends from the base of the recto-vaginal pouch of Douglas to the uro-genital diaphragm at the top of the perineal body. It is represented by the connective tissue interposed

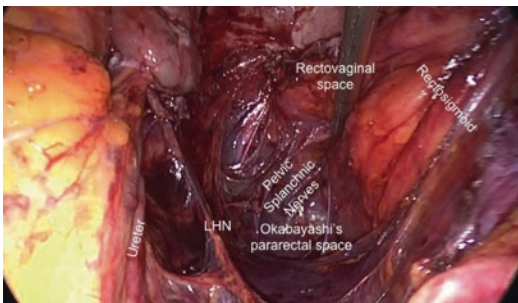


Fig. 5.12 Laparoscopic view of the medial para-rectal (Okabayashi's) space, evidencing the left hypogastric nerve (LHN), the pelvic splanchnic nerves, and, caudally, the recto-vaginal space, developed for the dissection of the rectosigmoid in case of DE infiltrating the bowel

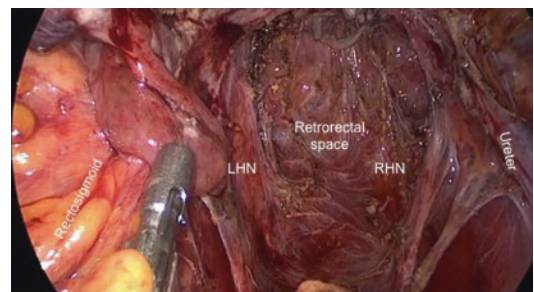


Fig. 5.13 Laparoscopic view of the retro-rectal space after complete dissection and resection of the rectosigmoid for DE. In detail, the left (LHN) and right (RHN) hypogastric nerves, arising from the superior hypogastric plexus

by the posterior vaginal wall and the anterior rectal wall, and its latero-caudad limit is represented by the levator ani muscle [16].

Koninckx et al. in 1993 classified DE infiltrating the RVS in three types:

- (a) DE formed by a conic infiltrative lesion with the deepest portion progressively thinner and thinner
- (b) Retraction of an area of the bowel above the lesion which is located in the RVS
- (c) A sphere-shaped lesion located in the context of the RVS

What is of major concern about surgery for DE is the development of RVS in order to remove pure nodules of this anatomical area or to free the infiltrated rectal wall from the retro-cervical area/ utero-sacral ligaments, in case of severe involvement of the posterior compartment. In literature there are two different (but comparable in efficacy) approaches for the opening of the RVS (Fig. 5.14).

The *classical* approach is “lesion oriented” and consists in the opening of this space along a cranio-caudad axis, cutting along the borders of the disease, the final step being the development of the same RVS.

A different approach, according with the nerve-sparing procedures, is the retroperitoneal one, which provides the development of the RVS in a latero-medial, cranio-caudad and dorso-ventral direction. By this way, para-rectal spaces are dis-

sected at first, to the level of the pelvic floor; then, dissection of the lateral borders of the RVS is approached caudally with respect to the lesion, which is the last to be resected. Thus, the concept is to work in the retroperitoneum, surrounding the disease from the back (pre-sacral planes), and to cut the disease when all important retroperitoneal structures, such as the ureter and the hypogastric nerves, have been yet identified and lateralized. This kind of procedure is routinely used in our institution and has proved to be safe and efficient [9, 11].

Vascularization: Uterine Artery

Uterine arteries come from the hypogastric trunk in variable manners. In 60% of cases, the uterine trunk comes directly from the anterior branch of the internal iliac artery and the obliterated umbilical artery from a separated trunk. In 40% of cases, the uterine artery represents a branch of the umbilical artery itself. More rarely it derives from the obturator artery. It directs medially and caudally descending at the level of the ischiatic spine and then leading toward the uterus transversally and then ascending siding the lateral uterine wall in a typical spiral manner [1, 2, 5].

The uterine artery crosses the ureter at about 1.5 cm from the uterine wall. Collateral branches are vesico-vaginal (up to five arising laterally to the ureteric cross); ureteric (inconstant), cervico-vaginal artery (arising as unique medially to the ureteric cross and dividing on an anterior and a posterior branch); and visceral branches for the cervix and uterine corpus.

Several anastomotic systems might cross-by in a complex fashion external iliac vessels, internal iliac vessels, aortic circle (i.e., the mesenteric arteries and lumbar vessels), so that if one of the two uterine arteries are sacrificed during surgical procedures, uterine vascular feeding might completely recover.

A more caudad dissection of the hypogastric trunk in the Latzko’s para-rectal spaces allows identification of the middle rectal artery (MRA) and the course of the deep uterine vein (DUV), which represents a constant anatomo-surgical landmark used to identify the plane dividing the

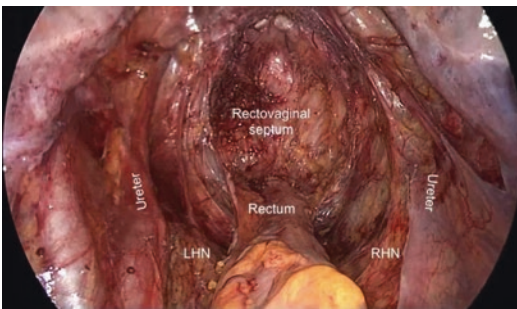


Fig. 5.14 Laparoscopic view of the recto-vaginal septum, developed till the level of the levator ani muscle, after vaginal resection for DE. Transperitoneal view of the ureters, in their relationships with the left and right hypogastric nerves (LHN and RHN, respectively)

parametrial *pars vasculosa* (ventrally and cranially) from the *pars nervosa* (dorsally and caudally).

Ureter

The portion of the ureter that lies above the pelvic area is rarely affected by endometriosis. However, the portion of the ureter that lies below the pelvic area and the urinary bladder can be affected by endometriosis in approximately 1% of patients.

There are two types of ureteral endometriosis usually described: an *extrinsic type* characterized by endometriotic lesion in the adventitial tissue and an *intrinsic type* marked by a proliferation of endometriosis in the muscular layer. The extrinsic form can be treated by ureterolysis, whereas the intrinsic requires resection of the involved segment with primary uretero-ureterostomy or ureteral reimplantation with or without a *Psoas-hitch* and/or a *Boari flap* procedure [17–19].

Ureteral lesion during laparoscopic surgery can be considered a rare event, estimated around 0.2–2%, but this is probably underestimated [20].

Nevertheless, endometriosis, altering the anatomy, increases the risk of ureteral trauma (38% of these lesions occur during surgery for endometriosis) [21, 22].

Thus, it is essential that every surgeon approaching endometriosis must be familiar with the special anatomy of the ureter.

The abdominal segment of the ureter extends from the renal pelvis to the pelvic brim. The right ureter begins behind the descending part of the duodenum. Just below their origin, the ureters are crossed by the ovarian vessels (the so-called *bridge over the water*). Behind the ureter the genito-femoral nerve (or its genital and femoral branches) runs on top of the psoas. On the left side, the sigmoid arteries and veins, embedded in the sigmoid mesocolon, run in front of the ureter toward the sigmoid colon. The inferior mesenteric artery and its terminal branch, the superior rectal artery, follow a curved course close to the left ureter. Proceeding from medial to lateral, the follow-

ing sequence of structures is found: superior rectal vessels, left ureter, and left ovarian vessels. Just above the entry to the pelvis, the ureter is still covered by peritoneum by virtue of the ureteric fold. Next to the ureteric fold, the gonadal vessels form an adjacent fold (in female, infundibulopelvic or suspensory ligament of ovary).

The pelvic segment of the ureter is about 15 cm long and accounts for roughly half of its total length. At the level of its beginning at the pelvic inlet, it crosses the common iliac vessels near their bifurcation (on the left side commonly anterior to the common iliac artery and on the right side commonly anterior to the external iliac artery). Within the pelvis the ureter can be divided into two portions. The descending part runs caudally still covered by peritoneum. It is dorsally accompanied by the internal iliac artery and its visceral branches as well as marked venous plexuses. Projected on to the lateral wall of the pelvis, the descending part of the ureter crosses the obturator artery, vein, and nerve. In the female, the descending part of the pelvic segment of the ureter courses posterior to the ovary. Following that, the bent part passes the middle rectal artery in the lateral ligament of the rectum (*paraproctium*), swings in a convex curve, and crosses the uterine vessels in a sagittal direction near, i.e., 1.5–2 cm (occasionally even 1–4 cm) away from the margin of the cervix of the uterus. At this level, the ureter reaches the base of broad ligament of the uterus (*paracolpium*) described by Mackenrodt as the *ligamentum transversalis colli* [23]. The inferior hypogastric plexus (or pelvic plexus) is bilaterally positioned more caudad than the ureter, with the middle rectal vessels piercing almost at its center. Finally, the terminal ureter runs forward, accompanied by the neuro-vascular bundle of the bladder. Just before entering the bladder, it passes the anterior vaginal fornix. As a rule, the left ureter has a more close relationship with the anterior wall of the vagina than the right ureter (this is the site where ureteral injuries most commonly occur during gynecological procedures).

Parametrium: Anterior, Lateral, Posterior

Anterior Parametrium

The anterior parametrium (Figs. 5.15 and 5.16), also called the *bladder pillar*, is defined after surgical opening and development of the vesico-uterine septum (vesico-cervical and vesico-vaginal spaces) and the medial and lateral para-vesical spaces. The bladder pillar is split into cranial and medial portions and into lateral

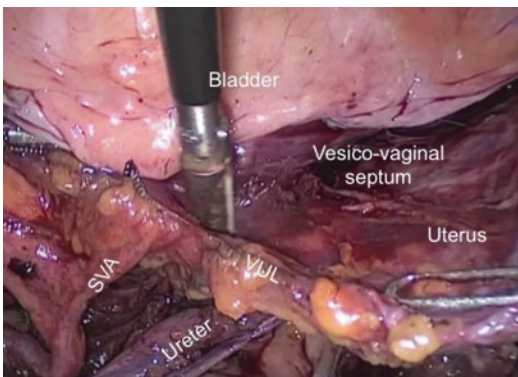


Fig. 5.15 Laparoscopic view of the left anterior parametrium in the course of nerve-sparing radical hysterectomy (Class C1, Querleu-Morrow). SVA superior vesical artery, VUL vesico-uterine ligament

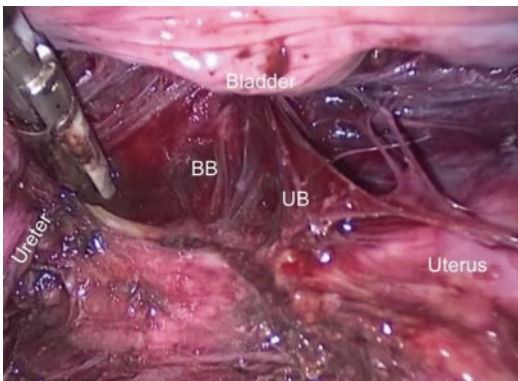


Fig. 5.16 Laparoscopic view of the left anterior parametrium in the course of nerve-sparing radical hysterectomy (Class C1, Querleu-Morrow): detail of the bladder branches (BB) and uterine branches (UB) of the pelvic plexus

and caudad portions by the ureter, which, respectively, corresponds to the vesico-uterine ligament and the lateral ligament of the bladder (or the cranial and caudad portions of vesico-uterine ligaments) [10, 11, 24].

Lateral Parametrium

What is commonly called the *lateral parametrium* or *paracervix* [10, 14, 25] is defined after the surgical opening and development of the medial and lateral para-vesical and para-rectal spaces (Fig. 5.9). It is split into cranial and medial portions and into lateral and caudad portions by the course of the ureter, which, respectively, correspond to the cardinal ligament (or Mackenrodt's ligament) and the paracervix. The cardinal ligament consists of tissue surrounding the uterine artery between the uterine corpus and the pelvic sidewall cranial to the ureter, corresponding to the superficial uterine pedicle (uterine artery and superficial uterine vein) and the related connective and lymphatic tissue. The paracervix consists of a cranial (anterior, superficial) vascular, connective, and lymphatic aspect and a caudad (posterior, deep) neural component [10, 14]. The deep uterine vein (DUV) is a constant landmark between the two components. Moreover, the structure named by surgeons as the *para-colpos* or *paracolpium* is included with the paracervix in the international anatomic nomenclature [3, 14].

Posterior Parametrium

The posterior parametrium, also called the *rectal pillar*, is defined after surgical opening of the recto-vaginal septum and the para-rectal spaces (Fig. 5.10). The rectal pillar corresponds to the utero-sacral ligament plus the recto-uterine and recto-vaginal ligament (RVL).

Heald et al. [25] in 1982 described the sharp dissection of total mesorectal excision (TME) for rectal cancer under direct view, emphasizing the anatomic isolation of spaces and septa, but the

anatomy of the lateral ligaments of the rectum (LLR) was not mentioned.

In the last decades, nerve-sparing techniques in radical pelvic surgery have been widely introduced and developed in gynecologic, urologic, and colo-rectal procedures and in radical surgery for DE [24]. The utero-sacral and rectovaginal ligaments (RVLs) are anatomic structures containing extensions of the visceral autonomic innervation for the uterus, vagina, bladder, and rectum, whose concentration is significantly greater near the origin of these ligaments at the pelvic side wall. Therefore, the more deep endometriosis infiltrates or extends to these ligaments, the more surgical radicality and the more neurologic morbidity are expected. The latter is due to surgical neuroablation of the aforementioned visceral autonomic ortho- and parasympathetic fibers contained in the pelvic posterior ligaments [3, 11–13, 16, 26].

According to wide anatomic studies based on hundreds of dissections in male and female cadaveric hemi-pelvis as well as clinical and surgical observations based on hundreds of laparoscopic and abdominal rectal and parametrial resections per year performed at our Institution, the *posterior parametrium* comprises the joining of three important anatomic structures (ligaments):

Cranial structure: the utero-sacral ligaments extending in the cranial portion of the retroperitoneum from the cervico-isthmic dorsal portion of the uterus to the ventral portion of the sacral bone.

Caudal structure: the RVLs extending in the caudal portion of retroperitoneum from the ventro-caudal portion of the rectum to the dorsal and caudal portions of the vagina up to the pelvic floor.

Latero-caudad structure: the lateral rectal ligaments (LLR), also termed *rectal stalks*, *rectal pillars* or *rectal wings*. These consist of band-like structures extending from the lateral pelvic wall to the mesorectum, better identified when the mesorectum is pulled medially. They run from the lateral border of the rectum (when the mesorectum wraps into the visceral

rectal fascia, also termed the fascia propria recti) to the latero-caudad pelvic wall (from the lateral border of the S2–S4 segments of the sacral bone to the parietal pelvic fascia covering the obturator and piriformis muscles). Parasympathetic innervation of the pelvic viscera, the recto-sigmoid, and the anal canal is given at this level by the PSN from the anterior rami of sacral roots S2–S4. The LLRs are constant anatomic structures and pathways of lympho-vascular vessels and autonomic nerve fibers toward the rectum. They represent the *neural soul* of the *posterior parametrium*, comprising a bilayer of visceral pelvic fascia covering the middle rectal vessels, the rectal branches of PP, and the soft areolar connective tissue running laterally and caudally to either side of the lower rectum [3]. They extend between the rectal visceral pelvic fascia (fascia propria recti) and the parietal pelvic fascia covering the levator ani muscle (caudally) and Waldeyer's recto-sacral fascia (dorsally) and terminating into the base of the distal rectum (laterally) [13].

Innervation (Hypogastric Nerves, Superior Hypogastric Plexus, Pelvic Splanchnic Nerves, Pelvic Plexus, Sacral Roots, Lumbo-sacral Trunk, Sciatic Nerve, Pudendal Nerve)

Radical surgery for endometriosis can induce urinary dysfunctions in 2.4–17.5% of patients owing to lesion of the autonomic nerves. The surgeon's knowledge of the anatomy of these nerves is the main factor for preserving postoperative urinary, rectal, and sexual functions. The following nerves are the intra-pelvic part of the autonomic nervous system: the hypogastric nerves, which derive from the superior hypogastric plexus and carry the sympathetic signals to the internal urethral and anal sphincters as well as to the pelvic visceral proprioception, and the pelvic splanchnic nerves, which arise from S2 to S4 and carry nociceptive and parasympathetic signals to the bladder, rectum, and the sigmoid and left colons [3]. The hypogastric and pelvic splanchnic nerves

merge into the para-rectal spaces to form the inferior hypogastric plexus. Most of the nerve-sparing techniques involve the dissection and exposure of the pelvic splanchnic nerves and the inferior hypogastric plexus. However, knowledge of the topographic anatomy and awareness of the landmarks for avoiding intra-operative nerve injuries seem to be the most important factors in avoiding post-operative bladder and bowel dysfunctions.

The neural fibers passing through the pelvic spaces and the parametrial ligaments are the superior hypogastric plexus (SHP), the right and left hypogastric nerves (HN), the right and left pelvic splanchnic nerves (PSN), and the right and left pelvic plexuses (PP), also called the *inferior hypogastric plexa*.

Superior Hypogastric Plexus (SHP)

The pelvic orthosympathetic innervation of the pelvic viscera receives their most important component by the SHP and the hypogastric nerves (HNs). The SHP lies caudally to the aortic bifurcation, originating by the two principal lumbar nerves which merge from the sympathetic para-vertebral chain at the level of L2–L3. It also receives postganglionic fibers from the inferior mesenteric plexus, of which it represents the caudal prolongation [8, 9]. The SHP is involved in the visceral endopelvic fascia, and its fibers are directed latero-caudally toward the common iliac veins and arteries to the level of the sacral promontorium, where it divides in the two HNs.

Hypogastric Nerves (HNs)

The HNs originate from the caudal pole of the SHP, at the level of the inferior limit of the sacral promontorium; they cross the pelvis in the context of the para-rectal space, laterally to the mesorectum and parallel to the hypogastric artery, 1 cm below the course of the ureter (Fig. 5.17). They lie in the context of the so-called mesoureter, which is the ventral prosecution of the pre-sacral fascia. They direct themselves parallel but finally laterally

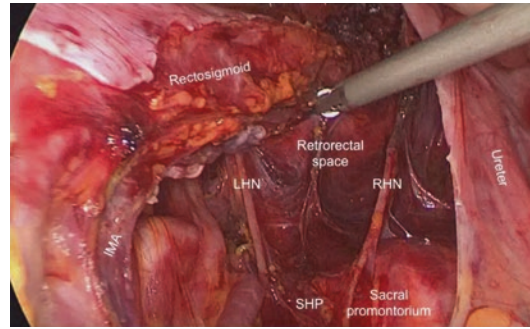


Fig. 5.17 Laparoscopic view of the visceral orthosympathetic innervation of the pelvis, including the superior hypogastric plexus (SHP), the right and left hypogastric nerves (LHN and RHN, respectively), after dissection of the retro-rectal space, propedeutic to recto-sigmoid segmental resection for DIE. It is also shown the profile of the inferior mesenteric artery

to the utero-sacral ligament, in the context of the recto-vaginal ligament, and in the final part, they cross laterally the ureter. At the level of the Douglas' pouch, at least at 2 cm below this level, they join their fibers with the parasympathetic component of the pelvic splanchnic nerves, forming the pelvic plexus [3]. The HNs are usually isolated and dissected at the level of the promontorium, during the dissection of the so-called *Heald's holy plane*, propedeutic to the preparation of the mesorectum in cases of bowel resection for DE. They are detached from the fascia propria recti and by Waldeyer's fascia and lateralized and caudalized before opening the recto-vaginal septum. In this way the nerve-sparing technique is completed, resecting only the afferent visceral neural component directed to the bowel segment to be resected [11].

Pelvic Plexus

At 1–2 cm lower than the pouch of Douglas, three to five branches of parasympathetic PSN (contained in the LLR) pierce the endopelvic fascial sheet covering the ventral part of piriformis muscle to join with the ending branches of each orthosympathetic HN almost 1 cm ventrally and form the mixed PP [3]. The PP is a bilateral neural network about 15–20 mm long and 10–20 mm

thick situated in the pre-sacral visceral pelvic fascia between the ureter (cranial) and the pelvic floor (caudad). It extends bilaterally between the antero-lateral surface of the rectum (just ventral to its LLR) and the postero-lateral vaginal fornix. Each PP is crossed by the middle rectal vessels.

From the PP arise several efferent branches of fibers directed to the pelvic target viscera [27]. These efferent branches could be divided (at the level of the LLRs) into three groups:

1. A branch of fibers directed medially toward the rectum together with the middle rectal vessels (rectal nerves or branches or middle rectal plexus) running mainly through the mesorectum, the LLRs, and the RVLs (posterior parametrium) termed the “medial efferent bundle”
2. A branch of fibers (cranial efferent bundle) mainly directed cranially toward the uterus (cervico-uterine nerves or branches) running through the cardinal ligament (cranial portion of the lateral parametrium)
3. A group formed by three or four main fibers (anterior efferent bundle) mainly directed anteriorly toward the bladder and the vagina (bladder and vaginal nerves or branches), which run caudally through the paracervix (caudad portion of lateral parametrium) up to the so-called anterior parametrium (cranial and caudad vesicouterine ligaments) (3, 27).

During surgical radical procedures requiring lateral or anterior parametrectomy (i.e., surgery for DE infiltrating the bladder), visualization of the PP at its origin in the posterior parametrium and identification of its three branches allow preservation of the visceral afferent and efferent fibers directed to the uterus, vagina, bladder, and, running dorsally, rectum.

References

1. Testut L. *Traité d'Anatomie Humaine*. 8th ed. Paris: Ed Doin; 1931.
2. Kamina P. *Anatomie Clinique*. Tome 4. Paris, Ed Maloine SA, 2008.
3. Ceccaroni M, Fanfani F, Ercoli A, Scambia G. *Innervazione Viscerale e Somatica della Pelvi Femminile*. Testa Atlante di Anatomia Chirurgica 2006. Edizioni CIC.
4. Ballester M, Belghiti J, Zilberman S, Thomin A, Bonneau C, Bazot M, Thomassin-Naggara I, Daraï E. Surgical and clinical impact of extraperitoneal pelvic fascia removal in segmental colorectal resection for endometriosis. *J Minim Invasive Gynecol*. 2014;21(6):1041–8.
5. Netter FH. *Atlante di Anatomia Fisiopatologia e Clinica*, Vol. 3. *Apparato Riproduttivo*, Collezione CIBA, 1999.
6. De Kleuver M, Kooijman MA, Kauer JM, et al. Pelvic osteotomies: anatomic pitfalls at the ischium. A cadaver study. *Arch Orthop Trauma Surg*. 1998;117(6–7):376–8.
7. *Traité d'anatomie humaine*. Publié sous la direction de P. Poirier et A. Charpy, 1899.
8. Peham HV, Amreich J. *Gynakologische operation-slehre*. Berlin: S Karger; 1930.
9. Peham HV, Amreich J. *Operative gynecology* (translated by Ferguson LK). Philadelphia: JB Lippincott; 1934.
10. Querleu D, Morrow CP. Classification of radical hysterectomy. *Lancet Oncol*. 2008;9(3):297–303.
11. Ceccaroni M, Clarizia R, Bruni F, D'Urso E, Gagliardi ML, Roviglione G, Minelli L, Ruffo G. Nerve-sparing laparoscopic eradication of deep endometriosis with segmental rectal and parametrial resection: the Negrar method. A single-center, prospective, clinical trial. *Surg Endosc*. 2012;26(7):2029–45.
12. Ceccaroni M, Pontrelli G, Spagnolo E, Scioscia M, Bruni F, Paglia A, Minelli L. Parametrial dissection during laparoscopic nerve-sparing radical hysterectomy: a new approach aims to improve patients' postoperative quality of life. *Am J Obstet Gynecol*. 2010;202(3):320.
13. Ceccaroni M, Clarizia R, Roviglione G, Ruffo G. Neuro-anatomy of the posterior parametrium and surgical considerations for a nerve-sparing approach in radical pelvic surgery. *Surg Endosc*. 2013;27:4386–94.
14. Ercoli A, Delmas V, Fanfani F, et al. Terminologia Anatomica versus unofficial descriptions and nomenclature of the fasciae and ligaments of the female pelvis: a dissection-based comparative study. *Am J Obstet Gynecol*. 2005;193:1565–73.
15. Heald RJ. The “holy plane” of rectal surgery. *J R Soc Med*. 1988;81:503–8.
16. Havenga YY, Sasaki H, Hatakeyama N, Murakami G. Discrepancies between classic anatomy and modern gynecologic surgery on pelvic connective tissue structure: harmonization of those concepts by collaborative cadaver dissection. *Am J Obstet Gynecol*. 2005;193(1):7–15.
17. Yohannes P. Ureteral endometriosis. *J Urol*. 2003;170:20–5.
18. Antonelli A, Simeone C, Zani D, Sacconi T, Minini G, Canossi E, et al. Clinical aspects and surgical treatment of urinary tract endometriosis: our experience with 31 cases. *Eur Urol*. 2006;49:1093–7.

19. Ostrzenski A, Radolinski B, Ostrzenska KM. A review of laparoscopic ureteral injury in pelvic surgery. *Obstet Gynecol Surv.* 2003;58:794–9.
20. Terzibachian JJ, Gay C, Bertrand V, Bouvard M, Knoepffler F. Value of ureteral catheterization in laparoscopy. *Gynecol Obstet Fertil.* 2001;29:427–32.
21. Grainger DA, Soderstrom RM, Schiff SF, Glickman MG, DeCherney AH, Diamond MP. Ureteral injuries at laparoscopy: insights into diagnosis, management and prevention. *Obstet Gynecol.* 1990;76:889–90.
22. Rafique M, Arif MH. Management of iatrogenic ureteric injuries associated with gynecological surgery. *Int Urol Nephrol.* 2002;34:31–5.
23. Yabuki Y, Sasaki H, Hatakeyama N, Murakami G. Discrepancies between classic anatomy and modern gynecologic surgery on pelvic connective tissue structure: harmonization of those concepts by collaborative cadaver dissection. *Am J Obstet Gynecol.* 2005;193:7–15.
24. Ceccaroni M, Pontrelli G, Spagnolo E, et al. Nerve-Sparing laparoscopic radical excision of deep endometriosis with rectal and parametrial resection. *J Minim Invasive Gynecol.* 2010;17:14–5.
25. Heald RJ, Husband EM, Ryall RD. *Br J Surg.* 1982;69(10):613–6.
26. Ceccaroni M, Clarizia R, Roviglione G, et al. Deep rectal and parametrial infiltrating endometriosis with monolateral pudendal nerve involvement: case report and laparoscopic nerve-sparing approach. *Eur J Obstet Gynecol Reprod Biol.* 2010;153:227–9.
27. Ercoli A, Delmas V, Gadonneix P, Fanfani F, Villet R, Paparella P, Mancuso S, Scambia G. Classical and nerve-sparing radical hysterectomy: an evaluation of the risk of injury to the autonomous pelvic nerves. *Surg Radiol Anat.* 2003;25(3–4):200–6.



Nerve-Sparing Routes in Radical Pelvic Surgery

6

Nucelio L.B.M. Lemos, Reitan Ribeiro,
Gustavo Leme Fernandes, Mauricio S. Abrão,
and Renato Moretti-Marques

Introduction

Wertheim's, Okabayashi's, and Meig's work, already in the early 1900s, progressively increased the radicality of hysterectomy for early-stage cervical cancer, mainly by increasing the extent of parametrial excision, correspondingly increasing survival rates [1]. Increased survival, however, charged its price by adding functional morbidity to cancer survivors—prevalence of urinary retention, constipation, and sexual dysfunction rose almost proportionally to survival rates [2, 3].

During the 1990s, radical laparoscopic resection of deeply infiltrating endometriosis (DIE) started to build on a similar history, improving symptomatic relief, especially in cases with severe debilitating symptoms [4, 5], and was progressively adopted by the majority of specialized endometriosis surgical teams. Not differently from cervical cancer treatment, the complete removal of DIE may damage the pelvic autonomic nerves, negatively affecting bladder, rectal, and sexual function (vaginal lubrication and swelling), even in single-sided injuries [6–9].

Those dysfunctions derive from the damage inflicted to the pelvic sympathetic and parasympathetic neural pathways—superior hypogastric plexus, hypogastric nerves, pelvic splanchnic nerves, and the inferior hypogastric (pelvic) plexus. Japanese gynecologists were the first to describe a technique for nerve-sparing cervical cancer surgery, already in the 1960s [10]. However, these techniques were kept unavailable to the Western world, since all were published in Japanese. It was only in the twenty-first century that this concept was introduced in Europe, when Possover et al. [11] and other groups [12–14] started developing nerve-sparing radical gynecologic procedures. Already under laparoscopic view, they named it LANN (laparoscopic neuronavigation) technique, because it is based on the use of intraoperative neurostimulation for identification and dissection of intrapelvic nerves [15, 16].

N. L. B. M. Lemos, M.D., Ph.D. (✉)
Department of Obstetrics and Gynecology, University
of Toronto, Women's College Hospital, 76 Grenville
Street, Room 5449, Toronto, M5S 1B2 ON, Canada

R. Ribeiro, M.D.
Gynecologic Oncology Department, Erasto Gaertner,
Instituto de Oncologia do Paraná, and Hospital
Marcelino Champagnat, Curitiba, PR, Brazil

G. L. Fernandes, M.D., Ph.D.
Gynecology Oncology Division, Department
of Obstetrics and Gynecology, Central Hospital
of Irmandade da Santa Casa de Misericórdia de São
Paulo, São Paulo, SP, Brazil

M. S. Abrão, M.D., Ph.D.
Ob/Gyn Department, Sao Paulo University,
Sao Paulo, SP, Brazil

R. Moretti-Marques, M.D., Ph.D.
Oncology Department, Hospital Israelita Albert
Einstein, São Paulo, SP, Brazil

Since then, several nerve-sparing procedures have been successfully adopted and shown to be effective in preserving neurologic pelvic functions with similar disease-free intervals and clinical outcomes [17–22].

Ceccaroni et al. [19], in a study comparing classical radical and nerve-sparing radical resection of DIE (Negrar method), reported a significantly higher rate of severe neurologic pelvic dysfunction in the first group (86.2% versus 1.6%), although no differences were found between the two groups in terms of colorectal dysfunction rates and bowel-rectal quality of life.

Other authors have also demonstrated the reproducibility of intraoperative nerve dissection and exposure [23, 24]. The goal of all the cited nerve-sparing approaches is to better identify the visceral nerve bundles at the level of the pararectal fossae and the parametria.

An alternative to exposing the autonomic nerves is to use landmarks to avoid operating at their surroundings and inadvertently transecting those nerves. This is the case of the mesorectum-sparing sigmoidectomy [21], which uses anatomical landmarks to avoid areas of high nerve density.

Nowadays, there has been a general attitude toward less radical and nerve-sparing treatments, with the objective of preserving function, reducing morbidity, and maintaining cure rates while improving the quality of life.

Laparoscopic identification of the hypogastric nerve and inferior hypogastric plexus is a feasible procedure for trained laparoscopic surgeons who have a good knowledge not only of the retroperitoneal anatomy but also of the pelvic neuroanatomy. Moreover, the simple awareness of pelvic neuroanatomy and the high nerve density areas is a key factor in reducing perioperative morbidity. Therefore, the objective of this chapter is to review the anatomy of the autonomic nerves of the pelvis and describe the steps of the LANN technique to expose and preserve the autonomic nerves, as well as the anatomical landmarks to preserve those nerves without the need of previously exposing them.

Neurophysiology of the Pelvic Floor

Neurophysiology of the Lower Urinary Tract (LUT)

The voluntary control of the LUT demands participation of different structures in the brain, brain stem, and spinal cord. The frontal cortex permits conscious control over micturition by allowing voluntary contraction of the striated rhabdosphincter and the levator ani muscle. Correspondingly, the pontine micturition center allows for the voluntary stimulation of the detrusor activity and coordinates the relaxation of the smooth and striated urethral sphincters during voiding [25].

Since the objective of this chapter is on nerve-sparing surgery, almost all the attention will be given to the nerve bundles crossing the pelvis: the superior hypogastric (presacral) plexus, the hypogastric nerves, the pelvic splanchnic nerves, the inferior hypogastric (pelvic) plexus, and the pudendal nerves.

The peripheral nervous system innervates the bladder and the urethra with autonomic efferent sympathetic fibers via the hypogastric nerves, originated from the thoracic-lumbar sympathetic division of the spinal cord (T10–L3), and the parasympathetic fibers via the pelvic splanchnic nerves (S2–S4) [25, 26]. The somatic efferent motoric innervation to the urethra striated rhabdosphincter and the pubovaginal (puboprostatic) branch of the pubococcygeus muscle runs in the pudendal nerves, while direct sacral fibers from S3 to S4—the levator ani nerves—innervate the posterior portions of the levator ani muscle [27, 28].

The somatic and sympathetic divisions promote storage, while the parasympathetic divisions promote voiding. During most of the time, baseline sympathetic stimuli are constantly fired through the hypogastric nerves, maintaining the internal urethral sphincter tonus and detrusor relaxation. The beta-adrenergic receptors on the detrusor muscle respond to norepinephrine causing relaxation and allowing the bladder to fill without an increase in pressure or change in tone.

At the same time alpha1-adrenergic receptors in the urethral smooth muscles respond to norepinephrine stimulating contraction [25, 29, 30].

When the bladder fills above a certain threshold, stretch receptors in the bladder wall generate nerve impulses transmitted along the hypogastric nerves to the thoracolumbar spinal cord. These afferent impulses reach the pontine micturition center (PMC) eliciting the pontine micturition reflex, which activates the parasympathetic nuclei of the conus medullaris that respond by firing impulses along the pelvic splanchnic nerves to the bladder and urethra with subsequent release of neurotransmitter acetylcholine, which stimulate M3 receptors at the detrusor, causing contraction and, at the urethra, causing relaxation. The PMC also sends impulses to the pudendal nerves, causing the urethral rhabdosphincter to relax. Concomitantly, other PMC impulses suppress sympathetic activity to the bladder and urethra [25, 29, 30].

Bowel Evacuation and Anorectal Neurophysiology

Fecal continence and evacuation are complex mechanisms that involve the pelvic floor muscles as well as the somatic and autonomic nervous systems (sympathetic and parasympathetic).

The efferent innervation, responsible for the motor activity of pelvic muscles and viscera, consists in a group of three nerves of somatic and autonomic nervous systems.

The sympathetic innervation of the descending colon, sigmoid, and rectum is provided by the lumbar splanchnic nerves (L1–L3), which synapse at the inferior mesenteric ganglion and run along the arterial irrigation to the intestine walls. The sympathetic fibers to lower parts of the rectum, anal canal, and internal anal sphincter are also originated from the same lumbar splanchnic nerves; however, these nerves come from the mesenteric ganglion to the superior hypogastric plexus and form the hypogastric nerves, that are going to integrate the inferior hypogastric plexus,

accompanying the pubococcygeus fascia and reaching the anus (space between sphincters) and integrating the myenteric plexus (of Auerbach). The areas above the splanchnic flexure of the colon are innervated by the vagus nerve [31–33]. Noradrenaline release by the sympathetic fibers activates the alpha1-adrenergic receptors, promoting internal anal sphincter contraction [34].

The parasympathetic signals originate from the pelvic splanchnic nerves (S2–S4). These nerves cross short distances in the pararectal fossae and form the inferior hypogastric plexuses that will innervate the upper two thirds of the rectum [15, 26]. The liberation of acetylcholine by these fibers stimulates the myenteric plexus.

The somatic nervous system is composed of the pudendal nerves (S2–S4), which pass through the Alcock's canal toward the perineum, where they divide in three branches: the inferior rectal nerves (motor innervation to external anal sphincter), the perineal nerves (innervation to transverse perineal, bulbocavernosus, bulbospongiosus, ischiocavernosus, urethral rhabdosphincter, anterior part of the pubococcygeus, and pubovaginal muscles), and the dorsal nerves of the clitoris (or penis) [25, 27]. Moreover, the levator ani nerve (S3–S4) innervates iliococcygeus and ischiococcygeus muscles (motor and sensitively) [28].

The rectal and vesical proprioception are controlled by myelinic fibers (A gamma) that ascend to pontine and hypothalamic centers by hypogastric nerves. In addition, those are responsible for nociception of the descending colon, sigmoid colon, and rectum, while the pelvic splanchnic nerves are responsible for their proprioception [35]. Fibers of the pelvic floor muscles also send signals through pudendal and levator ani nerves.

The role played by the extrinsic innervation in the bowel evacuation's mechanism is less important than it is in the bladder, since motility control is exerted by the myenteric plexus, whereas the sympathetic and parasympathetic systems only provide modulating or stimulating signals to this plexus [35]. Yet, the role of the pelvic floor muscles is fundamental to the anorectal function.

Simultaneous contractions of anterior and posterior parts of the pelvic floor promote increase of the anorectal angle and direct the rectal content upward, decreasing the afferent impulses and the defecation desire.

When there are signals to initiate defecation, the central nervous system reduces the stimuli to the pudendal nerve, relaxing the anterior part of the pelvic floor, contracting the posterior part of the levator ani muscles, decreasing the anorectal angle, and facilitating defecation [36].

Laparoscopic Anatomy of the Intrapelvic Nerves

Nerves of the Presacral and Pararectal Spaces

The superior hypogastric plexus is formed by fibers from para-aortic sympathetic trunk and gives rise to the left and right hypogastric nerves. The hypogastric nerves run over the presacral fascia in an anterior and distal direction. After crossing about two thirds of the distance between the sacrum and the uterine cervix or the prostate, its fibers spread to join the pelvic splanchnic nerves (described below) to form the inferior hypogastric plexus (Fig. 6.1).

The lateral limit of the presacral space is the hypogastric fascia, which is the formed by the

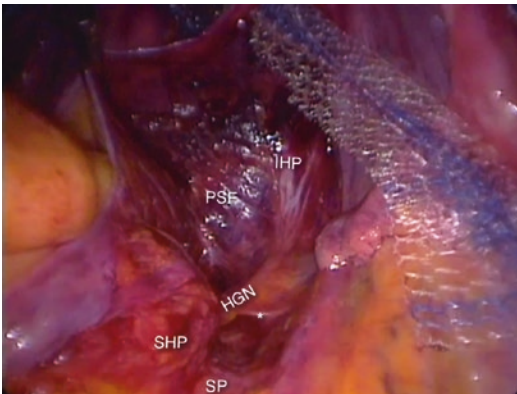


Fig. 6.1 Right hypogastric nerve (HGN) originating from the superior hypogastric plexus (SHP) and running anteriorly and distally over the presacral fascia (PSF) to spread out in thinner branches that will form the inferior hypogastric plexus (IHP)

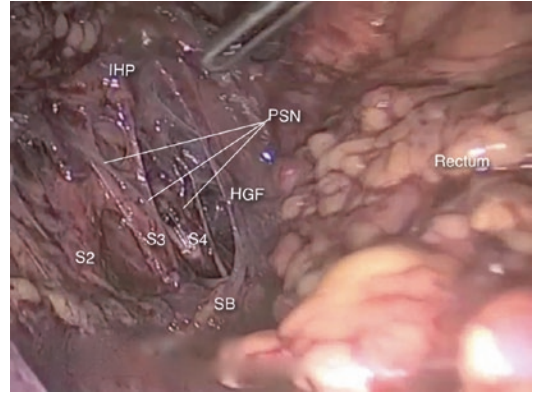


Fig. 6.2 Left pelvic splanchnic nerves (PSN) are thin fibers which arise from nerve roots S2–S4 to join the hypogastric nerves and form the inferior hypogastric plexus (IHP) (SB sacral bone)

medialmost fibers of the uterosacral ligaments. The sacral nerve roots can be found just laterally to this fascia. They leave the sacral foramina and run anteriorly and distally, lying over the piriformis muscle and crossing the internal iliac vessels laterally to them, to merge and form the nerves of the sacral plexus. Before crossing the internal iliac vessels, they give out the thin parasympathetic branches called pelvic splanchnic nerves, which promote detrusor contraction and provide extrinsic parasympathetic innervation to the colon descendens, sigmoid, and rectum. They also carry nociceptive afferent signals from the pelvic viscera. The pelvic splanchnic nerves join the hypogastric nerves to form the inferior hypogastric plexus in the pararectal fossae (Fig. 6.2).

Neuroanatomy of the Cardinal Ligaments/Lateral Paracervix

The cardinal ligaments are also known as lateral cervical ligaments. More recently, lateral paracervix is preferred as the anatomical term in the international anatomical nomenclature [37]. They are responsible for making a connection between the cervix and the pelvic sidewall, involving the uterine vessels and being crossed by the ureter.

The ureter divides the lateral paracervix not only in lateral and medial but also in superficial (supraureteral lateral parametrium) and deep paracervix (infraureteral lateral parametrium),

which is a more important division regarding the pelvic innervation. The superficial paracervix contains the uterine vessels and lymphatic tissue, while the deep paracervix contains the vaginal branches of hypogastric nerve and part of the inferior hypogastric plexus, which is mainly located posteriorly to the deep uterine vein [1] (Fig. 6.3).

The distal part of the deep paracervix has few lymphatic structures and contains mainly connective tissue and nerves as opposed to anterior parametria. The vesical plexus is located in both layers of the vesicouterine ligament and has a very close relationship with the distal ureter [1, 38]. Those are the reasons why type C1 radical hysterectomy [39], which includes resection of the lateral paracervix up to the deep uterine vein, is also called nerve-sparing radical hysterectomy, once the neural component is preserved (Fig. 6.4) except for the branches to the uterus and upper vagina (Fig. 6.5).

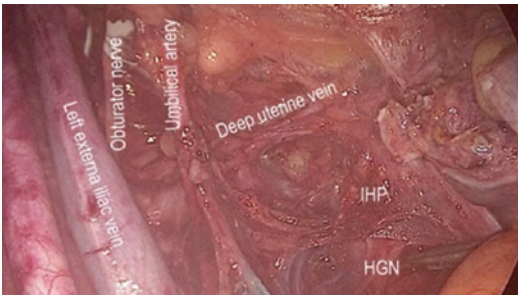


Fig. 6.3 Lateral paracervix, after removal of the uterine artery, showing the proximity of the deep uterine vein with the inferior hypogastric plexus (IHP) and hypogastric nerve (HGN)

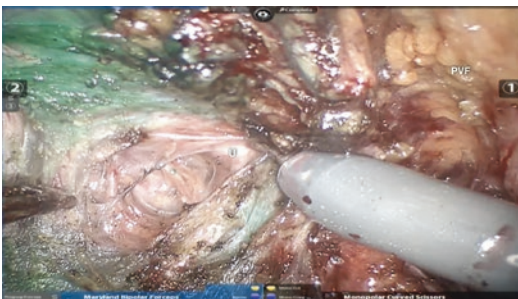

Fig. 6.4 The picture shows the right inferior hypogastric plexus (asterisk) located under the distal ureter (U) at Yabuki's fourth space dissection to perform the radical hysterectomy to early stage cervical cancer. Lymphatics are stained with indocyanine green. PVF paravesical fat

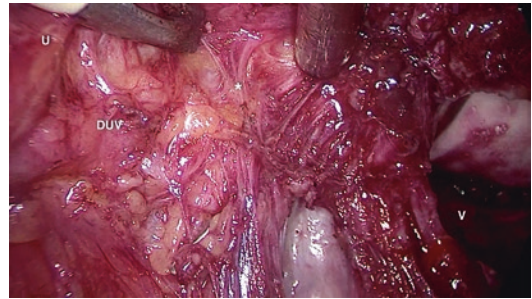


Fig. 6.5 The neural component of the paracervix caudal to the deep uterine vein (DUV—cauterized and transected) is shown after removal of the paracervix in type C1 radical hysterectomy. The ureter (U) is lateralized, and the vesical fibers (*) can be seen running to the bladder between the instruments. The vaginal cuff (V) has already been opened, revealing the cuff valve of the uterine manipulator

Nerve-Sparing Routes in Radical Endometriosis Surgery

Nerve-Sparing in Endometriosis Surgery by Direct Visualization of Nerve Bundles by Using the Laparoscopic Neuronavigation (LANN) Technique

The LANN technique is based on the concept of preservation by dissection and exposure of the nerve bundles before approaching the endometriotic foci [15, 16, 40]. This concept is similar to the one used to preserve the ureters, by starting the dissection of the nerves on healthy tissue, before they dive into the endometriotic area, to facilitate their identification in anatomically distorted regions [41].

Preservation of the Pelvic Splanchnic Nerves and the Inferior Hypogastric Plexus

The pelvic splanchnic nerves are thin bundles that can be easily mistaken for retroperitoneal connective trabeculae. Therefore, they can only be identified at their dorsal origin out of the sacral nerve roots close to the sacral foramina and exposed, allowing for neuropreservation through direct visualization. According to the LANN technique, identification of the different sacral roots is performed using a bipolar laparoscopic

forceps for electrostimulation and observing the motoric response [40, 41].

The sacral nerve roots are dissected by making an incision of the pararectal peritoneum medially to the ureter and opening the presacral fascia. The presacral space is developed by blunt dissection downward, using the sacral and coccygeal bones as posterior and distal references, respectively. The dissection is expanded laterally, toward the hypogastric fascia, which is transected revealing the piriformis muscle underneath. The sacral nerve roots run anteriorly and distally over the muscle fascia and can be precisely identified by means of the motoric response generated by intraoperative neurostimulation with a bipolar forceps delivering electrical impulses with a square-wave pulse duration of 10 ms, a pulse frequency of 2 Hz, and electric potential of 1.5 mA, generated by a surgical neurostimulator. Stimulation of S2 produces an outward rotation of the leg, plantar flexion of the foot, and a clamp-like squeeze of the anal sphincter from anterior and posterior, while S3 stimulation is visually shown as deepening and flattening of the buttock groove, a marked flexion of the large toe, and a less important flexion of the smaller toes. Following these roots ventrally will allow for the identification and exposure of the pelvic splanchnic nerves, as well as their pathways into the pararectal space to form the inferior hypogastric

plexus. Dorsally, the rectal splanchnic nerves are visualized in a horizontal direction, crossing the sacral hypogastric fascia and finally anastomosing to the homolateral inferior plexus in laterodorsal position to the level of the rectum. The vesical splanchnic nerves originate from the middle portion of sacral roots, adopting a vertical direction and remaining lateral of the sacral hypogastric fascia, anastomosing with the homolateral inferior hypogastric plexus at the level of the vagina. The stimulation of the vesical splanchnic nerves increases intravesical pressure ([15]; Fig. 6.6).

The parametria can be safely resected after the exposure of splanchnic pelvic nerves from their origin to their anastomosis in the homolateral inferior hypogastric plexus, preserving the parasympathetic nerves at level of neural part of the cardinal ligament or more ventrally at level of the rectovaginal ligament or at the level of bladder pillar [15].

Magnification, pneumoperitoneum facilitated dissection with minimum bleeding and directed lighting and visualization of the deeper spaces of pelvis, are important factors in favor of the laparoscopic surgery in the retroperitoneum. The improved access and visualization allowed for the development of the LANN technique which is substantially contributing to improve the knowledge of pelvic neuroanatomy. Also the technique proved to be reproducible in short

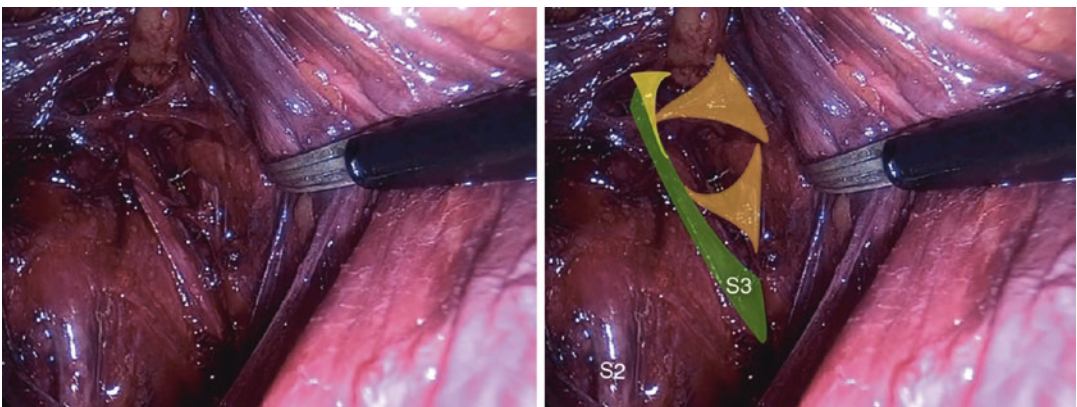


Fig. 6.6 Pelvic splanchnic nerves branching out of S3 on the left side. Colored map on the right side shows the more horizontal bundles (light brown) to the rectum and

the more vertical ones (yellow) to the inferior hypogastric plexus and bladder

operative time with notable reduction in postoperative functional morbidity after surgical treatment of endometriosis [15, 40, 41].

All these strategies work very well in patients with endometriosis in the proximities, but not when it is directly affecting the pelvic splanchnic nerves. Unfortunately, it is not possible to free the pelvic splanchnic nerves from endometriosis without tearing them. In these cases, bilateral exposure of the pelvic splanchnic nerves must be performed, and the surgeon must try to estimate the amount of nerve damage that will be inflicted upon endometriotic resection. In case of bilateral disease, some endometriosis will likely have to be left behind, unless this has been previously discussed and the patient has preoperatively opted to have self-catheterization instead of an incomplete resection [41].

Pelvic Wall and Somatic Nerves Endometriosis and Nerve Preservation

The complete exposure of sacral plexus and the identification of the somatic nerves require the development of the lumbosacral and obturator spaces, starting at the level of the iliolumbar fossa, situated laterally to the external iliac vessels and goes further in a latero-caudal direction, allowing for the identification of lumbosacral trunk and the proximal portion of the obturator nerve. When approaching the lateral pelvic wall, elective dissection and medial mobilization of the internal iliac vessels and its branches are required for a good anatomic exposure of the distal part of the sacral plexus—the sciatic nerve and its distal branches, the pudendal nerve, and the nerves to the levator ani muscles. This technique allows for a safe resection of the extensive endometriosis that infiltrates the sciatic foramen and the surroundings of the sciatic nerve and its branches. Moreover, pudendal nerves and vessels can be identified at the level of Alcock’s canal, and the transection of the sacrospinous ligament and the pudendal vessels might be necessary for further dissection [42–44].

Recognition of the neuroanatomy of the pelvis leads to isolation and removal of all the disease with adequate surgical radicality, freeing the somatic nerves with the possibility of complete resolution of symptoms [18].

In addition to the knowledge of surgical neuroanatomy, the main factor for effective treatment and neuropreservation in somatic endometriosis of the pelvic sidewalls is preoperative recognition of symptoms and topographic diagnosis, based on neurologic examination and MRI [44]. The main symptoms suggestive of endometriotic infiltration of the sciatic plexus are:

- Gluteal/perineal/lower limb pain or allodynia (pain on the dermatomes of the nerves of the lumbosacral plexus)
- Vaginal/rectal foreign body sensation
- Refractory urinary urgency associated with single-sided pain on the dermatomes of the nerves of the lumbosacral plexus
- Refractory dyschezia or proctalgia
- Vesical/rectal tenesmus, without signs of endometriotic infiltration of the bladder or rectum

Whenever one or more of these symptoms are present, careful preoperative assessment of the lumbosacral plexus must be performed, and the patient must only be taken to surgery after the exact site of entrapment (topographic diagnosis) has been performed [44].

Nerve Preservation Though the Use of Landmarks: The “Non-Touch” Technique

The above described technique is technically demanding which requires high-definition imaging, intraoperative neurostimulation, and surgeon’s training in laparoscopic nerve dissection. When those resources are not available due to lack of equipment or training, the use of surgical landmarks is recommended to avoid dissection in the areas of high nerve density and, therefore, higher risk of nerve injury. These are what we call “non-touch” techniques, since they involve reducing radicality to avoid inadvertent nerve injury.

Figure 6.7 shows the peritoneal view of the posterior cul-de-sac of a patient whose left sacral nerve roots, pelvic splanchnic nerves, and inferior hypo-

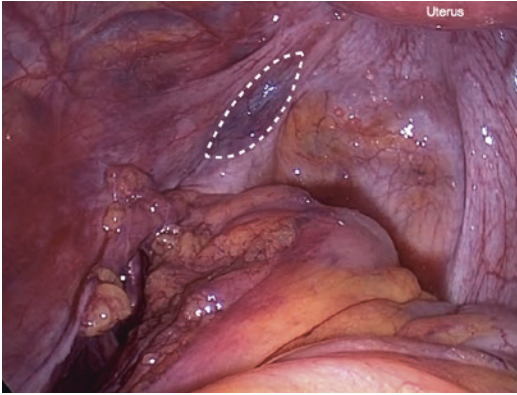


Fig. 6.7 Transperitoneal view of the area of the left hypogastric plexus (dashed perimeter)

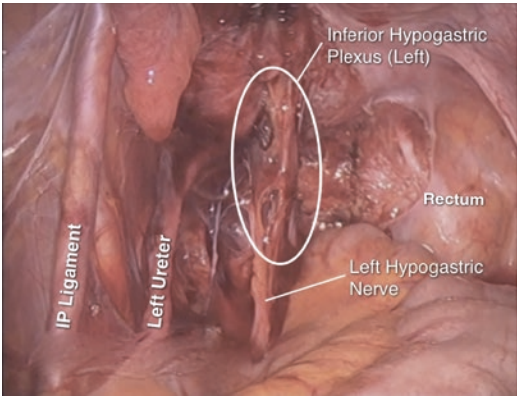


Fig. 6.8 Left hypogastric nerve and plexus, after peritonectomy of the ipsilateral pararectal and ovarian fossae (IP infundibulopelvic)

gastric plexus have been dissected. Observe the dissection area (dashed perimeter) in the pararectal fossa, deeper to the presacral fascia. Figure 6.8 shows the dissection of the left hypogastric nerve and inferior hypogastric plexus, to give a better understanding of the retroperitoneal anatomy.

Through these images, it is easy to come to conclusion that deeper dissections at the pararectal fossae without prior exposition of the inferior hypogastric plexus should be avoided, especially in case of bilateral disease [41].

Moreover, when dissecting the rectovaginal space, any dissection lateral to the rectum can damage the pelvic splanchnic nerves. The surgeon, therefore, must attempt to perform all dissections using the anterior rectal wall as a limit.

Bowel Resection and Nerve Preservation

Bowel endometriotic nodules can be removed using various techniques, including mucosal skinning, nodulectomy, full-thickness disc resection, and segmental resection [45].

The first intervention proposed for the treatment of intestinal endometriosis was anterior wall nodulectomy, which was described by Nezhat et al. in 1994 [4], prior to the development of laparoscopic staplers. However, many authors have proposed that this approach may leave residual disease tissue behind and increase the recurrence rate [46], especially when the lesion infiltrates deeper than the inner muscularis [47]. In addition, as segmental resections have become increasingly feasible because of the technological development of mechanical sutures, this more radical procedure has become the most commonly performed technique for this indication [48].

However, up to 45% of patients refer unchanged, worsened or de novo bowel dysfunction after segmental bowel resection for endometriosis [49]. This may be due to tight stenosis of the colorectal anastomosis, rectal denervation, colorectal intussusception through the anastomosis, and postoperative transit constipation [50]. In that sense, anterior rectal wall nodulectomy seems to be a more reasonable, benign disease-oriented procedure, since endometriosis is believed to infiltrate the bowel from the serosal to the mucosal layer. Its theoretical advantages include reduced devascularization and denervation of the descending and sigmoid colon, since much less dissection is needed in the pararectal fossae, which can damage the autonomic nerves of the inferior hypogastric plexus either by directly sectioning them or by lateral thermal widespread [50]. This model can explain why Fanfani et al. [7] observed a 14% versus 0 urinary retention rate in women undergoing segmental and discoid resection, respectively. Bowel function scores are also better in patients undergoing the more conservative approach. Therefore, nodulectomy should be preferred over segmental resection whenever possible [45, 51, 52].

Nerve-Sparing in Radical Pelvic Oncologic Procedures

Preservation of the Nerves of the Lumbosacral Plexus

Although not as important as during parametrectomy, nerve-sparing concepts must also be applied to pelvic lymphadenectomy. However, due to the easier visualization of nerve bundles during pelvic lymphadenectomy, nerve-sparing knowledge is not discussed in most of articles and shall, therefore, be reviewed here.

The first step of pelvic lymphadenectomy is the identification of the pelvic lymphadenectomy landmarks over peritoneal surfaces, starting by the external iliac artery and psoas muscle and, when visible, the genitofemoral nerve. After that, a wide peritoneal incision is created, starting at the umbilical artery, through the round ligament, and up to the parieto-colic gutter. The genitofemoral nerve must be identified superficially and laterally to external iliac vessels and dissected (Fig. 6.9).

Following those first steps, a blunt dissection of avascular plane lateral to the external iliac vessels and lymph nodes is performed, allowing the surgeon to develop the obturator fossa distally and the iliolumbar fossa cranially. Commonly

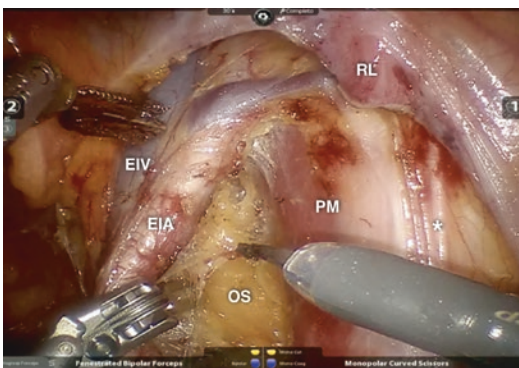


Fig. 6.9 Dissection of the right obturator fossa (OF) starts by a peritoneal incision at the level of the obliterated umbilical artery (not shown) and transection of the round ligament (RL) up to the parieto-colic gutter, followed by the development of avascular space between psoas muscle (PM) and external iliac vessels (EIV). The genitofemoral nerve (*) marks the lateral limit of this space

described as the deep limit of level I pelvic lymphadenectomy, the obturator nerve can be easily noted and dissected at the distal part of the obturator fossa. After carefully ligating small vessels from the pelvic wall, the obturator nerve can be gently mobilized from the lymphatic tissue up to its proximal part at iliolumbar fossa (Fig. 6.10).

In the less frequent situation of obturator metastasis resection, it is safer to start the procedure by identifying the lumbosacral trunk and sciatic nerve before the resection to avoid inadvertent injuries (Fig. 6.11).

Medial dissection starts after the obturator nerve has been mobilized laterally from the fat lymphatic tissue. The gas infiltration of connective tissue helps in visualizing the space dissection. The lateral paravesical space is opened by gentle blunt dissection under the medial peritoneal leaf until the umbilical artery can be identified and medialized.

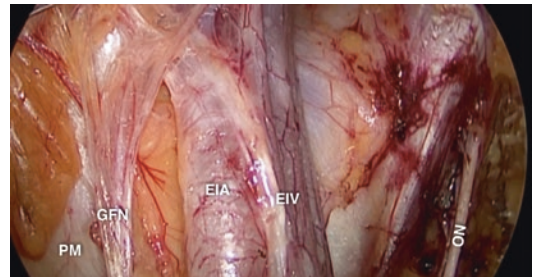


Fig. 6.10 The final aspect of left pelvic lymphadenectomy: Psoas muscle (PM), genitofemoral nerve (GFN), external iliac artery (EIA) and vein (EIV), and the obturator nerve (ON)

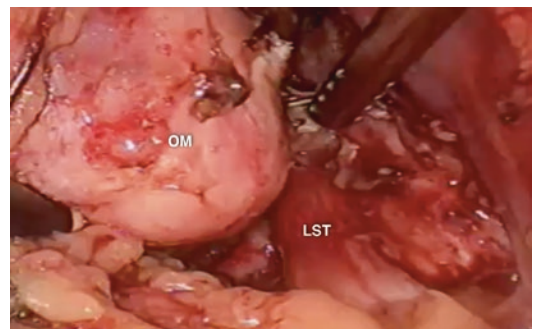


Fig. 6.11 Lumbosacral trunk (LST) dissection during obturator metastasis (OM) resection

Going deeper in this space, the obturator nerve and external iliac vessels can be observed on the lateral aspect of the dissection. By continuing the dissection another 1 or 2 cm, the levator ani muscle is reached, completing the lateral paravesical space dissection (Fig. 6.12).

Excessive traction to the obturator nerve should be avoided, in order to prevent nerve distention and/or tearing (Fig. 6.13).

Preservation of the Sympathetic Fibers of the Para-Aortic Trunk and the Superior Hypogastric Plexus

The common iliac area dissection, known as level II pelvic lymphadenectomy [39], is advocated in

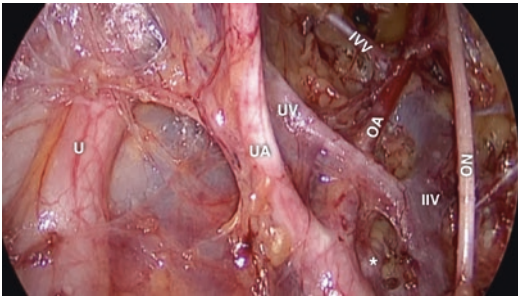
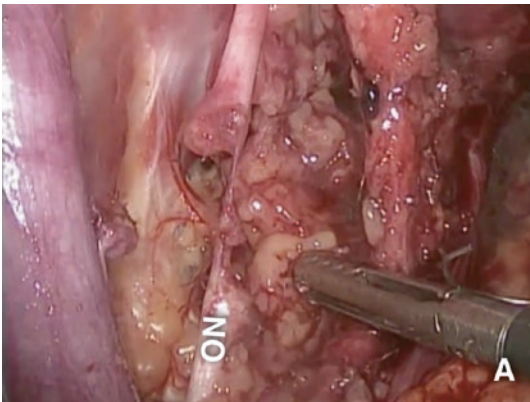


Fig. 6.12 Complete dissection of right paravesical space showing the right ureter (U), umbilical artery (UA), umbilical vein (UV), obturator artery (OA), inferior vesical vein (IVV), internal iliac vein (IIV), inferior gluteal artery (*), and the obturator nerve (ON)



endometrial, ovarian, and high-risk cervical carcinomas. The risk to nerve damage in this step would be to the superior hypogastric plexus (SHP) and hypogastric nerves (HN), which are commonly mistaken for lymphatic tissue. To avoid inadvertent transection of SHP, the surgeon must pull up the sigmoid colon and begin the craniocaudal dissection, following the preaortic nerve fibers to the SHP and HN bilaterally pulling them laterally (Figs. 6.14, 6.15, and 6.16).

Preservation of the Hypogastric Nerve Branches, Pelvic Splanchnic Nerves, and the Inferior Hypogastric Plexus

The local control in oncologic procedures is granted by the removal of the soft tissue surrounding the tumor. Mostly seen in radical trachelectomy and hysterectomy, this radicality could promote serious damage to bladder and anorectal function, with extremely negative impact to quality of life [1].

As in endometriosis, dissection and exposure of the nerve bundles are important before resection of the paracervix. Differently from endometriosis, in oncologic procedures, healthy tissue allows for a much easier dissection of the spaces and visualization of the nerves, as well as a more effective and less challenging use of non-touch techniques. On the other hand, extensive nerve

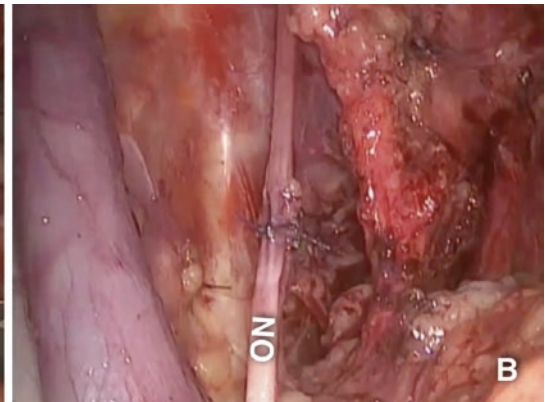


Fig. 6.13 Mechanical damage (a) and repair (b) of left obturator nerve (ON) during laparoscopic pelvic lymphadenectomy

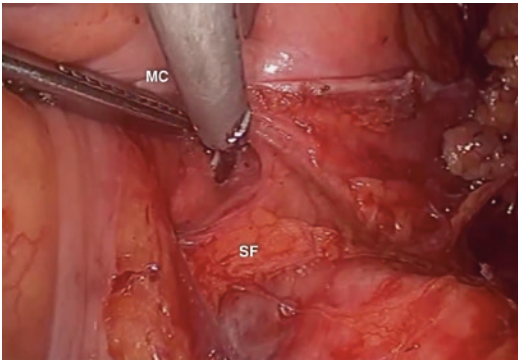


Fig. 6.14 Craniocaudal dissection of the sympathetic fibers is performed under anterior traction of the mesocolon (MC) and development of the avascular space underneath the peritoneum, revealing the sympathetic bundles (SB)

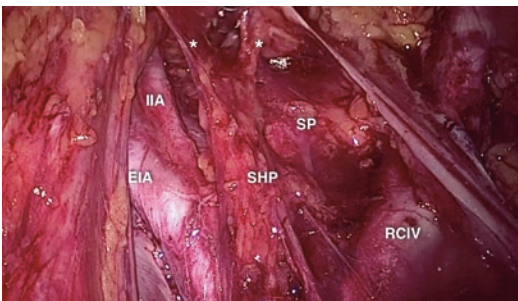


Fig. 6.15 Final aspect of nerve-sparing level II laparoscopic pelvic lymphadenectomy showing the superior hypogastric plexus (SHP), the hypogastric nerves (*), the sacral promontory (SP), the left external (EIA) and internal (IIA) iliac arteries, and the right common iliac vein (RCIV)

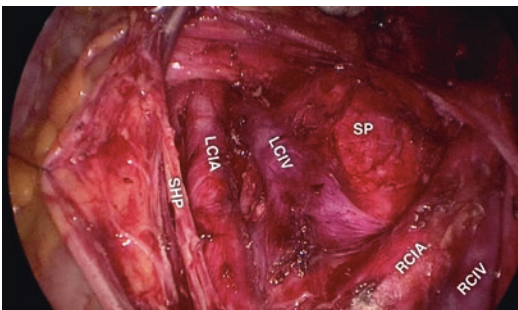


Fig. 6.16 Final dissection of sacral promontory (SP) area with the superior hypogastric plexus (SHP) under lateral traction, showing the aortic bifurcation into the left common iliac artery (LCIA) and right common iliac artery (RCIA) and the confluence of the left common iliac vein (LCIV) and right common iliac vein (RCIV)

resections may be necessary to control the tumor, and leaving disease behind is not an option.

As previously mentioned, both the hypogastric and the pelvic splanchnic nerves are thin bundles that can be easily mistaken for paracervical connective tissue. For this reason, nerve-sparing techniques in oncologic pelvic procedures are based on anatomical landmarks. Knowledge of four key spaces—medial paravesical, lateral pararectal (Latzko), medial pararectal (Okabayashi), and Yabuki's fourth space—is critical, as well as two structures: the ureters and the deep uterine veins (Figs. 6.3, 6.4, and 6.5).

After pelvic lymphadenectomy and with the lateral spaces opened, the medial paravesical space is developed by partially mobilizing the bladder up to 2 or 3 cm caudally to the cervix. The medial paravesical space is dissected then also using divergent forces, pushing the umbilical artery laterally and the vesical vessels medially while the medial space is dissected. In this fashion the surgeon could note the anterior parametria dissected (Fig. 6.17).

The pararectal space is dissected using medial traction of the IP ligament at the level of its crossing over the iliac artery. One or two centimeters posteriorly to this plane, the ureter is identified. Careful dissection of the pararectal space is performed by pushing the ureter medially, while divergent movements of the forceps dissect the avascular plane between it and the internal iliac artery. Dissection is carried down distally to the emergence of the uterine artery and 1–2 cm posteriorly to the ureter—hypogastric nerve branches

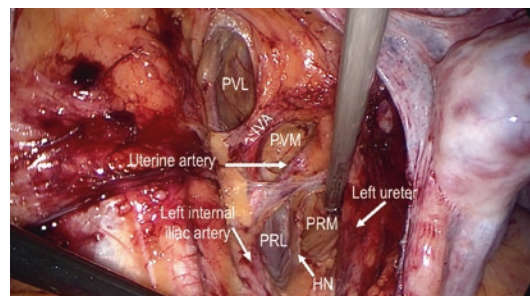


Fig. 6.17 The paravesical space is divided in medial (PVM) and lateral (PVL) by the inferior vesical artery (IVA). HN hypogastric nerve

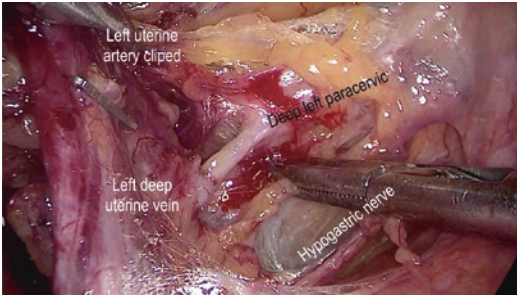


Fig. 6.18 Distal aspect of the lateral paravesical (Latzko's) space

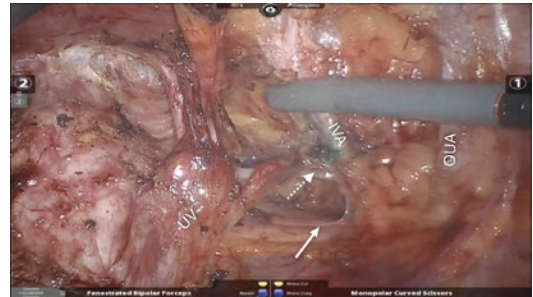


Fig. 6.19 Uterine vessels (UV) on the right side were coagulated, cut, and pulled medially, revealing the anterior (dashed arrow) and posterior (solid arrow) paracervix

can be observed on the medial aspect of the dissection and the deep uterine vein crossing the field anteriorly (Fig. 6.18). The hypogastric nerve can be dissected at this point, helping to prevent inadvertent injury later during the procedure. The hypogastric nerve divides the pararectal space laterally (Latzko's space) and medially (Okabayashi's space) (Fig. 6.17). Identification of the hypogastric nerve branches is mandatory, and dissection of the medial and lateral pararectal spaces cannot be neglected.

After vesicouterine and pararectal space dissection, the uterine vessels control must be performed priorly to the paracervical resection. During type B radical hysterectomy, the uterine artery can be coagulated and cut at the level of its crossing over the ureter. It can also be cut at its origin and then rolled over the ureter. The second option is preferred because it also removes possible lymph nodes in this area. The ureter can be used as reference for the paracervical part of the inferior hypogastric plexus [1]. Resection of the paracervix medially to the ureter and its branches to the uterus, cervix, and upper vagina will preserve the innervation to the bladder.

In type C radical hysterectomy, transection of the paracervix occurs at this junction with the internal iliac vascular system, so the uterine artery is coagulated and cut at its origin on the internal iliac artery. In the posterior aspect of the resection, the hypogastric nerve, previously dissected, is identified in the pararectal space and systematically preserved. The deep uterine vein is transected, but the neural component of the paracervix caudal to the vein is preserved. Dissection of the

neural component posterior to the vein should be avoided (non-touch technique).

The uterine artery is brought over the ureter, along the paracervical tissue surrounding it, and the deep uterine vein is brought under the ureter. The posterior part of the paracervix is also resected, and the ureter is mobilized completely. The deep uterine vein is the caudal limit of the lateral paracervical resection, located approximately 1–2 cm below the uterine artery and vein. Deeper to this vein, the branches of the deep hypogastric nerve plexus run to the bladder, and their section will result in urinary retention (Fig. 6.19).

The caudal-lateral part of paracervix (parametrium) includes the main part of the inferior hypogastric plexus. Because of this, the cranio-medial part of paracervix can be dissected although some of the fibers will be scarified. The distal part of the inferior hypogastric plexus lies deeper in the lateral wall of the vagina and in the caudal-dorsal part of the vesicouterine ligament. The medial paravaginal space (Yabuki's 4th space) is dissected on the lateral aspect of the vesicouterine space, revealing the ureter insertion into bladder, which is used as a reference to the nerves and contributes to preserving as much as possible from the plexus [54] (Fig. 6.20). By Restricting the colpectomy in the upper part of the vagina (no more than 2 cm), the surgeon can ensure that the majority of the fibers from the inferior hypogastric plexus, which run along the lateral wall of the vagina and of the bladder, will remain uncut, preserving the innervation of the urinary bladder (Fig. 6.21) [14, 53].

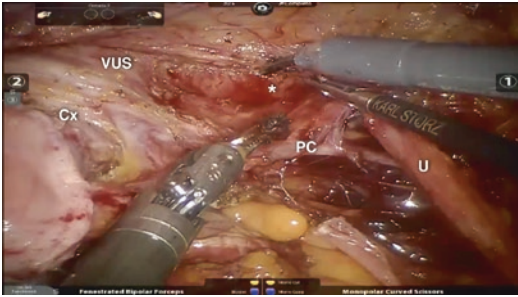


Fig. 6.20 Yabuki's space (*) is dissected on the lateral aspect of the vesicouterine space (VUS) to provide a clear notion of the ureteral (U) crossing through the paracervix (PC), which marks its medial (vascular) and its lateral (neural) portions

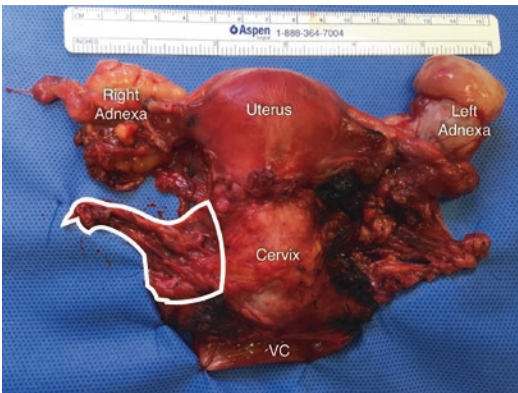


Fig. 6.21 Surgical piece of a nerve-sparing radical hysterectomy. Observe the triangular shape of the parametria (highlighted on the right side) and the length of the vaginal cuff (VC) of approximately 2 cm. This resection ensures radicality and preserves most of the bladder innervation

Conclusion

The preservation of autonomic nerves is essential to a successful approach of DIE and gynecologic cancers. For this reason, nerve-sparing techniques have been developed in different specialty areas and consist mainly of identifying and respecting, as far as possible, the nerves and neural plexuses. As described by Possover et al. [40], the main principle of this technique consists of identification of the pelvic splanchnic and hypogastric nerves and the inferior hypogastric plexuses before approaching any lesion of the rectovaginal space and parametria. If nerve exposition is

not feasible, landmarks should be used to guide the surgeon into avoiding high nerve density areas. In cases of rectal endometriosis, anterior wall nodulectomy is preferable over segmental resection.

References

1. Kraima AC, Derks M, Smit NN, van de Velde CJ, Kenter GG, DeRuiter MC. Careful dissection of the distal ureter is highly important in nerve-sparing radical pelvic surgery: a 3D reconstruction and immunohistochemical characterization of the vesical plexus. *Int J Gynecol Cancer*. 2016;26(5):959–66. <https://doi.org/10.1097/IGC.0000000000000709>.
2. Seski JC, Diokno AC. Bladder dysfunction after radical abdominal hysterectomy. *Am J Obstet Gynecol*. 1977;128(6):643–51.
3. Fishman IJ, Shabsigh R, Kaplan AL. Lower urinary tract dysfunction after radical hysterectomy for carcinoma of cervix. *Urology*. 1986;28(6):462–8.
4. Nezhat C, Nezhat F, Pennington E, Nezhat CH, Ambroze W. Laparoscopic disk excision and primary repair of the anterior rectal wall for the treatment of full-thickness bowel endometriosis. *Surg Endosc*. 1994;8:682–5.
5. Redwine DB, Wright JT. Laparoscopic treatment of complete obliteration of the cul-de-sac associated with endometriosis: long-term follow-up of en bloc resection. *Fertil Steril*. 2001;76(2):358–65.
6. Gabriel B, Nassif J, Trompoukis P, Lima AM, Barata S, Lang-Avérous G, Wattiez A. Prevalence and outcome of urinary retention after laparoscopic surgery for severe endometriosis—does histology provide answers? *Int Urogynecol J*. 2012;23(1):111–6. <https://doi.org/10.1007/s00192-011-1492-2>.
7. Fanfani F, Fagotti A, Gagliardi ML, Ruffo G, Ceccaroni M, Scambia G, et al. Discoid or segmental rectosigmoid resection for deep infiltrating endometriosis: a case-control study. *Fertil Steril*. 2010;94:444–9.
8. Ballester M, Chereau E, Dubernard G, Coutant C, Bazot M, Daraï E. Urinary dysfunction after colorectal resection for endometriosis: results of a prospective randomized trial comparing laparoscopy to open surgery. *Am J Obstet Gynecol*. 2011;204(4):303.e1–6. <https://doi.org/10.1016/j.ajog.2010.11.011>.
9. Dubernard G, Piketty M, Rouzier R, Houry S, Bazot M, Daraï E. Quality of life after laparoscopic colorectal resection for endometriosis. *Hum Reprod*. 2006;21(5):1243–7.
10. Fujiwara T. *Surgery for cervical cancer (in Japanese)*. Tokyo: Igakutoshyosyuppan; 1984.
11. Possover M, Stöber S, Plaul K, Schneider A. Identification and preservation of the motoric innervation of the bladder in radical hysterectomy type III. *Gynecol Oncol*. 2000;79(2):154–7.

12. Höckel M, Konerding MA, Heussel CP. Liposuction-assisted nerve-sparing extended radical hysterectomy: oncologic rationale, surgical anatomy, and feasibility study. *Am J Obstet Gynecol*. 1998;178(5):971–6.
13. Höckel M, Horn LC, Hentschel B, Höckel S, Naumann G. Total mesometrial resection: high resolution nerve-sparing radical hysterectomy based on developmentally defined surgical anatomy. *Int J Gynecol Cancer*. 2003;13(6):791–803.
14. Trimbos JB, Maas CP, Deruiter MC, Peters AA, Kenter GG. A nerve-sparing radical hysterectomy: guidelines and feasibility in western patients. *Int J Gynecol Cancer*. 2001;11(3):180–6.
15. Possover M, Chiantera V, Baekelandt J. Anatomy of the sacral roots and the pelvic splanchnic nerves in women using the LANN technique. *Surg Laparosc Endosc Percutan Tech*. 2007;17(6):508–10.
16. Possover M, Rhiem K, Chiantera V. The “Laparoscopic Neuro- Navigation” - LANN: from a functional cartography of the pelvic autonomous neurosystem to a new field of laparoscopic surgery. *Min Invas Ther Allied Technol*. 2004;13:362–7.
17. Kavallaris A, Banz C, Chalvatzas N, Hornemann A, Luedders D, Diedrich K, Bohlmann M. Laparoscopic nerve-sparing surgery of deep infiltrating endometriosis: description of the technique and patients’ outcome. *Arch Gynecol Obstet*. 2011;284(1):131–5. <https://doi.org/10.1007/s00404-010-1624-9>.
18. Ceccaroni M, Clarizia R, Alboni C, Ruffo G, Bruni F, Roviglione G, Scioscia M, Peters I, De Placido G, Minelli L. Laparoscopic nerve-sparing transperitoneal approach for endometriosis infiltrating the pelvic wall and somatic nerves: anatomical considerations and surgical technique. *Surg Radiol Anat*. 2010;32(6):601–4. <https://doi.org/10.1007/s00276-010-0624-6>.
19. Ceccaroni M, Clarizia R, Bruni F, D’Urso E, Gagliardi ML, Roviglione G, Minelli L, Ruffo G. Nerve-sparing laparoscopic eradication of deep endometriosis with segmental rectal and parametrial resection: the Negrar method. A single-center, prospective, clinical trial. *Surg Endosc*. 2012;26(7):2029–45. <https://doi.org/10.1007/s00464-012-2153-3>.
20. Spagnolo E, Zannoni L, Raimondo D, Ferrini G, Mabrouk M, Benfenati A, Villa G, Bertoldo V, Seracchioli R. Urodynamic evaluation and ano-rectal manometry pre- and post-operative bowel shaving surgical procedure for posterior deep infiltrating endometriosis: a pilot study. *J Minim Invasive Gynecol*. 2014;21(6):1080–5. <https://doi.org/10.1016/j.jmig.2014.05.012>.
21. Mangler M, Herbstleb J, Mechsner S, Bartley J, Schneider A, Köhler C. Long-term follow-up and recurrence rate after mesorectum-sparing bowel resection among women with rectovaginal endometriosis. *Int J Gynaecol Obstet*. 2014;125(3):266–9. <https://doi.org/10.1016/j.ijgo.2013.12.010>.
22. Che X, Huang X, Zhang J, Xu H, Zhang X. Is nerve-sparing surgery suitable for deeply infiltrating endometriosis? *Eur J Obstet Gynecol Reprod Biol*. 2014;175:87–91. <https://doi.org/10.1016/j.ejogrb.2014.01.027>.
23. Volpi E, Ferrero A, Sismondi P. Laparoscopic identification of pelvic nerves in patients with deep infiltrating endometriosis. *Surg Endosc*. 2004;18(7):1109–12.
24. Lemos N, Souza C, Marques RM, Kamergorodsky G, Schor E, Girão MJ. Laparoscopic anatomy of the autonomic nerves of the pelvis and the concept of nerve-sparing surgery by direct visualization of autonomic nerve bundles. *Fertil Steril*. 2015. pii: S0015-0282(15)01649-0. <https://doi.org/10.1016/j.fertnstert.2015.07.1138>.
25. DeGroat WC, Yoshimura N. Anatomy and physiology of the lower urinary tract, Handbook of clinical neurology, 3rd series. Oxford: Elsevier; 2015.
26. Mauroy B, Demondion X, Bizet B, Claret A, Mestdagh P, Hurt C. The female inferior hypogastric (= pelvic) plexus: anatomical and radiological description of the plexus and its afferences—applications to pelvic surgery. *Surg Radiol Anat*. 2007;29(1):55–66.
27. Wallner C, Maas CP, Dabhoiwala NF, Lamers WH, DeRuiter MC. Innervation of the pelvic floor muscles: a reappraisal for the levator ani nerve. *Obstet Gynecol*. 2006;108(3 Pt 1):529–34.
28. Grigorescu BA, Lazarou G, Olson TR, Downie SA, Powers K, Greston WM, Mikhail MS. Innervation of the levator ani muscles: description of the nerve branches to the pubococcygeus, iliococcygeus, and puborectalis muscles. *Int Urogynecol J Pelvic Floor Dysfunct*. 2008;19(1):107–16.
29. Petros PE, Ulmsten U. An integral theory of female urinary incontinence. *Acta Obstet Gynecol Scand*. 1990;69(Suppl 153):1–79.
30. Petros PE, Ulmsten UI. An integral theory and its method for the diagnosis and management of female urinary incontinence. *Scand J Urol Nephrol Suppl*. 1993;153:1–93.
31. Chung EA, Emmanuel AV. Gastrointestinal symptoms related to autonomic dysfunction following spinal cord injury. *Prog Brain Res*. 2006;152:317–33.
32. Kinugasa Y, Arakawa T, Murakami G, Fujimiya M, Sugihara K. Nerve supply to the internal anal sphincter differs from that to the distal rectum: an immunohistochemical study of cadavers. *Int J Color Dis*. 2014;29(4):429–36. <https://doi.org/10.1007/s00384-013-1811-9>.
33. Moszkowicz D, Peschard F, Bessede T, Benoit G, Alsaid B. Internal anal sphincter parasympathetic-nitric and sympathetic-adrenergic innervation: a 3-dimensional morphological and functional analysis. *Dis Colon Rectum*. 2012;55(4):473–81. <https://doi.org/10.1097/DCR.0b013e318245190e>.
34. Cook TA, Brading AF, Mortensen NJ. The pharmacology of the internal anal sphincter and new treatments of ano-rectal disorders. *Aliment Pharmacol Ther*. 2001;15(7):887–98.
35. Feng B, Brumovsky PR, Gebhart GF. Differential roles of stretch-sensitive pelvic nerve afferents inner-

- vating mouse distal colon and rectum. *Am J Physiol Gastrointest Liver Physiol.* 2010;298(3):G402–9. <https://doi.org/10.1152/ajpgi.00487.2009>.
36. Petros PE, Swash M. The musculo-elastic theory of anorectal function and dysfunction. *Pelvipерineology.* 2008;27:89–93. <http://www.pelvipерineology.org>
 37. Ercoli A, Delmas V, Fanfani F, Gadonneix P, Ceccaroni M, Fagotti A, Mancuso S, Scambia G. Terminologia Anatomica versus unofficial descriptions and nomenclature of the fasciae and ligaments of the female pelvis: a dissection-based comparative study. *Am J Obstet Gynecol.* 2005;193(4):1565–73.
 38. Bonneau C, Cortez A, Lis R, Mirshahi M, Fauconnier A, Ballester M, Daraï E, Touboul C. Lymphatic and nerve distribution throughout the parametrium. *Gynecol Oncol.* 2013;131(3):708–13.
 39. Querleu D, Morrow CP. Classification of radical hysterectomy. *Lancet Oncol.* 2008;9(3):297–303.
 40. Possover M, Quakernack J, Chiantera V. The LANN technique to reduce postoperative functional morbidity in laparoscopic radical pelvic surgery. *J Am Coll Surg.* 2005;201(6):913–7.
 41. Lemos N, Souza C, Marques RM, Kamergorodsky G, Schor E, Girão MJ. Laparoscopic anatomy of the autonomic nerves of the pelvis and the concept of nerve-sparing surgery by direct visualization of autonomic nerve bundles. *Fertil Steril.* 2015;104(5):e11–2. <https://doi.org/10.1016/j.fertnstert.2015.07.1138>.
 42. Possover M, Schneider T, Henle KP. Laparoscopic therapy for endometriosis and vascular entrapment of sacral plexus. *Fertil Steril.* 2011;95(2):756–8. <https://doi.org/10.1016/j.fertnstert.2010.08.048>. PubMed PMID: 20869701
 43. Possover M, Baekelandt J, Flaskamp C, Li D, Chiantera V. Laparoscopic neurolysis of the sacral plexus and the sciatic nerve for extensive endometriosis of the pelvic wall. *Minim Invasive Neurosurg.* 2007;50(1):33–6. PubMed PMID: 17546541
 44. Lemos N, D'Amico N, Marques R, Kamergorodsky G, Schor E, Girão MJ. Recognition and treatment of endometriosis involving the sacral nerve roots. *Int Urogynecol J.* 2015. <https://doi.org/10.1007/s00192-015-2703-z>.
 45. Abrão MS, Petraglia F, Falcone T, Keckstein J, Osuga Y, Chapron C. Deep endometriosis infiltrating the recto-sigmoid: critical factors to consider before management. *Hum Reprod Update.* 2015;21(3):329–39. <https://doi.org/10.1093/humupd/dmv003>.
 46. Remorgida V, Ragni N, Ferrero S, Anserini P, Torelli P, Fulcheri E. How complete is full thickness disc resection of bowel endometriotic lesions? A prospective surgical and histological study. *Hum Reprod.* 2005;20:2317–20.
 47. Abrao MS, Podgaec S, Dias JA Jr, Averbach M, Silva LF, Marino de Carvalho F. Endometriosis lesions that compromise the rectum deeper than the inner muscularis layer have more than 40% of the circumference of the rectum affected by the disease. *J Minim Invasive Gynecol.* 2008;15:280–5.
 48. De Cicco C, Schonman R, Craessaerts M, Cl V, Ussia A, Koninckx PR. Laparoscopic management of ureteral lesions in gynecology. *Fertil Steril.* 2009;92:1424–7.
 49. Dubernard G, Rouzier R, David-Montefiore E, Bazot M, Daraï E. Urinary complications after surgery for posterior deep infiltrating endometriosis are related to the extent of dissection and to uterosacral ligaments resection. *J Minim Invasive Gynecol.* 2008;15(2):235–40. <https://doi.org/10.1016/j.jmig.2007.10.009>. PubMed PMID: 18313000
 50. Armengol-Debeir L, Savoye G, Leroi AM, Gourcerol G, Savoye-Collet C, Tuech JJ, Vassilief M, Roman H. Pathophysiological approach to bowel dysfunction after segmental colorectal resection for deep endometriosis infiltrating the rectum: a preliminary study. *Hum Reprod.* 2011;26(9):2330–5.
 51. Koninckx PR, Ussia A, Adamyan L, Wattiez A, Donnez J. Deep endometriosis: definition, diagnosis, and treatment. *Fertil Steril.* 2012;98(3):564–71.
 52. Kamergorodsky G, Lemos N, Rodrigues FC, Asanuma FY, D'Amora P, Schor E, Girão MJ. Evaluation of pre- and post-operative symptoms in patients submitted to linear stapler nodulectomy due to anterior rectal wall endometriosis. *Surg Endosc.* 2015;29(8):2389–93. <https://doi.org/10.1007/s00464-014-3945-4>.
 53. Kavallaris A, Zygouris D, Dafopoulos A, Kalogiannidis I, Terzakis E. Nerve-sparing radical hysterectomy in early stage cervical cancer. Latest developments and review of the literature. *Eur J Gynaecol Oncol.* 2015;36(1):5–9.
 54. Yabuki Y, Asamoto A, Hoshiba T, Nishimoto H, Nishikawa Y, Nakajima T. Radical hysterectomy: an anatomic evaluation of parametrial dissection. *Gynecol Oncol.* 2000;77:155–63.

Part II

Endometriosis



Patient Language in Endometriosis Surgery

7

William Kondo, Nicolas Bourdel,
Monica Tessmann Zomer, and Michel Canis

Introduction

Endometriosis surgery is much more than simple surgical technique. The best outcomes for patients depend on a combination of multiple factors, not only in the preoperative evaluation but also in the intraoperative and postoperative management. In all these three phases of the patient's management, a multidisciplinary approach is important in order to obtain the best results in patient care.

Preoperatively, adequate work-up is very important [1–3]. The surgeon must have extreme knowledge of the disease [4] and treatment's options. Patient's symptoms and wishes are the key point during the preoperative evaluation of such women because endometriosis must be asymptomatic in some cases and highly symptomatic in others. Infertility and pain are not always managed in the same manner. Some patients will need surgery and medication for the management of endometriosis-related pain symptoms but will need assisted reproduction

techniques for the treatment of infertility. The surgeon must be able to individualize each patient in order to define who is the patient that deserves surgery and who is the one that needs a different treatment [5]. Whenever surgery is indicated, the best approach is by laparoscopy, and the concept of multidisciplinary team must be applied in order to have the best surgical results depending on the specific organs affected by the disease. Surgical strategy must be planned in the preoperative setting based on the patients' symptoms and imaging exams [3, 6, 7] and broadly discussed with the patient [8].

Intraoperatively, experience and expertise of the surgeon are very important to adequately identify the endometriosis lesions and to decide about the best surgical technique to be applied in each specific case. One of the major challenges of such procedures may lie in the visual diagnosis of endometriosis [9]. It has already been demonstrated that up to two thirds of women have some visual disease that many gynecologists have not been trained to recognize during surgery, and this may be the only manifestation of the disease [10]. Some endometriosis implants may appear atypically or nonpigmented [11, 12]. Deep infiltrating endometriosis implants located in the sub-peritoneal space may be non-visible in the surface of the peritoneum during laparoscopy [13] and may go completely unrecognized or be particularly difficult to visualize or to access during surgery. Although an experienced surgeon can detect

W. Kondo (✉) · M. T. Zomer
Department of Gynecology, Sugisawa Medical
Center, Curitiba, PR, Brazil

Department of Gynecology, Vita Batel Hospital,
Curitiba, PR, Brazil

N. Bourdel · M. Canis
Department of Gynecologic Surgery, CHU Estaing,
Clermont-Ferrand, France
e-mail: nbourdel@chu-clermontferrand.fr;
mcanis@chu-clermontferrand.fr

nodules during laparoscopic palpation of the posterior compartment of the pelvis [14], the implant can be hidden by peritoneal adhesions of the pouch of Douglas [15].

In addition, during this phase of the patient's management, surgical philosophy of each surgeon will probably be one of the most significant factors that will interfere on which surgical technique will be applied. Especially for the management of deep infiltrating endometriosis affecting the bowel, conservative and radical approaches may be applied, and some groups tend to be more conservative, and others tend to be more radical [16–19]. Bulky endometriosis lesions may be technically difficult and demanding. Therefore, this surgery requires an experienced surgeon, a good laparoscopic equipment, and an adequate surgical team.

Probably, knowledge of anatomy and dissection techniques plays one of the most important roles in the intraoperative phase of patient's care regarding completeness of surgery and risk of intraoperative complications. The surgeon must learn how to “read” the screen (what the authors here call “patient language”) and obtain all the informations that the patient is giving him to treat correctly and completely the disease, in order to be radical toward disease and conservative toward function. This capacity of progressively identifying the disease and its limits is going to guide the dissection throughout the surgical procedure and must be learned and developed by the surgeons.

Patient's wishes concerning fertility desire will differentiate the postoperative management of each patient. Postoperative medical treatment plays an important role in the secondary prevention of the disease and the management of pain [5].

In this chapter, the authors are going to discuss some issues about the “patient language” during surgery, important information that is frequently missed by surgeons but that must be well known in order to help in the decision-making process intraoperatively.

Surgical Treatment

Surgical treatment for endometriosis should be as complete as possible. In this way, the patient will obtain the better outcomes in terms of relief of

pain symptoms as well as improvement of fertility [5].

The technical principles of surgery for endometriosis are always the same, and theoretically they seem very simple [8]:

1. Restoration of the normal anatomy.
2. Dissection should be started in healthy tissue in order to identify anatomical landmarks, avascular spaces, and important structures in the pelvic cavity (ureters, nerves, vessels, etc.) that must be preserved.
3. Complete excision of the disease.
4. Avoid unnecessary dissection—the surgeon should not displace and dissect structures far from the disease if they are not infiltrated!

Nevertheless, it is not so easy to apply these principles during surgery. Surgeon's expertise and experience are essential issues that will be directly related to the quality of the surgical procedure. The identification of the exact limits between normal tissue, fibrosis, and endometriosis tissue is not really evident during surgery. The surgeon's own feeling, intuition, and experience are important factors that will directly impact on the intraoperative decision-making, but also the knowledge of the “patient language” is helpful. It refers to the intraoperative surgical semiology, including visual aspect of the tissue during dissection and tissue modification during the surgical procedure, which guides the watchful surgeon while he is performing the surgery.

Patient Language

Follow the Bubbles

One of the basic principles of laparoscopic surgery is that the CO₂ gas, in contact with the retroperitoneal space, infiltrates the loose areolar tissue and spreads easily, leading to the formation of some “bubbles” within the retroperitoneum (so-called champagne effect by the French surgeons). This “dissecting effect” of the pneumoperitoneum within the retroperitoneum may be seen when the surgeon cut the peritoneum. The CO₂ gas infiltrates beneath the peritoneum held under traction

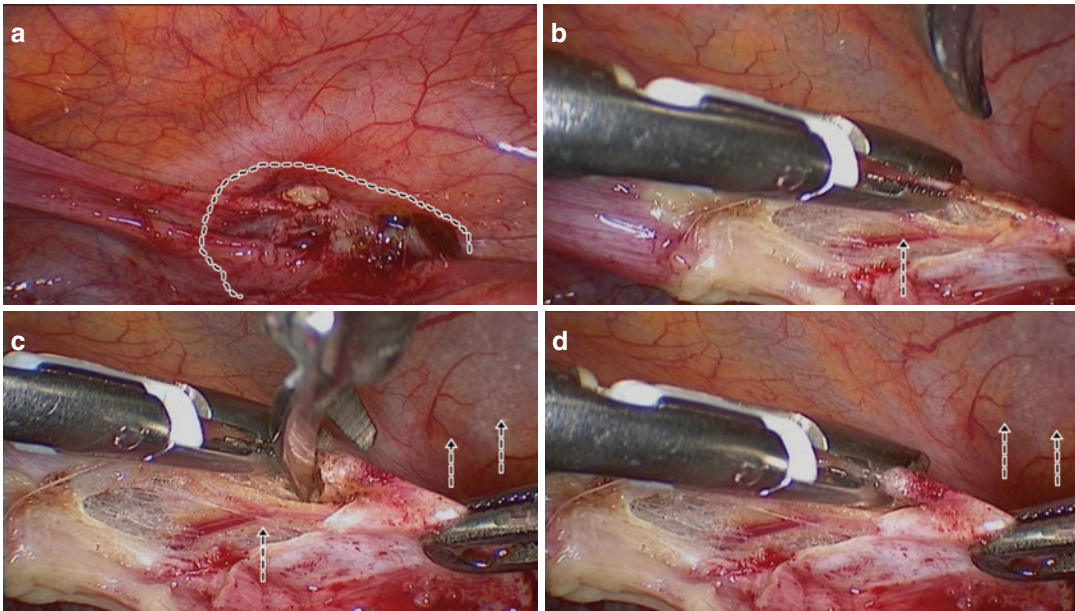


Fig. 7.1 (a) Deep infiltrating endometriosis affecting the anterior cul-de-sac. (b) The surgeon opens the peritoneum using bipolar forceps and scissors, and the CO₂ gas immediately spreads within the retroperitoneal space creating

a visual aspect of “bubbles” (arrow). (c and d) If the surgeon pays attention, he may see “bubbles” far away from the area of dissection (arrows)

by the assistant surgeon, detaching it from the loose areolar tissue. During dissection, the surgeon progressively develops the pelvic spaces, and the gas travels along the cleavage planes. This effect may be seen thanks to the creation of bubbles caused by the CO₂ gas separating the connective tissue which originally fills these virtual spaces [8]. In practice, these bubbles indicate the direction to follow in order to open these spaces. The surgeon may apply gentle divergent forces using two instruments which is going to enhance even more this “champagne effect.” Actually, these bubbles are of real help to the surgeon because they allow dissection to be more intuitive (Fig. 7.1).

Some important points in order to obtain the best “champagne effect” are:

1. The surgeon must not wash the pelvic cavity during the surgical procedure after opening the retroperitoneal space. The liquid infiltrates the loose areolar tissue and impairs the entrance of the CO₂ gas within this plane (Fig. 7.2).
2. Divergent traction using the operator’s two instruments must be used (Fig. 7.3).

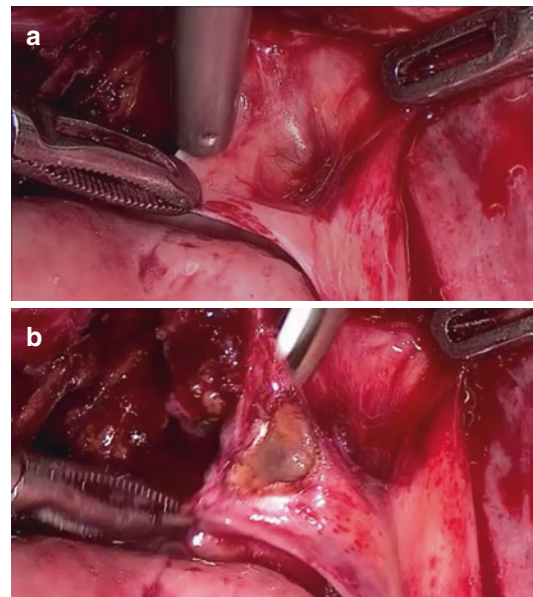


Fig. 7.2 Dissection of the right ovarian fossa a little bit medial to the ureter. If the surgeon washes the pelvic cavity, the liquid infiltrates the retroperitoneal space (a), and the “bubbles” do not travel within the loose areolar tissue (b)

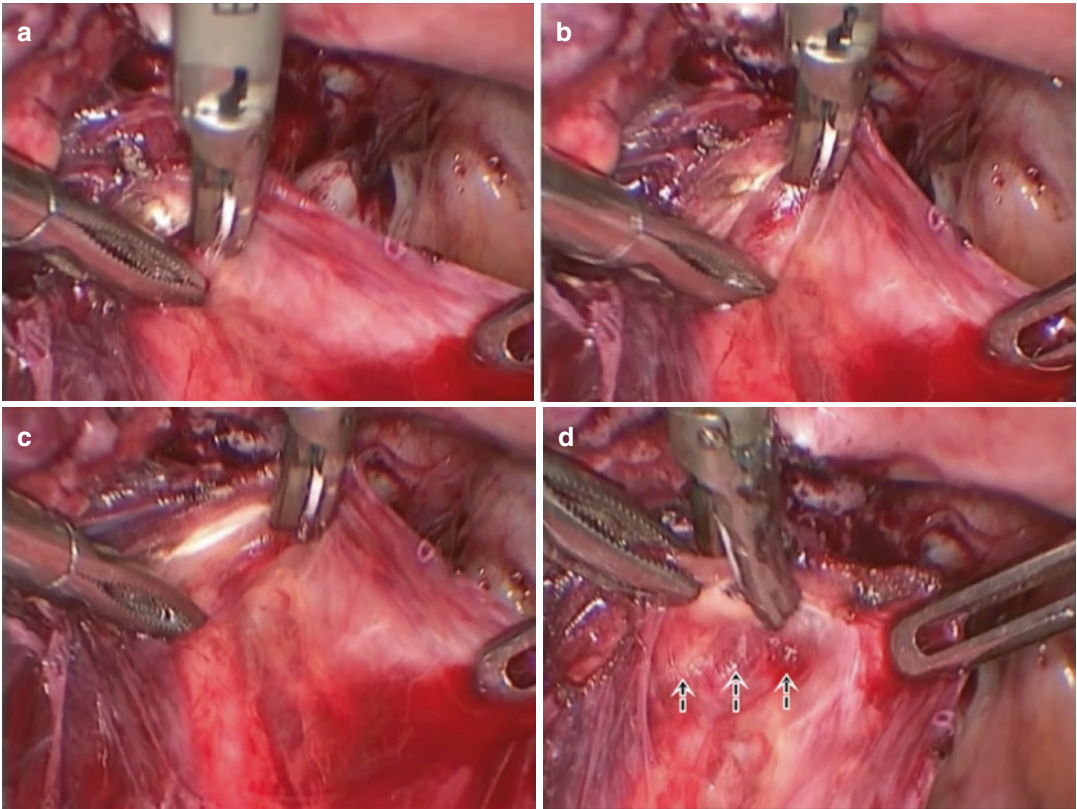


Fig. 7.3 Dissection of the left ovarian fossa at the anterior aspect of the ureter. Divergent forces are applied by the two instruments held by the surgeon (a–c). The CO₂

gas enters the retroperitoneal space (arrows), and the surgeon may continue the dissection (d)

3. Meticulous hemostasis should be performed in order to achieve a good anatomic vision during the retroperitoneal dissection. That is why the authors always operate using a bipolar forceps in the left hand (Fig. 7.1).
4. The use of harmonic scalpel may also enhance this effect and facilitate the surgical procedure. The very fast-forward and backward motion of the tip of the instrument in contact with the tissue produces changes in tissue pressures, leading to cell fragmentation and expansion of the tissue planes (cavitation effect) [20]. The cavitation effect adds to the “champagne effect” leading to the formation of even more bubbles within the retroperitoneal space (Fig. 7.4).

Arrows

The chronic inflammatory process coming from the disease leads to a fibrotic reaction within and

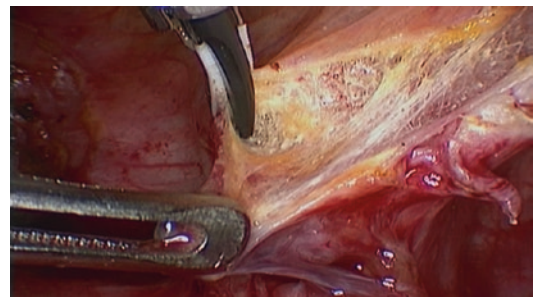


Fig. 7.4 Opening the peritoneum of the anterior cul-de-sac at the right side. The use of harmonic scalpel may add the cavitation effect to the “champagne effect” enhancing the formation of “bubbles” within the retroperitoneal space

around the endometriosis lesion, which retracts the healthy tissue (Fig. 7.5a). Whenever the surgeon starts the dissection around the disease, in a healthy area, he may look at the screen and realize that some “arrows” connecting the normal tissue and the diseased tissue appear, and these

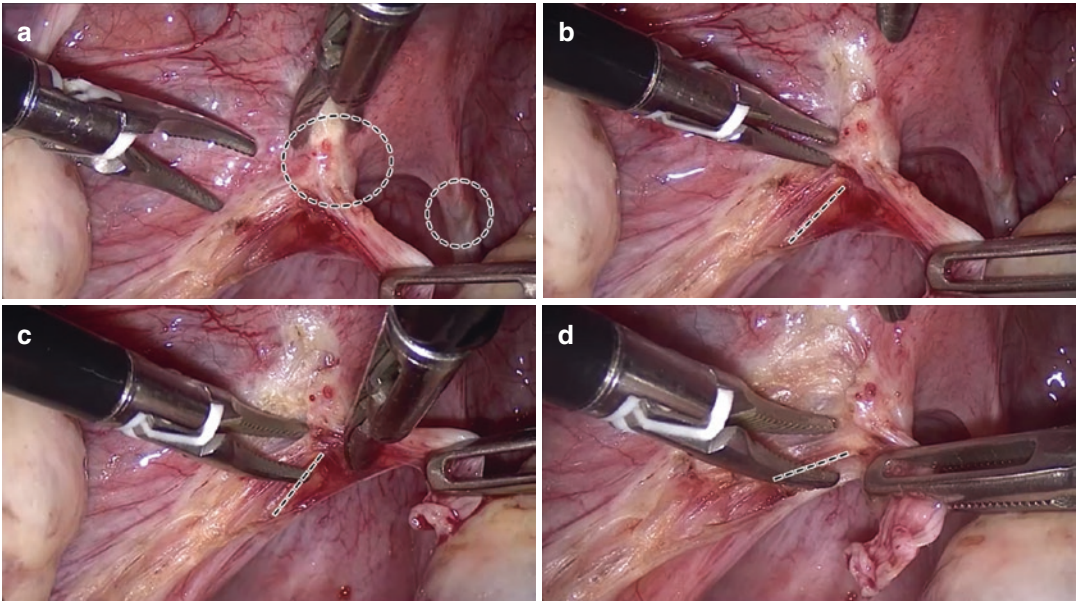


Fig. 7.5 (a) Endometriosis lesions promoting retraction of the uterosacral ligaments (circles). (b–d) During the laparoscopic excision of the endometriosis implants, the

surgeon may observe that there are some fibrous bands (what the authors call “arrows”) connecting the normal tissue to the endometriosis nodule (lines)

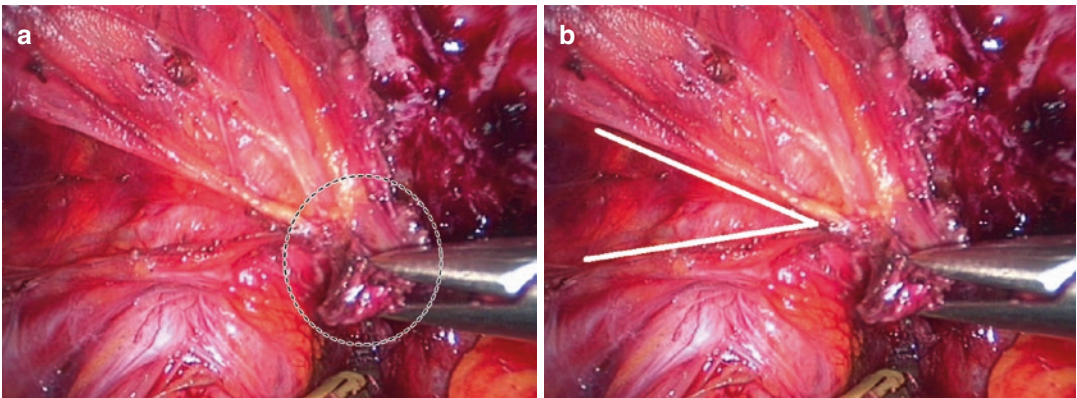


Fig. 7.6 The assistant surgeon is grabbing the endometriosis nodule (circle), and the surgeon may identify some “arrows” (lines) connecting the normal tissue with the

endometriosis lesion. The top of the “arrows” represents the exact place where the surgeon must coagulate and cut

“arrows” are exactly the place where the surgeon must coagulate and cut the tissue in order to separate the healthy tissue from the disease (Figs. 7.5 and 7.6).

These arrows may be identified not only during the ovarian cystectomy for an ovarian endometrioma [21] but also during the surgical excision of deep infiltrating nodules at the anterior and the posterior compartment of the pelvis [8].

During laparoscopic cystectomy for an ovarian endometrioma, the ovary must be mobilized

from its attachments at the uterosacral ligament or the posterior leaf of the broad ligament at the ovarian fossa. This breaks the most sensitive portion of the endometrioma, and a “chocolate fluid” is going to come out of the cyst. The opening at the ovarian endometrioma must be enlarged, and the cleavage plane between the ovarian parenchyma and the ovarian endometrioma is going to be identified. Divergent forces must be gently applied in order to separate the cyst from the ovary. The surface of the endometrioma in

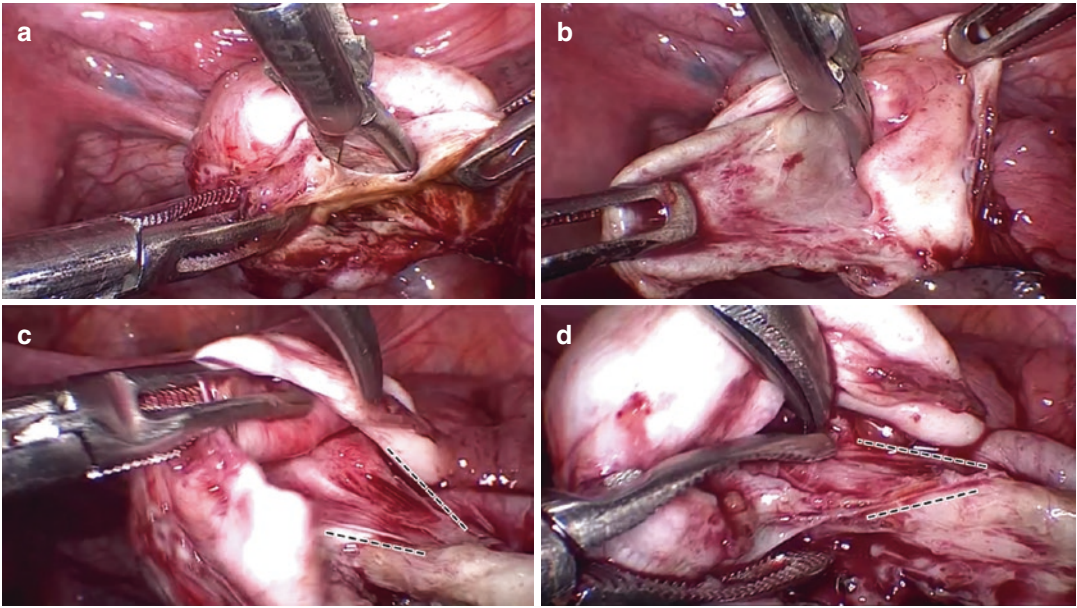


Fig. 7.7 (a) Identification of the cleavage plane between the endometrioma and the ovarian parenchyma. (b) The outer surface of the ovarian endometrioma is whitish. (c and d) The reddish bands appear as “arrows” (lines)

connecting the ovarian parenchyma to the surface of the endometrioma. The “arrow” must be coagulated and cut exactly on the surface of the ovarian endometrioma in order to avoid ovarian parenchyma loss

contact with the ovarian tissue is whitish, and the tissue connecting both endometrioma and ovary is reddish. The surgeon should realize that these reddish fibers appear as “arrows,” drawing a triangle with the apex located at the outer surface of the cyst and the base on the inner surface of the ovarian parenchyma [21]. The tip of the arrow is the exact place where surgeon should coagulate and cut, preserving the normal ovarian tissue and removing only the ovarian endometrioma (Fig. 7.7).

It has already been demonstrated in the literature that the level of expertise of the surgeon is inversely correlated with the amount of ovarian tissue inadvertently removed along with the endometrioma wall [22]. One of the reasons of such results is, probably, the lack of experience in the identification of the “patient language” during laparoscopic ovarian cystectomy. Therefore, at the end, the experience of the laparoscopist may affect the ovarian reserve after laparoscopic treatment of ovarian endometriomas.

The same principle may be used during the laparoscopic excision of deep infiltrating endo-

metriosis. The deep endometriosis nodule is formed by a hard fibrotic tissue surrounded by some degree of inflammation. The surgical approach for such lesions includes the identification of the boundaries of the endometriosis nodule in order to start the dissection in healthy tissue, around the disease. The identification of the surgical landmarks and the important structures that are close to the disease must be carried out. When dissection comes close to the nodule, the surgeon may observe that the fibrotic lesion is connected to the normal tissue by the “arrows,” which represent the exact place to be coagulated and cut. After cutting these fibrotic attachments, it is possible to realize that the nodule “moves” progressively if the assistant surgeon is able to hold the nodule under traction (Fig. 7.8). The surgeon may be smart enough to realize that sometimes the new “arrows” appear a little bit distant from the previous cut and must continue the dissection where the patient is indicating (Fig. 7.9).

At the anterior compartment of the pelvis, the endometriosis nodule may be attached to the

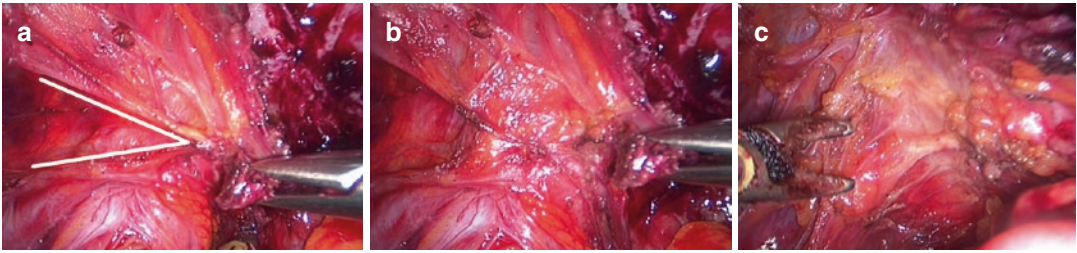


Fig. 7.8 The assistant surgeon grabs the endometriosis lesion, and the surgeon cuts the “arrows” (lines) at the top of them (a). After two or three cuts at the fibrotic attach-

ments, (b and c) the nodule is progressively displaced, and normal tissue remains in place

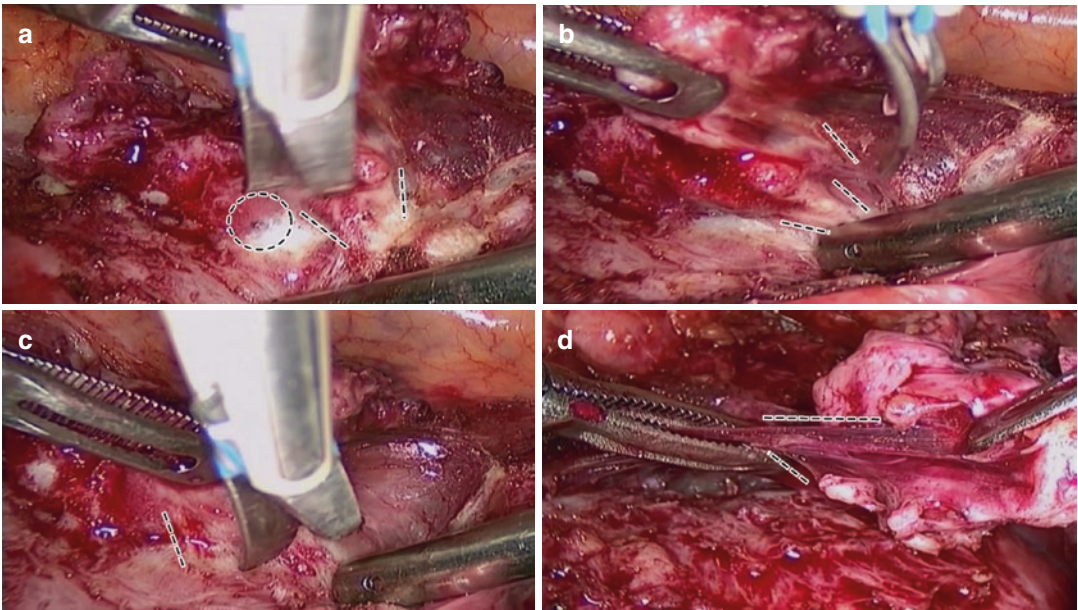


Fig. 7.9 Laparoscopic excision of a deep infiltrating nodule affecting the anterior cul-de-sac, the vesicouterine septum, and the serosa/myometrium of the anterior uterine wall using bipolar scissors. It is possible to identify

some “arrows” connecting the endometriosis nodule with the normal tissue (lines) (a–d) and a black spot (circle) within the nodule that is being excised (a)

peritoneum of the anterior cul-de-sac, the vesicouterine septum, the round ligaments, the bladder, and the serosa/myometrium of the anterior uterine wall. Whenever the detrusor muscle is infiltrated, partial bladder resection must be performed. The surgeon must pay attention to the infiltration at the serosa/myometrium, which must also be excised in order to achieve a complete resection of the disease (Fig. 7.9).

At the posterior compartment of the pelvis, the disease may affect the uterosacral ligaments, the posterior leaf of the broad ligaments, the ret-

rocervical area, the posterior vaginal fornix, the peritoneum of the posterior cul-de-sac, the rectovaginal septum, the bowel, and the ureters. During the dissection of the deep infiltrating nodule, if the surgeon does not know whether he should cut or not, the patient will show him. The assistant surgeon should grasp the nodule and retract it to expose the cleavage plane. Dissection is carried out using scissors (Fig. 7.10) as well as divergent forces (Fig. 7.3). The “arrows” connecting normal tissue with the disease mean cut here, please! Right after cutting the top of the

“arrow,” the surgeon may realize that the nodule moves away and normal tissue is found (Figs. 7.8 and 7.11).

Black Spots

The presence of black spots within the tissue at the area of resection means that the excision of

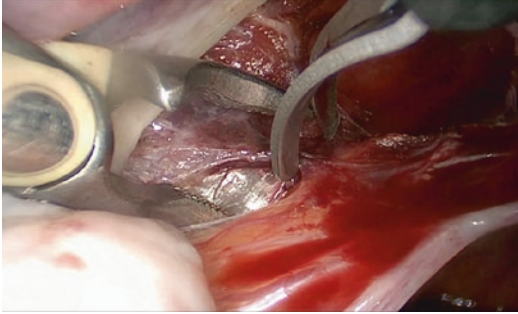


Fig. 7.10 Dissection using scissors and coagulation of the “arrow” using bipolar forceps

the disease is not complete. The identification of black spots means that there is presence of microcysts of endometriosis within the tissue, which finally indicates that the area of resection should be extended (Figs. 7.8a, and 7.12). This information given by the patient is of extreme value especially at the retrocervical area (Figs. 7.12, 7.13, and 7.14), the anterior wall of the uterus, the bladder (Fig. 7.15), the vagina, and the bowel. Whenever the surgeon leaves the black spots behind, he is also leaving disease in place. This is the only possible way the patient has to tell the surgeon that something is going wrong with the completeness of the resection; however, this “patient language” is not always understood by the surgeon.

Particularly when the deep infiltrating endometriosis lesion penetrates the posterior vaginal fornix, it is possible to identify not only black spots at the vaginal mucosa but also polyp-like lesions filled in with chocolate fluid (Figs. 7.12d and 7.13). The presence of such findings means

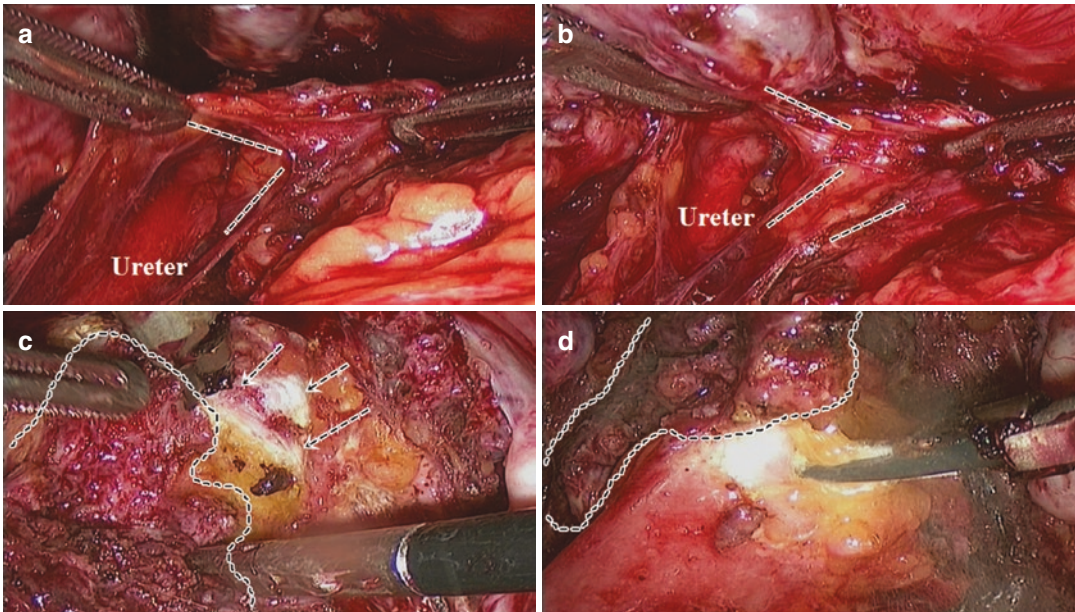


Fig. 7.11 Surgical treatment of deep infiltrating endometriosis at the posterior compartment of the pelvis affecting the uterosacral ligaments, retrocervical area, posterior cul-de-sac, and anterior rectal wall. (a and b) The surgeon may observe the “arrows” (lines) connecting the normal tissue to the endometriosis nodule over the left ureter. (c)

The nodule is separated from the posterior aspect of the cervix. It is possible to identify the normal fatty tissue at the right pararectal fossa. The white bands (arrows) represent fibrotic tissue around the disease. (d) Identification of the lateral limit of the nodule on the rectal wall. The normal fatty tissue has a yellowish appearance

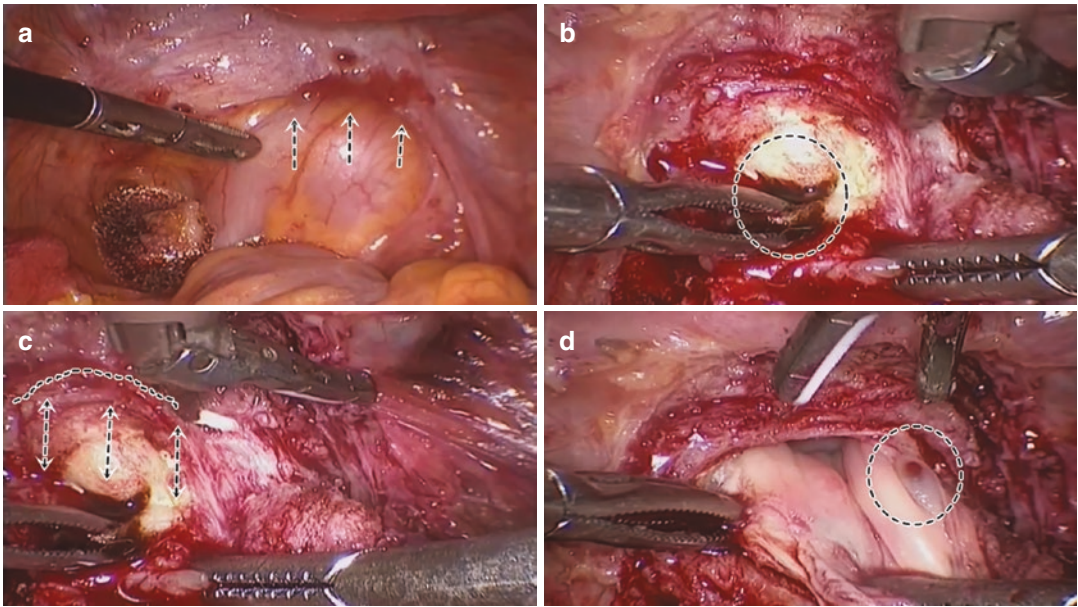


Fig. 7.12 (a) The endometriosis nodule (arrows) is obliterating the posterior cul-de-sac and infiltrating the retrocervical area, the posterior vaginal fornix, and the anterior rectal wall. (b) During the separation of the endometriosis nodule from the retrocervical area/posterior vaginal fornix, it is possible to see a black fluid coming from the resection area (circle), which means that there is still

disease in place. (c) The limits of the resection must be enlarged in order to achieve a complete resection of the disease (arrows and lines). (d) Detachment of the posterior vaginal fornix from the posterior aspect of the cervix. Endometriosis lesions infiltrating the vaginal mucosa can be seen (circle) and must be excised along with the posterior vaginal fornix

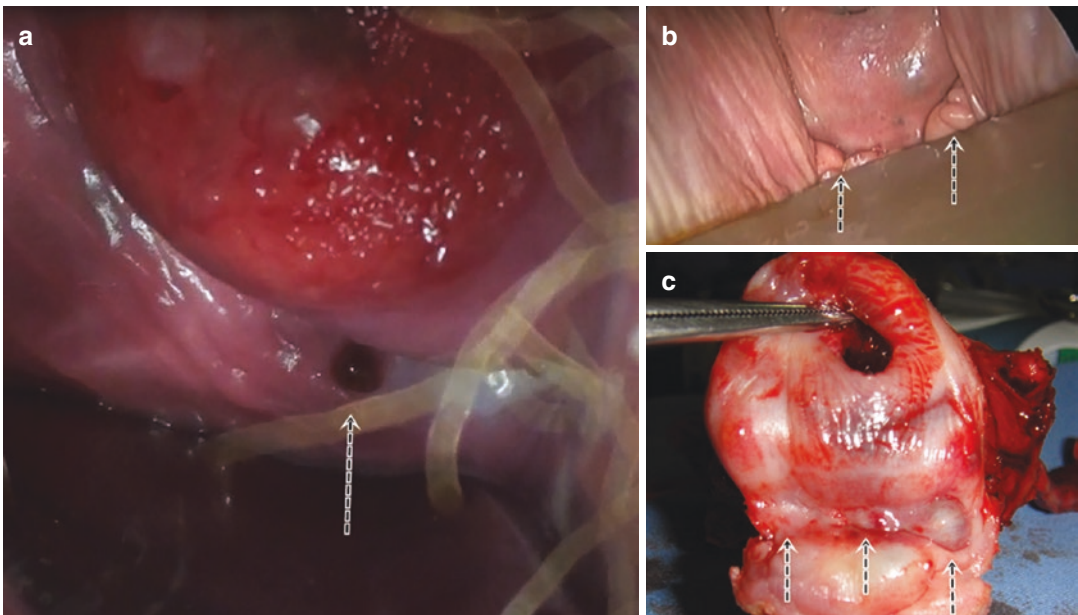


Fig. 7.13 (a) Vaginal examination demonstrating a black spot at the posterior vaginal fornix (arrow). (b) Vaginal examination showing polyp-like lesions at the posterior vaginal fornix. (c) Surgical specimen of total laparoscopic hysterectomy and complete resection of deep infiltrat-

ing endometriosis. It is possible to verify the presence of black lesions infiltrating the vaginal mucosa at the posterior vaginal fornix, which was resected en bloc with the cervix

that the posterior vaginal fornix must be resected in order to completely remove the disease (Figs. 7.12d and 7.14) [23]!

Importance of Fatty Tissue

Whenever the surgeon identifies fatty tissue (Fig. 7.11d) or normal muscle tissue, it means

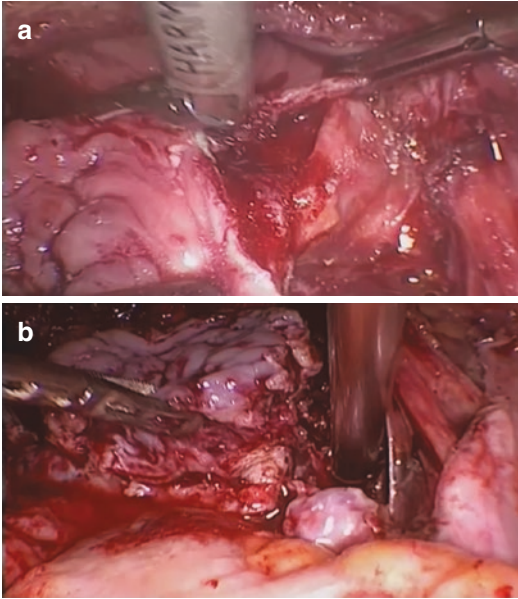


Fig. 7.14 Reverse technique for the treatment of recto-vaginal deep infiltrating endometriosis [16]. The posterior vaginal fornix is excised, and then the intestinal procedure is going to be performed

that the surgical resection is complete. Unhealthy or fibrous tissue is suspected during surgery when there are a whitish appearance (Fig. 7.11c) and a reduced tendency to bleed within the limits of the resection. This notion of interpretation is important especially close to the bowel and the bladder. Always, the fat belongs to the bowel (mesosigmoid and mesorectum) and the bladder (extraperitoneal fat at the paravesical pelvic space). Also, the identification of fatty tissue during the resection of an endometriosis nodule at the posterior cul-de-sac after opening the pararectal pelvic space means that the margins of the resection are free of disease (Fig. 7.16).

So, if the surgeon does not know if he can cut, he may ask the patient. Retraction of the nodule will expose the cleavage plane, and dissection is carried out using scissors. The visualization of fatty tissue means that the extent of the excision is enough.

Discussion

Surgical treatment is the most effective way of treating endometriosis in terms of long-term reduction in pain and improvement in fertility. However, surgical procedure can be technically demanding because of the presence of dense adhesions and distorted anatomy. Also, in a good number of patients, surgical intervention in non-gynecologic organs may be necessary, including the bowel, the ureter, and the bladder.

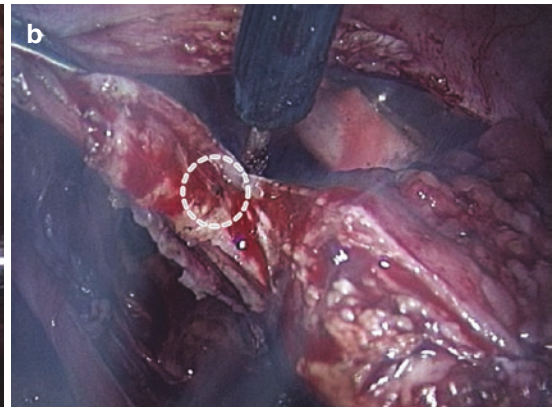
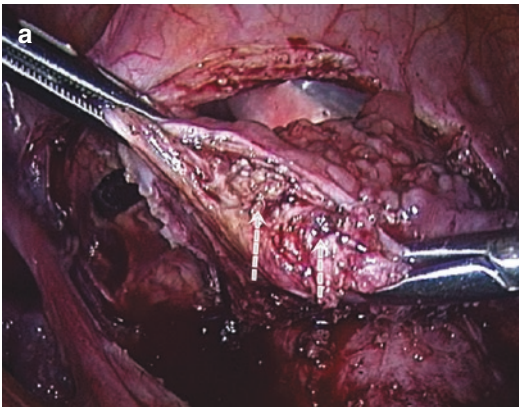


Fig. 7.15 Laparoscopic partial cystectomy for bladder endometriosis. (a) Black spots may be seen (arrows) within the endometriosis nodule. (b) The margins of the

excision should be extended in order to remove the entire endometriosis lesion (circle)

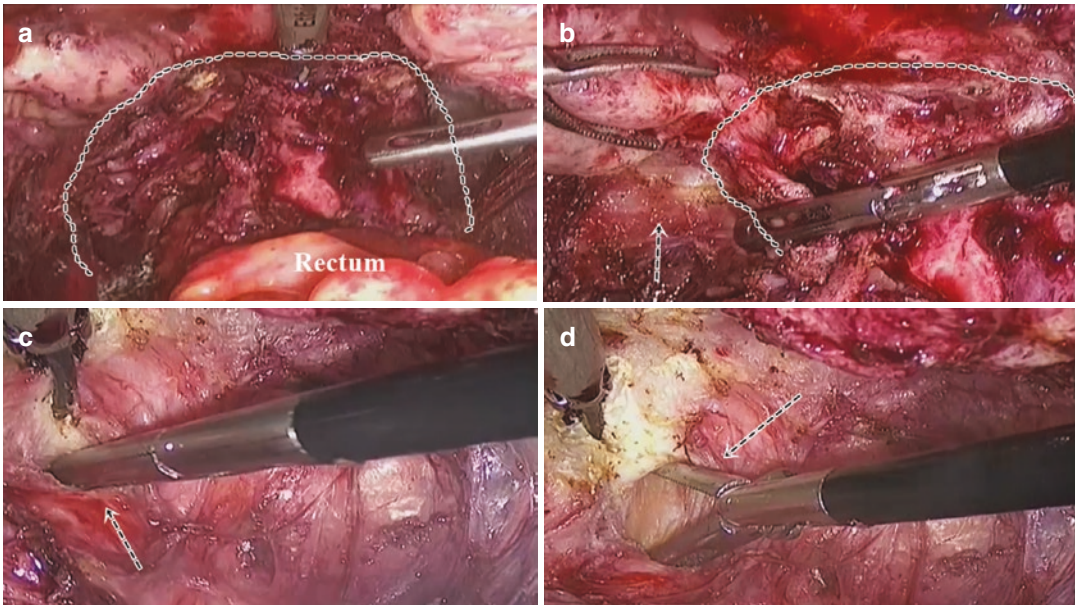


Fig. 7.16 (a) Deep infiltrating endometriosis affecting the posterior compartment of the pelvis (uterosacral ligaments, retrocervical area, posterior cul-de-sac, and anterior rectal wall). (b) Identification of the normal tissue

(arrow) at the left pararectal fossa. (c and d) Identification of the healthy rectovaginal septum (arrow) and the fatty tissue at the right pararectal fossa

The importance of the preoperative work-up in patients with deep infiltrating endometriosis has already been demonstrated in the literature [1–3, 6]. During surgery, complete excision of the disease is the goal of the intervention. Always, the surgeon must reevaluate the disease intraoperatively in order to confirm the preoperative findings on imaging exams. Dissection, identification of the healthy structures, and complete excision of the disease may be facilitated by the knowledge of the “patient language.” The most experienced the surgeon is, the best interpretation he can get during surgery. For the beginners, it is important to pay attention to all these details during surgery and to exercise them in order to become them instinctive.

Painful recurrences observed after surgical treatment of endometriosis are most often due to an incomplete treatment during the first intervention rather than a true recurrence. It has been already demonstrated in the literature that there is a learning curve for conservative laparoscopic surgery for rectovaginal endometriosis. There seems to be a reduction in the rate of laparoconversion, operating time, estimated intraoperative

blood loss, cases with incomplete surgery, and recurrence rate with increasing surgeon’s experience [24]. The notion of complete and incomplete surgery depends on the surgeon’s impression, and even in supposedly complete surgery, there might be some disease that remain behind that cannot be seen during the procedure [24]. That is why all surgeons should try to pay attention to the “patient’s language” during surgery in order to try not to leave disease behind.

Conclusion

Endometriosis is a complex disease, and the treatment of each patient must be individualized. Surgery has an important role in the management of these patients, but also expectant management, clinical treatment, and assisted reproduction technique may be used to obtain the patient’s needs.

The final decisions of whether or not to operate, when to operate, and what approach to use are still a matter of complicated interaction of experience, gut feelings, education, training, exposure, and the continuous strive to provide the best care possible for the

patient. Whenever surgery is indicated, the concept of complete removal of the disease must be kept in mind. During surgery, the surgeon may be helped by the patient if he understands the “patient language.”

References

- Chapron C, Fauconnier A, Vieira M, Barakat H, Dousset B, Pansini V, Vacher-Lavenu MC, Dubuisson JB. Anatomical distribution of deeply infiltrating endometriosis: surgical implications and proposition for a classification. *Hum Reprod.* 2003;18(1):157–61.
- Kondo W, Ribeiro R, Trippia C, Zomer MT. Deep infiltrating endometriosis: anatomical distribution and surgical treatment. *Rev Bras Ginecol Obstet.* 2012;34(6):278–84.
- Piketty M, Chopin N, Dousset B, Millischer-Bellaische AE, Roseau G, Leconte M, Borghese B, Chapron C. Preoperative work-up for patients with deeply infiltrating endometriosis: transvaginal ultrasonography must definitely be the first-line imaging examination. *Hum Reprod.* 2009;24(3):602–7.
- Fauconnier A, Chapron C. Endometriosis and pelvic pain: epidemiological evidence of the relationship and implications. *Hum Reprod Update.* 2005;11(6):595–606.
- Dunselman GA, Vermeulen N, Becker C, Calhaz-Jorge C, D’Hooghe T, De Bie B, Heikinheimo O, Horne AW, Kiesel L, Nap A, Prentice A, Saridogan E, Soriano D, Nelen W, European Society of Human Reproduction and Embryology. ESHRE guideline: management of women with endometriosis. *Hum Reprod.* 2014;29(3):400–12.
- Kondo W, Zomer MT, Pinto EP, Ribeiro R, Ribeiro MFC, Trippia CR, Trippia CH. Deep infiltrating endometriosis: imaging features and laparoscopic correlation. *J Endometriosis.* 2011;3(4):197–212.
- Trippia CH, Zomer MT, Terazaki CRT, Martin RLS, Ribeiro R, Kondo W. Relevance of imaging examinations in the surgical planning of patients with bowel endometriosis. *Clin Med Insights Reprod Health.* 2016;10:1–8. <https://doi.org/10.4137/CMRH.S29472>. eCollection 2016. Review.
- Kondo W, Bourdel N, Zomer MT, Slim K, Botchorishvili R, Rabischong B, Mage G, Canis M. Surgery for deep infiltrating endometriosis. Technique and rationale. *Front Biosci (Elite Ed).* 2013;1(5):316–32.
- Rizk B, Fischer AS, Lotfy HA, Turki R, Zahed HA, Malik R, Holliday CP, Glass A, Fishel H, Soliman MY, Herrera D. Recurrence of endometriosis after hysterectomy. *Facts Views Vis Obgyn.* 2014;6(4):219–27.
- Redwine DB. The visual appearance of endometriosis and its impact on our concepts of disease. *Prog Clin Biol Res.* 1990;323:393–412.
- Jansen RP, Russell P. Nonpigmented endometriosis: clinical, laparoscopic, and pathologic definition. *Am J Obstet Gynecol.* 1986;155(6):1154–9.
- Martin DC, Hubert GD, Levy BS. Depth of infiltration of endometriosis. *J Gynecol Surg.* 1989;5:55–60.
- Wright JT. The diagnosis and management of infiltrating nodular recto-vaginal endometriosis. *Curr Opin Obstet Gynecol.* 2000;12(4):283–7.
- Chapron C, Dubuisson JB. Laparoscopic treatment of deep endometriosis located on the uterosacral ligaments. *Hum Reprod.* 1996;11(4):868–73.
- Kinkel K, Chapron C, Balleyguier C, Fritel X, Dubuisson JB, Moreau JF. Magnetic resonance imaging characteristics of deep endometriosis. *Hum Reprod.* 1999;14(4):1080–6.
- Kondo W, Bourdel N, Jardon K, Tamburro S, Cavoli D, Matsuzaki S, Botchorishvili R, Rabischong B, Pouly JL, Mage G, Canis M. Comparison between standard and reverse laparoscopic techniques for rectovaginal endometriosis. *Surg Endosc.* 2011;25(8):2711–7.
- Kondo W, Bourdel N, Tamburro S, Cavoli D, Jardon K, Rabischong B, Botchorishvili R, Pouly J, Mage G, Canis M. Complications after surgery for deeply infiltrating pelvic endometriosis. *BJOG.* 2011;118(3):292–8.
- Kondo W, Zomer MT, Ribeiro R, Trippia C, Oliveira MA, Crispi CP. Laparoscopic treatment of deep infiltrating endometriosis of the intestine - technical aspects. *Braz J Video-Surg.* 2012;5(2):23–39.
- Kondo W, Ribeiro R, Trippia C, Zomer MT. Laparoscopic treatment of deep infiltrating endometriosis affecting the rectosigmoid colon: nodulectomy or segmental resection? *Gynecol Obstet.* 2013;S3:001. <https://doi.org/10.4172/2161-0932.S3-001>.
- Gossot D, Buess G, Cuschieri A, Leporte E, Lirici M, Marvik R, Meijer D, Melzer A, Schurr MO. Ultrasonic dissection for endoscopic surgery. The E.A.E.S. Technology Group. *Surg Endosc.* 1999;13(4):412–7.
- Kondo W, Bourdel N, Zomer MT, Slim K, Rabischong B, Pouly JL, Mage G, Canis M. Laparoscopic cystectomy for ovarian endometrioma - a simple stripping technique should not be used. *J Endometriosis.* 2011;3(3):125–34.
- Muzii L, Marana R, Angioli R, et al. Histologic analysis of specimens from laparoscopic endometrioma excision performed by different surgeons: does the surgeon matter? *Fertil Steril.* 2011;95:2116–9.
- Matsuzaki S, Houle C, Botchorishvili R, Pouly JL, Mage G, Canis M. Excision of the posterior vaginal fornix is necessary to ensure complete resection of rectovaginal endometriotic nodules of more than 2 cm in size. *Fertil Steril.* 2009;91(4 Suppl):1314–5.
- Carmona F, Martínez-Zamora A, González X, Ginés A, Buñesch L, Balasch J. Does the learning curve of conservative laparoscopic surgery in women with rectovaginal endometriosis impair the recurrence rate? *Fertil Steril.* 2009;92(3):868–75.



Endometriosis: From Diagnosis to Surgical Management

8

Mateus Moreira Santos Rosin
and Mauricio Simões Abrão

Introduction

Endometriosis is defined as endometrial glands or stroma that lies outside the uterus. Lesions are most often located in the pelvis affecting the peritoneum and ovaries and may affect the gastrointestinal and urinary tract [1, 2]. The estimated prevalence of endometriosis is 5–15% of all women of childbearing age. The prevalence is higher in some subgroups, such as infertile women—20% to 48% [3–5].

It is a benign, inflammatory, and estrogen-dependent condition that occurs most in women of reproductive age. Symptoms can vary from minimal to highly debilitating. Pelvic pain and infertility are the most common symptoms. In some cases, the symptoms can significantly affect the quality of life, especially in the case of severe conditions when the anatomy of the pelvis is completely distorted. Lesions are most often located in the pelvis affecting the peritoneum and ovaries and may affect the gastrointestinal and urinary tract [6, 7].

The disease can be divided according to location; there are three classical different presentations: peritoneal endometriosis, ovarian endometriosis cysts (endometriomas), and deeply infiltrative endometriosis, defined arbitrarily as

endometriosis infiltrating the peritoneum by more than 5 mm. Some patients may also present a combination of them, even with all forms together [8, 9].

Endometriosis is currently staged according to the American Society for Reproductive Medicine (ASRM) system—the most widely accepted, proposed in 1996, rating the extent of endometriosis on a scale of I (minimal) to IV (severe).

Several different criteria for the classification of endometriosis have been developed. Unfortunately, all classifications are subjective and correlate poorly with symptoms and fertility outcomes [10, 11].

The establishment of a widely accepted and clinically significant classification system remains elusive. Adamson and Pasta [12] have developed the endometriosis fertility index, which has been validated as a means of predicting non-IVF pregnancy rates in patients who have undergone surgical evaluation of endometriosis. More recently, a new staging system based on ultrasonographic findings of deep, infiltrating disease has been suggested as well. And the American Association of Gynecologic Laparoscopists (AAGL) is in the process of developing a new classification system for endometriosis [12–14].

Treatment of endometriosis may be surgical or clinical, including drugs such as gestagens, oral contraceptives, GnRH analogs, and analgesics. However, many surgeons claim that it is

M. M. S. Rosin • M. S. Abrão (✉)
Department of Obstetrics and Gynecology, University
of São Paulo Medical School, São Paulo, SP, Brazil

preferable to undergo minimally invasive surgical intervention instead of years of associated side effects of clinical therapy. In addition, conservative surgery is the ideal option for women seeking to become pregnant since almost all medications used to treat endometriosis interfere with ovulation. In most of the cases, the treatment requires a multidisciplinary team, able to provide the most radical approach needed and also to avoid any medicolegal implications [15–17].

Diagnosis

The diagnosis of endometriosis is still a dilemma in view of the nonspecific symptoms caused by the most diverse forms of the disease. A thorough history and careful physical examination are imperative to the diagnostic suspicion.

The main clinical manifestations of endometriosis include dysmenorrhea, which may be primary or secondary, dyspareunia, dyskinesia, uterine hemorrhagic disorders, infertility, and chronic acyclic pelvic pain. Women with endometriosis may also present gastrointestinal, urological, autonomic, and nonspecific symptoms similar to chronic fatigue. More than 60% of women with endometriosis also have clinically relevant depressive mood disorders, depression, or anxiety disorders [18].

Pelvic examination may suggest the diagnosis of deep infiltrative endometriosis by the presence of painful nodules and fibrosis in the cul-de-sac, but it is not very accurate in determining the extent of the disease. Through clinical examination, only 50% of deep endometriosis nodules larger than 3 cm in diameter were diagnosed. With clinical gynecologist experience and awareness, clinical diagnosis has been improved. However, the most important finding is that the vast majority of lesions of deep endometriosis will not be diagnosed by clinical examination but by complementary examinations [19–21].

Accurate mapping of endometriosis lesions is critical for optimal therapeutic planning and

patient counseling. We need for a reliable nonsurgical method to diagnose this highly prevalent disease and to determine the extent and location of lesions in the pelvic cavity during the preoperative evaluation in order to better plan the surgical approach. Clinical suspicion may be confirmed by transvaginal ultrasound or by magnetic resonance imaging, which are useful and most commonly used tools to estimate the extent of lesions [22, 23].

Transvaginal Sonography

Transvaginal ultrasonography is the first-choice imaging technique for the diagnosis of pelvic endometriosis and, in particular, deep infiltrative endometriosis. The preoperative systematic ultrasonography evaluation by an expert sonographer can give an accurate assessment of the presence and location of deep infiltrative endometriosis [24].

Endometriosis deep nodules involving the retrocervical region, uterosacral ligaments, vagina, and rectosigmoid should be accurately detected during preoperative assessment; they are identified by ultrasonography as a heterogeneous, hypoechogenic, and sometimes spiculated mass. Usually the normal uterosacral ligaments are not visible on the ultrasound (when affected by endometriosis, they present a hypoechoic thickening with regular or irregular margins seen within the peritoneal fat that surrounds them). The lesion may be isolated or may be part of a larger lump that extends into the vagina or other surrounding structures [25, 26].

Bowel deep infiltrative endometriosis usually appears on transvaginal ultrasound as a thickening of the hypoechoic muscularis propria or as hypoechoic nodules, with or without hyperechoic foci with blurred margins. The transvaginal ultrasound with intestinal preparation is able to define not only the size but also the number of lesions, the depth of invasion in the intestinal wall, and the distance from the anal border. The distance from the anal verge to the intestinal lesion can be

determined by the transvaginal ultrasound using the peritoneal reflection as the main reference point, which is located about 7–8 cm from the anal verge [27–30].

Transvaginal ultrasonography with or without the use of previous bowel preparation is an accurate examination for the presurgical and noninvasive detection of rectosigmoid endometriosis. It has shown a superior sensitivity (75–98%) for detecting deep infiltrative endometriosis compared with magnetic resonance imaging, transrectal ultrasonography, computed tomography, and clinical examination [19, 20, 31].

Rectal deep infiltrative endometriosis lesions may be associated with a second intestinal lesion in 54.6% of cases [27].

Transvaginal ultrasound is also the method of choice for assessing an adnexal mass, and in the presence of endometriomas, the method shows images most commonly associated with unilocular cysts with a homogeneous “ground-glass” appearance. The diagnosis of endometrioma is easily performed using a transvaginal ultrasound, which has a sensitivity of 90% and a specificity of 97% [32, 33].

The presence of the combination of endometrioma and pain should alert to the possibility of moderate to advanced stage disease and does not respond well to drug therapy [34, 35].

Kissing ovaries sign suggests that there are severe pelvic adhesions. Bowel and fallopian tube endometrioses are significantly more frequent in women with ovarian kissing compared to those without: 18.5% vs 2.5% and 92.6% vs 33%, respectively [36–38].

Each endometrioma and deep infiltrative endometriosis lesion should be measured systematically in three orthogonal planes, to obtain the length (midsagittal measurement), thickness (anteroposterior measurement), and transverse diameter. The obliteration of pouch of Douglas can be graded as partial or complete depending on whether one side, left or right, or both sides [39, 40].

Prediction of severe forms of deep infiltrative endometriosis as well as pouch of Douglas obliteration

using transvaginal ultrasound is helpful in planning a multidisciplinary surgical approach [28].

Magnetic Resonance Imaging

The preoperative mapping of the extent of deep infiltrative endometriosis is very important, first, to decide whether surgical intervention is indicated and second to plan the complete surgical excision, since the success of the treatment depends on the radical surgical removal [41].

Magnetic resonance imaging is now commonly used for the diagnosis of endometriosis; it has a great advantage over other diagnostic methods because it allows a complete survey of both the anterior and posterior compartments of the pelvic at the same time as well as provides information on areas inaccessible to laparoscopy and transvaginal ultrasonography. That is why extensive pelvic adhesions and ureteral involvement are both important indications for magnetic resonance imaging examination [42–45].

When the ultrasound characteristics of the ovarian masses are indeterminate, magnetic resonance imaging is the imaging examination of choice to rule out malignancy. Endometriomas usually present as hyperintense signals on fat-suppressed T1-weighted imaging with a sensitivity of 90%, specificity of 98%, and accuracy of 96% [46, 47].

Magnetic resonance imaging may be useful in the diagnosis of multifocal endometriosis, as well as in the definition of the anatomical location of endometriotic lesions. The use of contrast-enhanced mass or hyperintense foci in T1-weighted or fat-suppressed T1-weighted magnetic resonance imaging strongly suspects the presence of hemorrhagic foci or hyperintense cavities secondary to endometriosis. A hypointense nodule can be seen in the T2-weighted images with the sign of the mass of tissue close to that of the pelvic muscles. The sensitivity and specificity of magnetic resonance imaging to detect pelvic endometriosis are about 90% [25, 48].

Magnetic resonance imaging and transvaginal ultrasound have similar results in the identification of colorectal endometriosis. They suggest that these methods may have complementary roles in the identification of colorectal endometriosis depending on the affected site [49].

Magnetic resonance imaging is also useful to predict muscular infiltration of the bowel with a sensitivity of 100% and specificity of 75%. Introduction of ultrasound gel inside the rectum improves the anatomical definition of the pelvis, increasing the possibility of detecting small intestinal lesions; however, it is difficult to define which layer of the intestinal wall is affected by the disease. The measurement of the distance of the intestinal lesion from the anal border is more accurate in magnetic resonance of the pelvis, due to the better anatomical resolution in the sagittal T2 sequence. It is recommended to respect the rectal and sigmoid curvatures when measuring this distance [30, 50].

Surgical Management

Ovarian

Ovarian endometrioma is a cystic tumor caused by the presence of ectopic endometrial tissue within the ovary. It has thick, brown, tar-like fluid content that can be referred as a “chocolate cyst.” In practice, there is a great disparity between the radiological diagnosis and the endoscopic findings of patients undergoing laparoscopic surgery for endometriomas, usually presents strongly attached to surrounding structures such as the peritoneum, uterus, fallopian tubes, and intestine. This is one of the most common manifestations of endometriosis. Among patients with endometriosis, 17–44% have ovarian endometriomas [51, 52].

One-third to one-half of patients with endometriomas will have bilateral cysts. There are three theories of how the endometriomas are formed. The first was described by Hughesdon in 1957 in which he suggested that there is an invagination of the ovarian cortex after accumu-

lation of menstrual debris from bleeding of endometrial implants which results in a pseudocyst. In 1994 Brosens et al. demonstrated through ovariectomy that in most cases, endometriomas are formed by invagination of the cortex and that active implants are located at the site of invagination [53–55].

The second theory is that endometriomas result from metaplasia of coelomic epithelium covering the ovary. Finally, Nezhat et al. have postulated that large endometriomas may develop as a result of secondary involvement of functional ovarian cysts by endometrial implants located on the ovarian surface [56–58].

In early diagnostic laparoscopy, the excision of an endometrioma is ideal for two reasons: first, endometriomas larger than 1 cm in size are unlikely to be spontaneously resolved, and, second, excision allows anatomopathological examination of the tissue and confirmation of diagnosis. The risk of malignant transformation of an endometrioma is 2.5%, most commonly resulting in endometrioid carcinoma or clear-cell adenocarcinoma [59–61].

Endometriomas are understood to be pseudocysts. The cleavage plane between an endometrium and an ovarian cortex is not always clear. Several techniques have been proposed for the conservative laparoscopic treatment of endometriotic cysts. Laparoscopic cystectomy remains a first-line choice for the conservative treatment of endometriotic cysts [62].

The classic surgical treatment of endometriotic ovarian cysts is a technique of laparoscopic removal, using traction and contraction to remove the endometrioma capsule. Laparoscopic excision of an endometrioma is associated with a decrease in the symptoms as dysmenorrhea, dyspareunia, and non-menstrual pelvic pain [63].

A meta-analysis showed that stripping technique is a better method than drainage or ablative surgery in terms of recurrence of pain symptoms, increasing spontaneous pregnancy rates and decreasing recurrence and reoperation rates ([62–64]).

Some evidence has indicated that cyst drainage and vaporization or thermal coagulation may

be less harmful to ovarian reserve. Donnez et al. [65] proposed a technique consisting of excising a large part of the endometrioma wall using the stripping technique and then using CO₂ laser on the remaining endometrioma wall when approaching the hilus [65].

Both the presence of endometriomas and surgical excision of endometriomas appear to be damaging to ovarian function and ovarian reserve. In patients who are symptomatic and who have good ovarian reserve, unilateral endometriomas, and ovarian lesions with ultrasound characteristics related to malignancy or who do not wish to continue in vitro fertilization, surgery may be indicated. But these women need to be properly advised about the potential for ovarian reserve decline [66].

It is still unclear whether asymptomatic ovarian endometriomas require surgical treatment, and surgery in this area may damage adjacent normal ovarian tissue. The issue is relevant to no more than a few women, as only about 5–10% of all cases of endometriosis are considered asymptomatic [18] (Fig. 8.1).

Rectovaginal

Endometriosis is considered infiltrative when the lesions reach a depth of 5 mm in the peritoneum and may be located in the Douglas's pouch, vesicouterine space, and other regions of the pelvis. It should be remembered that one form of retrouterine infiltration of the disease may be retrocervical

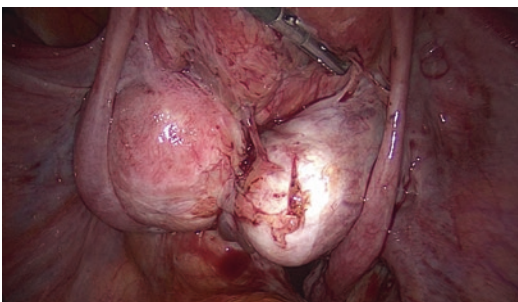


Fig. 8.1 Ovarian endometriosis. “Kissing ovaries” with the obliteration of the pouch of Douglas

when an affected area is situated between the lower third of the vagina and the rectum [67, 68].

Rectovaginal endometriosis is easily identified in the posterior vaginal fornix during palpation of the rectovaginal septum. The digital vaginal examination achieved sensitivity rates of 68 and 72% for retrocervical and rectosigmoid endometriosis, respectively. The involvement of the adjacent intestine and the sacrouterine ligaments may lead to partial or complete obliteration of the Douglas's pouch. This condition is associated with infertility, often severe pelvic pain, dyspareunia, loss of libido, and bowel symptoms frequently. This is due to the location of the invasive foci and the compromised innervation of adjacent structures [31, 69].

Dyspareunia, especially related to deep disease, is a characteristic of retrocervical endometriosis and is justified by endometriotic implants in the uterosacral ligaments, as well as the immobility of the pelvic organs that are trapped by infiltrative disease and dense adhesions. Currently the surgical treatment is widely used for symptomatic rectovaginal endometriosis [15–17, 70].

Several surgical techniques were developed for this purpose, all aimed at maximizing citoreduction of the disease when possible. In general, during surgery, the rectum, sigmoid, and ureters should be identified and isolated in order to perform the complete removal of retrocervical endometriosis lesions. The involvement of the bowel sometimes requires intestinal resections, just as parametrial infiltration may require ureterolysis due to ureteral involvement. So, the surgeon must be fit and ready to face these scenarios [71–74].

The serious complications of this type of surgery are specifically associated with inadvertent bowel perforation or fistulas. The most frequently reported postoperative symptom is urinary retention, probably due to parasympathetic plexus injury, resulting in temporary denervation of the bladder. The risk of urinary retention is increased when associated with segment resection of the bowel but can occur even when this is not necessary [75].

Nerve-sparing techniques are being applied with substantial reductions in time to return

spontaneous urination, decrease residual urine volume, and lower rate of self-catheterization at hospital discharge [76–78].

The patient must be fully informed about the nature of the procedure before it is performed [73, 74].

Bladder

Patients with endometriosis present urinary tract involvement in 0.03–5% of the time. Considering the urinary system, the bladder is the most commonly affected organ 80–84%, followed by ureter 15%, kidney 4%, and urethra 2% [79, 80].

The hypothesis of deep infiltrative endometriosis involving the bladder should be considered in patients with cyclic irritative urinary symptoms, which manifest as painful and noneffective vesical contractions, as well as microcirculatory disturbances in the urothelium, with micro- or resulting macrohematuria. Urine cultures are generally negative in these patients [81].

Invasive diagnostic techniques include cystoscopy and laparoscopy, but the cystoscopy still represents one of the most cost-effective tests. The cystoscopic findings may be normal due to the intraperitoneal origin of the lesion; small lesions affecting only the bladder peritoneum cannot be seen by cystoscopy. Failure to identify hematuria at cystoscopy does not rule out the possibility of bladder endometriosis. During the examination, cystoscopy may demonstrate an intraluminal mass of the posterior wall of the bladder or dome; they may be isolated or multifocal.

The calculation of the distance between the ureteric orifices and the inferior border of the endometriotic nodule is crucial to define the surgical approach. In patients not previously operated on, the distance between the caudal border of the endometriotic lesion and the interurethral ridge is rarely less than 2 cm. Lesions may be biopsied and ureter stents can be inserted cystoscopically if necessary. When the distance between the caudal border of the endometriotic lesion and the interurethral ridge is less than 2 cm, ureteral catheterization is recommended [82, 84, 85].

The primary treatment modality for symptomatic endometriosis of the bladder is surgery. In the presence of deep infiltration of the detrusor muscle, partial cystectomy is required. It consists of dissection of the vesicouterine space to mobilize the nodule and isolate the diseased bladder for subsequent excision of the entire lump along with some healthy tissue. Bladder suture is usually performed through a single layer, and at the end of the procedure, cystoscopy is mandatory to check the integrity of the urethra and good co-optation of the bladder wall. In most of the cases, it is a simple procedure with excellent results; some series show pain relief in 95–100% of patients. Transurethral urinary drainage is recommended for 6 days after surgery. Ureteral involvement can lead to serious complications when diagnosis is delayed, such as stenosis with hydroureter and hydronephrosis and finally loss of renal function [84, 86].

Endometriosis of the ureter can be either intrinsic or extrinsic. The extrinsic type is more common, and the goal of surgery is freeing (ureterolysis) and decompression of the ureter; intrinsic ureteric endometriosis is rare and infiltrates multiple layers of the ureter. It is present in less than 0.3% of all women with endometriosis; an additional objective is partial resection of the ureter with end-to-end anastomosis or direct ureteric neimplantation, with the psoas hitch technique [83].

A large number of patients with deep infiltration of endometriosis who experience ureteral involvement are asymptomatic. In 14% of the rectovaginal endometriotic nodules larger than 3 cm, ureteral involvement was observed. Therefore, preoperative urinary tract investigation is highly recommended in women with retrocervical injury [87–89, 90].

The most serious complication of this operation is the neurogenic bladder caused by bladder denervation, caused by endometriosis itself or by surgical resection of the lesion, which may require permanent catheterization or implantation of a bladder neurostimulator, usually in young patients with a significant reduction in quality of life [18] (Fig. 8.2).

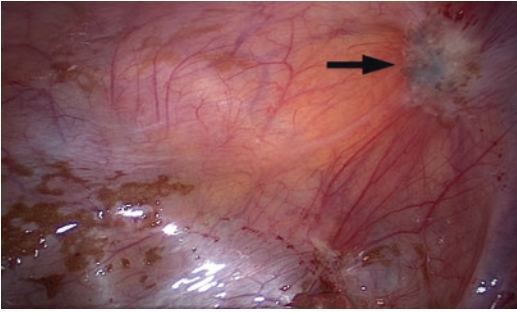


Fig 8.2 Bladder endometriosis. The arrow shows the black lesion with the involvement of peritoneum and bladder muscular layers

Bowel

Intestinal involvement may vary widely in patients with endometriosis and can be estimated at 3.8–37%. Intestinal endometriosis can be found in many areas between small bowel and anal canal, but the main locations of intestinal endometriosis are the rectum and rectosigmoid junction; in 90% of the cases, lesions of intestinal endometriosis are present in the rectum and sigmoid [91–93].

The rectum and the rectosigmoid junction are involved in 65.7% of the cases, followed by the sigmoid colon 17.4%, cecum and ileocecal junction 4.1%, appendix 6.4%, small intestine, 7%, and omentum 1.7% [94].

Symptoms such as tenesmus, dyschezia, diarrhea, and constipation are alterations of the intestinal habit due to colorectal involvement; hematochezia may occur, but it is a rare event. As a differential diagnosis, one should keep in mind irritable bowel syndrome, solitary rectal ulcer syndrome, and a rectal tumor [95].

The medical management of deep infiltrative endometriosis with colorectal extension is not curative; it is based only on the suppression of symptoms with nonsteroidal anti-inflammatory drugs, oral contraceptives, gestagens, anti-agonists, or GnRH agonists and is frequently associated with significant side effects [15–17, 96, 97].

In addition, it is unclear whether the medical management approach prevents disease progression, especially in more severe cases of endome-

triosis with colorectal extension. However, discontinuation of these medications usually results in recurrence [98].

There is a general consensus that symptomatic endometriosis, especially colorectal endometriosis, is best treated by a single laparoscopic operation in order to restore pelvic anatomy and improve pain, quality of life, and fertility. Complete removal of all visible lesions is considered appropriate treatment in order to reduce recurrence [99, 100].

The surgical treatment of colorectal endometriosis depends basically on the depth of invasion of the intestinal wall, the size of the lesion, and the number of lesions in the affected intestinal tract, leading to different surgical approaches [101].

Important features that must be considered to define the best strategy for surgical treatment of intestinal endometriosis are its multifocality, which is defined as the presence of endometriotic lesions in an area of 2 cm around the main lesion, and its multicentric involvement, which is defined as the presence of endometriotic lesions beyond 2 cm of the main lesion. Multifocality and multicentric involvement were observed in 62% and 38% of the surgical specimens, respectively [102].

Other relevant parameters include the distance between the intestinal lesion and the anal verge, the number of previous surgeries, and the extent of the associated pelvic lesions.

Two surgical techniques are employed in the treatment of intestinal endometriosis: one is colorectal resection, involving the removal of the rectal segment affected by the disease, and the other is excision of the endometriotic nodule, whether superficial, deep invasion or complete involvement of the intestinal wall [103].

Superficial rectal lesions can be excised from the bowel using the “shaving” technique, this approach may be performed without opening the rectum, and the integrity of the wall should be carefully assessed and checked with an air leak test [65].

For a small single nodule, full-thickness disc excision of the anterior rectal wall can be performed safely; nodule excision should be the preferred option over colorectal resection whenever

possible to prevent unfavorable functional bowel outcomes supposed to be significantly more frequent in women managed by colorectal resection [104].

The indications for intestinal segmental resection are invasion of more than 50% of the circumference of the intestinal loop, multiple nodules, or nodules larger than 3 cm in extension [105].

It was observed that intestinal lesions that infiltrate more deeply than the inner muscle layer usually compromise more than 40% of the rectosigmoid circumference, so these lesions usually require segmental bowel resection [106].

Preservation of the superior rectal artery is preferably performed as well as preservation of the lower hypogastric nerves and lower hypogastric plexus, especially when the lesions are located up to 8 cm from the anal border, which has been shown to improve sexual and urological functioning. The excised intestinal segment with sparing of the meso is removed through a 3 cm abdominal incision; alternatively the vaginal or rectal routes are options that should be considered in the operative time. After the preparation of the colorectal segment, the end-to-end anastomosis is performed with reconstruction of the intestinal transit using a circular stapler [76, 77, 107, 108].

Endometriosis recurrence rate, after bowel resection, has been reported in 4.7–25% of cases after a follow-up period of more than 2 years [109].

Many authors believe that incomplete excision of endometriosis is a major cause for clinical recurrence [110, 111].

The most frequent postoperative complications are rectovaginal and anastomotic fistulas; surgeries with resection and vaginal opening for removal of endometriotic lesions or the vaginal approach for performing anastomosis represent significant risk factors for developing these complications. Meuleman et al. [109] reported, considering the anastomosis group of patients who underwent intestinal resection, 55 (2.7%) presented rectovaginal fistula, 30 (1.5%) anastomotic effusions, and 7 (0.34%) pelvic abscesses [109].

The anastomotic fistula seems to occur mainly when the ultralow anastomosis is performed, less

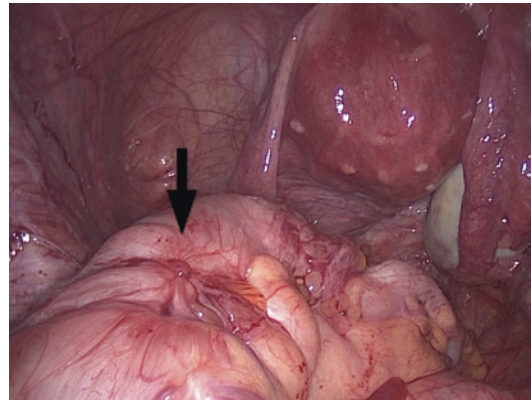


Fig. 8.3 Bowel endometriosis. The arrow points to the endometriosis nodule at the colorectal junction

than 10 cm away from the anal border, reaching high rates of up to 20% in these cases [112, 113].

When the intestinal tract is involved, a multidisciplinary approach is mandatory. Laparoscopic colorectal resection for endometriosis, while requiring adequate training, is a relatively safe procedure when there is collaboration between gynecologists and surgeons [114] (Fig. 8.3).

Conclusions

Endometriosis is a chronic, hormone-dependent disease of the uterus, with a highly variable clinical course. Thus, the treatment should be designed according to the patient's individual needs. This does not mean that it should be chosen arbitrarily [15–17].

Indications for deep endometriosis surgery are pain and/or infertility, and it is unclear whether a nodule without bowel occlusion that does not cause pain should be operated. Today, the indications should never be occasional findings by imaging techniques, in the absence of clinical symptoms [21].

The physician should discuss with the patient whether the primary reason for treatment is acute or chronic endometriosis-related pain or an as yet unfulfilled desire to bear children [115].

Precise preoperative assessment of disease extent is necessary to select an appropriate

treatment adapted to the individual case, as described previously [24, 31, 116].

Considering the complexity and morbidity of these procedures, colorectal endometriosis is therefore best managed by a multidisciplinary approach, requiring at least a laparoscopically experienced gynecologist, a colorectal surgeon, and a urologist [117].

Laparoscopy is the gold standard for the surgical treatment of endometriosis. Strong evidence is currently available on the surgical methods that are used for the management of deep infiltrative endometriosis, ovarian endometriosis, and bowel endometriosis [18].

References

1. Abrão MS, Dias JA Jr, Podgaec S. Histórico e aspectos epidemiológicos da endometriose: Uma doença prevalente e de conhecimento antigo. In: Abrão MS, editor. *Endometriose: Uma visão contemporânea*. Rio de Janeiro: Revinter; 2000. p. 1–11.
2. Koninckx PR, Meuleman C, Demeyere S, Lesaffre E, Cornillie FJ. Suggestive evidence that pelvic endometriosis is a progressive disease, whereas deeply infiltrating endometriosis is associated with pelvic pain. *Fertil Steril*. 1991;55:759–65.
3. Bulun SE. Endometriosis. *N Engl J Med*. 2009;360:268–79.
4. Leyendecker G, Herbertz M, Kunz G, Mall G. Endometriosis results from the dislocation of basal endometrium. *Hum Reprod*. 2002;17:2725–36.
5. Leyendecker G, Kunz G, Noe M, Herbertz M, Mall G. Endometriosis: a dysfunction and disease of the archimetra. *Hum Reprod Update*. 1998;4:752–62.
6. Abrão MS, Amaral VF, Ramos LO. Classificação da endometriose: É tempo de reavaliá-la. *Femina*. 1998;26:677–80.
7. Giudice LC, Kao LC. Endometriosis. *Lancet*. 2004;364:1789–99.
8. Donnez J, Nisolle M, Casanas-Roux F, Bassil S, Anaf V. Rectovaginal septum, endometriosis or adenomyosis: laparoscopic management in a series of 231 patients. *Hum Reprod*. 1995;10:630–5.
9. Koninckx PR, Martin DC. Deep endometriosis: a consequence of infiltration or retraction or possibly adenomyosis externa? *Fertil Steril*. 1992;58:924–8.
10. Canis M, Donnez JG, Guzik DS, Halme JK, Rock JA, Schenken RS, et al. Revised American Society for Reproductive Medicine classification of endometriosis: 1996. *Fertil Steril*. 1997;67:817–21.
11. Kennedy S, Bergqvist A, Chapron C, et al. ESHRE guideline for the diagnosis and treatment of endometriosis. *Hum Reprod*. 2005;20:2698–704.
12. Adamson GD, Pasta DJ. Endometriosis fertility index: the new, validated endometriosis staging system. *Fertil Steril*. 2010;94:1609–15.
13. Ad hoc Committees. Endometriosis classification. 2011. Available at: www.aagl.org/Committees-Ad-Hoc. Accessed 14 Apr 2012.
14. Coccia ME, Rizzello F. Ultrasonographic staging: a new staging system for deep endometriosis. *Ann N Y Acad Sci*. 2011;1221:61–9.
15. Vercellini P, Carmignani L, Rubino T, Barbara G, Abbiati A, Fedele L. Surgery for deep endometriosis: a pathogenesis-oriented approach. *Gynecol Obstet Investig*. 2009a;68:88–103.
16. Vercellini P, Crosignani PG, Abbiati A, Somigliana E, Vigano P, Fedele L. The effect of surgery for symptomatic endometriosis: the other side of the story. *Hum Reprod Update*. 2009b;15(2):177–88.
17. Vercellini P, Crosignani PG, Somigliana E, Berlanda N, Barbara G, Fedele L. Medical treatment for rectovaginal endometriosis: what is the evidence? *Hum Reprod*. 2009c;24:2504–14.
18. Halis G, Mechsner S, Ebert AD. The diagnosis and treatment of deep infiltrating endometriosis. *Dtsch Arztebl Int*. 2010;107(25):446–56.
19. Hudelist G, Ballard K, English J, Banerjee S, Mastorouides H, et al. Transvaginal sonography vs. clinical examination in the preoperative diagnosis of deep infiltrating endometriosis. *Ultrasound Obstet Gynecol*. 2011a;37:480–7.
20. Hudelist G, English J, Thomas AE, Tinelli A, Singer CF, Keckstein J. Diagnostic accuracy of transvaginal ultrasound for non-invasive diagnosis of bowel endometriosis: systematic review and meta-analysis. *Ultrasound Obstet Gynecol*. 2011b;37:257–63.
21. Koninckx PR, Ussia A, Adamyan L, Wattiez A, Donnez J. Deep endometriosis: definition, diagnosis, and treatment. *Fertil Steril*. 2012;98(3):564–71.
22. Ballester M, Santulli P, Bazot M, Coutant C, Rouzier R, Darai E. Preoperative evaluation of posterior deep-infiltrating endometriosis demonstrates a relationship with urinary dysfunction and parametrial involvement. *J Minim Invasive Gynecol*. 2011;18:36–42.
23. Exacoustos C, Malzoni M, Di Giovanni A, Lazzeri L, Tosti C, Petraglia F, et al. Ultrasound mapping system for the surgical management of deep infiltrating endometriosis. *Fertil Steril*. 2014;102(1):143–50.
24. Piketty M, Chopin N, Dousset B, Millischer-Bellaische AE, Roseau G, Leconte M, et al. Preoperative work-up for patients with deeply infiltrating endometriosis: transvaginal ultrasonography must definitely be the first-line imaging examination. *Hum Reprod*. 2009;24:602–7.
25. Bazot M, Darai E, Hourani R, Thomassin I, Cortez A, Uzan S, Buy JN. Deep pelvic endometriosis: MR

- imaging for diagnosis and prediction of extension of disease. *Radiology*. 2004;232:379–89.
26. Roseau G, Dumontier I, Palazzo L, Chapron C, Dousset B, Chaussade S, Dubuisson JB, Couturier D. Rectosigmoid endometriosis: endoscopic ultrasound features and clinical implications. *Endoscopy*. 2000;32:525–30.
 27. Goncalves MO, Podgaec S, Dias JA Jr, Gonzalez M, Abrão MS. Transvaginal ultrasonography with bowel preparation is able to predict the number of lesions and rectosigmoid layers affected in cases of deep endometriosis, defining surgical strategy. *Hum Reprod*. 2010;25:665–71.
 28. Guerriero S, Condous G, Van den Bosch T, Valentin L, Leone FPG, Van Schoubroeck D, et al. Systematic approach to sonographic evaluation of the pelvis in women with suspected endometriosis, including terms, definitions and measurements: a consensus opinion from the International Deep Endometriosis Analysis (IDEA) group. *Ultrasound Obstet Gynecol*. 2016;48:318–32.
 29. Hudelist G, Tuttlies F, Rauter G, Pucher S, Keckstein J. Can transvaginal sonography predict infiltration depth in patients with deep infiltrating endometriosis of the rectum? *Hum Reprod*. 2009;24:1012–7.
 30. Trippia CH, Zomer MT, Terazaki CRT, Martin RLS, Ribeiro R, Kondo W. Relevance of imaging examinations in the surgical planning of patients with bowel endometriosis. *Clin Med Insights Reprod Health*. 2016;10:1–8.
 31. Abrão MS, Gonçalves MO, Dias JA Jr, Podgaec S, Chamie LP, Blasbalg R. Comparison between clinical examination, transvaginal sonography and magnetic resonance imaging for the diagnosis of deep endometriosis. *Hum Reprod* 2007;22:3092–3097.
 32. Guerriero S, Ajossa S, Gerada M, D'Aquila M, Piras B, Melis GB. Tenderness-guided transvaginal ultrasonography: a new method for the detection of deep endometriosis in patients with chronic pelvic pain. *Fertil Steril*. 2007;88:1293–7.
 33. Van Holsbeke C, Van Calster B, Guerriero S, et al. Endometriomas: their ultrasound characteristics. *Ultrasound Obstet Gynecol*. 2010;35:730–40.
 34. Chapron C, Santulli P, de Ziegler D, Noel JC, Anaf V, Streuli I, et al. Ovarian endometrioma: severe pelvic pain is associated with deeply infiltrating endometriosis. *Hum Reprod*. 2012;27:702–11.
 35. Chopin N, Ballester M, Borghese B, Fauconnier A, Foulot H, Malartic C, et al. Relation between severity of dysmenorrhea and endometrioma. *Acta Obstet Gynecol Scand*. 2006;85:1375–80.
 36. Chapron C, Pietin-Vialle C, Borghese B, Davy C, Foulot H, Chopin N. Associated ovarian endometrioma is a marker for greater severity of deeply infiltrating endometriosis. *Fertil Steril*. 2009;92:453–45.
 37. Ghezzi F, Raio L, Cromi A, Duwe DG, Beretta P, Buttarelli M, Mueller MD. “Kissing ovaries”: a sonographic sign of moderate to severe endometriosis. *Fertil Steril*. 2005;83:143–7.
 38. Somigliana E, Infantino M, Candiani M, Vignali M, Chiodini A, Busacca M. Association rate between deep peritoneal endometriosis and other forms of the disease: pathogenetic implications. *Hum Reprod*. 2004;19:168–71.
 39. Hudelist G, Fritzer N, Staettner S, Tammaa A, Tinelli A, Sparic R, Keckstein J. Uterine sliding sign: a simple sonographic predictor for presence of deep infiltrating endometriosis of the rectum. *Ultrasound Obstet Gynecol*. 2013;41:692–5.
 40. Reid S, Lu C, Casikar I, Reid G, Abbott J, Cario G, Chou D, Kowalski D, Cooper M, Condous G. Prediction of pouch of Douglas obliteration in women with suspected endometriosis using a new real-time dynamic transvaginal ultrasound technique: the sliding sign. *Ultrasound Obstet Gynecol*. 2013;41:685–91.
 41. Dousset B, Leconte M, Borghese B, Millischer AE, Roseau G, Arkwright S, et al. Complete surgery for low rectal endometriosis: long-term results of a 100-case prospective study. *Ann Surg*. 2010;251:887–95.
 42. Chamie LP, Blasbalg R, Mendes APR, Warmbrand G, Serafini PC. Findings of pelvic endometriosis at transvaginal US, MR imaging, and laparoscopy. *Radiographics*. 2011;31(4):77–100.
 43. Guerriero S, Spiga S, Ajossa S, Peddes C, Perniciana M, Soggiu B, et al. Role of imaging in the management of endometriosis. *Minerva Ginecol*. 2013;65:143–66.
 44. Roy C, Balzan C, Thoma V, Sauer B, Wattiez A, Leroy J. Efficiency of MR imaging to orientate surgical treatment of posterior deep pelvic endometriosis. *Abdom Imaging*. 2009;34(2):251–9.
 45. Saba L, Guerriero S, Sulcis R, Ajossa S, Melis G, Mallarini G. Agreement and reproducibility in identification of endometriosis using magnetic resonance imaging. *Acta Radiol*. 2010;51(5):573–80.
 46. Kinkel K, Lu Y, Mehdizade A, Pelte MF, Hricak H. Indeterminate ovarian mass at US: incremental value of a second imaging test for characterization: meta-analysis and Bayesian analysis. *Radiology*. 2005;236:85–94.
 47. Li Y, Song QW, Sun MY, Wang HQ, Wang S, Wei Q, et al. Use of enhanced T2 star weighted angiography (ESWAN) and R2 values to distinguish ovarian cysts due to endometriosis from other causes. *Abdom Imaging*. 2015;40(6):1733–41.
 48. Grasso RF, Di Giacomo V, Sedati P, Sizzi O, Florio G, Faiella E, Rossetti A, Del Vescovo R, Zobel BB. Diagnosis of deep infiltrating endometriosis: accuracy of magnetic resonance imaging and transvaginal 3D ultrasonography. *Abdom Imaging*. 2010;35:716–25.
 49. Saba L, Guerriero S, Sulcis R, et al. MRI and “tenderness guided” transvaginal ultrasonography in the diagnosis of rectosigmoid endometriosis. *J Magn Reson Imaging*. 2012;35(2):352–60.
 50. Takeuchi H, Kuwatsuru R, Kitade M, et al. A novel technique using magnetic resonance imaging jelly for evaluation of rectovaginal endometriosis. *Fertil Steril*. 2005;83:442–7.

51. Jenkins S, Olive DL, Haney AF. Endometriosis: pathogenetic implications of the anatomic distribution. *Obstet Gynecol.* 1986;67:335–8.
52. Redwine DB. Ovarian endometriosis: a marker for more extensive pelvic and intestinal disease. *Fertil Steril.* 1999;72:310–5.
53. Brosens IA, Puttemans PJ, Deprest J. The endoscopic localization of endometrial implants in the ovarian chocolate cyst. *Fertil Steril.* 1994;61(6):1034–8.
54. Hughesdon PE. The structure of endometrial cysts of the ovary. *J Obstet Gynaecol Br Emp.* 1957;64(4):481–7.
55. Kurjak A, Arenas JB. Donald School Atlas of clinical application of ultrasound in obstetrics & gynecology. In: Carrera JM, Kurjak A, editors. *Ultrasonic assessment of adnexal masses*, vol. 1. New Delhi, India: Jaypee Brothers Medical Publishers; 2006. p. 393–422.
56. Donnez J, Nisolle M, Gillet N, Smets M, Bassil S, Casanas-Roux F. Large ovarian endometriomas. *Hum Reprod.* 1996;11(3):641–6.
57. Nezhat F, Nezhat C, Allan CJ, Metzger DA, Sears DL. Clinical and histologic classification of endometriomas: implications for a mechanism of pathogenesis. *J Reprod Med Obstet Gynecol.* 1992;37(9):771–6.
58. Nisolle M, Donnez J. Peritoneal endometriosis, ovarian endometriosis, and adenomyotic nodules of the rectovaginal septum are three different entities. *Fertil Steril.* 1997;68(4):585–96.
59. Nezhat F, Datta MS, Hanson V, Pejovic T, Nezhat C. The relationship of endometriosis and ovarian malignancy: a review. *Fertil Steril.* 2008;90:1559–70.
60. Schipper E, Nezhat C. Endometriomas. *World Clin Obstet Gynecol.* 2011;1:137–42. www.amazon.co.uk/Clinics-Obstetrics-Gynecology-Endometriosis-Volume/dp/9350358005
61. Van Gorp T, Amant F, Neven P, Vergote I, Moerman P. Endometriosis and the development of malignant tumours of the pelvis. A review of literature. *Best Pract Res Clin Obstet Gynaecol.* 2004;18:349–71.
62. Beretta P, Franchi M, Ghezzi F, Busacca M, Zupi E, Bolis P. Randomized clinical trial of two laparoscopic treatments of endometriomas: cystectomy versus drainage and coagulation. *Fertil Steril.* 1998a;70:1176–80.
63. Hart RJ, Hickey M, Maouris P, Bucket W. Excisional surgery versus ablative surgery for ovarian endometriomata. *Cochrane Database Syst Rev.* 2008;2:CD004992. <https://doi.org/10.1002/14651858.CD004992.pub3>.
64. Alborzi S, Momtahan M, Parsanezhad ME, Dehbashi S, Zolghadri J, Alborzi S. A prospective, randomized study comparing laparoscopic ovarian cystectomy versus fenestration and coagulation in patients with endometriomas. *Fertil Steril.* 2004;82(6):1633–7.
65. Donnez J, Lousse JC, Jadoul P, Donnez O, Squifflet J. Laparoscopic management of endometriomas using a combined technique of excisional (cystectomy) and ablative surgery. *Fertil Steril.* 2010;94:28–32.
66. Keyhan S, Hughes C, Price T, Muasher S. An update on surgical versus expectant management of ovarian endometriomas in infertile women. Hindawi Publishing Corporation. *BioMed Research International* Volume 2015, Article ID 204792, 9 pages <https://doi.org/10.1155/2015/204792>.
67. Cornillie FJ, Oosterlynck D, Lauweryns JM, Koninckx PR. Deeply infiltrating pelvic endometriosis: histology and clinical significance. *Fertil Steril.* 1990;53:978–83.
68. Martin DC, Batt RE. Retrocervical, retrovaginal pouch, and rectovaginal septum endometriosis. *J Am Assoc Gynecol Laparosc.* 2001;8:12–7.
69. Wang G, Tokushige N, Russell P, Dubinovsky S, Markham R, Fraser IS. Hyperinnervation in intestinal deep infiltrating endometriosis. *J Minim Invasive Gynecol.* 2009;16:713–9.
70. Schipper E, Nezhat C. Video-assisted laparoscopy for the detection and diagnosis of endometriosis: safety, reliability, and invasiveness. *Int J Womens Health.* 2012;4:383–93.
71. Donnez J, Jadoul P, Donnez O, Squifflet J. Laparoscopic excision of rectovaginal and retrocervical endometriotic lesions. In: Donnez J, editor. *Atlas of operative laparoscopy and hysteroscopy*. London: Informa UK Ltd; 2007a. p. 63–75.
72. Donnez J, Squifflet J, Donnez O, Jadoul P. Bladder endometriosis. In: Donnez J, editor. *Atlas of operative laparoscopy and hysteroscopy*. London: Informa UK Ltd; 2007b. p. 85–91.
73. Schonman R, De Cicco C, Corona R, Soriano D, Koninckx PR. Accident analysis: factors contributing to a ureteric injury during deep endometriosis surgery. *BJOG.* 2008;115:1611–5.
74. Slack A, Child T, Lindsey I, et al. Urological and colorectal complications following surgery for rectovaginal endometriosis. *BJOG.* 2007;114:1278–82.
75. Dubernard G, Rouzier R, David-Montefiore E, Bazot M, Darai E. Use of SF-36 questionnaire to predict quality-of-life improvement after laparoscopic colorectal resection for endometriosis. *Hum Reprod.* 2008;23:846–51.
76. Landi S, Ceccaroni M, Perutelli A, Allodi C, Barbieri F, Fiaccavento A, Ruffo G, McVeigh E, Zanolla L, Minelli L. Laparoscopic nerve-sparing complete excision of deep endometriosis: is it feasible? *Hum Reprod.* 2006;21:774–81.
77. Possover M, Quakernack J, Chiantera V. The LANN technique to reduce postoperative functional morbidity in laparoscopic radical pelvic surgery. *J Am Coll Surg.* 2005;21:913–7.
78. Volpi E, Ferrero A, Sismondi P. Laparoscopic identification of pelvic nerves in patients with deep infiltrating endometriosis. *Surg Endosc.* 2004;18:1109–12.
79. Donnez J, Spada F, Squifflet J, Nisolle M. Bladder endometriosis must be considered as bladder adenomyosis. *Fertil Steril.* 2000;74(6):1175–81.

80. Frenna V, Santos L, Ohana E, Bailey C, Wattiez A. Laparoscopic management of ureteral endometriosis: our experience. *J Minim Invasive Gynecol.* 2007;14(2):169–71.
81. Kondo W, Monica MT, Pinto EP, Ribeiro R, Ribeiro MFC, Trippia CR, Trippia CH. Deep infiltrating endometriosis: imaging features and laparoscopic correlation. *J Endometr Pelvic Pain Disord.* 2011;3(4):197–212.
82. Mettler L, Gaikwad V, Riebe B, Schollmeyer T. Bladder endometriosis: possibility of treatment by laparoscopy. *JLS.* 2008;12:162–5.
83. Pérez-Utrilla Pérez M, Aguilera Bazán A, Alonso Dorrego JM, Hernández A, de Francisco MG, Martín Hernández M, et al. Urinary tract endometriosis: clinical, diagnostic, and therapeutic aspects. *Urology.* 2009;73:47–51.
84. Hansen KA, Chalpe A, Eyster KM. Management of endometriosis-associated pain. *Clin Obstet Gynecol.* 2010;53:439–48.
85. Seracchioli R, Mabrouk M, Montanari G, Manuzzi L, Concetti S, Venturoli S. Conservative laparoscopic management of urinary tract endometriosis (UTE): surgical outcome and long-term follow-up. *Fertil Steril.* 2010;94(3):856–61.
86. Munhoz JL, Jimenez JS, Tejerizo A, Lopez G, Duarte J, Sanchez Bustos F. Rectosigmoid deep infiltrating endometriosis and ureteral involvement with loss of renal function. *Eur J Obstet Gynecol Reprod Biol.* 2012;162:121–4.
87. Al-Khawaja M, Tan PH, MacLennan GT, Lopez-Beltran A, Montironi R, Cheng L. Ureteral endometriosis: clinicopathological and immunohistochemical study of 7 cases. *Hum Pathol.* 2008;39:954–9.
88. Antonelli A, Simeone C, Zani D, Sacconi T, Minini G, Canossi E, et al. Clinical aspects and surgical treatment of urinary tract endometriosis: our experience in 31 cases. *Eur Urol.* 2006;49:1093–8.
89. Donnez J, Nisolle M, Squifflet J. Ureteral endometriosis: a complication of rectovaginal endometriotic (adenomyotic) nodules. *Fertil Steril.* 2002;77:32–7.
90. Seracchioli R, Mabrouk M, Manuzzi L, Guerrini M, Villa G, Montanari G, et al. Importance of retroperitoneal ureteric evaluation in cases of deep infiltrating endometriosis. *J Minim Invasive Gynecol.* 2008;15:435–9.
91. Darai E, Thomassin I, Barranger E, Detchev R, Cortez A, Houry S, Bazot M. Feasibility and clinical outcome of laparoscopic colorectal resection for endometriosis. *Am J Obstet Gynecol.* 2005;192:394–400.
92. Remorgida V, Ferrero S, Fulcheri E, Ragni N, Martin DC. Bowel endometriosis: presentation, diagnosis, and treatment. *Obstet Gynecol Surv.* 2007;62:461–70.
93. Vercellini P, Pietropaolo G, De GO, Pasin R, Chiodini A, Crosignani PG. Treatment of symptomatic rectovaginal endometriosis with an estrogen-progestogen combination versus low-dose norethindrone acetate. *Fertil Steril.* 2005;84:1375–87.
94. Chapron C, Chopin N, Borghese B, Foulot H, Dousset B, Vacher-Lavenu MC, et al. Deeply infiltrating endometriosis: pathogenetic implications of the anatomical distribution. *Hum Reprod.* 2006;21:1839–45.
95. Seaman HE, Ballard KD, Wright JT, de Vries CS. Endometriosis and its coexistence with irritable bowel syndrome and pelvic inflammatory disease: findings from a national case-control study--part 2. *BJOG.* 2008;115:1392–6.
96. Marana R, Paielli F, Muzii L, Dell'Acqua S, Mancuso S. GnRH analogs versus expectant management in minimal-mild endometriosis-associated infertility. *Acta Eur Fertil.* 1994;25:37–41.
97. Telimaa S. Danazol and medroxyprogesterone acetate inefficacious in the treatment of infertility in endometriosis. *Fertil Steril.* 1988;50:872–5.
98. Jatan AK, Solomon MJ, Young J, Cooper M, Pathmanathan N. Laparoscopic management of rectal endometriosis. *Dis Colon Rectum.* 2006;49:169–74.
99. Garry R. The effectiveness of laparoscopic excision of endometriosis. *Curr Opin Obstet Gynecol.* 2004;16:299–303.
100. Jacobson TZ, Duffy JM, Barlow D, Koninckx PR, Garry R. Laparoscopic surgery for pelvic pain associated with endometriosis. *Cochrane Database Syst Rev.* 2009;(4): CD001300. Doi:<https://doi.org/10.1002/14651858.CD001300.pub2>. PMID: 19821276.
101. Mereu L, Ruffo G, Landi S, Barbieri F, Zaccoletti R, Fiaccavento A, et al. Laparoscopic treatment of deep endometriosis with segmental colorectal resection: short-term morbidity. *J Minim Invasive Gynecol.* 2007;14:463–9.
102. Kavallaris A, Kohler C, Kuhne-Heid R, Schneider A. Histopathological extent of rectal invasion by rectovaginal endometriosis. *Hum Reprod.* 2003;18:1323–7.
103. Armengol-Debeir L, Savoye G, Leroi AM, Gourcerol G, Savoye-Collet C, Tuech JJ, et al. Pathophysiological approach to bowel dysfunction after segmental colorectal resection for deep endometriosis infiltrating the rectum: a preliminary study. *Hum Reprod.* 2011;26(9):2330–5.
104. Roman H, Loisel C, Resch B, Tuech JJ, Hochain P, Leroi AM, et al. Delayed functional outcomes associated with surgical management of deep rectovaginal endometriosis with rectal involvement: giving patients an informed choice. *Hum Reprod.* 2010;25(4):890–9.
105. Remorgida V, Ragni N, Ferrero S, Anserini P, Torelli P, Fulcheri E. The involvement of the interstitial Cajal cells and the enteric nervous system in bowel endometriosis. *Hum Reprod.* 2005;20:264–71.
106. Abrão MS, Podgaec S, Dias JA Jr, Averbach M, Silva LF, Marino de Carvalho F. Endometriosis lesions that compromise the rectum deeper than the

- inner muscularis layer have more than 40% of the circumference of the rectum affected by the disease. *J Minim Invasive Gynecol.* 2008;15:280–5.
107. Pereira RMA, Zanatta A, Pretty CDL, de Paula FJF, Motta ELA, Serafini PC. Should the gynecologist perform laparoscopic bowel resection to treat endometriosis? Results over 7 years in 168 patients. *J Minim Invasive Gynecol.* 2009;16:472–9.
 108. Van den Broeck U, Meuleman C, Tomassetti C, D’Hoore A, Wolthuis A, Van Cleynenbreugel B, et al. Effect of laparoscopic surgery for moderate and severe endometriosis on depression, relationship satisfaction and sexual functioning: comparison of patients 54 with and without bowel resection. *Hum Reprod.* 2013;28:2389–97.
 109. Meuleman C, Tomassetti C, D’Hoore A, Van Cleynenbreugel B, Penninckx F, Vergote I, et al. Surgical treatment of deeply infiltrating endometriosis with colorectal involvement. *Hum Reprod Update.* 2011;17(3):311–26.
 110. Chopin N, Vieira M, Borghese B, Foulot H, Dousset B, Coste J, et al. Operative management of deeply infiltrating endometriosis: results on pelvic pain symptoms according to a surgical classification. *J Minim Invasive Gynecol.* 2005;12:106–12.
 111. Vignali M, Bianchi S, Candiani M, Spadaccini G, Oggioni G, Busacca M. Surgical treatment of deep endometriosis and risk of recurrence. *J Minim Invasive Gynecol.* 2005;12:508–13.
 112. Fingerhut A, Hay JM, Elhadad A, Lacaine F, Flamant Y. Supraperitoneal colorectal anastomosis: hand-sewn versus circular staples - a controlled clinical trial. French associations for surgical research. *Surgery.* 1995;118:479–85.
 113. Park JS, Choi GS, Kim SH, et al. Multicenter analysis of risk factors for anastomotic leakage after laparoscopic rectal cancer excision: the Korean laparoscopic colorectal surgery study group. *Ann Surg.* 2013;257:665–71.
 114. Ruffo G, Scopelliti F, Scioscia M, Ceccaroni M, Mainardi P, Minelli L. Laparoscopic colorectal resection for deep infiltrating endometriosis: analysis of 436 cases. *Surg Endosc.* 2010;24(1):63–7.
 115. Marcoux S, Maheux R, Bérubé S. Laparoscopic surgery in infertile women with minimal or mild endometriosis. Canadian collaborative group on endometriosis. *N Engl J Med.* 1997;337:217–22.
 116. Meuleman C, D’Hoore A, Van Cleynenbreugel B, Beks N, D’Hooghe T. Outcome after multidisciplinary CO₂ laser excision of deep infiltrating colorectal endometriosis. *Reprod Biomed Online.* 2009;18:282–9.
 117. D’Hooghe T, Hummelshoj L. Multi-disciplinary centres/networks of excellence for endometriosis management and research: a proposal. *Hum Reprod.* 2006;21:2743–8.



Surgical Treatment of Deep Endometriosis

9

Rodrigo Fernandes, Karolina Afors,
and Arnaud Wattiez

Introduction

- Endometriosis is a complex gynecological disease, which presents a challenge for researchers and surgeons alike. Ectopic deposits of endometrial tissue typically found in the pelvis contribute to disease progression. Associated symptoms of pain and infertility are often attributed to adhesion formation and anatomical distortion frequently responsible for the clinical consequences of the disease [1]. Endometrial tissue within the uterine cavity is responsible for preparing the embryo implantation and nourishing the developing fetus. In the absence of a pregnancy, the corpus luteum degenerates, and hormone levels drop, the effect of which results in shedding of the endometrial lining. This continuous cycle exposes women to constant fluctuations in hormones levels, which in turn regulates the endometrium.
- Endometriosis most commonly affects the ovaries, posterior cul-de-sac, and uterosacral ligaments [2]. Less frequently affected sites

including the diaphragm, lungs, and even endometriotic implants involving the brain have been described [3].

Theories

- Although endometriosis is commonly encountered, its pathogenesis remains poorly understood. Since Sampson's report was first published, numerous theories have been proposed; however, none can fully explain the pathogenesis of this disease. Among these theories, three main concepts are most widely accepted.
- In 1927 Sampson's hypothesis attributed pathogenesis of endometriosis to retrograde menstruation [4]. His theory postulated that endometriosis occurs due to retrograde flow of endometrial debris into the peritoneal cavity during menstruation. He established his theory by observing 20 women presenting with ovarian cysts and implants containing endometrial tissue within the peritoneal cavity. Another theory proposed the existence of Müllerianosis, defined as residual cell of embryonic origin, composed of Müllerian rests with capacity to develop into endometriotic lesions. Müllerianosis was explained as a different disease mimicking endometriosis [5]. Other authors have also speculated about endometriosis arising from coelomic metaplasia [6].

R. Fernandes (✉) · K. Afors
ICESP, University of São Paulo, São Paulo, SP, Brazil

A. Wattiez
Department of Gynecology, Latifa Hospital,
Dubai, UAE

University of Strasbourg, Strasbourg, France

- Although Sampson's hypothesis remains the most accepted theory, researchers later discovered that 90–95% of women were found to have retrograde menstruation. This raised questions about the theory itself, implying that other factors similarly involved were playing a greater role. Studies have demonstrated a variety of changes mediated by interleukins resulting in a pro-inflammatory environment with neoangiogenesis, endometrial tissue growth, and invasion and inactivation of T and natural killer (NK) cells [6, 7]. As a result, the immune system is unable to eliminate these modified endometriosis cells, thus resulting in tissue proliferation spreading throughout the abdominal cavity. The combination of Sampson's theory together with immunogenic features could indicate why most women have retrograde menstruation but only some develop endometriosis.
- Deep endometriosis is defined as implants infiltrating the peritoneum at a depth of greater than 5 mm. Three types of deep endometriosis have been suggested during the last decades: type 1 conical suggesting infiltration, type 2 deep and covered by adhesions, and type 3 consisting of spherical implants with the largest diameter of disease lying under the peritoneum [8]. Typically type 1 lesions are present and surgically less complicated to remove. Type 2 and 3 lesions are normally unique to the rectum and bladder, but rare cases of two to three nodules may occur. These implants are typically encountered in the pelvis but have been reported in the liver and lungs with even brain dissemination. Besides dissemination throughout the pelvic peritoneum, implants are often found affecting the ovaries, tubes, and uterosacral ligaments. More aggressive cases of endometriosis can affect the digestive, urinary, and neural systems leading to more complex and extensive surgeries often effecting organ function.
- For some time, authors have tried to establish a universal classification of endometriosis matching distribution of the disease with infertility and degrees of pain. Unfortunately to date, none of these propositions are com-

prehensive. The most recognized classification is based on a publication of the American Society for Reproductive Medicine, where endometriosis distribution is divided into four stages according to complexity: minimal (I), mild (II), moderate (III), and severe (IV) [9].

Epidemiology

- Endometriosis is estimated to effect around 6–10% of women of reproductive age [1]. Most women report symptoms of varying degrees of pain; however, 5% of patients remain asymptomatic. Among patients with infertility, 50% are found to have some degree of endometriosis [10]. In the last few decades, an increase in the prevalence of severe endometriosis has been observed. It remains a subject of debate; however, this increase in prevalence may be attributed to improved diagnosis and greater awareness among both medical practitioners and members of the public [1]. Bowel endometriosis has been reported to affect 8–12% of all patients, and in 90% of cases, the rectum and sigmoid colon are typically involved [5, 11].
- Endometriosis can have a negative impact on women's health and quality of life often affecting personal relationships as well as leading to absenteeism at work [2]. Contributing health-care costs are also considerable; direct and indirect costs can vary greatly depending on the country and public health system. Direct costs were estimated to range from US\$ 1109 up to US\$ 12,118 and indirect costs from US\$ 3314 up to US\$ 15,737 [12, 13].

Symptoms

- Five percent of endometriosis patients remain asymptomatic. The remaining present with a variety of typical and atypical symptoms. Typical symptoms consist of dyspareunia, dyschesia, dysuria, dysmenorrhea, chronic

pelvic pain, and constipation, which can be used to map the disease allowing surgery to be tailored accordingly. These symptoms can be severe and can significantly impact on women's social life, work, personal relationships, and psychological well-being [14]. Dyspareunia is a common symptom affecting 32–70% of women with endometriosis. It is typically found in conjunction with rectovaginal and uterosacral nodules and can lead to significant pain during intercourse. These patients can present with reduced libido, lack of lubrication, and tension on the perineal muscles, all of which can contribute to pain and a negative experience of sexual intercourse. Dysmenorrhea can be a characteristic for the presence of adenomyosis and can be related to endometriomas. Dysuria is rare but may suggest a nodule involving the urinary tract, more commonly the bladder. Nodules affecting the ureters are largely asymptomatic and can lead to silent kidney loss in advanced cases. Dyschesia while not pathognomonic for intestinal tract involvement can be suggestive of the presence of disease located near the bowel [15]. Constipation is not typically associated with endometriosis but it can often coexist. Urinary and bowel dysfunction can be difficult to diagnose preoperatively. In some cases, urodynamics can be useful in diagnosing underlying bladder dysfunction and can be useful in preoperative counseling of patients while also providing documented evidence in the event of medicolegal dispute [16, 17].

- Chronic painful symptoms encountered in endometriosis can have a compensatory effect on pelvic floor muscle contractions. With time, continuous muscle spasms may themselves contribute to the origin of pain. Careful evaluation of the pelvis may result in the identification of specific trigger points. An evaluation of patients with chronic pelvic pain revealed the presence of trigger points in 58.3% compared to 4.2% in healthy women [18]. Patients with ongoing symptoms of pelvic pain following surgery may benefit from physiotherapy treatment.

Infertility

- Infertility is a matter of preoccupation for all women wishing to conceive [19]. Every year more and more women in developed countries choose to postpone their pregnancies for both social- and work-related reasons. Both age-related infertility and other causes can further impact on fertility and can lead to difficulties conceiving. To date, many causes of infertility have been identified; however, approximately 25% of women continue to suffer from unexplained infertility.
- The link between endometriosis and infertility remains controversial, and the exact etiology is poorly understood. It is the most common disease found in infertile patients, with endometriosis reported in up to 50% of women with infertility. In addition, women with endometriosis have a twofold greater risk of infertility compared to those without [20]. The causal effect of the disease process on infertility is yet to be identified. Stage IV disease is typically associated with distorted anatomy and dense adhesions, which can affect natural conception. Reduced embryo and oocyte quality, in addition to peritoneal inflammation, may also impact on fertility. It is still unclear whether severity of disease has a progressive association on infertility.
- Endometriosis cysts or so-called endometriomas have been the source of much discussion among surgeons and fertility specialists alike. Fertility specialists are often adamant to emphasize the potential negative impact of endometrioma surgery on ovarian reserves, due to the inadvertent removal of healthy tissue during ovarian stripping. For these reasons fertility experts often recommend a more conservative approach to the management of endometriomas, specifically in unilateral disease with endometriomas less than 3–4 cm in size. Some studies have found lower pregnancy rates and live birth rates, in addition to higher gonadotrophin requirements and need for longer ovarian stimulation in patients with a previous history of cystectomy, despite a

similar number of retrieved oocytes compared to the noncystectomy group [21]. Equally, deleterious effects on ovarian function may be a result of poor technique and lack of surgical experience. A meticulous surgical approach with the sparing use of diathermy and careful identification of surgical planes in the hands of an experienced surgeon can optimize ovarian preservation [22–24]. This demonstrates the controversy surrounding infertility in the presence of endometriomas [25, 26]. In addition, it cannot be ignored that in the presence of large endometriomas, specifically bilateral, disease is frequently associated with more extensive pelvic implants. Equally the nonselective use of ART in the presence of large endometriomas may serve as a trigger causing spread of mild endometriosis into more severe disseminated disease, resulting in a more difficult surgical approach [22–24, 27].

Diagnosis

- Accurate diagnosis of endometriosis requires both experience and knowledge of the disease. Patients often consult three to four gynecologists prior to a definitive diagnosis being made. Delay in diagnosis is a common problem worldwide. Developed countries like Germany, Austria, the United Kingdom, and Italy report an overall delay of 7–10 years. Ireland and Belgium report a delay of 4–5 years. In Brazil, diagnosis is delayed by 12.1 years (ranging from 8 to 17.2 years) [28].
- Diagnosis can be divided into clinical and imaging. Symptoms can serve as a useful guide to the clinician, with pain intensity differing from one patient to the next. Dysmenorrhea and dyspareunia are often encountered in the majority of patients. Dysuria, dyschesia, and chronic pelvic pain can also be present and, however, can vary in severity. Symptoms of constipation may not necessarily be related to endometriosis.
- Clinical examination is obligatory and can guide the surgeon as to the complexity of the disease while also prompting specific investigation necessary for a complete preoperative workup. Abdominal palpation can be useful in patients presenting with big endometriomas or even abdominal wall spread. Vaginal examination with a speculum can identify dark cysts of rectovaginal nodules protruding through the posterior cul-de-sac.
- Patient describing pain at the vaginal introitus, in the absence of a palpable nodule, may represent a sign of vaginismus. Deeper evaluation of all fornices can allow for the assessment of bladder nodules anteriorly, uterosacral nodules present at 5 and 7 o'clock, and rectovaginal nodules palpated more centrally. In this case, an acute angle between the nodule and the bowel is less suggestive of bowel invasion, while an obtuse angle represents the opposite. Due to pain experienced during vaginal examination itself, sometimes little information can be retrieved. Examination under anesthesia prior to surgery may provide more clinical information regarding the extent of disease allowing the surgeon to tailor their approach.
- Ultrasound mapping should always be performed as the first-line imaging tool. The method is operator dependent, and results are based on the experience of the individual specialist performing the scan [29]. Ultrasonography should include a complete evaluation of the pelvis including assessment of the renal pelvis, course of the ureters, and verification of whether there is any dilatation of the ureters. Lastly, a detailed analysis of the anterior and posterior cul-de-sac, specifically bowel wall layers, is recommended. This has proved to be a powerful tool in the hands of skilled physicians showing similar results to MRI exams. Mobilization of the probe can also assess for the presence of adhesions.
- Magnetic resonance imaging (MRI) has been reported to have 96.3% of sensibility and 100% of specificity but may vary depending on each evaluated site [29, 30]. The majority of devices use 1.5 Tesla providing good qual-

ity images. Recent use of 3.0 Tesla MRIs creates the possibility of better quality images and, consequently, more accurate diagnosis. Optimal timing for MRI evaluations remains unclear. Some authors advocate that during menstrual period, the uterus may demonstrate pseudo thickening, which can lead to misdiagnosis of adenomyosis [31, 32]. Others suggest that pelvic fluid present either in the periovulatory or menstruation phase can also affect image interpretation. However, most authors recommend a partially empty bladder, in addition to specific bowel preparation with the use of rectal and vaginal gel which provides more information with regard to limits of the pelvic structures [32].

- Irrespective of the benefits of both MRI and ultrasonography, both methods have their drawbacks. Compared to ultrasound, MRI can provide accurate diagnosis of more widespread foci of endometriosis. However, for the assessment of smaller nodules and implants, ultrasound may be more precise. Regardless of the technique or method used, surgeons should be able to retrieve information such as [8]:
 - Size of the lesion (longitudinal and transverse measurements)
 - Depth of an infiltration of the intestinal wall
 - Percentage of the intestinal circumference affected by the disease
 - Distance between the intestinal DIE lesion and anal verge
 - Presence of multifocal/multicentric intestinal DIE lesion
 - Bladder and bowel dysfunction following surgery is often a preoccupation. Urodynamics and anal manometry are useful tests and might demonstrate subtle changes often not recognized by patients. These changes may be suggestive of endometriosis affecting the inferior hypogastric plexus and its branches warning both the surgeon and the patient about the depth of disease and risk of potential functional impairment [33].

Treatment

- Depending on clinical examination, symptomatology, desire to conceive, and patient's wishes, endometriosis can be treated medically or surgically. Surgery should not always be considered first line, and women should be counseled appropriately regarding different treatment options. Patients can be divided into three main groups. The first group includes patients with few symptoms and no desire to conceive in whom medical treatment would be recommended. The second group includes patients with none or few symptoms but strong desire to conceive. These patients should promptly be referred to fertility specialists for further management. The third group consists of patients with severe pain with or without desire to conceive, with a clinical evaluation suggestive of extensive disease. This cohort is more optimally treated by surgery first. It should be emphasized that removal of disease prior to ovarian stimulation may play a positive role on pregnancy rates in women undergoing fertility treatment [34].
- The final group of patients are not often encountered and typically have minimal symptoms; however, coexisting organ failure such as kidney failure or bowel obstruction is present. These patients require surgery to preserve organ function and avoid severe sequelae.

Surgical Treatment

- The main objective of surgical treatment is to remove implants of endometriosis situated within the abdominal cavity. There continues to be much debate as to whether to ablate or excise disease present; this should be considered in the context of severity of disease, patient symptoms and wishes, as well as expertise of the surgeon. There are both general and specific approaches to the surgical management of endometriosis, which have

been reported by our group [35]. Patients should be limited to a minimal number of surgeries considering that repeat procedures are associated with greater risk of adhesion formation and fibrosis making additional surgery more challenging [36].

Peritoneal Endometriosis

- Peritoneal endometriosis is one of the trending topics nowadays. Superficial lesions were once been described as nonprogressive, typically undergoing self-limiting apoptosis. In theory, removing these spots should provoke scar formation as a result of the surgical intervention, causing permanent fibrosis. However, there is still no evidence as to which kind of lesion undergoes apoptosis or not [37]. Pain is usually related to deeper lesions as a result of intense inflammation, increased neural terminations, adhesions, or retraction [38]. Superficial lesions can also cause pain caused by imbalance in nerve fibers [39]. Some authors have demonstrated that even these small lesions may be responsible for significant painful symptoms. For this reason, emphasis is placed on the initial surgical intervention being conducted by an experienced surgical team with the specific skills to remove all disease while minimizing adhesion formation [36] (Fig. 9.1).

Ovarian Endometriosis

- Ovarian endometriosis is present in 22% of infertile women [35]. It can be accountable for symptoms of infertility, and thus, follicle evaluation and anti-Müllerian hormone should be included in preoperative investigations. Asymptomatic cysts less than 3–4 cm in size, found during routine examination, can be followed up with regular ultrasound. Management of larger endometriosis cysts incidentally found on ultrasound, on MRI, or during laparoscopy represents an endless discussion whether they should be completely removed or not due to the supposed damage to the ovarian reserve. Infertility experts defend cyst drainage with vaporization of the cyst wall, advocating minimal additional damage to surrounding normal ovarian tissue. Some surgeons defend the use of plasma jet or CO₂ laser ablation of the cyst capsule in order to minimize damage to normal ovarian tissue. Laparoscopic treatment consists of cyst drainage and vaporization with bipolar when less than 3–4 cm in size. For bigger cysts, inversion of the ovary facilitates stripping of the capsule. Precise technique with identification and dissection of the cleavage plane causes limited bleeding to the capsule, thereby limiting damage. There are pros and cons associated with both surgical approaches. Ablative

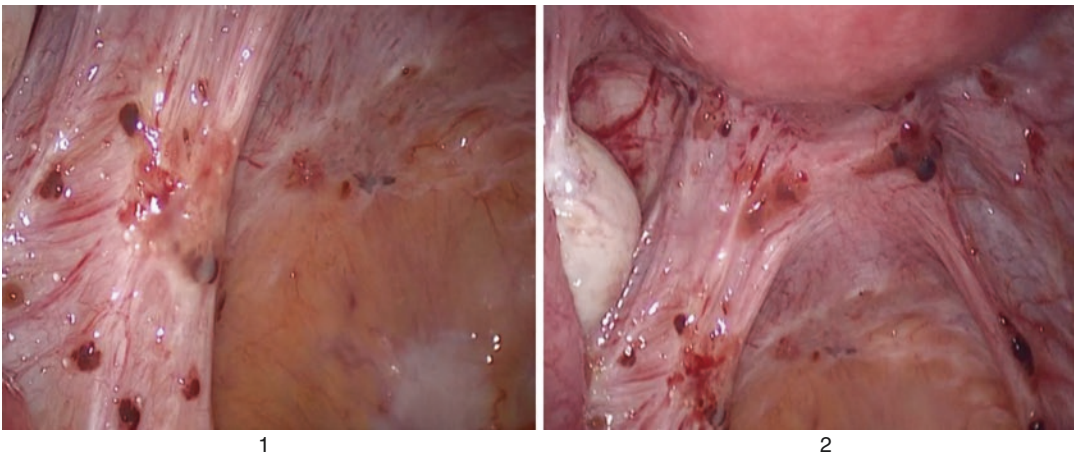


Fig. 9.1 Superficial endometriotic lesions

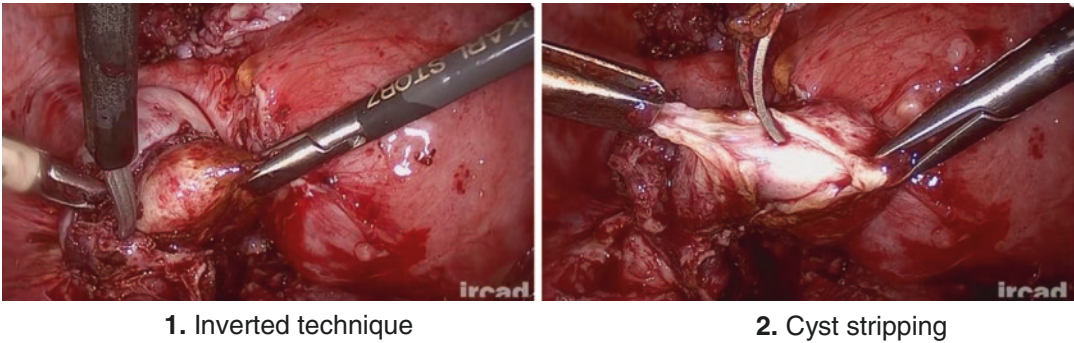


Fig. 9.2 Endometrioma stripping technique

techniques can lead to recurrent disease requiring additional surgery. In the long term, this could cause more damage to the ovarian reserve [40]. Equally, precise and careful stripping of the cyst wall is technically more challenging and can negatively impact on ovarian reserve but is associated with a lower rate of recurrence when performed by experienced surgeons (Fig. 9.2).

Posterior Cul-De-Sac

- The majority of cases of deep endometriosis involving the posterior cul-de-sac typically consists of ovaries attached to the ovarian fossa and uterosacral ligaments. Depending on the extent and severity of disease, it can extend to involve the vaginal wall, the ureters, the rectovaginal septum, and bowel. Surgeons expected to treat complex endometriosis must be aware that, even with good preoperative workup, the true extent of disease may be unexpected, making surgery more challenging. Surgical management of deep endometriosis can be both demanding and difficult and requires expertise in dissection, electrosurgery, transversal competences, and management of complications during and after surgery. Endometriotic nodules can often mimic icebergs, appearing on the surface as superficial disease, while deep nodules infiltrating surrounding tissue lie concealed. Strategy consists of identifying and normalizing anatomy and isolating the nodule from surrounding structures. For example, for simple uterosacral nodule dissection, one should be aware of the superficial hypogastric nerves, uterine vessels, ureters, and also bowel wall, even if not directly infiltrating these organs [35]. Ureters are often medialized due to the presence of adhesions. Dissection might reach the posterior aspect of the paracervix which can result in damage to uterine vessels, highlighting the need for precise coagulation. In the same manner, the underlying nerve plexus may be trapped within the disease requiring the surgeon to carefully consider whether to excise the disease and risk damage to the innervation or leave it in place in order to preserve bladder and bowel function [41].
- The frozen pelvis as a result of adhesion formation results in severe distortion of the anatomy. They can be caused by multiple adhesions due to repetitive surgeries, pelvic inflammatory disease, or stage IV endometriosis. A standardized strategic approach to a frozen pelvis starts with identification and understanding of the anatomical landmarks, followed by adequate exposure of the surgical field. Dissection should start on the left pelvic side wall with identification of the IP ligaments and the left ureter followed by dissection of the left pararectal fossa down to the uterosacral ligaments avoiding injury to the inferior hypogastric nerve. The ovaries are freed, and endometriomas if present are decompressed and suspended to the anterior abdominal wall if necessary. The same technique is repeated on the right side trying to isolate the bowel attachment and nodule.

These gestures diminish the amount of uncertainty when detaching the bowel nodule from the cervix/vagina. Further evaluation of the bowel should be performed to decide which specific surgical approach should be adopted.

Vaginal Endometriosis

- Nodules on the posterior cul-de-sac are often related to dyspareunia (Chapron). Vaginal nodules lie in close relationship with the torus uterus, paracervix, ureters, and bowel and should be excised with extreme caution. Deep nodules may represent full-thickness disease of the vaginal wall and can be palpated on digital examination of the posterior compartment of the vagina. Frequently, during dissection, the surgeon much addresses large nodules attaching the vagina to the rectosigmoid. Associated digital vaginal examination and cranial traction of the sigmoid by the assistant help to guide the surgeon and identify the anatomical limits of these different organs. Superficial excision of these nodules can be achieved in some cases avoiding vaginal wall opening. If the depth of nodule infiltration compels the surgeon to open the vagina, this defect should be closed with monofilament sutures to avoid granulomas and further dyspareunia. Adenomyomas of the uterine torus with extension to the vagina demand extreme expertise due to their close proximity to the cervical canal and associated risk of stenosis (Fig. 9.3).

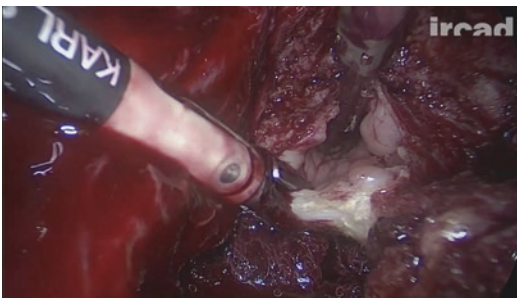


Fig. 9.3 Open vagina demonstrating nodule affecting the complete deepness of the vagina

Bowel Endometriosis

- Bowel endometriosis is only considered when it infiltrates the muscular layer [42]. Although simple attachments and serosal involvement are not incorporated into this classification, careful dissection of the surrounding structures and specific evaluation of the bowel are essential so as not to leave residual disease behind. Nodules are typically solitary accounting for 60–70% of the cases. Multifocal bowel endometriosis is defined as nodules greater than 2 cm in diameter, with multiple foci of nodules exist located greater than 2 cm from one another [43]. Treatment should be individualized and balanced according to the patient's desire, symptomatology, size of the nodule, lumen stenosis, and risk of possible complications.
- Initially bowel surgery performed by colorectal surgeons resulted in long segments of bowel resections due to adopting a radical oncology type approach to surgery. As practice evolved, in conjunction with greater experience and understanding by gynecologists, the way of managing the disease made more economical approaches possible. Bowel shaving, as the name suggests, describes specific excision of disease from the bowel wall where a variety of instruments can be used (cold scissors, monopolar energy, plasma jet, laser, etc.). Mucosal skinning is a variation of this technique when ablation of the disease only spares the mucosa. Depending on the result and damage of the muscular, reinforcement with sutures may be necessary. Discoid resections consist of full-thickness resection of the anterior bowel wall. It is indicated when the disease compromises the entire bowel wall until the mucosa; however, its size is limited to a maximum of 3 cm in diameter. It is a fast and simple procedure, with low rate of complications. Rectal bleeding following discoid resection has been reported in the literature and may be the result of lateral mesosigmoid vessels becoming trapped into the edges of the resection margins.
- Whether a radical approach should be adopted ensuring complete excision of all endometriosis

sis cells and evidence of disease with clear resection margins has been the matter of much debate. It is important to emphasize that this is not a malignant disease with some research suggesting death of the surrounding cells when the main bulk of disease is resected [44]. It is important to consider that more economical resections result in fewer functional complications [37]. Extensive dissections can cause damage to the inferior hypogastric plexus and neural terminations leading to permanent damage and functional problems.

Shaving

- Lesions affecting the superficial layers of the sigmoid rectum can be treated using “shaving” technique. After isolating the specific lesion, the bowel wall is incised, and the disease is peeled off separating it from the bowel. Once excision is complete, the remaining defect is assessed, and depending on the depth and size of the shaved rectal wall, reinforcement of the wall with an overlaying suture or even an anterior discoid stapling may be indicated. A careful reevaluation of the remaining suture or stapling line is mandatory. In the presence of extensive “shaving,” if the remaining bowel wall appears fragile and friable after suturing or substantial residual disease left behind, the surgeon should consider a segmental resection [45] (Fig. 9.4).

Discoid Resection

- Discoid resection is considered a simple, reliable, low-morbidity, and reproducible method. The technique is based on an anterior discoid

resection of the bowel wall. The circular stapler connected to the anvil is introduced through the anus up to the level of the disease. The system is opened, and with a suture attached to the lesion, the surgeon pushes the nodule inside the system. With an anterior orientation, the second assistant closes the anvil shooting the system with the nodule inside. Careful retraction of the stapler is needed not to cause tension on the stapling line. Limitations mainly include diameter, volume, and location of the disease, in addition to high lesions that are impossible to reach with the circular stapler. Nodules greater than 3–3.5 cm are considered too large for this type of approach [46].

- For bulky nodules an interesting option is to combine the shaving technique with a discoid resection. Excising the greater part of the nodule makes the bowel wall thinner, enabling it to fit inside the anvil (Fig. 9.5).

Segmental Resection

- Advanced bowel endometriosis usually presents with large, extensive, and multifocal disease. Individual excision of these nodules might leave the bowel wall fragile, extremely angulated, or even stenotic. Nevertheless, segmental bowel resections in deep endometriosis should maintain an economical approach to treatment [35]. The majority of nodules affecting the bowel wall can be found attached to the posterior aspect of the uterus. After development of both pararectal fossae and detachment of the bowel from the torus, the surgeon should identify the cranial and caudal limits of the dis-

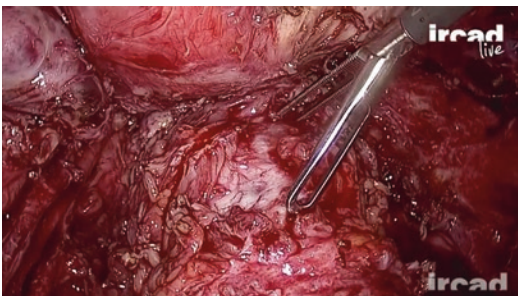


Fig. 9.4 Shaving of the rectal wall demonstrating

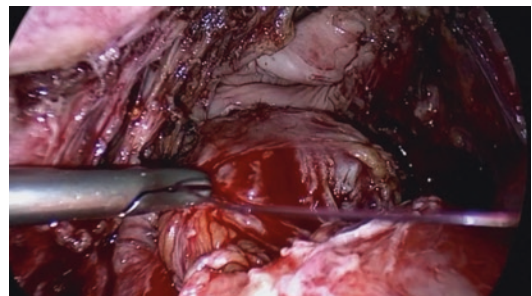


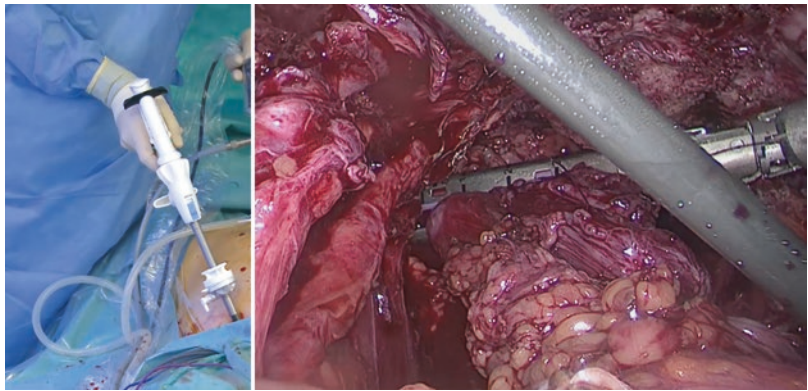
Fig. 9.5 Anterior rectal wall disc excision

ease bowel segment [47]. The mesosigmoid should be divided close to the bowel wall internal to the fascia propria of the rectum, thus sparing innervation and vascularization of the bowel. The caudal limit of the bowel segment is divided by means of a linear stapler, with exteriorization of the proximal part through a suprapubic incision. Extracorporeally, the diseased bowel segment is divided above the nodule; the anvil is introduced through this proximal segment and secured with a purse string suture. After resection of the diseased segment, the bowel is reintroduced into the abdominal cavity; a circular stapler is introduced in the rectum and both proximal and terminal extremities of the rectum reconnected. When firing the stapler, the surgeon should maintain the orientation of the bowel, making sure no surrounding structures are trapped between the anvil and the circular stapler (Fig. 9.6).

Natural Orifice Specimen Extractions (NOSE)

- Natural orifice specimen extractions in endometriosis are feasible but logistically complex.

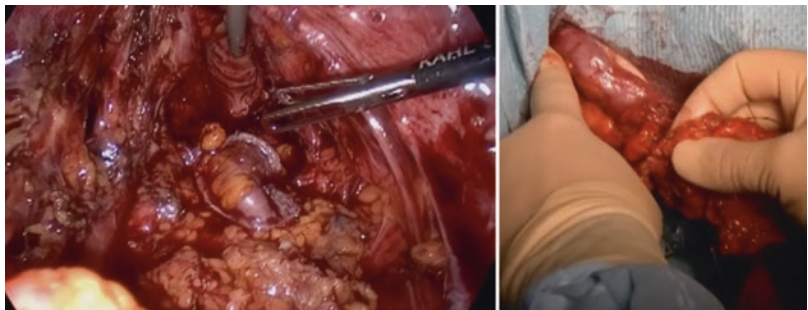
Fig. 9.6 Segmental bowel resection for rectal endometriosis nodule



Vaginal and anal extractions have been tested with excellent results and low morbidity. These techniques require longer length of the bowel to be mobilized and exteriorized through the anus, requiring more mesosigmoid to be divided, increasing the risk of compromising innervation and vascularization of the bowel [48].

- The fact that two suture lines lie in close proximity to one another can raise the risk of fistula formation. Vaginal NOSE should be only considered if the anvil can be introduced proximal to the lesion transanally. The bowel is divided caudal to the lesion and extracted through the vagina. The anvil, attached to a long suture, is introduced through a small incision and retrogradely displaced high in the sigmoid colon. Then the proximal segment of the bowel is divided cranial to the nodule with a laparoscopic stapler. The suture attached to the anvil is caught in the staple line. The specimen is extracted through the vagina and the anvil connected to the circular stapler reconstituting the anatomy of the bowel [49] (Fig. 9.7).

Fig. 9.7 Vaginal NOSE



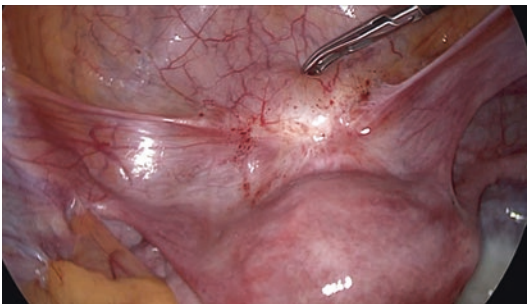
- Anal extraction is logistically more complex and demands a close collaboration among surgeons. A loop is placed below from the nodule and the rectosigmoid transected. After exteriorization, the anvil is introduced through the transected extremity attached to a long thread and pushed cranially. The rectum is once again divided cranially to the area of disease and reintroduced in the cavity. Once inside, the tip of the anvil is exteriorized through the rectosigmoid wall by fishing out the suture. The tip is removed and the anvil attached to the circular stapler. Once the reanastomosis is complete, the integrity of the anastomosis is tested by means of a gas and methylene blue safety. If positive, a reinforcement of the wall can be performed with sutures.
- Extensive manipulation of an open bowel wall has triggered discussions surrounding the morbidity related to bacterial contamination. Studies have shown that despite higher contamination, clinical outcomes were similar to those submitted to standard approach [50].

Urinary Endometriosis

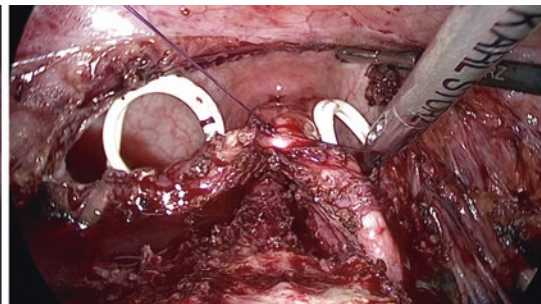
- Endometriosis affects the urinary tract in 1–5% of all patients. The bladder and ureter are, by far, the most commonly affected structures, while disease involving the kidney and urethra are rare. The ratio between both bladder and ureter involvements is approximately 8:1 making the bladder the most affected organ of the urinary tract [51].
- Bladder endometriosis can be divided into superficial and deep nodules. Superficial nod-

ules are often identified at surgery, and women typically remain asymptomatic. Deep nodules, however, typically invade the detrusor muscle greater than 5 mm in depth. The majority of nodules are distributed centrally, situated mainly at the bladder dome. Disease involving the trigone is less commonly encountered and is perhaps suggestive of disease dissemination from adenomyosis arising from the myometrium. Symptoms are more frequently encountered in deep infiltrating nodules and may include monthly dysuria, polyuria, tenesmus, and hematuria. Symptoms may temporarily be relieved with hormonal treatment; however, if discontinued, they often recur.

- Laparoscopic partial cystectomy is considered to be the gold standard of treatment. Complete removal of the disease often alleviates symptoms with little risk of relapse. Endometriosis involving the trigone is a complex disease due to the proximity of the ureter and risk of damage to bladder innervation. A structured surgical technique should be adopted. Analogs can be considered to decrease the size of the nodule, thereby increasing the distance of disease from the ureter. If nodules include the ureteral ostium, reimplantation may be required. Bladder closure can be performed using interrupted or continuous sutures in one or two layers. In our practice, we typically use monofilament. Postoperatively, the bladder should be rested by means of an indwelling urethral catheter for at least 10 days, allowing the bladder to heal and inflammation to resolve (Fig. 9.8).



1. During inspection



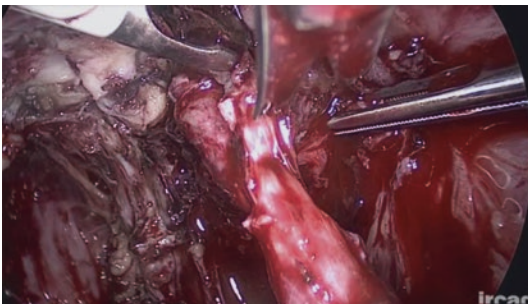
2. During bladder suture

Fig. 9.8 Bladder endometriosis nodule

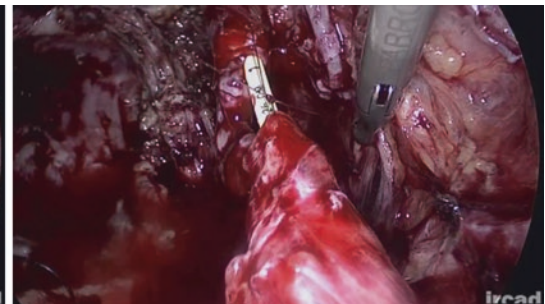
- While bladder nodules more often occur in isolation, ureteral disease is frequently associated with endometriosis involving the posterior cul-de-sac. Disease involving the left ureter is more frequently encountered, but bilateral disease is reported in 5–23% of cases. Extrinsic endometriosis surrounds the ureter and represents 70–80% of ureteral involvement. Intrinsic disease infiltrates the muscular or mucosa wall and accounts for 20–30% of cases. Specific symptoms are vague, occur in 70% of cases, and can include renal colic and pyelonephritis [51]. Silent renal loss is the most concerning complication in urinary endometriosis and may occur in up to 30% of cases. Preoperative workup may include ultrasound, uroCT, and uroMRI that can be performed if deemed necessary. Ureteric stenting may be indicated prior to surgery depending on the clinical history. Severity of the disease will dictate surgical management of ureteric endometriosis. Ureterolysis in isolation can be performed when there is no intrinsic disease and the ureter is easily dissected. Intrinsic and/or extensive involvement may require resection of the diseased segment and subsequent end-to-end reanastomosis. If following removal of disease there is insufficient remaining length of the ureter, a primary end-to-end anastomosis is impossible, and a psoas hitch may be needed [53]. Do not speak about Boari flap because it is poorly indicated in this benign disease (Fig. 9.9).

Postoperative Care

- Surgery for complex cases of endometriosis requires a team of experts with extensive knowledge of anatomy, understanding of transversal competencies, and meticulous attention to postoperative care. Daily, incremental improvements in the overall patient's clinical state should be observed, and any deterioration in the clinical picture should raise suspicion of a complication, and an early second look laparoscopy should be considered. Simple endometriosis cases can be discharged on the same day. More complex cases with bowel or urinary tract involvement may require hospitalization for 2–7 days. Antibiotics can be administered as a single dose when the vagina is opened or continued for 7 days if the bowel wall is breached [1]. At present, there are no specific blood tests to identify complications and guide an early second-look laparoscopy. C-reactive protein is a serum marker of inflammatory activity and tends to drop daily after surgery. Use of silicon drain depends on individual practice and experience of each surgical group. There is insufficient evidence to advocate the use of routine pelvic drainage; however, some clinicians may find it helpful in deciding on a second look and as an early detector of anastomotic leaks.
- The inferior hypogastric plexus is responsible for bowel, bladder, vagina, and uterus innervation [54]. Big endometriotic nodules, espe-



1. Ureterolysis of the ureter



2. End to end anastomosis

Fig. 9.9 Ureter endometriosis

cially those which invade the deep lateral aspects of pararectal fossae, might be damaged from endometriosis or from dissection [38]. Damage can reach every single part of the plexus but the most affected organ is the bladder [41]. If mostly sympathetic fibers are affected, patients may suffer from urgency and incontinence. If the parasympathetic fibers are involved, the bladder fails to contract appropriately resulting in incomplete voiding difficulties. These symptoms are typically transient and often resolve after weeks or months. Symptoms lasting for greater than 1.5 years have a greater risk of remaining permanent [55].

Complications

Surgical excision of deep endometriosis is both demanding and requires a high degree of expertise due to the involvement of surrounding structures such as the vagina, ureters, and bowel. While complete excision has been shown to control symptoms and reduce the rate of recurrence, radicality of surgery must be balanced against the risk of complications. Complication rates in endometriosis surgeries tend to be higher than in other gynecological procedures and should be performed by a competent, experienced surgeon in a specialist center in order to achieve acceptable complication rates. The complexity of endometriosis surgery and risk of associated complications can be attributed to the disease itself. Structures tend to be densely adherent to one another, making it difficult to distinguish and dissect organs from surrounding structures such as vessels and nerves. Overall complication rates associated with endometriosis surgery are reported to be around 10.2% but can increase depending on severity of disease and specific organ involvement [56].

The rate of complications associated with excision of bladder nodules is often low. The majority of nodules are located at the dome of the bladder, far away from the trigone. In 22 cases reported by Kovoov et al., major complications were mainly related to concomitant bowel procedures. No intraoperative injuries were reported.

Postoperative complications included two hematomas requiring transfusion and re-intervention and two vesicovaginal fistulas, one treated by laparoscopy and the other conservatively by means of an indwelling catheter for 15 days [52].

Ureteric injuries are often associated with retrovaginal nodules due to the presence of fibrosis and retraction resulting in medialization of the ureter with dense disease often surrounding the ureter. In 198 cases of ureteral endometriosis, Alves et al. reported 28 cases of hydronephrosis, where 15 ureterolyses, 12 reanastomoses, and 1 reimplantation were performed. Of these, three patients (10.7%) required further surgical management for treatment of ureterovaginal fistula, persistent pain, and ureteral dilatation [53].

Complications related to specific bowel involvement are more common and are associated with significant morbidity. Pandis reported 8.5% of complications when shaving; discoid and segmental resections were performed. Four patients were readmitted, two with pelvic hematoma, of whom only one required further surgical intervention. Of the other two, one presented with constipation and the other with rectal hemorrhage [56]. Ruffo et al. in 2012 reviewed 750 cases of mid-low rectum resection. Reoperation was necessary in 5.5% (40 patients). Anastomotic leakage was found in 3% (21 patients). Sixteen patients (2%) developed rectovaginal fistula, only two treated conservatively [57]. Another review from Kondo in 2010 reported 12 (2.1%) intraoperative complications including 2 ureteral lesions and 2 small bowel lesions [58]. Seventy-nine women (13.9%) presented with postoperative complications including eight cases of rectovaginal fistula, six ureteral fistula, two ureteral stenosis, and one ureterovaginal fistula. Donnez et al. in a series of 500 rectal shavings reported rectal perforation in 7 patients (1.4%) and 4 cases (0.8%) of urinary retention [59]. When evaluating functional outcomes in 41 patients, Roman et al. reported a higher rate or bowel dysfunction in patients who underwent segmental bowel resection when compared to economical nodule excision. Three patients from the segmental resection group reported severe constipation [17, 41].

Conclusion

Endometriosis is a complex, challenging, enigmatic disease. The true pathophysiology of this unique disease is yet to be elucidated. What should remain at the forefront of discussion when contemplating surgical management is to individualize treatment according to patient symptoms and disease localization. Endometriosis appears to be on the increase part of which may be attributed to greater awareness of the disease process within the public domain. Nevertheless, delay in diagnosis remains a reality due to lack of knowledge related to often subtle, nonspecific symptoms often overlooked by general practitioners. Ultrasound mapping and MRI are powerful tools in diagnosis but are dependent on interpretation by experienced operators and radiologists. Medical treatment is useful at initial stages of disease but should also be considered as an adjuvant in the presence of deep lesions or long-term infertility. Laparoscopic treatment of endometriosis is still considered the gold standard with enormous benefits, and its use should be encouraged and disseminated.

References

- Koninckx PR, Ussia A, Adamyan L, Wattiez A, Donnez J. Deep endometriosis: definition, diagnosis, and treatment. *Fertil Steril.* 2012;98(3):564–71.
- Studio dell'Endometriosi lo GIP. Prevalence and anatomical distribution of endometriosis in women with selected gynaecological conditions: results from a multicentric Italian study. Gruppo italiano per lo studio dell'endometriosi. *Hum Reprod.* 1994;9(6):1158–62.
- Sherif AM, Musa ER, Kedar R, Fu L. Subcapsular hepatic endometriosis: case report and review of the literature. *Radiol Case Rep.* 2016;11(4):303–8.
- Sampson JA. Metastatic or embolic endometriosis, due to the menstrual dissemination of endometrial tissue into the venous circulation. *Am J Pathol.* 1927;3(2):93–110.43.
- Batt RE, Smith RA, Buck Louis GM, Martin DC, Chapron C, Koninckx PR, et al. Müllerianosis. *Histol Histopathol.* 2007;22(10):1161–6.
- Abrao MS, Muzii L, Marana R. Anatomical causes of female infertility and their management. *Int J Gynaecol Obstet.* 2013;123(S2):S18–24.
- Yu J-J, Sun H-T, Zhang Z-F, Shi R-X, Liu L-B, Shang W-Q, et al. IL15 promotes growth and invasion of endometrial stromal cells and inhibits killing activity of NK cells in endometriosis. *Reproduction.* 2016;152(2):151–60.
- Trippia CH, Zomer MT, Terazaki CRT, Martin RLS, Ribeiro R, Kondo W. Relevance of imaging examinations in the surgical planning of patients with bowel endometriosis. *Clin Med Insights Reprod Health.* 2016;10:1–8.
- ASRM. Revised American Society for Reproductive Medicine classification of endometriosis: 1996. *Fertil Steril.* 1997;67(5):817–21.
- Dunselman GAJ, Vermeulen N, Becker C, Calhaz-Jorge C, D'Hooghe T, De Bie B, et al. ESHRE guideline: management of women with endometriosis. *Hum Reprod.* 2014;29:400–12.
- Akladios C, Faller E, Afors K, Puga M, Albornoza J, Redondo C, et al. Totally laparoscopic intracorporeal anastomosis with Natural Orifice Specimen Extraction (NOSE) techniques, particularly suitable for bowel endometriosis. *J Minim Invasive Gynecol.* 2014;21(6):1–24.
- Simoens S, Dunselman G, Dirksen C, Hummelshøj L, Bokor A, Brandes I, et al. The burden of endometriosis: costs and quality of life of women with endometriosis and treated in referral centres. *Hum Reprod.* 2012;27(5):1292–9.
- Soliman AM, Yang H, EX D, Kelley C, Winkler C. The direct and indirect costs associated with endometriosis: a systematic literature review. *Hum Reprod.* 2016;31(4):712–22.
- De Graaff AA, Van Lankveld J, Smits LJ, Van Beek JJ, Dunselman GAJ. Dyspareunia and depressive symptoms are associated with impaired sexual functioning in women with endometriosis, whereas sexual functioning in their male partners is not affected. *Hum Reprod.* 2016;31(11):2577–86.
- Renner SP, Boosz AS, Burghaus S, Maihöfner C, Beckmann MW, Fasching PA, et al. Visual pain mapping in endometriosis. *Arch Gynecol Obstet.* 2012;286(3):687–93.
- Rozsnyai F, Roman H, Resch B, Dugardin F, Berrocal J, Descargues G, et al. Outcomes of surgical management of deep infiltrating endometriosis of the ureter and urinary bladder. *JSLs.* 2011;15(4):439–47.
- Roman H, Loisel C, Resch B, Tuech JJ, Hochain P, Leroi AM, et al. Delayed functional outcomes associated with surgical management of deep rectovaginal endometriosis with rectal involvement: giving patients an informed choice. *Hum Reprod.* 2010;25(4):890–9.
- Bispo Dos APS, Ploger C, Loureiro AF, Sato H, Kolpeman A, Girão MJBC, et al. Assessment of pelvic floor muscles in women with deep endometriosis. *Arch Gynecol Obstet.* 2016;294(3):519–23.
- Somigliana E, Paffoni A, Busnelli A, Filippi F, Pagliardini L, Vigano P, et al. Age-related infertility and unexplained infertility: an intricate clinical dilemma. *Hum Reprod.* 2016;31(7):1390–6.

20. Prescott J, Farland LV, Tobias DK, Gaskins AJ, Spiegelman D, Chavarro JE, et al. A prospective cohort study of endometriosis and subsequent risk of infertility. *Hum Reprod.* 2016;31(7):1475–82.
21. Roustan A, Perrin J, Debals-Gonthier M, Paulmyer-Lacroix O, Agostini A, Courbiere B. Surgical diminished ovarian reserve after endometrioma cystectomy versus idiopathic DOR: comparison of in vitro fertilization outcome. *Hum Reprod.* 2015;30(4):840–7.
22. Witz CA, Burns WN. Endometriosis and infertility: is there a cause and effect relationship? *Gynecol Obstet Investig.* 2002;53(Suppl 1):2–11.
23. Witz CA, Allsup KT, Montoya-Rodriguez IA, Vaughan SL, Centonze VE, Schenken RS. Pathogenesis of endometriosis—current research. *Hum Fertil (Camb).* 2003;6(1):34–40.
24. Santulli P, Lamau MC, Marcellin L, Gayet V, Marzouk P, Borghese B, et al. Endometriosis-related infertility: ovarian endometrioma per se is not associated with presentation for infertility. *Hum Reprod.* 2016;31(8):1765–75.
25. Muzii L, Achilli C, Bergamini V, Candiani M, Garavaglia E, Lazzeri L, et al. Comparison between the stripping technique and the combined excisional/ablative technique for the treatment of bilateral ovarian endometriomas: a multicentre RCT. *Hum Reprod.* 2015;31(2):339–44.
26. Ata B, Urman B. Endometrioma excision and ovarian reserve; do assessments by antral follicle count and anti-Müllerian hormone yield contradictory results? *Hum Reprod.* 2014;29(12):2852–4.
27. Centini G, Afors K, Murtada R, Argay IM, Lazzeri L, Akladios CY, et al. Impact of laparoscopic surgical management of deep endometriosis on pregnancy rate. *J Minim Invasive Gynecol.* 2016;23(1):113–9.
28. Santos TMV, Pereira AMG, Lopes RGC, Depes DDB. Lag time between onset of symptoms and diagnosis of endometriosis. *Einstein (São Paulo).* 2012;10(1):39–43.
29. Abrao MS, Goncalves MODC, Dias JA, Podgaec S, Chamie LP, Blasbalg R. Comparison between clinical examination, transvaginal sonography and magnetic resonance imaging for the diagnosis of deep endometriosis. *Hum Reprod.* 2007;22(12):3092–7.
30. Hottat N, Larrousse C, Anaf V, Noel J-C, Matos C, Absil J, et al. Endometriosis: contribution of 3.0-T pelvic MR imaging in preoperative assessment—initial results. *Radiology.* 2009;253(1):126–34.
31. Manganaro L, Vittori G, Vinci V, Fierro F, Tomei A, Lodise P, et al. Beyond laparoscopy: 3-T magnetic resonance imaging in the evaluation of posterior culde-sac obliteration. *Magnetic Resonance Imaging.* 2012;30(10):1432–8.
32. Bazot M, Bharwani N, Huchon C, Kinkel K, Cunha TM, Guerra A, et al. European society of urogenital radiology (ESUR) guidelines: MR imaging of pelvic endometriosis. *Eur Radiol.* 27(7):2765–75.
33. Spagnolo E, Zannoni L, Raimondo D, Ferrini G, Mabrouk M, Benfenati A, et al. Urodynamic evaluation and anorectal manometry pre- and post-operative bowel shaving surgical procedure for posterior deep infiltrating endometriosis: a pilot study. *J Minim Invasive Gynecol.* 2014;21(6):1080–5.
34. Centini G, Afors K, Murtada R, Argay IM, Lazzeri L, Akladios CY, et al. The impact of laparoscopic surgical management of deep endometriosis on pregnancy rate. *J Minim Invasive Gynecol.* 2015;23(1):1–26.
35. Wattiez A, Puga M, Alborno J, Faller E. Surgical strategy in endometriosis. *Best Pract Res Clin Obstet Gynaecol.* 2013;27(3):381–92.
36. Koninckx PR, Gomel V. Introduction: quality of pelvic surgery and postoperative adhesions. *Fertil Steril.* 2016;106(5):991–3.
37. Koninckx PR, Donnez J, Brosens I. Microscopic endometriosis: impact on our understanding of the disease and its surgery. *Fertil Steril.* 2016;105(2):305–6.
38. Anaf V, Nakadi EI, De Moor V, Chapron C, Pistofidis G, Noël JC. Increased nerve density in deep infiltrating endometriotic nodules. *Gynecol Obstet Investig.* 2011;71(2):112–7.
39. Arnold J, de Arellano MLB, Ruster C, Vercellino GF, Chiantera V, Schneider A, et al. Imbalance between sympathetic and sensory innervation in peritoneal endometriosis. *Brain Behav Immun.* 2012;26(1):132–41.
40. Hart RJ HMMPBW. Excisional surgery versus ablative surgery for ovarian endometriomata (Review). 2013 Jan 1;:1–33.
41. Mei Zhang X, Feng Huang X, Xu H, Quinn M. Endometriosis: a consequence of varying injuries to pelvic autonomic nerves. *Fertil Steril. American Society for Reproductive Medicine.* 2012;98(6):e29.
42. CHAPRON C, Bourret A, CHOPIN N, Dousset B, Leconte M, Amsellem-Ouazana D, et al. Surgery for bladder endometriosis: long-term results and concomitant management of associated posterior deep lesions. *Hum Reprod.* 2010;25(4):884–9.
43. Anaf V, Nakadi EI, Simon P, Van de Stadt J, Fayt I, Simonart T, et al. Preferential infiltration of large bowel endometriosis along the nerves of the colon. *Hum Reprod.* 2004;19(4):996–1002.
44. Donnez J. Endometriosis: enigmatic in the pathogenesis and controversial in its therapy. *Fertil Steril.* 2012;98(3):509–10.
45. William Kondo, Reitan Ribeiro, Carlos Trippia, Monica Tessmann Zomer. Laparoscopic treatment of deep infiltrating endometriosis affecting the rectosigmoid colon: nodulectomy or segmental resection? *Gynecol Obstet.* 2013;03(01).
46. Afors K, Murtada R, Centini G, Fernandes RP, Meza C, Castellano J, et al. Employing laparoscopic surgery for endometriosis. *Womens Health.* 2014 Jul;10(4):431–43.
47. Afors K, Centini G, Fernandes RP, Murtada R, Zupi E, Akladios C, et al. Segmental and discoid resection are preferential to bowel shaving for medium-term symptomatic relief in patients with bowel endometriosis. *J Minim Invasive Gynecol.* 2016;23(7):1123–9.

48. Cherif Akladios MP, Emilie Faller MD, Karolina Afors MD, Marco Puga MD, Jaime Albornoz MD, Christina Redondo MD, et al. Totally laparoscopic intracorporeal anastomosis with Natural Orifice Specimen Extraction (NOSE) techniques, particularly suitable for bowel endometriosis. *J Minim Invasive Gynecol.* 2014;21(6):1–24.
49. Messori P, Faller E, Albornoz J, Leroy J, Wattiez A. Laparoscopic Sigmoidectomy for Endometriosis With Transanal Specimen Extraction. *J Minim Invasive Gynecol.* 2013;20(4):412.
50. Costantino FA, Diana M, Wall J, Leroy J, Mutter D, Marescaux J. Prospective evaluation of peritoneal fluid contamination following transabdominal vs. transanal specimen extraction in laparoscopic left-sided colorectal resections. *Surg Endosc.* 2011;26(6):1495–500.
51. Antonelli A. Urinary tract endometriosis. *Urologia.* 2012;79(3):167–70.
52. Kovoor E, Nassif J, Miranda-Mendoza I, Wattiez A. Endometriosis of bladder: outcomes after laparoscopic surgery. *J Minim Invasive Gynecol.* 2010;17(5):600–4.
53. Alves J, Puga M, Fernandes RP, Pinton A, Miranda I, Kovoor E, et al. Laparoscopic management of ureteral endometriosis and hydronephrosis associated with endometriosis. *J Minim Invasive Gynecol.* 2017;24(3):466–72.
54. Bertrand MM, Alsaid B, Droupy S, Ripoche J, Benoit G, Adalian P, et al. Anatomical basis of the coordination between smooth and striated urethral and anal sphincters: loops of regulation between inferior hypogastric plexus and pudendal nerve. Immunohistological study with 3D reconstruction. *Surg Radiol Anat.* Springer Paris; 2016:1–10.
55. Ceccaroni M, Clarizia R, Alboni C, Ruffo G, Bruni F, Roviglione G, et al. Laparoscopic nerve-sparing transperitoneal approach for endometriosis infiltrating the pelvic wall and somatic nerves: anatomical considerations and surgical technique. *Surg Radiol Anat.* 2010;32(6):601–4.
56. Pandis GK, Saridogan E, Windsor ACJ, Gulumser C, Cohen CRG, Cutner AS. Short-term outcome of fertility-sparing laparoscopic excision of deeply infiltrating pelvic endometriosis performed in a tertiary referral center. *Fertil Steril.* 2010;93(1):39–45.
57. Ruffo G, Sartori A, Crippa S, Partelli S, Barugola G, Manzoni A, et al. Laparoscopic rectal resection for severe endometriosis of the mid and low rectum: technique and operative results. *Surg Endosc.* 2012;26(4):1035–40.
58. Kondo W, Bourdel N, Tamburro S, Cavoli D, Jardon K, Rabischong B, et al. Complications after surgery for deeply infiltrating pelvic endometriosis. *BJOG Int J Obstet Gynaecol.* 2011;118(3):292–8.
59. Donnez J, Squifflet J. Complications, pregnancy and recurrence in a prospective series of 500 patients operated on by the shaving technique for deep rectovaginal endometriotic nodules. *Hum Reprod.* 2010;25(8):1949–58.



Endometrioma and Ovarian Reserve: A Surgical Approach

10

María-Angeles Martínez-Zamora, Gemma Casals, Sara Peralta, and Francisco Carmona

Introduction

Ovarian endometriomas (OEs) are cysts found in the ovaries with ectopic endometrial tissue lining. They occur in 17–40% of patients with endometriosis [1]. The origin of OE is unknown; however, they may originate from progressive invagination of the ovarian cortex after accumulation of menstrual debris from the shedding of superficial active implants [2]. OEs are usually associated with the symptoms of dysmenorrhea, chronic pelvic pain, dyspareunia, and infertility. Nevertheless, the effect of OE on women's fertility is still debated and controversial. Possible mechanisms of infertility among women with OEs and endometriosis include anatomical distortion, the toxic influence of peritoneal fluid, decreased oocyte and/or embryo quality, defective endometrial receptivity, or diminished ovarian reserve.

The ovarian reserve reflects the number and quality of follicles left in the ovary at any given time and predicts the response (number of

oocytes retrieved) to controlled ovarian stimulation (COS) in in vitro fertilization (IVF) cycles. At present, the serum anti-Müllerian hormone (AMH) and the antral follicle count (AFC) have shown the best accuracy in predicting ovarian response and are considered the best “ovarian reserve markers.”

The most common procedure for the treatment of OE involves opening and draining the cyst before performing a cystectomy (stripping technique) or electrocoagulation or laser ablation of the cystic wall (ablative technique) [3]. The safety of both techniques has been questioned in terms of potential risk of significant damage to the ovarian reserve [3–6].

The aim of this chapter is to describe the association between OEs, surgery, and diminished ovarian reserve, with a particular focus on spontaneous ovulation rates, markers of ovarian reserve, and response to ovarian stimulation. Based on current evidence, although there are plausible biological effects on the ovarian cortex surrounding OE and an impairment of the normal ovarian physiology, the clinical impact of OE per se is not significantly altered. There is a negligible detrimental effect on ovarian reserve with spontaneous ovulation not being impaired. Surgical removal of OE may worsen ovarian function by removing healthy ovarian cortex or compromising blood flow to the ovary. It is evident that surgical excision of OE acutely impairs ovarian function as measured by ovarian reserve

M.-A. Martínez-Zamora, M.D., Ph.D.
G. Casals, M.D., Ph.D. · S. Peralta, M.D.
F. Carmona, M.D., Ph.D. (✉)
Department of Gynecology, Institut Clínic of
Gynecology, Obstetrics and Neonatology,
Hospital Clínic of Barcelona, Barcelona, Spain
e-mail: mazamora@clinic.cat; gcasals@clinic.cat;
speralta@clinic.cat; fcarmona@clinic.cat

markers. Additionally, a reduced response of the ovaries to gonadotrophins has been described in different studies after surgical removal of OE. Whether the decrease of ovarian function represents progressive or long-term impairment remains the subject of ongoing research.

Effect of Unoperated Ovarian Endometrioma on Ovarian Reserve

The possible detrimental effect of OEs per se on ovarian reserve is still controversial. Several studies have addressed the impact of OE before any kind of surgery on ovarian function and reserve, and available evidence is conflicting. Although several investigations show a theoretical negative effect of OE on ovarian physiology and follicular reserve and therefore there is biological plausibility of this detrimental impact, its clinical relevance has not been demonstrated.

An OE contains proteolytic enzymes, free iron, reactive oxygen species, and inflammatory molecules in concentrations much higher than those present in other types of cysts [7]. These fluid components could produce modifications in the endometriotic cells as well as in the surrounding tissue, where the normal ovarian cortex is replaced by fibrosis. These changes are associated with smooth muscle metaplasia, intraovarian vascular injury, and follicular loss. Indeed, the comparative analysis of normal cortex biopsies from ovaries affected by OEs and contralateral normal gonads showed a lower follicular density in tissue surrounding OE [8].

Furthermore, ovaries with OEs exhibited an activation of early follicular development and increased follicular atresia compared to normal contralateral gonads: upregulation of follicular recruitment associated with demise of early follicles could lead to focal depletion of primordial follicles, and these changes have been observed in OE between 1 and 4 cm, that is, in early stages of development [9]. These findings could be associated with inflammation and fibrosis, reduced vascularization, and increased oxidative stress, which are characteristic changes in OE.

Therefore, the available molecular, histological, and morphological evidence supports a deleterious effect of OE on the adjacent ovarian cortical tissue, independent of the mechanical stretching and of its size.

According to the above evidence, the mere presence of OE may theoretically impair ovarian reserve. However, clinical research on the subject has failed to demonstrate a negative impact.

Some authors have studied spontaneous ovulation rates in women with unoperated unilateral OE. Two studies reported a 1:2 ratio of ovulation between the affected and contralateral ovary, thus suggesting a possible detrimental effect [10, 11]. However, in a recent study involving a higher number of patients, the incidence of ovulation from the affected and intact gonad was found to be similar [12].

Other investigations have focused on the study of the markers of ovarian reserve. Five studies published the results of preoperative serum AMH in women with OEs, and four of them did not observe any difference with controls [13–16]. Only one of them reported lower serum AMH in patients with OE [17].

On the other hand, ovarian responsiveness to hyperstimulation for IVF has been extensively studied. However, all studies and meta-analyses of this issue are exposed to confounders (inclusion of patients with and without previous surgeries and no distinction of unilateral and bilateral cases) and the difficulty in selecting an appropriate control group [18]. Several studies of IVF outcome in women with unilateral unoperated OEs compared the responsiveness in the affected ovary and the contralateral normal gonad, avoiding several confounders since a single patient provides both a case and a control. None of the available studies reported significant differences in ovarian responsiveness. A possible limitation of these investigations is the inclusion of patients with relatively small OEs, and a potential negative effect of the size of the cyst was found by some authors but could not be established by others [18]. On the other hand, women with unilateral unoperated OEs could represent a very selected population, the disease may be less severe both in pathologic findings and symptom-

atology, and the normal ovary may compensate for the affected one. Indeed, according to the results of a recent investigation, responsiveness to ovarian hyperstimulation is reduced in women with bilateral unoperated OEs compared with age-matched control women [19].

In summary, the presence of OE per se has the potential to negatively affect ovarian reserve, but the available research have failed to demonstrate an associated negative clinical impact. More investigations are needed to clarify this controversial issue.

Surgical Resection of Ovarian Endometrioma and Ovarian Reserve

Surgical Techniques

Given the evolving data about the potentially detrimental effect of surgical excision of OEs on ovarian reserve, it is possible that surgical technique is a critical component of preserving ovarian function. Of several surgical techniques for OE destruction, the three most common are the following [3]:

1. *Ovarian cystectomy or stripping*: this technique begins with adhesiolysis. Once the ovary is mobilized, the cortex is grasped with forceps introduced through a second trocar and is incised using scissors, laser, or a unipolar needle hook. The incision must be made on the antimesenteric surface, as far as possible from the ovarian hilus. The incision is extended with scissors, and hydrodissection can be used to separate the cyst wall from the ovarian stroma. If the cyst is opened and spillage occurs, which occurs very often, peritoneal irrigation must be performed to remove the chocolate-colored fluid. The cyst is decompressed by suction drainage and washed, and its wall is exposed and inspected to confirm the diagnosis of an OE. After identifying the correct plane of cleavage between the cyst wall and the ovarian tissue by applying opposite bimanual traction with two 5-mm
2. *Ablative surgery*: after adhesiolysis of the ovary, a 3- to 4-mm portion of the top of the cyst is excised, the chocolate-colored material is aspirated, and the cyst is completely opened and washed out with irrigation fluid. After being washed, the interior wall of the cyst is carefully examined to confirm the diagnosis of an OE and the absence of any intracystic lesions suspected of being malignant (ovarian cystoscopy). A biopsy of the cyst wall should be taken for routine histologic examination to confirm the diagnosis. The cyst wall is then destroyed using either bipolar coagulation or laser vaporization. With the CO₂ laser, at a power setting of 40 W and using continuous mode application, the interior wall of the cyst is vaporized to destroy the mucosal lining of the cyst. Vaporization continues until no further pigment can be seen.
3. *Three-step procedure*: A three-step procedure may be used for large OEs (more than 5–6 cm in size). During diagnostic laparoscopy, OE is emptied, completely opened, and washed out with irrigation fluid. A biopsy sample is also obtained at this time. For the next 12 weeks, GnRH agonist therapy is provided to decrease the cyst size. After drainage followed by the 12-week course of GnRH agonist, a decrease of 50% in cyst diameter is generally observed. Drainage alone (if not associated with a GnRH agonist) is ineffective. Three months after first-look laparoscopy, the second-look laparoscopy is performed. OE is opened, and the interior wall of the cyst is vaporized, as previously described. After 12 weeks of GnRH agonist therapy, the thickness of the endometrial cyst will be dramatically reduced, and epithelial lining will be atrophic and white.

Vaporization with the CO₂ laser allows very quick and easy vaporization of the internal wall, with minimal thermal damage to the normal ovarian cortex.

Not all the surgical techniques for removal of OEs may show the same impact on the outcome, although any type of surgery may be harmful to an already compromised ovarian function [20]. The damage happens through the removal of healthy ovarian tissue and vascular injury. When surgery is performed, healthy ovarian tissue accompanies the resected OE wall with no apparent relation to the type of surgical procedure performed. Compared to the stripping technique, only opening and vaporizing the inner surface of the OE may prevent the removal of ovarian cortex [4]. Nevertheless, there are undoubtedly more studies in favor of the stripping technique compared to the number of studies using ablation. It has been shown that electrocoagulation is related to ovarian vascular injury [21]. In addition, some studies indicate that ablative techniques using CO₂ laser vaporization or plasma energy may be less harmful to a healthy ovarian tissue compared to cystectomy alone [22–24].

Serum Markers

Most studies evaluate ovarian reserve assessed by serum AMH concentrations after the stripping technique, which is the most commonly preferred approach for removal of an OE. Two systematic reviews clearly demonstrated that OE excision by the stripping technique leads to a decline in ovarian reserve as assessed by serum AMH concentrations. The systematic review by Raffi et al. [25] included eight studies and reported a statistically significant decrease of 1.13 ng/ml [95% confidence interval (95% CI)—1.88 to -0.37 ng/ml] in serum AMH levels following surgical excision. It should be stressed that the follow-up was limited to 3 months in six of the eight studies. The systematic review by Somigliana [26] included three additional studies to those in the systematic review by Raffi et al. [25]. They included 11 studies and only 2 reported unchanged AMH levels.

Although the results of the two systematic reviews consistently demonstrated a significant decline in AMH levels following OE excision, they also identified two important gaps in knowledge, whether the decline in AMH levels was permanent and which factors determined the rate of loss. Several recent studies have analyzed the decline of postoperative AMH levels at 6–9 months after surgery [27–29]. All these studies showed that the initial decline of AMH level was significantly decreased after this longer follow-up. These results collectively suggest that OE excision with the stripping technique is associated with a significant and persistent decline in serum AMH levels in the long term.

A recent systematic review and meta-analysis compared the effect of hemostatic measures on ovarian reserve as measured by serum AMH levels [30]. The use of bipolar cauterization was demonstrated to produce a greater decline in AMH levels compared to alternative hemostatic methods (such as suture or the use of hemostatic sealants). A more recent study that compared the rate of decline in AMH with suturing or bipolar cauterization after OE excision reported significantly less harm on ovarian reserve with suturing [31]. Nevertheless, the quality of currently available evidence supporting alternative hemostatic methods is modest at best. Therefore, it cannot be strongly recommended abandoning bipolar cauterization in favor of suturing at the moment, although surgeons should strive to limit the use of bipolar cauterization during laparoscopic endometrioma excision in order to preserve ovarian reserve [6].

Recently, a randomized controlled trial compared the impact of cystectomy and the three-step laser ablation technique on ovarian reserve markers, mainly AMH [24]. Administration of GnRH analogs between the two operations reduced OE size by up to 50%, as well as mitotic glandular activity, stromal vascularization, and the presence of functional cysts like corpus luteum, and enhanced apoptosis of endometriotic cells [23]. These authors demonstrated that functional ovarian tissue was less compromised after the three-step procedure than after cystectomy for OE.

Sonographic Markers

Compared with serum markers, the study of AFC as a marker of ovarian reserve has the advantage of correlating with the reserve of a single ovary and may control for the laterality of the disease [32].

Several studies have investigated the impact of OE surgery on AFC with conflicting results. Indeed, the meta-analysis of Raffi et al. [25] included the evaluation of AFC as secondary outcome, and the authors concluded that there was no statistical significant change in AFC postoperatively. However, the authors mentioned that the results might be attributed to a beta-error due to the small number of patients included in the analysis. They also pointed out that AFC may be difficult to assess in the presence of OE and has also been shown to be less reproducible than AMH.

More recently, a systematic review and meta-analysis including a major number of studies has been published [32]. It specifically focused on the impact of OE surgery on AFC after surgical excision of OE compared with the data obtained before surgery. Additional analyses were performed to evaluate the difference in mean AFC between the ovary with the endometrioma and the unaffected contralateral gonad, both before and after excisional techniques. The mean AFC for the affected ovary was significantly lower than the contralateral gonad after the surgery. This was also true for the preoperative comparison, but statistical significance was not reached. Heterogeneity for all these comparisons was high.

According to the conclusions of this meta-analysis, surgery for OE does not significantly affect ovarian reserve as evaluated by AFC. However, it may be difficult to explain the different results of two reliable markers of ovarian reserve such as AFC and AMH in the evaluation of ovarian reserve after surgery of OE. Therefore, further research is needed to better understand the apparently contradictory behavior of these two markers after OE surgery.

Histologic Markers

The inadvertent removal of ovarian cortex while stripping the wall of the OE from the unaffected ovarian parenchyma is thought to be one mechanism by which OE resection may result in diminished ovarian reserve [5]. A few authors have attempted to characterize and quantify this effect using histologic studies clearly showing that oocytes are removed in the great majority of cases, so there may be a risk of premature ovarian failure, especially in cases of repeated surgery [3]. In a prospective study of 42 women undergoing laparoscopic cystectomy for treatment of benign ovarian cysts, histologic analysis revealed that excision of cysts with well-defined capsules such as dermoids and cystoadenomas resulted in inadvertent removal of healthy ovarian tissue in only 6% of patients as compared with 54% after excision of endometriomas [33].

Response to Gonadotropin Stimulation

OE may be present in up to 20–40% of women with endometriosis scheduled for IVF [34]. OE surgery prior to IVF should have a prophylactic effect on the possible risks associated to IVF with intact OE. The evidence on the risks of conservative management of OEs prior IVF are shown in Table 10.1 [18].

The impact of surgical intervention of OE on IVF/ICSI outcomes was analyzed in a recent meta-analysis [35] whose results are summarized management of OEs prior IVF are shown in Table 10.2.

Despite there is no doubt that surgery on OE has a detrimental impact on ovarian reserve, it is not possible to extrapolate such data to the IVF/ICSI outcomes from the current available published studies. In women who had surgical treatment in one ovary, a lower number of oocytes were retrieved compared with the contralateral normal ovary without OE of the same patient. But the physiological functional compensation of one ovary in the presence of a compromised contralateral ovary, coupled with the use of stronger gonadotrophin ovarian stimulation, as shown by the higher dose of FSH required in women who had surgery prior to

Table 10.1 Evidence on the risks of conservative management of ovarian endometriomas prior IVF (Modified from [18])

Risks	Theoretical relevance	Demonstrated clinical relevance	Effect of prophylactic surgery
Ovarian responsiveness	Medium	Not demonstrated	Detrimental
Oocyte competence	Medium	Not demonstrated	Ineffective
Technical difficulties	Low	Not demonstrated	Doubtful
Endometrioma rupture	Low	Not demonstrated	Effective
Injury to adjacent organs	Medium	Not demonstrated	Doubtful
Infection of the endometrioma	Medium	Low	Effective
Follicular fluid contamination with the endometrioma content	Low	Doubtful	Effective
Progression of endometriosis	Medium	Not demonstrated	Effective
Pregnancy complication	Medium	Doubtful	Doubtful
Occult malignancy missed	High	Not demonstrated	Effective
Cancer development after IVF	High	Low	Effective

Table 10.2 Impact of surgical intervention of endometrioma on IVF/ICSI outcomes

	Treated endometrioma versus intact endometrioma	Treated endometrioma versus peritoneal endometriosis
Live birth rate	No differences	No differences
Clinical pregnancy rate	No differences	No differences
Miscarriage rate	No differences	No differences
Cancelation rate	No differences	No differences
Mean number of oocytes retrieved	No differences	Lower
Total FSH dose	Higher	No differences

their IVF/ICSI, may well account for the observation that surgery did not have any apparent impact on the live birth rate (LBR). However, such compensatory mechanisms may not be present in those with an already lower ovarian reserve, where an even lower than usual cumulative LBR may be the result of the additive impact of lower oocyte yield in these patients and the presumptive effect on reducing the number of embryos potentially available for frozen embryo transfers. Hence, the presence of an OE would be a justifiable indication for the assessment of ovarian reserve prior to surgery even in younger patients. It is hence important to consider individualizing the care of women with OE prior to IVF/ICSI, adopting a more conservative approach in those who are asymptomatic and older or have established low ovarian reserve.

Special Considerations

Bilateral Endometriomas

In women operated on for bilateral OEs, there is a low but definite risk of postsurgical premature ovarian insufficiency [36], and menopause occurs earlier [37].

A systematic review of serum AMH concentrations after OE excision documented a statistically significant two- to threefold postoperative reduction in AMH concentration in women who underwent surgery to treat bilateral OEs [38]. A greater decrease in serum AMH concentration is noted in women who underwent surgery to treat bilateral OEs as compared with unilateral OE [25].

IVF outcomes in women with unoperated bilateral OEs show a lower response to hyperstimulation, but the quality of the oocytes retrieved and the chances of pregnancy are not affected [19]. Nevertheless, in patients with previous bilateral cystectomy, the chances of pregnancy are also affected (rates of clinical pregnancy and live births are lower) [38].

The management of women with bilateral OEs should be as conservative as possible in women with gestational desire, especially in older or with established low ovarian reserve. If the surgery is finally indicated, patients should be informed about the worsening effects in ovarian reserve/IVF results and may be offered a fertility preservation technique prior to surgery [39].

Recurrence of OE after Surgery

Another consideration is the potential for OE recurrence after surgical excision. Investigators have postulated that an ovary in which the primordial follicular pool is depleted after surgical OE excision has less potential for development of recurrent disease, based on the premise that OE originates from ovulatory events. Paradoxically, OE recurrence may therefore be viewed as a favorable marker of increased potential for ovarian responsiveness. This hypothesis was investigated by Somigliana et al. [38] in a retrospective study with several limitations but showing a significantly higher number of follicles identified in the ovaries with recurrent OEs compared to those without recurrent OEs.

Conclusion

In conclusion, the existing studies support an adverse effect of OEs on ovulation rates, markers of ovarian reserve, and response to ovarian stimulation. Surgical removal of OEs may worsen ovarian function by removing healthy ovarian cortex or compromising blood flow to the ovary. It is evident that surgical excision of OEs acutely impairs ovarian function as measured by serum ovarian reserve markers. Whether this represents long-term impairment is unclear. It is recommended to warn patients regarding the decline in ovarian reserve following surgery and to cautiously limit cauterization to the possible extent.

References

1. Busacca M, Vignali M. Ovarian endometriosis: from pathogenesis to surgical treatment. *Curr Opin Obstet Gynecol.* 2003;15:321–6.
2. Brosens IA, Puttemans PJ, Deprest J. The endoscopic localization of endometrial implants in the ovarian chocolate cyst. *Fertil Steril.* 1994;61:1034–8.
3. Jadoul P, Kitajima M, Donnez O, Squifflet J, Donnez J. Surgical treatment of ovarian endometriomas: state of the art? *Fertil Steril.* 2012;98:556–63.
4. Ruiz-Flores FJ, Garcia-Velasco JA. Is there a benefit for surgery in endometrioma-associated infertility? *Curr Opin Obstet Gynecol.* 2012;24:136–40.
5. Shah DK, Mejia RB, Levobich DI. Effect of surgery for endometrioma on ovarian function. *J Minim Invasive Gynecol.* 2014;21:203–9.
6. Ata B, Uncu G. Impact of endometriomas and their removal on ovarian reserve. *Curr Opin Obstet Gynecol.* 2015;27:235–41.
7. Sánchez AM, Viganò P, Somigliana E, Panina-Bordignon P, Vercellini P, Candiani M. The distinguishing cellular and molecular features of the endometriotic ovarian cyst: from pathophysiology to the potential endometrioma-mediated damage to the ovary. *Hum Reprod Update.* 2014;20:217–30.
8. Kitajima M, Defrère S, Dolmans MM, Colette S, Squifflet J, Van Langendonck A, Donnez J. Endometriomas as a possible cause of reduced ovarian reserve in women with endometriosis. *Fertil Steril.* 2011;96:685–91.
9. Kitajima M, Dolmans MM, Donnez O, Masuzaki H, Soares M, Donnez J. Enhanced follicular recruitment and atresia in cortex derived from ovaries with endometriomas. *Fertil Steril.* 2014;101:1031–7.
10. Horikawa T, Nakagawa K, Ohgi S, Kojima R, Nakashima A, Ito M, Takahashi Y, Saito H. The frequency of ovulation from the affected ovary decreases following laparoscopic cystectomy in infertile women with unilateral endometrioma during a natural cycle. *J Assist Reprod Genet.* 2008;25:239–44.
11. Benaglia L, Somigliana E, Vercellini P, Abbiati A, Ragni G, Fedele L. Endometriotic ovarian cysts negatively affect the rate of spontaneous ovulation. *Hum Reprod.* 2009;24:2183–6.
12. Leone Roberti Maggiore U, Scala C, Venturini PL, Remorgida V, Ferrero S. Endometriotic ovarian cysts do not negatively affect the rate of spontaneous ovulation. *Hum Reprod.* 2015;30:299–307.
13. Kitajima M, Khan KN, Hiraki K, Inoue T, Fujishita A, Masuzaki H. Changes in serum anti-Müllerian hormone levels may predict damage to residual normal ovarian tissue after laparoscopic surgery for women with ovarian endometrioma. *Fertil Steril.* 2011;95:2589–91.
14. Streuli I, de Ziegler D, Gayet V, Santulli P, Bijaoui G, de Mouzon J, Chapron C. In women with endometriosis anti-Müllerian hormone levels are decreased only in those with previous endometrioma surgery. *Hum Reprod.* 2012;27:3294–303.
15. Kim JY, Jee BC, Suh CS, Kim SH. Preoperative serum anti-mullerian hormone level in women with ovarian endometrioma and mature cystic teratoma. *Yonsei Med J.* 2013;54:921–6.
16. Vercellini P. Serum anti-mullerian hormone in reproductive aged women with benign ovarian cysts. *Eur J Obstet Gynecol Reprod Biol.* 2014;180:142–7.
17. Ata B. Prospective assessment of the impact of endometriomas and their removal on ovarian reserve and determinants of the rate of decline in ovarian reserve. *Hum Reprod.* 2013;28:2140–5.
18. Somigliana E, Benaglia L, Paffoni A, Busnelli A, Viganò P, Vercellini P. Risks of conservative management in women with ovarian endometriomas undergoing IVF. *Hum Reprod Update.* 2015;21:486–99.
19. Garcia-Velasco JA. In vitro fertilization outcome in women with unoperated bilateral endometriomas. *Fertil Steril.* 2013;99:1714–9.

20. Garcia-Velasco JA, Somigliana E. Management of endometriomas in women requiring IVF: to touch or not to touch. *Hum Reprod.* 2009;24:496–501.
21. Li CZ, Liu B, Wen ZQ, Sun Q. The impact of electrocoagulation on ovarian reserve after laparoscopic excision of ovarian cysts: a prospective clinical study of 191 patients. *Fertil Steril.* 2009;92:1428–35.
22. Roman H, Auber M, Mokdad C, Martin C, Diguët A, Marpeau L, Bourdel N. Ovarian endometrioma ablation using plasma energy versus cystectomy: a step toward better preservation of the ovarian parenchyma in women wishing to conceive. *Fertil Steril.* 2011;96:1396–400.
23. Donnez J, Lousse JC, Jadoul P, Donnez O, Squifflet J. Laparoscopic management of endometriomas using a combined technique of excisional (cystectomy) and ablative surgery. *Fertil Steril.* 2010;94:28–32.
24. Tsolakidis D, Pados G, Vavilis D, Athanatos D, Tsalikis T, Giannakou A, Tarlatzis BC. The impact on ovarian reserve after laparoscopic ovarian cystectomy versus three-stage management in patients with endometriomas: a prospective randomized study. *Fertil Steril.* 2010;94:71–7.
25. Raffi F, Metwally M, Amer S. The impact of excision of ovarian endometrioma on ovarian reserve: a systematic review and meta-analysis. *J Clin Endocrinol Metab.* 2012;97:3146–54.
26. Somigliana E, Berlanda N, Benaglia L, Viganò P, Vercellini P, Fedele L. Surgical excision of endometriomas and ovarian reserve: a systematic review on serum antimüllerian hormone level modifications. *Fertil Steril.* 2012;98:1531–8.
27. Uncu G, Kasapoglu I, Ozerkan K, Seyhan A, Oral Yilmaztepe A, Ata B. Prospective assessment of the impact of endometriomas and their removal on ovarian reserve and determinants of the rate of decline in ovarian reserve. *Hum Reprod.* 2013;28:2140–5.
28. Urman B, Alper E, Yakin K, et al. Removal of unilateral endometriomas is associated with immediate and sustained reduction in ovarian reserve. *Reprod Biomed Online.* 2013;27:212–6.
29. Alborzi S, Keramati P, Younesi M, Samsami A, Dadras N. The impact of laparoscopic cystectomy on ovarian reserve in patients with unilateral and bilateral endometriomas. *Fertil Steril.* 2014;101:427–34.
30. Ata B, Tukgeldi E, Seyhan A, Urman B. Effect on hemostatic method on ovarian reserve following laparoscopic endometrioma excision; comparison of suture, hemostatic sealant and bipolar desiccation: a systematic review and meta-analysis. *J Minim Invasive Gynecol.* 2015;22:363–72.
31. Song T, Kim WY, Lee KW, Kim HH. Effect on ovarian reserve on hemostasis by bipolar coagulation versus suture during laparoendoscopic single-site cystectomy for ovarian endometriomas. *J Minim Invasive Gynecol.* 2015;22:415–20.
32. Muzii L, Di Tucci C, Di Felicianantonio M, Marchetti C, Perniola G, Panici PB. The effect of surgery for endometrioma on ovarian reserve evaluated by antral follicle count: a systematic review and meta-analysis. *Hum Reprod.* 2014;29:2190–8.
33. Muzii L, Bianchi A, Croce C, Mancini N, Panici PB. Laparoscopic excision of ovarian cysts: is the stripping technique a tissue-sparing procedure? *Fertil Steril.* 2002;77:609–14.
34. Vercellini P, Chapron C, De Giorgi O, Consonni D, Frontino G, Crosignani PG. Coagulation or excision of ovarian endometriomas? *Am J Obstet Gynecol.* 2003;188:606–10.
35. Cheong Y. The impact of endometrioma on IVF/ICSI outcomes: a systematic review and meta-analysis. *Hum Reprod Update.* 2015;21:809–25.
36. Micucci G. Is operative laparoscopy safe in ovarian endometriosis? *Reprod Biomed Online.* 2009;18:167.
37. Scarselli G. Ovarian surgery for bilateral endometriomas influences age at menopause. *Hum Reprod.* 2011;26:3000–7.
38. Ragni G. IVF-ICSI outcome in women operated on for bilateral endometriomas. *Hum Reprod.* 2008;23:1526–30.
39. Vercellini P. Fertility preservation in women with endometriosis: for all, for some, for none? *Hum Reprod.* 2015;30:1280–6.

Part III

General Gynecologic Procedures



Vaginal Hysterectomy, Salpingectomy, and Adnexectomy

11

Iwona Gabriel and Rosanne Kho

Vaginal hysterectomy (VH) is the preferred route of hysterectomy for benign gynecological indications. The most recent Cochrane review (2015) [1] involving 47 studies and 5102 women concluded superiority of the vaginal route over abdominal, laparoscopic, and robotic-assisted hysterectomy. The vaginal approach provided faster return to normal activities, greater patient satisfaction and quality of life, fewer intraoperative visceral injuries, and less major long-term complications (such as fistula, pain, urinary and bowel, pelvic floor, and sexual dysfunction). Review of evidence revealed that VH should be performed in preference to abdominal hysterectomy (AH). When VH is not feasible, it is preferable to perform laparoscopic hysterectomy (LH) over AH. Considering changing demographics with a rising obese patient population, the American College of Obstetricians and Gynecologists (ACOG) in 2015 [2] recommended that vaginal hysterectomy be performed over other approaches for the obese patient in particular. The vaginal route with its single and

concealed incision is associated with less serious adverse events such as wound infection and thromboembolism [3]. In the face of available evidence and recommendations, it is important that the surgeon conducts a thorough discussion with the patient to allow full participation in the decision-making.

In the recent years, there has been a decline in the number of hysterectomies performed vaginally in the United States. An update on inpatient hysterectomy routes in the United States from 2012 showed that only 16.9% of hysterectomies were performed vaginally, which is half of the laparoscopic rate (31.8%) [2]. The number of hysterectomies performed due to genital prolapse in the same given period was only 20%. Another study revealed that <5% of gynecologic surgeons perform >10 vaginal surgeries in a year and a greater proportion (>80%) of surgeons perform <5 vaginal surgeries annually [4]. With the declining volume of vaginal surgeries performed, the training and skills of residents and practicing surgeons are adversely impacted. It was noted that even though 42% of residents reported vaginal route as their preferred route for hysterectomy [5], only 20% of first year fellows in Female Pelvic Medicine and Reconstructive Surgery fellowship training (FPMRS) are capable of performing vaginal hysterectomy alone [6].

The procedural challenges in VH include limited exposure and visualization, onerous entry into the anterior and posterior cul-de-sacs, difficulty

I. Gabriel, M.D.
Department of Obstetrics and Gynecology,
Medical University of Silesia, Bytom, Poland

R. Kho, M.D. (✉)
Department of Obstetrics and Gynecology,
Women's Health Institute, Cleveland Clinic,
Cleveland, OH, USA

in achieving hemostasis, manual morcellation of the large uterus, and, lastly, removal of the tubes and/or ovaries. We present here different techniques to address these challenges. The reader is invited to view the link—<https://www.aagl.org/vaghystwebinar/>—where all of the techniques mentioned below are illustrated.

Maximizing Exposure and Visualization

Self-retaining vaginal retractor system. To maximize exposure during vaginal surgery and avoid the need for two assistants at the bedside, we recommend the use of a self-retaining vaginal retractor system (such as the Magrina-Bookwalter vaginal retractor system, Symmetry Surgical, Tennessee). With the patient in high lithotomy position, the post is attached to the rail of the operating table, and the ring is placed flush against the patient's buttocks. Attachment of the blades to the ring enables consistent and reliable retraction of the anterior, lateral, and posterior vaginal walls. The posterior blade is attached first, followed by two lateral blades. The lateral blades are placed carefully and parallel to the vaginal walls to avoid undue pressure and sulcal lacerations. To begin, the small anterior blade is held manually, behind the ring, by the assistant until the anterior cul-de-sac is entered.

Table-mounted camera system. The use of a table-mounted camera system such as with the Vitom 90° camera (Karl Storz) allows for projection of the surgery onto an external monitor. The camera system not only provides greater illumination of the small operative field, it also provides magnification of the structures for the bedside assistant to better assist in the case. As in laparoscopic and robotic-assisted surgeries, allowing the entire operating room team to follow the surgery which ultimately facilitates the flow and provides greater safety and efficiency.

Narrowed introitus. In case of narrowed introitus (such as in nulliparous or menopausal patients), a superficial 4 cm long and 2–3 mm deep incision is made on the vaginal mucosa of the distal aspect of the posterior wall. This small

incision creates a wider vaginal opening to allow for safe placement of the posterior self-retaining blade and improved exposure.

Elliptical incision around the cervix. For the initial incision, we recommend an elliptical incision around the cervix as opposed to a round circumferential incision in order to achieve a larger culdotomy for lateral access to the vascular pedicles and greater room for morcellation of the large uterus.

Prior to this elliptical incision, 20 mL of 0.5% bupivacaine with 1:200,000 of epinephrine is injected into the uterosacral ligaments bilaterally. Dilute vasopressin is then injected circumferentially under the vaginal epithelium to minimize bleeding. Attention is directed to identify the cervico-vesical and cervico-rectal junctions. A long knife handle with a #10 blade is used to make the elliptical incision at the cervicovaginal junction, and the anterior vaginal epithelium is sharply dissected off the cervix with heavy Mayo scissors until the vesicouterine space is reached. With gentle blunt dissection using the index finger, the bladder pillars are pushed superiorly and laterally. No further attempt is made to enter the anterior cul-de-sac especially when there is minimal uterine descensus. Attention is now directed to entering into the posterior cul-de-sac.

Entry into the posterior cul-de-sac. Entry into the posterior cul-de-sac is often easier than entry into the anterior cul-de-sac. Exposure is achieved with the assistant retracting the posterior vaginal wall down and pulling up on the cervix to obtain the correct angle for entry. Sharp incision is made with heavy Mayo scissors. Scissors should be placed parallel to the plane of the cervix to avoid inadvertent rectal injury. A long self-retaining posterior blade is repositioned, inserted into the abdominal cavity, and reattached to the self-retaining ring. With the uterosacral ligaments now clearly visualized, these can be clamped, cut, and suture ligated using the traditional technique or sealed and divided with the vessel-sealing device.

Achieving hemostasis. Securing hemostasis can be achieved with the traditional clamp, cut, and tie technique when done methodically. A bipolar vessel-sealing device (VSD) to secure the

pedicles can also be used. There have been studies showing possibly shorter operative time, less bleeding, and postoperative pain associated with the use of VSD [7, 8]. It is important to understand the principles with the use of energy with VSD in vaginal surgery. Advanced vessel-sealing devices deliver bipolar energy that is able to seal vessels up to 7 mm. Because of lateral thermal spread of up to 2 mm, it is important to stay as close to the cervix and lower uterine segment during sealing of the cardinal ligaments in order to avoid injury to the ureter. Also, because the clamp gets hot, it is important not to lean on the vaginal walls, bowel, bladder, or metal retractors during sealing. We utilize a suction tip to quickly dissipate the heat and also retract nearby structures during sealing to prevent lateral thermal injury.

Anterior dissection and entry. After the uterosacral ligaments are divided, the cardinal ligaments can also be sealed and divided serially to allow further uterine descensus. Keeping the clamps lateral and inferior to the 3 and 9 o'clock positions is crucial to avoid bladder injury. With better uterine descensus, entry into the anterior cul-de-sac may now be attempted. The posterior blade is removed to allow maximum dorsal traction of the cervix. The anterior vaginal wall is picked up with forceps, and the bladder is dissected sharply from the anterior cervix using fine Metzenbaum scissors. Staying parallel to the plane of the cervix allows for entry into the avascular vesicouterine space. The vesicouterine peritoneum should be clearly visualized. Mastering this step is critical to safely enter the anterior cul-de-sac. Cutting into the cervix will feel hard against the tips of the scissors, while cutting into the softer striated detrusor muscle will manifest with excessive bleeding. The vesicouterine fold is identified as a crescent-shaped peritoneal fold that can be lifted and divided for entry. Palpation of this peritoneal fold can aid and confirm smooth texture of the thin peritoneum. Fine-toothed forceps and Metzenbaum scissors are preferred for precise incision.

In cases where scarring between the bladder and uterus is encountered (such as in patients with previous cesarean section), sharp dissection

and entry is best achieved lateral to the midline, away from the central dense adhesions. This step should only be performed when there is adequate exposure of the tissue planes. Further sealing and transecting of the cardinal ligaments from the lateral side is a technique that may allow better visualization of the operative field and safer entry into the anterior cul-de-sac.

Upon entering the anterior cul-de-sac, the smooth serosa of the uterine corpus can be palpated prior to proceeding with the rest of the hysterectomy.

Upon entry into the anterior cul-de-sac, the cardinal ligaments are serially sealed and divided by advancing toward the uterine vessels, which should be secured under direct visualization. Careful skeletonization and sealing of the uterine vessels should be performed to ensure hemostasis.

Manual morcellation of the large uterus. In uteri involved with fibroids and/or adenomyosis, manual morcellation is often required in order to decompress the uterus and safely secure the utero-ovarian ligaments. To morcellate, we divide the cervix in half and remove segments of the uterus using a core and wedge technique with the use of a long curved knife (Marina Medical, Florida) with a ten blade and double-toothed Schroeder tenaculum. We emphasize the need for thorough preoperative evaluation that includes imaging, Pap test, and endometrial biopsy to rule out malignant involvement prior to any manual morcellation.

After morcellation, the utero-ovarian ligaments can now be isolated. The surgeon places a finger around the cornua of the uterus for traction in order to isolate the ligament which now may be clamped using the Heaney clamp. The utero-ovarian ligament is then cut with the Mayo scissors. Once clamped, the utero-ovarian pedicle is suture ligated, passing a suture through the middle, and tied and carried around the pedicle as in a modified Heaney suturing technique.

Salpingectomy and/or Adnexectomy. In 2013, the Society of Gynecologic Oncology (and other international societies) recommended that risk-reducing salpingectomy be offered to all patients at average risk for ovarian cancer at the

time of hysterectomy [9]. This is in light of evidence suggesting that many ovarian cancers may actually arise from the distal fallopian tubes. We advocate the round ligament technique to facilitate access to the distal fallopian tube for its complete removal during VH [10].

At the beginning of salpingectomy, the tube and ovary are identified. The ovary is grasped with a long Allis clamp, while the fimbriated end of the fallopian tube is brought down to the operative field with a long Russian forceps. The round ligament is identified from the utero-ovarian complex (containing the round ligament, utero-ovarian pedicle, and the proximal fallopian tube) and divided using the monopolar cautery pencil (Bovie). To remove the fallopian tube, a window is then created in the mesosalpinx immediately inferior to the proximal tube. A clamp is placed, distal to the ovary, to isolate the utero-ovarian pedicle. The mesosalpinx is subsequently divided using the vessel-sealing device, and the entire fallopian tube is removed.

To remove both the tube and ovary, the long Allis clamp is placed on the ovary and proximal tube. The round ligament is identified and divided as described above. The curved ovarian clamp (Marina Medical, Florida) is placed on the ovarian ligament that is proximal to the ovary. This technique allows both the tube and ovarian tissue to be removed in their entirety. It is important not to place the clamp too close to the ovary in order to prevent leaving behind any ovarian tissue. A prepared polyglactin ligating loop with a delivery system (such as Surgitie, Covidien Surgical) suture can be used to secure the pedicle particularly if it is high in the pelvic brim.

Completion of hysterectomy. At the end of the procedure, a peritoneal suture (2–0 polyglactin suture) is placed to secure the peritoneum to the vaginal cuff in a running locked fashion between the uterosacral pedicle and the cardinal pedicle bilaterally. This is performed to ensure complete hemostasis. We perform prophylactic apical suspension by attaching the vaginal apex to the uterosacral ligaments bilaterally to prevent future prolapse [11]. First, a stitch (1–0 polyglactin suture on a CT-1 needle) is placed in the middle of the posterior vaginal cuff. The rectum is then retracted to the patient's right side in order to iden-

tify the left uterosacral ligament. The posterior vaginal fornix at 4 o'clock is grasped with toothed forceps to delineate the uterosacral ligament. An intermediate length Deaver retractor is then placed into the pelvic cavity at the 3 o'clock position to protect the ureter which would be found coursing in the 2–3 o'clock position. With upward traction of the vagina at the level of the uterosacral ligament, the proximal uterosacral ligament is clearly visualized. Adequate purchase of the uterosacral ligament is obtained with the suture placed 1–2 cm below the level of the ischial spine. The contralateral uterosacral ligament is similarly delineated and purchased. This midline McCall's suture is then brought out through the posterior vaginal wall lateral to the entry stitch and tagged.

The vaginal cuff is closed in an interrupted fashion with 2–0 polyglactin suture, and the uterosacral ligament suspension suture is tied. These sutures are tagged with a clamp until ureteral patency and absence of bladder injuries are confirmed with cystoscopy. Use of universal intraoperative cystoscopy at the time of hysterectomy is recommended in order to recognize most bladder and ureteral injuries prior to the end of the surgery [12].

Conclusion

Vaginal hysterectomy should be incorporated in the surgical armamentarium of minimally invasive surgeons given its many advantages [13]. This chapter describes the step-by-step approach to vaginal hysterectomy and manual morcellation, bilateral salpingectomy, adnexectomy, and support of the vaginal apex. Knowledge and familiarity of the anatomy, surgical principles, new tools, and techniques are helpful in overcoming many of the challenges in vaginal hysterectomy.

References

1. Aarts JW, et al. Surgical approach to hysterectomy for benign gynecological disease. *Cochrane Database Syst Rev.* 2015;(8):CD003677.
2. ACOG Committee Opinion No.619: gynecologic surgery in the obese women. *Obstet Gynecol.* 2015;125(1):274–8.

3. Desai VB, Xu X. An update of inpatient hysterectomy routes in the United States. *Am J Obstet Gynecol*. 2015;213(5):742–3.
4. Rogo-Gupta LJ, et al. The effect of surgeon volume on outcomes and resource use for vaginal hysterectomy. *Obstet Gynecol*. 2010;116(6):1341–7.
5. Antosh DD, et al. Resident opinions on vaginal hysterectomy training. *Female Pelvic Med Reconstr Surg*. 2011;17(1):314–7.
6. Guntupalli SR, et al. Preparedness of obstetrics and gynecology residents for fellowship training. *Obstet Gynecol*. 2015;126(3):559–68.
7. Gizzo S, et al. LigaSure vessel sealing system in vaginal hysterectomy: safety, efficacy and limitations. *Arch Gynecol Obstet*. 2013;288(5):1067–74.
8. Lakeman MM, et al. Electrosurgical bipolar vessel sealing versus conventional clamping and suturing for vaginal hysterectomy: a randomised controlled trial. *BJOG*. 2012;119(12):1473–82.
9. SGO. Clinical practice statement: salpingectomy for ovarian cancer prevention. Nov 2013. <https://www.sgo.org/clinical-practice/guidelines/sgoclinical-practice-statement-salpingectomy-for-ovarian-cancer-prevention/>.
10. Kho R, Magrina J. Round ligament technique and use of vessel-sealing device to facilitate complete salpingectomy at the time of vaginal hysterectomy. *J Minim Invasive Gynecol*. 2015;22(6):1084–7.
11. AAGL Advancing Minimally Invasive Gynecology Worldwide. AAGL practice report: practice guidelines on the prevention of apical prolapse at the time of benign hysterectomy. *J Minim Invasive Gynecol*. 2014;21(5):715–22.
12. Ch AM. Universal cystoscopy after benign hysterectomy: examining the effects of an institutional policy. *Obstet Gynecol*. 2016;127(2):369–75.
13. ACOG Committee Opinion No. 444: choosing the route of hysterectomy for benign disease. *Obstet Gynecol*. 2009;114(5):1156–8.



Minimally Invasive Myomectomy

12

Kirsten J. Sasaki and Charles E. Miller

Introduction

Uterine fibroids are the most common benign uterine tumor, occurring in up to 80% of women. Common symptoms include heavy vaginal bleeding, pelvic pain, pelvic pressure, and infertility. There are multiple medical and surgical options available, but in a patient who desires to preserve and improve fertility, a myomectomy is often the only surgical option. A myomectomy can be approached hysteroscopically, in cases of submucosal fibroids, or via laparotomy, laparoscopy, or with robotic assistance when large submucosal, intramural, subserosal, and pedunculated myomas require removal. The evidence behind laparoscopic and robotic-assisted myomectomies will be detailed in this chapter.

Advantages

The first laparoscopic myomectomy was reported in 1979 [1]. Compared to abdominal myomectomies, laparoscopic myomectomies have demonstrated multiple benefits including shorter hospitalization [2, 3], less blood loss [3], fewer

postoperative fevers [3], and less postoperative pain [4]. A Cochrane review of nine randomized controlled studies demonstrated decreased postoperative pain, shorter hospital stay, and fewer postoperative fevers in laparoscopic versus open myomectomies [5]. Furthermore, no difference was found in fibroid recurrence for laparoscopic compared to abdominal myomectomy [3, 6].

One randomized controlled trial by Palomba et al. evaluated total complication rates of laparoscopic versus minilaparotomic myomectomies. They found no difference between the laparoscopy and minilaparotomy cohorts for operative time (108 vs. 95 min, $p = 0.227$) and postoperative ileus (1 day vs. 1 day, $p = 0.061$) but did find a significant difference with decreased estimated blood loss (130 mL vs. 160 mL, $p = 0.001$), decreased postoperative analgesic use (3 vs. 6, $p < 0.001$), and shorter hospitalization (2 days vs. 3 days, $p < 0.001$) in the laparoscopic cohort [7].

Surgical Approach

Laparoscopic Technique

Timing

The timing of a laparoscopic myomectomy during the patient's menstrual cycle may depend on whether additional procedures, such as hysteroscopy, are being performed. The best time to perform a hysteroscopy is during the proliferative

K. J. Sasaki, M.D. · C. E. Miller, M.D. (✉)
The Advanced Gynecologic Surgery Institute,
Naperville, IL, USA

Department of Obstetrics and Gynecology,
Lutheran General Hospital, Naperville, IL, USA

phase when the endometrium is thin and there is minimal chance that the patient is pregnant. Therefore, if there is a hysteroscopic component of the planned procedure, it is best to perform the surgery early in the menstrual cycle, post-menses. Moreover, if the endometrial cavity is entered at the time of a laparoscopic or robotic-assisted myomectomy, it may be more difficult to close the cavity if the endometrium is thick and potentially lead to greater blood loss. If a laparoscopic myomectomy alone is planned and the endometrium is not entered, there does not seem to be an appreciable difference in hemostasis or blood loss based on the timing of the procedure. Kang et al. performed a retrospective comparative study of 220 patients who underwent a laparoscopic myomectomy during the menstrual, follicular, or luteal phase. They found that blood loss and hemoglobin change did not differ between those procedures performed in the menstrual, luteal, or follicular phase ($p = 0.231$, $p = 0.526$, respectively) [8]. Of note, although the estimated blood loss averaged 100–135 mL in each group, the transfusion rate ranged from 5.4% (menstruation group) to 11.8% (luteal phase group) ($p = 0.24$). The lack of difference in blood loss is consistent with the findings of a systematic review evaluating hemostatic factors during the menstrual cycle, which concluded that most studies report no cyclic variation in von Willebrand factor; factors VIII, XI, and XIII; and fibrinogen [9].

Port Placement

Proper port placement is essential to a successful laparoscopic myomectomy, especially in cases of large myomas. There are various methods for port placement, largely dependent upon suturing style [10], but three to four ports are generally placed cephalad, with instrument ports placed lateral to the uterus/fibroid mass. The camera port is generally placed at the umbilicus (5–12 mm) with at least one trocar on each side of the abdomen, lateral to the inferior epigastric vessels (Fig. 12.1). We always place a 12 mm port at the umbilicus if morcellation is necessary (refer to section on tissue removal). It is important that all ports are cephalad to the fibroids, to assist with traction/

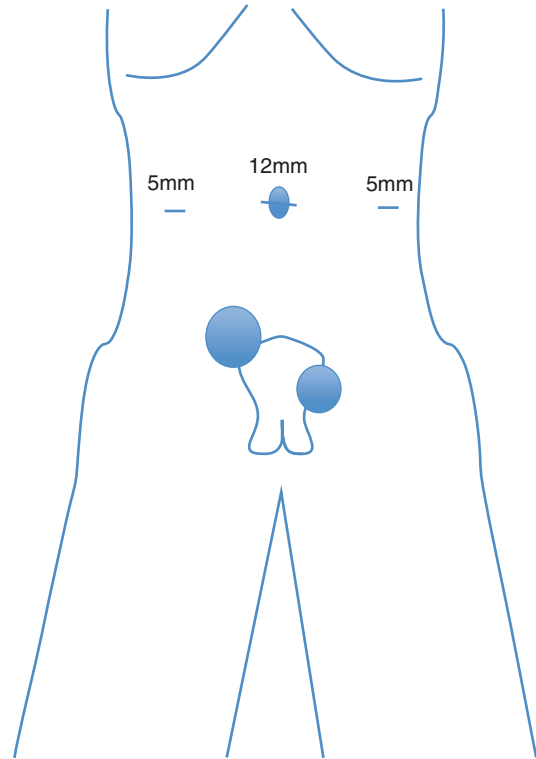


Fig. 12.1 Port configuration for three-port laparoscopic myomectomy

countertraction that is necessary to enucleate the fibroid and to facilitate suturing, often the most difficult part of the procedure. Thus, if large pathology is encountered, the ports should be placed cephalad, often with a port at Palmer's point for the camera with the lateral ports placed superior to the umbilicus and again with a 12 mm port at the umbilicus (Fig. 12.2).

Minimizing Blood Loss

Except in the case of a pedunculated fibroid, a laparoscopic or robotic myomectomy requires incising into the uterine myometrium in order to enucleate the fibroids from the surrounding capsule. This process can result in generous blood loss, as it takes time to remove the fibroid and close the hysterotomy. In order to decrease blood loss, several techniques have been developed, including medications and vascular occlusion techniques with clamps or sutures, both permanent and temporary.

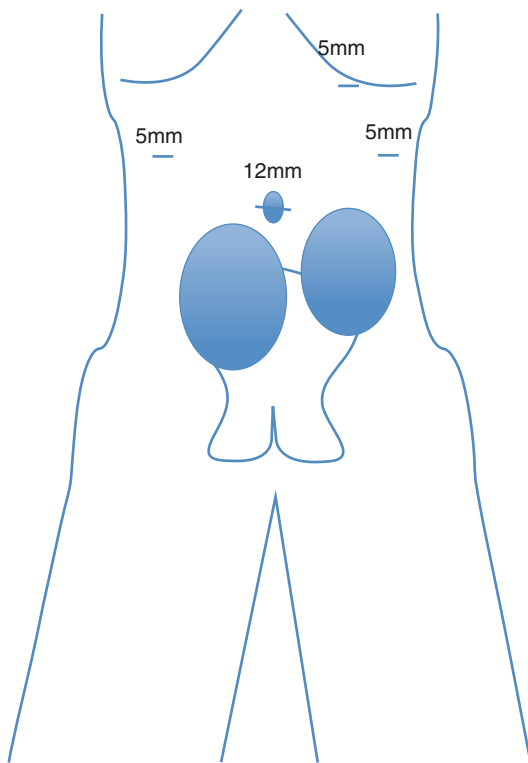


Fig. 12.2 Port configuration for 3+ port laparoscopic myomectomy in cases of large specimens

Medications can be used vaginally, intravenously, or intramyometrially before and during surgery to decrease operative blood loss. A recent Cochrane review found decreased blood loss associated with the following techniques for myomectomy: intramyometrial vasopressin or bupivacaine plus epinephrine, vaginal misoprostol or dinoprostone, and intravenous ascorbic acid or tranexamic acid [11]. Vasopressin is prohibited in some European countries, including France and Italy, due to potentially catastrophic complications including transient tachycardia, hypertension, arrhythmias, bronchospasm, and in some severe cases pulmonary edema, acute coronary spasm, and myocardial ischemia [12, 13]. Care must be taken to prevent intravenous injection, by withdrawing before injection to ensure that a blood vessel has not inadvertently been entered. Song et al. performed a randomized study on 60 patients undergoing a laparoscopic myomectomy. The two groups had either dilute

vasopressin or epinephrine injected into the uterine serosa or overlying myometrium. The study demonstrated no difference in operative blood loss and only transient, nonserious changes in blood pressure and heart rate in the epinephrine arm [14, 15].

In addition to medications to decrease operative blood loss, clamps and ties have also been used. Ostrzenski first described a technique of placing a suture around the uterine isthmus prior to a myomectomy in order to decrease blood loss [16]. Dubuisson et al. performed a cohort study of 53 patients who underwent a laparoscopic myomectomy with or without preventative uterine artery occlusion. Although the study found no significant difference in mean hemoglobin change between the two cohorts, those without preventative occlusion had a conversion rate of 11%, versus a 0% conversion rate for those with preventative occlusion [17]. All cases of conversion were due to bleeding at the site of the hysterotomy that required more rapid control than could be obtained laparoscopically. Vercellino et al. performed a multicenter randomized study evaluating operative and perioperative outcomes in 166 women who underwent a laparoscopic myomectomy, 80 with temporary uterine artery clipping and 86 without. The study found a statistically significant difference in hemoglobin drop in the clipping group (1.2 g/dL) versus in the control group (1.60 g/dL, $p < 0.05$). Although no patients required a transfusion, two patients in the uterine clipping arm and one patient in the control arm experienced a postoperative bleed [18].

Instrumentation and Suture

The majority of studies on laparoscopic myomectomies use either ultrasonic or monopolar energy. One randomized controlled trial by Litta et al. evaluated outcomes in 160 women undergoing laparoscopic myomectomy. They found that the use of ultrasonic versus electro-surgical energy was associated with a shorter operative time, a smaller change in hemoglobin, and a lower postoperative pain score at 24 h (all

$p < 0.05$) [19]. Additionally, a retrospective cohort study by Ou et al. found that ultrasonic energy was associated with decreased operative blood loss compared to electrosurgery [20]. Ultrasonic energy has also demonstrated greater tensile strength in healed tissue compared with the CO₂ laser and electrosurgery [21]. This is not surprising given the decreased lateral spread of energy with ultrasonic energy compared to ultrasonic energy [22].

Suturing of the myoma bed is one of the most challenging aspects of a laparoscopic myomectomy, and the integrity of this incision is extremely important, especially in patients who desire future fertility. The importance of this repair is not only to control operative bleeding but also to minimize dead space and prevent hematoma formation, which would impede the healing. There are currently no published, randomized, controlled trials evaluating types of uterine closure and future pregnancy rates or uterine rupture rates. Parker et al. performed a retrospective review of 19 cases of uterine rupture after a laparoscopic myomectomy and found that the use of electrosurgery was associated with an increased risk of uterine rupture, whereas a multilayered closure may decrease the risk [23]. The senior author avoids use of energy to obtain hemostasis and instead performs a meticulous multilayered closure. If the defect is large, a purse-string or running suture of 2–0 or 3–0 PDS® (polydioxanone) II (Ethicon, Cincinnati, OH) is placed in the myometrium, deep in the defect. Depending on the defect size, multiple running suture layers of PDS® II may be necessary, with multiple layers closed with the knot tied to the tail. Finally, interrupted or continuous baseball style sutures of 3–0 or 4–0 PDS® II are placed on the serosa. These sutures can all be tied extracorporeally with a knot pusher.

Due to the difficulty of tying multiple sutures in a small, confined space, some have preferred to use barbed suture for hysterotomy closure. The development of barbed suture, which is a monofilament suture with bidirectional barbs cut into it, negates the need for knot tying while providing a constant tension across tissue surfaces without back sliding [24]. Compared to traditional

suture for laparoscopic myomectomies, the use of barbed suture has demonstrated decreased operative time [25, 26] and decreased intraoperative blood loss [27, 28]. Alessandri et al. performed a randomized controlled trial comparing the use of barbed suture and conventional suture with intracorporeal knot tying in 44 patients, who underwent a laparoscopic myomectomy. They found no difference in total operative time between the two groups, but the time to close the uterine wall was significantly shorter (11.5 min vs. 17.4 min, $p < 0.001$) in the barbed versus conventional suture group.

A meta-analysis of seven studies comparing barbed versus conventional suturing in laparoscopic myomectomies found that barbed sutures were associated with a decrease in suturing time ($p < 0.001$), operative time ($p < 0.001$), intraoperative blood loss ($p = 0.021$), and postoperative hemoglobin drop ($p = 0.014$) [24].

Despite the benefits of barbed suture, it is imperative that there is minimal exposed suture, as its exposure increases the risk of postoperative adhesions and bowel obstruction. Lee and Wong describe a case report of a patient who experienced a small bowel obstruction 6 weeks after a laparoscopy myomectomy. The small bowel and rectum were found to be adherent to the uterus at the site of exposed barb on the uterus [29]. In order to minimize the risk of exposed sutures, the authors have long recommended use of a baseball style closure.

Limitations

Risk of Complications and Conversion

The limitations of laparoscopic myomectomy are dependent upon surgeon experience. Several studies have examined risk factors for complications and conversion to laparotomy. Over a 5 year period, the senior author performed 468 laparoscopic myomectomies. Major complications were noted in 7 (1.5%) cases, while 37 patients experienced minor complications. Major complications included two postoperative bleeds, hernia (5 mm secondary port), pulmonary embolism,

pelvic abscess, pelvic infection, and an evulsed uterine artery while removing a large broad ligament myoma. In this review, there was no correlation with complications based on size, number, or the location of the myomata.

Conversely, one of the largest prospective studies of 2050 laparoscopic myomectomies by Sizzi et al. found a total complication rate of 11.1% (225/2050), which included both major and minor complications. After excluding the minor complications (187/225), which included urinary tract infections, postoperative temperature > 38 °C, and uterine perforation from the manipulator, the rate of major complications was 2.02% (28/2050). Majority of these were hematomas [30] and hemorrhages [25], with only three patients requiring blood transfusions, two requiring repeat surgery, one experiencing transient postoperative kidney failure, and one with a postoperative bowel injury [31]. This study found that the risk of major complications increased in patients with myomas >5 cm, those with longer operative times, and those with interligamentous myomas [31].

Saccardi et al. performed an observational study over a 3-year period examining predictors of complications and conversion. Of the 444 patients who underwent a laparoscopic myomectomy for at least one fibroid >4 cm, only 2 (0.45%) required a transfusion, and 6 (1.35%) were converted to laparotomy. The size of the fibroid and type of myoma were predictors of increased blood loss, with intramural fibroids between 8 and 12 cm demonstrating increased blood loss compared to subserosal fibroids of the same size (275 mL vs. 200 mL, $p < 0.05$). Both intramural and subserosal fibroids >12 cm were associated with the greatest estimated blood loss, although there was no significant difference between the two groups (intramural, 450 mL vs. subserosal, 400 mL, $p > 0.05$) [32].

A recent retrospective cohort study by Sandberg et al. evaluated risks for conversion from laparoscopic myomectomy to laparotomy. Over a 3-year period, 966 myomectomies were performed, and of the 731 laparoscopic cases (343 robotic), only 8 (1.09%) of them were converted reactively to an open approach. It is impor-

tant to note that over 98% of the cases were performed by a fellowship-trained physician. Risk factors associated with conversion included increased number of fibroids (9.75 versus 3.49, $p = 0.003$) and heavier total myoma weight (667.9 versus 259.24 g, $p = 0.015$) [33]. When compared to nonconverted laparoscopic cases or planned open cases, the converted cases were found to have a higher estimated blood loss (1381.25 vs. 167.95 mL $p < 0.001$; 267.16, $p = 0.001$) and greater length of stay (3.13 vs. 0.55 days, $p < 0.001$; 2.15 days $p = 0.036$), compared to nonconverted laparoscopic cases and planned open cases, respectively [33].

Palomba et al. evaluated 136 women in a randomized controlled trial who either underwent a laparoscopic myomectomy or a minilaparotomic myomectomy. The laparoscopic group experienced no conversions (0/68, 0%) versus 6 (6/68, 8.8%) conversions from minilaparotomy to laparotomy ($p = 0.012$). The same study found no statistically significant difference in postoperative complications in the two groups (laparoscopic 2/68 (2.9%) vs. minilaparotomic 5/68 (7.4%)) [7].

Reducing Postoperative Adhesions

Postoperative adhesions can cause pain, bowel obstruction, infertility, and subsequent procedures to be increasingly more difficult with greater risk of complications [34, 35]. Laparoscopic myomectomies have demonstrated less postoperative adhesions compared to open myomectomies.

Bulletti et al. performed a case-controlled study that evaluated postoperative adhesion formation in 32 women, 16 laparoscopic and 16 open myomectomies. The study evaluated the 28 women who underwent second look on an average of 4 months after the initial surgery and found significantly fewer patients with adhesions in the laparoscopic group compared to the open group (mean adhesion score 3.0 vs. 6.7 (based on a range of 0–11)) [30].

Furthermore, Kumakiri et al. published a retrospective study of 307 patients who underwent

laparoscopic surgery after previously undergoing a laparotomy. They found adhesions in 220 patients (71.7%), and 41 patients experienced complications during the laparoscopic surgery. These complications occurred during abdominal wall or pelvic adhesiolysis in 37 patients, and the majority were due to bowel injury (35/41, 85.4%). They found that the risk of subsequent complications was strongly associated with a history of a prior abdominal myomectomy (OR 4.70, $p < 0.001$) [35].

Takeuchi et al. published a study on adhesion formation post-laparoscopic myomectomy by second look microlaparoscopy. The study included 372 patients who had undergone the procedure by one surgeon over a 10-year period. They found adhesions in 141 patients (37.9%) with the majority occurring on the posterior uterine wall (68.8% vs. 21.3% anterior and 9.9% both). They also found that postoperative adhesions were associated with larger diameter of removed fibroids and increasing number of fibroids removed. Adhesions were less common in patients who had an adhesion barrier placed including Seprafilm® (Genzyme Corporation, Cambridge, MA) and Interceed (Ethicon, Cincinnati OH) (all $p < 0.005$) [36].

There are a few different adjuncts to surgery that can be used to prevent adhesion formation. The most common classes include peritoneal instillates and exogenous barriers. Peritoneal instillates are left in the abdomen and pelvis and promote the separation of raw peritoneal surfaces, including crystalloid solutions, carboxymethylcellulose, and hyaluronic acid [37]. Exogenous barrier methods come in either a gel or solid form. Some common gel forms include SprayGel® (Confluent Surgical Inc., Waltham, MA) made of polyethylene glycol, Sepraspay® (Genzyme Corporation, Cambridge, MA) made of hyaluronic acid and carboxymethylcellulose, and Sepracoat® (Genzyme), a dilute hyaluronic acid. A Cochrane review of peritoneal instillates and gels found that gels and instillates were better at preventing adhesions versus no treatment (OR 0.34 $p < 0.00001$ and OR 0.16 $p = 0.005$, respectively). When gels were compared to instillates, gels were more effective at preventing adhesions (OR 0.36, $p = 0.001$) [38]. Solid forms

of barrier methods include Seprafilm® a mixture of hyaluronic acid with carboxymethylcellulose, SprayGel® (Confluent Surgical Inc., Waltham, MA) composed of two polyethylene glycol-based liquids, Interceed® oxidized regenerated cellulose, and Gore-Tex® (W.L. Gore and Associates Inc., Flagstaff, AZ) expanded polytetrafluoroethylene. A Cochrane review of the literature for gynecologic surgery found that Seprafilm®, Interceed®, and Gore-Tex® had less adhesion formation than no treatment [39].

Finally, a recent prospective randomized controlled trial from China evaluated the efficacy of a new crosslinked hyaluronan (NCH) in reducing adhesions after laparoscopy with a second look, 9 weeks postoperatively. The study evaluated 216 patients randomized to either nothing or NHC gel, and they found the gel group had a lower incidence of moderate and severe adhesions on second look (9.8% vs. 27.7%, $p < 0.001$) [40].

Single Versus Multi-port

Single-site laparoscopy is a relatively new technique used for ovarian cystectomies, hysterectomies, and myomectomies. Possible benefits of single-site surgery include improved cosmesis with one skin incision versus multiple incisions and potentially decreased postoperative pain [41, 42], although the results are inconclusive [43]. Kim et al. performed a retrospective study on 191 patients who underwent a single-, two-, or three-port laparoscopic myomectomy by three surgeons. [44]. The only difference identified was a longer operative time for the single- versus two- or three-port cases (165.8 ± 91.1 min, 129.5 ± 48.6 min, and 132.1 ± 54.7 min, respectively, $p = 0.005$). However, when the single-site cases were separated into an early and late period based on when the procedure was introduced at the institution, there was no difference in operative time during the late period ($p = 0.996$). Additionally, they found no difference in blood loss, transfusion rate, length of postoperative stay, conversion to laparotomy, or complications (all $p > 0.05$).

Song et al. performed a multicenter prospective randomized controlled trial on 100 subjects

assigned to either a conventional laparoscopic myomectomy or a single-site myomectomy. The study found no difference in operative time, perceived degree of surgical difficulty, operative blood loss, hemoglobin change, or length of hospital stay between the two groups (all $p > 0.05$). There were also no intraoperative or postoperative complications in either group, and there was no difference in postoperative pain scores up to 48 h after surgery (all $p > 0.05$). Although not statistically significant, there were three conversions from single site to traditional laparoscopy due to difficulty enucleating the fibroid and suturing the defect, and there were no conversions in the traditional laparoscopic myomectomy group (6% versus 0%, $p = 0.242$) [14, 15]. Despite the lack of difference in operative and perioperative outcomes between single-site and traditional laparoscopic myomectomy, the published studies are performed by only experienced, advanced laparoscopists. Cited challenges include instrument crowding and difficulty suturing due to the lack of triangulation.

Robotic-Assisted Laparoscopic Myomectomy

The only currently approved Food and Drug Administration (FDA) robotic platform is the da Vinci® Surgical System (Intuitive Surgical®, Sunnyvale, California), which was approved for use in gynecology in April of 2005. The da Vinci® platform offers the advantage of three-dimensional visualization, wristed motion, and tremor filtration. These qualities have proven especially useful for minimally invasive myomectomies due to the extensive suturing required for closure and hemostasis. Compared to abdominal myomectomies, robotic-assisted myomectomies have demonstrated less use of IV narcotics [45], shorter hospital stays [45–48], less blood loss [46–48], and less febrile morbidity [47].

There have been several studies that have demonstrated similar outcomes for robotic-assisted and laparoscopic myomectomies. All of the studies were retrospective [47, 49–53] or used a retrospective cohort for comparison in terms of blood loss, postoperative complications, and hospital stay [47, 49, 51, 54]. Although

Nezhat [51], Gargiulo [50], and Hsiao [55] found longer operative times for skilled surgeons with robotic-assisted versus laparoscopic myomectomies, Bedient [49], Barakat [47], Goçmen [54], Pluchino [52], and Sasaki [53] found similar operative times between the two. A recent meta-analysis of four of these studies demonstrated no difference in operative time, estimated blood loss, complications, and length of stay [56]. Moreover, in Gargiulo's study, barbed suture was used in almost 68% of cases in the laparoscopic cohort versus 5% of cases in the robotic-cohort.

We recently presented our data of 144 laparoscopic and robotic myomectomies for operative and perioperative outcomes including a number of fibroids found in situ postoperatively. This is a concern of robotics due to the lack of haptic feedback with robotic-assisted myomectomies. We found no difference between the laparoscopic and robotic cohort for operative time (162.2 min vs. 169.3 min, $p = 0.627$), estimated blood loss (126.4 mL vs. 111.9 mL, $p = 0.674$), overnight admission (15.6% vs. 25%, $p = 0.284$), as well as mean number (0.4 vs. 0.2, $p = 0.591$) or size of fibroids identified on postoperative ultrasound (all $p > 0.05$). The only difference identified was three (6.3%) conversions from robotic to a laparoscopic approach and no conversions in the laparoscopic cohort [53].

Single Site

Single-site, robotic-assisted surgery, with the da Vinci Si Surgical System, was approved by the FDA in 2013, for hysterectomies and adnexal surgery. Single-site robotic myomectomies are a relatively new surgical technique. Previously, the available single-site instrumentation limited complex suturing, as the instruments did not have all seven degrees of freedom as in multi-port robotic surgery. There are now wristed, single-site needle drivers on the market, which have allowed greater applications of single-site robotic surgery. Lewis et al. published a case series of four single-site robotic myomectomies using 5 mm semirigid robotic instruments, with a flexible CO₂ laser introduced through the 8 mm assistant port, to make the hysterotomy [57]. All cases were completed successfully, with a median operative time

of 210 min (range 202–254 min) and median blood loss of 103 mL (range 75–300 mL). The specimens were then hand morcellated through the 2.5 cm umbilical incision. There were no intraoperative or postoperative complications.

Tissue Removal Options

Given the FDA recommendation in April 2014 discouraging the use of power morcellation for laparoscopic myomectomies and hysterectomies [58], multiple methods have been presented in the literature for tissue removal. This will serve as a brief review of current options as well as the techniques we currently use and are investigating.

Alternatives for fibroid removal include extracorporeal hand morcellation in a bag [59], a minilaparotomy with direct extraction [60], extraction via a posterior colpotomy [61], and intracorporeal contained power morcellation via an insufflated bag [62]. We currently perform intracorporeal contained power morcellation via two techniques. The first is a multi-port technique, similar to that described by Cohen et al., but we utilize a different bag, the Espiner EcoSac 230 (Espiner Medical Ltd., North Somerset, United Kingdom), which is made of ripstop nylon [63]. Another method, also described by Cohen et al., includes creating a 3 cm umbilical incision through which the camera trocar and power morcellator are placed. Finally, we are currently investigating the use of a specifically designed bag that uses a multi-port technique but obviates the need to place a hole into the bag in order to visualize the specimen and morcellator.

Future Fertility

Effect on Fertility and Pregnancy rates

As many patients undergo a myomectomy to maintain and improve fertility, postoperative pregnancy is an important consideration. The data on the effect of myomectomy to improve fertility is controversial, but some findings are

more consistent in the literature. Pritts et al. found in a systematic review that fibroids with a submucous component, defined as FIGO type 0, 1, or 2 fibroids, decrease pregnancy rates, and their removal improves fertility [64]. Conversely, the removal of subserosal fibroids solely to improve fertility has not been supported by the literature [64]. The data on the effect of non-cavity-distorting intramural fibroids is mixed. Pritts et al. found that women with intramural fibroids had significantly lower clinical pregnancy, implantation, and ongoing pregnancy/live birth rates, as well as higher spontaneous abortion rates than those without fibroids. Despite these differences, they found no significant difference in clinical pregnancy, live birth, and spontaneous abortion rate after removal of intramural fibroids, but this was based on a very limited number of studies. Similarly, in a more recent meta-analysis of 19 studies, Sunkara et al. found a significant decrease in live birth (RR = 0.79, $p < 0.0001$) and clinical pregnancy rate (RR = 0.85, $p = 0.002$) in women with non-cavity-distorting intramural fibroids versus those without, after IVF treatment [65]. This study did not include any pregnancy data after myomectomy for this population.

Pregnancy rates after a laparoscopic or open myomectomy are similar. Seracchioli et al. performed a prospective randomized study on 131 women with a history of infertility and at least one fibroid of 5 cm or greater in size. Each patient underwent a laparoscopic or open myomectomy and was followed for almost 1 year. Of the patients that attempted pregnancy, the pregnancy rates in the two groups were similar with a rate of 55.9% in the open group and 53.6% in the laparoscopic group. [3]. A meta-analysis of two studies [3, 7] also found no difference in pregnancy rates after a laparoscopic versus open myomectomy (OR 1.11, 95% CI 0.41–2.99) [66].

Uterine Rupture

Despite similar pregnancy rates and lower complication rates after a laparoscopic myomectomy, one concern is uterine rupture during pregnancy after a

laparoscopic myomectomy. There is limited data on the amount of time one should wait after a laparoscopic myomectomy to attempt pregnancy, but most authors recommend at least a 3-month waiting period [67]. This recommendation is based on magnetic resonance imaging (MRI) evidence that it takes the uterus 12 weeks to heal after a myomectomy and even longer if a postoperative hematoma develops within the wall [68].

The rates of uterine rupture vary considerably in the literature but are generally quoted at less than 1% [69]. Koo et al. performed a retrospective study on 523 women who had an entire pregnancy followed after a laparoscopic myomectomy. In this study, hemostasis was achieved with suturing in 67.1% of cases and with bipolar energy or endoscopic loop ligation in the remaining 31.5% of cases. The mean interval between surgery and pregnancy was 14 months. There were three cases of uterine rupture (3/523, 0.6%), all prior to labor. One case occurred at 37 weeks at the uterine fundus, where a 5 cm intramural fibroid was removed, and is likely associated with excessive use of bipolar energy during the myomectomy. The second case occurred at 32 weeks in a twin IVF pregnancy, in a patient who had also previously undergone an abdominal myomectomy 6 years prior and had recently undergone a laparoscopic myomectomy for a 5 cm subserosal fibroid. The third case occurred at 21 weeks in a patient with a placenta accreta at the site of the myomectomy, which was a 7 cm subserosal fibroid in the lower uterine segment. The patient underwent an emergent hysterectomy at 21 weeks secondary to severe hemorrhage and resulted in fetal death. At the time of myomectomy, hemostasis was achieved with bipolar energy in all three cases and only a one layer closure in two of them. This study also noted a 4.2% (22/523) risk of placental abnormalities, including placenta previa, abruption, accreta, and percreta.

Several studies have demonstrated that the number, size, and type of myoma do not correlate with risk of rupture [69–71]. It was initially felt that uterine rupture may only occur after removal of deep intramural myomas, but multiple case reports have demonstrated uterine rupture after laparoscopic removal of serosal and pedunculated myo-

mas [72–74]. Parker describes 19 cases of uterine rupture during pregnancy, all prior to 36 weeks. All but one case was associated with a possible risk factor, including no repair of the uterine defect (3 cases), single suture closure (3 cases), one layer closure (4 cases), and the use of monopolar or bipolar energy for hemostasis (16 cases). There were no maternal deaths, but there were three fetal deaths occurring at 17, 28, and 33 weeks of gestation [23]. Pistofidis describes seven previously unpublished cases of uterine rupture, with six during pregnancy and one in labor, in Greece, over a 14-year time period [75]. Six of the myomas were subserosal and one was intramural. Bipolar energy was applied in all cases to obtain hemostasis, and in all but one of the cases, the incision was either not closed or only closed in one layer. Although the risk of uterine rupture is low, and many cases occur prior to the onset of labor, a cesarean section is often recommended in this population, in order to minimize the risk of rupture during labor.

Although not yet proven with prospective studies, it is often recommended that use of energy (bipolar or monopolar) to obtain hemostasis is avoided and the defect is closed in multiple layers in order to avoid a potential catastrophic obstetric event [76].

Conclusion

As demonstrated, there are multiple benefits to both laparoscopic and robotic-assisted myomectomies. However, the procedure is technically challenging and due to the risk of potential catastrophic complications, it is best suited in the hands of very skilled laparoscopic surgeons that can confidently enucleate the fibroid and repair the incision in a safe and efficient manner.

References

1. Semm K. New methods of pelviscopy for myomectomy, ovariectomy, tubectomy and adenectomy. *Endoscopy*. 1979;11:85–93.
2. Mais V, Ajossa S, Guerriero S, Mascia M, Solla E, Melis GB. Laparoscopic versus abdominal myomectomy: a prospective, randomized trial to evaluate

- benefits in early outcome. *Am J Obstet Gynecol.* 1996;175:654–8.
3. Seracchioli R, Rossi S, Govoni F, Rossi E, Venturoli S, Bulletti C, et al. Fertility and obstetric outcome after laparoscopic myomectomy of large myomata: a randomized comparison with abdominal myomectomy. *Hum Reprod.* 2000;15:2663–8.
 4. Seinara P, Arisio R, Decko A, Farina C, Crana F. Laparoscopic myomectomy: indications, surgical technique and complications. *Hum Reprod.* 1997;12:1927–30.
 5. Bhave Chittawar P, Franik S, Farquhar C. Minimally invasive surgical techniques versus open myomectomy for uterine fibroids. *Cochrane Database Syst Rev.* 2014;(10):CD004638.
 6. Rossetti A, Sizzi O, Soranna L, Cucinelli F, Mancuso S, Lanzone A. Long-term results of laparoscopic myomectomy: recurrence rate in comparison with abdominal myomectomy. *Hum Reprod.* 2001;16(4):770–4.
 7. Palomba S, Zupi E, Russo T, Falbo A, Marconi D, Tolino A, et al. A multicenter randomized, controlled study comparing laparoscopic versus minilaparoscopic myomectomy: short-term outcomes. *Fertil Steril.* 2007;88:942–51.
 8. Kang JH, Kim WY, Lee KW, Kim KH, Song T. Timing for laparoscopic myomectomy during the menstrual cycle. *J Minim Invasive Gynecol.* 2015;22:1191–5.
 9. Knol HM, Kemperman RFJ, Kluin-Nelemans HC, Mulder A, Meijer K. Hemostatic variables during normal menstrual cycle. A systematic review. *Thromb Haemost.* 2012;107:22–9.
 10. Hurst BS, Matthews ML, Marshburn PB. Laparoscopic myomectomy for symptomatic uterine myomas. *Fertil Steril.* 2005;32:1–23.
 11. Kongnyuy EJ, Wysonge CS. Interventions to reduce hemorrhage during myomectomy for fibroids. *Cochrane Database Syst Rev.* 2014;(8):CD005355.
 12. Hobo R, Netsu S, Koyasu Y, Tsutsumi O. Bradycardia and cardiac arrest caused by intramyometrial injection of vasopressin during a laparoscopically assisted myomectomy. *Obstet Gynecol.* 2009;113:484–6.
 13. Nezhat F, Admon D, Nezhat C, Dicorpo J, Nezhat C. Life-threatening hypotension after vasopressin injection during operative laparoscopy, followed by uneventful repeat laparoscopy. *J Am Assoc Gynecol Laprosc.* 1994;2:83–6.
 14. Song T, Kim MK, Kim M-L, Jung VW, Yun BS, Seong SJ. Use of vasopressin vs epinephrine to reduce haemorrhage during myomectomy: a randomized controlled trial. *Eur J Obstet Gynecol Reprod Biol.* 2015a;195:177–81.
 15. Song T, Kim T-J, Lee S-H, Kim T-H, Kim W-Y. Laparoendoscopic single-site myomectomy compared with conventional laparoscopic myomectomy: a multicenter, randomized, controlled trial. *Fertil Steril.* 2015b;104:1325–31.
 16. Ostrzenski A. A new laparoscopic myomectomy technique for intramural fibroids penetrating the uterine cavity. *Eur J Obstet Gynecol Reprod.* 1997;74:189–93.
 17. Dubuisson JB, Malartic C, Jacob S, Chapron C, Rambaud D. Preventive uterine artery occlusion combined with laparoscopic myomectomy: a valid procedure to prevent bleeding. *J Gynecol Surg.* 2004;20:105–12.
 18. Vercellino G, Erdemoglu E, Joe E, Hopfenmueller W, Holthaus B, Kohler C, et al. Laparoscopic temporary clipping of uterine artery during laparoscopic myomectomy. *Arch Gynecol Obstet.* 2012;286(5):1181–6.
 19. Litta P, Fantinato S, Calonaci F, Cosmi E, Filippeschi M, Zerbetto I, Petraglia F, Florio P. A randomized controlled study comparing harmonic versus electro-surgery in laparoscopic myomectomy. *Fertil Steril.* 2010;94:1882–6.
 20. Ou C, Harper A, Liu Y, Rowbotham R. Laparoscopic myomectomy technique. Use of colpotomy and the harmonic scalpel. *J Reprod Med.* 2002;47:849–53.
 21. Hambley R, Hebda P, Abell E, Cohen B, Jegasothy B. Wound healing of skin incision produced by ultrasonically vibrating knife, scalpel, electro-surgery and carbon dioxide laser. *J Dermatol Surg Oncol.* 1998;12:1213.
 22. Amaral JF. Ultrasonic dissection. *Endosc Surg Allied Technol.* 1994;2:181–5.
 23. Parker W, Einarsson J, Istre O, Dubuisson J. Risk factors for uterine rupture after laparoscopic myomectomy. *J Minim Invasive Gynecol.* 2010;17:551–4.
 24. Zhang Y, Ma D, Li X, Zhang Q. Role of barbed sutures in repairing uterine wall defects in laparoscopic myomectomy: a systematic review and meta-analysis. *J Minim Invasive Gynecol.* 2016;23:684–91.
 25. Einarsson J, Chavan N, Suzuki Y, Jonsdottir G, Vellinga T, Greenberg J. Use of bidirectional barbed suture in laparoscopic myomectomy: evaluation of perioperative outcomes, safety and efficacy. *J Minim Invasive Gynecol.* 2011;18:92–5.
 26. Tulandi T, Einarsson J. The use of barbed suture for laparoscopic hysterectomy and myomectomy: a systematic review and meta-analysis. *J Minim Invasive Gynecol.* 2014;21(2):210–6.
 27. Angioli R, Plotti F, Montero R, Daminai P, Terranova C, Orzoni I, et al. A new type of absorbable barbed suture for use in laparoscopic myomectomy. *Int J Gyn Obstet.* 2012;117:220–3.
 28. Alessandri F, Remorgida V, Venturini P, Ferrero S. Unidirectional barbed suture versus continuous suture with intracorporeal knots in laparoscopic myomectomy: a randomized study. *J Minim Invasive Gynecol.* 2010;17:725–9.
 29. Lee E, Wong F. Small bowel obstruction from barbed suture following laparoscopic myomectomy—a case report. *Int J Obstet Gynecol.* 2015;16:146–9.
 30. Bulletti C, Polli V, Negrini V, Giacomucci E, Flamigni C. Adhesion formation after laparoscopic myomectomy. *J Am Assoc Gynecol Laprosc.* 1996;3(4):533–6.
 31. Sizzi O, Rossetti A, Malzoni M, Minelli L, La Grotta F, Soranna L, et al. Italian multicenter study on complications of laparoscopic myomectomy. *J Minim Invasive Gynecol.* 2007;14:453–62.

32. Saccardi C, Gizzo S, Noventa M, Ancona E, Borhero A, Litta PS. Limits and complications of laparoscopic myomectomy: which are the best predictors? A large cohort single-center experience. *Arch Gynecol Obstet.* 2014;290:951–6.
33. Sandberg E, Cohen S, Jansen F, Einarsson JI. Analysis and risk factors for intraoperative conversion of laparoscopic myomectomy. *J Minim Invasive Gynecol.* 2016;23:352–7.
34. Iles DA, Ahmad G, Watson A. Adhesions: effects on fertility and prevention. In: Metwally M, Li TC, editors. *Reproductive surgery in assisted conception.* London: Springer; 2015. p. 153–69.
35. Kumakiri J, Kikuchi I, Kitade M, Kuroda K, Matsuoka S, Tokita S, et al. Evaluation of factors contributing to uterine scar formation after laparoscopic myomectomy. *Acta Obstet Gynecol.* 2010;89:1078–83.
36. Takeuchi H, Kitade M, Kikuchi I, Shimanuki H, Kumakiri J, Takeda S. Influencing factors of adhesions development and the efficacy of adhesion-preventing agents in patients undergoing laparoscopic myomectomy as evaluated by second-look laparoscopy. *Fertil Steril.* 2008;89:1247–53.
37. Kamel RM. Prevention of postoperative peritoneal adhesions. *Eur J Obstet Gynecol.* 2010;150:111–8.
38. Ahmad G, Mackie FL, Iles DA, O'Flynn A, Dias S, Metwally M, et al. Fluid and pharmacological agents for adhesion prevention after gynaecological surgery (review). *Cochrane Database Syst Rev.* 2014;(7):CD001298.
39. Ahmad G, O'Flynn H, Hindocha A, Watson A. Barrier agents for adhesion prevention after gynaecological surgery (review). *Cochrane Database Syst Rev.* 2015;(4):CD000475.
40. Liu C, Lu Q, Zhang Z, Xue M, Zhang Y, Zhang Y, et al. A randomized controlled trial on the efficacy and safety of a new crosslinked hyaluronan gel in reducing adhesions after gynecologic laparoscopic surgeries. *J Minim Invasive Gynecol.* 2015;22:853–63.
41. Fagotti A, Bottoni C, Vizzielli G, Alletti S, Scambia G, Marana E, et al. Postoperative pain after conventional laparoscopy and laparoendoscopic single site surgery (LESS) for benign adnexal disease: a randomized trial. *Fertil Steril.* 2011;96:255–9.
42. Yim G, Jung Y, Paek J, Lee S, Kwon H, Nam E, Kim S, Kim J, Kim Y, Kim S. Transumbilical single-port access versus conventional total laparoscopic hysterectomy: surgical outcomes. *Am J Obstet Gynecol.* 2010;203:26.e1–6.
43. Jung Y, Lee M, Yim G, Lee S, Paek J, Kwon H, Nam E, Kim S, Kim Y. A randomized prospective study of single-port and four-port approaches for hysterectomy in terms of postoperative pain. *Surg Endosc.* 2011;25:2462–9.
44. Kim S, Baek J, Park E, Jeung I, Choi J, Kim C, et al. A comparison of single-, two-, and three- port laparoscopic myomectomy. *J Soc Laparoendosc Surg.* 2015;19(4):e2015.00084.
45. Nash K, Feinglass J, Zei C, Lu G, Mengesha B, Lewicky-Gaupp B, et al. Robotic-assisted laparoscopic myomectomy vs. abdominal myomectomy: a comparative analysis of surgical outcomes and costs. *Arch Gynecol Obstet.* 2012;285:435–40.
46. Ascher-Walsh C, Capes T. Robot-assisted laparoscopic myomectomy is an improvement over laparotomy in women with a limited number of myomas. *J Minim Invasive Gynecol.* 2010;17:306–10.
47. Barakat EE, Bedaiwy MA, Zimberg S, Nutter B, Nosseir M, Falcone T. Robotic-assisted, laparoscopic and abdominal myomectomy: a comparison of surgical outcomes. *Obstet Gynecol.* 2011;117:256–65.
48. Gubern J, Rosemeyer C, Barter J, Steren A. Comparison of robotic, laparoscopic, and abdominal myomectomy in a community hospital. *J Soc Laparoendosc Surg.* 2013;17:116–20.
49. Bedient CE, Magrina JF, Noble BN, Kho R. Comparison of robotic and laparoscopic myomectomy. *Am J Obstet Gynecol.* 2009;201:566.e1–5.
50. Gargiulo A, Srouji S, Missmer S, Correia K, Vellinga T, Einarsson J. Robot-assisted laparoscopic myomectomy compared with standard laparoscopic myomectomy. *Obstet Gynecol.* 2012;120:284–91.
51. Nezhat C, Lavie O, Hsu S, Watson J, Barnett O, Lemyre M. Robotic-assisted laparoscopic myomectomy compared with standard laparoscopic myomectomy—a retrospective matched control study. *Fertil Steril.* 2009;91:556–9.
52. Pluchino N, Litta P, Freschi L, Russo M, Simi G, Santoro A, et al. Comparison of the initial surgical experience with robotic and laparoscopic myomectomy. *Int J Med Rob Comput Assisted Surg.* 2014;10:208–12.
53. Sasaki KJ, Steller CJ, Sulo S, Cholkeri-Singh A, Miller CE. Comparison of operative and peri-operative results for robotic and laparoscopic myomectomies. *J Minim Invasive Gynecol.* 2015;22(6):S7.
54. Goçmen A, Sanhkan F, Mustafa G. Comparison of robotic-assisted laparoscopic myomectomy outcomes with laparoscopic myomectomy. *Arch Gynecol Obstet.* 2013;287:91–6.
55. Hsiao S, Lin H, Peng F, Jen P, Hsiao C, Tu F. Comparison of robot-assisted laparoscopic myomectomy and traditional laparoscopic myomectomy. *J Obstet Gynaecol Res.* 2013;39(5):1024–9.
56. Pundir J, Pundir V, Walavalkar R, Omanwa K, Lancaster G, Kayani S. Robotic-assisted laparoscopic vs. abdominal and laparoscopic myomectomy: systematic review and meta-analysis. *J Minim Invasive Gynecol.* 2013;20:335–45.
57. Lewis E, Srouji S, Gargiulo A. Robotic single-site myomectomy: initial report and technique. *Fertil Steril.* 2015;103:1370–7.
58. US Food and Drug Administration. Laparoscopic uterine power morcellation in Hysterectomy and Myomectomy: FDA Safety Communicatio. <http://www.fda.gov/MedicalDevices/Safety/AlertsandNotices/ucm393576.htm>. Published April 17, 2014. Accessed July 1, 2017.

59. Serur E, Lakhi N. Laparoscopic hysterectomy with manual morcellation of the uterus. *Am J Obstet Gynecol.* 2011;204:566.e1–2.
60. Seidman DS, Nezhat CH, Nezhat F, Nezhat C. The role of laparoscopic-assisted myomectomy (LAM). *J Soc Laparoendosc Surg.* 2001;5(4):299–303.
61. Dubuisson JB, Chapron C, Levy L. Difficulties and complications of laparoscopic myomectomy. *J Gynecol Surg.* 1996;12:159–65.
62. Cohen S, Einarsson J, Wang K, Brown D, Boruta D, Scheib S, et al. Contained power morcellation within an insufflated isolation bag. *Obstet Gynecol.* 2014;124:491–7.
63. Steller CJ, Miller CE, Cholkeri-Singh A, Sasaki KJ. Review and outcomes of power morcellation using an innovative contained bag system. *J Minim Invasive Gynecol.* 2015;22(6):S100–1.
64. Pritts E, Parker W, Olive D. Fibroids and infertility: an updated systematic review of the evidence. *Fertil Steril.* 2009;91:1215–23.
65. Sunkara S, Khairy M, El-Toukhy T, Khalaf Y, Coomarasamy A. The effect of intramural fibroids without uterine cavity involvement on the outcome of IVF treatment: a systematic review and meta-analysis. *Hum Reprod.* 2010;25(2):418–29.
66. Jin C, Hu Y, Chen X, Zheng F, Lin F, Zhou K, et al. Laparoscopic versus open myomectomy—a meta-analysis of randomized controlled trials. *Eur J Obstet Gynecol Reprod Biol.* 2009;145:14–21.
67. Falcone T, Parker W. Surgical management of leiomyomas for fertility or uterine preservation. *Obstet Gynecol.* 2013;121:856–68.
68. Tsuji S, Takahashi K, Imaoka I, Sugimura K, Miyazaki K, Noda Y. MRI evaluation of the uterine structure after myomectomy. *Gynecol Obstet Investig.* 2006;61:106–10.
69. Koo Y, Lee J, Lee Y, Kwak D, Lee I, Lim K, et al. Pregnancy outcomes and risk factors for uterine rupture after laparoscopic myomectomy: a single-center experience and literature review. *J Minim Invasive Gynecol.* 2015;22:1022–8.
70. Seracchioli R, Manuzzi L, Vianello F, Gualerzi B, Savelli L, Paradisi R, Venturoli S. Obstetric and delivery outcome of pregnancies achieved after laparoscopic myomectomy. *Fertil Steril.* 2006;86:159–65.
71. Stringer N, Strassner H, Lawson L, Oldham L, Estes C, Edwards M, Stringer E. Pregnancy outcomes after laparoscopic myomectomy with ultrasonic energy and laparoscopic suturing of the endometrial cavity. *J Minim Invasive Gynecol.* 2001;8:129–36.
72. Lieng M, Istre O, Langebrenne A. Uterine rupture after laparoscopic myomectomy. *J Minim Invasive Gynecol.* 2004;11:92–3.
73. Oktem O, Gokaslan H, Durmusoglu F. Spontaneous uterine rupture in pregnancy 8 years after laparoscopic myomectomy. *J Minim Invasive Gynecol.* 2001;8(4):618–9.
74. Pelosi MA, Pelosi MA. Spontaneous uterine rupture at thirty-three weeks subsequent to previous superficial laparoscopic myomectomy. *Am J Obstet Gynecol.* 1997;177:1547–9.
75. Pistofidis G, Makrakis E, Balinakos P, Dimitriou E, Bardis N, Anaf V. Report of 7 uterine rupture cases after laparoscopic myomectomy: update of the literature. *J Minim Invasive Gynecol.* 2012;19:762–7.
76. Flyckt R, Falcone T. Editorial: Uterine rupture after laparoscopic myomectomy. *J Minim Invasive Gynecol.* 2015;22:921–2.



Salpingectomy in Benign Hysterectomy

Meritxell Gràcia, Jordina Munrós, Mariona Rius,
and Francisco Carmona

Introduction

Hysterectomy is one of the most frequent gynecologic surgeries over the world. Traditionally, concomitant oophorectomy has been often performed for prevention of ovarian cancer. Besides, epithelial ovarian carcinoma is the most lethal of the gynecologic cancers (among 225,000 women affected each year, 140,000 will die due to ovarian cancer) [1], with no effective screening method, and prevention as the only validated strategy considered with impact in mortality [2].

Regarding the physiopathology of ovarian cancer (see next section “New Insights in the Physiopathology of Ovarian Cancer”), prophylactic salpingectomy during benign surgeries (e.g., hysterectomy or tubal ligation for desire of sterilization) may reduce the risk of ovarian cancer. Tubal ligation has demonstrated this protective effect, especially in endometrioid and clear cell carcinomas (supporting the retrograde menses of endometrial cells theory) [3]. Bilateral salpingectomy with ovarian preservation may be a better option than bilateral salpingo-oophorectomy. The importance of salpingectomy

lies on the research findings showing that the distal fimbriated end comprises the majority of cancers and preinvasive lesions in both general population and *BRCA1* and *BRCA2* mutation carriers [4]. In the high-grade ovarian cancer, precursor lesions are not identified in the ovary but in the Fallopian tube, known as serous tubal intraepithelial carcinomas (STIC); staining has shown p53 mutations in these lesions [4].

Recent studies have shown the impact of surgical menopause (bilateral salpingo-oophorectomy, BSO) in bone, cardiovascular, sexual, and cognitive health [5].

Nevertheless, the approach to hysterectomy should not be influenced by this theoretical benefit. We have to keep in mind that this is an approach for women in average risk rather than high risk.

The British Columbia Ovarian Cancer Research (OVCARE) introduced the concept of opportunistic salpingectomy in 2010. It means the removal of the Fallopian tubes for primary prevention of epithelial carcinoma of the Fallopian tube, ovary, or peritoneum in a woman undergoing pelvic surgery for another indication.

Women should be counseled that there are currently no data regarding the impact on ovarian, Fallopian tubal, or peritoneal cancer of this intervention, so evidence is still limited, and surgeons differ widely in their practice. The rate of bilateral salpingectomy with ovarian conservation in women undergoing benign hysterectomy ranged

M. Gràcia, M.D. · J. Munrós, M.D. · M. Rius, M.D.
F. Carmona, M.D., Ph.D. (✉)
Gynecology Department, Institut Clínic de
Ginecologia, Obstetrícia i Neonatologia,
Hospital Clínic de Barcelona, Barcelona, Spain
e-mail: megracia@clinic.cat; jmunros@clinic.cat;
marius@clinic.cat; fcarmona@clinic.cat

from 0 to 72.2% among 744 hospitals across the United States [6] comparing with rates from 20 to 85% when bilateral salpingo-oophorectomy is performed [7]. This may reflect also a difference in patient preference or disparity in providing the choice of prophylactic procedures.

The two Nurses' Health Studies [8, 9] contribute with prospective comparative data regarding the impact of BSO. However, the data are indirect and not adequately powered to evaluate bilateral salpingectomy (BS) alone. This two studies demonstrated that the hazard ratio for deaths from all causes in women who had undergone hysterectomy that included bilateral oophorectomy was 1.12 (95% CI, 1.02–1.21) compared with women who underwent ovarian conservation. In a subgroup analysis, bilateral oophorectomy was associated with significantly greater mortality only in women under the age of 50 years (without estrogen replacement therapy), and there was no age at which bilateral oophorectomy improved survival. Cardiovascular mortality was higher in women who had undergone oophorectomy without estrogen replacement before the age of 45 years. The optimum age at which ovarian conservation benefited long-term survival in woman at average risk of ovarian cancer was through 65 years.

Prospective and randomized studies are needed and research proposals are already underway.

Recently, in 2015, the American College Of Obstetricians and Gynecologists published its recommendations [10]:

- Surgeon and patient should discuss the potential benefits of the removal of the Fallopian tubes during hysterectomy in a population of women at risk of ovarian cancer who are not having an oophorectomy.
- When counseling women about laparoscopic sterilization methods, clinicians can communicate that bilateral salpingectomy can be considered a method that provides effective contraception.
- Prophylactic salpingectomy may offer clinicians the opportunity to prevent ovarian cancer in their patients.

- Randomized controlled trials are needed to support the validity of this approach to reduce the incidence of ovarian cancer.

Moreover, apart from these recommendations in order to reduce the incidence of ovarian cancer, sparing the Fallopian tubes during hysterectomy shows no benefits. Complications such as hydrosalpinx, salpingitis, pyosalpinx, tubo-ovarian abscess, chronic pelvic inflammatory disease, tubal torsion, pelvic pain, and benign Fallopian tube tumors such as paraovarian cysts have been described after the retention of Fallopian tubes in women. Therefore, as Fallopian tubes can no longer fulfill their physiological function after hysterectomy, there seems to be no reason for not removing them concomitant to hysterectomy [11].

New Insights in the Physiopathology of Ovarian Cancer

The physiological role of the Fallopian tubes is the transport of the gametes to reach the fertilization. Functionally, Fallopian tube fimbriae collect the egg released from the ovary into the pelvis, and with the tubes' peristaltic movement, they permit the encounter with the sperm, thus being a frequent site of fertilization. But the Fallopian tubes are also responsible of multiple conditions due to their role as connectors between the uterus and the pelvis. Through them and in a retrograde way, multiple substances from the endometrium, cervix, vagina, and tubes itself reach the peritoneum of the abdominal cavity. Therefore, they can place an ectopic pregnancy, as well as be responsible of pelvic inflammatory disease by the inflammation and infection of their tissue causing salpingitis, pyosalpinx, or, even more severe, a tubo-ovarian abscess. Moreover, they are thought to be responsible of part of the etiopathogenesis of endometriosis (Sampson's theory) [11].

Apart from all these conditions where the Fallopian tubes play a crucial role, over the last decade, many investigations have led to a paradigm shift in the understanding of the pathogenesis of ovarian cancer and its etiology. It has been

demonstrated that the Fallopian tubes may be involved in the development of high-grade ovarian, Fallopian tube, and peritoneal serous carcinomas, all of them considered the spectrum of the same disease, since they are thought to share similar molecular profiles [12].

There are two types of ovarian tumors described [4, 12]. Type 1 carcinomas include low-grade serous, endometrioid, clear cell, seromucinous carcinomas, mucinous carcinomas, and malignant Brenner tumors. These types of tumors are less common, tend to present at a lower stage, and usually arise from a precursor lesion, usually being either borderline serous tumors or endometriosis [13]. On the contrary, type 2 includes high-grade serous carcinoma, carcinosarcoma, and undifferentiated carcinoma; they are associated with an advanced stage (stage 3 or 4) and account for the majority of the deaths.

The main molecular feature that differentiates type 1 from type 2 tumors is the genetic stability of the former in front of the chromosomal instability of the latter, in the form of global DNA copy number changes. The molecular profile of type 1 carcinomas is characterized by KRAS, BRAF, ERBB2, CTNBI, PTEN, PIK3CA, ARID1A, PPP2R1A, and BCL2 mutations. On the contrary, type 2 tumors show TP53 mutations, which are present in almost 96% of cases of high-grade serous ovarian carcinomas [14]. The differences between the two types of ovarian tumor in terms of molecular, pathologic, and clinical features are shown in Table 13.1 [12].

In the last few years, several studies have demonstrated that the main part of type 2 ovarian tumors may originate from a precursor lesion developed in the Fallopian tube, particularly in the fimbriae, named STIC (serous tubal intraepithelial carcinoma). It has been defined and consists in regions of dysplasia with secretory cells, lacks ciliated cells of a normal Fallopian tube, has a TP53 mutation, and is associated with a high degree of DNA repair pathway alterations including BRCA and BRCA-like mutations. Moreover, STICs have short telomeres, which is a feature associated with precancerous lesions. Detailed analyses and microsectioning of the ovaries and Fallopian tubes at the time of risk-

Table 13.1 Type 1 and type 2 ovarian carcinomas (differential features)

Features	Type 1	Type 2
Stage at diagnosis	Frequently early stage	Almost always advanced stage
Tumor grade	Low grade ^a	High grade
Proliferative activity	Generally low	Always high
Progression	Slow and indolent	Rapid and aggressive
Response to chemotherapy	Fair	Good, but frequent recurrence
Risk factors	Endometriosis	Lifetime ovulation cycles; BRCA germline mutations
Precursors	Atypical proliferative (borderline) tumors	Mostly STICs
Chromosomal instability	Low	High
TP53 mutation	Infrequent	Almost always

^aClear cell carcinoma is not graded, but many consider the tumor as high grade
BRCA breast cancer, STIC serous tubal intraepithelial carcinoma

reducing salpingo-oophorectomy in women with BRCA mutations have detected unsuspected small invasive and preinvasive lesions in 5–9% of cases, with the Fallopian tubes being involved in more than 70% of these cases. STIC lesions are also found in 50–60% of sporadic serous ovarian cancers. Both cases of ovarian cancer in BRCA mutation carriers as well as sporadic cases have shown TP53 mutations in more than 90% of serous high-grade ovarian cancers, and these mutations match the specific mutations seen in the precursor lesions found in the Fallopian tubes, thus suggesting a clonal origin. Therefore, it is thought that most high-grade serous cancers may be metastatic from the tube [4], following the hypothesis of peritoneal seeding by malignant cells from the fimbriated end of the tubes [13] (Fig. 13.1).

Taking into account that more than 70% of high-grade serous cancers present evidence of a precursor lesion in the Fallopian tube, it is a topic of interest whether the removal of the

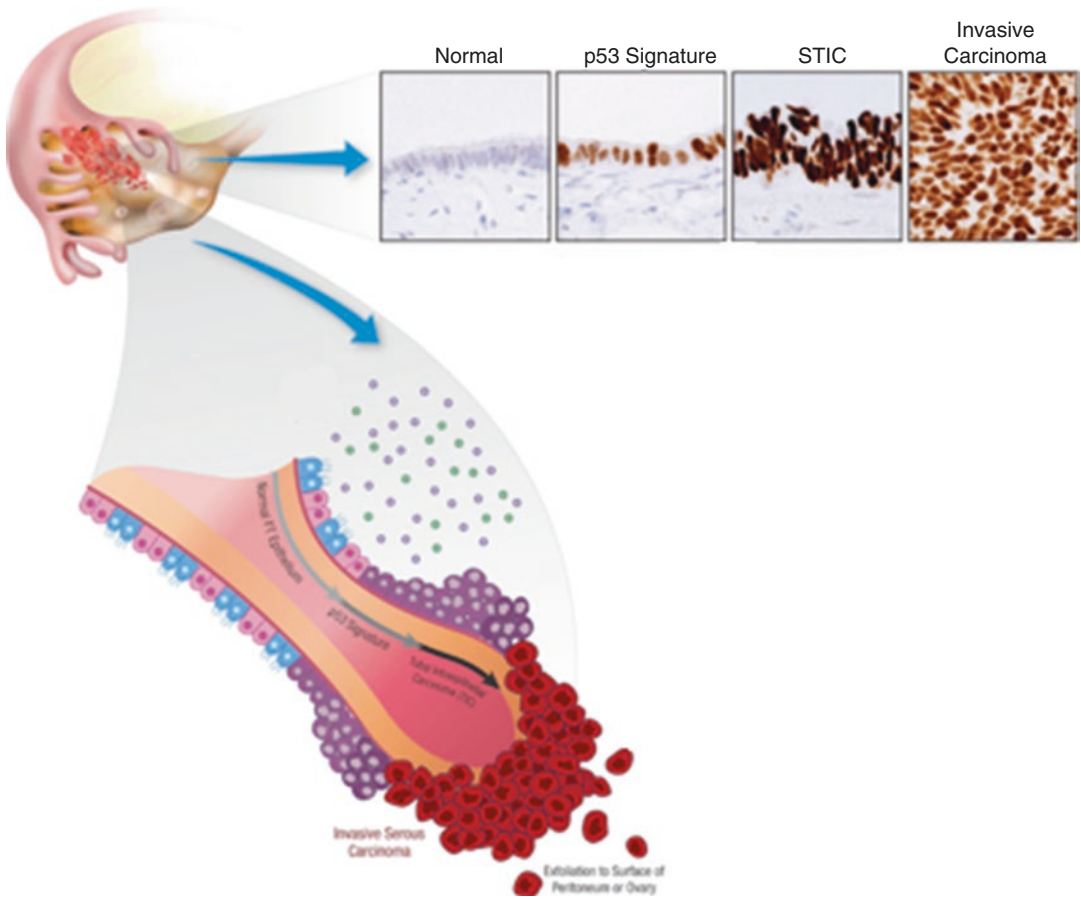


Fig. 13.1 Serous tubal intraepithelial carcinoma (STIC). Jones PM and Drapkin R. *Front. Oncol.*, 26 August 2013

Fallopian tubes would reduce the incidence and death rates from ovarian cancer. Ovarian cancer is the second most common gynecological malignancy in developed countries [13] and the most lethal [4]. Because early detection of high-grade serous carcinoma through screening using transvaginal ultrasonography and serum cancer antigen 125 concentrations as well as symptom detection has failed to reduce mortality, the only currently available strategy likely to affect mortality is prevention [4, 12]. Therefore, salpingectomy could reduce the incidence of type 2 ovarian cancer and may show some benefit in type 1 cancers in which endometriosis is involved in their pathogenesis.

There is epidemiologic evidence that tubal ligation is associated with a reduction in ovarian cancer in both general and high-risk popula-

tion. Cibula et al. concluded in a meta-analysis that previous tubal ligation in women without high-risk was associated with a 34% overall risk reduction in endometrioid and serous cancer, although no significant risk reduction was found for mucinous or borderline tumors [2]. Although there are few small studies regarding ovarian cancer risk reduction with tubal ligation in BRCA mutation carriers, it seems that there would be also benefit in this subgroup of women [4].

Therefore, bilateral salpingectomy should have at least the same benefit as bilateral tubal ligation. Nowadays, there is no data regarding the effect of bilateral salpingectomy in the reduction of ovarian cancer risk in general and high-risk population, and it will take decades to demonstrate it.

Surgical Approach

Prophylactic salpingectomy consists of the removal of the distal one-third (fimbria and infundibulum, portion of ampulla) of both Fallopian tubes (Fig. 13.2).

Before describing the technique, few anatomic considerations should be taken into account. First, the infundibulopelvic ligament should be identified since it contains the ovarian vessels encased in the peritoneum, and caution should be taken in order to avoid injury. Second, the ureter lies in close proximity to the infundibulopelvic ligament and must be identified medially to the ligament prior to starting the salpingectomy. The right ureter enters the pelvic cavity crossing the origin of the right external iliac artery and the left ureter crossing the common iliac artery bifurcation.

Once the anatomic landmarks are identified, first elevate the Fallopian tube and coagulate using bipolar energy (other types of energy could be used), and cut the tubo-ovarian ligament carefully to not damage the infundibulopelvic ligament (Fig. 13.3a, b). Then, continue with the coagulation and cutting of the mesosalpinx immediately below the tube all along the ampulla portion (Fig. 13.3c). Any cautery/dissection tool may be used. Finally, cauterize and cut the utero-

ovarian ligament and separate it from de uterus (Fig. 13.3d).

We can proceed then with the hysterectomy as current practice with the tubes removed en bloc (attached at the cornua of the uterus).

Salpingectomy at the time of hysterectomy seems to be safe, without an increase of complications compared with hysterectomy alone, with no differences in the rate of blood transfusion or readmission [15]. Studies have shown that salpingectomy performed with hysterectomy added an average of 16 min to operative time. Hysterectomy with salpingectomy was not associated with a longer hospital stay than hysterectomy alone [16]. Longer follow-up studies about surgical morbidity are needed.

Controversies

Hysterectomy is known to be associated with earlier menopause, although this effect is not well understood. Likewise, the risk and impact of salpingectomy on ovarian function are uncertain and controversial; some studies have shown no detrimental effect on ovarian function or hormonal levels, while some others have reported a reduction of ovarian reserve (a reduction in follicles and

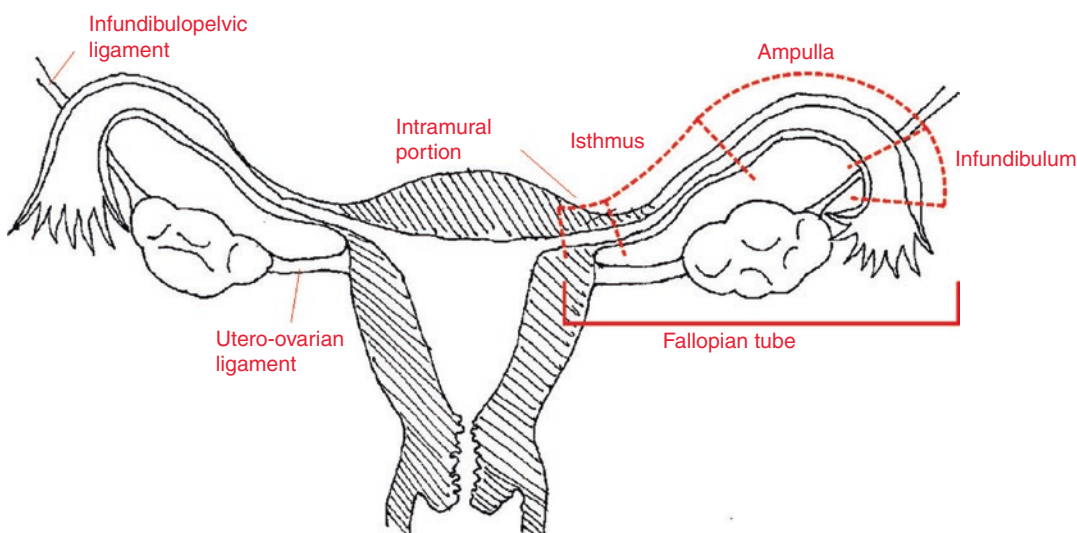


Fig. 13.2 Normal female internal genitalia anatomy

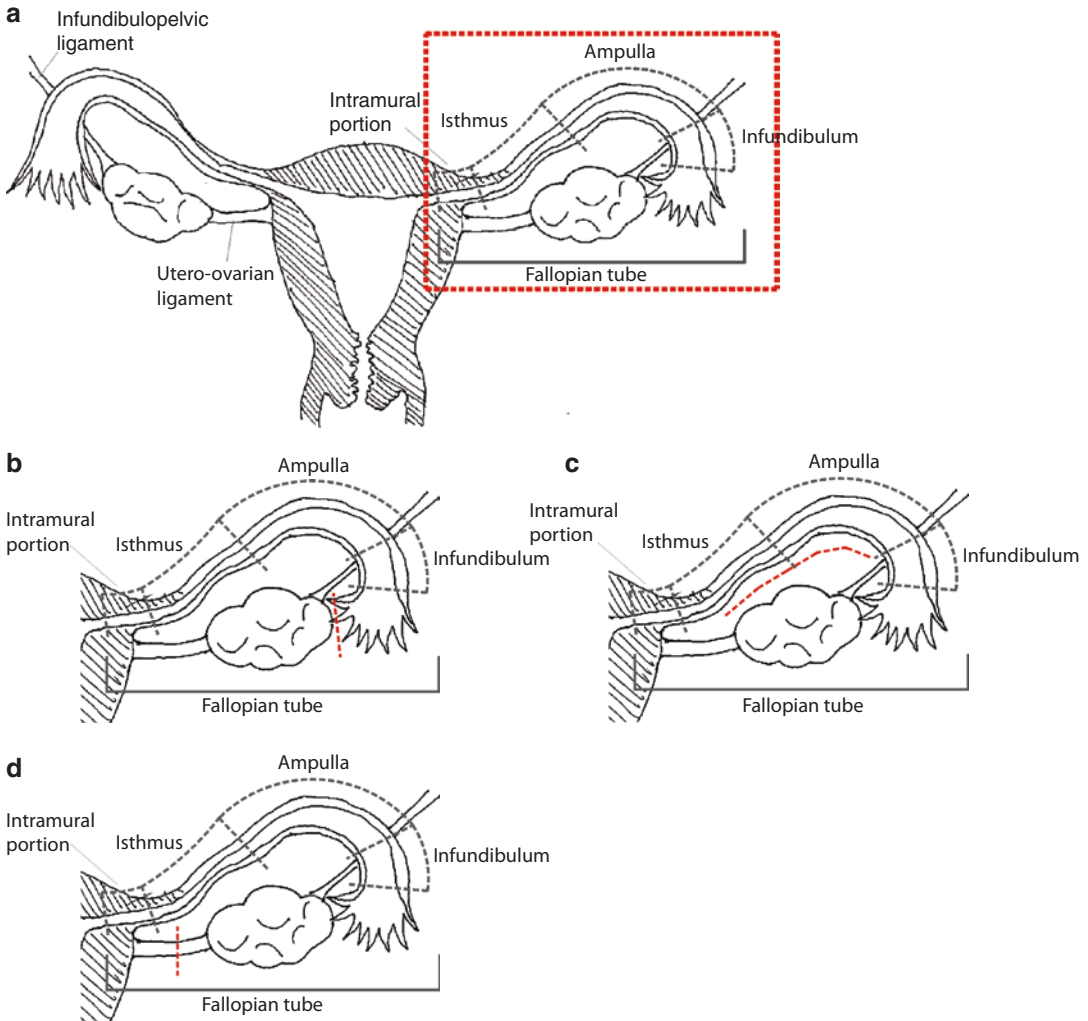


Fig. 13.3 Surgical technique (a) Fallopian tube detail. (b) Tubo-ovarian ligament section. (c) Mesosalpinx section. (d) Utero-ovarian ligament section

increases in follicle-stimulating hormone levels or changes in Doppler blood flow) [17].

A non-randomised trial designed by Morelli et al. concluded that no negative effects in terms of perioperative complications, ovarian US characteristics, and hormone levels between women who underwent laparoscopic hysterectomy with BS or alone [18].

Another issue would be to introduce the concept of salpingectomy during any pelvic surgery (not only hysterectomy). There are no randomized studies about this, but if we take into consideration

the effects of tubal ligation on reducing ovarian type 1 cancer, salpingectomy should provide the same benefits or even increase them in reducing type 2 carcinomas incidence rate. Falconer et al. published a cohort study comparing three procedures for benign disease: salpingectomy, tubal ligation, and hysterectomy with or without bilateral salpingo-oophorectomy. The results showed a lower risk of ovarian cancer in the group of salpingectomy with a reduction also in the other groups. Bilateral salpingo-oophorectomy provided a 50% reduction rather than unilateral [19].

Conclusions

Long-term studies of the outcomes of opportunistic salpingectomy are needed. Meanwhile, the Society of Gynecologic Oncologists of Canada (GOC), Society of Gynecologic Oncology, and American College of Obstetricians and Gynecologists support the potential benefit of opportunistic salpingectomy in the reduction of pelvic serous carcinoma incidence rates.

In terms of cost, although there are no data regarding it, opportunistic salpingectomy seems to increase slightly operative costs due to increased operative duration and possible use of additional instrumentation. Further data are needed to determine cost-effectiveness. But if ovarian cancer incidence is decreased, cost savings would be significant.

BRCA 1/2 invasive carcinomas have a presentation at earlier ages than STIC forms. The time lapse between overexpression of p-53, STIC, and development of invasive cancer is not known, making difficult the choice when preventive salpingectomy should be performed. According to this, a new indication perspective (to save the effects of early menopause) would be to perform the procedure in two stages: salpingectomy before menopause and oophorectomy after menopause in high-risk patients [20].

References

- Jemal A, Bray F, Center MM, et al. Global cancer statistics. *CA Cancer J Clin*. 2011;61:69–90.
- Cibula D, Widschwendter M, Májek O, Dusek L. Tubal ligation and the risk of ovarian cancer: review and meta-analysis. *Hum Reprod Update*. 2011;17(1):55–67.
- Rosenblatt KA, Thomas DB. Reduced risk of ovarian cancer in women with a tubal ligation or hysterectomy. The World Health Organization Collaborative Study of Neoplasia and Steroid Contraceptives. *Cancer Epidemiol Biomark Prev*. 1996;5:933–5.
- Walker JL, Powell CB, Chen L, Carter J, Bae Jump VL, Parker LP, Borowsky ME, Gibb RK. Society of Gynecologic Oncology recommendations for the prevention of ovarian cancer. *Cancer*. 2015;121(13):2108–20.
- Erekson EA, Martin DK, Ratner ES. Oophorectomy: the debate between ovarian conservation and elective oophorectomy. *Menopause*. 2013;20:110–4.
- Xu X, Desai V. Hospital variation in the practice of bilateral salpingectomy with ovarian conservation in 2012. *Obstet Gynecol*. 2016;127:297–305.
- Perera HK, Ananth CV, Richards CA, et al. Variation in ovarian conservation in women undergoing hysterectomy for benign indications. *Obstet Gynecol*. 2013;121:717–26.
- Parker WH, Feskanich D, Broder MS, et al. Long-term mortality associated with oophorectomy compared with ovarian conservation in the nurses' health study. *Obstet Gynecol*. 2013;121:709–16.
- Parker WH. Bilateral oophorectomy versus ovarian conservation: effects on long-term women's health. *J Minim Invasive Gynecol*. 2010;17:161–6.
- Committee on Gynecologic Practice. Committee opinion no. 620: salpingectomy for ovarian cancer prevention. *Obstet Gynecol*. 2015;125(1):279–81.
- Dietl J, Wischhusen J, Häusler SFM. The post-reproductive Fallopian tube: better removed? *Hum Reprod*. 2011;26(11):2918–24.
- Kurman RJ, Shih IM. The dualistic model of ovarian carcinogenesis: revisited, revised, and expanded. *Am J Pathol*. 2016;186(4):733–47.
- Nezhat FR, Apostol R, Nezhat C, Pejovic T. New insights in the pathophysiology of ovarian cancer and implications for screening and prevention. *Am J Obstet Gynecol*. 2015;213(3):262–7.
- Cancer Genome Atlas Research Network. Integrated genomic analyses of ovarian carcinoma. *Nature*. 2011;474:609–15. Erratum in: *Nature*. 2012;490:298.
- Mc Alpine JN, Hanley GE, Woo MM, et al. Opportunistic salpingectomy: uptake, risks, and complications of a regional initiative for ovarian cancer prevention. Ovarian Cancer Research Program of British Columbia. *Am J Obstet Gynecol*. 2014;210:471.
- Sandoval C, Fung-Kee-Fung M, Gilks B, et al. Examining the use of salpingectomy with hysterectomy in Canada. *Curr Oncol*. 2013;20(3):173–5.
- Gelbaya TA, Nardo LG, Fitzgerald CT, et al. Ovarian response to gonadotropins after laparoscopic salpingectomy or the division of fallopian tubes for hydro-salpinges. *Fertil Steril*. 2006;85:1464–8.
- Morelli M, Venturella R, Mocciano R, et al. Prophylactic salpingectomy in premenopausal low-risk women for ovarian cancer: primum non nocere. *Gynecol Oncol*. 2013;129:448–51.
- Falconer H, Yin L, Grönberg H, Altman D. Ovarian cancer risk after salpingectomy: a nationwide population-based study. *J Natl Cancer Inst*. 2015;107:1–6.
- Daly MB, Drescher CH, Yates M, Jeter J, Karlan B, Alberts D, Lu KH. Salpingectomy as a means to reduce ovarian cancer risk. *Cancer Prev Res*. 2015;8:342–8.



Ovarian Cysts: Preoperative Evaluation and Laparoscopic Approach

William Kondo, Monica Tessmann Zomer,
Nicolas Bourdel, and Michel Canis

Introduction

Benign ovarian tumors remain a common gynecologic problem. It is estimated that 5–10% of women in the United States will undergo a surgical procedure for an adnexal mass sometime during their lifetime [1, 2]. The prevalence of adnexal tumors in the general population is 0.17–5.9% in asymptomatic women and 7.1–12% in symptomatic women [3].

The management of an ovarian mass depends on the nature of the tumor, urgency of the presentation (e.g., ovarian torsion requires immediate intervention), and degree of suspicion for malignancy. The gynecologist must evaluate patient's symptoms, physical examination findings, imaging exam results, and serum tumor marker tests in order to decide whether the patient is a potential candidate for surgical approach [4].

Since the majority of adnexal masses are benign, the key point is to try to determine preoperatively whether the patient is at high risk for ovarian malignancy, in order to ensure proper management [1].

Today, laparoscopic surgery is considered to be the gold standard in the management of adnexal masses [5–7]. Adhesion prevention, better postoperative recovery, and good cosmetic outcomes are some of the important advantages of this surgical approach [8]. Disadvantages of the laparoscopic approach include steep surgeon learning curves and the need for special equipment, much of which is expensive [9].

The lack of a preoperative test that can definitively exclude malignancy makes surgical management of adnexal masses more complex. Important concerns remain about intraoperative rupture of an occult malignancy and subsequent risk of cancer dissemination [9]. Therefore, the surgeon should address every patient with adnexal mass as someone who is potentially facing a malignant neoplasm [4].

Patient's treatment success is based on the adequate preoperative work-up and the systematization of the surgical procedure. In this chapter, the authors review important topics on the preoperative assessment of women with ovarian tumors and describe different laparoscopic surgical techniques, step by step, in order to make them simple, understandable, and reproducible.

W. Kondo (✉) · M. T. Zomer
Department of Gynecology, Sugisawa Medical Center,
Curitiba, PR, Brazil

Department of Gynecology, Vita Batel Hospital,
Curitiba, PR, Brazil

N. Bourdel · M. Canis
Department of Gynecologic Surgery, CHU Estaing,
Clermont-Ferrand, France
e-mail: nbourdel@chu-clermontferrand.fr;
mcanis@chu-clermontferrand.fr

Preoperative Assessment of an Ovarian Mass

The goal of the clinical evaluation of an ovarian mass is to determine both whether the mass is more likely to be malignant or benign and whether the mass can be removed by laparoscopy without any type of harm to the patient [4]. It has already been demonstrated that ovarian cancer patients treated by gynecologic oncologists have better outcomes than those treated by general gynecologists and general surgeons [10].

Important factors that should be taken into account include patient's age, symptoms, medical history, physical examination findings, imaging studies, and laboratory test results [4]. All these information must be considered at the same time so that the surgeon can propose an operative approach or an expectant management.

Of course, it is impossible to be absolutely sure about the nature of the cyst without having the pathological examination of it. Indeed, there are different clinical-sonographic scores and mathematical models reported in the literature to try to predict the risk of malignancy/benignity of an ovarian mass in the preoperative setting. All these scores and models seem very interesting in a theoretical point of view; however, in the practical approach, their sensitivity and specificity are very good in the experience of the groups that created them or in a specific sample of patients. Whenever used in other centers, their effectiveness is widely reduced [11, 12], meaning that most of them are not very well reproducible. Even using pelvic MRI, there is no great increase in the sensitivity and specificity of the preoperative investigation [13].

In 2010, the International Ovarian Tumor Analysis (IOTA) group showed that polytomous risk prediction for the diagnosis of ovarian cancer is feasible [14]. Mathematical models were developed to predict four categories of tumors: benign, borderline, primary ovarian cancer, and secondary metastatic cancer. This work focused on comparing mathematical algorithms. Recently, the same group [15] reported the ADNEX (Assessment of Different NEoplasis in the adneXa) model (www.iotagroup/adnexmodel/)

as a potential tool to estimate the probability that an adnexal tumor is benign, borderline, stage I cancer, stage II–IV cancer, or secondary metastatic cancer. Nine variables were included in the model, including age, serum Ca-125 level, type of center, maximum diameter of the lesion, proportion of solid tissue, number of papillary projection, more than ten cyst locules, acoustic shadows, and ascites, and they stated that the ADNEX model has clear potential to optimize management of women with an adnexal tumor.

Anamnesis and Physical Examination

The woman's age is an important factor to be considered in the preoperative assessment of an ovarian mass. Malignant lesions are more likely to occur in postmenopausal than premenopausal women [16]. Irrespective of age, all women presenting with an adnexal mass should have a complete history and physical examination as well as laboratories and imaging exams [9].

The clinical examination will assess the patient's general condition and predict any difficulty in the laparoscopic approach, such as previous scar, obesity, etc. On physical examination, the surgeon should pay attention to the size, mobility, and consistency of the ovarian mass. Also, the possibility of extraovarian involvement may be considered in the presence of ascites, carcinomatosis, and lymphadenopathy.

Reproductive-aged women should be questioned about recent sexual history and use of any contraceptive method. A pregnancy test must be always obtained to exclude ectopic pregnancy or concomitant intrauterine pregnancy [9].

Ultrasound

Pelvic ultrasound is still a very important imaging exam in the evaluation of gynecologic patients. It is quick to perform and does not expose the patient to ionizing radiation; however, it is operator-dependent [17]. It may be performed transvaginally and complemented transabdominally whenever the size of the mass demands. The

examination report must be complete, thoroughly analyzing the cyst for intracystic content, presence of solid and/or liquid component, thickness of the cyst wall, presence of vegetations and/or septa, and presence of inner or outer vascularization, with evaluation of the vascularization pattern with Doppler sonography [18–20].

Benign adnexal masses have typical ultrasonographic features: low echogenicity, a thin cyst wall, unilocular (or, if septated, a thin septation), and absence of internal papillary excrescences [21].

The most important morphologic features on ultrasound that are of concern for malignancy include nonfatty solid (vascularized) tissue, thick septations, and papillary projections. Color Doppler ultrasound helps in the identification of solid, vascularized components within the mass [21].

Computed Tomography (CT) and Magnetic Resonance Imaging (MRI)

The CT scan has a limited role in the primary assessment of women with an adnexal mass due to its poor soft-tissue discrimination [4, 17]. Specifically in mature cystic teratomas, it may be useful to detect calcifications or macroscopic fat [17]. Nevertheless, if ovarian malignancy is present, CT scan can help in the evaluation of the extent of disease detecting lymphadenopathy, ascites, and metastatic disease [4, 17]. The main advantage of CT scan is that it is widely available and quick to perform [21].

On the other hand, MRI provides excellent tissue contrast resolution and characterization based on magnetic resonance properties of the tissues. Different imaging patterns may be seen in cystic and solid lesions as well as in those lesions with fat, hemorrhagic, mucinous, and fibrotic contents [17]. The use of gadolinium-based contrast agents also allows for the evaluation of the lesion's vascularity and enhancement [21].

However, preoperative evaluation of an ovarian mass using pelvic/abdominal MRI should not be systematic. It can be indicated in bulky lesions (or when ultrasound does not allow the evaluation of the entire ovarian mass), in young patients

(to try to plan the surgical approach in the preoperative setting, to evaluate the possibility of bilateral lesions, and to enable patient counseling about all fertility-sparing possibilities), and in ovarian endometrioma (to identify concomitant deep infiltrating endometriosis lesions) [22, 23].

Tumor Biomarkers

There are currently no approved laboratory tests for early detection of ovarian cancer [4]. Cancer antigen 125 (Ca-125) is the only serological biomarker in routine use for the management of women with epithelial ovarian/fallopian tube or primary serous peritoneal cancer [24]. Elevated concentrations of serum Ca-125 may be present in several benign gynecologic conditions (healthy premenopausal women during menses, pregnancy, ovarian cysts, endometriosis, adenomyosis, uterine leiomyomas, and pelvic inflammatory disease) and in several nonmalignant nongynecological diseases (peritoneal, pleural, and musculoskeletal inflammatory disorders and liver, renal, and cardiac disease) [25].

In women with epithelial ovarian cancer, serum levels of Ca-125 are elevated in 50–60% of patients with stage I ovarian cancer, 80–90% in stage II, and greater than 90% in stages III and IV [26, 27]. However, Ca-125 is not expressed in patients with pure mucinous tumors. Carcinoembryonic antigen and Ca-19-9 are better markers in these patients [28, 29].

Guidelines from the United Kingdom [30] and the United States [31] recommend that alpha-fetoprotein and hCG should be measured in all women under 40 years old with a complex ovarian mass because of the possibility of germ cell tumors. Guidelines from the United States also recommend measuring LDH in these women.

Why Is Laparoscopy the Best Surgical Approach?

The role of laparoscopic surgery in the management of adnexal masses has already been demonstrated in prospective randomized studies [6, 7].

The major concerns with this approach have been related to the rate of malignancy encountered, the risk of tumor rupture and upstaging, the incidence of port-site metastasis [4], fertility repercussions in the case of endometriomas [32], and risk of peritonitis in case of spillage in dermoid cysts [33]. Another important issue is that the learning curve for laparoscopic surgery seems to be longer than expected. Each surgeon has his own learning curve depending on his surgical experience and manual abilities. Experts in the management of adnexal masses probably have developed many tips and tricks that would help beginners, what should be reported and taught as often as possible [5].

The primary approach for an ovarian mass should be laparoscopic due to many reasons. First, preoperative work-up for an ovarian mass is generally effective in stratifying masses into those likely to be benign or malignant, but a malignant diagnosis can only be confirmed with pathology [9]. Regardless of the surgeon's experience level, when the surgeon tries to choose the type of incision for the surgery only based on the preoperative assessment, he may elect a totally inadequate surgical access route (Pfannenstiel incision) for the treatment of an ovarian cancer in up to 23% of the cases and a midline incision for the treatment of a benign ovarian cyst in up to 21% of the cases [11]. The systematic use of laparoscopy allows the surgeon to adapt the type of incision to the specific type of ovarian pathology with precision.

Second, the survival of ovarian cancer patients depends on the surgeon specialty [10, 34, 35]. Women affected by ovarian cancer should be systematically operated by gynecologic oncologists in order to achieve better outcomes [10]. However, it is not possible to refer all patients with suspicious ovarian masses to a gynecologic oncology center. In fact, all gynecologist surgeons could perform a laparoscopy to confirm or rule out malignancy if they are able to follow the basic rules to approach a suspicious mass [36]. Whenever malignancy is confirmed, the patient could be referred to a gynecologic oncologist for an early reintervention, what is completely feasible after the primary laparoscopic procedure. In

the prospective study conducted in Clermont-Ferrand [37], 247 suspicious masses were managed by laparoscopy first, as long as there was no evidence of disseminated cancer. They found that 85% of the masses were benign, sparing laparotomy in 93.8% of patients with a benign mass. Among the remaining 37 malignant tumors, 18.9% were treated by laparoscopy. Using this approach, they were able to reduce the number of unnecessary laparotomies.

Third, retrospective and prospective trials have demonstrated that laparoscopy reduced intraoperative blood loss and resulted in fewer postoperative complications, shorter hospitalization, an earlier return to normal activities, less adhesions, and a better cosmetic result compared with laparotomy [6, 7, 38, 39].

For all the abovementioned arguments, we believe that all ovarian masses, even the suspicious ones, should be addressed initially by laparoscopy.

Surgical Technique

Patient Positioning, Pneumoperitoneum Creation, and Port Placement

Under general anesthesia, the patient is placed in a supine position with abduction of lower limbs and with flexion of the thighs onto the pelvis of about 20°. This position allows concomitant abdominal and vaginal access without the need to change the position of the patient. In order to avoid injuries of the brachial plexus, the two arms are positioned alongside the body. The placement of the lower limbs should avoid compression of the sciatic nerve, external popliteal nerve, and calves. The buttocks of the patient should project slightly beyond the edge of the operating table to facilitate the uterine manipulation.

Classically, pneumoperitoneum is insufflated using the Veress needle placed at the Palmer's point (left hypochondrium, 2–3 cm below the costal margin, at the midclavicular line) [40, 41]. At this level, pneumoperitoneum creation is easy even in obese patients.

After the skin incision, a 10 mm trocar is placed inside the umbilicus for the zero-degree laparoscope. Systematically, we use three ancillary trocars: two 5 mm trocars for the main surgeon and one 5 mm trocar for the assistant surgeon. The two lateral trocars are placed about 2 cm medial to the anterior-superior iliac spine (and always lateral to the inferior epigastric vessels), and the third trocar is infraumbilical, in the midline, about 8–10 cm below the umbilical trocar (Fig. 14.1).

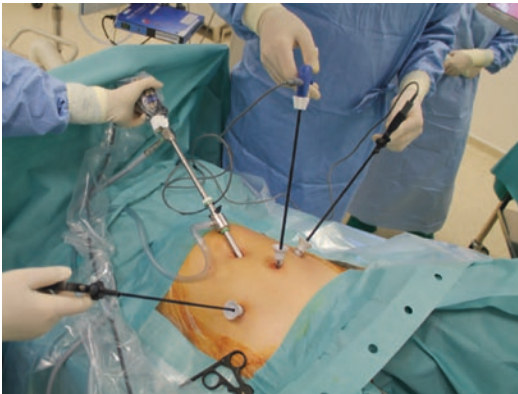

Fig. 14.1 Standard port placement: a 10 mm umbilical trocar for the laparoscope and three secondary 5 mm trocars for the instruments

The abovementioned port placement is useful for cysts up to 10 cm in diameter, in which the location of the lesion is almost exclusively within the pelvis. For ovarian masses larger than 10 cm that do not reach the navel, the Veress needle may be inserted at Palmer's point, and a 5 mm trocar is placed at the same site. A 5 mm laparoscope is then inserted through this trocar in order to define the limits of the mass and guide the correct positioning of the secondary trocars. For a very large mass (more than 20 cm) exceeding the umbilicus, but with essentially liquid component, an open laparoscopy with direct puncture of the mass using a conical trocar or a laparoscopic needle may be possible (Fig. 14.2a, b).

Always, the surgeon should not hesitate to place the trocars higher in the abdomen (more cranially) according to the volume of the mass to be operated.

Intraoperative Evaluation: Do Not Forget All the Steps!

Routinely, the throughout evaluation of the abdominal cavity must be performed [36, 42]. The surgeon has to conduct a 360-degree rotation with the laparoscope in order to evaluate the

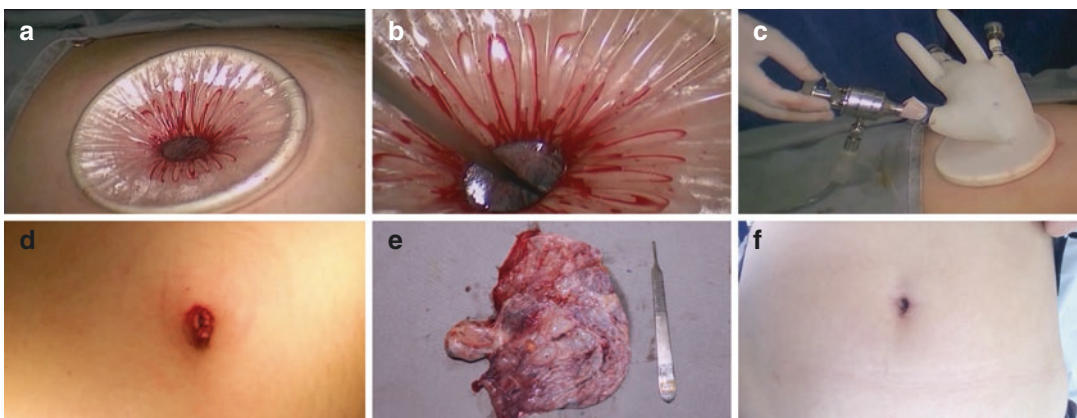


Fig. 14.2 In this case, a wound retractor was placed through the umbilicus (a), and the cystic lesion was punctured using a laparoscopic needle under direct visualization (b). The intracystic fluid was aspirated, and the puncture site was closed. An adapted single single-port

approach (c) was used in order to perform the left adnexectomy (e). The good cosmetic result could be appreciated immediately at the end of the procedure (d) and 7 days after the surgical intervention (f)

entire abdominopelvic cavity: right iliac fossa, right parieto-colic gutter, ascending colon, right side of the diaphragm, liver, stomach, omentum, transverse colon, left side of the diaphragm, left parieto-colic gutter, descending colon, left iliac fossa, small bowel, mesentery, and pelvis (peritoneum, uterus, and adnexa). The laparoscope has an effect of “magnifying glass” which allows full exploration of the peritoneum looking for granulations and/or vegetations [43, 44]. This is of extreme importance in patients undergoing laparoscopy for the evaluation of resectability of advanced ovarian carcinoma [45, 46].

Peritoneal Cytology

The next step is to get a sample for peritoneal cytology, what can be done by simple aspiration of the peritoneal fluid spontaneously present in the pouch of Douglas (Fig. 14.3) or after instillation of saline solution at the level of parieto-colic gutters, pelvis, and adnexa.

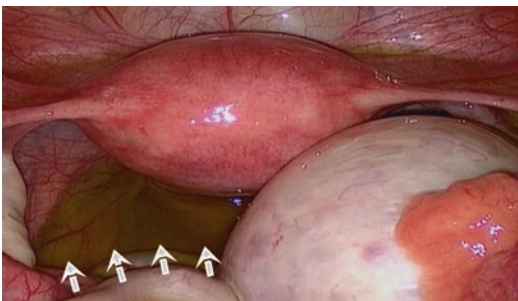


Fig. 14.3 Peritoneal fluid at the posterior cul-de-sac (arrows). The left ovary is normal, and the right ovary is enlarged

Intraoperative Assessment of the Ovarian Mass

Extracystic Evaluation

The surgeon must know the semiology of an ovarian mass. The semiology begins with the recognition of any suspicious signs of malignancy, which may have already been identified at the time of inspection of the abdominopelvic cavity: ascites, peritoneal vegetations, extracystic vegetations, intracystic vegetations, and anarchic vascularization of the cyst wall. The volume of peritoneal fluid becomes suspicious when it fills in completely the pouch of Douglas. Extracystic vegetations are often obvious, but its interpretation is often difficult and systematically requires a biopsy with frozen section examination. The intracystic vegetations are often diagnosed during the preoperative ultrasound, but they can also be visible through the ovary wall and the cyst wall, requiring caution during surgery if present. The irregular vascularization may sometimes confuse the surgeon, but its presence is a factor that speaks in favor of malignancy.

A more accurate semiology must be known to allow differentiation of functional and organic cysts (Table 14.1).

Intracystic Evaluation

The intracystic assessment [48] should include the inner cyst wall and the fluid. Usually, the ultrasonography already gives the surgeon some arguments in favor of the presence or absence of suspicious vegetations but also about the liquid content (pure anechoic cysts, hemorrhagic cysts, dermoid, mucinous, etc.). The perfect assessment can be made during surgery in three different moments:

Table 14.1 Laparoscopic findings to differentiate functional and organic cysts [47]

	Organic cysts	Functional cysts
Utero-ovarian ligament	Lengthened	Normal
Cyst wall	Thick	Thin
Ovarian vessels	Numerous and regular starting from the mesovarium	More scanty, coral-like
Cyst fluid	Variable (depending on the type of cyst)	Saffron yellow
Inner cyst wall	Smooth or fibrotic with areas of hypervascularization	Retina-like aspect
Ovarian cystectomy	Feasible	Impossible/difficult

- Before the treatment of the cyst: in this situation, the surgeon is going to puncture the cyst, aspirate the cyst fluid, and perform an ovarian cystoscopy.
- After the treatment of the cyst and before specimen extraction: in this case, the surgeon is going to perform first the ovarian cystectomy or the adnexectomy, and then the cyst will be punctured and widely opened. Then, ovarian cystoscopy is going to be performed.
- After the treatment of the cyst and after specimen extraction: in this situation, the cyst will be opened outside the abdomen, after being retrieved from the abdominal cavity.

The liquid within the cyst must always be evaluated during the laparoscopic procedure. The surgeon should think about malignant nature of the cyst in the presence of cloudy, dark-colored, and/or stringy fluid. After analyzing the fluid (intracystic content), the inner surface of the cyst must be evaluated [36, 42]. The presence of intracystic vegetations is frequently identified on the preoperative work-up during the transvaginal ultrasound. Suspicious findings are great number and volume of vegetations and also irregular and grayish papillary projections. During laparoscopy, the presence of intracystic vegetations may also be suspected by the external aspect of the cyst wall and the presence of a visible whitish thickening of the cyst wall.

Whenever the surgeon decides to puncture the cyst, the puncture technique must be as perfect as possible. It is important to try to prevent spillage of intracystic fluid into the peritoneal cavity. For cysts smaller than 8 cm, which represent the majority of cases, the cyst must be placed within an endoscopic bag before puncture. The puncture should be performed under visual control, perpendicularly to the surface of the cyst with the use of an endoscopic needle (Fig. 14.4) or a 5 mm conical trocar (Fig. 14.5), at the opposite side of the ovarian vascularization. The cyst content is aspirated with a syringe in the case of using the laparoscopic needle or directly with an aspiration cannula in the case of using a 5 mm trocar. During aspiration, the surgeon must ensure there is no leakage of intracystic content using one or two grasping forceps around the puncture site, allowing occlusion of the cyst at the puncture site (Fig. 14.5c, d). These grasping forceps should elevate the lateral walls of the cyst in order to prevent the flow of fluid out of the cyst. After aspiration of the cyst fluid, the puncture site will be enlarged with scissors, allowing the performance of an ovarian cystoscopy (Fig. 14.6d) to evaluate the inner cyst wall and check for the presence of any vegetations.

If the cyst was punctured in order to reduce its volume, especially in the case of a large ovarian cyst that does not fit within the endoscopic bag, the puncture site may be closed without perform-

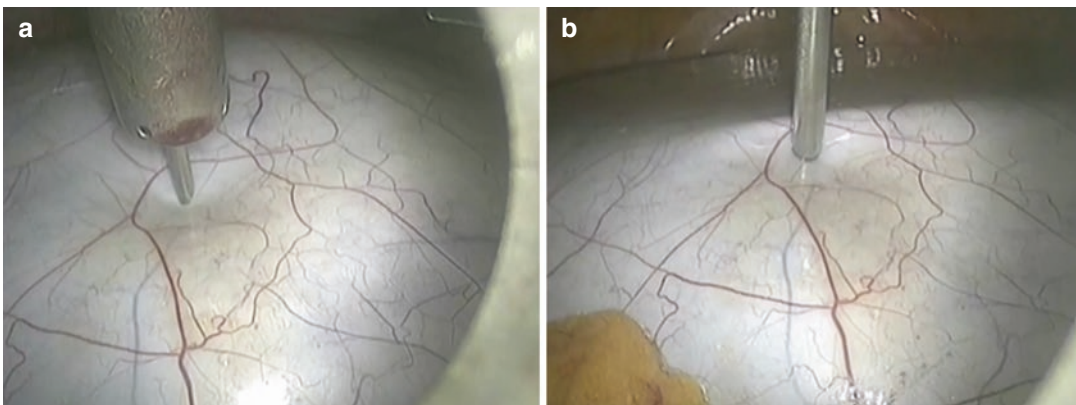


Fig. 14.4 Puncture of a presumed benign ovarian tumor using a laparoscopic needle

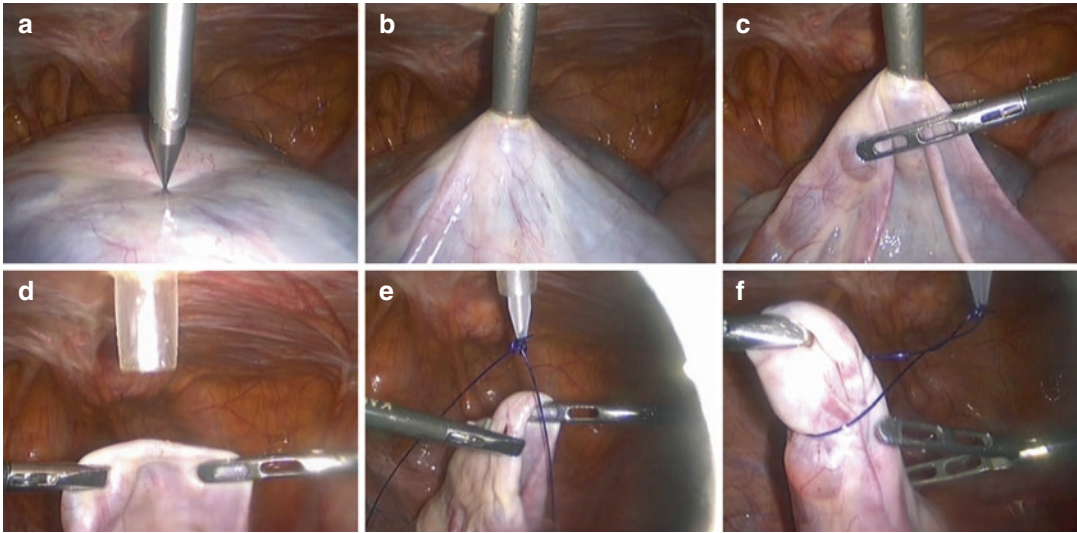


Fig. 14.5 (a–c) Puncture of a presumed benign ovarian cyst under visual control using a 5 mm conical trocar. After the puncture, the edges of the cyst are held on (d), and the puncture site is closed using an endloop (e, f)

ing an ovarian cystoscopy using an endloop (Fig. 14.5e, f).

If the ovarian cystectomy or the adnexectomy was performed without previous puncture, the cyst is going to be punctured before extraction, within the endoscopic bag using an endoscopic needle or after extraction of part of the endoscopic bag, under direct visualization. In the latter situation, the surgeon should enlarge the skin/aponeurosis incision to obtain a better visual control, if needed.

Different Surgical Approaches: Step by Step

Cystectomy After Puncture

This is the classical surgical approach for pure anechoic serous and mucinous adenomas or for ovarian cysts containing a single vegetation with low suspicious for malignancy. Six steps should be taken:

1. Puncture of the ovarian cyst followed by enlargement of this opening using scissors. The opening of the ovarian cyst wall should be wide and should start exactly at the level of the puncture site (Fig. 14.6b, c).
2. Inspection of the cyst lining (in situ ovarian cystoscopy) should be systematically performed. At this moment, it is possible to wash the cyst with saline solution in order to better expose the entire inner cyst wall.
3. Identification of the cleavage plane. It is necessary to follow the opening of the cyst wall in order to find the exact cleavage plane between normal ovarian parenchyma and cyst wall (Fig. 14.6d). If the plane is not exposed spontaneously, the surgeon should not hesitate to increase the opening of the cyst to find a better cleavage plane.
4. The surgeon should start the dissection using two forceps, one grasping the ovarian cyst and the other one grasping the ovarian parenchyma, exactly at the cleavage plane (Fig. 14.6e).
5. Once identified, the plane between ovarian cyst and normal ovarian cortex is developed further by application of divergent forces at the edge of the ovarian cortex and the cyst wall. Traction-countertraction and blunt dissection should be done gently, with brief gestures, in order to progressively peel the cyst wall from the underlying ovarian bed. For this purpose, it is necessary to frequently exchange the position of the graspers, so that they are always as close as possible to the cleavage plane (Fig. 14.6e). The systematic use

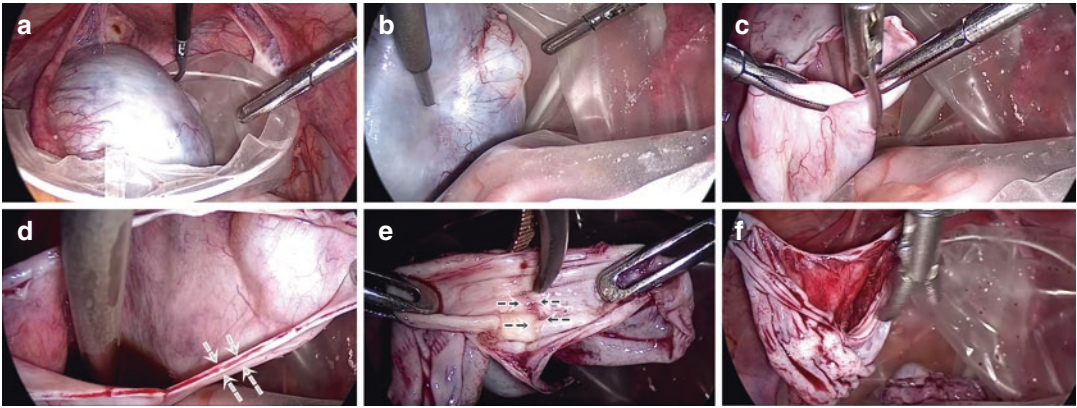


Fig. 14.6 The ovary is placed inside the endoscopic bag (a). The puncture is performed using a laparoscopic needle (b), and the puncture site is enlarged using scissors (c).

The cleavage plane is identified (d), and the cyst is progressively separated from the ovarian cortex (e). At the end of the cystectomy, hemostasis must be checked (f)

of three graspers allows for a constant and satisfactory exposure. This is imperative to be sure that the dissection progresses within the correct plane. The exposure is maintained by two graspers, and the third forceps grasps the tissue close to the plane of dissection and so on, without ever releasing the cyst and the ovary. If the dissection becomes more difficult, the surgeon should change the position of the graspers in order to be close to the cleavage plane again. The surgeon must avoid tissue slippage and tearing in order not to damage normal ovarian parenchyma. Extreme caution must be taken when working near the hilar vessels of the ovary. Small shots of bipolar energy may be useful at this moment to avoid inadvertent bleeding;

6. Hemostasis must be meticulous. However, the surgeon should be aware that ovarian cystectomy usually has little bleeding whenever the cleavage plane is respected. The surface of the cyst should be white, without reddish fibers (Fig. 14.6e). When this is not the case, the dissection is probably being done far from the cyst wall, and the surgeon must reidentify the plane of dissection close to the cyst wall. The use of three secondary trocars during the operative laparoscopy is the only possible way of installation that enables the surgeon to maintain the exposure, allow for coagulation/hemostasis of the remaining ovary and use the washing system at the same time, with no

need for a constant instrument change. At the end of the cystectomy, hemostasis should be checked (Fig. 14.6f). The surgeon should use the washing system in the right hand and the bipolar forceps in the left hand. The assistant surgeon should keep the exposition of the ovarian cyst bed using his grasping forceps.

Cystectomy Without Puncture

This is the classic treatment for dermoid cysts and is composed of six steps:

1. Positioning the ovary within an endoscopic bag (Fig. 14.7a) in order to prevent the risk of spillage during the procedure, which may lead to a serious complication called granulomatous peritonitis [33, 49].
2. Opening the ovary exactly at the opposite edge to the hilar vessels. Usually, the ovarian parenchyma may be grasped, and this opening is conducted using cold scissors. Whenever grasping the ovary is not possible, the surgeon may open the ovarian parenchyma using a small shot of monopolar energy setup on pure cut mode. The opening is widened/extended using scissors to about 50% of the circumference of the ovarian parenchyma in order to facilitate the enucleation of the dermoid cyst (Fig. 14.7b, c). Identification of the correct cleavage plane is essential (Fig. 14.7d). The surface of the cyst is yellowish-white (no red

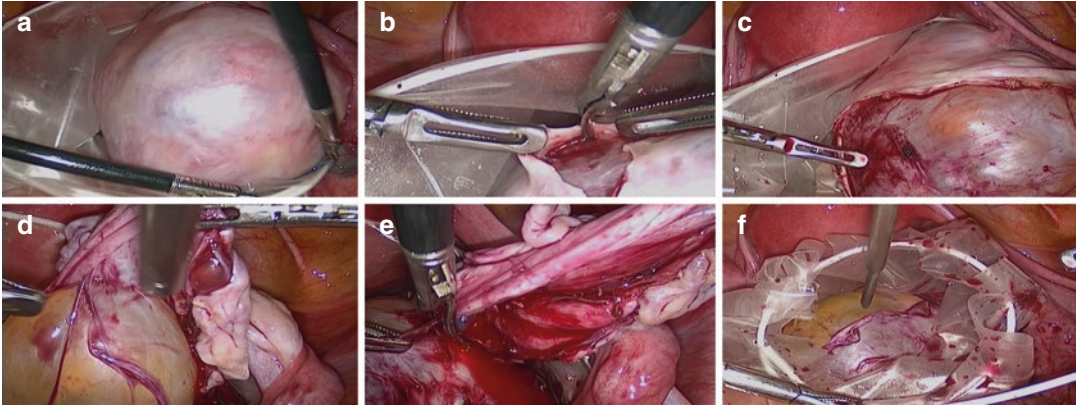


Fig. 14.7 The ovary is positioned within the endoscopic bag (a). The ovarian parenchyma is opened using scissors (b), and the cleavage plane is identified (c, d). A small bleeding may occur during the enucleation close to the

ovarian vessels (e). At the end, the cyst may be punctured in order to evacuate the intracystic contents to facilitate extraction (f)

fibers), and the cleavage plane should be avascular.

3. Two forceps grasp the edges of the ovarian parenchyma, and the surgeon must perform a movement as if he was “wearing” the cyst, supporting the bottom of the cyst on the ipsilateral pelvic wall or on the uterus. The enucleation of the cyst requires that the instruments work tangentially to the cyst. If the dissection is not easy, the surgeon may perform the dissection on one side and then on the other side of the cyst, using grasping forceps, bipolar forceps, and scissors.
4. When more than 50% of the cyst surface is dissected, the surgeon may raise the ovarian parenchyma and use the weight of the cyst to help in the dissection, what is going to act as a divergent force. Dissection may be completed using traction, focal coagulation, and section. Usually, some bleeding may occur close to the pelvic infundibulum (Fig. 14.7e), where bipolar coagulation is recommended before finalizing the freeing of the cyst from the ovarian parenchyma.
5. Hemostasis of the cyst bed allows the ovary to resume its normal shape. Suturing the ovary is rarely necessary.
6. Extraction should be performed by puncturing/aspirating the cyst within the endoscopic bag (Fig. 14.7f).

Cystectomy for Paraovarian/Paratubal Cyst

The surgical approach consists of six steps:

1. Placement of the cystic lesion within an endoscopic bag (Fig. 14.8a). It is important to remember that they are not always benign (2% are malignant lesions). The cyst content appears bluish when only liquid is present, and the cyst is covered only by the peritoneum (mesosalpinx). If the cyst wall appears whitish, probably there must be any intracystic vegetation within the cyst.
2. Incision of the peritoneum far from the fimbriae and tube (Fig. 14.8b).
3. Enlargement of the opening as described for the dermoid cyst (Fig. 14.8c, d).
4. Dissection is conducted according to the description of the dermoid cyst. When the dissection approaches the ovary, it is important to coagulate and cut the vascular and fibrous attachments (Fig. 14.8e).
5. Check the hemostasis and the good anatomical positioning of the fimbriae at the end of the dissection.
6. Extraction of the endoscopic bag after puncturing the cyst within the endoscopic bag (Figs. 14.8f and 14.9), as performed for the dermoid cyst.

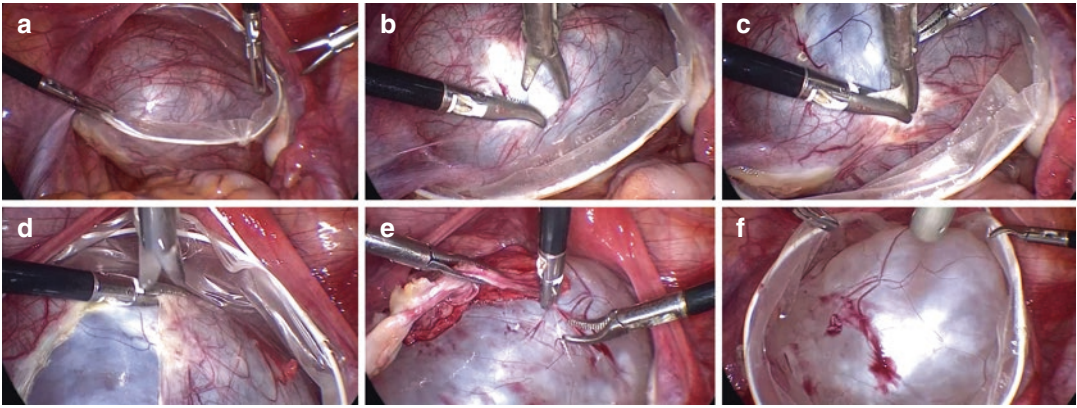


Fig. 14.8 The left paratubal cyst is placed inside the endoscopic bag (a). The mesosalpinx is opened using bipolar and scissors (b–d), and the cyst is progressively separated from the mesosalpinx, taking care with the dis-

tal part of the tube (e). At the end of the procedure, the cyst may be punctured within the endoscopic bag before extraction (f)

Cystectomy of Ovarian Endometrioma

The ovarian endometrioma contains three different zones [50]:

1. Zone of adhesion between the ovarian endometrioma and the posterior leaf of the broad ligament or the uterosacral ligament.
2. Zone of active tissue with a small amount of fibrosis, where dissection is easily performed.
3. Zone of intense fibrosis, where the cleavage plane is difficult to find. It is usually close to the hilar vessels.

The surgical procedure consists of seven steps:

1. Ovariolysis is performed with an aspiration cannula, separating the ovary from the attachments at the pelvic sidewall or at the uterosacral ligament. This maneuver must start at the level of the most dependent part of the ovarian adhesion to the pelvic sidewall and continues toward the utero-ovarian ligament (Fig. 14.10a). In this way, the ovary is released from the pelvic wall. In most cases, this maneuver ruptures the cyst, and the surgeon may see the typical chocolate fluid coming from the inner aspect of the cyst.
2. The pelvic cavity is washed, and the cystic contents are aspirated in order to clean the cavity. The inner cystic wall is inspected for vegetations or irregularities to exclude any signs of malignancy.
3. The cyst opening is enlarged using scissors, starting at the area where the cyst was ruptured (Fig. 14.10b). It is important not to perform a new opening in the ovarian parenchyma! The incision is widely enlarged until the surgeon can perfectly identify the cleavage plane (Fig. 14.10c).
4. The cleavage plane is dissected further by grasping the edge of the ovarian parenchyma and the cyst wall separately. Divergent traction movements should be slow, smooth, and limited in range to open the cleavage plane without tearing the cyst or the ovarian cortex. The surface of the cyst is whitish, the plane is avascular, and the bleeding must be minimal. This first step of the dissection is very easy and corresponds to 10–90% of the cyst wall, depending on the chronicity of the endometrioma (Fig. 14.10d).
5. In the second step of the dissection, divergent traction becomes less effective. The cyst wall is not uniformly whitish anymore, and some reddish fibers start appearing (Fig. 14.10e). At this moment, the surgeon should stop simple divergent traction maneuvers. Fibrosis is always stronger than the ovarian parenchyma. The red fibers, often triangular in shape,

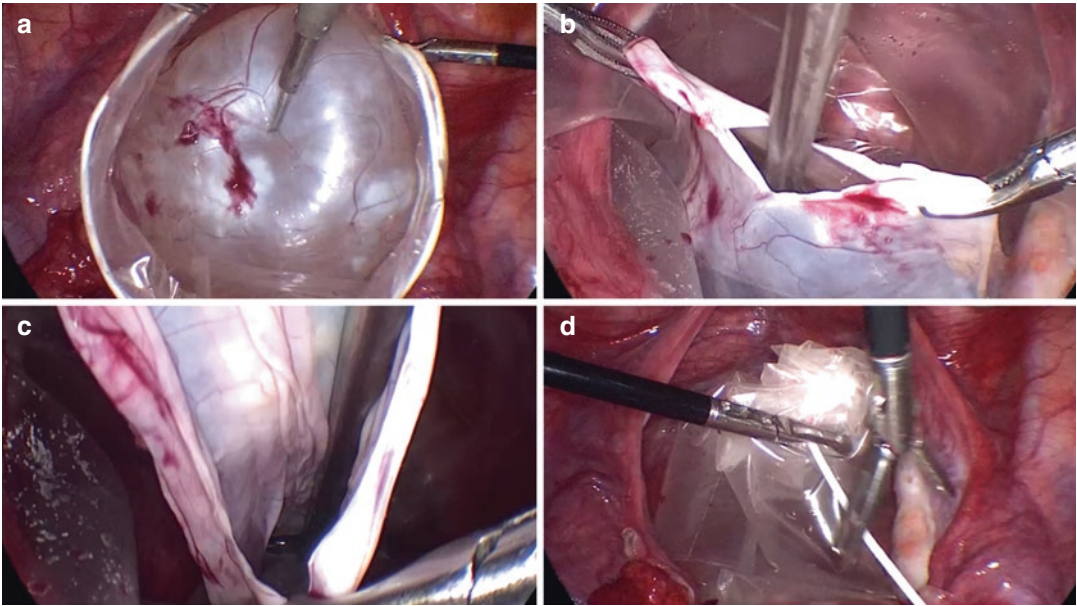


Fig. 14.9 The cyst is punctured inside the endoscopic bag (a), and the cyst fluid is aspirated (b). A cystoscopy is performed (c) in order to evaluate the inner cyst wall. The endoscopic bag is closed using the traction wire (d)

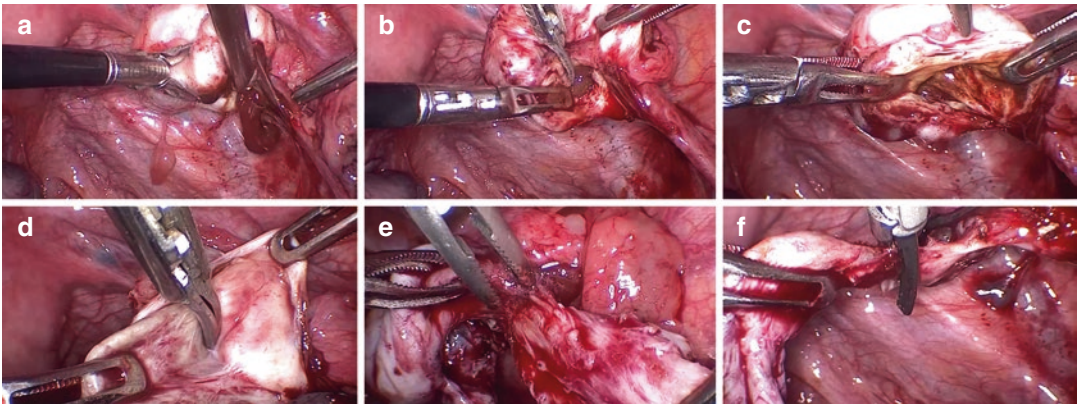


Fig. 14.10 Detachment of the ovarian adhesions (a) leading to the spontaneous rupture of the endometriosis cyst. Enlargement of the ruptured area using scissors (b) to find the exact cleavage plane (c). Separation of the ovarian endometrioma from the ovarian cortex (d) in the

active area (easy dissection). When the surgeon approaches the area close to the hilar vessels, some precise hemostasis using bipolar energy (e) or ultrasonic energy (f) may be carefully used

should be coagulated on the surface of the cyst, at the level of the triangle apex, and cut to find the exact cleavage plane close to the cyst.

- Most small surface bleeding stops spontaneously. Therefore, precise hemostasis is performed taking care not to be excessive (Fig. 14.10e, f). If the final ovarian shape is

not satisfactory, the surgeon may place some sutures inside the ovary.

- Extraction is carried out in the conventional manner using an endoscopic bag.

Adnexectomy

There are two major risks during adnexectomy: ureteral injury and incomplete removal of the ovary. In a classic situation, where there

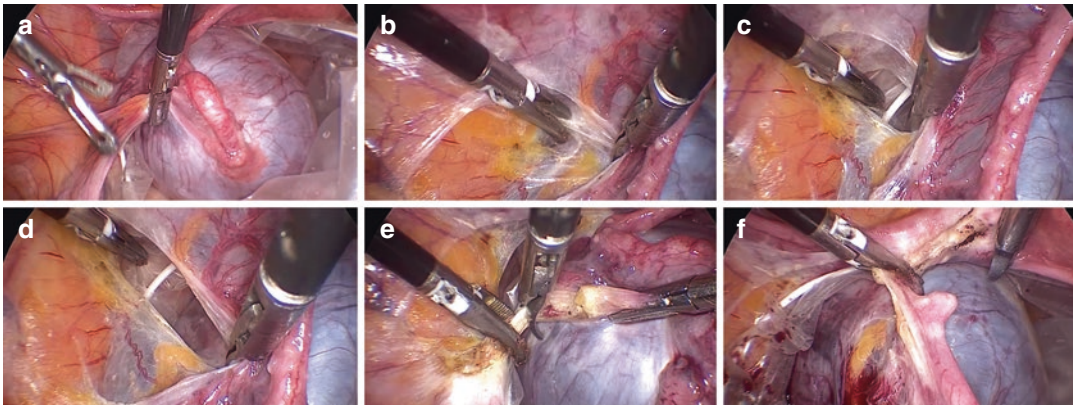


Fig. 14.11 Left adnexectomy. Medial traction of the adnexa is applied by the assistant (a), and the surgeon is going to fenestrate the broad ligament (b–d). Coagulation

and section of the ovarian vessels (e) and the tube/utero-ovarian ligament (f) are progressively performed using bipolar forceps and scissors

is no adhesion to the posterior leaf of the broad ligament and to the ureter, it consists of six steps:

1. Medial traction of the adnexa (Fig. 14.11a).
2. Coagulation and section of the peritoneum lateral to the ovarian pedicle (Fig. 14.11b).
3. Fenestration of the broad ligament (Fig. 14.11c, d). The surgeon should coagulate and cut the anterior and the posterior leaf of the broad ligament creating a window. If the surgeon places his two instruments inside this window and gently applies divergent forces in a cranial-caudal direction, he is able to widely open this window. In this manner, the ovarian pedicle is isolated coming medially to the window, and the ureter stays lateral to the window, thus avoiding the risk of ureteral injury during the next steps of the surgical procedure.
4. Progressive coagulation and section of the ovarian pedicle are performed (Fig. 14.11e). The surgeon must coagulate and cut the peritoneum around the lumbar-ovarian ligament before this vascular control because it increases the effectiveness of bipolar coagulation (the peritoneum around the vessels increases the tissue impedance).
5. Coagulation and section of the utero-ovarian ligament and the fallopian tube close to the uterus (Fig. 14.11f).
6. Placement and extraction of the specimen within an endoscopic bag.

There are some difficult situations in which the ovary is firmly attached to the posterior leaf of the broad ligament. In these situations, it is necessary to excise the peritoneum of the ovarian fossa in order to be complete in the oophorectomy; otherwise, the surgeon may leave some ovarian tissue behind attached to the peritoneum and there is a possibility of further development of an ovarian remnant syndrome. This intervention requires some degree of ureterolysis, depending on the specific situation. This ureteral dissection always starts cranial, identifying the ureter after the opening of the peritoneum in a healthy tissue. The main objective of the dissection is to lateralize the ureter in order to allow for a safe resection of the peritoneum involved by the disease. If necessary, this dissection must be carried out until the level of the uterine vessels.

Extraction of the Specimen Within the Endoscopic Bag

Extraction of the surgical specimen should always be performed in a protected manner, usually using an endoscopic bag.

The surgical specimen must be placed inside the endoscopic bag, and it can be completely closed using the traction wire. Extraction of the bag may be carried out through a trocar incision (Fig. 14.12) or by vaginal route (colpotomy)

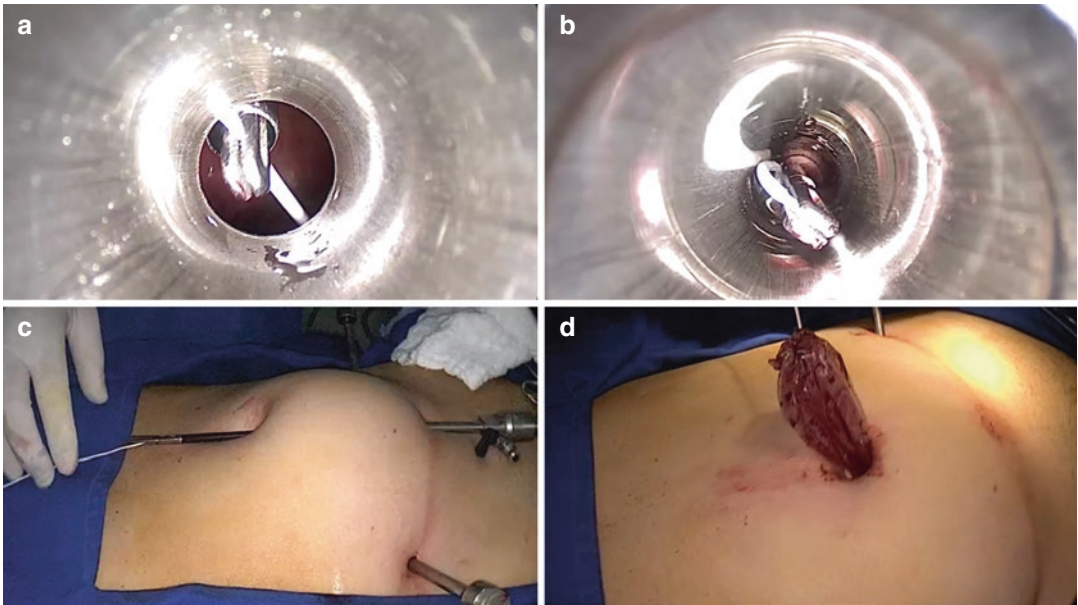


Fig. 14.12 The traction wire is grasped by the surgeon using the suprapubic trocar (a), and the forceps is moved forward through the umbilical trocar (b). The umbilical trocar is removed, and the traction wire is grasped outside the abdominal cavity (c). The endoscopic bag is exteriorized with the cyst inside (d)

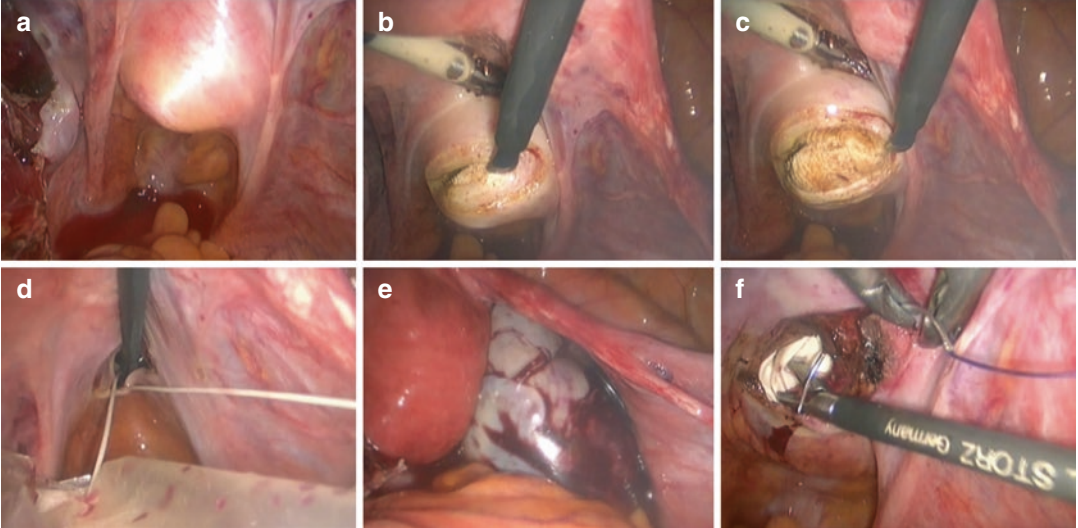


Fig. 14.13 A gauze is placed inside the vaginal cavity, exactly at the posterior vaginal fornix (a). The vagina is opened over the gauze using monopolar energy in pure cut mode (b, c). The endoscopic bag is extracted vaginally (d, e), and the vagina is closed laparoscopically (f)

(Fig. 14.13). In the former situation, the traction wire is simply pushed through the trocar and retrieved from the abdominal cavity. The skin/aponeurosis incision is enlarged according to the size of the cyst.

How to Approach the Ovarian Mass? Puncture? Conversion? Cystectomy? Adnexectomy?

The management of a patient with an ovarian mass must be individualized. The underlying management rationale is to minimize patient morbidity, trying to be conservative when possible, use laparoscopic techniques if appropriate (avoiding laparotomy when possible), and refer to a gynecologic oncologist if necessary.

Puncture

Based on the preoperative work-up, the surgeon must always think about the possibility or not to puncture the ovarian mass. It should not be systematic!

Whenever adnexal conservation is not considered, there is no indication for ovarian puncture before the surgical procedure:

1. Strong suspicion of malignancy (multiple intracystic vegetations on preoperative assessment, solid tumor, extracystic signs of malignancy)
2. Menopausal or climacteric women

Puncture of the ovarian mass should be considered in young women, when the puncture will help to diagnose the nature of the cyst and allow or not for an adnexal conservation. The presence of one small non-vascularized intracystic vegetation is not a contraindication to puncture the cyst. If there is any doubt in a young woman, the surgeon should not hesitate to carry out the ovarian puncture. Another indication for ovarian puncture is the presence of a large ovarian mass with pure cystic content with no index of suspicion for malignancy. In this case, the size of the mass prevents or hinders any laparoscopic approach of

this mass most likely benign. Figure 14.2 demonstrates an adapted laparoscopic single-port approach in such cases, which may also be managed using the conventional laparoscopic port placement (Fig. 14.1) after the puncture.

Laparotomy

Conversion to laparotomy should be systematic if:

1. Peritoneal carcinomatosis is confirmed and cytoreductive surgery is possible. If the surgeon is not able to completely perform the surgery, biopsies are taken, and the patient should be referred to an oncology center in order to be reoperated as soon as possible.
2. There is a major risk of rupture or spread of a suspected mass: a laparotomy is always preferable to a laparoscopic dissemination of an ovarian tumor.

Of course, selected patients may undergo a complete cytoreductive surgery by laparoscopic approach in experienced hands.

Adnexectomy

Adnexectomy should always be performed if:

1. The patient is menopausal (probably the patient will undergo a bilateral adnexectomy).
2. The patient is more than 45 years old and does not want to preserve her fertility (unilateral adnexectomy).
3. The ovarian mass is very suspicious (extra- and/or intracystic evaluation).

Cystectomy

Cystectomy should be performed in all other cases! The surgical technique should be adapted for each specific type of ovarian cyst, as discussed above.

Conclusions

Laparoscopy is currently the gold standard for the management of ovarian masses. It has proven advantages compared with laparotomy and is feasible, safe, and efficient after the surgeon's learning curve. A meticulous preoperative evaluation is recommended in order to try to exclude malignancy. During laparoscopy, systematization of the procedure is essential. The surgical technique must be adapted to the characteristics of the cyst and the patient. Experts should try to teach young surgeons the proper surgical technique in order to make it easier and reproducible.

References

- National Institutes of Health Consensus Development Conference Statement. Ovarian cancer: screening, treatment, and follow-up. *Gynecol Oncol.* 1994;55(3 Pt 2):S4–14.
- NIH consensus conference. Ovarian cancer. Screening, treatment, and follow-up. NIH consensus development panel on ovarian cancer. *JAMA.* 1995;273(6):491–7.
- Padilla LA, Radosevich DM, Milad MP. Accuracy of the pelvic examination in detecting adnexal masses. *Obstet Gynecol.* 2000;96(4):593–8.
- Hilger WS, Magrina JF, Magtibay PM. Laparoscopic management of the adnexal mass. *Clin Obstet Gynecol.* 2006;49(3):535–48.
- Canis M, Rabischong B, Houle C, Botchorishvili R, Jardon K, Safi A, Wattiez A, Mage G, Pouly JL, Bruhat MA. Laparoscopic management of adnexal masses: a gold standard? *Curr Opin Obstet Gynecol.* 2002;14(4):423–8.
- Mais V, Ajossa S, Piras B, Marongiu D, Guerriero S, Melis GB. Treatment of nonendometriotic benign adnexal cysts: a randomized comparison of laparoscopy and laparotomy. *Obstet Gynecol.* 1995;86(5):770–4.
- Yuen PM, Yu KM, Yip SK, Lau WC, Rogers MS, Chang A. A randomized prospective study of laparoscopy and laparotomy in the management of benign ovarian masses. *Am J Obstet Gynecol.* 1997;177(1):109–14.
- Canis M, Mage G, Pouly JL, Wattiez A, Manhes H, Bruhat MA. Laparoscopic diagnosis of adnexal cystic masses: a 12-year experience with long-term follow-up. *Obstet Gynecol.* 1994;83(5 Pt 1):707–12.
- Sisodia RM, Del Carmen MG, Boruta DM. Role of minimally invasive surgery in the management of adnexal masses. *Clin Obstet Gynecol.* 2015;58(1):66–75.
- Earle CC, Schrag D, Neville BA, Yabroff KR, Topor M, Fahey A, Trimble EL, Bodurka DC, Bristow RE, Carney M, Warren JL. Effect of surgeon specialty on processes of care and outcomes for ovarian cancer patients. *J Natl Cancer Inst.* 2006;98(3):172–80.
- Boll D, Geomini PM, Brölmann HA, Sijmons EA, Heintz PM, Mol BW. The pre-operative assessment of the adnexal mass: the accuracy of clinical estimates versus clinical prediction rules. *BJOG.* 2003;110(5):519–23.
- Mol BW, Boll D, De Kanter M, Heintz AP, Sijmons EA, Oei SG, Bal H, Brölmann HA. Distinguishing the benign and malignant adnexal mass: an external validation of prognostic models. *Gynecol Oncol.* 2001;80(2):162–7.
- Bouic-Pagès E, Perrochia H, Méridgeaud S, Giacalone PY, Taourel P. MR imaging of primary ovarian tumors with pathologic correlation. *J Radiol.* 2009;90(7–8 Pt 1):787–802.
- Van Calster B, Valentin L, Van Holsbeke C, Testa AC, Bourne T, Van Huffel S, Timmerman D. Polytomous diagnosis of ovarian tumors as benign, borderline, primary invasive or metastatic: development and validation of standard and kernel-based risk prediction models. *BMC Med Res Methodol.* 2010;10:96. <https://doi.org/10.1186/1471-2288-10-96>.
- Van Calster B, Van Hoorde K, Valentin L, Testa AC, Fischerova D, Van Holsbeke C, Savelli L, Franchi D, Epstein E, Kaijser J, Van Belle V, Czekierdowski A, Guerriero S, Fruscio R, Lanzani C, Scala F, Bourne T, Timmerman D, International Ovarian Tumour Analysis Group. Evaluating the risk of ovarian cancer before surgery using the ADNEX model to differentiate between benign, borderline, early and advanced stage invasive, and secondary metastatic tumours: prospective multicentre diagnostic study. *BMJ.* 2014;349:g5920. <https://doi.org/10.1136/bmj.g5920>.
- Yancik R, Ries LG, Yates JW. Ovarian cancer in the elderly: an analysis of surveillance, epidemiology, and end results program data. *Am J Obstet Gynecol.* 1986;154(3):639–47.
- Perera DS, Prabhakar HB. Imaging of the adnexal mass. *Clin Obstet Gynecol.* 2015;58(1):28–46.
- Schneider VL, Schneider A, Reed KL, Hatch KD. Comparison of Doppler with two-dimensional sonography and CA 125 for prediction of malignancy of pelvic masses. *Obstet Gynecol.* 1993;81(6):983–8.
- Timor-Tritsch LE, Lerner JP, Monteagudo A, Santos R. Transvaginal ultrasonographic characterization of ovarian masses by means of color flow-directed Doppler measurements and a morphologic scoring system. *Am J Obstet Gynecol.* 1993;168(3 Pt 1):909–13.
- Weiner Z, Beck D, Shteiner M, Borovik R, Ben-Shachar M, Robinzon E, Brandes JM. Screening for ovarian cancer in women with breast cancer with transvaginal sonography and color flow imaging. *J Ultrasound Med.* 1993;12(7):387–93.
- Jeong YY, Outwater EK, Kang HK. Imaging evaluation of ovarian masses. *Radiographics.* 2000;20(5):1445–70.

22. Kondo W, Zomer MT, Pinto EP, Ribeiro R, Ribeiro MFC, Trippia CR, Trippia CH. Deep infiltrating endometriosis: imaging features and laparoscopic correlation. *J Endometr.* 2011;3(4):197–212.
23. Trippia CH, Zomer MT, Terazaki CRT, Martin RLS, Ribeiro R, Kondo W. Relevance of imaging examinations in the surgical planning of patients with bowel endometriosis. *Clin Med Insights Reprod Health.* 2016;10:1–8.
24. Bast RC Jr, Klug TL, St John E, Jenison E, Niloff JM, Lazarus H, Berkowitz RS, Leavitt T, Griffiths CT, Parker L, Zurawski VR Jr, Knapp RC. A radioimmunoassay using a monoclonal antibody to monitor the course of epithelial ovarian cancer. *N Engl J Med.* 1983;309(15):883–7.
25. Sölétormos G, Duffy MJ, Othman Abu Hassan S, Verheijen RH, Tholander B, Bast RC Jr, Gaarenstroom KN, Sturgeon CM, Bonfrer JM, Petersen PH, Troonen H, CarloTorre G, Kanty Kulpa J, Tuxen MK, Molina R. Clinical use of cancer biomarkers in epithelial ovarian cancer: updated guidelines from the European Group on Tumor Markers. *Int J Gynecol Cancer.* 2016;26(1):43–51.
26. Duffy MJ, Bonfrer JM, Kulpa J, Rustin GJ, Soletormos G, Torre GC, Tuxen MK, Zwirner M. CA125 in ovarian cancer: European Group on Tumor Markers guidelines for clinical use. *Int J Gynecol Cancer.* 2005;15(5):679–91.
27. Liu J, Matulonis UA. Anti-angiogenic agents in ovarian cancer: dawn of a new era? *Curr Oncol Rep.* 2011;13(6):450–8.
28. Høgdall EV, Christensen L, Kjaer SK, Blaakaer J, Jarle Christensen I, Gayther S, Jacobs IJ, Høgdall CK. Protein expression levels of carcinoembryonic antigen (CEA) in Danish ovarian cancer patients: from the Danish ‘MALOVA’ ovarian cancer study. *Pathology.* 2008;40(5):487–92.
29. Kelly PJ, Archbold P, Price JH, Cardwell C, McCluggage WG. Serum CA19.9 levels are commonly elevated in primary ovarian mucinous tumours but cannot be used to predict the histological subtype. *J Clin Pathol.* 2010;63(2):169–73.
30. National Institute for Health and Clinical Excellence. Ovarian cancer: the recognition and initial management of ovarian cancer. NICE clinical guideline 122. London: NICE; 2011.
31. American College of Obstetricians and Gynecologists. Management of adnexal masses. ACOG Practice Bulletin No. 83. Washington DC: ACOG; 2007.
32. Goodman LR, Goldberg JM, Flyckt RL, Gupta M, Harwalker MJ, Falcone T. Effect of surgery on ovarian reserve in women with endometriomas, endometriosis and controls. *Am J Obstet Gynecol.* 2016;215(5):589.e1–6.
33. Kondo W, Bourdel N, Cotte B, Tran X, Botchorishvili R, Jardon K, Rabischong B, Pouly JL, Mage G, Canis M. Does prevention of intraperitoneal spillage when removing a dermoid cyst prevent granulomatous peritonitis? *BJOG.* 2010;117(8):1027–30.
34. Bristow RE, Berek JS. Surgery for ovarian cancer: how to improve survival. *Lancet.* 2006;367(9522):1558–60.
35. Bristow RE, Nugent AC, Zahurak ML, Khouzhami V, Fox HE. Impact of surgeon specialty on ovarian-conserving surgery in young females with an adnexal mass. *J Adolesc Health.* 2006;39(3):411–6.
36. Canis M, Jardon K, Rabischong B, Bourdel N, Mage G. Advanced ovarian cancer, an optimal surgical treatment is possible to all patients owing to laparoscopy. *Ann Chir.* 2006;131(8):423–5.
37. Canis M, Pouly JL, Wattiez A, Mage G, Manhes H, Bruhat MA. Laparoscopic management of adnexal masses suspicious at ultrasound. *Obstet Gynecol.* 1997;89(5 Pt 1):679–83.
38. Hidlebaugh DA, Vulgaropoulos S, Orr RK. Treating adnexal masses. Operative laparoscopy vs. laparotomy. *J Reprod Med.* 1997;42(9):551–8.
39. Pittaway DE, Takacs P, Bauguess P. Laparoscopic adnexectomy: a comparison with laparotomy. *Am J Obstet Gynecol.* 1994;171(2):385–9; discussion 389–91.
40. Delabaere A, Bourdel N, Botchorishvili R, Tran X, Jardon K, Rabischong B, Canis M, Mage G. How I do... laparoscopy with previous laparotomy. *Gynecol Obstet Fertil.* 2009;37(4):346–8.
41. Dubuisson J, Botchorishvili R, Perrette S, Bourdel N, Jardon K, Rabischong B, Canis M, Mage G. Incidence of intraabdominal adhesions in a continuous series of 1000 laparoscopic procedures. *Am J Obstet Gynecol.* 2010;203(2):111.e1–3.
42. Canis M, Jardon K, Niro J, Rabischong B, Bourdel N, Botchorishvili R, Pouly JL, Mage G. Endoscopic management of gynecological malignancies: an update. 2007. *Bull Acad Natl Med.* 2007;191(7):1357–65; discussion 1365–6.
43. Possover M, Morawski A, Hettenbach A. Laparoscopic treatment of ovarian tumors in menopausal women. *J Gynecol Obstet Biol Reprod (Paris).* 1994;23(7):784–9.
44. Possover M, Mader M, Zielinski J, Pietrzak K, Hettenbach A. Is laparotomy for staging early ovarian cancer an absolute necessity? *J Am Assoc Gynecol Laparosc.* 1995;2(3):285–8.
45. Chéreau E, Ballester M, Rouzier R, Coutant C, Daraï E. Advanced ovarian cancer: criteria of resectability. *Bull Cancer.* 2009;96(12):1189–97. <https://doi.org/10.1684/bdc.2009.0985>.
46. Fagotti A, Ferrandina G, Fanfani F, Ercoli A, Lorusso D, Rossi M, Scambia G. A laparoscopy-based score to predict surgical outcome in patients with advanced ovarian carcinoma: a pilot study. *Ann Surg Oncol.* 2006;13(8):1156–61.
47. Mage G, Canis M, Manhes H, Pouly JL, Bruhat MA. Ovarian cysts and celioscopy. Apropos 226 cases. *J Gynecol Obstet Biol Reprod (Paris).* 1987;16(8):1053–61.
48. Blanc B, D’Ercole C, Nicoloso E, Boubli L. Laparoscopic management of malignant ovarian cysts: a 78-case

- national survey. Part 2: follow-up and final treatment. *Eur J Obstet Gynecol Reprod Biol.* 1995;61(2):147–50.
49. Zomer MT, Ribeiro R, Branco AW, Branco Filho AJ, Kondo W. How do I treat ovarian dermoid cyst by laparoscopy? *Bras J Video-Surg.* 2011;4(2):84–90.
50. Kondo W, Bourdel N, Zomer MT, Slim K, Rabischong B, Pouly JL, Mage G, Canis M. Laparoscopic cystectomy for ovarian endometrioma—a simple stripping technique should not be used. *J Endometr.* 2011;3(3):125–34.



Laparoscopic Cerclage

15

Geraldo Gastal Gomes-da-Silveira,
Suzana Arenhart Pessini,
and Gustavo Py Gomes da Silveira

History and Introduction

Although there is a large amount of literature on this type of procedure, the vaginal technique described by Shirodkar in 1953 is considered to be the benchmark from which the operation was standardized [1]. In 1965, in an attempt to improve the success rates of vaginal surgery (which featured an index of faults of 15%), Berson and Durfee described the abdominal approach to cerclage, with a resolution of up to 89% of the cases [2, 3].

The transabdominal cerclage method should be reserved for patients with failure of prior vaginal cerclage and/or cervical shortening surgery, especially after radical trachelectomy, malformation, or cervical laceration.

Recently, with the development of minimally invasive surgery, abdominal cerclage was performed by laparoscopy. This resulted in the laparoscopic benefits of lower peri-operative morbidity and obstetric results similar to those performed by laparotomy.

The first publications about laparoscopic cerclage appeared in 1998 [4, 5], showing rates of 90–100% of newborns born alive [6–10, 2015].

G. G. Gomes-da-Silveira (✉)
CliniOnco, Porto Alegre, Rio Grande do Sul, Brazil

S. A. Pessini, M.D., Ph.D.
G. P. G. da Silveira, M.D., Ph.D.
Federal do Rio Grande do Sul (UFRGS) and
Universidade Federal de Ciências da Saúde de Porto
Alegre (UFCSPA), Porto Alegre, RS, Brazil

Laparoscopic cerclage is easier and safer to be performed in the interval between pregnancies.

Pre-operative Care

The procedure does not require specific preparation in addition to the normal pre-operative routine. Vaginal and cervical infections must be treated before genital manipulation.

Surgical Room and Patient Position

The operating bed is at the center of the room. The anesthesiologist and corresponding equipment are located at the patient's cranial end. The videolaparoscopy equipment is located between the legs of the patient.

The patient is placed on the operating bed with her legs in held in pneumatic boots, if available. The patient is positioned in the lithotomy position, with lower limbs in the Lloyd Davies position. The arms are placed next to the body.

Materials

This procedure uses mersilene tape with a needle. The use of this material is part of a technical advancement of isthmo-cervical cerclage. This operation can now be done without complete

dissection of the uterine vessels, thereby reducing surgical time and risk of bleeding.

This procedure also uses a uterine manipulator, which facilitates exposure of the isthmus in non-pregnant patients.

The laparoscopic approach also requires the use of normal surgical materials such as trocars (size 11 and 5/5.5 mm), needle holders, scissors, and a bipolar energy source.

Three or four trocars are used in this operation: one (11 mm) in the umbilical scar for optics and the other two or three (5 or 5.5 mm) in the iliac areas for the instruments.

Surgery

We start the procedure with the introduction of the Veress needle via the umbilicus, for access to the pneumo-peritoneum. In some situations, we perform an open trocar entry and then introduce instrumental trocars. An inventory of the peritoneum cavity and evaluation of the posterior compartment are performed, with trans-peritoneal visualization of the uterine vessels and ureters (bilaterally) (Figs. 15.1 and 15.2).

The incision of the vesico-uterine peritoneum is made with identification of the vesico-cervical space and mobilization of the bladder (Fig. 15.3).

The uterine vessels in the anterior compartment are identified (Fig. 15.4).

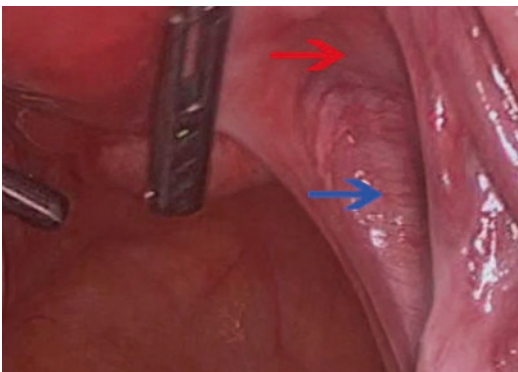


Fig. 15.1 Identification of the uterine vessels and ureter on the right side

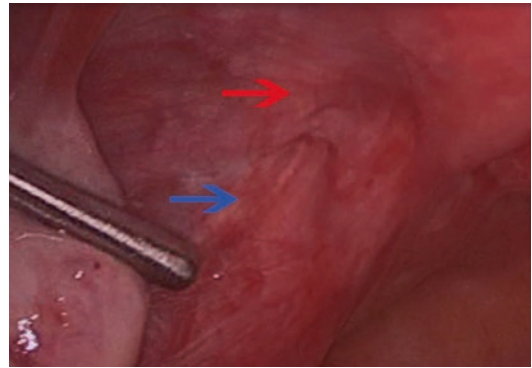


Fig. 15.2 Identification of the uterine vessels and ureter on the left side

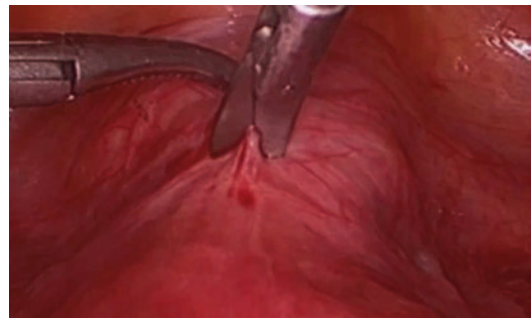


Fig. 15.3 Incision of the vesico-uterine peritoneum

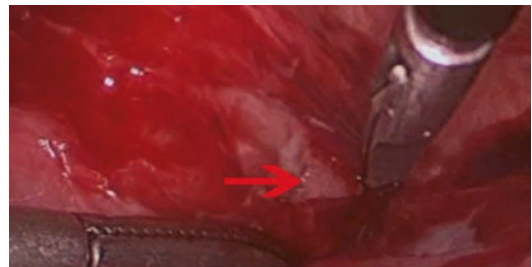

Fig. 15.4 Exhibition of the uterine vessels on the right

Introduction into the cavity of the 5-mm merisilene tape is then performed with straight needles, through the 11-mm trocar (Fig. 15.5).

The tape is transfixed, with the needle entry site just above the utero-sacral ligaments, medial/below the uterine vessels (Fig. 15.6). What is important at this time is the correct angle of the needle, so that it passes and remains perpendicular to the cervix at the point of isthmo-cervical

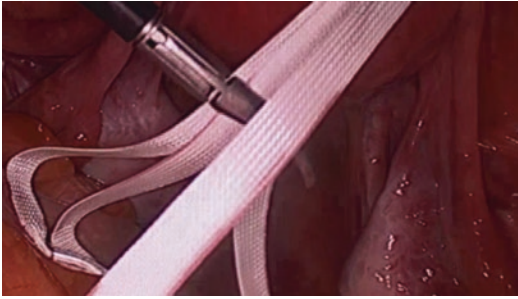


Fig. 15.5 Mersilene tape

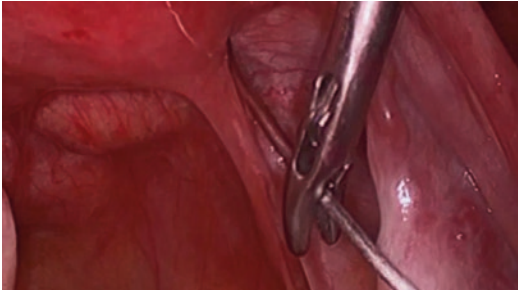


Fig. 15.6 Needle entry point

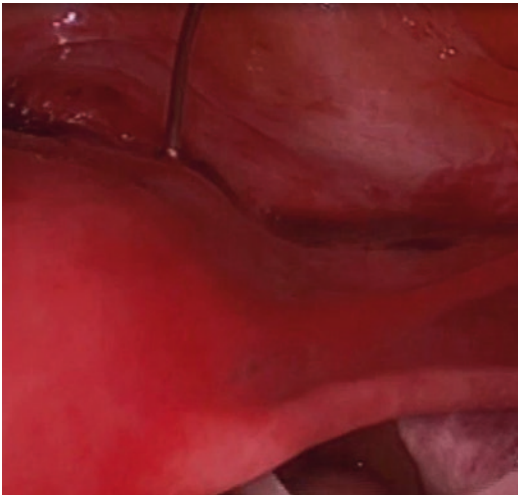


Fig. 15.7 Needle anterior exit

transition, to the exit point in the anterior compartment medial to uterine vessels previously exposed (Fig. 15.7).

The same procedure is then performed on the other side, taking care to check, before the passage of the second needle, that there is no twist in the tape (Figs. 15.8, 15.9, 15.10, and 15.11).

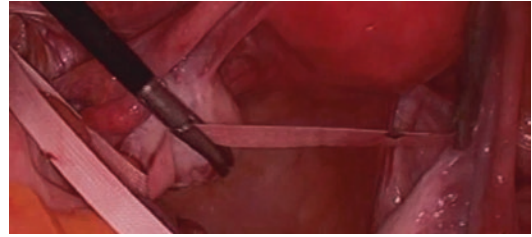


Fig. 15.8 Verification of the tape

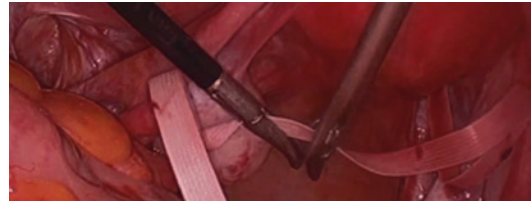

Fig. 15.9 Correction of the tape twist

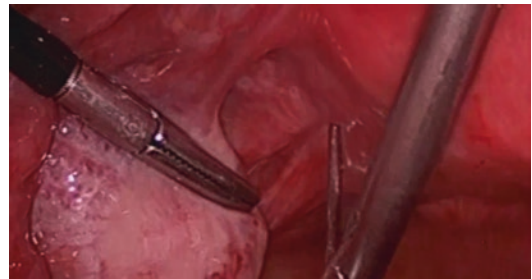


Fig. 15.10 Entry of the needle on the left

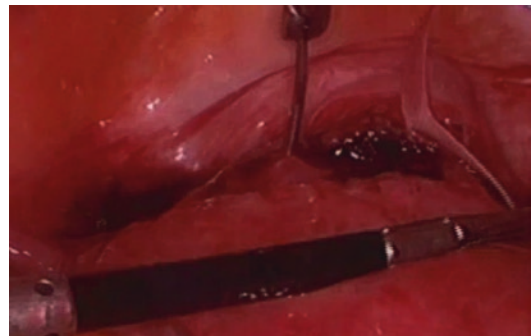


Fig. 15.11 Exit of the needle on the left

With the tape adjusted bilaterally, we cut the tape ends and withdraw the needles through the 11-mm trocar (Fig. 15.12).

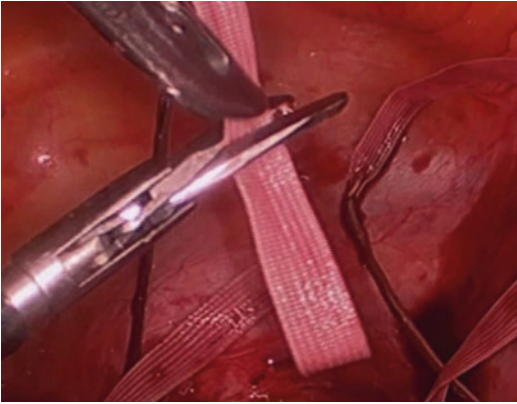


Fig. 15.12 Cutting the tape

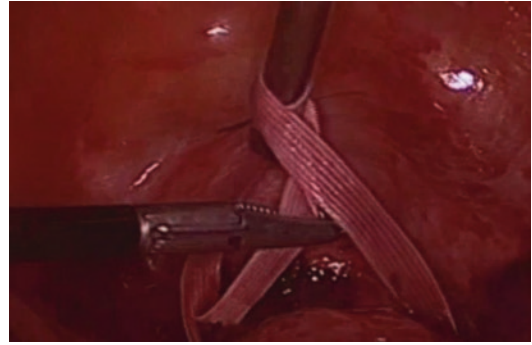


Fig. 15.14 Mersilene tape knots

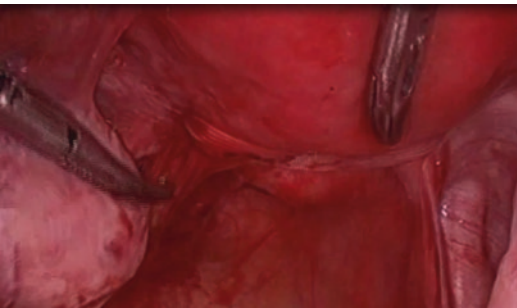


Fig. 15.13 Adjust the tape

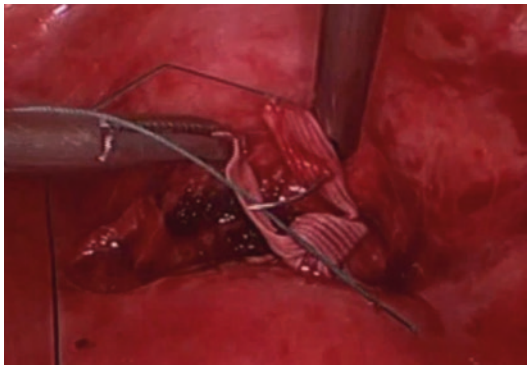


Fig. 15.15 Lock the tape ends

In the anterior compartment, knots are tied after adjusting the tape around the uterine circumference, leaving it without tension. Then a cerclage lock with a ethibond 2-0 suture transfixes the ends of tape (Figs. 15.13, 15.14, and 15.15).

Finally, we close the anterior compartment peritoneum with 2-0 vicryl (Fig. 15.16). In non-pregnant patients, you can use this opportunity to perform a tubal patency test, an additional advantage of pre-conceptional surgery.

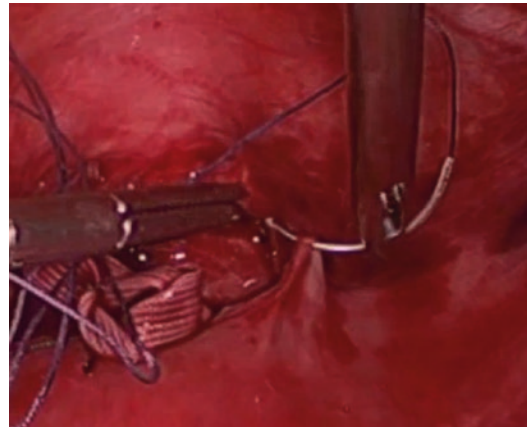


Fig. 15.16 Peritoneum closure

Post-surgery

An oral diet is initiated 3 h after the end of the surgery, consisting of liquid or a soft meal. Recommendations for post-surgery include analgesia, hydration, diuresis control, lower limb movements, and walking as soon as possible.

Conclusion

Laparoscopic cerclage is a low-risk and medium complexity procedure, with a low likelihood of complications.

The rate of complications in the literature is as 1.6–4.5% [11, 12]. Reported complications include bleeding from the uterine vessels, urinary tract infection, and injury to the bladder and the bowel. The conversion rate to laparotomy is higher in patients during pregnancy (4.4%) than in non-pregnant patients (0.8%) [6].

Cerclage by the abdominal approach (laparotomy or laparoscopy) is associated with increased morbidity compared with the vaginal route. This is because of the need to enter the peritoneal cavity on two occasions: during the surgery and at birth, as cesarean section is necessary.

After post-operative care, the patient returns to her obstetrician.

Key Points Transperitoneal uterine vessel and ureter identification in the posterior compartment. Identification of the uterine vessels after vesico-uterine dissection.

Correct angulation of the needle at the entry point.

Tape positioning, avoiding twisting.

Adjustment of tape without tension.

References

- Harger JH. Cerclage and cervical insufficiency: an evidence based analysis. *Obstet Gynecol.* 2002;100:1313–27.
- Berson RC, Durfee RB. Transabdominal cerclage during pregnancy cervicouterine for treatment of cervical incompetency. *Obstet Gynecol.* 1965;25:145–55.
- Cammarano CL, Herron MA, Parker JF. Validity of indications for transabdominal cerclage for cervical incompetence. *Am J Obstet Gynecol.* 1995;172:1871.
- Lesser KB, Childers JM, Surwit EA. Transabdominal cerclage: a laparoscopic approach. *Obstet Gynecol.* 1998;91:855–6.
- Scibetta JJ, Sanko SR, Phipps WR. Laparoscopic transabdominal cervicoisthmic cerclage. *Fertil Steril.* 1998;69:161–3.
- Burger NB, Brölmann HAM, Einarsson JI, Langebrette A, JAF H. Effectiveness of abdominal cerclage placed via laparotomy or laparoscopy: systematic review. *J Minim Invasive Gynecol.* 2011;18:696–704.
- Carter JF, Soper DE, Goetzl LM, Van Dorsten JP. Abdominal cerclage for the treatment of recurrent cervical insufficiency: laparoscopy or laparotomy? *Am J Obstet Gynecol.* 2009;201:111.e1–4.
- Tulandi T, Alghanaim N, Hakeem G, Tan X. Pre and post-conceptional abdominal cerclage by laparoscopy or laparotomy. *J Minim Invasive Gynecol.* 2014;21:987–93.
- Tusheva OA, Cohen SL, TF ME, Einarsson JI. Laparoscopic placement of cervical cerclage. *Rev Obstet Gynecol.* 2012;5:158–65.
- Ades DK, Cheung K, Umstad M. Transabdominal cerclage cervical: laparoscopy versus laparotomy. *J Minim Invasive Gynecol.* 2015;22:968–73.
- Burger NB, Einarsson JI, Brölmann HA, Vree FE, McElrath TF, Huirne JA. Preconceptional laparoscopic abdominal cerclage: a multicenter cohort study. *Am J Obstet Gynecol.* 2012;207:273.e1–12.
- Whittle WL, Singh SS, Allen L, Glaude L, Thomas J, Windrim R, Leyland R. Laparoscopic cervico-isthmic cerclage: surgical technique and obstetric outcomes. *Am J Obstet Gynecol.* 2009;201:364.e1–7.
- American College of Obstetricians and Gynecologists. ACOG Practice Bulletin No. 142: Cerclage for the management of cervical insufficiency. *Obstet Gynecol.* 2014;123:372–9.
- Brown R, Gagnon R, Delisle MF. Cervical insufficiency and cervical cerclage. *J Obstet Gynaecol Can.* 2013;35:1115–27.
- Lidegaard O. Cervical incompetence and cerclage in Denmark 1980-1990. A register based epidemiological survey. *Acta Obstet Gynecol Scand.* 1994;73: 35–8.



Cesarean Scar Defects: Hysteroscopic Treatment of Isthmocele in Menstrual Disorders and Infertility

Carlo Tantini, Gersia Araújo Viana,
and Giampietro Gubbini

Introduction

The increase in the incidence of cesarean births worldwide has concerned international institutions such as WHO, that has long recommended a reassessment of the medical indications of surgical deliveries, as many countries practice the technique contrary to international recommendations [1]. An incidence of cesarean births of 15 % is considered an acceptable rate to ensure maternal and fetal well-being and, at the same time, optimize the development of the puerperium and maintain full reproductive capacity. Unfortunately, some countries with diverse health systems and economic realities do not adhere to these recommendations, for reasons that are beyond the scope of this current investigation [2]. It is, however, important to mention the comparative incidence of cesarean births in some countries: in Europe, Iceland has a 14.7 % cesarean rate and Italy has a 37 % cesarean rate.

In the Americas, Peru has a 26 % cesarean rate, Brazil has a 56 % rate, while the USA has a rate of 31 %. China has a cesarean birth rate of 50 %, which is the highest rate in the Asian continent [3, 4].

Assessing the reasons for this situation are not part of this study's goal, which is rather to examine what are the different consequences of a vaginal physiological birth compared to surgical delivery.

Complications related to anesthesia, whether general or locoregional, are possible for cesarean births, but are also common for all surgical procedures. However, with cesarean surgery, the anesthetist is concerned not only with possible maternal complications, but also with fetal well-being.

Statistics show a higher probability of infants being sent to an Intensive Care Unit after a surgical delivery in relation to those born vaginally. In vaginal births, the incidence of Membrana Syndrome (respiratory disease in the newborn) is greatly reduced [5, 6].

Breastfeeding is also negatively influenced by surgical delivery, especially elective cesareans, because the mechanism for lactation may not be immediately triggered [7, 8].

When evaluating the reproductive capacity of a patient with a history of cesarean birth, compared to that of natural childbirth, an extremely important factor is the reduction of fertility of approximately 10 % in the first

C. Tantini, M.D. (✉)
Centro de Pesquisa e Assistência em Reprodução
Humana (CEPARH), Salvador, BA, Brazil

CENAFERT/INSEMINA, Centro de Medicina
Reprodutiva, Salvador, BA, Brazil

G. A. Viana, M.D.
CENAFERT/INSEMINA, Centro de Medicina
Reprodutiva, Salvador, BA, Brazil

G. Gubbini, M.D.
Clinica Madre Fortunata Toniolo, Bologna, Italy

group according to data in the literature. This observation leads us to believe that cesarean surgery, even without apparent complications, causes permanent damage to the reproductive system [9, 10].

For a long time this observation remained limited to an “expert opinion” (level of evidence 6), with no scientific relevance. However, in 1975 Stewart and Evans published information on the changes experienced by the uterus that had undergone a cesarean incision, which could pose a real threat of occurrence of a pathological syndrome [11].

The final confirmation of all symptomatology related to uterine damage post-cesarean occurred in 1995 when Morris established a definition for this post-surgical pathology: the cesarean scar defect (CSD) or isthmocele [12].

Isthmocele is an anatomical-functional condition similar to a diverticulum of the anterior wall of the uterine isthmus or hysterotomy scar focus. This pathology was first described by Morris, who studied the uterus after hysterectomy in patients with a history of cesarean deliveries.

From a clinical point of view, isthmocele can be asymptomatic or it can manifest symptoms such as: post-menstrual abnormal uterine bleeding (PAUB), chronic pelvic pain, dyspareunia, and infertility [13–21].

The incidence of the disease is extremely variable according to the literature. A recent review showed an incidence of isthmocele in women undergoing cesarean surgery ranging from 56 % to 84 % [22].

Patients of childbearing age complaining of abnormal uterine bleeding and with a history of cesarean delivery, should raise the suspicion of isthmocele, although this symptom is also common to hormonal dysfunctional disorders such as endometrial hyperplasia and organic pathologies like submucosal myomas, polyps, etc. [23].

Pathogenesis

Isthmocele is an anatomic impairment of the anterior wall of the isthmus as a consequence of one or more cesarean deliveries (Fig. 16.1).

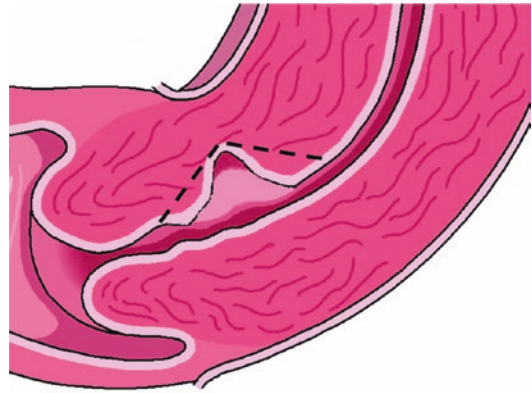


Fig. 16.1 Schematic representation of isthmocele

Isthmocele can be considered to be a very common iatrogenic condition in the female population because of the high worldwide incidence of this disorder, which leads to adverse anatomic changes in the lower uterine segment [12]. It is unclear as to why only some patients develop adverse post-cesarean anatomic changes.

The uterine surgical procedure most often performed in women of childbearing age is the cesarean section, and it is usually made across the lower segment [24, 25]. Hysterorrhaphy can be performed in a single plane or multiple planes, but currently the most widely used technique is single plane in a continuous suture (i.e., the Stark technique) [26]. The coming together of incision edges of different thicknesses is likely to contribute to the development of defects in the lower uterine segment. Since the mid-1980s, with the spread of this simplified Stark technique, there has been a reduction in surgical time and improvement in post-operative recovery. However, the replacement of the traditional suturing technique on two planes of the uterine wall with a single suture plane does not provide a perfect alignment of the uterine wall edges [26, 27].

It is possible that the larger tissue ischemia caused by suturing in a single plane may be another cause of the cicatrizing defects of a hysterotomy suture.

This problem was analyzed by Yazicioglu et al. (2006) in a randomized study of 78 patients, where different suture techniques were studied: (1) single plane covering all thicknesses, includ-

ing endometrial and (2) suture in separate planes excluding endometrial thickness. A comparison of the two techniques showed a lower level of incomplete cicatrization when suturing in two planes. Based on these observations, it was recommended to return to the technique of traditional cesarean section sutured in two planes, which included greater respect for anatomic structures [28]. However, this is a much-debated question and not all the authors agree on this point.

The isthmic structural defect also depends on other factors, including the degree of cervical dilation and the thickness of the lower segment at the time of surgery. The presence of a chronic inflammatory condition and the tissue reaction to the suture material also influences wound cicatrization.

Isthmocele is more common in the retroverted uterus and the frequency of cicatricial changes in these cases is double when compared to women with an anteverted uterus [29]. In cases of retroversion, the flexion point of the uterus maintains a greater degree of tension in the lower uterine segment, and this alters healing. This anatomic traction on the wound and altered vascular perfusion caused by reducing the thickness of the uterine segment are responsible for delayed wound healing with a decrease in collagen production [29].

The anatomic damage to the cervico-isthmic region is also linked to reducing the myometrial thickness at the isthmus level and is directly proportional to the number of hysterotomies the patient has been submitted to [29–31].

Symptomatology

Isthmocele is associated with numerous anatomic and functional alterations such as distortion and lower segment elongation, endometrial congestion at the scar, lymphocytic infiltration, capillary dilation, and the presence of red blood cells in the stroma at the scar [13].

These anatomic changes can cause PAUB, chronic pelvic pain, dyspareunia, and infertility. The menses can be lowered by the presence of isthmocele and blood may accumulate in the scar diverticulum. The presence of fibrotic tissue and the low contractility of uterine muscle fibers

around the scar hinder the expulsion of the accumulated material [12–14, 17, 18]. Blood can even be produced in situ, as suggested by Morris [12]. Dense and viscous mucoid material, due to chronic inflammation, accumulates in the diverticular space: the elimination of hematic mucus material of a dark color is the most common symptom in women with isthmocele and, in some cases, the hematic loss can occur at any stage of the menstrual cycle [12, 13, 17].

Often this anomalous bleeding is associated with heavy menstrual flow. Wider scars are generally associated with longer and more abundant bleeding.

The chronic pelvic pain and dyspareunia are caused by the phlogosis and dilatation of the lower uterine segment.

Secondary infertility is associated with isthmocele in a wide number of cases. Possible factors that may explain this condition are: chronic endocervicitis, changing the quality of cervical mucus and creating obstacles to the transport of sperm, as well as endometritis caused by diverticulum blood reflux hindering embryo implantation. Isthmocele can also hinder the embryonic transfer when assisted reproduction techniques are used [32–36].

Diagnosis

The diagnosis of isthmocele as described in the literature can be accomplished through various imaging techniques: transvaginal ultrasound, hysteroscopy, hysterosalpingography and magnetic resonance imaging [27, 37, 38] (Fig. 16.2).

Currently, the first test to be performed is transvaginal ultrasonography, preferably in the post-menstrual phase. The isthmus defect appears as a hypoechoic area in the form of an isosceles triangle, with the apex facing the anterior wall of the isthmus and the base against the posterior wall of the cervical canal [27, 30, 31, 39, 40] (Fig. 16.3).

The lesion is predominantly shown on the anterior wall of the cervical canal, expanded towards the 2 h mark in most cases [13, 17, 18]. This finding may be explained by the rotation of the gravid uterus to the right at the time of surgi-

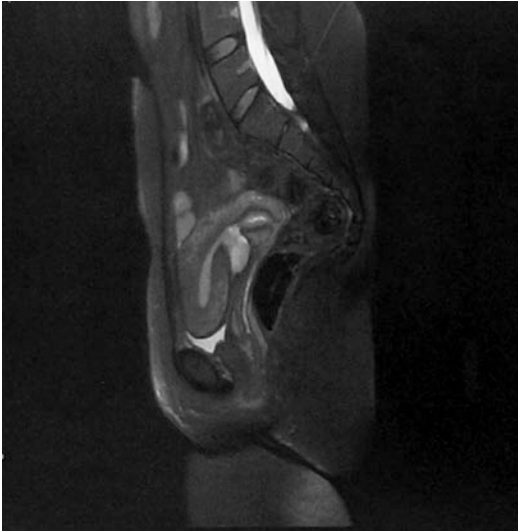

Fig. 16.2 Pelvic magnetic resonance of 3° grade isthmocele

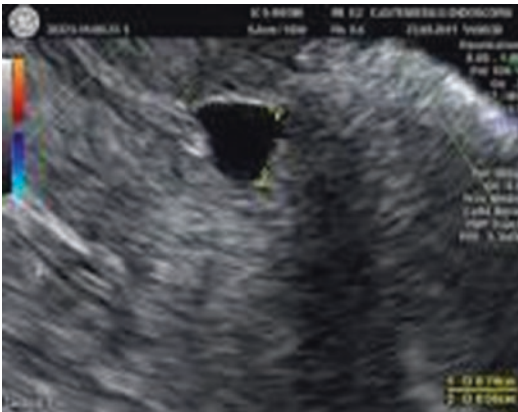

Fig. 16.3 Sonographic aspect

cal delivery, leading to the expansion of the incision towards the left parametria, which causes a suture dehiscence at this level after uterine postpartum physiological involution [13, 17, 18, 41].

Through ultrasonography, it is possible to measure the distance between the bottom of the cavity and the outside of the cervical canal, obtaining useful information for surgical planning. A sonographic classification was proposed based on the area of the isthmocele cavity: 1° degree $<15 \text{ mm}^2$, 2° degree between 16 and

25 mm^2 , 3° degree $>25 \text{ mm}^2$ (calculated with the formula: $\text{basis} \times \text{height}/2$ of triangle area) [17].

Hysteroscopy allows for the proper assessment of isthmocele, which appears as a diverticulum at the level of the cervical canal, often filled with mucus-hematic material with distortion of the “arbor vitae” in the affected area. The presence of abundant mucus may hinder the default view in inexperienced hands. The cavity wall has a marked vascularization and dishomogeneous mucosa with micro-polypoid areas, an expression of chronic phlogistic process. The uterine cavity can show a hyperemic endometrium and typical signs of chronic endometritis. When there is a suspicion of CSD, it is advisable to pay special attention when moving the hysteroscope within the endocervical region, using a liquid distention that allows for the washing of the diverticular cavity, thus draining the mucus-hematic material that has collected. It is recommended that care is taken in progression of the instrument, to prevent false passage and the risk of uterine perforation [41].

Hysteroscopic investigation precisely defines the isthmocele site while ultrasound determines the cavity volume (Fig. 16.4).

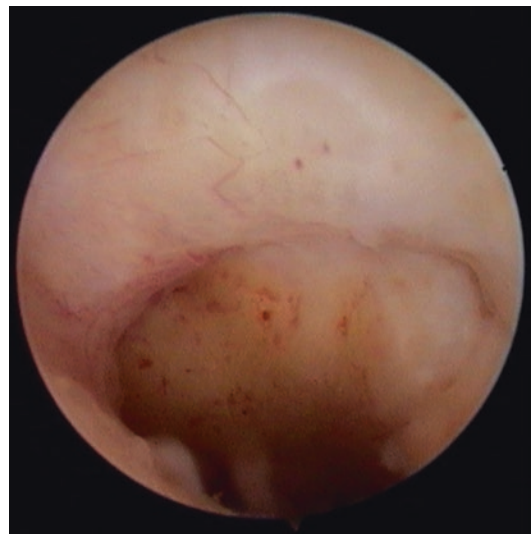


Fig. 16.4 Hysteroscopic aspect

Treatment

Treatment of isthmocele should be offered to symptomatic patients, who represent 10 % of women with this disease. For women of child-bearing age with further reproductive interest, treatment may be indicated as prevention of possible obstetric complications, such as cervical implantation of pregnancy, uterine rupture in the course of pregnancy or during labor, placenta previa, or accrete.

More severe diseases are observed in pregnant women with isthmocele. These include the presence of “locus minoris resistenciae,” which can cause a lower segment rupture during labor or during the third trimester of pregnancy, often resulting in emergency cesarean deliveries. The low implantation of the embryo within the previous cesarean scar is also common, with possible placenta previa and/or accreta, due to thin uterine wall thickness in the lower segment. In both cases, the obstetric outcomes are poor for both the fetus and the mother’s well-being [42, 43].

Regarding the type of treatment for isthmocele, there is a lack of adequate medical therapy so surgical intervention is the preferred procedure.

The choice of treatment for symptomatic patients can range from suspension of menstrual cycles to more aggressive treatments like a hysterectomy. On the other hand, women with further reproductive interests should undergo corrective surgery.

Isthmoplastia can be performed with the following surgical procedures: resectoscopy, laparoscopy, vaginal approach, and, exceptionally, laparotomy. Currently the surgical technique of choice is resectoscopic as proposed in 2005 by Fabres et al., and perfected by Gubbini et al. in 2008 [13, 41].

In the past, the most commonly used techniques were the vaginal and laparoscopic techniques. The vaginal technique involves the detachment of the bladder from the uterine cervix. This technique is technically accessible for every gynecological procedure because it is similar to the first stage of vaginal

hysterectomy or the correction of a cystocele. However, currently the vaginal technique is considered disproportionate to this type of pathology [44, 45].

In relation to the use of laparoscopy, the detachment of the bladder is a step performed with relative ease, while the suture of the cervix (a rigid structure) requires a skilled surgeon as identifying the exact point of injury may be difficult in some cases. Some authors recommend the laparoscopic technique only in cases of isthmocele with a very thin uterine wall thickness (less than 3 mm between the diverticular cavity and the anterior isthmic wall), in these cases possibly combining laparoscopic and hysteroscopic techniques [46].


The use of vaginal resectoscope has replaced the other access routes with great success, because of low invasiveness, high efficiency, and the patient’s rapid return home.

Isthmoplasty with a resectoscope of 26 Fr (Karl Storz, Germany) (the first instrument to be used) required a prior diagnostic hysteroscopy and sonographic evaluation of the distance between the bottom of the cavity and the bladder wall, as well as bladder filling with blue methylene solution, aiming to show small perforations that may go unnoticed. The procedure should be performed in the hospital with general anesthesia.

After dilation of the cervical canal, the most well-established technique involves the resection of the proximal edge of the diverticulum until the muscle tissue is reached, then approaching the distal edge and resulting in the elimination of the isthmocele cavity. When the bottom of the diverticulum appears completely visible, a roller-ball is used with the aim of cauterizing the entire surgical area, which enables recovery of the cervical canal’s physiologic function. The use of a resection loop in the bottom of the cavity is not advised because of the risk of damaging the bladder wall.

The introduction of Gubbini’s mini-resectoscope, with a diameter of 16 Fr, (Tontarra, Germany), significantly simplifies the surgery (Fig. 16.5).

Fig. 16.5 Gubbini's mini-resectoscope, 16 Fr



In 2008, by modifying Pagano's urethrotome of urological origin, Giampietro Gubbini produced a completely innovative instrument. He positioned the insulating ceramic on the outer sheath and managed to reduce the tool diameter to 16 Fr (5.3 mm) using continuous flow and pluriuse loops that are perfectly sterilizable and capable of using two types of electric current: mono- and bipolar. This new resectoscope greatly reduced costs for purchased materials, since the same loop can be used with all types of energy [47].

This innovation was immediately welcomed, because besides the reduced outer diameter (comparable to Bettocchi's hysteroscope) it has the advantage of using resection loops and no coaxial electrodes, which facilitates the approach of various intrauterine pathologies [48].

Another advantage is the possibility of entering the uterine cavity under direct vision without the need for dilation of the cervical canal with Hegar dilators. Thus, the risk of damage during the dilation process, which is more frequent in patients with a history of cesarean section, is removed and the cervical canal's integrity is maintained.

The reduced diameter of the mini-resectoscope also allows its use for diagnostic purposes, making a hysteroscopic preoperative assessment unnecessary. With regard to the surgical approach, the instrument is considered the best in the treatment of isthmocele, because the miniature loops allow resection of fibrotic tissue at the scar apex, thus establishing reconstitution and integrity of the cervical canal. Prior sonographic evaluation for surgery must be performed in order to evaluate the distance between the bottom of the cavity

and bladder, thus reducing the risk of intraoperative injuries [49].

The expected result in the surgical correction of the pathological condition is the removal of the diverticular sac and chronic phlogiston process, stimulating tissue repair.

A cubical cell mono-stratified mucosal is responsible for the re-epithelialization of the treated area, thus replacing the removed necrotic and inflammatory tissue [13, 14, 17, 18, 41].

Endometrial-conducted biopsies confirmed the presence of cubic cells in the isthmocele site at 8–12 weeks after reconstructive surgery in all patients who underwent the examination. At the 3-month follow-up visit, an increase in endometrial thickness up to 8.2 mm was also observed, according to Li et al. 2014 [50].

Isthmoplasty in Symptomatic Patients: Current Study

The current study comprised 412 isthmocele patients with a history of one or more cesarean deliveries, who underwent surgical correction with the resectoscopic technique in the period 2001–2015.

Material and Methods

The 412 included women were aged 28–45 years, with a history of one to three cesarean births from 2001 to 2015. All patients (100 %) had abnormal uterine bleeding symptoms (PAUB). In 27 % of cases, there was an associated secondary infertility manifestation, while 57.1 % of patients had

suprapubic pain and heavy menstrual flow. All patients underwent an office hysteroscopy using optical forum-oblique 30° and a diameter of 2.9 mm (Karl Storz, Germany) with a sheath of continuous flow. The hysteroscopic evaluation allowed the exclusion of other intracavitary pathologies and individualizing the diverticulum in the isthmus or cervical sites (Graphic 16.1).

The technique used for surgical correction of isthmocele includes hysteroscopic resection of the inferior and superior defect edges, with complete removal of fibrotic cicatricial tissue up to

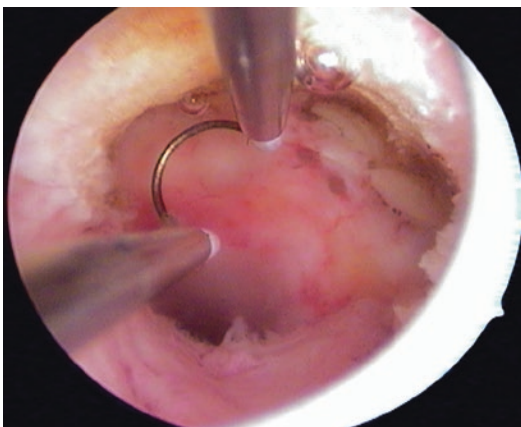


Fig. 16.6 Use of a loop for removing the niche's walls

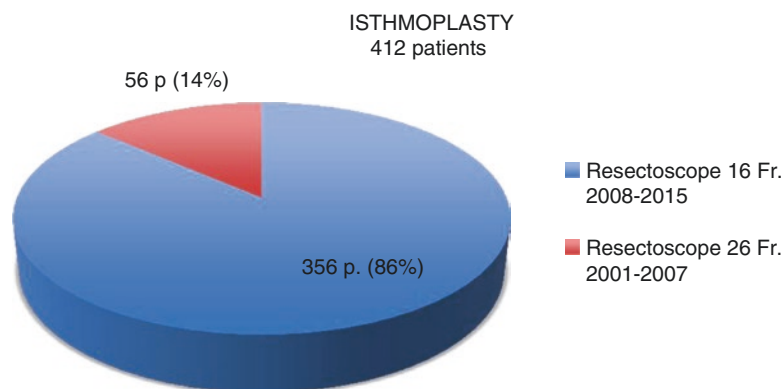
the exposition of the subjascente muscle tissue, using loop resection and an electric cutting current. The roller ball was used for electrocoagulation at the bottom of the niche cavity under direct vision, avoiding the accumulation of blood in situ (Figs. 16.6, 16.7, and 16.8).

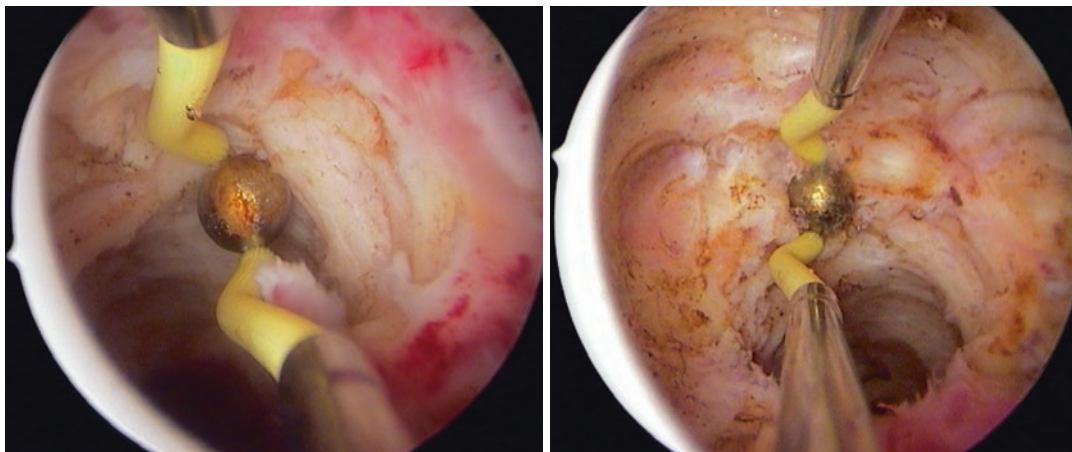
Since 2008, all isthmoplasties have been performed using the 16-Fr mini-resectoscope.

With regard to the histological examination of the removed material, diagnosis was obtained of chronic endocervicitis with an inflammatory infiltrate in 82 % of cases, fibrosis and necrotic tissue in 16 % of samples, and adenomyosis in 5 % of cases.

In most cases (70 %), the defect was identified in the superior third of the cervical canal or in the isthmus, but lower locations, as in the middle and inferior third, were also observed (30 %).

A correlation between the condition of cesarean delivery and the site of injury was also observed: the study showed that patients that underwent an elective surgical delivery had a superior cervical or isthmic location, while those who underwent a cesarean in emergency or in advanced labor, showed variation in the location related to the degree of dilation [51].





Figs. 16.7 and 16.8 Cauterization of the fundus

Complications

Correct pre-operative diagnostic investigation was necessary to reduce the risk of complications.

USTV verifies the presence of isthmocele but also allows for measurement of the distance between the bottom of the diverticulum cavity and bladder wall, which is essential for safe surgical planning. The filling of the bladder with methylene blue solution is also a valid strategy, as it allows the rapid identification of micro-bladder perforations.

When the procedures were performed using a 26-Fr resectoscope, the intraoperative complications were mainly linked to the use of Hegar in the cervical canal dilatation, but this was not seen after using the 16-Fr resectoscope. There were two hemorrhagic complications in the immediate post-operative period that were treated with cervical-isthmic package. Fibrotic sequelae, such as the Aschermann Syndrome, were not seen. In 9 % of cases, there was persistence of symptoms after surgery, requiring new isthmoplasty. When that was not effective, the indication was to insert an intrauterine levonorgestrel device (Mirena ©) [52].

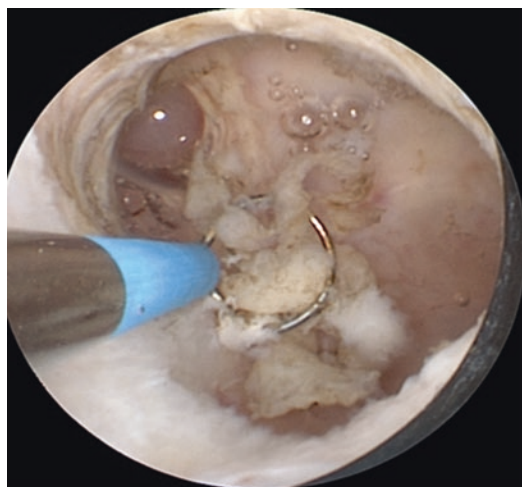

Fig. 16.9 Directed biopsy

Results

After 2–3 months of surgical correction, an office hysteroscopy was performed using the same instruments as in the pre-operative examination. It was possible to confirm the corrected defect, showing its wall in continuity to the cervical canal in the uterine cavity. An epithelial re-colonization with cubic epithelium of the endocervical treated area was observed by directed biopsy (Figs. 16.9 and 16.10).

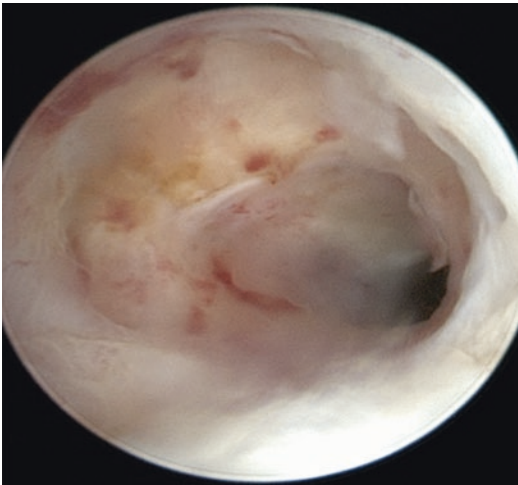


Fig. 16.10 Epithelial re-colonization

Conclusions

The scar that forms after a cesarean delivery may cause negative consequences to the integrity and functionality of the female genital tract with reproductive impact and can lead to cervical pregnancy implantation, secondary infertility, difficult access during embryo transfer, and implantation failure in assisted reproduction techniques. PAUB is the major symptom linked to isthmocele and requires a careful, differential diagnosis with organic pathologies such as polyps and myomas as dysfunctional causes.

Ultrasonographic evaluation and office hysteroscopy allows for the accurate identification of the isthmic-cervical defect with minimal invasive methods, providing essential information for proper surgical planning.

An improvement in clinical symptoms linked to the disease (e.g., PAUB, chronic pelvic pain, heavy menstrual flow, and dyspareunia) is possible after resectoscopic isthmoplasty, according to our experience.

With regard to secondary infertility, another study has demonstrated a recovery of fertility in 12–24 months after surgery in 30 % of cases after isthmoplastic correction. These results are yet to be confirmed, but the possibility of improving the reproductive potential

in these cases encourages more research in this area [41].

Currently, hysteroscopic surgery is the best alternative in the treatment of isthmocele, promoting effective results with minimal discomfort and lower surgery risk for the patients. The pregnancies that occurred after corrective surgery in the population evaluated in this study had a normal evolution and cesarean sections were performed as a precaution. The pregnancy complication risks after isthmoplasty are the same as in patients with previous cesarean histories and are not linked to the corrective surgery.

We emphasize, therefore, the importance of a correct diagnosis of the cervical canal defects in all patients with a history of cesarean birth, even those who are asymptomatic, in order to prevent negative outcomes in future pregnancies.

Encouraging the gynecologist to seek a proper diagnosis and secure treatment of isthmocele should be the goal. The development of an obstetric awareness that complies with international indications for a surgical delivery will result in the prevention of this iatrogenic uterine pathology.

References

1. Zizza A, Tinelli A, Malvasi A, Barbone E, Stark M, De Donno A, et al. Cesarean section in the world: a new ecological approach. *J Prev Med Hyg.* 2011;52(4):161–73.
2. Betran AP, Torloni MR, Zhang J, Ye J, Mikolajczyk R, Deneux-Tharoux C, et al. What is the optimal rate of caesarean section at population level? A systematic review of ecologic studies. *Reprod Health.* 2015;12:57.
3. Betrán AP, Ye J, Moller AB, Zhang J, Gülmezoglu AM, Torloni MR. The increasing trend in caesarean section rates: global, regional and national estimates: 1990–2014. *PLoS One.* 2016;11(2):e0148343.
4. Hellerstein S, Feldman S, Duan T. China's 50% caesarean delivery rate: is it too high? *BJOG.* 2015; 122(2):160–4.
5. Prefumo F, Ferrazzi E, Di Tommaso M, Severi FM, Locatelli A, Chirico G, et al. Neonatal morbidity after cesarean section before labor at 34(+0) to 38(+6) weeks: a cohort study. *J Matern Fetal Neonatal Med.* 2016;29(8):1334–8.

6. De Luca R, Boulvain M, Irion O, Berner M, Pfister RE. Incidence of early neonatal mortality and morbidity after late-preterm and term cesarean delivery. *Pediatrics*. 2009;123(6):e1064–71.
7. Farchi S, Di Lallo D, Franco F, Polo A, Lucchini R, Calzolari F, et al. Neonatal respiratory morbidity and mode of delivery in a population-based study of low-risk pregnancies. *Acta Obstet Gynecol Scand*. 2009;88(6):729–32.
8. Many A, Helpman L, Vilnai Y, Kupferminc MJ, Lessing JB, Dollberg S. Neonatal respiratory morbidity after elective cesarean section. *J Matern Fetal Neonatal Med*. 2006;19(2):75–8.
9. O'Neill SM, Kearney PM, Kenny LC, Henriksen TB, Lutomski JE, Greene RA, et al. Cesarean delivery and subsequent pregnancy interval: a systematic review and meta-analysis. *BMC Pregnancy Childbirth*. 2013;13:165.
10. Evers EC, McDermott KC, Blomquist JL, Handa VL. Mode of delivery and subsequent fertility. *Hum Reprod*. 2014;29(11):2569–74.
11. Stewart KS, Evans TW. Recurrent bleeding from the lower segment scar—a late complication of Cesarean section. *Br J Obstet Gynaecol*. 1975;82(8):682–6.
12. Morris H. Surgical pathology of the lower uterine segment caesarean sections: is the scar a source of clinical symptoms? *Int J Gynecol Pathol*. 1995;14(1):16–20.
13. Gubbini G, Casadio P, Marra E. Resectoscopic correction of the “isthmocele” in women with postmenstrual abnormal uterine bleeding and secondary infertility. *J Minim Invasive Gynecol*. 2008;15(2):172–5.
14. Chang Y, Tsai EM, Long CY, Lee CL, Kay N. Resectoscopic treatment combined with sonohysterographic evaluation of women with postmenstrual bleeding as a result of previous cesarean delivery scar defects. *Am J Obstet Gynecol*. 2009;200(4):370.e1–4.
15. Borges LM, Scapinelli A, de Baptista Depes D, Lippi UG, Coelho Lopes RG. Findings in patients with postmenstrual spotting with prior cesarean section. *J Minim Invasive Gynecol*. 2010;17(3):361–4.
16. Lin YH, Hwang JL, Seow KM. Endometrial ablation as a treatment for postmenstrual bleeding due to cesarean scar defect. *Int J Gynaecol Obstet*. 2010;111(1):88–9.
17. Gubbini G, Centini G, Nascetti D, Marra E, Moncini I, Bruni L, et al. Surgical hysteroscopic treatment of cesarean-induced isthmocele in restoring fertility: prospective study. *J Minim Invasive Gynecol*. 2011;18(2):234–7.
18. Florio P, Gubbini G, Marra E, Dores D, Nascetti D, Bruni L, et al. A retrospective case-control study comparing hysteroscopic resection versus hormonal modulation in treating menstrual disorders due to isthmocele. *Gynecol Endocrinol*. 2011;27(6):434–8.
19. Uppal T, Lanzarone V, Mongelli M. Sonographically detected cesarean section scar defects and menstrual irregularity. *J Obstet Gynaecol*. 2011;31(5):413–6.
20. Shih CL, Chang YY, Ho M, Lin WC, Wang AM, Lin WC. Hysteroscopic transcervical resection. A straightforward method corrects bleeding related to cesarean section scar defects. *Am J Obstet Gynecol*. 2011;204(3):278.e1–2.
21. Wang CJ, Huang HJ, Chao A, Lin YP, Pan YJ, Horng SG. Challenges in the transvaginal management of abnormal uterine bleeding secondary to cesarean section scar defect. *Eur J Obstet Gynecol Reprod Biol*. 2011;154(2):218–22.
22. Bij de Vaate AJ, van der Voet LF, Naji O, Witmer M, Veersema S, Brölmann HA, et al. Prevalence, potential risk factors for development and symptoms related to the presence of uterine niches following Cesarean section: systematic review. *Ultrasound Obstet Gynecol*. 2014;43(4):372–82.
23. Heller DS. Pathologic basis for abnormal uterine bleeding with organic uterine pathologies. *Menopause*. 2011;18(4):412–5.
24. Rayburn WF, Schwartz WJ 3rd. Refinements in performing a cesarean delivery. *Obstet Gynecol Surv*. 1996;51(7):445–51.
25. Hofmeyr GJ, Mathai M, Shah A, Novikova N. Techniques for caesarean section. *Cochrane Database Syst Rev*. 2008;1:CD004662.
26. Stark M. Clinical evidence that suturing the peritoneum after laparotomy is unnecessary for healing. *World J Surg*. 1993;17(3):419.
27. Fabres C, Aviles G, De La Jara C, Escalona J, Muñoz JF, Mackenna A, et al. The cesarean delivery scar pouch: clinical implications and diagnostic correlation between transvaginal sonography and hysteroscopy. *J Ultrasound Med*. 2003;22(7):695–700.
28. Yazicioglu F, Gökdogan A, Kelekci S, Aygün M, Savan K. Incomplete healing of the uterine incision after caesarean section: is it preventable? *Eur J Obstet Gynecol Reprod Biol*. 2006;124(1):32–6.
29. Hayakawa H, Itakura A, Mitsui T, Okada M, Suzuki M, Tamakoshi K, et al. Methods for myometrium closure and other factors impacting effects on cesarean section scars of the uterine segment detected by the ultrasonography. *Acta Obstet Gynecol Scand*. 2006;85(4):429–34.
30. Wang CB, Chiu WW, Lee CY, Sun YL, Lin YH, Tseng CJ. Cesarean scar defect: correlation between Cesarean section number, defect size, clinical symptoms and uterine position. *Ultrasound Obstet Gynecol*. 2009;34(1):85–9.
31. Osser OV, Jokubkiene L, Valentin L. Cesarean section scar defects: agrément between transvaginal sonographic findings with and without saline contrast enhancement. *Ultrasound Obstet Gynecol*. 2010;35(1):75–83.
32. Donnez O, Jadoul P, Squifflet J, Donnez J. Laparoscopic repair of wide and deep uterine scar dehiscence after cesarean section. *Fertil Steril*. 2008;89(4):974–80.
33. Fernandez E, Fernandez C, Fabres C, Alam VV. Hysteroscopic correction of cesarean section scars in women with abnormal uterine bleeding. *J Am Assoc Gynecol Laparosc*. 1996;3(4, Supplement):S13.

34. Kawakami S, Togashi K, Sagoh T, Kimura I, Noguchi M, Takakura K, et al. Uterine deformity caused by surgery during pregnancy. *J Comput Assist Tomogr.* 1994;18(2):272–4.
35. Reis FM, Cobellis L, Luisi S, Driul L, Florio P, Faletti A, et al. Paracrine/autocrine control of female reproduction. *Gynecol Endocrinol.* 2000;14(6):464–75.
36. Guzeloglu-Kayisli O, Kayisli UA, Taylor HS. The role of growth factors and cytokines during implantation: endocrine and paracrine interactions. *Semin Reprod Med.* 2009;27(1):62–79.
37. Poidevin LO, Bockner VY. A hystero-graphic study of uteri after caesarean section. *J Obstet Gynaecol Br Emp.* 1958;65(2):278–83.
38. Bockner V. Hystero-graphy and ruptured uterus. *J Obstet Gynecol Br Emp.* 1960;67:838–9.
39. Fabres C, Alam V, Balmaceda J, Zegers-Hochschild F, Mackenna A, Fernandez E. Comparison of ultrasonography and hysteroscopy in the diagnosis of intrauterine lesions in infertile women. *J Am Assoc Gynecol Laparosc.* 1998;5(4):375–8.
40. Ofili-Yebovi D, Ben-Nagi J, Sawyer E, Yazbek J, Lee C, Gonzalez J, et al. Deficient lower-segment Cesarean section scars: prevalence and risk factors. *Ultrasound Obstet Gynecol.* 2008;31(1):72–7.
41. Florio P, Filippeschi M, Moncini I, Marra E, Franchini M, Gubbini G. Hysteroscopic treatment of the cesarean-induced isthmocele in restoring infertility. *Curr Opin Obstet Gynecol.* 2012;24(3):180–6.
42. Li C, Tang S, Gao X, Lin W, Han D, Zhai J, et al. Efficacy of combined laparoscopic and hysteroscopic repair of post-cesarean section uterine diverticulum: a retrospective analysis. *Biomed Res Int.* 2016;2016:1765624.
43. Schepker N, Garcia-Rocha GJ, von Versen-Höynck F, Hillemanns P, Schippert C. Clinical diagnosis and therapy of uterine scar defects after caesarean section in non-pregnant women. *Arch Gynecol Obstet.* 2015;291(6):1417–23.
44. Klemm P, Koehler C, Mangler M, Schneider U, Schneider A. Laparoscopic and vaginal repair of uterine scar dehiscence following cesarean section as detected by ultrasound. *J Perinat Med.* 2005;33(4):324–31.
45. Luo L, Niu G, Wang Q, Xie HZ, Yao SZ. Vaginal repair of cesarean section scar diverticula. *J Minim Invasive Gynecol.* 2012;19(4):454–8.
46. Marotta ML, Donnez J, Squifflet J, Jadoul P, Darii N, Donnez O. Laparoscopic repair of post-cesarean section uterine scar defects diagnosed in nonpregnant women. *J Minim Invasive Gynecol.* 2013;20(3):386–91.
47. Dealberti D, Riboni F, Cosma S, Pisani C, Montella F, Saitta S, et al. Feasibility and acceptability of office-based polypectomy with a 16F mini-resectoscope: a multicenter clinical study. *J Minim Invasive Gynecol.* 2016;23(3):418–24.
48. Bettocchi S, Nappi L, Ceci O, Selvaggi L. Office hysteroscopy. *Obstet Gynecol Clin N Am.* 2004;31(3):641–54.
49. Papalampros P, Gambadauro P, Papadopoulos N, Polyzos D, Chapman L, Magos A. The mini-resectoscope: a new instrument for office hysteroscopic surgery. *Acta Obstet Gynecol Scand.* 2009;88(2):227–30.
50. Li C, Guo Y, Liu Y, Cheng J, Zhang W. Hysteroscopic and laparoscopic management of uterine defects on previous cesarean delivery scars. *J Perinat Med.* 2014;42(3):363–70.
51. Ricciardi R, Lanzone A, Tagliaferri V, Di Florio C, Ricciardi L, Selvaggi L, et al. Using a 16-French resectoscope as an alternative device in the treatment of uterine lesions: a randomized controlled trial. *Obstet Gynecol.* 2012;120(1):160–5.
52. Gupta J, Kai J, Middleton L, Pattison H, Gray R, Daniels J, ECLIPSE Trial Collaborative Group. Levonorgestrel intrauterine system versus medical therapy for menorrhagia. *N Engl J Med.* 2013;368(2):128–37.

Part IV

Uro-gynecology



Minimally Invasive Approach in Urogynecology: An Evidence-Based Approach

Tatiana Pfiffer Favero and Kaven Baessler

Introduction

Pelvic organ prolapse is a common condition affecting about 15–30% of parous women in the western world. Although it does not represent a life-threatening condition, it may have a considerable impact on the quality of life [1]. The most significant symptoms are the feeling and/or the observation of vaginal bulging. Obstructed voiding and defecation, dyspareunia, urinary and anal incontinence and pelvic pain are frequently associated complains. Usually there are multiple defects of the pelvic floor support system which has to be taken into consideration when planning a surgical approach.

Minimally invasive techniques in pelvic reconstructive surgery include endoscopic, abdominal and vaginal procedures. The correction of all three compartments, anterior, middle and posterior, as well as hysterectomy, continence procedures and mesh applications can be performed using both approaches.

Commonly performed laparoscopic operations are sacrocolpopexy, hysteropexy, uterosacral ligament fixation, Burch colposuspension and paravaginal repair. Vaginal approaches comprise anterior and posterior vaginal repairs with and without grafts or meshes, sacrospinous and uterosacral ligament fixation. The decision about the most appropriate technique for each patient should include the discussion of whether a hysterectomy will be necessary, potential use of meshes and the need of concomitant continence procedure. Factors to be considered are age of the patient, sexual activity, degree of POP, BMI, occupational heavy lifting, the presence of a levator avulsion, presence of cardiac and other comorbidities and particular patient and surgeon preferences and experience of the responsible surgeon. The shared decision process should be ideally guided by scientific evidence, balanced with the surgeon's skills and patient's preference. Although the clinician is responsible for the most appropriate technique, a joint decision with the patient is certainly recommended in order to adjust the procedure with individual needs and expectations.

Potential advantages of laparoscopic over open abdominal surgery are well known: reduced blood loss, shorter hospital stay and quicker return to activities of daily life, less pain and better aesthetics. Particularly with regard to urogynecologic interventions, it allows a broader and better view of the pelvic anatomy for the placement of prostheses and sutures with maximum

T. P. Favero, M.D. (✉)
Abteilung für Gynäkologie, Helios Mariahilf Klinik
Hamburg, Stader Straße 203C, 21075 Hamburg,
Germany
e-mail: Tatiana.Pfiffer@helios-gesundheit.de

K. Baessler, M.D., Ph.D
Franziskus und St. Joseph Krankenhäuser,
Beckenbodenzentrum, Budapester Straße 15-19,
10787 Berlin, Germany

precision and safety. Furthermore, endoscopic procedures may permit the correction of the three different compartments through a single approach. Nevertheless, there are some relevant particularities, such as altered appearance of anatomy due to pneumoperitoneum and Trendelenburg positioning, challenging orientation, additional difficulties due to fixed visual axis, loss of depth and magnification with 2D projection. Three-dimensional optics and robotic procedures may overcome some of these obstacles. Laparoscopic techniques demand a longer learning curve and training in comparison with other routes and should be performed by experienced professionals.

Anterior Compartment

Anterior vaginal wall prolapse (AWP) is the most common form of female POP, with 81% of prolapse repairs including the anterior vaginal wall [2]. Depending on the site of fascial detachment, cystocele can be central (midline defect of the endopelvic fascia) or lateral (detachment of the pubocervical fascia from the ATFP). A combination of lateral and central defects is also common. Surgical repair should address these defects accordingly although there are no studies that differentiated between cystocele defects and repairs.

Native Tissue Repairs - Anterior Colporrhaphy

The vaginally performed anterior colporrhaphy has been the standard procedure for the correction of anterior compartment prolapses, with moderate to good results. It consists in the opening of the anterior vaginal wall, dissection and plication of the fascia. There are some variations of the technique such as separated or continuous stitches, circular or longitudinal suture, one or two layers, fixation or not at the so-called pericervical ring and suburethral plication (so-called Kelly sutures). Usually, one layer of plication is sufficient, though more than one layer may be required in patients with advanced (stage III and

IV) cystoceles [3]. To minimise the risk of recurrence, the detached fascia should be reattached to the supported vaginal apex. There is no need to excise the excess vaginal skin, which could potentially compromise the required tension-free closure. Furthermore, excessive excision of the vaginal skin might result in vaginal stenosis.

There are no conclusive data about which procedure is the most effective, and many studies do not describe the employed technique in details. Nevertheless, the objective success rate ranges from 37 to 100% [4].

Adequate apical support is crucial in reducing the recurrence rate of cystocele. Eiber et al. demonstrated a reduction of the reoperation rate after 10 years from 20.2% to 11.3% by performing an apical suspension at the time of anterior colporrhaphy [5].

Vaginal Paravaginal Repair

Already in 1909, White referred to the importance of the paravaginal defects in anterior compartment prolapses [6]. DeLancey demonstrated that the dorsal detachment of pubocervical fascia from the arcus tendineus fascia pelvis (ATFP), at or near its lateral attachment, leads to a prolapse of the anterior vaginal wall [7]. Paravaginal defects have been shown to account for 60–80% of anterior compartment prolapse, and its repair offers the chance of a more effective treatment [3].

After opening the vaginal mucosa and dissection until the inferior pubic ramus reaching space of Retzius, the endopelvic fascia is sutured to the *arcus tendineus fasciae pelvis*. The sutures are placed from proximal to distal, 2–3 stitches on both sides. A cystoscopy is mandatory to rule out suture passage through the bladder and to confirm ureteral patency.

The success rates for the vaginal paravaginal repair vary from 67 to 100%; nevertheless significant complications have been reported. In a total from 145 patients, there were 21 major complications, 18 blood transfusions, 1 bilateral ureteric obstruction, 1 retropubic haematoma requiring surgery, long-term lower extremity neuropathy in 2 and 2 vaginal abscesses [8, 9]. Furthermore, it

remains open whether additional apical support procedures account for the high success rates.

Laparoscopic/Robotic Paravaginal Repair

Abdominal paravaginal cystocele repair was described by Richardson in 1976 [10]. Meanwhile the surgical technique of the laparoscopic repair is well developed. However, despite the report of success of 80% [11], there are no conclusive data about the efficacy of this approach. The advantages of this procedure compared to the vaginal route include reduced risk for vaginal shortening, safer attachment under vision and the possibility of performing concomitant laparoscopic procedures such as hysterectomy, sacrocolpopexy and/or Burch colposuspension, without the need for a vaginal incision. Furthermore, the advantages of the laparoscopy compared to the laparotomy are well known, such as improved visualisation, less risk of bleeding and faster recovery. On the other hand, the vaginal route permits the concomitant correction of a central anterior fascial defect. However, a sacrocolpopexy with anterior mesh extension to the bladder neck would also correct a median (pulsion) cystocele [12].

The laparoscopic access follows the standard procedures. The bladder is freed off the pelvic sidewalls by means of blunt and sharp dissection. The space of Retzius is exposed, with special attention to avoid the retropublic venous plexus. The dissection should be performed to expose the posterior border of the symphysis pubis, Cooper's ligaments, the white lines and the bladder neck. The surgeon places a finger in the vagina to guide the suture placement. A nonabsorbable suture is passed through the thickness of the vaginal skin avoiding the epithelium. The suture is then passed through the obturator internus fascia, including the white line. The suture may also be anchored at the ileopectineal ligament [13]. Sutures are placed in an interrupted fashion. This procedure is usually performed on both sides depending on the defects. Closing the perito-

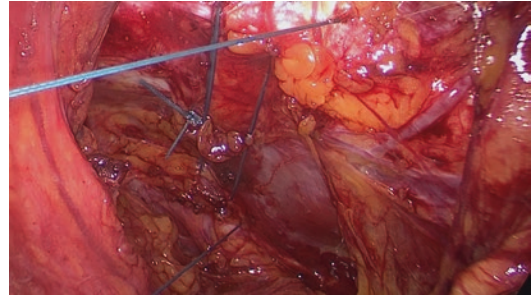


Fig. 17.1 Laparoscopic paravaginal repair: the suture is passed through the obturator internus fascia, including the white line, and then anchored at the ileopectineal ligament. Sutures are placed in an interrupted fashion

neum is not a mandatory step (Figs. 17.1, 17.2, 17.3, and 17.4).

A cystourethroscopy is performed to rule out suture passage through the bladder and to confirm ureteral patency.

The robotic approach is gaining importance; however, little information is available on the efficacy, complications and long-term outcomes.

Anterior Colporrhaphy with Meshes or Grafts

The reinforcement of the anterior vagina wall with grafts has gained importance over the last years. These meshes may be biological or synthetic, and the fixation may be by suturing or anchoring systems. Several studies and meta-analyses demonstrated better anatomical outcomes with mesh augmentation as compared to native tissues repair alone [14, 15]. On the other hand, besides exposures rates, mesh procedures are associated with longer operating times, greater blood loss, higher rates of cystotomy, de novo stress urinary incontinence and prolapse of the apical or posterior vaginal compartment, leading to a higher number of reoperations in comparison with anterior colporrhaphy [14–16]. Patient with levator avulsion have a higher risk for recurrence, which may justify the use of synthetic graft reinforcement [17, 18] (Figs. 17.5 and 17.6).

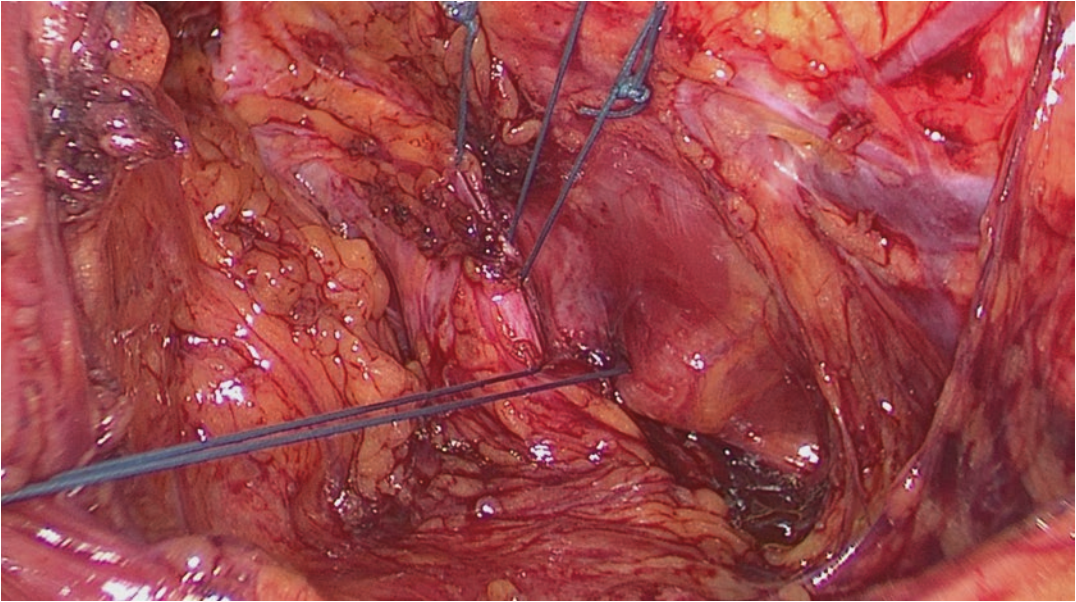


Fig. 17.2 Laparoscopic paravaginal repair: the posterior suture is passed through the obturator internus fascia, including the white line, correcting the paravaginal defect

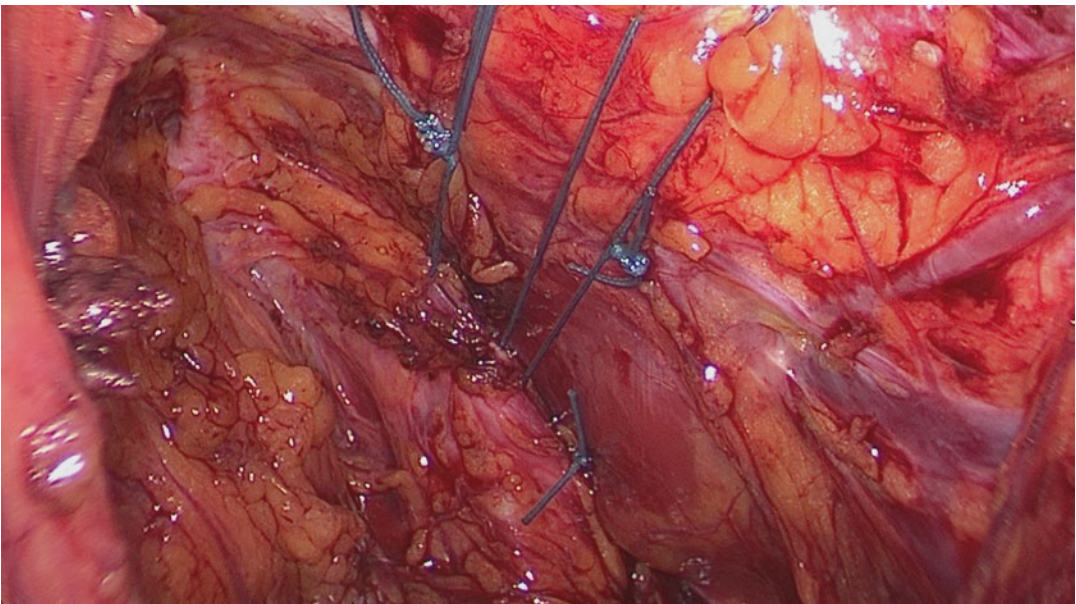


Fig. 17.3 Laparoscopic paravaginal repair, sutures placed on the right side

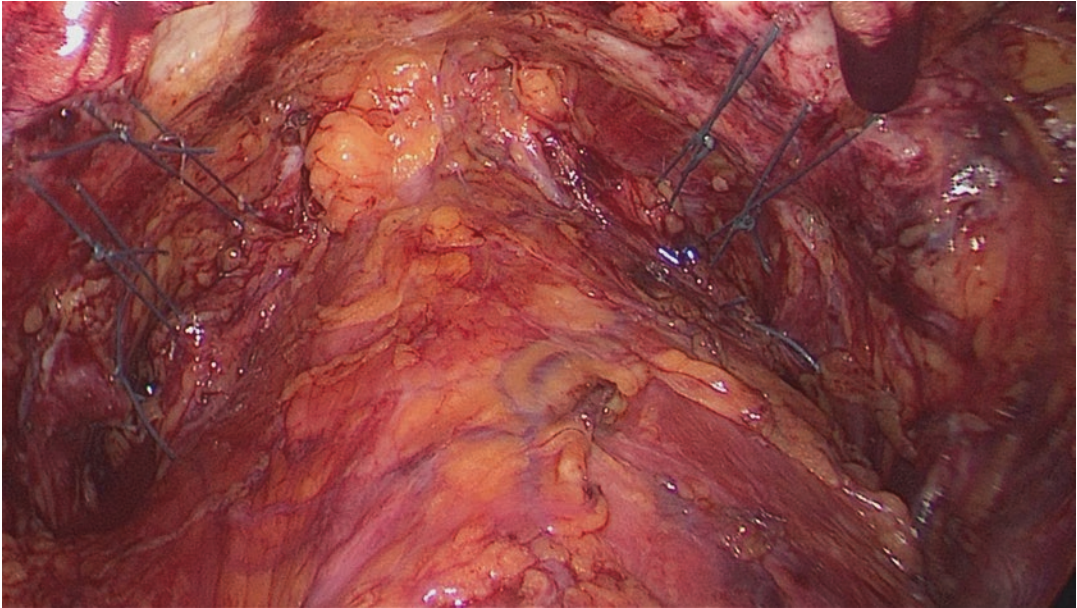
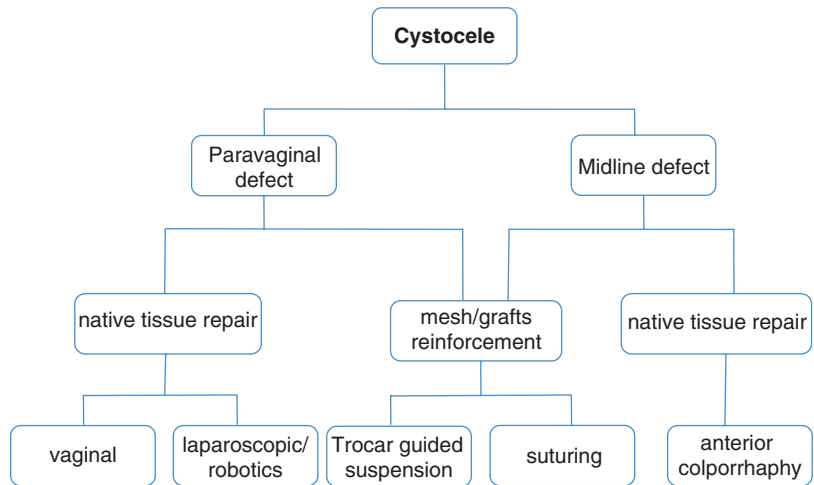


Fig. 17.4 Laparoscopic paravaginal repair final aspect

Fig. 17.5 Surgical approach for the correction of cystocele, based on the underlying defect and considering the available techniques



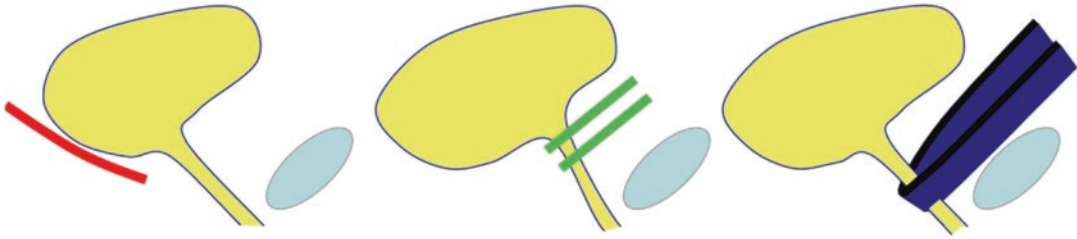


Fig. 17.6 Demonstrates actions of anterior repair, Burch colposuspension and mid-urethral sling on the urethra and bladder neck

Posterior Compartment

The prolapse of the posterior vaginal wall may be due to the herniation of the rectum, colon or small intestine into the lumen of the vagina. These conditions can occur isolated or in combination with each other support defects and will commonly be accompanied by a perineal defect and/or a widened genital hiatus [19]. Common symptoms are dragging sensation, pelvic heaviness, sexual dysfunction including slackness at intercourse and difficult and incomplete rectal emptying at defecation frequently requiring digitation [20]. Although a rectocele is a frequent finding in patients with defecation disorders, there may be several other causes, such as anismus or paradoxical pelvic floor contraction, intussusception and descending perineum syndrome [21]. An interdisciplinary collaboration with coloproctology can be useful, especially if bowel emptying disorders are present without a recognisable rectocele. Data are conflicting regarding the efficacy of posterior vaginal repair on improving defaecatory symptoms, and the association is incompletely understood [22, 23].

Rectoceles can also be associated with perineal insufficiency, which is usually corrected by means of perineorrhaphy. However, no data are available for this operation in the literature. The same is true for a concurrent enterocele, which is frequently corrected by “high peritonealisation” or obliteration of the pouch of Douglas [24].

Anatomic Considerations

The connective tissue between the vagina and the rectum, depending on the anatomical concept, is

referred to as the posterior endopelvic fascia, rectovaginal septum, rectal fascia or vaginal muscularis [24]. The distal support of the posterior vaginal wall, DeLancey level III, is primarily provided by the perineal body [25, 26]. This level of support has strong attachments to the levator ani complex and is thus less susceptible to pelvic pressure transmission that may cause prolapse: it imparts a physical barrier between the vagina and rectum. The puborectalis muscle provides a sling of support, enclosing the genital hiatus.

Disruption of the complex integrity of bony, muscular and connective tissue support may result in posterior vaginal wall prolapse. The surgical repair for posterior vaginal prolapse includes midline plication, site-specific technique, graft/mesh augmentation, transanal repair, ventral rectopexy and sacrocolpopexy in which mesh is extended to the distal portion of the posterior vaginal wall and/or perineum. The suture material ranges from resorbable polyglactin to non-resorbable sutures. The removal of so-called excess vaginal membranes should be more economical to avoid vaginal stenosis [27].

Midline Plication (Traditional Posterior Colporrhaphy)

This technique was introduced in the nineteenth century. Reported anatomic success rates of this technique range from 76 to 96% [19, 28]. The posterior vaginal wall is incised in the midline, and flaps are created by dissecting the underlying fibromuscularis layer off the vaginal epithelium. Plication of the fibromuscularis in the midline then starts proximally towards the hymen, decreasing the width of the posterior

vagina wall and theoretically increasing the strength of this layer.

The plication of the levator ani muscles used to be a frequent step of the posterior colporrhaphy. Although it helps to close the genital hiatus, this is not a normal anatomic position of the levator muscles. This may overly constrict the vaginal calibre and cause post-operative pain and dyspareunia while not improving anatomic outcome. Thus, in general, levator plication is obsolete [19, 28].

Site-Specific Posterior Vaginal Repair

After dissection of epithelium off the underlying connective tissue, the defects in the connective tissue are identified by placing a finger in the rectum. Any presented discrete breaks in the connective tissue are then approximated and closed using interrupted sutures. A midline plication can then be performed over the site-specific repairs, but no levator plication is performed. The correction of the rectovaginal fascia defect allows entrapment of faeces on straining in significant rectocele with 18% post-operatively needing vaginal digitation to defaecate and 18% experiencing post-operative dyspareunia [19, 28]. Furthermore, lower success rates following the discrete site-specific repair (70%) as compared to the midline fascial plication (86%) were described [29].

Graft or Mesh Augmentation of Posterior Vaginal Repair

Graft and mesh augmentations may be performed to reinforce the posterior colporrhaphy or as a substitute for the so-called fascia without the plication of the fascia and may be fixed to the sacrospinous ligament and to the perineum. Although there is variation in the surgical technique, typically, after creating vaginal flaps, the dissection is extended bilaterally to the pelvic sidewall. A midline colporrhaphy or site-specific repair is then typically performed. The graft or mesh is then placed over the repair and anchored along the sidewall. The vaginal epithelium is then closed over the graft or mesh.

Other techniques employ mesh kits with transischio-rectal passage of trocars to attach the mesh through the sacrospinous ligaments. However, there are no data to support any routine use. The posterior intravaginal sling technique was withdrawn because of severe mesh complications mainly related to the multifilament mesh [30].

To date no study has shown any benefit to graft or mesh overlay or augmentation of a vaginal suture repair for posterior vaginal wall prolapse [14, 19, 31]. The use of biological implants has so far shown no advantages compared to posterior vaginal plastic surgery. On the contrary, the posterior plastic was superior to the augmented surgeries and halved the recurrence risk in the meta-analysis with all comparative randomised and non-randomised controlled trials: RR 0.58; 95% CI 0.41–0.84 [11]. Therefore, the use of xenografts (biological implants) is to be dispensed within the posterior compartment due to missing advantages.

Sacrocolpopexy with Extension of Mesh Posteriorly

The technique is a modification of sacrocolpopexy with extension of the posterior mesh down to the distal posterior vaginal wall and/or the perineal body or levator ani muscle on both sides, while correcting a coexisting apical defect. The procedure can be performed through laparoscopic or robotic-assisted routes. The presacral space is opened, and the peritoneal dissection is extended posteriorly from the apex, entering the rectovaginal space. Dissection is continued to the perineal body or levator ani muscle. The mesh is then attached to the posterior vaginal wall distally, levator ani muscle and to the anterior longitudinal ligament of the sacrum in a tension-free fashion. The peritoneum is then typically closed over the mesh, burying it completely. The success rates for rectoceles vary from 45 to 90% [32–35].

While modified abdominal sacrocolpopexy results have been reported, data on how these results would compare to traditional transvaginal repair of posterior vaginal wall prolapse is lacking.

Transanal Repair of Rectocele

Three trials have evaluated transanal versus transvaginal repairs of rectoceles. Each trial had slightly different inclusion criteria. Based on these three trials, we can conclude that the results for transvaginal repair of rectocele are superior to transanal repair of rectocele, in terms of subjective and objective outcomes [16]. Post-operative enterocele was significantly less common following vaginal surgery as compared to the transanal group. Functional outcome based on a modified obstructed defecation syndrome patient questionnaire was better after transperineal repair compared to transanal repair.

Middle Compartment

The apical prolapse is represented not only by uterine or vaginal vault prolapse, but it is also co-responsible for approximately 60% of the bladder prolapse [36, 37]. There is growing recognition that adequate support for the vaginal apex is an essential component of a durable surgical repair for women with advanced prolapse [5].

To correct the apex, there are several good options with relatively high success rates. They can broadly be separated into those performed transvaginally and those performed abdominally. Nowadays, the abdominal approach is gradually being replaced by conventional laparoscopic or even robotically assisted laparoscopic techniques. The apical suspension procedures include both non-mesh (native tissue) procedures and mesh repairs. The individual woman's surgical history and goals, as well as her individual risks for surgical complications, prolapse recurrence and de novo symptoms affect surgical planning and choice of procedure for apical POP.

The surgical repair of defects in the middle compartment (Level 1 according to DeLancey [25]) may be performed as a single operation for uterine or vaginal vault prolapse but may be of particular importance as it frequently supplements the correction in the anterior or posterior compartment.

Sacrospinous Ligament Suspension (SSLS)

This technique was first described in 1958 [38] for vaginal vault prolapse and is one of the most popular and widely reported native tissue transvaginal procedures for correcting apical prolapse. The vaginal apex or uterus may be suspended to the sacrospinous ligament either unilaterally or bilaterally, using an extraperitoneal approach. The fixation can be performed with resorbable and non-resorbable sutures.

The reported apical success rates of unilateral sacrospinous fixation of vaginal vault are between 79 and 97%, on average 92%. Recurrences in the anterior compartment are more common, between 10 and 30%, on average 21%. In the posterior compartment, recurrences occur significantly less frequently, 0–11%, an average of 6% [39, 40].

Unilateral buttock/gluteal pain occurs in 3–15% of patients and typically resolves within 6 weeks after surgery [41]. Although infrequent, serious complications associated with SSLS include life-threatening haemorrhage from sacral or pudendal vascular injury with an overall transfusion rate from 2% [42].

Uterosacral Ligament Suspension (USLS)

The vaginal or laparoscopic sacrouterine ligament fixation consists of the fixation of the vaginal apex or the uterus to the uterosacral ligaments as high as possible using an intraperitoneal surgical approach. The normal vaginal axis is to be restored. McCall's operation also includes obliteration of the pouch of Douglas. Bob Shull proposed a modification where the sutures are transvaginally placed sequentially through the uterosacral ligaments and united with the anterior and posterior vaginal sheaths or vaginal fascia [43].

There are no different anatomical results whether the fixation is performed with resorbable or non-resorbable filaments [39, 41]. However, erosions may vary from 8 to 22% in women who

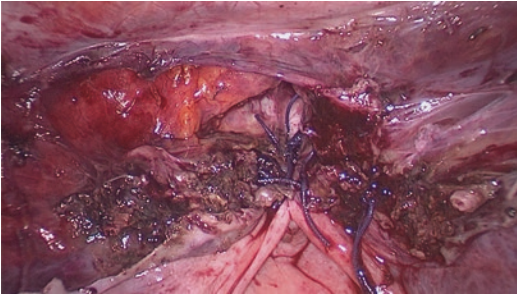


Fig. 17.7 Laparoscopic fixation of the vaginal apex to the uterosacral ligaments with obliteration of the pouch of Douglas

received non-resorbable filaments. Systematic reviews showed an apical success rate ranging from 85 to 98% [44, 45].

The laparoscopic fixation of the vaginal apex to the uterosacral ligaments (Fig. 17.7) has some advantages, such as no use of meshes, less erosion when performing a concomitant total hysterectomy, higher suture position, better visualisation of the ureters (Fig. 17.8), less interaction with radio- or chemotherapy in case of malignancies needing further treatments, potentially less complications when compared to meshes, like erosion, mesh retraction, vaginal discharge, pelvic pain and dyspareunia. Rardin reported a lower ureteral risk of injury (0 vs. 4%) by the laparoscopic procedure in a direct comparison with the vaginal access with simultaneous vaginal hysterectomy [46].

There are some retrospective studies and reviews that have examined the laparoscopic fixation of the uterosacral ligaments after simultaneous hysterectomy, and the reported apical failure rates were between 11 and 13% [46–50]. Despite some promising results, there is still no standard technique for the laparoscopic approach, and the outcomes from vaginal USLS cannot be extrapolated to L-USLS.

An intraoperative cystoscopy is recommended for the detection of disturbed urine passage. Other possible complications include transfusion-requiring bleeding (1.3%), bladder (0.1%) or rectum (0.2%) injury. In addition, nerve entrapment can cause numbness and pain in the area of S2–4 in about 4% of the patients [45].

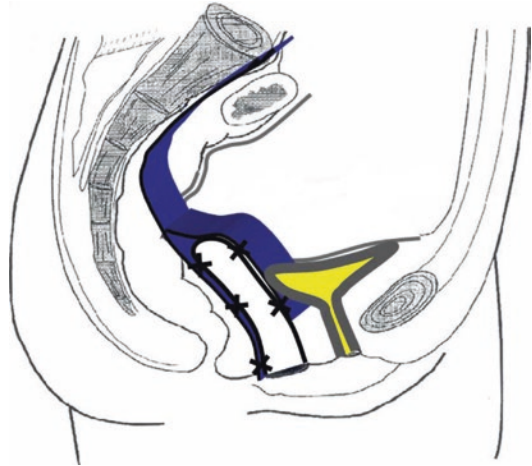


Fig. 17.8 Representation of the sacrocolpopexy

Sacrocolpopexy

Originally, sacrocolpopexy was an operation for the fixation of the vaginal vault. However, it was developed further in order to correct defects in the anterior and/or posterior compartment by placing mesh anteriorly between the vagina and the bladder as well as posteriorly between the vagina and the rectum, possibly down to the levator ani. Traditionally, sacrocolpopexy has been performed via a laparotomy, but the use of minimally invasive approaches, both laparoscopic and robotic, has become the norm over the last decade (Fig. 17.8).

Laparoscopic Sacrocolpopexy (LSC)

The dissection follows three phases: sacral promontory (opening of the retroperitoneum), anterior vaginal wall and rectovaginal septum (posterior vaginal wall). Appropriate sutures are placed to attach the anterior arm of the typically Y-shaped mesh to the anterior vaginal wall and the posterior arm to the posterior vaginal wall. If required, the posterior arm extends to the level of the levator ani muscle or is attached to it on both sides. The proximal end of the mesh is attached to the anterior longitudinal ligament at the promontory or S1 by means of stitches or mechanical suture. A systematic review of studies with original data

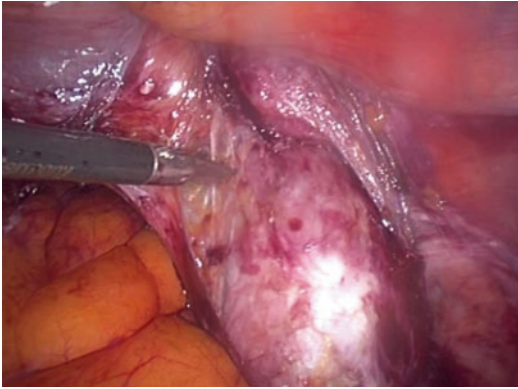


Fig. 17.9 Dissection of anterior vaginal wall: reflection of the bladder down to the bladder neck

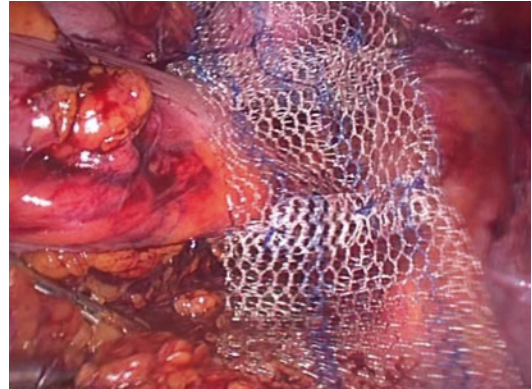


Fig. 17.11 The mesh is attached to the promontory without tension to allow normal mobility of the vagina. In order to achieve a mesh length of at least 17 cm (to allow fixation at the levator ani level and tension-free attachment at the promontory), the mesh pieces had to be sutured together

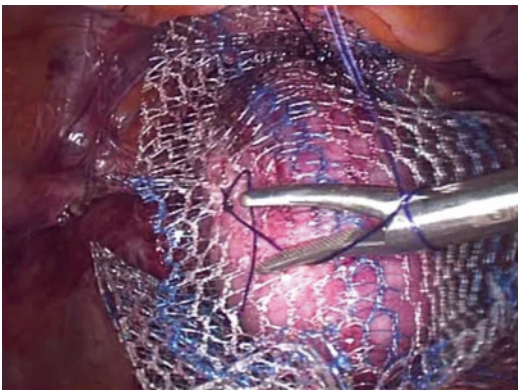


Fig. 17.10 Mesh fixation to the anterior vaginal wall with absorbable sutures (PDS)

showed that a more lower mesh placement at S2–4 does not result in better success rates [51] (Figs. 17.9, 17.10, and 17.11).

The mesh should be retroperitonealised to avoid bowel adhesions and subsequent complications like ileus. The use of type I macroporous monofilament synthetic polypropylene mesh is advised. Biografts and partially absorbable composite meshes (polyglactin + polypropylene) increase the risk of short-term apical and anterior recurrences [52, 53].

The laparoscopic approach of sacrocolpopexy has been adopted by many surgeons over the last decade as an alternative to ASC with the hopes of reproducing the high success rate of the ASC while decreasing the morbidity and delayed recovery

associated with laparotomy. The multiple prospective and retrospective case series demonstrate good short- to mid-term success rates with mean objective success rate of 91% (range 60–100%), subjective success rates of 79–98% and mean reoperation rate of 5.6% [44, 54]. The 2016 Cochrane review concluded that sacrocolpopexy in a direct comparison with vaginal surgeries is associated with lower risk of awareness of prolapse, recurrent prolapse on examination, repeat surgery for prolapse, post-operative SUI and dyspareunia than a variety of vaginal interventions [54].

Many of the open repairs used grafts other than polypropylene, such as polytetrafluoroethylene (Teflon), polyethylene (Mersilene, some Marlex) and silicon-coated polyester, which have been shown to increase risk of mesh exposure, chronic infection and abscess [55].

The chance of erosion increases five times with simultaneous total hysterectomy [44].

Sacrocolpopexy with total hysterectomy is not recommended due to higher erosion rates. Whether a supracervical hysterectomy with subsequent sacrocervicopexy will reduce erosion rates while maintaining excellent anatomical function outcomes remains open. Cases of transcervical net erosions with complete extrusion have been published, and the necessary morcellation of the uterine corpus must be considered.

Robotic Sacrocolpopexy (RSC)

Robotic surgical systems have been developed with the goal of facilitating technically difficult procedures by improving the surgeon's vision, dexterity and ergonomics. Because of the relatively shorter learning curve required for robotic-assisted surgery in comparison with LSC, many surgeons have turned to this route in order to offer patients a minimally invasive approach to sacrocolpopexy. A systematic review of 27 studies including 1488 RSCs found that the robotic approach to sacrocolpopexy is associated with objective cure rates of 84–100% and subjective cure rates of 92–95% with mesh erosion rates of 2% (range 0–8%) [56]. Overall, the post-operative complication rate in this meta-analysis was 11% (range 0–43%) with severe complications occurring in 2%. Conversion to ASC occurred in <1% (range 0–5%). A meta-analysis of six smaller studies found lower blood loss with RSC than LSC (50 vs. 155 mL, $p < 0.001$) but no difference in other complications [56].

Hysteropexy

Despite the fact that POP still represents one of the major indications for hysterectomy, the interest in organ preservation has recently gained popularity. The arguments in favour of uterine preservation are the idea to leave the fascial ring intact, the potential shortening of the operation time and the desire of a woman to maintain her body image and integrity. Moreover, some women want to maintain fertility. Nevertheless, conclusive data about the most adequate technique of hysteropexy regarding fertility, pregnancy and delivery is lacking.

Certainly, candidates for uterine conservation should be carefully selected to decrease the chances of subsequent hysterectomy due to other pathologies, which may be more challenging. Women at increased risk for endometrial, cervical or ovarian cancer and those with a personal history of oestrogen receptor-positive breast cancer, especially those taking tamoxifen, with history of recent postmenopausal bleeding, or other

abnormalities should be advised to have their uterus removed. Higher risk women with hereditary conditions (BRCA mutations, Lynch syndrome) and obesity should also consider hysterectomy with or without salpingo-oophorectomy during prolapse repair. Premenopausal women and those without postmenopausal bleeding have low rates of endometrial pathology. Level 3 evidence reveals low rates of unanticipated pathology (1.8%) and endometrial cancer (0.3%) with no cases of sarcoma identified during laparoscopic supracervical hysterectomy with power morcellation in women with low risk of malignancy and dysplasia undergoing prolapse surgery [11].

Patient with cervical elongation may have an almost 11-fold increased risk of failure of a sacrospinous hysteropexy [57], but success rates are about 96–100% after excluding patients with severe prolapse and performing partial trachelectomy for cervical elongation. Other studies have shown similar high success rates using partial trachelectomy at the time of hysteropexy.

A variety of hysteropexy techniques have been described to treat uterovaginal prolapse. Studies show short-term safety and efficacy with decreased blood loss, shorter operating time and more rapid recovery compared to hysterectomy. Although the quantity and quality of hysteropexy studies is growing, most studies lack controls and contain variable techniques and definitions of success. There are no published RCTs comparing different types of hysteropexy procedures. Hysteropexy procedures can be subdivided into native tissue and mesh repairs [44, 58].

Native Tissue Hysteropexy Procedures

Sacrospinous and uterosacral hysteropexy (vaginal, abdominal or laparoscopic) are the most commonly utilised native tissue procedures that preserve fertility and coital function.

LeFort colpocleisis involves obliteration of the vaginal lumen and is an excellent option for a specific subset of women, especially those with high operative risks and not sexually active.

Manchester procedure is essentially a repair for cervical elongation.

Sacrospinous Hysteropexy

Sacrospinous hysteropexy is performed by attaching the cervix to the sacrospinous ligament using permanent or delayed absorbable suture, with a reported success rate from about 92% [44, 58].

In a direct comparison of vaginal hysterectomy with additional vaginal vault fixation to the uterosacral ligaments and sacrospinous hysteropexy, no significant differences in outcomes were found [11, 44, 58].

Suspension of the Uterus on the Uterosacral Ligaments

Uterosacral hysteropexy involves shortening or plicating the uterosacral ligaments with permanent or absorbable sutures placed vaginally, abdominally or laparoscopically. There are a variety of techniques described, and RCTs and studies with a longer follow-up are still lacking.

Laparoscopic sacral hysteropexy is gaining popularity as a minimally invasive approach to uterine conservation with the potential for increased durability (Figs. 17.12, 17.13, 17.14, and 17.15).

Three retrospective studies evaluated the laparoscopic suspension of the uterus on the sacro-uterine ligaments but with different approaches. Krause et al. [59] and Maher et al. [60] placed the

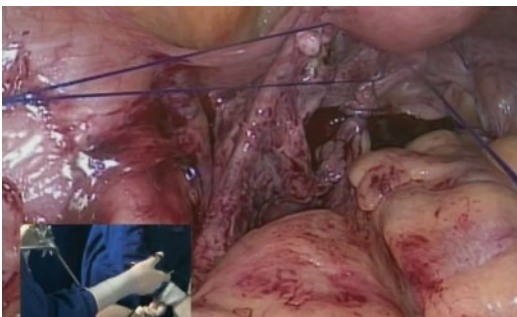


Fig. 17.12 Laparoscopic hysteropexy to the uterosacral ligaments

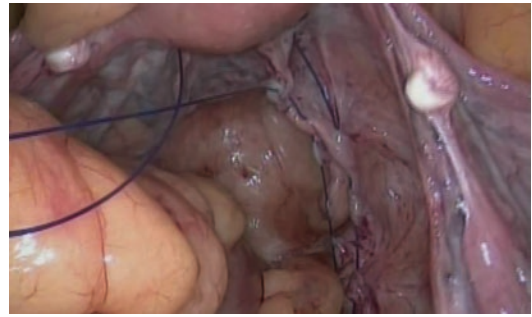


Fig. 17.13 Laparoscopic hysteropexy to the uterosacral ligaments—continuous suture with permanent suture (Prolene®)

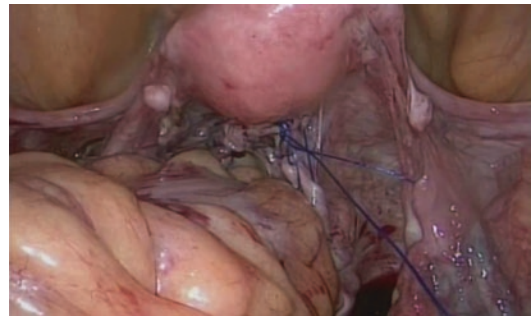


Fig. 17.14 Laparoscopic hysteropexy to the uterosacral ligaments—fixation on the cervix after anchoring the suture on the promontorium

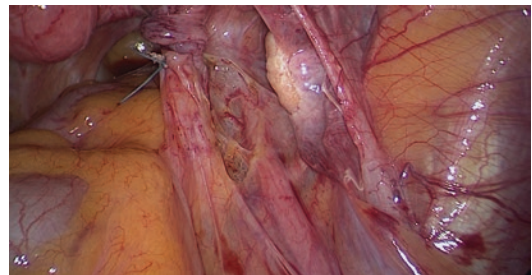


Fig. 17.15 Visualisation of the ureter during the laparoscopic hysteropexy on the uterosacral ligaments

sutures not only right and left through the cervix and the USL but also through the previously prepared anterior longitudinal ligament over the promontory. Uccella et al. [61] performed only the shortening of the USL without incorporating the cervix. These operations achieved subjective success rates between 81 and 88%.

Mesh Hysteropexy Procedures

The mesh hysteropexy may be performed as a vaginal mesh hysteropexy or sacral hysteropexy done abdominally or laparoscopically. There are several techniques and mesh types described for each of these procedures. Vaginal mesh repairs have declined due to concerns regarding mesh risks. The US Food and Drug Administration (FDA) has reclassified vaginal mesh repairs for prolapse from class II, moderate-risk devices, to class III, high-risk devices. Laparoscopic sacral hysteropexy is gaining popularity as a minimally invasive approach to uterine conservation with the potential for increased durability, though long-term data is lacking for this procedure.

Vaginal Mesh Hysteropexy

Vaginal mesh hysteropexy is performed with vaginal placement of mesh into the anterior wall with uterine conservation. In order to be a hysteropexy procedure, a concomitant apical support procedure must be performed such as a sacrospinous or uterosacral ligament suspension. Early anterior mesh kits did not include apical support unless a concomitant posterior mesh kit with apical support was inserted or a separate apical support procedure was performed. These products have been replaced by trocar-less anterior mesh kits that are anchored into the sacrospinous ligament via an anterior approach. The results seem promising, but consistent data are still lacking.

Sacral Hysteropexy

Sacral hysteropexy can be performed via laparotomic, laparoscopic or robotic approach. It typically involves the attachment of at least one graft from the cervix and uterus to the anterior longitudinal ligament near the sacral promontory. A variety of graft materials, configurations and operative techniques have been described. The most common technique involves a single polypropylene mesh strap extending posteriorly from the anterior longitudinal ligament of the sacrum to the uterus. The graft then bifurcates, and the two arms are passed through windows in the

broad ligament and secured to the anterior cervix. The length of graft extension down the anterior and posterior vaginal walls as well as the use of a second mesh strap varies and may explain differences in anterior wall recurrences and development of cervical elongation. Some studies use a single anterior graft attached to the proximal anterior vaginal wall similar to sacrocolpopexy; others anchor the anterior arm to a posterior graft.

The majority of studies compare sacral hysteropexy to hysterectomy and sacrocolpopexy with a few studies using native tissue controls.

Combined analysis reveals no difference in anatomic success rates (84% vs. 90%, $p = 0.06$); however, there were significantly more reoperations for prolapse in the hysteropexy group compared to hysterectomy group (7% vs. 0, $p < 0.01$). There were fewer mesh exposures (0 vs. 7%, $p < 0.01$) for hysteropexy compared to total hysterectomy and no mesh exposures amongst the 30 laparoscopic supra-cervical hysterectomy procedures [11]. Laparoscopic sacral hysteropexy may be reasonable in cases of young women who want to preserve fertility, with severe uterine prolapse. In this case, a single posterior graft without anterior cervical extension is preferred in order to decrease the risk of complications during pregnancy and delivery.

Colpocleisis

Special indications apply to surgical vaginal occlusion with complete or partial (e.g. technique according to LeFort) colpoclepsy because the function of the vagina as a sexual organ is lost. This procedure achieves high success with low morbidity and short operating time in an older population with advanced prolapse and multiple medical comorbidities who do not wish to maintain sexual function of the vagina.

A hysterectomy or a continence procedure (suburethral tape) can be performed simultaneously. Frequently, the plication of levator ani and perineorrhaphy are performed as well.

A systematic review by the American Pelvic Floor Disorders Network in 2006 documented an almost 100% success rate. General complications

(e.g. cerebrovascular and cardiac) occurred in 2% and specific complications (including pyelonephritis and transfusions) in 4% [62]. Colpocleisis is a valid option for the treatment of large genital prolapse, after a careful selection of the patient and an adequate informed consent.

Concomitant Continence Procedures

Genital prolapse and urinary incontinence have similar pathophysiologies and often coexist. About 55% of women with stage II POP have concurrent stress urinary incontinence (SUI). With increasing POP stages, there is a decreasing prevalence to 33% in women with stage IV POP [63]. After reduction of the prolapse, SUI might be demonstrated in 10–80% of otherwise continent women [64]. This occult urinary incontinence may occur due to kinking of the urethra and/or external compression by large prolapse [63].

The prolapse may be reduced digitally or with the help of a pessary, sponge holder or speculum; there is no established gold standard. Neither the speculum nor the pessary test to reduce the prolapse had acceptable positive predictive values to identify women in need of a concomitant continence procedure. The negative predictive values were however 92.5% (95% CI 90.3–1.00) and 91.1% (95% CI 88.5–99.7), respectively [65]. Therefore, women with preoperatively negative tests for occult SUI are at low risk to develop SUI post-operatively. There are no conclusive data that urodynamics may help to predict post-operative SUI.

Women with occult SUI are at risk to develop de novo SUI after POP repair: stress incontinence develops following surgical correction of the prolapse, amongst women who were without incontinence symptoms prior to surgery. The cause might be that POP surgery has unkinked the previously obstructed urethra. The Cochrane review on surgical management of POP found that new SUI symptoms were reported by 434 of 2125 women (20.4%) after prolapse surgery [16]. De

novo SUI is one of the major complaints after surgery, leading to frustration and disappointment. Many women would rather remain with the prolapse than be incontinent.

Preoperative SUI might be treated by prolapse repairs without an additional continence procedure [66].

Whether women with occult SUI should receive an additional continence procedure when the prolapse is repaired and which prolapse operation would be best suitable to prevent symptomatic post-operative SUI remain debatable issues [63].

Accordingly, patients with prolapse may be categorised in three different groups regarding SUI: continent patients, women with SUI and women with occult urinary incontinence.

Continent Women with Genital Prolapse

De novo stress incontinence is reported in 8% of women after surgical treatment of the anterior prolapse in women without prior stress incontinence [63].

As shown in a meta-analysis, anterior vaginal plastic surgery seems to have better results for de novo stress incontinence in comparison with transobturator anterior mesh procedures (RR 0.64 95% CI 0.42–0.97) [63] (Fig. 17.16). However, a study evaluated long-term data after 3 years and then did not notice a significant difference between the operations [67].

A simultaneous Burch colposuspension may be offered additionally in the case of sacrocolpopexy for the prophylaxis of post-operative stress incontinence [68] (Fig. 17.17).

Women with Symptomatic Stress Incontinence and Genital Prolapse

There are a number of options for the surgical treatment of prolapse with concomitant SUI: anterior colporrhaphy or anterior mesh repair,

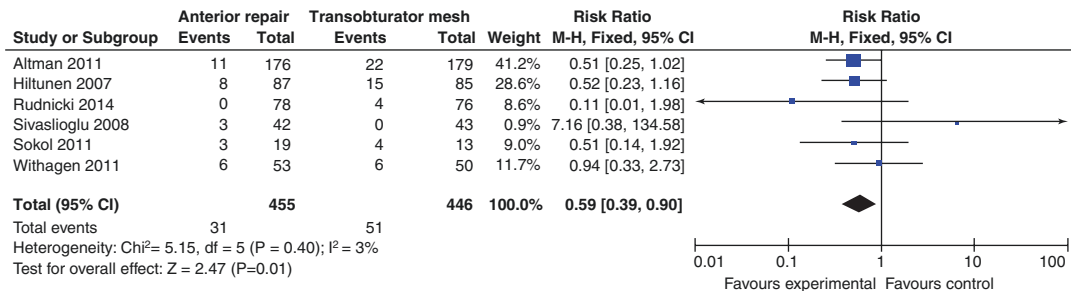


Fig. 17.16 De novo SUI: forest plot of six RCTs comparing anterior repair and transobturator mesh repairs [64]

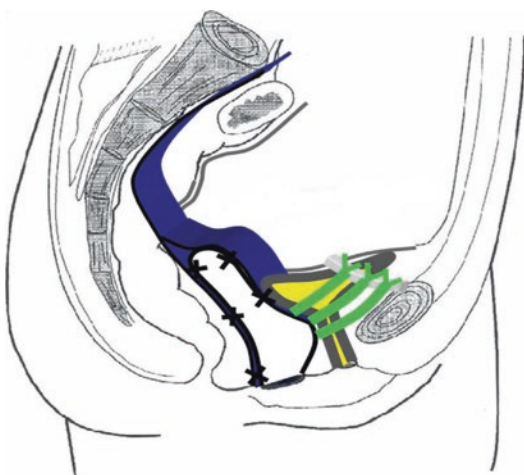


Fig. 17.17 Schematic representation of simultaneous Burch colposuspension and sacrocolpopexy

with or without additional mid-urethral sling, paravaginal repair and sacrocolpopexy with or without Burch colposuspension.

In women with POP and SUI, prolapse procedures alone (anterior repair and transobturator mesh) are associated with low success rates for SUI (48% and 66%, respectively) [63, 66]. Concomitant continence procedures reduce the risk of post-operative SUI.

One recent randomised trial compared vaginal POP repairs with and without an additional mid-urethral tape in incontinent. The concurrent continence procedure significantly increased SUI success rate, a greater number of women in the MUS group reported the absence of SUI

(86% vs. 48%; relative risk (RR) 1.79; 95% confidence interval (CI) 1.29–2.48) [69].

Prospective studies employing transobturator mesh show a cumulative SUI success if a mid-urethral tape is performed concomitantly of 92% [64].

Whether a mid-urethral tape (TVT) is inserted concomitantly or after 3 months did not result in significantly different success rates as demonstrated by Borstad et al. (83/87, 95% vs. 47/53, 89% 3 months later) [70]. However, 27/94 women (29%) were continent after the prolapse surgery and declined the planned TVT operation 3 months later.

Colombo et al. compared Burch colposuspension and anterior repair for the treatment of women with anterior vaginal wall prolapse and SUI and demonstrated that women benefited more from Burch colposuspension with regard to SUI (cure of SUI 30/35, 86% vs. 17/33, 52%), while anterior repair leads to higher success rates regarding the anterior prolapse (cure of cystocele 23/35 vs. 32/33) [66].

Costantini et al. compared whether incontinent women benefit from Burch colposuspension and sacrocolpopexy or sacrohysteropexy [71]. Contrary to all expectations, the post-operative stress incontinence rate increased with simultaneous Burch colposuspension (13/24, 54% vs. 9/23, 39%). The authors explain these results with the surgical technique: the anterior arm of the sacrocolpopexy was led up to the bladder neck and apparently ensured the continuity better than the colposuspension.

A randomised study compared whether a vaginal mid-urethral sling insertion or the Burch colposuspension is more successful during sacrocolpopexy in women with prolapse and stress incontinence. There was no difference in continence rates between both groups. However, the suburethral sling group reported better patient-centred secondary outcomes. This suggests that Burch colposuspension continues to be a viable and effective treatment for SUI for women undergoing laparotomy for other reasons [72].

The conclusion is that in women with POP and SUI, prolapse procedures alone (transobturator mesh and anterior repair) without concomitant suburethral tapes are associated with low success rates for SUI. Concomitant continence procedures reduce the risk of post-operative SUI. The procedure of choice remains debatable.

Women with Occult Stress Incontinence and Genital Prolapse

A suburethral sling insertion performed concurrently with the prolapse operation significantly reduced the incontinence rate post-operatively in women with occult urinary incontinence (RR 3.04, 95% CI 2.12–4.37) (Fig. 17.18) [64]. Besides the possible complications related to the sling insertion, there seems to be no higher risk for associated with concomitant procedures

regarding major adverse effects, prolonged bladder catheterisation or long-term obstructive micturition [64, 69, 73].

Summary: Indications for Continence Surgery at Time of Prolapse Surgery

Women with preoperative SUI and demonstrated occult SUI significantly benefit from concomitant prolapse and continence surgery. Adding a continence procedure in stress urinary incontinent women with POP increases the odds of post-operative continence 11 times (OR 10.9; 95% CI 7.9–15.0); for vaginal repairs + mid-urethral sling OR 15.1 (95% CI 9.6–23.6) and for vaginal mesh placement + MUS OR 11.3 (95% CI 6.3–20.5). In women with occult SUI, additional continence procedures similarly result in better continence rates (OR 9.8; 95% CI 7.1–13.6). The evidence does not support the addition of routine continence surgery at the time of prolapse surgery in symptomatically dry women without positive occult stress testing (OR 1.1; 95% CI 0.8–1.7) [64].

The decision process whether a concomitant procedure to treat the symptomatic or occult stress incontinence must include the patient (“decision-making process”). Complications and the individual circumstances (e.g. chronic asthma, high anaesthetic risk, obesity or severe physical work such as domestic nursing care) must be considered. The simultaneous suburethral sling insertion may be also favourable for a

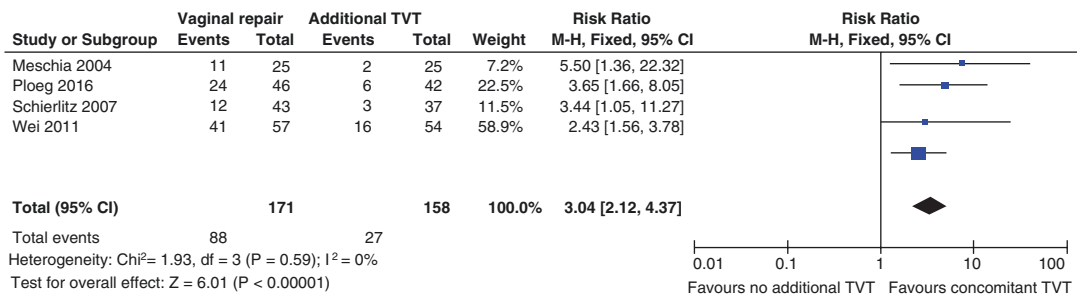


Fig. 17.18 The addition of a mid-urethral sling to vaginal prolapse repairs in women without SUI significantly reduces the risk of post-operative SUI

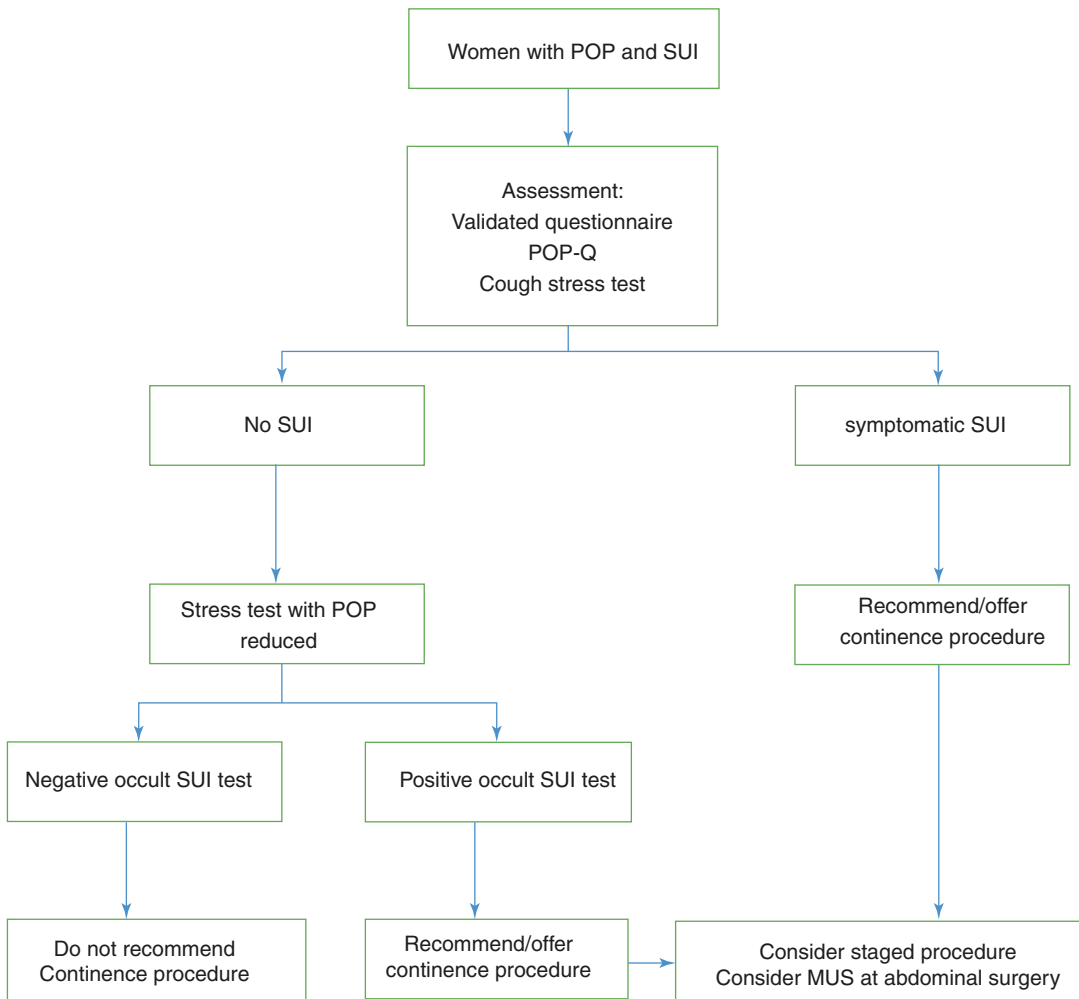


Fig. 17.19 Flow chart of decision-making based on incontinence symptoms and testing for occult SUI as proposed by ICI [64]. Abbreviations: *POP* pelvic organ prolapse, *SUI* stress urinary incontinence, *MUS* mid-urethral sling

woman who is professionally active, in order to avoid a second sick leave with a staged procedure. However, the two-step approach is also scientifically supported by a randomised study with similar success rates [70].

Figure 17.19 is a clinical flow diagram that has been developed to summarise the clinical pathway of women undertaking prolapse surgery based upon continence symptoms and testing for occult stress incontinence.

Conclusion

There is a wide range of minimally invasive procedures in urogynecology, considering that the vaginal approach also applies.

When planning the correction of a cystocele, the presence of a median or paravaginal defect should be noted. The anterior repair is an option for median fascial deficiency and the paravaginal defect correction for lateral suspension defects. The additional securing of

the middle compartment must be taken into account, as otherwise higher recurrence rates are to be expected.

The use of type 1 polypropylene mesh in the anterior compartment reduces recurrence rates, but with the increased risk of complications and reoperations. The patient must be informed about the higher complication and reoperation rates versus better anatomical outcomes. Especially in the case of a large prolapse, recurrent prolapse, comorbidity, levator avulsions and in patients with high expectation regarding safety and anatomical efficacy, the use of the mesh should be discussed. The use of biological materials remains controversial and has not been proven by studies.

The posterior colporrhaphy by means of a transvaginal midline fascial plication without levatorplasty has a superior objective outcomes compared with site-specific posterior repair and less dyspareunia rates than reported when levatorplasty is employed.

Furthermore, the transvaginal approach is superior to the transanal approach for repair of posterior wall prolapse, and there is no proven any benefit of mesh overlay or augmentation of a suture repair for posterior vaginal wall prolapse.

Data on how the results of abdominal sacrocolpopexy would compare with traditional transvaginal repair of posterior vaginal wall prolapse are lacking [19].

The sacrospinous colpopexy, vaginal or laparoscopic fixation at the uterosacral ligament and the laparoscopic or robot-assisted sacrocolpopexy can be used with good evidence to correct a prolapse in the middle

compartment with success rates in the literature of over 90%. The procedure should be chosen together with the patient, taking into account all the findings and symptoms, comorbidities, risk factors, planned total hysterectomy and patient's wishes and expertise.

Biological or resorbable meshes, as well as silicon meshes should be avoided. The higher recurrence of the anterior prolapse must be considered after a sacrospinous colpopexy, as well as a higher risk of ureter lesions during uterosacral ligament fixation.

If there are no uterine pathologies, the patient should be informed of the possibility of uterine-preserving procedures, without compromising the success of the prolapse surgery.

Persistent or de novo stress urinary incontinence is important issues to be discussed with the patient when counselling for a POP operation. Patients with SUI or occult urinary incontinence benefit from a simultaneous continence procedure. The additional risks, as well as the need for a second surgical procedure if POP repair is performed alone have to be taken in account.

During the decision-making process, the evaluation of the surgical or anaesthetic risk, as well as the risk of recurrence, is indispensable. They are to be discussed with the patient, as well as the success rates of the procedures. This permits a joint decision and adjusts the expectations and consequently the satisfaction of the patient about treatment (Fig. 17.20).

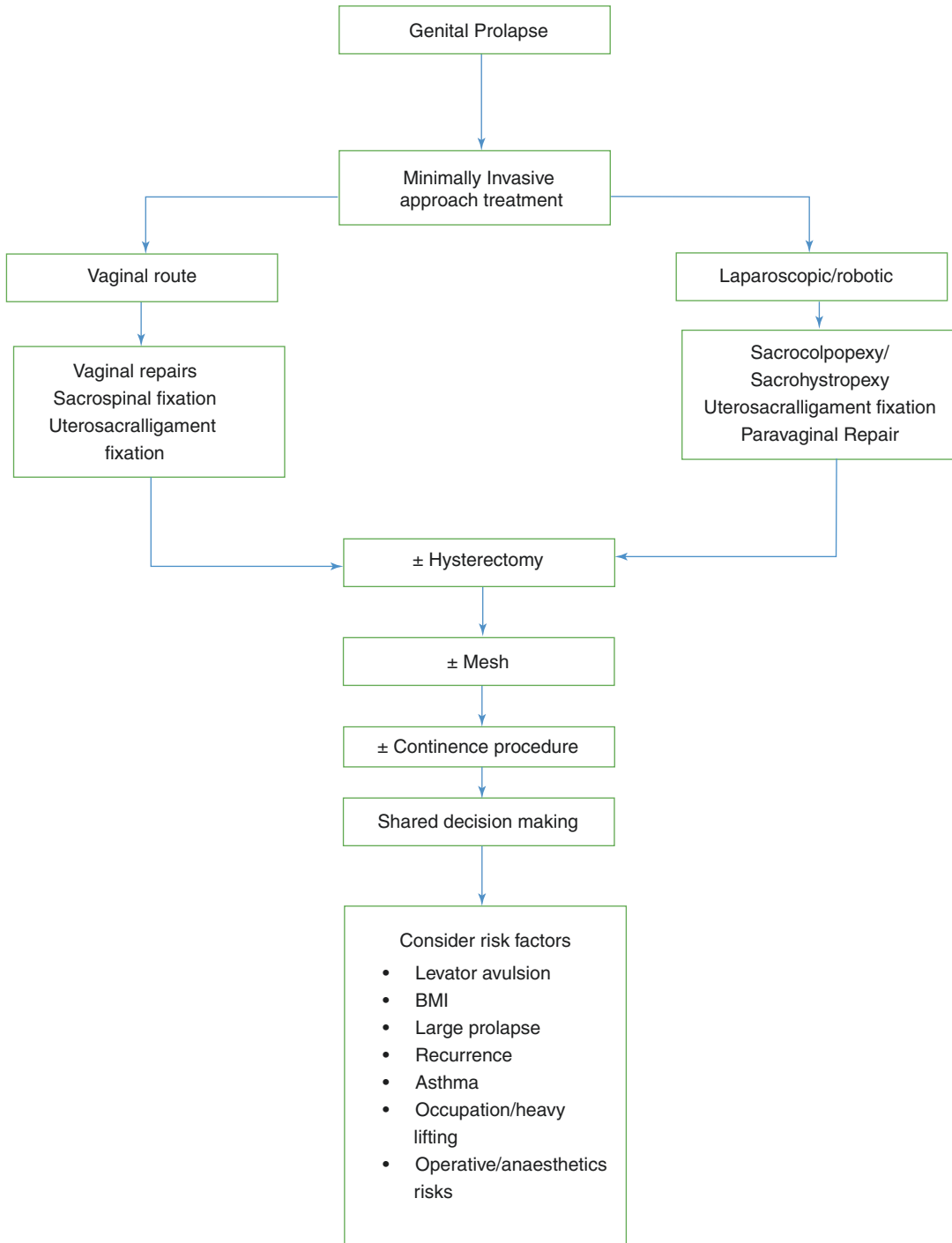


Fig. 17.20 Clinical flow diagram that has been developed to summarise the clinical pathway of women undertaking prolapse surgery

References

1. Sliker-ten Hove MC, et al. The prevalence of pelvic organ prolapse symptoms and signs and their relation with bladder and bowel disorders in a general female population. *Int Urogynecol J Pelvic Floor Dysfunct.* 2009;20(9):1037–45.
2. Olsen AL, et al. Epidemiology of surgically managed pelvic organ prolapse and urinary incontinence. *Obstet Gynecol.* 1997;89(4):501–6.
3. Gamal Mostafa Ghoniem, MD. Cystocele Repair. <http://emedicine.medscape.com/article/1848220-overview>.
4. Maher C, Baessler K. Surgical management of anterior vaginal wall prolapse: an evidence based literature review. *Int Urogynecol J Pelvic Floor Dysfunct.* 2006;17(2):195–201.
5. Eilber KS, et al. Outcomes of vaginal prolapse surgery among female Medicare beneficiaries: the role of apical support. *Obstet Gynecol.* 2013;122(5):981–7.
6. White GR. Cystocele. *JAMA.* 1909;853:1707–10.
7. Chen L, Ashton-Miller JA, DeLancey JO. A 3D finite element model of anterior vaginal wall support to evaluate mechanisms underlying cystocele formation. *J Biomech.* 2009;42(10):1371–7.
8. Mallipeddi PK, et al. Anatomic and functional outcome of vaginal paravaginal repair in the correction of anterior vaginal wall prolapse. *Int Urogynecol J Pelvic Floor Dysfunct.* 2001;12(2):83–8.
9. Young SB, Daman JJ, Bony LG. Vaginal paravaginal repair: one-year outcomes. *Am J Obstet Gynecol.* 2001;185(6):1360–6.
10. Richardson AC, Lyon JB, Williams NL. A new look at pelvic relaxation. *Am J Obstet Gynecol.* 1976;126:568.
11. Baessler et al. Diagnosis and Therapy of Female Pelvic Organ Prolapse. Guideline of the DGGG, SGGG and OEGGG (S2e-Level, AWMF Registry Number 015/006, April 2016). *Geburtshilfe Frauenheilkd.* 2016;76(12):1287–301. doi: 10.1055/s-0042-119648.
12. Chinthakanan O, Miklos JR, Moore RD. Laparoscopic paravaginal defect repair: surgical technique and a literature review. *Surg Technol Int.* 2015;27:173–83.
13. Shull BL, Baden WB. A six-year experience with paravaginal defect repair for stress urinary incontinence. *Am J Obstet Gynecol.* 1989;160:1432–40.
14. Maher C, et al. Transvaginal mesh or grafts compared with native tissue repair for vaginal prolapse. *Cochrane Database Syst Rev.* 2016;2:CD012079.
15. Maher C. Anterior vaginal compartment surgery. *Int Urogynecol J.* 2013;24(11):1791–802.
16. Maher C, et al. Surgical management of pelvic organ prolapse in women. *Cochrane Database Syst Rev.* 2013;4:CD004014.
17. Wong V, et al. Is levator avulsion a predictor of cystocele recurrence following anterior vaginal mesh placement? *Ultrasound Obstet Gynecol.* 2013;42(2):230–4.
18. Wong V, et al. Cystocele recurrence after anterior colporrhaphy with and without mesh use. *Eur J Obstet Gynecol Reprod Biol.* 2014;172:131–5.
19. Karram M, Maher C. Surgery for posterior vaginal wall prolapse. *Int Urogynecol J.* 2013;24(11):1835–41.
20. Weber AM, et al. Posterior vaginal prolapse and bowel function. *Am J Obstet Gynecol.* 1998;179(6 Pt 1):1446–9; discussion 1449–50.
21. Siproudhis L, et al. Defecatory disorders, anorectal and pelvic floor dysfunction: a polygamy? Radiologic and manometric studies in 41 patients. *Int J Color Dis.* 1992;7(2):102–7.
22. Grimes CL, Lukacz ES. Posterior vaginal compartment prolapse and defecatory dysfunction: are they related? *Int Urogynecol J.* 2012;23(5):537–51.
23. Grimes CL, et al. Outcome measures to assess anatomy and function of the posterior vaginal compartment. *Int Urogynecol J.* 2014;25(7):893–9.
24. Baessler K. Enterocoele. In: Cardozo L, Staskin D, editors. *Textbook of female urology and urogynecology.* Boca Raton: CRC Press; 2016. p. 942–53.
25. DeLancey JO. Anatomic aspects of vaginal eversion after hysterectomy. *Am J Obstet Gynecol.* 1992;166(6 Pt 1):1717–24; discussion 1724–8.
26. DeLancey JO. Structural anatomy of the posterior pelvic compartment as it relates to rectocele. *Am J Obstet Gynecol.* 1999;180(4):815–23.
27. Kahn MA, Stanton SL. Posterior colporrhaphy: its effects on bowel and sexual function. *Br J Obstet Gynaecol.* 1997;104(1):82–6.
28. Maher C, Baessler K. Surgical management of posterior vaginal wall prolapse: an evidence-based literature review. *Int Urogynecol J Pelvic Floor Dysfunct.* 2006;17(1):84–8.
29. Abramov Y, et al. Site-specific rectocele repair compared with standard posterior colporrhaphy. *Obstet Gynecol.* 2005;105(2):314–8.
30. Baessler K, et al. Severe mesh complications following intravaginal slingplasty. *Obstet Gynecol.* 2005;106(4):713–6.
31. Paraiso MF, et al. Rectocele repair: a randomized trial of three surgical techniques including graft augmentation. *Am J Obstet Gynecol.* 2006;195(6):1762–71.
32. Villet R, et al. Abdominal approach of rectocele and colpocele. *Ann Chir.* 1993;47(7):626–30.
33. Cundiff GW, et al. Abdominal sacral colpoproxy: a new approach for correction of posterior compartment defects and perineal descent associated with vaginal vault prolapse. *Am J Obstet Gynecol.* 1997;177(6):1345–53; discussion 1353–5.
34. Baessler K, Schuessler B. Abdominal sacrocolpopexy and anatomy and function of the posterior compartment. *Obstet Gynecol.* 2001;97(5 Pt 1):678–84.
35. Baessler K, Stanton SL. Sacrocolpopexy for vault prolapse and rectocele: do concomitant Burch colposuspension and perineal mesh detachment affect the outcome? *Am J Obstet Gynecol.* 2005;192(4):1067–72.
36. Rooney K, et al. Advanced anterior vaginal wall prolapse is highly correlated with apical prolapse. *Am J Obstet Gynecol.* 2006;195(6):1837–40.
37. Hsu Y, et al. Anterior vaginal wall length and degree of anterior compartment prolapse seen on dynamic MRI. *Int Urogynecol J Pelvic Floor Dysfunct.* 2008;19(1):137–42.

38. Sederl J. Surgery in prolapse of a blind-end vagina. *Geburtshilfe Frauenheilkd.* 1958;18(6):824–8.
39. Beer M, Kuhn A. Surgical techniques for vault prolapse: a review of the literature. *Eur J Obstet Gynecol Reprod Biol.* 2005;119(2):144–55.
40. Morgan DM, et al. Heterogeneity in anatomic outcome of sacrospinous ligament fixation for prolapse: a systematic review. *Obstet Gynecol.* 2007;109(6):1424–33.
41. Barber MD, et al. Comparison of 2 transvaginal surgical approaches and perioperative behavioral therapy for apical vaginal prolapse: the OPTIMAL randomized trial. *JAMA.* 2014;311(10):1023–34.
42. Sze EH, Karram MM. Transvaginal repair of vault prolapse: a review. *Obstet Gynecol.* 1997;89(3):466–75.
43. Shull BL, et al. A transvaginal approach to repair of apical and other associated sites of pelvic organ prolapse with uterosacral ligaments. *Am J Obstet Gynecol.* 2000;183(6):1365–73; discussion 1373–4.
44. Barber MD, Maher C. Apical prolapse. *Int Urogynecol J.* 2013;24(11):1815–33.
45. Margulies RU, Rogers MA, Morgan DM. Outcomes of transvaginal uterosacral ligament suspension: systematic review and metaanalysis. *Am J Obstet Gynecol.* 2010;202(2):124–34.
46. Rardin CR, et al. Uterosacral colpopexy at the time of vaginal hysterectomy: comparison of laparoscopic and vaginal approaches. *J Reprod Med.* 2009;54(5):273–80.
47. Diwan A, et al. Laparoscopic uterosacral ligament uterine suspension compared with vaginal hysterectomy with vaginal vault suspension for uterovaginal prolapse. *Int Urogynecol J Pelvic Floor Dysfunct.* 2006;17(1):79–83.
48. Gutman RE, et al. Vaginal and laparoscopic mesh hysteropexy for uterovaginal prolapse: a parallel cohort study. *Am J Obstet Gynecol.* 2016;
49. Bedford ND, et al. Effect of uterine preservation on outcome of laparoscopic uterosacral suspension. *J Minim Invasive Gynecol.* 2013;20(2):172–7.
50. Lin LL, et al. A review of laparoscopic uterine suspension procedures for uterine preservation. *Curr Opin Obstet Gynecol.* 2005;17(5):541–6.
51. Sturm P, Baessler K. Do technical differences during sacrocolpopexy affect the outcome? *Int Urogynecol J.* 2016;27(Suppl 1):S88.
52. Deprest J, et al. Medium term outcome of laparoscopic sacrocolpopexy with xenografts compared to synthetic grafts. *J Urol.* 2009;182(5):2362–8.
53. Granese R, et al. Laparoscopic sacrocolpopexy in the treatment of vaginal vault prolapse: 8 years experience. *Eur J Obstet Gynecol Reprod Biol.* 2009;146(2):227–31.
54. Maher C, et al. Surgery for women with apical vaginal prolapse. *Cochrane Database Syst Rev.* 2016;10:CD012376.
55. Cundiff GW, et al. Risk factors for mesh/suture erosion following sacral colpopexy. *Am J Obstet Gynecol.* 2008;199(6):688.e1–5.
56. Serati M, et al. Robot-assisted sacrocolpopexy for pelvic organ prolapse: a systematic review and meta-analysis of comparative studies. *Eur Urol.* 2014;66(2):303–18.
57. Lin TY, et al. Risk factors for failure of transvaginal sacrospinous uterine suspension in the treatment of uterovaginal prolapse. *J Formos Med Assoc.* 2005;104(4):249–53.
58. Gutman R, Maher C. Uterine-preserving POP surgery. *Int Urogynecol J.* 2013;24(11):1803–13.
59. Krause HG, et al. Laparoscopic sacral suture hysteropexy for uterine prolapse. *Int Urogynecol J Pelvic Floor Dysfunct.* 2006;17(4):378–81.
60. Maher CF, Carey MP, Murray CJ. Laparoscopic suture hysteropexy for uterine prolapse. *Obstet Gynecol.* 2001;97(6):1010–4.
61. Uccella S, et al. Laparoscopic uterosacral ligaments plication for the treatment of uterine prolapse. *Arch Gynecol Obstet.* 2007;276(3):225–9.
62. FitzGerald MP, et al. Colpocleisis: a review. *Int Urogynecol J Pelvic Floor Dysfunct.* 2006;17(3):261–71.
63. Baessler K, Maher C. Pelvic organ prolapse surgery and bladder function. *Int Urogynecol J.* 2013;24(11):1843–52.
64. Maher C, Baessler K, Barber M, Cheon C, Consten E, Cooper K, Deffieux X, Dietz V, Gutman R, van Iersel J, Sung V, DeTayrac R. Pelvic organ prolapse surgery. ICI.
65. Ellstrom Engh AM, et al. Can de novo stress incontinence after anterior wall repair be predicted? *Acta Obstet Gynecol Scand.* 2010;90(5):488–93.
66. Colombo M, et al. Randomised comparison of Burch colposuspension versus anterior colporrhaphy in women with stress urinary incontinence and anterior vaginal wall prolapse. *BJOG.* 2000;107(4):544–51.
67. Nieminen K, et al. Outcomes after anterior vaginal wall repair with mesh: a randomized, controlled trial with a 3 year follow-up. *Am J Obstet Gynecol.* 2010;203(3):235.e1–8.
68. van der Ploeg JM, et al. Prolapse surgery with or without stress incontinence surgery for pelvic organ prolapse: a systematic review and meta-analysis of randomised trials. *BJOG.* 2014;121(5):537–47.
69. van der Ploeg JM, et al. Vaginal prolapse repair with or without a midurethral sling in women with genital prolapse and occult stress urinary incontinence: a randomized trial. *Int Urogynecol J.* 2016;27(7):1029–38.
70. Borstad E, et al. Surgical strategies for women with pelvic organ prolapse and urinary stress incontinence. *Int Urogynecol J.* 2010;21(2):179–86.
71. Costantini E, et al. Burch colposuspension does not provide any additional benefit to pelvic organ prolapse repair in patients with urinary incontinence: a randomized surgical trial. *J Urol.* 2008;180(3):1007–12.
72. Trabuco EC, et al. Burch retropubic urethropexy compared with midurethral sling with concurrent sacrocolpopexy: a randomized controlled trial. *Obstet Gynecol.* 2016;128(4):828–35.
73. Matsuoka PK, et al. Should prophylactic anti-incontinence procedures be performed at the time of prolapse repair? Systematic review. *Int Urogynecol J.* 2015;26(2):187–93.



Urinary Incontinence: Minimally Invasive Techniques and Evidence-Based Results

18

Hemikaa Devakumar and G. Willy Davila

Introduction

Female stress urinary incontinence (SUI), defined as the involuntary leakage of urine on coughing, laughing, sneezing, or physical activity, is a widely prevalent condition that significantly affects women's quality of life [1]. It affects 20–40% of women [2]. By the year 2050, the percentage of women with urinary incontinence will increase 55% from 18.3 to 28.4 million [3]. Estimates for the cost of urinary incontinence (UI) totaled at \$20 billion in 2000 [4]. As our population ages, the demand and cost for treatment of UI have increased. By using surgical rate and population projection estimates, the total number of women undergoing surgical treatment for SUI will increase almost 50% from 210,700 in 2010 to 310,050 in 2050 [5], and the average lifetime risk of undergoing surgery for SUI or pelvic organ prolapse (POP) by the age of 80 is expected to be 20% [6].

Age, trauma of childbirth, prior pelvic surgery or trauma, obesity, postmenopausal status, and pelvic radiation are some of the well-recognized risk factors of SUI [7]. Treatment options for SUI include pelvic floor exercises [8], bladder training, behavioral modification, weight loss, vaginal estrogen in postmenopausal women, support pes-

saries [9, 10], pharmacotherapy, and surgery. Multiple surgeries have been described for the treatment of SUI. Traditional surgeries such as urethropexy, needle bladder neck suspension, and colposuspension were the recommended surgical treatments for SUI. However in 1995, Ulmsten invented the tension-free vaginal tape, which is now considered the gold standard treatment of SUI [11]. Surgical treatments for SUI are considered to be the most effective choice for young healthy women, when comparing cost-effectiveness of treatment options, surgical and nonsurgical [12]. A multicenter randomized controlled trial showed that retropubic mid-urethral sling (MUS) procedures produced superior subjective, objective cures and improvement rates 1 year after surgery compared to pessary and physiotherapy [13, 14].

This chapter will focus on the currently available minimally invasive MUS for SUI and cover the specific strengths and weaknesses of the available MUS approaches.

Continence Mechanism

Interaction of the anatomical and physiological properties of the bladder, urethra, urethral sphincter, and pelvic floor and their coordination by the nervous system contribute to the continence mechanism. There are different theories regarding the pathophysiology of SUI. In a normal

H. Devakumar • G. W. Davila (✉)
Section of Urogynecology and Reconstructive Pelvic Surgery, Cleveland Clinic Florida, Weston, FL, USA
e-mail: davilag@ccf.org

individual at rest, the urethral closure pressure exceeds the intravesical pressure. In a continent woman, any increase in intra-abdominal pressure (physical “stress”) results in an increase in the urethral closure pressure and vesical pressure equally, and there is no leakage. If there is no increase, or a concurrent reduction in the urethral closure pressure during a stress event (e.g., during a cough), this may result in leakage in a woman with SUI. The continence mechanism can be compromised by the weakening of the external urethral sphincter itself or loss of innervation via the pudendal nerve. Traditional surgeries such as the Burch colposuspension and Marshall-Marchetti-Krantz (MMK) procedures aimed at increasing urethral resistance were based on these mechanisms. However more recently the concept that support of the mid-urethra by the pubo-urethral ligaments contributes to the maintenance of continence has been proposed [15]. In 1994, DeLancey put forward a “hammock hypothesis” that combined the concept of sphincter and mid-urethral support [16]. These two theories emphasize mid-urethral support translating to improved urethral closure and continence during stress. The Integral Theory is the basis of the mid-urethral tapes for SUI [17]. The creation of these artificial “neo-ligaments” by mid-urethral tapes was the beginning of minimally invasive surgeries for SUI.

Diagnosis and Examination

Clinical evaluation including history, physical examination, urine analysis, and voiding diary is recommended. The diagnosis of SUI can be reached from the history, use of questionnaires, cough stress test, and urodynamics. It is important to determine the type of UI, whether SUI or urge urinary incontinence, or both (mixed UI). Urodynamic stress incontinence is the involuntary leakage of urine during filling cystometry, associated with an increase in the intra-abdominal pressure, in the absence of a detrusor contraction [1].

An accurate diagnosis of simple SUI does not require performance of urodynamics. However,

urodynamics can help assess SUI severity. As per the value of urodynamic evaluation study, two groups of patients with uncomplicated SUI were evaluated. One group underwent clinical evaluation including post-void residual and cough stress test alone. The other group had the same evaluations with the addition of urodynamics. At the end of 12 months after surgery, there was no difference in symptom improvement between the two groups (77.2% vs. 76.9%) [18]. The American Urological Association has also issued guidelines with respect to preoperative testing in patients planning treatment for SUI.

If a woman has complex SUI, as evidenced by mixed UI symptoms, urinary retention, associated POP, neurogenic problems affecting the pelvic floor, previous failed sling, or other systemic diseases such as diabetes or multiple sclerosis, then urodynamics are recommended prior to any surgical intervention. Many referral centers perform urodynamics to select the most optimal sling for an SUI patient, in order to achieve the highest successful outcome possible, especially if more severe degrees of SUI such as intrinsic sphincteric deficiency (ISD) is suspected (see below).

Treatment Options

Surgical Options for Stress Incontinence

Surgeries can be grouped into sub-urethral slings, retropubic urethropexy, bulking agents, and artificial sphincters. Urethral bulking agents are usually used in patients who cannot tolerate an operative procedure or those who have already had a surgical intervention, and there is a need for better improvement in SUI. Artificial sphincters are used as the last resort and used only if prior surgery has failed.

Retropubic Urethropexy

Elevation and stabilization of the bladder neck and the proximal urethra in a high retropubic position are the foundations of these procedures. The urethra is supported with sutures to either the Cooper’s (iliopectineal) ligament or to the

periosteum of the pubic bone. Sutures, when placed through the Cooper’s ligament, are referred to as the Burch procedure. The MMK procedure involves placement of sutures through the retropubic periosteum. Osteitis pubis was a rare complication associated with the MMK procedure (0.74–2.5%) and has been abandoned. Both these procedures can be done through an open incision as well as laparoscopically. However, these procedures were associated with longer operating times, wound infections, and hematoma. The Cochrane review in 2012 concluded that open Burch colposuspension is effective for SUI in the long term. The overall cure rate is approximately 85–90% in the first year. After 5 years, approximately 70% of patients can expect to be dry [19].

Needle Suspension Procedures

Needle suspension procedures are typically performed through either an abdominal or vaginal approach. A long needle is used to thread sutures from the vagina to the anterior abdominal fascia. Sutures are then looped through the peri-urethral tissue on either sides of the bladder neck, thereby

providing support and achieving continence. Pereyra described the first needle suspension of the bladder neck, and there have been various modifications of the procedure. Raz, Stamey, or Gitte’s are some of the variations of the index procedure based on site of approach, type of suture, or site of attachment of sutures. In the recent Cochrane database review of bladder neck suspension, it was established that these surgeries were inferior to open abdominal urethropexy for the treatment of SUI [20].

Mid-Urethral Slings

A sling is a supportive hammock that is placed under the urethra designed to increase urethral resistance during physical activities. Most slings are fashioned from a synthetic polypropylene mesh strip that is referred to as sub-urethral tape as well. Slings can be pubovaginal at the urethrovesical junction, mid-urethral (either retropubic or transobturator), single-incision, or mini-slings (Fig. 18.1). Mid-urethral slings have become the primary incontinence surgery in current clinical practice. Mesh complications related to the use of kits for prolapse surgeries are not commonly

Three generations Mid-Urethral Slings (MUS)


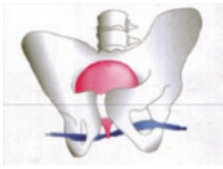


Type of MUS	First Generation TVT (1996)	Second Generation TOT (2001)	Third Generation SIS (2007)
Course of introducer & tape	 through the retropubic space	 through the obturator membrane	 vaginal incision only
Advantages and disadvantages	<ul style="list-style-type: none"> • Risk of bladder injury, bowel and vessel injury 	<ul style="list-style-type: none"> • Lesser voiding difficulty • faster recovery • More groin pain • Risk of obturator nerve and muscle injury 	<ul style="list-style-type: none"> • Avoiding penetration of obturator nerve and the upper leg muscles • Lesser surgical trauma and pain • Faster recovery
Current best tape property: monofilament polypropylene			

Fig. 18.1 Comparison of the three main types of mid-urethral slings

found with mesh slings. The FDA established that mesh slings were safe and effective in 2011.

Retropubic Slings

The FDA approved the use of TVT (tension-free vaginal tape) sling in the United States in 1998. The Gynecare TVT was one of the first retropubic MUS that was hypothesized to address the sub-urethral support mechanism of continence. Since its introduction, it has changed the treatment perspective of patients with SUI and is currently considered the standard of care for SUI treatment. It has several advantages including minimally invasive, vaginal approach, less operating time, and hospital stay. The data available currently also supports long-term and short-term success of these slings. TVT and all commercially available MUS are made of macroporous monofilament (type 1) polypropylene mesh.

This procedure is done by inserting two trocars through the retropubic space from a sub-urethral incision in the vagina to the suprapubic region. Alternatively, trocars can be placed, in a top-to-bottom approach, from the suprapubic region to the vagina. Intraoperative and postoperative complications can occur and must be identified and treated appropriately. The most common complications include bladder perforation. More serious complications include vascular injuries and injuries to the pelvic viscera, hemorrhage, mesh erosion or exposure, de novo urgency and urge incontinence, bladder outlet obstruction, voiding dysfunction, and urinary tract infection [20]. The numbers quoted widely in the literature for bladder perforation are 3–5%, mesh erosion or exposure after TVT 1–3%, and voiding dysfunction 2.1–3.4% [21, 22].

On comparing the outcomes between the two approaches, bottom-to-top and top-to-bottom, for retropubic sling placement, objective cure rates as measured by pad weight (83% vs. 95%; $p < 0.1$; 12% difference, 95% CI: 25.4% to -1.4%) and subjective measured by incontinence impact questionnaires (49.9 ± 25.6 vs. 45.3 ± 18.4 , $p = 0.46$) showed no difference between the two surgical approaches [23]. When comparing adverse events and perioperative complications

of these two approaches, there was no statistical difference. Less women experienced bladder perforation, voiding dysfunction, and tape erosion and exposure when a bottom-to-top approach was used [24].

Transobturator Slings

The other approach used for mid-urethral slings is the transobturator approach. Retropubic slings, during the relatively blind retropubic passage of the trocar, may cause inadvertent bladder perforations along with vascular and bowel injuries. In order to avoid these complications, Delorme described the transobturator technique in 2001, and this was then published by Dargent [25]. There are two different approaches by which specially designed trocars can be passed from either from the inner groin to the vaginal incision (outside-in) or from vaginal incision to inner groin (inside-out). The transobturator technique (TOT) has become very popular especially among gynecologists as it minimizes the risk of bladder, vascular, and bowel injuries. The rates of bladder perforation are 0.3%, and there is a lesser incidence of hematomas and voiding dysfunction [26]. The main complication associated with the transobturator approach is groin pain. The incidence is between 10 and 15%, mainly with the inside-out approach. The incidence of sexual dysfunction with pain in the female or both partners is seen in the transobturator approach more frequently than in the retropubic approach. However this complication is not observed widely [27].

Two meta-analyses assessed the TOT placement techniques: inside-out and outside-in [19, 28]. There were no significant differences in the subjective or objective cure rates between the two groups. Postoperatively, the incidence of de novo urgency or voiding difficulty was not different between the two groups. In a randomized controlled trial, no differences in outcomes were noted, but the outside-in technique was associated with more vaginal sulcus tears [29]. The inside-out technique was associated with fewer vaginal fornix injuries but at a higher rate of postoperative groin pain [30].

In a Cochrane review of randomized controlled trials comparing the retropubic versus transobturator route, including 36 trials with a total of 5514 subjects, there were no statistically significant differences in the short-term (12–36 months) subjective cure rates between the two groups [relative risk (RR) 0.98, 95% CI 0.96–1.00]. The short-term cure rates ranged from 62 to 98% for transobturator versus 71 to 97% for retropubic route. The mean short-term subjective cure rate across both groups was 83.3%. Four trials with a total of 714 women reported long-term results for subjective cure after 5 years. The long-term subjective cure rates ranged from 43 to 92% in the transobturator group and from 51 to 88% in the retropubic group. There was no statistical difference between the groups (RR 0.95, 95% CI 0.80–1.12). The mean long-term subjective cure rates in both groups were 84.3%. When looking at objective cure rates in the short and long term, as assessed by pad weights, urodynamics, and cough stress test, there was also no difference. The cure rate for obturator was 85.7% versus 87.2% for retropubic route [24].

Long-term follow-up after TVT has shown that mid-urethral slings are safe and effective even 11 years after placement [31]. Their cohort showed 77% subjective cure rate and 90% objective cure rates. The Cochrane library in 2009 published a meta-analysis of sling surgeries for SUI [26]. Sixty-two randomized studies involving 7101 women were included. Short-term cure rates for retropubic slings were between 73 and 82%. When comparing TVT versus Burch procedures, there was no significant difference in objective cure rates [odds ratio (OR), 1.18; 95% CI 0.73–1.89]. However, when mid-urethral slings (TVT and transobturator tape (TOT)) were compared to Burch procedures, lower rates of adverse events such as blood loss, pain, time under anesthesia, hospital stay, infection, hematoma, and bowel injuries were noted [27]. For subjective cure, when including all slings (TVT and TOT), the combined OR showed no significant difference but favorable to slings versus Burch procedure (OR, 1.12; 95% CI, 0.79–1.60) [27]. A Burch procedure results in lower rates of return to surgery for erosion, bladder outlet

obstruction, overactive bladder symptoms, and groin pain—as no mesh is used. Studies comparing retropubic slings with open Burch colposuspension have shown similar cure rates with open Burch colposuspension and TVT [19, 28].

Evidence from 20 trials comparing open Burch with mid-urethral slings (TVT or transobturator tape) found no significant difference in incontinence rates. In comparison with needle suspension, there was a lower rate of incontinence after colposuspension in the first year after surgery (RR 0.66; 95% CI 0.42–1.03), after the first year (RR 0.48; 95% CI 0.33–0.71), and beyond 5 years (RR 0.32, 95% CI 0.15–0.71) [19]. The TOMUS trial, the largest randomized controlled trial comparing retropubic and transobturator slings, showed that subjective and objective cure rates after retropubic slings were 62% and 81%, respectively. The objective cure was only 3% better than TOT, which was not statistically significant [21].

Besides differences in complication rates, retropubic and TO slings have been shown to differ in effectiveness in more complex SUI cases, such as recurrent SUI and intrinsic sphincteric deficiency.

ISD and Recurrent Incontinence

In the literature, ISD, more severe SUI, has been defined based on urodynamic findings of Valsalva leak point pressures less than 60 cm of H₂O or maximal urethral closure pressure of less than 20 cm of H₂O. This can or not be associated with urethral hypermobility. Urethral hypermobility is the downward displacement of the urethra with a maximal straining angle $\geq 30^\circ$ from the horizontal plane with Valsalva [32]. Women with ISD have more severe incontinence, are at a higher risk of treatment failure, and are difficult to treat.

Autologous fascial slings have been historically used to treat ISD. But now the newer minimally invasive slings are widely used for the treatment of ISD. In a study comparing retropubic route with transobturator route for the treatment of ISD, with a follow-up of 36 months, the subjective cure rates for TVT was 98.6% versus

TOT at 80%. At 3 years, 20% of women in the TVT group underwent repeat surgery, whereas 45% of women in the TOT group had repeat surgery ($p = 0.004$) [33]. The presence of hypermobility may be a predictor for success with mid-urethral slings in patients with ISD. In a group of 49 women treated with TVT for ISD, the cure rate was 74% and improvement in 12% [34]. Of the seven failures, five had fixed urethras. Although these numbers are small, the authors suggest that lack of hypermobility maybe a risk factor for failure. We have noted that cure rates are higher with primary slings as compared to repeat slings in women with ISD (81% vs. 55%, $p < 0.0001$) (Fig. 18.2). Repeat slings were 3.4 times more likely to fail (OR = 3.43, 95% confidence interval (CI) 2.1–5.6). Prior incontinence procedures, a positive supine stress test, and transobturator slings were independent risk

factors for failure. Among the types of repeat slings placed (transobturator, retropubic, tensioned pubovaginal), pubovaginal slings were most successful (OR = 2.7, 95% CI 1.4–5.2) [35]. In a systematic review, a total of 8 trials were included with 399 women. There was a statistically significant difference in short- and medium-term (≤ 5 years) subjective cure rates, with 150 out of 199 in the transobturator and 171 out of 200 in the retropubic group reporting cure. The relative risk reduction in achieving a cure with transobturator tape was 12% (RR 0.88, 95% CI 0.80–0.96). There was no statistically significant objective difference. However the long-term need to undergo repeat incontinence surgery (≥ 5 years) was higher with the transobturator group (RR 14.4, 95% CI 1.95–106, 147 women). The authors concluded that the retropubic route demonstrated higher subjective cure rates compared with the

	Repeat sling <i>n</i> = 80	Primary sling <i>n</i> = 557	<i>p</i> -value
PRIMARY OUTCOME : CURE*	44(55)	453(81)	<0.0001
No subjective SUI/mixed Incontinence	60(75)	474(85)	0.03
Self-assessment/cured	43(54)	376(68)	0.02
Incontinent episodes/day	1.38 ± 1.6	1.02 ± 1.6	0.02
• 0 Incontinence/Day— “Completely Dry”	40(50)	355(64)	0.02
Pad usage/day	1.18 ± 1.2	0.85 ± 1.1	0.01
• 0 Pad/Day—“Completely Dry”	36(45)	336(60)	0.01
Positive supine stress test	4(1.9)	8(1.4)	0.03
Re-intervention for SUI	24(30)	48(9)	<0.0001

Fig. 18.2 Outcomes of primary vs. repeat slings for severe SUI

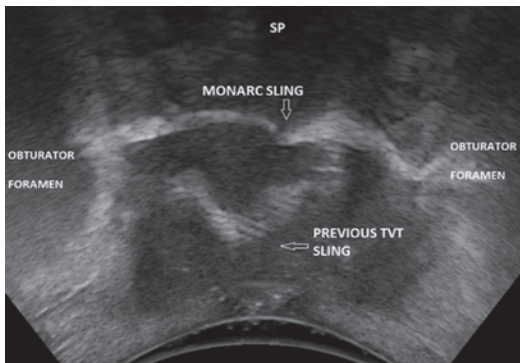


Fig. 18.3 3D ultrasound view of mid-urethral slings with a “U-shaped” TVT and flat configuration TO sling in a patient who had undergone both

transobturator routes in women with ISD [36]. This may be due to a more compressive effect of the retropubic sling on the urethra, as compared to a supportive horizontal support platform resulting from a TO sling (Fig. 18.3).

Single-Incision Slings

Single-incision or mini-slings were intended to reduce the degree of vaginal dissection and to reduce the need to make additional suprapubic or groin incisions. They were designed to reduce the operative time and use of anesthesia and possibly place these slings in the office setting. Single-incision slings are anchored into the obturator internus fascia or connective tissue of the endopelvic fascia of the retropubic space behind the pubic bone, depending on the approach chosen. The complications that occur are similar to those associated with retropubic or transobturator slings.

The difference between the different single-incision slings is based on how effectively the fixation system or anchors hold the tape in place. Slings that include a fixation system or anchor are MiniArc, CureMesh, Ajust, Contasure Needleless, and Tissue Fixation Systems. Those that do not include a fixation system or anchor are TVT-Secur and Ophira. The TVT-Secur, which does not have a fixation system, has been shown to be inferior compared to both inside-out transobturator and retropubic slings in achieving cure rates and higher adverse events. The lack of

a tissue fixation system may have been a contributor [37]. This sling has been withdrawn from clinical use.

Compared with transobturator and retropubic slings, the outcomes of mini-slings are reported to be more variable. Their cure rates are comparable [38–40]. In a meta-analysis involving 758 women, the subjective and objective cure rates were shown to be inferior for single-incision slings relative to transobturator and retropubic slings. The need for repeat surgery for SUI in patients with prior mini-slings was significantly greater (RR 6.72, 95% CI 2.39–18.89), and there was increased de novo urgency (RR 2.08, 95% CI 1.01–4.28). Shorter operative times and lower pain scores were noted [41]. We have noted that when comparing a single-incision sling with transobturator sling, there was no statistically significant difference in objective efficacy at 1 year. However, the transobturator sling had a significantly longer operative time (10.7 ± 4.8 min vs. 7.8 ± 4.9 min, $p < 0.001$) and greater blood loss (31.6 ± 26.6 L vs. 22.9 ± 22.1 mL, $p = 0.02$) [42]. More long-term data regarding success and safety is required.

Autologous Fascial Slings

An alternative to synthetic mesh is using autologous native tissue, fashioned as a sling to provide urethral support. The use of rectus fascia, fascia lata, or vaginal wall dates back by more than 80 years. Fascial slings are commonly used for treatment of recurrent SUI after a synthetic sling or in women who have had a complication after a synthetic sling. In a randomized controlled trial of 655 women with SUI randomized to rectus fascia sling or Burch colposuspension, success rates were higher for women who underwent the sling surgery at 24 months (47% vs. 38%, $p = 0.01$). However more women who underwent the sling procedure had urinary tract infections, voiding difficulty, and de novo urge incontinence [43]. In a systematic review of SUI surgeries, retropubic and autologous fascial slings had similar efficacy, although fascial slings had more voiding problems after surgery [44]. However, this cannot be considered a minimally invasive approach as it involves an incision approximately 7–8 cm

in the abdomen or two thigh incisions for the harvest of the fascial strip, thereby increasing the risks of infection, bleeding, operating time, harvest-site pain, and hospital stay. Voiding dysfunction, de novo urgency, and hernia formation at the site of the harvest are some of the long-term complications of this procedure. The Cochrane review from 2011 with 26 trials involving 2284 women showed that fascial slings are as effective as minimally invasive mid-urethral slings but with higher rates of voiding dysfunction and de novo urgency [45, 46]. As many women are shying away from mesh surgeries, the fascial slings may find resurgence.

Options to Slings

Women who do not wish an operative approach to their SUI, or are poor surgical candidates, have other options to be considered. Bulking agents are injectable materials designed to increase urethral resistance by producing coaptation of the urethral mucosa. These procedures can be performed in the office setting under local anesthesia and have greatest utility in mild SUI and as salvage therapy for persistent SUI after a sling procedure. Stem cell injections are currently being studied internationally for SUI. Data has been promising, but many factors are still unresolved such as source of the stem cells, volume and number of cells to be injected, and who optimal candidates may be. Novel approaches using radio-frequency and laser therapy for SUI are being studied. Early reports have shown promise, but studies are not controlled, and objective outcome measures not used. Office therapy for SUI is certainly very attractive for clinicians and patients, but to date no technique has been studied widely, and is as effective as the proven MUS.

Conclusions

As our population ages, the prevalence of SUI will increase. Women with this condition experience a significant decrease in their

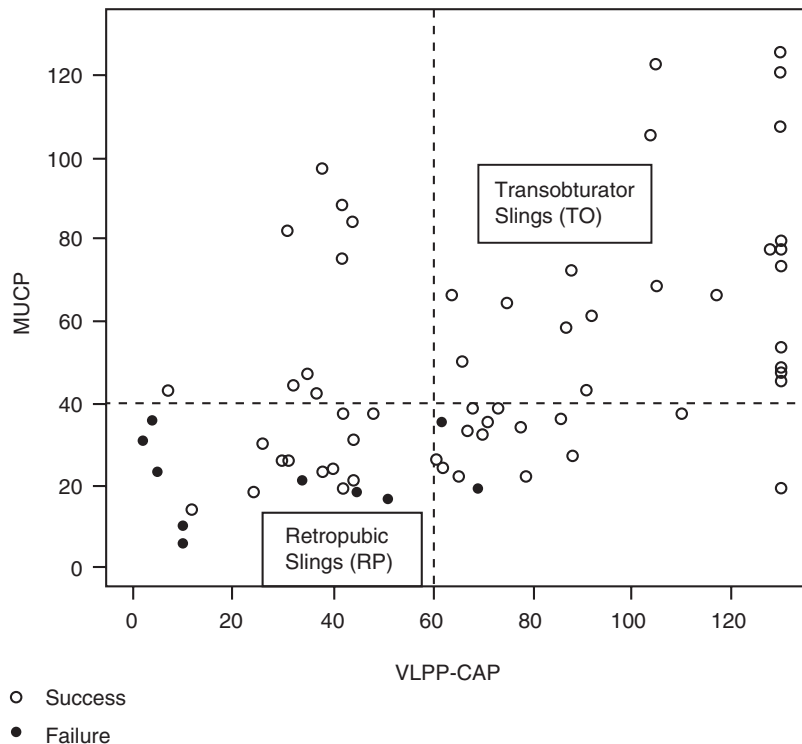
quality of life. As shown by different studies and cost analysis, surgical interventions are cost-effective. The treatment for SUI has come a long way from inpatient laparotomies to office-based minimally invasive sling surgeries.

Irrespective of the route of surgery, mid-urethral slings are highly effective in short term with a growing body of evidence demonstrating their long-term effectiveness. There is moderate quality of evidence that retropubic and transobturator tapes have comparable effectiveness and cure rates on incontinence. Excepting a twofold increase in groin pain with transobturator approach has lower incidence of adverse events. The retropubic approach has an eightfold increase in the incidence of bladder perforations and twofold increase of voiding dysfunction. Both methods comparably improve the quality of life and sexual function in women. At our center, we utilize urodynamic parameters in order to select the most appropriate approach for each SUI patient and focus on statistically demonstrable differences between TO and RP sling success rates when SUI severity is assessed [47] (Fig. 18.4).

Although all these surgeries are geared toward correcting and repositioning the weakened anterior pelvic anatomy, there has been promising research with skeletal muscle-derived stem cells in fashioning a stronger urethral sphincter. Well-designed clinical trials that are relevant to women, especially incorporating quality of life, sexual function, and long-term implications, should be performed.

The mid-urethral sling is currently under legal fire due its mesh construction. As urogynecologic surgeons, it is important for us to help emphasize the evidence-based proven utility of these techniques for our patients suffering from SUI [48].

Fig. 18.4 Recommended selection of TO or RP slings according to urodynamic (UPP and LPP) parameters



References

- Haylen BT, de Ridder D, Freeman RM, Swift SE, Berghmans B, Lee J, et al. An International Urogynecological Association (IUGA)/International Continence Society (ICS) joint report on the terminology for female pelvic floor dysfunction. *Int Urogynecol J*. 2010;21(1):5–26.
- Solans-Domenech M, Sanchez E, Espuna-Pons M, Pelvic Floor Research G. Urinary and anal incontinence during pregnancy and postpartum: incidence, severity, and risk factors. *Obstet Gynecol*. 2010;115(3):618–28.
- JM W, Hundley AF, Fulton RG, Myers ER. Forecasting the prevalence of pelvic floor disorders in U.S. Women: 2010 to 2050. *Obstet Gynecol*. 2009;114(6):1278–83.
- Wilson L, Brown JS, Shin GP, Luc KO, Subak LL. Annual direct cost of urinary incontinence. *Obstet Gynecol*. 2001;98(3):398–406.
- Wu JM, Kawasaki A, Hundley AF, Dieter AA, Myers ER, Sung VW. Predicting the number of women who will undergo incontinence and prolapse surgery, 2010 to 2050. *Am J Obstet Gynecol*. 2011;205(3):230.e1–5.
- JM W, Matthews CA, Conover MM, Pate V, Jonsson Funk M. Lifetime risk of stress urinary incontinence or pelvic organ prolapse surgery. *Obstet Gynecol*. 2014;123(6):1201–6.
- Stothers L, Friedman B. Risk factors for the development of stress urinary incontinence in women. *Curr Urol Rep*. 2011;12(5):363–9.
- Dumoulin C, Hay-Smith J. Pelvic floor muscle training versus no treatment, or inactive control treatments, for urinary incontinence in women. *Cochrane Database Syst Rev*. 2010;1:CD005654.
- Davila GW. Intra bladder neck support prosthesis: a nonsurgical urethropexy. *J Endourol*. 1996;10(3):293–6.
- Davila GW, Kondo A. Intra bladder neck support prosthesis: international clinical experience. *Int Urogynecol J Pelvic Floor Dysfunct*. 1997;8(5):301–6.
- Ulmsten U, Henriksson L, Johnson P, Varhos G. An ambulatory surgical procedure under local anesthesia for treatment of female urinary incontinence. *Int Urogynecol J Pelvic Floor Dysfunct*. 1996;7(2):81–5; discussion 5–6.
- Von Barga E, Patterson D. Cost utility of the treatment of stress urinary incontinence. *Female Pelvic Med Reconstr Surg*. 2015;21(3):150–3.
- Labrie J, Berghmans BL, Fischer K, Milani AL, van der Wijk I, Smalbraak DJ, et al. Surgery versus physiotherapy for stress urinary incontinence. *N Engl J Med*. 2013;369(12):1124–33.
- Richardson ML, Sokol ER. A cost-effectiveness analysis of conservative versus surgical management for the initial treatment of stress urinary incontinence. *Am J Obstet Gynecol*. 2014;211(5):565.e1–6.

15. Petros PE, Ulmsten UI. An integral theory and its method for the diagnosis and management of female urinary incontinence. *Scand J Urol Nephrol Suppl.* 1993;153:1–93.
16. DeLancey JO. Structural support of the urethra as it relates to stress urinary incontinence: the hammock hypothesis. *Am J Obstet Gynecol.* 1994;170(6):1713–20; discussion 20–3.
17. Petros PE, Ulmsten UI. An integral theory of female urinary incontinence. Experimental and clinical considerations. *Acta Obstet Gynecol Scand Suppl.* 1990; 153:7–31.
18. Nager CW, Brubaker L, Litman HJ, Zyczynski HM, Varner RE, Amundsen C, et al. A randomized trial of urodynamic testing before stress-incontinence surgery. *N Engl J Med.* 2012;366(21):1987–97.
19. Lapitan MC, Cody JD. Open retropubic colposuspension for urinary incontinence in women. *Cochrane Database Syst Rev.* 2012;6:CD002912.
20. Glazener, Cooper K. Bladder neck needle suspension for urinary incontinence in women. *Cochrane Database Syst Rev.* 2014;17(12):CD003636.
21. Richter HE, Albo ME, Zyczynski HM, Kenton K, Norton PA, Sirls LT, et al. Retropubic versus transob-
turator midurethral slings for stress incontinence. *N Engl J Med.* 2010;362(22):2066–76.
22. Brubaker L, Norton PA, Albo ME, Chai TC, Dandreo KJ, Lloyd KL, et al. Adverse events over two years after retropubic or transobturator midurethral sling surgery: findings from the Trial of Midurethral Slings (TOMUS) study. *Am J Obstet Gynecol.* 2011;205(5):498.e1–6.
23. Andonian S, Chen T, St-Denis B, Corcos J. Randomized clinical trial comparing suprapubic arch sling (SPARC) and tension-free vaginal tape (TVT): one-year results. *Eur Urol.* 2005;47(4):537–41.
24. Ford AA, Rogerson L, Cody JD, Ogah J. Mid-urethral sling operations for stress urinary incontinence in women. *Cochrane Database Syst Rev.* 2015;7:CD006375.
25. Dargent D, Bretones S, George P, Mellier G. Insertion of a sub-urethral sling through the obturator membrane for treatment of female urinary incontinence. *Gynecol Obstet Fertil.* 2002;30(7–8):576–82.
26. Ogah J, Cody JD, Rogerson L. Minimally invasive synthetic suburethral sling operations for stress urinary incontinence in women. *Cochrane Database Syst Rev.* 2009;4:CD006375.
27. Schimpf MO, Rahn DD, Wheeler TL, Patel M, White AB, Orejuela FJ, et al. Sling surgery for stress urinary incontinence in women: a systematic review and metaanalysis. *Am J Obstet Gynecol.* 2014;211(1):71.e1–e27.
28. Ward KL, Hilton P. Tension-free vaginal tape versus colposuspension for primary urodynamic stress incontinence: 5-year follow up. *BJOG.* 2008;115(2):226–33.
29. Abdel-Fattah M, Ramsay I, Pringle S, Hardwick C, Ali H, Young D, et al. Randomised prospective single-blinded study comparing 'inside-out' versus 'outside-in' transobturator tapes in the management of urodynamic stress incontinence: 1-year outcomes from the E-TOT study. *BJOG.* 2010;117(7):870–8.
30. Madhuvrata P, Riad M, Ammembal MK, Agur W, Abdel-Fattah M. Systematic review and meta-analysis of “inside-out” versus “outside-in” transobturator tapes in management of stress urinary incontinence in women. *Eur J Obstet Gynecol Reprod Biol.* 2012;162(1):1–10.
31. Nilsson CG, Palva K, Rezapour M, Falconer C. Eleven years prospective follow-up of the tension-free vaginal tape procedure for treatment of stress urinary incontinence. *Int Urogynecol J Pelvic Floor Dysfunct.* 2008;19(8):1043–7.
32. Crystle CD, Charne LS, Copeland WE. Q-tip test in stress urinary incontinence. *Obstet Gynecol.* 1971;38(2):313–5.
33. Schierlitz L, Dwyer PL, Rosamilia A, Murray C, Thomas E, De Souza A, et al. Effectiveness of tension-free vaginal tape compared with transobturator tape in women with stress urinary incontinence and intrinsic sphincter deficiency: a randomized controlled trial. *Obstet Gynecol.* 2008;112(6):1253–61.
34. Rezapour M, Falconer C, Ulmsten U. Tension-Free vaginal tape (TVT) in stress incontinent women with intrinsic sphincter deficiency (ISD)—a long-term follow-up. *Int Urogynecol J Pelvic Floor Dysfunct.* 2001;12(Suppl 2):S12–4.
35. Smith AL, Karp DR, Aguilar VC, Davila GW. Repeat versus primary slings in patients with intrinsic sphincter deficiency. *Int Urogynecol J.* 2013;24(6):963–8.
36. Ford AA, Ogah JA. Retropubic or transobturator mid-urethral slings for intrinsic sphincter deficiency-related stress urinary incontinence in women: a systematic review and meta-analysis. *Int Urogynecol J.* 2016;27(1):19–28.
37. Nambiar A, Cody JD, Jeffery ST. Single-incision sling operations for urinary incontinence in women. *Cochrane Database Syst Rev.* 2014;6:CD008709.
38. Barber MD, Weidner AC, Sokol AI, Amundsen CL, Jelovsek JE, Karram MM, et al. Single-incision mini-sling compared with tension-free vaginal tape for the treatment of stress urinary incontinence: a randomized controlled trial. *Obstet Gynecol.* 2012;119(2 Pt 1):328–37.
39. Bianchi-Ferraro AM, Jarmy-Di Bella ZI, Castro Rde A, Bortolini MA, Sartori MG, Girao MJ. Single-incision sling compared with transobturator sling for treating stress urinary incontinence: a randomized controlled trial. *Int Urogynecol J.* 2013;24(9):1459–65.
40. Lee JK, Rosamilia A, Dwyer PL, Lim YN, Muller R. Randomized trial of a single incision versus an outside-in transobturator midurethral sling in women with stress urinary incontinence: 12 month results. *Am J Obstet Gynecol.* 2015;213(1):35.e1–9.
41. Abdel-Fattah M, Ford JA, Lim CP, Madhuvrata P. Single-incision mini-slings versus standard midurethral slings in surgical management of female stress urinary incontinence: a meta-analysis of effectiveness and complications. *Eur Urol.* 2011;60(3):468–80.
42. Tieu AL, Hegde A, Castillo PA, Davila GW, Aguilar VC. Transobturator versus single incision slings: 1-year results of a randomized controlled trial. *Int Urogynecol J.* 2016;

43. Albo ME, Richter HE, Brubaker L, Norton P, Kraus SR, Zimmern PE, et al. Burch colposuspension versus fascial sling to reduce urinary stress incontinence. *N Engl J Med.* 2007;356(21):2143–55.
44. Novara G, Artibani W, Barber MD, Chapple CR, Costantini E, Ficarra V, et al. Updated systematic review and meta-analysis of the comparative data on colposuspensions, pubovaginal slings, and midurethral tapes in the surgical treatment of female stress urinary incontinence. *Eur Urol.* 2010;58(2):218–38.
45. Rehman H, Bezerra CC, Bruschini H, Cody JD. Traditional suburethral sling operations for urinary incontinence in women. *Cochrane Database Syst Rev.* 2011;1:CD001754.
46. Ogah J, Cody DJ, Rogerson L. Minimally invasive synthetic suburethral sling operations for stress urinary incontinence in women: a short version Cochrane review. *Neurourol Urodyn.* 2011;30(3):284–91.
47. Guerette NL, Bena JF, Davila GW. Transobturator slings for stress incontinence: using urodynamic parameters to predict outcomes. *Int Urogynecol J Pelvic Floor Dysfunct.* 2008;19(1):97–102.
48. Nager CW. Midurethral slings: evidence-based medicine vs the medicolegal system. *Am J Obstet Gynecol.* 2016;214(6):708.e1–5.

Part V

Onco-gynecology



Radical Wide Local Resection in Vulvar Cancer

19

Alejandro Soderini and Alejandro Aragona

Introduction

Carcinoma of the vulva accounts for approximately 4–5% of all the cases of gynecologic malignancies [1–7]. It is estimated that about 27,000 cases are diagnosed each year around the world. The knowledge of tumor biology and spread mechanisms, improved surgical techniques and the adoption of new therapeutic approaches. In this chapter, we describe our view about the radical wide resection and many other concepts about how to manage today the vulvar cancer.

In the last 20 years, given the changes in both social and sexual habits, the incidence of vulvar carcinoma has increased among young women, and this is closely related to the infection caused by the human papillomavirus (HPV) and the increase in the number of vulvar intraepithelial neoplastic lesions [8].

Vulvar intraepithelial neoplasia (VIN) occurs in young women, even in women under the age of 40 [9], and may be associated with lesions similar to those occurring in the cervix and vagina. VIN is a precursor lesion in some patients, and when diagnosed, it must be treated.

There is an association between the oncologic potential of HPV and the occurrence of VIN

(HPV-related vulvar cancer). HPV 16/18 is the most common form of the disease [3, 4, 9].

There is a non-HPV-related form of the disease (VIN usual, Bowenoid warty type) which has been related to chronic inflammatory lesions in the vulva (dystrophy, lichen sclerosus (LS)) and to squamous intraepithelial lesions (carcinoma in situ). This form of the disease usually occurs in older women. Posttreatment monitoring is vital, for the disease may recur or evolve into squamous cancer [3, 4, 9].

In order to determine the etiology of the condition, immunohistochemistry with P16 would be conclusive to establish the relation with HPV infection to define the disease prognosis. Non-HPV-related VIN may evolve into vulvar cancer more commonly than the non-HPV-related form of the disease [4].

Mean age at the time of diagnosis is about 70 [8, 9], and 75% of vulvar malignancies are squamous cell carcinomas [4, 10].

Although vulvar cancer may be cured if diagnosed and managed adequately early on, it is estimated that between 30 and 35% of the cases of vulvar cancer will be diagnosed at FIGO III or IV stages; and the tumors are unresectable from the beginning or else occur in patients with positive nodes [10, 11].

In 2009, FIGO conducted a revision and then published a staging system [12]. Vulvar cancer may also be staged according to the TNM staging system [13], which is used both by the American

A. Soderini, M.D., Ph.D. (✉) • A. Aragona, M.D.
University of Buenos Aires, Buenos Aires, Argentina

Oncologic Hospital of Buenos Aires “Marie Curie”,
Buenos Aires, Argentina

Joint Committee on Cancer (AJCC) and the Union for International Cancer Control (UICC).

Locally advanced tumors which cannot be excised by standard radical surgery are considered unresectable. This entity has not been clearly defined yet, and the definition may vary depending on the author [14]. No doubt, the knowledge of tumor biology, the spread mechanisms, improved surgical techniques and materials have led to a different mindset and to the adoption of new therapeutic approaches.

Anatomy of the Vulva

For years, the vulva was considered part of the lower genital tract. From the anatomic viewpoint, the vulva includes the Mound of Venus, the clitoris glans and clitoral hood, both the labia majora and labia minora, the vulvar fork, the vestibule, the urethral and vaginal openings, Skene's glands, and Bartholin's glands [2]. However, it must be considered an anatomical region.

Blood is supplied by the internal and external pudendal arteries. The ilioinguinal and genitofemoral nerves innervate the anterior region of the vulva. The posterior branch of the cutaneous nerve innervates the perineum. Vulvar cancer spreads mainly locally and to the lymph nodes.

The lymphatics drain as follows: the lateral vulvar regions drain to the superficial inguino-femoral nodes; the central areas, clitoris, and labia minora drain to the deep inguinal and internal iliac nodes [9].

Prognostic Factors

Node metastases and tumor size are known to be important prognostic factors. Table 19.1 summarizes the different prognostic factors and the relationship between overall survival (OS) and recurrence rate [15]. Bulky tumors and locoregional spread are the most common clinical presentations in developing countries. As for tumor size specifically, a "clear cut off point of ≥ 6 cm has been reported in the literature, after which survival is remarkably reduced" [15].

Table 19.1 Distribution of recurrences by stage, lymph node status, and tumor size according to Aragona et al. [15]

Stage (FIGO 2009)	n	%	Recurrence rate (%)
IB	33	39.8	76.7
II	22	26.5	81.5
IIIA	13	15.7	92.8
IIIB	8	9.6	72.7
IIIC	7	8.4	70.0
Overall	83	100	
<i>Pathological tumor size (cm)</i>			
>2–3.99	29	35.0	72.5
4–5.99	23	27.6	69.7
6–7.99	14	16.9	93.3
≥ 8	17	20.5	100
Overall	83	100	
<i>Number of positive lymph nodes</i>			
0	54	65.0	80.5
1	12	14.5	80.0
2	5	6.0	62.5
3–5	5	6.0	83.3
>5	7	8.5	77.7
Overall	83	100	

Therefore, tumor size must be considered an important prognostic factor when choosing a management strategy in order to adapt treatment for patients with bulky primary tumors, being neoadjuvant chemotherapy followed by surgery a possible new tendency or a treatment option. In these patients, even a less radical type of surgery is feasible [7]. In this case, at least an 8 mm tumor-free margin is still the main prognostic factor [16].

Surgery: Local Radical Resection

In the history of the surgical management of vulvar cancer, different techniques have been described, such as pelvic exenteration with vulvectomy, radical vulvectomy with en bloc removal of regional lymph nodes, radical vulvectomy with separate incisions for the lymph nodes, simple vulvectomy, and at present wide local excision [17, 18].

As mentioned above, both the knowledge of the different aspects of the tumor and prognostic factors led to a modification of the surgical strategy.

The surgical specimen with at least an 8 mm tumor-free margin is still the standard recommendation. In the early stages or in the case of 2–4 cm tumors, a local radical resection or a partial vulvectomy may be performed, which has proven not to change oncologic outcome; however, they had a remarkable benefit in terms of morbidity and psychosexual aspects [6, 16–19] (Fig. 19.1). The technique of choice will depend on the size, location, involvement of neighboring structures, and, therefore, the tumor stage.

It has been suggested that pre-op radiotherapy, chemoradiotherapy [20], or neoadjuvant chemoradiotherapy [5, 7] might reduce the need for ultraradical surgeries in case of tumors of a larger diameter in order to conduct less extensive resections [5, 7, 21–26] (Figs. 19.2 and 19.3).

The principles of neoadjuvant chemotherapy, as well as occur in cervix cancer, are reduction of the tumor's diameter increasing operability obtaining surgical specimens with tumor-free

margins and management of distant micrometastases; an effect on lymph nodes was also observed [27–30]. In some cases, after large resections, both for VIN and for invasive cancer, oncoplastic surgery must be considered [7, 31] (Figs. 19.4, 19.5, and 19.6).

Lymph node dissection is appropriate in all cases. There is growing evidence that, in early stages, removal of the sentinel node would suffice. It is suggested that this procedure should be performed in leading centers in the setting of clinical trials [17, 18].

In cases of tumor infiltration <1 mm, it has been reported that nodes removal may not be performed since involvement might be practically nonexistent and not affecting survival [18].

In the case of lateral tumors, investigation of the homolateral nodes would suffice; in the case of medial tumors, bilateral monitoring is necessary, either conventionally or using the sentinel node technique [18].

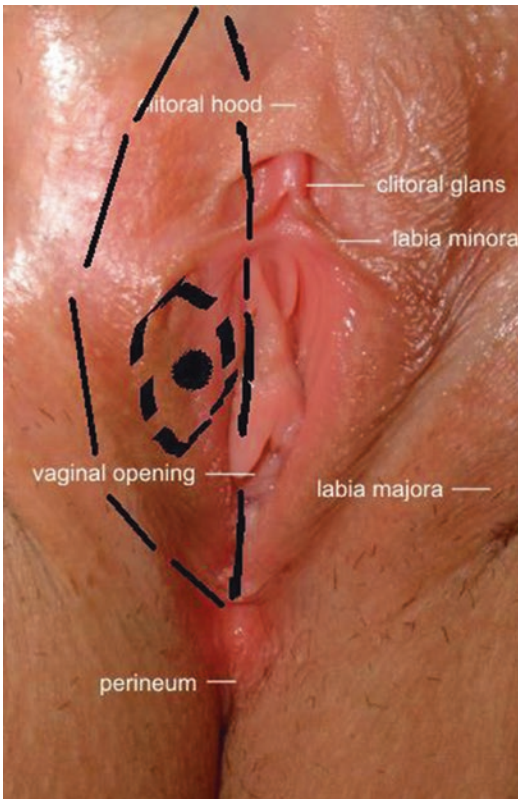


Fig. 19.1 Wide local resection and partial vulvectomy

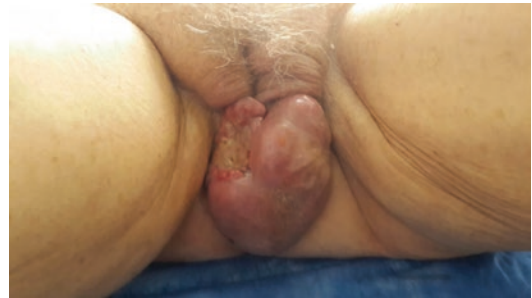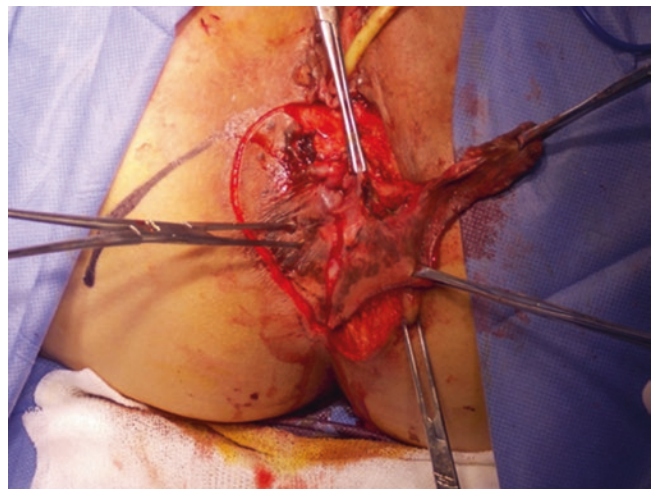


Fig. 19.2 Tumor treated with neoadjuvant chemotherapy followed by partial vulvectomy

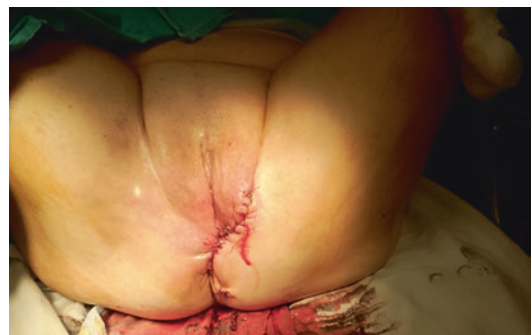
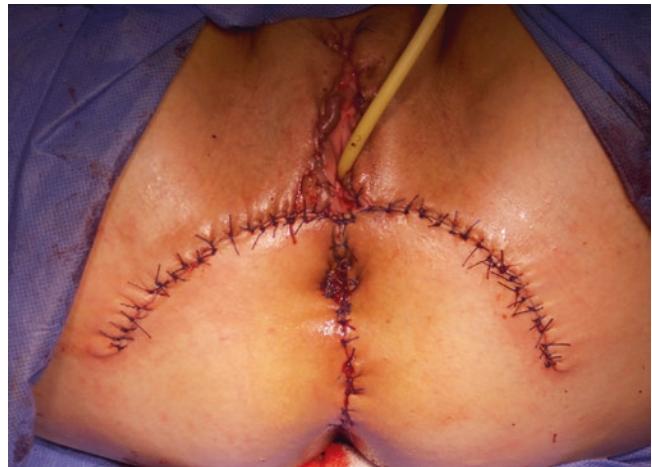
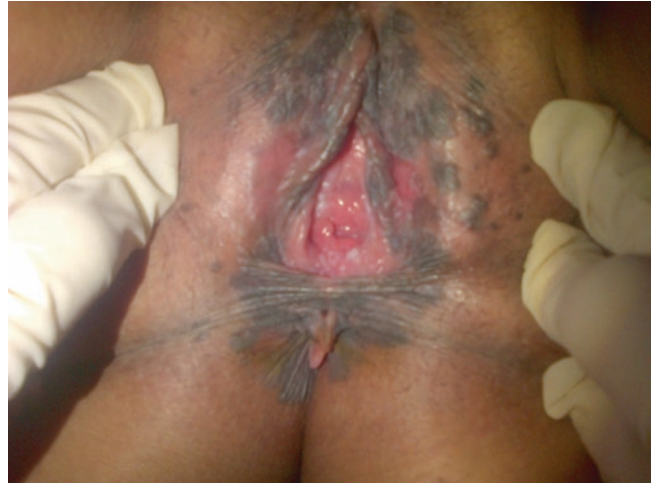Fig. 19.3 Tumor treated with neoadjuvant chemotherapy followed by partial vulvectomy

Figs. 19.4, 19.5, and 19.6 VIN
III. Extended vulvectomy followed by
oncoplastic surgery



In the presence of positive nodes, a complete inguinofemoral lymphadenectomy must be performed [17, 18]. When the nodes are fixed or ulcerated, other treatment options must be considered, with a neoadjuvant criteria, in order to achieve complete removal [7].

As conclusions, we may say the following:

- Vulvar carcinoma accounts for 4% of gynecologic malignancies.
- 30–35% of them are diagnosed in advanced stages.
- The clinical presentation with central bulky tumors is common in developing countries, and central tumor size must be considered an important prognostic factor in order to define the treatment strategy, as in the case of lymph nodes.
- Surgery is still the treatment of choice, and local resection and partial vulvectomies lead to similar oncologic outcomes as compared to traditional radical surgery and have a remarkable benefit for the patient in terms of morbidity and psychosexual issues.
- However, the “take-home message” is “tailoring each treatment option for each patient.”

Acknowledgments To Nick Reed and Nicasio Cuneo

References

1. Benedet JL, Bender H, Jones H 3rd, et al. FIGO staging classifications and clinical practice guidelines in the management of gynecologic cancers. FIGO Committee on Gynecologic Oncology. *Int J Gynaecol Obstet.* 2000;70:209–62.
2. Guixa-Otturi-Guixa. *Cap. Patología vulvar.* Compendio de Ginecología para alumnos. Quinta Edición. Lopez Libreros Editores. Buenos Aires; 1985. p. 395–404.
3. Ávila M, Castro G. *Patología de la vulva y vagina.* Provenzano-Lange-Tatti; Manual de Ginecología. Cap.26. Primera Edición. Editorial Corpus. Buenos Aires, 2006; p. 291–302.
4. Maldonado M, Susuki V. *Patología de la vulva y vagina.* Provenzano-Lange-Tatti; Manual de Ginecología. Segunda edición. Cap. 27. Editorial Corpus. Buenos Aires; 2014. p. 411–422.
5. Asociación Argentina de Ginecología Oncológica. *Cáncer de Vulva.* Guías para el diagnóstico, tratamiento y seguimiento del Cáncer ginecológico. Editorial Ascune. Buenos Aires; 2016. p. 129–149.
6. Levine D, De los Santos J, Fleming G, Barakat R, Markman M, Randall M. *The vulva.* Handbook for principles and practice of gynecologic oncology. Philadelphia: Lippicott Williams & Wilkins; 2010. 95–96.
7. Aragona AM, Cúneo N, Soderini AH, Alcoba E, Greco A, Reyes C, Lekmann S. Tailoring the treatment of locally advanced squamous cell carcinoma of the vulva: Neoadjuvant chemotherapy followed by radical surgery. Results from a multicenter study. *Int J Gynecol Cancer.* 2012;22(7):1258–63.
8. Judson PL, Habermann EB, Baxter NN, et al. Trends in the incidence of invasive and in situ vulvar carcinoma. *Obstet Gynecol.* 2006;107:1018.
9. Alkatout I, Schubert M, Garbrecht N, Weigel MT, Jonat W, Mundhenke C, Günther V. Vulvar cancer: epidemiology, clinical presentation, and management options. *Int J Womens Health.* 2015;7:305–13.
10. Jemal A, Siegel R, Ward E, et al. Cancer statistics. *CA Cancer J Clin.* 2006;56:106–30.
11. Stroup AM, Harlan LC, Trimble EL. Demographic, clinical and treatment trends among women diagnosed with vulvar cancer in the United States. *Gynecol Oncol.* 2008;108:577–83.
12. Pecorelli S. Revised FIGO staging for carcinoma of the vulva, cervix, and endometrium. *Int J Gynaecol Obstet.* 2009;105:103–4.
13. Sobin LH, Gospodarowicz MK, Wittekind CH, editors. *TNM classification of malignant tumours.* 7th ed. Oxford: Wiley-Blackwell; 2009.
14. Aragona AM, Soderini AH, Cuneo NA. Defining the concept of locally advanced squamous cell carcinoma of the vulva: a new perspective based on standardization of criteria and current evidence. *J Gynecol Oncol.* 2014;25(4):272–8.
15. Aragona AM, Cuneo NA, Soderini AH, Alcoba EB. An analysis of reported independent prognostic factors for survival in squamous cell carcinoma of the vulva: is tumor size significance being underrated? *Gynecol Oncol.* 2014;132(3):643–8.
16. De Hullu JA, Hollema H, Lolkema S, Boezen M, Boonstra H, Burger MP, et al. Vulvar carcinoma. The price of less radical surgery. *Cancer.* 1992;95(11):2331–8.
17. Chan JK, Sugiyama V, Pham H, Gu M, Rutgers J, Osann K, et al. Margin distance and other clinico-pathologic prognostic factors in vulvar carcinoma: a multivariate analysis. *Gynecol Oncol.* 2007;104:636–41.

18. Baiocchi G, Rocha RM. Vulvar cancer surgery. *Curr Opin Obstet Gynecol*. 2014;26(1):9–17.
19. Micheletti L, Preti M. Surgery of the vulva in vulvar cancer. *Best Pract Res Clin Obstet Gynaecol*. 2014;28(7):1074–87.
20. Moore DH, Thomas GM, Montana GS, Saxer A, Gallup DG, Olt G. Preoperative chemoradiation for advanced vulvar cancer: a phase II study of the Gynecologic Oncology Group. *Int J Radiat Oncol Biol Phys*. 1998;42(1):79–85.
21. Itala J, Belardi G, Sardi J, et al. Poliquimioterapia neoadyuvante en el tratamiento del carcinoma invasor de la vulva. *Rev Soc Obstet Ginecol B Aires*. 1986;865:239–45.
22. Shimizu Y, Hasumi K, Masubuchi K. Effective chemotherapy consisting of bleomycin, vincristine, mitomycin C, and cisplatin (BOMP) for a patient with inoperable vulvar cancer. *Gynecol Oncol*. 1990;36:423–7.
23. Domingues AP, Mota F, Durao M, et al. Neoadjuvant chemotherapy in advanced vulvar cancer. *Int J Gynecol Cancer*. 2010;20:294–8.
24. Raspagliesi F, Zanaboni F, Martinelli F, casso S, Laufer J, Ditto A. Role of paclitaxel and cisplatin as the neoadjuvant treatment for locally advanced squamous cell carcinoma of the vulva. *J Gynecol Oncol*. 2014;25(1):22–9.
25. Benedetti-Panici P, Greggi S, Scambia G, et al. Cisplatin (P), bleomycin (B), and methotrexate (M) preoperative chemotherapy in locally advanced vulvar carcinoma. *Gynecol Oncol*. 1993;50:49–53.
26. Geisler JP, Manahan KJ, Buller RE. Neoadjuvant chemotherapy in vulvar cancer: avoiding primary exenteration. *Gynecol Oncol*. 2006;100:53–7.
27. Sardi JE, Giaroli A, Sananes C, Di Paola GR. A possible new trend in the management of the carcinoma of the cervix uteri. *Gyn Oncol*. 1986;25:139.
28. Sardi J, Giaroli A, Sananes C, Ferreira M, Soderini A, Bermudez A, Snaidas L, Vighi S, Gomez Rueda N, di Paola G. Long term follow up of the first randomized trial using neoadjuvant chemotherapy in stage Ib squamous carcinoma of the cervix: the final results. *Gynecol. Oncologia*. 1997;67:61–9.
29. Sananes C, Giaroli A, Soderini A, Guardado N, Sanaidas L, Bermúdez A, Ferreira M, Di Paola G, Sardi J. Neoadjuvant chemotherapy followed by radical hysterectomy and postoperative adjuvant chemotherapy in the treatment of carcinoma of the cervix uteri: long-term follow up of a pilot study. *Eur J Gynaecol Oncol*. 1998;19(4):368–73.
30. Tierney J. Neoadjuvant chemotherapy for locally advanced cervical cancer: a systematic review and meta-analysis of individual patient data from 21 randomised trials. *Neoadjuvant Chemotherapy for Locally Advanced Cervical Cancer Meta-analysis Collaboration*. *Eur J Cancer*. 2003;39(17):2470–86. Review.
31. Soderini A, Aragona A, Reed N. Advanced vulvar cancers: what are the best options for treatment? *Curr Oncol Rep*. 2016;18(9); accepted. "In Press".



Classification of Radical Hysterectomy

20

Denis Querleu

Introduction

Tailoring has become a major issue in cancer surgery. Adaptation of radicality to tumor spread is a prominent topic of discussion in the field of cervical cancer. The concept of wide tumor excision has been validated in a number of other tumors, including melanomas, sarcomas, and aerodigestive tract, breast, and vulvar cancers. This has led to the development of ultra-radical surgeries on one hand and of more limited (“modified radical”) surgeries on the other hand, based on the concept of the surgical margin and on the estimation of the risk of pericervical spread, which may be high in bulky tumors on one hand [1] or negligible in low volume disease on the other [2].

As a result, the term “radical” or “extended” hysterectomy encompasses a variety of different surgeries. Since the first publications of a large series of surgeries for cervical cancer by Wertheim in Austria [3], later by Okabayashi in Japan [4] and Meigs in the United States [5], a lot of radical procedures corresponding to different degrees of radicality, giving different names for the same anatomical structures, describing different anatomical structures according to different interpretations of the anatomy, have been

described and performed. The initial publications in German or Japanese language are not routinely consulted. The wide use of eponyms adds to the confusion, as the original descriptions are altered with time, transmission by teaching, and addition of minor surgical variants, some of them original, some of them redundant and ignoring previous descriptions of the same variants.

There are several reasons for having a standardized international classification of radical hysterectomy. These include clarification of the details of common variations, standardization of nomenclature in reports and publications, clinical protocols and randomized controlled trials, evaluation of complications and side effects, education, and training. Investigators, trained gynecologic oncologists, general gynecologists who are not familiar with anatomy of the retroperitoneal space, fellows, and residents in training should speak the same language.

There are two common metrics for the outcome of the radical hysterectomy: (1) adverse effects such as bladder dysfunction, an outcome that is relatively easy to correlate with the anatomic extent of the resection and nerve preservation whenever the pelvic autonomic nerves are threatened as a result of the extent of resection, and (2) curative effect of the surgery, which is obviously correlated with the anatomic extent of the resection but requires documentation of the benefit/risk balance. In addition, combining radiation and/or chemotherapy with radical hysterectomy

D. Querleu, M.D.
Department of Surgery, Institut Bergonié,
Bordeaux, France

tomy results in profound alterations of the rationale for the extent of surgical excision.

The Piver-Rutledge-Smith Classification [6]

The Piver-Rutledge-Smith classification published in 1974 has achieved considerable popularity. However, this classification, which describes five classes of radical hysterectomy, has several major drawbacks. The original paper does not refer to clear anatomical landmarks and international anatomical definitions. The vaginal extent of resection is systematically attached to the pericervical extent, with excessive vaginal resection, from one third to three quarters of the vagina. It includes a class I, which is not a radical hysterectomy, and a class V, which is no longer used. The rationale and anatomy differentiating classes III and IV are not clear. There is a frequent need, in discussions among surgeons, to define intermediate classes between classes II and III (“II–III,” “II and a half”). The Piver and colleagues classification does not take into account the concepts of nerve preservation introduced in the 1950s [7] then refined by Japanese surgeons [7–9]. In addition, other types of ultra-radical surgical procedures [10–12] have been developed that are not included. On the other

hand, fertility-preserving surgery introduced by Dargent [13] is not included in the classification.

Another sophistication unknown at the time of publication of the Piver-Rutledge-Smith was the development of the technique of paracervical lymphadenectomy [14]. The rationale of this technique is that the lateral part of the paracervix (*cardinal ligament*) is essentially made of cellulo-lymphatic tissue, vessels, and nerves (Figs. 20.1 and 20.2). The paracervix is made of two parts: the medial part is a condensation of connective tissue; the lateral part is made of lymph node-bearing fatty tissue surrounding vessels and nerves. The most stable anatomical landmark marking the limit between the two parts is the terminal ureter. In Fig. 20.2, the paracervix, including the paracolpos of the upper third of the vagina, is visible. Its unique structure made of condensed fibrous tissue medially, and cellulo-lymphatic tissue laterally, is featured. The deep uterine vein is also visible, providing a landmark between the so-called “vascular” and “nervous” component. Anatomically, the nervous component is best described as the inferior hypogastric plexus that crosses the paracervix. The location of the inferior hypogastric plexus is circled.

Briefly, the medial part (medial to the ureter) of the so-called cardinal ligament is mainly fibrous and the lateral part (lateral to the ureter)

Fig. 20.1 Anatomical coronal section of the female pelvis. The red point shows the ureter. The black line shows the limit between the condensed part and the cellulo-lymphatic part of the paracervix. The paracolpos and the paracervix are the same structure (Courtesy Pr Mauroy, Laboratory of Anatomy, University of Lille, France)

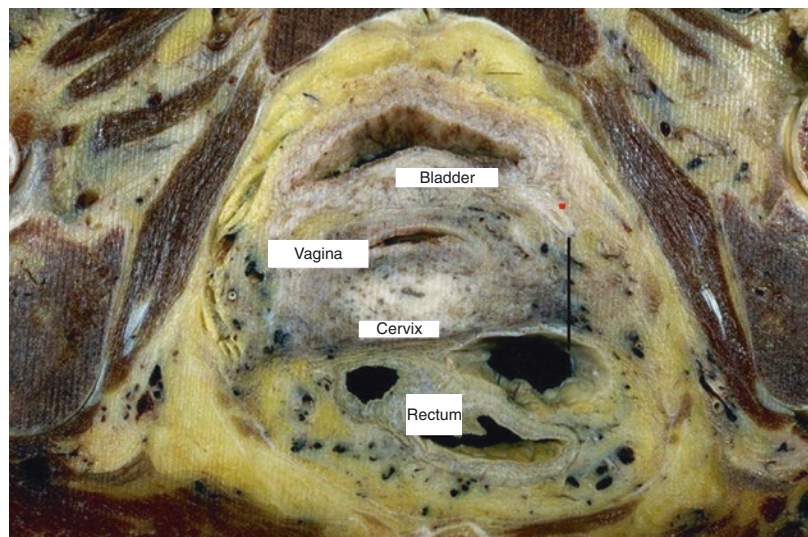
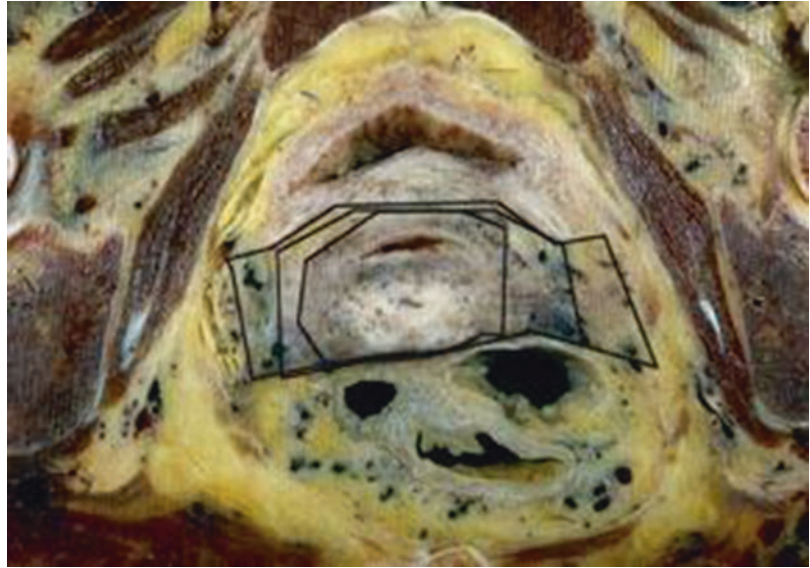


Fig. 20.2 Coronal anatomical section of the cervix. The lateral templates of types A, B, and C are shown



nonfibrous, made like any lymph nodal area of cellulo-lymphatic tissue surrounding nerves and vessels (Fig. 20.3). This implies that the node bearing tissue can be removed in a way similar to a lymph node dissection while preserving the vessels and nerves. Adding a lateral paracervical dissection to a “proximal-type” radical hysterectomy improves the lateral radicality and fulfills the requirements of a “distal type,” without increasing morbidity [14]. The clearing of the lateral part of the cardinal ligament has also been proposed using liposuction techniques in Germany [15] and even earlier in Japan (Fujiwara 1964, personal communication by N. Sakuragi).

Finally, the Piver-Rutledge-Smith classification applies only to open surgery, not allowing to take into account the development of laparoscopic techniques and the revival of vaginal surgery.

As a consequence, the Piver-Rutledge-Smith classification is both inherently deficient and largely misused by numerous authors and surgeons, as the tradition is orally transmitted without careful reading of the original paper. An alternative classification, based on the international anatomical nomenclature, has been proposed by Querleu and Morrow in 2008 [16].

Anatomical Nomenclature

The international anatomical nomenclature *Terminologia Anatomica* [17, 18] should be used wherever it clearly applies, which is not always the case in the surgical literature and daily language:

1. There is a wrong use by surgeons of anatomical terms defining spatial orientation. The widely used terms “anterior/posterior,” “deep/superficial,” and “internal/external” are confusing, depending on the surgical point of view, and should be replaced, respectively, by ventral/dorsal, caudal/cranial, and medial/lateral.
2. The dorsolateral attachment of the cervix is named paracervix (from the Greek *para* meaning “alongside of”) (Fig. 20.1). This term should replace the numerous other denominations such as cardinal or Mackenrodt’s ligament (it is not a ligament) or parametrium—it must be pointed that in international anatomical nomenclature, “parametrium” refers to the tissues surrounding the uterine artery between the uterine corpus and the pelvic sidewall, cranial to the ureter, corresponding to the “superficial” uterine pedicle (uterine artery and superficial uterine vein) and related

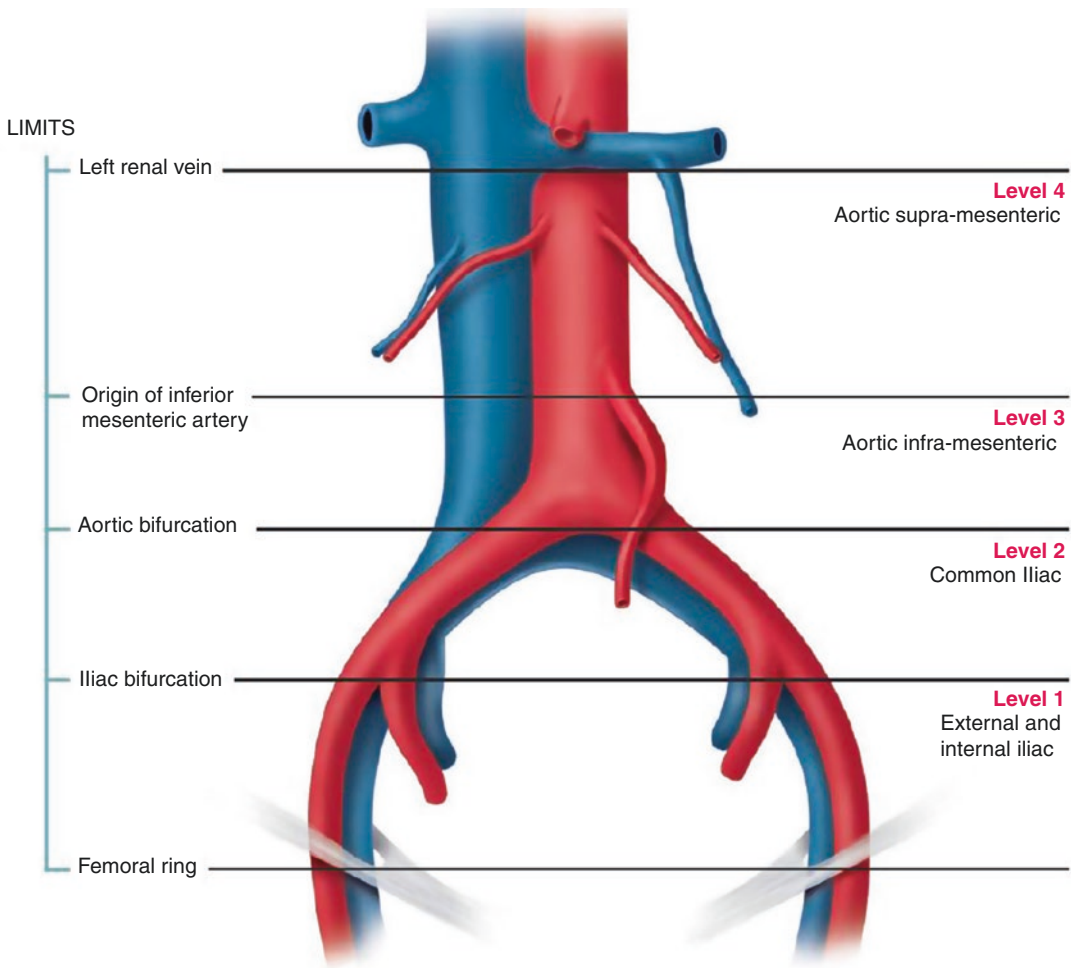


Fig. 20.3 Four levels of lymph node dissection (From Querleu D, Leblanc E, Ferron G, Morice P. *Techniques chirurgicales en oncologie gynécologique*, Elsevier-Masson, Paris)

connective tissue and lymph channels. In addition, the structure named by surgeons “paracolpos” or “paracolpium” is included in the paracervix in the international anatomical nomenclature. In the same way, the lateral attachments of the bladder and rectum are named lateral ligament of the bladder and rectum, respectively.

The term “meso” is strictly limited to the peritoneal attachment of intra-abdominal viscera. Actually, the so called mesoureter is a sheet of connective tissue extending dorsally from the ureter and containing the superior hypogastric nerve. The latter should be preserved during radi-

cal hysterectomy and common iliac and aortic dissection if a nerve sparing technique is considered. On the other hand, the term “mesometrium” refers to a functional view of cancer spread based on embryological development that deserves consideration but remains hypothetical [19]. As a consequence, only the purely descriptive denomination “paracervix” will be used in the surgical classification.

However, there are some drawbacks to the strict use of Terminologia Anatomica. Some structures relevant to surgical considerations, including the “paracolpos” or “paracolpium,” are not officially recognized. The anatomists themselves do not consistently abide by their own

rules, for example, routinely describing the “superior” and “inferior” hypogastric nerves or the “superficial” and “deep” uterine veins. On the other hand, the use of some surgical denominations will probably remain, as they refer to structures that are created by surgical dissection:

1. The so-called bladder pillar (otherwise referred to as ventral or “anterior parametrium”) is defined after surgical opening and developing of the vesicouterine/vesicovaginal septum and paravesical spaces. The bladder pillar is made of two portions, one medial and one lateral to the ureter, respectively, corresponding to the vesicouterine ligament and the lateral ligament of the bladder. It is also extended caudally to form a vesicovaginal ligament (called “posterior leaf of the vesicouterine ligament” by the Japanese authors).
2. The so-called rectal pillar (otherwise referred to as dorsal or “posterior parametrium”) is defined after surgical opening of the rectovaginal septum and pararectal spaces. The rectal pillar corresponds to the rectouterine and rectovaginal ligament (there is no “uterosacral ligament”) and to the hypogastric nerve that runs lateral to it; the two structures can be separated by developing the sacrouterine space [20].

The Querleu-Morrow Classification

The classification is only based, for simplification purposes, on the lateral extent of resection. However, knowing that the lateral, dorsal, and ventral extents are strongly correlated, a description of dorsal and ventral templates is added. Vaginal resection is not standardized but is a modifiable component adapted to the vaginal extension of the disease and any associated vaginal intraepithelial neoplasia. The management of the ureter, which is an essential feature of radical hysterectomy technique and a potential source of major complications, is described for each type.

Only four types of radical hysterectomy are described, adding when necessary a limited num-

ber of subtypes. Only stable anatomical landmarks, such as the crossing of the ureter with the uterine artery and paracervix and the vascular plane of the internal iliac system, are used to define the limits of resection. To make a clear distinction with the Piver-Rutledge-Smith current classification, letters are used rather than numbers to define classes. Simple (extrafascial) hysterectomy is not included in the classification. Lymph node dissection, which has been an essential component of the surgical management of cervical cancer since Wertheim, is considered separately.

Type A: Minimal Resection of the Paracervix (Fig. 20.2)

An extrafascial hysterectomy in which the position of the ureters is determined by palpation or direct vision (after opening the ureteral tunnels) without freeing the ureters from their beds, which allows to transect the paracervix medial to the ureter but lateral to the cervix. The uterosacral and vesicouterine ligaments are not transected at a distance from the uterus. In this regard, this operation is not a “simple” extrafascial hysterectomy but a radical hysterectomy with resection of the paracervix halfway between the cervix and ureter. Vaginal resection is generally minimal, routinely less than 10 mm, without removal of the vaginal part of the paracervix (“paracolpos”).

The goal of the operation is to make sure that the cervix is removed in its entirety, which is a crucial issue in the design of future trials testing the safety of a reduction in radicality for (1) the management of early invasive cervical cancers—less than 2 cm—with negative pelvic nodes and without lymph vascular space invasion, on the basis of the low prevalence of pericervical involvement in small cancers [1, 2], and (2) the final surgical management of advanced cervical cancers after radiation and/or chemotherapy. The described management of the ureter is added to avoid kinking or thermal injury to the ureter, while avoiding impairing the vascular supply to the terminal ureter.

Type B: Transection of the Paracervix at the Ureter

Partial resection of the uterosacral and vesicouterine ligaments is also a standard component of this category. The ureter is unroofed and rolled laterally permitting transection of the paracervix at the level of the ureteral tunnel.

The caudal (*posterior, deep*), neural component of the paracervix, caudal to the deep uterine vein, is not resected.

The operation corresponds to the “modified” or “proximal” radical hysterectomy. It is adapted to early cervical cancers. The radicality of this operation can be improved without increasing the postoperative morbidity by a lymph node dissection of the lateral part of the paracervix (paracervical lymph node dissection), thus defining two subtypes: **B1**, as described, and **B2**, with additional removal of the lateral paracervical lymph nodes.

The border between “paracervical” and “iliac” and “parietal” lymph node dissection is arbitrarily defined as the obturator nerve: paracervical nodes are medial and caudal to the obturator nerves. It is clear that the combination of the two is simply a comprehensive pelvic node dissection. However, the lateral part of the cardinal ligament has traditionally been fully resected in “type III–IV” or “distal” radical hysterectomy. Paracervical lymphadenectomy has been invented to avoid clamping the paracervix at the pelvic wall, along with nerves and vessels, during radical hysterectomy. It is thus logically inserted in the subclassification of type B, as the morbidity of type B2 is not different from type B1 [14], although the combination of B1 with paracervical lymph node dissection may be supposed to be equivalent to a type C1 (see below).

Type C: Transection of the Paracervix at the Junction with the Internal Iliac Vascular System

Transection of the uterosacral ligament at the rectum and the vesicouterine ligament at the bladder. The ureter is completely mobilized. Type C

corresponds to the different variants of classical radical hysterectomy. In type C, in opposition to types A and B in which the autonomic nerve supply to the bladder is not threatened, the issue of nerve preservation is crucial. Two subcategories are thus defined:

C1, with nerve preservation: the sacrouterine ligament is transected after separating the hypogastric nerves; the nerve is systematically identified and preserved by transection of only the uterine branches of the pelvic plexus; the bladder branches of the pelvic plexus are preserved in the lateral ligament of the bladder (lateral part of the “bladder pillar”); if the caudal part of the paracervix is transected, careful identification of bladder nerves is required.

C2, without preservation of autonomic nerves: the paracervix is completely transected including the caudal part to the deep uterine vein.

Type D: Laterally Extended Resection

This group of rare operations feature additional “ultra-radical” procedures.

D1: resection of the entire paracervix at the pelvic sidewall along with the hypogastric vessels exposing the roots of the sciatic nerve.

Involves total resection of the vessels composing the lateral part of the paracervix; these vessels (inferior gluteal, internal pudendal, obturator vessels) arise from the internal iliac system.

D2: D1 plus resection of the entire paracervix with the hypogastric vessels and adjacent fascial/muscular structures. This corresponds to the LEER procedure (laterally extended endopelvic resection).

The Cibula Two-Dimensional Adaptation [21]

Cibula et al. tried to address a limitation of Querleu-Morrow classification by proposing a description of parametrial resection in three dimensions, which may be helpful to practically complete a type C procedure.

The overall definition of the lateral border remains the medial aspect of the internal iliac artery and vein. However, Cibula et al. pointed

that the anatomical definition of the paracervical tissue excision in the two other dimensions is different in types C1 and C2.

In C1 type the ureter is unroofed and dissected from the cervix but only in an extent which allows for 1–2 cm resection of the vesicovaginal ligament (medial part of the “anterior parametrium”). Type C1 requires the creation of a sacrouterine space separating the two components of the structure described as “dorsal parametria”: medial part composed by the sacrouterine “ligament” (actually a peritoneal fold defining the lateral limits of the pouch of Douglas) and a lateral laminar structure containing hypogastric plexus, also called the mesoureter. The caudal limit is the deep uterine vein (vaginal vein). Finally, the bladder branches of the hypogastric plexus localized caudal to the course of the ureter are identified and preserved.

The C2 type requires complete dissection of the ureter from the vesicovaginal ligament down to the bladder wall. The resection line continues alongside the medial aspect of internal iliac vessels up to the pelvic floor. Sacrouterine, pararectal, and paravesical spaces are completely unified by dissecting all parametrial (medial) branches of internal iliac vessels together with splanchnic nerves in the caudal part. Bladder branches of hypogastric plexus are sacrificed; thus their identification is not needed. Both cranial and caudal (infra-ureteral) parts of the vaginal part of the paracervix (paracolpium) are removed.

However, C1 and C2 have in common an identical dorsal border formed by the level of rectal attachment to the sacrouterine “ligament.” The removal of the “dorsal parametrium” is limited to the course of main hypogastric plexus branches in C1, while it is deeply extended below the rectum attachment in C2.

Lymph Node Dissection (Fig. 20.3)

Anatomically, the most stable landmarks are arteries. As a consequence, four areas or levels are defined according to the corresponding arterial anatomy: level 1, external/internal iliac; level 2, common iliac (including presacral); level 3, aortic inframesenteric (IMA); level 4, aortic infrarenal.

While recognizing that lymph nodes can cross the borders, the limit between level 1 and 2 is the bifurcation of the common iliac, the limit between level 2 and 3 is the bifurcation of the aorta, and the limit between level 3 and 4 is the inferior mesenteric artery. This classification ignores the widely used pelvic versus aortic dissection, considering that the limit of the pelvis lies somewhere within the common iliac area. It also avoids the use of the term “interiliac” that describes the clearing of the area between the external and internal iliac artery. Although the term is convenient, neglecting the removal of lateral external iliac nodes has never been proven to be safe and to reduce the morbidity of lymph node dissection.

Another issue is the limit between paracervical lymphadenectomy, which is part of the radical hysterectomy, and the internal lymph node dissection. The arbitrary landmark is the obturator nerve. Tissues medial and caudal to the obturator nerve are classified as paracervix; tissues cranial and lateral to the obturator nerves are classified as iliac.

Within each of the levels, and independently from each other, several types of lymph node dissection must be defined in order to adequately describe the radicality of the procedure:

- Diagnostic: minimal sampling of sentinel node only or removal of enlarged nodes only or random sampling
- Systematic lymph node dissection
- Debulking, defined as the resection of all nodes larger than 2 centimeters

Conclusion

The Querleu-Morrow classification provides a simple and universal tool to translate different levels of radicality into a limited number of categories. Some surgeries may be asymmetrical (e.g., C1 or B on one side, C2 on the opposite side). The same classification clearly applies to fertility-sparing surgeries that correspond to type B like in the Dargent operation and to type A in new variants adapted to minimal disease or after neoadjuvant chemotherapy.

As it is clearly impossible to describe all the individual operations, the use of a simple classification does not preclude a careful description of any single operation. A list of required information should be a component of any quality control in the surgical management of cervical cancers. It should thus appear in the operative report:

- All the components of the definition of the type of radical hysterectomy, as detailed above; for example, a type C operation must include all the components of the definition, including the site of transection of the pericervical tissues and vagina.
- The mode of management of the uterine artery that is routinely divided at its origin from the internal iliac artery but may be divided in the broad ligament in class A or resected along with the vessels in type D.
- The surgical and pathological length of ventral, dorsal, and lateral extension of the resection; surgical length should be measured on the fresh specimen, without stretching; pathological length should be measured after fixation; measurements should be taken independently from the surgeon.
- The surgical and pathological minimum length of the vagina removed and when applicable the minimum distance between the tumor and section margin; again, measurements should be taken on the fresh specimen without stretching them after fixation, independently from the surgeon.
- In fertility-preserving surgery, information on pathological distance between the tumor and the endocervical resection margin must be added to the standard list of requirements.
- The approach used, separately considering the approach for radical hysterectomy and the approach for lymph node dissection that may be different: open abdominal, vaginal, laparoscopic, vaginal with preliminary laparoscopic steps, laparoscopic with preliminary vaginal steps, and robotic.
- The use of preoperative external radiation therapy and/or brachytherapy and/or chemotherapy.

The way hemostasis is achieved must also be defined in order to participate to the evaluation of the impact of new techniques or devices on radicality and outcome such as blood loss or complication rates. In addition, the achievement of lateral resection has been demonstrated to be dependent on hemostasis technique, which stresses the interest of technical improvements irrespective of classification [22]. This again puts in light the need for a precise technique and description of the technique used in the operative report. A “TNM”-type description of the operation, defining three classes of radicality in the ventral, dorsal, lateral, and deep lateral directions, respectively, may be developed [23]. However, this model has significant shortcomings: some of the TNM-like definitions are difficult to understand and end up with 91 possible subtypes.

Radical hysterectomy is not a single operation. The variations must balance the curative effects with the risk for adverse consequences.

- An internationally accepted classification of radical hysterectomy, as proposed in this paper with the goal of acceptance by individual surgeons, study groups, and national and international societies, is clearly needed. Evaluation of techniques and quality control will be in the future a basic component of every surgical activity. Since the writing of this chapter, the classification has been amended, with clarifications and specifications of the main types, that remain unchanged [24].

References

1. Landoni F, Boccolone L, Perego P, Maneo A, Bratina G, Mangioni C. Cancer of the cervix, FIGO stages IB and IIA: patterns of local growth and paracervical extension. *Int J Gynecol Cancer*. 1995;5:329–34.
2. Kinney WK, Hodge DO, Edward V, Egorshin MD, Ballard DJ, Podratz KC. Identification of a low-risk subset of patients with stage IB invasive squamous cancer of the cervix possibly suited to less radical surgical treatment. *Gynecol Oncol*. 1995;57:3–6.

3. Wertheim E. The extended abdominal operation for carcinoma uteri (based on 500 operative cases). *Am J Obstet Dis Women Childhood*. 1912;66:169–232.
4. Okabayashi H. Radical abdominal hysterectomy for cancer of the cervix uteri. *Surg Gynecol Obstet*. 1921;33:335–41.
5. Meigs JV. Carcinoma of the cervix—the Wertheim operation. *Surg Gynecol Obstet*. 1944;78:195–8.
6. Piver MS, Rutledge F, Smith JP. Five classes of extended hysterectomy for women with cervical cancer. *Obstet Gynecol*. 1974;44:265–72.
7. Yabuki Y, Asamoto A, Hoshihara T, Nishimoto H, Satou N. A new proposal for radical hysterectomy. *Gynecol Oncol*. 1996;62:370–8.
8. Sakuragi N, Todo Y, Kudo M, Yamamoto R, Sato T. A systematic nerve-sparing radical hysterectomy technique in invasive cervical cancer for preserving postsurgical bladder function. *Int J Gynecol Cancer*. 2005;15:389–97.
9. Fujii S, Tanakura K, Matsumura N, Higuchi T, Yura S, Mandai M, Baba T. Precise anatomy of the vesicouterine ligament for radical hysterectomy. *Gynecol Oncol*. 2007;104:186–91.
10. Mibayashi R. [Results in the treatment of cervical cancer at the Kyoto University obstetrical and gynecological clinic] [Article in Japanese]. *Jpn Obstet Gynecol Soc*. 1962;14:471–2.
11. Höckel M. Laterally extended endopelvic resection: surgical treatment of infrailiac pelvic wall recurrences of gynecologic malignancies. *Am J Obstet Gynecol*. 1999;180:306–12.
12. Palfalvi L, Ungar L. Laterally extended parametrectomy, the technique for radical pelvic sidewall dissection. Feasibility, technique, results. *Int J Gynecol Cancer*. 2003;13:914–7.
13. Dargent D, Martin X, Sacchetoni A, Mathevet P. Laparoscopic vaginal radical trachelectomy. *Cancer*. 2000;88:1877–82.
14. Querleu D, Narducci F, Poulard V, Lacaze S, Occelli B, Leblanc E, Cosson M. Modified radical vaginal hysterectomy with or without laparoscopic nerve-sparing dissection: a comparative study. *Gynecol Oncol*. 2002;85:154–8.
15. Höckel M, Konerding MA, Heussel CP. Liposuction-assisted nerve-sparing extended radical hysterectomy: oncologic rationale, surgical anatomy, and feasibility study. *Am J Obstet Gynecol*. 1998;178:971–6.
16. Querleu D, Morrow CP. Classification of radical hysterectomy. *Lancet Oncol*. 2008;9:297–300.
17. Whitmore I. Terminologia anatomica: new terminology for the new anatomist. *Anat Rec*. 1999;257:50–3.
18. Ercoli A, Delmas V, Fanfani F, Gadonneix P, Ceccaroni M, Fagotti A, et al. Terminologia Anatomica versus unofficial descriptions and nomenclature of the fasciae and ligaments of the female pelvis: a dissection-based comparative study. *Am J Obstet Gynecol*. 2005;193:1565–73.
19. Höckel M, Horn LC, Fritsch H. Association between the mesenchymatous compartment of uterovaginal organogenesis and local tumor spread in stage IB–IIB cervical cancer. A prospective study. *Lancet Oncol*. 2005;6:751–6.
20. Yabuki Y, Asamoto A, Hoshihara T, Nishimoto H, Nakamura S. Dissection of the cardinal ligament in radical hysterectomy for cervical cancer with emphasis on the lateral ligament. *Amer J Obstet Gynecol*. 1991;164:7–14.
21. Cibula D, Abu-Rustum NR, Benedetti-Panici P, Köhler C, Raspagliesi F, Querleu D, Morrow CP. New classification system of radical hysterectomy: emphasis on a three-dimensional anatomic template for parametrial resection. *Gynecol Oncol*. 2011;122:264–8.
22. Benedetti-Panici P, Scambia G, Baiocchi G, Maneschi F, Greggi S, Mancuso S. Radical hysterectomy: a randomized study comparing two techniques for resection of the cardinal ligament. *Gynecol Oncol*. 1993;50:226–3.
23. Trimbos JB. TNM-like classification of radical hysterectomy. *Gynecol Oncol*. 2009;113:397–8.
24. Querleu D, Cibula D, Abu-Rustum NR. 2017 Update on the Querleu-Morrow Classification of Radical Hysterectomy. *Ann Surg Oncol*. 2017;24:3406–12.



Laparoscopic Operative Staging in Cervical Cancer

21

Christhardt Köhler and Giovanni Favero

Introduction

Cancer of the uterine cervix is still one of the most common cancers among women worldwide with approximately 530,000 new cases and 275,000 deaths in 2008 [1]. Cervical cancer classically occurs in young patients with a mean age of 45 years, resulting in a potential loss of 26 years of life per affected individual [1, 2]. Unfortunately, about 60% of these cases are diagnosed with advanced disease and are no longer candidates for primary curative surgery. In countries with high resources, total incidence of invasive cervical cancer is decreasing due to effective screening with a shift toward earlier stages of disease [2]. However, percentage of patients with FIGO stages \geq IIB stagnates over years in many countries. This is probably due to women who never made use of screening programs. In Germany percentages of stages II, III, and IV are 25%, 8%, and 6% with 5-year survival of 71%, 51%, and 16%, respectively [3]. Between 2005 and 2008 in Beijing, distribution of FIGO stages II, III, and IV was 26%, 18% and 6%, respectively, mainly in unemployed women and housewives, farmers, and urban low-income people

[4]. There is also a higher risk for cervical cancer for older and/or uninsured people in the USA [5]. Socioeconomic situation influences probability for cervical cancer with higher risk for short-educated, older women living without partners in Denmark, as demonstrated by Ibfelt et al. [6]. Therefore therapy of cervical cancer in locally advanced stage is still a relevant problem.

Individual prognosis depends on many factors. Patient-related factors are age at diagnosis, HIV infection, smoking, and comorbidities like diabetes, thrombocytosis, and anemia. The most important factors are stage of disease (including tumor size, parametric involvement, depth of invasion, infiltration of adjacent organs) and lymph node involvement. Overall survival (5-year OS) for all stages in lymph node-negative patients is 92.1% compared to 64.1% with lymph node-positive histology [7]. Histologic subtype, lymphovascular space involvement, proliferation index, perineural sheath infiltration, peritoneal cytology, as well as tumor marker elevation may influence prognosis. According to the FIGO 26th Annual Report, 5-year overall survival rates are as follows: stage IB2, 75.7%; stage IIA, 73.4%; stage IIB, 65.8%; stage IIIA, 39.7%; stage IIIB, 41.5%; stage IVA, 22.0%; and stage IVB, 9.3% [7].

In NCCI and other national guidelines, primary chemoradiation (RCTX) is the preferred therapy in patients with locally advanced cervical cancer [8]. However, there are also indications for surgery in these stages of disease.

C. Köhler, M.D. (✉) · G. Favero, M.D.
Department of Advanced Operative and
Oncologic Gynecology, Asklepios Hospital,
Hamburg, Germany
e-mail: ch.koehler@asklepios.com

Definition of Locally Advanced Cancer

There is no general accepted definition of “locally advanced disease.” Mono- or multicentric studies have included patients with stage IIB–IVA cancer, others IB2–IVA or IB2–IBV (Lym), or even lymph node-positive tumors <4 cm. Due to this heterogeneity of patient cohort, comparison of these non-randomized trials is rather difficult. Incorporation of patients with positive para-aortic lymph nodes is questionable. According to FIGO classification, histologic-proven para-aortic lymph node metastases are considered as distant metastases (stage IVB Lym), but can be treated with curative intent by extended-field RCTX. Referring to vulvar cancer therapy, there is a tendency to define “locally advanced stages” as those that must be treated by multimodal approach and cannot be cured by one treatment modality alone [9]. However, this multimodal approach is associated with higher treatment-related toxicity and lower survival rate (due to initial tumor size, lymph node involvement, and/or infiltration to parametria or adjacent organs).

Clinical Versus Surgical Laparoscopic Staging

Clinical Staging

In 2009 FIGO committee has decided not to replace the clinical staging because of limited resources in many countries with high incidence of cervical cancer [7]. Therefore clinical staging and furthermore initial therapy mainly depend on the experience of examining gynecologic oncologist. Additionally, therapy-relevant information such as lymph node involvement, intra-abdominal spread, and relation to adjacent organs are not considered. Recommended tests are gynecologic bimanual examination, cystoscopy, rectoscopy, sonography of the kidneys, as well as chest x-ray.

However, reliable information on lymph node status is necessary for a stage-adjusted

therapeutic decision-making. Histologically confirmed pelvic lymph node metastases indicate the use of chemoradiation rather than radical surgery. Patients with proven para-aortic lymph node metastases indeed have a worse prognosis compared to those with pelvic lymph node metastases only. The use of extended-field radiation in the context of chemoradiation leads to long-term survival rates between 35 and 50%. Nearly all patients with unknown and untreated para-aortic lymph nodes will die. On the other side, patients with intraperitoneal spread would not benefit from a primary chemoradiation. In these cases, palliative chemotherapy is certainly more adequate (Fig. 21.1).

Imaging Modalities

Especially in countries with high economic resources, radiology is often used for staging of patients with advanced cervical cancer. However, for the exact determination of accurate tumor stage, parametrial invasion, as well as lymph node metastases, CT and MRI are of limited value [10]. Since the diagnosis of lymph node metastases with CT and MRI is based on the size and shape of lymph nodes, sensitivity of both imaging modalities is rather disappointing for lymph node staging. Several studies and pooled analyses have demonstrated sensitivities of 15–50% and 25–56% and specificities of 85–92% and 86–91% for CT and MRI, respectively, in the detection of lymph node metastases in patients with advanced cervical cancer [11]. The hope (and hype) that FDG-PET/CT would be able to overcome these limitations and therefore to replace surgical staging did not come to fulfillment. The spectrum of reported sensitivities that varies between 33 and 78% compared to histological result of removed para-aortic lymph nodes is therefore disappointing [12–19]. Even in a just-published large retrospective study by Vandepierre et al. (2015) on 336 patients with cervical cancer stage IB2–IVA, para-aortic lymph node metastases were detected in 8% despite negative PET-CT. This result is even more remarkable because para-aortic lymphadenectomy in this study was performed only up to

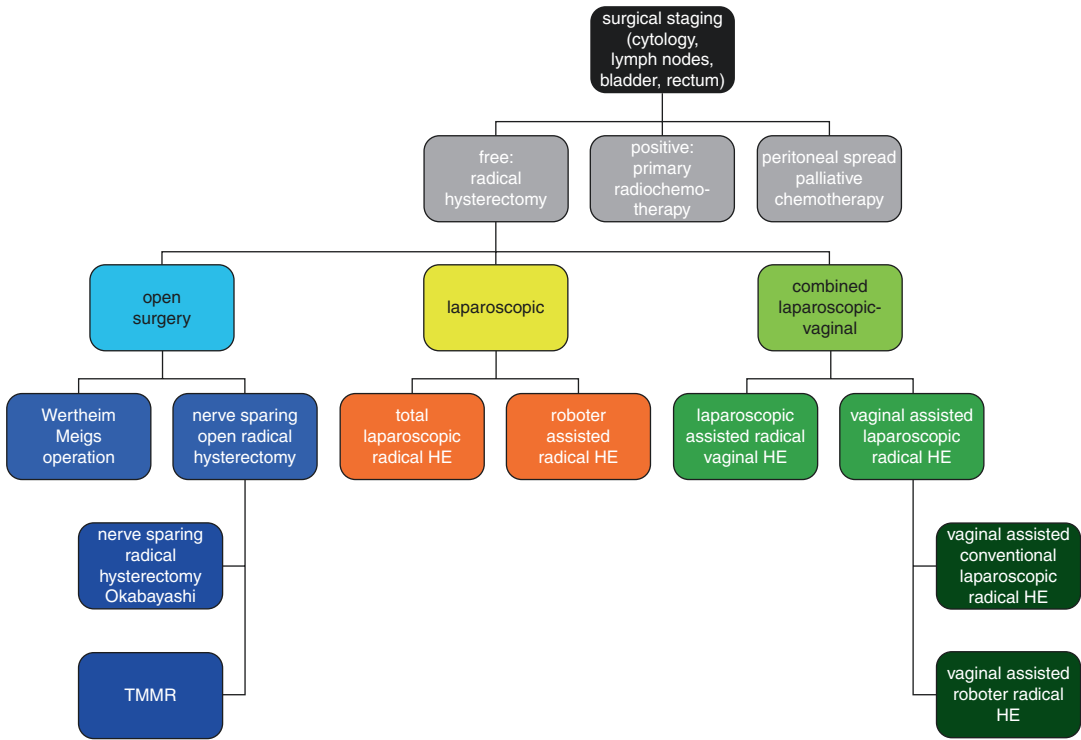


Fig. 21.1 Decision process in patients with locally operable cervical cancer after surgical laparoscopic staging

IMA and therefore only five lymph nodes on average were harvested.

However, there are some results that nodal SUV_{max} may be a prognostic biomarker for recurrence in locally advanced cervical cancer, perhaps in combination with other clinical factors as demonstrated by Sala et al. and Chong et al. [18, 19]. LiLACS trial that is ongoing in recruitment will provide powerful answers in this important field [20].

Laparoscopic Surgical Staging

Although the only alternative to clinical staging is the operative staging in order to evaluate the most important prognostic and therapeutic factors such as lymph node status, involvement of adjacent organs, and intra-abdominal tumor dissemination, surgical staging in patients with locally advanced cervical cancer has been discussed controversially for more than 30 years [21–23]. This is probably due to two reasons:

Firstly, surgical staging can be associated with operative morbidity, especially if it is done by open surgical approaches (10–48%) compared to laparoscopic (trans- or extraperitoneal) and robotic staging (0–7%). Complications arising from the surgical staging may defer in the beginning of primary RCTX and, consequently, negatively impact prognosis [24–27]. Also seldom, port site metastases after laparoscopic staging have been described (Fig. 21.2) [28, 29].

Presently, surgical staging should exclusively be done by transperitoneal or extraperitoneal laparoscopic or robotic approach in order to minimize hospital stay and perioperative morbidity and avoid delay of primary RCTX initiation [30–39].

Secondly, a couple of retrospective studies could demonstrate a significant rate of upstaging in a relevant percentage of patients comparing results of clinical staging with histologic features after surgery (please see passage below). If primary treatment adjusted according to findings of

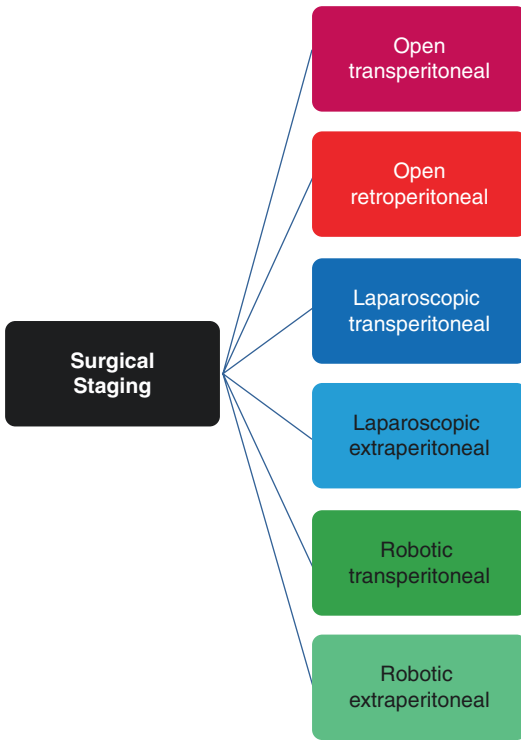


Fig. 21.2 Possible approaches for comprehensive surgical staging in patients with locally advanced cervical cancer

surgical staging is associated with survival, benefit still remains controversial. The one available randomized trial did not show any oncologic benefit. However, this study is very limited in its validity due to a small number of patients included and its premature termination and severe problems with the employed radiation technique [11].

Therefore, the aim was to evaluate this important issue in the treatment of patients with locally advanced cervical cancer in a large prospective randomized setting—international Uterus-11 study (Fig. 21.3).

Nearly all surgical staging procedures within Uterus-11 study were done laparoscopically with minimal perioperative morbidity and no delay in primary chemoradiation as demonstrated by Köhler et al. [37]. Treatment-related toxicity of primary RCTX in both arms was low and comparable to other studies in this field as shown by Marnitz et al. [38]. Oncologic results are expected in 2018. In patients younger than 40 years, ovarian transposition as high as possible (Fig. 21.4) can preserve ovarian function, even in cases of extended-field RCTX (Fig. 21.5) [13].

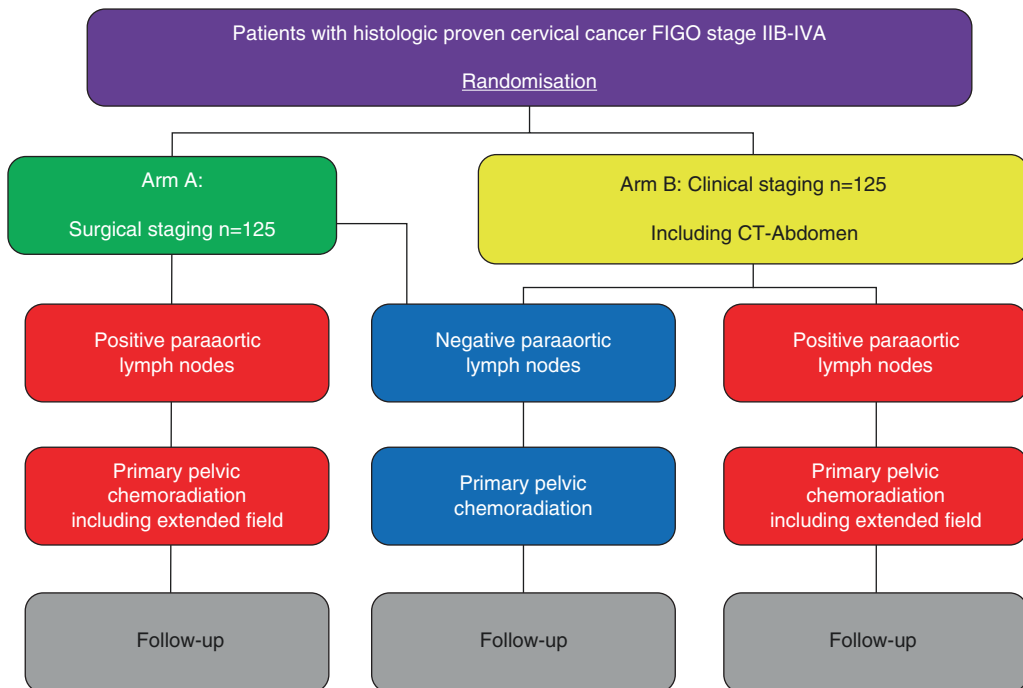


Fig. 21.3 Flowchart of Uterus-11 trial

Fig. 21.4 Transposition of ovaries within paracolic gutters as high and lateral as possible to minimize scattered radiation to the ovaries

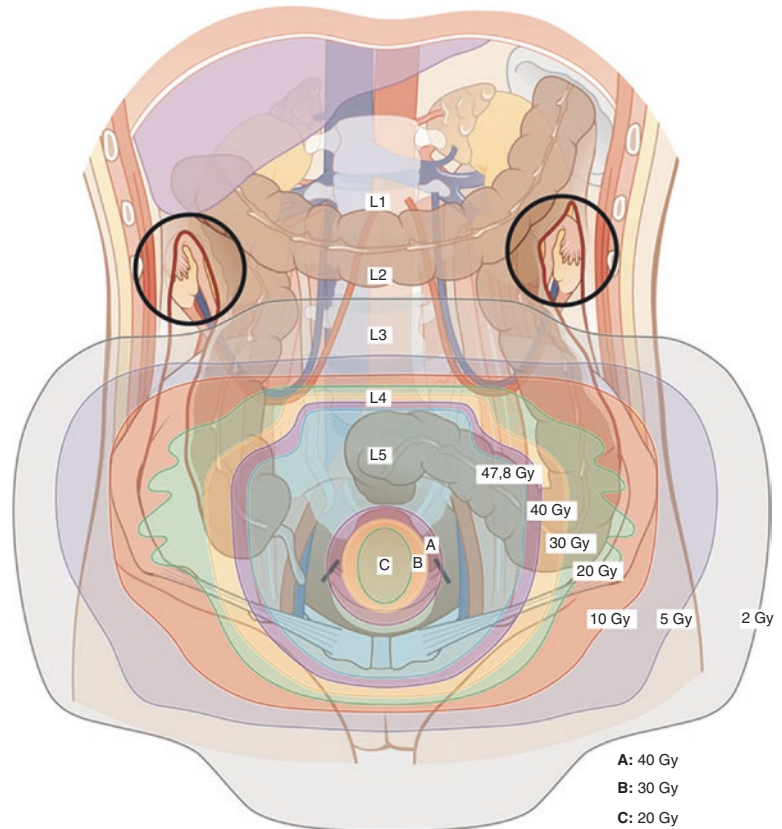
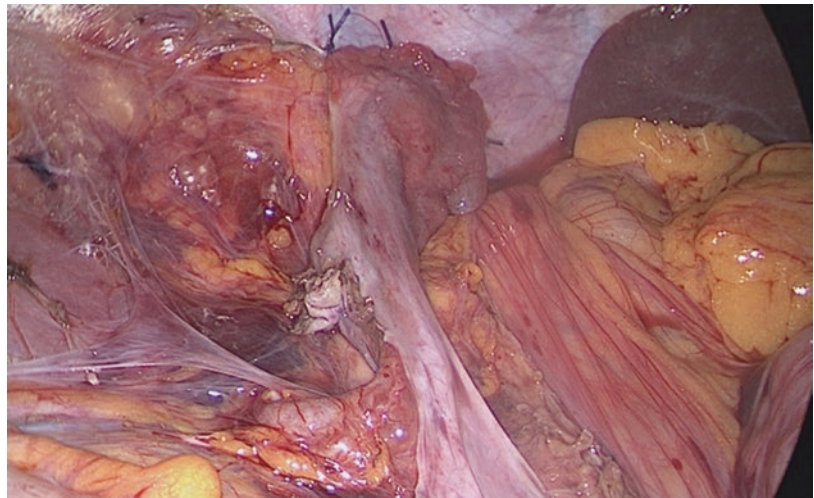


Fig. 21.5 Laparoscopic view of the transposed adnexa at the right side. To note is the correct position of the organ (lateral and high position—liver must be seen) and the application of metallic clips



Incidence of Lymph Node Metastases in Advanced Cervical Cancer

Intuitively, larger tumor size is associated with higher probability for pelvic and/or para-aortic lymph node metastases. Summarized incidence

of lymph node metastases varies considerably within prospective and retrospective studies from 22 to 53% for pelvic nodes and 0 to 38% for para-aortic nodes [34, 40–51]. After adjustment for tumor stage, one can expect para-aortic lymph node metastases in stages IB2, IIB, IIIB, and IVA in 2.3–20%, 0–27%, 9–60%, and

Fig. 21.6 Para-aortic lymph node metastasis in a patient with stage IIB cancer in surgical staging arm of Uterus-11 study with negative preoperative imaging

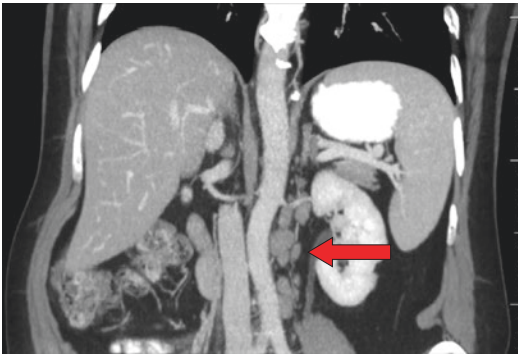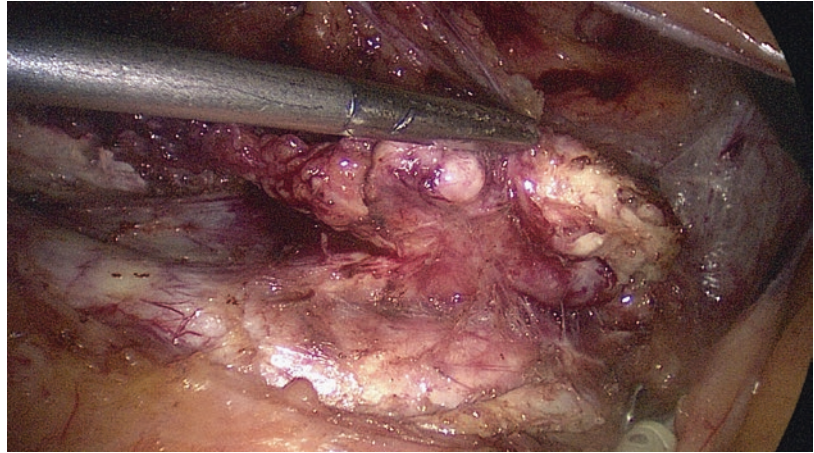


Fig. 21.7 Para-aortic lymph node recurrence in a patient with initial stage IIB cervical cancer and negative CT scan in clinical arm of Uterus-11 study

0–100%, respectively [12, 52–59]. Intra-abdominal tumor spread was detected in 5–20% of patients with locally advanced cervical cancer. Within randomized Uterus-11 trial, Tsunoda et al. found pelvic and para-aortic lymph node metastases after surgical staging in 51% and 24% of patients. In patients with stage IIB, pelvic and para-aortic lymph node metastases were confirmed in 45% and 20% and in stage IIIB in 71% and 37%, respectively [60–63]. If lymph nodes were involved, most often 1–3 pelvic and 1–5 aortic lymph node metastases were detected [64]. Especially the proof and pattern of extent of para-aortic lymph node metastases are important to adjust field of radiation within primary RCTX, because in the past prophylactic para-aortic radiation has demon-

strated conflicting oncologic results and considerable morbidity (Figs. 21.6 and 21.7) [64, 65].

References

1. Arbyn M, Castellsaque X, de Sanjose S, Bruni L, Saraiya M, Bray F, Ferlay J. Worldwide burden of cervical cancer in 2008. *Ann Oncol.* 2011;12:2675–86.
2. Covens A, Rosen B, Murphy J, et al. Changes in the demographics and perioperative care of stage IA2/IB1 cervical cancer over the past 16 years. *Gynecol Oncol.* 2001;81:133–7.
3. Krebs in Deutschland 2009/2010. 9. Ausgabe. Robert Koch-Institut (Hrsg) und die Gesellschaft der epidemiologischen Krebsregister in Deutschland e.V. (Hrsg). Berlin, 2013.
4. Wang T, Wu MH, Wu YM, Zhang WY. A population-based study of invasive cervical cancer patients in Beijing: 1993–2008. *Chin Med J.* 2015;128:3298–304.
5. Fedewa SA, Cokkinides V, Virgo K, Bandi P, Saslow D, Ward EM. Association of insurance status and age with cervical cancer stage at diagnosis: national cancer database, 2000–2007. *Am J Public Health.* 2012;102:1782–90.
6. Ibfelt E, Kjaer S, Johansen C, Hogdall C, Steding-Jessen M, Frederiksen K, Frederiksen BL, Osler M, Dalton S. Socioeconomic position and stage of cervical cancer in Danish women diagnosed 2005 to 2009. *Cancer Epidemiol Biomark Prev.* 2012;21(5):835–42.
7. Quinn MA, Benedet JL, Odicino F, Maisonneuve P, Beller U, Creasman WT, Heintz AP, Ngan HY, Pecorelli S. Carcinoma of the cervix uteri. FIGO 26th Annual report on the results of treatment in Gynecological Cancer. *Int J Gynaecol Obstet.* 2006;95(Suppl 1):S43–103.
8. http://www.nccn.org/professionals/physician_gls/f_guidelines.

9. Expert Panel on Radiation Oncology-Gynecology, Kidd E, Moore D, Varia MA, Gaffney DK, Elshaikh MA, Erickson B, Jhingran A, Lee LJ, Mayr NA, Puthawala AA, Rao GG, Small W Jr, Wahl AO, Wolfson AH, Yashar CM, Yuh W, Cardenes HR. ACR Appropriateness Criteria® management of locoregionally advanced squamous cell carcinoma of the vulva. *Am J Clin Oncol*. 2013;36:415–22.
10. Hricak H, Gatsonis C, Chi DS, Amendola MA, Brandt K, Schwartz LH, Koelliker S, Siegelman ES, Brown JJ, McGhee RB Jr, Iyer R, Vitellas KM, Snyder B, Long HJ 3rd, Fiorica JV, Mitchell DG, American College of Radiology Imaging Network 6651; Gynecologic Oncology Group 183. Role of imaging in pretreatment evaluation of early invasive cervical cancer: results of the intergroup study American College of Radiology Imaging Network 6651- Gynecologic Oncologic Group 183. *J Clin Oncol*. 2005;23:9329–37.
11. Choi HJ, Ju W, Myung SK, et al. Diagnostic performance of computer tomography, magnetic resonance imaging, and positron emission tomography or positron emission tomography/computer tomography for detection of metastatic lymph nodes in patients with cervical cancer: meta-analysis. *Cancer Sci*. 2010;101:1471–9.
12. Leblanc E, Gauthier H, Querleu D, Ferron G, Zerdoud S, Morice P, Uzan C, Lumbroso S, Lecuru F, Bats AS, Ghazdar N, Bannier M, Houvenaeghel G, Brenot-Rossi I, Narducci F. Accuracy of 18-Fluoro-2-deoxy-D: -glucose positron emission tomography in the pretherapeutic detection of occult para-aortic node involvement in patients with a locally advanced cervical carcinoma. *Ann Surg Oncol*. 2011;18:2302–9.
13. Ramirez PT, Jhingran A, Macapinlac HA, Euscher ED, Munsell MF, Coleman RL, Soliman PT, Schmeler KM, Frumovitz M, Ramondetta LM. Laparoscopic extraperitoneal para-aortic lymphadenectomy in locally advanced cervical cancer: a prospective correlation of surgical findings with positron emission tomography/computed tomography findings. *Cancer*. 2010;117:1928–34.
14. Dong Y, Wang X, Wang Y, Liu Y, Zhang J, Qian W, Wu S. Validity of 18FDG positron emission tomography/computed tomography for pretreatment evaluation of patients with cervical carcinoma. A retrospective pathology-matched study. *Int J Gynecol Cancer*. 2014;24:1642–7.
15. Gouy S, Morice F, Narducci F, Uzan C, Rey A, Bentivegna E, Pautier P, Deandreis D, Querleu D, Haie-Meder C, LeBlanc E. Prospective multicenter study evaluating the survival of patients with locally advanced cervical cancer undergoing laparoscopic para-aortic lymphadenectomy before chemoradiotherapy in the era of PET. *JCO*. 2013;31:3026–33.
16. Aravena D, Pruzzo R, Barrera N, Amaral H, Torres P, McConell Y, Ramirez S. Accuracy of 18FDG PET/CT for the detection of para-aortic lymph node metastasis in patients with early bulky and locally advanced uterine cervical carcinoma. First national experience. *Int J Gynecol Cancer*. 2015;25(Suppl 1):16.
17. Smits RM, Zusterzeel P, Bekkers R. Pretreatment retroperitoneal para-aortic lymph node staging in advanced cervical cancer. A review. *Int J Gynecol Cancer*. 2014;24:973–83.
18. Chong G, Jeong S, Park S, Lee Y, Lee S, Hong D, Kim J, Lee Y, Cho Y. Comparison of the prognostic value of F-18-PETmetabolic parameters of primary tumors and regional lymph nodes in patients with locally advanced cervical cancer who are treated with concurrent chemoradiotherapy. *PLoS One*. 2015;10:e0137743.
19. Sala E, Micco M, Burger I, Yakar D, Kollmaier M, Goldman D, Gonen M, Park K, Abu-Rustum N, Hricak H, Vargas H. Complementary prognostic value of pelvic MRI and whole-body FDG PET/CT in the pretreatment assessment of patients with cervical cancer. *Int J Gynecol Cancer*. 2015;25:1461–7.
20. Frumovitz M, Querleu D, Gil-Moreno A, Morice P, Jhingran A, Munsell M, Macapinlac H, LeBlanc E, Martinez A, Ramirez P. Lymphadenectomy in Locally Advanced Cervical Cancer Study (LiLACS): a phase III clinical trial comparing surgical to radiologic staging in patients with stages IB2-IVAcervical cancer. *J Minim Invasive Gynecol*. 2014;21:3–8.
21. Fastrez M, Goffin F, Vergote I, et al. Multi-center experience of robot-assisted laparoscopic para-aortic lymphadenectomy for staging of locally advanced cervical carcinoma. *Acta Obstet Gynecol Scand*. 2013;92:895–901.
22. Marnitz S, Kohler C, Roth C, et al. Is there a benefit of pretreatment laparoscopic transperitoneal surgical staging in patients with advanced cervical cancer? *Gynecol Oncol*. 2005;99:536–44.
23. Fagotti A, Fanfani F, Longo R, et al. Which role for pre-treatment laparoscopic staging? *Gynecol Oncol*. 2007;107:S101–5.
24. Fine BA, Hempling RE, Piver MS, Baker TR, McAuley M, Driscoll D. Severe radiation morbidity in carcinoma of the cervix: impact of pretherapy surgical staging and previous surgery. *Int J Radiat Oncol Biol Phys*. 1995;31:717–23.
25. Gouy S, Morice P, Narducci F, Uzan C, Gimore J, Kolesnikov-Gauthier H, Querleu D, Haie-Meder C, Leblanc E. Nodal staging surgery for locally advanced cervical cancer in the era of PET. *Lancet Oncol*. 2012;13:e212–20.
26. Haie C, Pejovic MH, Gerbaulet A, Horiot JC, Pourquier H, Delouche J, Heinz JF, Brune D, Fenton J, Pizzi G, Bey P, Brossel R, Pillement P, Volterrani F, Chassagne D. Is prophylactic para-aortic irradiation worthwhile in the treatment of advanced cervical carcinoma? Results of a controlled clinical trial of the EORTC radiotherapy group. *Radiother Oncol*. 1988;11:101–12.
27. Ghezzi F, Cromi A, Serati M, Uccella S, Formenti G, Bogani G, Vanoli P. Radiation-induced bowel complications: laparoscopic versus open staging of gynecologic malignancy. *Ann Surg Oncol*. 2011;18:782–91.

28. Martinez A, Querleu D, LeBlanc E, Narducci F, Ferron G. Low incidence of port-site metastases after laparoscopic staging of uterine cancer. *Gynecol Oncol.* 2010;118:145–50.
29. Park JY, Lim MC, Lim SY, Bae JM, Yoo CW, Seo SS, Kang S, Park SY. Port-side and liver metastases after laparoscopic pelvic and para-aortic lymph node dissection for surgical staging of locally advanced cervical cancer. *Int J Gynecol Cancer.* 2008;18:176–80.
30. Gouy S, Morice P, Narducci F, et al. Prospective multicenter study evaluating the survival of patients with locally advanced cervical cancer undergoing laparoscopic para-aortic lymphadenectomy before chemoradiotherapy in the era of positron emission tomography imaging. *J Clin Oncol.* 2013;31:3026–33.
31. Gil-Moreno A, Franco-Camps S, Cabrera S, et al. Pretherapeutic extraperitoneal laparoscopic staging of bulky or locally advanced cervical cancer. *Ann Surg Oncol.* 2011;18:482–9.
32. Del Pino M, Fuste P, Pahisa J, et al. Laparoscopic lymphadenectomy in advanced cervical cancer: prognostic and therapeutic value. *Int J Gynecol Cancer.* 2013;23:1675–83.
33. Diaz-Feijoo B, Gil-Ibanez B, Perez-Benavente A, et al. Comparison of robotic-assisted vs conventional laparoscopy for extraperitoneal paraaortic lymphadenectomy. *Gynecol Oncol.* 2014;132:98–101.
34. Hasenburg A, Salama JK, Van TJ, et al. Evaluation of patients after extraperitoneal lymph node dissection and subsequent radiotherapy for cervical cancer. *Gynecol Oncol.* 2002;84:321–6.
35. Denschlag D, Gabriel B, Mueller-Lantzsch C, et al. Evaluation of patients after extraperitoneal lymph node dissection for cervical cancer. *Gynecol Oncol.* 2005;96:658–64.
36. Vandepierre A, Van Limbergen E, Leunen K, Moerman P, Amant F, Vergote I. Para-aortic lymph node metastases in locally advanced cervical cancer: comparison between surgical staging and imaging. *Gynecol Oncol.* 2015;138:299–303.
37. Köhler C, Mustea A, Marnitz S, Schneider A, Chiantera V, Ulrich U, Scharf JP, Martus P, Vieira MA, Tsunoda A. Perioperative morbidity and rate of upstaging after laparoscopic staging for patients with locally advanced cervical cancer: results of a prospective randomized trial. *Am J Obstet Gynecol.* 2015;213:503.e1–7.
38. Marnitz S, Martus P, Köhler C, Stromberger C, Asse E, Mallmann P, Schmidberger H, Junior R, Nunes J, Sehouli J, Budach V. Role of surgical versus clinical staging in chemoradiated FIGO stage IIB-IVA cervical cancer patients—acute toxicity and treatment quality of the Uterus 11 multicenter phase III intergroup trial of the German Radiation Oncology Group and the Gynecologic Cancer Group. *Int J Radiat Oncol Biol Phys.* 2016;94:243–53.
39. Ghadjar P, Budach V, Köhler C, Jantke A, Marnitz S. Modern radiation therapy and potential fertility preservation strategies in patients with cervical cancer undergoing chemoradiation. *Radiat Oncol.* 2015;10:50.
40. Hertel H, Köhler C, Elhawary T, Michels W, Possover M, Schneider A. Laparoscopic staging compared with imaging techniques in the staging of advanced cervical cancer. *Gynecol Oncol.* 2002;87:46–51.
41. Del Pinto M, Fuste P, Pahisa J, Rovirosa A, Martinez-Serrano MJ, Martinez-Roman S, Alonso I, Vidal L, Ordi J, Torne A. Laparoscopic lymphadenectomy in advanced cervical cancer. Prognostic and therapeutic value. *Int J Gynecol Cancer.* 2013;23:1675–83.
42. Chung HH, Lee S, Sim JK, Kim JY, Seo SS, Park SY, Roh JW. Pretreatment laparoscopic surgical staging in locally advanced cervical cancer: preliminary results in Korea. *Gynecol Oncol.* 2005;97:468–75.
43. Lai CH, Huang KG, Hong JH, Lee CL, Chou HH, Chang TC, Hsueh S, Hang HJ, Ng KK, Tsai CS. Randomized trial of surgical staging (extraperitoneal or laparoscopic) versus clinical staging in locally advanced cervical cancer. *Gynecol Oncol.* 2003;89:160–7.
44. Michel G, Morice P, Castaigne D, Leblanc M, Rey A, Duvillard P. Lymphatic spread in stage IB and II cervical carcinoma. Anatomy and surgical implications. *Obstet Gynecol.* 1998;91:360–3.
45. Odunsi KO, Lele S, Ghamande S, Seago P, Driscoll DL. The impact of pre-therapy extraperitoneal surgical staging on the evaluation and treatment of patients with locally advanced cervical cancer. *Eur J Gynecol Oncol.* 2001;22:325–30.
46. Querleu D, Dargent D, Ansquer Y, LeBlanc E, Narducci F. Extraperitoneal endosurgical aortic and common iliac dissection in the staging of bulky or advanced cervical carcinomas. *Cancer.* 2000;88:1883–91.
47. Recio FO, Piver MS, Hempling RE. Pretreatment transperitoneal laparoscopic staging pelvic and para-aortic lymphadenectomy in large (≥ 5 cm) stage IB2 cervical carcinoma: report of a pilot study. *Gynecol Oncol.* 1996;63:333–6.
48. Tillmanns T, Lowe MP. Safety, feasibility and costs of outpatient laparoscopic extraperitoneal aortic nodal dissection for locally advanced cervical carcinoma. *Gynecol Oncol.* 2007;106:370–4.
49. Weiser EB, Bundy BN, Hoskins WJ, Heller PB, Whittington RR, DiSaia PJ, Curry SL, Schlaerth J, Thippen JT. Extraperitoneal versus transperitoneal selective paraaortic lymphadenectomy in the pretreatment surgical staging of advanced cervical carcinoma (a GOG study). *Gynecol Oncol.* 1989;33:283–9.
50. Zanvettor PH, Filho DF, Neves AR, Amorim M, Medeiros SM, Laranjeiras L, Morais JA, Araujo IO, Barbosa HS. Laparoscopic surgical staging of locally advanced cervix cancer (IB2 to IVA): initial experience. *Gynecol Oncol.* 2011;120:358–61.
51. Holcomb K, Abulafia O, Matthews RP, Gabbur N, Lee YC, Buhl A. The impact of pretreatment staging laparotomy on survival in locally advanced cervical carcinoma. *Eur J Gynaecol Oncol.* 1999;20:90–3.

52. LaPolla JP, Schlaerth JB, Gaddis O, Morrow CP. The influence of surgical staging on the evaluation and treatment of patients with cervical carcinoma. *Gynecol Oncol*. 1986;24:194–206.
53. Leblanc E, Narducci F, Frumovitz M, Lesoin A, Castelein B, Baranzelli MC, Taieb S, Fournier C, Querleu D. Therapeutic value of pretherapeutic extraperitoneal laparoscopic staging of locally advanced cervical carcinoma. *Gynecol Oncol*. 2007;111:304–11.
54. Margulies AL, Peres A, Barranger E, Perreti I, Brouland JF, Toubet E, Sarda-Mantel LE, Thoury A, Chis C, Walker F, Luton D, Delpech Y, Koskas M. Selection of patients with advanced-stage cervical cancer for para-aortic lymphadenectomy in the era of PET/CT. *Anticancer Res*. 2013;33:283–6.
55. Mortier DG, Stroobants S, Amant F, Neven P, van Limbergen E, Vergote I. Laparoscopic para-aortic lymphadenectomy and positron emission tomography scan as staging procedures in patients with cervical carcinoma stage IB2-IIIb. *Int J Gynecol Cancer*. 2008;18:723–9.
56. Vidauretta J, Bermudez A, di Paola G, Sardi J. Laparoscopic staging in locally advanced cervical carcinoma: a new possible philosophy. *Gynecol Oncol*. 1999;75:366–71.
57. Chu KK, Chang SD, Chen FP, Soong YK. Laparoscopic surgical staging in cervical cancer—preliminary experience among Chinese. *Gynecol Oncol*. 1997;64:49–53.
58. Heller PB, Malfetano JH, Bundy BN, Barnhill DR, Okagaki T. Clinical-pathologic study of stage IIB, III, and IVA carcinoma of the cervix: extended diagnostic evaluation for paraaortic node metastasis—a Gynecologic Oncology Group study. *Gynecol Oncol*. 1990;38:425–30.
59. Benedetti-Panici P, Perniola G, Tomao F, Fischetti M, Savone D, Di Donato V, Angioli R, Muzii L. An update of laparoscopy in cervical cancer staging: is it a useful procedure? *Oncology*. 2013;85:160–5.
60. Kasamutsa T, Onda T, Sasajima Y, Kato T, Ikeda S, Ishikawa M, Tsuda H. Prognostic significance of positive peritoneal cytology in adenocarcinoma of the uterine cervix. *Gynecol Oncol*. 2009;115:488–92.
61. Benedetti-Panici P, Bellati F, Manci N, Pernice M, Plotti F, DiDonato V, Calcagno M, Zullo MA, Muzii L, Angioli R. Neoadjuvant chemotherapy followed by radical surgery in patients affected by FIGO stage IVA cervical cancer. *Ann Surg Oncol*. 2007;14:2643–8.
62. Tsunoda A, Marnitz S, Andrade C, Neto C, Blohmer J, Herrmann J, Kerr L, Nunes J, Martus P, Schneider A, Favero G, Köhler C. Incidence of histologic proven pelvic and para-aortic lymph node metastases and rate of upstaging in patients with locally advanced cervical cancer—results of a prospective randomised trial. *Gynecol Oncol*, submitted.
63. Asiri MA, Tunio MA, Mohamed R, Bayoumi Y, Alhadab A, Saleh RM, AlArifi MS, Alobaid A. Is extended-field concurrent chemoradiation an option for radiologic negative paraaortic lymph node, locally advanced cervical cancer? *Cancer Manag Res*. 2014;6:339–48.
64. Yap ML, Cuartero J, Yan J, Pintilie M, Fyles A, Levin W, Manchul L, Milosevic M. The role of elective para-aortic lymph node irradiation in patients with locally advanced cervical cancer. *Clin Oncol (R Coll Radiol)*. 2014;26:797–803.
65. Park SG, Kim JH, Oh YK, Byun SJ, Kim MY, Kwon SH, Kim OB. Is prophylactic irradiation to para-aortic lymph nodes in locally advanced cervical cancer necessary? *Cancer Res Treat*. 2014;46:374–82.



Laparoscopic-Vaginal Radical Hysterectomy

22

Denis Querleu and Eric Leblanc

Considering that [1] all the components of a radical hysterectomy can be completed laparoscopically and [2] all the components of a radical hysterectomy but the lymph node dissection can be completed laparoscopically, a laparoscopic-vaginal operation combines at least the vaginal incision and the making of the vaginal cuff by the vaginal route and at least the lymph node dissection by the laparoscopic approach. The rest of the components can be performed by either route. The order of these 2 constant steps: i.e., vaginal cuff creation and lymph node dissection, is not fixed, as the operation can start vaginally and can be completed laparoscopically or the other way. Overall, the vaginal route is not adapted to the management of stage II or bulky tumors, which implies that the scope of this chapter is to describe technical options adapted to the surgical management of stage IA2 and IB1 cervical cancers.

History [1, 2]

The concept was pioneered by Dargent in the late 1980s. Following the principles of Mitra, an Indian surgeon who performed an open extraperitoneal pelvic lymph node dissection via two lateral abdominal incisions and then a full Schauta (radical vaginal hysterectomy), he proposed to combine an extraperitoneal endoscopic dissection with a Schauta operation. Dargent has also been the inventor of the radical vaginal trachelectomy, a fertility-sparing Schauta operation limited to the cervix, retaining the isthmus, uterus, and adnexae.

From 1989, the concurrent successful development of the transperitoneal laparoscopic pelvic node dissection induced a modification of the endosurgical approach, which combined a laparoscopic step including visual examination of the pelvis and abdomen and surgical staging.

The synchronous development of reliable hemostasis techniques such as bipolar cautery made possible the completion of full laparoscopic radical hysterectomies and at the same time favored in the minds of those surgeons skilled in radical vaginal techniques the advent of a new idea: a combination of laparoscopic and of vaginal steps to complete the radical hysterectomy itself, making the most of both approaches while sparing the patient the discomfort associated with the perineotomy routinely performed at the beginning of the traditional Schauta operation.

D. Querleu, M.D. (✉)
Department of Surgical Oncology,
Institut Bergonie, Bordeaux, France
e-mail: denis.querleu@esgo.org

E. Leblanc, M.D.
Department of Gynaecologic Oncology,
Oscar Lambret Center, Lille, France
e-mail: e-leblanc@o-lambret.f

The Original Laparoscopically Assisted Vaginal Radical Hysterectomy (LAVRH)

The original description of the LAVRH published in 1991 in the French language literature [3] and in 1993 in the English language literature [4] is a modified or class II radical hysterectomy and since then was classified as a type B1 radical hysterectomy including the excision of the paracervix (“cardinal ligament”) from the cervix to the ureter. Overall, the modern vaginal route, without perineotomy, is not adapted to the type C operation required for the management of stage II or bulky tumors.

Technique

Laparoscopic Approach

The operative procedure requires 4.5 mm scissors, grasping forceps, irrigation-aspiration device, and bipolar coagulation forceps. We advise the use of bipolar grasping forceps with flat tips for fine hemostasis close to the ureter, bowel, or large vessels. Endoscopic clips must be available to control bleeding from large vessels or to radiologically localize fixed nodes. Sponges are convenient to clean the operative field and facilitate suction. More sophisticated instruments such as argon beam coagulator, ultrasonic dissectors, or thermal fusion devices can be used at surgeon’s choice but do not add the safety and duration of the procedure.

A pneumoperitoneum is created. We routinely use a left upper quadrant approach for the Veress needle. A 10 mm laparoscope is introduced through a minimal umbilical incision in patients without history of laparotomy. In case of previous laparotomy, a syringe test is routinely performed in order to choose the safest location, usually above the umbilicus. As an additional precaution, the direct vision technique using the Endotip® trocar is used for the introduction of the 10 mm trocar. The video camera is attached.

Pelvic Lymphadenectomy

The boundaries of dissection are, laterally, the external iliac vessels, the psoas muscle, and

then the pelvic wall; medially, the superior vesical artery; caudally, the circumflex iliac vein crossing over the external iliac artery, the Cooper’s ligament, and the pubic bone; and cranially, the common iliac bifurcation and the ureter. The arbitrary deep limit is the obturator nerve.

The first step is the opening of the paravesical space between the round and infundibulopelvic ligaments. The peritoneum is incised. The external iliac vessels are exposed from the circumflex iliac vein caudally, up to the common iliac bifurcation cranially. Medially the obliterated superior vesical artery is found out that will be the internal limit of dissection. The bladder is moved medially. The obturator vasculo-nervous bundle is reached and will represent the inferior limit of dissection. All specimens are removed through the 10–12 mm suprapubic trocar, previously placed in a bag if they appear too large.

Laparoscopic Preparation of the Radical Vaginal Hysterectomy

In the original technique, the infundibulopelvic ligaments and the round ligaments are divided laparoscopically. The pararectal space is opened. The origin of the uterine artery is identified and skeletonized. The uterine artery is divided after bipolar cautery or placement of clips (Fig. 22.1).

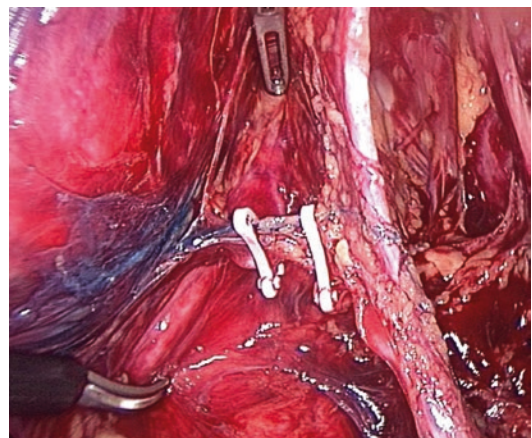


Fig. 22.1 The uterine artery is divided laparoscopically, using bipolar cautery of Hemolok® clips

Vaginal Step

The role of the laparoscopic preparation is to make easier the vaginal step. The development of the paravesical and pararectal space makes the uterus more mobile. The division of the upper ligaments frees the uterine fundus. The division of the uterine artery, at a point which cannot be reached from the vaginal route, ensures hemostasis. All combined, the components of the laparoscopic step make the vaginal step easier. For this reason, there is no need for an episiotomy to perform the radical hysterectomy.

It is generally recognized that the template for vaginal resection is not governed by “set menus” like in the Piver model but should only be driven by the objective to get a clear margin. Even though no data is available to set a standard, a 1–2 cm margin aiming at getting at least a 5 mm pathological margin seems to be a reasonable objective. In stages IA2 and low-volume IB1, colpectomy is not mandatory. However, a 1 cm vaginal cuff is made for purely technical reasons. A vaginal cuff is necessary to handle the specimen.

The vaginal step starts with the making of the vaginal cuff using long Kocher forceps (Fig. 22.2). The cuff is firmly pulled down, creating a fold which is infiltrated with vasopressin. The external layer of the fold is incised, forming the vaginal cuff. The vaginal cuff is closed by a series of forceps joining the ventral and dorsal aspect of the vaginal specimen. The cuff can then

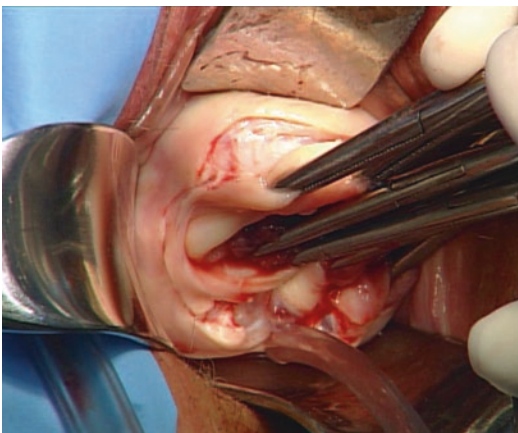


Fig. 22.2 Making the vaginal cuff

be grasped and oriented in order to facilitate the following steps of the surgery, generally by pulling in the opposite direction, e.g., pulling ventrally to show the pouch of Douglas or pulling dorsally and left laterally to work in the right bladder pillar area.

The next step is dorsal. The pouch of Douglas is opened as widely as possible. The peritoneal incision is extended in the direction of the posterior leaf of the broad ligament in order to mobilize the uterus. The lateral aspect of the two rectovaginal ligaments is then delineated by creating the pararectal space. To achieve this, two forceps are placed at the 3 and 4 o'clock positions on the left side and 9 and 10 o'clock positions on the right side. The pararectal space is created by opening the areolar tissue separating the deep surface of the vagina from the rectovaginal ligament. The rectovaginal ligaments are then cauterized, preferentially using bipolar cautery, and then divided.

The following step is ventral. The ventral edge of the vaginal incision is firmly elevated to facilitate the opening of the vesicovaginal septum and to avoid a bladder injury. The vesicouterine septum is then developed up to the vesical peritoneal fold and laterally to the broad ligament. The arch of the uterine artery must be clearly visible on both sides to ensure that the right plane has been developed. A retractor is placed in the vesicouterine septum. It will be kept in the septum until the end of the operation and oriented according to the needs of lateral steps.

The crucial step of the dissection of the ureters can now be undertaken. Only the dissection of the left will be described. The right side is exactly symmetrical. The key is to understand that the ureter runs within a surgical structure named “bladder pillar,” which joins the uterus and the paracervix (“cardinal ligament”) to the bladder base. The bladder pillar is then made of two components: a medial vesicouterine ligament component, which must be divided in order to completely separate the bladder base and the terminal ureter from the uterus, and a lateral component, the lateral ligament of the bladder, which must be spared in a type B operation. In addition, the ureter is moved down by

the traction exerted on the vaginal cuff, thus forming a “knee” as its lowest point. The uterine artery, which crosses over the ureter, seems to come out from the knee in its course toward the uterus.

The bladder pillar runs between the vesicovaginal and vesicouterine septum medially and the paravesical space laterally. Consequently, the key of the dissection of the ureter is the development of the paravesical space. To achieve this, two forceps are placed at the 2 and 3 o’clock position on the edge of the vaginal incision. The two forceps are pulled by the assistant, which creates a dimple close to the deep surface of the vaginal wall. The dimple is enlarged and deepened, up to the point where the endopelvic fascia is crossed. A retractor can then be placed in the paravesical space. The bladder pillar is the structure which runs from the uterus to the bladder between the retractor placed in the paravesical space and the retractor placed in the vesicouterine septum (Fig. 22.3).

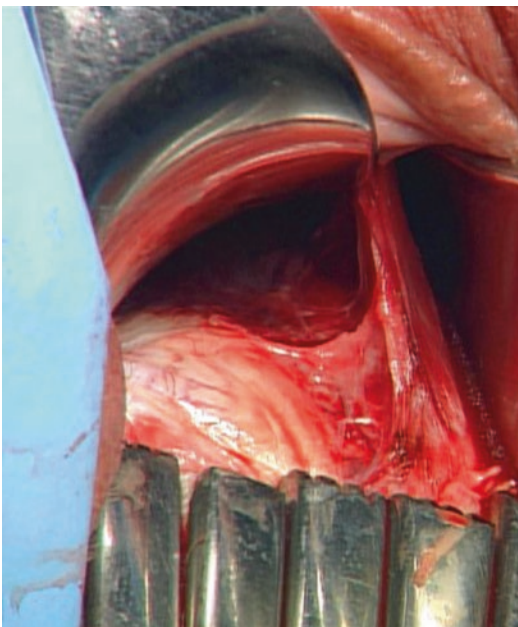


Fig. 22.3 The left bladder pillar. The vaginal cuff is grabbed in a group of Chrobak forceps. A retractor is placed in the vesicouterine septum and another in the left paravesical space

The ureter is palpated within the bladder pillar, using a forefinger placed in the vesicouterine septum, while the retractor placed in the paravesical septum is used as an anvil to make the palpation more characteristic (Fig. 22.4). Recognizing the typical “pop” of the ureter is a crucial part of the operation and a major component of the learning curve.

A right-angle dissector is then placed under the knee of the ureter, which delineates the vesicouterine ligament. The vesicouterine ligament is divided after bipolar cautery. After achieving this bilaterally, the bladder base is made detached from the uterus, and the ventral aspect of the paracervix is visible. The dorsal aspect is then detached from the vaginal route by blunt or sharp dissection of the paracolpos, which gives access to the dorsal aspect of the paracervix. Bipolar cautery and division of the paracervix are made possible.

The rest of the operation consists of “retrieving” the uterine artery by simply pulling on it—the artery has been divided at the time of the laparoscopic step—and of opening the vesical peritoneal fold. The specimen is removed, and the vaginal incision is closed after checking of the hemostasis. No drainage is used, but a bladder catheter is placed, generally for 2 days in our experience.

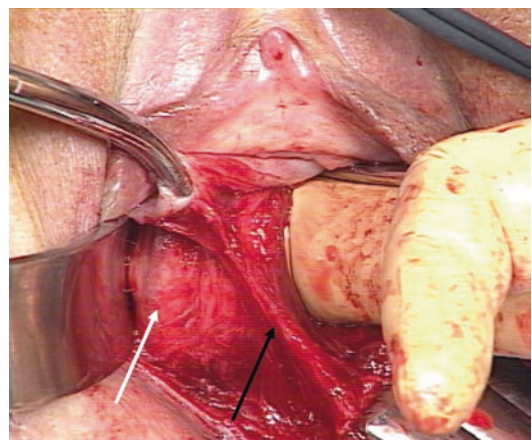


Fig. 22.4 Palpating the ureter (white arrow) in the right bladder pillar. A retractor is placed in the paravesical space. The finger is placed in the vesicouterine septum. The vesicouterine ligament is visible (black arrow), ready for division after bipolar cautery

Results

Several experimental randomized studies by independent investigators have provided evidence that the node count of laparoscopic dissections is not inferior to open dissections. The complication rate is extremely low in experienced hands [5–7]. Obesity is not a contraindication and is not associated with a reduction in the number of retrieved nodes. Feasibility is high in patients with a BMI under 35 [8].

After the initial description of laparoscopically assisted radical vaginal hysterectomy, large series have been published, with reassuring results [9–11]. As a consequence, radical vaginal hysterectomy combined with laparoscopic lymphadenectomy is an acceptable alternative to full radical hysterectomy.

Variants of the Original Technique

Tailoring Radicality

Type A Vaginal Surgeries

The original LAVRH is typically a type B surgery, a surgery in which the paracervix is excised at the ureter. However, there is evidence that parametrial involvement is extremely unfrequent in node-negative low-volume (less than 2 cm in diameter) early cervical cancers with no deep stromal invasion and/or lymph-vascular space invasion. Tumors featuring these low-risk characteristics might not require a modified radical hysterectomy. On the other hand, simple extrafascial hysterectomy may result in incomplete excision of the cervix or in cut-through incomplete operations when the preoperative workup misses deep stromal invasion. As a consequence, a radical hysterectomy or a radical trachelectomy, removing only the proximal part of the cardinal ligament, midway between the uterus and ureter (type A) is a logical trade-off. Reducing radicality aims at reducing the risk of urinary dysfunction and of ureteric fistula.

In a type A vaginal surgery, the ureters are localized by palpation after opening of the paravesical space and of the vesicouterine septum but

not necessarily dissected. The paracervix is individualized in the same way than in the original operation but divided halfway between the uterus and ureter. Bipolar cautery is an ideal tool to precisely cauterize before cutting.

Fertility-Sparing Surgery

Although full laparoscopic radical trachelectomy has been described, the vaginal radical trachelectomy pioneered by Dargent remained the most cost-efficient option in experienced hands. Radical vaginal trachelectomy is a fertility-sparing procedure adapted to selected patients, with node-negative exocervical squamous cell carcinomas less than 2 cm in diameter. The procedure starts with a laparoscopic pelvic lymphadenectomy and is finished vaginally with a laterally extended removal of the cervix inspired from the Schauta operation, with the difference that the uterine isthmus and at least 5 mm of endocervical canal are preserved. A permanent cerclage is placed and a uterovaginal anastomosis is performed. Independent reports have confirmed the oncological safety and obstetrical results of the procedure [12].

Paracervical (Parametrial) Lymphadenectomy [13]

The high short- and long-term urinary dysfunction or complication rate of classical (type C2) radical hysterectomy has motivated the evolution toward a reduction in radicality. Stage I cervical carcinomas are presently managed by modified radical hysterectomy (type B1), with no apparent increase in the rate of lateropelvic recurrence. However, the well-documented finding of pathologically or biologically positive parametrial nodes in patients at risk (tumors larger than 2 cm with lymph-vascular space invasion and/or deep stromal invasion) suggests a risk of late development of micrometastasis [14].

The paracervical lymphadenectomy (see chapter on classification of radical hysterectomy) is a removal of the lymph node-bearing tissue of the lateral part of the paracervix sparing the nerves and vessels which form the skeleton of this part of the so-called cardinal ligament. The use of laparoscopic magnification is logically

associated with a safe dissection and preservation of the vascular and nerve content of the distal part of the cardinal ligament. This nerve-sparing dissection of the lateral part of the cardinal ligament is supposed to prevent late lateropelvic recurrences without further impairing urinary function. In other terms, the type B2 combination of a modified (laparoscopic, vaginal, or laparoscopic-vaginal) radical hysterectomy with a parametrial lymph node dissection combines the radicality of extensive parametrial resection (type C) with the low morbidity of a modified radical hysterectomy (type B).

Increasing Radicality

In 1993, Dargent proposed a modification of the technique involving a wider resection of the cardinal ligament, to which he gave the name of “coelio-Schauta” (coelioscopie is the French name for laparoscopy). The paracervix was divided laparoscopically at the internal iliac vessels by the application of an Endo-GIA[®], ensuring the equivalent of a type C operation [15].

Schneider et al. developed a vaginal technique involving a wide resection of the paracervix using the original techniques of Schauta and followers [10].

Starting Vaginally

Starting the operation vaginally has several potential advantages, first and foremost to take advantage of one of the major benefits of the vaginal route: a precise incision adapted to the vaginal extent of the disease. Indeed, the laparoscopic opening of the vagina is often arbitrary and potentially imprecise. Another theoretical advantage is to complete the laparoscopic operation without any risk of spillage of tumor content in the abdomen, an event which is potentially harmful during laparoscopic operations.

Schauthem

Eric Leblanc carved the word Schauthem to describe a technical variant which starts

vaginally like a Schauta operation and is finished laparoscopically like a Wertheim operation. The vaginal cuff is made using the technique described above. It is closed using interrupted or continuous suturing. Stay sutures are kept, and the vaginal introitus is made airtight by placing a balloon device or the cheaper glove packed with a sponge. The laparoscopic part of the operation can start. The infundibulopelvic (or cornual pedicles) and the round ligaments are divided. The ureters are identified and freed. The origin of the uterine artery is skeletonized and then divided. A type A or B radical hysterectomy is then completed after dividing the peritoneal of the vesical fold, of the rectouterine peritoneal fold, and of the pouch of Douglas. Of note, the opening of the peritoneum does not provide a direct access to the vaginal cavity (Fig. 22.5). A fine layer of connective tissue still separates the vesicouterine and rectovaginal septums from the vaginal route. This layer must be incised to complete the operation, which is finished by the division of the cardinal ligament at the appropriate distance from the uterus.

Schauta Sine Utero [16]

Patients referred after the finding of cervical carcinoma on a simple hysterectomy specimen may be proposed an additional surgery

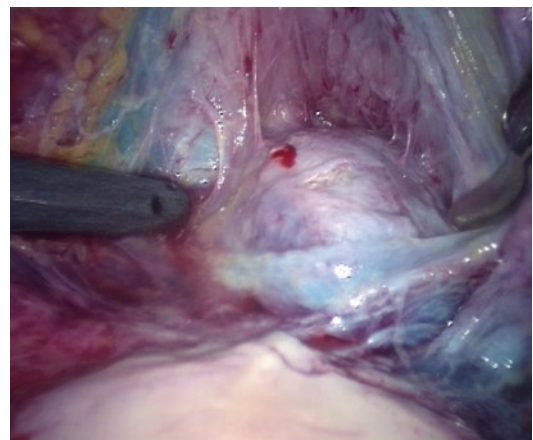


Fig. 22.5 After the incision of the vesical fold, the sponge placed in the vagina is visible under a fine membrane which must be incised to gain access to the vaginal cavity

involving upper colpectomy and parametrectomy. While the lymph node dissection can be completed laparoscopically, the rest of the procedure can be completed laparoscopically. The technique is similar to the “Schautheim” technique.

Conclusion

Laparoscopy has gained acceptance as a tool in the armamentarium of the gynecologic oncologist. Robotic-assisted surgery is not more than an additional tool to achieve major surgeries by a minimal invasive approach. Laparoscopic/robotic programs are burgeoning worldwide in cancer centers and gynecologic oncology services. However, only a few centers use routinely the whole range of available techniques, as a consequence of additional operating room costs, inadequate equipment, lack of training, lack of definitive evidence-based demonstration, and/or theoretical concerns supported by experimental data and papers mentioning surgical complications or oncological drawbacks. Evidence is growing that a number of these concerns are not justified, although continuing effort to carefully evaluate laparoscopic surgery in gynecological cancer is warranted.

In clinical practice, the three “minimally invasive” techniques for radical hysterectomy are not concurrent but complementary, and indication of each method is adapted to the individual patient. In the French experience, node-negative stage I cervical cancers less than 2 cm are proposed for upfront surgery; a full laparoscopic or a laparoscopic-vaginal (Querleu) or a vaginolaroscopic (“Schautheim” by Leblanc) is routinely performed. Only Morrow-Querleu type A or type B—without (B1) or with (B2)—para-cervical lymph node dissection or thus is required. On the other hand, the radicality required to manage larger tumors (stage IB1 larger than 2 cm) cannot be obtained in our experience without episiotomy. Consequently, a full laparoscopic radical hysterectomy, type B2, is proposed. In all

cases, the radicality of surgery is achieved via minimal invasive surgery without any doubt.

References

1. Querleu D, Childers J, Dargent D. *Laparoscopic surgery in gynecologic oncology*. Oxford: Blackwell; 1999.
2. Querleu D, Leblanc E, Ferron G. Laparoscopic surgery in gynaecological oncology. *Eur J Surg Oncol*. 2005;32:853–8.
3. Querleu D. Hystérectomies élargies coelio-assistées xxxxxx. *J Gynecol Obstet Biol Repr*. 1991;20:747.
4. Querleu D. Laparoscopically assisted radical vaginal hysterectomy. *Gynecol Oncol*. 1993;51:248–54.
5. Abu-Rustum NR, Chi DS, Sonoda Y, et al. Transperitoneal laparoscopic pelvic and para-aortic lymph node dissection using the argon-beam coagulator and monopolar instruments: an 8-year study and description of technique. *Gynecol Oncol*. 2003;89:504–13.
6. Köhler C, Klemm P, Schau A, Possover M, Krause N, Tozzi R, et al. Introduction of transperitoneal lymphadenectomy in a gynecologic oncology center: analysis of 650 laparoscopic pelvic and/or paraaortic transperitoneal lymphadenectomies. *Gynecol Oncol*. 2004;95:52–61.
7. Querleu D, Leblanc E, Cartron G, Narducci F, Ferron G, Martel P. Audit of preoperative and early complications of laparoscopic lymph node dissection in 1000 gynecologic cancer patients. *Am J Obstet Gynecol*. 2006;195:1287–92.
8. Scribner DR, Walker JL, Johnson GA, Mc Meekin DS, Gold MA, Mannel RS. Laparoscopic pelvic and paraaortic lymph node dissection in the obese. *Gynecol Oncol*. 2002;84:426–30.
9. Park CT, Lim KT, Chung HW, et al. Clinical evaluation of laparoscopic-assisted radical vaginal hysterectomy with pelvic and/or paraaortic lymphadenectomy. *J Am Assoc Gynecol Laparosc*. 2002;9:49–53.
10. Hertel H, Kohler C, Michels W, Possover M, Tozzi R, Schneider A. Laparoscopic-assisted radical vaginal hysterectomy (LARVH): prospective evaluation of 200 patients with cervical cancer. *Gynecol Oncol*. 2003;90:505–11.
11. Steed H, Rosen B, Murphy J, Laframboise S, De Petrillo D, Covens A. A comparison of laparoscopic-assisted radical vaginal hysterectomy and radical abdominal hysterectomy in the treatment of cervical cancer. *Gynecol Oncol*. 2004;93:588–93.
12. Plante M, Gregoire J, Renaud MC, Roy M. The vaginal radical trachelectomy: an update of a series of 125 cases and 106 pregnancies. *Gynecol Oncol*. 2011;121:290–7.
13. Querleu D, Narducci F, Poulard V, et al. Modified radical vaginal hysterectomy with or without laparoscopic

- nerve-sparing dissection: a comparative study. *Gynecol Oncol.* 2002;85:154–8.
14. Girardi F, Pickel H, Winter R. Pelvic and parametrial lymph nodes in the quality control of the surgical treatment of cervical cancer. *Gynecol Oncol.* 1993;50:330–3.
 15. Dargent D. Laparoscopic surgery and gynecologic cancer. *Curr Opin Obstet Gynecol.* 1993;5:294–300.
 16. Kohler C, Tozzi R, Klemm P, Schneider A. “Schauta sine utero”: technique and results of laparoscopic-vaginal radical parametrectomy. *Gynecol Oncol.* 2003;91:359–68.



Laparoscopic and Robotic Radical Hysterectomy

23

Farr Nezhat, Maria Andrikopoulou,
and Ashley Bartalot

Introduction

Although primary and secondary prevention has dramatically reduced the incidence of cervical cancer, it still remains the seventh most common malignant tumor worldwide and third in female population [1]. Traditionally, early stages of cervical cancer have been treated with radical abdominal hysterectomy and pelvic lymphadenectomy, whereas more advanced stages with radiation and recently with chemoradiation.

Over the past 20 years, there has been an emerging role of laparoscopy and computer-enhanced telesurgery called robotic-assisted laparoscopic surgery in gynecologic oncology. It is well established that laparoscopic treatment is associated with less blood loss, less postoperative pain, shorter hospital stays, faster return to normal activities, and better cosmetic results.

F. Nezhat, M.D., FACOG, FACS (✉)
Weill Cornell Medical College, Cornell University,
Ithaca, NY, USA

Department of Obstetrics, Gynecology and
Reproductive, Medicine School of Medicine,
Stony Brook University, Stony Brook, NY, USA

Minimally Invasive Gynecologic Surgery and
Robotics, Winthrop University Hospital,
Mineola, NY, USA
e-mail: farr@farnezhatmd.com

M. Andrikopoulou, M.D. • A. Bartalot, M.D.
NYU- Winthrop University Hospital,
Mineola, NY, USA

Additionally, advantages of present robotic surgery include faster operative times, increased accuracy and dexterity, three-dimensional views, and tremor reduction [2–4]. Recently, there is growing evidence that laparoscopic and robotic radical hysterectomies are safe and feasible approaches to early cervical cancer with similar survival outcomes to open surgery.

Radical Hysterectomy

The term radical hysterectomy includes resection not only of the uterus but also the parametrium. Additionally, pelvic lymphadenectomy is performed for early stages of cervical cancer. A radical hysterectomy is warranted for stages IA2-IIA1. Even though radical hysterectomy is associated with good surgical outcomes in cases where lymph nodes are not affected by the disease, it can be associated with higher risk of complications involving the bowel and urinary tract along with increased blood loss. Historically, in 1974, Piver et al. described five classes of radical hysterectomy [5]. Later, in 2008, Querleu and Morrow suggested a new classification of radical hysterectomy based on the lateral extent of resection and described lymphadenectomy classification separately [6].

The first described laparoscopic radical hysterectomy with pelvic and para-aortic lymphadenectomy for cervical cancer was performed in June 1989 and reported in 1990, 1991, and

1992 by Nezhat et al. [7–9]. Since then, given that gynecologic surgical oncology is evolving toward utilizing a minimally invasive approach, there have been many groups that have reported their experiences on radical laparoscopic hysterectomy, complications, and short- and long-term oncological outcomes. Even though the advantages of laparoscopy over laparotomy are well established, there are still some drawbacks [3]. Advanced laparoscopic surgery is associated with longer learning curves. Additionally, the use of two-dimensional image given that most instruments are nonarticulating makes laparoscopic radical hysterectomy challenging.

Recently robotic-assisted surgery has also emerged as an alternative minimally invasive method. In 2006, the first robotic-assisted radical hysterectomy was reported by Sert et al. [10], and case series were reported in 2008 by Nezhat et al. and Fanning et al. on the use of robotic technology in treatment of cervical cancer [3, 11]. Since then many authors have expanded, and many series on the use of robot in the treatment of early cervical cancer have been reported.

Surgical Technique

Laparoscopic Radical Hysterectomy [7, 9, 12]

After ensuring informed consent is obtained, this procedure is performed under general anesthesia. The patient is in dorsal lithotomy position using Allen stirrups with lower extremity compression device in place to prevent vein thrombosis. Prophylactic antibiotics are administered, and urinary Foley catheter is inserted. We prefer to place a uterine manipulator with a cervical cap (1) to aid in the exposure of the pelvic cavity and (2) to delineate the vaginal fornices from the cervix for later identification of the colpotomy plane. Insertion of ports using a four-port technique (one place in the umbilicus for the camera and three additional ports placed suprapubically) is established, and careful inspection of the pelvis and upper abdomen is performed to identify pos-

sible metastatic disease. Any lesions potentially malignant are evaluated and removed. If metastatic disease outside of the uterus such as the adnexa or at uterine wall to peritoneal cavity is confirmed by frozen section, the procedure is abandoned. If indicated (bulky lesions), para-aortic and common iliac lymphadenectomy is performed first. A peritoneal incision is made above the sacral promontory and right common iliac artery, using ultrasonic shears or electro-surgical scissors. The incision is extended cephalad on the right side and above the bifurcation of the aorta toward the duodenal bulb excising lymph nodes overlying the vena cava. The dissection is then performed over the surface of the aorta, inferior to the level of the inferior mesenteric artery (Fig. 23.1).

The dissection is extended to the level immediately below the aortic bifurcation to remove the lymph nodes below the bifurcation of aorta and over the left common iliac vein. Dissection is then performed over the aorta superior to the inferior mesenteric artery to the level of the left renal vein. Additional lymph nodes are excised below and above the inferior mesenteric artery up to the left renal vein. Frozen section is obtained from suspicious lymph nodes, and if they are positive for malignancy, the radical hysterectomy is abandoned, and patient is referred for chemoradiation. If no metastatic disease is identified, then proceed with radical hysterectomy and pelvic lymphadenectomy.

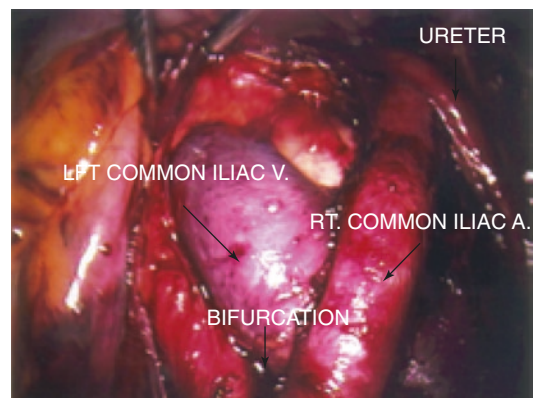


Fig. 23.1 Below the level of the bifurcation after para-aortic lymph node dissection

For pelvic lymphadenectomy, pelvic wall dissection is performed in a triangle between the round ligament anteriorly, external iliac vessels laterally, and infundibular pelvic ligament medially (Fig. 23.2a). Peritoneum is incised cephalad and the ureter identified at the level of the pelvic brim and traced down medially toward its insertion into the bladder. The paravesical, obturator, and para-rectal spaces are developed laterally and medially to the superior vesical artery (Fig. 23.2b–d).

This is achieved mostly by blunt dissection with coagulating small perforating blood vessels. The uterine vessels are identified at their origin from the hypogastric artery and vein (Fig. 23.3).

The lymph node packets are removed from the external iliac vessels, obturator fossa, and hypogastric vessels. For external iliac vessels, the lymph nodes are excised between the mid-common iliac artery superiorly and the deep circumflex vein inferiorly (Fig. 23.4). We prefer not to go beyond these vessels, to avoid lower extremity lymphedema, unless they are grossly involved with metastatic disease. For the obturator fossa, the obturator nerve is identified, and the

lymph nodes are mobilized from the obturator internus muscle and excised anteriorly and posteriorly to the nerve. Removal of the hypogastric lymph nodes should be done carefully to avoid injury to the hypogastric vein. Dissection can be continued inferiorly to the parametrium with removal of the parametrial lymph nodes done separately.

For the radical hysterectomy, we prefer to start by developing the rectovaginal space first (Fig. 23.5a). The peritoneum between the uterosacral ligaments is incised laterally and extended medially toward the peritoneal reflection between the vagina and rectum. The rectovaginal space is entered using gentle blunt dissection, pushing the rectum down [7]. The use of a uterine manipulator with a cervical cap or placing a ring forceps (sponge stick) in the vagina can also help to identify this space. The vesicovaginal space is developed by incising the anterior leaf of the broad ligament and mobilizing the bladder off the cervix and upper vagina. Different surgical modalities can be used for transection and desiccation such as, CO₂ laser, electrosurgery or ultrasonic shears, etc. (Fig. 23.5b).

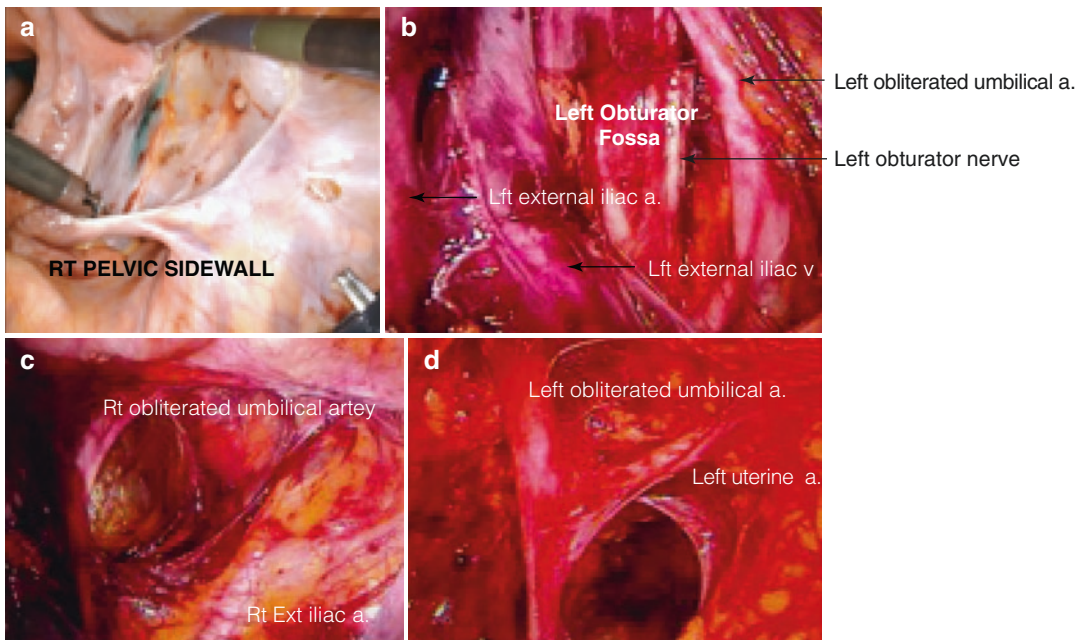


Fig. 23.2 (a) Right pelvic sidewall dissection for pelvic lymphadenectomy. (b) Developed left obturator space. (c) Developed right paravesical space. (d) Developed left pararectal space

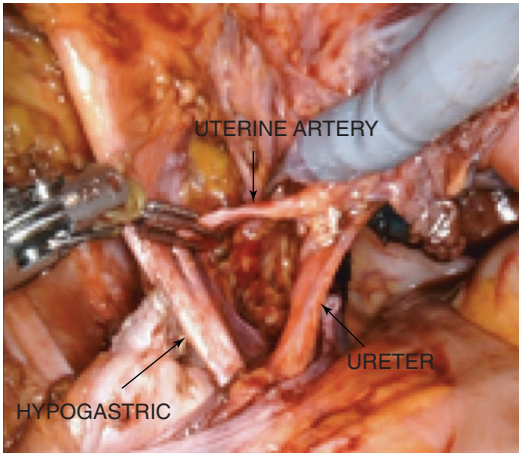


Fig. 23.3 Uterine artery identified at the level of its origin from the hypogastric artery

The uterine vessels which have been identified previously are desiccated or clipped at the level of its origin from the hypogastric vessels. Dissection is continued inferiorly and deeply so that the deep uterine vein can be identified, clipped, and cut (Fig. 23.6a). Whenever possible, the splanchnic (parasympathetic) nerves can be identified and protected from transection (Fig. 23.6b). The uterine vessels are then mobilized and rotated off the ureter anteriorly. The ureter bilaterally is then completely unroofed from the ureteral tunnel to the level of its insertion into the bladder (Fig. 23.6c).

This is achieved by using a narrow-tipped dissector with gentle traction while desiccating and cutting the surrounding tissue and at times applying surgical clips to avoid thermal damage to the

Fig. 23.4 Right pelvic sidewall after pelvic lymph node dissection

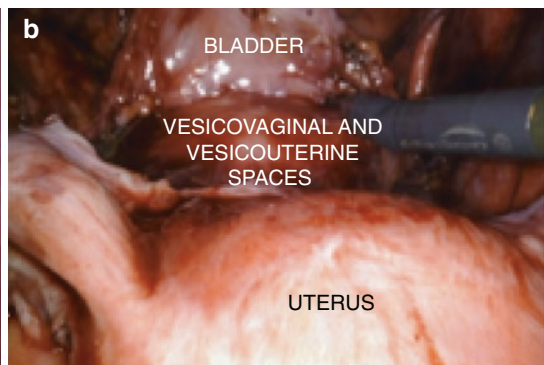
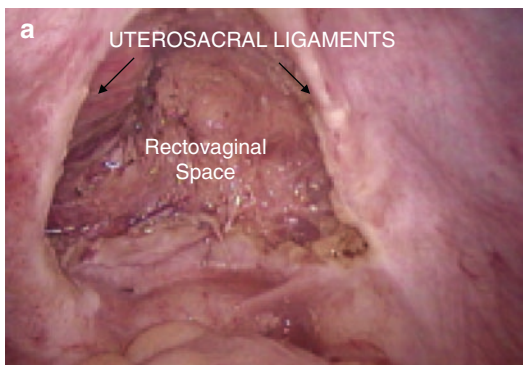
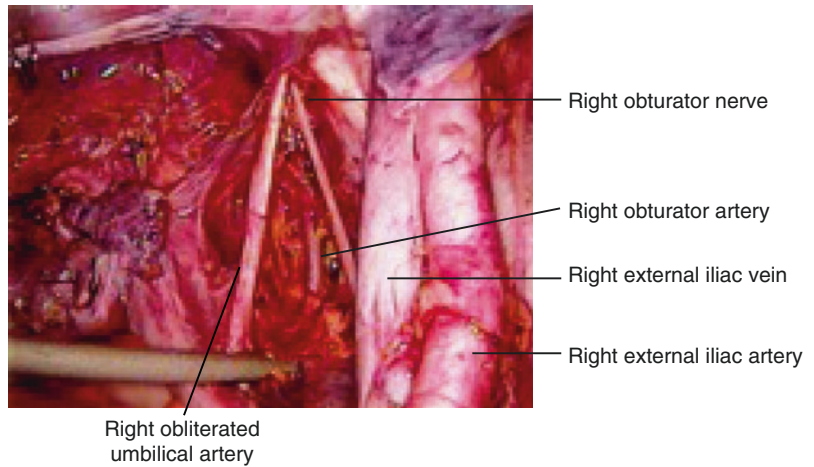


Fig. 23.5 (a) Developed rectovaginal space. (b) Developed vesicovaginal and vesicouterine spaces

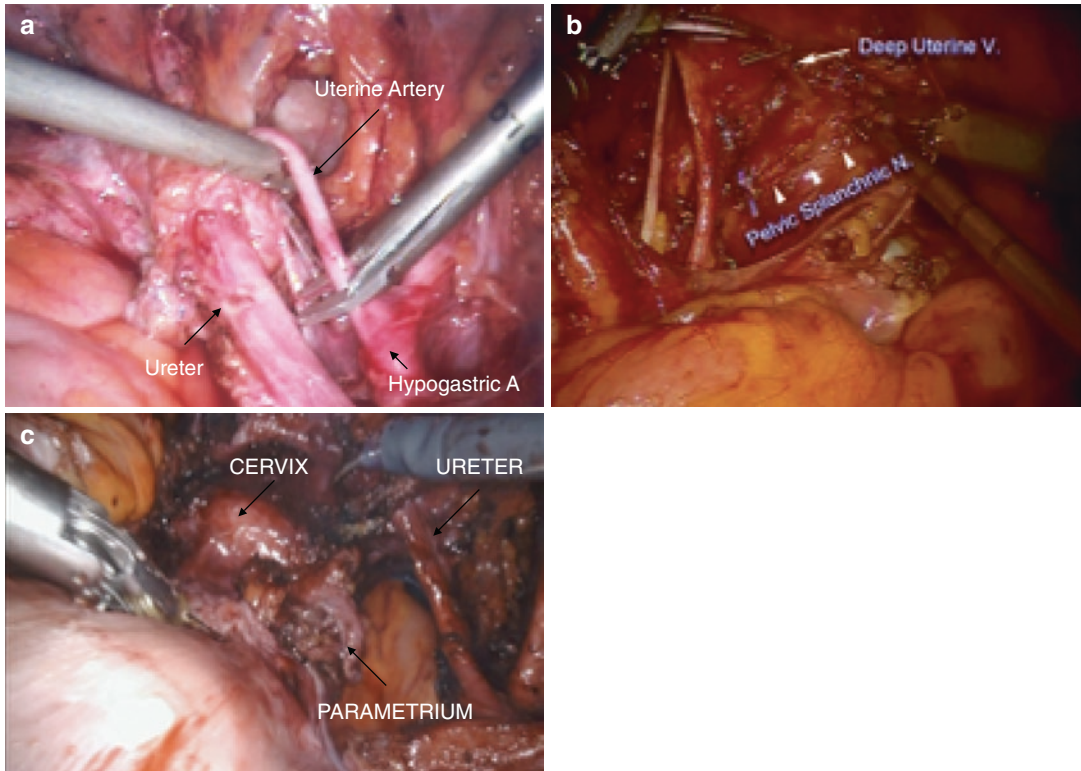


Fig. 23.6 (a) Clipping uterine artery at its origin from the hypogastric artery. (b) Sparing splanchnic nerve after clipping uterine vein. (c) Rotating uterine artery off the ureter and unroofing the ureter from the parametrium

ureter. The parametrium is now exposed. The size of the initial tumor determines the lateral and inferior extent to which the parametrium is desiccated and cut in reference to the cervix using a blood vessel-sealing device (ultrasonic shears or laparoscopic stapling device) [13]. Nerve-sparing surgery can be achieved by avoiding transection of the inferior hypogastric nerve lateral to the uterosacral ligaments. The radical hysterectomy is completed by incising the vagina approximately 2–3 cm distal to the cervix. The vaginal margin is then identified with the guidance of the uterine manipulator's cervical cap and incised in a circumferential fashion using ultrasonic shears, monopolar scissors, bipolar spatula, or hook (Fig. 23.7).

This can also be accomplished vaginally. The vagina is closed laparoscopically or vaginally in a transverse fashion using an absorbable suture with caution to avoid kinking the ureters or damaging

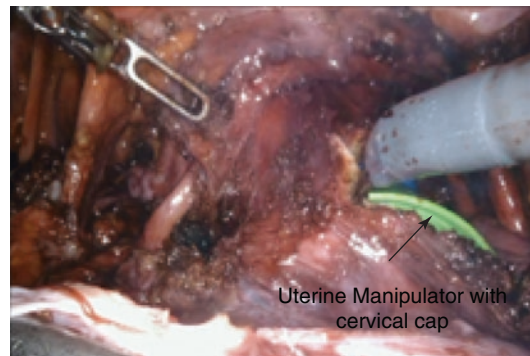

Fig. 23.7 Incising vaginal margin under guidance of the uterine manipulator's cervical cap

the bladder/rectum (Fig. 23.8a). After completion of the procedure, careful inspection of the abdomen and pelvis is performed to be sure that excellent hemostasis under low intraperitoneal pressure

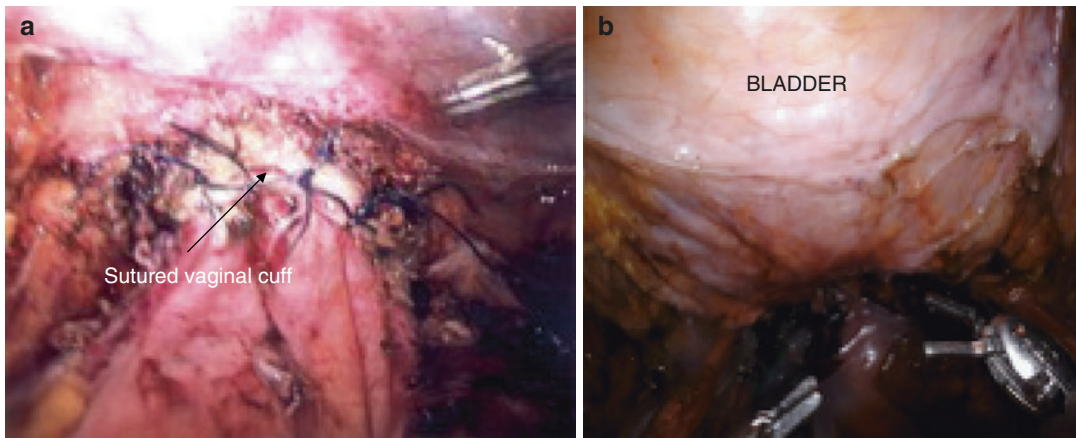


Fig. 23.8 (a) Laparoscopic closure of vaginal cuff. (b) Post-procedure cystoscopy with intact bladder

is achieved. We prefer to also perform a cystoscopy after closing the vaginal cuff to ensure the integrity of the bladder and the ureters (Fig. 23.8b).

Laparoscopic-Assisted Vaginal Radical Hysterectomy [12, 14, 15]

In the same fashion as discussed above, the transection of the round ligaments, pelvic sidewall dissection, and development of the paravesical, obturator, and pararectal spaces as well as pelvic lymphadenectomy are performed laparoscopically. However, during laparoscopic-assisted vaginal radical hysterectomy, careful bladder dissection, development of vesicovaginal and rectovaginal spaces, identification of the ureters, uterine artery ligation, and parametrial ligation 3 cm from the cervix are performed vaginally. For more details regarding the technique, please refer to *Nezhat's Video-Assisted and Robotic-Assisted Laparoscopy and Hysteroscopy 4th Edition*. (Chapter 17.6 Schauta radical vaginal hysterectomy and total laparoscopic hysterectomy. Yukio Sonoda and Nadeem R. Abu-Rustum).

Robotic Radical Hysterectomy [3, 16–18]

Following the approval of the “da Vinci” robotic system by the FDA in 2000, this technical innovation has been used for variety of surgeries

across a plethora of surgical specialties. In 2005, the introduction of robotic-assisted surgery to the gynecologic field led to the broad use of this innovation for variety of surgeries ranging from myomectomies to radical hysterectomies for treatment of early cervical cancer in 2006 [2, 11].

The advantages of this approach include three-dimensional vision of the pelvic anatomy for the surgeon sitting at the console. The flexibility and improved articulation of the instrument along with superior visualization enhance the surgeon’s dexterity with shorter learning curves when compared with conventional laparoscopic surgery. On the other hand, some of the drawbacks of robotic-assisted surgery include increased cost of the procedure secondary to the expensive equipment used as well as the duration of the operation and the lack of tactile feedback.

The surgical technique of this procedure is similar to conventional laparoscopy with modification for port placement (Fig. 23.9a). A 12 mm port or 8 mm (Xi system) is inserted at the umbilicus for camera placement, and the patient is placed in steep Trendelenburg position. Two 8 mm robotic ports are placed bilaterally 8–10 cm lateral to umbilical port, and a 10–12 mm non-robotic port or an additional 8 mm robotic assistant port is placed laterally in the lower or upper abdomen. The robotic monopolar scissors are placed through the right lateral port and the fenestrated bipolar forceps placed through the left lateral port (Fig. 23.9b). As new robotic instruments have become available, such as

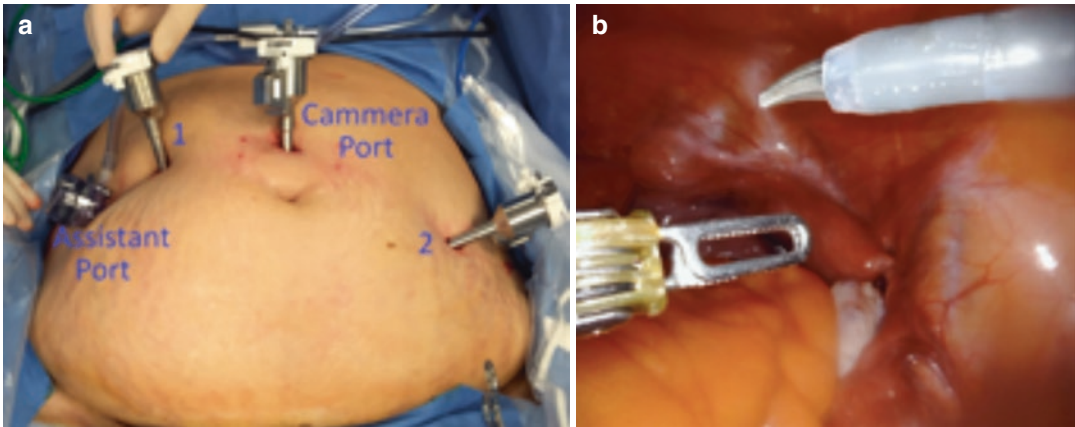


Fig. 23.9 (a) Proper robotic port placement. (b) Robotic scissors in the right arm and bipolar in the left arm

blood vessel-sealing or stapling devices, they can also be utilized.

Since 2006, there have been many reports on the safety and feasibility of robotic-assisted radical hysterectomy in the management of early-stage cervical cancer. However, to date, there are no results on randomized controlled trials reported.

Short- and Long-Term Outcomes

Laparoscopic-Assisted Radical Hysterectomy

Since the initial reports by Nezhat et al., numerous authors have reported their experiences [15, 19]. Many studies report reduced blood loss, lower transfusion rates, shorter hospital stay, less postoperative pain [20], same operative time in laparoscopic compared to open radical hysterectomy, and at the same time similar complication rates [21–23]. Most of these studies however are observational. A Cochrane review which included only one RCT which compared open to laparoscopic approach showed similar complication rates; however, the study did not reach power secondary to small study numbers [24].

In terms of surgical outcomes and long-term survival, there is evidence that the laparoscopic approach has similar outcomes to the open method in cervical cancer surgery. Bogani et al. concluded that a 5-year disease-free survival did

not differ significantly between open and laparoscopic radical hysterectomy [20]. A systematic review and meta-analysis of Cao et al. showed similar 5-year disease-free survival, 5-year overall survival, and recurrence rate in both methods of radical hysterectomy [25]. Nam et al. reported on a large number of patients with early cervical cancer who underwent radical hysterectomy over an 11-year period. This was a matched cohort study comparing laparoscopic to open radical hysterectomy. The mean operative time was 247 min with an average blood loss of 300 mL, with 76 patients (29%) requiring transfusion. There were 6.8% intraoperative and 9.2% postoperative complications. The average lymph node count was 34 with 2.3% of patients having positive lymph nodes. The 5-year recurrence-free survival was 92.8% [26].

Robotic-Assisted Radical Hysterectomy

There is an increasing number of publications reporting on the robotic-assisted radical hysterectomy with encouraging conclusions regarding complications and surgical outcomes [4, 27, 28]. However information on long-term outcomes is still scant. A large series of Hoogendam et al. in the Netherlands presented similar complication and oncologic outcomes in patients who were robotically treated compared to nonrobotically treated [29]. A recent meta-analysis of 25 nonrandomized

studies comparing robotic, laparoscopic, and open approach on radical hysterectomy for early-stage cervical cancer showed that the robotic approach was associated with lower blood loss, shorter hospital stay, and less febrile morbidity and wound complications compared to open radical hysterectomy. Additionally, there was no significant difference of intraoperative outcomes and complication rate between robotic and laparoscopic radical hysterectomies [30]. Many other studies have also confirmed similar complication rates and equivalent surgical outcomes when robotic-assisted approaches were used, including a recent multi-institutional study reported by Sert et al. in April 2016 [31]. Mendivil et al. assessed retrospectively the 5-year survival of cervical cancer patients and concluded that irrespective of the approach, the overall survival rate and 5-year disease-free survival rates were similar [32].

Well-designed long-term randomized controlled trials are needed to confirm these results. Currently there is an international, multicenter phase 3 randomized clinical trial (LACC trial) underway comparing laparoscopic or robotic radical hysterectomy with abdominal radical hysterectomy in patients with early-stage cervical cancer [33].

Cost

The data on comparison of cost of the procedures is controversial. Some studies suggest that open approach is associated with the highest cost [34], whereas other studies report that robotic [35] or laparoscopic radical hysterectomies are more expensive [36]. These differences can be attributed to the difference in equipment used in different institutions as well as discrepancy in the method of cost calculation.

Conclusion

Conventional laparoscopy and robotic technologies have dramatically changed the approach of management of early cervical cancer. Current results show that minimally invasive approaches are associated with less blood loss, shorter hospital stay, and less

febrile morbidity and wound complications compared to open radical hysterectomy. They may have equivalent results with open radical hysterectomy in terms of staging, progression-free survival, and overall survival.

Further randomized controlled trials with long-term follow-up are needed to confirm these results.

References

1. Siegel R, Naishadham D, Jemal A. Cancer statistics, 2013. *CA Cancer J Clin.* 2013;63(1):11–30.
2. Nezhat C, Saberi N, Shahmohamady B, Nezhat F. Robotic-assisted laparoscopy in gynecological surgery. *JLS.* 2006;10(3):317–20.
3. Nezhat FR, Datta MS, Liu C, Chuang L, Zakashansky K. Robotic radical hysterectomy versus total laparoscopic radical hysterectomy with pelvic lymphadenectomy for treatment of early cervical cancer. *JLS.* 2008;12(3):227–37.
4. Kruijdenberg CB, Van Den Einden LC, Hendriks JC, Zusterzeel PL, Bekkers RL. Robot-assisted versus total laparoscopic radical hysterectomy in early cervical cancer, a review. *Gynecol Oncol.* 2011;120(3):334–9.
5. PIVER MS, RUTLEDGE F, SMITH JP. Five classes of extended hysterectomy for women with cervical cancer. *Obstet Gynecol.* 1974;44(2):265–72.
6. Querleu D, Morrow CP. Classification of radical hysterectomy. *Lancet Oncol.* 2008;9(3):297–303.
7. Nezhat CR, Burrell MO, Nezhat FR, Benigno BB, Welander CE. Laparoscopic radical hysterectomy with paraaortic and pelvic node dissection. *Am J Obstet Gynecol.* 1992;166(3):864–5.
8. Nezhat C, Nezhat F. Videolaserotomy for the treatment of upper, mid, and lower peritoneal cavity pathology. Annual Meeting of AAGL, November 1990.
9. Nezhat C, Nezhat F, Silfen S. Videolaparoscopy: the CO2 laser for advanced operative laparoscopy. *Obstet Gynecol Clin N Am.* 1991;18(3):585–604.
10. Sert BM, Abeler VM. Robotic-assisted laparoscopic radical hysterectomy (Piver type III) with pelvic node dissection—case report. *Eur J Gynaecol Oncol.* 2006;27(5):531–3.
11. Fanning J, Fenton B, Purohit M. Robotic radical hysterectomy. *Am J Obstet Gynecol.* 2008;198(6):649–e1.
12. Nezhat CR, Nezhat FR, Burrell MO, Ramirez CE, Welander C, Carrodeguas J, Nezhat CH. Laparoscopic radical hysterectomy and laparoscopically assisted vaginal radical hysterectomy with pelvic and paraaortic node dissection. *J Gynecol Surg.* 1993;9(2):105–20.
13. Nezhat F, Mahdavi A, Nagarsheth NP. Total laparoscopic radical hysterectomy and pelvic lymphadenectomy using harmonic shears. *J Minim Invasive Gynecol.* 2006;13(1):20–5.

14. Pergialiotis V, Rodolakis A, Christakis D, Thomakos N, Vlachos G, Antsaklis A. Laparoscopically assisted vaginal radical hysterectomy: systematic review of the literature. *J Minim Invasive Gynecol.* 2013;20(6):745–53.
15. Sonoda Y, Abu-Rustum NR. Chapter 17.6: Schauta radical vaginal hysterectomy and total laparoscopic hysterectomy. In: Nezhat C, Nezhat F, Nezhat C, editors. *Nezhat's video-assisted and robotic-assisted laparoscopy and hysterectomy*. 4th ed: Cambridge University Press; 2013. p. 484–97.
16. Boggess JF, Gehrig PA, Cantrell L, Shafer A, Ridgway M, Skinner EN, Fowler WC. A case-control study of robot-assisted type III radical hysterectomy with pelvic lymph node dissection compared with open radical hysterectomy. *Am J Obstet Gynecol.* 2008;199(4):357–e1.
17. Kho RM, Hilger WS, Hentz JG, Magtibay PM, Magrina JF. Robotic hysterectomy: technique and initial outcomes. *Am J Obstet Gynecol.* 2007;197(1):113–e1.
18. Ramirez PT, Soliman PT, Schmeler KM, dos Reis R, Frumovitz M. Laparoscopic and robotic techniques for radical hysterectomy in patients with early-stage cervical cancer. *Gynecol Oncol.* 2008;110(3):S21–4.
19. Zakashansky K, Chuang L, Gretz H, Nagarsheth NP, Rahaman J, Nezhat FR. A case-controlled study of total laparoscopic radical hysterectomy with pelvic lymphadenectomy versus radical abdominal hysterectomy in a fellowship training program. *Int J Gynecol Cancer.* 2007;17(5):1075–82.
20. Campos LS, Limberger LF, Stein AT, Kalil AN. Postoperative pain and perioperative outcomes after laparoscopic radical hysterectomy and abdominal radical hysterectomy in patients with early cervical cancer: a randomised controlled trial. *Trials.* 2013;14(1):1.
21. Bogani G, Cromi A, Uccella S, Serati M, Casarin J, Pinelli C, Ghezzi F. Laparoscopic versus open abdominal management of cervical cancer: long-term results from a propensity-matched analysis. *J Minim Invasive Gynecol.* 2014;21(5):857–62.
22. Cai J, Yang L, Dong W, Wang H, Xiong Z, Wang Z. Retrospective comparison of laparoscopic versus open radical hysterectomy after neoadjuvant chemotherapy for locally advanced cervical cancer. *Int J Gynecol Obstet.* 2016;132(1):29–33.
23. Cho JE, Nezhat F. Robotics and gynecologic oncology: review of the literature. *J Minim Invasive Gynecol.* 2009;16(6):669–81.
24. Kucukmetin A, Biliatis I, Naik R, Bryant A. Laparoscopically assisted radical vaginal hysterectomy versus radical abdominal hysterectomy for the treatment of early cervical cancer. *Cochrane Database Syst Rev.* 2013;(10):CD006651.
25. Cao T, Feng Y, Huang Q, Wan T, Liu J. Prognostic and safety roles in laparoscopic versus abdominal radical hysterectomy in cervical cancer: a meta-analysis. *J Laparoendosc Adv Surg Tech.* 2015;25(12):990–8.
26. Nam JH, Park JY, Kim DY, et al. Laparoscopic versus open radical hysterectomy in early-stage cervical cancer: long term survival outcomes in a matched cohort study. *Ann Oncol.* 2012;23(4):903–11.
27. Kim YT, Kim SW, Hyung WJ, Lee SJ, Nam EJ, Lee WJ. Robotic radical hysterectomy with pelvic lymphadenectomy for cervical carcinoma: a pilot study. *Gynecol Oncol.* 2008;108(2):312–6.
28. Sert B, Aberler V. Robotic radical hysterectomy in early-stage cervical carcinoma patients, comparing results with total laparoscopic radical hysterectomy cases. The future is now? *Int J Med Robot.* 2007;3(3):224–8.
29. Hoogendam JP, Verheijen RH, Wegner I, Zweemier RP. Oncological outcome and longterm complications in robot-assisted radical surgery for early stage cervical cancer: an observational cohort study. *BJOG Int J Obstet Gynaecol.* 2014;121(12):1538–45.
30. Shazly SA, Murad MH, Dowdy SC, Gostout BS, Famuyide AO. Robotic radical hysterectomy in early stage cervical cancer: a systematic review and meta-analysis. *Gynecol Oncol.* 2015;138(2):457–71.
31. Sert BM, Boggess JF, Ahmad S, Jackson AL, Stavitski NM, Dahl AA, Holloway RW. Robot-assisted versus open radical hysterectomy: a multi-institutional experience for early-stage cervical cancer. *Eur J Surg Oncol.* 2016;42(4):513–22.
32. Mendivil AA, Rettenmaier MA, Abaid LN, Brown JV, Micha JP, Lopez KL, Goldstein BH. Survival rate comparisons amongst cervical cancer patients treated with an open, robotic-assisted or laparoscopic radical hysterectomy: a five year experience. *Surg Oncol.* 2016;25(1):66–71.
33. Obermair A, GebSKI V, Frumovitz M, Soliman PT, Schemer KM, Levenback C, Ramirez PT. A phase III randomized clinical trial comparing laparoscopic or robotic radical hysterectomy with abdominal radical hysterectomy in patients with early stage cervical cancer. *J Minim Invasive Gynecol.* 2008;15(5):584–8.
34. Halliday D, Lau S, Vaknin Z, Deland C, Levental M, McNamara E, Gotlieb R, Kaufer R, How J, Cohen E, Gotlieb WH. Robotic radical hysterectomy: comparison of outcomes and cost. *J Robot Surg.* 2010;4(4):211–6.
35. Desille-Gbaguidi H, Hebert T, Paternotte-Villemagne J, Gaborit C, Rush E, Body G. Overall care cost comparison between robotic and laparoscopic surgery for endometrial and cervical cancer. *Eur J Obstet Gynecol Reprod Biol.* 2013;171(2):348–52.
36. Wright JD, Herzog TJ, Neugut AI, Burke WM, Lu YS, Lewin SN, Hershman DL. Comparative effectiveness of minimally invasive and abdominal radical hysterectomy for cervical cancer. *Gynecol Oncol.* 2012;127(1):11–7.



Robotic Radical Hysterectomy: Surgical Technique

24

Antonio Gil-Moreno and Javier F. Magrina

Introduction

Radical hysterectomy remains the preferred method of treatment for patients with early cervical cancer (FIGO stages IA2-IB1-IIA1). The incorporation of robotic technology in the USA and other countries changed the avenue from laparotomy to a minimally invasive approach, something that laparoscopic technology did not fully do. Some of the major advantages of robot-assisted over conventional laparoscopy are its superior visualization (3D versus 2D) imaging of the operative field, its mechanical improvements such as its seven degrees of freedom (similar to the human arm and hand, while rigid conventional instruments have four degrees of freedom), the stabilization of instruments within the surgical field (in conventional laparoscopy, small movements by the surgeon are amplified including hand tremor), and its improved ergonomics for the operating surgeon. The technique of robotic radical hysterectomy or robotic-assisted radical hysterectomy will be described in this chapter. The reader must be knowledgeable of the

indications, limitations, and location of metastatic nodes to indicate or not a robotic approach and to determine whether preoperative chemoradiotherapy is needed. Whenever chemoradiotherapy is contemplated, the radical hysterectomy should be avoided due to the increased morbidity of using both treatment modalities. In these cases systematic pelvic and aortic lymphadenectomy is done to limit the irradiation field.

A nerve-sparing approach, something which is not the scope of this chapter, is always preferable. Our results of robotic radical hysterectomy have been published elsewhere [1, 2] and compared with a laparoscopic and laparotomy approach [1]. In our hands, robotic radical hysterectomy has a shorter operating time than with laparoscopy and is therefore our preferred minimally invasive approach. The surgical steps and technique of the robotic radical hysterectomy described here follow those originally reported by Okabayashi in 1921 [3], which was designed to minimize the transection of the pelvic autonomic nerves and sympathetic and parasympathetic nerves. The Mayo classification of radical hysterectomy was previously reported by Symmonds in 1976 [4] and included simple, wide, modified radical, radical, and extended radical types. The extent of paracervical resection described with the robotic technique here is designated as radical hysterectomy types B1–C1 of the newly revised classification of radical hysterectomy [5]. Nerve-sparing technique was first

A. Gil-Moreno, M.D., Ph.D.
Unit of Gynecologic Oncology, Department of
Obstetrics and Gynecology, Hospital Materno-Infantil
Vall d'Hebron, Barcelona, Spain

J. F. Magrina, M.D. (✉)
Department of Obstetrics and Gynecology, Mayo
Clinic Arizona, Phoenix, AZ, USA
e-mail: jmagrina@mayo.edu

introduced in this standard classification. The nerve-sparing radical hysterectomy type C1 has been shown to decrease bladder and rectal dysfunction [6, 7] without compromising recurrence or survival rates [6, 8].

Indications

The B1 technique is indicated for patients with cervical cancer ≤ 2 cm, and the type C1 is indicated for cases >2 cm diameter, up to 4 cm. The extent of vaginal resection is dependent on the location of the tumor margins. The location of the ectocervical margin of the tumor will dictate whether a small or a longer segment of vaginal cuff is needed for adequate margins. In patients with a margin near or involving the vaginal fornix, a longer segment of vagina will be necessary. This technique is also applicable to patients with endometrial cancer with cervical stromal invasion.

Patient Set-Up

Patients are placed in the semi-lithotomy position using the Allen stirrups (Allen Medical, Acton MA) with the arms loosely tucked to each side. Foam padding is used to protect both arms and legs. Patients are placed with a naked back directly on an anti-skid foam material (Tyco/Kendall Prod #3-472, Mansfield, MA), which we evaluated and found to be satisfactory [9]. The operating table is placed in Trendelenburg position and observed if the patient descends or not. Patient is then returned to the supine position and then prepped and draped.

Technique Entry

A transumbilical open technique with a 12 mm trocar (8 mm with the da Vinci Xi) is used for all patients. The upper abdomen is explored in the supine position. Patient is then placed in the Trendelenburg position to a degree enough to displace the sigmoid and small bowel out of the pelvis and allow a safe pelvic operation.

Robotic Column Placement

The standard da Vinci, da Vinci Si, or da Vinci Xi robotic systems (Intuitive Surgical, Sunnyvale, CA) are adequate for the operation. The robotic column is side docked lateral to the patient's right knee. The robotic arms are fastened to the robotic trocars once these are inserted (see below).

Trocar Placement and Instrumentation

Two robotic trocars (8 mm each) are introduced 8 cm to the right and left of the umbilical optical trocar and in a position somewhat below the umbilicus. An assistant trocar (10 mm) is placed midway between the umbilical and left trocar and 2 cm cranial to the umbilicus in all patients. Another robotic trocar (8 mm), designated as fourth robotic arm, is introduced 7–8 cm lateral and 3 cm caudal to the right trocar (right lateral robotic arm). The configuration of the trocars is like a crescent with upper convexity (Fig. 24.1).

Instrumentation

An EndoWrist PK grasper (Intuitive Inc., Sunnyvale, CA) is used on the left robotic arm, and an EndoWrist monopolar scissors or spatula (Intuitive Inc., Sunnyvale, CA) is used in the

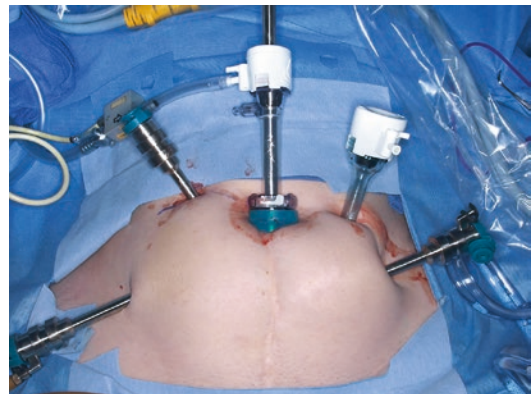


Fig. 24.1 Trocar position for robotic radical hysterectomy with the da Vinci S or Si system

right robotic arm. The EndoWrist Prograsper (Intuitive Inc., Sunnyvale, CA) is used in right lateral robotic arm to assist with retraction. An EndoWrist needle holder (Intuitive Inc., Sunnyvale, CA) is used to replace the monopolar scissors/spatula to suture the vaginal cuff.

The assistant sits to the left of the patient and performs the functions of sealing and division of vascular pedicles with a vessel sealer device, suction and irrigation, peritoneal cytology, sentinel node determination with polar probe, removal of small specimens (e.g., sentinel nodes), tissue retraction, and insertion and removal of sutures for closure of the vaginal cuff. A second assistant, sitting between the legs of the patient, manipulates a vaginal probe (Apple Medical, Marlborough, MA) for bladder dissection and during colpotomy and removes the uterus and lymph nodes vaginally (with endobags). The nurse, sitting to the right of the patient, cleans the lens of the laparoscope, switches the monopolar spatula for a needle holder, and maintains pneumoperitoneum during vaginal transection. A colpo-occluder balloon (Rumi Colpo-occluder, Cooper Medical, Trumbull, CT) is placed in the vagina to maintain pneumoperitoneum after removal of the specimen. No uterine manipulator is used.

Development of Lateral Retroperitoneal Spaces

The abdominal cavity was inspected and the retroperitoneal spaces were opened. A lateral peritoneal incision is made transecting the round ligament and anterior broad ligament peritoneum to above the pelvic brim. The paravesical and pararectal spaces are developed at start to identify the paracervix (also known parametria or lateral parametrium). The ureters are identified on the pelvic peritoneum and traced to the crossing with the uterine arteries.

Management of the Adnexa

In case of adnexal removal, a peritoneal window is made between the ureter and the infundibulopelvic

ligament, which is then divided with a vessel sealer at the level of the pelvic brim. This window prevents ureteral injury at this level. If the adnexa are preserved, the tubo-ovarian pedicles are divided, as well as their peritoneal attachments, and placed above the pelvic brim. If there are other risk factors, an ovariopexy was carried out in order to remove the ovary of a possible field of pelvic radiation.

Pelvic and Aortic Lymphadenectomy

A systematic bilateral pelvic lymphadenectomy from the common iliac artery to the inferior boundary of the circumflex iliac vein was performed after the sentinel node procedure. The external iliac nodes, from the bifurcation of the common iliac vessels to the inguinal ligament, the obturator nodes above and below the obturator nerve, the ventral and lateral nodes of the hypogastric artery, and the ventral and lateral common iliac nodes from the middle of the common iliac vessels, are removed bilaterally using the PK grasper and monopolar scissors/spatula. We have the availability of obtaining frozen section of the removed nodes, which facilitates whether additional pelvic nodes and the aortic nodes need removal.

In the presence of positive sentinel node or positive pelvic nodes, a bilateral aortic lymphadenectomy is carried out to the renal vessels. Using the same trocar placement and instruments, the inframesenteric nodes can be safely removed. For the infrarenal nodes, the robotic system arms are undocked and the operating table rotated 180 degrees, resulting in the robotic column being now located at the patient's head or lateral to the right shoulder. You can also change the location of the robot (lateral to the right shoulder) without having to rotate the operating table. Two to three trocars are placed suprapubically, one to two for the assistant and one for the endoscopic camera (12 mm but 8 mm with da Vinci Xi). The robotic arms redocked, and using the same robotic instruments, the aortic lymphadenectomy is extended to the infrarenal group of nodes, up to the level of the renal vessels. The benefit of removing positive aortic nodes has

been addressed in the recent literature [10–12]. Our technique and experience with infrarenal aortic lymphadenectomy and rotation of the operating table has been described [13, 14]. The new da Vinci Xi system allows rotation of the robotic arms after undocking them from the pelvic position without the need to rotate the operating table or modify the location of the robot column. Once the arms are rotated 180 degrees, they are docked again. However, it still requires the placement of additional trocars suprapubically for the optical trocar and assistant.

Parametrial Division

With the paravesical and pararectal spaces dissected, the vascular portion of the paracervix or lateral parametrium is transected at the origin of its vessels from the internal iliac artery and vein with successive applications of a vessel sealer and continuing dorsally to the level of the deep uterine vein (Fig. 24.2). This level of transection separates the ligamentous portion from the neural portion of the lateral parametrium and serves to preserve the dorsal neural portion which contains the parasympathetic pelvic splanchnic nerves arising from the S2, S3, and S4 ventral root.

Uterosacral Ligament Division

The ureters are first separated from their pelvic peritoneal attachments, from the pelvic brim to

the uterine arteries. The peritoneum of the cul-de-sac is divided horizontally with the monopolar scissors or spatula and to the level of the ureters laterally. The rectovaginal space is developed caudally to the upper vaginal half (Fig. 24.3). With the rectovaginal space developed and the ureters freed from their peritoneal attachments, the uterosacral ligaments are identified and transected with a vessel sealer at the level of the anterior rectal wall. The transection is directed toward the upper posterior vaginal third (and not to the sacrum) in order to preserve the caudal portion of the sympathetic nerves (lower hypogastric nerves), which are a continuation of the superior hypogastric plexus (the sympathetic fibers come from T11 to L2). They can be isolated and preserved on the lateral aspect of the uterosacral ligaments. For nerve-sparing technique it is important to identify and preserve the parasympathetic splanchnic nerves and sympathetic lower hypogastric nerves, who will join the inferior hypogastric plexus below the deep uterine vein, which emerge autonomic nerve fibers directly into the bladder. This technique decreases long-term associated morbidity such as bladder dysfunction, sexual dysfunction, and colorectal motility disorders.

In conclusion, laparoscopic robotic-assisted radical hysterectomy with nerve-sparing technique is an attractive surgical approach for early invasive cervical cancer. Robotic technology allows a stereoscopic visualization of blood vessels and autonomic nerve supplies (sympathetic and parasympathetic branches) to the bladder and rectum making nerve sparing a safe and feasible procedure.

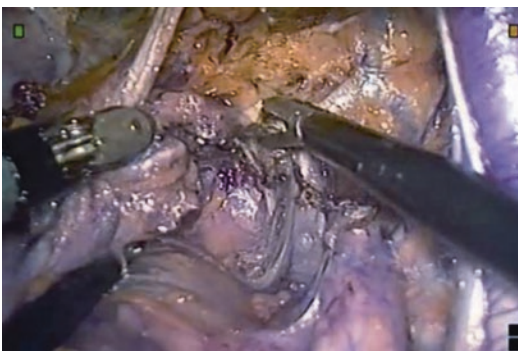


Fig. 24.2 Division of the lateral parametrial vessels from the internal iliac artery and vein to the deep uterine vein

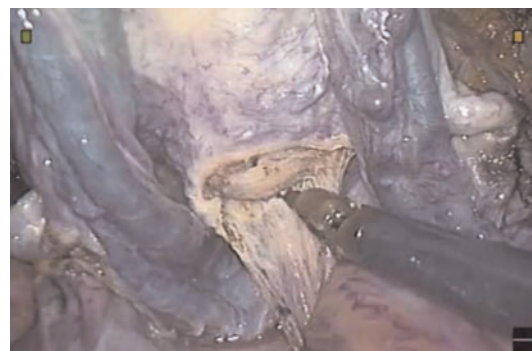


Fig. 24.3 Dissection of the rectovaginal space to the upper vaginal half

Bladder and Ureteral Dissection

The cervicovaginal peritoneum is divided horizontally with the monopolar scissors or spatula. The assistant then advances the vaginal probe to the anterior vaginal fornix, which facilitates the separation of the bladder from the cervix and vagina. The dissection is carried caudally to the upper vaginal third to half. The extent of lateral paracervical resection is shown here prior to ureteral dissection (Fig. 24.4). The ureters must be dissected completely in order to remove the entire resected parametrium.

The ureter is followed till its entrance into the parametrial tunnel. A space is created with the monopolar scissors or spatula and the PK grasper immediately above the ureter at the 12 o'clock position until the instrument appears on the vesicovaginal space. The space is widened until the posterior blade of the vessel sealer can be introduced in the created space above the ureter (Fig. 24.5). The ventral part of the vesicouterine ligament is then transected. These steps are repeated until the ventral vesicouterine ligament is transected completely and the ureter is unroofed. It is then mobilized laterally by dividing with the monopolar device its loose attachments to the dorsal aspect of the vesicouterine ligament, until the latter is exposed and identified. While the assistant is holding the ureter ventrally, the avascular space located immediately below the entrance of the ureter into the bladder is identified and widened with

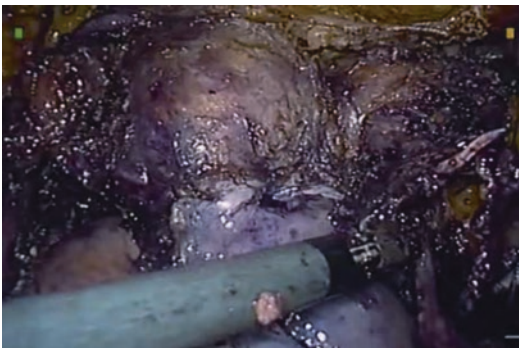


Fig. 24.4 The bladder has been dissected from the anterior vaginal wall, and the lateral extent of parametrial resection can be noted on the right side; it is cut out of the picture on the left

the monopolar spatula, clearly delineating the dorsal vesicouterine ligament (Fig. 24.6), which is transected by the assistant using a vessel sealer. The ureter is now totally free from its attachments and can be further elevated ventrally.

Paravaginal Tissues

With the ureter suspended ventrally and laterally with the monopolar spatula, the paravaginal tissues are divided by the assistant using a vessel sealer distal to the dorsal margin of the transected lateral parametrium and uterosacral ligaments and until reaching the lateral aspect of the vaginal wall.

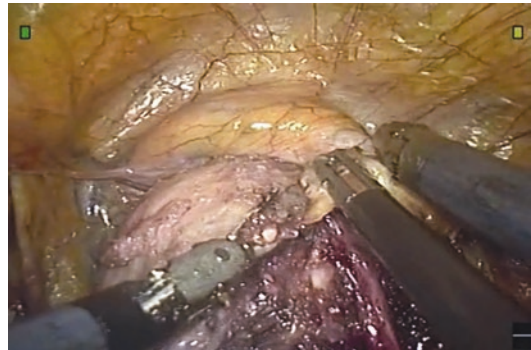


Fig. 24.5 Dissection of the right ureteral tunnel (vesicouterine ligament). The right anterior vesicouterine ligament is then transected with a vessel sealer as first step of the ureteral tunnel dissection

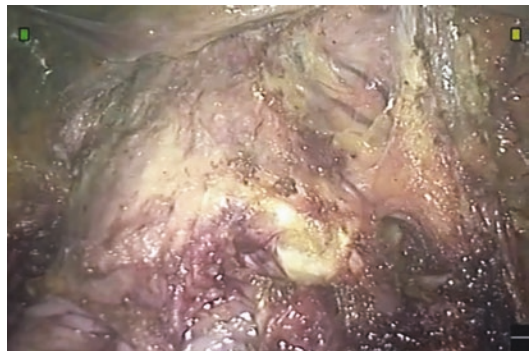


Fig. 24.6 The dorsal posterior ligament on the right side is exposed here with the middle and inferior vesical veins. The right anterior vesicouterine ligament has been already divided, and the right ureter has been mobilized and elevated out of the picture and not seen here (ventral to the dorsal vesicouterine ligament)

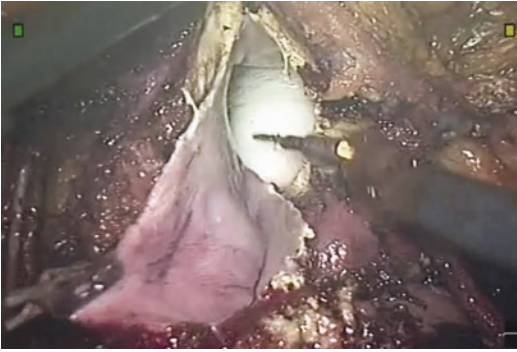


Fig. 24.7 Colpotomy with an adequate vaginal margin for this patient post-conization. The vaginal probe is seen

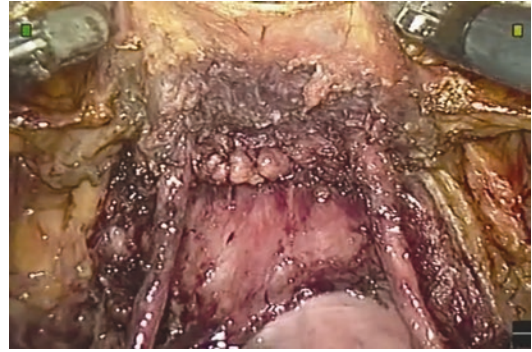

Fig. 24.8 The vaginal cuff has been closed. The ureters are dissected to their entrance to the bladder to remove the entire vesicouterine ligaments

Vaginal Resection

The assistant advances the vaginal probe to the anterior vaginal fornix, and the junction of the vagina and exocervix is identified. From there, we measure the length of the vaginal margin to excise using the diameter of the instruments as a measuring tool. It is important to consider that margins obtained with a stretched vagina will be shorter once the tension is removed. The vagina is entered at the 12 o'clock position and divided with the monopolar device (using cutting current) (Fig. 24.7). The assistant removes the uterus with the help of a Schroeder tenaculum (Aesculap, Germany) introduced vaginally. It is also possible to remove the lymph nodes with bags.

Vaginal Cuff Closure

The vaginal cuff is closed with a continuous suture of 2-0 V-loc (Ethicon Endo Surgery, Cincinnati, OH) incorporating a minimum of 5 mm of vagina with each bite and 5 mm of separation in between sutures, in order to avoid vaginal failure (Fig. 24.8). The pelvis is irrigated with physiological saline solution and inspected for complete hemostasis by lowering the CO₂ pressure. No drains are used and the lateral pelvic peritoneum is left open.

Postoperative Course

The patient remains in the hospital overnight. Oral intake of liquids, food, and medications is started on the same day of the operation. Ambulation is started as soon as possible. The Foley catheter is removed at the beginning of deambulation, and residual urine measurements obtained on two separate occasions should be less than 100 mL. A postoperative visit is performed a week and 2 weeks to check the residual urine (must be less than 100 mL) and at 6 weeks from surgery to inspect the vaginal vault.

Conflict of Interest The authors have neither commercial, proprietary, nor financial interests in the products and companies described in this chapter.

References

1. Magrina JF, Kho RM, Weaver AL, Montero RP, Magtibay PM. Robotic radical hysterectomy: comparison with laparoscopy and laparotomy. *Gynecol Oncol.* 2008;109:86–91.
2. Gil-Ibáñez B, Díaz-Feijoo B, Pérez-Benavente A, Puig-Puig O, Franco-Camps S, Centeno C, Xercavins J, Gil-Moreno A. Nerve sparing technique in robotic-assisted radical hysterectomy: results. *Int J Med Robot.* 2013;9(3):339–44.
3. Okabayashi H. Radical abdominal hysterectomy for cancer of the cervix uteri, modification of the Takayama operation. *Surg Gynecol Obstet.* 1921;33:335–41.

4. Symmonds RE. Some surgical aspects of gynecologic cancer. *Cancer*. 1975;36(2):649–60.
5. Querleu D, Morrow CP. Classification of radical hysterectomy. *Lancet Oncol*. 2008;9:297–303.
6. Sakamoto S, Takizawa K. An improved radical hysterectomy with fewer urological complications and with no loss of therapeutic results for invasive cervical cancer. *Baillieres Clin Obstet Gynaecol*. 1988;2(4):953–62.
7. Cibula D, Velechovska P, Sláma J, Fischerova D, Pinkavova I, Pavlista D, et al. Late morbidity following nerve-sparing radical hysterectomy. *Gynecol Oncol*. 2010;116(3):506–11.
8. van den Tillaart SA, Kenter GG, Peters AA, Dekker FW, Gaarenstroom KN, Fleuren GJ, Trimbos JB. Nerve-sparing radical hysterectomy: local recurrence rate, feasibility, and safety in cervical cancer patients stage IA to IIA. *Int J Gynecol Cancer*. 2009;19(1):39–45.
9. Klauschie J, Wechter ME, Jacob K, Zanagnolo V, Montero R, Magrina J, Kho R. Use of anti-skid material and patient-positioning to prevent patient shifting during robotic-assisted gynecologic procedures. *J Minim Invasive Gynecol*. 2010 Jul-Aug;17(4):504–7.
10. Leblanc E, Narducci F, Frumovitz M, Lesoin A, Castelain B, Baranzelli MC, Taieb S, Fournier C, Querleu D. Therapeutic value of pretherapeutic extraperitoneal laparoscopic staging of locally advanced cervical carcinoma. *Gynecol Oncol*. 2007;105:304–11.
11. Gold MA, Tian C, Whitney CW, Rose PG, Lanciano R. Surgical versus radiographic determination of para-aortic lymph node metastases before chemoradiation for locally advanced cervical carcinoma. A Gynecologic Oncology Group study. *Cancer*. 2008;112:1954–63.
12. Gil-Moreno A, Magrina JF, Pérez-Benavente A, Díaz-Feijoo B, Sánchez-Iglesias JL, García A, Cabrera-Díaz S, Puig O, Martínez-Gómez X, Xercavins J. Location of aortic node metastases in locally advanced cervical cancer. *Gynecol Oncol*. 2012;125(2):312–4.
13. Magrina JF, Long JB, Kho RM, Giles DL, Montero RP, Magtibay PM. Robotic transperitoneal infrarenal aortic lymphadenectomy: technique and results. *Int J Gynecol Cancer*. 2010;20(1):184–7.
14. Díaz-Feijoo B, Correa-Paris A, Pérez-Benavente A, Franco-Camps S, Sánchez-Iglesias JL, Cabrera S, de la Torre J, Centeno C, Puig OP, Gil-Ibañez B, Colas E, Magrina J, Gil-Moreno A. Prospective randomized trial comparing transperitoneal versus extraperitoneal laparoscopic aortic lymphadenectomy for surgical staging of endometrial and ovarian cancer: the STELLA trial. *Ann Surg Oncol*. 2016;23(9):2966–74.



Paraaortic Laparoscopic Node Dissections

25

Eric Leblanc, Fabrice Narducci, Delphine Hudry,
Lucie Bresson, Arnaud Wattiez, Audrey Tsunoda,
and Denis Querleu

Paraaortic lymph node dissection (PA lnd) is an important staging technique, with significant implications. Beyond the poor prognostic impact of involved paraaortic nodes, this knowledge alters further primary tumor management. Although not considered in FIGO staging system of cervix carcinoma, demonstration of paraaortic node involvement usually triggers the extension of pelvic chemoradiation fields up to the renal pedicle. In endometrial carcinoma, positive nodes upstage the disease to stage IIIC2, and extended-field radiation therapy and chemotherapy are considered. In ovarian carcinomas, this situation corresponds to a FIGO IIIC disease and implies chemotherapy.

Since the early 1990s, laparoscopy has been developed to perform this procedure. Nezhat et al. in the USA [1] and Querleu in France [2] were the first who independently reported the

technique of transperitoneal laparoscopic paraaortic dissection. Vasilev in 1995 published his first experience with the extraperitoneal approach [3], followed by Daniel Dargent in France who really promoted this approach worldwide [4].

Paraaortic Node Anatomy [5]

Lymphatic nodes and vessels are scattered around the inferior vena cava (IVC) and aorta. Common iliac nodes receive lymph from external and internal iliac nodes. From them, lymph reaches paraaortic nodes. Lymph from the liver, spleen, stomach, and bowel flows into lymphatics around their respective pedicles and collects into celiac, mesenteric nodes, located around the origins of these preaortic arteries. From these nodes, efferent lymphatics gather to form a single or multiple intestinal lymphatic trunks that take part into creation of the thoracic duct and that transport lymph from the abdomen and the intercostal spaces into the general venous circulation, through the left (preferentially), right, or both sub-clavicular veins.

Latero-vascular nodes are displayed laterally along the aorta and IVC. They receive lymph directly from lymphatics of the posterior abdominal wall, kidneys, and adnexas. Through mesenteric and common iliac nodes, they receive lymph from inferior limbs, pelvic organs, and bowel as well. Their collectors form right and left lymphatic lumbar trunks.

E. Leblanc, M.D. (✉) • F. Narducci, M.D.
D. Hudry, M.D. • L. Bresson, M.D.
Department of Gynecologic Oncology, Centre Oscar
Lambret, Lille, France
e-mail: e-leblanc@o-lambret.f

A. Wattiez, M.D., Ph.D.
University of Strasbourg - France, Head of
Gynecology department Latifa Hospital, Dubai, UAE

A. Tsunoda, M.D.
Department of Gynecologic Oncology, Hospital
Israelita Albert Einstein Curitiba, São Paulo, Brazil

D. Querleu, M.D.
Department of Surgery, Institut Bergonié,
Bordeaux, France
e-mail: querleu@aol.com

The inferior part of the thoracic duct arises from the convergence of these big collectors located at the level of L1-L2 vertebrae, between the aorta and the right diaphragmatic pillar. In a small proportion of people, this area forms a sacciform expansion called cisterna chyli (or Pecquet's cisterna). It collects lymph from the whole abdomen, diaphragm, and the last intercostal spaces before forming the thoracic duct. The size and shape of this cisterna are highly variable.

Approach to paraaortic nodes needs mobilization of both the duodeno-pancreas and the right colon, in order to adequately expose the IVC and aorta from left renal pedicle to both common iliac bifurcations caudally. Indeed, it corresponds to the usual template of PA dissection for gynecologic indications. Pre- and latero-caval, interaortocaval, and pre- and latero-aortic nodes are thus to be removed. Of interest is the fact that latero-aortic and interaortocaval nodes are mixed with the postganglionic nervous fibers that arise from each latero-vertebral sympathetic chains. In addition, the latero-vascular and interaortocaval nodes are in close relationships with the lumbar pedicles, a possible source of significant bleeding. To finally remove the rare retro-vascular PA nodes, some lumbar vessels have to be divided between ligatures (maneuver called the "split and roll" technique by urologists). Above the renal pedicle, superior mesenteric and celiac nodes are more challenging to approach. However, they are exceptionally involved by gynecologic diseases; thus a systematic dissection at this level is not justified as a routine.

Of importance during a lymphadenectomy is the fact that lymphatic channels are especially large around both common iliac pedicles and the left renal pedicle, especially in the interaortocaval space and laterally to the aorta. A thorough lymphostasis is important at these levels to prevent the secondary development of lymphocysts or a lymphascites. It is obtained by the use of clips, coagulation, or sealing with specific integrated devices.

General Instrumentation

Whatever the approach, a laparoscopic PA Ind does not require sophisticated instruments: a 0° or 30° laparoscope, two fenestrated grasping for-

ceps, scissors, bipolar forceps, an irrigation-suction device, and endoscopic bags.

To facilitate ad secure dissections, recent integrated sealing dissecting devices may be useful. They use either bipolar energy or a blade for cutting LigaSure® (Medtronic, USA), ultrasound energy in the Ultracision® device (Ethicon, USA), or a combination of both as in the Thunderbeat® device (Olympus, Jpn). The choice depends on surgeon's preference. However, a good knowledge of their functioning and limits is mandatory to avoid vascular or nervous damage.

Finally, a set of instruments for laparotomy along with some instruments for vascular surgery must be always available in the operating theater to fix a huge hemorrhage.

Three trocars are generally required: a 10 mm balloon trocar for the optique, one 10–12 mm, and one 5 mm operative trocars. Exceptionally a fourth 5 mm trocar can be necessary. A set of general surgery is necessary for the direct dissection of the iliac space (two Farabeuf retractors, scissors, and a grasping forceps).

Transperitoneal Laparoscopic Paraaortic Node Dissection

Patient and Staff Positioning

The patient under general anesthesia and tracheal intubation is placed flat on the table, arms tucked along the trunk, but legs apart in stirrups. The stomach and bladder are drained during the procedure.

The most popular operative positioning is the surgeon between patient's legs, while his assistant is holding the camera on left patient's side. One/two video monitor(s) is/are placed at patient's head, for operators.

Trocar Placement

Four trocars are necessary: Two 10 mm umbilical and mid-suprapubic trocars are placed for the optique/instruments. Two 5 mm trocars are displayed in the flanks for instruments. Optionally, a 5 mm operative trocar can be placed in the left

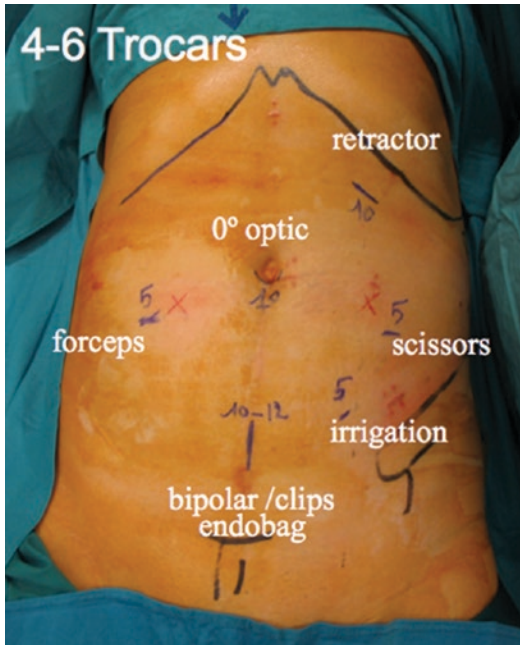


Fig. 25.1 Trocar placement for a transperitoneal PA Ind

iliac fossa (for another instrument) and a 10 mm under the left costal margin (for an endoscopic retractor) (Fig. 25.1).

The Procedure, Step by Step

Thanks to a steep Trendelenburg and a slight left tilt of the table, great omentum, transverse colon, and bowel loops are stored in the upper abdomen to adequately expose the infra-duodenal posterior peritoneum that covers the great vessels.

Peritoneal incision starts at the level of the right common iliac artery, just above its crossing with the right ureter. It follows cranially the vessel and beyond the aorta, on the midline, up to the third duodenum. At this point, the duodeno-pancreas is elevated to expose the left renal vein, upper limit of the dissection. The duodeno-pancreas is separated from great vessels and maintained elevated, thanks to the lateral suspension of peritoneal leaflets by sutures or disposable devices such as T-lift® (Vectec, France), or the placement of an endoscopic retractor (Endoretract® Covidien) placed under

the duodeno-pancreas through a 10 mm port introduced under the left costal margin on the midclavicular line. This retractor is controlled by the assistant. A sort of a tent is thus created that should facilitate future dissections.

The orders of operative steps may differ, according to the clinical situation or surgeon's preferences.

1. Usually, preaortic nodes are first separated from the underlying great vessel, starting at the bifurcation level up to left renal vein following the midline. This technique enables to recognize the origins of different collaterals: IMA on the left side, 4–5 cm cranial to the aortic bifurcation and above, both gonadal arteries (immediately desiccated and divided as soon as identified). Care must be paid when meeting variant vessels such as renal polar arteries (see below). At the upper part, the left renal vein (LRV) is clearly identified as well as termination of the left gonadal vein and azygo-lumbar vein. Then preaortic nodes are separated from the big perirenal lymphatics using clips or thorough sealing. Then, starting again from the aortic bifurcation, precaval nodes are progressively detached from the great vessel. A careful dissection is necessary at this level, in order not to injure possible lympho-venous anastomoses, frequently located at the inferior part of cava close to its crossing with the right common iliac artery and at the upper part of the interaortocaval space. The fragile right gonadal vein flows into vena cava and needs to be systematically divided between clips, to secure the upper dissection up to the left renal vein. The lateral mobilization of tissues from vena cava enables to identify the right psoas, ureter, and gonadal pedicle. The latero-caval nodes are exposed and are gently detached from the vessel medially and right latero-vertebral structures (right sympathetic chain, psoas muscle, and genito-femoral nerve) laterally. The upper limit of this dissection is the gonadal vein stump on cava or the right renal vein.

(a) Medially, the interaortocaval nodes are approached. They are elevated from the vertebral plane. Lumbar pedicles and

right postganglionic sympathetic nervous fibers are intermixed with these nodes and, according to the difficulty, are either spared or divided. Under the left renal vein (LRV), great attention must be paid with frequent large lymphatic vessels that must be thoroughly clipped to avoid huge lymphorrhea. A right renal artery in a low position can be suspected when observing arterial pulsations just underneath LRV. If necessary, retrocaval nodes can finally be approached by the cautious retraction of cava from its right and left side, taking care of lumbar veins.

- (b) Then the latero-aortic nodes are approached. They are resected in two parts separated by IMA. Under IMA as for the right side, the latero-aortic tissues are gently pushed on the left side. The left psoas, genitofemoral nerve, sympathetic chain, ureter, and gonadal vein must be successively identified before going on. Then they are followed cranially beyond IMA up to LRV. Then latero-aortic nodes are separated from the lateral aspect of the left common iliac artery and beyond the aorta, under and above IMA. As on the right side, they are finally elevated from the latero-vertebral plane, encompassing vertebrae, the left sympathetic chain, lumbar pedicles, and the left psoas. It may be sometimes easier to divide this step into an infra- and supramesenteric dissection. At the vicinity of the left renal vein, attention must be paid not to injure a possible left renal artery in a low position and, especially, the quite constant azygo-lumbar vein/trunk which flows into LRV. Its position is exactly opposite to the end of the left gonadal vein flowing into LRV. This aspect may facilitate its identification. A lympho-anastomose may exist with this vein and should be clipped. Finally a constant big lymphatic collector is to be clipped close to the axilla between LRV and the aorta.
- (c) The last step is the resection of presacral nodes located caudally to the aortocaval

bifurcation. They are gently separated from the left common iliac vein crossed by the right common iliac artery. Lympho-venous anastomoses as well as presacral vessels may be found at this level. Nodal resection is pushed caudally until both common iliac bifurcations are cleared.

- (d) Then all nodes are collected, and extracted from the peritoneal cavity through the umbilical or suprapubic port, globally or by chains, always using endoscopic bag(s).
- (e) Posterior peritoneum is left widely opened, and suspensions are removed. Except if significant lympho-hematic oozing, no drainage is necessary (Fig. 25.2).

Additional Aspects

IMA is an obstacle to latero-aortic part of the dissection. Some authors claim that it can be safely divided as general surgeons do when performing a colorectal resection. In the literature there is one report of a sigmoid necrosis after IMA had been sacrificed during a laparoscopic PA Ind [6], highlighting the necessity of a conservative management of this vessel.

In obese patients with short mesentery, suspension of lateral peritoneal leaflets is often necessary, and the placement of the optique in the

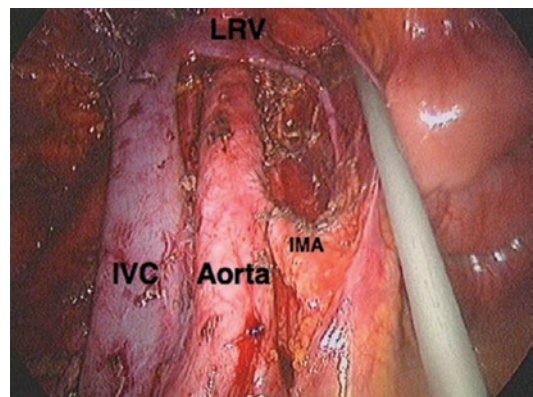


Fig. 25.2 Transperitoneal PA Ind final aspect

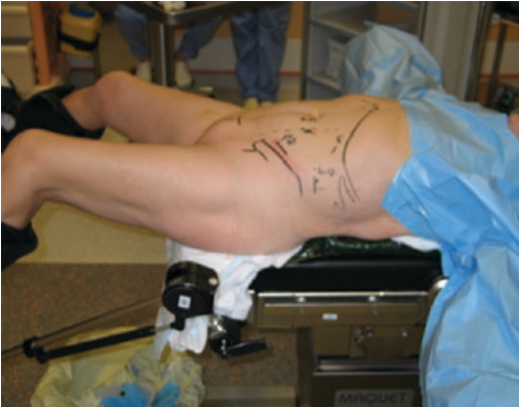

Fig. 25.3 Patient and trocar positioning

suprapubic 10 mm port may facilitate the inferior part of PA dissection.

A lateral transperitoneal approach has been reported as a variant. This choice is strictly based on surgeon's preferences.

Extraperitoneal Laparoscopic Paraaortic Node Dissection

Patient and Staff Positioning

Since most nodes are located laterally to aorta and in the absence of obvious right-sided involvement (that would indicate a right-sided iliac dissection), a left internal iliac approach is favored.

The patient, under general anesthesia with intubation, stomach and bladder emptied, is installed flat on the table, the abdomen close to the left table edge, and the left arm apart at 90°. The right arm can be tucked on the trunk. A slight Trendelenburg positioning and right-sided table tilt are helpful to expose retroperitoneal structures especially in overweighted patients (Fig. 25.3).

Technical Description

The operation starts by a diagnostic laparoscopy to rule out any carcinomatosis or evidence of intra-abdominal metastasis. For this purpose, a 10 mm umbilical trocar for the laparoscope and a

5 mm trocar for an instrument in the right iliac fossa are necessary.

Extraperitoneal Space Creation

1. To enter the left iliac extraperitoneal space, two methods are available:

- (a) Our usual approach is direct. The 2 cm skin incision is performed three fingerbreadths above the anterior iliac spine and one fingerbreadth medial to the iliac crest. The three muscular layers (muscular fibers of the external oblique, internal oblique, and transverse muscles) are penetrated along their fibers until the peritoneum becomes visible. At this point the surgeon's left forefinger is introduced in the extraperitoneal space to delicately detach the peritoneum from the medial aspect of the transverse muscle laterally and the quadratus lumborum then the psoas muscle posteriorly. Under finger control, a 10–12 mm trocar is introduced in the flank (on the mid-axillary line), midway between the iliac crest and the costal margin. When placed in the extraperitoneal space, CO₂ inflation is started (up to a stable pressure of 12 mmHg that warrants absence of peritoneum injury). The laparoscope is introduced through this port to control the extraperitoneal space and to place the second 5 mm operative trocar under the costal margin (mid-clavicular line) through the transverse muscle after having detached the peritoneum away with the finger. Then the finger is replaced by the balloon trocar placed in the space under visual control. The laparoscope is then introduced in this iliac trocar and the instruments in the other trocars. The lymphadenectomy can start.
- (b) Another technique consists of the incision of the skin in the iliac fossa (with the same recommendations) followed by the penetration of the surgeon's forefinger through the three layers of abdominal wall muscles, under the visual control of the diagnostic laparoscopy. The peritoneum is

then gently separated from the muscles to enable the placement of the operative trocars in the flank and subcostal margin. Then the finger is replaced by a balloon trocar and the extraperitoneal space is inflated, while the pneumoperitoneum is deflated. The optique is then placed in the iliac trocar, while the instruments are in the other trocars.

The Procedure, Step by Step

Dissection is based on clearance of great vessels from cellulo-lymphatic tissue, which is finally separated from the intact posterior peritoneum and duodenum.

1. Instrumental development of the extraperitoneal space by elevating the peritoneum from the psoas muscle laterally (the kidney is elevated as well) and cranially (up to the level of renal pedicle) is the initial step. This space is maintained only by gas pressure (not exceeding 15 mm of Hg). Positions of the left ureter and infundibulopelvic ligament are immediately checked; they are kept attached to the peritoneum, and this will avoid their damage.
2. Node dissection starts with the mobilization of the ilio-latero-aortic node.

The anterior aspect of left common iliac artery is cleared from nodes from the crossing with ureter caudally (level of common iliac bifurcation) up to the left hypogastric nerve that crosses the aorta and its bifurcation. This nerve is followed laterally to identify the inferior postganglionic fiber arising from the left sympathetic chain. This fiber is anatomically important since it exactly crosses the origin of the inferior mesenteric artery (IMA). By retracting this fiber from the aorta, IMA is identified, and this fiber can be sacrificed. Then the lateral aspect of the aorta is progressively freed. The origin of the tiny left gonadal artery is found out. It should be differentiated from a renal polar artery that, at the difference of gonadal artery, does not move when the left gonadal vein, at the top of the space, is mobilized. Once recognized, it is immediately desiccated and divided.

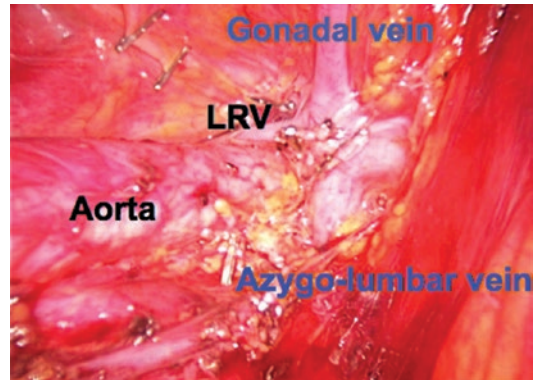


Fig. 25.4 Crossroad with azygo-lumbar vein opposite to left gonadal vein, both flooding into the left renal vein (LRV)

The upper limit of node dissection is the left renal vein (LRV). It can be found out by following the left gonadal vein at the ceiling of the space, since it flows into LRV. Of interest is the fact that opposite to this junction, the azygo-renal junction is easily identified (Fig. 25.4). This azygo-lumbar vein is formed by the 12th intercostal vein and ascending lumbar vein.

Latero-aortic nodes are then elevated from the posterior structures (sympathetic chain and vertebral plane). Care must be paid not to damage the nervous chain (limb sympathetic syndrome) nor lumbar vessels. These vessels are located directly on the vertebral plane and are crossed anteriorly by the sympathetic chain. Thus, following the anterior aspect of the sympathetic chain will facilitate their identification and preservation.

Close to the renal vein, there is constantly a big lymphatic collector that must be clipped to avoid an important lymph leakage. Then, the latero-aortic nodes are detached from the renal pedicle. At this point, the left renal artery and a possible lympho-azygos anastomosis must be identified and adequately managed.

3. The next step is the mobilization of pre-aorto- and interaortocaval nodes. The anterior aspect of the left renal vein is cleared, and the preaortic nodes are elevated from the renal vein cranially to IMA origin caudally. The interaortocaval nodes are mobilized. The use

of clips or sealing systems will prevent oozing during this step. While elevating the nodes, the origin of the right gonadal artery becomes visible and, as for the opposite one, is immediately desiccated and divided. Usually the anterior aspect of the vena cava is identified. It is followed cranially to join with the left renal vein and caudally at the level of IMA. Precaval nodes are carefully elevated from the cava. Any vessel going into a node must be preventively desiccated and cautiously divided to avoid a possibly life-threatening hemorrhage. When dissection above IMA is completed, the inframesenteric dissection is started.

4. The inframesenteric dissection is the last step of the procedure. Once the aortic bifurcation is cleared, the left common iliac vein is carefully identified and below the promontory (Fig. 25.5). Following the right common iliac artery, the right ureter is identified and elevated. We are at the level of the right common iliac bifurcation. Then nodes are separated from the artery until the psoas muscle is visible. Then preaortic nodes below IMA are elevated until the right hypogastric nerve is visible. The inferior part of the vena cava is just behind this nerve. After nerve division, the anterior aspect IVC is progressively cleared from nodes paying the same care to the “fellow’s veins” frequent at this level.
5. Node resection: Finally pre-vascular, interaortocaval, and latero-cavo-iliac nodes, separated

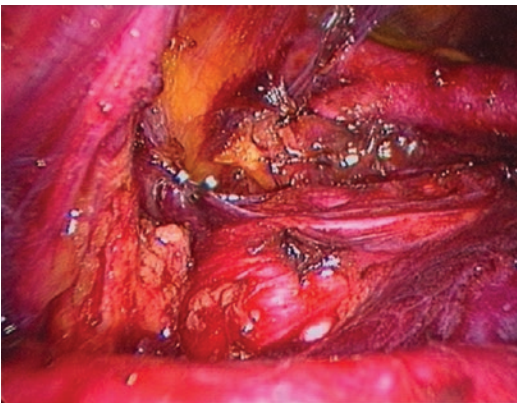


Fig. 25.5 Aortic bifurcation and promontory

from great vessels, are to be detached from the posterior peritoneum. Starting at the renal vein, nodes are separated from the duodeno-pancreas, and the lymphatic channels are carefully clipped and divided. Then they are separated from the posterior peritoneum by simple sweeping down to common iliac bifurcations. The nodes, stored laterally to the psoas, are placed in a bag and extracted through the iliac port site. After replacement of the balloon trocar, lympho-hemostasis is carefully checked and completed if requested (Fig. 25.6).

Final Steps

To prevent lymphocyst formation, a large opening of the left paraocolic gutter is recommended, which is called “preventive marsupialization.” Although feasible by the extraperitoneal space (taking care not to open the sigmoid colon!), it is easily and safely performed transperitoneally (after re-insufflation of the pneumoperitoneum). A 10 cm incision, away from the iliac trocar, seems a good size (Fig. 25.7). No drainage is necessary.

Then all trocars are removed and incisions carefully closed.

Perioperative Care

According to operative timetable, patients are discharged on the same or the first postoperative day. Level one analgesics are prescribed for the first days. Isoagulation using low-molecular-weight heparins is prescribed for the 3 postoperative weeks.

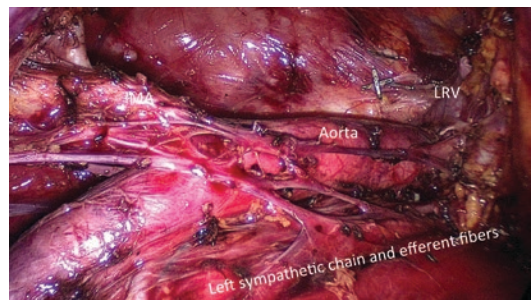


Fig. 25.6 Extraperitoneal PA IInd final aspect

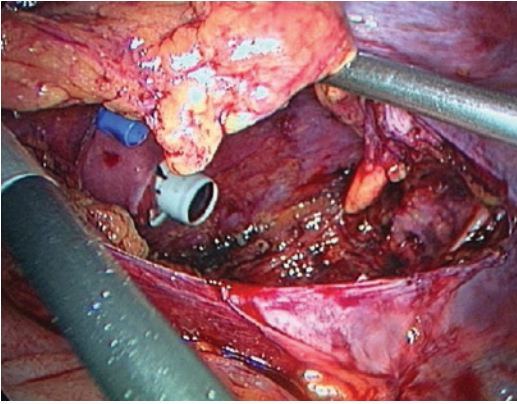


Fig. 25.7 Preventive fenestration of left paracolic gutter

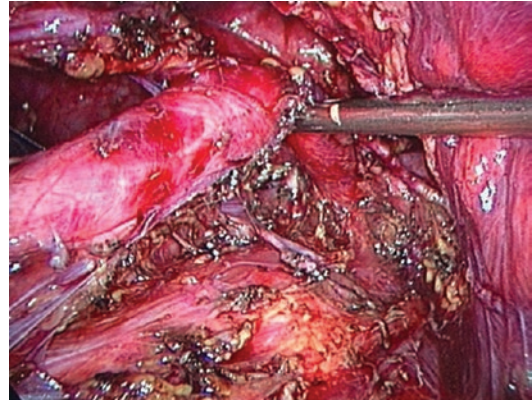


Fig. 25.8 Aorta mobilization for inter aorto-caval dissection

Additional Aspects

Complete Interaortocaval Dissection

Mobilization of interaortocaval nodes is not easy by the extraperitoneal approach, especially from the anterior part of the space. Only superficial nodes are usually removed. If a thorough resection is requested, the aorta must be mobilized to the vertebral plane. Lumbar arteries are isolated, clipped (Hemolock® clips are secure), and divided (Fig. 25.8). Of interest is that division of lumbar veins is not necessary and that lumbar arteries are always paired as the legs of a horse rider: if a left one is visible, the right one is just opposite. Concerning a possible risk of damage of the Adamkiewicz artery (AKA), which results in a definitive paraplegia, the upper pair of lumbar arteries, caudal to the renal pedicle, should be preserved, as if the AKA arises from branches of T11-L1 lumbar arteries, and the risk of presence of AKA at this level (L2) is less than 2% and is nil underneath.

After dividing two or three pairs of such lumbar arteries, the aorta can be elevated giving access to the deep interaortocaval nodes. They are detached from the prevertebral plane and retrieved directly or from the anterior part of this space.

Through this approach, the vena cava can be elevated as well from the vertebral plane to collect rare retrocaval nodes, but, if necessary, a

contralateral right-sided extraperitoneal dissection is to be preferentially considered.

Great care must be paid during these maneuvers since the risk of hemorrhage is important and potentially life-threatening. In addition, it should be attempted with great care in aged or atheromatosis patients, to avoid the risk of atheromatous thrombosis and/or embolization (one case in our experience).

Gonadal Pedicle Resection

This step is required in case of ovarian cancer staging. Gonadal veins are more easily identified at their junction with cava or the left renal vein. They are strongly clipped and divided at this level. The respective arteries usually join the veins. Then gonadal pedicles are followed until their crossing with ureters from which they must be clearly differentiated and separated. They are divided caudally close to common iliac pedicles.

Nerve-Sparing Dissection

Three pairs of postganglionic sympathetic fibers can be found: on the left side three arising lateral to the aorta and three arising from the interaortocaval space for the right side. If a nerve preservation is useful to preserve antegrade ejaculation in men, the advantages in women is more unclear, but their sacrifice may be responsible of some degree of constipation.

Technical Difficulties During Paraaortic Dissection (Whatever the Approach)

Hemorrhage

This is the most frequent complication due to direct vascular injury (electricity/ultrasound) or mechanical tearing. The ultimate management will depend of the importance of the damage and hemorrhage. If some caval injuries can be controlled laparoscopically, aortic injuries generally require an immediate conversion into laparotomy for an efficient and safe reparation. Whatever the situation, blind use of electricity, instrument, or clip application should be avoided, to prevent increase in vascular damage. The only first, efficient, and safe method of hemostasis is local package with surrounding tissues or swabs. It will temporarily contain/control blood loss while enabling convenient blood pressure restauration. After a while, blood around the bleeder is sucked, and when a correct vision is obtained, this compression is gently released. If bleeding remains important, decision of laparotomy should no longer be delayed while applying compression on the bleeder again. If bleeding has reduced enough, a precise control and an adapted hemostasis method can be applied such as clip/bipolar coagulation/hemostatic swab or foam or even a suture.

Fixed Node

Whatever the approach, presence of a fixed node (with risk of great vessel damage) remains a challenging situation for a laparoscopic debulking (Fig. 25.9). However vascular wall involvement is a very late step in disease evolution, and it is not exceptional to finally find the correct plane between the enlarged node and vessel. When this situation is anticipated at preoperative imaging, the extraperitoneal approach offers the advantage of a lateral view of the plane and may be more adapted to deal with this risky dissection. However, in addition to tumor size, node frailty must be considered as well in order not to spill out tumor cells in the operative field.

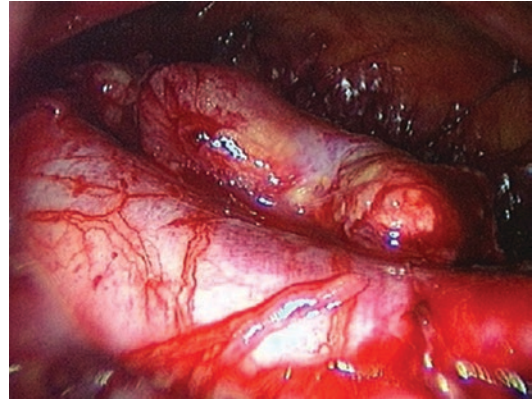


Fig. 25.9 Fixed node on the common iliac artery

If safety conditions cannot be all fulfilled, an open approach should be preferably considered (preferably extraperitoneal). In addition, if an obvious involved node is removed through an extraperitoneal approach, the preventive peritoneal marsupialization should be avoided, to prevent abdominal cavity contamination.

Lymph Leakage

A thorough lymphostasis is necessary all along the procedure. However, in spite of efforts (desiccation, sealing, clips), a (chylous or not) lymph leakage may be observed, especially from the interaortocaval space or from perirenal or high latero-aortic lymphatics. The additional placement hemostatic foam may stop it. Suction drainage is to be avoided.

Bowel Injury

Control of all instruments must be a constant preoccupation for the surgeon. If a bowel injury is observed during the procedure, bowel must be thoroughly inspected, since injury can perforate both side of bowel. Usually, a single- or two-layer suture will fix the damage. Bowel resection or ostomy is rare. At distance, attention must be paid to any abnormal postoperative course. Especially the association of fever, abdominal pain, and inflammatory process implies a CT scan to check absence of urinary damage and a laparoscopic revision in order not to miss a peritonitis (CT scan is not helpful due to the residual CO₂ pneumoperitoneum).

Ureter Injury

They can be observed during node dissection especially of fixed nodes. An IV injection of blue may help the diagnosis. The placement of ureteral stent will protect the single-layer suture. More problematic is the secondary ureter necrosis, some days or weeks after surgery. A uro-TDM/uro-MRI will confirm the ureter fistula and its level. An attempt of stent placement under cystoscopy along with a scanno-guided drainage may temporarily control the situation. If impossible, local drainage and nephrostomy enable to delay the secondary damage repair. Finally, ureter stenosis may occur after difficult dissections, and, if symptomatic, the endoscopic placement of endoprosthesis may be indicated.

Anatomical Variations [7]

Thirty percent of patients have anatomical variations [8]. This stresses the necessity of checking preoperative imaging and not dividing any vessel before it is clearly identified:

- (a) Low positioning of renal arteries. Most of the time, origins of both renal arteries are located above or behind the left renal vein. As for any rule, exceptions are not rare, and damage can occur in case of mistake with a lymph node. Any pulsation at a supposed lymph node under left renal vein should be suspected to be a renal artery, and a careful dissection is mandatory to confirm or not the presence of a lymph node at this level (Fig. 25.10).

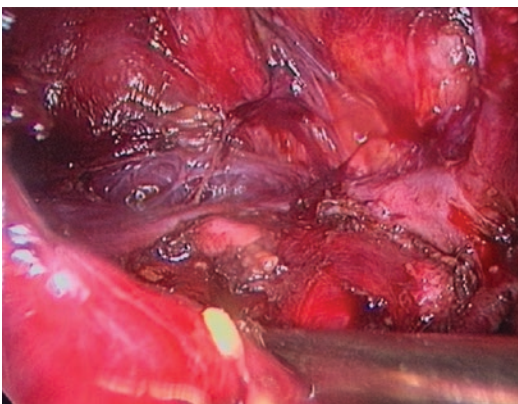


Fig. 25.10 Origin of a right renal artery in the interaortocaval space

- (b) The most frequent variant is presence of renal polar arteries. If the left side is more frequently concerned (Fig. 25.11), a right polar artery is possible. The problem is to distinguish a polar renal from a gonadal artery. A large caliber usually belongs to a polar vessel. Following the vessel will lead to the kidney. In addition, mobilization of the gonadal vein will help the identification of the gonadal artery as movements are transmitted, but not in the case of a polar vessel.
- (c) Presence of a retro-aortic left renal vein (Fig. 25.12) should be anticipated by checking the preoperative imaging. Following the course of the left gonadal vein will help.
- (d) Congenital anomalies of IVC are infrequent [9]. Left-sided cava is observed in less than 1% of people. In this situation, left renal vein is very short, and left gonadal vein floods directly into the cava (similar to the right side). A right-sided cava must be checked. If

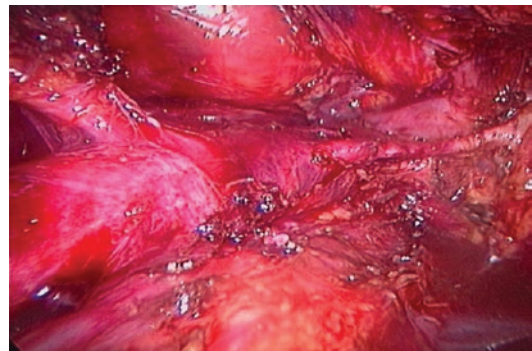


Fig. 25.11 Left renal polar artery

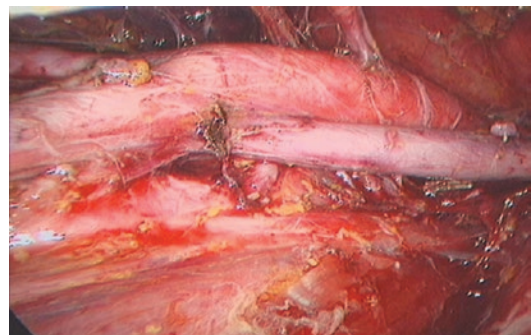


Fig. 25.12 Retroaortic left renal vein

present, the two vena cavae usually join high on the anterior part of the aorta, quite at the level of a regular preaortic left renal vein. If cava duplication is complete, common iliac veins follow their ipsilateral arteries, and consequently there is no vein below the aortic bifurcation.

- (e) Ureter variations are not infrequent, such as duplications which can be more or less complete. As for blood vessels, their anatomy should be controlled on preoperative imaging [10]. For laparoscopic extraperitoneal PAI, since ureters are kept attached onto posterior peritoneum, they are less at risk of injury. Only gonadal pedicle resections can be problematic.
- (f) Kidney variations. Only a horseshoe kidney is a very rare but challenging anatomy [11] especially for a paraaortic dissection. If latero-aortic dissection is usually possible, a right-sided dissection will require an elective approach.

Postoperative Complications

- (a) Lymphatic complications. Development of lymphocyst seems more frequent with the extraperitoneal approach. If the preventive “marsupialization” may have decreased its incidence, it was not annihilated. Only symptomatic lymphocysts (pain, fever, venous or ureter compression) must be treated. Simple scanno-guided puncture exposes to a recurrence rate of 60%. External image-guided drainage is the most effective method. To reduce the risk of recurrence, some advocate the instillation of polyvidone or alcoholization in the cyst with inconstant results. In case of failure or infection, a surgical drainage or exceptionally the ligature of the leaking channel if identified should be considered. In the case of chylous leakage or ascites, a conservative management is advocated based on drainage, a low-fat diet [12]. If recurrent, octreotide injections may help in solving this problem [13].
- (b) Leg lymphedema. This complication is quite rare after a paraaortic node dissection, but its incidence increases if it is associated to a pelvic dissections or radiation therapy [14]. Education, physiotherapy, and adapted contention stocks are the usual components of treatment [15].

Limits for Laparoscopic Paraaortic Node Dissections

- (a) Previous retroperitoneal surgery
Any retroperitoneal surgery will make further retroperitoneal dissection more complex. If adrenal gland, renal surgery, or even left colectomy is not a definitive contraindication (an attempt is necessary), a history aortoiliac surgery, renal grafting, and extraperitoneal mesh placement for herniation are clearly examples of limits, especially for the extraperitoneal approach.
- (b) Morbid obesity
If BMI does not fully summarize obesity description, it is a reliable reflect and can be a limiting factor for this operation [16]. Indeed, overweighted patients are a better indication for the extraperitoneal approach, since it avoids prolonged pneumoperitoneum and steep Trendelenburg and provides a more direct access to vessels and nodes [17]. However, it remains a challenge especially when coexist other comorbidities. In borderline situation, an honest effort should be attempted.
- (c) Advanced age
As obesity, age is not, by itself, a limit for such a procedure as previously claimed [18], and the association with other comorbidities may represent the real limiting factor. However, if required, mobilization of arteries should be carefully performed, to avoid endovascular complications.
- (d) Carcinomatosis
Management will depend on the clinical situation. If local carcinomatosis is not a contraindication, prognosis of distant carcinomatosis will not be altered by the finding of node involvement.

Alternative Approaches

- (a) Single-port extraperitoneal approach
It is possible to perform this operation through a single-port approach [19]. Different devices are available to enable this procedure. The SILS® (Ethicon) and Gelpoint® (Applied) systems have been tried. A significant experience in laparoscopic surgery is mandatory to master this approach, which is really challenging especially when dissecting the right side. The question is the real advantage provided by single-port approach compared to a three-port extraperitoneal dissection.
- (e) Robotic extraperitoneal approach
Initial experience in robotically assisted laparoscopic extraperitoneal PA Ind was first reported by Diaz Feijoo and was retrospectively compared to laparoscopy to perform extraperitoneal PA Inds performed by the same team. Robotic approach provided a higher node count with lower blood loss with no difference in perioperative morbidity [20]. Narducci et al. published the French preliminary experience and confirmed the feasibility of the procedure with few complication, except for postoperative lymphocysts [21].

Other Current Developments

1. Surgical radioprotection in locally advanced cervix cancer
These tumors are usually managed by a cisplatin-based pelvic or extended-field chemoradiation. The risk of radiation-induced bowel damage is as high as and this complication is unfortunately often durable. In the future this rate may decrease, thanks to the use of conformational irradiation techniques. Meanwhile, some simple techniques may prevent these complications: first the suspension of a long sigmoid loop in the left paracolic gutter by one or two stitches using the epiploic appendices will avoid a possible future stenosis. Similarly the interposition between the rectum and uterus of an omental J-flap, harvested from the right and transverse colon, will

prevent small bowel to fall in the Douglas cul-de-sac and widen the space between the anterior aspect of the rectum and the enlarged cervix, thus reducing dramatically the risk of radiation rectitis or enteritis [22].

2. Revision of the patterns of dissection
Another way to reduce operative time or complication is to reduce the pattern of dissection. If a complete dissection up to the left renal vein is requested for the staging of endometrial or ovarian carcinomas, this statement is debatable in cervix cancer. In a prospective multicentric study, we confirmed that the rate of skip metastasis above IMA is extremely low in advanced cervix cancer when inframesenteric nodes are negative, justifying to limit the dissection for this indication from both common iliac bifurcation caudally up to the origin of IMA cranially [23].
3. Revision of indications of PA Ind
As required by FIGO staging, all ovarian carcinoma should be dissected from pelvic to infrarenal paraaortic level, thoroughly (including interaortocaval dissection) and bilaterally [24]. However mucinous cancer may be an exception especially in their expansile subtype (at the difference with the infiltrative subtype) [25].

Similarly, in early endometrial carcinomas, usually managed by laparoscopic approach, all type 2 and intermediate- to high-risk type 1 tumors should remain an indication for a complete ilio-infrarenal staging [26].

In cervix cancer, the indication of PA Ind is accepted in case of pelvic positive nodes but is controverted in locally advanced carcinomas, as the advantage in survival is uncertain. Some randomized trials are ongoing to clarify the indication [27].

Results of Laparoscopic Lymphadenectomies in Gynecologic Oncology

In a recent review, Gouy et al. compared the results of open and laparoscopic paraaortic node dissections from retrospective series [28]. With

0–2% of complications, laparoscopic node dissections are safer than their open counterpart, whatever its approach trans- or extraperitoneal.

There are few studies comparing the two approaches, and all are retrospective and summarized in the Table 1. Only in preliminary experiences, comparative studies showed a little bit more complications with the EP approach, especially conversions into a transperitoneal approach (due to peritoneal perforation but with training and experience, this rate remained low [29]. In Pakish et al. experience, 34 extraperitoneal laparoscopic PA lnd were compared to 108 transperitoneal laparoscopic or 52 robotic PA lnds. In fine, node count was always superior when using the laparoscopic extraperitoneal approach compared to each transperitoneal routes, although BMI and operative time were significantly higher in this group. By contrast postoperative outcomes did not differ across the different groups [17]. In Morales series comparing 28 extraperitoneal and 19 transperitoneal laparoscopic PA dissections, node counts were not different between the approaches. Only operative room time and length of stay in recovery unit were shorter with the extraperitoneal approach [30]. In Akladios et al. series, 51 transperitoneal were compared to 21 extraperitoneal PA lnds. Operative time was longer when using the transperitoneal approach, but they retrieved a higher node count (17 vs. 13), with no difference in outcomes nor morbidity. There was one laparo-conversion in this group and none in the extraperitoneal group (but three extraperitoneal laparoscopies had to be transformed into transperitoneal due to peritoneal perforations) [31].

Our single-center experience (yet unpublished data) started earlier (1991 for the transperitoneal and 1995 for the extraperitoneal laparoscopic approach). From 1991 to 2017, 1023 patients were operated for a PA lnd: 170 by a transperitoneal and 853 by an extraperitoneal approach (among them 50 extraperitoneal and 12 transperitoneal laparoscopic PA lnd were assisted by Da Vinci robotR). According to the level of dissection (infrarenal or inframesenteric), numbers of resected nodes were always significantly superior when using the extraperitoneal route. In addition, the number of resected nodes by the extraperitoneal approach

was not different from the one obtained after a transperitoneal laparotomy. This result is due to the anatomical fact that most of paraaortic nodes are located laterally to the aorta and the surgical fact that the left extraperitoneal left-sided iliac approach enables a more comprehensive dissection at this level. Comparison of morbidity rates revealed 2% of intraoperative complications with no significant difference between the different approaches. By contrast more lymphatic complications (7.7%) (i.e symptomatic lymphocysts, lymph ascites) were observed within the extraperitoneal group. Unfortunately, but the experience is still small, the robotic assistance did not demonstrate any advantage of this device (same patients' characteristics, equivalent number of nodes but longer OR time ... and costs). If the prophylactic fenestration of the paracolic gutter reduces the incidence of symptomatic lymphoceles, the incidence of this complication remains significantly higher when compared to the transperitoneal approach. The addition of thorough clipping and/or sealing of any lymph channel might with time erase this difference.

Conclusions

Laparoscopic paraaortic node dissection is a recognized procedure, safe reproducible, but both a specific training (videos, mentoring) and a regular practice are necessary to maintain these results.

Whatever the indication or the level of dissection, the extraperitoneal laparoscopic approach provided more nodes than the transperitoneal counterpart.

However, beyond surgeon's preference, the transperitoneal approach is adapted when it follows a transperitoneal pelvic dissection or in case of failure of the extraperitoneal dissection. However, in elective indications or in overweighted patients, the extraperitoneal approach is better indicated.

The use of single-port or robotic technology to perform the procedure is just an affair of possibility or choice.

This stresses the fact that both approaches should be equally mastered by any gynecologic oncologist.

References

1. Nezhat CR, et al. Laparoscopic radical hysterectomy with paraaortic and pelvic node dissection. *Am J Obstet Gynecol.* 1992;166(3):864–5.
2. Querleu D. Laparoscopic paraaortic node sampling in gynecologic oncology: a preliminary experience. *Gynecol Oncol.* 1993;49(1):24–9.
3. Vasilev SA, McGonigle KF. Extraperitoneal laparoscopic paraaortic lymph node dissection: development of a technique. *J Laparoendosc Surg.* 1995;5(2):85–90.
4. Dargent D, Ansquer Y, Mathevet P. Technical development and results of left extraperitoneal laparoscopic paraaortic lymphadenectomy for cervical cancer. *Gynecol Oncol.* 2000;77(1):87–92.
5. Panici PB, et al. Anatomical study of para-aortic and pelvic lymph nodes in gynecologic malignancies. *Obstet Gynecol.* 1992;79(4):498–502.
6. Haberstich R, et al. [Left colon necrosis after endoscopic para-aortic lymph node exploration in a cervical carcinoma stage IIB]. *Ann Chir.* 2006;131(9):553–5.
7. Pomel C, et al. Systematic (complete) para-aortic lymphadenectomy: description of a novel surgical classification with technical and anatomical considerations. *BJOG.* 2012;119(2):249–53.
8. Klemm P, et al. Vascular anomalies in the paraaortic region diagnosed by laparoscopy in patients with gynaecologic malignancies. *Gynecol Oncol.* 2005;96(2):278–82.
9. Spentzouris G, et al. The clinical anatomy of the inferior vena cava: a review of common congenital anomalies and considerations for clinicians. *Clin Anat.* 2014;27(8):1234–43.
10. Reisner DC, et al. Congenital and acquired disorders of uterular course. *Curr Probl Diagn Radiol.* 2016.
11. Natsis K, et al. Horseshoe kidney: a review of anatomy and pathology. *Surg Radiol Anat.* 2014;36(6):517–26.
12. Zhao Y, et al. Chylous ascites after laparoscopic lymph node dissection in gynecologic malignancies. *J Minim Invasive Gynecol.* 2014;21(1):90–6.
13. Kim EA, et al. Octreotide therapy for the management of refractory chylous ascites after a staging operation for endometrial adenocarcinoma. *J Obstet Gynaecol Res.* 2014;40(2):622–6.
14. Todo Y, et al. Risk factors for postoperative lower-extremity lymphedema in endometrial cancer survivors who had treatment including lymphadenectomy. *Gynecol Oncol.* 2010;119(1):60–4.
15. Salani R, et al. Swelling among women who need education about leg lymphedema: a descriptive study of lymphedema in women undergoing surgery for endometrial cancer. *Int J Gynecol Cancer.* 2014;24(8):1507–12.
16. Scribner DR Jr, et al. Laparoscopic pelvic and paraaortic lymph node dissection in the obese. *Gynecol Oncol.* 2002;84(3):426–30.
17. Pakish J, et al. A comparison of extraperitoneal versus transperitoneal laparoscopic or robotic para-aortic lymphadenectomy for staging of endometrial carcinoma. *Gynecol Oncol.* 2014;132(2):366–71.
18. Scribner DR Jr, et al. Surgical management of early-stage endometrial cancer in the elderly: is laparoscopy feasible? *Gynecol Oncol.* 2001;83(3):563–8.
19. Gouy S, et al. Single-port laparoscopy and extraperitoneal para-aortic lymphadenectomy for locally advanced cervical cancer: assessment after 52 consecutive patients. *Surg Endosc.* 2014;28(1):249–56.
20. Diaz-Feijoo B, et al. Comparison of robotic-assisted vs conventional laparoscopy for extraperitoneal paraaortic lymphadenectomy. *Gynecol Oncol.* 2014;132(1):98–101.
21. Narducci F, et al. Extraperitoneal para-aortic lymphadenectomy by robot-assisted laparoscopy in gynecologic oncology: preliminary experience and advantages and limitations. *Int J Gynecol Cancer.* 2015;25(8):1494–502.
22. Leblanc E, et al. A new laparoscopic method of bowel radio-protection before pelvic chemoradiation of locally advanced cervix cancers. *Surg Endosc.* 2014;28(9):2713–8.
23. Leblanc E, et al. Should systematic infrarenal para-aortic dissection be the rule in the pretherapeutic staging of primary or recurrent locally advanced cervix cancer patients with a negative preoperative para-aortic PET imaging? *Int J Gynecol Cancer.* 2016;26(1):169–75.
24. Kleppe M, et al. Lymph node metastasis in stages I and II ovarian cancer: a review. *Gynecol Oncol.* 2011;123(3):610–4.
25. Muyldermans K, et al. Primary invasive mucinous ovarian carcinoma of the intestinal type: importance of the expansile versus infiltrative type in predicting recurrence and lymph node metastases. *Eur J Cancer.* 2013;49(7):1600–8.
26. Kumar S, et al. Prospective assessment of the prevalence of pelvic, paraaortic and high paraaortic lymph node metastasis in endometrial cancer. *Gynecol Oncol.* 2014;132(1):38–43.
27. Kohler C, et al. Perioperative morbidity and rate of upstaging after laparoscopic staging for patients with locally advanced cervical cancer: results of a prospective randomized trial. *Am J Obstet Gynecol.* 2015;213(4):503.e1–7.
28. Gouy S, et al. Nodal-staging surgery for locally advanced cervical cancer in the era of PET. *Lancet Oncol.* 2012;13(5):e212–20.
29. Vergote I, et al. Laparoscopic lower para-aortic staging lymphadenectomy in stage IB2, II, and III cervical cancer. *Int J Gynecol Cancer.* 2002;12(1):22–6.
30. Morales S, et al. Surgical outcome of extraperitoneal paraaortic lymph node dissections compared with transperitoneal approach in gynecologic cancer patients. *J Minim Invasive Gynecol.* 2013;20(5):611–5.
31. Akladios C, et al. Comparison between transperitoneal and extraperitoneal laparoscopic paraaortic lymphadenectomy in gynecologic malignancies. *J Minim Invasive Gynecol.* 2015;22(2):268–74.



Transperitoneal Para-aortic Lymphadenectomy: Surgical Technique, Results, Challenges, and Complications

Audrey Tiekō Tsunoda, Carlos Eduardo Mattos da Cunha Andrade, Bruno Roberto Braga Azevedo, José Clemente Linhares, and Reitan Ribeiro

Background

One of the more important prognostic factors in gynecological malignancies is the lymph node status. A combination of risk factors, the organ anatomy and drainage, the histology, and the stage are the key factors related to lymph node metastasis that may range from 1.5% up to 70%.

Minimally invasive surgery (MIS) is the best approach to be offered for staging purposes and in the absence of a systemic disease. All potential

benefits provided by MIS techniques are significant toward lower morbidity rates, reduced time to adjuvant therapies, and earlier return to regular daily activities. In locally advanced cervical cancer patients, the rates of upstaging after a surgical staging may range from 18% up to 33% in the literature [1–3].

Another interesting indication for surgical para-aortic MIS transperitoneal lymphadenectomy is debulking. After a multidisciplinary evaluation, patients referred for surgery due to bulky nodal metastases might achieve better local control when the volume of disease is debulked through a MIS surgery, with low morbidity, in order to achieve minimal volume of disease to be treated. The multidisciplinary approach is fundamental for patient counseling, to delineate the objectives of the surgical procedure, the correct timing of the surgery aligned with the multimodal therapeutic plan, and the best surgical route.

The para-aortic lymphadenectomy (retroperitoneal lymphadenectomy) in gynecologic cancer encompasses the dissection and removal of all lymphovascular tissues between common iliac vessels (distal limit), ureters (lateral limits), psoas muscles (posterior and lateral limits), and left renal vein (proximal limit). A transperitoneal para-aortic lymphadenectomy (TPAL) technique is developed through the peritoneal cavity, with the patient in a Trendelenburg position.

Electronic supplementary material The online version of this chapter (https://doi.org/10.1007/978-3-319-72592-5_26) contains supplementary material, which is available to authorized users.

A. T. Tsunoda, M.D., Ph.D. (✉) · R. Ribeiro, M.D.
Gynecologic Oncology Department, Hospital Erasto Gaertner, Instituto de Oncologia do Paraná, Universidade Positivo and Hospital Marcelino Champagnat, Curitiba, PR, Brazil

C. E. M. da Cunha Andrade, M.D., M.Sc.
Gynecologic Oncology Department, Hospital de Câncer de Barretos, Barretos, SP, Brazil

B. R. B. Azevedo, M.D.
Instituto de Hematologia e Oncologia do Paraná and Hospital São Vicente, Curitiba, PR, Brazil

J. C. Linhares, M.D., M.Sc.
Breast and Gynecologic Oncology Department, Instituto de Oncologia do Paraná, Erasto Gaertner Hospital, Curitiba, PR, Brazil

The surgical team usually faces a screen nearby the cranial portion of the patient.

Some advantages of the TPAL technique should be mentioned: anatomic vision, as observed in the anatomical textbooks, a comfortable position for the entire surgical team, one strategic port placement for the entire abdominal cavity, and good surgical field exposition and favorable access to all dissection sites, including the right vena cava and intraaortocaval and retrocaval sites, when applicable.

Potential limitations to TPAL are Trendelenburg; occasional challenging access to the supramesenteric and left infrarenal space; heavy mesentery, due to dense fat tissue and heavy small bowel loops, with difficult exposure; and eventual longer learning curve.

Technical Principles: Step-by-Step in Video 26.1

Patient Positioning

The patient is positioned after general anesthesia, with or without regional blockage. Lower limbs are placed in Allen stirrups, with the application of an intermittent compression device, in a low lithotomy position (Lloyd Davis).

The upper limbs are securely positioned along the body, the IV lines and monitoring devices adequately protected from traction and/or compression. A heating system is paramount to preserve normothermia.

Some devices may play an important role to prevent a patient mobilization (sliding over the table) while placed in Trendelenburg. Most useful ones are permanent gel cushion, single-use foam cushion fixed on the table by straps, vacuum cushion, shoulder cushions, etc. Advantages and disadvantages are system related, although it is important to check for lesions, excessive pressure, or nervous injury.

Trocar Placement

First access is performed at the umbilical scar, and the pneumoperitoneum is obtained according to the team routine. If a more proximal dissection

is required, nearby the left renal vein, it is preferable to position this 11 mm trocar in the cranial part of the umbilical site, in order to gain 1 cm more distance from the pubic region, thus reducing instrument collisions. When the aim of the procedure is only pelvic dissection, the incision might be better placed in the center of the umbilical site or even inside it, distally (less apparent scar).

Three 6 mm trocars are positioned and aligned in the left lower quadrant, hypogastrum, and right lower quadrant, proximal and medial to the anterior iliac spines.

Some surgeons do prefer to place an additional 11 mm trocar, routinely, while others may add this trocar only in more complex cases (i.e., debulking procedures) or even when the first assistant is not yet used to the 30° scope in the umbilical port. This fifth trocar is used to insert the scope, and the umbilical trocar is used by the second assistant to retract and improve exposure, to aspirate the surgical field, and to insert 10 mm clips, needles, or eventually gauze. Main limitation is the collision of instruments that may be increased by this fifth trocar.

Team and Instrument Positioning

The surgical table must allow a steep Trendelenburg, of 25–30°, with safety and efficiency. The surgeon is positioned between the lower limbs, with the right-hand instrument in the left quadrant trocar and the right-hand instrument in the hypogastric trocar.

The first assistant stands in the right side of the patient, with the left hand on the 30° scope and the right hand with the auxiliary grasping or suctioning device through the right quadrant port.

When the fifth 11 mm trocar is inserted in the suprapubic region, the surgeon stands in the right side of the patient and the first assistant between the lower limbs. The surgeon uses both right quadrant and hypogastric trocars, while the first assistant holds the scope with the left hand and the auxiliary instrument with the right hand through the left quadrant trocar. A second assistant stands by the left side of the patient and holds an instrument through the umbilical port (suction

device, retractor below the duodenum, or grasping forceps).

Energy sources (generators) are positioned nearby the right side of the patient, close to the right shoulder. The screen is placed over the head or by the patient's shoulder. The scrub nurse is positioned by the surgeon's right side, on the left side of the patient.

If possible, an accessory table is placed fixed on the surgical table, at the level of the patient's shoulder, to protect the face and to keep the instruments that are more used during the procedure in a shorter distance.

Surgical Field

After a steep Trendelenburg, the patient is tilted to the right side. The omentum is positioned over the liver (if possible), and the small bowel loops are gently flipped over to the right and upper side of the abdominal cavity. A peritoneal incision starts at the level of the right common iliac artery (easiest anatomical landmark), ascending toward the duodenum. The right psoas muscle is identified as the posterior and lateral limit. The right gonadal vessels and the right ureter are identified and retracted laterally, as the lateral limits of the dissection. The duodenum is then retracted, and the incision proceeds cranially crossing over the great vessels, ascending to the left side of the abdomen, along the duodenum. Suspension transparietal stitches or suspension devices are useful to keep the small bowel loops outside this surgical field. With stitches placed for duodenum suspension, the dissection proceeds to the left side, and the left side suspension is placed as soon as the inferior mesenteric artery (IMA), left psoas muscle, and left ureter are identified. With adequate exposure, it is possible to identify and preserve the complete left renal vein.

Large and heavy bowel loops and mesentery may demand more suspension peritoneal transparietal stitches. In selected cases, six or eight stitches are needed to guarantee a good exposure. These stitches are placed through the abdominal wall with a straight and long needle, and the thread is multifilament or monofilament, usually permanent, and long. Other commercial

suspension devices are available and are safely and quickly applied.

Dissection Technique and Instruments

Exposure accomplishment and anatomical landmark identification are key steps for TPAL. Dissection of the lymphovascular tissue may be performed by bipolar and scissors or atraumatic grasping forceps and advanced energy device (i.e., bipolar vessel sealer or ultrasonic instrument). All team members must be aware of the benefits, limitations, and potential risks of each instrument, for a better efficiency and cost harmonization. Usually, the easier starting sites are the paracaval and precaval spaces. During this step, the first assistant retracts laterally the right ureter, and the surgeon must apply gentle and precise movements. In the precaval region, there are small venous perforators draining from the precaval nodes directly to the anterior and distal vena cava wall, described as fellow veins. Careful tissue handling and dissection allow precise dissection and prevent a vena cava tearing due to a fellow vein traction.

The dissection between the vena cava and aorta is challenging and demands preserving the lumbar vessels and the superior hypogastric plexus (SHP). Both can be dissected and preserved, mainly in the absence of bulky nodes.

The SHP is lateralized along the IMA while dissecting the preaortic and para-aortic sites. Left psoas muscle is the posterior and right lateral limit, along with the left ureter, which may have its entire tract well defined. A left sympathetic chain, lateral and parallel to the vertebrae, should be preserved whenever possible. It is well identified after lumbar artery identification at the same level, some millimeters laterally, as a whitish and long structure, posterior to the level of the lymphovascular tissue. Proximal to the IMA, anteriorly and laterally, there is a plane of delicate branches of autonomic nerves. This branch preservation is more challenging through a transperitoneal approach. Furthermore, most of the vascular anatomical variations do occur in this topography. Preoperative imaging is crucial to

avoid vascular injuries in this site. Precise dissection and identification of the entire left renal vein allow dissection and ligation of the proximal lymphovascular tissue, medial to the left perirenal fat tissue. This lymphovascular tissue can be removed en bloc or separated from the distal IMA tissue.

To separate the surgical specimens by topographies may contribute to enhance the number of lymph nodes identified by the pathologist.

Final Aspects

At the end of the dissection, the total blood loss is precisely measured, and the hemostasis is carefully reviewed. Irrigation during the dissection steps usually impairs the surgical planes and the efficiency of the energy devices. Field irrigation with warm saline solution is restricted to the final review of the surgical field and has the objective of removing dissection debris and blood clots. There is no need of placing drains, unless clinically indicated, i.e., necessity of monitoring a specific risk site.

TPAL with adequate identification of the anatomical landmarks, neuropsychic preservation, and careful dissection is related to low morbidity rates and short recovery times.

Suspension stitches are removed, the bowel loops and the omentum are returned to their anatomical place, and the procedure is finished.

All the surgical specimens are retrieved inside endobags, for protected extraction.

Extraction can be performed vaginally (after a hysterectomy), through the umbilical incision (for very small nodes), a low transverse incision (if large nodes and no hysterectomy).

Trocar removal is under direct vision, to control eventual abdominal wall bleeding. The pneumoperitoneum is removed through the 11 mm umbilical trocar, to avoid the chimney effect.

All aponeurosis incisions larger than 8 mm should be systematically sutured, with a significant reduction in port site herniation. The subcutaneous is irrigated with saline, and the skin is sutured with intradermal absorbable sutures.

Postoperative Care

Diet restarts 4–6 h after surgery. Intermittent lower limb compression is maintained for 12 h or until the patient walks. Patient is allowed to walk in the same day, or in the early morning after surgery, unless clinically restricted. Discharge is programed for the next morning. Low weight heparin prophylaxis reduces venous thromboembolism events. Return to regular activities in 14–21 days and adjuvant therapies may start in 5–14 postoperative days. Patients with locally advanced cervical cancer selected for surgical staging may start chemoradiation in 14 days of the surgery, according to a prospective and randomized trial [1, 2].

Limitations and Challenges

A standard TPAL technique is applicable in all clinical situations, for staging or debulking purposes.

Patient performance status and tumor stage and biology are crucial for a better TPAL indication.

Surgical equipment and team training are basic resources that may impact the final results.

A major limitation for TPAL technique is the long learning curve [4]. Currently, there is a limited number of training centers for advanced laparoscopy in gynecologic oncology, and that is one of the reasons why TPAL has not been widely indicated [5]. Unfavorable situations may reduce indications or even increase complications of TPAL. Obese patients, previous abdominal surgeries, other anatomical distortions and/or variations, previous radiation therapy, and bulky nodes are some of the major challenges when TPAL is concerned. Most of these situations are preventable or controllable, and a careful review of the clinical information, prior treatments, and imaging (lymphadenopathy, anatomical variations) potentially prevent significant complications.

On the other hand, minimally invasive access is related to less complications, even in challenging situations, i.e., obesity [6, 7].

Complications

TPAL is frequently performed along with pelvic lymphadenectomy and hysterectomy, and isolated complications related to TPAL are uncommon. Lymphadenectomy complications are classified as vascular, nervous, urinary, or intestinal.

Vascular injuries are the most common operative complications. Among them, fellow vein injuries are the most frequent. Mostly result from an excessive traction of the lymph nodes over the distal vena cava. Local compression is one of the best resources to control a millimetric lesion, under low blood pressure, although there are situations where clipping with titanium clips or vascular suture may become necessary. Lumbar veins or arterial injuries are related to moderate blood loss but controlled under pressure. Dissection of the vessel for better identification and injury correction is mandatory, to avoid further lesions. Frequently, the injured lumbar vessel can be successfully ligated with clips. Gonadal arteries arise directly from the aorta and can be pulled and detached from it. If there is no remaining vessel and the orifice is opened directly at the aortic wall, there is a demand for suturing with a permanent monofilament thread (polypropylene), 4.0 or 5.0. IMA injuries can occur in the same fashion as the gonadal arteries, by avulsion from the aorta. The correction is the same, with suturing if no residual IMA at the aortic wall or clipping if there is a residual segment of IMA. Due to the vascular anastomosis, there is little chance of sigmoid/upper rectum necrosis, but this risk should be reviewed at the end of the surgery and during follow-up.

Vascular injuries may occur independently of the route, but laparoscopy presents lower blood loss when compared to open techniques [8].

Nerve or autonomic plexus injuries are related to partial left colon denervation, after resection of the superior mesenteric plexus or the intermesenteric plexus. Temporary adynamic ileus or colonic hypokinesia may occur. When lesions of the sympathetic paravertebral trunk occur, a significant difference of thermal sensation between the lower limbs may be seen postoperatively.

Urinary lesions are uncommon. Ureteric lesions are related to lack of correct identification and dissection of the ureter, resulting in thermal injuries or, rarely, ureteric resection or ligation along with the lymph nodes. Small injuries can be sutured under double-J ureteric stenting, with stitches of monofilament absorbable suture. Major ureteric injuries demand dissection of the ureter and eventually dissection of the kidney with reposition in a ptosis situation (to reduce distance from the proximal and distal ureter). An appendicular interposition and segment of ileum are options for large ureteric defects.

Bowel injuries are rare. In the majority of the cases, a failure to keep the bowel loops outside the operative field results in one assistant mobilizing the bowel without direct vision or while entering or retrieving instruments from the cavity. Another potential lesion may occur when the second assistant mobilizes the duodenum. Bowel injuries must be identified and repaired immediately, with suturing with monofilament permanent or absorbable sutures. When there is mucosal injury, one must remember to modify the antibiotic prophylaxis and execute the adequate surgical repair of the injury.

Postoperative complications account for 5% and most commonly are related to deep venous thromboembolism (VTE), lymphocysts, and bleeding. To apply a surgical technique that preserves the integrity of the vessels, with careful handling and dissection, associated with thromboprophylaxis with low-weight heparin for 28 postoperative days, is the current recommendation. There is a trend toward reducing the time for postoperative prophylaxis, but phase III trials are pending. Lymphoceles and lymphocysts occur in less than 20% of the patients undergoing pelvic and para-aortic lymphadenectomy [9], although less than 5% become symptomatic. Most symptomatic patients may be treated with simple percutaneous puncture, image guided. In cases of recurrence, percutaneous drainage and surgical marsupialization are options to be considered.

Hemostatic agents may play a role in the prevention or therapeutic approach of lymphocysts, although costs may limit the indication of these agents.

Bleeding is rare in the postoperative period. Patients without hemodynamic instability or coagulation abnormality may be considered for conservative approaches. On the other hand, patients with hematomas with expansion or hemodynamic instability are potential candidates for reoperation by laparoscopy or even a laparotomy.

Among patients operated in a randomized trial, comparing surgical staging versus clinical staging for locally advanced cervical cancer, surgical morbidity was 7.3%. Two patients presented intraoperative bleeding of more than 500 cm³, but without blood transfusion, and no deaths or reoperations [1, 2].

Results

TPAL is a standardized, feasible and effective technique, with a significant reduction in surgical morbidity. Several studies demonstrated the oncological safety of TPAL when compared to open/laparotomic techniques [10–12].

Oncological results are currently measured by three key points: (1) number of removed lymph nodes (extension of the lymphadenectomy), (2) the relevance of the lymph node status in the management, and (3) potential overall survival benefit.

In retroperitoneal lymphadenectomies, both laparotomic and minimally invasive approaches are comparable regarding the number of lymph nodes retrieved [1, 2, 11, 12]. Mean number of retrieved para-aortic nodes is 17 [1, 2].

Surgical staging may improve peritoneal spread evaluation and adjust/modify final stage in 33% of the cases [1, 2]. The stage modification leads to treatment plan modifications, i.e., extended field indication or, in case of peritoneal spread, palliative chemotherapy.

There are not enough data to correlate surgical staging and overall survival. Oncological results in locally advanced cervical cancer surgical staging are pending.

Conclusion

TPAL is a feasible and standardized surgical technique, with low morbidity, significant

oncological indications, and a potential therapeutic benefit.

Key Points

TPAL is a complex procedure. It demands surgical training in gynecologic oncology and significant team work. When performed by experienced groups, it is associated with a significant morbidity reduction, with relevant oncological outcomes.

References

1. Köhler C, Mustea A, Marnitz S, Schneider A, Chiantera V, Ulrich U, et al. Perioperative morbidity and rate of upstaging after laparoscopic staging for patients with locally advanced cervical cancer: results of a prospective randomized trial. *Am J Obstet Gynecol.* 2015;213(4):503.e1–7. <https://doi.org/10.1016/j.ajog.2015.05.026>.
2. Köhler C, Kyeyamwa S, Marnitz S, Tsunoda A, Vercelino F, Schneider A, Favero G. Prevention of lymphoceles using FloSeal and CoSeal after laparoscopic lymphadenectomy in patients with gynecologic malignancies. *J Minim Invasive Gynecol.* 2015;22(3):451–5. <https://doi.org/10.1016/j.jmig.2014.12.007>.
3. Ramirez PT, Jhingran A, Macapinlac HA, Euscher ED, Munsell MF, Coleman RL, Ramondetta LM. Laparoscopic extraperitoneal para-aortic lymphadenectomy in locally advanced cervical cancer: a prospective correlation of surgical findings with positron emission tomography/computed tomography findings. *Cancer.* 2011;117(9):1928–34. <https://doi.org/10.1002/cncr.25739>.
4. Peña-Fernández M, Solar-Vilariño I, Rodríguez-Álvarez MX, Zapardiel I, Estévez F, Gayoso-Diz P. Assessment of morbidity in gynaecologic oncology laparoscopy and identification of possible risk factors. *Ecancermedicinescience.* 2015;9:606. <https://doi.org/10.3332/ecancer.2015.606>.
5. Melamed A, Keating NL, Clemmer JT, Bregar AJ, Wright JD, Boruta DM, et al. Laparoscopic staging for apparent stage I epithelial ovarian cancer. *Am J Obstet Gynecol.* 2016;216:50.e1. <https://doi.org/10.1016/j.ajog.2016.08.030>.
6. Scribner DR, Walker JL, Johnson GA, McMeekin DS, Gold MA, Mannel RS. Laparoscopic pelvic and para-aortic lymph node dissection in the obese. *Gynecol Oncol.* 2002;84(3):426–30. <https://doi.org/10.1006/gyno.2001.6548>.
7. Uccella S, Bonzini M, Palomba S, Fanfani F, Ceccaroni M, Seracchioli R, Ghezzi F. Impact of obesity on surgical treatment for endometrial cancer: a multicenter study comparing laparoscopy vs

- open surgery, with propensity-matched analysis. *J Minim Invasive Gynecol.* 2016;23(1):53. <https://doi.org/10.1016/j.jmig.2015.08.007>.
8. Palomba S, Falbo A, Mocchiato R, Russo T, Zullo F. Laparoscopic treatment for endometrial cancer: a meta-analysis of randomized controlled trials (RCTs). *Gynecol Oncol.* 2009;112:415. <https://doi.org/10.1016/j.ygyno.2008.09.014>.
 9. Zikan M, Fischerova D, Pinkavova I, Slama J, Weinberger V, Dusek L, Cibula D. A prospective study examining the incidence of asymptomatic and symptomatic lymphoceles following lymphadenectomy in patients with gynecological cancer. *Gynecol Oncol.* 2015;137(2):291–8.
 10. Bennich G, Rudnicki M, Lassen PD. Laparoscopic surgery for early endometrial cancer. *Acta Obstet Gynecol Scand.* 2016;95(8):894–900. <https://doi.org/10.1111/aogs.12908>. PubMed PMID: 27100141.
 11. Favero G, Anton C, Le X, Silva E, Silva A, Dogan NU, Pfiffer T, Köhler C, Barakat EC, Carvalho JP. Oncologic safety of laparoscopy in the surgical treatment of type II endometrial cancer. *Int J Gynecol Cancer.* 2016;26(9):1673–8. PubMed PMID: 27552404.
 12. Koskas M, Jozwiak M, Fournier M, Vergote I, Trum H, Lok C, Amant F. Long-term oncological safety of minimally invasive surgery in high-risk endometrial cancer. *Eur J Cancer.* 2016;65:185–91. <https://doi.org/10.1016/j.ejca.2016.07.001>.



Radical Vaginal Trachelectomy

27

Suzana Arenhart Pessini, Gustavo Py Gomes da Silveira, and Denis Querleu

Introduction

Cervical cancer is the fourth most common cancer in women, with estimated rates of incidence age standardized (ASRs) ranging from 5.5 per 100,000 in Australia/New Zealand to 42.7 in Eastern Africa. Around 84% of new cervical cancer and 87% of cervical cancer deaths occur in the less developed regions [1].

The peak age of developing cervical cancer is 47 years, and approximately 47% of women with invasive cervical cancer are younger than 35 years of age at diagnosis [2].

The incidence of cervical cancers in young women is increasing. Between 2000 and 2009, the incidence in women aged 20–29 increased annually by an average of 10.3% [3]. Besides that, 14.9% of

the women with cervical cancer are between 20 and 34 years of age, and 26.2% are between 35 and 44 years old [4, 5]. In the USA, about 50% of all fertile women with a diagnosis of early-stage cervical cancer fit the criteria for RVT [6].

Based in these facts, there is no area in which conservative surgery makes more sense than cervical carcinoma, allowing young women to preserve their childbearing potential.

History

Professor Daniel Dargent, from Hôpital Edouard Herriot in Lyon, France, proposed a radical vaginal removal of the cervix, the upper part of vagina, and the proximal part of the parametria (radical vaginal trachelectomy (RVT)) combined with laparoscopic pelvic lymphadenectomy. Dargent started this procedure in 1986 and published his first results in 1994 [7, 8]. Other centers, like Berlin with Achim Schneider, Quebec with Michel Roy and Marie Plant, London with John Sheperd, and Toronto with Allan Covens, adopted and published their experience [9–12]. Professor Denis Querleu, in 1998, included and described this procedure in his book *Techniques Chirurgicales em Ginecologie* [13]. In 2000 Dargent analyzed 47 patients submitted to RVT with median follow-up of 52 months (7–123 months). Recurrences were observed in 2 patients (4.3%), and 20 pregnancies occurred in 13 patients with 10 normal newborn.

Electronic supplementary material The online version of this chapter (https://doi.org/10.1007/978-3-319-72592-5_27) contains supplementary material, which is available to authorized users.

S. A. Pessini, M.D., Ph.D. (✉)
G. P. G. da Silveira, M.D., Ph.D.
Federal do Rio Grande do Sul (UFRGS) and
Universidade Federal de Ciências da Saúde de Porto
Alegre (UFCSA), Porto Alegre, RS, Brazil
e-mail: spessini@terra.com.br

D. Querleu, M.D.
Department of Surgery, Institut Bergonié,
Bordeaux, France

Tumor diameter more than 2 cm and lymphovascular space invasion (LVSI) were the most important risk factors for recurrence [14]. In Brazil, the first RVT was performed by our group, from Santa Casa Hospital, Porto Alegre, in 2000.

Indications

The first condition is for the patient to desire to preserve fertility.

The other criteria are epidermoid, adenocarcinoma, or adenoescamoso histology; stages IA1 with LVSI, IA2, and IB1 up to 2 cm in size; invasion of the connective tissue of less 10 mm; negative lymph nodes; and 5 mm clear margin after resection.

For patients with early-stage cervical cancer who desire fertility preservation, radical trachelectomy (vaginal, abdominal, or laparoscopic) and pelvic lymphadenectomy are considered a standard treatment.

Preoperative

The criteria for the indications must be followed.

For the clinical staging, a pelvic examination provides the dimensions and the parametrial status. X-ray examination of the lungs and pyelography or ultrasound of the renal tract is recommended by FIGO. Cystoscopy and proctoscopy are used for more advanced stages. Blood tests should include full blood count and renal and liver functions, and syphilis and HIV serology need to be considered. Magnetic resonance imaging (MRI) is the best technique to show tumor size, depth of stromal invasion, and distance between the superior part of the tumor and internal os [15, 16].

For detecting lymph node metastatic disease, the most precise method is sentinel node. Computed tomography (CT), MRI, and positron-emission tomography (PET) have low precision [17].

Cone biopsy for precise diagnosis is important to some authors [18].

Technique

The abdomen and pelvis are carefully examined at the beginning of the operation by inspection of the peritoneal cavity, including a detailed examination of the fallopian tubes and ovaries. Frozen section of any suspicious peritoneal or ovarian growth, or of enlarged nodes, is required before starting the procedure, which must be abandoned in case of metastatic disease.

A laparoscopic pelvic lymphadenectomy is performed prior to the trachelectomy procedure. Identification of sentinel lymph node following intracervical injection of radiocolloid, blue dye, or fluorescence-emitting indocyanine green is the first step of the procedure. Pelvic nodes from the common iliac bifurcation proximally to the circumflex vein distally, including the pelvic nodes from the external iliac, internal iliac, and obturator regions, are then removed. The fertility-sparing procedure is abandoned, and a para-aortic lymph node sampling is performed if positive nodes are found. Only negative node patients are candidates for radical trachelectomy.

Vaginal Trachelectomy (Dargent Operation) (Movie from Denis Querleu)

The procedure begins with delineating an adequate vaginal margin of approximately 1–2 cm. Six or eight Kocher's forceps are placed circumferentially, and dilute epinephrine solution is injected under the vaginal mucosa to reduce bleeding and facilitate dissection. The vaginal mucosa is incised; the anterior and posterior aspects of the vaginal incision are folded together using Krobach clamps placed horizontally. The posterior cul-de-sac is opened posteriorly, the rectovaginal space is created, and the rectovaginal ligament is divided. The specimen is then

pulled downward, and the vesicouterine space is entered and developed by blunt dissection. The most tricky and specific part of radical vaginal surgery, which is the identification and dissection of the pelvic ureters, can be undertaken. The ureters are located within the so-called bladder pillar that is a structure defined by the vesicouterine space medially and the paravesical space laterally on each side. The paravesical spaces must then be widely opened in order to delineate the bladder pillar. Once the prevesical and paravesical spaces are developed, the ureter can be palpated and then dissected within the midportion of the bladder pillar. The uterovesical ligament can then be transected distal to the ureter. The lateral parametrium (paracervix) is clamped or coagulated and divided. Only the descending branch of the uterine artery, the cervicovaginal branch, is coagulated or ligated and divided without disturbing the main blood supply to the uterus. The cervix is transected ideally 1 cm below the internal cervical os and 1 cm above the upper limit of the tumor. A frozen section of the superior margin of the cervix can be performed to ensure safe negative endocervical margins. When the clear margin is less than 5 mm, removing another 3–5 mm of the residual cervix is recommended to improve tumor clearance. After ensuring that a proper oncological surgery with sufficient margins is obtained, the reconstruction is carried out. A prophylactic permanent cerclage is placed at the level of the internal os to avoid cervical incompetence. Finally, the cervical stump is sutured to the vaginal mucosa at a distance from the internal os.

Abdominal Radical Trachelectomy

To complete an abdominal radical trachelectomy, radicality is ensured by dividing the cardinal ligaments after dissection of the ureters. The preservation of the uterus and adnexa is made possible by refraining from dividing the upper pedicles of the uterus. After the vaginal incision and the division of cardinal ligament at the appropriate level, the cervix is divided and then

sutured to the vaginal wall after placement of a permanent cerclage. The rest is similar to the equivalent steps of radical hysterectomy. The preservation of uterine arteries is more difficult than it is from below. The uterine arteries can be carefully preserved or repaired after division. However, the benefit of preserving the uterine arteries is not clear [19].

Laparoscopic or Robotic-Assisted Radical Trachelectomy

The laparoscopic or robotic-assisted operation mimics the abdominal operation. The surgery may involve a vaginal step for the excision of the specimen after division of the cardinal surgery, the placement of cervical cerclage, and for the completion of the uterovaginal anastomosis.

Postoperative Care and Complications

A Foley catheter is placed in all patients for 48 h after the procedure. Postoperative bladder function is assessed at day 2 by measuring the post-void residual urine volume. If it is higher than 50 mL, the residual urine volume is measured after each miction and is stopped when obtaining two post-void residual urine volumes of less than 100 mL or one post-void residual urine volume less than 50 mL. In cases of urinary retention, patients are discharged with home self-intermittent catheterization.

Complications and Morbidity

The most common perioperative morbidities are bleeding and urinary tract injuries (1.7 and 1.6%). Postoperative morbidities are lymphocytosis, lymphedema, dyspareunia, menstrual disorders, and cervical stenosis [20, 21]. Cervical stenosis is a specific postoperative complication, with incidence of 8.1% in

RVT, less than abdominal and laparoscopic route [22].

Oncological Results

A recent systematic review, from Institute Gustave Roussy group, Villejuif, France [20], analyzed six different fertility-sparing surgery approaches for patients with cervical cancer. Dargent's procedure was identified in 1523 patients from 21 series. The recurrence was 3.8% (58/1523), and 24 patients died from the disease (1.6%).

In other publications, the 5-year recurrence and mortality rates are 2–6% and 1.6–6% [21, 23–26], comparable to classical radical abdominal hysterectomy. Another review, with 1293 radical trachelectomy, identified recurrence risk range of 0–16.8% [27]. Hauerberg et al. [28] observed 5.1% of recurrence, 10.5% in women with adenocarcinoma, and 2.5% in women with epidermoid.

The pattern of cancer recurrence in 10/320 (3.1%) patients treated with RVT was described by Mangler et al. [29]. Recurrence appeared at a mean time of 26.1 months (3–108), and five patients (1.6%) died within 8.8 months (4–15). None of the ten patients showed significant high-risk factors, which concluded there seems to be no pattern in the recurrence after RVT.

Fertility and Obstetric Outcomes

Speiser et al. [26] suggest possible changes caused by surgery that might influence fertility: cervical mucus reduced or altered, cervical stenosis, adhesions, and reduced blood flow.

The pregnancy rate, determined from series with complete data and based on total number of patients attempting to become pregnant and the number succeeding, is 63%. Pregnancies occurred in 487/1523 patients (32%), fetal loss in 103/487 (21%), and preterm delivery in 104 (21.3%) [20].

According to Speiser et al. [30], most patients were not planning a pregnancy after fertility-sparing surgery. From 212 patients treated by them, only 76 (35.8%) were planning after

0–5 years follow-up surgery, and 50/76 (65.8%) were pregnant. The pregnancy rate for all patients was 24% (50/212), but the really important rate, which shows the true success, is referred to how many patients would like to be pregnant after surgery (65.8%). Fifty women had 60 pregnancies and 45 live births (75%).

Second-trimester miscarriage and severe prematurity before 32 weeks are related to trachelectomy. The main reason of preterm delivery is premature rupture of the amniotic membranes [26, 27, 31].

Personal Experience

It seems that the first radical trachelectomy in Brazil was performed by our group in 2000. Until 2016, 26 patients were eligible, and 8 were excluded (4 by positive sentinel node, 3 by involvement of the up cervical channel, and 1 by neuroendocrine histology). From 18 patients (25–38 years old) with up to 188 months follow-up, the survival was 94.4%, and the spontaneous pregnancy rate was 83%, with 50% third-trimester deliveries and baby at home.

Careful Pregnancies

A minimum of 3 months seems a good interval between surgery and the first attempt to conceive [17].

All pregnancies must be considered high-risk pregnancies and the delivery cesarean section be done in a reference center with perinatology unit.

During pregnancy, the team of Charles University, Prague, recommends cephalosporin antibiotics at weeks 16, 20, and 24 and clindamycin vaginal treatment to prevent intraovular infection at weeks 16 and 20 [17]. Other authors prefer prophylactic use of oral metronidazole during weeks 15–21 and sexual abstinence during the second and third trimesters [32].

Speiser et al. [26] suggest to avoid elective dental treatment, by the bacteremia risk; vaginal intercourse between 14 and 34 weeks of gestation, by urinary and vaginal infection risk; and digital vaginal examinations.

Abdominal cerclage should be offered—by laparoscopy if not pregnant and by laparotomy if pregnant [26].

Prognostic Factors

Neuroendocrine tumors, tumor size more than 2 cm, and LVSI are the most important factors associated with recurrence and death [14, 25].

The analysis of 1523 patients submitted to RVT, those with IB1 tumors more than 2 cm had 17% recurrent disease, and those with IB1 up to 2 cm had 4% ($p = 0.001$) [20].

The LVSI data are more difficult to analyze, because some series did not mention this factor. From 473 patients with tumors up to 2 cm with details on LVSI or not, the recurrence was 5 and 7% ($p = 0.15$) [20].

Follow-Up

Review every 3 months for the first 2 years after surgery and then every 6 months for the next 3 years. After 5 years, annual follow-up [26].

Conclusion

Fertility-sparing surgery for cervical cancer must be offered to patients who desired to conceive, with respect to the criteria.

Cervical cancer occurs in young women, and they become pregnant more and more before age 30. Sonoda et al., from Memorial Sloan Kettering Cancer Center, New York, identified that 48% of patients who undergone radical hysterectomy between 1985 and 2001 may have been eligible by fertility-sparing surgery [6].

RVT with laparoscopic lymphadenectomy seems the standard fertility-sparing procedure for the cervical cancer patients [11].

Although there are no randomized controlled trials regarding oncological outcomes, because it's not feasible for women who wish to preserve fertility, many studies show similar rates of survival and recurrence in RVT compared with radical hysterectomy.

References

1. IARC. International Agency for Research on Cancer. <https://www.iarc.fr>.
2. Gattoc L, Viswanathan AN, Perez CA, Tew WP, Makhija S. Cervical cancer. Cancer management. Cancernetwork 2015. <http://www.cancernetwork.com/cancer-management/cervical>.
3. Patel A, Galaal K, Burnley C, Faulkner K, Martin-Hirsch P, Bland MJ, Leeson S, Beer H, Paranjothy S, Sasieni P, Naik R. Cervical cancer incidence in young women: a historical and geographic controlled UK regional population study. *Br J Cancer*. 2012;106:1753–9.
4. Covens A, Rosen B, Murphy J, Laframboise S, DePetrillo AD, Lickrish G, Colgan T, Chapman W, Shaw P. Changes in demographics and perioperative care of stage IA2 IB1 cervical cancer over the past 16 years. *Gynecol Oncol*. 2001;81:133–7.
5. Quinn MA, Benedet JL, Odicino F, Maisonneuve P, Beller U, Creasman WT, Heintz AP, Ngan HY, Pecorelli S. Carcinoma of the cervix uteri. FIGO 26th annual report on the results of treatment in gynecological cancer. *Int J Gynaecol Obstet*. 2006;95:43–103.
6. Sonoda Y, Abu-Rustum NR, Gemignani ML, Chi DS, Brown CL, Poyner EA, Barakat RR. A fertility-sparing alternative to radical hysterectomy: how many patients may be eligible? *Gynecol Oncol*. 2004;95:534–8.
7. Dargent D, Brun JL, Remy I. Pregnancies following radical trachelectomy for invasive cervical cancer. Society of Gynecologic Oncologists. *Abstr Gynecol Oncol*. 1994;52:105–8.
8. Dargent D, Brun JL, Roy M, Mathevet P, Remy I. La trachelectomie élargie (TE), une alternative à l'hystérectomie radicale dans le traitement des cancers infiltrants développés sur la face externe du col utérin. *JOBGYN*. 1994;2:2859–92.
9. Covens A, Shaw P. Is radical trachelectomy a safe alternative to hysterectomy for early stage IB carcinoma of the cervix. Society of Gynecologic Oncologists. *Abstr Gynecol Oncol*. 1999;72:443–4.
10. Roy M, Plante M. Pregnancies after radical vaginal trachelectomy for early-stage cervical cancer. *Gynecol Oncol*. 1996;62:336–9.
11. Schneider A, Drause N, Kuhne Heid R, et al. Erhaltung des Fertilität bei fruhem Zervix Karzinom: Trachelektomie mit laparoskopischer lymphonodektomie. *Zentralbl Gynakol*. 1996;118:6–8.
12. Sheperd JH, Crawford R, Oram D. Radical trachelectomy: a way to preserve fertility in the treatment of early cervical cancer. *Br J Obstet Gynaecol*. 1998;105:912–6.
13. Querleu D. *Techniques Chirurgicales em Gynecologie*. 2nd ed. Ed Masson; 1998.
14. Dargent D, Martin X, Sacchetoni A, Mathevet P. Laparoscopic vaginal radical trachelectomy. A treatment to preserve the fertility of cervical carcinoma patients. *Cancer*. 2000;88:1877–82.

15. Bermudez A, Bhatla N, Leung E. Cancer of the cervix uteri. *Int J Gynecol Obstet.* 2015;131:S88–95.
16. Lakhman Y, Akim O, Park KJ, Sarasohn DM, Zheng J, Goldman DA, Sohn MJ, Moskowitz CS, Sonoda Y, Hricak H, Abu-Rustum NR. Stage IB1 cervical cancer: role of preoperative MR imaging in selection of patients for fertility-sparing radical trachelectomy. *Radiology.* 2013;269:149–58.
17. Halaska MJ, Robova H, Pluta M, Rob L. The role of trachelectomy in cervical cancer. *Ecanermedicalscience.* 2015;9:506.
18. Uzan C, Gouy S, Desroque D, Pomel C, Duvillard P, Balleyguier C, Haie-Meder C, Morice P. Analysis of a continuous series of 34 young patients with early-stage cervical cancer selected for a vaginal radical trachelectomy: should “staging” conization be systematically performed before this procedure? *Int J Gynecol Cancer.* 2013;23:331–6.
19. Tang J, Li J, Wang S, Zhang D, Wu X. On what scale does it benefit the patients if uterine arteries were preserved during ART? *Gynecol Oncol.* 2014;134:154–9.
20. Bentivegna E, Gouy S, Maulard A, Chargari C, Leary A, Morice P. Oncological outcomes after fertility-sparing surgery for cervical cancer: a systematic review. *Lancet Oncol.* 2016;17:240–53. www.thelancet.com/oncology.
21. Schneider A, Erdemoglu E, Chiantera V, Reed N, Morice P, Rodolakis A, Densclag D, Kesic V. Clinical recommendation radical trachelectomy for fertility preservation in patients with early-stage cervical cancer. *Int J Gynecol Cancer.* 2012;22:659–66.
22. Li X, Li J, Wu X. Incidence, risk factors and treatment of cervical stenosis after radical trachelectomy: a systematic review. *Eur J Cancer.* 2015;51:1751–9.
23. Dursun P, Leblanc E, Nogueira MC. Radical vaginal trachelectomy (Dargent’s operation): a critical review of the literature. *Sur Surg Oncol.* 2007;33:933–41.
24. Lanowska M, Mangler M, Spek A, Grittner U, Hasenbein K, Chiantera V, Hertel H, Schneider A, Köhler C, Speiser D. Radical vaginal trachelectomy (RVT) combined with laparoscopic lymphadenectomy; prospective study of 225 patients with early-stage cervical cancer. *Int J Gynecol Cancer.* 2011;21:1458–64.
25. Plante M, Gregoire J, Renaud MC, Roy M. The vaginal radical trachelectomy: na update of a series of 125 cases and 106 pregnancies. *Gynecol Oncol.* 2011;121:290–7.
26. Speiser D, Köhler C, Schneider A, Mangler M. Radical vaginal trachelectomy. *Dtsch Arztebl Int.* 2013;110:289–95.
27. Gizzo S, Ancona E, Saccardi C, Patrelli TS, Berreta R, Anis O, Noventa M, Bertocco A, Fagherazzi S, Longone M, Vendemiati L, D’Antona D, Nardelli GB. Radical trachelectomy: the first step of fertility preservation in young women with cervical cancer (review). *Oncol Rep.* 2013;30:2545–54.
28. Hauergerg L, Hogdall C, Loft A, Bjoern SF, Mogaard BJ, Nedergaard L, Lajer H. Vaginal radical trachelectomy for early stage cervical cancer. Results of the Danish National Single Center Strategy. *Gynecol Oncol.* 2015;138:304–10.
29. Mangler M, Lanowska M, Köhler C, Vercellino F, Schneider A, Speiser D. Pattern of cancer recurrence in 320 patients after radical vaginal trachelectomy. *Int J Gynecol Cancer.* 2014;24:130–4.
30. Speiser D, Mangler M, Köhler C, Hasenbein K, Hertel H, Chiantera V, Gottschalk E, Lanowska M. Fertility outcome after radical vaginal trachelectomy. A prospective study of 212 patients. *Int J Gyn Onc.* 2011;21:1635–9.
31. Sheperd JH. Challenging dogma: radical conservation surgery for early stage cervical cancer in order to retain fertility. *Ann R Coll Surg Engl.* 2009;91:181–7.
32. Perrson J, Imboden S, Reynisson P, Andersson B, Borgfeldt C, Bossmar T. Reproducibility and accuracy of robot-assisted laparoscopic fertility sparing radical trachelectomy. *Gynecol Oncol.* 2012;127:484–8.

Laparoscopic Radical Trachelectomy Vaginal-Assisted Nerve Sparing: Description of the Surgical Technique and Early Results in a Reference Oncology Brazilian Center

Marcelo de Andrade Vieira,
Geórgia Fontes Cintra, Ricardo dos Reis,
and Carlos Eduardo Mattos da Cunha Andrade

Surgical Procedure

The patient is placed in gynecological position, with arms along the body, in Allen stirrups, and with intermittent pneumatic compression to prevent thromboembolism. After a systematic survey for extrauterine disease, the patient is placed in steep Trendelenburg position (Fig. 28.1).

The surgical team consists of the surgeon (purple cap), a first assistant (beige-green cap) to the left of the patient behind the surgeon, a second assistant (red cap), and a scrub nurse (green cap) to the right of the patient (Fig. 28.2).

Description of Surgical Technique

We divide the surgical procedure into two steps: the laparoscopic approach and the vaginal approach.

M. de A. Vieira (✉) • G. F. Cintra • R. dos Reis
C. E. M. da C. Andrade
Gynecologic Oncology Department,
Hospital de Câncer de Barretos, Barretos, SP, Brazil

The Laparoscopic Approach

The trocars are placed as follows: one 11 mm in the umbilical scar and three 5 mm trocars in the suprapubic and the right and left iliac fossa (Fig. 28.3).

We always start with the assessment of the pelvic lymph nodes. Routinely we have performed sentinel lymph node biopsy. Although intraoperative nodal evaluation by frozen section is known to have a poor negative predictive value, we perform it in order to acknowledge the indication of chemoradiation prior to performing such a challenging procedure as a radical trachelectomy. In the final pathology report, these nodes are evaluated through pathological ultrastaging technique.

Then, we proceed to the systematic pelvic lymphadenectomy. This surgical step is standardized and consists of the removal of the lymphatic tissues around the external iliac vessels, common iliac, anterior hypogastric vessels, and obturator fossa. The following are used as anatomical limits: obliterated umbilical artery (medial), genital branch of the genitofemoral nerve (lateral), bifurcation of the common iliac artery (cranial), circumflex vein (caudal), and obturator nerve (posterior). This procedure can be achieved using

Fig. 28.1 Patient positioning

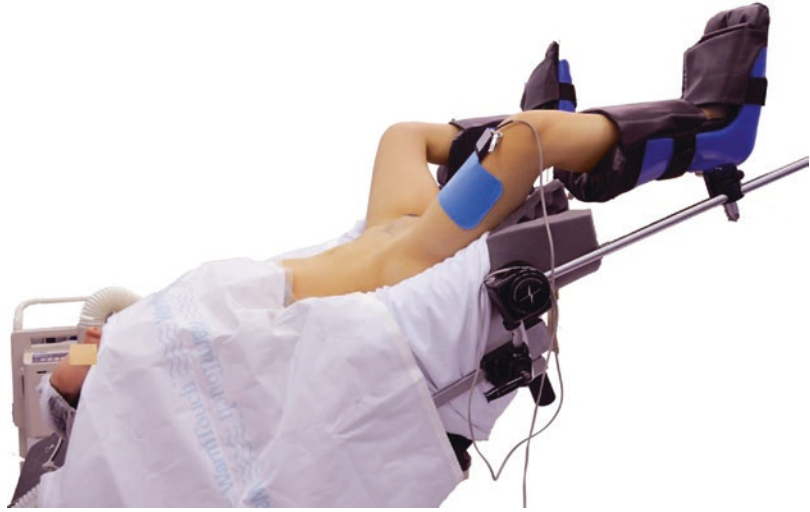
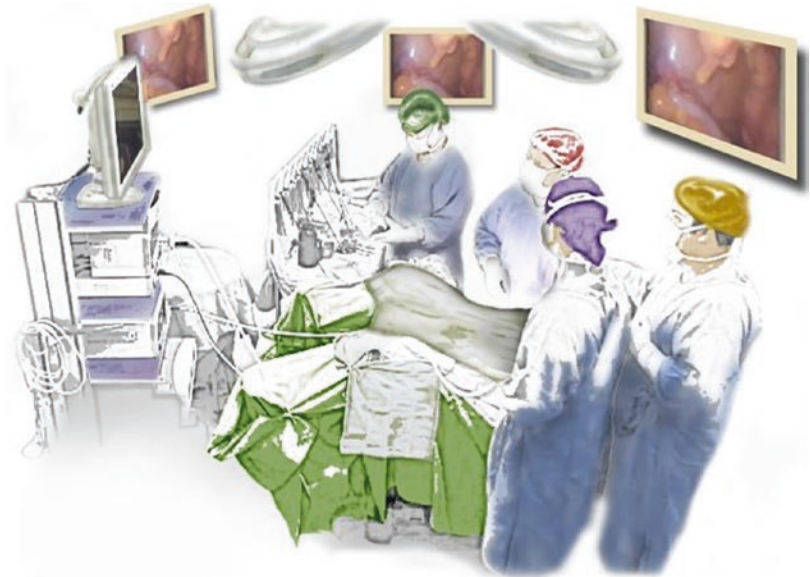
Fig. 28.2 Surgical team positioning in the OR



a bipolar forceps and scissors, an ultrasonic device, or an electrical thermal bipolar sealer/divider.

The lymph nodes are fixed in alcohol-based preparation for better identification and final count.

The next step is the dissection and isolation of the uterine vessels at the emergence of the internal iliac artery.

The medial paravesical and pararectal spaces are identified by exposing the tissue that divides them, the so-called parametrium. At this time of

surgery, it is possible to visualize the path of the inferior hypogastric plexus which is located 2 cm posterior to the ureter. The knowledge of this structure is crucial in performing a nerve-sparing technique (Fig. 28.4).

Isolation and tunelization of the ureter followed by the section of the anterior parametrium (vesicouterine ligament), lateral parametrium (cardinal ligament), and posterior parametrium (uterosacral ligament) are performed.

The final step of the laparoscopic approach is the accomplishment of the colpotomy.

The Vaginal Approach

The istmocervical transition is sectioned with a cold scalpel. Another 3 mm deeper layer is sectioned and sent for frozen section. When invasive

neoplasia is found at this margin, a completion of the hysterectomy is performed.

If the frozen section is negative, a cerclage is then performed with a number 6 Hegar dilator inside the endocervical canal. An endocervical device (DUDA®) is sutured in the endocervical canal and kept for 30 days to prevent late stenosis (Fig. 28.5).

And finally cervicovaginal anatomy is restored.

Finally a review of intra-abdominal hemostasis and washings with saline solution is performed.

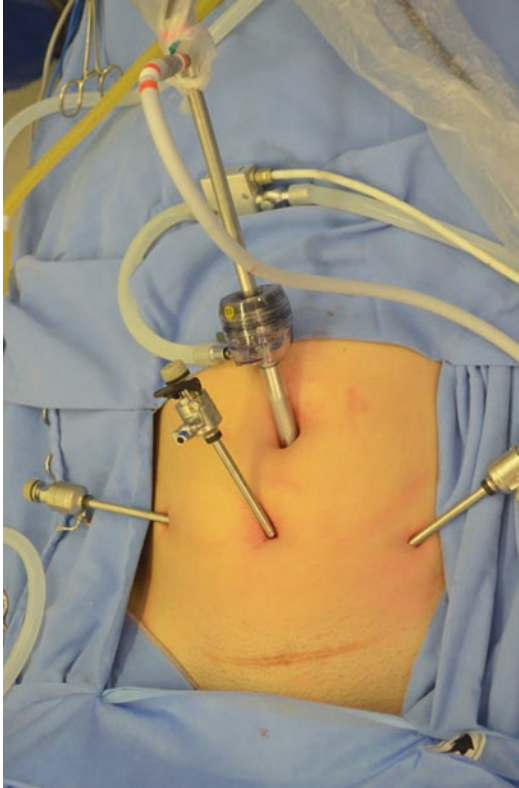


Fig. 28.3 Trocars' position

Results

Twenty-two patients with early-stage cervical cancer (IA1 with lymphovascular invasion to IB2) were submitted to vaginally assisted laparoscopic radical trachelectomy.

One patient received neoadjuvant chemotherapy, and all the remaining 21 had surgery as primary treatment. The mean age was 30 years and the mean BMI was 23.6 (Table 28.1).

Mean surgical time was 211 min ranging from 150 to 335 min. There was no conversion to laparotomy. No patient required completion to radical hysterectomy. Mean estimated bleeding was 56 mL (maximum 300 mL). There was no intraoperative transfusion. In seven patients (31.8%),

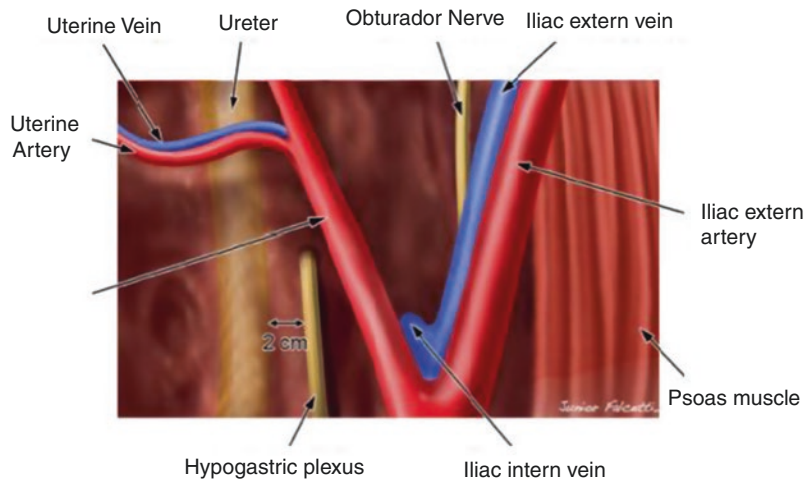


Fig. 28.4 Anatomical landmarks and hypogastric plexus in relation to the ureter

Fig. 28.5 Intracervical device to avoid stenosis (DUDA®). DUDA®—Developed in Barretos Cancer Hospital

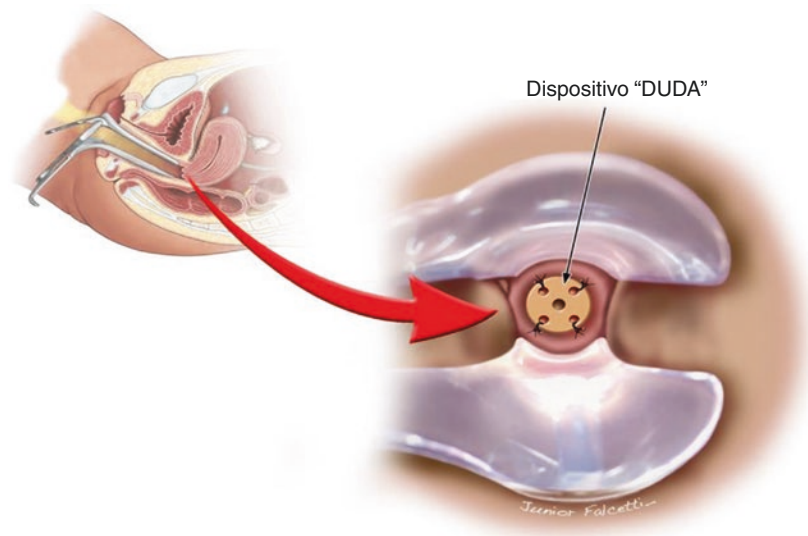


Table 28.1 Demographic and preoperative data ($n = 22$)

	n (%)
Age (years) mean (min–max)	30 (20–38)
Matrimonial status	
Single	11 (50)
Married	11 (50)
Mean BMI ^a (kg/m ²) (min–max)	23,6 (17–30)
Parity	
0	13 (59)
1	7 (31,8)
FIGO stage	
IA1 + LVSI ^b	1 (4,5)
IA2	5 (22,7)
IB1	15 (68,1)

^aBMI Body mass index

^bLVSI Lymphovascular space invasion

the ascending branch of the uterine artery was preserved.

Two intraoperative complications occurred, the first requiring unilateral salpingectomy and the second requiring a ureteral re-implantation due to ureteric section at the level of the bladder trigone. Both procedures were performed laparoscopically (Table 28.2).

The final pathology analysis showed an average size of 23.2 mm of the left parametrium (14–37 mm) and 23.3 mm of the right parametrium (15–35 mm). On average, 16 (5–31) pelvic lymph nodes were harvested. In four cases, only sentinel lymph node biopsy was performed. The length of hospital stay was 1 day in all patients evaluated (Table 28.3).

Table 28.2 Intra- and postoperative data ($n = 22$)

	N (min–max)
Surgical time (min)	211 (150–335)
Estimated blood loss (mL)	56.5 (20–300)
Right parametrium (mm)	23.3 (14–37)
Left parametrium (mm)	23.2 (10–37)
Pelvic nodes (N)	16 (5–31)
Intraoperative complication (N) (%)	2 (9)
Hospital stay (days)	1

Regarding the final histology, in eleven cases (50%) with squamous cell carcinoma, eight cases (36.6%) were adenocarcinoma and three cases (13.6%) adenosquamous. Lymphovascular invasion was evidenced in only two cases (9%).

International Federation of Gynecology and Obstetrics (FIGO) IB1 stage was the most frequent, found in 14 patients (63.6%).

There was one case of IB2 tumor (4.4 cm). There were only three cases of tumors larger than 2 cm (13.3%) and four patients (18.1%) with deep stromal infiltration. Positive pelvic lymph nodes occurred in two patients (9%) (Table 28.3).

Four patients (18.1%) required adjuvant treatment. A 33-year-old patient with grade 3 squamous cell carcinoma with Lymphovascular invasion (ILV) and IB1 staging (≤ 2 cm) underwent radical trachelectomy and pelvic lymphadenectomy. During the surgical procedure, a vaginal cuff of 1.5 cm and a bilateral parametrial average size of

Table 28.3 Final pathology (*n* = 22)

Variable	<i>n</i> (%)
Histology	
Squamous cell carcinoma	11 (50)
Adenocarcinoma	8 (36.6)
Adenosquamous	3 (13.6)
Tumor grade	
1	4 (18.1)
2	12 (54.5)
3	4 (18.1)
Tumor size (cm)	
≤2 cm	20 (86.7)
>2 cm	2 (13.3)
Deep stromal invasion	4 (18.1)
LVSI ^a	2 (9)
Lymph node metastasis	2 (9)
Parametrial metastasis	2 (9)

^aLVSI Lymphovascular space invasion

3 cm were resected. Although the intraoperative frozen section analysis of the margin was negative, in the final pathology analysis, although deep stromal invasion was not observed, margins of the vaginal cuff and parametrium were found to be focally compromised by squamous cell carcinoma. We performed an extra-pelvic oophoropexia 37 days after the first surgical procedure, followed by adjuvant radiation therapy with 45 cGy. Despite this surgical procedure, this patient presented ovarian failure after treatment and is currently under combined hormone replacement therapy to control postmenopausal symptoms. In another 27-year-old patient with grade 2 squamous cell carcinoma with ILV and IB1 staging (>2 cm), a vaginal cuff of 2 cm and bilateral parametrial mean size of 2.5 cm were resected during the surgical procedure and negative margins on frozen section. In the final pathology analysis, deep stromal invasion and a positive pelvic lymph node were identified (1/29). She was submitted to extra-pelvic oophoropexia 42 days after the first surgical procedure and then to four cycles of chemotherapy (cisplatin 75 mg/m² and paclitaxel 175 mg/m², q21). It was an individualized treatment due to strong fertility preservation desire and refusal of radiotherapy. This patient is in the 54th month of follow-up with no evidence of relapse.

The mean follow-up was 29.8 months (1–55 months). There were two patients (9%)

who presented recurrence of the disease. The first patient was the patient with IB2 tumor who underwent neoadjuvant chemotherapy with no response. A radical trachelectomy was performed as an individualized treatment due to the patient's age (20 years) and the patient initial refusal to radiotherapy due to a strong fertility preservation desire. The recurrence occurred 7 months after the radical trachelectomy, when she was underwent chemoradiation, with disease progression. She was then submitted to a total pelvic exenteration and a new immediate relapse coming to die 16 months after the initial treatment. The second patient, 36 years old, presented a squamous cell carcinoma IB1 without lymphovascular space invasion, which relapsed 10 months after radical trachelectomy with a small local recurrence. She underwent a salvage hysterectomy a month ago with no evidence of relapse.

Discussion

Radical trachelectomy is a feasible, reproducible procedure with similar oncological outcomes when compared to radical hysterectomy. The minimally invasive approach (laparoscopic or robotic), when compared to the traditional open surgery, has less intraoperative bleeding, better visualization of the intra-abdominal structures, shorter hospitalization time, and earlier return to daily activities [1–4].

In our series we were able to fully reproduce the nerve-sparing technique, standardizing it in steps to facilitate its reproducibility/learning curve. Our patients had similar characteristics to other series with a mean age of 30 years. Current data show that over 25% of patients have the diagnosis of cervical cancer with less than 40 years of age [1, 5–8].

Among the criteria for indicating this surgery, the most important is the tumor size, preferentially being indicated for lesions smaller than 2 cm. The most frequent stage in the literature on radical trachelectomy is IB1, reaching 71% of cases [9–11], which was a similar number found in our series (63.3%).

Currently, there are some publications on the use of this technique in tumors larger than 2 cm, associated or not with neoadjuvant chemotherapy. However, one should keep in mind the increased chance of conversion to radical hysterectomy and a greater chance of adjuvant treatment indication [12, 13]. Tumor size and deep stromal invasion are directly related to a worse prognosis [1, 14, 15]. In the present study, 13.3% of the patients had tumors larger than 2 cm and 18.1% had deep stromal invasion.

As noted in our series, the absence of immediate postoperative complications has also been reported in other laparoscopic trachelectomy studies [15, 16]. In their series of cases, Park JY et al. showed 5.1% of intraoperative complication, which was a conversion to laparotomy due to an inferior vena cava lesion [1]. Lu, Q et al., in a study of 140 patients operated by the laparoscopic technique, had a 0.7% rate of intraoperative complications and 6.4% of postoperative complications [14]. In the case series of this study, there were two (9%) intraoperative complications previously described. The need of intraoperative blood transfusion is a factor that indicates, in most cases, intraoperative complication or technical difficulty. No patient in this study required blood transfusion, with a mean intraoperative estimated blood loss of 56.5 mL. However, a study with 79 patients, operated by the laparoscopic approach between 2004 and 2012, presented a rate of 21.5% intraoperative transfusion, with a mean of 393 mL of intraoperative blood loss [17]. Another recently published study also showed a rate of up to 22% of intraoperative transfusion [1, 15]. In a review by Lu, the mean intraoperative blood loss ranged from 85 to 650 mL, with minimal blood transfusion rates [14].

The mean intraoperative time, according to the literature, varies from 250 min [1, 18] to 353 min [14, 19]. In the present case series, the mean surgical time of 211 min is considered to be below that shown in the literature. There was no conversion to radical hysterectomy and/or laparotomy in any of our cases. When compared to the literature data, the completion rate to radical hysterectomy due may reach 18.5% [15]. The study comparing the completion rate to radical

hysterectomy in laparotomy versus robotic surgery showed similar results (24% and 33%, respectively) [10]. Persson et al. compared radical vaginal versus robotic trachelectomy and demonstrated only one case (7.7%) of completion to radical hysterectomy due to compromised endocervical margin [20].

All patients were discharged between 12 and 24 h (1 day) after the surgical procedure, which was lower than the results published in the literature, ranging from 4 [21] to 17.5 days [5]. Park et al. described an average of 9 days of hospitalization (3–28 days) [1]. In the present series, there is only one case in which the length of hospital stay was 1 day [15].

The uterine vessel ascending branches were preserved in seven cases of this series, probably due to the improvement of the technique, since this procedure is considered complex and technically challenging. In the current literature, there are few reports of preservation of these branches during this procedure [22].

It is currently controversial whether the preservation of ascending branches of uterine vessels may or may not influence the patient's future fertility. Some studies report that decreased uterine vascularization could impair obstetric outcomes [23]. However, there are no randomized studies evaluating obstetric outcomes comparing the impact of preserving the ascending uterine vessel branches or not.

It is believe that the effort to preserve the ascending branches is beneficial because of a study in uterine fibroids comparing two techniques with uterine vessel embolization prior to surgery versus laparoscopic myomectomy without definitive ligation of the uterine vessels at the origin which showed a better obstetric outcome in the later technique [23].

Late complications such as amenorrhea or menstrual irregularity and cerclage suture migration are frequently described in the literature; however, the most feared complication that usually requires a surgical approach is cervical stenosis, with rates of up to 14%. This may be related to cervical cerclage and/or failure of the use of some antistenosis devices of the endocervical canal [9]. Nick AM et al. observed that

when using the device (Smit Sleeve) or Foley catheter to try to maintain cervical patency and thus increase the chance of spontaneous pregnancy, the cervical stenosis rate fell to 0% in favor of Smit Sleeve (Nucletron) [10, 24]. In the present study, all 22 patients had the first episode of regular menstruation in the first month after surgery. However, in four patients (18.1%), cervical dilatation due to late amenorrhea after cervical stenosis associated with major dysmenorrhea was required. There was one case of cerclage suture migration.

With a follow-up rate ranging from 1 to 55 months, mean 29.8 months, there were two cases of tumor recurrence to date. Typically, more than 75% of recurrences occur within the first 2–3 years after initial treatment. This suggests the role of a more frequent follow-up during this period [25–27]. In published studies evaluating the role of minimally invasive surgery, the recurrence of the disease ranged from 2.5 to 11% [1, 8, 15]. Park et al. demonstrated a direct relationship between tumor size and disease recurrence, with a recurrence rate of 6% in patients with tumors smaller than 2 cm and 20.7% in lesions of 2–4 cm [1]. Other studies published so far, in agreement with the results of this one, also did not observe tumor recurrence after using this surgical technique, although they also present series with a small number of patients [10, 16, 28].

The histological types most frequently found in these patients were squamous cell carcinoma and adenocarcinoma. In our series of cases, 36.3% were adenocarcinoma, which differs from the current literature, with an average 25% of this histology [29]. Most of our cases were squamous cell carcinoma (50%), which is consistent with studies that demonstrated that 70–75% of cases are of the spinocellular subtype [1, 9, 11]. However, according to the current literature, the number of adenocarcinoma cases has been increasing in recent years [30, 31].

Regarding the oncological surgical quality pattern that must be respected, two of them deserve to be highlighted, namely, the number of lymph nodes removed and the size of the parametrial tissue resected. Cervical neoplasia is predominantly disseminated through lymphatic and/

or direct extension [32]. Pelvic lymph node staging is an important surgical step in the treatment of cervical cancer, with lymph node status being the main risk factor related to prognosis. The technique of pelvic lymphadenectomy is already systematized in the literature [33, 34]. In the case series of this study, the mean number of lymph nodes removed was 16 (5–31). Nick et al. demonstrated that the number of pelvic lymph nodes removed was similar by comparing the minimally invasive and laparotomic approaches [10]. Also, Kim et al. reported an adequate number of pelvic lymph nodes removed (24 lymph nodes) via a minimally invasive surgery [15]. Regarding the parametrial extension resected, we obtained a mean of 23.3 mm on the right and 23.2 mm on the left. According to recent publications, the laparoscopic or abdominal route of radical trachelectomy can remove a greater extension of parametrial tissue compared to the vaginal route [10].

In the case series of this study, there were two patients with positive lymph node in the final pathology report. One of them refused to undergo radiotherapy because of strong desire to preserve fertility. Therefore, she underwent adjuvant chemotherapy alone. This patient is in the 55th month of follow-up without presenting recurrence and, at the moment, in treatment to become pregnant with assisted reproductive technology.

Case series studies demonstrated rates of 3.8% of lymph node metastases, which were not detected by intraoperative frozen section [1]. Studies evaluating the prognosis of pelvic node micrometastases in patients who did not undergo adjuvant radiotherapy due to the strong desire for gestation showed that this finding did not prove to be an independent risk factor for relapse [1].

Regarding the obstetric results, despite the three patients who underwent pelvic radiation, we had a case of spontaneous pregnancy after trachelectomy.

According to recent publications, about half of the patients submitted to radical trachelectomy are able to conceive only with the aid of assisted reproductive techniques [35]. This is an important aspect that should be addressed with the patient prior to surgery, especially in developing countries, where access to assisted reproductive

techniques financed by the public health system is difficult. Half of the patients in this study do not wish to become pregnant at the time, but they have preserved their reproductive potential. Nick et al. also reported a rate of only 36% of patients with gestation after surgery [10].

All the studies on radical trachelectomy, regardless of the access route (laparotomic, vaginal, or laparoscopic/robotic), conclude that fertility-preserving surgery is feasible, respecting the technical-surgical limits of each service and with safe oncological results, similar to radical hysterectomy. Therefore, radical trachelectomy should be suggested as a safe oncologic treatment option in patients with early-stage cervical cancer and who wish to preserve fertility.

We are aware of the limitation of our data because of the small sample of patients and a short follow-up time; however, if more patients have the opportunity of being treated by this technique, there is a possibility of obtaining more reliable oncological and obstetric results.

Conclusions

Our results demonstrate that the nerve-sparing vaginally assisted laparoscopic radical trachelectomy technique is feasible and potentially reproduced in cancer centers in developing countries. In our case series, the low rate of intraoperative complications, lower hospitalization time, low intraoperative blood loss, and satisfactory oncological outcomes demonstrate that this technique should be encouraged and stimulated in specialized services in the treatment of early-stage cervical cancer.

The oncological safety of this case series was demonstrated by the adequate number of pelvic lymph nodes removed, surgical margins status, and extent of resected parametrial tissue, when compared to publications with larger number of patients.

References

1. Park JY, Joo WD, Chang SJ, Kim DY, Kim JH, Kim YM, et al. Long-term outcomes after fertility-sparing laparoscopic radical trachelectomy in young women with early-stage cervical cancer: an Asan Gynecologic Cancer Group (AGCG) study. *J Surg Oncol.* 2014;110:252.
2. Persson J, Kannisto P, Bossmar T. Robot-assisted abdominal laparoscopic radical trachelectomy. *Gynecol Oncol.* 2008;111(3):564–7.
3. Hoogendam JP, Verheijen RH, Wegner I, Zweemer RP. Oncological outcome and long-term complications in robot-assisted radical surgery for early stage cervical cancer: an observational cohort study. *BJOG.* 2014;121(12):1538–45.
4. Ramirez PT, Schmeler KM, Malpica A, Soliman PT. Safety and feasibility of robotic radical trachelectomy in patients with early-stage cervical cancer. *Gynecol Oncol.* 2010;116(3):512–5.
5. Ebisawa K, Takano M, Fukuda M, Fujiwara K, Hada T, Ota Y, et al. Obstetric outcomes of patients undergoing total laparoscopic radical trachelectomy for early stage cervical cancer. *Gynecol Oncol.* 2013;131(1):83–6.
6. Sonoda Y, Abu-Rustum NR, Gemignani ML, Chi DS, Brown CL, Poyner EA, et al. A fertility-sparing alternative to radical hysterectomy: how many patients may be eligible? *Gynecol Oncol.* 2004;95(3):534–8.
7. Watson M, Saraiya M, Benard V, Coughlin SS, Flowers L, Cokkinides V, et al. Burden of cervical cancer in the United States, 1998–2003. *Cancer.* 2008;113(10 Suppl):2855–64.
8. Diaz JP, Sonoda Y, Leitao MM, Zivanovic O, Brown CL, Chi DS, et al. Oncologic outcome of fertility-sparing radical trachelectomy versus radical hysterectomy for stage IB1 cervical carcinoma. *Gynecol Oncol.* 2008;111(2):255–60.
9. Pareja R, Rendon GJ, Sanz-Lomana CM, Monzon O, Ramirez PT. Surgical, oncological, and obstetrical outcomes after abdominal radical trachelectomy—a systematic literature review. *Gynecol Oncol.* 2013;131(1):77–82.
10. Nick AM, Frumovitz MM, Soliman PT, Schmeler KM, Ramirez PT. Fertility sparing surgery for treatment of early-stage cervical cancer: open vs. robotic radical trachelectomy. *Gynecol Oncol.* 2012;124(2):276–80.
11. Marchiole P, Benchaib M, Buenerd A, Lazlo E, Dargent D, Mathevet P. Oncological safety of laparoscopic-assisted vaginal radical trachelectomy (LARVT or Dargent's operation): a comparative study with laparoscopic-assisted vaginal radical hysterectomy (LARVH). *Gynecol Oncol.* 2007;106(1):132–41.
12. Li J, Wu X, Li X, Ju X. Abdominal radical trachelectomy: is it safe for IB1 cervical cancer with tumors ≥ 2 cm? *Gynecol Oncol.* 2013;131(1):87–92.
13. Pareja R, Rendon GJ, Vasquez M, Echeverri L, Sanz-Lomana CM, Ramirez PT. Immediate radical trachelectomy versus neoadjuvant chemotherapy followed by conservative surgery for patients with stage IB1 cervical cancer with tumors 2cm or larger: a literature review and analysis of oncological and obstetrical outcomes. *Gynecol Oncol.* 2015.
14. Lu Q, Liu C, Zhang Z. Total laparoscopic radical trachelectomy in the treatment of early-stage cervical

- cancer: review of technique and outcomes. *Curr Opin Obstet Gynecol.* 2014;26(4):302–7.
15. Kim JH, Park JY, Kim DY, Kim YM, Kim YT, Nam JH. Fertility-sparing laparoscopic radical trachelectomy for young women with early stage cervical cancer. *BJOG.* 2010;117(3):340–7.
 16. Chen Y, Xu H, Zhang Q, Li Y, Wang D, Liang Z. A fertility-preserving option in early cervical carcinoma: laparoscopy-assisted vaginal radical trachelectomy and pelvic lymphadenectomy. *Eur J Obstet Gynecol Reprod Biol.* 2008;136(1):90–3.
 17. Chuang LT, Lerner DL, Liu CS, Nezhath FR. Fertility-sparing robotic-assisted radical trachelectomy and bilateral pelvic lymphadenectomy in early-stage cervical cancer. *J Minim Invasive Gynecol.* 2008;15(6):767–70.
 18. Cibula D, Ungar L, Palfalvi L, Bino B, Kuzel D. Laparoscopic abdominal radical trachelectomy. *Gynecol Oncol.* 2005;97(2):707–9.
 19. Lee CL, Huang KG, Wang CJ, Yen CF, Lai CH. Laparoscopic radical trachelectomy for stage Ib1 cervical cancer. *J Am Assoc Gynecol Laparosc.* 2003;10(1):111–5.
 20. Persson J, Imboden S, Reynisson P, Andersson B, Borgfeldt C, Bossmar T. Reproducibility and accuracy of robot-assisted laparoscopic fertility sparing radical trachelectomy. *Gynecol Oncol.* 2012;127(3):484–8.
 21. Kucukmetin A, Biliatis I, Ratnavelu N, Patel A, Cameron I, Ralte A, et al. Laparoscopic radical trachelectomy is an alternative to laparotomy with improved perioperative outcomes in patients with early-stage cervical cancer. *Int J Gynecol Cancer.* 2014;24(1):135–40.
 22. Tang J, Li J, Wang S, Zhang D, Wu X. On what scale does it benefit the patients if uterine arteries were preserved during ART? *Gynecol Oncol.* 2014;134(1):154–9.
 23. Wang YF, Chen GW, Li WS, Weng HN, Lu XG. Total laparoscopic radical trachelectomy with ascending branches of uterine arteries preservation. *Chin Med J.* 2011;124(3):469–71.
 24. Noyes N, Abu-Rustum NR, Ramirez PT, Plante M. Options in the management of fertility-related issues after radical trachelectomy in patients with early cervical cancer. *Gynecol Oncol.* 2009;114(1):117–20.
 25. Greer BE, Koh WJ, Abu-Rustum NR, Apte SM, Campos SM, Chan J, et al. Cervical cancer. *J Natl Compr Cancer Netw.* 2010;8(12):1388–416.
 26. Elit L, Fyles AW, Oliver TK, Devries-Aboud MC, Fung-Kee-Fung M, Members of the Gynecology Cancer Disease Site Group of Cancer Care Ontario's Program in Evidence-Based Care. Follow-up for women after treatment for cervical cancer. *Curr Oncol.* 2010;17(3):65–9.
 27. Samlal RA, Van Der Velden J, Van Eerden T, Schilthuis MS, Gonzalez Gonzalez D, Lammes FB. Recurrent cervical carcinoma after radical hysterectomy: an analysis of clinical aspects and prognosis. *Int J Gynecol Cancer.* 1998;8(1):78–84.
 28. Burnett AF, Stone PJ, Duckworth LA, Roman JJ. Robotic radical trachelectomy for preservation of fertility in early cervical cancer: case series and description of technique. *J Minim Invasive Gynecol.* 2009;16(5):569–72.
 29. Ries LAG, Krapcho M, Stinchcomb DG, Howlander N, Horner MJ, Mariotto A, Miller BA, Feuer EJ, Altekruse SF, Lewis DR, Clegg L, Eisner MP, Reichman M, Edwards BK, editors. SEER cancer statistics review, 1975-2005. National Cancer Institute; 2008.
 30. Smith HO, Tiffany MF, Qualls CR, Key CR. The rising incidence of adenocarcinoma relative to squamous cell carcinoma of the uterine cervix in the United States—a 24-year population-based study. *Gynecol Oncol.* 2000;78(2):97–105.
 31. Wang SS, Sherman ME, Hildesheim A, Lacey JV Jr, Devesa S. Cervical adenocarcinoma and squamous cell carcinoma incidence trends among white women and black women in the United States for 1976-2000. *Cancer.* 2004;100(5):1035–44.
 32. Koh WJ, Greer BE, Abu-Rustum NR, Apte SM, Campos SM, Chan J, et al. Cervical cancer. *J Natl Compr Cancer Netw.* 2013;11(3):320–43.
 33. Levenback C, Coleman R, VdZ AGJ. Clinical lymphatic mapping in gynecologic cancers. London: Martin Dunitz Ltd.; 2004.
 34. Kavallaris A, Kalogiannidis I, Chalvatzas N, Hornemann A, Bohlmann MK, Diedrich K. Standardized technique of laparoscopic pelvic and para-aortic lymphadenectomy in gynecologic cancer optimizes the perioperative outcomes. *Arch Gynecol Obstet.* 2011;283(6):1373–80.
 35. Vieira MA, Rendón GJ, Munsell M, Echeverri L, Frumovitz M, Schmeler KM, Pareja R, Escobar PF, Reis RD, Ramirez PT. Radical trachelectomy in early-stage cervical cancer: A comparison of laparotomy and minimally invasive surgery. *Gynecol Oncol.* 2015;138(3):585–9.



Laparoscopic Surgery in Endometrial Carcinoma

29

Natalia R. Gomez-Hidalgo and Pedro T. Ramirez

Introduction

Endometrial carcinoma is the fourth most common malignancy and the most common gynecologic malignancy in the United States with about 60,050 estimated new cases in 2016 and over 10,470 estimated deaths annually [1]. The prognosis for patients with endometrial cancer depends on the stage of the disease. The overall 5-year survival rate for patients with endometrioid type is approximately 75–80% [2–4]. The treatment of early endometrial cancer remains hysterectomy with bilateral salpingo-oophorectomy, with pelvic and para-aortic lymphadenectomy based on preoperative and intraoperative risk factors. These include histological subtype, grade, myometrial invasion, cervical involvement, or evidence of extrauterine disease [5, 6]. In the past, the standard approach in the management of patients with endometrial cancer was exploratory laparotomy. However, given the documented benefits of minimally invasive surgery, such as less blood loss and transfusion rates, shorter length of stay, and lower

rates of postoperative complications, the minimally invasive approach has become the preferred management in patients diagnosed with endometrial cancer.

Literature Review

Numerous retrospective studies have confirmed the benefits of a minimally invasive approach in the management of patients with endometrial cancer (Table 29.1). At least, nine randomized trials (RCTs) comparing laparotomy with laparoscopy, evaluating more than 3500 patients, have confirmed the advantages of a laparoscopic approach [7].

Single-Center Randomized Trials

One of the first randomized controlled trials comparing laparoscopy to laparotomy in the management of endometrial cancer was published by Fram [8], and this was a single-center trial that compiled 61 patients with stage I endometrial cancer. The goal of the study was to evaluate operative and postoperative complications: operative time, lymph node count, and length of hospital stay (LOS). The patients were randomly allocated into two groups. The study group consisted of 29 patients who underwent laparoscopic-assisted vaginal hysterectomy (LAVH) + bilateral

N. R. Gomez-Hidalgo
Department of Surgery, Memorial Sloan Kettering
Cancer Center, New York, NY, USA

P. T. Ramirez (✉)
Department of Gynecology Oncology and
Reproductive Medicine, The University of Texas MD
Anderson Cancer Center, Houston, TX, USA
e-mail: peramire@mdanderson.org

Table 29.1 Endometrial carcinosarcoma minimally invasive approach

Author	Year	Study design	Participants	Intervention	Outcome
Fram et al.	2002	Single-center RTC; no blinding	61 patients with stage I EC	LAVH + BSO ± LPLA ($n = 29$) vs. TAH + BSO ± PLA ($n = 32$)	Operative/postoperative complication; operative time; lymph node count, LOS
Zorlu et al.	2005	Single-center RTC; no blinding	52 patients with stage I–III EC	LAVH + BSO ± LPLA ($n = 26$) vs. TAH + BSO ± PLA ($n = 26$)	Intraoperative/postoperative complications; operative time; lymph node count, LOS
Malzoni et al.	2009	Single-center RTC; no blinding	159 patients with stage I EC	LAVH + BSO ± LPLA ($n = 81$) vs. TAH + BSO ± PLA ($n = 78$)	OS, disease-free survival, recurrence; intraoperative/postoperative complications; operative time; lymph node count; LOS
Kluivers et al.	2011	Single-center RTC; no blinding	17 patients with stage I EC	TLH + BSO ± LPLA ($n = 11$) vs. TAH + BSO ± PLA ($n = 16$)	Intraoperative/postoperative complications; recurrence; operative time, LOS, QoL
Walker et al.	2009	Multicenter RTC; no blinding	2616 patients stage I–IV EC	LAVH + BSO + LPLA/LPALA ($n = 1630$) vs. TAH/TRAH + BSO ± PLA ± PALA ($n = 868$)	Recurrence-free survival, perioperative adverse events, conversion to laparotomy, length of hospital, stay after surgery, operative time, quality of life, sites of recurrence, survival
Mourits et al.	2009	Multicenter RTC; no blinding	283 patients stage I EC	LAVH + BSO + LPLA/LPALA ($n = 1630$) vs. TAH/TRAH + BSO ± PLA ± PALA ($n = 868$)	Intraoperative/postoperative complications; operative time, lymph node count, LOS
Janda et al.	2010	Multicenter RTC; no blinding	332 patients stage I EC	TLH + BSO ± LPLA ($n = 185$) vs. TAH + BSO ± PLA ($n = 94$)	Intraoperative/postoperative complications; operative time, lymph node count, LOS, QoL

BSO Bilateral salpingo-oophorectomy, *EC* endometrial carcinoma, *LAVH* laparoscopically assisted vaginal hysterectomy, *LOS* length of hospital stay, *LPLA* laparoscopic para-aortic lymphadenectomy, *LPLA* laparoscopic pelvic lymphadenectomy, *PALA* para-aortic lymphadenectomy, *QoL* quality of life, *RCT* randomized clinical trial

salpingo-oophorectomy (BSO) ± laparoscopic pelvic lymphadenectomy (LPLA) (group A). The second group was composed of 32 patients who underwent surgery via a traditional approach, total abdominal hysterectomy (TAH) + BSO ± pelvic lymphadenectomy (PLA) (group B). The authors found that the rate of blood loss in group A was significantly lower than in group B (145.5 mL vs. 501.6 mL; $p < 0.05$). The length of hospital stay was also shorter in group A (2.3 vs. 5.5 days, respectively; $p < 0.05$). However, the operating time was longer in group A (136.2 min vs. 101.9 min, respectively; $p < 0.05$). There was no significant difference in the number of lymph nodes obtained in both groups (21.3 in group A vs. 21.9 in group B; $p > 0.05$). Complications encountered in the laparoscopic group were superficial thrombophlebitis in one patient, urinary tract infection in one patient, and vault hematoma in one patient. In the laparotomy group, two patients had bladder trauma. The authors concluded that the laparoscopic approach was associated with significantly less blood loss and shorter hospitalization; however, it was also associated with significantly longer operative times.

Zorlu et al. [9] evaluated the feasibility of laparoscopy in the management of early-stage endometrial cancer. They reported on a study of 52 patients with endometrial cancer who underwent surgical staging consisting of total hysterectomy, bilateral salpingo-oophorectomy with pelvic lymph node dissection, and cytology. A total of 26 patients underwent laparotomy and the remaining 26 patients underwent laparoscopic surgery. The mean number of harvested lymph nodes was 18.2 in the laparoscopic group and 21.1 in the laparotomic group ($p > 0.05$). Pelvic lymph node metastases were detected in 7.7% of the patients in the laparoscopy group and 15.4% in the laparotomy group, and the difference was not significant. Adjuvant radiotherapy was recommended to 42.3% of patients in the laparoscopy group and 38.5% of patients in the laparotomy group. Perioperative morbidity was higher in the laparotomy group mainly because of postoperative wound infection, and the patients in the laparotomy group had a longer hospital

stay. The laparoscopic group had significantly shorter hospitalization than did the laparotomy group (4.1 vs. 8.2 days; $p < 0.05$). But the operative time of laparoscopy was close to that of laparotomy (155 vs. 144 min; $p > 0.05$). Wound complications occurred in five patients in the laparotomy group, of which one was evisceration and needed reoperation for closure. Eight units of red blood cell were transfused in the laparotomy group patients and 6 units in the laparoscopy group. The authors concluded that lymph node number and detection of lymph node metastasis did not differ significantly between laparotomic and laparoscopic approaches.

Tozzi et al. [10] reported a prospective, randomized trial comparing survival outcome in staging of patients with endometrial cancer. Sixty-three patients were allocated to the laparoscopy arm, and 59 patients to the laparotomy arm. Median follow-up for all patients was 44 months (range: 5–96 months). Eight patients (12.6%) in the laparoscopy group had a recurrence versus five patients (8.5%) in the laparotomy group ($p = 0.65$). At median follow-up, disease-free survival (DFS) and overall survival (OS) in the laparoscopy group and laparotomy group were 87.4% versus 91.6% ($p = 0.38$) and 82.7% versus 86.5% ($p = 0.33$), respectively. Cause-specific survival was 90.5% in the laparoscopy group versus 94.9% in the laparotomy group ($p = 0.47$). The authors concluded that laparoscopy and laparotomy had a comparable survival outcome.

Malzoni et al. [11] reported on a series of 159 women evaluating the feasibility, safety, and morbidity of total laparoscopic hysterectomy (LPS) and abdominal hysterectomy with lymphadenectomy (LPT) for early-stage endometrial cancer. The secondary end points of the study were to assess the disease-free survival and recurrence rate. The mean operative time was 136 min ± 31 (95% CI 118–181) in the LPS group and 123 min ± 29 (95% CI 111–198) in the LPT group ($p < 0.01$). The mean blood loss was 50 mL ± 12 in the LPS group (95% CI 20–90) and 145 mL ± 35 in the LPT group (95% CI 60–255) ($p < 0.01$). The mean length of hospital stay was 5.1 ± 1.2 in the LPT group and 2.1 ± 0.5 in the LPS group ($p < 0.01$). The

conclusion of this study was that laparoscopy is a suitable procedure for the treatment of patients with early endometrial cancer and it does not seem to modify the disease-free survival and the overall survival.

Kluiters et al. [12] published a randomized trial on recovery and long-term outcomes after laparoscopic hysterectomy versus abdominal hysterectomy in endometrial cancer patients. The main outcome measures were quality of life and recovery in the first 12 weeks after surgery. Three questionnaires were used in the study: the RAND-36, Quality of Recovery-40 (QoR-40), and Recovery Index-10 (RI-10). The difference between groups in the RAND-36 total score was 142 units (95% confidence interval (CI) 46; 236) in favor of laparoscopic hysterectomy. The conclusion of that study was that laparoscopic hysterectomy results in better postoperative quality of life in the first 12 weeks after surgery when compared with abdominal hysterectomy.

Multicenter Randomized Trials

The most definitive study evaluating the role of laparoscopy in patients with endometrial cancer was the Gynecologic Oncology Group Study LAP2 [13] published in 2009. In this study, patients with clinical stage I to IIA uterine cancer were randomly assigned to laparoscopy ($n = 1696$) or open laparotomy ($n = 920$), including hysterectomy, salpingo-oophorectomy, pelvic cytology, and pelvic and para-aortic lymphadenectomy. The main study end points were 6-week morbidity and mortality, hospital length of stay, conversion from laparoscopy to laparotomy, recurrence-free survival, site of recurrence, and patient-reported quality-of-life outcomes. Laparoscopy was initiated in 1682 patients and completed without conversion in 1248 patients (74.2%). The most common reason for conversion from laparoscopy to laparotomy was poor visibility in 246 patients (14.6%). Laparoscopy had fewer moderate to severe postoperative adverse events than laparotomy (14% vs. 21%, respectively; $p < 0.0001$) but similar rates of intraoperative complications, despite

having a significantly longer operative time (median, 204 min vs. 130 min, respectively; $p < 0.001$). Hospitalization of more than 2 days was significantly lower in laparoscopy versus laparotomy patients (52% vs. 94%, respectively; $p < 0.0001$). Pelvic and para-aortic nodes were not removed in 8% of laparoscopy patients and 4% of laparotomy patients ($p < 0.0001$). No difference in overall detection of advanced stage (stage IIIA, IIIC, or IVB) was seen (17% of laparoscopy patients vs. 17% of laparotomy patients; $p = 0.841$). The conclusion of this landmark study was that laparoscopic surgical staging for uterine cancer is feasible and safe in terms of short-term outcomes and results in fewer complications and shorter hospital stay.

In a subsequent trial published by Mourits et al. [14], the authors reported on data collected from 21 hospitals in the Netherlands. A total of 283 patients with stage I endometrioid adenocarcinoma or complex atypical hyperplasia were randomly allocated (2:1) to the intervention group (TLH, $n = 187$) or control group (TAH, $n = 96$). The primary outcome was major complication rate (bowel, ureter, and bladder injuries, infection, hematoma and hemorrhage, wound dehiscence, wound infection, ileus requiring intervention, and death), recorded intraoperatively and postoperatively until 6 weeks after surgery. The severity of a complication was assessed according to the Common Terminology Criteria of Adverse Events. The proportion of patients with a major complication was 14.6% (27 of 185) in the TLH group versus 14.9% (14 of 94) in the TAH group ($p = 0.95$). Secondary outcomes were minor complications (pulmonary, urinary tract infection, urinary retention, fever, wound infection not requiring intervention, minor anesthetic problems, hemorrhage or hematoma without transfusion or intervention), treatment-related outcomes, and quality of life (QoL). Treatment-related outcomes were the conversion rate, operating time, blood loss, hospital stay, use of pain medication, and resumption of daily activities. The proportion of patients with a minor complication was 13.0% (24 of 185) in the TLH group and 11.7% (11 of 94) in the TAH group ($p = 0.76$). The conversion to laparotomy occurred in 10.8%

(20 of 185) of patients. TLH was associated with significantly less blood loss ($p < 0.0001$), less use of pain medication ($p < 0.0001$), a shorter hospital stay ($p < 0.0001$), and a faster recovery ($p = 0.002$), but it took longer than TAH ($p < 0.0001$). The results of the study showed no evidence of a benefit for TLH over TAH in terms of major complications (intraoperative or postoperative), but TLH was beneficial in terms of a shorter hospital stay, less pain, and quicker resumption of daily activities.

Janda et al. [15] compared total laparoscopic hysterectomy (TLH) with total abdominal hysterectomy (TAH) for stage I endometrial cancer (LACE Trial). The primary objective of that study was to assess whether TLH resulted in equivalent or improved quality of life (QoL) up to 6 months after surgery compared with TAH. There were 361 participants enrolled in the QoL substudy at 19 centers across Australia, New Zealand, and Hong Kong; 332 patients completed the QoL analysis. Patients who had TLH reported significantly greater improvement in QoL from baseline compared with those who had TAH, in all subscales apart from emotional and social well-being. QoL over time was analyzed by computing change scores between baseline measurements and postoperative measurements at early (1 and 4 weeks) and late (3 and 6 months) time points for each variable. This study reported on perioperative parameters. Operating time was significantly longer in the TLH group (138 min [SD 43]) than in the TAH group (109 min [SD 34]; $p = 0.001$). However, the proportion of intraoperative adverse events was similar between groups (TAH 8 of 142 [5.6%] vs. TLH 14 of 190 [7.4%]; $p = 0.53$). Postoperatively, twice as many patients in the TAH group experienced adverse events of grade 3 or higher (33 of 142 [23.2%] vs. 22 of 190 [11.6%] in the TLH group; $p = 0.004$). Postoperative serious adverse events occurred more commonly in the TAH group (27 of 142 [19.0%]) than in the TLH group (16 of 190 [7.9%]; $p = 0.002$). The conclusion of this study was that the QoL improvements from baseline during early and later phases of recovery, and the adverse event profile, favor TLH compared with TAH for treatment of stage I endometrial cancer.

In summary, this is the most recent systematic review for the treatment of uterine cancers, confirming the benefits of laparoscopic surgery: shorter hospital stay, lower rate of postoperative complications, and comparable oncologic and surgical results with longer operating times [7].

Surgical Technique

There are multiple options when considering the technique for the minimally invasive approach in patients undergoing surgery for endometrial cancer. Here, we provide the details when performing laparoscopic surgery for standard hysterectomy and staging.

The patient is placed in a dorsal lithotomy position. It is important to carefully place the patient to avoid neurologic injury, provide for ergonomic surgeon positioning, and allow adequate access to the vagina, if necessary. At the start of the procedure, the table should be in level position, with the height lowered to allow for relaxed arm positioning for all operators [16].

Gynecologic laparoscopic entry is commonly at or through the umbilicus [17]. However, in patients with previous surgery with a prior midline incision, one should consider initial entry at Palmer's point as described below. Options for entry include any of the following: blind entry using a Veress needle, optical trocars for direct visualization, or open entry. None of these have shown a benefit over the other with regard to reducing complication rates, and thus choice of entry is often left to surgeon preference. To avoid injury to nerves or blood vessels in the abdominal wall (notably the ilioinguinal and iliohypogastric nerves, superficial and inferior epigastric arteries), the lower quadrant ports are placed approximately 2 cm medial and 2 cm caudal to the anterior superior iliac spine, lateral to the border of the rectus muscle [18]. We also advocate for an additional 5 mm port in the midline over the pubic symphysis. Once the abdomen has been insufflated, the patient is placed in steep Trendelenburg position, and the pelvis is exposed, by mobilizing the bowel to the upper abdomen. If pelvic or intra-abdominal adhesions are present,

it is important to mobilize the pelvic organs by dividing omental, intestinal, or abdominal wall adhesions. Restoring normal anatomy allows for visualization of important pelvic structures.

At this point, the round ligaments are coagulated and transected. The retroperitoneum is entered by extending the incision, on the posterior leaf of the broad ligament superolaterally, remaining lateral to both, the infundibulopelvic ligament and the iliac vessels. Blunt or sharp dissection clears the loose connective tissue overlying the external iliac artery. By following the external iliac artery superiorly to its bifurcation, the ureter can be identified as it crosses the common iliac artery. The ureter is left attached to the medial or posterior leaf of the broad ligament so as not to disrupt its blood supply. To perform the salpingo-oophorectomy, the broad ligament opening is extended superiorly to the infundibulopelvic ligament. When performing a salpingo-oophorectomy, the infundibulopelvic ligament is coagulated. The bladder is mobilized off the lower uterine segment to prepare for amputation of the uterus by a combination of sharp and blunt dissection with laparoscopic instruments. The anterior leaf of the broad ligament is incised, continuing along the line of the vesicouterine peritoneal reflection. If perivesicular fat is encountered, this indicates proximity to the bladder and should guide the surgeon to avoid that area. When dealing with difficult bladder adhesions, instruments with cautery should be avoided in favor of dissection with laparoscopic scissors in order to limit potential thermal damage to the bladder. In some cases, the full bladder flap dissection can be delayed until after transection of the cardinal ligament/uterine vascular complex in order to gain access to the plane along the pubocervical fascia.

The uterine vessels are identified and are skeletonized by incising the posterior broad ligament peritoneum and dissecting away surrounding adventitia. After confirming the position of the ureter, the uterine vasculature is desiccated at the level of the internal cervical os. It is important to elevate the uterus in a cephalad direction using the uterine manipulator or laparoscopic instruments in order to increase distance from the elec-

trosurgical instrument to the ureter. An incision is made in the desiccated uterine vasculature, and this area is lateralized to create a discrete vascular pedicle that can be cauterized safely in the event of inadequate hemostasis. A colpotomy is made in a circumferential fashion around the cervix, typically using an ultrasonic scalpel or monopolar instrument. When using a uterine manipulator, the rim is a useful guide. Cephalad elevation on the manipulator will help to delineate vaginal fornices and distance the ureter from the colpotomy site. The specimen is delivered through the vagina. A moist sponge is then placed in the vagina. Alternatively, a pneumo-occluder device (such as a sterile glove packed with surgical sponges or plastic bulb) may be placed in the vaginal canal to prevent loss of pneumoperitoneum.

One of the most important prognostic factors for endometrial carcinoma is the presence of extrauterine disease, particularly pelvic and para-aortic lymph node metastases. Whether to perform lymph node assessment is controversial, particularly in women presumed to have early-stage disease. The use of sentinel lymph node (SLN) mapping is becoming increasingly more popular in the management of patients with endometrial cancer. SLN mapping entails the injection of a radioactive tracer or colored dye (often blue or fluorescent green) to locate hot nodes or visualize colored nodes. There are three different types of SLN mapping techniques based on site of injection: (1) uterine subserosal, (2) cervical, or (3) endometrial via hysteroscopy [19, 20].

At Memorial Sloan Kettering Cancer Center (MSKCC) [21], the investigators have found that a cervical injection is adequate for effective SLN mapping. The rationale for using a cervical injection includes the following: the main lymphatic drainage to the uterus is from the parametria; therefore, a combined superficial (1–3 mm) and deep (1–2 cm) cervical injection is adequate; the cervix is easily accessible; the cervix in women with endometrial carcinoma is rarely distorted by anatomic variations, such as myomas; and the majority of early-stage endometrial carcinoma patients do not have disease infiltrating and ulcerating the uterine fundal serosa [22]. The colored

dye, such as isosulfan blue 1% (lymphazurin), methylene blue 1%, patent blue 2.5% sodium (Bleu Patente V sodique), or indocyanine green (ICG), is injected, while the patient is under anesthesia. The 4 mL can be divided into four separate injections, one into each quadrant of the cervix (1 mL each). However, most centers propose that a 1 mL injection at 3 and 9 o'clock positions is ideal for adequate mapping [20].

The routine protocol used for pathologic SLN evaluation uses HE staining for the initial examination; if it is negative, two adjacent 5 nm sections are cut from each paraffin block at each of two levels 50 nm apart. At each level, one side is stained with HE and the other with immunohistochemistry (IHC) using the anti-cytokeratin AE1:AE3 (Ventana Medical Systems) for a total of four slides per block. With this IHC ultrastaging, the pathologist is able to detect an additional 3–4% of micrometastasis to SLN, which may have been missed by routine HE staining [23].

Otherwise, to perform bilateral pelvic and para-aortic lymphadenectomy, the following steps should be followed:

- The retroperitoneum is accessed by incising the peritoneum along the psoas muscle lateral to the level of the pelvic vessels. On the left side, any adhesions of the sigmoid colon are divided sharply.
- The pararectal and paravesical spaces are then developed with a combination of sharp and blunt dissection. A useful landmark is the obliterated umbilical artery, which is usually visualized as a discrete fold on either side of the bladder. Developing the area between the obliterated umbilical artery and the external iliac vessels exposes the paravesical space medially and the obturator fossa laterally.
- The pararectal space can be developed in the area between the ureter medially and the origin of the hypogastric vessels laterally.
- The pelvic lymph node dissection is then initiated by dissecting the lateral nodal tissue away from the psoas muscle. The external iliac vessels can be gently retracted medially; the space between the vessels and the psoas muscle is developed. As the dissection is carried caudad, the assistant places an instrument into the paravesical space for medial retraction. The dissection continues until the circumflex iliac vein is clearly visualized.
- At this point, the fibrofatty tissue surrounding the external iliac vessels is elevated. The fibrous sheath overlying the external iliac artery is incised in order to mobilize the specimen. The surgeon then grasps the specimen and retracts it medially.
- Any adhesions to the medial portion of the external iliac artery can then be incised. The space between the external iliac artery and vein is sharply and bluntly developed. Next, the tissue adherent to the external iliac vein is gently dissected free.
- The surgeon then dissects within the obturator fossa. The fibrofatty tissue of the lymph node bundle is retracted medially, and a plane is created underneath the external iliac vein. Sharp and blunt dissection is performed within the fossa until the obturator nerve is visualized; this nerve can be isolated along its entire course within the obturator fossa. Accessory obturator vessels are often found in this space arising from the undersurface of the external iliac vein; these can be clipped or cauterized only after the obturator nerve is clearly delineated and the ureter is safely retracted out of the field of dissection. Particular care must be taken at the proximal aspect of the fossa, where the bifurcation of the common iliac artery is found and the lymph nodes may be more adherent to the hypogastric vessels.

To continue with the para-aortic lymphadenectomy, an incision is made in the peritoneum over the right common iliac artery and is extended cephalad along the aorta to the level of the duodenum. Once the bifurcation of the aorta is identified, the peritoneum over the left common iliac artery is incised. The mesentery of the sigmoid colon is retracted anteriorly. The areolar tissue between the left common iliac artery (and aorta) and the mesentery of the sigmoid colon is opened with a combination of blunt and sharp dissection until the left psoas muscle is identified.

- The left ureter is also identified and retracted laterally so that it is safely out of the field of dissection. It is very important to identify the inferior mesenteric artery (IMA) prior to starting the lymph node dissection.
- Once adequate exposure has been achieved, the surgeon grasps the nodal bundle adjacent to either the aorta or proximal left common iliac artery and lifts anteriorly while dissecting the plane between the great vessels and the lymph nodes that lie adjacent to them. The dissection is then extended in a cephalad direction with blunt and sharp dissection. To remove the right para-aortic nodes, the dissection is continued laterally over the aorta to reach the right para-aortic lymph nodes covering the inferior vena cava. The right ureter is identified and the lymph node bundle over the inferior vena cava is then carefully dissected.
- The nodal chain is then transected at the cephalad end near the IMA. The cephalad border of dissection remains a topic of debate; however, most would advocate for a complete dissection to the level of the renal vessels. Care must be taken to avoid the insertion of the right gonadal vein into the vena cava when performing the right para-aortic node dissection.

Special Points of Interest

Obesity

The greatest risk factor for endometrial cancer is obesity. Nearly two-thirds of women in the United States are either overweight or obese, and over 6% are morbidly obese (body mass index ≥ 40 kg/m²) [24, 25]. Obesity has been shown to be a significant risk factor for endometrial cancer and is associated with approximately 40% of all cases [4–8]. Peritoneal access restrictions and difficulty accessing the pelvic organs and performing adequate lymphadenectomy are associated with a proportional increase in conversion rate to laparotomy with increasing BMI. Increased blood loss, increased rate of wound infection and dehiscence, and increased risks of thrombosis

and pulmonary embolism associated with laparotomy in obese patients encourage the use of laparoscopic surgery.

In a study by Tinelli et al. [26], the investigators demonstrated the advantages of laparoscopy versus laparotomy for treatment of obese women with early-stage endometrial cancer. Seventy-five obese patients with BMI >35 kg/m² and clinical stage I endometrial cancer underwent hysterectomy and bilateral salpingo-oophorectomy; all patients underwent systematic pelvic lymphadenectomy by laparoscopy (mean BMI of 38 ± 7.3 kg/m² or laparotomy (mean BMI of 39 ± 8.1 kg/m²). In all cases, the laparoscopic procedures were successfully completed without conversion to laparotomy. The authors concluded that laparoscopy can be considered a safe and effective therapeutic procedure for managing early-stage endometrial cancer in obese women with a lower complication rate, lower surgical site infection, and postoperative hospitalization compared to laparotomy.

In another study, Bouwman et al. [27] evaluated the association between body mass index (BMI), perioperative complications, and outcomes in endometrial cancer (EC) patients. Patient characteristics, surgical complications, and intra- and postoperative outcomes were evaluated across BMI groups: BMI <30 kg/m², BMI ≥ 30 kg/m², and BMI ≥ 40 kg/m². In total, the authors identified 627 women, of which 514 were included; 249 patients had a BMI <30 kg/m², 195 women had a BMI of 30–39.9 kg/m², and 70 women were morbidly obese (BMI ≥ 40 kg/m²). Obese women (BMI ≥ 30 kg/m²) had significantly more postoperative surgical complications, including wound complications and antibiotics use. The authors concluded that laparoscopic surgery may well prevent the majority of postoperative complications in this group of patients and should therefore be the favored approach.

Conversion Rates

In the GOG-LAP2 study [13], one of the end points of the study was conversion from laparoscopy to laparotomy. There were 434

participants (25.8%) randomly assigned to laparoscopy who required conversion to laparotomy to complete the procedure. Poor exposure was cited in 246 patients (14.6% of patients randomly assigned to laparoscopy arm, or 56.7% of the converted group) as the reason to convert from laparoscopy to laparotomy. Cancer requiring laparotomy for resection was the reason for conversion in 69 patients (4.1%). Excessive bleeding was cited as the reason for conversion in 49 patients, and other reasons for conversion were equipment failure ($n = 10$) or other cause ($n = 70$). Failure to successfully complete laparoscopy was greater with increasing age (odds ratio [OR] 1.27; 95% CI, 1.14–1.42 for a 10-year increase in age; $p < 0.0001$), increasing BMI (OR 1.11; 95% CI, 1.09–1.13 for a one-unit increase in BMI; $p < 0.0001$), and metastatic disease (OR 2.54; 95% CI, 1.90–3.41; $p < 0.0001$). All subgroups demonstrated increased estimated risk with increasing BMI.

Port-Site Metastasis

Port-site metastasis is an uncommon complication of laparoscopy, occurring in 1–2% of all oncology-related laparoscopic surgeries [28–33]. However, the exact incidence of port-site metastasis is not known. Ramirez et al. [30] reviewed all reported cases of laparoscopic port-site metastases in patients with gynecological malignancies and the potential etiologies as well as options for prevention. Two hundred forty-eight laparoscopic surgery procedures were performed during the study period. The median follow-up time for all of the patients was 8 months (range, 1–33). Port-site metastases were detected in 2 of the 181 patients (1.1%). Seventy-one percent of port-site recurrences (15 of 21) were isolated to a tissue-manipulating port. The authors concluded that the rate of port-site metastasis after laparoscopic surgery in women with gynecologic cancer is low and similar to the rate for laparoscopic procedures.

Zivanovic et al. [28] described the rate of laparoscopic trocar-related subcutaneous tumor implants in women with underlying malignant disease.

Laparoscopic procedures were performed in 1694 patients with a malignant intra-abdominal condition. Port-site metastases were documented in 20 of 1694 patients (1.2%). Of these, 15 patients had a diagnosis of epithelial ovarian or fallopian tube carcinoma, 2 had breast cancer, 2 had cervical cancer, and 1 had uterine cancer. Nineteen of 20 patients (95%) had simultaneous carcinomatosis or metastases to other sites at the time of port-site metastasis. The conclusion from that study was that the rate of port-site tumor implantation after laparoscopic procedures in women with malignant disease is low and almost always occurs in the setting of synchronous, advanced intra-abdominal, or distant metastatic disease.

Oncologic Outcomes

The published recurrence and survival results of the GOG-LAP2 study [13] demonstrate that the laparoscopic approach does not adversely affect the overall survival, recurrence-free survival, recurrence rate, or the patterns of recurrent disease [34]. Thus, comprehensive surgical staging of endometrial cancer can be performed laparoscopically with a negligible difference in recurrence rates (estimated difference at 3 years, 1.14%). In conclusion, longer follow-up is ongoing to determine whether there are differences in recurrence and survival between laparotomy and laparoscopy groups [35].

Robotic Surgery

Since its FDA approval for gynecologic procedures in 2005, robotic-assisted surgery rapidly gained acceptance by surgeons as an effective tool for the staging of uterine malignancies. In the setting of endometrial cancer, robotic surgery reduces perioperative and postoperative complications, particularly abdominal wound complications, while maintaining adequate pelvic and para-aortic lymph node retrieval counts, overall survival, and recurrence rates when compared with open surgery.

To goal of this section is to summarize comparative studies describing clinical outcomes of robotic-assisted surgeries compared with traditional laparoscopic or laparotomy techniques for the treatment of endometrial cancer. A systematic review that included eight studies with a total of 1591 patients, robot-assisted laparoscopic endometrial carcinoma staging was compared with conventional laparoscopy and laparotomy [36]. Patients underwent total hysterectomy, bilateral salpingo-oophorectomy, and lymphadenectomy (robotic 589, laparoscopic 396, and laparotomy 606). The advantages of robotic procedures were mainly in comparison with laparotomy. Blood loss was significantly lower with robotic surgery than laparotomy (an average of 186 mL less) and conventional laparoscopy (an average of 86 mL less, a difference that is unlikely to be clinically significant). The rate of transfusion was not significantly reduced compared with either laparotomy (OR 0.3, 95% CI 0.1–1.2) or conventional laparoscopy (OR 0.5, 95% CI 0.1–2.2). The rate of wound and other complications (stroke, ileus, lymphedema, nerve palsy, acute renal failure, lymphocyst, urinary retention) were significantly reduced for robotic surgery compared with laparotomy (wound, OR 0.1, 95% CI 0.04–0.4, and other complications, OR 0.3, 95% CI 0.1–0.6), but not conventional laparoscopy. The primary disadvantage of robotic procedures was longer operative duration (an average of 89 min longer than laparotomy). The conclusions of that study were that the perioperative clinical outcomes for robotic and laparoscopic hysterectomy appear similar with the exception of less blood loss for robotic cases and longer operative times for robotic and laparoscopy cases.

Recently, the complications and charges of robotic vs. laparoscopic vs. open surgeries in morbidly obese patients treated for endometrial cancer were compared by Chan et al. [36]. Of 1087 morbidly obese (BMI ≥ 40 kg/m²) endometrial cancer patients (median age, 59 years; range, 22–89), 567 (52%) had open surgery (OS), 98 (9%) had laparoscopic (LS) surgery, and 422 (39%) had robotic surgery (RS). A total of 23% of OS, 13% of LS, and 8% of RS patients experienced an intraoperative or postoperative compli-

cation, including blood transfusions, mechanical ventilation, urinary tract injury, gastrointestinal injury, wound debridement, infection, venous thromboembolism, and lymphedema ($p < 0.0001$). RS and LS patients were less likely to receive blood transfusions compared to OS (5% and 6% vs. 14%, respectively; $p < 0.0001$). The median lengths of hospitalization for OS, LS, and RS patients were 4, 1, and 1 days, respectively ($p < 0.0001$). Median total charges associated with OS, LS, and RS were \$39,281, \$40,997, and \$45,030 ($p = 0.037$), respectively. In morbidly obese endometrial cancer patients, minimally invasive robotic or laparoscopic surgeries were associated with fewer complications and less days of hospitalization relative to open surgery. Compared to laparoscopic approach, robotic surgeries had comparable rates of complications but higher charges.

Park et al. [37] compared the recurrence and survival outcomes in women who underwent either robotic or open surgical procedures to treat endometrial cancer. A total of 936 patients were included in the study. Of those, 350 patients had robotic-assisted surgery and 586 had laparotomy. Both groups were comparable in terms of age, race, body mass index, and comorbid conditions. The laparotomy group had significantly more patients with grade 2–3 tumors, non-endometrioid histology, and stage III–IV disease. In a multivariate analysis, surgical approach was not an independent prognostic factor for intraoperative complications, but robotic surgery was associated with decreased postoperative complications and readmission rate. Median duration of follow-up was 30 months in the robotic cohort and 42 months in the laparotomy cohort. Estimated 3-year progression-free survival was 90.9% for the robotic group and 78.3% for the laparotomy group ($p < 0.001$), and estimated 5-year overall survival was 89.1% for the robotic group and 79.5% for the laparotomy group ($p < 0.001$). The conclusion for the study was that robotic staging for endometrial cancer compared to laparotomy is associated with less postoperative morbidity without compromising short-term recurrence rates or survival outcomes.

To date, there have been no prospective randomized control trials comparing laparotomy, laparoscopic, and robotic-assisted laparoscopic staging procedures for treatment of uterine malignancies. Four meta-analyses, evaluating 2913 robotic, 2196 laparoscopic, and 1219 laparotomy-treated patients, indicate similarities with laparoscopy in most categories, except for reduced blood loss and fewer conversions to laparotomy in robotic surgeries [35, 38–40]. Robotic and traditional laparoscopic surgery have improved outcomes compared to laparotomy in terms of blood loss, blood transfusions, perioperative and postoperative complications, wound infection, postoperative pain, shorter recovery time, and decreased length of hospital stay. Moreover, recent cost analysis studies indicate that the shorter operating times and the efficiencies gained with robotic surgical experience may translate into significant reductions in operating room costs [41, 42].

Summary

A minimally invasive approach should be considered the surgical treatment option of choice in endometrial cancer patients. Robotic platform overcomes some of the limitations of standard laparoscopic instrumentation and increases the accessibility of gynecologists to minimally invasive techniques. With evolving techniques of laparoscopic surgery, the accumulation of clinical experience, and continuous improvement of laparoscopic instruments, complication rates will likely continue to decrease, and the efficacy of laparoscopic treatment for uterine malignant tumors may be superior to that of the traditional laparotomy.

References

1. Siegel RL, Miller KD, Jemal A. Cancer statistics, 2016. *CA Cancer J Clin.* 2016;66(1):7–30.
2. Rodriguez M. Endometrial cancer: part 1—epidemiology, diagnosis and work-up. *Menopause Manage.* 2001;10:19–21.
3. Purdie DM, Green AC. Epidemiology of endometrial cancer. *Best Pract Res Clin Obstet Gynaecol.* 2001;15:341–5.

4. German Working Group on Gynaecologic Oncology. Recommendations for diagnosis and treatment in patients with endometrial carcinoma. *Zentralbl Gynakol.* 2002;1:58–62.
5. Morrow CP, Bundy BN, Kurman RJ, Creasman WT, Heller P, Homesley HD, et al. Relationship between surgical-pathological risk factors and outcome in clinical stage I and II carcinoma of the endometrium: a Gynecologic Oncology Group study. *Gynecol Oncol.* 1991;40:55–65.
6. Zaino RJ, Kurman R, Herbold D, Gliedman J, Bundy BN, Voet R, et al. The significance of squamous differentiation in endometrial carcinoma. Data from a Gynecologic Oncology Group study. *Cancer.* 1991;68:2293–302.
7. He H, Zeng D, Ou H, Tang Y, et al. Laparoscopic treatment of endometrial cancer: systematic review. *J Minim Invasive Gynecol.* 2013;20:413–23.
8. Fram KM. Laparoscopically assisted vaginal hysterectomy versus abdominal hysterectomy in stage I endometrial cancer. *Int J Gynecol Cancer.* 2002;12:57–61.
9. Zorlu CG, Simsek T, Seker Ari E. Laparoscopy or laparotomy for the management of endometrial cancer. *JSLs.* 2005;9:442–6.
10. Tozzi R, Malur S, Koehler C, Schnedder A. Laparoscopy versus laparotomy in endometrial cancer: first analysis of survival of a randomized prospective study. *J Minim Invasive Gynecol.* 2005;12:130–6.
11. Manzoni M, Tinelli R, Cosentino F, et al. Total laparoscopic hysterectomy versus abdominal hysterectomy with lymphadenectomy for early stage endometrial cancer: a prospective randomized controlled trial. *Am J Obstet Gynecol.* 2009;200:296.e1–9.
12. Kluijvers KB, Florian A, Cate T, Bongers MY, Hans AM, et al. Total laparoscopic hysterectomy versus total abdominal hysterectomy with bilateral salpingo-oophorectomy for endometrial carcinoma: a randomized controlled trial with 5-year follow up. *Gynecol Surg.* 2011;8:427–34.
13. Walker JL, Piedmonte MR, Spirtos NM, et al. Laparoscopy compared with laparotomy for comprehensive surgical staging of uterine cancer: Gynecologic Oncology Group study LAP2. *J Clin Oncol.* 2009;27:5331.
14. Mourits MJ, Bijen CB, Arts HJ, et al. Safety of laparoscopy versus laparotomy in early-stage endometrial cancer: a randomized trial. *Lancet Oncol.* 2010;11:763.
15. Janda M, GebSKI V, Brand A, et al. Quality of life after total laparoscopic hysterectomy versus total abdominal hysterectomy for stage I endometrial cancer (LACE): a randomized trial. *Lancet Oncol.* 2010;11:772.
16. Chandler JG, Corson SL, Way LW. Three spectra of laparoscopic entry access injuries. *J Am Coll Surg.* 2001;192:478.
17. Mayol J, Garcia-Aguilar J, Ortiz-Oshiro E, et al. Risks of the minimal access approach for laparoscopic surgery: multivariate analysis of morbidity related to umbilical trocar insertion. *World J Surg.* 1997;21:529.

18. Kavallaris A, Kalogiannidis I, Chalvatzas N, et al. Standardized technique of laparoscopic pelvic and para-aortic lymphadenectomy in gynecologic cancer optimizes the perioperative outcomes. *Arch Gynecol Obstet*. 2011;283:1373.
19. Khoury-Collado F, Abu Rustum NR. Lymphatic mapping in endometrial cancer: a literature review of current techniques and results. *Int J Gynecol Cancer*. 2008;18:1163–8.
20. Abu Rustum NR, Khoury-Collado F, Gemignani ML. Techniques of sentinel lymph node identification for early stage cervical and uterine cancer. *Gynecol Oncol*. 2008;111:S44–50.
21. Abu Rustum NR. Update on sentinel node mapping in uterine cancer: 10-year experience at Memorial Sloan -Kettering Cancer center. *J Obstet Gynaecol*. 2014;40(2):327–34.
22. Khoury-Collado F, Glaser GE, Zivanovic O, et al. Improving sentinel lymph node detection rates in endometrial cancer: how many cases are needed? *Gynecol Oncol*. 2009;115:453–5.
23. Kim CH, Barber EL, Khoury -Collado F, et al. Pathologic ultrastaging improves micrometastasis detection in sentinel lymph nodes during endometrial cancer staging. *Int J Gynecol Cancer*. 2013;23:964–70.
24. Ogden CL, Carroll MD, Kit BK, Flegal KM, et al. Prevalence of childhood and adult obesity in the United States, 2011–2012. *JAMA*. 2014;311(8):806–14.
25. DeSantis CE, Lin CC, Mariotto AB, Siegel RL, Stein KD, Kramer JL, et al. Cancer treatment and survivorship statistics, 2014. *CA Cancer J Clin*. 2014;64(4):252–71.
26. Tinelli R, Litta P, Meir Y, et al. Advantages of laparoscopy versus laparotomy in extremely obese women (BMI>35) with early-stage endometrial cancer: a multicenter study. *Anticancer Res*. 2014;34:2497–502.
27. Bouwman F, Smits A, Lopes A, Das N, Pollard A, et al. The impact of BMI on surgical complications and outcomes in endometrial cancer surgery. An institutional study and systematic review of the literature. *Gynecol Oncol*. 2015;139(2):369–76.
28. Zivanovic O, Sonoda Y, Diaz JP, et al. The rate of port-site metastases after 2251 laparoscopic procedures in women with underlying malignant disease. *Gynecol Oncol*. 2008;111(3):431–7.
29. Dobronte Z, Wittmann T, Karascony G. Rapid development of malignant metastases in the abdominal wall after laparoscopy. *Endoscopy*. 1978;10:127–30.
30. Ramirez PT, Frumovitz M, Wolf JK, Levenback C. Laparoscopic port-site metastases in patients with gynecological malignancies. *Int J Gynecol Cancer*. 2004;14:1070–7.
31. Childers JM, Aqua KA, Surwit EA, Hallum AV, Hatch KD. Abdominal-wall tumor implantation after laparoscopy for malignant conditions. *Obstet Gynecol*. 1994;84:765–9.
32. Kruitwagen RF, Swinkels VM, Keyser KG, Doesburg WH, Schijf CP. Incidence and effect on survival of abdominal wall metastases at trocar or puncture sites following laparoscopy or paracentesis in women with ovarian cancer. *Gynecol Oncol*. 1996;60:233–7.
33. Abu-Rustum NR, et al. Subcutaneous tumor implantation after laparoscopic procedures in women with malignant disease. *Obstet Gynecol*. 2004;103:480–7.
34. Scalici J, Laughlin BB, Finan MA, Wang B, Rocconi RP. The trend towards minimally invasive surgery (MIS) for endometrial cancer: an ACS-NSQIP evaluation of surgical outcomes. *Gynecol Oncol*. 2015;136:512–5.
35. Gaia G, Holloway RW, Santoro L, et al. Robotic-assisted hysterectomy for endometrial cancer compared with traditional laparoscopic and laparotomy approaches: a systematic review. *Obstet Gynecol*. 2010;116(6):1422–31.
36. Chan JK, Gardner AB, Taylor K, Thompson CA, et al. Robotic versus laparoscopic versus open surgery in morbidly obese endometrial cancer patients. A comparative analysis of total charges and complication rates. *Gynecol Oncol*. 2015;139(2):300–5.
37. Park HK, Helenowski IB, Berry E, Lurain JR, Neubauer NL. A comparison of survival and recurrence outcomes in patients with endometrial cancer undergoing robotic versus open surgery. *J Minim Invasive Gynecol*. 2015;22(6):961–7.
38. Lu D, Liu Z, Shi G, et al. Robotic assisted surgery for gynaecological cancer. *Cochrane Database Syst Rev*. 2012;1.
39. Gala RB, Margulies R, Steinberg A, et al. Systematic review of robotic surgery in gynecology: robotic techniques compared with laparoscopy and laparotomy. *J Minim Invasive Gynecol*. 2014;21:353–61.
40. Ran L, Jin J, Xu Y, et al. Comparison of robotic surgery with laparoscopy and laparotomy for treatment of endometrial cancer: a meta-analysis. *PLoS One*. 2014;9:e108361.
41. Wright JD, Ananth CV, Tergas AI, et al. An economic analysis of robotically assisted hysterectomy. *Obstet Gynecol*. 2014;123:1038–48.
42. Leitao MM Jr, Bartashnik A, Wagner I, et al. Cost-effectiveness analysis of robotically assisted laparoscopy for newly diagnosed uterine cancers. *Obstet Gynecol*. 2014;123:1031–7.



Ovarian Cancer: Current Applications of Minimally Invasive Techniques

30

Giovanni Favero, Christhardt Köhler,
Alexandre Silva e Silva, and Jesus Paula Carvalho

Introduction

In developed countries, ovarian cancer is the second most frequent cancer of the female genital tract and is certainly the most lethal [1]. The incidence and the mortality related to this neoplasm have significantly increased over the last decades, and it will certainly constitute a major healthcare problem in the near future [2]. It is estimated that 125,000 women worldwide die each year due to this condition [3]. Despite a number of screening efforts, approximately 75% of patients are diagnosed with advanced forms of the disease (advanced ovarian cancer, AOC) [4]. In fact, surgery represents the cornerstone of treatment for this condition, and diverse studies have clearly demonstrated that achievement of complete cytoreduction (no macroscopic residual

tumor) has a substantial impact on survival [5, 6]. Unfortunately, due to the magnitude of disease dissemination, only in about 20–50% of the patients with AOC is primary optimal debulking surgery technically possible [4, 6, 7]. In this scenario, alternative strategies such as neoadjuvant chemotherapy (NACT), leading to higher rates of adequate resection, may be beneficial to a number of patients who are initially considered inoperable [4, 8]. The recent introduction into clinical practice of NACT for AOC, coupled with the development of modern technology and an increased number of skilled laparoscopic surgeons, has created a more favorable scenario for endoscopic debulking, at least in selected cases. However, there is currently a notorious paucity of data regarding the feasibility and oncologic safety of this new strategy.

Operative treatment for gynecologic tumors has historically been performed via laparotomy. Over the last decades, minimally invasive surgery has progressively gained popularity in this particular field. Indeed, laparoscopy significantly reduces procedure-related morbidity [9]. On the other hand, several important oncologic concerns have limited the widespread use of laparoscopy especially in ovarian cancer, such as possible port site metastasis, peritoneal tumor dissemination, inadequate staging, and a questionable quality of cytoreduction [10]. Particularly in the case of AOC, the magnitude of cancer spread in the peritoneum and visceral organs has discouraged

G. Favero, M.D., Ph.D. (✉)

Department of Gynecology, Instituto do Câncer do Estado de São Paulo – ICESP Faculdade de Medicina da Universidade de São Paulo, São Paulo, Brazil

Department of Advanced Gynecologic Surgery and Oncology, Asklepios Hospital Hamburg, Hamburg, Germany

C. Köhler, M.D., Ph.D.

Department of Advanced Gynecologic Surgery and Oncology, Asklepios Hospital Hamburg, Hamburg, Germany

A. Silva e Silva, M.D. • J. P. Carvalho, M.D., Ph.D.

Department of Gynecology, Instituto do Câncer do Estado de São Paulo (ICESP), Faculdade de Medicina da Universidade de São Paulo, São Paulo, SP, Brazil

and intimidated surgeons from performing endoscopic debulking surgery. Therefore, in contrast to other gynecologic malignancies, the use of laparoscopy in this pathology has frequently been viewed with skepticism and considered the ultimate boundary for the method.

Meaningful considerations will ensure that the patient benefits from the laparoscopic surgery while avoiding the undue morbidity and without compromising the long-term survival. Key points in ovarian cancer treatment include the indication and feasibility of the laparoscopic surgery for cancer, the cost and benefit of laparoscopy in ovarian cancer for the patients and surgeons, and the survival and recurrent outcome of the treatment. These points are discussed as follows.

Important Issues Regarding the Use of Endoscopy in Ovarian Cancer

Does Rupture or Spill from the Cyst Matter?

A concern of laparoscopic cancer surgery is cyst rupture and tumor spillage during operation, which may result in potential unfavorable prognosis and affect the overall survival. The rate of cyst rupture in laparoscopy has been reported as 6–27%, which is supposed to be higher than laparotomy as a risk of tumor spillage, although the data are not conclusive [11–14]. An earlier study indicated that a ruptured cyst was associated with a reduced 5-year survival in stage I epithelial ovarian cancer [15]. However, subsequent studies have shown that intraoperative cyst rupture is not associated with reduced survival. Some authors showed that there was a statistically significant reduction in survival in the group whose cyst ruptured before surgery compared with the group with intraoperative cyst rupture [15–19]. A recent retrospective analysis of 1545 patients with stage I disease found that intraoperative cyst rupture had an independent unfavorable prognostic effect on disease-free survival (hazard ratio, 1.64; 95% confidence interval, 1.07–2.51; $p = 0.002$) [20]. One of the major changes in the latest 2014 FIGO ovarian, fallopian tube, and

peritoneal cancer staging system was the differentiation among diverse oncological situations such as intraoperative tumor rupture, surface involvement by tumor cells, or presence of malignant cells in the ascites or peritoneal washings that warrants a stage of IC. Presently, it is classified as follows [21]:

- IC1: Surgical spill
- IC2: Capsule ruptured before surgery or tumor on ovarian or fallopian tube surface
- IC3: Malignant cells in the ascites or peritoneal washings

Does Pneumoperitoneum Cause the Acceleration of Spread of Malignant Cells?

The peritoneal organ has several biologic functions, including immunoregulation, inflammation, fibrinolysis, angiogenesis, and remodeling processes [22]. Surgical trauma results in mesothelial cell damage and triggers an inflammatory response [23]. Endoscopic procedures introduce new components in the abdominal cavity, such as increased abdominal pressure, CO₂ gas, and decreased intra-abdominal temperatures. These entities induce alterations in peritoneal integrity and physiology, causing local hypoxia, acidosis, and hypofibrinolysis [24]. The final consequence of this process is a considerable attenuation of the inflammatory response [22]. A number of studies utilizing animal models have demonstrated an impaired immune function of the peritoneum when exposed to elevated pressures and to insufflation gases. Consequently, a more favorable environment is created for tumor cell implantation in the nontraumatized peritoneum.

A unique immunological microenvironment is a marked characteristic of the peritoneal cavity. As a first line of defense, the local macrophages and neutrophils (polymorphonuclear neutrophils) are of major importance in protecting the organ. Air exposure triggers a higher transmigration (from blood to peritoneum) and decreases apoptosis of polymorphonuclear neutrophils in the face of CO₂ exposure [25, 26]. The minimally

invasive character of laparoscopic surgery reduces the surgical insult to the peritoneum and probably provokes a reduced antigenic exposure to the cell-mediated immunological system [27]. Conversely, one may speculate if the massive exposure of the peritoneum during open procedures to different antigenic agents may create a local “immunological boost” and, consequently, a more hostile environment for tumor dissemination. The immune interaction between the tumor and its environment is a key factor for impeding cancer progression and dissemination. Differently from other pathologies, the peritoneal organ has a supreme importance in the clinical course of ovarian cancer. If a reduced inflammatory reaction may be beneficial for the surgical treatment of a number of benign and malignant conditions due to the lower formation of adhesions, in cases of ovarian cancer, it may have negative oncologic consequences.

The duration of the procedure is certainly an important component of peritoneal immunoprotection. Probably, the peritoneal alterations during brief endoscopic interventions in AOC (diagnostic or staging/scoring laparoscopies) are not intense enough to determine significant changes in prognosis, as previously demonstrated in a number of publications. On the other hand, longer peritoneal and tumor exposure to high pressures, CO₂, lower temperatures, intense illumination, and dissection seems to be decisive in cases of cytoreductive procedures.

Is the Incidence of Port Site Metastasis Significantly Increased?

The occurrence of intraperitoneally cancer dissemination and/or abdominal wound (port site) metastases after laparoscopic procedures has been reported by numerous authors [20, 28–41]. The incidence of port site metastasis has been reported to range from 0 to 16% in a variety of cancers, which seemed no higher than that with laparotomy. However, port site metastasis could be an isolated occurrence or as part of a disseminated state, and the presentation of a port site metastasis after cancer laparoscopy varies from a

few days to several years. Prognosis of patients with port site metastasis after cancer laparoscopy varies widely according to sites of origin and histology.

Establishment of port site metastasis needs the presence of seeds and appropriate soil. Various possible mechanisms have been postulated as the cause of port site recurrence, such as advanced malignancy, direct contamination of cancer cells following extensively unprotected manipulation or presence of ascites, gas leak around port sites in the pressure of pneumoperitoneum (chimney effect), and tissue acidosis in the use of carbon dioxide. Increased traumatic injuries at the port site or predilection of tumor cell growth in the subcutaneous tissue may facilitate such process, since borderline malignant tumors can harbor sole abdominal wall implants without poor outcome. Some procedures to minimize the risk of port site implants have been recommended, including:

1. Using wound protectors
2. Minimizing tumor manipulation
3. Anchoring ports to prevent dislodgment
4. Avoiding carbon dioxide leakage and sudden deflating
5. Using gasless laparoscopy
6. Irrigating and suctioning abdomen, instruments, and ports before removal
7. Using heparin or 0.25–1% povidone-iodine solution to irrigate wounds and abdomen
8. Excising trocar sites and deliberate closure of all abdominal layers including the peritoneum after laparoscopy or postoperative port site radiation
9. Resuming to definitive surgery or chemotherapy early
10. Using 5-fluorouracil, topical taurolidine, or intraperitoneal endotoxin

Despite the vast amount of literature on this issue, solid evidence, however, is lacking on the effectiveness of preventive interventions [42, 43].

For ovarian malignancy, the real incidence of port site metastasis is not known, but there is more than 44 cases reported in the English

language literature [44, 45]. In an earlier study of patients of ovarian cancer in stage III and IV exclusively, 6 deaths were noted in 7 (86%) who had abdominal wall metastases as compared with 63 deaths in 137 (46%) who had no wound tumors [34]. However, the difference did not achieve significance because of the small sample size. Another study reported that by defining the breakpoint at 17 days, the prolonged interval of staging laparotomy after initial laparoscopic surgery was an independent prognostic factor for the stage of disease [38]. A later series also found a significant correlation between the development of port site implants and the longer interval before the start of chemotherapy or cytoreductive surgery; however, this study concluded that the presence of port site implants ($n = 9$) did not significantly impact the outcome [39]. Generally, most of the reports involved small case numbers and limited follow-up periods; the true incidence, mechanism, and long-term prognosis of these patients are still unclear.

Application of Laparoscopy in Different Oncological Scenarios

Surgery for ovarian cancer is the mainstream of oncological therapy and is classically performed via laparotomy. Standard debulking/cytoreductive procedure must at least include hysterectomy, bilateral salpingo-oophorectomy, pelvic and para-aortic lymphadenectomy, omentectomy, and resection of all suspicious lesions on the peritoneal surface. Major objective of the intervention is to obtain no macroscopic residual tumor. Taking into consideration that these patients often have relevant medical comorbidities, minimally invasive surgery has been shown to be a proper, if not preferred, alternative to the traditional approach, since some standard surgical principles are respected. It may significantly reduce procedure-related morbidity and expedite recovery especially in this patient population [9]. In addition, image magnification, improved dissection in critical areas, the possibility of performing concomitant procedures, a shorter hospital stay, reduced blood loss, a reduction in

the need for postoperative analgesics, and earlier initiation or continuation of chemotherapy are also potential advantages of the endoscopic techniques [9, 10, 46]. On the other hand, several important oncologic concerns have limited the widespread use of laparoscopy in ovarian cancer surgery. Possible inadequate staging or debulking, port site metastasis, iatrogenic tumor rupture, and potential cancer cell dissemination are frequent causes for fierce debate among specialists worldwide [47, 48].

Despite several oncologic and technical limitations, there have been an increasing number of publications in recent years about the use of laparoscopic techniques in ovarian cancer. Presently, the potential roles of endoscopy in ovarian cancer surgery may be divided into four categories according to the clinical stage of the disease:

- (A) Laparoscopic evaluation, diagnosis, and staging of apparent early ovarian cancer, including the operative evaluation of suspicious adnexal tumors
- (B) Laparoscopic diagnosis and assessment to determine whether the patient is suitable for upfront debulking surgery or for neoadjuvant chemotherapy in advanced ovarian cancer
- (C) Laparoscopic upfront cytoreductive surgery or postneoadjuvant chemotherapy in selected advanced ovarian cancer cases
- (D) Laparoscopic reassessment or second-look operation and resection of the isolated recurrences

(A) Laparoscopic Evaluation, Diagnosis, and Staging of Apparent Early Ovarian Cancer, Including the Operative Evaluation of Suspicious Adnexal Tumors

The difficulties to confirm an initial ovarian cancer are the unspecific presentation in its early stage, the lack of a reliable preoperative diagnostic criteria, and the low prevalence of the malignancy in the general population (about 30–50 cases per 100,000 women) [49, 50]. A number of series of laparoscopic management of suspicious

adnexal tumors have been published in the literature. In a series of 1011 patients operated by laparoscopy, four ovarian cancers were revealed intraoperatively in 1209 adnexal masses ranging from 2 to 25 cm in size, and an Austrian survey found an incidence of 6.5 unexpected ovarian cancer in 1000 women with adnexal mass managed by laparoscopy [51]. Another French survey found 78 cases of malignant ovarian cysts out of 5307 ovarian lesions treated by laparoscopy (1.47%), in which 18 of the 78 cases (0.34%) were ovarian cancers and the remaining 60 were borderline tumors [52]. A recent review concluded that the unexpected ovarian malignancy was estimated to be 1% or less in premenopausal patients under strict selection criteria; however, in postmenopausal patients, this rate rises to 3.0% [53]. Therefore, the rate of unexpected malignancies depends mostly on the selection criteria used. Certainly, laparoscopy is the method of choice for the definitive diagnostic and evaluation of clinically suspicious adnexal masses [9–13] (Figs. 30.1 and 30.2).

In cases of confirmed malignancies, all the minimally necessary procedures can be safely performed by endoscopy. Several retrospective and case series reports have demonstrated the feasibility and safety of a laparoscopic approach to the management of early-stage ovarian cancers [53–55]. These studies show laparoscopy to be associated with several perioperative benefits such as decreased blood loss, shorter hospital stay, and faster return of bowel function without compromising safety. Importantly, retrospective

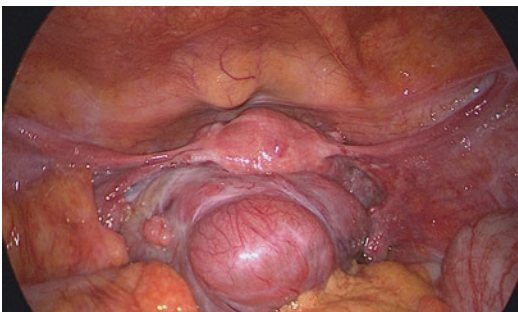


Fig. 30.1 Suspected adnexal mass arising from the left ovary. Histology confirmed a primary ovarian carcinosarcoma restricted to the organ (stage I)

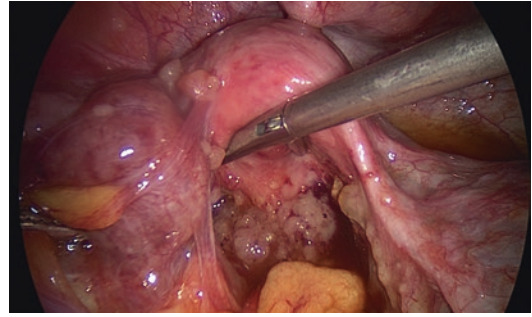


Fig. 30.2 Ovarian carcinoma (left side) with peritoneal carcinosis in the Douglas pouch (FIGO stage II)

evidence in early ovarian cancer also suggests similar recurrence rates after laparoscopic and open staging procedure, suggesting that the laparoscopic technique does not compromise the outcome of early-stage ovarian carcinoma [54, 55].

(B) Laparoscopic Diagnosis and Assessment to Determine Whether the Patient Is Suitable for Upfront Debulking Surgery or for Neoadjuvant Chemotherapy in Advanced Ovarian Cancer

As previously mentioned, the mainstay of treatment for advanced ovarian cancer is optimal cytoreduction, followed by platinum-based combination chemotherapy. Optimal cytoreduction, to microscopic disease, is certainly associated with best survival rates [56, 57]. To assess the resectability of advanced ovarian cancer, patient selection should be done with a view to either optimal primary cytoreductive surgery or neoadjuvant chemotherapy (NACT) followed by interval debulking operation. With the objective to better identify candidates to each of the above cited therapy strategy (upfront surgery versus NACT), Fagotti et al. (2006) developed a score based on laparoscopic findings that can more accurately predict potential suboptimal cytoreduction than radiology methods [58]. The rationales behind this procedure are to increase the rates of optimal cytoreduction, to avoid unsuccessful laparotomies, and, consequently, to expedite the initiation of neoadjuvant chemotherapy.

The analyzed parameters during staging laparoscopy are the following:

- *Omental cake*
- *Peritoneal carcinosis*
- *Diaphragmatic carcinosis*
- *Mesenteric retraction*
- *Bowel infiltration*
- *Stomach infiltration*
- *Liver metastases*

Each parameter receives 0 (no disease) or 2 (presence of disease), and the operability predictive index is the sum of points for all seven parameters.

Interpretation:

- The minimum predictive index: 0.
- The maximum predictive index: 14.
- The higher the score, the less likely that the patient will be optimally debulked at definitive surgery.
- The authors observed that patients with score ≥ 8 cannot be optimally operated in 100% of the cases. Conversely, in cases of score under 4, a complete cytoreduction can be obtained in 78% of the patients (Figs. 30.3, 30.4, 30.5, 30.6, and 30.7).

(C) Laparoscopic Upfront Cytoreductive Surgery or Postneoadjuvant Chemotherapy in Selected Advanced Ovarian Cancer Cases

The frequent impossibility of performing adequate debulking surgery due to either clinical or technical reasons has motivated some authors to investigate the use of NACT. The rationale behind this strategy is to achieve a reduction in

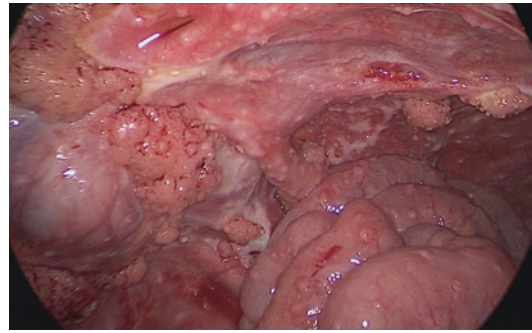


Fig. 30.4 Massive peritoneal carcinosis and bowel metastasis in the upper abdomen

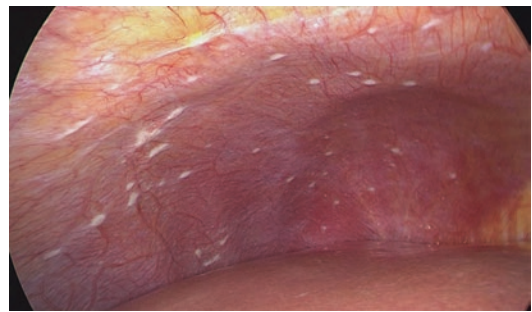


Fig. 30.5 Detection of peritoneal nodes in the area of the right diaphragm

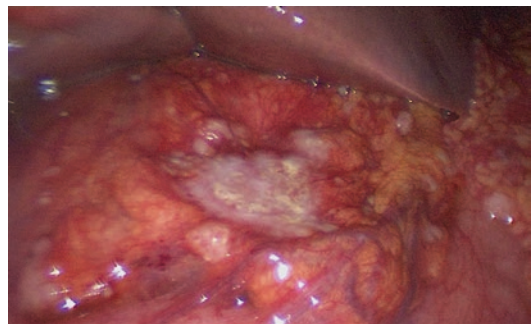

Fig. 30.6 Infiltration of the small omentum (bursa omentalis) in the gastric lesser curvature

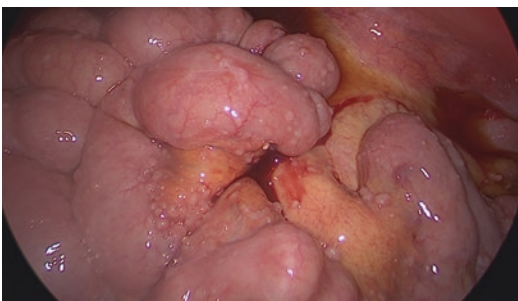

Fig. 30.3 Ovarian cancer with multiple metastases in the small intestinal loops and mesenteric retraction

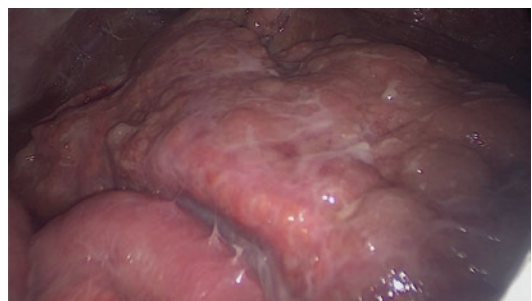


Fig. 30.7 Laparoscopic view of an omental cake

tumor size and peritoneal dissemination that would consequently elevate the probability of achieving complete tumor resection with less morbidity. For example, up to 30% of these patients may present a complete pathological response [7]. Although the results of a meta-analysis involving 835 patients suggested that this approach was associated with worse oncologic outcomes, recent randomized clinical trials have demonstrated that NACT followed by interval debulking surgery is at least non-inferior to the standard therapy [4, 7]. From the surgical perspective, shrinkage in tumor volume is the key factor for the implementation of minimally invasive techniques in AOC. The operative results obtained by Favero et al. (2015) and Guell Alletti et al. (2016) demonstrate that laparoscopic cytoreduction is technically feasible. Potential clinical and operative complications associated with previous chemotherapy are not relevant [59, 60]. Although there are a limited number of publications that have specifically analyzed the impact of NACT on laparoscopic procedures, abdominal surgery in this situation may be more difficult and associated with relevant morbidity. Empirically, one may say that the magnitude of the procedure is directly associated with increased risks. However, in the available series we observed unequivocal advantages, such as a short hospital stay and low blood loss, coupled with an operating time and complication rates that were acceptable. Additionally, potential psychological and aesthetic benefits associated with laparoscopy must be taken into consideration.

On the other hand, some authors are concerned about the oncological results obtained by laparoscopy. Favero et al. (2015) have observed a marked higher mortality rate (20% versus 0%) and a shorter chemotherapy-free interval among patients endoscopically operated [59]. Important concerns about the application of laparoscopy in this scenario include inadequate staging and tumor resection in difficult areas, most noticeably in the upper abdomen. One might argue that the inferior oncological results obtained by laparoscopy are due to overlooked and unresected lesions in regions of limited access (posterior diaphragm or retrohepatic area) and the fact that these cases were yet considered R0. Moreover,

laparoscopy induced changes in peritoneal physiology that certainly has a major importance for the inferior results, as previously described and discussed.

In fact, this type of procedure should be considered only in highly selected cases. In our opinion, negativity of CA-125 and CT scans without signs of peritoneal carcinomatosis and tumors in critical areas are good predictors of endoscopic optimal cytoreduction. Certainly, larger prospective trials are needed to confirm the observed results.

(D) Laparoscopic Reassessment or Second-Look Operation and Resection of the Isolated Recurrences

In the last decades, second-look operation was suggested as part of the therapeutic triage of patients with advanced ovarian cancer submitted to standard oncological treatment (surgery and chemotherapy) to confirm the absence of residual disease. More recently, with the incorporation into clinical practice of the neoadjuvant chemotherapy concept, laparoscopy can be used to access the tumor response and reevaluate the possibility of interval debulking previously to an explorative laparotomy. This procedure is only performed in clinical trials or in selected cases with uncertain clinical response to initial therapy. The rationales behind this interventional are to optimize the chemotherapy agents, accelerate the implementation cytoreductive surgery, or even avoid unsuccessful laparotomies in cases of poor response. Similar results have been reported regarding the efficacy of laparoscopy compared to laparotomy in assessing the pelvic and upper abdomen in these cases [61].

The role of secondary cytoreduction surgery for advanced ovarian carcinoma is debatable. Recently, several authors suggested some criteria such as isolated recurrence, the lack of ascites, and optimal debulking on the primary surgery as indications for secondary debulking [62, 63]. In these selected cases, laparoscopic secondary cytoreduction has been reported with acceptable results with regard to the efficacy and the outcomes [64–67] (Figs. 30.8, 30.9, and 30.10).

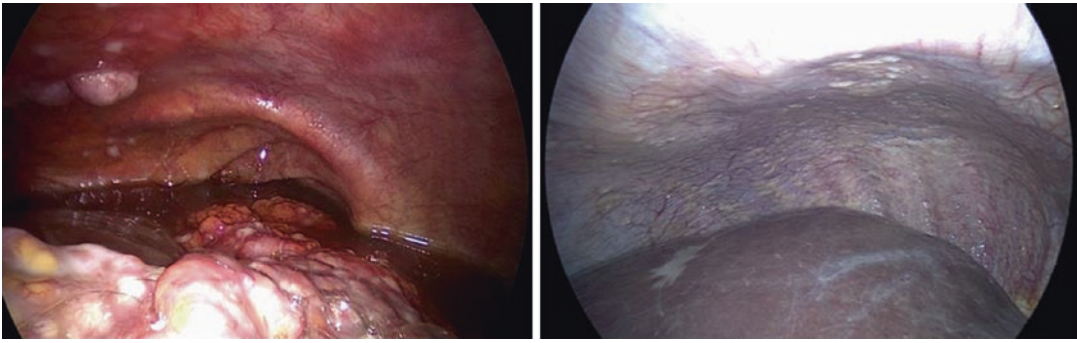


Fig. 30.8 Tumor regression after NACT (three cycles) in the upper abdomen (liver and diaphragm)

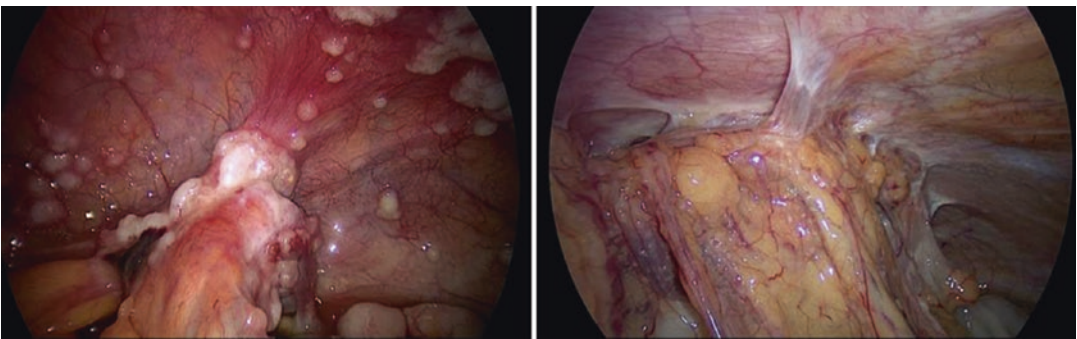


Fig. 30.9 Response to NACT (three cycles) with a massive regression of the peritoneal carcinosis

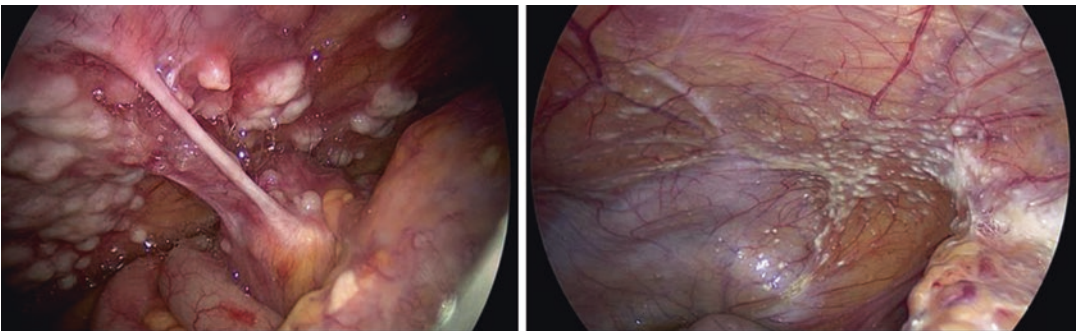


Fig. 30.10 Tumor regression after NACT (three cycles) in the pelvis

Conclusion

As early-stage ovarian cancer is rarely diagnosed preoperatively, most are encountered incidentally during laparoscopic operation for benign adnexal mass. In the past, conversion to laparotomy was recommended to ensure an optimal staging and to avoid the presence of potential residual disease. However, recent advancement in technology offers different

options of minimally invasive techniques to enable surgeons to manage patients with early-stage ovarian cancer. In this circumstance, endoscopic surgery is at least oncologically non-inferior to laparotomy [6, 9], but it may be beneficial in terms of invasiveness and leads to faster recovery that potentially expedites the initiation of adjuvant chemotherapy.

Some disadvantages of laparoscopic surgery for ovarian cancer could exist and should be considered before the operation, including the difficulty to remove large ovarian masses, inability to examine the full extent of the intestines, potential risk of cancer dissemination due to tumor rupture or manipulation, and possible trocar site metastasis. However, some spillage preventive measures can be used in cases of suspicious adnexal mass without a histological diagnosis of ovarian cancer, such as removal of the entire tumor without fragmentation and its exteriorization through protective pouches. If ovarian malignancy is diagnosed during an operation, adequate irrigation of povidone solution and closure of the peritoneum and all layers of abdominal wall at port site is recommended. If ovarian malignancy is diagnosed days after laparoscopy, standard laparotomic cytoreductive surgery should include the excision of all port sites.

The implementation of endoscopic debulking surgery for advanced ovarian cancer, despite the perspective of shorter recovery time, availability of increased number of skilled laparoscopic surgeons, team approach in well-equipped operating rooms, and incorporation of advanced medical technology including robotic surgery, according to the current literature, must be only developed in a context of clinical trial. On the other hand, laparoscopic staging to evaluate operability and to define the most adequate upfront treatment (surgery versus NACT) is progressively gaining popularity, and it is presently considered an integral part in the management of AOC.

References

1. Siegel R, Naishadham D, Jemal A. Cancer statistics, 2012. *CA Cancer J Clin.* 2012;62:10–29.
2. Goss PE, Lee BL, Badovinac-Crnjevic T, et al. Planning cancer control in Latin America and the Caribbean. *Lancet Oncol.* 2013;14:391–436.
3. Ferlay J, Shin HR, Bray F, et al. Estimates of worldwide burden of cancer in 2008: GLOBOCAN 2008. *Int J Cancer.* 2010;127:2893–917.
4. Vergote I, Tropé CG, Amant F. Neoadjuvant chemotherapy or primary surgery in stage IIIC or IV ovarian cancer. *N Engl J Med.* 2010;363:943–53.
5. Bristow RE, Tomacruz SR, Armstrong DK, et al. Survival effect of maximal cytoreductive surgery for advanced ovarian carcinoma during the platinum era: a meta-analysis. *J Clin Oncol.* 2002;20:1248–59.
6. Elattar A, Bryant A, Winter-Roach BA, et al. Optimal primary surgical treatment for advanced epithelial ovarian cancer. *Cochrane Database Syst Rev.* 2011;8:CD007565.
7. Kang S, Nam BH. Does neoadjuvant chemotherapy increase optimal cytoreduction rate in advanced ovarian cancer? Meta-analysis of 21 studies. *Ann Surg Oncol.* 2009;16:2315–20.
8. Morrison J, Haldar K, Kehoe S, et al. Chemotherapy versus surgery for initial treatment in advanced ovarian epithelial cancer. *Cochrane Database Syst Rev.* 2012;8:CD005343.
9. Cho JE, Liu C, Gossner G, et al. Laparoscopy and gynecologic oncology. *Clin Obstet Gynecol.* 2009;52:313–26.
10. Mettler L, Meinhold-Heerlein I. The value of laparoscopic surgery to stage gynecological cancers: present and future. *Minerva Ginecol.* 2009;61:319–37.
11. Yuen PM, Yu KM, Yip SK, Lau WC, Rogers MS, Chang A. A randomized prospective study of laparoscopy and laparotomy in the management of benign ovarian masses. *Am J Obstet Gynecol.* 1997;177:109–14.
12. Fanfani F, Fagotti A, Ercoli A, Bifulco G, Longo R, Mancuso S, Scambia G. A prospective randomized study of laparoscopy and minilaparotomy in the management of benign adnexal masses. *Hum Reprod.* 2004;19:2367–71.
13. Havrilesky LJ, Peterson BL, Dryden DK, Soper JT, Clarke-Pearson DL, Berchuck A. Predictors of clinical outcomes in the laparoscopic management of adnexal masses. *Obstet Gynecol.* 2003;102:243–51.
14. Gal D, Lind L, Lovecchio JL, Kohn N. Comparative study of laparoscopy vs. laparotomy for adnexal surgery: efficacy, safety, and cyst rupture. *J Gynecol Surg.* 1995;11:153–8.
15. Webb MJ, Decker DG, Mussey E, Williams TJ. Factor influencing survival in stage I ovarian cancer. *Am J Obstet Gynecol.* 1973;116:222–8.
16. Sevelde P, Dittrich C, Salzer H. Prognostic value of the rupture of the capsule in stage I epithelial ovarian carcinoma. *Gynecol Oncol.* 1989;35:321–2.
17. Dembo AJ, Davy M, Stenwig AE, Berle EJ, Bush RS, Kjorstad K. Prognostic factors in patients with stage I epithelial ovarian cancer. *Obstet Gynecol.* 1990;75:263–73.
18. Vergote IB, Kaern J, Abeler VM, Pettersen EO, De Vos LN, Tropé CG. Analysis of prognostic factors in stage I epithelial ovarian carcinoma: importance of degree of differentiation and deoxyribonucleic acid ploidy in predicting relapse. *Am J Obstet Gynecol.* 1993;169:40–52.
19. Sjøvall K, Nilsson B, Einhorn N. Different types of rupture of the tumor capsule and the impact on

- survival in early ovarian carcinoma. *Int J Gynecol Cancer*. 1994;4:333–6.
20. Morice P, Camatte S, Larregain-Fournier D, Thoury A, Duvillard P, Castaigne D. Port-site implantation after laparoscopic treatment of borderline ovarian tumors. *Obstet Gynecol*. 2004;104:1167–70.
 21. Prat J, FIGO Committee on Gynecologic Oncology. Staging classification for cancer of the ovary, fallopian tube, and peritoneum. *Int J Gynecol Obstet*. 2014;124(1):1–5.
 22. Brokelman WJ, Lensvelt M, Borel Rinkes IH, et al. Peritoneal changes due to laparoscopic surgery. *Surg Endosc*. 2011;25:1–9.
 23. Bergström M, Ivarsson ML, Holmdahl L. Peritoneal response to pneumoperitoneum and laparoscopic surgery. *Br J Surg*. 2002;89:1465–9.
 24. Rosário MT, Ribeiro U Jr, Corbett CE, et al. Does CO₂ pneumoperitoneum alter the ultra-structure of the mesothelium? *J Surg Res*. 2006;133:84–8.
 25. Hynninen J, Lavonius M, Oksa S, et al. Is perioperative visual estimation of intra-abdominal tumor spread reliable in ovarian cancer surgery after neoadjuvant chemotherapy? *Gynecol Oncol*. 2013;128:229–32.
 26. Moehrlen U, Schwobel F, Reichmann E, et al. Early peritoneal macrophage function after laparoscopic surgery compared with laparotomy in a mouse model. *Surg Endosc*. 2005;19:958–63.
 27. Moehrlen U, Ziegler U, Boneberg E, et al. Impact of carbon dioxide versus air pneumoperitoneum on peritoneal cell migration and cell fate. *Surg Endosc*. 2006;20:1607–13.
 28. Hsiu JG, Given FT Jr, Kemp GM. Tumor implantation after diagnostic laparoscopic biopsy of serous ovarian tumors of low malignant potential. *Obstet Gynecol*. 1986;68(3 Suppl):90S–3S.
 29. Maiman M, Seltzer V, Boyce J. Laparoscopic excision of ovarian neoplasms subsequently found to be malignant. *Obstet Gynecol*. 1991;77:563–5.
 30. Gleeson NC, Nicosia SV, Mark JE, Hoffman MS, Cavanagh D. Abdominal wall metastases from ovarian cancer after laparoscopy. *Am J Obstet Gynecol*. 1993;169(3):522.
 31. Shepherd JH, Carter PG, Lowe DG. Wound recurrence by implantation of a borderline ovarian tumour following laparoscopic removal. *Br J Obstet Gynaecol*. 1994;101:265–6.
 32. Childers JM, Aqua KA, Surwit EA, Hallum AV, Hatch KD. Abdominal-wall tumor implantation after laparoscopy for malignant conditions. *Obstet Gynecol*. 1994;84:765–9.
 33. Lecuru F, Darai E, Robin F, Housset M, Durdux C, Taurelle R. Port site metastasis after laparoscopy for gynecological cancer: report of two cases. *Acta Obstet Gynecol Scand*. 2000;79:1021–3.
 34. Kruitwagen RF, Swinkels BM, Keyser KG, Doesburg WH, Schijf CP. Incidence and effect on survival of abdominal wall metastases at trocar or puncture sites following laparoscopy or paracentesis in women with ovarian cancer. *Gynecol Oncol*. 1996;60:233–7.
 35. Kadar N. Port-site recurrences following laparoscopic operations for gynaecological malignancies. *Br J Obstet Gynaecol*. 1997;104:1308–13.
 36. Wang PH, Yuan CC, Lin G, Ng HT, Chao HT. Risk factors contributing to early occurrence of port site metastases of laparoscopic surgery for malignancy. *Gynecol Oncol*. 1999;72:38–44.
 37. Leminen A, Lehtovirta P. Spread of ovarian cancer after laparoscopic surgery: report of eight cases. *Gynecol Oncol*. 1999;75:387–90.
 38. Lehner R, Wenzl R, Heinzl H, Husslein P, Sevelada P. Influence of delayed staging laparotomy after laparoscopic removal of ovarian masses later found malignant. *Obstet Gynecol*. 1998;92:967–71.
 39. van Dam PA, DeCloedt J, Tjalma WA, Buytaert P, Becquart D, Vergote IB. Trocar implantation metastasis after laparoscopy in patients with advanced ovarian cancer: can the risk be reduced? *Am J Obstet Gynecol*. 1999;181:536–41. *Taiwan J Obstet Gynecol* 2009 • Vol 48 No 1.
 40. Morice P, Viala J, Pautier P, Lhomme C, Duvillard P, Castaigne D. Port-site metastasis after laparoscopic surgery for gynecologic cancer: a report of six cases. *J Reprod Med*. 2000;45:837–40.
 41. Nduka CC, Monson JR, Menzies-Gow N, Darzi A. Abdominal wall metastases following laparoscopy. *Br J Surg*. 1994;81:648–52.
 42. Balli JE, Franklin ME, Almeida JA, Glass JL, Diaz JA, Reymond M. How to prevent port-site metastases in laparoscopic colorectal surgery. *Surg Endosc*. 2000;14:1034–6.
 43. Canis M, Botchorishvili R, Wattiez A, Pouly JL, Mage G, Manhes H, Bruhat MA. Cancer and laparoscopy, experimental studies: a review. *Eur J Obstet Gynecol Reprod Biol*. 2000;91:1–9.
 44. Ramirez PT, Wolf JK, Levenback C. Laparoscopic port-site metastases: etiology and prevention. *Gynecol Oncol*. 2003;91:179–89.
 45. Nagarsheth NP, Rahaman J, Cohen CJ, Gretz H, Nezhat F. The incidence of port-site metastases in gynecologic cancers. *JLSLS*. 2004;8:133–9.
 46. Jernigan AM, Auer M, Fader AN, et al. Minimally invasive surgery in gynecologic oncology: a review of modalities and the literature. *Womens Health*. 2012;8:239–50.
 47. Nezhat FR, DeNoble SM, Liu CS, et al. The safety and efficacy of laparoscopic surgical staging and debulking of apparent advanced stage ovarian, fallopian tube, and primary peritoneal cancers. *JLSLS*. 2010;14:155–68.
 48. Rutten MJ, Gaarenstroom KN, Van Gorp T, et al. Laparoscopy to predict the result of primary cytoreductive surgery in advanced ovarian cancer patients (LapOvCa-trial): a multi-centre randomized controlled study. *BMC Cancer*. 2012;12:31.
 49. NIH consensus conference. Ovarian cancer: screening, treatment, and follow-up. NIH Consensus Development Panel on Ovarian Cancer. *JAMA*. 1995;273:491–7.
 50. ACOG Committee on Gynecologic Practice. The role of the generalist obstetrician-gynecologist in the

- early detection of ovarian cancer. *Gynecol Oncol.* 2002;87:237–9.
51. Wenzl R, Lehner R, Husslein P, Sevelde P. Laparoscopic surgery in cases of ovarian malignancies: an Austria-wide survey. *Gynecol Oncol.* 1996;63:57–61.
 52. Blanc B, Boubli L, D'Ercole C, Nicoloso E. Laparoscopic management of malignant ovarian cysts: a 78-case national survey, part 1: pre-operative and laparoscopic evaluation. *Eur J Obstet Gynecol Reprod Biol.* 1994;56:177–80.
 53. Muzii L, Angioli R, Zullo M, Panici PB. The unexpected ovarian malignancy found during operative laparoscopy: incidence, management, and implications for prognosis. *J Minim Invasive Gynecol.* 2005;12:81–9; quiz 90–1.
 54. Tozzi R, Schneider A. Laparoscopic treatment of early ovarian cancer. *Curr Opin Obstet Gynecol.* 2005;17:354Y358.
 55. Weber S, McCann CK, Boruta DM, et al. Laparoscopic surgical staging of early ovarian cancer. *Rev Obstet Gynecol.* 2011;4:117–22.
 56. Winter WE III, Maxwell GL, Tian C, et al. Gynecologic Oncology Group Study. Prognostic factors for stage III epithelial ovarian cancer: a Gynecologic Oncology Group Study. *J Clin Oncol.* 2007;25:3621–7.
 57. Winter WE III, Maxwell GL, Tian C, et al. Tumor residual after surgical cytoreduction in prediction of clinical outcome in stage IV epithelial ovarian cancer: a Gynecologic Oncology Group Study. *J Clin Oncol.* 2008;26:83–9.
 58. Fagotti A, Ferrandina G, Fanfani F, et al. A laparoscopy-based score to predict surgical outcome in patients with advanced ovarian carcinoma: a pilot study. *Ann Surg Oncol.* 2006;13:1156–61.
 59. Favero G, Maceroux N, Pfiffer T, Köhler C, da Costa Miranda V, Estevez Diz Mdel P, Fukushima JT, Baracat EC, Carvalho JP. Oncologic concerns regarding laparoscopic cytoreductive surgery in patients with advanced ovarian cancer submitted to neoadjuvant chemotherapy. *Oncology.* 2015;89(3):159–66.
 60. Gueli Alletti S, Bottoni C, Fanfani F, Gallotta V, Chiantera V, Costantini B, Cosentino F, Ercoli A, Scambia G, Fagotti A. Minimally invasive interval debulking surgery in ovarian neoplasm (MISSION trial-NCT02324595): a feasibility study. *Am J Obstet Gynecol.* 2016;214(4):503.e1–6.
 61. Abu-Rustum NR, Barakat RR, Siegel PL, et al. Second-look operation for epithelial ovarian cancer: laparoscopy or laparotomy? *Obstet Gynecol.* 1996;88:549–53.
 62. Schorge JO, Wingo SN, Bhore R, et al. Secondary cytoreductive surgery for recurrent platinum-sensitive ovarian cancer. *Int J Gynaecol Obstet.* 2010;108:123–7.
 63. Frederick PJ, McQuinn L, Milam MR, et al. Preoperative factors predicting survival after secondary cytoreduction for recurrent ovarian cancer. *Int J Gynecol Cancer.* 2011;21:831–6.
 64. Amara DP, Nezhat C, Teng N, et al. Operative laparoscopy in the management of ovarian cancer. *Surg Laparosc Endosc.* 1996;6:38–45.
 65. Chi DS, Abu-Rustum NR, Sonoda Y, et al. Laparoscopic and hand-assisted laparoscopic splenectomy for recurrent and persistent ovarian cancer. *Gynecol Oncol.* 2006;101:224–7.
 66. Trinh H, Ott C, Fanning J. Feasibility of laparoscopic debulking with electrosurgical loop excision procedure and argon beam coagulator at recurrence in patients with previous laparotomy debulking. *Am J Obstet Gynecol.* 2004;190:1394–7.
 67. Nezhat FR, Denoble SM, Cho JE, et al. The safety and efficacy of video laparoscopic surgical debulking of recurrent ovarian, fallopian tube, and primary peritoneal cancers. *JLS.* 2010;14:155–68.



Sentinel Node in Gynecological Cancer

31

Cecilia Escayola Vilanova and Denis Querleu

Introduction

Sentinel node biopsy has profoundly reshaped both therapeutic and diagnostic approaches to gynecological cancers. While it is undeniable that the sentinel node procedure has simplified the surgical treatment and significantly reduced the morbidity of it, it has also been proven that sentinel node leads to a more accurate staging and therefore to a better planning of adjuvant treatment. Nowadays, sentinel node biopsy is the standard of care in breast cancer and vulvar cancer and strongly recommended in cervical cancer and endometrial cancer due to the new imaging technologies.

Sentinel Node in Endometrial Cancer

Introduction

Endometrial cancer is the most common gynecological cancer in developed countries, the incidence being 13.6 per 100,000. Almost all cases

are diagnosed in women >50 years. Only 4% of those with endometrial cancer are younger than age 40. Eighty percent of cases are early stage (stage 1) with a high overall survival rate. The presence of nodal disease changes the stage of this cancer and negatively impacts survival rate.

Endometrial cancer has been classified into two types: type 1 which develops in the presence of high levels of unopposed estrogen and is normally detected at an early stage (endometrioid adenocarcinoma, 90% of cases) and type 2 (non-endometrioid, such as serous, clear cells, undifferentiated carcinomas, carcinosarcomas, malignant mixed Mullerian tumors, comprising 10% of cases), less hormonally dependent and more often detected at an advanced stage. Each type has different genetic alterations. In addition, based on the definitive pathological study, three at-risk groups have been established: low risk (type 1, stage IA grade 1 or 2), intermediate risk (type 1, stage IA grade 3, or stage IB grade 1 or 2), and high risk (type 1 stage IB grade 3 or type 2). In cases of hereditary endometrial cancer (HNPCC, Lynch syndrome), the proportion of type 2 is higher than in sporadic cases. Factors such as obesity, polycystic ovary syndrome, nulliparity, and long-term use of unopposed estrogens for hormone replacement therapy correlate positively with the risk of endometrial cancer [1–3]. According to this classification and following the European guidelines, patients at low risk should undergo simple hysterectomy without adjuvant

C. E. Vilanova, M.D.
Hospital Pilar Quiron Salud,
Barcelona, Spain

D. Querleu, M.D. (✉)
Department of Surgery, Institut Bergonié,
Bordeaux, France
e-mail: querleu@aol.com

treatment; patients at intermediate risk should be treated with hysterectomy, pelvic and para-aortic lymphadenectomy, and adjuvant brachytherapy to decrease vaginal recurrence; and patients at high risk should be surgically treated like patients with epithelial ovarian cancer plus radiotherapy and chemotherapy in certain cases.

Sentinel Node Biopsy Versus Lymphadenectomy

Endometrial cancer is staged according to the International Federation of Gynecology and Obstetrics. The affection of the lymphatic nodes makes up part of the staging and therefore has a direct relation with adjuvant treatment. However, lymphadenectomy involves complications such as vascular or nerve injury, deep vein thrombosis, lymphocysts, lower leg lymphedema, and lymphangitis. It also increases surgical time, blood loss, and the rate of conversion from laparoscopy to laparotomy to complete the correct staging. These complications may negatively affect survival and quality of life in the numerous patients for whom the procedure will ultimately have been of minimal or no benefit. The application of the sentinel node technique will decrease the morbidity of the lymphadenectomy, giving an added plus in diagnostic accuracy, which places it halfway between systematic lymphadenectomy and the omission of lymph node dissection. Without doubt it would improve quality of life in low-risk patients, decreasing as well morbidity in those who are obese and of advanced age, and therefore more prone to complications, and also help to identify nodal metastases in uncommon locations, leading many groups to propose sentinel node mapping and ultrastaging [4–6].

The growing popularity of the sentinel node biopsy in endometrial cancer is essentially based on its low morbidity and high negative predictive value. The rate of detection of sentinel nodes is directly related to anatomic factors, technique used, site of injection, and tracers employed. The only prospective study evaluating the feasibility of SN in endometrial cancer is the French multi-

center study SENTI-ENDO [7]. One hundred thirty-three patients with stage I-II endometrial cancer were enrolled. Patients underwent SN biopsy via cervical dual injection with technetium and patent blue, followed by systematic pelvic node lymphadenectomy. The results showed that both sensitivity and negative predictive value were 100% when the hemipelvis was considered as the unit of analysis.

Technique of Sentinel Node Detection

Within the application of the sentinel node, three main issues need to be addressed. First of all, there are two different techniques for the detection of the SN based on the site of injection: cervical and subendometrial via hysteroscopy. In contrast to cervical and vulvar cancer in which tumors are much more accessible, localization of the tumor in the uterus remains a challenge. The lymphatic pathways of the uterus are extremely complex. While the principal lymphatic channels of the uterus follow the course of the uterine vessels to the iliac nodes, tumors located in the fundus can potentially drain into the para-aortic nodes following the gonadal vessels. The hysteroscopic injection requires a learning curve and familiarity with hysteroscopic skills, and it is a more time-consuming technique. The simplicity of the cervical injection as well as its excellent detection rate makes it the most accepted. The main concern regarding it is the supposedly lower detection rate of para-aortic nodes when compared to the hysteroscopic injection. In a prospective nonrandomized study, the authors showed that the combined superficial and deep cervical injection is the easiest way and accurate enough for patients with stage I endometrial cancer [8]. In order to adopt cervical injection as a reliable technique for accurately detecting sentinel nodes in patients at high-risk endometrial cancer, a properly designed validation study must be undertaken.

The second point to be addressed is the tracers used to detect sentinel nodes. The best results are obtained through the combination of technetium-99 injected into the cervix prior to the surgery

with an intraoperative cervical injection of blue dye. In the study of Abu-Rustum et al., 42 patients with stage I endometrial carcinoma were enrolled [9]. Preoperative lymphoscintigraphy detected sentinel nodes in 71% of patients, whereas intraoperative detection was possible in 86%. The sensitivity in all the patients who had a sentinel node identified was 100%. Nevertheless, the use of these two tracers has some pitfalls. Regarding blue dye, allergic reactions although uncommon can appear, and as a general rule, dyes are mainly used to detect superficial lymph nodes. Concerning the radiolabeled colloid, its use requires a nuclear medicine unit not uniformly available in all hospitals. More recently, fluorescent organic molecules have been introduced in order to overcome the pitfalls encountered with the aforementioned tracers. Jewell et al. conducted a study aimed to assess the detection rates of sentinel nodes using indocyanine green (ICG) and near-infrared fluorescence imaging for uterine and cervical cancer [10]. Two hundred twenty-seven patients were enrolled and with the majority of them diagnosed with grade 1 or 2 endometrial cancer. ICG was diluted in 20 cc of aqueous sterile water and then injected into the cervix prior to the surgery. The overall detection rate was 95%, and the bilateral detection one was 79%. Moreover, the authors proved that the addition of blue dye injection did not achieve higher detection rates, rendering it unnecessary.

Intraoperative Evaluation and Low-Volume Disease

The third point is the ultrastaging which will detect a higher number of patients with low-volume disease which would have probably been missed through routine hematoxylin and eosin (H&E) assessment, the clinical significance of which are still unclear. Low-volume metastatic disease includes a focus of metastatic tumor measuring >0.2 mm and <2 mm defined as micrometastases and isolated tumor cells which includes cluster or single cells <0.2 mm. Sentinel node protocol involves cutting two adjacent 5-m sections at each of two levels, from each paraffin block lacking

metastatic carcinoma on routine H&E. At each level, one slide is stained with H&E and the other with immunohistochemistry using the anti-cytokeratin AE1/AE3. A recent retrospective study including 508 patients successfully mapped showed that ultrastaging detected an additional 23 patients with low-volume disease in the sentinel nodes [11]. Among these 23 patients, 19 had isolated tumor cells and 4 had micrometastases. In this study lymphatic mapping was performed using blue dye superficial and deep injection. The authors also proved that the incidence of ultrastage-detected metastases can be correlated to the depth of myoinvasion stating that sentinel node ultrastaging can be spared in patients without myoinvasion. This study proves that these patients, according to the protocols, should not have undergone a complete lymphadenectomy and consequently would not have received adjuvant treatment. Another retrospective study including 103 patients with low- or intermediate-risk endometrial cancer analyzed the role of sentinel node biopsy in the staging of the disease. The results showed that 12 patients with presumed preoperative low-risk disease and 7 with intermediate-risk were upstaged by definitive histology [12]. A sub-analysis of the prospective multicenter study SENTI-ENDO [5] proved that preoperative lymphoscintigraphy detected a higher rate of aberrant drainage especially in the para-aortic area.

Intraoperatively, the diagnosis is more accurate using frozen section, but the sensibility is low, principally due to micrometastasis and isolated tumor cells. New techniques using a one-step nucleic acid amplification (OSNA) assay are currently under study in order to obtain a swifter and more reliable diagnosis of the sentinel node. Nagai et al. analyzed primary tumor samples from 200 patients with endometrial cancer [13]. The results showed that an OSNA assay using cytokeratin 19 mRNA was applicable for detection of lymph node metastases in patients with endometrial carcinoma. OSNA assays require less time for analysis than immunohistochemistry, which is time-consuming and inapplicable for intraoperative diagnosis.

The importance of adhering to a sentinel node mapping algorithm was highlighted in the recent

study of Barlin [14]. Their algorithm included peritoneal and serosal evaluation and washings, excision of all mapped sentinel nodes and removal of all suspicious nodes regardless of mapping, and a side-specific pelvic lymphadenectomy when there was no mapping in one hemipelvis. The study included 498 patients who received blue dye (superficial and deep) cervical injection and underwent sentinel node mapping. At least one sentinel node was identified in 81%. When applying it to the algorithm, the false-negative rate dropped from 15 to 1.9%. It has to be stressed that sentinel node mapping must be applied to patients with apparent stage I endometrial cancer, knowing that the risk of isolated para-aortic nodes with negative pelvic nodes remains between 1 and 3%. It is worth mentioning that this rate could possibly decrease if we take into account that sentinel node ultrastaging improves the detection of low-volume disease that until now has been undetected by routine histologic examination.

In order to evaluate clinic and pathological factors that may influence overall survival in patients with endometrial cancer, Barlin et al. conducted a classification and regression tree (CART) analysis [15]. They reviewed data from 1920 patients who had at least 1 lymph node removed. Their results proved that in the case of endometrial cancer, the two factors that really matter are the final stage and grade, but not the total number of nodes removed.

Sentinel Node in Cervical Cancer

Introduction

Cervical cancer is the third most common malignancy in women worldwide. Half of those with invasive cervix carcinoma are diagnosed prior to age 35. There are large differences in incidence between developed and underdeveloped countries, and it constitutes the leading cause of cancer mortality in recent years, surpassing breast cancer. In developed countries its incidence has stabilized over recent years, being approximately 7.2 cases per 100,000 inhabitants/year. Worldwide, over 500,000 die annually from this type of cancer.

Cervical cancer is the only gynecological cancer that is clinically classified according to the FIGO score. The incidence of positive nodes increases with FIGO stage and varies from 5–19% in stage I to 34–70% in stage IV. Despite lymph node affectation being one of the most important prognostic factors, lymph node metastasis is not included in the classification. Moreover, lymph node status is essential to address adjuvant treatment.

The Lymphatic Drainage

The most common pattern of spreading of cervical cancer is by direct local extension and lymphatic embolization. Direct extension usually represents involvement of the parametria, cardinal ligaments, and, in cases with large-volume tumors, the mid and distal third portion of the vagina. The main lymphatic drainage of the cervix is through the lateral channels to the external iliac, hypogastric, obturator, and common iliac nodes (Fig. 31.1). There are also anterior lymphatic channels that pass behind the bladder and terminate in the external iliac lymph nodes and posterior lymphatic channels that pass through the uterosacral ligaments and terminate in the common iliac, subaortic, para-aortic, and superior rectal nodes. Three major para-aortic lymph node chains can be identified: the left one that lies to the left of the aorta, the aorto-caval one

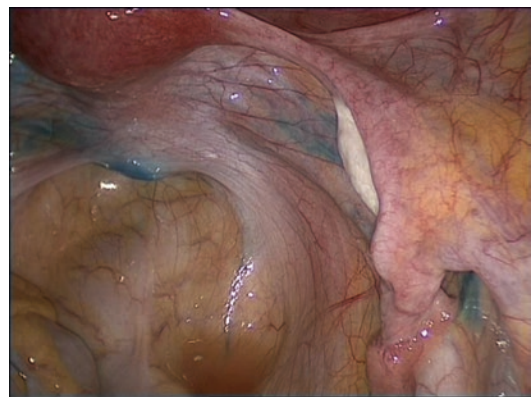


Fig. 31.1 Blue dye in the cervix, the right and left lateral lymphatic channels, and the right pelvic nodes

that lies between the aorta and the vena cava, and the right one that lies to the right of the cava. Involvement of para-aortic nodes without pelvic node metastases can be possible through the posterior trunks.

Surgery in cervical cancer has evolved over the last decades, becoming less radical with the passing of time. Currently the gold standard for initial stages is radical hysterectomy with bilateral pelvic lymphadenectomy. This treatment strategy, despite achieving excellent survival rates, is also associated with numerous complications. Patients often present dysfunctions of the lower urinary track, sexual dysfunctions, and disorders of the intestinal motility associated with autonomic nerve damage following a conventional radical hysterectomy. Lymphadenectomy is associated with short- and long-term morbidities such as lymphedema, vascular injury, lymphocyst formation, prolonged surgery, increased blood loss, and venous thromboembolism. The appearance of surgical laparoscopy in the 1990s allowed the determination of lymph node metastases in several neoplastic diseases, reducing mortality with respect to laparotomy [16]. Despite this, complications persist in both the short and long term derived from lymphadenectomy, complications that can seriously worsen in the case of posterior administration of radiotherapy [17].

However, the rate of metastatic affectation of the pelvic nodes in early stages is 7% in the case of IA2 and around 20% in IBI [18], which is why many unnecessary lymphadenectomies are performed without direct benefit. This data has led the scientific community to investigate the application of sentinel node biopsy in cervical cancer from the late 1990s [19]. Since its application in other tumors such as in melanoma and breast and vulvar cancer, a great scientific interest has been generated with regard to performing sentinel node determination in cervical cancer [20–23]. The benefits are clear with respect to complete lymph node dissection, achieving more accurate detection of small metastases [11, 24], the identification of uncommon drainages [25], and consequently an improved decision management of the patient's disease. Several articles reinforce the application of this technique [26–28], but

nevertheless the determination of sentinel node in cervical cancer has not been included among the recommendations in early-stage cervix cancer management.

Localization of Sentinel Nodes

Different aspects must be evaluated. Firstly, we know that in cervical cancer, around 10% of the sentinel nodes are not found in regions usually explored during systematic lymphadenectomy [25, 29]. In a multicenter prospective study aimed to detect unexpected drainage pathways conducted by Bats et al., 145 patients diagnosed with early-stage cervical cancer were included [30]. Whereas 80.6% of the sentinel nodes were found in common areas, up to 5.1% of patients had sentinel nodes only in uncommon ones. Another prospective study including 211 patients [31] showed that 16.6% of them presented at least 1 sentinel node in uncommon regions such as the common iliac, the presacral, and the para-aortic region. The determination of these nodes permits to diagnose more precisely the extent of the disease and to consequently design a better treatment strategy.

Technique of Sentinel Node Detection

Secondly, sentinel node detection techniques have shown to be feasible and effective. We have evidence supporting this fact thanks to two prospective clinical trials, SENTICOL I and AGO study group [26, 28]. The French prospective multicenter study enrolled 139 patients with early cervical cancer. Almost all patients received the combined technique, preoperative technetium-99 lymphoscintigraphy, and patent blue injection, followed by laparoscopic lymph node mapping, sentinel node biopsy, and complete pelvic lymphadenectomy. Sentinel nodes were detected in 97.8% of patients, whereas bilateral detection was achieved in 76.5%. In the second study included 507 patients, and all underwent lymph node detection after injection with T-99 m the day

before surgery, blue dye after induction of anesthesia, or a combination of both. The highest detection rate of 93.5% was achieved when the combined technique was used. Furthermore, pre-operative sentinel node detection by lymphoscintigraphy achieves low detection rates compared to intraoperative lymphatic mapping, but can provide the surgeons with valuable information by identifying unusual drainage basins [30]. The timing of the administration of radiocolloid varies according to the protocol employed, being long (day prior to surgery), short (a few hours before), or ultrashort (when the patient is asleep in the operating room). One of the problems with this detection technique is that not all centers have access to a nuclear medicine unit, so its application is fairly limited and costly. In addition, the patient and sanitary personal are exposed to radiation, even though the doses are quite small. The risks for patients in combined detection techniques are mainly due to allergic reactions, although these are very infrequent.

In uterine and cervical cancers, sentinel node detection must be bilateral. A failed mapping in one of the hemipelvis must be followed by a side-specific lymphadenectomy. In order to improve the ability to detect sentinel nodes and overcome certain pitfalls, new imaging approaches are emerging. Over the last years, sentinel node detection in gynecological pathologies with indocyanine green (fluorescent determination using special infrared cameras) has proven to be just as effective as the combined technique, as well as being less costly [32–34]. A study conducted by Jewell et al. analyzed the detection rate of sentinel nodes using indocyanine green (ICG) and near-infrared fluorescence imaging for uterine and cervical cancers [10]. Two hundred twenty-seven patients were enrolled in which ICG was injected prior to the start of the surgery. The overall detection rate of the sentinel node was 95% and 79% if bilateral.

The sentinel node procedure was developed in order to identify the first lymphatic drainage of tumors and therefore avoid a lymphadenectomy reducing its morbidity. Thus, the determination of the sentinel node must have a high sensitivity and a false-negative rate of almost zero. This is

achieved with the identification of sentinel nodes in both sides of the pelvis. The only prospective study using sentinel node ultrastaging conducted to date is the French study SENTICOL I, aimed to assess the reliability of the SN biopsy [26]. The results showed an overall sensitivity of 92%, but among the patients with bilateral sentinel node detection, none had a false-negative result yielding a sensitivity of 100%. The largest retrospective study on sentinel node in patients with cervical cancer was conducted by Cibula et al. and enrolled 645 patients [35]. For the whole group of patients, sensitivity was 91% whereas for the subgroup of bilateral detection was 97%. Their results confirmed those shown in the French study.

Pathologic Evaluation and Low-Volume Disease

Without doubt one of the great advantages of the determination of the sentinel node is the possibility of a more exhaustive study of the nodes with respect to the lymphatic system. As in other pathologies, the concept of macrometastases (≥ 2 mm), micrometastases (< 2 mm y > 0.2 mm), and isolated tumor cells (≤ 0.2 mm) has appeared in cervical cancer. The prognostic significance of micrometastases in cervical cancer is still a matter of concern. Two studies have been published addressing this issue [35, 36]. The first one was a multicenter retrospective study including 645 patients. Sentinel node ultrastaging allowed the detection of 14.7% patients with macrometastases, 10.1% with micrometastases, and 4.5% with isolated tumor cells (ITCs). Data from the study showed that patients with micrometastases had a significantly reduced overall survival, comparable to those with macrometastases, whereas no prognostic significance was linked to ITC. The second one used data from the same patient population to assess whether pelvic lymphadenectomy improved the survival of patients with micrometastases in the SN. The results confirmed that in patients with low-volume disease in the sentinel node, survival was improved when more than 16 non-sentinel nodes were removed.

In order to clarify whether adjuvant radiotherapy could achieve the same results in patients with positive lymph nodes not surgically removed, a prospective clinical trial must be performed.

The third striking aspect of the sentinel node procedure is the intraoperative selection of patients in order to determine the best treatment option. Unfortunately, several studies have shown that there exists a significant rate of intraoperative false negatives (sensitivity of only 20%), involving harm to the patient [31, 37, 38]. In a prospective study aimed to compare 2 methods of detection for the SN, 211 patients with early-stage cervical cancer were included [31]. In the group of patients with bilateral SN detection, frozen section showed a false-negative rate of 41.7%, missing seven cases of micrometastases, two of ITC, and one of macrometastases. The French study confirmed that intraoperative examination of SN by frozen section has a poor diagnostic value [37]. Seventeen cases of false negatives were detected in 15 patients, including 4 macrometastases, 4 micrometastases, and 9 ITCs. In a more recent study including 225 patients, the intraoperative examination of the sentinel node showed a poor sensitivity, missing 8 macrometastases, 18 micrometastases, and 8 ITCs [38]. Moreover, the results showed that false-negative rate was higher in patients with bigger tumors and in those with lymphovascular space involvement.

The immunohistochemical technique cannot be performed at the moment of surgery, due to which many cases of nodal metastases (principally macrometastasis and isolated cells) are not identified at that moment. To solve this problem, new techniques of molecular diagnosis are emerging. A recent study aimed to detect HPV-mRNA in lymph nodes in 54 patients with HPV-positive cervical cancer has been published [39]. The findings showed that HPV-mRNA was detected in four patients with otherwise negative sentinel nodes, resulting in a sensitivity of 100%. It should be mentioned that similar diagnostic techniques already exist for other tumors, as, for example, one-step nucleic acid amplification (OSNA) in breast cancer. This molecular technique has also been tested in cervical cancer

using cytokeratin 19 messenger RNA [40]. Okamoto et al. published the results of their study which assessed 239 lymph nodes from 59 patients using this technique. The authors pointed out that OSNA could detect lymph node metastases as accurately as standard histopathological techniques. Moreover, OSNA is easy to perform and rapid enough to be done during surgery, compared to immunohistochemistry technique which is time-consuming, difficult, and costly.

Another option would be to design a two-step therapeutic strategy that first seeks identification and resection of the SN and later, with the results of deferred analysis through immunohistochemistry, indicates the most adequate surgical procedure, thus avoiding cases of false negatives during the intraoperative test.

Sentinel Node in Vulvar Cancer

Introduction

Vulvar cancer is the fourth most common gynecological cancer, accounting for 5% of all malignancies of the female genital tract. The majority of cases are squamous cell carcinoma (SCC), followed by melanoma and sarcoma. SCC can be classified into two main groups. The first one is associated with human papillomavirus (HPV) infection that causes vulvar intraepithelial neoplasia, predominantly found in younger patients and mainly manifested as a wart. The second one found in older women, HPV-negative, keratinizing type, is associated with lichen sclerosus. Women suffering from VIN III will develop invasive vulvar cancer in 80% of the cases if they remained untreated.

Vulvar cancer is staged by the FIGO system of staging and TNM. Both systems are very similar and classify it based on the size of the tumor, the affectation of lymph nodes, and the presence of distant metastases. Approximately, 80% of the patients are diagnosed at an early stage. Lymph node metastases are the most important prognostic factor, followed by histology, size, and age. Data from the SEER (Surveillance, Epidemiology, and End Results) program showed in a recent

study [41] that compared to women <50 years, women 50–64 had a twofold risk of death, women 65–79 years had a fourfold higher risk of death, and those >80 years had a sevenfold higher risk of death.

Due to the absence of anatomical barriers, the spread of vulvar cancer is as follows: first into the contiguous organs, vagina, urethra, and anus, then to the regional lymph nodes, and finally to distant organs by hematogenous spread. The lymphatic system is so complex and rich that any of the nodal groups may be involved at the time of presentation. Because vulvar carcinoma spreads primarily to the lymphatic system, the standard of care of patients with early stage consists of complete excision of the tumor with selective inguinal-femoral lymphadenectomy. This surgical procedure has significant short-term and long-term morbidity such as wound breakdown, infections, negative effects on body image and sexual function, prolonged hospitalization, and lymphedemas. However, only 10% and 27% of patients with stage I and II disease, respectively, will have lymph node metastases [42]. The remaining group of patients will not benefit from a complete lymphadenectomy but will suffer the consequences of having it. Conversely, only 30% of the patients having three or more unilateral nodal metastases are estimated to be alive at 5 years [43]. Among patients with stage III, 60–80% have groin lymph node metastases, and a great majority will have a recurrence in the first year after initial treatment. In 1986, the GOG group published the results of a randomized study that compared radiation therapy versus pelvic node resection in patients with invasive SCC of the vulva and positive groin nodes after radical vulvectomy and bilateral groin lymphadenectomy [44]. Pelvic irradiation therapy proved to be superior to pelvic node resection in particular for women with either clinically suspected or fixed ulcerated nodes or with two or more pathologic positive groin nodes. These results changed the landscape of vulvar cancer treatment in patients with groin node metastases. More recently, in 2009, Kunos et al. published the results of a randomized controlled trial aimed to report long-term survival and

toxicity of radiation therapy compared with pelvic node resection for node-positive vulvar cancer patients [45]. The authors enrolled 114 patients with primary invasive SSC of the vulva that were amenable to radical vulvectomy and bilateral inguinal lymphadenectomy. The results showed that radiation after radical vulvectomy and inguinal lymphadenectomy significantly reduced local relapses and decreased cancer-related deaths. In multivariable analyses 20% nodal positivity remained highly statistically significant for recurrence-free survival, cancer-related death, and overall survival. Improvements in radiation techniques such as intensity-modulated radiation therapy (IMRT) have shown promising results, thus reducing unnecessary doses to the bladder, rectum, and small bowel [46].

Sentinel Node Detection

In breast cancer and melanoma, the sentinel node procedure has shown a low false-negative rate and a low nodal recurrence rate, in addition to a lower morbidity, an improved quality of life, and a shorter hospital stay. In 2008, the results of the Groningen International Study on Sentinel nodes in Vulvar cancer (GROINSS-V) were published. Since then, the surgical treatment of patients with vulvar cancer has changed dramatically, and SN biopsy has been incorporated in the standard of care for these patients in many institutions. This was the first study on the application of the SN procedure in early-stage vulvar cancer and was conducted by Van der Zee [47]. It was a multicenter prospective observational study using radioactive tracer and blue dye in patients with squamous cell cancer (less than 4 cm), with a depth of invasion more than 1 mm and without clinically suspicious inguinal-femoral lymph nodes. When the sentinel node was found to be negative at pathologic ultrastaging, no lymphadenectomy was performed. Their results showed a low groin recurrence rate (3% in multifocal disease, 2.3% in unifocal disease) and a disease-specific survival rate of 97% at 3 years. Treatment-related morbidity is also worthy of mentioning. In the short term, patients who underwent sentinel

node removal alone had less wound breakdown, less cellulitis, and shorter hospital stay, compared to patients who underwent inguinal-femoral lymphadenectomy. In the long term, recurrent erysipelas and lymphedema of the legs were less frequent among patients who had a negative sentinel node and skipped the lymphadenectomy. The authors concluded that the sentinel node procedure performed by a high-quality controlled multidisciplinary team should be part of the standard treatment in selected patients with early-stage vulvar cancer. Recently, the same authors published the long-term follow-up of those patients focusing on local recurrences and survival. Isolated groin recurrence rate was 2.5% for SN-negative patients and 8% for SN-positive patients, at 5 years [48]. Disease-specific 10-year survival was 91% for SN-negative patients and 65% for SN-positive patients. On the other hand, local recurrence rate for SN-negative patients was 24.6% and 36.4% at 5 and 10 years, respectively. For SN-positive patients, local recurrence rate was 33.2% and 46.4% at 5 and 10 years, respectively. These results reveal that a large proportion of patients will develop local recurrence regardless of SN status.

In 2012, Levenback et al. reported the results of the GOG-173 protocol, a prospective multi-institution validation trial to determine whether sentinel node biopsy could replace inguinal-femoral lymphadenectomy [49]. Two previous GOG studies had failed to demonstrate the superiority of a less radical surgery or radiotherapy toward full inguinal-femoral lymphadenectomy. In 1992, members of the GOG randomized 58 patients with SCC and nonsuspicious inguinal nodes to receive either lymphadenectomy or groin radiation. The study was closed prematurely due to an excessive number of groin relapses in the groin radiation group [50]. Also in 1992, the GOG published the results of a prospective study aimed to evaluate a modified radical hemivulvectomy with an ipsilateral superficial lymphadenectomy in patients with clinical stage I vulvar cancer. The authors found a significant increased risk of recurrence when compared to patients treated with radical vulvectomy and bilateral inguinal-femoral lymphadenectomy [51].

In the study of Levenback, 452 patients underwent lymphatic mapping [49]. Among them, 418 had at least 1 sentinel node identified and were suitable for evaluation. The incidence of lymph node metastases was 31.6%. More specifically, in patients with tumors between 2 and 3.9 cm in size, the rate of lymph node metastases was 26.4%. Patients with tumors up to 6 cm had a rate of 40.9%. Regarding the false-negative predictive value, it was 2% for women with tumors smaller than 4 cm and 7.4% for those with tumors 4–6 cm.

Technique of Sentinel Node Detection

Regarding which is the best technique for sentinel node identification, the combination of blue dye and radiocolloid is thought to help learners become familiar with the procedure and to shorten the learning curve. Sutton et al. [52] published a study of cost-effectiveness of sentinel lymph node biopsy vs inguinal-femoral lymphadenectomy in vulvar cancer showing that the combination of ^{99m}Tc , blue dye, and ultrastaging was found to be the most effective strategy based on the outcome of survival free of morbidity for 2 years.

Preoperative planar lymphoscintigraphy in patients with vulvar cancer can serve as a useful adjuvant tool in sentinel node biopsy planning [53]. It can help to identify the location of sentinel nodes and whether lymphatic drainage is unilateral or bilateral. Tumors not involving the midline but <2 cm from the midline with unilateral lymphoscintigraphy drainage are at low risk, for contralateral nodal metastases lymphadenectomy may be avoided. The risk of contralateral lymph node metastases increases as the lesion approaches the midline.

Some form of preoperative imaging such as CT, sonography, PET, or MRI, to rule out grossly involved lymph nodes, is of vital importance as missing metastases in the lymph nodes have fatal consequences. Literature regarding which of these preoperative examinations is the best for the surgical planning is scarce. In a recently

published Danish prospective study [54], preoperative CT scanning was evaluated as a useful tool in the preoperative management of patients with vulvar cancer. The results showed that CT scan did not significantly change the initial surgical treatment plan and was inaccurate compared to the sentinel node examination of the local nodes. The authors concluded that CT scan may delay treatment and adds unnecessary costs. Another review aimed to correlate PET-CT staging prior to planned radical vulvectomy and inguinal-femoral lymphadenectomy. The sensitivity was 50%, the specificity was 100%, positive predictive value was 100%, and the negative predictive value was 57.1%. The poor sensitivity encountered made PET-CT unsuitable as a substitute for staging lymphadenectomy [55]. Some years earlier, in 2013, a retrospective study was performed with 60 patients in order to evaluate ultrasonography as a predictor of inguinal lymph node involvement. The results showed that ultrasonography correctly predicted the presence or absence of inguinal node metastases in 86% of the cases [56]. Other retrospective studies [57, 58] have showed similar results.

The sentinel node technique has some disadvantages. Conventional methods for detecting sentinel nodes include the use of radioisotope and blue dye which achieves high detection rates but exposes the patient to ionizing radiation and requires a nuclear medicine unit not always available in all clinics. Moreover, blue dye has a rapid transit and losses visibility in dense fat. Near-infrared (NIR) fluorescence imaging with indocyanine green has been tested for sentinel node procedure in different malignancies. Indocyanine green (ICG) is a negatively charged, tricarbo-cyanine dye that rapidly binds to plasma proteins, is excreted by the liver, and is not nephrotoxic. After illumination by a near-infrared ray, ICG in the blood generates a near-infrared fluorescence of 800–850 nm wavelength. The near-infrared light can maximally penetrate 1 to 2 mm of soft tissue. Recently, a prospective pilot study was conducted in order to assess the feasibility of NIR in gynecological cancers [59]. The results showed a 100% sentinel node detection rate and



Fig. 31.2 Sentinel node fluorescence

maximum specificity and sensitivity following the learning curve and dose optimization. In the case of vulvar cancer, percutaneous detection of inguinal sentinel nodes prior to surgical incision reduced SLN detection times. The fluorescence could be visualized as early as 6 minutes postinjection. Two other pilot studies have demonstrated the feasibility of NIR fluorescence for sentinel node biopsy in patients with vulvar cancer [60, 61] (Fig. 31.2).

To conclude, sentinel node biopsy in vulvar cancer is a safe procedure that should be performed in carefully selected patients, with small tumors (less than 4 cm) and unifocal disease, without suspicion of pathological nodes either at clinical examination or on imaging and, above all, by an experienced team. Patients with lesions within 2 cm of the midline or that cross the midline should undergo bilateral sentinel node procedure. When a sentinel node is not identified intraoperatively, a complete lymphadenectomy should be performed. Furthermore, patients with a history of groin surgery, with multifocal disease, or who previously received radiotherapy of the vulva should be excluded as they may have disrupted lymphatic drainage.

New Imaging Technologies to Detect Lymph Node Invasion

Image tests have been studied to determine nodal status, avoiding surgical staging. As a general rule, transvaginal ultrasound and/or magnetic

resonance is used to assess local tumor extension, while PET-CT or CT alone assesses lymph node metastases and distant spread. In the case of PET-CT, the ability to detect metastatic lymph nodes is limited by lymph node size. The most accepted criteria for diagnosing nodal involvement is a short-axis diameter greater than 8–10 mm. A prospective study including 30 patients with endometrial cancer and 15 with cervical cancer aimed to evaluate the accuracy of 18F-fluorodeoxyglucose PET-CT in detecting pelvic and para-aortic lymph node metastases; the results showed a low sensitivity of 50% [62]. New emerging modalities are appearing in order to improve diagnostic performance. Diffusion-weighted MRI (DWI) is a functional imaging technique whereby the contrast is derived from the random motion of water molecules within biological tissue [63]. In a retrospective study including 47 patients with endometrial cancer, DWI magnetic resonance proved to be accurate in assessing myometrial invasion [64]. Another study proved that body DWI images were useful in the detection of pelvic lymph nodes in patients with gynecological malignancies [65]. Furthermore, DWI-MRI can be a useful alternative for patients who are allergic to contrast agents or at risk of nephrogenic systemic fibrosis [66].

Selman et al. conducted a systematic review including 72 studies in order to determine the diagnostic accuracy of magnetic resonance imaging (MRI), computed tomography (CT), positron emission tomography (PET), and sentinel node biopsy in the detection of lymphatic spreading in patients with cervical cancer [67]. The authors found that PET and SN biopsy were significantly better methods for detecting lymph node involvement. MRI and CT showed a low rate of sensitivity (55.5% and 57.5%, respectively). A review published by Gouy et al. showed that PET has high sensitivity for detecting extrapelvic organ metastases, but its ability to detect small-volume metastases (especially those ≤ 5 mm) was very disappointing. In their study, the proportion of negative para-aortic PET nodes proven to be positive in histological analysis was 12%. This false-negative rate reached 22% among patients with

positive pelvic PET nodes [68]. In the study of Leblanc et al. [69], 125 patients with locally advanced cervical cancer were included. Among patients with pathologically proven para-aortic metastases, 66.7% of them had a negative PET-CT. Therefore, until the results of ongoing trials are reported, no conventional imaging seems powerful enough to substitute surgical staging when PET is deemed negative. New imaging techniques are emerging to overcome these pitfalls.

A new lymph node-specific contrast agent composed of ultrasmall particles of iron oxide (USPIO) has proved to increase the sensitivity of MRI in the prediction of lymph node metastases without losing specificity [70]. These particles are administered intravenously and taken up by macrophages resulting in a marked loss of signal intensity. However, this contrast agent has been withdrawn by the manufacturer pending further validation. It is highly likely that new contrast agents will appear in the future providing the clinician with valuable information in planning the optimal surgical treatment.

Conclusions

The role of lymphadenectomy in endometrial cancer remains controversial. There are currently no prospective randomized studies that demonstrate the efficacy in sentinel node determination in endometrial cancer or long-term results with respect to survival. Therefore the relapse risk present in the case of solely applying sentinel node in endometrial adenocarcinoma remains unknown. Sentinel node technique has also heightened the debate about whether, in the presence of tumoral disease, a complete lymphadenectomy must be performed or if adjuvant treatment with radiotherapy would be enough. There exists no current scientific evidence as to the benefit of lymphadenectomy in these cases, but it is evident that sentinel node increases the detection of nodal metastases, mainly due to micrometastases and isolated tumor cells, and we should consequently adapt the treatment in these patients. Further studies are warranted in order to address the

safety of the procedure in oncologic terms as well as the significance of low-volume disease. The results of an ongoing randomized study comparing sentinel node biopsy to current French initial staging protocols in early-stage endometrial cancer at intermediate and high risk of recurrence will be decisive (NCT02598219).

All the literature published to date provides substantial evidence confirming the utility of SN application in cervical cancer, but the reality is that only a few groups worldwide employ it without performing a systematic lymphadenectomy. The interminable doubt is whether lymphadenectomy has a therapeutic role or not. Leblanc et al. proved that patients with minimal para-aortic nodal involvement treated with extended-field radiotherapy had similar survival as patients without nodal metastases [41]. These patients with nodal metastases less than 5 mm would have probably been missed by PET. It appears possible that the future lies in the new imaging methods as well as the determination of prognostic factors based on the genomic state of the tumor. Furthermore, the currently ongoing controlled studies will hopefully answer whether sentinel node biopsy can replace complete lymphadenectomy.

The ongoing multicenter observational study GROINSS-V II will help the medical community to see how effective surgery and/or radiation therapy is in the treatment of vulvar cancer. The primary objective of the study is to investigate the safety of replacing complete inguinal-femoral lymphadenectomy by adjuvant radiotherapy in early-stage vulvar cancer in patients with a sentinel node metastases ≤ 2 mm. An interim analysis revealed high rates of groin recurrences among patients with sentinel node metastases higher than 2 mm. The study was therefore modified so that patients with negative SN are observed, patients with SN metastases ≤ 2 mm receive radiation alone, and patients with SN metastases > 2 mm undergo an inguinal-femoral lymphadenectomy. The results are expected to be released in 2017.

References

1. Zhang Y, Liu H, Yang S, Zhang J, Qian L, Chen X. Overweight, obesity and endometrial cancer risk: results from a systematic review and meta-analysis. *Int J Biol Markers*. 2014;29:e21–9.
2. Ali AT. Reproductive factors and the risk of endometrial cancer. *Int J Gynecol Cancer*. 2014;24(3):384–93.
3. Barry JA, Azizia MM, Hardiman PJ. Risk of endometrial, ovarian and breast cancer in women with polycystic ovary syndrome: a systematic review and meta-analysis. *Hum Reprod Update*. 2014;20(5):748–58.
4. Burke TW, Levenback C, Tornos C, Morris M, Wharton JT, Gershenson DM. Intraabdominal lymphatic mapping to direct selective pelvic and para-aortic lymphadenectomy in women with high-risk endometrial cancer: results of a pilot study. *Gynecol Oncol*. 1996;62(2):169–73.
5. Frati A, Ballester M, Dubernard G, Bats AS, Heitz D, Mathevet P, Marret H, Querleu D, Golfier F, Leblanc E, Rouzier R, Daraï E. Contribution of lymphoscintigraphy for sentinel lymph node biopsy in women with early stage endometrial cancer: results of the SENTI-ENDO study. *Ann Surg Oncol*. 2015;22(6):1980–6.
6. Abu-Rustum NR. Sentinel lymph node mapping for endometrial cancer: a modern approach to surgical staging. *J Natl Compr Canc Netw*. 2014;12(2):288–97.
7. Ballester M, Dubernard G, Lécure F, Heitz D, Mathevet P, Marret H, Querleu D, Golfier F, Leblanc E, Rouzier R, Daraï E. Detection rate and diagnostic accuracy of sentinel-node biopsy in early stage endometrial cancer: a prospective multicentre study (SENTI-ENDO). *Lancet Oncol*. 2011;12(5):469–76.
8. Mariani A, Dowdy SC, Cliby WA, Gostout BS, Jones MB, Wilson TO, Podratz KC. Prospective assessment of lymphatic dissemination in endometrial cancer: a paradigm shift in surgical staging. *Gynecol Oncol*. 2008;109(1):11–8.
9. Abu-Rustum NR, Khoury-Collado F, Pandit-Taskar N, Soslow RA, Dao F, Sonoda Y, Levine DA, Brown CL, Chi DS, Barakat RR, Gemignani ML. Sentinel lymph node mapping for grade 1 endometrial cancer: is it the answer to the surgical staging dilemma? *Gynecol Oncol*. 2009;113(2):163–9.
10. Jewell EL, Huang JJ, Abu-Rustum NR, Gardner GJ, Brown CL, Sonoda Y, Barakat RR, Levine DA, Leitao MM Jr. Detection of sentinel lymph nodes in minimally invasive surgery using indocyanine green and near-infrared fluorescence imaging for uterine and cervical malignancies. *Gynecol Oncol*. 2014;133(2):274–7.
11. Kim CH, Soslow RA, Park KJ, Barber EL, Khoury-Collado F, Barlin JN, Sonoda Y, Hensley ML, Barakat RR, Abu-Rustum NR. Pathologic ultrastaging improves micrometastasis detection in sentinel lymph nodes during endometrial cancer staging. *Int J Gynecol Cancer*. 2013;23(5):964–70.

12. Ballester M, Naoura I, Chéreau E, Seror J, Bats AS, Bricou A, Daraï E. Sentinel node biopsy upstages patients with presumed low- and intermediate-risk endometrial cancer: results of a multicenter study. *Ann Surg Oncol.* 2013;20(2):407–12.
13. Nagai T, Niikura H, Okamoto S, Nakabayashi K, Matoda M, Utsunomiya H, Nagase S, Watanabe M, Takeshima N, Yaegashi N. A new diagnostic method for rapid detection of lymph node metastases using a one-step nucleic acid amplification (OSNA) assay in endometrial cancer. *Ann Surg Oncol.* 2015;22(3):980–6.
14. Barlin JN, Khoury-Collado F, Kim CH, Leitao MM Jr, Chi DS, Sonoda Y, Alektiar K, DeLair DF, Barakat RR, Abu-Rustum NR. The importance of applying a sentinel lymph node mapping algorithm in endometrial cancer staging: beyond removal of blue nodes. *Gynecol Oncol.* 2012;125(3):531–5.
15. Barlin JN, Zhou Q, St Clair CM, Iasonos A, Soslow RA, Alektiar KM, Hensley ML, Leitao MM Jr, Barakat RR, Abu-Rustum NR. Classification and regression tree (CART) analysis of endometrial carcinoma: Seeing the forest for the trees. *Gynecol Oncol.* 2013;130(3):452–6.
16. Querleu D, Leblanc E, Castelain B. Pelvic lymphadenectomy under celioscopic guidance. *J Gynecol Obstet Biol Reprod (Paris).* 1990;19(5):576–8. French. No abstract available.
17. Achouri A, Huchon C, Bats AS, Bensaid C, Nos C, Lécuro F. Complications of lymphadenectomy for gynecologic cancer. *Eur J Surg Oncol.* 2013;39(1):81–6.
18. DiSaia PJ, Creasman TC. *Clinical gynecologic oncology.* 5th ed. St. Louis: Mosby; 1997.
19. Echt ML, Finan MA, Hoffman MS, Kline RC, Roberts WS, Fiorica JV. Detection of sentinel lymph nodes with lymphazurin in cervical, uterine, and vulvar malignancies. *South Med J.* 1999;92(2):204–8.
20. Tax C, Rovers MM, de Graaf C, Zusterzeel PL, Bekkers RL. The sentinel node procedure in early stage cervical cancer, taking the next step; a diagnostic review. *Gynecol Oncol.* 2015;139(3):559–67.
21. Smith B, Backes F. The role of sentinel lymph nodes in endometrial and cervical cancer. *J Surg Oncol.* 2015;112(7):753–60.
22. Cibula D, Oonk MH, Abu-Rustum NR. Sentinel lymph node biopsy in the management of gynecologic cancer. *Curr Opin Obstet Gynecol.* 2015;27(1):66–72.
23. Holman LL, Levenback CF, Frumovitz M. Sentinel lymph node evaluation in women with cervical cancer. *J Minim Invasive Gynecol.* 2014;21(4):540–5.
24. Cibula D, Abu-Rustum NR, Dusek L, Slama J, et al. Bilateral ultrastaging of sentinel lymph node in cervical cancer: Lowering the false-negative rate and improving the detection of micrometastasis. *Gynecol Oncol.* 2012;127(3):462–6.
25. Bats AS, Mathevet P, Buenerd A, Orliaguet I, et al. The sentinel node technique detects unexpected drainage pathways and allows nodal ultrastaging in early cervical cancer: insights from the multicenter prospective SENTICOL study. *Ann Surg Oncol.* 2013;20(2):413–22.
26. Lécuro F, Mathevet P, Querleu D, Leblanc E, Morice P, Daraï E, Marret H, Magaud L, Gillaizeau F, Chatellier G, Dargent D. Bilateral negative sentinel nodes accurately predict absence of lymph node metastasis in early cervical cancer: results of the SENTICOL study. *J Clin Oncol.* 2011;29(13):1686–91.
27. Gortzak-Uzan L, Jimenez W, Nofech-Mozes S, Ismiil N, Khalifa MA, Dubé V, Rosen B, Murphy J, Laframboise S, Covens A. Sentinel lymph node biopsy vs. pelvic lymphadenectomy in early stage cervical cancer: is it time to change the gold standard? *Gynecol Oncol.* 2010;116(1):28–32.
28. Altgassen C, Hertel H, Brandstädt A, Köhler C, Dürst M, Schneider A, AGO Study Group. Multicenter validation study of the sentinel lymph node concept in cervical cancer: AGO Study Group. *J Clin Oncol.* 2008;26(18):2943–51.
29. Gil-Moreno A, Magrina JF, Pérez-Benavente A, Díaz-Feijoo B, Sánchez-Iglesias JL, García A, Cabrera-Díaz S, Puig O, Martínez-Gómez X, Xercavins J. Location of aortic node metastases in locally advanced cervical cancer. *Gynecol Oncol.* 2012;125(2):312–4.
30. Bats AS, Frati A, Mathevet P, Orliaguet I, Querleu D, Zerdoud S, Leblanc E, Gauthier H, Uzan C, Deandreis D, Daraï E, Kerrou K, Marret H, Lenain E, Froissart M, Lecuru F. Contribution of lymphoscintigraphy to intraoperative sentinel lymph node detection in early cervical cancer: Analysis of the prospective multicenter SENTICOL cohort. *Gynecol Oncol.* 2015;137(2):264–9.
31. Roy M, Bouchard-Fortier G, Popa I, Grégoire J, Renaud MC, Têtu B, Plante M. Value of sentinel node mapping in cancer of the cervix. *Gynecol Oncol.* 2011;122(2):269–74.
32. Buda A, Crivellaro C, Elisei F, Di Martino G, Guerra L, De Ponti E, Cuzzocrea M, Giuliani D, Sina F, Magni S, Landoni C, Milani R. Impact of indocyanine green for sentinel lymph node mapping in early stage endometrial and cervical cancer: comparison with conventional radiotracer ^{99m}Tc and/or blue dye. *Ann Surg Oncol.* 2016;23(7):2183–91.
33. Darin MC, Gómez-Hidalgo NR, Westin SN, Soliman PT, Escobar PF, Frumovitz M, Ramirez PT. Role of indocyanine green in sentinel node mapping in gynecologic cancer: is fluorescence imaging the new standard? *J Minim Invasive Gynecol.* 2016;23(2):186–93.
34. Plante M, Touhami O, Trinh XB, Renaud MC, Sebastianelli A, Grondin K, Gregoire J. Sentinel node mapping with indocyanine green and endoscopic near-infrared fluorescence imaging in endometrial cancer. A pilot study and review of the literature. *Gynecol Oncol.* 2015;137(3):443–7.
35. Cibula D, Abu-Rustum NR, Dusek L, Zikán M, Zaal A, Sevcik L, Kenter GG, Querleu D, Jach R, Bats AS, Dyduch G, Graf P, Klat J, Lacheta J, Meijer CJ, Mery E, Verheijen R, Zweemer RP. Prognostic sig-

- nificance of low volume sentinel lymph node disease in early-stage cervical cancer. *Gynecol Oncol.* 2012;124(3):496–501.
36. Zaal A, Zweemer RP, Zikán M, Dusek L, Querleu D, Lécuru F, Bats AS, Jach R, Sevcik L, Graf P, Klát J, Dyduch G, von Mensdorff-Pouilly S, Kenter GG, Verheijen RH, Cibula D. Pelvic lymphadenectomy improves survival in patients with cervical cancer with low-volume disease in the sentinel node: a retrospective multicenter cohort study. *Int J Gynecol Cancer.* 2014;24(2):303–11.
 37. Bats AS, Buénerd A, Querleu D, Leblanc E, Daraï E, Morice P, Marret H, Gillaizeau F, Mathevet P, Lécuru F, SENTICOL Collaborative Group. Diagnostic value of intraoperative examination of sentinel lymph node in early cervical cancer: a prospective, multicenter study. *Gynecol Oncol.* 2011;123(2):230–5.
 38. Slama J, Dunder P, Dusek L, Cibula D. High false negative rate of frozen section examination of sentinel lymph nodes in patients with cervical cancer. *Gynecol Oncol.* 2013;129(2):384–8.
 39. Köhler C, Le X, Dogan NU, Pfiffer T, Schneider A, Marnitz S, Bertolini J, Favero G. Molecular diagnosis for nodal metastasis in endoscopically managed cervical cancer: the accuracy of the APTIMA test to detect high-risk human papillomavirus messenger RNA in sentinel lymph nodes. *J Minim Invasive Gynecol.* 2016. pii: S1553-4650(16).
 40. Okamoto S, Niikura H, Nakabayashi K, Hiyama K, Matoda M, Takeshima N, Watanabe M, Nagase S, Otsuki T, Yaegashi N. Detection of sentinel lymph node metastases in cervical cancer: assessment of KRT19 mRNA in the one-step nucleic acid amplification (OSNA) method. *Gynecol Oncol.* 2013;130(3):530–6.
 41. Rauh-Hain JA, Clemmer J, Clark RM, Bradford LS, Growdon WB, Goodman A, Boruta DM II, Dizon DS, Schorge JO, del Carmen MG. Management and outcomes for elderly women with vulvar cancer over time. *BJOG.* 2014;121(6):719–27.
 42. Hacker NF, Leuchter RS, Berek JS, Castaldo TW, Lagasse LD. Radical vulvectomy and bilateral inguinal lymphadenectomy through separate groin incisions. *Obstet Gynecol.* 1981;58(5):574–9.
 43. Homesley HD, Bundy BN, Sedlis A, Yordan E, Berek JS, Jahshan A, Mortel R. Assessment of current International Federation of Gynecology and Obstetrics staging of vulvar carcinoma relative to prognostic factors for survival (a Gynecologic Oncology Group study). *Am J Obstet Gynecol.* 1991;164(4):997–1003.
 44. Homesley HD, Bundy BN, Sedlis A, Adcock L. Radiation therapy versus pelvic node resection for carcinoma of the vulva with positive groin nodes. *Obstet Gynecol.* 1986;68(6):733–40.
 45. Kunos C, Simpkins F, Gibbons H, Tian C, Homesley H. Radiation therapy compared with pelvic node resection for node-positive vulvar cancer: a randomized controlled trial. *Obstet Gynecol.* 2009;114(3):537–46.
 46. Beriwal S, Heron DE, Kim H, King G, Shogan J, Bahri S, Gerszten K, Lee J, Kelley J, Edwards RP. Intensity-modulated radiotherapy for the treatment of vulvar carcinoma: a comparative dosimetric study with early clinical outcome. *Int J Radiat Oncol Biol Phys.* 2006;64(5):1395–400.
 47. Van der Zee AG, Oonk MH, De Hullu JA, Ansink AC, Vergote I, Verheijen RH, Maggioni A, Gaarenstroom KN, Baldwin PJ, Van Dorst EB, Van der Velden J, Hermans RH, van der Putten H, Drouin P, Schneider A, Sluiter WJ. Sentinel node dissection is safe in the treatment of early-stage vulvar cancer. *J Clin Oncol.* 2008;26(6):884–9.
 48. Te Grootenhuys NC, van der Zee AG, van Doorn HC, van der Velden J, Vergote I, Zanagnolo V, Baldwin PJ, Gaarenstroom KN, van Dorst EB, Trum JW, Slangen BF, Runnebaum IB, Tamussino K, Hermans RH, Provencher DM, de Bock GH, de Hullu JA, Oonk MH. Sentinel nodes in vulvar cancer: long-term follow-up of the GROningen International Study on Sentinel nodes in Vulvar cancer (GROINSS-V) I. *Gynecol Oncol.* 2016;140(1):8–14.
 49. Levenback CF, Ali S, Coleman RL, Gold MA, Fowler JM, Judson PL, Bell MC, De Geest K, Spirtos NM, Potkul RK, Leitao MM Jr, Bakkum-Gamez JN, Rossi EC, Lentz SS, Burke JJ II, Van Le L, Trimble CL. Lymphatic mapping and sentinel lymph node biopsy in women with squamous cell carcinoma of the vulva: a gynecologic oncology group study. *J Clin Oncol.* 2012;30(31):3786–91.
 50. Stehman FB, Bundy BN, Thomas G, Varia M, Okagaki T, Roberts J, Bell J, Heller PB. Groin dissection versus groin radiation in carcinoma of the vulva: a Gynecologic Oncology Group study. *Int J Radiat Oncol Biol Phys.* 1992;24(2):389–96.
 51. Stehman FB, Bundy BN, Dvoretzky PM, Creasman WT. Early stage I carcinoma of the vulva treated with ipsilateral superficial inguinal lymphadenectomy and modified radical hemivulvectomy: a prospective study of the Gynecologic Oncology Group. *Obstet Gynecol.* 1992;79(4):490–7.
 52. Sutton AJ, Barton P, Sundar S, Meads C, Rosenthal AN, Baldwin P, Khan K, Roberts TE. Cost-effectiveness of sentinel lymph node biopsy vs inguinofemoral lymphadenectomy in women with vulval cancer. *Br J Cancer.* 2013;109(10):2533–47.
 53. Coleman RL, Ali S, Levenback CF, Gold MA, Fowler JM, Judson PL, Bell MC, De Geest K, Spirtos NM, Potkul RK, Leitao MM Jr, Bakkum-Gamez JN, Rossi EC, Lentz SS, Burke JJ II, Van Le L, Trimble CL. Is bilateral lymphadenectomy for midline squamous carcinoma of the vulva always necessary? An analysis from Gynecologic Oncology Group (GOG) 173. *Gynecol Oncol.* 2013;128(2):155–9.
 54. Andersen K, Zobbe V, Thranov IR, Pedersen KD. Relevance of computerized tomography in the preoperative evaluation of patients with vulvar cancer: a prospective study. *Cancer Imaging.* 2015;15:8.

55. Kamran MW, O'Toole F, Meghen K, Wahab AN, Saadeh FA, Gleeson N. Whole-body [18F]fluoro-2-deoxyglucose positron emission tomography scan as combined PET-CT staging prior to planned radical vulvectomy and inguinofemoral lymphadenectomy for squamous vulvar cancer: a correlation with groin node metastasis. *Eur J Gynaecol Oncol.* 2014;35(3):230–5.
56. de Gregorio N, Ebner F, Schwentner L, Friedl TW, Deniz M, Látó K, Kreienberg R, Janni W, Varga D. The role of preoperative ultrasound evaluation of inguinal lymph nodes in patients with vulvar malignancy. *Gynecol Oncol.* 2013;131(1):113–7.
57. Hall TB, Barton DP, Trott PA, Nasiri N, Shepherd JH, Thomas JM, Moskovic EC. The role of ultrasound-guided cytology of groin lymph nodes in the management of squamous cell carcinoma of the vulva: 5-year experience in 44 patients. *Clin Radiol.* 2003;58(5):367–71.
58. Moskovic EC, Shepherd JH, Barton DP, Trott PA, Nasiri N, Thomas JM. The role of high resolution ultrasound with guided cytology of groin lymph nodes in the management of squamous cell carcinoma of the vulva: a pilot study. *Br J Obstet Gynaecol.* 1999;106(8):863–7.
59. Laios A, Volpi D, Tullis ID, Woodward M, Kennedy S, Pathiraja PN, Haldar K, Vojnovic B, Ahmed AA. A prospective pilot study of detection of sentinel lymph nodes in gynaecological cancers using a novel near infrared fluorescence imaging system. *BMC Res Notes.* 2015;8:608.
60. Hutteman M, van der Vorst JR, Gaarenstroom KN, Peters AA, Mieog JS, Schaafsma BE, Löwik CW, Frangioni JV, van de Velde CJ, Vahrmeijer AL. Optimization of near-infrared fluorescent sentinel lymph node mapping for vulvar cancer. *Am J Obstet Gynecol.* 2012;206(1):89.
61. Crane LM, Themelis G, Arts HJ, Buddingh KT, Brouwers AH, Ntziachristos V, van Dam GM, van der Zee AG. Intraoperative near-infrared fluorescence imaging for sentinel lymph node detection in vulvar cancer: first clinical results. *Gynecol Oncol.* 2011;120(2):291–5.
62. Kitajima K, Murakami K, Yamasaki E, Kaji Y, Sugimura K. Accuracy of integrated FDG-PET/contrast-enhanced CT in detecting pelvic and para-aortic lymph node metastasis in patients with uterine cancer. *Eur Radiol.* 2009;19(6):1529–36.
63. Haldorsen IS, Salvesen HB. Staging of endometrial carcinomas with MRI using traditional and novel MRI techniques. *Clin Radiol.* 2012;67(1):2–12.
64. Rechichi G, Galimberti S, Signorelli M, Perego P, Valsecchi MG, Sironi S. Myometrial invasion in endometrial cancer: diagnostic performance of diffusion-weighted MR imaging at 1.5-T. *Eur Radiol.* 2010;20(3):754–62.
65. Nakai G, Matsuki M, Inada Y, Tatsugami F, Tanikake M, Narabayashi I, Yamada T. Detection and evaluation of pelvic lymph nodes in patients with gynecologic malignancies using body diffusion-weighted magnetic resonance imaging. *J Comput Assist Tomogr.* 2008;32(5):764–8.
66. Lin G, Ho KC, Wang JJ, Ng KK, Wai YY, Chen YT, Chang CJ, Ng SH, Lai CH, Yen TC. Detection of lymph node metastasis in cervical and uterine cancers by diffusion-weighted magnetic resonance imaging at 3T. *J Magn Reson Imaging.* 2008;28(1):128–35.
67. Selman TJ, Mann C, Zamora J, Appleyard TL, Khan K. Diagnostic accuracy of tests for lymph node status in primary cervical cancer: a systematic review and meta-analysis. *CMAJ.* 2008;178(7):855–62.
68. Gouy S, Morice P, Narducci F, Uzan C, Gilmore J, Kolesnikov-Gauthier H, Querleu D, Haie-Meder C, Leblanc E. Nodal-staging surgery for locally advanced cervical cancer in the era of PET. *Lancet Oncol.* 2012;13(5):e212–20.
69. Leblanc E, Gauthier H, Querleu D, Ferron G, Zerdoud S, Morice P, Uzan C, Lumbroso S, Lecuru F, Bats AS, Ghazzar N, Bannier M, Houvenaeghel G, Brenot-Rossi I, Narducci F. Accuracy of 18-fluoro-2-deoxy-D-glucose positron emission tomography in the pretherapeutic detection of occult para-aortic node involvement in patients with a locally advanced cervical carcinoma. *Ann Surg Oncol.* 2011;18(8):2302–9.
70. Rockall AG, Sohaib SA, Harisinghani MG, Babar SA, Singh N, Jeyarajah AR, Oram DH, Jacobs IJ, Shepherd JH, Reznick RH. Diagnostic performance of nanoparticle-enhanced magnetic resonance imaging in the diagnosis of lymph node metastases in patients with endometrial and cervical cancer. *J Clin Oncol.* 2005;23(12):2813–21.

Part VI

Complications



Complications of Laparoscopy

32

Jamal Mourad, Stephanie Henderson,
and Javier Magrina

Introduction

Since its inception more than a century ago when Dr. Hans Christian Jacobaeus performed the first laparoscopy on a human patient [1], laparoscopy and minimally invasive surgery have transformed medicine in a quest to continuously evolve by improving diagnostic capabilities and offering management of complex ailments in a variety of different specialties. Gynecologists pioneered the specialty of minimally invasive surgery and are credited with its wide acceptance. This movement was fueled by the need to reduce morbidity and mortality related to surgical procedures. For example, in the eighteenth century, hysterectomies had a reported mortality rate of 70%, but with significant advances in aseptic techniques, use of antibiotics and anesthesia, and minimally invasive technique, mortality rates today are less than 0.02% [2].

It is important to be able to classify and define complications in a clear and concise manner. Although there is some variation in the literature, the most commonly accepted definition of complication is “an unintended and undesirable event

or condition during or following medical intervention, to such an extended disadvantage to the patient’s health condition that adjustment of medical intervention is necessary, and/or irreparable damage has occurred” [3]. Overall complication rates for gynecologic laparoscopy have remained at <1% for several decades [4–7] with an overall mortality rate of 3.33 per 100,000 patients [5].

This chapter is designed to discuss possible complications related to laparoscopic surgery from the time of abdominal access to the postoperative period. Mastery of surgical technique, superior anatomical knowledge, and a continuous quest to improve are essential tools for all surgeons, while prevention remains the most important factor in avoiding complications. Early recognition and management of complications in a timely, safe, and efficient fashion is the key to overcoming the pitfalls of laparoscopy.

Complications from Abdominal Wall Entry and Port Placement

Complications occurring during abdominal wall entry are among the more common causes of surgical injury during laparoscopy. Prospective studies have shown that up to one-third to one-half of complications occur at time of abdominal entry [5, 8, 9], occurring with an incidence of 1.1–5.5 per 1000 cases [6, 10, 11]. Many techniques have been described for abdominal wall

J. Mourad, M.D. (✉) • S. Henderson, M.D.
J. Magrina, M.D.
The Women’s Institute, Banner University
Medical Center - Phoenix, University of Arizona
College of Medicine—Phoenix, 1441 N 12th Street,
Phoenix, AZ 85006, USA
e-mail: swwcjm@mac.com

entry including closed (Veress) entry, open (Hassan) entry, direct entry, direct visualization entry, and radially expanding entry. Retrospective and prospective studies have shown no significant differences in major complication rates between each entry technique; thus there is no clear consensus as to the superior method of laparoscopic entry into the peritoneal cavity [12], and entry technique should be determined by surgeon training and experience. Regardless of entry approach, there are innate risks associated with the surgical requirement for introduction of trocars through the anterior abdominal wall. The most common complications associated with abdominal wall entry include failure to gain abdominal entry, extraperitoneal insufflation, gas embolism, abdominal wall vessel and nerve injury, bowel injury, bladder injury, and major vascular injury [13].

Failure to Gain Entry

Failed entry seems to be most likely in the closed (Veress) entry technique with rates as high as 0.06% [12] and is more common in the setting of previous abdominal surgery with subsequent adhesive disease. A failed entry site should routinely be inspected to assess for injury. If bile, stool, or blood returns at placement of the Veress needle or initial trocar, the device should be left in place, and alternative access gained immediately. If entry fails but there is no complication, access can be reattempted at the same site [14]. Alternative access type (laparoscopic or open laparotomy) should be based on the surgeon's ability to perform corrective procedures and degree of bleeding if a vascular injury is suspected (see section "Major Vascular Injury" below).

Extraperitoneal Insufflation

Extraperitoneal insufflation, or inadvertent creation of an air pocket external to the peritoneal layer, is an uncommonly reported complication

of laparoscopy, occurring with a frequency of 0.001–0.59% of laparoscopic cases [13], although it is probably underreported because of its limited clinical significance. It is most likely to occur with a closed abdominal entry technique [15, 16] when entry into the peritoneal cavity is not visually confirmed prior to flow of carbon dioxide (CO₂) for establishment of pneumoperitoneum. It can result in difficult or failed abdominal entry or poor operative visualization after identification and correction because of the distention of subcutaneous tissue the anterior abdominal wall. Mild to severe subcutaneous emphysema is also a known complication, and subcutaneous emphysema can extend into the labia, scrotum, legs, chest, head, and neck when gas tracks along the prefascial planes [17]. It presents as crepitus under the skin or slowly rising CO₂ level intraoperatively and typically resolves within 1–2 days [18]. Severe subcutaneous emphysema, while rare, is associated with serious complications such as pneumothorax, pneumomediastinum, pneumopericardium, and hypercarbia [19, 20]. These outcomes may be a result of direct ascension of extraperitoneal gas or a result of passage of gas through congenital defects of the diaphragm [21]. These complications are more likely in the setting of longer operative time (>200 min), higher maximum measured end-tidal CO₂, greater number of surgical ports (>6), and older patient age (>65 years) [22].

Gas Embolism

Carbon dioxide is the best gas for pneumoperitoneum insufflation as it is nontoxic, nonflammable, colorless, highly soluble, easily buffered in the blood, and rapidly excreted through the lungs [19, 21]. Subclinical carbon dioxide embolism is common, occurring with a frequency of 100% in a recent study using continuous transesophageal echocardiography during total laparoscopic hysterectomy [23]. However, clinically relevant carbon dioxide embolism is an uncommon, often fatal risk of laparoscopic surgery that results from direct entry of the gas into a vein, artery, or

solid organ [24]. The incidence of clinically significant carbon dioxide embolism is rare, ranging from 0.001 to 0.59% [25–27] but with a mortality rate of 28.5% [28]. Gas embolism usually occurs during or soon after insufflation and presents as sudden onset of tachycardia or bradycardia, systemic hypotension, cyanosis, arrhythmia, or asystole [24].

When a carbon dioxide embolism is suspected based on timing of cardiovascular collapse, a series of steps must be immediately initiated [24]:

1. The surgeon should discontinue carbon dioxide insufflation.
2. The anesthesiologist should discontinue nitrous oxide and ventilate with 100% oxygen to improve ventilation perfusion mismatch and hypoxemia.
3. The patient should be positioned in steep Trendelenburg and left lateral decubitus position to allow gas to rise to the apex of the right atrium (RA) and prevent entry into the pulmonary vasculature.
4. The surgical team should initiate cardiopulmonary resuscitation with:
 - (a) Aggressive volume expansion to increase central venous pressure
 - (b) Administration of inotropic agents and vasopressors to maintain cardiac output
 - (c) Placement of a central venous or pulmonary artery catheterization for aspiration of gas from the RA or right ventricle (RV)
5. If available, consider cardiopulmonary bypass and/or hyperbaric oxygen therapy.

Abdominal Wall Vascular Injury

Abdominal wall injury occurs with an incidence of 0.52% and most often involves laceration of the deep inferior and superficial epigastric vessels during lateral port placement [9]. Serious complications are rare but can lead to transfusion, hematoma, abscess formation, and reoperation to control bleeding [29]. Lateral port placement should be carefully chosen to avoid

these vessels with both direct laparoscopic transperitoneal visualization of the path of the inferior epigastric vessels deep to the muscle and fascia along the abdominal wall, transillumination of the superficial epigastric vessels, and a thorough understanding of the anatomic relationship of these vessels along the anterior abdominal wall. Cadaveric dissection, imaging series, and intraoperative mapping studies have shown that the inferior epigastric vessels branch from the external iliac lateral to the medial umbilical ligament and medial to the round ligament and then travel along the anterior abdominal wall 4–8 cm from the midline [30–32]. This distance becomes more lateral, up to 11 cm from the midline, in obese patients and under insufflation [32]. The “safe zone” is generally considered to be >8 cm from the midline at a level superior to the anterior superior iliac spine (ASIS). Choosing appropriate insertion sites based on an understanding of abdominal wall anatomy may minimize the risk of vessel injury; however, because of anatomic variation, strategies for managing abdominal wall vessel injury are required [29].

Abdominal vessel injury may present as oozing or dripping along the shaft of the trocar into the abdominal cavity or may not become apparent until a port is removed because of the tamponading effect of both the trocar and the pneumoperitoneum. If bleeding is identified, electrocautery may be sufficient to control superficial bleeding. However, the injured vessels may retract from the incision, so if bleeding persists, alternative techniques should be immediately employed. A Foley catheter may be inserted through the port site, inflated, and placed on gentle traction for 24 h to tamponade the site. Alternatively, suture ligation of the proximal and distal ends of the vessel may be required. This can be accomplished in several ways: (1) transabdominally, placed 1 cm away from the skin edge with through-and-through sutures (to be removed 12–24 h later); (2) transabdominally with extension of the skin incision, exploration of the incision and deep U-stitches; or (3) laparoscopically with a fascial closure device used within the trocar site [18].

Abdominal Wall Nerve Injury

Abdominal wall nerve injury is an uncommon but recognized complication of laparoscopic surgery. Ilioinguinal and iliohypogastric nerve injury has been reported in up to 3.7% of procedures performed through Pfannenstiel incisions [33] but occurs with low frequency in laparoscopy. This is because the ilioinguinal and iliohypogastric nerves enter the abdominal wall inferior and medial to the ASIS [34], an uncommon location for placement of ports in gynecologic laparoscopy. Thus, abdominal wall surgical sites inferior and medial to the ASIS increase the risk for abdominal wall nerve injury and entrapment [35] and should be avoided.

Intraoperative Complications

Major Vascular Injury (MVI)

A major vascular injury (MVI) is defined as laceration of the aorta, inferior vena cava, or the iliac vessels. Fortunately, the incidence of MVI at the time of laparoscopy is low and ranges from 0.1 to 6.4 per 1000 procedures; however, the mortality rate from these events approaches 12.5% [21]. Most vascular injuries occur at the time of intraperitoneal access and are related to insufflation of the abdomen with a Veress needle (39%) or placement of the primary trocar (37.9%) [36]. MVI can also occur during operative laparoscopy, especially in more complex procedures that require retroperitoneal dissection of vessels and lymph nodes. Most MVIs are arterial in nature involving the aorta or common iliac. Injury to these vessels can lead to severe hemodynamic changes due to voluminous blood loss in a very short period of time. The most commonly affected vein is the inferior vena cava [37].

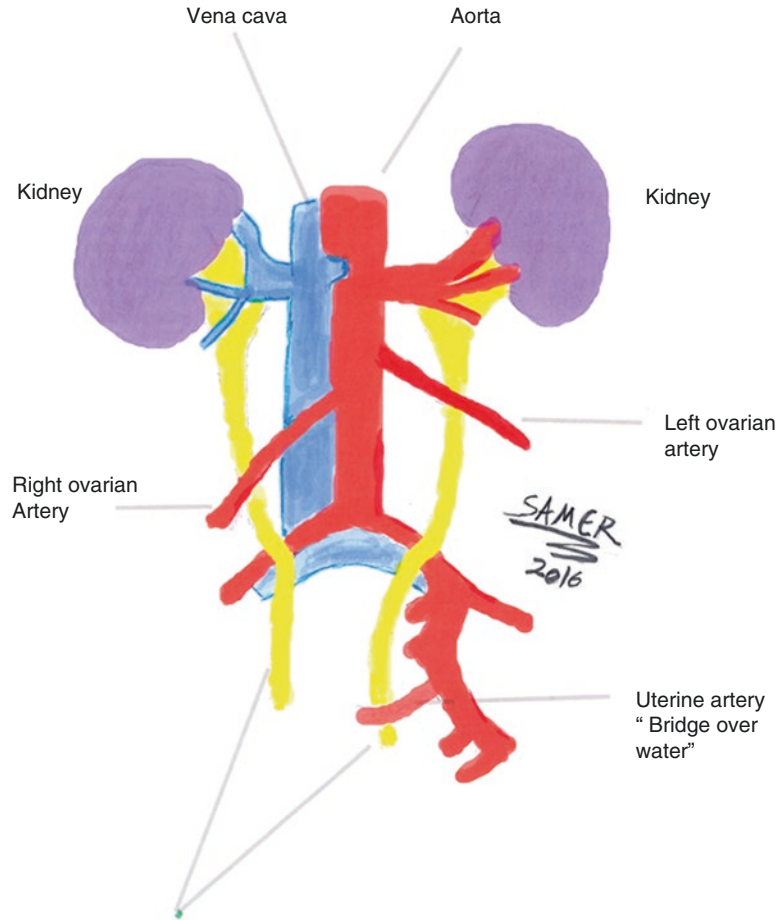
In a review of nearly 30,000 gynecologic laparoscopic procedures, it was noted that the surgeon's experience was correlated with the overall complication rate but not with the incidence of MVI [5]. This emphasizes the importance of

awareness of possible complications regardless of the surgeon's level of expertise. Prevention remains the best recipe: understand the pathology, study the relevant anatomy, review risk factors, and plan the surgical approach carefully prior to entering the operating room.

Immediate recognition of MVI is a key step to improve outcomes. Identification of free blood in the abdominal cavity is appreciated with larger lacerations of one of the major vessels; however, MVIs may not be immediately recognized due to retroperitoneal containment of hemorrhage. In these circumstances, hemodynamic changes may be noted by the anesthesiologist first. A thorough understanding of physiologic/hemodynamic changes that take place during a hemorrhagic event, and clear and immediate communication with all members of the surgical team, is crucial to improve patient outcomes and survival. Identifying a retroperitoneal hematoma, dark venous blood pooling in the abdomen, or bright red pulsatile blood should alert the surgeon that an MVI has occurred (Fig. 32.1), and steps to identify the injury, secure the blood vessel, and control the bleeding should be taken immediately.

It is important to remain calm and help your team understand the urgency of the situation. Immediately notify anesthesia and nursing to prepare for resuscitation efforts, emergency laparotomy, and massive transfusion protocols. Vascular and/or trauma consultants should be called to assist as soon as a MVI is identified. Once your team is appropriately briefed on the urgent nature of the event, proceed with a midline laparotomy, and apply direct pressure to the bleeding site with dry sponges. It is also helpful to have your assistant apply manual compression of the aorta at the level of the esophageal hiatus to decrease blood flow to the injury site. If the site of injury is easily identified, maintain direct pressure on the injured vessel until the vascular surgeon arrives. If a vascular surgeon is not available, pack the abdomen tightly with multiple dry laparotomy sponges, and close the abdomen under tension. Initiate emergency transport to a tertiary medical center.

Fig. 32.1 Relationship of the ureter to pelvic vasculature. Note the course of the ureter as it descends over the pelvic brim over the bifurcation of the common iliac. Once it enters the deep pelvis, the ureter travels on the lateral aspect of the uterosacral ligament to then penetrate the base of the broad ligament. It then passes under the uterine artery—“bridge over water”—traveling medially over the anterior vaginal fornix before it enters the trigone



Bowel Injury

Injury to the intestinal tract remains low with an incidence of 0.03–0.18% of all patients undergoing laparoscopic surgery [38], while the incidence in gynecological procedures seems to be higher, ranging from 0.06 to 0.65% [18]. Immediate recognition and management of bowel injury is essential to decrease morbidity and mortality associated with this type of injury. Mortality rates from bowel injury at the time of laparoscopy approach 2.5–5% [21], and in cases of delayed diagnosis, mortality rates approach 28% [18]. Since most bowel injuries are not immediately diagnosed, a worsening postoperative course complicated by pain, fever, leukocy-

tosis, and eventually peritonitis and sepsis should prompt immediate concern and action.

Bowel injury often is a result of a puncture wound with a Veress needle or primary trocar at the time of abdominal wall entry, but it can also take place during adhesiolysis or with the use of electro-surgical instruments. Approximately 50% of all bowel injuries occur at the time of intra-peritoneal access, and the vast majority occur in patients who have had prior surgery or adhesive disease.

The key factors in minimizing the likelihood of bowel injury are surgical planning, superior knowledge of surgical anatomy, thorough understanding of the pathology at hand, and respect for the tissue. Intraoperative injury should be

immediately recognized and managed. Bowel injury at the time of Veress needle insertion should be suspected when one of the following signs is present: high intra-abdominal pressure (>10 mmHg), aspiration of fecal material, malodorous smell, or asymmetric distention of the abdomen. Routine inspection of the point of entry at time of laparoscopy, a thorough survey of the abdomen and pelvis, as well as the use of intraoperative bowel integrity test, also called a “flat tire” test when sigmoid injury is suspected, are important tools to aid in recognition of bowel injury. The intraoperative bowel integrity test can be easily accomplished by filling the pelvis with water and introducing air into the rectum. The proximal colon can be obstructed with a blunt instrument while introducing air from the distal end. The presence of air bubbles is diagnostic of a sigmoid perforation. Once an intraoperative bowel injury is recognized, repair should take place without delay. The abdomen should be copiously irrigated and intravenous antibiotics initiated. The entire length of the bowel should be inspected to ensure no occult injury exists. The repair will be determined by the type, location, and size of the injury. Injury can be classified as mechanical (needle or trocar) or thermal (electrosurgical) and can be located in the small or large bowel.

Small needle puncture wounds may be managed expectantly, but larger defects need to be repaired. It is acceptable to perform the repair laparoscopically if the surgeon has the expertise and the procedure is technically feasible [39]. Small injuries can be repaired primarily; large lacerations may require segmental resection. Colostomy should only be used in the presence of gross contamination and/or advanced peritonitis as prophylactic colostomy has been shown to increase morbidity without an improvement in anastomotic leaks. Superficial lacerations involving the serosa or submucosal layers can be oversewn with a delayed absorbable suture in a single layer. Deeper lacerations need to be closed in two layers: close the mucosa, submucosa, and muscularis in one layer using a delayed absorbable suture, and follow with interrupted silk sutures including the submucosa to the serosa. Repairs should always be closed transversely to avoid luminal strictures.


Unrecognized bowel injury offers a tremendous increase in morbidity and mortality for the patient. Immediate evaluation of postoperative complaints of pain, fever, nausea, and vomiting is an essential first step. While an unrecognized bowel laceration will usually present within the first or second postoperative days, an unrecognized bowel thermal injury may not present until 7–10 days postoperatively. While symptoms can vary from very mild and nonspecific to severe pain, fever, and ultimately sepsis, it is crucial to critically evaluate all postoperative complaints with an elevated degree of suspicion. Initial evaluation always includes a thorough history and physical exam, laboratory evaluation, and imaging via computed tomography with oral contrast. If the diagnostic tests are inconclusive but clinical findings are suspicious for bowel injury, a diagnostic laparoscopy should be considered.

Urologic Injuries

Injuries to the urinary bladder and ureter occur at a frequency of 0.02–1.7% of gynecologic laparoscopic procedures [21]. As previously discussed, prevention, recognition, and early management of injury are essential to optimize outcomes and minimize morbidity. Failure to recognize bladder or ureteral injury at the time of surgery will inevitably lead to postoperative complications, peritonitis, fistulas, and impaired renal function.

Injury to the bladder occurs at a much higher frequency than injury to the ureters. Types of injury vary depending on complexity of the procedure and surgical experience. The most common type of bladder injury is perforation of the bladder with a Veress needle or placement of suprapubic trocars. Simple steps to minimize injury to the bladder include bladder decompression with a Foley catheter prior to surgical incisions and placement of accessory ports under direct laparoscopic guidance. Needle punctures and small lacerations can be managed conservatively; however, larger lacerations (>10 mm) should be repaired in two layers using a delayed absorbable suture. Integrity of the repair should

Fig. 32.2 The Pink Pad from Xodus Medical products is placed over the OR table and secured in place with Velcro straps. The drawsheet facilitates tucking of the arms and patient transfer after procedure is completed. The pad is intended for direct contact with patient's skin to eliminate sliding during the procedure



be confirmed by backfilling the bladder and observing for leakage. A Foley catheter should be kept in place for at least 7 days for complex injuries or those located near the bladder trigone. Thermal injury to the bladder can occur when dissecting the bladder from the lower uterine segment. This is more common when dense adhesions are present from prior cesarean sections or in the presence of advanced endometriosis in the anterior cul-de-sac. Meticulous surgical technique that includes releasing the bladder from a lateral to medial approach, utilizing sharp dissection instead of electrocautery, and avoiding blunt dissection techniques will help prevent bladder injury.

Ureteral injuries are infrequent but are associated with due to tremendous morbidity. The ureter can be inadvertently transected, crushed, devascularized, or burned intraoperatively. Risk factors for ureteral injury during laparoscopy include surgeon inexperience, large fibroids, large adnexal mass, severe adhesive disease, and endometriosis. Most ureteral injuries happen at the level of the cardinal ligament or infundibulopelvic ligament but may also occur at the lateral border of the uterosacral ligament, ovarian fossa, and ureteric canal. Understanding the course of the ureter as it descends over the pel-

vic brim over the bifurcation of the common iliac is essential to prevent injury (Fig. 32.2) and for intraoperative mapping. Once the ureter enters the deep pelvis, it travels on the lateral aspect of the uterosacral ligament to then penetrate the base of the broad ligament. It then passes under the uterine artery—"bridge (*uterine artery*) over water (*ureter*)"—traveling medially over the anterior vaginal fornix before it enters the bladder. Radiologic studies [40] demonstrated that the ureter can be located as close as 5 mm from the cervix. Careful dissection, gentle handling of tissue, and thorough knowledge of pelvic anatomy will help reduce and prevent ureteral injury. Visualization of the ureter is imperative prior to desiccation and transection of tissue. If the surgeon is unable to visualize the ureter vermiculating transperitoneally, a retroperitoneal dissection should be carried out to expose the ureter. Mobilizing the bladder in a caudad fashion away from the cervicovaginal junction, skeletonizing the uterine arteries, and developing a posterior peritoneal reflection will also protect the ureters and bladder. Cephalic displacement of the uterus allows for lateral deviation of the ureters, effectively increasing the distance between the ureters and the cervicovaginal junction.

If a ureteral injury is suspected, prompt evaluation should be undertaken. The surgeon should inspect the ureter as it courses down the pelvic side wall and enters the bladder. Presence of vermuculation does not rule out injury. If a partial or complete transection is identified, extravasation of urine will confirm the diagnosis. When needed, intravenous indigo carmine can be administered to facilitate visualization of the injured area. Ureteric crush injuries and complete obstruction of the ureter by either suture ligation or sealing devices will be identified more readily at the time of cystoscopy by observing a lack of ureteral efflux on the injured side. Treatment of intraoperatively recognized ureteral injury is determined by the type and severity of the injury and its anatomical location. Most commonly, a urologist is consulted to aid in the repair of the ureter. As a rule, it is always preferable to reimplant the ureter rather than to anastomose it due to a lower risk of complications with this approach. It also always more favorable to mobilize the bladder to reach the ureter than to mobilize the ureter to reach the bladder, since the latter may result in ureteral ischemia. By dividing the peritoneum on both sides of the bladder, the bladder can easily reach the end of a transected ureter at the level of the pelvic brim. Severe thermal and crush injuries to the ureter require resection of the affected area and reanastomosis or reimplantation of the resulting segments.

The great majority of bladder injuries are recognized intraoperatively, but similar to bowel injury, ureteric damage is not always diagnosed at the time of surgery, leading to significant delays in management and increased morbidity to the patient. Postoperative complaints of fever, nausea, vomiting, pain, hematuria, abdominal distention/ascites, voiding dysfunction, and leakage of fluid from the incision sites or vagina should immediately raise a concern for a delayed diagnosis of ureteral or bladder injury. These complications often manifest themselves postoperative day 2–7 but can present as late as 33 days postoperatively [41]. Immediate evaluation should be undertaken to determine if an injury has occurred, where it is located, and what the severity is. A renal ultrasound may be performed

to identify the presence of hydronephrosis, ureteral dilation, or urine ascites in the abdomen. A urogram (computed tomography) with contrast and a retrograde pyelogram are also effective imaging modalities. Once the diagnosis is made, establishment of renal drainage is essential either via percutaneous nephrostomy tubes, ureteral stents, Foley catheter, or a combination of these three methods. Supportive treatment should be initiated by evacuation of urinoma/ascites, antibiotics if needed, and surgical repair when patient is stable. Bladder injuries can be accompanied by ureteral injuries, and the latter must be ruled out. The reverse is also true: bladder injuries must be ruled out in the presence of ureteral injuries.

Neuropathic Injury

The incidence of nerve injury after gynecologic surgery is low and approaching 2% [42], but the consequences are high, often leading to minor discomfort and paresthesias, but occasionally, depending on the type and severity of the injury, to loss of motor function and permanent disability. Neuropathic injuries can happen at any time during the operative period, from the time the patient is positioned in preparation for surgery to the moment anesthesia is reversed and the patient is transferred to the recovery room. In an otherwise uncomplicated surgery, when the patient complains of postoperative pain, paresthesias, loss of sensation, or motor weakness, you should be suspicious of a nerve injury. In addition to direct injury, such as transection, entrapment, or thermal injury during the operative portion of the procedure, the surgeon must be cognizant of the possibility of compression or stretching from patient positioning or patient shifting during the procedure.

Most gynecological laparoscopic procedures require positioning the patient in the lithotomy position and some degree of Trendelenburg. Steep Trendelenburg ($>30^\circ$) is an independent risk factor for brachial plexus injury [21], while prolonged operative time (>4 h), obesity, and frequent patient repositioning during surgery add significant risk for neuropathic injury. Most commonly, the

femoral, sciatic, and peroneal nerves are involved when a lower extremity nerve injury is suspected after a procedure in the lithotomy position and the mechanism of injury is often due to compression of the nerve involved.

Clinical presentation will generally allow for identifying which nerve is involved. For example, if a patient presents with weakness without pain of the quadriceps resulting in difficulties with walking and climbing stairs, suspicion of a femoral nerve injury should be considered. A femoral nerve injury is usually due to compression against the inguinal ligament with severe hyperflexion of the leg. This can also happen as the femoral nerve is stretched when the leg is externally rotated and/or abducted at the hip. When the patient presents with posterior leg pain and weakness radiating from buttocks to leg, a sciatic nerve injury is usually the culprit. A sciatic nerve injury can occur with stretch injury with high lithotomy position when the knee is straightened in the stirrups and from direct compression of the nerve during long procedures. When a patient presents with a foot drop and weakness or numbness of the dorsal part of the foot, a peroneal nerve injury is to blame. This is usually a result of compression of the lateral portion of the knee against the stirrup.

As with any other type of complication, prevention is infinitely better than remediation. The surgical team should take all necessary steps to identify patients at risk for neuropathic injury, especially the morbidly obese, complex procedures that may extend beyond 4 h, patients with arthritic deformities that may preclude from appropriately positioning the extremity, and patients with preexisting neuropathies. A thorough history and detailed physical examination should be documented preoperatively with evaluation of preexisting conditions and, if necessary, have a neurological consultation and assessment prior to surgery. Once in the operating room, the surgeon is ultimately responsible for positioning the patient and ensuring that there are no pressure points or variations of malpositioning that may lead to nerve injury. This responsibility is of paramount importance, and it should not be delegated to another member of the team. Upper

extremities can be protected by tucking the arms in the military position. Eliminate the possibility of any pressure points by padding the elbows, wrists, and hands. When possible, avoid prolonged (>4 h) lithotomy position and shoulder braces. If the circumstances allow, consider repositioning of the patient when the operative time is approaching 4 h. This will allow for temporary relief and decompression of affected nerves and an opportunity to better position the patient if shifting or migration on the table has occurred.

Another important step in prevention of injury during surgery is avoidance of steep (30–45°) Trendelenburg. Prior to transferring the patient to the OR table, a foam pad is secured on to the table with Velcro straps, and a drawsheet is placed to allow for tucking of the arms and also for transferring the patient to the transport bed after the procedure is completed (Fig. 32.2). The pad is intended for direct contact with patient's skin to eliminate sliding during the procedure effectively eliminating the need for beanbags and shoulder braces.

When nerve injury is recognized, supportive treatment should be initiated with physical therapy and medications targeted to decrease neuropathic pain such as tricyclic antidepressants and anticonvulsants. Nerve tissue recovers at a slow pace, and it takes approximately 3–4 months to regenerate. Patience and reassurance will go a long way. Referral to a neurologist should be considered if symptoms are severe and refractory to conservative therapy.

Morcellation-Related Injury

With the advancement of minimally invasive surgery, industry innovation, and the introduction of efficient mechanical morcellation devices, the number of complex procedures that could be completed in a minimally invasive manner increased tremendously. The evolution from utilizing scalpels laparoscopically to manual morcellation devices to electric mechanical power tools facilitated tissue extraction but introduced a new dimension of surgical risk. Reports of visceral and vascular injury [43] in addition to the

potential risk of seeding of benign or malignant cellular tissue during open power morcellation have led to a reevaluation of the use of these devices. Disclosure of possible risks and written informed consent are essential when considering any tissue morcellation in the peritoneal cavity as small fragments left behind during the process can lead to significant morbidity in the form of pain, infection, parasitic leiomyomatosis, and the potential for seeding malignant tissue. When faced with the challenge of selecting a minimally invasive approach for a patient with a large mass, ruling out the possibility of malignant disease is imperative. Every effort needs to be made to not increase morbidity and mortality to favor a minimally invasive approach. For example, recent literature from Japan [44] suggests that using multiple predictors for the preoperative identification of patients at risk for leiomyosarcoma are important tools in the formulation of a preoperative sarcoma score and include imaging studies (TVUS and MRI), endometrial biopsy, and serum LDH levels. In addition, when performing a laparoscopic hysterectomy, every effort should be made to remove the specimen intact through the vagina or a minilaparotomy site. When morcellation is an option for extraction of large specimens in a minimally invasive approach, containment of tissue throughout the procedure is recommended. Many techniques and tools have been described and utilized for tissue extraction. Recently, the US Food and Drug Administration (FDA) approved the first tissue containment system for use with certain laparoscopic power morcellators to isolate uterine tissue that is not suspected to contain cancer. Regardless of the tools or techniques used for tissue extraction, appropriate documentation of informed consent and a detailed description of the procedure must be included in the operative report.

Postoperative Complications

Port Site Infection

Port site infection is a type of surgical site infection (SSI) subsequent to a laparoscopic surgery and that

presents within 1 month of the operative procedure [45]. Wound infections after laparoscopic surgery are uncommon in the setting of preoperative antibiotics, sterile technique, and hemostasis but are more likely to occur in patients with history of nicotine use, diabetes, steroid administration, obesity, cancer, or malnutrition. When infections develop, they present in the typical manner with localized erythema, induration, warmth, and drainage over the laparoscopic port site. Some patients may have systemic evidence including fever and leukocytosis. Necrotizing fasciitis is characterized by copious drainage and devitalized subcutaneous tissue and fascia. Port site infections are most common in the umbilical port, correlated with larger trocar sites and specimen extraction. Superficial infections, typically presenting as erythema and warmth, can easily be treated with local wound care and antibiotics. Deep infections, typically presenting as fluctuance or purulent discharge, require exploration, irrigation, packing, and, if indicated, mechanical debridement.

Port Site Herniation

Post-laparoscopy port site herniation occurs with an incidence of 0.21–5.4% [46–48]. These hernias are most likely to occur when large ports (≥ 10 mm) are used, such as for single-site procedures [49]. The most important risk factors for development of hernia include older age, higher body mass index, preexisting hernia, bladed trocar design, trocar diameter ≥ 10 mm, increased duration of surgery, multiple ancillary ports and extension of the port site for specimen extraction, stapling, or single-site surgery. Hernia development has been reported for 5 and 7 mm port sites as well as ≥ 10 mm port sites that underwent primary fascial closure.

Port site herniation typically presents with the presence of an intermittent or continuous incisional bulge at the site of a previous laparoscopy port. This may be a cosmetic concern or may cause varying degrees of pain but is typically worsened by exertion or Valsalva. Patients can also present with clinical signs of bowel obstruction or infarction such as nausea, vomiting,

abdominal distention, persistent pain, fever, tachycardia, and electrolyte imbalance. This can occur several years after a laparoscopic surgery and may have higher incidence the more remote the patient is from the incident surgery [48]. When port site hernia is identified following laparoscopy, the site should be repaired. Often a laparoscopic, simple suture repair is sufficient for port site hernias, but surgical repair should be individualized based on clinical status, size, and location of defect.

Postoperative Shoulder Pain

Postoperative shoulder is commonly attributed to irritation along the peritoneal undersurface of the diaphragm resulting in a referred pain phenomenon commonly seen in postoperative surgical patients. This occurs because the diaphragm is innervated by left and right phrenic nerves which carry sensory and motor neurons from spinal cord levels C3–C5. When the sensory component of the phrenic nerve is activated by retained insufflation gas, blood, or irrigation fluid or by stretching of the nerve from pneumoperitoneum or pressure from abdominal organs in Trendelenburg position, the nerve sends afferent signals that are processed in the dorsal horn of cervical segments 3–5. Sensory axons from the shoulder converge in the same dorsal horns, and the body misinterprets the afferent signals arising from the phrenic nerve as arriving from the shoulder. This convergence is thought to be the basis for referred pain [21]. The process is self-limiting and management is reassurance and symptomatic care.

References

- Hatzinger M, Häcker A, Langbein S, Kwon S, Hoang-Böhm J, Alken P. Hans-Christian Jacobaeus (1879-1937): the inventor of human laparoscopy and thoracoscopy. *Urologe A*. 2006;45(9):1184–6.
- Sutton C. Past, present, and future of hysterectomy. *J Minim Invasive Gynecol*. 2010;17(4):421–35.
- Jansen FW. Complications. In: Istre O, editor. *Minimally invasive gynecological surgery*. 1st ed. Berlin: Springer; 2015. p. 177–90.
- Miranda CS, Carvajal AR. Complications of operative gynecological laparoscopy. *JLS*. 2003;7:53–8.
- Chapron C, Queleu D, Bruhat MA, et al. Surgical complications of diagnostic and operative gynaecological laparoscopy: a series of 29,966 cases. *Hum Reprod*. 1998;13:867–72.
- Jansen FW, Kapiteyn K, Trimbos-Kemper T, et al. Complications of laparoscopy: a prospective multicentre observational study. *Br J Obstet Gynaecol*. 1997;104:595–600.
- Johnston K, Rosen D, Cario G, et al. Major complications arising from 1265 operative laparoscopic cases: a prospective review from a single center. *J Minim Invasive Gynecol*. 2007;14:339–44.
- Mac Cordick C, Lécure F, Rizk E, Robin F, Boucaya V, Taurelle R. Morbidity in laparoscopic gynecological surgery: results of a prospective single-center study. *Surg Endosc*. 1999;13(1):57–61.
- Hashizume M, Sugimachi K. Needle and trocar injury during laparoscopic surgery in Japan. *Surg Endosc*. 1997;11:1198–201.
- Molloy D, Kaloo PD, Cooper M, et al. Laparoscopic entry: a literature review and analysis of techniques and complications of primary port entry. *Aust N Z J Obstet Gynaecol*. 2002;42:246–54.
- Garry R. Towards evidence-based laparoscopic entry techniques: clinical problems and dilemmas. *Gynaecol Endosc*. 1999;8:315–26.
- Ahmad G, Gent D, Henderson D, O'Flynn H, Phillips K, Watson A. Laparoscopic entry techniques. *Cochrane Database Syst Rev*. 2015;8:CD006583. <https://doi.org/10.1002/14651858.CD006583.pub4>.
- Cuss A, Bhatt M, Abbott J. Coming to terms with the fact that the evidence for laparoscopic entry is as good as it gets. *J Minim Invasive Gynecol*. 2015;22(3):332–41.
- Pryor A, Gracia G. Abdominal access techniques used in laparoscopic surgery. *UpToDate*. 2015.
- Angioli R, Terranova C, De Cicco Nardone C, et al. A comparison of three different entry techniques in gynecological laparoscopic surgery: a randomized prospective trial. *Eur J Obstet Gynecol Reprod Biol*. 2013;171:339–42.
- Byron JW, Markenson G, Miyazawa K. A randomized comparison of Verres needle and direct trocar insertion for laparoscopy. *Surg Gynecol Obstet*. 1993;177:259–62.
- Celik H, Cremins A, Jones KA, Harmanli O. Massive subcutaneous emphysema in robotic sacrocolpopexy. *JLS*. 2013;17(2):245–8.
- Makai G, Isaacson K. Complications of gynecologic laparoscopy. *Clin Obstet Gynecol*. 2009;52(3):401–11.
- Ott DE. Subcutaneous emphysema—beyond the pneumoperitoneum. *JLS*. 2014;18(1):1–7.
- Kalhan SB, Reaney JA, Collins RL. Pneumomediastinum and subcutaneous emphysema during laparoscopy. *Cleve Clin J Med*. 1990;57:639–42.
- Magrina J. Complications of laparoscopic surgery. *Clin Obstet Gynecol*. 2002;45:469–80.

22. Murdock CM, Wolff AJ, Van Geem T. Risk factors for hypercarbia, subcutaneous emphysema, pneumothorax, and pneumomediastinum during laparoscopy. *Obstet Gynecol.* 2000;95(5):704–9.
23. Kim CS, Kim JY, Kwon JY, Choi SH, Na S, An J, Kim KJ. Venous air embolism during total laparoscopic hysterectomy: comparison to total abdominal hysterectomy. *Anesthesiology.* 2009;111(1):50–4.
24. Park EY, Kwon JY, Kim KJ. Carbon dioxide embolism during laparoscopic surgery. *Yonsei Med J.* 2012;53(3):459–66.
25. Mintz M. Risks and prophylaxis in laparoscopy: a survey of 100,000 cases. *J Reprod Med.* 1977;18:269–72.
26. Hynes SR, Marshall RL. Venous gas embolism during gynaecological laparoscopy. *Can J Anaesth.* 1992;39(7):748–9.
27. Bonjer HJ, Hazebroek EJ, Kazemier G, et al. Open versus closed establishment of pneumoperitoneum in laparoscopic surgery. *Br J Surg.* 1997;84:599–602.
28. Cottin V, Delafosse B, Viale JP. Gas embolism during laparoscopy: a report of seven cases in patients with previous abdominal surgical history. *Surg Endosc.* 1996;10(2):166–9.
29. Hurd WW, Pearl ML, DeLancey JO, et al. Laparoscopic injury of abdominal wall blood vessels: a report of three cases. *Obstet Gynecol.* 1993;82(S):673–6.
30. Hurd WW, Rude RO, DeLancey JO, Newman JS. The location of abdominal wall blood vessels in relationship to abdominal landmarks apparent at laparoscopy. *Am J Obstet Gynecol.* 1994;174(3):642–6.
31. Saber AA, Mesleman AM, Davis R, Pimentel R. Safety zones for anterior abdominal wall entry during laparoscopy: a CT scan mapping of epigastric vessels. *Ann Surg.* 2004;239(2):182–5.
32. Burnett TL, Garza-Cavazos A, Groesch K, et al. Location of the deep epigastric vessels in the resting and insufflated abdomen. *J Minim Invasive Gynecol.* 2016;23(5):798–803.
33. Luijendijk RW, Jeekel J, Storm RK, et al. The low transverse Pfannenstiel incision and the prevalence of incisional hernia and nerve entrapment. *Ann Surg.* 1997;225:365–9.
34. Rahn DD, Phelan JN, Roshanravan SM, White AB, Corton MM. Anterior abdominal wall nerve and vessel anatomy: clinical implications for gynecologic surgery. *Am J Obstet Gynecol.* 2010;202(3):234.
35. Whiteside JL, et al. Anatomy of ilioinguinal and iliohypogastric nerves in relation to trocar placement and low transverse incisions. *Am J Obstet Gynecol.* 2003;189(6):1574–8.
36. Philips PA, Amaral JF. Abdominal access complications in laparoscopic surgery. *J Am Coll Surg.* 2001;192:525–36.
37. Sandadi S, Johannigman JA, Wong VL, Blebea J, Altose MD, Hurd WW. Recognition and management of major vessel injury during laparoscopy. *J Minim Invasive Gynecol.* 2010;17(6):692–702.
38. Pryor A, Mann W, Garcia G. Complications of laparoscopic surgery. UpToDate. 2016.
39. Chapron C, Fauconnier A, Goffinet F, Breart G, Dubuisson JB. Laparoscopic surgery is not inherently dangerous for patients presenting with benign gynaecologic pathology. *Hum Reprod.* 2002;17:1334–42.
40. Gemer O, Simonovsky A, Huerta M, Kapustian V, Anteby E, Linov L. A radiological study on the anatomical proximity of the ureters and the cervix. *Int Urogynecol J Pelvic Floor Dysfunct.* 2007;18(9):991–5.
41. Sharp HT, Swenson C. Hollow viscus injury during surgery. *Obstet Gynecol Clin N Am.* 2010;37:461–7.
42. Cardosi RJ, Cox CS, Hoffman MS. Postoperative neuropathies after major pelvic surgery. *Obstet Gynecol.* 2002;100:240–4.
43. Milad MP, Sokol E. Laparoscopic morcellator-related injuries. *J Am Assoc Gynecol Laparosc.* 2003;10:383–5.
44. Nagai T, Yakahori TY, Ishida H, Hanaoka T, et al. Highly improved accuracy of the revised Preoperative Sarcoma Score (PRESS) in the decision of performing surgery for patients presenting with a uterine mass. *Springer Plus.* 2015;4:520.
45. Sasmal PK, Mishra TS, Rath S, Meher S, Mohapatra D. Port site infection in laparoscopic surgery: a review of its management. *World J Clin Cases.* 2015;3(10):864–71.
46. Montz FJ, Holschneider CH, Munro MG. Incisional hernia following laparoscopy: a survey of the American Association of Gynecologic Laparoscopists. *Obstet Gynecol.* 1994;84(5):881.
47. Bunting DM. Port-site hernia following laparoscopic cholecystectomy. *JLS.* 2010;14(4):490–7.
48. Bensley RP, Schermerhorn ML, Hurks R, Sachs T, Boyd CA, O'Malley AJ, Cotterill P, Landon BE. Risk of late-onset adhesions and incisional hernia repairs after surgery. *J Am Coll Surg.* 2013;216(6):1159–67.
49. Marks JM, Phillips MS, Tacchino R, Roberts K, et al. Single-incision laparoscopic cholecystectomy is associated with improved cosmesis scoring at the cost of significantly higher hernia rates: 1-year results of a prospective randomized, multicenter, single-blinded trial of traditional multiport laparoscopic cholecystectomy vs single-incision laparoscopic cholecystectomy. *J Am Coll Surg.* 2013;216(6):1037.

Index

A

Abdominal hysterectomy (AH), 5, 7, 9, 24, 131
Abdominal myomectomy (AM), 22, 143
Abdominal paravaginal cystocele repair, 197
Abdominal radical trachelectomy, 307
Abdominal vessel injury, 365
Abdominal wall injury, 365, 366
Adnexectomy, 133, 168, 169, 171
Advanced ovarian cancer (AOC), 333, 337–339, 341
Advincola Arch, 18, 20, 24
Advincola Delineator, 18, 20
AirSeal port, 33
American Society for Reproductive Medicine (ASRM) system, 91
Anal manometry, 109
Anterior colporrhaphy
 with meshes/grafts, 197, 200
 native tissue repairs, 196
Anterior parametrium, 51, 55, 58, 241, 243
Anterior rectal wall disc excision, 113
Anterior vaginal wall prolapse (AWP), 196, 209
Aorta mobilization for inter aorto-caval dissection, 290
Arcus tendineus fascia pelvis (ATFP), 196
Aschermann syndrome, 188
Assessment of Different NEoplasia in the adneXa (ADNEX) model, 158
Assisted reproductive techniques, 317
Autologous fascial slings, 221, 223, 224

B

Benign ovarian tumors

 adnexal tumors, prevalence of, 157
 adnexectomy, 168, 169, 171
 cystectomy, 171
 after puncture, 164, 165
 ovarian endometrioma, 167, 168
 for paraovarian/paratubal cyst, 166–168
 without puncture, 165, 166
 endoscopic bag, 169–171
 intraoperative assessment
 extracystic evaluation, 162
 intracystic evaluation, 162–165
 laparoscopic surgery, 157, 159, 160

 laparotomy, 171
 preoperative assessment
 ADNEX model, 158
 anamnesis and physical examination, 158
 CT and MRI, 159
 factors, 158
 IOTA group, 158
 tumors biomarkers, 159
 ultrasound, 158, 159
 puncture, 171
 surgical technique
 intraoperative evaluation, 161, 162
 patient positioning, 160
 peritoneal cytology, 162
 pneumoperitoneum creation, 160, 161
 port placement, 161
 Beta-adrenergic receptors, 62
 Bilateral aortic lymphadenectomy, 277
 Bilateral cysts, 94
 Bilateral endometriomas, 126
 Bilateral oophorectomy, 150
 Bilateral pelvic lymphadenectomy, 277, 327, 349
 Bilateral salpingectomy, *see* Salpingectomy
 Bilateral salpingo-oophorectomy (BSO), 150, 154, 321–323
 Biografts, 204
 Bipolar desiccation process, 6, 8
 Bladder dissection, 270, 277, 279
 Bladder endometriosis, 88, 96, 97, 115
 Bladder injuries, 370
 Bladder pillar, *see* Anterior parametrium
 Bogros' space, 49
 Bowel and fallopian tube endometriosis, 93
 Bowel deep infiltrative endometriosis, 92
 Bowel endometriosis, 98
 anastomotic fistula, 98
 colorectal endometriosis, 97
 deep infiltrative endometriosis, 92
 definition, 112
 differential diagnosis, 97
 discoid resection, 112, 113
 intestinal involvement, 97
 intestinal segmental resection, 98
 medical management, 97

- Bowel endometriosis (*cont.*)
 mucosal skinning, 112
 multifocality and multicentric involvement, 97
 parameters, 97
 postoperative complications, 98
 radical approach, 112
 recurrence rate, 98
 segmental resection, 113, 114
 shaving, 112, 113
 superior rectal artery, 98
 surgical techniques, 97
 symptoms, 97
 vaginal NOSE, 114
- Bowel endometriotic nodules, 68
- Bowel evacuation's mechanism, 63
- Bowel function scores, 68
- Bowel injury, 291, 367, 368
- Bulky endometriosis lesions, 80
- Burch colposuspension, 208–210, 218, 219, 221
- Burch procedures, 221
- C**
- Carbon dioxide embolism, 364, 365
- Cardinal ligaments, 64, 133
- Cell-mediated immunological system, 335
- Cervical cancer, 241
 chemoradiation, 265
 clinical laparoscopic staging, 248, 249
 early stages, 265
 FIGO stages, 247
 imaging modalities, 248, 249
 incidence, 247, 265
 laparoscopic surgical staging, 249–251
 locally advanced disease, 248
 lymph node metastases, incidence of, 251, 252
 overall survival, 247
 patient-related factors, 247
 pelvic lymphadenectomy, 265
 radiation, 265
 radical abdominal hysterectomy, 265
- Cervical injection, 326, 346
- Cervicovaginal peritoneum, 279
- Cesarean births, 181
- Cesarean scar defect (CSD), *see* Isthmocele
- Champagne effect, 80–82
- Chocolate cyst, 94
- Circumferential culdotomy, 12
- Coelomic epithelium, 94
- Colorectal endometriosis, 94, 97
- Colorectal resection, 20, 97, 98
- Colpocleisis, 207, 208
- Colpotomy, 11, 12, 280
- Computed tomography (CT), 159, 248
- Computer-enhanced telesurgery, *see* Robotic-assisted laparoscopic surgery
- Culdotomy, 2, 11, 12
- Cystectomy, 171
 after puncture, 164, 165
 ovarian endometrioma, 167, 168
 for paraovarian/paratubal cyst, 166–168
 without puncture, 165, 166
- Cystoscopy, 13
- Cystourethroscopy, 197
- D**
- da Vinci robotic system, 270
- da Vinci Xi robotic systems, 276
- da Vinci[®] Surgical System, 143
- Dargent's procedure, 308
- De novo stress incontinence, 208
- Debulking, 243, 298, 333, 336–339
- Deep endometriosis (DE)
 anal manometry, 109
 clinical examination, 108
 complications, 117
 definition, 106
 epidemiology, 106
 hypogastric nerves, 57
 infertility, 106–108
 magnetic resonance imaging, 108
 Müllerianosis, 105
 parametrium
 anterior, 55
 lateral, 55
 posterior, 55, 56
 pelvic plexus, 57–58
 pelvic spaces
 Bogros' space, 49
 lateral Latzko's Paravesical Space, 49–50
 lateral pararectal space, 50–51
 medial pararectal space, 52
 medial paravesical space, 51, 52
 rectovaginal septum, 52, 53
 retropubic (Retzius' space), 48–49
 retrorectal space, 52
 pelvic splanchnic nerves, 57
 pelvis
 cornus uterinus, 47
 hypogastric artery, 47
 iliococcygeus muscle, 45, 46
 ischiococcygeus muscle, 45, 46
 paravesical space, 47
 presacral fascia, 46
 pubococcygeus muscle, 45, 46
 retropubic (Retzius') space, 47
 sacral promontorium, 46
 Sampson's artery, 47
 transperitoneal profiles, 46
 umbilical (or obliterated) artery, 46
 wide extensive infiltration pattern, 46
 peritoneal surfaces
 broad ligament, 48
 rectouterine fold, 48
 vesicouterine fold, 47
 postoperative care, 116, 117
 Sampson's hypothesis, 105, 106
 SHP, 57
 stages, 106

- surgical treatment, 112
 - bowel (*see* Bowel endometriosis)
 - ovarian, 110
 - peritoneal, 110
 - patients groups, 109
 - posterior cul-de-sac, 111
 - urinary, 115, 116
 - vaginal, 112
 - symptoms, 106–107
 - types, 106
 - ultrasound mapping, 108
 - urodynamics, 109
 - ureter, 54
 - uterine artery, 53
 - Deep infiltrating nodule, 85
 - Deeply infiltrating endometriosis (DIE), 61, 79, 81, 86, 91–93, 96
 - advanced-stage, 20
 - clinical presentation, 19
 - EEA sizers, 21
 - extensive ureterolysis, 20
 - Fornix presenter, 21
 - outcome measures, 21
 - ovarian cystectomies, 20
 - posterior vaginal resections, 20
 - prevalence, 19
 - rectovaginal septum, 20
 - robotic instruments, 21
 - robotic-assisted laparoscopic colorectal resection, 20
 - surgical resection, 20
 - symptom, 19
 - 2-0 V-Loc™ barbed suture, 21
 - unilateral/bilateral uterosacral ligament resection, 20
 - DeLancey level III, 200
 - Discoid resection, 112, 113
 - Doppler sonography, 159
 - Dyspareunia, 95
- E**
- Endometrial carcinoma
 - bilateral salpingo-oophorectomy, 321
 - cervical involvement, 321
 - complications, 323
 - conversion rates, laparoscopy to laparotomy, 328
 - extrauterine disease, 321
 - 5-year survival rate, 321
 - grade, 321
 - gynecologic malignancy, 321
 - histological subtype, 321
 - laparoscopic surgery
 - anatomic variations, 326
 - blunt and sharp dissection, 326, 327
 - cephalad elevation, manipulator, 326
 - complication rates, 324
 - gynecologic laparoscopic entry, 325
 - harvested lymph nodes, 323
 - hospitalization, 324
 - infundibulopelvic ligament, 326
 - intraoperative adverse events, 325
 - minimally invasive approach, 325
 - pelvic lymph node metastases, 323
 - postoperative adverse events, 324, 325
 - postoperative quality of life, 324
 - prognostic factors, 326
 - quality of life and recovery, 324
 - randomized trial, 324
 - treatment-related outcomes, 324
 - uterine vasculature, 326
 - wound complications, 323
 - management, 321
 - minimally invasive approach, 321, 322
 - myometrial invasion, 321
 - obesity, 328
 - pelvic and para-aortic lymphadenectomy, 321
 - port-site metastasis, 329
 - postoperative complications, 321
 - preoperative and intraoperative risk factors, 321
 - prognosis, 321
 - randomized controlled trials, 321
 - surgical staging, 323, 329
 - treatment, 321
- Endometrioma, 93, 107.
 - See also* Ovarian endometriomas (OEs)
- Endometrioma stripping technique, 111
- Endometriosis
 - ASRM system, 91
 - definition, 91
 - diagnosis
 - clinical manifestations, 92
 - deep infiltrative endometriosis, 91, 92
 - magnetic resonance imaging, 93–94
 - transvaginal ultrasonography, 92, 93
 - ovarian endometriosis cysts, 91
 - peritoneal, 91
 - prevalence, 91
 - staging system, 91
 - surgical management
 - bladder, 96, 97
 - bowel, 97, 98
 - ovarian endometrioma, 94, 95
 - rectovaginal, 95–96
 - symptoms, 91
 - treatment, 91
- Endometriosis fertility index, 91
- Endometriosis nodule, 87
- Endometriosis surgery, 80–88
 - intraoperative management, 79
 - patient language
 - arrow, 82–86
 - black spots, 86, 87
 - champagne effect, 80–82
 - fatty tissue, 88
 - postoperative management, 80
 - preoperative management, 79
 - surgical treatment, 80
- Endometriotic cysts, 94
- Endometriotic infiltration, 52, 67
- Endometriotic nodule, 68, 97, 111
- Enterocoele, 200

Exogenous barrier methods, 142
 Extraperitoneal insufflation, 364
 Extraperitoneal laparoscopic paraaortic node dissection
 extraperitoneal space, 287, 288
 gonadal veins, 290
 ilio-latero-aortic node, 288
 inframesenteric dissection, 289
 interaortocaval nodes, 290
 latero-aortic nodes, 288
 left renal vein, 288
 lympho-hemostasis, 289
 nerve preservation, 290
 patient and staff positioning, 287
 postoperative care, 289
 pre-aorto- and interaortocaval nodes, 288, 289
 pre-vascular and latero-cavo-iliac nodes, 289
 skin incision, iliac fossa, 287

F

Fertility-preserving surgery, 238, 318
 Fertility-sparing surgery, 261, 308, 309
 Fibrotic sequelae, 188
 Functional ovarian cysts, 94

G

GelPoint system, 33
 Genital prolapse, 208, 210, 213
 occult stress incontinence, 210
 symptomatic stress incontinence, 209, 210
 Gore-Tex®, 142
 Groningen International Study on Sentinel nodes in
 Vulvar cancer (GROINSS-V), 352
 Gubbin's mini-resectoscope, 186
 Gynecologic laparoscopy
 abdominal vessel injury, 365
 abdominal wall entry, 363, 364
 abdominal wall injury, 365
 abdominal wall nerve injury, 366
 anatomical knowledge, 363
 carbon dioxide embolism, 364, 365
 complex ailments, management of, 363
 diagnostic capabilities, 363
 extraperitoneal insufflation, 364
 failed entry site, 364
 gas embolism, 364
 prevention, 363
 surgical technique, 363

H

Hemostasis, 82, 132, 165, 166, 244, 257, 291
 High-grade serous carcinoma, 152
 Holy plane of Heald, 52
 Human papillomavirus (HPV), 231, 351
 Hysterectomy, 149, 153
 advantage, 24
 +/- EEA sizer, 26
 laparotomy, 24

LH, 24
 RALH, 24–26
 robotic instruments, 26
 2-0 V-Loc™ barbed suture, 26
 uterine manipulator, 26
 Hysteropexy, 205
 mesh, 207
 sacral, 207
 sacrospinous, 206
 uterosacral, 206
 vaginal mesh, 207
 Hysteroscopy, 137, 184

I

Iliococcygeus muscle (ilio-CM), 46
 Inferior hypogastric nerve, 62
 Inferior hypogastric plexus, 62
 Inferior mesenteric artery (IMA), 286, 288, 289, 294,
 299–301
 Inguinofemoral lymphadenectomy, 235
 Integral theory, 218
 Interaortocaval nodes, 285
 Interceed®, 142
 International Ovarian Tumor Analysis (IOTA) group, 158
 Intestinal endometriosis, 68, 97
 Intestinal segmental resection, 98
 Intramural fibroids, 141, 144
 Intrapelvic nerves
 cardinal ligaments, 64
 lateral paracervix, 64, 65
 pararectal spaces, 64
 presacral space, 64
 superficial paracervix, 65
 Intrinsic sphincteric deficiency (ISD), 218, 221–223
 Ischiococcygeus muscle (ischio-CM), 46
 ISD, *see* Intrinsic sphincteric deficiency (ISD)
 Isthmocele, 186–189
 definition, 182
 diagnosis, 183, 184
 pathogenesis of, 182, 183
 in symptomatic patients
 complications, 188
 directed biopsy, 188
 epithelial re-colonization, 189
 materials and methods, 186, 187
 symptomatology, 183
 symptoms, 182
 treatment, 185, 186

K

Kelly sutures, 196
 Kissing ovaries sign, 93, 95
 Koh-Efficient colpotomizer, 18

L

Laparo-endoscopic single-site surgery (LESS)
 advantages, 39

- AirSeal port, 33
- assistant grasper instrument, 36
- camera placement, 35, 36
- candidate selection, 35
- capacitive coupling, 38
- core principles, 31, 32
- disadvantages, 39
- ENDOCONE, 34
- extracorporeal morcellation, 37, 38
- GelPoint system, 33
- hysterectomy *vs.* conventional laparoscopy, 39
- learning curve, 38
- noncommercial ports, 34
- omega incision, 32
- operating electrosurgical instrument, 37
- perioperative outcomes, 39
- port orientation, 35
- primary outcome measures, 39
- retroperitoneal surgery, 39
- robotic-assisted LESS, 40
- set up and instrumentation, 34–35
- SILS Port, 33
- single-incision laparoscopy, 39
- suturing, 38
- target zone, 38
- traction-countertraction, 38
- TriPort, 33, 34
- vertical skin incision, 32
- X-CONE, 33, 34
- Laparoscopic cerclage, 176–178
 - history, 175
 - materials, 175, 176
 - mersilene tape, 177
 - adjustment, 178
 - cutting, 178
 - knots, 178
 - lock ends, 178
 - twist correction, 177
 - verification, 177
 - needle anterior exit, 177
 - needle entry point, 177
 - peritoneum closure, 178
 - post-surgery, 178
 - pre-operative care, 175
 - surgical room and patient position, 175
 - uterine vessels, 176
 - vesico-uterine peritoneum, incision of, 176
- Laparoscopic endometrioma excision, 6
- Laparoscopic hysterectomy (LH)
 - abnormal uterine bleeding, 5
 - bipolar desiccation process, 6
 - case analysis, 6
 - clinical background, 5–6
 - definition, 5
 - EndoGIA, 8
 - first record, 6
 - preoperative preparation
 - bladder mobilization, 10–11
 - colpotomy, 11, 12
 - culdotomy, 12
 - cystoscopy, 13
 - exploration, 10
 - incisions, 10
 - laparoscopic vaginal vault closure, 12
 - morcellation, 12
 - retroperitoneal dissection, 10
 - skin closure, 13–14
 - underwater examination, 13
 - upper uterine blood supply, 11
 - ureteral dissection, 10
 - uterine vessel ligation, 11
 - vaginal preparation, 10
 - suture, 8–9
 - TLH
 - development of, 6–8
 - endometriosis, with uterine preservation, 9
 - laparoscopic vaginal vault closure, with vertical uterosacral ligament suspension, 9
 - uterine vessel ligation, 9
- Laparoscopic lymphadenectomies in gynecologic oncology, 294, 295
- Laparoscopic myomectomy (LM), 140–142
 - vs.* abdominal approach, 21
 - advantages, 137
 - gold standard approach, 21
 - fertility and pregnancy rates, 144
 - instrumentation and suture, 139, 140
 - limitations
 - complications and conversion, risk of, 140, 141
 - reducing postoperative adhesions, 141, 142
 - vs.* minilaparotomic myomectomies, 137
 - minimizing blood loss, 138, 139
 - port placement, 138, 139
 - power morcellation, 144
 - robotic-assisted laparoscopic myomectomy, 143
 - single *vs.* multi-port, 142, 143
 - timing, 137, 138
 - uterine rupture, 144, 145
- Laparoscopic neuronavigation (LANN) technique, 61, 65–67
- Laparoscopic oophorectomy, 6
- Laparoscopic partial cystectomy, 88, 115
- Laparoscopic pelvic lymphadenectomy (LPLA), 70, 261, 305, 306, 323
- Laparoscopic radical hysterectomy
 - advantages, 266
 - blunt dissection, 267
 - complications, 266, 271
 - description, 265
 - 5-year disease-free survival, 271
 - under general anesthesia, 266
 - hemostasis under intraperitoneal pressure, 269
 - intraoperative and postoperative complications, 271
 - long-term survival, 271
 - oncological outcomes, 266
 - operative time, 271
 - para-aortic lymph node dissection, 266
 - peritoneal cavity, 266
 - peritoneal reflection, 267
 - post-procedure cystoscopy, 270

- Laparoscopic radical hysterectomy (*cont.*)
- procedure cost, 272
 - prophylactic antibiotics, 266
 - rectovaginal space, 268
 - splanchnic (parasympathetic) nerves, 268
 - surgical modalities, 267
 - surgical outcomes, 271
 - uterine artery, 268
 - uterine manipulator's cervical cap, 269
 - vaginal cuff closure, 270
 - vaginal margin incision, 269
 - vesicovaginal and vesicouterine spaces, 268
- Laparoscopic radical trachelectomy vaginal-assisted nerve sparing
- adjuvant treatment, 314
 - amenorrhea, 316
 - anatomical landmarks and hypogastric plexus, 313
 - case studies, 317
 - cerclage suture migration, 316
 - deep stromal invasion, 315, 316
 - demographic and preoperative data, 314
 - disease recurrence, 315, 317
 - dysmenorrhea, 317
 - histological types, 317
 - inferior vena cava lesion, 316
 - intra- and postoperative data, 314
 - intracervical device, 314
 - intraoperative bleeding, 315
 - intraoperative blood transfusion, 316
 - intraoperative complications, 314, 316, 318
 - laparoscopic approach, 311
 - menstrual irregularity, 316
 - neoadjuvant chemotherapy, 313, 316
 - oncological outcomes, 315
 - oncological safety, 318
 - oncological surgical quality pattern, 317
 - pathology analysis, 314, 315
 - patient positioning, 312
 - pelvic lymph node, 315
 - postoperative complications, 316
 - primary treatment, 313
 - radical hysterectomy, 313
 - reproducibility/learning curve, 315
 - salvage hysterectomy, 315
 - small local recurrence, 315
 - spontaneous pregnancy after trachelectomy, 317
 - surgical procedure, 311
 - surgical team positioning, 312
 - trocars' position, 313
 - tumor recurrence, 317
 - tumor size, 315–317
 - ureteral re-implantation, 314
 - uterine vascularization, 316
 - uterine vessel ascending branches, 316
 - vaginal approach, 313
- Laparoscopic sacral hysteropexy, 207
- Laparoscopic sacrocolpopexy (LSC), 26, 27, 203, 204
- Laparoscopic surgery, 331
- endometrial carcinoma (*see* Endometrial carcinoma)
 - recurrence and survival outcomes, 329–331
 - with robotic-assisted surgeries, 330
- Laparoscopic/robotic paravaginal repair, 197–199
- Laparoscopic-assisted vaginal hysterectomy (LAVH), 321
- Laparoscopic-vaginal radical hysterectomy (LAVRH), 259–262, 270
- history, 257
 - increasing radicality, 262
 - laparoscopic preparation, 258
 - lymph node dissection, 257
 - modified/class II radical hysterectomy, 258
 - pelvic lymphadenectomy, 258
 - pneumoperitoneum, 258
 - requirements, 258
 - Schauta Sine Utero, 262
 - Schauthem, 262
 - tailoring radicality
 - fertility-sparing surgery, 261
 - paracervical (parametrial) lymphadenectomy, 261, 262
 - type A vaginal surgeries, 261
 - type B1 radical hysterectomy, 258
 - vaginal step, 260
 - bladder pillar, 259, 260
 - pararectal space, 259
 - peritoneal incision, 259
 - rectovaginal ligaments, 259
 - vaginal cuff, 257, 259
 - vesicouterine ligament, 260
 - vesicouterine septum, 259
- Lateral cervical ligaments, *see* Cardinal ligaments
- Lateral Latzko's paravesical space, 49–50
- Lateral paracervix, 64, 65
- Lateral parametrial vessels, 278
- Lateral parametrium, 49–52, 55, 58, 277, 278, 307
- Lateral pararectal space, 50–51
- Lateral rectal ligaments (LLR), 56
- Lateral transperitoneal approach, 287
- Latero-aortic nodes, 286
- Latero-vascular and interaortocaval nodes, 284
- Latero-vascular nodes, 283
- Latzko's space, *see* Lateral pararectal space
- LAVRH, *see* Laparoscopic-vaginal radical hysterectomy (LAVRH)
- LeFort colpocleisis, 205
- Local radical resection, 232, 233, 235
- Locally advanced disease, 248
- Locus minoris resistenciae, 185
- Lower urinary tract (LUT), 62
- Lumbosacral trunk (LST), 69
- Lymph node dissection, 233, 240, 241, 243, 328
- Lymph node metastatic disease, 306
- Lymphadenectomy, 284
- Lymphatic pathways of the uterus, 346
- Lymphostasis, 284
- Lympho-venous anastomoses, 286
- M**
- Magnetic resonance imaging (MRI), 159

- Major vascular injury (MVI), 366
 Manchester procedure, 206
 Marshall-Marchetti-Krantz (MMK) procedures, 218, 219
 Medial pararectal space, 52
 Medial paravesical space, 51, 52
 Membrane syndrome, 181
 Mesh hysteropexy, 207
 Mesometrium, 240
 Mesorectum-sparing sigmoidectomy, 62
 Mesoureter, 240
 Midline plication, 200, 201
 Mid-urethral slings (MUS), 217, 219, 220
 Minilaparotomic myomectomies, 141
 vs. laparoscopic myomectomy, 137
 power morcellation, 144
 Minimally invasive gynecology, 1, 2
 for hospitals, 3
 laparoscopic hysterectomy, 1
 laparoscopic surgery
 development of, 2
 history of, 1
 minimally invasive concept, 1, 2
 scientific societies, participation of, 2, 3
 Minimally invasive surgery (MIS), 297
 Morcellation, 133, 371, 372
 Mucosal skinning, 112
 Müllerianosis, 105
 Myomectomy, 22, 143, 144
 cytotec/vasopressin, 24
 diagnosis, 21
 fertility and pregnancy reates, effects on, 144
 interceed, 24
 laparoscopic myomectomy (*see* Laparoscopic myomectomy)
 laparotomy, 21
 robotic instruments, 24
 robotic-assisted laparoscopic myomectomy
 barbed suture, 143
 operative and perioperative outcomes, 143
 single-site, 143, 144
 versus laparoscopic myomectomies, 143
 vs. abdominal myomectomies, 143
 2-0 V-Loc™ barbed suture, 24
 uterine fibroids, 21, 137
 uterine manipulator, 24
- N**
 Narrowed introitus, 132
 Native tissue repairs, 196
 Natural orifice specimen extractions (NOSE), 114–115
 Needle suspension procedures, 219
 Negrar method, 62
 Neoadjuvant chemotherapy, 233
 Nerve-sparing, 61, 65–73, 269, 275, 278
 in radical endometriosis surgery
 bowel endometriotic nodules, 68
 endometriotic infiltration, 67
 inferior hypogastric plexus, 66
 intestinal endometriosis, 68
 non-touch technique, 67–68
 pelvic splanchnic nerves, 65
 somatic nerves, 67
 radical gynecologic procedures, 61
 radical hysterectomy, 65
 in radical pelvic oncologic procedures
 hypogastric nerve, 72
 hypogastric nerves, 71
 inferior hypogastric plexus, 72
 lumbosacral plexus, 69–70
 para-aortic trunk, 70
 pelvic splanchnic nerves, 71
 superior hypogastric plexus, 70
 Yabuki's space, 73
 Neuropathic injuries, 370, 371
 New crosslinked hyaluronan (NCH), 142
 Nodal resection, 286
 Nodules, 68, 73
 Non-Touch technique, 67–68
- O**
 Okabayashi's pararectal space, *see* Medial pararectal space
 One-step nucleic acid amplification (OSNA)
 assay, 347, 351
 Ovarian cancer
 BRCA mutation, 151
 complications, 150
 cytoreduction, 333
 diagnosis, 333
 disease dissemination, 333
 endoscopic debulking surgery, 334, 341
 endoscopy
 abdominal wound (port site) metastasis, 335
 cancer progression and dissemination, 335
 chemotherapy/cytoreductive surgery, 336
 cyst rupture and tumor spillage, 334
 cytoreductive procedures, 335
 immunological microenvironment, 334
 inflammatory response, 334
 intraperitoneally cancer dissemination, 335
 local macrophages and neutrophils, 334
 peritoneal immunoprotection, 335
 staging laparotomy, 336
 surgical trauma, 334
 fallopian tubes, 150, 151
 female genital tract, 333
 incidence, 333
 laparoscopy applications
 bowel metastasis, 338
 categories, 336
 chemotherapy, 336, 340
 debulking surgery, 338, 339
 debulking/cytoreductive procedure, 336
 disadvantages, 341
 image magnification, 336
 implementation cytoreductive surgery, 339
 laparoscopic secondary cytoreduction, 339
 mesenteric retraction, 338

- Ovarian cancer (*cont.*)
- neoadjuvant chemotherapy, 337
 - oncologic and technical limitations, 336
 - operability predictive index, 338
 - optimal cytoreduction, 337
 - optimal debulking, 339
 - parameters, 337
 - perioperative benefits, 337
 - peritoneal carcinosis, 337, 338, 340
 - peritoneal nodes, 338
 - platinum-based combination chemotherapy, 337
 - procedure-related morbidity, 336
 - secondary cytoreduction surgery, 339
 - small omentum infiltration, 338
 - staging and tumor resection, 339
 - suspicious adnexal tumors, 336, 337
 - therapeutic triage of patients, 339
 - tumor regression after NACT, 340
- mortality, 333
- neoadjuvant chemotherapy, 333
 - operative treatment, 333
 - peritoneal tumor dissemination, 333
 - physiopathology of, 149
 - port site metastasis, 333
 - procedure-related morbidity, 333
 - quality of cytoreduction, 333
 - salpingectomy, 153, 154
 - hysterectomy, 153
 - normal female internal genitalia anatomy, 153
 - type 2 ovarian cancer, 152
 - staging, 333
 - STIC, 149, 151, 152
 - treatment, 333, 334
 - tubal ligation, 152
 - type 1 carcinomas, 151
 - type 2 carcinomas, 151
 - with unilateral salpingo-oophorectomy, 2
- Ovarian cortex, 94, 121, 124, 125, 164, 165, 167
- Ovarian cystectomy, 84, 123, 163–165
- Ovarian endometriomas (OEs), 94, 95, 121, 123–127, 167, 168
- detrimental effect, 122
 - infertility, 121
 - IVF/ICSI outcomes, 122
 - limitation, 122
 - negative impact, 122
 - occurrence, 121
 - origin, 121
 - ovarian reserve markers, 121
 - spontaneous ovulation rates, 122
 - surgical resection
 - ablative surgery, 121, 123
 - bilateral endometriomas, 126
 - histologic markers, 125
 - IVF/ICSI outcomes, 125, 126
 - ovarian cystectomy/stripping, 121, 123
 - recurrence, 127
 - risks of conservative management, 126
 - serum marker, 124
 - sonographic markers, 125
 - three-step procedure, 123
 - symptoms, 121
 - theoretical negative effect, 122
- Ovarian endometriosis, 8, 95, 110
- Ovarian endometriosis cysts, *see* Ovarian endometriomas (OEs)
- Ovarian reserve markers, 121
- Ovariolysis, 167
- P**
- Pagano's urethrotome, 186
- Para-aortic lymphadenectomy, 327
- Paraaortic lymph node dissection, 266, 292, 293
- aging, 293
 - anatomical variations, 292
 - congenital anomalies, IVC, 292, 293
 - kidney variations, 293
 - renal arteries, 292
 - renal polar arteries, 292
 - retro-aortic left renal vein, 292
 - ureter variations, 293
 - aortic bifurcation and promontory, 289
 - azygo-lumbar vein, 288
 - bowel injury, 291
 - carcinomatosis, 293
 - chemotherapy, 283
 - dissection patterns, 294
 - in endometrial carcinoma, 283
 - extended-field radiation therapy, 283
 - extraperitoneal approach, 283, 289, 294
 - fixed node, 291
 - gynecologic oncology, 295
 - hemorrhage, 291
 - indications, 294, 295
 - instrumentation, 284
 - interaortocaval space, 292
 - left renal polar artery, 292
 - lymph leakage, 291
 - lymphatic complications, 293
 - lymphostasis, 291
 - morbid obesity, 293
 - ovarian carcinomas, 283
 - patient and trocar positioning, 287
 - pelvic chemoradiation, 283
 - primary tumor management, 283
 - radiation-induced bowel damage, 294
 - retroaortic left renal vein, 292
 - retroperitoneal dissection, 293
 - single-port approach, 294, 295
 - staging technique, 283
 - surgical radioprotection, advanced cervix cancer, 294
 - transperitoneal, 286
 - trocar placement, 285
 - ureter necrosis, 292
 - ureter stenosis, 292
- Para-aortic lymphadenectomy, 327
- Paraaortic node anatomy, 283, 284
- Paracervical (parametrial) lymphadenectomy, 238, 243, 261, 262
- Paracervix (parametrium), 72, 278
- Parametrial resection, 279

- Parametrium, 55, 56
 - anterior, 55, 241, 243
 - definition, 239
 - dorsal, 243
 - lateral, 55
 - posterior, 241
 - anatomic studies, 56
 - caudad structure, 56
 - cranial structure, 56
 - definition, 55
 - laterocaudal structure, 56
 - TME, 55
- Paraovarian/paratubal cyst, 166–168
- Pararectal space (PRS)
 - lateral, 50, 51
 - medial, 52
- Parasympathetic neural pathways, 61
- Paravaginal tissues, 279
- Paravesical space (PVS)
 - lateral, 49, 50
 - medial, 51–52
- Parietal pelvic fascia, 45
- Partial trachelectomy, 205
- Pelvic and aortic lymphadenectomy, 275
- Pelvic floor
 - efferent innervation, 63
 - fecal continence and evacuation, 63
 - LUT, 62
 - parasympathetic signals, 63
 - rectal and vesical proprioception, 63
 - sympathetic innervation, 63
- Pelvic lymph node dissection, 268
- Pelvic lymph node staging, 317
- Pelvic lymphadenectomy, 69, 258, 346
 - pelvic wall dissection, 267
 - right pelvic sidewall dissection, 267
- Pelvic organ prolapse (POP)
 - anterior compartment
 - anterior colporrhaphy with meshes/grfts, 197, 200
 - laparoscopic/robotic paravaginal repair, 197–199
 - native tissue repairs, 196
 - vaginal paravaginal repair, 196, 197
 - colpocleisis, 207, 208
 - concomitant continence procedures, 208–211
 - laparoscopic surgery, advantages of, 195
 - middle compartment
 - apical prolapse, 202
 - hysteropexy, 205
 - LSC, 203, 204
 - mesh hysteropexy, 207
 - native tissue hysteropexy procedure, 205, 206
 - RSC, 205
 - sacral hysteropexy, 207
 - sacrocolpopexy, 203
 - sacrospinous hysteropexy, 206
 - SSLS, 202
 - USLS, 202, 203
 - uterosacral hysteropexy, 206
 - vaginal mesh hysteropexy, 207
 - pelvic reconstructive surgery, 195
 - posterior compartment
 - anatomic considerations, 200
 - graft and mesh augmentations, 201
 - midline plication, 200, 201
 - perineal insufficiency, 200
 - sacrocolpopexy with extension of posterior mesh, 201
 - site-specific posterior vaginal repair, 201
 - symptoms, 200
 - transanal repair of rectocele, 202
 - symptoms, 195
 - vaginal approaches, 195
- Pelvic plexus (PP), 57–58
- Pelvic spaces
 - Bogros' space, 49
 - lateral Latzko's paravesical space, 49–50
 - lateral pararectal space, 50–51
 - medial pararectal space, 52
 - medial paravesical space, 51, 52
 - rectovaginal septum, 52, 53
 - retropubic (Retzius' space), 48–49
 - retrorectal space, 52
- Pelvic splanchnic nerves (PSN), 51, 56, 57, 61–68
- Pelvic sympathetic pathway, 61
- Pelvic vasculature, 367
- Pelvis
 - cornus uterinus, 47
 - hypogastric artery, 47
 - iliococcygeus muscle, 45, 46
 - ischiococcygeus muscle, 45, 46
 - paravesical space, 47
 - presacral fascia, 46
 - pubococcygeus muscle, 45, 46
 - retropubic (Retzius') space, 47
 - sacral promontorium, 46
 - Sampson's artery, 47
 - transperitoneal profiles, 46
 - umbilical (or obliterated) artery, 46
 - wide extensive infiltration pattern, 46
- Pericervical ring, 196
- Perineal insufficiency, 200
- Peripheral nervous system, 62
- Peritoneal cancer staging system, 334
- Peritoneal carcinomatosis, 171
- Peritoneal endometriosis, 91, 110
- Peritoneal surfaces
 - broad ligament, 48
 - rectouterine fold, 48
 - vesicouterine fold, 47
- Piver-Rutledge-Smith classification, 238, 239
- Pontine micturition center (PMC), 63
- Port site infection, 372
- Posterior intravaginal sling technique, 201
- Posterior parametrium
 - anatomic studies, 56
 - caudad structure, 56
 - cranial structure, 56
 - definition, 55
 - laterocaudal structure, 56
 - TME, 55
- Post-laparoscopy port site herniation, 372

- Post-menstrual abnormal uterine bleeding (PAUB), 182, 183, 186
- Postoperative shoulder pain, 373
- Presacral fascia, 46, 52, 64, 66, 68
- Presacral node resection, 286
- Preventive marsupialization, 289
- Pubococcygeus muscle (pubo-CM), 46
- Q**
- Querleu-Morrow classification, 240–243
- laterally extended resection
 - Cibula two-dimensional adaptation, 242, 243
 - D1 resection, 242
 - D2:D1 plus resection, 242
 - lymph node dissection, 240, 243
 - paracervix
 - minimal resection of, 241
 - transection at junction with internal iliac vascular system, 242
 - transection, at ureter, 242
- R**
- Radiation proctitis/enteritis, 294
- Radical abdominal hysterectomy, 308
- Radical endometriosis surgery
 - bowel endometriotic nodules, 68
 - endometriotic infiltration, 67
 - inferior hypogastric plexus, 66
 - intestinal endometriosis, 68
 - non-touch technique, 67–68
 - pelvic splanchnic nerves, 65
 - somatic nerves, 67
- Radical hysterectomy, 237, 241
 - adverse effects, 237
 - anatomical nomenclature, 239–241
 - cervical cancer treatment, 275
 - classification, 265
 - complications, 265
 - curative effect of surgery, 237
 - IA2-IIA1 stages, 265
 - parametrium resection, 265
 - Piver-Rutledge-Smith classification, 238, 239
 - Querleu-Morrow classification (*see* Querleu-Morrow classification)
 - uterus resection, 265
- Radical pelvic oncologic procedures
 - hypogastric nerves, 71, 72
 - inferior hypogastric plexus, 72
 - lumbosacral plexus, 69–70
 - para-aortic trunk, 70
 - pelvic splanchnic nerves, 71
 - superior hypogastric plexus, 70
 - Yabuki's space, 72
- Radical vaginal trachelectomy (RVT), 257
 - abdominal cerclage, 309
 - blunt dissection, 307
 - cancer recurrence, 308
 - cephalosporin antibiotics, 308
 - clinical staging, 306
 - cone biopsy, 306
 - fertility preservation, 306, 308
 - fertility-sparing surgery, 308
 - history, 305
 - indications, 306
 - Kocher's forceps, 306
 - with laparoscopic lymphadenectomy, 309
 - perioperative morbidities, 307
 - postoperative bladder function, 307
 - postoperative complications, 307
 - pregnancies, 308
 - preterm delivery, 308
 - prognostic factors, 309
 - rectovaginal ligament, 306
 - sentinel node, 306
 - urinary retention, 307
- Rectal deep infiltrative endometriosis, 93
- Rectal pillar, *see* Posterior parametrium
- Rectoceles, 200–202
- Rectovaginal deep infiltrating endometriosis, 88
- Rectovaginal endometriosis, 95
- Rectovaginal fascia defect, 201
- Rectovaginal septum (RVS), 20, 52, 53
- Rectovaginal space dissection, 278
- Retroperitoneal lymphadenectomies, 302
- Retropubic (Retzius' space), 48–49
- Retropubic slings, 220, 221
- Retropubic urethropexy, 218, 219
- Robot docking, 18
- Robotic- assisted sacrocolpopexy (RASC), 27
- Robotic extraperitoneal approach, 294
- Robotic gynecology, 19–21
 - deeply infiltrating endometriosis
 - advanced-stage, 20
 - clinical presentation, 19
 - EEA sizers, 21
 - extensive ureterolysis, 20
 - Fornix presenter, 21
 - outcome measures, 21
 - ovarian cystectomies, 20
 - posterior vaginal resections, 20
 - prevalence, 19
 - rectovaginal septum, 20
 - robotic instruments, 21
 - robotic-assisted laparoscopic colorectal resection, 20
 - surgical resection, 20
 - symptom, 19
 - 2-0 V-Loc™ barbed suture, 21
 - unilateral or bilateral uterosacral ligament resection, 20
 - hysterectomy, 24
 - myomectomy, 22
 - laparotomy, 21
 - LM, 21
 - RALM (*see* Robotic-assisted laparoscopic myomectomy (RALM))
 - uterine fibroids, 21
 - patient positioning, 18

- port placement, 18, 19
 - robot docking, 18, 19
 - sacrocolpopexy, 26, 27
 - uterine manipulator, 18, 20
 - Robotic laparoscopy, 17
 - Robotic radical hysterectomy
 - advantages, 270, 275
 - ambulation, 280
 - cervical cancer treatment, 270
 - cervical stromal invasion, 276
 - complications, 271
 - cost, high, 270
 - drawbacks, 270
 - endometrial cancer treatment, 276
 - 5-year survival of cervical cancer, 272
 - indications, 276
 - intraoperative outcomes, 272
 - laparoscopic and laparotomy approach, 275
 - long-term randomized controlled trials, 272
 - oncologic outcomes, 271
 - paracervical resection, 275
 - patient set up, 276
 - postoperative visit, 280
 - preoperative chemoradiotherapy, 275
 - procedure cost, 272
 - robotic port placement, 271
 - robotic scissors, 271
 - safety and feasibility, 271
 - surgical outcomes, 271
 - surgical steps and technique, 275
 - surgical technique, 270
 - treatment modalities, 275
 - trocarr position, 276
 - Robotic sacrocolpopexy (RSC), 205
 - Robotic-assisted laparoscopic myomectomy (RALM)
 - vs. abdominal myomectomies, 22, 143
 - advantages, 22
 - barbed suture, 143
 - da Vinci robot, 22
 - disadvantages, 22
 - vs. laproscopic myomectomy, 22, 143
 - operative and perioperative outcomes, 143
 - pregnancy outcomes, 23
 - pregnancy rate, 23
 - preterm delivery rates, 23
 - short-term benefits, 22
 - single-site, 143, 144
 - symptom recurrence, 23
- S**
- Sacral hysteropexy, 207
 - Sacrocolpopexy (SC), 26–27, 201, 203
 - Sacrospinous hysteropexy, 206
 - Sacrospinous ligament suspension (SSLS), 202
 - Salpingectomy, 133, 134, 153, 154
 - hysterectomy, 153
 - issue, 154
 - normal female internal genitalia anatomy, 153
 - type 2 ovarian cancer, 152
 - Sampson's hypothesis, 105
 - Schauta Sine Utero, 262
 - Schauthem technique, 262
 - Secondary infertility, 183
 - Second-trimester miscarriage, 308
 - Self-retaining vaginal retractor system, 132
 - Sentinel lymph node (SLN) mapping, 326
 - Sentinel node biopsy
 - allergic reactions, 347
 - applications, 346
 - cervical and subendometrial through hysteroscopy, 346
 - in cervical cancer
 - complications, 349
 - detection techniques, 349, 350
 - FIGO stage, 348
 - immunohistochemical technique, 351
 - intraoperative selection of patients, 351
 - lymphadenectomy, 346, 349
 - lymphatic embolization, 348
 - metastatic affectation of pelvic nodes, 349
 - para-aortic nodes, 349
 - surgery in, 349
 - systematic lymphadenectomy, 349
 - therapeutic strategy, 351
 - ultrastaging, 350
 - cervical dual injection with technetium, 346
 - clinic and pathological factors, 348
 - detection of, 346
 - in endometrial cancer, 345, 346
 - hysteroscopic injection, 346
 - image tests, 354, 355
 - lymph node-specific contrast agent, 355
 - preoperative lymphoscintigraphy, 347
 - surgical treatment, 355
 - techniques, 346
 - ultrastaging, 347
 - validation study, 346
 - in vulvar cancer
 - bilateral inguinal lymphadenectomy, 352
 - bilateral sentinel node procedure, 354
 - disadvantages, 354
 - female genital tract malignancies, 351
 - FIGO system of staging, 351
 - GOG-173 protocol, 353
 - inguinal lymphadenectomy, 352
 - inguinal-femoral lymphadenectomy, 353
 - intensity-modulated radiation therapy, 352
 - lymphatic mapping, 353
 - lymphatic system, 352
 - preoperative planar lymphoscintigraphy, 353
 - radiation therapy vs. pelvic node resection, 352
 - radical vulvectomy, 352
 - randomized controlled trial, 352
 - standard of care of patients, 352
 - surgical procedure, 352
 - technique, 353
 - TNM staging, 351
 - treatment-related morbidity, 352
 - unilateral nodal metastases, 352

- Sentinel node fluorescence, 354
 Sepracor[®], 142
 Seprafilm[®], 142
 Sepraspay[®], 142
 Serous tubal intraepithelial carcinomas (STIC), 149
 Shaving technique, 112, 113
 Single- port extraperitoneal approach, 294
 Small needle puncture wounds, 368
 Somatic nervous system, 63
 SprayGel[®], 142
 Squamous cell carcinoma (SCC), 351
 Stark technique, 182
 Stress urinary incontinence (SUI)
 Burch colposuspension, 209
 cost of, 217
 de novo, 208
 definition, 217
 diagnosis and examination, 218
 mechanism, 217, 218
 occult, 208, 210
 preoperative, 208
 treatment options
 autologous fascial slings, 223, 224
 bulking agents, 224
 ISD and recurrent incontinence, 221–223
 mid-urethral slings, 219
 needle suspension procedures, 219
 radio-frequency and laser therapy, 224
 retropubic urethropexy, 218, 219
 retropubic slings, 220
 single-incision slings, 223
 stem cell injections, 224
 TO or RP slings, selection of, 224
 TO/RP slings, selection of, 225
 transobturator approach, 220, 221
 TVT, 209
 Stripping technique, 94, 123
 Subserosal fibroids, 141, 145
 SUI, *see* Stress urinary incontinence (SUI)
 Superficial endometriotic lesions, 110
 Superficial paracervix, 65
 Superficial thrombophlebitis, 323
 Superior hypogastric plexus (SHP), 57, 64
 Superior rectal artery, 98
- T**
 Table-mounted camera system, 132
 Tamoxifen, 205
 Tension-free vaginal tape (TVT), 220–222
 TNM staging system, 231
 TOT, *see* Transobturator technique (TOT)
 Total abdominal hysterectomy (TAH), 323, 325
 Total laparoscopic hysterectomy (TLH), 87, 325
 development of, 6–8
 endometriosis, with uterine preservation, 9
 laparoscopic vaginal vault closure, with vertical
 uterosacral ligament suspension, 9
 uterine vessel ligation, 9
 Total mesorectal excision (TME), 55
 Total vaginal hysterectomy (TVH), 5
 Traditional posterior colporrhaphy, 200, 201
 Transabdominal cerclage method, 175
 Transobturator technique (TOT), 220, 221
 Transperitoneal laparoscopic paraaortic
 node dissection, 283
 patient and staff positioning, 284
 procedure, 285, 286
 trocar placement, 284
 Transperitoneal para-aortic lymphadenectomy (TPAL)
 technique
 advantages, 298
 anatomical landmarks identification, 299, 300
 aponeurosis incisions, 300
 bleeding, 302
 bowel injuries, 301
 exposure accomplishment, 299
 hemostatic agents, 301
 instrument positioning, 298, 299
 large and heavy bowel loops and mesentery, 299
 limitations, 298
 long learning curve, 300
 low weight heparin prophylaxis, 300
 lymphovascular tissue dissection, 297, 299
 nerve/autonomic plexus injuries, 301
 neuropreservation, 300
 oncological safety, 302
 patient mobilization, 298
 patient performance status, 300
 patient positioning, 298
 peritoneal cavity, 297
 peritoneal incision, 299
 postoperative complications, 301
 preoperative imaging, 299
 prognostic factors, 297
 surgical equipment and team
 training, 300
 surgical morbidity, 302
 surgical specimens, 300
 surgical staging, 302
 therapeutic benefit, 302
 thermal injuries, 301
 tissue handling and dissection, 299
 total blood loss, 300
 tumor stage and biology, 300
 umbilical trocar placement, 298
 urinary lesions, 301
 vascular injuries, 301
 Transumbilical open technique, 276
 instrumentation, 276
 paravesical and pararectal spaces, 277
 retroperitoneal spaces, 277
 robotic column placement, 276
 umbilical optical trocar placement, 276
 Transurethral urinary drainage, 96
 Transvaginal ultrasonography, 92, 183
 TriPort, 33, 34
 Tumor biomarkers, 159
 Tumor management, primary, 283
 TVT, *see* Tension-free vaginal tape (TVT)

Type I macroporous monofilament synthetic polypropylene mesh, 204

U

Ultrasonography, 184

Ultrasound

benign ovarian tumors, 158, 159

mapping, 108

transvaginal, 21, 92–94

Unilateral salpingo-oophorectomy, 2

Ureteral dissection, 10, 279

Ureteral endometriosis, 54

Ureteral injuries, 117, 369

Ureteral tunnel dissection, 279

Urinary endometriosis, 115, 116

Urodynamics, 107, 109, 218

Urologic injuries, 368–370

USTV, 188

Uterine fibroids, 137

by age, 21

diagnosis, 21

Uterine vessel ligation, 9, 11

Uterosacral hysteropexy, 206

Uterosacral ligament suspension (USLS), 202, 203, 278

V

Vaginal cuff closure, 280

Vaginal endometriosis, 112

Vaginal hysterectomy (VH)

abdominal, 131

anterior dissection and entry, 133

completion procedure, 134

due to genital prolapse, 131

elliptical incision, 132

hemostasis, 132

laparoscopic, 131

narrowed introitus, 132

posterior cul-de-sac and entry, 132

robotic-assisted, 131

self-retaining vaginal retractor system, 132

table-mounted camera system, 132

Vaginal mesh hysteropexy, 207

Vaginal paravaginal repair, 196, 197

Vasopressin, 139

Vesicouterine ligament dissection, 279

Vessel-sealing device (VSD), 132, 134, 269

Vulvar carcinoma

diagnosis, 231

incidence of, 231

local radical resection, 232, 233, 235

prognostic factors, 232

vulva, anatomy of, 232

Vulvar intraepithelial neoplasia

(VIN), 231, 233

X

Xenografts, 201