

A
Handbook
of
Operative Surgery
and
Surgical Anatomy
with
Chapters on Instruments

by

Karuna K. Chatterji, F.R.C.S.I.,

LIEUT.-COLONEL, I.T.F.,

Honorary Colonel, Calcutta University Training Corps

Professor of Surgery and in charge of the Department of Surgery, Carmichael Medical College, Calcutta; Fellow of the University of Calcutta; Fellow of the State Medical Faculty, Bengal; Fellow of the Royal Society of Tropical Medicine, London; Visiting Surgeon, Chittaranjan Hospital; Consulting Surgeon, Chittaranjan Seva Sadan, Calcutta; Author of 'Tropical Surgery and Surgical Pathology' and 'Syphilis with special reference to the Tropics'

With 282 illustrations, 17 in colour

Third edition, re-written and enlarged

BUTTERWORTH & CO. (INDIA) LTD.
AVENUE HOUSE, CHOWRINGHEE SQUARE, CALCUTTA

BOMBAY: JEHANGIR WADIA BLDG., ESPLANADE ROAD
MADRAS: 317 LINGA CHETTY STREET

1936

Dedication

To the sacred memory of
the late Rev. Protap Chunder Mozoomdar,
the inspiration of my boyhood and a guide
in later years.

PREFACE

As a science Surgery is progressive; as an art it is undergoing constructive evolution. The teaching and practice of Surgery must keep pace with the rapid advances that are constantly taking shape, and as is only natural, the Indian Medical Council, the various Universities and the Faculties of Medicine are making increased demands on teaching centres, the courses of instruction synchronise with the latest advances in the science. This is indisputably true, and text-books must of necessity be re-edited continuously.

With regard to the present book, I had held up the manuscript of the third edition until the ideas of various authorities had become standardized as was bound to be the case, where all are working for a common end. I found this essential at the present time, owing to conflicting methods and was forced to delay publication to render the book of greater utility to teachers, pupils and practitioners.

The study of anatomy is the landmark of the Renaissance of medicine, and gross anatomy in its relation to surgery, particularly to operative surgery, has a most practical and direct bearing on the subject. In schools of medicine, the department of Surgery is responsible for the proper approach to gross anatomy. With these ends in view, I have attempted to deal in detail with regional, topographic and organ anatomy, elaborating surgical approaches in sequential order to pathologic conditions for which particular operations are planned. It is my hope that this will help the student to anticipate and visualise matters, and infuse in the practitioner a sense of confidence and preparedness to meet eventualities and unforeseen conditions in the wards and operating theatres.

I have felt it incumbent on me to introduce much additional matter in every chapter and also to add new chapters. For instance new matter will be found in the chapters on operations on nerves, muscles, bones and joints. New chapters on the surgery of the Central and Sympathetic Nervous Systems and the Thorax have been introduced, and several additional chapters on Abdominal and Urogenital Surgery have been added. The last chapter in the text is on Electrosurgical methods of operation.

Tropical Surgery has become more or less a special branch and this is why the short chapter on this has been deleted and references in the text made to my book on Tropical Surgery and Surgical Pathology (John Bale Sons & Danielsson, London). I have had to introduce many additional illustrations, 108 in number.

These have been kindly lent by the publishers of Bickham's Operative Surgery (an encyclopædic work of a very high standard), Prof. Wilkie's book on Operative Surgery, Operative Surgery by Grey Turner, Callander's Surgical Anatomy, Jaimeson's Illustrations of Regional Anatomy, Nelson's Loose-leaf Surgery, Straub's Surgery of the Chest, Gask and Ross' Surgery of the sympathetic nervous system.

Due acknowledgement has been made in the text for any use that has been made of these authorities but should there be an inadvertent omission, I hope it will be kindly overlooked.

I desire to express my sense of appreciation of the help rendered by two of my younger colleagues of the Department of Surgery, Carmichael Medical College, Mr. Amiya Sen, M.B., F.R.C.S., has made various suggestions and looked through manuscripts and proof sheets. Mr. P. N. Ray, M.B., F.R.C.S., who is also connected with the Calcutta Medical College, rendered me assistance in the early stages of the book. One of my former House Surgeons Dr. K. M. Seal, M.Sc., M.B., has been good enough to help me in the labour of writing and arranging the press matter with my Publishers.

I also take this opportunity to thank my publishers, Messrs. Butterworth & Co., for rendering me very valuable services in many ways. Indeed Mr. Judson's patience and courtesy has been of a character that only a hard pressed author can properly appreciate; more particularly when authorship conflicts with the calls of practice.

K. K. C.

WOOD STREET, CALCUTTA,

3rd August, 1936.

LIST OF ILLUSTRATIONS.

FIG.	PAGE.
1. Dinner Knife method of holding knife	2
2. Penholder method of holding knife	2
3. Violin bow method of holding knife	2
4. Interrupted suture	6
5. Continuous suture	7
6. Continuous blanket suture	7
7. Manner of placing the subcuticular suture	8
8. Tension suture	9
9. Granny-knot	10
10. Reef-knot	10
11. Surgeon's Knot	11
12. Staffordshire Knot	12
12A. Clove Hitch	14
13. Surface markings of the arteries of the upper extremities	16
14. Ligation of the subclavian artery (Right) <i>Plate Facing</i>	17
15. Ligation of the axillary and brachial arteries ..	19
16. Ligation of the brachial artery at the elbow ..	21
17. Incisions for ligating right radial and ulnar arteries, and superficial and deep palmar arches ..	23
18. Ligation of the radial artery <i>Plate Facing</i>	24
19. Ligation of the ulnar artery <i>Plate Facing</i>	24
20. Points of trephining for hæmorrhage from the middle meningeal artery .. <i>Plate Facing</i>	25
21. Surface markings of the middle meningeal artery ..	26
22. Anatomy of the head and neck <i>Plate Facing</i>	28
23. Ligation of the common carotid artery <i>Plate Facing</i>	29
23A. Incisions for ligation of chief arteries of head and neck	29
23B. Superficial arteries of the neck <i>Plate Facing</i>	30
24. Triangles of the neck .. <i>Plate Facing</i>	31
24A. Blood supply of the faucial tonsil <i>Plate Facing</i>	33
25. Ligation of the lingual artery	34
26. Superficial arteries of the face <i>Plate Facing</i>	35
27. Course and distribution of the intercostal arteries <i>Plate Facing</i>	38
28. Structures on posterior wall of abdomen <i>Plate Facing</i>	40
29. Incisions for ligations of vessels in the abdomino- pelvic region	42
30. Incisions for ligations of vessels about the buttock	44
31. Ligation of right internal pudic and sciatic arteries upon the buttock, below the pyriformis ..	45

FIG.	PAGE.
32. Ligation of right gluteal artery upon the buttock, above the pyriformis	47
33. Ligation of the external iliac artery	48
34. Surface markings of the arteries of the lower extremity	51
35. Ligation of the femoral artery	53
36. Ligation of the popliteal artery	56
37. Surface marking of the anterior tibial artery	58
38. Ligation of the anterior tibial artery	59
39. Surface marking of the posterior tibial artery	62
40. Ligation of the posterior tibial artery	63
41-45. Methods of nerve-suturing	66
46. Nerve anastomosis	66
47-50. Nerve grafting	67
51. Incisions for the exposure of supraorbital, infraorbital and mental nerves (surface anatomy)	68
52. Parotid gland and superficial nerves of the head	69
53. Injection of third division of the fifth nerve	70
54. Surgical approach to the phrenic nerve	72
55. Exposure of the great sciatic nerve at the lower border of the gluteus maximus	74
56. Wolf's method of uniting a tendon to the bone by implantation upon freshened bone and suture to adjacent periosteum	76
57-60. Tenorrhaphy	77
61-64. Less usual forms of tendon lengthening	78
65-68. Tendon shortening by doublings of the freshened tendon upon itself, followed by suturing	79
69. Tendon grafting	80
70. Incision for ligature of the upper part of the popliteal artery and the posterior tibial artery, and incisions for tenotomy of tibialis posticus and tendo achillis	82
71. Myorrhaphy	87
72. Muscle lengthening by multiple cone method	88
73. Muscle lengthening by inverted V-shaped section	89
74. Manner of manipulating the long amputating knife in dividing the soft parts upon the far side of the limb	93
75. Manner of manipulating the long amputating knife in dividing the soft parts upon the near side of the limb	94
76. Circular amputation	95
77. Incising skin and fascia in flap amputation	95
77A-78A. Modified circular amputation	96
79. Amputation : flap method	97
80. Amputation : Racket method	99

FIG.	PAGE.
81. Technic of the osteoplastic method of amputating—I	100
82. Technic of the osteoplastic method of amputating—II	101
83. Wilm's tendino-plastic method of amputation ..	102
84. Thomas' forceps-tourniquet for controlling hæmorrhage during operations upon the extremities ..	104
85. Amputation of the whole finger by disarticulation through the metacarpophalangeal joint ..	108
86. Disarticulation at elbow	117
87. Disarticulation of the shoulder joint	122
88. Amputation of the great toe by disarticulation through the metatarsophalangeal joint	128
89. Lisfranc's amputation	133
90. Incisions for Chopart's amputation	135
91. Separating the os calcis from the astragalus in Farabeuf's sub-astragaloid disarticulation ..	136
92. Dorsal and plantar incisions in Syme's amputation of the foot at the ankle-joint	138
93. Formation of the heel-flap in Syme's amputation at the left ankle	139
94. Guyon's supra-malleolar amputation of the leg ..	143
95. Method of sawing the tibia	147
96. Method of sawing the bones of the leg	147
97. Incision for Stephen Smith's disarticulation at the knee-joint	151
98. Disarticulation at the knee-joint by Stephen Smith's method	152
99. Stump left after Stephen Smith's disarticulation at the knee-joint	153
100. Arthrotomy of the knee-joint	163
101. Excision of the upper jaw	168
102. Excision of the lower jaw	170
103. Resection of ribs	173
104. Linear osteotomy	176
105. Cuneiform osteotomy	177
106. Barker's method of suturing fractured patella ..	180
107. Stimson's method of suturing fractured patella ..	181
108. Suturing the fractured patella	182
109. Arthrodesis	185
110 & 111. Author's modification of continuous irrigation by capillary drainage	186
112. The tendons concerned in excision of the wrist ..	189
113. Excision of the wrist-joint	190
114. Excision of the elbow-joint by posterior median incision—I	192
115. Excision of the elbow-joint by posterior median incision—II	193
116-118. Excisions of the shoulder-joint	<i>Plate Facing</i> 195

FIG.	PAGE.
119. Excision of the ankle-joint by a transversely curved external incision — Kocher's operation ..	197
120. Excision of the knee-joint	198
121. Excision of the knee-joint by an anterior transversely curved incision	199
121A. Operations in the middle line of the neck (surgical anatomy)	203
122. Incisions for opening the pharyngo-laryngo-tracheal tract and adjacent anatomic structures ..	204
123. Infrahyoid pharyngotomy	208
124. Position of the patient in laryngotomy and tracheotomy operations	209
125. Laryngotomy—Transverse intercrico-thyreotomy ..	210
126. High tracheotomy—I	213
127. High tracheotomy—II	214
128. Tracheotomy tube in position	215
129. Low tracheotomy	216
130. Incisions generally used in operating for goitre ..	217
131. Thyroidectomy for simple goitre, by the 'Collar' incision—I	218
132. Thyroidectomy, for simple goitre, by the 'Collar' incision—II	219
133. Diagram representing the midsagittal view of the brain stem, etc.	222
134. Relations of the middle meningeal artery with the cranium, insula and lateral ventricles ..	224
135. The Neisser-Pollack cerebral puncture points localized upon the Kocher craniometric lines ..	226
136. Wagner's osteoplastic resection on skull, brain exposed	227
137. Cisterna puncture	230
138. Sauerbruch's para-vertebrate extrapleural thoracoplasty incision	238
139. Stages of rib resection in Sauerbruch's para-vertebral extrapleural thoracoplasty	239
140. Sauerbruch's para-vertebral extrapleural thoracoplasty	<i>Plate Facing</i> 240
141. Closure of the wound and drainage	240
142. Points of election for pericardiocentesis	242
143. External cesophagotomy	244
144. Excision of the breast	247
145. Lembert sutures	256
146. Czerny-Lembert sutures	256
147-149. Intestinal anastomosis	258, 259
150. Anterior subphrenic abscess from perforation of an ulcer in the anterior wall of the stomach ..	264

FIG.	PAGE.
151. Posterior subphrenic abscess in the lesser sac of the peritoneum	265
152. Retro-peritoneal subphrenic abscess from a gastric ulcer adherent to the back of the lesser sac ..	266
153. Ssabanajew-Franck's method of gastrostomy—I ..	272
154. Ssabanajew-Franck's method of gastrostomy—II ..	273
155. Gastro-enterostomy—I	276
156. Gastro-enterostomy—II	277
157. Gastro-enterostomy—III	278
158. Gastro-enterostomy—IV	279
159. Gastro-enterostomy—V	280
160. Gastro-enterostomy—VI	280
161. Gastro-enterostomy—VII	281
162. Gastro-enterostomy—VIII	281
163. Gastro-enterostomy—IX	282
164. Gastro-enterostomy—X	282
165. Gastro-enterostomy—XI	283
166. Suture of edges of mesocolon to stomach ..	283
167. Hernioplasty—I	286
168. Hernioplasty—II	286
169. Hernioplasty—III	286
170. Hernioplasty—IV	291
171. Hernioplasty—V	291
172. Hernioplasty—VI	291
173. Hernioplasty—VII	293
174. Hernioplasty—VIII	293
175. Appendicectomy—I	301
176. Appendicectomy—II	301
177. Appendicectomy—III	303
178. Appendicectomy—IV	303
179. Appendicectomy—V	303
180. Appendicectomy—VI	303
181. Intussusception of the Enteric variety ..	310
182. Intussusception of the Ileocæcal variety ..	310
183. Intussusception of the Ileocolic variety ..	311
184. Intussusception of the Colic variety ..	312
185. Technic of treating irreducible intussusception ..	313
186. Suturing of the longitudinal defect in the bowel wall	314
187. Some of the more usual incisions for exposing the pancreas, spleen, etc.	322
188. Anorectal and peri-ano-rectal abscess in coronal section	329
189. Author's modification of Mitchell's operation for hæmorrhoids	334
190. Abdomino-perineal excision of the rectum ..	339
191. The Broedel triangular subcapsular kidney fixation sutures	344

FIG.		PAGE.
192.	End-to-side anastomosis of the ureter	347
193.	Ureterocolostomy—I	348
194.	Ureterocolostmy—II	349
195.	Amputation of the penis—I	373
196.	Amputation of the penis—II	373
197.	Plication and overlapping of the hydrocele sac—I ..	378
198.	Plication and overlapping of the hydrocele sac—II ..	378
199.	Plication and overlapping of the hydrocele sac—III ..	378
200.	Spark gap type electro-surgical units	382
201-272.	Appendix (Figures of instruments) ..	409-422

CHAPTER I

GENERAL PRINCIPLES

The responsibilities of an operating surgeon are as much shared by his assistants as the credit of a satisfactory result from it. The operator uses his judgement and discretion in selecting his assistants,—the personnel of his team. For efficient and successful teamwork there should be a sense of mutual understanding and cooperation between them. From the time of the preparation of the patient to the completion of the operation and subsequent dressing of the wound, asepsis and antisepsis have to be maintained, and all possible sources of sepsis should be eliminated by the united efforts of all concerned. A careful study of the clinical conditions and a consideration of indications and contra-indications for operations, attention to the minutest details of technique, untiring patience and thoroughness will help to bring the operation to a successful issue. These are moments of intense concentration when each one of the operating team exerts all his faculties and instincts to attain one goal, that is, completing the operation with quickness and thoroughness. The object of an operation is to do the patient the greatest good as expeditiously and with as little damage to the tissues as possible. The best assistant is he who knows how to get surgically clean and keep clean, is foresighted and resourceful and is steady and patient. Such an assistant has learned to obey; he is quick but not in a hurry; he does his part but is not meddling; he keeps the field of operation clean but his hands away from it. He knows the stages of operations, anticipates events, follows the operator at every step, and has the right thing ready at the right moment. He understands the operator's unspoken language.

The operator is quick, cool and deliberate, but he does not sacrifice details thoroughness and conservation of tissues for speed, yet he does not prolong his operation due to dilatoriness, wavering or indecision. He knows every step of the operation. He knows what he may find and what he may not find. He follows a definite plan for each operation. Each operation consists of units, steps or stages, each unit should be complete and satisfactory, so should be the aggregate of the units constituting the complete operation. This is achieved by simplicity and directness of purpose in personal technique, calmness and patience under most trying circumstances, attention to detail by each unit of the operating team.

A patient is safer in the hands of an apparently timid and painstaking surgeon than in those of a bold, destructive operator. Boldness is an asset but it is the judicious boldness that comes

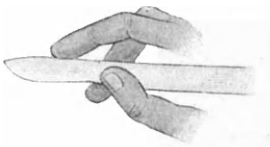
from a close study of the case, a thorough knowledge of anatomy and a genuine inspired confidence in the surgeon himself.

Consistent with the nature of the case the operation should be performed expeditiously because prolongation of the operation means prolongation of the anæsthesia, of exposure of tissues, of trauma caused by retraction, manipulation and handling of structures which affect prejudicially the end results of the operation and the patient's recovery. The desirable acquisitions for a surgeon are 'the eye of an eagle, the hands of a woman' and 'the soul of a man'.

THE KNIFE AND ITS MANIPULATIONS

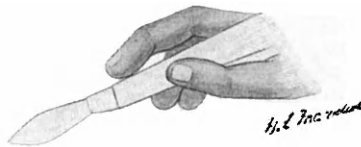The knife is meant for cutting the skin and deeper structures. The skin incision is the key to the further stages of the operation. It should be made in such a way that the position, direction and length of the incision allow free access and facilitate further stages to the operation. The margins should be clean and not ragged and the depth should be uniform throughout, i.e. there should not be any 'tailing' of the ends. The cut margins should come together naturally when closing the wound. In order to attain these the knife should be held first in the stab-incision position at right angles to the skin which punctures the skin for its whole thickness, then the knife is lowered so that the edge is at an acute angle with the skin; the knife is now held in a dinner-knife position (*Fig. 1*) and the whole length of the skin incision is made with a sweep of the belly of the knife but just before completing the incision the first stab-incision position is resumed. The knife therefore enters the skin in the stab-incision position, changes to dinner-knife position and reverts to stab-incision position.

The knife is to be manipulated in different ways for further stages of the operation. It should be held in the pen-holding method (*Fig. 2*) for careful dissections and separation of delicate structures. By violin-bow method (*Fig. 3*) a more delicate and



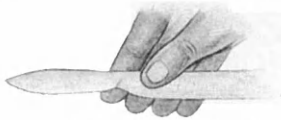Dinner Knife method

FIG. 1.



Penholder method

FIG. 2.



Violin bow method

FIG. 3.

controlled belly-sweep of the knife is used by which one can judge the force exerted and the depth of the desired incision. The stab-incision method is useful for the skin incision, for cutting through hard tissues such as the sole of the foot or when cutting through soft tissues down to the bone.

THE SKIN INCISION

Steady the skin with the left hand by stretching it between the forefinger and the thumb, otherwise the edges will be serrated particularly in lean individuals. Avoid superficial veins as far as possible. The incision should be longer in fat patients. The incision should expose the involved regions freely, give free access to the parts and facilitate freedom of manipulation. A free incision will conserve tissues from avoidable damage as is sure to happen if manipulations have to be made through restricted skin opening.

INCISION FOR DEEPER STRUCTURES

The deep fascia and soft parts should be incised for the whole length of the skin wound, otherwise it will result in a funnel shaped wound. These incisions should be made in the line of cleavage of the structures, layer by layer, as far as possible ; cutting across muscle fibres should be avoided as much as possible. Incision should be clean cut, blunt dissections should be avoided.

SUTURES AND LIGATURES

Sutures are used to bring into apposition structures or tissues which are separated due to pathological or traumatic causes, or in the course of surgical operations. The function of sutures are mechanical and temporary, to keep the separated parts in contact till a natural tissue-union takes place and the rôle played by sutures is completed ; some sutures are absorbed and non-absorbable sutures are removed if they keep irritating or offending the tissues, otherwise they are allowed to get incorporated in the tissues. The length of time required for tissue-union and absorption of the suture material varies and it is desirable to see that the material selected for suturing correspond with the anticipated time of tissue-union. Another function of sutures is to counteract the strain due to muscular and mechanical movements exerted on the parts that are brought together. The principles of suturing are that they should hold the parts in easy but secure apposition, i.e. they should not strangulate or cause tissue necrosis either directly or indirectly.

Sutures may be applied to deeper structures like muscles, pleura, peritoneum, etc. or to superficial tissues like the skin, subcutaneous tissue and fascia. For surface sutures non-absorbable material may

be used but for approximation of deeper tissues sutures should be sterilizable, non-irritating and absorbable.

Ligatures are materials used to tie parts such as pedicles, to obliterate lumens such as of vessels (to arrest hæmorrhage), the appendix etc.

Sutures and Ligatures are classified by Pearson as follows:—

(i) *Absorbable and absorbent*: Catgut, Kangaroo tendon (also reindeer, whale and ox tendons).

(ii) *Non-absorbable*:—

(1) *Non-absorbent*: silver, gold, aluminium, aluminium-bronze and other metallic threads, silkworm-gut.

(2) *Absorbent*: silk, Irish linen thread, Pagenstecher's or Braun's thread which is celluloid hemp; horsehair.

SILK

Silk obtained from the cocoon of the silkworm is a non-absorbable suture material. It may be twisted or braided, white or dyed black. They are of assorted thickness and are numbered 1 to 20 according to increasing thickness. Silk suture is sterilizable by boiling in water or in 1 per cent. watery solution of sodium carbonate. Fine silk is mainly used for intestinal sutures for which the black dyed variety is often selected. Thicker silk is sometimes used for buried sutures, pedicles and large vessels but absorbable sutures are fast replacing silk even for these purposes.

CATGUT

Catgut is strictly speaking a misnomer, because it is made not from the gut of the cat, but of the sheep. The submucosa of the small intestine of the sheep is obtained by macerating and treating the gut and spun into threads. It is arbitrarily sorted in fourteen sizes from 000000 up to 8 according to its thickness but the sizes that are ordinarily used are 00, 0, 1, 2, 3, and 4. Surgeons prefer to use the thinner qualities of catgut as they tie more securely and are less liable to carry infection as the preparatory solutions permeate these more satisfactorily than the thicker varieties.

As catgut cannot and should not be sterilized by boiling in water, various other methods of sterilizing have been devised.

The tendency of catgut to cause suppuration is lessened by using treated catgut than by using plain sterile catgut. Catgut is sterilized by the iodine method, cumol method, formalin method, etc.

Catgut may get absorbed sooner than it is desired, particularly the plain sterile catgut. The period of absorption is generally prolonged by treating with iodine, etc. but it is further prolonged by treating it with a solution of chromic acid. The tensile property

of catgut may be affected by the treatment it is put through. Catgut is not used for skin sutures as the material used for this purpose should be least absorbent and they need not be absorbable as they can be easily removed after the requisite number of days. For apparent reasons catgut is preferable to silk in septic wounds.

KANGAROO-TENDON

Kangaroo-tendon is made from the tendo-achilles or the tail of the Kangaroo. It is absorbable like catgut though it takes longer time ; it is stronger and is less liable to harbour organisms. It is sterilized by chemical solutions as it cannot be sterilized by boiling.

SILKWORM GUT

Silkworm gut is again a misnomer, as it has nothing to do with the gut of the silkworm. It is a fibre drawn out from the silkworm when it is just ready to spin its cocoon. The silk-forming gland of the silkworm is stretched and straightened and allowed to dry. It should therefore be called 'silkworm suture' or 'silkworm fibre'. It should be sterilized by prolonged boiling in water or steam-sterilized under pressure. It is white in its natural stage but is often dyed blue, red or green for easy identification. Silkworm gut is supplied in three strengths, strong, medium and fine.

HORSE HAIR

Black hair from the tail of horses is used. It is non-absorbable and is sterilized by boiling. It minimizes scarring.

PAGENSTECHER'S THREAD

It is prepared by immersing linen thread in celluloid solution. These are made in three qualities, fine, medium and heavy. It is sterilized by boiling but is liable to become brittle if boiled too often. It is used for the same purposes as silk but is smoother and very much stronger.

METALLIC WIRE SUTURES

Silver wire is made from pure un-alloyed silver. It is advisable to sterilize it by passing it through flame to red-heat as it anneals it and makes it less brittle. It is used in bone-surgery and the ideal method is to remove it after union takes place. Strong silk-worm gut suture very often serves the purpose. Aluminium wire is used for the same purpose and are now being largely used as it is absorbed though after a varying and uncertain length of time. Either pure aluminium or aluminium-bronze is used. It is sterilized by boiling. Gold wire and other metallic wires are also used.

WOUND SUTURING

Sutures are meant to bring into apposition structures anatomically and functionally similar which were temporarily divided. For instance while closing an abdominal wound (in the case of a medial laparotomy wound), the structures to be united layer by layer are peritoneum to peritoneum, deep layer of rectus sheath to the deep layer of the sheath, rectus to rectus, superficial layer of rectus sheath to the superficial layer, fascia to fascia and skin to skin.

The approximation should be accurate and there should not be undue tension on the parts. This temporary approximation should be such as to lead to a permanent tissue-union which would be mechanically and functionally strong and bear the strain satisfactorily.

Too close and too tight approximation defeats the objects in view by causing tissue-necrosis. This should be remembered in skin-suturing and allowance should always be made for the preliminary oedema and swelling of the parts.

Some tissues undergo tissue-union more readily than others, for instance endothelial tissue unites in twenty-four hours, that is why very fine absorbable sutures are used for peritoneum, pia mater, pleura, etc. Tissues also vary in their power of absorbing absorbable suture material.

DIFFERENT METHODS OF SUTURING WOUNDS

1. THE INTERRUPTED SUTURE

The threaded needle enters the skin about $\frac{1}{4}$ " from the margin on one side of the incision, enters the raw surface of the other side of the cut margin also $\frac{1}{4}$ " away and emerges upon the skin and the two ends are tied off on one or the other side of the incision by a double knot or a friction knot (*see* LIGATURES). Interrupted sutures may be for deeper structures, buried sutures and for the skin. The interval between each stitch depends on the tissues apposed. This is the safest and best method of suturing. (*Fig. 4.*)

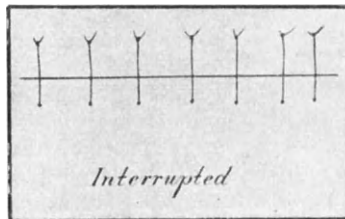


FIG. 4.

2. THE CONTINUOUS SUTURE

It is begun by making a stitch at the near end of the incision and knotting it off. It is carried from side to side $\frac{1}{4}$ " to $\frac{1}{3}$ " from the margins adjusting the tension accurately by pulling up each loop in turn till the far end of the incision is reached where it is completed by securing it with a knot. The only advantage of this suture is that it is rapid. It is used in suturing serous membranes, etc. (*Fig. 5.*)

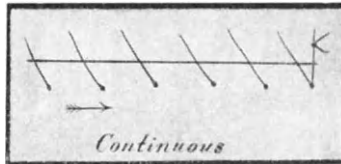


FIG. 5.

3. THE CONTINUOUS BLANKET SUTURE

It is a continuous suture in which each loop is caught up with the needle as it passes. The needle passes through the line of the incision at right angles, and, after piercing, passes over the suture, while it is held down on the side of the emerging needle under finger of the opposite hand. (*Fig. 6.*)

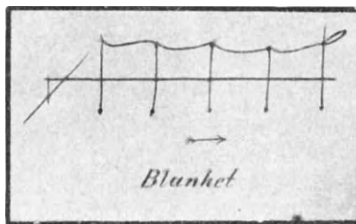


FIG. 6.

It is a right-angled method of continuous suturing. It is commenced with a knot and completed by tying the looped end with the free end.

4. SUBCUTICULAR CONTINUOUS SUTURE

The advantage of this suture is that it minimizes skin infection and scarring. The disadvantage is that if it gives way at one spot the whole suturing is rendered useless. The needle enters the skin $\frac{1}{4}$ " from the margin and pierces the deeper layer of the skin and subcutaneous tissue of the wound from side to side for

the whole end of the wound. The free ends of the suture are left outside the wound and pulled taut to approximate the edges. (*Fig. 7.*)

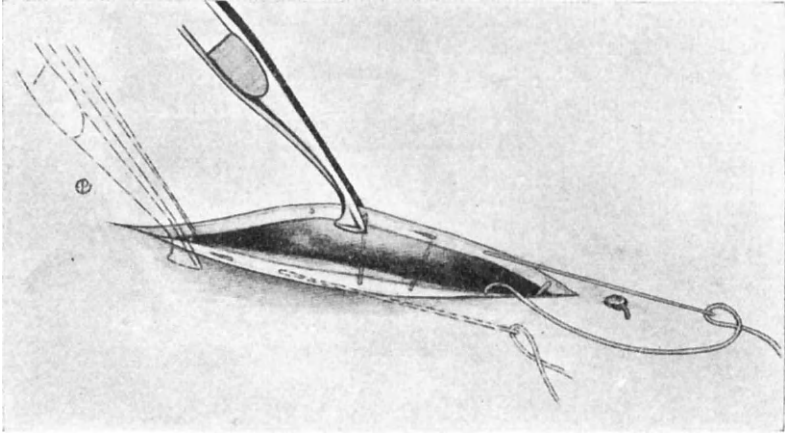


FIG. 7.

MANNER OF PLACING THE SUBCUTICULAR SUTURE:—Having anchored the end of beginning, and brought the suture into the wound, the needle then passes through the resistant layer of the true skin, alternately upon the two sides near to, and paralleled with their surfaces—while the margins of the skin are held in easy relationship for the on-coming needle, by means of special skin-forceps—the opposite borders of the wound being presented in alteration.

5. TENSION OR RELAXATION SUTURE

If there is a tendency for the wound to gape due to tension, interrupted tension sutures or mattress sutures are applied. The interrupted tension sutures (*Fig. 8*) are applied alternately with the ordinary interrupted approximation sutures. *Mattress sutures* are applied by inserting the needle about $\frac{3}{4}$ " away from one margin of the wound and emerging it at a corresponding point on the other side; it is then carried in a rectangular fashion, parallel to the edge of the wound for about $\frac{3}{4}$ ", made to enter again and emerge through the former edge of the skin about $\frac{3}{4}$ " from the point at which the free end of the suture is lying and tied off there. Split shots, buttons, glass rods, rubber tubings, etc. are sometimes placed under the tension sutures to take off undue strain on the punctures.

6. METALLIC SUTURES

Michel's suture clips and other devices have been introduced for suturing skin. They leave less linear scars and allow escape of serum and fluids without capillary or other drainage.

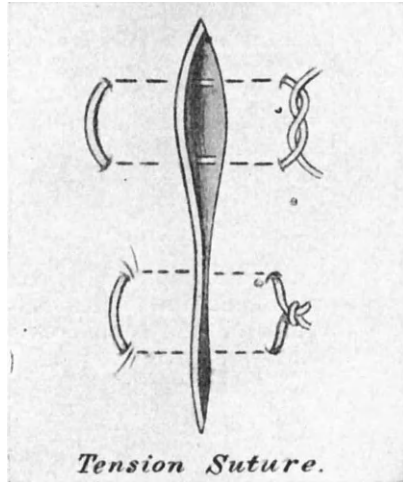


FIG. 8.

LIGATION OF ARTERIES

Divided ends of arteries are ligatured to arrest hæmorrhage. The vessel-end is picked up in its axis and secured by hæmostatic forceps and the part of the vessel just proximal to the tip of the forceps is tied by a reef-knot or surgical knot.

Arteries are also tied in its continuity but the indications for this form of ligation of vessels are getting less with the advance of the knowledge of surgery and improvements in surgical technique. This is however freely practised on the cadaver.

The chief indications are :—

1. Aneurysms—the artery is ligatured either proximal or distal to the aneurysm.
2. As a preliminary step to some operations for the arrest of hæmorrhage, e.g., the common carotid is tied before the removal of the upper jaw or of a parotid tumour, the lingual artery before excision of the tongue.
3. In some cases of primary or secondary hæmorrhage.
4. To arrest hæmorrhage from malignant tumours.

The following are some of the methods of applying ligatures. Items of importance are the knot and knot-tying. The ligature should be of sufficient length so that while manipulating it and tying the knot a sufficient length is available for a purchase in the palms of the hands besides the part actually required for applying

the knot on the vessel. The knot should be so constructed that it should be able to counteract the factors which tend to loosen, undo, or slip it.

In tying a knot the ligature has to be twisted. A half-hitch means twisting one end of the ligature completely round the other. On the manipulation or disposition of these half-hitches depends the quality and strength of the knot.

THE FALSE OR 'GRANNY' KNOT

The false or 'granny' knot should not be practised in surgery; this can easily be untied as in this the loop of one knot passes in front of one limb of the ligature and behind the other; in other words the two half-hitches are made in the same direction. (*Fig. 9.*)

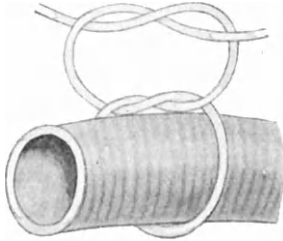


FIG. 9.

THE REEF-KNOT OR THE SQUARE KNOT

The loop of the knot passes in front of both the limbs of the ligature at one end and behind both limbs of the ligature at the other end, i.e. the second half-hitch is the reverse of the first one. (*Fig. 10.*)

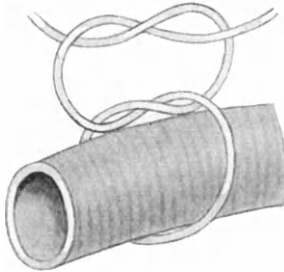


FIG. 10.

A FRICTION-KNOT

A friction-knot is made by carrying the ligature twice round, i.e. by making a double hitch.

A TRUE OR SURGEON'S KNOT

A true or surgeon's knot is made by making a friction knot and completing it by applying the second stage or phase of the reef-knot. (*Fig. 11.*)

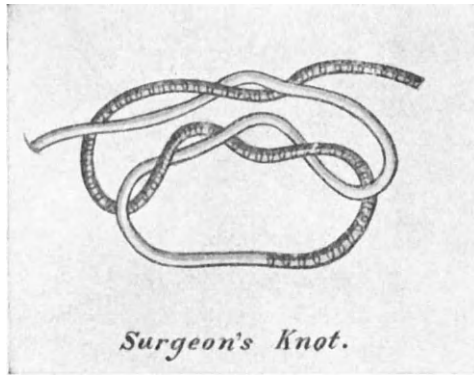


FIG. 11.

For pedicles of organs such as the kidneys, testicles, spleen, etc., of growths (neoplasms), for excision of tissues and structures such as the omentum, mesentery, etc., the ideal surgical method would be to ligate the individual vessels and structures constituting the pedicle independently, but as it is not always possible the following methods and their modifications among others have been devised for the purpose.

TRANSFIXING LIGATURE

Pass a looped ligature through the middle of the pedicle by means of a blunt needle or a fine pair of forceps avoiding vessels while doing so; pull out the loop and divide it and tie the two half-sections of the pedicle separately and finish up by taking the ends round the whole pedicle and tying it. Each half of the pedicle has a separate ligature and the whole pedicle has another one. Large pedicles may be taken in three sections or tied by interlocking ligatures described later.

STRAFFORDSHIRE KNOT LIGATURE

Pass a double ligature through the pedicle. Pass the loop over the organ or growth and then pass one of the ends of the

ligature above the loop and the other below. Pull the ends of the ligature tight and tie. Bring the ends of the ligature round and tie again, if necessary. (*Fig. 12.*)

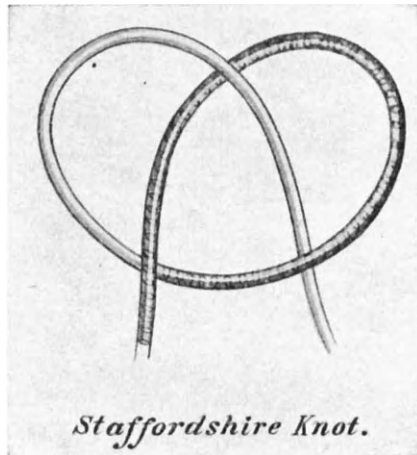


FIG. 12.

INTERLOCKING OR CHAIN LIGATURE

This is suitable for large or thick pedicles, for omentum, mesentery, etc. Pointed hæmostatic or other forceps are passed through the tissues and loops of ligature are drawn through from the less accessible to the more accessible side. These loops are divided at their domes so that each one forms two units; then the adjacent limbs are interlocked so that one limb of each loop crosses the adjacent limb of the neighbouring loop and each ligature is tied by the limbs of its own loop.

In the ligation of arteries certain general rules are followed and the steps of the operation are as follows :—

OPERATION

Position of the Patient. The patient and the operator should be in such positions as to ensure easy access to the field of operation. The operator ordinarily stands on the side of the patient to be operated on and places the limb or the part in such posture as to mark the anatomical line of the artery easily.

The Line of Artery. This is to be ascertained by means of anatomical points and marking these after placing the part or limb in the necessary position, e.g. turning the head on one side

or the other, placing the hand or leg in an extended, flexed, or abducted position.

The Incisions. The method of making the skin incision has been described. Make the incision sufficiently long, i.e. long enough to bring clearly into view the deeper parts of the field of operation. Avoid superficial veins as much as possible.

Divide the deep fascia or aponeurosis in the line of the skin incision and for the whole extent of it. This exposes the underlying soft structures, muscles, tendons, etc.; identify these and the intermuscular spaces and septa. Separate these for the full extent of the incision and if necessary change the position of the part or limb to relax the muscles.

Retract the skin, subcutaneous tissue and muscles to get a good view of the depth of the wound. If the incisions are made as described above, the wound will be of uniform length throughout and not funnel shaped.

Exposure and Identification of the Artery. Feel for the artery with the finger, it would feel like a thick, elastic thong with an axial depression in the centre, i.e. the margins will feel thicker than the middle part if palpated along the length of the artery. The *vene comites* may be seen and the discerning eye might see the *vasa vasorum*.

The nerves are uniformly rounded and thick like a cord. The veins are correspondingly larger, they are thinner, less elastic and easily compressed.

Opening the Sheath. Pick up the sheath with a pair of dissecting forceps in the centre or middle line of the artery so that the fold of the sheath is at right angles to the long axis of the artery. Hold the knife in the violin-bow position in such a way that the flat surface of its blade is parallel to the vessel wall and the edge at right angles to the fold and make a nick or opening in the sheath for about 5 to 10 m.m. according to the size of the artery.

Passing the Ligature. The cellular space between the artery and its sheath is now in view; keep holding on to the sheath with the forceps with the left hand and with the unthreaded aneurysm needle held by the right hand clear this space all round the vessel. Commence from your side and clear it half way towards the deep aspect of the vessel and then working from the off side down till the whole circumference of the artery is cleared of its sheath and the needle emerges from underneath the artery; about one centimetre of the artery is cleared.

In order to tie the ligature pass the aneurysm needle unthreaded from the more dangerous side, i.e. the side on which veins, nerves, and other structures are in close relation to the artery to the free or less dangerous side but always from the side of the forceps holding the sheath. Move the needle gently from side to side to

make sure that it is resting quite free. Thread the needle as its tip and eye emerge, hold one end of the ligature and draw the needle back gently with the other end.

Tying the Knot. Take the two ends of the ligature in either hand, get a good hold of it in the palm and tie the first phase of the surgical knot and in doing so let the tips of the two forefingers meet upon the artery and to tighten it either let the distal knuckles of these fingers come in contact or use the two thumbs for it; now complete the second phase of the knot similarly. The ligature should be exactly at right angles to the long axis of the artery.

Comment:—1. Some prefer using a reef-knot. 2. The knot should be tight enough to obliterate the lumen but not tighter. 3. Do not pull the artery out of its bed. 4. Do not use force but pull steady. 5. Cut sheath with exact precision holding the flat surface of the knife parallel. 6. Do not release hold on the sheath till the ligature is pulled through. 7. Hold the needle always at right angles to the long axis of the vessel. 8. Do not be too anxious to separate the *vene comites*; some transverse branches may be cut and the oozing obscure the view. These *vene comites* are present in the arteries of the leg below the knee, the arm, forearm, and hand; in the smaller arteries of the trunk, the pudic, deep epigastric, deep circumflex, and the internal mammary. The arteries of the head and neck have accompanying single veins excepting the lingual.

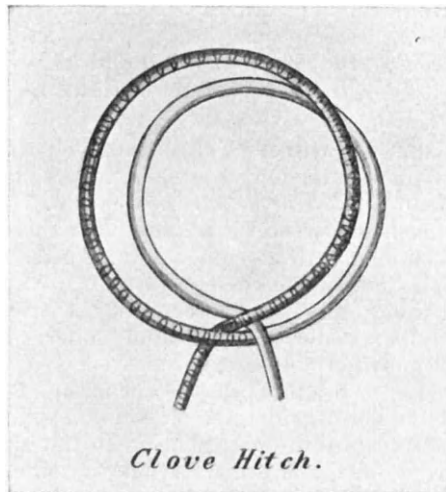


FIG. 12A.

CHAPTER II

LIGATION OF ARTERIES

PRELIMINARY REMARKS

In ligating an artery in its continuity: (1) Define the anatomical landmarks and the line of the artery. (2) Make the incision. (3) Expose sheath. (4) Pick sheath up with dissecting forceps. (5) Hold scalpel by the violin-bow method with the blade parallel to the sheath (*Fig. 3*) and make a small nick in it just enough to pass the aneurysm needle and the ligature conveniently. (6) Pass the unthreaded needle from the side of the artery which has important structures close to it, towards the opposite (less dangerous) side, thus avoid injuring these structures or including contiguous structures in the ligature. (7) Thread the needle and bring it back. (8) Tie a reef or surgical knot (and in doing so, pass the tips of your forefingers down to the vessel) tight enough to obliterate its lumen but not tighter. (9) Do not pull the artery from its bed. (10) Do not jerk. (11) Do not use force but pull steadily, the ligature will not snap then. (12) Do not use ligature too thin, it might cut through the coats of the artery.

ARTERIES OF THE UPPER EXTREMITY

SURGICAL ANATOMY

THE SUBCLAVIAN

The Subclavian arises on the right side from the innominate, behind the right sterno-clavicular articulation and on the left side at a slightly lower level from the arch of the aorta. It becomes axillary at the outer (lateral) border of the first rib opposite the middle of the clavicle. The scalenus anticus (scalenus anterior) divides the subclavian into three parts: the first part, from the origin of the artery to the inner (medial) margin of the scalenus anticus (scalenus anterior), the second part, behind that muscle, and the third part, from the outer (lateral) margin of that muscle to the outer margin of the first rib.

THE AXILLARY

The Axillary is divided into three stages: the first stage, from the outer border of the first rib to the upper border of the pectoralis minor, the second stage, behind it and the third stage, from its lower border to the lower border of the teres major. (*Fig. 13.*)

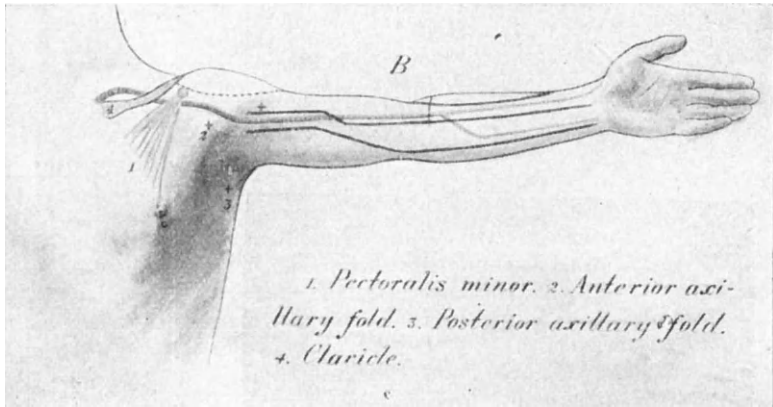


FIG. 13.

SURFACE MARKINGS OF THE ARTERIES OF THE UPPER EXTREMITIES.

THE BRACHIAL

The Brachial extends from the lower border of teres major to a little below the middle of the bend of the elbow. The ulnar and the radial, the terminal branches of the brachial, commence at the inner side of the neck of the radius. (*Fig. 13.*)

THE ULNAR

The Ulnar artery ends by passing over the anterior annular (transverse carpal) ligament at the wrist to form with a branch of the radial, the superficial palmar (volar) arch. (*Fig. 13.*)

THE RADIAL

The Radial artery terminates by passing backwards over the radius above its styloid process to reach the dorsal surface of the hand; it then passes between the two heads of the first dorsal interosseus muscle to enter into the formation of the deep palmar (volar) arch. (*Fig. 13.*)

INDICATIONS FOR LIGATION

The following are the main indications for ligaturing the arteries of the upper extremity:—

(1) Hæmorrhage from an injured artery (due to fractures, dislocations or wounds). (2) Secondary hæmorrhage. (3) Aneurysm. (4) Preliminary to amputations, etc. (5) In vascular sarcomata, to check its growth and arrest hæmorrhage.

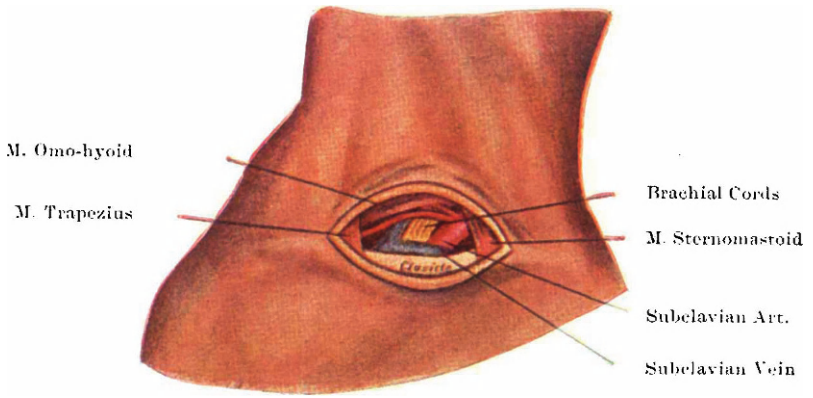


FIG. 14.

LIGATION OF THE SUBCLAVIAN ART. (RIGHT).

LIGATION OF THE SUBCLAVIAN ARTERY

(In its third part)

POSITION

Dorsal position on the edge of the table. Raise thorax, turn head on opposite side, depress shoulder by pulling arm down along the side of the body. Stand facing the shoulder. An assistant stands between the head and the shoulder of the same side.

SURFACE MARKING

The cervical course of the subclavian artery is represented by a curved line from the sterno-clavicular joint to the mid-point of the corresponding clavicle, the convexity of the line extending upwards into the supra-clavicular fossa for about $\frac{3}{4}$ " to 1" above the clavicle. The outer (lateral) border of the scalene muscle usually corresponds to the outer border of the sterno-mastoid (sterno-cleido-mastoideus) muscle, and consequently the third part of the subclavian artery is represented by that part of the curve, which lies between the outer border of the sterno-mastoid and the mid-point of the clavicle. It is ligatured in the third part.

OPERATION

Draw down the skin over the posterior triangle of the neck with the left hand to avoid wounding the external jugular vein. Make an incision from the outer margin of sterno-mastoid (sterno-cleido-mastoideus) to the inner (medial) margin of the trapezius (base of posterior triangle), through the skin down to the clavicle, about 3" long; allow the skin to retract; the wound is now seen half an inch above the clavicle. This incision cuts through integument, platysma and some supra-clavicular nerves and exposes the deep cervical fascia. Divide this in the whole length of the skin incision. Retract external jugular vein or cut it between two ligatures. Define outer margin of scalenus anticus (sclenus anterior) and omohyoid, seek with the finger for the scalene tubercle of the first rib and the vessel as it rests on the rib. Expose the lowest cord of the brachial plexus by dissection. The subclavian vein lies at the lowest part of the incision. The transverse cervical and the supra-scapular (transverse scapular) arteries may or may not be seen. Pass needle from above downwards and from behind forwards, avoiding the subclavian vein below (*Fig. 14*).

Comment :—(1) Draw down the skin and cut down on the bone. (2) Do not prick or scrape with the knife. (3) Do not pass the needle from below, you may include the lowest brachial cord. (4) Do not injure the subclavian vein. (5) Do not injure the pleura.

COLLATERAL CIRCULATION

(1) Supra-scapular (transverse scapular) from thyreoid axis (thyreocervical trunk) and posterior scapular (descending branch) from transversalis colli (transversalis cervicis) with acromio-thoracic (thoraco-acromial) and subscapular from axillary. (2) Superior intercostal (costo-cervical) aortic intercostal and internal mammary with long thoracic (lateral thoracic) and subscapulars.

LIGATION OF THE AXILLARY ARTERY

SURFACE MARKING

Take a point at the middle of the clavicle. Divide the space between anterior and posterior folds of the axilla vertically into three parts. Take a point at the junction of the upper third with lower two-thirds of this line. Join the point at the middle of the clavicle to this point. This line represents the line of the artery. This artery is ligatured in its first part or third part (*see Fig. 13*).

A. *In the First Part of the Artery*

POSITION

Same as for ligation of the subclavian artery : do not depress shoulder but let the arm lie along the side of the body.

OPERATION

A curved incision with the convexity downwards is made, three inches in length about half an inch below the clavicle, in such a way that the centre of the incision is opposite the centre of the clavicle. The skin for this incision need not be pulled up or down, as there are no veins of any importance lying under the superficial structures. The skin, superficial fascia, platysma, and deep fascia are divided, and the clavicular head of the pectoralis major muscle is cut for the entire length of the wound. The costo-coracoid membrane (coracoclavicular fascia) is seen and the cephalic vein noted as it comes inwards (medialwards) in the groove between the deltoid and the pectoralis major muscles piercing this membrane and entering the axillary vein. The cephalic vein is a good guide to the axillary artery : the latter lies above and to the outer side of the axillary vein. The subclavian muscle may appear in the wound above, the pectoralis minor below. The axillary vein lying below and to the inner side slightly overlaps the artery. The thick axillary sheath is opened in the usual way and the aneurysm needle passed from within outwards.

- Comment* :—(1) Do not injure the axillary vein.
 (2) See that none of the cords of the brachial plexus is caught in the ligature.

*B. In the Third Part of the Artery***POSITION**

Abduct arm at right angles to the trunk. Stand between the arm and the trunk facing the axilla. Assistant stands in front between the head and the shoulder.

OPERATION

Make an incision three inches long horizontally along the line of the artery dividing integument and fascia. This exposes the inner (medial) margin of the coraco-brachialis with the musculocutaneous nerve entering it. Retract this outwards. Seek for the artery which is surrounded by large branches of the brachial plexus. The median nerve lying in front and to the outer (lateral) side is included in the retractor for the coraco-brachialis. The musculospiral (radial nerve) is behind the artery. The ulnar nerve and the veins are on the inner side. Pass the needle from within outwards (*Fig. 15*).

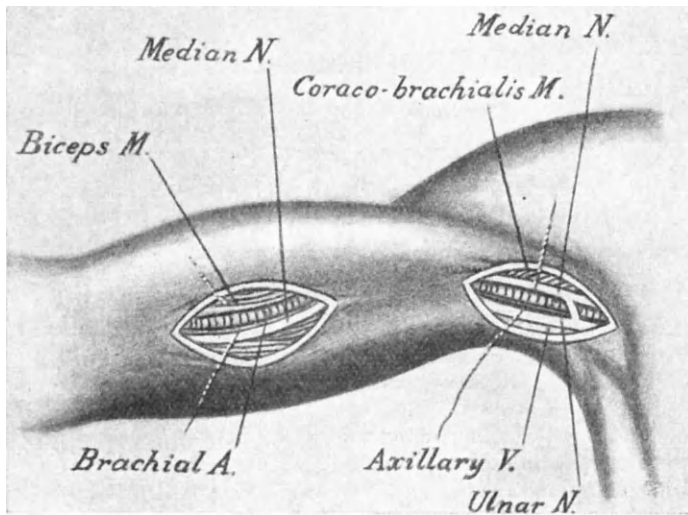


FIG. 15.

LIGATION OF THE AXILLARY AND BRACHIAL ARTERIES.

Comment :—(1) The coraco-brachialis is the guide on its inner side. (2) Do not include any of the nerves or veins surrounding the artery in the ligature. (3) An aberrant slip from the latissimus dorsi may be passing across the vessels to join the pectoralis major or biceps, this should not be mistaken for coraco-brachialis muscle.

COLLATERAL CIRCULATION

Superior profunda (arteria profunda brachii) with subscapular, anterior (humeral) circumflex and posterior (humeral) circumflex.

LIGATION OF THE BRACHIAL ARTERY

This artery is ligatured in the middle of the arm or at the bend of the elbow.

SURFACE MARKING

Place the arm and the forearm in the position as for axillary artery. Take the point where the axillary artery ends. Take another point at the mid-point at the front of the bend of the elbow at a level of the head of the radius. The line joining these two points is the line of the artery. The last point represents its bifurcation into radial and ulnar arteries (*see Fig. 13*).

A. In the Middle of the Arm

POSITION

Abduct arm to a right angle and supinate forearm. Stand between the limb and the trunk. Place assistant opposite, on the other side of the arm. The arm rests on a small block placed under the olecranon. The middle of the upper arm should be free from any pressure from underneath to avoid pushing triceps forwards.

OPERATION

Make an incision two and a half inches in length along the inner (medial) edge of the biceps in the line of artery. The thin fascia is divided. Identify the inner margin of the biceps carefully. Dissect gently and expose the median nerve lying in front of the artery. Retract the nerve outwards (lateralwards), separate venæ comites, if possible; pass aneurysm needle according to choice avoiding veins and nerves (*see Fig. 15*).

Comment :—(1) Do not rest the upper arm on the block, the triceps may be pushed up and mistaken for the biceps. (2) The median nerve though usually in front may pass behind the artery. (3) An abnormal high bifurcation of the brachial into ulnar and radial is not unusual. (4) The artery may be retracted with the retractor for the biceps. (5) The basilic vein, the median nerve and the inferior profunda (superior ulnar collateral) artery have sometimes been mistaken for the brachial artery.

*B. At the Bend of the Elbow (Cubital Fossa)***POSITION**

Same as for the previous operation. Flex and extend the elbow joint to determine the exact position of the biceps tendon and leave it in a slightly flexed position for the operation.

OPERATION

Make a slightly oblique incision two inches long through the skin and deep fascia along the inner (medial) edge of the biceps, the centre being on the crease of the elbow and its lower end pointing towards the thumb. Retract the superficial nerves and veins. The bicipital fascia is now exposed with its fibres directed obliquely downwards and inwards (medialwards). Divide the fascia in the line of skin incision, i.e. against the direction of its fibres. This exposes the artery with its venæ comites. The artery may be embedded in fat and freely movable. The median nerve may be seen on the inner side, at the upper part of the incision. The ulnar nerve does not come into view. Pass the needle from the inner (medial) side avoiding the median nerve (*Fig. 16*).

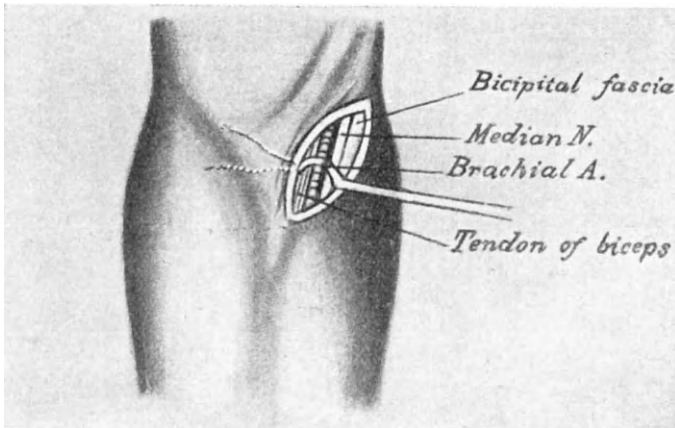


FIG. 16.

LIGATION OF THE BRACHIAL ARTERY AT THE ELBOW.

LIGATION OF THE RADIAL ARTERY**POSITION**

Arm abducted at right angles and forearm supinated. Operator stands on the outer (lateral) side of the arm.

SURFACE MARKING

Draw a line from the middle of the antecubital fossa at a level of the head of the radius to its styloid process outside the scaphoid (navicular) tuberosity (*see Fig. 13*). It can be ligatured in four situations.

A. In the Upper Third of the Forearm

OPERATION

Make an incision two and a half inches long in the line of the artery, dividing the skin, superficial and deep fasciæ. This exposes the interval between the longitudinal fibres of supinator longus (brachio-radialis) and oblique fibres of pronator radii teres (pronator teres) muscles. The artery will be found under cover of the brachio-radialis muscle. The needle can be passed from either side as the nerve is not in relation with it.

B. In the Middle Third of the Forearm

OPERATION

Divide skin and superficial tissues in the line of the artery. This exposes supinator longus (brachio-radialis). Define its inner (medial) border. Retract it outwards. The artery is found lying on the insertion of pronator radii teres (pronator teres). Separate venæ comites. Pass needle from the radial side as the nerve lies on this side (*see Figs. 17, 18*).

C. In the Lower Third of the Forearm

OPERATION

Make an incision one and a half inches long in the line of the artery between the tendons of brachio-radialis and flexor carpi radialis. Divide the thin fascia. The artery is exposed with the radial vein lying in front of it. The venæ comites are firmly attached to it. Separate them if possible. Pass needle according to choice (*Fig. 17*).

D. At the Back of the Wrist (in the tabatière anatomique)

POSITION

Hand rests on its ulnar border, the thumb extended and abducted, and the fingers extended by the assistant.

SURFACE MARKING

Draw a line from the tip of the styloid process of the radius to the upper angle of the first interosseus space. This indicates the line of the artery.

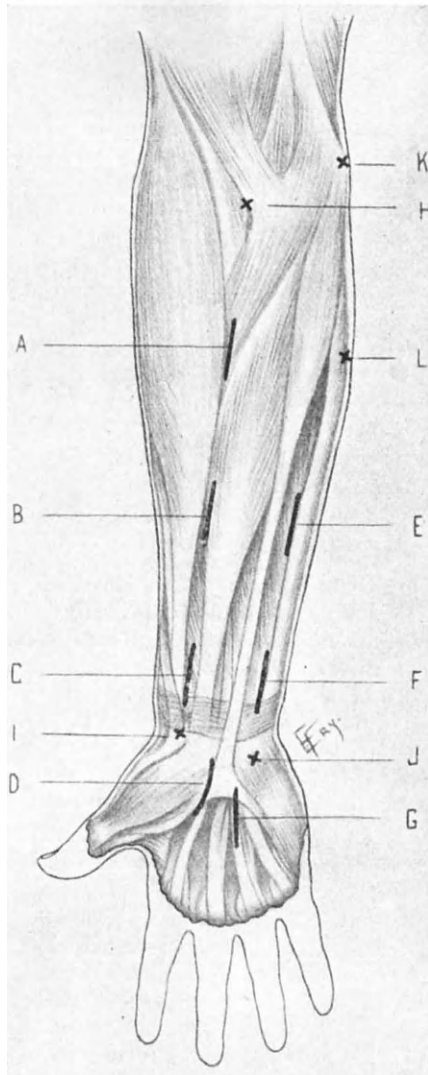


FIG. 17.

INCISIONS FOR LIGATING RIGHT RADIAL AND ULNAR ARTERIES, AND SUPERFICIAL AND DEEP PALMAR ARCHES:—A, Ligation of radial in upper third of forearm; B, of radial in middle third; C, of radial in lower third; D, of deep palmar arch; E, Ligation of ulnar in middle third of forearm; F, of ulnar in lower third; G, of superficial palmar arch; H, Center of bend of elbow; I, Antero-internal aspect of styloid process of radius; J, Radial side of pisiform bone; K, Anterior aspect of inner condyle of humerus; L, Point on inner aspect of forearm at junction of upper and middle thirds.

REPRODUCED FROM BICKHAM'S OPERATIVE SURGERY
By the Courtesy of THE W. B. SAUNDERS CO.

OPERATION

Make an incision one inch long in the centre of the space between the extensor ossis metacarpi pollicis (abductor pollicis longus) and extensor brevis pollicis. This incision crosses the line of the artery almost at right angles and when deepened exposes the artery. Pass needle from either side.

Comment :—(1) Deepen incision cautiously as the artery is liable to be cut across. (2) Do not open the tendon sheaths.

LIGATION OF THE ULNAR ARTERY

POSITION

As for the radial artery.

SURFACE MARKING

Take a point (*a*) at the tip of the internal condyle (medial epicondyle) of the humerus and another (*b*) at the outer (lateral) side of the pisiform bone. Join these points by a line and divide it into three equal parts. Take a third point (*c*) at the junction of the upper third with the lower two-thirds of this line (*a*, *b*). Take a fourth point (*d*) at the middle point of the elbow, at a level of the head of the radius. Join the three points (*d*, *c*, *b*). This represents the line of the artery (*see Fig. 13*). This artery can be ligatured in the middle or the lower third of the forearm.

A. In the Middle of the Forearm

OPERATION

Make an incision three inches in length along the line of the artery exposing the thin deep fascia. Incise the fascia a little to the outer side of the skin incision. This exposes the white intermuscular line between flexor carpi ulnaris and flexor sublimis digitorum. Now, flex the wrist to relax the muscles. Retract flexor carpi ulnaris inwards (medialwards) and flexor sublimis digitorum outwards (lateralwards). The ulnar nerve is exposed. The artery is on the outer (lateral) side of the nerve. Pass the needle from within avoiding the nerve (*see Figs. 17 and 19*).

B. In the Lower Third of the Forearm

OPERATION

Make a two inches long incision along the line of the artery just to the radial side of the flexor carpi ulnaris tendon, the lower end of the incision ending above the pisiform bone (*see Fig. 17*).

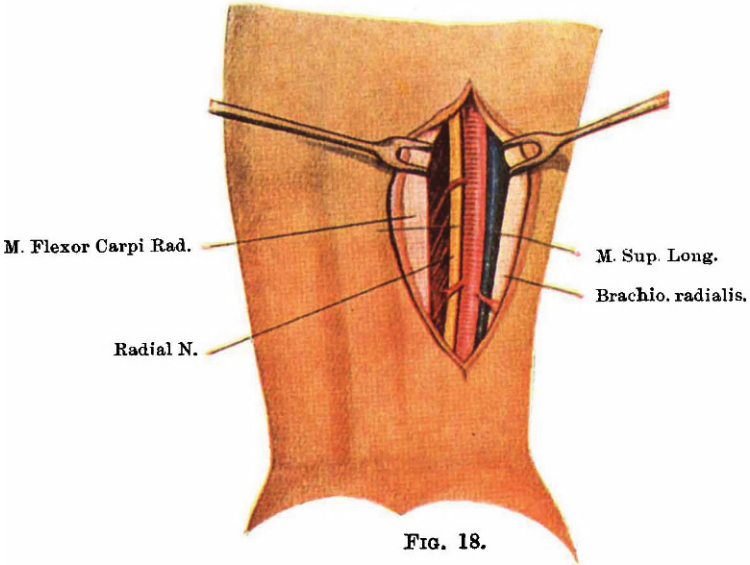


FIG. 18.

LIGATION OF THE RADIAL ARTERY.

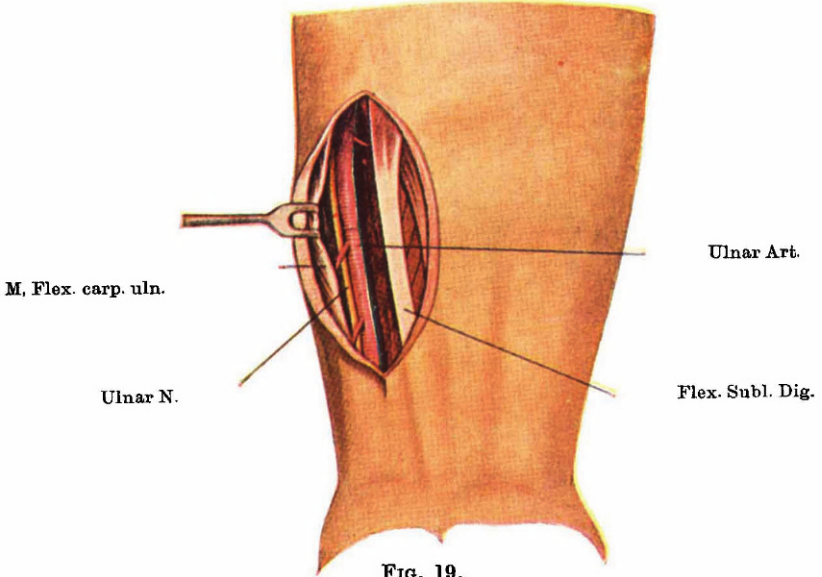


FIG. 19.

LIGATION OF THE ULNAR ARTERY.

To face page 24.

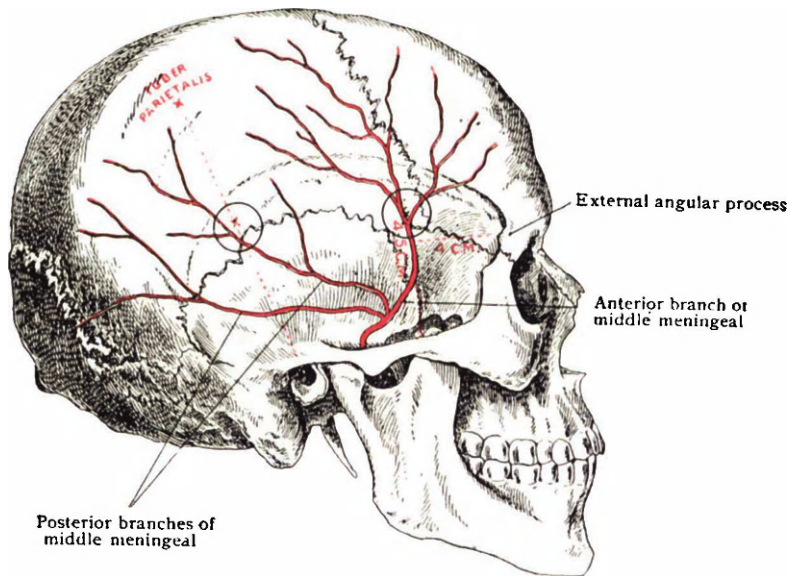


FIG. 20.

POINTS OF TREPHINING FOR HÆMORRHAGE FROM THE MIDDLE MENINGEAL ARTERY. The course of the artery has been marked on the outer surface of the skull.

REPRODUCED FROM DAVIS' APPLIED ANATOMY
By the Courtesy of THE J. B. LIPPINCOTT CO.

Divide the deep fascia. Expose and define the flexor carpi ulnaris, flex the wrist to relax the tendon and retract it inwards. The artery is attached to the flexor (digitorum) profundus by a fascia. Divide it carefully. The ulnar nerve is close to its inner side. Pass the needle from the ulnar side avoiding the nerve.

COLLATERAL CIRCULATION

After ligation of radial or ulnar arteries: Anterior (volar) and posterior (dorsal) interossei with anterior (volar) carpal, posterior (dorsal) carpal and recurrent branch of the deep palmar (volar) arch.

Comment :—(1) Do not cut too deep. (2) Flex and extend, pronate and supinate to determine the various muscles. (3) The direction of the fibres of the brachio-radialis and pronator radii teres (pronator teres) are vertical and oblique respectively. (4) The flexor carpi ulnaris is tendinous at its insertion on its outer (lateral) side, but has muscular fibres attached to its inner (medial) side. (5) Position of the operator and assistant may be varied according to convenience. (6) For hæmorrhage from the ulnar or radial, proximal and distal ligatures should be applied in consideration of the free anastomotic circulation through the palmar arch.

ARTERIES OF THE HEAD AND NECK

LIGATION OF THE MIDDLE MENINGEAL ARTERY

INDICATIONS

The middle meningeal artery is ligatured in cases of hæmorrhage from this vessel giving rise to symptoms of compression of the brain.

SURGICAL ANATOMY

The middle meningeal artery is a branch of the internal maxillary. It enters the skull through the foramen spinosum, and lies in a groove in the temporal bone. It takes a variable course in the middle fossa of the skull and at a point just above the centre of the zygoma, bifurcates into anterior and posterior branches. The anterior branch is larger and is more liable to injury since: (a) its cranial protection of the temporal bone in this region is very thin and (b) it is strongly adherent to the dura, so that any impact on the skull which tends to separate this membrane from the skull tends to rupture the vessel.

POSITION

The head is turned to the opposite side. The operator stands on the side he is going to trephine. The assistant stands exactly opposite to him.

SURFACE MARKING

The Anterior Branch

Draw a line horizontally backwards from the external angular (zygomatic) process of the frontal bone; mark off points one, one-half, and two inches on that line behind that process. Drop lines at right angles to the above line from the above three points on to the zygoma and measure these vertical lines; at the first point the artery lies an inch, at the second point an inch and a half and at the third point two inches. Join the upper terminations of these vertical lines. This will form an oblique line representing the anterior branch of the middle meningeal artery (*Fig. 21*).

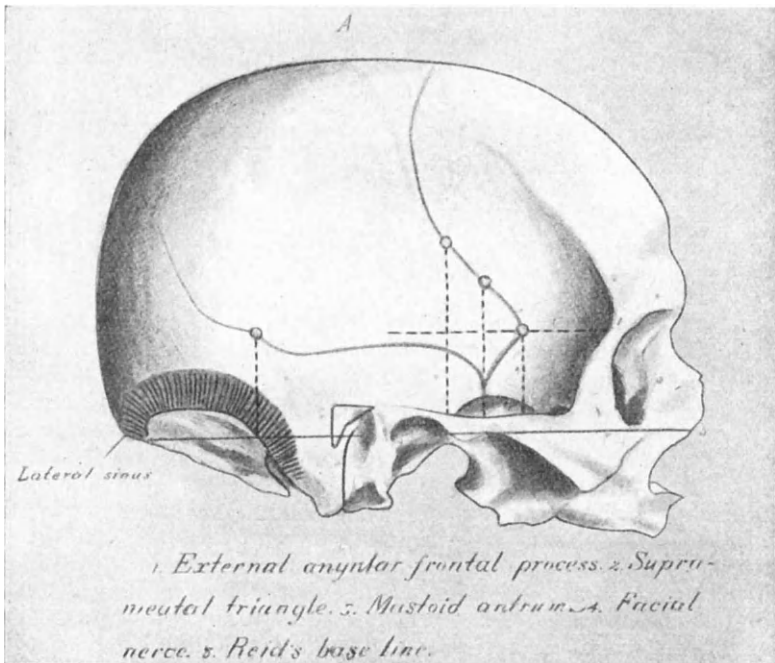


FIG. 21.

The Posterior Branch

The posterior branch may be reached by placing the trephine just below and in front of the parietal eminence, one and a half inch above the external auditory meatus.

The Main Trunk

The main trunk may be secured by working a little lower i.e. nearer the zygoma.

INSTRUMENTS—Group VIII

OPERATION

Take any of the three points in the oblique line. Put the trephine pin on the point, drive it through the scalp on to the skull, making a superficial impression on the bone. A semi-circular scalp-deep incision is made with the convexity upwards. The scalp is reflected. Now the choice lies between a muscle-flap operation or a split-muscle operation. The latter has distinct advantages. The temporal muscle is split down to the pericranium on a line with the puncture made by the trephine pin. Along the edges of the split the muscle is reflected from the skull and retracted outwards and inwards; with the impression on the bone as a guide, a trephine, an inch or three-quarters of an inch in diameter is applied. After the circular impression on the bone is made deep enough, the pin is withdrawn and trephine impression is deepened by steady and cautious circular movement till the dura is reached. The bone-dust is removed and sawing is stopped as the dura mater is reached. The circular piece of bone is raised by an elevator and removed. The artery is seen lying on the dura mater with its vein. It is separated from the dura, and the aneurysm needle passed so as to include the two veins with the artery. In some cases it will be found necessary to pass a fully curved threaded needle through the dura mater under the artery. The split fibres of the temporal muscle are allowed to come together and close the trephine hole and the scalp flap allowed to return.

Comment:—While using the trephine avoid injuring the dura, brain or the artery by manipulating this instrument and the elevator cautiously.

LIGATION OF THE COMMON CAROTID ARTERY

INDICATIONS

The common carotid is ligatured: (1) in cases of aneurysm of the innominate, the internal carotid and the cerebral arteries; (2) to control hæmorrhage from the face and neck; (3) for pulsat-

ing and the so-called idiopathic exophthalmos ; (4) as a preliminary measure to removal of tumours ; (5) for elephantiasis of the face ; (6) for epilepsy.

POSITION

Dorsal position near the edge of the table ; raise shoulder, turn head on opposite side. The operator stands on the side of operation and the assistant opposite to him.

SURFACE MARKING

Take three points : (*a*) angle of the jaw, (*b*) tip of the mastoid process, (*c*) sterno-clavicular articulation. Join (*a*) and (*b*), and take its middle point (*d*). Join (*c*) and (*d*), this line marks the line of the artery. The seat of election for the ligature of the artery is above the point where the anterior belly of omo-hyoid crosses it, here the artery is more superficially placed and less surrounded by complicated structures.

A. At the site of Election.—(Above the Omo-hyoid.)

OPERATION

Determine the position of the cricoid cartilage, make an incision two inches long dividing the skin and the platysma in the line of the artery keeping its centre on a level of this (*see Fig. 23A*). This exposes the deep fascia. Divide it along the anterior margin of the sterno-mastoid (sterno-cleido-mastoideus). Define the edge of the muscle and follow it till the omo-hyoid muscle is felt. Demonstrate the angle of the meeting of these two muscles. Retract the sterno-mastoid outwards (lateralwards) and the omo-hyoid downwards. Feel for the (pulsation of) artery as it crosses the prominence of the carotid tubercle. The sterno-mastoid vessels, middle thyreoid vein and the sheath of the artery are thus exposed. Open the sheath on the inner side avoiding the descendens nomi (hypoglossi) nerve lying on it and the internal jugular vein lying on the outer side. Separate the sheath from the artery with great care and pass the needle from without inwards (lateral to medial side) keeping close to the coat of the artery (*see Fig. 23*).

COLLATERAL CIRCULATION

(1) Superior thyreoid, lingual, facial (external maxillary) and occipital with corresponding vessels of the opposite side. (2) Superior thyreoid and inferior thyreoid. (3) Vertebral with the vertebral of the opposite side. (4) Princeps cervicis (ramus descendens) of occipital and deep cervical (cervicalis profunda) branch of the superior intercostal.

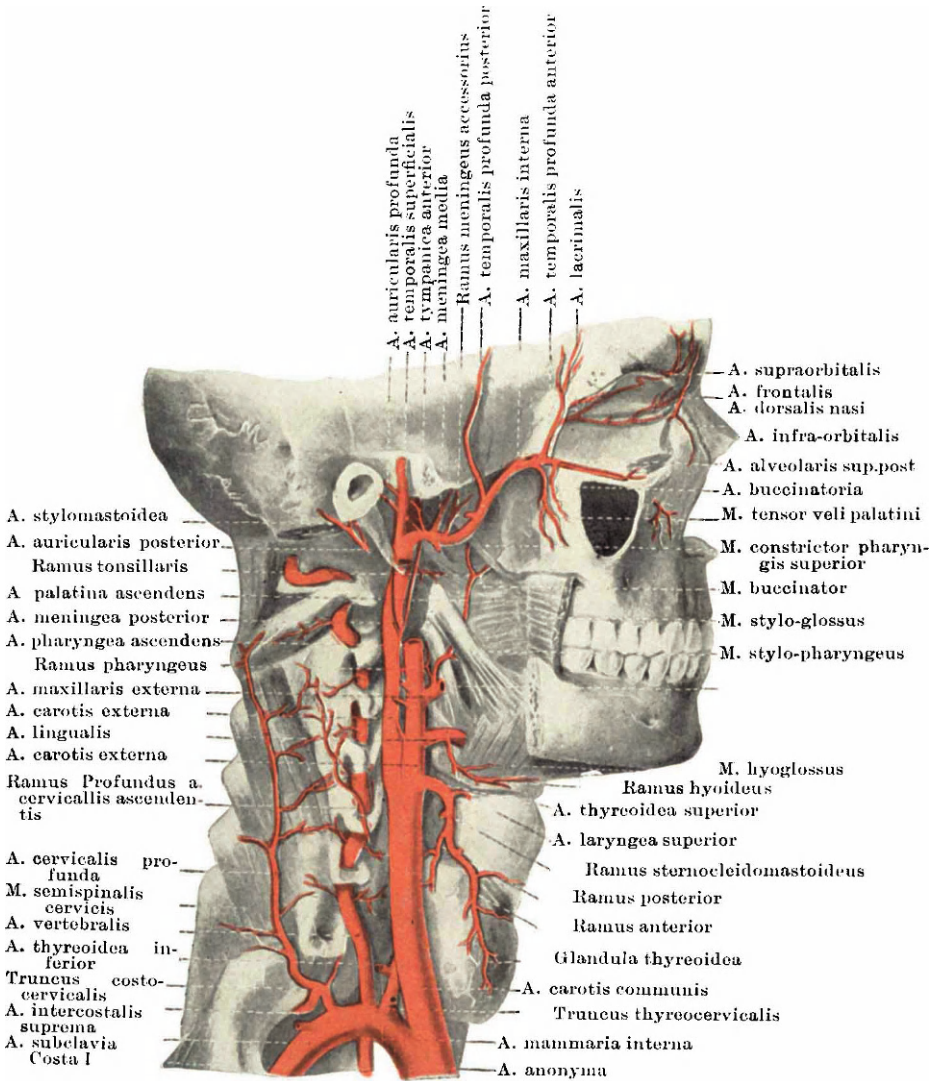


FIG. 22.
 ANATOMY OF THE HEAD AND NECK.

To face page 28.

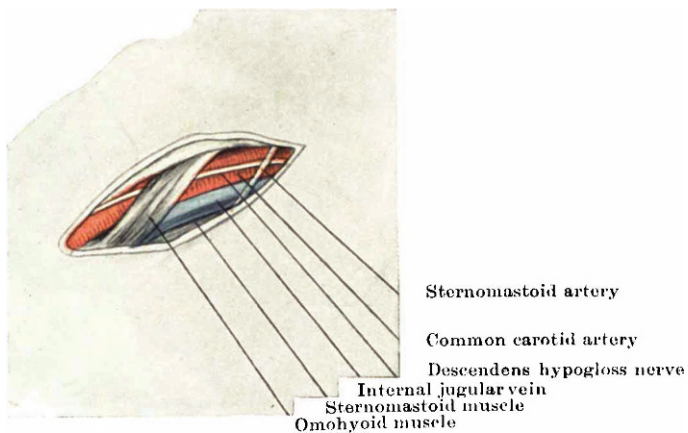


FIG. 23.

LIGATION OF THE COMMON CAROTID ARTERY.

REPRODUCED FROM DAVIS' APPLIED ANATOMY
 By the Courtesy of THE J. B. LIPPINCOTT CO.

Comment :—(1) Do not turn the head too far to the opposite side, this may lead to the overlapping of the vessels by the sterno-mastoid (sterno-cleido-mastoid). (2) The anterior jugular vein may have to be divided between two ligatures. The small sterno-mastoid artery and other small veins may be found to cross the artery. (3) Open the sheath well on the inner side, because the internal jugular vein is on the outer side and may even be overlapping the artery. The needle must be passed with great care, closely in contact with the vessel and passing directly between it and the sheath, and by this you will avoid transfixing the artery and including descendens nemi (hypoglossi), the pneumogastric (vagus), recurrent laryngeal or even the sympathetic in the ligature.

B. Below the Omo-hyoid

OPERATION

Incision about three inches long in the line of the artery, commencing a little below the cricoid cartilage and extending to the sterno-clavicular articulation (*see Fig. 23A*). The steps of the operation are the same as in the previous operation, but omo-hyoid is drawn upwards and the sterno-thyreoid and sterno-hyoid inwards. The sheath is opened on the inner side and the needle is passed from without inwards (*see Fig. 23*).

Comment :—(1) The vessel lies deeply in the neck and renders the operation dangerous and difficult. (2) The inferior thyreoid and the internal jugular veins may obscure the view of the artery. (3) Other points of comment apply to this as to the previous operation. (4) In some cases of ligature of the common carotid, hemiplegia may follow due to extension of thrombus from the site of ligature along internal carotid to the cerebral arteries, an attenuated form of infection being a probable factor.

LIGATION OF THE INTERNAL CAROTID ARTERY

SURGICAL ANATOMY

It commences from the bifurcation of the common carotid artery on a level of the upper border of the thyreoid cartilage and extends to the carotid canal in the base of the skull. The line of the vessel is practically an extension of the common carotid. It lies rather posterior and lateral to the external carotid (*see Fig. 23A*).

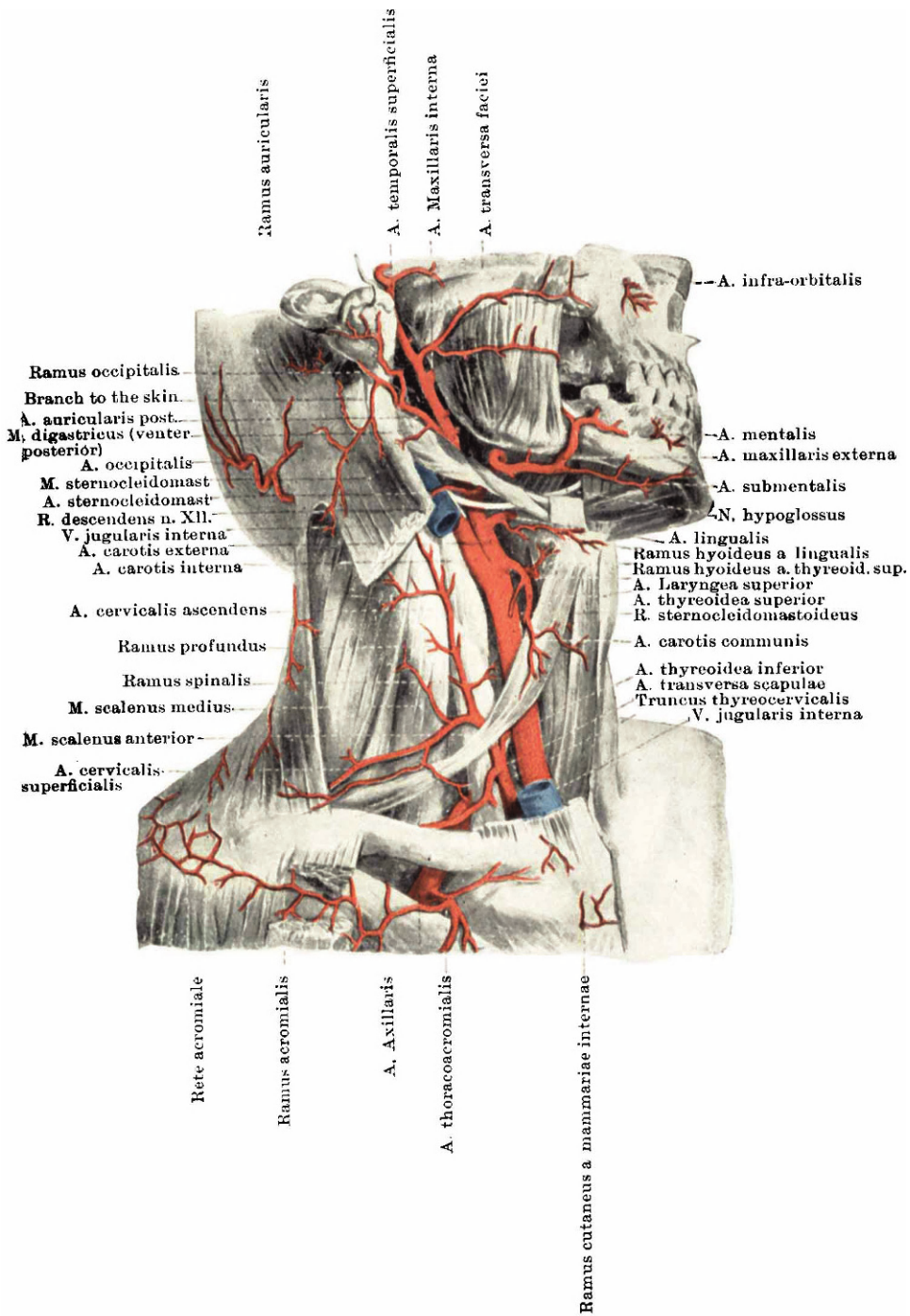


FIG. 23B.
SUPERFICIAL ARTERIES OF THE NECK.

To face page 30.

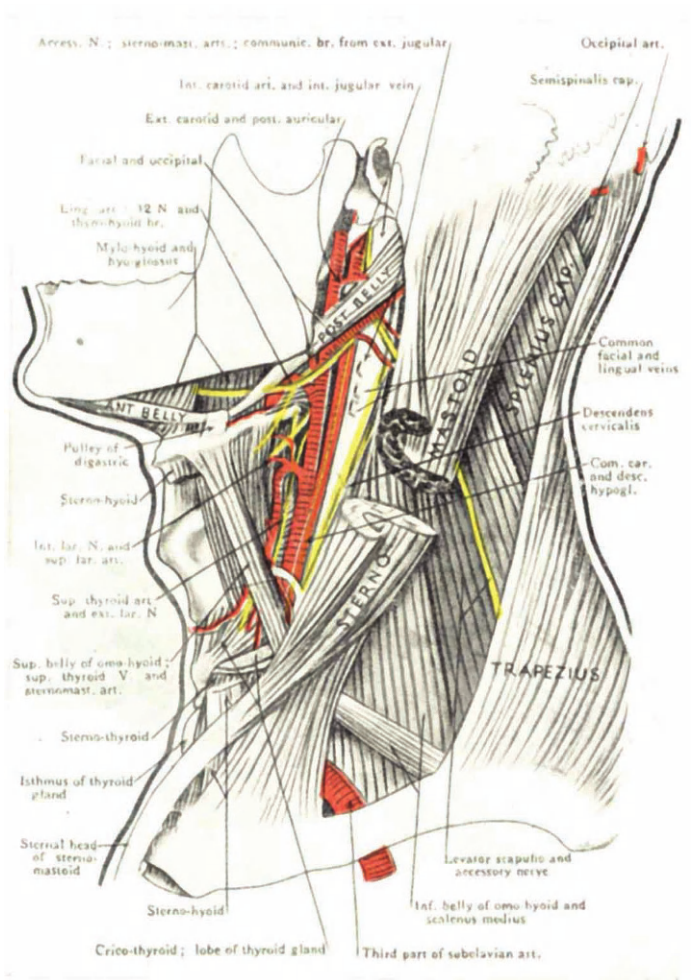


FIG. 24.

TRIANGLES OF NECK.

REPRODUCED FROM JAMIESON'S ILLUSTRATIONS OF REGIONAL ANATOMY

By the Courtesy of E. & S. LIVINGSTONE.

To face page 31.

INDICATIONS

(1) Wounds of the artery. (2) Aneurysm of the internal and common carotid arteries. (3) Orbital aneurysm. (4) Traumatic exophthalmos.

OPERATION

This artery is not often ligatured and whenever this is done it can only be tied just after it leaves the common carotid and the method of operation is almost the same as that of the common carotid artery. Make an incision in the line of the artery over the medial border of the sterno-mastoid (sterno-cleido-mastoideus), its centre being on a level with the superior border of the thyroid cartilage. This brings the external carotid into view and when this is retracted medially, the internal carotid is exposed. The needle is passed from the medial to the lateral aspect close to its origin and the vessel ligatured. Care is taken to avoid the vagus or sympathetic nerve trunks which lie behind it.

LIGATION OF THE EXTERNAL CAROTID ARTERY

POSITION

The same as in the previous operation.

SURGICAL ANATOMY

The common carotid artery divides at the level of the upper border of the thyroid cartilage into the internal and external carotids. The external carotid about an inch from its origin lies very superficially being only covered by skin and fascia, and overlapped by the sterno-mastoid (sterno-cleido-mastoideus) muscle. It terminates behind the condyle of the jaw by dividing into superficial temporal and internal maxillary arteries. From below upwards, the following branches are given off: ascending pharyngeal, superior thyroid, lingual (opposite the greater cornu of the hyoid bone), facial (external maxillary), and occipital. The hypoglossal nerve crosses the external carotid artery an inch above its origin (*Fig. 24*).

SURFACE MARKING

(1) A direct prolongation upwards of the common carotid line. (2) Draw a line from the tip of the lobule of the ear to the greater cornu of the hyoid bone.

OPERATION

At the site of election, i.e. between the superior thyroid and lingual branches of the artery (*Fig. 24*).

Make an incision, about three inches long, in the line of the artery commencing on a level with the middle of the thyroid

cartilage and terminating near the angle of the jaw ; the centre of the incision will correspond to the greater cornu of the hyoid bone and it divides the skin and platysma only (*see Fig. 23A*). Expose the anterior border of the sterno-mastoid (sterno-cleido-mastoid) in the lower part of the wound. Retract it outwards, search for the posterior belly of the digastric at the upper angle of the wound. Below this, the hypoglossal nerve is seen. Expose the artery opposite the level of the tip of the great cornu. Pass the needle from without inwards, avoiding the facial (anterior facial) and superior thyreoid veins (*see Fig. 24*).

Comment :—(1) There are large veins running over and in relation to this vessel. (2) The hypoglossal nerve is often a good guide. (3) The artery has complicated relations with important structures. It must be identified from its own numerous branches and from the internal carotid which has no branches in the neck. (4) The branches of the external carotid of either side anastomose so freely that the ligation of one vessel does not materially affect the hæmorrhage in the regions supplied by these vessels.

COLLATERAL CIRCULATION

The circulation is re-established by the free communications between (*a*) most of the large branches of the artery (facial, lingual, superior thyreoid, occipital) and the corresponding arteries of the opposite side ; (*b*) by the anastomosis of its branches with those of the internal carotid ; (*c*) of the occipital with branches of the subclavian.

LIGATION OF THE INFERIOR THYREOID ARTERY

INDICATIONS

In cases in which thyreoidectomy is contra-indicated and in some cases of thyreoidectomy, the vessel is ligatured as a preliminary measure with the object of curtailing the blood supply to the gland and reducing its size.

SURGICAL ANATOMY

The inferior thyreoid is the most important branch of the thyreoid axis. It is in close relation to the carotid sheath. The recurrent laryngeal nerve crosses behind the bend of the artery and ascends upon the longus colli muscle.

OPERATION

Make a transverse incision commencing in the middle line on the lower third of the neck from the lower part of the thyreoid

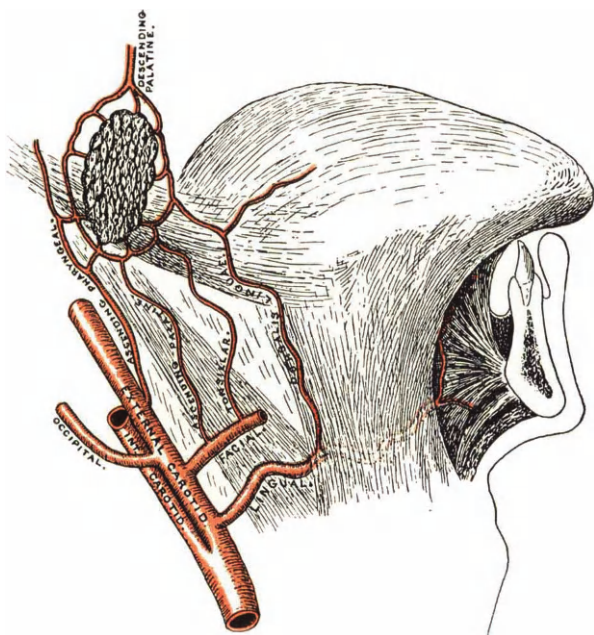


FIG. 24A.

BLOOD SUPPLY OF THE FAUCIAL TONSIL.

REPRODUCED FROM DAVIS' APPLIED ANATOMY

By the Courtesy of THE J. B. LIPPINCOTT CO.

gland laterally to the medial border of the sterno-cleido-mastoid muscle. Divide the skin, platysma and deep fascia, retract the sterno-cleido-mastoid outwards (laterally) and the sterno-thyroid inwards (medially). The carotid sheath is now exposed on the outer (lateral) part of the wound and the thyroid gland in, the inner (medial) part. If the carotid sheath and its contents are gently retracted outwards (laterally) the inferior thyroid is found lying behind. Pass the aneurysm needle from without in, taking great care to avoid the recurrent laryngeal nerve which lies posteriorly and crosses the vessel.

LIGATION OF THE LINGUAL ARTERY

INDICATIONS

(1) Preliminary to excision of the tongue. (2) In cases of inoperable cancer of the tongue to check the rate of its growth and to restrain hæmorrhage. (3) In cases of hæmorrhage due to wounds of the vessel. (4) In cases of macroglossia.

SURGICAL ANATOMY

The lingual artery arises from the external carotid opposite the greater cornu of the hyoid bone. It first ascends to a point a little above the level of the hyoid bone; here it is covered by the skin, platysma, fasciæ, and some veins, and it lies upon the middle constrictor of the pharynx. It then descends and runs just above the greater cornu still lying upon the middle constrictor and is covered by hyoglossus and mylo-hyoid muscles. The hypoglossal nerve and the lingual vein are separated from it by the hyoglossus muscle. Finally, it emerges from under the hyoglossus muscle and runs to the under surface of the tongue with a tortuous course as ranine artery being covered only by its mucous membrane (*Fig. 24A*).

A. At its Origin

Incision as for ligation of the external carotid artery and the operation corresponds to its ligation at the site of election. Pass the ligation from without inwards (*see Fig. 25*).

B. At the site of Election—i.e. beneath the hyoglossus

POSITION

Patient is close to the edge of the table in dorsal position with the shoulder raised and face turned to the opposite side. The operator stands on the side of operation. One assistant keeps the chin drawn well upwards and the lower jaw fixed. A second assistant stands by the side of the operator to retract the digastric tendon.

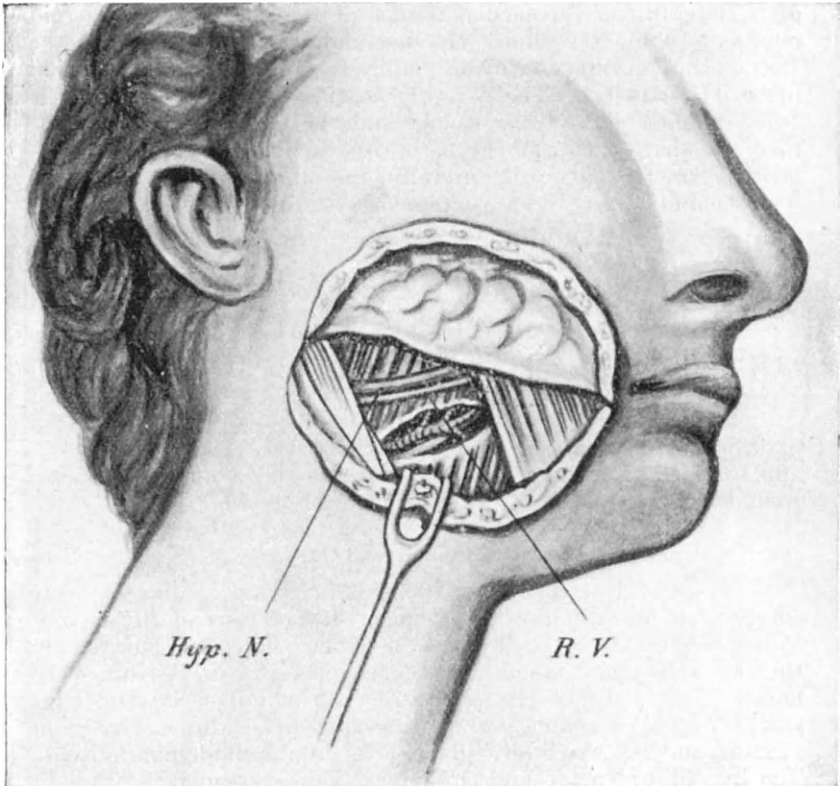


FIG. 25.

LIGATION OF THE LINGUAL ARTERY.

OPERATION

Commence the incision from a point a little below and external to the symphysis menti curving down to a point near the cornu of the hyoid bone, and then curving upwards to terminate below and in front of the angle of the mandible (*see Fig. 23A*). Divide the skin, superficial fascia, platysma and then the deep fascia. The sub-maxillary gland which is now exposed is separated from its deep attachments and retracted upwards on to the face. This exposes the digastric triangle with the anterior belly of the digastric and the mylo-hyoid muscle in front, and the posterior belly of the digastric behind, the floor being formed by the hyoglossus muscle. Running across the floor on the muscle are the hypoglossal nerve above and the ranine vein (*vena comitans hypoglossi*) below; displace these

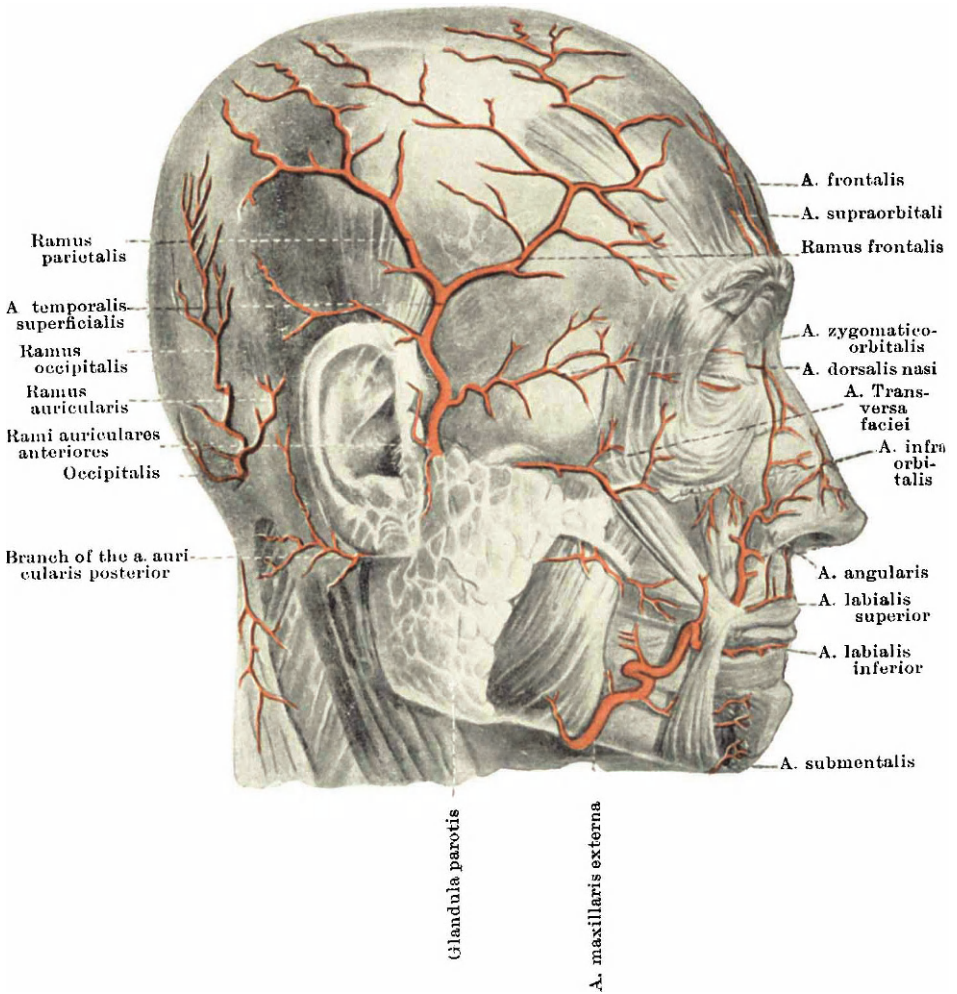


FIG. 26.
 SUPERFICIAL ARTERIES OF THE FACE.

To face page 35.

two structures upwards and pull the digastric tendon downwards with a blunt hook. Make a small transverse incision on the hyoglossus muscle (across its fibres) below and parallel to the ranine vein. The artery will come into view as soon as the whole thickness of the muscle is divided. The needle is passed from above downwards.

Comment :—(1) Ligaturing this artery presents certain difficulties :—(a) The soft structures may be matted together due to old cellulitis, (b) there may be large veins, e.g. lingual and facial, (c) in old people the artery may lie at a considerable depth in the wound, (d) there may be enlarged lymphatic glands and the submaxillary salivary gland may be unusually large. (2) The hypoglossal nerve is a surer and better guide than the ranine vein (*vena comitans hypoglossi*) due to its variation in position and abnormal conditions. (3) The hyoglossus muscle is to be divided by repeated light touches of the scalpel to avoid injury to the underlying artery. (4) Fix the digastric tendon securely and pull it down effectively in order to obtain a good view of the field of operation and put the hyoglossus muscle on the stretch before division.

LIGATION OF THE FACIAL ARTERY (EXTERNAL MAXILLARY)

INDICATIONS

(1) Wounds of the artery. (2) Preliminary to excision of the lower jaw.

SURGICAL ANATOMY

The facial (external maxillary) artery comes off the external carotid in the neck about an inch above its bifurcation, passes up to the submaxillary gland and is embedded in it, crosses the jaw at the anterior edge of the masseter and then goes to the side of the face (*see Figs. 23A and 26*).

OPERATION

A small horizontal incision is made along the lower edge of the jaw from the anterior edge of the masseter through the skin, fascia and platysma. The artery is at once exposed. Pass the needle from behind forwards as the facial (anterior facial) vein lies behind the artery.

LIGATION OF THE (SUPERFICIAL) TEMPORAL ARTERY

INDICATIONS

Wounds and aneurysms of the artery.

SURGICAL ANATOMY

The superficial temporal artery is one of the terminal branches of the external carotid. It is given off at the bifurcation of the external carotid behind the jaw at a point midway between the condyle of the jaw and the tragus. It then passes over the root of the zygoma, ascends for about two inches and then divides into anterior and posterior branches under the covering of the dense parotid fascia (*see Fig. 26*).

OPERATION

Make a vertical incision one inch long, in the line of the artery with the mid-point opposite the root of the zygoma, cutting through the superficial and deep fasciæ (*see Fig. 23A*). This exposes the artery with the auriculo-temporal nerve lying in front and the temporal vein behind. Pass the needle from behind forwards.

LIGATION OF THE OCCIPITAL ARTERY

INDICATIONS

Wounds of the vessel (stabs, gun-shot wound, etc.) and cirroid aneurysm of the scalp.

SURGICAL ANATOMY

It comes off as a posterior branch of the external carotid from a point corresponding to the branching of the facial. It makes an upwards course under cover of the digastric and stylo-hyoid muscles to the interval between the transverse process of the atlas and the mastoid process. It then turns backwards, lying at first in a groove of the temporal bone and then on the complexus (*semispinalis capitis*) being covered by the posterior cervical muscles. Then running vertically upwards and piercing the trapezius, it ascends to the scalp (*see Fig. 26*).

OPERATION

An oblique incision two inches long extending from the tip of the mastoid process towards the external occipital protuberance, dividing the superficial structures and exposing the sterno-mastoid (*sterno-cleido-mastoid*) insertion (*see Fig. 23A*). The artery is now found lying in the space between the mastoid process and the transverse process of the atlas under cover of the posterior belly of the digastric. Pass the needle according to convenience.

LIGATION OF THE VERTEBRAL ARTERY

INDICATIONS

(1) Wounds. (2) Traumatic aneurysm. (3) In epilepsy, to reduce the blood supply to the hind-brain.

SURGICAL ANATOMY

The vertebral is the first branch of the subclavian and springs from its upper and back part. It passes along the inner margin of the scalenus anticus (anterior) and enters the foramina transversarium of the upper six cervical vertebræ to become the basilar artery by uniting with its fellow of the opposite side.

POSITION

Same as that for ligation of the common carotid.

OPERATION

Make an incision three inches long, along the lower part of the posterior border of the sterno-mastoid (sterno-cleido-mastoid) extending down to the clavicle and dividing the skin, superficial fascia and platysma. Now, divide the deep fascia taking care not to injure the external jugular vein which lies superficial to it. Retract the sterno-mastoid forwards and define the scalenus anticus (anterior) at the carotid tubercle. Displace the carotid sheath inwards. The artery can be felt immediately below the tubercle. Pass the needle from without inwards, keeping clear of the veins.

Comment :—(1) The artery is deep in situation and there is a fair amount of venous oozing. (2) Relax the muscles of the neck in order to get as good a view as possible. (3) The carotid tubercle is a good guide to the artery. (4) Contraction of the corresponding pupil on applying the ligature indicates that the vertebral has been secured.

LIGATION OF THE INTERNAL MAMMARY ARTERY

INDICATIONS

Hæmorrhage from the artery due to punctured, stab, or gunshot wounds or due to fractured ribs.

SURGICAL ANATOMY

Coming off the first part of the subclavian, it descends along the external margin of the sternum, half an inch external to it, lying on the pleura and triangularis sterni (transversus thoracis)

muscle. It terminates behind the sixth costal cartilage by dividing into musculo-phrenic and superior epigastric (*Fig. 27*).

OPERATION

Make a transverse incision about one and half inches long from the outer margin of the sternum in an intercostal space according to indication (*see Fig. 23A*). Split the fibres of the pectoralis major and retract; cut the anterior intercostal aponeurosis (membrane) and the internal intercostal muscle avoiding anterior perforating vessels and nerve. The artery is now exposed. Pass the needle from without inwards.

Comment.—It is often difficult to isolate the artery. Do not injure the pleura while cutting through internal intercostal. Do not injure the artery.

LIGATION OF INTERCOSTAL ARTERIES

SURGICAL ANATOMY

The nine pairs of aortic intercostal arteries usually arise separately from the back of the aorta. The thoracic aorta lies on the left of the vertebral column; the right intercostals have to cross the front of the column and pass posterior to the oesophagus, the thoracic duct, and the vena azygos; these are therefore longer than the left intercostals. As each artery runs postero-laterally, across the side of the vertebral column to an intercostal space, it passes posterior to the pleura and is crossed opposite the head of a rib by the sympathetic trunk. The lower arteries are crossed by the splanchnic nerves also; the left intercostals are crossed by the hemiazygos and accessory hemiazygos veins. Each artery gives off a posterior branch as it passes laterally between the neck of two contiguous ribs. In its course it passes along the intercostal space to the costal groove (*Fig. 27*). In its forward course it lies between the internal and external intercostal muscles; in the costal groove the artery has its corresponding vein above and the nerve below.

POSITION

Supine; a sand-bag supports the back and renders the side of operation prominent and widens the intercostal spaces. Operator stands on the side of operation, the assistant opposite.

OPERATION

Pull the skin from the intercostal space up on the corresponding superior rib and make a two-inch incision down to the bone following the curve of the rib. As you let the skin go down, the

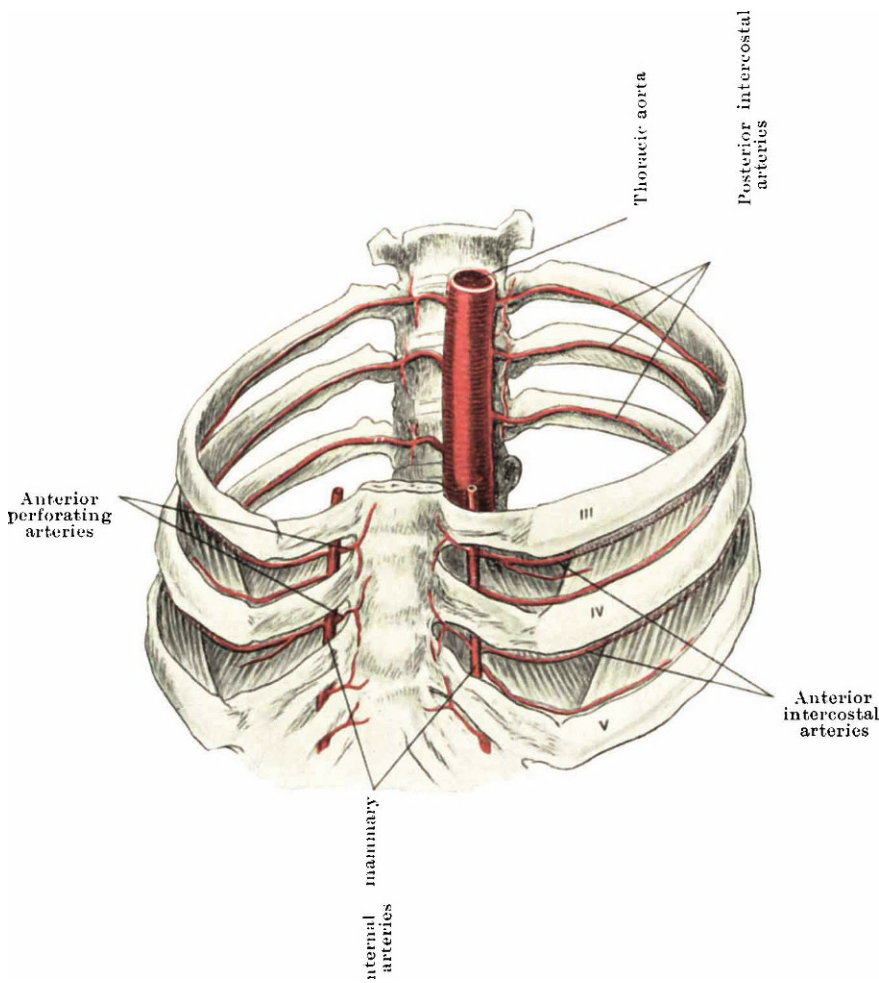


FIG. 27.

COURSE AND DISTRIBUTION OF THE INTERCOSTAL ARTERIES.

REPRODUCED FROM DAVIS' APPLIED ANATOMY

By the Courtesy of THE J. B. LIPPINCOTT CO.

incision falls in a line with the intercostal space. Feel for the sub-costal groove and clear it by light touches of the knife and cutting the fibres of the external intercostal muscle. The artery will be seen lying between the vein above and the nerve below. Clear the nerve and the vein from the artery, pass the aneurysm needle from below lifting the artery up from its bed and apply proximal and distal ligatures.

Comment :—(1) The above operation is the one generally indicated and commonly performed for ligation of the portion of the artery anterior to the angle of the rib. For ligation posterior to the angle, remember that the artery lies between the two ribs and has not as yet reached the costal groove of the upper of the two ribs. It has to be sought for in the intercostal space. (2) If difficulty is experienced in exposing the artery expose the rib subperiosteally and find the artery through a partial semi-linear excision (Hartley's method). (3) Proximal and distal ligatures should be applied as the blood supply comes from both directions.

CHAPTER III

LIGATION OF ARTERIES (*Continued*)

THE ABDOMINAL AORTA AND THE ILIAC ARTERIES

SURGICAL ANATOMY

The thoracic aorta enters the abdomen to become the abdominal aorta through an opening in the diaphragm opposite the lower border of the twelfth dorsal vertebra. It descends between the pillars of the diaphragm in front of the lumbar vertebræ, at first in the median line, later inclining to the left of the spine (*Fig. 28*).

The site of bifurcation of the aorta corresponds to a point $\frac{1}{2}$ inch below and a little to the left of the umbilicus, or a little to the left of the mid-point of a line joining the highest points of the iliac crests.

The vena cava in the upper part is anterior to the aorta, the right crus of the diaphragm lying between the two vessels; in the lower part the vein lies somewhat posteriorly and in contact with the aorta. At the seat of election for ligation, the aorta is covered by peritoneum. Between the serous covering and the artery are sympathetic nerve cords from the aortic plexus lying along the aorta between the superior and inferior mesenteric arteries to the hypogastric plexus between the common iliacs.

The abdominal aorta bifurcates opposite the middle of the body of the fourth lumbar vertebra to form the two terminal branches, namely the common iliac arteries (*arteriæ iliacæ communes*) a little to the left of the mid-line of the body. Each of these arteries passes downwards and laterally across the bodies and intervertebral disc of the fourth and fifth lumbar vertebræ to the level of the lumbo-sacral articulation anterior to the corresponding sacro-iliac joints and terminate by dividing into the external iliac and internal iliac (*hypogastric*) branches. The point of bifurcation of the aorta being a little to the left of the mid-line, the right artery is a little longer than the left. The coeliac axis, its first branch, is about four inches above the umbilicus and the superior mesenteric is just below it. The renal vessels are about half an inch below the superior mesenteric and three inches above the umbilicus. Then come the internal spermatic (*testicular*) or ovarian arteries and a little below that the inferior mesenteric artery about one inch above the umbilicus. Owing to these numerous important branches, the aorta is ligatured at a point

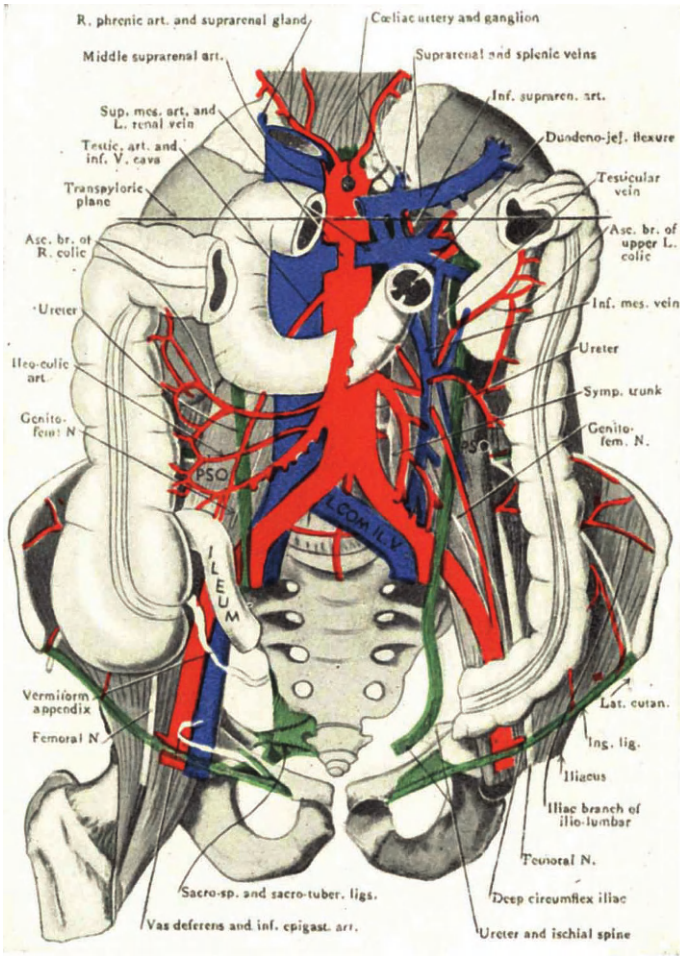


FIG. 28.
STRUCTURES ON POSTERIOR WALL OF ABDOMEN.

To face page 40.

between the origin of the inferior mesenteric and bifurcation of the aorta.

The common iliac arteries resulting from the bifurcation of the aorta pass downwards and outwards over the body of the fifth lumbar vertebra to the pelvic brim and bifurcate opposite the upper border of sacro-iliac synchondroses into internal and external iliac arteries.

The internal iliac (hypogastric) artery about $1\frac{1}{2}$ inches long descends into the pelvis to reach the upper margin of the great sacro-sciatic foramen and divides into anterior and posterior branches.

The external iliac is larger and about $3\frac{1}{2}$ to 4 inches long, runs obliquely downwards and outwards along the brim of pelvis and inner border of psoas muscle, passes under Poupart's ligament midway between, anterior superior iliac spine and symphysis pubis to become femoral. The external iliac vein at first lies at its inner and posterior aspect but lower down on its inner side.

LIGATURE OF THE ABDOMINAL AORTA

SURFACE MARKING

Take a point about four inches vertically above the umbilicus and a point a little below and to its left. A line joining these two points indicate the line of the artery.

OPERATION (INTRAPERITONEAL)

The aorta can be reached intraperitoneally or extraperitoneally.

Position dorsal with the shoulders slightly raised. Make a median vertical laparotomy *incision* about four inches long with the umbilicus as its centre and slightly to its left (*see Fig. 29*). Feel for the aorta, make a small nick in the peritoneum and identify the inferior mesenteric artery and the bifurcation of the aorta; clear the vessel at this part and pass the needle close to the vessel and thus avoid including the sympathetic in the ligature.

Retroperitoneal ligation is seldom done..

THE ILIAC ARTERIES

THE COMMON ILIAC ARTERY

INDICATIONS

(1) Aneurysm of the external iliac. (2) Wounds (gunshot, stabs, etc.) causing immediate or secondary hæmorrhage. (3) Pulsating tumours.

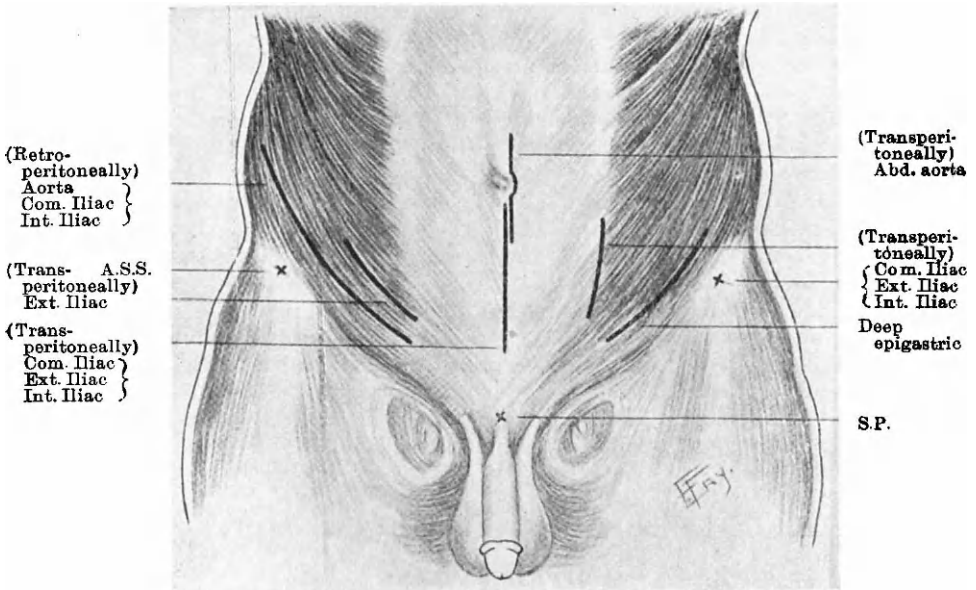


FIG. 29.

INCISIONS FOR LIGATIONS IN THE ABDOMINO-PELVIC REGION.

REPRODUCED FROM BICKHAM'S OPERATIVE SURGERY
By the Courtesy of THE W. B. SAUNDERS CO.

SURFACE MARKING

Draw a line from a point about half an inch below and half an inch to the left of the umbilicus to the centre of a line joining the anterior superior iliac spine and the symphysis pubis. Divide this line into three equal parts. The upper third represents the common iliac and the rest of it the external iliac.

OPERATION

The artery can be ligatured either extraperitoneally or trans-peritoneally.

Extraperitoneal method

Make an incision six inches long, two inches above, and to the outer side of the middle of Poupart's (inguinal) ligament curving at first towards the anterior superior iliac spine, then directly upwards and, finally, bending slightly in the direction of the

umbilicus (*Fig. 29*). Subsequent stages of the operation are similar to ligation of the external iliac (*see p. 47*); in this case it has to be traced upwards till the common iliac is found.

Transperitoneal method

Open the abdomen by a median incision four inches long. The further stages of the operation resemble those for the ligation of the external iliac by transperitoneal route (*Fig. 29*).

COLLATERAL CIRCULATION

(1) Internal mammary and lower intercostals with the deep (inferior) epigastric. (2) Lumbar arteries with the ilio-lumbar and circumflex iliac. (3) Middle sacral with lateral sacral. (4) Superior hæmorrhoidal with middle and inferior hæmorrhoidals.

LIGATION OF THE INTERNAL ILIAC (HYPOGASTRIC)

INDICATIONS

(1) Gluteal and sciatic aneurysms. (2) Hæmorrhage from punctured and other wounds. (3) Inoperable uterine tumours and pelvic sarcomata. (4) Prophylactic, against hæmorrhage in pelvic operations, e.g. panhysterectomy and abdomino-perineal excision of cancerous rectum. (5) According to some older surgeons to bring about atrophy of the enlarged senile prostate.

OPERATION

This vessel can be ligatured transperitoneally or extraperitoneally. The incision and preliminary parts of the operation are the same as those for the ligation of the common iliac artery (*Fig. 29*). Look for the bifurcation and the external iliac branch which is comparatively superficial in situation. Identify the upper margin of the great sacro-sciatic (sciatic) notch which corresponds with the lower end of the artery. Pass the needle from within out; avoid the ureter (*Vide Chapter XXVIII*).

BRANCHES OF THE INTERNAL ILIAC (HYPOGASTRIC)

The internal iliac (hypogastric) artery bifurcates into anterior and posterior divisions. These divisions give off several branches; of these, ligations of the terminal branches of anterior division, namely the sciatic and internal pudic (pudendal) and the gluteal branch of the posterior division will be described.

LIGATION OF THE SCIATIC BRANCH OF THE ANTERIOR BRANCH OF THE INTERNAL ILIAC

SURGICAL ANATOMY

The sciatic, the larger of the two terminal branches descends over the sacral plexus and pyriformis muscle to the great sacrosciatic foramen ; it escapes from the pelvis between pyriformis and coccygeus muscles with the pudic artery in front and internal to it.

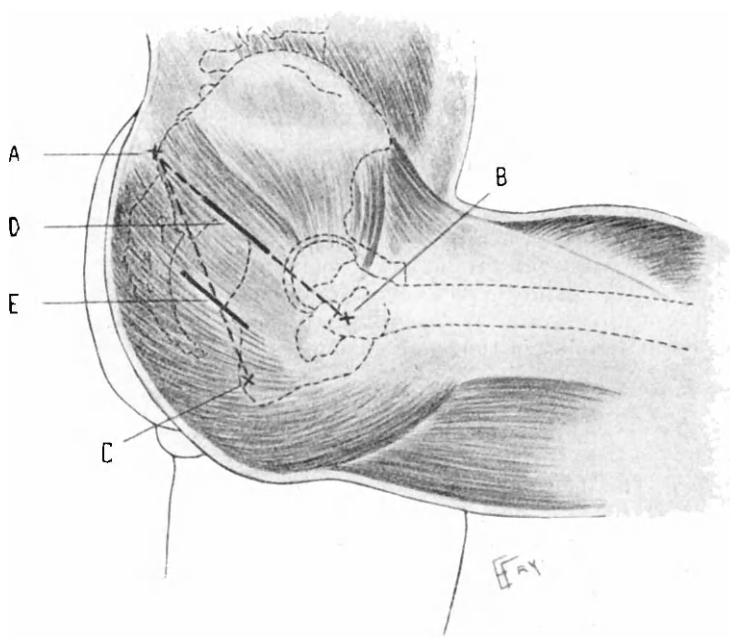


FIG. 30.

INCISIONS FOR LIGATIONS ABOUT THE BUTTOCK:—A, Posterior superior iliac spine; B, Great trochanter; C, Tuberosity of ischium; D, Incision for exposure of gluteal branch of internal iliac at its emergence from upper part of great sacrosiatic notch; E, For exposure of sciatic and internal pudic branches of internal iliac at their emergence from lower part of great sacrosiatic notch.

REPRODUCED FROM BICKHAM'S OPERATIVE SURGERY
By the Courtesy of THE W. B. SAUNDERS CO.

SURFACE MARKING

Flex thigh slightly and rotate inwards. Divide a line joining posterior superior iliac spine and ischial tuberosity into three parts; at the junction of the middle and lower thirds the sciatic and pudic arteries emerge from the sciatic foramen in the gluteal region (*Fig. 30*).

POSITION

Semi-prone position with the side for operation uppermost; flex knee and rotate thigh inwards. Stand on side of operation with the assistant opposite.

OPERATION

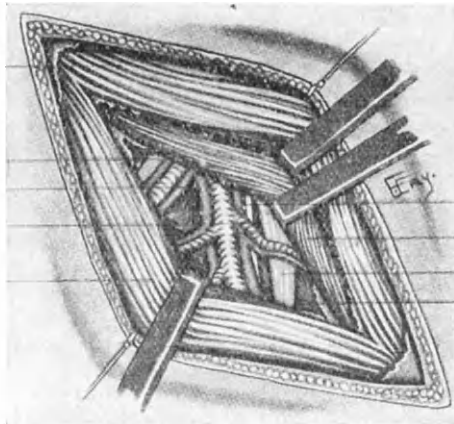
Make a 4-inch incision from above and behind, downwards and forwards (i.e. in the direction of the fibres of gluteus maximus) across the line of the artery at the junction of its middle third with the lower third. Split the fibres of gluteus maximus and retract fibres up and down. Identify the pyriformis and trace up sacro-sciatic ligament to the spine of ischium. Apply ligature to the artery as it emerges from beneath the pyriformis lying posterior and external to the pudic (pudendal) artery (*Figs. 30 and 31*).

Gluteus maximus
(Incised & retracted)

Internal pudic nerve

Pudic artery and
venæ comites

Sciatic artery and
venæ comites



Small sciatic nerve
Pyriformis (lower
border retracted
upward)
Great sciatic nerve

Obturator internus,
with gemellus superior
and inferior,
above and below

FIG. 31.

LIGATION OF RIGHT INTERNAL PUDIC AND SCIATIC ARTERIES UPON THE BUTTOCK, BELOW THE PYRIFORMIS.

REPRODUCED FROM BICKHAM'S OPERATIVE SURGERY
By the Courtesy of THE W. B. SAUNDERS CO.

LIGATION OF THE INTERNAL PUDIC (PUDENDAL) BRANCH OF THE INTERNAL ILIAC

The operation is the same as for the sciatic branch ; the arteries lie side by side at their exit from the pelvis (*see Figs. 30, 31*).

INDICATIONS

Injury to the vessels and aneurysms.

LIGATION OF THE GLUTEAL BRANCH OF THE POSTERIOR DIVISION OF THE INTERNAL ILIAC

SURGICAL ANATOMY

The gluteal, continuation of the posterior division of the internal iliac is the largest branch. It leaves pelvis at the upper part of sacro-sciatic notch above pyriformis with gluteal vein and superior gluteal nerve. It emerges from the pelvis under gluteus maximus and gives off its branches just above the upper border of the pyriformis.

INDICATIONS

Injury ; aneurysm.

SURFACE MARKING

Flex thigh slightly and rotate inwards. A point dividing a line from posterior superior iliac spine to the tip of greater trochanter, into upper and middle thirds corresponds with the emergence of the artery from the sciatic notch (*see Fig. 30*).

POSITION OF PATIENT

Same as for ligation of sciatic or pudic arteries.

OPERATION

Incision on the line of artery about 4 inches long. Divide skin, superficial fascia and gluteal fascia ; gluteus maximus is exposed with its fibres parallel to skin incision ; split its fibres for its whole thickness. Look for the interval between gluteus medius and pyriformis guided by a branch of gluteal artery if encountered. Divide fascia below this muscle and feel for upper margin of sciatic notch. The gluteal artery with the vein and superior gluteal nerve will be found between lower border of gluteus medius and upper border of pyriformis (*Fig. 32*).

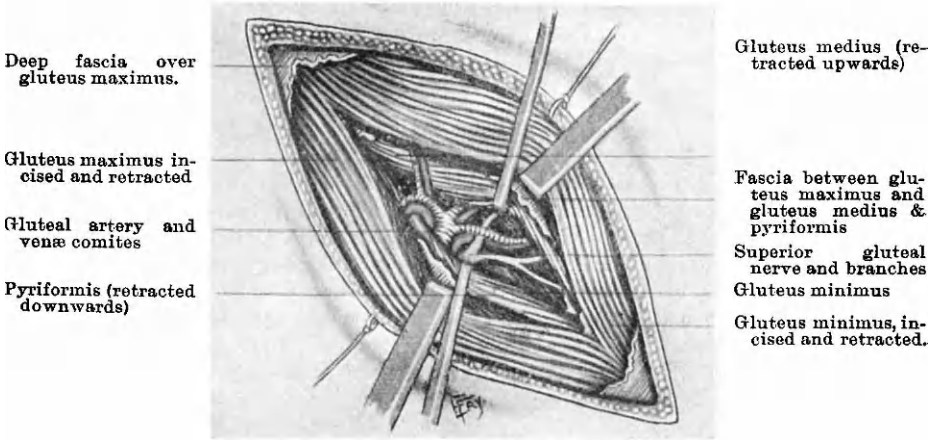


FIG. 32.

LIGATION OF RIGHT GLUTEAL ARTERY UPON THE BUTTOCK, ABOVE THE PYRIFORMIS.

REPRODUCED FROM BICKHAM'S OPERATIVE SURGERY
By the Courtesy of THE W. B. SAUNDERS CO.

LIGATION OF THE EXTERNAL ILIAC ARTERY

INDICATIONS

The chief indications are : (1) Aneurysm of the upper part of the femoral. (2) Wounds of the external iliac. (3) Aneurysm of the common iliac (distal operation). (4) Elephantiasis of the lower extremity (disproved theory).

SURFACE MARKING

Same as for the common iliac. The lower two-thirds of the line represents the line of the external iliac.

OPERATION

This vessel can be ligatured by extraperitoneal or transperitoneal routes.

Extraperitoneal method—(Old method)

POSITION

Dorsal position. Operator stands on the side to be operated on, facing the patient. Assistant stands on the opposite side. Two

classical methods have been described : (a) Cooper's method by oblique incision ; (b) Abernethy's method—by vertical incision.

OPERATION

(a) Cooper's Method (modified).—An oblique incision, three and half inches long is commenced at a point $1\frac{3}{4}$ inches external to the pubic spine (tubercle) and carried parallel to the Poupart's (inguinal) ligament, half an inch above it and then curved upwards and inwards to terminate at a point an inch above and internal (medial) to the anterior superior iliac spine (*see Fig. 29*). This incision divides the skin and subcutaneous tissues. The aponeurosis of the external oblique is divided in the entire length of the skin wound. This exposes the spermatic cord and the internal oblique muscle. Define the external border of the conjoined tendon (falx inguinalis) and retract it. The lower fibres of the internal oblique are drawn upwards and divided close to their attachment to Poupart's (inguinal) ligament. The transversalis fascia is exposed and divided in a transverse direction, avoiding the deep (inferior) epigastric artery. Remove by carefully loosening the subperitoneal tissue. The peritoneum is then peeled off the artery by gauze-covered fingers. The artery is now found lying on the inner side of the psoas (*Fig. 33*). Pass the needle from within out. Close the abdominal incision by bringing together the individual muscles.

Comment :—The parietal incision somewhat corresponds to the incision for inguinal hernia. While making these incisions : (1) avoid injury to external ring (subcutaneous inguinal ring) spermatic cord and circumflex iliac vein ; (2) avoid wounding the peritoneum ; (3) avoid injury to the genito-crural (genito-femoral) nerve or its inclusion in the ligature ; (4) the ilio-inguinal nerve may be exposed when dealing with the muscles, do not injure it ; (5) the deep (inferior) epigastric artery may be injured while dividing the transversalis fascia ; (6) the artery should be ligatured at least one and three-quarter inches above Poupart's (inguinal) ligament, i.e. at a safe distance from the point from which the larger branches (deep epigastric and deep circumflex iliac) are given off.

(b) Abernethy's method.—This method differs from Cooper's in the direction and position of the incision. This is made by commencing at a point an inch above and an inch to the inner side of the anterior superior iliac spine, then curving downwards and inwards to terminate at a point $1\frac{1}{2}$ inches above and slightly

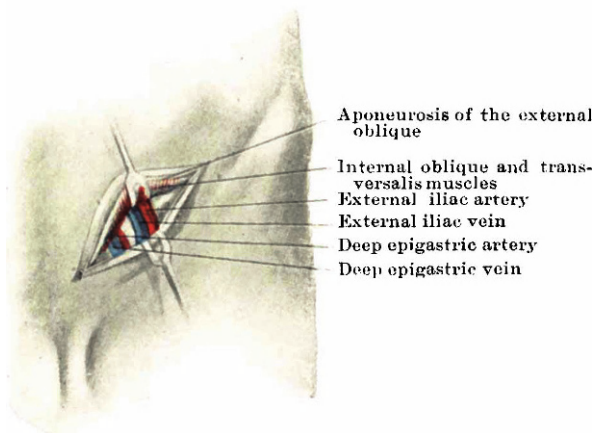


FIG. 33.
LIGATION OF THE EXTERNAL ILIAC ARTERY.

external to the centre of Poupart's (inguinal) ligament. The rest of the operation follows the same method as Cooper's.

Comparison of the two methods

The one *advantage* claimed for Abernethy's operation is that the ligature is placed higher up than in the other method, and this is a matter of consideration if the operation is undertaken for aneurysm of the femoral artery. Its *disadvantages* are many, viz. : (1) There is a greater risk of post-operative (ventral) hernia. (2) One has to work at a greater depth to secure the artery. (3) Therefore, there is a greater risk of wounding the vein.

The advantages claimed for Cooper's method are : (1) This operation is easier to perform. (2) There is less division of muscles. As a matter of fact that operation can be performed by splitting the muscles and not dividing across their fibres. (3) There is less disposition to ventral hernia. (4) The peritoneum in this part is not so firmly adherent to the vessel sheath as it is higher up.

Transperitoneal methods

OPERATION

A laparotomy incision, three inches long, is made through the pararectal route (vide infra) commencing one inch above the umbilicus. The artery is exposed and ligatured as in the above methods.

Comment :—The advantages of this operation are manifold. (1) The artery is fully and easily exposed. (2) Important pelvic structures can be better avoided. (3) It affords greater care and accuracy. (4) The danger of opening the peritoneum and its infection, which was a strong point in favour of extraperitoneal methods in pre-antiseptic days can now be disregarded.

COLLATERAL CIRCULATION

(1) Deep (inferior) epigastric with internal mammary, lower intercostals and lumbar. (2) Deep circumflex iliac with ilio-lumbar, lumbar and gluteal. (3) Gluteal (superior gluteal) and sciatic (inferior gluteal) with internal and external circumflex (medial and lateral femoral circumflex). (4) Obturator with circumflex and epigastric. (5) Internal pudic (pudendal) with external pudic (pudendal).

ARTERIES OF THE LOWER EXTREMITIES

THE FEMORAL ARTERY

SURGICAL ANATOMY

It is a continuation of the external iliac and extends from the lower border of Poupart's (inguinal) ligament to the tendinous opening in the adductor magnus at the junction of the upper two-thirds with the lower third of the femur. In the upper half of its course the artery lies in Scarpa's triangle (the femoral trigone), which is a triangular space bounded by Poupart's (inguinal) ligament above, the inner (medial) margin of the sartorius externally and the inner margin of the adductor longus internally, the floor being formed by the psoas, iliacus, pectineus and adductor longus muscles. The base of the triangle is formed by the Poupart's ligament and the apex at the point where the sartorius and adductor longus muscles meet. In the lower half of its course it lies deeply in Hunter's canal (adductor canal) this is a musculo-aponeurotic sheath or tunnel in the middle third of the thigh extending from the apex of the Scarpa's triangle to the femoral opening in the adductor magnus. It has the vastus internus (vastus medialis) on its outer side, adductores longus and magnus behind and the roof is formed by an aponeurotic sheath extending from the vastus internus to adductores longus and magnus on which lies the sartorius muscle.

The femoral vein lies on the inner side of the artery in Scarpa's triangle and at its apex it goes behind the artery. It crosses the artery from behind in its passage through Hunter's canal and gets to its outer (lateral) side at the lower part of the canal.

SURFACE MARKING

Place the limb slightly flexed at the hip, abducted and everted. Take the mid-point between the anterior superior iliac spine and the symphysis pubis and join it to the most prominent part of the internal condyle (medial epicondyle, adductor tubercle). This represents the line of the femoral artery. Upper third of this line represents the artery in Scarpa's (femoral) triangle; middle-third represents it in Hunter's (adductor) canal and from the lower-third, it becomes the popliteal artery (*see Fig. 34*).

LIGATION OF THE FEMORAL

A. At the base of Scarpa's or femoral triangle

INDICATIONS

(1) Wounds. (2) Removal of growths from the Scarpa's (femoral) triangle. (3) Erosion of the artery by new growths or

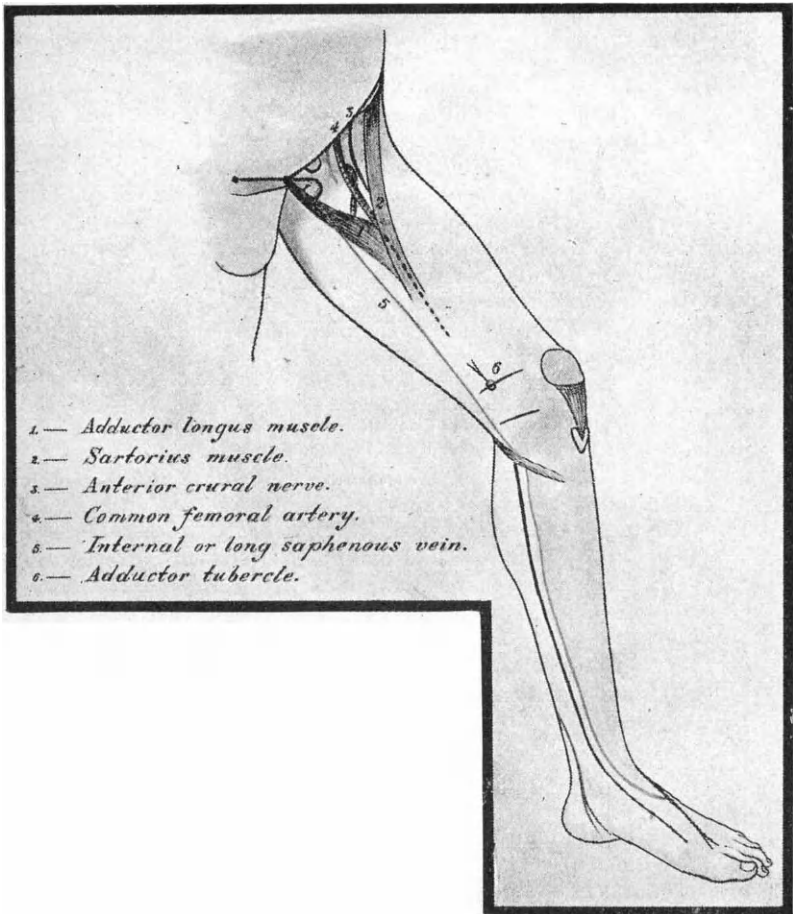


FIG. 34.
 SURFACE MARKINGS OF THE ARTERIES OF THE LOWER
 EXTREMITY.

septic processes. (4) Aneurysms of the superficial femoral (femoral) and popliteal. (5) Aneurysmal varix of the groin. (6) As a preliminary measure to amputation at the hip-joint.

POSITION

Flex hip slightly, abduct and rotate the thigh outwards and flex the knee; the leg rests on external surface. Operator stands on outer side of the limb and the assistant opposite to him.

OPERATION

Skin incision, two inches long, commencing a little above Poupart's (inguinal) ligament in the line of the artery. Divide a layer of fatty tissue covering fascia lata, avoiding superficial veins and lymphatic glands. Divide the cribriform fascia. Avoid external pudic (external pudendal) and superficial epigastric arteries. The femoral sheath is exposed, the artery will be found in the outermost of the three compartments. Clear the sheath. The crural branch of the genito-crural (lumbo-inguinal) nerve lies upon the sheath on its outer side. The vein lies in the middle compartment and the crural (femoral) canal is the innermost. Open the sheath carefully on the outer side, avoiding the genito-crural (genito-femoral) nerve. Pass the needle from the inner side, i.e. from the side of the vein (*see Fig. 35*).

Comment :—(1) The middle of Poupart's ligament is outside the line of the vessel and does not correspond with the mid-point between symphysis pubis and anterior superior iliac spine. (2) The vein lying in the middle compartment is not likely to be injured, but do not wound any of the superficial veins or arteries as they are needed for collateral circulation. (3) Cut the sheath slightly on the outer side so as to avoid the genito-crural (genito-femoral) nerve, which must not be included in the ligature.

COLLATERAL CIRCULATION

(1) Superficial circumflex iliac with external (lateral femoral) circumflex. (2) Gluteal (superior gluteal) and sciatic (inferior gluteal) with circumflex and superior (first) perforating. (3) Comes (comitans) nervi ischiadici with perforating of profunda and articular of popliteal. (4) Obturator with internal (medial femoral) circumflex.

B. At the apex of Scarpa's (femoral) triangle—i.e. at the site of election

INDICATIONS

(1) Popliteal aneurysm. (2) Aneurysmal varix. (3) Wounds of the femoral artery. (4) Hæmorrhage from the femoral artery. (5) To reduce the blood supply in cases of elephantiasis of the leg and sarcomata.

POSITION

As for ligation of common femoral.

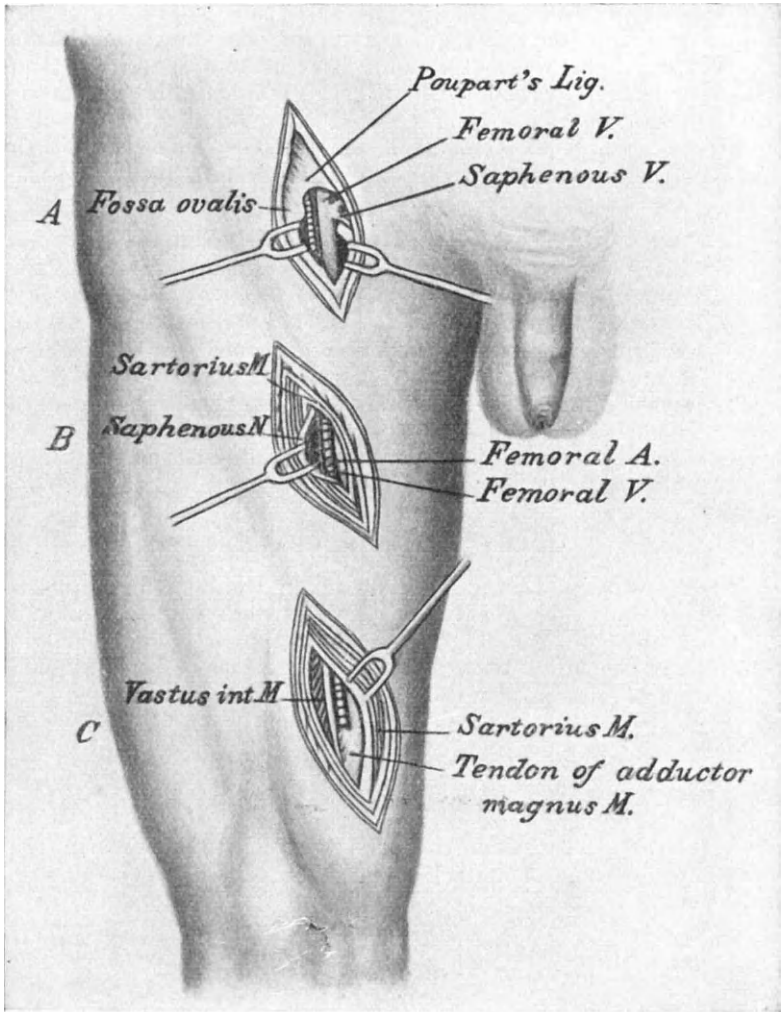


FIG. 35.
LIGATION OF THE FEMORAL ARTERY.

OPERATION

Make an incision, in the case of the right thigh, from above downwards, and on the left, from below upwards, three inches long, in the line of the artery, the centre of the incision corresponding to the apex (see Fig. 35). The tributary to the internal (great) saphenous vein is exposed, retract it. Divide the fascia lata.

The sartorius is exposed at the lower and outer part of the wound, retract it outwards; identify it by the fibres which have a downward and inward direction. Now, feel for the artery (and its pulsation). Superficially, branches of the internal cutaneous (médial femoral cutaneous) nerves are seen and deeper, on its outer side the long saphenous (the saphenous) nerve. Open the sheath and pass the needle from within outwards, keeping it close to the coats of the artery (*see Fig. 35*).

Comment :—(1) Roughly speaking, the upper end of the incision could be a hand's breadth below Poupart's ligament. (2) Scarpa's (femoral) triangle is smaller than is seen in a dissected specimen. (3) Sartorius is the only muscle in that region, which has its fibres running obliquely downwards and inwards. (4) Do not wound internal (great) saphenous vein, which is rather superficial. (5) Remember that the femoral vein lying behind the artery, may be injured while passing the needle.

COLLATERAL CIRCULATION

(1) External and internal circumflex and perforating branches of the profunda (deep femoral) with branches of popliteal and anterior tibial recurrent. (2) Comes nervi ischiadici (arteria comitans n. ischiadici) with perforating branches of the profunda (deep femoral) and branches of popliteal.

B. In Hunter's (adductor) canal

INDICATIONS

(1) Hæmorrhage from the stump after amputation in the lower-third of thigh or knee. (2) Wounds incised, punctured, etc. (3) Aneurysm.

POSITION

As for the previous operation.

OPERATION

Make an incision, three inches long, in the line of the artery in the middle part of the thigh. The internal (medial femoral) cutaneous nerve and the long saphenous vein may be seen in the subcutaneous tissue. Retract them inwards (medialwards). Divide fascia lata exposing the sartorius, identifying it by the direction of its fibres running downwards and inwards. Retract it by its outer edge inwards. The roof of Hunter's canal is now exposed, formed by a fascia, with its fibres running transversely from the vastus internus (medialis) to adductors magnus and longus. Make

an incision in the roof in the line of the original wound. This opens Hunter's canal and exposes the artery. The vein lies behind and partly to the outer side. Pass needle from either side (*see Fig. 35*).

COLLATERAL CIRCULATION

After ligation of the femoral artery below its profunda branch the external circumflex artery anastomoses with the muscular branches of the femoral, anastomotica magna and superior articular arteries. The perforating arteries anastomose with the muscular branches below the ligature and with the superior articular arteries.

Comment.—(1) Keep rigidly in the line of the artery and in the middle-third of the thigh in making the incision, for (*a*) if the incision is made too far outwards (lateralwards) the vastus externus (lateralis) is exposed instead of the sartorius. The vastus fibres run downwards and outwards, the sartorius fibres downwards and inwards; (*b*) if it is made lower than the middle-third, the vessel is exposed below the opening in the adductor magnus after it has become the popliteal. (2) Avoid the vein and internal saphenous nerve (the saphenous nerve). (3) The site of the canal is best demonstrated by fully adducting the thigh which makes the fibres of adductors magnus and longus prominent.

LIGATION OF THE POPLITEAL ARTERY

INDICATIONS

(1) Injury to the popliteal artery (e.g., due to dislocation, fracture, punctured and crushed wounds, or during osteotomy). (2) Aneurysm of the lower part of the popliteal. (3) Wounds of the leg with hæmorrhage of uncertain origin (e.g., from anterior or posterior tibial).

SURGICAL ANATOMY

This vessel commences at the opening in the adductor magnus near the junction of the upper two-third with the lower-third of the femur on its inner aspect. The vessel at first passes obliquely downwards and outwards to the mid-point of the popliteal space and then vertically downwards to the lower border of the popliteus muscle. Here it terminates by dividing into anterior and posterior tibial arteries. The point of bifurcation corresponds with the tubercle (tuberosity) of the tibia. It can be tied best at its commencement on the inner side of the thigh, where it is found between the tendons of semi-membranosus and adductor magnus.

A. In its upper part—(i.e. on the inner side of the thigh)

POSITION.

Flex hip slightly. Fully abduct the thigh and rotate it outwards. Flex knee-joint at right angles. Operator stands on the outer side and bends over the limb. The assistant stands opposite.

OPERATION

Incision, three inches long, on the right side, from above downwards and on the left side, from below upwards, begins at the junction of the middle and lower-thirds of the thigh. It runs parallel with and just behind the tendon of the adductor magnus. The subcutaneous fat is exposed with a branch of the internal cutaneous nerve (the medial femoral cutaneous nerve). Retract the nerve outwards. Define the anterior edge of the sartorius and retract it backwards. If the internal (great) saphenous vein is exposed lying on this muscle, it is retracted with the muscle. Divide the deep fascia, seek for the adductor magnus. Draw it forwards. Expose the semi-membranosus, retract it backwards. The artery will be found in the interval between the semi-membranosus and the adductor magnus, surrounded by much connective tissue and lying close to the bone. The internal popliteal nerve (tibial nerve) lies on the outer side of the artery. The artery is most superficial of all these three structures. Take an aneurysm needle with a large lateral curve and pass it from below upwards (*Fig. 36*).

Comment :—(1) This operation is the easier of the two and the one most commonly performed. (2) The internal (great) saphenous vein is on the surface of the sartorius muscle and the deep branch of the anastomotica magna artery (highest genicular artery) along the anterior surface of the adductor magnus tendon; avoid both. (3) The tendon of the adductor magnus is a good guide to the vessel.

COLLATERAL CIRCULATION

(1) Anastomotica magna, (highest genicular), superior articular (superior genicular) and descending branch of external (lateral) circumflex with inferior articular and recurrent anterior tibial (anterior tibial recurrent).

B. In its lower part—(i.e. in the popliteal space)

POSITION:

Place patient in prone position. Extend leg fully. Operator stands on the outer side of the left limb and the inner side of the right. Assistant stands opposite.

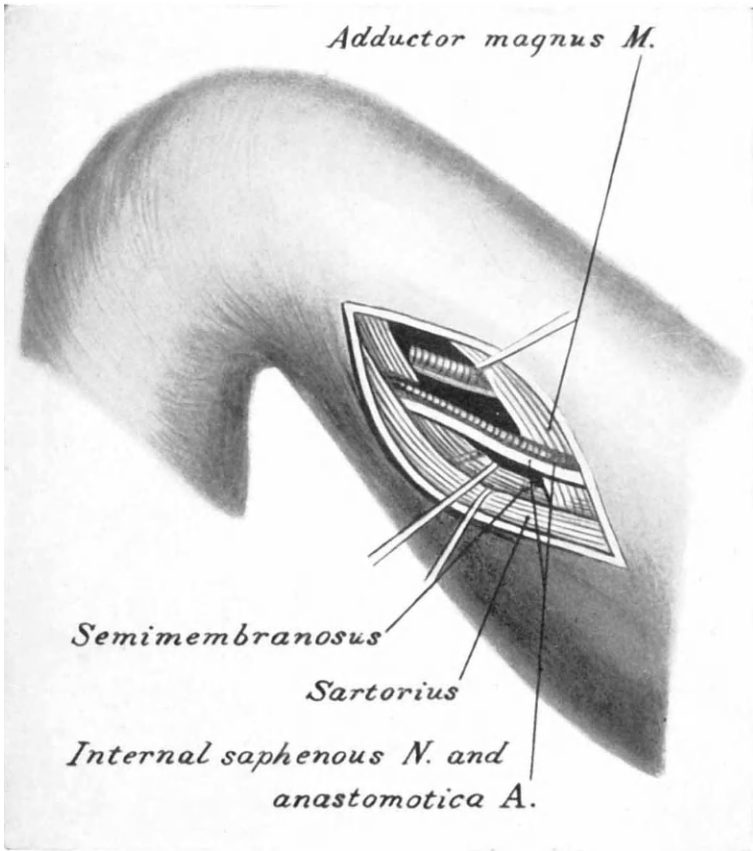


FIG. 36.
LIGATION OF THE POPLITEAL ARTERY.

OPERATION

Make a vertical incision three and half inches long in the middle line of the popliteal space, commencing about the level of the knee-joint, and extending downwards over the interval between the two heads of the gastrocnemius. This divides the skin and superficial fascia and exposes the short saphenous vein and nerve (sural nerve). Divide the deep fascia in the same vertical line. Identify the heads of the gastrocnemius muscle and separate them widely. The following structures are now exposed ; plantaris, crural (tibial) arteries and the communicans tibialis nerve (medial sural cutaneous nerve). Draw these to one side. The short saphenous (small saphenous) vein is the guide to the vessel. Flex the knee-joint to relax the gastrocnemius. The following structures are now found in order from behind forwards ; first the internal popliteal nerve (tibial nerve), then the popliteal vein and then the artery. Draw the nerve and vein to the inner (medial) side, clean the artery and its sheath and pass the needle from the inner side.

Comment :—(1) Avoid injury to the vein by retracting it carefully together with the internal popliteal nerve. (2) Knee should be fully flexed to relax the muscles before passing the needle.

COLLATERAL CIRCULATION

As after the previous operation.

LIGATION OF THE ANTERIOR TIBIAL ARTERY

INDICATIONS

(1) Wounds to the vessel (incised, punctured, gunshot, due to fracture and after amputations). (2) Traumatic aneurysm of the tibial artery. (3) Aneurysm of the popliteal artery (according to some authorities).

SURGICAL ANATOMY

The popliteal artery bifurcates at the lower border of the popliteus muscle behind the knee-joint, into anterior and posterior tibial arteries. The anterior tibial passes over the upper border of the interosseous membrane along the anterior and outer aspect of the limb (*see Figs. 34, 37*).

SURFACE MARKING

Take a point midway between the head of the fibula and the tuberosity of the tibia ; take another point midway between the internal and external (medial and lateral) malleoli. Join these two points to indicate the line of the artery.

POSITION

The patient lies on his back. The leg lies straight upon the table with the foot projecting beyond its edge. Extend foot

forcibly and rotate leg fully inwards. Operator stands on the outer side and assistant opposite to him.

A. In the upper third of the leg

OPERATION

Incision for the right side from above downwards and for the left from below upwards, three and half inches long over the line of

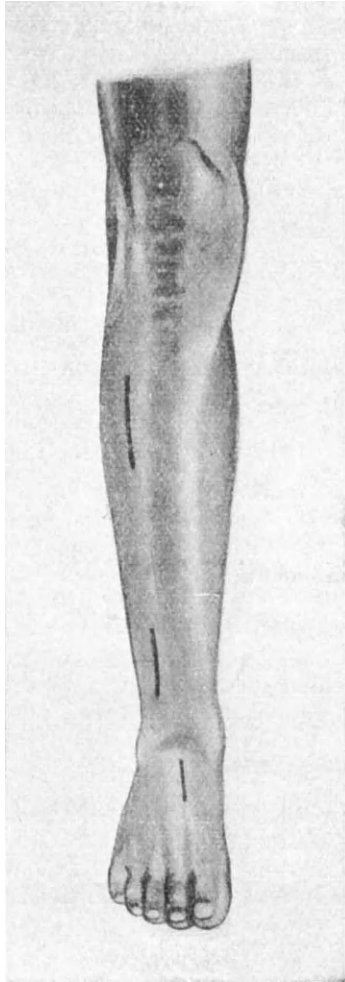


FIG. 37.

SURFACE MARKING OF THE ANTERIOR TIBIAL ARTERY.

the artery, its upper end being about one inch below the head of the tibia (*Fig. 37*). The strong deep fascia, which is exposed, is divided. The intermuscular line between the tibialis anticus (anterior) and extensor longus digitorum is now seen. Relax these

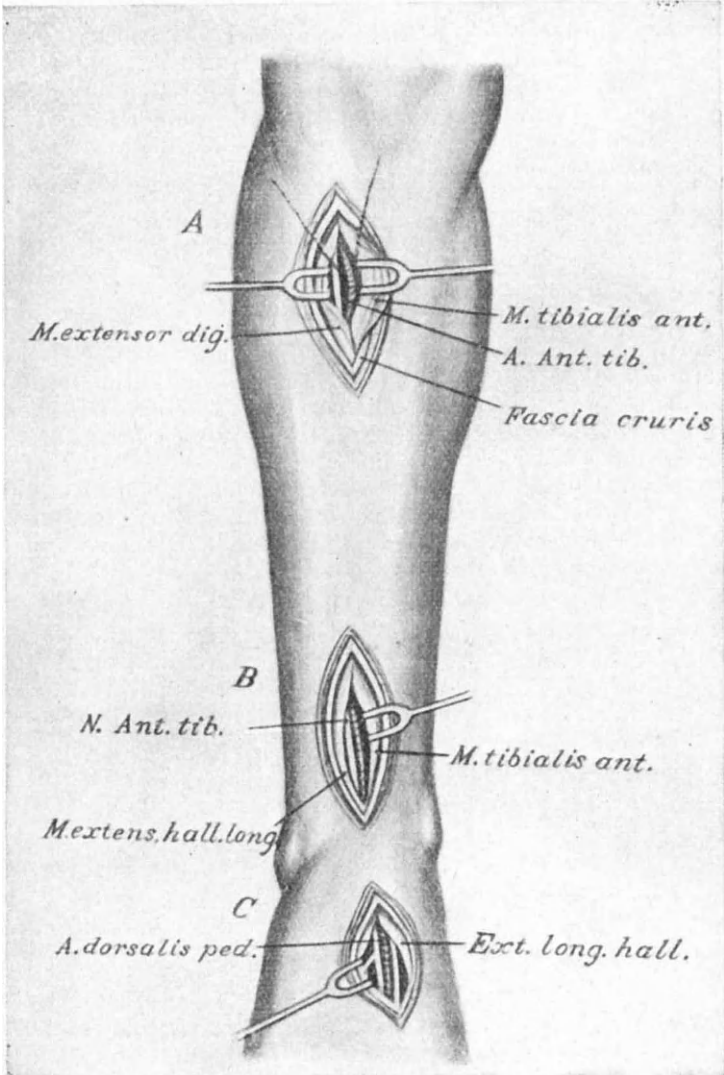


FIG. 38.
LIGATION OF THE ANTERIOR TIBIAL ARTERY.

muscles now by flexing the foot. Separate these two muscles, retract them and look for the external border of the tibia. The artery will be found lying bound down on the interosseous membrane. The nerve lies on the outer side of the artery. The needle is passed from without inwards and the artery ligatured with the *venæ comites* as the latter can hardly be separated (*see Fig. 38*).

Comment :—(1) Before incision try to define the *tibialis anticus* (anterior). (2) One and half inch or a thumb's breadth on the outer side of the anterior crest or shin of the tibia will roughly define the line of the artery. (3) If the intermuscular line is not distinct, feel for it with your finger.

B. In the middle third of the leg

OPERATION

Make an incision three inches long on the line of the artery with its centre opposite the centre of the limb, dividing the skin and the deep fascia (*see Fig. 37*). The white line indicating the intermuscular septum between the *tibialis anticus* (anterior) and *extensor longus hallucis* is now exposed. Flex the foot to relax these muscles and separate them along this line and retract them. The artery will be found lying on the interosseous membrane. On its outer side is the *extensor longus hallucis* and in its front is the anterior tibial nerve (deep peroneal nerve). The needle is passed from its inner side (*see Fig. 38*).

Comment :—(1) Missing of the intermuscular septum can be avoided by (a) identifying the *tibialis anticus* (anterior) which is the first muscle external to the (anterior) crest of the tibia and (b) keeping close round its outer margin while opening the intermuscular septum. (2) Flex the foot to relax the muscles while looking for the artery.

C. In the lower third of the leg

POSITION

As for ligation of the upper third, without the inward rotation of the foot.

OPERATION

Make an incision two to three inches long along the line of the artery on its lower third (*see Fig. 37*).

Clearly identify tendon of *tibialis anticus* (anterior). Divide the upper part of the superior band of the anterior annular ligament in the line of the wound. In the interval between the tendon of

the tibialis anterior and the tendon of extensor longus hallucis will be found the anterior tibial artery, accompanied by two venæ comites and with the anterior tibial nerve on the outer side. Pass the needle from the nerve. In closing the wound, suture the anterior annular ligament (*see Fig. 38*).

LIGATION OF THE DORSALIS PEDIS ARTERY

INDICATIONS

(1) Wounds of the vessels. (2) Traumatic aneurysms. (3) Hæmorrhage from the plantar arch from trauma, or (4) secondary hæmorrhage due to septic processes in the sole.

SURFACE ANATOMY

It is a direct continuation of the anterior tibial artery commencing midway between the external and internal malleoli. It runs downwards through the first interosseous space to join the external plantar artery and thus forms the plantar arch.

SURFACE MARKING

Take the mid-point between the two malleoli and join it by a line to the first interosseous space. The artery lies between the tendon of extensor longus hallucis (on the inner side) and extensor longus digitorum (on the outer side) (*see Fig. 37*).

POSITION

Flex the knee, the sole of the foot rests on the table. The assistant holds the foot in that position. Operator stands on the outer side.

OPERATION

Make an incision two inches long on the line of the artery between the tendons of extensor longus digitorum externally and extensor longus hallucis internally. The artery is found on the fatty tissue lying on the bone, the anterior tibial nerve being on its outer side. Pass the needle from the nerve (*see Fig. 38*).

THE POSTERIOR TIBIAL ARTERY

LIGATION OF THE POSTERIOR TIBIAL ARTERY

INDICATIONS

(1) Wounds (punctured, incised, gunshot, etc.). (2) Traumatic aneurysm.

SURGICAL ANATOMY

The posterior tibial artery formed by the bifurcation of the popliteal at the lower border of the popliteus muscle, continues down the back of the leg between the superficial (gastrocnemius, soleus, and plantaris) and deep (flexor longus digitorum) muscles on the posterior aspect of the tibia.

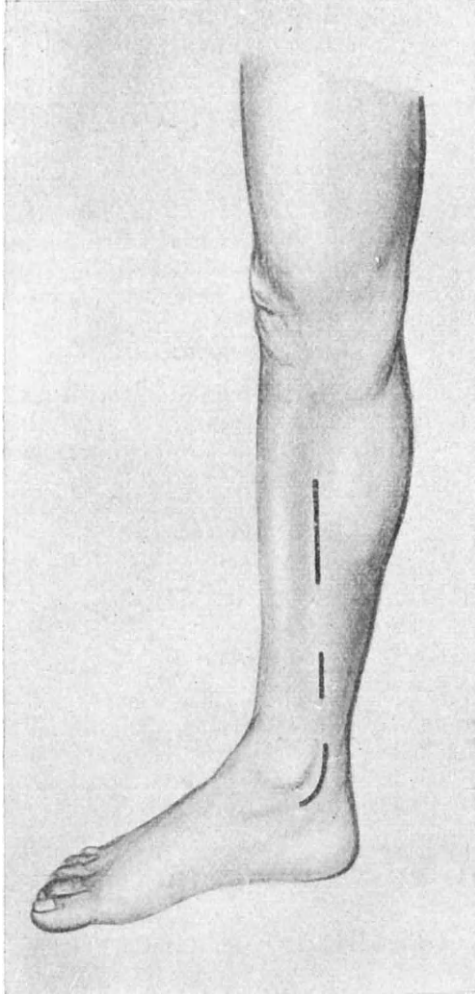


FIG. 39.
SURFACE MARKING OF THE POSTERIOR TIBIAL ARTERY.

SURFACE MARKING

A line drawn from a point at the lower part of the centre of the popliteal space to another point midway between the tendo Achillis and the internal malleolus (see *Figs. 34, 39*).

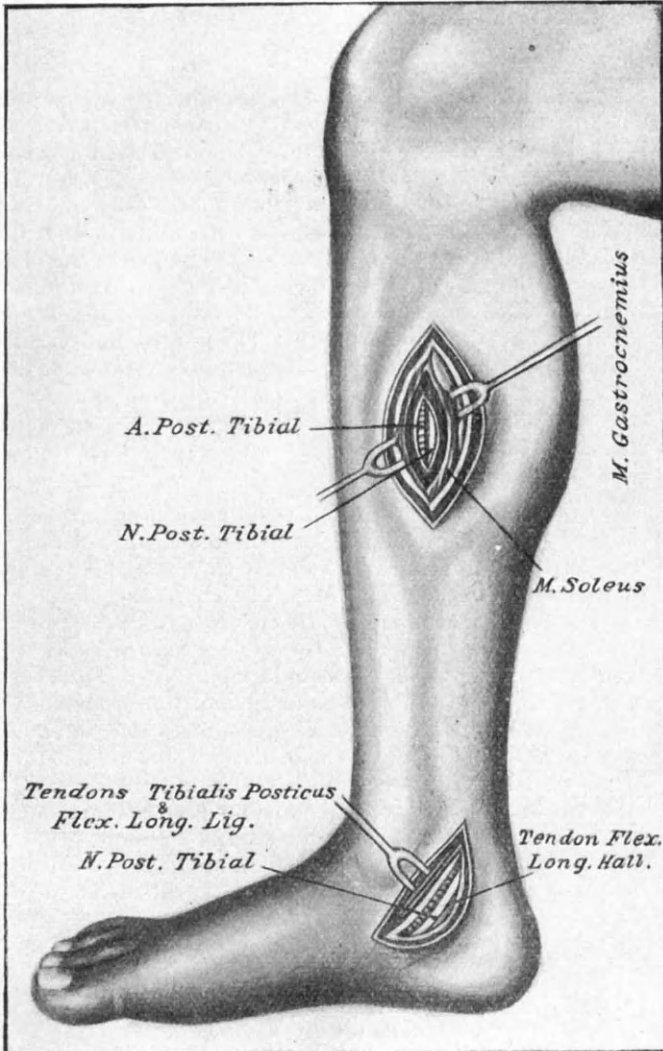


FIG. 40.
LIGATION OF THE POSTERIOR TIBIAL ARTERY.

POSITION

Flex the knee and place the leg on its outer side. The assistant holds the leg in that position standing on the inner side of the leg. The operator stands on the outer side.

A. In the middle of the Calf

OPERATION

Make an incision four inches long parallel to and a finger's breadth behind the inner border of the tibia, its centre corresponding to the mid-point of the leg (*Fig. 39*). Divide the skin avoiding the internal saphenous vein and then the deep fascia. If the gastrocnemius comes into view, draw the inner border downwards. This exposes the fibrous aponeurosis of the soleus. Divide this and the muscular fibres of the soleus along the length of the incision. Retract the cut margins. This brings into view the intermuscular aponeurosis which covers the vessels and the deeper muscles of the leg. Split this up for the whole length. The flexor longus digitorum with its fibres running obliquely downwards is exposed. Plantar-flex the foot and also the knee to relax the calf muscles. The vessel will be seen bound down to the deep muscles by a fascia. The posterior tibial nerve lies on the outer side. Pass the needle from the nerve (*Fig. 40*).

Comment :—(1) In muscular subjects, fleshy fibres of the gastrocnemius may be mistaken for soleus. The latter muscle can be recognized by the direction of its fibres running obliquely whereas those of the gastrocnemius run parallel to the long axis of the limb. (2) Sometimes the interval between the superficial and deep calf muscles is difficult to recognize and the deep muscles may be detached from the tibia by mistake. To avoid this, recognize the intermuscular aponeurosis of the soleus. (3) The fibres of the flexor longus digitorum may hide the artery and this can be obviated by searching for the artery behind the posterior surface of the tibia and not in the middle of the wound. (4) In dividing the soleus keep the knife towards the tibia or too much of the soleus will be cut.

B. At the lower third of the Leg

OPERATION

Make an incision two inches in length on the line of the artery midway between the margin of the tendo Achillis and inner edge of the tibia (*see Fig. 39*). Divide superficial and deep

fasciæ with the upper part of the internal annular ligament. The artery is seen lying on the flexor longus digitorum with the nerve on its outer side. Pass the needle from the nerve and ligature it including the venæ comites.

C. Behind the Internal Malleolus

OPERATION

Make a curved incision with the convexity towards the heel, half an inch behind the internal malleolus and corresponding to its curve (*Fig. 39*). Divide the skin and the superficial fascia. The strong deep fascia which forms the internal annular ligament is exposed and divided. The artery is thus exposed with venæ comites lying on either side. It is separated from these and the needle passed from the nerve (*see Fig. 40*).

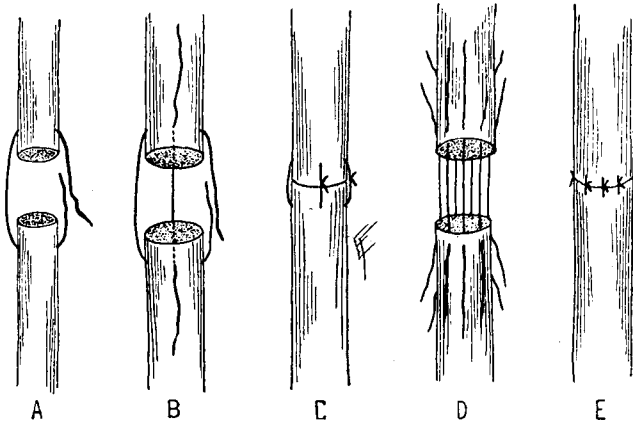
Comment :—(1) From the inner margin of the internal malleolus towards the heel are found four compartments: (*a*) the first compartment contains tibialis posticus (posterior) in its sheath; (*b*) the second, flexor longus digitorum; (*c*) the third, in order, the vein, artery, another vein and the nerve; (*d*) the fourth compartment contains flexor longus hallucis tendon. (2) Remember the order of the compartments and do not cut the tendon sheaths.

CHAPTER IV

OPERATION ON NERVES

Nerves may have to be exposed for the following objects:—

1. For nerve stretching (neurectasy), e.g. the sciatic for sciatica.
2. For the division of a nerve trunk (neurotomy) for neuralgia, e.g. the fifth cranial nerve.
3. For resection of nerve (neurectomy), e.g. the spinal accessory for spasmodic torticollis.
4. For extrication of a nerve from cicatrix or callus (neurolysis).
5. For suturing (neurorrhaphy) in cases of accidental division or rupture, e.g. the median in the forearm (*Figs. 41–45*).



FIGS. 41–45.

METHODS OF NERVE-SUTURING:—1,—A, B, C, Sutures passing through entire thickness of nerve and sheath; D, E, Sutures passing through nerve-sheath only.

REPRODUCED FROM BICKHAM'S OPERATIVE SURGERY
By the Courtesy of THE W. B. SAUNDERS CO.

6. For nerve anastomosis, nerve bridging (neuroplasty) and nerve transplantation, e.g. the facial with the hypoglossal or spinal accessory nerves (*Fig. 46*).

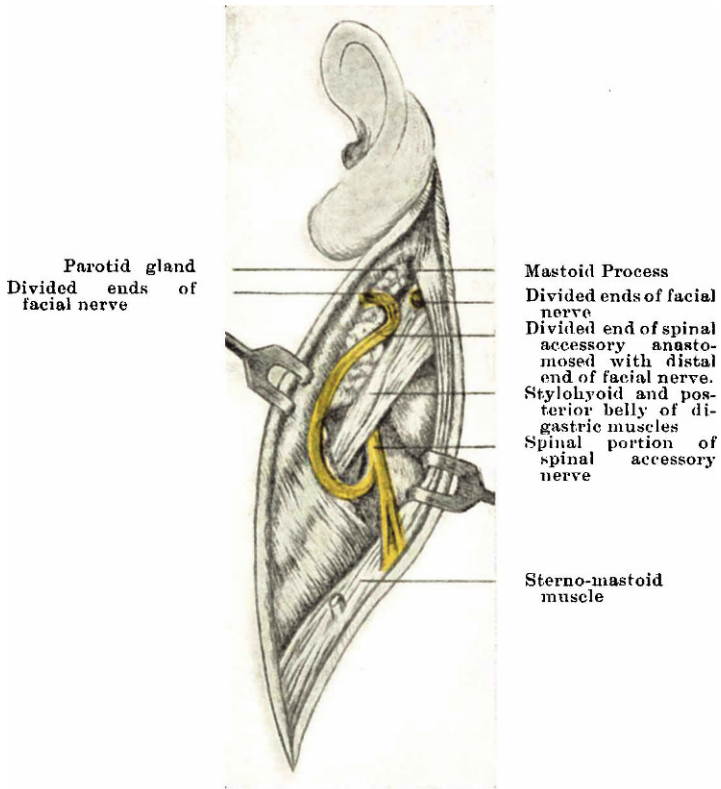
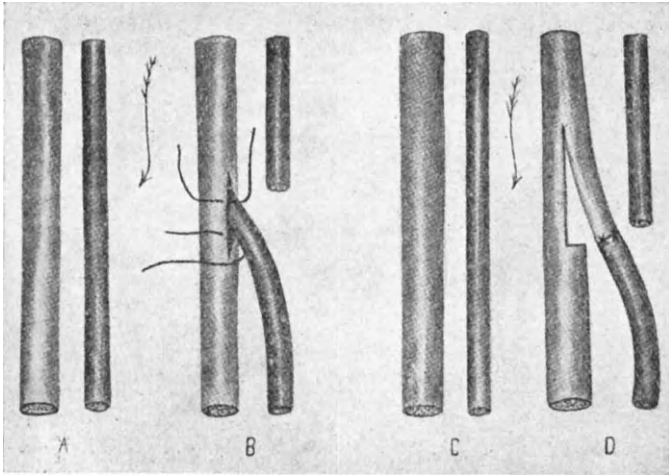


FIG. 46.
NERVE ANASTOMOSIS

REPRODUCED FROM BICKHAM'S OPERATIVE SURGERY
By the Courtesy of THE W. B. SAUNDERS CO.

7. For nerve implantation or nerve grafting (*Figs. 47-50*).
8. For nerve avulsion, i.e. tearing away of a nerve from its proximal and distal connections.



FIGS. 47-50.

NERVE GRAFTING—III:—A, The darker, smaller nerve has lost all function; B, is divided transversely and its distal end sutured into the sound nerve. C, The darker nerve has lost all function; D, is divided and sutured to the split portion of the sound nerve.

REPRODUCED FROM BICKHAM'S OPERATIVE SURGERY
By the Courtesy of THE W. B. SAUNDERS CO.

EXPOSURE OF NERVES OF HEAD AND NECK

THE SUPRA-ORBITAL NERVE

SURGICAL ANATOMY

The nerve leaves the orbit through the supra-orbital foramen which is situated at the junction of the middle with the inner third of supra-orbital margin. The supra-orbital vessels are on its outer side and superficial to it.

OPERATION

Steady the skin over the supra-orbital region with the left hand and make an incision about three-fourths of an inch long

horizontally along the superciliary ridge (arch) keeping the supra-orbital notch at its centre. On cutting through the integuments and the orbicularis muscle, the nerve is exposed. The vertical incision cuts across the fibres of the muscle and is not recommended (*Fig. 51*).

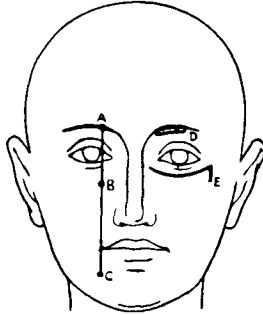


FIG. 51.

Showing positions of supraorbital (A), infraorbital (B) and mental (C) foramina, and the lines of incision (D, E).

THE INFRA-ORBITAL NERVE

SURGICAL ANATOMY

This nerve is a branch of the second division of the fifth and emerges through the infra-orbital foramen on the front of the superior maxilla (the maxilla). To find the infra-orbital foramen, draw a line from the supra-orbital notch to the interval between the two lower bicuspid (premolar) teeth which is in a line with the mental foramen (*Fig. 51*); the foramen lies on this line about half an inch below the infra-orbital margin.

OPERATION

Make a transverse incision three-fourths of an inch long and one-fourth of an inch below the lower margin of the orbit, crossing the infra-orbital foramen. This incision cuts through the subcutaneous fat and orbicularis (oculi) muscle and exposes levator labii superioris (quadratus labii superioris). This is divided and the nerve is reached.

THE FACIAL NERVE

SURGICAL ANATOMY

The seventh or the facial nerve after traversing the internal auditory (acoustic) meatus and aqueductus Fallopii (canalis facialis) emerges through the stylo-mastoid foramen. It now runs forward and slightly downwards along the upper border of the posterior

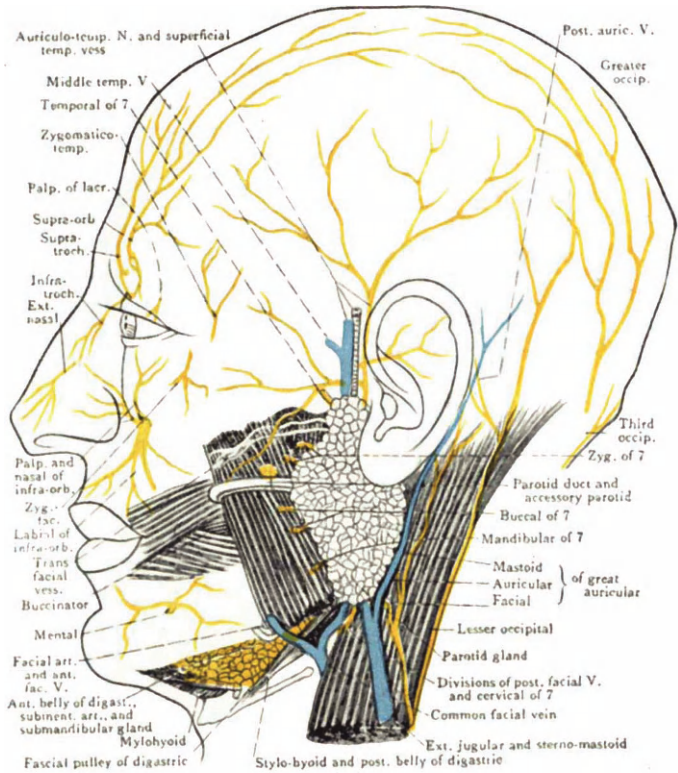


FIG. 52.
 PAROTID GLAND AND SUPERFICIAL NERVES OF HEAD.

To face page 69.

belly of the digastric, gives off the posterior auricular nerve and muscular branches, and enters the substance of the parotid gland at the level of the lower margin of the tragus, opposite the posterior border of the ramus of the lower jaw. On the face it divides into five branches: Temporal, Zygomatic, Buccal, Mandibular, and Cervical (*Fig. 52*).

POSITION

Same as for ligature of common carotid artery.

OPERATION

Make an incision similar to that employed for ligature of the external carotid but at a slightly higher level. This divides the skin and the fascia; the sterno-mastoid (sterno-cleido-mastoideus) is cleared and retracted backwards. Similarly the parotid gland is cleared and pulled forward. This part is cleared up to the posterior belly of digastricus; the nerve is found above it and accidental stimulation gives rise to facial spasm. The nerve is raised on an aneurysm needle and traced back to the stylo-mastoid foramen (*see Fig. 46*).

THE SPINAL ACCESSORY NERVE

SURGICAL ANATOMY

The nerve leaves the cranial cavity through the jugular foramen and runs down the neck between the internal carotid and the jugular vein. It then passes obliquely downwards and backwards across the vein beneath the posterior belly of the digastric and piercing the sterno-mastoid (sterno-cleido-mastoideus) at its deep surface, it passes through the muscle, crosses the posterior triangle to become distributed to the trapezius (*see Figs. 24 and 46*).

POSITION

Patient lies on his back and in order to expose the anterior and posterior triangles of the neck a sand-bag is placed behind the shoulder and the chin turned to the opposite side.

OPERATION

Make an incision three inches long from the apex of the mastoid process along the anterior border of sterno-mastoid muscle dividing the skin and then the deep cervical fascia. Feel for the transverse process of the atlas. Bend the neck slightly on the same side and retract the sterno-mastoid backwards. Identify the posterior belly of the digastricus and the nerve will be seen emerging from beneath it a little below and external to the transverse process of the atlas. It can now be stretched or excised for severe spasmodic wry-neck.

TRIGEMINAL NEURALGIA

A few words on the treatment of Trigeminal Neuralgia will not be out of place here.

Two methods of treatment are known :

Alcohol injection of the gasserian ganglion and section of the sensory root of the fifth nerve. Other operative methods, such as section of the main divisions, or partial or total excision of the ganglion are obsolete.

INJECTION OF THE GASSERIAN GANGLION

The needle may be entered in the cheek, opposite the upper second molar tooth, as recommended by Purves Stewart, or $\frac{1}{4}$ inch in front of and below the eminentia articularis of the zygoma. The needle is so directed that it is at an angle of 110° with the vertical plane so that when seen from the front it is aimed at the pupil, and from the side, directly deep to the eminentia articularis. A protractor may be used to measure the angle (*Fig. 53*). The



FIG. 53.

INJECTION OF THIRD DIVISION OF FIFTH NERVE. Method of measuring angle (110 degrees) in vertical plane with protractor.

injection must in every case be checked by the sensation of the patient, and, therefore, local anæsthesia or morphine and scopolamin are preferable to general anæsthesia. No alcohol must be injected

before a preliminary injection of a few drops of novocaine solution, which should cause anæsthesia of the corresponding side of the face. If the needle is in the ganglion, definite resistance is felt while pushing the piston. After anæsthesia has been secured by novocaine the needle is left *in situ*, and a syringe containing absolute alcohol is attached. From 1 to 2 c.c. of alcohol are injected very slowly, a careful watch being kept upon the sensation of the patient and upon the other cranial nerves.

RESECTION OF THE SENSORY ROOTS

The alcohol injection being easier and without much risk and therefore popular, this procedure is seldom adopted.

OPERATIONS ON THE PHRENIC NERVE IN THE TREATMENT OF PULMONARY TUBERCULOSIS

Amongst the various methods which aim at a diminution in the volume and mobility of the lung, when its lower part is affected, section of the motor nerve to the diaphragm is becoming quite popular. It is specially helpful in cases in which due to extensive adhesions, an artificial pneumothorax is undesirable and is of little benefit.

SURGICAL ANATOMY

The anatomical relations of the phrenic nerve are very variable. In many persons it is duplicated in the neck and in some even three trunks have been found. It receives filaments from the sympathetic, sometimes from the nerve to the subclavius muscle and from the hypoglossal, the spinal accessory, the vagus or suprascapular nerves. Section high in the neck may leave the accessory nerves intact and no hemidiaphragmatic paralysis occurs.

RADICAL PHRENICECTOMY

Goetze's operation involves considerable dissection to expose the nerve and to cut it low down in the neck, below its anastomosis with the inferior cervical sympathetic ganglion.

It appears that for practical purposes only the accessory phrenics are to be considered, while the other fibres, arising with the nerve to the subclavius, are so rare that they may be disregarded and the simpler operation of phrenic avulsion is sufficient.

PHRENIC AVULSION, PHRENIC EXERESIS

This operation is almost invariably done under local infiltration anæsthesia.

An incision of about $1\frac{1}{2}$ to 2 inches in length is made along the posterior border of the sterno-cleido-mastoideus, the centre of the incision being at the level with the cricoid cartilage. The alternate incision is one over the posterior triangle, parallel to the clavicle and a few centimeters above it. Better cosmetic results have thus been obtained. Dissecting down, the scalenus anterior is exposed and, if the nerve is in its normal position, it is seen crossing the muscle from above, downward and medially. After the nerve has been surely identified, it is cut as high as possible the distal end seized with forceps and released from its muscular sheath as low as possible.

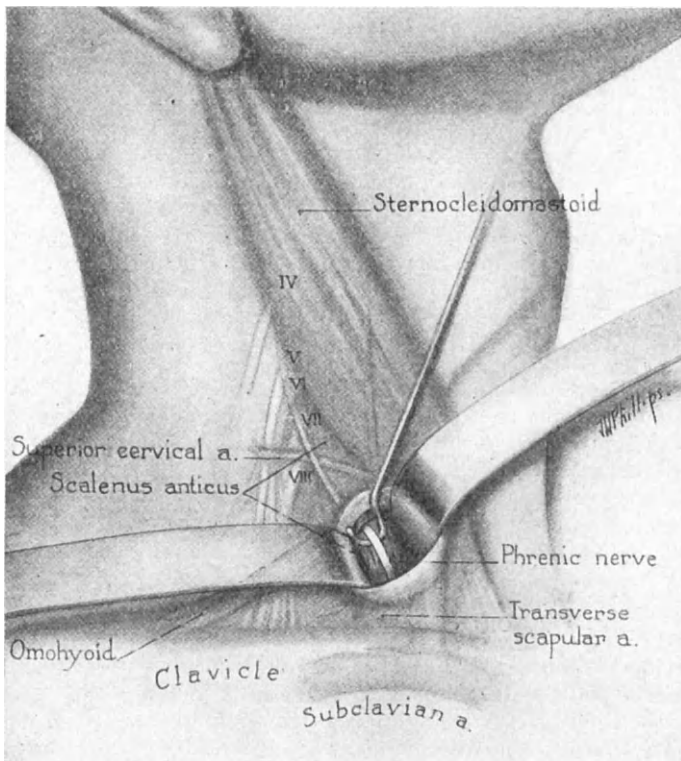


FIG. 54.

SURGICAL APPROACH TO THE PHRENIC NERVE.

It is then twisted and pulled out. Ten to twelve, at times as much as 25 or 30 c.m. are pulled out including the main terminal branches, while all the accessory branches are thus ruptured. To

secure the desired result at least 11 c.m. of the distal portion of the nerve must be cut (*Fig. 54*).

Comments :—Simple as it appears, the operation is not always so easy. In some subjects it cannot be easily found. The recurrent laryngeal, the cervical sympathetic trunk and the vagus have been mistaken for the phrenic and severed with the consequent results of permanent aphonia, Horner symptom-complex or instant death. Injury to the cervical veins may be responsible for air embolism, and to the thoracic duct give rise to a chylous fistula.

EXPOSURE OF THE NERVES OF THE UPPER EXTREMITY

THE MEDIAN NERVE

This nerve has to be exposed for suturing after accidental division. It may be exposed in three different situations, viz. : (a) in the middle of the upper arm, (b) at the bend of the elbow, and (c) above the wrist.

(a) In the middle of the arm.—It can be exposed by the same process as the brachial artery. The nerve is seen first and then the artery (*see Fig. 15*).

(b) In the front of the elbow.—The operation is similar to that for the exposure of the brachial artery in this situation. The incision, however, can with advantage be made about half an inch internal to the biceps tendon. The nerve lies one-fourth of an inch internal to the artery (*see Fig. 16*).

(c) Above the wrist.—It can be exposed about an inch above the transverse crease on the front of the wrist. A vertical incision there exposes the palmaris longus tendon and the nerve will be found lying either beneath or just on the radial side of this tendon.

THE ULNAR NERVE

This nerve is generally injured in the ulnar groove at the back of the elbow or just above the wrist.

(a) In the upper arm.—The nerve can be exposed by the same incision as for the brachial artery (*see Fig. 15*). It lies on the inner side of the vessel. *Lower down*, the nerve can be exposed by an incision on the ulnar groove at the back of the internal condyle (medial epicondyle) or by prolonging the incision upwards.

(b) In the forearm.—The nerve can be exposed by the same incision as for the ulnar artery. It lies internal to the vessel.

THE MUSCULO-SPIRAL (RADIAL) NERVE

This nerve is frequently damaged in fractures of the shaft of the humerus or it may get caught in the callus after the fracture is united. It may give rise to wrist-drop. It is usually exposed at the back of the arm.

At the back of the arm.—Flex the elbow at right angles holding the upper arm in the vertical position. Make a vertical incision four inches long in the middle line of the posterior aspect of the arm, the centre of the incision being opposite the centre of the bone. The triceps is exposed and its fibres separated vertically. The nerve is found in the musculo-spiral groove (*sulcus nervi radialis*) with the superior profunda (*profunda brachii*) vessels crossing the line of incision obliquely.

EXPOSURE OF THE NERVES OF THE LOWER EXTREMITY

THE SCIATIC NERVE

SURGICAL ANATOMY

The nerve appears immediately below the inferior border of the gluteus maximus. It lies on the adductor magnus between it and the hamstring muscles. This nerve is exposed for stretching in cases of obstinate sciatica but this operation is, however, becoming very rare.

POSITION

The patient lies prone with his head turned to one side. The operator stands on the side to be operated on.

OPERATION

Commence an incision at a point midway between the ischial tuberosity and the great trochanter and carry it vertically downwards for three inches. This exposes the gluteus maximus above and hamstring muscles at the inner margin of the wound. They are retracted upwards and inwards respectively. The sciatic nerve is found lying on the posterior surface of the adductor magnus in the depth of the wound (*Fig. 55*).

THE EXTERNAL POPLITEAL (COMMON PERONÆAL) NERVE

SURGICAL ANATOMY

This nerve is one of the two terminal branches of the sciatic nerve and lies close to the outer side of the popliteal space, and

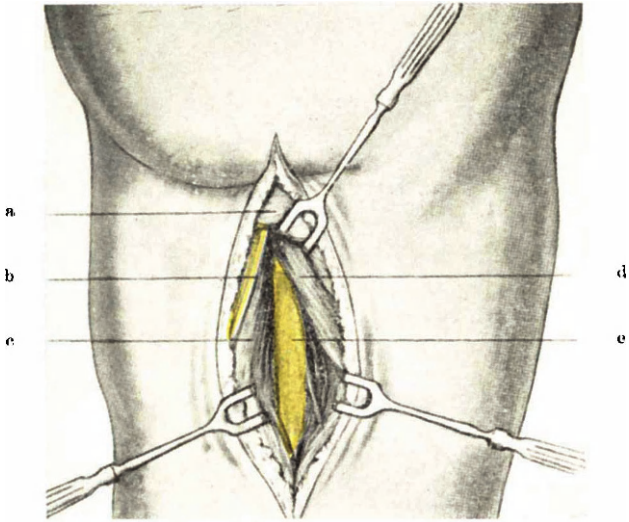


FIG. 55.

EXPOSURE OF THE GREAT SCIATIC NERVE AT THE LOWER BORDER OF THE GLUTEUS MAXIMUS:—a, Gluteus maximus; b, Small sciatic nerve; c, Semitendinosus; d, Biceps femoris; e, Great sciatic nerve and a muscular branch.

REPRODUCED FROM BICKHAM'S OPERATIVE SURGERY
By the Courtesy of THE W. B. SAUNDERS CO.

crosses the outer head of the gastrocnemius to the neck of the fibula immediately behind or below the tendon of the biceps femoris.

POSITION

Flex the limb and rotate it fully inwards.

OPERATION

Identify the biceps femoris tendon and make an incision two inches long and parallel to it in such a way that the centre of the incision corresponds to the point of insertion of the tendon. Divide the skin and retract the flaps; the nerve will be found behind and below the tendon.

CHAPTER V

OPERATIONS ON TENDONS AND MUSCLES

OPERATIONS ON TENDONS

A tendon may be divided completely, complete tenotomy, or only a part of the thickness of the tendon may be divided, partial tenotomy.

Tenodesis or tendon fixation to bones or periosteum (*Fig. 56*).

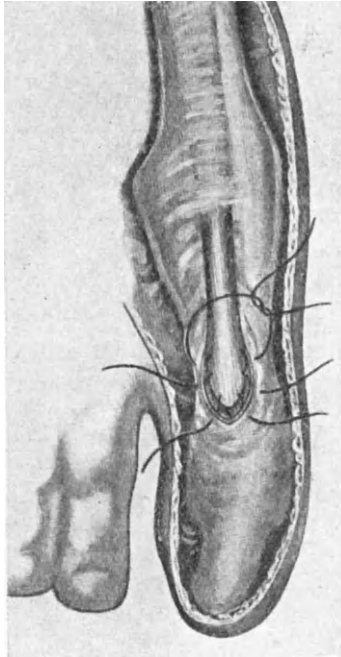
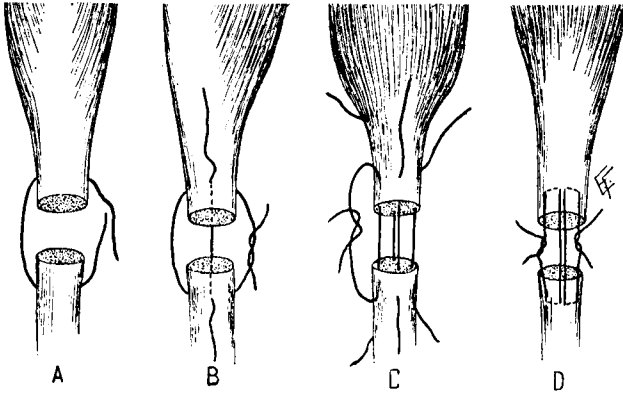


FIG. 56.

WOLFF'S METHOD OF UNITING A TENDON TO THE BONE
BY IMPLANTATION UPON FRESHENED BONE AND
SUTURE TO ADJACENT PERIOSTEUM.

REPRODUCED FROM BICKHAM'S OPERATIVE SURGERY
By the Courtesy of THE W. B. SAUNDERS CO.

Tenorrhaphy or tendon-suturing.—In recent cases the divided ends may be approximated but in old cases tendon lengthening may be required (*Figs. 57-60*).

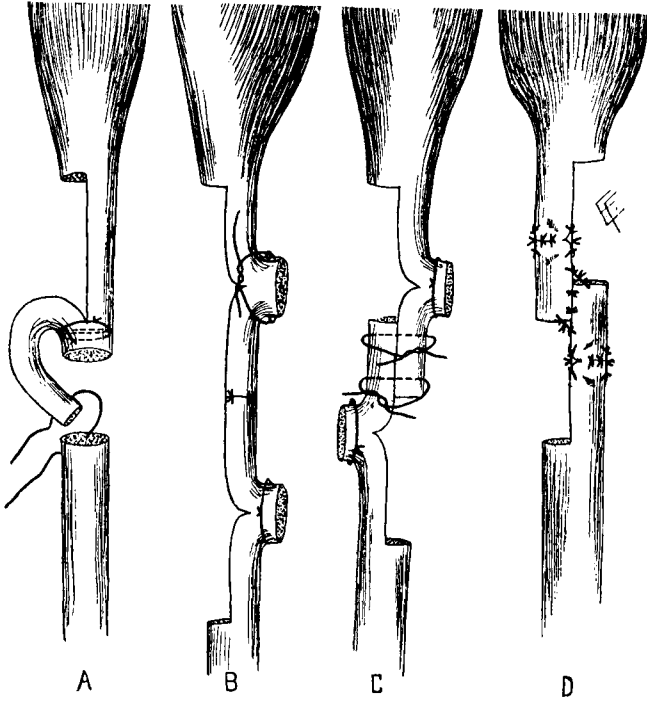


FIGS. 57-60.

TENORRHAPHY :—A, Single suture through entire thickness of tendon ; B, Two sutures entirely through tendon, in opposite directions ; C, Peripheral sutures ; D, Woelfler's quilt sutures.

REPRODUCED FROM BICKHAM'S OPERATIVE SURGERY
By the Courtesy of THE W. B. SAUNDERS CO.

Tendon lengthening is required as a secondary tenorrhaphy (*Figs. 61-64*).

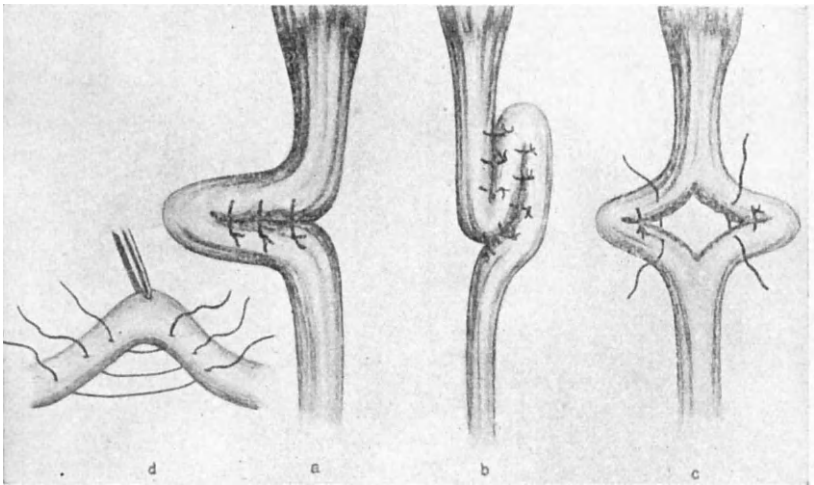


Figs. 61-64.

LESS USUAL FORMS OF TENDON LENGTHENING:—A, Splitting one end longitudinally and transversely, reinforcing where bent, and suturing split end into opposite unsplit end; B, Splitting both ends longitudinally and transversely, reinforcing where bent, and suturing split portions end to end; C, Same, with suturing of split portions laterally, D, Same as last, with different sutures (lateral knotted and ordinary).

REPRODUCED FROM BICKHAM'S OPERATIVE SURGERY
By the Courtesy of THE W. B. SAUNDERS CO.

Tendon shortening—when the muscle action is impaired due to lengthening of tendon or muscle contraction is lessened, as in paralysis and in the deformity known as talipes calcaneus. Partial tenectomy is one of the methods of tendon shortening (*Figs. 65-68*).



FIGS. 65-68.

TENDON SHORTENING BY DOUBLINGS OF THE FRESHENED TENDON UPON ITSELF, FOLLOWED BY SUTURING:—a, Single doubling of tendon upon itself, with suturing together of its freshening lateral aspects: b, Double doubling, with the same technic; c, Median splitting, followed by doubling of the two split halves and suturing: d, The method of placing the sutures, in c, seen in a.

REPRODUCED FROM BICKHAM'S OPERATIVE SURGERY
By the Courtesy of THE W. B. SAUNDERS CO.

Tendon grafting—tendon transplantation or tendon implantation. By grafting or transplantation is meant grafting one tendon upon another, strictly speaking, by implantation; the receiving tendon is cut to take into its substance the received or entering tendon. This operation is performed in cases in which a particular tendon is destroyed and the deficiency is too great for bringing into apposition the distal and proximal ends or in cases of paralysis of tendons, one or more of the paralysed tendons is grafted to an unparalysed group; e.g. for the relief of talipes valgus the tendon of peroneus brevis is sometimes divided and inserted into the tendon of tibialis anticus (anterior) (*Fig. 69*).

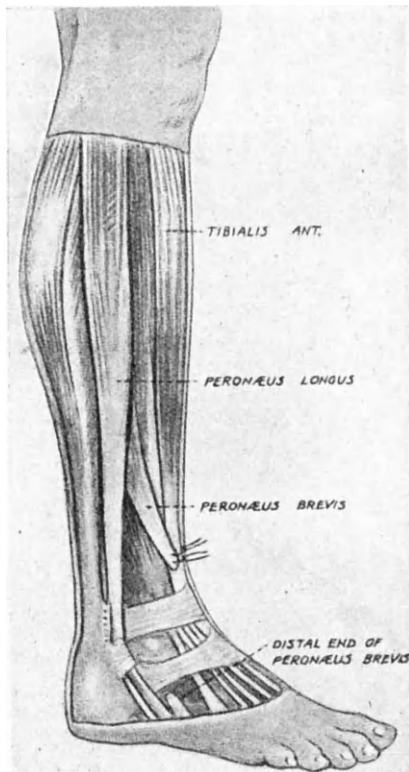


FIG. 69.

TENDON GRAFTING:—The paralysed peroneus brevis tendon is grafted into the normal tibialis anterior tendon.

REPRODUCED FROM TURNER'S OPERATIVE SURGERY
By the Courtesy of CASSELL & CO., LTD.

TENOTOMY

Tenotomy can be performed in one of two ways :

(a) *The subcutaneous method* has for its object the division of the tendon with the least disturbance of the surrounding parts and with the smallest opening in the skin. In pre-antiseptic days this was the operation of choice, but at present the open method is advocated. The subcutaneous method has certain advantages : (1) It is simple and leaves no scar. (2) It is suitable for well-defined tendons which have no important structures near it.

(b) *The open method* should be chosen : (1) When there are important structures surrounding the tendon. (2) When tenotomy is only a part of the operation for the cure of deformity. The objects for which tenotomy is performed may in many cases be achieved by tendon lengthening and tendon shortening.

Indications.—

- (1) For correction of deformities :—
 - (a) Those due to infantile paralysis.
 - (b) Those resulting from spastic paraplegia ; in these cases improvement follows the division of tendons of such muscles as are in a state of spastic contraction.
 - (c) Those of traumatic origin ; these are due to cicatricial contraction from the wounds, burns, etc., especially if the patient keeps his limb in a particular position for any length of time.
- (2) For torticollis of the non-spasmodic form.
- (3) In certain cases of congenital deformities.
- (4) To prevent tilting of the heel after certain operations such as, Chopart's amputation.

INSTRUMENTS.—Group XXXI.

OPERATION

Subcutaneous tenotomy. The tendon, if it is not already prominent, should be made so by the disposition of the limb, but it should not be over-stretched. Attempt should be made to cut the tendon without opening its synovial sheath. There are two methods :—

(1) The sharp tenotome is entered through the skin close to the tendon to make a way for the blunt-pointed tenotome. The latter is now introduced through the opening, in the flat position, so that the edge, on entrance, is not in contact with the tendon. It enters on the deeper side of the tendon, i.e. the tendon lies between it and the skin. The edge is now directed towards the

tendon, and it is cut with a sawing movement while the assistant is putting the tendon more and more on the stretch.

(2) In the other method, after the skin puncture, the blunt-pointed tenotome is introduced superficial to the tendon, i.e. between the tendon and the skin and the tendon is cut from the side of the skin towards the deeper structures. The left forefinger is kept on the skin at the site of operation in order to feel the movements of the tenotome and to control it. The division of the tendon is felt by a creaking sensation and a snap.

TENDO ACHILLIS (TENDO CALCANEUS)

INDICATIONS

(1) Chiefly for talipes equinus. (2) To rectify deformity which may be caused by Chopart's amputation ; but this amputation has practically been given up. (3) It is occasionally necessary in order to reduce a dislocation or fracture of the foot, e.g. Pott's fracture.

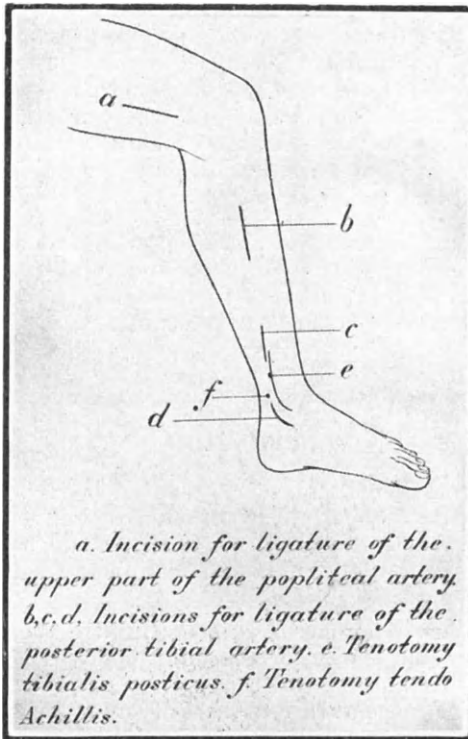


FIG. 70.

OPERATION

Select the position and divide the tendon about an inch and a half above the heel where it is narrowest (*see Fig. 70: f*).

TIBIALIS POSTICUS (TIBIALIS POSTERIOR)**INDICATIONS**

In cases of congenital club-foot and other deformities.

SURGICAL ANATOMY

The tendon passes along the posterior aspect of the tibia into the first of the four compartments behind the inner malleolus, occupying a special synovial sheath (*see Fig. 70: e*). It is inserted into the scaphoid (navicular), the cuneiforms, the cuboid and the second and third metatarsal bones. It is in close relation to important structures as described before.

OPERATION

It should be divided by the open method either (*a*) above, immediately before it passes under the internal annular or lacinate ligament or (*b*) below, just behind its insertion into the tuberosity of the scaphoid (navicular).

TIBIALIS ANTICUS (TIBIALIS ANTERIOR)**INDICATIONS**

This muscle which is a powerful adductor of the foot is divided to overcome deformities such as talipes equino-varus.

SURGICAL ANATOMY

After passing through the innermost sheath in the anterior annular ligament, the tendon of the tibialis anticus crosses the ankle in front lying upon the astragalus (talus), scaphoid (navicular), and the internal (first) cuneiform bones and the ligaments uniting them, to be inserted into the internal cuneiform and the base of the first metatarsal on their inner aspects. It has its own synovial sheath.

OPERATION

It is divided as it crosses the scaphoid bone on the inner side of the foot to gain insertion into the base of the first metatarsal and the internal cuneiform bones.

HAMSTRING TENDONS

INDICATIONS

(1) In cases of ankylosis of the extra-articular type of the knee due to the contraction of these tendons from injury, disease or after operation. (2) These tendons are exposed as a preliminary measure to an operation for shortening them or for tendon grafting, in cases of extensor paralysis of the infantile type.

SURGICAL ANATOMY

Hamstring tendons consist of the biceps, semi-membranosus and semi-tendinosus. The biceps tendon is the strong cord which forms the outer boundary of the popliteal space. It is inserted into the head of the fibula. Along its posterior border runs the external popliteal nerve (the common peronæal nerve). The semi-membranosus and the semi-tendinosus tendons with the sartorius and gracilis form the inner boundary of the popliteal space. The semi-tendinosus is smaller, more superficial and placed nearer the middle line than the semi-membranosus. The gracilis and the sartorius tendons are more difficult to feel.

Division of the biceps femoris tendon :—In consideration of its close relation to the external popliteal (common peronæal) nerve which can be easily injured during subcutaneous tenotomy, the open method should be adopted. An incision half an inch long is made on the outer aspect of the tendon ; the tendon is defined and separated from the nerve. It is then divided in the usual way.

Division of the semi-membranosus and semi-tendinosus tendons :—A subcutaneous tenotomy is not attended with any particular risk. The tenotome is introduced beneath the tendons and cut towards the skin.

Comment :—Tendon lengthening or transplantation would naturally be a more rational surgical procedure than tenotomy for the above conditions.

PERONEI TENDONS

INDICATIONS

(1) Rarely in advanced cases of talipes valgus due to infantile paralysis. (2) These tendons are exposed for tendon grafting (*see Fig. 69*).

SURGICAL ANATOMY

The two peronei tendons pass into the foot behind the outer malleolus, grooving it deeply as they run beneath it. They have

a common synovial sheath, the peroneus brevis being the upper of the two tendons. The peroneus longus crosses the foot obliquely and is inserted into the undersurface of the internal or first cuneiform and the base of the first metatarsal bones.

OPERATION

For tenotomy it is divided two inches above the external malleolus, the guide being the posterior margin of the fibula.

THE STERNO-MASTOID (STERNO-CLEIDOMASTOIDEUS).

INDICATIONS

(1) Permanent wry-neck is generally seen in early infancy, as a result of injury during childbirth or in later life due to gummatous infiltration. The sternal head is more contracted and is often converted into a firm fibrous cord. In this respect it differs from deformities of the talipes variety due to infantile paralysis, where the contraction occurs in healthy muscles.

(2) The tendons of origin have sometimes to be divided in the course of certain operations, e.g. ligature of the innominate artery. This part of the sterno-mastoid muscle is in close relation with important veins, viz. the internal jugular on its deep surface, the external jugular behind its posterior border and the anterior jugular crossing its inner margin. Moreover, the deep cervical fascia (fascia colli) makes a separate sheath for this tendon and undergoes contraction with the tendon. In tenotomy of this tendon the fascia has to be divided and an attempt to perform this by the subcutaneous method is attended with the risk of injuring the veins. This operation should, therefore, be performed by the open method. The tendon should be rendered tense by a sand-bag placed under the neck. An oblique incision is made across the lower end of the sterno-mastoid and tenotomy is performed through this opening (*see Fig. 22*).

OPERATIONS ON MUSCLES

The following operations are performed on muscles.

MYOTOMY

Division of a muscle (*a*) preliminary to muscle lengthening, (*b*) for deformities and (*c*) for exposure of underlying structures.

MYECTOMY

Excision of part of muscle as in Mikulicz's operation of excision of lower two-thirds of sternocleidomastoid for marked torticollis.

MYOPLASTY

Portions of partly detached muscles are utilized for correcting defects or deformities.

MYORRHAPHY

Muscle suturing may be required for muscles which have been cleanly divided in the course of an operation or for ruptured muscles with uneven and irregular proximal and distal ends. The limb or other parts should be so placed that the muscles are fully relaxed. While looking for ruptured ends of muscles it must be remembered that these retract considerably. Ragged ends of muscles have to be trimmed before suturing. The skin incision should be placed away from the proposed line of muscle suture in order to avoid fibrous adhesion between the two sutured structures. The muscle sutures should be applied in mattress fashion at right angles to the line of cleavage of the muscles otherwise they are apt to give way. Rather too many than too few sutures should be used. After operation the limb should be so immobilized that the sutured muscles are in a state of complete relaxation. (*see Fig. 71.*)

MUSCLE LENGTHENING

INDICATIONS

Muscle lengthening or muscle shifting is practised in cases in which due to contraction or loss of muscle tissue, approximation of

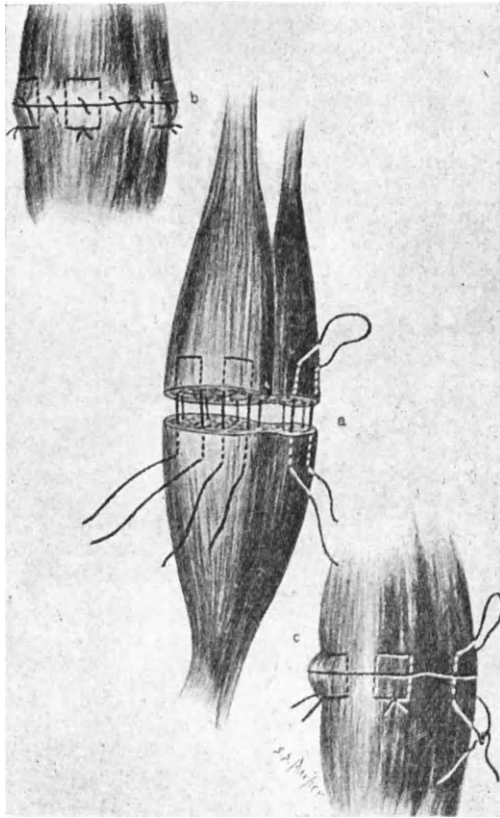


FIG. 71.

MYORRHAPHY:—a, By mattress-sutures alone—which are here being placed through the anterior and posterior aspects of the biceps muscle; c, The mattress-sutures tied; b, The approximation is here accomplished by mattress-sutures, reinforced by a continuous marginal stitch.

REPRODUCED FROM BICKHAM'S OPERATIVE SURGERY
By the Courtesy of THE W. B. SAUNDERS CO.

the separated ends is rendered impossible as in the following conditions:—

1. To enable parts other than the muscle, below to be approximated, e.g. the triceps in case of fracture of the olecranon or the quadriceps extensor, in cases of fracture of the patella.

2. Contracted muscles in cases of deformities, old dislocations and fractures.

OPERATION

Make a free skin incision to reach the muscle by the shortest, safest and most accessible route. Isolate the muscle; the muscle can now be lengthened by several methods, two of the most practised methods will be described.

(a) The 'multiple cone' method. The mass of muscle is divided in a multiple cone fashion. The cones or serrations of the proximal and distal masses are sutured together separately and then the united proximal and distal cones are sutured. By this means two inches or more in length can be gained. (*Fig. 72.*)

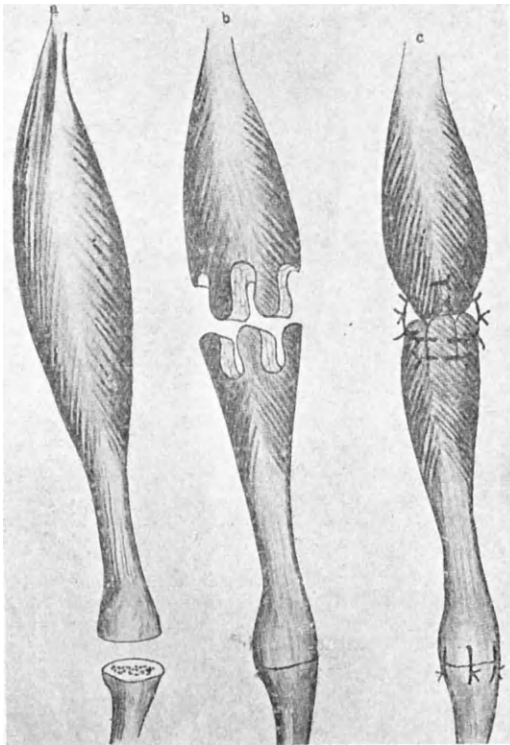


FIG. 72.

MUSCLE LENGTHENING BY MULTIPLE CONE METHOD.

REPRODUCED FROM BICKHAM'S OPERATIVE SURGERY
By the Courtesy of THE W. B. SAUNDERS CO.

(b) Inverted V-section of the muscle. The muscle is divided so that the proximal division looks like an inverted hollow V and

distal is an inverted fleshy U. The apex of the U is slid partly into the hollow of the V and sutured in such a way that the distal part of the U is not included in the suture, the muscle gaining in its length by this part of the disengaged V. (*Fig. 73.*)

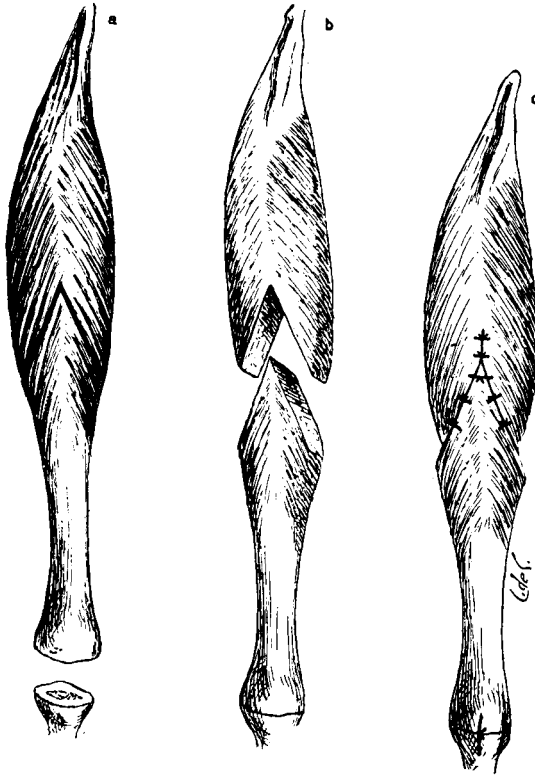


FIG. 73.

MUSCLE LENGTHENING BY INVERTED V SECTION :—a, Lines of section; b, Separated ends of muscle; c, Sectioned ends so sutured as to increase the total length to an extent corresponding with the amount of the two limbs of the upper portion of muscle sutured together in the median line.

REPRODUCED FROM *BICKHAM'S OPERATIVE SURGERY*
By the Courtesy of *THE W. B. SAUNDERS CO.*

MUSCLE-SLIDE OPERATIONS

Tenotomy is indicated when a single muscle has undergone organic shortening. But where large muscle groups are shortened, wholesale division is open to serious objections, not only because

much potential power is sacrificed, but because the resulting scar is liable to contract afresh and repeat the deformity.

In such cases operations are designed to free the whole muscle from its attachment to bone, with blood and nerve supply intact. The best known examples of this principle are Steindler's operation for the correction of *pes cavus*. Soutter's operation for hip flexion due to contracture of the tensor fascia lata and glutei, and Max Page's operation for Volkmann's ischæmic contracture.

In Steindler's operation, the planter fascia, short flexors of the toes and deep planter ligaments are detached from the os calcis (calcaneus) and allowed to slide forwards. The original operation was carried out through a large horse-shoe-shaped incision passing round the back of the heel. Instead of this two lateral incisions are now commonly employed, one on the inner side following the middle third of the planter arch, and one on the outer side passing backwards for 2 inches from the base of the fifth metatarsal. These incisions leave scars which are less exposed to pressure than that of the original approach ; besides, they allow ready access to the short ligaments of the tarsus, which may require division.

The same principle forms the basis of Soutter's and of Max Page's operation. In the former the tensor fascia lata and anterior fibres of the gluteus medius and minimus are detached from the iliac crest and anterior superior iliac spine. In the latter, after isolation of the ulner nerve, the whole flexor group of the forearm is cleared from the internal epicondyle and supracondylar ridge.

A similar operation is performed for torticollis due to shortening of the sterno-cleido-mastoideus, the attachments of this muscle being dissected away from the mastoid process and the superior curved line of the occipital bone. The incision lies entirely in the hairy scalp. The operation is inadvisable where more than one inch of lengthening is needed to correct the deformity, since greater mobilization of the muscle may damage the spinal accessory nerve.

CHAPTER VI

AMPUTATIONS

Preliminary Remarks

In former days, in amputating a limb, there used to be one object in view, quickness of operation. Since the introduction of anæsthetics and antiseptic and aseptic methods in surgical technique, the operator is guided by other ideas, viz. : (1) to avoid unnecessary sacrifice of tissues, (2) to obtain the best end-results of amputation by keeping sufficient skin and muscle covering for the stump for wearing an artificial limb, and (3) rapid healing of the wound.

The word amputation denotes any operation by which a limb or any integral portion of a limb is severed from the rest of the body. It is, however, preferable to subdivide amputations into two distinct groups, viz. : (1) amputations proper, i.e. those in which the limb is removed after division of bone, and (2) disarticulations, i.e. those in which removal is effected through one of the joints.

INDICATIONS FOR AMPUTATIONS

Advances in modern technique and wound treatment have greatly reduced the number of amputations, either in civil or military practice. Each case is considered on its merits. Amputation of a limb should never be performed, unless it is absolutely necessary for saving the patient's life or if it is considered that an artificial limb would be more useful than a maimed limb. Esmarch's indications were based on sound surgical judgment ; these can be classified and summarized as follows :—

(1) Extensive fractures of bones, e.g. comminuted simple fractures or severe compound fractures in which sepsis cannot be eliminated, avulsion of limbs, compound dislocations.

(2) Extensive irreparable laceration of soft tissues, the skin, muscles, vessels, and nerves.

(3) Injury to large blood vessels which might lead to gangrene due to obstruction to circulation ; in some cases of aneurysm.

(4) Gangrene of a part of a limb, effects of extreme heat and cold.

(5) Severe septic conditions of the bone or soft tissues, e.g. diffuse spreading cellulitis, diffuse osteomyelitis, necrosis, etc. endangering the patient's life or rendering the limb useless.

(6) Malignant tumours of the soft tissues or of the bone, some cases of elephantiasis.

(7) Certain conditions of the limb when it is an useless encumbrance to the patient, e.g. irreparable deformities with callosities, contracture and ankylosis.

INSTRUMENTS.—Group III.

POSITION

(1) Dorsal position lying on near side of the table ; for the upper extremities nearer the upper end of the table so that the limb may be held away at right angle ; for the lower extremities nearer the lower end of the table so that the limb may be either held away from the side of the table or beyond its lower end.

(2) The operator or surgeon takes his position so that he could grasp the limb with the left hand between the saw-line and the trunk ; generally speaking he stands on the outer side of right limbs and inner side of left limbs. Taking these positions he obtains freedom of movement and does not get wedged in between the limb and the table.

(3) The assistant stands facing the operator and grasps the limb not at right angles but parallel to the limb so that he can steady the limb against the movement of the saw, and so manipulate it that the saw is not caught in the bone as it is divided.

METHODS OF AMPUTATION

The oldest method of amputation was the circular method as was practised by Celsus. It consisted of a simple transverse incision of all the soft tissues down to the bone in the same plane. Various methods have since developed, in which much deliberation and economy are exercised in fashioning skin flaps, muscle-and-skin flaps and the cutting of skin and muscle at different levels. It should be borne in mind that the retraction of skin and muscles vary in different limbs and in different parts of the same limb and allowances should be made accordingly. The objects to be aimed at are as follows :—

(1) To leave the maximum of healthy tissues.

(2) The flaps to be so designed that they should have ample blood supply and the danger of sloughing is avoided.

(3) The skin and the muscles are cut in such a way that the bony stump has sufficient cushion of muscles, and the muscles an adequate covering of skin.

(4) The skin flaps are so fashioned that the resulting scar is in a position in which it will not be subjected to pressure or friction. The following are the methods generally adopted.

1. *Circular amputation*

It is only done when the question of rapidity of operation overweighs all other considerations. It leaves the scar over the divided bone. The edges of skin are difficult to approximate without putting them under considerable tension. It is most unsuitable for the lower limbs. It may, however, in rare instances, be performed on the upper extremities.

OPERATIONS

The right hand holds the knife, in such a manner that the tip of the blade points towards the operator's chest and the heel of the knife is applied to the skin to commence the incision (*Fig. 74*).

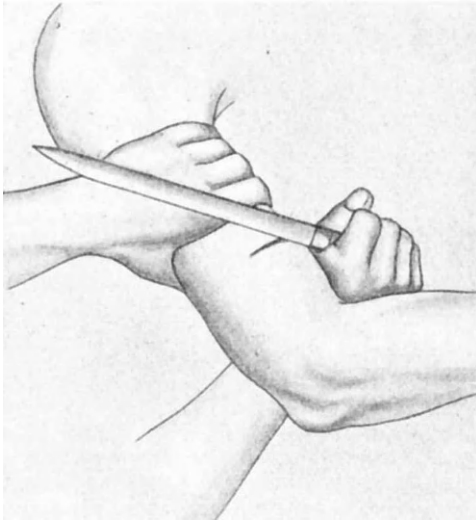


FIG. 74.

MANNER OF MANIPULATING THE LONG AMPUTATING
KNIFE IN DIVIDING THE SOFT PARTS UPON
THE FAR SIDE OF THE LIMB.

REPRODUCED FROM *BICKHAM'S OPERATIVE SURGERY*
By the Courtesy of THE W. B. SAUNDERS CO.

With one clean sweep of the knife a circular division of the skin and superficial fascia is made for the whole circumference by drawing the knife from its heel to point. In some cases about three-fourths of the circumference is thus divided, the knife is withdrawn and re-applied with its heel at the point of the com-

mencement of the incision and the circle is completed in like manner (*Fig. 75*). Throughout this manœuvre the knife is

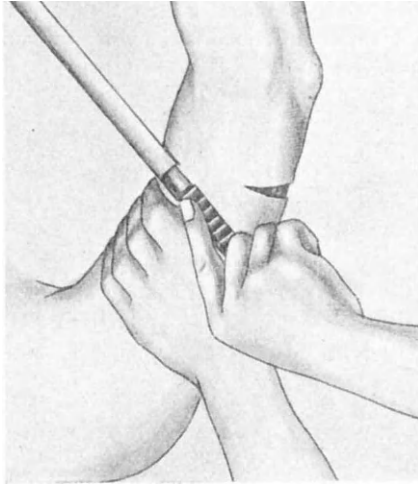


FIG. 75.

MANNER OF MANIPULATING THE LONG AMPUTATING
KNIFE IN DIVIDING THE SOFT PARTS UPON
THE NEAR SIDE OF THE LIMB.

REPRODUCED FROM BICKHAM'S OPERATIVE SURGERY
By the Courtesy of THE W. B. SAUNDERS CO.

kept at right angles to the skin. The skin now retracts. The assistant forcibly retracts it further up as much as possible. The muscles and periosteum are then divided down to the bone with another circular sweep of the knife on a level with the retracted skin (*Fig. 76*).

In dividing muscles some discrimination is made between the superficial and deeper layers. The superficial layer is first divided with one sweep of the knife and allowed to retract and then forcibly retracted as far up proximally as possible; now the layers of muscle are circularly divided on a level with the retraction of the superficial layer and so planned that this incision comes down on the bone sufficiently distal to the saw line to provide for a musculo-periosteal flap. The soft tissues and the bone (or bones) are cut in such a way that the resulting proximal stump is of the shape of a funnel of which the sawed end of the bone is the apex and the skin the base, the muscles and soft tissues, in a way, forming its sloping wall. The distal part after being removed is cone-shaped, the sawed end of the bone projecting from the

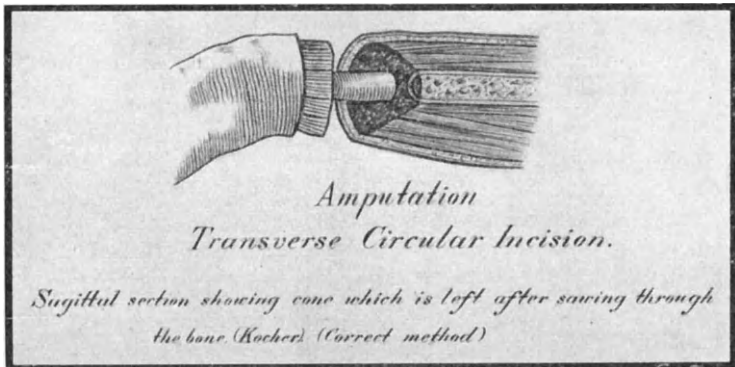


FIG. 76.

CIRCULAR AMPUTATION.

soft tissues and the muscles projecting beyond the skin. The muscles are then retracted and the periosteum is reflected up to the line of the future bone-section by a periosteal elevator. The assistant now retracts all the divided soft tissues by retractors as high up as possible. Now the saw is used on the bone working it from point to heel.

The assistant must hold the limb in such a way that the saw is not caught in the bone while dividing it.

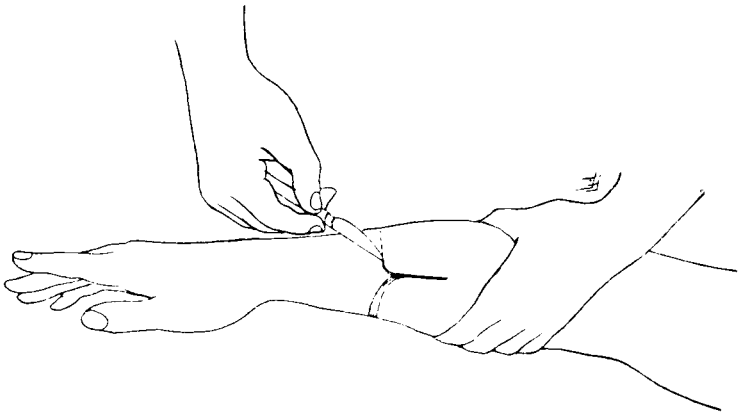


FIG. 77.

INCISING SKIN AND FASCIA IN FLAP AMPUTATION—I:—In cutting rounded flaps.

REPRODUCED FROM BICKHAM'S OPERATIVE SURGERY
By the Courtesy of THE W. B. SAUNDERS CO.

II. *Modified circular amputation*

This method has greatly replaced the circular amputation and is suitable for the arm and the forearm.

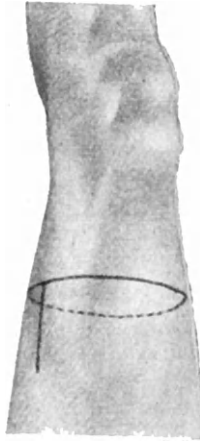


FIG. 77A.

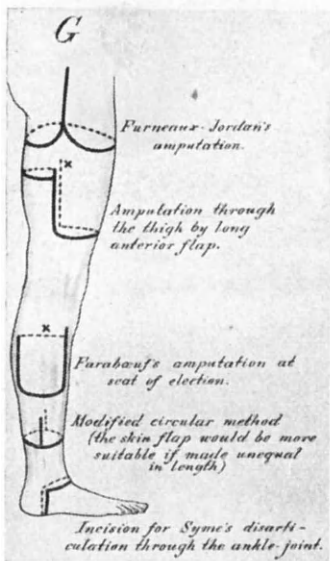


FIG. 78.

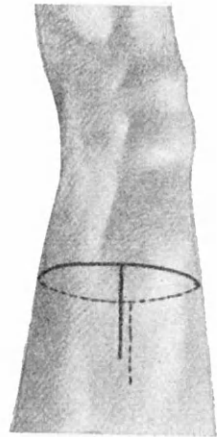


FIG. 78A.

OPERATION

There are three different modifications for the skin flaps. The muscles are divided circularly as in circular amputations in each case.

(a) A circular cut is made through the skin and fascia as in the circular method. A vertical incision is then made from above downwards to join the original one (see *Fig. 77*). The skin raised from the vertical cut towards the circle forms two rather imperfect skin-flaps.

(b) Two vertical incisions are made to join the circular wound. Two square skin-flaps are dissected up (see *Fig. 78*).

(c) Two short semi-lunar flaps of equal width and length are dissected up (*Fig. 79*). They are composed of the skin and sub-

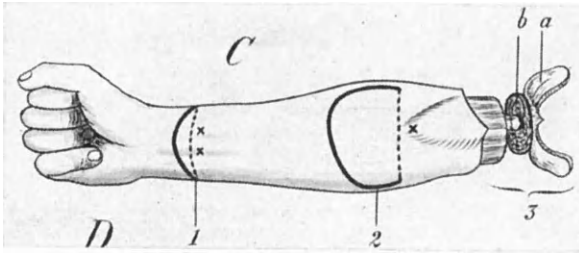


FIG. 79.

cutaneous tissue. The small flaps having been raised, the skin is retracted as a whole.

This form of amputation is more common than the typical circular amputation.

III. Elliptical or Oval Method

This is an intermediate method between the circular method and amputation by a single flap. The skin incision takes the shape of an ellipse. The skin and subcutaneous tissues are reflected and retracted. The muscles are divided as in the circular method.

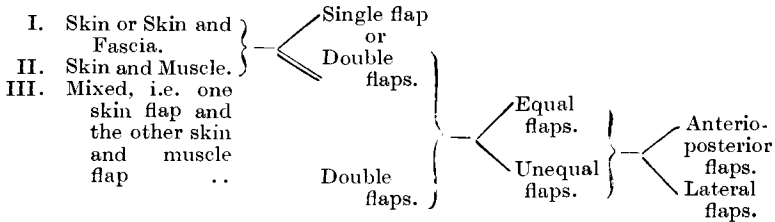
IV. The Flap Method

By this method one or two flaps composed of skin and subcutaneous tissue (skin-flaps), or those composed of skin and muscle (skin-and-muscle flaps) are raised. When there are two flaps they may be equal or unequal in length and they may be so fashioned that one is placed anteriorly and other posteriorly in relation to limbs, antero-posterior flaps, or they may be placed laterally, lateral flaps.

The skin-flaps are liable to slough from insufficient blood-supply unless they are raised from the neighbourhood of joints where the skin has a greater vascular supply, e.g. Stephen Smith's disarticulation of the knee-joint.

The skin-and-muscle flaps naturally have a better blood-supply, but they are sometimes rather unwieldy.

Amputation flaps by this method may be classified as follows :—



The length of the flaps.—The skin retracts about one-third of its original length when divided and therefore in fashioning flaps, the length of a single flap or the combined length of two flaps should at least be equal to the diameter of a limb plus one-third, at the level of the bone-section.

Methods of cutting flaps.—(1) Cutting by transfixion, i.e. cutting from within outwards. Mark out the skin and fascia by an incision as in all other amputations by cutting from without inwards to ensure the skin margin reaching a lower level than the margin of the muscle flap. Take a sharp-pointed amputation knife the blade of which is at least one and half as long as the diameter of the limb at the level of bone-section, enter it parallel to the bone and the sharp edge pointing distally at the level of the bone-section through the skin and soft tissues till it touches the bone; push the knife forward and while doing so feel the flat surface of the knife graze the bone by keeping it in close contact with it till the point pierces the soft tissues and emerges on the off side of the limb. Work the knife with a sawing movement hugging the bone all the time and cut your way forward (distally) towards the demarcating skin and fascia incision, till it reaches near it, then hold the knife at such an angle that it cuts the muscle in a sloping bevelled fashion down to the free margin of the skin. Retract this flap and cut the opposite flap in a similar fashion. The many disadvantages of this method of raising flaps outweighs the only advantage of quickness. The flaps are cut with less precision, and they may be thin at places, particularly while bevelled the muscles; the vessels may be split or otherwise injured. This method is not much practised now and is used for a few special amputations only.

(2) The simple skin flap.—The flap or flaps are marked out by an incision, skin, and subcutaneous tissue deep. The flap is raised and allowed to retract; the muscular tissue is cut unevenly

in such a fashion that the thinnest section lies nearer the margin of the flap and the thickest at its base.

(3) The skin-and-muscle flap.—Mark out the flap by a skin incision. The skin is allowed to retract evenly. The muscles are then cut obliquely from near the margin of the skin flap, and the deeper part of the soft tissues are either raised by dissection or peeled off from the bone.

V. The Racket Method

This method consists of a vertical incision representing the handle of a racket which bifurcates at its lower end into two incisions, which may be called the two arms or limbs of the racket. This part of the incision, therefore, takes the shape of λ .

The ends of these two incisions are joined by another slightly rounded one. The limbs of the racket may be equal or unequal according to the position in which the line of suture can be left with advantage (*Fig. 80*). This method is suitable in dis-

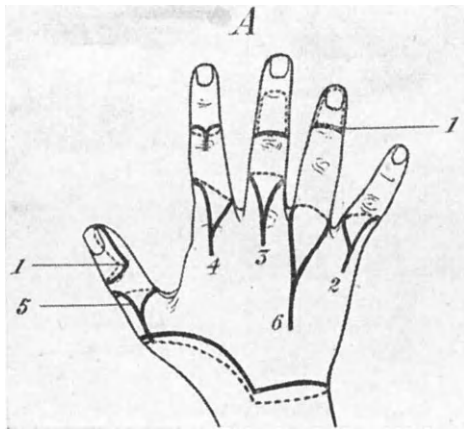


FIG. 80.

articulating the shoulder and some of the smaller joints, e.g. the toes and fingers.

Formerly the bone and periosteum were divided at the same level leaving no periosteal covering for the bony stump. Later, in the methods as described above the periosteum is divided at a distal level than the bone-section, raised like a sleeve and allowed to cover the bone-stump. It was, however, contended by some that this periosteum gives rise to the formation of irregular bony spicules and by others that the medulla gets swollen; both these conditions

according to them give rise to painful stumps. In order to obviate these, osteoplastic and periosteal methods have been devised.

VI. Osteoplastic Method (Bier)

The sawn end of the bone stump is covered by an osteo-periosteal flap raised from a contiguous proximal portion of the bone (*Fig. 81*). Though the bone of this flap is divided the

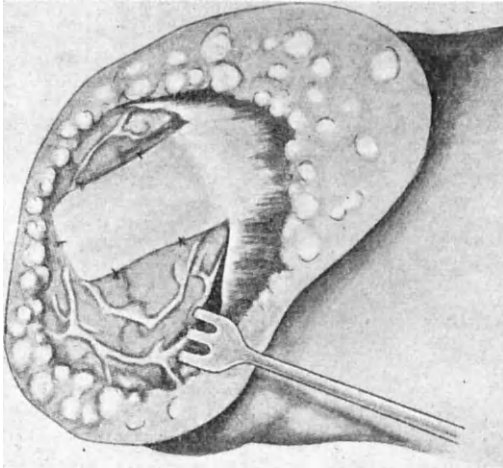


FIG. 81.

ILLUSTRATING THE PRACTICAL TECHNIC OF THE OSTEO-PLASTIC METHOD OF AMPUTATING—I:—Retracting the soft parts and raising the periosteal flap.

REPRODUCED FROM BICKHAM'S OPERATIVE SURGERY
By the Courtesy of THE W. B. SAUNDERS CO.

periosteal flap covering it retains its continuity with the main periosteum covering the bone. A thickness of the bone is first cut into vertically and then the requisite portion shaved off the bone by working horizontally by a Butcher type saw or Gigli saw and then the saw is worked vertically upwards to complete the division of the bone flap, without touching the periosteum. A slightly redundant area of periosteum is reflected with this flap and the proximal undivided end of the periosteum keeps its normal relation with the periosteum of the rest of the bone. The graft is apposed to the free margin of the bone-section of the stump and maintained there by stitching the redundant margin of the periosteum to the musculo-periosteal margin of the stump (*Fig. 82*).

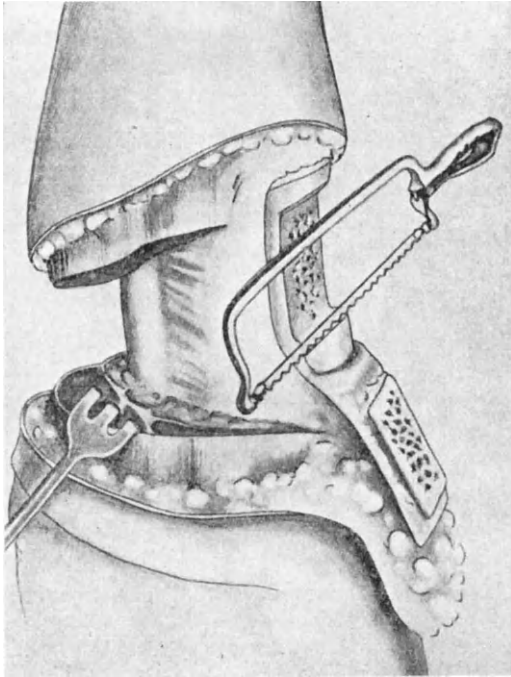

FIG. 82.

ILLUSTRATING THE PRACTICAL TECHNIC OF THE OSTEO-PLASTIC METHOD OF AMPUTATING—II:—Suturing the periosteal flap to the musculoperiosteal margins of the sawn tibia and fibula.

REPRODUCED FROM BICKHAM'S OPERATIVE SURGERY
By the Courtesy of THE W. B. SAUNDERS CO.

VII. *Aperiosteal Method* (Hirsch, Bunge)

The periosteum is divided a little (about 1 c.m.) above the level of bone-section and a ring of periosteum is detached from the bone to prevent terminal ossification (Hirsch); the medulla is scooped out from the medullary canal for a similar extent to destroy sensitive endosteum (Bunge).

VIII. *Tendinoplastic Method* (Wilms)

While dividing the soft tissue one of the broad tendons is left long to be reflected round the bony stump; this is stitched to the periosteum and soft tissues so as to cover the entire sawn surface (see *Fig. 83*).

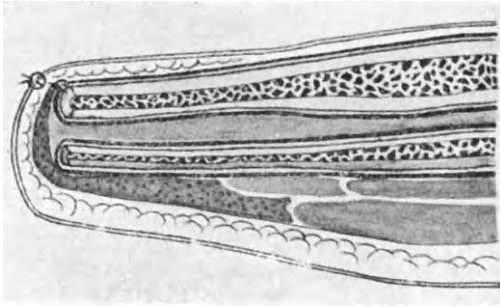


FIG. 83.

WILMS' TENDINO-PLASTIC METHOD OF AMPUTATION:—The sawn bone is covered by a broad tendon from one aspect of the limb—which is sutured to the periosteum and fibrous tissue of the opposite aspect.

REPRODUCED FROM BICKHAM'S OPERATIVE SURGERY
By the Courtesy of THE W. B. SAUNDERS CO.

IX. *Musculo-periosteal Method*

In the periosteal method of amputation advantage may be taken of the overlying muscles by raising a flap consisting of the periosteum and muscles in one adherent layer, i.e. without separating the muscle from the periosteum.

DISARTICULATION

In disarticulation the separation of a limb is effected through a joint and the stump consists of the articular end of the bone covered over with skin, or skin and muscle. Advantage is often taken of the capsule of the joint to cover the stump (capsulo-periosteal flap); sometimes the interposed cartilage is utilized as in the case of disarticulation of the knee-joint in which the semi-lunar cartilages are preserved and act as pads or cushions.

Comment:—These methods of amputation have their advocates and adherents.

The old method of dividing the periosteum on the saw-line has been carried to a further stage in the aperiosteal method by denuding the lower part of the bone-stump of a narrow ring of periosteum.

The musculo-periosteal method is an advance on the periosteal method of amputation as in the former case the bone-stump has a covering of periosteum and muscle. This is certainly an improvement as it gives a more substantial and secure covering to the

stump, there is a better vascular supply and it protects the medulla in cases of accidental sepsis. It is however open to one objection, namely formation of osteophytes.

The aperiosteal method claims this advantage; it prevents proliferation of the cells of the periosteum and thus avoids the formation of hypertrophied callus and involvement of nerve-endings in it. It also prevents irregular outgrowths of bone like osteophytes which make the stump tender. Hirsch on the other hand thinks that tender stump is due to the sensitive endosteum and the outgrowth of bone of medullary margin.

There is some risk of necrosis in the osteoplastic method. Apparently, the osteoplastic method would seem most logical but the periosteal or even better the musculo-periosteal method is most physiological, particularly if the periosteum is raised evenly and with care from the bone. As a matter of fact the formation of osteophytes giving rise to a painful stump may to a great extent be minimized, if not avoided by raising the periosteum in an intact layer and not in indifferent shreds and ribbons and apposing it carefully to the periosteum and soft tissues on the off side.

Some surgeons (Binnie) use free transplants of bone to cover the bone-stump.

Tendinoplastic method is suitable for amputations through the ankle, knee, and humerus where advantage could be taken of the tendo achillis, tendo calcaneus, quadriceps extensor, quadriceps femoris, and triceps tendon.

CHARACTERISTICS OF A GOOD AMPUTATION

1. There should be the least sacrifice of healthy tissue.
2. The operation should be simple and performed with reasonable rapidity.
3. Vessels should be divided transversely.
4. Muscles should be cut transversely excepting on rare occasions when the muscle flap is to be bevelled.
5. Nerves should be cut short and the sheaths brought round to cover the nerve fibres or stumps completely to prevent terminal neuromata and a even more dangerous and troublesome condition—ascending perineuritis nodosa.
6. The wound area should not be unnecessarily large and the skin and muscle suture should be so placed that these are not

exposed to pressure from within by the bony stump and from without by artificial limbs.

7. There should be a good vascular supply to the flap and there should not be undue tension on them. The muscles may be apposed independently by quilting or other sutures. It should be remembered that skin on different aspects of limbs retracts differently and that muscles retract unequally.

8. The bone-stump should always be well-covered with a musculo-periosteal or other suitable flap. In determining the saw-line the age of the patient should be considered; in children the bone continues to grow up to a certain age, allowance should be made in the muscle and skin flap for this.

Bearing these in mind and following the technique of individual amputations in detail, conical stumps and painful stumps, the two great misfortunes of amputation surgery will be avoided.

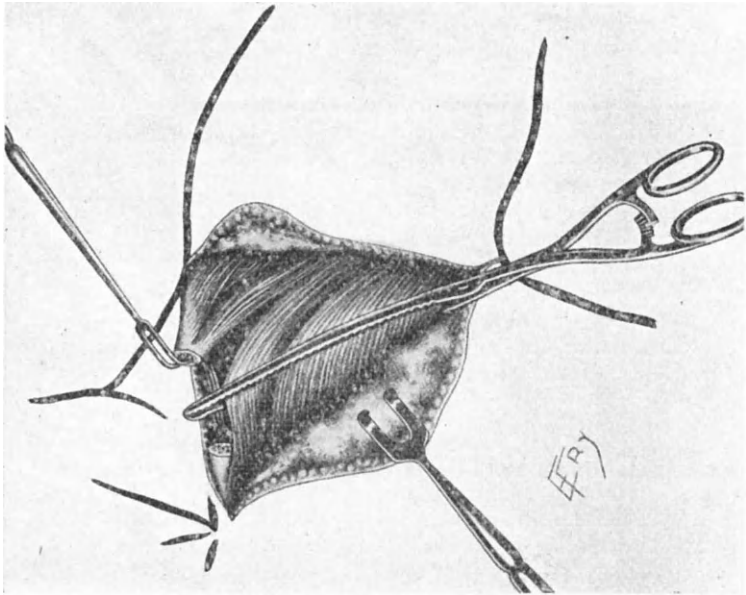


FIG. 84.

THOMAS' FORCEPS-TOURNIQUET FOR CONTROLLING HEMORRHAGE DURING OPERATIONS UPON THE EXTREMITIES:—
The probe-pointed blade passes under the pectoral muscles and axillary vessels and nerves, and the serrated blade over these structures—the former coming out above the region of the previously divided clavicle.

REPRODUCED FROM BICKHAM'S OPERATIVE SURGERY
By the Courtesy of THE W. B. SAUNDERS CO.

HÆMORRHAGE

Hæmorrhage in amputations can be controlled by one of the following methods :—

(1) Digital compression as in the case of disarticulation of the shoulder.

(2) Postural method, viz.: (a) elevation of the limb, (b) Trendelenburg position in cases of amputations of the lower limbs.

(3) Preliminary ligature of the main artery on the proximal side.

(4) Tourniquets: (a) The metal screw-tourniquet by which the pressure is limited to the main artery only. (b) Esmarch's elastic tourniquet, in this case Esmarch's rubber bandage is applied tightly from the distal to the proximal part rendering the part bloodless and then the elastic tourniquet is applied where the rubber bandage ends, proximally. The elastic bandage is then removed before the operation is commenced. This serves two purposes. First of all, the bandage expels blood from the part to be amputated, and secondly, the tourniquet prevents entrance of blood any more into the vessels. (c) Pneumatic tourniquet of Perthes, a hollow rubber band is used which is inflated with air by means of a tubing and pump. (d) Lynn-Thomas' forceps tourniquet which has one blade serrated and the other smooth rounded and probe-pointed. The probe-pointed blade is inserted through a small opening into the soft tissues, deeper to the vessels. The serrated blade is applied to the skin. The skin and the soft tissues with the vessels in it are compressed between the two blades, and when the forceps are clamped, it effectually stops bleeding. (*Fig. 84.*)

(5) Previous administration of calcium chloride and normal serum, etc.

CHAPTER VII

AMPUTATIONS OF THE UPPER EXTREMITY

I. THE FINGERS AND THE THUMB

An attempt should always be made to leave as much as possible of a digit, particularly that of the thumb and index finger. Even a small stump which is not neat looking is wonderfully useful. Even when other fingers have to be amputated, as much of the little and ring fingers should be saved as possible. A very well contrived artificial limb can never take the place of partially amputated limb. Divide the bone as low as possible. The base of the terminal phalanx has the flexor digitorum profundus tendon attached to it, it should be preserved whenever possible. In the second phalanx, at least the upper third should be saved to preserve the flexor sublimis digitorum. Failing this, the tendon with their sheaths should be stitched to the periosteum, theca or soft tissues. Try to ascertain the line of interphalangeal and metacarpo-phalangeal articulations. The prominence of the knuckles which are formed by the distal ends of the proximal phalanges on the dorsum of the fingers when the joints are flexed, lie above the joint line. The last interphalangeal joint is $\frac{1}{2}$ " , the first interphalangeal joint $\frac{1}{6}$ " and the metacarpo-phalangeal joint $\frac{1}{3}$ " beyond the prominence of the knuckle.

In making a flap they should be cut comparatively long, as the long bones of the fingers do not have a correspondingly soft tissues to cover them. The palmar skin is thicker and more vascular than the dorsal, so an attempt should always be made to keep as much of palmar flap to cover the stump as is available. Besides, the flap should be so fashioned that the scar is not over the stump or upon its palmar aspect. Whenever possible, the fibrous sheath of the tendons should be closed, as while the tendons themselves retract, the sheaths do not, and they may form a channel for the passage of sepsis in cases of accidental or unavoidable infection. While suturing the sheaths it is desirable to secure the tendons in the suture. Suturing the ends of divided tendons to the periosteum or tissues and suturing of the divided ends of flexor and extensor tendons over the ends of bones greatly facilitates control of movements of the finger or stump.

POSITION

The operator stands in front and holds the finger to be amputated between his fore-finger and thumb. The assistant,

standing on one side, holds the adjacent fingers out of the operator's way or retracts them by gauze retractors.

A. *The Terminal Phalanx*

Amputation of the terminal phalanx by disarticulation through the terminal or distal interphalangeal joint.

OPERATION

Make an incision down to the joint on the dorsal aspect of the finger about $\frac{1}{2}$ " below the knuckle of the terminal joint. Open the joint and cut the collateral ligaments; now pass the blade of the knife through the joint transfixing the soft tissues round the base of the terminal phalanx, keeping the knife closely applied to the bone and carry it towards the tip of the finger. Complete this flap by bringing the knife out at right angles to the palmar surface. The small phalangeal vessels hardly need ligaturing (see *Fig. 80*).

Comment:—(1) Do not make the flap pointed or triangular, keep a broad margin to it. (2) Do not scrape the inter-articular cartilage of the middle phalanx. (3) This operation can also be performed by raising the palmar flap from without inwards from the tip of the finger upwards and then disarticulating the joint. (4) This amputation can also be performed by sawing through the phalanx just distal to its base which has the insertion of the deep flexor tendon. (5) Suture the deep flexor tendon to the periosteum of the flap if it had to be cut through or in case of disarticulation.

B. *The Second Phalanx*

Partial amputation of the finger (the middle and distal phalanges). This operation can be performed in two ways:—

1. By disarticulation through the first or proximal interphalangeal joint. In this case both the superficial and deep flexor tendons are divided and these should be sutured to the periosteum, sheath or glenoid (accessory volar) ligament. According to others, the flexor and extensor tendons are sutured round the head of the first phalanx.

2. By sawing through the bone just below its base so that the superficial flexor tendon retains its attachment though the deep flexor tendon is divided; this should be attached by suture into the mouth of the fibrous sheath which ends at the middle of the second phalanx and to the periosteum.

OPERATION

Ascertain the line of the joint which is about $\frac{1}{8}$ " below the knuckle and keep a palmar flap as in the previous amputation.

C. The Metacarpo-phalangeal Joint

Amputation of the whole finger by disarticulation through the metacarpo-phalangeal joint (*Fig. 85*).

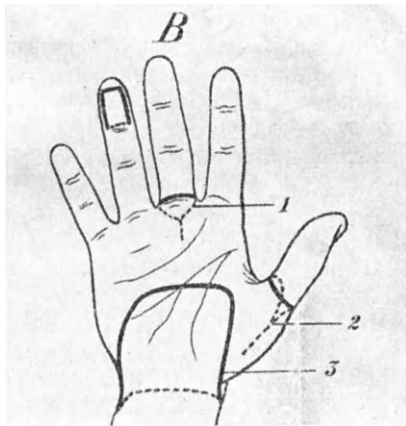


FIG. 85.

This may be done by the racket method: (*a*) in the case of the two central fingers with equal arms or limbs to the racket (*see Fig. 80*), (*b*) for the thumb, little and index fingers with unequal limbs to the racket (*see Fig. 80*). The joint is found a third of an inch below the knuckle.

OPERATION

A vertical incision commences at the lower third of the metacarpal bone, and carried down in the middle line beyond the base of the phalanx; it then bifurcates and its equal limbs run obliquely towards the palmar aspect ending in a line with the free margin of the web. A transverse palmar incision, just below the crease between the finger and the palm, joins the two limbs. Enter the knife upon the dorsum from one side to the other and then deepen it into the palmar cut. Hyper-extend the finger, deepen the palmar incision to the bone, cutting through the flexor tendon. Turn the finger first to the right, then to the left, in order to carry the lateral incision to the bone. The digital arteries are now cut across and the lumbrical and extensor tendon expansions are also

cut. Dissect the flaps back as far as the joint line. Return to the palmar aspect, extend the finger and open the joint. Cut the glenoid and the lateral collateral ligaments and then the extensor tendon. The synovial sheath may be closed. The glenoid ligament is left in the stump and the digital arteries ligatured. The flaps are united in a vertical direction.

AMPUTATION OF THE INDEX AND LITTLE FINGERS BY MODIFIED RACKET METHOD

A modification of the racket incision is necessary in the case of these two fingers, in order to keep the cicatrix away from an exposed position and pressure. To obtain this result the limbs of the racket should be unequal (*see Fig. 80*).

FOR THE INDEX FINGER

The incision on the dorsum representing the handle of the racket is made nearest to the middle finger. The incision representing the outer limb of the racket runs more vertically downwards than that for the inner limb which runs more transversely inwards, towards the web. This leaves a larger outer flap which when united to the inner flap leaves the scar on the inner side and not exposed towards the thumb.

FOR THE LITTLE FINGER

The vertical cut is made on the side nearest the ring finger and the incision for the limbs made in such a way, that it leads to a larger internal flap. The cicatrix lies towards the ring finger and therefore not exposed to pressure and injury.

AMPUTATION OF THE THUMB BY DISARTICULATION THROUGH THE METACARPO-PHALANGEAL JOINT

POSITION

The hand is held in a pronated or supinated position according to convenience and the stages of the operation. The assistant stands facing the operator, steadies the hand and holds other fingers out of the way of the operator.

OPERATION

The racket method is most suitable. The incision is commenced three-quarters of an inch above the joint on the dorsum, and is

carried along the outer side of the long extensor tendon to a little beyond the base of the first phalanx. Here it bifurcates to form the two limbs. The inner limb is carried directly across the web of the thumb on to the palmar aspect. The outer limb is carried down almost to the interphalangeal knuckle. The lower ends of the limbs are then joined by an incision on the palmar aspect. The rest of the operation is similar to that of disarticulation of a finger through metacarpo-phalangeal joint. The two extensor tendons are divided opposite the joint line. Flexor longus pollicis tendon is cut at the level of the palmar incision and attached to the sesamoid bone which is left on the stump. The *dorsalis pollicis* and the two branches of the *princeps pollicis* are secured (*see Fig. 85*).

DISARTICULATION OF THE INDEX FINGER WITH ITS METACARPAL

Make a mid-dorsal incision as for the previous operation for the handle of the racket, but in bifurcating it for the two limbs of the racket, make the lateral (radial) limb which is to be the longer of the two, slope more vertically down the dorsal aspect thus making a larger angle with the handle than the shorter medial (ulnar) limb of the racket. Let these limbs meet on the palmar aspect as usual. Secure the digital, *radialis indicis* and *dorsalis indicis* (dorsal digital) arteries, and suture the wound in a vertical (dorsal) line which places it conveniently out of pressure line.

DISARTICULATION OF THE LITTLE FINGER WITH ITS METACARPAL

Make the mid-dorsal incision as in the previous two operations, but the long ulnar limb diverges only slightly from the medial incision and slopes gently downwards and inwards and then across the palmar aspect to meet the short radial limb which slopes more abruptly towards the web between the little and ring fingers. This method of racket incision with unequal limbs places the cicatrix in a position out of the way of pressure. Close the synovial sac and preserve the hypothenar muscles as much as possible. Suture the wound in a single dorsal line.

DISARTICULATION OF THE THUMB WITH ITS METACARPAL

Commence a mid-dorsal incision just above the carpo-metacarpal joint line and extend it carefully and superficially down the

'snuff-box' so as not to injure the radial artery, then along the middle of the dorsum of the thumb to the neck of the metacarpal; here bifurcate the incision, carrying the long arm of the racket slightly diverging it in a gently sloping direction to meet on the palmar aspect the short limb which diverges more sharply on a level with the free margin of the web. Clear the dorsal aspect and while dividing the extensor tendons keep them sufficiently long to suture these to the wound. Preserve the thenar eminence and divide the muscles inserted to the base of the first phalanx close to the sesamoid bone. Clear the palmar aspect of the bone and when dividing the flexor longus pollicis, keep it long to suture it to the wound and close its sheath. Disarticulate the joint from the dorsum by dividing the ligaments and extensor ossis metacarpi pollicis (abductor pollicis longus). Ligature the arteria princeps pollicis or its branches and the dorsalis pollicis (dorsal carpal).

Comment :—1. Throughout the operation keep the knife close to the bone. 2. Suture the tendons and muscles into the wound and close their sheaths if opened. 3. The skin suture when completed lies in the mid-dorsal line. 4. The cut ends of the tendons need not be attached as the entire finger having been removed there is nothing for them to work. 5. Sometimes for æsthetic or other purposes the head of the metacarpal may have to be removed. In that case, the soft tissues are raised up to the neck, the head seized with lion forceps and removed by sawing with metacarpal or gigli saw and bevelling the bone from behind downward and forward from the medial or lateral aspects towards the middle line of the hand.

DISARTICULATION OF TWO CONTIGUOUS FINGERS WITH THEIR METACARPALS. (EXCLUDING THE THUMB AND LITTLE FINGER)

The operation is essentially the same as that for a single finger with metacarpal. The handle of the racket commences just above the carpo-metacarpal joint line and extends vertically down the dorsum midway between the two metacarpals to about their middle, then divides; the outer (radial) limb passing to the radial side of the outer of two metacarpals and inner (ulnar) limb correspondingly to the ulnar side of the inner of the two metacarpal bones to the junction of the fingers and webs and meet in the digito-palmar crease. Deepen the incision, clear metacarpals, cut tendons keeping them long and suture them into the wound.

Comment :—1. In some cases one or more fingers with parts of metacarpals may be amputated. The operation is in principle the same as for disarticulation. The metacarpal is freed of soft tissues up to the saw-line and the bone sawn by a gigli saw and so bevelled that the thin margin is not towards the dorsum or the free end.

II. THE METACARPALS

AMPUTATION OF THE FINGERS AND THUMB TOGETHER WITH THE METACARPALS

POSITION

The limb is held in pronation. The operator grasps the finger with his own hand in supine position. The assistant stands opposite, steadies the hand and keeps the other fingers out of the way by gauze retractors.

OPERATION

Determine the joint line. Commence a mid-dorsal incision for the handle of the racket just above the articulation, carry it down on the dorsum of the metacarpus to the base of the knuckle. Here the two equal limbs cross the web and meet on the palmar aspect at the digito-palmar fold. This incision is only skin deep. Now deepen the dorsal incision and divide the extensor tendons on a level with the upper end of the skin incision. Free the sides of the shaft of the metacarpal bone, of all structures keeping the blades of the knife close to the bone. The finger can be rotated inwards or outwards to facilitate this. Retract the skin and introduce the knife between the bases of the contiguous metacarpal bones to divide the interosseous ligament; turning to the lower ends of the incision at the head of the metacarpal bones, the soft tissues near the web of the finger and those on the palmar aspect are cut through. The flexor tendons are now cut across along the level of the neck of the metacarpal bones; now, over-extend the finger. Divide the ligaments of the joint, separate the soft tissues from the shaft on the palmar aspect of the bone as far back as possible. Now pull it back upon the dorsum of the hand and divide such structures as may be still holding the shaft on the palmar aspect. The digital arteries will be cut near the web.

In the case of the index and little fingers, the skin incision will have to be modified in the same way as in amputations through the metacarpo-phalangeal joints.

THE WRIST

AMPUTATIONS OF THE HAND BY DISARTICULATION THROUGH THE WRIST-JOINT

The different methods for this operation are :

- (1) By an elliptical incision.
- (2) By a long external radial flap of Dubrueil (*see Fig. 80*).
- (3) By a modified circular incision.
- (4) By a long palmar flap.

The last is recommended because : (i) it gives the best covering for the stump, (ii) the cicatrix lies on the dorsal aspect and (iii) the flap carries a good arterial and nerve supply.

This will be described.

DISARTICULATION OF THE WRIST BY A LONG PALMAR FLAP

POSITION

Abduct the arm. The operator stands facing the palm with the assistant facing him.

OPERATION

Make an U-shaped incision on the palmar surface commencing about half an inch below the styloid process of the radius, vertically downwards over the thenar eminence, to the middle of the metacarpal bone of the index finger. Angle it inwards and carry it across the palm at a level of the middle of the metacarpal bones in an arched fashion towards the ulnar margin of the hand, and then turn it upwards to a point half an inch below the styloid process of the ulna (*see Fig. 85*). The incision cuts the skin and the superficial fascia. Now, pronate the hand and connect the upper ends of the incision from styloid to styloid by a cut on the dorsum of the hand. Deepen the palmar incision and dissect the flap up including the thenar and hypo-thenar eminences and other soft tissues down to the flexor tendons. Turn this flap upwards to the level of the wrist-joint. Turn again to the dorsum and dissect a small dorsal flap up to the joint line. Cut through the extensor tendons which are now exposed on the back of the wrist, at the level of the retracted skin. Now hold the hand again in the pronated position. The assistant draws up the flap on the back. Open the joint from the dorsum commencing on the radial side, taking care not to injure the triangular fibro-cartilage connected to the ulnar and the radio-ulnar articulation. The hand remains connected to the forearm only by the flexor tendons.

These are severed by cutting boldly from above downwards. This completes the operation.

For an *elliptical incision* make the palmar flap longer and the dorsal flap with a definite convexity upwards. For a *modified circular* amputation, two small flaps are made on the dorsal and palmar aspects about an inch below the level of the joint.

Dubrueil's amputation is performed when the soft tissues on the ulnar aspect of the arm are not available. There is no reason, however, why the whole or part of the thumb should not be saved if sufficient healthy soft tissues on the radial side of the palm can be obtained.

Comment:—1. This operation (disarticulation) is preferable to amputation through the forearm because (*a*) pronation and supination are usually maintained and (*b*) the stump is better adapted to an artificial limb. 2. Do not remove the styloid processes especially the radial styloid as the supinator longus (brachio-radialis) is attached to it. 3. Commence disarticulating from the dorsum as this is easier. 4. Do not injure the radio-ulnar articulation; it does not enter into the wrist-joint. 5. The palmar flap though unyielding is preferable for many reasons; keep it long to give the joint a good covering. 6. After operation maintain the forearm in a position between pronation and supination by a splint.

THE FOREARM

A. Amputation through the lower third of the Forearm

INSTRUMENTS—Group III.

POSITION

Abduct the arm and stand on the outer side in the case of the right limb and on the inner side in the case of the left. Assistant stands on the left of the operator to steady the arm and retract flaps. For the lower third of the forearm, it should be amputated by the modified circular method and if possible below the insertion of the pronator radii teres (pronator teres). This gives a fairly good covering for the stump and the movements possible by the pronator (radii) teres muscle are not interfered with.

OPERATION

Estimate on the skin the line of bone-section. The bone should be divided below the insertion of the pronator radii teres

which corresponds to the middle of the shaft of the radius. Incision is made for an antero-posterior, modified circular flap, the lowest point of the transverse line of the incisions reaching one and half inches below the line of the future bone-section. Pronate the arm for the posterior incision and supinate it for the anterior one. The two incisions meet on the ulnar and radial sides of the forearm. Dissect up the flap with gentle touches of the knife. Retract the flaps and divide the muscles at the level of the retracted skin by a circular sweep of the knife. Enter the knife into the interosseous space and divide the interosseous membrane transversely. Cut the periosteum on the saw line and raise it with a periosteal elevator. Retract the muscles with the periosteum. Saw through both bones at the same time, holding the arm in supination. Allow the muscles to cover the bones and appose the skin flap (*see Fig. 79*).

Comment :—(1) Let the periosteum cover each bone completely, preventing union between the bones as this would affect movement. (2) The radial, ulnar and the anterior (volar) and posterior (dorsal) interosseous arteries will need ligature. (3) The total covering would be equal to $1\frac{1}{2}$ diameters of the forearm at the site of bone section, i.e. each half of the flap will be three-fourths of the diameter. Of each of these flaps, the distal half would be of skin and fascia only and the proximal half should include muscles and soft tissues. Remember that in a muscular individual the transverse diameter is much greater than the antero-posterior diameter.

B. Amputation through the upper third of the Forearm

This can be performed by equal antero-posterior flaps or by long anterior and short posterior flaps, and the flaps would with advantage be skin and muscle flaps.

POSITION

Same as for the previous operation.

OPERATION

The combined length of the flaps must be one-third longer than the diameter of the limb at the point of bone-section in order to make an allowance for skin retraction. Measure the antero-posterior diameter of the limb at the point of bone-section between the finger and the thumb. In the case of the right limb, for the anterior flap, the incision is carried downwards through the skin and fascia along the ulnar margin for about two inches or according

to the diameter of the limb, then transversely across the flexor aspect to the radial margin. It is then carried upwards along this margin for a similar distance. Thus an U-shaped flap is marked out on the flexor aspect. The assistant flexes the elbow presenting the extensor aspect to the operator ; a similar U-shaped flap is now fashioned on that aspect (*see Fig. 79*). Supinate the arm. Raise a skin-and-fascia flap on the anterior aspect for about half an inch ; and cut more and more deeply into the muscles as the knife goes upwards till, by the time it reaches the line of the bone-section, the flap has all the soft tissues in it down to the bone. Change the position of the arm again and raise a similar flap from the posterior aspect. Clean the bone, raise the periosteum and make the saw cut as in the previous operation, the assistant having retracted the soft tissues.

Comment :—(1) The vessels to be secured are the same as in the previous operation. (2) For this and the previous operation a three-tailed gauze retractor will be found useful. (See Appendix.)

THE ELBOW

Amputation of the forearm by disarticulation through the elbow-joint

INSTRUMENTS—Group III.

Several methods have been recommended :—

METHODS OF AMPUTATION

(1) Modified circular, (2) Elliptical, by (*a*) an anterior ellipse and (*b*) posterior ellipse. (3) Lateral flaps, i.e., long internal and short external flaps. (4) Antero-posterior flaps, i.e., long anterior and short posterior flaps. (5) Long antero-internal and short postero-external flaps.

The selection of the method will depend on the sound skin and soft tissues available and upon individual choice. The antero-posterior flap method will be described.

POSITION

The forearm is semi-flexed and supinated. The operator stands on the inner side of the left limb and outer side of the right.

OPERATION

The base of the large anterior flap should be longer than half the circumference of the limb and should be U-shaped. The

anterior incision commences either an inch below the internal or an inch and a half below the external condyle of the humerus according to whether it is the right or the left elbow to be disarticulated. For the right limb, the incision is commenced at a point one inch below the internal condyle and is carried for about three and a half inches down to the ulnar border of the forearm. This forms the inner limb of the U. It is then carried along the flexor aspect of the forearm slightly curved downwards, representing the bend of the U to the radial side of the forearm, and then carried upwards (representing the outer limb of U) to a point an inch and a half below the external condyle (lateral epicondyle). (*Fig. 86.*) The skin and fascia are raised for about

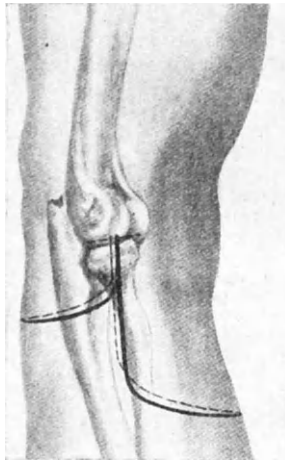


FIG. 86.

DISARTICULATION AT ELBOW:—By long anterior and short posterior flaps.

REPRODUCED FROM BICKHAM'S OPERATIVE SURGERY
By the Courtesy of THE W. B. SAUNDERS CO.

an inch, then the knife goes deeper and deeper encroaching more and more on the underlying muscles till it is carried to the elbow-joint. This exposes the joint. Turning to the posterior aspect of the forearm, a posterior flap, skin and fascia deep, is raised from one extremity of the anterior flap to the other. This incision when deepened exposes the posterior aspect of the joint. These flaps are retracted by the assistant. The knife is inserted on the outer aspect of the joint and the external (radial collateral) ligament, the anterior, posterior, and the internal lateral (ulnar collateral) ligaments are cut through; the tendon of the triceps is detached from the olecranon process.

This completes the disarticulation. The radial and the ulnar arteries are found on the anterior flap superficially, the interosseous artery more deeply. The superior profunda (arteria profunda brachii) is in front of the external condyle (lateral epicondyle) and the inferior profunda (superior ulnar collateral) behind the internal condyle (medial epicondyle).

Comment :—(1) Open the joint from the outer side as the radio-humeral joint is then more easily found. The joint line of the elbow corresponds with the radio-humeral line. Look for a depression at the back of the elbow which corresponds to the interval between the head of the radius and the capitulum of the humerus which is also the interval between the anconeus on the ulnar side and the brachio-radialis with the extensors on the radial side. (2) The internal condyle (medial epicondyle) is more prominent and is on a lower level than the external condyle (lateral epicondyle). (3) When cutting through the joint remember that the humero-radial articulation is horizontal but humero-ulnar articulation slopes slightly downwards. (4) The stump after disarticulation is better adapted for artificial limbs than after amputation. (5) The stump (lower end of humerus) is large, so a liberal flap of skin and soft tissues should be made more so for the large and prominent internal epicondyle. (6) The muscles on the outer (radial) side particularly the supinator longus (brachio-radialis) retract more powerfully than those on the inner side.

THE ARM

Amputation of the upper arm

POSITION

Dorsal position, near edge of the table. The arm is generally in an abducted position but it may have to be held vertically or across the chest during various stages of the operation.

1. AMPUTATION BY MODIFIED CIRCULAR METHOD

OPERATION

The skin incision for the flap is made according to the rule for modified circular flap. The skin-flaps are so raised that the lowest limit of the skin incision is at a distance below the saw line equal to three-fourths of the diameter of the limb at the saw

line, this secures a covering of $1\frac{1}{2}$ diameters. These skin flaps (which are generally anteroposterior) having been raised, the muscles are divided by the following method :—Hold the amputating knife in the usual way. Divide the superficial layer of muscles including the biceps and the triceps at a little lower level to allow for their retraction. Divide the deep muscles at a slightly higher level down to the bone. The periosteum is elevated in the usual way and the bone sawn through at the contemplated site well up the level of the base of the skin-flap.

The divided ends of the following vessels and nerves are seen:—

On the inner side the brachial with the median nerve ; the superior profunda (arteria profunda brachii) with the musculo-spiral (radial) nerve on the postero-external aspect, inferior profunda (superior ulnar collateral) with the ulnar nerve on the inner side of the brachial. Some muscular branches are also seen.

Comment :—(1) The biceps and triceps retract much more than the deeper muscles, so cut these on a lower level to cover the bone stump well. (2) The musculo-spiral (radial) nerve in its groove in the humerus should be freed from the bone and cut short and closed otherwise it will be caught in the callus of the stump and may give rise to a neuritis and a painful stump. (3) Whenever possible amputate below the middle of the arm, below the insertion of the deltoid and the pectoralis major. These will contribute greatly to the after-movement of the stump and give better facilities for an artificial limb.

2. AMPUTATION BY UNEQUAL ANTERO-POSTERIOR FLAPS OF THE ARM (UPPER TWO-THIRDS)

This operation is performed by two unequal U-shaped flaps and in order to avoid splitting the brachial artery and to keep it in the posterior flap, the incisions are so placed that the inner vertical limbs of the 'U' are not in the line of the artery ; this is achieved by making one flap a large antero-external with a deep U incision and the other a short postero-internal with a shallow U incision.

The base of each flap should be equal to one half the circumference of the limb at the saw line. The length of the large antero-external flap is one diameter of the limb and that of the short postero-internal flap equal to half the diameter.

Having made the skin incisions, retract the skin and divide the muscles as follows :—

Along the vertical limbs of the U divide the muscles vertically down to the bone, for the distal transverse rounded part of the

flap cut obliquely upwards beveling the muscles and a little before reaching the saw line divide the periosteum and raise it with the muscles in order to provide a musculo-periosteal covering for the bone-stump. Free the musculo-spiral nerve and treat it as described above and cut the nerves in the anterior flap short, as the flap has to be taken round the bony stump for suturing. Tie the brachial artery (which will be found in the short postero-internal flap) and other vessels, namely the superior and inferior profunda and muscular branches.

AMPUTATION OF THE ARM AT THE SURGICAL NECK OF THE HUMERUS

This amputation is performed by a single large external U-shaped flap composed chiefly of the deltoid muscle, the vertical limbs of the U being placed in the mid-anterior and mid-posterior lines and the base of flap 1" below the saw line ; its width should be half the circumference and its length equal to the diameter of the limb. The upper free ends of the vertical limbs of the U are joined by a cut slightly sloping downwards on the inner (axillary) aspect of the arm.

The deltoid flap is raised in a bevelled fashion securing the vessels as they are encountered, but the axillary vessels on the inner aspect of the wound are divided after applying proximal and distal ligatures. Divide the periosteum below the bicipital groove and raise it with the biceps tendon ; cut the tendon low down (so as not to open the synovial sheath) together with the coraco-brachialis. Preserve the pectoralis major and detach the latissimus dorsi and teres major subperiosteally. Raise the flap and saw the bone at the lowest part of surgical neck. Close the wound by quilting muscle and suturing the skin.

The disadvantages of this operation are : (1) the preserved epiphysis may lead to the growth of the bone ; (2) the stump may undergo strong abduction. The advantages over disarticulation are : (1) mortality is less ; (2) more suitable for an artificial limb ; (3) muscular atrophy is less.

THE SHOULDER-JOINT

Disarticulation of the Shoulder-joint

SURGICAL ANATOMY

The following anatomical points should be noted. The spine of the scapula terminates in the acromian process which overhangs the joint. Exactly below this as the arm hangs by the side of the body, is the greater tuberosity of humerus which can be felt externally ; the supraspinatus, infraspinatus, and teres minor are

inserted to this from above downwards. A little below this and more towards the front of the joint is the lesser tuberosity to which is inserted the subscapularis. The greater tuberosity faces in the same direction as the external condyle (lateral epicondyle). Between the tuberosities is the bicipital (intertubercular) groove in front of the joint. Near the groove, a little below the clavicle, is the coracoid process of the scapula. The anterior fold of the axilla is formed by the pectoralis major and the posterior fold by the latissimus dorsi and subscapularis. The skin over the deltoid is thick and less retractile than that over the pectoralis major.

There are numerous methods of removing the arm. Among them are:—(1) By external and internal flaps. (2) By external or deltoid flap. (3) By antero-posterior flaps. (4) By Furneaux Jordan's method, viz. a preliminary circular high amputation of the arm and then a final disarticulation, and (5) by Spence's anterior racket method.

Hæmorrhage can be controlled by one of the following methods:—(i) Digital or instrumental compression of the subclavian; (ii) preliminary high ligation of the axillary; (iii) ligation of the subclavian artery; (iv) compression by Esmarch's cord securing it by pins or sutures, and (v) digital compression of the axillary in the flap before it is cut; (vi) compression of the vessels in the axillary flap by forceps-tourniquet.

Spence's racket method has advantages over other methods of disarticulation and will be described. In this method hæmorrhage can be controlled either by preliminary ligature of the vessels or by the assistant compressing them with the soft tissues in the posterior aspect by his fingers or by forceps-tourniquet of Lynn Thomas type (*see Fig. 84*).

POSITION

The arm is held abducted and slightly rotated externally the patient being placed near the edge of the table. Elevate shoulder and turn head to opposite side. Operator stands on outer side of the shoulder either for left or right side or he may stand on the inner side for the left. One assistant stands between the shoulder and the head to retract parts and control hæmorrhage by compressing the flap; the second assistant stands away near the elbow to manipulate the limb.

DISARTICULATION OF THE SHOULDER-JOINT

(*By Spence's Anterior racket method*)

OPERATION

1. The axillary vessels may be secured between two ligatures in its third part as a preliminary measure.

2. An incision is commenced on the outer side of the coracoid process and carried vertically downwards cutting through all the soft tissues down to the neck and shaft of the humerus as far as the lower limit of the anterior fold of the axilla. This incision divides the anterior fibres of the deltoid and the insertion of the pectoralis major.

3. The incision is carried outwards dividing all the structures down to the bone as far as the back of the arm.

4. An incision, skin deep, is made from the lower end of the vertical cut round the inner side of the arm to join the deep outer incision (*Fig. 87*).



FIG. 87.

5. The large external flap with the deltoid and the posterior (humeral) circumflex artery entering into its deep surface, is raised by the hand from the bone and the joint. It is retracted by gauze or broad metal retractors.

6. The muscles attached to the tuberosities are divided by cutting directly down to the bone. The capsular muscles, the capsule and the long head of the biceps are divided. The head of the humerus is rotated inwards or outwards and the arm is held with the elbow flexed at right angles to facilitate this. Rotate head inwards, the greater tuberosity appears, cut through the insertions of the supraspinatus, infraspinatus, and teres minor; rotate head outwards, the lesser tuberosity presents, sever the insertion of subscapularis.

7. The head is then pushed out of the glenoid cavity and the posterior flap is dealt with as follows:—(a) if the artery has already been ligatured, the soft tissues are cut across about the level of the posterior skin incision; (b) if the vessels have not been previously ligatured, the assistant holds the soft tissues on the axillary aspect between his thumb and palm from either side, compressing the vessels as the operator holds the disarticulated head and pulls it away from the wound. The soft tissues are now cut across below the assistant's hands and the vessels secured. The nerves are cut short. The disarticulation is now complete.

Comment:—(1) At least two assistants are necessary for this operation. (2) Digital or instru-

mental compression of the subclavian is not always satisfactory. (3) Controlling hæmorrhage by passing an elastic tubing under the axilla and fixing it above the shoulder is not reliable ; it may slip at a critical moment unless they are efficiently secured. (4) The best methods are those already described, namely preliminary ligature of the vessels or controlling it by the thumb and the hand in the posterior flap. (5) The axillary artery is divided between the origin of the posterior (humeral) circumflex and superior profunda (arteria profunda brachii). The vertical incision may cut the humeral branch of the acromio-thoracic artery and deeper down the anterior (humeral) circumflex. (6) The operation should be done as subperiosteally as possible conserving the periosteal attachments of the pectoralis major, latissimus dorsi and teres major ; this facilitates the movements of the artificial limbs and protects important soft structures from injury especially the circumflex nerve and posterior (humeral) circumflex artery. Keep the knife closely approximated to the bone when detaching muscles, tendons, etc.

INTERSCAPULO-THORACIC DISARTICULATION OF THE UPPER LIMB TOGETHER WITH SCAPULA AND PART OF THE CLAVICLE

This operation devised by Berger consists of the following stages :—

1. *Subperiosteal Excision of the middle third of the Clavicle and Division after Ligature of the Subclavian Vessels*

Patient in dorsal position at the edge of table, shoulder raised and arm abducted to the side. Incision down to the bone in the middle line of the clavicle for its whole length commencing from the lateral margin of sterno-mastoid. Superficial veins ligatured. Periosteum raised all round and by a gigli saw the clavicle is divided at the junction of inner and middle thirds. The distal portion of clavicle is elevated by lion forceps and sawed at the junction of middle and outer third and the detached middle third removed. The subclavian vessels are exposed through a linear incision in the periosteum covering the subclavius muscle and the fascia. First artery and then the vein are divided between proximal and distal ligatures.

2. *The Antero-inferior (Pectoro-axillary) Flap*

Same position, but arm further abducted and head to opposite side. Operator stands between arm and trunk. Commence skin and fascia incision at middle of clavicular incision, carry it down just external to the coracoid process along anterior part of deltoid and anterior axillary fold across the lower border of pectoralis major, then transversely across from the anterior to the posterior axillary fold and downwards and inwards to the inferior angle of the scapula. Deepen this incision cut the tendinous part of pectoralis major, pectoralis minor near coracoid process, brachial plexus near first rib and posteriorly the latissimus dorsi. This frees the shoulder anteriorly.

3. *The Postero-superior (Cervico-scapular) Flap*

Same position, draw arm across the chest to bring scapula into prominence; stand on the outer side. Commence a skin and fascia incision at the distal end of the clavicular incision, carry it back over the scapular spine to join the former incision at the inferior scapular angle. Retract the skin flap and divide the trapezius which is exposed at its attachment to clavicle and scapula.

4. *Separation of Scapula from the Trunk*

Retract the flaps and let the limb fall away from the body, cut away from the bone, in order from above downwards, omohyoid, levator angulæ scapulæ, rhomboideus minor, rhomboideus major, and serratus magnus. The separation is completed. Teres major and minor, subscapularis, supraspinatus, and infraspinatus need not be divided as they are muscles connecting the scapula and the humerus.

5. *Closure of the Wound*

Cut nerves short; suture skin in a vertical oblique line; muscles can hardly be sutured.

Hæmorrhage.—1. Preliminary ligation of the subclavian vessels controls the major part. 2. In forming the anterior flap branches of the acromio-thoracic, long thoracic, and subscapular are ligatured. 3. In forming the posterior flap muscular branches should be secured. 4. In severing the scapula, the suprascapular near the omohyoid as it enters the supraspinous fossa and the posterior scapular vessels after dividing the levator angulæ scapulæ are ligatured.

Comment.—1. The clavicle may be disarticulated at the acromion after division. 2. Try to ligature the suprascapular and posterior scapular

arteries while exposing the clavicle, this reduces hæmorrhage to a minimum. 3. If the operation approach is made posteriorly (Littlewood's operation), it simplifies the operation regarding the ligation of the subclavian artery (which is posterior in situation) first and then the vein.

CHAPTER VIII

AMPUTATIONS OF THE LOWER EXTREMITY

THE TOES AND METATARSALS

AMPUTATIONS OF THE TOES

General considerations and surgical anatomy

The weight of the body is chiefly supported on the heel behind, and on the heads of the metatarsal bones in front. The inner side of the foot being the main support, the heads of the metatarsal bones and the whole of the great toe should be saved whenever possible; the outer four digits do not have a similar importance.

A portion of a toe is of little or no use and it is considered preferable to disarticulate the outer four toes at the metatarsophalangeal joint. This is not the case with the great toe in which the base of the first phalanx should be saved whenever possible and failing this the tendon attachments should be removed subperiosteally and sutured to the tissues of the stump.

The amputation scar should be planned to lie on the dorsal aspect of the foot away from plantar pressure. In dividing bones, a metatarsal or gigli saw should be used and not bone-forceps which would crush these bones. In disarticulating, the dorsal approach is preferable. In freeing flaps, the knife should be kept very close to the bone in view of the proximity of the digital arteries to the bone.

INSTRUMENTS—Group III.

POSITION

The foot should be brought well beyond the end of the table. The operator stands at the end of the table, facing the foot, and the assistant stands facing him.

A. THE TERMINAL PHALANX

Amputation by disarticulation of the terminal phalanges of the toes

These amputations are done by the same method as for the fingers; a long plantar flap corresponds to the long palmar flap.

OPERATION

Hold the toe between the thumb and the first two fingers of the left hand. Make an incision down to the bone, commencing from the joint line along the inner (tibial) side of the terminal phalanx nearer the dorsal than the plantar aspect. This is continued across the tip of the toe beneath the free margin of the nail, along the outer (fibular) aspect, as far as the joint line. The plantar flap is thus marked out. Deepen the incision and dissect the flap up from the bone. The joint is opened on the plantar aspect. Flex the terminal phalanx. Make the dorsal incision from the upper extremities of the lateral incisions on the dorsal aspect of the joint. This incision divides the extensor tendon and opens the joint. The internal and external lateral ligaments are cut, the toe being rotated outwards and inwards while doing this. The cicatrix lies on the dorsum.

Comment :—(1) The two small dorsal digital arteries will be seen at the corners of the dorsal incision. (2) The two plantar digital arteries lie buried in the flap and should not be cut if the knife is kept close to the bone.

B. THE SECOND (MIDDLE) PHALANX

Amputation of the second phalanx or disarticulation at the first inter-phalangeal joint, corresponds to similar operations of the second phalanx of finger.

Comment :—(1) In this disarticulation either remove the head of the first phalanx or amputate through this bone on a level with the head, as the large head will act like a foreign body, the muscles of the sole of the foot being mostly inserted at its base. (2) Use a fine metatarsal saw for dividing the bone and do not try to cut the bone with bone-cutting forceps as this is liable to crush the bone. (3) The two dorsal and the two plantar digital arteries will be cut.

C. METATARSO-PHALANGEAL JOINT

Disarticulation at the Metatarso-Phalangeal Joint

In disarticulating through these joints the following points should be observed :—1. The disarticulation should be made from the dorsal aspects as it would be easier to get at it than from the plantar aspect the joint line being some distance above the web. 2. Owing to the disproportionately large size of the head, ample

provisions should be made in the flap to cover it ; the heads should not be removed. 3. The cicatrix should be on the dorsal aspect away from the planter surface which is exposed to pressure.

D. AMPUTATION OF THE GREAT TOE BY DIS- ARTICULATION AT THE METATARSO- PHALANGEAL JOINT

This is performed by the racket incision with unequal limbs. The head of the metatarsal bone is of large size, and sufficient flap must be kept on the inner aspect to cover it.

OPERATION

Commence an incision three-fourths of an inch behind the joint on the inner side of the extensor tendon and extend it forwards over the joint and then let it bifurcate.

The outer limb of the incision crosses transversely on the dorsum towards the second phalanx and from thence round to the plantar aspect. The inner limb is practically a continuation of the first vertical incision. It is brought forward along the inner aspect of this first phalanx to the proximal side of the inter-phalangeal joint to meet the outer limb on the plantar aspect. Dissect the flaps up. Locate the joint exactly by rotating the toe in different directions. Open the capsule from the plantar aspect preserving the sesamoid bone (*Fig. 88*).

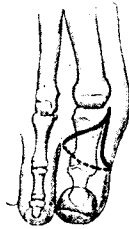


FIG. 88.

Comment :—(1) The external plantar digital artery is cut close to the web, the internal at the free end of the inner flap. The dorsal digital vessels will also be seen. (2) Remember that the large size of the head should be well covered with plantar skin as it has to bear the weight of the body. (3) The sesamoid bones should be preserved ; they are situated under the head and in the tendon of the flexor brevis pollicis (flexor hallucis brevis). (4) Try to preserve

the base of the first phalanx whenever possible as it has many of the muscles of the sole inserted into it and strengthens the sole of the foot. (5) The line of the joint is sometimes difficult to find, even after raising the flap; movement of the toes by rotation, flexion, and extension will help to determine its position. While cutting into the joint keep the blade of the knife close to the base of the phalanx.

E. DISARTICULATION OF THE LITTLE TOE AT THE METATARSO-PHALANGEAL JOINT

This is also performed by racket incision with unequal limbs.

OPERATION

An incision about half an inch long is made from behind the dorsal and outer (lateral) aspect of the head of the fifth metatarsal bone to the line of the joint. Another incision is made from the termination of the first incision transversely towards the fourth toe. The first incision is carried along the outer side of the little toe as far as the inter-phalangeal joint and then round the toe to the plantar aspect, to complete the racket. In this case, as in the case of the great toe, one limb of the racket passes almost transversely across the toe while the other (the outer in this case) is carried forwards for some distance in continuation of the vertical incision, before encircling the plantar aspect of the toe. The amputation is completed in the usual manner, the joint being opened from the outer side.

Comment :—In forming the flaps in all amputations of the toes, consideration must be given to the fact that the heads of the metatarsal bones are large and require a larger flap with more soft tissues in it to cover them than a cursory examination would lead the operator to suppose.

F. AMPUTATION OF OTHER TOES

The operation resembles very closely amputation through the corresponding joint of the finger.

Comment :—(1) The joint lines are further back than in the case of the hand. (2) Always see that the cicatrix comes on the dorsal aspect; it should not be on the sole which has to bear the weight of the body.

THE METATARSALS

(A) DISARTICULATION OF THE GREAT TOE WITH THE METATARSAL BONE

The operation is exactly similar to that for removing the whole of the great toe (through the metatarso-phalangeal joint) except that the incision on the dorsum commences at the base of the metatarsal bone.

(B) DISARTICULATION OF THE LITTLE TOE WITH THE METATARSAL BONE

It is performed on the same lines as the previous operation, the outer flap being kept longer than the inner.

THE FOOT

GENERAL CONSIDERATION AND SURGICAL ANATOMY

1. On the dorsal aspect :—Extend the foot, and feel for the head of the astragalus (talus) in front of the ankle joint.

2. Medially : from behind forwards :—(a) Internal tuberosity of the os calcis (calcaneus); (b) sustentaculum tali (lesser process of os calcis) 1" below internal (medial) malleolus; (c) tuberosity of scaphoid (navicular) 1" to 1½" in front of internal (medial) malleolus; (d) internal (first) cuneiform (very slightly); (e) base (not clearly), shaft and head of the first metatarsal; (f) base of the first phalanx of the great toe and the internal sesamoid bone.

3. Laterally, from behind forwards :—(a) outer tuberosity (lateral process) of the os calcis (calcaneus), its outer surface and anterior end, (b) trochlear process (peroneal tubercle) if present, 1" below the lateral malleolus, (c) base of the fifth metatarsal, its shaft and head, (d) base of the first phalanx.

4. On the plantar aspect, inferior surface of the os calcis (calcaneus) and the head of metatarsals.

5. Line of mid-tarsal articulation :—Take two points, the astragalo-scaphoid articulation medially and the calcaneo-cuboid articulation laterally; these joined transversely is the line.

6. Astragalo-scaphoid articulation :—Over-extend foot, the joint is just behind the scaphoid tubercle.

7. Line of tarso-metatarsal articulation :—From the prominent base of fifth metatarsal (cubo-metatarsal) joint a line obliquely forward across the foot to a point on the medial side of the foot 1" to 1½" below the scaphoid tuberosity. The second tarso-metatarsal joint (second metatarsal with cuneiform) is ½" to ¾" higher in level than the rest of the line.

8. The ankle joint is somewhat like a ball and socket joint, the prominent rounded superior surface of the astragalus (talus), representing the ball is received into the socket constituted by the concave articular surface of the lower end of the tibia above and the two malleoli on either side.

9. The line of the ankle-joint runs transversely in front of the foot on a level $\frac{1}{2}$ " above the tip of the internal malleolus.

10. The external (lateral) malleolus projects $\frac{1}{2}$ " below the medial and lies $\frac{1}{2}$ " behind the posterior plane.

11. Movements of the ankle joint: *Extension* (plantar flexion):—Gastrocnemius, soleus, plantaris, tibialis posticus (posterior), peroneus longus and brevis, flexor longus digitorum, and hallucis. *Flexion* (dorsi flexion):—Tibialis anticus (anterior), peroneus tertius, extensor long digitorum, extensor prop. hallucis. *Inversion*:—Tibialis anticus (anterior) and posticus (posterior). *Eversion*:—Peroneus longus and brevis.

12. Vessels to be considered in amputation flaps:—*Arteries*, branches of anterior tibial: internal and external malleolar and dorsali's pedis. Branches of the posterior tibial: internal calcaneal and through its peroneal branch: anterior and posterior peroneals and external calcaneal. *Veins*:—Tributaries of internal (great) and external (small) saphenous.

AMPUTATION OF THE FOOT

General remarks

1. Conserve as much as possible of the metatarsals of the great toe and little toe as they support the weight of the body to a great extent.

2. Much useful purpose will not be served by amputating a toe with part or the whole of the metatarsals, the exception being in the case of the great toe. If the metatarsals have to be removed it is best to do it as subperiosteally as possible.

3. In amputations of the foot, there is a tendency now to consider the foot as a whole or unit disregarding of the various joints.

4. A plantar flap and dorsal or terminal sutures should be aimed at to protect the scar from pressure. Plantar, lateral or medial sutures should always be avoided.

5. Lisfranc's disarticulation gives a good stump but there is hardly a disease or injury in which this operation would be feasible; for instance, for sarcoma of the foot a higher amputation is indicated; for crushed and other injuries a Lisfranc plantar flap would hardly be available, for septic or tubercular disease of the foot Lisfranc's or even Chopart's amputation could hardly be expected to extirpate the disease due to the anatomical arrangements of the joints and their synovial membranes. In Chopart's

disarticulation, the unopposed action of the tendo Achillis (tendo calcaneus) tilts the front of os calcis (calcaneus) downwards and the weight of the body is thrown on its anterior articular surface. Sub-astragaloid disarticulation which leaves a long limb with ankle movement is an operation of some merit. Syme's disarticulation at the ankle-joint or one of its modifications have met with greater approval of surgeons.

Amputations through the various joints of the foot

The following operations are performed :—

- A. Lisfranc's—through the tarso-metatarsal joint.
- B. Chopart's—through the mid-tarsal joint.
- C. Farabœuf's—sub-astragaloid amputation.
- D. Syme's—through the ankle-joint.
- E. Pirogoff's—intra-calcaneal amputation.

A. LISFRANC'S DISARTICULATION THROUGH THE TARSO-METATARSAL JOINT

SURGICAL ANATOMY

Note two bony landmarks, the tip of the base of the fifth metatarsal bone laterally and the tuberosity of the scaphoid (navicular), medially.

POSITION

The foot projects well beyond the end of the table. The opposite limb is tied or held out of the way by assistant. The operator stands facing the sole of the foot. Place the forefinger and thumb of the left hand on the landmarks, the palm of the hand being on the sole. Hold the foot in full extension.

OPERATION

An incision is made across the dorsum of the foot, joining a point one inch in front of the tuberosity of the scaphoid (navicular) to the base of the fifth metatarsal bone, and curving in such a way that it is convex towards the toes. This incision divides all the soft structures including the tendons down to the bone leaving a free skin margin of about $\frac{1}{4}$ ". Now, flex the foot and map out a plantar flap by an incision made on the outer (lateral) side of the foot, starting from the termination of the dorsal incision on that side ; it is then carried forwards along the plantar edge of the under-surface of the fifth metatarsal bone until it reaches a point half an inch behind the metatarso-phalangeal joint, whence it is carried back along the inner (medial) side of the foot to join the extremity of the original dorsal incision, an inch in front of the

tuberosity of the scaphoid (navicular) bone. The flap thus mapped out is raised by a knife, keeping its edge as close to the bone as possible. The joints are to be opened from the outer (lateral) aspect.

Commencing at the base of the fifth metatarsal bone, the edge of the knife is inserted behind the tuberosity of that bone and carried forwards for about one-fourth of an inch. The blade is now introduced into the joint, between the fifth metatarsal bone and the cuboid, and then working from without inwards the two succeeding tarso-metatarsal joints are opened. The three articulations, i.e. the fifth, the fourth, and third tarso-metatarsal joints, are almost in a straight line. After division of these three joints the blade of the knife meets a bony obstruction formed by the base of the second metatarsal bone which projects further backwards than the bases of the other metatarsal bones. The knife is withdrawn and inserted between the metatarsal of the great toe and

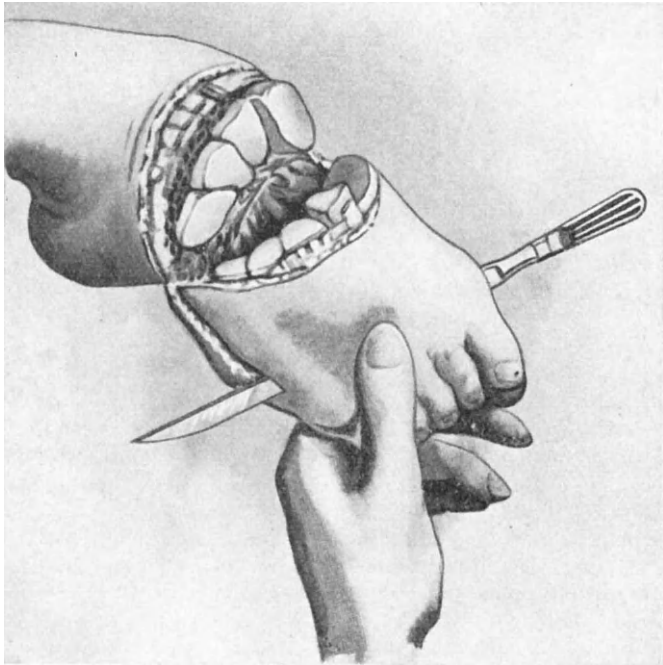


FIG. 89.

LISFRANC'S AMPUTATION—performed by first disarticulating from the dorsum—and then cutting the plantar flap from within outward.

REPRODUCED FROM BICKHAM'S OPERATIVE SURGERY
By the Courtesy of THE W. B. SAUNDERS CO.

internal cuneiform bone on the inner side, disarticulating this joint. The second tarso-metatarsal joint is now disarticulated. The foot is over-extended and the ligamentous band (Lisfranc's ligament) which binds the base of the second metatarsal and the internal cuneiform bone is cut. The plantar flap is turned over the stump. The transverse cicatrix lies on the dorsum (*see Fig. 89*).

HÆMOSTASIS

The following vessels have to be ligatured in dorsal flap : four dorsal metatarsal and communicating branch of the dorsalis pedis ; in the plantar flap, five plantar metatarsal branches of the external (lateral) plantar or possibly the external (lateral) plantar itself and the internal (medial) plantar at its termination.

Comment :—(1) The medial part of the flap should be sufficient to cover this side of the foot which is thicker. (2) The free edges of the flaps should be wide and not pointed. (3) Do not mistake the scaphoid-cuneiform articulation for the cuneiform-metatarsal articulation.

B. CHOPART'S AMPUTATION

(*Through Mid-tarsal Joints*)

POSITION

As in Lisfranc's operation.

OPERATION

The forefinger and thumb are placed behind the spur on the base of the fifth metatarsal bone and behind the scaphoid (navicular) tuberosity. These two points are joined on the dorsum by an incision curving downwards towards the toes, cutting through all structures down to the bone.

A plantar incision is made commencing from the outer extremity of the dorsal incision and carried to the middle of the shaft of the fifth metatarsal bone. It is then carried across the sole of the foot in an arched manner (convexity towards the toes) and finally backwards along the inner aspect of the foot, to reach the inner extremity of the dorsal incision. This incision is deepened to the bone. The joint is opened from the inner side, behind the tuberosity of the scaphoid (navicular), disarticulating it from the astragalus (talus). The knife is now carried across to the outer side of the foot through the joint between the cuboid and the os calcis (calcaneus) (*Fig. 90*).

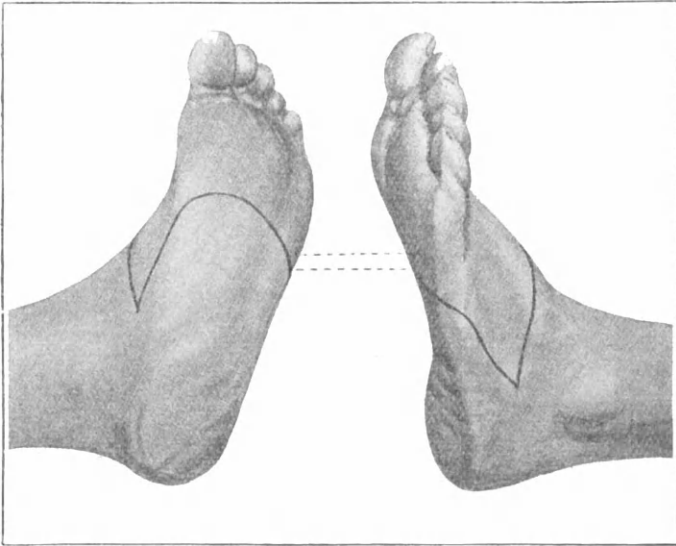


FIG. 90.

INCISIONS FOR CHOPART'S AMPUTATION

HÆMOSTASIS

Dorsalis pedis artery is cut in the dorsal flap. Near the inner part of the plantar flap the internal plantar artery is cut and near the base of the second metatarsal, the external plantar. Digital branches and metatarsal and tarsal branches are also cut.

Comment :—(1) When entering the knife into the inner side of the joint, take care to see that it is not entered in front of the scaphoid (navicular), i.e. between the scaphoid (navicular) and the internal (medial) cuneiform bones. (2) Two deformities may result—the posterior aspect of the os calcis (calcaneus) may be drawn up and in walking the weight comes on the anterior articular surface of the bone or the patient walks on the outer aspect of the os calcis (calcaneus) in a varus position.

C. SUBASTRAGALOID DISARTICULATION OF THE FOOT (FARABŒUF)

In this operation the whole of the foot is removed excepting the astragalus (talus), leaving the ankle-joint intact : in other words the disarticulation is effected through the astragalo-scaphoid

(talo-navicular) and astragalo-calcaneal (talo-calcaneal) articulations (*Fig. 91*).

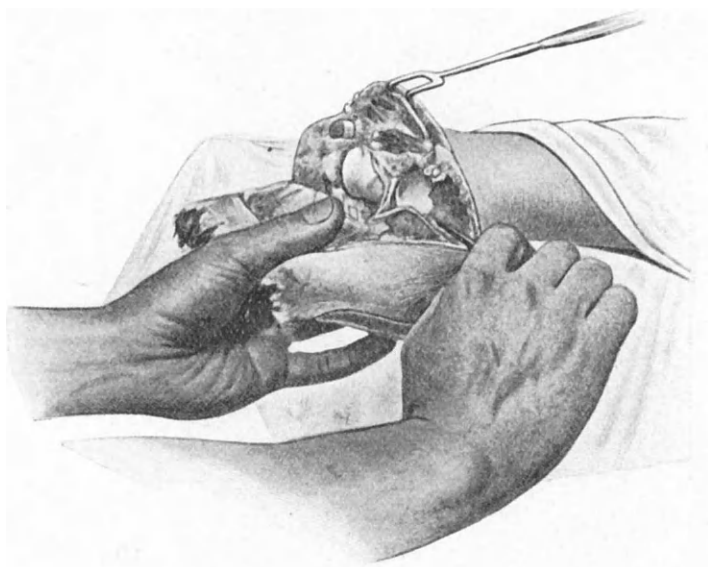


FIG. 91.

SEPARATING THE OS CALCIS FROM THE ASTRAGALUS IN FARABCEUF'S SUB-ASTRAGALOID DISARTICULATION:—The knife is being drawn from left to right; it has divided the interosseous ligament between the os calcis and the astragalus and is proceeding to divide the tendo Achillis at the extreme right.

REPRODUCED FROM BURGHARD'S 'AMPUTATIONS'.

POSITION

Place leg on its inner side; foot projects beyond the table. Stand facing the foot.

OPERATION

A modified racket incision is most convenient.

It is commenced at the outer part of the tuberosity of the os calcis (calcaneus) at the insertion of tendo Achillis; the incision is then carried along the outer margin of the foot, about half an inch below the external malleolus, until a point just behind the spur on the base of the fifth metatarsal bone is reached. A curved incision is next carried across the dorsum of the foot, with the convexity towards the toes. This incision should reach the inner side of the foot at the level of the first metatarso-phalangeal joint; it then traverses the sole to reach the starting point of the incision

at the tubercle of the os calcis. These incisions involve the skin and fascia only. When the skin has retracted, a second incision is made along the same route dividing all the structures down to the bone.

The tendo Achillis is divided at the starting point of the incision, and the flap on the dorsum of the foot separated from the underlying bones. The posterior aspect of the joint between the astragalus and os calcis is opened, and the knife brought forward from this position in order to divide the interosseous ligaments which bind the astragalus (talus) and the os calcis. With the foot twisted outwards, the soft tissues on the inner and inferior aspects of the os calcis can be freed and the disarticulation completed.

Comment :—Hæmostasis. In the outer part of the flap are the anterior and the posterior peroneals and branches of the tarsal and metatarsal arteries. In the inner part are the dorsalis pedis and tarsal arteries. In the inner part of the dorsum and the sole are the internal and external (medial and lateral) plantars.

D. SYME'S DISARTICULATION OF THE FOOT AT ANKLE-JOINT

Disarticulation of the foot at ankle-joint with removal of malleoli and articular surface of tibia.

This is a good operation for tubercular disease of the tarsus or for crushed injuries of the anterior part of the foot in which a heel-flap is available.

POSITION

Leg rests on a support (block) and foot projects beyond the table ; operator sits facing the foot, assistant stands opposite and steadies the leg.

OPERATION

Two bony landmarks are felt for, viz. the internal and external malleoli. There are four stages of the operation : (1) raising the heel-flap by a plantar 'stirrup' incision ; (2) the dorsal incision ; (3) the disarticulation ; and (4) removal of the malleoli and the lower articular end of the tibia.

(i) *The heel-flap*.—Hold the ankle with the left hand and make the plantar incision which is to be like a stirrup as follows :—Enter the knife just below the tip of the internal malleolus and carry it vertically down to the margin of the heel ; then carry it transversely across the sole to the opposite margin of the heel ; next carry it vertically upwards along the inner side of the ankle to a point

half an inch below the tip of the inner malleolus. This 'stirrup' incision, throughout its length is made deep down to the bone and marks the line of the heel-flap: an excision knife will be useful.

Pull the heel-flap up from the bone by the thumb and fore-finger covered with gauze and raise it with touches of the knife its point strictly directed towards the bone. Dissect the flap first from the tuberosity of the os calcis and then from its posterior surface.

(ii) *The dorsal incision.*—Hold the foot in full extension. The upper ends of the incision are joined across the dorsum in front of the joint by the shortest route; this incision divides all the tissues down to the bone. The ends of the dorsal and plantar incisions meet almost at right angles (*Fig. 92*).

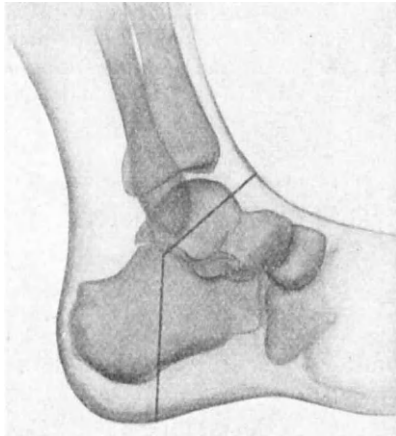


FIG. 92.

DORSAL AND PLANTAR INCISIONS IN SYME'S AMPUTATION
OF THE FOOT AT THE ANKLE-JOINT, I.

REPRODUCED FROM BICKHAM'S OPERATIVE SURGERY
By the Courtesy of THE W. B. SAUNDERS CO.

(iii) *The disarticulation.*—Cut through the anterior annular (transverse crural) ligament thus exposing the joint. Introduce the knife into the joint and divide the lateral ligaments cutting from within outwards. Cut the posterior ligament, clear the upper surface of the os calcis and divide the tendo Achillis. This completes the disarticulation.

(iv) *The removal of the malleoli.*—Clear the two malleoli and the lower end of the tibia of all soft structures by knife and periosteal elevator. Apply the saw a quarter of an inch above the

inferior margin of the tibia and cut through the exposed bones horizontally. The flaps can now be brought together (*Fig. 93*).

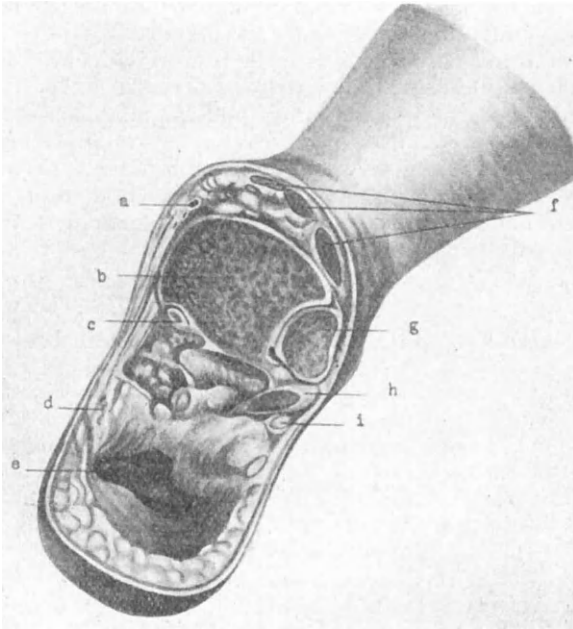


FIG. 93.

FORMATION OF THE HEEL-FLAP IN SYME'S AMPUTATION AT THE LEFT ANKLE:—a, Anterior tibial vessels; b, Sawn tibia; c, Posterior tibial tendon; d, Internal plantar vessels; e, Severed tendo achillis in the upper aspect of the heel-flap; f, Extensor tendons; g, Sawn fibula; h, Tendon of peroneus brevis; i, Tendon of peroneus longus.

REPRODUCED FROM BICKHAM'S OPERATIVE SURGERY
By the Courtesy of THE W. B. SAUNDERS CO.

Comment:—1. The following vessels have to be secured:—The anterior tibial artery in the dorsal flap at about its middle; the external (lateral) and internal (medial) plantar arteries in the inner section of the heel-flap; the internal malleolar (posterior medial malleolar) of the posterior tibial behind the inner malleolus; the anterior peroneal (perforating branch of peroneal) in front of the tibio-fibular joint; the external (anterior lateral) and internal (anterior medial) malleolars of the anterior tibial in front of their corresponding malleoli; the internal (great) saphenous vein in the dorsal flap, the external (small) in the

heel-flap. 2. The inner vertical limb of the stirrup incision is better cut from above downwards commencing half an inch below the tip of the heel incision. 3. While raising the heel-flap do not button-hole the flap. The knife should be rigidly kept close to the bone and in raising the flap with the thumb the periosteum may be taken up from the os calcis. 4. In cutting for the dorsal flap from the tip of the inner malleolus do not go behind the tip, as by doing so the posterior tibial artery may be divided before its bifurcation and by this the internal (medial) calcaneal branch of the external (lateral) plantar which is the main artery of the flap may be lost.

A MODIFICATION OF SYME'S AMPUTATION

Instead of dissecting up the heel-flap from below, as described in the previous operation, and opening the joint at a later stage, it is thought more convenient by some to open the ankle-joint freely (after the incisions are made) through the anterior incision by dividing the ligaments and dislocating the astragalus (talus) forward, so as to expose the superior non-articular surface of the os calcis. The tendo Achillis is severed, and still working from the dorsal aspect, all the lateral and inferior attachments of the soft tissues to the os calcis are separated from that bone by rapid strokes of the knife. The foot can now be removed, and the operation completed.

Syme's amputation can be very readily performed by this method, but great care is necessary not to injure the heel-flap when separating it from the posterior aspect of the os calcis.

E. PIROGOFF'S INTRA-CALCANEAL OSTEOPLASTIC AMPUTATION OF THE FOOT, DISARTICULATION OF THE FOOT AT THE ANKLE-JOINT WITH REMOVAL OF MALLEOLI, ARTICULAR SURFACE OF THE TIBIA AND ANTERIOR PART OF OS CALCIS (CALCANEUS).

This operation resembles Syme's with the exception that the os calcis (calcaneus) is sawn through and its posterior part is left in the heel-flap. The lower ends of the tibia and fibula are sawn through and the surface of the os calcis is brought into apposition with it (i.e. with the sawn surface of the tibia and fibula).

THE LEG

AMPUTATION OF THE LEG

SURGICAL ANATOMY

The fibula is on a posterior plane than the tibia. The lower third of tibia has no muscles attached to it; its lower end which has no crest, is rounded. The interosseous space is narrow at the upper and lower parts and wide in the middle part.

The muscular prominence lateral to the crest of the tibia is caused by the tibialis anticus (anterior), extensor longus digitorum and extensor proprius (longus) hallucis. Further laterally, the peroneii give the muscular contour. Medially is the shaft of the tibia and posterior to it the muscular prominence representing the calf is formed by the soleus and gastrocnemius tapering off into tendo Achillis and beneath these are the flexor muscles of the toes and tibialis posticus (posterior). The soft parts of the lower third of the leg consist more of tendons than muscles.

The popliteal artery bifurcates about two inches below the knee-joint which corresponds to the level of the base of the tibial tubercle (tuberosity).

General considerations regarding amputations of the leg

For lower and middle third amputations of the leg, large posterior skin and muscle flaps are recommended as the bulk of the muscles are in the posterior aspect.

For upper third amputations, the muscles being chiefly postero-external, external (lateral) flaps furnish the best covering.

Both bones may be divided at one sawing but it is preferable to divide the fibula first in order to avoid splintering it, besides, it is desirable to divide the fibula on a higher level, otherwise the projecting end of fibula may hurt the soft tissues in the flap.

If these bones are divided transversely, the sharp anterior crest of the tibia and the sharp margin of the fibula are likely to hurt the soft tissues. In order to avoid this the anterior border or crest of the tibia is bevelled from above downwards and from before backwards and the fibula is bevelled from above downwards and from without inwards. (See *infra*, 'Farabœuf's amputation of the leg', page 144.)

Divide the interosseous membrane by cutting transversely in order to avoid splitting the blood vessels which run vertically downwards.

Take special care to cut the nerves short and deal with the ends as have been described.

If the amputation is one inch below the head of the fibula the popliteal artery only is cut, if two inches below two main arteries are cut, namely the anterior and posterior tibials and if

three inches below three arteries are cut, the two tibials and the peroneal.

In artificial limbs, the pressure on the stump is from the sides except in peg legs in which the pressure is terminal; scars should be placed accordingly.

In amputations of the leg generally, the patient is brought to the edge of the table and the limb made to project beyond it to a greater or less extent.

In the leg the following amputations may be performed:—

1. In the lower third—

- (A) Supramalleolar amputation by elliptical flap (Guyon).
- (B) Antero-posterior flaps with long anterior and short posterior flaps (Teale, Lister).
- (C) Antero-posterior flaps with short anterior and long posterior flaps (Farabœuf).

2. In the middle third antero-posterior flaps with short anterior and long posterior flaps (Hey).

3. In the upper third, lateral or medio-lateral flaps, namely a large external (lateral) flap and a nominal internal (medial) flap.

In these amputations, particularly in amputations of the lower third of the leg, the osteoplastic method is suitable. The osteo-cutaneous flap may be raised from the subcutaneous medial aspect of the tibial shaft as recommended by Kocher and others to cover the bony stump of the tibia, the fibula which is divided at a higher level not requiring a bony transplant. To ensure a satisfactory and accurate apposition of these bony grafts, he suggests a concave sawn surface of the tibia and a convex raw surface of the bone flap.

After the skin incision, the muscles are divided at the line of retracted skin and are allowed to retract, taking care not to separate the skin, subcutaneous tissue and periosteum from the tibia. An incision is now made into the periosteum on the subcutaneous surface of tibia in order to map out a bone-flap sufficient to cover the sawn surface of the tibia and fibula or of tibia only as the case may be. A small wedge-shaped cut is made into the tibia at the transverse distal cut in the periosteum and a gigli saw or a butcher saw or a Helferich type of saw being introduced into this, a flap of the desired depth consisting of bone periosteum and skin is raised in one piece; at the proximal end of this flap the bone-flap is broken across by an elevator conserving the periosteum and soft tissues which act like a hinge. The periosteum is raised a little further up and the tibia and fibula are sawn through at this level. This bone-periosteum-skin flap is turned over and apposed to the sawn surface of the tibia or tibia and fibula and secured there by suturing the periosteum and soft tissues or by wiring or pegging the bones.

GUYON'S SUPRAMALLEOLAR AMPUTATION

This operation resembles Syme's disarticulation to some extent; the tibia and fibula are sawn through at a level below their medullary canal, and the stump is covered by a heel-flap. The joint however is not opened.

Take the anterior mid-point of the ankle and the highest point on the convexity of the heel. Join these two points by a skin incision running obliquely backwards and downwards on either side skirting the two malleoli. Deepen this incision dividing the soft tissues and tendons and making a musculo-periosteal flap all round about two inches in extent. Divide tibia and fibula on the same level slightly above the bases of the malleoli. The anterior and posterior tibial and peroneal arteries are secured. The convex heel-flap is apposed to the dorsal flap (*Fig. 94*).

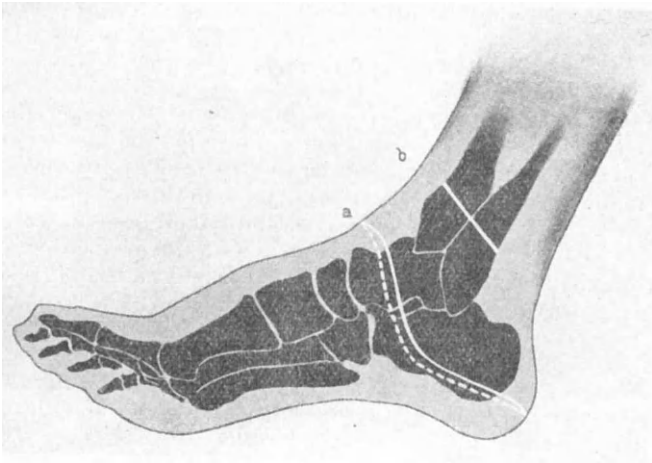


FIG. 94.

GUYON'S SUPRA-MALLEOLAR AMPUTATION OF THE LEG:—
a, Line of skin incision; b, Line of bone division.

REPRODUCED FROM BICKHAM'S OPERATIVE SURGERY
By the Courtesy of THE W. B. SAUNDERS CO.

AMPUTATION THROUGH THE LOWER THIRD OF THE LEG BY LONG ANTERIOR AND SHORT POSTERIOR FLAPS

These amputations have certain disadvantages. It has already been remarked that it is difficult to obtain sufficient soft coverings for anterior flaps unless a considerable length of the limb

be sacrificed by a high bone-section. In Teale's amputation, a rectangular anterior (extensor) flap equal in length and breadth to half the circumference of the limb at the saw line and a similar rectangular (flexor) flap but one quarter of this have to be made. Lister's amputation is much the same. Both these involve a high bone-section.

AMPUTATION THROUGH THE LOWER THIRD OF THE LEG BY SHORT ANTERIOR AND LONG POSTERIOR FLAPS—FARABŒUF'S AMPUTATION

POSITION

Patient supine, leg projects beyond the table. Operator stands on the outer side of right and inner side of left limb. Assistant steadies leg and manipulates it.

OPERATION

Say for the right leg. Assistant presents the inner (medial) side of leg. Commence an incision at the saw line on the medial side, carry it along medial border of tibia for a distance equal to $1\frac{1}{4}$ diameters of the limb at the saw line and take it round across the posterior aspect of the leg. Assistant now presents the outer (lateral) aspect of the limb; commence a similar incision of the same length from the saw line but on the external (lateral) side of the limb, carry it along the fibula vertically downwards and round it off to meet the first (medial) incision. Make the small anterior flap by a slightly convex line joining two points a little below the two proximal ends of the vertical incision so that it is about a fourth in length of the posterior flap. The skin and fascia are allowed to retract and the tendo Achillis (calcaneus) is cut at the level of the retracted skin. The medial aspect of the leg is now presented; the upper end of the medial vertical incision is deepened for about two inches and the muscles separated from the tibia. The leg is turned again to present its lateral aspect and in a similar manner the muscles are freed for two inches. Introducing the thumb and index fingers the soft parts are picked up from the bones, a long-bladed knife is put through and the muscles are divided with the line of the retracted skin bevelling off towards the free edge of the flap. The soft parts are freed back to the saw line, the interosseous membrane being divided transversely and the periosteum divided circularly at a sufficient distance below the saw line and reflected up. The bones are divided and the sawn ends bevelled, the fibula being divided first in order to avoid splintering and the tibia next. The limb should be kept flexed in the different stages of this operation.

The peroneal and anterior and posterior tibial arteries and the internal and external saphenous veins are secured. The posterior tibial nerve is cut short and dealt with.

AMPUTATION THROUGH THE MIDDLE THIRD OF THE LEG BY ANTERO-POSTERIOR FLAPS

In this amputation the greater part of skin-and-muscle flap is obtained from the posterior aspect of the leg.

The posterior flap which is U-shaped has a width equal to hemi-circumference and its length equal to one diameter of the limb at the saw line. Commence the incision about one inch below the level of saw line just behind the medial border of the tibia, bring it vertically down, and rounding at its termination carry it transversely towards the posterior aspect of the limb to meet the other limb of the U which consists of a similar vertical incision carried just behind the fibula posterior to the peronei muscles. Make the anterior flap which is one-third the length of the posterior by joining the vertical limbs at their upper third by a transverse incision slightly convex downwards across the front of the leg.

The peroneal and anterior and posterior tibial arteries are secured. Musculo-periosteal coverings are closed over the stump taking special care that the muscles are quilted as the posterior flap tends to sag backwards. The skin flaps are now sutured.

TIBIO-FEMORAL OSTEOPLASTIC AMPUTATION OF THE LEG

A rather ingenious osteoplastic amputation has been devised by Sabanajeff. For this operation the upper part of tibia and soft tissues of the leg should be healthy and available.

An anterior flap is raised from the front of the leg by median and lateral incisions rounding off and meeting in the front of the leg at the level of the junction of the upper and middle thirds of the limb. The posterior flap is one-half the length of the anterior.

A transcondylar section of the femur is made. Then a bone flap is raised from the upper and anterior part of the tibia by sawing from its articular surface vertically down the shaft of the tibia to a level below the tubercle (tuberosity) and attachment of the ligamentum patellæ and then the bone is separated by a few strokes of the saw applied transversely. This tibial bone-flap with the soft tissues and patella attached to it is grafted to the sawn surface of the femoral epicondyles.

FARABOEUF'S AMPUTATION OF THE LEG (AT THE SEAT OF ELECTION)

The bone-section goes through tibia and fibula about a hand's breadth below the knee-joint, a little above the great nutrient foramen of the tibia or at a lower level (*see Fig. 78*).

POSITION.

The knee-joint projects beyond the end of the table. The other leg is held out of the way. For the right leg stand on the outer side of the limb, for the left, at the end of the table, for the skin incision. For the rest of the operation, the operator has to change his position as necessary. The assistant standing at the end of the table manipulates the leg in such a way that its inner or outer side is presented to the operator as required for different stages of operation. A second assistant will be useful for supporting the thigh and retracting the soft tissues. The knee is flexed.

OPERATION

The flap is to be taken from the outer side of the leg where sufficient muscular tissue to cover the bones is available. The large external flap is U-shaped consisting of two limbs anterior and posterior, representing the two vertical incisions, the lower ends of these limbs being joined by a line slightly curved downwards. The length of this flap equals a third of the circumference at the level of bone-section (saw line).

1. The anterior limb of the U-incision commences opposite the line of bone-section, and is carried down the leg slightly on the inner side and parallel with the anterior crest of the tibia. The posterior limb of the U commences on the calf directly opposite the anterior limb about half an inch below the corresponding point of the anterior limb. It is carried vertically downwards till its lower end is on a level with the lower end of the anterior limb. These two lower points are joined by a transverse incision slightly sloping downwards. Free the skin along the edge of whole length of the incision and allow it to retract.

2. Turn the limb outwards. Draw the knife across the inner side of the leg from the upper end of the posterior incision to a point on the anterior cut, half an inch below its upper end. The incision is only skin deep. Free the skin slightly along this incision.

3. Turn the limb with its inner surface downwards. After the skin of the great U-flap has been undercut for about half an inch all round the flap, the external flap is raised in the following manner. Insert a dissector or your fingers between the outer side of the crest of the tibia and the tibialis anticus (anterior) and separate it from the bone up to the lower limit of the flap. Turning to the

lower margin of the flap, raise the muscle-and-skin flap by cutting the muscles obliquely, so that it is thin at the lower part and gets thicker at the upper part ; in other words the distal free end of the muscle-and-skin flap is bevelled. Raise the muscles from the two bones and the interosseous membrane and, in doing so, do not raise this flap up too high, where the anterior tibial artery pierces the interosseous membrane, as it may then be accidentally divided.

4. Turn to the smaller, inner flap and cut across the soft tissues on a level with the retracted skin. Retract the soft tissues by a three-tailed gauze retractor.

5. Divide the interosseous membrane transversely in the line of the bone-section. Raise the periosteum from the bones to a point just above the saw line. Stand on outer side of the right leg and on the inner side of the left. Saw the fibula first in a direction from above downwards and inwards at a slightly higher level than the line of section of the tibia. Hold the saw in such a way that its point be directed towards the floor in the case of left limb and towards the ceiling in the case of the right. In sawing the tibia it is necessary to make the anterior part of the sawn tibia smooth by applying the saw an inch or more above the intended line of amputation, and dividing the crest obliquely from above downwards and backwards until the level for the transverse division of the bone is reached (*Figs. 95, 96*). The coverings of the stump

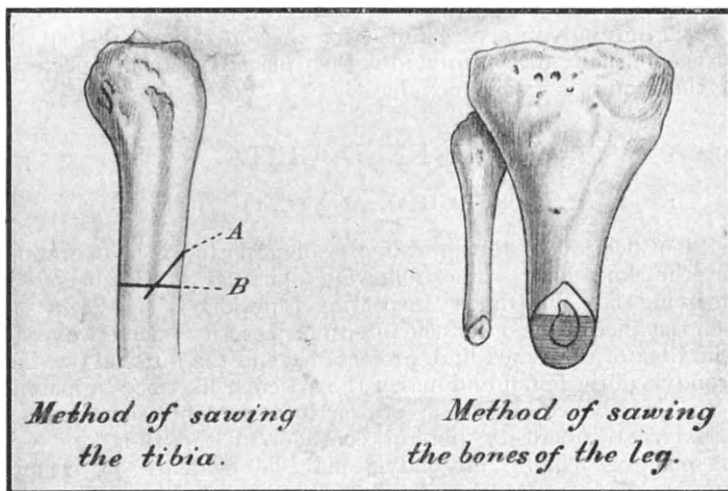


FIG. 95.

FIG. 96.

will thus rest on smooth bevelled surface instead of sharp edges of the bones, if the latter be treated in the manner described.

Comment :—The following vessels have to be ligatured. The anterior tibial artery is divided at the free margin of the internal flap. The posterior tibial and peroneal vessels lie close together on the inner flap. The muscular branches to gastrocnemius and soleus are also cut. The nutrient artery of the tibia will be divided as it enters the bone. If the great muscles in the outer flap are raised too high up, the anterior tibial artery will be in danger of being divided as it pierces the interosseous membrane ; the vitality of the flap depends upon the integrity of this artery.

AMPUTATION THROUGH THE UPPER THIRD BY BILATERAL FLAPS (STEPHEN SMITH)

Two points are taken, one posteriorly corresponding to the saw line and the other anteriorly on the crest (anterior crest) of the tibia at a point three-fourths of the diameter of the limb at the saw line. Two incisions are made from the posterior point along the medial and lateral aspects of the leg at first vertically downwards, then curving forwards to meet the anterior point. A skin-and-fascia flap is raised for about an inch and the muscles are circularly divided and retracted to the saw line ; these form the bilateral hooded flaps and are sutured vertically.

The only advantages claimed for this operation are that the scar is eventually drawn up and is then placed vertically posterior and the stump is freely movable.

THE KNEE-JOINT

SURGICAL ANATOMY

Identification of the joint-line is of importance in operations near the knee-joint. The following landmarks are useful in identifying the joint-line. Inspecting anteriorly : (1) Cross one leg on the knee of the other, the internal tuberosity (medial condyle) of the tibia of the flexed limb projects beyond the internal (medial) epicondyle of the femur and makes the articular line more apparent. (2) In the above disposition of the limb a depression between the external tuberosity (lateral condyle) of the tibia and the corresponding femoral epicondyle may be evident. (3) $\frac{3}{4}$ inch above the prominence of the tuberosity (tubercle) of the tibia is the joint-line. (4) Extend the limb, the joint-line is slightly above the apex of the patella. (5) Semi-flexing the leg, if you pass a needle just below the apex of the patella it will enter the joint. Inspecting posteriorly : (6) The transverse crease in the popliteal space is practically on a level with the joint-line.

The upper aspect of the head of the fibula is on a level with the upper border of the tubercle of the tibia ; it can be felt at the lateral and posterior aspect between the tendons of biceps above and peroneus longus below.

Palpating on the popliteal aspect may be felt : from the lateral side, ilio-tibial band of fascia lata, the biceps tendon, and the popliteal nerve ; from the medial aspect, sartorius (best felt while manipulating the limb), gracilis with semimembranosus and semitendinosus.

GENERAL CONSIDERATIONS REGARDING DISARTICULATIONS AND AMPUTATIONS AT THE KNEE-JOINT

Disarticulation through the knee-joint, preserving the semi-lunar cartilages gives good results ; it gives a rounded stump with a broad base to carry the weight of the limb and body and takes artificial limbs better. Besides, as the tendon of adductor magnus is attached to the adductor tubercle the muscle is best utilized. One drawback is that the artificial knee-joint comes either above or below the level of the normal knee and the manufacturers of artificial limbs naturally prefer an amputation at the so-called ' seat of election ' for this reason.

The patella should be retained whenever possible as the patella itself and the thick and dense skin makes a stronger flap ; besides, the anterior flap depends for its blood supply to a great extent on the integrity of the pre-patellar anastomosis and the detachment of the patella from this flap might so interfere with the blood supply that it may slough.

In cases of tubercular or septic arthritis and osteomyelitis, the joint structures and articular cartilages may be disorganized and it may be necessary to divide the femur either through the condyles (transcondyloid amputation) or above it (supracondyloid amputation). If the patella can be conserved it may be grafted to the sawn surface of the femur (osteoplastic transcondyloid or supracondyloid amputation). The upper part of the anterior aspect of the tibia may also be sawn off the bone and grafted to the sawn surface of the femur.

This amputation has in the past been designated as ' amputation at the seat of election '. In pre-antiseptic days in amputations with bone-sections between the ankle and tibial tubercle, it was found that the stump could not bear the weight of the body and the patient had to rest the anterior aspect of the bent knee on some type of artificial leg with the stump projecting behind. The inconvenience of a long projecting stump could only be obviated by amputating the leg as high up as possible, leaving just enough of the tibia and fibula for the patient to rest on the anterior surface of the knee. With the introduction of asepsis and improved technique of amputations, such as tendinoplastic and osteoplastic amputations, it is now possible to obtain a good and useful stump at any level

in the leg. The term 'seat of election' has therefore lost its significance and is of historical interest only.

AMPUTATIONS IN THE REGION OF THE KNEE-JOINT

The following methods of amputations in this region are known :—

- A. Stephen Smith's disarticulation by lateral flaps.
- B. Carden's trans-condyloid amputation through the condyles of the femur, by long anterior flap and removal of the patella.
- C. Lister's trans-condyloid amputation by oblique division of the femoral condyles.
- D. Gritti's supracondyloid osteoplastic amputation by long anterior flap with removal of the articular surface of the patella and apposing it to the sawn surface of the femur.
- E. Stokes' supracondyloid osteoplastic amputation (higher) by long anterior flap, the patella being treated as in Gritti's method.

A. STEPHEN SMITH'S DISARTICULATION AT THE KNEE-JOINT BY LATERAL FLAPS

The two lateral flaps consist of integuments only, the internal flap being slightly longer than the external. The soft structures behind the knee are divided transversely about the level of the articulation. The operation can be performed with great rapidity.

POSITION

Pull the leg down, beyond the end of the table, till the knee is quite beyond the edge. Stand on the outer side. The assistant holds the leg and rotates it as required.

OPERATION

Mark out two points with the thumb and a finger of the left hand :—(a) the mid-point of the transverse crease in the popliteal space behind, opposite the line of the joint, and (b) a point about two inches below the tubercle of the tibia in front. The operation can be described in four stages.

1. *The skin incision.*—Bend over the limb which is rolled outwards. Commence an incision in the middle of the popliteal space, carry it obliquely downwards, inwards, and forwards to a point at the junction of the upper with middle-third of the tibia. When it approaches the crest of the tibia, curve it upwards to end at a point two inches below its tubercle. This marks out the outline of the inner (medial) flap. Now the assistant lifts the leg up vertically. Commence another incision below the tubercle of

the tibia where the former incision ends. Carry it downwards, backwards and then upwards on the back of the leg to meet the original incision in the popliteal space. This marks out the outline of the outer (lateral) flap. The lower point of this incision is on a slightly higher level than that of the inner. These incisions divide the skin and superficial fascia only (*Fig. 97*).

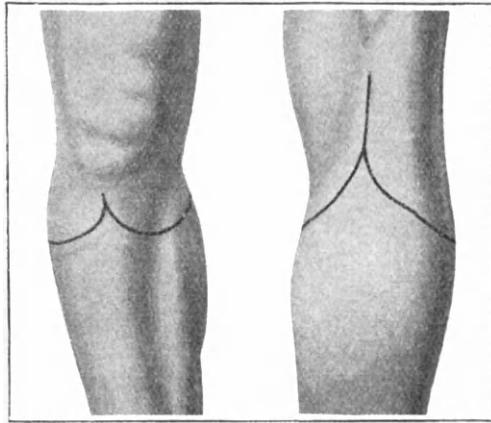


FIG. 97.

INCISION FOR STEPHEN SMITH'S DISARTICULATION AT THE KNEE-JOINT :—It will be noted that the incision extends slightly lower down on the inner than on the outer side.

REPRODUCED FROM BURGHARD'S 'AMPUTATIONS'.

2. *The skin-flaps*.—Free the margin all round and raise these flaps, which include the skin and the structures down to the tendons and muscles. Cut transversely the lateral ligaments, structures along the upper margin of the tibia on the anterior and lateral aspects, ilio-tibial band, tendons of the sartorius, semitendinosus and biceps and the anterior parts of the capsule of the joint. Enter the knife between the semi-lunar fibro-cartilages (lateral and medial menisci) and the head of the tibia cutting through all the soft structures. Flex the knee and divide the crucial (cruciate) ligaments close to the tibia as they meet the knife leaving the semi-lunar cartilages (menisci) with the stump (*Fig. 98*).

3. *The posterior aspect*.—Divide all structures by a transverse cut on this aspect of the leg which include the posterior ligament, the popliteal vessels, muscles, and tendons.

Hæmorrhage.—The following vessels have to be secured. The popliteal artery and veins are the vessels of importance; the muscular arteries, the azygos (middle genicular) artery, branches of the superior articular (genicular) vessels (on the outer or lateral

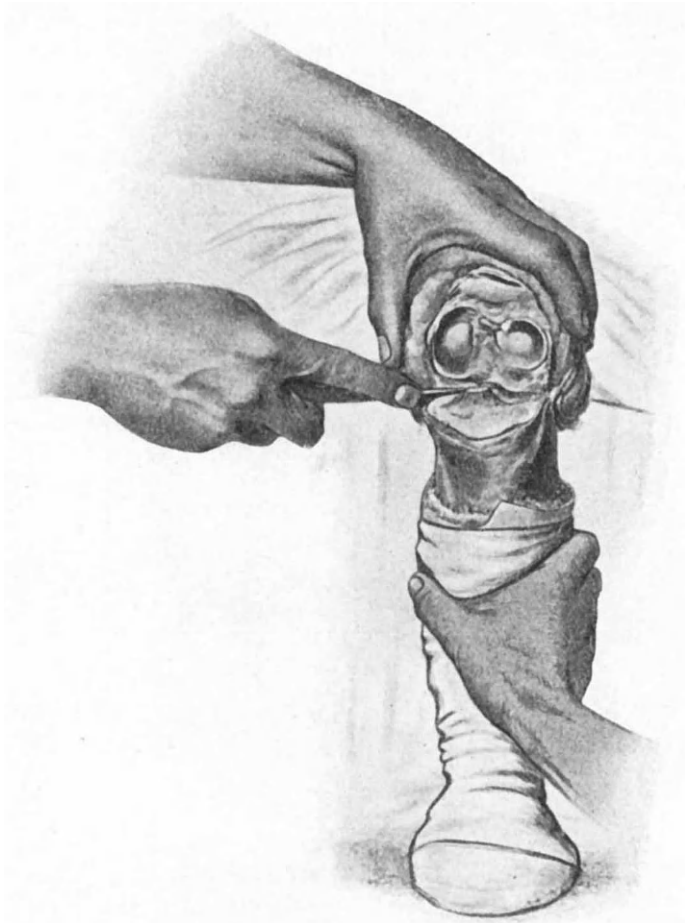


FIG. 98.

DISARTICULATION AT THE KNEE-JOINT BY STEPHEN SMITH'S METHOD:—The semi-lunar cartilages are seen in contact with the condyles of the femur. The knife is dividing the posterior ligament of the knee-joint and the popliteal vessels.

REPRODUCED FROM BURGHARD'S 'AMPUTATIONS'.

side) and the superficial division of the anastomotica magna or highest genicular artery or arteria genu suprema (on the inner or medial side).

Comment:—(1) The internal flap is longer than the external in order to provide an adequate covering for the internal (medial) condyle which is larger and

on a lower level than the external (lateral). The skin flaps, after amputation on the dead subject, may look disproportionately long and rather thin ; this is, however, not so when the operation is performed on the living. The drainage is efficient from between the flaps as the wound is vertical and its lower end looks directly downwards when the patient lies in bed. (2) The scar lies well behind and between the condyles (*Fig. 99*). (3) The semi-lunar cartilages left under the condyles form a natural cushion for the stump.

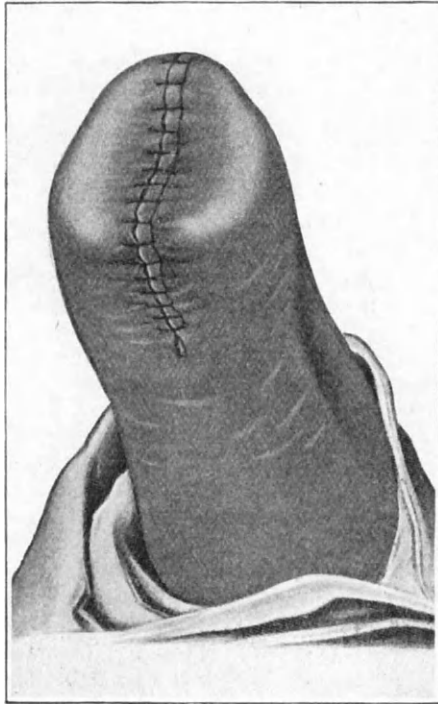


FIG. 99.

STUMP LEFT AFTER STEPHEN SMITH'S DISARTICULATION
AT THE KNEE-JOINT.

REPRODUCED FROM BURGHARD'S 'AMPUTATIONS'.

**B. & C. TRANS-CONDYLOID AMPUTATION. (CARDEN,
LISTER)**

In Carden's original operation, the femur is divided through the condyle and the patella is removed. A long anterior flap is

made by an incision commencing from one condyle and extending vertically downwards for about four inches, carrying across the front of the tibia, a little below the level of the tubercle, and then upwards to the opposite condyle. A small posterior flap is made by a sweep of the knife through the skin and superficial fascia across the back of the knee-joint. The long anterior flap, occasionally, sloughs due to want of vascular supply. Lister modified this operation by cutting transversely across the front of the limb from side to side at a level of the tuberosity of the tibia, and joining the horns of this incision posteriorly, by carrying the knife at an angle of 45 degrees to the axis of leg through the skin and fat. The flap consisting of skin and subcutaneous tissue are raised as in circular amputation.

The soft tissues are cut transversely across. The periosteum covering condyle and the femur is divided and a saw applied not at right angles to the bone, but at a slight angle so as to cut a little lower on the inner side, thus maintaining the normal obliquity of the condyles. The patella is generally removed with the tendon of quadriceps extensor. The muscles can be brought together over the bony stump by a few sutures.

D. & E. SUPRA-CONDYLOID OSTEOPLASTIC AMPUTATION. (STOKES-GRITTI METHOD)

In this amputation the flaps are made as in Carden's operation, i.e. by long anterior and short posterior flaps. The ligamentum patellæ is divided and the anterior flap, including the patella, is turned up. The condyles of the femur are cleared and a portion of the lower end of the femur is removed. In Gritti's amputation the saw traversed the bone in a transcondylar plane, whereas in Stokes' operation it is carried at a higher level through the cancellous tissue about $\frac{1}{2}$ to $\frac{3}{4}$ inches above the upper limit of the condyles or above the adductor tubercle. With a small butcher's or a metacarpal saw the articular surface of the patella is removed. The anterior flap is now turned over to meet the posterior flap, and while doing so the sawn surface of the patella is apposed to a similar surface of the divided femur. In Gritti's method the femur is divided at a lower level, so that the cut surface is broader; it is often difficult to appose the patella resting on the anterior surface of femur; besides, there is a disproportion between the sawn surfaces of two bones. In Stokes' operation the femur is divided higher up so that the sawn surfaces of the bone can be more accurately apposed.

Amputations in the region of the knee-joint

Methods	Operation	Flaps	Line of bone-section	Advantages	Disadvantages
A. Stephen Smith's.	Disarticulation.	Lateral.	Between semi-lunar cartilages (menisci) and head of tibia; no bone-section.	(1) Scar in inter-condyloid space where no pressure. (2) Semi-lunar cartilages (menisci) act as cushions. (3) Flaps form a good covering. (4) Quick operation. (5) Less shock. (6) Broad-ended stump. (7) Useful for labouring classes.	(1) False joint of artificial limb at a lower level. (2) Unsuitable from an aesthetic point of view.
B. Carden's	Transcondyloid amputation.	Long anterior, short posterior.	Transverse trans-condyloid with removal of patella.	(1) Suitable for artificial limbs. (2) Broader base than Stokes. (3) Posterior scar.	(1) Flap liable to slough due to bad vascular supply. (2) Patella is not utilized for stump.
C. Lister's modification of Carden's.	Do.	Modified circular.	Oblique transcondyloid; removal of patella.	(1) Muscles made to cover the stump. (2) Normal obliquity of condyles maintained. (3) Scar anteriorly and not over stump.	Patella is not utilized.
D. Gritti's	Supracondyloid.	Long anterior, short posterior.	Transcondyloid plane; articular surfaces of patella removed and fixed to femoral stump.	(1) Broad base of stump. (2) Patella utilized. (3) Scar posteriorly and not over stump.	(1) Defective apposition of patella and femur. (2) Patella may rest on anterior surface of femur. (3) Defective blood supply of anterior flap.
E. Stokes'	Do.	Do.	Supracondyloid plane, and articular surface of patella removed and fixed to femoral stump.	Better apposition of patella and femur.	Narrow base of stump.

THE THIGH

GENERAL ANATOMICAL CONSIDERATIONS

The portions of femur which can be palpated are the greater trochanter, the two condyles and tuberosities (epicondyles) and the adductor tubercle at the upper part of the medial condyle. The shaft of the femur which is superficial only in its lower third between the vastus externus (vastus lateralis) and the biceps.

The head of the femur is just below and a little lateral to the mid-point of the inguinal ligament.

The medullary canal is only present in the middle two-fourths of the shaft of femur.

The skin of the thigh is thick in front and on the lateral aspect, soft and thin medially; it is non-adherent except at the inter-muscular septa. The fascia underlying the skin is dense.

AMPUTATIONS OF THE THIGH

Amputations through the thigh should be performed as near its lower-third as possible, because the longer the stump the better is the leverage for an artificial limb and it is thus better suited for it; besides, being further removed from the trunk, it gives less shock to the patient.

Most of the muscles of the femoral region are attached to the femur, the exception being the semitendinosus, semimembranosus, sartorius, gracilis and to some extent the triceps; the muscles after division therefore retract unequally. This is the reason why circular amputations or its modifications are not suitable for the thigh; the muscles on its inner and posterior aspects retracting considerably more there is the risk of a conical stump. The operation of choice, therefore, is amputation by antero-posterior flaps, the anterior flap being the larger of the two. The femoral artery should, as far as possible, be left in the small posterior flap, in order to avoid its being twisted round the end of the bone.

The anterior flap would, with advantage, be made an antero-external (antero-lateral) flap, and the posterior, postero-internal (postero-medial). This is done in order to leave the inner (medial) vertical limb for the incision outside the line of the artery and avoid its accidental splitting, or leaving the artery too close to the margin of a flap. The length of the anterior flap should exceed the antero-posterior diameter of the limb at the line of bone-section; this is necessary to allow for the retraction of the skin and muscles. The only excuse for a circular amputation is quickness in old and debilitated persons or in emergent cases. The femur should be sawn at right angles and with care at the *linea aspera* to avoid splintering. The ordinary circularly applied tourniquet should do for the middle and lower thirds; for higher amputations it should

be applied in a spica fashion round the groin and secured by a loop bandage.

AMPUTATION OF THE THIGH BY LARGE ANTERIOR FLAP

POSITION

The limb is pulled down so that the body rests by its buttocks on the edge of the table. The other leg is kept out of the way. The operator stands on the right side of the limb in case of either leg; one assistant supports the leg behind him and another stands in front of him to retract flaps.

OPERATION

A large U-shaped flap is marked out on the anterior surface of the limb. The length of the flap should be $1\frac{1}{2}$ the diameter of the thigh at the future bone-section and its breadth a little more than half the circumference. The lower end of this incision could, if necessary, extend down over the patella. Commence the incision at the inner or outer side of the thigh at the level of the bone-section, and carry it vertically down for a distance, equal in length to the antero-posterior diameter and a half of the thigh, then horizontally across the front of the thigh to a corresponding point on the opposite side. For the other vertical limb of the U, carry the incision upwards from this point until the two limbs are of equal length. The whole of this incision is skin and fascia deep. Now, mark out the posterior flap by carrying the knife across the back of the limb, cutting through the skin and fascia a little below the upper limits of the other incision, so that the length of this flap is one-third of the anterior flap (*see Fig. 78*).

Now, raise the anterior flap. Begin by dissecting up the skin and fascia alone for about an inch all round the incision. The knife then cuts deeper and deeper from without inwards and upwards through the muscles in a sloping manner till, by the time it reaches the base of this flap it has cut through all the muscles and reached the bone. The base of this flap which is bevelled at the distal free margin corresponds with the level for the future line of bone-section. The posterior bevelled flap is fashioned similarly by cutting the muscles in a sloping manner. Raise sufficient periosteal flap to cover the divided bone. One assistant now retracts the flaps by a double-tailed gauze retractor or metal retractors, and the other holds the leg steadily in the horizontal position, and the femur is sawn through. Some surgeons recommend cutting the posterior flap by transfixion, but the method described above is one of greater precision.

Comment :—(1) The main vessels to be ligatured are in the posterior flap in low amputations, and in the anterior flap at or above the middle of the thigh ; e.g., in amputations above the middle of the thigh, in the anterior flap will be cut, the femoral, profunda femoris, descending branches of the external (lateral) circumflex and muscular branches ; in the posterior flap, perforating branches. In amputations below the middle, in the anterior flap will be cut the descending branches of the external (lateral) circumflex and muscular branches and in the posterior flap, femoral anastomotica magna (A. genu suprema) and perforating branches. (2) The question of avoiding the splitting of the vessels by making the flaps antero-external and postero-internal has been discussed. (3) The anterior flap drops over the bone stump and is taken round it to be sutured to the posterior flap, the suture being of a musculo-periosteal type. The muscles, especially the heavy muscles, should be quilted with deep sutures. (4) The nerves should be cut short, particularly the sciatic, and their ends treated in one of the ways described.

THE HIP-JOINT

GENERAL ANATOMICAL CONSIDERATIONS

The pubic spine (tubercle) is 2" medial to the antero-medial margin of the acetabulum and is nearly on a level with the upper border of the great trochanter which latter is on a level with the centre of the joint.

The femoral artery rests on the psoas magnus (psoas major) muscle which separates it from the capsule of the joint.

AMPUTATION THROUGH THE HIP-JOINT BY DISARTICULATION

Disarticulation of the hip is attended with much shock, and should not be performed unless the measure is justified by the urgency of its indications. Several methods have been devised by surgeons in order to perform this operation expeditiously and with the least amount of shock. Some of these methods are :—

1. External racket incision—Furieux Jordan's.
2. Anterior racket incision.
3. Antero-posterior flaps.
4. Lateral flaps.
5. Flaps by transfixion.

FURNEAUX JORDAN'S OPERATION

External Racket Method

POSITION

The pelvis rests on the extreme lower edge of the table with both limbs projecting beyond it. The sound limb is held out of the way by an assistant. The patient is turned over on the sound side with the postero-external aspect of the hip for operation fully exposed to view. The body is then brought to a Trendelenburg position. The operator stands at the outer aspect of the limb, facing the patient. One assistant manipulates the leg, another attends to the rubber tourniquet and third stands facing the operator.

OPERATION

The operation can be described in the following stages:—

1. The limb is adducted, slightly flexed, and rotated inwards. An incision is commenced two inches above the great trochanter, carried vertically down along the outer side of the thigh for about six inches. It divides skin and superficial fascia. At its lower end, the incision is carried inwards and outwards in order to form a large inverted Y (*see Fig. 78*).

2. The two limbs of the inverted Y are then joined by an oblique skin- and fascia-deep incision made after everting the thigh. The thigh may be rotated outwards and inwards as necessary.

3. The thigh is now adducted, rotated in, and flexed. The vertical incision is deepened down to the bone for its whole extent. The muscles attached to the greater trochanter are then divided close to the bone. The trochanter is cleared, and in doing so, the gluteus medius and the obturator externus are cut. Extreme adduction and internal rotation of the limb will be helpful, and the excision knife will also be useful for this stage of the operation. The upper part of the shaft of the femur is cleared for the full extent of the vertical incision. Other soft tissues are also divided, viz., insertions of the gluteus maximus, quadratus femoris, psoas, iliacus, pectineus, adductor longus, and superior portion of quadriceps extensor (femoris). The assistant reflects the soft tissues and thus exposes the bone.

4. Disarticulation of the bone is now commenced. The capsule is divided at the upper and posterior part while the limb is in extreme adduction, and anterior part of capsule is divided when the limb is somewhat flexed. The limb is now brought to a position of complete outward rotation. The joint is opened and the teres ligament (lig. teres femoris) divided.

5. The muscles on the inner side of the limb are cut by a short and circular sweep of the knife the vessels being secured with forceps.

DISARTICULATION OF THE HIP-JOINT

BY ANTERIOR RACKET INCISION

The handle of the racket, i.e. the vertical limb is made on a line with the femoral vessels; these latter are exposed and ligatured, the remaining portion of the racket is made and the operation completed as in the previous operation.

AMPUTATION BY TRANSFIXION

A long transfixion knife is introduced between the trochanter and iliac crest and plunged through all the soft tissues of the thigh emerging on the inner aspect just below the level of the scrotum. The knife passes on a plane between soft tissues and anterior surface of the femur behind the femoral vessels; it is then worked downwards with a sawing movement for about three inches and divides all the tissues from within outwards. Just before cutting the femoral vessels, the first assistant passes his fingers between the soft tissues and the bone, and controls these. The vessels are then secured, the flap raised, the joint opened and the head of the femur levered out. The blade of the knife is then passed behind the head of the bone and carried backwards through the soft tissues and skin, thus forming the posterior flap.

Comment :—1. The following vessels have to be secured. The external (lateral) and the internal (medial) circumflex, the sciatic or inferior gluteal artery, branches of the gluteal (superior gluteal), the femoral and profunda arteries, femoral and profunda veins. Control of hæmorrhage is an important step of this operation. Of the various methods adopted for it, the following are the more effective :— (i) A figure of eight elastic rubber tourniquet to compress the vessels. (ii) Passing skewers (Wyeth needles) in different directions through the soft tissues and applying an elastic tourniquet. (iii) A preliminary ligature of the femoral vessels. (iv) Compression of the common iliac per rectum by Davy's rectal lever. (v) Compression of the external or common iliac artery through abdominal incision. (vi) Compression of the abdominal aorta by abdominal tourniquet. (vii) By preliminary ligature of the large vessels. (viii) By Lynn Thomas' forceps tourniquet.

2. The operations can be performed in two stages with advantage. A modified circular subtrochanteric amputation by an external vertical incision joined to a circular incision round the limb may be performed and if the object can be attained, it is completed ; if not, then the vertical incision is extended upwards and the limb disarticulated.

3. Of the various methods of disarticulation, the external racket method has the following advantages :—(i) Hæmorrhage can be controlled by the elastic tourniquet. (ii) The vessels and the muscles are divided transversely. (iii) The gluteal and sciatic (superior and inferior gluteal) vessels are divided low and as such hæmorrhage from these is comparatively less. (iv) The approach to the femur is through the least vascular tissues. (v) The hip can be explored before disarticulation and therefore if after inspection an amputation is not considered necessary, excision can be performed. (vi) It gives a good stump. (vii) The ischium being well covered, the cicatrix is brought to the outside and a good drainage provided for. (viii) The transfixion method has the great advantage that it can be rapidly performed and was the operation of choice before the introduction of chloroform.

4. The muscles should be raised as subperiosteally as possible and they should be quilted as much as possible.

CHAPTER IX

OPERATIONS ON CARTILAGES

Operations on cartilages, in their nature and technique, correspond to similar operations on bones, e.g. chondrotomy and osteotomy, chondroplasty and osteoplasty.

Cartilage transplantation.—Though it is claimed that living cartilage cells reproduce, it is also admitted that perichondrium helps in the regeneration of parts which would otherwise degenerate; as a matter of fact it is known that very little disturbance with the nutrition of cartilage would disturb its growth. Cartilage grafts may be homoplastic or autoplastic. Costal cartilage is generally utilized.

Cartilage grafts are used for repairing defects such as in the nose or larynx and for depressed areas; often a mixed bone and cartilage transplant is used. Cartilage is also used in the same way as fat to interpose between articular surfaces in cases of ankylosis of joints with destruction of articular cartilages. Cartilage is also used to cover osseous stumps in some amputations.

RESECTION AND EXCISION OF CARTILAGES

Chondroplastic resection of nasal cartilages for the exposure of the nares and naso-pharynx (Rouge)

The upper lip is raised and the cartilaginous portion of the nose and the septum is reflected by a transverse incision in the mucous membrane of the lip at its reflection from one bicuspid to another. After obtaining a satisfactory view of the interior and dealing with the trouble if any, the reflected portion is apposed to the maxilla by sutures.

EXCISION OF SEMILUNAR CARTILAGE OF THE KNEE-JOINT

The internal semilunar cartilage (meniscus) is usually displaced. It is generally caused by indirect violence; if with the knee in a flexed position, the thigh is suddenly rotated inwards or the leg rotated outwards, the meniscus gets displaced and the knee gets 'locked' in a flexed position. Next to this, locking of the joint may take place due to trivial injuries. Other injuries to the knee may result in laceration and disorganization of the cartilage.

INDICATIONS FOR OPERATION

1. Operative interference is not really indicated after the first displacement; manipulative and postural treatment by fixation with an adjustable knee-cap may be sufficient. 2. Recurrent displacements causing pain and effusion. 3. When the patient is disabled from the ordinary pursuits of life particularly from games and exercise for his health. 4. When it interferes with his occupation.

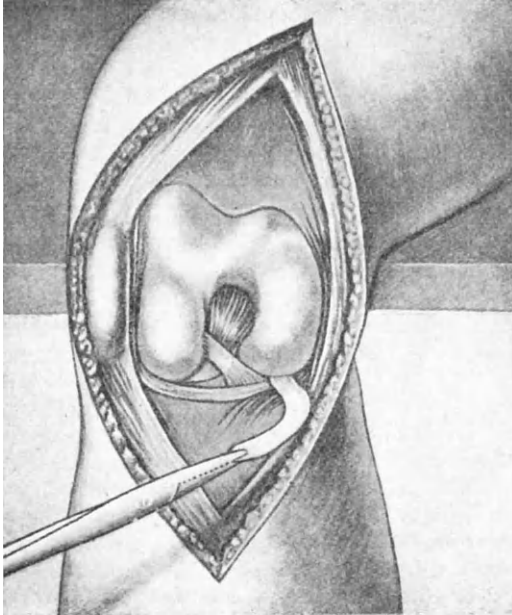


FIG. 100.

ARTHROTOMY OF THE KNEE-JOINT:—The patella displaced outwards; internal cartilage being removed. (After Timbrell Fisher.)

REPRODUCED FROM TURNER'S OPERATIVE SURGERY
By the Courtesy of CASSELL & CO., LTD.

OPERATION

Position of the patient.—The patient lies on his back with knee slightly bent on sand-bags. Apply a tourniquet. Commence an antero-lateral incision from a point on a level with tibial tuberosity and an inch internal to the ligamentum patellæ and carry it upwards for about $2\frac{1}{2}$ inches with the tibio-fibular interval as the mid-point of the incision. If at a later stage the knee-joint has to be explored, this incision can be prolonged upwards and downwards

and the patella displaced internally. Open capsule, retract its edges and let the little fluid if any escape ; a good inspection of the meniscus can be made now. The following abnormalities may be found : The anterior extremity detached and curled in ; the anterior and posterior ends being attached, the intervening portion lying in the inter-condyloid notch ; the whole of the cartilage abnormally moveable antero-posteriorly ; rarely, on further flexing the knee and drawing on the cartilage, a posterior detachment may be seen.

Secure the cartilage by a pair of forceps of the Mayo-Oschner type and detach it, commencing from its anterior aspect and proceeding backwards (*see Fig. 100*). This is facilitated by the assistant flexing the knee further and further. Remove the whole cartilage and then the tourniquet ; render the wound dry. Extend knee, suture capsule with catgut and close wound. Keep knee in slightly flexed position.

Comment :—1. Other incisions such as an anterior transverse incision with a slight curve downwards and vertical splitting of the patella have been recommended. Even the closest approximation of the patella does not leave a satisfactorily smooth posterior surface for the femoral articular surface. Oblique antero-lateral incision is attended with risk to the internal lateral ligament. Do not injure this ligament at any stage of the operation ; it would weaken the joint. 2. Avoid irritation by unnecessary handling of the joint structures ; this would cause synovitis, effusion and fibrous adhesions. Perfect hæmostasis is necessary for the same reason. See that the wound is perfectly dry after the tourniquet is removed. 3. Make a close inspection of the joint, look for injuries to other structures such as the anterior crucial ligament, fracture or detachment of the tibial spine, tags of ligament, detached portions or loose bodies. 4. Early passive and active movements should be practised.

CHAPTER X

OPERATIONS ON BONES

The following operations are performed on bones :—

- I. Periosteotomy and Periosteorrhaphy.
- II. Osteotomy :—
 - A. Linear Osteotomy : (a) Subcutaneous method ; (b) Open method.
 - B. Cuneiform Osteotomy.
 - C. Special Osteotomies : (a) For correction of deformities ; (b) For osteitis and Osteomyelitis.
- III. Osteoclastis.
- IV. Sequestrotomy : sequestrectomy.
- V. Obliteration of bone cavities.
- VI. Operative Osteorrhaphy : Operative treatment of fractures.
 - A. For Recent Fractures.
 - B. For old fractures ; (a) delayed union ; (b) non-union ; (c) malunion ; long bones : shafts or proximal and distal ends ; short bones, e.g. patella, olecranon, etc.
 - C. For osteosynthesis.
 - D. For pseudarthrosis.
- VII. Excision or resection of bones.
- VIII. Bone transplantation.

EXCISION OF BONES

GENERAL REMARKS

Excision or removal of bones may be total, i.e. removal of the whole bone ; in the case of long bones it consists of its shaft and articular ends. It may also be partial, i.e. removal of a part of an irregular or flat bone or part of the shaft of a long bone.

Resection strictly means removal of the whole thickness of a bone, for instance a joint is excised by the resection of the articular ends of bones ; the terms have however come to be used more or less synonymously.

Osteoplastic resection signifies removal of a bone or a part of it together with the soft structures covering it in order to expose the deep-seated structures and then replacing the flap consisting of skin, muscles, periosteum, and bone.

Bones may be excised by the sub-periosteal method or the open method as in the case of joints. Every effort should be made

to raise the periosteum and preserve it whenever possible. In the young the periosteum is thick and can be easily peeled off the bone ; in the old and in cadavers it is thinner and more adherent ; in chronic inflammation of bones it can be easily detached but serves less useful purpose.

INDICATIONS

Partial or complete excision of bones have to be performed for the following conditions :—

1. Osteomyelitis, caries, and necrosis.
2. Extensive syphilitic or tuberculous diseases.
3. Actinomycosis and mycetoma of the bone.
4. Simple or compound fractures of a severe nature.
5. Some cases of deformity.
6. Neoplasms of bone.

EXCISION OF THE UPPER JAW

The superior maxillary bone (maxilla) of one side only, or the whole of the upper jaw may be removed.

INDICATIONS

(1) Tumours such as epulis, fibromata, sarcomata, carcinomata, odontomata (epithelial or follicular), dental cysts, chondromata, and osteomata. (2) Extensive destruction of bone due to necrosis and caries from antral disease, syphilitic disease, cancerum oris, etc.

POSITION

Dorsal or lateral position with the shoulder raised on sand-bags or blocks, the side to be operated on being uppermost. The operator stands on the right side in either case. One assistant stands opposite to him and another steadies the head.

INSTRUMENTS—Group VI.

The line of incision.—Commencing at the mid-line of the upper lip in the naso-labial groove upwards to the nostril, curving round the ala of the nose vertically up, along the side of the nose and the naso-facial groove to the inner canthus, then outwards in the line of the lower margin of the orbit to the outer canthus.

OPERATION

The operation can be described in five stages :—

1. Skin incision.
2. Raising the cheek-flap.

3. Separation of the nasal cartilages and division of the nasal bone, the orbital plate and the malar bone.

4. Division of the palate.

5. Extraction of the maxilla.

1. *The skin incision.*—The assistant compresses the lip on either side of the median line. Split the lip with the knife along its median line and carry the incision down to the bone upwards along the line of incision above described, to the inner canthus. Then carry it a little superficially along the lower margin of the orbit for the rest of the incision.

2. *Raising the cheek-flap.*—The flap thus marked out is raised from the bone and should contain all the soft structures down to the maxilla.

3. *Division of the bones, etc.*—Detach the nasal cartilages from the maxilla and with the help of a fine saw and a chisel divide the nasal process of the bone. Cut through the periosteum along the lower margin of the orbit and raise it with the origin of the inferior oblique muscle from the floor of the orbit. Divide as much of the orbital plate as necessary. With a pair of sharp bone-cutting forceps, commencing at the nasal process of the maxilla and ending at the spheno-maxillary (inferior orbital) fissure. Divide the malar bone obliquely from above downwards and outwards about the middle of the bone so that it extends into the spheno-maxillary fissure (*Fig. 101*) by a gigli saw passed through this fissure and zygomatic fossa.

4. *Division of the palate.*—Open the mouth wide by a gag applied on the opposite side. Extract the upper central incisor tooth on the side of the jaw to be removed. Cut through the muco-periosteal covering of the hard palate in the median line. Make a muco-periosteal incision by introducing the knife through the nostril on the floor of the nose close to the septum.

Make a similar muco-periosteal incision in the medial line of the palate along the intermaxillary and interpalatal sutures from the alveolar process to the nasal spine dividing the muco-periosteal covering of the hard palate.

Make a transverse incision through the mouth at the junction of the soft and hard palates, separating them. Saw through the hard palate as much in the median line as possible, by introducing a narrow bladed saw of the key-hole pattern through the nostril in the same line as the muco-periosteal incision.

5. *Extraction of the maxilla.*—Take a pair of lion forceps with broad blades. Grasp the maxilla by applying one of the blades to the orbital plate and the other to the alveolus. Wrench the bone out by separating a few other attachments, the chief among them being the one with the pterygoid process.

Comment :—(1) Hæmorrhage from the flap can to a great extent be controlled by pressure on the facial

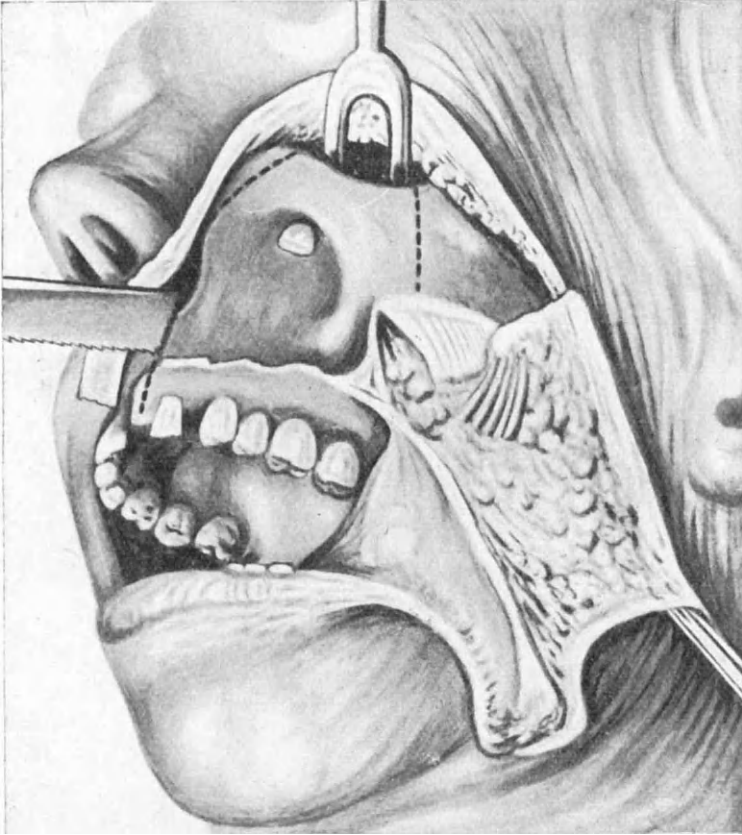


FIG. 101.
EXCISION OF THE UPPER JAW.

(external maxillary) artery; from the superior coronary (superior labial) arteries it is controlled by the assistant holding the lip on either side of the median line between the finger and the thumb. On the side of the nose and near the inner canthus the following vessels are cut: the angular artery and vein, the lateral nasal artery, artery to the nasal septum and the branches of the infra-orbital artery. While raising the cheek-flap the infra-orbital artery is divided and while sawing through the palate, the palatine arteries. (2) In raising the cheek-flap do not waste time in trying to save the periosteum. (3) Begin an incision below

at the lip and proceed upwards. If the incision is begun above, the oozing obscures the field of operation below. Extract the incisor tooth and divide the palate last, to avoid unnecessary hæmorrhage into the mouth. (4) Some surgeons recommend a preliminary tracheotomy but this is hardly necessary. (5) In stitching up the flap, appose accurately, keeping the muco-cutaneous margin in tact to prevent disfigurement.

EXCISION OF THE LOWER JAW

INDICATIONS

(1) Extensive caries, necrosis, osteomyelitis, syphilitic and tuberculous diseases. (2) Phosphorus necrosis. (3) Actinomycosis and mycetoma. (4) Neoplasms.

The mandible may have to be excised either for its whole extent (complete excision) or a portion of it (partial excision), which includes removal of wedge-shaped portions from the ramus or the condyles.

INSTRUMENTS—Group VI.

EXCISION OF ONE-HALF OF THE LOWER JAW

POSITION

The patient lies upon the back close to the edge of the table. The operator stands facing the patient on the side to be operated on. The shoulders are raised, the head is turned to the opposite side, one assistant stands facing the operator and another by his side.

OPERATION

This can be described in the following four stages :—

1. Expose the facial (external maxillary) artery, and divide it between two ligatures. Commence an incision just below the lower lip and carry it vertically downwards through all the soft tissues down to the bone. From the lower end of this carry a horizontal incision along or just below the inferior border of the jaw, and then vertically upwards along the posterior margin of the ascending ramus up to a point opposite the lobule of the ear.

Separate the muscles attached to the external surface of the mandible by periosteal elevators or rougines and reflect these with the skin upwards. The mental and masseteric vessels should be ligatured as they are divided at this stage. Divide the mucous membrane of the mouth, where it meets the alveolus and thus open the buccal cavity.

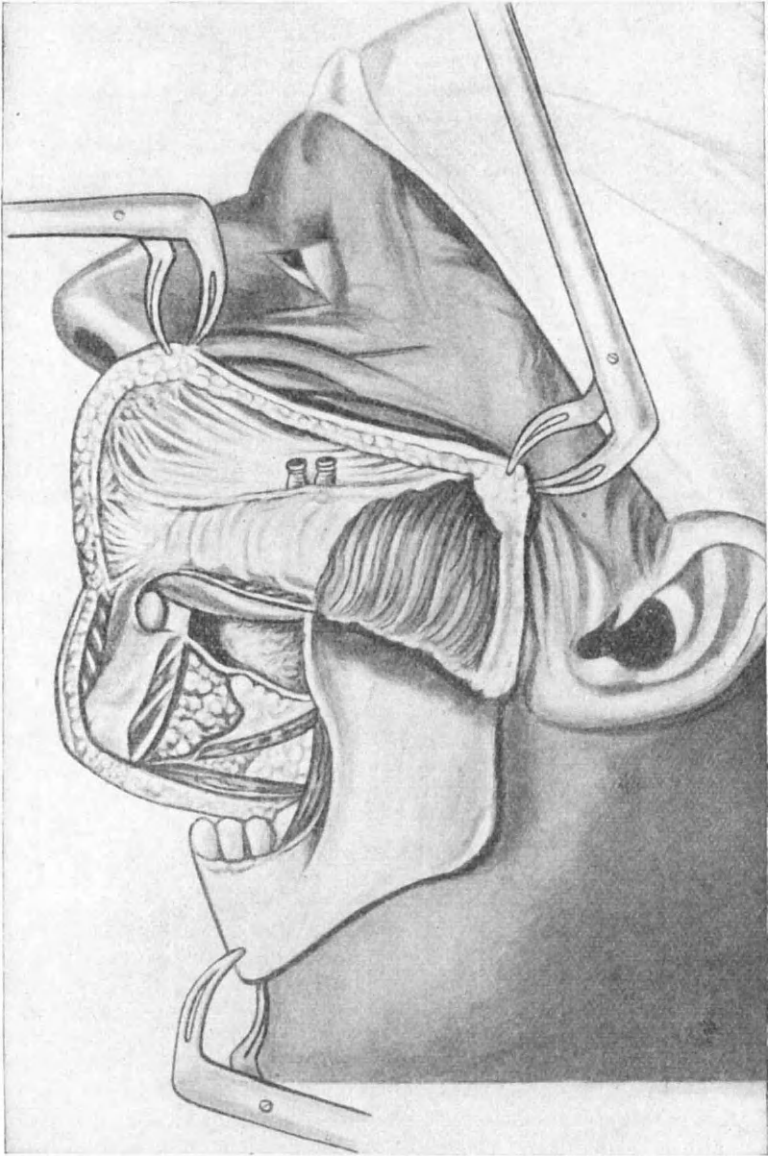


FIG. 102.

EXCISION OF THE LOWER JAW.

2. Remove one of the incisor teeth, preferably the lateral incisor and divide the jaw a little away from the symphysis, by means of a narrow bladed saw or Gigli's saw completing the section if necessary, with suitable bone-cutting forceps. Separate the attachments of geniohyoid, genio-hyoglossus (genio-glossus), and digastric muscles from the inner surface of the jaw.

3. Pull the cut end of the mandible outwards and separate the attachment of the mylo-hyoid muscle with a blunt pointed knife cutting close to the bone. Now raise the lower border of the mandible outwards and separate the internal pterygoid muscle from the bone. Secure the inferior dental (inferior alveolar) vessels and nerve and divide them.

4. Forcebly depress the anterior portion of the jaw, exposing the coronoid process and divide the tendon of the temporal muscle, with a suitable pair of scissors. Depress the jaw further bringing the condyle into view. Detach the external pterygoid muscle from it and divide it. Cut through the capsule and free the condyle. Cut through internal lateral (spheno-mandibular), stylo-maxillary (stylomandibular) and the pterygo-mandibular ligaments if they have not already been separated. Secure all bleeding points and unite the wound by silkworm gut sutures. Pack the anterior part of the wound and allow it to drain posteriorly (*Fig. 102*).

Comment :—(1) Throughout the operation the knife or the periosteal elevator should be kept close to the bone. (2) During the third stage of the operation avoid injury to the sub-maxillary and sub-lingual glands. (3) Do not twist or rotate the jaw but only depress it during the latter part of the operation, otherwise the internal maxillary artery may be injured by the neck of the jaw.

RESECTION OF RIBS

INDICATIONS

1. Caries and necrosis of ribs.
2. Some cases of empyema.
3. Fracture of a rib (simple or compound) with signs of injury of internal organs, e.g. the lung or pleura.
4. Wounds of intercostal vessels.
5. New growths either secondary or primary or extension from the adjacent tissues or organs.
6. Some cases of abscesses in the liver.
7. Thoracoplasty or excision of several ribs to effect a permanent and massive collapse of the lung, e.g., in tuberculosis.

POSITION

Place the patient at the edge of the table, supported on a sand-bag, in such a way that he lies partly on the sound side. The hand is held away from the side by an assistant.

INSTRUMENTS—Group VII.

OPERATION

Select the rib and steady the skin over it with the fingers and thumb of the left hand. With a strong scalpel or excision knife make a longitudinal incision about three inches long, along the middle line of the rib down to the bone. Another touch of the knife may be necessary to divide the periosteum. Elevate the periosteum by an elevator from the superficial aspect of the rib towards the two flaps, above and below; with a curved periosteal elevator raise the periosteum from the upper or lower margins of the rib keeping rigidly close to the bone so as not to injure the intercostal vessels and nerve in the groove along the lower border of the rib. Then insinuate a curved elevator between the periosteum and the deep aspect of the rib, separating it from the bone, taking great care not to injure the pleura or lung. The rib is now free of all soft tissues. Pass a gauze retractor behind the rib, protecting the soft tissues. Now the rib can be cut in one of the following ways: (i) make two vertical impressions on the rib by means of small metacarpal or Hey's saw on the lines up to which the periosteum has been raised. Remove a portion of the rib between these two impressions by cutting with the rib-shear; (ii) pass the wire of the Gigli's saw round the rib and cut through the bone on the intended lines; (iii) some use rib-shear directly, without making a previous impression with the saw, which may, however, crush or splinter the rib (*see Fig. 103*).

Comment:—(1) Make the incision along the middle line of the rib, i.e. midway between the upper and lower borders. (2) While reflecting the periosteum, avoid injuring the intercostal vessels and nerve, the pleura and the lung. (3) Do not leave any portion of the rib denuded of periosteum but let a periosteal flap cover it otherwise it would undergo necrosis. (4) Use a Hey's saw or a metacarpal saw. Gigli's saw will also be handy but must not be used without a protector. (5) Ordinarily, it may be necessary to resect one-half to two inches of the rib, but under exceptional circumstances more of one rib or even two or more ribs may have to be excised. (6) For empyema an effective drainage can be obtained by




FIG. 103.

RESECTION OF RIBS.

the resection of the ninth rib between the scapular and posterior axillary lines. (7) For accidental injury to the intercostal vessels they can be compressed between the finger and the deep surface of the rib and a ligature passed round the rib including the vessels.

EXCISION OF THE ASTRAGALUS (Talus)

INDICATIONS

1. Tubercular disease confined to the bone.
2. Some cases of talipes and flat-foot.
3. Old unreduced dislocations.

OPERATION

(a) *Incision*.—Two incisions are made : (i) external incision two inches long from a point above and front of the external malleolus downwards to the middle of the dorsum of the cuboid bone ; (ii) internal incision two inches long from below the tip of the internal malleolus curving upwards and forwards to a point in front of the tibia just above the internal malleolus. (b) Raise two small flaps, deepen the incision to the bone ; invert and extend the foot strongly to stretch the external ligaments. (c) Divide the ligaments which bind the astragalus (talus) to the tibia and fibula, scaphoid (navicular) and os calcis (calcaneus). Turn to the inner side and divide the ligaments on this aspect including the astragalocalcaneal (talo-calcaneal) ligaments. Now expose the upper articular extremity of the astragalus (talus) and protrude it through the outer incision by inverting and extending the foot. (d) Deliver the astragalus through this wound by grasping it with lion forceps and pulling it in a vertical direction.

Comment :—No muscles have to be cut as there is no muscular attachment to the astragalus.

OSTEOTOMY

By osteotomy is meant a simple division of bone. In linear osteotomy the bone is divided in its continuity ; generally the division is made along a single transverse line. In cuneiform osteotomy a wedge-shaped piece is removed from the bone.

INDICATIONS

1. For correction of deformities such as due to (a) rickets, e.g. genu valgum and genu varum, (b) congenital causes, e.g. coxa vara, and (c) other causes, e.g. talipes varus.
2. For correction of a deformity due to faulty ankylosis.
3. For rectifying malunion after a fracture.

INSTRUMENTS—Group V.

OPERATION

Osteotomy can be performed in two ways.

Subcutaneous Method

Make a clean cut down to the bone with a stout knife, such as an excision knife parallel to the long axis of the shaft. Clear the bone of all soft tissues by a raspatory, pass the saw or osteotome flat-wise along this opening. Now turn these instruments so that the cutting edge is at right angles to the shaft, and divide the bone. The bone can be divided entirely for its whole thickness or the major portion of the bone is divided and then fractured.

Open Method

Make an incision sufficiently long to expose the bone and then divide it as in the previous operation. It may sometimes require some form of fixation apparatus to keep the ends of the divided bone in position.

Comment.:—What has been called the subcutaneous osteotomy is hardly a subcutaneous operation. While performing this operation due regard should be made of the important structures, such as vessels or nerves in the immediate vicinity of the bone. It is much safer to make a wound large enough to expose the bones and other structures; besides, in these days of aseptic surgery smallness of the wound is not an essential point.

The bone can be divided by linear or cuneiform osteotomy either in the subcutaneous or open method.

Linear Osteotomy

Place the limb in a suitable position steadying it by means of sand-bags. Make an incision as has been described but so place it that it avoids important structures and allows the easiest and nearest access to the bone. Do not withdraw the knife but use it as a guide for the osteotome or the saw. Hold the osteotome by the left hand and drive it through the bone by steady strokes of the mallet. Hold the chisel in such a way that the cutting edge is directed towards you and the division of the bone is commenced from a part farthest from you. An approximate idea of the thickness of the bone should be made and the extent of bone-cut should be gauged by the graduations on the osteotome (*Fig. 104*).

Cuneiform Osteotomy

Determine the exact shape, size, and position of the wedge to be removed to correct the deformity. The incision in the soft tissues must be comparatively larger. Expose the bone and raise the

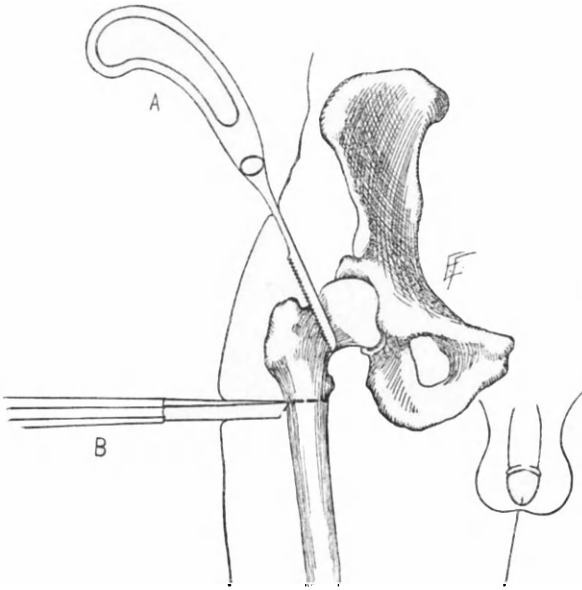


FIG. 104.

LINEAR OSTEOTOMY.

REPRODUCED FROM BICKHAM'S OPERATIVE SURGERY.

periosteum with the elevator. In dividing the bone use an osteotome, a chisel or a saw, and while using the former two instruments, hold them in such a way that the bevelled edge is towards the portion to be removed. Small wedges can be removed in one piece but larger wedges in sections. Let the periosteal flaps come together and close the wound (*Fig. 105*).

SUPRA-CONDYLAR OSTEOTOMY (Macewen)

INDICATIONS

Genu valgum of a severe type in which the separation between the malleoli is more than three inches and a half.

POSITION

Abduct and rotate the thigh outwards, flex the knee to an angle of about 140° and let it rest on its outer side on a firm sand-bag, so that the inner aspect of the limb is exposed to the operator. The operator stands on the outer side of the limb and the assistant stands facing him.

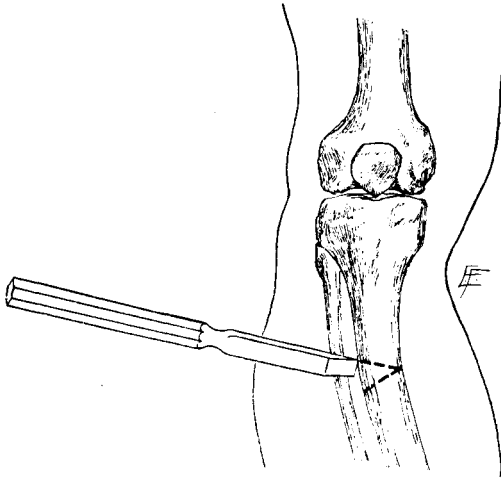


FIG. 105.

CUNEIFORM OSTEOTOMY.

REPRODUCED FROM BICKHAM'S OPERATIVE SURGERY
By the Courtesy of THE W. B. SAUNDERS CO.

OPERATION

Draw a line horizontally across thigh, a finger's breadth above the upper limit of the external (lateral) condyle and another line vertically a finger's breadth in front of adductor tubercle to meet the former line. Plunge the knife at this junction down to the bone and introduce the osteotome flat-wise guided by the blade of the knife. Now withdraw the knife and hold the osteotome firmly against the bone and divide the bone by light strokes of the hammer or mallet three quarters of its thickness, and then fracture it by bending the limb sharply inwards. Then bring the limb to the fully corrected position. Close the wound and fix the limb by splints in corrected position.

SEQUESTROTOMY, SEQUESTRECTOMY

INDICATIONS

1. For the removal of a sequestrum resulting from acute infective osteomyelitis.
2. For the removal of sequestrum caused by traumatic septic necrosis, e.g., after a compound fracture.
3. For removing sequestra caused by specific infection such as (a) syphilitic, (b) tuberculous, etc.
4. In quiet necrosis.

INSTRUMENTS—Group V.

OPERATION

I. Removal of sequestrum resulting from acute infective osteomyelitis

Consider the following points:—(1) The period at which to operate. Early intervention is indicated because (a) the wound heals earlier and the patient will not need prolonged stay in bed and a long course of dressing; (b) the longer one waits the less will be prospects of regeneration of the new bone to take the place of the sequestrum. (2) The periosteum should be preserved as much as possible as this is the only source of new bone formation. (3) The period and the extent of demarcation between the living and the dead bone should be determined by a skiagram.

Make an incision down to the bone in order to expose the whole of the affected part. Reflect the divided periosteum with rougine or periosteum elevator but avoid injuring the periosteum. This exposes the necrosed bone; remove its whole extent even if it be the whole shaft of the bone. Bring the reflected periosteum together if necessary, with sutures. Bring together the soft tissues and stitch up the skin leaving enough room for drainage. Immobilize the limb by means of splints or plaster of Paris bandage.

II. Removal of sequestrum in chronic cases

Make one or more longitudinal incisions including in them the opening on any sinuses in the skin. Reflect the periosteum exposing one or more of the cloacæ and cut through the involucrem with chisels, gouges and bone nippers between the cloacæ working upwards and downwards; the sequestrum will be found more or less loose in the antrum. If it is a small sequestrum it can be removed in one piece, but if it is a large piece and it cannot be removed entire without damaging the involucrem, divide and remove it piecemeal; scrape away unhealthy granulation tissue from the walls of the antrum, purify it and pack it. Now attend to the skin, snip away with scissor any unhealthy margins of the skin as will be found at the opening of the sinus and bring the edges of the skin together by interrupted sutures leaving opening for efficient drainage.

Comment:—It is often advisable to perform sequestrotomy in two stages, the first stage consisting of incision and drainage, the second stage being the actual sequestrotomy after an interval during which the septic process has been brought under control.

CHAPTER XI

OPERATIONS OF FRACTURES

Two different views are held regarding the treatment of fractures of bones. According to one school, all fractures simple and compound should be treated by open operation but in view of the lowered resistance and vitality of patients in the tropics we generally limit operative interference to such conditions as are mentioned below :—

INDICATIONS

1. Certain fractures which cannot be treated otherwise than by an open operation such as fractures of the patella and olecranon in which due to muscular action, there is generally a considerable amount of distraction.

2. Some cases of oblique fractures of the bones of the leg and forearm where first of all apposition is difficult to bring about and secondly cross-union and malunion are very common.

3. Cases in which deformity cannot be reduced by any other means.

4. Fractures in the neighbourhood of joints.

5. Fractures complicated with dislocations.

6. Fractures in which there is interposition of soft tissues between the fractured ends.

7. Cases of multiple fractures.

8. In some cases of comminuted fractures.

9. Compound fractures in which there is sepsis due to free communication between the fracture and the external wound.

10. In cases of long-standing fractures with malunion, delayed union or non-union.

OPERATION

The proximal and distal ends of fracture can be brought together by various materials : (a) absorbable sutures, e.g. catgut ; (b) unabsorbable sutures, e.g. silk, silkworm gut, wire ; (c) nails, screws, and pegs of metal or ivory ; (d) metal plates and collars, e.g. Lane's plates.

SUTURING THE PATELLA

Fragments of fractured patella can be apposed by various methods.

1. Barker's fixation by subcutaneous method.—The suture is passed through the skin, behind the patella (through the

knee-joint) and brought out through the skin again and then tied (*Fig. 106*). This operation is quite out of date.

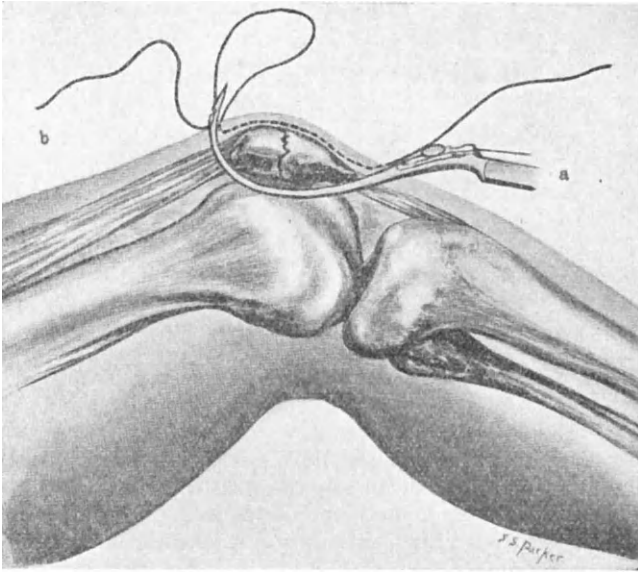


FIG. 106.

BARKER'S METHOD OF SUTURING FRACTURED PATELLA.

REPRODUCED FROM BICKHAM'S OPERATIVE SURGERY
By the Courtesy of THE W. B. SAUNDERS CO.

2. Silk suture (Stimson's method).—The patella is exposed by incision and sutures are passed transversely through the ligamentum patellæ below, carried upwards and passed transversely again through the quadriceps extensor and the ends tied (*Fig. 107*).

3. Suture of the capsule (Valas's method).—The patella is exposed and several blanket sutures are passed through the capsule and tied off tight.

4. Suturing of the patella by open method.—All fractures of the patella with the exception of stellate and vertical fractures should be sutured for the following reasons:—

(i) In transverse fracture there is much distraction of the fragments and their coaptation is impossible.

(ii) Unless the fragments are united by suture, fibrous union is the rule.

(iii) The lower fragment is generally tilted in such a way that apposition of the fractured surfaces is difficult or impossible without suturing.

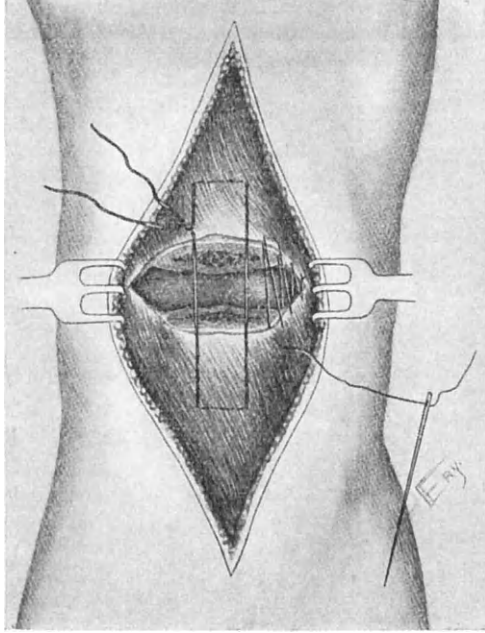


FIG. 107.

STIMSON'S METHOD OF SUTURING FRACTURED PATELLA.

REPRODUCED FROM *BICKHAM'S OPERATIVE SURGERY*
By the Courtesy of THE W. B. SAUNDERS CO.

(iv) The capsule or periosteum is generally torn at a lower level than the line of fracture and as such its free margin hangs as a fringe from the upper fragment, interposing between the fractured surfaces.

(v) Fracture of the patella is generally associated with rupture of the lateral expansions of the quadriceps extensor tendon.

(vi) It being an intra-articular fracture there is much effusion and collection of blood clot in the joint and between the fragments.

(vii) Suturing the patella facilitates early union and passive movement can be commenced earlier and ankylosis is rare.

INSTRUMENTS—Group IV.

POSITION

The patient lies on his back with the affected limb near the edge of the table, the operator stands facing it and the chief assistant stands opposite to him : another assistant stands at the foot of the

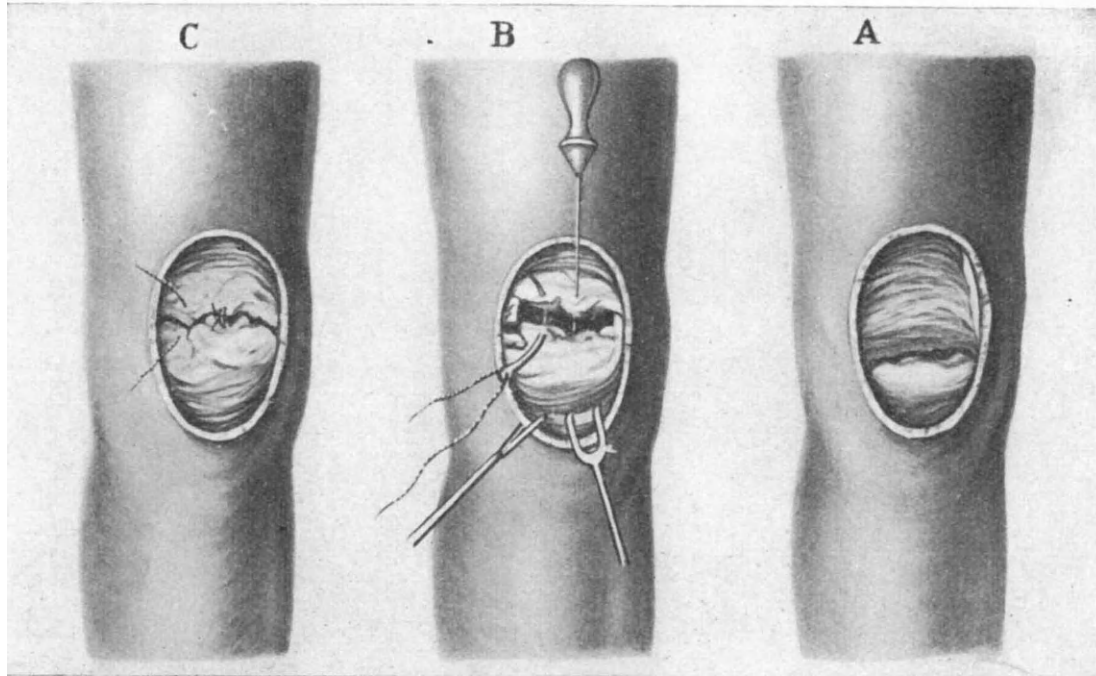


FIG. 108.
SUTURING THE FRACTURED PATELLA.

table supporting the leg, in order to flex and extend the limb as required.

OPERATION

Different operations have been recommended but Lord Lister's classical method will be described here.

Incision.—A horse-shoe shaped or semi-lunar incision is commenced at a point a little lower than the line of fracture, carried upwards so that its convex upper limit lies a little above the patella and then downwards to a point corresponding to the commencement of the incision. It is so placed that the vertical parts of the incision are about three-fourths of an inch away from the outer and inner margins respectively of the patella.

The flap.—Turn down the skin-flap by light touches of the knife. This opens the prepatellar bursa, exposes the fracture and the torn capsule (*Fig. 108*).

Wash out all blood clot and cut away any soft tissue interposed between the fragments. Freshen the fractured surfaces by scraping away any fibrous tissue, clots, etc., that may have formed especially in old-standing fractures.

Suturing the patella.—Make a small puncture through the soft tissues down to the bone on the upper fragment about half an inch above the broken margin. Introduce a bone drill through this puncture in such a direction that it emerges from the fractured surface just in front of the articular cartilage. Pass the suturing material, silver wire, silkworm gut, silk or catgut along the groove of the drill; this can also be conducted by means of a hole in the drill or by a needle passed along the track left on withdrawing the drill. The lower fragment is drilled in a similar manner taking care that the hole is on a corresponding point and as near the apex as possible. The free end of the suture emerging from the fractured surface of the upper fragment is now introduced through the same surface of the lower fragment and taken out through its anterior surface. If there are indications for further strengthening the union, a second suture may be applied in a similar way. The limb is now over-extended and the fragments brought together by manipulating from above and below.

It is then tied by twisting or knotting and then buried into the anterior surface of the bone. If there are more than two fragments, the lower fragment being split into two, these can be brought together by separate sutures.

The capsular ligament and the lateral expansion.—It is important to bring together the ruptured capsular ligament and the lateral expansion of the quadriceps extensor by a few catgut or silk sutures. Close the wound without drainage.

CHAPTER XII

OPERATIONS ON JOINTS

General Considerations

Joints are particularly susceptible to infection. In operation on joints, therefore, meticulous asepsis is essential. Mechanical injury to the tissues in and around the joint must also be the minimum.

Complete and prolonged rest to the joint-wound combat infective processes and also hasten repair. On the other hand prolonged immobilization brings about shrinkage of the capsule, intra-articular and periarticular adhesions, degeneration of articular cartilage, fibrous and bony ankyloses, and muscular atrophy. To prevent these, early movement of the joint is essential. Thus there is a conflict in the methods of treatment after operations on joints. In practice nowadays early movements are begun after it is evident that no virulent sepsis is present in the joint.

Operations on the joints are as follows:—Puncture, irrigation, simple drainage, wide exposure of the joint, resection, artificial production of a fixed joint, artificial mobilization of a fixed joint and finally disarticulations.

Paracentesis.—This is done either for diagnostic or therapeutic purposes or for both.

Irrigation.—After puncture the capsule may be irrigated with a suitable antiseptic solution through a cannula.

Drainage.—In severe infections, continuous drainage is demanded. Rubber tissue is generally used. The drains should not project into the joint cavity itself but they should merely hold apart the soft tissues between the articular capsule and the surface. Glass drains are seldom used.

Arthrotomy.—The joint is opened either for exploration or for removing foreign bodies or loose bodies in the joint, circumscribed portions of capsule which are injured or diseased or diseased portions of cartilage. The frequent indications are suppurative arthritis and septic compound fractures involving the joint.

Arthrectomy.—In this operation the entire joint or the articular ends of the bones and the capsule are removed.

Arthrodesis or artificial production of ankylosis is indicated when the muscles controlling a joint are deficient due to development of a flail joint, tubercular arthritis, etc. The limb is thus rendered more useful (*Fig. 109*).

Arthroplasty or operative mobilization of a joint is attempted when corrective procedures have failed after prolonged trial or when,

because of bony ankylosis, there is no possibility of success with them.

Disarticulation—is the removal of an extremity or of a portion of it at a joint.

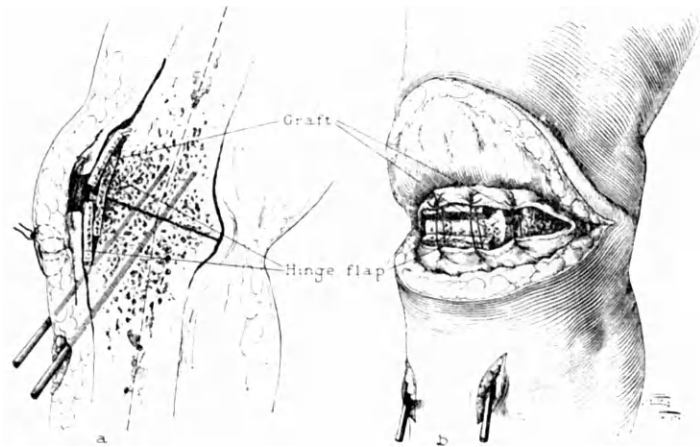


FIG. 109.

ARTHRODESIS.—Surfaces coapted, wire nails *in situ* and bone graft in position.

REPRODUCED FROM 'AMERICAN JOURNAL OF SURGERY'.

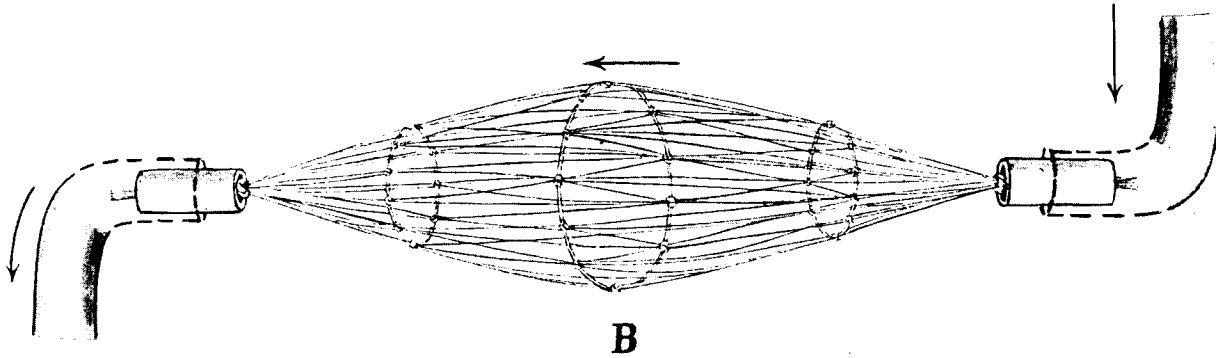
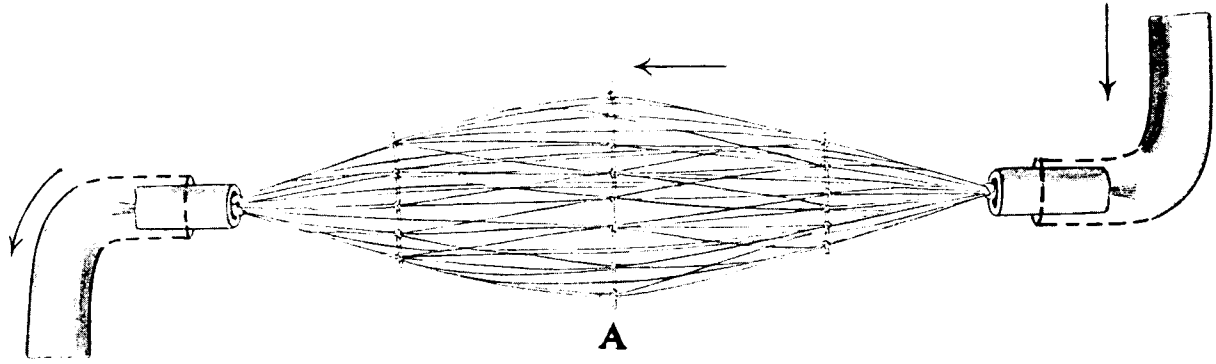
ARTHROTOMY

INDICATIONS

(*Vide supra*)

OPERATION

One or more incisions should be made to ensure free drainage. Scrape away unhealthy granulations. Fix the limb in sterilizable interrupted splint to facilitate dressing in a position which allows the greatest space to the joint. The space can be packed, treated by continuous irrigation by Carrel-Dakin method or the author's modification by continuous capillary drainage (*see Figs. 110 and 111*), in which strands of silk-worm gut are placed in the affected parts either arranged in the form of a spindle (B) or a flat band (A). The irrigating fluid runs in at one end and flows out at the other. The silk-worm gut effectively drains the tissues by capillary action.



FIGS. 110 & 111.

ARTHROTOMY OF THE KNEE-JOINT

INDICATIONS

The knee-joint may require opening for : (i) drainage, (ii) exploration, and (iii) removal of foreign or loose bodies, loose cartilages or hypertrophied synovial fringes.

INSTRUMENTS—Group IV

OPERATION

A lateral incision or one on either side of the patella is usually made. The patella is displaced to one side after splitting the fibres of the quadriceps extensor without seriously damaging them and displacing the patellar ligament. For drainage, rubber tubes are generally used.

EXCISION OF JOINTS

By excision of a joint is meant the removal of articular extremities of bones entering into the formation of the joint, together with the joint structures and periarticular tissues. This is subject to two exceptions in which only one of the two articular extremities is removed, e.g. in excision of hip-joint and the shoulder-joint.

INDICATIONS

Excisions are performed for : (a) Diseased conditions of articular ends and articular and periarticular structures (chronic septic arthritis, tuberculosis or in cases of early malignancy). (b) Ankylosis due to (i) traumatic lesions such as dislocations, fracture-dislocations, and (ii) chronic pathological conditions giving rise to adhesions, e.g. arthritis deformans. (c) Providing an artificial movable joint as for ankylosed elbow-joint. (d) Providing a fixed joint in good position by bony ankylosis e.g., the knee-joint.

There are two methods of excision : —

1. *The Subperiosteal Method.*—In this an attempt is made, if possible, to save the whole of periosteum covering the portions of bone to be excised. The attachments of the ligaments and the capsule are preserved, the joint being in a way shelled out from the surrounding periosteum. This is an ideal method of excision in theory, but it is attended with much difficulty. The peeling off of the periosteum is difficult, and more so, when operating upon the dead subject. Besides, it takes up much longer time and it is difficult to decide whether the periosteum is healthy or not.

2. *The Open Method.*—This consists in removing extremities of bone and diseased tissues regardless of the periosteum. The

ligaments of the joint are equally divided, the soft tissues are not damaged and the tendons attached to the bones are generally spared by separation of the periosteum.

Comment :—It will be useful to remember the following general principles of the operation of excision: The operation should be devised and performed in such a way that (i) the soft tissues suffer the least injury, (ii) epiphyses are preserved whenever possible, (iii) all diseased tissues are carefully removed without the operation being devastating, and (iv) best endeavour is made to give the patient a joint which is more useful after the operation than before it.

THE UPPER EXTREMITY

EXCISION OF THE WRIST-JOINT

Complete excision of the wrist-joint means removal of the entire carpus, the lower extremities of radius and ulna and the proximal ends of the metacarpal bones. The large number of tendons and the firm ligamentous attachments make the operation rather difficult (*Fig. 112*). Various operations are known but Kocher's method by dorso-ulnar incision is the best.

Kocher's Excision of the Wrist by Dorso-ulnar Incision

OPERATION

Flex the hand slightly. Commence an incision skin-and-fascia deep, three and half inches long opposite the middle of the fifth metacarpal bone on the ulnar aspect and carry it with a convexity towards the thumb in an upward and outward direction to the middle of the dorsum of the wrist, and then a short distance up the middle line of the forearm. Avoid the dorsal branch of the ulnar nerve at the lower end of the incision. Deepen the incision by cutting through the posterior annular ligament, thus exposing the tendon sheaths. The sheaths including the extensor communis digitorum and extensor minimi (extensor digiti quinti proprius) tendons are retracted outwards. The ligaments connecting the base of the fifth metacarpal, unciform (hammate) and cuneiform (triquetral) bones and the lower end of ulna are divided. Open the capsule of the wrist-joint on the ulnar aspect, and divide the tendon of the extensor carpi ulnaris. Remove the flexor carpi ulnaris tendon from the groove in the ulna above and detach the capsule further from the lower end of that bone. Separate the pisiform bone from the cuneiform, the tendon of the flexor carpi ulnaris retaining its connection with the pisiform. Cut across the

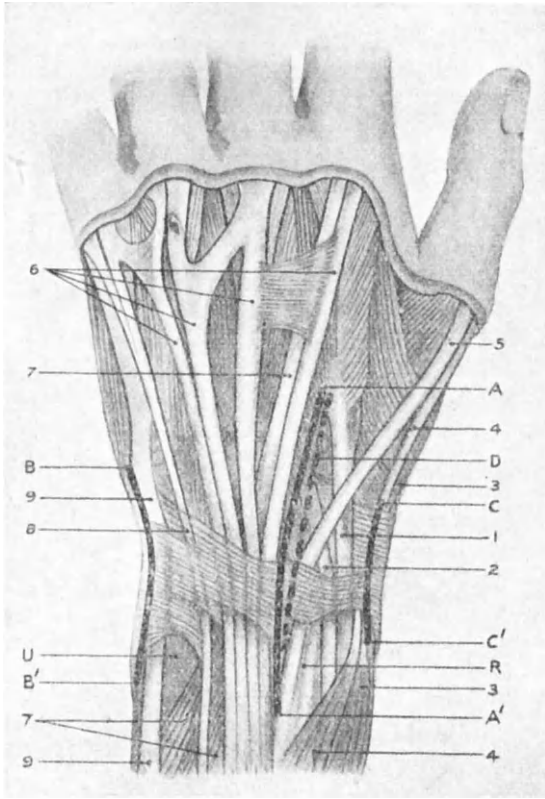


FIG. 112.

THE TENDONS CONCERNED IN EXCISION OF THE WRIST:— AA', BB', CC', the three incisions usually employed by M. Ollier. D, the incision of Boeckel, sometimes described as Langenbeck's, the two being practically identical. R, Radius. U, Ulna. 1 and 2, Radial extensors of the carpus. 3, Extensor ossis metacarpi pollicis. 4, Extensor pollicis brevis. 5, Extensor pollicis longus. 6, Extensor communis. 7, Extensor indicis. 8, Extensor minimi digiti. 9, Extensor carpi ulnaris.

hook of the ulnar bone saving the deep branch of the ulnar artery which passes round it. Lift out the flexor tendons on the palmar surface *en masse*; cut through the ligamentous attachments between the inner three metacarpal bones, preserving the tendons attached to the second and third metacarpal bones. Divide the anterior and posterior ligaments. Dislocate the whole hand towards the flexor and radial side. Remove the carpal bones, saw through the lower ends of radius and ulna and the proximal ends of the metacarpal bones (*see Fig. 113*).

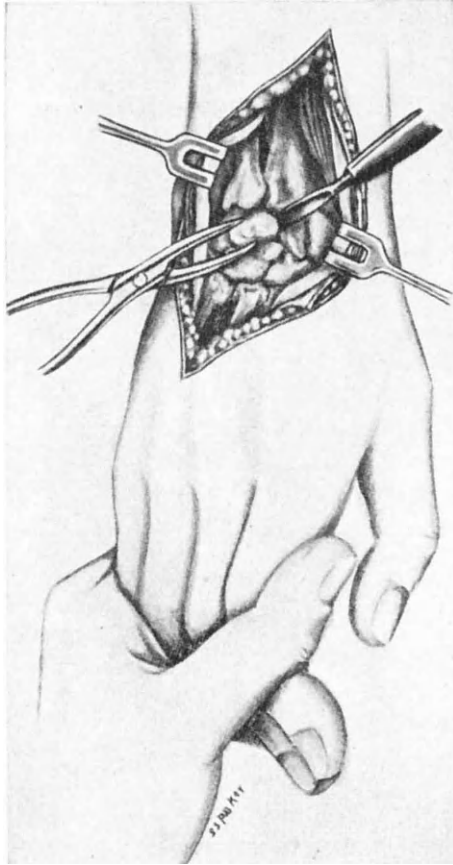


FIG. 113.

EXCISION OF THE WRIST-JOINT.

REPRODUCED FROM BICKHAM'S OPERATIVE SURGERY

Access to the wrist-joint for excision may be obtained by other incisions as in Ollier's, Lister's, and Langenbeck's operations.

EXCISION OF THE ELBOW-JOINT

SURGICAL ANATOMY

With the arm extended. (1) The humeral epicondyles are on a line with the tip of the olecranon. When the forearm is flexed, the olecranon gradually becomes prominent and sinks below the

horizontal level of the intracondylar line. In right-angle flexion of the forearm, it lies on the same plane as the posterior surface of the shaft of the humerus and represents the apex of an inverted equilateral triangle, the base angles of which are located at the epicondyles of the humerus. In full flexion of the forearm, the olecranon tip is carried further downward and lies anterior to the articular end of the humerus; the triceps tendon can be traced down to it. (2) Just below the external epicondyle in the dimple the head of the radius can be felt rotating if the forearm is pronated and supinated. (3) Just to the outer side of the internal epicondyle, and between it and the olecranon is a deep groove in which the ulnar nerve can be rolled under the finger.

The epiphyseal junction of the humerus corresponds to a transverse line drawn across the humerus just above the tips of the epicondyles. The humero-radial articulation is transverse and is three-fourths of an inch below the external epicondyle. The humero-ulnar articulation is more than an inch below the internal epicondyle.

Various incisions are made use of in order to obtain free access to the elbow-joint, *viz.* (i) posterior median incision (Langenbeck), (ii) long radial incision (Hüter), (iii) longitudinal and transverse incisions (Nélaton), and (iv) H-shaped incision (Syme). Of these the first is recommended.

EXCISION OF THE ELBOW-JOINT BY POSTERIOR MEDIAN INCISION (Langenbeck)

POSITION

Put the patient near the edge of the table and stand on the side to be operated upon. Flex the elbow and draw the forearm across the chest, making the elbow prominent. The assistant stands on the opposite side of the table and supports the arm and forearm with his two hands. A second assistant will be useful to retract the soft parts.

INSTRUMENTS—Group IV.

OPERATION

The operation is performed in four stages:—

(a) *Incision.*—A posteromedian incision is made along the posterior aspect of the elbow-joint four inches long and so placed that the middle of the incision lies over the tip of the olecranon. It is carried deep down to the bone, the upper half dividing the tendon of the triceps vertically and the lower half the soft tissues covering the olecranon process and ulna. (For this an excision knife is useful.) This opens the articulation through posterior ligaments (*see Fig. 114*).

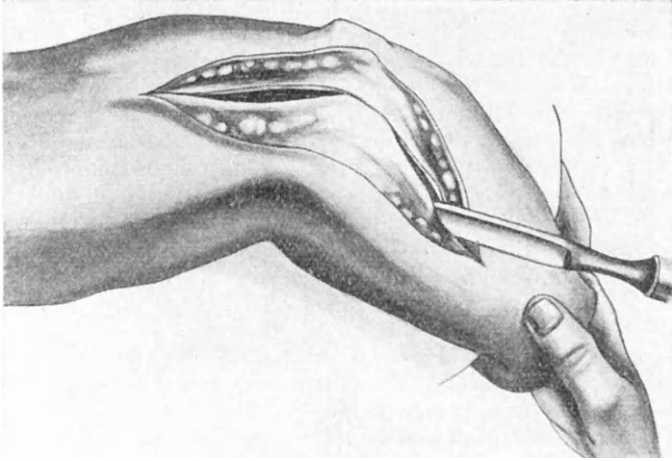


FIG. 114.

EXCISION OF THE ELBOW-JOINT BY POSTERIOR MEDIAN INCISION—I:—The incision, down through periosteum and capsule, to humerus and ulna, and into the joint.

REPRODUCED FROM BICKHAM'S OPERATIVE SURGERY
By the Courtesy of THE W. B. SAUNDERS CO.

(b) *Clearing of the soft tissues from the bone*, i.e. from the epicondyle of the humerus and olecranon. For this stage of the operation the excision knife should be used and periosteal elevators and a blunt dissector will also be useful.

First, turn to the inner part of the incision. Begin by peeling off the triceps with the periosteum from the olecranon. Raise the soft tissues from the depression, between the olecranon and the internal epicondyle thus exposing the bone. The soft tissues include the muscles, the ulnar nerve, the internal lateral (ulnar collateral) ligaments and the periosteum, carrying with it the origin of flexor muscles.

Next, turn to the outer part of the incision and in a similar manner separate the soft tissues on this aspect until the outer epicondyle is laid bare. These tissues include the outer half of the triceps tendon, the anconeus, the external lateral (radial collateral) ligament, the origin of the extensor muscles, and the supinator brevis (supinator). The posterior (dorsal) interosseous nerve may come into view and should be saved. Retract the soft tissues on the inner and outer aspects of the incision. The joint is now entirely free on its posterior aspect and the bones can be protruded out of the wound.

(c) *Sawing off the end of the humerus.*—Flex the elbow fully and get your assistant to protrude the lower end of the humerus

forcibly through the wound. Clear the bone of any attachment in front, retract and protect the soft parts with gauze retractors. Grasp the bone with lion forceps and hold it vertically; apply the saw to the bone at right angles to its long axis just below the tip of the condyles and saw through the bone horizontally (*Fig. 115*).




FIG. 115.

EXCISION OF THE ELBOW-JOINT BY POSTERIOR MEDIAN INCISION—II:—The articular ends of humerus, ulna, and radius exposed, cleared, and being removed by Gigli saw. Less of the articular ends is usually excised than here shown.

REPRODUCED FROM BICKHAM'S OPERATIVE SURGERY
By the Courtesy of THE W. B. SAUNDERS CO.

(*d*) *Sawing off the ends of the radius and ulna.*—Protrude the upper end of the radius and ulna through the wound, hold the olecranon process with lion forceps vertically. Apply gauze retractors as in the cases of the humerus. Place the saw horizontally in such a manner that it passes below the base of the olecranon and the coronoid processes and just above the bicipital tuberosity of

the radius. Saw through the upper ends of both the bones on these lines. Displace the supinator brevis (supinator) downwards before sawing and try to spare as much of the attachment of brachialis anticus (brachialis) to the coronoid process as possible. Smooth off any sharp edges of the cut ends of the bone with bone-cutting forceps.

Comment :—(1) Remove sufficient amount of the bones to give an efficient movable joint. The level of the section of the humerus is below the level of the tips of the epicondyles but it can go higher. The level of the section of radius and ulna has been described. Do not interfere with the insertion of the biceps tendon to the bicipital tuberosity of the radius. (2) Take care not to wound the ulnar nerve just behind the internal epicondyle internally, and the posterior interosseous nerve externally. (3) Keep the knife well down upon the bone, and the edge of the blade turned towards it. Make short and firm cuts. Use the periosteal elevator and the blunt resector more freely than the knife. (4) While peeling off the soft structures on the outer aspect, separate the triceps and anconeus in one piece. (5) Do not let your assistant twist the arm or forearm as this would disturb the anatomical relations and confuse you.

EXCISION OF THE SHOULDER-JOINT

SURGICAL ANATOMY

The following anatomical points are worth remembering :—
 (1) In the groove between the deltoid and the pectoralis major at the front of the joint are the cephalic vein and the acromio-thoracic artery. (2) Under the outer third of the clavicle and through the fibres of the deltoid and pectoralis major can be felt the coracoid process. (3) The bicipital groove with the tendon of the biceps lying in it can be felt when the arm is slightly rotated outwards. (4) The tip of the acromion can be easily felt overhanging the joint. (5) The greater tuberosity can be felt deeply through the deltoid ; to this are attached the supra-spinatus, infra-spinatus, and teres minor. The lesser tuberosity, more in front, has subscapularis attached to it.

INDICATIONS

This operation consists of an excision of the upper end of the humerus. The socket of the joint, i.e. the glenoid fossa of the scapula, is not generally disturbed. Occasionally, however, portions of the articular surface and the bone of this fossa have to be gouged

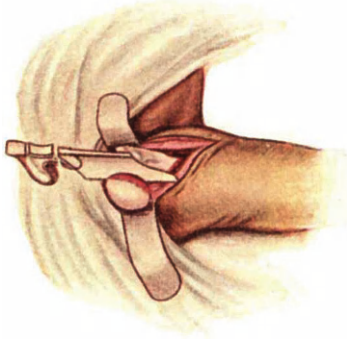


FIG. 118.

Sawing the head of the Humerus in Excision of the Shoulder-joint. The soft parts are protected by a spatula.

FIG. 117.

Disarticulation of the head of the Humerus in Excision of the Shoulder-joint. The arm is vertical and the head of the bone can be pushed well up out of the wound.

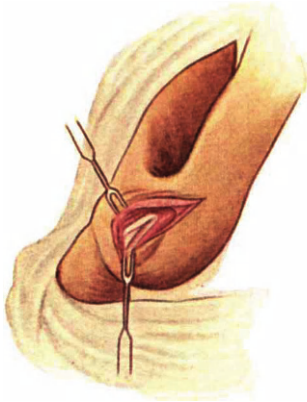
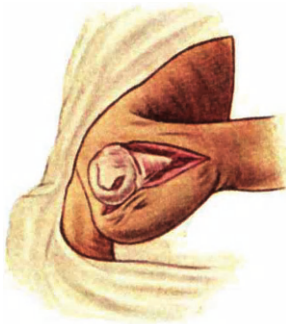

FIG. 116.

Excision of the Shoulder-joint. The Biceps has been lifted out of its groove.

EXCISION OF THE SHOULDER-JOINT.

out. The operation is rarely performed, the special indications for it being: (1) Chronic disorganizing disease of the joint, tuberculous or otherwise. (2) Old standing injury or disease giving rise to ankylosis. It must be remembered that considerable movement of the arm is possible with an ankylosed shoulder through the movements of the scapula on the trunk. (3) Gunshot injuries, compound dislocations and compound fractures with much damage to the capsule and cartilage, the large vessels and nerves being in tact.

INSTRUMENTS—Group IV.

POSITION

The patient lies close to the edge of the table. Raise the shoulder, flex the elbow and slightly abduct it. Stand facing the shoulder; the assistant stands behind you manipulating the arm.

OPERATION

Several incisions can be made use of to gain a free access to the shoulder-joint, *viz.*: (1) The anterior incision. (2) Langenbeck's vertical incision which is placed more externally than the above. (3) The anterior flap method. (4) Kocher's posterior curved incision.

Of these four, the anterior incision is the one most commonly adopted because (i) it gives free access to the joint without much injury to the muscles or their nerve supply, (ii) this incision can be easily converted into the one for Spence's disarticulation, should it be found necessary during the operation, to remove the limb in consideration of extensive involvement of the bones.

The operation is completed in four stages:—

1. *The incision.*—Make an incision about four inches long from the coracoid process downwards and outwards through the anterior fibres of the deltoid muscle, cutting through all the soft tissues down to the shaft of the humerus. The coraco-acromial arch and the capsule are exposed. Feel for the biceps tendon in the bicipital groove, and do not injure it. Open the capsule of the joint on the outer side of the tendon (*Fig. 116*).

2. *Clearing of the outer aspect of the wound.*—Clear all soft tissues from the bone at the outer margin of the wound and retract them outwards. The assistant rotates the arm strongly inwards and forces the head of the bone forwards. The greater tuberosity is exposed with the tendons of the supra-spinatus, infra-spinatus, and teres minor inserted into it. These are separated by cutting down upon the tuberosity with an excision knife. Clear this aspect of the head of the humerus of the capsule.

3. *Clearing of the inner aspect of the wound.*—Rotate the humerus outwards. Separate the parts in a similar manner, retract and protect the biceps tendon. The lesser tuberosity with the insertion of the subscapularis is exposed. Divide it by cutting down upon the tuberosity. Push the head of the humerus upwards, dislocating it from the glenoid cavity, the biceps tendon being retracted inwards. Clear the posterior part of the neck of the humerus (*see Fig. 117*).

4. *Excision of the head through the neck.*—Hold the head of the bone with lion forceps with your left hand. Protect the soft tissues with gauze retractors. Apply a small butcher's saw or gigli's wire saw to the bone and remove the head either through the anatomical neck, or below the tuberosities as is required (*see Fig. 118*). The glenoid cavity may be examined and gouged, if necessary.

Comment:—(1) Avoid the cephalic vein as it lies between the deltoid and pectoralis major. (2) Take special care not to injure the tendon of the biceps. (3) In sawing through the neck, incline your saw from without slightly downwards and inwards to avoid any sharp edge being left on the inner side, as this may injure the axillary vessels and nerves. Do not remove more bone than is necessary.

LOWER EXTREMITY

EXCISION OF THE ANKLE-JOINT

Excision of the ankle-joint used to be performed for tuberculous disease of the joint but it has been abandoned now because it often fails to eradicate the disease and to restore the function of the joint owing to peculiar anatomical conditions (*vide supra*).

In young patients injury to the joint without involvement of vessels and nerves sometimes justifies excision.

INSTRUMENTS—Group IV.

OPERATION

Exposure is obtained by Kocher's external curved incision. The anterior annular ligaments are divided and the tendons of the extensor digitorum longus are drawn outwards. The anterior tibial vessels and the extensor hallucis longus are retracted inwards. The peronei tendons are divided and the joint capsule is opened. The articular surface of the astragalus (talus) together with the lower ends of the tibia and fibula are removed (*Fig. 119*).

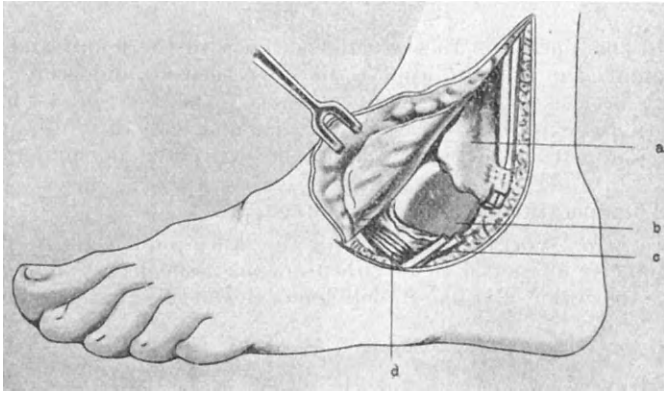


FIG. 119.

EXCISION OF THE ANKLE-JOINT BY A TRANSVERSELY CURVED EXTERNAL INCISION—KOCHER'S OPERATION—I:—The flap made by the incision is raised and retracted inward, followed by the division of the peronei tendons and the outer aspect of the capsule of the joint. A, external malleolus; B, malleolar surface of the astragalus; C, divided peroneus longus and brevis tendons; D, extensor brevis digitorum muscle.

REPRODUCED FROM BICKHAM'S OPERATIVE SURGERY
By the Courtesy of THE W. B. SAUNDERS CO.

EXCISION OF THE KNEE-JOINT

SURGICAL ANATOMY

(1) The lower epiphysis of the femur is on a level with the adductor tubercle. (2) The upper tibial epiphysis is along a transverse line across the head of the tibia, just taking in the articular facet for the head of the fibula externally, and the point for the insertion of the semi-membranosus internally. In front, it comes to a lower level and includes the tibial tuberosity. (3) The popliteal artery lies directly against the knee-joint posteriorly, separated from it only by the posterior ligament and some fat.

INSTRUMENTS—Group IV.

POSITION

Place the limb close to the margin of the table with the lower part of the leg projecting a little beyond in order to facilitate flexion, extension and other movements during the operation. The operator stands on the outer side and the assistant opposite to him. A second assistant is helpful to manipulate the limb for different positions.

OPERATION

In this operation the articular surfaces of the femur and tibia are removed in order to appose the sawn surfaces and bring about bony ankylosis in the straight position. The *indication* for this operation is extensive disease of the articular ends of the joint and other joint structures which cannot be extirpated by milder measures.

The operation is done in five stages :—

1. *The skin incision.*—Hold the knee-joint slightly flexed and make an incision skin and subcutaneous tissue deep, commencing at the posterior margin of one femoral condyle and carrying it

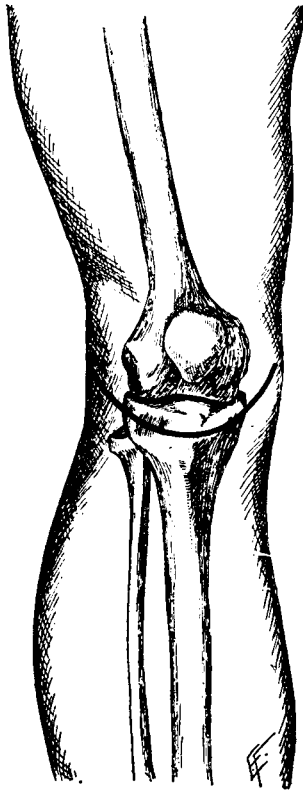

FIG. 120.

EXCISION OF KNEE-JOINT :—By curved transverse anterior incision. (Barker.)

REPRODUCED FROM BICKHAM'S OPERATIVE SURGERY
By the Courtesy of THE W. B. SAUNDERS CO.

down in a curved manner with the convexity downwards to the insertion of the patellar ligament, and carrying it up again to end at the posterior margin of the opposite condyle (*Fig. 120*). (Barker's curved anterior incision.)

2. *Division of ligaments*.—Flex the knee further. Cut through the anterior part of the capsule and the patellar ligament by one sweep of the knife. The joint is thus opened below the patella. Reflect the patella and soft tissues upwards. Flex the knee even further and cut through the lateral and the two crucial ligaments.

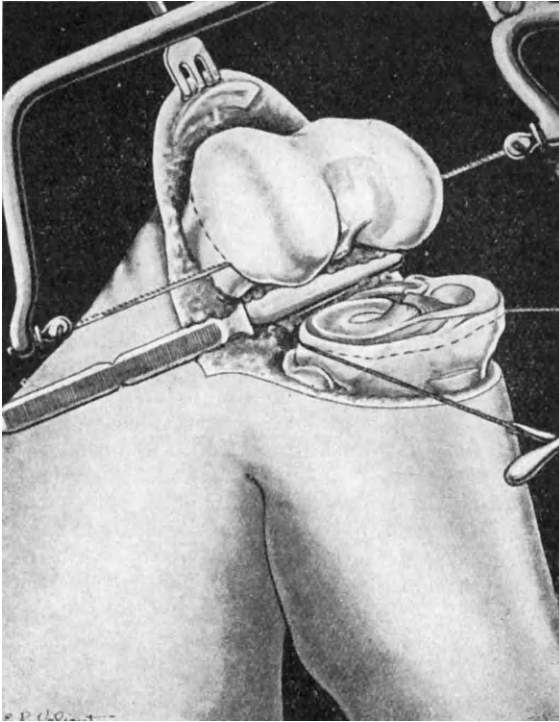


FIG. 121.

EXCISION OF THE KNEE-JOINT BY AN ANTERIOR, TRANSVERSELY CURVED INCISION:—The incision has been carried through the ligamentum patellæ and capsule of the joint—the crucial ligaments cut—and the articular surfaces exposed. The articular end of the femur is being excised by means of a Helderich saw—and the articular end of the tibia, by a Gigli saw. The section of the bones is being here made in a purely transverse direction.

REPRODUCED FROM BICKHAM'S OPERATIVE SURGERY
By the Courtesy of THE W. B. SAUNDERS CO.

3. *Sawing of the femur.*—Flex the knee to a right angle, the sole of the foot rests on the table and the femur rests on the tibia. Clear the lower end of the femur up to the saw line, of all soft tissues, particularly those on the posterior aspect, including the popliteal vessels and nerve and protect these by gauze retractors. The lower end of the femur with the condyle is grasped with a large pair of lion forceps. Saw the femur from before backwards, so that the plane of the saw cuts at right angles to the long axis of its shaft (*see Fig. 121*).

4. *Sawing of the tibia.*—The upper end of the tibia is now pushed forwards, the sole being firmly supported on the table. Clear the bone of any remaining soft tissues and saw a thin slice of its upper edge, working the saw from before backwards and keeping it strictly parallel to the articular surface, i.e. at right angles to the shaft.

5. *The patellar and synovial membranes* should be treated now. The patella may be removed if unhealthy, otherwise not. Remove all diseased synovial sac including the pouch under the quadriceps extensor. Every particle of diseased tissue from the ligaments must be removed.

Comment :—(1) Particular attention has to be paid towards proper and adequate apposition of the sawn surfaces. The bones must be divided in such a way that their sawn surfaces are in the same plane as their normal articular surfaces. (2) In making the skin incision do not go too far behind the internal condyle and thus avoid cutting the internal saphenous nerve. (3) Do not saw through or above the epiphyseal lines of either bone. (4) Take good care to protect the soft tissues in the posterior aspect of the joint. They contain vessels and nerves. The posterior cruciate ligament should be spared as much as possible, as it lends a good support to that aspect of the joint.

OPERATIONS ON THE HIP-JOINT

LANDMARKS AND SURGICAL ANATOMY

The upper border of the greater trochanter is on a level with the centre of the hip-joint. Top of the greater trochanter is about 2 cm. below the level of the head of the femur. The greater trochanter is about 7.5 to 10 cm. below the iliac crest and a little in front of its centre. Head of the femur lies just below Poupart's ligament and just external to its centre.

Bryants' Lines (or Triangle)—(with patient supine): first line is dropped vertically to the table, from the anterior superior iliac spine, the second passes in a straight direction along the long axis of the thigh from the top of the greater trochanter to meet the first line, the third runs from the anterior superior iliac spine to the top of the greater trochanter. On the damaged or diseased side the second line will be shortened.

Nélaton's Line.—A line drawn from the anterior superior iliac spine to the most prominent part of the ischial tuberosity crosses the centre of the acetabulum and the upper border of the greater trochanter.

The antero-internal margin of the acetabulum is about 5 cm. external to the pubic spine. The synovial membrane of the hip joint begins at the border of the cartilaginous surface of the head of femur, covers its neck within joint, is reflected to inner surface of capsular ligaments, covers both surfaces of cotyloid ligament (*lebrum glenoidale*) and fat at bottom of acetabulum and is prolonged around *ligamentum teres* to head of femur. Between the front of the joint and *psoas* and *iliacus* there is a bursa which often communicates with the joint.

There are few, if any, indications for arthrotomy, etc. of the hip-joint.

EXCISION OF THE HIP-JOINT

By this operation is meant excision of the upper end of the femur, and treatment of the socket, i.e. the acetabulum in a manner similar to that of the glenoid cavity in excision of the shoulder-joint.

Several methods of this operation are known but the one through an anterior incision is recommended because soft tissues are least disturbed and traumatised and it gives a better access to the joint.

INDICATIONS

Same as for the shoulder-joint.

POSITION

Dorsal position near the edge of the table is suitable. The operator stands on the affected side and the assistant faces him. A second assistant takes charge of the limb and does the necessary manipulations.

OPERATION

Make an incision through the skin and fascia on the outer aspect of the thigh, commencing about half an inch below the anterior superior iliac spine and carrying it downwards and inwards for about three and a half inches. Separate the muscles by blunt dissection. Retract *sartorius* and *rectus femoris* inwards, and *tensor fascæ femoris* (*tensor fascæ latæ*) and *gluteus medius* and *minimus* outwards. Through an interval between the muscles the capsule is reached and cut. With the head of the bone still

in the socket, the neck of the femur is divided by a narrow saw, such as Adam's. Deliver the head out of the socket by means of a curved periosteal elevator.

OTHER OPERATIONS ON THE HIP-JOINT

OPERATIONS FOR DISLOCATIONS OF THE HIP

In traumatic dislocations of long standing, operation promises little results and is associated with grave complications.

In dislocations due to disease sometimes excision of the head of the femur or arthroplasty is practicable when the dislocation is not due to tubercular disease. In most cases, however, and specially in tuberculosis, subtrochanteric osteotomy is much better and safer.

In congenital dislocations in the young, Lorenz' bloodless manipulations are recommended.

OSTEOARTHRITIS OF THE HIP-JOINT

Operations are, nowadays, performed in the later stages of osteoarthritis of the hip for the relief of pain, correction of faulty position or for mobilization.

The procedures are : (1) excision of capsule and osteophytes, (2) reconstructive excision of the femoral head, and (3) arthrodesis.

(1) *Excision of capsule and osteophytes*.—When the limitation of movement is due to bony outgrowths in the capsule relief may be obtained by an excision of these. The capsule has generally to be treated at the same time.

(2) *Reconstructive excision of the femoral head (Whitman's operation)*.—The deformed femoral head is excised and the neck rounded off before being thrust deeply into the acetabulum. The trochanter previously detached to allow access to the joint, is then attached to the femur at a considerably lower level than before. This gives a long femoral neck, and ensures the mechanical advantage of abducted leverage.

(3) *Arthrodesis (Albee's operation)*.—When deformity is advanced, arthrodesis of the hip is more useful. The upper margin of the acetabulum and the upper surface of the head and neck of the femur are cut away to form a shelf on which is laid a massive pedicled graft from the outer surface of the greater trochanter and adjoining part of the femur.

CHAPTER XIII

OPERATIONS IN THE MIDDLE LINE OF THE NECK

SURGICAL ANATOMY

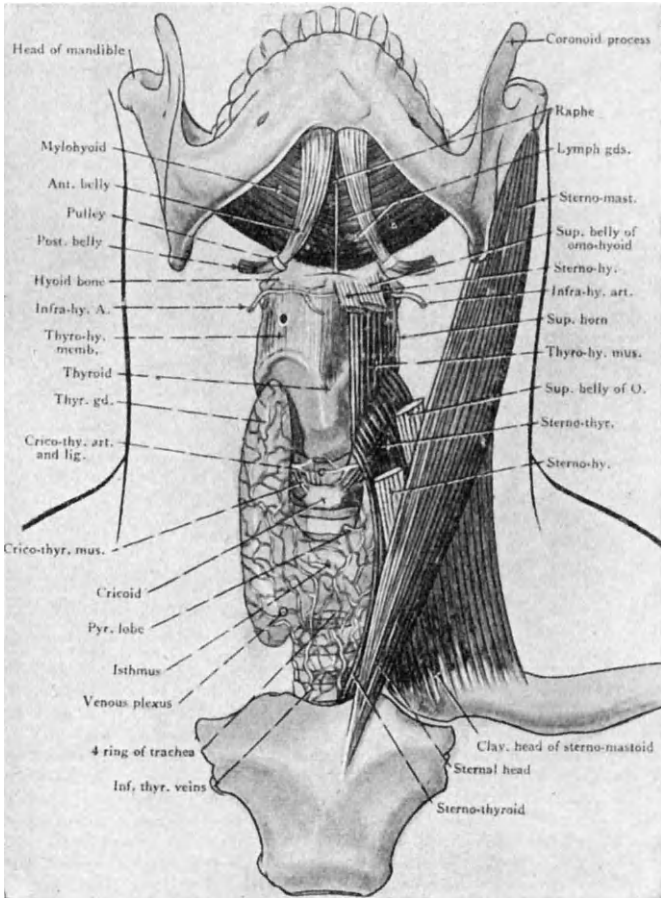


FIG. 121A.

Certain anatomical landmarks are important. From above downwards, the following structures can be felt in the middle line of the neck (*Figs. 121A and 122*) :—

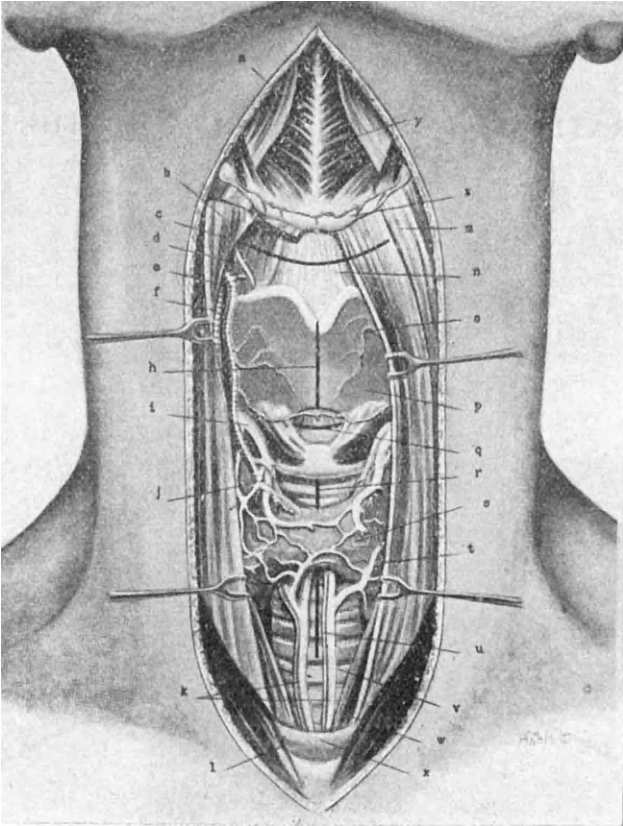


FIG. 122.

INCISIONS FOR OPENING THE PHARYNGO-LARYNGO-TRACHEAL TRACT AND ADJACENT ANATOMIC STRUCTURES:—a, Anterior belly of digastric; b, sternohyoid (partly cut to show anatomy beneath it); c, incision for subhyoid pharyngotomy; d, superior laryngeal nerve entering the larynx with the superior laryngeal artery; e, superior thyroid artery; f, external carotid artery; h, incision for median thyrotomy; i, superior thyroid vein; j, cricoid cartilage; k, inferior thyroid veins; l, sternocleidomastoid muscle; y, mylohyoid muscle; z, hyoid bone and artery; m, omohyoid muscle; n, thyrohyoid membrane; o, thyroid artery; p, thyroid cartilage; q, transverse incision for laryngotomy through the cricothyroid membrane; r, incision for high tracheotomy; s, isthmus of the thyroid gland, beneath which, when divided, median tracheotomy is performed; t, branches of inferior thyroid artery; u, incision for low tracheotomy; v, rings of the cervical trachea; w, sternothyroid; x, notch of the sternum.

REPRODUCED FROM BICKHAM'S OPERATIVE SURGERY
By the Courtesy of THE W. B. SAUNDERS CO.

1. The symphysis menti.
2. The median raphe of the mylo-hyoid muscles.
3. The body and the cornua of the hyoid bone.
4. The thyreo-hyoid membrane, lying between the hyoid bone and the thyreoid cartilage.
5. The body of the thyreoid cartilage which has the notch above, the pomum Adami next (well-marked in the male) and then its anterior border, which is distinctly palpable.
6. The crico-thyreoid membrane lying between the thyreoid and the cricoid cartilages.
7. The cricoid cartilage.
8. The first two or three rings of the trachea are between the lower border of the cricoid cartilage above and the isthmus of the thyreoid gland below. These three can be indistinctly felt only in thin subjects on deep palpation.
9. The isthmus of the thyreoid gland with the superior thyreoid vessels on either side, encroaching by their terminations on to the middle line.
10. The supra-sternal notch.

The deep cervical fascia (fascia colli) is of considerable importance from the surgical point of view. It lies under cover of the platysma and invests the muscles of the neck, it also forms sheaths for the carotid vessels and for the structures situated in front of the vertebral column.

The investing portion of the fascia is attached behind to the ligamentum nuchæ and the spinous process of the seventh cervical vertebra. It forms a thin investment for the trapezius, and from the anterior border of this muscle it is continued forwards to the posterior border of the sternocleido-mastoideus where it assumes the appearance of a fascial membrane. It encloses this muscle and at the anterior margin again forms a single lamella, which covers the anterior triangle of the neck and reaches forwards to the middle line where it becomes continuous with the corresponding part from the opposite side. In the middle line of the neck it is fixed to the symphysis menti and the body of the hyoid bone.

Above, the fascia is attached to the superior nuchal line of the occipital bone behind, to the mastoid process of the temporal bone laterally and to the inferior border of the body of the mandible in front. The parotideo-masseteric fascia, which ensheathes the parotid gland is derived from the fascia colli; below, the fascia is attached to the acromion, the clavicle, and the manubrium sterni along its two borders. Between these two layers is the suprasternal space or space of Burns which contains loose areolar tissue, lower portion of the anterior jugular veins and the connecting branch, sternal heads of the sternocleidomastoideus and sometimes a lymph gland.

From the fascia lining the deep surface of the sternomastoid muscle four processes pass off: (1) One envelops the tendon of the

Omohyoidius and binds it down to the sternum and the first costal cartilage. (2) The carotid sheath encloses the carotid artery, internal jugular vein and the vagus nerve. (3) The prevertebral fascia extends medialwards behind the carotid vessels and passes in front of the prevertebral muscles. With the pretracheal layer it forms a compartment in which are contained larynx, trachea, the thyreoid gland, the pharynx and the oesophagus. The prevertebral layer is fixed above to the base of the skull and below it is continued into the thorax in front of the longus colli muscles. Between the lamellæ of this prevertebral layer, which enclose the constrictor muscles of the pharynx and the skull above and the posterior mediastinum is the retropharyngeal space. The prevertebral fascia is prolonged downwards and is continued under the clavicle as the axillary sheath and is attached to the costo-coracoid membrane (coraco-clavicular fascia). (4) The pretracheal fascia extends medialwards in front of the carotid vessels, and forms part of the carotid sheath. It is continued behind the infrahyoid muscles and after enveloping the thyreoid gland is prolonged in front of the trachea to meet the corresponding layer from the opposite side. Above, it is fixed to the hyoid bone, below, it is carried down and blends with the fibrous pericardium.

The following operations are performed in the middle line of the neck :—

- | | | | |
|---|---|---|-----------------------------|
| | { | (a) Suprahyoid pharyngotomy. | |
| I. Pharyngotomy | | (b) Infrahyoid pharyngotomy, subhyoid pharyngotomy (or supra-thyreoid laryngotomy). | { |
| | | | |
| | | | Transthyreoid pharyngotomy. |
| II. Thyrotomy. | | | |
| III. Laryngotomy, (Laryngo-tracheotomy, Laryngo-fissure). | | | |
| IV. Tracheotomy | { | (a) high tracheotomy. | |
| | | (b) low tracheotomy. | |
| V. Thyreoidectomy. | | | |

I. PHARYNGOTOMY

INDICATIONS

This operation may have any of the following objects in view :—

1. To get an access to the lower part of the posterior wall of the pharynx.
2. To remove growths from the epiglottis or upper part of the larynx.
3. To extract foreign bodies from the pharynx or upper part of the larynx.

SUPRAHYOID PHARYNGOTOMY

Suprahyoid pharyngotomy is performed in order to remove tumours at the base of the tongue or on the epiglottis. Make a transverse skin incision with concavity upwards just above the hyoid bone. Divide transversely mylo-hyoid and genio-hyoglossus muscles. Open the pharynx without injuring the epiglottis. This exposes the pharynx, soft palate, tonsils, epiglottis and the base of the tongue.

INFRAHYOID PHARYNGOTOMY (SUBHYOID PHARYNGOTOMY)

POSITION

Dorsal position. Extend head by placing sandbags under neck and shoulder. The assistant steadies head, keeping the chin rigidly in the middle line of the body, so that the chin and the sternal notch are in a line. Stand on the left side of the body, facing the chin. Steady the larynx with left hand.

INSTRUMENTS—Group XI.

OPERATION

Make a transverse cutaneous incision parallel to the hyoid bone and immediately below it (*see Fig. 122*). Divide in succession platysma, omo-hyoid and sterno-thyreo-hyoid muscles and then the thyreo-hyoid membrane leaving enough of these structures above and below in order to unite them by sutures. Divide the mucosa as it bulges through the wound and retract its upper edge by means of a suture. Insert a suture into the epiglottis and pull it out. The larynx and pharynx are now exposed (*see Fig. 123*).

Comments :—There are certain dangers of these operations—(1) Hæmorrhage. (2) Infection: The deep fascial planes of the neck are opened up and the peculiar attachments of the fascia-collis may be responsible for wide extension of cellulites. (3) Aspiration pneumonia is a frequent sequel. (4) Respiratory obstruction and œdema glottis. (5) Difficulty in providing sufficient nourishment.

II. THYROTOMY

This operation may be performed for removing growths which cannot be removed through the mouth but at the same time do

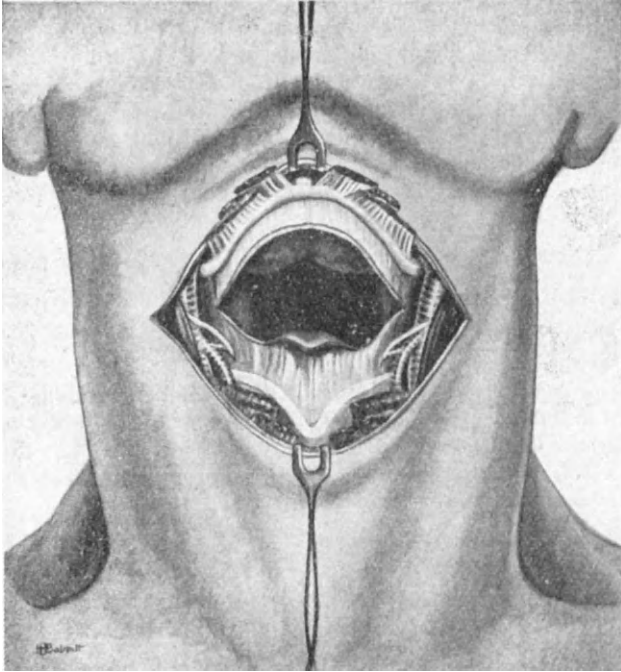


FIG. 123.

INFRAHYOID PHARYNGOTOMY.

The thyrohyoid membrane has been incised transversely, above the entrance of the superior laryngeal nerves and arteries—revealing, in the background, the epiglottis and the base of the tongue.

REPRODUCED FROM BICKHAM'S OPERATIVE SURGERY
By the Courtesy of THE W. B. SAUNDERS CO.

not require severe operations on the larynx itself. Due to the improvements of the endolaryngeal methods of operation, thyrotomy is now seldom called for in the treatment of new growths.

III. LARYNGOTOMY

In this operation the larynx is opened by a transverse incision through the crico-thyreoid membrane. This opening, by itself, allows only a small amount of room which is available between the cricoid and thyreoid cartilages. So this operation is generally combined with tracheotomy by cutting through the cricoid cartilage and the first two rings of the trachea (*laryngo-tracheotomy*, *laryngofissure* or *transverse intercricio-thyreotomy*).

INDICATIONS

(1) Sudden impaction of large foreign bodies, threatening suffocation.

(2) Before operations on the tongue, jaws, tonsils, etc. likely to be attended with such bleeding as may require plugging of the pharynx.

(3) In cases of œdema glottis or acute temporary obstruction of anginal origin.

POSITION

As for infrahyoid pharyngotomy. (*Fig. 124.*)

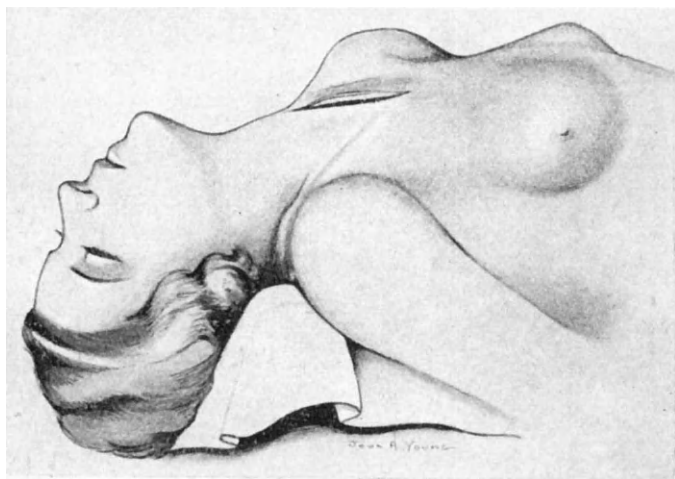


FIG. 124.

POSITION OF THE PATIENT IN LARYNGOTOMY AND TRACHEOTOMY OPERATIONS. The head thrown backwards, and the neck rendered prominent by means of a support beneath it.

REPRODUCED FROM BICKHAM'S OPERATIVE SURGERY
By the Courtesy of THE W. B. SAUNDERS CO.

INSTRUMENTS—Group XI.

OPERATION

Having steadied the larynx with the fingers of the left hand, make a median vertical incision, skin and fascia deep, commencing at the middle of the thyreoid cartilage. The interval between the sterno-thyreoid and crico-thyreoid muscles of either side is felt and widened. The crico-thyreoid membrane which is now exposed

is divided horizontally, directly above the upper border of the cricoid cartilage.

This opens into the larynx. The laryngotomy tube which is shorter, of a sharper curve and flattened antero-posteriorly is introduced (*Fig. 125*).

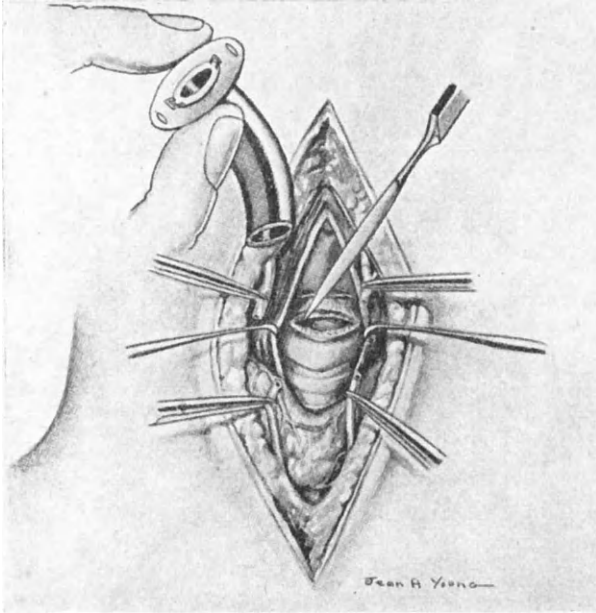


FIG. 125.

LARYNGOTOMY—TRANSVERSE INTERCRICO-THYROTOMY.

REPRODUCED FROM BICKHAM'S OPERATIVE SURGERY
By the Courtesy of THE W. B. SAUNDERS CO.

Comment.—(1) Keep the knife rigidly in the middle line to avoid injuring the crico-thyroid vessels. (2) Make sure that the larynx is properly opened before introducing the tube. It is not an uncommon mistake to pass the tube into the areolar tissue between the cricothyroid membrane and the wind-pipe. (3) The operation has two advantages, the rapidity with which it can be performed and the ease with which it can be carried out. (4) It has, however, certain disadvantages. It is not suitable for children owing to the narrowness of the cricothyroid space and proximity of the vocal cords, which are liable to be injured unless a suitable tube

is properly adjusted; besides, it is very unsuitable for cases in which a tube has to be worn for a long time.

IV. TRACHEOTOMY

This is often an emergency operation and may have to be performed at a short notice. It is a simple operation on the dead subject but in the living it requires a thorough knowledge of its technique. Coolness, deliberation, dexterity and quickness have to be combined in order to make the operation a success.

INDICATIONS

A. For extrinsic conditions, i.e. conditions which cause partial or complete obliteration of the trachea due to pressure from without, causing respiratory difficulty (dyspnœa), e.g. from (i) inflammatory conditions such as cellulitis of the neck (angina Ludovici) and retro-pharyngeal abscess; (ii) pressure from (a) tumours (simple or malignant) in the neighbourhood of the trachea or larynx, (b) goitre, (c) aneurysm of the thoracic aorta, and (iii) spasmodic conditions due to tetanus, nerve lesions, etc.

B. For intrinsic conditions including all conditions which give rise to respiratory difficulty, due to obstruction inside the larynx or in the lumen of the trachea. These may be enumerated as follows:—(i) Traumatic, such as (a) impaction of foreign bodies in the larynx or trachea, (b) cut-throat wounds, and (c) inhalation of strong irritants giving rise to laryngitis. (ii) Infective and other conditions such as (a) diphtheria, (b) certain types of croup, (c) acute septic laryngitis, œdema glottis, and (d) syphilitic and tubercular ulcerations. (iii) New growths, simple or malignant of the larynx, e.g. papillomata, epitheliomata, etc.

C. As a preliminary measure to certain operations, e.g. excision of the tongue or the jaws in order (i) to enable the operator to plug the larynx after tracheotomy and thus prevent aspiration pneumonia, and (ii) to facilitate the administration of anæsthesia through the tracheal opening.

D. For the extraction of foreign bodies impacted in a situation proximal to the tracheotomy wound, or in the bronchi for inspection (through the tracheotomy wound) of the trachea or bronchi for foreign bodies or pathological conditions (tracheo-bronchoscopy).

The operations for tracheotomy can be 'high' or 'low', according to the position where the trachea is opened. High tracheotomy is the operation of choice; low tracheotomy is only performed where it is specially indicated, as will be discussed later.

POSITION

The patient is brought to the right edge of the table, his head hanging beyond the upper end. A sand-bag is placed under the neck. The neck is so extended that the vertex points almost towards the floor (*see Fig. 124*). This position has the following advantages :—(*a*) it steadies the trachea, (*b*) it draws as much of the trachea as possible into the neck, (*c*) it makes the upper part of the trachea more superficial, and (*d*) it helps to empty the superficial veins. The operator stands on the right side of the table facing the trachea. The assistant stands at the head end of the table holding the head straight, in the same manner and with the same precautions as for pharyngotomy, described above.

INSTRUMENTS—Group X.

The tracheotomy tube should be of such construction as it may be easily introduced and manipulated. It should be of proper size, considering the age of the patient, i.e. not too long to touch the posterior tracheal wall and not too broad in comparison with the diameter of the trachea.

A. HIGH TRACHEOTOMY

The trachea is opened between the cricoid cartilage above, and the isthmus of the thyroid gland below. This operation should always be performed in preference to the low operation, for the following reasons :—

1. From above downwards the trachea slopes posteriorly and, therefore, the first part of the trachea is more superficially situated.
2. This part of the trachea is most fixed.
3. It can be made more accessible and tense, by extending the neck.
4. There are no large vessels or other important structures in its close proximity.

OPERATION

The operation is done in three stages :—

1. Exposure of the trachea.
2. Opening of the trachea.
3. Introduction of the tube.

1. *Exposure of the trachea.*—Define the cricoid cartilage accurately, steady the skin and trachea with left hand keeping the right hand free. Make an incision from the centre of the cricoid, precisely in the middle line of the neck, vertically down

for an inch to an inch and a half (*see Fig. 122*). This incision cuts through the skin, subcutaneous fat and the anterior layer of the cervical fascia. This exposes the interval between the sternohyoid muscles on either side. Separate the muscles in the middle line by a fine dissector and dissection forceps. Divide carefully the deep cervical fascia (pretracheal layer) which is now exposed. The first two rings of the trachea and the isthmus of the thyroid gland are now exposed. Displace the isthmus downwards by the blunt hook. Look for the first two or three tracheal rings and feel them with your left forefinger (*Fig. 126*).

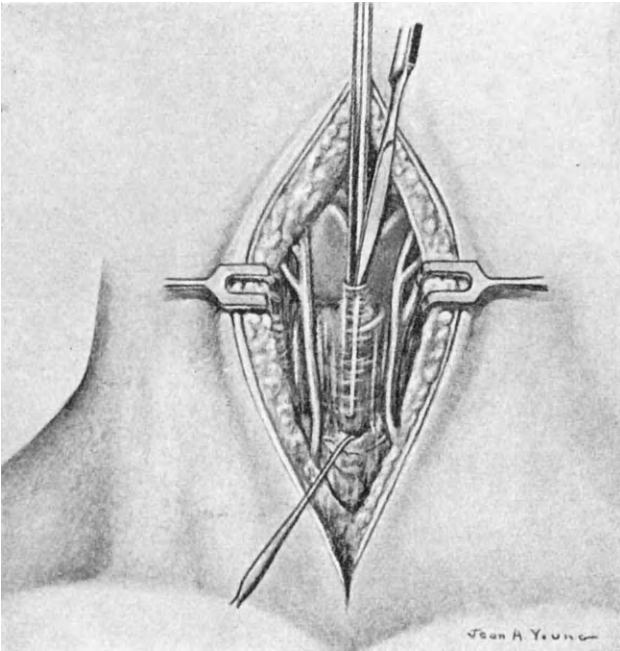


FIG. 126.

HIGH TRACHEOTOMY—I:—Following the superficial incision, and retraction, or clamping of overlying veins, the fascial connection of the upper border of the thyroid isthmus is incised, and the isthmus drawn downwards, thereby exposing sufficient extent of trachea between the cricoid and isthmus. The connective tissue is being divided in the median line, upon a grooved director.

REPRODUCED FROM BICKHAM'S OPERATIVE SURGERY
By the Courtesy of THE W. B. SAUNDERS CO.

2. *Opening the trachea.*—Introduce the sharp hook into the cricoid cartilage and give it to the assistant who holds it precisely in the middle line, to fix and draw it forwards. (The hook

should be allowed a certain amount of play with the movements of respiration.) Take a short narrow-bladed scalpel and hold it with the sharp edge directed towards the chin, by the handle and the blade between your forefinger and thumb, so that the portion of the blade beyond your thumb and forefinger is enough to stab the anterior wall of the trachea, but not too long to reach its posterior wall. Stab the trachea from the third ring below in the middle line and cut up to the lower border of the cricoid (*Fig. 127*).

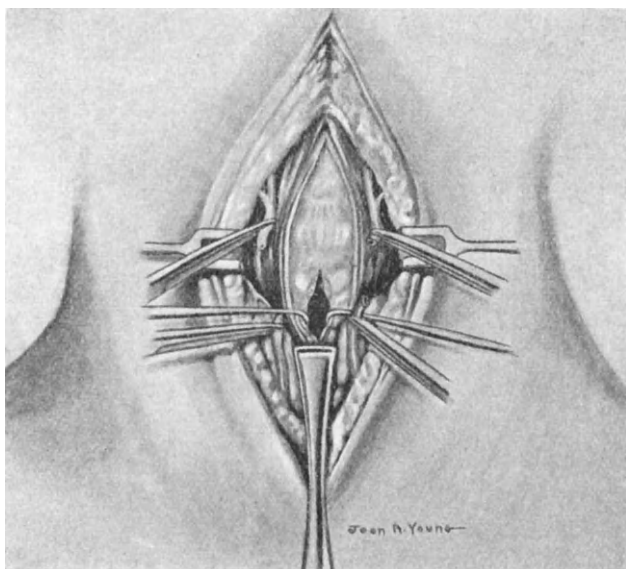


FIG. 127.

HIGH TRACHEOTOMY—II:—The obstructing veins have been clamped and divided—the inner borders of the sternohyoid muscles displaced outwards—and the second and first tracheal rings incised, from below upwards—and are here shown retracted to each side, exposing the tracheal opening for the entry of the tracheotomy tube.

REPRODUCED FROM BICKHAM'S OPERATIVE SURGERY
By the Courtesy of THE W. B. SAUNDERS CO.

3. *Introduction of the tube.*—The cricoid is still held fixed by the assistant. Introduce the tracheal dilator into the opening and hold it open by the left hand. After the first gush of mucus and possibly a piece of membrane (in diphtheria) is expelled and the dyspnoea relieved, introduce, with the right hand, outer, female part of the tracheotomy tube. If it is a bivalve tube, compress it

between the finger and thumb and introduce it. Remove the sharp and blunt hooks. Introduce the inner, male tube (*Fig. 128*).

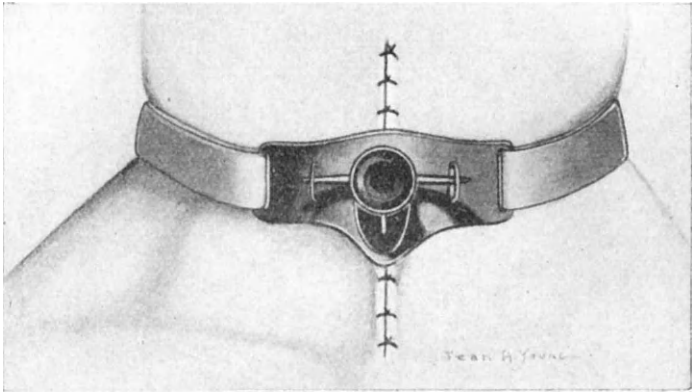


FIG. 128.

TRACHEOTOMY TUBE IN POSITION.

REPRODUCED FROM BICKHAM'S OPERATIVE SURGERY
By the Courtesy of THE W. B. SAUNDERS CO.

Some surgeons are in the habit of introducing both tubes at the same time.

Comment.—(1) Get your instruments together in one lot and keep cannulæ of different sizes at hand. (2) The positions of the operator, the assistant and the patient are of utmost importance. The neck should be completely extended and the chin kept rigidly steady in the middle line throughout the operation. (3) Do not remove the sharp hook till the tube is introduced. (4) Divide the cervical fascia precisely and cleanly, otherwise the tube may be introduced between the trachea and the fascia by mistake. (5) Satisfy yourself not only by seeing the white rings of the trachea but by feeling them. (6) In making the tracheal stab and cut, the knife should be well controlled as described. (7) In fat subjects the skin incision should necessarily be longer.

B. LOW TRACHEOTOMY

This operation is similar to that for high tracheotomy with the following differences :—

1. The incision is longer, reaching almost to the sternal notch.

2. It needs a deeper dissection.
3. The isthmus of the thyroid is retracted upwards.
4. The structures met with are practically the same but the veins are larger; the inferior thyroid vein will need division between two ligatures. The intermuscular line between the sterno-thyroid is less distinct (*see Fig. 122 and Fig. 129*).

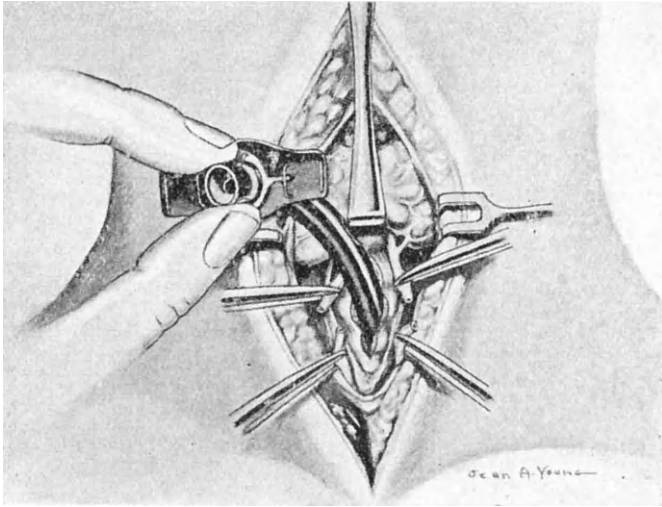


FIG. 129.

LOW TRACHEOTOMY:—The isthmus of the thyroid body has been displaced upwards to give additional room. The inferior thyroid veins have been doubly clamped and divided.

REPRODUCED FROM BICKHAM'S OPERATIVE SURGERY
By the Courtesy of THE W. B. SAUNDERS CO.

INDICATIONS

The indications for this operation are only two:—

1. For disease involving the lower part of the larynx or upper part of the trachea.
2. As a preliminary measure to laryngectomy.

The disadvantages and risks attending this operation are many:—

1. The branches of veins are larger and thicker, such as the inferior thyroid, etc.; the thyroidea-ima artery may also be in the field of operation.
2. Proximity of large blood vessels to it, e.g. the innominate artery and vein.

3. In children the thymus gland is large and may extend into the field and thus complicate the operation.

4. The trachea is more mobile and deep and cannot be steadied as in the high operation.

5. By the suction action of the chest, the trachea is more liable to be pulled back into the wound.

6. In case of accidental sepsis, the pus can be conducted into the mediastinum.

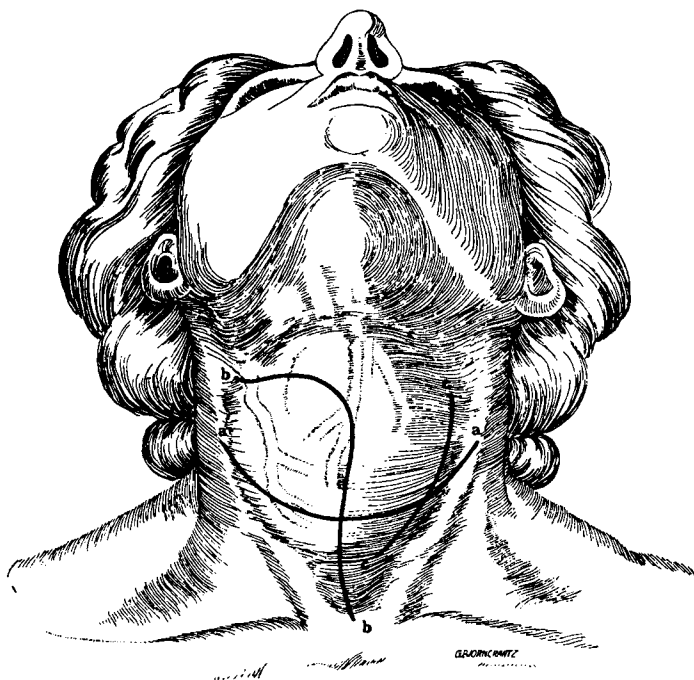


FIG. 130.

INCISIONS GENERALLY USED IN OPERATING FOR GOITRE (shown upon a normal neck in connection with normal landmarks):—a, Kocher's "collar" incision, usually employed for symmetric goitres; b, Kocher's angular incision, especially adapted to difficult and asymmetric goitres, extending high or low in the neck; c, oblique incision along the inner border of the sternomastoid, for the limited exposure of parts of the thyroid gland, as in the removal of nodules and cysts.

REPRODUCED FROM BICKHAM'S OPERATIVE SURGERY
By the Courtesy of THE W. B. SAUNDERS CO.

V. THYREOIDECTOMY

INDICATIONS

(1) Dyspnoea—gradually increasing or sudden and acute. (2) Dysphagia. (3) Steady or rapid enlargement, with or without dyspnoea, if the growth tends to be substernal. (4) Gross deformity of the neck. (5) Pain and other symptoms due to pressure on the nerves. (6) In selected cases of exophthalmic goitre and of hyperthyroidism. (5) Malignant goitre.

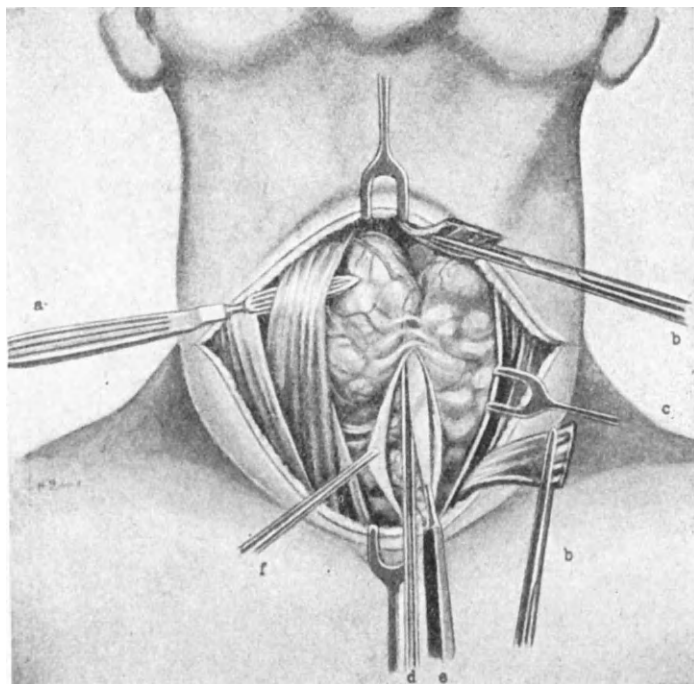


FIG. 131.

THYREOIDECTOMY, FOR SIMPLE GOITRE, BY THE "COLLAR" INCISION:—Exposing the goitre: a, Kocher's grooved director beneath the sternohyoid, upon which it will be divided; b, b, ends of divided sternohyoid muscle; c, retracted sternothyroid (which is usually severed); d, grooved director passed beneath the nicked fascial or surgical capsule—which is being divided by knife, e, while the cut margins, f, are being drawn apart.

REPRODUCED FROM BICKHAM'S OPERATIVE SURGERY
By the Courtesy of THE W. B. SAUNDERS CO.

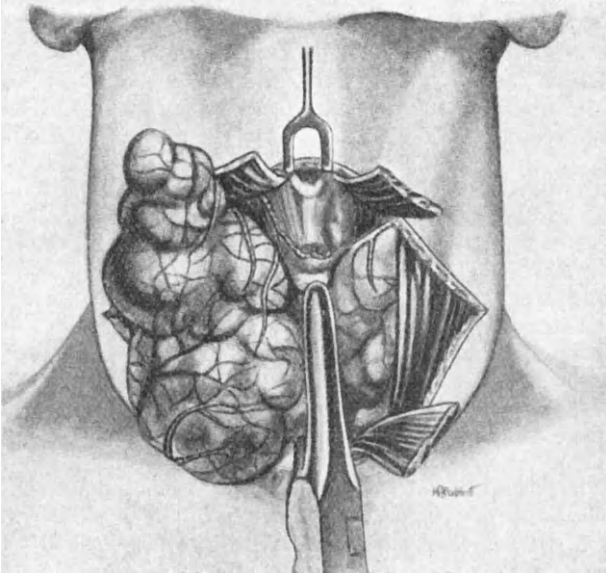


FIG. 132.

THYREOIDECTOMY, FOR SIMPLE GOITRE, BY THE "COLLAR" INCISION:—Compression of the isthmus of the thyroid with Kocher's angiotribe clamp preparatorily to ligating and dividing it.

REPRODUCED FROM BICKHAM'S OPERATIVE SURGERY
By the Courtesy of THE W. B. SAUNDERS CO.

OPERATION

Local anæsthesia is preferred and failing this local and general (combined) anæsthesia should be employed. Various incisions have been described but Kocher's method is generally adopted. The collar incision is made transversely across the neck along the lower crease. The anterior border of the sterno-mastoid is defined. Sterno-hyoid and sterno-thyroid muscles are divided or widely separated by a blunt dissector; the goitre is then freed along its outer and posterior aspects, the tumour is dislocated forward out of the wound and separated up to the isthmus. The superior thyroid vessels are crushed in two places by Kocher's clamps, secured and divided, the inferior thyroid vessels are also secured in the same manner avoiding the recurrent laryngeal nerve. After the isthmus is transfixed and ligatured the tumour is removed (*see Figs. 130, 131 and 132*).

Comment.—The operation has been recently considerably improved. Division of the infrahyoid

muscles is being abandoned except for operations upon large colloid goitres. The whole gland is not dislocated and separated from its bed, as in classical Kocher's operation; when the thyreoid capsule has been exposed, the overlying muscles are freed from it by sweeping the finger round on both sides to the limits of the thyreoid bed or by gauze dissection; automatic retractors are put in to keep the infrahyoid muscles widely apart, the goitre can then be brought forward into the wound. The upper pole on one side is next divided between double ligatures which include the superior thyreoid artery and veins, when the lobe can be brought further forward. A series of artery forceps are applied to the posterolateral aspect of the lobe, each including any vessel which are seen entering the capsule and a good bite of the underlying thyreoid tissue, and the lobe is then sliced across in the coronal plane towards the trachea, leaving a small wedge-shaped portion of the posterior part lying between the trachea and the œsophagus medially and the carotid sheath laterally. This method of intracapsular dissection leaving the posterior strip of the lateral lobe in position, has replaced complete lobectomy for all conditions except carcinoma, since it involves less handling and avoids risks of damage to the recurrent laryngeal nerve, or of removal of the parathyroids.

CHAPTER XIV

OPERATIONS ON THE CENTRAL AND SYMPATHETIC NERVOUS SYSTEMS

OPERATIONS ON THE BRAIN AND THE SPINAL CORD

SURGICAL ANATOMY

The Scalp.—It is formed by the mobile soft tissues which cover the skull. It is composed of three layers, skin, superficial fascia, and the occipito-frontalis muscle with its aponeurosis. It is attached to the underlying pericranium by loose connective tissue. The pericranium is also loosely attached to the bones except at the sutures.

Blood supply of the scalp: from the frontal, supraorbital, ophthalmic, temporal, posterior auricular and occipital arteries. The venous return is through the frontal, temporal and occipital veins. These have free communications, through the emissary veins, with the intracranial venous sinuses, and by these routes infection may travel from the scalp to the interior of the cranium. The important emissary veins are mastoid, condyloid, occipital and parietal. The lymphatics of the scalp pass to the parotid, occipital, mastoid and submandibular groups of glands.

The cranium and its contents.—The calvaria is the part of the cranium that holds the brain. Its floor has various projections that subdivide the lower part of the cavity into three separate compartments called fossæ,—anterior for the frontal lobes, middle for the temporal lobes, the posterior for the cerebellum, pons and medulla oblongata which are roofed over by the tentorium cerebelli and keeps the weight of the occipital lobes off the cerebellum.

The outer table is the more elastic of the two layers of the calvaria and is nourished chiefly by vessels from the pericranium; the inner table is thin and fragile and on its internal surface are the grooves for the meningeal vessels and cerebral sinuses.

The intermediate layer, the *diploë*, is highly vascular and branches of the meningeal vessels anastomose freely in its porous substance.

The membranes of the brain:—The *dura mater* is a fibro-serous membrane the outer layer of which constitutes the endocranium and in it the meningeal vessels ramify. Along certain lines the two layers split to enclose the venous sinuses. The *dura* is separated by a narrow lymph space,—the *subdural space*—from the

arachno-pial membrane, which consists of two layers, the outer, *arachnoid* which envelopes the brain but does not pass into the sulci, and the inner, *pia mater*, which closely invests the brain and lines its sulci. The two layers are adherent to each other at the convex surfaces of the gyri; but at the sulci and at the base of the brain they are separated at intervals and the spaces are collectively called the subarachnoid space. This space is occupied by a loose sponge-work of fine fibrous strands (subarachnoid tissue) in which the cerebrospinal fluid circulates. At the base of the brain the subarachnoid space is wider than elsewhere forming *cisterns* filled with cerebrospinal fluid.

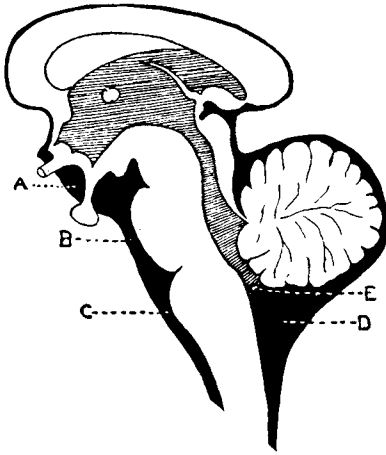


FIG. 133.

DIAGRAM REPRESENTING THE MIDSAGITTAL VIEW OF THE BRAIN STEM, SHOWING THE VENTRICULAR SYSTEM (IN CROSS LINES) AND THE SUBARACHNOID SYSTEM (IN BLACK).—The communication between the two systems is at E (foramen of Magendie); the foramina of Luschka are not shown; A, cisterna interpeduncularis; B, cisterna pontis; C, D, cisterna cerebellomedullaris (cisterna magna). (Dandy and Blackfan.)

REPRODUCED FROM CALLANDER'S SURGICAL ANATOMY.

THE CISTERNS

Cerebrospinal fluid.—The apparent source of cerebrospinal fluid is the choroid plexuses of the cerebral ventricles. It bathes the brain and is probably drained away by the arachnoid villi. The function is chiefly mechanical—assisting in regulating intracranial pressure and controlling effects of mechanical shock to the brain.

Infection and adhesions in meningitis may obstruct the median aperture of Magendie and the lateral apertures of Luschka in the roof and sides respectively of the fourth ventricle, through which openings cerebrospinal fluid normally passes from the ventricles into the subarachnoid space. In this way a hydrocephalus may result.

There are thus two cerebrospinal fluid systems,—the central or ventricular and the peripheral (subarachnoid), and these two systems are in communication through foramina. The central system is surrounded by soft brain tissue, whereas the peripheral system is surrounded by the rigid skull case. The arachnoidal membrane has prolongations on the vessels. From this it would be evident that on hydrostatic and physiological principles, pressure from any source would be communicated and distributed and re-adjustment of pressure can take place to some extent, till it exceeds the physiological limits and gives rise to symptoms of cerebral compression. Interruption in the communications between central and peripheral systems or in the track of either system would give rise to signs of local compression in addition to those of general compression with or without focal symptoms in accordance with the area of brain involved and grave symptoms in accordance with the pressure in the fourth ventricle with the ‘vital centres’ in its floor.

Each cerebral hemisphere consists of five lobes, called the frontal, parietal, occipital, temporal and central or island of Reil. The principal fissures are four in number, viz.: the longitudinal fissure, the fissure of Sylvius (lateral cerebral), the fissure of Rolando (central) and the parieto-occipital fissure. The transverse fissure is the cleft which separates the cerebrum from the cerebellum, the corpora quadrigemina and the pineal body.

Cerebral localisation is graphically represented by a cranio-cerebral topography (see *Fig. 135*).

Operations on the brain undertaken for symptoms of compression will now be described.

Cerebral compression may be due to:—

- I. Pressure caused by (a) hæmorrhage; (b) œdema; (c) trauma (fractures, etc.); (d) inflammatory and suppurative lesions: meningitis and abscesses; (e) specific lesions: syphilitic, tubercular and parasitic; (f) cerebral neoplasms; (g) sinus phlebitis and thrombosis of lateral, sagittal or cavernous sinuses.
- II. Irritative lesions of the brain, e.g. Jacksonian epilepsy or tumours of the skull.

Access to the brain may be obtained either by trephining or by osteoplastic craniotomy (Wagner's operation). The nature and extent of operation will naturally depend on the clinical findings and indications.

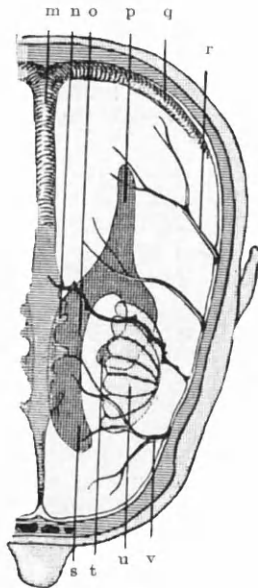
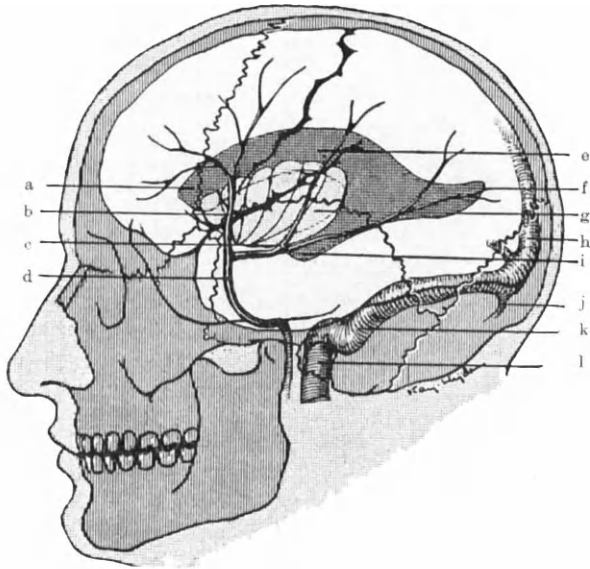


FIG. 134.

RELATIONS OF THE MIDDLE MENINGEAL ARTERY WITH THE CRANIUM, INSULA, AND LATERAL VENTRICLES. (AFTER CUSHING):—a, Cornu anterius ventriculi lateralis; b, Ramus anterior a.

meningæ mediæ; c, Ramus posterior a. meningæ mediæ; d, A. meningæ mediæ; e, Pars centralis ventriculi lateralis; f, Cornu posterius ventriculi lateralis; g, Insula; h, Sinus sagittalis superior; i, Cornu inferius ventriculi lateralis; j, Sinus occipitalis; k, Sinus transversus; l, V. jugularis interna; m, Sinus sagittalis superior; n, Lacunæ laterales; o, Pars centralis ventriculi lateralis; p, Cornu posterius ventriculi lateralis; q, Sinus transversus; r, Ramus posterior a. meningæ mediæ; s, Cornu anterius ventriculi lateralis; t, Cornu inferius ventriculi lateralis; u, Insula; v, Ramus anterior a. meningæ mediæ.

REPRODUCED FROM CALLANDER'S SURGICAL ANATOMY.

Trephining

1. Simple trephining when a positive diagnosis as to the site and nature of the lesion can be made, e.g. intracranial hæmorrhage, suppuration, localised cysts, fracture depressed or otherwise of the vault, basal fractures, bullet wounds, etc.

2. Trephining with incision of dura mater (*a*) a vertical or transverse, (*b*) semicircular or (*c*) crucial.

3. Trephining and exploration of brain for hæmorrhage, abscesses, and other conditions enumerated above.

INSTRUMENTS—Group VIII.

OPERATION

A horse-shoe shaped flap with its convexity upwards is reflected; if possible, it should be so planned as to have the temporal or the occipital artery running in its base. The incision is carried down to the bone so that the pericranium is included in the flap. All emissary veins should be gently pulled out of their foramina and ligated (*see Fig. 20*).

The trephine is then applied. The centre pin is pushed into the bone just to fix it sufficiently deep so that the trephine saw can be worked round it as a pivot.

As soon as a uniform groove has been made by the saw, the centre pin is removed and the sawing continued until the diploë is entered. Great care must be taken to avoid perforating the bone at one part of the circle sooner than at another. From time to time the trephine should be removed and its teeth and the field cleared of bone dust.

After the diploë has been traversed the trephine meets with some resistance from the inner table which should be evenly and gently sawn through.

When the circle of bone has been isolated it generally comes away with the trephine, if not, it should be removed with special elevators.

Opening of the dura mater is best done by cutting a flap in it; when near the longitudinal sinus the base of the flap should be towards the sinus; when near the floor of the skull it should be downwards. The incision in the dura may be vertical, occasionally transverse, semicircular or still better crucial, and should not be

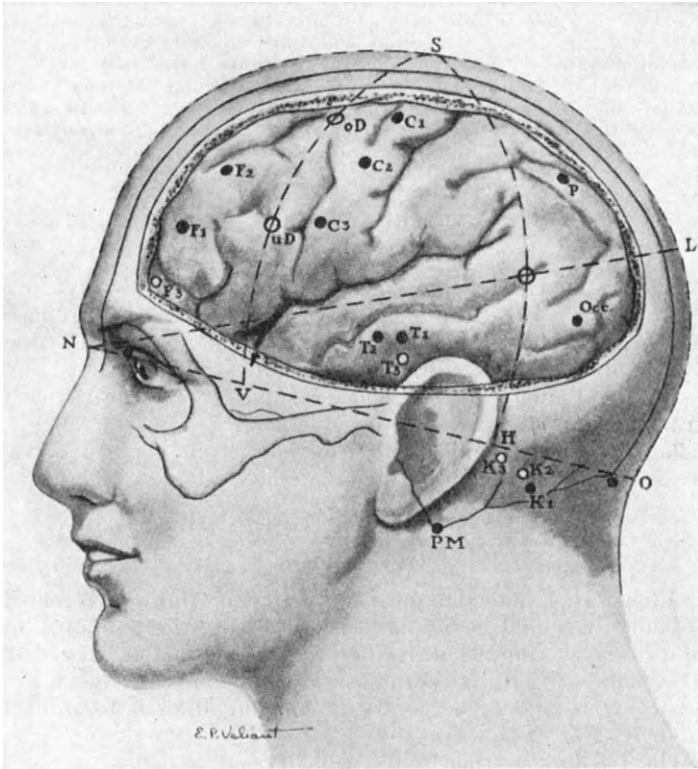


FIG. 135.

THE NEISSER-POLLACK CEREBRAL PUNCTURE-POINTS—LOCALIZED UPON THE KOCHER CRANIOMETRIC LINES. Kocher craniometric lines; O, Neisser-Pollack abscess-points; O, points for puncturing individual brain-lobes; S, parietal-point, midway between N (root of nose) and O (external occipital protuberance); NVHO, equatorial, or base, line; NSO, sagittal meridian; SV, anterior oblique meridian (precentral line); SH, posterior oblique meridian (linea limitans); NL, nasolambdaidea (the part between the two meridians, SV and SH, being called linea temporalis I); oD, upper trisection-point of precentral sulcus; uD, lower trisection-point of precentral sulcus; PM, tip of mastoid. (Modified from Neisser and Pollack.)

REPRODUCED FROM BICKHAM'S OPERATIVE SURGERY
By the Courtesy of THE W. B. SAUNDERS CO.

flush with the bone (saw line); when incising the dura the arachnoid should not be injured.

The further steps will vary according to the objects of the operation.

WAGNER'S OSTEOPLASTIC RESECTION OF THE SKULL

This operation is to be preferred to trephining for cases in which it is necessary to expose a considerable area of the brain in order to deal with an extensive tumour, or when it is primarily of an explorative character.

The preliminary steps are the same as for trephining. The area of bone to be reflected is delimited by a needle scratch on the scalp at each of its four corners. The incision in the scalp is eventually to be omega (Ω) shaped but to begin with only the curves of the omega opposite each corner are made. Each of these incisions goes down to the bone and the small flaps are reflected. With a $\frac{1}{4}$ inch trephine a circle of bone is removed at the four corners. A flexible grooved director is then passed between the bone and the dura mater and along this director is slipped the Gigli saw and each of the four sides of the bone flap is in turn sawn through from within outwards, care being taken to cut the bone obliquely so that the sawn surfaces are bevelled. The advantage of this is that when the osteocutaneous flap is replaced the bevelling prevents its sinking in upon the dura mater.

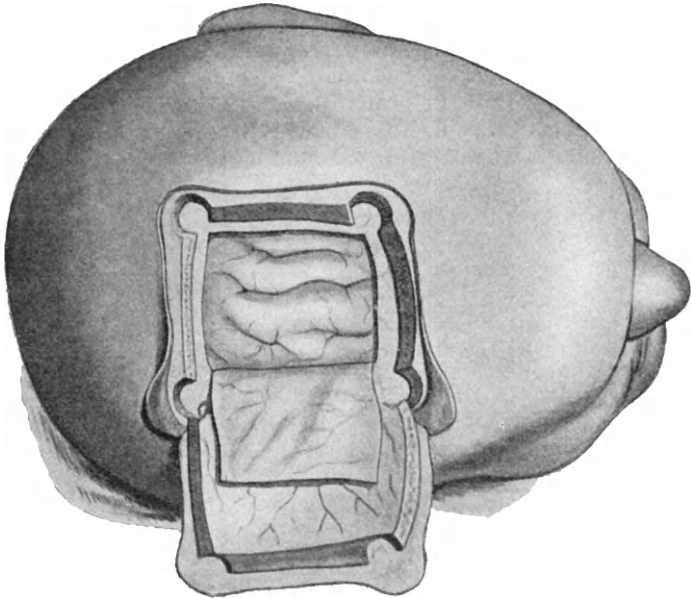


FIG. 136.

WAGNER'S OSTEOPLASTIC RESECTION ON SKULL, BRAIN EXPOSED.

REPRODUCED FROM 'MANUAL OF SURGERY'
by THOMSON, MILES AND WILKIE.

After the four sides of the bone flap have thus been divided, an elevator is passed in at the upper two trephine openings, and, the intact skull edge acting as a fulcrum, the bone is gently raised. The flap is now turned downwards on its base. As this is being done the dura mater should be gently separated from its deep surface. The flap should be wrapped in gauze wrung out of hot saline solution.

Now the tension of the dura mater, the pulsation of the brain and the consistence of the underlying cortex should be noted. A localized tumour of the cortex can usually be recognized but not so, deeper encapsulated growths.

The dura mater is then incised, the flaps reflected, and the exposed area of the brain examined. A tumour of the cortex, an arachnoid cyst, or a cyst in the brain matter may be visible on the surface or may be recognized by palpation. When a subcortical tumour is present the convolutions are flattened, the sulci obliterated and the cortex presents a dry lustreless appearance. It is then necessary to explore the brain by means of an aspirator needle or a special probe. An encapsulated tumour can often be easily shelled out, but no attempt should be made to remove a tumour which is not circumscribed; considerable benefit may however result by the relief of intra-cranial tension only.

After removal of the tumour the dural flaps are apposed by sutures; the osteo-cutaneous flap is replaced and the scalp sutured. If removal of the growth has not been possible, the dura is not closed and it may be advisable to leave a defect in the bony skull to provide extra space for the bulging brain substance.

OPERATION FOR MIDDLE MENINGEAL HÆMORRHAGE (DECOMPRESSION)

See Chapter II, p. 25.

OPERATION FOR HÆMORRHAGE FROM VENOUS SINUSES

Firm pressure with a pad of gauze is usually sufficient to control the bleeding temporarily. If possible the rent in the wall of the vein should be closed by lateral sutures of fine catgut. If this be not possible a flap of the dura may be stitched over it to cover the defect. If the wound is large and irregular and the above measures fail, gauze packing is the only procedure.

OPERATION FOR TRAUMATIC EPILEPSY

The preliminary steps are as in the Wagner's Operation. After opening of the dura, search should be made for organizing blood clots, fibrous tissue, traumatic arachnoid cysts or spicules of bones and if found these are removed.

If no visible lesion is discovered, the cortical area governing the muscles in which the fits originate may be excised.

OPERATION FOR INTRACRANIAL SUPPURATION

(a) When the abscess is secondary to an infected fracture of the skull, the scalp wound is enlarged and any loose fragments of bone removed or depressed fragments elevated. The infected bone should be snipped away.

(b) When the abscess is secondary to middle ear disease, the mastoid antrum is properly treated.

(c) When the infection is from the frontal sinus the overlying scalp is reflected and a $\frac{1}{2}$ inch trephine circle of skull is removed. The pus is removed and the cavity purified and drained.

EXPLORATORY PUNCTURE OF THE VENTRICLES

The lateral ventricle may be punctured by different routes. Keen's method is as follows :—

The puncture is made at a point 3 cm. behind and 3 cm. above the external auditory meatus, the needle being carried towards the tip of the opposite ear. The ventricle is reached at 5 cm. from the surface.

The safest route to the *fourth ventricle* is through an osteoplastic flap of the mid-cerebellar region. Directly at the angle formed by the furrows made by the dura of the two cerebellar hemispheres meeting the dura of the medulla oblongata, an exploratory needle is introduced through the dura, and carried with great care, inwards and forwards, in the median line, at an angle of 45 degrees, until entry into the ventricle is corroborated by the escape of cerebrospinal fluid.

CISTERNA PUNCTURE

Fluid may be withdrawn from the cisterna magna by puncture of the atlanto-occipital membrane.

The patient's head is flexed forward to open the atlanto-occipital space, and the point of a graduated needle is entered in the midline in the depression above the spine of the axis. The needle is pushed forwards and slightly upwards, its direction being in a plane which passes through the glabella and the upper margin of the external auditory meatus. The atlanto-occipital membrane is reached at a depth of 4 to 6 cm. The needle may occasionally strike the posterior margin of the foramen magnum, when it will be necessary to withdraw it slightly and tilt it further downwards. The ligament is a tough structure and can easily be felt. When it is penetrated there is a sudden cessation of resistance and cerebrospinal fluid is at once obtained (*Fig. 137*).

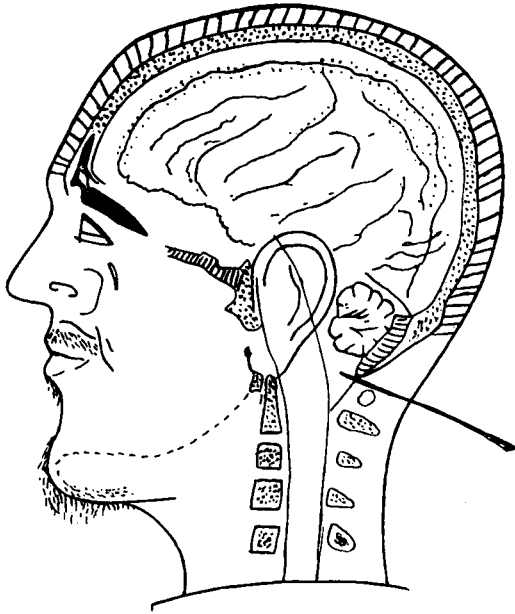


FIG. 137.

CISTERNA PUNCTURE.

OPERATIONS ON THE SPINE AND SPINAL CORD

Lumbar Puncture (Thecal puncture)

POSITION

Whenever possible the patient should sit upright upon the edge of the table, with feet upon a chair, and leaning forward, supporting himself by hands upon knees; this posture rounds out the back convexly, increases the transverse width of the intervertebral spaces and cerebrospinal fluid gravitates down; if, however, the patient cannot sit up, he may lie on his side in Sims' position, with back similarly arched and head and shoulders elevated.

The spinous processes of the fourth and fifth lumbar vertebrae are identified. The exploratory or aspirating needle is entered at a point about one centimeter to the right and just below the tip of the spinous process of the fourth lumbar vertebra and is made to penetrate slowly in a direction, forward, inward and slightly upward into the interlaminous space between the fourth and fifth lumbar vertebrae. The distance thus penetrated is generally between 6.5 and 7.5 centimeters. The pressure under which the fluid escapes should be noted preferably by a manometer otherwise by watching the rate of flow of the fluid and not more than 20 to

50 c.c. should be withdrawn at a time. After removal of the needle the puncture is sealed with collodion. The patient should remain in bed for 24 hours after a spinal puncture.

Laminectomy and Osteoplastic Resection of Vertebral Arch

INDICATIONS

(1) Injuries of the cord or spine ; (2) hæmorrhage ; (3) tumours of the spine, cord and its membranes or nerve-roots ; (4) tubercular and other forms of caries ; (5) deformities, such as spina bifida ; (6) severe neuralgia of the spinal nerves ; (7) inflammatory or infective involvement of the meninges.

INSTRUMENTS—Group XXXIII.

POSITION

The position of the patient is important, on account of the necessity of providing unimpeded respiration and free exposure. In operating upon the dorsal and lumbar regions the patient usually lies in the right semiprone posture ; in operating upon the cervical region it is necessary to have full dorsal exposure. The head and thorax should be on a lower level to guard against escape of spinal fluid in case of thecal opening.

OPERATION

The spinous processes corresponding with the laminæ to be removed should be very clearly located before commencing the incision. After ascertaining the site a free *incision* should be made to expose the necessary number of spinous processes, say up to five or six of them. The incision may be placed directly over the spinous processes in the middle line or a rectangular or a semi-lunar flap of skin and fascia is raised and reflected medialwards. The separation of muscles and aponeuroses will be clean and even if made by a stout knife welded in such a manner as to cut into the acute angle formed by the attachment of the muscle and aponeuroses to the parts of the vertebral column. Bleeding is arrested by forceps and firm pressure with gauze. The muscles are retracted by broad retractors and the interspinous ligaments divided with scissors. The spinous processes are snipped off at their bases from above downwards with bone pliers.

Through the incision made by the knife a chisel is carried directly to the depth of the wound, guided by the surgeon's left index finger. In osteoplastic resections the blade of the chisel rests against the transverse processes in the dorsal and lumbar regions and against the articular processes, in the cervical region, and from these as fulcra, the soft parts are levered off towards the spines. In laminectomy the chisel-blade rests against the

spinous processes, and from these as fulcra, the soft parts are cleared out of the bony groove towards the transverse processes or the articular processes.

The laminæ to be divided are then cleared with a periosteum elevator as far as their junctions with the pedicles, the ligamenta subflava divided with scissors and a suitable saw, Doyen's or Horsley's applied. In using the saw, care must be taken to cut the bone obliquely from without inwards; if the section is made vertically it will pass through the pedicle into the body of the vertebra and thus miss the canal. If there is difficulty in dividing the bone completely with the saw, the section may be completed with special bone-pliers (laminectomy forceps). In cases of injury, if the bony arches are comminuted, the laminæ may be snipped away with rongeur forceps.

Removal of causes of pressure. In some traumatic cases the posterior aspect of the cord is pressed upon by fragments of the neural arches driven in upon it and by blood extravasated in the extra dural space (hæmatorrhachis); to relieve the pressure it is only necessary to pick out the detached pieces of bone and wash away the clots. In fracture-dislocations, if the displacement cannot be rectified by manipulation the projecting edge of the bone may have to be chipped off with a chisel. If the pressure be due to a hæmatomyelia, the theca should be opened in the middle line and the effused blood washed away with a stream of warm saline solution.

The opening in the theca is sutured water-tight and the wound in the soft parts closed in layers.

Laminectomy for the relief of pressure in Pott's disease is rarely required or justifiable. The two indications for operation are—(1) disease limited to the laminæ, (2) severe and exhausting pain.

DIVISION OF THE POSTERIOR NERVE ROOTS

Foerster's operation is performed chiefly to eliminate spasm in cases of spastic paralysis and to relieve gastric crises of tabes and severe neurites of peripheral nerves. The dura is exposed through the laminectomy wound and the posterior nerve roots are resected on one or both sides as required.

OPERATIONS ON THE SYMPATHETIC NERVOUS SYSTEM

A. *Sympathectomy for disorders of circulation*

PERIARTERIAL SYMPATHECTOMY (NEURECTOMY)

This operation, originally employed in the treatment of perforating ulcers of the foot, is recently being adopted for thrombo-angitis obliterans, arterio-sclerosis, gangrene and other vasomotor trophic disturbances. (Raynaud's disease is a contraindication.)

Leriche suggests that many of these disturbances of nutrition may be caused by the reflex action of morbid conditions in the periphery upon the vasomotor mechanism, and, as such a reflex must travel through the periarterial network of sympathetic nerves which runs in the outer coat of the larger arteries supplying the limbs, the removal of a circular strip of their coat should break the injurious reflex and abolish the vasomotor spasm, thus providing, by vasodilatation and hyperæmia, conditions more favourable for the nutrition of the diseased part.

The operation consists in exposure of the main artery to the limb, and careful resection of the adventitious coat from the whole circumference of the vessel for a length of about one inch, leaving the media bare.

An alternative method of injecting absolute alcohol in the sheath or of painting the vessel deep to the sheath with a 7 p.c. isophenol is also employed.

Periarterial neurectomy is sometimes useful in (*a*) diabetic gangrene, (*b*) intermittent claudication, (*c*) chronic ulcers (due to trophic disturbances), and (*d*) leprosy.

B. *Sympathectomy for disorders of the visceral motor mechanism*

When chronic intestinal stasis is due to overaction of the sympathetic leading to inhibition of the viscus and contraction of its sphincter, sympathectomy may give relief. Such conditions are—megacolon (Hirschsprung's disease in children) and chronic stasis in adults, cardiospasm or achalasia of the cardia and pyloric spasm of the stomach.

C. *Sympathectomy for relief of pain*

Sympathectomy has sometimes been done to relieve the pain of dysmenorrhœa, vesical pain, renal pain, angina pectoris and causalgia.

CHAPTER XV

OPERATIONS ON THE THORAX

Thoracic surgery is so vast and technical that we shall deal with the operative technic of the more common conditions. For a detailed study of other conditions some of the excellent monographs may be consulted.

INJURIES OF THE THORAX

Injuries of the thorax generally give rise to hæmothorax, pneumothorax, cutaneous (surgical) emphysema, etc.

The treatment varies according to the nature of the injury.

Hæmorrhage from small lung vessels often stops spontaneously on account of higher clotting properties of pulmonary blood, low blood pressure in the pulmonary circulation and the contraction of the lung, but those from the vessels of the hilum need immediate operation (thoracotomy).

A small aseptic pneumothorax of the closed variety is generally absorbed without surgical intervention.

In cases of open pneumothorax, immediate suture is advocated. Devitalised tissues are to be removed, vessels ligated and the wounds in the lung and the pleura closed air tight.

THE HEART AND THE PERICARDIUM

WOUNDS OF THE HEART

Wounds of the heart unless they are sutured within a short time of infliction are almost invariably fatal. These may be approached either by extra-pleural or transpleural route, but transpleural thoracotomy has several advantages: its rapidity; it facilitates evacuation of the pleural cavity and the resulting pneumothorax aids hæmostasis.

The incision will vary according to the site of injury but in most cases the reflection outward of a square flap containing the costal cartilages of the 4th, 5th and 6th ribs on the left side will give good exposure. During suture, the heart may be steadied by holding the apex with a pair of blunt forceps or a temporary suture; vaselined silk is the suitable material to use.

THE LUNGS

SURGICAL TREATMENT OF PULMONARY TUBERCULOSIS

Numerous operative procedures have been devised for the treatment of pulmonary tuberculosis, but three of these will be considered here: artificial pneumothorax, phrenic avulsion, and thoracoplasty.

These operations aim at immobilization of the diseased lung either by producing pneumothorax, paralysis of the diaphragm or reducing the capacity of the thorax by partial elimination of the bony constituents of the wall. Their applicability varies according to the extent and nature of the disease or the choice of the operator.

ARTIFICIAL PNEUMOTHORAX

INDICATIONS

- (1) Exudative and fibro-caseous affection of the upper two-thirds of a lung, without serious active disease of the contralateral lung, and with relatively sound pleura.
- (2) Unilateral progressive tuberculosis of pregnant women.
- (3) Dry tuberculous pleurisy.
- (4) Hæmoptysis of any serious degree.

CONTRAINDICATIONS

- (1) Active tuberculosis of the other lung.
- (2) Grave renal involvement or bilateral tuberculosis of the kidneys.
- (3) Advanced intestinal and laryngeal tuberculosis.
- (4) Advanced heart disease and diabetes mellitus.

OPERATION

The patient is placed on his side in a comfortable recumbent position with the healthier side down. The site of election, if there is no contraindication, is the posterior axillary line below the scapular angle. The patient should be warned not to move. For anæsthetizing the skin, ethyl chloride may be used. A fine needle is then introduced through the interspace and in order to avoid injury to the intercostal vessels it should be closer to the upper edge of the lower rib than to the lower edge of the upper rib. The passage of the needle through the pleura is usually felt distinctly and the fluid in the syringe now begins to run automatically into the negative pressure area of the pleural space. Usually 2 c.c., or less of a 1 per cent. percaïne with adrenalin is adequate for complete anæsthesia.

When the pneumothorax needle has entered the pleural space its stylet is withdrawn and the manometer rubber tubing connected. Negative pressure reading of the manometer, oscillating with respiration will indicate that the end of the needle is in the pleural cavity.

Air is then allowed to enter slowly and the manometer is constantly watched. A positive pressure higher than 5 mm. should never be reached. The pulse, respiration, and colour of the patient should be under constant observation.

Not more than 100 c.c. of air should be introduced at a time controlled by taking manometer readings. Any serious discomfort to the patient or any rise of positive pressure above 5 mm. is an indication to stop.

The interval between refills is to be determined by X-ray pictures and fluoroscopically. It is generally one week at first and later on as much as four weeks.

Comment :—(1) Contraindications as enumerated above should be observed. (2) The first introduction is more difficult than refills. (3) Air-embolism is a rare but dangerous accident. (4) Hæmorrhage from the injured intercostal vessels may enter the pleural space and remain undetected. (5) The liquid contents of cavities or pneumonic areas may be squeezed out into the contralateral lung or bronchi and set up an aspiration pneumonia.

PHRENIC AVULSION

See Chapter IV, p. 71.

THORACOPLASTIC OPERATIONS

Thoracoplastic operations are those which permanently reduce the volume of the lung by means of mobilization or removal of the skeletal constituents of the chest wall.

INDICATIONS

The indications for thoracoplasty may be summed up as follows :—

(1) Unilateral tuberculosis with cavities and definite sclerotic tendency, including cases with displacement of the mediastinum and its contents. (2) Inefficient and incomplete pneumothorax. (3) Recurrent pulmonary hæmorrhage. (4) Obstinate, persistent pneumothorax with effusion. (5) Tuberculous empyema including mixed infections and external thoracic fistulæ. (6) Non-tuberculous, chronic inflammation of the lungs and lung abscess. (7) Bronchiectasis.

CONTRAINDICATIONS

(1) Age over 50 or under 15. (2) Pronounced constitutional inferiority. (3) Grave diabetes. (4) Malaria. (5) Kala-azar. (6) Syphilis. (7) Severe nephritis. (8) Pregnancy. (9) Tuberculosis of other organs, such as bilateral renal tuberculosis, intestinal tuberculosis, tuberculosis of bones and joints and of the larynx and tuberculous septicæmia. (10) Circulatory diseases, such as cardiac decompensation, advanced myocarditis and secondary emphysema. (11) Respiratory diseases, such as chronic bronchitis, bronchial asthma, tuberculous pneumonia, pleuritic adhesions.

PREPARATION OF THE PATIENT

The general preparation of the patient includes the production of a certain mental and psychical attitude towards the surgeon and the operation, attention to the heart and circulation, improvement of bronchial affections and regulation of bowels.

He is prepared as for any major surgical operation and before the operation the cavities are emptied out, as far as possible, by making the patient expectorate in Quincke's position.

Anæsthesia. Regarding the selection of an anæsthetic there is much controversy. But regional anæsthesia aided by light general anæsthesia with nitrous oxide is preferable. The procedure is as follows: With sharp fine needles perineural injection of each intercostal nerve is made about 4 cm. lateral to the spine. The lower border of each rib is palpated. The needle is then inserted in a caudal direction until the bony resistance of the rib is felt. Then inclining the syringe towards the skin surface, the point of the needle is pushed to the outside of the rib, towards the lower border until the resistance of the endothoracic fascia is encountered. Now the point of the needle is in the neighbourhood of the intercostal nerve. After aspiration has excluded its presence in a vessel 5 c.c. of the solution is injected perineurally. The needle is left in situ for orientation and the next intercostal space is injected in a similar manner with a second needle; now the skin is infiltrated along the line of incision.

OPERATION

(Sauerbruch's paravertebral, extrapleural thoracoplasty)

The arm is pulled forward and toward the middle line so that the posterior border of the scapula is removed as much as possible from the spine and the posterior thoracic wall. The incision begins at the height of the 5th or 6th dorsal spine and at a distance of about three fingers' width from the spinal column. It runs in a caudal direction parallel to the spinous processes and after curving forward at the 9th rib terminates in the anterior or midaxillary line (*Fig. 138*).

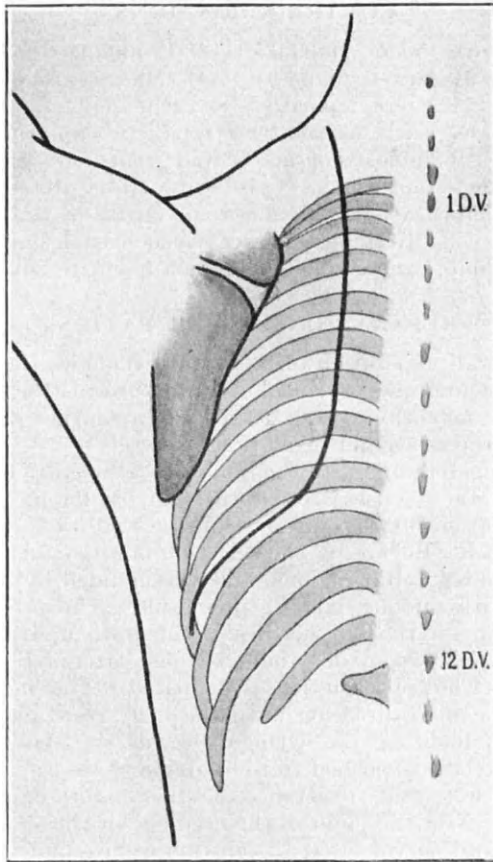


FIG. 138.

SAUERBRUCH'S PARAVERTEBRAL EXTRAPLEURAL
THORACOPLASTY INCISION.

REPRODUCED FROM 'SURGERY OF THE CHEST'
by G. F. STRAUB, M.D., F.A.C.S.

The incision penetrates all the soft tissues down to the ribs and the structures are retracted far back by means of special retractors. Bleeding vessels are clamped.

It is desirable to commence resection at the 10th rib, which is followed by rapid sub-periosteal resection of the 9th to the 5th rib (*Fig. 139*). After this, the 11th rib is cut. The entire operative field is firmly packed with gauze and compressed with the hand by an assistant. It is important that the lung be supported each time the patient coughs.

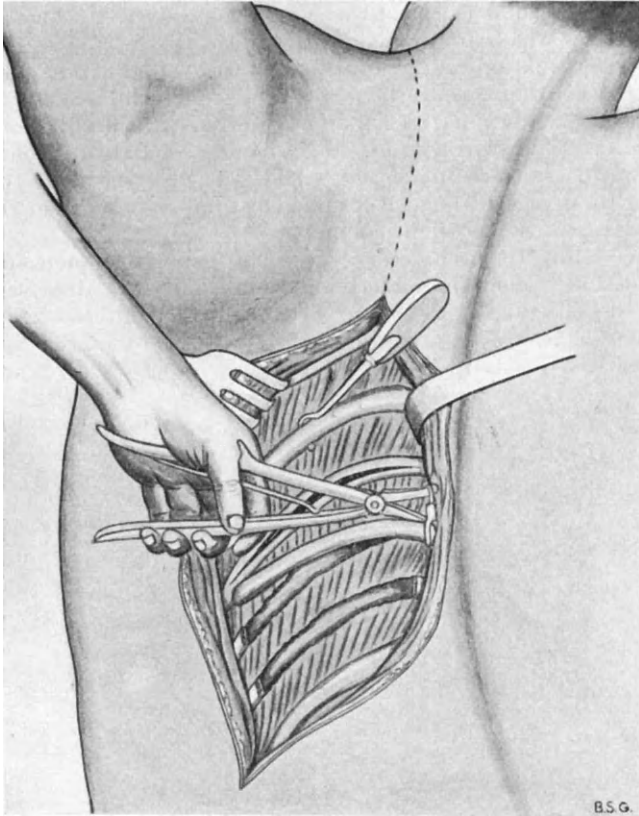


FIG. 139.

STAGES OF RIB RESECTION IN SAUERBRUCH'S PARA-
VERTEBRAL EXTRAPLEURAL THORACOPLASTY.

REPRODUCED FROM 'SURGERY OF THE CHEST'
by G. F. STRAUB, M.D., F.A.C.S.

The cutaneous incision is now prolonged in a cranial direction up to the neck line. This two-stage incision minimizes the loss of blood and shock. The fasciæ and muscles are divided and retracted with broad retractors. The scapula is thus freed along the vertebral border and may be rotated and lifted from the thoracic wall. Resection of the 5th to the 2nd rib is now carried out. The size of the resected pieces should in this instance amount to at least 6-8 cm. each, if the seat of the disease is chiefly in the upper lobe. Resection of the first rib comes last (*Fig. 140*). It is advisable to prolong the incision into the anterior surface of the trapezeus muscle and to lift the upper border of this muscle.

This divides two branches of the superficial cervical and transverse colli arteries which are ligated.

Strong traction on the upper end of the wound exposes the first rib with the insertion of the scalenus anterior, subclavian artery, and nerve plexus. By means of a special instrument (Lilienthal's) a piece of the first rib 3 cm., long is resected and any remaining vertebral portions is further shortened. The soft parts are pushed back with a periosteal elevator and the stumps of the other ribs are excised up to the vertebral column.

According to circumstances the soft parts are then stripped extrapleurally from the underlying pleura and after dissection are removed. In doing so, the larger vessels, the intercostal artery and vein may be spared or they may be treated by double ligation. The nerve is resected.

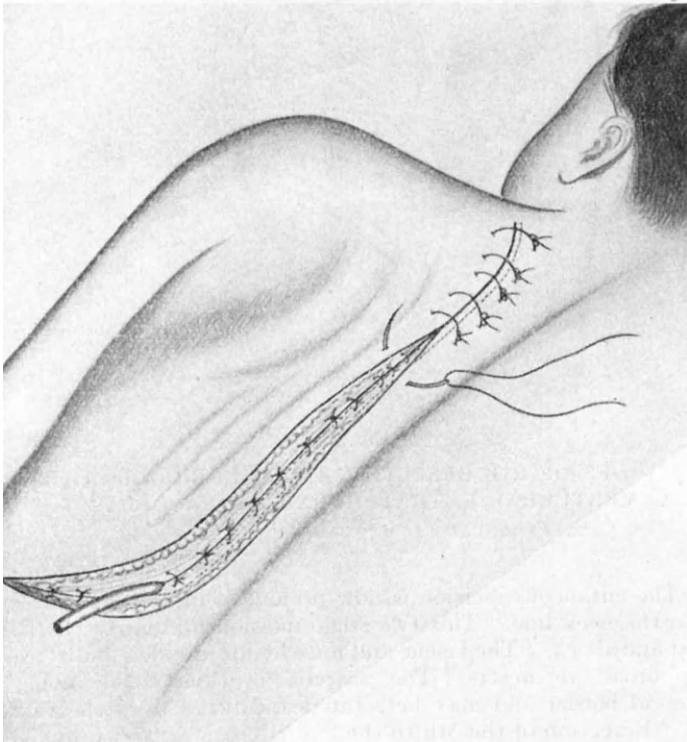


FIG. 141.

CLOSURE OF THE WOUND AND DRAINAGE.

REPRODUCED FROM 'SURGERY OF THE CHEST'
by G. F. STRAUB, M.D., F.A.C.S.

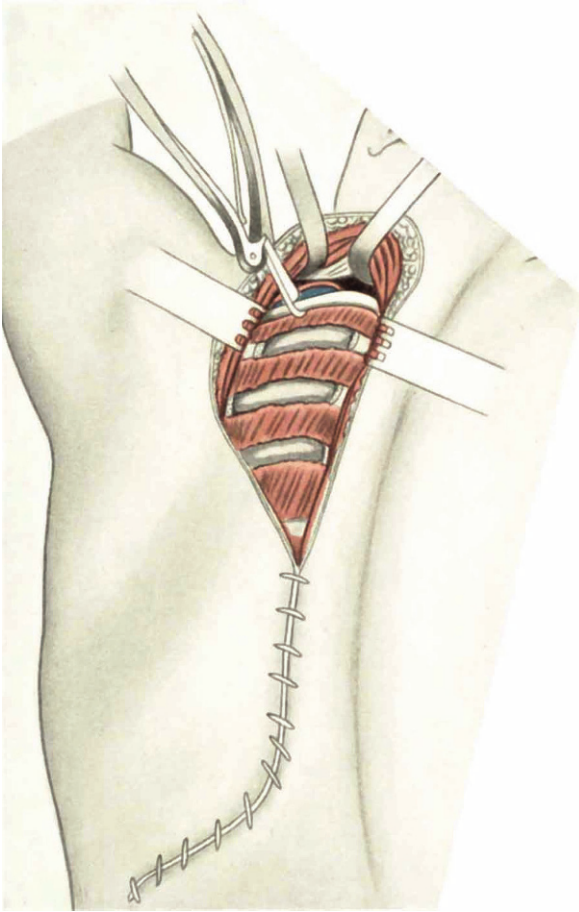


FIG. 140.

SAUERBRUCH'S PARAVERTEBRAL EXTRAPLEURAL
THORACOPLASTY: Resection of the first rib.

REPRODUCED FROM 'SURGERY OF THE CHEST'
by G. F. STRAUB, M.D., F.A.C.S.

With a heavy long needle the cut musculature is then reunited along with the fascia. In the upper part of the wound where the thick layer of scapular muscles was divided two layers of suture are recommended.

A long perforated drain is carried up to the neighbourhood of the first rib all through the wound and left to protrude at the lower end of the incision. This is followed by cutaneous suture and a compression bandage (*see Fig. 141*).

EMPHYEMA

See Chapter X, p. 171.

PARACENTESIS PERICARDII

INDICATION

Puncture of the pericardium is chiefly done for diagnosis and sometimes therapeutically for the withdrawal of fluid in hæmopericardium or hydropericardium. In pyo-pericardium, pericardiectomy should preferably be performed.

POSITION

Supine, preferably with a cushion under the back.

SITES OF PUNCTURE

The different sites of puncture are shown in the diagram which depict these more clearly than would a descriptive note (*Fig. 142*).

OPERATION

A preliminary incision on the site of puncture is preferred. Grasping the needle with right forefinger and thumb pierce the intercostal space near the left border of the sternum, penetrate straight backwards for about $\frac{5}{16}$ of an inch (thickness of sternum), then penetrate inwards towards the posterior surface of the sternum for about $\frac{3}{4}$ to $\frac{13}{16}$ of an inch, thence downwards and inwards through the pericardium.

Comment.—The dangers and accidents of pericardiocentesis are: (1) Dry puncture. (2) Aspiration of pleural instead of pericardial fluid. (3) Puncture of the heart. (4) Puncture of the pleura. (5) Puncture of the lung. (6) Wounding the internal mammary vessels. (7) Sudden death (reflex).

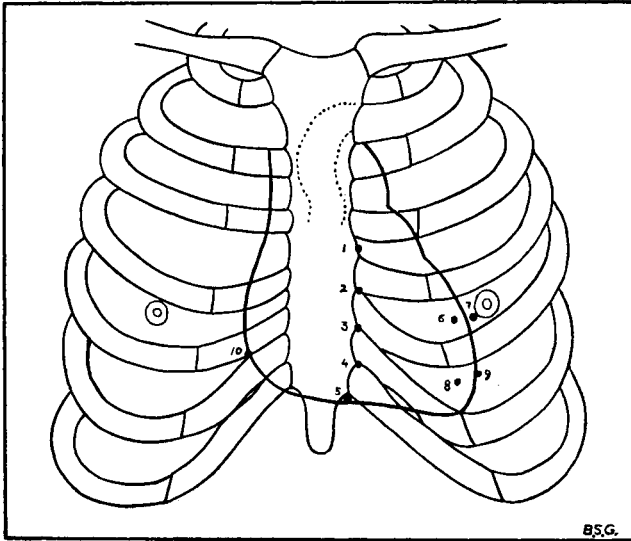


FIG. 142.

POINTS OF ELECTION FOR PERICARDIOCENTESIS:—1, Sharp, Schub. 2, Champouillon, Karanajew, Pirogoff, Trousseau. 3, Aran, Roger, West, etc. 4, Delorme, Hare, etc. 5, Allingham, Kehrer, Roberts, etc. 6 & 8, Dieulafoy, Rosenbach, etc. 7 & 9, Curschmann. 10, Rotch, Wilson, etc.

PERICARDIOTOMY

Pericardiotomy is usually performed for the purpose of evacuating purulent pericardial fluid, for the establishment of drainage after such evacuation, for exploration, for the removal of foreign bodies or the repair of wounds. There are many methods but one only will be described.

OPERATION

Incision.—Directly in a line with the centre of the 5th costal cartilage, beginning over the centre of the sternum and ending just beyond the chondrocostal articulation.

Incise skin, superficial fascia, pectoralis major and deep fascia down to the 5th costal cartilage. Divide the sternal and costal ends of the 5th cartilage preferably with a Gigli saw. Ligate the intercostal vessels at both ends of the wound and divide them between the ligatures. Divide tissues which intervene between the cartilage and internal mammary vessels. Cut internal mammary artery between ligatures and draw it outward. Incise triangularis sterni (transversus thoracis) if necessary. Displace the pleura

outwards after careful separation from the pericardium and sternal structures.

The pericardium is now exposed. It is steadied between two toothed forceps and carefully incised obliquely downwards and outwards. The external wound is sutured in greater part and drainage provided from the interior of the pericardium through the part of the thoracic wound left open.

OPERATIONS ON THE ŒSOPHAGUS

Operations on the œsophagus may be undertaken for congenital malformations, injuries, foreign bodies, inflammatory conditions, stricture, dilatation, diverticula and neoplasms.

In congenital malformations the outlook for relief is not very poor. Being devoid of scar tissue, congenital strictures yield fairly easily to dilatation or division through the œsophagoscope (knife, cautery or electrolysis) and do not have much tendency to recur.

Œsophageal injuries are often associated with injuries of other thoracic structures and are therefore often fatal. Treatment should be outlined according to the nature of injuries sustained.

Foreign bodies can generally be easily extracted. In some cases external œsophagotomy may be required.

Strictures and stenosis (intrinsic and extrinsic) may be congenital, inflammatory, spastic or due to scars or neoplasms. The usual locations are near the physiological isthmuses,—level of the larynx, bifurcation of trachea and hiatus in the diaphragm.

Strictures may be dilated or divided. Dilation is done by means of bougies. Treatment of strictures of the œsophagus is protracted and complicated therefore a preliminary gastrostomy is performed to feed the patient through the opening, which is also sometimes utilized for the subsequent operation of division of the structure by Abbe's string. Strictures due to malignant infiltration of the œsophagus may be temporarily relieved by intra-œsophageal application of radium.

SURGICAL APPROACH TO THE ŒSOPHAGUS

The surgical approach to the œsophagus will vary according to the location of the injury or disease. If the pleura is uninjured, posterior extrapleural mediastinotomy at the level of the injury is indicated. In cases of accompanying traumatic pleurisy, the transpleural route is preferable. The upper portion of the œsophagus can also be reached through an incision in the neck (external cervical œsophagotomy).

External Œsophagotomy

The patient's shoulders are elevated and the face is turned to the right. Incision starts from the level of the thyroid cartilage

downwards along the anterior border of the left sternocleidomastoideus (*Fig. 143*). The platysma, fasciæ of the neck and

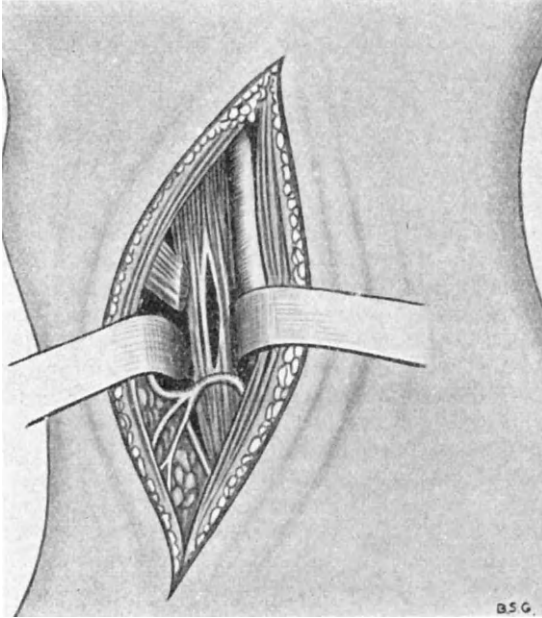


FIG. 143.

EXTERNAL OESOPHAGOTOMY.

REPRODUCED FROM 'SURGERY OF THE CHEST'
by G. F. STRAUB, M.D., F.A.C.S.

the omohyoid are divided. The thyreoid and the trachea are retracted to the right and the vessels of the neck to the left. It is often necessary to sever the sternal attachment of the sternocleidomastoideus. This results in exposure of the oesophagus.

CHAPTER XVI

OPERATIONS ON THE BREAST

SURGICAL ANATOMY

The female breast consists of the parenchyma or gland tissue supported by a stroma or connective tissue framework and the circummammary fat. These three collectively form corpus mammæ or the mammary gland. It is embedded in the superficial fascia of the chest-wall. It extends vertically from the lower border of the second rib to the lower border of the sixth costal cartilage, and horizontally from the edge of the sternum to the mid-axillary line. The pectoral fascia separates it from the pectoralis major (partly), pectoralis minor, serratus anticus and obliquus externus muscles.

It receives its blood supply from the thoracic branches of the axillary and perforating branches of the internal mammary and intercostal arteries.

The lymph vessels are arranged in two groups, the cutaneous and the glandular. The cutaneous group arises from two plexuses, the subareolar plexus (Sappey) in the central part and the fascial plexus in the peripheral part. The glandular lymphatics arise from the perilobular connective tissue and following the course of the milk-ducts enter the subareolar fascial plexus of the skin. The lymphatics anastomose freely with the neighbouring lymphatics; this fact explains the spread of breast cancer to other parts. For instance, in the middle line, the lymphatics anastomose with those of the opposite side. In the epigastric region they communicate with the lymphatics of the parietal wall and parietal peritoneum. Some lymphatics accompany the intercostal vessels. The lymphatic vessels pass in different directions to various glands, namely the axillary gland along axillary vessels; the pectoral glands between the pectoral and serratus anticus muscles on the anterior border of axilla; the subscapular glands along the posterior border of axilla, the infra-clavicular, supra-clavicular, sternal and mediastinal glands.

SUPPURATIVE MASTITIS OR MAMMARY ABSCESS

Mammary abscesses may be grouped into three classes according to their situation. A *pre-mammary abscess* is a collection of pus under the areola. It is a superficial abscess and should be treated by a simple incision in a radiating manner. An *intra-mammary*

abscess lies in the substance of the breast and may burrow in different directions to form a multilocular abscess cavity. These abscesses are not infrequently seen in both the breasts.

Retro-mammary abscess is a collection of pus in the areolar tissue between the breast and the pectoral muscles.

OPERATION

A free incision radiating from the nipple, with counter-openings for free drainage; any septa inside the abscess cavity should be broken down with the finger. The ducts must not be cut across. In some cases with sinuses, etc., it may be necessary to excise a wedge-shaped segment of the breast including the sinuses; if the breast is much disorganized its complete excision may be necessary.

A retro-mammary abscess is opened by a free incision in the mammary-thoracic fold.

EXCISION OF THE BREAST

The radical operation for breast cancer entails the removal *en masse* of the following tissues: (a) the entire mammary gland with a sufficient amount of overlying skin; (b) an extent of the deep thoracic fascia limited above by the clavicle, internally by the mid-axillary line, below to the tip of the ensiform cartilage; (c) sterno-costal portion of the pectoralis major and pectoralis minor muscles; (d) the lymphatic glands, fat and connective tissue extending below from the axilla surrounding the vessels and nerves to beyond the first rib, where the axilla communicates beneath the clavicle with the root of the neck.

INSTRUMENTS—Group II.

POSITION

Dorsal position. Raise shoulder slightly and support them by a sandbag, the arm being abducted to a right angle. The operator stands on the side to be operated, between the arm and the trunk, the assistant stands opposite to him on the other side of the arm near the shoulder.

OPERATION

The operation will be described in six stages:—

(i) *The skin incisions.*—The incision takes the shape of an ellipse with two limbs at its far ends. The upper of the two limbs is extended upwards and outwards in a curved direction over the anterior axillary fold to the upper part of the arm. The lower limb is prolonged downwards and inwards to a point in the middle line, about two inches below the tip of the ensiform cartilage. The shape of the ellipse proper is fashioned according to the particular

quadrant of the breast that is involved in the growth. These incisions cut into the skin and subcutaneous fat (*Fig. 144*).

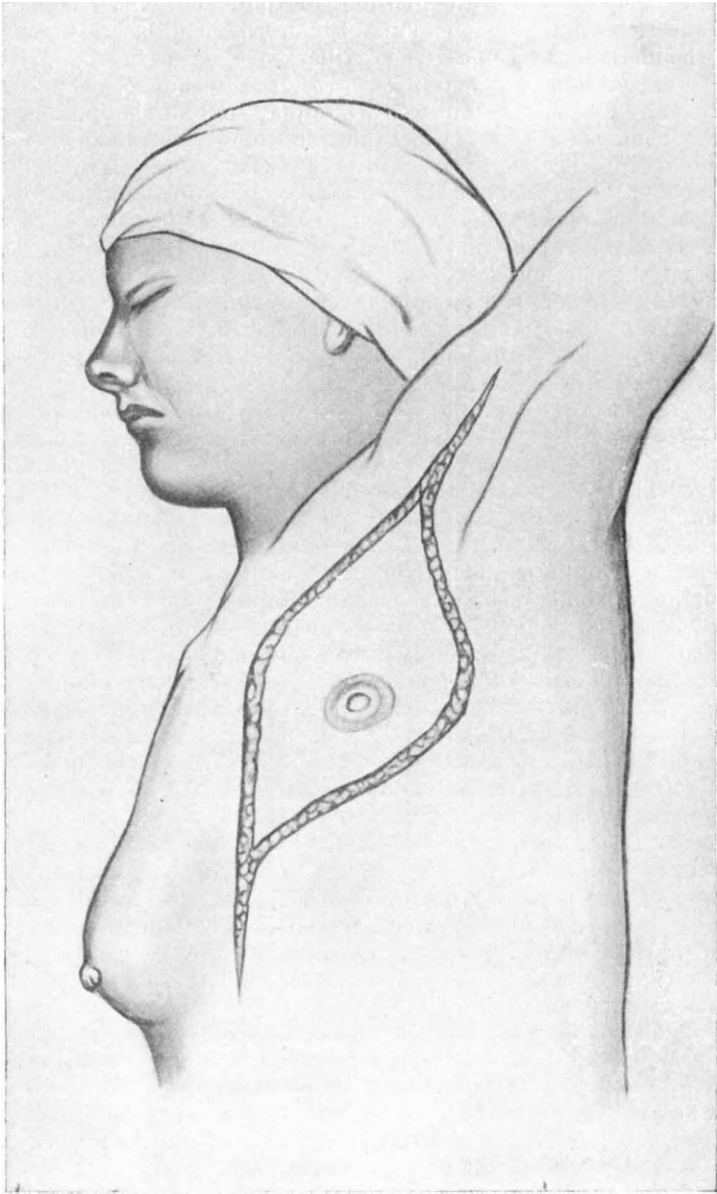

FIG. 144.
EXCISION OF THE BREAST.

(ii) *Exposure of the axilla and its contents.*—Reflect the skin over the axilla with the subcutaneous fatty tissue by dissecting down from the lower limb of the incision. Expose and define the margin of the latissimus dorsi tendon. Divide the deep fascia in the line of the incision ; this exposes the axillary vessels and brachial nerves.

(iii) *Exposure of the inner area and division of the pectoral muscles.*—Reflect the skin from the upper limb of the incision in a similar manner. This exposes the area from subclavicular region to mid-sternal line. Define the interval between the clavicular and costo-sternal portions of the pectoralis major, introduce the index finger from below, underneath the pectoralis major, between it and the axillary vessels and divide the muscle close to the humerus ; retract the cut muscles towards the chest. The pectoralis minor and the costo-coracoid membrane are brought into view ; introduce the index finger under this muscle and divide it close to its insertion into the coracoid process. The axilla is now exposed in its full extent.

(iv) *Clearing of the axilla of connective tissue, lymphatics and lymphatic glands.*—The axillary vessels and large nerve trunks are invested by a quantity of loose fatty tissue and a membranous layer which forms a sheath containing numerous lymphatic vessels. Commencing at the outermost part of the wound, strip this membrane, taking with it the loose axillary tissue, the lymphatics and the lymphatic glands, off the nerves and vessels. This is best done by blunt dissection and gauze-wiping. Branches of axillary vessels as they come have to be divided and secured. On reaching the apex of the axilla, glands will be found in relation to the axillary vein, another chain of glands will be found behind the main vessels in the space between the subscapularis, externally and serratus magnus, internally ; all these glands have to be included in the entire mass which is dissected out from the axilla. This mass with the two pectorals which have been divided are drawn inwards. The clearing of the axilla is now complete.

(v) *Detachment of the breast together with its investing fatty tissue, the pectoral muscles and the deep fascia.*—The assistant draws up the dissected mass with the breast towards the middle line. Commence by reflecting the superficial tissues at the outer side of the elliptical incision. Carry the knife deeply into the fatty tissue to make sure that no portion of the mammary gland tissue is left behind ; undercut this flap up to the mid-axillary line in such a manner that the deep fascia covering the serratus magnus and the upper digitations of the external oblique are exposed. Turn to the sternal side of the incision. The assistant carries the breast across to the outer side, detach the superficial tissues from the infra-clavicular and upper sternal regions downwards and towards the mid-sternal line. Put the forefinger in the interval between the two divisions of the pectoralis major which has already been defined, and divide this muscle from its costo-sternal attachments close to

the sternum. The assistant draws all the divided structures with the breast further away from the chest-wall. Divide the attachments of the pectoralis minor to the third, fourth and fifth ribs. To free the breast from the chest, detach the deep fascia from the underlying muscles, namely serratus magnus, external oblique and rectus abdominis as far down as the lower limit of the incision in the substernal region.

(vi) *Apposition of the skin*.—This operation leaves rather an enormous wound and the edges of the skin can hardly be brought together; much can be done, however, by under-cutting the skin all round and by bringing the arm to the side.

Comment.—(1) *Hæmorrhage*. A large number of vessels are cut in this extensive operation. In the second and third stages, the axillary vein must be carefully guarded; if it is hopelessly adherent to the glands a portion of it may have to be excised under compulsion. The knife should be sparingly used. Wiping with gauze-covered fingers is less risky. Near the costo-coracoid membrane some branches of the thoracic axis are cut. In the fourth stage, some branches of the axillary vessels from the main trunk have to be divided. In the fifth stage some vessels have to be cut during deep dissection at the outer side of the elliptical incision. At the costo-sternal junction, perforating branches of the internal mammary artery are divided. In the living subject they are liable to retract, so they should be clamped before division. (2) *Nerves*. The brachial cords and their larger branches should not be injured. In the fourth stage, the posterior thoracic nerve supplying the serratus magnus and in relation to its outer surface and the long scapular running along the posterior wall of the axilla to pierce the latissimus dorsi, should be preserved. The intercosto-humeral nerve may have to be cut. (3) Throughout the operation keep rigidly clear of mammary gland substance.

PARTIAL EXCISION OF THE BREAST

In cases of (*a*) localized mastitis of parenchymatous or interstitial variety; (*b*) localized tuberculous deposits; (*c*) simple cysts or non-malignant tumours of the breast which have been confirmed by diagnosis, the tumour can be excised or the whole of the mammary gland may have to be removed. This can be performed by an incision preferably on the inferior aspect of the breast. If the whole breast has to be removed it can be done by an incision round the outer limit of the breast and removing the gland without interfering with the fascia and muscles.

CHAPTER XVII

ABDOMINAL OPERATIONS

LAPAROTOMY : CELIOTOMY—(ABDOMINAL SECTION)

SURGICAL ANATOMY

The *linea alba* extends from the ensiform cartilage to the symphysis pubis in the middle line of the abdomen. On either side of this line are the recti muscles. The outer border of these muscles on either side are represented by two lines, *lineæ semilunares*, slightly curved outwards. They extend from the seventh rib down to the spine of the pubis. In the umbilical line the distance between the *linea alba* and *lineæ semilunares* is about three inches.

The disposition of parietal layers in the space between the *lineæ semilunares*, taken from before backwards is as follows : In the upper three-quarters are the external oblique, the anterior tendon of the internal oblique, the rectus, the posterior tendon of the internal oblique, the transversalis tendon, fascia transversalis, subperitoneal areolar tissue and peritoneum. In the lower quarter all the tendons pass in front of the rectus so the arrangements here would be, the tendon of the external oblique, internal oblique, the transversalis, then the rectus muscle, transversalis fascia, the subperitoneal areolar tissue and peritoneum. Further out than this area, i.e. beyond the *lineæ semilunares*, the layers of muscles of the parieties are arranged from before backwards as follows : The external oblique, the internal oblique and transversalis, then the transversalis fascia, subperitoneal areolar tissue and the peritoneum.

The disposition of the fibres of the muscles are as follows : The external oblique muscle has its fibres directed downwards and inwards. They are muscular above the level of the anterior superior iliac spine and are tendinous below it. The fibres of the internal oblique are generally directed upwards and inwards with the exception of the portion which is below the level of anterior superior spine of the ilium ; in this portion the fibres follow the direction of those of the transversalis muscle. The fibres of the transversalis muscle are directed transversely inwards towards the middle line except in the lower portion where in combination with lower fibres of the internal oblique they arch downwards and are inserted in the pubis. The anterior sheath of the rectus is formed above by the blending of the aponeurosis of the external oblique and outer lamella of the internal oblique, below by the blending of the aponeurosis of the two oblique muscles and transversalis. The

posterior sheath above by blending of inner lamella of internal oblique and transversalis and below semilunar fold of Douglas by the transversalis fascia only.

The opposing muscles are : the recti opposing the erector spinæ and the obliques opposing the diaphragm ; the latter muscles help to maintain intra-abdominal pressure, the aponeurotic part of these muscles direct a constant pull in a transverse direction. The direction of the pull on the rectus muscle itself is vertical and its sheath transverse.

THE VESSELS

The abdominal parieties are supplied by three groups of vessels, which anastomose freely with one another but slightly with those of the opposite side. Group I.—Running forwards are the two lower intercostals, the subcostal and the lumbar arteries. They lie between the transversalis and the internal oblique with the nerves. Group II.—The superior epigastric artery runs downwards and lies in the substance of rectus muscle. Group III.—The deep epigastric artery arises from the external iliac just above the Poupart's ligament, runs upwards and inwards to the inner side of internal abdominal ring and the spermatic cord to enter the sheath of the rectus. The deep circumflex iliac artery arises on the same level as the last one, runs upwards and outwards behind the Poupart's ligament, along the crest of the ilium, till it reaches the anterior superior iliac spine where it sends an ascending branch which lies between the internal oblique and transversalis.

THE NERVES

The abdominal parieties are supplied by seven sets of nerves namely, the lower six intercostals and the ilio-hypogastric. The seventh nerve emerges from the tip of the costal cartilage at the outer border of the rectus and 4 inches below upper limit of its sheath. The remaining nerves run in loops between the internal oblique and transversalis at regular intervals and enter the sheath of the rectus, the tenth nerve entering at the level of the umbilicus and the anterior branch of the twelfth (last dorsal) is distributed midway between the umbilicus and pubis. The ilio-hypogastric branch of the first lumbar runs in front of quadratus lumborum to iliac crest passing between transversalis and internal oblique ; its hypogastric branch pierces internal oblique and aponeurosis of external oblique just external to the abdominal ring and supplies the skin of that region.

The upper four inches and the whole of the inner half of the rectus are devoid of main nerve trunks. The seventh and eighth intercostals run upwards and inwards and supply upper third of the abdominal wall ; ninth and tenth run transversely inwards and supply the middle third ; the ilio-hypogastric and ilio-inguinal run

downwards and inwards and supply the lower part, and the ilio-inguinal regions.

INSTRUMENTS—Group XIII.

INCISIONS FOR LAPAROTOMY

1. *The median incision* above or below the umbilicus has the advantage of being almost bloodless, cutting no muscle fibres, injuring no nerves and giving access to both sides of the abdomen. Above the umbilicus the incision through the linea alba directly exposes transversalis fascia. Below the umbilicus on the other hand, the linea alba becomes an intermuscular septum between the two recti and the median incision exposes the edge of one or the other of these muscles. This is the classical method of opening the abdomen, but if precautions are not taken it is often followed by a ventral hernia.

2. *The para-median incision* (incision through rectus sheath and muscle) is made at one or the other side of the median line. After incision of the anterior layer of the rectus sheath, the muscle is split in the vertical direction exposing the posterior sheath. This is opened and the peritoneum reached in the usual way. In closure, the edges of the incision come together readily, and the wound heals with a strongly resistant scar which minimizes the risk of post-operative hernia. The chief advantage of this incision over those in the lateral rectus margin with mesial retraction of the muscle, is that the nerve supply of the rectus is not endangered and that it affords good access to structures near the median line.

3. *The para-rectal incision* in the semilunar line divides the aponeurosis of the flat muscles above described in a direction which is against the fibres of the muscles. This is destructive to the muscle fibres as well as the nerves supplying the rectus and should be avoided whenever possible (*vide supra*). Battle's incision for appendix lies along this line.

4. *An oblique incision* by a typical 'muscle-splitting' method is very useful in the lower part of the abdomen. The skin is incised in the direction of the fibres of the external oblique. This muscle thus exposed is split between its fibres and retracted. The internal oblique which is now exposed is treated in a similar manner by splitting its fibres and the transversalis is opened with it. Thus the transversalis fascia is reached. This and the peritoneum are divided in the manner described below. A classical example of this incision is that of Macburney (gridiron) incision for appendix.

5. *Iliac incision*.—An incision parallel to and in front of the anterior portion of the iliac crest is usually employed to reach the extraperitoneal structures at or below the pelvic brim.

6. *Oblique subcostal incision*.—An oblique subcostal incision carried from the xiphoid process laterally across the rectus sheath

and across the lateral abdominal aponeurosis affords excellent access to the gall-bladder, bile passages and the inferior surface of the liver. The incision need divide no nerves which supply the rectus except the ninth thoracic, which lies almost directly in its course if the incision is extended. A supposed contraindication to this incision is the section of the rectus muscle but it is also maintained that a transverse rectus incision in healing leaves merely an added tendinous intersection which does not weaken the muscle.

7. *Pfannenstiel incision.*—It is a suprapubic, superiorly convex, transverse incision along the pubic hair line. The superficial layers and the anterior sheaths of the recti are incised transversely. The recti are displaced laterally and the abdomen is opened through the posterior sheath and the peritoneum. No nerves are cut and no visible scar remains after healing. This is an ideal incision for gynæcological operations particularly in obese patients.

8. *Lumbar incision.*—An incision 10 cm. long between the last rib and middle of the crest of the ilium along the outer edge of the quadratus lumborum is usually enough for delivering a not too enlarged kidney. If necessary, the incision can be prolonged along the iliac crest.

These are the standard incisions. Special incisions for easy access to various abdominal organs will be described with the description of those operations.

Comment.—In opening the abdomen the following rules should be observed: (1) The incision should be so placed that the object for which the operation is being performed is most easily attained. (2) Large (motor) nerves and blood-vessels should be avoided. (3) It is generally maintained that whenever possible the muscles should be split between their fibres and not cut across. Blunt dissection with a dissector or the fingers is better than free use of the knife. (4) The different layers of the wall should be divided from end to end of the skin wound. (5) The transversalis fascia and the peritoneum are opened by picking them up with forceps, holding the knife in the violin-bow position: these structures should be divided by cutting them between your fingers with blunt pointed scissors.

Closure of an abdominal wound.—Three layers of sutures should be employed. The first layer approximates the peritoneal margins which may include the posterior rectus sheath, if the incision has been made through it; interrupted or continuous sutures of some absorbable material is the best. The second layer passes through the linea alba, the sheath of the rectus or other aponeurosis, taking the transversalis fascia in the deeper part. The third layer

apposes the integument. In other situations, the peritoneum is sutured by continuous stitches and the muscles and fascia in layers by interrupted stitches as described later.

PARACENTESIS ABDOMINIS

Puncture of the peritoneal cavity is done for diagnostic purposes or for the evacuation of peritoneal fluid. The site is generally the linea alba midway between the umbilicus and symphysis pubis. It can also be done in the semilunar line or midway between the anterior superior iliac spine and the umbilicus. Before the trocar is introduced the skin should be punctured by a stab incision. If paracentesis is done in the linea alba the patient should sit upright, since, in that position, the fluid gravitates to the lower abdomen and pelvis.

CHAPTER XVIII

ABDOMINAL OPERATIONS—(Contd.)

INTESTINAL SUTURES

In closing an opening in the intestine the mucous and the muscular walls should be first apposed, these should be inverted or invaginated into the lumen of the gut. This brings the contiguous serous coats together ; the most important part in suturing lies in bringing the serous surfaces into an accurate and permanent apposition. This can be achieved by one of the following methods :—

1. LEBERT SUTURES

This is an interrupted suture and introduced on the transverse axis of the gut about one-eighth inch away from the cut margin and brought out again one-sixteenth inch from the same margin. This is then carried across to the opposite side of the wound, introduced at about one-sixteenth inch away from its margin and brought out again one-eighth inch from the same margin. These sero-muscular non-penetrating sutures pass through all the coats except the mucosa (*Fig. 145*).

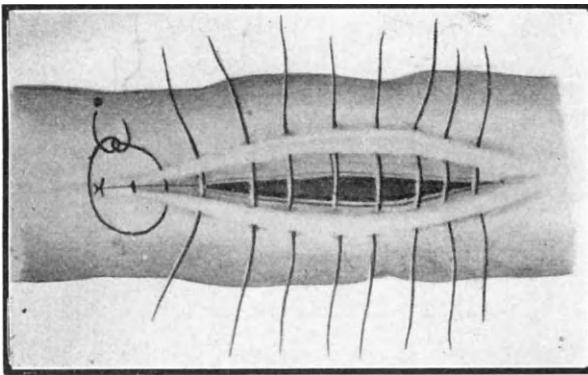


FIG. 145. LEBERT SUTURES.

2. CZERNY-LEMBERT SUTURES

In the Lembert suture the mucous and the muscular coats are not apposed separately ; in Czerny-Lembert method the mucous membrane is first united by a continuous penetrating suture and then the anastomosis is completed by Lembert sutures (*Fig. 146*).

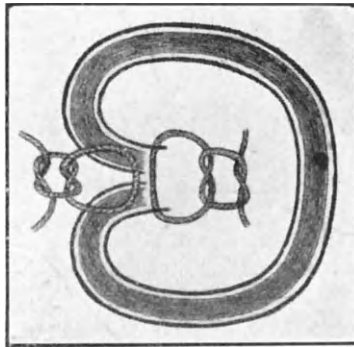


FIG. 146. CZERNY-LEMBERT SUTURES.

3. DUPUYTREN SUTURE

Dupuytren suture consists of continuous Lembert sutures.

4. HALSTEAD SUTURE

Halstead suture is a Lembert suture introduced in the mattress fashion.

5. CUSHING SUTURE

Cushing suture consists in passing the needle in the Lembert fashion but parallel to and not in a direction transverse to the long axis of the wound in the gut.

6. PURSE-STRING SUTURE

Purse-string suture is used for (i) drawing the intestine tightly round a Paul's tube or Murphy's button, (ii) invaginating the stump of the appendix after appendicectomy, (iii) closing an opening in the wall of the gut, and (iv) closing the ends of the divided intestine. This sero-muscular suture is made by carrying a continuous Lembert (Dupuytren) suture circularly round the entire circumference of the opening through the serous and muscular coats (*see Fig. 71*). It is placed a quarter of an inch to half an inch away from the central opening. The ligatured stump or central opening is pushed in while the purse-string suture is tightened by its free ends. This invaginates the stump and closes the suture line concentrically on it, bringing the serous surfaces effectively into close apposition. Finally, the suture is secured by a double knot.

INTESTINAL ANASTOMOSIS

INDICATIONS

One part of the intestine is joined to another in the following conditions :—

1. In order to bring about short-circuiting of the intestinal contents by excluding an obstructed portion of the gut, a part of the intestine proximal to the obstruction is opened and connected to a similar opening in the intestine distal to the obstruction. This is generally done in cases of obstruction to the passage of the contents due to adhesions, kinking, tumours, etc.

2. In cases where a portion of the intestine has to be resected, the proximal and distal cut ends of the gut are shut off by sutures, and lateral anastomosis is then performed.

The indications for resection of intestine are : (a) Gangrene due to strangulation, external or internal. (b) Wounds of the intestine due to gunshot, stabs, etc., or severe transparietal contusions of the gut. (c) Strictures of the intestine. (d) New growths. (e) Irreducible intussusceptions. (f) Some cases of volvulus. (g) Mesenteric growths. (h) For the cure of certain cases of fœcal fistula and artificial anus.

Intestinal anastomosis can be performed by one of the following methods :—

1. Lateral anastomosis.
2. End-to-end anastomosis.
3. End-to-side anastomosis or termino-lateral junction.
4. Anastomosis by means of artificial appliances.

I. LATERAL INTESTINAL ANASTOMOSIS

Two conditions are necessary, viz. the portions of intestine to be united should be freely movable and the waves of peristalsis should be in the same direction, i.e. they should be iso-peristaltic.

INSTRUMENTS—Group XIII.

OPERATION

This can be described in five stages :—

1. *Approximation*.—Bring the loops of the gut outside the parietal wound; place them together in iso-peristaltic direction. Empty the parts by milking away the contents and apply intestinal clamps to keep them empty for about five inches.

2. *Posterior sero-muscular suture*.—Unite the loops by Cushing or continuous Lembert sutures parallel to and not far from the

mesenteric border and leave the tail end of the thread long and the other end with the needle still threaded (*Fig. 147*).

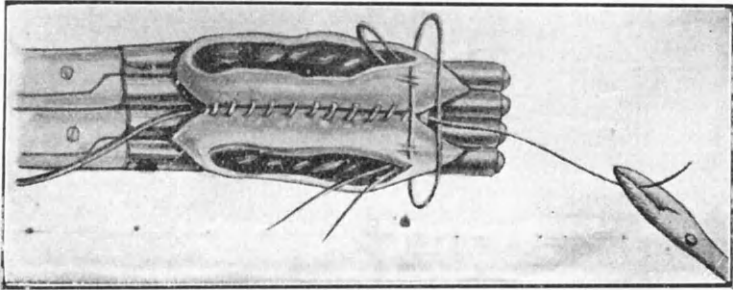


FIG. 147.

3. *Opening the gut*.—Make openings in the loops an inch shorter than the sutures and at a safe distance from them (*Fig. 147*).

4. *Intestinal junction*.—Unite the corresponding cut edges in the gut by continuous sutures taking in all the coats (*Fig. 148*).

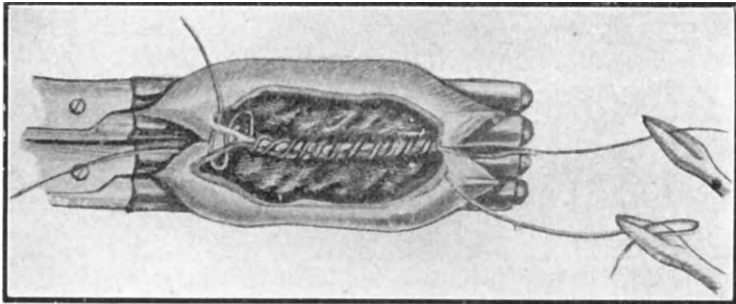


FIG. 148.

5. *Anterior sero-muscular suture and completion of anastomosis*.—Continue the posterior row of Cushing or Lembert sutures completely round the site of the anastomosis (*Fig. 149*).

6. *Examine the line of sutures*, put one or two sutures in doubtful spots, remove the clamps and return the gut into the abdomen.

II. END-TO-END ANASTOMOSIS

In this method the two transversely cut ends are brought together and sutured.

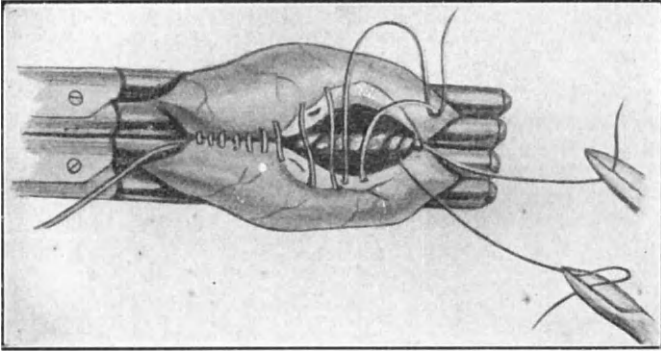


FIG. 149.

INSTRUMENTS

As for previous operation.

OPERATION

The portion of the gut is brought out of the abdominal wound and clamped.

1. *Mesenteric Section.*—A V-shaped portion of the mesentery is marked out. The apex of the V is ligatured and tied, taking care not to obstruct the arterial supply to the mesentery. The V-shaped portion of the mesentery is now excised after ligaturing a few more smaller vessels.

2. *Resection of the gut.*—The gut is now divided on each side near the clamp in a slightly oblique fashion, so that more is removed from its convex than its mesenteric border.

3. *The intestinal junction.*—The open extremities of the gut are brought alongside each other. The first line of suture penetrates all the coats of the bowel close to the cut margin. This is done by a continuous suture running round the entire circumference of the gut. Care should be taken in approximating portions of the gut which have mesenteric attachments to provide against any leakage. Remove the clamps. Any unsecured vessels may be controlled by an additional under-running stitch.

4. *The sero-muscular suture.*—This is a continuous sero-muscular Cushing suture and includes the adjacent layers of the mesentery which may have formed a triangular gap at the mesenteric border. This inverts the first line of suture and brings the serous surfaces into contact.

5. *A non-penetrating suture* may then be taken all round the bowel.

III. END-TO-SIDE, ENDO-LATERAL ANASTOMOSIS OR TERMINO-LATERAL JUNCTION

The open extremity of the lower (transversely cut distal) segment is closed and the similar proximal segment is implanted into a lateral opening in a distal portion lower down.

IV. ANASTOMOSIS BY MEANS OF ARTIFICIAL APPLIANCES

Various appliances have been devised with a view to facilitate the junction of divided segments of the bowel such as Murphy's button, bone rings, bobbins, etc.

Murphy's (metallic) button consists of two halves ; the male half is heavier of the two as it contains a spring and a flange ; this should always be inserted into the distal part of the intestine to facilitate its escape with faeces. Purse-string sutures are inserted round the divided ends of the gut. The female half of the button is introduced into the proximal end of the intestine and the suture is pulled tight and tied. The male half is likewise fixed into the distal end of the gut. The two halves of the button are then pushed together gently and steadily till they are clamped. A few supporting Lembert sutures may be introduced round the button.

Comment :—Comparison of the merits of different methods of anastomosis :—

(a) Lateral anastomosis is preferred for the following reasons : (1) The union is made through a part of the bowel which has complete peritoneal covering and therefore ensures strong and early adhesions. (2) The incision in the bowel is made at some distance from its mesenteric attachment and therefore bleeding is slight and circulation of the intestine is not interfered with. (3) It is easy to perform, particularly if it is done by Halstead's method. (4) The avoidance of the mesenteric border of the bowel obviates any risk of extravasation. (5) The opening in the bowel can be made of sufficient length to ensure a better channel of communication between the proximal and distal ends.

(b) End-to-end anastomosis has certain disadvantages : (1) Nearly half an inch of the circumference of the gut at the mesenteric attachment is devoid of peritoneum, consequently this is a weak point in the union. (2) Stricture is more likely to result. (3) It is more difficult to perform. (4) If a portion of small intestine, which has a smaller calibre, is to be united

to the colon which has a larger calibre, the operation is still more complicated.

(c) Murphy's button method has the following objections: (1) The apposed surfaces may get gangrenous and the button may perforate through the wall of the gut. (2) The opening, left after the Murphy's button has travelled down, may become very small or even disappear. (3) The button after having got loose may get impacted lower down especially at the ileo-cæcal valve causing intestinal obstruction. The only point in its favour is the rapidity with which operation can be performed.

CHAPTER XIX

THE PERITONEUM, MESENTERY AND OMENTUM

THE PERITONEUM

GENERAL CONSIDERATION AND SURGICAL ANATOMY

The disposition of the peritoneum will not be described here; for this the reader may consult text-books of anatomy.

The following points are of surgical importance and should be remembered.

The foramen (epiploicum) of Winslow is the communication between the greater and lesser sacs. It is bounded above by the caudate lobe of the liver, first part of duodenum and first part of the hepatic artery; anteriorly by ligamentum hepatoduodenale containing common bile duct, portal vein and hepatic artery—in order from right to left between its folds; posteriorly, the inferior vena cava.

The liver, stomach, spleen, first portion of duodenum, jejunum, ileum, transverse colon, cæcum, sigmoid flexure of colon, upper part of rectum, uterus and ovaries are almost entirely covered by peritoneum.

Descending and transverse parts of duodenum, ascending and descending colons, midportion of rectum, upper part of vagina and posterior wall of bladder are partially covered by peritoneum.

Kidneys, suprarenals, and pancreas are in contact with peritoneum without being wrapped up by it.

Lower end of rectum, neck, base and anterior aspect of bladder, anterior and inferior portions of the posterior wall of vagina are uncovered by peritoneum.

The peritoneum is richly supplied by blood vessels, and the omentum, which plays such an important part in peritoneal infection, is primarily a sheet of interlaced vessels, which has the secondary property of storing fat.

Existence of formerly described stomata, whereby the subserous lymphatics were supposed to communicate directly with the coeliac cavity, has been disproved. Immediately subjacent to the surface cells of the peritoneum are thin-walled spaces lined with endothelium and connected with underlying lymphatic channels. These are most numerous over the abdominal surface of the diaphragm and the floor of the pelvis. Absorption of fluids and particles from the abdominal cavity takes place here more effectively.

ACUTE PERITONITIS

Peritonitis is an invasion of the peritoneum by bacteria. An aseptic peritonitis may originate from escape of blood or other body fluids into the abdominal cavity but infection rapidly supervenes. Bacteria may be carried into the abdominal cavity by penetrating wounds, by the blood stream in septicaemia, from the gastrointestinal tract as the result of perforation or by migration through the wall or from an inflammatory process in any abdominal viscus.

Death in peritonitis is not from peritoneal toxæmia but from intestinal toxæmia, the result of intestinal obstruction. The cessation of peristalsis is an attempt to rest inflamed tissues and localise the infective process, and the localised state is a helpful factor. Where infection becomes widespread, the same cessation of movement leads to a rapid increase in the toxicity of the intestinal contents and defeats its own curative object.

The principles of treatment therefore are: (1) combating the infection in the peritoneum, and (2) alleviating the intestinal toxæmia.

OPERATION

These operations almost always require a thorough exploration. A long median incision render such exploration easy. The edges of the wound are carefully protected to prevent contamination (a frequent cause of failure or of long convalescence). Then the cause is looked for and dealt with accordingly.

Cleaning the peritoneum which was practised even up to a few years ago has been very much modified now. The peritoneum itself possesses excellent resistance which is only lowered by much handling, application of irritants or long exposure to air. Gastric or intestinal contents are quickly removed by irrigation of normal saline, other fluids may be gently mopped out.

Drainage though universally done is almost useless as the drain itself is rapidly walled off by coils of intestines and exudates. When done it must be by the shortest route to the infective focus.

For the paralytic ileus sometimes the intestine has to be punctured and drained and thus help it to regain its muscular power.

The after-treatment will naturally depend on the operative findings and the various methods are learnt best by following up cases in the wards.

CHRONIC PERITONITIS

A. *Chronic adhesive peritonitis*

In itself it rarely requires surgical intervention since it is to be considered more as a protective mechanism than as a destructive

process. The adhesions are sometimes modified by the intestinal movements and are likely to become lengthened and rounded and thus form the bands and cord-like structures—so often the causes of intestinal obstruction. These adhesions may sometimes be separated by blunt dissection with or without ligature.

B. *Tubercular peritonitis*

In tubercular peritonitis, particularly when chronic ascitic accumulation or diffuse or localized pus is present the operative interference consists of removal of the fluid and closure of the abdomen. Accessible adhesions may be carefully detached but a prolonged search for such adhesions is dangerous. The results of operative treatment are not encouraging.

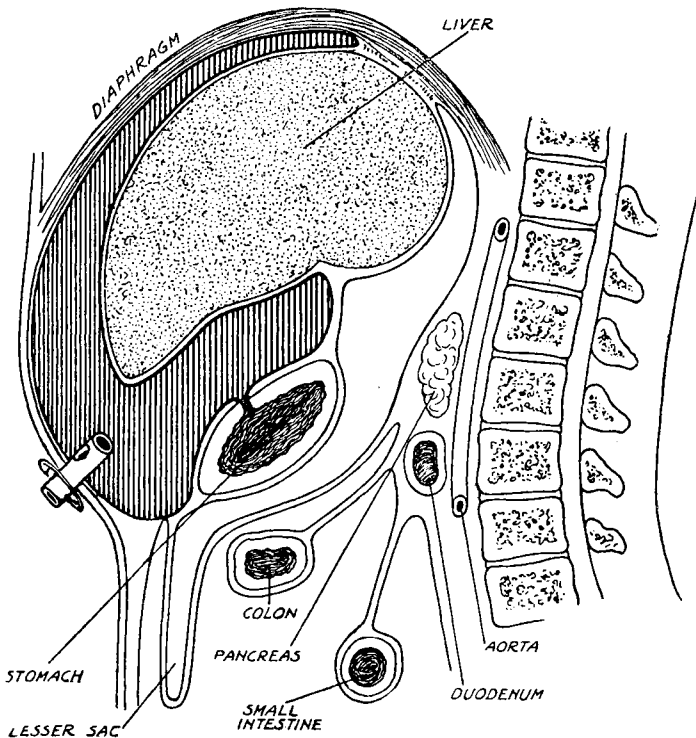


FIG. 150.

ANTERIOR SUBPHRENIC ABSCESS FROM PERFORATION OF AN ULCER IN THE ANTERIOR WALL OF THE STOMACH.

REPRODUCED FROM TURNER'S OPERATIVE SURGERY.

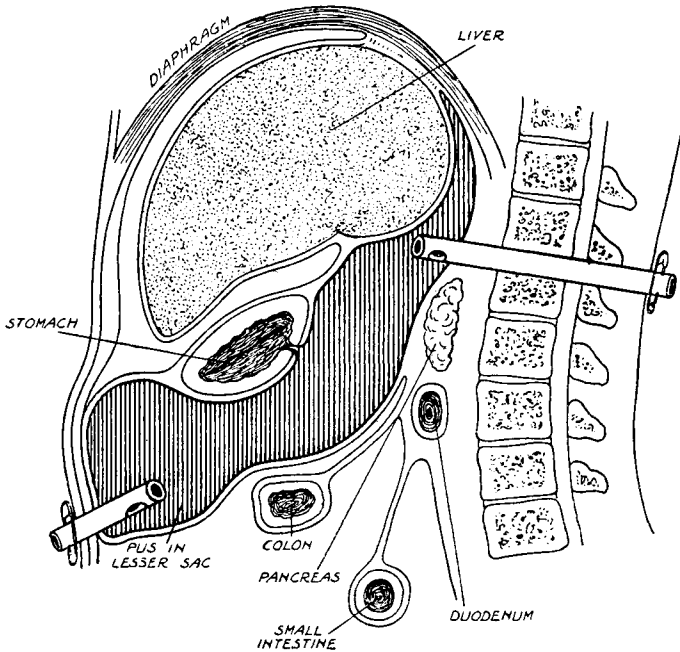


FIG. 151.

POSTERIOR SUBPHRENIC ABSCESS IN THE LESSER SAC OF THE PERITONEUM:—Drainage-tubes are shown front and behind.

REPRODUCED FROM TURNER'S OPERATIVE SURGERY.

C. Amoebic peritonitis

Infection of the peritoneum may also take place from a tropical hepatic abscess. For detailed description the reader is referred to Author's Hand-book of Tropical Surgery.*

SUBPHRENIC ABSCESS

An abscess may form under the diaphragm due to spread of infection from diseases of the stomach, duodenum, appendix, liver, spleen, kidney or any other abdominal viscus. Less commonly the source of infection is in the chest (e.g. empyema) or in the ribs or spine.

Subphrenic abscesses may be extra or intra peritoneal in situation. In relation with the dome of the diaphragm it may be right-sided or left-sided and anterior or posterior (*Figs. 150-152*).

* Hand-book of Tropical Surgery and Surgical Pathology (John Bale Sons & Danielsson).

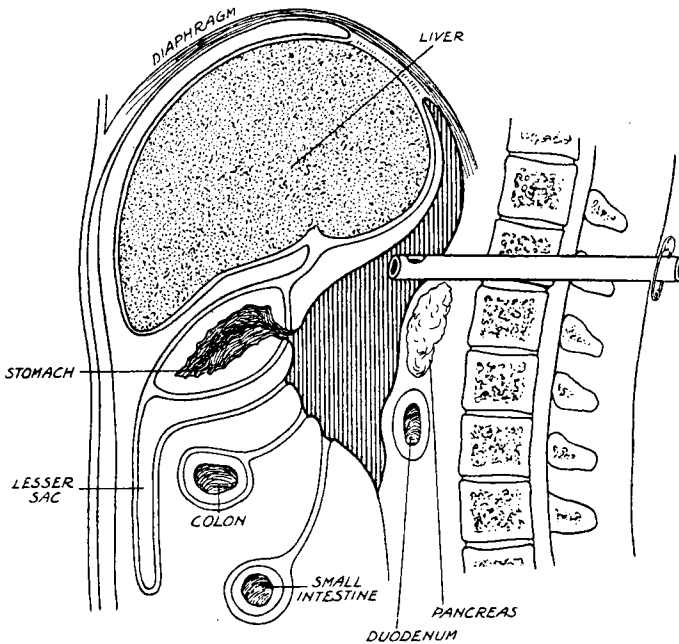


FIG. 152.

RETRO-PERITONEAL SUBPHRENIC ABSCESS FROM A GASTRIC
ULCER ADHERENT TO THE BACK OF THE LESSER SAC.

REPRODUCED FROM TURNER'S OPERATIVE SURGERY.

OPERATION

An access to the subphrenic abscess may be either trans-thoracic or *via* abdominal parieties.

(a) *By Transthoracic route*

An incision four inches long is made over the tenth or eleventh interspace extending downwards and forwards from the posterior axillary line. The intercostal muscles are divided near the lower rib and the plura is either incised and displaced upwards or stitched to the diaphragm. The ribs having been separated the diaphragm is incised and the fingers are introduced to feel for the abscess which is now incised and drained with a large rubber tube containing a much longer one of smaller size extending into the deepest part of the cavity. Careful search is made for other abscesses or loculi. The tubes are secured by a stitch to the wound margins and the cavity irrigated daily. In some cases one or more ribs have to be resected in order to gain free access and efficient drainage.

(b) Through the abdominal wall

In some cases an oblique lateral incision is made at a suitable spot parallel with the costal margin and the abscess drained either here or through a counter incision in the loin. If the peritoneal cavity is opened before the abscess is found, a gauze pack is carefully placed to protect the peritoneum.

In a few gastric cases a subdiaphragmatic abscess bulges in the epigastrium and calls for incision here. Should the abscess involve the lesser sac of the peritoneum it may be opened through the gastrohepatic or gastro-colic omentum after the general peritoneal cavity has been shut off by careful gauze packing, but it is sometimes advisable to drain it through the left loin.

OPERATIONS UPON THE OMENTUM AND MESENTERY

SURGICAL TREATMENT OF ASCITIS

A. *Talma-Morison operation*

The abdomen is opened by an incision made above the umbilicus and near the middle line, the right rectus being drawn outwards. The fluid is drained and the peritoneum mopped dry. As far as possible the peritoneal surfaces of the liver, spleen, and parietes are roughened by gauze-friction and the great omentum extensively sutured to the parietal peritoneum which has also been rawed by friction. Drainage is rather excluded on account of the risk of secondary infection; it is better to tap the peritoneum later if necessary.

B. *Author's operation**

A strip of fascia lata measuring about 6" long and 3" wide is dissected out from the antero-lateral aspect of the thigh through a longitudinal incision in it. This piece is anchored by four pieces of catgut and stripped off into four narrower pieces so that each strip though of the original length is about $\frac{3}{4}$ " wide. These strips are cleared of fat and areolar tissue and kept in warm normal saline solution. A right paramedian laparotomy incision is made with the umbilical line as its mid-point. The ascitic fluid is allowed to escape and the abdomen inspected and explored for abnormal conditions; the liver and spleen are palpated to ascertain variations in size, consistence and surface conditions for evidences of cirrhosis.

Through the incision the free lateral and distal margins of the omentum are delivered. To the free margin and to the extent of

* First published in the Journal of the Indian Medical Association, 4: 3, 105-109.

about two inches from it, the four fascial strips are planted at equal intervals by catgut single-point sutures. These are led out of the laparotomy wound and while doing so, secured by its edges to and about the edges of the peritoneal incision. These strips are then insinuated between the aponeurotic layers of the external and internal oblique muscles taking care that throughout their length the strips are loose and without least tension. The distal ends of the strips are secured to the aponeuroses by single point sutures of catgut. Two c.c. of sterile adrenalin chloride solution (1 in 1,000) is let into the peritoneal cavity. The peritoneum is closed by interrupted sutures the points of emergence of the fascial strips being secured by additional sutures if necessary thus guarding against prolapse. The parietes is closed by judicious overlapping of the aponeuroses and muscles of the parts lateral and medial to the incision. The skin incision is then closed.

The postoperative events of clinical interest are an irregularly elongated zone of oedema and induration corresponding to the site of the distal transplants of the fascial strips ; a diffuse oedematous condition of the right ileo-inguinal region often extending to the right femoral triangle and anterior and lateral aspects of the thigh ; engorgement of the superficial abdominal veins on the right side and a progressively increasing renal output as evidenced by the quantity and character of urine.

The abdomen reduces in size, perhaps in some cases after one or two initial postoperative paracentesis and maintains its circumferential diminutions at least for the period under observation. There is a definite improvement in the general condition of the patient, improved digestive and nutritional conditions as evidenced by increase in body weight and physical strength and activity. It looks as if the patient who was running down a steep downhill into a marasmic condition doomed to a fatal end, makes a steady progress towards normal health and vigour. The dysfunctioning liver, slowly and steadily, tries to return to its normal duties and the kidneys in like manner wake up to their secretory and excretory obligations.

CHAPTER XX

OPERATIONS ON THE STOMACH

SURGICAL ANATOMY AND GENERAL CONSIDERATIONS

Relations.—The stomach rests on the transverse mesocolon which covers the pancreas, solar plexus, aorta, thoracic duct, vena cava and still posteriorly crura of the diaphragm; further to the left of the stomach are the left suprarenal body, kidney and spleen.

In front of the stomach are the diaphragm, abdominal parietes and the liver. Superiorly are the gastrohepatic omentum, the liver and diaphragm. Below is the greater omentum, transverse colon and to the left of the body and fundus the gastrosplenic ligament.

Blood supply.—The gastric, hepatic and splenic branches of the cœliac axis.

Although the cardiac end of the stomach has a rich arterial network, the pyloric end is supplied by straight terminal vessels which do not anastomose. Embolism of these branches, resulting in ischæmia of the mucosa may account for the frequency of pyloric ulcers.

Of the veins, the right gastro-epiploic empties into the superior mesenteric and the left into the splenic and thus into the portal vein. The pyloric and coronary veins empty direct into the portal vein.

Nerves.—The parasympathetic fibres come through the vagi (the right on the posterior surface, and the left on the anterior surface); the sympathetic fibres are derived from the solar plexus.

Lymphatics.—The lymphatic nodes of the stomach are found principally around the region of the pylorus—inferior nodes drain the greater curvature toward the pylorus while the superior nodes drain the lesser curvature and the cardiac end. The fundus is drained into nodes which accompany the splenic artery. Sometimes there are additional nodes along the greater curvature.

Topography of the stomach.—The position and contour of the viscus vary; for instance, when empty it lies far back in the abdominal cavity beneath the left lobe of the liver and in front of the pancreas. In moderate distension its cardiac end lies beneath the left seventh costosternal articulation, about 2·5 cm. beyond the sternum. Its pyloric end lies opposite a point near the end of the eighth right chondrosternal articulation.

Curvatures of stomach are represented, approximately, by curves of the characteristic contour between the points just given,—the greater curvature reaching at first to the left, then downward to

the intercostal line. The lesser curvature crosses the vertebral column on a level with the first lumbar vertebra. The greater curvature crosses the epigastrium on a line connecting the ninth and tenth costal cartilages, which is about two-finger breadths above the umbilicus.

A triangular area of the anterior stomach wall lies in direct contact with the abdominal parietes and is bounded below by the transverse colon, above and to the left by the seventh, eighth and ninth costal cartilages and above and to the right by the anterior border of the liver.

Preparation of the patient for operation :—

- (1) Oral hygiene, particularly attention to teeth several days in advance of operation.
- (2) Unless contraindicated the gastrointestinal tract should be regularly cleaned by appropriate purgation for several days before operation.
- (3) Nothing but sterile liquid nourishment should be given for at least 24 hours prior to operation.
- (4) In emergency cases preparations have to be modified as the conditions indicate.
- (5) A pre-operative lavage of the stomach should be undertaken.

Some preliminary investigations are necessary in order to decide upon the nature of operation. These will be enumerated ; for fuller details of the technic text-books on clinical surgery and diagnosis should be consulted.

(a) A detailed history of the illness and appearance of symptoms in sequence.

(b) A thorough clinical examination, e.g. palpation, percussion, ausculto-percussion, etc.

(c) Examination of gastric contents, chemical, microscopic, etc.

(d) An opaque meal skiagram with a control.

(e) Gastroscopy.

The following are the more common operations performed on the stomach :—

- A. Gastrotomy.
- B. Gastrostomy.
- C. Gastro-enterostomy.
- D. Pylorotomy.
- E. Gastrectomy.
- F. Pyloroplasty.
- G. Gastroplasty.

A. Gastrotomy, i.e. opening the stomach with the object of removal of foreign bodies or exploration of the interior of the stomach and then closing it up. The stomach is exposed by a median incision through the abdominal parietes above the umbilicus.

A small opening is at first made in the anterior wall of the stomach for digital exploration. For the removal of foreign bodies or a complete inspection, the opening may be enlarged. To close it, a deep layer of sutures through all the coats is passed and then Lembert sutures for the seromuscular layer.

Gastrostomy for simple inspection of mucous membrane of the stomach is rarely done now as for this purpose the gastroscope is used.

B. Gastrostomy consist in making a permanent opening into the stomach.

INDICATIONS

(1) Obstruction of the œsophagus due to (*a*) malignant stricture, (*b*) cicatricial stricture of traumatic or syphilitic origin, (*c*) pressure of inoperable tumours, etc., from without. (2) Cancerous disease of the pharynx, tonsils and back of the tongue. (3) Obstruction due to stricture, etc. of the cardiac end of the stomach.

Several methods of gastrostomy are known, viz. :—

- (1) Senn's operation.
- (2) Kader's operation.
- (3) Witzel's operation.
- (4) Frank and Albert's operation.

The last-named method will be described.

FRANK AND ALBERT'S METHOD OF GASTROSTOMY

INSTRUMENTS—Group X.

POSITION

Place patient in dorsal position. Stand on the right side ; the assistant stands opposite.

OPERATION

Make an incision three inches long, skin and fascia deep, commencing from the level of the ensiform cartilage through the left rectus muscle. The anterior sheath of the rectus is exposed and divided. The fibres of the rectus muscles are separated and the posterior sheath opened. The peritoneum and transversalis fascia with the subperitoneal fatty tissue is caught up with forceps and opened with a scalpel held in the violin-bow position. The opening is enlarged. This exposes the stomach. A conical pouch of its anterior wall is pulled up through the wound (*Fig. 153*).

The assistant supports the stomach by a pair of suitable forceps. Now proceed as follows : Fix the stomach by a layer of seromuscular sutures through its wall (on its right side) and the

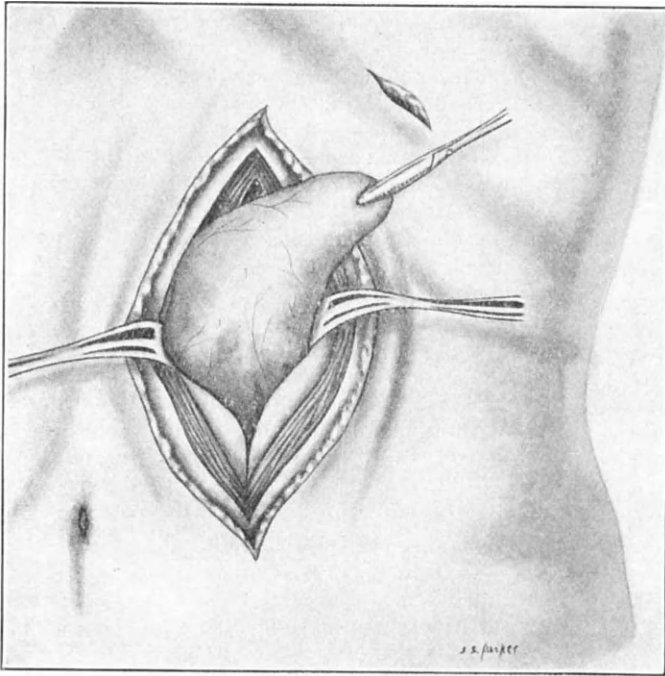


FIG. 153.

SSABANAJEW-FRANCK'S METHOD OF GASTROSTOMY:—

The cone of presenting portion of stomach has been drawn out of the abdominal wound—through the incised peritonium, and between the split fibres of the left rectus muscle—preparatorily to anchoring the base of the cone to the margins of deeper plane of the abdominal wound—and drawing the base of the cone over the costal arch and out through an opening in the skin, to the margins of which it will be anchored.

REPRODUCED FROM BICKHAM'S OPERATIVE SURGERY
By the Courtesy of THE W. B. SAUNDERS CO.

parietal peritoneum and transversalis fascia to the posterior sheath of the rectus. Make another incision about one inch long through the skin, subcutaneous tissue and the posterior sheath of the rectus, and an inch and a half above and external to the first incision. Introduce a pair of suitable forceps of Kocher type through this second incision towards the first one. The assistant now releases the stump which is seized with the forceps and pulls it under the skin through the small (second) opening. The base of the cone is stitched with the parietal peritoneum and posterior rectal sheath to avoid dangerous constriction. Pass a few sutures through the seromuscular coat of the stomach pouch and the margin of the

second skin incision and close the abdominal wound in the usual way (*Fig. 154*). Make an opening into the stomach after forty-

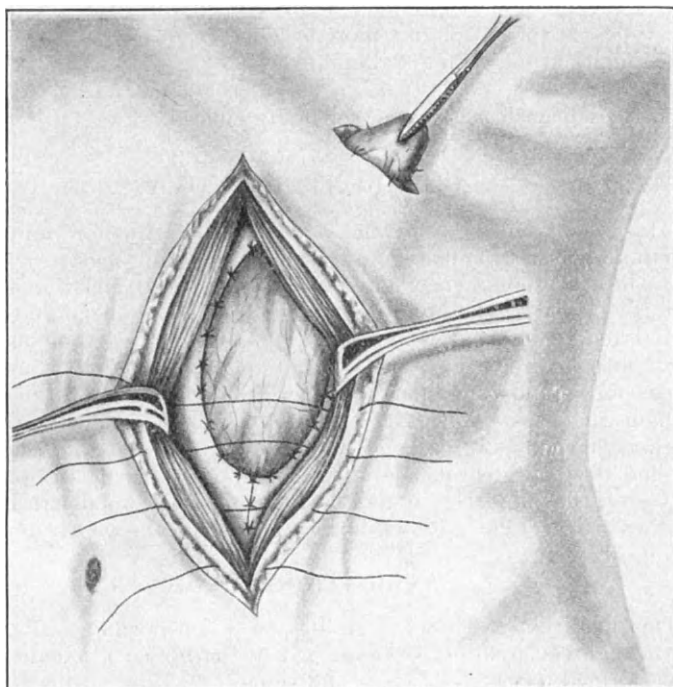


FIG. 154.

THE SSABANAJEW-FRANCK METHOD OF GASTROSTOMY—
The cone of stomach has been drawn through the split fibers of the left rectus through the small skin wound above the costal arch, where it is being anchored with sutures. The serosa and muscularis of the stomach is shown sutured, on one hand, to the parietal peritoneum, the subserous areolar tissue, transversalis fascia, and posterior layer of the rectal sheath, on the other thus surrounding the base of the stomach cone. The anterior rectal sheath and the split fibers of the rectus are being sutured together.

REPRODUCED FROM BICKHAM'S OPERATIVE SURGERY
By the Courtesy of THE W. B. SAUNDERS CO.

eight hours. Pulling the stomach pouch under the skin produces a valvular arrangement to the opening and prevents regurgitation of food.

The other operation of gastrostomy are those of Witzel, Kader, Senn, Marwedel and some modified operation of Kocher and Hahn. They cannot, however, be described in a book of this size. Broadly speaking there are two general types, which more or less merge into

each other, in principles of their action. One is more particularly characterized by the formation, out of the stomach wall, of artificial valve like openings between stomach cavity and skin surface—such as the methods of Witzel, Senn, Kader and others. In the other type, the formation of a more or less tortuous canal is resorted to—as in the Frank, Marwedel and others.

In both, use is made more or less of the constricting effect of variously displaced parts of the left rectus muscle.

C. GASTRO-ENTEROSTOMY

This is a short circuiting between the stomach and the duodenum (gastro-duodenostomy) or the jejunum (gastro-jejuno-stomy) near its commencement. Gastro-duodenal anastomosis is rarely performed as the jejunum is more accessible and more easily manipulated. Most surgeons are of opinion that so long as the pyloric outlet is free the gastric contents pass in this direction even after gastro-jejuno-stomy has been performed. Therefore in cases in which the escape of gastric contents beyond the pylorus is not desirable such as in cases of duodenal ulcer, the pylorus should be occluded by surgical measure. There is a divergence of opinion however on the subject as it has been argued that duodenal ulcers often heal after a longer or shorter period of the gastro-jejunal anastomosis.

INDICATIONS

The operation is, therefore, indicated when normal passage of food through the pylorus is obstructed by pathological conditions. It is performed for the following conditions :—

1. Pathological conditions resulting from gastric or duodenal ulcers, e.g. (a) pyloric stenosis due to cicatrisation, (b) perigastric adhesions interfering with the movements of the stomach, and (c) hour-glass contraction of the stomach with a large cardiac and small pyloric pouches.

2. Congenital hypertrophic stenosis of the pylorus.

3. As a palliative measure in inoperable cancer of the stomach.

4. Gastric or duodenal ulcers.

5. Traumatic conditions such as corrosion of the gastric mucosa due to ingestion of chemical irritants.

6. As a preliminary measure to the operation of gastrectomy.

The jejunum can be anastomosed either to the anterior wall of the stomach (anterior gastro-jejuno-stomy) or to its posterior wall (posterior gastro-jejuno-stomy). There are certain objections to the former :—

1. The loop of jejunum has to be brought up in front of the transverse colon in order to reach the anterior wall of the stomach and this loop presses on the colon.

2. The drainage through the stoma is not free.

3. The two intestinal arms descending from the stomach are apt by gravity and traction, to become parallel, and a spur formation thus occurs at the stoma, by converting the original curve at their point of meeting into an angularity and thus a vicious circle, i.e. the return of the stomach contents from the jejunum back into the stomach, is more common after anterior than after the posterior gastro-jejunostomy which is the operation of choice and will be described.

POSTERIOR GASTRO-JEJUNOSTOMY

INSTRUMENTS—Group XIV.

POSITION

Same as for previous operation.

OPERATION

1. *The parietal incision.*—A vertical incision commencing from the costal arch about four inches in length is made slightly to the right of the middle line. The various strata are divided as for the operation of gastrostomy.

2. *Exposure of the stomach.*—The most dependent part of the stomach is identified. The stomach with the transverse colon and the greater omentum is lifted out of the abdomen, inspected and turned over on the lower part of the chest-wall. This brings into view the transverse meso-colon, which passes from the transverse colon to the posterior abdominal wall and hides the posterior wall of the stomach from view. A non-vascular area (Riolan's area) in the meso-colon is selected and an opening made in it with a pair of scissors and enlarged with fingers. Thus the lesser peritoneal sac and the posterior wall of the stomach are exposed to view. The stomach is drawn out through the meso-colic aperture and its dependent part noted. A fold of the gastric wall from this part is raised and grasped with a suitable clamp in such a way that their tips point towards the right shoulder and the handles to the left hip of the patient.

3. *Exposure of the jejunum.*—Pass fingers along the root of the transverse meso-colon beneath the ligament of Treitz, the first loop of intestine on the left of the spine is the duodeno-jejunal flexure which can be identified by its firm attachment to the posterior abdominal wall. The ligament of Treitz and its peritoneal coverings are developmentally different individuals and their recognition is important in posterior gastro-jejunostomy, for it is just below this ligament that the incision in the jejunum is made. Draw out a loop of jejunum about six to eight inches from the flexure, inspect

it and clamp it in a similar way, keeping the tips of the blades towards the right shoulder (*Figs. 155-166*).

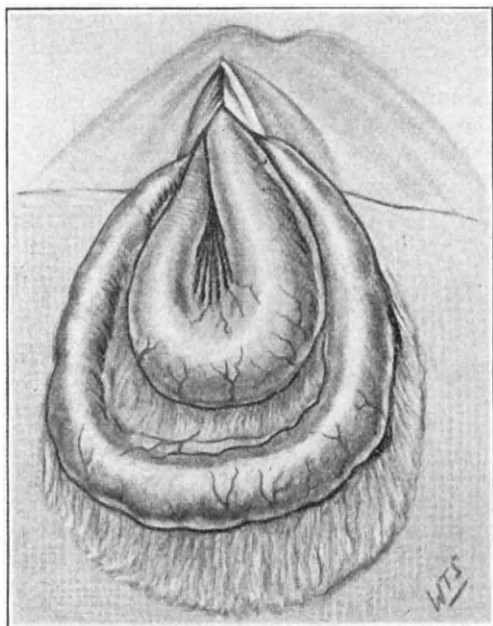


FIG. 155.

GASTRO-ENTEROSTOMY:—Stomach and colon withdrawn for inspection.

REPRODUCED FROM NELSON'S LOOSE-LEAF SURGERY.

4. *The anastomosis.*—Only the stomach and the jejunum held by the clamps are kept outside the wound which is protected with abdominal gauze pads, the rest being returned to the abdomen. The clamps are brought alongside each other and approximated for suturing. The anastomosis is now carried out as in lateral intestinal anastomosis in the following manner (*see Figs. 147, 148, 149*):—

(a) The posterior line of sero-muscular suture consists of non-penetrating Dupuytren's continuous suture for three inches, carried from left to right and about a quarter of an inch away from the future line of anastomotic opening. Leave a long tail to the thread at its commencement on the left, with the needle still threaded at the right end.

(b) Opening the stomach and jejunum. Open the stomach one-fourth inch from and parallel to the line of above suture in such a way that this incision falls short of the suture line by one-third

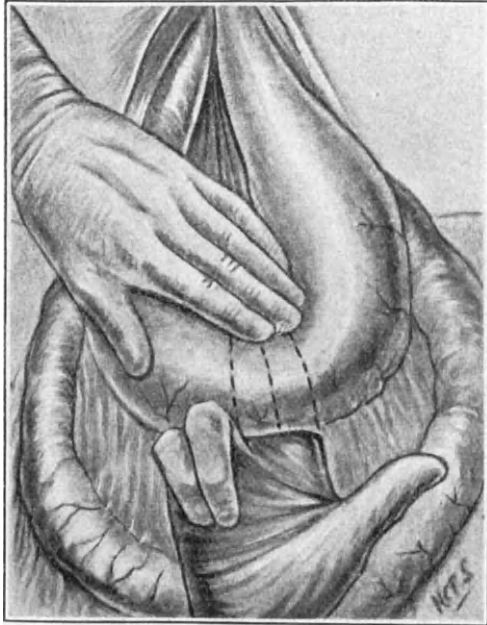

FIG. 156.

GASTRO-ENTEROSTOMY :—Examination of posterior surface of Stomach.

REPRODUCED FROM NELSON'S LOOSE-LEAF SURGERY.

inch at each extremity. The incision should go through all the coats but the mucous membrane. Now, pick up the mucous membrane and remove an elliptical portion of it with a pair of scissors. The jejunal opening is made in a similar way.

(c) Suture of the margins of the gastric and jejunal openings. This is accomplished by a layer of continuous suture penetrating all the coats of stomach and jejunum. Commence at the left and proceed towards the right connecting the posterior margin of the aperture ; then continue the suture back from right to left connecting the anterior margin. On reaching the starting point tie off the two ends of the thread with a knot. At any doubtful spot put one or two independent sutures, particularly at the two far ends where the sutures turn.

(d) The anterior line of the sero-muscular suture. Remove the clamps. Pick up the threaded needle left at the right end of the sero-muscular suture and carry a similar suture back to the left, to its starting point and tie it off securely with a double knot. Make a careful inspection of the suture line and supplement it

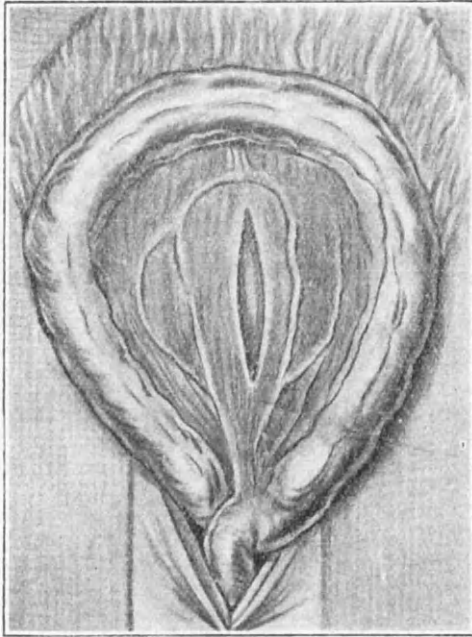


FIG. 157.

GASTRO-ENTEROSTOMY :—Opening made in the under-surface of the Mesocolon.

REPRODUCED FROM NELSON'S LOOSE-LEAF SURGERY.

with a suture here and there in case of doubt. This suture inverts the inner penetrating line of sutures.

5. *Closure of the meso-colic aperture.*—Pass a few sutures closing the meso-colic aperture and connect it to the stomach or jejunum close to its junction with the stomach.

6. *Closure of the abdominal wall.*—The anastomosed stomach and jejunum are returned into the abdomen and the parietal wound closed in the way already described. (*Vide supra.*)

D. PYLORECTOMY

This means excision and removal of the pyloric portion with more or less of adjacent part of stomach. When a large part of the stomach is removed with the pylorus, the operation becomes partial gastrectomy.

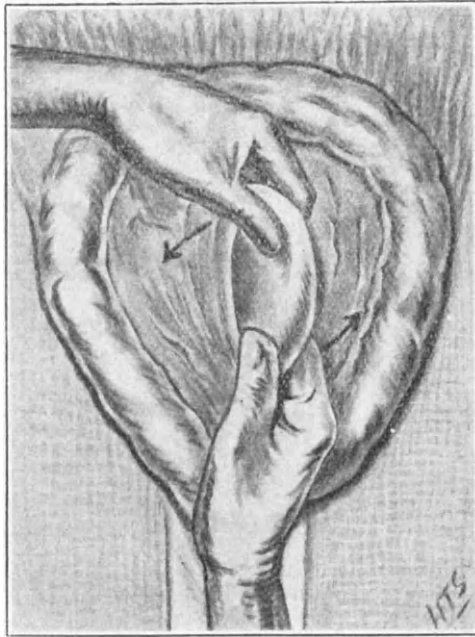


FIG. 158.

GASTRO-ENTEROSTOMY :—Stomach drawn through the Mesocolon and rotated.

REPRODUCED FROM NELSON'S LOOSE-LEAF SURGERY.

INDICATIONS

(1) Multiple ulcers of the pylorus, (2) a large complicated ulcer or (3) when malignancy is suspected.

OPERATION

Make a right paramedian incision, from the xiphoid process to 2 to 4 cm. below the umbilicus.

Generally there are adhesions about the pylorus. Free them by blunt dissection and control oozing carefully.

Pass a heavy, curved, broad ligament or pylorotomy or gastrectomy clamp under the pylorus, through the gastrocolic and gastrohepatic ligaments. Keep the points of the clamp close to the posterior surface of the duodenum, thereby avoiding injury to the pancreas and gastro-duodenal vessels. Spread the jaws of the clamp to make a tear in the two ligaments.

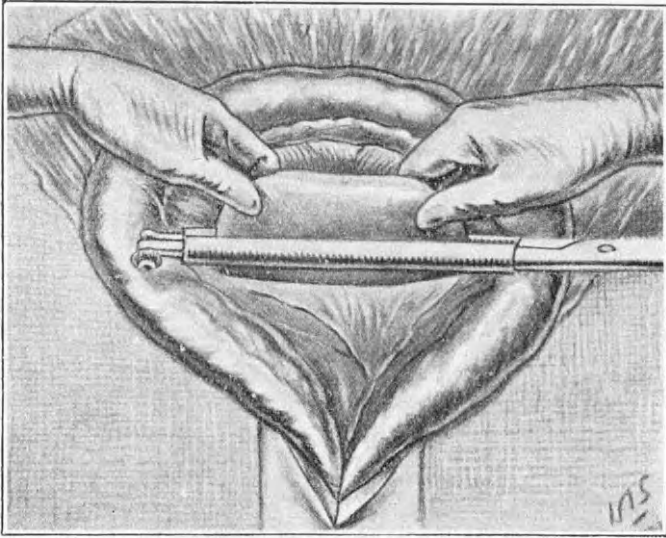


FIG. 159.

GASTRO-ENTEROSTOMY :—Application of gastric clamp.
 REPRODUCED FROM NELSON'S LOOSE-LEAF SURGERY.

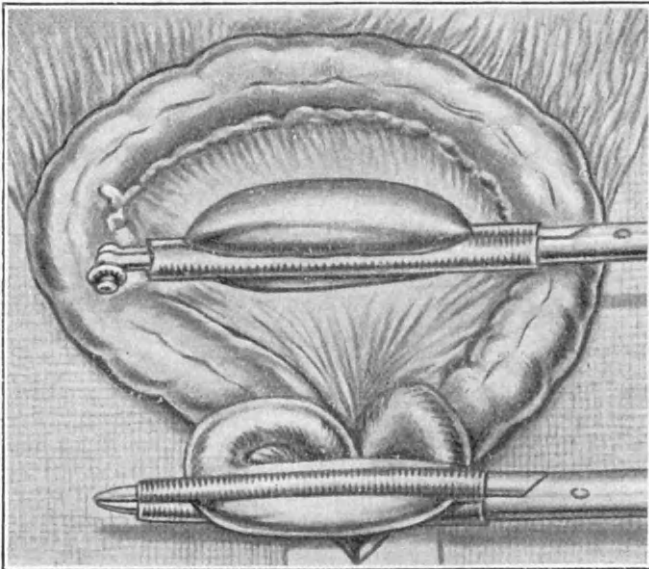


FIG. 160.

GASTRO-ENTEROSTOMY :—Application of Jejunal clamp.
 REPRODUCED FROM NELSON'S LOOSE-LEAF SURGERY.

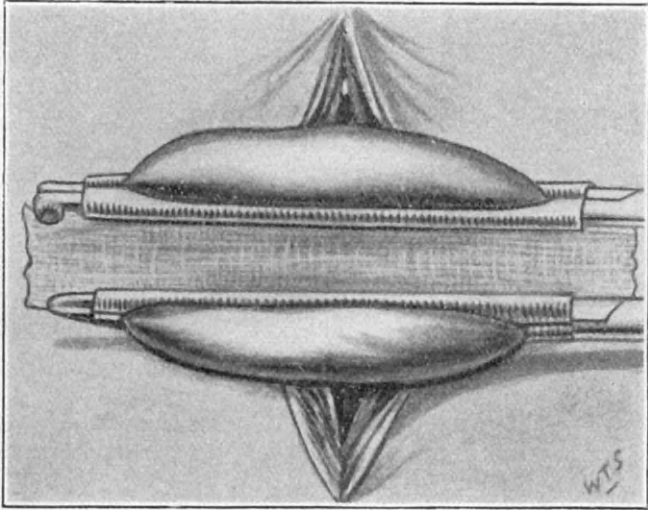


FIG. 161.

GASTRO-ENTEROSTOMY :—Pad placed between Stomach and Jejunum.

REPRODUCED FROM NELSON'S LOOSE-LEAF SURGERY.

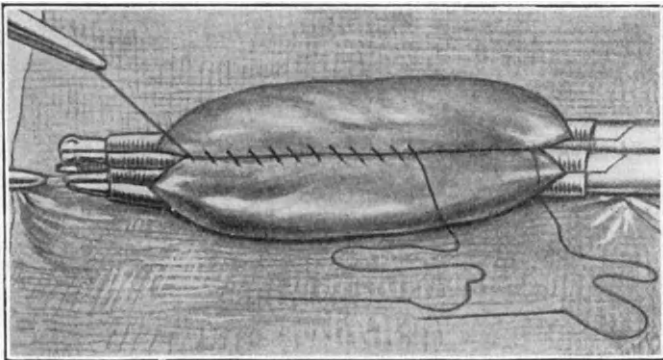


FIG. 162.

GASTRO-ENTEROSTOMY :—Insertion of posterior seromuscular suture.

REPRODUCED FROM NELSON'S LOOSE-LEAF SURGERY.

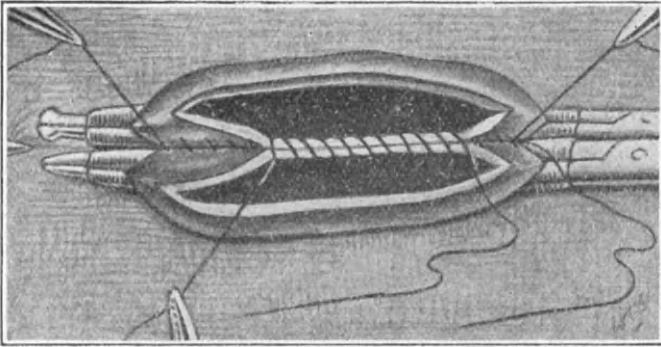


FIG. 163.

GASTRO-ENTEROSTOMY :—Insertion of posterior penetrating (haemostatic) suture.

REPRODUCED FROM NELSON'S LOOSE-LEAF SURGERY.

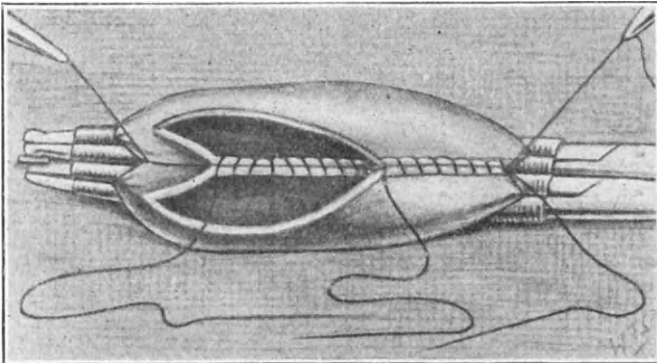


FIG. 164.

GASTRO-ENTEROSTOMY :—Insertion of anterior penetrating (haemostatic) suture.

REPRODUCED FROM NELSON'S LOOSE-LEAF SURGERY.

Remove these clamps. Now pass a strong Kocher forceps on the duodenal side, and a heavy crusher on the stomach side, catching these in their bite. Crush about 2-3 cm. of stomach. With a scalpel, cut the stomach close to the crusher.

Invaginate the end of the duodenum with a purse string suture and to reinforce the closing sutures pass two or three interrupted sutures.

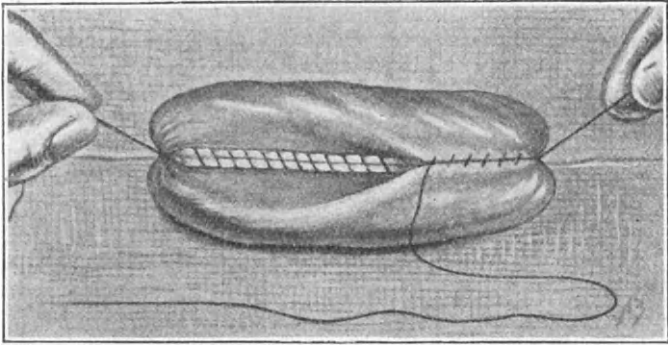


FIG. 165.

GASTRO-ENTEROSTOMY :—Insertion of anterior seromuscular suture.

REPRODUCED FROM NELSON'S LOOSE-LEAF SURGERY.

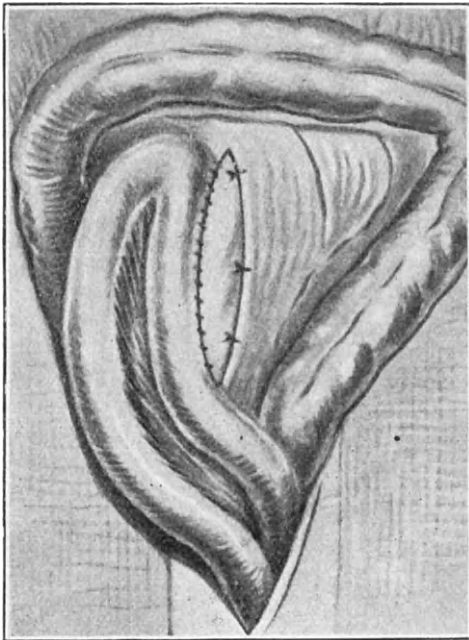


FIG. 166.

SUTURE OF EDGES OF MESOCOLON TO STOMACH.

REPRODUCED FROM NELSON'S LOOSE-LEAF SURGERY.

Now mobilize the stomach. Place ligatures around the gastric vessels above and around the gastro-epiploic vessels below, at the site of the proposed place of resection of the stomach.

Four clamps should be applied, two of them protected by rubber tubing. These clamps should not be applied too close to each other, for when the stomach is cut, there is a strong tendency for the walls to retract through the rubber covered jaws of the clamp.

After resection close the stomach wound through and through.

To establish communication between stomach and bowel perform a gastro-jejunostomy now.

E. GASTRECTOMY

These operations are occasionally performed in cases of early stages of malignant disease of stomach or pylorus. These are, however, practically given up as such cases when they come to the surgeon, are gone too far due to the extension of the disease, formation of adhesions, and metastases.

F. PYLOROPLASTY

An operation devised by Finney and others for stenosis of the pyloric orifice due to cicatrization of a healed gastric ulcer.

G. GASTROPLASTY

A similar operation to above for relieving hour-glass constriction of the stomach. These operations have been greatly superseded by gastro-enterostomy as even after this elaborate operative measure the conditions recur.

CHAPTER XXI

OPERATIONS ON THE SMALL INTESTINES

SURGICAL ANATOMY

The small intestine begins at the pylorus and ends at the ileocæcal valve. Average length $22\frac{1}{2}$ feet, duodenum 10–12 inches, jejunum $8\frac{1}{2}$ feet, ileum $12\frac{1}{2}$ feet.

The duodenum is the thickest, widest, and most fixed portion of the small intestine. Structurally it is more allied to the stomach than to the rest of the intestine; hence pathological conditions of the stomach and duodenum are more or less alike.

The duodenum is composed of 4 portions. The first portion is from the pylorus to the neck of the gall bladder. Above and in front of it are the quadrate lobe of the liver and the gall bladder; below is the pancreas and behind the gastroduodenal artery, the portal vein, the common bile duct, and the vena cava. The second portion runs down the right side of the bodies of the lumbar vertebræ to the lower border of the third. In front of it are the liver, neck of the gall bladder, and the transverse colon; behind are the right renal vessels, ureter and kidney, and right psoas muscle. Medially pancreas and vena cava, laterally the right colic flexure. The third portion runs diagonally upwards across the body of the third lumbar vertebra to its left side. In front of it are the superior mesenteric artery and the mesentery; behind vena cava, aorta and left psoas muscle. Sudden pull of the root of the mesentery and the superior mesenteric vessels across the third part of the duodenum is considered to be a cause of postoperative gastric dilatation and a partial obstruction is known as arterio-mesenteric ileus. The fourth portion of the duodenum ascends to the left side of the second where it takes a sharp turn and is continued as the jejunum. It is on the left of the aorta and lies in front of the left psoas and left renal vessels, and is covered in front by peritoneum of the mesentery. The point of ending of the duodenum and beginning of the jejunum is marked by a sharp band called the duodenojejunal flexure. The folded edge of peritoneum containing some muscle fibres running from this flexure to the posterior parietal peritoneum is called the *suspensory ligament of Treitz*. The fossa which is behind it is the superior duodenojejunal fossa of Treitz while that below is the inferior duodenal fossa. Below the fossæ runs the inferior mesenteric artery and near the left edge of the ligament runs the inferior mesenteric vein. Into the Treitz's fossa, if abnormally large, the intestines may enter and produce a retroperitoneal hernia. While the constricting band, ligament of Treitz,

is being cut there is danger of dividing the inferior mesenteric vein.

The small intestine decreases in size and thickness from its upper to its lower end. From 6 to 11 feet of its commencement it has the longest mesentery and therefore these coils may be found in the pelvis.

Sometimes about 12 to 30 inches above the ileo-cæcal valve a finger like projection from the ileum may be found. This is called Meckel's diverticulum and may become the site of a diverticulitis as in other parts of intestine. From its extremity a fibrous band may run to the umbilicus and may be a cause of strangulation.

The small intestines are supplied by the pyloric and superior pancreatico-duodenal branches of the hepatic, inferior pancreatico-duodenal and other branches of the superior mesenteric artery; veins correspond with arteries. The lymphatics end in mesenteric lacteals. Nerve supply is from the cæliac plexus of the sympathetic and the vagus.

The mesentery extends from the left side of the body of the second lumbar vertebra to the right sacro-iliac joint. It is 6-8 inches long at the root and spreads out like a fan. From the root to the coils it is about 6-7 inches long. In it run the arteries, veins, nerves, and lymphatics. The lymphatic nodes are numerous, from 130 to 150 in number. They are frequently involved in carcinoma and tuberculosis and may form masses resembling tumours. They may be inflamed and cause abscesses or get calcareous.

Rupture, embolism or thrombosis of a mesenteric vessel may cause gangrene of the corresponding portion of intestine; hence great care should be taken not to injure these vessels. In searching the abdomen for the source of a concealed hæmorrhage the intestines are first to be pushed down and to the left and then right half of the abdomen examined.

Pushing the intestines above and to the right exposes the left half. Irregular and rough handling of the intestine may damage the mesenteric vessels.

The mesentery is normally 6-7 inches long but in hernia it is further lengthened to allow the descent of the gut. Sometimes openings are present in it which may give rise to internal hernias which may get strangulated.

THE HERNIAS

Hernia is the protrusion of any abdomino-pelvic viscus or tissue through any part of the abdomino-pelvic wall. This definition does not strictly apply to internal or retroperitoneal herniæ which can more correctly speaking be included under intestinal obstruction.

Herniæ may be classified as follows :—

I. Topographically :—

1. Inguinal :
 - (a) External or oblique,
 - (b) Internal or direct.
2. Umbilical.
3. Ventral :

Anterior	}	Epigastric,
Lateral	}	Incisional.
4. Lumbar.
5. Femoral.
6. Diaphragmatic.
7. Obturator.
8. Sciatic.
9. Perineal.
10. Pudendal.
11. Internal (a variety of intestinal obstruction) :
 - (a) into fossa of Treitz,
 - (b) „ foramen of Winslow,
 - (c) „ pericæcal fossæ,
 - (d) „ intersigmoid fossa.

II. According to the nature of the contents :—

1. Intestines or enterocele.
2. The colon—(sliding hernia).
3. Omentum or epiplocele.
4. The bladder or cystocele.

III. Clinically :—

1. Reducible.
2. Irreducible.
3. Obstructed.
4. Inflamed.
5. Strangulated.

There are two main indications for operating on a hernia : (a) relief of obstruction, as in strangulated hernia and 'radical cure' (hernioplasty) by reconstruction of the hernial tract. The characteristic feature for the relief of an acutely constricted hernia is the division of the tissues causing compression and for the radical cure of a hernia attempt is made to bring about such plastic repair of the opening that any further protrusion is rendered impossible or unlikely.

The hernia is composed of a sac and its contents. The sac consists of various structures which had formed barriers to the exit of the hernia and differ according to the locality of the rupture, the innermost layer of the sac almost always being

the peritoneum. The contents of the sac also vary according to circumstances but usually it is some part of the intestine.

The general principle of all hernioplasties, therefore, are: exposure and identification of the peritoneal sac, opening of this sac, restoration of its contents to the abdominal cavity, excision of the sac, the closure of the peritoneal opening, and plastic repair of the hernial canal or an attempt at its obliteration.

The incidence of hernias has been estimated as follows: inguinal 90 p.c., femoral 7 p.c., umbilical 2·5 p.c., and ventral hernias ·5 p.c.

1. THE INGUINAL HERNIAS

The Inguinal hernias are of two varieties:—

1. External or oblique,
2. Internal or direct.

The oblique hernia receives the following covering during its exit: at the internal ring—peritoneum, subserous areolar tissue, infundibuliform process of fascia transversalis; in the canal, it passes under internal oblique and transversus muscles and receives a covering from the cremaster; at the external ring—intercolumner fascia; in the scrotum—superficial fascia and skin.

The inferior epigastric artery lies on its inner side and the seat of constriction is generally at the internal (deep) ring.

A direct inguinal hernia is a protrusion either through the internal or middle inguinal fossa between the medial umbilical fossa and lateral umbilical fossa or between the latter and the inferior epigastric vessels. The commoner forms of direct inguinal hernia have the following coverings in order: peritoneum, subserous areolar tissue, fascia transversalis, conjoint tendon of internal oblique and transversus, intercolumner fascia, superficial fascia and skin. The inferior epigastric artery lies at its outer side and the seat of constriction is generally at the internal ring but may also be where it gets the covering from the conjoint tendon.

Inguinal herniæ are rare in women, but when present offer additional difficulties during operation as the round ligament cannot be easily separated from the sac.

INSTRUMENTS—Group XVII.

OPERATION: HERNIOPLASTY

(For Oblique Inguinal Hernia.)

I. BASSINI'S METHOD

1. *Skin incision.*—An oblique incision about four inches long, commencing a little external to the middle of Poupart's ligament

parallel to and an inch above it, is carried downwards and inwards towards the external ring. This divides the skin and fascia and exposes the external oblique aponeurosis (*Fig. 167*).

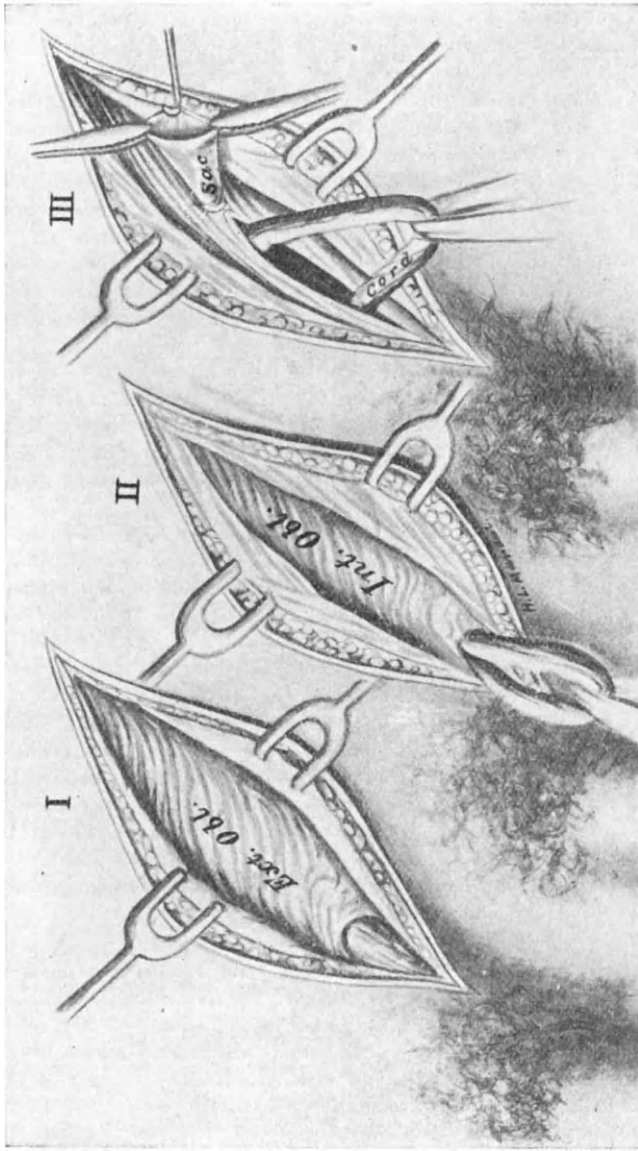


FIG. 167.

FIG. 168.

FIG. 169.

2. *Division of the external oblique.*—This aponeurosis is divided, commencing from its opening at the external abdominal ring upwards, for the whole extent of the skin wound. The cut margins are caught with forceps and the aponeurosis is raised above and below in the form of two flaps. Retract the flaps. Now define the conjoined tendon, the Poupart's ligament and the internal oblique muscle (*Fig. 168*).

3. *Isolation of the hernial sac.*—A mass of tissue is now exposed; these consist of the spermatic cord with an investment of the cremaster muscle, the transversalis fascia, and the hernial sac. The sac is more or less blended with the other tissues. Catch the fundus of the sac with a pair of forceps and isolate it from the surrounding structures with the finger covered with gauze or by blunt dissection and light touches of the knife. When the sac is isolated up to the level of the parietal peritoneum, open its fundus and inspect inside for its contents or adhesions. Return contents into the peritoneal cavity and separate adhesions if any, carefully (*Fig. 169*).

4. *Excision of the sac.*—Apply a clamp on the sac at the level of the parietal peritoneum; transfix it with a needle and ligature it. Remove the fundus of the sac beyond the ligature. Let the stump of the sac retract into the abdominal cavity. Put a finger into the internal ring to make sure that the stump is free in the abdominal cavity.

5. *Suture of the internal oblique muscle to Poupart's ligament.*—The cord is held aside by gauze or suitable retractors, approximate the conjoined tendon and internal oblique muscle with the deep aspect of Poupart's ligament by interrupted sutures. All the sutures lie at the inner side of the internal ring except one which lies on the outer side of this ring; thus a floor is formed. Release the cord and let it rest on this floor (*Fig. 170*).

6. *Suture of the external oblique.*—The cut margins of the tendon of the external oblique muscle are brought together by a continuous or a series of interrupted sutures; while doing this, the external abdominal ring is narrowed just short of causing any constriction of the cord as it passes through it (*Figs. 171 and 172*).

7. *Closure of the wound.*—The skin wound is closed by silk-worm gut sutures leaving a small opening for drainage if it is at all considered necessary. If Mitchell's clips are used for suturing, no drainage will be necessary.

Comment:—(1) In making the superficial skin incision confine it as much as possible to the abdominal wall avoiding the scrotum. (2) Before transfixing the sac make it absolutely certain by inspection and exploration with the finger that hernial contents are not transfixed with the sac. (3) In returning the stump, see that it is free of any attachments with the internal ring or its neighbourhood.

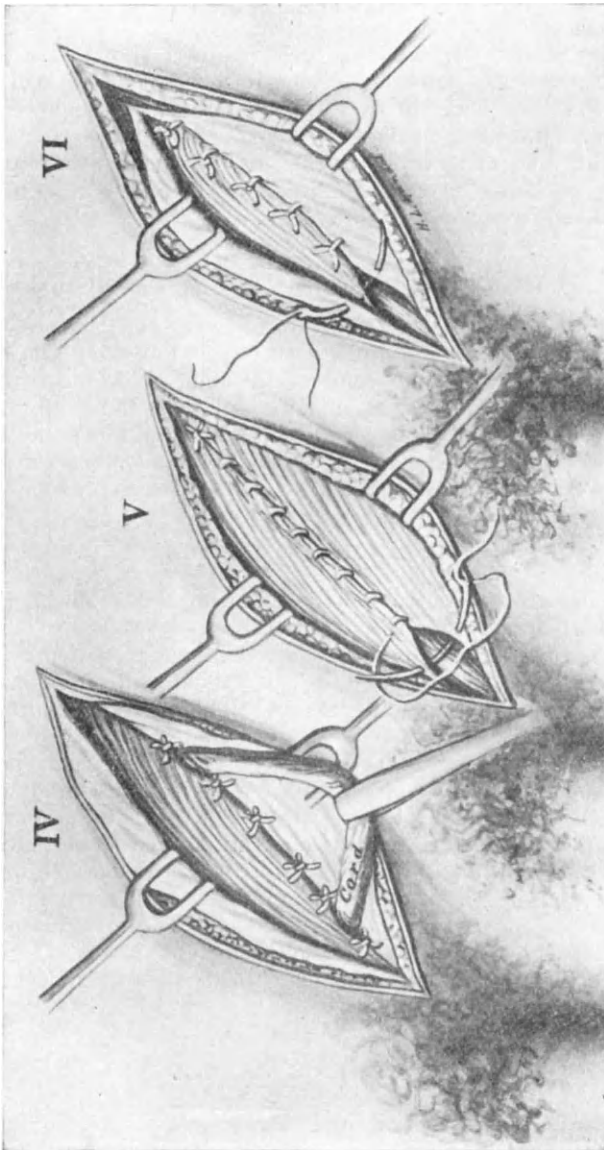


Fig. 172.

Fig. 171.

Fig. 170.

(4) In operating on a dead subject who had no hernia, no sac will naturally be found. (5) As a modification of Bassini's operation the cord may be left behind the internal oblique.

II. HALSTEAD'S METHOD

The first five stages of this operation correspond with Bassini's method. Halstead modified the sixth stage by suturing the external oblique with an overlap. The edge of the lower flap is attached to the deep surface of the upper one and the upper flap is brought down and sutured to the surface of the lower flap. Thus there is a double layer strengthening the inguinal canal. The wound is closed in the usual way.

III. AUTHOR'S MODIFICATION OF BASSINI-HALSTEAD METHOD

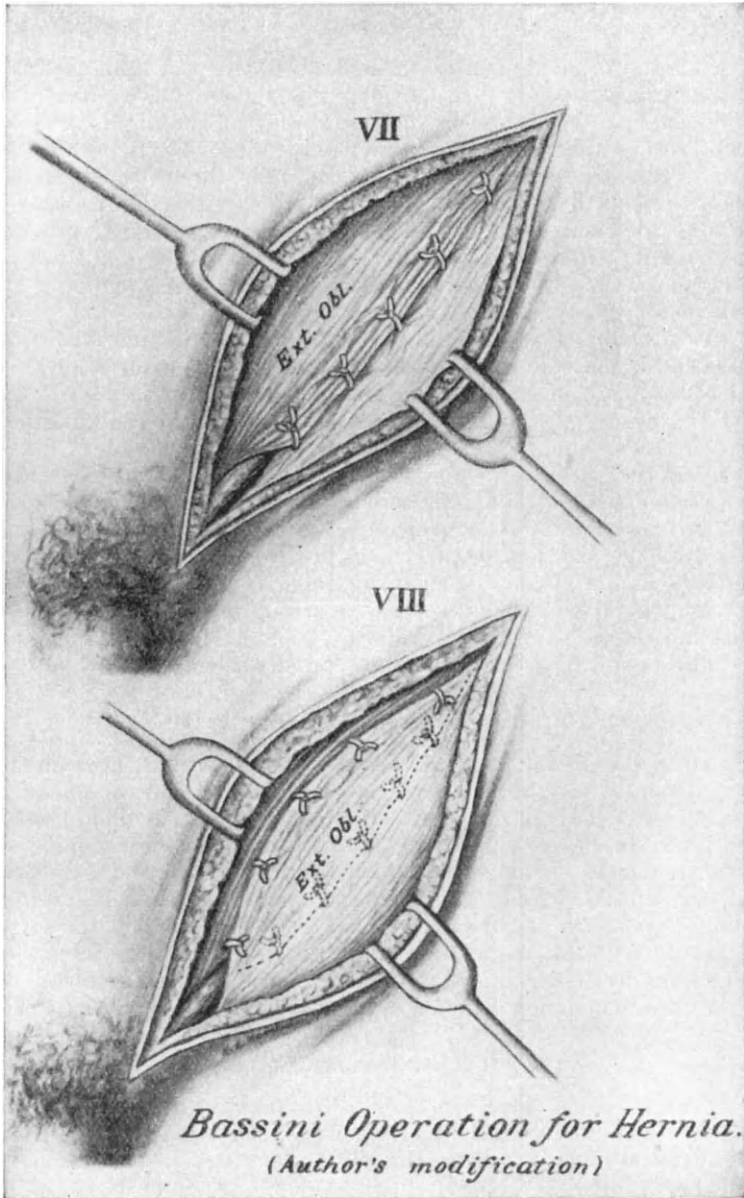
After completing Bassini's fifth stage I overlap the external oblique in Halstead fashion, but while doing so I plicate fibres of the external oblique, taking in here and there a few fibres of the internal oblique and transversalis. This strengthens the anterior wall and at the same time does not split the fibres of external oblique as is sometimes seen in Halstead's operation (*Figs. 173 and 174*).

IV. KOCHER'S METHOD

Kocher treats the sac in the following way: The hernial sac is invaginated or turned inside out before it is excised. The lowermost part of the fundus of the sac is seized with a pair of Kocher forceps and is pushed into the sac itself thus invaginating it into peritoneal cavity. The external oblique is not divided as in Bassini's and other operations. The tip of the forceps is pushed to a point above and to the outer side of the internal abdominal ring, and it is made to bulge into the anterior abdominal wall. A small incision is made cutting through all the tissues excepting parietal peritoneum on the bulging point. As the sac covered by parietal peritoneum and held by forceps protrudes through the small incision, it is immediately caught by two clip forceps. A small nick is made in the parietal peritoneum. The invaginated sac is pulled through it, and the Kocher forceps removed from the inguinal canal. The sac is then transfixed by its neck to the parietal peritoneum.

V. MACEWEN'S METHOD

Macewen treats the sac by transfixing it with a curved needle several times from its fundus upwards so that on drawing the suture the sac becomes puckered up. The ends of the suture are then threaded on to a hernia-needle and guided into the canal by finger and it is made to transfix the muscular wall of the abdomen from within outwards, about one inch above and to the outer side of the internal abdominal ring. It is secured there and fixed to



FIGS. 173-174.

the aponeurosis of the external oblique so that the sac (thus puckered up) lies like a button in this situation.

OTHER OPERATIONS

Bassini's original operation which has in the past been used for these herniæ is however now considered by some wrong in principle. Its object is to reinforce the posterior wall of the inguinal canal medial to the internal ring, whereas the weak spot lies lateral to the point of emergence of the cord. If the lower fibres of the internal oblique are sutured to inguinal ligament, they either fail to adhere and acquire their normal position or they degenerate and are converted into fibrous tissue. For early herniæ therefore, Bassini's operation is plastic surgery misapplied, for larger herniæ it is inadequate.

As an oblique hernia enlarges, the communication with the abdomen becomes wider, and the neck of the sac thrusts inwards above the point of emergence. The inferior epigastric vessels are pushed towards the pubic spine and the dilated internal ring lies more or less behind the external. The cremaster, the lower fibres of the internal oblique, as well as the external oblique are stretched and weakened and thus the normal protective mechanism is so damaged that it cannot prevent a recurrence even after removal of the sac and repair of the transversalis fascia. The operation should therefore aim at a new mechanism in which the inguinal canal should again be of valvular nature with strong anterior and posterior walls and the rings placed far apart.

Two operations aim at these and are described below.

VI. WILLYS ANDREWE'S OPERATION

After the hernial sac has been removed at its neck as in Bassini's operation the isolated cord is displaced outwards and a new posterior wall is made by suturing the internal oblique and cremaster muscles to inguinal ligament behind the cord leaving at the outer end an opening just large enough for the cord. This new wall is reinforced by suturing the upper leaf of the divided external oblique aponeurosis to the inguinal ligament behind the cord for the same distance. The cord is then replaced and the lower half of the external oblique sutured to the aponeurosis superficial to the cord, which now lies in a new canal between two aponeurotic layers.

VII. GALLIE'S OPERATION

The object of this operation is to provide a strong fibrous posterior wall and a rigid internal ring, formed in each case from fascial strips taken from the thigh. The fascial suture is securely anchored into the conjoined tendon and sheath of the rectus close to their insertion into the bone, and then passed through the periosteum into the spine of the pubes and the inner end of the inguinal ligament. The suture is then continued in an outward direction, closing the internal oblique muscle down to the edge of

the inguinal ligament, behind the cord, until the position of the internal ring is reached. There, a lockstitch is inserted and the suture is continued to the outer side of the cord. In this way the cord is surrounded in the region of the internal ring by a strong ring of fascia, which should permanently prevent recurrence of hernia. A second row of stitches is then inserted, interwoven with the first, which pass from the abdominal aponeurosis and rectus sheath to the inguinal ligament. The internal oblique covers the peritoneum with a layer of muscle which will prevent the possibility of a hernia through the chinks in the superficial layer of fascial strips.

2. UMBILICAL HERNIA

SURGICAL ANATOMY

1. Congenital umbilical hernia is a condition due to developmental error.

2. The infantile form occurs in the early years of life. The contents protrude either through the umbilical ring or through the weakened abdominal wall just by the side of the umbilicus.

The coverings of an umbilical hernia are: peritoneum, subserous areolar tissue, transversalis fascia, stretched and distended umbilical scar tissue, superficial fascia and skin.

OPERATION

In childhood the normal structure of the parts should be restored. The hernial sac is excised, and the abdominal wall closed in layers. The anterior and posterior walls of the rectus sheath are sutured separately.

In adults the attempt to pull into the midline, muscles which have long been displaced outwards is unsound. In the Mayo operation, which is ideal for this condition, the sac is excised and the resulting gap in the abdominal wall is enlarged transversely as far as the muscular fibres of the rectus. The upper leaf of the enlarged opening in the aponeurosis is now lapped over the lower and held by two layers of sutures.

If the opening is very big a superficial layer of fascial sutures should be used.

3. VENTRAL HERNIA

Ventral hernias are mostly incisional. The operative repair consists of removal of their covering of skin over the weak area by an elliptical incision, exposure of healthy tissue at the edge of the gap and approximation of these edges.

For larger defects the method of Gallie and LeMesurier is advisable. In this the edges are sutured together by means of fascial strips.

4. LUMBAR HERNIA

This is a rare type of hernia which escapes through the Petit's triangle, the operative treatment of which will be on the same lines as in other types of ventral hernia.

5. FEMORAL HERNIA

SURGICAL ANATOMY

The femoral sheath consists of three compartments. In the outermost compartment is the femoral artery; in the middle the femoral vein and the innermost compartment consists of the crural canal. The upper end of the crural canal, i.e. the crural ring is closed by the septum crurale which is formed by a thin process of fascia transversalis and a lymph gland with some areolar tissue. The crural canal is bounded by the femoral vein externally, Poupart's ligament above, Gimbernat's ligament internally, and pectineal fascia covering the pectineus muscle lying on the horizontal ramus of the os pubis behind. In femoral hernia the sac protrudes through the septum crurale pushing in front of it the lymph gland and areolar tissue. The sac with its contents descends along the crural canal forcing its way downwards under Poupart's ligament through the cribriform fascia of the saphenous opening. The deep epigastric artery lies above and to the outer side of the femoral hernia and its branch: an abnormal obturator artery may lie in front of it or to its inner side.

INDICATIONS

(1) All femoral herniæ should be radically treated by operation, because they may at any moment become irreducible, inflamed or strangulated; also because the femoral hernia is difficult to control by applying a truss. (2) All irreducible femoral herniæ. (3) Femoral herniæ threatening to become strangulated or already strangulated. (4) Femoral herniæ which incapacitate the sufferer from following his ordinary vocations. (5) In order to obtain physical fitness to enter public service. (6) In women in whom femoral herniæ tend to become strangulated during parturition.

INSTRUMENTS—Group XVII.

OPERATION

The operation for femoral hernia has now been considerably improved. Operation from below does not permit isolation of the sac up to its neck, or closure of the canal at its commencement; on

the other hand in the operation from above much damage is done to the fibrous structures of the canal which renders closure difficult. An operation by the combined route is therefore recommended, the steps of which are as follows :—

An incision is made along the inguinal canal and the lower flap dissected down till the saphenous opening is exposed. The coverings of the hernia are divided in turn and the peritoneal sac isolated up to the crural canal, where it is clamped, and the remainder cut away. The inguinal canal is now opened, the cord or round ligament lifted from its bed, thus exposing the posterior wall of the inguinal canal consisting of transversalis fascia. This is incised immediately above and parallel to inguinal ligament. The neck of the sac is opened from above and pulled up into the inguinal incision. Any omentum which may be adherent is traced and the edges of the opening in the peritoneum are trimmed so that it can be closed without leaving a depression on the abdominal aspect. The hernial opening is now closed at its abdominal end by extending the attachment of the conjoined tendon further along the ileopecteneal line, so that it lies close to the femoral vein and interposes a barrier of muscle between the abdominal cavity and the crural canal. The crural canal itself is reinforced by drawing the fatty coverings of the sac into the empty space left by its removal. Two or three mattress sutures of stout catgut are passed from the conjoined tendon through Cooper's ligament, then down through the crural canal into the fatty covering of the sac which have been left *in situ*, then back through the crural canal to the conjoined tendon. When these sutures are tied, the lower edge of the conjoined tendon is drawn down to the pelvic brim just medial to femoral vein, and a fatty plug from the saphenous opening is drawn up under inguinal ligament, forming a firm pad. The cord is then replaced, the cremaster and external oblique muscles sutured and the skin wound closed.

If the hernia is big and consequently also the gap, Gallie's fascial strips should be used.

6. DIAPHRAGMATIC HERNIA

SURGICAL ANATOMY

Hernia of the abdominal contents through the diaphragm may be either congenital or acquired. The acquired cases are either pure diaphragmatic hernia where a complete peritoneal sac exists or a false one in which there is no sac and are always traumatic. In the true hernia a second serous sac is formed by the overlying pleura. The sites at which diaphragmatic herniæ occur are numerous and they are at the hiatus or where a vessel or a muscle pass through the diaphragm.

OPERATION

Two routes of approach are available, transpleural and transperitoneal. In approaching through the thorax better access to the tumour is secured and freedom in general operative manipulation.

The method of approach is usually through major intercostal thoracotomy. The operation is highly technical and the reader is advised to consult larger text-books.

7. OBTURATOR HERNIA

An obturator hernia protrudes through the obturator canal and then passes into the upper part of the thigh. The coil of intestine forces the parietal peritoneum through the obturator canal, carrying the extra-peritoneal tissue and pelvic fascia before it into the region of the thigh, whence it passes upwards and forwards above the upper border of the obturator externus muscle, so that it comes to be behind the pectineus. The obturator vessels are generally on its outer side.

It occurs most frequently in elderly women and is generally not diagnosed until the abdomen is opened.

The general principles of operation are the same as in other varieties of hernia.

8. SCIATIC HERNIA

A sciatic hernia is a protrusion through the sacro-sciatic foramen. The operative procedure is similar to that of obturator hernia.

9 & 10. PERINEAL AND PUDENDAL HERNIAS

In perineal hernia the abdominal viscera force their way through the pelvic floor. Cystocele, rectocele, and prolapse of the uterus belong to this type and are dealt with in textbooks of Gynæcology. When the intestines are involved an operation by the abdominal route is indicated, the general principles of which are the same as in operation for other hernias.

11. INTERNAL HERNIAS

These are also called retroperitoneal hernias. The chief varieties are: (1) duodenal, left and right, (2) mesocolic, (3) infraduodenal, (4) pericæcal, (5) intersigmoid, (6) hernia through the foramen of Winslow and, sometimes, (7) hernia into an iliac fossa.

Diagnosis is rarely made before laparotomy for the relief of intestinal obstruction.

OPERATION

After opening the abdomen attempts should be made to reduce the hernia by a combination of pressure upon the sac and traction upon the intestine. In some cases it may be possible to enlarge the orifice by stretching, in others the prominent margin may be divided, due care being taken to avoid large blood vessels. A strangulated hernia through the foramen of Winslow is often beyond all operative interference as the important structures round it do not allow any division.

CHAPTER XXII

OPERATIONS ON THE APPENDIX

APPENDICECTOMY

SURGICAL ANATOMY

The vermiform appendix is a narrow blind tube, arising from the inner and back part of the cœcum about three-fourths of an inch below the ileocœcal junction. Its length varies from an inch to nine inches; generally, it is three and a half inches long. It is completely covered by peritoneum and has a mesentery—the meso-appendix. The appendicular artery runs near the free border of the mesentery which does not in all cases extend to the tip of the appendix.

SURFACE MARKING

McBurney's point is represented by a point at a junction of the outer and middle thirds of a line drawn from the right anterior superior iliac spine to the umbilicus. This is the usual seat of maximum pain on palpation during an attack of appendicitis. This, however, does not coincide with the anatomical position of the cœcal orifice of the appendix. It may be more accurately located by a point where the inter-tubercular (the line joining the tubercles of the crests of the ilia) and the right mid-Poupart lines intersect. This is the usual situation of the orifice but the appendix can be found in any of the following situations: (1) Curling upwards and inwards, under cover of the lower end of the ileum. This is the commonest situation of the appendix. (2) Hanging downwards over the brim of the pelvis. (3) Directed upwards behind and towards the outer side of the cœcum.

INSTRUMENTS—Group XV.

OPERATION

1. *The parietal incision.*—Various forms of incision have been devised for reaching the appendix. Two objects must be in view, viz. providing a good access to the iliac fossa and inflicting minimum damage to the muscles and nerves of the abdominal wall. McBurney's muscle-splitting method or the grid-iron incision (*Fig. 175*), fulfils the above two conditions. It has been complained that this method does not allow sufficient room, particularly, if the

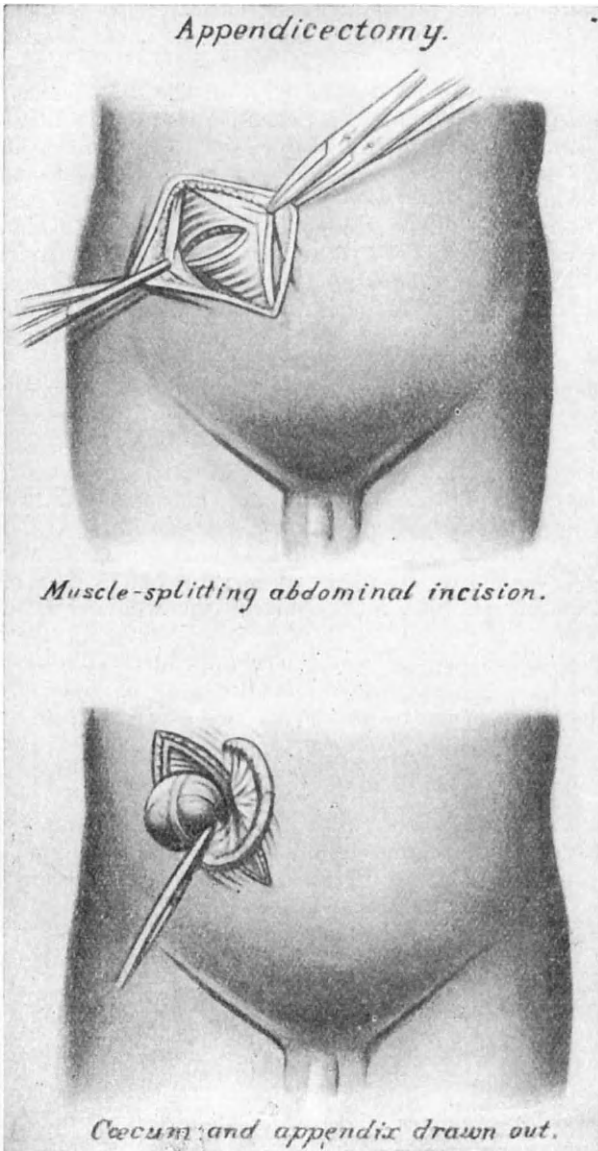


FIG. 175.

FIG. 176.

appendix is not in the first of the three situations. The incision can, however, be extended and the patient placed in the Trendelenburg position to overcome this difficulty. Battle's pararectal incision in a vertical direction about an inch internal to

the right semilunar line, is useful when the exact position of the appendix has not been previously ascertained. (*See abdominal incisions, p. 252.*)

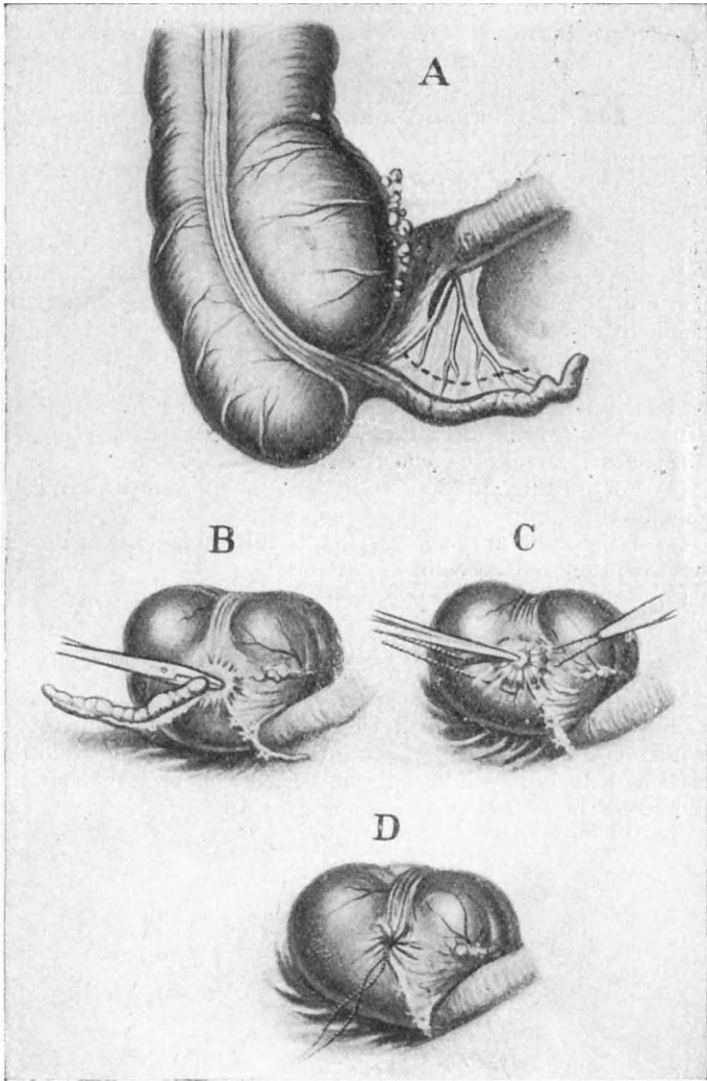
Make a three-inch incision skin deep, in the direction of the fibres of the external oblique aponeurosis, its mid-point being situated about one and a half inch above, and to the outer side of McBurney's point. This exposes the external oblique. Separate the fibres of this muscle for the whole length of the wound by blunt dissection and retract its edges. This exposes the internal oblique and transversalis whose fibres are in a direction at right angles to the skin wound. The fibres of these muscles are separated in a similar manner. The transversalis fascia and peritoneum are picked up with two pairs of forceps and a small opening made in it with a knife held in the violin-bow position. The opening is then enlarged by a pair of scissors using two fingers as a guide.

2. *Isolation and delivery of the appendix.*—The colon is sought for by digital exploration, sweeping the finger round the iliac fossa. It is recognized by the longitudinal muscular bands—the taeniæ coli, and appendices epiploicæ. If the anterior band of muscular fibres of the cæcum be followed it will lead to the appendix. The appendix is pulled out of the wound. If there is difficulty in finding the appendix, enlarge the wound for better view (*Fig. 176*).

3. *Section of the meso-appendix.*—The appendix with a portion of the cæcum having been drawn out through the wound, the meso-appendix is made tense and one or two sutures are inserted into it in the manner shown (*Fig. 177*). The meso-appendix is divided with scissors along its attachment to the appendix (*Fig. 177*).

4. *Removal of the appendix and treatment of the stump.*—The appendix is seized close to the cæcum with hæmostatic forceps or a crushing clamp (*Fig. 178*). All the layers are crushed but the serous coat. The clamp is removed and the crushed portion secured by ligature (*Fig. 179*). The appendix is cut across at the distal end of the ligature. The stump is invaginated by means of purse-string suture, or buried in the wall of the cæcum by means of seromuscular Lembert protection sutures. A piece of omentum may be grafted on the suture line as a further protection. Some surgeons are still in favour of it. It is best to put in a couple of interrupted Lembert sutures to make the sealing secure (*Fig. 180*). Inspect the gut and return it into the abdominal cavity.

5. *Closure of the abdominal wound.*—The abdominal wound is closed in four layers, the first line of sutures is for the peritoneum and transversalis fascia the second for the transversalis and internal oblique muscles, the third for external oblique muscle, and the fourth for the skin and superficial fascia.



FIGS. 177, 178, 179, 180.

The appendix is found in other positions in 40% of cases. In those cases it has to be isolated, freed from adhesions and dealt with in the same way. Difficulties however may arise if it is retrocaecal in situation and buried in adhesions. If with careful dissections the appendix can be freed from adjoining structures

and adhesional bands appendicectomy is performed and its bed shut off with sutures. If however it is so adherent to important structures such as the iliac vessels, the female pelvic adnexa or if it is inaccessibly placed behind the cæcum it is divided between proximal and distal ligatures and left *in situ* with a drain.

APPENDICOSTOMY

(*Weir's Operation*)

By appendicostomy is meant opening the appendix and fixing the stump to the abdominal parietes necessarily resulting in an appendicular fistula.

INDICATIONS

- (1) Drainage, lavage and medication of the intestinal tract e.g. in cases of chronic intractable amœbic and other forms of colitis.
- (2) Obstinate chronic constipation.
- (3) For the introduction of nutrient enemata in cases of gastric carcinoma.
- (4) Temporary drainage and fixation in some case of ileocæcal intussusception and volvulus of cæcum.
- (5) Relief of intestinal overdistension in peritonitis.

OPERATION

Weir's operation is best performed by a McBurney incision for the valvular and sphincteric action that it produces. The appendix is freed of adhesion and brought out of the wound and excised as if for appendicectomy and then the proximal stump is anchored to the parietes.

CHAPTER XXIII

OPERATIONS ON THE LARGE INTESTINES

SURGICAL ANATOMY

The large intestine comprises of (1) cæcum (and appendix), (2) ascending colon, (3) transverse colon, (4) descending colon, (5) sigmoid flexure, and (6) rectum and anal canal.

Its length is about $4\frac{1}{2}$ feet. It is distinguished from small intestines by three longitudinal bands—*tæniæ coli*—which are arranged as follows:—one is anterior, one postero-external and the other postero-internal; these blend together on the rectum forming a longitudinal layer. Sacculations of the colon is due to these longitudinal bands being one-sixth shorter in length than the colon itself. These sacculations tend to disappear with distension but are never totally obliterated.

The cæcum is a blind pouch and lies in the right iliac fossa on the iliacus and psoas muscles. It is in contact with the abdominal wall above the outer half of the inguinal ligament. The ileo-cæcal valve marks the junction of ileum and large intestine. It corresponds to a point one inch below the middle of a line joining the anterior superior iliac spine and the umbilicus.

The surgical anatomy of the appendix has been dealt with (in chapter XXII).

There are three folds and three fossæ formed by the peritoneum in the neighbourhood of the cæcum. The superior ileo-cæcal fold runs from the upper surface of the mesentery just above the ileum to the upper anterior surface of the cæcum. In it runs the anterior ileo-cæcal artery. Beneath it, with the opening towards the left is the superior ileo-cæcal fossa, which may sometimes contain the appendix. The retrocolic fold passes from the lower and outer surface of the cæcum to the peritoneum beneath; the fossæ on each side of it are called the retrocolic fossæ.

The ascending colon lies on the *quadratus lumborum* muscle and kidney behind; the *psoas* is on its medial side. The hepatic flexure is just in front of the kidney.

The transverse colon passes diagonally up and to the left across the abdomen. The omentum as it passes from the colon to the stomach forms the *gastro-colic omentum*, which hangs over the transverse colon and covers it. Instead of running upwards and to the left, the transverse colon may form a large curve downwards reaching almost to the pelvis. The transverse mesocolon passes backward and one layer goes up and covers the pancreas while the other goes down to the mesentery.

The descending colon begins at the splenic flexure where it is more deeply situated than the hepatic flexure and then descends to the front of the left iliac fossa where the sigmoid flexure begins. In doing a colostomy through the loin, the external border of the quadratus lumborum muscle is the guide to the descending colon. It lies $\frac{1}{2}$ inch behind the middle of the crest of the ileum.

The arterial supply to the ascending colon, right colic flexure and transverse colon is derived from the right and middle colic branches of the superior mesenteric artery. The left colic branch and the sigmoid arteries from the inferior mesenteric supply the descending and sigmoid colon. The veins drain into the portal system via superior and inferior mesenteric trunks.

The lymphatics drain into four groups of glands—epicolic, paracolic, intermediate and the central or main and thence to the group of glands about the upper part of the superior mesenteric artery where they join the efferents to the common intestinal lymphatic trunk.

COLOSTOMY

The colon is brought out through an abdominal wound and an opening is made into it for the passage of fæces.

INDICATIONS

1. Malignant disease of the colon or rectum.
2. Stricture of the rectum.
3. Recto-vesical fistula.
4. Certain forms of colitis.
5. Certain forms of congenital malformations of the rectum and anus.
6. As a preliminary or palliative measure in certain cases of malignant disease of the colon or rectum, giving rise to signs of obstruction.
7. Cases of obstruction of the colon due to kinking by bands such as by costo-colic ligament.

INGUINAL OR ILIAC COLOSTOMY

The abdomen is opened in the left iliac region; the pelvic colon is identified and the point of junction with iliac colon having been found, it is drawn out in the form of a loop sharply bent upon itself. It is then secured in the wound. It is important that the intestinal contents should not pass on into the part of the intestine distal to the opening. The contents should flow freely through the artificial opening.

OPERATION

1. *The parietal incision* is made on the left side and corresponds in its direction to that employed for exposing the appendix on the right side, i.e. by McBurney's muscle-splitting or grid-iron method (see Fig. 175). The length of the incision should be from two to two and a half inches.

2. *Exploration for the colon*.—A distended colon may be easily found on digital exploration. Sometimes, however, the small gut or the great omentum may cover it. Sweep the fingers from without inwards along the floor of the iliac fossa and get hold of the fixed portion of the intestine, this is the iliac colon. Follow this downwards, toward the brim of the true pelvis and find out the pelvic colon which can be recognized by the *tæniæ coli*, the sacculations and the *appendices epiploicæ*. Now deliver the pelvic colon out of the wound.

3. *Fixing the colon*.—A small aperture is made in the mesocolon avoiding any blood-vessels running in it. A glass rod is passed through the aperture and allowed to rest on the abdominal wall to support the gut. A curved needle, threaded with silk, is introduced about half an inch to an inch from one edge of the abdominal wound about its middle. It traverses the whole thickness of the abdominal wall from the skin to the peritoneum and passes through the mesocolon at a selected spot, free from vessels; it is then carried through the corresponding point on the other side of the abdominal wound passing through its wall from peritoneum to skin. The needle now returns through the same opening in the mesocolon without traversing the abdominal wall. The two ends of the thread are therefore on the same side of the abdominal wound. The glass rod is removed. Two pieces of rubber tubing are introduced through the anterior and posterior threads of silk, the threads pulled tight and knotted (Ward stitch).

4. *Opening the colon*.—If the need for opening the colon is urgent, the gut is opened, a purse-string suture applied, a Paul's tube introduced, and the suture tightened. If the case is not so urgent, three or four days may be allowed to form adhesions and the gut opened either by an incision on its convexity or by excising a portion of the loop.

Comments:—(1) The parietal wound should be as small as possible, i.e. just enough to permit the bowel being drawn through. (2) Open the gut at the highest part. (3) The gut should be so fixed that a spur is made out of the posterior wall of the intestine which will prevent the *faeces* from passing on to the distal part of the opening.

Colostomy can also be performed on the right side—right inguinal colostomy—ascending colostomy or in the lumbar region

—lumbar colostomy or the transverse colon may be opened anteriorly near the umbilicus—transverse colostomy.

ASCENDING COLOSTOMY

An opening is made in the ascending colon on the right side. Some difficulty will be encountered in drawing the bowel forwards, unless as it occasionally happens, it is provided with a mesentery. This is only indicated when an obstruction exists in the transverse colon. The operation is similar to left inguinal colostomy.

TRANSVERSE COLOSTOMY

The following are the advantages of a transverse colostomy :—

(1) Operation is easier because of a longer mesentery. (2) An artificial anus near the centre of the body admits of easier emptying by the patient himself and a retentive apparatus can be more comfortably kept in position and (3) The rectus muscle affords a certain degree of muscle control over the bowel movements.

CÆCOSTOMY

Cæcostomy is indicated as a temporary measure in certain cases of (1) obstruction, (2) inflammation of colon, or (3) volvulus of cæcum.

The operation is done through a small grid-iron incision. The cæcum is incised and a rubber tube is introduced. The tube is fixed to the cæcum by a purse string suture which efficiently prevents leakage.

LUMBAR COLOSTOMY

This consists in making an opening posteriorly, through the loin over the descending or ascending colon—extraperitoneally. Formerly when opening the abdomen was accompanied by a very high mortality lumbar colostomy was frequently performed ; at the present time however, the operation has practically been discarded.

COLOPLICATION FOR MEGACOLON

Congenital dilatation of the colon is a characteristic feature of Hirschsprung's disease and one of the means of dealing with this condition consists in plicating a part of the colonic wall upon itself sufficiently to reduce the calibre of the large bowel. Two, three or more axial tiers of suturing are applied in such a way as to infold the wall of the bowel upon itself and at the same time to bury these folds within the general contour of the narrowed bowel.

Megacolon in adult is characterised more by thickening and stasis in the bowel than any dilatation. Its treatment by ganglionectomy is discussed elsewhere in this book.

CHAPTER XXIV

INTESTINAL OBSTRUCTION

SURGICAL ANATOMY

The most frequent cause of acute intestinal obstruction is hernia. Almost invariably there is some interference with the circulation due either to distension of the intestinal loop or to direct pressure upon the vessels in the mesentery. As the veins are easily compressed they are involved earlier than the arteries. The stasis thus caused is responsible for further distension and thus a vicious circle is established.

Aside from strangulated hernia the other frequent causes of obstruction are torsion of the gut and mesentery, intussusception, volvulus, obstruction by adhesions, kinks and bands (Meckel's diverticulum, Jackson's membrane, etc.) and carcinoma of the large bowel.

Foreign bodies such as stercoliths, injected foreign body or a mass of intestinal parasites (round worm) may cause acute ileus.

Peritoneal adhesions and bands are frequent causes of ileus. These bands are generally post-operative but some are congenital.

A hernia may escape into an aperture or slit of the peritoneum and get strangulated. These apertures or slits may be congenital or traumatic; the different retroperitoneal fossæ being instances of the former variety while a carelessly left rent in the meso-colon as in gastrojejunostomy is an instance of the latter variety.

Intussusception is a condition in which one proximal part of the bowel invaginates into another distal part and is a very common cause of acute intestinal obstruction in children. There are four varieties, viz. : (1) Enteric—when only the small intestine is involved, (2) Ileocæcal—which is an exaggeration of the normal invagination present at the ileocæcal valve, the apex being the ileocæcal valve, (3) Ileocolic—in which the apex passes through the ileocæcal valve, and (4) Colic when only the colon is involved (*Figs.* 181–184).

Volvulus is a condition produced by axial rotation of a portion of the bowel, frequently the pelvic colon. Two factors are concerned in the production of a volvulus; predisposing—such as unduly narrow attachment of the mesentery to a loop of intestine or a point of adhesion at the convexity of a loop, which can serve as an axis for rotation or a redundancy of the mesentery; and exciting—such as a sudden strain or induced strong peristalsis (caused by coarse food, strong purgatives, etc.).

Chronic obstruction caused by benign and malignant strictures of the intestine may eventually lead to an acute ileus. The sigmoid and the rectum are the frequent sites.

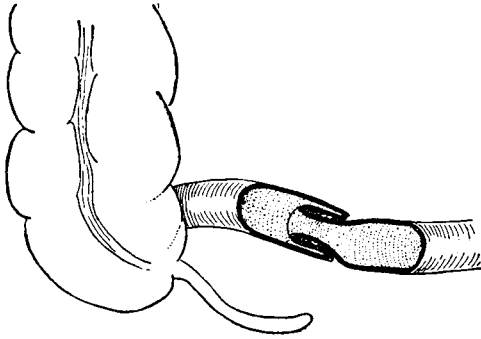


FIG. 181.

INTUSSUSCEPTION OF THE ENTERIC VARIETY :—The ileum is invaginated into itself.

REPRODUCED FROM NELSON'S LOOSE-LEAF SURGERY.

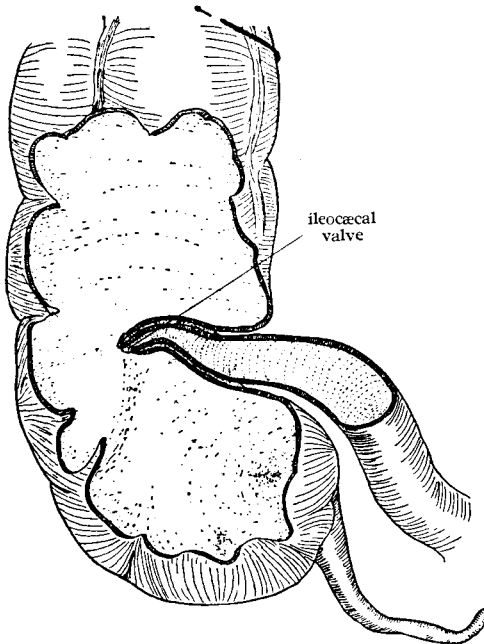


FIG. 182.

INTUSSUSCEPTION OF THE ILEOCÆCAL VARIETY :—The ileocaecal valve forms the head of the invaginated portion. The invagination is done at the expense of the large bowel.

REPRODUCED FROM NELSON'S LOOSE-LEAF SURGERY.

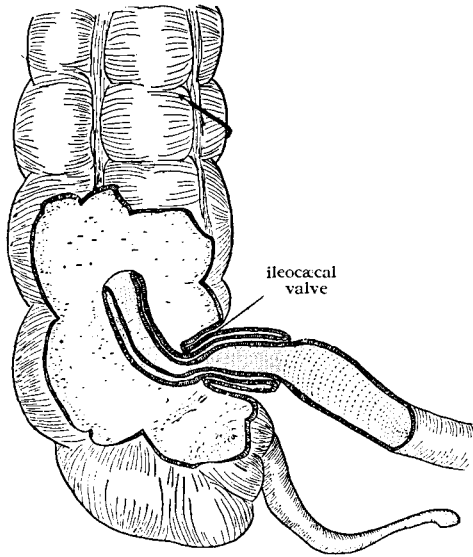


FIG. 183.

INTUSSUSCEPTION OF THE ILEOCOLIC VARIETY:—The invagination began primarily in the terminal ileum, the invaginated portion passing through the ileocaecal valve into the cecum and ascending colon. The intussusception is occurring largely at the expense of the small bowel.

REPRODUCED FROM NELSON'S LOOSE-LEAF SURGERY.

The mechanical causes of ileus have been enumerated above. But an acute obstruction may also result from paralysis of the gut due to absorption of toxins or irritants from the peritoneal cavity—as in late cases of septic peritonitis, appendicitis, acute hæmorrhagic pancreatitis or ruptured ectopic. This variety of obstruction is known as dynamic ileus. In mechanical ileus also if the condition is not promptly treated, paralysis of the gut due to absorption of toxins ultimately sets in. Perhaps the abdominal sympathetic system plays a significant part in this type of ileus.

TREATMENT OF ACUTE ILEUS.

The preoperative treatment of these cases is very important. Prevention or adequate treatment is the first requisite. In intestinal obstruction there is hypochloræmia and loss of fluid, hence intravenous saline infusion is indicated. Preoperative gastric lavage keeps the patient quiet during operation and reduces the risks of aspiration pneumonia. Due to absorption of toxins as well as

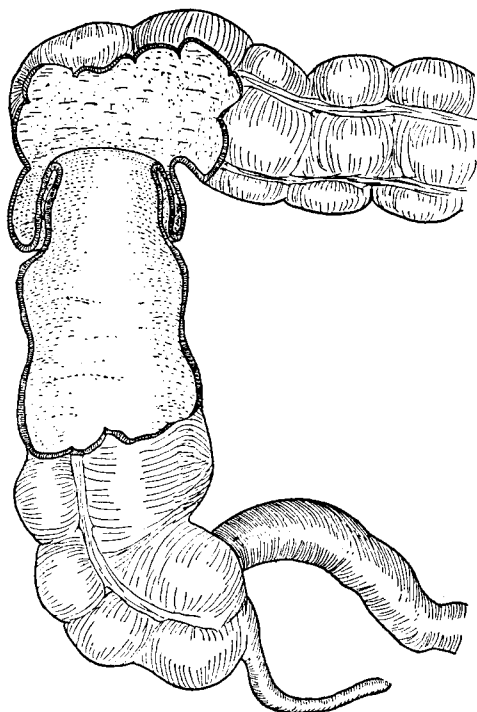


FIG. 184.

INTUSSUSCEPTION OF THE COLIC VARIETY :—Invagination of the colon into itself.

REPRODUCED FROM NELSON'S LOOSE-LEAF SURGERY.

distension, the heart is involved fairly early in these cases and should be given proper attention.

OPERATION

A small laparotomy incision is made and the hand is introduced to locate the site of obstruction. Palpation of the ileocaecal fossa is valuable in determining the approximate site. If the caecum is dilated the obstruction is distal to it if shrunken, the obstruction is proximal to it. The loop of intestine containing the abnormality is delivered out of the wound and the extent of mischief examined.

If the distension is great no attempt should be made to remove the cause at once because the distended intestine is thinned and very friable and any attempt to operate on it may cause tears in it with subsequent release of the highly toxic contents into the peritoneal cavity.

Under these circumstances it is best to relieve the obstruction first, and when the patient has sufficiently recovered from the toxæmia the cause should be removed.

The obstruction is best relieved by an enterostomy or a colostomy through which the gut is emptied. (*See page 306.*)

In the less advanced cases in which the distension is relatively slight an attempt should be made to remove the cause of obstruction. Often, this can be very simply done as by dividing a band of adhesions, reducing an intussusception or untwisting a volvulus. After the obstruction has been relieved and before the gut is returned to the cavity its viability must be determined. The colour and lustre of the wall, the return of peristalsis after relief of obstruction and the pulsation of the arterioles in its mesentery will indicate viability.

The general operative treatment of ileus has been described. Treatment of some special conditions are given below.

INTUSSUSCEPTION

If there is no evidence of gangrene, attempt should be made to reduce the invagination by exerting digital pressure (milking) on the apex of the intussusceptum, very gentle traction on the proximal portion may also be applied. If reduction is difficult placing a warm towel around the tumour and even pressure on it may reduce the œdema and decrease its size. If a reduction is found impossible one blade of a pair of scissors is inserted between the intussusceptum and the intussusciens and the contracting ring cut. The intestinal wound is then sutured (*Figs. 185, 186*).

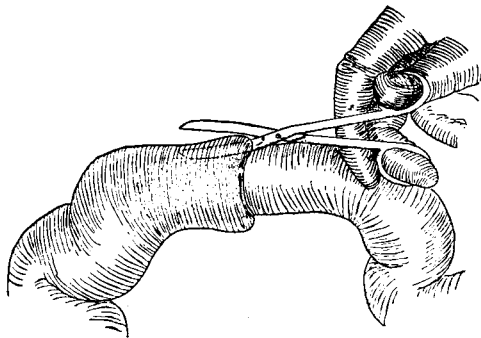


FIG. 185.

TECHNIC OF TREATING IRREDUCIBLE INTUSSUSCEPTION, ACCORDING TO THE METHOD OF BROWN:—One blade of a pair of scissors is inserted between the intussusciens and the intussusceptum. The constricted neck is divided, which allows the reduction of the intussusception.

REPRODUCED FROM NELSON'S LOOSE-LEAF SURGERY.

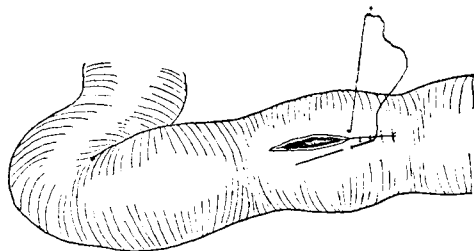


FIG. 186.

SUTURING OF THE LONGITUDINAL DEFECT IN THE BOWEL WALL BY MEANS OF CONTINUOUS LEMBERT SUTURE, FOLLOWING REDUCTION OF THE INTUSSUSCEPTION.

REPRODUCED FROM NELSON'S LOOSE-LEAF SURGERY.

If the intussusception is gangrenous it should be resected, with a re-establishment of the intestinal tract by an entero-anastomosis.

VOLVULUS

After the abdomen is opened attempt should be made to untwist the volvulus. If that fails the volvulus should be emptied with a trocar and cannula. After emptying it and closing the perforation with a purse string suture further attempts at reduction should be made and these then generally succeed.

The coil should be fixed to the parietes to prevent recurrence. This is best done by suturing the loop and its mesentery to the postero-lateral wall of the abdomen.

If the loop is gangrenous or the volvulus persistent and recurrent, it should be resected and an end to end anastomosis performed.

KINKS, BANDS, ADHESIONS

In cases of obstruction due to kinks, bands and adhesions, bands should be excised, adhesions separated and the raw surface thus created should be covered by omental grafts in order to prevent future adhesions.

Regarding kinks, the cause should be ascertained and treated according to individual conditions.

CHRONIC INTESTINAL OBSTRUCTION

Cases of chronic intestinal obstruction should be investigated by clinical and radiographic examinations and such surgical measures adopted as would remedy the condition.

CHAPTER XXV

OPERATIONS ON THE LIVER AND GALL-BLADDER

SURGICAL ANATOMY

The right lobe of liver cannot be palpated excepting its lower edge which can be felt slightly below the costal margin in the erect posture, but it cannot be felt in the recumbent position. The left lobe of the liver intervenes between the stomach and the anterior abdominal wall and as such it can be palpated in the left hypochondrium. The falciform or suspensory ligament divides the subphrenic space into two compartments, and accumulation of pus in these compartments are accordingly called right and left subphrenic abscess. On percussion the liver dulness reaches the level of the fourth intercostal space in the mammary line. The inferior surface of the right lobe is in relation with important structures, namely, the hepatic flexure of the colon, the duodenum at the junction of its first and second portions, the right kidney and suprarenal capsule. Access to the liver can be obtained by the following routes : (i) subcostal or pararectal route for its lower margin and inferior surface ; (ii) by dividing the costal cartilages below the reflection of the pleura (eighth to eleventh) to the upper aspect of the liver ; (iii) the transpleural route after dividing the ribs, pleura and diaphragm to the convex surface of the liver.

The gall-bladder, bile-ducts and blood vessels are on the inferior surface of the liver. The fundus of the gall-bladder projects slightly beyond the free margin of the liver in a line with ninth or tenth right costal cartilage. The cystic duct joins the hepatic duct to form common bile-duct. The hepatic duct formed by the junction of a branch from each lobe and issuing through the transverse fissure of the liver descends within gastro-hepatic omentum to join the cystic duct thus forming the common bile-duct (ductus communis choledochus). In the gastro-hepatic omentum the hepatic vein is intermediate and slightly posterior in position with the artery to its left and the duct to its right. The duct passes behind the first part of duodenum and then on the inner and posterior aspect of second part where it is in close relation to the head of the pancreas ; along with the pancreatic duct, it perforates the muscular coat of the duodenum and opens into it by a common orifice. This duct is dilated just behind the orifice forming the ampulla of Vater which is a common site for the lodgment of gall-stones.

An accurate knowledge of the normal and abnormal anatomy of the biliary apparatus is very essential. The arrangement of the

vessels and ducts given as normal in textbooks is found perhaps in a quarter of the cases.

The occasional presence of the right hepatic or cystic artery in front instead of behind or to the left of the common hepatic or common bile duct may lead to trouble and so may the presence of the gastroduodenal or superior pancreatico-duodenal artery in front of the common duct either above the duodenum or just above the ampulla of Vater. An accessory right hepatic duct is very liable to be divided and if the bile escapes into the peritoneal cavity it may lead to death. The cystic artery has very often an abnormal course and is likely to be injured.

The cystic duct too may be abnormal. It may be absent (Walton), unduly short or abnormally inserted into the common bile duct, behind or on the left side of the latter. It may open into the retroduodenal part of the bile duct so that there may not be any common bile duct above the duodenum.

The pelvis of the gall-bladder may enlarge and extend in front or behind the common bile duct, to which it may be intimately adherent, so that the latter may be mistaken for the cystic duct and divided.

Lymphatic nodes are found in the portal fissure and accompanying both the common and cystic ducts. They are specially involved in carcinoma. The importance of the close connection of the lymphatics of the gall-bladder and those of the pancreas must be remembered. Lymphatics of the gall-bladder course immediately beneath the posterior surface of the upper portion of the head of the pancreas. There is also an intimate connection of the gall-bladder lymphatics with those of the adjoining liver parenchyma.

OPERATIONS ON THE LIVER

I. ABSCESSSES OF THE LIVER

Owing to vastness of the subject it was thought desirable to treat it separately and the reader is referred to books on Tropical Surgery for fuller details.

Operations for the treatment of abscesses of the liver (*see* Author's 'Tropical Surgery and Surgical Pathology').

II. WOUNDS OF THE LIVER

SURGICAL ANATOMY

Traumatic lesions of the liver are of two kinds: (1) where the abdominal wall is intact and (2) where the continuity of the skin and wall has been broken. The lesions may be in the form of lacerations or hæmatomas, subcapsular or intrahepatic; syphilis, malaria, etc., predispose to rupture. In lacerations, the bleeding

is profuse due to lack of valves in the veins and scarcity of elastic fibres in the liver ; also admixture with bile retards coagulation.

OPERATION

After combating the shock the abdomen should be opened as soon as possible. If the source of bleeding can be traced to a severed vessel it should be ligated. But often such vessel cannot be detected or are inaccessible. Under these circumstances, if the cut surfaces of the liver are not too irregular they must be sutured together in the hope that the bleeding will then stop of itself. If bleeding is profuse and contusion irregular tamponade and suture are the only effective measures. In suturing, thick catgut and blunt round needle should be used to avoid further damage to the liver tissue. The sutures may be applied in a mattress fashion and should this not be sufficient they may further be strengthened by omental grafts.

In subcapsular or intrahepatic hæmatoma the bleeding is not so severe and any interference is not indicated. When these are found on laparotomy they are best left alone.

III. CYSTS OF THE LIVER

Cysts of the liver are usually parasitic—echinococcal ; non-parasitic cystic collection in the liver may sometimes be encountered.

For echinococcal cysts enucleation is absolutely indicated. Intervention in other cases of cysts of the liver will depend on its nature and symptoms.

OPERATIONS ON THE GALL-BLADDER

EXPOSURE OF THE GALL-BLADDER

The gall-bladder can be exposed by various incisions. Each method claims its superiority over others. Three methods will be described :—

1. A vertical incision in the *linea semilunaris* about three inches long just below the tip of the ninth costal cartilage on the right side.

2. Kocher's incision. This is an oblique incision about four inches long, an inch and a half below the right costal margin. It commences over the right rectus muscle near the middle line and is carried obliquely downwards and outwards parallel to the costal margin. The abdomen is opened. The upper edge of the wound is raised up with the costal margin and the lower edge retracted downwards. The round ligament extending from the umbilicus to the umbilical fissure in the lower margin of the liver is seen ; the gall-bladder is found on the right side of the ligament projecting from under the liver.

3. Draw a vertical line from the middle of the right Poupart's ligament upwards ; the point where this line cuts the lower margin of the costal arch (at the right ninth costal cartilage) is considered by some as the position of the gall-bladder. An incision on this line will expose it.

I. CHOLECYSTOTOMY OR CHOLECYSTENDYSIS

In this the gall-bladder is opened either for exploration or removal of stones and the opening then closed. As in these cases the gall-bladder is more or less infected or diseased, it is either drained (cholecystostomy) or excised (cholecystectomy).

II. CHOLECYSTOSTOMY

The gall-bladder is opened, fixed to the abdominal wound by stitches and drained.

INSTRUMENTS—Group XIX.

INDICATIONS

The indications for cholecystostomy may be summarized as follows :—

A. *For inflammatory and other conditions* :—

1. When the gall-bladder is unhealthy ; (a) hydrops, and (b) empyema of the gall-bladder.
2. When the gall-bladder is infected ; (a) infective cholecystitis ; (b) phlegmonous or gangrenous cholecystitis with or without perforation, when the patient's general condition is too low for more radical measures ; (c) secondary infective pancreatitis.

B. *For traumatic rupture of the gall-bladder.*

C. *For gall-stones* :—

1. In the gall-bladder and it has to be drained after their removal, (cholelithotomy).
2. In the cystic duct when it is healthy and patent.
3. In the common duct when it is healthy and patent.

D. *As a palliative measure* in cases of cancer of the common duct or of the head of the pancreas causing mechanical obstruction to the flow of bile.

III. CHOLECYSTECTOMY

INDICATIONS

Resection of the gall-bladder may be undertaken for the following conditions when the general condition of a patient admits of this operation :—

1. Empyema of the gall-bladder.
2. Phlegmonous or gangrenous cholecystitis.
3. Ulcerative perforation of the gall-bladder.
4. Cicatricial stricture of the cystic duct with dilatation of the gall-bladder.
5. Biliary fistula of the gall-bladder caused by stricture or otherwise which cannot be closed by plastic operation.
6. Contraction and distortion of the gall-bladder resulting from recurrent cholecystitis.
7. Traumatic rupture of the gall-bladder due to gun-shot and other injuries.
8. Malignant growth of gall-bladder when the disease is localized.

OPERATION

After a Kocher incision has been made the bleeding vessels are tied and the peritoneum opened. The falciform ligament is clamped and divided if necessary. The whole biliary apparatus is carefully examined, the common bile duct palpated throughout as well as the head of the pancreas.

The surrounding structures are well protected by gauze packs and adhesions are carefully detached and the fundus of the gall-bladder is seized with special gall-bladder forceps and pulled forwards. By incising the peritoneum of the small omentum, the cystic duct is exposed. The duct is then dissected and tied at a point about a quarter of an inch from its termination and divided. The cystic artery and vein are similarly isolated, tied and divided.

The gall-bladder is now separated from the liver from behind forwards by blunt dissection. The peritoneal covering is saved as far as possible. It is then so divided with scissors that the edges can be sewn together to cover the raw surface of the liver. This arrests hæmorrhage and minimises adhesions.

The stump of the cystic duct is buried and the raw surface of the liver covered by sewing the flaps of the peritoneum over it. If there is any oozing, it is wise to drain the wound at its outer angle for thirty-six hours.

The parietal wound is then accurately closed in layers.

IV. CHOLECYSTENTEROSTOMY

By this is meant the establishment of an anastomosis between the small intestine and the fundus of the gall-bladder by suturing or by introducing Murphy's button.

INDICATIONS

1. Irremediable obstruction of the common bile-duct.
2. A persistent biliary fistula (after operations on the gall-bladder or due to stricture).

3. Some cases of cholecystitis.
4. Chronic pancreatitis.
5. Obstruction of the common duct due to malignant disease of the head of the pancreas.

V. CHOLEDOCHOTOMY

Opening of the common bile-duct to relieve obstruction due to impacted gall-stones or other causes. When a stone is removed after opening the duct it is called choledocholithotomy. The common bile-duct can be opened in two situations :—

- (a) It can be opened in its supra-duodenal part and the impacted stone can be slipped into that part from below and removed through this opening. This part of the duct is more easily accessible. This operation is called supra-duodenal choledochotomy.
- (b) When the calculus is impacted too low down and it cannot be dislodged, the duct will have to be opened in its retro-duodenal portion. This operation is called retro-duodenal choledochotomy.

In the dead subject the gall-bladder is small and bound down under the liver, so it is difficult to perform an operation on such a gall-bladder. It can, however, be exposed and any of the above operations attempted if possible.

CHAPTER XXVI

OPERATION ON THE PANCREAS AND THE SPLEEN

EXPOSURE OF THE PANCREAS

From the front the pancreas may be reached either (1) through an incision in the gastrohepatic omentum, (2) below the stomach *via* anterior layer of the gastrocolic omentum, or (3) through the transverse mesocolon. It can also be approached from the sides both intraperitoneally and extraperitoneally (*Fig. 187*).

I. WOUNDS OF THE PANCREAS

Incised wounds are carefully sutured. Where the gland is much lacerated or disorganized a portion may have to be resected. If the duct is divided attempt should be made to restore its continuity by an end to end anastomosis.

In operations on the pancreas care should be taken to prevent the free escape of the pancreatic fluid into the peritoneal cavity. All pancreatic wounds should be drained.

II. ACUTE INFLAMMATION OF THE PANCREAS

There is no other treatment for the condition than early incision and drainage.

On opening the abdomen the liver is retracted upward, the stomach downward and through an incision in the gastro-hepatic omentum the pancreas is brought into the field. The surrounding region is packed off as well as possible and several knife-point punctures or small incisions are made in the gland.

Drainage may be accomplished by a large gauze packing or cigarette drain, or a composite rubber tube and gauze drain, emerging through the laparotomy incision or by a counter opening in the lumbar region.

III. CYSTS OF THE PANCREAS

In large cysts with extensive adhesions marsupialization is only to be considered. The operation is generally done in two stages, the first stage being incision and drainage.

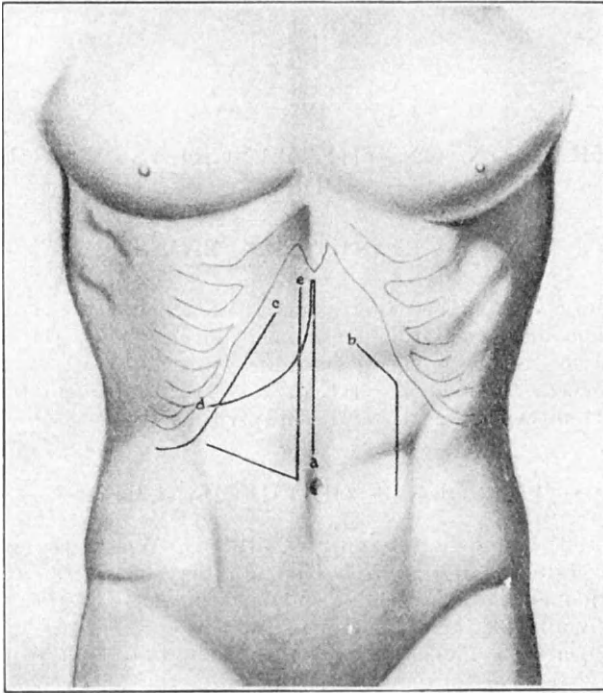


FIG. 187.

SOME OF THE MORE USUAL INCISIONS FOR EXPOSING THE PANCREAS, SPLEEN, LIVER, AND BILIARY DUCTS:—a, Median incision for exposing the pancreas;—b, Bevan's or Mayo's incision (with or without the angular extension inwards) for the spleen;—c, oblique, paracostal incision, for the liver and bile-ducts;—d, Kehr's bow-shaped incision for the liver and bile-ducts;—e, Perthe's angular incision for the liver and bile-ducts.

REPRODUCED FROM BICKHAM'S OPERATIVE SURGERY
By the Courtesy of the W. B. SAUNDERS CO.

Smaller, pedunculated cysts with few adhesions should be extirpated. Pseudocysts of the pancreas are generally due to traumatic effusion into the lesser sac. The treatment consists of incision and drainage.

IV. NEOPLASMS OF THE PANCREAS

In cancer of the pancreas the operation is generally very complicated because of wide metastases and adhesions. If however the tail only is involved and there are no metastases to liver and the lymph nodes are not heavily infiltrated, excision of this part of the pancreas may prolong the life of the patient.

When the head of the gland is involved resection is almost useless and much more difficult. But a partial resection may be undertaken to relieve the obstruction of the bile passages, caused by the tumour.

Sarcomata of the pancreas are extremely rare and the treatment for the condition is the same as above.

CHAPTER XXVII

OPERATIONS ON THE RECTUM AND ANUS

SURGICAL ANATOMY

The rectum which is the lowermost part of the bowel consists of two segments, the upper, i.e. the rectum proper is five inches long, commences from the termination of the pelvic colon in front of the body of the third sacral vertebra and terminates in the anal canal below, at a point one inch beyond the coccyx. The lower segment consists of the anal canal, one-and-half inches long, extending from the termination of rectum proper to the margin of the true skin. The rectum proper or ampulla has a thick vascular mucous membrane which is arranged in horizontal folds in its upper part, two or three of which are more prominent and are called *Houston's valves*. The muco-cutaneous junction in the anal canal is marked by a white line, the pectinate line, also called *Hilton's white line*. From this, thickened processes of mucous membrane pass vertically upwards and are known as *columns of Morgagni*. Between these columns are a series of short semilunar valves with small crypts—the *valves and crypts of Morgagni*. The external sphincter is composed of voluntary striped muscles and surrounds the anal canal. The internal sphincter is composed of a thick portion of the circular muscle fibres of the middle coat of the bowel and encircles the upper part of the anal canal; it terminates about the level of Hilton's white line. The rectum is supplied by the superior hæmorrhoidal, the middle hæmorrhoidal, the inferior hæmorrhoidal and the middle sacral arteries. It is thus supplied both by portal and systemic arteries. The veins commencing in the hæmorrhoidal plexus carry blood by the superior hæmorrhoidal vein through the inferior mesenteric into the portal circulation. The middle and inferior hæmorrhoidals and the middle sacral vein, carry blood through the systemic circulation to the inferior vena cava.

The rectum is covered anteriorly by the peritoneum from the promontory to the lowest portion of the *pouch of Douglas*. The deepest portion of this pouch is at about the distance of the tip of the examining finger from the anal orifice which in the male is at the level of the seminal vesicles and in the female a little below the posterior fornix. These facts are of importance while making a digital examination for carcinoma of the rectum, as it allows one to estimate fairly accurately whether the tumour is intraperitoneal, extraperitoneal or both. Below the peritoneal reflection the rectum is encircled by layers of the fascia propria.

The lymphatics of the anal portion of the rectum drain downwards into the inguinal glands. Those of the lower part drain into

glands on the levator ani muscles and under the rectovesical fascia and laterally into a gland near the obturator vessels. Those from the middle and upper parts run along the inferior hæmorrhoidal veins and terminate in glands at the promontory and from there into glands in the mesocolon or along the inferior vena cava.

EXAMINATION OF THE RECTUM

The rectum should be examined, in order to ascertain the cause of the complaint and to decide upon the operation which might be required. Position :—The patient may be placed in the left lateral position with the right thigh acutely flexed on the pelvis, in the genupectoral position or the exaggerated lithotomy position.

A digital examination or bimanual (bidigital) examination, viz. one finger in the rectum and a finger or fingers above the pubes in front or in the female in the vagina is useful.

Endoscopic examination by a speculum of which there are many varieties or the proctoscope carrying a light or throwing in reflected light from a forehead mirror is also useful; in this examination the rectum may be inflated with air if necessary.

CONGENITAL DEFORMITIES OF THE RECTUM

Many deformities due to developmental anomalies are seen in the rectum. The following are the more important ones.

1. Developmental anomalies of the hind gut, absence of whole large bowel, fæcal opening being at the umbilicus.
2. Developmental anomalies of the post-allantoic gut may result in imperforation of the rectum and of urethral, vesical and vaginal outlets.
3. Developmental anomalies of the proctodeum may result in imperforation of anal, vulvar and anterior urethral outlets. These may be associated with deformities in the region of the perineum and scrotum and undeveloped anal canal.
4. Persistence of post-anal gut as a diverticulum or tumour.

OCCCLUSIONS

A. *Superficial Membranaceous*.—These are generally transversely anteroposterior or semilunar in direction and they occlude the anus only partially.

OPERATIONS

Excise the central portions of these bands by transverse incisions at both ends; the free cut edges shrivel up. If however the bands are so disposed that they cause more or less complete obstruction to the anus a crucial incision and removal of the free tags are required. The opening so made should be dilated daily with lubricated finger tips.

B. *Imperforate Anus*.—Two clinical varieties are seen. In one case there is a complete absence of any visible indication of the anus and in the other variety a rudimentary anus may be seen as a dimple at or near the site of the normal anal aperture.

The following facts should be considered before deciding upon the nature of operation : (1) The distal end of the rectal cul-de-sac is often not on an axial line with the rudimentary anal canal or the normal site of the anus. (2) The extent to which the rectum has approached the anal site, i.e. the length of space intervening between these. Is the rectum within reach through perineal incision ? (3) Is the rectum in open relation with some hollow viscus ? (4) As sometimes happens, is there a peritoneal fold extending into the space between the undeveloped rectum and anus ? (5) Is there a complete absence of the rectum or distal part of the colon ? (6) Is there a noticeable discoloration at the site of the anus ? (7) Is there a visible bulging at the anal site when the child strains or cries or on pressure on the abdomen ?

In view of the anatomical peculiarities it is unsurgical to casually explore the rectum with a hollow needle on the off chance of striking the blind pouch of the rectum or drawing some meconium.

Insufficiency of room and tender age of child are some of the primary difficulties of operation. The operative risks and the post-operative shock are also matters for consideration but the only means of saving life is by establishing an opening either by perineal dissection, exploration and anchorage of the rectum to the anal site or if inaccessible, a preliminary colostomy with subsequent plastic operation if possible.

OPERATION

When the rectal pouch is not far from the anal opening and is in axial line with it or with slight deviation, the anal pouch is incised, the rectal pouch sought for, incised and anchored to the opened upper end of the anal pouch. If there be no guide as to the lower end of the rectal pouch a median perineal incision is advisable and dissection in the direction of the tip of the coccyx will reveal the blind end of the rectal pouch.

When the rectum is arrested high up in the pelvis, the operation is much more difficult. A straight median perineal incision is made beginning at the hind end of the anus or when it is absent at the base of the scrotum or posterior commissure of the vagina and is extended towards the tip of the coccyx. The external sphincter is split and the halves carefully guarded. By careful dissection with scissors in the direction of the hollow of the sacrum the blind rectal pouch may be encountered. It is caught with delicate rubber covered clamps and drawn down.

If held by attachments, these may be snipped and if the bulk of the pouch is a hindrance to work it may be aspirated and the hole closed again with a ligature. The blind end is now incised

and the mucous membrane sutured to the skin with stitches, at intervals, penetrating through all the coats of the rectum and the margins of the perineal wound.

If the rectum is arrested still higher up and cannot be brought down, the coccyx and sacrum may have to be split and dissected out and the rectum anchored between the split portions of the sacrum thus prepared, the perineal wound being closed in the usual manner.

Comments :—(1) A sound in the bladder or in the vagina when possible may be of considerable help during dissections. (2) If a fibrous band attached to the anal pouch be discovered during dissections it must be carefully followed up as it often leads to the blind end of the rectal pouch. (3) Counter-pressure on the abdomen may further bulge and bring down the rectal pouch and help in locating it. (4) If operation is too difficult or long, a colostomy should be done and the perineal wound packed with gauze for a time, for subsequent exploration. (5) Children bear anaesthesia badly hence the operation should preferably be done—without it. (6) Keith's estimate is that in 95 per cent. of cases the rectal pouch can be pulled down to the perineum.

C. *Atresia ani vaginalis*.—In this condition the anal pouch is blind and the rectum opens directly into the vagina. It is best to operate later when the child is about 5 years of age when a sphincteric control around the vagina may have developed. In Rizzoli's operation it is sought to transplant this and the rectal pouch into the position of the normal anus,—the perineum having been temporarily cut through up to the normal anus; the posterior vaginal wall incised, the rectal pouch dissected from its abnormal position, including the sphincteric vaginal opening, and implanted at the normal site, after which the posterior vaginal wall is restored and the temporarily divided perineum repaired.

D. *Atresia ani uterinæ* is an exceedingly rare condition and the operative treatment is unsatisfactory. If the rectum cannot be brought down to its normal outlet, a colostomy may be the only other recourse.

E. *Atresia ani vesicalis*.—When the rectum opens into the bladder attempt may be made to separate the two viscera and bring down the rectum.

F. *Atresia ani urethralis*.—When the rectum communicates with the urethra, the plastic operation is simpler and the chances of cure better.

RECTAL CRYPTITIS

The crypts of morgagni occasionally get inflamed and might be precursors of rectal fissures and fistulæ. Much discomfort and

trouble entailing a rectal operation may be saved by a thorough proctoscopic examination, and snipping off the distal ends of the crypts and applying soothing ointments.

VALVOTOMY

Houston's valves if hypertrophoid due to chronic inflammation may have to be incised. After they are viewed through a suitable speculum they are brought down and steadied by means of blunt hooks and divided with a scalpel or an electric knife.

ABSCESSSES IN THE ANO-RECTAL REGION

SURGICAL ANATOMY

Cellular spaces in the perianal and perirectal regions and the ischio-rectal and perirectal spaces are liable to inflammation or suppuration, the infection spreading either from within or without. The abscesses may travel in different directions along muscular and fascial planes or through the lymph channels. Abscesses in one situation may form communications with those in other situations even working through anatomical barriers. Insufficient drainage, exploration or breaking down septa lead to perpetuation of discharge and complications such as tortuous fistulæ with thick indurated walls.

The pelvi-rectal space is the space which has the levator ani below, the peritoneum above, the rectal wall medially and the obturator internus covered with its fascia and upper part of the levator ani laterally (*Fig. 188*).

The ischio-rectal fossa is a pyramidal space about 2 inches deep between the lower part of rectum and the ischial tuberosity. Its apex is at the point of separation of the obturator fascia and the fascia covering the outer aspect of the levator ani muscle. It is bounded anteriorly by the line of junction of the superficial perineal fascia with the base of the triangular ligament, posteriorly by the border of the gluteus maximus and the great sacrosciatic ligament; medially by the sphincter ani, levator ani and coccygeus muscles; and laterally by the ischial tuberosity and the fascia covering the obturator internus. The fossa is occupied by a large mass of fatty areolar tissue, small vessels and nerve filaments.

OPERATIONS

(a) *Perianal abscess*.—An incision commencing centrally near the anus and radiating outwards, if necessary guided by a probe-pointed, grooved director is made. Do not cut beyond the protective granulation tissue layer. Swab it with tincture of iodine and then pack it with gauze.

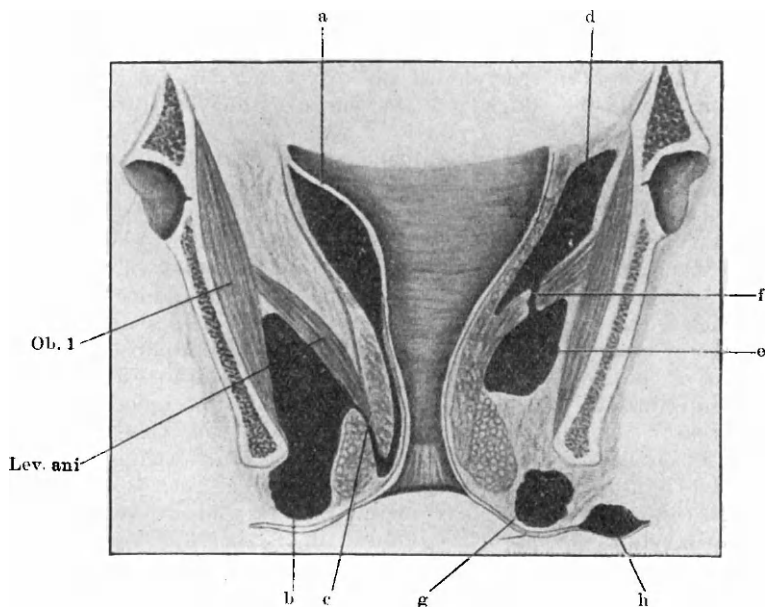


FIG. 188.

ANORECTAL AND PERI-ANORECTAL ABSCESES IN CORONAL SECTION:—a, Intramural (submucous) abscess, between rectal mucosa and muscularis;—b, large ischioanal abscess, involving the greater part of the ischioanal fossa;—a, b, intramural and ischioanal abscesses communicating between internal and external sphincters (or the one terminating in the other, at c);—d, anterolateral superior pelvic abscess, above the levator ani;—e, ischioanal abscess in the upper part of the ischioanal fossa;—d, e, anterolateral superior pelvic and ischioanal abscesses communicating, by dissection, through the levator ani muscle, or the reverse, at f;—g, subcutaneous abscess;—h, cutaneous abscess.

REPRODUCED FROM BICKHAM'S OPERATIVE SURGERY
By the Courtesy of the W. B. SAUNDERS CO.

(b) *Perirectal and submucous abscesses*.—Identify the situation and extent and make an incision from the superficial aspect. Do not allow the abscess to burst into the rectum or the knife cut through its walls.

(c) *Ischioanal Abscess*.—There may be presuppurative cellulitis in the ischioanal space with signs of inflammation and suppuration. Generally, it is unilateral but the process may extend to the opposite side. At first there is inflammatory induration of the fossa and superficial tissues and later the destruction of the supporting structures proceed to such an extent that the rectum may lie suspended in the broken down honey-combed area. This shows the importance of early surgical interference.

Make an incision parallel but external to the sphincter between it and the ischial tuberosity. A carefully deepened incision is better than a stab, the depth not exceeding two inches. The incision should be longer on the surface and narrowed as it approaches the apex.

Break down the disintegrating tissues, preferably with the fingers making sure that all tracks and inter-communications are opened up. Remove all sloughs and necrotic tissues.

A rubber drainage tube will ordinarily do but if the abscess has extensive side tracks posteriorly and in cases of bilateral abscesses, continuous irrigation is indicated. Introduce a rectal drainage tube. Sometimes in bilateral cases a postero-median incision or two lateral incisions are required to drain both cavities.

(d) *Pelvirectal abscess*.—The same procedure as for ischiorectal abscess is indicated. The incision is deepened two inches and on the levator ani being encountered this is divided, this structure being often partly disintegrated; the pelvirectal space is reached at a depth of 2 to 3 inches.

In this operation the peritoneum, bladder and urethra should be cautiously avoided and rough curetting is therefore harmful.

ANORECTAL FISTULÆ

These fistulous tracts lined with infected granulations and surrounded by indurated tissues are channels of communication between anus, rectum and anorectal region and adjacent or distant surfaces, tissues or organs. They result from neglected and incompletely drained abscesses and vary considerably in size, shape and the course they take.

These fistulæ are classified in different ways and operative treatment will depend on the particular variety.

CLASSIFICATION

I. According to completeness.

1. Incomplete—when there is one opening :—

- (a) if opening extend to anorectal canal, blind external ;
- (b) if opening internal, blind internal.

2. Complete—having two openings one of which is in the anorectal region.

II. According to their course—simple, linear, curved, branching, tortuous, Y-shaped, horse-shoe shaped, etc.

III. Complicated when one end communicates with internal organs.

IV. According to etiology :—

- (a) septic, pyogenic ;
- (b) specific—amoebic, tubercular, syphilitic, etc. ;
- (c) neoplastic—due to malignant growths :
- (d) due to radium necrosis.

OPERATION

Various methods of operation for this troublesome complaint have been devised ; simple incision, incision and curetting, cauterising, electrocautery, electrosurgical (diathermy), excision or excision and suturing.

First of all, take a good view of the rectum through a suitable speculum of bi-valve or some other type. Ascertain if it is complete or incomplete. Minute internal openings may be overlooked ; therefore injections of solutions of some dyestuff such as methylene blue or brilliant green through the distal opening is useful not only for detecting a proximal opening but also during later stages of operation, in bringing into view the ramifications of the fistulous tract.

Introduce a probe pointed grooved director into the fistulous opening. Then slit open the entire fistulous tract with all its ramifications and diverticula. After this the granulations may be scraped and the raw surface cauterised and packed with gauze.

The indurated fistulous tract may be excised and a flap of mucous membrane stitched over it ; or the whole fistulous area may be excised and the margins apposed by sutures leaving a small distal opening for drainage.

Some recommend electrocautery but the more modern method of electrosurgical excision by a diathermy needle or knife is more rational.

Comments :—The sphincter has to be temporarily put out of action. This can be done by dilating it or by its division. It should not be divided at more than one place,—and that at right angles, because repair is more satisfactory after this than after oblique division.

Late complications such as stricture of the anus and rectum or incontinence of fæces have to be appropriately treated.

ANAL FISSURES

Anal fissures are solutions in the continuity of muco-cutaneous tissues with superficial ulcerations on these surfaces.

In the olden days the treatment was by repeated forcible dilatation and the retention of bougies. This is of course abandoned now as being brutal and as they very often resulted in severe damages. They can be cured by curetting or excision and suturing.

PRURITUS ANI

For this troublesome complaint the surgical treatment is only symptomatic and consists of dividing either subcutaneously (Lynch's operation) or after raising two semi-elliptical flaps (Ball's operation) with their convexities outwards, and dividing the sensory nerves and re-suturing the flaps.

HÆMORRHOIDS

Varieties.—Three varieties are recognized: (1) Internal piles are those which implicate the terminal branches of superior hæmorrhoidal veins and are covered by mucous membrane; they originate in the lowermost part of rectum and the anal canal. (2) External piles are those which implicate the branches of the inferior hæmorrhoidals and are seen in the part of anal canal that is lined by skin. (3) Mixed piles are those in which both the varieties co-exist.

INDICATIONS AND CONTRAINDICATIONS FOR OPERATIONS

Indications.—(1) Repeated loss of blood leading to secondary anæmia. (2) Persistent tendency for the piles to protrude. (3) Lowering of the patient's general health due to loss of blood and constant irritation and pain.

Contraindications.—Hæmorrhoids are generally associated with diseases or congestion of the liver and unless these are appropriately treated the operation is useless. In hæmophilic patients the operation is naturally contraindicated.

Preparation of the patient.—After thoroughly emptying the intestinal tract a few days in advance of the operation, the patient should be given a thorough rectal wash prior to operation. The circumanal region should be shaved. The bladder must be empty. After dilatation of the sphincter the rectum and anus are swabbed out with a suitable antiseptic. The patient should be kept on antitetanic diet for some time. The dilation of the sphincter must be carefully done and during stretching anæsthesia withheld, otherwise fatal accidents may occur.

POSITION

Lithotomy position.—Surgeon sits facing the patient's perineum and the assistant stands on his left.

INSTRUMENTS—Group XVIII.

OPERATIONS

There are many operations for hæmorrhoids. All of them can hardly be described here. In the choice of operation certain

principles should however be followed. The following can be taken as general rules : (a) For minor grades of external or internal hæmorrhoids excision and suture or incision, ligation and suture ; (b) for intermediate grades of internal or external hæmorrhoids—subcutaneous excision, ligation and suture ; (c) for the minimum grades of mixed involvement including anorectal relaxation and prolapse, one of the varieties of Whitehead's operation followed by necessary ligation ; and (d) for thrombotic hæmorrhoids incision, evacuation of the clot and suture or one of the radical operations.

1. *Ligation and excision.*—This is suitable for pedunculated piles. Introduce both thumbs within the bowel and dilate the sphincter steadily and slowly first in the transverse and then in the antero-posterior direction. This brings the piles into view and enable them to be caught and drawn down beyond the anal orifice. The individual piles are defined, seized with forceps and its neck grasped by crushing forceps ; a catgut ligature is applied securely on the groove thus formed. The portion of the pile beyond forceps is cut away with scissors. In some piles with broad pedicles, the base is transfixed and secured in two halves by Staffordshire knot.

2. *Excision and suture.*—(Mitchell's operation.) Mitchell of Belfast describes an operation which is very widely practised now. The anus is dilated and the base of each pile is clamped in the long axis of the bowel with a pair of narrow bladed hæmostatic forceps. The redundant portion of the pile is removed. A catgut suture is applied at the tip of the forceps, secured with a knot and carried as a continuous suture including the forceps and the tissues around the base of the pile. Now the forceps is removed and the suture tightened almost simultaneously. The remaining piles are treated in a similar way. These sutures not only arrest hæmorrhage but close the wound without leaving a raw surface.

3. *Author's modification of Mitchell's operation.*—I adopt Mitchell's method modifying the sutures as follows : I introduce a catgut suture at the tip of Kocher's forceps, but instead of tying a knot here at the commencement, I leave a long end of the catgut free and then carry the suture as in Mitchell's operation, leaving another long end at its termination (*Fig.* 189). After withdrawing the needle I pick up these ends of the suture with the left hand, and pull it taut as I release the blades of the forceps and take it off. I immediately tighten the suture further and finish off with a knot securely tied. This operation seems to have some advantages : (i) hæmostasis is more perfect, (ii) accessory sutures or ligatures are not required, (iii) the apposed raw surfaces are brought together as if after a purse-string suture, (iv) the operation can be done more quickly, and (v) the wound heals rapidly.

4. *Excision of the pile-bearing area.*—(Whitehead's operation.) The piles are made to protrude as in the previous operation. Carry an incision round the circumference of the anus separating the mucous membrane from the skin. Catch the mucous membrane

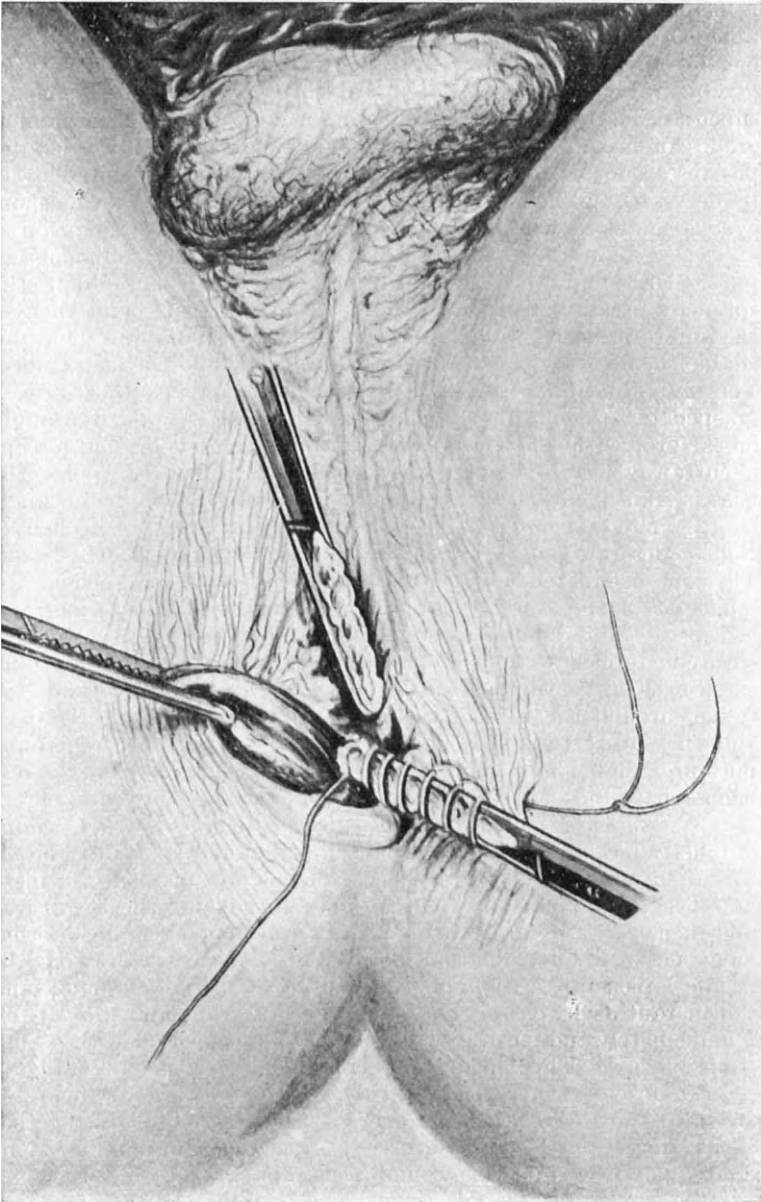


FIG. 189.

AUTHOR'S MODIFICATION OF MITCHELL'S OPERATION
FOR HÆMORRHOIDS.

with forceps and peel it down by a blunt dissector from the submucous tissue for the whole extent of pile-bearing area. On reaching the upper limit of the piles, cut transversely across the healthy mucous membrane and bring this down to the line of former incision at the anal margin. The cut margins are brought together by interrupted catgut sutures.

5. *Clamp and cautery method.*—The piles are brought down, the pedicles crushed with clamps and the projected portion, burnt off with cautery at a dull red heat. This operation is seldom performed now.

INJECTION TREATMENT OF PILES

Lately the 'injection treatment of piles' has come much into vogue. One of the following solutions is slowly injected into the submucous tissue around the base of the piles but not into them. Too superficial or too deep injections are ineffective, besides, they may cause much sloughing and pain.

The solutions used are: (a) a 5% solution of carbolic acid in olive oil, (b) a 5% solution of quinine urea hydrochloride, (c) a 10–25% solution of carbolic acid in glycerin, or (d) colloidal silver solution.

The injection treatment is contraindicated in diabetes, cirrhosis of the liver, fibrous hæmorrhoids and hæmorrhoids complicated by fissure in ano, sphincter spasm or in chronic prolapsed hæmorrhoids.

OPERATIONS FOR PROLAPSE OF THE RECTUM

The following operations for the prolapse of the rectum deserve special mentioning:—

(1) Linear cauterisation—suitable for small prolapses: After introducing a speculum the blade of the thermocautery is drawn edgewise along the lower three or four inches of the posterior rectal wall. If required the anterior or lateral walls may also be cauterised. The cauterisation must not be too deep.

(2) Excision of elliptical pieces of mucous membrane and suturing the margins of the wound have the advantage of preventing hæmorrhage and hastening cure.

(3) Complete removal of the prolapse though a radical operation is more severe and has many risks. It should be done only in those cases in which other methods have failed or fatal complications (gangrene, etc.), threaten.

It consists of amputation of the bowel and suturing the divided edges at the margin of the anus. Occasional presence of small intestine in the herniated peritoneal pouch and hæmorrhage make the operation difficult.

(4) Plastic operation to restore the sphincter ani sometimes by narrowing the orifice help in keeping the bowel inside.

(5) Submucous injections of paraffin has many practical disadvantages and is rarely done.

(6) Proctopexy (Lockhurt-Mummery) aims at formation of fibrous tissue between the sacrum and rectum which may thus be retained in position. A $2\frac{1}{2}$ inches long incision is made between coccyx and anus and the space between rectum and sacrum opened up. This space is filled up with vaseline gauze and allowed to heal up by granulation. A secondary operation to restore the sphincter ani may be necessary.

(7) Colopexy in which the pelvic colon is sutured to the psoas muscle promises uncertain results.

OPERATIONS FOR STRICTURE OF THE RECTUM

Stricture of the rectum may be—congenital, inflammatory, catarrhal, tubercular, dysenteric, syphilitic, gonorrhœal, neoplastic (intra- and extra-mural), spasmodic and traumatic.

Treatment may be palliative and curative; dilatation is often palliative but may sometimes cure the condition. It may be done by fingers or graduated dilators and bougies.

OPERATION

The operative treatment consists of proctotomy in less severe cases and excision of the strictured portion or even sigmoido-rectostomy by lateral entero-anastomosis in more complicated cases.

Proctotomy: Internal—(superficial and complete).—After dilating the sphincter under anæsthesia a probe pointed bistoury, guarded by the left forefinger is introduced into the rectum and a superficial, longitudinal incision is made through the stricture. Multiple incisions may be made. The rectum is dilated and a suitable bougie left in for at least 48 hours.

In complete proctotomy the incision is on the posterior rectal wall and divides the tissues completely down to the sacrum and coccyx.

In external proctotomy the approach is made through an incision on the back, if required by incising the sacrum and coccyx.

Excision of the strictured portion—may be done through the perineal or the sacral route. In the former when the stricture is within 6 cm. from anus the rectum is dissected out with or without the internal sphincter, according as it is or is not involved and the strictured portion resected out by a circular incision. After this the lower end of the upper segment is either brought down to the level of the skin and sutured there or it is sutured with the internal sphincter.

The sacral method is applicable when the stricture lies above 6 cm. from the anus. The technic is almost similar to that of Kraske's excision of the rectum for malignancy.

Sigmoido-rectostomy by lateral entero-anastomosis.—Consists of an anastomosis between a loop of sigmoid above and rectum below the stricture by means of a murphy's button.

EXCISION OF THE RECTUM

It is almost exclusively done for epithelioma or adenocarcinoma of the rectum and anus provided there is no involvement of neighbouring viscera by local extension. The operative approach may be through the perineum, the vagina or by the transsacral route; sometimes the abdominal or the abdomino-perineal routes may be necessary.

Partial proctotomy is done in early cases where the growth is within $2\frac{1}{2}$ inches from the anus.

A. *Perineal Resection of the Rectum* (Lockhart Mummery's operation) is better done in two stages,—the first stage being a high colostomy. Advantage is taken of the laparotomy wound and a thorough examination of the abdominal contents is made.

The second operation is performed about ten days later during which time the lower bowel and rectum are daily irrigated with a suitable antiseptic. The patient is in lithotomy position.

Before operation a stiff rubber catheter is introduced into the bladder to serve as a guide and anus is closed by silk sutures.

Make an incision commencing from the base of the scrotum and carry it forward in the middle line, encircling the anus and meeting about one and a half inches behind it. The incision is then deepened and the coccyx disarticulated and detached from the sacrum. The deep fascia in front of the sacrum is opened and the levator ani muscles on both sides are cut well away from the rectum. The rectum is then dissected from the prostate or vagina in front. The peritoneum should now be cut open along the sides and the mesorectum divided as high up as possible. Clamps are now applied and with a cautery knife the bowel is divided. The stump of the sigmoid in the upper clamp is now invaginated and closed by purse string sutures. The peritoneum is closed now. The infiltrated pelvic cellular tissue and glands should now be removed without making the operation unusually long. The wound is now closed with a cigarette drain.

B. *Trans-sacral Resection of the Rectum* (Kraske's operation).—The patient is prepared as previously described. A preliminary left inguinal colostomy should preferably be done two weeks ahead of the operation.

The skin incision passes directly to the bone over the middle of the sacrum and coccyx, beginning over the second sacral spine

and ending within about 2.5 cm., behind the anus. The soft structures are retracted to the sides.

The gluteus maximus and sacrosciatic ligaments are detached from both sides of the sacrum and coccyx as well as the coccygii and part of the pyriformes. Next, by means of a periosteal elevator the soft structures are elevated from the hollow of the sacrum.

The coccyx and as much of the sacrum as is considered necessary are now removed preferably by a gigli saw and all bleeding vessels tied. The pelvic connective tissue is now incised down to the rectum, the peritoneal pouch opened and the peritoneum stripped off as much as possible. The pelvic mesocolon is also divided after which a complete mobilisation of the bowel would be possible.

The affected portion of the bowel is then divided between ligatures. The method of restoring the intestinal canal will depend upon whether or not the sphincters and anus are retained and whether the divided ends can be apposed.

C. *Abdominal and abdomino-perineal resections* are favourably looked upon by many surgeons because of their offering more opportunities for closer examination and wider resection. They are suitable when the growth is in the pelvic colon or high up in the rectum.

In Miles' abdomino-perineal resection, spinal anaesthesia is universally given. With the patient in high Trendelenberg position the abdomen is opened through a left paramedian incision. The cavity is now rapidly explored to see if there are distant visceral metastases, in which case resection should be abandoned. A self-retaining retractor is now applied and the intestines are displaced upwards and retained in the upper abdomen by gauze pack. The pelvic colon is brought out of the wound and held forwards while the reflexion of the mesocolon to the left iliac fossa is picked up and incised. The inferior mesenteric vessels are now tied just below the level of the bifurcation of the aorta. The bowel is now separated from the sacrum as far as the sacro-coccygeal joint and also anteriorly from the bladder and seminal vesicles. The lateral fibrous attachments are snipped off when the bowel becomes free. About an inch of the pelvic colon is now crushed with clamps, the crushed part is tied at either end by strong ligatures and divided between the ligatures. The ends are protected by pieces of rubber sheeting tied over them. The upper end is used for making the colostomy. The other end of the bowel is placed in front of the lower part of the sacrum. The pelvic peritoneum is brought up and sewn above the pelvic colon. The gauze packs are removed; the lower margin of the great omentum is brought down into the pelvis and the abdomen is closed.

The patient is now placed in the right lateral position with the thighs well flexed. The anus is closed with a purse-string suture. A three inches long transverse incision is made over the sacro-

coccygeal joint from the middle of which another incision is carried down in the middle line to within an inch of the anus. The skin flaps are raised and the coccyx is disarticulated from the rectum. The pelvic fascia is divided and this exposes the loop of the pelvic colon and rectum to be removed. Muscles of the pelvic floor are divided on either side close to the lateral wall of the pelvis. Anteriorly the separation from prostate, urethra or vagina is now completed. The inferior hæmorrhoidal vessels are tied and divided. The bowel is now removed along with the fatty tissue of the ischio-rectal fossæ.

The large cavity thus made is swabbed with a 1-500-biniiodide of mercury lotion and is packed with gauze to support the new pelvic floor.

A self-retaining catheter is inserted into the colon at the colostomy wound and is used for introducing nutrients or an outlet for intestinal gas (*Fig. 190*).

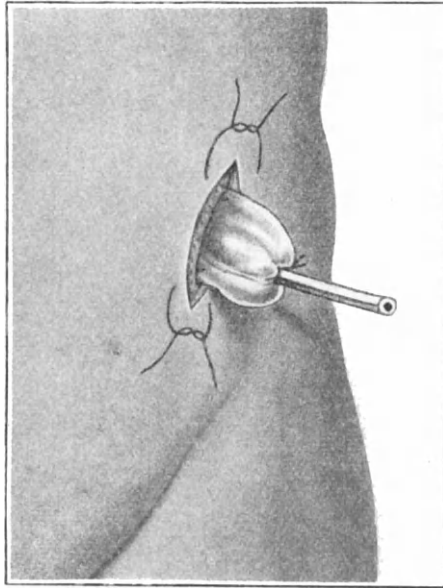


FIG. 190.

ABDOMINO-PERINEAL EXCISION OF THE RECTUM :—Colostomy with catheter fixed in the inverted end of the colon for the administration of glucose salines.

REPRODUCED FROM TURNER'S OPERATIVE SURGERY.

OPERATIVE TREATMENT FOR NEOPLASMS OF THE RECTUM

For localised papillomata (villous growths) the rectum is dilated by means of a suitable dilator, preferably of a bivalve type after which the mass is secured with a pair of forceps and excised. For other types of growths which have invaded the rectal wall deeply, excision of the rectum is advisable.

For malignant growths one of the methods of extensive excision detailed above should be attempted.

CHAPTER XXVIII

OPERATIONS ON THE UROGENITAL TRACT

THE KIDNEYS AND THE URETERS

SURGICAL ANATOMY

Normal kidneys have the following dimensions : length 12 cm., breadth 6 cm., thickness 3 cm. The right kidney is thicker and the left a little longer.

The upper pole of the right kidney is at the level of the eleventh thoracic vertebra and the lower pole about the level of the upper border of the third lumbar vertebra. The left kidney is therefore half an inch higher.

The posterior surface at its upper portion rests on the psoas, quadratus lumborum and transversalis muscles. Between the kidney and the quadratus lumborum run the twelfth thoracic, ilio hypogastric and ilio inguinal nerves.

Between the fibres of the diaphragm which arise from the internal arcuate ligament (over quadratus lumborum) and the fibres arising from the twelfth rib, a triangular space exists with its base downward. It is called the *hiatus* and if large it allows the pleura and the kidney to come in contact with each other. This favours the passage of pus from the perirenal region to the pleural cavity and the lung.

The anterior surface of the kidney is in contact, on the right side, with the suprarenal gland, the liver, duodenum, and right colic flexure ; on the left side, with the suprarenal, stomach, pancreas, spleen, left colic flexure and coils of jejunum.

There are two capsules of the kidney,—one fibrous and the other a fatty one. The fibrous capsule can be stripped from the healthy kidney but in certain diseased conditions it becomes adherent. The fatty capsule surrounds the kidney and is continuous below with the subperitoneal fat.

Two layers of fascia, which form the perirenal fascia envelope the kidney over the fatty capsule. The anterior layer is continuous with the fascia of the opposite side medially and at the lateral margin of the kidney it blends with the posterior layer. The posterior layer is attached medially to the bodies of the lumbar vertebræ. Above, these layers are attached to the diaphragm ; below, they blend into the subperitoneal tissue of the iliac fossa.

Of the renal arteries, the right is a little longer and higher and passes out beneath the vena cava, head of the pancreas, and

second portion of duodenum. The left renal artery passes behind the pancreas. Each renal artery divides into two primary branches—one anterior and one dorsal, and they do not anastomose freely, leaving an exsanguinous zone dividing the kidney into anterior and posterior segments. This line (avascular frontal plane of Brodel) is the line of election for renal incisions and lies about 1 c.m. behind the lateral longitudinal renal border. Renal arteries are end-arteries and do not anastomose; therefore, a lesion in any one vessel results in an infarct of the area it supplies. Supplementary or supernumerary renal arteries may be present and in operations on the kidney, the possibility of their presence must be remembered. A supernumerary artery at the lower pole may cause a kink of the ureter and give rise to urinary obstruction and hydronephrosis.

The arrangement of structures at the hilum is, pelvis posteriorly, then the arteries and lastly the veins most anteriorly. Spread of malignancy into the left renal vein may involve the left internal spermatic vein (which drains into it and meet at about an angle of 90°) with resulting varicocele. There are two sets of lymphatics of the kidney. The superficial system drains the fatty and the fibrous capsules. The deep system drains the parenchyma. The vessels of both systems are afferent to lymph nodes located for the most part behind the pelvis at the hilum. These nodes are involved in renal carcinoma. Efferent vessels from the renal lymph nodes drain into the lumbar lymph glands along the aorta and inferior vena cava.

EXPOSURE OF THE KIDNEY

The kidneys can be exposed by an anterior transperitoneal route or by the posterior lumbar route. The lumbar route is chosen in a large majority of cases for the following reasons: (1) It allows sufficient room for access and operative handling of the kidney. (2) It is much safer than the transperitoneal route particularly in the presence of sepsis in and around the kidney.

The transperitoneal route is only recommended when, due to the large size of an abnormal kidney its delivery through a lumbar opening is difficult or impossible, or if there are numerous adhesions.

INSTRUMENTS—Group XX.

POSITION

The patient lies on the opposite side with an air cushion introduced into the iliocostal space of that side. This gives maximum space between the last rib and iliac crest on the side to be operated. The operator can stand on either side but preferably behind the patient: the assistant stands opposite to him.

OPERATION

Define the boundaries of the iliocostal space by the following three landmarks: (a) Outer border of the erector spinæ (sacrospinalis) muscle which is about a hand's breadth from the middle line (spine), (b) the crest of the ilium below, and (c) the twelfth rib above.

Incision.—Commence an incision at the junction of the twelfth rib and the erector spinæ muscle and carry it obliquely downward and forward towards the anterior superior iliac spine. The length of the incision is about 4 inches. This divides the skin and superficial fascia and exposes the latissimus dorsi above and the external oblique below.

Divide these muscles and also the internal oblique and transversus which are now exposed. The lumbar aponeurosis is now divided. Clear the upper angle of the incision, when the quadratus lumborum muscle will be exposed. Anterior to its edge is some loose fat covering the peritoneum. Clear the fatty tissue posterior to it and thus expose the peri-renal fascia. Now feel for the kidney. Divide the fascia in its posterior aspect along the whole length of the incision. The lower pole of the kidney can now be seen.

Delivery of the kidney.—Catch the retrorenal fascia in front of the opening with a pair of forceps. Separate the fatty tissue surrounding the kidney and clear its upper and lower poles.

Exploration of the kidney.—Compress the pedicle between the index finger and thumb of the left hand. Examine the exterior of the kidney and its pelvis, palpate the ureter. If required, the interior of the pelvis and kidney can be explored through an incision in the pelvis (Pyelotomy) or through an incision in the kidney (Nephrotomy).

Comment :—(1) In defining the iliocostal space make sure of the twelfth rib: it is a good custom to count the ribs from above. If the eleventh rib is mistaken for the twelfth the pleura may be opened into. (2) In dividing the skin and muscles avoid cutting the twelfth thoracic nerve above and the ileo-hypogastric nerve below.

I. NEPHROPEXY

Operative fixation of a mobile kidney does not always give relief unless the usually associated ptosis of viscera, the long-standing dyspepsia and constipation or the uterine or ovarian troubles are corrected.

The indications for nephropexy are :—

(1) Frequent, severe and spasmodic attacks of pain or Dietl's crises; (2) early hydronephrosis; (3) extreme mobility of the

kidney which cannot be retained by any apparatus; and (4) the presence of albumin and casts in the urine associated with undue mobility of the kidney.

Various types of operation are performed. They may be broadly classified into two groups: (A) After stripping capsule and (B) without stripping capsule. Eidbohl's operation belongs to the former group and in it the kidney is anchored by its capsule to the muscles of the posterolateral abdominal wall. Kelly's operation which is described here belongs to the other group.

After the kidney is exposed it is brought into the wound and the fatty capsule is grasped with clamps to hold the kidney in position for manipulation. The first lumbar nerve at the lower and inner aspect of the wound is guarded.

Three suspension sutures of strong, fine, white silk, carried upon a small curved needle, are used. The sutures should not pass

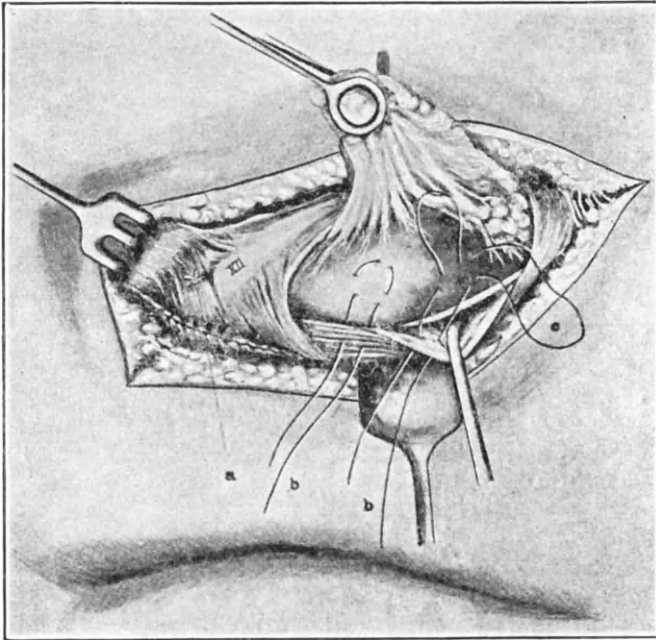


FIG. 191.

THE BROEDEL TRIANGULAR SUBCAPSULAR KIDNEY FIXATION SUTURES:—a, The uppermost fixation suture has been tied above the twelfth rib;—b, b, second and third fixation sutures piercing the quadratus lumborum;—b, c, one of the fixation sutures shown in detail. The first lumbar nerve is seen passing downward and forward.

REPRODUCED FROM BICKHAM'S OPERATIVE SURGERY.
By the Courtesy of THE W. B. SAUNDERS CO.

to a greater depth than 1 cm. into the kidney parenchyma, otherwise the calyces will be injured.

The first suture from the posterior surface of the kidney near its upper pole goes around the twelfth rib. It is carefully conducted beneath the rib under guidance of the left index finger. The second suspending suture is placed in the middle of the posterior surface of the kidney, and the third near the lower pole upon the same surface. The free ends of the middle and lower sutures are carried through the outer border of the quadratus lumborum muscle. When tying the sutures the kidney should be lifted upward with the hand, towards the site of anchorage. The fatty capsule is also anchored to the quadratus lumborum muscle by means of sutures. The wound is then closed in the usual way.

II. NEPHROSTOMY

INDICATIONS

(1) Pyonephrosis and abscess of the kidney, acute ascending pyelonephritis. (2) Hydronephrosis: when the parenchyma is not entirely destroyed. (3) Exploratory, in cases of obscure renal symptoms it may be done for diagnostic purposes.

OPERATION

The kidney is incised a little behind its convex border while the vessels of the pedicle are controlled by fingers or suitable clamps. The pelvis and calyces are then examined. The renal incision is closed usually round a drainage tube with stout catgut sutures, tied gently but firm enough to arrest bleeding.

III. NEPHROLITHOTOMY AND PYEOLITHOTOMY

INDICATIONS

(1) Continuous hæmaturia without evidence of nephritis. (2) Renal colic causing obstruction of urine. (3) Longstanding lithiasis and oxaluria. (4) Calculous anuria.

POSITION

The patient is placed on the sound side, with an air cushion under the flank, the lower thigh and knee flexed and the upper arm secured on a comfortable rest to prevent the body rolling forwards.

OPERATION

An incision 4 inches long is made $\frac{1}{2}$ inch below and parallel to the last rib beginning about $2\frac{1}{2}$ inches from the spine. The skin and

fascia being divided, the fibres of the latissimus dorsi, and external and internal oblique muscles are cut through. The lumbar fascia is then incised near the posterior end of the wound. If the twelfth thoracic nerve crosses the line of incision, it should be drawn aside with its accompanying vessels or left untouched if possible. The perirenal fat, covered by the thin perirenal fascia now bulges into the wound and is incised at the upper and inner corner of the wound, so as to avoid wounding the peritoneum which is in front. The lower border of the last rib is defined and the rib mobilized by dividing the external arcuate ligament and pushing up the pleura which may be in front of it. The perirenal fat is now incised up to the posterior surface of the kidney which is separated from the fat by sweeping the fingers round it.

By pressure on the abdomen the kidney is pushed out into the wound and a careful palpation of its surfaces, of the pelvis and the ureter is made. The position of the calculus having been ascertained, it is removed: if small, it is delivered through the incision on the convex border of the kidney and if large, through an incision made directly over it.

One or two Lembert sutures of fine catgut closing the incision in the fibrous capsule is all that is required, as hæmorrhage is rarely profuse or troublesome.

Multiple stones, occurring in separate calyces, may be removed in a similar manner by multiple incisions. This is always preferable to a wide incision of the kidney which should be avoided whenever possible.

IV. NEPHRECTOMY

The indications for a total removal of a kidney are: (1) Neoplasms of the kidney, benign or malignant; (2) cysts (hydatid. etc.); (3) tuberculosis; (4) extensive infection; (5) calculus with complications; (6) pyonephrosis; (7) aneurysm of the renal artery; (8) injuries and (9) some involvements of the ureter.

Under no circumstances is total nephrectomy warrantable unless it be demonstrated in advance that the opposite kidney is present and performing reasonable compensatory function.

Nephrectomy may be performed through the lumbar, anterior (extraperitoneal), transperitoneal or combined routes. Usually the first route is chosen.

OPERATION

After the kidney has been exposed (*vide supra*) the perirenal capsule is incised and incision carried deep down up to the fibrous capsule. With blunt dissector or better still with fingers the capsules are pulled off as completely as possible from the kidney, ureter and renal vessels. The structures of the pedicle are ligated either separately or *en masse* according to convenience and divided

and the kidney removed. The wound is generally packed and drained for some time.

In the case of involvement of the ureter and perirenal tissues and structures the lumbar incision is extended downwards and anteriorly for a more radical extirpation of all involved tissues and the ureter. In further extensive involvements, either one of the anterior incisions or a combined route is to be adopted.

THE URETER

A. *Obstruction in the Ureter*

It is generally due to impaction of a calculus in the ureter but it may rarely be due to stricture or valvular condition at the opening of the ureter into the renal pelvis. The impaction occurs generally at one of the following sites: (1) At or above the lumen of the renal pelvis; (2) in the pelvic portion of the ureter at the pelvic brim; (3) low down in the pelvis as it opens into the bladder.

Operation is imperative when the particular ureter of the only active kidney is obstructed resulting in anuria. When the calculus is too large to travel down the ureter into the bladder or when there are evidences of septic complications, operative interference is also desirable.

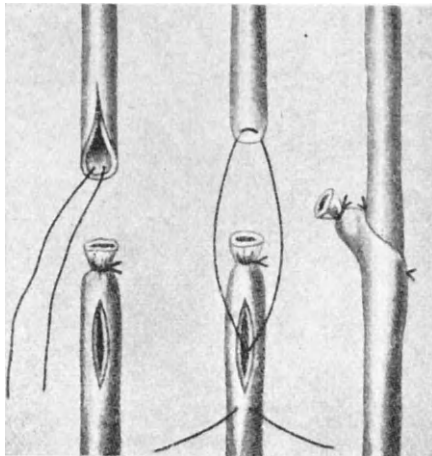


FIG. 192.

END-TO-SIDE ANASTOMOSIS OF THE URETER.
VAN HOOK'S METHOD.

REPRODUCED FROM TURNER'S OPERATIVE SURGERY

The operative approach naturally varies according to the site of impaction.

B. *Injuries to the Ureter*

Injuries to the ureter may be traumatic or due to accidental division or removal of a piece during the course of certain abdominal operations.

In traumatic rupture diagnosis is generally late and the immediate treatment consists of incision and drainage of the extravasation. A plastic operation on the ureter may be performed later.

In accidental division attempt should be made to restore the continuity by an anastomosis by endo-lateral or end-to-end method. If, however, it is found that the divided end can be implanted into the bladder, this procedure should be preferred to other methods.

Implantation of the ureter into a hollow viscus

After division of the ureter or after excision of a part, the lower end of the proximal portion may be implanted into the bladder,

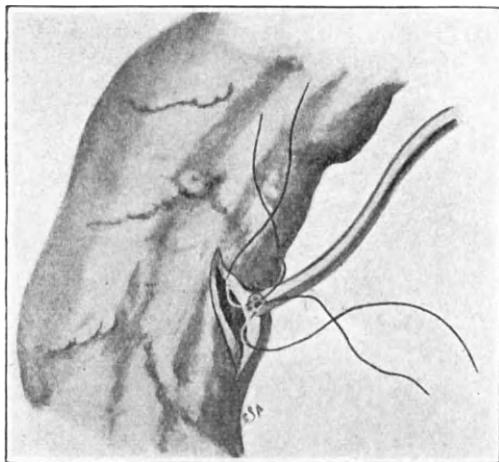


FIG. 193.

URETEROCOLOSTOMY OR URETERORECTOSTOMY—Chaput's Method—I:—An oblique incision is made into the lateral wall of the rectum, at first through only the outer coats. The outer coats of the ureter are then sutured to the outer coats of the rectum (here represented by the middle tied suture). The rectal mucosa is then incised and the mucosa of the ureter is sutured to the mucosa of the rectum (here represented by the two long, loose sutures). These steps are repeated upon the anterior lips of the ureteral and rectal wounds.

REPRODUCED FROM BICKHAM'S OPERATIVE SURGERY.
By the Courtesy of THE W. B. SAUNDERS CO.

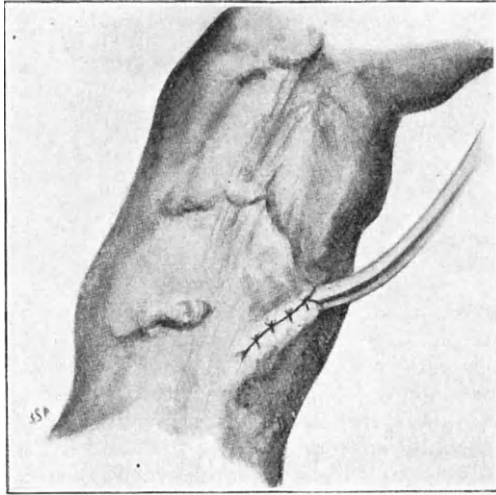


FIG. 194.

URETEROCOLOSTOMY OR URETERORECTOSTOMY—II:—The rectal wall is then sutured about the ureter in such a way as to bury the ureter obliquely in the rectal wall—the line of suturing being at a right angle to the line of incision.

REPRODUCED FROM RICKHAM'S OPERATIVE SURGERY.
By the Courtesy of THE W. B. SAUNDERS CO.

large intestine (sigmoid or rectum), vagina, the opposite ureter or the pelvis of opposite kidney. The distal end is ligated and left *in situ*.

Uretero-intestinal anastomosis.—The divided proximal end of the ureter is brought into contact with the postero-internal wall of the colon, where it is anchored to the yet unopened colon by two or three non-penetrating stitches placed posteriorly. These stitches pass only through the fibromuscular coat of the ureter, on the one hand and the seromuscular coats of the colon, on the other. An oblique incision is now made through the wall of the colon about 1 cm. in length and a few millimeters below the site of anchorage. The posterior muco-mucous sutures of fine catgut are next applied and then the anterior muco-mucous sutures and finally the anterior musculo-muscular sutures. Last of all the incision into the colon is apposed together and around the implanted ureter, in such a way as to approximate the lips of the colonic incision at a right angle to the direction of the original incision.

CHAPTER XXIX

OPERATIONS ON THE UROGENITAL TRACT (*Contd.*)

THE BLADDER

SURGICAL ANATOMY

The urinary bladder is a fibro-muscular sac acting as a reservoir for the urine up to a certain limit, namely 8 to 10 ounces, beyond which it usually tends to void. It lies in the anterior part of the pelvis, just behind the pubis. Its position and shape varies according to age, sex, the amount of its contents and the state of distension of the adjacent organs. In the adult, when empty, it is wholly intrapelvic. When it is distended, part of it rises gradually above the pubis and becomes intra-abdominal. In the female, the bladder as a whole lies deeper in the pelvis and even when distended it does not rise up into the abdomen as high as in the male.

In the child, the bladder is at a higher level than in the adult. This is due to the greater relative size of bladder and the smaller relative size of the pelvis. Here the neck of the bladder lies almost on a level with the upper border of the symphysis pubis and most of the bladder occupies the abdomen, even when empty. So it is more liable to be injured in the child than in the adult in a median laparotomy.

When empty and firmly contracted, the bladder looks like a tetrahedron, its cavity being merely a slit and its walls in apposition. Its upper or postero-superior surface is covered by the peritoneum of the anterior wall of the pelvis. This surface is triangular in shape; its apex, which is directed forwards, lies behind the symphysis and is connected with the urachus, the lateral or basal angles correspond to the points at which the ureters reach the bladder. The interval between the angles, indicated by a ridge, is the posterior or basal margin of the bladder. The vertical axis is greater in the male, whereas the transverse axis is greater in the female.

When the bladder is distended, it undergoes marked alterations. The posterior and lateral boundaries become rounded and the organ becomes ovoid in shape. The lateral surfaces are increased and consequently more of the bladder comes into relation with the pelvic organs.

As the bladder expands, it mounts gradually over the pubis. The pubovesical reflexion of the peritoneum rises a variable extent, so that the antero-inferior surface of the bladder lies directly against the abdominal wall, except for some intervening cellular tissue,

extending for one to two inches above the pubis through which it may be punctured or incised without opening the peritoneum for aspirating the over-distended bladder suprapubically, and in the operation of suprapubic cystotomy. Posteriorly the peritoneum dips down, in the male, between the bladder and the rectum forming the rectovesical pouch and in the female, between the bladder and the uterus. Laterally, the peritoneum passes on to the sides of the pelvis.

The bladder, like the rectum, is encompassed partly by the extraperitoneal areolar, connective tissue spaces, an arrangement which accommodates the distension demanded of the viscus. Of the tissue spaces, the perivesical area is clinically important because of the infections set up in it or propagated to it.

Space of Retzius (or perivesical space) lies partly in the pelvis and partly in the abdomen, and is a division of the extraperitoneal space which extends from the pelvic floor to the umbilicus. The space is bounded anteriorly by the posterior sheath of the rectus muscle and the posterior surface of the pubis, posteriorly by the bladder, laterally it is continued into the general space occupied by the extraperitoneal fat of the abdominal wall and below into the cellular tissue of the pelvis. The continuity of the extraperitoneal areas about the inguinal and femoral hernial regions explains the presence of a segment of bladder in herniæ. The capacity and relations of the space is best recognized in cases of extravasation of urine from rupture of the anterior wall of the bladder and below the peritoneal reflection.

The bladder is anchored securely only at its base where it is fixed by continuity with the prostate and urethra, which, in turn, are bound to the urogenital diaphragm or triangular ligament. The neck of the bladder is fixed also by the pubovesical and puboprostatic ligaments which bind it to the symphysis. The ligaments are bundles of fibres (involuntary muscles) derived from the visceral layer of the pelvic fascia. The median umbilical ligament, containing the urachus, maintains the bladder in position anteriorly and superiorly. The lateral umbilical ligaments, containing the atrophied supravesical portions of the foetal umbilical arteries, stabilize the bladder. Posteriorly, the bladder is reinforced by the rectovesical fascia. After difficult deliveries, the bladder may be loosened from its attachments to the pelvic floor and may prolapse into the perineum, appearing at the vulva as a cystocele.

Antero-inferiorly, the bladder is related to the pubic bones, symphysis, retro-pubic fat, anterior vesical venous plexus (Santorini) and the vesical portion of the pelvic fascia. Laterally, it is related to the levator ani and obturator interni muscles, the parietal layer of the pelvic fascia and the vesico-prostatic venous plexus. Posteriorly, in the male, it is related to the rectum, but it is separated from it by the seminal vesicles, the ductus deferens and their ampullæ and the rectovesical fascia. A small interval exists

between the ductus deferens and the inferior reflection of the bladder serosa. This area, the interdeferent triangle, increases as the bladder distends. For puncture of the bladder by the old-fashioned rectal route, a trocar was passed through this extraperitoneal area. The terminal parts of the ureters lie between the upper rounded extremities of the seminal vesicles and the bladder wall. In the female, the bladder is related posteriorly to the shallow uterovesical pouch of peritoneum separating it from the body of the uterus. Below this peritoneal pouch, the bladder is in direct relation with the cervix and the anterior vaginal wall. Postero-superiorly it is overlain by the fundus and body of the uterus. In the male, it is in relation with the pelvic colon and loops of small intestines. The erosion of adhesions between the bladder and small bowel may form an intestino-vesical fistula.

The mucous membrane of the bladder is devoid of glands and lymphatics and is loosely adherent to the muscle layer through a relatively loose submucosa. In the contracted organ, the mucosa is thrown into folds and presents a wrinkled appearance. In the distended condition the mucosa has fewer folds, but there remains some corrugation even when fully distended. It is comparatively smooth over a triangular area near the urethral orifice and is known as the trigone. The apex of the trigone lies at the urethral orifice, the base corresponds to an imaginary line, indicated usually by a well-defined elevation, the inter-ureteric ridge (2-3 cm. long) which connects the orifices of the ureters. The centre of the trigone is depressed towards the urethral orifice and is the most frequent area of the localization of the diseases of the bladder. The urethral orifice is not circular because of a median elevation, the vesical crest or uvula, in its posterior circumferences (caused by the so-called middle lobe of the prostate). Inflammatory lesions about the urethral orifice are characterized by painful and frequent urination, often accompanied by muscle spasm and urinary retention. The obliquely placed ureteral orifices open upon the mesial extremities of a well-defined ureteric fold. They are usually slit-like but may be oval or round and their direction is obliquely transverse. The lateral margin of each orifice is guarded by a valve-like projection while the mesial margin lies embedded in the fold.

The interior of the fundus of the bladder or retro-trigonal fossa is depressed. When the fossa is rendered large and deep by increased intravesical pressure from prostatic hypertrophy, urinary residues accumulate within it and stagnation occurs. Foreign bodies gravitate to the fossa and bladder ruptures occur through it.

The *mucosa of the bladder* is located midway in the genito-urinary tract and is prone to pathologic changes, of which cystitis is the most common. Infection is transmitted from the kidneys or from the urethra, trigonitis develops early and eventually cystitis. So long as the epithelial covering of the mucous membrane is intact

there is no absorption from the bladder, this being in contrast with the urethra, which absorbs rapidly. In the absence of inflammation, the mucous membrane, except in the region of the neck, is but slightly sensitive, hence a foreign body may be present without giving rise to symptoms and the contact of instruments employed for exploration is scarcely appreciated except while passing through the neck.

Arteries.—Small branches from the internal pudendal and obturator arteries supply the anterior portion of the bladder. The superior vesicular arteries, which are the unobliterated portion of the umbilical arteries, supply the supero-lateral walls. They reach the bladder under the lateral reflection of the pelvic peritoneum. The inferior vesicular arteries from the hypogastric artery share their distribution between the floor of the bladder, the prostate and the prostatic urethra. A vesicular branch from the middle hæmorrhoidal artery partially supplies the posterior surface of the bladder and the seminal vesicles. These vessels form a perivesical network and their rami penetrate the mucosa. Erosion of these vessels explains the hæmaturia so common in bladder disease.

Veins.—The veins form a complicated plexus on the inferior surface and fundus near the prostate and end in the hypogastric veins.

Lymphatics.—The lymphatics draining the bladder are connected with glands arranged along the external iliac and hypogastric vessels.

Nerves.—The nerves of the bladder are fine medullated fibres from the 2nd, 3rd and 4th sacral nerves and non-medullated fibres from the hypogastric plexus. They are connected with ganglions in the outer and submucous coats, and are finally distributed as non-medullated fibres, to the muscular layer and epithelial lining of the viscus.

SUPRAPUBIC PARACENTESIS OF THE BLADDER

A distended bladder may be punctured by several routes. Those are, in the male, (1) the suprapubic, (2) trans-symphyseal, (3) subpubic, (4) perineo-urethral, (5) transprostatic, and (6) rectal; in the female, (1) the suprapubic, (2) trans-symphyseal, (3) subpubic, (4) vagino-urethral, and (5) vaginal.

The suprapubic puncture, under local analgesia, is now the operation of choice and will be described here.

PREPARATION

Having shaved the suprapubic region analgesiate the suprapubic area.

POSITION

Patient in supine position, surgeon on the patient's right, facing him.

OPERATION

Mark out the distended bladder by percussion and having steadied it by the left thumb and index finger, a trocar and cannula held by the right hand is thrust sharply but gently into the bladder in the median line immediately above the symphysis pubis. The instrument is so held with the index finger upon the shaft, that the depth to which it may enter the bladder is controlled. The trocar is then withdrawn and urine flows through the cannula *in situ* of its own accord and aided by gentle abdominal pressure. Then the cannula is taken off and the point of puncture is sealed with cotton wool and collodion.

Comment :—A preliminary small skin incision before puncturing the bladder will be helpful. Puncture of the peritoneum is exceedingly rare provided the bladder is fully distended. In very rare cases the peritoneal reflexion is too low down behind the symphysis.

The urine should be allowed to flow out very slowly and intermittently to avoid congestion and hæmorrhage into the mucous membrane due to sudden relief of pressure.

CYSTOTOMY

This means making an opening into the bladder.

VARIETIES

It may be extra- or transperitoneal. Extraperitoneal methods may be by the suprapubic or perineal routes. Perineal cystotomy may again be median, lateral, bilateral or mediolateral. In the male, the suprapubic and median perineal methods are the two now practised and of these again the suprapubic is the operation of choice. In the female also, the suprapubic operation is done most often and occasionally the vaginal.

SUPRAPUBIC CYSTOTOMY

The operation means opening into the bladder through the suprapubic region.

INDICATIONS

Vesical calculi (large and encysted), vesical growths, foreign bodies in the bladder, exploration, drainage, enlarged prostate, cystitis (some cases), intravesical catheterisation of the ureters, bladder wounds.

INSTRUMENTS—Group XXI.

PREPARATION

Intravesical irrigation with antiseptic solutions and urinary antiseptics, such as urotropine orally. The pubic region is shaved.

POSITION

The patient lies on his back in the semi-Trendelenburg position. Operator stands on the right side and the assistant opposite to him.

OPERATION

This is described in five stages :—

1. *Distention of the bladder.*—Distend the bladder by injecting about ten ounces of fluid into it or with air, so that the upper limit of the bladder rises about half way between the upper margin of the symphysis and umbilicus.

2. *Exposure of the bladder.*—Make a skin incision about three inches long precisely in the middle line, the lower limit of the incision being over the middle of the symphysis pubis. Deepen the incision by separating the recti and pyramidalis of either side in the middle line and retract them. The transversalis fascia which is attached to the posterior aspect of the symphysis is exposed. Divide it in the middle line carefully. The vesico-pubic reflection of the peritoneum is exposed. Retract it upwards. The bladder is now exposed. It is recognised by the fluctuating resistance it gives to the palpating finger, the irregular arrangement of the fibres of the muscular coat and the vesical veins which run on the surface.

3. *Opening of the bladder.*—Protect the peritoneum at the upper angle with gauze and a retractor. Pick up the bladder wall by its muscular coats with two pairs of forceps applied on either side of the middle line. Open it by an incision through its walls from a point below the peritoneal reflection down towards the symphysis, avoiding the veins. Secure the cut-edges of the bladder with catgut or silk passing only through its muscular coat. Intravesical procedures can be taken up now according to necessities of the case.

4. *Treatment of the bladder wound.*—At the upper end of the wound is the vesico-pubic reflection of the peritoneum. This aspect

is shut off by suture carried through the muscular wall of the bladder, the transversalis fascia, and the muscles of the abdominal parietes. The lateral aspects towards the opening at the subperitoneal fat is similarly shut off. At the lower angle of the wound the lower part of the space of Retzius is also shut off in like manner. The bladder wound may either be closed or left open for drainage. These should be carried out as follows :—

- (i) *Closure of the bladder wound.*—This is done by layers of sutures through the muscular and submucous layers.
- (ii) *Suprapubic drainage.*—The bladder wall is sutured in a manner similar to the above, leaving just enough space for the introduction of a drainage-tube.

5. *Closure of the abdominal wound.*—The abdominal wound should be closed entirely in the usual way if the bladder has been sutured, the recti and the pyramidales being allowed to meet in the middle line. A small drain may be left through the most dependent part. If the bladder is to be drained, the abdominal wound is partially closed.

Comment :—1. Protect the vesico-pubic reflection of the peritoneum throughout the operation. 2. In opening the bladder do not extend the incision too high up towards the peritoneal reflection or too low down into the space of Retzius. 3. In suturing the bladder, take great care not to enter into the mucous surface; deposits may take place on the ligature material to form a nucleus for a future calculus.

MEDIAN PERINEAL CYSTOTOMY

Median perineal cystotomy with guide, i.e. by a sound in the urethra.

Incision of the bladder through the perineal region (if for stone, called median lithotomy) by cutting through the apex of the prostate and the membranous portion of the urethra.

INDICATIONS

For removal of small calculi, etc.

INSTRUMENTS

Group XXI and medially grooved lithotomy staff and a long, narrow, straight knife with a double cutting edge.

PREPARATION

Rectum emptied and the bladder irrigated. Perineum shaved. Recognition of calculus by sound.

POSITION

Patient rests on back with the buttocks well over the edge of the table. A median grooved staff is passed into the bladder and an assistant standing on the left holds it steadily, in the middle line, with his right hand while he supports the penis and scrotum with his left. The patient is brought to and kept in the characteristic lithotomy position by two assistants throughout the rest of the operation. The surgeon sits at the end of the table facing the patient's perineum.

INCISION

Begin at a point half inch anterior to the anus in the median raphe and extend for one inch.

OPERATION

The operator puts his left gloved index finger into the rectum and presses it against the staff, which has already been inserted and held as just mentioned, pressing against the staff at the apex of the prostate gland, thereby steadying and recognising the deep relations, guarding the rectum, and following the penetration of the knife. The long, narrow, double-edged knife, with the main cutting edge upward, held at right angles to the perineum, is first thrust directly inwards and made to strike at once and enter the grooved staff at the apex of the prostate, passing through the apex of the gland itself where the finger within the rectum steadies it. The knife is then made to cut upward in the groove of the staff and, in the act of withdrawal, makes a wound in the soft parts of about one inch, depressing the handle of the knife in cutting the urethra and elevating it in cutting the superficial parts, incising the following structures: integument, two layers of the superficial fascia, anterior part of the external sphincter ani, central tendinous point of the perineum, lower margin of the perineal ligament, membranous urethra, compressor urethræ, and apex of the prostate.

As the knife is withdrawn the index finger is introduced into the bladder directly upon the staff or such an instrument as Little's director is introduced upon the staff through the perineal wound and the original staff then removed and the finger introduced upon the second director through the neck of the bladder, which is often entered with difficulty.

The bladder cavity is thus examined through the original wound or the opening through the neck of the bladder may be first dilated, if necessary. In completing the operation a perineal

lithotomy drainage tube is usually used or the wound is simply left open protected by a thick perineal dressing.

Comments :—Instead of conducting the operation in the manner above described and avoiding the introduction of finger into the rectum and the change of gloves, the surgeon, while the staff is steadied by an assistant, may incise in the middle line of the perineum, bulged out by the convexity of the staff, the incision coming to within half inch of the rectum. This incision exposes the bulb, the membranous urethra is made prominent in the wound by depressing the handle of the staff. The surgeon then locates the central groove of the staff with his finger nail, and guided by this, incises the floor of the membranous urethra in the median line. The point of the knife with its handle paralleling the urethra, is pushed on until the beginning of the prostatic urethra is cut, after which the knife is withdrawn. A grooved gorget is then introduced into the wound, with the bulbous tip in the incised urethra, the tip of the gorget following the groove of the staff into the bladder, after which the staff is withdrawn, and the surgeon passes the finger into the bladder along the groove of the gorget.

Free bleeding may follow the perineal operation, for which a graduated form of gauze tampon may be useful.

SUPRAPUBIC LITHOTOMY

This is an operation for removal of stone from the bladder after performing suprapubic cystotomy.

INDICATIONS

(*a*) In cases of hard stones ; (*b*) for stones of more than an inch and a half in their shortest diameter ; (*c*) for stones of soft consistency which may stick to the jaws of the lithotrite, e.g. in cases of calculi which have been formed round a soft foreign substance ; (*d*) in cases of encysted stones ; (*e*) in cases where the bladder is sacculated ; (*f*) in cases where there is obstruction in the urethra or the neck of the bladder through which the lithotrite cannot be passed, e.g. stricture of the urethra and enlarged prostate ; and (*g*) in cases where due to cystitis, the bladder has to be drained after removal of the calculus.

INSTRUMENTS—Group XXI.

POSITION

Same as for suprapubic cystotomy.

OPERATION

The operation can be described in five stages, the first four of which correspond to those for suprapubic cystotomy.

In the fifth stage, the bladder is anchored by tissue-forceps or by retaining sutures. Now, an assistant introduces his finger into the rectum and pushes the stone anteriorly; or the rectum may be dilated by means of a pneumatic bag. The left forefinger is introduced into the bladder and the stone felt for. It can now be delivered with two fingers or a finger and a lithotomy scoop; or it may be caught in the blades of lithotomy forceps guided by the finger and then removed. A soft rubber catheter should be introduced into bladder through the urethra, the bladder irrigated and all blood clots washed out. The wounds in the bladder or abdominal wall can be closed or kept open as circumstances indicate.

Comment.:—(1) The wounds of the bladder and the abdominal wall should be closed whenever possible as the constant soakage of the dressings and the irritation caused by it is very troublesome to the patient. (2) The incision in the bladder should be made corresponding to the size of the stone. (3) Any attempt at delivery of a large stone through a small opening in the bladder forcibly will lacerate the edges of the wound; this must be avoided. (4) the catheter should be left *in situ*. (5) Encysted stones in the bladder should be removed by gently peeling the mucous membrane and extracting them by working binually with the operator's finger in the bladder and the assistant's finger in the rectum.

LITHOLAPAXY

A lithotrite is introduced into the bladder, the stone crushed and evacuated.

INDICATIONS

(1) A medium sized stone, not too hard for the lithotrite to crush it; (2) nor too soft which would stick to the blades of the lithotrite; (3) the urethra admits and tolerates the passage of the lithotrite; (4) the prostate is not enlarged; (5) the bladder is not irritable or septic nor congested or contracted due to hypertrophy or otherwise; and (6) the patient is in a condition to undergo prolonged anæsthesia.

POSITION—Dorsal position.

INSTRUMENTS—Group XXII.

OPERATIONS

The bladder is first emptied of urine and then distended by injecting four to eight ounces of saline solution or boric lotion. The lithotrite is locked and introduced then unlocked and the stone crushed and the instrument is withdrawn after locking. The evacuating cannula is then introduced, the evacuator adjusted to it and worked till the fragments are sucked into it. This process is repeated two, three or more occasions till it is ascertained that no more stones or fragments are left. The cystoscope is then introduced and the interior of bladder inspected to see if any fragments are left. The bladder is then washed out. This completes the operation.

Comment:—Different sizes of lithotrites and cannulæ should be selected and prepared and two evacuators should be kept ready. It is difficult to anæsthetise a patient with irritable bladder for this operation.

Removal of stones by the lateral or median perineal lithotomy is seldom if ever undertaken nowadays.

THE PROSTATE

SURGICAL ANATOMY

The prostate is a musculo-glandular body about the size and shape of a chestnut ($1\frac{1}{2}$ " wide, $1\frac{1}{4}$ " long, 1" antero-posteriorly) surrounding the first part of the urethra. It lies in the pelvic cavity, behind the lower part of the symphysis pubis in front of the rectum. It has got a base, an apex, a posterior, an anterior and two lateral surfaces.

The base looks upwards and is almost in direct continuity with the bladder wall. The urethra passes between the junction of the anterior and middle third of the prostate. Its apex is directed downwards and rests upon the superior fascia of the urogenital diaphragm. The posterior surface is in contact with the rectum having rectovesical fascia within them and can be palpated through the rectum, about $1\frac{1}{4}$ " above the anus. The ejaculatory ducts traverse the gland downwards and forwards and end in the posterior wall of the urethra. The urethra divides the gland into an upper, smaller and a lower, larger part. The upper portion is generally destitute of glands and constitutes the so-called 'middle lobe'. The lower one is the main mass of gland. The anterior surface is about 1" behind the pubis, separated by a plexus of veins and fatty tissue.

The urethra emerges a little above the apex. The lateral surfaces are covered by the anterior parts of the levatores ani.

It is held in position by the puboprostatic ligaments anteriorly, by the superior layer of the urogenital fascia which invests the prostate and the membranous urethra, and laterally by the anterior parts of the levatores ani.

The prostate has an intrinsic and an extrinsic sheath. The *prostatic capsule* consists of fibromuscular tissue forming part of the stroma of the organ. The *prostatic sheath* is formed antero-laterally by periprostatic connective tissue in which the prostatico-vesical plexus of veins lies. A few veins lie between the sheath and the capsule. Posteriorly, the sheath is formed by the avascular rectovesical fascia. This fascia is of fair thickness and acts as an efficient barrier to the spread of prostatic or rectal malignant disease. In the enucleation of the glandular elements of the prostate, injury to the prostatic venous plexuses must be avoided; the sheath must not be damaged either, it might lead to urinary extravasation into the extraperitoneal tissues of the pelvis.

The arteries supplying the prostate are derived from the internal pudendal, inferior vesicular and middle hæmorrhoidal arteries. Its veins form a plexus around the sides and base of the gland and receive in front the dorsal vein of the penis and end in the hypogastric veins. The nerves are derived from the pelvic plexus.

THE SEMINAL VESICLES

The seminal vesicles are oblong, flattened, nodular bodies which lie above and behind the prostate, against the base of the bladder, to which they are loosely attached by a small quantity of connective tissue. Their long axes are directed downwards and forwards, so that the two vesicles converge at their lower ends and meet at the base of the prostate. The upper, broader end of each is covered by the rectovesical reflection of the peritoneum and lies in close relationship with the ureter. The lower end is tubular, and towards its mesial aspect is the terminal portion of the vas deferens, with which it joins to form the ejaculatory duct and this opens on the floor of the prostatic urethra. The vesicles, which serve as a storehouse for the spermatic fluid, are lined with columnar epithelium, secreting a fluid which nourishes the spermatozoa. The seminal fluid is ejected during the sexual act into the posterior urethra by muscular contraction of the vesicles in unison with those of the prostate.

The vesicles are more easily examined, per rectum, if the bladder is full. They are not readily identified unless diseased.

PROSTATECTOMY

INSTRUMENTS—Group XXIII.

VARIETIES

The prostate can be removed in different ways :—

- (1) Perineal prostatectomy (Young).
- (2) Combined perineal and suprapubic prostatectomy.
- (3) Partial prostatectomy (MacGill).
- (4) Freyer's suprapubic prostatectomy.

The last and the first named operations will be described.

SUPRAPUBIC PROSTATECTOMY

Total enucleation of the prostate (Freyer).

INDICATIONS

(1) Enlargement of the prostate giving rise to overdistention of the bladder, overflow incontinence and frequency of micturition ; (2) recurring retention of urine ; (3) increasing quantity of residual urine ; (4) cases in which ' catheter life ' has given rise to cystitis, hæmorrhage and other complications ; and (5) enlarged prostate with calculi.

POSITION

The patient lies on his back in the semi-Trendelenburg position with thighs separated and secured. Operator stands on the left side of the patient and assistant opposite to him.

INSTRUMENTS—Group XXIII.

OPERATION

Wash out the bladder and then fill it with warm boric lotion with a soft rubber catheter. Leave catheter *in situ*.

The operation can now be described in four stages :—

1. *Suprapubic cystotomy*—is performed as has been described.
2. *The enucleation*.—Introduce the left index finger into the rectum and push the prostate upwards towards the cavity of the bladder. Introduce the right index and middle fingers into the bladder through the suprapubic wound and tear through the mucous membrane of the bladder over the prostate round the urethral opening with the finger and the finger nails. Seek for the intercapsular plane, i.e. the plane between the true and false capsules. Once in this plane, sweep the finger round the gland, tearing through the prostatic urethra in the process. The gland will thus be loose in the bladder cavity and can be removed. The index fingers of both hands will be in active co-operation during the whole process.

3. *Toilet of the wound and drainage of the bladder.*—Squeeze and massage the capsule of the prostate left behind with two fore-fingers. Wash out the bladder with hot sterile water or Goulard's lotion. Introduce a large rubber drainage-tube and close the bladder wound by catgut suture. The bladder drains both by supra-pubic drain and the catheter which has been left *in situ*. I had satisfactory results by continuous irrigation of the bladder through the catheter and the tube.

4. *Closure of the abdominal wound.*—Introduce a drain in the space of Retzius and close the parietal wound partially by interrupted sutures first taking in the recti on either side and then other muscles, leaving enough space for the drainage tube.

YOUNG'S PERINEAL PROSTATECTOMY

Though H. H. Young of Baltimore claims superiority of his operation, modern European and even American surgeons still advocate the suprapubic route.

PREPARATION AND POSITION

The bladder and urethra having been washed out and the patient placed in the exaggerated lithotomy position so that the perineum looks almost upwards. The genitals are thoroughly cleansed and isolated by aseptic towels. A sound is passed into the prostatic urethra and held by an assistant.

INCISION

A curved perineal incision is made, crossing the middle line $1\frac{1}{2}$ " in front of the anus and ending on either side half-way between the anus and the tuber ischii. The central tendinous point of meeting of the perineal muscles is sought and a transverse incision is made through it separating the accelerator urinæ and transverse perineal muscles from the point of insertion of the sphincter ani. The rectum and its fibrous sheath are now displaced backwards by blunt dissection to expose the posterior surface of the prostate. The wound is well opened with a wide retractor to protect the rectum and with a bifid one to encircle and display the urethra in front. The latter is opened exactly in the middle line upon the staff well above the triangular ligament and through the apex of the prostate to avoid any injury of the sphincter urethræ. The urethral opening is retracted with tissue forceps, the sound which is thereby displayed is now withdrawn.

Young's tractor is then passed through this opening well into the bladder and traction is then made with the blades of the instrument upon different lobes bringing the necessary part of the prostate

downwards and backwards well into view. When the shiny surface of the prostatic sheath is displayed, two lateral incisions, 2 cm. apart to avoid the ejaculatory ducts, are made through it to expose the true capsule within. The lobes are then separately enucleated with the aid of the blunt dissectors and the index finger and then withdrawn. If a stone is present in the bladder, it may be removed by the scoop which is always passed to seek one.

All bleeding points are carefully tied and the anterior wall of the rectum is carefully examined and protected by sutures. A Davis rubber bag is inserted to prevent hæmorrhage, to bring down mucous membrane in position and to drain the bladder. The wound is closed around the tubes and tape holding the bag in position. The tube is closed by a clip and the tape is clamped over a pad outside the wound, to keep it in position. The large rubber tube drains the bladder and is used for irrigation. According to the condition of the bleeding the bag is adjusted and ultimately removed. The perineal wound is kept clean and irrigated during dressings and after defæcation and at times vesical irrigation may be done.

CHAPTER XXX

OPERATIONS ON THE UROGENITAL TRACT (Contd.)

THE URETHRA

SURGICAL ANATOMY

The length of the urethra in the male averages about eight inches. Clinically it is divided into two parts; from the meatus to the opening of the triangular ligament, measuring about six inches it is called the *anterior urethra*, the remaining portion of it is called the *posterior or deep urethra*.

The anterior urethra is again sub-divided into four parts: navicular, penile, scrotal and bulbous. (i) *The navicular* portion corresponds to the glans penis; it extends from the meatus which is the narrowest part of the whole urethra, then it widens out and contracts again at its junction with the penile portion. (ii) *The penile*, the most mobile portion, varies in length and can be easily palpated. (iii) *The scrotal* portion is deeper and more fixed and can be palpated through the scrotum. (iv) *The bulbous portion* half an inch in length, is fixed to the anterior surface of the triangular ligament. It is wide and distensible. It cannot be palpated normally; it can, however, be palpated when a bougie has been passed into it or when the walls are indurated. It is the most dependent part of the urethra and is the commonest seat of stricture, gonorrhœal or traumatic. The opening in the triangular ligament represents the junction of anterior and posterior parts of the urethra. This is the most fixed and next to the meatus, the narrowest part of the urethra. False passages are commonly made here.

The posterior urethra consists of two portions, the membranous and the prostatic. (i) *The membranous portion* half an inch long in its anterior wall and three-fourth inch long in its posterior wall, is situated about one inch below the lower border of the symphysis pubis. It is surrounded by the compressor urethrae muscle. An instrument in this portion of the urethra can be felt by the finger introduced into the rectum, just anterior to the prostate. (ii) *The prostatic urethra* an inch and a quarter long, is the widest and most distensible portion of the whole canal. It can be palpated per rectum through the prostate.

OPERATIONS ON THE URETHRA

1. *Meatotomy*, i.e. cutting into the meatus where there is narrowing (congenital, traumatic or post-inflammatory) or prelimi-

nary to the introduction of the urethral bougies or sounds. Pass a probe-pointed knife for about three-fourths of an inch to a point immediately behind the meatal narrowing and cut with a sawing movement in the middle line below. Keep the wound open by passing a sound and applying a little sterile vaseline.

2. *Operations for stricture of the urethra.*—These include :—

- (A) Internal urethrotomy.
- (B) Urethrectomy (excision of the stricture).
- (C) External urethrotomy.
- (D) Dilatation by bougies.

(A) INTERNAL URETHROTOMY

Division of the stricture from inside the urethra by introducing an urethrotome into the canal.

INDICATIONS

- (1) For strictures which are localised and annular.
- (2) For strictures situated in the urethra from the meatus up to the bulbo-membranous junction.
- (3) When the stricture is resilient or valvular and repeated dilatations have failed.
- (4) When the urethra is so sensitive that the patient cannot bear dilatation.

It is contra-indicated in : (1) strictures which are not localised ; (2) when there is peri-urethral inflammation and septic complications ; and (3) when it is feared from previous experience with individuals that there may be hæmorrhage.

There are two methods of this operation—(1) in which the stricture is divided from before backwards, and (2) in which it is divided from behind forwards. After the division of the stricture, a full sized bougie should be passed from time to time to prevent the part from cicatrising again.

(B) URETHRECTOMY

This is an operation in which a part or whole of the circumference of the urethra is removed. It is best to preserve a portion of the urethra to help apposition. The site of the stricture is at first ascertained. An opening is made through the skin into that part ; if it is excised from the penile portion, it is penile urethrectomy, and if from a lower portion, through the perineum it is perineal urethrectomy. A sound is passed as a guide, the urethra is opened ; the strictured portion is removed and the ends brought into apposition by catgut sutures. Even after healing it leaves a scar and a sound has to be passed from time to time to keep it dilated.

(C) EXTERNAL URETHROTOMY**INDICATIONS**

- (1) For impermeable strictures.
- (2) For strictures in which internal urethrotomy is inapplicable.
- (3) For traumatic strictures in which cicatrisation is extensive.
- (4) In strictures complicated with peri-urethral abscesses, fistulæ and false passages.
- (5) In extravasation of urine with peri-urethral cellulitis.
- (6) In cases of stricture with cystitis.

POSITION

Lithotomy position. Operator sits facing the perineum and the chief assistant in charge of the staff stands on the left side facing him ; another assistant stands on the operator's left to help in retracting parts. There are two methods of external urethrotomy.

**(1) EXTERNAL URETHROTOMY WITH A GUIDE
(SYME'S OPERATION)**

In this operation the stricture allows the passage of some instrument such as a Syme's staff, a filiform bougie or a median grooved lithotomy staff as a guide for the further stages of operation. Ascertain the site of the stricture. Cut down upon it, and while doing so, incise contiguous portions of healthy urethra ; introduce a probe-pointed director into the bladder guided by the groove of the staff. Now withdraw the staff. The urethra is now dilated ; retract its cut edges. Then pass a Teale's gorget through this opening into the bladder guided by the director. Introduce a full sized catheter.

**(2) EXTERNAL URETHROTOMY WITHOUT GUIDE
(WHEELHOUSE OPERATION)**

This operation is indicated for strictures through which no instrument could be passed. Pass a straight grooved staff of Wheelhouse pattern down to the face of the stricture. The assistant steadies it precisely in the middle line with the grooved side towards the operator. Cut down on the groove, distal to the stricture into the urethra ; the assistant now turns the staff round and retracts the proximal end of the cut with the hooked end of the staff. Retract the cut edges of the urethra on either side. Look for the stricture, cut into it in the middle line till at the proximal end of the stricture, healthy urethra is seen. The probe-pointed director is introduced through this opening in the stricture, into the bladder and the operation completed as in the previous one.

(D) DILATATION BY BOUGIES

An uncomplicated stricture can be dilated by passing a series of these instruments at regular intervals.

POSITION

Dorsal position. Operator stands on the left side facing the patient and assistant stands opposite.

OPERATION

Hold the bougie lightly with the right hand parallel to Poupart's ligament. Grasp the penis with the left hand and introduce the tip of the bougie through the meatus into the navicular portion; introduce it as far as it would easily go, keeping it in contact with the floor of the urethra in order to prevent it from being caught in the lacunæ situated on the roof of this portion. Now, bring the bougie round to the middle line of the body, making an arc of a circle with the hand. Now pass the tip through the bulbous portion. A slight obstruction will be felt at the junction of the bulbous and membranous portions. Bring the hand down between the thighs of the patient depressing the handle to keep the tip in contact with the roof of the membranous portion. This will avoid a false passage being caused by perforation of the floor. Now, pass the tip through the membranous portion. The sound is now passing between the two layers of the triangular ligament and surrounding it is the compressor urethræ muscle. With a slight coaxing, the tip will pass through these into the dilated prostatic portion and then into the bladder.

Comment:—Obstructions may be felt at the following situations: (i) At the meatus; if it is too narrow it has to be slit (*meatotomy*). (ii) At the lacunæ of the navicular portion; avoid this by keeping the tip on the floor. (iii) At the bulbous portion if there is a stricture. (iv) At the junction of the membranous and bulbous portions; keep the tip in contact with the roof. (v) In the membranous portion due to contraction of the compressor urethræ muscle; introduce your left forefinger into the rectum and guided by it, insinuate the tip through the bulbous into the membranous portion. (vi) In the prostatic portion and its opening into the bladder; a finger in the rectum will be helpful as a guide particularly if the prostate is enlarged.

HYPOSPADIAS

It is a congenital defect, in which the urethra terminates upon the inferior aspect of the penis at some point behind its

normal ending. It is usually accompanied by some deformity of the penis (incurvation). It occurs more frequently than epispadias.

VARIETIES

It may be (1) glandular, when the urethra opens upon the glans; (2) penile when opening is on the body of the penis, either just behind the frænum, or at the penoscrotal angle, or midway between the two; and (3) scrotal, penoscrotal or perineoscrotal. The first named being most frequent, the last being the least frequent.

When the penis is fairly straight and the defect is near the glans, operation may not be done. The reverse is the case when the patient keeps the skin of the vicinity constantly wet and eczematous and is unable to have sexual intercourse, as in cases of opening being posterior to the junction of the anterior and middle thirds of the penis. Operation should be performed before puberty at about six years of age. Preparatory measures for straightening the penis may be done for some months. Provision for temporary bladder drainage, either perineal or suprapubic, is usually made preliminarily to operation upon the urethra. The operation is simpler, if the defect occurs nearer the glans.

EPISPADIAS

This is also a congenital deformity characterised by an absence of a part or whole of the roof of the urethra, i.e. the urethral opening is on the upper aspect of the penis posterior to its normal site. It is less frequently seen than hypospadias. Ectopia vesicæ is generally associated with it, but it is not necessarily accompanied by the exstrophy of the bladder.

VARIETIES

It may be (1) glandular, involving the glans penis; (2) penile, involving the spongy urethra; (3) spongio-glandular, involving both the glans and the spongy urethra; and (4) complete, when the urethra from the meatus to the pubis is involved.

As it is usually associated with ectopia vesicæ, it is very difficult to treat. Here an attempt is made to form a penile tube which will conduct urine, passively to a permanently worn urinal, as a vesical sphincter cannot be formed. In complete epispadias, apart from ectopia vesicæ, the penis itself being rudimentary, the chance of surgical relief is exceedingly poor. In such cases, the two methods of operation usually applied are: (1) the approximation of the margins of the epispadiac groove, or (2) some more or less complicated form of plastic operation.

THE PENIS

SURGICAL ANATOMY

The penis is composed of the two corpora cavernosa, which lies towards the dorsum, and the corpus spongiosum, which occupies the groove on the ventral aspect of the corpora cavernosa, and is traversed by the urethra. These are composed of erectile tissue and are enclosed by fibrous sheaths. The expanded anterior end of the penis is known as the glans, and the loose skin covering it as the prepuce.

The lymphatics of the external genitals drain chiefly into the glands around the femoral and external iliac vessels.

CIRCUMCISION

In this operation a portion of the prepuce is removed.

INDICATIONS

- (1) For phimosis with a small aperture, long prepuce.
- (2) Paraphimosis.
- (3) For the proper treatment of gonorrhœa with phimosis.
- (4) Ulcers of the prepuce, e.g. chancre, etc.
- (5) Tumours of the prepuce, non-malignant or malignant.

OPERATION

Circumcision can be performed in two ways :—

(a) *First method.*—Draw the prepuce slightly forwards, clamp it with a suitable pair of forceps in an oblique fashion, sloping from above downwards and forwards in order to leave sufficient skin on the under-surface of the penis to cover the raw triangular area which is produced. Shave the foreskin off in front of the forceps with a sharp knife or scissors and remove the forceps. The mucous membrane is left rather long after this ; slit it with a pair of scissors on the dorsum and remove sufficient quantity of it to meet the cut edge of the skin. The dorsal and the frænal vessels which are cut have to be secured ; bring the cut edges of the skin and mucous membrane together by stitches.

(b) *Second method.*—Slit the foreskin up the dorsum of the penis with a pair of scissors to the level of the middle of the glans. Carry the division round the penis taking the same precautions on the under-surface as in the previous operation. Snip off any redundant mucous membrane and bring the edges together.

Comment :—(1) When clamping the prepuce with forceps do not clamp the apex of the glans with it and do not clamp the prepuce too far back as proper

allowance must be made for retraction of the skin.
 (2) Do not remove too much of the skin and mucous membrane from near the frænum, as it will then leave a lozenge-shaped raw area. On the other hand do not leave too much skin behind as it may give rise to an unsightly lump there.

I. AMPUTATION OF THE PENIS

Amputation of the penis may be partial or complete. In the former, more or less the free portion of the organ is removed, followed by the covering of the stump by some part of the adjacent penile skin and anchoring the divided urethra at the end of the remaining portion of the organ. In the latter, the entire organ is removed, including the whole of the corpus spongiosum and the crura, together with the division of the posterior urethra and the anchorage of its proximal end in the perineal wound. In both cases, the superficial and deep inguinal glands should also be removed on both sides.

INDICATIONS

The penis is generally amputated for malignant growths (epithelioma). It may on rare occasions have to be amputated for chronic ulcers or new growths, e.g. papilloma when it is suspected that they are undergoing malignant changes and for some bad cases of injury.

INSTRUMENTS—Group XXVI.

1. *Partial amputation of the penis.*—Partial amputation can be performed by circular method or a flap can be cut from the dorsum or from the under-surface of the penis. I have adopted the last-named method as it has advantages over the other two. By this method when the flap from the under-surface is apposed to the dorsal skin incision, the opening for the urethra is made in the large flap and so it lies below the suture line. There is, therefore, no chance of urine dribbling on to the sutures and infecting the part. But the dorsal flap method is usually adopted.

A. Long Dorsal and Short Ventral Flap Method.—The covering of the stump comes from both dorsal and ventral aspects of the organ, chiefly from the former.

PREPARATION

The perineal region and both inguinal regions are prepared in the usual way. The distal end of the organ and the lesion after thorough disinfection are protected with gauze dressing to avoid soiling the sound part of the wound.

POSITION

Patient in supine position, at the edge of the table. Surgeon on the patient's left, the assistant on the right side.

INCISION

The dorsal or anterior flap will have a width of one-half the circumference of the penis and a length of about one diameter of the penis. The ventral or posterior flap will have the same width and a length of half the diameter.

OPERATION

Having tied the penis with an elastic band near the root, make out the line of section of the penis, cut the dorsal flap with the skin and connective tissue and turn it back having tied the dorsal arteries. A narrow bladed knife is thrust horizontally through the organ on a level with the base of the anterior flap between the cavernosa and spongiosum and cuts its way through, passing at first directly forwards in the groove and then rounding abruptly downwards, thus forming an inferior flap composed of corpus spongiosum, urethra and skin. The urethra is now dissected out from the inferior flap, up to the base of the flap. The corpora cavernosa are cut transversely from within upwards at the level of the highest point of transfixion. The vessels of the corpora cavernosa are tied. Make a vertical opening in the centre of the anterior flap opposite the urethra and just large enough to receive it. The urethra is drawn through the opening and is slightly slit above and below and sutured into the margins of the opening. The two flaps are then sutured together where their free ends meet. A dressing is applied, leaving room for urination. The arteries of the corpus spongiosum and of the septa may need ligating.

Following this operation, the inguinal lymphatic glands of both sides are to be removed by independent dissection.

B. Author's method or the long ventral and short dorsal flap method.

OPERATION

It can be described in the following three stages :—

1. *Constriction of the penis.*—Constrict the penis by tying an elastic band round it in front of the pubis and scrotum (*Fig. 195*).
2. *The skin incision.*—Make an incision for unequal antero-posterior flaps with the long flap on the under-surface in such a way that the lower end of the incision is entirely free of any diseased tissue. Raise the flap from the under-surface without injuring the urethra and deepen the dorsal skin incision to the corpora cavernosa (*Fig. 195*).

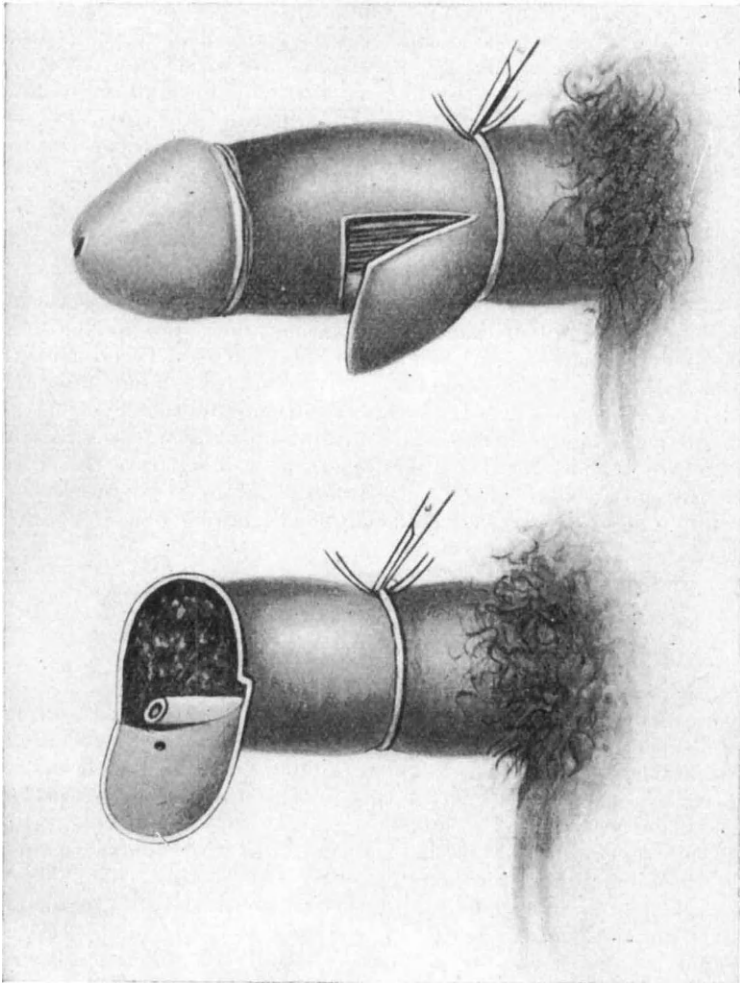


Fig. 195.

Fig. 196.

Amputation of the penis (Author's modification).

3. *The section of the urethra.*—The assistant draws the penis up presenting the under-surface towards the operator. Dissect out about half an inch of the urethra from the corpus spongiosum in front of the future section of the corpora cavernosa and the corpus spongiosum. Cut across the urethra leaving enough to come through the future opening in the flap. Secure the urethra with a pair of forceps and cut through the body of the penis from below upwards commencing above the level of the urethra (*Fig. 196*).

Remove the constricting band. The hæmorrhage from the corpora cavernosa and corpus spongiosum can be controlled by transfixion ligature (*vide supra*). Make a small puncture in the centre of the flap and pull the urethra through it; slit it in the middle line and secure it to the edges of the puncture in the flap. Appose the lower flap to the dorsal skin incision. This completes the operation.

II. COMPLETE AMPUTATION OF THE PENIS (GOULD'S METHOD)

This operation is performed as follows: Split the scrotum completely along the median raphe exposing the corpus spongiosum. Separate the corpus spongiosum from the corpora cavernosa up to the level of the triangular ligament passing a sound into the urethra, if necessary. Isolate the urethra up to the level of the triangular ligament; carry the scrotal incision all round the root of the penis. Divide the suspensory ligament and separate the crura from the pubic bone; slit the urethra and secure it to the scrotal wound. The vessels of the crura will need ligaturing.

THE TESTICLE AND ITS COVERINGS

SURGICAL ANATOMY

The *scrotum* is the pendulous bag which contains the testes. Its skin is dark in colour particularly in tropical people. Its raphe extends from under the penis in front towards the anus behind. Its superficial fascia which is devoid of fat contains muscular tissue, the dartos; the contraction of this muscle diminishes the size of the scrotum and its laxity renders it pendulous. The dartos forms a mesial septum dividing the scrotum into two compartments, each containing the corresponding testicle and its adnexa. There is a loose areolar tissue underlying the dartos which contains blood-vessels and lymphatics.

The testicles.—The testes consist of the body and epididymis, the latter being divided into a globus major (the head), globus minor (the tail) and an intermediate portion; it lies in the posterior aspect of the body of testes.

The spermatic cord—extends from testis to the internal abdominal ring. It consists of the vas deferens with its artery and veins lying posteriorly. The spermatic artery lies in front of the vas and the cremaster ramifies in the superficial tissues of the cord. The veins of the cord form a plexus, the spermatic or pampiniform plexus which accompanies the spermatic artery. There are numerous lymphatics of the cord draining into the lumbar glands and the cord contains the genital branch of genito-crural nerve and sympathetic twigs.

Coverings of the cord and testes.—The testes and the cord derive the following coverings from the abdominal wall. From the external oblique, the external spermatic or intercolumnar fascia, from the internal oblique, the cremaster muscle and fascia and from the transversalis fascia, the internal spermatic or infundibuliform fascia. The testes have a covering of a serous sac, the tunica vaginalis, originally derived from the peritoneum. It consists of two layers, the visceral and the parietal, between which is a potential space, the cavity of the tunica vaginalis. Under normal conditions, the sac of the tunica vaginalis is separated from the peritoneal cavity for the whole extent of the inguinal canal. The following abnormal conditions may, however, be present: (1) The congenital type, in which the sac of the tunica vaginalis communicates with the general peritoneal cavity through a patent funicular process. If fluid accumulates in such a sac it is called *congenital hydrocele*. (2) The infantile type; in this the funicular process becomes obliterated near the internal abdominal ring; a collection of fluid in the tunica vaginalis extends up the cord into inguinal canal and is known as *infantile hydrocele*. (3) The funicular type; the funicular process is closed at its lower end. Fluid distending this space produces a sausage-shaped swelling in the inguinal canal. This produces a *hydrocele of the funicular process* and may be mistaken for inguinal hernia.

TAPPING A HYDROCELE

Hydrocele can often be tapped as a palliative measure. Sometimes repeated tapplings have been reported to cause a permanent cure. It is also tapped in cases where a more radical operation is contra-indicated either due to old age or cardiac, pulmonary and renal diseases; even for most of these cases the radical operation can be performed under local anæsthesia. Tapping is contra-indicated in cases where the hydrocele sac communicates with the peritoneal cavity through an opening (congenital hydrocele).

OPERATION

Select a point in the scrotum a little above the centre of the swelling and free from superficial veins. Make a small puncture with the point of a knife to facilitate the introduction of the trocar and cannula. Keep in mind the posterior situation of the testicle. Make the hydrocele tense with the left hand and with the right plunge the point of the trocar, with the cannula in a backward and upward direction through the skin puncture for a short distance into the sac of the tunica vaginalis. Withdraw the trocar and push the cannula a little further in. Let all the fluid drain out slowly. When evacuation is complete pinch the sac and the scrotum on the cannula and draw it out.

Comment :—It is best to support the scrotum by a bandage as the sudden relief of pressure may cause pain and it may also cause a certain amount of oozing from the wall of the sac in some cases. The puncture can be dressed with collodion and cotton wool.

OPERATIONS FOR THE CURE OF THE HYDROCELE

The operation for the radical cure of hydrocele should have the following objects in view : (1) Removal of the fluid in the sac. (2) Prevention of the re-accumulation of fluid. (3) Reduction of the size of testicle and scrotum so that the part may attain as much of its normal size and contour as possible. (4) Attainment of the above results with as little disturbance of the anatomical relations of the part as possible.

INDICATIONS

- (1) For patients who are desirous of entering public services.
- (2) To correct disfigurement in an awkward situation.
- (3) To relieve a sense of weight and dragging pain that are caused by it; these prevent the patient from taking physical exercise.
- (4) Hydrocele predisposes to hernia, varicocele, lymphangiectasis and elephantiasis.
- (5) Accidental trauma may give rise to hæmatocele or infection may lead to suppuration in the sac.

INSTRUMENTS—Group XXVIII.

POSITION

Dorsal position, the thighs kept apart.

OPERATION

The following operations are more commonly practised for the cure of hydrocele.

A. EXCISION OF THE SAC (BERGMANN)

The operation can be described in three stages :—

- (1) *Skin incision and exposure of the sac*.—Make a vertical incision about three inches long or if necessary longer, through the skin extending from near the spine of pubis. Expose the sac by

separating it from all its coverings by blunt dissection and gauze-wiping and deliver it.

(2) *Treatment of the sac.*—Open the sac and trim it off close to the testicle; apply a continuous suture all along the cut margin of the sac to stop oozing which is not inconsiderable. Return it into the scrotum.

(3) *Closure of the wound.*—Close the inguino-scrotal wound by interrupted sutures with or without drainage.

B. EVERSION OF THE SAC (JABOULAY)

(1) *Skin incision and exposure of the sac* as in the previous operation.

(2) *Treatment of the sac.*—Open the sac, turn it inside out and secure it behind the testicle by bringing together its cut edges by a few interrupted catgut stitches. Return the sac and testicle into the scrotum.

(3) *Closure of the wound.*—As in the previous operation.

C. PPLICATION AND OVERLAPPING OF THE SAC (CHATTERJI)

1. *Skin incision and exposure of the sac.*—As in the above operations (*Fig. 197*).

2. *Treatment of the sac.*—Make a full length incision in the sac. The testicle and the sac need not be delivered out of the scrotum. Roughen the visceral and parietal layers of the sac by means of a rough dry gauze or a spoon. Take one half of the sac, draw it across the testicle and fix it by its cut margin with a few sutures to the line of reflection of tunica vaginalis from the testicle (*Fig. 198*). Treat the other half of the sac similarly, but let it overlap and be transplanted on the superficial aspect of the first half of the sac. If the sac is large and redundant, plicate it particularly at the upper and lower parts or even excise a portion (*Fig. 199*).

3. *Closure of the wound.*—As in previous operations.

Comment:—Judging from the nature of the operation the last method satisfies the conditions laid down for the cure of hydrocele. Plication and overlapping of the sac is suitable for practically all hydroceles. In the case of those with very large sacs, portions of it can be excised. In the case of much thickened sacs the thickening may be removed with scissors or a fine scalpel. In the first two methods the hydrocele loses its natural covering and lies exposed anteriorly and by the eversion method the antero-posterior diameter of the testicle is much increased. All these drawbacks are avoided in the third (author's) method.

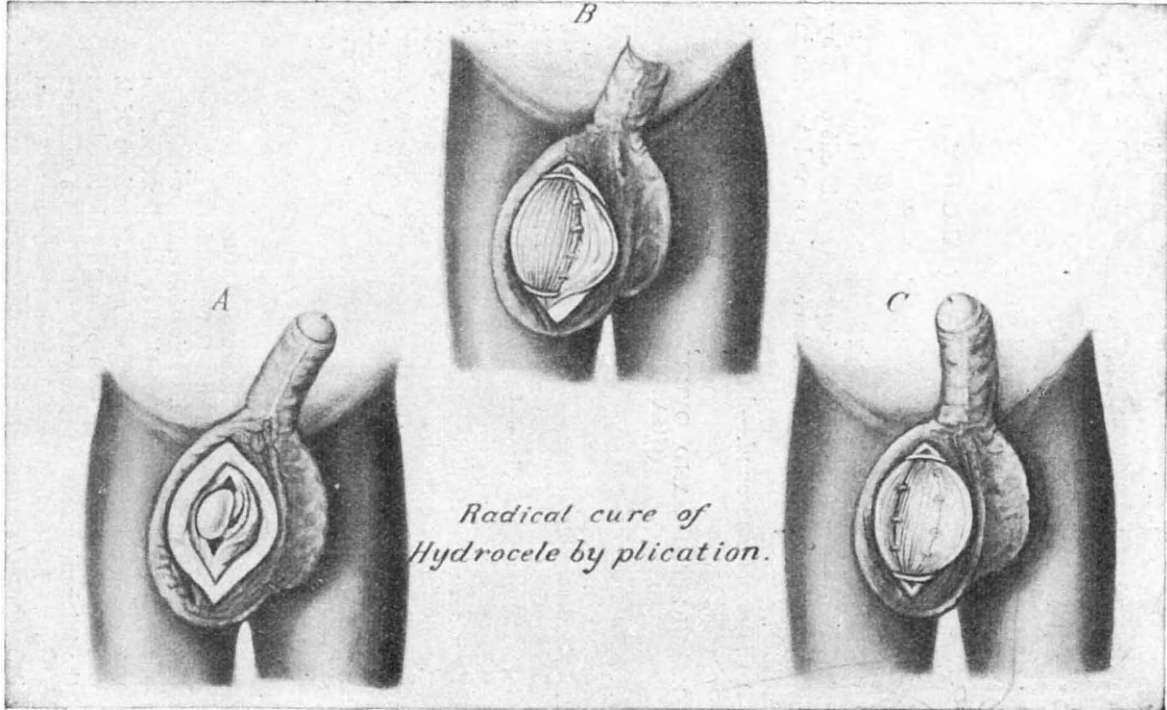


FIG. 197.

FIG. 198.

FIG. 199.

Plication and overlapping of the hydrocele sac (Chatterji).

CASTRATION INDICATIONS

Excision of the testicle as a whole is indicated in the following conditions :—

(1) Tumour of the testicle. In some cases of non-malignant tumours and in all cases of malignant tumours so long as the spermatic cord is not extensively involved.

(2) Tuberculous disease of the testicle.

(3) Some cases of syphilitic disease of the testicle when it is hopelessly disorganised.

(4) In old hæmatoceles in which due to pressure or otherwise, the testicle has been atrophied and is an useless appendage particularly if septic infection has also taken place.

(5) In cases of retained testes : (a) because it cripples the patient due to repeated inflammation and when there is torsion of the cord ; (b) when it is associated with hernia and the operation of radical cure of hernia cannot be effected without removing the testicle ; (c) because it predisposes to malignancy.

(6) In cases of elephantiasis of the scrotum where the testicle is atrophied from pressure or filarial orchitis and hopelessly adherent to the scrotal and subscrotal tissues.

(7) In former days castration used to be performed for enlarged senile prostate and after amputation of the penis, but the object for which this was practised can be attained by vasectomy.

INSTRUMENTS—Group XXVII.

OPERATION

Make an incision skin deep three and a half inches long, from the spine of the pubis upwards and outwards just above Poupart's ligament parallel to it and to a point on a level with its middle. Feel for the cord and draw the testicle out from the scrotum through the wound. Separate its attachments to sub-scrotal tissues if any. The testicle is now free. The cord is secured as high as possible with a Staffordshire knot or by transfixion ligature (*vide supra*), and it is cut across a little distal to it.

Comment :—Before removing one testicle, make sure that the other testicle can supply the internal secretion and retain its physiological function.

OPERATION FOR VARICOCELE

INDICATIONS

The indications for the removal of the pampiniform plexus of veins of the spermatic cord for their varicose condition are as follows :—

(1) When the varicosity is steadily increasing, causes distress, annoyance and pain.

(2) Where it interferes with the usual pursuit of life and legitimate physical exercise.

(3) When the patient desires to enter public service and is debarred by it.

(4) When the testicle is undergoing atrophy.

INSTRUMENTS—Group II.

POSITION—Dorsal position.

OPERATION

Make an incision in the inguinal canal a finger's breadth above and parallel with the inner third of Poupart's ligament. Divide the tissues till the cord is exposed. Pick up the whole mass of the cord and isolate it from the external abdominal ring to the testicle. Feel for the vas deferens and separate it with its artery and vein and if necessary one more vein from the remaining mass of pampiniform plexus of veins. Apply crushing forceps to this plexus proximally at the external ring and distally near the testicle. Remove the clamps and apply catgut ligature on the groove left by these, keeping the ends of the ligature long. Remove the intervening portion of the veins between these ligatures. Appose the venous stumps by means of the long ends of the ligatures. Close the wound.

Comment :—High incision is useful as the cord is more accessible in the inguinal region and there is less chance of sepsis. The venous stumps are brought together to reduce the length of the cord. If the scrotum is pendulous, a portion of it may be excised so that the small scrotum may lend a better support to the testes.

CHAPTER XXXI

ELECTROSURGICAL METHODS OF OPERATION

The electrosurgical operative methods consist of application of high frequency currents for the destruction of diseased tissues or for cutting through normal tissue with the minimum amount of bleeding. The action is due to intense heat generated in the tissues themselves just below the small (active) electrode.

The heat so generated can be regulated, according to physical laws, by varying the strength of the current, the time factor or the resistance. The resistance is, in this instance, offered by the tissues, and it varies according to their structure, site and vascularity. The size and form of the active electrode has great influence on the heat production because the smaller it is in size the greater is the concentration of energy in its immediate neighbourhood.

Apart from destruction of tissues (surgical diathermy) these methods can also be used for other therapeutic purposes, e.g. in medical diathermy, in which using a suitable electrode moderate heat is generated in the diseased tissues to increase their vascularity, aid absorption of exudates and enhance the natural reparative processes.

Surgical diathermy procedures can be broadly classified under three headings:—

(1) *Electrodesiccation*—in which minute sparks are allowed to jump from a pointed electrode to the diseased or morbid tissues, the electrode not actually touching the parts. The shower of these tiny sparks thus dehydrates the affected parts which shrivel up. Blood vessels are effectively sealed and there is no bleeding. This is the biterminal method of desiccation.


A slight modification of this method in which the voltage of the current is further raised is known as Oudin's electrodesiccation.

(2) *Electrocoagulation*.—Here the active electrode, necessarily of somewhat larger dimensions, is placed in actual contact with the diseased tissue. The intense heat generated around it coagulates the tissues—as if boiling them in their own juices—which are cast off after some time as a slough, leaving a healthy uninfected bed, which heals rapidly.

(3) *Diathermy cutting (acusection)*.—A thin flat blade or a fine needle or a loop of fine wire when used as the active electrode can pass through the tissues almost without any resistance and thus make a clean incision. A very thin film of coagulum forms on either side of the incision and effectively seals the small blood and lymph vessels. Healing is by first intention provided there is no deeper coagulation or charring of the tissues.

The various forms of electrodes used are shown in the accompanying diagram (*Fig. 200*).

Some idea of one of the types of the electrosurgical units and the different types of electrodes can be gathered from the figure given below.



Spark-gap type Electrosurgical Unit

FIG. 200.

THE SKIN

In pyogenic infections of the skin mild uniterminal currents applied by means of needles effectively sterilise areas of suppuration.

Electrosurgery is particularly useful for the treatment of carbuncles. Either the uniterminal or the biterminal current may be used. If coagulating current is used it would effectively sterilise the whole area or the entire infected area can be excised quickly by a suitable needle, the great advantage being the associated hæmostasis reducing the absorption of toxin to a minimum. This can further be assured by spraying. By these methods granulation and epithelization are prompt.

Small papillomata or pigmented moles are effectively removed by electrodesiccation. The scar left after it is softer and less disfiguring than after knife excision.

Cavernous hæmangioma is best treated by reducing it in the first instance by irradiation and then removing by electrosurgical methods. For hæmangiomata, the short spark should be used.

Other benign neoplasms of the skin can also be effectively treated.

Malignant tumours are also treated by uniterminal Oudin currents if small, or stronger current of more amperage for larger growths. The electrosurgical needle is inserted into several points

and retained until the adjacent tissues are quite blanched and structureless. This method is adopted circumferentially till a zone of tissue surrounding the growth is totally blanched. The second stage of the operation is the application of the dehydrating current till the tissue is mummified. If necessary, at a second sitting, by means of the electrosurgical needle and curette, the tumour may be completely eradicated. In some cases it may require several sittings and the operation completed in stages, step by step.

Any raw surface after eradication is best treated by application of murcurochrome solution and scarlet red ointment.

For lesions of the face and oral cavity the same procedures, as for tumours, should be adopted, the advantage being that there is no oozing.

Epithelioma of the tongue is effectively treated first by electrosurgical excision and then applying a strong coagulating current with the object of producing a protecting coagulum and to guard against the spilling of cancer cells.

Lymphangiomata of the face and neck are treated on the same principles as hæmangiomata.

Basal celled carcinoma are suitable growths for treatment by electrosurgery. Basal celled and prickle celled growths of the face in the neighbourhood of the lips are treated on the same principles.

Metastatic lymph nodes are excised as mass enucleation.

For hæmostasis the vessels are clamped, proximally and distally, by hæmostatic forceps, then divided and the button electrode is brought into contact with the hæmostats and the current conducted through them effects sealing and closure of the vessels. In order to prevent the current passing to larger vessels which are not meant to be closed or sealed a protecting rubber sheet or pad is applied. This is termed clamp coagulation.

THE THYROID GLAND

For the skin incision either an ordinary scalpel or an electrosurgical needle for a cutting current is used. For the rest of the operation the cooking and cutting currents are used and the vessels sealed by clamp coagulation, the protective rubber sheet being utilised wherever necessary. The special advantages of thyroidectomy by electrosurgery is hæmostasis and coagulation and sealing of blood and lymph vessels which reduce the absorption of toxins to a minimum.

THE THORAX

Electrosurgery is utilised in cases of pneumothorax. It is a well-known fact that simple pneumothorax, single or repeated, are often ineffective in producing pneumolysis. Such adhesions can

be broken down by coagulating and cutting currents through a thoroscopic cannula. On visualising the adhesional bands the thinnest parts in the bands are divided by the cutting current and the cut ends of these bands are sealed by coagulating current.

THE BREAST

The Halstead operation can be performed by the electro-surgical knife. A fine electrosurgical needle with a cutting current is used for the skin and thicker needles and the knife for the deeper structures and the muscles. Clamp coagulation for the smaller vessels and the branches of the axillary vessels and the use of a rubber tissue protection are the main features. By this method the advantages are quickness of operation, hæmostasis, and prevention of spilling of cancer cells.

THE ABDOMEN

I have performed cholelithotomy, cholecystostomy and gastro-jejunoscopy by electrosurgery without using the scalpel. The special advantages I have noticed are the use of fewer instruments, hæmostasis, and easier separation of adhesions during operations on the gall-bladder. In gastrojejunoscopy I have observed that while incising the stomach and intestinal walls a much stronger current was required and that the gastrojejunal stoma had much less tendency to contract than when done by the usual methods.

GENITO-URINARY SYSTEM

I have performed several operations for excision of the elephantiasic scrotum and I have found this method particularly suitable. Primary union has almost invariably taken place, the loss of blood was minimum and the convalescence shortened.

Amputation of penis for cancer with electrosurgical knife renders the operation simpler and easier.

Contractures of the prostate, obstruction at the neck of the bladder by bands and benign hypertrophy have all been treated by electrosurgery either *via* an endoscope, or through a suprapubic opening.

Tumours of the bladder such as papillomata (villous growths) can be removed through a cystotomy opening: the bladder however must be kept dry as otherwise much of the current is conducted away by the fluid accumulating: and this can be obviated by using a suction apparatus. Highly vascular papillomata can be excised by the cutting and coagulating current or clamp coagulation.

Operations on the ureter and kidneys are performed on the same lines.

Hæmorrhoids and rectal polypii are treated by excision, electro-coagulation and dehydration. The thoroughness of the operation and hæmostasis are great advantages. External piles are just dehydrated and within a day or two they fall off as a dry mass.

CENTRAL NERVOUS SYSTEM

It has been said that tumours and abscesses of the brain are treated by electrosurgery. Harvey Cushing, one of the pioneers of brain and nerve surgery, says 'We now have at our command a device which makes it possible to extirpate tumours hitherto so inaccessible that the attempted removal would have been regarded as foolhardy in the extreme'¹

¹ Macewen Memorial Lecture, 1927.

CHAPTER XXXII

SELECTION OF INSTRUMENTS FOR OPERATIONS

(Arranged in Groups)

I. *Instruments generally required for Most Operation.*—Scalpel, artery forceps, dissecting forceps, scissors, director, dissector, suture needles, straight and curved, wound retractors, tissue forceps, sutures and ligatures and skin forceps.

II. *Ligation of Vessels, etc.*—Aneurysm needles and Group I.

III. *Amputations.*—Tourniquet, periosteal elevator, amputation knife, amputation saw, bone forceps, lion forceps, gouge, amputation flap retractors, gouge forceps and Group I.

IV. *Excision of Bones and Joints and Bone-suturing.*—Tourniquet, excision knife, Gigli's saw with guide and protector, lion forceps, saw periosteal elevator, spoon, gouge, bone forceps, sequestrum forceps, bradawl, drill, chisel, mallet, gouge forceps, bone-suture needles and wire guide, suture material and Group I.

V. *Sequestrotomy and Osteotomy.*—Bone nippers, sequestrum forceps, raspatory, gouge, gouge forceps, periosteal elevator, chisel, mallet, osteotome (McEwen's, etc.), osteotomy saw, lion forceps and Group I.

VI. *Excision of the Jaws.*—Gag, tooth forceps, key-hole saw, Hey's saw or Horsley's saw and Group IV.

VII. *Resection of Ribs.*—Rib-shears, Hey's or Horsley's saw, sequestrotomy forceps and Group IV.

VIII. *Trephining and Operation on the Skull.*—Trephines, gouge forceps, skull forceps (De-vilibis, etc.), periosteal elevator, bone forceps, gouge forceps, Gigli's wire-saw with guide and protector, fine toothed forceps and Group I.

IX. *Tonsillectomy.*—Gag, volsellum forceps, tonsil scissors, tonsil guillotines, tongue depressor, sponge holders, straight and curved, blunt pointed scissors and tonsil compression forceps.

X. *Tracheotomy, etc.*—Blunt and sharp hooks, tracheotomy dilator, tracheotomy tubes and tape, a short narrow bladed scalpel, special forceps for removing foreign bodies and Group I.

XI. *Laryngotomy.*—Laryngotomy tube and Groups I and X.

XII. *Paracentesis.*—Exploring syringe, small scalpel, scissors, trocar and cannula, aspirating trocar and cannula, aspirating bottle and pump.

XIII. *Intestinal Operations*.—Peritoneal forceps, intestinal clamps (Doyen's, etc.), abdominal retractors, intestinal suture needles, straight, curved and semi-curved (Murphy's button), and Group I.

XIV. *Operations on the Stomach*.—Kocher's clamps and Group XIII.

XV. *Appendicectomy*.—Appendix crushing clamps and Group XIII.

XVI. *Colostomy*.—Glass rod, Paul's tube and Group XIII.

XVII. *Herniotomy*.—Hernia needles, large clamps, hernia director, peritoneal forceps, retractors, full curved Doyen's needle and Group I.

XVIII. *Operation for Piles, etc.*—Pile clamps rectal specula, needle holder, vulsellum forceps, curved needles, petticoat tube and Group I.

XIX. *Operations on Gall-bladder*.—Cholecystotomy forceps, stone scoop and Group XIII.

XX. *Operations on Kidney*.—Pedicule clamp, retractors, renal calculus forceps, scoop, sound, pedicle needle, nephrectomy needle, nephrectomy scissors, fine trocar and cannula, dilating lance forceps, fine pointed scissors, pus seeker, fine pointed director and Group XIII.

XXI. *Suprapubic Cystotomy*.—Catheters, syringes, irrigation apparatus, hollow sound (Thomson's), sharp hook, long curved forceps, lithotomy forceps, straight and curved of different sizes, lithotomy scoops (stone), blunt hook, retractor, fully curved needles, needle holder, long bladed scalpel or straight bistoury, vulsellum, needles on handles with protected and concealed eyes and Group I.

XXII. *Litholapaxy*.—Lithotrites of different sizes, evacuators, evacuating cannulæ of assorted sizes, sounds irrigation apparatus, rubber tube, Jacque's catheter.

XXIII. *Prostatectomy*.—Same as in Group XXI.

XXIV. *Internal Urethrotomy*.—Internal urethrotome, catheters, syringe, bougies.

XXV. *External Urethrotomy*.—Wheelhouse staff, long straight bistoury, Teal's probe-pointed director, probe gorget, median grooved staff, Syme's staff, perineal tube (metallic) of different sizes and Group I.

XXVI. *Amputation of the Penis*.—Fine toothed forceps, rubber tube, clamps, curved needles, Jacque's catheters and Group I.

XXVII. *Castration*.—Clamps, dissector and Group I.

XXVIII. *Operations on Hydrocele*.—Scraper, spoon and Group I.

XXIX. *Elephantiasis*.—Retractors, clamps, tissue forceps and Group I.

XXX. *Subcutaneous Tenotomy*.—Sharp or blunt pointed tenotome, sutures.

XXXI. *Open Tenotomy*.—Blunt hooks and Group I.

XXXII. *Intravenous Injection*.—Cannula, India-rubber tubes, graduated flasks, elastic tubes, aneurysm needles and Group I.

CHAPTER XXXIII

RECOGNITION AND USE OF INSTRUMENTS

The operation assistant should know the instruments that are required for each operation. He should also have acquired a knowledge of the use of the instruments. They should be brought in one lot and arranged in order of sequence in which they will be required. In handing over the instruments, these should preferably be held by means of a pair of Cheatle forceps. In the absence of Cheatle forceps they should be held in such a way that cutting parts and parts coming in direct contact with the wound are not touched by the assistant's hands. The significance of this warning is obvious.

I. GENERAL INSTRUMENTS

- (1) Scalpel, should have a sharp point and a good bellied blade.
- (2) Dissection Forceps, for separating tissues (*Fig. 201*).
- (3) Artery Forceps (Spencer-Well's).—These serve as a temporary means for stopping hæmorrhage till the vessel is permanently occluded by torsion or ligature (*Fig. 202*).
- (4) Scissors.—There should be at least two pairs, one for cutting sutures, ligatures, etc. and another for the tissues.
- (5) Director (*Fig. 203*).—This serves two objects, as a probe and also as a protector for the soft tissues; when cutting along its groove, point the cutting edge of the knife away from the groove and do not cut down on the groove or it will damage the edge of the knife.
- (6) Needles, straight and curved.
- (7) Wound retractors.—These may be either single or double ended (*Fig. 218*).

II. INSTRUMENTS FOR LIGATURE OF VESSELS

- (8) Aneurysm needle for passing a ligature round a vessel after it has been separated from its sheath. It is best passed unthreaded and a good needle should, therefore, have a sufficiently large eye so that it can be easily threaded after it has been passed round the vessel (*Fig. 204*).
- (9) Blunt hook for retracting tendons, nerves, etc.
- (10) Dissector for fine dissection and separation of soft tissues from important structures.

III. INSTRUMENTS FOR AMPUTATION

(11) Amputation knife.—This should be sharp pointed and single edged (*Fig. 205*). Double edged knives have no special advantages and are dangerous. The handles should be made for a firm grip and be well balanced with the blade.

(12) Amputation flap retractors.—These may be of two kinds (*a*) gauze retractor, either double-tailed or three-tailed or (*b*) metal retractors (*Fig. 206*). The metal retractors are applied by separating the blades entirely and placing one blade so that the bone lies in the apex of its notch. The other blade is then passed to the other side of the limb and pushed into the grooves of the first applied blade, the bone being thus encircled in the retractors. The soft tissues are now protected by the metal blades and can be retracted as desired. A little gauze may be tucked between the retractors and the soft tissues.

(13) Periosteal elevator (*Fig. 207*).

(14) Rougine (*Figs. 208 and 209*).—This can also be used as a periosteum elevator, it is stronger and sharper.

(15) Amputation saw.—This should have an aseptic jointed back (*Fig. 210*).

(16) Butcher's saw.—With this saw less damage is likely to be done to the soft tissues and it also has interchangeable blades (*Fig. 211*).

Note.—When using an amputation saw most pressure should be applied when it is being drawn towards the operator.

(17) Bone forceps (*Figs. 212 and 213*), a cutting forceps for bevelling off the sharp edges of the stump after sawing through the bone.

(18) Bone gouge (*Figs. 214 and 215*) for rounding off sharp edges of the stump.

(19) Bone gouge forceps (*Fig. 216*).

(20) Lion forceps (*Fig. 217*) for holding the bone during amputation when sawing through the bone.

(21) Metacarpal and metatarsal saws.—These have long narrow blades so that they can be worked through small spaces between contiguous bones.

IV. INSTRUMENTS FOR SPECIAL OPERATIONS

(22) Artery forceps for torsion.—Spencer-Well's forceps have transverse serrations on the inner surface of the jaws and can be used for torsion as well as compression (*Fig. 202*). They may be straight, angular or angled on flat. Bryant's forceps and its modifications are now out of date.

(23) Fenestrated artery forceps.—These crush the vessel in one spot only.

(24) Greig Smith's artery and compression forceps.—These have no transverse serrations on the jaws but have a double hawk's bill arrangement and claim superiority over others in not being liable to slip.

(25) Compression forceps.—These are similar to Spencer-Well's artery forceps but are heavier and have greater power (*Fig. 219*).

(26) Pedicle forceps.—These are used for crushing pedicles of tumours, for castration, ovariectomy, etc. Kocher's have transverse serration with teeth at the tip. Jordan Lloyd's are grooved lengthwise. Rutherford Morison's have grooves in two directions crossing each other.

(27) Tissue forceps (*Fig. 220*) for holding flaps, pulling tissues and fixing towels along the line of the skin incision.

(28) Bullet forceps (*Fig. 221*).—These are of various designs, the one in the figure shows the teeth for round bullets, but bullets are often flattened out. Use a probe as a guide. A skiagram is also helpful and essential in most cases.

V. INSTRUMENTS FOR SUTURING

(29) Suture needles for the skin and soft tissues.—These may be bayonet-shaped, i.e., triangular in section or with a bevelled point. They may be straight, half curved, full curved or half circled. They may have a single eye or be spring-eyed to facilitate threading.

(30) Fistula needles.—These are similar to any of the above patterns, but shorter and stouter.

(31) Scalp needles.—Doyen's flat half curved are the best for this purpose.

(32) Intestinal needles.—These should be round-bodied and may be straight, half curved, full curved or half circled. They should always have spring eyes.

(33) Needles in handles.—These may be fixed to the handles or interchangeable. They may be of various angles and have ordinary eyes, slot eyes or spring eyes. They may also be of the "forceps needle" pattern (Carwardine).

(34) Reverdin's needles (*Fig. 222*).—The eyes of these needles are opened and closed by a slide working from the handle.

Note.—Handled needles are useful for hernia operations (*Fig. 223*) ruptured perineum, transfixion, ligature of pedicles, castration, deep sutures, etc.

(35) Needle holders.—These are used for deep sutures and are always necessary for bayonet-shaped or sharp-edged needles, because the latter are liable to cut through the gloves if they slip

between the finger while pulling through. Needle holders should be selected with the simplest mechanism as they are easier to keep clean.

(36) Metallic sutures (Mitchell's) (*Figs. 224 and 225*).—These are metal clips for superficial suturing and a set of instruments consists of a pair of spring tenaculum forceps for holding the edges of the wound together and a magazine attached to same for carrying the clips, compression forceps for applying the clips and extraction forceps for removing the clips.

VI. INSTRUMENTS FOR OPERATIONS ON BONES

For suturing bones and for apposing divided bones

(37) Awls.—These may be plain, grooved or tubular with eyes at the end for suturing materials.

(38) Bone drills.—These may be used with a bevelled wheel action drill stock or with the ordinary brace (*Fig. 226*).

(39) Bone holding forceps.—These are made in different patterns and sizes for holding the patella and other bones.

(40) Bone lever for raising the fractured ends of bones and apposing them for suturing or plating.

(41) Raspatories (*Fig. 227*) for stripping the periosteum from the surface of the bone.

(42) Needle for wiring bone.

(43) Wire guides.—These are made grooved or tubular and are used for introducing wire through the holes in the bone.

(44) Bone plates, etc.—Staples, clamps, metal plates and screws of different sizes and shapes are used for uniting fractured bones. Some metal plates can be bent in order to adapt them to the bones.

Instruments for resection and excision of bones and joints

(45) Resection knives (*Figs. 228 and 229*).—These are meant to cut down to the bone through the soft tissues. The handles are large to give a good grip and the blades are short and sharp for strength. Care should be taken that these knives are particularly sharp.

(46) Thread saw (*Figs. 230 and 231*).—With this saw the bones can be excised through a small opening and without damage to the soft tissues. The director is passed through the soft tissues threaded with silk. It is then withdrawn leaving the thread *in situ* and the saw is attached to the silk and drawn into position. The handles are now fixed to the ends of the saw and it is worked to and fro, but care must be taken not to bend it at an angle or it is liable to break. These saws are also provided with a spatula-shaped protector for the soft tissues. These saws are useful for excision of the elbow, shoulder and hip, and for resection of ribs,

craniectomy, etc. A third handle is useful when the wire breaks (*Fig. 231*).

Note.—For use on the skull small circular holes are drilled with a quarter inch trephine round the piece of bone to be removed and the director with the protector and the saw is then introduced from one hole to the other and the intervening bone is cut from within outward.

VII. INSTRUMENTS FOR TREPHINING, OPERATIONS ON THE BRAIN, MASTOID AND LAMINECTOMY

(47) Trephines (*Fig. 232*).—These are circular saws which can be worked by hand, hand motor or electric motor. They are of various sizes and some trephines are guarded in order that they may not accidentally work too deep beyond the depth of the skull. For mastoid operations they should be one-eighth inch in diameter and for the skull up to two inches in diameter.

(48) Osteotribes and burrs.—These are used in mastoid and other operations for enlarging openings in the bones.

(49) Elevators.—These are used for raising the duramater and also in cases of depressed fracture of the skull.

(50) Instruments for enlarging the trephine hole.—Gouges, gouge forceps (*Fig. 233*), and saws (*Fig. 234*). Hey's or Horsley's saws are recommended, the latter having a convex edge and therefore a large sawing surface and it is stronger. Gouge forceps (*Fig. 233*). The mechanism of the gouge forceps should be such that the brain will be protected while the nibbling is carried on from the outer cranial aspects. Dean's De Vilbiss', Doyen's and Hoffman's are a few of the different varieties. They are so constructed that considerable force can be exerted with the jaws while at various angles.

(51) Instruments for localising operations on the surface of the skull.—A rolandometer (*Fig. 235*) should be used longitudinally on the skull and the short limb which is graduated and at an acute angle should be pointed to the front. In cases of suspected abscess in the brain pus seekers of different kinds are used.

(52) Facial nerve protectors or mastoid guide (*Fig. 236*).—These are used in mastoidectomy operations in order to protect the facial nerve. The nerve lies in the concavity of the tip.

(53) Mastoid gouges (*Fig. 237*).

(54) Mastoid probes.—These are malleable in order that they can be bent in any direction to find out the position of the cavity.

(55) Mastoid scoops (*Fig. 238*).—These and also ring curettes are used for removing debris of bone and granulations.

(56) Mastoid retractors.—These have sharp ends and are powerful for retracting the cartilage.

(57) Mastoid ossicle hooks.—These are used in the complete operation.

(58) Laminectomy chisels.—These have a sharp bevelled edge with a spur at one end and are made for use on the right or left side; laminectomy (bone) forceps.

(59) Laminectomy saws.—These saws can be fixed to the handle at any angle.

(60) Laminectomy rasps.—These can also be fixed to the handle at any angle.

VIII. INSTRUMENTS FOR OPERATIONS ON THE NOSE, PHARYNX, LARYNX, ŒSOPHAGUS, ETC.

(61) Adenoid currettes.—These generally have a straight shaft, but in some cases are fixed at an angle to the handle. Some have sharp hooks attached to a cage which is fixed by a hinge to the shaft. These are meant to catch the growth and prevent it from dropping into the air passages.

(62) Adenoid punch forceps.—These are used for cutting or crushing the adenoids.

(63) Hæmorrhage plugs.—These consist of inflatable rubber bags and are used for stopping bleeding from the posterior nares.

(64) Polypi forceps.—These are of different sizes and strengths. Some have crocodile jaws, others have longer or shorter blades with an antero-posterior or lateral action.

(64*a*) Polypi snares.—These are instruments by means of which a loop of wire is passed round the pedicle or polypi and on tightening, the polypi come off due to a crushing action and bleeding is also checked.

(65) Nasal septum forceps.—These are for deviated nasal septum. These generally have smooth and flat blades to hold the septum from either side.

(66) Instruments for submucous resection.—Partial resection of the septum by the submucous route is performed by means of instruments designed by Watson Williams and others. They consist of different kinds of knives, raspatories and currettes generally set at different angles in order to raise the submucous flap, then remove the cartilage and finally allow the flap to cover the raw surface.

(67) Turbinectomy instruments.—These consist of cutting and punching forceps, saws, gouges, ring knives (plain or with swivel action), guarded knives and scissors of different curves.

(68) Guillotines.—For the removal of tonsils, various kinds of guillotines are made. Mackenzie's (*Fig. 239*) can be supplied with reversible blades, i.e., can be used for right or left tonsil with the right hand. Some guillotines are guarded and fitted with forks to secure the tonsil. The French pattern guillotine has a more or less rounded blade and is fitted with forks.

(69) Tonsil knives (*Fig. 240*).—These have blades of different shapes and sizes either for excision of the tonsils or opening tonsillar and peritonsillar abscesses or slitting open the tonsil in cases of lacunar tonsillitis.

(70) Tonsil bistoury (*Fig. 241*).

(71) Tonsil scissors (*Fig. 242*).—These are used by some for removing tonsils. Erichsen's scissors have hooks for fixing the tonsil. Other scissors have smaller blades with sharper curves without hooks. When using scissors, tonsils are caught with forceps. These scissors are particularly suitable for the removal of sessile and soft tonsils.

(72) Tonsil punch forceps.—These should have stout blades and are useful for vertically elongated tonsils.

(73) Tonsil compression forceps.—These are for preventing hæmorrhage after removal of the tonsil and the blades after covering with gauze are placed one inside and one outside the jaw.

Note.—A tongue depressor and a tongue forceps are also necessary for tonsil operations.

(74) Instruments for removal of the uvula.—Uvulatomes with sliding action blades. Uvula scissors with long handles and probe-pointed blades. The blades are at an angle to the handle in order that the surgeon's hand is not in the line of his vision.

(75) Instruments for laryngeal growth.—Ring curettes are used, working either laterally or antero-posteriorly.

(76) For small growths ecraseurs or laryngeal forceps can be used. Most of these are characterised by being bent rectangularly for adaptability.

(77) Instruments for laryngeal obstruction.—These consist of intubation tubes made of vulcanite or metal with an obturator and introducer and an extractor for removing the tubes. The tubes are usually made in seven sizes. A mouth gag (*Fig. 243*) and tongue forceps are also required.

(78) Laryngotomy cannulæ (*Fig. 244*).—These differ from tracheotomy tubes in being shorter and having a flat section and slightly sharper curve in order to adapt themselves to the transverse incision also avoid injuring the vocal cords.

(79) Instruments for tracheotomy.—Tracheal dilating forceps (*Fig. 245*) are a simple cross-action spring forceps, the blades of which are olive ended or blunt pointed and form a more or less obtuse angle with the handle.

(80) Tracheotomy cannulæ (*Fig. 246*).—These consist of an inner male tube and an outer female tube, the latter having a flange with slots for tapes to pass through for tying round the neck. To the flange of the inner tube is fixed an arrangement for easy withdrawal and cleaning of the tube. The outer tubes may be of one piece (Bryant's) or flexible (Howse's). The inner tube may be of one piece (Bryant's), bivalve (Fuller's), or lobster curved (Durham's).

Tracheotomy tubes are generally made in eight sizes. There are also India-rubber cannulæ which can be used to replace the metal tubes a few days after the operation; these correspond in sizes. Tracheal dilators are not required to be used with the bivalve cannula. Sharp hook (*Fig. 247*) should be fixed to the cricoid cartilage in order to steady the trachea. Double blunt hooks may be used as retractors.

(81) For cases of cut-throat with transverse wound in the trachea 'T-shaped' tracheal tubes are used. They can be introduced in two halves above and below the part where the two halves of the horizontal limbs meet, and are kept in place by slipping on to them another tube with a screw arrangement for fixing.

(82) For constriction of the oesophagus, bougies are used. These are made of gum elastic or silk web. Their ends may be bulbous, conical or cylindrical. Catgut bougies are used only as guides. Bougies are also made of whale-bone with metal olive ends of various sizes for screwing on to same.

(83) Oesophagotomes.—These are knives provided with flexible metal sheaths.

(84) Oesophageal forceps. These are made with blades which open either laterally or antero-posteriorly and are used for removing foreign bodies.

(85) Probangs.—These are instruments for removing small foreign bodies and consist of a long flexible stem or shaft with a bristle attachment at one end which is made to expand in an umbrella fashion from the handle. These are particularly useful for fish bones, etc. For coins a coin-catcher is used. It consists of flexible stem with a double ring at the far end. The free edges of the ring being turned backwards from its attachment so that when introduced into the oesophagus, it passes the coin but on its return journey the coin is caught in the free loop of one of the rings.

IX. INSTRUMENTS FOR OPERATIONS ON THE MOUTH AND JAWS

(86) For hare-lip, special forceps for controlling hæmorrhage are used. These may be single with the blades at right angles to the shanks or T-shaped with blades made to compress the vessels on both sides with one pair of forceps.

(87) Hare-lip pins. These are now seldom used. They consist of long needles, the point being sharp and flattened at one end and a knob at the other.

X. INSTRUMENTS FOR THE OPERATION OF CLEFT PALATE

(88) Forceps which are long and fine, the jaws being serrated or with tenaculum points (*Fig. 248*).

(89) Hooks.

(90) Knives with short blades and long shafts, the former being at various angles to the shaft. In some cases the blades are double-edged (Smith's).

(91) Cleft palate needles.—Small handles may be used with long needle holders (Lane's), or needles on handles of various curves may be used.

(92) Raspatories set at different angles (*Fig.* 208).

(93) Angular scissors with blunt and sharp points.

(94) Silver wire, wire twister and wire cutter. For excision of the upper and lower jaws the usual bone instruments are required, e.g. bone cutting forceps, thread saws (*Fig.* 230), meta-carpal and metatarsal saws, periosteal elevator, sequestrum and lion forceps.

(95) Tooth forceps.

(96) Sponge holder (*Fig.* 249).

(97) Bone drills.

(98) Cheek Retractor (*Fig.* 250).

XI. INSTRUMENTS FOR OPERATIONS OF EMPYEMA

(99) Stout scalpel or excision knife.

(100) A periosteal elevator with convenient angle for elevating the periosteum from the inner side of the rib.

(101) A small Hey's or Horsley's saw (*Fig.* 234).

(102) A thread saw with protector (*Fig.* 230).

(103) Empyema tubes with arrangement for fixing.

(104) Rib-shears or rib-cutting forceps consists of a bone-cutting forceps which works in scissors fashion. Of the two blades one is sharp and the other is deeply grooved and bent in such a fashion that the grooved side is concave towards the sharp blade, and the other side is conveniently smooth and convex. The sharp blade fits into the groove of the other blade. In order to cut a rib the blades are opened, the blunt blade introduced under the rib with the grooved edge uppermost and the convex smooth edge towards the pleura. On apposing the blade the rib is cut. The handles of the shears act on a convenient spring (*Fig.* 251).

XII. INSTRUMENTS FOR OPERATIONS ON STRICTURE OF THE URETHRA

(105) Teal's probe-pointed director. It is a grooved director with the upper third from the tip shaped like a olive-ended probe. It is introduced through the strictured portion of the urethra after dividing it. The probe gorget is then introduced guided by the groove of the director (*Fig.* 252), and then the perineal drainage tube (*Fig.* 255) is introduced.

(106) Fistula director is a probe-pointed director of the Teal pattern. It is of lighter weight (*Fig. 253*).

(107) Wheelhouse staff consists of a straight grooved staff with the groove running for its whole extent excepting for about $\frac{1}{4}$ " at the tip; at this point it has a smooth blunt hook directed towards the non-grooved side of the staff. The groove is utilized for cutting down on the urethra distal to the stricture, after which the staff is reversed and the hook is used as a retractor (*Fig. 254*).

(108) Lister's bougie (*Fig. 256*). These are of solid steel, nickel-plated. These are so graduated that the diameter increases by three sizes from the tip upwards, e.g. size $\frac{3}{8}$ means that diameter 3 at the point and 6 at the middle of the shaft in millimeters.

(109) English gum elastic bougie (*Fig. 257*).

(110) French gum elastic bougie (*Fig. 258*).

(111) Acorn-headed bougie (*Fig. 259*), to determine the site and calibre of the stricture.

(112) Miller's bougie (*Fig. 260*), same use as the last named.

(113) Filiform bougie (*Fig. 261*), a fine bougie used in cases of narrow strictures.

XIII. INSTRUMENTS FOR SUPRAPUBIC LITHOTOMY AND LITHOTRITY

(114) Thompson's hollow sound is a hollow sound with sharp bend and a short beak in order to facilitate exploration of the bladder without injuring its mucous membrane. It has graduations with an indicator which slips up and down. It is introduced into the bladder which is distended by fluid injected through it. The stone can be felt and measured by graduations and the indicator (*Fig. 262*).

(115) Lithotomy forceps. The blades consist of two scoops which have roughened concave surfaces. One of the handles consist of a complete ring and the other open ring to facilitate handling (*Fig. 263*).

(116) Lithotomy scoops. These scoops are of different sizes and the concave surfaces are rough. They are usually double-ended (*Fig. 264*).

(117) Lithotrite consists of two blades, a male and a female. The former fitting into a groove of the latter. The blades can be locked by a slider or screw. The two blades can be approximated either by a sliding movement or by screwing movement after they are locked. The stone is gripped by working the blades with a sliding movement. The lithotrite is then locked and the stone crushed by the great force that can be exerted by a screwing movement.

The lithotrite should be apposed and locked before its introduction and withdrawal (*Fig. 265*).

(118) Evacuator. After crushing the stone the bladder is filled by means of an evacuating cannula (*Fig. 267*) which has a sharp bend and short beak and broad slot eye near the tip. The evacuator (*Fig. 266*) is filled with liquid and adapted to the cannula water-tight, through which the bladder and evacuator communicates; when the bulb of the evacuator is squeezed the fluid in the evacuator is forced into the bladder, and on relieving the pressure the fluid in the bladder containing the stone is aspirated in the evacuator. By means of a valvular arrangement the fragments received in the evacuator is prevented from returning in the bladder.

XIV. TENOTOMY

(119) Tenotomy knives (*Figs. 268 and 269*). These consist of narrow bladed sharp and blunt knives. The puncture is made with the sharp one and then the cut is made with a blunt tenotome (*Fig. 269*).

XV. HERNIOTOMY

(120) Hernia needle (*Fig. 223*). These are handled needles of different curves. They are meant for apposing the conjoined tendon and Poupart's ligament.

(121) Hernia director (*Fig. 270*). This is a broad director with shallow groove and is introduced behind the constriction at the neck of the hernia with grooved end towards the constriction. The constricting band is divided by cutting down on the groove.

XVI. INSTRUMENTS FOR OPERATION ON PILES

(122) Pile clamps. It is used for clamping piles before excision.

(123) Petticoat tube. This consists of rubber or metal tube round which a piece of gauze is tied in a petticoat fashion (*Fig. 271*).

A GLOSSARY OF THE INTERNATIONAL (B.N.A.) ANATOMICAL TERMINOLOGY

THE BONES

OLD TERMINOLOGY	B.N.A. TERMINOLOGY
Ensiform process	Processus xiphoideus
Supra-sternal notch	Incisura jugularis
Frontal	Os frontale
Lateral angular process	Processus zygomaticus
Parietal	Os parietale
Temporal ridges	Lineæ temporales
Groove for lateral sinus	Sulcus transversus
Occipital	Os occipitale
Sphenoid	Os sphenoidale
Spinous process	Spina angularis
Internal pterygoid plate	Lamina medialis processus pterygoidei
External pterygoid plate	Lamina lateralis processus pterygoidei
Cavernous groove	Sulcus caroticus
Temporal bone	Os temporale
Aqueduct of Fallopius	Canalis facialis [Fallopil]
Hiatus Fallopii	Hiatus canalis facialis
Digastric fossa	Incisura mastoidea
Fossa sigmoidea	Sulcus sigmoideus
Glenoid cavity	Fossa mandibularis
Eustachian canal	Semicanalis tubæ auditivæ
Nasal bone	Os nasale
Superior maxillary bone	Maxilla
Facial or external surface	Facies anterior
Antrum of Highmore	Sinus maxillaris
Malar process	Processus zygomaticus
Palate bone	Os palatinum
Vertical plate	Pars perpendicularis
Horizontal plate	Pars horizontalis
Malar bone	Os zygomaticum
Zygomatic process	Processus temporalis
Temporo-malar canal	Foramen zygomatico-orbitale
Malar foramen	Foramen zygomatico-faciale
Inferior maxillary bone	Mandibula
Genial tubercle or spine	Spina mentalis
Inferior dental foramen	Foramen mandibulare
Inferior dental canal	Canalis mandibulæ
Spheno-maxillary fossa	Fossa pterygo-palatina
Posterior nares	Choanæ
Sphenoidal fissure	Fissura orbitalis superior
Spheno-maxillary fissure	Fissura orbitalis inferior
Supra-scapular notch	Incisura scapularis
Bicipital groove	Sulcus intertubercularis
Musculo-spiral groove	Sulcus nervi radialis
Internal condyle	Epicondylus medialis
External condyle	Epicondylus lateralis
Greater sigmoid cavity	Incisura semimularis
Lesser sigmoid cavity	Incisura radialis

OLD TERMINOLOGY

Bicipital tuberosity
 Sigmoid cavity
 Scaphoid
 Semilunar
 Cuneiform
 Trapezium
 Trapezoid
 Os magnum
 Unciform
 Innominate bone
 Superior curved line
 Spine of the ischium
 Great sacro-sciatic notch
 Lesser sacro-sciatic notch
 Descending ramus of pubis
 Ascending ramus of pubis
 Symphysis pubis
 False pelvis
 True pelvis
 Digital fossa of femur
 Spiral line " "
 Inner condyle " "
 Outer condyle " "
 Spine of tibia
 Tubercle of tibia
 Internal malleolus
 External malleolus
 Astragalus
 Os calcis
 Inner cuneiform
 Middle cuneiform
 Outer cuneiform

B.N.A. TERMINOLOGY

Tuberositas radii
 Incisura ulnaris
 Os naviculare
 Os lunatum
 Os triquetrum
 Os multangulum majus
 Os multangulum minus
 Os capitatum
 Os hamatum
 Os coxæ
 Linea glutæa posterior
 Spina ischiadica
 Incisura ischiadica major
 Incisura ischiadica minor
 Ramus inferior oss. pubis
 Ramus superior oss. pubis
 Facies symphyseos
 Pelvis major
 Pelvis minor
 Fossa trochanterica
 Linea intertrochanterica
 Condylus medialis
 Condylus lateralis
 Eminentia intercondyloidea
 Tuberositas tibiæ
 Malleolus medialis
 Malleolus lateralis
 Talus
 Calcaneus
 Os cuneiforme primum
 Os cuneiforme secundum
 Os cuneiforme tertium

THE LIGAMENTS

Ligaments of the Spine

Ligamenta subflava	Lig. flava
Odontoid or check ligaments	Lig. alaria

The Jaw

External lateral ligament	Lig. temporo-mandibulare
Internal lateral ligament	Lig. speno-mandibulare
Stylo-maxillary ligament	Lig. stylo-mandibulare

Upper Extremity

Rhomboid ligament	Lig. costo-claviculare
Internal lateral ligament of elbow-joint	Lig. collaterale ulnare
External lateral ligament	Lig. collaterale radiale
Orbicular ligament	Lig. annulare radii
Internal lateral ligament of the carpus	Lig. collaterale carpi ulnare
External lateral ligament of the carpus	Lig. collaterale carpi radiale
Palmer ligaments of the metacarpophalangeal joints	Lig. accessoria volaria

Lower Extremity

OLD TERMINOLOGY	B.N.A. TERMINOLOGY
Great sacro-sciatic ligament	Lig. sacro-tuberosum
Small sacro-sciatic ligament	Lig. sacro-spinosum
Cotyloid ligament	Labrum glenoidale
Y-shaped ligament	Ligamentum iliofemorale
Ischio-capsular band	Lig. ischio-capsulare
Long external lateral ligament	Lig. collaterale fibulare
Internal lateral ligament	Lig. collaterale tibiale
External semilunar cartilage	Meniscus lateralis
Internal semilunar cartilage	Meniscus medialis
Superior tibio-fibular articulation	Articulatio tibio-fibularis
Internal lateral ligament of ankle	Lig. deltoideum
Anterior fasciculus of external lateral ligament	Lig. talo-fibulare anterius
Posterior fasciculus of external lateral ligament	Lig. talo-fibulare posterius
Inferior calcaneo-navicular ligament	Lig. calcaneo-naviculare plantare
Superior astragalo-scaphoid ligament	Lig. talo-naviculare dorsale

THE MUSCLES

Levator anguli scapulæ	Levator scapulæ
Serratus magnus	Serratus anterior

Muscles of Upper Extremity

Biceps	Biceps brachii
Brachialis anticus	Brachialis
Triceps	Triceps brachii
Pronator radii teres	Pronator teres
Supinator longus	Brachio-radialis
Supinator brevis	Supinator
Extensor carpi radialis longior	Extensor carpi radialis longus
Extensor carpi radialis brevior	Extensor carpi radialis brevis
Extensor indicis	Extensor indicis proprius
Extensor minimi digiti	Extensor digiti quinti proprius
Extensor ossis metacarpi pollicis	Abductor pollicis longus
Abductor pollicis	Abductor pollicis brevis
Extensor primi internodii pollicis	Extensor pollicis brevis
Extensor secundi internodii pollicis	Extensor pollicis longus
Anterior annular ligament	Lig. carpi transversum
Posterior annular ligament	Lig. carpi dorsale

Muscles of Lower Extremity

Tensor fasciæ femoris	Tensor fasciæ latæ
Hunter's canal	Canalis adductorius (Hunteri)
Scarpa's triangle	Trigonum femorale
Crural canal	Canalis femoralis
Crural ring	Annulus femoralis
Vastus externus	Vastus lateralis
Crureus	Vastus intermedius
Vastus internus	Vastus medialis
Tibialis anticus	Tibialis anterior
Tendo Achillis	Tendo calcaneus
Tibialis posticus	Tibialis posterior
Accessorius	Quadratus plantæ

OLD TERMINOLOGY

Upper anterior annular ligament
 Internal annular ligament
 Erector spinæ
 Multifidus spinæ

B.N.A. TERMINOLOGY

Lig. transversum cruris
 Lig. laciniatum
 Sacro-spinalis
 Multifidus

Muscles of Head and Neck

Occipito-frontalis
 Compressor naris
 Dilatores naris
 Epicranial aponeurosis
 Orbicularis palpebrarum
 Depressor anguli oris
 Levator labii superioris
 Zygomaticus major
 Levator anguli oris
 Depressor menti
 Platysma myoides

Epicranius
 Pars transversa (nasalis)
 Pars alaris (nasalis)
 Galea aponeurotica
 Orbicularis oculi
 Triangularis
 Caput infraorbitale
 Zygomaticus
 Caninus
 Mentalis
 Platysina

Muscles of the Tongue

Genio-hyo-glossus
 Superior lingualis
 Inferior lingualis

Genio-glossus
 Longitudinalis superior
 Longitudinalis inferior

Muscles of the Pharynx

Azygos uvulæ
 Levator palati
 Tensor palati

M. uvulæ
 Levator veli palatini
 Tensor veli palatini

Muscles of Thorax

Triangularis sterni

Transversus thoracis

Muscles of the Abdomen

Poupart's ligament
 Gimbernat's ligament
 Intercolumnar fibres
 Triangular fascia

Ligamentum inguinale (Pouparti)
 Ligamentum lacunaræ (Gimbernati)
 Fibræ intercrurales
 Ligamentum inguinale reflexum
 (Collesi)

External abdominal ring
 Internal pillar
 External pillar
 Conjoined tendon
 Transversalis muscle
 Fold of Douglas
 Internal abdominal ring

Annulus inguinalis subcutaneus
 Crus superius
 Crus inferius
 Falx aponeurotica inguinalis
 M. transversus abdominis
 Linea semicircularis (Douglasi)
 Annulus inguinalis abdominalis

Perineum and Pelvis

Transversus perinei
 Compressor urethræ
 Triangular ligament
 White line of pelvis
 Anterior true ligaments of bladder

Transversus perinei superficialis
 M. sphincter urethræ membranaceæ
 Diaphragma urogenitale
 Arcus tendineus fasciæ pelvis
 Ligamenta puboprostatica

THE NERVES

Cranial Nerves

OLD TERMINOLOGY	B.N.A. TERMINOLOGY
Third nerve	N. oculomotorius
Fourth nerve	N. trochlearis
Fifth nerve	N. trigeminus
Gasserian ganglion	Ganglion semilunare (Gasseri)
Superior maxillary nerve	N. maxillaris
Meckel's ganglion	Ganglion spheno-palatinum
Sixth nerve	N. abducens
Seventh nerve	N. facialis
Auditory nerve	N. acusticus
Jugular ganglion	Ganglion superius
Recurrent laryngeal nerve	N. recurrens
Spinal accessory	Nervus accessorius

Spinal Nerves

Superficial cervical nerve	N. cutaneus colli
Suprasternal nerves	Nn. supraclaviculares anteriores
Supraclavicular nerves	Nn. supraclaviculares medii
Supra-acromial nerves	Nn. supraclaviculares posteriores
Intercosto-humeral nerve	Nn. intercosto-brachiales
Long subscapular nerve	N. thoraco-dorsalis
Lesser internal cutaneous nerve	N. cutaneus brachii medialis
Cutaneous branch of musculo-cutaneous nerve	N. cutaneus antibrachii lateralis
Internal cutaneous nerve	N. cutaneus antibrachii medialis
Anterior branch	Ramus volaris
Internal branch	Ramus ulnaris
Circumflex nerve	N. axillaris
Anterior interosseous	N. interosseus volaris
Palmar cutaneous branch of the median nerve	Ramus palmaris N. mediani
Collateral palmar digital branches of median nerve	Nn. digitales volares proprii
Dorsal cutaneous branch of ulnar nerve	Ramus dorsalis manus
Palmar cutaneous branch of ulnar nerve	Ramus cutaneus palmaris
Musculo-spiral nerve	N. radialis
Upper external cutaneous branch of musculo-spiral nerve	N. cutaneus brachii posterior
Lower external cutaneous branch of musculo-spiral nerve	N. cutaneus antibrachii dorsalis
Radial nerve	Ramus superficialis
Posterior interosseous nerve	N. interosseus dorsalis
Dorsal digital nerves	Nn. digitales dorsales
Genito-crural nerve	N. genito-femoralis
Crural branch of genito-crural nerve	N. lumbo-inguinalis
External cutaneous nerve	N. cutaneus femoris lateralis
Anterior crural nerve	N. femoralis
Long saphenous nerve	N. saphenus
Patellar branch of long saphenous nerve	Ramus infrapatellaris
Great sciatic nerve	N. ischiadicus
External popliteal nerve	N. peronæus communis
Musculocutaneous nerve	N. peronæus superficialis

OLD TERMINOLOGY

Anterior tibial nerve
 Internal popliteal nerve
 Nervus communicans tibialis
 Short saphenous nerve
 Internal plantar
 External plantar
 Pudic nerve

B.N.A. TERMINOLOGY

N. peronæus profundus
 N. tibialis
 N. cutaneus suræ medialis
 N. suralis
 N. plantaris medialis
 N. plantaris lateralis
 N. pudendus

THE BLOOD VESSELS

Arteries

Innominate artery	A. anonyma
Superior thyroid artery	A. thyreoidea superior
Ranine artery	A. profunda linguae
Facial artery	A. maxillaris externa
Inferior dental artery	A. alveolaris inferior
Small meningeal artery	Ramus meningæus accessorius
Buccal artery	A. buccinatoria
Posterior dental artery	A. alveolaris superior posterior
Arteria comes nervi phrenici	A. pericardiacophrenica
Anterior intercostal arteries	Rami intercostales
Thyroid axis	Truncus thyreo-cervicalis
Suprascapular artery	A. transversa scapulae
Superior intercostal	A. intercostalis suprema
Transversalis colli	A. transversa colli
Superior thoracic artery	A. thoracalis suprema
Acromio-thoracic artery	A. thoraco-acromialis
Long thoracic artery	A. thoracalis lateralis
Anterior branch of superior profunda	A. collateralis radialis
Inferior profunda	A. collateralis ulnaris superior
Anastomotica magna	A. collateralis ulnaris inferior
Anterior radial carpal	Ramus carpeus volaris
Posterior radial carpal	Ramus carpeus dorsalis
Dorsal interosseous arteries	Aa. metacarpeæ dorsales
Radialis indicis	A. volaris indicis radialis
Deep palmar arch	Arcus volaris profundus
Posterior interosseous artery	A. interossea dorsalis
Posterior interosseous recurrent artery	A. interossea recurrens
Anterior interosseous artery	A. interossea volaris
Posterior ulnar carpal	Ramus carpeus dorsalis
Anterior ulnar carpal	Ramus carpeus volaris
Superficial palmar arch	Arcus volaris superficialis
Palmar digital arteries	Aa. digitales volares communes
Internal iliac artery	A. hypogastrica
Internal pudic artery	A. pudenda interna
Deep epigastric artery	A. epigastrica inferior
Cremasteric artery	A. spermatica externa
Superficial and deep external pudic arteries	Aa. pudenda externa
Internal circumflex artery	A. circumflexa femoris medialis
External circumflex artery	A. circumflexa femoris lateralis
Anastomotica magna	A. genu suprema
Superior external articular artery	A. genu superior lateralis
Superior internal articular artery	A. genu superior medialis
Azygos articular artery	A. genu media

OLD TERMINOLOGY

Inferior external articular artery
 Inferior internal articular artery
 External malleolar artery
 Internal malleolar artery
 Anterior peroneal artery
 Posterior peroneal artery
 Internal malleolar artery
 External calcanean artery
 Internal calcanean artery
 Internal plantar artery
 External plantar artery
 Digital branches
 Collateral digital branches

B.N.A. TERMINOLOGY

A. genu inferior lateralis
 A. genu inferior medialis
 A. malleolaris anterior lateralis
 A. malleolaris anterior medialis
 Ramus perforans
 A. malleolaris posterior lateralis
 A. malleolaris posterior medialis
 Rami calcanei laterales
 Rami calcanei mediales
 A. plantaris medialis
 A. plantaris lateralis
 Aa. metatarsæ plantares
 Aa. digitales plantares

Veins

Superior longitudinal sinus
 Inferior longitudinal sinus
 Suprascapular vein
 Acromio-thoracic vein
 Transversalis colli vein
 Internal iliac vein
 Deep epigastric vein
 Internal saphenous vein
 External saphenous vein

Sinus sagittalis superior
 Sinus sagittalis inferior
 V. transversa scapulae
 V. thoraco-acromialis
 Vv. transversæ colli
 V. hypogastrica
 V. epigastrica inferior
 V. saphena magna
 V. saphena parva

THE VISCERA

Digestive Apparatus

Anterior palatine arch
 Posterior palatine arch
 Stenson's duct
 Bicuspid teeth
 Pharyngeal aponeurosis
 Valvulae conniventes
 Crypts of Lieberkuhn
 Ileo-cæcal valve
 Columns of Morgagni
 Valves of Houston
 Peyer's patches

Arcus glosso-palatinus
 Arcus pharyngo-palatinus
 Ductus parotideus (Stenonis)
 Dentes præmolares
 Tela submucosa
 Plicæ circulares
 Gl. intestinales
 Valvula coli
 Columnæ rectales
 Plicæ transversales recti
 Noduli lymphatici aggregati (Peyeri)

Respiratory Apparatus

Adam's apple
 Superior thyroid notch
 True vocal cord
 False vocal cord
 Glottis spuria
 Thyroid cartilage
 Thyro-hyoid membrane
 Glottis vocalis
 Thyroid gland
 Superior turbinate bone
 Middle turbinate bone
 Inferior turbinate bone
 Antrum of Highmore

Prominentia laryngea
 Incisura thyreoidea superior
 Plica vocalis
 Plica ventricularis
 Rima vestibuli
 Cartilago thyreoidea
 Membrana hyo-thyreoidea
 Pars intermembranacea (rimæ glottidis)
 Glandula thyreoidea
 Concha nasalis superior
 Concha nasalis media
 Concha nasalis inferior
 Sinus maxillaris

Urogenital Apparatus

OLD TERMINOLOGY

Hydatid of Morgagni (male)
 Vas deferens
 Glands of Littré
 Cowper's gland
 Hydatids of Morgagni (female)
 Internal os (of uterus)
 External os
 Canal of Nuck
 Bartholin's gland

B.N.A. TERMINOLOGY

Appendix testis
 Ductus deferens
 Gl. urethrales
 Glandula bulbo-urethralis (Cowperi)
 Appendices vesiculosi
 Orificium internum uteri
 Orificium externum
 Processus vaginalis
 Glandula magna vestibuli

Peritoneum

Lesser peritoneal sac
 Foramen of Winslow
 Costo-colic ligament
 Pouch of Douglas

Bursa omentalis
 Foramen epipolicum
 Lig. phrenico-colicum
 Excavatio recto-uterina (cavum
 Douglassi)

The Ear

Mastoid antrum

Antrum tympanicum

APPENDIX



FIG. 201.—Dissection forceps.

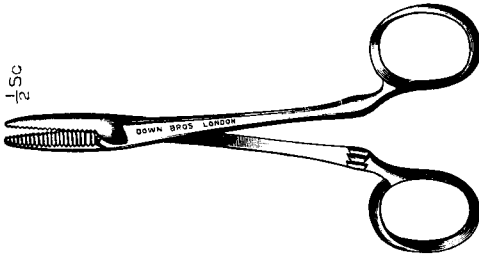


FIG. 202.—Spencer-Wells artery forceps.




FIG. 203.—Director ear scoop.




FIG. 204.—Aneurysm needle.



FIG. 205.—Amputation knife.


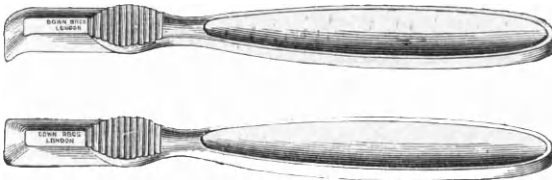


FIG. 206.—Amputation flap retractor.



FIG. 207.—Raspatory (periosteal elevator).



FIGS. 208 & 209.—Rougines straight and curved.

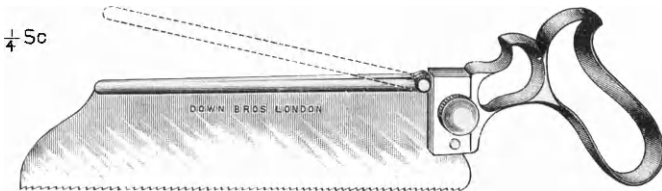


FIG. 210.—Amputation saw.

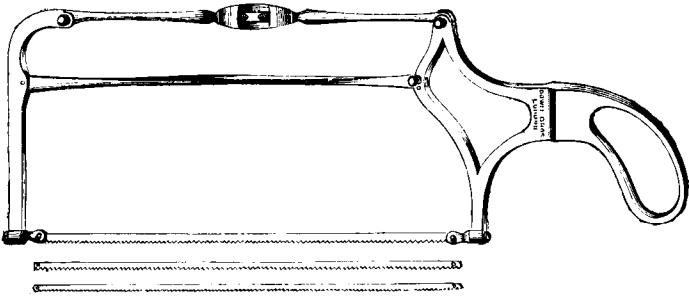


FIG. 211.—Butcher saw.



FIG. 212.—Bone forceps (flat angle).

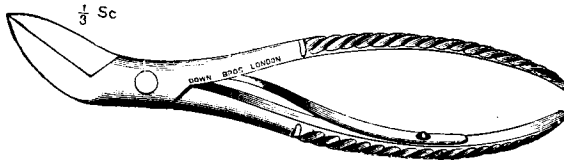


FIG. 213.—Bone forceps curved.



FIG. 214.—Bone gouge.

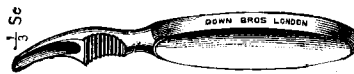

FIG. 215.—Bone gouge.




FIG. 216.—Gouge forceps.




FIG. 217.—Lion forceps.




FIG. 218.—Wound retractor (double ended).

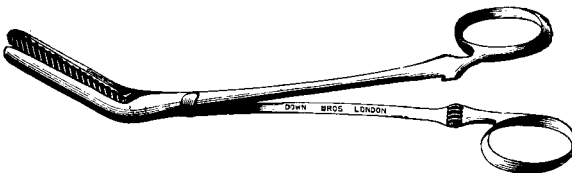


FIG. 219.—Compression forceps (angle or flat).

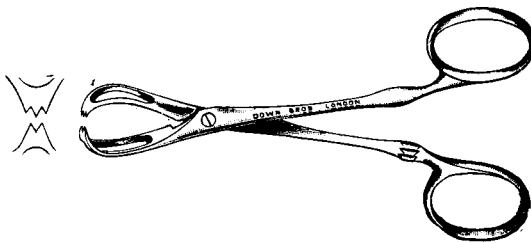


FIG. 220.—Tissue forceps.

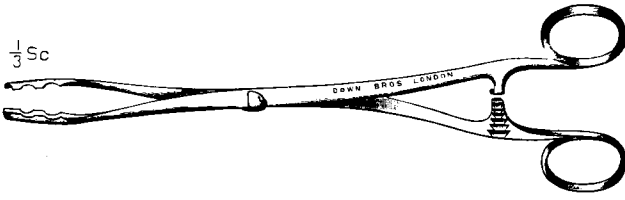


FIG. 221.—Bullet forceps.

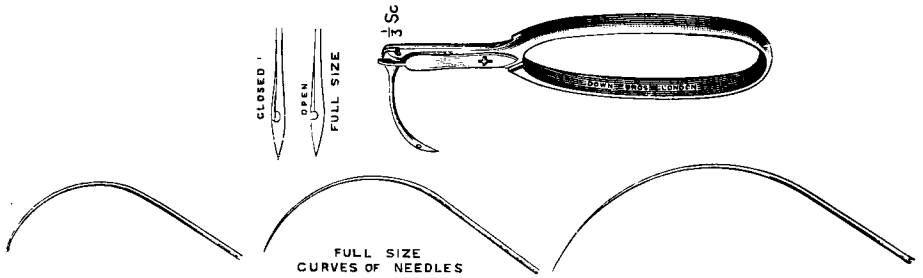


FIG. 222.—Reverdin needle.

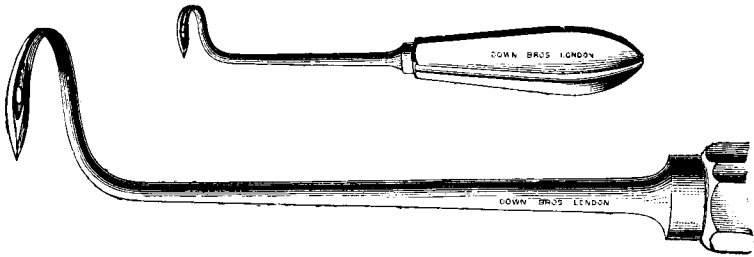


FIG. 223.—Hernia needles.




FIG. 224.—Mitchell's clip.

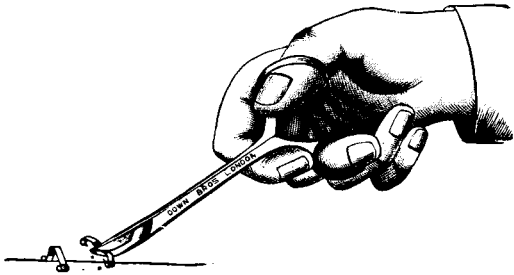


FIG. 225.—Mitchell's clip.

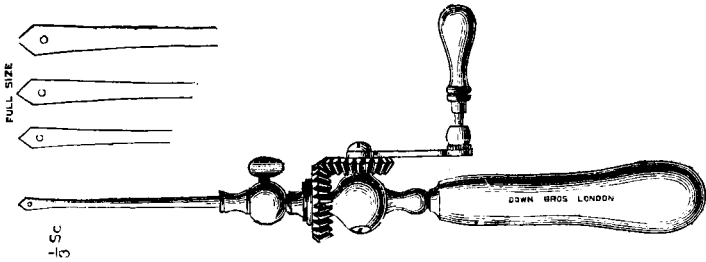


FIG. 226.—Bone drill.

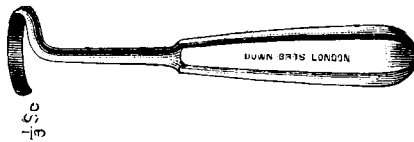


FIG. 227.—Raspatory for ribs.



FIG. 228.—Excision or resection knife.



FIG. 229.—Excision or resection knife.

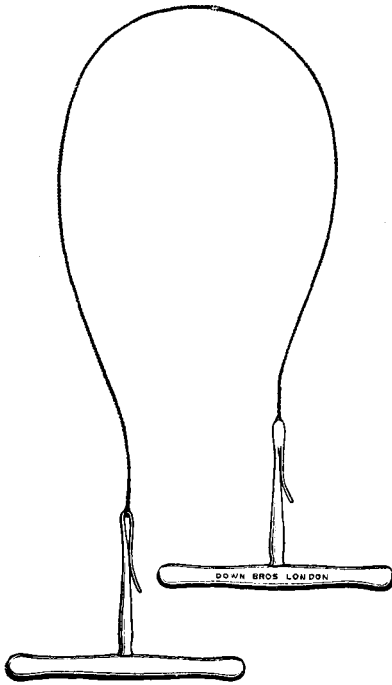


FIG. 230.—Wire or thread saw.

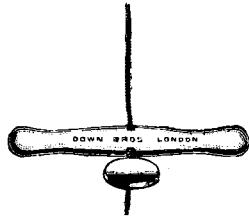


FIG. 231.—Wire or thread saw (third handle).

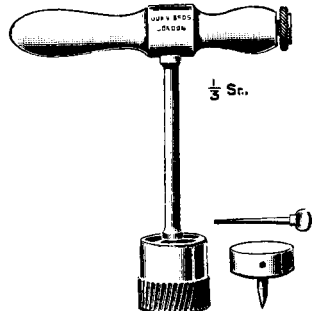


FIG. 232.—Skull trephine.




FIG. 233.—Skull gouge forceps.

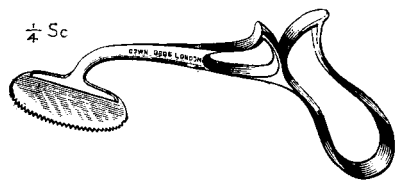


FIG. 234.—Skull saw.

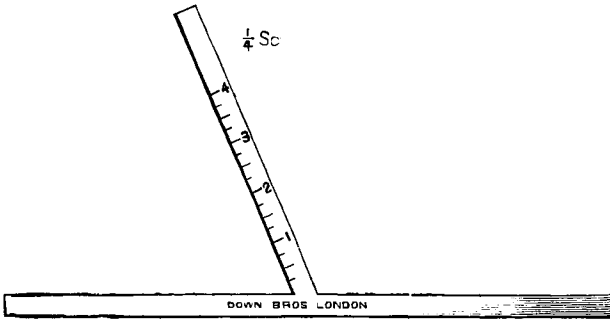


FIG. 235.—Rolandometer.

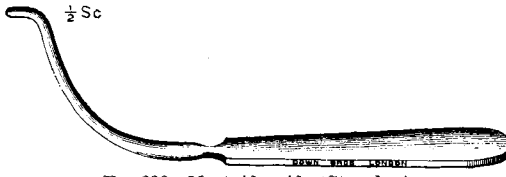


FIG. 236.—Mastoid guide (Staeckes).

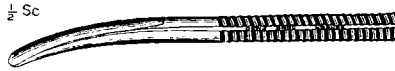

FIG. 237.—Mastoid gouge.



FIG. 238.—Mastoid scoop.

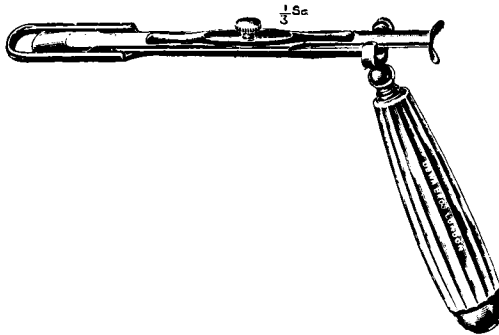


FIG. 239.—Tonsil guillotine.

FIG. 241.

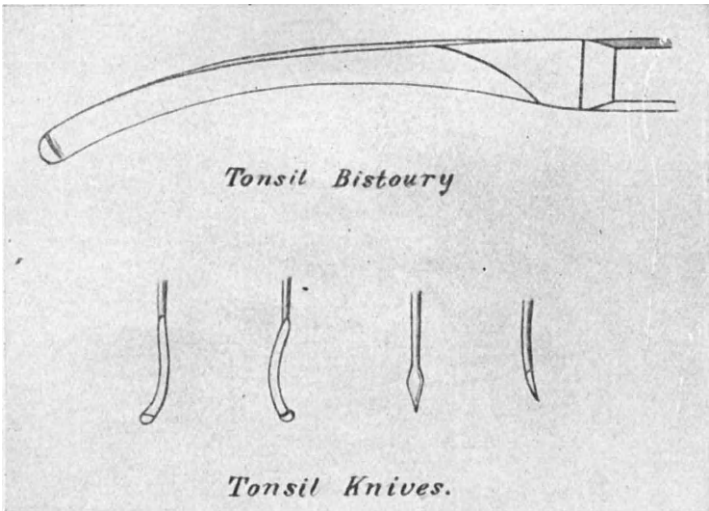


FIG. 240.

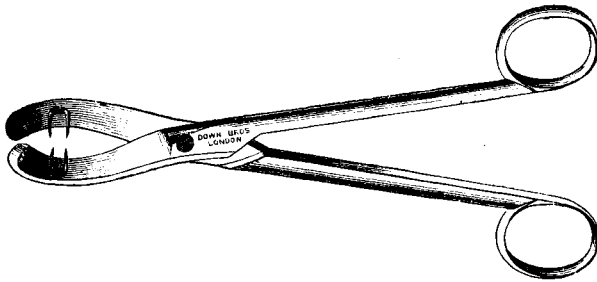


FIG. 242.—Tonsil scissors.

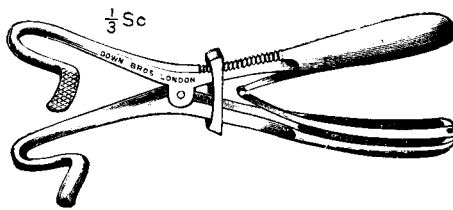


FIG. 243.—Mouth gag.

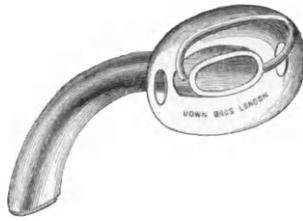


FIG. 244.—Laryngotomy cannula.

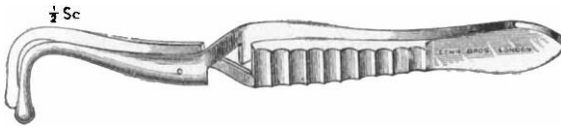


FIG. 245.—Tracheal dilating forceps.

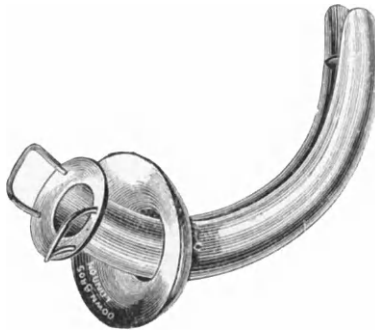

FIG. 246.—Tracheotomy cannula.



FIG. 247.—Sharp hook.



FIG. 248.—Teal's surgical forceps.

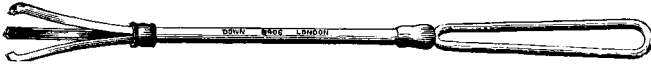

FIG. 249.—Sponge holder.

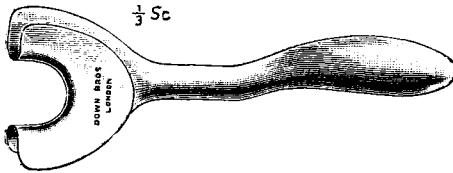


FIG. 250.—Cheek retractor.

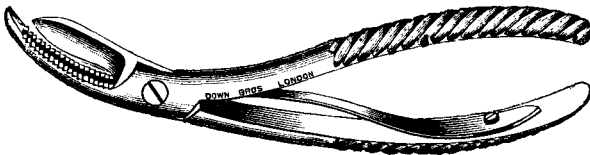


FIG. 251.—Rib shears.



FIG. 252.—Perineal section director.



FIG. 253.—Fistula director



FIG. 254.—Perineal section staff.

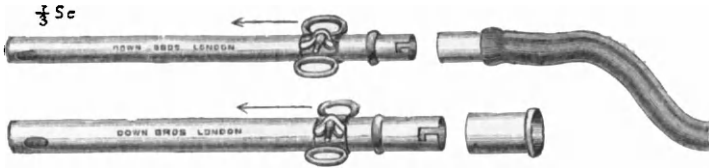


FIG. 255.—Perineal drainage tube.

FIGS. 256.




Lister's Bougie

257.



English gum-elastic Bougie

258.



French gum-elastic Bougie

259.



Acorn-headed Bougie

260.



Miller's Bougie

261.



Filiform Bougie



FIG. 262.—Lithotomy sound

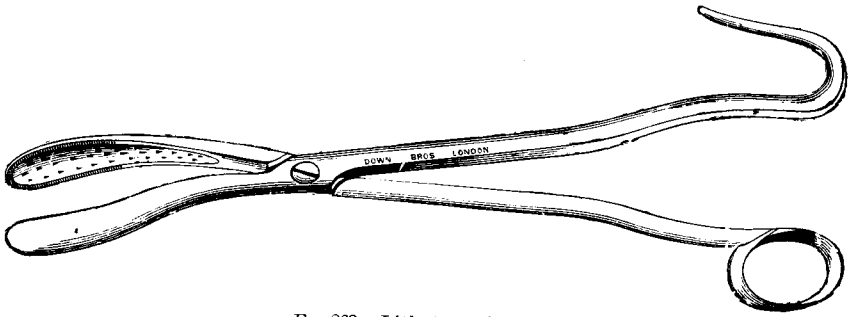


FIG. 263.—Lithotomy forceps.

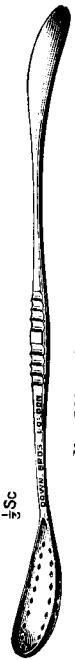


FIG. 264.—Lithotomy scoop.



FIG. 265.—Lithotrite.

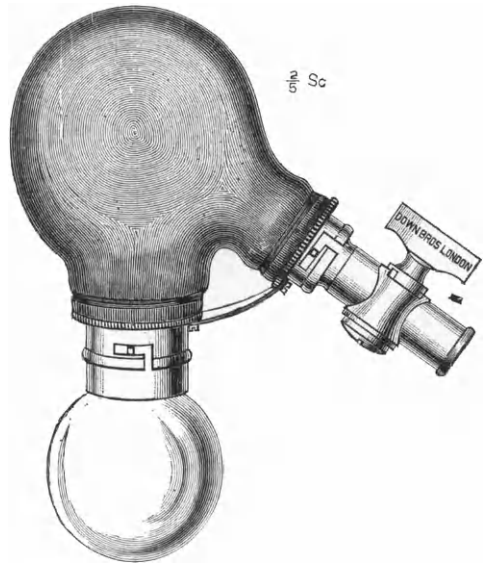
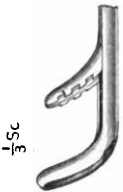


FIG. 266.—Evacuating apparatus litholapaxy.




FIG. 267.—Evacuating catheter and pilot.



FIG. 268.—Tenotomy knife sharp

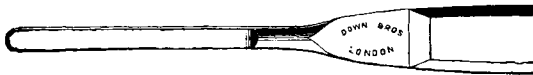

FIG. 269.—Tenotomy knife blunt.



FIG. 270.—Hernia director.

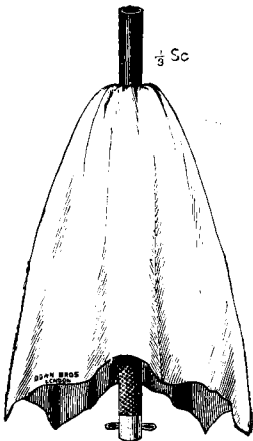


FIG. 271.—Petticoat tube.

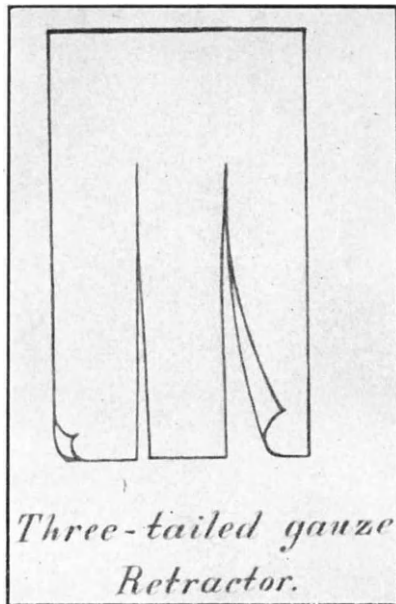


FIG. 272.

INDEX.

A	PAGES	PAGES
Abdomen—		
electro-surgical methods of		
operation ...	384	
Abdominal—		
incisions for Laparotomy ...	252	
instruments ...	252	
intestinal sutures ...	255	
nerves ...	251	
operations ...	250	
paracentesis ...	254	
surgical anatomy ...	250	
vessels ...	251	
wound closure ...	253	
Abdominal and abdomino-		
perineal resection of the		
rectum ...	338	
Abdominal Aorta and the Iliac		
Arteries ...	40	
Abdominal Aorta—		
ligation of ...	41	
Abdomino-perineal Excision of		
the Rectum ...	339	
Abernathy method of Ligation		
of the External Iliac artery	48	
Abscess—		
anorectal ...	328	
inframammary ...	245	
liver ...	316	
mammary ...	245	
premammary ...	245	
retromammary ...	246	
subphrenic ...	265	
Acorn-headed bougie	398	
Acusection ...	381	
Acute Ileus—		
treatment of ...	311	
Acute inflammation of Pancreas	321	
Adenoid—		
curettes ...	394	
punch forceps ...	394	
Advantages and disadvantages		
of amputation in the region		
of the Kneejoint ...	155	
Amputation—		
aperiosteal method ...	101	
at the metatarsophalangeal		
joint ...	127	
at the seat of election (Leg)	146	
Bier method ...	100	
circular method ...	93	
characteristics of good		
amputation ...	103	
Amputation (<i>contd.</i>)—		
Chopart's ...	134	
disarticulation in ...	102	
Dubrueil's ...	114	
elbow ...	116	
elliptical method ...	97	
Faraboeuf ...	135	
fingers and the thumb ...	106	
flap method ...	97	
flaps—classified ...	98	
flap refractors ...	390	
forearm ...	114	
Gritti's ...	150, 154	
hæmorrhage in ...	105	
hand by disarticulation		
through Wrist ...	113	
Hirsch, Bunge method ...	101	
hipjoint ...	158	
indications for ...	91	
instruments for ...	92	
in the region of the		
Kneejoint ...	150	
knife ...	390	
length of the flaps ...	98	
Lisfranc's ...	132	
metacarpals ...	112	
metacarpophalangeal joints	108	
metatarsals ...	130	
metatarsophalangeal joints	127	
methods of ...	92	
modified circular method ...	97	
musculoperiosteal method ...	102	
of the finger ...	72	
of the fingers and thumb,		
together with the meta-		
carpals ...	112	
of the foot ...	131	
of the forearm, at the elbow	116	
of the forearm at the lower		
third ...	114	
of the forearm at the upper		
third ...	115	
of the great toe ...	128	
of the index finger	109, 110	
of the leg ...	141	
of the little finger	109, 110	
of the lower extremity ...	126	
of the other toes ...	129	
of the penis ...	371	
of the penis, indications ...	371	
of the penis, instruments for	371, 387	
of the second phalanx	197, 127	

	PAGES		PAGES
Amputation (<i>contd.</i>)—		Anus—	
of the shoulder joint	... 120	imperforate	... 326
of the terminal phalanx	107, 126	occlusions	... 325
of the thigh	... 156	operations	325, 326
of the thumb	... 109, 110	Aorta abdominal—	
of the toes	... 126, 129	ligation of	... 41
of the upper arm	... 118	Aperiosteal method	of
of the upper extremity	... 106	amputation	... 101
of the wrist	... 113	Appendicectomy	... 300
osteoplastic method (Bier)	100	instruments for	... 387
oval method	... 97	Appendicostomy	... 304
Pirogoff's	... 140	indication	... 304
position	... 92	operation	... 304
preliminary remarks	... 91	Appendix—	
racket method	... 99	instruments for operation of	300
saw	... 390, 410, 411	isolation and delivery of	... 302
skin and muscle flap	... 98	operation of	... 300
skin flap	... 98	removal of	... 302
Stoke's supracondylar	... 154	surface marking of	... 300
supramalleolar	... 142	vermiform—	
Syme's	... 137	surgical anatomy of	... 300
Syme's modification	... 140	Arm—	
tendonoplastic method		methods of removing	... 121
(Wilms)	... 101	Arteries—	
through the hipjoint by		ligation of	9, 15, 40
disarticulation	... 158	chief indications	... 9
through the various joints		general rules	... 12
of the foot	... 132	methods	... 9
trans-condyloid (Carden's)	... 153	operation	... 12
Anal Fissures	... 331	preliminary remarks of	15
Anastomosis intestinal	... 257	of the bladder	... 353
Anatomical terminology	... 400	of the head and neck	... 25
Aneurysm Needle	... 389	of the lower extremity	... 50
Ani-pruritus	... 332	of the upper extremity	... 15
Ankle joint—		Artery forceps	... 389
excision of	... 196	Bryant's	... 390
instruments for excision of	196	compression	... 391
operation of the	... 196	fenestrated	... 391
Anorectal fistula—		for torsion	... 390
classification	... 330	Greig Smith's	... 391
operation	... 331	Spencer-Well's	... 389
Anorectal region—		Arthrotomy—	
abscess	... 323	indications	... 185
surgical anatomy	... 323	of the knee	... 187
operation	... 323	operation	... 185
Anterior branch of the middle		Ascending Colostomy	... 308
meningeal artery	... 26	Ascitis	... 267
Anterior tibial artery—		Astragalus—	
indications for its ligation	57	excision of	... 174
ligation in the lower third		indications for excision of	... 174
of the leg	... 60	operation on	... 174
ligation in the middle third		Atresia ani—	
of the leg	... 60	urethralis	... 327
ligation in the upper third		uterinæ	... 327
of the leg	... 58	vaginalis	... 327
ligation of	... 57	vesicalis	... 327
position of the patient	... 57	Author's operation for ascites	267
surface marking of	... 57	Awls	... 392
surgical anatomy of	... 57		

	PAGES		PAGES
Axilla—		Breast (<i>contd.</i>)—	
clearing of the ...	248	detachment of the ...	248
exposure of the ...	248	electrosurgical method of	
Axillary artery—		operation on the ...	384
collateral circulation ...	20	excision of the ...	246
ligation of the first part ...	18	mammary abscess ...	245
ligation of the third part ...	19	operations on the ...	245
surface marking of ...	18	partial excision of the ...	249
		suppurative mastitis ...	245
		surgical anatomy of ...	245
		Bryant's forceps ...	392
B		Bullet forceps ...	391, 413
Bassini's Operation for		Burrs ...	393
inguinal hernia ...	288	Butcher's saw ...	390
Biceps femoris tendon—			
division of the ...	84	C	
Bier method of amputation ...	100	Cæcostomy ...	308
Bladder—		Carden's transcondyloid	
arteries of ...	353	amputation ...	153
exposure of the ...	355	Cartilages ...	162
cystotomy ...	354	excision and resection of ...	162
cystotomy—median perineal	356	excision of semilunar	
cystotomy—suprapubic ...	354	cartilages of the joint ...	162
lymphatics of ...	353	operations ...	379
mucosa of the ...	352	resection and excision of ...	162
nerves of ...	353	Castration ...	379
opening of the ...	205	indications of ...	379
operation on the ...	203	instruments for ...	387
suprapubic paracentesis ...	353	operations ...	379
surgical anatomy of ...	350	Catgut ...	4
veins of ...	353	Celiotomy ...	250
wound—treatment of the ...	355	Central and sympathetic	
Blanket suture ...	7	nervous system ...	221
Blunt hook ...	389	operations on ...	221
Bone—		Central nervous system—	
drills ...	392	electrosurgical methods of	
excision of ...	165	operation on ...	385
forceps ...	390, 411	Chain ligature ...	12
general remarks ...	165	Cheek retractor ...	397
gouge ...	390, 411	Cholecystectomy ...	318
indications of excision of ...	166	indication of ...	318
instruments for excision of ...	386	operation ...	319
instruments for operation on ...	392	Cholecystendysis ...	318
operations on ...	165	Cholecystenterostomy ...	319
plates ...	392	indications ...	319
suturing instruments for ...	392	Cholecystostomy ...	318
Brachial artery—		instruments for ...	318
ligature of ...	20	Cholecystotomy ...	318
ligature of—at the bend of		Choledochotomy ...	320
elbow ...	21	Chopart's amputation ...	134
ligature of—in the middle of		hæmorrhage in ...	135
arm ...	20	operation ...	134
surface marking of ...	20	position ...	134
Brain and spinal cord—		Chronic intestinal obstruction ...	314
cisterns ...	222	Circular amputation ...	93
instruments ...	393	Circular amputation—modified ...	96
operations on ...	221	Circumcision ...	370
surgical anatomy of ...	221	indications ...	370
Breast—			
abscess mammary ...	245		

	PAGES		PAGES
Circumcision (<i>contd.</i>)—		Common femoral artery (<i>contd.</i>)—	
operation ...	370	ligation of the—at the base	
Cisterns of the brain ...	222	of Scarpa's triangle ...	50
Cleft palate—		ligation of the—in the	
forceps ...	396	Hunter's canal ...	54
instruments for operation of	396	Common iliac artery—	
needles ...	397	collateral circulation after	
Clove hitch ...	14	ligation of ...	43
Coin-catcher ...	396	indications for ligation of ...	41
Collateral circulations after		ligation of ...	41
ligation of the—		operation ...	42, 43
axillary artery ...	20	surface markings of ...	42
common carotid artery ...	28	Congenital deformities of the	
common iliac artery ...	43	rectum ...	325
external carotid artery ...	32	Congenital hydrocele ...	375
external iliac artery ...	49	Continuous blanket suture ...	7
femoral artery—		Continuous subcuticular suture	7
at the apex of the Scarpa's		Continuous suture ...	7
triangle ...	54	Cryptitis rectal ...	327
at the base of the Scarpa's		Cuneiform osteotomy ...	175
triangle ...	52	Cushing suture ...	256
in the Hunter's canal ...	55	Cystotomy ...	354
popliteal artery ...	56	median perineal ...	356
radial artery ...	25	suprapubic ...	354
subclavian artery ...	18	varieties of ...	354
ulnar artery ...	25	Cysts of the pancreas ...	321
Colon—		Czerny-Lembert sutures ...	255
exploration for ...	307		
fixing the ...	307	D	
opening of ...	307	Davy's rectal lever ...	160
Coloplication for megacolon	308	Dean's gouge ...	393
Colostomy ...	306	Decompression ...	228
ascending ...	308	Deformities of the rectum ...	325
iliac ...	306	Deeper structures incision ...	3
indications of ...	306	Detachment of the breast ...	248
inguinal ...	306	De Vilbiss' gouge ...	393
inguinal—operation ...	307	Diaphragmatic hernia ...	297
instruments for ...	387	operation of ...	298
lumbar ...	308	surgical anatomy ...	297
transverse ...	308	Dialthermy cutting ...	381
Common carotid artery—		Dilatation of the urethra by	
collateral circulation after		bougies ...	368
ligature of ...	28	comment on ...	368
indications for ligature of ...	27	operation ...	368
ligature at the site of elec-		position ...	368
tion (above the omohyoid)	28	Dinner knife method of	
ligature (below the omohyoid)	30	holding knife ...	2
ligature of ...	27	Director ...	389, 409
operation ...	28	Disarticulation—	
position ...	28	at the ankle-joint ...	137
surface markings of ...	28	at the knee-joint ...	150
Common femoral artery—		of great toe ...	128
collateral circulation after		of hip-joint ...	160
ligation of ...	52, 54, 55	of index finger ...	110
indications for ligation of		of little finger ...	110
50, 52, 54		of little toe ...	129
ligation of the—at the apex		of the second phalanx ...	127
of Scarpa's triangle ...	52	of the shoulder joint ...	120

	PAGES
Exploratory puncture of the ventricle	229
Exposure of the—	
kidney by the lumbar route	342
nerves of head and neck	67
pancreas	321
External carotid artery—	
collateral circulation after ligation of	32
ligation of	31
operation for ligation of ...	31
position for ligation of ...	31
surface marking of	31
surgical anatomy of	31
External iliac artery—	
collateral circulation	49
comparison of the two methods	49
indications for ligation of ...	47
ligation by extra-peritoneal method	47
ligation by transperitoneal method	49
ligation of	47
ligation of—Abernathy's method	48
ligation of—Cooper's method	48
operation for ligation of ...	48
position	47
surface marking of	47
External Oesophagotomy ...	243
External popliteal nerve—	
operation of	75
surgical anatomy of	74
External Urethrotomy—	
indications of	367
instruments for	387
position	367
with a guide	367
without a guide	367
F	
Facial artery—	
indications for ligation of ...	35
ligation of	35
operation of	35
surgical anatomy of	35
Facial Nerve—	
operation on	69
position	69
protector	393, 416
surgical anatomy of	68
False knot	10
Farabœuf's amputation—	
of the leg (at the seat of election)	146
do. comment on	148
do. operation	146

	PAGES
Farabœuf's amputation (<i>contd.</i>)—	
do. position	146
Subastragaloid disarticulation	
of the foot	135
do. comment on	137
do. operation	136
do. position	136
Femoral artery—	
collateral circulations	52, 54, 55
comments	52, 54, 55
indications	50, 52, 54
ligation of the—	
at the apex of Scarpa's triangle	52
at the base of Scarpa's triangle	50
in the Hunter's canal ...	54
operations	52, 53, 54
positions	51, 52, 54
surface marking of	50
surgical anatomy of	50
Femoral hernia	296
indications for operation of	296
instruments for operation of	296
operation of	296
surgical anatomy of	296
Femoral trigone	50
Femur—	
sawing of	200
Fenestrated artery forceps ...	321
Filiform bougie	398
Fissures anal	331
Fistula—	
director	398
in ano	330
needles	391
Foot—	
amputation of	131
amputation through various joints	132
general consideration of ...	130
surgical anatomy of	130
Forceps—	
artery	389
bone	390, 411
bone gouge	390, 411
bone holding	392
Bryant's	390
bullet	391, 413
compression	391, 412
fenestrated	391
gouge	390, 393, 412, 415
Greig Smith's	391
Jordan Lloyd's	391
Kocher's	391
lion	390, 412
pedicle	391
Rutherford Morison's	391
Spencer-Well's	389

	PAGES
Forceps (<i>contd.</i>)—	
tissue ...	391, 412
torsion ...	390
tracheal dilating ...	395
Forearm—	
amputation of the ...	114
do. lower third ...	114
do. upper third ...	115
comment on amputation of ...	115, 116
operation ...	114, 115
position ...	114, 115
Fractures—	
indications for operation of ...	179
operation of ...	179
Frank and Albert's gastrostomy ...	271
Freyer's prostatectomy ...	362
Friction knot ...	11
Funicular Process—	
hydrocele of the ...	375
Furneau Jordan's method of removing the arm ...	121
Furneau Jordan's operation of the hip ...	159
G	
Gall bladder—	
exposure of ...	317
operations on ...	317
do. instruments for ...	387
surgical anatomy of ...	315
Gallie's operation for hernia ...	294
Gastrectomy ...	284
Gastro-duodenostomy ...	274
Gastro-enterostomy ...	274
do. indications for ...	274
Gastro-jejunostomy ...	274
do. posterior ...	275
Gastroplasty ...	284
Gastrostomy ...	271
Frank and Albert's method ...	271
indications of ...	271
several methods of ...	271
Gastrotomy ...	270
General instruments ...	389
General principles ...	1
Genito-urinary tracts—	
operations on the ...	341, 350, 365
do. by electrosurgical method ...	384
Gouge ...	400
bone ...	390, 411
forceps ...	390, 393, 412, 415
Dean's ...	393
De Vilbiss' ...	393
Doyen's ...	393
Hoffman's ...	393
Gouges ...	393, 411, 415

	PAGES
Granny Knot ...	10
Great toe—	
amputations of ...	128
do. the terminal phalanx ...	126
comment ...	128
disarticulation of ...	128, 230
operation ...	128
Grid-iron incision ...	300
Gritti's amputation ...	154
Guillotines—tonsil ...	394, 416
Gum elastic bougie ...	398
Gut—	
resection of ...	259
Guyon's supramalleolar amputation ...	143

H

Hæmorrhage—	
in amputation ...	105
of middle meningeal artery—	
operation for ...	228
plugs for ...	394
Hæmorrhoids—	
author's modification of Mitchell's operation ...	333
clamp and cautery method ...	335
contraindications for operation ...	332
excision and suture ...	333
excision of the pile-bearing area ...	333
indications for operation ...	332
injection treatment for ...	335
instruments for operation of ligature and excision of ...	333
Mitchell's operation ...	333
position ...	332
preparation ...	332
varieties ...	332
various methods of operation Whitehead's operation ...	333
Halstead operation for hernia ...	292
Halstead suture ...	256
Hamstring tendons—	
comment ...	84
indications of tenotomy ...	84
surgical anatomy of ...	84
Hare-lip pins ...	396
Head and neck—	
arteries of the ...	25
Heart and the pericardium ...	234
wounds of the ...	234
Hernia ...	286
Author's modification of Bassini-Halstead method ...	292
Bassini's method of operation ...	288

	PAGES		PAGES
Hernia (<i>contd.</i>)—		Hydrocele (<i>contd.</i>)—	
classification of ...	287	tapping a ...	375
diaphragmatic ...	297	Hypospadias ...	368
director ...	399	varieties of ...	369
femoral ...	296		
Halstead's operation of ...	292	I	
indications for operation of ...	287	Iliac artery external—	
inguinal ...	288	ligation of ...	47
internal ...	298	Iliac colostomy ...	306
Kocher's method ...	292	comments for ...	307
lumbar ...	296	operation of ...	307
Macewen's method ...	292	Incisions—	
needle ...	399	for deeper parts ...	3
obturator ...	298	for skin ...	3
other operations of ...	294	Furneau Jordan's ...	121
perineal and pudendal ...	298	gridiron ...	300
sciatic ...	298	Incisions for laparotomy—	
umbilical ...	295	comment on ...	253
ventral ...	295	iliac ...	252
Willys Andrew's operation ...	294	lumbar ...	253
Hernial sac ...	287	median ...	252
excision of ...	290	oblique ...	252
isolation of ...	290	oblique subcostal ...	252
Herniotomy—		paramedian ...	252
instruments for ...	387, 399	pararectal ...	252
Hernioplasty ...	288	Pfannenstiel ...	253
Hey's saw ...	393, 415	Index ...	423
High tracheotomy ...	212	Index finger—	
Hip-joint—		amputation of ...	109, 110
amputation through ...	158	Indications for—	
disarticulation of ...	160	amputations ...	91
excision of ...	201	amputation of the penis ...	370
Furneau Jordan's operation ...	159	arthrotomy ...	185
general consideration of ...	158	castration ...	379
indication for operation of ...	201	circumcision ...	370
landmarks of ...	200	colostomy ...	306
operation on ...	200	excision of astragalus ...	174
osteoarthritis of ...	202	excision of bones ...	165
other operations on ...	202	excision of joints ...	187
position for operation of ...	201	excision of lower jaw ...	169
various methods of dis-		exposure of nerves ...	67, 73, 74
articulation of ...	158	intestinal anastomosis ...	257
Horse-hair ...	5	ligation ...	16
Horsley's saw ...	393	ligation of anterior tibial	
Hüter incision ...	191	artery ...	57
Hydrocele—		ligation of common iliac	
Bergmann's operation ...	376	artery ...	41
Chatterji's operation ...	377	ligation of external iliac	
congenital ...	375	artery ...	47
eversion of the sac ...	377	ligation of dorsalis pedis	
excision of the sac ...	376	artery ...	61
indications for operation of ...	376	ligation of femoral artery ...	50
infantile ...	375	ligation of internal carotid	
instruments for operation of ...	387	artery ...	31
Jaboulay's operation ...	377	ligation of internal iliac	
of the funicular process ...	375	artery ...	43
operations for the cure of ...	376	ligation of internal mam-	
plication and overlapping of		mary artery ...	37
the sac (Chatterji) ...	377		

PAGES	PAGES
Indications for (<i>contd.</i>)—	
ligation of lingual artery	33
ligation of occipital artery	36
ligation of popliteal artery	55
ligation of posterior tibial artery	61
ligation of temporal artery	36
ligation of vertebral artery	37
litholapaxy	359
low tracheotomy	216
operation for varicocele	379
operations on fractures	176
operative interference of liver abscess	316
osteotomy	174
pharyngotomy	206
resection of ribs	171
sequestrotomy	177
suprapubic lithotomy	358
tenotomy	81
tenotomy of hamstring tendons	84
tenotomy of peronei tendons	84
tenotomy of sternomastoid	85
tenotomy of tendo Achillis	82
tenotomy of tibialis anticus	83
tenotomy of tibialis posticus	83
thyroidectomy	219
tracheotomy	211
Infantile hydrocele	375
Inferior thyroid artery—	
ligation of	32
Inflammation of pancreas	321
Infraorbital nerve—	
operation on	68
surgical anatomy of	68
Inguinal canal—	
surgical anatomy of	288
Inguinal colostomy	306
Inguinal Hernia	288
author's modification of	
Bassini-Halstead method	292
Bassini's method	288
Gallies method	294
Halstead method	292
Kocher's method	292
Macewen's operation	292
other operations	294
Willys Andrew's method	294
Injuries of the thorax	234
Instruments—	
for operations—selection of	386
for most operation	386
for operations on bones	392
for special operations	390
for suturing	391
recognition and use of	389
Intercostal artery—	
ligation of	38
Interlocking ligature	12
Internal carotid artery—	
indications for ligation	31
ligation of	31
operation	31
surgical anatomy of	30
Internal hernia	298
operation of	299
Internal iliac artery—	
branches of	43
indications for ligation of	43
ligation of	43
operation of	43
Internal-mammary artery—	
indications for ligation of	37
ligation of	37
surgical anatomy of	37
Internal urethrotomy	366
contra-indications	366
indications	366
instruments for	387
methods	366
Interrupted suture	6
Intestinal anastomosis—	
by artificial appliances	260
comment	260
end to end	258
end to side	260
endo-lateral	260
indications of	257
lateral	257
lateral—advantages of	260
termino-lateral junction	260
Intestinal obstruction	309
chronic	314
surgical anatomy	309
Intestinal Operations—	
instruments for	387
Intestinal Sutures	255
Cushing	256
Czerny lembert	255
Dupuytren	256
Halstead	256
pursestring	256
Lembert	255
Intestine small	285
hernias	286
surgical anatomy	285
Intracranial suppuration	229
Intra-mammary abscess	245
Intussusception	313
Ischio-rectal abscess	329
J	
Jaws—	
excision of the	166

	PAGES		PAGES
Jaws (<i>contd.</i>)—		Knot (<i>contd.</i>)—	
instruments for excision of		false knot ...	10
the ...	386	friction knot ...	11
Jejunum—		granny knot ...	10
exposure of the ...	275	interlocking ligature ...	12
posterior gastrojejunostomy	275	reef knot ...	10
Joints—		square knot ...	10
excision of ...	187	Staffordshire knot ...	11
indications for the excision of	187	surgeon's knot ...	11
instruments for excision of	386	transfixing ligature ...	11
operation on ...	184	true knot ...	11
Jordan Lloyd's forceps ...	391	Kocher's excision of the wrist	188
		Kocher's—forceps ...	391
		Kocher's incision (Gall bladder)	317
		Kocher's operation for inguinal	
		hernia ...	292
		Kraske's operation (Rectum)	337
K		L	
Kangaroo-tendon ...	5	Laminectomy—	
Kidney—		chisels ...	394
delivery of the ...	343	instruments for ...	231, 393
exploration of the ...	343	rasps ...	394
exposure of the—by the		saws ...	394
lumbar route ...	342	Laminectomy and Osteoplastic	
nephrectomy ...	346	resection of vertebral arch	231
nephrolithotomy ...	345	indication ...	231
nephropexy ...	343	instruments for ...	231, 393
nephrostomy ...	345	operation ...	231
nephrotomy ...	343	position ...	231
operation ...	343	Landmarks and surgical ana-	
operation on—instruments		tomy of hip-joint ...	200
required in ...	341, 387	Lane's needle-holders ...	397
pyelolithotomy ...	345	Lane's plates ...	179
pyelotomy ...	343	Langenbeck's incision ...	191
surgical anatomy of ...	341	Laparotomy ...	250
Kinks (adhesions, bands) ...	314	comment ...	253
Knee-joint—		iliac incision ...	252
amputations in the region of	150	lumbar incision ...	253
arthrotomy of the ...	187	median incision ...	252
Carden's transcondyloid		muscle splitting ...	252
amputation of the ...	153	oblique subcostal ...	252
excision of ...	197	paramedian incision ...	252
excision—comment ...	200	pararectal incision ...	252
excision—instruments ...	197	Pflanzenstiel incision ...	253
excision—operations ...	198	Large intestine—	
excision—position ...	197	colostomy ...	306
excision—surgical anatomy	197	operations ...	305
general considerations re-		surgical anatomy ...	305
garding disarticulations		Laryngeal growth—	
and amputations at the		instruments for ...	395
knee ...	149	Laryngeal obstruction—	
Gritti's supracondyloid ...	154	instruments for ...	395
Lister's transcondyloid ...	153	Laryngo-fissure ...	208
methods of amputation ...	150	Laryngotomy ...	208
Stephen Smith's disarticula-		comment ...	210
tion ...	150	cannulae ...	395, 418
Stoke's supracondyloid ...	154	indication ...	209
surgical anatomy of ...	148		
Knife—			
its manipulations ...	2		
Knot—			
chain ligature ...	12		

	PAGES
Laryngotomy (<i>contd.</i>)—	
instruments ...	209, 386
operation ...	209
position ...	209
Laryngo-tracheotomy ...	208
Larynx—	
instruments for operation of	394
Leg—	
amputation of ...	141
do. at the seat of elec- tion ...	146
do. Farabœuf's ...	146
do. Guyon's supramal- leolar ...	143
do. through lower third of leg by long anterior and short posterior flaps ...	143
do. do. by short ante- rior and long posterior flaps	144
do. through middle of leg by ante- roposterior flaps	145
do. tibiofemoral osteo- plastic ...	145
do. upper third of the leg by bilateral flaps ...	148
general considerations for amputation ...	141
surgical anatomy of ...	141
Lembert sutures ...	255
Ligament—	
Lisfranc's ...	134
Ligation—	
general rules of ...	12
indications for ...	9, 16
instruments for ...	386, 389
methods ...	9
of anterior tibial artery ...	57
of aorta ...	41
of arteries ...	9, 15, 40
do. —in the head and neck ...	25
do. —in the leg, lower third of ...	60
do. —in the leg, middle third of ...	60
do. —in the leg, upper third of ...	58
do. —preliminary remarks	15
of axillary artery ...	18
operation of the first part	18
operation of the third part	19
of brachial artery ...	20
operation at the cubital fossa ...	21

	PAGES
Ligation (<i>contd.</i>)—	
operation in the middle of the arm ...	29
of common carotid artery ...	27
above the omohyoid ...	28
at the site of election ...	28
below the omohyoid ...	30
of common iliac artery ...	41
by extraperitoneal method	42
by transperitoneal method	43
of dorsalis pedis artery ...	61
of external carotid artery ...	31
at the site of election ...	31
of external iliac artery ...	47
Abernathy's method ...	48
comparison of two methods	49
Cooper's method ...	48
extraperitoneal method ...	47
transperitoneal method ...	49
of external mammary artery ...	35
of facial artery ...	35
of femoral artery—	
at the apex of Scarpa's triangle ...	52
at the base of Scarpa's triangle ...	50
in the Hunter's canal ...	54
of hypogastric artery ...	43
of iliac artery ...	41
of inferior thyreoid artery ...	32
of intercostal artery ...	38
of internal carotid artery ...	30
of internal iliac artery ...	43
gluteal branch of ...	46
pudendal branch of ...	46
sciatic branch of ...	44
of internal mammary artery ...	37
of lingual artery ...	33
at its origin ...	33
at the site of election ...	33
of middle meningeal artery ...	25
of occipital artery ...	36
of popliteal artery ...	55
in its lower part ...	56
in its upper part ...	56
in the popliteal space ...	56
on the inner side of thigh	56
of posterior tibial artery ...	61
at the lower third of leg ...	64
behind the internal mal- leolus ...	65
in the middle of the calf ...	64
of radial artery ...	21
of subclavian artery ...	17
of temporal artery ...	36
of ulnar artery ...	24
of vertebral artery ...	37
Ligatures (<i>see</i> Knot) ...	9
and sutures ...	9

	PAGES		PAGES
Ligatures (<i>contd.</i>)—		Lord Lister's method—	
chain ...	12	operation on patella ...	183
interlocking ...	12	Lower Jaw—	
transfixing ...	11	comment ...	171
Ligature and sutures ...	3	excision of ...	169
catgut ...	4	excision on one half of ...	169
horsehair ...	5	indication of operation for ...	169
metallic wire suture ...	5	instruments for ...	169
Pagenstecher's thread ...	5	operation of ...	169
silk ...	4	position in operation of ...	169
silkwork gut ...	5	Lower extremity—	
Linear osteotomy ...	175	amputations of ...	126
Lingual artery—		arteries of the ...	50
comment ...	35	excision of ...	196
indications ...	33	Low tracheotomy ...	215
ligation of the ...	33	indications of ...	216
at its origin ...	33	Lumbar colostomy ...	308
at the site of election ...	33	Lumbar hernia ...	296
beneath the hyoglossus ...	33	Lumbar puncture ...	230
operation for ...	34	Lungs ...	235
position for ...	33		
surgical anatomy of ...	33	M	
Lion forceps ...	390, 412	Macewen's operation for hernia ...	292
Lisfranc's amputation ...	133	Macewen's osteotomy ...	176
hæmostasis in ...	134	Main trunk of the middle	
Lisfranc's disarticulation ...	132	meningeal artery ...	27
operation ...	132	Mammary abscess ...	245
position ...	132	Mandible—	
surgical anatomy ...	132	excision of ...	169
Lisfranc's ligament ...	134	Manipulations of knife ...	2
Lister's bougie ...	398, 420	Mastitis suppurative ...	245
Lister's transcondyloid am-		Mastoid—	
putation ...	153	gouges ...	393, 416
Litholapaxy—		guide ...	393, 416
indications of ...	359	instruments for operation ...	393
instruments for ...	387	ossicle hooks ...	394
operation ...	360	probes ...	393
Lithotomy—		retractors ...	393
forceps ...	398, 421	scoops ...	393, 416
scoops ...	398, 421	Mattress suture ...	8
suprapubic ...	358	Maxilla—	
Lithotrite ...	398, 421	extraction of ...	166
Little finger—		McBurney's—	
amputation of the ...	109, 110	muscle splitting method ...	300
Little toe—		point ...	300
amputation of the ...	129	Meatotomy ...	365
disarticulation of ...	129, 130	Median nerve—	
operation on ...	129	exposure of ...	73
Liver—		Median perineal cystotomy ...	356
abscesses of ...	316	Megacolon—	
cysts of ...	317	coloplication for ...	308
operations on ...	316	Mesentery—	
surgical anatomy of ...	315	operation on ...	267
wound of ...	316	Mesoappendix—	
Liver and gall bladder—		section of ...	302
operations on ...	315	surgical anatomy of ...	300
Lockhart Mummery's operation		Mesocolic aperture—	
(æctum) ...	337	closure of ...	278

	PAGES
Metacarpals ...	112
Metacarpophalangeal joints 108, 109, 110, 111	
Metallic clip suture—	
Mitchell's ...	8
Metallic sutures ...	8
Metallic wire sutures ...	5
Metatarsals ...	130
Metatarsophalangeal joints—	
amputation at the	127, 128, 129
Methods of amputation ...	92
Methods of removing	
the arm ...	118, 121
Methods of suturing wound ...	6
continuous ...	7
continuous blanket ...	7
continuous subcuticular ...	7
interrupted ...	6
metallic ...	8
relaxation ...	8
tension ...	8
Middle meningeal artery—	
anterior branch of ...	26
comment on operation of ...	27
hæmorrhage—operation in ...	228
indications of ...	25
instruments for operation of	27, 386
ligation of ...	25
main trunk of ...	27
operation for ligation of ...	27
position of ...	26
posterior branch of ...	27
surface marking of ...	26
surgical anatomy of ...	25
Miller's bougie	398, 420
Mitchell's clip	392, 413, 414
Mitchell's metallic suture ...	8
Modified circular amputation	96, 118
Mouth—	
gag ...	395, 417
instruments for operation on	396
Mucosa of the bladder ...	352
Murphy's button	256, 260, 261
Muscle—	
lengthening ...	86
indication of ...	86
operation for ...	88
myectomy ...	86
myoplasty ...	86
myorrhaphy ...	86
myotomy ...	86
operations on ...	86
slide operations ...	89
splitting incision ...	252
Musculospiral nerve—	
exposure of ...	74

	PAGES
Nasal septum forceps ...	394
Neck—	
operations in the middle	
line of ...	203
surgical anatomy of ...	203
Needles—	
aneurysm ...	389, 409
bayonet shaped ...	391
Doyen's ...	391
fistula ...	391
handled ...	391, 413
hernia ...	391, 413
holders ...	391
in handles ...	391
intestinal ...	391
Reverdin's ...	391, 413
scalp ...	391
skin suture ...	391
spring eyed ...	391
wiring bone ...	392
Nelaton's incision ...	191
Neoplasm of pancreas ...	322
Neoplasm of rectum—operation	
for ...	340
Nephrectomy ...	346
Nephrolithotomy ...	345
Nephropexy ...	343
Nephrostomy ...	345
Nephrotomy ...	343
Nerves—	
avulsion ...	67
exposure in head and neck	67
external popliteal—	
surgical anatomy of ...	74
external popliteal—operation	
on (common peroneal) ...	75
facial—operation on ...	68
gassarian ganglion—	
injection of the ...	70
grafting ...	67
indication for exposure ...	66
infraorbital—operation on	68
median—exposure of ...	73
musculo-spiral, exposure of	74
of the abdomen ...	251
of the lower extremity—	
exposure of ...	74
of the upper extremity—	
exposure of ...	73
operation on ...	66
Phrenic—	
avulsion ...	71
comments on operations of	73
exeresis ...	71
operations on—	
in pulmonary tuber-	
culosis ...	71
surgical anatomy of ...	71

	PAGES		PAGES
Nerves (contd.)—		Operations (contd.)—	
phrenicectomy radical ...	71	on breast ...	245
posterior root—division ...	232	on cartilage ...	162
sciatic, operation on ...	74	on central and sympathetic nervous systems ...	221
sciatic, surgical anatomy of ...	74	on joints ...	184
spinal accessory, operation on ...	69	on liver and gall bladder ...	315
supra-orbital—operation on ...	67	on œsophagus ...	243
trigeminal neuralgia ...	70	on spinal accessory nerve ...	69
ulnar—exposure of ...	73	on stomach ...	269
Neurectasy ...	66	on supraorbital nerve ...	67
Neurectomy ...	66, 232	on sympathetic nervous system ...	232
Neurolysis ...	66	on the bladder ...	354, 355, 357
Neuroplasty ...	66	on the genito-urinary tract ...	341, 350, 365
Neurorrhaphy ...	66	on the hip-joint ...	200
Neurotomy ...	66	other operations ...	202
Nose—		on the large intestine ...	305
instruments for—operation of ...	394	on the mesentery ...	267
O			
Obstruction—of intestines ...	309	on the muscles ...	86
Obturator hernia ...	298	on the nerves ...	66
Occipital artery—		on the omentum ...	267
indications for ligation of ...	36	on the pancreas and spleen ...	321
ligation of ...	36	on the rectum and anus ...	324
operation of ...	36	on the skull instruments for ...	386
surgical anatomy of ...	36	on the small intestine ...	285
Œsophageal forceps ...	396	on the spine and spinal cord ...	230
Œsophagotomes ...	396	on the stomach ...	269
Œsophagotomy external ...	243	on the tendons ...	76
Œsophagus—		on the urogenital tract ...	341
instruments for operations on the ...	394	responsibilities of ...	1
operations on the ...	243	to bring to successful issue ...	1
surgical approach to the ...	243	Operative treatment of—	
Omentum—operations on ...	267	neoplasm of rectum ...	340
Open tenotomy—instruments for ...	388	Operator—qualifications of ...	1
Operations—		Osteoarthritis of hip-joint ...	202
abdominal ...	250	Osteoplastic resection of skull ...	227
assistant—qualification of ...	1	Wagner's ...	227
electrosurgical method of ...	381	vertebral arch ...	231
for exposure of the kidney ...	342	Osteotomy—	
for fractures ...	179	cuneiform ...	175
for hæmorrhage from venous sinuses ...	228	indications for ...	174
for intracranial suppuration ...	229	instruments for ...	174
for middle meningeal hæmorrhage ...	228	linear ...	175
for prolapse of rectum ...	335	open method ...	175
for stricture of rectum ...	336	operation ...	174
for traumatic epilepsy ...	228	subcutaneous method ...	175
for varicocele ...	379	supracondyloid—	
in the middle line of the neck ...	203	indications ...	176
on appendix ...	300	operation ...	177
on bones ...	165	position ...	176
on bones, instruments for ...	392	Osteotribes ...	393
on brain and spinal cord ...	221		
		P	
		Pagenstecher's thread ...	5
		Palate—division of ...	167

PAGES	PAGES
Pancreas—	Peritoneum—
acute inflammation of ... 321	acute peritonitis ... 263
cysts of the ... 321	amoebic peritonitis ... 265
exposure of ... 321	chronic peritonitis ... 263
neoplasm of ... 322	chronic adhesive peritonitis ... 263
operation on ... 321	general considerations of ... 262
wound of the ... 321	surgical anatomy of ... 262
Paracentesis—	tubercular peritonitis ... 264
abdominis ... 254	Peronei tendons—
bladder—suprapubic ... 353	indications of tenotomy of ... 84
for peritoneal effusion ... 254	operations of ... 85
instruments for ... 386	surgical anatomy of ... 84
pericardii ... 241	Petticoat tube ... 399, 422
Partial excision of the breast ... 249	Phalanges ... 126
Patella—	Pharyngotomy ... 206
Barker's fixation by sub-	comments ... 207
cutaneous method ... 179	indications of ... 206
instruments ... 181	infrahyoid ... 207
Lord Lister's method of	instruments for ... 207, 395
operation (classical) ... 183	operation ... 207
position ... 181	position ... 207
silk suture ... 180	subhyoid ... 207
suturing by open method ... 180	suprahyoid ... 207
suturing by Stimson's method ... 180	Pharynx—
suture of the capsule ... 180	instruments for operation
suturing the ... 179	of the ... 394
suturing, Valas' method ... 180	Phrenic avulsion ... 236
Paul's tube ... 256	Pile Clamps ... 399
Pelvi-rectal abscess ... 330	Piles ... 332
Penholder method of holding	instruments for operations of
knife ... 2	operation for—instruments
Penis—	required in ... 387
amputation of ... 371	Pirogoff's amputation ... 140
author's modification of ... 372	Pneumothorax artificial ... 235
circumcision of ... 370	comment ... 236
complete amputation of ... 374	contraindications ... 235
Gonld's method of amputa-	indications ... 235
tion ... 374	operations ... 235
indication of ... 370	Polypi—
operation of ... 370	forceps ... 394
partial amputation of ... 371	snare ... 394
surgical anatomy of ... 370	Popliteal artery—
Peri-anal abscess ... 328	collateral circulation after
Peri-arterial sympathectomy ... 232	ligation of ... 56
Pericardium and the heart ... 234	indications of ligation ... 55
Pericardiotomy ... 242	ligation in its inner side
operation ... 242	of the thigh ... 56
Pericardii—paracentesis ... 241	ligation in its lower part ... 56
indication of ... 241	ligation in its upper part ... 56
operation ... 241	ligation in the popliteal space
position in ... 241	of ... 55
sites of puncture ... 241	surgical anatomy of ... 55
Perineal cystotomy median ... 356	Posterior branches of the
Perineal drainage tube ... 420	middle meningeal artery ... 27
Perineal hernia ... 298	Posterior tibial artery—
Perineal resection of rectum ... 337	indications for ligation of ... 61
Periosteal elevator ... 390, 410	ligation at the lower third
Peri-rectal abscesses ... 329	of the leg ... 64

	PAGES		PAGES
Posterior tibial artery (<i>contd.</i>)—		Radial artery (<i>contd.</i>)—	
ligation behind the internal		ligation of ...	21
malleolus ...	65	position ...	21
ligation in the middle of the		surface marking of ...	22
calf ...	64	surgical anatomy of ...	16
ligation of ...	61	Raspatories ...	392, 410, 414
relation near the internal		Rectal cryptitis ...	327
malleolus (comment) ...	65	Rectum—	
surface marking of ...	63	abdominal and abdomino-	
surgical anatomy of ...	62	perineal resections of ...	338
Posterior nerve root division ...	232	abdomino-perineal excision	
Postural method ...	105	of ...	339
Preliminary remarks for opera-		and anus—operation on ...	324
tions (general principles) ...	1	congenital deformities of ...	325
Premammary abscess ...	245	examinations of ...	325
Principles general ...	1	excision of the ...	337
Probangs ...	396	neoplasm of—operative treat-	
Probe gorget ...	397, 419	ment of ...	340
Prolapse rectum, operation ...	335	perineal resection of ...	337
Prostatectomy ...	361	proctotomy ...	336
combined perineal and		prolapse of—operations on	335
suprapubic ...	362	sigmoido-rectostomy ...	337
Freyer's ...	362	stricture of—operations for	336
instruments for ...	361, 387	surgical anatomy of ...	324
Macgill's ...	362	trans-sacral resection of ...	337
partial suprapubic	362	Recognition and use of instru-	
suprapubic ...	362	ments ...	389
varieties of ...	362	Reef Knot ...	10
Young's perineal	363	Resection—	
Prostate gland—		knives ...	392, 414
surgical anatomy of ...	360	of cartilages ...	162
Prostatic capsule ...	361	of ribs ...	171
Prostatic sheath ...	361	indications of ...	171
Pruritus ani ...	332	instruments for ...	386
Pudendal hernia ...	298	operations ...	172
Pulmonary tuberculosis—		positions ...	172
surgical treatment of ...	235	of skull—osteoplastic—	
Purse-string suture ...	256	Wagner's ...	227
Pyelotomy ...	343	Retractors—	
Pyelolithotomy ...	345	amputation flap ...	390, 410
Pylorectomy ...	278	wound ...	389, 412
indication ...	279	Retroduodenal choledochotomy ...	320
operation ...	279	Retromammary abscess ...	246
Pyloplasty ...	284	Retzius space ...	351
		Reverdin's needle ...	391
R		Ribs—	
Racket method of amputation ...	99	excision of ...	171
Radial artery—		indications of resection of ...	171
collateral circulation ...	25	instruments for resection of	386
ligation at the back of wrist	22	operations on ...	172
ligation in the lower third of		position ...	172
the forearm ...	22	shears ...	397, 419
ligation in the middle of the		Rolandometer ...	393, 416
forearm ...	22	Rougine ...	390, 410
ligation in the tabatiere		Rutherford Morison forceps ...	391
anatomique ...	22		
ligation in the upper third		S	
of the forearm ...	22	Saw—	
		amputation ...	390, 410

	PAGES
Saw (<i>contd.</i>)—	
butcher's ...	390, 411
metacarpal and metatarsal ...	390
thread ...	392, 397, 415
Scalp—surgical anatomy ...	221
Scalpel ...	389
Sciatic hernia ...	298
Sciatic nerve—	
exposure of ...	74
operation ...	74
position ...	74
surgical anatomy of ...	74
Scissors ...	389
angular ...	397
Scrotum—	
surgical anatomy of ...	374
Second phalanx—	
amputation of ...	127
disarticulation of ...	127
Selection of instruments for operations ...	386
Semilunar Cartilage of the knee joint—	
comment ...	164
excision of ...	162
indications for operation ...	163
operation ...	163
position of the patient ...	163
Seminal vesicles ...	361
Sequestrectomy ...	177
Sequestrotomy ...	177
comment ...	178
indications ...	177
instruments for operation ...	178
Sequestrum—	
removal of ...	177, 178
Sharp hook ...	396, 418
Shoulder-joint—	
disarticulation of ...	120, 121
excision of ...	194
comment ...	196
indication ...	194
instruments for operation ...	195
operation ...	195
position ...	195
surgical anatomy ...	194
operation ...	121
position ...	121
Spence's anterior racket method ...	121
surgical anatomy of ...	120
Silk ...	4
Silkworm gut ...	5
Skin incisions ...	3
electrosurgical methods of ...	382
Skull—	
Wagner's osteoplastic resection of ...	227

	PAGES
Small intestine ...	285
operations on ...	285
surgical anatomy of ...	285
Smith's knives ...	397
Space of Retzius ...	351
Spencer-Well's forceps ...	389, 409
Spence's anterior racket method ...	121
Spence's disarticulation ...	195
Spermatic cord ...	374
Spinal accessory nerve ...	69
operation on ...	69
surgical anatomy of ...	69
Spinal cord and Brain ...	221
arachnoid ...	222
cerebral hemisphere ...	223
cerebral localisation ...	223
cerebrospinal fluid ...	222
cisterna puncture ...	229
cisterns ...	222
cranium and its contents ...	221
decompression ...	228
deploe ...	221
dramater ...	221
exploratory puncture of ventricles ...	229
instruments ...	225, 393
intracranial suppuration ...	229
laminectomy ...	231
lobes ...	223
lumbar puncture ...	230
membranes ...	221
middle meningeal hæmorrhage ...	228
operation—	
for hæmorrhage from middle meningeal artery ...	228
for hæmorrhage from venous sinuses ...	228
for intracranial suppuration ...	229
for traumatic epilepsy ...	228
operations on ...	221
osteoplastic resection of skull—Wagner's ...	227
scalp ...	221
thecal puncture ...	230
traumatic epilepsy ...	228
trephining ...	225
ventricles—	
exploratory puncture of ...	229
fourth ...	229
lateral ...	229
vertebral arch ...	231
Wagner's operation ...	227
Sponge holder ...	397, 419
Square knot ...	7
Staffordshire knot ...	11
Staples ...	392

	PAGES		PAGES
Stephen Smith's disarticulation—		Suprapubic lithotomy—	
amputation through upper		comment on	359
third of leg	148	indication of	358
at the knee-joint	150	instruments for	358
Sternomastoid—indications of		operation	359
tenotomy	85	position	359
Stoke's supracondylar amputation	154	Suprapubic lithotomy and	
Stomach—		lithotrixy—	
exposure	275	instruments for	398
general considerations	267	Suprapubic paracentesis of the	
indications	271	bladder	354
instruments	387	comment	354
operations	271	operation	354
surgical anatomy of	269	position	354
Stricture of the rectum—		preparation	353
operations for	336	Suprapubic Prostatectomy	
Stricture of the urethra—instru-		(Freyer)—	
ments for operation on	397	indication	362
operations for	366	instruments	362
Structure deeper—incisions	3	operation	362
Subclavian artery—		position	362
collateral circulation	18	Suprathyroid laryngotomy	206
comment	17	Surface marking of—	
ligation of	17	abdominal aorta	41
operation for ligation	17	anterior tibial artery	57
position	17	arteries of the lower ex-	
surface marking	17	tremity	50
surgical anatomy	15	arteries of the upper ex-	
Subcutaneous tenotomy	81	tremity	16
instruments for	388	axillary artery	18
Subcuticular continuous suture	7	brachial artery	20
Subhyoid pharyngotomy	207	common carotid artery	28
Subperiosteal method of ex-		common iliac artery	42
cision of joints	187	dorsalis pedis artery	61
Subphrenic abscess	265	external carotid artery	31
operation for	266	external iliac artery	47
Suppurative mastitis	245	femoral artery	50
Supracondylar osteotomy—		gluteal branch of posterior	
indications	176	branch of internal iliac	46
operation	177	McBurney's point	300
position	176	middle meningeal artery	26
Supraduodenal choledochotomy	320	posterior tibial artery	63
Suprahyoid Pharyngotomy	207	radial artery	22
Supra-malleolar amputation	143	sciatic branch of anterior	
Supra-orbital nerve—		branch of internal iliac	45
exposure of	67	subclavian artery	17
operation of	67	ulnar artery	24
surgical anatomy of	67	Surgeon's knot	11
Suprapubic cystotomy	354	Surgical anatomy of—	
comment	356	abdomen	250
indication of	355	anterior tibial artery	57
instruments for	387	arteries	15
operation	355	bladder	350
position	355	brain and spinal cord	221
preparation	355	breast	245
Suprapubic drainage	356	dorsalis pedis artery	61
		elbow-joint	190
		external carotid artery	31
		facial artery	35

PAGES	PAGES
Surgical anatomy of (<i>contd.</i>)—	Suture (<i>contd.</i>)—
facial nerve 68	needles 391
femoral artery 50	purse-string 256
femoral hernia 296	relaxation 8
foot 130	subcutaneous 7
hamstring tendons 84	tension 8
hip-joint 200	Sutures and ligatures—
inferior thyroid artery 32	(<i>see</i> ligatures and sutures).
infraorbital nerve 68	Suturing—
intercostal artery 38	instruments for 391
internal carotid artery 30	patella 179
internal mammary artery 37	wounds—methods of 6
kidney 341	Syme's amputation 137
knee-joint 148	comment 139
large intestine 305	modification of 140
leg 141	operation 137
lingual artery 33	position 137
liver 315	Syme's incision 191
middle meningeal artery 25	Syme's operation (urethrotomy) 367
neck 203	Sympathetic nervous system
occipital artery 36	and central nervous system—
penis 370	operation on 221
peronei tendons 84	Sympathetic nervous system—
popliteal artery 55	operation on 232
prostate gland 360	Sympathectomy 232
rectum and anus 324	
seminal vesicles 361	T
shoulder-joint 120	Talma-Morison operation 267
small intestine 285	Talus—excision of 74
spinal accessory nerve 69	Tapping—
spinal cord and brain 221	hydrocele 375
supraorbital nerve 67	operation 375
temporal artery 36	Teal's probe-pointed director
testicle 374	397, 419
tibialis anticus 83	Temporal artery 36
tibialis positicus 83	indications of ligation 36
ulnar artery 16	ligation of 36
ureters 341	surgical anatomy of 36
urethra 365	Tendino-plastic method of am-
vermiform appendix 300	putation 101
vertebral artery 37	Tendo-achillis—
Surgical treatment of pulmo-	indications for operation 82
nary tuberculosis 235	operation on 83
Suture—	Tendon—
and ligature 3	biceps femoris division of 84
blanket 7	grafting 80
continuous 7	hamstring 84
continuous blanket 7	kangaroo 5
continuous subcuticular 7	lengthening 78
Cushing's 256	operation 83
Czerny Lembert 255	peronei indications of teno-
Dupuytren's 256	tomy 84
Halstead's 256	operation 85
interrupted 6	surgical anatomy 84
intestinal 255	semimembranosus and semi-
Lembert 255	tendinosus—division of the
mattress 8	84
metallic 8	shortening 79
Mitchell's 8	sternomastoid 85

	PAGES		PAGES
Tendon (<i>contd.</i>)—		Tibialis posticus—	
tendoachillis ...	82	indications for operation ...	83
tibialis anticus ...	93	operations on ...	83
tibialis posticus ...	93	surgical anatomy of ...	83
Tenodesis ...	76	Tibia—	
Tenotome ...	399, 422	sawing of ...	200
Tenorrhaphy ...	77	Tibio-femoral osteoplastic am-	
Tenotomy ...	76, 81	putation of the leg ...	145
indication of ...	81	Tissue forceps ...	390
instruments for ...	388, 399	Toes—	
knives ...	399, 422	amputation of ...	126, 129
of tibialis anticus—indica-		great—amputation of ...	128
tion ...	12	little—amputation of ...	129
open method ...	81	Tonsil—	
operation ...	81	bistoury ...	395
subcutaneous method ...	81	compression forceps ...	395
Tension suture ...	8	knives ...	395, 417
Terminal phalanges—		punch forceps ...	395
disarticulation of ...	126	scissors ...	395, 417
Terminal phalanx—		Tonsillectomy—	
amputation of ...	126	instruments for ...	386
comment ...	127	Torsion forceps ...	390
operation ...	127	Tourniquets ...	105
Testicle—		varieties of ...	105
coverings of cord and testis	375	Tracheal dilating forceps	395, 418
surgical anatomy of ...	374	Tracheal tubes T-shaped ...	396
Testis and cord—		Tracheotomy ...	211
coverings of the ...	375	cannulae ...	395, 418
Thigh—		exposure of the trachea ...	212
amputations of ...	156	high ...	212
amputation of—by large an-		indication of ...	211
terior flap ...	157	indications for extrinsic	
amputation of—comment on	158	conditions ...	211
general anatomical con-		instruments for ...	212, 386
sideration ...	156	introduction of the tube ...	214
various methods of ampu-		low ...	215
tations ...	156, 157	low—indications ...	216
Thompson's hollow sound	398, 420	opening the trachea ...	213
Thoracoplastic operation ...	236	position ...	212
contraindications of ...	237	Transfixion ligature ...	11
indications of ...	236	Transsacral resection of the	
operation ...	237	rectum ...	337
preparation ...	237	Transverse colostomy ...	308
Thorax—		Traumatic epilepsy ...	228
electrosurgical treatment ...	383	Treatment of acute ileus ...	311
injuries of ...	234	operation of ...	312
operation on ...	234	Trephines ...	225
Thread saw ...	392, 397, 415	Trephining—	
Thyroidectomy ...	218	instruments for ...	386, 393
electrosurgical method of		operation ...	225
operation ...	383	True knot ...	11
indications for ...	218	Turbinectomy—	
operation ...	219	instruments ...	394
Thyrotomy ...	207		
Tibialis anticus—		U	
indications of tenotomy of	83	Ulnar artery—	
operations on ...	83	collateral circulation ...	25
surgical anatomy of ...	83	ligation in the lower third	
		of the forearm ...	24

PAGES	PAGES
Ulnar artery (<i>contd.</i>)—	
ligation in the middle of the forearm 24	
ligation of 24	
surface marking of 24	
surgical anatomy of 16	
Ulnar nerve—	
exposure of 73	
Umbilical hernia 295	
operation 295	
surgical anatomy 295	
Upper arm—	
amputation of 118	
methods of amputation of 118, 119, 120	
Upper extremity—	
arteries of the 15	
excision of the 1	
Upper jaw—	
comment 167	
excision of 166	
indication of excision of 166	
instruments 166	
operation 166	
position 116	
Upper limb—	
interscapulo-thoracic disarticulation with scapula and partly clavicle 123	
Ureter—	
implantation of the ureter to a hollow viscus 348	
injuries to the 348	
obstruction in the operation 347	
surgical anatomy of 341	
Ureterocolostomy 349	
Uretero-intestinal anastomosis 349	
Urethra—	
dilatation by bougies 368	
instruments for operation on stricture of the 397	
operations for stricture of the operations on the 366	
surgical anatomy 365	
Urethrectomy 366	
external 367	
external with a guide 367	
indications for 366, 367	
instruments for 387	
internal 366	
Use of knife 2	
Uvula—	
instruments for removal of 395	
scissors 395	
Uvilatomes 395	
V	
Valvotomy 328	
	Varicocele—
	indication 379
	instruments 380
	operation for 380
	position 380
	Venous sinuses hæmorrhage—
	operation for 228
	Ventral hernia 295
	Ventricles puncture 229
	Vertebral arch—resection of 231
	Vertebral artery 37
	comment 37
	indications for ligation of 37
	ligation of 37
	operation 37
	position 37
	surgical anatomy 37
	Vessels of abdomen 251
	Violin bow method of holding knife 2
	Volvulus 314
	W
	Wagner's osteoplastic resection of the skull 227
	Ward stitch 307
	Weir's operation (Appendicostomy) 304
	Wheel-house operation 367
	Wheel-house staff 398, 419
	Willys Andrew's operation for hernia 294
	Wire—
	cutter 397
	guides 392
	twister 397
	Wound of the heart 234
	Wounds of the pancreas 321
	Wound retractors 389, 412
	Wound suturing 6
	Wound suturing method 16
	Wrist—
	amputation of 113
	back of 22
	comments 113
	operation 113
	position 113
	Kocher's excision 188
	Wrist-joint—
	disarticulation through 113
	Dubrueil's amputation 114
	excision of 188
	Wyeth needles 160
	Y
	Young's perineal prostatectomy 363