

Angela Creditt · Jordan Tozer
Michael Vitto · Michael Joyce
Lindsay Taylor



Clinical Ultrasound

A Pocket Manual

EXTRAS ONLINE

 Springer

Clinical Ultrasound

Angela Creditt • Jordan Tozer
Michael Vitto • Michael Joyce
Lindsay Taylor

Clinical Ultrasound

A Pocket Manual

 Springer

Angela Creditt
Emergency Medicine
Virginia Commonwealth
University
Richmond, Virginia, USA

Jordan Tozer
Emergency Medicine
Virginia Commonwealth
University
Richmond, Virginia, USA

Michael Vitto
Emergency Medicine
Virginia Commonwealth
University
Richmond, Virginia, USA

Michael Joyce
Emergency Medicine
Virginia Commonwealth
University
Richmond, Virginia, USA

Lindsay Taylor
Virginia Commonwealth
University
Richmond, Virginia, USA

ISBN 978-3-319-68633-2

ISBN 978-3-319-68634-9 (eBook)

<https://doi.org/10.1007/978-3-319-68634-9>

Library of Congress Control Number: 2017961310

© Springer International Publishing AG 2018

This work is subject to copyright. All rights are reserved by the Publisher, whether the whole or part of the material is concerned, specifically the rights of translation, reprinting, reuse of illustrations, recitation, broadcasting, reproduction on microfilms or in any other physical way, and transmission or information storage and retrieval, electronic adaptation, computer software, or by similar or dissimilar methodology now known or hereafter developed.

The use of general descriptive names, registered names, trademarks, service marks, etc. in this publication does not imply, even in the absence of a specific statement, that such names are exempt from the relevant protective laws and regulations and therefore free for general use.

The publisher, the authors and the editors are safe to assume that the advice and information in this book are believed to be true and accurate at the date of publication. Neither the publisher nor the authors or the editors give a warranty, express or implied, with respect to the material contained herein or for any errors or omissions that may have been made. The publisher remains neutral with regard to jurisdictional claims in published maps and institutional affiliations.

Printed on acid-free paper

This Springer imprint is published by Springer Nature

The registered company is Springer International Publishing AG

The registered company address is: Gewerbestrasse 11, 6330 Cham, Switzerland

Preface

Point-of-care ultrasound is quickly becoming the way of the future for improving clinical care and patient safety. Its use has become increasingly prominent in recent years and is now a routine expectation in almost all fields of medicine due to its ability to enhance care and expedite diagnosis. This is mainly due to its real-time, portable, nonionizing image acquisition without the risks of traditional imaging such as radiation exposure. In addition, due to its low cost and ease of deployability, it is rapidly becoming available for point-of-care use anywhere health care is delivered. Providers are traveling to developing countries with portable ultrasound machines, military hospitals are using ultrasound on the frontlines, rural practice offices are integrating ultrasound within their patient visits, and emergency medical systems are placing ultrasound machines on their ambulances and helicopters. Furthermore, medical schools are incorporating ultrasound education into their core curriculum as they are realizing the positive impact it has on the future career of their learners.

With this increasing prevalence, the need for a reliable and easy-to-follow comprehensive resource is obvious. While training our own resident physicians here at Virginia Commonwealth University, we realized there were no instructional resources available to provide concise step-by-step instructions, as well as normal and abnormal images. Frequently, learners would have to leave the ultrasound machine to find a computer or book in order to look up the image they were interested in obtaining. This is where we came up with the idea of a pocket manual that can be easily

carried around and provide a quick reference for learning on the job.

Whether you are an emergency medical technician or senior physician, it is our hope that this manual will ease some of the intimidation of learning ultrasound. Utilizing simple bullet point instructions and a vast library of point-of-care images, this book will be there with you at the bedside to help with any study you want to complete!

Angela Bray Creditt

Jordan Tozer

Michael Vitto

Michael Joyce

Lindsay Taylor

Richmond, VA

Richmond, VA

Richmond, VA

Richmond, VA

Richmond, VA

Acknowledgments

Thank you to our VCU Emergency Medicine family for your persistent support and encouragement. Thank you to those who have helped contribute to this book including L. Das Narla M.D., Rashida Woods M.D., Tim Layng D.O., Rohit Manaktala M.D., Trecia Henriques M.D., Evie Louka, and Morgan Williams. Lastly, a tremendous thank you to Dr. Dave Evans, Ultrasound Fellowship Director at VCU, for educating our medical students, residents, faculty, and other medical professionals in ultrasound.

Contents

1	Introduction: Basic Ultrasound Principles	1
	Basic Terminology	1
	Transducer Selection	8
	Transducer Position	11
	Ultrasound Artifact	13
	References.	18
2	Extended Focused Assessment with Sonography for Trauma	19
	Clinical Application and Indications	19
	Normal EFAST Anatomy	20
	Image Acquisition	22
	EFAST Pathology	34
	References.	44
3	Cardiac Ultrasound	47
	Normal Cardiac Anatomy.	48
	Image Acquisition	49
	Parasternal Long Axis	49
	Parasternal Short Axis.	51
	Apical Four- and Two-Chamber.	53
	Subxiphoid.	56
	Inferior Vena Cava.	57
	Measuring Global Left Ventricular Systolic Function	59
	Cardiomyopathies	61
	Right Ventricular Dilation	64
	Pericardial Effusion and Tamponade.	66
	References.	72

4	Thoracic Ultrasound	75
	Indications/Clinical Application	75
	Normal Thoracic Anatomy	76
	Image Acquisition	78
	Image Acquisition	80
	Thoracic Pathology	84
	References	89
5	Head and Neck Ultrasound	91
	Tonsillar Ultrasound	91
	Thyroid Ultrasound	95
	Tracheal Ultrasound	100
	Carotid Artery Ultrasound	104
	Salivary Gland	105
	References	110
6	Musculoskeletal Ultrasound	113
	Clinical Application and Indications	113
	Normal Musculoskeletal Anatomy	114
	Image Acquisition	115
	Shoulder Joint	119
	Tendons	121
	Knee Joint	126
	Bone	128
	Nerves	130
	References	133
7	Abdominal Aortic Aneurysm Ultrasound	135
	Clinical Application/Indications	135
	Normal Aortic Anatomy	136
	Image Acquisition	138
	Abdominal Aortic Pathology	142
	References	147
8	Biliary Ultrasound	149
	Clinical Application and Indications	149
	Normal Biliary Anatomy	150
	Imaging Overview	150
	Gallbladder Pathology	156

Common Bile Duct Pathology	162
References.....	164
9 Renal and Bladder Ultrasound	167
Clinical Application and Indications.....	167
Genitourinary Anatomy	168
Image Acquisition	169
Renal Pathology.....	176
Bladder Pathology	181
References.....	184
10 Abdominal Ultrasound	185
Clinical Application and Indications.....	185
Normal Abdominal Anatomy.....	186
Image Acquisition	186
Abdominal Pathology	188
References.....	195
11 Gynecologic Ultrasound	197
Clinical Application and Indications.....	197
Normal Gynecologic Anatomy.....	198
Image Acquisition	199
Gynecologic Pathology	204
References.....	211
12 Obstetric Ultrasound.....	213
Clinical Application and Indications.....	213
Normal Gynecologic Anatomy.....	214
Image Acquisition	214
Evaluation for Intrauterine Pregnancy	220
Obstetric Pathology	226
References.....	235
13 Testicular Ultrasound	237
Clinical Application and Indications.....	237
Normal Testicular Anatomy	238
Image Acquisition	238
Testicular Pathology.....	241
References.....	252

14 Lower Extremity Venous Ultrasound	253
Clinical Application/Indications	254
Lower Extremity Venous Anatomy	254
Image Acquisition	255
Lower Extremity Venous Pathology	262
References	266
15 Skin and Soft Tissue Ultrasound	267
Clinical Application and Indications	267
Normal Skin and Soft Tissue Anatomy	268
Image Acquisition	268
Skin and Soft Tissue Pathology	270
References	277
16 Ocular Ultrasound	279
Clinical Application and Indications	279
Normal Ocular Anatomy	280
Image Acquisition	281
Ocular Pathology	283
References	290
17 Pediatric Ultrasound	293
Appendicitis	293
Intussusception	298
Pyloric Stenosis	300
Testicular Torsion	303
References	307
18 Ultrasound-Guided Procedures	309
Ultrasound-Guided Peripheral Intravenous Access	309
Central Venous Catheterization	319
Paracentesis	326
Regional Anesthesia	330
Lumbar Puncture	339
References	344
Index	347

List of Contributors

Drew Clare, M.D. Department of Emergency Medicine, Virginia Commonwealth University Medical Center, Richmond, VA, USA

Angela Bray Creditt, D.O. Department of Emergency Medicine, Virginia Commonwealth University Medical Center, Richmond, VA, USA

Michael Joyce, M.D., R.D.M.S., R.D.C.S. Department of Emergency Medicine, Virginia Commonwealth University Medical Center, Richmond, VA, USA

Lindsay Taylor, M.D., R.D.M.S., R.D.C.S. Department of Emergency Medicine, Virginia Commonwealth University Medical Center, Richmond, VA, USA

Jordan Tozer, M.D., M.S., R.D.M.S., R.D.C.S. Department of Emergency Medicine, Virginia Commonwealth University Medical Center, Richmond, VA, USA

Michael Vitto, D.O., M.S., R.D.M.S., R.D.C.S. Department of Emergency Medicine, Virginia Commonwealth University Medical Center, Richmond, VA, USA

Chapter 1

Introduction: Basic Ultrasound Principles

Learning ultrasound can be overwhelming and confusing, especially for those who are becoming familiar with equipment and images for the first time. This chapter will provide an overview of basic point-of-care ultrasound physics and procedures. It will explain ultrasound-specific terminology for image optimization, transducer types, clinical application and positioning, and different scanning modes such as brightness mode, motion mode, and Doppler. Lastly, common ultrasound artifacts, their characteristics, and how to recognize them will be described.

Basic Terminology

(a) Brightness Mode (B-mode)

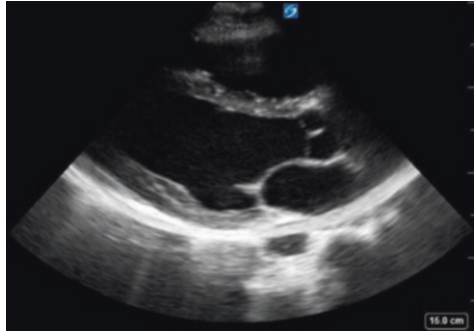
- The standard ultrasound mode for all clinical imaging
- Converts ultrasound waves into a grayscale image [1]
- Figure 1.1 – B-mode imaging
- Video 1.1 – B-mode imaging

(b) Motion Mode (M-mode)

- Evaluates the movement of structures within the body [2]

Electronic Supplementary Material The online version of this chapter (doi:[10.1007/978-3-319-68634-9_1](https://doi.org/10.1007/978-3-319-68634-9_1)) contains supplementary material, which is available to authorized users.

FIGURE 1.1
B-mode imaging:
Brightness mode
imaging of the
heart. Brightness
mode or B-mode is
the standard ultra-
sound mode for all
clinical imaging



- Records movement of a structure over time
 - A vertical line is placed through the structure of interest.
 - The machine then converts ultrasound echoes measured at this line onto the vertical axis of a graph with time on the horizontal axis [2].
- Figure 1.2—M-mode imaging

(c) Frequency

- The number of sound waves per unit time.
- For clinical imaging, this typically ranges from 2 megahertz (MHz) to 15 MHz [1].
- Higher-frequency transducers have less tissue penetration but provide more detailed image resolution.
- Lower-frequency transducers have greater tissue penetration but sacrifice image resolution.

(d) Gain

- Controls amplification of returning ultrasound waves [2].
- This translates to brightness of the ultrasound image [2].
- Gain can be manually controlled by the sonographer and should be optimized for image clarity.
 - If the gain is too high, the image will be bright.

Figure 1.3—High gain

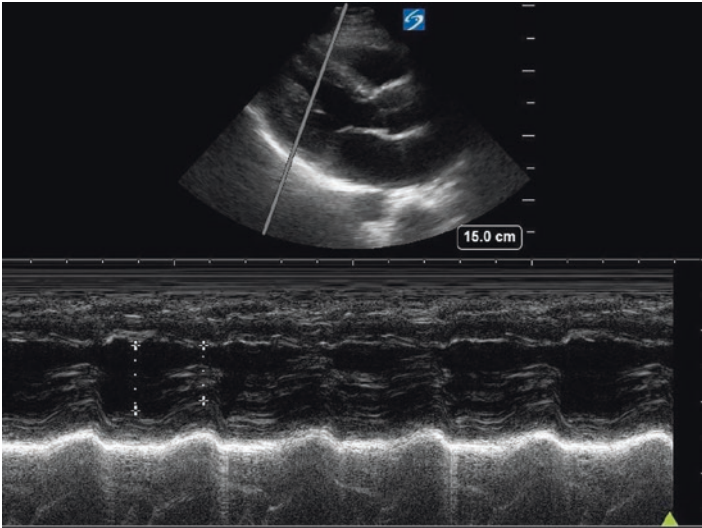


FIGURE 1.2 M-mode imaging: Motion mode imaging of the heart. Motion mode or M-mode cardiac evaluates the movement of structures within the body. This image demonstrates the utilization of M-mode to evaluate movement of the left ventricle over time

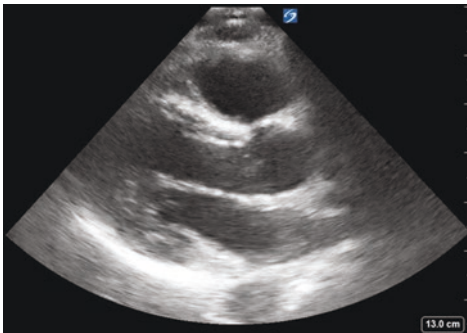
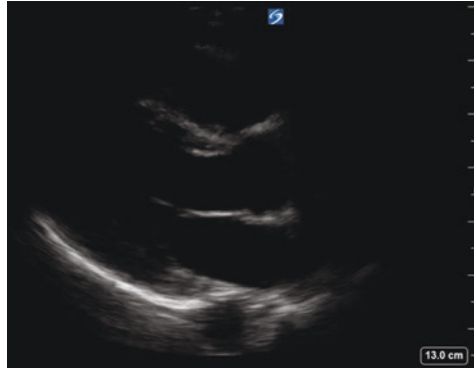


FIGURE 1.3 High gain: This image demonstrates the parasternal long view of a heart with high gain. Gain is related to brightness of the image. When the gain is too high, the image will be bright and details are lost

FIGURE 1.4 Low gain: This image demonstrates the parasternal long view of a heart with low gain. Gain is related to brightness of the image. When the gain is too low, the image will be dark and details are lost



- If the gain is too low, the image will be dark.

Figure 1.4—Low gain

(e) Depth

- Refers to how far sound travels prior to returning to the transducer, typically reported in centimeters.
 - If depth is increased, the ultrasound machine listens for returning echoes for a longer period of time to collect data [2] necessary to create an image.
 - If depth is decreased, the machine will listen for a shorter period of time.
- This can be manually controlled by the sonographer.
- Depth should be optimized so that the structure of interest is imaged within the center of the screen.
 - Figure 1.5—High depth
 - Figure 1.6—Shallow depth
 - Figure 1.7—Ideal depth

(f) Doppler

- Measures frequency shift
 - Doppler shift is defined as a change in frequency that occurs when sound reflects off a moving structure [2].
- Calculates blood velocity
 - An increase in velocity causes an increase in Doppler shift.

FIGURE I.5 High depth: This image demonstrates the parasternal long view of a heart with the depth set too deep. The structure of interest should be centered in the screen

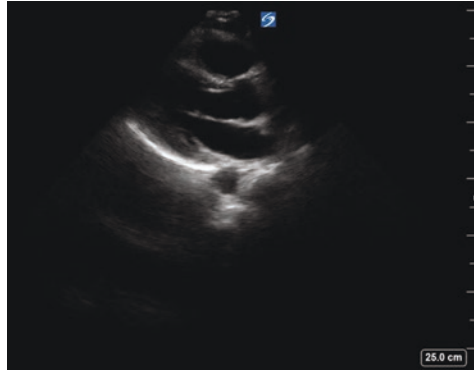


FIGURE I.6 Shallow depth: This image demonstrates the parasternal long view of a heart with the depth set too low. The structure of interest should be centered in the screen

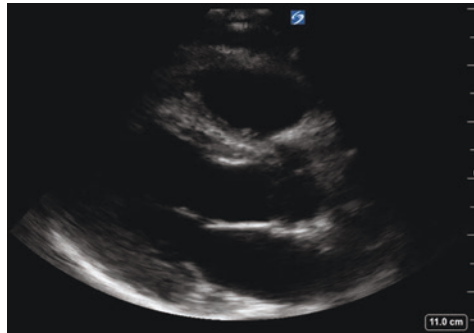
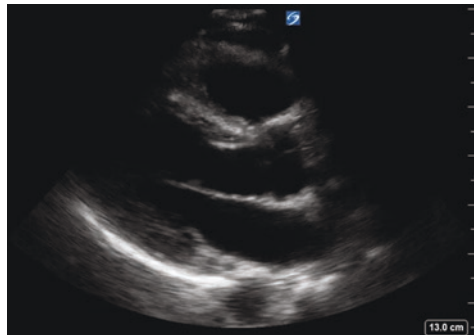


FIGURE I.7 Ideal depth: This image demonstrates the parasternal long view of a heart with ideal depth and gain settings to properly vision the entire structure of interest as well as the appropriate level of detail



- Color Doppler
 - Shifts in velocity are color coded according to direction of flow in relationship to the transducer.
Flow away from the transducer will appear blue.
Flow toward the transducer will appear red.
This can be remembered as “BART,” *Blue Away*
Red Toward.
 - Figure 1.8—Color Doppler
 - Video 1.2—Color Doppler
- Power Doppler
 - Displays a signal in color if there is any motion detected at all
Does not indicate velocity or direction
 - Higher sensitivity than color Doppler allowing for imaging slower flow [2]

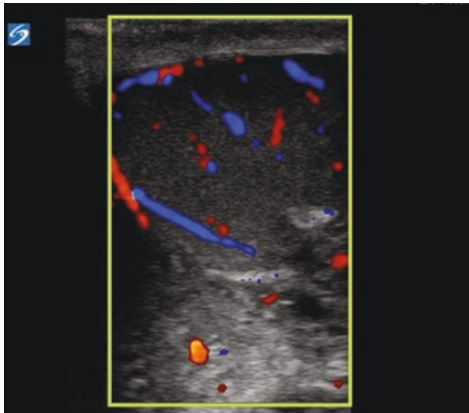


FIGURE 1.8 Color Doppler: Color Doppler measures shifts in velocity which are color coded according to direction of flow in relationship to the transducer; flow away from the transducer will appear *blue*, and flow toward the transducer will appear *red*. Note that it does not relate to venous and arterial flow. In this image, the testicles are being assessed for vascular flow with color Doppler

- Good for low-flow applications such as the testicle and ovary
- Figure 1.9—Power Doppler
- Video 1.3—Power Doppler

(g) Transducer

- Contains piezoelectric crystals that have the unique ability to translate electrical signal into sound waves.
 - Sound waves are sent to tissues then reflected back to the transducer.
 - Reflected sound waves are translated into electric signals by the same piezoelectric crystals.
- Computer software processes these signals into an ultrasound image.

(h) ALARA

- “As low as reasonably achievable” [1,2]
- Ultrasound principle to use the least amount of ultrasound possible on each patient

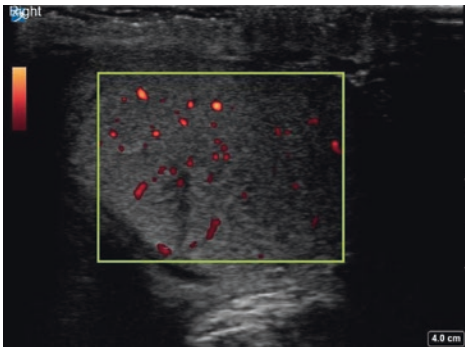

FIGURE 1.9 Power Doppler: Power Doppler will display a signal in color if there is any motion at all. It does not indicate velocity or direction. In this image, the testicles are being assessed for vascular flow with power Doppler

Transducer Selection

- Curvilinear Transducer
 - Low frequency with a wide field of view.
 - Greater tissue penetration allows for imaging of deeper structures.
 - Ideal for abdominal imaging.
 - Typical frequency range is 2–5 MHz [3].

Figure 1.10—Curvilinear transducer

- Phased Array Transducer
 - Smaller flat footprint.
 - Uses electronic beam steering to produce a pie-shaped field of view.
 - Allows for imaging through small areas such as between ribs.
 - Most commonly used for cardiac imaging.
 - Typical frequency range is 2–7 MHz [4].

Figure 1.11—Phased array transducer

- Linear Array Transducer
 - Produces a rectangular image.
 - High frequency makes this transducer ideal for imaging superficial structures including soft tissue, muscles, nerves, arteries, and veins.
 - Often used for procedural guidance.
 - Typical frequency range is 5–10 MHz [2].

Figure 1.12—Linear transducer

FIGURE 1.10
Curvilinear transducer: Curvilinear transducers exhibit low frequency and a wide field of view

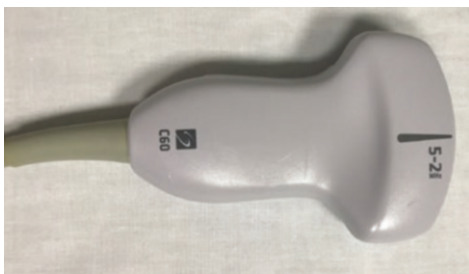

FIGURE I.11 Phased array transducer: Phased array transducers have smaller flat footprints and exhibit a pie-shaped field of view



FIGURE I.12 Linear transducer: Linear transducers produce rectangular images using high frequency

- Endocavitary Transducer

- Produces an image with a wide field of view, up to 180° [2].
- Specialized high-frequency curvilinear transducer that is commonly used for obstetric, gynecologic, or ear, nose, and throat (ENT) applications.
- Typical frequency range is 8–13 MHz [2].

Figure 1.13—Endocavitary transducer

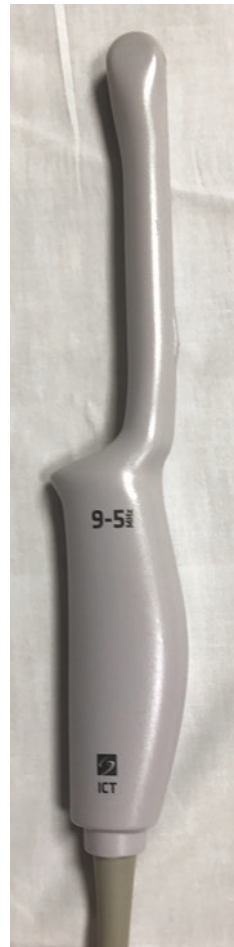

FIGURE 1.13 Endocavitary transducer: Endocavitary transducers exhibit high frequency and a wide field of view

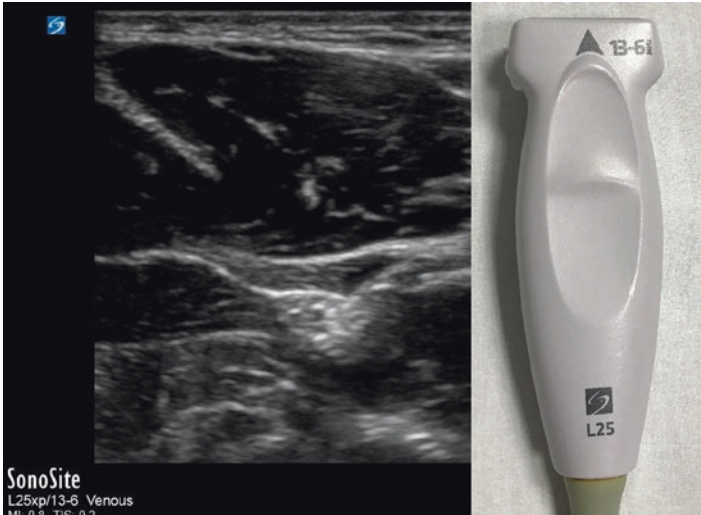

FIGURE 1.14 Marker correlation: Transducer bump on the left side of the transducer corresponds to the blue box (or dot on some machines) on the left side of the image screen

Transducer Position

- Each transducer has a “marker” or position indicator.
 - The marker on the transducer corresponds to the marker indicator on the image screen, which will be identified as a blue dot.
 - This helps the sonographer with image orientation and facilitates an understanding of what is being seen on the screen.

Figure 1.14—Marker correlation

- Standard ultrasound imaging planes include transverse, sagittal, and coronal.
 - Transverse

Also called cross sectional or axial.

Transducer marker will be pointed toward patient’s right.

Figure 1.15—Transverse plane.

FIGURE 1.15
Transverse plane:
Transducer place-
ment for imaging
in a transverse
plane. Transducer
marker is directed
toward the
patient's right side

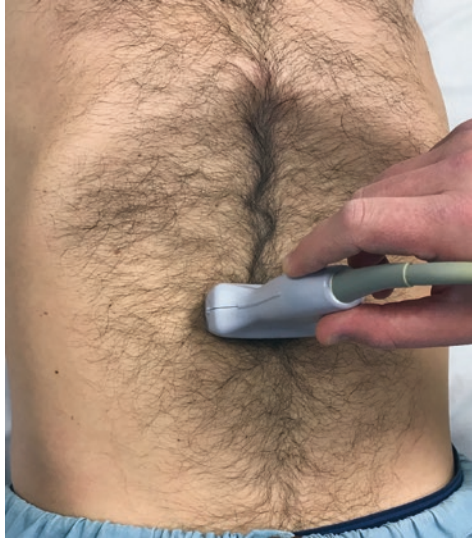
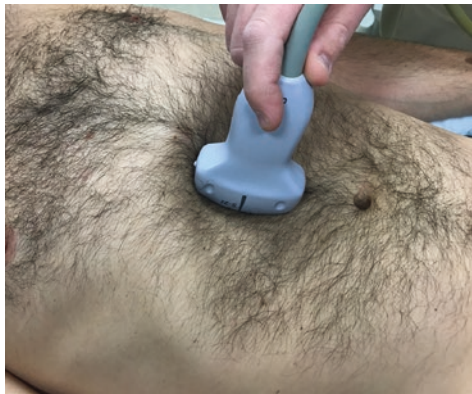
FIGURE 1.16
Sagittal plane:
Transducer place-
ment for imaging
in a sagittal plane.
Transducer marker
is directed toward
the patient's head,
and the transducer
is positioned in the
patient's midline



– Sagittal

With the transducer in an anterior or posterior position relative to the patient's body, the marker should point toward the patient's head or cephalad.

Figure 1.16—Sagittal plane

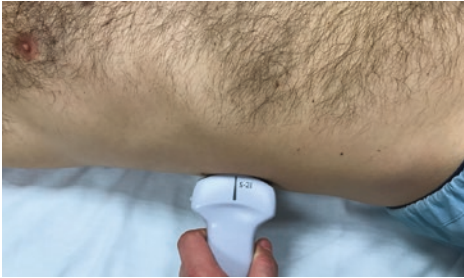

FIGURE 1.17 Coronal plane: Transducer placement for imaging in a coronal plane. Transducer marker is directed toward the patient’s head, and the transducer is positioned on the patient’s lateral side

- Coronal

With the transducer in a lateral position relative to the patient’s body, the marker should point toward the patient’s head or cephalad.

Figure 1.17—Coronal plane

- Cardiac Imaging.

- With cardiac ultrasound, conventional transducer positioning does not apply.
- For this technique, the marker position during cardiac imaging is variable depending on what image is being obtained.
- See Chapter 3 (“Cardiac Ultrasound”) for detailed information.

Ultrasound Artifact

- Artifacts in ultrasound imaging arise due to errors by the machine in interpreting the returning sound waves.
- A basic understanding of artifacts is necessary to identify normal and pathologic findings.
- The most common artifacts are due to sound absorption or redirection, defined as falsely placing signals on the image screen that are not truly there.

- Types of Artifacts.

- Posterior acoustic shadowing

Occurs when sound cannot pass through an impermeable or almost impermeable tissue such as bone or a calcified structure

Figure 1.18—Bone shadowing

Video 1.4—Bone shadowing

Figure 1.19—Gallstone shadowing

Video 1.5—Gallstone shadowing

FIGURE 1.18 Bone shadowing: Ribs exhibit posterior acoustic shadowing. Ultrasound waves cannot penetrate bone and calcified structures causing posterior acoustic shadowing

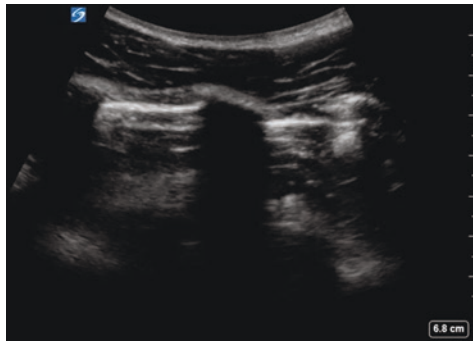
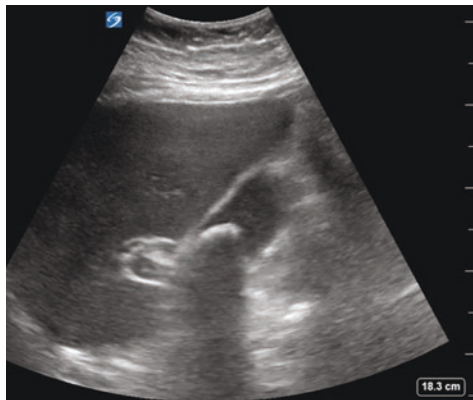


FIGURE 1.19 Gallstone shadowing: Posterior acoustic shadowing helps properly identify gallstones within the gallbladder and can help distinguish stones from other structures such as polyps



– Posterior acoustic enhancement (PAE)

Occurs when a sound passes through a fluid-filled structure, without significant attenuation causing in an increase in acoustic energy [1].

This results in structures posterior to the fluid-filled structure appearing brighter or more echogenic.

Common examples include simple cysts, the gallbladder, the bladder, or large vessels.

Figure 1.20—Gallbladder with PAE

Video 1.6—Gallbladder with PAE

– Reverberation artifact

Occurs when sound bounces between two greatly reflective structures [1] causing sound to reverberate over and over, creating a line of sound down the image screen

Figure 1.21—Lung with reverberation artifact

Video 1.7—Lung with reverberation artifact

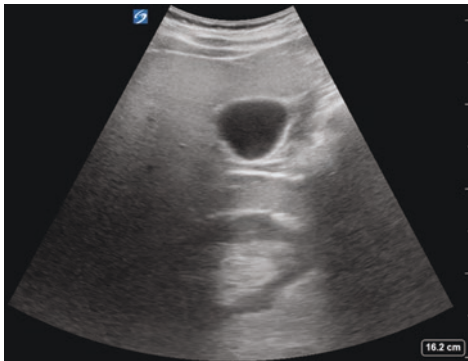


FIGURE 1.20 Gallbladder with PAE: As sound passes through fluid-filled structures, such as the gallbladder seen here, acoustic energy is increased resulting in posterior acoustic enhancement in which the structures posterior to the structure appear brighter

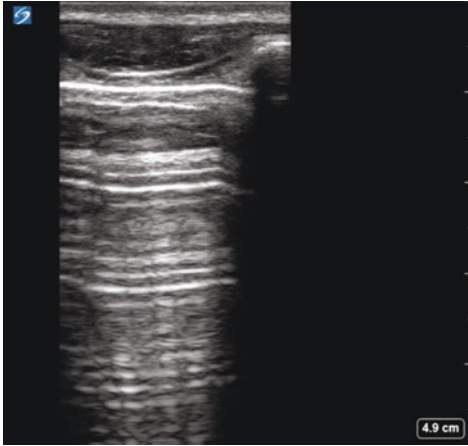


FIGURE 1.21 Lung with reverberation artifact: When sound bounces between two greatly reflective structures, it will reverberate over and over, creating a line of sound down the image screen known as reverberation artifact, as seen here with the pleural line of the lungs

– Mirror artifact

When ultrasound waves hit a highly reflective structure, such as the diaphragm, the machine can interpret the images as coming back twice.

Figure 1.22—Liver with mirror artifact.

Video 1.8—Liver with mirror artifact.

– Edge artifact

Caused by refraction of the ultrasound beam as it hits a highly reflective rounded structure, directing the beam away from the structure and not back to the transducer

Can be mistaken for posterior acoustic shadowing

Figure 1.23—Gallbladder with edge artifact

Video 1.9—Gallbladder with edge artifact

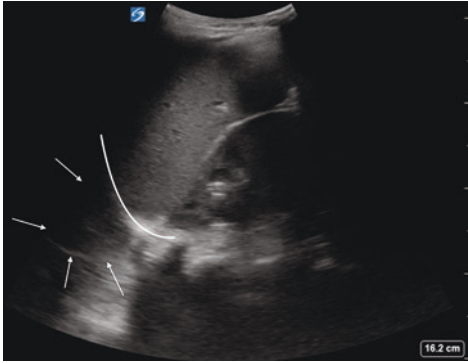


FIGURE I.22 Liver with mirror artifact: When ultrasound waves hit a highly reflective structure, such as the diaphragm, the machine can interpret the images as coming back twice. Here there appears to be two livers, one above and one below the diaphragm

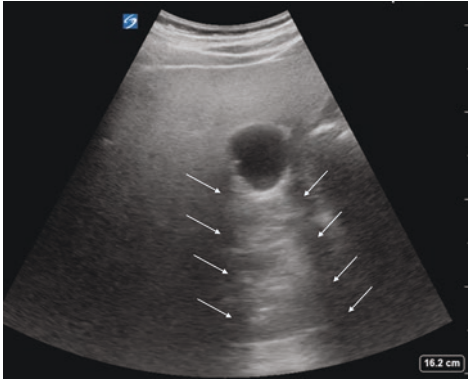


FIGURE I.23 Gallbladder with edge artifact: Edge artifact occurs when sound waves hit a highly reflective rounded structure, such as the walls of a gallbladder; the ultrasound beam is directed away from the structure creating a shadow effect similar to posterior acoustic shadowing

Key Points

- Dim ambient lights to improve image on screen.
- Increase contact with patient's body by applying pressure with the face of the transducer or increasing the amount of gel.

References

1. Hecht C, Manson W. Chapter 3: physics and image artifacts. In: Ma OJ, Mateer JR, Reardon RF, Joing SA, editors. Emergency ultrasound. 3rd ed. China: McGraw-Hill Education; 2014. p. 33–46.
2. Scruggs W, Fox JC. Chapter 2: equipment. In: Ma OJ, Mateer JR, Reardon RF, Joing SA, editors. Emergency ultrasound. 3rd ed. China: McGraw-Hill Education; 2014. p. 15–32.
3. Saul T, Del Rios Rivera M, Lewiss R. Focus on: ultrasound image quality. ACEP News website. 2011. <https://www.acep.org/Content.aspx?id=79787>. Accessed 17 April 2017.
4. Rasalingham R, Makan M, Perez JE. The Washington manual of echocardiography. Saint Louis, MO: Department of Medicine, Washington University School of Medicine, Lippincott Williams & Wilkins; 2013.

Chapter 2

Extended Focused Assessment with Sonography for Trauma

Ultrasound has revolutionized our ability to rapidly and noninvasively assess for life-threatening injuries requiring operative intervention in patients who have sustained blunt or penetrating trauma. The Extended Focused Assessment with Sonography for Trauma, or the EFAST exam, allows physicians to look inside the abdomen to assess for hemorrhage, the heart for pericardial effusion or tamponade, and the lungs for pneumo- or hemothorax. In an unstable trauma patient, the EFAST exam will help determine proper disposition including immediate operative intervention vs. further workup such as with computed tomography imaging. This chapter will review indications for performing an EFAST exam, basic anatomy, image acquisition, normal ultrasound anatomy, and interpretation of EFAST pathology.

Clinical Application and Indications

- Blunt trauma
- Penetrating trauma
- Unexplained hypotension or alerted mental status

Electronic Supplementary Material The online version of this chapter (doi:[10.1007/978-3-319-68634-9_2](https://doi.org/10.1007/978-3-319-68634-9_2)) contains supplementary material, which is available to authorized users.

Normal EFAST Anatomy

- The basic EFAST exam evaluates the abdomen for free intraperitoneal fluid, the heart for pericardial fluid, and the lungs for pneumothorax or hemothorax.
- Right Upper Quadrant (RUQ).
 - Visualize the liver and kidney looking for the potential space between the two called the hepatorenal recess.
 - The diaphragm is seen at the superior edge of the liver as a hyperechoic curved stripe.
 - Lower right lung base will be located above the diaphragm.
- Left Upper Quadrant (LUQ).
 - Visualize the spleen and left kidney with the potential space between the two organs called the splenorenal recess.
 - The diaphragm can be seen at the superior edge of the spleen as a hyperechoic curved stripe.
 - Lower left lung base will be located above the diaphragm.
- Pelvis.
 - Visualize the bladder which will appear as a hypoechoic collection of fluid surrounded by a well-defined echogenic border.
 - To the right and left of the bladder will be a paracolic gutter.
 - Uterus or prostate can be seen posterior to the bladder.
- Subxiphoid.
 - Visualize the heart, pericardial sac, and potential space between the heart and pericardium.
 - The liver will be seen anterior to the heart.
 - Posterior to the liver will be the right ventricle and right atrium.

- The most posterior structures will be the left ventricle and left atrium.
- Please see the cardiac chapter for more detailed cardiac anatomy.
- Lung Apices.
 - The lungs sit within the thorax encaged by the ribs and muscular chest wall.
 - Each lung is surrounded by a visceral pleura and parietal pleura with a potential space between the two.

The pleural line will appear as a hyperechoic horizontal line between two rib spaces.
 - Please see the thoracic chapter for more detailed lung anatomy.
- Inferior Vena Cava.
 - The inferior vena cava (IVC) is the largest vein in the human body.
 - Delivers deoxygenated blood back to the heart from the body inferior to the thorax.
 - The IVC will be seen posterior to the liver entering the right atrium.
 - The IVC normally collapses with inspiration and dilates with expiration.
- Free intraperitoneal fluid or blood accumulates within dependent areas of the abdomen including:
 - Hepatorenal recess between the liver and kidney within the RUQ

This space is also known as Morrison's pouch.
 - Splenorenal recess between the spleen and kidney within the LUQ
 - Left subphrenic space between the diaphragm and spleen
 - Paracolic gutters within the pelvis
 - Rectovesical pouch

Most dependent area in the supine male

- Rectouterine pouch

Also known as the pouch of Douglas

Most dependent area in the supine female

- Fluid can accumulate around the heart, within the pericardium.
- Fluid can accumulate within the pleural cavity.

Image Acquisition

1. Transducer Selection

- (a) Curvilinear
- (b) Phased array

2. Patient Position

- (a) The patient should be lying supine.
- (b) Can also place patient in Trendelenburg or reverse Trendelenburg to increase the dependency of the fluid.

3. Standard Exam Views

(a) Right upper quadrant

- Place the transducer over the patient's right flank between mid-axillary and anterior axillary line with the transducer marker directed toward the patient's head.
 - Morrison's pouch is usually best imaged between rib 8 and rib 11.
 - Figure 2.1—Transducer placement RUQ.
 - Figure 2.2—RUQ normal EFAST.
 - Video 2.1—RUQ normal EFAST.
- When scanning through the liver-renal interface, be sure to image the tip of the left side of the liver as this is where blood or fluid will accumulate first in a supine patient [1].
 - Figure 2.3—Liver tip
 - Video 2.2—EFAST liver tip

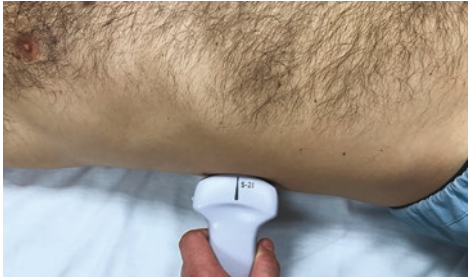

FIGURE 2.1 Transducer placement RUQ: Place the transducer over the patient’s right flank between the mid-axillary and anterior axillary line with the transducer marker directed toward the patient’s head

FIGURE 2.2 RUQ normal EFAST: Normal RUQ EFAST showing no free fluid. Imaging should include the tip of the liver, area between the liver and right kidney, and the diaphragm above the liver

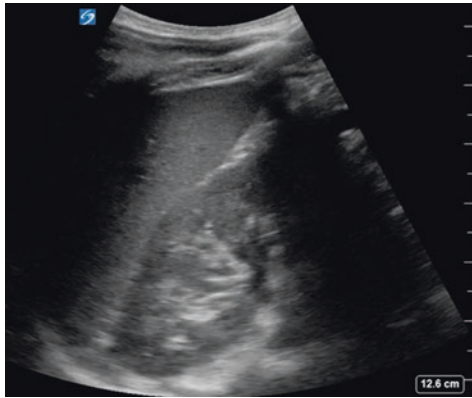


FIGURE 2.3 EFAST liver tip: RUQ view demonstrating the liver tip above the right kidney. Hemoperitoneum can be detected first around the liver tip; therefore, it is important to image this specific area of the RUQ

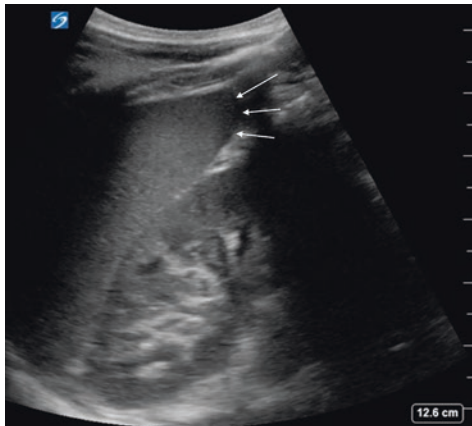
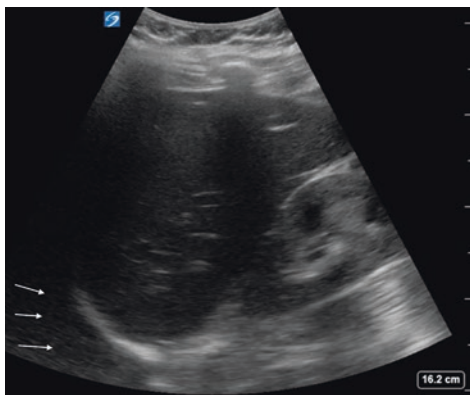


FIGURE 2.4 RUQ EFAST view with hemithorax: Evaluation of the RUQ should include the right hemithorax, visualized above the liver and hyper-echoic diaphragm



- Scan through the area including the inferior right hemithorax located above the diaphragm.
 - Figure 2.4—RUQ EFAST view with hemithorax

(b) Left upper quadrant

- Place the transducer over the patient's left flank between the mid and posterior axillary line near the 10th rib space with the marker pointed toward the patient's head.
 - Figure 2.5—Transducer placement LUQ
 - Figure 2.6—LUQ standard view
 - Video 2.3—LUQ standard view
- There is also a potential space located between the spleen and diaphragm; therefore, it is important to image above the spleen.
 - Figure 2.7—LUQ above spleen view
- Scan through the area including the left hemithorax located above the diaphragm.
 - Figure 2.8—Left hemithorax

FIGURE 2.5
 Transducer placement LUQ: Place the transducer over the patient's left flank between the mid-axillary and posterior axillary line near the 10th rib space with the marker pointed toward the patient's head

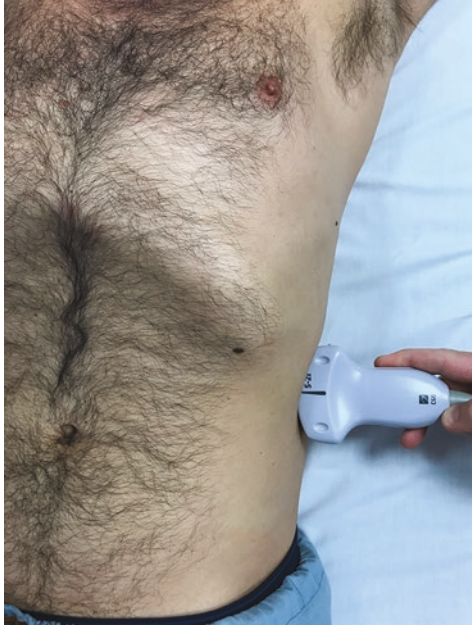

FIGURE 2.6 LUQ standard view: LUQ EFAST view showing no free fluid. Imaging should include the spleen, area between the spleen and left kidney, and views of the diaphragm above the spleen

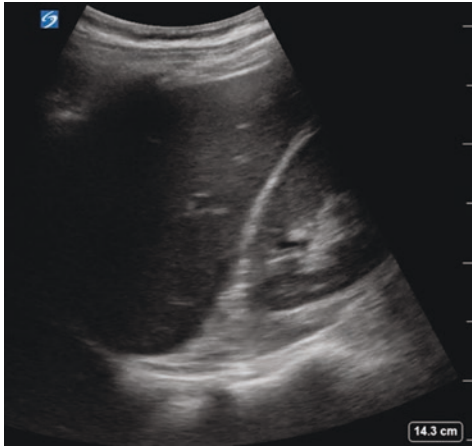


FIGURE 2.7 LUQ EFAST imaging above the spleen: Free fluid will typically accumulate above the spleen first in the LUQ making it important to always image this area

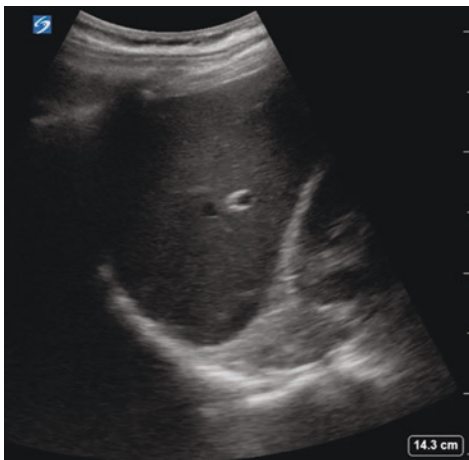
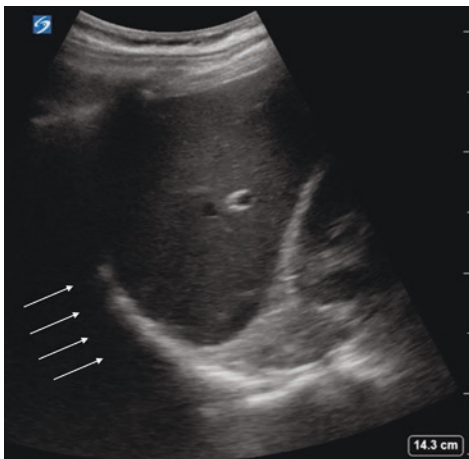


FIGURE 2.8 LUQ EFAST view with left hemithorax: Evaluation of the LUQ should include the left hemithorax, visualized above the spleen and hyper-echoic diaphragm



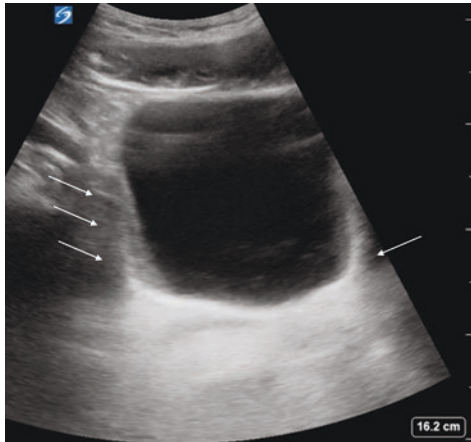
(c) Pelvis

- Place the transducer superior to the pubic bone angled inferiorly with the transducer marker pointed toward the patient's right in the transverse plane.
 - Figure 2.9—Transducer placement pelvis, transverse

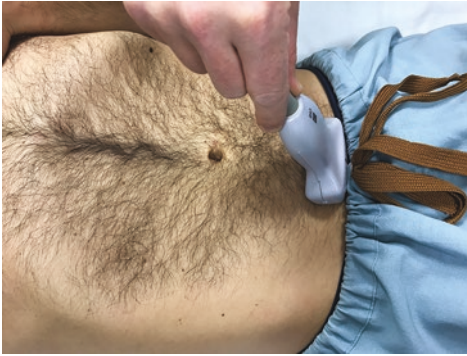

FIGURE 2.9 Transducer placement pelvis, transverse: Place the transducer superior to the pubic bone angled inferiorly with the transducer marker pointed toward the patient's right in the transverse plane

FIG 2.10 Paracolic gutters in transverse: Normal pelvis and bladder EFAST view in a transverse plane. Note bilateral paracolic gutters on each side of the bladder



- Scan through from superior to inferior to visualize the paracolic gutters and area posterior to the bladder.
 - Figure 2.10—Paracolic gutters in transverse
 - Video 2.4—Paracolic gutters in transverse

- Rotate the transducer 90° clockwise to image the pelvis in sagittal plane with the transducer marker pointed to patient's head.
 - Figure 2.11—Transducer placement bladder in sagittal
 - Figure 2.12—Sagittal view of the pelvis
 - Video 2.5—Sagittal view of the pelvis
- Scan through by fanning from right to left.

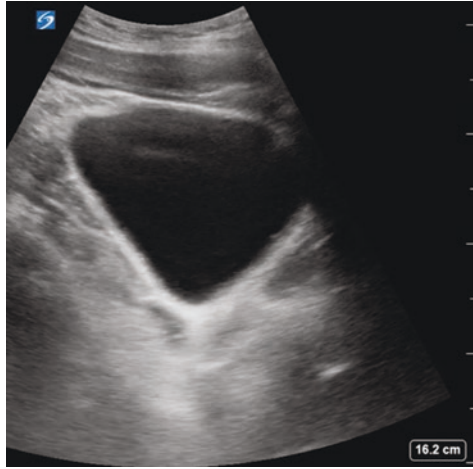
(d) Subxiphoid

- Place the transducer inferior to the xiphoid process with the marker oriented toward the patient's right.
 - EFAST should be completed in abdominal mode on the ultrasound machine; however, if in cardiac mode, to image the heart, be sure to hold the transducer with the marker pointed toward the patient's left.

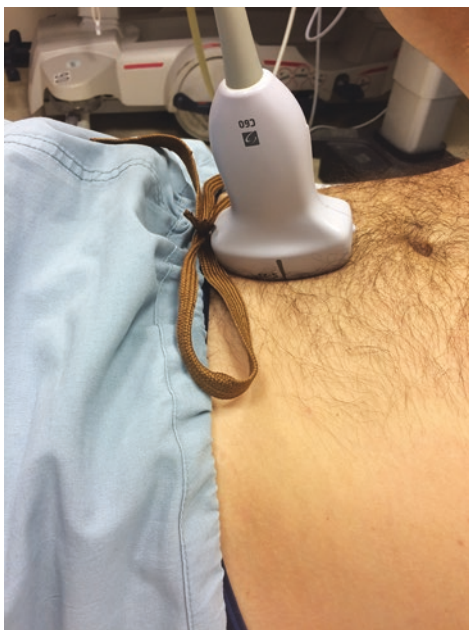

FIGURE 2.11
Transducer placement bladder in sagittal: From a transverse position, rotate the transducer 90° clockwise to image the pelvis in sagittal plane with the transducer marker pointed to patient's head

FIG 2.12 Sagittal view of bladder: Normal pelvis and bladder EFAST view in a sagittal plane



- Place operator's hand on top of the transducer, use a moderate amount of force to press the transducer into the patient's abdomen, and angle the transducer superior and leftward toward the left shoulder.
 - Figure 2.13—Subxiphoid EFAST transducer placement
 - Adjust depth to adequately visualize the entire heart.
 - Figure 2.14—Subxiphoid EFAST view
 - Video 2.6—Subxiphoid EFAST view
- (e) Bilateral lung apices
- Can use curvilinear, linear, or phased array transducer.
 - Place the transducer on the anterior chest in a sagittal orientation with the marker pointed toward the patient's head over the 2nd intercostal space.
 - Figure 2.15—Transducer placement lungs
 - Figure 2.16—Lung view EFAST
 - Video 2.7—Lung sliding
 - Evaluate for lung sliding, which occurs due to the visceral pleura sliding against the parietal pleura.

FIG 2.13
Subxiphoid EFAST
transducer placement: Place the
transducer inferior to the xiphoid pro-
cess with the
marker oriented
toward the patient's
right. Place opera-
tor's hand on top of
the transducer, use
a moderate amount
of force to press
the transducer into
the patient's abdo-
men, and angle the
transducer superior
and leftward
toward the left
shoulder

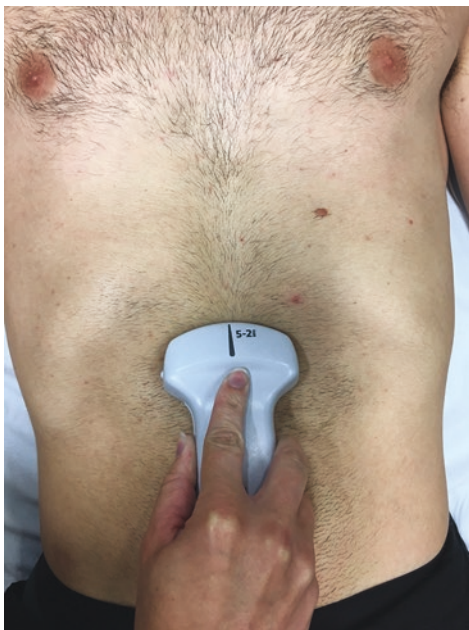

FIGURE 2.14
Subxiphoid
EFAST view:
Normal EFAST
demonstrating a
subxiphoid view of
the heart. The liver
is used as the
acoustic window to
view cardiac struc-
tures and pericar-
dium. The right
heart sits closest to
the liver

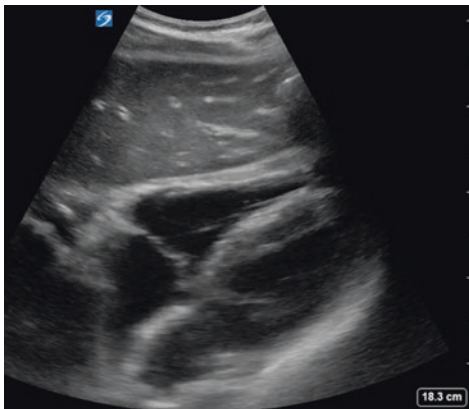
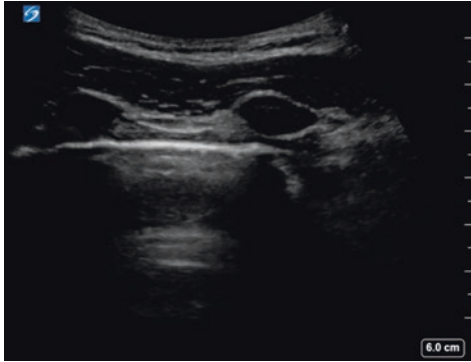


FIG 2.15
Transducer placement lungs: Place the transducer on the anterior chest in a sagittal orientation with the marker pointed toward the patient's head over the 2nd intercostal space

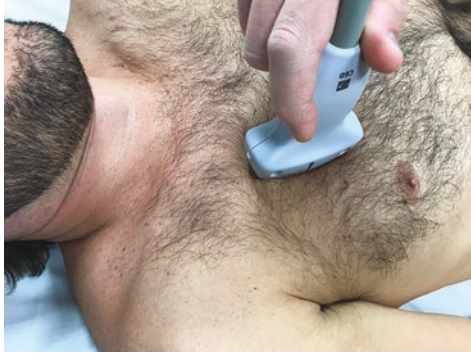

FIGURE 2.16 Lung view EFAST: Normal EFAST demonstrating lung sliding. Note two anechoic ribs with posterior acoustic shadowing and the hyperechoic pleural line between them



- Lung sliding appears as horizontal movement of two thin hyperechoic lines in a to-and-fro movement.
- Decrease the gain to help visualize the pleura.
- Use M-mode to confirm findings or if unable to determine the presence of lung sliding.
 - Place the M-mode line between two ribs, so it crosses perpendicularly over the pleura.
 - Identify “seashore sign” with normal lung sliding.

Horizontal lines represent the static chest wall [2]. Granular pattern represents movement of the lung beyond the pleural line [2].

Figure 2.17—M-mode spike position.

Figure 2.18—Normal sliding lung M-mode.

FIGURE 2.17
M-mode spike
position: The
M-mode spike
should be placed
between the two
rib shadows over-
lying the hyper-
echoic pleural line

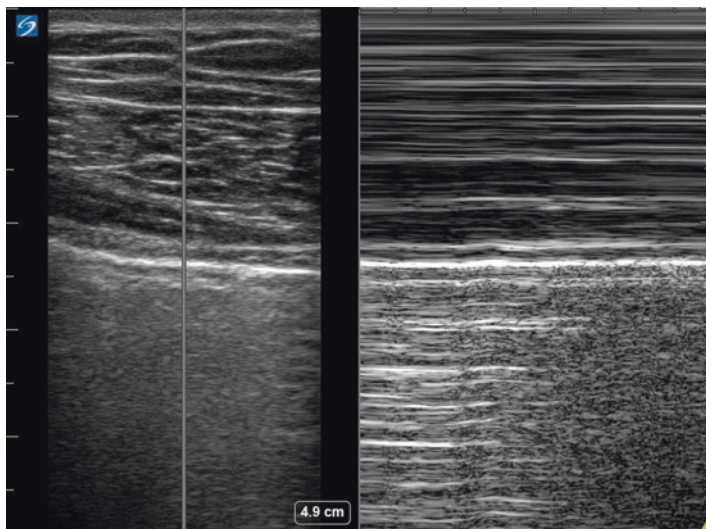
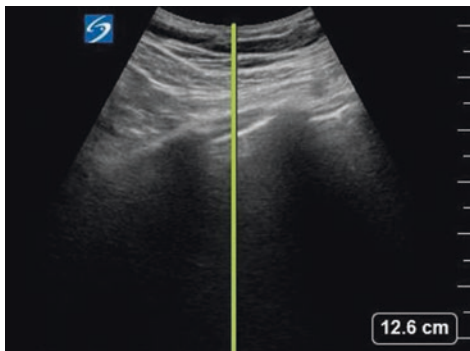


FIGURE 2.18 Normal sliding lung M-mode: M-mode ultrasonography of a normal lung demonstrates the static chest wall in the top half of image and movement of the lungs in the bottom half consistent with normal respiration. Sometimes referred to as “seashore” sign

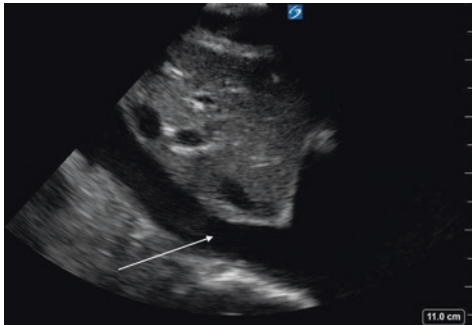
(f) Inferior vena cava

- Place the transducer inferior to the xiphoid process, slightly to the right of midline, with the marker oriented toward the patient's head.
- Figure 2.19—Transducer placement IVC
- Figure 2.20—IVC view
- Video 2.8—IVC view

FIGURE 2.19
Transducer placement IVC: Place the transducer inferior to the xiphoid process, slightly to the right of midline, with the marker oriented toward the patient's head

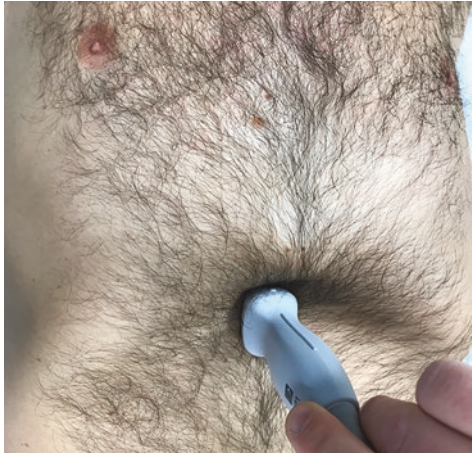

FIGURE 2.20 IVC view: Normal EFAST view of the IVC as it passes by the liver and drains into the right atrium of the heart



EFAST Pathology

(a) Hemoperitoneum

- Accumulation of blood within the peritoneum.
- Blood will be seen as an anechoic, hypoechoic, or echogenic fluid collection:
 - Between the liver and kidney

Figure 2.21—Positive EFAST Morrison’s pouch

Video 2.9—Positive EFAST Morrison’s pouch

- Around the liver tip

Figure 2.22—Positive EFAST liver tip

Video 2.10—Positive EFAST liver tip

- Between the spleen and kidney

Figure 2.23—Positive EFAST LUQ

Video 2.11—Positive EFAST LUQ

- Between the spleen and diaphragm

Figure 2.24—Positive EFAST LUQ above the spleen

Video 2.12—Positive EFAST LUQ above the spleen

FIGURE 2.21
Positive EFAST
Morrison’s pouch:
Free fluid is
located within
Morrison’s pouch
between the liver
and right kidney

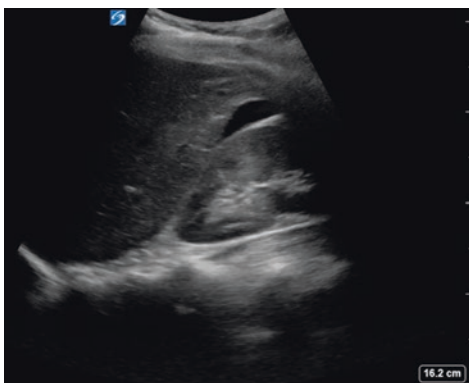

FIG 2.22 Positive EFAST liver tip: Free fluid is seen here surrounding the liver tip

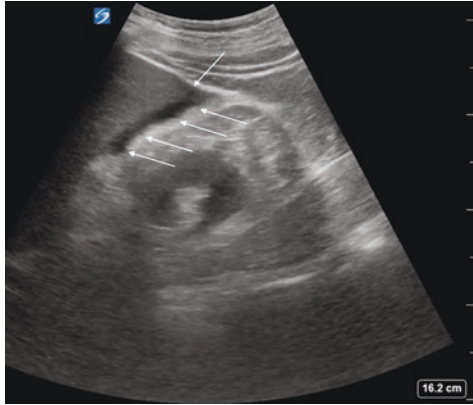
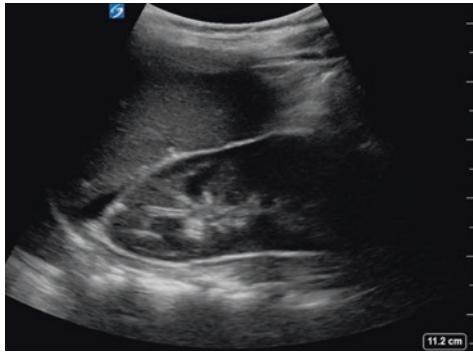


FIGURE 2.23 Positive EFAST LUQ: Free fluid is seen here between the spleen and left kidney



- Posterior to or on either side of the bladder

Figure 2.25—Positive EFAST bladder transverse

Video 2.13—Positive EFAST bladder transverse

Figure 2.26—Positive EFAST bladder sagittal

Video 2.14—Positive EFAST bladder sagittal

- Depending on the amount of fluid, can be a large pocket or a small anechoic stripe.

(b) Hemothorax or Pleural Effusion

- Abnormal accumulation of blood or fluid between the two pleural layers

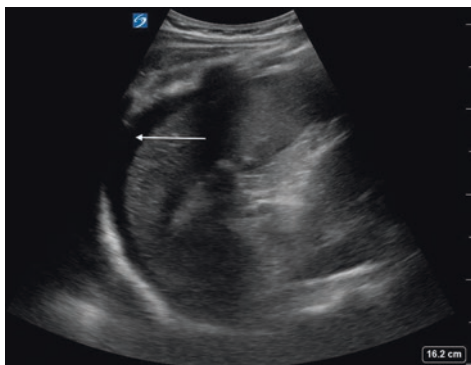
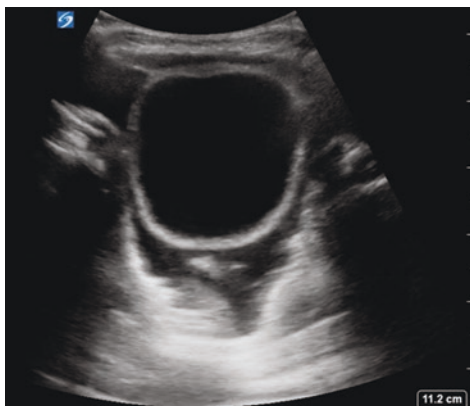


FIGURE 2.24 Positive EFAST LUQ above spleen: Free fluid is located superior to the spleen and inferior to the diaphragm. Fluid will typically accumulate above the spleen first in the LUQ making it important to always image this area

FIGURE 2.25 Positive EFAST bladder transverse: Free fluid is surrounding the bladder in a transverse plane. Note the anechoic fluid posterior to the bladder and in both paracolic gutters



- Anechoic or hypoechoic fluid collected above the diaphragm within the thoracic cavity between the visceral and parietal pleura
 - Can be seen when imaging the right or left upper quadrants
 - Will accumulate posteriorly if the patient is supine and inferiorly between the diaphragm and lung if the patient is upright

FIGURE 2.26
Positive EFAST
bladder sagittal:
Free fluid is found
around the bladder
in the sagittal
plane

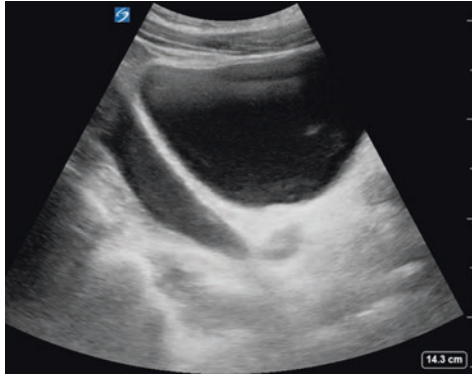
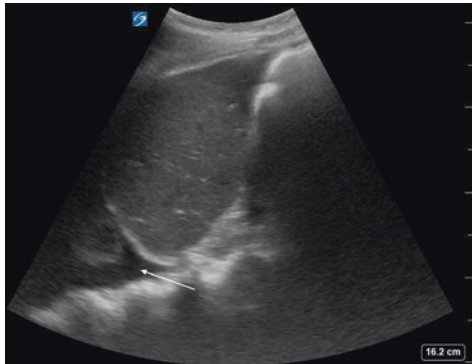


FIGURE 2.27
Positive pleural
fluid above the
diaphragm: A
small pleural effu-
sion (*arrow*) is
noted above the
diaphragm

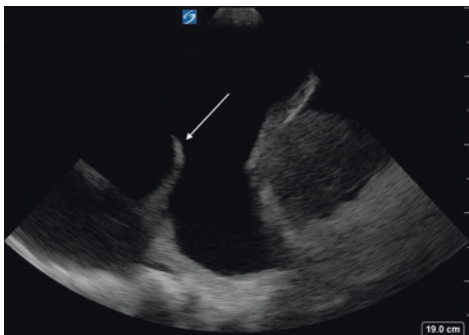


- Figure 2.27—Pleural effusion
- Video 2.15—Pleural effusion
- May see “curtain” or “flag” sign which occurs with the lung slides into the effusion during respirations
 - Figure 2.28—Large pleural effusion with flag sign
 - Video 2.16—Large pleural effusion with flag sign

(c) Pneumothorax

- Caused by separation of the lung pleura away from the chest wall, resulting in a collapsed lung

FIGURE 2.28 Large pleura effusion with flag sign: With large pleural effusions, the lung will appear to be floating in the fluid, creating what looks like a flag flapping in the wind (flag sign)



- Absent lung sliding due to the separation of the visceral pleura from the parietal pleura [2]
 - Video 2.17—Absent lung sliding
- If lung sliding is absent, move the transducer superior or inferior to locate the lung point sign.
 - Lung point sign is the transition point between normal lung sliding and a pneumothorax with the absence of lung sliding.
 - This is not always present, especially with a large pneumothorax [2].
 - Lung point sign is 100% specific for pneumothorax [2].
 - Video 2.18—Lung point.
- Use M-mode to confirm the absence of sliding as described above.
 - M-mode will demonstrate no movement of the lungs, which is sometimes referred to as barcode sign due to the horizontal lines seen throughout the entire image [2].
 - Figure 2.29—Barcode sign.

(d) Hemopericardium or Pericardial Effusion

- Accumulation of blood or fluid between the visceral and parietal pericardium surrounding the heart.

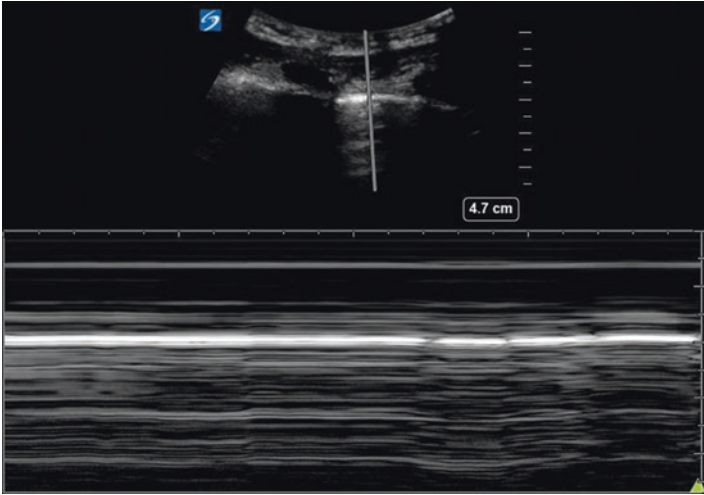


FIGURE 2.29 Barcode sign: M-mode through the pleural line demonstrates no movement as evidenced by the horizontal lines in the bottom half of the image. This is sometimes referred to as “barcode sign” given the similar appearance to retail barcodes

- Appears as a hypoechoic stripe between the heart and brightly echogenic pericardium at the inferior border of the heart, which can be seen next to the liver.
 - Figure 2.30—Pericardial effusion
 - Video 2.19—Pericardial effusion
- The sonographer can distinguish a left pleural effusion from a pericardial effusion by the pattern of fluid.
 - Pericardial fluid will be present posterior to the left ventricular wall and anterior to the descending aorta [3].
 - Left-sided pleural effusion will occur posterior to the left ventricular wall and will not be present anterior to the descending aorta [3].
 - Figure 2.31—Comparing pleural fluid vs. pericardial fluid.

FIGURE 2.30
Pericardial effusion: Anechoic fluid surrounds the right heart indicating a pericardial effusion

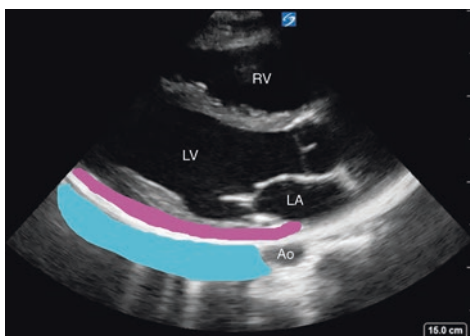
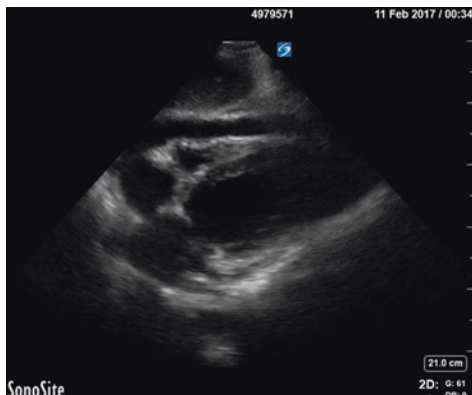
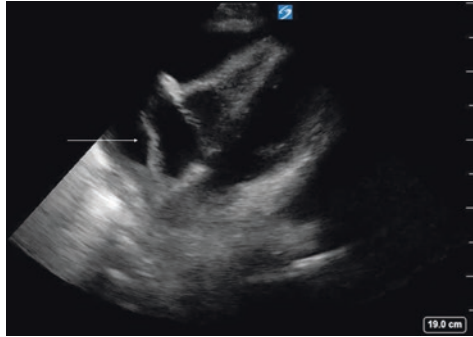


FIGURE 2.31 Comparing pleural fluid and pericardial fluid: In a parasternal long view, pericardial fluid will be present posterior to the left ventricular wall and anterior to the descending aorta. A left-sided pleural effusion will occur posterior to the left ventricular wall and will not be present anterior to the descending aorta

(e) Cardiac Tamponade

- Occurs when fluid within the pericardium generates excessive external pressure, which then impairs the ability for the heart chambers to fill eventually causing hypotension and shock

FIGURE 2.32 Right atrial systolic collapse in tamponade: In cardiac tamponade, the pressure within the pericardium exceeds the pressure within the right atrium causing it to collapse during systole



- Affects the thin-walled right atrium and right ventricle first.
- Right atrial systolic collapse [3, 4] is the most sensitive sign of tamponade.

Usually the first echocardiographic sign

Figure 2.32—Right atrial systolic collapse in tamponade

Video 2.20—Right atrial systolic collapse in tamponade

- Right ventricular diastolic collapse [4] is the most specific sign of tamponade [3].

Figure 2.33—Right ventricle collapse

Video 2.21—Right ventricle collapse

- Will also see a dilated IVC with minimal collapse [4]
 - Figure 2.34—Plethoric IVC
 - Video 2.22—Plethoric IVC

FIGURE 2.33 Right ventricle collapse: In cardiac tamponade, the pressure within the pericardium exceeds the pressure within the right ventricle causing it to collapse during diastole

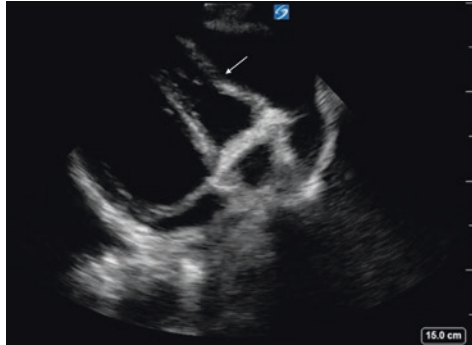
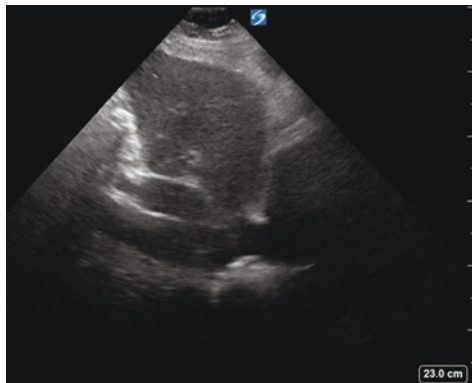


FIGURE 2.34 Plethoric IVC: Here the IVC is visualized passing the liver and draining into the right atrium. Note that the IVC is quite large indicating the IVC is plethoric



Key Points

- To have a positive EFAST, as little as 100 cc of fluid can be detected with ultrasound [1, 5].
- Use EFAST as a serial screening exam; rapidly repeat with any change in patient status.
- Hemoperitoneum can be anechoic or echogenic depending on if clot formation has begun.
 - If presentation following trauma is delayed, blood within the peritoneum will often be clotted and can be missed [6].

- Morrison's pouch is the most sensitive location of identifying hemoperitoneum.
 - In children, fluid will accumulate in the pelvis before the RUQ.
- Fluid will most often accumulate between the diaphragm and spleen first, before splenorenal recess, when there is blood in the LUQ [1].
 - However, blood from a splenic injury will usually accumulate in the RUQ before demonstrating evidence of hemoperitoneum in the LUQ.
- Placing the patient in Trendelenberg and reverse Trendelenberg and waiting about 5 min for fluid to accumulate by gravity will increase the sensitivity of the EFAST exam.
- Ultrasound cannot determine the etiology of the fluid within the abdomen. Fluid that is seen on ultrasound may or may not be blood and may or may not be the result of trauma.
- The sonographer cannot visualize the retroperitoneum using the EFAST exam. Therefore, bleeding from retroperitoneal structures such as the kidneys or aorta will be difficult to assess.
- Use both transverse and sagittal views to examine for intraperitoneal fluid in the pelvis.
- Care must be taken to differentiate between intra-abdominal organs and fluid, such as bowel.
- When evaluating for a pericardial effusion, an epicardial fat pad can be confused with a small pericardial effusion.
 - An epicardial fat pad will be anterior to the right ventricle in the parasternal long view.
 - Can sometimes be distinguished from blood or fluid by a speckled appearance [3].
 - More common in diabetics, obese, elderly, and females [3].

- If unable to visualize the heart adequately in a subxiphoid window, obtain an image using a parasternal long technique (see Chap. 3 for more details).
 - Can also try having the patient take a deep breath in and hold it, which may push the cardiac structures into view
- EFAST exam will be limited by morbid obesity and subcutaneous emphysema.
- EFAST has been shown to have a higher sensitivity than chest X-ray when evaluating for pneumothorax [7].

References

1. Ma OJ, Mateer JR, Kirkpatrick AW. Chapter 5: Trauma. In: Ma OJ, Mateer JR, Reardon RF, Joing SA, editors. *Emergency Ultrasound*. 3rd ed. China: McGraw-Hill Education; 2014. p. 61–92.
2. Husain LF, Hagopian L, Wayman D, Baker WE, Carmody KA. Sonographic diagnosis of pneumothorax. *J Emerg Trauma Shock*. 2012;5(1):76–81. <https://www.ncbi.nlm.nih.gov/pmc/articles/PMC3299161/>. Accessed 26 April 2017.
3. Rasalingam R, Makan M, Perez JE. *The Washington Manual of Echocardiography*. Philadelphia: Wolters Kluwer Health/Lippincott Williams & Wilkins; 2013.
4. Mallin M & Dawson M. *Introduction to bedside ultrasound: volume 2*. United States of America: emergency ultrasound solutions; 2013. iBook. <https://itun.es/us/ueELM.1>.
5. Fleming S, Bird R, Ratnasingham K, Sarker SJ, Walsh M, Patel B. Accuracy of FAST scan in blunt abdominal trauma in a major London trauma centre. *Int J Surg*. 2012;10(9):470–4. <http://www.sciencedirect.com/science/article/pii/S1743919112001082>. Accessed 20 April 2017
6. Lewis RE, Saul T, Del Rios M. Focus on: EFAST—Extended Focused Assessment With Sonography for Trauma. January 2009. ACEP News Website. <https://www.acep.org/Clinical---Practice-Management/Focus-On--EFAST---Extended-Focused->

- [Assessment-With-Sonography-for-Trauma/](#). Accessed 20 April 2017
7. Abdulrahman Y, Musthafa S, Hakim SY, Nabir S, Qanbar A, Mahmood I, Siddiqui T, Hussein W, Ali HH, Afifi I, El-Menyar A, Al-Thani H. Utility of extended FAST in blunt chest trauma: is it the time to be used in the ATLS algorithm? *World J Surg.* 2015;39(1):172–8. <https://link.springer.com/article/10.1007%2Fs00268-014-2781-y> Accessed 20 April 2017.

Chapter 3

Cardiac Ultrasound

Cardiac ultrasound, often referred to as echocardiography, is a very broad and technical field. It can take years to master the intricacies; however, with simple training and education of basic heart function and image acquisition, echocardiography can be performed well and accurately by a novice sonographer. Patients young and old can benefit from point-of-care echocardiography to diagnose and ultimately guide treatment, disposition, and further care for their condition. This chapter will introduce the basic skills needed for obtaining standard echocardiographic views that can be used in all fields of medicine. It will review cardiac ultrasound indications, basic anatomy, image acquisition, normal ultrasound anatomy, and interpretation of pathology.

Clinical Application and Indications

- Visualize overall cardiac activity and gross estimation of ejection fraction.
- Guide resuscitation during cardiac arrest.
- Evaluate for cardiac cause of undifferentiated hypotension.
- Evaluate for wall motion abnormalities in patients with suspected myocardial infarction.

Electronic Supplementary Material The online version of this chapter (https://doi.org/10.1007/978-3-319-68634-9_3) contains supplementary material, which is available to authorized users.

- Evaluate for pericardial effusion or cardiac tamponade.
- Evaluate for signs of right ventricular strain.
- Evaluate inferior vena cava.

Normal Cardiac Anatomy

- The heart is a four-chambered structure that is surrounded by a pericardium and lies within the mediastinum.
- Atria are fluid-filled thin-walled structures.
- The most anterior chamber is the right ventricle, which has thicker walls than the atria but thinner than the left ventricle.
- The left ventricle has the thickest wall and lies posterior to the right ventricle, separated by the interventricular septum.
- Central Circulation.
 - Blood enters the heart through the inferior and superior vena cava, draining directly into the right atrium.
 - It then passes through the tricuspid valve and enters the right ventricle.
 - During systole, blood is ejected from the right ventricle through the pulmonary valve and into the pulmonary arteries.
 - Blood returns from the pulmonary circulation through the four pulmonary veins and drains directly into the left atrium.
 - Blood passes through the mitral valve and enters the left ventricle.
 - During systole, blood is ejected from the left ventricle through the aortic valve and into the proximal aorta.
- Valves.
 - Mitral valve has two leaflets— anterior and posterior [1].
 - Aortic valve has three leaflets—left, right, and noncoronary [1].

Congenital bicuspid valve occurs in 1–2% of the population [1].

- Tricuspid valve has three cusps—anterior, posterior, and septal [1].
- The pulmonary valve has three cusps—anterior, right, and left [1].

Image Acquisition

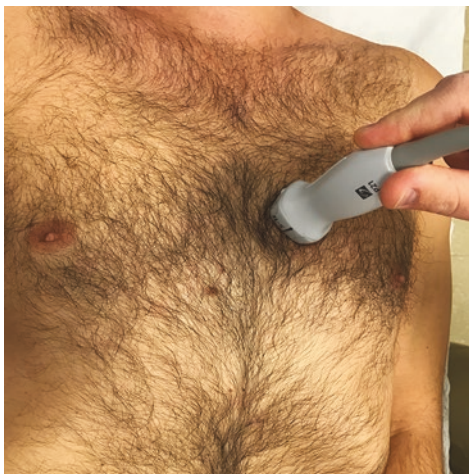- Transducer Selection.
 - Phased array

Be sure to select cardiac mode on the ultrasound machine.
- Patient Position and Procedure.
 - Place the patient in a supine position.
 - For subxiphoid views, the patient should have their knees bent to relax abdominal muscles for easier visualization.
 - A left lateral decubitus position can bring the heart closer to the chest wall and improve cardiac windows, especially for apical views.
- Standard Exam Views.
 - Parasternal long axis
 - Parasternal short axis
 - Apical four-chamber
 - Apical two-chamber
 - Subxiphoid
 - Inferior vena cava (IVC)

Parasternal Long Axis

- Transducer Placement.
 - Place the transducer on the anterior chest at the second or third intercostal space to the left of the sternum with the transducer marker toward the patient's right shoulder.
 - Slide the transducer inferior or superior, one rib space at a time, to find the optimal cardiac window.
 - Figure 3.1—Parasternal long transducer placement

FIGURE 3.1
Parasternal long
transducer place-
ment: Place the
transducer on the
anterior chest at
the second or third
intercostal space to
the left of the ster-
num with the
transducer marker
toward the
patient's right
shoulder



- Ultrasound Anatomy.

- Figure 3.2—Parasternal long.
- Apex points toward the left of the screen with the base of the heart and great vessels on the right of the screen.
 - Right ventricle is the most anterior chamber of the heart and will be visualized at the top of the screen.
 - Left ventricle at the bottom of the screen with the left atrium to the lower right.
 - Systole will be visualized when the mitral valve is closed and the left ventricular walls are shortened.

During systole, the aortic valve will be open as blood flows from within the left ventricle to the ascending aortic arch.

- Diastole will be visualized when the mitral valve is open and the left ventricle fills with blood.

During diastole, blood flows from the left atrium through the mitral valve into the left ventricle.

- The descending aorta is visualized immediately posterior to the bright, echogenic pericardial sac.
- Video 3.1—Parasternal long.

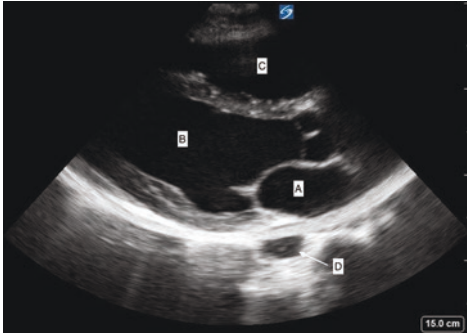


FIGURE 3.2 Parasternal long: Parasternal long cardiac view in between cardiac cycles with both mitral and aortic valves closed. Blood flows from the left atrium (a) through the mitral valve, into the left ventricle (b), and out to the body through the aortic valve. The right ventricle can be seen at the top of the screen (c). The descending thoracic aorta is posterior to the heart (d)

Parasternal Short Axis

- Transducer Placement.
 - From the long axis position, rotate the transducer approximately 90° clockwise so the marker points toward the left shoulder.
 - This will give you a cross-sectional view of the left ventricle.
 - Figure 3.3—Parasternal short transducer placement.
- Ultrasound Anatomy.
 - Figure 3.4—Parasternal short
 - Left ventricle appears as a muscular circle that, in the absence of pathology, contracts concentrically.
 - The bicuspid mitral valve is located centrally within the left ventricle that has the appearance of a “fish mouth” opening and closing.

Figure 3.5—Mitral valve fish mouth in parasternal short

Video 3.2—Parasternal short at the mitral valve

FIGURE 3.3
Parasternal short transducer placement: From the long axis position, rotate the transducer approximately 90° clockwise so the marker points toward the left shoulder

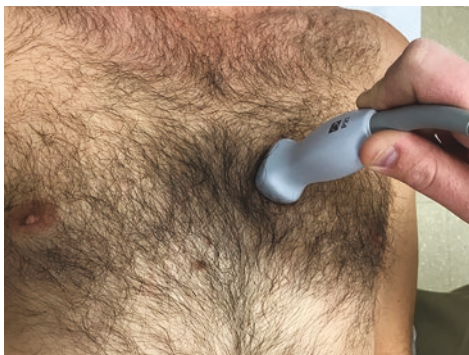

FIGURE 3.4
Parasternal short labeled: Parasternal short cardiac view at the level of the papillary muscles (arrows). LV cavity (a) is circular, not elongated or ovoid. The RV cavity (b) can be seen in upper left

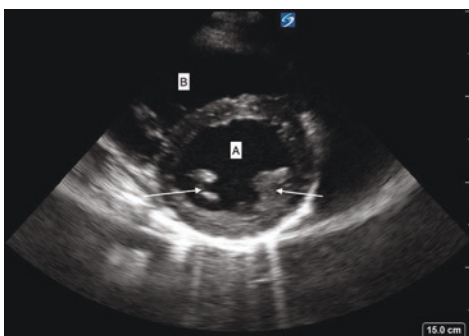


FIGURE 3.5 Mitral valve fish mouth in parasternal short: Mitral valve parasternal short view displaying the “fish mouth” of the mitral valve in short axis. The anterior leaflet (a) can be seen above the posterior leaflet (b)

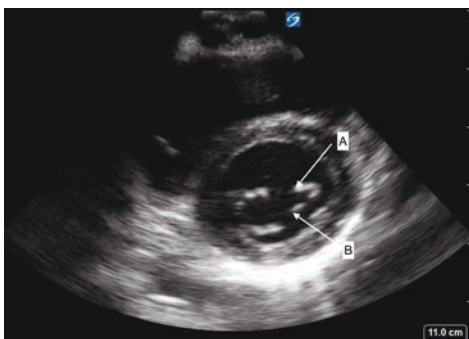
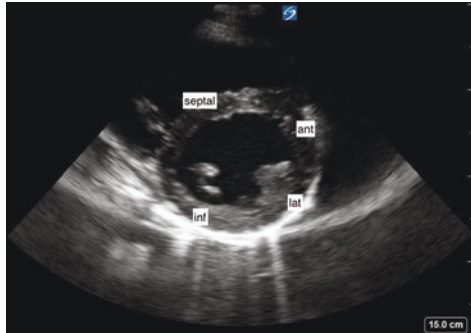


FIGURE 3.6 Walls of LV labeled in parasternal short: Parasternal short cardiac view at the level of the papillary muscles showing the relative wall sections



- Sliding the probe toward the apex will allow visualization of the two papillary muscles in short axis.

Each papillary muscle is usually located at 4 and 8 o'clock within the circular left ventricle.

Video 3.3—Parasternal short at the apex.

- Right ventricle will appear as a “C”-shaped structure on the left side of the screen, separated from the left ventricle by the septal wall.
- Myocardial infarction or ischemia can be identified by wall motion abnormalities and a loss of concentric contraction of the left ventricle.

Anterior wall is closest to the transducer.

Septal wall is to the left of the screen.

Lateral wall is to the right of the screen.

Interior wall is in the far field.

Figure 3.6—Walls of LV labeled in parasternal short.

Apical Four- and Two-Chamber

(a) Transducer Placement

- Place the transducer on the point of maximal impulse (PMI) with the marker pointed toward the patient's left elbow.
 - Figure 3.7—Apical four-chamber transducer placement.

FIGURE 3.7 Apical four-chamber transducer placement: Place the transducer on the point of maximal impulse (PMI) with the marker pointed toward the patient's left elbow

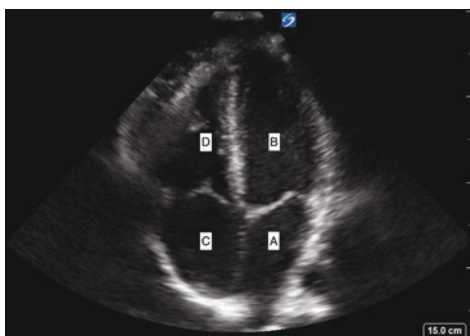
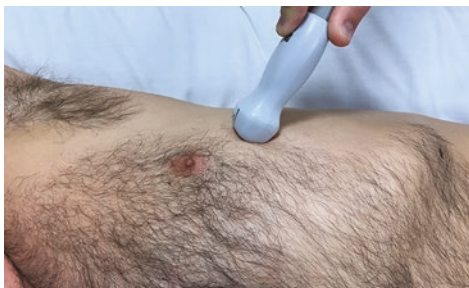

FIGURE 3.8 Apical four-chamber: Apical four-chamber view in systole, with apex of the heart located at the *top* of the screen, base located at the *bottom*. Ideal orientation is with septal wall (between **d** and **b**) located in vertical orientation, perpendicular to the face of the cardiac transducer. Cardiac chambers are as follows: left atrium (**a**), left ventricle (**b**), right atrium (**c**), and right ventricle (**d**)

- This will allow visualization of the four chambers of the heart, viewed from apex to base.
- Rotate the transducer counterclockwise to obtain a two-chamber view of the left atrium and left ventricle.

(b) Ultrasound Anatomy

- Four-chamber
 - Figure 3.8—Apical four-chamber ultrasound image.

- Left ventricle and atrium will be seen on the right side of the screen.

The left ventricle wall on the far right is the lateral wall.

- The septal wall separates the two ventricles and is in the middle of the screen in a vertical orientation.
- Right ventricle and atrium will be seen on the left side of the screen.
- Video 3.4—Apical four-chamber.
- Two-chamber
 - Figure 3.9—Apical two-chamber.
 - Only the left ventricle and left atrium will be seen in this view.
 - This view allows visualization of the anterior and inferior walls of the left ventricle.
 - Video 3.5—Apical two-chamber.

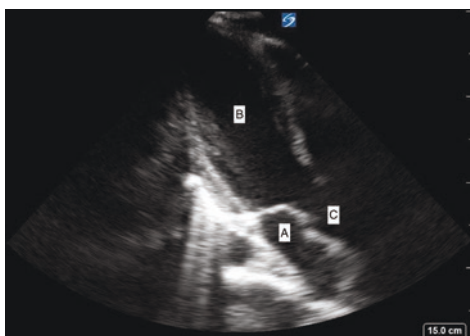
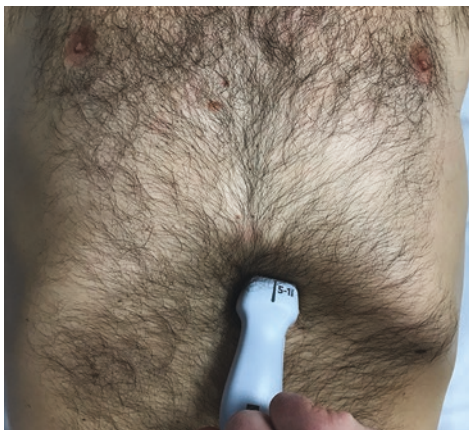

FIGURE 3.9 Apical two-chamber: Apical two-chamber cardiac view demonstrating vertical orientation of the heart. Inferior wall of the left ventricle (**b**) is to the left of the image, anterior wall to the right. Left atrium (**a**) and aortic outflow (**c**) are also demonstrated

FIGURE 3.10
Subxiphoid transducer placement: Place the transducer just below the xiphoid process with the marker pointed toward the patient's left



Subxiphoid

- Transducer Placement
 - Place the transducer just below the xiphoid process with the marker pointed toward the patient's left.
 - Place operator's hand on top of the transducer, use a moderate amount of force to press the transducer into the patient's abdomen, and angle the transducer superior and leftward toward the left shoulder.
 - Adjust depth to adequately visualize the entire heart.
 - Figure 3.10—Subxiphoid transducer placement.
- Ultrasound Anatomy
 - Figure 3.11—Subxiphoid ultrasound image.
 - The liver is anterior to the heart.
 - Posterior to the liver is the right ventricle and right atrium.
 - Posterior to the right heart is the left ventricle and left atrium.
 - Video 3.6—Subxiphoid.

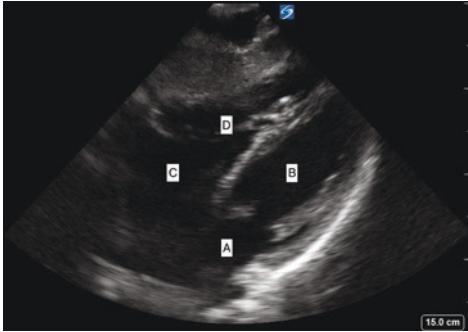


FIGURE 3.11 Subxiphoid: Subxiphoid cardiac view demonstrating the heart viewed through the liver window. Cardiac chambers are identified as follows: left atrium (a), left ventricle (b), right atrium (c), right ventricle (d)

Inferior Vena Cava

(a) Transducer Placement

- Place the transducer just below the xiphoid process, slightly to the right of midline, with the marker pointed toward the patient's head.
- The transducer should be perpendicular to the spine.
- Figure 3.12—IVC transducer placement.

(b) Ultrasound Anatomy

- Figure 3.13—IVC ultrasound image.
- IVC will be seen posterior to the liver entering the right atrium.
 - Video 3.7—IVC
- IVC normally collapses with inspiration and dilates with expiration.
 - Dilated IVC with minimal collapse indicates volume overload; impaired cardiac filling, such as with

FIGURE 3.12 IVC transducer placement: Place the transducer just below the xiphoid process, slightly to the right of midline, with the marker pointed toward the patient's head

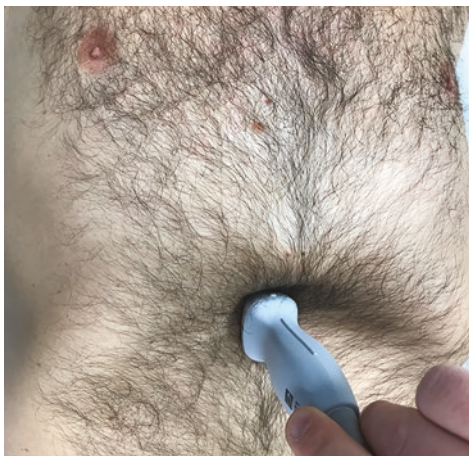
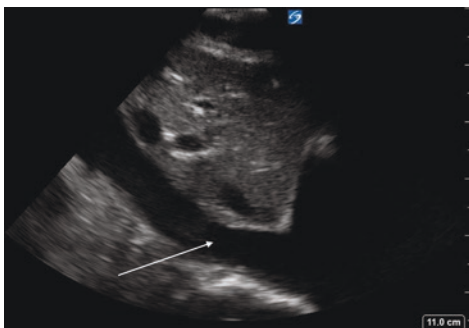
FIG 3.13 IVC: Inferior vena cava demonstrated in long axis passing by the liver and emptying into the right atrium



tamponade; outflow obstruction, such as with PE; or cardiogenic shock.

Figure 3.14—Dilated IVC

Video 3.8—Dilated IVC

- Increased IVC collapse may indicate hypovolemia.

Figure 3.15—Collapsed IVC

Video 3.9—Collapsed IVC

FIGURE 3.14
Dilated IVC:
Dilated IVC passing by the liver
and emptying into the right atrium

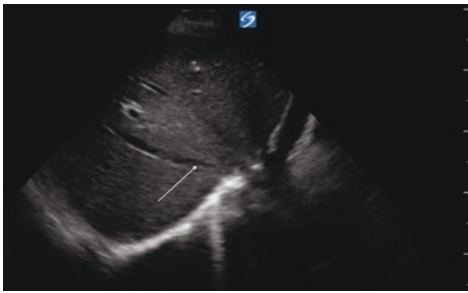
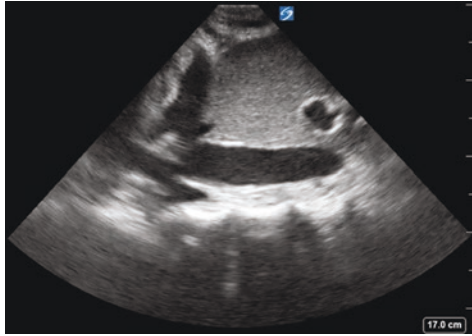


FIGURE 3.15 Collapsed IVC: Collapsed IVC (arrow) passing the liver on its course to the right atrium. At times a collapsed IVC can be so small that it can be difficult to find and image

Measuring Global Left Ventricular Systolic Function

- (a) Qualitative scale includes normal, mildly reduced, moderately reduced, or severely reduced:
- Video 3.10—Normal LV systolic function
 - Video 3.11—Mildly reduced LV systolic function
 - Video 3.12—Moderately reduced LV systolic function
 - Video 3.13—Severely reduced LV systolic function

(b) This corresponds to the following quantitative scale:

- Normal ejection fraction (EF) = greater than 50% [2].
- Mildly reduced = 40–49%.
- Moderately reduced = 30–39%.
- Severely reduced = less than 25% [2].
- Ejection fraction is the percent of blood ejected from the left ventricle into systemic circulation via the aorta.

(c) If possible, obtain all cardiac views to evaluate:

- Endocardial wall motion and left ventricular wall thickening during systole
 - Degree of contractility correlates with left ventricular wall thickening during contraction.
 - Normally the entire left ventricular wall should thicken during systole as the left ventricular cavity decreases in size.
- Left ventricular cavity size during cardiac cycle
 - Left ventricular cavity size should decrease by slightly more than half, indicating a normal ejection fraction.
 - Abnormal cavity size can be seen with dilated and hypertrophic cardiomyopathy.
- Mitral valve movement during diastole and mitral annulus movement during cardiac cycle
 - Visualize movement of the anterior leaflet of the mitral valve.
Anterior leaflet will be closest to transducer.
 - With normal left ventricular function, the anterior leaflet of the mitral valve should touch or come very close to the septum during diastole.
 - Figure 3.16—Mitral valve leaflet touching septum.
 - Video 3.14—Normal EF with mitral valve touching the septum.

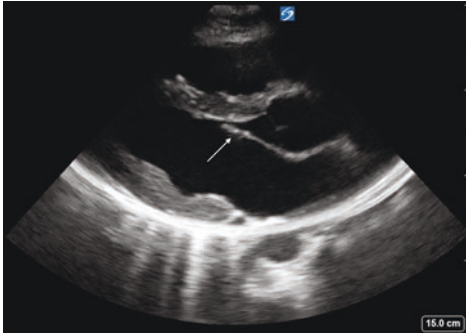


FIGURE 3.16 Mitral valve leaflet touching septum: Parasternal long axis image with anterior leaflet of mitral valve (arrow) touching septum during diastole, which is the common state associated with normal ejection fraction

(d) To summarize, with overall reduced function:

- Endocardial walls have less contractility.
- Walls may be hypertrophied or the chamber dilated.
- Anterior leaflet of the mitral valve will not touch the septum.

Cardiomyopathies

- Dilated Cardiomyopathy
 - Dilation and decreased left ventricular function [3].
 - Left ventricle will appear like a “water balloon.”
 - Characterized by decreased wall thickness and enlarged cavity size.
 - Little change in cavity size during the cardiac cycle.
 - Figure 3.17—Dilated cardiomyopathy.
 - Video 3.15—Dilated cardiomyopathy.
- Hypertrophic Cardiomyopathy
 - Left ventricular walls appear uniformly thickened with increased overall mass [1].

FIGURE 3.17
Dilated CM:
Parasternal long
axis image demon-
strating ballooning
of LV typical of
dilated cardiomy-
opathy

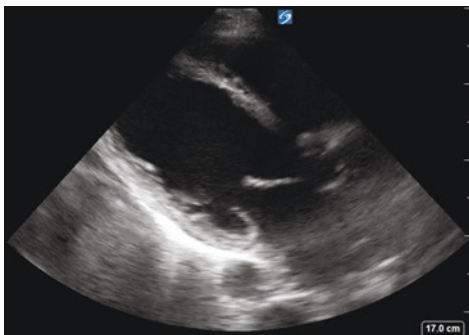
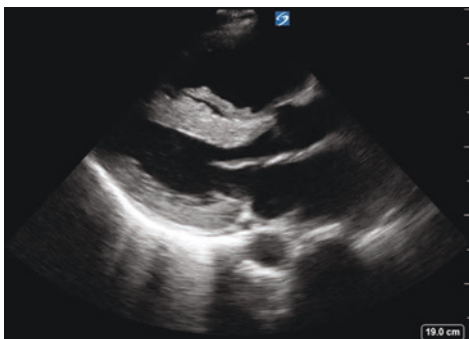

FIGURE 3.18
Hypertrophic CM:
Parasternal long
axis image demon-
strating thickened
left ventricular
walls indicating
hypertrophic car-
diomyopathy



- EF can be normal, increased, or decreased.
- Figure 3.18—Hypertrophic cardiomyopathy.
- Video 3.16—Hypertrophic cardiomyopathy.
- Takotsubo Cardiomyopathy
 - Also known as Stress-induced cardiomyopathy.
 - Left ventricle will have apical ballooning and dyskinesia [3].
 - Base of the left ventricle maintains its normal structure.
 - Figure 3.19—Takotsubo cardiomyopathy.
 - Video 3.17—Takotsubo cardiomyopathy.
- Hypertrophic Obstructive Cardiomyopathy
 - Septal hypertrophy that leads to impaired outflow due to obstruction [1]

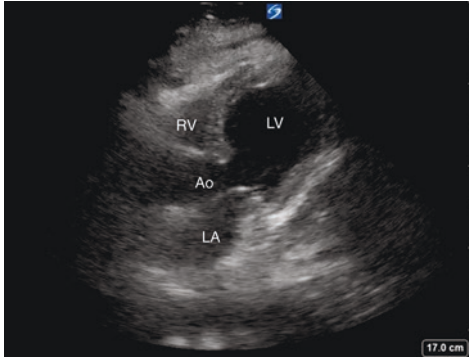


FIGURE 3.19 Takotsubo cardiomyopathy: Note the isolated apical dilation of the left ventricle (LV) in this subxiphoid view of takotsubo cardiomyopathy, named after the Japanese word for octopus trap

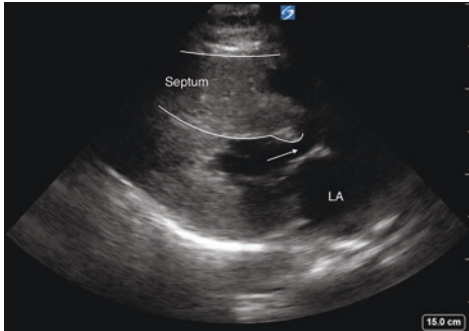


FIGURE 3.20 Hypertrophic obstructive cardiomyopathy: This is a parasternal long view of HOCM. Note the enlarged septum denoted by white lines and the subsequent small outflow tract (arrow)

- Can cause sudden cardiac death in young adults with exercise
- Figure 3.20—Hypertrophic obstructive cardiomyopathy
- Video 3.18—Hypertrophic obstructive cardiomyopathy

Right Ventricular Dilation

- (a) Right ventricular imaging is used to evaluate for enlargement or strain, particularly in the setting of acute pulmonary embolism (PE).
- (b) In a non-acute setting, it can be used to evaluate for other causes of elevated right heart pressures such as pulmonary hypertension.
- (c) Evaluate the heart using all cardiac views if possible.

- Parasternal long

- May see right ventricle enlargement or flattening of the septal wall into the left ventricle cavity [2]
- Figure 3.21—Parasternal long dilated RV
- Video 3.19—PSL dilated RV

- Parasternal short

- Allows size comparison of the right ventricle to the left ventricle.
- Enlarged right ventricle may cause the left ventricle to appear “D”-shaped indicating septal flattening or bowing into the left ventricular cavity [2].

Highly suggestive of acute PE in the appropriate clinical setting

Figure 3.22—Parasternal short with dilated RV

Video 3.20—PSS with dilated RV

- Apical four-chamber

- Optimal view to directly compare the right and left ventricle cavity size.
- Normal RV/LV cavity ratio is 0.6:1 in diastole [4].

Ratio of 0.7–1:1 suggests mild to moderate enlargement [4].

Ratio of greater than 1:1 represents severe dilation [4] and is highly suggestive of acute pulmonary embolism in the in appropriate clinical setting.

FIGURE 3.21
Parasternal long
dilated right ven-
tricle: Parasternal
long axis image
showing severely
dilated right ven-
tricle and associ-
ated collapsed left
ventricle

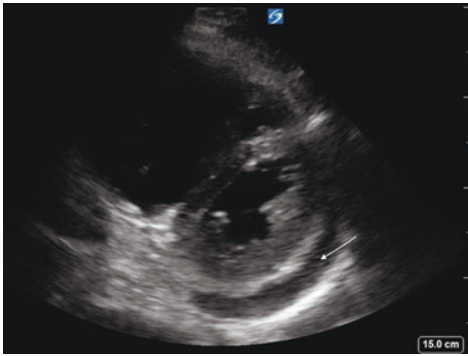
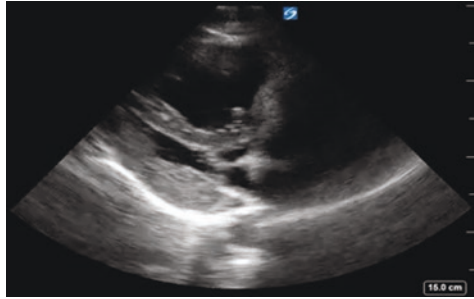
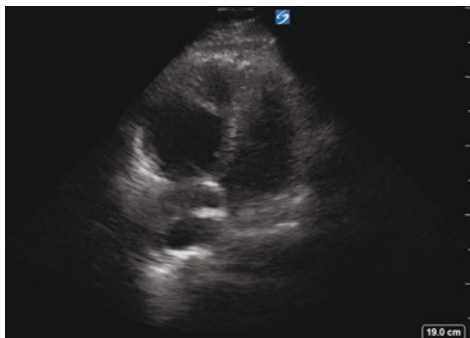


FIGURE 3.22 Parasternal short dilated right ventricle: Parasternal short axis image showing enlarged RV when compared to the LV. This results in septal bowing toward the LV that causes it to appear “D-shaped.” Small effusion denoted by arrow

- Figure 3.23—Apical four-chamber RV dilation.
- Video 3.21—Apical four-chamber with RV dilation.
- Inferior vena cava (IVC)
 - With an acutely enlarged right ventricle, evaluating the IVC will provide adjunctive information.
 - Dilated, plethoric IVC further supports the diagnosis of elevated right heart pressures.

FIGURE 3.23
Apical four-chamber
right ventricle
dilation: Apical
four-chamber
image showing
RV/LV ratio of
greater than 1:1,
indicating severe
RV dilation



Pericardial Effusion and Tamponade

(a) Pericardial effusion occurs when fluid accumulates between the visceral and parietal pericardium.

- Normally, there is approximately 10–50 mL of fluid within the pericardial space which is considered physiologic [5].
- Appears as a hypoechoic stripe between the heart and brightly echogenic pericardium.
 - Figure 3.24—Pericardial effusion
 - Video 3.22—Pericardial effusion parasternal long
 - Video 3.23—Pericardial effusion parasternal short
- An epicardial fat pad may be present anterior to the right ventricle and can be confused with small pericardial effusion in the parasternal long view.
 - An epicardial fat pad will be anterior to the right ventricle in the parasternal long view.
 - Can sometimes be distinguished from blood or fluid by a speckled appearance [1].
 - More common in diabetics, obese, elderly, and females [1].
 - Figure 3.25—Epicardial fat pad.

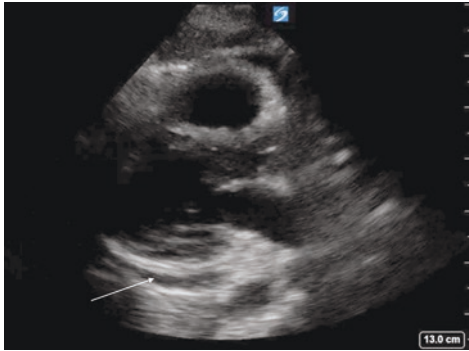


FIGURE 3.24 Pericardial effusion: Small pericardial effusion (arrow) seen in parasternal long view, seen during diastole. Note the fluid extending anterior to the descending thoracic aorta, differentiating it from pleural effusion

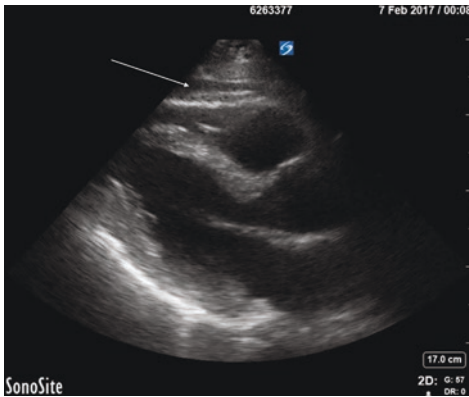


FIGURE 3.25 Epicardial fat pad: An epicardial fat pad may be present anterior to the right ventricle and can be very similar in appearance to a small pericardial effusion in a parasternal long view; often they can be indistinguishable. However, small pericardial effusions will typically be seen posterior to the left ventricle, and an epicardial fat pad will be seen anterior to the right ventricle

- You can distinguish a left pleural effusion from a pericardial effusion by the pattern of fluid.
 - Pericardial fluid will be present posterior to the left ventricular wall and anterior to the descending aorta [1].
 - Left-sided pleural effusion will occur posterior to the left ventricular wall and will not be present anterior to the descending aorta [1].
 - Figure 3.26—Pericardial effusion vs. left-sided pleural effusion.

(b) Pericardial Effusion Grading

- Trace pericardial effusions appear as a thin stripe of dependent hypochoic fluid between the two pericardial layers.
- For circumferential effusions:
 - Small effusions have a hypochoic stripe measuring less than 5 mm [1, 3].

Figure 3.27—Small pericardial effusion (<0.5 cm)

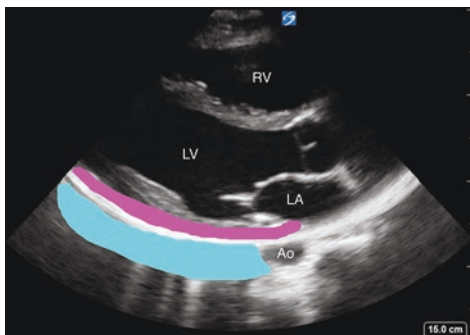


FIGURE 3.26 Pericardial effusion vs. left-sided pleural effusion: This parasternal long view demonstrates the distinguishing features of the relative locations for where pericardial effusions (pink) and pleural effusions (blue) would appear. Notice the pericardial effusion will travel anterior to the descending aorta, whereas the pleural effusion will not

FIGURE 3.27 Small pericardial effusion (<0.5 cm): Small-sized pericardial effusion seen posterior to the left ventricle (arrow) in this parasternal long view

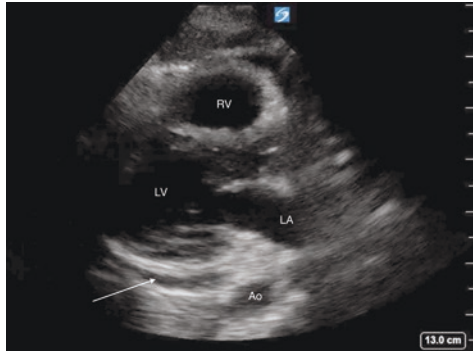
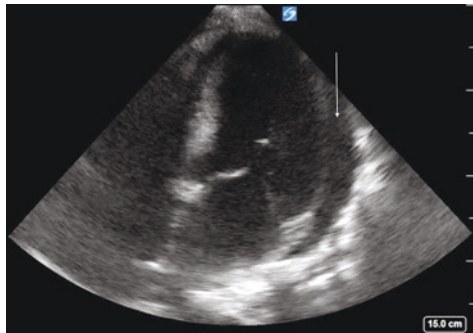


FIG 3.28 Moderate pericardial effusion (0.5–2 cm): Moderate-sized pericardial effusion (arrow) seen in an apical four-chamber view



- Moderate effusions have approximately 5–20 mm of separation between pericardial layers [1, 3].

Figure 3.28—Moderate pericardial effusion (0.5–2 cm)

- Large effusions have greater than 20 mm of separation from the left ventricular wall [1, 3].

Corresponds to greater than 500 mL of fluid [5].

Figure 3.29—Large pericardial effusion (>2 cm).

(c) Tamponade

- Occurs when fluid within the pericardium generates excessive external pressure, which then impairs the

FIGURE 3.29 Large pericardial effusion (>2 cm): Large-sized pericardial effusion is noted here in this parasternal long view

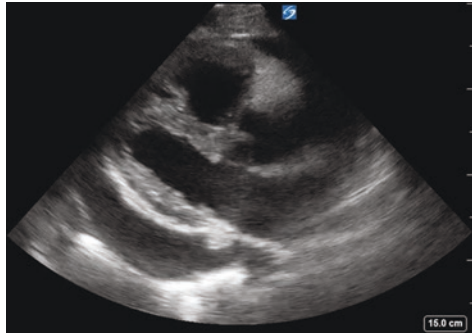
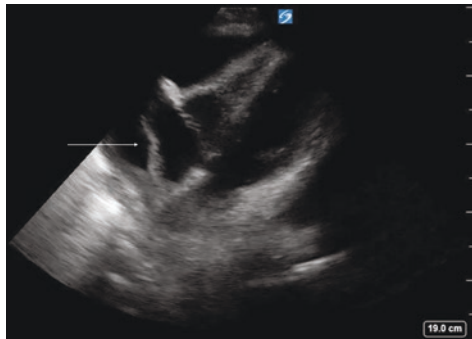


FIGURE 3.30 RA collapse in tamponade: RA collapse in pericardial tamponade (arrow). This is the most sensitive sign for pericardial tamponade



ability for the heart chambers to fill eventually causing hypotension and shock

- Affects the thin-walled right atrium and right ventricle first.

Video 3.24—Tamponade parasternal long

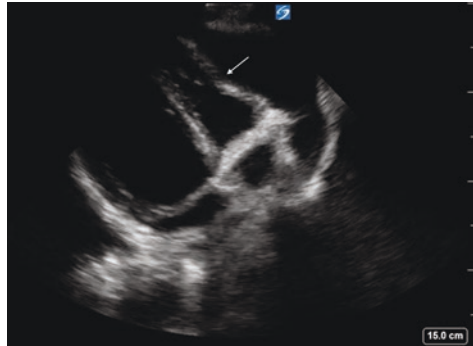
Video 3.25—Tamponade subxiphoid

- Right atrial systolic collapse [3, 4] is the most sensitive sign of tamponade.

Usually the first echocardiographic sign

Figure 3.30—RA collapse in tamponade

FIGURE 3.31 RV collapse in tamponade: RV collapse during diastole is seen here (arrow) in this subxiphoid view of pericardial tamponade. This is the most specific sign for pericardial tamponade



- Right ventricular diastolic collapse [3,4] is the most specific sign of tamponade.

Figure 3.31—RV collapse in tamponade

- Plethoric IVC.

Will also see a dilated IVC with minimal collapse [4]

Key Points

- Echocardiography is a difficult skill and requires repeated practice to become competent.
- Depending on the patient, you may have to adjust your transducer or move up or down a rib space to find the optimal window.
- Placing the patient in a left lateral decubitus position can improve image quality by moving the heart leftward and away from the sternum.
- It can be possible to diagnose endocarditis by transthoracic echocardiography, but this is rare.
 - Endocarditis can be diagnosed by visualizing an echogenic, mobile lucency attached to one or more valves.
 - Figure 3.32—Endocarditis

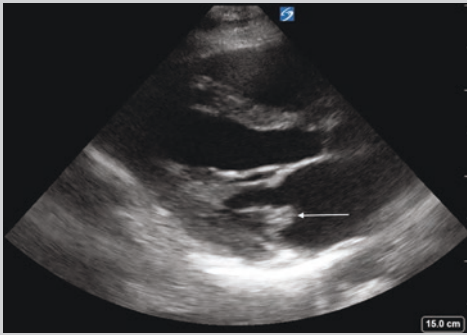


FIGURE 3.32 Endocarditis: Parasternal long image showing posterior mitral valve leaflet vegetation (arrow) on upstream atrial side of leaflet

- Video 3.26—Endocarditis
- Transesophageal echocardiography is the imaging modality of choice and gold standard to diagnose endocarditis.
- Limitations to adequate transthoracic echocardiography include:
 - Morbidly obese patients
 - COPD
 - Positive pressure ventilation
 - Subcutaneous emphysema
 - Patients' status post-midline sternotomy

References

1. Rasalingam R, Makan M, Perez JE, editors. The Washington manual of echocardiography. Philadelphia: Wolters Kluwer Health/Lippincott Williams & Wilkins; 2013.
2. Reardon RF, Laudenbach A, Joing SA. Chapter 6: Cardiac. In: Ma OJ, Mateer JR, Reardon RF, Joing SA, editors. Emergency ultrasound. 3rd ed. New York: McGraw-Hill Education; 2014. p.93–168.

3. Otto CM. Textbook of clinical echocardiography. 5th ed. Philadelphia, PA: Elsevier Saunders; 2013.
4. Mallin M, Dawson M. Introduction to bedside ultrasound: volume 2. United States of America: emergency ultrasound solutions; 2013. iBook. <https://itun.es/us/ueELM.l>.
5. Jung HO. Pericardial effusion and pericardiocentesis: role of echocardiography. Korean Circ J. 2012;42(11):725–34. <https://www.ncbi.nlm.nih.gov/pmc/articles/PMC3518705/>. Accessed 30 April 2017.

Chapter 4

Thoracic Ultrasound

Frequently patients with numerous comorbidities seek the care of a physician for evaluation of shortness of breath. Thoracic ultrasound has improved our diagnostic capability to rapidly determine the cause of their symptomology and guide management, which is specifically advantageous in patients with respiratory distress. It can diagnose conditions such as pneumothorax, pulmonary edema, pleural effusion, or pneumonia. Importantly, thoracic ultrasound can help differentiate between chronic obstructive pulmonary disease exacerbations and decompensated heart failure, two common conditions that can appear similar, be quite severe, and require vastly different treatment. Thoracic ultrasound is easy to learn and quick to employ and can be potentially lifesaving for patients. This chapter will review the indication, basic anatomy, image acquisition, normal ultrasound anatomy, and interpretation of pathology.

Indications/Clinical Application

- Evaluate for etiology of acute dyspnea including pneumothorax, pleural effusion, consolidation, pulmonary contusion, and pulmonary edema.

Electronic Supplementary Material The online version of this chapter (doi:[10.1007/978-3-319-68634-9_4](https://doi.org/10.1007/978-3-319-68634-9_4)) contains supplementary material, which is available to authorized users.

- Guidance for thoracentesis or thoracostomy tube placement.
- Guidance for intercostal nerve block.

Normal Thoracic Anatomy

- Chest wall is composed of 12 ribs on either side.
 - Ribs 1–7 are true ribs, 8–10 false ribs, and 11–12 floating ribs.
- There are two lungs within the thoracic cavity, with the right lung larger than the left lung due to the heart taking up space on the left.
 - Right lung has three lobes: upper, middle, and lower.
 - Left lung has two lobes: upper and lower.

The left lung does have a lingula between the upper and lower lobes. The lingula is sometimes referred to as a lobe.

- The lungs are enclosed by a pleural sac, which is made up of the parietal pleura and visceral pleura.
 - Between these two pleurae is a potential space, which is called the pleural cavity and normally will contain less than 20cc of pleural fluid.
- Terminology of Thoracic Ultrasound
 - A-lines: reverberation artifact due to the reflection of ultrasound waves from the pleura seen as multiple echogenic horizontal lines (repetitions of the pleural line) separated by a distance equal to the thickness of the chest wall [1, 2]

A-lines will be seen throughout normal lung parenchyma.

They are often absent in the setting of interstitial disease, consolidation, and pleural effusions.

Figure 4.1—A-lines.

FIGURE 4.1 A-lines: Normal lung findings include horizontal A-lines (arrows) throughout the lung caused by reverberation artifact from the pleural line

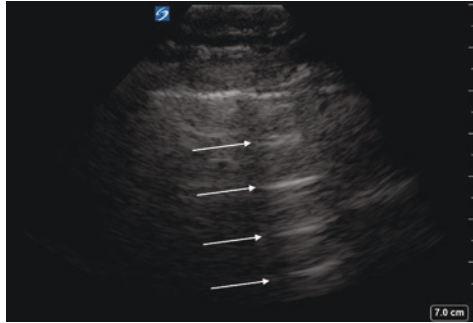
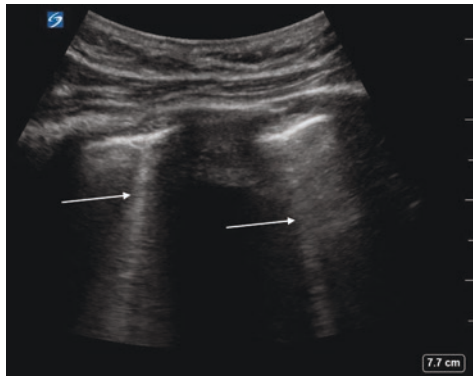


FIGURE 4.2 B-lines: B-lines extend from the pleural line down to the bottom of the screen without fading. Up to three B-lines per lung field is considered normal



- B-lines: ray-like or comet-tail vertical lines that extend from the pleural line down to the bottom of the screen without fading [2, 3]

B-lines will move synchronously with lung sliding.
Generated by alveoli [2].

It is normal to have up to three B-lines in one field of view.

Greater than three is abnormal and can be seen with pulmonary edema and conditions that cause thickened inter-alveolar soft tissue.

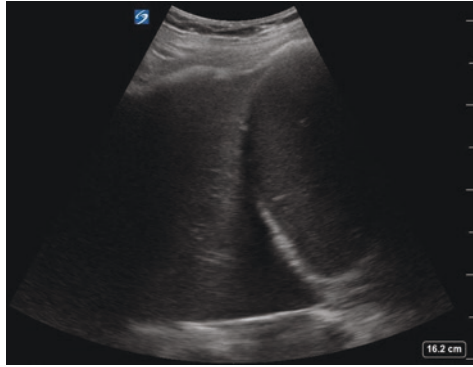
Figure 4.2 – B-lines.

Video 4.1 – B-lines.

FIGURE 4.3

Hepaticization:

Lung tissue above the diaphragm (left side) appears similar to liver tissue below the diaphragm (right side). Also noted is a pleural effusion



- E-lines: similar to B-lines but arise from the chest wall, not the pleural line

A type of reverberation artifact that occurs due to subcutaneous emphysema [2]

- Hepaticization: alteration of lung tissue creating an appearance similar to liver tissue

Due to consolidation [4] from disease processes such as pneumonia or contusions

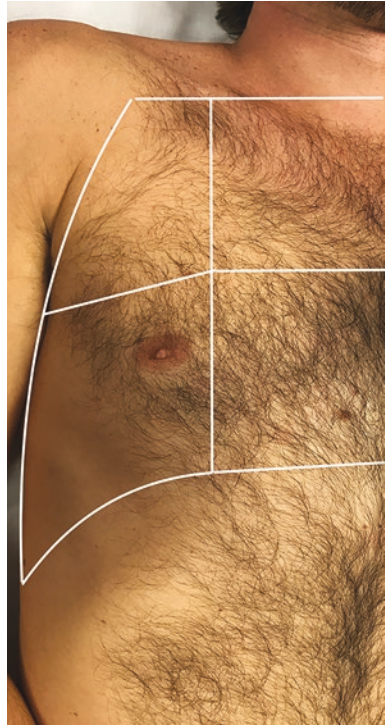
Figure 4.3—Hepaticization

Video 4.2—Hepaticization

Image Acquisition

- Transducer Selection
 - Linear array: allows best visualization of the pleura and superficial lung fields
 - Curvilinear: allows visualization of multiple rib spaces at once, good for viewing deep lung fields
 - Phased array: allows the ability to image between rib spaces and view deeper lung fields
- Patient Position
 - Ideally, the patient should be imaged while sitting upright to obtain optimal views, especially to evaluate for pleural effusion.

FIGURE 4.4 Lung zones: Anterior and lateral lung zones are outlined here. When imaging the lung, it is important to evaluate multiple zones for completeness



- If the patient is unable to sit up, they can be imaged supine for anterior and lateral views and in a lateral recumbent position for posterior views.
- Standard Exam Views
 - A complete lung scan includes at least eight zones: Anterior, lateral, posterior, and costophrenic angles on each side. If concern for effusion, you can obtain similar views on the posterior aspect to better visualize fluid.
 - Figure 4.4—Lung zones (photo of chest with locations outlined)

FIGURE 4.5 Normal pleural line:
Normal pleural line is hyperechoic and linear (A) located between rib shadows (B)

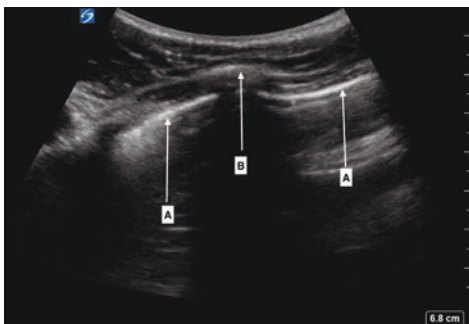


Image Acquisition

(a) Lung Fields

- Place the transducer vertically with the marker pointed cephalad.
- Begin by evaluating for lung sliding.
 - Lung sliding occurs due to the visceral pleura sliding against the parietal pleura during normal respirations.
 - Adjust the depth so that the lung pleura are optimally visualized in the middle of the screen.
 - Visualize at least two ribs with a hyperechoic horizontal line between them representing the pleural line.

Figure 4.5—Normal pleural line view

- Lung sliding will appear as two thin hyperechoic lines moving horizontally against each other in a to-and-fro movement.

Video 4.3—Lung sliding.

Decrease the gain to help visualize pleura.

- If unable to determine if the pleura is sliding, utilize M-mode for further evaluation.
 - Place the M-mode line between two ribs so it crosses perpendicularly over the pleura.

Figure 4.6—M-mode with correct spike position

FIGURE 4.6
M-mode with correct spike position: The M-mode spike should be placed between the two rib shadows overlying the hyper-echoic pleural line

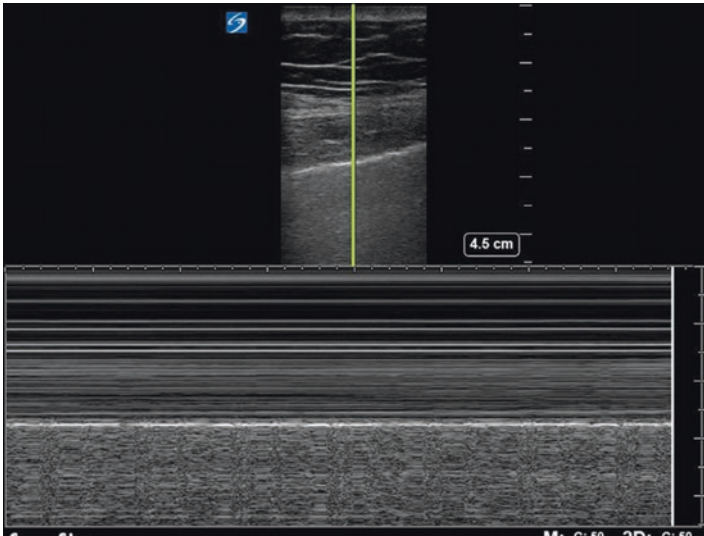
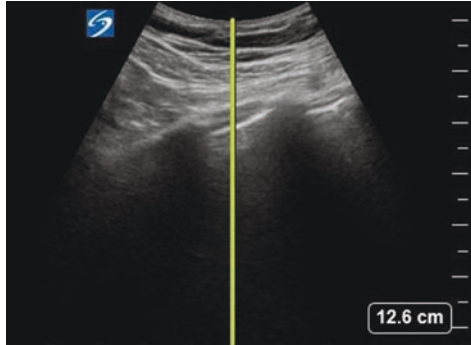
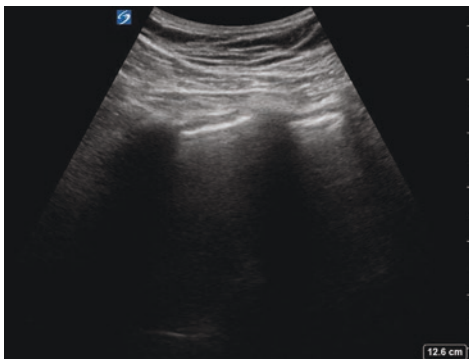

FIGURE 4.7 Normal sliding lung M-mode “seashore sign”: M-mode ultrasonography of a normal lung demonstrates the static chest wall in the top half of image and movement of the lungs in the bottom half consistent with normal respiration. Sometimes referred to as “seashore” sign

- Horizontal lines represent the static chest wall [3].
- Granular pattern represents movement of the lung beyond the pleural line [3].

Figure 4.7—Normal sliding lung M-mode “seashore sign”

FIGURE 4.8 Lung fields: Depth increased for better visualization of entire lung field



- Next, increase the depth to obtain views of the entire lung.
 - Image each lung field (see above for recommended scanning locations).
 - Evaluate for A-lines, B-lines, and signs of pathology such as consolidation.
 - Figure 4.8—Lung fields with depth increased

(b) Costophrenic Angles

- Place the transducer inferior and posterolaterally where the diaphragm meets the liver or spleen with the transducer marker pointed cephalad.
 - Figure 4.9—Photo of transducer location for costophrenic angle
- Visualize the hyperechoic diaphragm superior to the liver or spleen.
- The lung parenchyma is seen superior to the diaphragm.
 - Figure 4.10—Right costophrenic angle
 - Figure 4.11—Left costophrenic angle

FIGURE 4.9
Transducer location for right costophrenic angle: The transducer should be placed at each costophrenic angle bilaterally

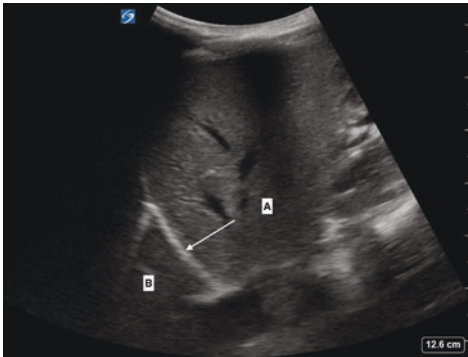
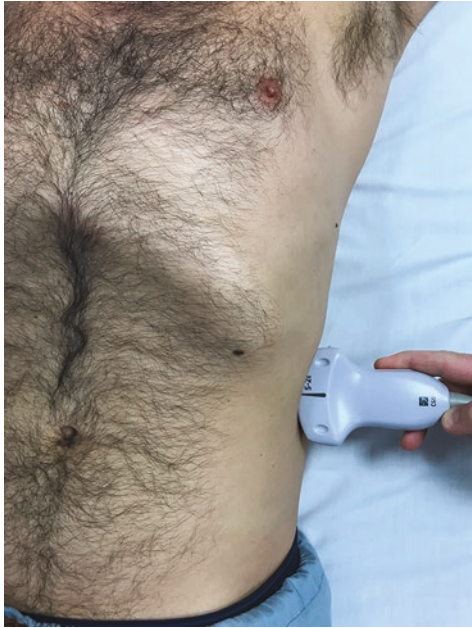
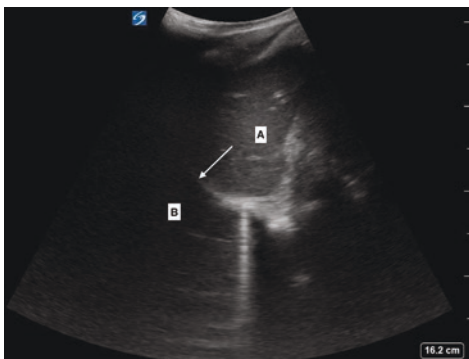


FIGURE 4.10 Right costophrenic angle: The hyperechoic diaphragm (arrow) is seen separating the liver (A) and lung tissue (B) at the costophrenic angle

FIGURE 4.11 Left costophrenic angle: The hyperechoic diaphragm (arrow) is seen separating the spleen (A) and lung tissue (B) at the costophrenic angle



Thoracic Pathology

- Pneumothorax
 - Caused by separation of the lung pleura away from the chest wall, resulting in a collapsed lung.
 - Common causes include spontaneous, trauma, or iatrogenic.
 - On ultrasound, there is absent lung sliding due to the separation of the visceral pleura from the parietal pleura [3].

Video 4.4—Pneumothorax

- If lung sliding is absent, move the transducer superior or inferior to locate the lung point sign.

Lung point sign is the transition point between normal lung sliding and a pneumothorax with the absence of lung sliding.

Video 4.5—Lung point sign.

Lung point sign is 100% specific for pneumothorax [3]. This is not always present, especially with a large pneumothorax [3].

- Use M-mode to confirm absence of sliding, as described above.

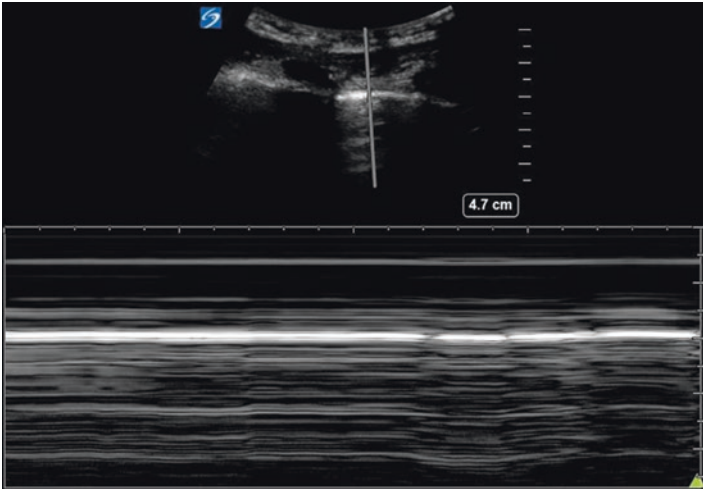


FIGURE 4.12 Barcode sign: M-mode through the pleural line demonstrates no movement as evidenced by the horizontal lines in the bottom half of the image. This is sometimes referred to as the barcode sign given the similar appearance to retail barcodes

M-mode will demonstrate no movement of the lungs, sometimes referred to as a barcode sign due to the horizontal lines throughout the entire image [3].

Figure 4.12—Barcode sign.

- Pulmonary Edema
 - Pulmonary edema is an abnormal collection of fluid in the interstitium or alveoli of the lung.
 - Can be seen in patients with heart failure, acute respiratory distress syndrome (ARDS), fluid overload, kidney failure, or liver failure.
 - On ultrasound, it is defined by the presence of three or more B-lines that are identified in two or more lung fields bilaterally [1, 5].

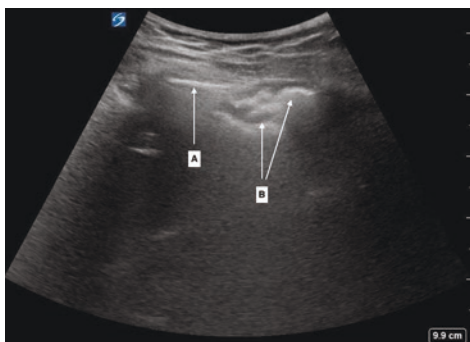
Figure 4.13—Pulmonary edema

Video 4.6—Pulmonary edema

FIGURE 4.13
Pulmonary edema:
Diffuse B-lines taking up the entire lung field suggest pulmonary edema in the right clinical setting

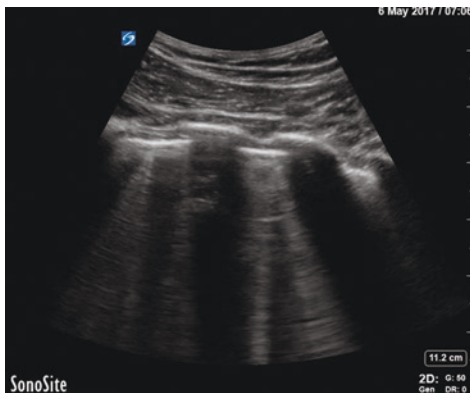

FIGURE 4.14
Consolidation:
Disruption of the pleural line (A) showing consolidation (B) of the lung tissue



- Pneumonia
 - Infection of a focal area of the lung tissue.
 - Identified as consolidation on ultrasound in the presence of clinical signs and symptoms of pneumonia.
 - Consolidation is identified by an area of hypoechoic heterogeneous echotexture.

Can appear similar to the liver, called hepatization [4].
The margin of the consolidation can be blurred and irregular [6].

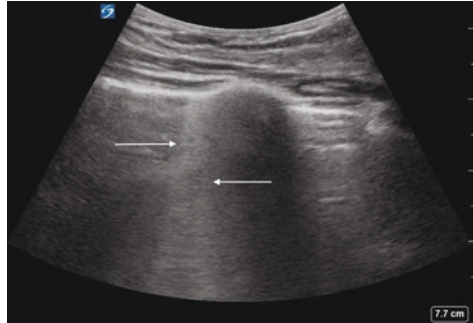
Behind the consolidation, B-lines may be seen.

Figure 4.14—Consolidation.

Video 4.7—Consolidation.

- Unilateral and focal B-lines are strongly suggestive of pneumonia even if consolidation is not seen.

FIGURE 4.15
Pulmonary contusion: In the setting of trauma, isolated B-lines suggest pulmonary contusion



- Air bronchograms and fluid bronchograms may also be identified [1].

Air-filled bronchi can be identified as echogenic tubular structures within the consolidation [1, 6].

Fluid bronchograms are identified as anechoic tubular structures within the consolidation [1].

- Pulmonary Contusion

- Caused by blunt trauma to the lung parenchyma.
- Initially, trauma can cause alveolar disruption [1].

This will be seen as B-lines, which represents interstitial edema that is developing [1].

- As contusions evolve, alveolar bleeding will displace air from the affected parenchyma causing hepatization of pulmonary tissue and the presence of subpleural consolidation [1].
- Figure 4.15—Pulmonary contusion.
- Video 4.8—Pulmonary contusion.

- Pleural Effusion

- Abnormal collection of fluid between the two pleural layers.
- Acute effusion is seen in dependent areas of the lung due to gravity.

Long-standing effusions can become organized or loculated and be visualized in nondependent areas.

FIGURE 4.16
Pleural effusion: A small pleural effusion (arrow) is noted above the diaphragm

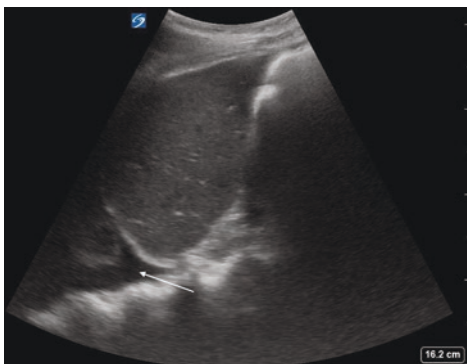
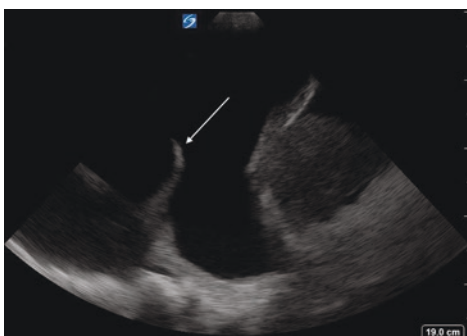

FIGURE 4.17
Floating lung: With large pleural effusions, the lung will appear to be floating in the fluid, creating what looks like a flag flapping in the wind (flag sign)



- On ultrasound, a pleural effusion is identified as an anechoic or hypoechoic area between the visceral and parietal pleura.

Will accumulate posteriorly if the patient is supine

Will accumulate inferiorly between the diaphragm and lung in an upright patient

Figure 4.16—Pleural effusion

Video 4.9—Pleural effusion

- Transudative effusion is typically anechoic without internal echoes [2, 7].
- With exudative or hemorrhagic effusions, internal echoes will often be identified [2, 7].
- Curtain of flag sign can be identified by the lung sliding into the effusion during respirations.

Figure 4.17—Floating lung

Key Points

- Ultrasound to evaluate for lung sliding has a negative predictive value of approximately 99.2–100% indicating that the presence of lung sliding in most cases rules out pneumothorax [3].
- Lung sliding can be absent in other disease processes such as acute respiratory distress syndrome (ARDS), consolidation, right mainstem intubation [3], and shallow breathing.
- Absence of B-lines can also be an indicator that pneumothorax is present.
 - The presence of B-lines is strong evidence against a pneumothorax [2], but their absence is not a sensitive sign of a pneumothorax.
- Diffuse B-lines bilaterally can be present in conditions other than pulmonary edema such as ARDS, interstitial lung disease, and multifocal pneumonia [5].
- Typical pneumonia will appear as consolidation as listed above, but atypical pneumonia will not have focal findings.

References

1. Silva FR, Mills LD. Chapter 7: Pulmonary. In: Ma OJ, Mateer JR, Reardon RF, Joing SA, editors. Emergency ultrasound. 3rd ed. China: McGraw-Hill Education; 2014. p. p169–90.
2. Saraogi A. Lung ultrasound: present and Future. Lung India. 2014;32(3):250–7. <https://www.ncbi.nlm.nih.gov/pmc/articles/PMC4429387/>. Accessed 25 April 2017 (Lung).
3. Husain LF, Hagopian L, Wayman D, Baker WE, Carmody KA. Sonographic Diagnosis of Pneumothorax. Journal of Emergencies, Trauma, and Shock. 2012;5(1):76–81. <https://www.ncbi.nlm.nih.gov/pmc/articles/PMC3299161/> Accessed 26 April 2017.
4. Durant A, Nagdev A. Ultrasound Detection of Lung Hepatization. Western Journal of Emergency Medicine. 2010;11(4):322–3. <https://www.ncbi.nlm.nih.gov/pmc/articles/PMC2967681/>. Accessed 26 April 2017 (US Detect).

5. Martindale JL, Wakai A, Collins SP, Levy PD, Diercks D, Hiestand BC, Fermann GJ, deSouza I, Sinert R. Diagnosing acute heart failure in the emergency department: a systematic review and meta-analysis. *Acad Emerg Med*. 2016;23(3):223–42.
6. Lee FCY. Lung ultrasound—a primary survey of the acutely dyspneic patient. *J Intensive Care*. 2016;4(1):57. <https://www.ncbi.nlm.nih.gov/pmc/articles/PMC5007698/>. Accessed 26 April 2017.
7. Prina E, Torres A, Roberto C, Carvalho R. Lung ultrasound in the evaluation of pleural effusion. *J Bras Pneumol*. 2014;40(10):1–5. <https://www.ncbi.nlm.nih.gov/pmc/articles/PMC4075927/>. Accessed 26 April 2017.

Chapter 5

Head and Neck Ultrasound

Using point-of-care ultrasound to evaluate head and neck pathology is a relatively new and evolving entity. One of the more routine but common indications to perform this exam is to assess for and assist with incision and drainage of a peritonsillar abscess. However, there are other areas of interest such as the thyroid gland, parotid gland, and carotid artery. In addition, assessing for proper endotracheal tube location can now be done immediately following intubation using ultrasound techniques. While head and neck ultrasound may be intimidating to the novice sonographer, the technical skills needed to obtain and interpret these images are quite simple due superficial and easy-to-identify structures. Therefore, with minimal practice, one can become an expert in head and neck ultrasound. This chapter will review indications to perform a head or neck ultrasound, basic anatomy, image acquisition, normal ultrasound anatomy, and interpretation of pathology.

Tonsillar Ultrasound

(a) Clinical Application and Indications

- Asymmetrical tonsillar enlargement.
- Evaluate for peritonsillar abscess.

Electronic Supplementary Material The online version of this chapter (doi:10.1007/978-3-319-68634-9_5) contains supplementary material, which is available to authorized users.

(b) Tonsillar Anatomy

- Paired lymphatic structures located in the posterior oropharynx

(c) Transducer Selection

- Endocavitary transducer

(d) Patient Position

- Have the patient sit upright with the back of their head supported by the head of the bed [1].

(e) Standard Exam Views

- Insert the transducer into the patient's mouth.
- Place the head of the transducer against the affected tonsil.
 - Figure 5.1—Endocavitary transducer in mouth
- Very slowly fan the transducer to evaluate for signs of a fluid collection indicating peritonsillar abscess or cobblestoning indicating tonsillar edema.
- Compare to the unaffected side.
- Identify the carotid artery posterior to the tonsil.
 - Figure 5.2—Carotid artery posterior to the tonsil
 - Video 5.1—Carotid artery posterior to the tonsil

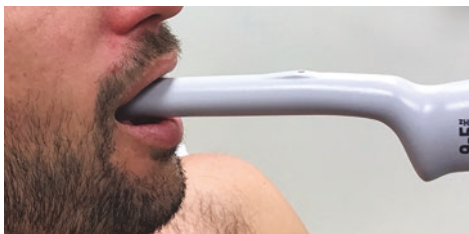

FIGURE 5.1 Endocavitary transducer position for tonsillar ultrasound: The endocavitary probe should be inserted to view the affected tonsil. It can help to have the patient direct you as they will be more comfortable this way

FIGURE 5.2 Carotid artery posterior to tonsil: The carotid artery (B) can be visualized posterior to the tonsil. A peritonsillar abscess can be seen in this image (A)

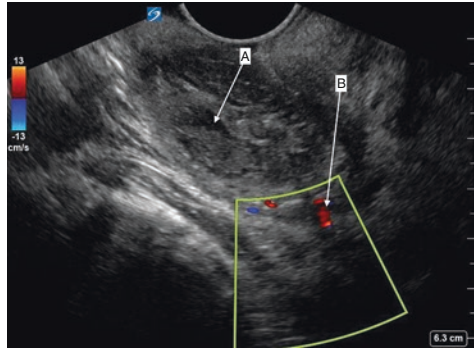
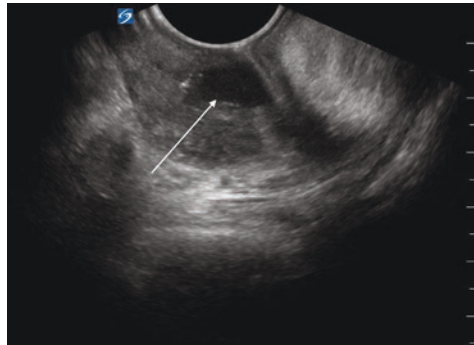


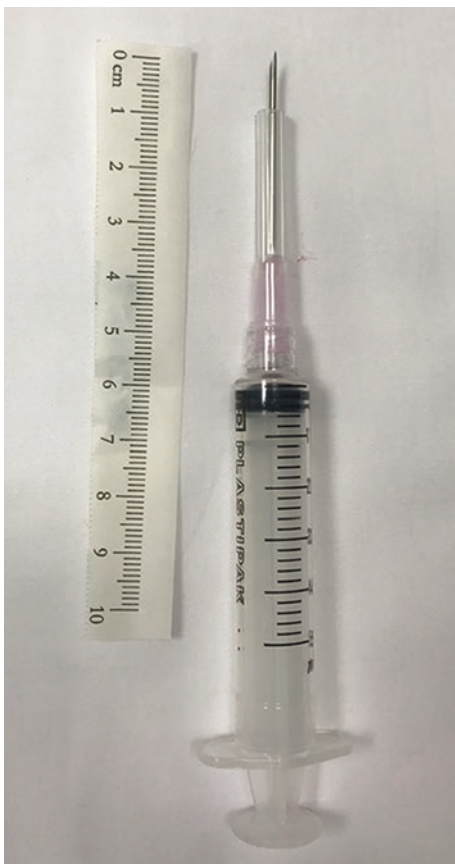FIGURE 5.3 Peritonsillar abscess: A large area of hypoechoic fluid (arrow) represents a peritonsillar abscess



(f) Peritonsillar Abscess

- Walled-off bacterial infection resulting in a collection of purulent fluid within the tonsil, usually due to sequelae of bacterial pharyngitis.
- Will appear as a hypoechoic fluid collection within an asymmetrically enlarged tonsil.
 - Can contain complex fluid with internal echoes and debris
 - Figure 5.3—Peritonsillar abscess
 - Video 5.2—Peritonsillar abscess
- Measure the size of the abscess.
- Measure the depth of the abscess cavity from the transducer [1].
 - Based on this measurement, choose the appropriate needle length.

FIGURE 5.4 Needle with plastic cap cut: To avoid entering too far into the peritonsillar space, a needle cap can be cut to only allow a set amount of needle to enter



- Place the plastic cap on the needle and cut the cap a distance back from the needle tip that is just longer than this measurement.

Figure 5.4—Needle with plastic cap cut

- This will ensure the needle does not enter the tonsil too far putting the carotid artery at risk for injury.
- Perform incision and drainage of the abscess using landmarks or direct ultrasound guidance.
- Reimage the tonsil to evaluate for improvement of the fluid collection.

(g) Key Points

- When evaluating for a peritonsillar abscess, the patient may have limited ability to open the mouth secondary to trismus.
- Have the patient hold their tongue down themselves with a tongue depressor or even a laryngoscope as they will know their own gag reflex.

Thyroid Ultrasound

(a) Clinical Application and Indications

- Evaluation of a palpable neck mass [2]
- Thyroid enlargement
- Abnormal thyroid function labs
- Further evaluation of an incidental finding on other imaging studies such as thyroid nodule or cyst [2]

(b) Thyroid Anatomy

- A superficial endocrine organ in the neck that overlies the trachea.
- The isthmus of the thyroid is the connection between the right and left lobes and usually lies over the second or third tracheal ring.
- Each lobe is located anterior and lateral to the trachea, with the carotid artery and internal jugular veins located posteriorly.

(c) Transducer Selection

- Linear array transducer

(d) Patient Position

- The patient should be supine or in a semi-recumbent position with their neck extended.

(e) Standard Exam Views

- Begin by imaging the thyroid gland in a transverse plane.

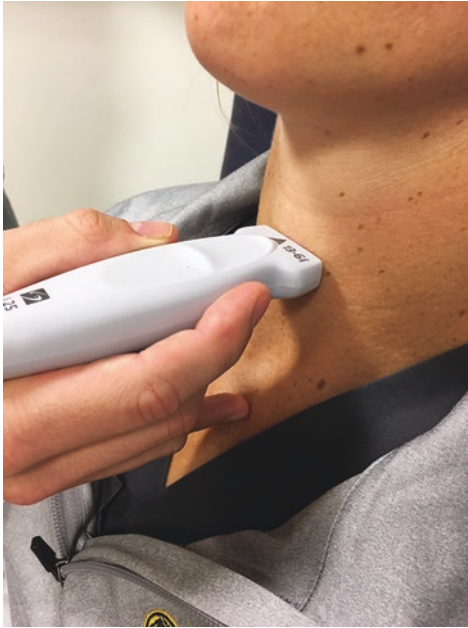

FIGURE 5.5 Transducer position on neck: For thyroid ultrasound, having the patient sit in a supine position slightly recumbent can facilitate easy scanning of the neck

- Place the transducer below the laryngeal prominence with the marker pointed toward the patient's right.
 - Figure 5.5—Transducer position
- Scan inferiorly until the isthmus of the thyroid is visualized.
 - Thyroid gland will appear as a uniform, finely granular structure that is slightly more echogenic than the surrounding musculature [3].
 - Isthmus will be seen anterior to the hyperechoic trachea with the left and right lobes on either side, respectively.
 - Figure 5.6—Isthmus of the thyroid.

FIGURE 5.6 Isthmus of thyroid: The isthmus of the thyroid (arrow) will be seen anterior to the hyperechoic trachea

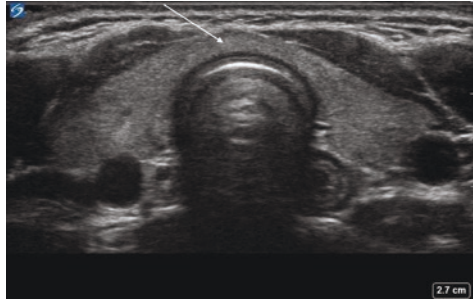
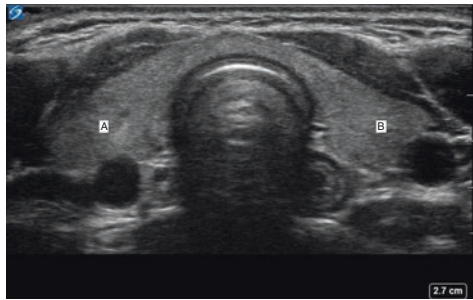


FIGURE 5.7 Thyroid lobes: Right (A) and left (B) thyroid lobes



- Move the transducer laterally to each side to image the right and left lobes of the thyroid.
 - Figure 5.7—Thyroid lobes.
 - Lateral to each lobe will be the paired thick-walled anechoic and pulsatile carotid artery followed by the thinner-walled internal jugular vein [4].
 - The esophagus is often found posterior to the left thyroid lobe and anterior to the cervical vertebral body [3].

Visualized as an oval or flattened structure with alternating hypo- and hyperechogenicity [3].

- Figure 5.8—Thyroid and surrounding structures.
- Video 5.3—Thyroid ultrasound.

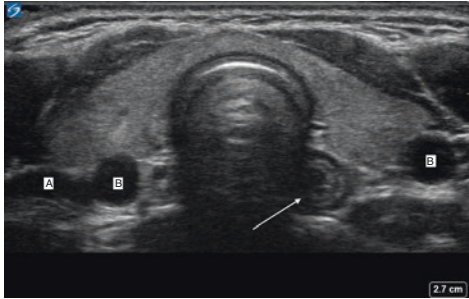
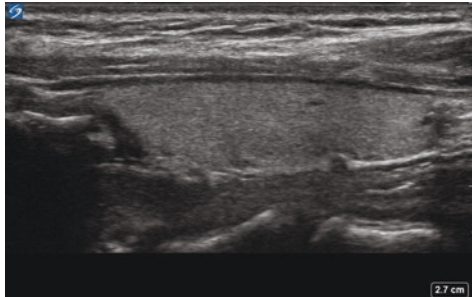


FIGURE 5.8 Thyroid with surrounding structures: Lateral to each thyroid lobe will be the paired thick-walled anechoic and pulsatile carotid arteries (B) followed by the thinner-walled internal jugular veins (A). The esophagus (arrow) is often found posterior to the left thyroid lobe and anterior to the cervical vertebral body

FIGURE 5.9 Thyroid in a sagittal plane: Left lobe of the thyroid visualized in sagittal plane



- Rotate the transducer clockwise 90° with the marker pointed cephalad. Image each lobe of the thyroid in a sagittal plane.
 - Figure 5.9—Thyroid in a sagittal plane
 - Video 5.4—Thyroid in sagittal plane
- Apply color Doppler to each area of the thyroid to evaluate vascular flow.
 - Figure 5.10—Color Doppler of the thyroid gland
 - Video 5.5—Color Doppler of the thyroid gland

FIGURE 5.10 Color Doppler of the thyroid gland: Normal vascular flow of the thyroid gland using color Doppler

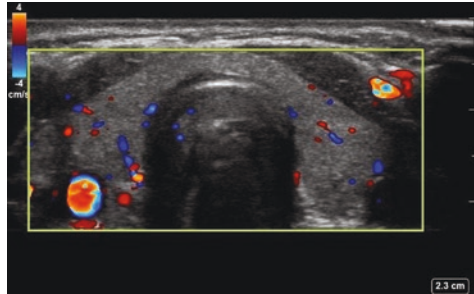
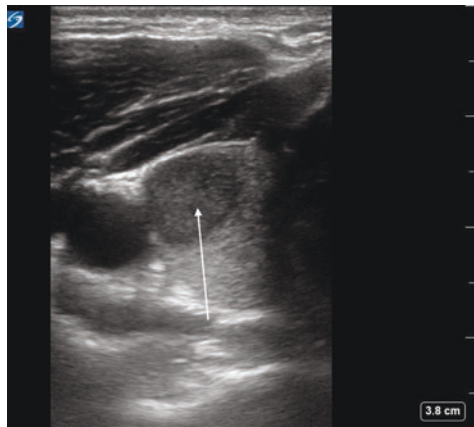


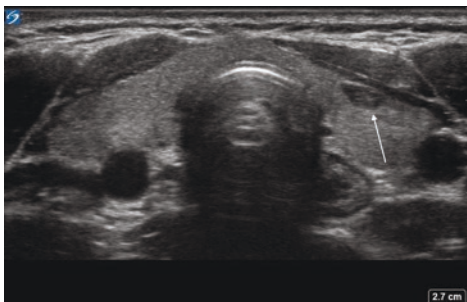
FIGURE 5.11 Thyroid nodule: A thyroid nodule (arrow) is a distinct lesion within the thyroid that is formed by an overgrowth of thyroid cells



(f) Thyroid Pathology

- Thyroid nodule
 - Lesion within the thyroid gland caused by an overgrowth of thyroid cells.
 - Majority of thyroid nodules are benign with only about 5% malignant [5].
 - Common incidental findings on computed tomography or with ultrasound of the thyroid.
 - Will appear as a discrete lesion that distorts the normal thyroid echotexture [4].
 - Figure 5.11 – Thyroid nodule.

FIGURE 5.12 Thyroid cyst: Thyroid cysts (arrow) are a type of benign nodule that can be simple, colloid, or hemorrhagic



- Thyroid Cyst
 - A type of benign thyroid nodule.
 - Can be simple, colloid, or hemorrhagic
 - Simple cysts will appear as round, anechoic, or hypoechoic structures with posterior acoustic enhancement.
 - Figure 5.12—Thyroid cyst.
 - Video 5.6—Thyroid cyst.
- Thyroiditis
 - Inflammation of the thyroid gland
 - Will appear as decreased echogenicity with increased vascularity resulting in increased flow with color Doppler [6]
 - Figure 5.13—Thyroiditis
 - Video 5.7 Thyroiditis

Tracheal Ultrasound

- Clinical Application and Indications
 - Confirm endotracheal tube placement.
- Trachea Anatomy
 - Located superficially in the anterior neck.
 - Membranous tube that connects the pharynx and larynx to the lungs.

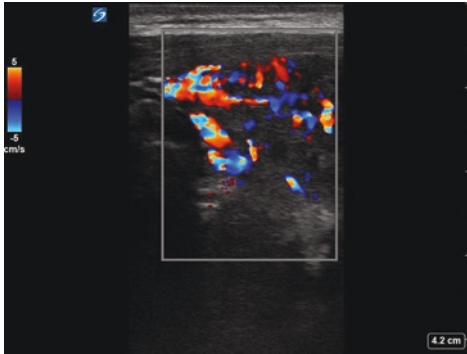


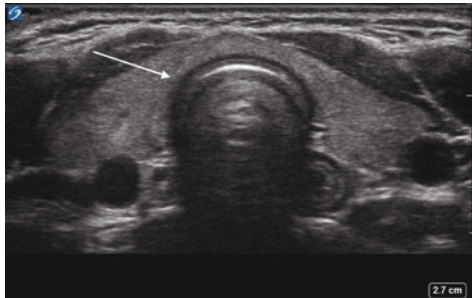
FIGURE 5.13 Thyroiditis: With any inflammatory state of the thyroid, there will be increased vascular flow as evidenced here by placing color Doppler over the thyroid gland.

- Reinforced by anterior rings of cartilage.
- The cricothyroid membrane sits between the thyroid cartilage superiorly and cricoid cartilage inferiorly.
- Transducer Selection
 - Linear array transducer
- Patient Position
 - This exam will typically be performed on an intubated patient; therefore, the patient should be supine or with the head of the bed elevated to 30°.
- Standard Exam Views
 - Place the transducer on the midline anterior neck in a transverse plane.
 - Figure 5.14—Transducer placement over the trachea.
 - The trachea will appear as an echogenic curved stripe with posterior acoustic shadowing.
 - Figure 5.15—Trachea.
 - Video 5.8—Trachea.
 - Scan both cranially and caudally to evaluate the trachea.

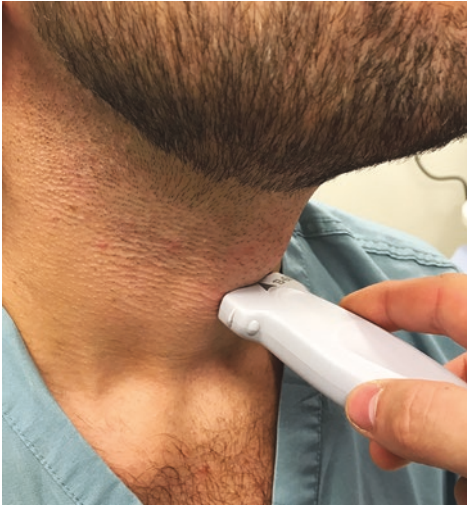

FIGURE 5.14 Transducer placement over trachea: To visualize the trachea, place the transducer in a transverse orientation over the center of the neck

FIGURE 5.15 Trachea: The trachea (arrow) will appear as an echogenic curved stripe with posterior acoustic shadowing



- Attempt to visualize the esophagus located to the left; this can be enhanced by asking the patient to swallow.

Typically found posterior to the left lobe of the thyroid gland

Figure 5.16—The trachea and esophagus

FIGURE 5.16 Image of trachea with esophagus identified: Attempt to visualize the esophagus (arrow), which is located to the left of the trachea (on the right of the image) as seen here

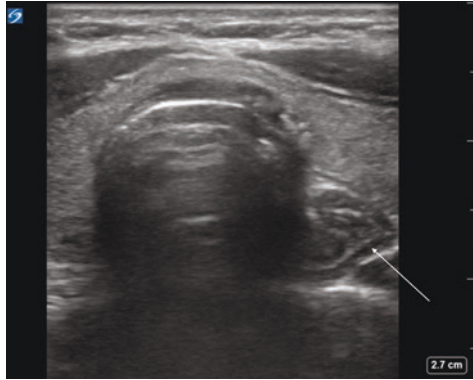
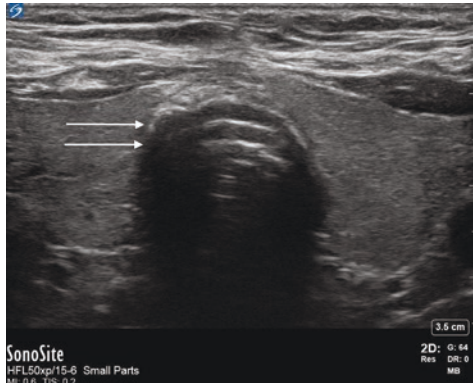


FIGURE 5.17 Correct ETT placement: With correct placement of an endotracheal tube, two curved parallel echogenic lines (arrows) will be seen



- Confirmation of Endotracheal Tube Placement
 - Ultrasound the trachea as described above.
 - With correct placement of an endotracheal tube, two curved parallel echogenic lines will be seen [3] with more prominent posterior acoustic enhancement [7] and an increased amount of B-lines.

Figure 5.17—Correct ETT placement

Video 5.9—Correct ETT placement

- Slight shaking or movement of the tube will demonstrate movement of the trachea on ultrasound.

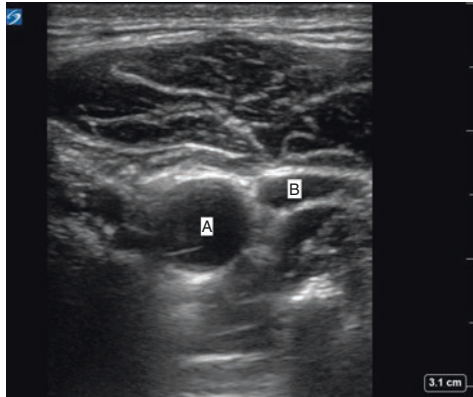
- Esophageal Intubation
 - Incorrect placement of an endotracheal tube will be visualized as an echogenic curved line with posterior acoustic shadowing posterior and lateral to the trachea [7].

Usually posterior to the left lobe of the thyroid gland [3]
Occasionally referred to as “double trachea sign” [7]
- Key Points
 - Endotracheal tube confirmation can also be performed in real time by visualizing the tube [7] in long [3] or short axis as the tube is placed.
 - Using ultrasound to confirm endotracheal tube placement has been found to have a sensitivity and specificity of 98% [8].

Carotid Artery Ultrasound

- Clinical Application and Indications
 - Evaluate for carotid artery dissection.
- Carotid Artery Anatomy
 - The right carotid artery is a branch of the brachiocephalic artery.
 - The left carotid artery branches directly off the arch of the aorta.
 - Splits into the external and internal carotid arteries at the level of the fourth cervical vertebrae, just distal to the carotid bulb.
- Transducer Selection
 - Linear array transducer
- Patient Position
 - Have the patient lay supine or in a semi-recumbent position with their neck extended and head facing away from the side being imaged.
- Standard Exam Views
 - Place the transducer in a transverse plane, just above the clavicle to obtain a short axis view of the carotid artery.

FIGURE 5.18 Short axis of the carotid artery: In a transverse plane, the carotid artery will be imaged in short axis appearing as a thick-walled anechoic vessel (A) next to the thin and collapsible vein (B)



- Scan cranially to evaluate the entire length of the carotid artery.

Figure 5.18—Short axis of the carotid artery

- Switch to long axis by rotating the transducer marker toward the patient’s head and scan cranially to evaluate the carotid bulb.

Figure 5.19—Long axis with carotid bulb

- Carotid Artery Dissection
 - Separation of the inner wall of the carotid artery creating a false lumen.
 - Appears as a hyperechoic linear stripe within the lumen of the carotid artery.

Salivary Gland

(a) Clinical Application and Indications

- Preauricular pain and/or swelling

(b) Basic Anatomy

- Parotid gland
 - Located anterior to the ear bilaterally with the upper portion nearly in line with the external auditory meatus [3].

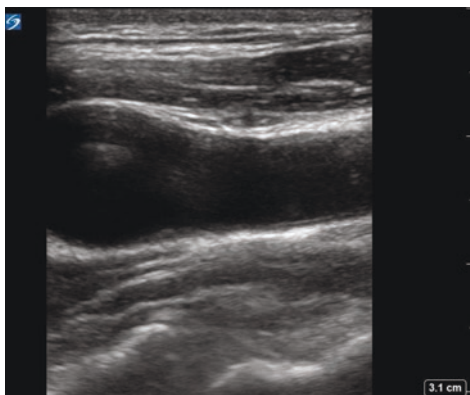


FIGURE 5.19 Long axis with carotid bulb labeled: In long axis, with the transducer oriented so the marker is pointed toward the patient's head, the carotid artery will appear as an anechoic tube with the carotid bulb locater more superior

- Parotid gland duct courses from the anterior surface of the gland through buccal fat and buccinator muscle. It enters the mouth adjacent to the second upper molar as the parotid papilla [3].
 - Submandibular gland
 - Triangular shaped within the submandibular triangle [3] inferior to the mandible.
 - Submandibular duct courses medially then superiorly where it enters the mouth as a papilla near the lingual frenulum [3].
- (c) Transducer Selection
- Linear array transducer
- (d) Patient Position
- Position the patient in a position of comfort. They can be supine, semi-recumbent, or sitting up with the back of their head supported.
 - When imaging the submandibular gland, it may be helpful to tilt the patient's head up.

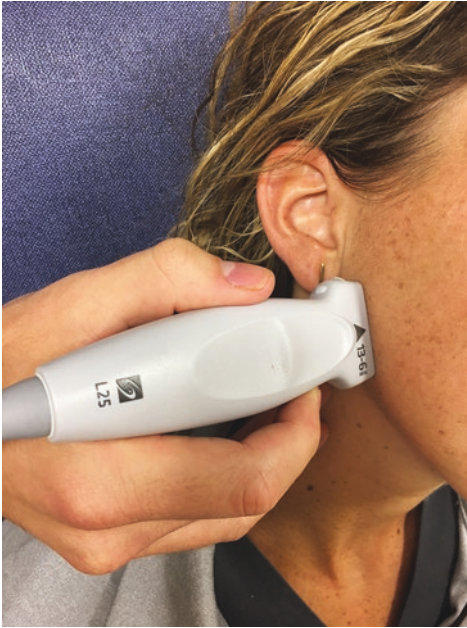

FIGURE 5.20 Transducer position parotid gland: Place the transducer near the angle of the jaw with the marker pointed superiorly

(e) Standard Exam Views

- Parotid gland
 - Begin by imaging the parotid gland in a sagittal plane with the transducer marker pointed superiorly.

Figure 5.20—Transducer position parotid gland

- Parotid gland will have a homogeneous, finely granular echotexture [3].

Figure 5.21—Parotid gland

Video 5.10—Parotid gland

- Scan through the gland looking for any abnormalities.

FIGURE 5.21 Parotid gland: The parotid gland is seen just below the skin with a homogenous, finely granular echotexture

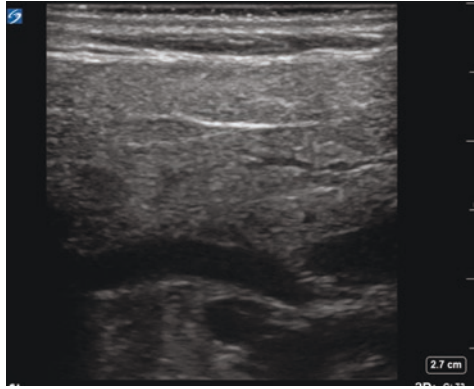
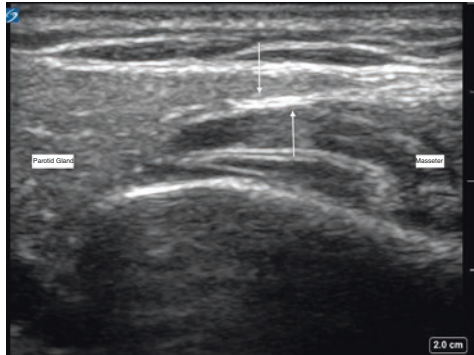


FIGURE 5.22 Parotid duct: The parotid duct will appear as two thin parallel hyperechoic lines coursing over the masseter muscle (arrows)



- Rotate the transducer counterclockwise with the transducer marker pointed toward the patient’s right to image the parotid duct in a transverse plane.
- Line the transducer up with the earlobe near mid-cheek to identify the duct as two thin hyperechoic lines close together and parallel [3].

Figure 5.22—Parotid duct

- Submandibular gland
 - Place the transducer within the submandibular space anterior to the angle of the mandible.

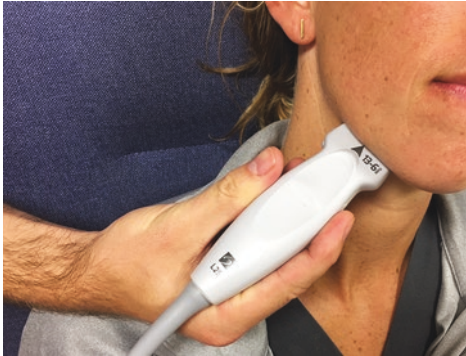

FIGURE 5.23 Transducer placement submandibular gland: Place the transducer inferior to the mandible within the submandibular space to visualize the submandibular gland

Figure 5.23—Transducer placement submandibular gland

- Identify the gland just beneath the subcutaneous tissue as a homogeneous structure with intermediate echogenicity [9], similar to the parotid gland.

Figure 5.24—Submandibular gland

Video 5.11—Submandibular gland

- The facial artery and vein will be seen near the gland [9].

(f) Salivary Gland Pathology

- Sialolithiasis
 - Stone within a salivary gland or duct.
 - Found within the parotid gland and, more commonly, the submandibular gland [3] or duct.
 - Visualized as echogenic foci with posterior acoustic shadowing [3], similar to gallstones or renal stones.
 - If obstructed, the duct will become dilated representing a small anechoic tube leading to an echogenic stone [3].

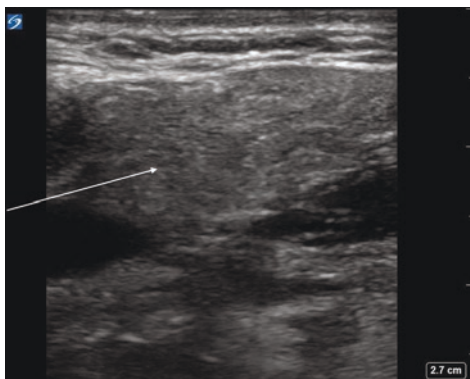


FIGURE 5.24 Submandibular gland: Submandibular gland (arrow) appears as a homogenous structure, similar to the parotid gland, just deep to the subcutaneous tissue

- Sialadenitis
 - Inflammation or infection of a salivary gland.
 - Gland will appear enlarged with a more heterogeneous, echogenic architecture as compared with normal salivary gland tissue [3].
 - Can also see increased blood flow on color Doppler [3].
- Salivary gland mass
 - Benign (most common) or malignant lesion of a salivary gland, usually the parotid gland [3].
 - Solid masses will appear with mixed echogenicity with some hypoechoic areas. There may be posterior acoustic enhancement [3].
 - Cystic masses will typically appear similar to cysts elsewhere as an anechoic lesion [3].

References

1. Mallin M, Dawson M. Introduction to bedside ultrasound: volume 2. United States of America: emergency ultrasound solutions; 2013. iBook. <https://itun.es/us/ueELM.I>.

2. American Institute of Ultrasound in Medicine. Thyroid and Parathyroid Ultrasound Examination. 2003. AIUM Practice Parameter Website. <http://www.aium.org/resources/guidelines/thyroid.pdf>. Updated 2007 and 2013. Accessed 1 May 2017.
3. Dewitz A. Chapter 18: Musculoskeletal, soft tissue, and miscellaneous applications. In: Ma OJ, Mateer JR, Reardon RF, Joing SA, editors. Emergency ultrasound. 3rd ed. China: McGraw-Hill Education; 2014. p. 503–68.
4. Xie C, Cox P, Taylor N, LaPorte S. Ultrasonography of thyroid nodules: a pictorial review. *Insights Imaging*. 2016;7(1):77–86. <https://www.ncbi.nlm.nih.gov/pmc/articles/PMC4729706/>. Accessed 1 May 2017.
5. Yeung MJ, Serpell JW. Management of the solitary thyroid nodule. *The Oncologist*. 2008;13(2):105–12. <http://theoncologist.alphamedpress.org/content/13/2/105.full.pdf+html>. Accessed 1 May 2017.
6. Shah C, Johnson PT. Diffuse thyroiditis. *Sonoworld Website*. https://sonoworld.com/CaseDetails/Diffuse_thyroiditis.aspx?CaseId=50. Accessed 1 May 2017.
7. Chao A, Gharahbaghian L. Tips and tricks: airway ultrasound. *ACEP Website*. <https://www.acep.org/content.aspx?id=102309>. Accessed 1 May 2017.
8. Das SK, Choupoo NS, Haldar R, Lahkar A. Transtracheal ultrasound for verification of endotracheal tube placement: a systematic review and meta-analysis. *Can J Anesth*. 2015;62(4):413–23. <http://link.springer.com/article/10.1007%2Fs12630-014-0301-z>. Accessed 1 May 2017.
9. Dahiya N, Dogra VS. Small parts and superficial structures. Philadelphia, PA: Elsevier Inc.; 2014. <https://books.google.com/books?id=3lXOAwAAQBAJ&printsec=frontcover#v=onepage&q&f=false>. Accessed 1 May 2017.

Chapter 6

Musculoskeletal Ultrasound

Utility of ultrasound in musculoskeletal evaluation is a rapidly evolving area of interest. Ultrasound is a quick, noninvasive way to assess for many different musculoskeletal ailments such as dislocated joints, tendinopathies, knee effusions, fractures, and nerve inflammation. It gives providers the ability to efficiently diagnose pathology and subsequently start patients on the appropriate treatment to achieve recovery. In addition, with information gained on ultrasound, procedures to reduce pain, such as a hematoma block or nerve block, can be performed to improve patient comfort. This chapter will review indications for performing a musculoskeletal ultrasound, basic anatomy, image acquisition, normal ultrasound anatomy, and interpretation of pathology.

Clinical Application and Indications

- Dislocated joints
- Tendinopathies
- Knee effusion
- Bone fractures
- Median nerve inflammation (carpal tunnel syndrome)

Electronic Supplementary Material The online version of this chapter (doi:10.1007/978-3-319-68634-9_6) contains supplementary material, which is available to authorized users.

Normal Musculoskeletal Anatomy

- Bone
 - Can be divided into long bones, short bones, flat bones, and irregular bones:
 - Long bones: clavicles, humeri, radii, ulnae, metacarpals, femurs, tibiae, fibulae, metatarsals, and phalanges
 - Short bones: carpal bones, tarsal bones, patellae, sesamoid bones
 - Flat bones: skull, mandible, scapulae, sternum, and ribs
 - Irregular bones: vertebrae, sacrum, coccyx, and hyoid
 - Outermost surface is the periosteum which covers the bone and provides nutrients.
 - Next layer is the cortical bone, which provides strength:
 - This layer is thick and protects the layers beneath it.
 - Cancellous bone and bone marrow make up the inside of the bone, but are not visualized on ultrasound.
- Tendons
 - Band of fibroelastic connective tissue that connects muscle to a bone.
 - Tendons transmit force from muscle to the bone and can withstand a large amount of tension.
- Ligaments
 - Similar to tendons, however, connect one bone to another bone
- Nerves
 - Make up the peripheral nervous system, allowing various parts of the body to communicate with the brain and spinal cord, or the central nervous system.
 - Each nerve has an outer layer of dense connective tissue called the epineurium that surrounds fascicles or bundles of nerve axons.

- Deep to the epineurium is the perineurium which is a delicate sheath of connective tissue that forms a sleeve around a fascicle of nerve axons.
- The endoneurium surrounds each individual nerve axon.
- Shoulder Joint
 - Ball and socket joint with articulation between the head of the humerus and glenoid fossa of the scapula.
- Knee Joint
 - A hinge joint composed of two different articulations:
 - Patella and femur
 - Femur and tibia
 - The fibula courses lateral to the tibia, and while it articulates with the tibia, it is not part of the knee joint.

Image Acquisition

1. Transducer Selection

- (a) Linear array transducer
- (b) May need curvilinear transducer for deeper structures

2. Patient Position

- (a) Dependent on the structure to be imaged
- (b) Shoulder joint:
 - Patient should sit upright on edge of bed facing away from operator.
 - Figure 6.1—Shoulder patient position.
- (c) Tendons:
 - Achilles tendon:
 - Ideally, the patient should lay prone with their forefoot off the edge of the bed [1] to allow for a relaxed position of the Achilles tendon.
 - Figure 6.2—Achilles tendon patient position:

FIGURE 6.1 Shoulder patient position: Have the patient in a seated position with arm bent at 90°, place the transducer with the transducer indicator laterally

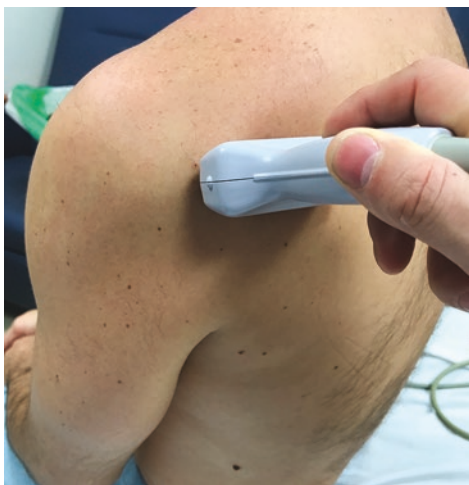
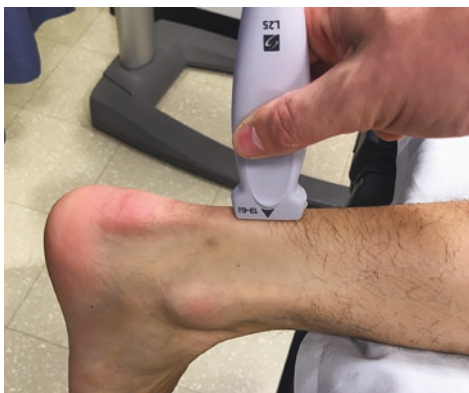

FIGURE 6.2 Achilles tendon patient position: If possible, having the patient in the prone position allows for easy visualization of the Achilles tendon



- Patellar and quadriceps tendons:
 - Have the patient lay supine or seated with their knees flexed to 90°.
 - Figure 6.3—Quadriceps tendon patient position.
 - Figure 6.4—Patella tendon patient position.
- Finger tendons:
 - To image the flexor tendons, position the patient's hand in supination with their fingers in as much extension as patient will allow.
 - Utilize a water bath for better image acquisition:

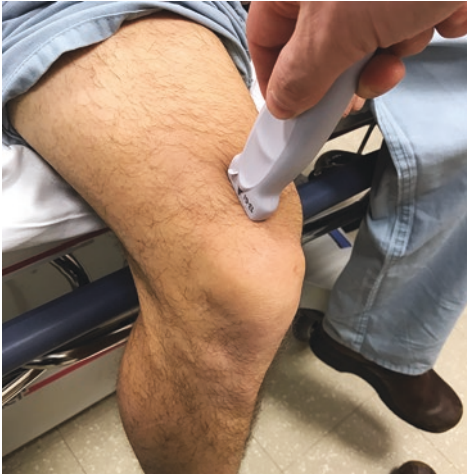

FIGURE 6.3 Quadriceps tendon patient position: Have the patient lay supine or seated with their knee flexed to 90° . Place the transducer proximal to the knee over the quadriceps tendon attachment site to the patella

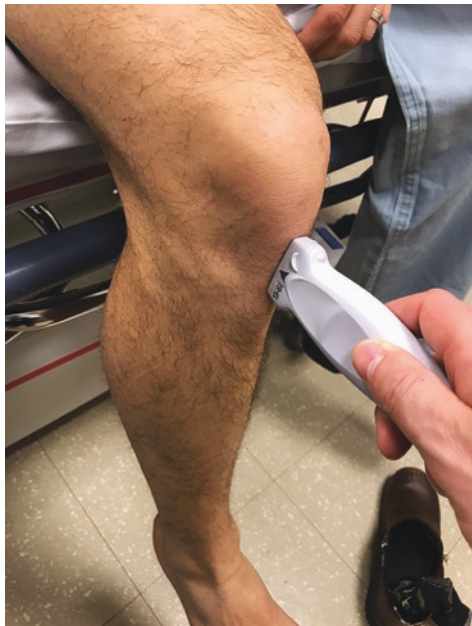
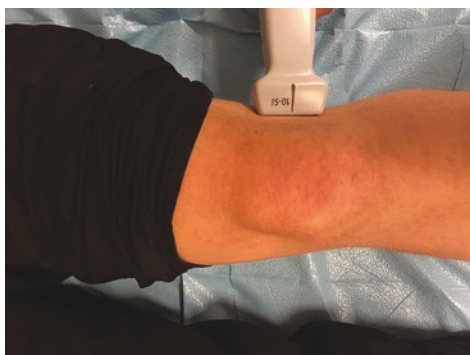
FIGURE 6.4 Patella tendon position: With the patient's leg hanging over the side, the bed flexed at 90° , place the transducer over the patella tendon attachment site inferior to the patella



FIGURE 6.5 Water bath example: To facilitate visualization of small parts, you can have the patient place the affected area in a container of water, and hover the probe over the area of interest

FIGURE 6.6 Knee joint patient position: To view the knee joint, a lateral or medial approach is preferred. For patient comfort, a towel roll can be placed beneath the knee



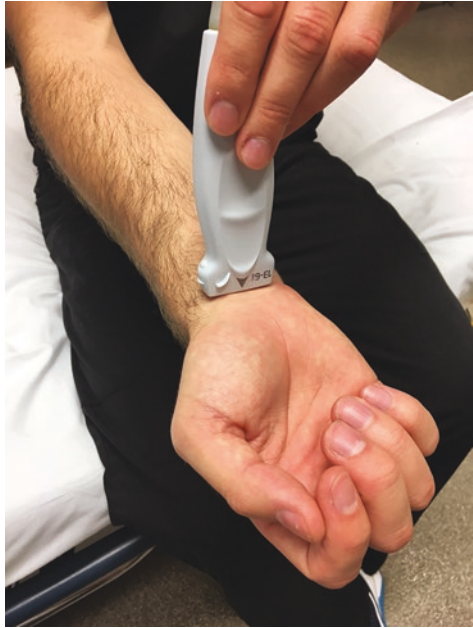Place area of interest within a basin filled with just enough water to submerge the area entirely, and then place just the tip of the transducer into the water over the affected area.

Figure 6.5—Water bath example.

(d) Knee joint:

- Patient should lay supine with a towel rolled and placed under their knee to provide support and approximately 20° of knee flexion.
- Figure 6.6—Knee joint patient position.

FIGURE 6.7 Median nerve patient position: With the arm extended and in supination, place the transducer over the forearm to locate the median nerve, and then slide the transducer down the arm to the wrist while following the median nerve



(e) Bone/fractures:

- Dependent on which bone will be imaged.
- Typically, the patient will be laying supine, in a position of comfort for lower extremity fractures.

(f) Median nerve:

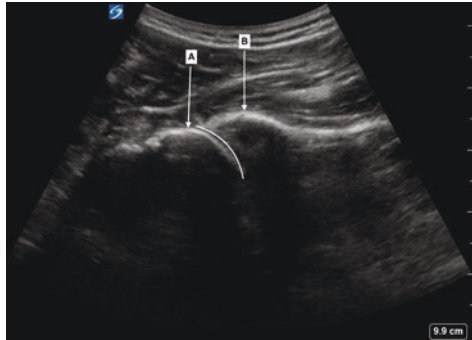
- Position the forearm in supination and place on a flat surface.
- Figure 6.7—Median nerve patient position.

Shoulder Joint

(a) Standard Exam Views

- Begin by placing the transducer posteriorly on the proximal humerus in a transverse plane and trace it proximally to find the glenohumeral joint.

FIGURE 6.8 Normal shoulder on ultrasound: In the normal shoulder, you can see the humeral head (A) sitting in the glenoid joint fossa (*curved line*) created by the scapula (B)



- If the patient can range the joint, obtain a video clip of internal and external rotation:
 - Video shoulder internal external rotation

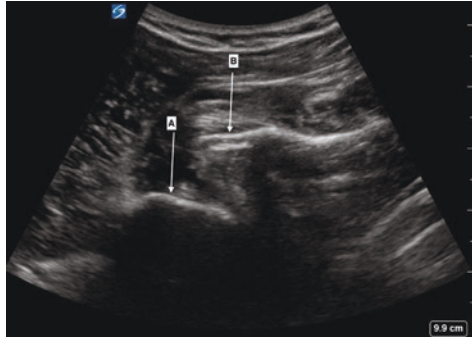
(b) Ultrasound Anatomy

- The bony cortex of humeral head and glenoid fossa will appear hyperechoic with posterior acoustic shadowing:
 - Figure 6.8—Normal shoulder on ultrasound
 - Video 6.1—Shoulder joint
- Normally, the humerus will be 0.5–1.0 cm posterior to the glenoid [2]:
 - Compare to contralateral side as needed.
- Infraspinatus muscle can be seen as a hypoechoic band superior to the joint [1] attaching to the greater tuberosity of the humerus.

(c) Shoulder Pathology

- Shoulder dislocation:
 - Studies have shown ultrasound to be 100% sensitive in detecting shoulder dislocations and nearly 100% sensitive with detecting complete reduction [3].

FIGURE 6.9 Anterior shoulder dislocation: With an anterior dislocation, the humeral head (A) will be displaced anteriorly away from the scapula (B)



- With anterior shoulder dislocations, which are most common, the humeral head will be anterior and inferior to the glenoid:

From a posterior approach as described above, the humeral head will be seen as a deeper structure on the ultrasound image.

Figure 6.9—Anterior shoulder dislocation.

Video 6.2—Anterior shoulder dislocation.

- In a posterior shoulder dislocation, which is much less common and typically only occurs due to seizures or electrocutions, the humeral head will be posterior and inferior to the glenoid and appear more superficial on the ultrasound image.
- A hypoechoic area may also be seen which is indicative of a joint effusion:

Figure 6.10—Shoulder effusion

Tendons

(a) Standard Exam Views

- Tendons should be imaged in both transverse or cross-sectional and longitudinal planes.

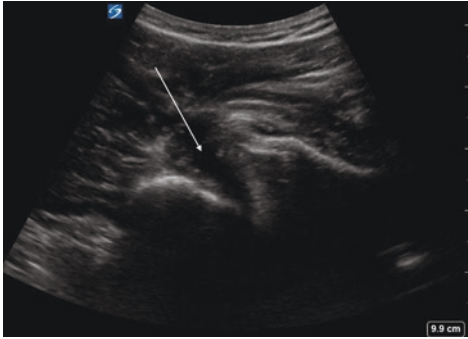


FIGURE 6.10 Shoulder effusion: A shoulder effusion can be visualized as a hypoechoic area between the humeral head and scapula. Heterogeneous material may sometimes be visualized if blood has started to clot

- Be sure to scan through the entire length of the tendon to confirm the tendon is intact without tears or rupture.
- Obtain similar views of contralateral tendon for comparison as needed.

(b) Ultrasound Anatomy

- In a longitudinal plane, visualize the dense hyperechoic organized parallel fibers [1]. Occasionally a surrounding sheath may also be seen:
 - Figure 6.11—Tendon in long axis
 - Video 6.3—Tendon in long axis
 - It is important to distinguish muscles from tendons.

Grossly, the location of the transducer can help with this.

On ultrasound, muscles appear as hypoechoic tissue separated by fine hyperechoic fibrillary septa with a striated appearance.

Figure 6.12—Muscle.

FIGURE 6.11 Tendon in longitudinal plane: A normal tendon appears with long fibular strands between a hyper-echoic sheath (arrows)

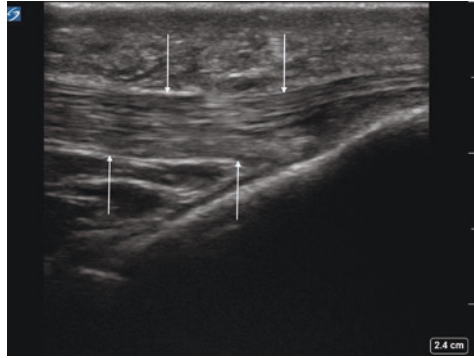
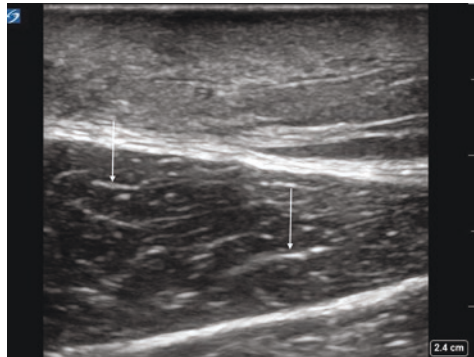
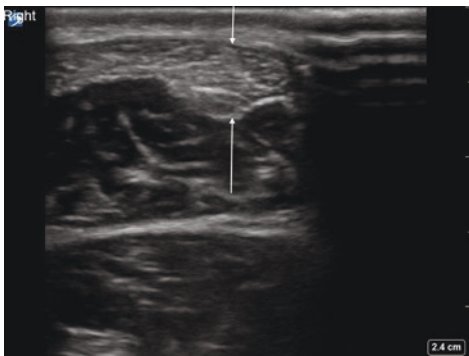


FIGURE 6.12 Muscle: Muscle is more hypoechoic and less organized than tendons, with hyper-echoic striations (arrows)



- In a transverse plane, tendons will appear as a circular or oval collection of hyperechoic, punctate structures:
 - Figure 6.13—Tendon in short axis
 - Video 6.4—Tendon in short axis
- Tendons elicit a phenomenon called anisotropy which can distinguish a tendon from nerves:
 - Anisotropy means that the echogenicity of tendons will change based on the angle of the transducer:

FIGURE 6.13 Tendon in cross section: In cross section, tendons will have hyperechoic punctate structures



When the transducer is perpendicular to the tendon, it will appear hyperechoic [1] and organized.

As the transducer moves away from a perpendicular plane and is angled down (e.g., at a 45 angle), the structure will become more hypoechoic [1].

Video 6.5—Anisotropy.

(c) Tendon Pathology

- Tendon rupture:
 - Disruption of tendon fibers can be partial or complete.
 - Partial internal tears may just have hypo- or anechoic areas within the tendon [1] that lacks anisotropy:

Figure 6.14—Partial tendon tear

Video 6.6—Partial tendon tear

- Complete rupture will be visualized as a complete disruption of the tendon fibers, usually with surrounding anechoic fluid due to hemorrhage and/or edema from inflammation [1]:

Figure 6.15—Complete tendon rupture

Video 6.7—Complete tendon rupture short axis

Video 6.8—Complete tendon rupture long axis

FIGURE 6.14 Partial tendon rupture: The normal tendon (*arrow*) becomes edematous then has a noticeable defect (A) where it is torn. The hypoechoic area is blood filling the defect

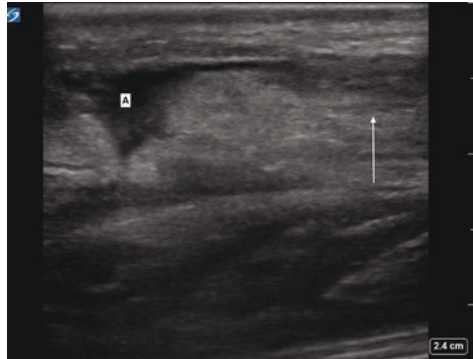
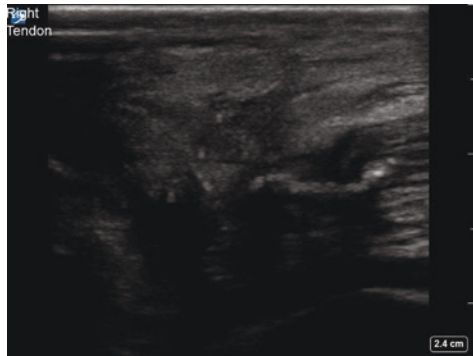
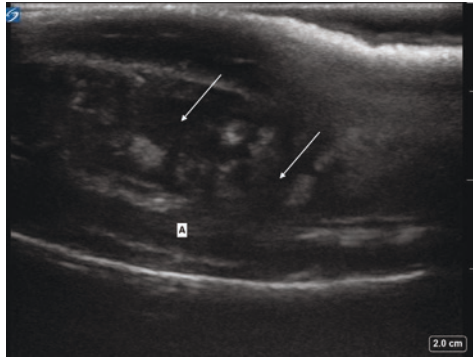


FIGURE 6.15 Complete tendon rupture: With a complete tendon rupture there is complete loss of normal tendon architecture, as well as swelling of the tendon due to inflammation



- Flexor tenosynovitis:
 - Acute inflammation usually due to infection within the flexor tendon sheath of a finger.
 - On a normal finger, the flexor tendon sheath is normally not visualized.
 - With flexor tenosynovitis, the tendon sheath will be thickened. Inside the sheath the tendon will course through surrounding hypoechoic or anechoic fluid [1, 4].
 - Figure 6.16—Flexor tenosynovitis.
 - Video 6.9—Flexor tenosynovitis.

FIGURE 6.16 Flexor tenosynovitis: The flexor tendon (A) is seen to have a thickened flexor tendon sheath with hypoechoic fluid surrounding the tendon (*arrows*)



Knee Joint

(a) Standard Exam Views

- With the patient positioned appropriately, place the transducer anteriorly on the knee joint and scan through from the distal femur to the superior portion of the patella.
- A transverse view in the appropriate location may facilitate ultrasound-guided arthrocentesis:
 - See the procedural chapter for more details.

(b) Ultrasound Anatomy

- Visualize the hyperechoic cortex of the femur superior and deep with the patella more inferior and superficial.
- Normal synovial fluid within the suprapatellar bursa will appear anechoic and will be less than 2 mm when measured [5].
- The quadriceps tendon will be seen attaching to the patella in this view.
- Figure 6.17—Normal knee.
- Video 6.10—Normal knee.

FIGURE 6.17 Normal knee: Articulation of the femur and patella using a lateral transducer placement

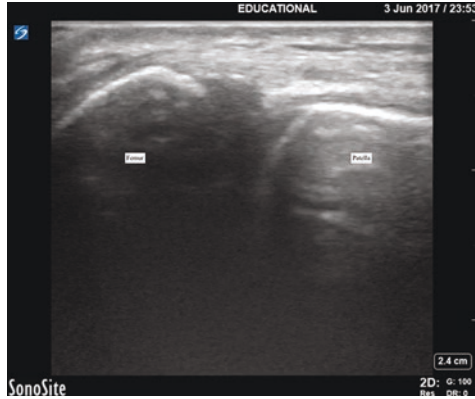
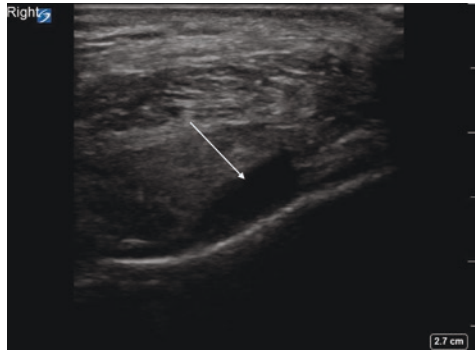

FIGURE 6.18 Knee effusion: A small knee effusion (arrow)



(c) Knee Pathology

- Knee effusion:
 - Excess fluid within or around the joint.
 - Typically, a fluid collection will be seen in the suprapatellar bursa [1]:

This will appear as an anechoic or hypoechoic collection between the femur and patella.

Figure 6.18—Knee effusion.

Video 6.11—Knee effusion.

- The echogenicity of the fluid collection can help to identify the type of fluid:

Simple fluid will appear anechoic [1].

Inflammatory fluid will be anechoic with loculations in the joint space [1].

Hemorrhagic fluid can appear anechoic initially but typically will have increased echogenicity due to clot formation [1].

If there is debris within the effusion, consider infection, hemorrhage, and fat (lipohemarthrosis) [5].

Bone

- Standard Exam Views

- Over the area of interest, obtain both transverse and longitudinal clips:

Begin by scanning in a transverse plane to identify bone and optimize the image on the screen by adjusting depth and gain [1].

Rotate the transducer to image the bone in a long axis and scan through to identify any irregularities representing a fracture [1].

- Obtain similar views of contralateral bone for comparison as needed.

- Ultrasound Anatomy

- Normal bones can be identified by a thick hyperechoic line representing the bony cortex with underlying posterior acoustic shadowing [1].
- The cortex should be continuous without disruptions.
- Figure 6.19—Normal bone.
- Video 6.12—Normal bone.

FIGURE 6.19 Normal bone: Normal bone is hyperechoic with posterior shadowing

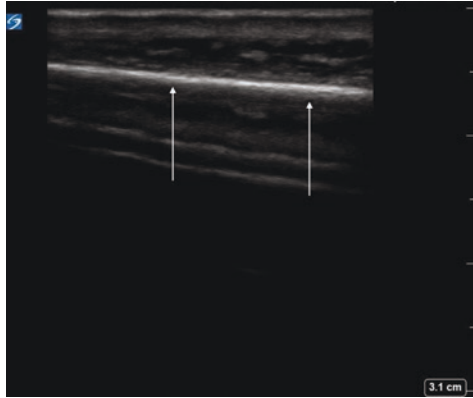
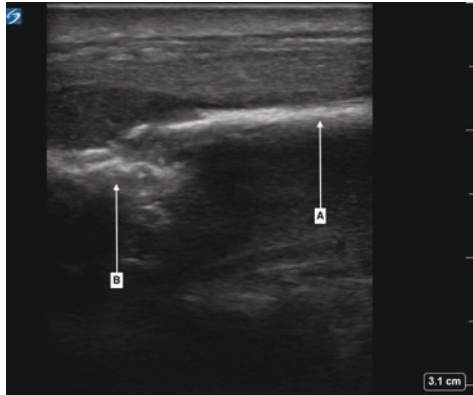


FIGURE 6.20 Fracture: Bone (A) loses its typical appearance and will be seen as a disruption of the bony cortex at the site of the fracture (B)



- Bone Pathology
 - Fractures:

Will appear as a disruption of the echogenic bony cortex [1] or with more displaced fractures, a step-off

May see surrounding anechoic or hypoechoic collection suggestive of a hematoma

Figure 6.20—Fracture

Video 6.13—Fracture

Nerves

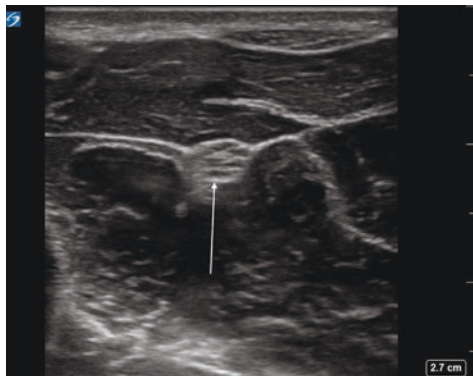
1. Standard Exam Views

- (a) Identify the nerve of interest, place the transducer over this area with the patient in a position of comfort, then scan through the area:
 - Nerves are best visualized in a transverse plane.
- (b) For the median nerve, place the transducer over the flexor retinaculum. This can be found at the level of the scaphoid on the flexor surface of the wrist:
 - Measure the nerve to evaluate for inflammation.

2. Ultrasound Anatomy

- (a) Nerves have a fascicular appearance with individual fascicles being hypoechoic and surrounded by hyperechoic connective tissue resembling a honeycomb [6]:
 - Figure 6.21—Normal median nerve
 - Video 6.14—Normal median nerve
- (b) Nerves in a longitudinal axis appear as hyperechoic tubes with small parallel linear hypoechoic internal echoes [6].
- (c) Nerves can easily be mistaken for tendons; however, they do not exhibit anisotropy as tendons do.

FIGURE 6.21 Normal median nerve: Normal median nerves resemble a honeycomb with individual hypoechoic fascicles surrounded by a hyperechoic connective tissue border



3. Nerve Pathology

(a) Carpal tunnel syndrome:

- Compression of the median nerve within the carpal tunnel causing a range of symptoms depending on the severity of the condition.
- The median nerve within the carpal tunnel will appear enlarged [6] with some internal edema and an increased cross-sectional area of the nerve:
 - Measure the cross-sectional area (CSA) of the median nerve at the level of the scaphoid and pisiform:

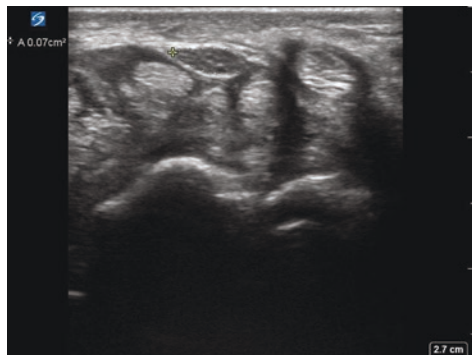
Figure 6.22—Median nerve cross-sectional area

- CSA >10 mm is suggestive of carpal tunnel syndrome [6, 7]:

Figure 6.23—Enlarged median nerve cross-sectional area

- Additionally, may see flattening of the nerve distally and enlargement of the nerve proximally [6].

FIGURE 6.22 Median nerve cross-sectional area: Normal cross-sectional area (CSA) measurement of the median nerve as it enters the carpal tunnel



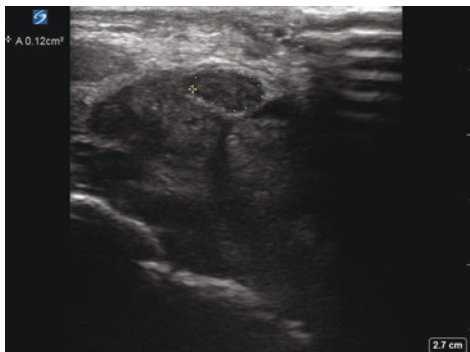


FIGURE 6.23 Enlarged median nerve cross-sectional area: Enlarged median nerve in the carpal tunnel with a cross-sectional area (CSA) measuring greater than 10 mm

Key Points

- When in doubt, compare to the contralateral side.
- After identifying shoulder dislocations, consider injecting lidocaine into the joint under ultrasound guidance. This may allow for reduction without procedural sedation:
 - Ultrasound guidance can also be used to facilitate arthrocentesis and hematoma blocks for fractures.
- Always use anisotropy to differentiate tendons from surrounding structures.
- Tendon pathology will be seen as a hypoechoic defect. Because anisotropy can cause this appearance, it is important to determine if true pathology exists [1] by repositioning the transducer and imaging in both short and long axis.
- Light pressure may help reveal subtle fractures.

References

1. Dewitz A. Chapter 18: Musculoskeletal, soft tissue, and miscellaneous applications. In: Ma OJ, Mateer JR, Reardon RF, Joing SA, editors. *Emergency ultrasound*. 3rd ed. China: McGraw-Hill Education; 2014. p. 503–68.
2. Dawson M, Mallin M. *Introduction to bedside ultrasound: volumes 1 and 2*. Lexington, Kentucky: Emergency Ultrasound Solutions; 2012.
3. Abbasi S, Molaie H, Hafezimoghadam P, et al. Diagnostic accuracy of ultrasonographic examination in the management of shoulder dislocation in the emergency department. *Ann Emerg Med*. 2013;62(2):170–5.
4. Padrez K, Bress J, Johnson B, Nagdev A. Bedside ultrasound identification of infectious flexor tenosynovitis in the Emergency Department. *The West J Emerg Med*. 2015;16(2):260–2.
5. Razek AAKA, Founda NS, Elmetwaley N, Elbogdady E. Sonography of the knee joint. *J Ultrasound*. 2009;12(2):53–60. <https://www.ncbi.nlm.nih.gov/pmc/articles/PMC3553228/>. Accessed 27 April 2017.
6. Lawande AD, Warriar SS, Joshi MS. Role of ultrasound in evaluation of peripheral nerves. *Indian J Radiol Imaging*. 2014;24(3):254–8. <https://www.ncbi.nlm.nih.gov/pmc/articles/PMC4126140/>. Accessed 27 April 2017.
7. Wong SM, Griffith JF, Hui AC, et al. Carpal tunnel syndrome: diagnostic usefulness of sonography. *Radiology*. 2004;232(1):93–9.

Chapter 7

Abdominal Aortic Aneurysm Ultrasound

Abdominal aortic aneurysm is a potentially life-threatening condition depending on the size and characteristics of the aneurysm. Ultrasound is a useful modality to quickly assess the aorta for the presence of an aneurysm, or arterial dissection, and to determine the relative risk of impending rupture. To do this, it is important for an ultrasonographer to learn how to accurately image and measure the diameter of an aortic aneurysm. This chapter serves to educate the novice learner on how to take these measurements as well as how to overcome limitations to doing so. It will review indications for performing an aortic ultrasound, basic anatomy, image acquisition, normal ultrasound anatomy, and interpretation of pathology.

Clinical Application/Indications

- Evaluate the aorta as a cause for abdominal pain, flank pain, hypotension, syncope, or high-risk medical screening:
 - Common pathology includes abdominal aortic aneurysm (AAA), dissection, and thrombus.

Electronic Supplementary Material The online version of this chapter (doi:10.1007/978-3-319-68634-9_7) contains supplementary material, which is available to authorized users.

Normal Aortic Anatomy

- The abdominal aorta begins at the aortic hiatus of the diaphragm at the 12th thoracic vertebrae.
- It is a retroperitoneal structure that courses anterior to the spine until it bifurcates into the iliac arteries at the level of the umbilicus or second lumbar vertebrae.
- A normal aorta will have an anechoic lumen and a maximum diameter of less than 3.0 cm when measuring from outer wall to outer wall [1–3]:
 - Average diameter in men is 2.1 cm and in women is 1.8 cm [1].
- Near the iliac bifurcation, the aorta tapers and courses more anteriorly due to lumbar lordosis.
- Transverse Anatomy
 - The aorta lies to the left of midline, just anterior to the spine and adjacent to the more rightward inferior vena cava (IVC):

Figure 7.1—Transverse aorta

Video 7.1—Normal transverse aorta

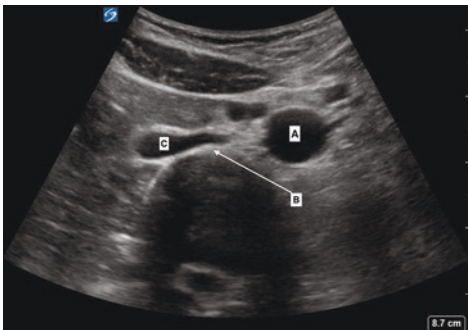


FIGURE 7.1 Transverse aorta: The normal aorta in transverse will be a circular structure with hyperechoic walls and a hypoechoic center (A), usually located directly anterior to the vertebral body (B) or just lateral to it. The IVC, sometimes collapsed, will be visualized to the patients right (C)

FIGURE 7.2 Celiac trunk with seagull sign: Arising from the aorta (A) is the celiac trunk (C), branching into the hepatic artery (B) and splenic artery (D)

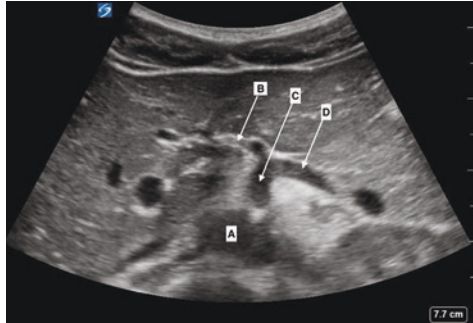
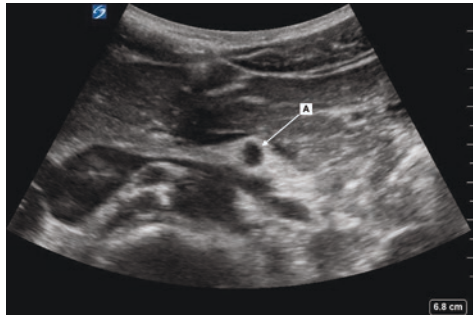


FIGURE 7.3 Superior mesenteric artery: Superior mesenteric artery (A) is the second main branch from the abdominal aorta, just inferior to the celiac trunk



- The celiac artery is the first branch off the aorta:

Arises from the anterior wall of the aorta.

The celiac artery branches into the common hepatic artery on the right and the splenic artery on the left, known as the “seagull sign” [3].

The celiac trunk and SMA may share a common trunk; this is a normal variant.

Figure 7.2—Celiac trunk with seagull sign

Video 7.2—Celiac trunk

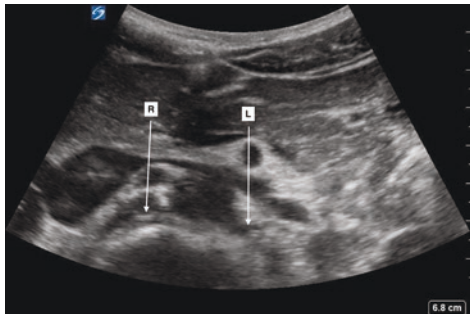
- The superior mesenteric artery (SMA) is the second branch from the aorta:

Arises from the anterior wall of the aorta just inferior to the celiac artery

Figure 7.3—Superior mesenteric artery

Video 7.3—Superior mesenteric artery

FIGURE 7.4 Renal arteries: Left (L) and right (R) renal artery branches



- The renal arteries take off from each side of the aorta approximately 2 cm inferior to the SMA:

The right renal artery courses under the IVC.

Figure 7.4—Renal arteries.

Video 7.4—Renal arteries.

- Distal to the renal arteries are the gonadal arteries (testicular and ovarian) followed by the inferior mesenteric artery (IMA), each of which are difficult to image by ultrasound [1].
- The aorta bifurcates into the left and right common iliac arteries near the level of the umbilicus:

Figure 7.5—Aortic bifurcation

Video 7.5—Bifurcation

- Sagittal Anatomy

- The aorta can be viewed as a single continuous vessel in the sagittal plane, lying just anterior to the spinal column:

Figure 7.6—Sagittal aorta

Video 7.6—Sagittal aorta

Image Acquisition

(a) Transducer Selection

- Curvilinear
- Phased array

FIGURE 7.5 Aortic bifurcation: Near the umbilicus, the aorta will bifurcate into the right and left iliac arteries (arrows)

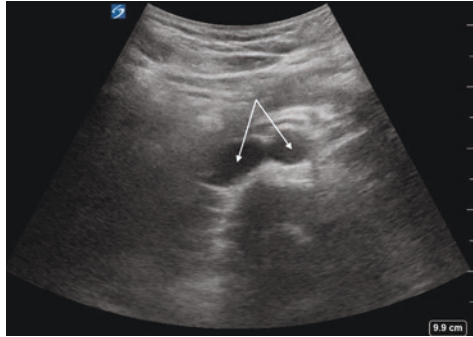
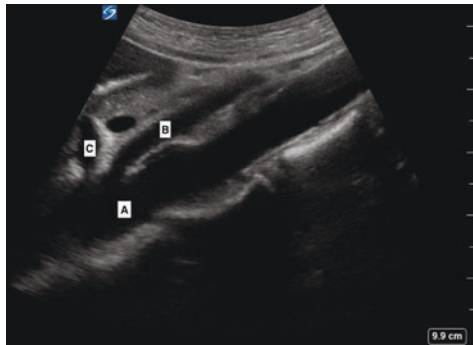


FIGURE 7.6 Sagittal aorta: Sagittal view of the aorta (A) at the level of the superior mesenteric artery (B) and celiac artery (C)



(b) Patient Position

- The patient should be placed in a supine position for optimal imaging.
- If there is an excessive amount of bowel gas, left or right lateral decubital position can be utilized.

(c) Standard Exam Views

- Transverse or cross-sectional imaging:
 - Place the transducer over the epigastrium just inferior to the xiphoid with the transducer marker pointed toward the patient's right.
 - Keep the transducer perpendicular to the long axis of the aorta and follow the aorta down through the bifurcation at approximately the level of the umbilicus:

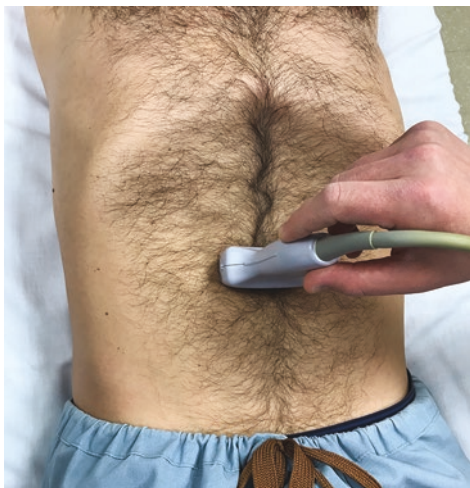

FIGURE 7.7 Transducer placement for imaging the aorta in a transverse plane: Beginning just below the xiphoid process, scan the aorta from proximal to the distal bifurcation in a transverse orientation

Figure 7.7—Transducer placement for imaging the aorta in a transverse plane

- Sagittal imaging:
 - Place the transducer over the epigastrium with the transducer marker pointed cephalad.
 - Figure 7.8—Transducer placement for imaging the aorta in a sagittal plane.
- The abdominal aortic diameter should be measured from outer wall to outer wall in cross-sectional and anterior-posterior planes:
 - Figure 7.9—Normal aorta measurement proximal
 - Figure 7.10—Normal aorta measurement distal

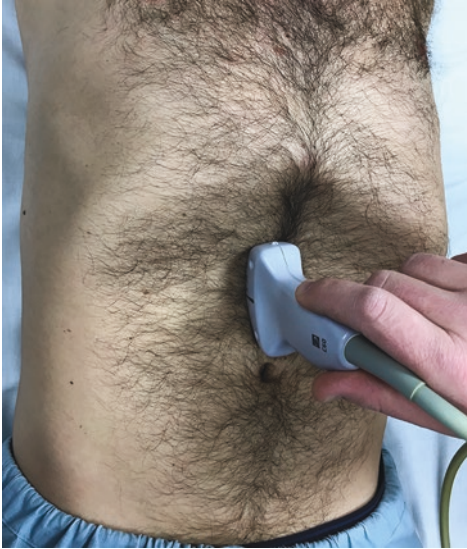

FIGURE 7.8 Transducer placement for imaging the aorta in a sagittal plane: Orient the transducer with the marker pointed cephalad to obtain a sagittal view of the aorta. Slide the transducer inferior or superior to visualize the entire aorta

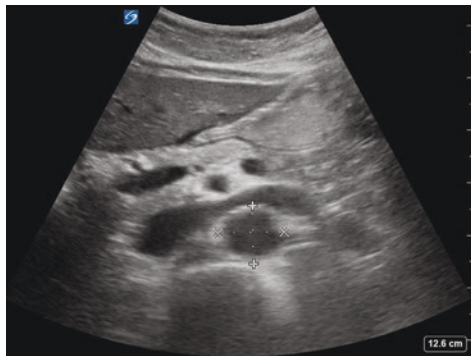
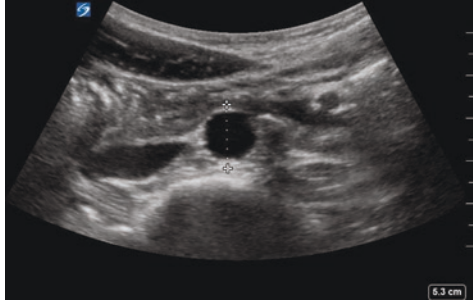


FIGURE 7.9 Normal aorta measurement proximal: Proximal measurement of the aorta measuring outer wall to outer wall

FIGURE 7.10 Normal aorta measurement distal: Distal measurement of aorta from outer wall to outer wall



Abdominal Aortic Pathology

(a) Abdominal Aortic Aneurysm

- Defined as an aortic diameter of greater than 3.0 cm [1–3].
- Will most often be located infrarenal [1].
- Can be fusiform or saccular (less common):
 - Fusiform aneurysms are demonstrated by a uniform concentric dilation of the circumference of the aorta [1]:

Figure 7.11—Fusiform aneurysm in a sagittal plane

Video 7.7—Fusiform aneurysm in a sagittal plane

Figure 7.12—Fusiform aneurysm in transverse

Video 7.8—AAA (fusiform) in transverse plane

- A saccular aneurysm is characterized by a localized outpouching of a portion of the aortic wall [1]:

Figure 7.13—Saccular aneurysm

- Mural thrombus can often be seen within the periphery of a AAA, with a central lumen for blood flow:
 - Care must be taken to measure the outer wall-to-outer wall diameter of a AAA, including the thrombus if present, to avoid falsely measure the central lumen only:

Figure 7.14—AAA with thrombus

Video 7.9—AAA with thrombus

FIGURE 7.11
Fusiform aneurysm: Uniform concentric dilation of a fusiform aneurysm in a sagittal plane

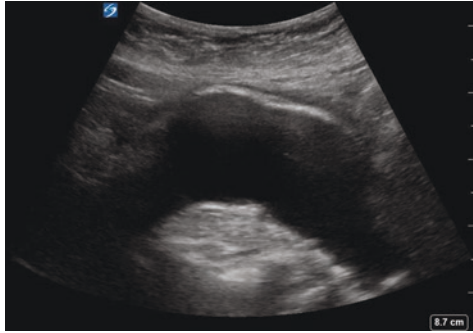

FIGURE 7.12
Abdominal aortic aneurysm: Transverse view of a fusiform aneurysm measuring greater than 3.0 cm

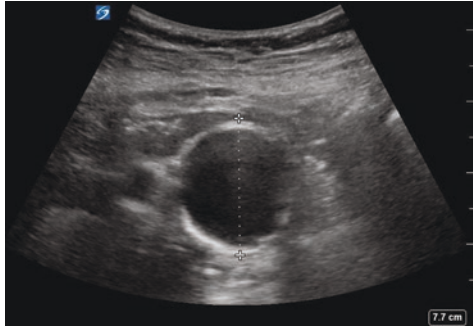


FIGURE 7.13
Saccular aneurysm: Noticed here in sagittal plane is an outpouching of the aorta creating a saccular aneurysm

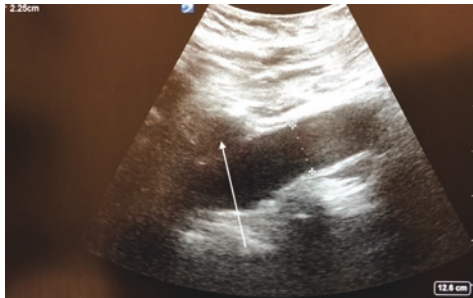

FIGURE 7.14 AAA with thrombus:
Large dilated aorta, with internal thrombus (A). Note the small area of continued flow (B)

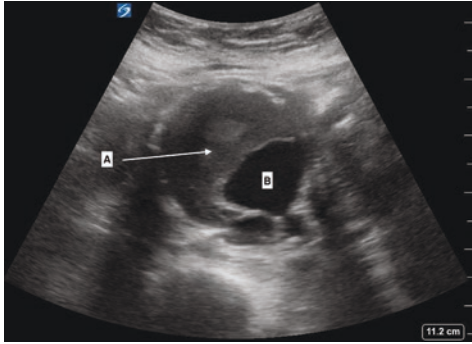
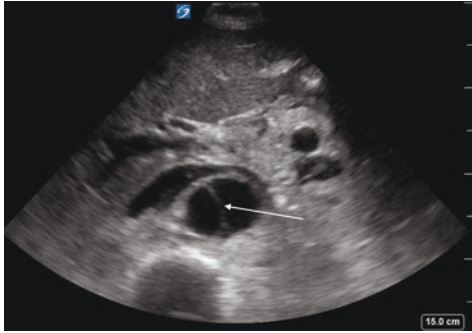


FIGURE 7.15
Dissection:
Hyperechoic dissection flap (arrow) is seen in the middle of this aorta



(b) Abdominal Aortic Dissection

- A dissection occurs when the inner wall of an artery (in this case Aorta) tears causing blood to flow between layers of the wall of the aorta creating a “false” lumen.
- Dissection flap, if present, will be visualized within the lumen of the aorta:

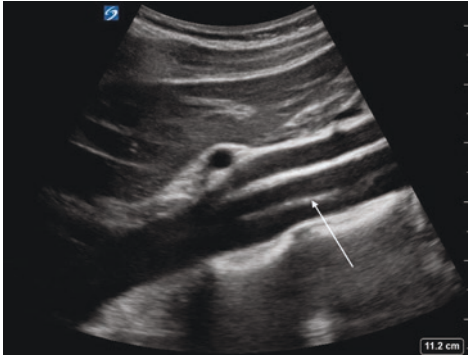


FIGURE 7.16 Artifact: This image displays a mirror artifact where the aorta wall is doubled (*arrow*). Note there is no beginning or end to the flap, and it only is where the wall is next to another vessel, thus raising suspicion for artifact. Imaging in multiple planes will help delineate this

- Appears as a hyperechoic linear band through the lumen.
- Figure 7.15—Dissection.
- Video 7.10—Aortic dissection.
- Scans must be taken in multiple planes to distinguish true dissection from artifact.
- Figure 7.16—Artifact.
- Video 7.11—Artifact.
- Color Doppler may show flow only in one portion of the aorta in a transverse orientation, and not the false lumen [1] or with more turbulent flow in the false lumen:
 - Figure 7.17—Dissection with color Doppler
 - Video 7.12—Dissection with color Doppler

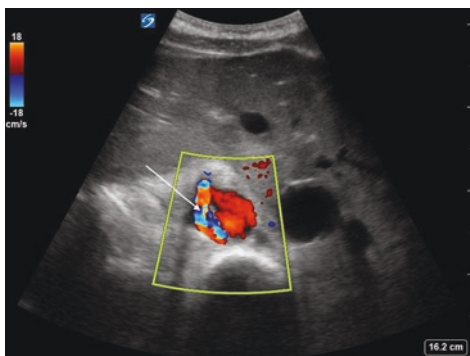


FIGURE 7.17 Dissection with color Doppler: Color flow imaging of dissection shows more turbulent flow in the dissected portion of the aorta (*arrow*)

Key Points

- Bowel gas can obscure all or part of the aorta:
 - To improve visualization:
 - Attempt to roll the patient
 - Attempt to image the aorta in the coronal plane
 - Apply firm, increasing pressure to the abdomen to displace bowel gas
 - Wait and rescan after a brief time to allow peristalsis to move bowel gas forward
- Obesity can limit the evaluation of an abdominal aorta:
 - It may be helpful to place the patient in a right or left lateral decubital position to move the pannus out of the way.
- Most abdominal aortic aneurysms are infrarenal; therefore, it is important to image the aorta all the way to the bifurcation [1].

- It is important to obtain measurements of the aortic diameter in both transverse and sagittal planes to ensure accuracy:
 - In a sagittal plane, off-axis measurements can occur in which the image is not over the center of the vessel resulting in an underestimation of the true diameter [3].
- Ultrasound is not sensitive for diagnosing aortic rupture:
 - Most ruptured AAA's will result in retroperitoneal bleeding which is difficult to visualize with ultrasound.

References

1. Reardon RF, Clinton ME, Madore F, Cook T. Chapter 9: Abdominal aortic aneurysm. In: Ma OJ, Mateer JR, Reardon RF, Joing SA, editors. *Emergency Ultrasound*. 3rd ed. China: McGraw-Hill Education; 2014. p. 225–46.
2. Wu S, Blackstock U, Lewiss R, Saul T, Bagley W. Focus on: bedside ultrasound of the abdominal aorta. ACEP News Website. May 2010. <https://www.acep.org/Clinical---Practice-Management/Focus-On--Bedside-Ultrasound-of-the-Abdominal-Aorta/>. Accessed 17 April 2017.
3. SonoSim Ultrasound Training Solution [Video]. Santa Monica, CA: SonoSim Inc.; 2017.

Chapter 8

Biliary Ultrasound

Abdominal pain is one of the most common ailments among patients within all facets of medicine. Right upper quadrant pain and its associated pathology, such as cholecystitis and cholelithiasis, can occur in patients seeing their primary care physician, seeking care in the emergency department, and in those admitted to the intensive care unit, general floor, or long term care facilities. Ultrasound is an efficient, easy, and economical modality for a provider to evaluate the gallbladder and its surrounding structures for disease processes. This chapter will focus on performing the biliary ultrasound, basic gallbladder and biliary system anatomy, image acquisition, and interpretation of pathology.

Clinical Application and Indications

- Evaluate for causes of right upper quadrant pain, specifically cholelithiasis, cholecystitis, and choledocholithiasis

Electronic Supplementary Material The online version of this chapter (doi:10.1007/978-3-319-68634-9_8) contains supplementary material, which is available to authorized users.

Normal Biliary Anatomy

- The gallbladder is a fluid-filled, hollow structure that lies inferior to the liver within the gallbladder fossa, medial and anterior to the kidney, and lateral to the inferior vena cava (IVC).
- There are three distinct regions of the gallbladder: the fundus, body, and neck
 - The body and fundus contain stored bile and are variable in size depending on the patient's prandial state.
 - The neck is contiguous with the cystic duct, which joins the common hepatic duct to form the common bile duct.
 - A normal fully distended gallbladder will be no larger than 8 cm × 4 cm:

Average gallbladder measurements include length 6.16 ± 1.09 cm, height 2.75 ± 0.58 cm, and width 2.98 ± 0.59 cm [1].

- The gallbladder wall is normally less than 3 mm thick [2–4]:

Average gallbladder wall thickness is 2.29 ± 0.525 [3].
- Common Bile Duct
 - The common bile duct (CBD) travels anterior to the main portal vein and often to the right of the hepatic artery [2] forming the portal triad.

Imaging Overview

(a) Transducer Selection

- Curvilinear transducer
- Phased array transducer

(b) Patient Position

- The patient should be lying in a supine position.
- A left lateral decubitus position may bring the gallbladder out from beneath the ribcage and closer to the skin, allowing easier visualization.

- Imaging on deep inspiration with a breath hold can also help bring the gallbladder out from beneath the ribcage, allowing easier visualization.

(c) Standard Exam Views

- Image the gallbladder in long axis:
 - Begin with the transducer placed below the rib margin at approximately the midclavicular line with the marker pointed cephalad.
 - With the transducer, follow the rib margin laterally until you find the gallbladder, which is typically located between the nipple line and the anterior axillary line.
 - Once you locate the gallbladder, orient the transducer to mirror the long axis of the gallbladder to obtain a long axis view.
 - Scan through the gallbladder by fanning the transducer from left to right:

Figure 8.1—Gallbladder in long axis

Video 8.1—Gallbladder in long axis

- Image the gallbladder in short axis:
 - Rotate the transducer approximately 90° counter-clockwise to obtain a short axis view. The marker should be pointing toward the patient's right for this view.

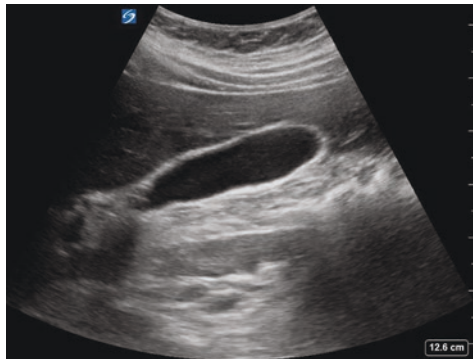
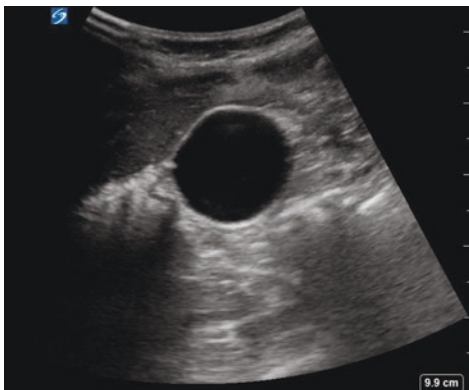


FIGURE 8.1
Gallbladder in long axis: Gallbladder imaged in long axis

FIGURE 8.2
Gallbladder in
short axis:
Gallbladder imaged
in short axis



- Scan through the gallbladder in short axis by fanning from fundus to neck:
 - Figure 8.2—Gallbladder in short axis
 - Video 8.2—Gallbladder in short axis
- Measure the anterior gallbladder wall when in short axis view:
 - Avoid measuring the gallbladder wall at the lateral or posterior positions. Ultrasound artifacts (edge artifact, shadowing, and posterior acoustic enhancement) will preclude accurate measurement in those locations.
 - If unable to obtain a clear image of the anterior wall in short axis, measure the gallbladder wall that abuts against the liver in long axis.
 - Figure 8.3—Anterior wall measurement in short axis.
 - Figure 8.4—Wall measurement in long axis.
- Image the common bile duct:
 - Place the transducer inferior to costal margin at the midclavicular line with the transducer perpendicular to the costal margin and the marker pointed cephalad.

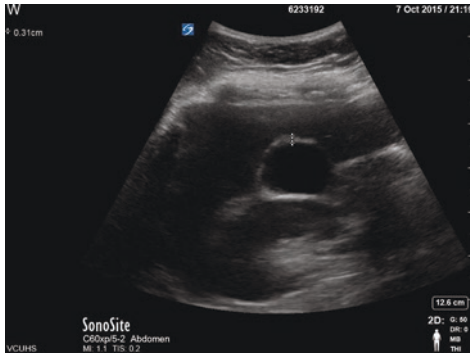


FIGURE 8.3 Gallbladder wall measurement in short axis: The gallbladder wall should ideally be measured at the thickest location of the anterior wall when in short axis

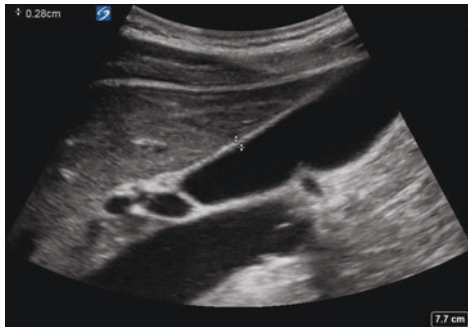

FIGURE 8.4 Wall measurement in long axis: If unable to obtain an anterior wall measurement, measure the gallbladder wall that abuts against the liver in long axis at the thickest location

- Locate the gallbladder, then rotate the transducer to the patients right to find the portal vein.
- Locate the portal vein, which is a thick hyperechoic walled vein posterior to the neck of the gallbladder. Rotate the transducer so the portal vein is visualized longitudinally:

Figure 8.5—Portal vein

FIGURE 8.5 Portal vein: The portal vein (A) has a thick hyperechoic wall (arrows), which makes it easy to identify within the liver

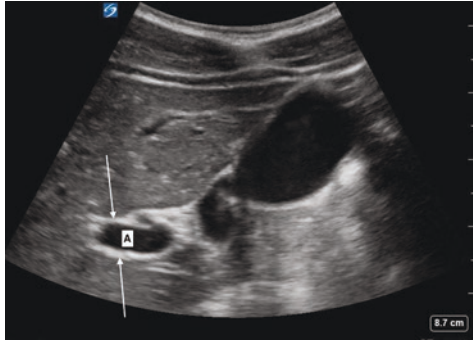
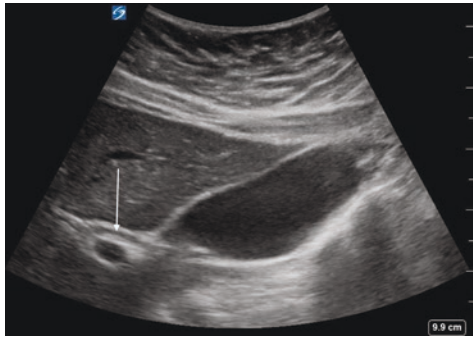


FIGURE 8.6 CBD: Common bile duct (arrow) lies anterior to the portal vein



- The CBD will be found anterior to and parallel to the portal vein, appearing as if they share a wall:

Figure 8.6—CBD

Video 8.3—Common bile duct

- A normal CBD can be difficult to differentiate from the hepatic artery:

Use color flow Doppler to assist in confirmation of the CBD.

Both the portal vein and hepatic artery will demonstrate color Doppler indicating flow, whereas the CBD should not.

Figure 8.7—Portal triad with color Doppler.

Video 8.4—Portal triad with color Doppler.

FIGURE 8.7 Portal triad with color Doppler: Color Doppler can assist in locating the CBD. The portal vein and hepatic artery will both demonstrate color flow, whereas the common bile duct will not

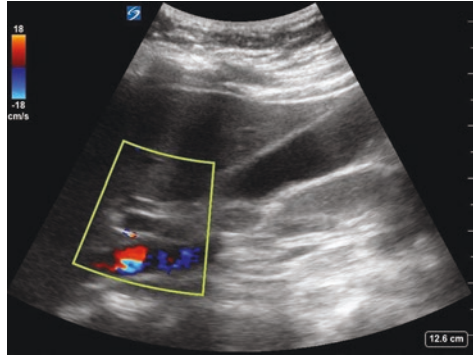
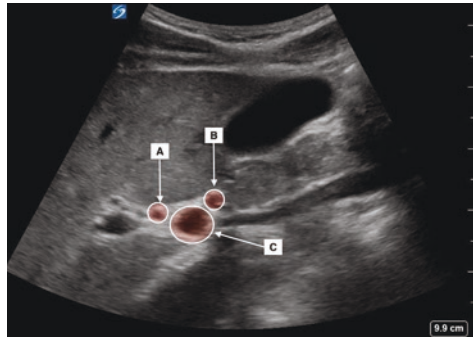


FIGURE 8.8 Mickey Mouse sign: In cross section, the portal triad will appear as three hypoechoic circles, referred to as mickle mouse sign: common bile duct (A), hepatic artery (B) and the portal vein (C)



- In cross section, the portal triad appears as three hypoechoic circles, commonly referred to as “Mickey Mouse sign” [2]:

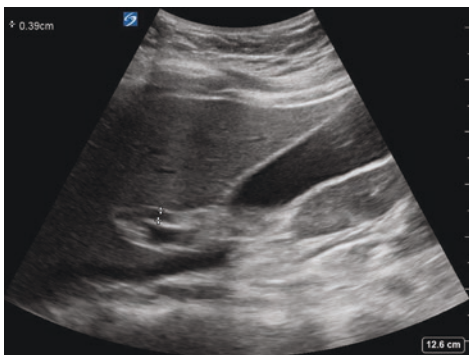
The larger portal vein is located at the base.

The smaller hepatic artery will be more medial at approximately the 2 o'clock position relative to the portal vein.

The CBD will be more lateral at approximately the 10 o'clock position relative to the portal vein.

Figure 8.8—Mickey Mouse sign.

FIGURE 8.9 Normal CBD measurement: Measure the common bile duct should be measured from inner wall to inner wall as pictured here



- Measure the common bile duct diameter from inner wall to inner wall:

Normal common bile duct diameter is less than 7 mm [2].

Figure 8.9—Normal CBD measurement.

In patients who are status post cholecystectomy, CBD diameter should be less than 10 mm [5].

Gallbladder Pathology

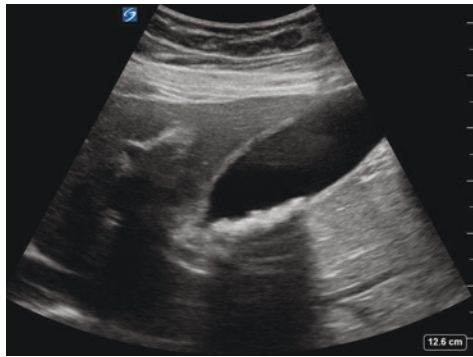
(a) Cholelithiasis

- Cholelithiasis is the presence of stones within the gallbladder.
- Stones appear as hyperechoic, round or oval shaped structures within the gallbladder and exhibit almost complete posterior acoustic shadowing:
 - Figure 8.10—Large gallstone
 - Video 8.5—Large gallstone
 - Figure 8.11—Multiple small gallstones
 - Video 8.6—Multiple small gallstones
- Gallstones are usually mobile, such that rolling the patient will cause the stones to move within the gallbladder.

FIGURE 8.10 Large Gallstone: Large gallstone with posterior acoustic shadowing

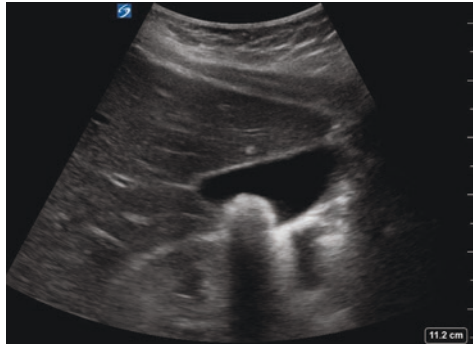

FIGURE 8.11 Multiple gallstones: Multiple small gallstones with posterior acoustic shadowing



- Wall echo shadow (WES) sign is a specific sign that indicates a contracted gallbladder filled with multiple stones [2] or a single large stone [6]:
 - Sometimes referred to as “double arc shadow” sign [6, 7].
 - It is often difficult to appreciate, as the shadowing from multiple stones is often confused with bowel gas shadowing [7, 8]:

Gallstones will produce clean shadowing, whereas bowel gas will produce irregular shadowing [8].

FIGURE 8.12 Wall echo shadow sign in short axis: Wall echo sign (*arrow*) is seen when the gallbladder is contracted around many small stones or a single large stone

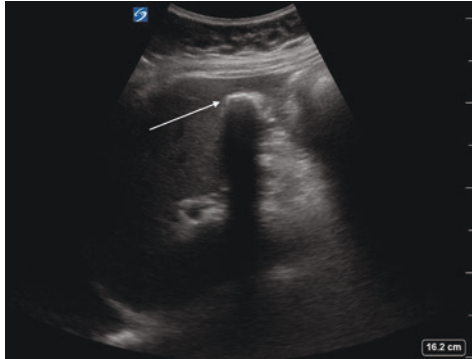
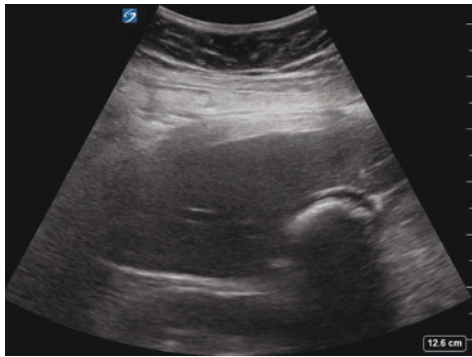


FIGURE 8.13 Wall echo shadow sign in long axis: A long axis view depicting WES sign with a gallbladder that is completely full of stones, leaving no to very little cavity visible

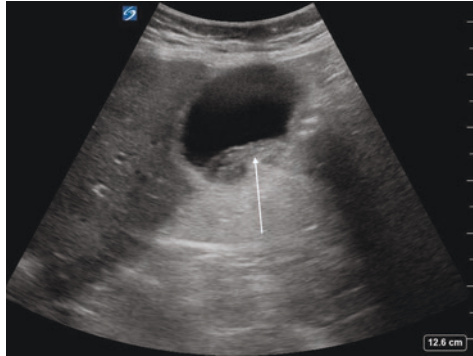


- This finding will also preclude visualization of the gallbladder anatomy:
- Figure 8.12—Wall echo shadow sign in short axis.
- Figure 8.13—Wall echo shadow sign in long axis.
- Video 8.7—Wall echo shadow sign.

(b) Biliary Sludge

- Particulate solids that have precipitated from bile but have not formed into stones.
- Sludge will appear as hyperechoic fluid layering within the gallbladder in a gravity dependent fashion.
- Sludge will move when the patient is rotated.
- Figure 8.14—Sludge.
- Video 8.8—Biliary sludge.

FIGURE 8.14 Sludge: Sludge appears as hyperechoic fluid layering in the dependent portions of the gallbladder, without posterior shadowing



(c) Acute Cholecystitis

- Inflammation of the gallbladder.
- Findings on ultrasound consistent with acute cholecystitis include thickened gallbladder wall, pericholecystic fluid, and sonographic Murphy's sign [2]:
 - Video 8.9—Acute cholecystitis
- Thickened gallbladder wall:
 - Will measure greater than 3 mm on the anterior wall [2–4]
 - Figure 8.15—Thickened wall in short axis
 - Figure 8.16—Thickened wall in long axis
- Pericholecystic fluid:
 - Fluid surrounding the gallbladder that develops secondary to inflammation
 - Will appear as a hypoechoic stripe between the liver and gallbladder
 - Figure 8.17—Pericholecystic fluid
 - Video 8.10—Pericholecystic fluid
- Sonographic Murphy's sign:
 - Defined as reproduction of the patient's pain while compressing the gallbladder with the transducer under direct visualization

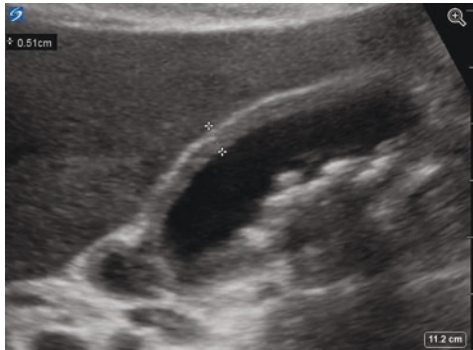
FIGURE 8.15

Thickened wall in short axis: Anterior gallbladder wall is measuring 5 mm, consistent with a thickened wall and concerning for acute cholecystitis

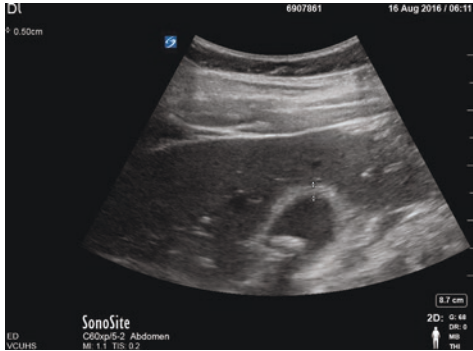

FIGURE 8.16

Thickened wall in long axis: In long axis, the gallbladder wall is 5.1 mm consistent with thickened wall and concerning for acute cholecystitis



(d) Chronic Cholecystitis

- The gallbladder will appear contracted with thickened gallbladder walls due to fibrosis [2] from recurrent acute cholecystitis.

(e) Acalculous Cholecystitis

- Similar to acute cholecystitis due to cholelithiasis, however, the gallbladder will be devoid of stones.
- Typically seen as echogenic sludge within a dilated gallbladder that has a thickened wall.
- Most commonly occurs with reduced gallbladder function such as in trauma, postoperative, burn, sepsis, and immobilized patients [9].

FIGURE 8.17
Pericholecystic
fluid:
Pericholecystic
fluid (*arrows*) is
seen between the
gallbladder and
liver due to inflam-
mation and likely
acute cholecystitis

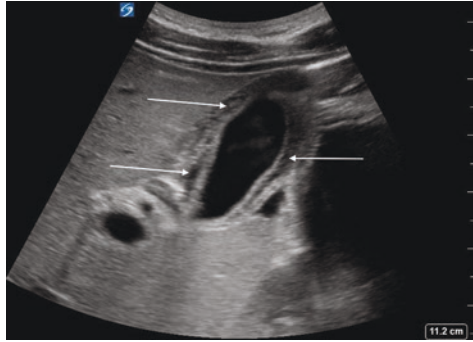
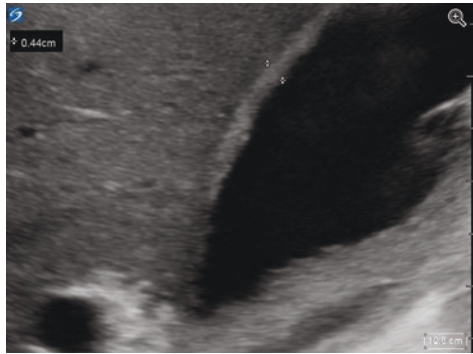


FIGURE 8.18
Acalculous chole-
cystitis: Thickened
gallbladder wall in
the absence of
gallstones

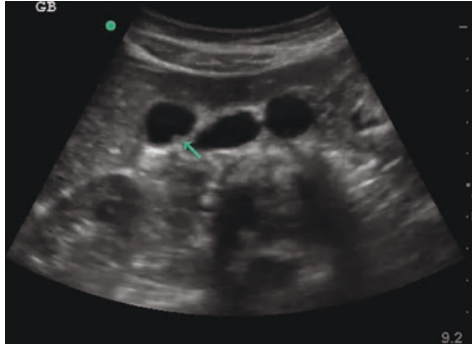


- Figure 8.18—Acalculous cholecystitis.
- Video 8.11—Acalculous cholecystitis.

(f) Emphysematous Cholecystitis

- Rare form of cholecystitis in which necrosis of the gallbladder occurs due to gas-forming bacteria resulting in air within the gallbladder wall [2].
- Will appear as small brightly echogenic areas along the anterior wall with reverberation artifact [10] or “dirty” shadowing from the gallbladder wall.
- More often associated with acalculous cholecystitis.
- Will often progress to gangrenous cholecystitis and perforation if untreated.

FIGURE 8.19
Gallbladder polyp:
Outgrowth from
the gallbladder
wall that has no
posterior acoustic
shadowing and is
not mobile with
patient movements



(g) Gallbladder Polyps

- Non-shadowing, non-mobile outgrowths of the gallbladder wall
- Often incidental in nature:
 - Rarely become malignant
 - May cause obstruction if they are very large and located near the neck
 - Figure 8.19—Gallbladder polyp

Common Bile Duct Pathology

- Common Bile Duct Dilation
 - Considered dilated once it becomes greater than 7 mm in normal patients or 10 mm in post-cholecystectomy patients [2, 5].
 - Normal size can increase with age.
 - Most common cause is obstruction, which can occur with an impacted stone, obstructing mass of the CBD or pancreas, or stricture of the CBD.
 - Non-obstructing causes of CBD dilation include cirrhosis and rarely, medications.
 - Figure 8.20—Dilated CBD.

FIGURE 8.20
Dilated CBD:
Common bile duct
in this patient is
measuring
12.1 mm indicating
a dilated duct,
which is most com-
monly due to
obstruction

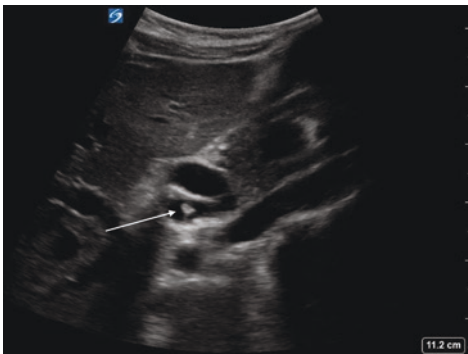
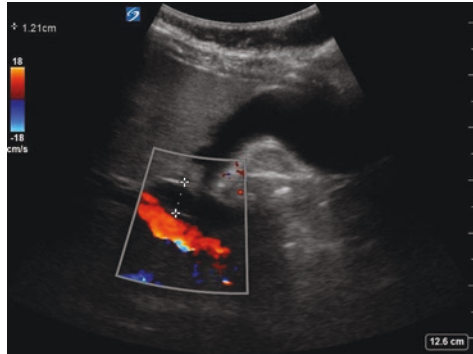


FIGURE 8.21 Cholelithiasis: A gallstone located within the common bile duct (*arrow*)

- Cholelithiasis
 - Gallstone within the common bile duct.
 - Dilation of the CBD is usually the only ultrasound finding that a patient may have cholelithiasis. This is because the distal CBD is rarely visualized secondary to overlying bowel gas.
 - Figure 8.21—Cholelithiasis.
 - Video 8.12—Cholelithiasis.

Key Points

- This chapter describes locating the gallbladder by initially placing the transducer in a sagittal plane with the marker pointed cephalad, then orienting the transducer to visualize the gallbladder in long axis. This can also be done but beginning in a transverse plane and following the same steps.
- Patients who are recently postprandial may have a small, contracted gallbladder. A contracted gallbladder may give the appearance of a thickened wall [2].
- Gallbladder wall thickening can be seen in conditions that are unrelated to the gallbladder including pancreatitis [2], cirrhosis, congestive heart failure, renal failure, and ascites [2].
- Posterior acoustic shadowing may not be seen with stones less than 2 mm [2].

References

1. Adeyekun AA, Ukadike IO. Sonographic evaluation of gallbladder dimensions in healthy adults in Benin City, Nigeria. *West Afr J Radiol.* 2013;20(1):4–8. <http://www.wajradiology.org/article.asp?issn=1115-3474;year=2013;volume=20;issue=1;spage=4;epage=8;aulast=Adeyekun>. Accessed 24 April 2017.
2. Lewiss RE, Theodoro DL. Chapter 10: hepatobiliary. In: Ma OJ, Mateer JR, Reardon RF, Joing SA, editors. *Emergency ultrasound*. 3rd ed. China: McGraw-Hill Education; 2014. p. 247–72.
3. Mohammed S, Tahir A, Ahidjo A, Mistapha Z, Franza O, Okoye I, Shugaba A. Sonographic gallbladder wall thickness in normal adult populations in Nigeria. *South Afr J Radiol.* 2010;14(4):84. <https://www.ajol.info/index.php/sajr/article/view-File/70566/59167>. Accessed 24 April 2017.
4. Blackstock U, Wu S, Lewiss R, Saul T, Bagley W. Focus on: bedside biliary ultrasound. ACEP News Website. November 2010. <https://www.acep.org/Content.aspx?id=64648>. Accessed 24 April 2017.

5. Sharma S, Goyal S, Goyal RA. Prospective study to determine the effect of cholecystectomy on common bile duct diameter in Indian population. *Int J Clin Exp Physiol.* 2015;2(1):61–5. <http://www.ijcep.org/article.asp?issn=2348-8832;year=2015;volume=2;issue=1;spage=61;epage=65;aualast=Sharma>. Accessed 24 April 2017.
6. Datta A, Garg N, Lema PC. The significance of the wall echo shadow triad on ultrasonography: a case series. *Crit Ultrasound J.* 2010;2(3):107–8. <http://link.springer.com/article/10.1007/s13089-010-0038-z>. Accessed 24 April 2017.
7. Raptopoulos V, D’Orsi C, Smith E, Reuter K, Moss L, Kleinman P. Dynamic cholecystosonography of the contracted gallbladder: the double-arc-shadow sign. *Am J Roentgenol.* 1982;138(2):275–8. <http://www.ajronline.org/doi/pdf/10.2214/ajr.138.2.275>. Accessed 24 April 2017.
8. Brown BS, Hoffmann B, Noble VE. Chapter 45: emergency biliary ultrasonography. In: Adams JG, Barton ED, Collings J, PMC DB, Gisondi MA, Nadel ES, editors. *Emergency medicine: clinical essentials*. 2nd ed. Philadelphia, PA: Saunders, an imprint of Elsevier Inc.; 2013. p. 370–81.
9. Huffman JL, Schenker S. Acute acalculous cholecystitis: a review. *Clin Gastroenterol Hepatol.* 2010;8(1):15–22. [http://www.cghjournal.org/article/S1542-3565\(09\)00880-5/pdf](http://www.cghjournal.org/article/S1542-3565(09)00880-5/pdf). Accessed 24 April 2017.
10. Smith EA, Dillman JR, Elsayes KM, Menias CO, Bude RO. Cross-sectional imaging of acute and chronic gallbladder inflammatory disease. *Am J Roentgenol.* 2009;192(1):188–96. <http://www.ajronline.org/doi/full/10.2214/AJR.07.3803>. Accessed 15 June 2017.

Chapter 9

Renal and Bladder Ultrasound

Point-of-care evaluation of the urinary system is focused on assessing the kidneys and bladder. Commonly, renal ultrasound is used to evaluate for hydronephrosis and/or evidence of renal stones in patients who present with signs and symptoms of nephrolithiasis. It is also frequently used to image the bladder to obtain measurements for calculating bladder volume in patients who report urinary retention and also allows providers to evaluate for causes of gross hematuria and pain with indwelling catheter. At times, incidental findings are noted, such as a bladder or renal mass, that will necessitate further management making it important to learn how to recognize these structures. This chapter will review the basic genitourinary anatomy, image acquisition, normal ultrasound anatomy, and interpretation of pathology.

Clinical Application and Indications

- Evaluate for the cause of abdominal pain, flank pain, pelvic pain, hematuria, and urinary retention:

Electronic Supplementary Material The online version of this chapter (doi:[10.1007/978-3-319-68634-9_9](https://doi.org/10.1007/978-3-319-68634-9_9)) contains supplementary material, which is available to authorized users.

- Common pathology includes renal stones, ureteral stones, renal mass, hydronephrosis, hydroureter, enlarged prostate, bladder mass, and malfunctioning urinary catheter.
- Calculate bladder volume.

Genitourinary Anatomy

- Kidney
 - Paired retroperitoneal structures:
 - Right kidney is found inferior to the liver.
 - Left kidney is found inferior to the spleen.
 - The renal capsule surrounds the kidney with adjacent perinephric fat.
 - Just deep to the capsule will be the renal parenchyma that consists of the cortex, medulla, and medullary pyramids:
 - Medullary pyramids empty urine into minor calyces which form major calyces. Major calyces then unite to form the renal pelvis.
 - Within the hilum is the renal vasculature and renal pelvis which connects to the ureter.
 - Ureters course posteriorly within the abdomen toward the bladder.
- Bladder
 - The bladder is a highly distensible structure.
 - Surrounding the bladder is the bladder wall composed largely of the detrusor muscle [1].
 - Ureters from the right and left kidney drain into the bladder at the trigone.

Image Acquisition

1. Transducer Selection

- (a) Curvilinear
- (b) Phased array

2. Patient Position

- (a) The patient should be lying supine.
- (b) Occasionally a right lateral decubitus position may be needed to bring the left kidney closer to the skin surface.

3. Standard Exam Views

(a) Right kidney:

- Position the transducer at the right anterior axillary line just inferior to the costal margin with the transducer marker pointed cephalad.
- The liver will be used as an acoustic window to image the right kidney.
- Visualize the kidney in long axis:
 - Figure 9.1—Right kidney.
 - Video 9.1—Right kidney.

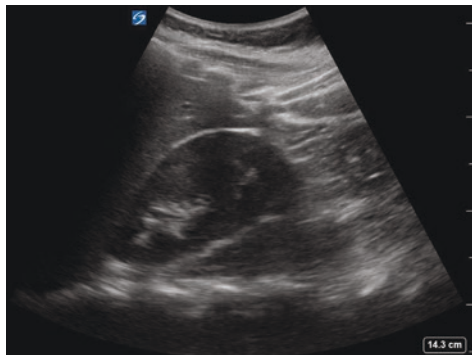


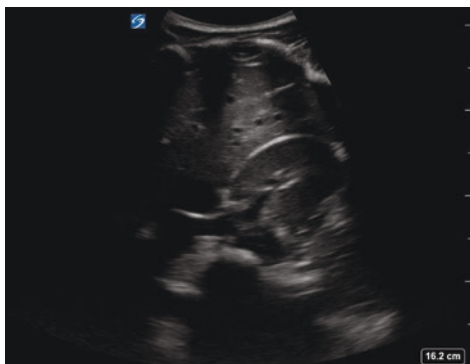FIGURE 9.1 Right kidney: The right kidney is visualized next to the liver in long axis

- The echogenic renal capsule appears bright white.
- Internal to this is the renal parenchyma containing the outer renal cortex which appears hypoechoic and the medullary pyramids which appear more anechoic [1].
- Rotate the transducer 90° counterclockwise and view the kidney in short axis:
 - Figure 9.2—Right kidney in short axis
 - Video 9.2—Right kidney in short axis
- Alternatively, the right kidney can also be imaged with the transducer placed anteriorly just beneath the costal margin and the marker pointed cephalad.

(b) Left kidney:

- Position the transducer at the left posterior to midaxillary line inferior to the costal margin with the transducer marker pointed cephalad.
- The spleen will be used as an acoustic window to image the left kidney.
- The left kidney is typically located more superior than the right; therefore, the transducer may need to be placed higher up, occasionally as high as the tenth or eleventh intercostal space:

FIGURE 9.2 Right kidney in short axis: In short axis, the kidney will appear more rounded



- Figure 9.3—Left kidney in long axis
- Video 9.3—Left kidney in long axis
- Rotate the transducer 90° counterclockwise and visualize the left kidney in short axis:
 - Figure 9.4—Left kidney in short axis
 - Video 9.4—Left kidney in short axis

(c) Bladder:

- The transducer should be placed superior to the pubic bone, angled inferiorly, with the transducer marker pointed toward the patient's right to obtain a cross-sectional view:

FIGURE 9.3 Left kidney: The left kidney is visualized next to the spleen in long axis

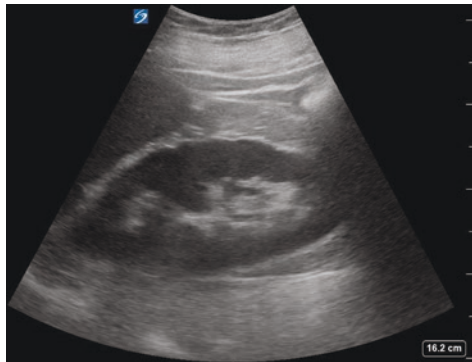

FIGURE 9.4 Left kidney in short axis: The left kidney in short axis next to the spleen

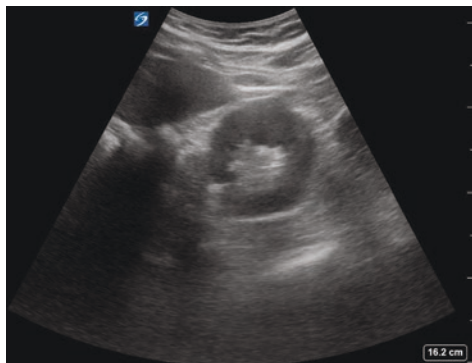


FIGURE 9.5 Bladder in transverse: Cross-sectional view of the bladder

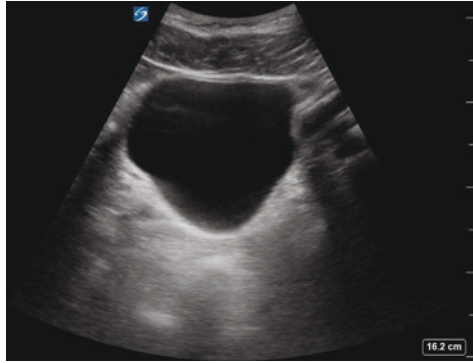
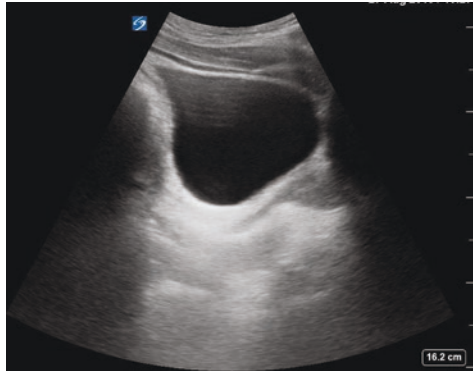


FIGURE 9.6 Bladder in sagittal: Sagittal view of the bladder. Note the posterior acoustic enhancement that is normal for fluid filled structures



- Figure 9.5—Bladder in transverse
- Video 9.5—Bladder in transverse
- Rotate the transducer 90° with the marker pointed cephalad to obtain a longitudinal/sagittal view:
 - Figure 9.6—Bladder in sagittal
 - Video 9.6—Bladder in sagittal
- The bladder appears as an anechoic fluid collection surrounded by a thin hyperechoic line representing the bladder wall.
- In females, the uterus will be posterior and superior to the bladder:
 - Figure 9.7—Uterus posterior to the bladder

FIGURE 9.7 Uterus posterior to bladder: In females, the uterus is located directly posterior to the bladder (*arrow*)

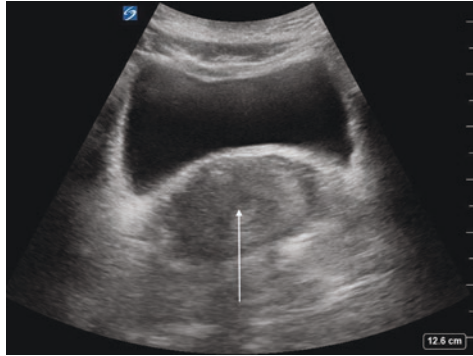
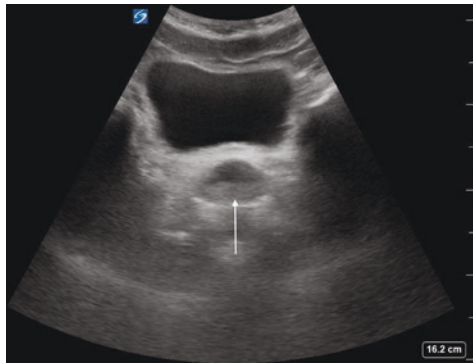


FIGURE 9.8 Prostate posterior to bladder: In males, the prostate is located posterior to the bladder (*arrow*)



- In males, the prostate, a hypoechoic round mass, will be posterior to the bladder:
 - Figure 9.8—Prostate posterior to the bladder
- Normal bladder wall thickness is 5 mm when empty and 3 mm when full [2]:
 - Figure 9.9—Normal bladder wall thickness
- In a cross-sectional view, visualize ureteral flow jets representing urine entering the bladder:
 - Video 9.7—Ureteral flow jets.
 - Color or Power Doppler can be a useful adjunct to image this process.

FIGURE 9.9 Normal bladder wall thickness: Bladder wall thickness measured at 0.15 cm. Normal bladder wall thickness is less than 5 mm when empty and less than 3 mm when full

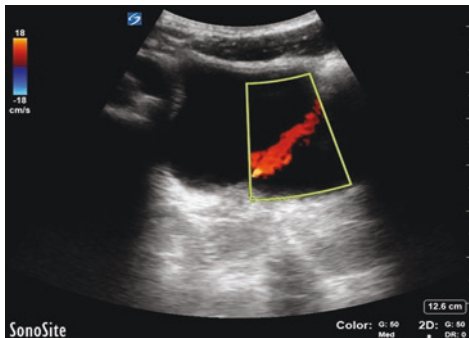
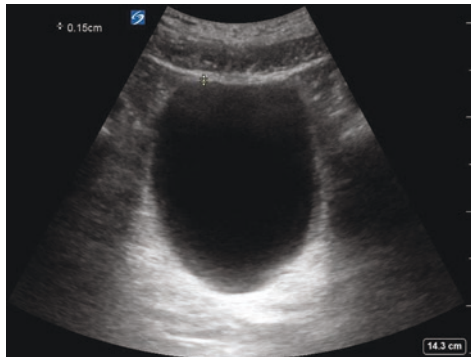


FIGURE 9.10 Ureteral flow jets with color Doppler: In a transverse plane, ureteral flow jets representing urine entering the bladder can be seen. Color Doppler can enhance the detection of ureteral flow jets

- Figure 9.10—Ureteral flow jets with color Doppler.
- Video 9.8—Ureteral flow jets with color Doppler.
- Measuring bladder volume:
 - Bladder volume is estimated by measuring height, width, and depth:

Most ultrasound machines have bladder volume calculators.

Alternatively, the formula length (L) times width (W) times height (H) times 0.75 ($L \times W \times H \times 0.75$) can be used [3].

- Width and depth measurements are taken while in the transverse/cross-sectional window:

Figure 9.11—Bladder volume measurement in transverse

- Height is measured in the longitudinal/sagittal view with a measurement caudal to cephalad:

Figure 9.12—Bladder volume measurement in sagittal

- A normal post-void residual volume is less than 50 mL².

FIGURE 9.11 Bladder volume measurement in transverse: In a transverse plane, measure across the bladder to obtain length (L) and from anterior to posterior to obtain width (W)

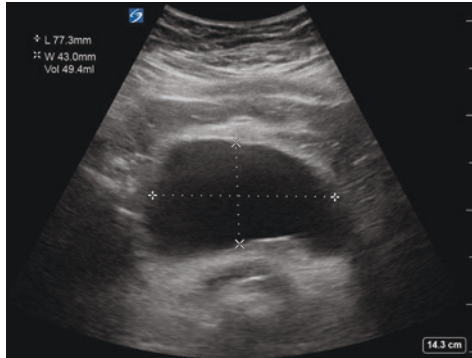
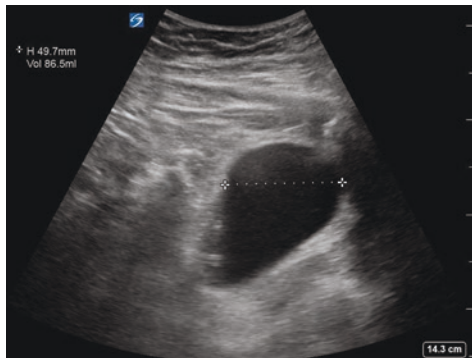


FIGURE 9.12 Bladder volume measurement in sagittal: In sagittal orientation, measure superior to inferior to obtain the height (H) measurement



Renal Pathology

(a) Hydronephrosis

- Dilation of the renal collecting system due to intrinsic or extrinsic obstruction:
 - Common etiologies include large ureteral stone, enlarged prostate, bladder mass, and extrinsic compression of collecting system.
- Appears as an anechoic fluid collection within the renal sinus.
- Hydronephrosis can be mild, moderate, or severe:
 - Mild: Dilation of renal pelvis and anechoic areas within the hyperechoic renal sinus [1]:
Figure 9.13—Mild hydronephrosis
Video 9.9—Mild hydronephrosis
 - Moderate: Separation of minor and major calyces [1]:
Figure 9.14—Moderate hydronephrosis
Video 9.10—Moderate hydronephrosis
 - Severe: Notable for thinning of the renal cortex [3] and significant dilation of the renal pelvis and minor and major calyces [1]:

FIGURE 9.13 Mild hydronephrosis: Mild dilation of the collecting system (arrows)

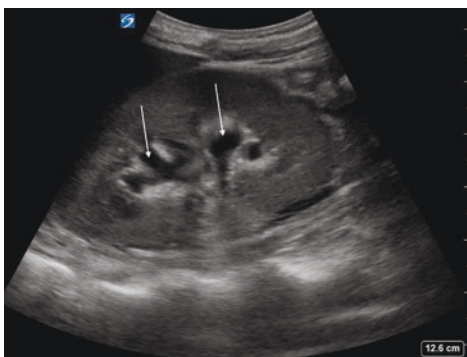


FIGURE 9.14 Moderate hydronephrosis: Moderate dilation of the collecting system (*arrows*) with associated hydroureter (A)

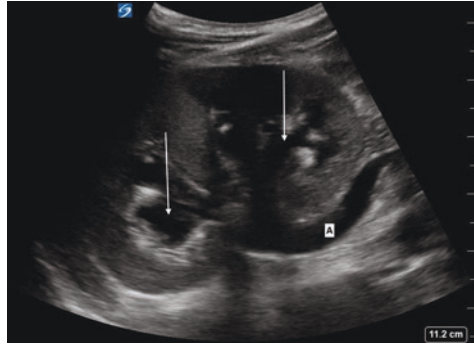


FIGURE 9.15 Severe hydronephrosis: Significant dilation of the renal pelvis and collecting system with thinning of the renal cortex

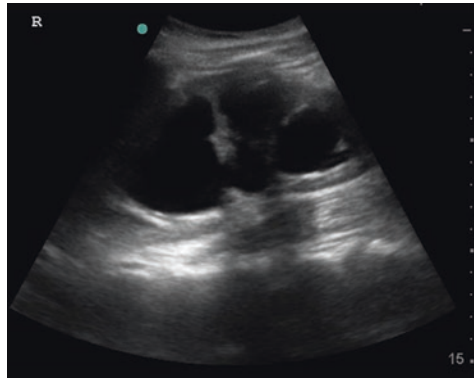


Figure 9.15—Severe hydronephrosis
Video 9.11—Severe hydronephrosis

(b) Hydroureter

- Dilated ureter
- Can be seen with severe hydronephrosis
- Figure 9.16—Hydroureter
- Video 9.12—Hydroureter
- Figure 9.17—Hydroureter with color Doppler

(c) Nephrolithiasis

- Stones within the kidney.
- Appear brightly echogenic and are usually found within the renal pelvis or parenchyma.

FIGURE 9.16 Hydro-ureter: The ureter is seen exiting the renal collecting system and is dilated (*arrow*)

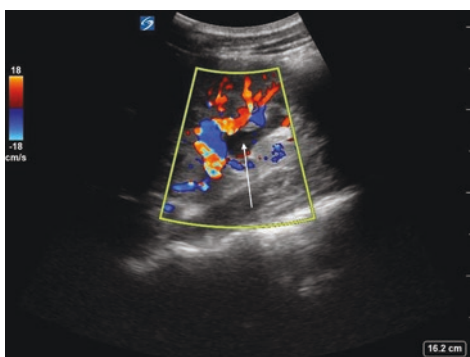
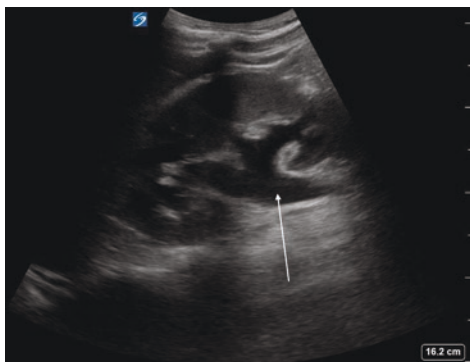

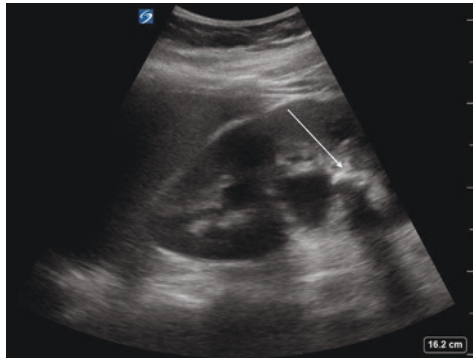
FIGURE 9.17 Hydroureter with color Doppler: Place color Doppler over the ureter to help verify the ureter is what is being imaged and that the structure is not renal vasculature. The ureter (*arrow*) will not exhibit color flow

- Demonstrate posterior acoustic shadowing, similar to a gallstone.
- Rarely, stones can be visualized in the urinary tract, more commonly at the ureteropelvic or ureterovesicular junctions [3].
- Figure 9.18—Stone within the renal pelvis.
- Figure 9.19—Parenchymal stone.
- Video 9.13—Renal stone.

FIGURE 9.18 Stone within the renal pelvis: Large renal stone within the renal collecting system, with posterior shadowing. Also, note the moderate hydronephrosis and hydroureter

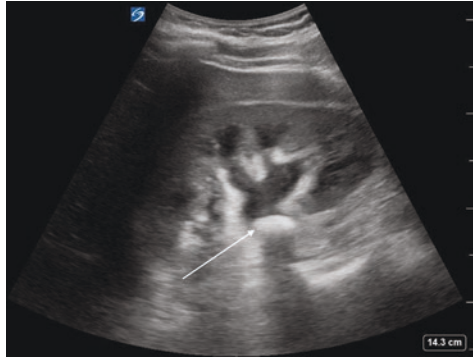

FIGURE 9.19 Parenchymal stone: A stone (*arrow*) within the parenchyma of the kidney will not cause dilation of the collecting system



(d) Renal Cyst

- Abnormal cystic structure that appears within the renal parenchyma and distorts the typical architecture of the normal kidney:
 - Seen more frequently in elderly patients
- On ultrasound appears as an anechoic fluid collection.
- Will have a smooth, thin wall, round or oval shape, and posterior enhancement without any internal echoes or solid components [3]:
 - Figure 9.20—Simple renal cyst
 - Video 9.14—Simple renal cyst

FIGURE 9.20 Simple renal cyst: A large renal cyst (*arrow*) with a smooth, thin outer wall and simple, anechoic fluid

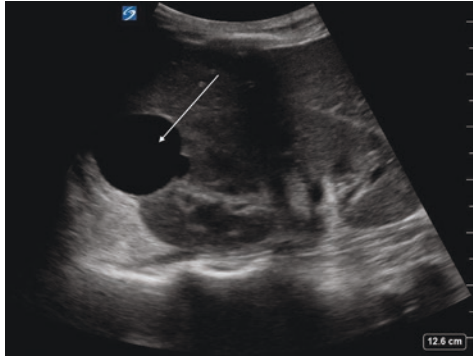
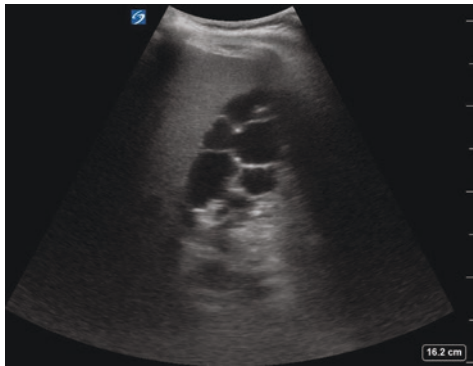

FIGURE 9.21 Polycystic kidney disease: Multiple cysts of variable sizes distorting the normal architecture of the kidney



- Polycystic kidney disease will have numerous variable sized cysts, typically bilateral:
 - Figure 9.21 – Polycystic kidney disease
 - Video 9.15 – Polycystic kidney disease

(e) Renal Mass

- Benign or malignant growth within the kidney parenchyma.
- Renal cell carcinoma tumors appear heterogeneous on ultrasound and may be hyperechoic, hypoechoic, or isoechoic to the renal parenchyma [3].
- Can also have a cystic appearance [3].

Bladder Pathology

- Bladder Mass

- Benign and malignant masses can appear as an irregular growth projecting from the bladder wall into the lumen of the bladder or as a focal area of bladder wall thickening [3]:

Figure 9.22—Bladder mass

Video 9.16—Bladder mass

- In patients with gross hematuria, it is important to consider that a bladder mass can be a hematoma:

In this situation, it would be appropriate to consider bladder irrigation and then reimagine the bladder for resolution or change in the appearance of the mass.

Figure 9.23—Bladder hematoma.

Video 9.17—Bladder hematoma.

- Thickened Bladder Wall

- A bladder wall is considered thickened if it is greater than 5 mm when non-distended and greater than 3 mm when distended [1]:

Artifact can contribute to a thickened bladder wall when non-distended.

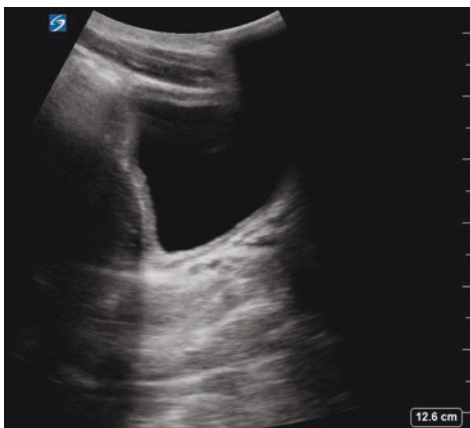
FIGURE 9.22 Bladder mass: A bladder mass will appear as large irregular growth originating from the bladder wall

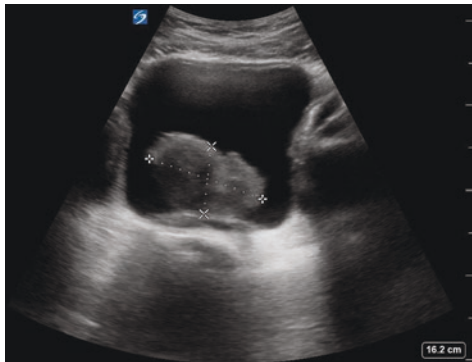

FIGURE 9.23 Bladder hematoma:
Bladder hematoma, as seen here, can be easily confused with a bladder mass

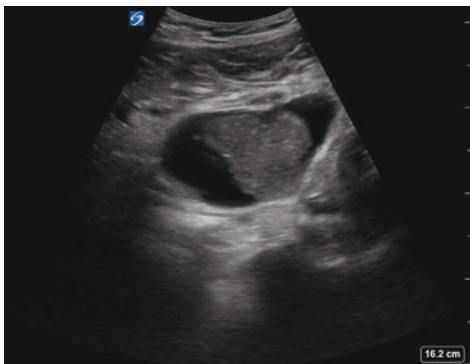

FIGURE 9.24 Thickened bladder wall:
Thickened bladder wall throughout the entire bladder



- Generalized bladder wall thickening can have multiple etiologies including: cystitis from radiation, recurrent urinary tract infection, and neurogenic bladder:

Figure 9.24—Thickened bladder wall

- Focal wall thickening can be due to hematoma, benign or malignant tumor, polyp, and less commonly cystitis.
- Enlarged Prostate
 - A normal prostate measures up to 5 cm in diameter [3].
 - A prostate that measures greater than 5 cm is abnormal.

- Prostate enlargement can extend into the bladder and be mistaken for a bladder mass. Therefore, it is important to image any abnormality in multiple planes.
- Benign prostatic hyperplasia (BPH) and prostate cancer can appear similar on ultrasound; further studies will be needed to determine the cause of prostate enlargement:

Figure 9.25—Enlarged prostate due to BPH

Figure 9.26—Enlarged prostate due to prostate cancer

Video 9.18—Enlarged prostate

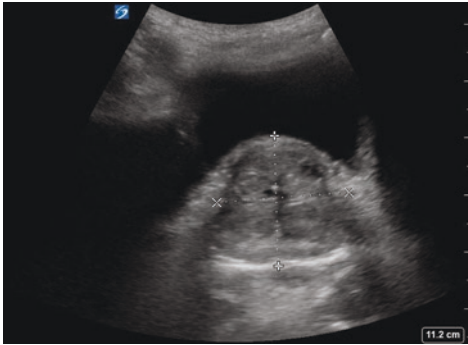
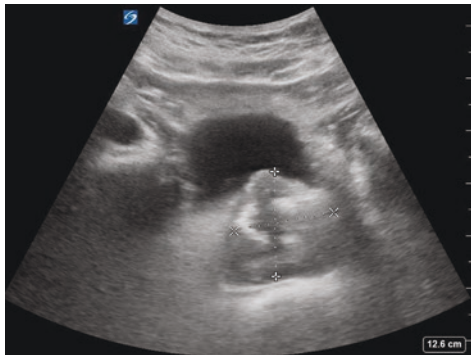


FIGURE 9.25 Enlarged prostate due to BPH: Symmetrically enlarged prostate posterior to the bladder in a transverse plane. With these characteristics, this enlargement is likely due to BPH

FIGURE 9.26
Enlarged prostate due to prostate cancer: Enlarged prostate with abnormal and irregular shape indicates that this is more likely to be due to prostate cancer



Key Points

- Considerations when evaluating for hydronephrosis:
 - Right-sided hydronephrosis is common in pregnancy.
 - Bilateral mild hydronephrosis can occur in a well-hydrated patient without pathology and in patients with a full bladder [1]—it is important to have patients void and then reimagine their kidneys for comparison.
 - A dehydrated patient may not demonstrate signs of hydronephrosis.
 - It is possible for a large abdominal aortic aneurysm to compress the ureter and cause hydronephrosis.
- Always consider AAA in the differential diagnosis in any patient who presents with flank pain, signs or symptoms of renal colic, and are over the age of 50.
- If uncertain about a possible abnormality, compare with the other kidney.
- Renal cysts should be simple in appearance with an anechoic center. If a cyst appears to be complex with internal echoes, septations, etc., consider malignancy.

References

1. SonoSim Ultrasound Training Solution [Video]. Santa Monica, CA: SonoSim Inc.; 2017.
2. Patel U. Chapter 2: Imaging modalities used for assessment of the bladder. In: Patel U, editor. Imaging and urodynamics of the lower urinary tract. 2nd ed. Germany: Springer-Verlag London Limited; 2010. p. 9–21.
3. Seif D, Swadron S. Chapter 12: Renal. In: Ma OJ, Mateer JR, Reardon RF, Joing SA, editors. Emergency ultrasound. 3rd ed. China: McGraw-Hill Education; 2014. p. 319–52.

Chapter 10

Abdominal Ultrasound

As ultrasound becomes more immersed within our routine bedside evaluation of patients, its use is becoming more pervasive. Ultrasound can now be used to evaluate the abdomen for pathology such as appendicitis, small bowel obstruction, and intussusception. Given that most cases of appendicitis and intussusception occur more often in younger patients, the utility of ultrasound is particularly advantageous to prevent unnecessary radiation. This chapter will review indications for performing an abdominal ultrasound, basic abdominal anatomy, image acquisition, normal ultrasound anatomy, and interpretation of pathology.

Clinical Application and Indications

- Acute abdominal pain with concern for appendicitis, bowel obstruction, ileus, and intussusception
- Evaluate for ascites
- Evaluate for free air in the abdomen

Electronic Supplementary Material The online version of this chapter (doi:[10.1007/978-3-319-68634-9_10](https://doi.org/10.1007/978-3-319-68634-9_10)) contains supplementary material, which is available to authorized users.

Normal Abdominal Anatomy

- Abdominal Wall
 - Abdominal wall layers include (from superficial to deep) the skin, subcutaneous tissue, superficial fascia, external oblique muscle, internal oblique muscle, transversus abdominis muscle, transversalis fascia, preperitoneal adipose, and, finally, the peritoneum [1]:

Nerves, blood vessels, and lymphatics are present throughout each layer.
- Appendix
 - A blind-ended pouch arising from the cecum typically located in the right lower quadrant:

Position can be variable such as in pregnancy, displacing the appendix more lateral and superior.
- Small Bowel
 - Composed of the duodenum, jejunum, and ileum
 - Tubelike structure that contains plicae circulares
- Large Bowel
 - Includes the cecum (and appendix), ascending, transverse, descending, and sigmoid colon, rectum, and anus
 - Contains longitudinal bands called taeniae coli and haustra

Image Acquisition

(a) Transducer Selection

- Curvilinear
- Phased array
- Linear array transducer:
 - Can be used on thinner patients or when evaluating for the appendix

(b) Patient Position and Procedure

- The patient should be supine with the head of the bed flat and their knees flexed to allow abdominal muscles to relax.

(c) Standard Exam Views

- Appendix:
 - Have the patient point to the site of maximal pain and begin with transducer at this site in a transverse plane with the marker pointed toward the patient's right:

Scan both inferior and superior and try to identify the appendix.

The terminal ileum will cross over the psoas muscle where it connects with the cecum [2].

The appendix will usually be visualized anterior to the iliac vessels originating from the cecum.

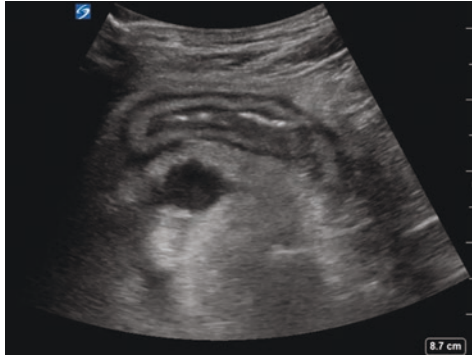
The appendix is a compressible tubular structure with a blind end and an outer diameter of less than 6 mm.

Rotate the probe 90° with the marker pointed toward the patient's head to obtain views in a sagittal plane.

- Alternatively, place the transducer at the hepatic flexure and trace the ascending colon down to the cecum.
- Use graded compression by exerting gentle pressure over the areas of interest with the ultrasound transducer in effort to displace bowel gas to better visualize intra-abdominal structures.
- A normal appendix will exhibit peristalsis and compressibility [3].
- Small and Large Bowel
 - Begin with the transducer in a transverse plane with the marker pointed toward the patient's right.

FIGURE. 10.1

Appendicitis. Acute appendicitis, as identified in this image, can be identified as an aperistaltic, non-compressible, blind-ended tubular structure



- Scan through and obtain images from the patient's epigastrium, bilateral colic gutters, and suprapubic region.
- Apply gentle downward pressure every few centimeters to assess for bowel compression.
- Normal large intestine will have a wall thickness less than 4 mm [3].

Abdominal Pathology

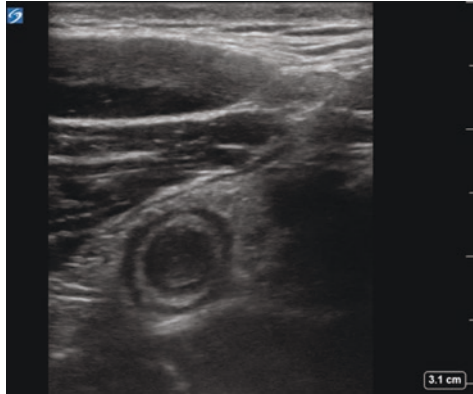
(a) Appendicitis

- Inflammation of the appendix.
- Typically identified on ultrasound as an aperistaltic, noncompressible, blind-ended tubular structure with an outer diameter of greater than 6 mm [3]:
 - Figure 10.1—Appendicitis
 - Video 10.1—Appendicitis
 - Figure 10.2—Appendicitis with measured diameter
- The following may also indicate acute appendicitis:
 - Target sign appearance:
 - Figure 10.3—Target sign
 - Video 10.2—Target sign
 - Appendicolith with posterior acoustic shadowing [4]:

FIGURE 10.2
Appendicitis with
diameter measuring
>6 mm. A diameter
greater than 6 mm
is indicative of
acute appendicitis

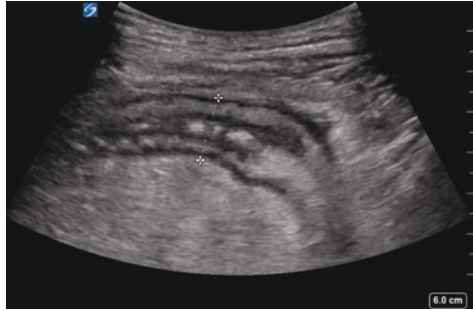

FIGURE 10.3 Target
sign. In short axis,
acute appendicitis
will often look simi-
lar to a target
thereby earning the
classic finding of
“target sign”



- Figure 10.4—Appendicolith
- Video 10.3—Appendicolith
- Periappendiceal fluid collection [4]:
 - Figure 10.5—Appendicitis with surrounding fluid
 - Video 10.4—Appendicitis with surrounding fluid
- Wall thickness greater than 3 mm [5].
- Increased periappendiceal echogenicity due to fat stranding [6].
- Color Doppler can be used to demonstrate increased vascularity in the setting of acute appendicitis, often termed “ring of fire” [3].

FIGURE 10.4
Appendicolith.
Within the inflamed appendix may be a fecalith which is visualized as a hyperechoic rounded structure with posterior acoustic shadowing

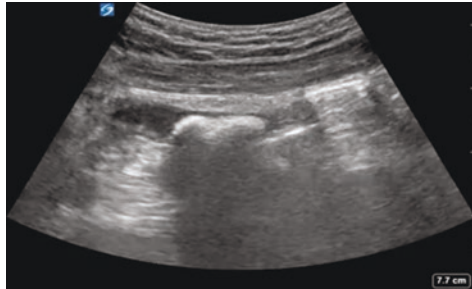
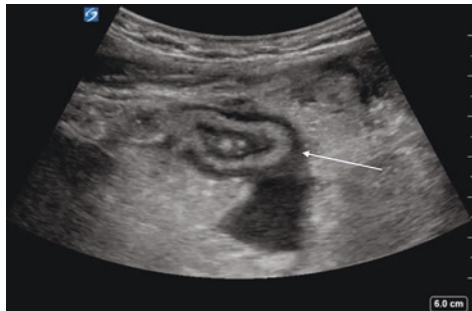


FIGURE 10.5
Appendicitis with surrounding fluid.
Another ultrasonographic finding of acute appendicitis is periappendiceal fluid (arrow)



- Perforation may be identified by a fluid collection, hypoechoic mass, or thickening of adjacent bowel wall:
 - Complex abscess fluid collections may also be present.

(b) Small Bowel Obstruction

- (a) Mechanical blockage of food and liquid from passing through the small intestine.
- (b) Look for dilated, noncompressible small bowel proximal to a collapsed, compressible bowel:
 - Small bowel will be greater than 2.5 cm in diameter, more often greater than 3.0 cm [2].

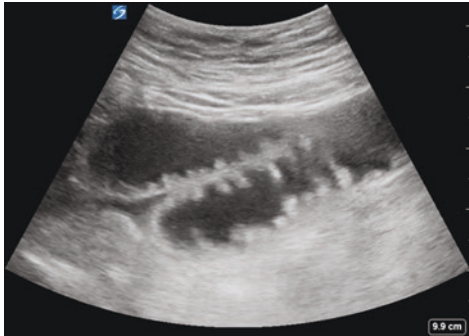
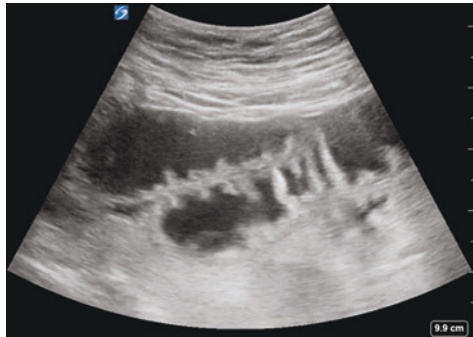
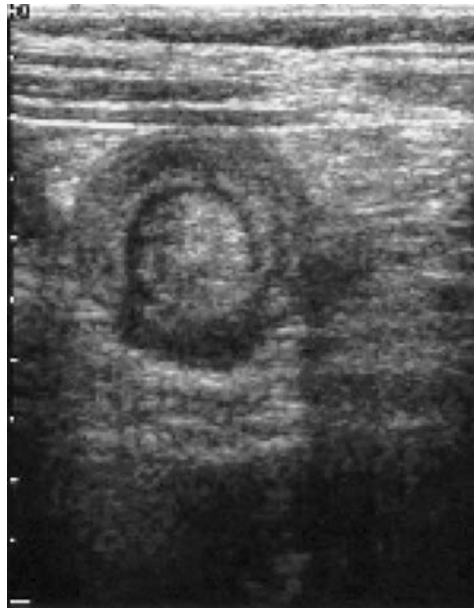FIGURE 10.6 Small bowel obstruction. Small bowel obstruction can be identified by dilated, noncompressible small bowel that is greater than 2.5 cm in diameter. There will typically be echogenic material within the lumen of the bowel exhibits and to-and-fro whirling pattern

FIGURE 10.7 Keyboard sign. Keyboard sign can be seen with small bowel obstruction due to prominent plicae circulares, representing piano keys, silhouetted against small bowel contents



- (c) Typically, there will be fluid and echogenic material within the lumen of the bowel moving to-and-fro in a whirling pattern:
 - Figure 10.6—Small bowel obstruction
 - Video 10.5—Small bowel obstruction
- (d) Piano key or keyboard sign can be seen due to prominent plicae circulares silhouetted against small bowel contents:
 - Figure 10.7—Keyboard sign
 - Video 10.6—Keyboard sign

FIGURE 10.8
Intussusception.
Intussusception is characterized by telescoping of one section of bowel into another. In a transverse plane, there will be concentric alternating hypoechoic and hyperechoic rings representing layers of bowel with adjacent free fluid and inner fecal matter



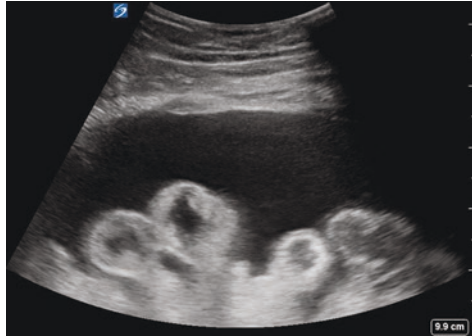(c) Large Bowel Obstruction

- Mechanical blockage of stool from passing through the large intestine.
- Dilated colon proximal to the obstruction that will typically be seen in the periphery of the abdomen [2].
- A dilated colon due will often cause the haustra to become more widely spaced [2].

(d) Intussusception

- Telescoping of one section of bowel into another commonly occurs at the ileocecal junction.
- In a transverse plane, there will be concentric alternating hypoechoic and hyperechoic rings representing layers of bowel with adjacent free fluid and inner fecal matter [3]:
 - Termed “doughnut” or “target sign”
 - Figure 10.8—Intussusception

FIGURE 10.9 Ascites. Ascites is identified by anechoic free intraperitoneal fluid within the abdomen often appearing as if the bowel is floating within the fluid



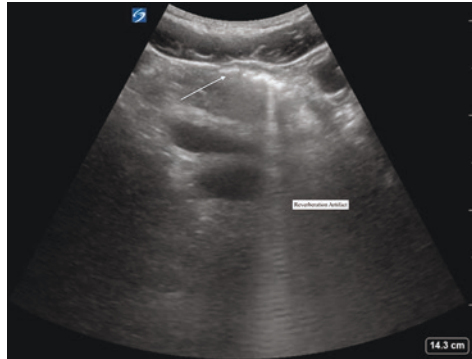
(e) Ascites

- Free intraperitoneal fluid caused by varying pathology, most commonly due to cirrhosis.
- Simple fluid collects in dependent portions of the abdomen:
 - Figure 10.9—Ascites
 - Video 10.7—Ascites
- See Chap. 18 for procedural guidance on obtaining sample of peritoneal fluid.

(f) Pneumoperitoneum

- Free intraperitoneal air usually due to perforated viscus.
- It is easiest to detect pneumoperitoneum in the right upper quadrant [7] over the ventral surface of the liver.
- Free air will appear as an echogenic line with posterior reverberation artifacts [7].
- Reverberation artifacts can also be seen throughout the abdomen in areas where air has collected:
 - Figure 10.10—Free intraperitoneal air
 - Video 10.8—Free intraperitoneal air
- B-lines and dirty air shadowing may be present.

FIGURE 10.10 Free intraperitoneal air. Free intraperitoneal air will appear as an echogenic line (arrow) with reverberation artifact as seen in this image of a patient with perforated gastric ulcer



Key Points

- When scanning the abdomen, use an organized approach to make sure you scan each area:
 - Can visualize the abdomen as a lawn and need to pass over each area with the lawn mower
- A normal appendix is only seen less than 15% of the time [3] due to its small size and non-inflamed pathology:
 - Inability to visualize a normal appendix does not rule out the presence of appendicitis.
- Bowel wall thickening greater than 4 mm can be suggestive of colitis [3]:
 - Figure 10.11 – Thickened bowel wall
 - Video 10.9 – Thickened bowel wall

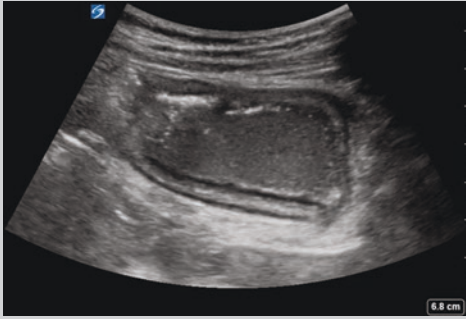


FIGURE 10.11 Thickened bowel wall. Bowel wall thickening greater than 4 mm is suggestive of colitis, as seen in this image of a patient with pancolitis

References

1. Gray JE, Mizell JS. Anatomy of the abdominal wall. UpToDate website. <https://www.uptodate.com/contents/anatomy-of-the-abdominal-wall>. Updated November 5, 2015. Accessed 17 Apr 2017.
2. Ogata M. Chapter 9: General Surgery Applications. In: Ma OJ, Mateer JR, Blaivas M, editors. Emergency ultrasound. 2nd ed. Columbus, OH: The McGraw-Hill Companies, Inc.; 2008. p. 193–228.
3. SonoSim Ultrasound Training Solution [Video]. Santa Monica, CA: SonoSim Inc.; 2017.
4. Chao A & Gharahbaghian L. Tips and tricks: ultrasound in the diagnosis of acute appendicitis. American College of Emergency Physicians website. <https://www.acep.org/Content.aspx?id=101803>. April 2015. Accessed 15 Apr 2017.
5. Paspulati RM. Chapter 23: Ultrasonography of Bowel Disorders. In: Dogra V, Rubens D, editors. Ultrasound secrets. Philadelphia, PA: Elsevier Health Sciences; 2004. p. 207–11.
6. Old JL, Dusing RW, Yap W, Dirks J. Imaging for suspected appendicitis. Am Fam Phys. 2005; 71(1):71–78. <http://www.aafp.org/afp/2005/0101/p71.html>. Accessed 15 Apr 2017.
7. Hefny AF, Abu-Zidan FM. Sonographic diagnosis of intraperitoneal free air. J Emerg Trauma Shock. 2011; 4(4):511–513. <https://www.ncbi.nlm.nih.gov/pmc/articles/PMC3214511/>. Accessed 17 Apr 2016.

Chapter 11

Gynecologic Ultrasound

In outpatient clinics and, more specifically, within the emergency department, women frequently present for evaluation of pelvic complaints. Fortunately, with increasing knowledge and the advancement of ultrasound, a more thorough assessment can be completed without exposing patients to unnecessary radiation. Transvaginal ultrasound allows providers to obtain valuable information about pelvic organs to aid in the diagnostic discovery of a patient's complaint such as acute pelvic pain or abnormal vaginal bleeding. To this point, in most cases, gynecologic problems are best imaged using ultrasound. This chapter will focus on performing a gynecologic ultrasound, basic pelvic anatomy, image acquisition using a transvaginal approach, and interpretation of pathology.

Clinical Application and Indications

- Lower abdominal or pelvic pain in a female
- Evaluate for ovarian cyst, ovarian torsion, or tubo-ovarian abscess
- Evaluate for uterine pathology such as fibroids and intra-uterine device location

Electronic Supplementary Material The online version of this chapter (doi:[10.1007/978-3-319-68634-9_11](https://doi.org/10.1007/978-3-319-68634-9_11)) contains supplementary material, which is available to authorized users.

Normal Gynecologic Anatomy

- The uterus and paired ovaries are centrally located in the pelvis between the more anterior bladder and more posterior rectum.
- The uterus is a muscular organ comprised of outer myometrium and inner endometrium:
 - It is typically anteverted, meaning the fundus or superior most part of the uterus points anteriorly above the bladder.
 - Alternatively, the uterus can be retroverted, meaning the fundus points posteriorly away from the bladder.
 - The endometrium varies in thickness in a cyclical fashion that mirrors the menstrual cycle, sloughing off at each menstruation before developing again in anticipation of egg implantation.
 - In women of reproductive age, the average uterus will measure $7 \times 4 \times 5$ cm [1].
- The adnexa are bilateral structures that include the ovaries, fallopian tubes, and ligaments:
 - Each ovary is ovoid in shape.
 - Ovarian size is variable based on patient age and timing of the reproductive cycle:

Ovarian size is typically measured by volume with a calculated formula of length \times width \times height \times 0.523 [2]. Normal ovarian volume in premenopausal women is less than 20 cm [3] in premenopausal women and less than 10 cm [3] in postmenopausal women [2].
 - The paired fallopian tubes project from the more fundal and lateral portion of the uterus and end in fingerlike fimbria that lie adjacent to the ovary.

Image Acquisition

(a) Transducer Selection

- Endocavitary transducer:
 - Also known as transvaginal transducer
 - On the endocavitary transducer, the handle acts as the transducer marker:

Figure 11.1—Endocavitary transducer

Figure 11.2—Transducer position for sagittal images

Figure 11.3—Transducer position for transverse images

- Curvilinear transducer can also be used for transabdominal imaging. However, transvaginal ultrasound provides better image resolution, quality, and therefore diagnostic capability.

FIGURE 11.1
Endocavitary transducer. Endocavitary transducer, also known as transvaginal transducer

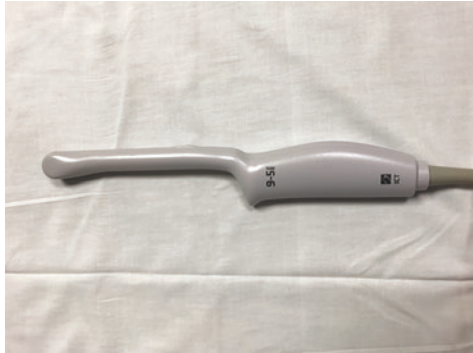

FIGURE 11.2 Transducer position for sagittal images. To obtain sagittal views of the uterus, the “trigger” or transducer marker should be pointed toward the floor

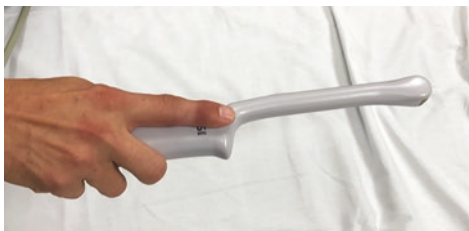

FIGURE 11.3 Transducer position for transverse images. To obtain transverse views of the uterus and ovaries, the “trigger” or transducer marker is pointed toward the patient’s left

(b) Patient Position

- Patient should be placed in the lithotomy position, ideally on a pelvic specific stretcher with footrests.
- The patient should be covered during all portions of the procedure, except during transducer insertion when direct visualization is required.
- Ensure the patient has an empty bladder:
 - A full bladder can cause discomfort as well as distort the anatomy and make visualizing the ovaries more difficult.

(c) Standard Exam Views

- Sagittal view:
 - Insert the transducer into the vagina with the handle pointed toward the floor and the transducer footprint in a vertical orientation.
 - In this view, the bladder will be visualized on the left side of the image and can be visualized more completely by lowering the scanning hand to point the transducer head toward the ceiling:

Figure 11.4—Bladder in sagittal view

- The uterus lies in the mid position and should be fully evaluated by fanning from one side to the other.

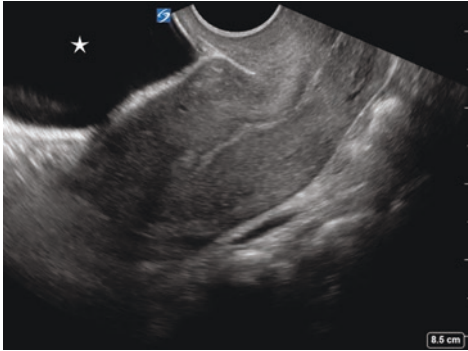
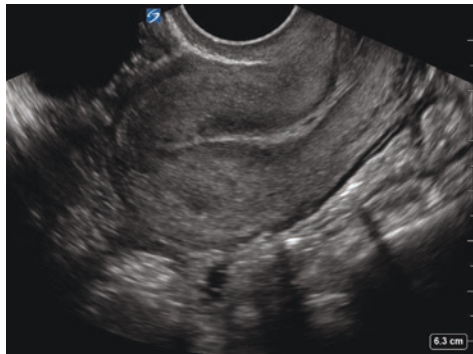


FIGURE 11.4 Bladder in sagittal view. In a sagittal plane using an endovaginal approach, the bladder (star) will be seen anterior to the uterus or on the left of the image. The uterine stripe is seen traversing the center of the uterus

FIGURE 11.5 Long axis of uterus. The uterus is imaged in a sagittal plane from cervix (on the right of the image) to fundus (left of the image) with the echogenic uterine stripe in the midline



- Identify the long axis of the uterus by finding the endometrial stripe, a hyperechoic line within the uterus, extending from the fundus to the cervix:

Figure 11.5—Long axis of uterus

Video 11.1—Long axis of uterus

- The posterior cul-de-sac, also known as rectouterine pouch or pouch of Douglas, can be seen by raising the scanning hand to point the transducer head toward the floor:

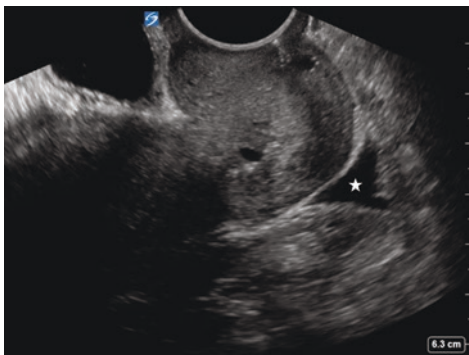


FIGURE 11.6 Pouch of Douglas. Posterior to the uterus and anterior to the rectum is the posterior cul-de-sac or pouch of Douglas. A small amount of free fluid is visualized here within the pouch of Douglas (star), which can be normal in reproductive-aged females

Figure 11.6—Pouch of Douglas

Video 11.2—Pouch of Douglas

- Transverse View

- Return to a midline sagittal view centered on the endometrial stripe and rotate the transducer 90° counterclockwise, so the transducer handle is pointed toward the patient's left:

Figure 11.7—Uterus in transverse

Video 11.3—Uterus in transverse

- View the uterus completely by fanning the transducer up and down:

Lowering the scanning hand will image toward the fundus.

Raising the scanning hand will image toward the cervix.

- The adnexa should be imaged initially in the transverse plane by directing the transducer toward the adnexa in question:

FIGURE 11.7 Uterus in transverse. In a transverse plane, the uterus is seen in short axis with the echogenic uterine stripe visualized as a small horizontal line within the center of the uterus

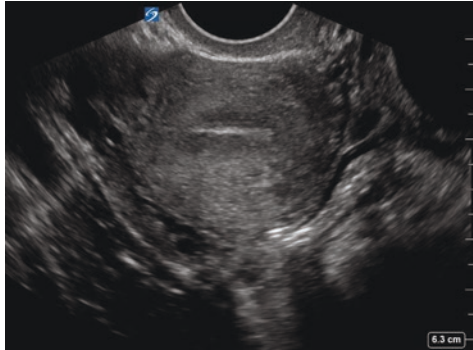
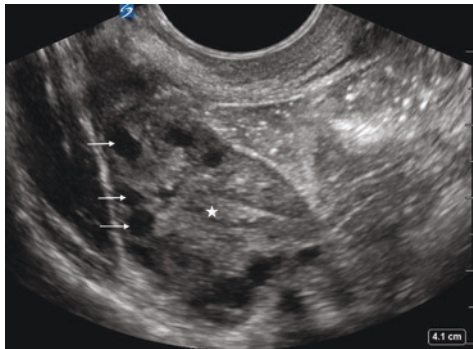


FIGURE 11.8 Normal ovary. Multiple small cysts (arrows) in the cortex surround the medulla (star) in this normal ovary, giving the appearance of what is often referred to as a “chocolate chip cookie”



Moving the scanning hand toward the patient's left will move the transducer head toward the patient's right, and therefore image the right adnexa and vice versa.

- Once the transducer head is directed toward the adnexa of choice, fan the transducer up and down to search for the ovaries.
- The ovaries are hyperechoic structures with hypoechoic follicles that are located lateral to the uterus and medial and anterior to the iliac vessels:

Figure 11.8—Normal ovary

Video 11.4—Normal ovary

- Fallopian tubes are more difficult to image.

Gynecologic Pathology

- Simple Cyst
 - A simple ovarian cyst is a collection of fluid surrounded by a membrane within or on the surface of an ovary.
 - Simple cysts are anechoic with smooth walls, posterior acoustic enhancement, and no internal echoes:

Referred to as a physiologic cyst when the diameter measures less than 2.5 cm and a follicular cyst when it is greater than 2.5 cm [1]

Figure 11.9—Simple physiologic cyst

Figure 11.10—Simple follicular ovarian cyst

Video 11.5—Simple ovarian cysts

FIGURE 11.9 Simple physiologic ovarian cyst. When the diameter of a simple ovarian cyst measures less than 2.5 cm, it is referred to as a physiologic cyst

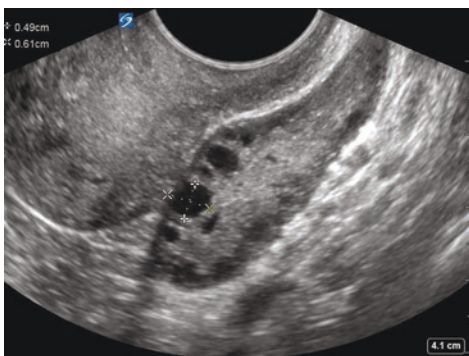
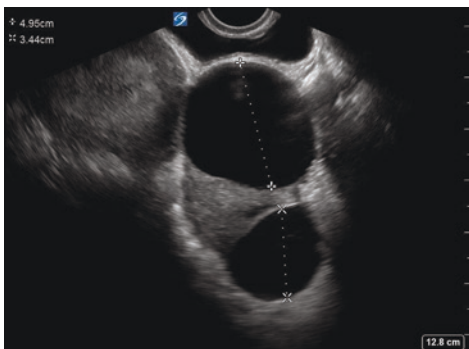


FIGURE 11.10 Simple ovarian cyst. When the diameter of a simple ovarian cyst measures greater than 2.5 cm, it is referred to as a simple follicular cyst



- Polycystic Ovarian Syndrome
 - Syndrome that occurs due to imbalance of reproductive hormones with an unknown cause
 - Will appear as multiple small, usually less than one centimeter, simple cysts along the periphery of the ovary:

Sometimes referred to as “beads on a string” [1]
Figure 11.11—Polycystic ovarian syndrome

- Complex Cyst
 - A complex ovarian cyst contains both fluid and solid components:

Figure 11.12—Complex ovarian cyst.

Video 11.6—Complex ovarian cyst.

Complex cysts can be benign or malignant.

FIGURE 11.11 Poly-
cystic ovarian syn-
drome. Polycystic
ovarian syndrome
often appears as
“beads on a string”
(between parenthe-
sis) with multiple
small simple cysts
lining the periphery
of the ovary

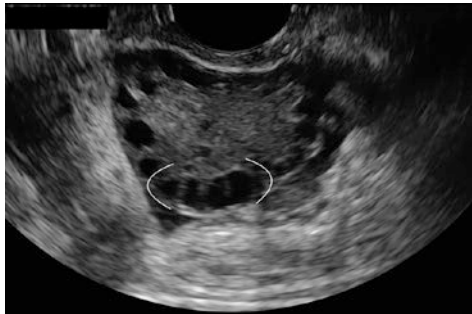
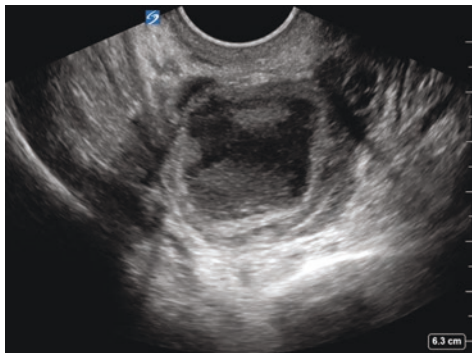


FIGURE 11.12 Com-
plex ovarian cyst.
Complex ovarian
cysts will have vary-
ing echogenicities
within the cyst
itself, often repre-
senting hemorrhage
or other complex
fluid



Benign complex cysts include hemorrhagic, endometriomas, and dermoid cysts.

A complex cyst can also represent a tubo-ovarian abscess (TOA) in the right clinical setting.

It is not always possible to determine the type of complex cyst on ultrasound.

- Hemorrhagic cysts contain hyperechoic internal echoes: They also may contain fluid levels, exhibit a fishnet appearance, or appear as a clot

- Ovarian Torsion

- Occurs when the ovary twists causing occlusion of blood supply to the ovary.
- Large ovarian cysts are the most common risk factor for torsion, with cysts greater than 5 cm and larger being classically associated with this condition [3].
- A torsed ovary is typically enlarged [1] and heterogeneous due to edema:

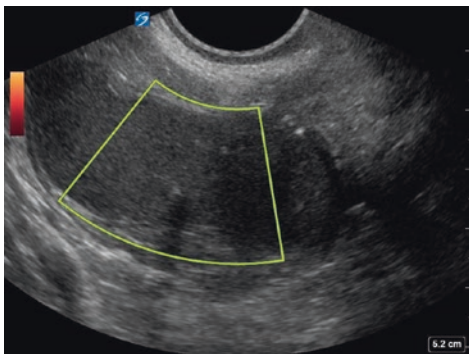
Unilateral enlargement greater than 4 cm [4]

Figure 11.13—Ovarian torsion

Video 11.7—Ovarian torsion

- The ovary may demonstrate both hyperechoic and hypoechoic areas if hemorrhage and necrosis are presents [3].

FIGURE 11.13 Ovarian torsion. Note the enlarged ovary with loss of architecture and absence of color flow with power Doppler (orange color bar) in this image of ovarian torsion



- Peripherally arranged follicles can be present [1, 3, 5].
- Free fluid is often found within the pouch of Douglas or around the ovary [5].
- Evaluate the ovary for blood flow using color Doppler:

The presence of flow using color Doppler does not rule out torsion.

A complete absence of blood flow is typically a late finding.

Compare flow to the contralateral side to evaluate for decreased flow of the ovary in question.

Figure 11.14—Ovary with color Doppler.

Figure 11.15—Ovarian torsion with color Doppler.

Video 11.8—Ovary with color Doppler.

Video 11.9—Ovarian torsion with color Doppler.

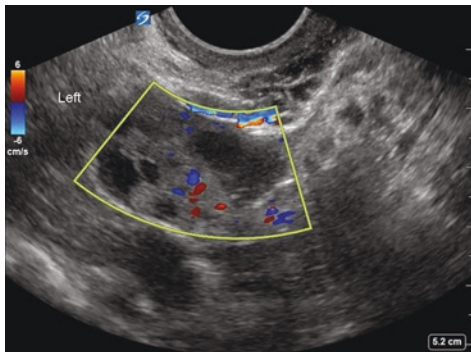
- Evaluate the ovary for blood flow using power Doppler, adjust the color gain to the appropriate sensitivity to detect small amount of flow:

Figure 11.16—Ovary with power Doppler

- Tubo-Ovarian Abscess

- Consider TOA in a nonpregnant female with clinical signs or symptoms of pelvic inflammatory disease and a complex adnexal mass found on ultrasound [6].
- TOA will appear as a peri-uterine or adnexal mass with echogenic fluid within the pelvis:

FIGURE 11.14 Ovary with color Doppler. Normal appearing ovary with normal flow on color Doppler



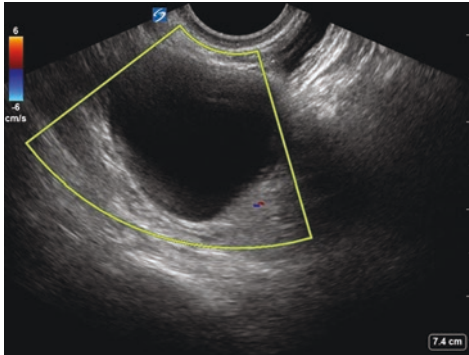


FIGURE 11.15 Ovarian Torsion with color Doppler. Large ovarian cyst with reduced flow using color Doppler. In ovarian torsion, blood flow may be reduced or in advanced cases completely absent. Importantly, the presence of flow using color Doppler does not rule out ovarian torsion

FIGURE 11.16 Ovary with power Doppler. Power Doppler is the preferred method for evaluating ovarian flow because it is more sensitive to low flow states

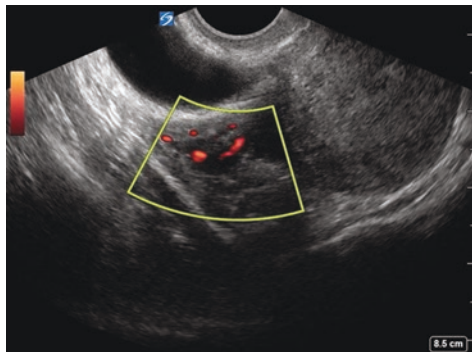


Figure 11.17—TOA

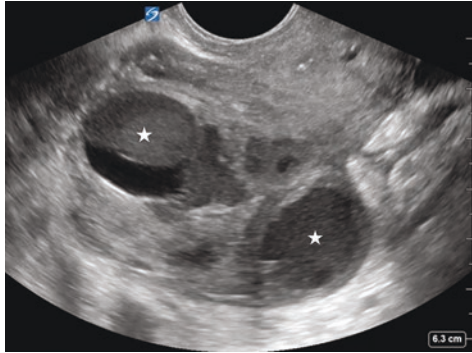
Video 11.10—TOA

- “Cogwheel sign” may also be visualized:

On cross-section, the fallopian tube contains prominent folds projecting inward with central anechoic fluid [7].

- Confirmation of Intrauterine Device Placement
 - Obtain a sagittal and transverse view of the uterus.

FIGURE 11.17 TOA. A tubo-ovarian abscess (star) will appear as a peri-uterine or adnexal mass containing complex fluid



- Evaluate for a highly echogenic structure within the endometrium, which will typically have posterior acoustic shadowing:

Figure 11.18—IUD

Video 11.11—IUD Placement

- If unable to identify an IUD in the correct place, consider displacement of the device or device migration cause perforation of the uterus.
- Uterine Fibroids
 - Abnormal growth of the myometrium causing a benign smooth muscle tumor
 - Visualized as hyperechoic, hypoechoic, or isoechoic masses within the myometrium [1]
 - Figure 11.19—Uterine fibroid

FIGURE 11.18 IUD.
An IUD will appear
as a brightly echo-
genic structure
(arrows) with pos-
terior acoustic
shadowing

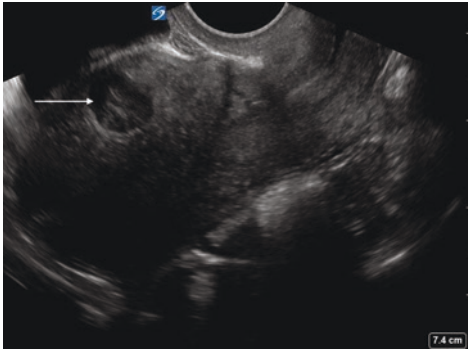
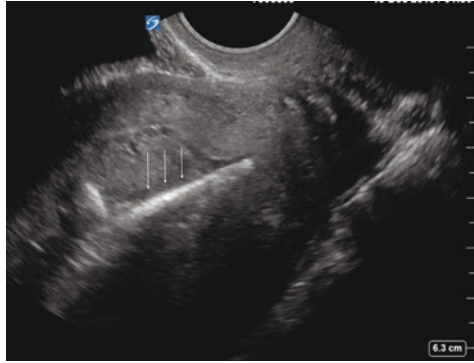
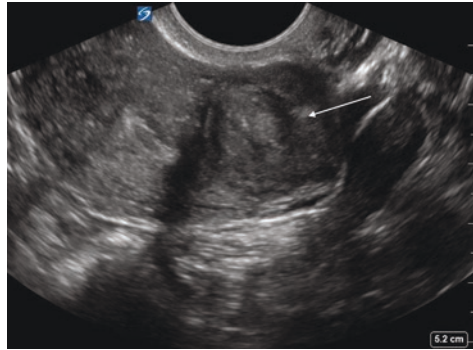


FIGURE 11.19 Uterine fibroid. Small uterine fibroid located in myometrium (arrow). Fibroids can have varying size, shape, echogenicity, and number but almost uniformly represent as benign smooth muscle tumors within the myometrium

- Video 11.12—Uterine fibroid
- Figure 11.20—Uterine fibroid

FIGURE 11.20 Uterine fibroid. Large uterine fibroid (arrow) appears similar to the uterine architecture representing the varying appearance of fibroids



Key Points

- Transvaginal ultrasound can be confusing as orientation quickly changes with slight movements of the transducer. If needed return to midline and the sagittal uterus view then reorient to the image.
- Ovarian lesions with irregular walls, nodules, solid echogenic elements, or thick septations are concerning for malignancy.
- Diagnosis of ovarian torsion is difficult, and it is important to remember that the ovaries receive dual blood supply so you can detect blood flow via color Doppler in a torsed ovary.
 - The presence of arterial flow, venous flow, or both does not rule out ovarian torsion.

References

1. Fox JC, Lambert MJ. Chapter 16: Gynecologic concepts. In: Ma OJ, Mateer JR, Reardon RF, Joing SA, editors. Emergency ultrasound. 3rd ed. New York: McGraw-Hill Education; 2014. p. 455–78.
2. Pavlik EJ, DePriest PD, Gallion HH, Ueland FR, Reedy MB, Kryscio RJ, van Nagell Jr JR. Ovarian volume related to age. *Gynecol Oncol.* 2000; 77(3):410-412. <http://www.sciencedirect.com/science/article/pii/S0090825800957834?via%3Dihub>. Accessed 23 Apr 2017.

3. Damigos E, Johns J, Ross J. An update on the diagnosis and management of ovarian torsion. *Obstet Gynaecol.* 2012; 14(4):229-236. <http://onlinelibrary.wiley.com/doi/10.1111/j.1744-4667.2012.00131.x/pdf>. Accessed 18 Apr 2017.
4. Chang HC, Bhatt S, Dogra VS. Pearls and pitfalls in diagnosis of ovarian torsion. *RadioGraphics.* 2008; 28(5):1355-1368. <http://pubs.rsna.org/doi/pdf/10.1148/rg.285075130>. Accessed 18 Apr 2017.
5. Mashlach R, Melamed N, Gilad N, Ben-Shitrit G, Meizner I. Sonographic diagnosis of ovarian torsion, accuracy and predictive factors. *Am Inst Ultrasound Med.* 2011; 30:1205-1210. <http://edus.ucsf.edu/sites/edus.ucsf.edu/files/wysiwyg/1205.full.pdf>. Accessed 18 Apr 2017.
6. Adhikari S, Blaivas M, Lyon M. Role of bedside transvaginal ultrasound in the diagnosis of tuboovarian abscess in the emergency department. *J Emerg Med.* 2008; 34:4429-433. <http://www.sciencedirect.com/science/article/pii/S0736467907007627>. Accessed 18 Apr 2017.
7. Lambert MJ & Villa M. Gynecologic ultrasound in emergency medicine. *Emerg Med Clin North Am.* 2004; 22(3):683-696. <http://www.sciencedirect.com/science/article/pii/S073386270400046X>. Accessed 18 Apr 2017.

Chapter 12

Obstetric Ultrasound

There are many pathologic conditions that can affect the pregnant patient, some more concerning than others. Perhaps the most severe is ectopic pregnancy due to its associated morbidity and mortality if undiagnosed. Ultrasound is the standard imaging modality for the diagnosis of intrauterine pregnancy and evaluation of pregnancy-related complaints. A novice sonographer will need to understand how to accurately identify intrauterine pregnancy, determine gestational age and heart rate using specified measurements, and diagnose ectopic pregnancy. This chapter will focus on performing an obstetric ultrasound, basic pelvic anatomy, image acquisition using transvaginal and transabdominal techniques, and interpretation of pathology.

Clinical Application and Indications

- Evaluate for intrauterine pregnancy.
- Evaluate for cause of vaginal bleeding, abdominopelvic pain, syncope, or shock in the setting of pregnancy.

Electronic Supplementary Material The online version of this chapter (doi:[10.1007/978-3-319-68634-9_12](https://doi.org/10.1007/978-3-319-68634-9_12)) contains supplementary material, which is available to authorized users.

Normal Gynecologic Anatomy

- The uterus and paired ovaries are centrally located in the pelvis between the more anterior bladder and more posterior rectum.
- The uterus is a muscular organ comprised of outer myometrium and inner endometrium:
 - It is typically anteverted, meaning the fundus or superior most part of the uterus points anteriorly above the bladder.
 - Alternatively, the uterus can be retroverted, meaning the fundus points posteriorly away from the bladder.
 - The endometrium varies in thickness in a cyclical fashion that mirrors the menstrual cycle, sloughing off at each menstruation before developing again in anticipation of egg implantation.
- The adnexa are bilateral structures that include the ovaries, fallopian tubes, and ligaments:
 - Each ovary is ovoid in shape.
 - Ovarian size is typically measured by volume with a calculated formula of length \times width \times height \times 0.523 [1].

Normal ovarian volume in premenopausal women is less than 20 cm [2] in premenopausal women and less than 10 cm [2] in postmenopausal women [1].

 - The paired fallopian tubes project from the more fundal and lateral portion of the uterus and end in fingerlike fimbria that lie adjacent to the ovary.

Image Acquisition

(a) Transducer Selection

- Curvilinear transducer:
 - Can be used later in the first trimester of pregnancy to visualize the developing fetus, obtain fetal heart rate, and obtain dating measurements from a trans-abdominal perspective.

- Use with caution in early pregnancy or if suspicion for ectopic is high.
- Linear transducer:
 - Provides higher-resolution imaging from a transabdominal perspective
 - May be used to visualize intrauterine pregnancy in patients with thin body habitus and an anteverted uterus
- Endocavitary transducer:
 - Also called transvaginal transducer
 - Provides higher-resolution imaging of pelvic organs
 - Preferred for imaging in early pregnancy
 - Not affected by bowel gas or obesity

(b) Patient Position

- Transabdominal:
 - Patient should lay supine with their knees bent to relax abdominal wall muscles.
 - Try to ensure the patient has a full bladder as this will provide a better acoustic window for imaging pelvic organs.
- Transvaginal:
 - Patient should be placed in the lithotomy position, ideally on a pelvic specific stretcher with footrests.
 - The patient should be covered during all portions of the procedure, except during transducer insertion when direct visualization is required.
 - Ensure the patient has an empty bladder:

A full bladder can cause discomfort as well as distort the anatomy and make visualizing the ovaries more difficult.

(c) Transabdominal Ultrasound Standard Exam Views

- Transverse view:
 - Place the transducer above the pubic bone with the marker pointed toward the patient's right.

- Fan up and down to obtain transverse images of the uterus from fundus to cervix.
- Figure 12.1—Transabdominal transverse gravid uterus.
- Video 12.1—Transabdominal transverse gravid uterus.
- Move the transducer slightly to the left and right of the uterus to visualize each adnexa.
- Sagittal view:
 - Rotate the transducer 90° so that the marker is pointed cephalad.
 - Fan left and right to visualize the uterus in a sagittal or long axis orientation:

Visualize the endometrial stripe and follow it from fundus to cervix.

Figure 12.2—Transabdominal uterus in sagittal.

Video 12.2—Transabdominal uterus in sagittal.
- In both transverse and sagittal planes, evaluate the rectouterine pouch (pouch of Douglas) for free intra-peritoneal fluid.

(d) Transvaginal Ultrasound Standard Exam Views

- Sagittal view:

FIGURE 12.1 Transabdominal transverse gravid uterus. Using a transabdominal approach, the gravid uterus is visualized here in a transverse plane. The fetus, in this case, is lying in a sagittal plane

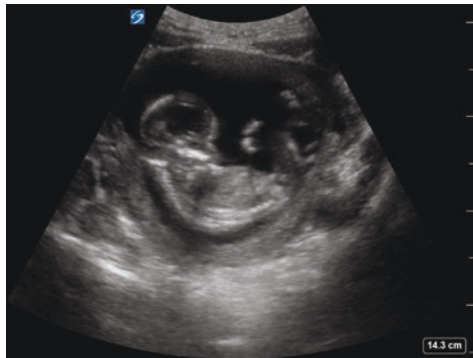

FIGURE 12.2 Trans-abdominal uterus in sagittal. Using a transabdominal approach, the gravid uterus is visualized here in a sagittal view. The fetal head is a hyperechoic structure within hypoechoic fluid (arrow)

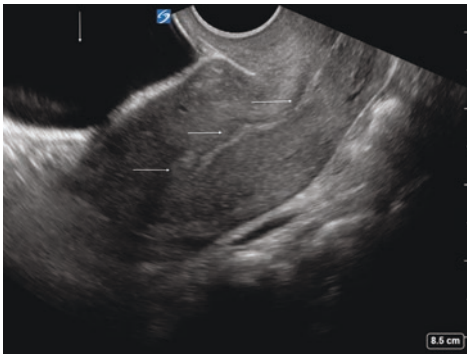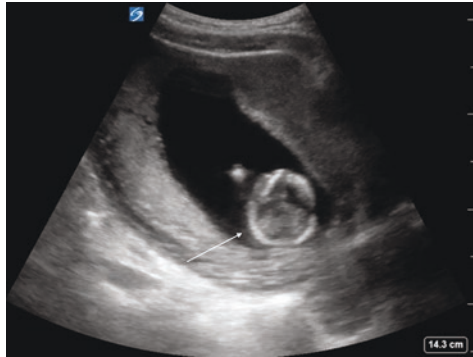


FIGURE 12.3 Bladder with uterus in sagittal plane. In this non-gravid uterus, the uterine stripe can be seen in the midline of the uterus (horizontal arrows) with the bladder noted to the left (vertical arrow). This uterus is anteverted, the most common uterine position

- Insert the transducer into the vagina with the handle pointed toward the floor and the transducer footprint in a vertical orientation.
- In this view, the bladder will be visualized on the left side of the image and can be visualized more completely by lowering the scanning hand to point the transducer head toward the ceiling:

Figure 12.3—Bladder with uterus in sagittal plane

- The uterus lies in the mid position and should be fully evaluated by fanning from one side to the other.
- Identify the long axis of the uterus by finding the endometrial stripe, which is a hyperechoic line within the uterus and extends from the fundus to the cervix:

Figure 12.4—Long axis of gravid uterus (sagittal view)

Video 12.3—TVUS gravid uterus sagittal

- The posterior cul-de-sac (also known as rectouterine pouch or pouch of Douglas) can be seen by raising the scanning hand to point the transducer head toward the floor:

Figure 12.5—Pouch of Douglas

- Transverse view:

- Rotate the transducer 90° counterclockwise so the transducer handle is pointed toward the patient's left:

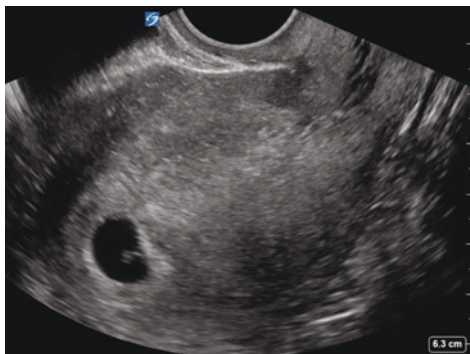

FIGURE 12.4 Transvaginal gravid uterus, sagittal. Using a transvaginal approach, the gravid uterus is visualized in a sagittal plane. Note the hypoechoic circular structure in the midline of the uterine stripe within the uterine fundus. This represents a gestational sac containing a yolk sac

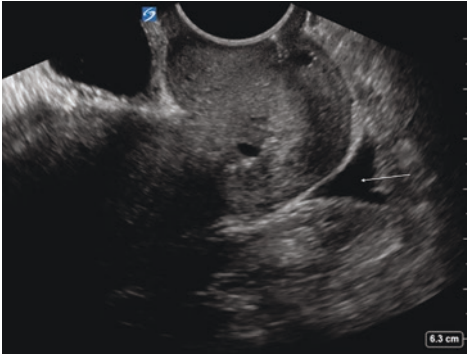

FIGURE 12.5 Pouch of Douglas. The pouch of Douglas, also referred to as the cul-de-sac or rectouterine pouch, lies posterior to the uterus and anterior to the rectum (arrow) seen in this sagittal transvaginal view. Trace to small amount of physiologic free fluid is not unusual in women of childbearing age

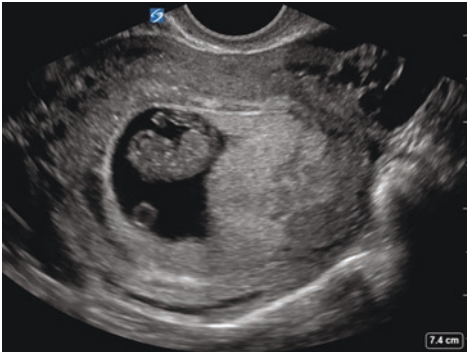

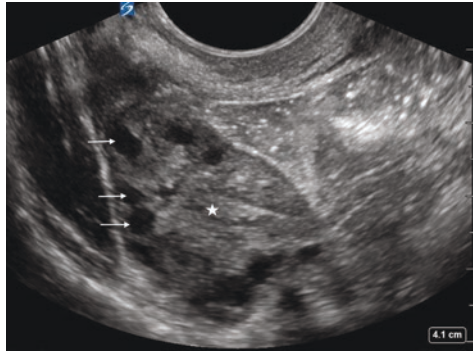
FIGURE 12.6 Transvaginal gravid uterus, transverse. Using a transvaginal approach, the gravid uterus is visualized in a transverse plane with a large gestational sac on the left of the image. A yolk sac and developing fetus are clearly visible

Figure 12.6—Gravid uterus in transverse

Video 12.4—TVUS gravid uterus transverse

- View the uterus completely by fanning the transducer up and down:

FIGURE 12.7 Normal ovary. Multiple small cysts (arrows) in the cortex surround the medulla (star) in this normal ovary, giving the appearance of what is often referred to as a “chocolate chip cookie”



Lowering the scanning hand will image toward the fundus.

Raising the scanning hand will image toward the cervix.

- The adnexa should be imaged initially in the transverse plane by directing the transducer toward the adnexa in question:

Moving the scanning hand toward the patient’s left will move the transducer head toward the patient’s right and therefore image the right adnexa and vice versa

- Once the transducer head is directed toward the adnexa of choice, fan the transducer up and down to search for the ovaries.
- The ovaries are hyperechoic structures with hypoechoic follicles that are located lateral to the uterus and medial and anterior to the iliac vessels:

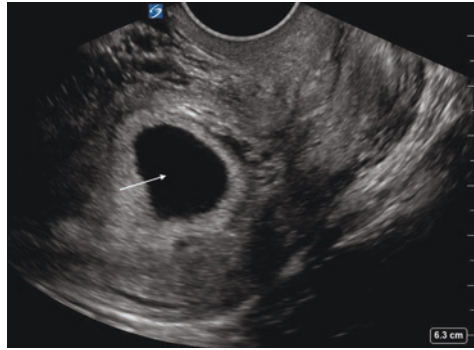
Figure 12.7—Normal ovary

Evaluation for Intrauterine Pregnancy

(a) Gestational Sac

- A gestational sac can be identified at approximately 5 weeks of gestation [3] and in the majority of patients with a bHCG greater than 1000–2000 mIU/mL [1–3].

FIGURE 12.8 Empty gestational sac. An empty gestational sac (arrow) is visualized here within the uterus. This is the first early sign of a developing pregnancy, but does not in itself confirm an intrauterine pregnancy



- It will appear as a round or oval hypoechoic fluid collection within the uterine stripe, typically in the fundus:
 - Figure 12.8—Empty gestational sac
 - Video 12.5—Empty gestational sac
- This can be present in a normal pregnancy prior to development of a yolk sac or fetal pole within the intrauterine gestation sac.
- However, this also can be seen with an ectopic pregnancy, termed pseudogestational sac.
- The presence of a gestational sac without a yolk sac and fetal pole does not confirm intrauterine pregnancy, especially in cases where ectopic pregnancy is suspected.

(b) Double Decidual Sac

- Visualized as alternating hyperechoic rings separated by a thin hypoechoic layer of fluid surrounding a gestational sac:
 - The inner ring is called the decidua capsularis.
 - The outer ring is called the decidua parietalis.
- The presence of a double decidual sac without a yolk sac and fetal pole is not confirmatory of an intrauterine pregnancy.
- Figure 12.9—Double decidual sac.
- Video 12.6—Double decidual sac.

FIGURE 12.9 Double decidual sign. Note the alternating hyperechoic rings separated by a thin hypoechoic layer of fluid surrounding a gestational sac

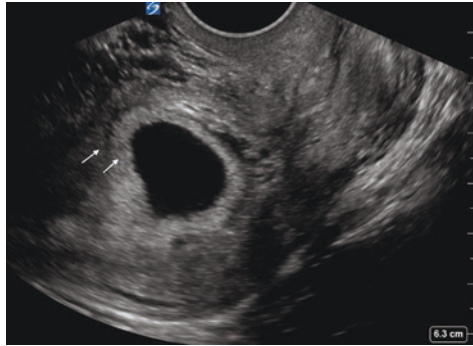
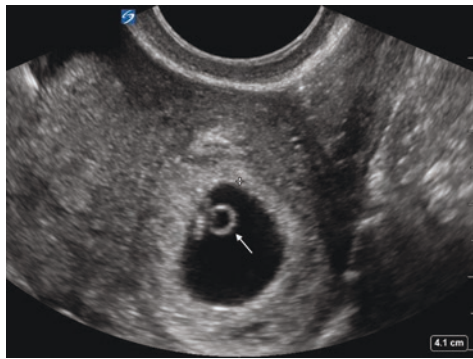


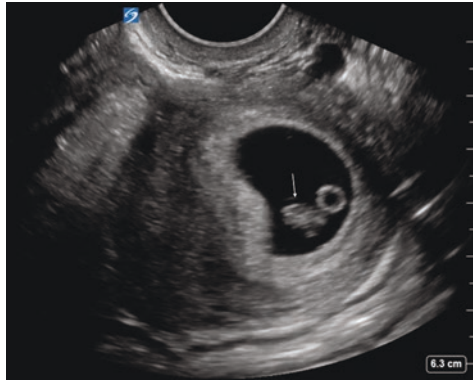
FIGURE 12.10 Yolk sac. A yolk sac (arrow) is the first true ultrasonographic confirmation of intrauterine pregnancy



(c) Yolk Sac

- Located within a gestational sac.
- Will appear as a small, thin-walled, spherical structure with an anechoic center:
 - Figure 12.10—Yolk sac
 - Video 12.7—Yolk sac
- This is the first confirmatory sign of true intrauterine pregnancy [3].
- Usually appears at approximately 5–6 weeks of gestation and disappears by 12 weeks [3].

FIGURE 12.11 Fetal pole. A fetal pole (arrow) first appears as a thickened area on the yolk sac at approximately 6 weeks of gestational age by transvaginal ultrasound. The circular yolk sac is also visualized



(d) Fetal Pole

- Located within a gestational sac.
- Visualized as a hyperechoic mass of cells which appears to grow out of the yolk sac.
- Typically appears by approximately 6 weeks of gestation [3].
 - Figure 12.11—Fetal pole
 - Video 12.8—Fetal pole
- In early pregnancy, distinct fetal parts will not be seen.
- A cardiac flicker may be seen within the fetal pole:
 - Appears as a fluttering motion.
 - Diagnostic for a viable intrauterine pregnancy.
 - Fetal heart rate can be detected at approximately 6–6.5 weeks of gestation [2] once the fetal pole is greater than 5 mm [3].

(e) Fetal Heart Rate

- Normal heart rate within the first trimester is 110–175 bpm [4].
- Normal heart rate after the first trimester is 120–160 bpm [5].
- Use M-mode to calculate fetal heart rate:

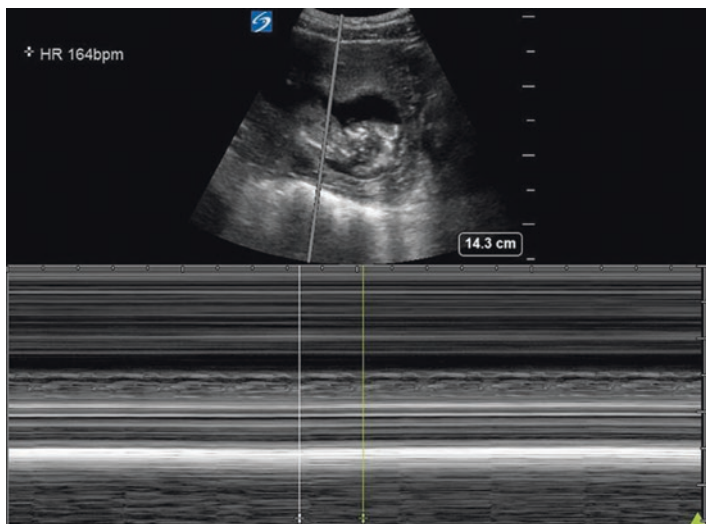


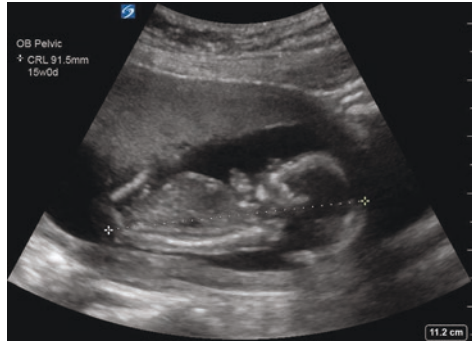
FIGURE 12.12 Fetal heart rate using M-mode. Place the M-mode spike over the fetal heart, plot the fetal heart tracing on the M-mode graph, and use the preprogrammed software to calculate a fetal heart rate by measuring between one cardiac cycle length. Here, the fetal heart rate is 164

- Place the vertical line through the fetal heart.
- Plot the fetal heart tracing on the M-mode graph.
- Use the preprogrammed ultrasound software to calculate the fetal heart rate by measuring between one cardiac cycle length [5].
- Figure 12.12—Fetal heart rate using M-mode.

(f) Gestational Age Measurements

- There are several different measurements that can be done to estimate gestation age. However, the easiest to perform are crown-rump length (CRL) and biparietal diameter (BPD).
- Gestational age measurements are most accurate in first trimester.

FIGURE 12.13
Crown-rump
length. To obtain a
crown-rump length
measurement, use
calipers to measure
from the top of the
fetal head to base
of the rump



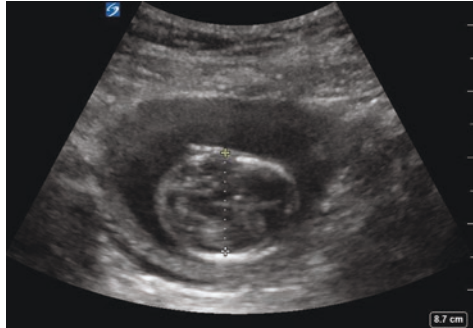
- Crown-rump length:
 - This measurement can be obtained at about 6 weeks of gestation [3].
 - Image the fetus to visualize the spine in a longitudinal plane.
 - Use calipers to measure from the top of fetal head to bottom of the buttocks:

Figure 12.13—Crown-rump length

- Use this measurement to compare with standardized CRL-to-gestational age charts or, if available, use built in software to determine gestational age.
- Biparietal diameter:
 - This measurement can be obtained toward the end of the first trimester and within the second trimester [3].
 - Obtain a transverse view of the fetal head with the thalami visible and symmetric.
 - Use calipers to measure from the outer edge of one bony table to the inner edge of the other [3], across the widest portion.

Figure 12.14—Biparietal diameter

FIGURE 12.14 Biparietal diameter. For biparietal diameter, measure from the inner edge of the near skull wall to the outer edge of the far skull wall



- Use this measurement to compare with standardized BPD-to-gestational age charts or, if available, use built in software to determine gestational age.

Obstetric Pathology

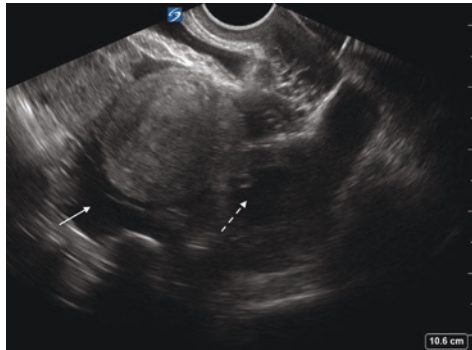
1. Free Intraperitoneal Pelvic Fluid

- (a) Free fluid is most commonly seen posterior to the uterus in the pouch of Douglas.
- (b) A small amount of fluid may be a normal physiologic finding in women of childbearing age:
 - Figure 12.15—Small amount of free fluid in pouch of Douglas
 - Video 12.9—Small amount of free fluid in pouch of Douglas
- (c) A moderate or large amount of fluid is generally considered abnormal and should prompt investigation into potential causes:
 - Figure 12.16—Large amount of free fluid in pelvis.
 - Video 12.10—Large amount of free fluid in pelvis.
 - In the presence of a positive pregnancy test and an empty uterus, an ectopic pregnancy should be suspected.

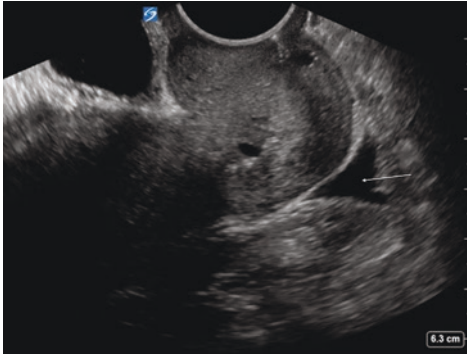

FIGURE 12.15 Small amount of free fluid in pouch of Douglas. In a sagittal transvaginal image, the pouch of Douglas will be located posterior to the uterus or on the right side of the screen. Here, a small amount of fluid is seen within the pouch of Douglas (arrow)

FIGURE 12.16 Large amount free fluid in the pelvis. This sagittal transvaginal view shows a large amount of fluid extending above the fundus (arrow) in this patient with an ectopic pregnancy (dotted arrow)



- Other causes include ruptured ovarian cyst, trauma, or ascites.

2. Ectopic Pregnancy

- (a) A pregnancy that implants outside the uterus:
- (b) Figure 12.17—Ectopic pregnancy
- (c) Suspect an ectopic pregnancy in any pregnant patient with vaginal bleeding or abdominal pain in the setting of a positive pregnancy test.

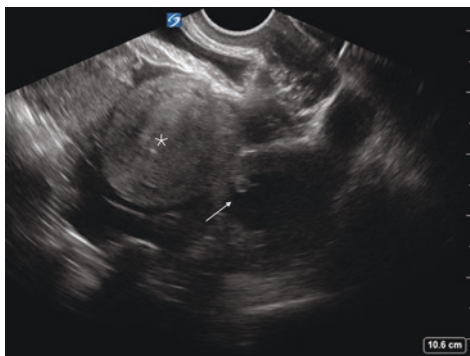

FIGURE 12.17 Ectopic pregnancy. An ectopic pregnancy is defined by a gestational sac that implants outside of the uterus. In this sagittal transvaginal image, there is a gestational sac containing a yolk sac (arrow) located posterior to the uterus (star) representing an ectopic pregnancy

(d) Suspicion should be raised in a sonographically empty uterus.

(e) Consider the following:

- Pseudogestational sac:
 - Difficult to distinguish from a normal gestational sac
 - Does not contain fetal parts and is centrally located within the endometrial cavity
- Pelvic free fluid:
 - The greater the amount of fluid, the higher the likelihood of ectopic pregnancy, including ruptured ectopic pregnancy.
 - Small amount of fluid can be normal.
 - With simple, echo-free fluid the risk for ectopic pregnancy is dependent upon the amount present:

Trace: Fluid is found posterior to the cervix, confined to the pouch of Douglas.

Small: Fluid extends along the lower 1/3 of the posterior wall of the uterus [4].

Moderate: Fluid extends between 1/3 and 2/3 the height of the posterior uterus [4].

Large: Fluid extends up more than 2/3 the height of the uterus or above the fundus [4].

- Patients with moderate to large pelvic free fluid have about an 86% chance of having an ectopic pregnancy [3].
- Patients with free fluid extending up to Morrison's pouch have almost 100% chance of having an ectopic pregnancy [3].
- Echogenic fluid can represent blood and should raise suspicion for ectopic pregnancy [6]:

Figure 12.18—Echogenic blood

- Tubal ring sign:
 - A concentric hyperechoic structure surrounding a mass or gestational sac within the adnexa [6].

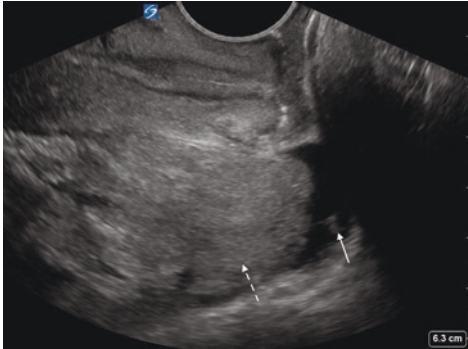


FIGURE 12.18 Echogenic blood. Blood within the pelvis can appear anechoic or echogenic, representing clotted blood, which increases the suspicion for ectopic pregnancy. Note both new bleeding (solid arrow) and clotted blood (dotted arrow) posterior to the uterus in this sagittal transvaginal view. The uterus and uterine stripe are seen closest to the transducer or at the top of the image

- When present there is about a 95% chance the patient has an ectopic pregnancy [3].
- Adnexal mass:
 - If visualized, highly suspicious for ectopic pregnancy.
 - The ampulla or isthmic portion of the fallopian tube is the most common extrauterine site of implantation [6]:

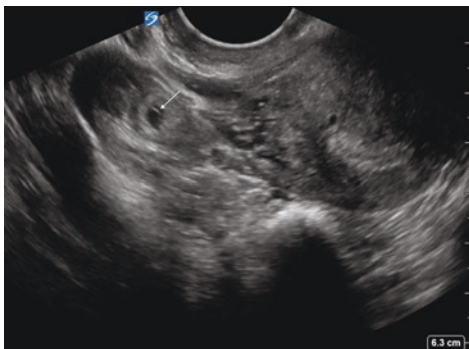Figure 12.19—Adnexal mass
Video 12.11—Adnexal mass
 - Generally, appears as a distinct mass, apart from the ovary:

Intraovarian ectopic pregnancies are very rare.
 - Frequently will demonstrate increased flow using power Doppler resembling a “ring of fire” [3, 6].

2. Interstitial Ectopic Pregnancy

- (a) Eccentric location of an intrauterine gestational sac high in the fundus near the highly vascular area at the insertion of the fallopian tubes
- (b) Uncommon, but carries a higher risk of mortality due to close proximity of uterine artery [7]

FIGURE 12.19
Adnexal mass. This transverse transvaginal image shows a mass outside of the uterus with gestational sac and yolk sac (arrow), located within the adnexa, that represents an ectopic pregnancy



- (c) Can be diagnosed by measuring the uterine mantle which is the thickness of the myometrium surrounding the gestational sac:
- Figure 12.20—Interstitial pregnancy.
 - Figure 12.21—Interstitial pregnancy.
 - Video 12.12—Interstitial pregnancy.
 - Myometrium that measures less than 5 mm suggests interstitial ectopic pregnancy [7, 8].
 - Figure 12.22—Mantle measurement.

FIGURE 12.20 Interstitial pregnancy. Interstitial pregnancy occurs when an intrauterine gestational sac is eccentrically located high in the fundus of the uterus. Note the separation from the uterine stripe

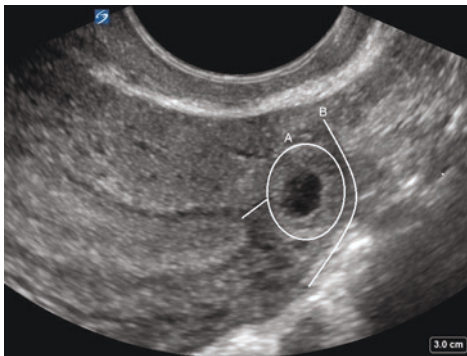
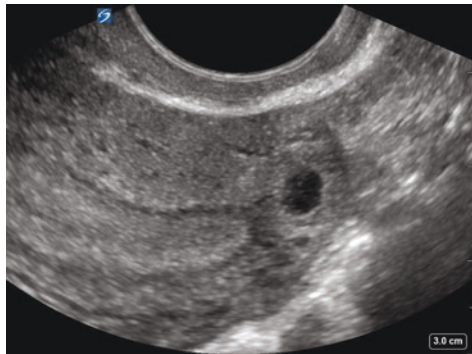


FIGURE 12.21 Interstitial pregnancy. To help diagnose an interstitial pregnancy, the uterine mantle should be measured. Uterine mantle is the thickness of the myometrium that surrounds a gestational sac. This measurement can be made by measuring the distance between the gestational sac (A) and the outer edge of the uterine wall (B).

FIGURE 12.22 Mantle measurement. A mantle measurement less than 5 mm is highly concerning for interstitial ectopic pregnancy

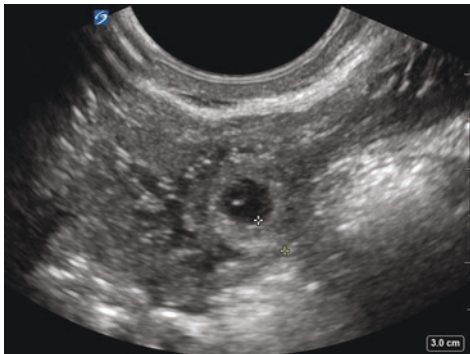
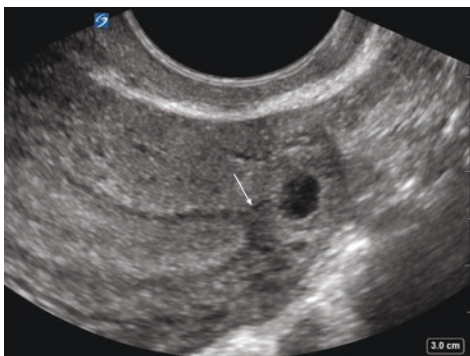


FIGURE 12.23 Interstitial line sign. Typically, a hyperechoic line will be seen connecting the interstitial ectopic pregnancy with the endometrial stripe, known as interstitial line sign (arrow)



(d) Interstitial line sign:

- Appears as a hyperechoic line connecting the interstitial ectopic mass and the endometrium [7, 8]
- Figure 12.23—Interstitial line sign

3. Cornual Ectopic Pregnancy

- (a) Distinct entity from interstitial ectopic pregnancy but often used interchangeably.
- (b) Occurs when gestational sac and pregnancy develop within one horn (cornua) of a bicornuate or septate uterus [7].

- (c) The gestational sac will be surrounded by thin myometrium measuring less than 5mm^7 , similar to interstitial pregnancy.

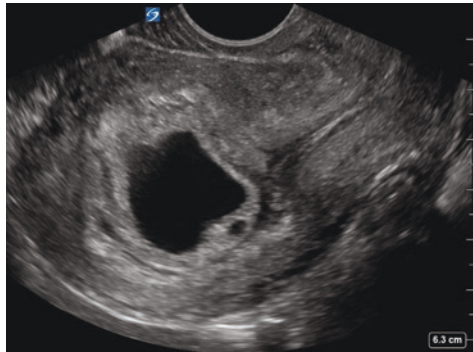4. Heterotopic Pregnancy

- (a) Simultaneous intrauterine and extrauterine pregnancies
 (b) Rare but occurs more commonly in patients undergoing infertility treatment including medications and in vitro fertilization [6]

5. Fetal Demise

- (a) Findings that may indicate an abnormal pregnancy or fetal demise include:
- Gestational sac that is distorted or irregular in shape
 - Empty gestational sac greater than 20 mm [3]:
 - Known as blighted ovum
 - Figure 12.24—Blighted ovum (large empty sac)
 - Video 12.13—Blighted ovum
 - Fetal heart rate less than 70 bpm [4]
 - A fetal pole without cardiac activity at 7 to 8 weeks of gestation

FIGURE 12.24
 Blighted ovum
 (large empty sac).
 An empty, irregular gestational sac greater than 2 cm seen here in this sagittal transvaginal view represents a blighted ovum



- Cardiac activity should be present in embryos with a CRL greater than 5 mm [3].

6. Molar Pregnancy (Hydatidiform mole)

(a) Most common benign form of gestational trophoblastic disease

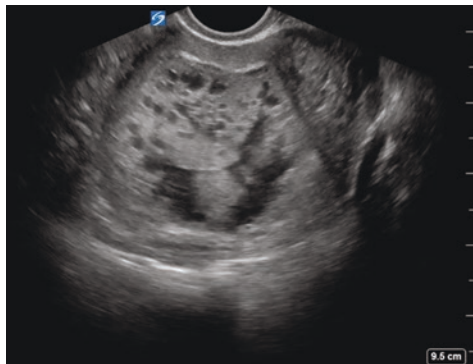
(b) Complete mole:

- Usually occupy an enlarged uterine cavity and appears as tissue with variable echogenicity within which are scattered anechoic spaces
 - Often referred to as a “cluster of grapes” [3]
 - Figure 12.25—Molar pregnancy
 - Video 12.14—Molar pregnancy

(c) Incomplete or partial moles:

- Will appear similar to complete mole [9].
 - Contains tissue with variable echogenicity within uterus.
 - Placenta may be enlarged with diffuse anechoic lesions.
- Presence of fetal parts on ultrasound is consistent with partial mole [9]:
 - Fetus and gestational sac are usually malformed.

FIGURE 12.25 Molar pregnancy. A molar pregnancy will often appear as tissue with variable echogenicity within which are scattered anechoic spaces, commonly referred to as a “cluster of grapes”



Key Points

- Expected beta-human chorionic gonadotropin (bHCG) levels in which an IUP should be seen include:
 - Transvaginal discriminatory zone: greater than 2000 mIU/mL [3].
 - Transabdominal discriminatory zone: 6000–6500 [10].
 - An empty uterus and a bHCG greater than the discriminatory zone can be seen with ectopic pregnancy, spontaneous miscarriage, twin pregnancy, molar pregnancy, and normal pregnancy.
- In a normal pregnancy, bHCG typically doubles every 48 h.
- Ectopic pregnancies can have exhibit any bHCG level; therefore, this cannot be used to rule out an ectopic pregnancy:
 - Because patients who have an ectopic pregnancy can have a very low bHCG, patients who have signs and symptoms of an ectopic pregnancy should have a transvaginal ultrasound [11].

References

1. Pavlik EJ, DePriest PD, Gallion HH, Ueland FR, Reedy MB, Kryscio RJ, van Nagell Jr JR. Ovarian volume related to age. *Gynecol Oncol*. 2000; 77(3):410–412. <http://www.science-direct.com/science/article/pii/S0090825800957834?via%3Dihub>. Accessed 23 Apr 2017.
2. Murray H, Baakdah H, Bardell T, Tulandi T. Diagnosis and treatment of ectopic pregnancy. *Can Med Assoc J*. 2005; 173(8):905–912. <https://www.ncbi.nlm.nih.gov/pmc/articles/PMC1247706/>. Accessed 23 Apr 2017.
3. Reardon RF, Hess-Keenan J, Roline CE, Caroon LV, Joing SA. Chapter 14: First trimester pregnancy. In: Ma OJ, Mateer JR, Reardon RF, Joing SA, editors. *Emergency ultrasound*. 3rd ed. New York: McGraw-Hill Education; 2014. p. 381–424.

4. Campos P, Wang RC. Chapter 24: First-Trimester Pregnancy. In: Soni NJ, Arntfield R, Kory P. Point-of-Care Ultrasound. Philadelphia, PA, Saunders; 2015; p 184–198.
5. Byars DV, Knapp BJ. Chapter 15: Second and third trimester pregnancy. In: Ma OJ, Mateer JR, Reardon RF, Joing SA, editors. Emergency ultrasound. 3rd ed. New York: McGraw-Hill Education; 2014. p. 425–54.
6. Bhatt S, Ghazale H, Dogra VS. Sonographic evaluation of ectopic pregnancy. Radiograph Clin North Am. 2007; 45(3):549–560. <http://www.sciencedirect.com/science/article/pii/S0033838907000243>. Accessed 22 Apr 2017.
7. Lin EP, Bhatt S, Dogra VS. Diagnostic clues to ectopic pregnancy. RadioGraphics. 2008; 28(6):1661–1671. <http://pubs.rsna.org/doi/pdf/10.1148/rg.286085506>. Accessed 23 Apr 2017.
8. Rastogi R, Meena GL, Rastogi N, Rastogi V. Interstitial ectopic pregnancy: a rare and difficult clinicasonographic diagnosis. J Hum Reprod Serv. 2008; 1(2):81–82. <https://www.ncbi.nlm.nih.gov/pmc/articles/PMC2700669/>. Accessed 23 Apr 2017.
9. Shah C, Johnson PT, Durrani H. Partial molar pregnancy. SonoWorld website. https://sonoworld.com/CaseDetails/Partial_molar_pregnancy.aspx?ModuleCategoryId=306. Accessed 24 Apr 2017.
10. Nyer ENB, Arrington J, Warsof SL. Chapter 24: Pregnancy of Unknown Viability. In: Stadtmauer LA, Tur-Kaspa I Ultrasound imaging in reproductive medicine New York, Springer Science + Business Media; 2014, p 315–328.
11. Robertson J, Koyfman A. Ectopic pregnancy. EmDocs Practice Updates website. <http://www.emdocs.net/ectopic-pregnancy/>. December 11, 2014. Accessed 23 Apr 2017.

Chapter 13

Testicular Ultrasound

There are many conditions that can affect the testes and scrotum, some of which are more concerning than others. The most severe, testicular torsion occurs when blood supply to one testicle is blocked resulting in death of the testicle if not diagnosed in a timely manner. For other disorders, such as malignancy, hydrocele, epididymitis, and orchitis, while not imminently threatening, it is important that these be diagnosed and treated to prevent sequelae of disease. Ultrasound has proven to be an important imaging modality to evaluate for and diagnose these conditions as it is quick and easy to perform. This chapter will review indications of performing a testicular ultrasound, basic testicular and scrotal anatomy, image acquisition, normal ultrasound anatomy, and interpretation of pathology.

Clinical Application and Indications

- Acute testicular pain or concern for testicular torsion.
- Palpable mass or scrotal swelling.
- Evaluate for infection such as epididymitis or orchitis.

Electronic Supplementary Material The online version of this chapter (doi:[10.1007/978-3-319-68634-9_13](https://doi.org/10.1007/978-3-319-68634-9_13)) contains supplementary material, which is available to authorized users.

Normal Testicular Anatomy

- Testicles are oval-shaped structures that measure approximately $4 \times 3 \times 2.5$ cm in size [1] and are found suspended within the scrotum.
- The tunica vaginalis surrounds the testes [2].
- Along the posterior aspect of each testicle is the epididymis, which has a head, body, and tail:
 - The head is typically positioned posterolateral to the upper pole of the testicle [2]
- In most males, one or both testicles will have a testicular appendix which represents a developmental remnant. It is typically found on the upper pole of the testis near the epididymal head.
- Some males may also have an epididymal appendix, also a developmental remnant that can be found as an appendage off the epididymal head.
- The spermatic cord contains the neurovascular supply to the testicle.

Image Acquisition

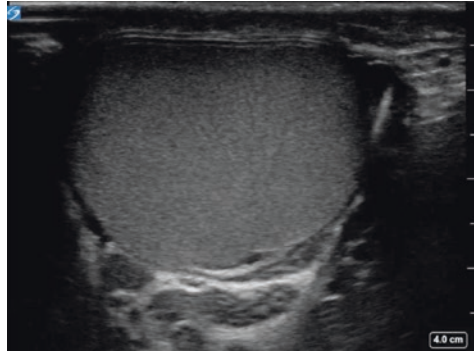
(a) Transducer Selection

- Linear transducer

(b) Patient Position

- The patient should be supine.
- Support the testicles in a sling-like fashion with a towel draped over the patient's legs and the scrotum sitting on top of the towel.
- Cover sensitive areas that are being scanned with a second towel.

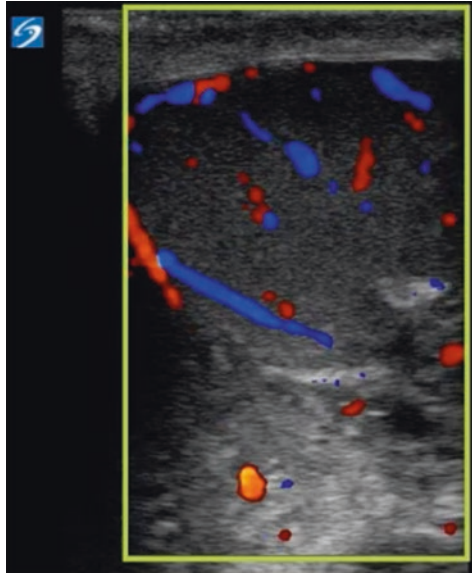
FIGURE 13.1 Normal testicle. Longitudinal view of normal testicle using linear probe showing homogenous testicular architecture



(c) Standard Exam Views

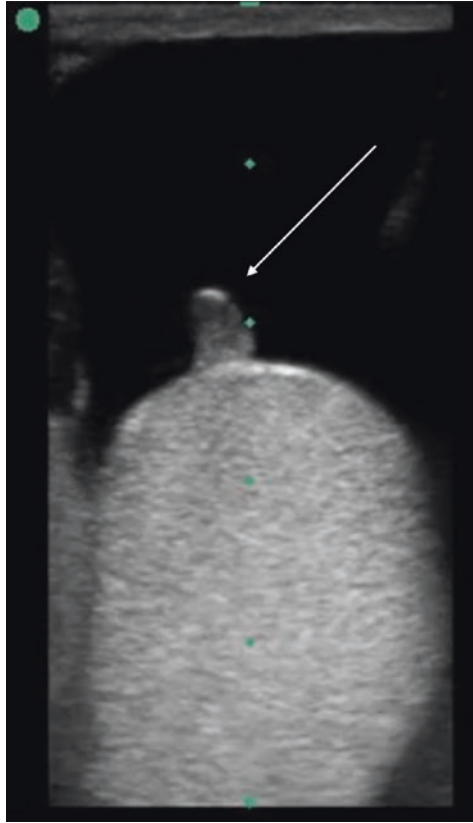
- Obtain an image of both testicles side-by-side to demonstrate any echogenicity differences between the normal and symptomatic testicle.
- Examine the asymptomatic testicle first in transverse and longitudinal planes:
 - A normal testicle is an oval-shaped homogenous mildly echogenic structure.
 - Note the echogenicity, texture, and size:
 - Figure 13.1—Normal testicle
 - Video 13.1—Normal testicle
 - Use color Doppler and note flow patterns:
 - Figure 13.2—Color Doppler
 - Video 13.2—Color Doppler
- Examine the symptomatic testicle in transverse and longitudinal planes:
 - Compare echogenicity, texture, and size to the unaffected side.
 - Compare color Doppler flow patterns to the unaffected side.

FIGURE 13.2 Color Doppler. Longitudinal view of normal testicle showing normal blood flow with color Doppler



- Attempt to image the appendix testis and appendix epididymis:
 - Figure 13.3—Appendix testis
- Image each epididymis by placing the transducer posterior to each testis:
 - The epididymis has similar homogenous echogenicity to the testes, though slightly brighter:
 - Figure 13.4—Normal epididymis
 - Video 13.3—Normal epididymis
 - Obtain color Doppler if there is concern for epididymitis.
- Obtain images of each inguinal canal, if indicated to evaluate for a hernia.

FIGURE 13.3
Appendix testis.
Testicular appendix
(arrow), which represents a developmental remnant, is typically found on the upper pole of the testis near the epididymal head



Testicular Pathology

1. Hydrocele

- (a) Hydrocele is a collection of fluid between the visceral and parietal layers of the tunica vaginalis.
- (b) Congenital hydrocele is common and occurs due to a direct communication with the peritoneum [1].
- (c) Acquired hydroceles are typically associated with infection, tumor, trauma, torsion, or radiation therapy [1].

FIGURE 13.4 Normal epididymis. Normal epididymis (arrow) seen adjacent to the testicle

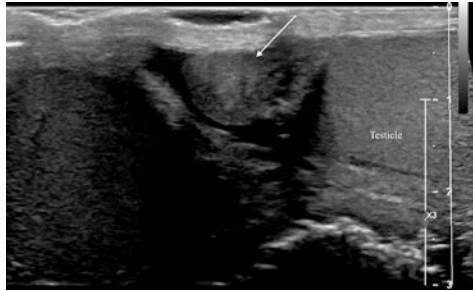
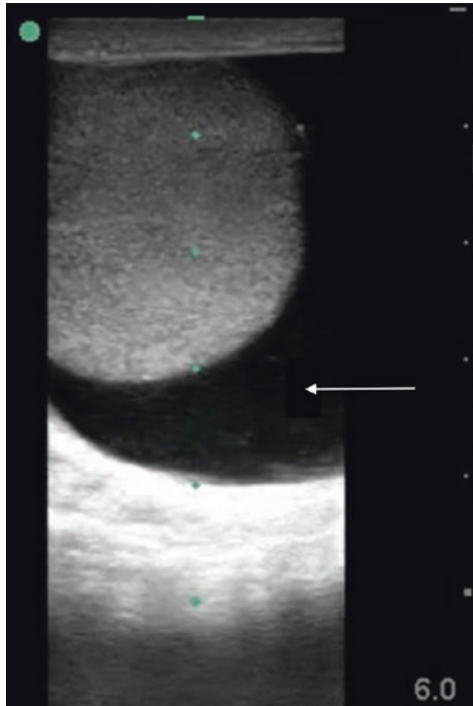
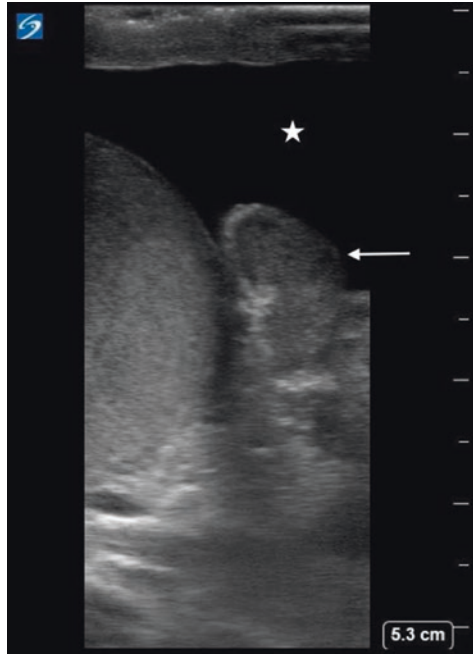


FIGURE 13.5 Hydrocele. Moderate-sized hydrocele (arrow) seen adjacent to a normal testicle



- (d) Hydrocele will appear as anechoic fluid surrounding the testicle without layering or septations:
- Figure 13.5—Hydrocele
 - Video 13.4—Hydrocele
 - Figure 13.6—Hydrocele near testes and epididymis
- (e) A complex hydrocele, such as hematocele or pyocele, will contain internal echoes with septations or loculations.

FIGURE 13.6
Hydrocele near testes and epididymis. Normal epididymis (arrow) within small hydrocele (star) adjacent to a normal testicle



2. Varicocele

(a) Varicocele is an abnormal enlargement of the pampiniform venous plexus within the spermatic cord [1]:

- Usually idiopathic which is caused by valvular incompetence of the internal spermatic vein resulting in retrograde flow into the pampiniform plexus [1]:
 - Ninety-nine percent of idiopathic varicoceles occur on the left [1] due to anatomical differences in between the right and left spermatic veins:

The right spermatic vein drains directly into the inferior vena cava [1].

The left spermatic vein drains into the left renal vein at almost a 90° angle [1].

- Secondary causes are usually due to compression of the spermatic vein due to various pathology such as a mass, hydronephrosis, or hepatomegaly [1]. Malignancy should also be considered.

FIGURE 13.7
Varicocele.

Varicoceles appear as a cluster of enlarged or engorged vascular structures in the pampiniform plexus adjacent to the testicle. Having the patient perform the Valsalva maneuver will increase the size

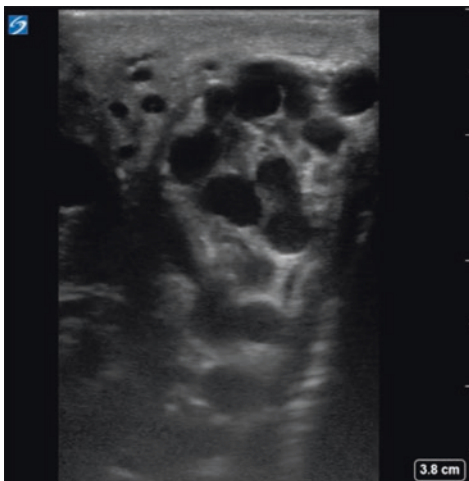
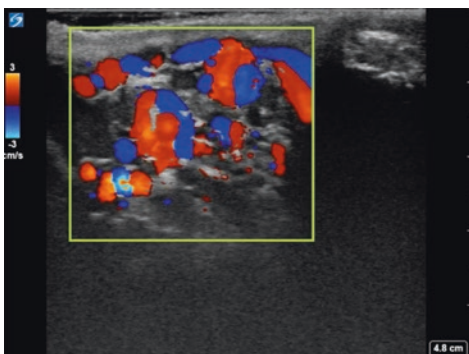


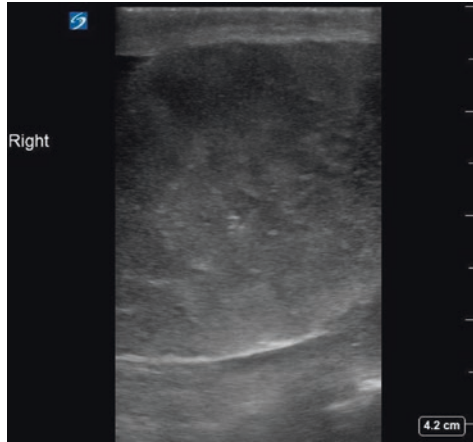
FIGURE 13.8

Varicocele with color. Varicocele shown in this case with pronounced color flow. This can be augmented with by having the patient perform the Valsalva maneuver



- (b) Varicoceles appear as a cluster of hypoechoic vascular structures adjacent to the testicle:
- Figure 13.7—Varicocele
 - Video 13.5—Varicocele
- (c) Color Doppler will demonstrate pronounced vascular flow to these hypoechoic areas:
- Figure 13.8—Varicocele with color Doppler
 - Video 13.6—Varicocele with color Doppler
- (d) Valsalva maneuver can increase size and flow pattern of varicoceles.

FIGURE 13.9
Testicular torsion.
The affected testicle
will appear enlarged,
as compared with
the normal testicle,
with loss of the typi-
cal homogenous
architecture



3. Testicular Torsion

- (a) Twisting of the spermatic cord results in venous congestion and obstruction followed by decreased arterial flow and eventually complete arterial obstruction leading to ischemia and infarction [1, 2].
- (b) Severity of torsion ranges from 180 to 720°, and complete occlusion of blood flow is thought to occur after 450° of torsion [2].
- (c) B-mode (2D) imaging:
 - The affected testicle will appear enlarged and hypoechoic with less homogeneity compared with the unaffected testicle.
 - Figure 13.9—Testicular torsion
 - Figure 13.10—Advanced testicular torsion
 - Video 13.7—Testicular torsion
 - The epididymis may appear hypoechoic and enlarged, similar to how it appears in epididymitis.
- (d) Color Doppler:
 - Decreased color Doppler signal will be seen or, in cases of complete torsion, the absence of color Doppler signal:
 - Figure 13.11—Color Doppler of a normal testicle.

FIGURE 13.10
Advanced testicular torsion. This testicular image shows delayed presentation of torsion. There is loss of normal architecture and variable echogenicity within the parenchyma

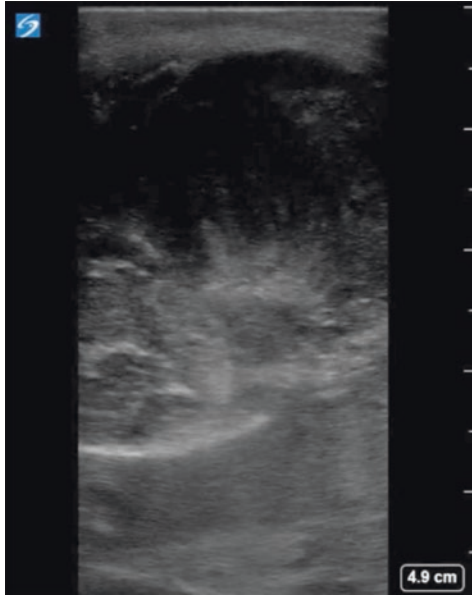
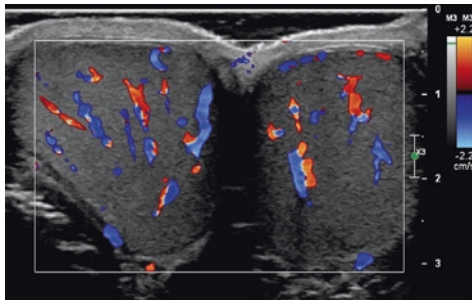


FIGURE 13.11 Color Doppler of a normal testicle. This sunrise view shows normal color Doppler signal to both testicles. Not also the equal signal between each side



- Figure 13.12—Color Doppler testicular torsion.
- Video 13.8—Color Doppler testicular torsion.
- Always compare the color Doppler signal to the unaffected side.

FIGURE 13.12 Color Doppler testicular torsion. Loss of normal testicular architecture with absent flow on color Doppler indicating testicular torsion

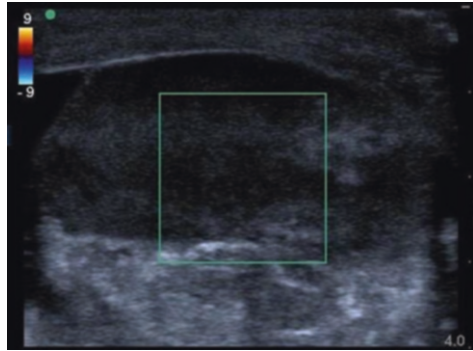
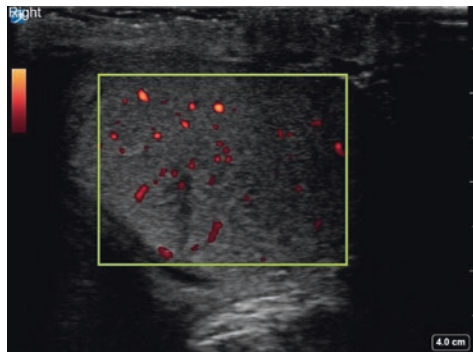

FIGURE 13.13 Power Doppler of a normal testicle. Single testicle in longitudinal view showing normal flow by power Doppler



(e) Power Doppler, which can identify low flow states, should also be used to evaluate for torsion:

- The absence of flow within the testicle using power Doppler is diagnostic of testicular torsion [1]:
- Figure 13.13—Power Doppler of a normal testicle
- Video 13.9—Power Doppler of a normal testicle
- Figure 13.14—Power Doppler in testicular torsion
- Figure 13.15—Power Doppler in testicular torsion long axis
- Video 13.10—Power Doppler in testicular torsion

FIGURE 13.14 Power Doppler in testicular torsion. Right testicle with the absence of flow using color Doppler indicating testicular torsion

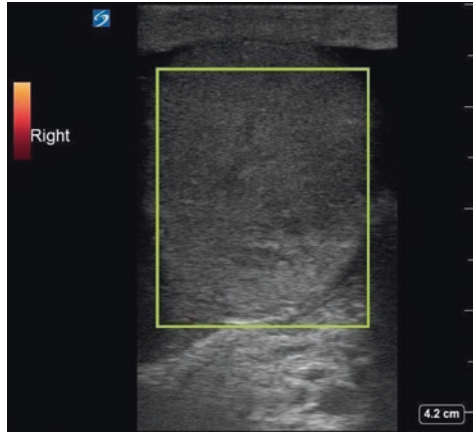
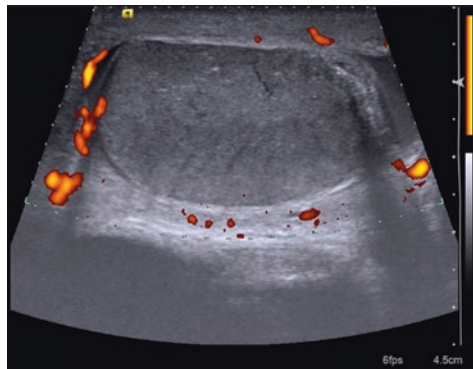


FIGURE 13.15 Power Doppler in testicular torsion. Longitudinal view of testicle with power Doppler showing absence of flow



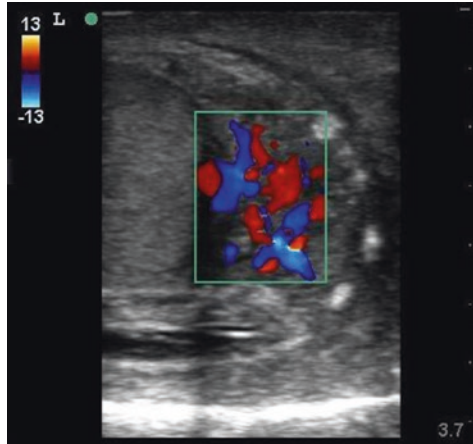
(f) Ultrasound may also demonstrate the twisted spermatic cord just superior to the testis and epididymis with the transducer oriented in a sagittal plane [1]:

- This can resemble a “whirlpool” [2].

4. Torsion of Appendix Testis or Appendix Epididymis

- (a) Self-limiting and does not threaten testicular viability [2].
- (b) Palpable nodule with a bluish discoloration near the testicle [2].

FIGURE 13.16
Epididymitis color
Doppler. Color
Doppler will demon-
strate increased vas-
cularity and blood
flow to the infected
epididymis

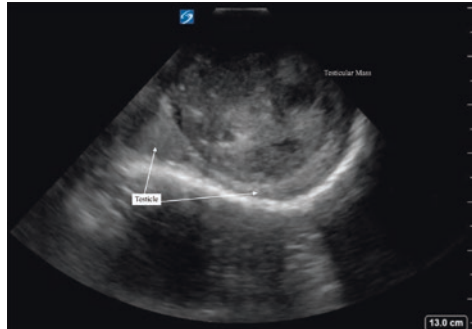


- (c) Ultrasound will show a hyperechoic mass with a central hypoechoic area adjacent to the testis or epididymis [2].
- (d) Can result in inflammation of the epididymis and characteristic ultrasound findings of epididymitis [1].

5. Epididymitis

- (a) Epididymitis is characterized by a tender epididymis, dysuria, and occasionally a fever due to retrograde spread of an infection from the bladder or prostate.
- (b) Most common cause of acute scrotal pain in postpubertal males [2].
- (c) Epididymis will be enlarged compared to the unaffected side.
- (d) Color Doppler will demonstrate increased vascularity and blood flow to the infected epididymis:
 - Figure 13.16—Epididymitis color Doppler
 - Video 13.11—Epididymitis color Doppler
- (e) Reactive hydrocele can also be present [2].

FIGURE 13.17
Testicular mass or neoplasm. Large testicular mass with various echogenicity distorting normal testicular architecture



6. Orchitis

- (a) Infection of the testicle that typically begins as epididymitis.
- (b) Ultrasound will show an enlarged testicle with decreased echogenicity [1].
- (c) On color Doppler, increased blood flow will be seen:
 - With B-mode imaging, torsion and orchitis will appear similar. Color Doppler must be used to differentiate between the two [1].
- (d) You may also see scrotal wall thickening and reactive hydrocele.

7. Testicular Neoplasm

- (a) Typically, a painless mass within the testicle or scrotum:
 - About 10% cause pain [2].
- (b) Ultrasound will most often show a homogeneous well-defined hypoechoic lesion within the testicular parenchyma:
- (c) Figure 13.17—Testicular mass or neoplasm
- (d) Video 13.12—Testicular mass

8. Fournier's Gangrene

- (a) Severe necrotizing soft tissue infection of the scrotum and perineum
- (b) Thickening of the scrotal wall with scattered foci of dirty shadowing indicating subcutaneous air [1]
- (c) Figure 13.18—Fournier's gangrene

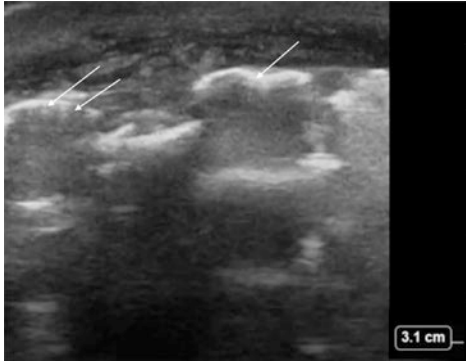


FIGURE 13.18 Fournier's gangrene. Fournier's gangrene will appear similar to necrotizing fasciitis by ultrasound. In the presence of gas forming bacteria, it will be visualized by identifying dirty shadowing (arrows) caused by air-tissue interface

Key Points

- Once full torsion has occurred and there is no blood flow, infarction and loss of the testicle occur rapidly:
 - Salvage rates are approximately 100% at 3 h, 90% at 6 h, 50% at 12 h, and 10% at 24 h [2].
- Sonographic findings of testicular torsion are variable depending on the duration and extent of vascular compromise.
- Torsion remains a clinical diagnosis, and ultrasound cannot rule out torsion [2] especially in cases of partial torsion and intermittent torsion.
- If obtaining color Doppler flow is difficult, switch to power Doppler mode:
 - Set the gain to the highest setting that allows a distinct signal within vessels without surrounding artifact.
 - See Chap. 1 for details on power Doppler.

- A sunrise view can be used to image both testicles simultaneously by placing the transducer on to the scrotum from an inferior location:
 - This can be difficult with a small footprint linear transducer.
 - If available, use a wider linear transducer or, as an alternative, use the curvilinear transducer.
 - Figure 13.19—Sunrise view.

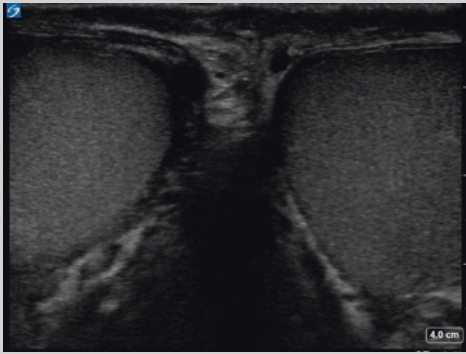


FIGURE 13.19 Sunrise view. Sunrise view shows both testicles side-by-side allowing for comparison

References

1. Adhikari S. Chapter 13: Testicular. In: Ma OJ, Mateer JR, Reardon RF, Joing SA, editors. *Emergency ultrasound*. 3rd ed. New York: McGraw-Hill Education; 2014. p. 353–80.
2. Goldenberg E, Gilbert BR. Chapter 4: Scrotal ultrasound. In: Gilbert BR, editor. *Ultrasound of the male genitalia*. New York: Springer; 2015. p. 75–124.

Chapter 14

Lower Extremity Venous Ultrasound

Venous thromboembolism is a common condition found in patients of all walks of life, whether idiopathic, secondary to a clotting disorder, or provoked due to recent surgery, trauma, or supplemental hormone use. Point-of-care ultrasound allows for rapid screening and diagnosis of deep venous thrombosis in patients who may present in the outpatient setting with a painful or swollen leg or those immobilized in the intensive care unit. While there are multiple different causes of a painful and/or swollen leg such as cellulitis, thrombophlebitis, injury, lymphadenopathy, etc., deep venous thrombosis can become life-threatening if the clot propagates toward the heart and enters the pulmonary arteries causing a pulmonary embolism. For this reason, diagnosing and treating deep venous thrombosis is of great importance. This chapter will review basic lower extremity venous anatomy, image acquisition, normal ultrasound anatomy, and interpretation of pathology.

Electronic Supplementary Material The online version of this chapter (doi:[10.1007/978-3-319-68634-9_14](https://doi.org/10.1007/978-3-319-68634-9_14)) contains supplementary material, which is available to authorized users.

Clinical Application/Indications

- Lower extremity pain or swelling.
- Evaluation for deep venous thrombosis (DVT).
- Evaluate for DVT in a hemodynamically stable patient who is suspected to have a pulmonary embolism but is unable to undergo CTA for diagnosis.

Lower Extremity Venous Anatomy

- (a) The common femoral vein is located just inferior to the inguinal ligament:
 - The common femoral vein runs parallel with the common femoral artery and femoral nerve:
 - From medial to lateral: vein, artery, and nerve
 - Branches of the common femoral vein include:
 - Greater saphenous vein, superficial femoral vein, and deep femoral vein
 - From proximal to distal:
 - Greater saphenous vein branches from the medial aspect of the common femoral vein.
 - Common femoral vein then bifurcates into the superficial and deep femoral veins.
- (b) The popliteal vein can be found just proximal to the popliteal fossa and trifurcates into the posterior tibial, anterior tibial, and peroneal veins before entering the proximal calf.
 - The popliteal vein is most often located superficial to the popliteal artery.
- (c) Under ultrasound, veins are thin walled with an anechoic (black) lumen. In the absence of pathology, they are easily compressible under pressure.
- (d) Comparatively, arteries are thick walled and pulsate, and they will not collapse.
- (e) Figure 14.1 – Comparison between vein and artery.
- (f) Video 14.1 – Comparison between vein and artery.

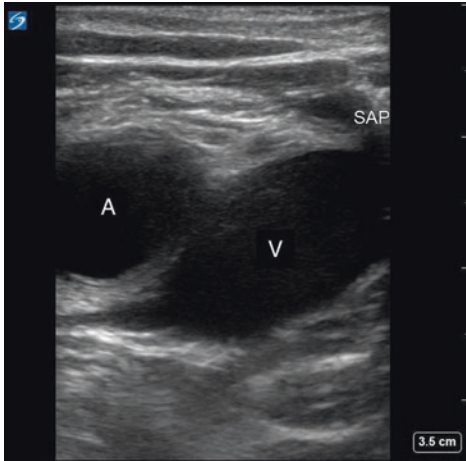


FIGURE 14.1 Comparison between vein and artery. Arteries (A) have a thick muscular wall that is pulsatile and maintains its circular structure with compression. Veins (V) have a thin wall with increased compliance and therefore lack a specific shape; they are easily compressible under pressure

Image Acquisition

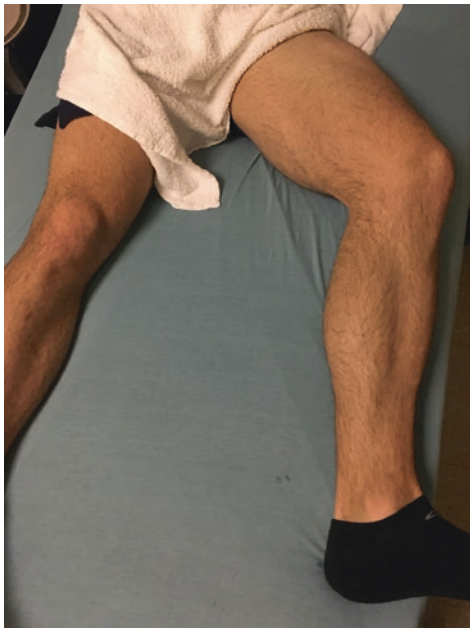- Transducer Selection
 - Linear array.
 - Curvilinear transducer may be needed for obese patients.
- Patient Position
 - For imaging the proximal lower extremity veins including common femoral, saphenous, superficial femoral, and deep femoral:

The patient should be placed in a supine position with their leg externally rotated, knee slightly flexed, and the head of the bed elevated or with the bed in reverse Trendelenburg.

Figure 14.2—Patient position for proximal veins.

- For imaging the popliteal vein and popliteal trifurcation:

FIGURE 14.2 Patient position for proximal vein imaging. To assess the proximal lower extremity veins, externally rotate the patient's leg and slightly flex the knee



With the patient supine, slightly externally rotate the leg then flex the knee.

Figure 14.3—Patient position for popliteal vein imaging.

Alternatively, the patient can lay in a lateral recumbent position with their knee slightly flexed [1].

- Standard Exam Views

- Place the transducer just inferior to the inguinal ligament on the anteromedial thigh to visualize the common femoral vein:

Figure 14.4—Transducer placement inferior to inguinal ligament

Figure 14.5—Common femoral vein

Video 14.2—Common femoral vein

- With the transducer perpendicular to the vein, apply direct and even downward pressure with the transducer and observe for complete compressibility of the vein:

FIGURE 14.3 Patient position for popliteal vein imaging. Flex the knee with slight external rotation of the patient's leg

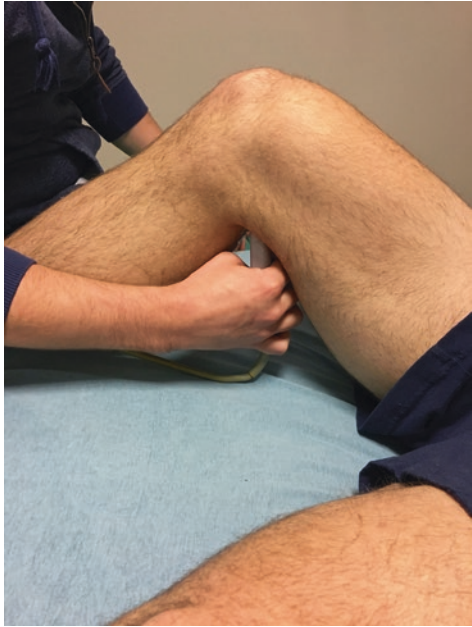

FIGURE 14.4 Transducer placement inferior to inguinal ligament. The transducer is placed just below the inguinal ligament perpendicular to the femoral vessels

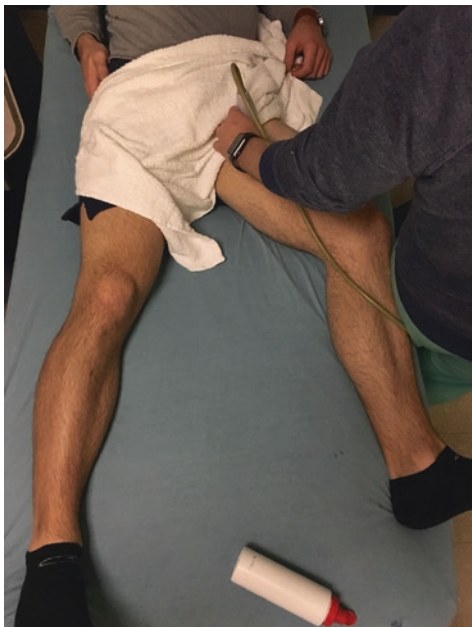

FIGURE 14.5
Common femoral vein. The common femoral vein (CFV) runs parallel with the common femoral artery (CFA) and femoral nerve. Commonly the CFV will sit medial to the femoral artery and nerve, respectively

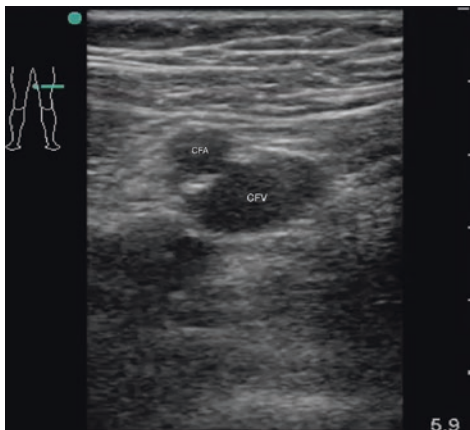


FIGURE 14.6
Common femoral vein compressed. Common femoral vein is completely compressed under direct pressure

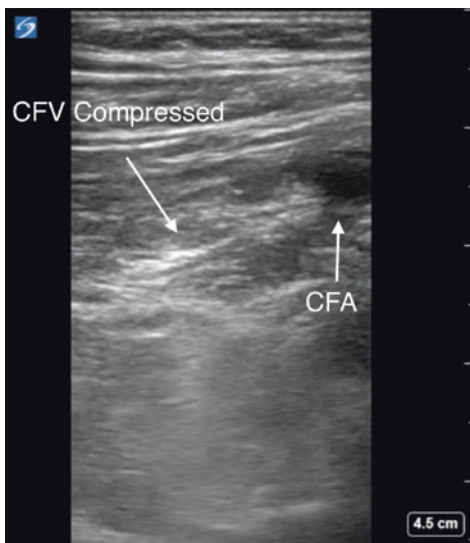
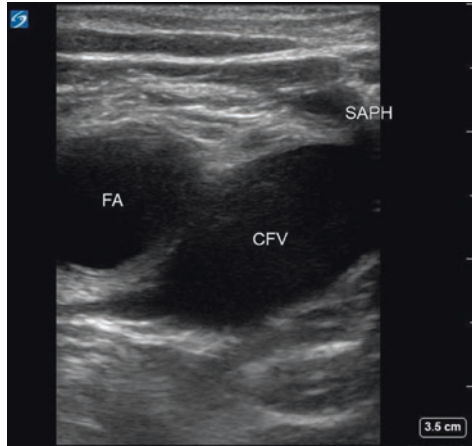


Figure 14.6—Common femoral vein compressed

- Slowly move the transducer distally tracing the common femoral vein until the area where the greater saphenous vein drains into the common femoral vein can be seen:

Figure 14.7—Common femoral vein with greater saphenous vein.

FIGURE 14.7
Common femoral vein with greater saphenous vein. Greater saphenous vein (SAPH) drains into the common femoral vein from the medial side of the vessel. The femoral artery (FA) is located lateral, or to the left, of the common femoral vein in this image



Video 14.3—Common femoral vein with greater saphenous vein.

Apply pressure and observe for collapse of the greater saphenous vein and the common femoral vein.

The greater saphenous vein is technically a superficial vein. However, it can easily travel into the common femoral vein and therefore will need anticoagulation [2].

- Again, move the transducer distally until the bifurcation of the common femoral vein into the superficial and deep common femoral veins is visualized:

Apply compression with the transducer; both veins should collapse under pressure.

Figure 14.8—Bifurcation into superficial and deep femoral veins.

Video 14.4—Bifurcation into superficial and deep femoral veins.

Figure 14.9—Bifurcation in long axis.

- Trace the superficial femoral vein distally compressing every 2 cm until just proximal to the knee.
- Next, place the transducer within the popliteal fossa and image the popliteal vein:

FIGURE 14.8
Bifurcation with superficial and deep femoral veins. The common femoral vein bifurcates into the superficial (SFV) and deep femoral vein (DFV). The superficial femoral vein is in the near field and the deep femoral vein is in the far field

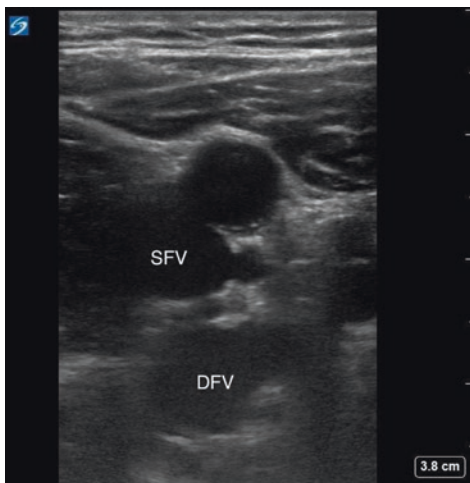
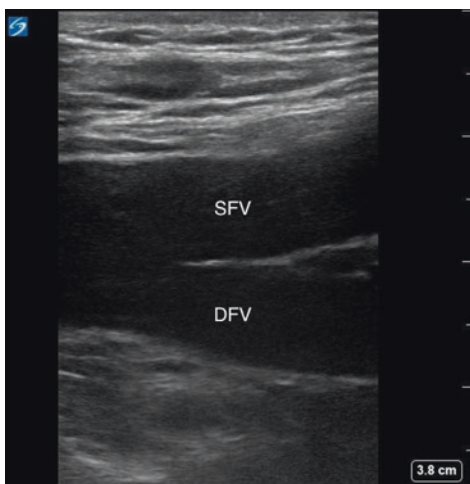


FIGURE 14.9
Bifurcation in long axis. Long axis view of the common femoral vein bifurcating into the superficial femoral vein (SFV) and deep femoral vein (DFV)



The popliteal vein will be located superficial or anterior to the popliteal artery.

Compress the popliteal vein and visualize complete occlusion of the vessel.

Figure 14.10—Popliteal vein.

Video 14.5—Popliteal vein.

FIGURE 14.10
Popliteal vein.
Popliteal vein is in
the near field above
the popliteal artery

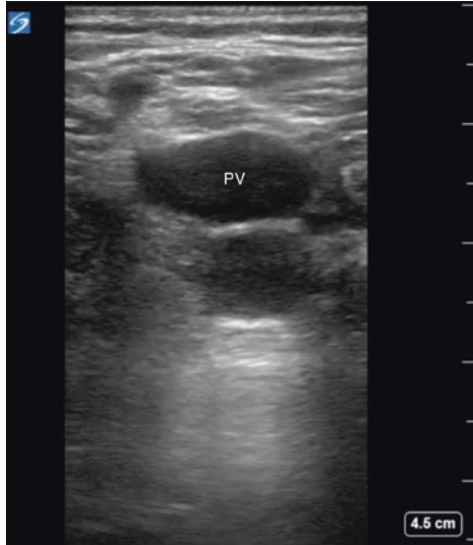
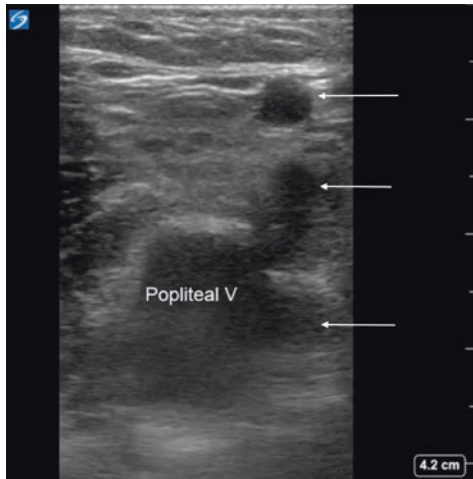


FIGURE 14.11
Trifurcation. The
popliteal vein tri-
furcates into the
anterior tibial, pos-
terior tibial, and
peroneal veins
within the distal
popliteal fossa just
before entering the
proximal calf



- Complete the scan by fanning the transducer distally to image the trifurcation of the popliteal vein into the anterior tibial, posterior tibial, and peroneal veins:

Apply pressure with the transducer and visualize compression of each vein.

Figure 14.11—Trifurcation.

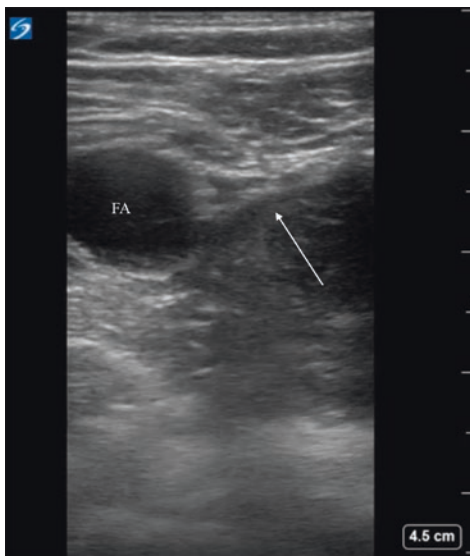
Video 14.6—Trifurcation.

Lower Extremity Venous Pathology

(a) Deep Venous Thrombosis

- Blood clot within one of the deep veins of the lower extremity.
- When assessing for compressibility of the deep veins, the walls of the vein must completely collapse and touch (or “kiss”) to be considered normal:
 - Figure 14.12—Completely compressed vein
 - Video 14.7—Completely compressed vein
- A deep venous thrombosis (DVT) will be diagnosed when the walls of the vein cannot be completely compressed:
 - Figure 14.13—Noncompressible vein
 - Video 14.8—Noncompressible common femoral vein
 - Video 14.9—Noncompressible deep and superficial femoral veins
- At times, a thrombus will be noted within the vein prior to performing a compression test:

FIGURE 14.12
Completely compressed vein. In the absence of a deep venous thrombosis (DVT), a vein will completely compress with direct and even pressure. The common femoral vein (CFV) here is actively collapsing under pressure. The femoral artery (FA) is seen with a slight flattening



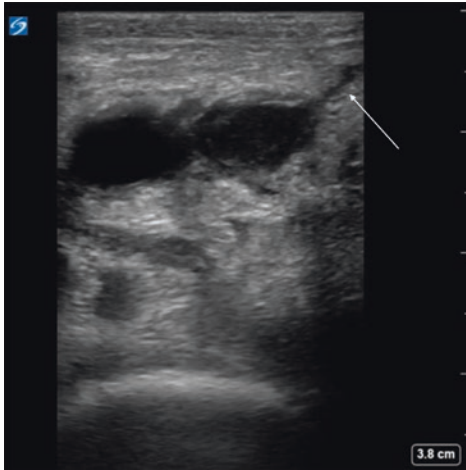


FIGURE 14.13 Noncompressible vein. This vein does not collapse under pressure. Notice flattening to the top of the common femoral vein and an obvious vessel lumen, demonstrating an inability to compress the vein. This is a finding concerning for a deep venous thrombosis (DVT), especially when there is echogenic material inside the lumen of the vessel. Of note, the greater saphenous vein (arrow) is completely compressed which means enough pressure is applied to collapse the vein and there is no clot burden in this portion of the vessel

- An acute thrombus will most often appear hypoechoic, and may be indistinguishable from a normal vein until compression testing is done.

Figure 14.14—Acute thrombus

Video 14.10—Acute thrombus

- A chronic thrombus will appear more hyperechoic than an acute DVT:

It can also have a rougher, less smooth appearance than an acute thrombus [1].

Overtime, a chronic thrombus will become recanalized centrally allowing blood to flow through the DVT [1]. This can cause the vein walls to appear thickened and irregular [3].

Figure 14.15—Chronic thrombus.

Video 14.11—Chronic thrombus.

FIGURE 14.14 Acute thrombus. An acute thrombus appears as a noncompressible vein with hypoechoic material within the lumen of the vein

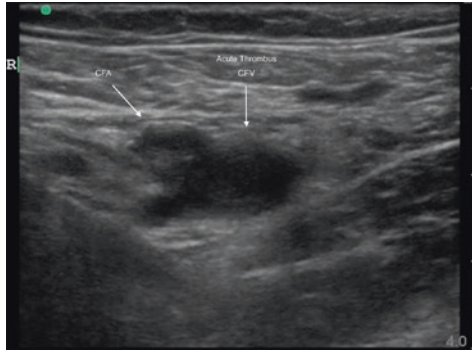
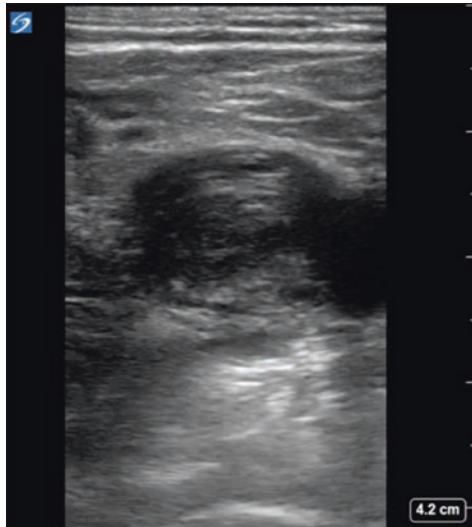

FIGURE 14.15 Chronic thrombus. A chronic deep vein thrombus appears a noncompressible vein with hyperechoic material within the lumen of the vein



(b) Superficial Venous Thrombosis

- Blood clot within a superficial vein of the lower extremity.
- Appears similar to a DVT.
- No indication for anticoagulation; it is recommended patients follow up for reevaluation within 1 week [1].

Key Points

- Using point-of-care ultrasound to evaluate patients in the emergency department has been shown to decrease length of stay when compared with patients who receive studies performed by the radiology department [4].
- Classically the femoral vein lies medial to the femoral artery; however, a common anatomic variant is for the femoral artery to travel anterior to the femoral vein [1].
- Veins collapse easily with pressure. If you cannot visualize a vein, apply less pressure with the transducer.
- Apply direct and even pressure over the vein to assess its compressibility:
 - A false-positive DVT can be diagnosed if uneven pressure is applied, therefore, resulting in an inability to completely compress the vein.
 - This can also occur with patients who have larger body habitus as it is harder to apply direct and even pressure.
- Noncompressible veins can also be seen with chronic DVTs:
 - When a DVT re-cannulates, it can cause the walls of the vein to become stiffer and less responsive to compression.
- Do not rely on visualization of the clot for diagnosis of a DVT as the appearance changes with maturation:
 - If a vein does not completely compress, this is diagnostic of a DVT even if no thrombus is visualized within the lumen [2].
- While a chronic DVT may appear more echogenic with thickened irregular walls, these findings may not be present and it may not be possible to distinguish an acute from a chronic thrombus [3].

- Point-of-care ultrasound for DVT without the use of color Doppler can be less reliable in patients with recurrent DVT:
 - Approximately 50% of ultrasounds can be abnormal 1 year after initial diagnosis of a DVT [5].

References

1. Costantino TG, Goett HJ, Peterson MA. Chapter 17: Deep venous thrombosis. In: Ma OJ, Mateer JR, Reardon RF, Joing SA, editors. Emergency ultrasound. 3rd ed. Beijing: McGraw-Hill Education; 2014. p. 479–502.
2. Del Rios M, Lewiss RE, Saul T. Focus on: emergency ultrasound for deep vein thrombosis. ACEP News website. March 2009. <https://www.acep.org/clinical-practice-management/focus-on-emergency-ultrasound-for-deep-vein-thrombosis/>. Accessed 25 Apr 2017.
3. Katz DS, Fruauff K, Kranz AO, Hon M. Imaging of deep venous thrombosis: a multimodality overview. Applied Radiology website. <http://appliedradiology.com/articles/imaging-of-deep-venous-thrombosis-a-multimodality-overview>. 5 March 2014. Accessed 25 Apr 2017.
4. Lewiss RE, Kaban NL, Saul T. Point-of-care ultrasound for a deep venous thrombosis. Global Heart. 2013; 8(3):329–333. <http://www.sciencedirect.com/science/article/pii/S2211816013001646>. Accessed 25 Apr 2017.
5. Bassi B, Nickels LC, Flach FE, DePortu G, Ganti L. Acute on chronic venous thromboembolism on therapeutic anticoagulation. Case Rep Emerg Med. 2013;2013:295261. 3 pages, doi:10.1155/2013/295261. Accessed 25 Apr 2017

Chapter 15

Skin and Soft Tissue Ultrasound

Ultrasonography is routinely used for the evaluation of skin and soft tissue complaints. It is relatively easy to perform due to the superficial location of each structure, allowing for high-frequency imaging, thereby producing high-resolution, detailed images. Commonly, ultrasound is used to evaluate for abscess, cellulitis, and foreign bodies within the skin and soft tissue. Recently, evidence demonstrates that ultrasound is becoming more useful and efficient in the diagnosis of necrotizing fasciitis, a life-threatening condition that requires timely recognition. This chapter will review basic skin and soft tissue anatomy, image acquisition, normal ultrasound anatomy, and interpretation of pathology.

Clinical Application and Indications

- Evaluate for soft tissue infections.
- Evaluate soft tissue mass for abscess, hematoma, lymph nodes, or cyst.
- Identify foreign bodies.

Electronic Supplementary Material The online version of this chapter (doi:[10.1007/978-3-319-68634-9_15](https://doi.org/10.1007/978-3-319-68634-9_15)) contains supplementary material, which is available to authorized users.

Normal Skin and Soft Tissue Anatomy

- From superficial to deep: Epidermis, dermis, and hypodermis containing fat and blood vessels, fascia, muscle, and bone:
 - Deeper tissues (muscle and bone) will be described in the musculoskeletal chapter.

Image Acquisition

(a) Transducer Selection

- Linear array transducer for most applications:
 - High frequency provides better-resolution images of superficial structures of interest.
- Curvilinear for evaluation of deeper structures in larger habitus patients

(b) Patient Position

- Depends on the location to be evaluated
- Water bath:
 - Ideal for hand/finger/foot/toe applications.
 - Place area of interest within a basin filled with just enough water to submerge the area entirely, and then place just the tip of the transducer into the water over the affected area.
 - This will allow you to visualize the structure without having to apply direct pressure to the area, as well as visualize very superficial findings [1].
 - Figure 15.1—Water bath positioning.
 - Figure 15.2—Water bath ultrasound.

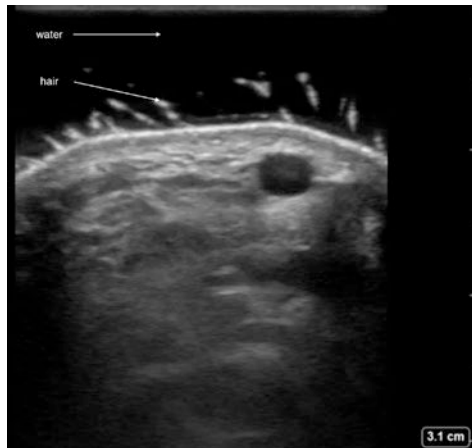
(c) Standard Exam Views

- Scan through the area in two planes 90° apart.
- Begin the exam over normal tissue to identify normal anatomy:



FIGURE 15.1 Water bath positioning. To facilitate visualization of small parts, have the patient place the affected area in a container of water, and hover the probe over the area of interest

FIGURE 15.2 Water bath ultrasound. Dorsal hand ultrasound using a water bath showing separation of transducer from the tissue of interest



- From superficial to deep:

Epidermis and dermis will appear as thin hyperechoic bands at the top of the screen [2].

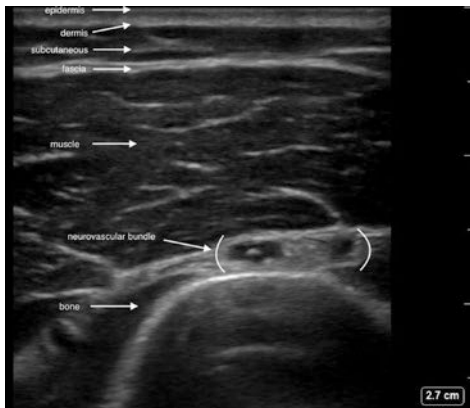
Hypodermis, containing subcutaneous tissue, is more anechoic and thicker [2]; on occasion, blood vessels can be seen within this layer.

Fascia will appear as a thin hyperechoic line [2].

Muscle will be visualized as a hypoechoic striated band; depending on this location, this can be thick or thin.

Bone will have a brightly echogenic surface with posterior acoustic shadowing.

FIGURE 15.3 Soft tissue layers. Soft tissue layers identified from superficial to deep including epidermis, dermis, subcutaneous tissue (hypodermis), fascia, muscle, bone



- Figure 15.3—Soft tissue layers
- Video 15.1—Normal skin and soft tissue ultrasound
- Next scan toward the affected area to evaluate for pathology.
- Obtain size measurements of any abnormal mass or fluid collection using the caliper function.

Skin and Soft Tissue Pathology

- Cellulitis
 - Disruption of the skin with invasion of bacteria causing an infection of the dermis and subcutaneous fat.
 - Cellulitis can be identified by increased echogenicity and thickening of the subcutaneous tissue with hyper-echoic areas of inflamed soft tissue outlined by hypoechoic fluid between these areas [1, 2]:

This is referred to as cobblestoning [1].

These findings are due to the accumulation of subcutaneous edema.

FIGURE 15.4
Cellulitis. Cellulitis typically appears as cobblestoning of the subcutaneous tissue with associated thickening of the dermal layers

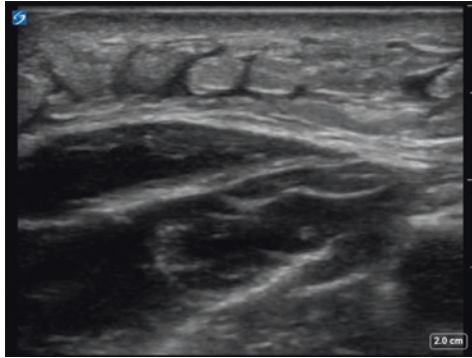
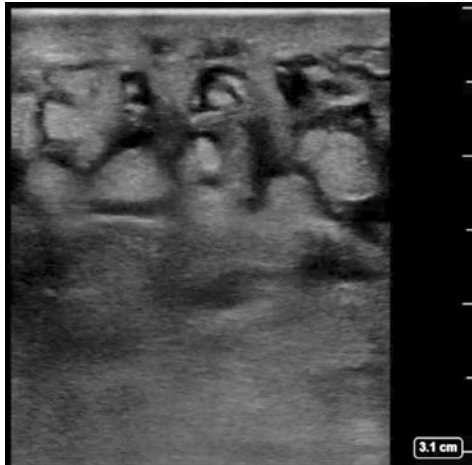


FIGURE 15.5
Cellulitis with increased soft tissue edema. As cellulitis becomes more severe or with concomitant edema, there will be increased fluid within the subcutaneous tissue visualized by thicker anechoic pockets

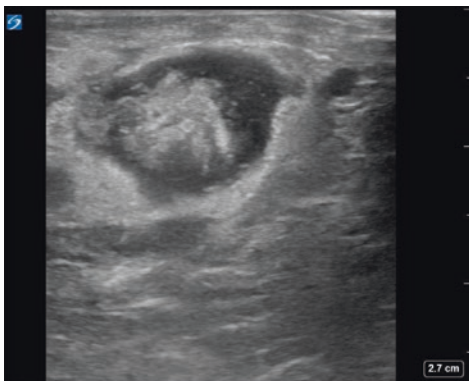


- Figure 15.4—Cellulitis.
- Video 15.2—Cellulitis.
- Figure 15.5—Cellulitis with increased soft tissue edema.
- Video 15.3—Cellulitis with increased soft tissue edema.
- Abscess
 - Walled off bacterial infection resulting in a collection of purulent fluid.

FIGURE 15.6

Abscess.

Hypoechoic fluid collection with thick echogenic material representing a small abscess



- Will be identified as a hypoechoic fluid collection containing debris [1] with irregular borders and the absence of posterior enhancement:

Figure 15.6—Abscess

Video 15.4—Abscess

- Internal swirling of the fluid will typically occur with compression and can help distinguish fluid-filled collection from solid mass:

Video 15.5—Abscess with internal swirling from compression

- There will be an absence of internal Doppler flow.
- Air in the abscess cavity is significant for gas-forming organisms and will need emergent treatment:

This can be identified as echogenic areas within the abscess cavity [2] with dirty posterior shadowing and posterior reverberations.

- Necrotizing Fasciitis
 - Severe infection that causes death of tissue and spreads rapidly along the fascial planes.
 - Early necrotizing fasciitis will often resemble cellulitis with a cobblestone appearance.

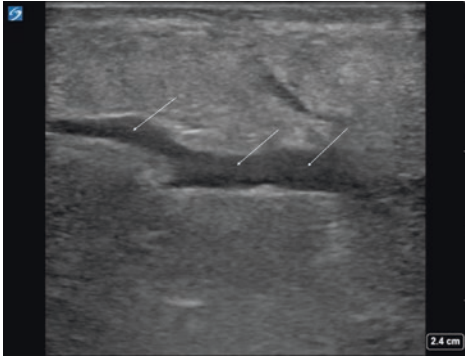


FIGURE 15.7 Necrotizing fasciitis with per fascial fluid. Fluid tracking along the fascial plane with thickened subcutaneous tissue and a loss of normal architecture. Per fascial fluid greater than 4 mm likely indicates a diagnosis of necrotizing fasciitis

- In advanced cases, the skin will be thickened and the fascia will appear thickened and brightly echogenic with adjacent accumulation of fluid [2–4]:

A fluid layer measuring greater than 4 mm deep to the fascia greatly increases the likelihood for the diagnosis of necrotizing fasciitis [2, 3].

Figure 15.7—Necrotizing fasciitis with per fascial fluid.
Video 15.6—Necrotizing fasciitis with per fascial fluid.

- The presence of air in the soft tissue only occurs if gas-forming organisms are present and is the key ultrasound finding for this process:

Will appear as dirty shadowing with reverberation artifact [2]

Figure 15.8—Necrotizing fasciitis with dirty shadowing

- Hematoma
 - Collection of blood, usually due to trauma or in patients who have recently had procedures completed, such as cardiac catheterization
 - Hypoechoic fluid collection, often with a layered appearance [5]

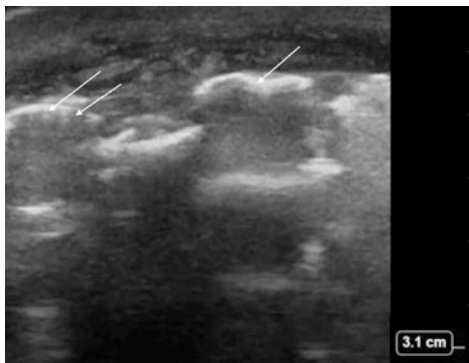
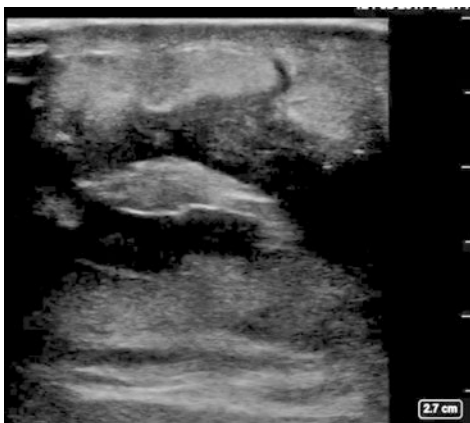

FIGURE 15.8 Necrotizing fasciitis with subcutaneous air. Necrotizing fasciitis can be a subtle entity to diagnose with ultrasound. In the presence of gas-forming bacteria, it will be visualized by identifying dirty shadowing (arrows) caused by air-tissue interface

FIGURE 15.9 Hematoma. Hypoechoic fluid collection representing abdominal hematoma. On ultrasound, may be indistinguishable from abscess



- May resemble abscess, but clinical history will help differentiate the fluid containing soft tissue collections:
- Figure 15.9—Hematoma
- Video 15.7—Hematoma
- Foreign Body
 - Will appear as hyperechoic as compared with the surrounding structures.

FIGURE 15.10
Foreign body.
Finger ultrasound
in water bath with
embedded foreign
body (arrows)

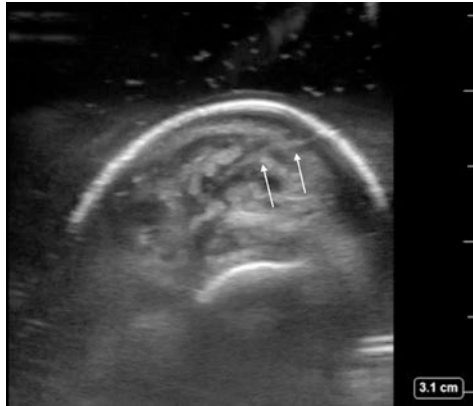
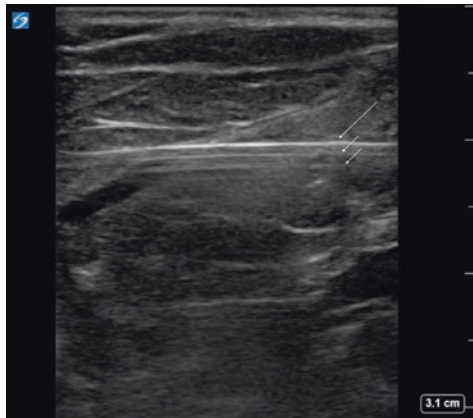


FIGURE 15.11 Metal
foreign body.
Brightly echogenic
foreign body repre-
sents a broken need-
le within the neck
of a patient from
intravenous drug
abuse



- Wood or plastic foreign bodies will generally have posterior shadowing [2]:

Figure 15.10—Wood/plastic foreign body with posterior shadowing

- Metal objects will have comet tail artifacts or posterior reverberations [2]:

Figure 15.11—Metal foreign body

Video 15.8—Metal foreign body long axis

Video 15.9—Metal foreign body short axis

Key Points

- Cobblestoning can occur with other disease processes that cause edema of the soft tissue. Therefore, ultrasound cannot be used to determine the presence of cellulitis in areas of existing edema.
- Soft tissue ultrasound is best used to rule in an abscess, not to rule out or diagnose cellulitis.
- Be sure to image the base of the abscess—if you are unable to visualize this, it is likely that this is not a simple superficial abscess and this will require further imaging or surgical consult
- Ultrasound cannot rule out necrotizing soft tissue infections.
- Lymph nodes can appear similar to an abscess, especially in the axilla, neck, and groin. Abscesses, unlike lymph nodes, will have swirling on compression and will not have internal color flow with application of a Doppler window:

Figure 15.12—Lymph node

Video 15.10—Lymph node

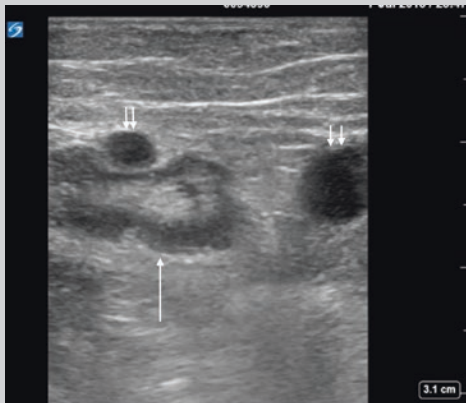


FIGURE 15.12 Lymph node. Lymph node (single arrow) with hyperechoic medulla surrounded by hypoechoic cortex. Vascular structures denoted by double arrows

References

1. SonoSim Ultrasound Training Solution [Video]. Santa Monica, CA: SonoSim Inc.; 2017.
2. Dewitz A. Chapter 18: Musculoskeletal, soft tissue, and miscellaneous applications. In: Ma OJ, Mateer JR, Reardon RF, Joing SA, editors. *Emergency ultrasound*. 3rd ed. New York: McGraw-Hill Education; 2014. p. 503–68.
3. Yen Z, Wang H, Ma H, Chen S, Chen W. Ultrasonographic screening of clinically-suspected necrotizing fasciitis. *Acad Emerg Med* 2002; 9(12):1448–1451. <http://onlinelibrary.wiley.com/doi/10.1197/aemj.9.12.1448/epdf>. Accessed 17 Apr 2017.
4. Wronski M, Slodkowski M, Cebulski W, Karkocha D, Krasnodebski I. Necrotizing fasciitis: early sonographic diagnosis. *J Clin Ultrasound* 2011; 39(4):236–239. <http://edus.ucsf.edu/sites/edus.ucsf.edu/files/wysiwyg/Necrotizing%20fasciitis%3A%20Early%20sonographic%20diagnosis.pdf>. Accessed 17 Apr 2017.
5. Jacobson JA. Chapter 6: Hip and thigh ultrasound. In: Jacobson JA, editor. *Fundamentals of musculoskeletal ultrasound*. 2nd ed. Philadelphia, PA: Sanders; 2013. p. 162–211.

Chapter 16

Ocular Ultrasound

Ultrasound now gives physicians the utility to evaluate patients who have experienced acute vision loss more efficiently and accurately. It gives providers the ability to see behind the superficial structures and assess the lens, retina, vitreous body, ocular nerve, and ocular vasculature for pathology. Some disease processes, such as retinal detachment or central retinal artery occlusion, need to be treated in a timely manner to prevent sequelae of disease; ultrasound gives us this ability. In addition to ocular pathology, using the same technique, we can evaluate for neurologic conditions such as increased intracranial pressure. This chapter will review indications for performing an ocular ultrasound, basic ocular anatomy, image acquisition, normal ultrasound anatomy, and interpretation of pathology.

Clinical Application and Indications

- Loss of vision
- Ocular pain

Electronic Supplementary Material The online version of this chapter (doi:[10.1007/978-3-319-68634-9_16](https://doi.org/10.1007/978-3-319-68634-9_16)) contains supplementary material, which is available to authorized users.

- Evaluate for vitreoretinal disorders such as foreign body, vitreous hemorrhage, vitreous detachment, retinal detachment, and lens dislocation or subluxation.
- Evaluate for increased intracranial pressure (ICP) or papilledema.

Normal Ocular Anatomy

- Superficial Ocular Anatomy
 - The conjunctiva is a transparent membrane that covers the surface of the eye and inner surface of the eyelids.
 - The sclera covers almost the entire surface of the eye (except for the cornea) and is white in appearance.
 - The cornea is located on the central portion of the eye and is confluent with the sclera. Posterior to the cornea are the iris and pupil.
- Intraocular Anatomy
 - The anterior chamber is a fluid-filled space bordered by the cornea anteriorly and the iris and pupil posteriorly.
 - Iris is a disc-shaped structure that gives color to the eye with a hole in the middle giving rise to the pupil.
 - Posterior to the pupil is the lens, a biconvex structure.
 - Vitreous body encompasses a large space between the lens and retina. It is composed of vitreous humor which is a gelatinous substance.
 - Retina is a thin membrane that courses along the posterior inner wall of the orbit and is adhered at the optic disc and the ora serrata.
 - Optic nerve originates posterior to the globe and is surrounded by the optic nerve sheath.
 - Macula is lateral to the optic nerve.
 - The central retinal artery arises from the ophthalmic artery and courses in the middle of the optic nerve.

Image Acquisition

(a) Transducer Selection

- Linear array transducer

(b) Patient Position

- The patient should be supine with the head of the bed at approximately 30° .
- The patient's head should be tilted upward, so the plane of the orbit is relatively horizontal to the ground.
- Apply at least a centimeter of gel on the patient's eye to prevent compression of the globe.
- Be careful not to apply pressure on the patient's eye—you can rest your hand on the patient face or nose for ease of scanning.
- Figure 16.1—Patient position.

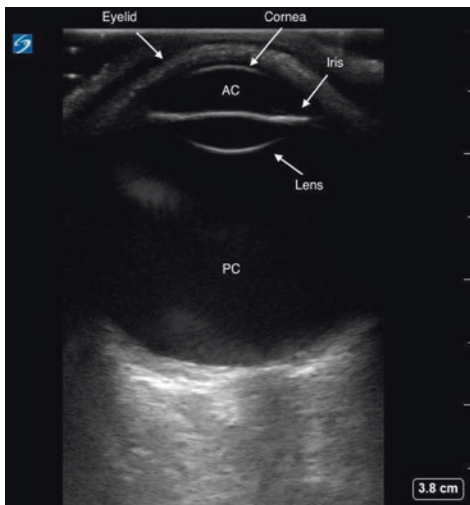
(c) Standard Exam Views

- Image the eye in both transverse and sagittal plane.
- Place the transducer on the patient's eye with the transducer marker pointed toward the patient's right to obtain a transverse view:
 - Visualize the eye with the anterior chamber seen superficially and the lens posterior to this followed by the posterior chamber and retina.

FIGURE 16.1 Patient position. Lean the patient's head back and apply a copious amount of gel on top of a closed eyelid

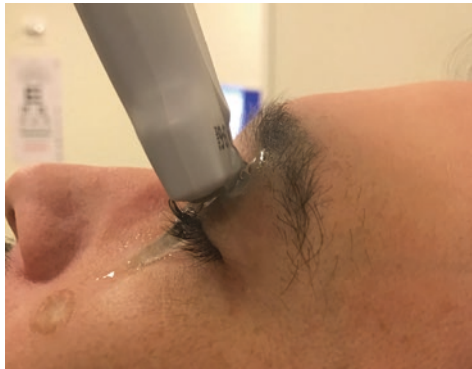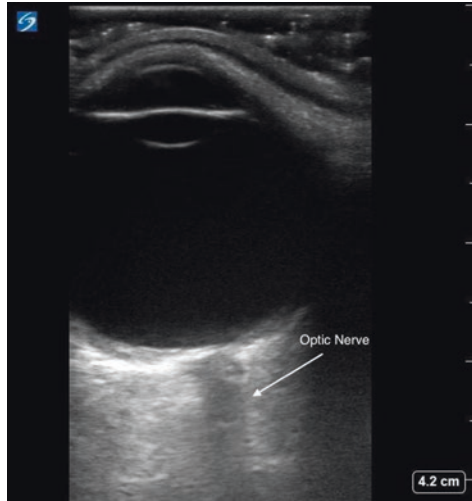


FIGURE 16.2 Normal ocular ultrasound. A normal eye will maintain its shape with a round cornea, anterior chamber, iris, lens, and posterior chamber. Adjust the depth to visualize the entire globe and optic nerve



- The vitreous body, which makes up most of the posterior chamber, is anechoic.
- The optic nerve courses from posterior to the globe and is surrounded by the optic nerve sheath.
- The central retinal artery and central retinal vein can be seen in the center of the optic nerve. These structures can be identified by using color Doppler.
- Have the patient look from side to side with their eye closed for dynamic imaging. This may enable visualization of otherwise subtle findings such as vitreous detachment, retinal detachment, or vitreous hemorrhage.
- Figure 16.2—Normal eye and normal eye with labels.
- Video 16.1—Normal eye.
- Rotate the transducer 90° so the transducer marker is pointed cephalad:
 - Visualize the same anatomy as in the transverse view.
 - Have the patient look up and down with their eye closed.

FIGURE 16.3 Optic nerve. The nerve is hypoechoic and will be flanked on both sides by its more hyperechoic sheath



- Obtain an optic nerve sheath diameter (ONSD) measurement bilaterally:
 - Used to assess for increased intracranial pressure.
 - Identify the optic nerve and its accompanying nerve sheath:

The nerve is hypoechoic and will be flanked on both sides by its more hyperechoic sheath.

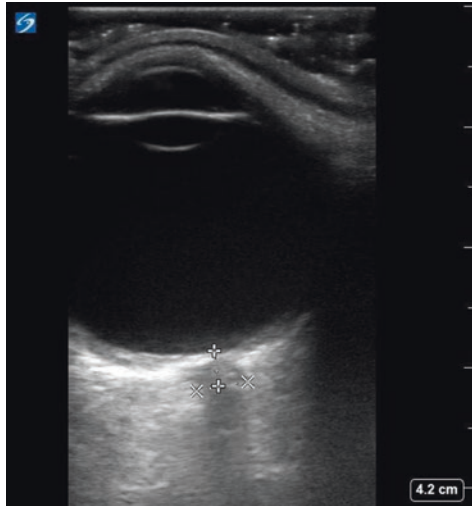
Figure 16.3—Optic nerve.

- Measure the diameter 3 mm posterior to the optic disc [1].
- Normal ONSD is up to 5.7 mm in diameter [2, 3].
- Figure 16.4—ONSD measurement.

Ocular Pathology

- Vitreous Hemorrhage
 - Extravasation of blood into the posterior chamber is most commonly due to posterior vitreous detachment (PVD), however, can be also be due to trauma or even be idiopathic

FIGURE 16.4 ONSD measurement. Measure the diameter 3 mm posterior to the optic disc



- Appears as echogenic debris within the posterior chamber:
 - Can appear as layering of echogenic material posteriorly [2]
- May only be visualized during dynamic eye imaging as swirling of echogenic debris while the eye is moving
- Figure 16.5—Vitreous hemorrhage
- Video 16.2—Vitreous hemorrhage
- Retinal Detachment (RD)
 - Separation of the retina from the underlying epithelium.
 - Thick echogenic band posteriorly.
 - With dynamic eye movements, there will be little movement of the echogenic band, which will remain attached to an area near the optic nerve and the ora serrata [1]:
 - The attachment points help differentiate a retinal detachment from a posterior vitreous detachment.
 - Often associated with vitreous hemorrhage.
 - Figure 16.6—Retinal detachment.
 - Video 16.3—Retinal detachment.

FIGURE 16.5 Vitreous hemorrhage. During dynamic movement of the eye, echogenic debris (arrows) swirls in the posterior chamber of the eye

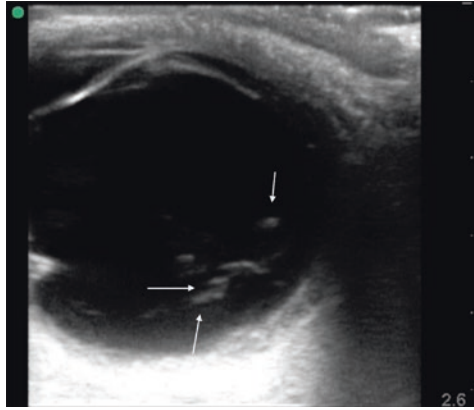
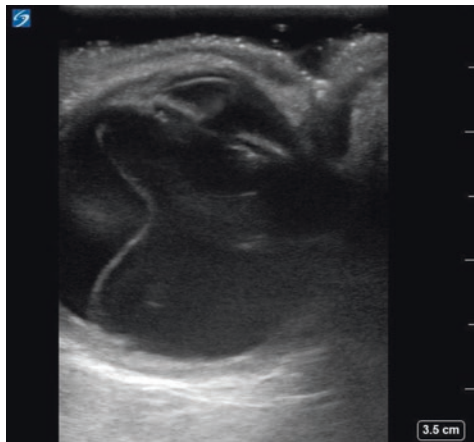
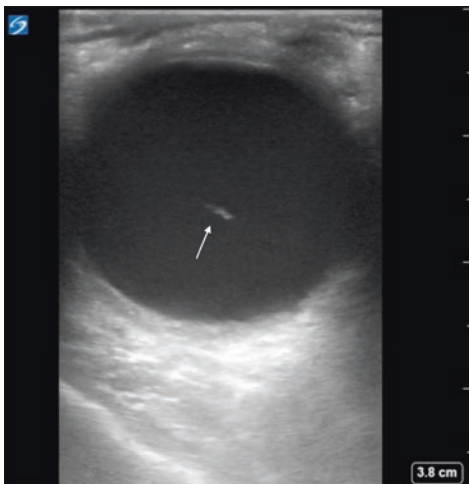


FIGURE 16.6 Retinal detachment. Thick echogenic band posteriorly. With dynamic eye movements, you will see that the retina is attached to an area near the optic nerve and the ora serrata



- Posterior Vitreous Detachment
 - Degenerative process in which the vitreous gel loses its attachment to the membrane.
 - Increase the gain to identify PVD, which will appear as a smooth, thin membrane and echogenic material within the posterior chamber.
 - With dynamic movements of the eye, echogenic material will swirl within the posterior chamber [2].

FIGURE 16.7 Posterior vitreous detachment. With increased gain the PVD (*arrow*) will appear as a smooth, thin membrane. This echogenic membrane is freely mobile with dynamic movements of the eye without attachment to the optic disc, such as with retinal detachment



- Can be confused with retinal detachment.

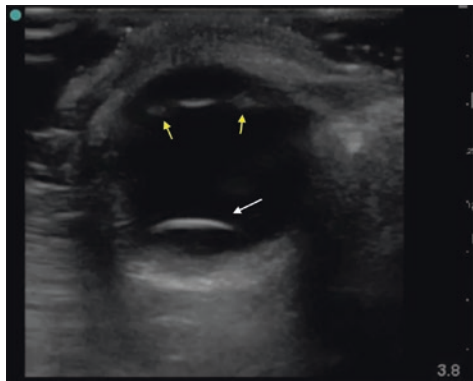
The retina will remain attached at the optic nerve or ora serrata.

- Figure 16.7—Posterior vitreous detachment.
- Video 16.4—Posterior vitreous detachment.
- Retrobulbar Hematoma
 - A collection of blood posterior to the globe that appears hypoechoic compared to the surrounding tissue.
 - It can distort the globe due to pressure caused by the hematoma on the eye [1]
 - Figure 16.8—Retrobulbar hematoma
- Lens Dislocation
 - With a complete dislocation, the lens will not be seen in its usual central location just posterior to the anterior chamber.
 - Figure 16.9—Lens dislocation.
 - Video 16.5—Lens dislocation.
 - Lens subluxation can also occur which can be described as a partial dislocation:

FIGURE 16.8
Retrobulbar hema-
toma. Echolu-
cency posterior to the
globe. It often takes
the shape of a gui-
tar pick

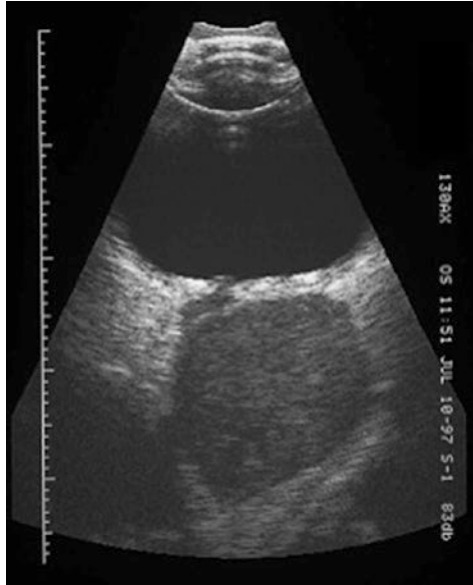

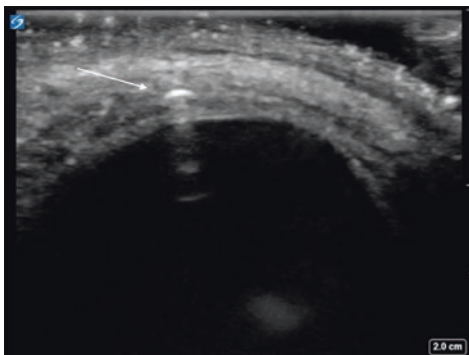
FIGURE 16.9 Lens
dislocation. In this
complete disloca-
tion, the lens is seen
at the bottom of the
posterior chamber
(*white arrow*). Note
absence of the lens
in its typical loca-
tion near the ciliary
bodies (*yellow
arrows*)



The lens may appear to be in its normal location; how-
ever, with eye movement the lens will move independ-
ently of other ocular structures [1].

Video 16.6—Lens subluxation.

FIGURE 16.10
Foreign body.
Hyperechoic material within the outer surface of the eye (*arrow*). Metal objects will demonstrate reverberation artifact posterior to the foreign body



- Foreign Body
 - Foreign bodies appear as hyperechoic structures located within the vitreous body or embedded in the superficial structures of the eye:

Likely accompanied by a vitreous hemorrhage

Figure 16.10—Foreign body

Video 16.7—Foreign body

- Central Retinal Artery Occlusion
 - Utilize color Doppler just posterior to the globe to evaluate blood supply:

Figure 16.11—Central retinal artery color and pulsed wave Doppler

- May also visualize an area of echogenicity centrally within the optic nerve sheath just posterior to the optic disc, termed retrobulbar spot sign [4]:

Figure 16.12—Central retinal artery occlusion, B-mode

- Increased Optic Nerve Sheath Diameter
 - Defined as greater than 5.7 mm in diameter [2, 3]:

Predicts an increased intracranial pressure of greater than 20 mmHg [2].

With severe increases in ICP, the optic nerve sheath can separate from the optic nerve. This will appear as a hyperechoic circle within the optic nerve sheath, called the “crescent sign” [1].

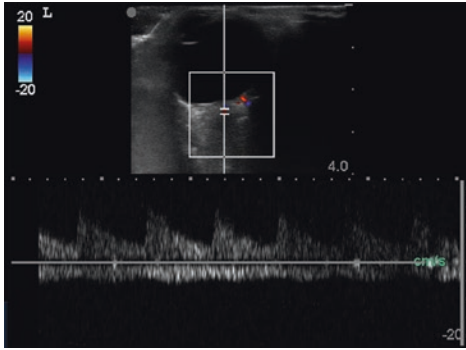
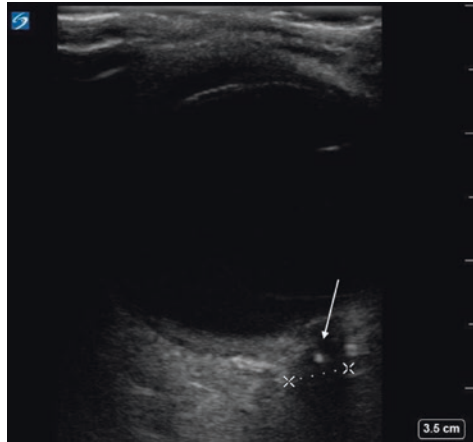


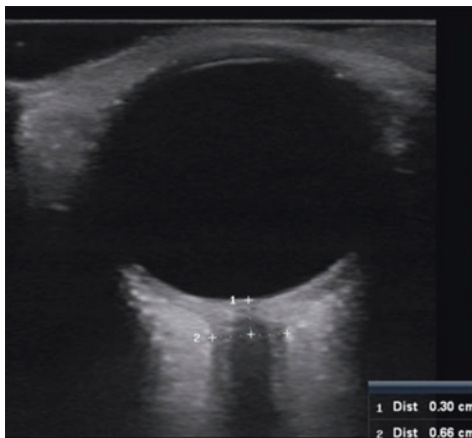
FIGURE 16.11 Central retinal artery color and pulsed wave Doppler. Utilize color and/or pulsed wave Doppler just posterior to the globe to evaluate blood supply. Color is present within the Doppler gates. This is an example of central retinal artery waveform

FIGURE 16.12 Central retinal artery occlusion, B-mode. A hyperdense echogenicity located in the center of the retinal artery just posterior to the optic disc; commonly termed retrobulbar spot sign (*arrow*)



- If the finding is bilateral, it may indicate increased intracranial pressure.
- If unilateral, it may indicate optic neuritis.
- Figure 16.13—Increased ONSD.

FIGURE 16.13
Increased
ONSD. Greater
than 5.7 mm in
diameter is consid-
ered pathologic



Key Points

- A ruptured globe is typically a contraindication for ocular ultrasound.
- It is important to use a liberal amount of gel to obtain optimal images as well as to avoid compression of the globe.
- Always increase the gain to identify artifact, hemorrhage, PVD, or RD within the posterior chamber.
- In children, increased intracranial pressure can be identified by ONSD greater than 4.5 mm [1, 2].
 - In children less than 1 year of age, ONSD greater than 4.0 mm suggests increased ICP [1].

References

1. Lyon M, von Kuenssberg JD. Chapter 19: Ocular. In: Ma OJ, Mateer JR, Reardon RF, Joing SA, editors. Emergency ultrasound. 3rd ed. Beijing: McGraw-Hill Education; 2014. p. 569–86.
2. SonoSim Ultrasound Training Solution [Video]. Santa Monica, CA: SonoSim Inc.; 2017.

3. Tran V, Irwin Z. Chapter 22: Ocular ultrasound. In: Fox JC, editor. *Clinical emergency radiology*. 2nd ed. Cambridge: Cambridge University Press; 2017. p. 324–30.
4. Nedelmann M, Graef M, Weinand F, Wassill K, Kaps M, Lorenz B, Tanislav C. Retrobulbar spot sign predicts thrombolytic treatment effects and etiology in Central Retinal Artery Occlusion. *Stroke*. 2015; 46(8) 2322-2324. June 25, 2015. <https://doi.org/10.1161/STROKEAHA.115.009839>. Accessed 14 Apr 2017.

Chapter 17

Pediatric Ultrasound

This chapter is focused on pediatric point-of-care ultrasound evaluation. Focused ultrasound is being used more frequently in pediatric emergency departments to diagnose conditions without the use of harmful radiation and to expedite care. This chapter will review the indications, image acquisition, and interpretation of patients who present with symptoms concerning for appendicitis, pyloric stenosis, intussusception, and testicular torsion.

Appendicitis

(a) Indications

- Right lower quadrant or periumbilical abdominal pain
- Anorexia
- Fever
- Vomiting

Electronic Supplementary Material The online version of this chapter (doi:[10.1007/978-3-319-68634-9_17](https://doi.org/10.1007/978-3-319-68634-9_17)) contains supplementary material, which is available to authorized users.

(b) Image Acquisition

- Transducer selection:
 - Linear array:

Preferred transducer for evaluation of the appendix on thinner patients
 - Curvilinear
 - Phased array
- Patient position:
 - The patient should be supine with the head of the bed flat and their knees flexed to allow abdominal muscles to relax.
- Have the patient point to the site of maximal pain and begin with transducer at this site:
 - Place the transducer in a transverse plane with the marker pointed toward the patient's right.
 - Scan both inferior and superior to try to identify the appendix.
 - The appendix will be visualized originating from the cecum, anterior to the iliac vessels:

Normally, the appendix is a compressible tubular structure with a blind end and an outer diameter of less than 6 mm. The upper limit of normal in the pediatric population is 5.7 mm and 6 mm in adults.

- Rotate the transducer 90° with the marker pointed toward the patient's head to obtain views in a sagittal plane.
- Alternatively, place the transducer at the hepatic flexure, and trace the ascending colon down to the cecum.
- Use graded compression by exerting gentle pressure over the area of interest with the ultrasound transducer in effort to displace bowel gas to better visualize intra-abdominal structures.
- A normal appendix will exhibit peristalsis and compressibility [1].

FIGURE 17.1
Appendicitis. A
blind-ended tubular
structure with an
outer diameter of
greater than 5.7 mm

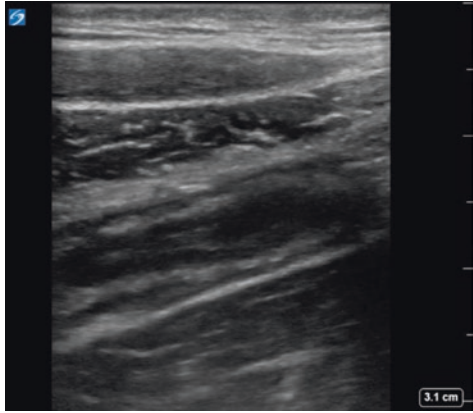
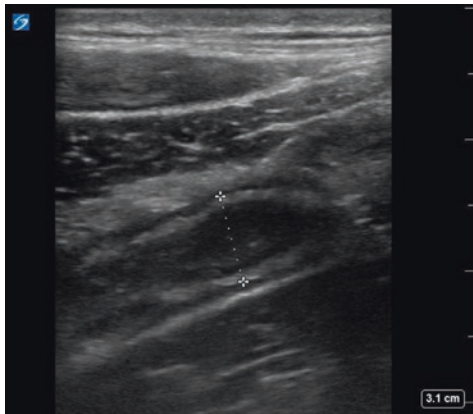


FIGURE 17.2
Diameter greater
than 5.7 mm. The
diameter in pedi-
atric appendicitis
is greater than 5.7 mm
as measured in this
figure



(c) Pathology

- Aperistaltic, noncompressible, blind-ended tubular structure with an outer diameter of greater than 6 mm [1–3]:
 - For pediatric patients, consider a diameter greater than 5.7 mm to diagnose acute appendicitis [2].
 - Figure 17.1—Appendicitis.
 - Figure 17.2—Diameter greater than 5.7 mm.
 - Video 17.1—Appendicitis in long axis.

FIGURE 17.3 Target sign. When the appendix is inflamed, it can resemble a target with hypoechoic and hyperechoic concentric rings

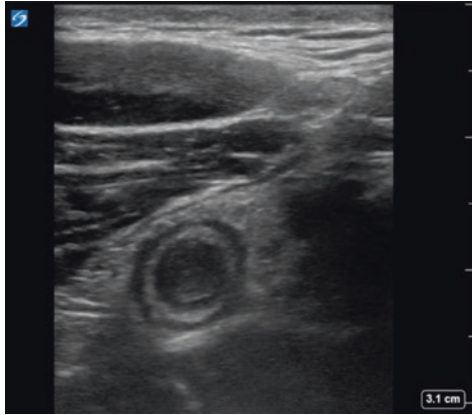
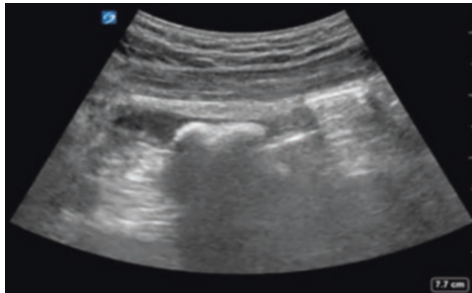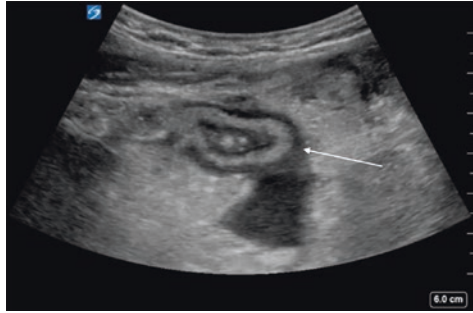


FIGURE 17.4 Appendicolith. Hyperechoic foci within the lumen of the appendix that causes posterior shadowing



- The following may also indicate acute appendicitis:
 - Target sign appearance:
 - Figure 17.3—Target sign
 - Video 17.2—Target sign
 - Wall thickness greater than 3 mm [4].
 - Appendicolith with posterior acoustic shadowing [3, 5]:
 - Figure 17.4—Appendicolith
 - Video 17.3—Appendicolith

FIGURE 17.5
Appendicitis with
periappendiceal
fluid. Inflammatory
fluid surrounds the
appendix depicted
by the arrow



- Periappendiceal fluid collection [5]:

Figure 17.5—Appendicitis with periappendiceal fluid

Video 17.4—Appendicitis with periappendiceal fluid

- Increased periappendiceal echogenicity due to fat stranding [6].
- Color Doppler can be used to demonstrate increased vascularity in the setting of acute appendicitis, often termed “ring of fire” [1].
- Perforation may be identified by a fluid collection, hypoechoic mass, or thickening of adjacent bowel wall:
 - Complex abscess fluid collections may be present.

(d) Key Points

- A normal appendix is only seen less than 15% of the time [1] due to its small size and lack of inflammatory findings.
- Inability to visualize a normal appendix does not rule out the presence of appendicitis.

Intussusception

(a) Indications

- Colicky abdominal pain
- Vomiting
- Currant jelly stool
- Lethargy

(b) Image Acquisition

- Transducer selection:
 - Curvilinear
 - Phased array
 - Linear array: can be used with thinner patients
- Patient position:
 - The patient should be supine with the head of the bed flat and their knees flexed to allow abdominal muscles to relax.
- Place the transducer in the right lower quadrant, and follow the path of the large intestine:
 - It is rare to have an intussusception of the small intestine, though it is possible.
- Alternatively, another way to evaluate for intussusception is to slide the transducer using an up-and-down lawn mower technique to cover the entire abdomen.
- The majority of intussusceptions are located in the right upper quadrant.

(c) Pathology

- Telescoping of one section of the bowel into another:
 - Commonly occurs at the ileocecal junction
 - Figure 17.6—Intussusception
- In a transverse plane, there will be concentric alternating hypoechoic and hyperechoic rings representing layers of the bowel with adjacent free fluid and inner fecal matter [1]:

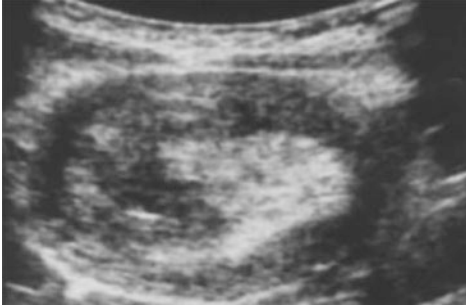
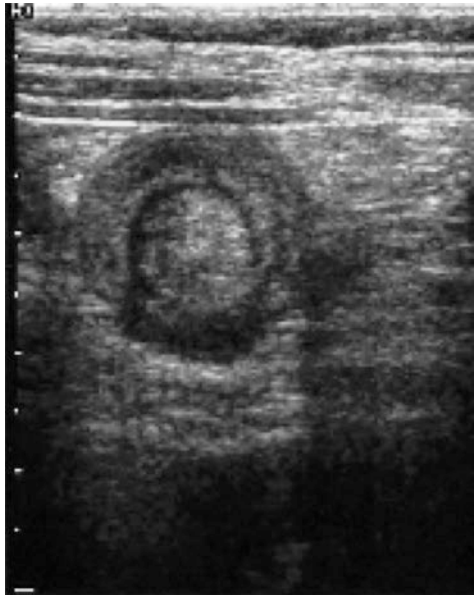

FIGURE 17.6 Intussusception. In a longitudinal plane, there is an invagination of the bowel into itself causing a telescoping-like effect. This is commonly referred to as a “pseudokidney” as it looks like a kidney in appearance

FIGURE 17.7 Doughnut sign. In a transverse plane, there will be concentric alternating hypoechoic and hyperechoic rings representing layers of the bowel with adjacent free fluid and inner fecal matter



- Termed “doughnut” or “target sign”
- Figure 17.7—Doughnut sign

Pyloric Stenosis

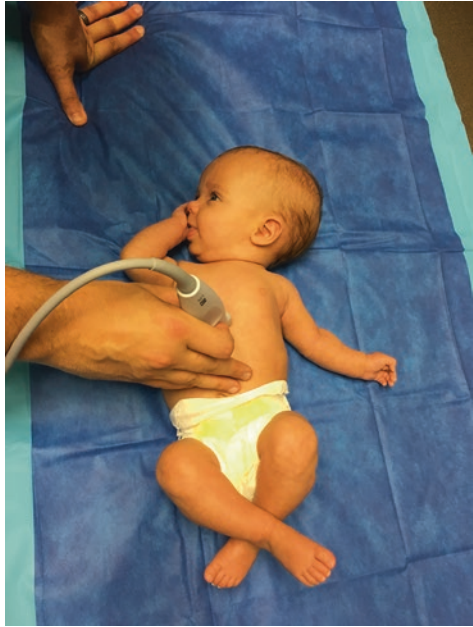(a) Indications

- Projectile non-bilious vomiting:
 - Commonly occurs within the first weeks of life (4–8 weeks)
- Palpable olive-shaped mass in the upper abdomen

(b) Image Acquisition

- Transducer:
 - Linear array
- Patient position:
 - The patient should be supine with the head of the bed flat.
- Place the transducer in an oblique position over the epigastrium with the marker pointed toward the patient's left shoulder:
 - Figure 17.8—Transducer placement for pyloric stenosis
- Fan the transducer up and toward the right shoulder, and then fan the transducer down toward the right hip:
 - If the patient has a lot of bowel gas, use graded compression by exerting gentle pressure over the area of interest with the ultrasound transducer in effort to displace the bowel gas.
 - Or reposition the patient by placing them in the right lateral decubitus position to move air up into the fundus of the stomach and fluid down.

FIGURE 17.8
 Transducer placement for pyloric stenosis. The patient should be supine with the head of the bed flat. Place the transducer in an oblique position over the epigastrium with the marker pointed toward the patient's left shoulder



(c) Pathology

- Pyloric stenosis occurs when the pylorus becomes hypertrophied blocking food from exiting the stomach into the small intestine.
- Identify the pyloric channel:
 - The outer thick muscular wall will appear hypoechoic compared to the more hyperechoic inner mucosa:

Figure 17.9—Pyloric stenosis short axis

- Measure the pyloric muscle thickness:
 Greater than 3 mm is diagnostic [7, 8].

FIGURE 17.9 Pyloric stenosis—short axis. The outer thick muscular wall will appear hypoechoic compared to the more hyperechoic inner mucosa

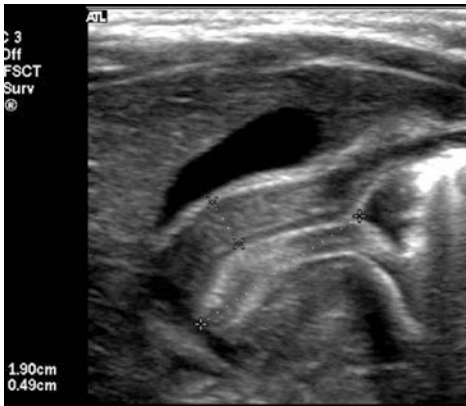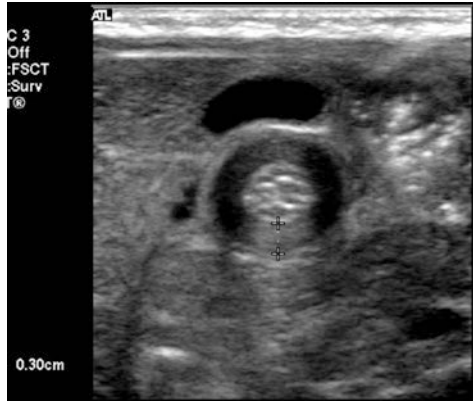


FIGURE 17.10 Pyloric stenosis measurements. Measurement of the pyloric muscle thickness greater than 3 mm, channel length greater than 14–20 mm, and diameter greater than 12 mm and pyloric channel diameter measurement. You will also see fluid in the stomach

- Other findings suggestive of pyloric stenosis:
 - Pyloric channel length greater than 14–20 mm [8]
 - Pyloric diameter greater than 12 mm [8]
 - Pyloric volume (fluid in the stomach) greater than 12cc [9]
- Figure 17.10—Pyloric stenosis measurements.

Testicular Torsion

(a) Indications

- Acute onset testicular pain
- Any concern for testicular torsion

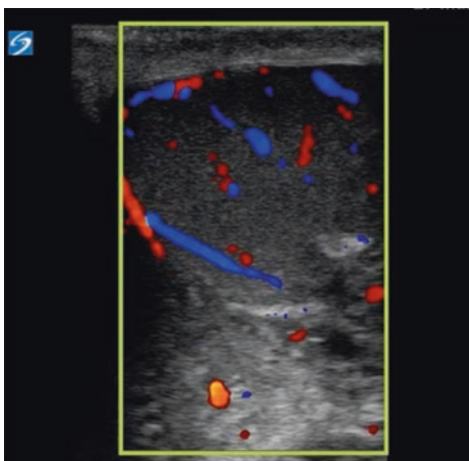
(b) Image Acquisition

- Transducer:
 - Linear array
- Patient position:
 - The patient should be supine.
 - Support the testicles in a sling-like fashion with a towel draped over the patient's legs and the scrotum sitting on top of the towel.
 - Cover sensitive areas that are being scanned with a towel.
- Obtain an image of both testicles side by side to demonstrate echogenicity differences between the normal and symptomatic testicles.
- Examine the asymptomatic testicle first in transverse and longitudinal planes:
 - A normal testicle is an oval-shaped homogenous mildly echogenic structure.
 - Note the echogenicity, texture, and size:
 - Figure 17.11—Normal testicle
 - Video 17.5—Normal testicle
 - Use color Doppler and note flow patterns:
 - Figure 17.12—Color Doppler
 - Video 17.6—Normal testicle color Doppler
- Examine the symptomatic testicle in transverse and longitudinal planes:
 - Compare echogenicity, texture, and size to the unaffected side.
 - Compare color Doppler flow patterns to the unaffected side.

FIGURE 17.11
Normal testicle.
B-mode image of a
normal testicle
which has a homog-
enous echotexture

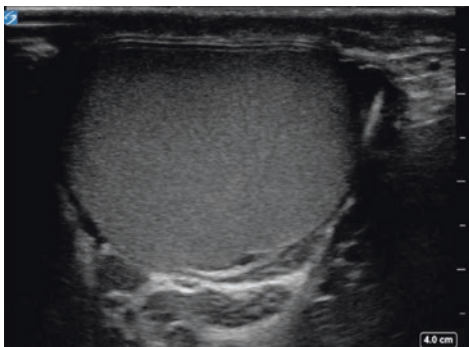

FIGURE 17.12 Color
Doppler. Color
Doppler image of a
normal testicle with
normal flow

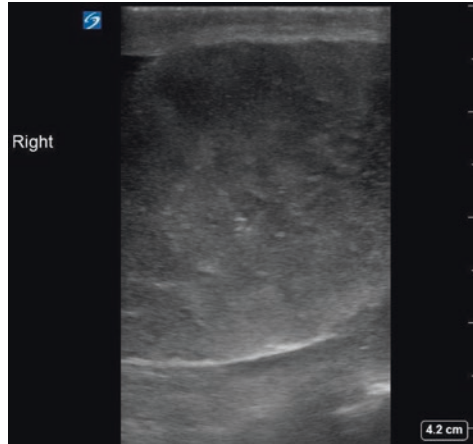


- See Chap. 13, Testicular Ultrasound, for complete testicular ultrasound procedure and details.

(c) Pathology

- Testicular torsion occurs when the spermatic cord twists causing venous congestion and obstruction followed by decreased arterial flow and eventually complete obstruction leading to ischemia and infarction [10, 11].

FIGURE 17.13
Testicular torsion.
The testicle is
enlarged and
hypoechoic with less
homogeneity con-
cerning for testicular
torsion

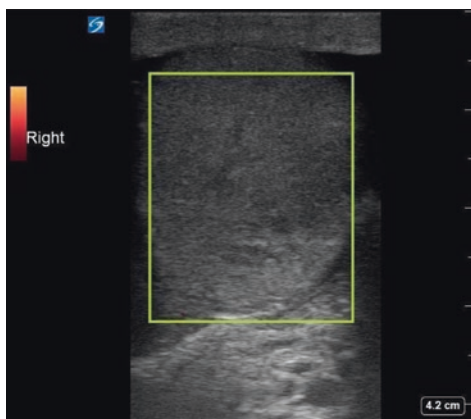


- Severity of torsion ranges from 180–720°, and complete occlusion of blood flow is thought to occur after 450° of torsion [11].
- B-mode (2D) imaging:
 - The affected testicle will appear enlarged and hypoechoic with less homogeneity compared with the unaffected testicle.
 - Figure 17.13—Testicular torsion.
 - Video 17.7—Testicular torsion.
- Color Doppler:
 - Decreased Doppler color signal will be seen or, in cases of complete torsion, the absence of Doppler color signal.
 - Always compare the Doppler color signal to the unaffected side.
 - Video 17.8—Torsion with color Doppler.
- Power Doppler:
 - Will evaluate low flow state.
 - Absence of power Doppler is diagnostic of testicular torsion [12].
 - Figure 17.14—Testicle with power Doppler.
 - Figure 17.15—Testicular torsion with power Doppler.

FIGURE 17.14
Testicle with power
Doppler. Testicle
with power Doppler
demonstrating a low
flow state

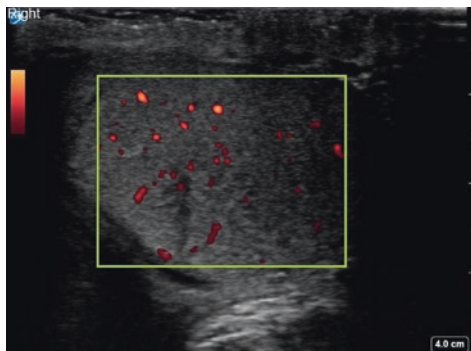

FIGURE 17.15
Testicular torsion
power Doppler. No
flow appreciated on
power Doppler as
depicted by the
absence of color
within the testicular
tissue



- Ultrasound may also demonstrate the twisted spermatic cord just superior to the testis and epididymis with the transducer oriented in a sagittal plane:
 - This can resemble a “whirlpool” [11].

(d) Key Points

- Once full torsion has occurred and there is no blood flow, infarction and loss of the testicle occur rapidly:
 - Salvage rates are approximately 100% at 3 h, 90% at 6 h, 50% at 12 h, and 10% at 24 h [11].

- Sonographic findings of testicular torsion are variable depending on the duration and extent of vascular compromise.
- Torsion remains a clinical diagnosis, and ultrasound cannot rule out torsion [11] especially in cases of partial torsion and intermittent torsion.
- If obtaining color Doppler flow is difficult, switch to power Doppler mode:
 - Set the gain to the highest setting that allows a distinct signal within vessels without surrounding artifact.
 - See Chap. 1 for more details on power Doppler.

Pediatric Key Points

- Use distraction to help the patient tolerate the exam.
- If available, use warm ultrasound gel to make the exam more comfortable.

References

1. SonoSim Ultrasound Training Solution [Video]. Santa Monica, CA: SonoSim Inc.; 2017.
2. Park NH, Oh HE, Park HJ, Park JY. Ultrasonography of normal and abnormal appendix in children. *World J Radiol.* 2011; 3(4):85–91. <https://www.ncbi.nlm.nih.gov/pmc/articles/PMC3084437/>. Accessed 17 Apr 2017.
3. Janitz E, Naffaa L, Rubin M, Ganapathy SS. Ultrasound evaluation for appendicitis focus on the pediatric population: a review of the literature. *J Am Osteopath Coll Radiol.* 2016; 5(1):5–14. <http://www.jaoacr.org/articles/ultrasound-evaluation-for-appendicitis-focus-on-the-pediatric-population-a-review-of-the-literature>. Accessed 17 Apr 2017.
4. Paspulati RM. Chapter 23: Ultrasonography of bowel disorders. In: Dogra V, Rubens D, editors. *Ultrasound secrets*. London: Elsevier Health Sciences; 2004. p. 207–11.

5. Chao A, Gharahbaghian L. Tips and tricks: ultrasound in the diagnosis of acute appendicitis. American College of Emergency Physicians website. April 2015. <https://www.acep.org/Content.aspx?id=101803>. Accessed 15 Apr 2017.
6. Old JL, Dusing RW, Yap W, Dirks J. Imaging for suspected appendicitis. *Am Fam Phys*. 2005; 71(1):71–78. <http://www.aafp.org/afp/2005/0101/p71.html>. Accessed 15 Apr 2017.
7. Costa Dias S, Swinson S, Torrao H, Goncalves L, Kurochka S, Vaz CP, Mendes V. Hypertrophic pyloric stenosis: tips and tricks for ultrasound diagnosis. *Insights Imag*. 2012; 3(3):247–250. <https://www.ncbi.nlm.nih.gov/pmc/articles/PMC3369120/>. Accessed 17 Apr 2017.
8. Hussain M. Sonographic diagnosis of infantile hypertrophic pyloric stenosis – use of simultaneous grey-scale and colour Doppler examination. *Int J Health Sci*. 2008; 2(2):134–140. <https://www.ncbi.nlm.nih.gov/pmc/articles/PMC3068743/> Accessed 17 Apr 2017.
9. Rohrschneider WK, Mittnacht H, Darge K, Troger J. Pyloric muscle in asymptomatic infants: sonographic evaluation and discrimination from idiopathic hypertrophic pyloric stenosis. *Pediatr Radiol*. 1998; 28(6):429–434. <http://link.springer.com/article/10.1007%2Fs002470050377> Accessed 17 Apr 2017.
10. Fischer JW, Sivitz AB, Abo AM. Chapter 20: Pediatric applications. In: Ma OJ, Mateer JR, Reardon RF, Joing SA, editors. *Emergency ultrasound*. 3rd ed. Beijing: McGraw-Hill Education; 2014. p. 587–630.
11. Goldenberg E, Gilbert BR. Chapter 4: Scrotal ultrasound. In: Gilbert BR, editor. *Ultrasound of the male genitalia*. New York: Springer; 2015. p. 75–124.
12. Adhikari S. Chapter 13: Testicular. In: Ma OJ, Mateer JR, Reardon RF, Joing SA, editors. *Emergency ultrasound*. 3rd ed. Beijing: McGraw-Hill Education; 2014. p. 353–80.

Chapter 18

Ultrasound-Guided Procedures

Ultrasound-Guided Peripheral Intravenous Access

(a) Procedure Indications

- Difficult intravenous (IV) access:
 - Risk factors for difficult IV access include:
 - Dialysis patient
 - Sickle cell patient
 - Diabetic patient
 - Chemotherapy patient
 - Dehydration
 - Obesity
 - Edema
 - IV drug abuse
 - History of difficult access
- Multiple previous attempts without successful IV placement

Electronic Supplementary Material The online version of this chapter (doi:[10.1007/978-3-319-68634-9_18](https://doi.org/10.1007/978-3-319-68634-9_18)) contains supplementary material, which is available to authorized users.

(b) Procedure Complications

- Infection, phlebitis, hematoma
- Extraluminal placement
- Dislodgement and infiltration

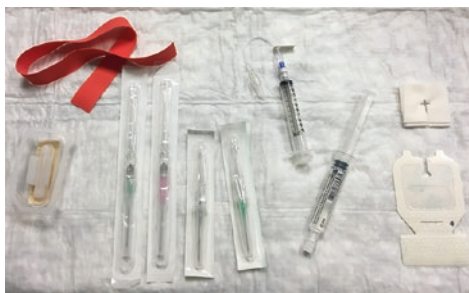(c) Transducer Selection

- Linear array

(d) Equipment

- IV needle with angiocatheter:
 - Long catheters are preferred if available.
 - Figure 18.1—Long and short IV catheters.
- Ultrasound gel:
 - Sterile surgical lubricant is recommended for deep vein access or when drawing blood cultures.
- Antiseptic swab:
 - Chlorhexidine is recommended for deep vein access.
- Tourniquet
- Luer lock adapter
- Saline flush
- Adhesive dressing
- Gloves

FIGURE 18.1 Long and short IV catheters. Peripheral IV setup with short catheters (1.6 cm) and long catheters (2.1 cm)



(e) Patient Position and Anatomical Landmarks

- The patient should be supine with their arm extended and externally rotated:
 - Figure 18.2—Patient position for PIV placement
- Blood vessels appear anechoic:
 - Veins are thin walled and compressible.
 - Arteries have thicker walls, typically pulsate, and are not compressible.
 - Figure 18.3—Ultrasound of the artery and vein.
- The brachial vein runs adjacent to the brachial artery and median nerve within the upper medial arm.
- The basilic vein runs medial to the brachial vessels.
- Figure 18.4—Brachial and basilic vein positions.

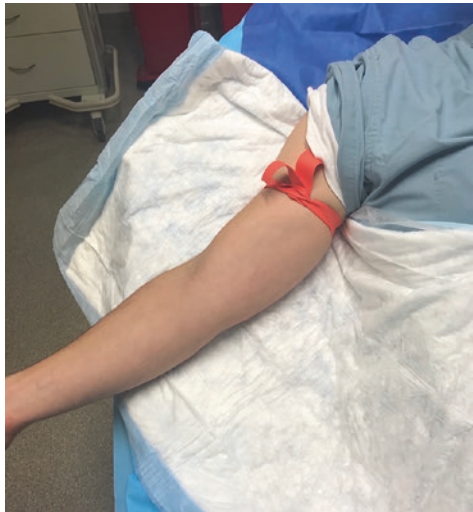

FIGURE 18.2
Patient position
for PIV place-
ment. Extend and
externally rotate
the patient's arm
when preparing for
ultrasound-guided
peripheral intrave-
nous catheter place-
ment

FIGURE 18.3 Ultra-
sound of the artery
and vein. Arteries are
circular with thick
walls and pulsate when
pressure is applied.
Veins have thinner
walls and will com-
press with pressure

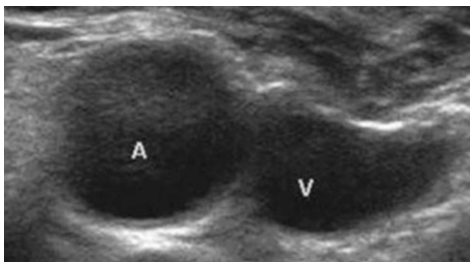
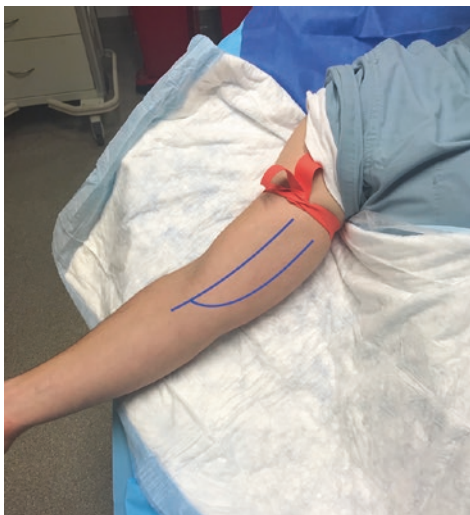

FIGURE 18.4 Bra-
chial and basilic vein
positions. Approxi-
mate location of
where the brachial
and basilic veins lie
within the arm



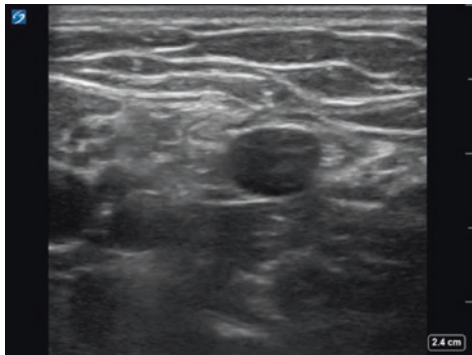
(f) Preparation

- Universal precautions should be utilized at all times.
- Apply tourniquet.
- Identify the vessel with ultrasound:
 - Success rate increases when the vein is less than 1.5 cm from the skin surface [1].
- Clean transducer with antiseptic cloth.
- Hold transducer with nondominant hand and place over the vessel:
 - Be careful not to apply pressure with the transducer as this will displace the vessel deeper within the arm and can compress the vein.
 - Figure 18.5—Transducer placement.

FIGURE 18.5 Transducer placement over the area of the basilic vein

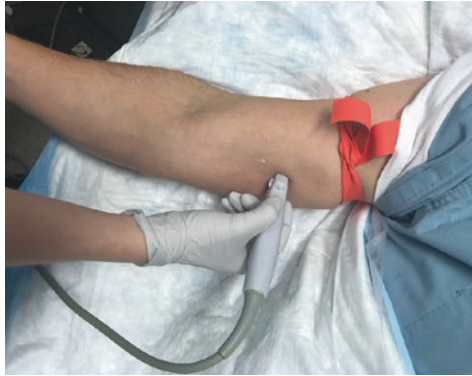

FIGURE 18.6 Ideal image for ultrasound-guided peripheral IV placement. Success rate increases when the target vessel is within 1–1.5 cm depth and in the center of the screen



- Adjust depth so that the vessel is in the center of the screen.
- Increase gain so that needle will show up bright on the screen.
- Figure 18.6—Ideal image for ultrasound-guided peripheral IV placement.

(g) Technique

- Two approaches (in-plane or out-of-plane):
 - Figure 18.7a—In-plane
 - Figure 18.7b—Out-of-plane

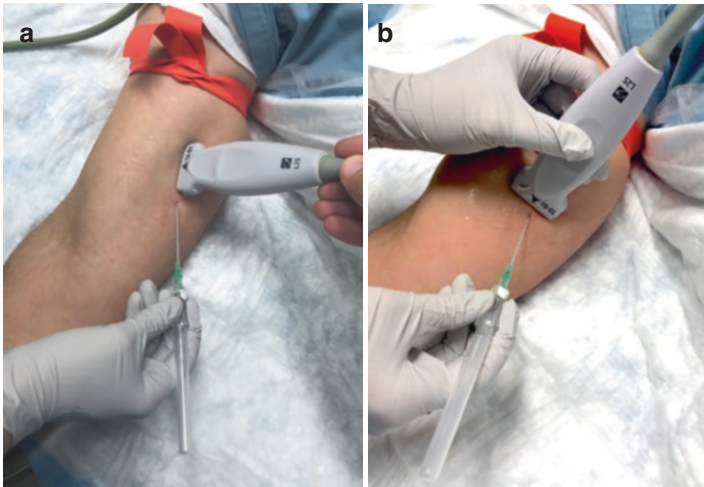


FIGURE 18.7 In-plane vs. out-of-plane. (a) Is an in-plane approach and (b) is an out-of-plane approach

- Out-of-plane:
 - The vein will be imaged using a transverse or cross-sectional view.
 - The transducer marker should point in the same direction on the patient as on the ultrasound monitor.
 - Identify the vein in cross section:

Make sure the vessel is compressible before attempting access.

- Insert the needle just distal to the transducer and enter the skin at a 15–30° angle:

Figure 18.8—Needle position relative to transducer

- Needle tip will be visualized in the subcutaneous tissue as a small bright white dot:

Figure 18.9—Needle tip

- As the needle is advanced closer to the vessel, the transducer should slide with the advancement to keep the needle tip visualized at all times.

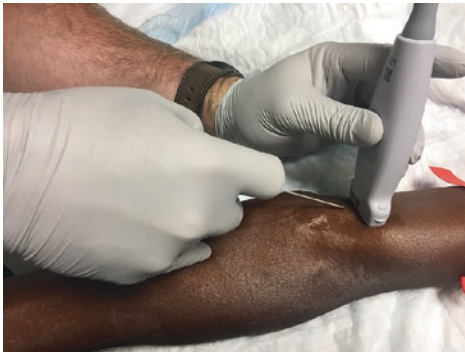

FIGURE 18.8 Transducer with needle entering into the skin. Place the transducer centrally over the vessel of choice with the nondominant hand. The dominant hand holds the needle with catheter at the center of the transducer ready to enter the skin at a 15–30° angle

FIGURE 18.9 Needle tip above the vessel. The needle tip is hyperechoic and seen just anterior to the vessel. Follow the needle tip through the layers of the skin and into the vein

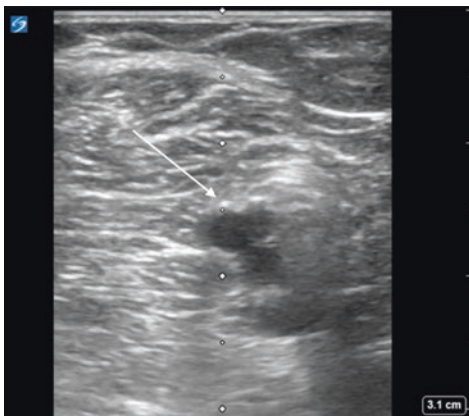
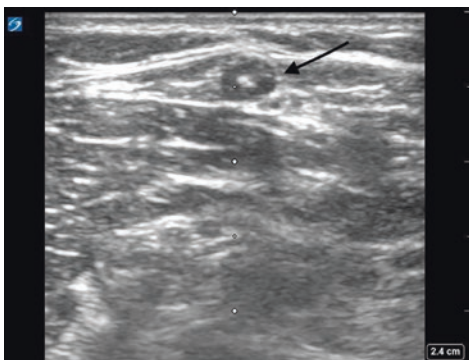


FIGURE 18.10 Needle in the vessel, out-of-plane. The hyperechoic needle tip is seen within the center of the vein



- Once the needle tip enters the vessel, drop the angle of the needle, and advance at least 2 mm to ensure the needle and the catheter are within the vessel lumen:

Figure 18.10—Needle in the vessel.

Remember: catheter tip sits back slightly from needle bevel so at the initial flash, it may not be far enough into the vessel to advance the catheter.

- Stabilize the needle and slowly advance the catheter until it is completely within the vessel lumen.

- Video 18.1—Out-of-plane peripheral IV placement.
 - In-plane:
 - The vein will be imaged using a longitudinal view of the vessel.
 - Place the transducer over the vessel with the marker pointed toward the needle:
- This can also be done with the marker pointed away from the needle.
- In this view, the vein will appear as an anechoic tube.
 - Insert the needle just distal to the leading edge of the transducer and enter the skin at a 15–30° angle:

Figure 18.11—Transducer and needle placement in long axis

- If the needle is directly under the transducer beam, it will reflect the entire needle, and you can visualize it along its course into the vessel:

Figure 18.12—Long axis of needle toward the vein

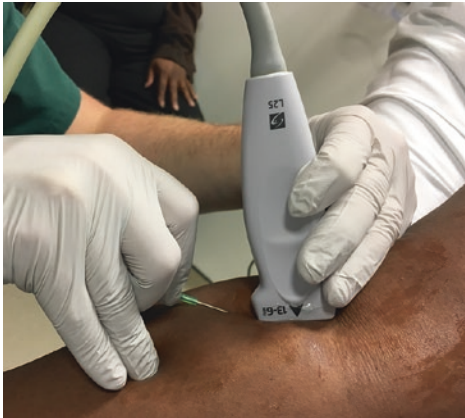

FIGURE 18.11 Transducer and needle placement in long axis. Place the transducer centrally over the vessel of choice with the nondominant hand. The dominant hand holds the needle with catheter at the center of the transducer ready to enter the skin at a 15–30° angle

FIGURE 18.12 Long axis of needle toward the vein. Advance the needle toward the vessel, ensuring to visualize the entire needle and vessel the entire time

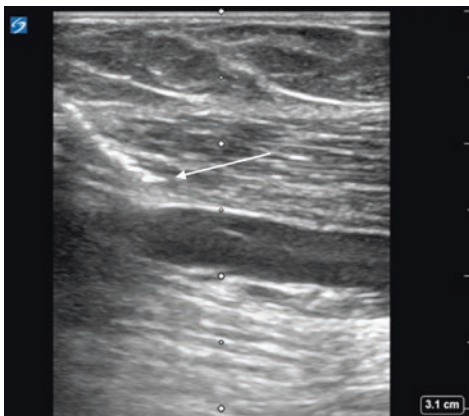
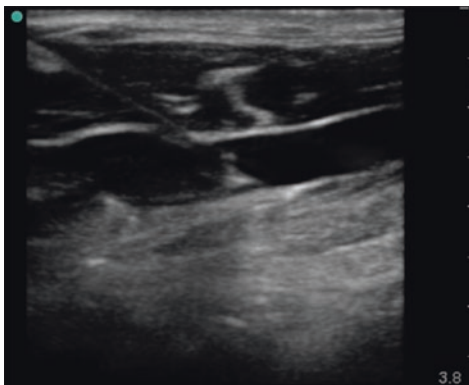


FIGURE 18.13 Needle in the vessel, in-plane. The in-plane approach allows for visualization of the entire needle as it enters the vein



- Once the needle tip enters the vessel, drop the angle, and advance 2 mm to ensure the needle and the catheter are within the vessel lumen:

Figure 18.13—Needle in the vessel, long axis. Remember: catheter tip sits back slightly from needle bevel so at the initial flash, it may not be far enough into the vessel to advance the catheter.

- Stabilize the needle and slowly advance the catheter until it is completely within the vessel lumen.
- Video 18.2—In-plane peripheral IV placement.
- Completing the procedure:
 - Remove the tourniquet.
 - Flush the luer lock and tubing with saline to remove air bubbles, attach it to the catheter, and secure it in place with adhesive dressing.
 - Flush the catheter once inside the vessel:

The IV should flush easily.

If there is resistance or pain with the flush, the catheter is likely outside the lumen of the vessel and needs to be removed.

(h) Key Points

- Ultrasound improves efficiency of IV access when blind landmark attempts have failed and decreases the number of needle sticks [2].
- Tissue movement can help localize the approximate location of the needle tip prior to actually visualizing the needle tip [2].

Central Venous Catheterization

1. Procedure Indications

- (a) Inability to obtain peripheral IV access
- (b) Emergent venous access
- (c) Hemodynamic resuscitation
- (d) Transvenous pacer placement
- (e) Use of caustic or vasoactive medications

2. Procedure Contraindications

- (a) Absolute:
 - Thrombus
 - Infection over the site of needle insertion

(b) Relative:

- Anticoagulation.
- Bleeding dyscrasia.
- The patient is unable to cooperate.

3. Procedure Complications

- (a) Arterial puncture
- (b) Bleeding or hematoma
- (c) Pneumothorax
- (d) Thrombosis
- (e) Infection
- (f) Nerve injury

4. Transducer Selection

- (a) Linear array

5. Equipment

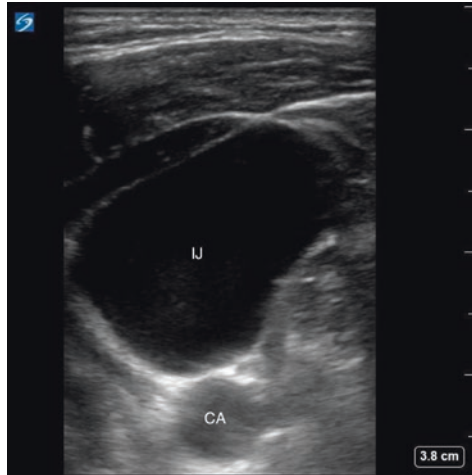
- (a) Central venous catheterization (CVC) kit
- (b) Sterile transducer cover
- (c) Sterile ultrasound gel
- (d) Antiseptic swab (chlorhexidine)
- (e) Sterile saline flush
- (f) Sterile personal protective equipment
- (g) Sterile adhesive dressing

6. Patient Position and Anatomical Landmarks

(a) Internal jugular (IJ) vein:

- The patient should be supine with their head turned slightly to the opposite side of insertion site.
- If the patient is hypovolemic, position the patient in Trendelenburg, or have them Valsalva to assist visualizing the IJ lumen.
- Figure 18.14—Internal jugular vein.
- Video 18.3—Internal jugular vein.

FIGURE 18.14
Internal jugular
vein on ultrasound.
The internal jugu-
lar (IJ) vein is a
larger vessel with
thin walls that
is compressible
under pressure. The
carotid artery (CA)
is seen below the
IJ vein



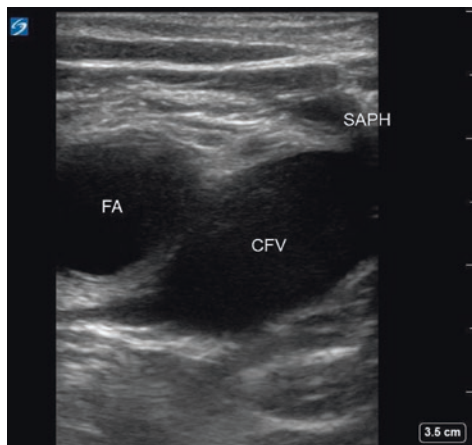
(b) Femoral vein:

- Place the transducer at the inguinal ligament, and slide distally until the thin-walled vein is visualized just medial to the femoral artery:
 - Alternatively, feel for a femoral pulse, and place the transducer over this site to locate the femoral vein.
- For patients who are hypovolemic, reverse Trendelenburg may assist to expand the vessel:
 - Use caution with collapsed veins as it is easier to penetrate the posterior wall.
- Figure 18.15—Femoral vein.
- Video 18.4—Femoral vein.

7. Preparation

- (a) Sterile personal protective equipment.
- (b) Identify the vessel using ultrasound.
- (c) Clean transducer with antiseptic cloth.
- (d) Sterilize the area of interest with chlorhexidine.

FIGURE 18.15 Femoral vein on ultrasound. The common femoral vein on the left is compressible under pressure, and the femoral artery on the right with a thick muscular wall is pulsatile under pressure



- (e) Apply sterile field to the patient.
- (f) Apply sterile transducer cover:
 - Assistance will be required for this.
- (g) Flush all three ports of the CVC with normal saline to remove air bubbles.

8. Technique

- (a) Ultrasound assistance for this procedure is similar to peripherally inserted catheters.
- (b) Hold transducer with nondominant hand and place over the vessel:
 - Be careful not to apply pressure with the transducer as this will displace the vessel deeper within the arm and can compress the vein.
 - Ask for assistance to adjust the depth so that the vessel is in the center of the screen and to adjust the gain.
- (c) Out-of-plane:
 - The vein will be imaged using a transverse or cross-sectional view.

- The transducer marker should point in the same direction on the patient as on the ultrasound monitor.
- Identify the vein in cross section:
 - Make sure the vessel is compressible before attempting access.
- Insert the needle about 1 cm from the transducer and enter the skin at a 30–45° angle.
- Needle tip will be visualized in the subcutaneous tissue as a small bright white, hyperechoic dot.
- While advancing the needle, constant back pressure should be applied to the syringe plunger.
- The transducer should slide concomitantly with needle advancement to keep the needle tip visualized at all times.
- Once the needle tip enters the vessel, drop the angle, and advance 2 mm to ensure the needle is within the vessel lumen.
- Under constant back pressure of the syringe plunger, blood will fill the syringe effortlessly once inside the lumen of the vessel.
- At this point, stabilize the needle to prevent movement out of the vessel.
- Videos 18.5 and 18.6—Out-of-plane central line placement.

(d) In-plane confirmation:

- Rotate the transducer 90° so that the marker is pointed toward the needle insertion site.
- Using an in-plane technique with the vessel in long axis, identify the needle tip within the vessel and compress the vessel to ensure line placement is within the vein and not the artery:
 - Video 18.7—In-plane central line needle
 - Video 18.8—In-plane wire confirmation
- Stabilize the needle, slowly advance the wire, and visualize it in the vessel lumen.

- The above steps should be performed before dilating the skin and placing the CVC.
- For complete CVC procedural details, please reference a procedural book or other resources as needed.

(e) Completing the procedure:

- Draw back and flush each line of the CVC to assess for adequate flow.
- Secure the CVC in place with a suture, and cover the area at the skin with a biodisc and sterile dressing.

(f) Confirmation of correct CVC placement:

- Traditional method:
 - Placement can be confirmed by ordering a STAT chest X-ray to evaluate the location of catheter tip.
 - Chest X-ray can also identify a pneumothorax for a CVC that was placed in the IJ (or subclavian) vein.
- Ultrasound method:
 - Place a phased array transducer in the subxiphoid region, and obtain a subxiphoid view of the heart:
See Chap. 3 for more detailed information.
 - Inject saline into the CVC, and watch for bubbles to reach the right atrium and ventricle; this is called rapid atrial swirl sign (RASS):

Figure 18.16a—Before RASS

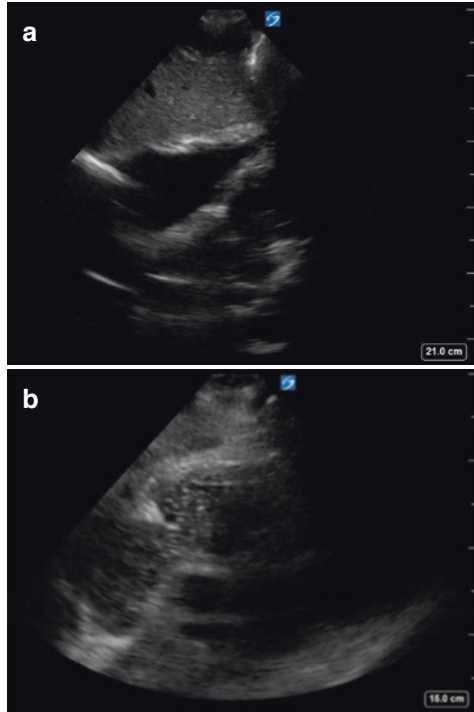
Figure 18.6b—RASS

Video 18.9—RASS

- If the catheter is appropriately located, the rapid atrial swirl should be seen within 2 s after flushing the CVC from an IJ or less than 3 s after flushing from a femoral CVC.
- Evaluate the ipsilateral lung for sliding lung to make sure there is no pneumothorax:

See Chap. 4 for more detailed information.

FIGURE 18.16 Bubbles in RA/RV—RASS. (a) Is taken before injection of the saline flush, and (b) shortly after injection of saline into the CVC, bubbles will reach the right atrium and ventricle; this is called rapid atrial swirl sign (RASS)



9. Key Points

(g) Anatomic variations occur among patients:

- The internal jugular vein and femoral vein can be seen anterior to the artery. In this situation, use caution to not penetrate the posterior wall of the vein as this can cause perforation of the artery.
- The internal jugular vein and femoral vein can also be seen posterior to the artery. In this situation, it is advised to look at the opposite side for a more optimal location.

(h) Ultrasound improves success rate of central venous access.

(i) Using ultrasound for CVC placement has become the standard of care.

Paracentesis

- Procedure Indications
 - Diagnostic:
Evaluation of the fluid for blood, ascites, stool, gastric contents, urine, malignancy
Diagnosis of infection, specifically spontaneous bacterial peritonitis (SBP)
 - Therapeutic:
Respiratory compromise secondary to ascites
Abdominal pain secondary to ascites
- Procedure Contraindications
 - Absolute:
Acute surgical abdomen
 - Relative:
Abdominal wall cellulitis
Dilated bowel
Distended bladder
Pregnancy
Intra-abdominal adhesions
Disseminated intravascular coagulation
- Procedure Complications
 - Blood vessel puncture
 - Bleeding and/or hematoma
 - Infection at site of insertion
 - Bowel perforation
 - Introduction of infection into the peritoneum causing bacterial peritonitis
- Transducer Selection
 - Curvilinear
- Equipment
 - Paracentesis kit
 - Sterile transducer cover

- Sterile ultrasound gel
- Antiseptic swab (chlorhexidine)
- Sterile personal protective equipment
- Patient Position and Anatomical Landmarks
 - Place the patient in a left lateral or right lateral decubitus position to form a gravity-dependent fluid collection.
 - Alternatively, if unable to tolerate, the patient can be in a supine position.
- Preparation
 - Universal precautions.
 - Clean transducer with antiseptic cloth and cover the transducer in a sterile sheath.
 - Hold the transducer with nondominant hand.
 - Adjust depth so that the bowel is identified in the far field:

Figure 18.17—Ascites with the bowel in far field

Video 18.10—Ascites with the bowel in far field

- Technique
 - Pre-scan the abdomen to evaluate for pockets of fluid.
 - Identify the location of the bowel, mesentery, and bladder.
 - Look in the lower quadrants for adhesions, dilated loops of the bowel, or overlying arterial structures.

FIGURE 18.17 Ascites with the bowel in far field. Ascites is anechoic and the bowels are seen in the far field

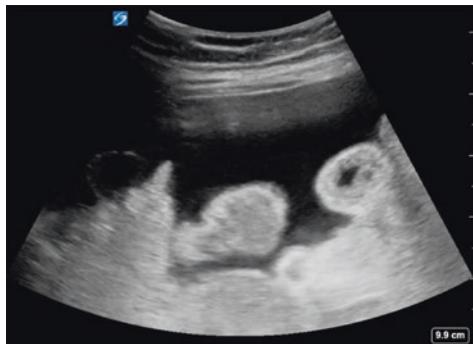
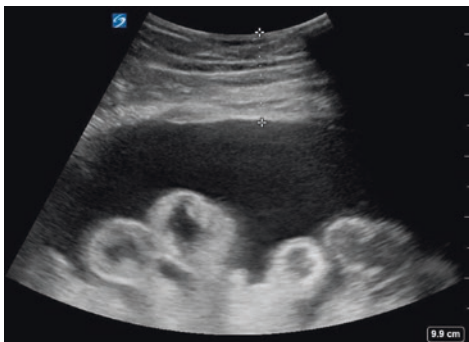
FIGURE 18.18 Skin measurement. Measurement of the thickness of the skin. This will help determine how long the needle will need to be get into the peritoneum



- Measure the thickness of the skin to help pick the correct needle length:

Figure 18.18—Skin measurement

- Identify the largest pocket of fluid.
- Note the depth of the pocket of fluid and how deep the bowel is from the insertion point.
- Choose a long enough needle that can penetrate through the thickness of the skin and penetrate the peritoneum.
- Once the largest pocket is identified, make a mark on the skin to locate the site of needle insertion.
- Using sterile precautions, use chlorhexidine to sterilize the skin, and drape the site of insertion with sterile towels or paper sheets.
- Using a small gauge needle, anesthetize the insertion site with lidocaine with or without epinephrine.
- Using ultrasound guidance to allow direct visualization, insert the needle and advance into the peritoneum:

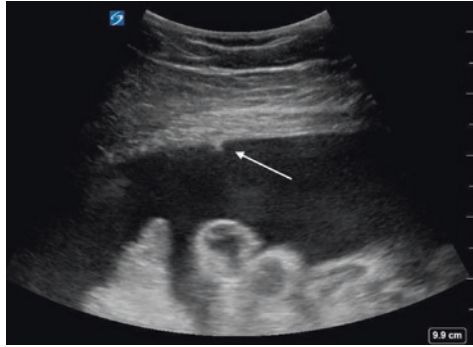
The needle will appear hyperechoic.

Figure 18.19—Needle in the peritoneum and ascites.

Video 18.11—Needle in the peritoneum and ascites.

- Once the needle is within the ascites, pull back on the plunger of the syringe and aspirate the fluid.

FIGURE 18.19 Needle in the peritoneum and ascites. Direct visualization of the needle entering into the peritoneum. The needle will appear hyperechoic



- Visualize the advancement of the catheter over the needle under ultrasound guidance.
- Connect the tubing to the sterile vacuum containers if performing a therapeutic paracentesis.
- **Completing the Procedure**
 - Apply gauze with pressure to the insertion site as ascites and blood may continue to ooze from the puncture site.
 - Label all collection tubes with patient identification.
 - Discard waste in the proper sanitary location.
- **Key Points**
 - Thrombocytopenia and elevated international normalized ratio (INR) are not contraindications to paracentesis [3].
 - The ultrasound-guided technique decreases the complication rate and improves first time success rate [4].
 - Success rates are best when the patient is in left or right lateral decubitus forming a gravity-dependent fluid collection.
 - Ultrasound improves efficiency of paracentesis when compared to blind landmark attempts.
 - All emergency physicians should be proficient at US-guided paracentesis.

Regional Anesthesia

(a) Also Known as Nerve Blocks

(b) Procedure Indications

- Pain control:
 - Femoral nerve: femoral neck fractures, femur fractures, patella injuries, thigh abscess incision and drainage [4]
 - Radial, median, and ulnar nerves: injuries to the hand [5]
 - Popliteal sciatic nerve: distal tibia and fibula fractures, foot fractures, and other injuries to the distal lower extremities [6]
 - Posterior tibial nerve: injuries to the sole of the foot [7]
- Alternative to procedural sedation

(c) Procedure Contraindications

- Cellulitis of the skin over the nerve of choice
- Allergy to the anesthetic
- Risk of the limb developing compartment syndrome
- Inability to adequately assess the area of nerve distribution secondary to the patient's mental capacity, such as with intoxication, altered mental status, or lack of cooperation
- Neurologic deficit that would decrease the ability to assess the effects of anesthesia pre- and postinjection

(d) Procedure Complications

- Infection
- Bleeding and/or hematoma
- Intraneural injection:
 - Paresthesia to the injected nerve

(e) Transducer Selection

- Linear array

(f) Equipment

- 22 gauge, 3 inch spinal needle
- 10 cc syringe
- Extension tubing
- 1% lidocaine
- Ultrasound gel:
 - Sterile surgical lubricant recommended
- Antiseptic swab:
 - Chlorhexidine recommended
- Eye protection
- Gloves

(g) Patient Position and Anatomical Landmarks

- Forearm:
 - The patient should be supine with their arm extended and supinated.
 - Radial nerve:

Located in the mid forearm.

Identify the radial artery at the wrist, and follow it proximally to the mid forearm where the nerve will be located lateral to the artery [5].

Also located above the elbow on the lateral aspect of the arm. Identify the humerus and look superior to it. The radial nerve is isolated in the fascia between muscles.

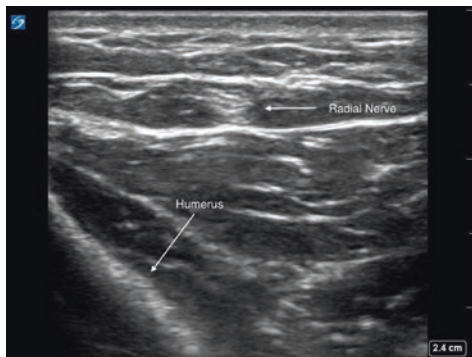


FIGURE 18.20
Radial nerve. The radial nerve isolated above the elbow on the lateral aspect of the arm

Figure 18.20—Radial nerve.

– Ulnar nerve:

Located in the proximal forearm

Medial to the ulnar artery; appears as a small hyperechoic triangle [4]

Figure 18.21—Ulnar nerve

– Median nerve:

Located in the middle of the mid forearm.

Identify the flexor tendons, and move the transducer proximally until the tendons disappear and median nerve remains [5].

Figure 18.22—Median nerve.

• Lower Extremity

– Femoral nerve:

- Patient position: extended, slightly abducted, and slightly externally rotated.
- The nerve travels under the inferior ligament lateral to the femoral artery [4].
- Place the transducer inferior to the inguinal ligament, identify the femoral vein and artery, and move the transducer laterally. Identify the femoral nerve and use an in-plane technique to perform nerve block.
- Figure 18.23—Femoral nerve.

FIGURE 18.21 Ulnar nerve. The ulnar nerve runs alongside the ulnar artery. It is commonly located on the medial side of the ulnar artery

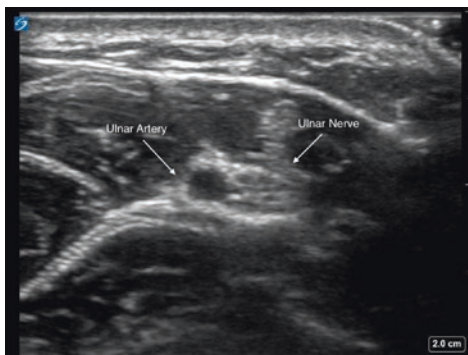


FIGURE 18.22
Median nerve. Iso-
lated in the middle
of the volar aspect
of the forearm.
Note there are no
surrounding blood
vessels

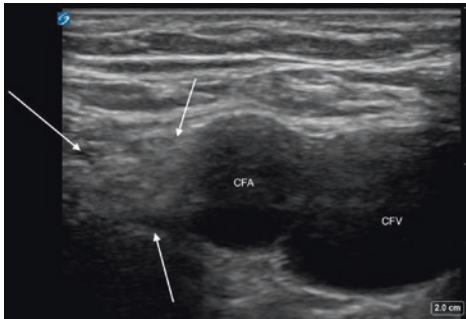
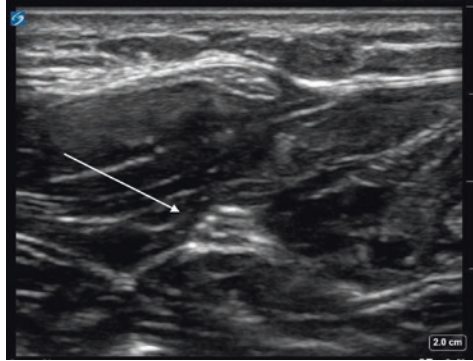
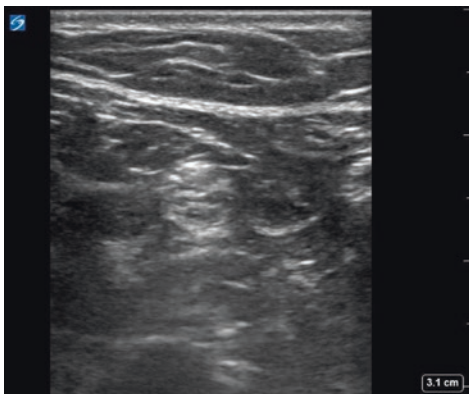


FIGURE 18.23 Femoral nerve. The neurovascular bundle consists of the femoral nerve surrounded by arrows, the common femoral artery (CFA), and the common femoral vein (CFV). Anatomically these structures are organized from lateral to medial, respectively

- Popliteal sciatic nerve:
 - Two position options:
 - Patient lying prone on the stretcher with leg straight
 - Patient lying supine with leg slightly flexed at the knee with the foot flat on the stretcher
 - Bifurcates into the tibial nerve and common peroneal nerve proximal to the popliteal fossa.
 - Identify the tibial nerve superficial and lateral to the popliteal vessels in the popliteal fossa [4],

FIGURE 18.24 Popliteal sciatic nerve. Large honeycomb-looking structure proximal to the popliteal fossa



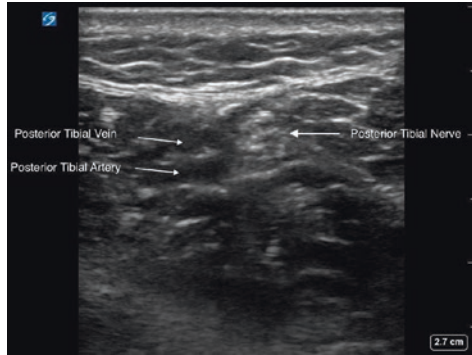
and move transducer proximally following the nerve until it merges with the common peroneal nerve to form the sciatic.

- Figure 18.24—Popliteal sciatic nerve.
- Posterior tibial nerve:
 - Patient position: the patient should lay supine with the hip externally rotated and knee slightly flexed exposing the medial foot.
 - The posterior tibial nerve travels posterior to the medial malleolus, usually just posterior to the posterior tibial artery [8].
 - Place the linear array transducer posterior to the medial malleolus parallel to the sole of the foot. Locate the posterior tibial artery and then identify the posterior tibial nerve posterior to this [7].
 - Figure 18.25—Posterior tibial nerve.

(h) Preparation

- Universal precautions.
- Identify the nerve using ultrasound.
- Flush the tubing with lidocaine to remove air bubbles.
- Clean transducer with antiseptic cloth.
- Hold the transducer with nondominant hand.

FIGURE 18.25 Posterior tibial nerve. The posterior tibial nerve travels posterior to the medial malleolus and just posterior to the posterior tibial artery and vein



- Adjust depth so that the nerve is in the center of the screen.

(i) Technique

- Two approaches (in-plane or out-of-plane):
 - Majority of nerve blocks should be performed with the needle in-plane for complete visualization of the needle during the procedure.
- In-plane:
 - The needle approaches the nerve in-plane with the transducer, but the nerve is in its short axis:

Nerves in cross section are hyperechoic with small hypoechoic internal echoes that resemble a honeycomb [9].

Figure 18.26—Normal nerve.

Figure 18.27—In-plane approach for nerve block.

- Hold the transducer over the nerve with the marker pointed toward the needle insertion site.
- Insert the needle just distal to the leading edge of the transducer, and enter the skin parallel to the transducer.
- If the needle is directly under the transducer beam, it will reflect the entire needle, and you can visualize it along its course toward the nerve:

FIGURE 18.26 Normal nerve on ultrasound. Nerves in cross section are hyperechoic with small hypoechoic internal echoes that resemble a honeycomb

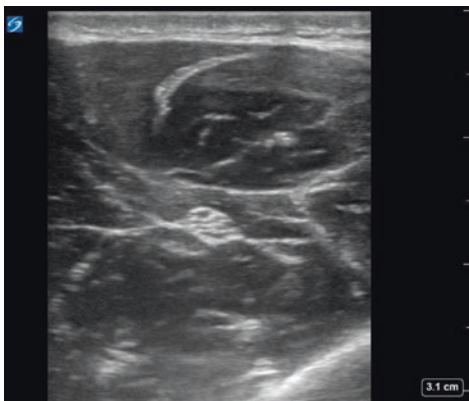
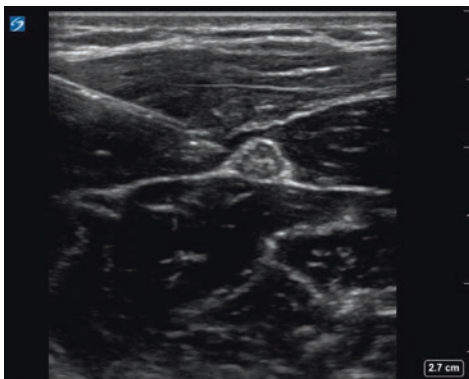

FIGURE 18.27 In-plane approach for nerve block. Visualization of the needle as it courses through the tissue toward the nerve



Video 18.12—Needle tip near the nerve

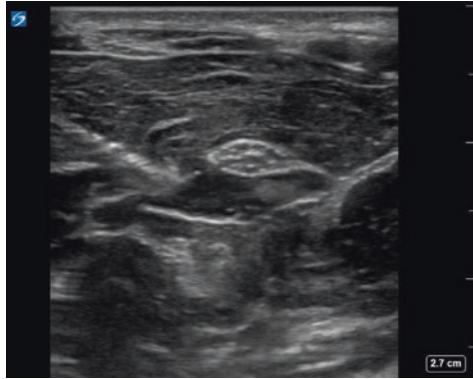
- Once you are near the nerve, inject a small amount of anesthetic:

Video 18.13—Injection of anesthetic around the nerve

- The plane of tissue around the nerve should expand with hypoechoic fluid:

Figure 18.28—Nerve with needle tip and anesthetic around it.

FIGURE 18.28 Needle tip with anesthetic around nerve injection. Anesthetic is ejected from the tip of the needle and hydrodissects around the nerve



If the nerve size enlarges, the needle may be intra-neural and should be retracted.

- Inject the lidocaine above and below the nerve, and attempt to create a bath of anesthetic around the nerve.
- Out-of-plane:
 - Nerves in cross section are hyperechoic with small hypoechoic internal echoes that resemble a honeycomb [9]:
 - See musculoskeletal chapter for more detailed information.
 - Adjacent blood vessels appear anechoic.
 - This view is only used in situations where the nerve is very superficial and an in-plane method is not feasible.
 - The transducer indicator should point in the same direction on the patient as on the ultrasound monitor.
 - Identify the nerve.
 - Insert the needle just distal to the transducer and enter the skin at a 30–45° angle.
 - Needle tip will be visualized in the subcutaneous tissue as a small bright white dot.

- As the needle is advanced closer to the nerve, the transducer should slide away to keep the needle tip visualized at all times.
- Once near the nerve, begin to inject anesthetic and watch the hypoechoic fluid bathe the nerve.
- Completing the procedure:
 - Reevaluate the patient's neurologic status post-procedure.
 - Educate the patient on the following:
 - Length of time nerve block is expected to last
 - Expected sensations when the block is wearing off
 - Precautions to take to prevent injury to the affected limb

(j) Key Points

- Great adjunct for pain control.
- Recognize and know how to treat local anesthetic systemic toxicity:
 - Avoiding bupivacaine and only using lidocaine with or without epinephrine will help reduce this risk.
- Visualize the needle tip at all times.
- The patient should be awake during the procedure so they can alert you if they feel pain/paresthesia during the procedure:
 - This will help reduce intraneural injections.
- If you have trouble identifying a nerve, follow its course:
 - If it is a tendon, it will eventually become a muscle and will move with flexion and extension of the muscle:
 - Tendons exhibit anisotropy, whereas nerves do not. See musculoskeletal chapter for more detailed information.

- To differentiate from a vascular structure, apply color Doppler over the area; if there is color signal, then the structure of interest is a blood vessel.
- Ultrasound-guided nerve blocks are a useful adjunct for pain control and a good alternative for conscious sedation in patients who are at high risk for complications.

Lumbar Puncture

(a) Procedure Indications

- Evaluation of cerebral spinal fluid (CSF) to identify meningitis and subarachnoid hemorrhage.
- Improve success of lumbar puncture (LP) in patients who are obese and infants and after multiple failed attempts by traditional technique.

(b) Procedure Contraindications

- Cellulitis of the skin over the insertion site
- Increased intracranial pressure

(c) Procedure Complications

- Infection
- Bleeding and/or hematoma
- Post-LP headache
- Damage to nerves or surrounding structures

(d) Transducer Selection

- Linear array for thin and pediatric patients
- Curvilinear for obese patients

(e) Equipment

- Sterile personal protective equipment
- Lumbar puncture kit
- 22 gauge spinal needle:
 - Longer needles for more obese patients

- 10 cc syringe
- 1% lidocaine
- Ultrasound gel:
 - Sterile surgical lubricant recommended
- Antiseptic swab:
 - Chlorhexidine recommended
- Sterile dressing surrounding the insertion site
- Face mask with eye protection
- Bouffant cap

(f) Patient Position and Anatomical Landmarks

- Lateral decubitus or sitting upright.
- In either position, the low back should be rounded and chest flexed anteriorly resembling a fetal position.

(g) Preparation

- Universal precautions.
- Clean transducer with antiseptic cloth.

(h) Technique

- Static approach:
 - The goal is to identify the interspinous space.
- Place the transducer over the pre-identified lumbar space using traditional landmarks with the marker pointed toward the patient's right:
 - Center the transducer over the spinous process:

The bony spinous process will appear as a hyper-echoic crescent with posterior shadowing [4].
Figure 18.29—Spinous process in transverse.
Video 18.14—Spinous process in transverse.
 - Mark the skin above and below the transducer to illustrate the midline [10]:

Figure 18.30—Midline LP marks

FIGURE 18.29 Spi-
nous process in
transverse. The
spinous process
appears as a hyper-
echoic crescent with
posterior shadowing

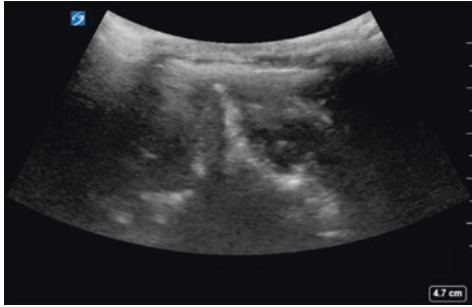
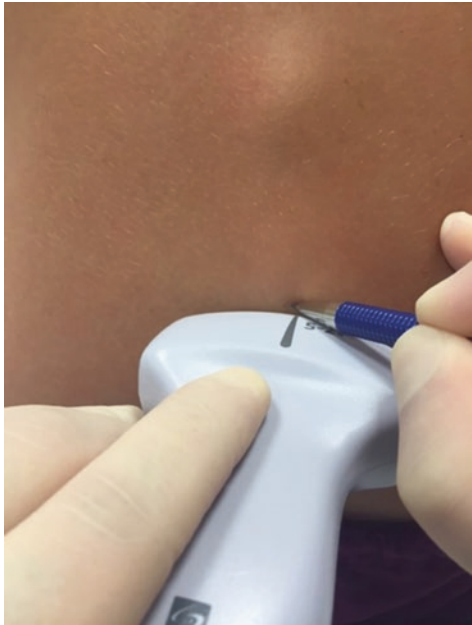

FIGURE 18.30 Mid-
line LP marks with
transducer in trans-
verse plane. Mark
the skin above and
below the trans-
ducer to help map
out the midline of
the spine



- Rotate the transducer into a sagittal plane with the marker pointed cephalad:
 - Center the interspinous space in the middle of the screen:

Figure 18.31—Spinous process in sagittal

Video 18.15—Spinous process in sagittal

FIGURE 18.31 Spi-
nous process in
sagittal view. The
interspinous space
is centered in the
middle of the screen

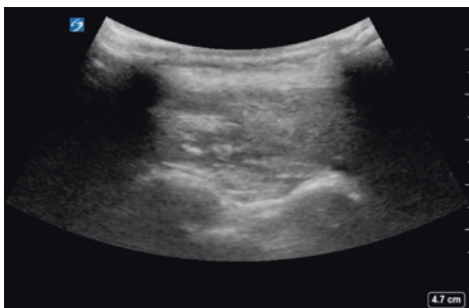
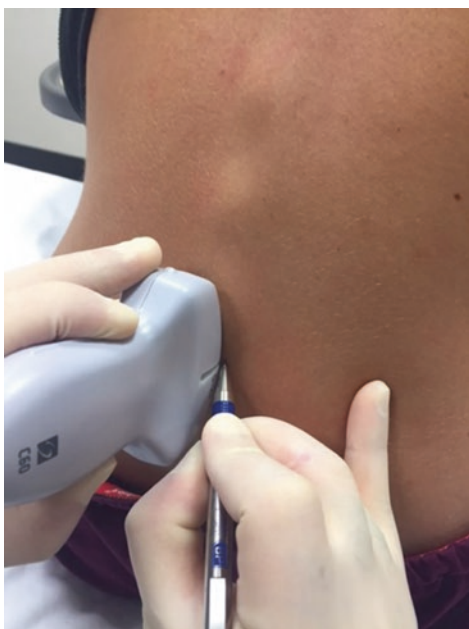
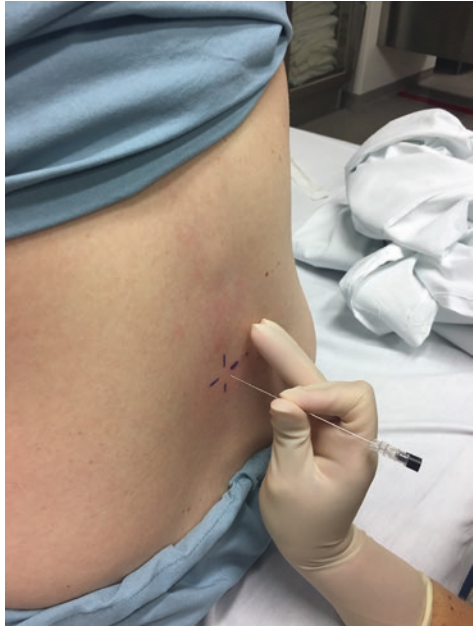
FIGURE 18.32 Sagit-
tal plane marks.
Mark the skin at the
middle of the
transducer



- Mark the skin at the middle of the transducer [4, 10]. This will mark the site for needle insertion:
 - Figure 18.32—Sagittal plane marks
 - Figure 18.33—Needle insertion mark on the skin
- Use ultrasound to assess the optimal angle to insert the needle and navigate between the spinous processes.

FIGURE 18.33 LP needle insertion site. Once the two planes have been mapped out from the sagittal and transverse views, the combined skin markings make a site for needle insertion. Note: this is a demonstration of how to use the landmarks, in reality the patient would have a sterile drape and the procedure is performed with universal precautions



- Assess the depth where the subarachnoid space is located to help choose the proper length of the spinal needle.
- After the insertion site has been identified and marked, place the transducer down, and sterilize the insertion site as directed in the LP kit.
- Once the area has been imaged and marked, the patient cannot be moved; any movement can change the underlying anatomy and trajectory.
- Proceed with performing the lumbar puncture in typical fashion.

(i) Completing the Procedure

- Remove the spinal needle and sterile dressing.
- Hold pressure.
- Place a bandage over the insertion site.

(j) Key Points

- A sterile transducer cover is not necessary because sterile technique is used after ultrasound localization.
- Keep the patient still after the area has been marked to avoid distortion of pre-identified landmarks.
- Using ultrasound decreases the rate of failed lumbar punctures, saves time, is easy to use, and decreases the rate of post-lumbar puncture complications [4].

References

1. McNamee J, Jeong J, Patel N. 10 Tips for Ultrasound-Guided Peripheral Venous Access. ACEP Now website. <http://www.acepnow.com/article/10-tips-ultrasound-guided-peripheral-venous-access/4/>. December 17 2014. Accessed 27 Apr 2017.
2. Rose JS, Bair AE, Parikh AK. Chapter 21: Vascular access. In: Ma OJ, Mateer JR, Reardon RF, Joing SA, editors. Emergency ultrasound. 3rd ed. Beijing: McGraw-Hill Education; 2014. p. 631–44.
3. Runyon BA, Chopra S, Robson KM. Diagnostic and therapeutic abdominal paracentesis. UpToDate website. <https://www.uptodate.com/contents/diagnostic-and-therapeutic-abdominal-paracentesis>. Updated September 23, 2015. Accessed 27 Apr 2017.
4. Mallin M, Dawson M. Introduction to bedside ultrasound: volume 2. Lexington, KY: Emergency Ultrasound Solutions; 2013. iBook. <https://itun.es/us/ueELM.1>.
5. Sohoni A, Herring A, Stone M, Nagdev A. Focus on: ultrasound-guided forearm nerve blocks. ACEP News website. October

2011. <https://www.acep.org/Content.aspx?id=82259>. Accessed 27 Apr 2017.
6. Johnson B, Lovallo E, Mantuani D, Nagdev A. How to perform ultrasound-guided distal sciatic nerve block in the popliteal fossa. ACEP Now website. June 15, 2015. <http://www.acepnow.com/article/how-to-perform-ultrasound-guided-distal-sciatic-nerve-block-in-the-popliteal-fossa/>. Accessed 27 Apr 2017.
 7. Bunting LV. Posterior tibial nerve block—ultrasound-guided ankle blocks. Sonoguide website. 2008. http://www.sonoguide.com/posterior_tibial_nerve_block.html. Accessed 27 Apr 2017.
 8. Herring AA, Miss J, Nagdev A. Ultrasound-guided posterior tibial nerve block. ACEP Now website. December 1, 2012. <http://www.acepnow.com/article/ultrasound-guided-posterior-tibial-nerve-block/2/>. Accessed 27 Apr 2017.
 9. Lawande AD, Warriar SS, Joshi MS. Role of ultrasound in evaluation of peripheral nerves. *Indian J Radiol Imaging*. 2014; 24(3):254-258. <https://www.ncbi.nlm.nih.gov/pmc/articles/PMC4126140/>. Accessed 27 Apr 2017.
 10. Dewitz A, Jones RA, Resnick JG, Stone MB. Chapter 22: Additional ultrasound-guided procedures. In: Ma OJ, Mateer JR, Reardon RF, Joing SA, editors. *Emergency ultrasound*. 3rd ed. Beijing: McGraw-Hill Education; 2014. p. 645–708.

Index

A

- Abdominal aortic aneurysm
 - anatomy, 136–138
 - clinical applications and indications, 135
 - image acquisition
 - patient position, 139
 - standard exam views, 139–142
 - transducer selection, 138
 - pathology
 - abdominal aortic aneurysm, 142
 - abdominal aortic dissection, 144–146
- Abdominal aortic dissection
 - with color Doppler, 145–146
 - dissection flap, 144
 - in inner wall of artery, 144
- Abdominal ultrasound
 - anatomy, 186
 - clinical application and indications, 185
 - image acquisition
 - patient position and procedure, 187
 - standard exam views, 187–188
 - transducer selection, 186
 - pathology
 - appendicitis, 188–190
 - ascites, 193
 - bowel wall thickening, 195
 - intussusception, 192
 - large bowel obstruction, 192
 - pneumoperitoneum, 193–194
 - small bowel obstruction, 190–191
- Abdominal wall, 186
- Abscess, 271–272
- Adnexa, 214
- Adnexal mass, 230
- Anechoic lumen, 136
- Aorta measurement
 - distal, 142
 - proximal, 141
- Aortic hiatus, 136
- Appendicitis
 - appendicolith, 188, 190
 - hypoechoic mass, 190
 - image acquisition, 294
 - indications, 293
 - inflammation of the appendix, 188
 - pathology, 295–297
 - periappendiceal fluid collection, 189
 - target sign appearance, 188, 189
- Appendicolith, 189–190
- Appendix, 186
- Appendix testis, 241
- Appendix testis torsion, 248–249

Artifact

- edge artifact, 16, 17
- to identify pathologic findings, 13
- machine errors, 13
- mirror artifact, 16, 17
- posterior acoustic enhancement, 15
- posterior acoustic shadowing, 14
- reverberation artifact, 15, 16
- sound absorption or redirection, 13

Ascites, 193**B**

- Barcode sign, 39
- Bifurcation, with superficial and deep femoral veins, 260

Biliary ultrasound

- anatomy, 150
- clinical applications and indications, 149
- common bile duct pathology
 - choledocholithiasis, 163
 - dilation, 162
- imaging overview
 - patient position, 150–151
 - standard exam views, 151–156
 - transducer selection, 150

Bladder

- clinical applications and indications, 167–168
- genitourinary anatomy, 168
- image acquisition
 - bladder exam views, 171–175
 - left kidney exam views, 170–171
 - patient position, 169
 - right kidney exam views, 169–170
 - transducer selection, 169

- volume measurement in sagittal, 175

- volume measurement in transverse, 175

pathology

- bladder hematoma, 181, 182
- bladder mass, 181
- prostate enlargement, 182–183
- thickened bladder wall, 181–182

- in sagittal view, 200–201

Bone

- anatomy, 128–31
- fractures, 129
- standard exam views, 128

C**Cardiac tamponade, 40–42****Cardiac ultrasound****anatomy**

- atria, 48
- central circulation, 48
- congenital bicuspid valve, 48
- four-chambered structure, 48
- left ventricle, 48
- mitral valve, 48
- pulmonary valve, 49
- right ventricle, 48
- tricuspid valve, 49

- apical four-chamber, 53–55

- apical two-chamber, 55

of cardiomyopathies

- dilated cardiomyopathy, 61
- hypertrophic cardiomyopathy, 61–62
- hypertrophic obstructive cardiomyopathy, 62–63
- Takotsubo cardiomyopathy, 62, 63

- clinical applications and indications, 47–48

- global left ventricular systolic
 - function measurement
 - endocardial wall motion
 - evaluation, 60
 - left ventricular cavity size
 - evaluation, 60
 - mitral annulus movement
 - evaluation, 60
 - mitral valve movement
 - evaluation, 60
 - quantitative scale,
 - 59–60
- image acquisition, 49
- inferior vena cava
 - anatomy, 57–59
 - transducer placement, 57
- parasternal long axis
 - anatomy, 50–51
 - transducer placement,
 - 49–50
- parasternal short axis
 - anatomy, 51–53
 - transducer placement, 51
- pericardial effusion
 - accumulation of fluid,
 - 66, 67
 - appears as hypoechoic
 - stripe, 66
 - epicardial fat pad, 66, 67
 - in parasternal long
 - view, 67
 - pericardial diffusion
 - grading, 68–69
 - and tamponade, 69–71
- right ventricular dilation
 - apical four-chamber,
 - 64–65
 - apical four-chamber,
 - evaluation, 64
 - to evaluate enlargement
 - or strain, 64
 - inferior vena cava
 - (IVC), 65
 - parasternal long,
 - evaluation, 64, 65
 - parasternal short,
 - evaluation, 64, 65
- subxiphoid
 - anatomy, 56–57
 - transducer placement, 56
- Cardiomyopathies
 - dilated cardiomyopathy, 61
 - hypertrophic cardiomyopathy,
 - 61–62
 - hypertrophic obstructive
 - cardiomyopathy, 62–63
 - Takotsubo cardiomyopathy,
 - 62, 63
- Carotid artery
 - anatomy, 104
 - carotid artery dissection, 105
 - clinical applications and
 - indications, 104
 - patient position, 104
 - standard exam views, 104–105
 - transducer selection, 104
- Carpal tunnel syndrome, 131–132
- Celiac trunk, 137
- Cellulitis, 270–271
- Central retinal artery
 - occlusion, 288
- Central venous catheterization
 (CVC)
 - anatomical landmarks,
 - 320–322
 - after completed
 - procedure, 324
 - complications, 320
 - contraindications, 319–320
 - equipment, 320
 - indications, 319
 - patient position, 320–322
 - preparation, 321–322
 - technique
 - in-plane, 323–324
 - out-of-plane, 322–323
 - traditional method, 324
 - transducer selection, 320
 - ultrasound method, 324–325
- Cholecystitis
 - acalculous, 160
 - acute, 159
 - chronic, 160
 - emphysematous, 161

- Cholelithiasis, 163
- Cholelithiasis
 - irregular shadowing, 157
 - presence of stone in
 - gallbladder, 156
 - stones appear as hyperechoic, 156
 - wall echo shadow (WES)
 - sign, 157, 158
- Common bile duct (CBD), 150
- Common femoral vein (CFV), 256, 258–259
- Complex ovarian cyst, 205–206
- Cornual ectopic pregnancy, 232–233
- Curvilinear transducer, 8, 199
 - obstetric ultrasound, 214–215

D

- Deep venous thrombosis (DVT)
 - acute thrombus, 263–264
 - blood clot, 262
 - chronic thrombus, 263–264
 - compressibility, 262
 - noncompressible vein, 262, 263
- Dilated cardiomyopathy, 61
- Double decidual sac, 221–222

E

- Echocardiography Cardiac
 - ultrasound
- Ectopic pregnancy
 - adnexal mass, 230
 - cornual, 232–233
 - interstitial, 230–232
 - pelvic free fluid, 227–229
 - pseudogestational sac, 228
 - sagittal transvaginal image, 227–228
 - tubal ring sign, 229–230
- Edge artifact, 16, 17
- Endocavitary transducer, 10, 199, 215
- Epicardial fat, 66

- Epicardial fat pad, 66, 67
- Epididymitis, 249
- Extended focussed assessment
 - sonography for trauma (EFAST)
 - anatomy
 - fluid accumulation within pericardium, 22
 - fluid accumulation within pleural cavity, 22
 - free intraperitoneal fluid, 21–22
 - inferior vena cava (IVC), 21
 - left upper quadrant (LUQ), 20
 - lung apices, 21
 - pelvis, 20
 - right upper quadrant (RUQ), 20
 - subxiphoid, 20–21
 - clinical applications and indications, 19
 - image acquisition
 - bilateral lung apices, 29, 31
 - inferior vena cava, 33
 - left upper quadrant (LUQ), 24–26
 - patient position, 22
 - pelvis, 26–28
 - right upper quadrant (RUQ), 22–24
 - subxiphoid, 28–30
 - transducer selection, 22
 - M-mode spike position, 32
 - pathology
 - cardiac tamponade, 40–42
 - hemopericardium or pericardial effusion, 38–40
 - hemoperitoneum, 34–35
 - hemothorax or pleural effusion, 35–38
 - pneumothorax, 37–38
 - Positive EFAST bladder, 36, 37
 - transducer placement
 - lungs, 31

F

- Femoral nerve, 332, 333
- Femoral vein, 321, 322
- Fetal demise, 233–234
- Fetal heart rate, 223–224
- Fetal pole, 223
- Forearm, 331–332
- Fournier's gangrene, 250–251
- Free intraperitoneal pelvic fluid, 226–227

G

- Gallbladder, 150
 - with edge artifact:, 17
 - with PAE, 15
 - pathology
 - acalculous cholecystitis, 160
 - acute cholecystitis, 159
 - biliary sludge, 158–159
 - cholelithiasis, 156–158
 - chronic cholecystitis, 160
 - emphysematous cholecystitis, 161
 - gallbladder polyps, 162
- Gallstones
 - irregular shadowing of bowel gas, 157
 - produce clean shadowing, 157
 - wall echo shadow (WES) sign, 157, 158
- Gestational age measurements, 224
 - biparietal diameter, 225–226
 - crown-rump length, 225
- Gestational sac, 220–221
- Gynecologic ultrasound
 - anatomy, 198
 - clinical application, 197
 - image acquisition
 - patient position, 200
 - standard exam views, 200–203
 - transducer selection, 199–200

indications, 197

pathology

- complex cyst, 205–206
- intrauterine device placement, 209
- ovarian torsion, 206–207
- polycystic ovarian syndrome, 205
- simple cyst, 204
- tubo-ovarian abscess, 207–209
- uterine fibroids, 209–211

H

- Head and neck ultrasound
 - thyroid
 - anatomy, 95
 - clinical applications, 95
 - pathology, 99
 - patient position, 95
 - standard exam views, 95–99
 - thyroid cyst, 100
 - thyroiditis, 100
 - transducer selection, 95
 - tonsillar
 - anatomy, 92
 - clinical applications and indications, 91
 - Endocavitary transducer in mouth, 92
 - hold tongue with tongue depressor, 95
 - limited ability to open mouth, 95
 - patient position, 92
 - peritonsillar abscess, 93–94
 - transducer selection, 92
 - tracheal
 - anatomy, 100–101
 - clinical applications and indications, 100

Head and neck ultrasound (*cont.*)
 endotracheal tube
 placement, 103
 endotracheal tube
 placement,
 confirmation of, 103
 esophageal intubation, 104
 and esophagus
 identification, 103
 patient position, 101
 standard exam views,
 101–102
 transducer selection, 101
 Hematoma, 273–274
 Hemopericardium/pericardial
 effusion, 38–40
 Hemoperitoneum, 34–35
 Hemothorax or pleural effusion,
 35–38
 Heterotopic pregnancy, 233
 Hydrocele, 241–243
 Hydronephrosis
 mild, 176
 moderate, 177
 severe, 177
 Hypertrophic cardiomyopathy,
 61–62
 Hypertrophic obstructive
 cardiomyopathy, 62–63

I
 Iliac arteries, 138
 Inferior vena cava
 transducer placement, 57
 ultrasound anatomy, 57–59
 Internal jugular (IJ) vein,
 320–321
 Interstitial ectopic pregnancy,
 230–232
 Interstitial line sign, 232
 Intraocular anatomy, 280
 Intrauterine device (IUD)
 placement, 209–210
 Intrauterine pregnancy
 evaluation
 double decidual sac, 221–222
 fetal heart rate, 223–224

fetal pole, 223
 gestational age
 measurements, 224–226
 gestational sac, 220–221
 yolk sac, 222–223
 Intussusception, 192, 298–299

K

Keyboard sign, 191
 Knee joint
 anatomy, 126
 pathology
 knee effusion, 128
 rupture, 124
 standard exam views, 126

L

Large bowel, 186
 Large bowel obstruction, 192
 Large pleura effusion, 38
 Left upper quadrant (LUQ),
 20, 24–26
 Lens dislocation, 286, 287
 Linear array transducer, 8, 9
 Linear transducer, 215
 Lower extremity venous, 253
 anatomy, 254–255
 clinical application/
 indications, 254
 image acquisition
 patient position, 255–257
 standard exam views, 256–261
 transducer selection, 255
 pathology
 deep venous thrombosis,
 262–264
 superficial venous
 thrombosis, 264
 Lumbar puncture
 anatomical landmarks, 340
 after completed procedure, 343
 complications, 339
 contraindications, 339
 equipment, 339–340
 indications, 339
 patient position, 340

- preparation, 340
 - technique, 340–343
 - transducer selection, 339
- M**
- Median nerve, 332, 333
 - Mirror artifact, 16, 17
 - Molar pregnancy, 234
 - Musculoskeletal ultrasound
 - anatomy
 - bone, 114
 - knee joint, 115
 - ligaments, 114
 - nerves, 114–115
 - shoulder joint, 115
 - tendons, 114
 - clinical applications and indications, 113
 - image acquisition
 - patient position, 115–119
 - transducer selection, 115
- N**
- Necrotizing fasciitis, 272–273
 - Nephrolithiasis
 - posterior acoustic shadowing, 178
 - rarely stones in urinary tract, 178
 - stone within kidney, 177
 - Nerves
 - pathology, 131–132
 - standard exam views, 130
 - ultrasound anatomy, 130
- O**
- Obstetric ultrasound
 - anatomy, 214
 - clinical application, 213
 - image acquisition
 - patient position, 215
 - transabdominal
 - ultrasound standard exam views, 215–216
 - transducer selection, 214–215
 - transvaginal ultrasound
 - standard exam views, 216–220
 - indications, 213
 - intrauterine pregnancy
 - evaluation
 - double decidual sac, 221–222
 - fetal heart rate, 223–224
 - fetal pole, 223
 - gestational age
 - measurements, 224–226
 - gestational sac, 220–221
 - yolk sac, 222–223
 - pathology
 - cornual ectopic pregnancy, 232–233
 - ectopic pregnancy, 227–230
 - fetal demise, 233–234
 - free intraperitoneal
 - pelvic fluid, 226–227
 - heterotopic pregnancy, 233
 - interstitial ectopic
 - pregnancy, 230–232
 - molar pregnancy, 234
 - Ocular ultrasound
 - anatomy, 280
 - clinical application and indications, 279–280
 - image acquisition
 - patient position, 281
 - standard exam views, 281–283
 - transducer selection, 281
 - pathology
 - central retinal artery
 - occlusion, 288
 - foreign body, 288
 - increased optic nerve
 - sheath diameter, 288–290
 - lens dislocation, 286, 287
 - posterior vitreous
 - detachment, 285–286
 - retinal detachment, 284–285

- Ocular ultrasound (*cont.*)
 retrobulbar hematoma, 286, 287
 vitreous hemorrhage, 283–284
- Optic nerve sheath diameter (ONSD), 283
- Orchitis, 250
- Ovarian torsion, 206–207
 with color Doppler, 207–208
 with power Doppler, 209
- P**
- Paracentesis
 anatomical landmarks, 327
 after completed procedure, 329
 complications, 326
 contraindications, 326
 equipment, 326–327
 indications, 326
 patient position, 327
 preparation, 327
 technique, 327–329
 transducer selection, 326
- Parenchymal stone, 179
- Pediatric ultrasound
 appendicitis
 image acquisition, 294
 indications, 293
 pathology, 295–297
 intussusception, 298–299
 pyloric stenosis
 image acquisition, 300, 301
 indications, 300
 pathology, 301–302
 testicular torsion
 image acquisition, 303–304
 indications, 303
 pathology, 304–306
- Pelvic free fluid, 228–229
- Pericardial effusion
 accumulation of fluid, 66, 67
 appears as hypochoic stripe, 66
 epicardial fat pad, 66, 67
 in parasternal long view, 67
 pericardial diffusion grading, 68–69
 and tamponade, 69–71
- Peripheral intravenous access
 anatomical landmarks, 311–312
 after completed procedure, 319
 complications, 310
 equipment, 310
 indications, 309
 patient position, 311–312
 preparation, 312–313
 technique
 in-plane, 314, 317–319
 out-of-plane, 314–317
 transducer selection, 310
- Phased array transducer, 8, 9
- Pleural effusion, 87–88
- Pneumonia, 86–87
- Pneumoperitoneum, 193–194
- Pneumothorax, 37–38, 84–85
- Polycystic ovarian syndrome, 205
- Popliteal sciatic nerve, 334–335
- Popliteal vein, 261
- Posterior tibial nerve, 334, 335
- Posterior vitreous detachment (PVD), 285–286
- Prostate, 173
- Pseudogestational sac, 228
- Pulmonary contusion, 87
- Pulmonary edema, 85–86
- Pyloric stenosis
 image acquisition, 300, 301
 indications, 300
 pathology, 301–302
- R**
- Regional anesthesia
 anatomical landmarks, 331–335
 after completed procedure, 338
 complications, 330
 contraindications, 330
 equipment, 331

- indications, 330
- patient position, 331–335
- preparation, 334–335
- technique
 - in-plane, 335–337
 - out-of-plane, 337–338
- transducer selection, 330
- Renal arteries, 138
- Renal cyst
 - abnormal cystic structure, 179
 - anechoic fluid collection, 179
 - polycystic kidney disease, 180
 - simple cyst, 180
- Renal ultrasound
 - clinical applications and indications, 167–168
- cyst
 - abnormal cystic structure, 179
 - anechoic fluid collection, 179
 - polycystic kidney disease, 180
 - simple cyst, 180
- genitourinary anatomy, 168
- image acquisition
 - bladder exam views, 171–175
 - left kidney exam views, 170–171
 - patient position, 169
 - right kidney exam views, 169–170
 - transducer selection, 169
 - volume measurement in sagittal, 175
 - volume measurement in transverse, 175
- pathology
 - hydronephrosis, 176–177
 - hydroureter, 177, 178
 - nephrolithiasis, 177–179
 - parenchymal stone, 179
 - stone within renal pelvis, 179
 - renal mass, 180
- Retinal detachment (RD), 284–285
- Retrobulbar hematoma, 286, 287
- Reverberation artifact, 15, 16, 76, 78
- Right atrial systolic collapse, 70
- Right upper quadrant (RUQ), 20–24
- Right ventricular diastolic collapse, 71
- Right ventricular dilation
 - apical four-chamber, 64–65
 - to evaluate enlargement or strain, 64
 - inferior vena cava (IVC), 65
 - parasternal, evaluation, 64, 65
- S**
- Sagittal aorta, 139
- Salivary gland
 - anatomy
 - parotid gland, 105–106
 - submandibular gland, 106
 - clinical applications and indications, 105
 - patient position, 106–107
 - salivary gland pathology
 - salivary gland mass, 110
 - sialadenitis, 110
 - sialolithiasis, 109
 - standard exam views
 - parotid gland, 107–108
 - submandibular gland, 108–109
 - transducer selection, 106
- Shoulder joint
 - anatomy, 120
 - shoulder pathology, 120–121
 - standard exam views, 119–120
- Simple ovarian cyst, 204
- Skin and soft tissue
 - anatomy, 268
 - clinical application and indications, 267
 - image acquisition
 - patient position, 268
 - standard exam views, 268–270
 - transducer selection, 268

- Skin and soft tissue (*cont.*)
 pathology
 abscess, 271–272
 cellulitis, 270–271
 foreign body, 274–275
 hematoma, 273–274
 necrotizing fasciitis, 272–273
- Small bowel, 186
- Small bowel obstruction
 collapsed, compressible
 bowel, 190
 fluid and echogenic material, 191
 keyboard sign, 191
 mechanical blockage of food and liquid, 190
 noncompressible small bowel, 191
- Subxiphoid, 20–21, 28, 30
 anatomy, 56–57
 transducer placement, 56
- Superficial ocular anatomy, 280
- Superficial venous
 thrombosis, 264
- Superior mesenteric artery (SMA), 137
- T**
- Takotsubo cardiomyopathy, 62, 63
- Tamponade
 causes hypotension and shock, 70
 fluid within pericardium generate excessive pressure, 69
 parasternal long view, 69
 right atrial systolic collapse, 70
 right ventricular diastolic collapse, 71
- Tendons
 pathology
 flexor tenosynovitis, 125–126
 rupture, 124
 standard exam views, 121–122
 ultrasound anatomy, 122–124
- Testicular neoplasm, 250
- Testicular torsion
 image acquisition, 303–304
 indications, 303
 pathology, 304–306
- Testicular ultrasound
 anatomy, 238
 clinical application and indications, 237
 image acquisition
 patient position, 238
 standard exam views, 239–242
 transducer selection, 238
 pathology
 appendix testis torsion, 248–249
 epididymitis, 249
 Fournier's gangrene, 250–251
 hydrocele, 241–243
 orchitis, 250
 testicular neoplasm, 250
 testicular torsion, 245–248
 varicocele, 243–244
- Thoracic ultrasound
 anatomy
 B-lines, 77
 E-lines, 78
 hepatization, 78
 horizontal A-lines, 76, 77
 left lung with lingula, 76
 reverberation artifact, 76, 78
 right lung with three lobes, 76
 upper and lower lobes, 76
 image acquisition
 anterior and lateral lung zones, 79
 costophrenic angles, 82–84
 lung fields, 80–82

- M-mode “seashore sign,” 81
 - M-mode spike position, 80–81
 - patient position, 78–79
 - transducer selection, 78
 - indications and clinical applications, 75–76
 - thoracic pathology
 - pleural effusion, 87–88
 - pneumonia, 86–87
 - pneumothorax, 84–85
 - pulmonary contusion, 87
 - pulmonary edema, 85–86
 - transudative effusion, 88
 - Thyroid ultrasound
 - anatomy, 95
 - clinical applications, 95
 - pathology, 99
 - patient position, 95
 - standard exam views, 95–99
 - thyroid cyst, 100
 - thyroiditis, 100
 - transducer selection, 95
 - Tonsillar ultrasound
 - anatomy, 92
 - clinical applications and indications, 91
 - endocavitary transducer in mouth, 92
 - hold tongue with tongue depressor, 95
 - limited ability to open mouth, 95
 - patient position, 92
 - peritonsillar abscess, 93–94
 - transducer selection, 92
 - Tracheal ultrasound
 - anatomy, 100–101
 - clinical applications and indications, 100
 - endotracheal tube placement, 103
 - esophageal intubation, 104
 - and esophagus identification, 103
 - patient position, 101
 - standard exam views, 101–102
 - transducer selection, 101
 - Transducer position
 - cardiac imaging, 13
 - coronal plane, 13
 - marker or position indicator, 11
 - sagittal plane, 12
 - transverse plane, 11, 12
 - selection
 - curvilinear transducer, 8
 - endocavitary transducer, 10
 - linear array transducer, 8, 9
 - phased array transducer, 8, 9
 - Transudative effusion, 88
 - Transverse aorta, 136
 - Trifurcation, 261
 - Tubal ring sign, 229–230
 - Tube-ovarian abscess (TOA), 207–209
- U**
- Ulnar nerve, 332
 - Ultrasound principles
 - ALARA (As low as reasonably achievable), 7
 - artifact
 - edge artifact, 16, 17
 - to identify pathologic findings, 13
 - machine errors, 13
 - mirror artifact, 16, 17
 - posterior acoustic enhancement, 15
 - posterior acoustic shadowing, 14
 - reverberation artifact, 15, 16
 - sound absorption or redirection, 13
 - brightness mode (B-mode), 1, 2
 - color Doppler, 6
 - depth, 4, 5

Ultrasound principles (*cont.*)
Doppler, 4
frequency, 2
gain, 2–4
motion mode (M-mode), 1, 3
power Doppler, 6
transducer, 7
position of, 11–13
selection of, 8–11
Ureteral flow, 174
Uterine fibroids,
209–211

Uterus, 173, 214
long axis of, 201
in transverse, 202–203

V

Varicocele, 243–244
Vitreous hemorrhage, 283–284

Y

Yolk sac, 222–223