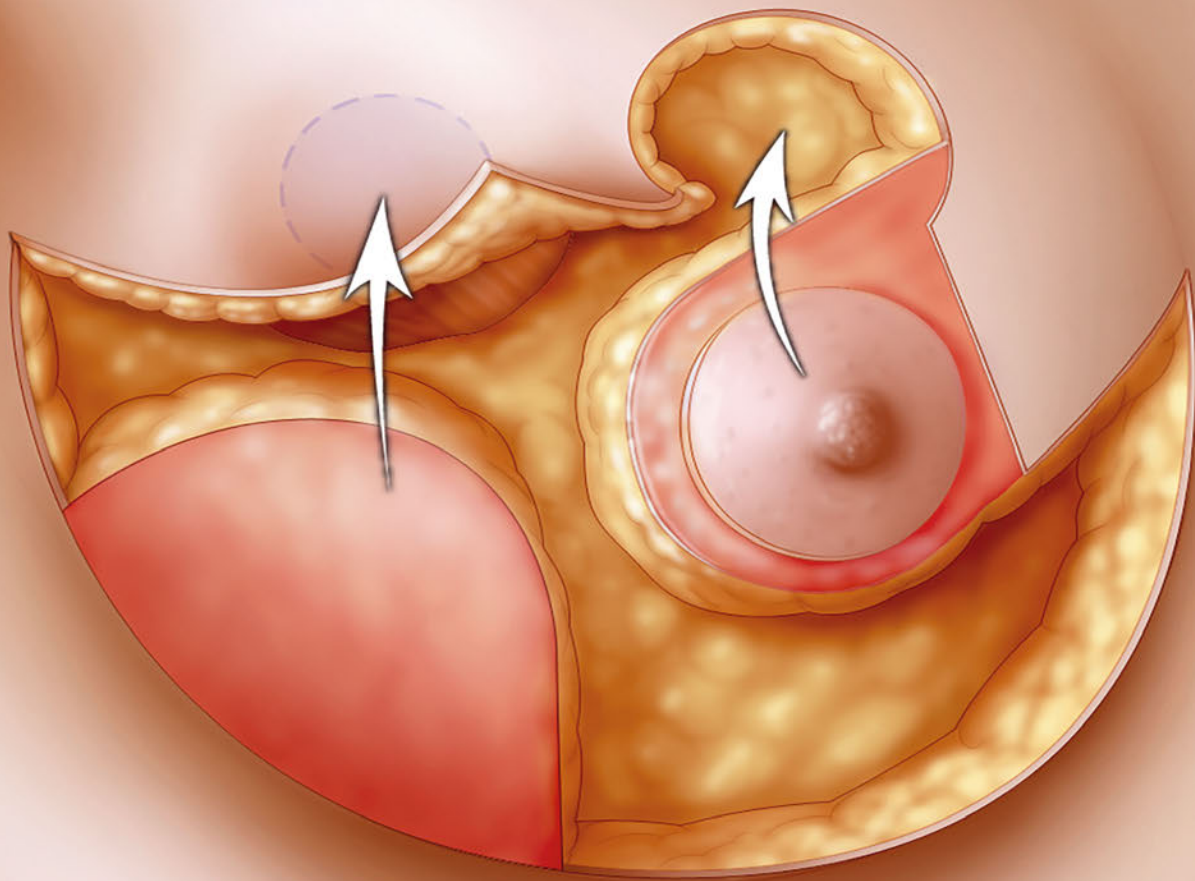


Partial Breast Reconstruction

Techniques in Oncoplastic Surgery

Second Edition



Albert Losken • Moustapha Hamdi

Watch supplemental video material online at MediaCenter.Thieme.com!

Simply visit MediaCenter.thieme.com and, when prompted during the
registration process, enter the code below to get started today.

9R8L-X8C3-3KFB-2FL3



Connect with us on social media

PARTIAL BREAST RECONSTRUCTION

Techniques in Oncoplastic Surgery

PARTIAL BREAST RECONSTRUCTION

Techniques in Oncoplastic Surgery

S e c o n d E d i t i o n

Edited By

Albert Losken, MD, FACS

William G. Hamm Professor and Program Director,
Emory Division of Plastic and Reconstructive Surgery,
Department of Surgery, Emory University School of Medicine,
Atlanta, Georgia

Moustapha Hamdi, MD, PhD, FCCP

Professor and Chairman,
Department of Plastic Surgery,
Brussels University Hospital,
Brussels, Belgium

Illustrations by
Jennifer N. Gentry

Executive Editor: Sue Hodgson
Managing Editor: Elizabeth Palumbo
Editorial Assistant: Haley Paskalides
Developmental Editor: Sheila Black
Project Manager: Makalah Boyer
Director, Editorial Services: Mary Jo Casey
Production Editor: Naamah Schwartz
International Production Director: Andreas Schabert
International Marketing Director: Fiona Henderson
International Sales Director: Louisa Turrell
Director of Sales, North America: Mike Roseman
Senior Vice President and Chief Operating Officer: Sarah Vanderbilt
President: Brian D. Scanlan

Library of Congress Cataloging-in-Publication Data

Names: Losken, Albert, editor. | Hamdi, Moustapha, editor.
Title: Partial breast reconstruction : techniques in oncoplastic surgery / [edited by] Albert Losken, MD FACS Associate Professor of Surgery, Division of Plastic and Reconstructive Surgery, Department of Surgery, Emory University School of Medicine, Atlanta, Georgia, Moustapha Hamdi, MD, PhD Professor, Chairman, Department of Plastic Surgery, Brussels University Hospital, Vrije Universiteit Brussel, Brussels, Belgium.
Description: Second edition. | New York : Thieme, [2017]
Identifiers: LCCN 2016051468 | ISBN 9781626236912 (print) | ISBN 9781626237643 (ebook)
Subjects: LCSH: Breast--Cancer--Surgery. | Mammaplasty.
Classification: LCC RD539.8 .P37 2017 | DDC 616.99/449059--dc23
LC record available at <https://lcn.loc.gov/2016051468>

©2017 Thieme Medical Publishers, Inc.

Thieme Publishers New York
333 Seventh Avenue, New York, NY 10001 USA
+1 800 782 3488, customerservice@thieme.com

Thieme Publishers Stuttgart
Rüdigerstrasse 14, 70469 Stuttgart, Germany
+49 [0]711 8931 421, customerservice@thieme.de

Thieme Publishers Delhi
A-12, Second Floor, Sector-2, Noida-201301
Uttar Pradesh, India
+91 120 45 566 00, customerservice@thieme.in

Thieme Publishers Rio de Janeiro, Thieme Publicações Ltda.
Edifício Rodolpho de Paoli, 25º andar
Av. Nilo Peçanha, 50 – Sala 2508,
Rio de Janeiro 20020-906 Brasil
+55 21 3172-2297 / +55 21 3172-1896

Cover design: Thieme Publishing Group
Typesetting by Debra Clark, Chris Lane

Printed in China by Everbest Printing Co.

ISBN 9781626236912

Also available as an ebook:
eISBN 9781626237643

Important note: Medicine is an ever-changing science undergoing continual development. Research and clinical experience are continually expanding our knowledge, in particular our knowledge of proper treatment and drug therapy. Insofar as this book mentions any dosage or application, readers may rest assured that the authors, editors, and publishers have made every effort to ensure that such references are in accordance with **the state of knowledge at the time of production of the book.**

Nevertheless, this does not involve, imply, or express any guarantee or responsibility on the part of the publishers in respect to any dosage instructions and forms of applications stated in the book. **Every user is requested to examine carefully** the manufacturers' leaflets accompanying each drug and to check, if necessary in consultation with a physician or specialist, whether the dosage schedules mentioned therein or the contraindications stated by the manufacturers differ from the statements made in the present book. Such examination is particularly important with drugs that are either rarely used or have been newly released on the market. Every dosage schedule or every form of application used is entirely at the user's own risk and responsibility. The authors and publishers request every user to report to the publishers any discrepancies or inaccuracies noticed. If errors in this work are found after publication, errata will be posted at www.thieme.com on the product description page.

Some of the product names, patents, and registered designs referred to in this book are in fact registered trademarks or proprietary names even though specific reference to this fact is not always made in the text. Therefore, the appearance of a name without designation as proprietary is not to be construed as a representation by the publisher that it is in the public domain.



5 4 3 2 1

This book, including all parts thereof, is legally protected by copyright. Any use, exploitation, or commercialization outside the narrow limits set by copyright legislation, without the publisher's consent, is illegal and liable to prosecution. This applies in particular to photostat reproduction, copying, mimeographing, preparation of microfilms, and electronic data processing and storage.

DEDICATION

*To my friends and family for their love and support, and to my children,
Madeline, Alex, Olivia, and Graham,
for keeping me whole*

Albert Losken



For Jad, Ruby, Yussef, Sofie, and Mimi

Moustapha Hamdi

CONTRIBUTORS

Katrina Abuabara, MD, MA, MSCE

Assistant Professor, Department of Dermatology,
University of California, San Francisco, San Francisco,
California

Liliana Barone Adesi, MD

Department of Plastic and Reconstructive Surgery,
Women's and Children's Health, Catholic University,
A. Gemelli Hospital, Rome, Italy

Benjamin O. Anderson, MD

Director, Breast Health Clinic, Professor of Surgery
and Global Health Medicine, Departments of Surgery
and Global Health, University of Washington, Seattle,
Washington

Werner P. Audretsch, MD

Director, Department of Senology and Breast Surgery,
Certified Breast Cancer Center, Marien Hospital
Dusseldorf, Dusseldorf, Germany

Guido Baroni, PhD

Professor, Department of Electronics Information and
Bioengineering, Politecnico di Milano, Milan, Italy

Kristine E. Calhoun, MD

Associate Director, Breast Health Clinic; Associate
Professor of Surgery, Department of Surgery,
University of Washington, Seattle, Washington

Daniel Calva, MD

Plastic and Reconstructive Surgeon, Plastic and
Reconstructive Surgery, Miami Breast Center, Key
Biscayne, Florida

Grant W. Carlson, MD, FACS

Wadley R. Glenn Professor of Surgery, Department of
Surgery, Emory University, Atlanta, Georgia

Lena F. Carstensen, MD

Associate Professor, Department of Cellular and
Molecular Medicine, University of Copenhagen,
Copenhagen, Denmark

Krishna B. Clough, MD

Medical Director, L'Institut du Sein, Paris, France

James Walter Dutton, Jr., MD

Plastic and Reconstructive Surgery Department,
Emory University, Atlanta, Georgia

Steven Eric Finkelstein, MD

Oncologist, Phoenix, Arizona

Gianluca Franceschini, MD

Associate Professor of Surgery and Breast Center,
Department of Women's and Children's Health,
Catholic University, A. Gemelli Hospital, Rome, Italy

Allen Gabriel, MD, FACS

Clinical Associate Professor, Department of Plastic
Surgery, Loma Linda University Medical Center,
Loma Linda, California

Cristina Garusi, MD, EBOPRAS

Senior Vice Director, Plastic Surgery Unit, European
Institute of Oncology, Milan, Italy

Rolf Gemperli, MD, PhD

Professor, Plastic Surgery Division, University of São
Paulo School of Medicine, São Paulo, Brazil

Moustapha Hamdi, MD, PhD, FCCP

Professor and Chairman, Department of Plastic
Surgery, Brussels University Hospital, Brussels,
Belgium

Dennis C. Hammond, MD

Surgeon, Partners in Plastic Surgery, Grand Rapids, Michigan

Diana Harcourt, PhD

Professor, Centre for Appearance Research, University of the West of England, Bristol, United Kingdom

Alexandra M. Hart, MD

Physician, Division of Plastic and Reconstructive Surgery, Emory University School of Medicine, Atlanta, Georgia

John Hijjawi, MD, FACS

Attending Plastic Surgeon, Department of Plastic and Reconstructive Surgery, Intermountain Healthcare, Salt Lake City, Utah

Roger K. Khouri, MD, FACS

Miami Breast Center, Key Biscayne, Florida

Kuylhee Kim, MD

Director, The Plastic Surgery in Seoul Nonhyeon-ro, Gangnam-go, Seoul, Republic of Korea

Steven J. Kronowitz, MD, FACS

Kronowitz Plastic Surgery, Houston, Texas

Albert Losken, MD, FACS

William G. Hamm Professor and Program Director, Emory Division of Plastic and Reconstructive Surgery, Department of Surgery, Emory University School of Medicine, Atlanta, Georgia

R. Douglas Macmillan, MB, ChB, MD, FRCS

Consultant Oncoplastic Breast Surgeon, Nottingham Breast Institute, Nottingham, United Kingdom

Alessandra Marchi, MD

Plastic Surgeon, Division of Plastic and Reconstructive Surgery, Azienda Ospedaliera di Verona, Verona, Italy

Riccardo Masetti, MD

Professor of Surgery and Head of the Breast Center, Department of Women's and Children's Health, Catholic University, A. Gemelli Hospital, Rome, Italy

G. Patrick Maxwell, MD, FACS

Clinical Professor, Department of Plastic Surgery, Loma Linda University Medical Center, Loma Linda, California

Stephen J. McCulley, MD, MBChB, FCS(SA), FRCS

Consultant Plastic Surgeon, Nottingham University Hospitals, Nottingham, United Kingdom

Hunter R. Moyer, MD

Clinical Professor, Division of Plastic Surgery, Emory University, Atlanta, Georgia; Adjunct Faculty, Department of Biomedical Engineering, Georgia Institute of Technology, Cumming, Georgia

Alexandre Mendonça Munhoz, MD, PhD

Chief, Breast Reconstruction Division, Cancer Institute, University of São Paulo School of Medicine; Professor, Postgraduate Course, Hospital Sírio-Libanês, São Paulo, Brazil

Maurice Y. Nahabedian, MD

Professor and Vice Chairman, Department of Plastic Surgery, Georgetown University, Washington, DC

Mary S. Newell, MD, FACR

Associate Professor, Department of Radiology and Imaging Sciences, Emory University, Atlanta, Georgia

Claude Nos, MD

Surgical Oncologist, L'Institut du Sein, Paris, France

Jean-Yves Petit, MD

Former Director, Department of Plastic Surgery, European Institute of Oncology, Milan, Italy

Richard Myles Rainsbury, MBBS BSc, MS, FRCS

Past President, Association of Breast Surgery; Royal College of Surgeons of England, London; Consultant Oncoplastic Breast Surgeon, Department of Symptomatic and Screening Breast Surgery, Royal Hampshire County Hospital, Winchester, United Kingdom

Gino Rigotti, MD

Plastic Surgeon, Head of Regenerative Surgery, Clinica San Francesco, Verona, Italy

Marzia Salgarello, MD

Professor, Department of Plastic Surgery, University Hospital, A. Gemelli Hospital, Rome, Italy

Isabelle Sarfati, MD

Plastic and Aesthetic Surgeon, L'Institut du Sein, Paris, France

Chirag Shah, MD

Associate Staff, Director of Clinical Research, Department of Radiation Oncology, Taussig Cancer Institute, Cleveland Clinic, Cleveland, Ohio

Sumner A. Slavin, MD, FACS

Clinical Associate Professor of Surgery, Harvard Medical School; Co-Director, Harvard Aesthetic Surgery Fellowship, Beth Israel Deaconess Medical Center, Boston, Massachusetts

Santos Soto, MD

Breast Surgeon, Breast Center Hospital Medica Sur, Mexico City, Mexico

Aldona J. Spiegel, MD

Associate Professor, Department of Plastic Surgery, Houston Methodist Hospital, Houston, Texas

Toncred Marya Styblo, MD, MS, FACS

Associate Professor, Department of Surgery, Emory University, Atlanta, Georgia

Veronique K. Tan, MBBS, MMed (Surg), MSc, FRCS (Edinb)

Consultant Oncoplastic Breast Surgeon, Division of Surgical Oncology, National Cancer Centre Singapore, Singapore

Sunil S. Thomas, MB, BCh, MS, FAIS, FRCS(Plast)

Consultant Cosmetic Plastic and Reconstructive Surgeon, Queen Elizabeth Hospital Birmingham, Birmingham, United Kingdom

Frank A. Vicini, MD, FACR

Professor of Radiation Oncology and Chief Academic Officer, Michigan Healthcare Professions; National Director of Breast Care Services and National Director of Clinical Outcomes – Twenty-first Century Oncology, Radiation, Clinical Research, St. Joseph Mercy Oakland, Farmington Hills, Michigan

Giuseppe Visconti, MD

Department of Plastic and Reconstructive Surgery, Women's and Children's Health, Catholic University, A. Gemelli Hospital, Rome, Italy

Sarosh Zafar, MD

Virginia Hospital Center, Arlington, Virginia

Hisamitsu Zaha, MD

Director, Department of Breast Surgery, Nakagami Hospital, Okinawa, Japan

FOREWORD

As plastic surgery has evolved over the past fifty years, the principles of reconstruction have merged and overlapped with those of aesthetic surgery. This phenomenon has exploded in aesthetic and reconstructive breast surgery, so much so that in many cases the stigma of the surgical treatment of breast cancer can be completely eliminated. Oncoplastic breast surgery is the epitome of this evolution in which the reconstructive breast surgeon must also be a skilled aesthetic surgeon.

Since the first edition of *Partial Breast Reconstruction: Techniques in Oncoplastic Surgery*, the awareness and utilization of oncoplastic breast concepts have become routine across the globe. Yet there remains a pervasive hunger for new and updated knowledge about breast-conserving treatment and oncoplastic techniques among breast specialists from the disciplines of surgery, plastic surgery, radiation oncology, medical oncology, and pathology. Fortunately, with the publication of the second edition of this excellent text, we have an updated compendium of authoritative information to fill the knowledge gap with the latest concepts and proven techniques in oncoplastic surgery.

From the first descriptions of oncoplastic concepts in Europe in the early 1990s and demonstrations of their efficacy, surgeons around the world have been compelled to begin incorporating these methods into the treatment of their patients. Innovations have rapidly advanced the field of oncoplastic surgery worldwide. Over the past two decades, breast-conserving procedures have progressed from rare cases treated by a few practitioners to mainstream procedures at the most well-recognized breast centers internationally. A major goal of the treatment of breast cancer is to resect the tumor so that breast shape is preserved or even improved. With the introduction of oncoplastic concepts, surgeons have been able to perform larger resections while reducing the risk of local recurrence. The resecting surgeon is free to remove any portion of the breast that is involved or at risk, knowing that the breast can be rearranged or new tissue can be brought in to create an aesthetic breast shape.

The introduction of oncoplastic techniques has had a positive impact on our patients, allowing more women to be treated with breast-conserving protocols. This book provides a road map for all specialists who provide surgical and adjunctive therapy for women facing breast cancer treatment. The second edition is replete with new chapters on external tissue expansion, new flaps, and much more detail on autologous fat grafting to the breast, a technique that has been truly revolutionary for breast reconstruction. Additionally, this new edition has greatly expanded video coverage and offers an e-book version so that the information can literally be available on a smartphone or tablet for ready access everywhere.

Drs. Albert Losken and Moustapha Hamdi, both experienced and internationally recognized plastic surgeons, have brought together the world's acknowledged experts in the practice of oncoplastic surgery to provide in-depth descriptions of the concepts and techniques used in modern breast centers. Each author contributes a unique and broad personal experience in oncoplastic methods, providing an exciting blend of ideas throughout the chapters. This book is the first of its kind to provide insights into and specific information about how oncoplastic breast surgery can and should be practiced. It has become the benchmark by which all other books on the subject are measured.

Drs. Losken and Hamdi have again spent innumerable hours editing and collating clinical cases and contributions to the second edition in addition to updating many of the chapters themselves. The result is a lasting and unique work for all physicians who set out to become practitioners of the art of oncoplastic surgery.

We sadly note the passing of Dr. Umberto Veronesi, whose landmark research in the field of breast-conserving surgery forged the trail for all of us who follow behind. Dr. Veronesi encouraged the development of the field of partial breast reconstruction and oncoplastic techniques even into the twilight of his life. May his spirit continue to permeate these pages and inspire the worldwide medical community to the great benefit of the many women who must battle breast cancer.

James C. Grotting, MD

Clinical Professor, Division of Plastic Surgery,
The University of Alabama at Birmingham;
Clinical Adjunct Professor,
Division of Plastic Surgery, The University of Wisconsin;
Private Practice, Grotting and Cohn Plastic Surgery,
Birmingham, Alabama

PREFACE

The oncoplastic approach to partial breast reconstruction continues to gain acceptance and popularity as a reliable treatment option for women with breast cancer who wish to preserve their breasts. Since our initial publication of this book, there has been an exponential increase in the number of publications on this topic and likely an increase in the number of patients who have benefited from this approach. Since more women are now choosing to preserve their breasts, this form of partial breast reconstruction has helped broaden the indications for breast conservation therapy as well as improved the aesthetic results. The oncoplastic approach is now being adopted by all members of the multidisciplinary breast cancer team, and the importance of team awareness cannot be underscored.

The second edition of *Partial Breast Reconstruction: Techniques in Oncoplastic Surgery* evolved from improved traction and increased acceptance over the last decade. The first book was a comprehensive review of the topic from the various specialties all over the world. Although our perspectives differ on the basis of geography (American versus European), we share a common enthusiasm for partial breast reconstruction techniques and their potential benefits for our patients. The first edition was well received and is testament to the continued excitement that many feel about partial breast reconstruction. This edition was intended to update the content and add some newer perspectives and refined techniques. Newer video content, updated original chapters and additional chapters have been added to improve the overall impact. Longer follow-up and newer techniques in this edition also improves our understanding of the topic.

The concept of reconstructing quadrantectomy-type defects originated in Europe and has slowly gained acceptance and popularity in the United States and throughout the world. Given the global interest and controversial nature of some of the oncoplastic techniques that have been developed, we felt it only appropriate that this book provide a truly international perspective. Thus we are gratified at the international experts who have joined us in this writing endeavor; they hail from South America, the United Kingdom, Europe, and the United States. Many of these individuals have helped to pioneer and refine the breast conservation and partial breast reconstruction techniques discussed in this book. Chapter 1, for example, was written by Werner Audretsch, who coined the widely used term *oncoplastic*.

Because breast-conserving therapy crosses specialty lines and often requires a multidisciplinary team approach, this work covers a broad range of topics. Although the main focus of this book is on surgical techniques, it also covers oncologic principles, organizational strategies, indications for breast-conserving therapy, psychological aspects, challenges

related to radiotherapy, postoperative cancer surveillance, and other variables that must be taken into consideration to maximize patient safety and subsequently improve outcomes. To provide the patient with the best care possible, it is imperative that we understand and appreciate the contributions of all members of the multidisciplinary team.

This book focuses on prevention of the BCT deformity as well as amelioration of that deformity when it occurs. It also explores the risks and benefits of delayed versus immediate reconstruction of the partial mastectomy defect and how timing decisions and resection techniques affect care and aesthetics. Our goal is to provide our readers with the range of current options available for breast preservation and reconstruction. Thus comprehensive chapters are included on topics such as reduction and mastopexy techniques with parenchyma autoaugmentation, central defect reconstruction, fat grafting, and local flap and perforator flap reconstruction. Readers are taken systematically through the presentation, workup, surgical technique, and follow-up for each of the various approaches presented.

Finally, outcomes, complications, and surveillance are also addressed as the ultimate test of the worth of each procedure. Concepts are fully elucidated with numerous color illustrations, patient examples, key concepts, and critical issues highlighted throughout each chapter. The book is provided in both print and ebook format for ready access everywhere. Eight videos are included to document key techniques described in the book.

As we look ahead to the future of the oncoplastic approach, we can expect further refinements and technologic milestones in diagnosis, management, and outcomes—newer protocols for adjuvant and neoadjuvant therapy, improved imaging equipment, and advances in partial breast irradiation and radiotherapy techniques. One day, we may even be able to manage breast cancer on a cellular level. Each of these developments, along with newer surgical techniques, will offer surgeons and their patients a wealth of alternatives; the options and outcomes for women with breast cancer can only improve.

A final verdict on the oncoplastic approach must await the development of specific protocols for indications, benefits, and risks. The ultimate value of any new procedure or treatment plan depends on the positive impact that it has on our patients. We are now witnessing patient reported outcomes from patients demonstrating improvement in things like body image, self-esteem and sexuality when the oncoplastic approach is performed despite being treated for breast cancer. We recognize that this approach is not appropriate for all patients and all situations. Although we are encouraged by the advances being made in breast-conserving therapy and oncoplastic techniques, we also recognize that there is a paucity of large studies and long-term outcome data related to the oncoplastic approach. Therefore we challenge our international colleagues to embark on collaborative efforts to provide further insights into the most effective treatment protocols based on patient selection, surgical technique, and outcome measures. Our hope is that others will build on the existing foundation and will use this book as the inspiration for future growth and creativity.

Albert Losken
Moustapha Hamdi

ACKNOWLEDGMENTS

Many people have contributed to the production of this book. It represents the culmination of ideas and concepts from all over the world. I would like to acknowledge all of the experts and friends who helped to make it possible. The enthusiasm of Sue Hodgson to engage Moustapha Hamdi and myself and encourage us to update and refine the first edition was the initiating event and was greatly appreciated.

The first edition was meant to provide comprehensive educational material on oncoplastic breast reconstruction for the multidisciplinary team. It is a topic that truly covers many specialties and our goal was to bring it all together in one text and expose the topic to members of the team who might otherwise not have been exposed to such information. This was partially accomplished, and our goal with the second edition was to update the information and broaden our reach. Moustapha Hamdi and I have continued to communicate about partial breast reconstruction and we share each other's excitement on the topic. I appreciate his friendship and assistance with bringing the European component into the mix since this has been a topic adopted earlier on that side of the ocean.

A special word of thanks is also due to the contributing authors. Each of the individuals was chosen for his or her special expertise. They are a stellar group, including many who have led the way in this field. I am grateful for their willingness to share their wisdom and to invest their time in this effort.

My interest in the field of partial breast reconstruction began in the 1990s, while I was training under Dr. John Bostwick III at Emory University. He was one of the American pioneers in this field, and his excitement and enthusiasm for the art and science of reconstructive breast surgery were contagious. Partial breast defects were being reconstructed at the time using reduction techniques and latissimus dorsi flaps. It was clear to him that this was an invaluable approach, a concept that has now, more than 10 years later, attracted enormous interest and gained widespread acceptance. Although Dr. Bostwick is no longer with us, his teachings live on and continue to inspire.

When I joined the faculty at Emory, the value of oncoplastic techniques had already been established. The divisions of plastic surgery and surgical oncology had a close working relationship, and all aspects of breast reconstruction were being offered to patients.

My ability to expand on the partial breast reconstruction component of my practice was dependent on referrals from surgical oncology colleagues. I was truly fortunate that these individuals had the vision to understand the benefits of oncoplastic techniques and to support this effort. Toncred Marya Styblo is an Emory surgical oncologist with whom I have worked closely on this topic. She was an early adopter on oncoplastic breast surgery

and has continued to expand the indications for these procedures to offer the best care for her patients. I would like to recognize these surgeons, Toncred Styblo, Ragsberg Phillips, Monica Rizzo, Yara Robertson, William Wood, and Sheryl Gabram for the insights they have shared with me, for their continued support, and for allowing me to participate in the care of their patients. Their recognition of the importance of partial breast reconstruction for selected patients is an excellent example of how together we can achieve the best possible outcomes for breast cancer patients who wish to preserve their breasts.

I would also like to recognize my chief Grant Carlson and the Emory plastic surgery faculty for not only being great mentors and role models to me during my training, but also for their commitment to the principles and practice of plastic and reconstructive surgery. The Emory plastic surgery residents are an integral part of my practice and their enthusiasm is contagious and their assistance with all my patients is greatly appreciated. While in Atlanta, I have been honored to be associated with leaders and pioneers in the field of reconstructive breast surgery; their enthusiasm and creative energy have nurtured an environment that is conducive to excellence. This also has been made possible by the many contributions and achievements of additional local clinical faculty, including Frank Elliott, Mark Codner, James Namnoun, Foad Nahai, and Carl Hartrampf. I would also like to express my gratitude to the loyal staff at Emory for their tireless efforts in providing administrative support in an environment where the demands and expectations seem endless. Geraldine Tanner and Jane Baab keep me organized and maintain the clinical flow with ease and efficiency.

We are grateful for the creativity and expertise of the Thieme staff in crafting this beautiful second edition. This team of dedicated publishing professionals gave unflagging attention to every detail of the editing and production of this book.

These acknowledgments would be incomplete if I did not recognize my father, Wolfgang Losken, from whom I inherited my love of plastic surgery. He exposed me to the field at an early age, and his excitement and enthusiasm were truly inspiring. His guidance, his love, his example, and his support have instilled in me the value of being the best surgeon I can possibly be. Above all, he taught me the importance of being a good person.

Finally, I would like to acknowledge the rest of my family for their love, support, guidance, and endless patience throughout all my endeavors. My mother, Daisy, has taught me the importance of dedication and hard work, and has fostered a value system that has allowed me to achieve my goals. My sisters, Erica and Monica, have always been there for me emotionally, as have many other friends and family. Most important in my life are my children, Madeline, Alex, Olivia, and Graham, who continue to inspire me and are the source of endless joy.

Albert Losken



During my career, I have had the good fortune to be inspired and mentored by master surgeons who have helped to shape our specialty. When I was a medical student at Damascus University, I saw Dr. Carl R. Hartrampf on television demonstrating a pedicled TRAM flap for breast reconstruction. Dr. Hartrampf's skill and innovations inspired me to become a plastic surgeon. Four years later I entered the excellent training program at the Free University of Brussels in Belgium. There I learned the essentials of aesthetic and reconstructive breast surgery under the tutelage of four gifted surgeons: Madeline Lejour, Albert DeMay, Bruno Coessens, and Rika Deraemaeker. Next, during a microsurgery fellowship in Glasgow, I was encouraged to challenge conventional thinking by studying breast reconstruction with perforator free flaps. Martyn Webster, a true gentleman and wonderful teacher, guided me and helped me to increase my self-confidence when performing perforator flap reconstruction. Ultimately, I relocated to Gent, under the wise leadership of Stan Monstrey. While in Gent, I have worked extensively with Koen Van Landuyt and Phillip Blondeel to explore the amazing potential that perforator flaps offer for reconstructive surgery.

Other professional colleagues and friends have contributed much to my professional career. They have led by example and have been great sources of support. During the past 7 years at Gent University Hospital, I have felt a strong sense of teamwork and cooperation among the breast surgeons. I would like to extend sincere thanks to my colleagues in the senology group, especially Herman Depypere, for his faith in my abilities as I developed my own clinically proven techniques in partial breast reconstruction.

I also wish to express my appreciation to the assistants, nurses, trainees, and staff of the Plastic Surgery Department at Gent University Hospital for their unlimited support.

My deep personal appreciation goes to my friend and co-editor, Albert Losken. It has been a pleasure working with Bert on this book; his skill and dedication are truly impressive and are evident throughout the pages of this work.

I would also like to thank all of the contributing authors for their excellent chapters and for the insights that they were willing to share. All of these mentors and friends have shaped my destiny, and I am sincerely grateful to them for the roles that they have played.

Finally, I must acknowledge the achievements of the many innovators in the emerging field of oncoplastic surgery and partial breast reconstruction. These men and women are dedicated to providing the ultimate care to patients who require breast cancer therapy and breast reconstruction. I honor them for believing that our patients deserve only the best and their unwillingness to settle for anything less.

Moustapha Hamdi

CONTENTS

PART ONE **Evolution of Oncoplastic Surgery**

- 1** Fundamentals of Oncoplastic Breast Surgery 3
Werner P. Audretsch
- 2** Current Approach to Oncoplastic Breast Surgery 23
 The European Experience
 R. Douglas Macmillan

 The American Experience
 G. Patrick Maxwell, Allen Gabriel
- 3** How to Incorporate Oncoplastic Surgery Into Your Practice 37
Albert Losken, Moustapha Hamdi

PART TWO **Principles and Considerations of Oncoplastic Breast Conservation**

- 4** Applied Anatomy and Breast Aesthetics: Definition and Assessment 49
Albert Losken
- 5** Breast-Conserving Therapy 75
Hunter R. Moyer, Toncred Marya Styblo
- 6** Breast-Conserving Therapy: Decision-Making and Anticipating the Unfavorable Aesthetic and Functional Result 89
John Hijjawi
- 7** Oncologic Safety of the Oncoplastic Approach for Breast Conservation Surgery 107
Kristine E. Calhoun, Benjamin O. Anderson

- 8** Improving the Partial Mastectomy Deformity 121
Grant W. Carlson
- 9** Improving the Quadrantectomy Defect 141
Jean-Yves Petit
- 10** Breast Radiotherapy in Oncoplastic Surgery 157
Steven Eric Finkelstein, Frank A. Vicini, Chirag Shah
- 11** Indications and Benefits of Oncoplastic Breast Surgery 171
Maurice Y. Nahabedian
- 12** Designing the Oncoplastic Operation 181
Gianluca Franceschini, Marzia Salgarello, Giuseppe Visconti, Liliana Barone Adesi, Riccardo Masetti
- 13** Timing of the Oncoplastic Reconstruction: Immediate, Delayed, and Delayed-Immediate 201
Alexandre Mendonça Munhoz, Rolf Gemperli
- 14** Psychosocial Aspects of Oncoplastic Breast Conservation 221
Diana Harcourt

PART THREE Immediate Partial Breast Reconstruction

- 15** Reduction Techniques to Optimize Results 233
Steven J. Kronowitz
- 16** Reduction and Mastopexy Techniques With Parenchymal Autoaugmentation 257
Albert Losken, Alexandra M. Hart, James Walter Dutton, Jr.
- 17** Central Defect Reconstruction 285
Stephen J. McCulley, R. Douglas Macmillian
- 18** The Role of Local Flaps as Volume Replacement in Oncoplastic Reconstruction 305
Alexandre Mendonça Munhoz, Rolf Gemperli

- 19** Latissimus Dorsi Mini flap Reconstruction 325
Richard Myles Rainsbury
- 20** Endoscopic Latissimus Dorsi Flap Reconstruction 355
Albert Losken
- 21** Omental Flap Reconstruction 369
Hisamitsu Zaha
- 22** Pedicled Perforator Flap Reconstruction 387
Moustapha Hamdi
- 23** Partial Breast Reconstruction Using Distant Flaps 415
Aldona J. Spiegel, Sarosh Zafar

PART FOUR **Correction of the Breast-Conserving Therapy Deformity: Delayed Partial Breast Reconstruction**

- 24** Classification and Analysis of the Breast-Conserving Therapy
Deformity 433
Krishna B. Clough, Isabelle Sarfati, Sunil S. Thomas, Claude Nos
- 25** Rearrangement Surgery 455
Dennis C. Hammond, Kuylhee Kim
- 26** Correction of the Breast-Conserving Therapy Deformity Using Local
Flaps 471
Albert Losken, Katrina Abuabara, Sumner A. Slavin
- 27** Perforator Flap Reconstruction of Breast-Conserving Therapy
Deformities 489
Moustapha Hamdi
- 28** Local Perforator Flaps in Oncoplastic Breast-Conserving Surgery: The
Nottingham Experience 505
R. Douglas Macmillan, Lena F. Carstensen, Veronique K. Tan, Stephen J. McCulley
- 29** Breast Lumpectomy Reconstruction With External Vacuum Expansion and
Autologous Fat Grafting 519
Daniel Calva, Roger K. Khouri

30 Fat Grafting in the Breast-Conserving Therapy Deformity 539
Gino Rigotti, Alessandra Marchi, Guido Baroni

31 Can Implants Correct a Breast-Conserving Therapy Deformity? 555
Albert Losken, Allen Gabriel

PART FIVE Outcomes and Future Directions

32 Cancer Surveillance After Partial Breast Reconstruction 571
Albert Losken, Mary S. Newell

33 Complications and Outcomes After Immediate Partial Breast
Reconstruction 587
Moustapha Hamdi, Albert Losken

34 Outcomes and Tumor Recurrence After Oncoplastic Surgery of the Breast:
Eighteen-Year Follow-up 609
Cristina Garusi, Santos Soto

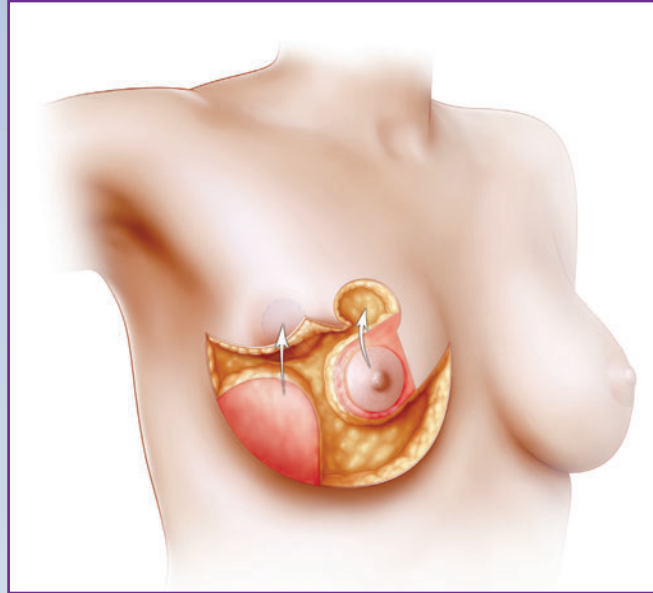
Credits 625

Index 627

VIDEOS

- 9** Improving the Quadrantectomy Defect
 - 9-1 Optimizing Results Using Local Tissue Manipulation
- 12** Oncoplastic Breast Surgery
 - 12-1 Tissue Displacement Technique With J-Scar Pattern
- 15** Partial Breast Reconstruction Using Reduction Techniques
 - 15-1 Partial Breast Reconstruction Using Reduction Techniques
- 19** Latissimus Dorsi Mini flap Reconstruction
 - 19-1 Latissimus Dorsi Mini flap Reconstruction: Markup
 - 19-2 Latissimus Dorsi Mini flap Reconstruction: Resection
 - 19-3 Latissimus Dorsi Mini flap Reconstruction: Flap Harvest
 - 19-4 Latissimus Dorsi Mini flap Reconstruction: Reconstruction
- 22** Pedicled Thoracodorsal Artery Perforator Flap
 - 22-1 Pedicled Thoracodorsal Artery Perforator Flap
- 27** Lateral Intercostal Artery Perforator Flap
 - 27-1 Lateral Intercostal Artery Perforator Flap

PART ONE



Evolution of Oncoplastic Surgery

1

Fundamentals of Oncoplastic Breast Surgery

Werner P. Audretsch



One of the main measures of successful breast cancer surgery is local control. It has been demonstrated that undertreatment followed by local failure is deleterious in some subgroups of patients. This knowledge has led to a shift in the treatment strategy for patients with breast cancer. Rather than rely on systemic interventions in response to inadequate surgical approaches, surgeons now place greater emphasis on meticulous planning and skilled execution combined with radiotherapy to minimize local relapse while maintaining cosmesis.¹ Oncoplastic surgery effectively accomplishes this goal by incorporating partial resection with immediate reconstruction. Today oncoplastic surgery is primarily performed to cope with unfavorable anatomy, relative tumor size and location, to challenge complex local treatments and postradiation breast surgery, and to remove the cancer without mutilation and with the tumor not touching ink for invasive disease and with at least 10 mm in ductal intraepithelial neoplasia (DIN). Oncoplastic surgery was not invented to extend unnecessary margins but to reduce reexcisions, recalls for distortion after prior breast-conserving surgery (BCS), and to lower the rate of mastectomies thus saving social and medical resources.²

ORIGIN OF ONCOPLASTIC SURGERY

The term oncoplastic surgery was introduced in 1993³ and published a year later.⁴ It encompasses unique approaches suggested by different surgeons and focuses on tumor resection and breast aesthetics through partial breast reconstruction techniques that minimize potential breast deformities.

The initial focus of oncoplastic surgery was on breast deformities after quadrantectomy,^{5,6} and it became another alternative to consider during the initial surgical planning and decision-making process.

The oncoplastic surgical approach allowed surgeons to tailor techniques to prevent deformities, minimize margins, and reduce potential for local recurrence.

Terms such as cosmetic quadrantectomy,⁷ aesthetic diagnostic round-block technique,⁸ *low pole tumor reduction mammoplasty*,⁹ and *central tumor reduction*¹⁰ define the basic principles that formed the roots of oncoplastic surgery. These techniques bridge the gap between resection and immediate reconstruction to save form and function, which are integral parts of the body image. Independent from its linguistic roots, the term *oncoplastic* is a distinctive label for tumor-specific immediate reconstruction. The term *tumor-specific immediate reconstruction* (TSIR) was introduced by John Bostwick III in 1996.¹¹ This concept covers the complete spectrum of available techniques, from partial to total immediate breast reconstruction (IBR).

TSIR represented a decisive stage in the evolution of oncoplastic breast cancer surgery; it includes delayed procedures, total reconstruction, and salvage procedures. The oncoplastic concept implies not only the reconstruction of partial defects, but also the planning of resection in cosmetic units, if possible, to provide the most natural-appearing, aesthetic breast. These two terms, TSIR and oncoplastic, are similar in meaning; however, the oncoplastic approach also includes delayed and salvage procedures. Regardless of the terminology used, partial breast reconstruction has been a valuable addition to the management of women and men with breast cancer. Initially, the benefits were evident in Europe, where the techniques were used to treat quadrantectomy-type defects. More recently, the techniques have become common in the United States for lumpectomy defects.

Today, on a worldwide basis, oncoplastic surgery does not interfere with treatment protocols and is oncologically based on the Milan I trial. In addition, it has enabled breast cancer patients to have fewer fears about disfigurement.¹²

ANATOMIC CLASSIFICATION

The anatomic classification for the oncoplastic approach to partial mastectomy defects should include planning for a potential completion mastectomy.

The wider the excision, depending on the type of tumor,¹³ the lower the risk of local failures potentially contributing to compromised cosmesis. To this end, two options have emerged: (1) partial reconstruction and (2) skin-sparing mastectomy (SSM) with reconstruction.¹⁴

The main factors that influence the approach to treating the deformity are:

- The location of the tumor (such as in the cleavage)
- The tumor/breast ratio
- The surgical resection (which may lead to nipple-areola distortion, retraction, and volume/size asymmetry)
- Radiotherapy (which may lead to skin effects, color differences, shrinkage, and fat necrosis)

A smaller tumor/breast ratio should yield better cosmetic results; however, similar ratios might yield different results, depending on the tumor location.

Any anatomic classification of breast tumors for an oncoplastic approach to partial mastectomy defects should include the location, size, shape, symmetry, tumor/breast ratio, and NAC.

Box 1-1 Anatomic Classification of Breast Tumors

Sites of Tumors and What They Affect

Upper outer quadrant—affects the lateral flow
 Lower outer quadrant—affects the lateral flow
 Central or borderline—retracts the nipple-areola complex
 Upper inner quadrant—affects the cleavage
 Lower inner quadrant—affects the crease
 Superior pole—distorts upper pole fullness

Tumor/Breast Ratio

Lower is favorable
 Higher is unfavorable

Nipple-Areola Complex

Central/subareolar, raising nipple-areola loss or retraction.

Noncentral/borderline of the breast quadrants, raising deep margin problems; these relate to the difficulties of deep clear margin resection, because the thin breast layer in the borderline of the breast makes achieving sufficient clearance in the third dimension, close to the muscle, difficult.

Avoiding Asymmetry

The most favorable anatomic situation for a partial mastectomy is asymmetry, especially when the affected breast is larger. The aim of avoiding asymmetry as a result of quadrantectomy was expressed in Veronesi's definition referring to quadrantectomy as a "bilateral approach," such as the "mirror" technique that was performed in the 1970s and 1980s as a way of balancing the volume of resection and the NAC position.¹⁵ The latter technique contributed to recentralization techniques, introduced by Petit and Rietjens.¹⁶ Oncoplastic planning often includes similar resections on the opposite side, such as a mirror biopsy, to improve symmetry. One approach is to perform the contralateral procedure after radiotherapy to allow edema and any breast fibrosis time to resolve.

TRAINING ONCOPLASTIC SURGEONS

Specialized training is an often-debated issue. The concept of a specialized breast surgeon on a European, American, or worldwide level is important, because breast cancer is a silent epidemic. It is estimated that 1.152 million women will be diagnosed with breast cancer in the coming year. Of these, 411,000 will die of tumor-specific causes. It is also estimated that 20.6 million survivors have been treated for breast cancer.¹⁷ Breast centers and specialized breast surgeons are required to have proper accreditation. This ensures that patients are offered the best treatments possible, but it also offers trainees a solid aim for their fellowship, which includes curriculum as well as accreditation. The leading surgeons in this field are the individuals driving this specialty forward—they have established guidelines for training breast cancer specialists, including breast surgeons,¹⁸ and have created and published a good practice guide¹⁹; these resources exemplify the current level of quality

of the curriculum in our daily practice. In Europe, the entry requirement of candidates for training and accreditation in breast surgery is to be currently licensed to practice as a general surgeon, plastic surgeon, or gynecologist. The training facility is based at a certified breast center consisting of integrated departments of senology (surgical breast oncology) and plastic surgery, including microsurgery.

The training facility should provide training options for physicians to acquire sufficient skills and practice to establish breast centers of excellence. Training options should include oncologic surgery, plastic and aesthetic surgery, principles of oncoplastic surgery, radiology, nuclear medicine, pathology, systemic therapy, radiotherapy, and others. Training options in the United States and other countries may vary; however, the ultimate goals are the same. These are detailed more extensively in Chapter 2.

TECHNICAL INSIGHTS

The following section highlights some of the oncoplastic techniques that are thoroughly detailed in other chapters. Terms that are common to oncoplastic breast surgery are also introduced. In short, this section demonstrates the depth, complexity, and constant evolution of the oncoplastic approach.

Cosmetic Quadrantectomy

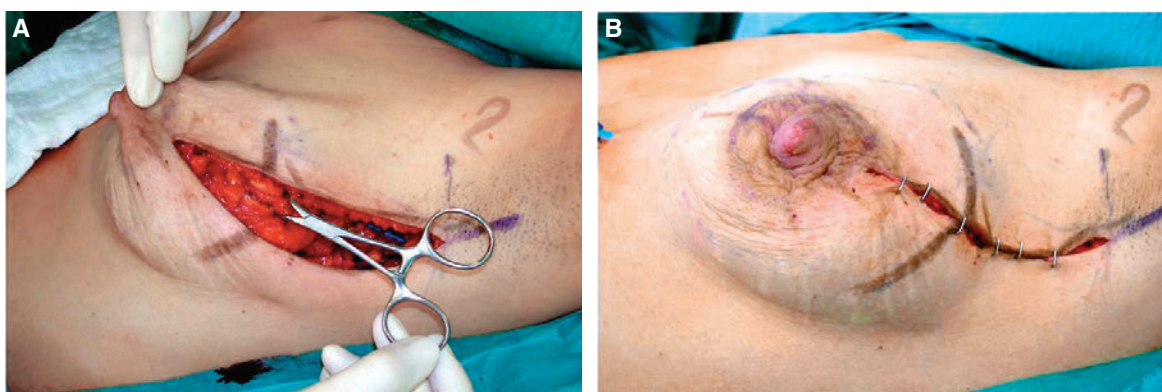
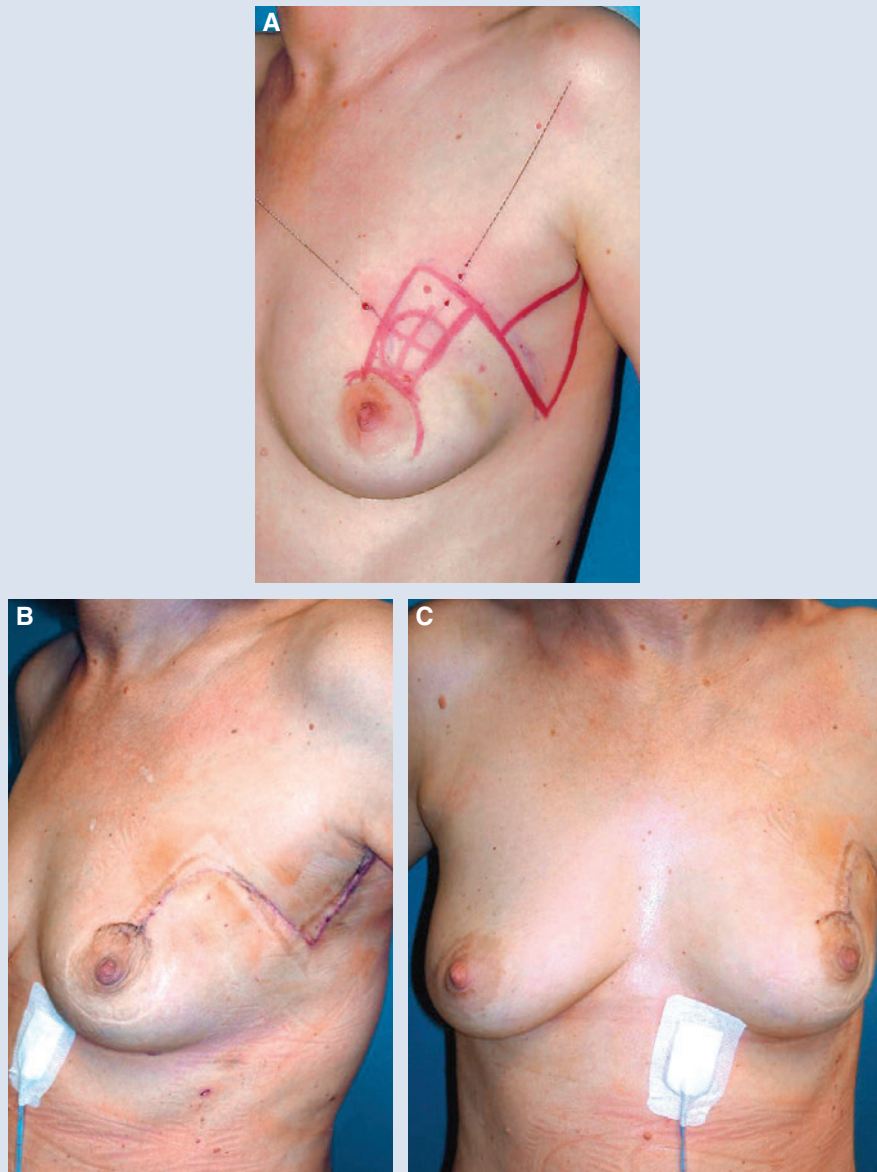


Fig. 1-1

Cosmetic quadrantectomy is one form of resection in which the aesthetic subunits of the breast are carefully considered. The goal is to perform the resection in a way that preserves a natural shape, depending on the patient's body image. The skin "pouch" technique (A), with its resultant shrinking of the skin (B), is one way to accomplish this.

Surgical Sequence

- Needle framing (to localize the extent or center of the tumor by ultrasound-guided needle localization in a 90-degree angle)
- Composite resection/ductectomy/quadrantectomy
- Margin and papilla biopsy
- Full-thickness defect closure with nipple-areola recentralization

PATIENT EXAMPLES**LOCAL FLAP RECONSTRUCTION (MATRIX ROTATION)****Fig. 1-2**

This patient had BCT with matrix rotation of the outer quadrant. She is shown both preoperatively (A) and 2 days postoperatively (B and C).

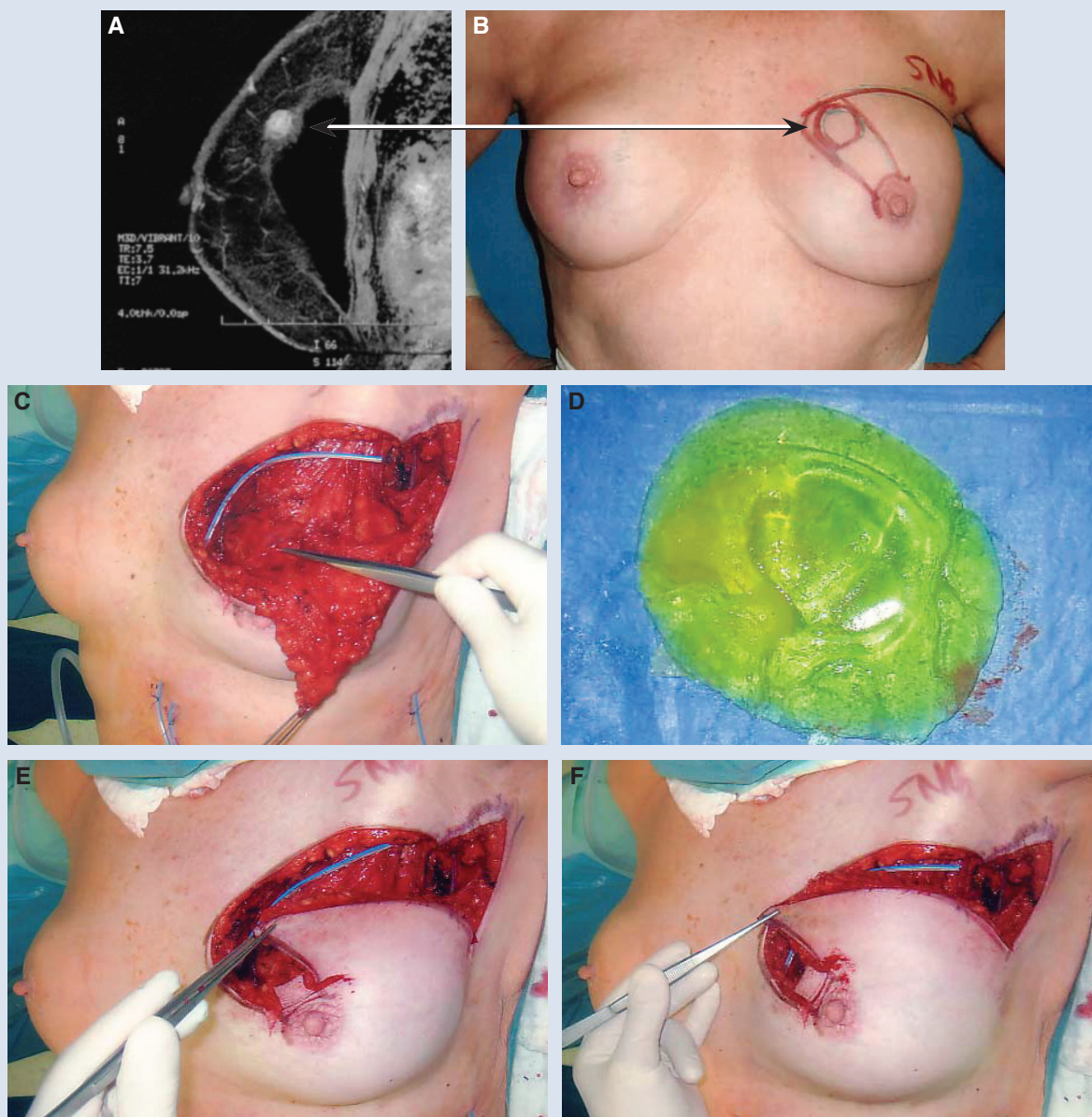


Fig. 1-3, A-F

This MRI shows a submuscular implant (A), and the clinical view of the prepectoral cancer in the upper inner quadrant on the left side (B). The sector resection included the muscle stripe and the removed implant (C and D). The new implant had complete muscle coverage. The lateral breast matrix and skin were rotated into the defect (E and F).

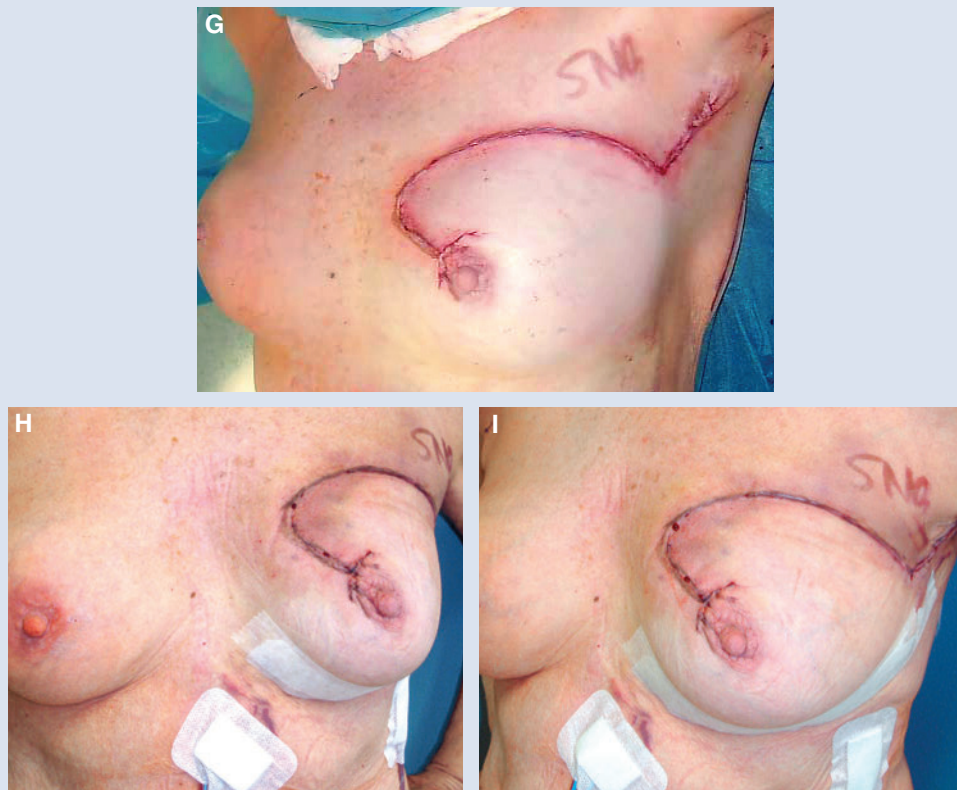


Fig. 1-3, G-I

The patient had safe coverage, with immediate partial reconstruction (G through I). This example demonstrates the advantage of oncoplastic surgery with an implant.

Local flaps are a useful option for reconstructing defects in the upper inner quadrant, which is often called *no-man's land*.¹⁰ Breast tissue and skin are rotated to fill in the defect.

Surgical Sequence

- Needle framing
- Axilla triangle
- Parallel sector resection
- Margin and papilla biopsy
- Nipple-areola complex shifting
- Matrix rotation

Latissimus Dorsi Myocutaneous Flap

The latissimus dorsi myocutaneous flap is considered the workhorse of flaps and can be used for one-third partial breast, hemibreast, or complete breast reconstruction. It is an ideal tool for volume and skin replacement, as with quadrantectomy defects.

The latissimus dorsi myocutaneous flap is used with large volume resections (approximately 200 g), severe size discrepancies, or difficult tumor locations.

It can be used in a unilateral or bilateral approach, as described in the following patient examples.

Surgical Sequence

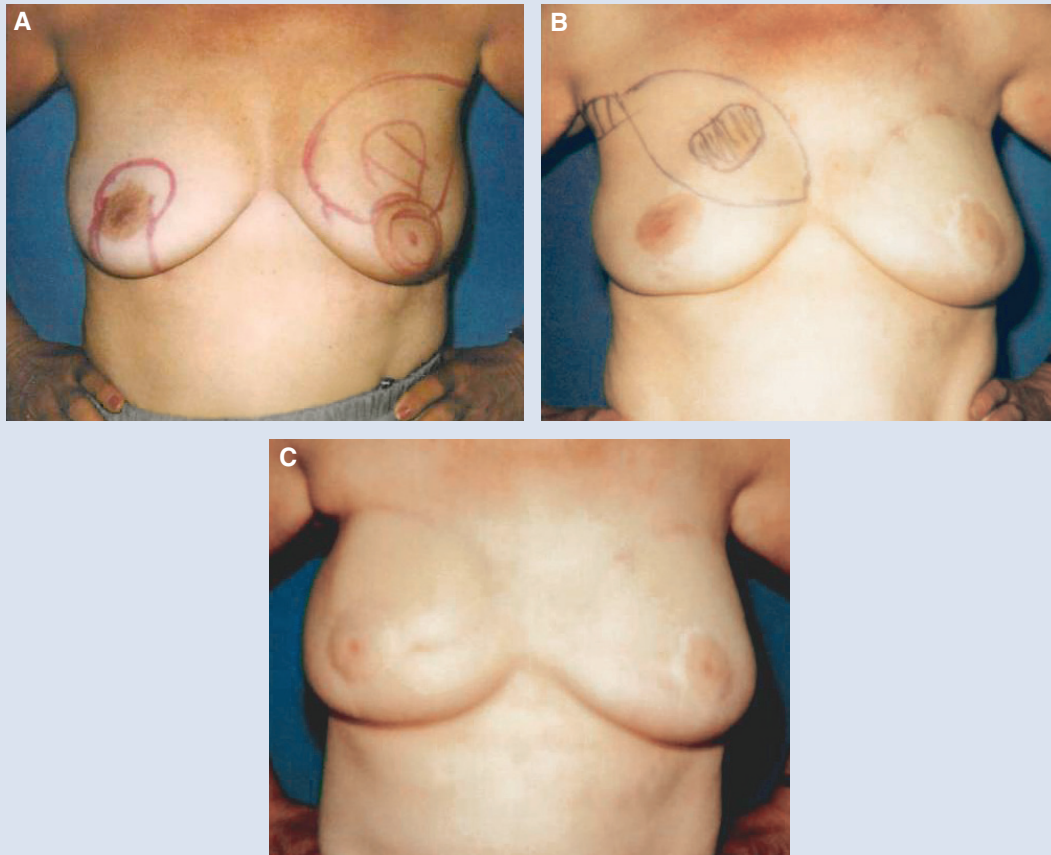
- Needle framing
- Quadrant resection
- Skin island design
- Flap harvest
- Flap rotation
- Flap inset

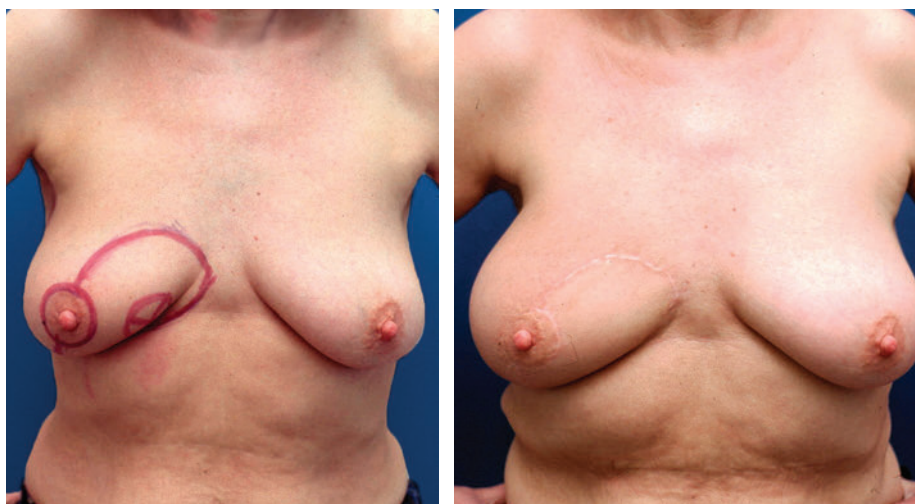

Fig. 1-4

This patient had an asymmetry unfavorable for the affected right breast and an inner quadrant defect. She underwent treatment with a unilateral approach. The defect was reconstructed, and symmetry was achieved, using a latissimus dorsi myocutaneous flap.

PATIENT EXAMPLE

**Fig. 1-5**

This patient had a left quadrantectomy defect and underwent reconstruction with a bilateral approach mirror technique (A). The defect was reconstructed with a latissimus dorsi myocutaneous flap and a contralateral mastopexy. A right quadrantectomy was performed 10 years later using mirror technique reconstruction with a right latissimus dorsi myocutaneous flap (B). The postoperative view shows preservation of breast tissue, shape, and symmetry (C).

PLANNING

Planning includes the following procedures:

- Ultrasound and drawings
- True-cut biopsy/final histology
- Photographs—anterior, oblique, and lateral views
- Framework of tumor-specific planning:
 - Entrance to the tumor bed
 - Access to the axilla
 - Two-dimensional shape of the skin pattern
 - Three-dimensional volume of resection
 - Pretherapeutic sentinel node biopsy (SNB) in cN+ patients (those with clinically positive nodes)

Preoperative Planning

- Imaging cartography ultrasound/ \pm magnetic resonance tomography (MRT)/ \pm positron emission tomography (PET)
- Preoperative blueprint
- Ultrasound needle framing of resection volume
- Preoperative drawing and photo documentation
- Clipping of resection bed
- Postoperative cartography, clip positioning to support radiotherapy planning, and margin tracing

PATIENT EXAMPLE

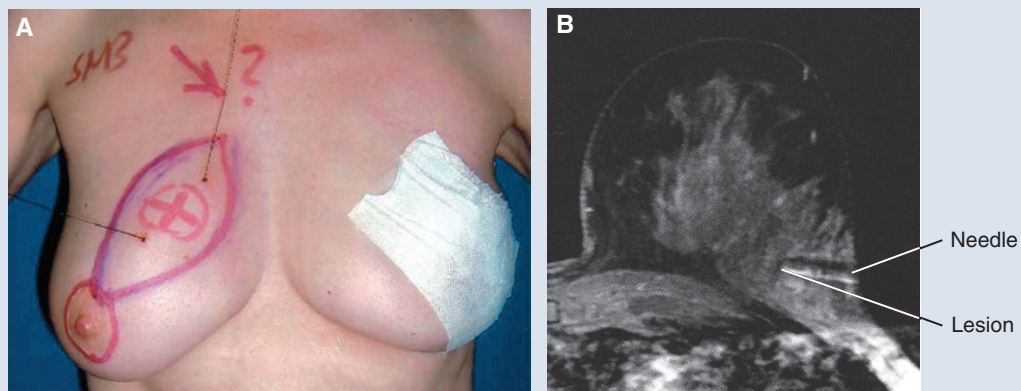


Fig. 1-6, A and B

This patient underwent reconstruction with a bilateral latissimus dorsi myocutaneous flap after an asymptomatic lesion was detected in the contralateral breast using MRI (A and B). The diagnosis was confirmed with MRI wire localization and ultrasound contralocalization. MRI planning has been shown to change the surgical approach in about 40% of cases.²⁰

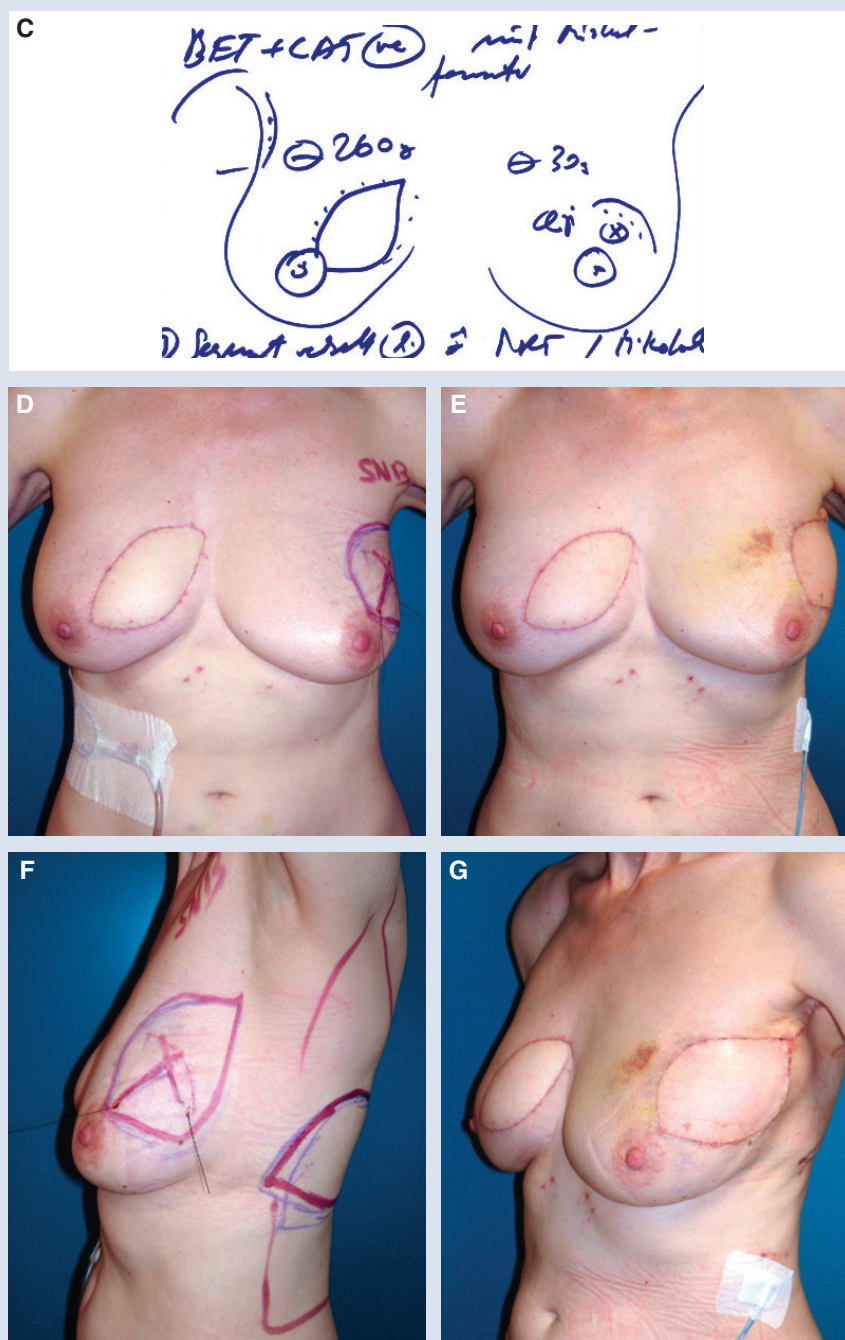


Fig. 1-6, C-G

The early subsequent bilateral latissimus dorsi myocutaneous flap was drawn and planned (C). A quadrantectomy and latissimus dorsi myocutaneous flap reconstruction were performed on the right breast (D and E). The left breast was also resected and reconstructed (F and G). This example demonstrates the effectiveness of MRI and the reliability of early simultaneous bilateral latissimus dorsi flaps for partial reconstruction.

The Phipp Chart

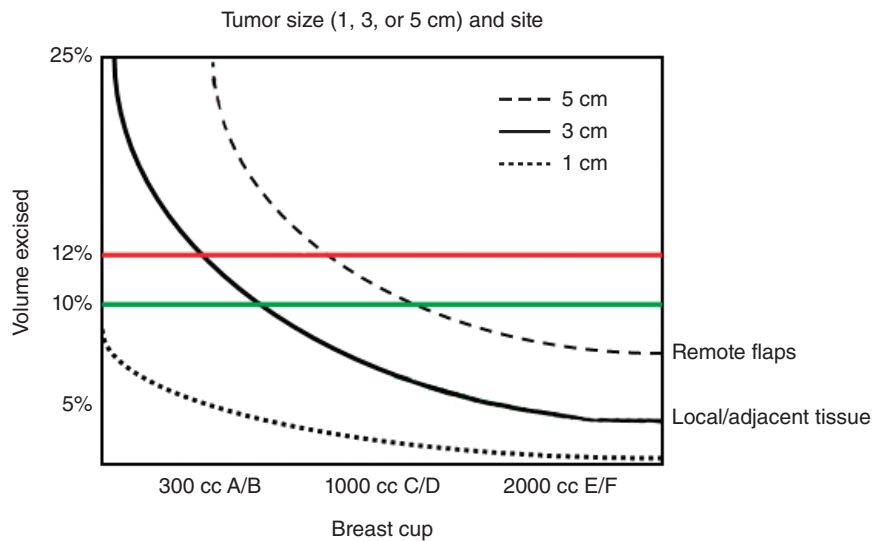


Fig. 1-7

The Phipp chart may be useful with regard to the relative tumor size and the target volume of resection.²¹ Although it does not provide information about the tumor's location in the four quadrants of the breast, it can be helpful for procedure selection.

The Phipp chart can be used to match the technique (oncoplastic tactics) with the problem (the relative tumor size and site).

The green line represents the “easy” local donor side (that is, reduction, rotation, and thoracoepigastric techniques), and the red line refers to tissue replacements from remote locations (for example, the latissimus dorsi myocutaneous flap). The concept of applying anatomy to the tumor location in the breast is also important in terms of selecting the individual tumor-adapted technique for defect closure. This method may help the surgeon to decide between the use of adjacent local tissue or remote transplanted tissue for partial mastectomy reconstruction and to determine the skin pattern of SSM and IBR.

Backup Options

As part of the oncoplastic approach, it is important that consideration be given to the potential for completion mastectomy and reconstruction.

If possible, incisions should be placed in a way that avoids jeopardizing potential SSM options.

The following steps need to be considered:

- Making a wide excision
- Converting a partial into an extended partial mastectomy
- Converting a partial mastectomy into a mastectomy and breast reconstruction procedure
- Managing the opposite breast

PATIENT EXAMPLES

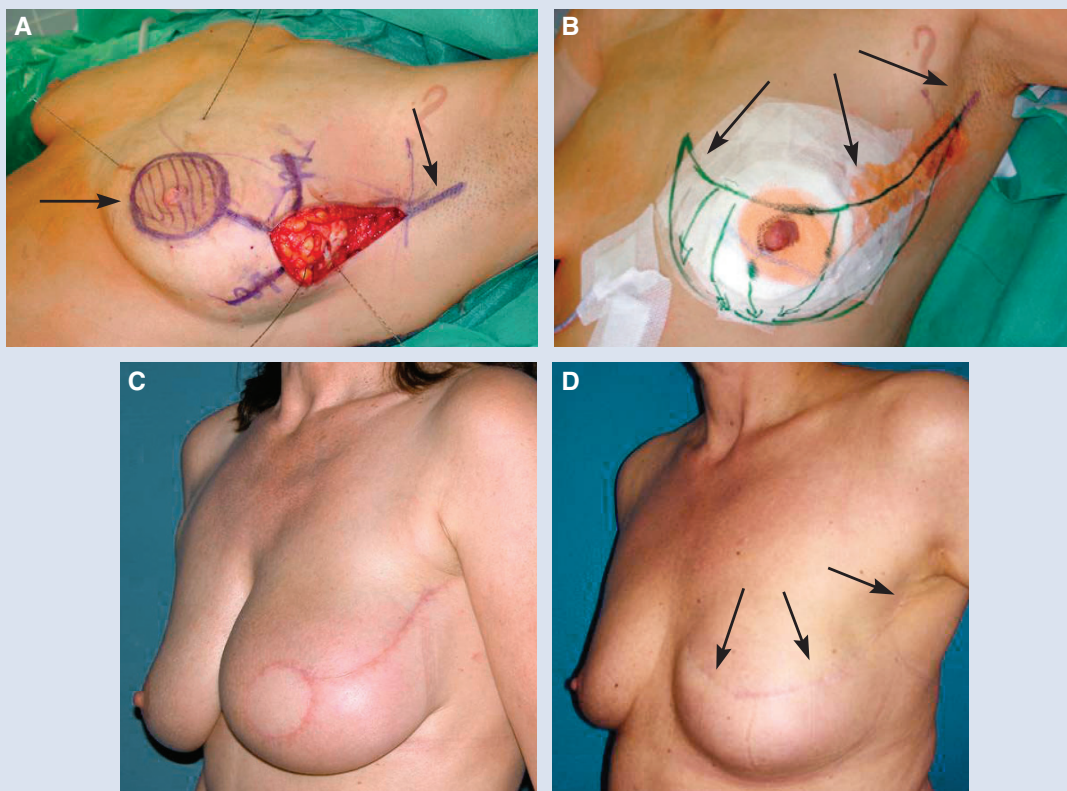
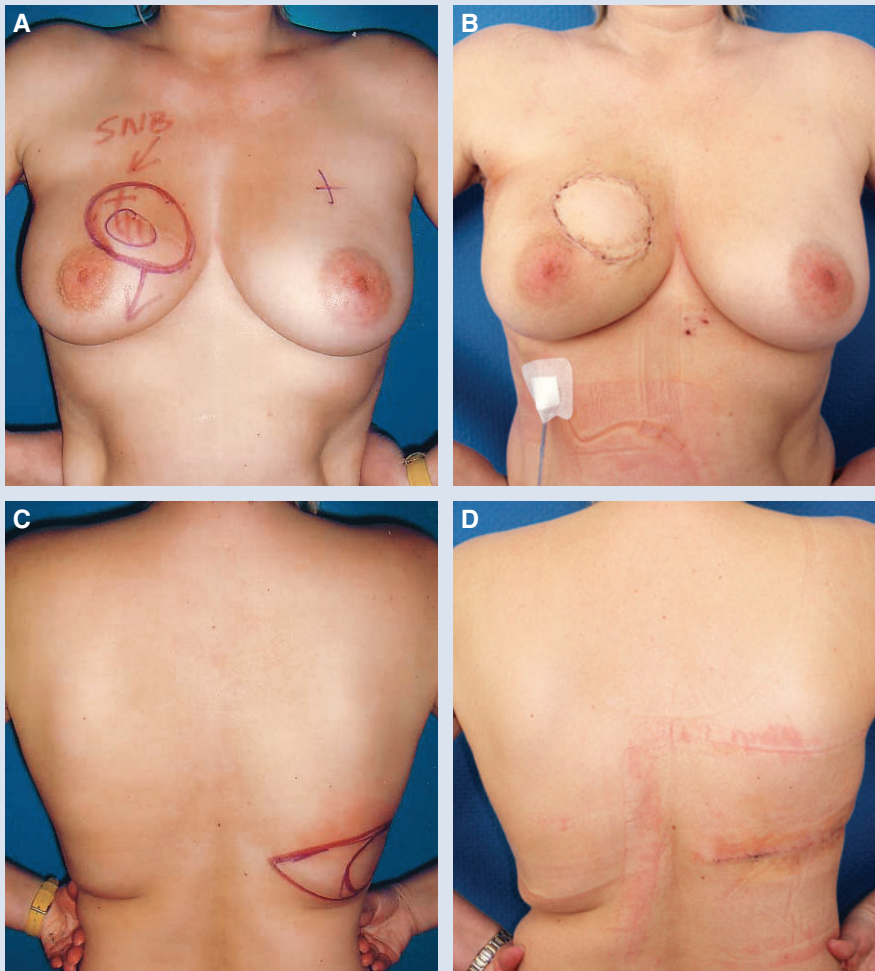


Fig. 1-8

A periareolar or oblique skin incision (A) can readily be incorporated into a “smile” mastectomy (B). This type of mastectomy is named for the shape of the mastectomy scar or the SSM with “tennis racket” incision and DIEP immediate breast reconstruction (C). The smile incision pattern is well suited for delayed implant reconstruction (D).

**Fig. 1-9**

This patient presented with cancer recurrence in the index tumor sector (the upper, inner quadrant) of the right breast after BCS and radiotherapy. The markings of the reexcision plan show how the excision was to be widened by using a latissimus dorsi myocutaneous flap (A). The partial mastectomy was converted into an extended partial mastectomy by the use of oncoplastic surgery. The result was improved symmetry (B). The donor side of the latissimus dorsi was also marked before surgery (C). Some asymmetry did result from the donor side wound closure (D).

MANAGING THE OPPOSITE BREAST

Managing the opposite breast provides another way to improve results and symmetry. The indications for the opposite breast include: symmetry, shape, size, oncology, and prophylaxis.

The following options are available for managing the opposite breast:

- None is best
- Mirror technique
- Reduction
- Augmentation
- Risk reduction

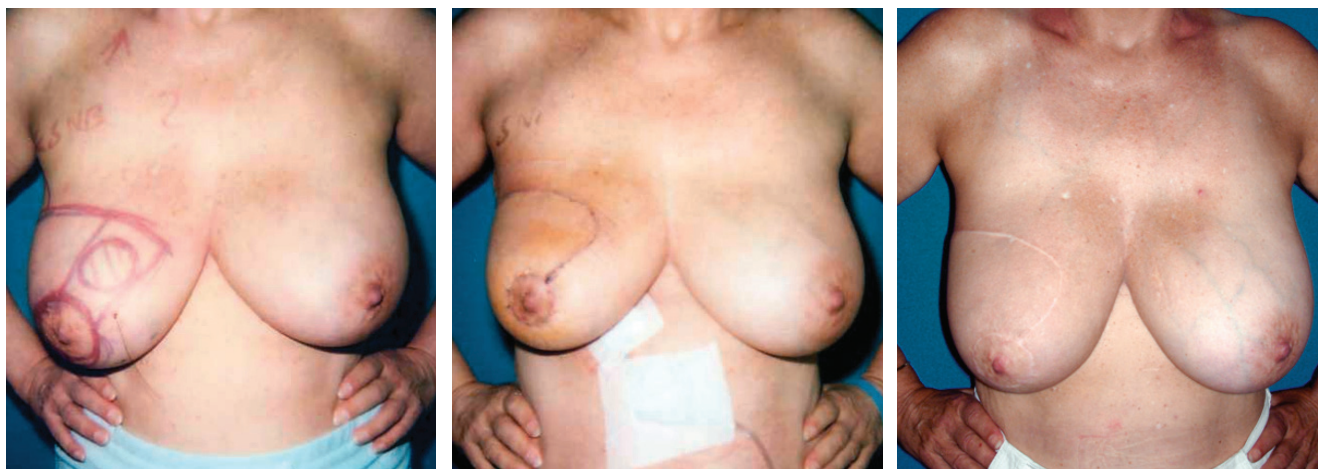


Fig. 1-10

The easiest situation to manage is the presence of some asymmetry when no contralateral matching procedure is required, because the asymmetry favors the tumor side. In this patient, the matrix rotation technique was performed after the tumor resection; it was enough to achieve symmetry.

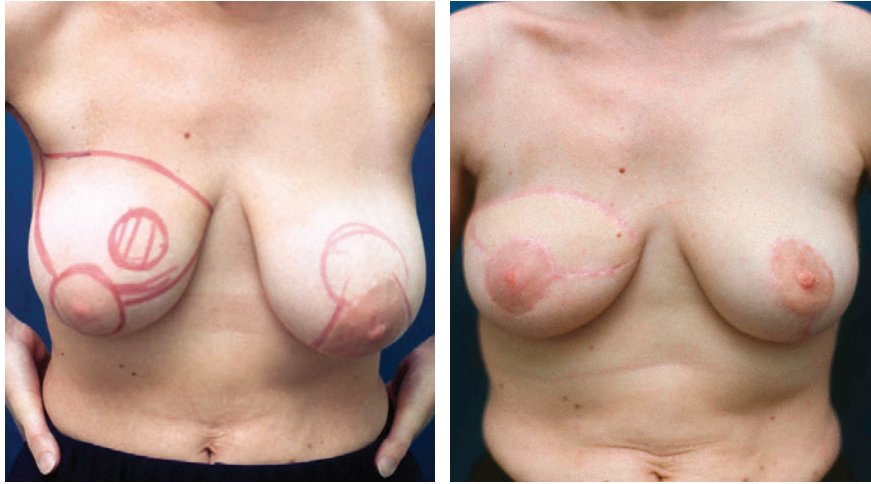


Fig. 1-11

Other situations require more aggressive management of the opposite breast. This woman underwent a right quadrantectomy and latissimus dorsi reconstruction. The contralateral breast was reduced to improve her shape and symmetry.

ALTERNATIVES TO BREAST CONSERVATION

The complete oncoplastic approach should offer alternatives to BCS.

SSM with autologous reconstruction is one way to avoid radiotherapy in some patients and is an alternative to breast conservation.

This option is often appropriate for women—especially younger patients—with DCIS or invasive cancer without lymph node involvement. The absence of lymph node involvement is often the basis for avoiding radiotherapy, an integral part of the local modality in BCT. This N-zero staging of an invasive tumor serves as a plausible rationale to discuss with the patient in the context of her preference for either SSM and immediate autologous reconstruction or, in some cases, implant reconstruction to avoid a 6-week protocol of radiotherapy and a more complex follow-up imaging protocol for the treated breast. Currently, no randomized data are available comparing BCS and radiotherapy with SSM and autologous IBR.

CONCLUSION

Oncoplastic breast surgery is a broad and comprehensive specialty. Effective management of women with breast cancer requires a complete understanding of the various options throughout the entire treatment process. Breast surgery is evolving and becoming more complex, but the goal remains the same: maximize local control and minimize poor cosmetic results.

To keep up with the ever-expanding demand for breast conservation, and to minimize the risk of poor cosmetic outcomes in 20% to 50% of patients, breast surgery itself needed to change. It was under these circumstances that the oncoplastic approach was introduced—it required meticulous attention to detail and involved both oncology and cosmesis, and it also encompassed the entire process, from planning to reconstruction. Oncoplastic surgery was developed to create cosmetic outcomes in cases with relative size and location problems and to broaden the indications for breast conservation. As a result, women who wish to preserve breast tissue are now able to preserve shape and symmetry as well, and they no longer need to live with a deformity. Oncoplastic procedures and SSM with immediate reconstruction help to avoid unforeseen predicaments for margin clearance, based on the tumor extension diagnosed using advanced imaging (MRI) and advanced histology techniques for the breast matrix and lymph nodes. Oncoplastic surgery and translational oncoplastic surgery, together with SSM and reconstruction, are the keys to achieving maximal outcomes.

One complicating factor to any BCT is the addition of postoperative irradiation. Radiotherapy is not a negligible therapeutic modality and must be balanced with its side effects and long-term sequel. In terms of an aesthetic outcome comparable to that achieved with BCT, the only surgical option that avoids the use of radiation is SSM with immediate autologous reconstruction.

As long as we continue to demonstrate safe and effective outcomes using oncoplastic techniques, this approach will continue to gain popularity and acceptance. Long-term follow-up studies will provide further insight into the oncologic and cosmetic benefits of these procedures. Debates about this procedure will continue, because there is no clear consensus regarding training and organization in terms of a two-team or a single-surgeon approach. Despite these differences, the ultimate goals are the same.

Critical Issues

- Defining terminology
 - The term oncoplastic has been coined by modern breast surgeons and is used to indicate tumor-specific immediate reconstruction
- Establishing comprehensive breast centers
 - Benign and malignant disorders
- Curriculum training for oncoplastic surgery
 - Accreditation of specialized breast surgery
- Specific approach to BCS
 - Breast imaging
 - Lymph node mapping
 - Surgical planning
 - Composite resection
 - Reconstruction
 - Management of the opposite breast
 - Backup plans
- Quality control through an accredited specialty

Acknowledgment

I wish to express my profound appreciation and thanks to Christoph Andree and Arati Sherlekar, to the fellows who contributed their comments, and to the editors, Albert Losken and Moustapha Hamdi, for their valuable support and editorial advice.

References

1. Borgen P, Sacchini V, Zurrida S, et al. At last local control matters. *Breast Diseases: A Year Book Quarterly* 17:210, 2006.
2. Menes TS, Tartter PL, Bleiweiss I, et al. The consequence of multiple reexcisions to obtain clear lumpectomy margins in breast cancer patients. *Ann Surg Oncol* 12:881, 2005.
3. Audretsch W, Kolotas C, Rezai M, et al. Oncoplastic surgery in breast conserving therapy and flap supported operability. Presented at the Annual Symposium on Breast Surgery and Body Contouring, Santa Fe, New Mexico, Aug 1993.
4. Audretsch W, Rezai M, Kolotas C, et al. Oncoplastic surgery: “target” volume reduction, (BCT mastopexy), lumpectomy reconstruction (BCT reconstruction), and flap supported operability in breast cancer. *Proceedings of the Second European Congress on Senology*, Vienna, Austria, Oct 1994; Bologna, Italy: Monduzzi Editore, 1994.
5. Berrino P, Campora E, Santi P. Postquadrantectomy breast deformities: classification and techniques of surgical correction. *Plast Reconstr Surg* 79:567, 1987.
6. Pearl RM, Wisnicki J. Breast reconstruction following lumpectomy and irradiation. *Plast Reconstr Surg* 76:83, 1985.

7. Silverstein M. Cosmetic quadrantectomy. Presented at the Annual Miami Breast Cancer Conference, Miami, Mar 1993, and at the Thessaloniki Panhellenic Breast Cancer Conference, Oct 1993.
8. Goes JCS. Correcao immedia da mamma apos ressecoes glandulares amplas. In Transactions of the Thirteenth Brazilian Congress of Plastic Surgery, Porto Alegre, Brazil, Oct 1976.
9. Clough KB, Nos C, Salmon RJ, et al. Conservative treatment of breast cancers by mammaplasty and irradiation: a new approach to lower quadrant tumors. *Plast Reconstr Surg* 96:363, 1995.
10. Grisotti A. Immediate reconstruction after partial mastectomy. *Oper Tech Plast Reconstr Surg* 1:1, 1994.
11. Audretsch WP, Rezai M, Kolotas C, et al. Tumor-specific immediate reconstruction (TSIR) in breast cancer patients. *Perspect Plast Surg* 11:71, 1998.
12. Baildam AD. Oncoplastic surgery for breast cancer. *Br J Surg* 95:4, 2008.
13. Rezai M, Veronesi U. Oncoplastic principles in breast surgery. *Breast Care* 2:277, 2007.
14. Audretsch W, Andree C. Is mastectomy still justified—and if so, in which patients? *Onkologie* 29:243, 2006.
15. Veronesi U. Cosmetic aspects of primary treatment. *Eur J Cancer Suppl* 30:7, 1994.
16. Petit JY, Rietjens M. Deformities after conservative breast cancer treatment. In Noone RB, Low DW, eds. *Plastic and Reconstructive Surgery of the Breast*. Hamilton, Ontario: BC Decker, 1991.
17. Anderson BO, Yip CH, Smith RA, et al. The Breast Health Global Initiative: a catalyst for cancer control in limited resource countries. The Sixth European Breast Cancer Conference, Berlin, April 2008. *Eur J Cancer Suppl* 6:166, 2008.
18. Cataliotti L, de Wolf C, Holland R, et al. European Society of Mastectomy guidelines on the standards for the training of specialised health professionals dealing with breast cancer. *Eur J Cancer* 43:660, 2007.
19. Association of Breast Surgery at BASO, Association of Breast Surgery at BAPRAS, Training Interface Group in Breast Surgery, et al. Oncoplastic breast surgery: a guide to good practice. *Eur J Surg Oncol* 33(Suppl 1):S1, 2007.
20. Bagley FH. The role of magnetic resonance imaging mammography in the surgical management of the index breast cancer. *Arch Surg* 139:380, 2004.
21. Phipp LH, Hurd KB, Wilson ARM, et al. Preoperative prediction of cosmesis and patient satisfaction after breast conserving surgery (the Phipp chart). Abstract presented at the Eighth Nottingham International Breast Cancer Conference, Nottingham, England, Sept 2003.

2

Current Approach to Oncoplastic Breast Surgery

THE EUROPEAN EXPERIENCE

R. Douglas Macmillan

Advances in the management of breast cancer over the past 30 years are so significant that modern practice now bears little resemblance to its earlier form. There are many reasons for this, but the effective alliance of all the varied specialties that treat the disease is an important one.

Breast surgery is now a completely different entity for current surgeons than it was for the generation that preceded them, and the difference is most stark for those who practice oncoplastic surgery.

What then are the key milestones in the evolution of oncoplastic surgery? This term was originally coined to reflect the integration of chemotherapy and radiotherapy planning with conservative forms of breast surgery for more advanced disease, but now it is used ubiquitously to describe surgery that aims to maintain quality of life and breast appearance while being uncompromising on oncologic effectiveness.¹ The cosmetic outcome of breast cancer surgery has not always been viewed as a priority, with survival itself being the overriding concern. Perhaps then the early developments in oncoplastic surgery served to show that even in locally advanced disease, obvious deformity could be safely avoided.

As survival from breast cancer has become the outcome for the large majority of patients, attention has correctly focused on the consequences of surgical treatment, both short and long term, not just the effectiveness of it. In other words, what do we leave women to live with for the rest of their lives? Breast cancer has so many negative connotations and insults to a woman's sense of being whole that it seems startlingly obvious that if the negative impact of surgery can be mitigated, then it should.

The first major step in this regard was the widespread use of breast-conserving surgery as an alternative to mastectomy. Offering a choice in this regard and expanding the indications for breast conservation was a key goal of oncoplastic surgery. Some of the milestone innovations that developed this goal were:

- The use of breast reduction techniques, initially to remove cancers that were located in areas of the breast that could be removed as part of a standard reduction technique, but later to include the use of modified techniques to allow resection of any part of the breast
- Volume replacement techniques, initially using variations on latissimus dorsi flaps, but later using local perforator-based flaps
- Various techniques to allow en bloc closure of breast defects from simple patterns of skin reduction to modifications of cosmetic mastopexies

Most of these techniques were developed in Europe.²⁻⁸

The many pioneers of oncoplastic surgery had a common background and overcame a common hurdle: they had training that enabled them to apply plastic surgery techniques to the surgery that was required oncologically, and they had developed a practice that enabled breast oncologists and breast plastic surgeons to work in harmony. By showing what was possible, these pioneers inspired others to follow. However, to emulate their example and widen the net for who could be offered oncoplastic surgery, it was essential to challenge the traditional two-surgeon model where one surgeon “made a hole” and another surgeon “filled it.” The flaws and limitations in that approach only really become obvious to those who practice it once other methods of service delivery are experienced.

Oncoplastic surgery has to be considered, planned, and indications for different techniques recognized at the point of primary presentation and treatment planning.

Essentially, all breast surgery needs to be viewed as oncoplastic. We would ask why anyone without aesthetic skills would operate on the breast and why anyone without oncologic knowledge should operate on a breast cancer patient. The logic of this argument is surely incontestable. However, that is not to say that any one surgeon can offer all options, because no one can; breast surgery will always require a mixture of oncologic, plastic, and microsurgery skills provided by a team of specialists.

The point is more that any surgeon performing breast cancer surgery requires a minimum skill set; this has to include knowledge of all techniques and working ability in many of the techniques of breast oncology and breast plastic surgery.

For all this to happen, traditional territorial divides needed to be challenged. Those who benefit from the surgery that can now be offered owe much to those who navigated through this minefield. Again, Europe appears to have led the way.

Globally, the biggest barrier to oncoplastic surgery is the degree to which the specialties of breast surgery and plastic surgery prioritize their own self-interest. Harsh though this sounds, and though many would not admit it and no one would intentionally wish this, the tribalism that is perpetuated in many countries is the main reason that oncoplastic surgery has not developed at the rate it should.

It is difficult to overstate the significance of this factor or the detrimental effect it has on the quality and choice of surgery that is offered to women. In many countries it has required a generational shift in attitude and a slow attrition of the stalwarts who wish to keep things as they are. In all countries that have made progress, it has required challenges to dogma and the generous sharing of knowledge and skills.

There are perhaps many reasons that oncoplastic surgery has flourished in Europe more than other regions, but the main one has probably been overcoming the difficulties outlined previously at an earlier stage and at a more rapid rate. Increasing specialization amongst breast and plastic surgeons is another.

However, making the transition to oncoplastic surgeon from either a plastics or breast oncology background is not an easy one, and it takes time. Hence another critical reason in the United Kingdom, and in Europe has helped oncoplastic surgery develop, is the creation of integrated training fellowships.

The concept of an oncoplastic breast surgeon coming from a background of general, oncologic, or plastic surgery and acquiring cross-specialty skills that were previously unique to the parent specialty started to gain momentum in the United Kingdom in the late 1990s. Two key factors were catalytic in advancing this concept: recruitment difficulties in breast surgery, and a new oncoplastic interface training initiative. Foreshortened training programs, a shorter working week, and an increase in consultant numbers stripped the breast surgeons in the United Kingdom of the wide skill base of the general surgeon. These were not replaced by other technical skills and challenges, and as a result, by the end of the twentieth century, breast surgery became an increasingly unattractive option for trainees who regarded it as technically unchallenging compared with other specialties.⁹ In some cases, this led to its being an attractive specialty for less technically gifted surgeons, a situation not in the interests of women with breast cancer. This issue was addressed in 1996 in the United Kingdom's revised Specialist Advisory Committee's curriculum for general surgical trainees with a subspecialty interest in the breast, which for the first time included a comprehensive reconstruction module.¹⁰ It was the first curriculum in Europe to include such a module.

Of the few trainees selecting breast surgery as a career at that time, 84% wished to acquire technical skills in breast reconstruction.⁹ In response to a proposal made by the Association of Breast Surgery to the Council of the British Association of Plastic Surgeons, an "Interface" Breast-Plastic Surgery Training Group was established in 2000. The concept of an oncoplastic or "total" breast surgeon trained in all aspects of diagnosis, resection, reconstruction, and clinical management was born. The stated goals of the Interface Group are threefold:

1. To improve service to patients by facilitating interface training.
2. To develop cross-specialty training opportunities for specialist registrars and consultants.
3. To move training in oncoplastic surgery to an earlier stage in a trainee's career.

Ultimately, a different model of training for breast surgeons is required that does not rely on acquisition of traditional general surgery skills, most of which are not relevant to oncoplastic breast surgery.

These goals underpinned a successful proposal to the United Kingdom Department of Health to fund nine new training fellowships in oncoplastic surgery. Senior-level trainees were appointed for 12 months to large multidisciplinary oncoplastic training centers in England. The program, now expanded, has increasingly become the recognized pathway for general and plastic surgeons to pursue a career in oncoplastic breast surgery.

While much of the early emphasis of oncoplastic surgery was on providing better outcomes in breast-conserving surgery and expanding the indications for it, an equally important development was seen in mastectomy and breast reconstruction.

The ability to perform an oncoplastic mastectomy is a basic requirement of any oncoplastic surgeon, whether they be breast oncology or plastics based. It is a much more difficult skill to acquire than many assume and is the basis of any good reconstruction. Inadequately performed, it is also the basis of most early complications. The application of the many techniques available to achieve good functional and aesthetic outcomes from any form of mastectomy, with or without immediate reconstruction, has enabled a dramatic improvement in the quality of reconstructions. Importantly, oncoplastic training has led to a significant increase in rates of breast reconstruction. A diverse skill set has been crucial, and although a team approach is required so that all appropriate options can be offered and combined operating is often useful, the two-surgeon model is restrictive and inefficient.

Clearly, the specific specialty providing these services is less important than the standard of training and experience of the teams performing these techniques.

The current approach to oncoplastic surgery in Europe varies from country to country and within countries.

The model posited by many as the ideal is that of a surgical team whose individual members are trained in either general or plastic surgery but who are all oncoplastic surgeons and have considerable skill overlap.

Another common model is based around a team of oncoplastic surgeons providing almost all aspects of the service, with separate microsurgery input. In places where the two-surgeon model still exists, the input of plastic surgery is increasingly sought, but the limitations of a nonintegrated skill set are obvious. There will be many local reasons for different models of service delivery, and one will not fit all. However, oncoplastic surgery is definitely now the norm, and the results, and increasingly the patients, provide the momentum to drive the specialty forward.

With the advances in service delivery and the quality of outcome offered, patient expectations have been raised, and this should be seen as a motivator to further improve quality rather than as a burden. We have not yet achieved what can ultimately be offered with oncoplastic surgery, but the countries that have been slow to adopt these newer models begin to look like lapped back-runners in a rapidly expanding field where new techniques and technologies are continually being integrated.

The need to more clearly define and validate standards, to better accredit training, to support continued professional development, and to evaluate practice has become a priority.

Many guidelines now exist, and national audits have identified areas where practice is at significant variance with the best.¹¹ However, much more is required in this regard, and this perhaps represents the subsequent set of milestones in the evolution of oncoplastic surgery. The next pioneers who will solve these issues will be technically gifted surgeons that have been trained by both plastic and breast oncologic surgeons, and attracted into an exciting, challenging, and most of all, rewarding specialty.

Critical Issues

- Any surgeon performing breast cancer surgery requires a minimum skill set and this has to include knowledge of all, and ability in many of the techniques of breast oncology and breast plastic surgery.
- The two-surgeon model of service delivery is inefficient and dated.
- Integrated training fellowships and ultimately a different model of breast surgery training are essential.

References

1. Audretsch W, Rezai M, Kolotas C, et al. Tumour-specific immediate reconstruction in breast cancer patients. An approach to the repair of partial mastectomy defects. *Semin Plastic Surg* 11:71, 1998.
2. Petit JY, Rigaut L, Zekri A, et al. [Poor esthetic results after conservative treatment of breast cancer. Technics of partial breast reconstruction] *Ann Chir Plast Esthet* 34:103, 1989.
3. Clough KB, Kroll SS, Audretsch W. An approach to the repair of partial mastectomy defects. *Plast Reconstr Surg* 104:409, 1999.
4. Clough KB, Lewis JS, Couturaud B, et al. Oncoplastic techniques allow extensive resections for breast-conserving therapy of breast carcinomas. *Ann Surg* 237:26, 2003.
5. McCulley SJ, Macmillan RD. Planning and use of therapeutic mammoplasty—Nottingham approach. *Br J Plast Surg* 58:889, 2005.
6. Rainsbury RM. Surgery insight: oncoplastic breast-conserving reconstruction—indications, benefits, choices and outcomes. *Nat Clin Pract Oncol* 4:657, 2007.
7. Hamdi M, Van Landuyt K, de Frene B, et al. The versatility of the inter-costal artery perforator (ICAP) flaps. *J Plast Reconstr Aesthet Surg* 59:644, 2006.
8. Clough KB, Kaufman GJ, Nos C, et al. Improving breast cancer surgery: a classification and quadrant per quadrant atlas for oncoplastic surgery. *Ann Surg Oncol* 17:1375, 2010.
9. Rainsbury RM, Browne JP. Specialisation in breast surgery: opinions of the UK higher surgical trainee. *Ann R Coll Surg Eng* 83(Suppl):S298, 2001.
10. The training of a general surgeon with an interest in breast disease. The Breast Surgeons Group of the British Association of Surgical Oncology. *Eur J Surg Oncol* 22(Suppl A):S1, 1996.
11. Available at www.orbsweb.com.

THE AMERICAN EXPERIENCE

G. Patrick Maxwell, Allen Gabriel

The management of women with breast cancer in the United States incorporates a great deal from the European experience; however, it does have some fundamental differences. Rather than a single surgeon performing resection and reconstruction, our approach has traditionally involved either a general surgeon or surgical oncologist performing the resection and managing the breast cancer, with a second team led by a plastic surgeon performing the reconstruction. This two-team approach remains part of a bigger multidisciplinary team in an attempt to further refine treatment options and improve outcomes. All of these advances could not have been possible without the elaborate collaboration of multiple medical and surgical disciplines. This tailored approach allows individualized treatment for each patient.

VALUE OF THE TEAM APPROACH

The importance of the team approach is well known in the field of breast cancer.

In 1996 a paper by Gillis and Hole¹ showed that the 5- and 10-year survival rates of patients with breast cancer improved using a multidisciplinary team approach. Since then, numerous countries, including the United States, have started adopting this concept. With the growing specialty-specific evidence on how to manage and treat disease, this concept becomes even more important because of what panel experts contribute to best serve the patient (Box 2-1).

Evidence from other sources indicates that a collective decision regarding the therapeutic plan is often more valid than individual decisions.¹ This holds true for many of the pathologic processes. A report on increased survival outcomes for patients with ovarian cancer in Scotland led to an investigation of whether these differences were caused by prognostic factors or by the organization and delivery of cancer services.² The study showed that survival was improved with management by a multidisciplinary team. In addition, lower short-term recurrence, increased survival, and improved salvage of a functional extremity are reported in patients with skeletal and soft tissue sarcoma of the extremity who are treated with a multidisciplinary management approach.³ The challenges inherent in coordinating care for women with breast cancer may contribute to the underuse of effective therapies.

Models of the delivery of breast cancer care range from centralized breast surgery centers with multispecialty consultation in one place at the same time to a fully decentralized model with specialists in different cities and different institutions or centers. Studies have shown that better coordination of inpatient care is associated with lower inpatient morbidity and mortality and higher patient satisfaction.⁴⁻⁶ Similarly, better coordination of outpatient care is associated with higher levels of perceived health status and receipt of preventive services.⁷⁻¹⁰

Patients benefit from prompt referral and diagnosis and a coordinated decision regarding adjuvant treatment after or before surgery. Because two surgical teams are used, effective communication and coordination are required to facilitate timely management of the breast cancer. Most centers that offer total breast reconstruction are familiar with this process, and switching to the oncoplastic approach using this two-team strategy should largely be a smooth transition.

Box 2-1 The Multidisciplinary Team

Clinical social worker	Physical therapist
Clinical trial nurse	Plastic surgeon
Genetic counselor	Primary care physician
Medical oncologist	Radiation oncologist
Multidisciplinary cancer care coordinator	Radiologist specializing in women's imaging
Nutritionist	Surgical oncologist
Pathologist	

There is a growing trend toward freestanding cancer care centers, which are beginning to fully incorporate the multidisciplinary approach at one center. Many specialties are involved in treating patients with breast cancer, and each plays an integral part in coordinating patient care. Medical oncologists, for example, have an increasingly prominent role in caring for patients with cancer, whereas radiation oncologists provide an important modality of local and regional cancer therapy. It is clear that all specialties play a vital role in providing support to patients with breast cancer.

The critical components of these centers are multidisciplinary cancer care, direct care and support services, a commitment to clinical trials, and a comprehensive program for quality assurance.

As a result, patients receive better care and greater support from experienced ancillary services. This translates into a better quality of life—the patients generally live longer, with greater hope for a cure.

Currently in the United States, there are no formalized oncoplastic breast fellowships; however, trends indicate that this is a possibility for the future. Additional training in this specialized field will be necessary to educate our future oncoplastic surgeons. Whereas multiple oncoplastic fellowships are offered across Europe under the auspices of the Royal College of Physicians, no specific training programs are currently available in the United States. However, specific breast fellowships—designed for both plastic and general surgeons, with different educational tracks—are offered throughout the United States. The combination of these training programs may be necessary to train the future generation of oncoplastic surgeons. In addition, clinical programs will be necessary to enhance the understanding of the field and to support the long-term goals of the training programs, with the expectation that all individuals involved in this field will have the latest information about breast cancer reconstruction and the newest treatment options.

BREAST SURGERY

Today, many patients have high, unrealistic expectations of the cosmetic outcome after breast cancer surgery. This stresses the importance of informed consent, patient education, available case photographs, and having a support system in place to ensure that patients have a thorough understanding of the procedure and realistic expectations about the outcome. It is important for patients to understand the type of treatment route that is chosen and its consequences, especially when radiation therapy is involved. This is why the term *breast conservation* should be rephrased to something that truly describes the outcome. *Breast lumpectomy and radiation* is a more appropriate term, given that both treatment modalities are being performed.

Although patients who undergo breast reconstruction tend to be more satisfied with the result of their treatment, many women today are not offered this option, for numerous reasons. A recent study in the United States showed that in 44% of breast cancer centers, fewer than 25% of eligible patients were referred for a reconstruction opinion.¹¹ Overall, 57% of general breast surgeons said they felt that reconstruction was not important to patients. Another study showed that most general surgeons do not discuss reconstruction with their breast cancer patients before surgical treatment. When such a discussion does occur, however, it significantly influences women's treatment choices, making many women more likely to choose mastectomy.¹²

Failure to fully educate patients about the full range of options is addressed with the development of multidisciplinary care models that facilitate an informed decision-making process regarding surgical treatment.

In the past, it was believed that reconstructive surgery did not contribute to a patient's survival. However, several studies have shown that a patient's overall self-esteem and quality of life improve as a result of reconstruction.¹³⁻¹⁵ In addition, other studies have shown that an improved quality of life leads to more healthy activities and increased involvement in the community, encouraging cancer survivors to have a will to live—to have “something to live for.”¹³⁻¹⁵

CURRENT OPINION IN THE UNITED STATES

A survey was recently sent by the American Society of Breast Surgeons (ASBS) to its members as well as to the American Society of Plastic Surgeons (ASPS) members to better understand the current surgeon mind-set relative to the oncoplastic approach. Most breast surgeons (69.7%) felt that partial breast reconstruction following lumpectomy was not limited in their practice. Fifty percent of plastic surgeons felt that it was limited, because they were not getting the referrals. Both groups agreed that complex partial reconstructions were best performed by the team approach. Margin involvement was a major concern in both groups, and the groups agreed that the aesthetic benefits were a major driving force. It was thought that future adoption of these techniques will rely on increased training and increased awareness of these procedures.¹⁶ There seems to be general agreement surrounding the concerns and benefits of immediately reconstructing the partial mastectomy defect. Disparity does exist between the two groups in terms of delivery, likely because of the system-based inadequacies in the United States.

PATTERNS OF CARE FROM THE MULTIDISCIPLINARY TEAM

After the diagnosis of cancer is established, it should be communicated and thoroughly explained to the patient. It is always helpful to have a family member or significant other present during this discussion. A thorough explanation of the treatment plan, potential complications, and expected outcomes is essential. A referral to the appropriate subspecialist—a medical oncologist, radiation oncologist, surgical oncologist, and/or plastic surgeon—is often necessary. Nurses, social workers, physical therapists, occupational therapists, and clergy are also important members of the health care team.

Many specialists are often involved in caring for a patient with cancer; however, the primary care physician is a vital part of the multidisciplinary team. Sometimes the oncologist becomes the patient's default primary care physician when patients feel more attached to their oncologist.

Patients often look to their primary health care provider to help them understand the complicated aspects of their cancer management. Subspecialists also appreciate the unique perspective of the primary care physician for assessing the effects of other chronic diseases on future care. The primary care physician should continue to counsel the patient and family even after the diagnosis of cancer is established.

Clinical research is being performed to improve the care of patients with breast cancer and other oncologic processes. Patients who are referred to tertiary care cancer centers are often candidates for participation in clinical research trials, either through cooperative groups or pharmaceutical companies. Patients should be encouraged to participate in clinical trials to obtain the best possible care for their cancer and to help develop new and innovative cancer treatments for the future.

Breast surgeons in the United States do not necessarily perform breast reductions or flap reconstructions, but they have embraced the oncoplastic approach in ways that minimize potential deformities through adherence to certain oncoplastic principles. Breast or general surgeons communicating with a plastic surgeon is important so all of the aesthetic principles of the breast area are addressed.

Smaller defects are being manipulated using advancement flaps and minimal parenchymal remodeling techniques, without necessarily requiring the cooperation of plastic surgeons. The concept of preventing deformities and focusing on aesthetics has contributed to patient satisfaction—lessons learned from European colleagues and the oncoplastic principles.

The team approach in breast cancer surgery brings together highly trained experts to deliver the best outcome for the patient. For example, with the surge of nipple-sparing mastectomies, patients are turning more to their breast surgeons and requesting this procedure. Just because the patient is an oncologic candidate for a nipple-sparing mastectomy, it does not mean that they are a reconstructive candidate.¹⁷ The patient is first evaluated by the breast or general surgeon and the candidacy of nipple-sparing mastectomy is determined and then the patient is referred to the plastic surgeon to see if the patient is even a reconstructive candidate for nipple preservation mastectomy.¹⁷ It is this important team approach that improves patient outcomes.

CONCLUSION

The ideal approach in managing the oncoplastic patient in the United States is a work in progress. It is clear that patients benefit from a multidisciplinary team; however, these organizations and their issues will differ. The current model incorporates two separate surgical teams; however, in the future, it might include specialized breast surgeons, similar to what is practiced in parts of Europe. Issues such as training, credentialing, and specialty board status are important and will need to be addressed appropriately.

Critical Issues

- The multidisciplinary team approach is important for the development of oncoplastic surgery.
- Surgeons need to focus on streamlined patient care and improved outcomes.
- There is a growing trend toward using freestanding accredited breast centers.
- Appropriate training and certification are needed.
- The United States has no formal oncoplastic surgery fellowships or specific curricula.
- Quality assessment standards are a critical component of centers that offer multidisciplinary cancer care.
- All-inclusive protocols need to be developed for breast-conserving surgery.

References

1. Gillis CR, Hole DJ. Survival outcome of care by specialist surgeons in breast cancer: a study of 3786 patients in the west of Scotland. *BMJ* 312:145, 1996.
2. Junor EJ, Hole DJ, Gillis CR. Management of ovarian cancer: referral to a multidisciplinary team matters. *Br J Cancer* 70:363, 1994.
3. Morton DL, Eilber FR, Weisenburger TH, et al. Limb salvage using preoperative intraarterial adriamycin and radiation therapy for extremity soft tissue sarcomas. *Aust N Z J Surg* 48:56, 1978.
4. Association of Breast Surgery at BASO; Association of Breast Surgery at BAPRAS; Training Interface Group in Breast Surgery, et al. *Oncoplastic breast surgery: a guide to good practice*. *Eur J Surg Oncol* (33 Suppl 1):S1, 2007.

5. Baildam AD. Oncoplastic surgery of the breast. *Br J Surg* 89:532, 2002.
6. Baildam AD. Oncoplastic surgery for breast cancer. *Br J Surg* 95:4, 2008.
7. Cleary PD, Edgman-Levitan S, Walker JD, et al. Using patient reports to improve medical care: a preliminary report from 10 hospitals. *Qual Manag Health Care* 2:31, 1993.
8. Knaus WA, Draper EA, Wagner DP, et al. An evaluation of outcome from intensive care in major medical centers. *Ann Intern Med* 104:410, 1986.
9. Parker VA, Wubbenhorst WH, Young GJ, et al. Implementing quality improvement in hospitals: the role of leadership and culture. *Am J Med Qual* 14:64, 1999.
10. Young GJ, Charns MP, Desai K, et al. Patterns of coordination and clinical outcomes: a study of surgical services. *Health Serv Res* 33:1211, 1998.
11. Kaur N, Petit JY, Rietjens M, et al. Comparative study of surgical margins in oncoplastic surgery and quadrantectomy in breast cancer. *Ann Surg Oncol* 12:539, 2005.
12. Alderman AK, Hawley ST, Waljee J, et al. Understanding the impact of breast reconstruction on the surgical decision-making process for breast cancer. *Cancer* 112:489, 2007.
13. Heim ME, v d Malsburg ML, Niklas A. Randomized controlled trial of a structured training program in breast cancer patients with tumor-related chronic fatigue. *Onkologie* 30:429, 2007.
14. Humpel N, Iverson DC. Depression and quality of life in cancer survivors: is there a relationship with physical activity? *Int J Behav Nutr Phys Act* 4:65, 2007.
15. Kendall AR, Mahue-Giangreco M, Carpenter CL, et al. Influence of exercise activity on quality of life in long-term breast cancer survivors. *Qual Life Res* 14:361, 2005.
16. Losken A, Kapadia S, Egro FM, et al. Current opinion on the oncoplastic approach in the USA. *Breast J* 2016 Apr 9. [Epub ahead of print]
17. Maxwell GP, Storm-Dickerson T, Whitworth P, et al. Advances in nipple-sparing mastectomy: oncological safety and incision selection. *Aesthet Surg J* 31:310, 2011.

3

How to Incorporate Oncoplastic Surgery Into Your Practice

Albert Losken, Moustapha Hamdi

Partial breast reconstruction using oncoplastic techniques has increased in popularity as the demand for breast conservation continues to rise. The number of indications for breast conservation is growing with improved neoadjuvant chemotherapy and breast imaging, the increased use of postmastectomy radiotherapy, and the application of oncoplastic techniques. Women no longer need to tolerate poor cosmetic results to preserve their breasts, and, to this end, partial breast reconstruction has become an invaluable addition to the management of women with breast cancer. The therapeutic advantages of combining partial mastectomy with partial breast reconstruction are numerous. However, given the logistics of breast cancer treatment in certain countries, incorporating this approach into your practice can be difficult.

The first decision that needs to be made is whether the surgeon will perform these techniques using a single-surgeon approach or as part of a surgical team.

Although these two approaches differ in some aspects (see Chapter 2), they both essentially rely on a multidisciplinary team for comprehensive patient management. When the same surgeon performs both the resections and reconstructions, the inherent difficulties with incorporating oncoplastic techniques into your practice are less numerous.

Some centers specialize in this approach and have shown excellent results; however, most involve a two-surgeon team, with one focusing on the tumor resection and the other focusing on reconstruction. It is critical in these situations that both surgeons have a thorough understanding of breast cancer management and breast aesthetics to effectively treat the patient.

Reconstructive breast surgery is not simply filling a defect; it encompasses a wide knowledge of tissue handling, perfusion, and healing, in addition to achieving good aesthetic results.

Individual cases should be discussed at multidisciplinary team meetings, and surgical treatment can then be planned easily and included within protocols.

This chapter focuses mainly on the two-team approach from our perspective as reconstructive surgeons and provides some insight into the various ways to incorporate oncoplastic surgery into your practice.

WHO BENEFITS FROM THE ONCOPLASTIC APPROACH

The first question that needs to be addressed when using the oncoplastic approach is, “Who benefits from the oncoplastic approach to breast conservation?” The answer is threefold. The patient benefits because she is able to preserve her breast, with a reduced chance for a deformity. The ablative surgeon benefits because he or she is able to remove the tumor with generous margins. As reconstructive or plastic surgeons with an interest in breast reconstruction, we benefit from our continued involvement in the management of these patients. If reconstructive surgeons do not choose to participate in partial breast reconstruction, it might be lost to other specialties.

The Patient’s Perspective

Patients often seek the advice and expertise of members of the health care team and trust them in the decision-making process. Women with breast cancer are no exception. We are expected to provide them with all treatment options and to educate them on the various approaches. Together, we decide on the most appropriate treatment plan for their anatomy, pathology, and desired outcome. However, with the increased use and availability of the Internet, patients are now educated consumers and often have treatment plans in mind at the initial consultation.

Reconstructive surgeons do not determine the initial treatment plan and do not necessarily control the inflow of patients with breast cancer in most centers. One way to increase the use of oncoplastic techniques in their practices is through patient education.

If patients are familiar with the concepts and know to inquire about possible oncoplastic options, the potential for more referrals to the reconstructive surgeon increases. The

ablative surgeon may not always consider this as a good alternative; however, the patient raising the issue may stimulate reconsideration. Patients are now becoming more aware of the options available to conserve their breasts, with patient demand being one of the driving forces for the rise in breast-conserving surgeries. Patients need to realize that they do not necessarily need to live with a deformed breast and that reconstructive options are available to minimize the potential for a partial mastectomy deformity. If patients know to ask about breast conservation and reconstructive options, not only will quality control be enhanced, but the creation or development of oncoplastic teams may be encouraged in your practice.

Educational Tools for Patients

The following options may be used to distribute necessary information to your patients:

- Develop educational seminars on breast reconstruction, including partial breast reconstruction.
- Provide brochures on partial breast reconstruction that include available options and patient examples.
- Establish support groups for women with breast cancer who decide to conserve their breasts.
- Inform patients about helpful education sites on the Internet.

The Ablative Surgeon's Perspective

Most surgeons who treat women with breast cancer have witnessed an increase in breast conservation. The indications, in addition to patients' desires for breast conservation, have led to an increase in poor cosmetic outcomes. Surgeons often face difficult situations. For example, even though a patient has requested them, a surgeon may hesitate to use breast-conserving techniques if there is the potential for poor cosmetic results or if there are concerns regarding the inability to obtain clear margins. If surgeons know and understand the available options for partial breast reconstruction, these predicaments could be minimized.

Many ablative surgeons are not aware of reconstructive procedures that could broaden the indications for breast conservation and improve aesthetic results. Ablative surgeons are often involved in the initial decision-making process regarding breast cancer management; therefore, their participation in this approach is paramount to our involvement as plastic surgeons.

Without appropriate preoperative coordination, partial breast reconstruction will only be performed in the delayed setting for patients who are unhappy with their results, and this is often more challenging.

If we are interested in incorporating oncoplastic techniques into our practices, we need to educate ablative surgeons about the reconstructive options available. They also should gain a thorough understanding of the concepts of the ideal breast shape and breast aesthetics. Educational seminars should involve patient examples that demonstrate improved

cosmetic results and should provide insight into the many other oncologic advantages of these techniques (for example, generous resection). We also need to demonstrate both the benefits of partial reconstruction before irradiation therapy in select patients and the oncologic safety of combined techniques. In addition, we must explain that postoperative surveillance is not impaired by reconstruction of partial mastectomy defects. Once they are familiar with the options, ablative surgeons also can offer breast reduction techniques for women with large breasts to improve breast conservation and symptoms of macromastia. Margin status is always a concern and needs to be addressed by discussing the possibility of performing the reconstruction once the final margin status is confirmed. With time, it will become clear that there are many benefits to managing these patients as part of a surgical team. As patients become more educated and request certain treatment plans and alternatives to breast conservation to improve their outcomes, ablative surgeons also stand to benefit, from a productivity standpoint, by incorporating this approach into their practices.

The ablative surgeon should be able to predict which patients have the potential for poor cosmetic results and which patients may benefit from a referral to a reconstructive surgeon.

Because most reconstructive surgeons already have ablative surgeons with whom they coordinate total breast reconstruction, this concept would be a good educational starting point. Educating community surgeons further increases awareness of your work and enhances the incorporation of oncoplastic techniques into your practice. Communication and teamwork are essential. Developing a good relationship with a reconstructive surgeon allows the ablative surgeon to offer the entire spectrum of state-of-the-art treatment options for women with breast cancer. It would be difficult to establish a breast center of excellence without somehow incorporating partial breast reconstruction into the treatment plan.

Ablative surgeons do not always rely on a reconstructive colleague for closure of the partial mastectomy defect, and many cases use careful planning, meticulous resection, and limited local maneuvers to minimize the potential for poor cosmetic results. In these situations, the principles of the oncoplastic approach are applied without requiring the two-surgeon team. More complex reconstructions often involve a reconstructive surgeon. If the ablative surgeon intends to perform the reconstruction, he or she requires appropriate surgical training and expertise in breast aesthetics and breast reconstruction.

Reimbursement is an important issue at many surgical centers. Many resective surgeons would prefer not to lose potential reimbursement or operating room time by referring these cases to reconstructive teams. These issues can be minimized by coordinating a business plan to ensure that funds and operating room time are adequately balanced and cost effective for both teams.

Educational Tools for Ablative Surgeons

The following options may be used to provide and receive education:

- Develop a referral system by teaming with reconstructive surgeons.
- Provide educational seminars within your institution and in the community to demonstrate various options for partial breast reconstruction (techniques and case examples).
- Demonstrate why the oncoplastic approach is a favorable alternative to skin-sparing mastectomy (SSM) and reconstruction.
- Provide peer-reviewed articles with data focusing on margin status, local recurrence, survival, and cosmesis.
- Teach courses at national meetings and symposia.
- Provide educational brochures and patient testimonials.

The Reconstructive Surgeon's Perspective

Most plastic surgeons who are interested in incorporating partial breast reconstruction into their practices probably already have a breast reconstruction practice. To appropriately manage women with breast cancer, a basic understanding of breast cancer management is required, even for reconstructive surgeons.

Partial breast reconstruction requires that reconstructive surgeons understand the size of the tumor and the extent of the resection.

Breast imaging results (mammograms, ultrasounds, and MRIs) need to be reviewed. This information allows surgeons to make a more educated decision regarding the most appropriate reconstruction option. They also need to be more proficient in understanding margin status, because positive margins could potentially compromise the reconstruction. Most reconstructive surgeons already have an interest in breast cancer reconstruction, a knowledge of breast cancer management, and the required skill sets (for example, reduction techniques, local flaps, and the latissimus dorsi flap). Another requirement is a referral source from ablative surgeons. Most plastic surgical training programs thoroughly cover the various reconstructive tools necessary to perform partial breast reconstruction. The various principles are essentially the same as those practiced in aesthetic and reconstructive breast surgery. A referral source can be established from within your institution, within the community, or even from patients. Adequately educating the involved parties on the various aspects of partial breast reconstruction and familiarizing them with the options will invariably increase the number of partial breast reconstructions in your practice.

Educational Tools for Reconstructive Surgeons

Box 3-1 Topics to Include in Educational Seminars for Referring Physicians

- An introduction and discussion of the trend for more breast conservation
 - Patient or physician demand
 - Improved breast imaging
- Chemotherapy down-staging
 - More postmastectomy radiation
 - Poor candidates for SSM and reconstruction
- The unfavorable result: how to predict and prevent it
 - Tumor/breast ratio
 - Tumor size
 - Tumor location
 - Breast size and shape
- Indications for partial breast reconstruction
 - Which patients and why?
 - Broadening the indications for BCT
 - Minimizing poor cosmetic results
 - The techniques available for partial breast reconstruction
- Volume replacement techniques
- Volume displacement techniques
- Patient examples with photodocumentation
- Why oncoplastic techniques would be beneficial to the patient, the ablative surgeon, and the reconstructive surgeon
- The oncologic safety of this approach
 - Margins
 - Timing
 - Surveillance
- How to establish a relationship that will effectively and efficiently deliver the most comprehensive treatment options for the patient
 - Patient flow
 - Information flow
 - Scheduling

The above options may be used to provide and receive education:

- Establish a referral source.
- Participate at local breast tumor board meetings.
- Provide patient education at local support group meetings.
- Attend senology group meetings (multidisciplinary team conference).
- Review imaging studies together with the breast surgeon and the radiologist.
- Gain an understanding of breast conservation, including the margins and the extent of the resection.
- Teach courses at national meetings and symposia.
- Gain a greater understanding of breast irradiation.

Another alternative is to develop a multidisciplinary breast clinic at your institution for the management of women with breast cancer. This approach has all of the necessary specialties available for rapid coordination of care and lends itself well to the oncoplastic approach. It also encourages communication and ensures that all appropriate alternatives are discussed and available to the patient. It also is important that protocols are developed to address reimbursement issues.

Current Opinions in the United States

Table 3-1 Partial Breast Reconstruction at the Time of Lumpectomy Is Limited in Your Practice by (Please Select All That Apply):

Answer Options	ASBS (%)	ASPS (%)
No available plastic surgeon	10.3	0.5
No breast surgeon referring these patients	2.7	50.2
Scheduling difficulties	10.8	9.3
Financial constraints	5.8	2.9
It is not limited	69.7	33.2
Other	8.3	15.1

A recent survey reflects the opinions of breast surgeons (American Society of Breast Surgeons [ASBS]) and plastic surgeons (American Society of Plastic Surgeons [ASPS]) when it comes to the oncoplastic approach. Some of the opinions are summarized in the above table and those to follow.

When asked about who should be performing the partial reconstruction, 42.8% of breast surgeons felt that any combination would work as agreed on by the team, and 50.7% of plastic surgeons felt that it was better for a breast surgeon and a plastic surgeon to perform the procedure.

Most respondents in both groups (51.4% of breast surgeons versus 62.1% of plastic surgeons) felt that reconstructing partial mastectomy defects using complex flaps and reduction techniques were best performed using the team approach.

The majority (77%) of breast surgeons felt that it is best to perform partial reconstruction at the time of lumpectomy, compared with 55% of plastic surgeons. More plastic surgeons felt that it was best only once clear margins had been confirmed (28.7% of plastic surgeons versus 17.3% of breast surgeons).

Table 3-2 Your Main Concern About Partial Breast Reconstruction at the Time of Lumpectomy Is (Please Select All That Apply):

Answer Options	ABS (%)	ASPS (%)
None	15.5	8.8
Ensuring no margin involvement	73.8	72.7
Long-term oncologic safety	10.5	30.7
The aesthetic result	20.4	26.8
Limited indications	9.9	10.2
Other (please specify)	3.1	4.4

The majority of breast surgeons (73.8%) and plastic surgeons (72.7%) felt that the main concern with partial reconstruction at the time of lumpectomy was ensuring clear margins.

Table 3-3 What Do You Believe Is the Primary Driving Factor for Partial Reconstruction of the Lumpectomy Defect?

Answer Options	ABS (%)	ASPS (%)
Oncologic benefits	0.4%	0.5%
Aesthetic benefits (patient quality of life)	58.5%	59.4%
Oncologic <i>and</i> aesthetic benefits	35.2%	29.2%
Financial benefits	3.6%	4.5%
Other (please specify)	2.2%	6.4%

Pearson Chi2 = 5.8876; degrees of freedom = 4; *p* value = 0.208 NS.

Aesthetic benefits were agreed on for both breast surgeons (58.5%) and plastic surgeons (59.4%) as the main driving force for performing partial reconstruction of the lumpectomy defect.

Both breast and plastic surgeons agree that an increased awareness will be required to further expand the adoption of these techniques in the treatment of breast cancer. Sixty-seven percent of breast surgeons felt that this could be achieved by better training breast surgeons in oncoplastic techniques, whereas 74.9% of plastic surgeons felt that increased awareness for breast and plastic surgeons would improve adoption.

CONCLUSION

The oncoplastic techniques are exciting additions to the management of women with breast cancer who wish to preserve their breasts. The combination of thoughtful resections and reconstructions, when necessary, is beneficial for numerous reasons, and it has been a challenging, yet fun, addition to our reconstructive practices. As is true for any surgical procedure, it takes marketing and promotions to be able to incorporate this approach into your practice. For most of us, it is important to establish a relationship with an ablative or reconstructive surgeon and offer state-of-the-art procedures through a multidisciplinary team. The single-surgeon approach is also an option and lends itself well to rapidly being able to incorporate these techniques into your practice; however, it does require sufficient training and expertise in both ablative and reconstructive surgery.

We owe it to our patients and colleagues to maintain an oncoplastic database with clinical data regarding procedures, complications, and outcomes. This book details much of the information necessary for incorporating oncoplastic techniques into your practice, refining techniques, improving outcomes, and achieving optimal patient satisfaction.

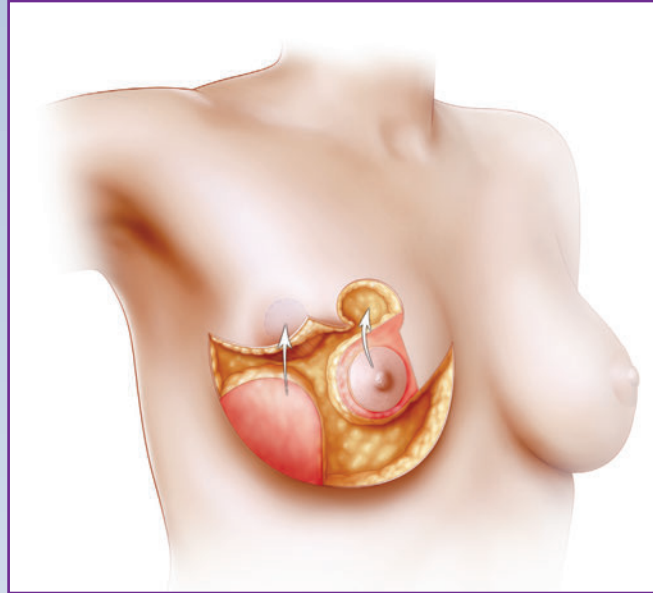
Critical Issues

- Provide patient care, support, and education.
- Offer the entire spectrum of options to the patient.
- Establish a viable oncoplastic model.
- Stress the importance of the team approach.
- Ensure that everyone involved—patients and surgeons—will benefit from incorporating these oncoplastic techniques into your practice.

Suggested Reading

Losken A, Kapadia S, Egro FM, et al. Current opinion on the oncoplastic approach in the USA. *Breast J* 2016 Apr 9. [Epub ahead of print]

PART TWO



Principles and Considerations of Oncoplastic Breast Conservation

4

Applied Anatomy and Breast Aesthetics: Definition and Assessment

Albert Losken



As surgical approaches to breast surgery continue to evolve and improve, some aspects remain the same, such as breast anatomy and our understanding of the qualities that make an aesthetically pleasing breast form. It is crucial to have a thorough understanding of breast anatomy and an aesthetic ideal or goal when performing breast surgery. In this chapter we discuss basic breast anatomy and the factors that define the aesthetic ideal of breast form. These concepts should be reviewed and applied to every surgical procedure performed on the breast.

BREAST EMBRYOLOGY AND DEVELOPMENT

The breast is a specialized gland that originates from the ectoderm. The fetal breast begins to form during the sixth week of gestation, with the growth of a milk ridge extending from the axilla to the groin. By the eighth to tenth week of development, the epithelium in the pectoral region begins to differentiate into breast tissue.

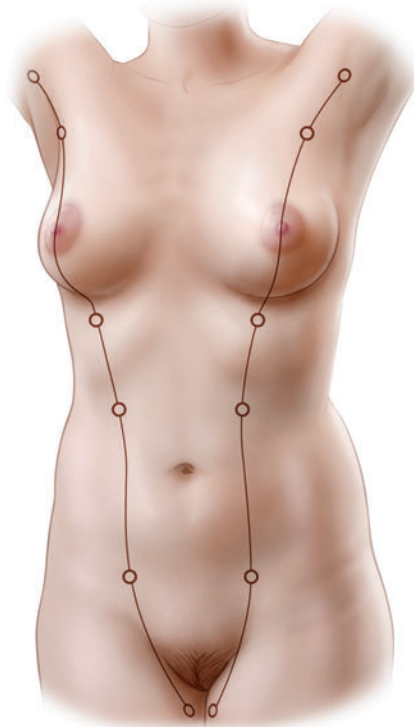


Fig. 4-1

Supernumerary breasts and nipples can be found anywhere along the milk ridge and may be capable of both lactation and cancer formation.

After birth, an infant's breast may secrete milk for a short time because of high levels of circulating maternal hormones. The breast tissue becomes dormant until puberty, which normally occurs between the ages of 9 and 14. At this time, a breast bud develops just beneath the nipple and may be firm and tender. During puberty, the breast bud begins to grow in response to increased levels of circulating hormones. Lobular units develop, and ducts elongate and branch. Breast development usually concludes when the individual reaches her maximum vertical height. The postpubertal breast continues to change according to cyclic variations in the circulating hormones.

Congenital breast asymmetry may occur. If cancer is diagnosed in the larger breast, then symmetry may be improved after breast-conserving therapy (BCT), as long as the breast shape is preserved.

BREAST COMPOSITION

The breast comprises many subunits: skin, glandular parenchyma, fat, blood vessels, nerves, lymphatics, and connective tissue. Each of these breast subunits must be considered when closing or reconstructing partial mastectomy defects to avoid potential contour irregularities and deformities.

The breast is also closely associated with the underlying muscle and chest wall, which contribute to the overall form, shape, and appearance of the breast. The breast's boundaries extend from the clavicle to the inframammary crease in the craniocaudal direction and from the midsternum to the lateral breast fold in the mediolateral direction. The breast's axillary tail extends through the axillary fascia into the axillary tissue. Fascial attachments anchor the breast to the chest wall and skin.

The Skin

The breast skin is a very important component of breast anatomy. The quality, elasticity, and thickness of the skin significantly influence the overall appearance of the breast. Differences in skin types alter outcomes in breast surgery. For instance, patients with thin, poorly elastic skin develop recurrent ptosis after mastopexy at a much faster pace than those with thick, more elastic skin.

The patient's age, hormone levels, and weight fluctuations—as well as gravity and external factors such as radiotherapy—can significantly alter the quality of the breast skin. If the skin becomes overstretched, striae and tears can occur. If the skin is thin and stretched too much during breast surgery, scars may widen. The thickness of the dermis varies in different regions of the breast. The dermis is very thin in the central portion of the breast around the nipple and areola. This contributes to the protrusion of glandular tissue through this region, resulting in deformities such as tubular or tuberous breasts. The dermis becomes much thicker and adheres more to the epithelium near the inframammary crease, which is why it is more difficult to deepithelialize skin in this region. Breast remodeling should minimize the use of skin for shaping.

The surgeon must thoroughly understand the blood and nerve supply to the breast skin to prevent ischemia or numbness after breast surgery. To minimize morbidity, the surgeon must also be aware of previous incisions when planning breast surgery. The primary blood supply is from the subdermal plexus, which communicates with underlying parenchymal and chest wall perforators. Innervation of the breast skin is segmental and follows typical dermatomal patterns. Breast skin innervation comes primarily from the anteromedial and anterolateral branches off the intercostal nerves at the level of T3-5. Upper breast sensation also derives from branches emanating from the lower cervical plexus.

Skin replacement is often required to preserve shape, especially in women with smaller breasts who undergo quadrantectomy-type resections.

Skin replacement is intentionally overcorrected in anticipation of fibrosis. To minimize skin necrosis, skin flaps should not be extensively undermined. The flap should be designed and inset in a manner that reconstructs aesthetic units to minimize the patchwork appearance.

The Glandular Parenchyma

The majority of the breast volume consists of glandular parenchyma and fat. The proportions of each of these components vary from person to person. Factors such as genetics, hormones, weight fluctuations, age, and the percentage of body fat influence this balance.

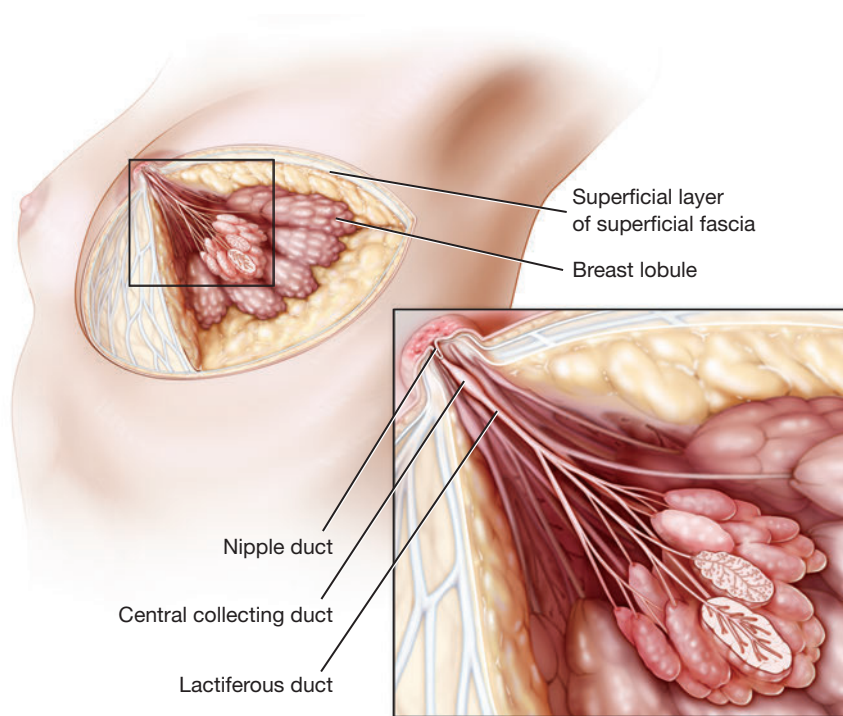


Fig. 4-2

The glandular component of breast parenchyma is specialized for producing and secreting milk. It consists of an intricate system of breast lobules that are distributed radially throughout the breast tissue. The functional subunits of each breast lobule are hundreds of secretory acini that empty their secretions into interlobular ducts. The interlobular ducts then drain into lactiferous ducts, which carry secretions to central collecting ducts located below the nipple. These secretions exit the nipple through nipple ducts.

This ductal system allows bacteria to colonize the breast. *Staphylococcus epidermidis* may be cultured in breast tissue and can increase the risk of a postoperative wound infection.

The Fat

The fat content affects the shape, contour, softness, and texture of the breast. Fattier breasts are generally softer and more supple, but they tend to develop ptosis more quickly. In addition, fatty breasts are more likely to develop fat necrosis. Densely glandular breasts tend to be firm and more irregular but usually maintain their shape longer. After menopause the content of breast fat increases and the amount of glandular tissue decreases. Exogenous hormone administration slows this process.

The Connective Tissue

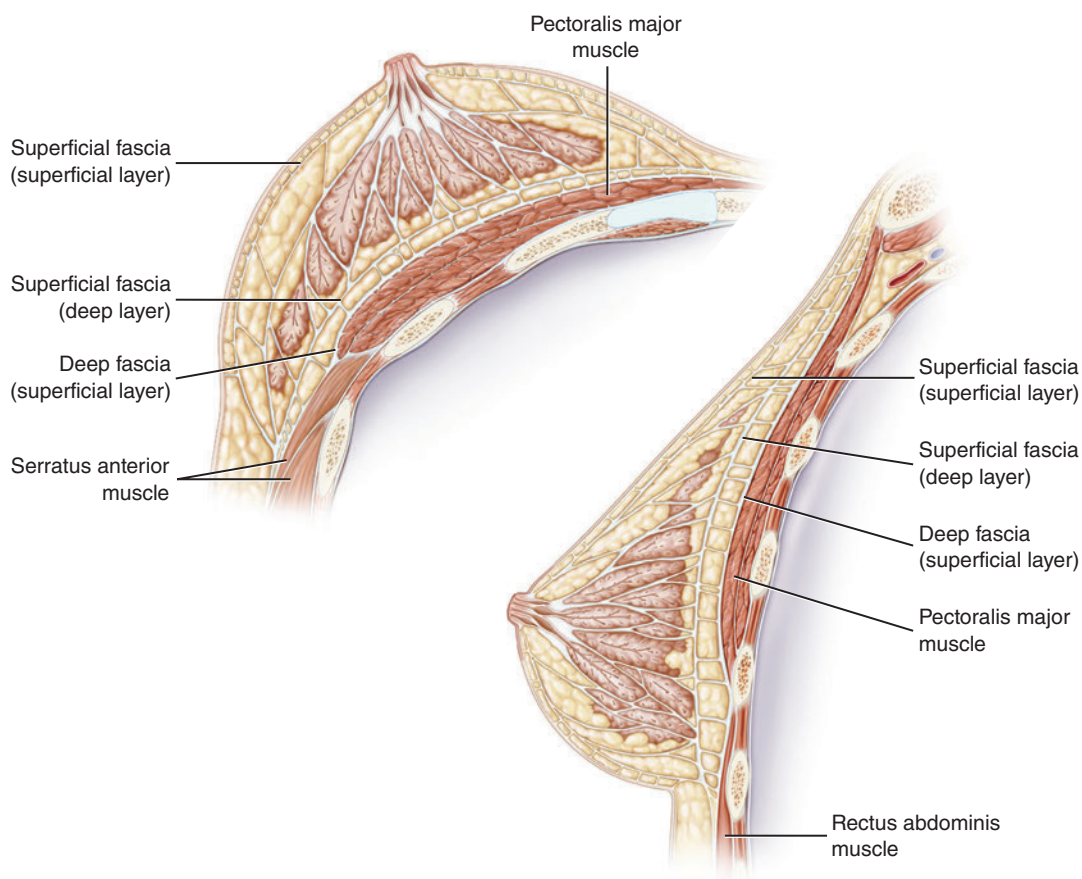


Fig. 4-3

Within the breast, multiple supporting layers of connective tissue help to maintain the form, shape, and appearance. The fascia is divided into superficial and deep layers. The superficial layer is further subdivided into superficial and deep layers. The superficial layer of the superficial fascia is located just beneath the dermis; it is the outermost covering of the breast parenchyma. Depending on the individual, there may be a thin layer of subcutaneous fat between the dermis and the superficial fascia. This is the location of the subdermal plexus of blood vessels, which supplies blood to the skin.

The deep layer of the superficial fascia is located on the posterior surface of the breast and separates the parenchyma from the underlying deep fascia covering the chest muscles. A thin layer of loose areolar connective tissue separates these two fascial planes. The deep fascia covers the pectoralis major, serratus anterior, external oblique, and upper portion of the rectus abdominis muscles beneath the breast.

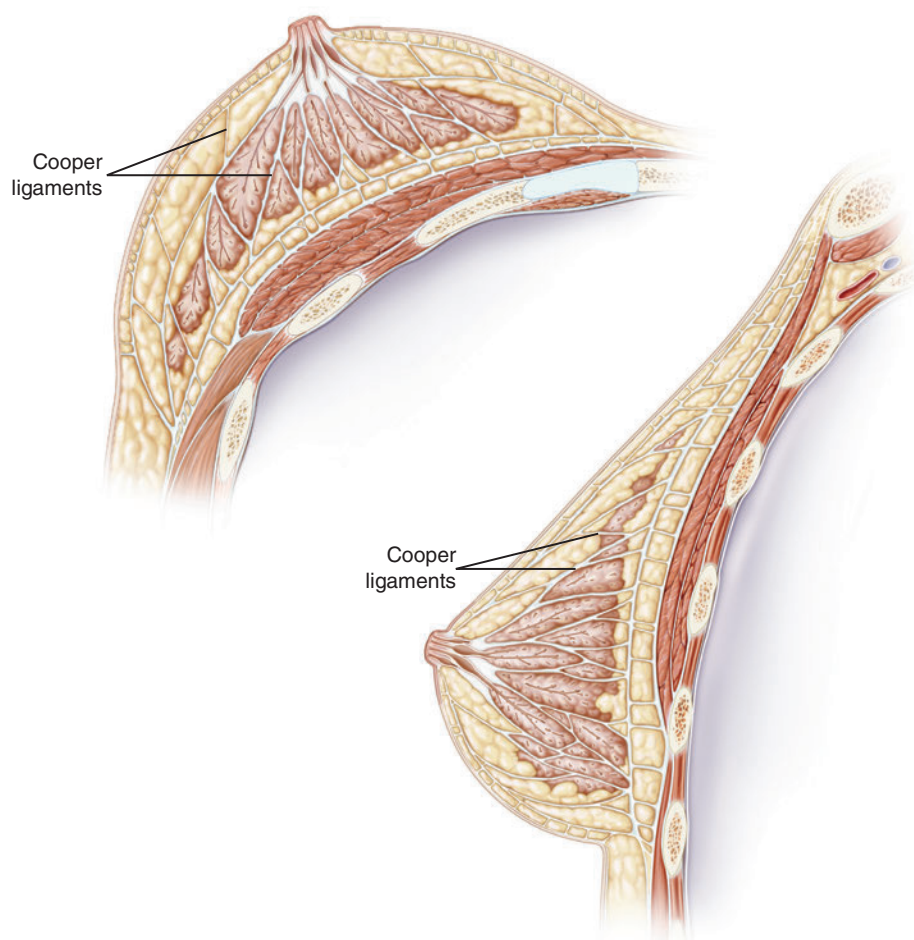


Fig. 4-4

The suspensory ligaments of Cooper contribute to breast form, shape, and elasticity. These connective tissue bands attach to the deep fascia and pass through both layers of the superficial fascia and the breast parenchyma before attaching to the dermis. Cooper

ligaments stretch with weight fluctuations, aging, and pregnancy, causing elongation and decreased elasticity and contributing to breast ptosis. Appreciating the ligamentous structures of the breast is required to accurately reposition the breast subunits when local parenchymal flaps are used.

The Muscles

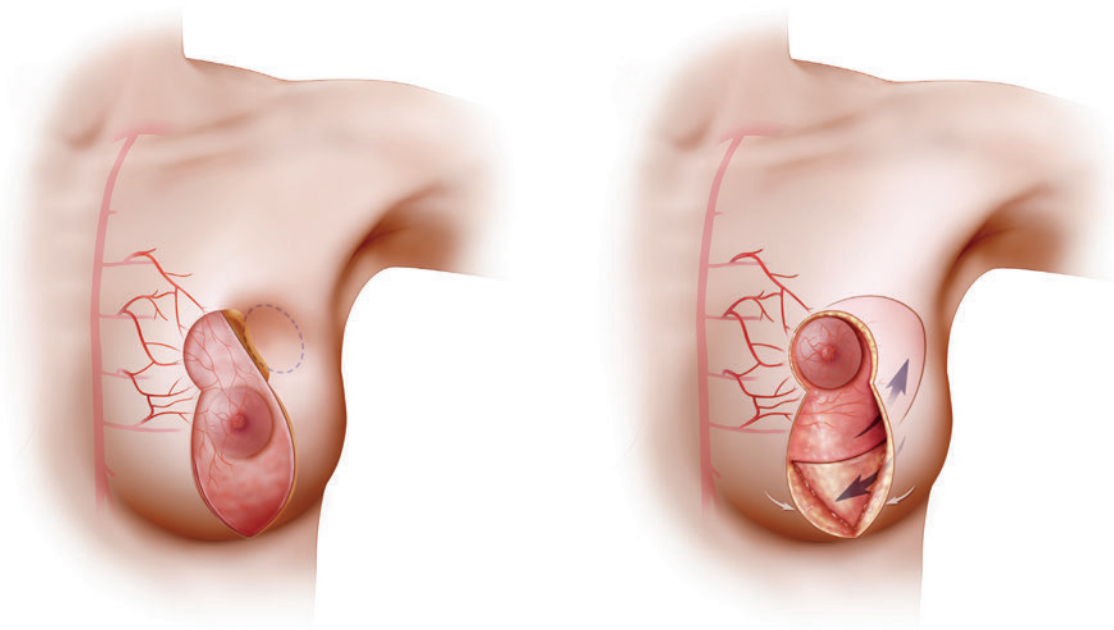
It is important to understand the musculature of the anterolateral chest wall because of its shared blood, nerve, and lymphatic supply with the breasts. These muscles also play a prominent role in breast reconstruction and aesthetic breast surgery. Additionally, their absence or partial absence, as in Poland's syndrome, has a profound impact on the appearance of the breast.

Table 4-1 Anatomy of the Major Anterior Chest Wall and Abdominal Muscles

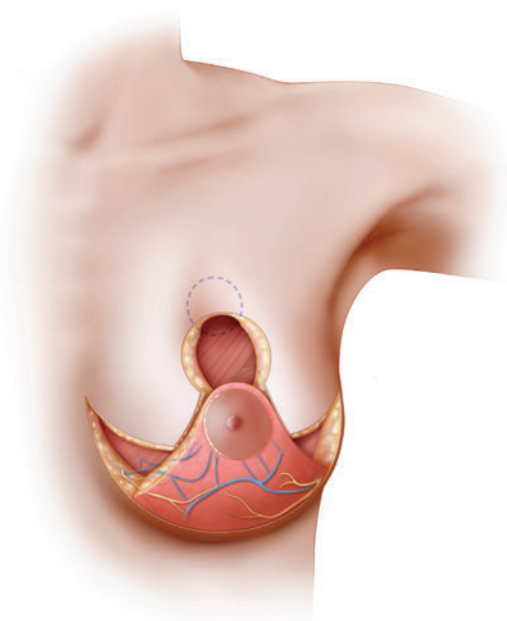
Muscle	Origin	Insertion	Nerve Supply	Blood Supply
Pectoralis major	Sternum, clavicle, rectus fascia, external oblique fascia	Humerus	Medial pectoral nerve, lateral pectoral nerve	Mammary perforators, thoracoacromial artery, anteromedial and anterolateral intercostal perforators
Pectoralis minor	Third to sixth ribs	Scapula	Medial pectoral nerve	Pectoral branch of thoracoacromial artery
Serratus anterior	First to eighth ribs	Scapula	Long thoracic nerve	Intercostal perforators
Rectus abdominis	Pubis	Fifth to seventh costal cartilages	Intercostal nerve branches	Superior and inferior epigastric arteries
External oblique	Fifth to twelfth ribs	Iliac crest, inguinal ligament	Lower six intercostal nerves	Intercostal artery

The major muscles of interest are the pectoralis major and minor muscles, which lie beneath the upper central and lower medial portions of the breast. The lower lateral breast tissue covers the serratus anterior, the upper portion of the rectus abdominis, and the upper external oblique muscles.

The Blood Supply



Superomedial pedicle showing blood supply



Inferior pedicle showing venous drainage and nerves

Fig. 4-5

The blood supply to the breast comes from numerous sources and allows many different approaches to breast surgery. Multiple factors can influence how robust each of these sources of inflow may be. The patient's age, endocrine activity, overall health, and microcirculation alter the inflow. After menopause, blood flow to the breast decreases. Likewise,

the quality of the microcirculation is altered by conditions such as diabetes, atherosclerotic disease, collagen vascular disease, smoking, and radiotherapy. Because of the substantial collateralization of arterial flow within breast tissue, survival of the entire breast is possible with only a fraction of the inflow.

It is very important to understand the intimate relationships among the blood supply to the chest wall, the breast parenchyma, and the overlying breast skin when planning reconstructive and aesthetic breast surgical procedures. In addition, it is critical to appreciate the blood supply when raising large parenchymal flaps and to maximize the blood supply to prevent ischemia in breast surgery. Suture plication should be minimized to prevent tissue ischemia.

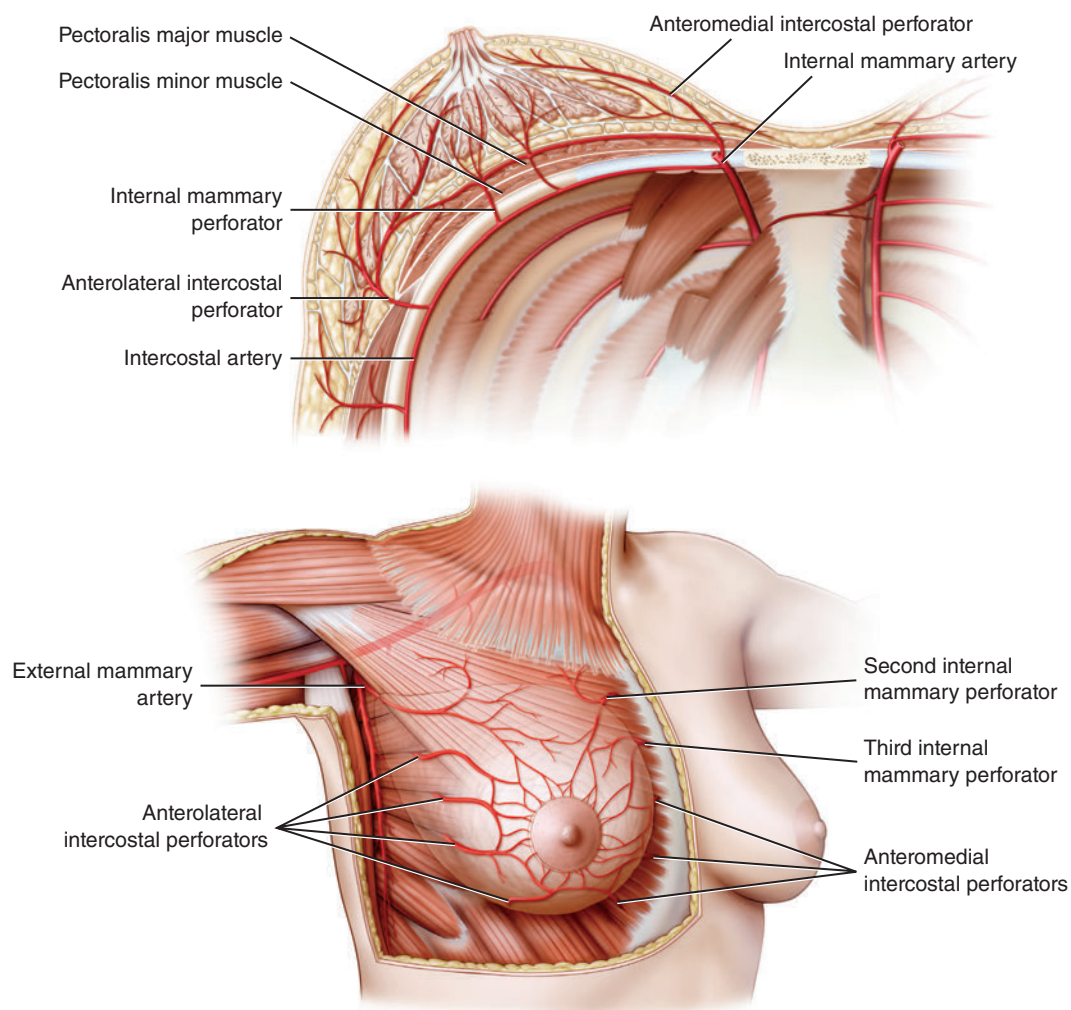


Fig. 4-6

The major sources of inflow to the breast, from medial to lateral, are the internal mammary segmental perforators, the intercostal perforators, the thoracoacromial perforators, and the external mammary artery. The internal mammary perforators penetrate the medial intercostal spaces between the second and sixth ribs. They supply the pectoralis major

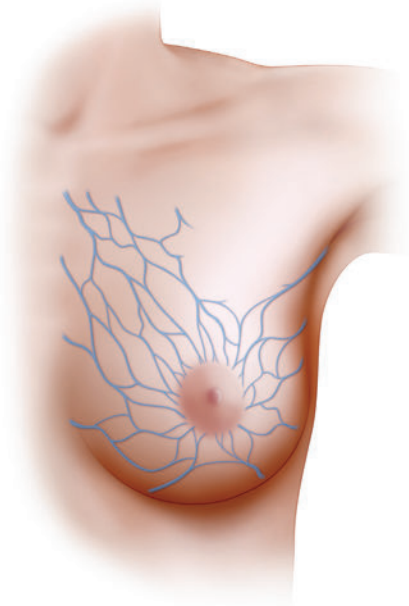
muscle, the breast tissue, and the overlying skin. The second and third perforators are the largest, and they supply the primary blood flow to the upper medial breast. These provide the dominant blood supply to the pedicle in the superomedial reduction mammaplasty technique.

The intercostal perforators exit from the intercostal arteries in the third through sixth intercostal spaces. They penetrate the chest wall at the lateral margin of the pectoralis major muscle, pass through the serratus anterior muscle, and enter the breast parenchyma. These perforators supply the lateral breast tissue and skin, and they send branches to the latissimus dorsi muscle.

Another group of intercostal perforators (anteromedial) supplies the central and lower medial aspect of the breast parenchyma. These perforators penetrate the chest wall in the fourth through sixth intercostal spaces. They are the primary source of blood flow to the pedicle in the inferior central mound reduction mammaplasty technique. The anteromedial and anterolateral intercostal perforators extend to the NAC and are major contributors to vascularization of the nipple.

The thoracoacromial artery enters the pectoralis major muscle and supplies perforators to the overlying upper, central, and lower breast tissue. During augmentation mammaplasty, these perforators are divided in the subglandular dissection but are preserved in the submuscular dissection. The external mammary artery enters the upper lateral breast after exiting the axillary artery. This artery may be as large as 2 to 3 mm in diameter and may provide nourishment to the entire breast.

Unnecessary undermining on the breast periphery should be minimized, because it could jeopardize the use of perforators from the intercostal muscles that could be used as perforator flaps. This could also compromise breast perfusion, resulting in skin and fat necrosis.

**Fig. 4-7**

The venous drainage of the breast is a dual system based on a superficial subdermal plexus and a deep system, which parallels the deep arterial supply. The subdermal venous plexus originates in the periareolar region and drains superiorly and medially. Eventually it meets up with the deep system. The deep veins generally follow the arterial supply. The internal mammary perforator veins drain into the internal mammary vein, which empties into the innominate vein. Other deep veins empty into the external mammary and axillary veins. The anterolateral intercostal perforating veins empty into the azygos vein and then into the superior vena cava.

The Nerve Supply

The nerve supply to the breast is abundant, with a significant amount of overlap between contributing segmental nerve providers. The medial and central breast sensations come from the second through the sixth anteromedial intercostal nerves. The third, fourth, and fifth anteromedial intercostal nerves and the corresponding anterolateral intercostal nerves contribute to nipple-areola sensation. The lateral and anterolateral intercostal nerves combine to provide sensation to the lateral breast tissue and overlying skin. Supraclavicular sensory nerves emanating from the cervical plexus travel beneath the platysma muscle to supplement the innervation of the upper breast skin. The second anterolateral intercostal nerve, known as the *intercostobrachial nerve*, supplies sensation to the upper medial arm. This nerve is often divided during axillary dissection and occasionally during endoscopic transaxillary augmentation mammaplasty, causing anesthesia and paresthesia of the upper medial arm.

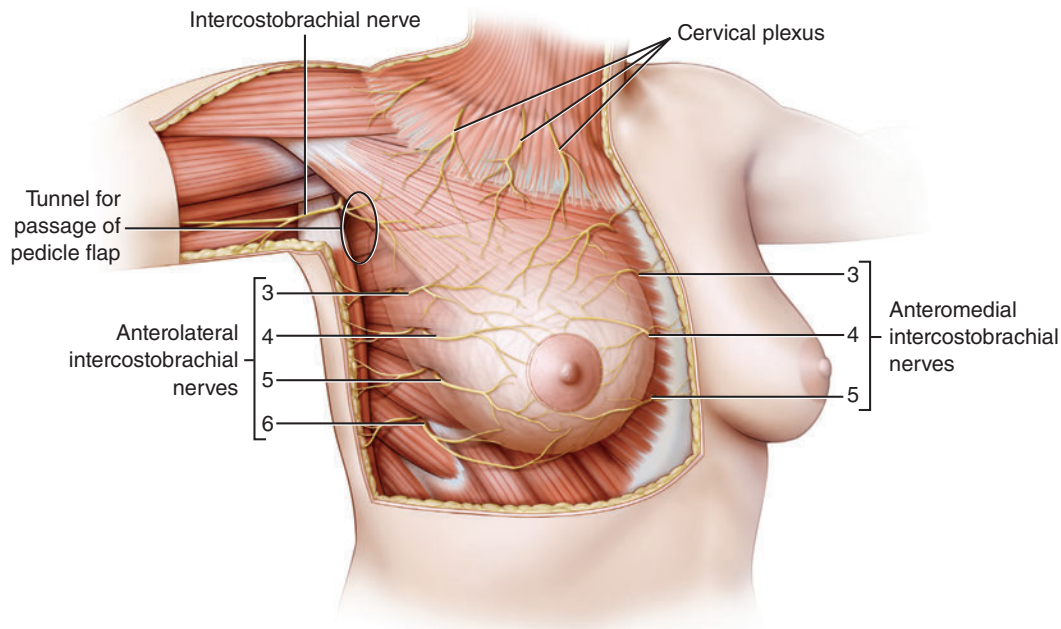


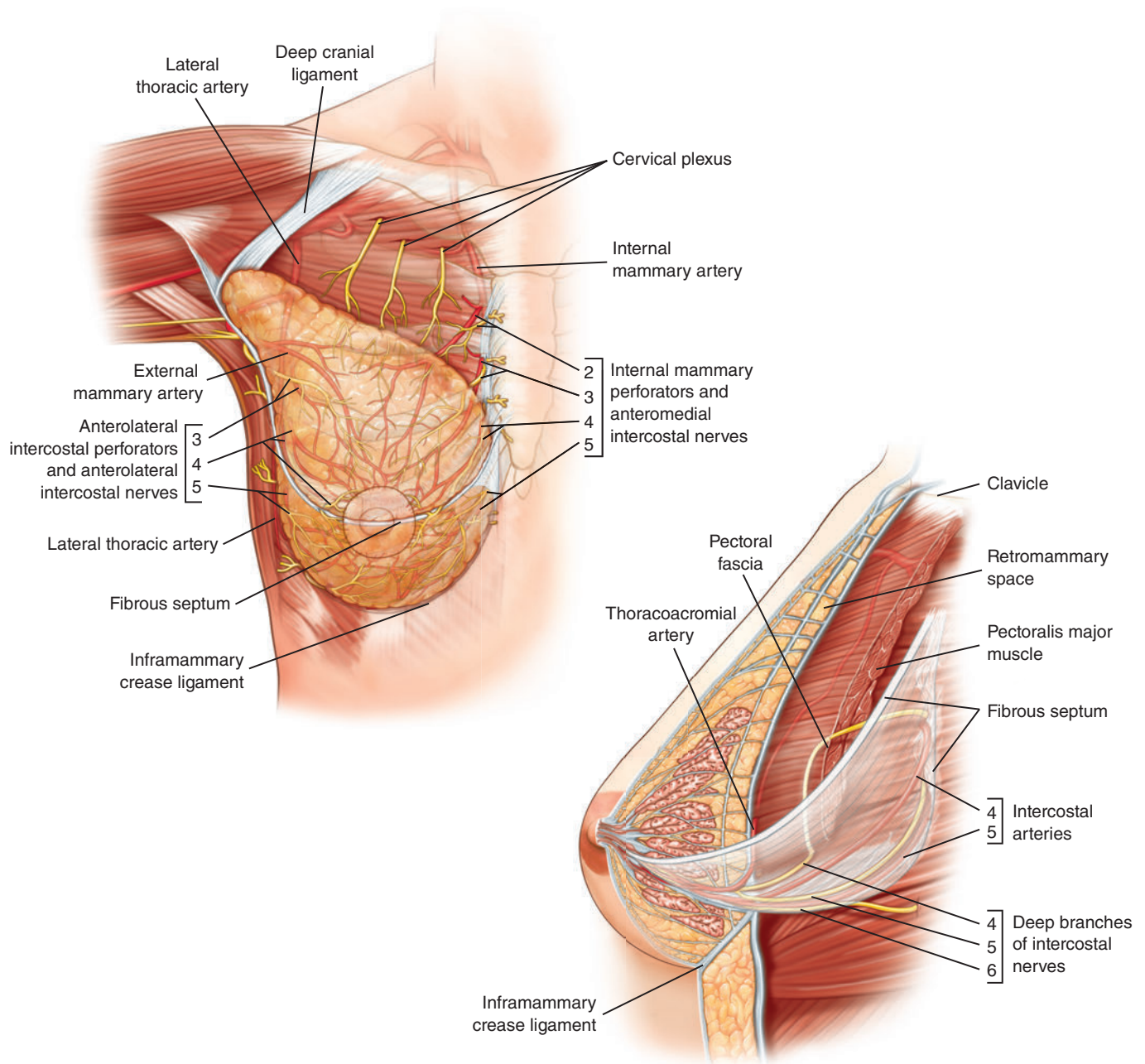
Fig. 4-8

Painful neuromas may form after dividing the anterolateral intercostal nerves; these occasionally require surgical excision. Note that in this surgery, a high dissection tunnel was made to accommodate passage of the latissimus dorsi muscle, preserving the neurovascular attachments and cosmetic units on the lateral chest wall.

Careful consideration of the nerve supply during surgery helps to maximize nipple sensation. When pedicled flaps are passed into partial mastectomy defects, the tunnel should be created high enough to avoid lateral denervation to the breast.

The Würinger Septum

Würinger described a suspension apparatus, which is attached to the thoracic wall, mainly following the borders of the pectoralis major. This ligamentous suspension carries the whole weight of the breast like a sling. The horizontal septum takes its origin from the periosteum of the fifth rib and merges medially into a vertical medial ligament, which attaches to the sternum. Laterally, the septum merges into a lateral vertical ligament, which originates from the pectoral fascia at the lateral edge of pectoralis minor. These ligaments continue into the superficial fascia of the breast in an anterior direction.

**Fig. 4-9**

A ligamentous structure also originates that inserts into the overlying skin, thereby determining the shape of the breast. It builds the cleavage medially as well as the inframammary fold inferiorly. Laterally, it forms a strong ligament heading into the skin of the axilla, the suspensory ligament of the axilla, which shapes the axillary hollow.

The ligamentous suspension not only has an important shaping potential, but also is the guiding structure of the main nerves and vessels to the nipple. Rising from the thoracic wall, the neurovascular structures attach to the ligamentous sling, while traveling to the

nipple, where they build a subdermal plexus. The neurovascular supply runs along two main pathways, namely a central source along the horizontal septum, as well as a superficial source along the vertical ligaments merging into the capsule of the breast. Either part of this rich neurovascular supply is sufficient to nourish the nipple-bearing pedicle: the superficial dermal path through a dermal pedicle, or a parenchymal path including the horizontal septum. This septum was incorporated in different techniques of mammaplasty and has an increasing benefit in displacement technique for oncoplastic surgery.

The Lymphatic System

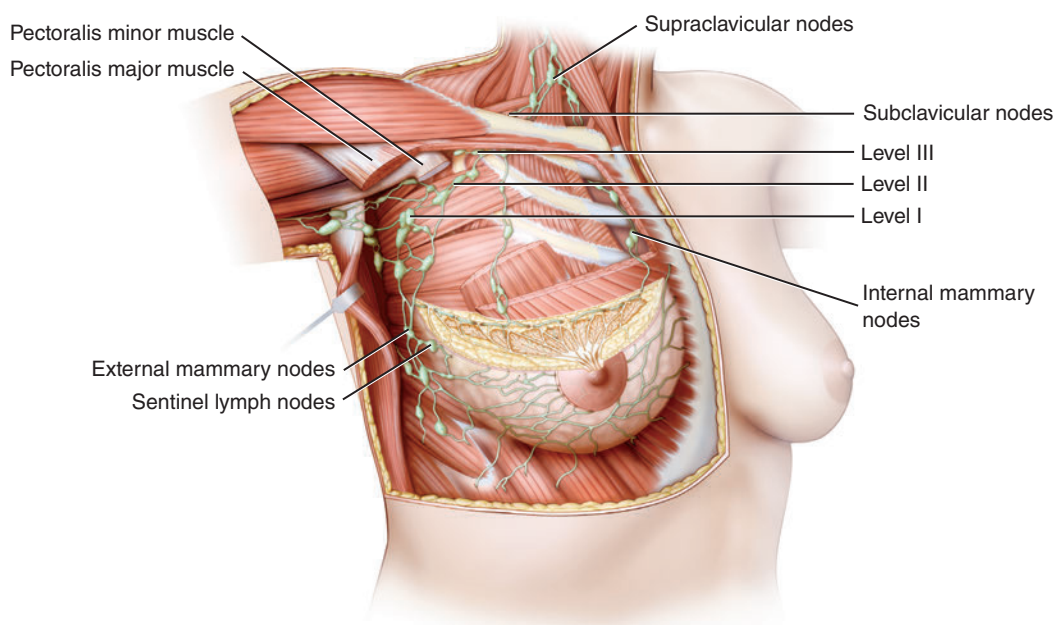


Fig. 4-10

Similar to the venous drainage system, there is a superficial and a deep lymphatic network in the breast. The superficial system parallels the subdermal venous plexus in the peri-areolar region. The deep lymphatic system drains each lactiferous duct and lobule. The deep lymphatics penetrate the deep fascia and muscle and empty into the deep pectoral or subscapular nodes. They travel to the central axillary, apical axillary, and supraclavicular nodes.

Medially, another set of lymphatic channels drains in parallel with the internal mammary perforators to the parasternal nodes. Disrupting the lymphatic channels during breast surgery can increase the risk of lymphedema of the upper extremity.

During lymph node sampling, preservation of the thoracodorsal system and various perforators ensures that all of the reconstructive options are still available.

BREAST AESTHETICS AND ASSESSMENT

Principles

Every surgical procedure of the breast should be considered and planned with an understanding of what constitutes an aesthetically pleasing breast. Although the aesthetic ideal varies among different people and cultures, breast surgeons generally agree about what features are aesthetically pleasing. The breast form should appear soft, with gentle curves and a proper nipple position. The transition from the chest wall to the breast should be smooth and tapered. The lateral breast border and inframammary crease should be well defined. The NAC should be positioned at the point of maximal breast projection, with an appropriate ratio of parenchymal tissue above and below the nipple. With the patient in the upright position, approximately one third of the breast tissue should be located above the nipple, with two thirds below. It is extremely important that the breast be in proportion with the remainder of the patient's body. The breast skin should be smooth, soft, and elastic.

Achieving these aesthetic ideals in breast surgery typically requires that the surgeon address the size, shape, and symmetry of the breast, as well as the locations of previous and future scars. In the following paragraphs, we discuss these defining components and the effects of differing body types on the appearance of the breast.

Size

The concept of an ideal breast size probably varies the most, with differing personal and societal preferences. It is important to balance a woman's breast size with the rest of her figure. Extremely small breasts on a large-framed woman appear abnormal, as do extremely large breasts on a small-framed woman. Likewise, large breasts on a large woman give the impression that she is overweight. Good communication between the patient and surgeon regarding an appropriate breast size is crucial to obtaining a positive outcome. Consideration of the patient's breast base width helps to minimize complications from implant rippling, rupture, and extrusion when choosing the implant size during augmentation mammoplasty and implant reconstruction. With breast reconstruction, the patient's wish for a specific breast size may significantly alter the reconstructive options offered.

Shape

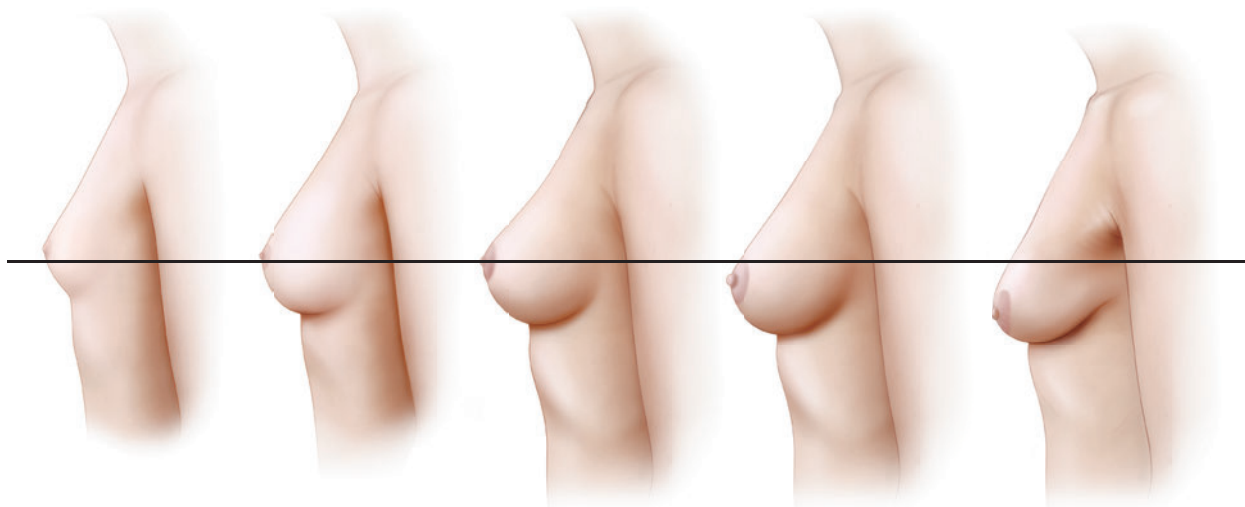


Fig. 4-11

The ideal breast shape incorporates the appropriate volume, projection, and contour. The breast shape changes significantly with age. The pubertal breast is typically round, with fairly equal distribution of breast tissue above and below the nipple. The upper breast becomes flatter, and the lower, outer breast becomes fuller as a woman matures. Flattening of the upper breast continues with aging, and the glandular parenchyma and NAC continue to descend inferiorly and laterally.

The volume of breast tissue and the quality and elasticity of a woman's skin alter the speed at which this aging process occurs. Additionally, the integrity of the fascia and of Cooper ligaments affects the degree of ptosis that occurs. The ratio of fat to glandular tissue in the breast also significantly alters this process. Cyclic breast volume changes, pregnancy, lactation, and fluctuations in body weight will influence each of these factors and may lead to changes in the breast shape.

A proper breast evaluation includes grading the breast ptosis. Many variations in the classification of breast ptosis have been reported; however, most breast surgeons accept the system described by Regnault in 1976. Regnault's description of breast ptosis is based on the relationship between the NAC and the inframammary fold. The modern-day classification of ptosis may be summarized as the following:

- *Grade 1: Mild ptosis* The nipple is just below the inframammary fold, but is still above the lower pole of the breast.
- *Grade 2: Moderate ptosis* The nipple is further below the inframammary fold, but some lower pole tissue is still below the nipple.
- *Grade 3: Severe ptosis* The nipple is well below the inframammary fold, with no lower pole tissue below the nipple.
- *Pseudoptosis* Inferior pole ptosis is evident, with the nipple at or above the inframammary fold (usually observed in postpartum breast atrophy).

When performing breast surgery, it is desirable to create or restore a youthful breast shape and appearance. This involves placing the NAC in the correct position and maintaining the lateral breast border and inframammary crease. The midline must not be crossed. The breast projection should start at the level of the second or third rib and gradually increase to the nipple. The nipple should be located above the inframammary crease by one or two rib intercostal spaces.

Many women who undergo breast surgery request that superomedial breast fullness or cleavage be created. Patients should understand that this is not a naturally occurring breast appearance and instead is created artificially by support garments. Maintaining this type of superomedial fullness over time without clothing support is unlikely. When indicated, the parenchymal volume should be replaced with subcutaneous fat from local flaps to preserve shape.

Symmetry

Every effort should be made during an aesthetic and reconstructive breast surgery to create a symmetrical appearance between the breasts. They should be comparable in size, shape, and nipple-areola position.

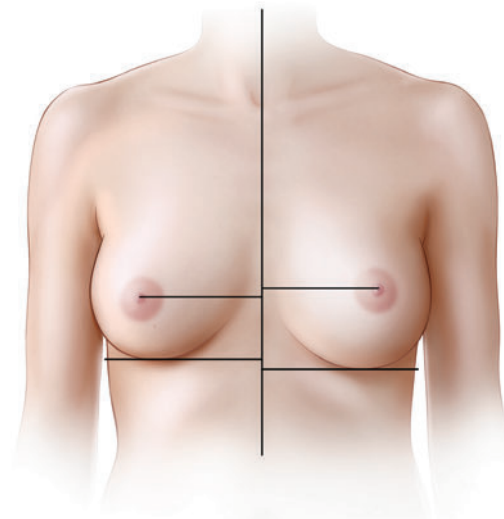


Fig. 4-12

Most commonly, the breasts are slightly different sizes. Subtle differences in the skeletal and muscular composition of the chest wall are also relatively common. Even small postural changes can accentuate small differences between breasts. The surgeon should point these differences out to the patient before surgery, and a discussion regarding the possibilities for improving symmetry should be included in the treatment plan. The breast size, shape, and degree of ptosis are all critical elements that need to be considered when discussing the potential for poor cosmetic results and designing the best reconstructive option.

One of the biggest concerns among patients undergoing breast surgery is asymmetry. In reality, multiple asymmetries exist naturally in paired structures, and the breasts are no exception.

The ideal breast shape should be appreciated to know what to reconstruct or what to preserve. Often the opposite breast is used as a goal in terms of size and shape, especially when flaps are used. Tissue remodeling techniques often adjust both sides.

Scars

The placement of incisions should be carefully considered when developing a surgical plan. A history of hypertrophic scarring or keloids is significant when determining how to proceed with aesthetic breast surgery. Previous breast scars should also be noted to prevent complications with tissue loss. If possible, previous scars can be incorporated into the tissue that will be removed, or they may be used as the access points for the current procedure. In general, all incisions should be planned to leave the scars in the most inconspicuous places possible. Periareolar, vertical, and inframammary crease scars are generally well hidden and accepted by the patient. Scars should be oriented to allow favorable healing.

Aesthetic Subunits of the Breast

Various aesthetic subunits of the breast have been described, outlined by tissue, color, or texture changes. Examples include:

- The breast skin to the areola
- The areola to the nipple
- The breast skin to the chest wall at the inframammary fold
- The anterior axillary line
- The breast to the sternal skin

It has also been demonstrated that expanded concentric circles around the nipple are acceptable, because we are accustomed to viewing a circular areola on the breast. This must be considered when planning resection designs for the oncoplastic technique.

Surgeons performing the oncoplastic approach should focus on the aesthetic subunits when planning cosmetic quadrantectomies, resections, and reconstructions.

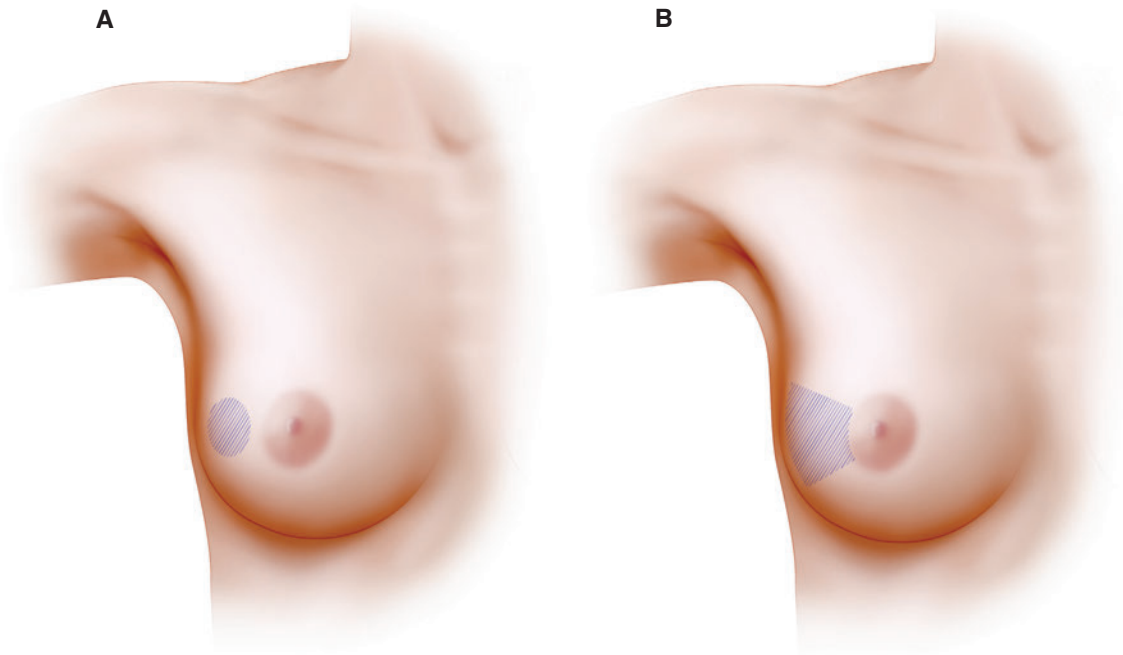


Fig. 4-13

Incisions and flaps should be designed with these units in mind to blend scars or flaps into topographical units and to allow smooth transitions onto the breast mound. Flap reconstruction of partial mastectomy defects is more cosmetically acceptable when the transition points are minimized or when the flap border becomes a transition point. If the aesthetic unit is violated, the reconstructed breast is more likely to have a patchlike appearance (A). Reconstruction of the aesthetic unit improves the appearance, and the flap is less prominent (B).

PATIENT EXAMPLE

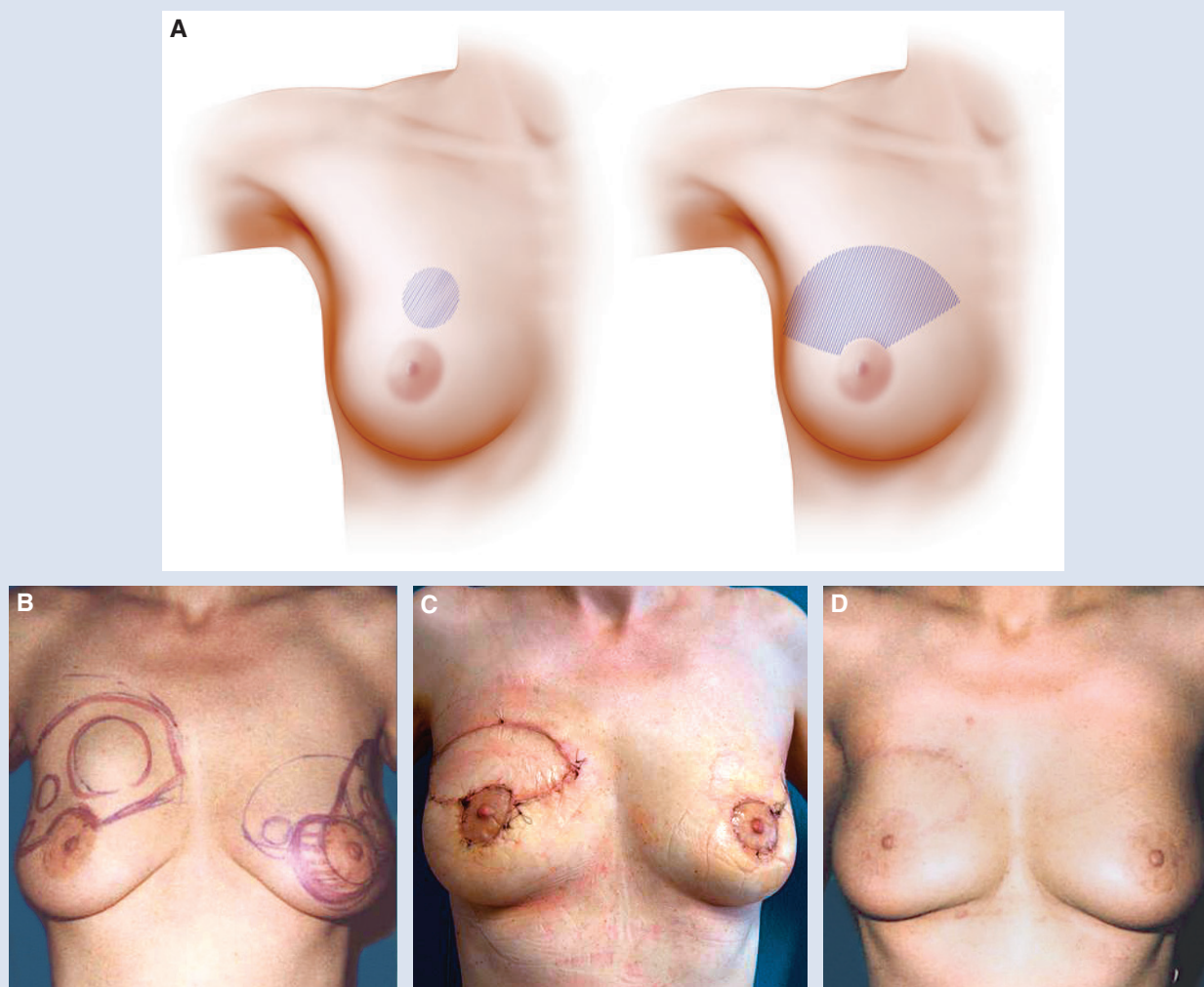


Fig. 4-14

This patient presented with bilateral tumors and wished to avoid involved margins. We had to determine whether she was a good candidate for breast-conserving surgery (BCS), or if a mastectomy with reconstruction would be a better option. The anatomy was unfavorable for the index tumor on each side for either BCS or a mastectomy without a flap (A). This information led to a patient-centered decision, according to her preference and the translation of oncoplastic principles to obtain local clearance. To obtain the highest degree of local control and a cure, she required neoadjuvant chemotherapy, local resection, and radiotherapy. This case was complex, and we used translational oncoplastic surgery with MRI cartography and the preoperative “blueprint” skin markings (B). The plan includes latissimus dorsi reconstruction on the right and tumor-specific reconstruction on the left (C). The patient is shown after the completion of radiotherapy (D).

ASSESSMENT

Knowledge of the anatomic landmarks and their relationship to proper breast proportions is extremely important for planning and executing successful breast surgical procedures. The NAC is the focal point of the breast and is used as a reference point for planning breast surgery. Carefully measuring the breast parenchyma and nipple—as they relate to defining points on the chest—helps to direct the surgical approach.

The breast examination should start with an evaluation of the breast skin. The elasticity, the thickness of the epidermis and dermis, scars, and any defining marks such as tattoos, stretch marks, and contour irregularities should be noted and taken into account during surgical planning. The assessment of the parenchyma includes a breast examination to feel for masses or abnormalities, a nipple inspection for discharge, and a detailed documentation of breast sensation, particularly that of the nipple. Breast ptosis should be noted and graded. Mammography should be performed in all women who meet the criteria, and the threshold for selection should be low. Some advocate mammograms for all women over the age of 40, unless the patient has a strong family history, in which case mammograms should be obtained earlier. The following measurements should be recorded: the base width of each breast, the height of the nipple, the width of the NAC, and the distances from the suprasternal notch to the nipple and from the nipple to the inframammary crease.

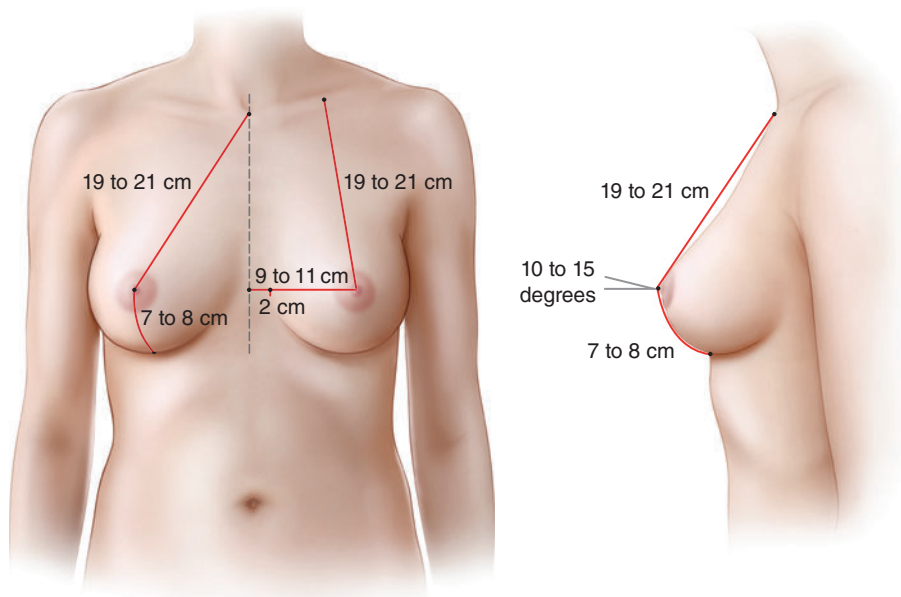


Fig. 4-15

Breast surgeons generally agree that the nipple should be positioned approximately 19 to 21 cm from the sternal notch in the midbreast line. The midbreast line is defined by a line drawn from the midclavicle, through the nipple, to the inframammary crease. The nipple should also be approximately 9 to 11 cm from the midsternal line and 7 to 8 cm from the

inframammary crease. A slight upward and medial nipple tilt of 10% to 15% is considered aesthetically pleasing. The ideal areolar diameter is generally believed to be 35 to 45 mm, with a nipple diameter of 5 to 8 mm and a nipple projection of 4 to 6 mm.

All of these measurements are merely guidelines in breast surgery, and nothing should be thought of as absolute. It is important to take into account the differences in body types when performing breast surgery, and adjustments should be made accordingly. Thin patients with narrow torsos and a low percentage of body fat usually have sharply defined breast borders with thin yet highly elastic skin. This group usually has problems with widening scars and has less subcutaneous and parenchymal tissue available to cover implants.

Women with broader shoulders and compact bodies usually have a greater percentage of total body fat and lower pole fullness in their breasts. These qualities facilitate scar concealment and make more tissue available for implant coverage.

Overweight women with rounded bodies often have a high percentage of total body fat, a wide chest, a full abdomen, and ptotic breasts. The lateral breast border is usually poorly defined because of a large amount of axillary fat. Larger incisions are often required to address this problem. Liposuction may be useful laterally.

Obese women are among the most challenging patients for breast surgeons. These patients often have comorbidities. In addition, their breasts are often fatty, ptotic, and extremely wide. The lateral breast borders are typically absent because of a large amount of axillary fat, and the skin frequently is thin and inelastic with striae. Careful consideration must be given when performing breast reduction to minimize the risk of nipple ischemia or necrosis.

EVALUATING RESULTS

Evaluating the results of cosmetic and reconstructive breast surgery is a topic of ongoing discussion and investigation. This is a particularly difficult task because of the differences in patient preferences and cultural influences. Differing patient body types also make it difficult to ascribe a specific ideal to all patients undergoing breast surgery. Trends in reconstructive surgery have moved toward creating two aesthetically pleasing breasts rather than merely restoring the patient to their previous form. Symmetry procedures in patients who have undergone breast reconstruction are garnering greater interest.

Symmetry with the opposite breast is the ultimate goal; however, shape and size are equally important in terms of outcome and patient satisfaction. The breast shape and size following radiotherapy is not constant and might change with time, resulting in some asymmetry and the need for minor corrections.

Objectively evaluating the results is a challenge. Imaging certainly plays a significant role, and multiple rating scales have been discussed, but it is difficult to draw anything but generalities from these data. Perhaps the ongoing dialogue regarding what constitutes an ideal outcome is as important as any rating scale. We must continue to engage in this dialogue and critique our results to learn from our experiences and to continue to make progress.

CONCLUSION

Thorough knowledge of breast anatomy is necessary to maximize outcomes and patient safety when performing breast surgery. Understanding each patient's wishes and the aesthetic ideals of her breast size and shape helps surgeons to customize their procedures to provide the best result.

Critical Issues

- Breast surgeons must have a thorough understanding of breast anatomy, physiology, and the qualities of an aesthetically pleasing breast shape.
- To decrease the potential for breast deformities, breast surgeons must think in terms of aesthetic subunits during resection and reconstruction.
- Meticulous handling of breast tissue is essential to avoid necrosis, decreased sensation, and lymphedema.
- It is crucial to avoid unnecessary undermining, which might violate perforators.
- The breast size, shape, and degree of ptosis must be considered when discussing the potential for poor cosmetic results and designing the best reconstructive option.
- Natural breast asymmetry and factors that accentuate it should be pointed out to the patient before surgery.
- The surgeon should establish an objective grading system for shape evaluation.
- Objective rating scales are required to accurately evaluate results after a partial breast reconstruction.

Suggested Readings

- Arey LB. Developmental Anatomy, ed 7. Philadelphia: WB Saunders, 1965.
- Baruchin AM, Rosenberg L. Re: axillary breast tissue: clinical presentation and surgical treatment. *Ann Plast Surg* 36:661, 1996.
- Bostwick J III. Plastic and Reconstructive Breast Surgery. Anatomy and Physiology, ed 2. St Louis: Quality Medical Publishing, 2000.
- Carramenha e Costa MA, Carriquiry C, Vasconez LO, et al. An anatomic study of the venous drainage of the transverse rectus abdominis musculocutaneous flap. *Plast Reconstr Surg* 79:208, 1987.
- Clemente CF, ed. Gray's Anatomy of the Human Body, ed 30. Philadelphia: Lea & Febiger, 1985.
- Cooper AP. On the Anatomy of the Breast. London: Longmans, 1840.
- Courtiss EH, Goldwyn RM. Breast sensation before and after plastic surgery. *Plast Reconstr Surg* 58:1, 1976.
- Crosby JF Jr. Aesthetics: the ideas and ideals of beauty. In Masters FW, Lewis JR Jr, eds. Symposium on Aesthetic Surgery of the Nose, Ears, and Chin, vol 6. St Louis: CV Mosby, 1973.
- De Cholnoky T. Accessory breast tissue in the axilla. *N Y State J Med* 51:2245, 1951.
- de la Torre J. Breast mastopexy, 2005. Available at <http://www.emedicine.com/plastic/topic128.htm>.
- Fredericks S. Skeletal and postural relations in augmentation mammoplasty. *Ann Plast Surg* 1:44, 1978.
- Giuliano AE, Guenther JM, Kirgafi DM, et al. Lymphatic mapping and sentinel lymphadenectomy for breast cancer. *Ann Surg* 220:391, 1994.
- Goldman LD, Goldwyn RM. Some anatomical considerations of subcutaneous mastectomy. *Plast Reconstr Surg* 51:501, 1973.
- Goldwyn RM. Plastic and Reconstructive Surgery of the Breast. Boston: Little Brown, 1976.
- Hamdi M, Van Landuyt K, Tonnard P, et al. Septum-based mammoplasty: a surgical technique based on Würinger's septum for breast reduction. *Plast Reconstr Surg* 123:443, 2009.
- Hoffman GW, Elliott LF. The anatomy of the pectoral nerves and its significance to the general and plastic surgeon. *Ann Surg* 205:504, 1987.
- Hoffman S. Reduction mammoplasty: a medicolegal hazard? *Aesthetic Plast Surg* 11:113, 1987.
- Hollingshead H. Textbook of Anatomy, ed 3. New York: Harper & Row, 1974.
- Holman PD, Hetter GP, Peterson RA. Aesthetic concepts of augmentation mammoplasty: breast dynamics in plastic surgery. In Owsley JW, Peterson RA, eds. Symposium on Aesthetic Surgery of the Breast. St Louis: CV Mosby, 1978.
- Kaye BL. Axillary breasts: an aesthetic deformity of the trunk. *Clin Plast Surg* 2:397, 1973.
- Kuzbari R, Deutinger M, Todoroff BP. Surgical treatment of developmental asymmetry of the breast. Long term results. *Scand J Plast Reconstr Surg Hand Surg* 27:203, 1993.
- Letterman G, Schurter M. Suggested nomenclature for aesthetic and reconstructive surgery of the breast. I. Breast reduction. *Aesthetic Plast Surg* 7:187, 1983.
- Letterman G, Schurter M. Suggested nomenclature for aesthetic and reconstructive surgery of the breast. II. Augmentation mammoplasty and mastopexy. *Aesthetic Plast Surg* 9:293, 1985.
- Letterman G, Schurter M. Suggested nomenclature for aesthetic and reconstructive surgery of the breast. III. Gynecomastia. *Aesthetic Plast Surg* 10:55, 1986.
- Letterman G, Schurter M. Suggested nomenclature for aesthetic and reconstructive surgery of the breast. IV. Congenital anomalies of the breast. *Aesthetic Plast Surg* 13:59, 1989.
- Mathes SJ, Nahai F. Reconstructive Surgery: Principles, Anatomy, and Technique. St Louis: Quality Medical Publishing, 1997.
- Miller LB, Bostwick J III, Hartrampf CR Jr, et al. The superiorly based rectus abdominis flap: predicting and enhancing its blood supply based on anatomic and clinical study. *Plast Reconstr Surg* 81:713, 1988.

- Nahai F. The Art of Aesthetic Surgery. Principles and Techniques. Applied Anatomy of the Breast. St Louis: Quality Medical Publishing, 2005.
- Newman M. Supernumerary nipples. *Am Fam Physician* 38:183, 1988.
- Pearl RM, Johnson D. The vascular supply to the skin: an anatomical and physiological reappraisal. Part 2. *Ann Plast Surg* 11:196, 1983.
- Regnault P. Breast ptosis: definition and treatment. *Clin Plast Surg* 3:193, 1976.
- Rouvière H. Anatomy of the Human Lymphatic System. Ann Arbor, MI: Edwards Brothers, 1938.
- Schlenz I, Kuzbari R, Gruber H, et al. The sensitivity of the nipple-areola complex: an anatomic study. *Plast Reconstr Surg* 105:905, 2000.
- Spear SL, Davidson SP. Aesthetic subunit of the breast. *Plast Reconstr Surg* 12:440, 2003.
- Wood WC, Scandalakis JE. Anatomic Basis of Tumor Surgery. St Louis: Quality Medical Publishing, 1999.
- Würinger E. Refinement of the central breast reduction by application of the ligamentous suspension. *Plast Reconstr Surg* 103:1400, 1999.
- Würinger E, Mader N, Posch E, et al. Nerve and vessel supplying ligamentous suspension of the mammary gland. *Plast Reconstr Surg* 101:1486, 1998.

5

Breast-Conserving Therapy

Hunter R. Moyer, Toncred Marya Styblo

Since 1894, when William Halsted¹ first described the radical mastectomy, surgical resection for breast cancer has been the mainstay of treatment. In fact, radical mastectomy was the operation of choice for all breast malignancies for the next 75 years. Fortunately, advances in breast screening, increased knowledge of tumor physiology, and better patient education have led to the earlier detection of breast cancer. As a result, many of the tumors requiring treatment are smaller and less advanced. In addition, surgical and medical oncologists in the later half of the twentieth century began to seek alternatives to standard treatments, including ever smaller resection sizes (modified radical mastectomy and simple mastectomy) and the addition of new modalities (chemotherapy and radiotherapy). Breast-conserving therapy (BCT) is a culmination of these efforts and has been validated by multiple, well-controlled, prospective randomized clinical trials as being an equally safe and efficacious treatment for early-stage breast cancer.²⁻⁹

BCT involves excising a tumor with negative pathologic margins. This can be performed with or without an axillary staging procedure and is usually followed by adjuvant radiation. Successful BCT for invasive breast cancer includes the following:

1. Tumor resection with negative margins
2. Ipsilateral node assessment
3. Preservation of healthy parenchyma and breast aesthetics

Successful treatment is measured by local and distant disease-free survival, cosmesis, and patient satisfaction. If established guidelines for BCT are followed, survival is equal to that of mastectomy, recurrence rates should be less than 1% per year, and cosmesis and patient satisfaction should be equal to or better than conventional treatments.

INDICATIONS AND PATIENT SELECTION

The use of BCT for early-stage breast cancer is widely accepted and is now the treatment of choice in the United States.¹⁰ Most early-stage breast cancers (T1 and T2 cancers with or without nodal involvement) are amenable to conservation therapy; however, there are exceptions. Traditionally, absolute contraindications to BCT were (1) patients with a high probability of recurrence, especially those with multicentric disease,¹¹ and (2) patients who are pregnant, those with collagen vascular disease, or those who have a history of prior radiation.¹² Relative contraindications include (1) patients with a high probability of subsequent cancers (BRCA mutations) and (2) patients who are likely to have a poor cosmetic result, which includes patients with a high tumor/breast ratio,¹³⁻¹⁶ medially and inferiorly based tumors,^{17,18} and tumors that require removal of the nipple-areola complex. Finally, age is an independent prognostic factor that can increase the incidence of failure and the risk of metachronous breast cancer.

The addition of neoadjuvant chemotherapy and recent advances in oncoplastic surgical techniques is changing these contraindications and increasing the range of patients amenable to conservation therapy. Preoperative chemotherapy has demonstrated complete pathologic response rates of up to 30%¹⁹ and significant tumor regression in 40% to 70% of patients.²⁰ In clinical trials, up to 90% of non-BCT candidates were eligible for BCT after induction chemotherapy.^{21,22} For patients with multicentric disease, induction chemotherapy and BCT have shown survival and recurrence rates equal to those of mastectomy.²³ BCS following neoadjuvant chemotherapy has been demonstrated to be equally oncologically safe compared to mastectomy for high stage patients and broadens the indications for BCS for high stage patients.^{24,25} The optimal timing of breast reconstruction following BCS or mastectomy for patients requiring radiotherapy is unclear; both implant and autologous reconstruction may be negatively impacted by radiotherapy and therefore are often delayed.²⁶

Oncoplastic techniques integrate oncologic principles with aesthetic principles. The combination of surgical oncology and plastic surgery broadens the indications for BCT and minimizes the potential for poor aesthetic results.

Examples include patients with larger tumors and tumors in cosmetically sensitive locations. Together, these modalities aid in achieving the goals and increasing the success of conservation therapy.

TECHNIQUE

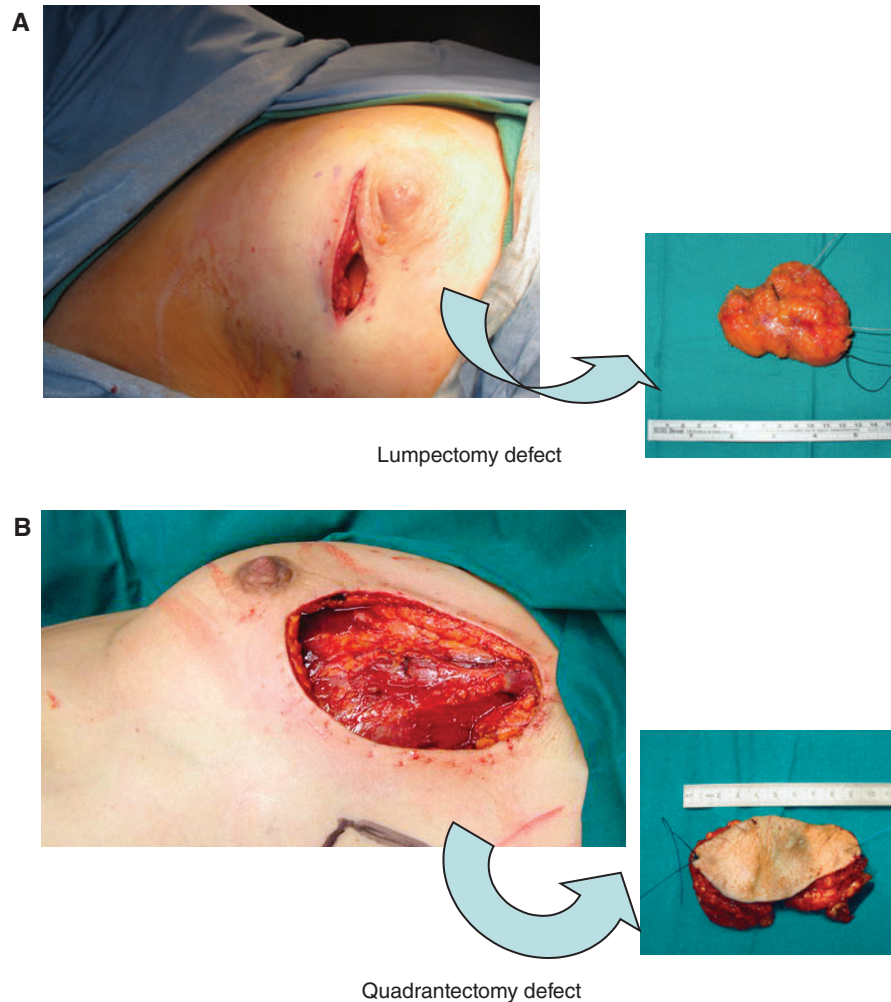


Fig. 5-1

BCT entails the complete removal of the breast tumor with a concentric margin of healthy tissue, performed with more attention to aesthetics and usually followed by radiotherapy.²⁷ The evaluation of axillary nodes is customarily performed, and thus the current and most widely practiced technique entails wide local excision (also called lumpectomy, segmentectomy, or partial mastectomy), sentinel lymph node biopsy, and postoperative radiotherapy totaling 45 to 50 Gy with a boost to the tumor bed (A). Quadrantectomy refers to removal of an additional 1 to 2 cm of healthy parenchyma around the tumor (B). This technique is more frequently performed in Europe and has been demonstrated to give a lower rate of local recurrence; however, cosmetic results are worse with quadrantectomy when compared with lumpectomy.

Tumor Resection

Excision of the tumor with negative margins is essential, and it is accepted that additional procedures may be necessary to achieve this goal. A recent consensus conference stated that most oncologists were comfortable with a 1 to 2 mm margin.²⁷ However, the width of the negative margin remains controversial and the term close margin has been coined for cancers within 1 mm of the resection edge.

A concentric or transverse skin incision should be made directly over the tumor or in close proximity in an attempt to “hide” the scar (periareolar incision for central or medial tumors and axillary incision for tail tumors). Tumors can be marked with clips or wires from a previous biopsy or mammogram-guided placement to identify tumor location. Dissection should proceed directly to the cancer without tunneling, and resection should include a concentric portion of healthy parenchyma. Once removed, the specimen is oriented and marked for pathologic review; we prefer to use a long marking stitch on the lateral aspect of the specimen and a short stitch superiorly. Hemostasis is obtained, and the margins of resection are marked with radioopaque clips. The wound is packed and covered, and attention is then turned to the axilla while the specimen is sent for frozen section analysis. If the resection margin is clear of cancer, the superficial skin and fascia are closed, and then the remaining defect is left to fill with serous fluid.

The Axilla

The axilla is considered separately. Axillary node analysis helps in staging, treating, and dictating adjuvant therapies.

The identification of positive axillary nodes indicates a poorer prognosis and often leads to additional adjuvant treatments.

With the patient in the supine position, the boundaries of the axilla include the latissimus dorsi muscle posteriorly, the lateral edge of the pectoralis muscles anteriorly, the serratus muscle medially, the axillary vein cranially, and the tail of the breast caudally. Important structures within the axilla include the axillary artery and vein; the long thoracic nerve, which innervates the serratus anterior muscle; the thoracodorsal nerve, which innervates the latissimus muscle; and the intercostobrachial nerve, which innervates the lower arm. The axillary lymph nodes are categorized according to their relation to the pectoralis minor muscle: level I lateral, level II inferior, and level III medial.

The sentinel node is the first node to receive lymphatic drainage from the tumor site and can be identified by color or radioactive emission. The first technique requires injecting 3 ml of blue dye (isosulfan blue or methylene blue) into the tumor site, followed by gentle massage for several minutes to increase lymphatic drainage. After creating the axillary incision and identifying the pectoralis major muscle, the surgeon performs a delicate search

for any blue-stained nodes. Stained nodes—often there are several—are removed and sent to pathology. For the second technique, approximately 5 ml of technetium-labeled sulfur colloid is injected into the tumor bed 2 to 4 hours before the operation. A handheld gamma detection probe is used to identify the “background noise” and the area of highest activity in the axilla.

The axillary incision is made over the site of high activity, keeping in mind that a complete axillary dissection may be necessary.

Dissection is guided by the detection counter, and the “hottest” node is identified and removed. Additional nodes measuring greater than 10% of the sentinel node are removed, and the resection continues until the nodal basin emits less than twice the background. The finding of a positive node dictates a complete level I and level II axillary dissection. A consensus conference has stated that the standard for sentinel node biopsy ought to include both technetium and blue dye, which, when combined, is more than 95% accurate.²⁸

Axillary dissection is achieved through a small transverse incision that is centered in the axilla and spans the borders of the pectoralis and latissimus muscles. Superior and inferior skin flaps are developed through sharp dissection, and retractors are placed to open the wound. Identifying and dissecting free the lateral border of the pectoralis major muscle allows its retraction and aids in exposing the adjacent lymph nodes (Rotter nodes) and the underlying pectoralis minor muscle. Retracting the pectoralis minor muscle after ligating the medial pectoral nerve allows access to the level II nodes. The level I nodes are isolated by meticulous dissection of the axillary vein from lateral to medial. Continuing the dissection inferiorly allows identification first of the thoracodorsal nerve (running with the subscapular vein) and then of the long thoracic nerve. Once the axillary contents are removed and oriented, hemostasis is obtained, a drain is placed within the cavity, and the skin and superficial fascia are closed.

Radiotherapy

Postoperative radiotherapy is an integral part of the multidisciplinary approach to cancer treatment.

The goal of radiation is to decrease the local recurrence risk to below 1% per year.

A standard course delivers approximately 50 Gy to the whole breast over a 5-week period, followed by 2 weeks of an additional boost of approximately 15 Gy to the tumor bed. A recent advancement, called partial breast irradiation, delivers the same amount of radiation

in 5 days through intracavitary catheters, balloon catheters, or an external beam. Although it is currently being used, partial breast irradiation has not yet undergone a long-term evaluation. Radiation is given either in continuous low doses or fractionated high doses.

OUTCOMES

Because BCT and mastectomy are equivalent local treatments for most patients, the ultimate choice is not only a medical choice but also a quality-of-life decision made by the patient. The success of conservation therapy is measured by patient survival, the local failure rate, cosmesis, and the patient's satisfaction.

Table 5-1 Prospective Trials Comparing BCT With Mastectomy

Trial	Year	Number	Therapy	Length of Follow-up (yr)	Endpoints	Mastectomy	BCT (%)
National Cancer Institute (NCI)	1995	237	BCT (+AXD/+XRT)	10.1	Overall survival	75	77
			Mastectomy		Disease-free survival	69	72
European Organization for the Research and Treatment of Cancer (EORTC) 10801	2000	868	BCT (+AXD/+XRT)	13.4	Overall survival	66	65
			Mastectomy		Local recurrence*	12	20
Milan Cancer Institute	2002	701	BCT (Quad/+AXD/+XRT)	20	Overall survival	43	44
			Radical mastectomy		Local recurrence†	2.3	8.8
National Surgical Adjuvant Breast Project (NSABP) B-06	2002	1851	Lumpectomy	20	Overall survival	46	47
			Lumpectomy + XRT Mastectomy		Recurrence	10.2	26.78‡

*p = 0.01.

†p < 0.001.

‡The recurrence rates for lumpectomy alone and lumpectomy plus XRT were 39.2% and 14.3%, respectively.

AXD, Axillary dissection; BCT, breast-conserving therapy; Quad, quadrantectomy; XRT, radiotherapy.

Many prospective, randomized trials have proven that BCT provides a survival benefit similar to mastectomy for early-stage breast cancer.²⁻⁹ The survival of breast cancer patients depends on prognostic factors such as nodal metastases, the tumor size, the tumor grade, and the systemic therapy.^{12,29}

Local recurrence rates after BCT are higher than after a mastectomy. The goal set forth by the Consensus Conference on Breast Conservation is a 10-year local recurrence rate between 5% and 10%,²⁷ which translates into a risk of developing a recurrence of 1% per annum—a good percentage to use when counseling patients.

Local recurrence in BCT is higher, especially when postoperative radiotherapy is omitted (39.2% versus 14.3%)⁴; however, local failures can be salvaged with a mastectomy at no detriment to survival.

Larger, tumor-free margins following surgery can reduce local recurrence rates; however, the optimal margin remains controversial, with varying results in clinical trials.³⁰⁻³² In addition, reexcision of close or positive margins is not associated with a survival advantage.^{31,33,34} At our institution, we employ a multidisciplinary approach and patients routinely receive postoperative radiotherapy following BCT. We require negative surgical margins in all patients to limit local failure.

Patients report a better quality of life and a superior body image after conservation therapy.³⁵⁻³⁸ Satisfaction is linked to prognosis, the quality of life, social conditions, and breast aesthetics. Cosmetic results depend on the patient's age and race, the original size and symmetry of the breast, the location of the tumor, the amount of tissue removed, and the amount of radiation given.^{15-17,30,39} The best results are thought to occur in younger women with smaller, symmetrical breasts who have a minimal amount of tissue excised and a homogenous radiation dose applied. Unfortunately, excellent cosmetic results can be difficult to obtain, and several series report poor outcomes.^{40,41} Oncoplastic techniques to immediately reconstruct the conserved breast can improve aesthetic outcomes and increase patient satisfaction.

ONCOPLASTIC SURGERY

Until about 10 years ago, the surgical treatment of breast cancer focused on two major options: (1) breast-conserving surgery (BCS) or (2) mastectomy with or without reconstruction. The conflict between optimal oncologic resection and the desire to minimize the risk of unacceptable local deformity has led to the evolution of procedures that can both reconstruct the resection defect and prevent the need for mastectomy.⁴²

With increasing refinement of oncoplastic resections, oncoplastic breast-conserving reconstruction has emerged as a third alternative for reconstructing resection defects by volume replacement or by volume displacement. Both techniques are adaptations of conventional methods of breast reconstruction or breast reduction. Emerging data on the oncologic and cosmetic outcomes of oncoplastic breast-conserving reconstruction are confirming the clinical utility of this approach to the surgical management of patients with breast cancer. Mastectomy and BCS are associated with similar rates of long-term survival, but breast-conserving techniques are generally associated with superior cosmetic and psychological outcomes.^{4,43}

Factors that are associated with poor cosmetic outcome following BCS include the proportion of breast tissue excised and the location of the resection in the breast. In other words, a large breast is more “forgiving” of a 40 mm resection than a small breast. Resections in the medial and inferior quadrants of the breast are associated with poorer cosmesis than other locations.⁴² Additional indications for oncoplastic breast conservation are emerging. The absolute oncologic requirement of clear pathologic margins must be adhered to during any breast-conserving procedure, making oncoplastic breast conservation most appropriate for unifocal tumors. As with all elective procedures, the anesthetic risk and comorbidities that could affect tissue viability and wound healing must be considered when optional or complex surgical procedures are considered.

When compared with breast conservation and mastectomy, the benefits of oncoplastic breast-conserving reconstruction are numerous.

Oncoplastic breast conservation has the potential to allow extensive local surgical excision with the resulting oncologic benefits.⁴⁴

The oncoplastic technique broadens the indication for BCS to include larger tumor sizes and results in fewer positive margins because it enables a more generous resection.⁴⁵ The impact of the oncoplastic technique on local recurrence has yet to be determined.⁴⁵ Patient satisfaction has also been reported as higher with the oncoplastic technique compared to BCS alone.⁴⁵ The oncoplastic technique has also been demonstrated to be equally oncologically effective as BCS in treating high stage patients.^{46,47} Neoadjuvant chemotherapy for high stage patients may also broaden the indications for oncoplastic reduction.^{48,49,50}

This may eliminate the need for mastectomy and reconstruction, which may be associated with greater morbidity, sensory loss, and a poorer cosmetic outcome than oncoplastic breast conservation.⁵¹ A further indication of this technique is the secondary correction of marked deformities after BST and radiotherapy.⁵²

Defects occurring after wide local resection of breast tissue can be reconstructed in one of two ways. The first method is volume replacement, which involves transposition of tissue from one location to another. The second approach is tissue displacement, involving volume displacement techniques in which breast parenchyma is rearranged to reconstruct the defect. Both of these techniques transpose and engage local glandular or dermoglandular flaps into the resection site.

Table 5-2 Factors Influencing the Choice of Oncoplastic Techniques

	Volume Replacement	Volume Displacement
Breast size	Small or medium	Medium or large
Tumor position	Any site	Central or lower pole
Scars	Breast and back	Bilateral breast
Operating time	2 to 3 hours	1 to 2 hours (per side)
Complications	Donor site, flap loss	Flap ischemia, fat necrosis
Timing	Immediate = delayed	Immediate >delayed

The choice of technique depends on many factors, including the extent of resection, the timing of surgery, the breast size and tumor location, and the wishes of the patient. Volume replacement techniques can maintain the original size and shape of the breast without the need for any contralateral breast surgery, but they may be associated with longer operations and complications in the flap and donor site. Surgery for volume displacement avoids donor site complications, but may be associated with ischemia of the dermoglandular pedicle and may require contralateral breast surgery to achieve symmetry, depending on the extent of resection.

Tumor resection and reconstruction before irradiation may be performed simultaneously as a one-stage procedure or using a two-stage approach (see Chapter 13). The two-stage approach allows the formal histopathologic tissue confirmation of complete excision during the first stage. The second stage is reconstruction of the tissue defect.

Table 5-3 Outcomes of Oncoplastic Replacement and Total Mastectomy

	Oncoplastic Replacement (%)	Total Mastectomy/ Reconstruction (%)
Postoperative complications	8	14
Additional surgical interventions needed	12	79
Nipple sensory loss	2	98
Restricted activities	54	73

In a recent series, the outcomes of oncoplastic breast conservation using volume replacement were significantly more favorable than those of skin-sparing mastectomy (SSM) with reconstruction, as reported by Gendy et al.⁵¹

CONCLUSION

Table 5-4 Outcomes of Oncoplastic Breast Conservation

	Volume Replacement	Volume Displacement
Total number of studies	7 ^{51,53-56}	11 ⁵⁷⁻⁶⁴
Total number of patients	189	433
Median follow-up (months)	24 to 53	21 to 54
Local recurrence (%)	0 to 5	0 to 7
Cosmetic failure (%)	0 to 9	0 to 18

Oncoplastic breast conservation is extending the role of BCS and obviating the need for mastectomy in selected patients. It enables a very wide resection of the tumor without the cosmetic defect that often accompanies the removal of greater than 20% of the breast. Oncoplastic breast conservation techniques use tissue replacement from another location or tissue displacement within the breast. These techniques draw on the skills of both the surgical oncologist and reconstructive surgeon, who work as a team while performing one procedure. During the last century, advances in the understanding of breast cancer biology have enabled more conservative surgical options for patients with breast cancer. Despite the advances in primary chemotherapy, surgery plays a major role in the management of this disease. Oncoplastic breast conservation enables patients to avoid mastectomy without cosmetic or oncologic penalties.

Critical Issues

- The management of women with breast cancer has recently shifted toward more breast preservation.
- BCT requires resection of the tumor with negative margins, ipsilateral node analysis, and postoperative breast irradiation.
- Although local recurrence rates are higher, overall survival is equivalent to that of mastectomy.
- Most early-stage breast cancers are amenable to breast conservation.
- Neoadjuvant chemotherapy now allows non-BCT patients to be candidates for breast conservation.
- Partial mastectomy defects include those that result from quadrantectomy and lumpectomy.
- The goals of BCT are to maintain a high survival rate and a good cosmetic result.
- Poor cosmetic results are not uncommon after BCT.
- Oncoplastic techniques minimize the potential for poor cosmetic results and broaden the indications for BCT.

References

1. Halsted WS. The results of operations for the cure of cancer of the breast performed at the Johns Hopkins Hospital from June, 1889 to January, 1894. *Johns Hopkins Hosp Rep* 4:297, 1894.
2. Arriagada R, Le MG, Rochard F, et al. Conservative treatment versus mastectomy in early breast cancer: patterns of failure with 15 years of follow-up data. Institut Gustave-Roussy Breast Cancer Group. *J Clin Oncol* 14:1558, 1996.
3. Blichert-Toft M, Rose C, Andersen JA, et al. Danish randomized trial comparing breast conservation therapy with mastectomy: six years of life-table analysis. Danish Breast Cancer Cooperative Group. *J Natl Cancer Inst Monogr* 11:19, 1992.
4. Fisher B, Anderson S, Bryant J, et al. Twenty-year follow-up of a randomized trial comparing total mastectomy, lumpectomy, and lumpectomy plus irradiation for the treatment of invasive breast cancer. *N Engl J Med* 347:1233, 2002.
5. Fisher B, Bauer M, Margolese R, et al. Five-year results of a randomized clinical trial comparing total mastectomy and segmental mastectomy with or without radiation in the treatment of breast cancer. *N Engl J Med* 312:665, 1985.
6. Jacobson JA, Danforth DN, Cowan KH, et al. Ten-year results of a comparison of conservation with mastectomy in the treatment of stage I and II breast cancer. *N Engl J Med* 332:907, 1995.
7. van Dongen JA, Voogd AC, Fentiman IS, et al. Long-term results of a randomized trial comparing BCT with mastectomy: European Organization for Research and Treatment of Cancer 10801 trial. *J Natl Cancer Inst* 92:1143, 2000.

8. Veronesi U, Cascinelli N, Mariani L, et al. Twenty-year follow-up of a randomized study comparing breast-conserving surgery with radical mastectomy for early breast cancer. *N Engl J Med* 347:1227, 2002.
9. Veronesi U, Salvadori B, Luini A, et al. Breast conservation is a safe method in patients with small cancer of the breast. Long-term results of three randomised trials on 1,973 patients. *Eur J Cancer* 31A:1574, 1995.
10. Cancer Trends Progress Report: 2007 Update. Bethesda, MD: National Cancer Institute, 2007.
11. Kurtz JM, Jacquemier J, Amalric R, et al. Breast-conserving therapy for macroscopically multiple cancers. *Ann Surg* 212:38, 1990.
12. Benda RK, Mendenhall NP, Lind DS, et al. Breast-conserving therapy (BCT) for early-stage breast cancer. *J Surg Oncol* 85:14, 2004.
13. de la Rochefordière A, Abner AL, Silver B, et al. Are cosmetic results following conservative surgery and radiation therapy for early breast cancer dependent on technique? *Int J Radiat Oncol Biol Phys* 23:925, 1992.
14. Olivetto IA, Rose MA, Osteen RT, et al. Late cosmetic outcome after conservative surgery and radiotherapy: analysis of causes of cosmetic failure. *Int J Radiat Oncol Biol Phys* 17:747, 1989.
15. Taylor ME, Perez CA, Halverson KJ, et al. Factors influencing cosmetic results after conservation therapy for breast cancer. *Int J Radiat Oncol Biol Phys* 31:753, 1995.
16. Staradub VL, Rademaker AW, Morrow M. Factors influencing outcomes for breast conservation therapy of mammographically detected malignancies. *J Am Coll Surg* 196:518, 2003.
17. Vrieling C, Collette L, Fourquet A, et al. The influence of patient, tumor and treatment factors on the cosmetic results after breast-conserving therapy in the EORTC 'boost vs. no boost' trial. EORTC Radiotherapy and Breast Cancer Cooperative Groups. *Radiother Oncol* 55:219, 2000.
18. Waljee JF, Hu ES, Newman LA, et al. Predictors of breast asymmetry after breast-conserving operation for breast cancer. *J Am Coll Surg* 206:274, 2008.
19. Bear HD, Anderson S, Brown A, et al. The effect on tumor response of adding sequential preoperative docetaxel to preoperative doxorubicin and cyclophosphamide: preliminary results from National Surgical Adjuvant Breast and Bowel Project Protocol B-27. *J Clin Oncol* 21:4165, 2003.
20. Jacquillat C, Weil M, Baillet F, et al. Results of neoadjuvant chemotherapy and radiation therapy in the breast-conserving treatment of 250 patients with all stages of infiltrative breast cancer. *Cancer* 66:119, 1990.
21. Bonadonna G, Valagussa P, Brambilla C, et al. Primary chemotherapy in operable breast cancer: eight-year experience at the Milan Cancer Institute. *J Clin Oncol* 16:93, 1998.
22. Zurrida S, Greco M, Veronesi U. Surgical pitfalls after preoperative chemotherapy in large size breast cancer. *Eur J Surg Oncol* 20:641, 1994.
23. Oh JL, Dryden MJ, Woodward WA, et al. Locoregional control of clinically diagnosed multifocal or multicentric breast cancer after neoadjuvant chemotherapy and locoregional therapy. *J Clin Oncol* 24:4971, 2006.
24. Cho JH, Park JM, Park HS, et al. Oncologic safety of breast-conserving surgery compared to mastectomy in patients receiving neoadjuvant chemotherapy for locally advanced breast cancer. *J Surg Oncol* 108: 531, 2013.
25. Shin HC, Han W, Moon HG, et al. Breast-conserving surgery after tumor downstaging by neoadjuvant chemotherapy is oncologically safe for stage III breast cancer patients. *Ann Surg Oncol* 20:2582, 2013.
26. Berbers, J "Reconstruction: before or after post-mastectomy radiotherapy? A systematic review of the literature." *Eur J Cancer* 50:2752, 2014.
27. Schwartz GF, Veronesi U, Clough KB, et al. Consensus Conference on Breast Conservation. *J Am Coll Surg* 203:198, 2006.
28. Schwartz GF, Giuliano AE, Veronesi U. Proceedings of the Consensus Conference on the Role of sentinel lymph node biopsy in carcinoma of the breast. Philadelphia, April 2001; *Cancer* 94:2542, 2002.

29. Dabakuyo TS, Bonnetain F, Roignot P, et al. Population-based study of breast cancer survival in Cote d'Or (France): prognostic factors and relative survival. *Ann Oncol* 19:276, 2008.
30. Gage I, Schnitt SJ, Nixon AJ, et al. Pathologic margin involvement and the risk of recurrence in patients treated with breast-conserving therapy. *Cancer* 78:1921, 1996.
31. Smitt MC, Nowels KW, Zdeblick MJ, et al. The importance of the lumpectomy surgical margin status in long-term results of breast conservation. *Cancer* 76:259, 1995.
32. Tartter PI, Kaplan J, Bleiweiss I, et al. Lumpectomy margins, reexcision, and local recurrence of breast cancer. *Am J Surg* 179:81, 2000.
33. Pittinger TP, Maronian NC, Poulter CA, et al. Importance of margin status in outcome of breast-conserving surgery for carcinoma. *Surgery* 116:605; discussion 608, 1994.
34. Swenson K, Decher L, Haselow R, et al. Prognostic factors after conservative surgery and radiation therapy for early stage breast cancer. *Am J Clin Oncol* 21:111, 1998.
35. Curran D, van Dongen JP, Aaronson NK, et al. Quality of life of early-stage breast cancer patients treated with radical mastectomy or breast-conserving procedures: results of EORTC trial 10801. The European Organization for Research and Treatment of Cancer (EORTC), Breast Cancer Cooperative Group (BCCG). *Eur J Cancer* 34:307, 1998.
36. Ganz P, Schag A, Lee J, et al. Breast conservation versus mastectomy. Is there a difference in psychological adjustment or quality of life in the year after surgery? *Cancer* 69:1729, 1992.
37. Moyer A. Psychosocial outcomes of breast-conserving surgery versus mastectomy: a meta-analytic review. *Health Psychol* 16:284, 1997.
38. Pusic A, Thompson T, Kerrigan C, et al. Surgical options for early-stage breast cancer: factors associated with patient choice and postoperative quality of life. *Plast Reconstr Surg* 104:1325, 1999.
39. Wazer DE, DiPetrillo T, Schmidt-Ullrich R, et al. Factors influencing cosmetic outcome and complication risk after conservative surgery and radiotherapy for early-stage breast carcinoma. *J Clin Oncol* 10:356, 1992.
40. Deutsch M, Flickinger JC. Patient characteristics and treatment factors affecting cosmesis following lumpectomy and breast irradiation. *Am J Clin Oncol* 26:350, 2003.
41. D'Aniello C, Grimaldi L, Barbato A, et al. Cosmetic results in 242 patients treated by conservative surgery for breast cancer. *Scand J Plast Reconstr Surg Hand Surg* 33:419, 1999.
42. Cochrane RA, Valasiadou P, Wilson AR, et al. Cosmesis and satisfaction after breast-conserving surgery correlates with the percentage of breast volume excised. *Br J Surg* 90:1505, 2003.
43. Clough KB, Kroll SS, Audretsch W. An approach to the repair of partial mastectomy defects. *Plast Reconstr Surg* 104:409, 1999.
44. Veronesi U, Volterrani F, Luini A, et al. Quadrantectomy versus lumpectomy for small size breast cancer. *Eur J Cancer* 26:671, 1990.
45. Losken A, Dugal CS, Styblo TM, et al. A meta-analysis comparing breast conservation therapy alone to the oncoplastic technique. *Ann Plast Surg* 72:145, 2014.
46. Emiroglu M, Sert I, Karaali C, et al. The effectiveness of simultaneous oncoplastic breast surgery in patients with locally advanced breast cancer. *Breast Cancer* 2015 Jan 14. [Epub ahead of print]
47. Bogusevicius A, Cepulienė D, Sepetauskiene E. The integrated evaluation of the results of oncoplastic surgery for locally advanced breast cancer. *Breast J* 20:53, 2014.
48. Regano S, Hernaz F, Redondon-Figuero C, et al. Oncoplastic techniques extend breast conserving surgery to patients with neoadjuvant chemotherapy response unfit for conventional techniques. *World J Surg* 33:2082, 2009.
49. Mazouni C, Naveau A, Kane A, et al. The role of oncoplastic breast surgery in the management of breast cancer treated with primary chemotherapy. *Breast* 22:1189, 2013.
50. Broecker JS, Hart A, Losken A, et al. Neoadjuvant chemotherapy combined with oncoplastic reduction for high stage breast cancer patients. Presented at the Society of Surgical Oncology Symposium, Boston, Mar 20, 2016.

51. Gendy RK, Able JA, Rainsbury RM. Impact of skin-sparing mastectomy with immediate reconstruction and breast-sparing reconstruction with miniflaps on the outcomes of oncoplastic breast surgery. *Br J Surg* 90:433, 2003.
52. Slavin SA, Love SM, Sadowsky NL. Reconstruction of the radiated partial mastectomy defect with autogenous tissues. *Plast Reconstr Surg* 90:854; discussion 866, 1992.
53. Raja MA, Straker VF, Rainsbury RM. Extending the role of breast-conserving surgery by immediate volume replacement. *Br J Surg* 84:101, 1997.
54. Dixon JM, Venizelos B, Chan P. Latissimus dorsi mini-flap: a technique for extending breast conservation. *Breast* 11:58, 2002.
55. Kat CC, Darcy CM, O'Donoghue JM, et al. The use of the latissimus dorsi musculocutaneous flap for immediate correction of the deformity resulting from breast conservation surgery. *Br J Plast Surg* 52:99, 1999.
56. Losken A, Schaefer TG, Carlson GW, et al. Immediate endoscopic latissimus dorsi flap: risk or benefit in reconstructing partial mastectomy defects. *Ann Plast Surg* 53:1, 2004.
57. Galimberti V, Zurrida S, Zanini V, et al. Central small size breast cancer: how to overcome the problem of nipple and areola involvement. *Eur J Cancer* 29A:1093, 1993.
58. Chang E, Johnson N, Webber B, et al. Bilateral reduction mammoplasty in combination with lumpectomy for treatment of breast cancer in patients with macromastia. *Am J Surg* 187:647; discussion 650, 2004.
59. Nos C, Fitoussi A, Bourgeois D, et al. Conservative treatment of lower pole breast cancers by bilateral mammoplasty and radiotherapy. *Eur J Surg Oncol* 24:508, 1998.
60. Masetti R, Pirulli PG, Magno S, et al. Oncoplastic techniques in the conservative surgical treatment of breast cancer. *Breast Cancer* 7:276, 2000.
61. Newman LA, Kuerer HM, McNeese MD, et al. Reduction mammoplasty improves breast conservation therapy in patients with macromastia. *Am J Surg* 181:215, 2001.
62. Spear SL, Pelletiere CV, Wolfe AJ, et al. Experience with reduction mammoplasty combined with breast conservation therapy in the treatment of breast cancer. *Plast Reconstr Surg* 111:1102, 2003.
63. Monticciolo DL, Ross D, Bostwick J III, et al. Autologous breast reconstruction with endoscopic latissimus dorsi musculocutaneous flaps in patients choosing breast-conserving therapy: mammographic appearance. *AJR Am J Roentgenol* 167:385, 1996.
64. Clough KB, Kroll SS, Audretsch W. An approach to the repair of partial mastectomy defects. *Plast Reconstr Surg* 104:409, 1999.

6

Breast-Conserving Therapy: Decision-Making and Anticipating the Unfavorable Aesthetic and Functional Result

John Hijjawi

THE GOALS OF BREAST-CONSERVING THERAPY

The goals of traditional breast-conserving therapy (BCT) include tumor resection with negative margins, nodal assessment when indicated to direct adjuvant chemotherapy, and the bedrock concept separating BCT from mastectomy, the preservation of healthy breast parenchyma with the maintenance, if not the improvement, of breast aesthetics. When these goals are met the oncologic safety of breast conservation therapy is as irrefutable today as it was when it was introduced following the Milan Trials more than 20 years ago. Combining tumor removal, whether lumpectomy, partial mastectomy, quadrantectomy, or segmental mastectomy (choose your term; they are all loosely defined) with adjuvant radiotherapy is without question an effective method for treating stage I or II breast cancer. The results of multiple studies have demonstrated parity between BCT and mastectomy in regard to overall and disease-free survival.¹⁻⁵ This remains true as long as a certain subset of patients are avoided, namely those with multicentric or multifocal disease.

Tumor resection with negative margins leads to recurrence-free and disease-free survival.

Of course, the factors that predispose patients to recurrence following BCT will equally predispose an equivalent population treated with mastectomy to recurrence.⁶ These factors include young age at recurrence, intrinsic tumor characteristics, not performing chemotherapy, and a failure to achieve adequate surgical margins.⁶⁻⁸

The appeal of BCT to a large proportion of the breast cancer population is also clear. The promise of outpatient surgery in most cases, a smaller scar, no surgical drains, and preservation of the majority of the patient's breast—and what is most important, the nipple-areola complex (NAC)—is a welcome option for many. Certainly, the perception that BCT

represents cumulatively “less treatment” is one that is difficult to refute with the nonmedical patient population.

WHEN DOES THE PROMISE OF BREAST-CONSERVING THERAPY FAIL TO DELIVER?

Unfortunately, the dual goals of maximum disease-free survival and the preservation of breast aesthetics don't always follow a parallel course. Although several studies over the last twenty years have demonstrated good to excellent aesthetic results of BCT in well over 85% of the patients being treated, these studies typically used the treating physicians as the judges of the outcomes and did not include input from the patients being treated.^{9,10} In more recent studies that included an assessment of cosmesis by the patients, nearly 100% of patients noted asymmetry and 28% to 35% of the patients reported dissatisfaction with the aesthetic results of their treatment.^{11,12} These studies would indeed suggest that the simultaneous goals of adequate oncologic treatment and the maintenance of breast aesthetics are not easily obtained, but rather represent competing interests.¹³

The definition of success in the treatment of early-stage breast cancers has evolved beyond the simplistic outcomes of low recurrence rates and patients embracing the early perception of “less treatment” as it applies to BCT versus mastectomy. Without long-term patient satisfaction with all of the outcomes of care, including excellent overall and disease-free survival, acceptable breast aesthetics not limited to symmetry, and increasingly, the concept of *functional breasts*, treatment can hardly be defined as complete and successful.^{12,14} By “functional breasts” we mean that there is adequate symmetry of breast volume, shape, and the breast footprint,¹⁵ including the inframammary fold (IMF) position. This allows the patient to comfortably and confidently wear any type of bra and clothing without resorting to the use of external prostheses, specially constructed undergarments, or bulky outer clothes.¹⁶

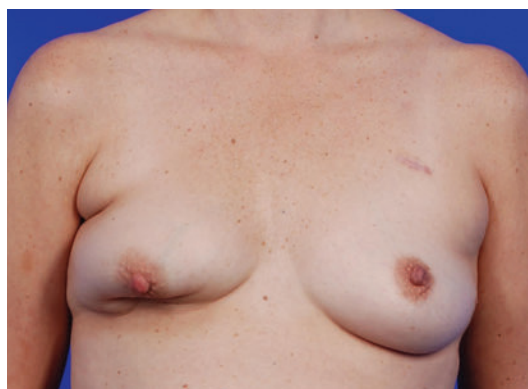

Fig. 6-1

As a result of a lumpectomy and radiotherapy in the inferior pole of her right breast, this patient developed asymmetry of volume and shape as well as a discrepancy in the position of her inframammary fold, making it difficult to keep her bra strap in place.

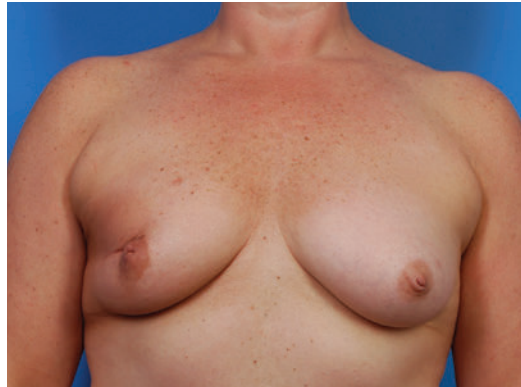

Fig. 6-2

This patient underwent BCT to the right breast that led to a volume asymmetry requiring her to wear a 250 cc partial prosthesis to feel comfortable in clothing.

A cancer-free patient whose IMFs differ in height by 3 cm will probably have difficulty wearing a bra, because the bra strap will ride up on the side with the lower IMF, causing discomfort and requiring constant adjustment. Equally, a patient enjoying her ninth disease-free year after cancer treatment who needs to wear a 250 cc external prosthesis to feel that her breasts are symmetrical in clothing may not be as satisfied with her “breast preservation” as hoped for at the beginning of her treatment.^{11,17} A patient left with a glaring contour deformity, even if it is only visible when she has no clothes on, may still cringe at the sight of her breasts every time she changes clothes or looks down in the shower years after her “oncologically successful” treatment. It is hard to imagine that these patients can ever truly move past their cancer history because of the daily reminders.^{18,19}

We have entered a new era of patient expectations in regard to the results of breast cancer treatment and breast reconstruction. In part, this is because of the blurring of lines between the results seen in patients treated with risk-reducing mastectomy for genetic disorders and those treated for actual cancer. Of course, the challenges of reconstruction in someone who is spared chemotherapy, radiotherapy, and even the sacrifice of her NAC in a risk-reducing procedure are far less than the challenges in treating a patient with cancer. Increasingly, a large subset of women have the expectation that their breasts will not only look the same after cancer treatment, but indeed expect an improvement in the shape, ptosis, and perceived size of their breasts. Although this expectation has in part been created by treating surgeons, the proliferation of information on the Internet and in cancer support groups has contributed as well.²⁰

Today's patients have an expectation that their breasts will not only look the same after cancer treatment but will also have an improvement in shape, ptosis, and perceived size.

PREDICTING A POOR AESTHETIC RESULT IN BCT: MANAGING DEAD SPACE

One of the most difficult questions plastic surgeons are asked by patients deciding between BCT and mastectomy with reconstruction is “Will my breast look okay after a lumpectomy and radiation?”²¹ This question cannot be answered by a simple “Yes” or “No.” This question is often left to the plastic surgeon by the treating breast surgeon who will actually be performing the resection. This ostensibly occurs because of an understanding that if the patient is dissatisfied with her result, it is the plastic surgeon who will be relied on for advice and further treatment. Complicating the challenge of predicting the aesthetic results of another surgeon’s resection is the difficulty of predicting the impact of the radiotherapy that must accompany lumpectomy for satisfactory oncologic care. Although this team-oriented approach is ultimately beneficial for the patient, it is helpful if all members of the team are sensitive to factors that have an impact on final cosmesis.

Box 6-1 Predictive Patient and Surgical Factors for Treatment After BCT

- Estimated volume of the tumor relative to the overall breast
- Location of the tissue to be resected
- Patient’s desire for a change in the size of her breasts
- Potential for the creation of direct contact between deep dermis and fascia

Fortunately, there are several straightforward predictive factors that can be assessed before any surgery that can help to identify the course of treatment that will provide the patient with the highest degree of satisfaction.

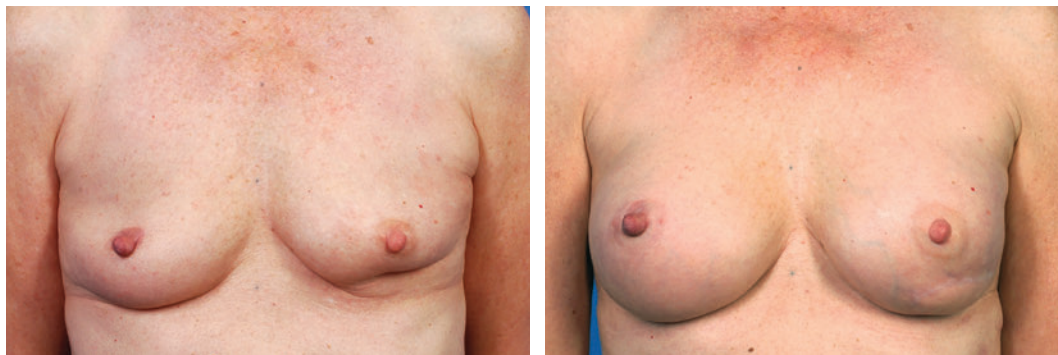

Fig. 6-3

This patient stated that she had wanted larger breasts for many years, but she had focused on her cancer care related to treatment of a left breast cancer. After BCT, a muscle-sparing

latissimus dorsi flap reconstruction was followed by bilateral breast augmentation with implants. Placement of the breast implants was delayed until after the introduction of nonirradiated, healthy tissue from the back into the irradiated breast.

It is essential to ask the patient whether she has any desire to change the size of her breasts, either larger or smaller. For a patient who wants larger breasts, BCT alone will always fail to satisfy. For a patient who wants to reduce the size of her breasts, a breast reduction executed as part of an oncoplastic approach is far preferable to a breast reduction done months or years after BCT, when the breast has already been irradiated.^{22,23}

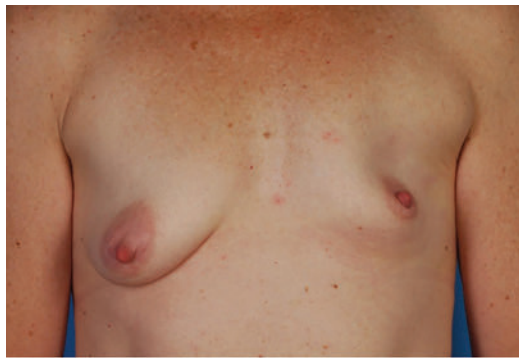

Fig. 6-4

This patient with small breasts had a relatively modest 80 g lumpectomy that resulted in significant asymmetry.

The surgeon must also consider the size of the proposed resection relative to the overall volume of the patient's breast. This is ultimately a question of dead space. The reality is that significant dead space within a soft tissue construct like the breast will ultimately collapse, resulting in distortion of the breast architecture.^{13,24} In smaller-breasted patients, the removal of as little as 12% to 20% of their overall breast volume can create a volume discrepancy that is aesthetically unpleasant and functionally difficult. Resection of up to 30% of the total breast volume may be tolerated in larger-breasted women without the need for reconstructive techniques. However, these patients should still be informed that a symmetry procedure may be required on the opposite breast to permit comfortable bra fitting. The increased use of preoperative imaging in the planning of breast cancer surgery has facilitated our ability to truly assess the volume of tissue that will need to be resected to obtain adequate margins.^{14,25-28}

Even small resections can lead to significant distortion of the breast when the tissue is removed from aesthetically sensitive areas. These areas include the superomedial breast or cleavage area and the area directly under the NAC. One should also consider what the likely effect of radiotherapy will be on the position of the NAC as tissue retracts during healing from surgery, as fibrosis occurs following radiation, or both. Resections immediately adjacent to the NAC will often result in retraction of the NAC as the dead space adjacent to the NAC collapses.

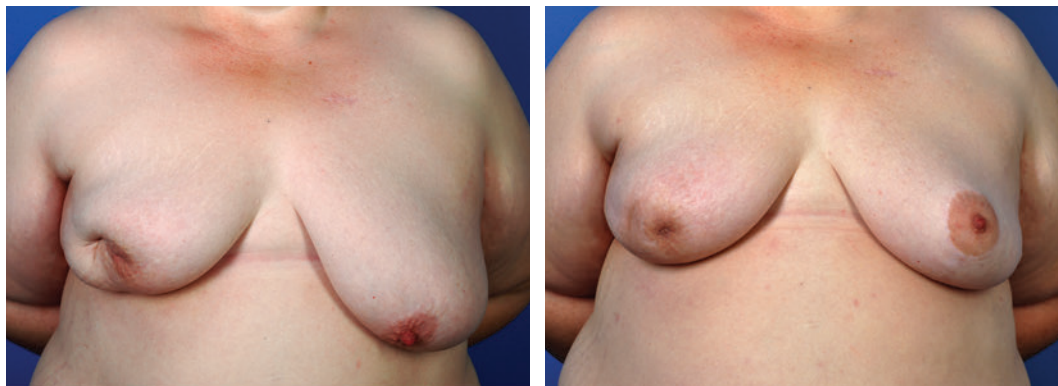

Fig. 6-5

This patient underwent resection of a tumor, leaving the deep dermis in contact with the fascia, which led to nipple retraction after healing and radiotherapy. Autologous fat grafting of the right breast and a contralateral mastopexy improved her symmetry and reduced the retraction.

The resection of a specimen that leaves no breast tissue between the dermis and the serratus or pectoral fascia will inevitably result in adherence of the dermis to the fascia once healing occurs. In cases where the specimen is resected from the extreme lateral or inferior borders of the breast, the defect may not be severe. However, virtually everywhere else in the breast, this adherence can cause NAC distortion or contour deformities of the breast itself.

ANTICIPATING THE IMPACT OF RADIOTHERAPY

The addition of radiotherapy to lumpectomy is a key component of BCT in most patients. However, it is the addition of radiotherapy to the milieu that is considered by many to be one of the least predictable influences on the development of breast deformity and asymmetry after treatment.^{29,30} Several patient factors that most surgeons agree contribute to worse outcomes after BCT include breasts that are smaller, more ptotic, and have a higher proportion of fatty tissue than glandular tissue.³¹

The total prescribed radiation dose, including higher boost irradiation energy, can have a negative impact on long-term cosmesis.³² In addition to total dosage, the radiation delivery technique has been further evaluated and is a distinct variable. The use of accelerated partial-breast irradiation (APBI) using three-dimensional conformal radiotherapy versus whole-breast irradiation has also been found to have an adverse impact on cosmesis at 3 years after treatment as well as progressive deterioration of breast cosmesis.³³ However, other studies with significantly smaller study groups have found that APBI delivered through brachytherapy results in better cosmesis than whole-breast irradiation.³⁴ The fractionation schedule of whole-breast irradiation may also play a role, at least in terms of acute skin toxicity. Hypofractionated whole-breast irradiation, or delivery of the dose over a shorter time frame, results in fewer acute and short-term skin toxicities than conventional fractionation.^{35,36} The long-term correlation of these findings to overall breast cosmesis and pain-free survival has not been confirmed.

Radiotherapy delivery factors to be considered include APBI versus whole-breast irradiation; external beam radiotherapy versus brachytherapy; and a hypofractionated versus a conventional fractionated delivery schedule.

CAN RADIOTHERAPY BE AVOIDED?

It has been found that patients over 70 years of age who have estrogen receptor–positive breast tumors will likely have similar survival outcomes, with or without the inclusion of radiotherapy after lumpectomy.³⁷ The results of BCT in such a patient group would be significantly more predictable. Patients with collagen vascular disease, particularly scleroderma or active systemic lupus, have an enhanced response to radiation, with aggressive development of radiation-induced fibrosis in their tissues.³⁸ These patients are not considered candidates for BCT. Women with a previous history of mantle irradiation for the treatment of Hodgkin's lymphoma who present with breast cancer should at least be engaged in a frank discussion of the possibility of contralateral cancer developing at some point and what the role of mastectomy might be in reducing that risk.³⁹ Although BCT may be considered in these patients, the impact of additional radiotherapy should be weighed carefully.

MANAGING EXPECTATIONS AND SHARED DECISION-MAKING

As noted earlier, the consultation process when helping a patient decide between BCT and mastectomy with reconstruction does not usually end in an easy “Yes” or “No” answer. In breast reconstruction the wishes, expectations, and tolerance of treatment that patients bring to their care affect many of the choices that are made. It is essential to gain an understanding of the patient's overall tolerance of possible asymmetry in her breasts, potential contour deformities in the treated breast, the strength of her desire to preserve breast tissue, and the possibility of delayed partial breast reconstruction months or years after completion of oncologic treatment. This information is used in conjunction with a reasonable assessment of what the aesthetic impact of BCT will be on a patient's breasts, given the parameters discussed previously, to present a picture of what might be required to obtain satisfactory results if BCT is pursued versus a mastectomy with or without reconstruction.

The surgeon must assess the patient's overall tolerance of potential breast asymmetry and contour deformities in the treated breast, the strength of her desire to preserve breast tissue, and the possibility of partial breast reconstruction delayed for months or years later. For an optimal outcome, the patient must be included in the decision-making regarding her treatment.

A consultation in which the patient is deciding between mastectomy and BCT is more difficult than one where mastectomy is a certainty. Such dialogs require the ability to “read” a patient’s responses to questions about asymmetry, contour distortion, and further treatment, none of which can be precisely defined before surgery. Other potential techniques in reconstructive breast surgery must be discussed, such as fat grafting, oncoplastic surgery, and tissue transfer for partial breast reconstruction.

THE ROLE OF NEOADJUVANT CHEMOTHERAPY AND BREAST IMAGING IN BCT MANAGEMENT

Although the percentage of women opting for mastectomy is clearly on the rise,^{17,40-42} many new strategies and modalities have expanded the patient population that might benefit from BCT. Neoadjuvant chemotherapy has introduced the concept of the “mastectomy to BCT turnover patient.” That is, patients whose initial tumors were deemed too large to be amenable to treatment with BCT may become eligible for BCT alone or possibly an oncoplastic approach following the shrinking of their tumor with successful neoadjuvant chemotherapy.⁴³⁻⁴⁵

Nodal assessment guides adjuvant chemotherapy.

Improved breast imaging allows more accurate assessment of tumor response to neoadjuvant chemotherapy and is critical to safely pursuing a breast-conserving approach in patients with tumors originally deemed too large for BCT.^{46,47} Such imaging not only helps confirm the patient’s response to neoadjuvant chemotherapy, but can also help with the precise planning of lumpectomy. Precise imaging allows preoperative planning to ensure that adequate tissue is removed without leading to the excessive removal of normal tissue.²⁴⁻²⁶ Although these patients may still opt for mastectomy, there can be no doubt that it is advantageous to expand the options available to patients with initially large tumors. Patients who feel involved in the decisions related to their care are more satisfied with the results of that care.^{48,49}

LARGE RESECTIONS AND ONCOPLASTIC SURGERY: ARE THERE BENEFITS?

The power of oncoplastic surgery is the elimination of dead space within the breast by either volume replacement involving flap reconstruction⁵⁰⁻⁵³ or volume displacement through breast rearrangement and reduction techniques.^{16,22,23} This treatment is by definition provided before the delivery of radiotherapy. Breast-reduction techniques performed as part of delayed partial breast reconstruction (those occurring after the delivery of radiotherapy) tend to have higher complication profiles, so fat grafting or flap techniques are preferred in these cases.²³

There are oncologic benefits of oncoplastic surgery that go far beyond breast aesthetics and the maintenance of normal breast contours. When compared with BCT alone, oncologic resection combined with oncoplastic techniques has been demonstrated in several studies to produce vastly superior margins.^{54,55} Since recurrence rates are virtually identical when oncoplastic techniques are compared with BCT alone, this is a rare win-win situation in surgery.^{56,57} In fact, not only have recurrence rates been shown to be similar with these two techniques, but also the comparative similarity holds up even when the sizes of the tumors are larger in the oncoplastic group than in the BCT-only group.⁵⁶

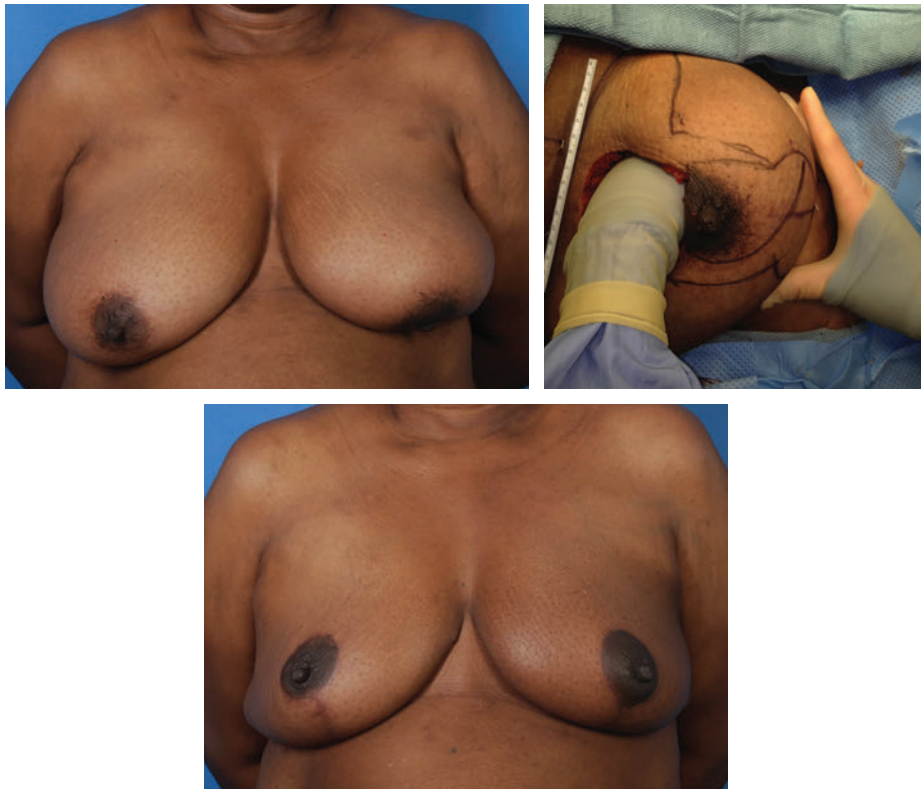

Fig. 6-6

This patient presented before radiotherapy after her lumpectomy and one reexcision with persistent positive margins. A third resection (a second reexcision) was performed, bringing the cumulative resection to more than 400 g. An oncoplastic reconstruction based on a superomedial pedicle was performed. The patient's results are seen 6 months after radiotherapy.

Care must be taken in regard to the timing of oncoplastic reconstruction, since this technique will commit the patient to a mastectomy and eliminate the possibility of a reexcision if positive margins are found after the initial lumpectomy. For this reason, many surgeons wait several days for the final pathologic analysis to confirm clear margins before proceeding with reconstruction. This allows reexcision in the case of a close or positive margin.

A truly satisfied patient is not simply the one whose breasts look the best after treatment. Any technique that interferes with or delays adjuvant treatment will be potentially perceived by the patient as detrimental to her overall outcome. It would seem intuitive that the larger incisions and more complex techniques associated with oncoplastic surgery might delay the initiation of adjuvant care such as radiotherapy. In fact, one meta-analysis has demonstrated no difference in the complication rate between patients treated with oncoplastic techniques and those treated with BCT alone.⁵⁸ It is not surprising then that the initiation of adjuvant treatment is no different between patients treated with these two approaches.⁵⁹

Mammographic surveillance is another important factor in the long-term management of breast cancer patients. Again, we need to look beyond breast aesthetics alone and ensure that patients who have undergone more complex reconstructive techniques to avoid contour deformities and asymmetries are not relegated to years of stress created by difficulty with breast imaging.^{60,61} When comparing patients undergoing oncoplastic reconstruction with those undergoing BCT alone, Losken et al⁶² found similar rates of qualitative changes, such as the development of oil cysts and benign calcifications. They also found that the time for the patients to reach mammographic stability was similar, but that their group undergoing oncoplastic reconstruction required almost three times more diagnostic biopsies. Importantly, that same study found that the lumpectomy specimens removed in the oncoplastic group, at an average of 291 g, were more than four times larger than those removed in the BCT-alone group. The large difference in the specimen sizes raises an important question.

Was the Losken study really comparing two similar patient groups? Probably not. It is very unlikely that patients requiring a lumpectomy in the range of 290 g would ever be amenable to BCT alone as treatment without the use of some oncoplastic technique. Therefore, although the biopsy rate was higher in the Losken oncoplastic group than in the BCT group, the true alternative in this group would have been mastectomy, not BCT alone. If this is explained carefully to patients, they are much more likely to accept later biopsies if they understand that those tests are in lieu of a mastectomy.

Ironically, it is sometimes reassuring to hear that a very large-breasted patient prefers breast conservation to mastectomy and reconstruction. This can convert the challenge of an implant-based breast reconstruction in a large-breasted patient to a more manageable oncoplastic reconstruction.⁶³ A comparison of studies reveals that implant-based breast reconstruction in an obese patient being treated for breast cancer carries with it significantly higher complication rates.^{64,65}

THE DELAYED MANAGEMENT OF UNFAVORABLE RESULTS IN BCT

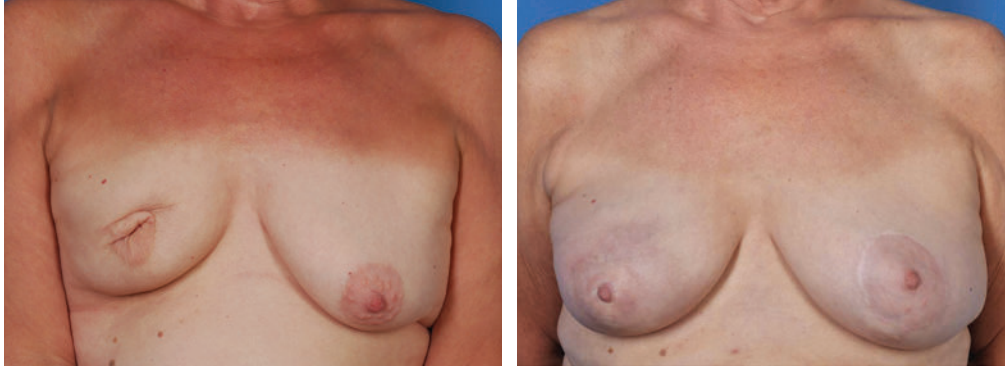

Fig. 6-7

This patient developed nipple retraction and asymmetry following a right BCT. After two rounds of fat grafting and a contralateral mastopexy, all performed as outpatient procedures, her breast symmetry and retraction are significantly improved.

It is important to appreciate just how difficult the management of poor results after BCT can be; the value of carefully considering the impact of lumpectomy and radiotherapy on a given patient must be emphasized. Although the introduction of fat grafting/lipofilling to the breast has had a significant impact on the management of small to moderate contour deformities in breasts treated with BCT,⁶⁶⁻⁷⁰ the contralateral breast still frequently requires some form of a procedure to create symmetry if any degree of ptosis exists. Before embarking on fat grafting for the reconstruction of unfavorable BCT deformities, it is important to have an understanding of the impact of such treatment on cancer surveillance. Fat grafting of BCT deformities will have some impact on mammography, and the incidence of benign findings such as oil cysts and calcifications have been reported to be approximately 15% to 20%.^{67,71} However, patients undergoing BCT alone are also found to have qualitative changes in their mammograms, with 18% requiring biopsy at some point following treatment.⁶² Moreover, in patients undergoing breast-reduction surgery who have no history of cancer, findings such as oil cysts and benign calcifications are found on almost 30% of their postsurgical mammograms.⁷² Given the broad acceptance of reduction mammoplasty despite these findings, it seems reasonable that fat grafting of BCT deformities is certainly acceptable from the perspective of changes in breast imaging.

The relationship between fat grafting and breast cancer recurrence is also an important issue to address, since there were some concerns in the past about injecting fat into the breast of any woman, let alone those who have had breast cancer. Several groups have evaluated patients after fat grafting to BCT deformities and found recurrence rates in the range of 1.3% to 4%, which falls very near the recurrence rates in patients undergoing BCT alone.^{71,73,74}

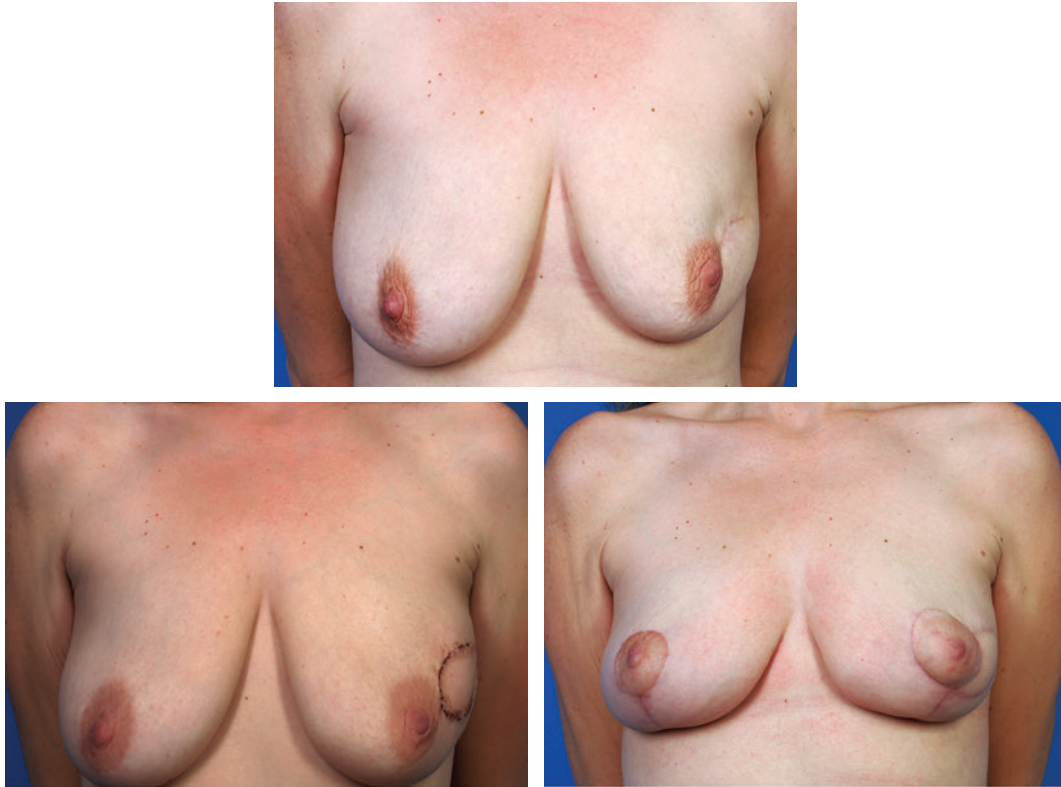

Fig. 6-8

This patient presented several years after BCT requesting larger, more symmetrical breasts. The first stage of her care involved a pedicled thoracodorsal artery perforator (TDAP) flap to the left breast to increase her breast volume. Her second reconstructive surgery was a bilateral mastopexy.

Depending on the degree of asymmetry and the patient's desired breast size, fat grafting alone may not be a reasonable option. It may be necessary to transfer more significant volumes of tissue, such as pedicled flaps or even free flaps, to manage volume differences, and the contralateral breast may still require breast reduction or mastopexy.⁵⁰ The addition of complex procedures years after the patient has decided her cancer treatment is concluded is not likely to result in a happy patient, even if the reconstruction increases her satisfaction by restoring shape and symmetry.

Breast-reduction techniques, which are generally very manageable before radiotherapy, become more complicated when referral for reconstruction occurs after radiotherapy has concluded.²² Kronowitz and colleagues^{23,75} determined that BCT patients undergoing a breast-reduction technique were more than twice as likely to develop a significant complication when the reduction was performed after delivery of radiotherapy versus those who completed surgery before delivery of radiation. In some cases, breast reduction by liposuction alone may allow adequate reduction of an irradiated breast without the need for incisions.^{76,77}

CONCLUSION

The complex decisions surrounding a choice between BCT and mastectomy have become increasingly multifaceted over the past decade. The expanded availability of neoadjuvant chemotherapy, complex imaging technology, and techniques for oncoplastic and delayed partial breast reconstruction combined with growing expectations from patients have contributed to this. Although any improvement in techniques and technology is certainly advantageous to physicians treating patients with breast cancer, it is certain that communicating the expanded options to patients is difficult.

Ultimately, the first priority must be excellent oncologic care. This will almost always be the primary concern of the patient as she embarks on the initial stages of her journey through breast cancer. Because many patients will be primarily focused on their oncologic outcome early in their care, it is essential that physicians be aware of the aesthetic and functional impact of different treatment options on their patient's breasts. The patient who is perfectly happy "just to be alive" immediately after treatment may find herself increasingly dissatisfied as the years pass by and her breast asymmetry becomes more inconvenient.

Therefore the consideration of the factors outlined is critical to predicting unfavorable outcomes in BCT. Particularly given the challenges of delayed reconstruction in a patient undergoing radiotherapy, awareness by the entire treatment team from the moment a treatment plan is first formulated will help to avoid unnecessarily complex treatment in a delayed fashion for many patients.

Physicians must also be aware of the possibility of breast cancer recurrence in any patient opting for BCT. Treatment in such a case will, by definition, occur in a patient whose breast has already been irradiated and who will require a completion mastectomy. Donor sites for autologous total breast reconstruction should not be sacrificed in an effort to provide partial breast reconstruction without clear communication with the patient.

Ultimately, the best results will be obtained when a multidisciplinary team in close communication can interact with the patient in a manner that provides the best possibility of a shared decision-making process that includes all of the factors involved in total breast cancer care.

Critical Issues

- Oncologically successful breast-conserving therapy depends on several factors, the most important of which is margin status.
- It is critical that the clinician understand final margin status and the implications of positive margins before embarking on any reconstructive plan.
- Patient satisfaction with BCT alone is not as high as once thought. Unfavorable aesthetic and functional outcomes are as high as 25% to 35% in BCT.
- Understanding the patient's tolerance of asymmetries, her aesthetic expectations, and her desire to either preserve her breast tissue or, conversely, to have it all removed, is critical to understanding her tolerance for, and the success of, various treatments.
- Reconstruction of BCT deformities is more straightforward before radiotherapy is performed.
- This makes the anticipation of unfavorable outcomes important. This is true both with *replacement* techniques and *displacement* techniques.
- Key factors in unfavorable aesthetic outcomes include the tumor-to-breast ratio, the resection of significant skin, the creation of communication between the deep dermis and fascia, and the resection of tissue in sensitive areas.
- Key factors in favorable patient satisfaction outcomes include understanding her goals for breast size, her tolerance of various treatments, her concern over leaving breast tissue behind, and her inclusion in the decision-making process.
- The reconstruction of partial breast deformities should not sacrifice donor sites that might be valuable in the event of a recurrence requiring mastectomy and reconstruction.
- The use of neoadjuvant chemotherapy and advanced imaging technologies are helpful in reducing the amount of normal tissue that is resected to achieve adequate tumor margins.
- BCT with oncoplastic reconstruction is often the treatment of choice in very large-breasted patients.
- Patients with previous implant-based breast augmentation frequently experience unfavorable results from breast irradiation.

References

1. Arriagada R, Le MG, Rochard F, et al. Conservative treatment versus mastectomy in early breast cancer: patterns of failure with 15 years of follow-up data. Institut Gustave-Roussy Breast Cancer Group. *J Clin Oncol* 14:1558, 1996.
2. Blichert-Toft M, Rose C, Andersen JA, et al. Danish randomized trial comparing breast conservation therapy with mastectomy: six years of life-table analysis. Danish Breast Cancer Cooperative Group. *J Natl Cancer Inst Monogr* 11:19, 1992.

3. Fisher B, Anderson S, Redmond CK, et al. Reanalysis and results after 12 years of follow-up in a randomized clinical trial comparing total mastectomy with lumpectomy with or without irradiation in the treatment of breast cancer. *N Engl J Med* 333:1456, 1995.
4. Jacobson JA, Danforth DN, Cowan KH, et al. Ten-year results of a comparison of conservation with mastectomy in the treatment of stage I and II breast cancer. *N Engl J Med* 332:907, 1995.
5. Veronesi U, Luini A, Galimberti V, et al. Conservation approaches for the management of stage I/II carcinoma of the breast: Milan Cancer Institute trials. *World J Surg* 18:70, 1994.
6. Clarke M, Collins R, Darby S, et al. Effects of radiotherapy and of differences in the extent of surgery for early breast cancer on local recurrence and 15-year survival: an overview of the randomised trials. *Lancet* 366(9503):2087, 2005.
7. Mazouni C, Fina F, Romain S, et al. Post-operative nomogram for predicting freedom from recurrence after surgery in localised breast cancer receiving adjuvant hormone therapy. *J Cancer Res Clin Oncol* 141:1083, 2015.
8. Toesca A, Botteri E, Lazzeroni M, et al. Breast conservative surgery for well-differentiated ductal intraepithelial neoplasia: risk factors for ipsilateral breast tumor recurrence. *Breast* 23:829, 2014.
9. Chao KK, Vicini FA, Wallace M, et al. Analysis of treatment efficacy, cosmesis, and toxicity using the MammoSite breast brachytherapy catheter to deliver accelerated partial-breast irradiation: the William Beaumont Hospital experience. *Int J Radiat Oncol Biol Phys* 69:32, 2007.
10. Dewar JA, Benhamou S, Benhamou E, et al. Cosmetic results following lumpectomy, axillary dissection and radiotherapy for small breast cancers. *Radiother Oncol* 12:273, 1988.
11. Wang HT, Barone CM, Steigelman MB, et al. Aesthetic outcomes in breast conservation therapy. *Aesthet Surg J* 28:165, 2008.
12. Bajaj AK, Kon PS, Oberg KC, Miles DA. Aesthetic outcomes in patients undergoing breast conservation therapy for the treatment of localized breast cancer. *Plast Reconstr Surg* 114:1442, 2004.
13. Moyer HR, Carlson GW, Styblo TM, Losken A. Three-dimensional digital evaluation of breast symmetry after breast conservation therapy. *J Am Coll Surg* 207:227, 2008.
14. Landercasper J, Attai D, Atisha D, et al. Toolbox to reduce lumpectomy reoperations and improve cosmetic outcome in breast cancer patients: the American Society of Breast Surgeons Consensus Conference. *Ann Surg Oncol* 22:3174, 2015.
15. Blondeel PN, Hijjawi J, Depypere H, et al. Shaping the breast in aesthetic and reconstructive breast surgery: an easy three-step principle. *Plast Reconstr Surg* 123:455, 2009.
16. Blondeel PN, Hijjawi J, Depypere H, et al. Shaping the breast in aesthetic and reconstructive breast surgery: an easy three-step principle. Part III—reconstruction following breast conservative treatment. *Plast Reconstr Surg* 124:28, 2009.
17. Throckmorton AD, Esserman LJ. When informed, all women do not prefer breast conservation. *J Clin Oncol* 27:484, 2009.
18. Jagsi R, Li Y, Morrow M, et al. Patient-reported quality of life and satisfaction with cosmetic outcomes after breast conservation and mastectomy with and without reconstruction: results of a survey of breast cancer survivors. *Ann Surg* 261:1198, 2015.
19. Hamelinck VC, Bastiaannet E, Pieterse AH, et al. Patients' preferences for surgical and adjuvant systemic treatment in early breast cancer: a systematic review. *Cancer Treat Rev* 40:1005, 2014.
20. Attai DJ, Cowher MS, Al-Hamadani M, et al. Twitter social media is an effective tool for breast cancer patient education and support: patient-reported outcomes by survey. *J Med Internet Res* 17:e188, 2015.
21. Collins ED, Moore CP, Clay KF, et al. Can women with early-stage breast cancer make an informed decision for mastectomy? *J Clin Oncol* 27:519, 2009.
22. Losken A, Elwood ET, Styblo TM, Bostwick J III. The role of reduction mammoplasty in reconstructing partial mastectomy defects. *Plast Reconstr Surg* 109:968; discussion 976, 2002.
23. Kronowitz SJ, Hunt KK, Kuerer HM, et al. Practical guidelines for repair of partial mastectomy defects using the breast reduction technique in patients undergoing breast conservation therapy. *Plast Reconstr Surg* 120:1755, 2007.

24. Faermann R, Sperber F, Schneebaum S, et al. Tumor-to-breast volume ratio as measured on MRI: a possible predictor of breast-conserving surgery versus mastectomy. *Isr Med Assoc J* 16:101, 2014.
25. Parvaiz MA, Yang P, Razia E, et al. Breast MRI in invasive lobular carcinoma: a useful investigation in surgical planning? *Breast J* 22:143, 2016.
26. Jochelson MS, Lampen-Sachar K, Gibbons G, et al. Do MRI and mammography reliably identify candidates for breast conservation after neoadjuvant chemotherapy? *Ann Surg Oncol* 22:1490, 2015.
27. Painter TJ, Dipasco PJ, Misra S, et al. Effect of magnetic resonance imaging on breast conservation therapy versus mastectomy: a review of the literature. *Int J Surg Oncol*. Epub 2011 Apr 19.
28. Akazawa K, Tamaki Y, Taguchi T, et al. Preoperative evaluation of residual tumor extent by three-dimensional magnetic resonance imaging in breast cancer patients treated with neoadjuvant chemotherapy. *Breast J* 12:130, 2006.
29. de la Rochefordière A, Abner AL, Silver B, et al. Are cosmetic results following conservative surgery and radiation therapy for early breast cancer dependent on technique? *Int J Radiat Oncol Biol Phys* 23:925, 1992.
30. Pierce SM, Recht A, Lingos TI, et al. Long-term radiation complications following conservative surgery (CS) and radiation therapy (RT) in patients with early stage breast cancer. *Int J Radiat Oncol Biol Phys* 23:915, 1992.
31. Hille-Betz U, Vaske B, Bremer M, et al. Late radiation side effects, cosmetic outcomes and pain in breast cancer patients after breast-conserving surgery and three-dimensional conformal radiotherapy: risk-modifying factors. *Strahlenther Onkol* 192:8, 2016.
32. Murphy C, Anderson PR, Li T, et al. Impact of the radiation boost on outcomes after breast-conserving surgery and radiation. *Int J Radiat Oncol Biol Phys* 81:69, 2011.
33. Peterson D, Truong PT, Parpia S, et al. Predictors of adverse cosmetic outcome in the RAPID trial: an exploratory analysis. *Int J Radiat Oncol Biol Phys* 91:968, 2015.
34. Bitter SM, Heffron-Cartwright P, Wennerstrom C, et al. WBRT vs. APBI: an interim report of patient satisfaction and outcomes. *J Contemp Brachytherapy* 8:17, 2016.
35. Jagsi R, Griffith KA, Boike TP, et al. Differences in the acute toxic effects of breast radiotherapy by fractionation schedule: comparative analysis of physician-assessed and patient-reported outcomes in a large multicenter cohort. *JAMA Oncol* 1:918, 2015.
36. Shaitelman SF, Schlembach PJ, Arzu I, et al. Acute and short-term toxic effects of conventionally fractionated vs hypofractionated whole-breast irradiation: a randomized clinical trial. *JAMA Oncol* 1:931, 2015.
37. Hughes KS, Schnaper LA, Bellon JR, et al. Lumpectomy plus tamoxifen with or without irradiation in women age 70 years or older with early breast cancer: long-term follow-up of CALGB 9343. *J Clin Oncol* 31:2382, 2013.
38. Wo J, Taghian A. Radiotherapy in setting of collagen vascular disease. *Int J Radiat Oncol Biol Phys* 69:1347, 2007.
39. Alm El-Din MA, El-Badawy SA, Taghian AG. Breast cancer after treatment of Hodgkin's lymphoma: general review. *Int J Radiat Oncol Biol Phys* 72:1291, 2008.
40. McGuire KP, Santillan AA, Kaur P, et al. Are mastectomies on the rise? A 13-year trend analysis of the selection of mastectomy versus breast conservation therapy in 5865 patients. *Ann Surg Oncol* 16:2682, 2009.
41. Fisher CS, Martin-Dunlap T, Ruppel MB, et al. Fear of recurrence and perceived survival benefit are primary motivators for choosing mastectomy over breast-conservation therapy regardless of age. *Ann Surg Oncol* 19:3246, 2012.
42. Dragun AE, Huang B, Tucker TC, et al. Increasing mastectomy rates among all age groups for early stage breast cancer: a 10-year study of surgical choice. *Breast J* 18:318, 2012.
43. Fitzal F, Riedl O, Mittlböck M, et al. Oncologic safety of breast conserving surgery after tumour downsizing by neoadjuvant therapy: a retrospective single centre cohort study. *Breast Cancer Res Treat* 127:121, 2011.

44. Fitzal F, Mittlboeck M, Steger G, et al. Neoadjuvant chemotherapy increases the rate of breast conservation in lobular-type breast cancer patients. *Ann Surg Oncol* 19:519, 2012.
45. Buchholz TA, Mittendorf EA, Hunt KK. Surgical considerations after neoadjuvant chemotherapy: breast conservation therapy. *J Natl Cancer Inst Monogr* 2015:11, 2015.
46. Vriens BE, de Vries B, Lobbes MB, et al. Ultrasound is at least as good as magnetic resonance imaging in predicting tumour size post-neoadjuvant chemotherapy in breast cancer. *Eur J Cancer* 52:67, 2016.
47. Marinovich ML, Macaskill P, Irwig L, et al. Agreement between MRI and pathologic breast tumor size after neoadjuvant chemotherapy, and comparison with alternative tests: individual patient data meta-analysis. *BMC Cancer* 15:662, 2015.
48. Nicolai J, Buchholz A, Seefried N, et al. When do cancer patients regret their treatment decision? A path analysis of the influence of clinicians' communication styles and the match of decision-making styles on decision regret. *Patient Educ Couns* 99:739, 2015.
49. Covelli AM, Baxter NN, Fitch MI, et al. 'Taking control of cancer': understanding women's choice for mastectomy. *Ann Surg Oncol* 22:383, 2015.
50. Hamdi M, Van Landuyt K, Hijjawi JB, et al. Surgical technique in pedicled thoracodorsal artery perforator flaps: a clinical experience with 99 patients. *Plast Reconstr Surg* 121:1632, 2008.
51. Hamdi M, Van Landuyt K, Monstrey S, Blondeel P. Pedicled perforator flaps in breast reconstruction: a new concept. *Br J Plast Surg* 57:531, 2004.
52. Zaha H, Onomura M, Nomura H, et al. Free omental flap for partial breast reconstruction after breast-conserving surgery. *Plast Reconstr Surg* 129:583, 2012.
53. Izumi K, Fujikawa M, Tashima H, et al. Immediate reconstruction using free medial circumflex femoral artery perforator flaps after breast-conserving surgery. *J Plast Reconstr Aesthet Surg* 66:1528, 2013.
54. Kaur N, Petit JY, Rietjens M, et al. Comparative study of surgical margins in oncoplastic surgery and quadrantectomy in breast cancer. *Ann Surg Oncol* 12:539, 2005.
55. Giacalone PL, Roger P, Dubon O, et al. Comparative study of the accuracy of breast resection in oncoplastic surgery and quadrantectomy in breast cancer. *Ann Surg Oncol* 14:605, 2007.
56. Chakravorty A, Shrestha AK, Sanmugalingam N, et al. How safe is oncoplastic breast conservation? Comparative analysis with standard breast conserving surgery. *Eur J Surg Oncol* 38:395, 2012.
57. Rietjens M, Urban CA, Rey PC, et al. Long-term oncological results of breast conservative treatment with oncoplastic surgery. *Breast* 16:387, 2007.
58. Losken A, Dugal CS, Styblo TM, et al. A meta-analysis comparing breast conservation therapy alone to the oncoplastic technique. *Ann Plast Surg* 72:145, 2014.
59. Dogan L, Gulcelik MA, Karaman N, et al. Oncoplastic surgery in surgical treatment of breast cancer: is the timing of adjuvant treatment affected? *Clin Breast Cancer* 13:202, 2013.
60. Roberts JM, Clark CJ, Campbell MJ, et al. Incidence of abnormal mammograms after reduction mammoplasty: implications for oncoplastic closure. *Am J Surg* 201:611, 2011.
61. Dolan R, Patel M, Weiler-Mithoff E, et al. Imaging results following oncoplastic and standard breast conserving surgery. *Breast Care (Basel)* 10:325, 2015.
62. Losken A, Schaefer TG, Newell M, et al. The impact of partial breast reconstruction using reduction techniques on postoperative cancer surveillance. *Plast Reconstr Surg* 124:9, 2009.
63. Tong WM, Baumann DP, Villa MT, et al. Obese women experience fewer complications after oncoplastic breast repair following partial mastectomy than after immediate total breast reconstruction. *Plast Reconstr Surg* 137:777, 2016.
64. Nguyen KT, Hanwright PJ, Smetona JT, et al. Body mass index as a continuous predictor of outcomes after expander-implant breast reconstruction. *Ann Plast Surg* 73:19, 2014.
65. Fischer JP, Nelson JA, Kovach SJ, et al. Impact of obesity on outcomes in breast reconstruction: analysis of 15,937 patients from the ACS-NSQIP datasets. *J Am Coll Surg* 217:656, 2013.
66. Kronowitz SJ, Mandujano CC, Liu J, et al. Lipofilling of the breast does not increase the risk of recurrence of breast cancer: a matched controlled study. *Plast Reconstr Surg* 137:385, 2016.

67. Pérez-Cano R, Vranckx JJ, Lasso JM, et al. Prospective trial of adipose-derived regenerative cell (ADRC)-enriched fat grafting for partial mastectomy defects: the RESTORE-2 trial. *Eur J Surg Oncol* 38:382, 2012.
68. Schultz I, Lindegren A, Wickman M. Improved shape and consistency after lipofilling of the breast: patients' evaluation of the outcome. *J Plast Surg Hand Surg* 46:85, 2012.
69. Chirappapha P, Rietjens M, De Lorenzi F, et al. Evaluation of lipofilling safety in elderly patients with breast cancer. *Plast Reconstr Surg Glob Open* 3:e441, 2015.
70. Petit JY, Maisonneuve P, Rotmensz N, et al. Safety of lipofilling in patients with breast cancer. *Clin Plast Surg* 42:339, 2015.
71. Brenelli F, Rietjens M, De Lorenzi F, et al. Oncological safety of autologous fat grafting after breast conservative treatment: a prospective evaluation. *Breast J* 20:159, 2014.
72. Rubin JP, Coon D, Zuley M, et al. Mammographic changes after fat transfer to the breast compared with changes after breast reduction: a blinded study. *Plast Reconstr Surg* 129:1029, 2012.
73. Petit JY, Lohsiriwat V, Clough KB, et al. The oncologic outcome and immediate surgical complications of lipofilling in breast cancer patients: a multicenter study—Milan-Paris-Lyon experience of 646 lipofilling procedures. *Plast Reconstr Surg* 128:341, 2011.
74. Petit JY, Botteri E, Lohsiriwat V, et al. Locoregional recurrence risk after lipofilling in breast cancer patients. *Ann Oncol* 23:582, 2012.
75. Kronowitz SJ. State of the art and science in postmastectomy breast reconstruction. *Plast Reconstr Surg* 135:755e, 2015.
76. Jakubietz RG, Jakubietz DF, Gruenert JG, et al. Breast reduction by liposuction in females. *Aesthetic Plast Surg* 35:402, 2011.
77. Abboud MH, Dibo SA. Power-assisted liposuction mammaplasty (PALM): a new technique for breast reduction. *Aesthet Surg J* 36:35, 2016.

7

Oncologic Safety of the Oncoplastic Approach for Breast Conservation Surgery

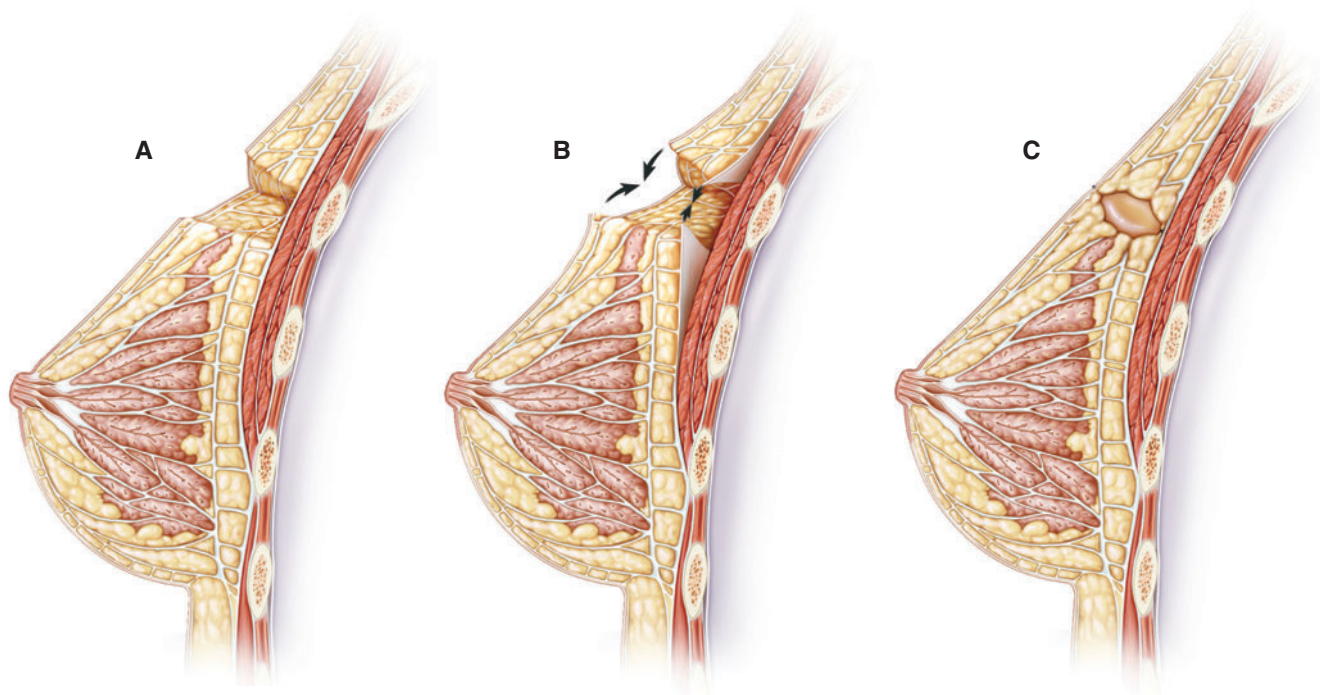
Kristine E. Calhoun, Benjamin O. Anderson

T

he increasing popularity of breast oncoplastic surgery has refocused attention on how the partial mastectomy can best be performed to maximize the width of surgical margins at the same time that cosmetic outcome is optimized. The simple “scoop and run” approach to lumpectomy can work well for excision of small malignant lesions. However, unless special surgical procedures are used, saucerization and/or disfiguring deviation of the nipple-areolar complex can result from large breast resections. Ductal carcinoma in situ (DCIS), with or without invasive cancer, commonly follows the segmental ductal anatomy of the breast and can track in narrow long segments (several centimeters in length) from the periphery of the breast toward the nipple.

Most oncoplastic partial mastectomy techniques have not been studied formally in longitudinal studies that address key oncologic issues such as local recurrence rates. Asgeirsson et al¹ reported their intermediate follow-up (up to 4½ years), with local recurrence rates that varied from 0% to 1.8% per year. In 2013, Haloua et al² published a literature review of 88 articles on oncoplastic breast-conserving surgery and found that (1) most studies showed significant weaknesses including lack of robust design and important methodological shortcomings, (2) current evidence supporting the efficacy of these oncoplastic procedures is based on poorly designed and underpowered studies, and (3) there is a need for robust comparative studies possibly using randomized controlled trials and/or well-designed multicenter prospective longitudinal studies. The overall oncologic safety of oncoplastic partial mastectomy for cancer therapy is based more on rationale than data, having been extrapolated from the general literature on partial mastectomy. As oncologists, we recognize that such rationale could be logical but inaccurate.

This chapter focuses on the oncologic goals of breast conservation and how oncoplastic procedures for partial mastectomy address these goals. The oncologic problems or issues that may arise with the use of these procedures are also discussed. In addition, the chapter details how careful attention to imaging, surgical margin assessment, and tumor bed marking can optimize the oncologic outcomes. These findings are meant to highlight how surgeons should adapt or modify their decision-making in patient selection for oncoplastic partial mastectomy procedures.



Mastopexy fibroglandular flap advancement closure

Fig. 7-1

A full-thickness tissue resection is completed (A). The fibroglandular tissue is elevated off the chest wall in preparation for mastopexy closure (B). The flap is advanced and breast tissue is closed at the chest wall, and final skin closure is performed, leaving a small cavity for transient seroma formation that will resolve during radiation therapy (C).

These long segmental cancers can be difficult or impossible to excise with clear margins using traditional lumpectomy techniques. Thus special lumpectomy approaches and closure techniques can be used to follow the segmental contour of the cancer (A). The breast tissue is closed in a way that preserves the breast shape but without moving the nipple-areolar complex on the breast's skin envelope. The flap advancement and closure of the breast tissue leaves a small cavity for transient seroma formation that resolves during radiotherapy (B and C).

THE ONCOLOGIC SIGNIFICANCE OF ONCOPLASTIC BREAST CONSERVATION

For breast conservation to be effective, the surgeon needs to obtain complete excision of the cancer with an adequate surgical margin width and achieve a surgical result that maintains the breast's shape and appearance.³ The oncoplastic lumpectomy with mam-moplasty flap advancement allows the surgeon to perform lumpectomy on larger cancers.⁴ The more advanced volume-displacement techniques, which are based on the key principles of breast-reduction surgery, can greatly increase the options for breast conservation in more complex cancer cases. Two oncologic questions arise regarding the application of these procedures: (1) Does the larger size of the primary breast cancer (DCIS or invasive) alter the rate of successful local regional control if the surgical margin width is deemed adequate? (2) Do the volume displacement techniques in any way influence the outcome, as measured by local control of disease at 5 to 10 years?

The NSABP-B-06 trial was designed to assess the treatment outcome for early-stage breast cancer. At entry to this randomized trial, patients had to have a stage I or II cancer measuring less than 4 cm in diameter.⁵ Thus, B-06 gives us no direct data about the outcome in treatment of cancers measuring more than 4 cm. Similarly, Veronesi's breast conservation randomized trial (Veronesi et al⁶) comparing radical mastectomy to quadrantectomy plus breast irradiation therapy was even more restrictive with cancer size being limited to 2 cm or less.

The landmark randomized trials that are used to justify the use of breast conservation therapy with 20-year follow-up actually do not provide direct evidence that breast conservation with larger (T3) cancers is actually similar to smaller cancers as measured by cancer disease-free and overall survival.

The use of breast conservation therapy with large cancers is really based on extrapolation rather than direct prospective randomized trial results.

Similarly, the oncologic implication of resecting large areas of DCIS has not been explored in prospective randomized trials. The extent of disease for DCIS, as measured by the linear margin width, was originally found to be a predictor of heightened local recurrence rates. In their original reports, the Van Nuys group, led by Silverstein et al,⁷ originally suggested that patients with larger DCIS may be best treated with a mastectomy, because their local

recurrence rates were high, even when radiotherapy was given. After subsequent reports and data reevaluations, however, it was suggested that the surgical margin width is the more important predictor of local recurrence with DCIS and that the size of the DCIS (larger than 4 cm) is a secondary factor. Restated, if a surgeon can remove the disease en bloc with wide surgical margins, the original dimensions of the disease become relatively unimportant, according to Silverstein.⁸

Studies from the 1990s show that BCS was underutilized in the United States, despite clear evidence of the oncologic safety of BCT in multiple settings.^{9,10} Today, with oncoplastic surgical techniques, the opposite issue needs to be addressed. Larger, partial mastectomy procedures have since been developed and are becoming more and more common. In individual cases, oncoplastic surgeons will use or adapt a variety of oncoplastic approaches—such as batwing mastopexy, radial segmental resection, donut mastopexy, and mastopexy closure—for the partial mastectomy. These oncoplastic approaches are used to creatively address the challenges that may result from variances like breast size, tumor size and location, and degree of breast ptosis—all of which are inevitably seen in breast surgical practices.⁴ This variability of oncoplastic technical application, which is part of the surgical artistry of preserving or improving breast shape and appearance, limits the feasibility of developing meaningful randomized trials of different oncoplastic surgical techniques to determine how these compare with standard lumpectomy techniques in terms of breast cancer local recurrence and survival. A careful prospective follow-up of patients will be important in the next 5 to 10 years to confirm that local control is indeed being maintained. In the interim, oncologic safety must be measured by using surrogate markers to predict local recurrence and survival; the most obvious question is whether the width of the surgical margin can be used as an accurate predictor of “complete” surgical excision of the disease.

In 2005, Kaur et al¹¹ reported a nonrandomized comparative analysis of 30 consecutive patients who underwent oncoplastic partial mastectomies and 30 consecutive patients who underwent standard breast excisions for cancer. They found that the mean volume of the excised specimens was significantly higher in the oncoplastic surgery group (200 cm² versus 118 cm²) than the standard resection group, demonstrating that more tissue was successfully being removed in the oncoplastic operations. Furthermore, they observed that negative margins (>2 mm) were achieved in 83% of the oncoplastic surgery resections but in only 57% of the standard resections. In a more recent study, Giacalone et al¹² prospectively compared two groups of patients with breast cancers measuring >15 mm who underwent either a standard partial mastectomy or an oncoplastic resection. The patients who underwent oncoplastic surgery were younger than the standard surgery patients but otherwise, all other demographic and oncological preoperative data were comparable. The investigators observed that (1) the median volume of the excised specimen in the oncoplastic group was higher than in the quadrantectomy group, (2) the nearest lateral margin widths were larger in the oncoplastic group than in the quadrantectomy group, and (3) free surgical margins >5 mm and >10 mm were obtained more frequently using oncoplastic surgery than standard partial mastectomy. However, no difference was observed between the two groups in terms of the need for secondary surgeries resulting from problematic surgical margins. These findings confirm, albeit in a nonrandomized fashion, that on-

coplastic approaches to the partial mastectomy really do remove more tissue with wider margins while improving the cosmetic outcome.

While the data regarding increased surgical margin width in oncoplastic breast conservation is reasonably persuasive, there is limited published data regarding the use of mam-moplasty advancement flap–volume displacement closure (see Fig. 7-1) in relation to subsequent breast cancer local recurrence rates in the breast. Grubnik's review of therapeutic mam-moplasty found reported local recurrence rates of less than 10% with acceptable cosmesis in over 80% of patients.¹³ Could the additional incisions made in the breast tissue with mastopexy advancement somehow cause tumor seeding that could later increase local recurrence rates? Other cancers with aggressive local characteristics have been shown to recur locally, such as gallbladder carcinoma recurring in laparoscopic port tracks and phyl-lodes tumors in the breast.¹⁴

Although tumor seeding is a theoretical concern, it has not been shown to be a significant issue with typical ductal or lobular carcinoma in the breast.

To the contrary, the development of clinically significant needle-track seeding with breast cancer is rarely reported, and in the few studies that describe tumor seeds being histologically detectable in needle sampling tracks, no study has shown these needle tracks to be associated with significantly adverse clinical outcomes. The hypothetical concern of mastopexy advancement seems to be nothing more than theory at present.

DETERMINING THE EXTENT OF THE DISEASE

In many circumstances, removing enough tissue to obtain adequate surgical margins may require extensive resections. The lack of surgical planning and forethought can lead to a postoperatively deformed breast. There is value in applying surgical approaches that allow the removal of adequate tissue, yet leave the breast shape and contour intact. To plan an optimal surgical resection, the surgeon should not only understand the distribution of cancer within the breast, but also know the degree to which imaging can accurately predict the true histologic extent and orientation of disease in the breast. In addition to accurate planning, these modalities also minimize the potential for positive margins.

Standard Breast Imaging

The combination of mammography and ultrasonography often helps to predict the orientation and extent of cancer within the breast. Invasive cancers form tumor masses that can be seen well with the two imaging studies used in combination. Ultrasonography complements mammographic imaging of invasive cancers, particularly when masses are concealed by dense fibroglandular tissue on radiographs.

Mammography and ultrasonography can be less reliable in determining the distribution of noninvasive cancers. DCIS can be visualized using mammography when microcalcifications are present and can be seen on radiographs. However, the extent of mammographically visualized calcifications can seriously underestimate the degree of histologic spread when the calcifications form centrally but are absent in the periphery of the cancerous lesion.¹⁵ Because DCIS typically fails to induce masslike changes, ultrasonography is of little or no use in determining the extent of DCIS in preparation for a lumpectomy. One benefit of standard imaging is that it can help to predict the distribution of locally extended cancers; however, it may fail to predict the full extent of segmentally extended cancers in many cases, particularly when they have a significant noninvasive component.

Incomplete excisions are more probable when the mammographic abnormality does not correspond to the entire extent of the lesion.¹⁶ This failed visualization is particularly likely to occur with low-grade DCIS, because microcalcification deposition is absent.⁵ With such cases, the surgical margins are often found to be positive at resection, even when specimen radiographic images are obtained and indicate that all disease has been removed. Second operations need to be performed, either with an oncoplastic segmentally orientated reexcision or with mastectomy. Therefore it is important for the surgeon to (1) use all imaging information to carefully assess the location and extent of disease at the time of surgical planning, and (2) consider the possibility of positive margins when performing an initial excision. Ideally, the incision should be placed in a location that will not prevent a cosmetically pleasing reexcision result. A reexcision of cavity margins is usually undertaken through the same incision without any need to extend the incision. A subsequent mastectomy requires an extended or new incision.

MRI Breast Imaging

Mammography may underestimate the extent of DCIS by as much as 1 to 2 cm, especially when the fine-granular microcalcifications seen with well-differentiated DCIS are present.¹⁷ Because breast MRI uses gadolinium enhancement to highlight metabolically active tissues, cancers that are mammographically occult may be clearly identified on MRI. Compared with mammographic and ultrasonographic images, the extent of disease seen on MRI may correlate best with the extent of tumor found at the pathologic evaluation. In addition, MRI has the lowest false-negative rate in detecting invasive lobular carcinoma.¹⁸ Of course, no imaging technique is perfect. Although its sensitivity is high, MRI has a low specificity of 67.7% in the diagnosis of breast cancer before biopsy.¹⁹ About 20% to 30% of MRI studies will show some area of enhancement that needs further assessment but ultimately proves to be histologically benign breast tissue.

A 2005 consensus statement from the American Society of Breast Surgeons supports the use of MRI for determining the ipsilateral tumor extent or the presence of contralateral disease in patients with a proven breast cancer (especially those with invasive lobular carcinoma) when dense breast tissue precludes an accurate mammographic assessment.²⁰ Lehman et al²¹ published a multicenter trial in which a 3% rate of mammographically and clinically occult cancer was found by MRI in the contralateral breast. For cancers contain-

ing both invasive and noninvasive components, a combination of imaging methods (mammography with magnification views, ultrasonography, and/or MRI) may yield the best estimate of overall tumor size.²²

Localization of Breast Lesions

Breast MRI can demonstrate the presence of mammographically occult cancer. Often, subsequent breast ultrasonography directed to the same area shows the lesion of concern, and the lesion can be localized preoperatively under ultrasound guidance. A core needle biopsy of the occult lesion can confirm more extensive disease and enable the surgeon to plan a proper oncoplastic resection. In other cases, the distinct area of malignancy fails to be detected on ultrasound. In such cases, MRI-guided biopsy techniques can be used to place clips in the breast that can be localized using mammography at the time of the lumpectomy.

Boetes et al²³ compared the accuracy of MRI with mammography and ultrasonography for assessing the extent of breast tumors in 61 tumors among 60 women undergoing mastectomy for carcinoma. The index tumor failed to be seen in 10% of cases with mammography and in 15% with ultrasonography, but only in 2% with MRI. On mammograms and sonograms, the tumor size was underestimated significantly (by 14% and 18%, respectively), but MRI showed no significant difference in the size compared with that found in a pathology evaluation in this series. Mammography showed 31% of the additional invasive lesions, ultrasonography showed 38%, and MRI 100%. MRI may be particularly useful in assessing the extent of disease of invasive lobular carcinoma (ILC).¹⁸ Compared with mammography and ultrasonography, contrast-enhanced MRI has the lowest false-negative rate in detecting ILC and is the most accurate in measuring the size of the ILC. However, a negative MRI does not obviate the need for a biopsy in the setting of suspicious mammographic findings. Occasionally, cancers, particularly DCIS, may fail to enhance on MRI, but they may be visualized on mammography because of radiographically detectable microcalcifications.^{19,24}

Preliminary data regarding MRI are encouraging; however, a significant limitation of MRI is in its high rate of false-positive studies.

Approximately one out of three MRI studies will show some area of enhancement that requires further evaluation but ultimately proves to be dense but histologically benign breast tissue.^{25,26} Practically speaking, using MRI if it is not possible to perform MRI-guided sampling or clip placement is ill advised, because, in many cases, the questions raised by the study are not able to be resolved before the lumpectomy. In addition, MRI does not always accurately predict the extent of noninvasive cancer, particularly when low-grade DCIS is present.

OPERATIVE MANAGEMENT

Bracketing Wires to Localize the Extent of Resection

Accurate localization of the lesion is important in planning any partial mastectomy surgical approach. When a lesion is nonpalpable—for example, with DCIS, or with an invasive cancer after a good clinical response to preoperative chemotherapy—the approach to wire localization can make the difference between complete excision with negative margins and surgical reexcision.

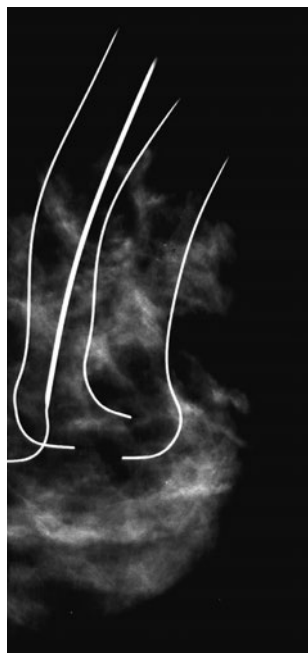


Fig. 7-2

Hooked wires have been widely used for the preoperative localization for nonpalpable lesions, especially DCIS. When planning oncoplastic resections, surgeons need to accurately identify the area requiring resection. Silverstein et al²⁷ suggest the preoperative placement of two to four bracketing wires to delineate the boundaries of a single lesion. The wire placement brackets the targeted microcalcification in the breast at the 12 o'clock position, and the targeted region within the breast shows the area of tissue to be removed. Calculations start 1 cm deep to the skin entry site and span approximately 5 cm superiorly to inferiorly. In a study by Liberman et al,²⁸ calcific lesions were bracketed, and complete removal of suspicious calcifications was accomplished in 34 (81%) of cases. It has been suggested that single-wire localization of large breast lesions is more likely to result in positive margins, because the surgeon lacks landmarks to determine where the true boundaries of nonpalpable disease are located. This can be particularly problematic with large areas of mammographically detected DCIS where natural landmarks distinguishing normal

and diseased tissue are lacking. Bracketing wires may also assist the surgeon in achieving complete excision. The bracketing wire technique does not guarantee complete removal of the lesion, but makes it more likely.⁸ Specimen radiography and orientation should be performed in wire-directed cases, because they can provide accurate and immediate feedback regarding the adequacy of the excision.

In the setting of mass lesions that can be seen using ultrasound, intraoperative ultrasound can be used to direct the parenchymal excision and to assess the thoroughness of the wide local excision.²⁹ In some settings, intraoperative ultrasound can be used in place of wire localization, if the target lesion appears to have a similar extent on mammographic and ultrasound imaging.³⁰

Differential Inking Techniques

The operating surgeon can best define the proper specimen orientation at the time of the surgical excision. The commonly used technique of suture marking as “long-lateral, short-superior” is not ideal because the specimen can be significantly altered during the process of specimen radiography—before it reaches the hands of the pathologist.

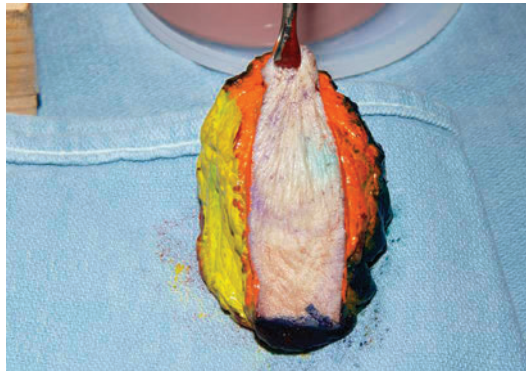


Fig. 7-3

Differential color inking of breast surgical specimen to facilitate orientation (superior, lateral, inferior, medial, posterior, anterior). The color inks, which can be recognized microscopically as well as grossly, provide correct orientation, in case the surgical margins are positive. The inks also mark margins that are full thickness in the mastectomy plane (anterior and posterior) that would not require surgical reexcision were the margin microscopically close, since there would be no additional breast tissues in these planes.

Inking kits are now available with inks in six colors (black, blue, yellow, green, orange, and red); these are very useful for labeling specimen margins (superior, inferior, medial, lateral, superficial, and deep). Most of the specimens excised using oncoplastic techniques have a complex shape and are not a “cubic” piece of tissue. The relationship of the tissue faces to the breast anatomy is best understood by the operating surgeon.

If the surgeon personally places the ink on the specimen, he or she will have markedly improved confidence in resolving any margin issues that may arise regarding the orientation.

The surgeon will recognize tears or splits on the surface of the specimen that arose during its manipulation and avoids depositing ink in these areas, because it may lead to a false-positive final margin.

After inking the specimen, acetic acid or a similar fixative is used to prevent ink from running on the specimen surface during transport. Careful specimen margin inking has been shown to be associated with improved outcomes, as measured by residual tumor in the breast.³¹ With full-thickness excisions, the superficial and deep margins are already taken in the mastectomy plane and, therefore, would not be improved by additional surgery. The surgeon can accurately paint these mastectomy plane margins. This approach may help to avoid additional and unnecessary reexcision before radiotherapy. However, to adopt an intraoperative inking protocol, a collaborative agreement needs to be established between the surgeon and pathologist to avoid a misunderstanding and/or miscommunication.

Intraoperative Placement of Perimeter Clips

Most radiation therapists request or require the placement of perimeter clips of titanium or stainless steel to outline the resection limits of the lumpectomy and to guide the postoperative tumor boost volume during teletherapy (external beam) or for precise brachytherapy planning. Most surgeons place at least four perimeter clips at the radial limits of the resection and one or two clips at the posterior center of the resection bed before closing the wound. Multilayer wound closures performed during oncoplastic procedures, such as mastopexy advancement flap–volume displacement closure, inevitably alter the final position of these marker clips, especially in the mastectomy pectoral plane. The appearance of these clips on plain radiographs or during three-dimensional CT treatment planning is very confusing to radiation therapists, even if they are familiar with the closure types used in oncoplastic surgery. Specific and clear communication between the surgeon and radiation therapist is essential for achieving the final 1 to 2 cm additional treatment margins needed for an effective boost dose.

Additional Techniques

Some institutions advocate intraoperative imaging to ensure that the tumor is within the specimen. Others use separate cavity sampling and frozen sections to further reduce the potential for positive margins. Most recently, a randomized trial by Chagpar et al³² showed that the routine use of cavity shave margins may reduce the rate of positive final margins and reexcisions among patients undergoing breast conservation surgery. A limitation of the study was that the control group not having shave margins had a very high 34% positive margin rate, suggesting that the technique is most useful when surgeons are not successful in limiting positive margin frequency with other more selective approaches.

Reexcision for Positive Margins

If reexcision is needed to eliminate positive surgical margins after the initial resection, both the surgical approach and timing of the operation must be considered.⁴ In most instances, the same incision may be used. In some situations, however, a new incision may be technically advantageous—the previous excision is given time to heal. When the positive margin involves only a minority of the specimen, the entire biopsy cavity does not need to be reexcised. Instead, only the one or two involved margins of the previous biopsy cavity need to be taken, assuming the initial specimen inking was thorough and accurately oriented. When all the margins are positive, a mastectomy may be needed to attain satisfactory surgical clearance. In this instance, it may be technically challenging to include both the initial oncoplastic incision and the nipple-areola complex in a total mastectomy. If reexcision is delayed for 3 to 4 weeks, the previous seroma cavity may be nearly reabsorbed, leaving a fibrous biopsy cavity that is located easily using intraoperative palpation. For noninvasive cancer, Silverstein et al²⁷ suggest that it is feasible to delay reexcision for up to 3 months, at which point the seroma cavity has been fully reabsorbed. Interestingly, when examining specimens that were removed in a delayed fashion, one group found that fewer cases contained residual carcinoma when the time to reexcision was longer, presumably because of the process of fibrosis, which consumes microscopically involved margins.³² This study suggests that local acute repair mechanisms may be responsible for the destruction of up to 50% of the residual tumor load and may complement the cytocidal effects of radiotherapy. This effect was apparent within 2 months of the initial excision (13 to 69 days). The reexcision of positive margins after extensive glandular rearrangement or flap reconstruction is often challenging and needs to be performed in conjunction with the reconstructive surgeon. The completion mastectomy with reconstruction is an alternative option when reexcision is not indicated.

OPERATIVE COMPLICATIONS AND POSSIBLE ADJUVANT TREATMENT DELAY

Complex operations that had increased complication rates could delay the timely delivery of adjuvant systemic treatment. Wound infection, fat necrosis, and delayed healing of complex skin closures (for example, T-junctions in a reduction mastopexy lumpectomy) are potential complications of oncoplastic operations. A meta-analysis comparing the oncoplastic techniques to BCT alone proved no significant difference in complication rate between the two groups. To the contrary, Kahn and colleagues found no differences in time to chemo or therapy initiation comparing oncoplastic breast conservation, wide local excision, mastectomy or mastectomy with immediate reconstruction.^{33,34} The blood supply of the external nipple arises from underlying fibroglandular tissue using major lactiferous sinuses rather than the collateral circulation from surrounding areolar skin, so nipple necrosis may occur if dissection extends high up behind the nipple.¹ Fact, there is data to suggest that oncoplastic volume-displacement partial mastectomies are less complication prone than are partial breast myocutaneous flap reconstruction techniques. In a review of 84 women who underwent partial mastectomy and radiation therapy, Kronowitz et al³⁵ showed that immediate repair of partial mastectomy defects with local tissues results in a lower risk of complications (23% versus 67%) and better aesthetic outcomes (57% versus 33%) than that with a latissimus dorsi flap, which some surgeons used for delayed reconstruction.

CONCLUSION

Oncoplastic partial mastectomy techniques are becoming increasingly recognized and accepted. These procedures allow the removal of larger cancers that otherwise would require mastectomy with improved cosmetic outcome. The concern of removing larger cancers with breast conservation techniques that could translate into heightened local recurrence risk appears to be offset by the apparent widening of surgical margins by virtue of designing resections that follow the segmentally distributed contour of cancers using full-thickness resection techniques. However, long-term (5 to 10 year) local recurrence rates have not been evaluated in large surgical series, suggesting that surgeons using oncoplastic techniques should be careful and meticulous, especially in relation to paying close attention to complete excision based on imaging findings and surgical margins on pathology. When larger resections using volume-displacement techniques are performed, the radiation oncologist should be informed so that the radiation techniques can be adjusted appropriately, especially in the application of boost doses that need to target the actual tumor bed and not just where there is evidence of surgical dissection in the breast.

Critical Issues

- Strict adherence to oncologic principles is essential.
- Positive margins need to be avoided to reduce local recurrence rates.
- Preoperative imaging helps to determine the extent of the disease.
- Wire bracketing assists in determining the needed extent of resection.
- Oncoplastic techniques permit generous tissue resections while preserving or improving cosmetic outcome, thereby reducing reoperation rates for inadequate margins.
- Intraoperative margin assessment is important.
- Longer-term studies are required to determine if oncoplastic techniques independently reduce local recurrence rates.

References

1. Asgeirsson KS, Rasheed T, McCulley SJ, Macmillan RD. Oncological and cosmetic outcomes of oncoplastic breast conserving surgery. *Eur J Surg Oncol* 31:817, 2005.
2. Haloua MH, Krekel NM, Winters HA, et al. A systematic review of oncoplastic breast-conserving surgery: current weaknesses and future prospects. *Ann Surg* 257:609, 2013.
3. Masetti R, Pirulli PG, Magno S, et al. Oncoplastic techniques in the conservative surgical treatment of breast cancer. *Breast Cancer* 7:276, 2000.
4. Anderson BO, Masetti R, Silverstein MJ. Oncoplastic approaches to partial mastectomy: an overview of volume-displacement techniques. *Lancet Oncol* 6:145, 2005.

5. Fisher B, Anderson S, Bryant J, et al. Twenty-year follow-up of a randomized trial comparing total mastectomy, lumpectomy, and lumpectomy plus irradiation for the treatment of invasive breast cancer. *N Engl J Med* 347:1233, 2002.
6. Veronesi U, Cascinelli N, Mariani L, et al. Twenty-year follow-up of a randomized study comparing breast-conserving surgery with radical mastectomy for early breast cancer. *N Engl J Med* 347:1227, 2002.
7. Silverstein MJ, Lagios MD, Craig PH, et al. A prognostic index for ductal carcinoma in situ of the breast. *Cancer* 77:2267, 1996.
8. Silverstein MJ. An argument against routine use of radiotherapy for ductal carcinoma in situ. *Oncology (Williston Park)* 17:1511; discussion 1533, 1539, 1542 passim, 2003.
9. Lazovich D, Solomon CC, Thomas DB, et al. Breast conservation therapy in the United States following the 1990 National Institutes of Health Consensus Development Conference on the treatment of patients with early stage invasive breast carcinoma. *Cancer* 86:628, 1999.
10. Chen CY, Sun LM, Anderson BO. Paget disease of the breast: changing patterns of incidence, clinical presentation, and treatment in the U.S. *Cancer* 107:1448, 2006.
11. Kaur N, Petit JY, Rietjens M, et al. Comparative study of surgical margins in oncoplastic surgery and quadrantectomy in breast cancer. *Ann Surg Oncol* 12:539, 2005.
12. Giacalone PL, Roger P, Dubon O, et al. Comparative study of the accuracy of breast resection in oncoplastic surgery and quadrantectomy in breast cancer. *Ann Surg Oncol* 14:605, 2007.
13. Grubnik A, Benn C, Edwards G. Therapeutic mammoplasty for breast cancer: oncological and aesthetic outcomes. *World J Surg* 37:72, 2013.
14. Chaney AW, Pollack A, McNeese MD, et al. Primary treatment of cystosarcoma phyllodes of the breast. *Cancer* 89:1502, 2000.
15. Holland R, Hendriks JH. Microcalcifications associated with ductal carcinoma in situ: mammographic-pathologic correlation. *Semin Diagn Pathol* 11:181, 1994.
16. Page DL, Dupont WD, Rogers LW, et al. Continued local recurrence of carcinoma 15-25 years after a diagnosis of low grade ductal carcinoma in situ of the breast treated only by biopsy. *Cancer* 76:1197, 1995.
17. Holland R, Faverly DRG. The local distribution of ductal carcinoma in situ of the breast: whole-organ studies. In Silverstein MJ, ed. *Ductal Carcinoma in Situ of the Breast*. Philadelphia: Lippincott Williams & Wilkins, 2002.
18. Boetes C, Veltman J, van Die L, et al. The role of MRI in invasive lobular carcinoma. *Breast Cancer Res Treat* 86:31, 2004.
19. Bluemke DA, Gatsonis CA, Chen MH, et al. Magnetic resonance imaging of the breast prior to biopsy. *JAMA* 292:2735, 2004.
20. Dardik A. Use of magnetic resonance imaging in breast oncology. *J Am Coll Surg* 200:742, 2005.
21. Lehman CD, Gatsonis C, Kuhl CK, et al. MRI evaluation of the contralateral breast in women with recently diagnosed breast cancer. *N Engl J Med* 356:1295, 2007.
22. Silverstein MJ, Lagios MD, Recht A, et al. Image-detected breast cancer: state of the art diagnosis and treatment. *J Am Coll Surg* 201:586, 2005.
23. Boetes C, Mus RD, Holland R, et al. Breast tumors: comparative accuracy of MR imaging relative to mammography and US for demonstrating extent. *Radiology* 197:743, 1995.
24. Rosen EL, Smith-Foley SA, DeMartini WB, et al. BI-RADS MRI enhancement characteristics of ductal carcinoma in situ. *Breast J* 13:545, 2007.
25. Van Ongeval C. MR imaging of the breast—present indications. *JBR-BTR* 83:80, 2000.
26. Trecate G, Tess JD, Vergnaghi D, et al. Breast microcalcifications studied with 3D contrast-enhanced high-field magnetic resonance imaging: more accuracy in the diagnosis of breast cancer. *Tumori* 88:224, 2000.
27. Silverstein MJ, Larson L, Soni R, et al. Breast biopsy and oncoplastic surgery for the patient with ductal carcinoma in situ: surgical, pathologic, and radiologic issues. In Silverstein MJ, Recht A, Lagios M, eds. *Ductal Carcinoma in Situ of the Breast*. Philadelphia: Lippincott Williams & Wilkins, 2002.

28. Liberman L, Kaplan J, Van Zee KJ, et al. Bracketing wires for preoperative breast needle localization. *AJR Am J Roentgenol* 177:565, 2001.
29. Kaufman CS, Jacobson L, Bachman B, Kaufman LB. Intraoperative ultrasonography guidance is accurate and efficient according to results in 100 breast cancer patients. *Am J Surg* 186:378, 2003.
30. Rahusen FD, Bremers AJ, Fabry HF, et al. Ultrasound-guided lumpectomy of nonpalpable breast cancer versus wire-guided resection: a randomized clinical trial. *Ann Surg Oncol* 9:994, 2002.
31. Neuschatz AC, DiPetrillo T, Steinhoff M, et al. The value of breast lumpectomy margin assessment as a predictor of residual tumor burden in ductal carcinoma in situ of the breast. *Cancer* 94:1917, 2002.
32. Chagpar AB, Killelea BK, Tsangaris TN, et al. A randomized, controlled trial of cavity shave margins in breast cancer. *N Engl J Med* 373:503, 2015.
33. Nasir N, Rainsbury RM. The timing of surgery affects the detection of residual disease after wide local excision of breast carcinoma. *Eur J Surg Oncol* 29:718, 2003.
34. Khan J, Barrett S, Forte C, et al. Oncoplastic breast conservation does not lead to a delay in the commencement of adjuvant chemotherapy in breast cancer patients. *Eur J Surg Oncol* 39:887, 2013.
35. Kronowitz SJ, Feledy JA, Hunt KK, et al. Determining the optimal approach to breast reconstruction after partial mastectomy. *Plast Reconstr Surg* 117:1; discussion 12, 2006.

8

Improving the Partial Mastectomy Deformity

Grant W. Carlson



he long-term success of BCT is measured by the rate of local control and the cosmetic appearance of the conserved breast. Larger resection margins improve local control to a small degree but negatively affect the final cosmetic outcome. Studies have reported the results of breast conservation to be excellent to good in 80% of cases.¹ Most of these studies were conducted by radiation oncologists and involved self-reporting by patients. The patient selection and surgery are greater confounding factors than radiation in the overall cosmetic result of breast conservation.

The selection criteria for BCS are ill defined. In randomized trials, a small tumor size was the primary indication for BCS.² Large tumors in small- to moderate-sized breasts were generally treated with a total mastectomy and immediate reconstruction. Neoadjuvant chemotherapy and hormone therapy can be used to decrease the tumor size, making more patients candidates for a partial mastectomy.

A reconstruction is performed whenever the partial mastectomy causes a noticeable breast deformity. The surgical approach is determined by the size of the defect in relation to the size of the breast. Patients with small defects in large- or medium-sized breasts generally do not need reconstruction. This chapter focuses on improving the partial mastectomy deformity, without altering the nipple position or performing contralateral symmetry procedures. Resections that remove more than 15% to 20% of the breast volume require volume replacement with distant flaps or volume displacement through parenchymal rearrangement. These techniques are discussed in other chapters.

PATIENT ASSESSMENT

The magnitude of the parenchymal and cutaneous excision correlates directly with the cosmetic outcome. When large volumes of tissue are excised, the risk of an unfavorable cosmetic result increases.^{3,4}

The ratio of the resection volume to the breast volume is critical in the decision-making process to determine whether oncoplastic reconstruction is necessary.

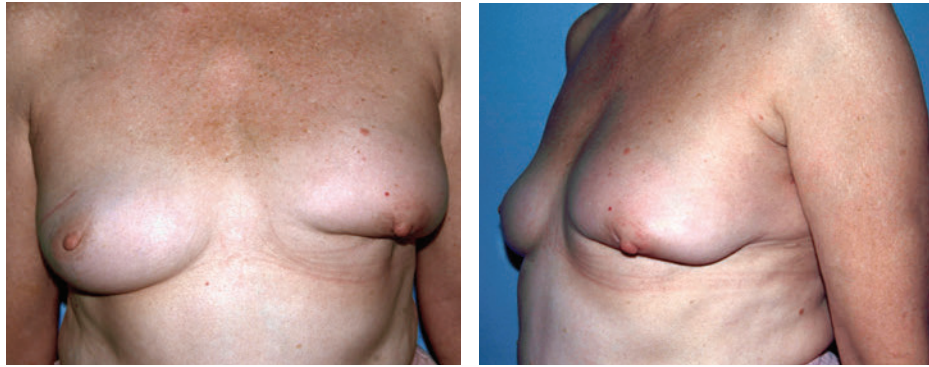
Stevenson et al⁵ found that excising more than 12% of the breast predicted poor cosmesis. Cochrane et al⁶ evaluated 151 women undergoing breast conservation. They assessed the cosmetic outcome relative to the estimated percentage of breast volume excised. In patients in whom less than or equal to 10% of the total breast volume was excised, 83.5% were very satisfied with the results, compared with only 37% of the patients in whom more than 10% of the breast volume was excised.

Surgeons should be aware that removing medial and inferior tumors can be very disfiguring.⁷

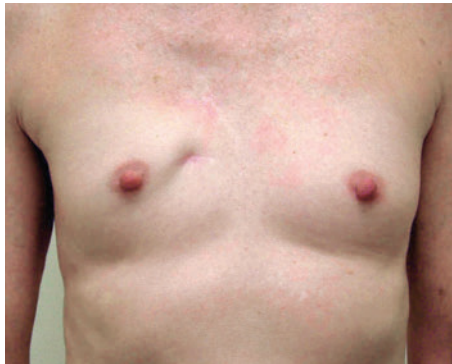

Fig. 8-1

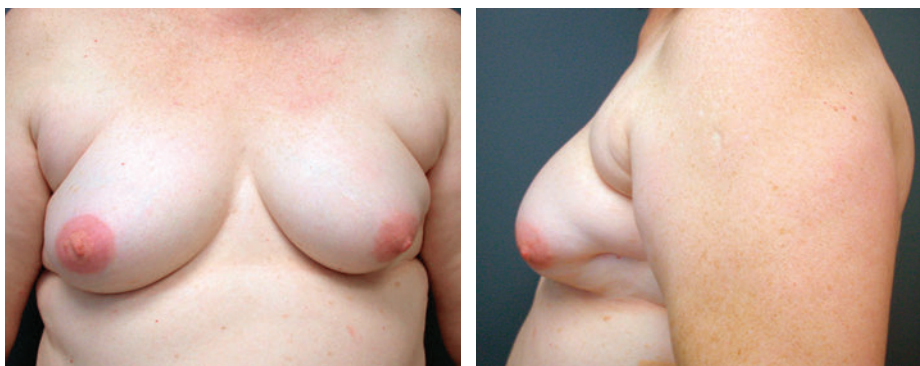
Medial defects can result in a contour deformity after a lumpectomy that is very noticeable, even if the patient is clothed.

**Fig. 8-2**

Tumor resections in the inferior quadrant can result in a “snoopy nose deformity,” with the NAC prolapsing over the excision site. This deformity is accentuated by postradiation sequelae, such as fibrosis and retraction. Removing skin at the time of a partial mastectomy distorts the nipple position, especially in the lower quadrants. Because younger women have less breast fat, the cavity that forms after the tumor resection is less likely to collapse and create a deformity. Larger breasts tolerate the removal of larger amounts of tissue without disfigurement but are more prone to the postradiation sequelae of fibrosis and retraction.

TREATMENT DECISION-MAKING

The traditional approach to managing a lumpectomy or partial mastectomy defect in the United States is to close the skin over the underlying parenchymal defect. A recent review by Morrow et al⁸ stated that a superior cosmetic result is usually achieved when the breast tissue is not reapproximated. This purportedly allows the breast to remodel after the resultant defect fills in with fluid. This technique is useful in larger breasts with a deep tumor location. Fluid reabsorption and scar contracture can frequently result in skin dimpling after superficial tumors are resected, particularly in smaller-breasted women with minimal breast fat.

**Fig. 8-3**

Breast reapproximation after a partial mastectomy is often performed in Europe but has not been widely adopted in the United States. This approach can cause the nipple to deviate if the skin envelope has not been separated from the underlying breast. It can, however, help to avoid some of the breast contour deformities seen with a skin-only closure technique—lateral breast distortion, skin retraction, and deviation of the NAC toward the scar. It is especially useful in defects in the upper quadrant of the breast. The use of breast advancement flaps to close lumpectomy defects is described later.

Preoperative Planning

Box 8-1 Predictors of Residual Disease at the Time of Local Resection

- Large tumor size
- Nodal positivity
- High tumor grade
- Palpable cancer on presentation
- Extensive intraductal component
- Patient is younger than 45 years of age

Delineating the extent of the tumor in the breast is crucial to treatment planning. It is especially helpful to carefully review the mammogram and ultrasound results with the radiologist. A percutaneous core needle biopsy performed before the definitive treatment can provide valuable information and reduce the incidence of involved margins at the time of the resection. Bracketing guidewires are useful in guiding the surgical resection of nonpalpable lesions. Contrast-enhanced MRI scanning has improved the sensitivity of determining the tumor extent and is being studied as an adjunct in preoperative planning.

Positive margins after a lumpectomy or quadrantectomy for invasive cancer or ductal carcinoma in situ occur in up to 25% of cases.⁹ Risk factors for involved margins at the

time of definitive treatment include aggressive tumor biology; an extensive, noninvasive component to the tumor; and a young patient age. An intraoperative margin analysis by touch preparation cytology or frozen section histology has been shown to reduce this risk. These techniques are time consuming and expensive and can be technically difficult because of tissue artifact from fat or sampling errors. If performed properly, however, they can significantly reduce the risk of reoperation.

Choice of Incisions

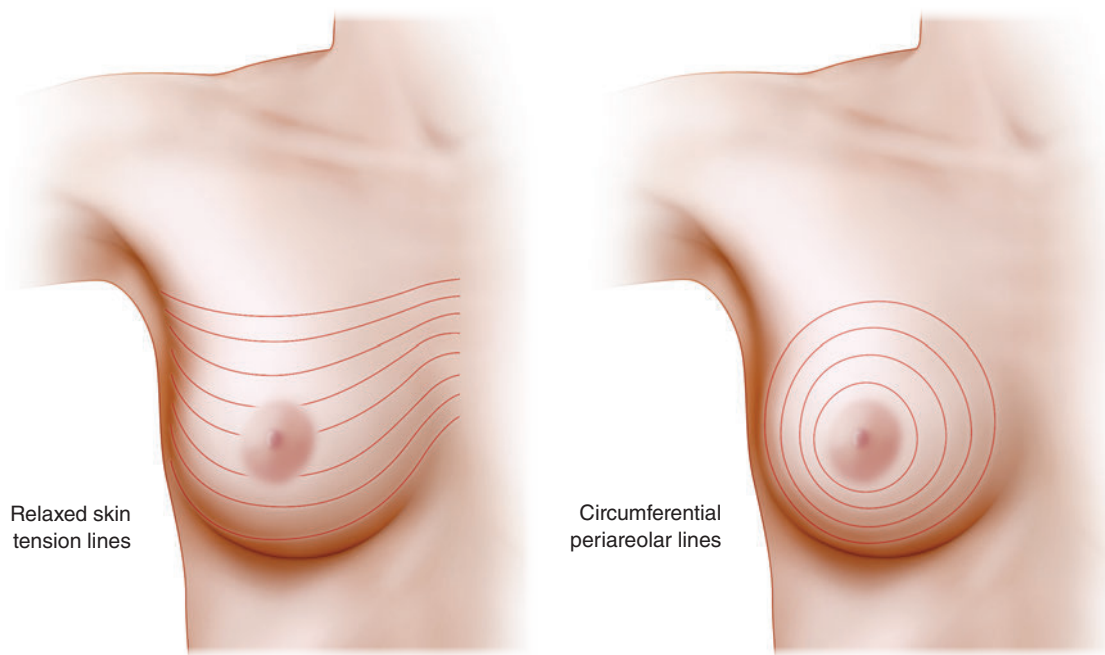


Fig. 8-4

The breast incisions should be planned with the patient in the upright position in the event that a mastectomy is needed. Relaxed skin tension lines (RSTL) of the breast follow the natural wrinkle lines. Incisions within these lines generally produce the best cosmetic results. Incisions configured as concentric circles radiating from the central NAC have been advocated by many breast surgeons. These incisions are frequently perpendicular to the relaxed skin tension lines and can be disfiguring, especially in the medial quadrant of the breast.

Periareolar incisions can provide outstanding cosmesis and are especially useful if the tumor is in close proximity to the nipple-areola complex. In patients with a moderate- or large-diameter areola, these incisions can also be used to remove peripheral tumors. This approach requires a wide separation of the breast skin from the underlying parenchyma and is especially pertinent to removing benign lesions, such as fibroadenomas.

An inframammary fold incision can provide good exposure to deep tumors in the inferior pole of the breast. The breast is elevated off of the pectoralis major fascia, and the tumor is approached from underneath the breast. The incision is inconspicuous in women with moderate- to large-sized breasts. This approach is especially useful in conjunction with wire localization of nonpalpable lesions. Vertically or radially oriented incisions have been advocated to minimize nipple retraction when resecting tumors in the lower hemisphere. These incisions are especially useful in ptotic breasts with lesions located in the 9 o'clock and 3 o'clock positions. In these situations, marking the planned incision preoperatively with the patient standing is easier and ensures that incisions will be placed along the relaxed skin tension lines.

Choice of Technique

Most partial mastectomies performed in patients with moderate or large breasts require no form of parenchymal remodeling to avoid a deformity. In these patients, large resections involving more than 15% to 20% of the breast volume can often be reconstructed with either volume replacement, using distance flaps, or with breast reshaping, using parenchymal rearrangement and NAC repositioning, depending on the degree of ptosis. These techniques generally require a contralateral symmetry procedure and are discussed in other chapters.

Even small resections can be disfiguring in women with small, size A or B cup breasts. A total mastectomy and immediate reconstruction should be considered in these patients when more than 10% of the breast volume must be resected.

Local tissue rearrangement using breast tissue advancement flaps is a good option for patients with moderate-sized breasts (B or C cup bra size) and minimal ptosis, in whom 10% to 15% of the breast volume is to be resected. This technique is especially useful when the defect is located in the outer quadrant and does not involve skin removal.

Central tumors that encroach on the nipple have traditionally been treated with a total mastectomy. A central quadrantectomy followed by radiation has been shown to have rates of local recurrence that are similar to those of more peripheral resections.¹⁰ The resulting defect can be closed with various techniques, including direct closure, dermoglandular advancement flaps, or inferior-based reduction mammoplasty techniques.

Fortunately, most breast cancers can be excised without removing the overlying skin. This avoids tethering of the NAC and flattening of the breast contour.

If skin is removed in the inferior and lateral quadrants, dermoglandular advancement flaps via an incision along the lateral inframammary fold can provide a satisfactory closure. Thoracoepigastric flaps and thoracodorsal fasciocutaneous flaps can also provide closure of medial and lateral full-thickness defects, respectively.

Small, full-thickness defects in the upper quadrants can be closed, separating the remaining skin from the underlying parenchyma. The breast is closed separately using parenchymal advancement flaps. The skin is closed separately, with care taken to ensure that the length of the skin excision is three to four times longer than the width to avoid shifting the position of the nipple-areolar complex.

SURGICAL TECHNIQUE

Breast Tissue Advancement Flaps

Operative exposure is obtained most often through incisions in the resting skin tension lines overlying the tumor location. In the upper and medial poles of the breast, incisions should be placed as close to the areola as possible to prevent the incision from showing through clothes. Circumferential periareolar incisions are useful when tumors are in close proximity to the nipple and when the areolar diameter is large enough to allow adequate exposure. Inframammary fold incisions are used in select cases when deep lesions are located in the inferior quadrant.

Skin flaps are widely developed above the superficial fascia of the breast to expose the tumor location and to prevent nipple malposition or skin dimpling. This approach allows the breast parenchyma to be reapproximated, without causing tension on the Cooper ligaments. A wedge-shaped or elliptical parenchymal excision is planned in a radial axis extending from the nipple, if possible. This excision is often perpendicular to the direction of the overlying skin incision, further reducing the risk of a NAC malposition. In the periphery of the breast in the upper quadrants, this involves a full-thickness excision down to the pectoralis major fascia to facilitate local tissue rearrangement after wide breast undermining off of the pectoralis major muscle. The deep edges of the resection margins are reapproximated with absorbable sutures by parenchymal advancement within the retromammary bursa. A second row of sutures is placed in the superficial margins to close the lumpectomy defect. The skin is redraped over the repair; a tension-free closure is performed.

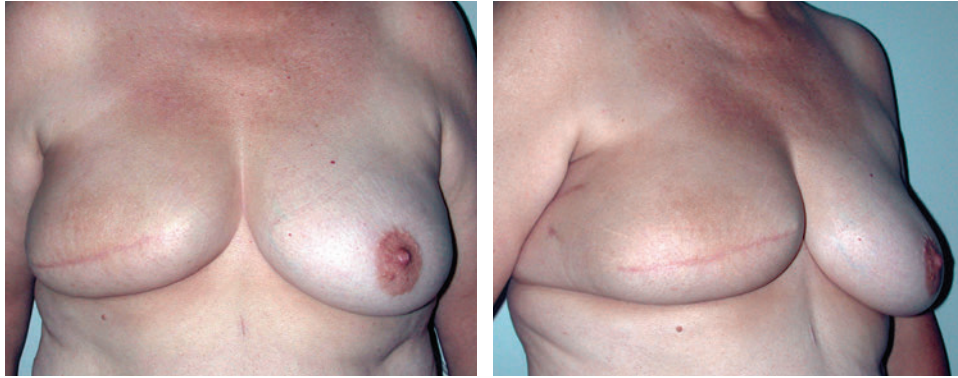
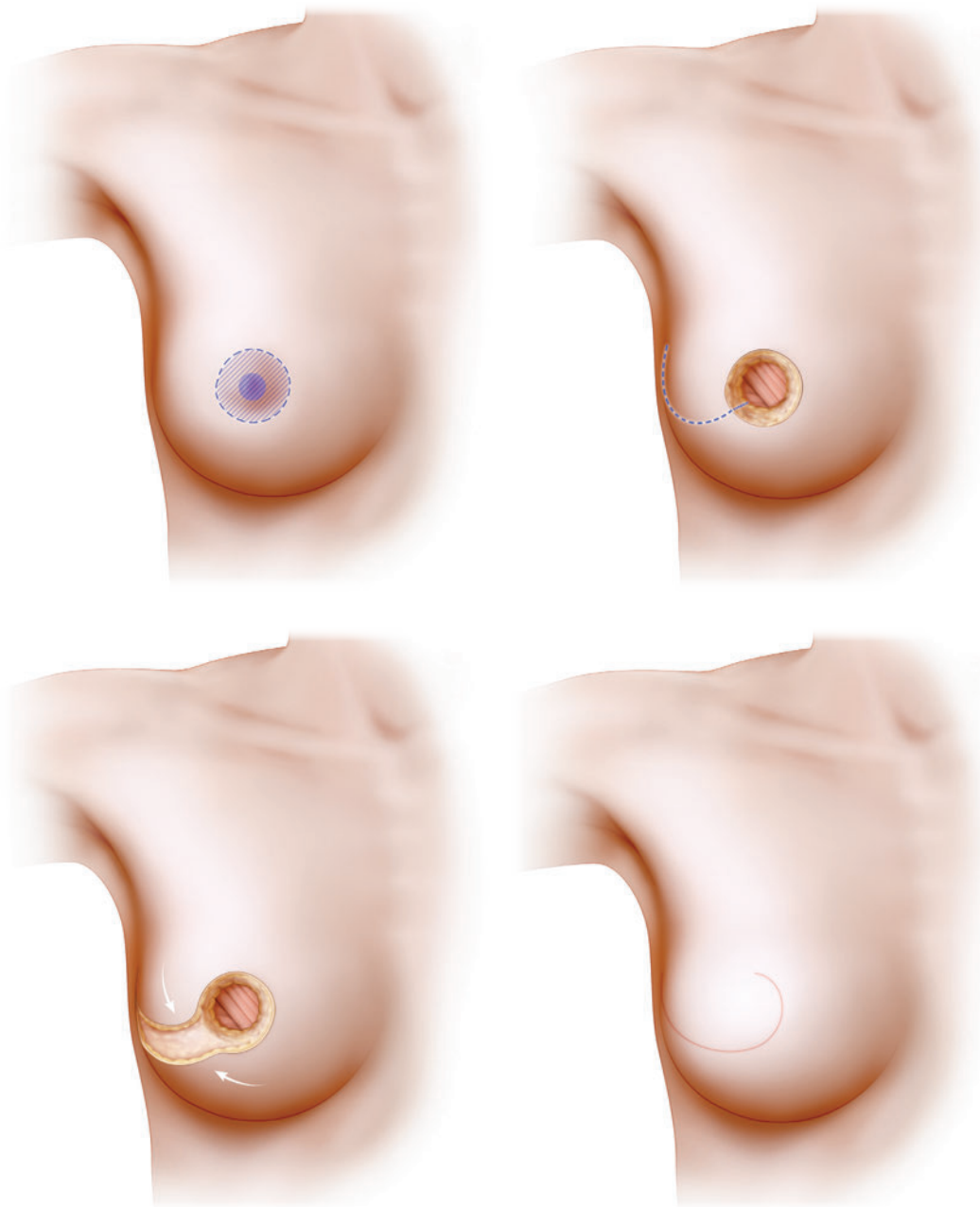


Fig. 8-5

A transverse elliptical excision may be used for central quadrantectomies. The remaining part of the breast is mobilized off of the chest wall, and the edges are reapproximated. This tends to flatten the breast, but the results are acceptable in moderate- to large-sized breasts. This patient is shown after radiotherapy; the breast shape is preserved.

Dermoglandular Advancement Flaps

Dermoglandular advancement flaps are useful to reconstruct central mound excisions, including the nipple-areola complex, as well as full-thickness defects in the inferolateral quadrant (see Fig. 8-6). This dermoglandular flap (Grisotti flap) is based on the inferolateral pole of the breast.¹¹ The incision is extended laterally along the inframammary fold, and the breast is widely undermined from the underlying fascia to allow better rotation. The flap width depends on the size of the breast and the degree of ptosis. A portion of the flap can be deepithelialized to fill the soft tissue defect, and the remaining part can be used to reconstruct the areola in central defects. This technique sometimes results in a malpositioned nipple or an areolar size discrepancy, which can be avoided by performing the NAC reconstruction as a second-stage procedure (see Fig. 8-11). This technique also shifts the defect from the breast to the axilla, where it is less noticeable. A contralateral symmetry procedure is seldom needed.

**Fig. 8-6**

Another variant of this technique involves the creation of a laterally based dermoglandular flap dissected in a full-thickness fashion down to the chest wall. This technique is used for central defects, and the flap is advanced medially to fill the defect and preserve the breast shape.

Periareolar Mastopexy

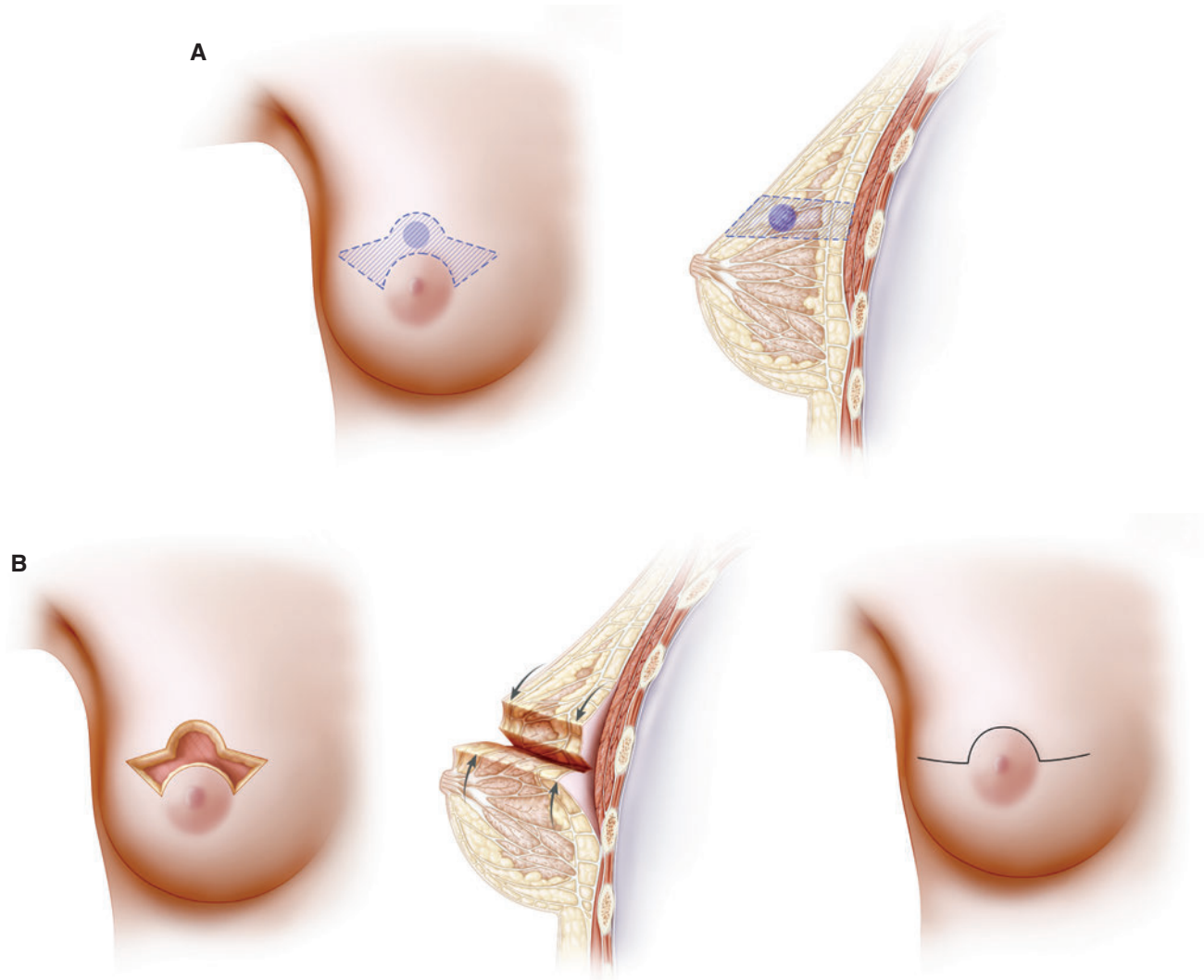


Fig. 8-7

Periareolar mastopexy, sometimes called batwing mastopexy, is useful for tumors located superior and adjacent to the NAC that do not directly infiltrate the major ducts. A periareolar incision is made that includes the skin overlying the lesion (A). In a small breast, a full-thickness excision is performed, and the resultant defect is closed with an inferiorly based parenchymal advancement flap, including the NAC (B). (See also Fig. 8-10.) Care must be taken to closely approximate the parenchymal edges to avoid a depression and NAC distortion. The lateral skin and breast excess are removed, leaving transverse incisions on either side of the 180-degree periareolar incision. In patients with moderate ptosis, periareolar tumors located either superior or inferior to the NAC can be resected and closed with a superior or inferior pedicle mastopexy–reduction technique.

Breast Advancement Flap Closure of Partial Mastectomy Defects

Surgical Plan

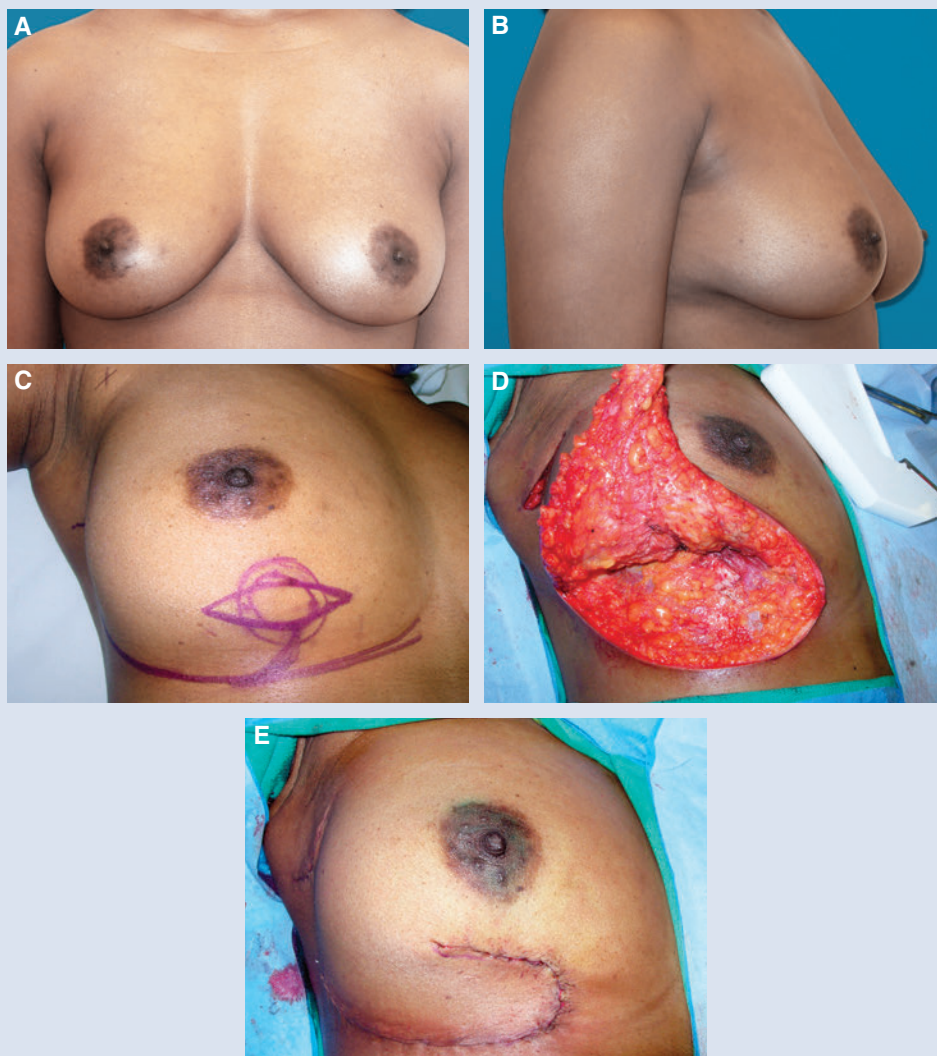- Breast advancement flap closures are useful in peripheral tumor locations. Full-thickness radial wedge-shaped or elliptical parenchymal excisions are planned. The maximum width of the resection depends on the breast size. In small breasts, the maximum width that allows tension-free closure is 4 cm. In large breasts, resections up to 8 cm wide may be closed with parenchymal advancement. The skin incisions are often perpendicular to the long axis of the parenchymal excisions. In the outer quadrant of the breast in large resections, radial skin incisions may allow good exposure with acceptable cosmesis.
- Skin flaps are developed above the superficial fascia of the breast to allow wide exposure.
- A full-thickness resection is performed using the scalpel to allow precise control of the margins and a pathologic evaluation of the specimen.
- After the margin status is confirmed on frozen sections, the remaining part of the breast is elevated off of the chest by dissection through the retromammary bursa. The perimeter edges are elevated off of their skin attachments to allow flap rotation and advancement.
- The deep edges are approximated with a row of interrupted absorbable sutures.
- Further undermining may be necessary if there is excessive tension on the closure. If the skin is adequately elevated off of the breast, it will not be distorted by the parenchymal flap advancement. The superficial edges are then approximated with a second row of sutures.
- The skin is redraped over the breast. The NAC should not be distorted.

Dermoglandular Advancement Flaps

Surgical Plan

- Dermoglandular flaps are useful for reconstructing central mound excisions and full-thickness defects in the inferolateral quadrant of the breast.
- The flap is designed along the lateral inframammary fold. In central defects, the incision extends from the middle of the inframammary fold up to the inferior edge of the defect.
- The lateral breast flap is widely dissected off of the chest wall to allow tension-free advancement.
- A portion of the flap is deepithelialized to fill the soft tissue defect, and the remaining part may be used to reconstruct the areola in central defects. A nipple malposition or an areolar size discrepancy may result.
- This result may be avoided by advancing the flap into the defect and performing the nipple-areola reconstruction at a second stage.

PATIENT EXAMPLES

**Fig. 8-8, A-E**

This 38-year-old woman presented with a 2 cm palpable mass in the inferior pole of her right breast (A and B). The tumor was very superficial, and a full-thickness resection was performed (C and D). A laterally based dermoglandular flap was used to reconstruct the defect (E). The patient underwent adjuvant radiotherapy.

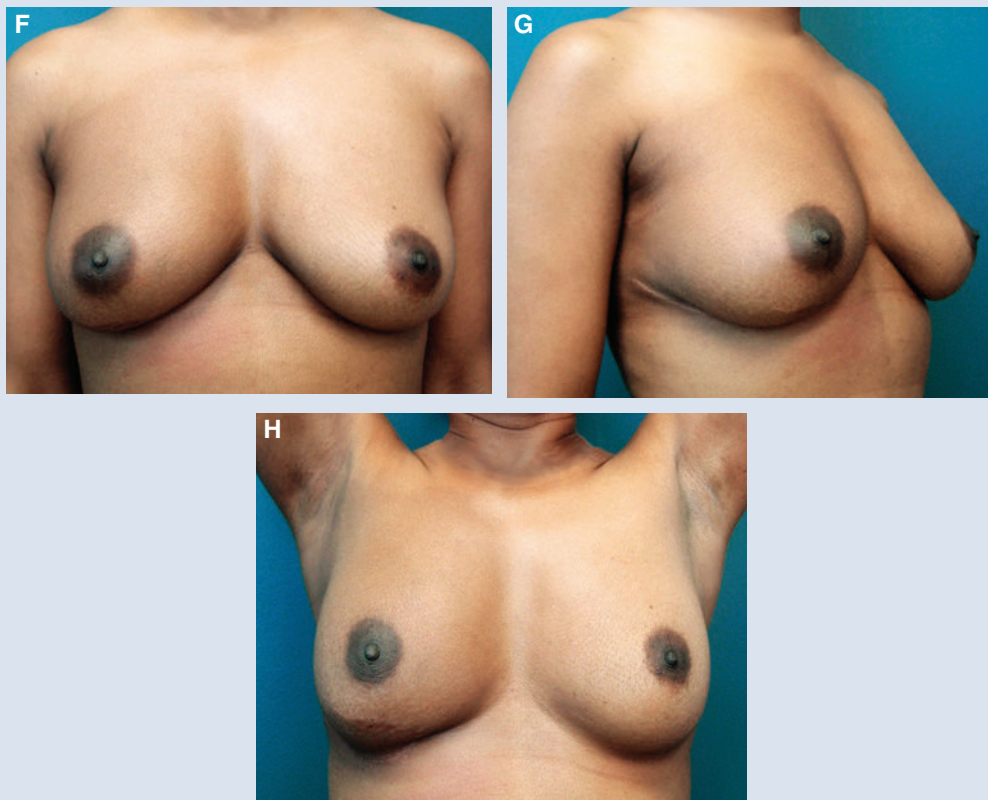
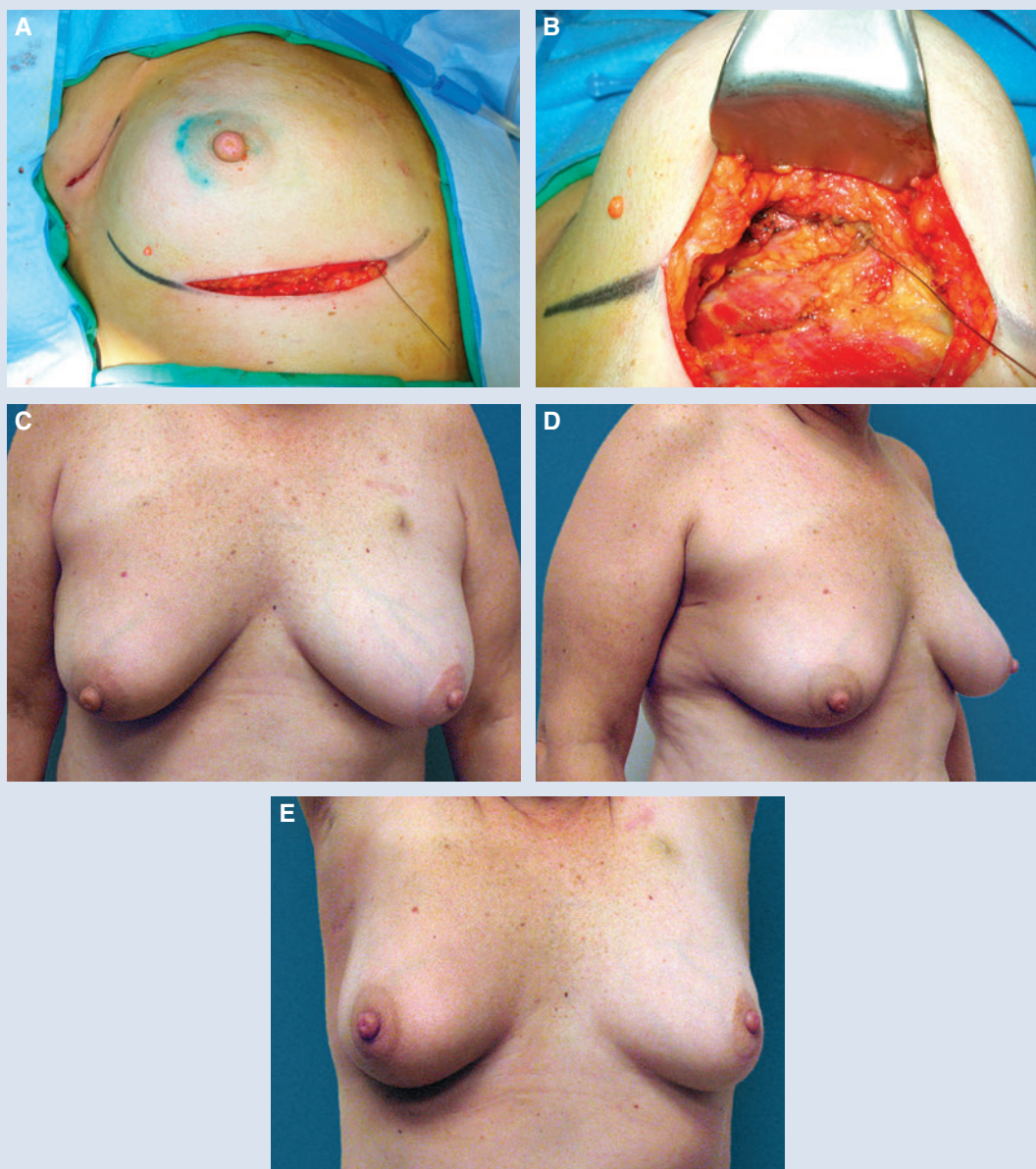
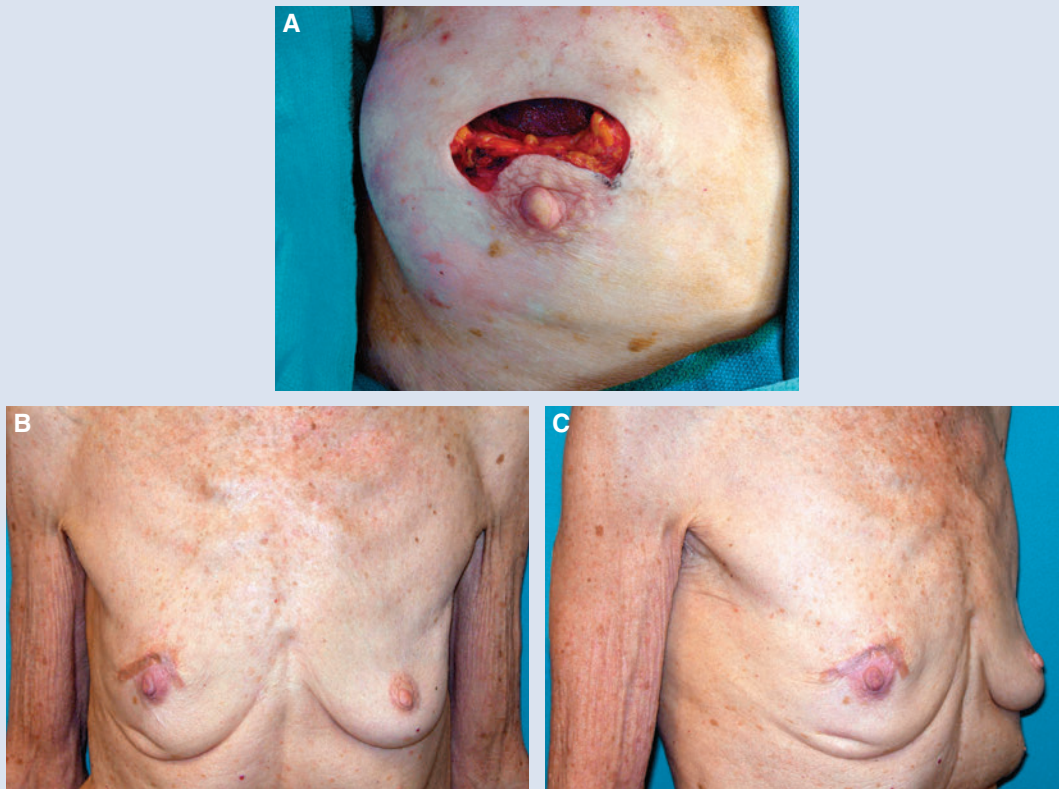


Fig. 8-8, F-H

She is shown 1 year after treatment (*F* through *H*).

**Fig. 8-9**

This 54-year-old woman presented with a mammographically detected cancer in the deep central portion of her right breast. The excision was performed through an inframammary fold incision using wire localization (A). The breast was mobilized off of the pectoralis major muscle, and the guidewire was brought through the incision (B). Adjuvant radiation was administered. The patient is shown 1 year after treatment (C through E).

**Fig. 8-10**

This 76-year-old woman presented with a 1 cm palpable mass just above the NAC in her right breast. A full-thickness resection was performed through a periareolar incision (A). The inferior part of the breast was undermined off of the pectoralis muscle and sutured to the superior edge of the resection. The lateral skin excess was removed in a transverse manner (B and C). Radiotherapy was not administered.

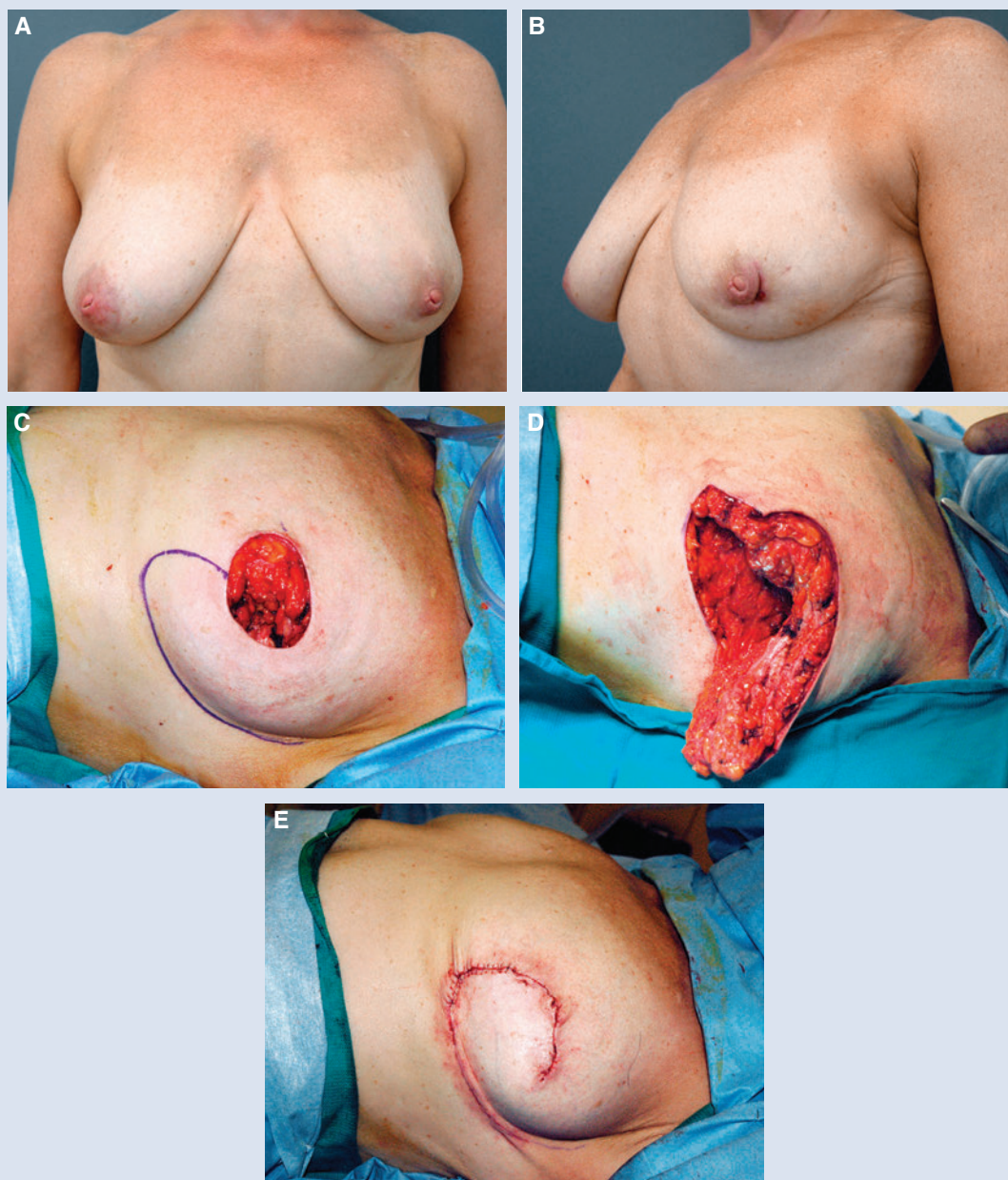


Fig. 8-11, A-E

This 53-year-old woman presented with a history of a chronic left subareolar abscess (A). She had undergone multiple drainage procedures (B). A central mound resection was performed (C and D). The defect was reconstructed using a laterally based dermoglandular flap (E).

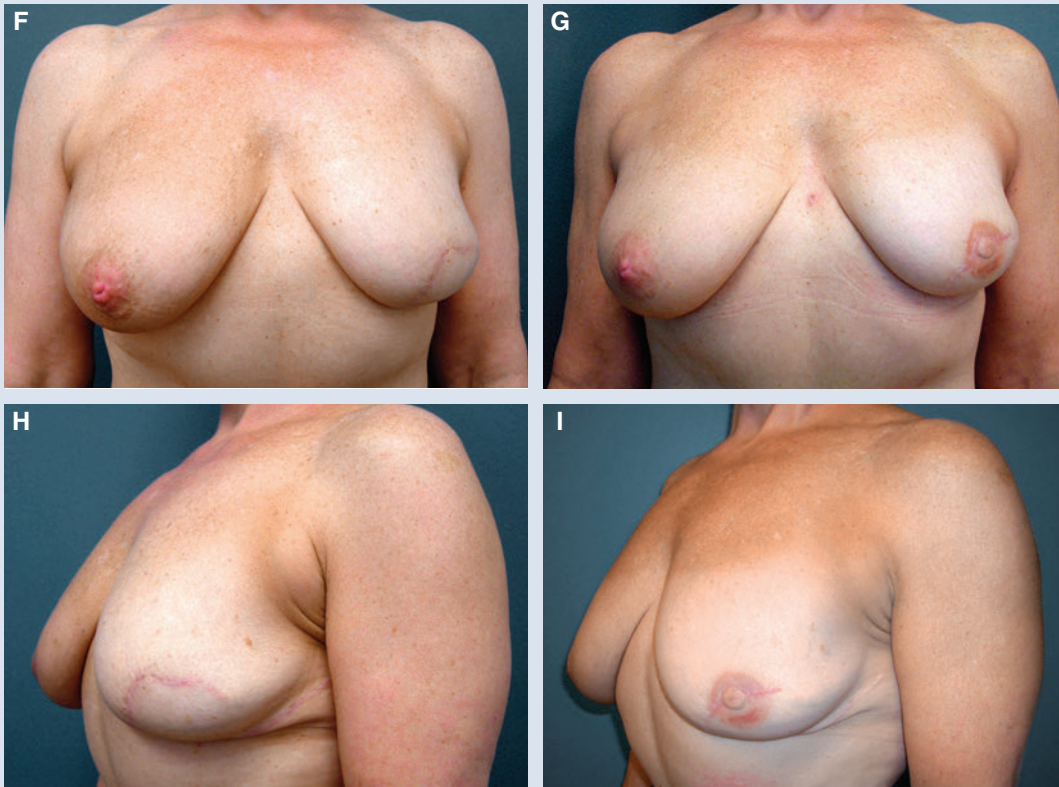


Fig. 8-11, F-I

The patient is shown 2 years postoperatively (*F* and *H*). Nipple reconstruction was performed at a second stage, 3 months after the original surgery (*G* and *I*).

CONCLUSION

Most parenchymal resections comprising less than 10% of the breast volume need no form of reconstruction. However, breast and dermoglandular advancement flaps are useful techniques for reconstructing moderate-sized defects without altering the opposite breast to achieve symmetry.

Critical Issues

- Patient selection—patients with medium- to-large breasts generally do not need reconstruction if the defect comprises less than 15% of the breast volume.
- Breast advancement flaps are useful for closing defects in the upper quadrants of the breast.
- When reapproximating the breast after a partial mastectomy, separating the skin envelope and the underlying breast parenchyma is important for preventing deformities of the nipple-areola complex.
- Radially based wedge excisions or elliptical excisions help to reduce the risk of creating a malpositioned nipple-areola complex.
- The breast should be widely undermined within the retromammary bursa to facilitate rotation.
- Deep and superficial parenchymal edges are approximated to close the lumpectomy defect.

References

1. Harris JR, Levene MB, Svensson G, et al. Analysis of cosmetic results following primary radiation therapy for stage I and II carcinoma of the breast. *Int J Radiat Oncol Biol Phys* 5:257, 1979.
2. Fisher B, Redmond C, Poisson R, et al. Eight-year results of a randomized clinical trial comparing total mastectomy and lumpectomy with or without irradiation in the treatment of breast cancer. *N Engl J Med* 320:822, 1989.
3. Mills JM, Schultz DJ, Solin LJ. Preservation of cosmesis with low complication risk after conservative surgery and radiotherapy for ductal carcinoma in situ of the breast. *Int J Radiat Oncol Biol Phys* 39:637, 1997.
4. Olivotto IA, Rose MA, Osteen RT, et al. Late cosmetic outcome after conservative surgery and radiotherapy: analysis of causes of cosmetic failure. *Int J Radiat Oncol Biol Phys* 17:747, 1989.
5. Stevenson J, Macmillan RD, Downey S, et al. Factors affecting cosmetic outcome after breast conserving therapy. *Eur J Cancer* 37:31, 2001.
6. Cochrane RA, Valasiadou P, Wilson AR, et al. Cosmesis and satisfaction after breast-conserving surgery correlates with the percentage of breast volume excised. *Br J Surg* 90:1505, 2003.

7. Clough KB, Nos C, Salmon RJ, et al. Conservative treatment of breast cancers by mammaplasty and irradiation: a new approach to lower quadrant tumors. *Plast Reconstr Surg* 96:363, 1995.
8. Morrow M, Strom EA, Bassett LW, et al. Standard for breast conservation therapy in the management of invasive breast carcinoma. *CA Cancer J Clin* 52:277, 2002.
9. Mullenix PS, Cuadrado DG, Steele SR, et al. Secondary operations are frequently required to complete the surgical phase of therapy in the era of breast conservation and sentinel lymph node biopsy. *Am J Surg* 187:643, 2004.
10. Simmons RM, Brennan MB, Christos P, et al. Recurrence rates in patients with central or retroareolar breast cancers treated with mastectomy or lumpectomy. *Am J Surg* 182:325, 2001.
11. Grisotti A. Immediate reconstruction after partial mastectomy. *Oper Tech Plast Reconstr Surg* 1:1, 1994.

9

Improving the Quadrantectomy Defect

Jean-Yves Petit



esthetic resections and attention to parenchymal closure have recently been advocated to avoid poor cosmetic results after large quadrantectomies. Several techniques of partial breast reconstruction, such as flaps or reduction mammoplasty procedures,¹⁻³ have been proposed; however, these require training in reconstructive plastic surgery. Most T1 and small T2 tumors can be managed without mastering such elaborate plastic surgery procedures. In these cases the final outcome can be impaired because of unfavorable and visible scarring, asymmetry of the areolas, localized glandular defects, or asymmetry of breast volume.⁴

In this chapter, we present several surgical approaches for improving the final cosmetic result of breast-conserving treatment. These techniques refer to the level 1 oncoplasty defined by Clough.⁵ Surgical techniques allow the removal of a large tumor, avoiding the mastectomy, and decrease the occurrence of involved margins.⁶ Oncologic results of conservative treatment with oncoplasty techniques confirm the good results.⁷

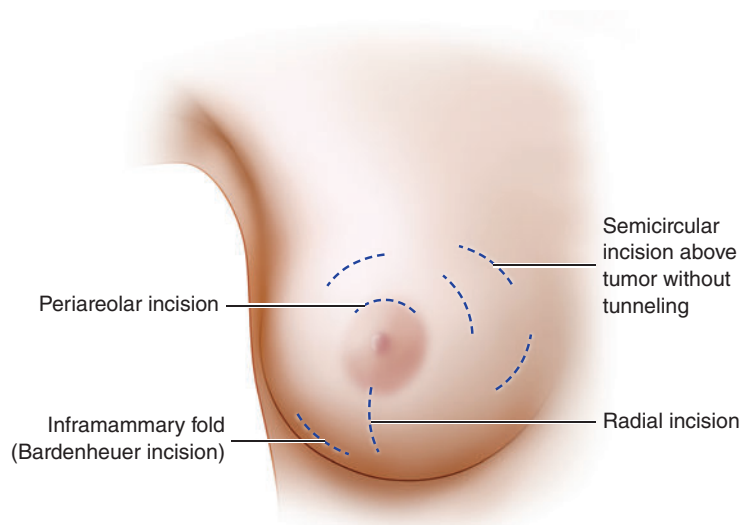
SURGICAL TECHNIQUE

Preoperative Markings

The day before surgery, the surgeon must discuss with the patient the planned surgical approach and the final location of the scars. The breasts are analyzed with the patient in the standing position, and any asymmetry of breast shape, size, or areolar position should be noted and discussed with the patient.

Asymmetry may be caused by increased breast volume from the tumor or residual edema or hematoma after previous biopsies. Such asymmetry should be distinguished from congenital asymmetry.

The result will be better in women with large breasts than in women with smaller breasts. This information should be discussed with the patient.



Basic oncoplastic rules for skin incisions

Fig. 9-1

The midline should be marked between the breasts and inframammary folds. These markings are used to assess symmetry after the operation. The planned skin incisions are drawn in permanent marker with the patient still standing. There is general agreement among breast surgeons that radial incisions are performed in the lower middle part of the breast and circumareolar incisions in the upper middle part.

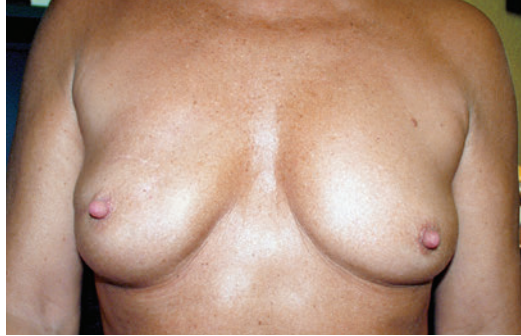

Fig. 9-2

This patient shows good scar positioning, with asymmetry of the NAC.

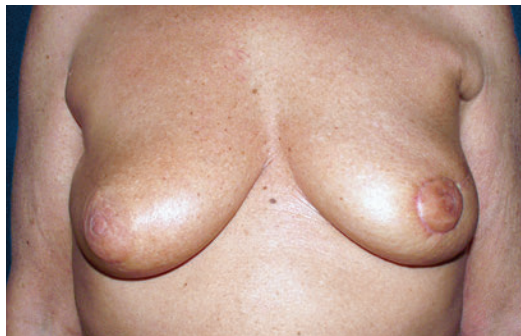

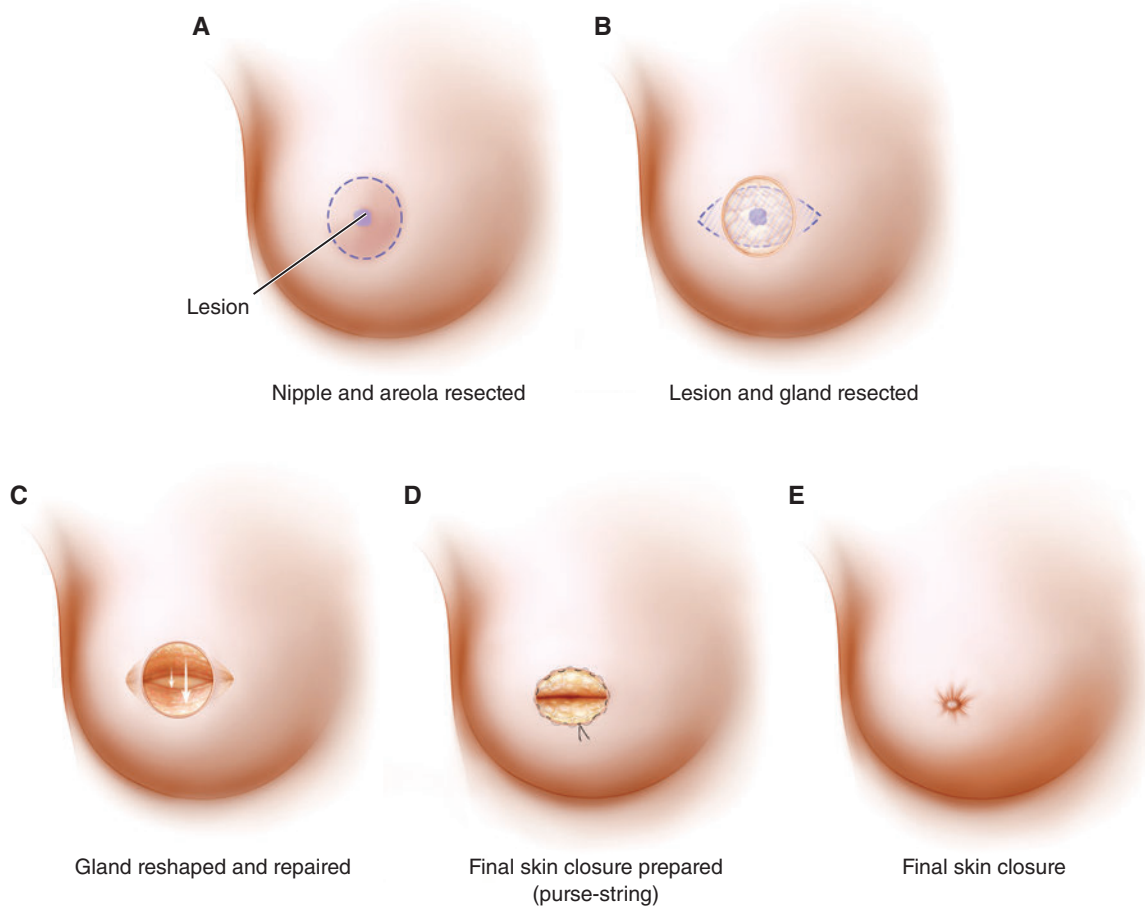
Fig. 9-3

This patient's postoperative results after right breast radiotherapy are satisfactory. The left NAC was relocated.

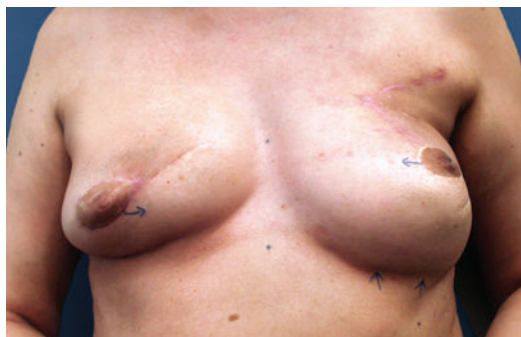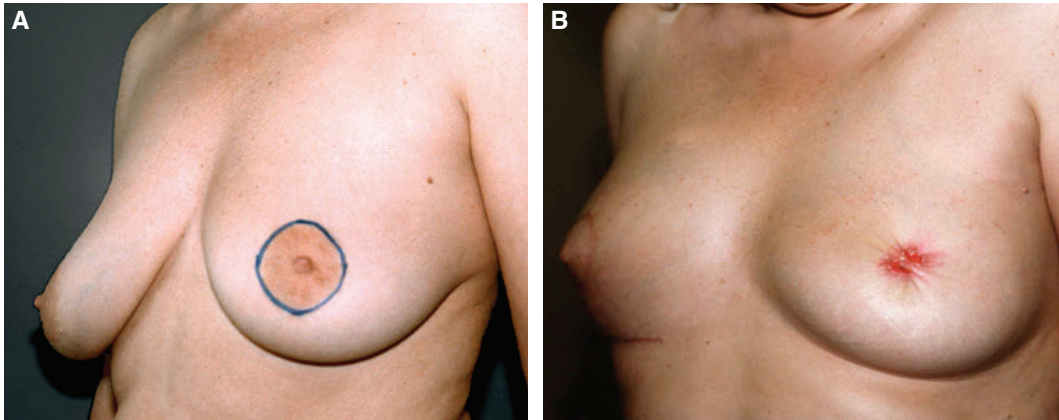


Fig. 9-4

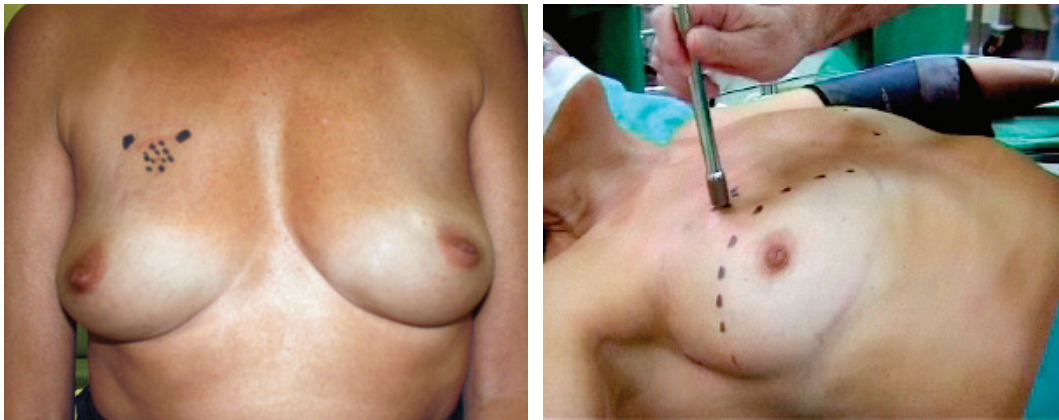A circumareolar incision in the inferior quadrants could create a disfiguring crease between the areola and the inframammary fold. A radial scar in the upper part of the breast may be too visible if it exceeds the décolleté line. This patient shows poor results, because the radial scar is evident in the décolleté area and the external position of the NAC.

**Fig. 9-5**

Periareolar⁵ incisions provide good results if the tumor is located close to the areola; otherwise extended skin undermining can leave disfiguring skin retractions. Subareolar tumors can be performed by periareolar excision of the NAC and tumor, with purse-string closure and glandular plication (*A* through *E*). When the tumor is located in the upper outer quadrant, a radial scar allows good exposure of the tumor site, but it is recommended that the scar be lowered to avoid crossing the décolleté line. If the scar must extend toward the axilla for lymph node dissection, using a broken line is suggested to decrease scar contraction and skin retraction.

**Fig. 9-6**

This patient had a central tumor (A). She is shown after a central quadrantectomy with a glandular defect, skin undermining, gland closure, and purse-string skin closure (B).

**Fig. 9-7**

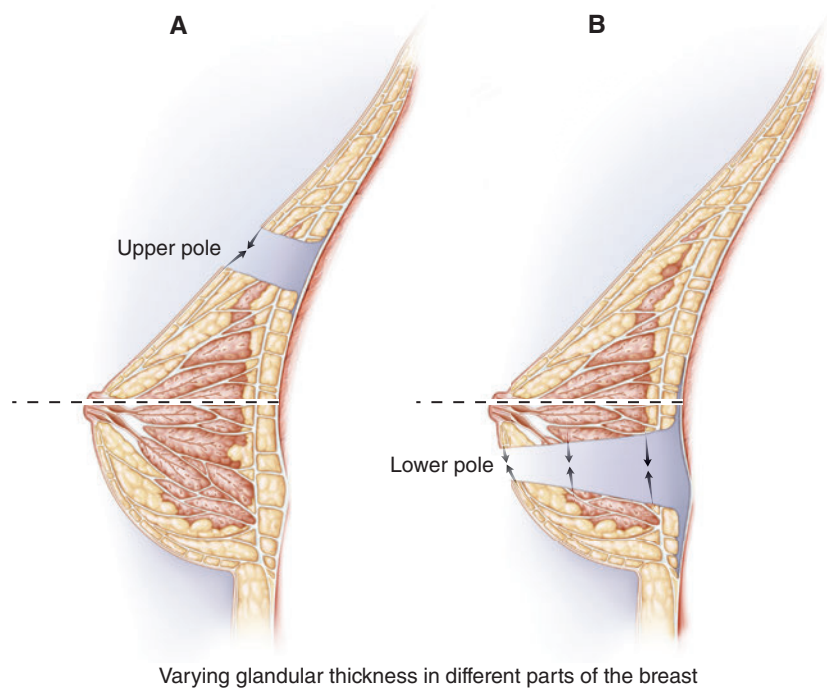
The need for skin resection generally depends on the possible connection between the tumor and the dermis, especially tumors located superficially in the gland. When the tumor is deeper within the glandular tissue, an inframammary incision works well.

The marking should be made 1 cm above the inframammary fold to ensure that it will not be visible under the bra. The length of the incision should be 5 to 6 cm but can easily be extended toward the axilla to perform a sentinel node biopsy or complete node dissection. An inframammary incision with extensive undermining of the breast allows the surgeon to explore the whole breast and remove a tumor in any quadrant, without modifying the breast's shape. The patient shown here underwent a radio-active, probe-guided tumorectomy using a retroglandular approach and an inframammary incision.

Quadrantectomy Technique

A sharp skin incision is recommended, leaving more dermis than epidermis to maximize the blood supply to the dermis and improve approximation of skin margins. The tumorectomy should be performed in the glandular tissue, with at least 1 cm of free margins from the tumor. The gland should be resected straight down to the pectoralis fascia. Closure of the glandular defect is important. Several authors suggest leaving it open, which increases the risk of its filling immediately with hematoma or seroma; however, after radiotherapy, the defect will reappear beneath the skin. The glandular closure is usually performed by simple approximation of the glandular pillars. It can be facilitated by glandular undermining above the pectoralis fascia. This procedure creates an opportunity to manually check the deeper part of the gland, which can sometimes lead to the discovery of occult lesions. Any suspicious nodule should be sent to the pathologist.

To better reshape the tumor bed, superficial undermining between the glandular tissue and the skin can be performed, preserving the skin's blood supply. In cases of simultaneous superficial and deeper undermining of the glandular tissue, the blood supply to the glandular flap can be compromised, especially in women with fatty breasts. This may cause secondary glandular fat necrosis several days after surgery. The quality of the glandular tissue should be evaluated preoperatively with mammography, since breasts with fatty tissue are more prone to local necrosis.



Varying glandular thickness in different parts of the breast

Fig. 9-8

Glandular tissue is anatomically thinner in the upper pole of the breast, making closure of the defect in the upper pole less important (A). To avoid skin depression from the defect, tumor resection should include more glandular tissue than skin, with the specimen being

shaped somewhat like a pyramid. In this area, a smooth skin depression can result, and it is usually not a concern to the patient. Alternatively, glandular reshaping is required in the inferior pole; the glandular defect in that location must be carefully repaired (*B*).

The periareolar approach for quadrantectomy is also useful and can be used for tumor resection and NAC repositioning.

Skin closure should be performed carefully, following the principles of plastic surgery: approximation of the dermal layer with interrupted absorbable sutures and intradermal continuous 4-0 or 5-0 absorbable sutures. For patients with a history of hypertrophic scars or inflammatory reactions to absorbable sutures, intradermal nonabsorbable sutures such as 3-0 or 4-0 nylon are recommended and should be removed after 10 to 12 days. Occasionally, the periareolar incision can be sutured with a permanent nonabsorbable suture. Some surgeons propose that using nonabsorbable sutures reduces the risk of large periareolar scars.

It is not always necessary to insert a drain; however, it should be placed when wide undermining has been performed.

Improvement in Symmetry

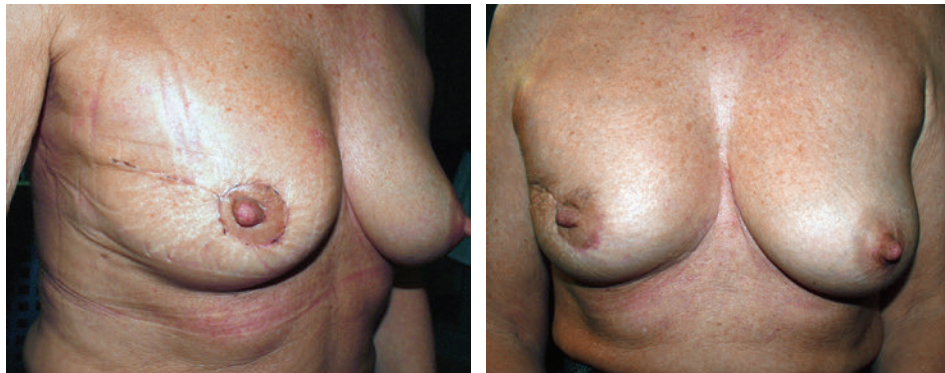

Fig. 9-9

Symmetry with the contralateral healthy breast should be assessed before final closure, after the glandular defect is refilled. The skin can be temporarily approximated with staples. To better evaluate symmetry, the surgeon must analyze the breasts from several views. With the patient in the supine position, the surgeon assesses the patient's breasts from the head and then the feet to compare the shape of the breasts from both perspectives. These points of view allow essential evaluation of breast projection and width and areola position. The patient is then repositioned sitting upright to make a final evaluation of symmetry; the level of the inframammary creases and areolas and the width of the breasts are carefully analyzed. In the patient seen here, the result appears to be acceptable on the lateral view; however, areolar asymmetry is evident in the frontal view.

There is a high risk of inaccurate analysis if the lateral view alone is used to assess symmetry. The frontal view must always be evaluated as well, and final analysis must be done with the patient in a sitting position.

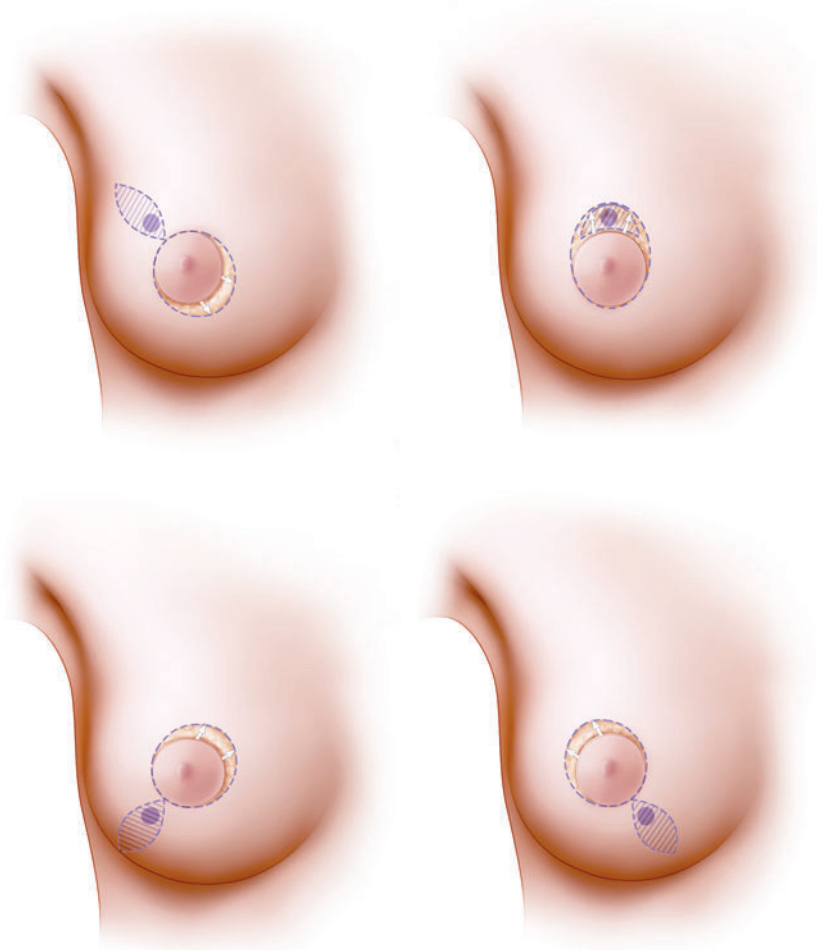


Fig. 9-10

Variations of the nipple and areolar centralization technique using periareolar deepithelialization are shown. Breast asymmetry can be caused by nipple-areola malposition or different sizes or positions of the breasts. The following techniques can be used to correct these malpositions:

- Nipple-areola malposition is more common and can be improved by a surgeon with no specific training in plastic surgery. Nipple and areolar centralization can be obtained by asymmetrical periareolar deepithelialization. A crescent-shaped area of epidermis, sparing the dermis, is removed around the areola on the side opposite the quadrantectomy. The skin is sutured using intradermal absorbable sutures. The

resultant skin tension from this suture and dermal plication pushes the glandular tissue toward the defect of the tumorectomy, improving the shape.

- When the lack of symmetry is caused by differences in the breast position and volume, improvement usually requires the expertise of a plastic surgeon. This procedure can be performed during the same procedure as the quadrantectomy, or it can be delayed and performed as a second operation. Only in cases of mild shape asymmetry can simple correction of the contralateral breast be planned and performed safely by a surgeon with no training in plastic surgery. Periareolar deepithelialization of the healthy breast is recommended to correct mild differences in ptosis. Reduction of the skin envelope also helps to perform a mastopexy; however, these procedures often flatten the breast by increasing areolar tension. The breast projection can be improved by remodeling the gland after widely undermining the lateral skin envelope; however, this often requires sufficient training in plastic surgery.

PATIENT EXAMPLES

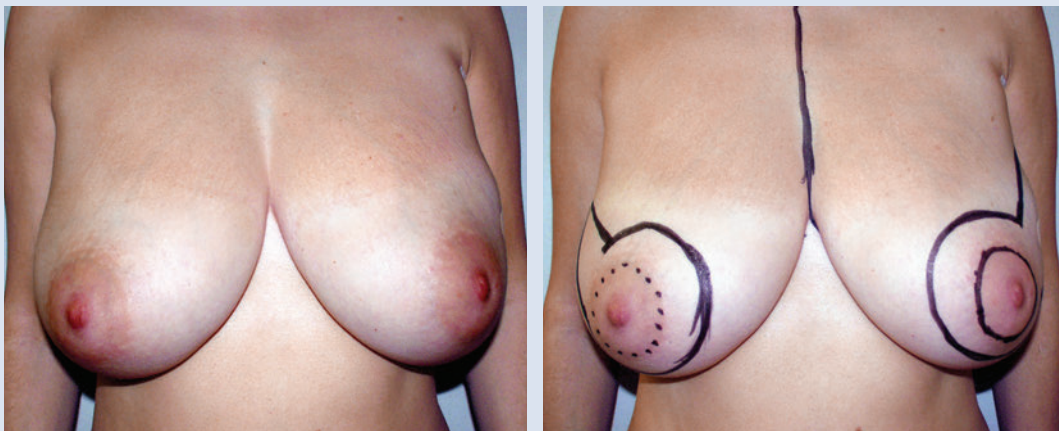


Fig. 9-11

When asymmetry results from an upper outer quadrantectomy performed with an oblique incision, it is possible to improve symmetry with the “mirror tumorectomy” technique. The same resection is performed on the opposite breast in the upper outer quadrant (similar to the quadrantectomy previously shown). To avoid the common displacement of the areola toward the axilla, it is often necessary to centralize the areola with periareolar deepithelialization or to break the scar with a Z-plasty. The symmetry procedure on the healthy breast can be considered an opportunity to check the contralateral glandular tissue. Any suspicious glandular area should be removed and sent to the pathologist. The mammograms of patients who require a symmetry procedure should be carefully studied before surgery to detect any abnormal glandular structure. This patient required periareolar deepithelialization and a lateral triangular resection.

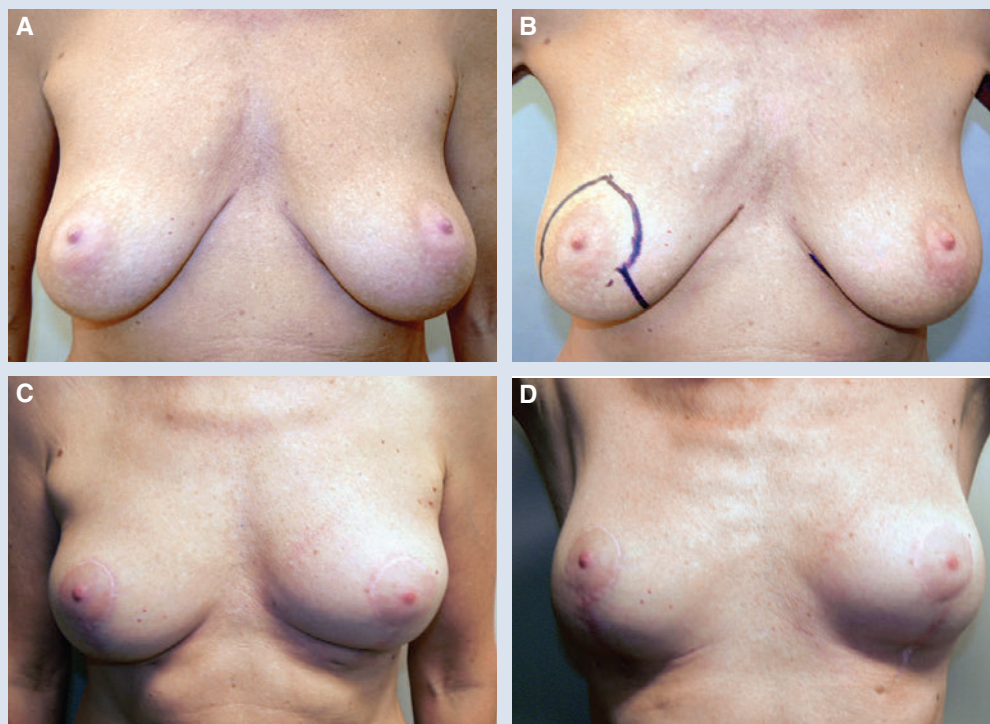
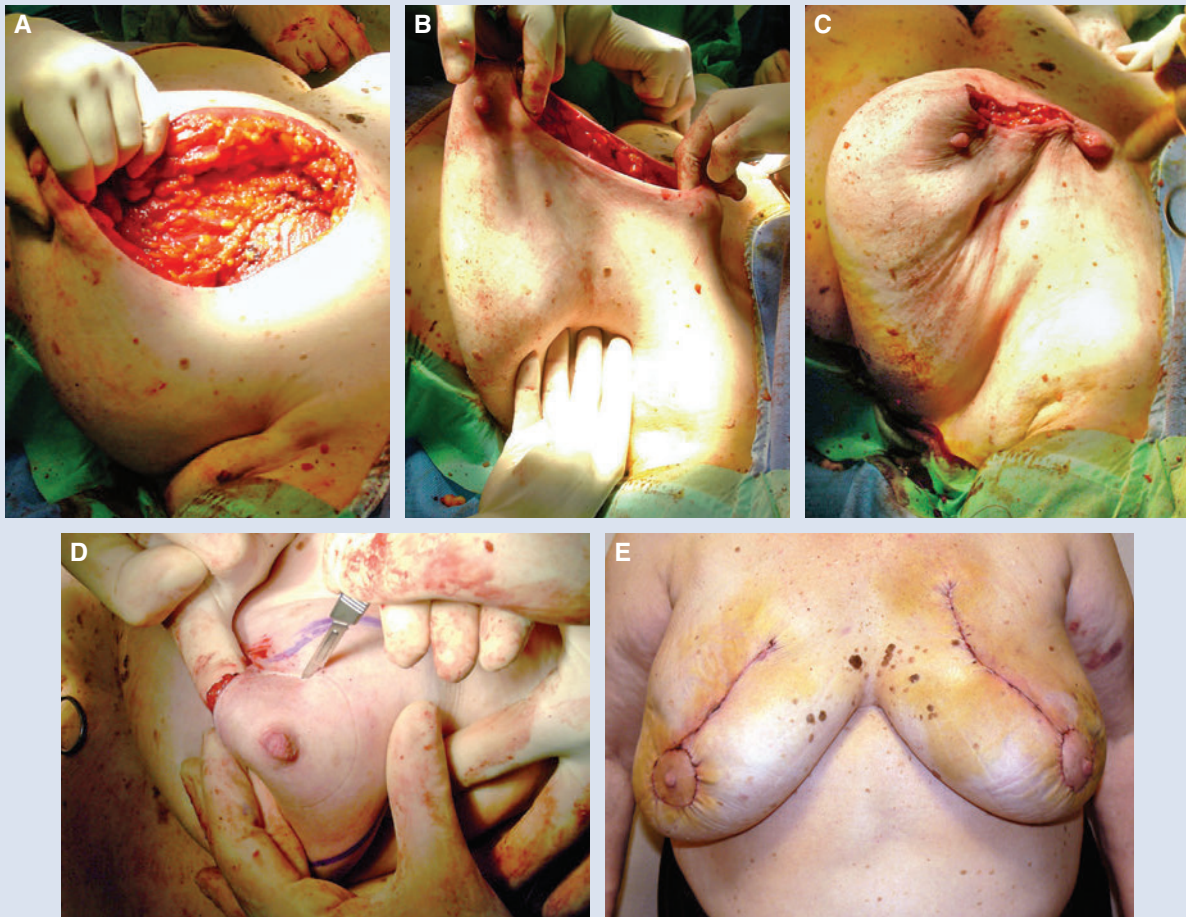


Fig. 9-12

This patient presented with a tumor in her right breast (A). She underwent a right inferior quadrantectomy and superior areolar pedicle technique (B). The final results are shown 1 year after symmetrization of the left breast (C and D).

**Fig. 9-13**

This patient underwent an unusual quadrantectomy that resulted in a large defect after 232 g of tissue were removed (*A* and *B*). The first step was to approximate the glandular plane (*C*). After the glandular remodeling, it was possible to adequately reduce the skin envelope with a periareolar deepithelialization (*D*). The patient is shown in the early postoperative period, after bilateral large and unusual quadrantectomies and bilateral breast remodeling (*E*).

For some patients, tissue rearrangement is complex, and the plastic surgeon establishes a treatment plan based on the glandular and skin defects. Traditional mammoplasty techniques are often sufficient and allow the plastic surgeon to use a familiar technique to reconstruct the defect, depending on the tumor location.

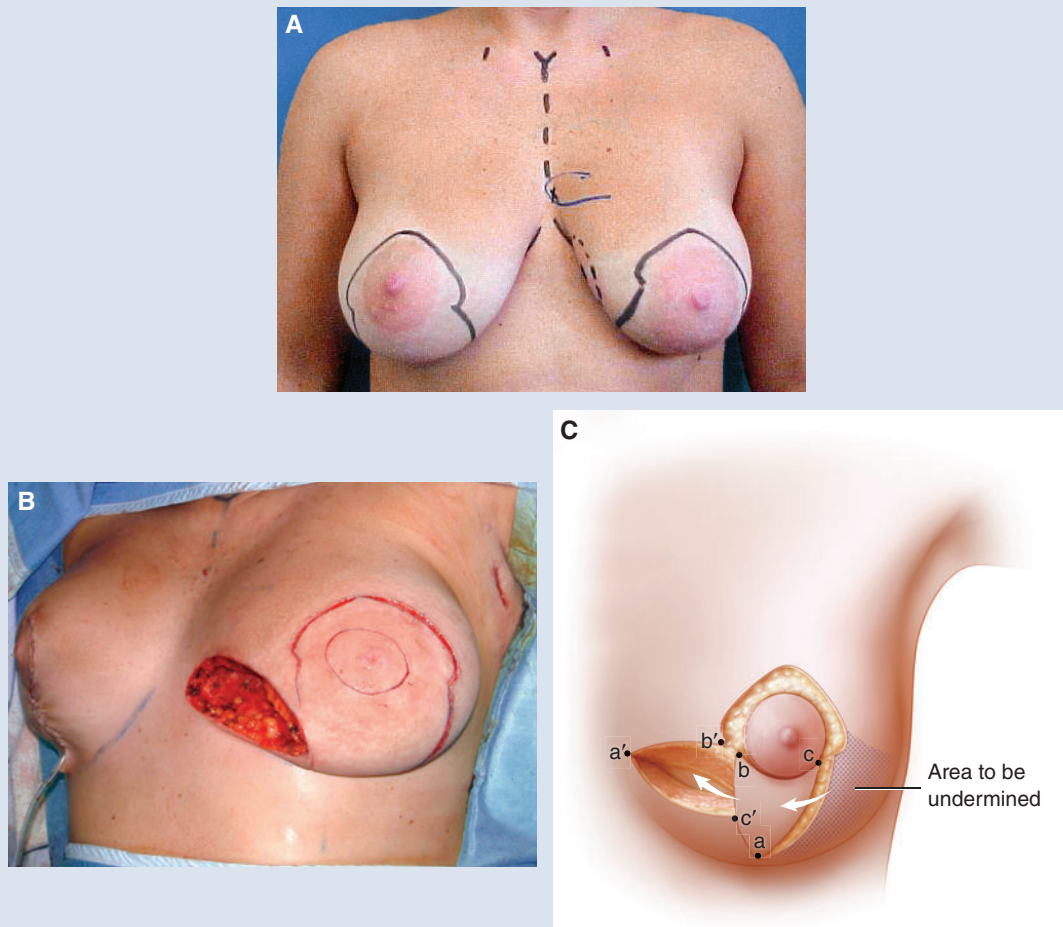


Fig. 9-14, A-C

This 30-year-old woman with medium-sized breasts presented with moderate ptosis and a T2N0 tumor in the inferior internal quadrant of her left breast (A). A quadrantectomy, sentinel node biopsy, and breast reshaping were performed. The quadrantectomy left a 9 by 5 cm skin defect (B). The total breast volume removed was 100 g. A contralateral reduction mammoplasty was performed according to the Lejour technique,² with a 120 g resection to compensate for potential radiation-induced loss of breast volume on the involved side. The defect on the right breast involved the skin and breast mound. A preoperative drawing of the defect, flap, and undermining is shown (C).

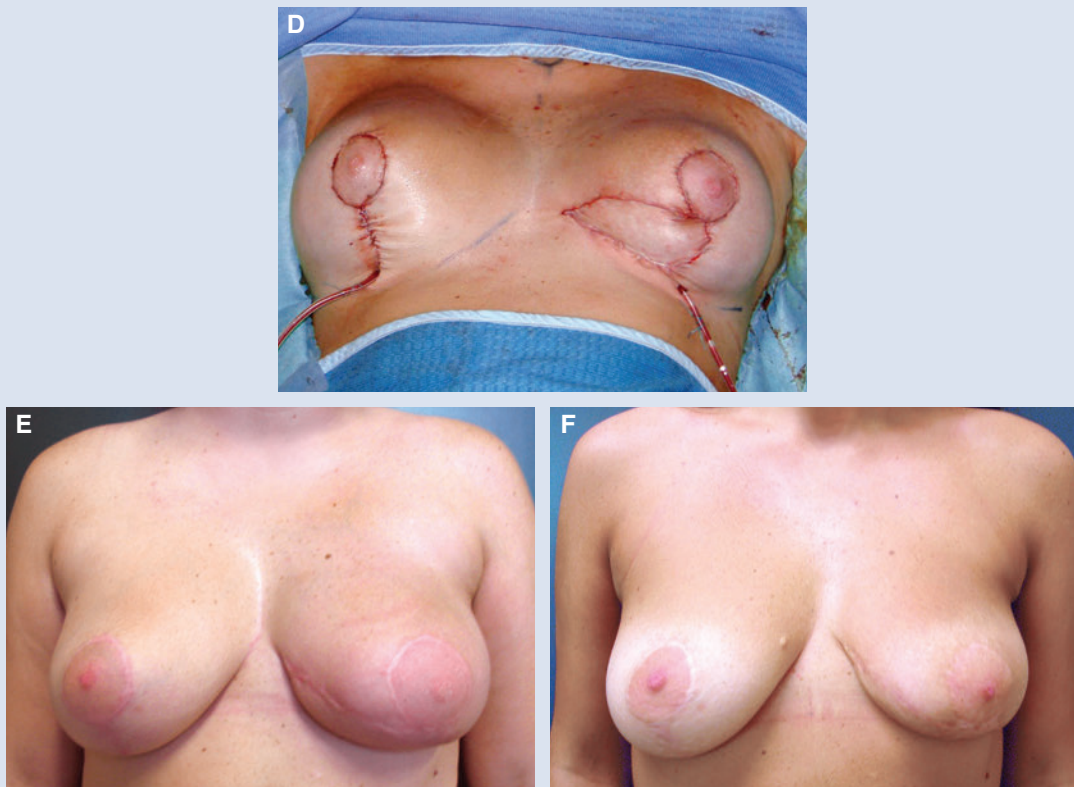


Fig. 9-14, D-F

A superiorly based glandular flap with an inferior skin area was elevated off the fascia as a full-thickness flap, and rotated to fill the defect. The patient is shown immediately postoperatively (*D*) and 1 and 4 years (*E* and *F*) postoperatively, after radiotherapy.

CONCLUSION

The following maneuvers can improve the results of breast-conserving treatment:

- Careful preoperative evaluation with drawings
- Patient positioning and preparations with both breasts in the operative field
- Mobilization of the glandular tissue after tumor removal
- Approximation of the gland and skin according to plastic surgery recommendations
- Mobilization of the areola
- Periareolar deepithelization
- Mirror tumorectomy to check the opposite breast and improve symmetry

It is important to first perform an oncologically safe resection of the cancer before considering the cosmetic result.

Aesthetic outcomes should not influence the principles of the cancer surgery based on radical tumor excision. The ability to remodel the breast provides the surgeon with more confidence to perform wide quadrantectomies and therefore radical cancer surgery.

Critical Issues

- The quadrantectomy defects should be carefully designed.
- Consideration should be given to performing the quadrantectomy through remote incisions for better aesthetic outcomes.
- Glandular closure, especially in the lower pole, minimizes deformities.
- Nipple centralization techniques often improve the shape.
- Contralateral symmetry procedures are required when the breast size and shape have been altered.

References

1. Pitanguy I. Surgical treatment of breast hypertrophy. *Br J Plast Surg* 20:78, 1967.
2. Lejour M. Vertical mammoplasty and liposuction of the breast. *Plast Reconstr Surg* 94:100, 1994.
3. Spear SL, Pelletiere CV, Wolfe AJ, et al. Experience with reduction mammoplasty combined with breast conservation therapy in the treatment of breast cancer. *Plast Reconstr Surg* 111:1102, 2003.
4. Wazer DE, DiPetrillo T, Schmidt-Ullrich R, et al. Factors influencing cosmetic outcome and complication risk after conservative surgery and radiotherapy for early-stage breast carcinoma. *J Clin Oncol* 10:356, 1992.
5. Clough KB, Ihrai T, Oden S, et al. Long-term oncoplastic surgery for breast cancer based on tumour location and a quadrant-per-quadrant atlas. *Br J Surg* 99:1389, 2012.
6. Kaur N, Petit JY, Rietjens M, et al. Comparative study of surgical margins in oncoplastic surgery and quadrantectomy in breast cancer. *Ann Surg Oncol* 12:539, 2005.
7. De Lorenzi F, Hubner G, Rotmensz N, et al. Oncological results of oncoplastic breast-conserving surgery: long term follow-up of a large series at a single institution: a matched-cohort analysis. *Eur J Surg Oncol* 42:71, 2016.

10

Breast Radiotherapy in Oncoplastic Surgery

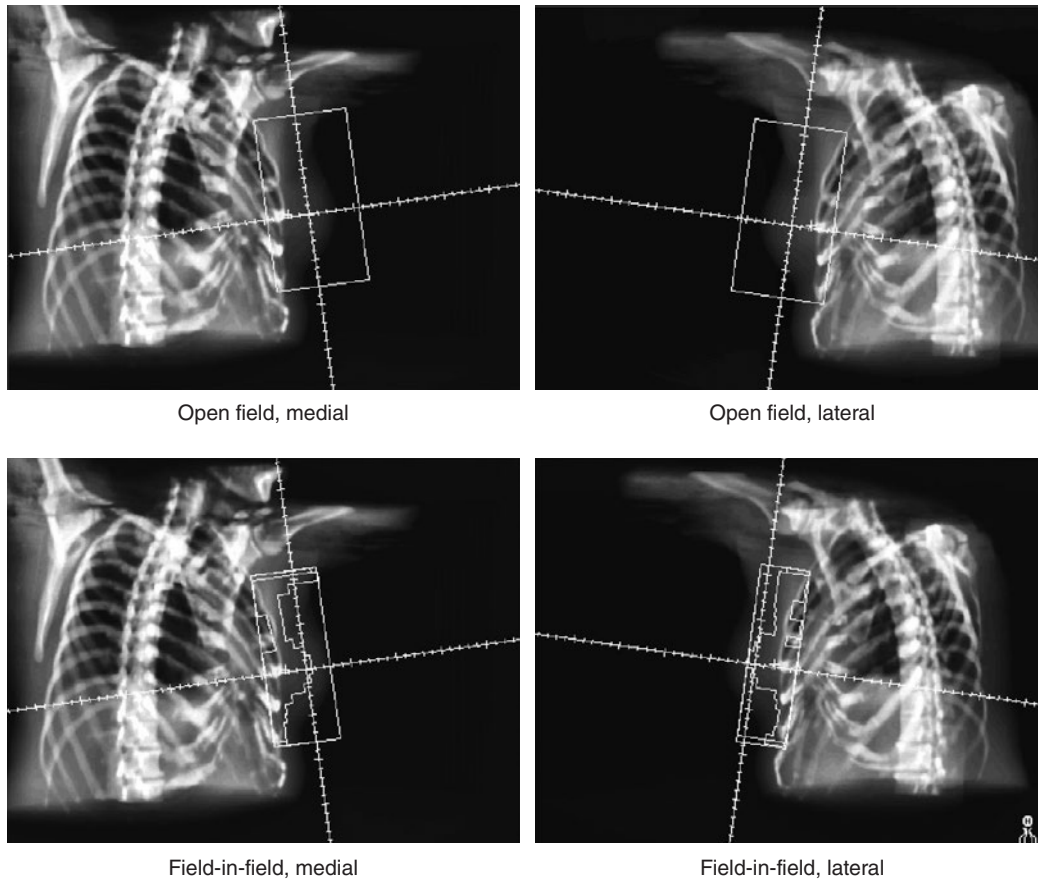
Steven Eric Finkelstein, Frank A. Vicini, Chirag Shah

Breast conservation represents a major advancement in the treatment of breast cancer, offering women the potential to preserve their breast without impairing their oncologic outcomes. Continued advancements in surgical and radiotherapy techniques over the past several decades has led to the evolution of breast conservation and the ability for more women to be eligible for the treatment. Recently, surgical methods known as oncoplastic techniques have been devised and are increasingly being used to offer women undergoing breast conservation the ability to enhance breast cosmesis, symmetry, and quality of life without impacting oncologic outcomes. The purpose of this chapter is to evaluate outcomes in patients undergoing oncologic surgery and radiotherapy.

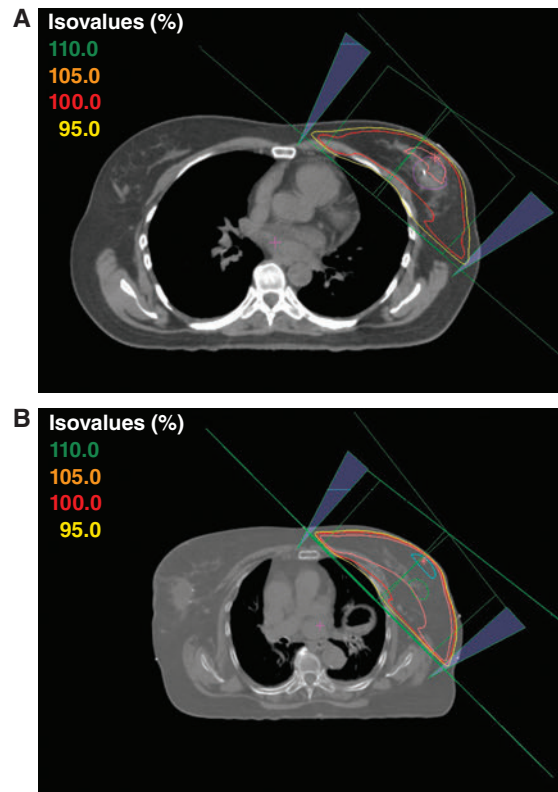
BREAST CONSERVATION AND BREAST IRRADIATION TECHNIQUES

Breast-conserving therapy (BCT) represents a standard of care approach for women with invasive and noninvasive breast cancers. Multiple randomized studies with long-term follow-up have demonstrated the equivalence of BCT and mastectomy in patients with invasive disease, while studies with long-term outcomes have demonstrated the efficacy of BCT in women with ductal carcinoma in situ (DCIS).¹⁻⁵ Furthermore, multiple studies have shown the increase in local recurrence with the omission of radiotherapy, with meta-analyses demonstrating reduction in local recurrence for invasive and noninvasive cancers and reduction in breast cancer mortality for invasive cancers with radiotherapy.⁶⁻⁷ Breast-conserving therapy has also been shown to improve quality of life and breast cosmetic outcomes for patients compared with mastectomy.^{8,9} An important distinction between BCT and mastectomy is that BCT requires continued follow-up with imaging of the involved breast as well as monitoring for skin and subcutaneous tissue toxicity and evaluation of symmetry and cosmesis.^{10,11}

Traditionally, radiotherapy was delivered using whole-breast irradiation with two-dimensional techniques. Over the past several decades, radiotherapy has evolved to incorporate three-dimensional planning.¹²

**Fig. 10-1**

Radiotherapy planning techniques use anatomic landmarks and target volumes to delineate the organs at risk and to localize the borders of the irradiation fields. When a patient receives a breast cancer treatment, the tissues targeted for full-dose irradiation include the whole breast and regional nodes, when indicated. Critical normal tissues—the heart, lungs, and contralateral breast—are avoided or are subject to dose reduction or modulation when possible. Currently the most commonly used technique to treat the whole breast is called a *tangential beam* irradiation. This field arrangement is designed to minimize the exposure of the intrathoracic structures, especially the heart and lungs, to radiation. Treatment plans are able to evaluate the dose to the breast, lumpectomy cavity, as well as organs at risk. More recently, intensity-modulated radiotherapy has been used to further optimize treatment plans and reduce the dose to critical structures, including the heart, with initial data demonstrating reduction in acute and chronic toxicities.¹³⁻¹⁵



Comparison of radiation therapy plans for small-breasted and large-breasted women

Fig. 10-2

Techniques to deliver breast radiotherapy can differ, depending on the size of the breast. *A* and *B* both show radiation fields for patients who have tangents with standard, fixed-angle wedges. The isodose values on the left of each image correspond to the percentage of the prescribed dose. Lines of the same color on the CT simulation axial slice show the corresponding dose distribution in the breast tissue. *B* demonstrates that in a large-breasted patient, the 105% isodose covers a larger volume of breast tissue, whereas *A* reveals that the 110% isodose is not present at all in the smaller-breasted patient. An increased-dose inhomogeneity is inherent for larger-breasted patients, because it is affected by the size and shape of the breast and by the separation distance across the posterior field edge from the medial to the lateral field border. A larger breast size or a larger separation, especially more than 25 cm, results in greater dose inhomogeneity in the treatment volume. Homogeneity within 7% to 10% of the prescribed dose is desirable.

There are various compensation methods used to modulate the dose distribution to achieve improved homogeneity. One such technique is the open-field, uncompensated treatment plan (see Fig. 10-1). One technique that is widely used to ameliorate dose inhomogeneity is the placement of compensator devices in the beam, often using wedge compensators of fixed angles or, more recently, virtual wedges of variable compensation degrees. The wide part of the wedge (or compensator) is placed in the beam in the same orientation as the tip of the triangle of the breast, to compensate for the thinner tissue separation at the apex of the breast at the nipple area.

After multileaf collimation (MLC) became available, custom compensation using field-in-field MLC shaping became increasingly popular. With this technique, the MLC is used to shape smaller fields that correspond to the areas of high-dose inhomogeneity, covering the high-dose regions with custom-shaped fields for small portions of the total dose to improve homogeneity. Another technique, intensity-modulated radiotherapy, typically involves three-dimensional planning using dose-volume constraints for target tissues and normal organs, with either forward or inverse planned dose calculations. Each compensation method can reduce and redistribute the “hot spots” (isodose regions in excess of 100% of the prescribed dose) compared with open fields with no compensation.

Despite advances in radiotherapy techniques (3D-CRT) and treatment delivery (IMRT), concerns exist regarding toxicity and cosmetic outcomes in women undergoing BCT. Although some of this is associated with radiotherapy, much of the difference in symmetry and cosmesis can be attributed to the reduction in breast volume after breast-conserving surgery.

Oncoplastic surgery first and foremost is an oncologic procedure that allows excision of the tumor with incorporation of multiple techniques (reduction mammoplasty, mastopexy, tissue transfer/rearrangement) to enhance cosmetic outcomes and patient satisfaction after BCT.^{16,17}

At this time, limited data are available on clinical, cosmetic, and toxicity-related outcomes with radiotherapy in patients undergoing oncoplastic procedures. However, in light of the growing use of such techniques, it is imperative that clinicians be aware of the data currently available.

ONCOPLASTIC TECHNIQUES

Oncoplastic techniques do not represent a single procedure but rather a combination of techniques used in conjunction with each other based on the patient's breast size, anatomy, tumor location, and lumpectomy cavity size to enhance cosmetic outcomes without impairing oncologic outcomes.

The most commonly used oncoplastic technique is tissue rearrangement and includes local glandular transfers or flaps as well as transfer or rearrangement from local or regional sites. These techniques work to minimize the defects after BCS and/or shift the defect to a less visible area.¹⁶ A second technique commonly employed is mastopexy, which can be particularly helpful in patients with significant breast ptosis or in large-breasted patients; with this technique, the contralateral breast may also be treated to enhance symmetry. Finally,

reduction mammoplasty can be used bilaterally to enhance symmetry in large-breasted women, with the contralateral breast reduced to match the breast after resection. The contralateral breast can be operated on initially or in a delayed setting to allow changes after adjuvant treatment.¹⁷

COSMESIS AND TOXICITY OF TRADITIONAL RADIOTHERAPY

The predominant toxicities associated with breast cancer radiotherapy include skin or subcutaneous tissue toxicity and the potential for impaired cosmesis as a result. Acute reactions typically include skin erythema, hyperpigmentation, rash, and possibly dry or moist desquamation. Acute toxicity occurs in skin and other acute-reacting tissues, with the likelihood of toxicity related to breast size. Other acute toxicities include breast swelling, edema of the skin, chest wall inflammation, fatigue, and subacute pneumonitis. There is no technical reason to postulate that oncoplastic reconstructions would be associated with worsened acute toxicities than those seen after a standard lumpectomy. Chronic toxicities are largely caused by the development of fibrosis and microvascular compromise in the treated tissues during the months after radiotherapy. Fibrosis can lead to distortion or asymmetry of the breast, although this is usually a relatively subtle effect. The risk of late fibrosis is related in part to the dose inhomogeneity, which is more pronounced in larger-breasted patients. It is also probably attributable to the extent of postoperative scarring, and thus more extensive surgery may also increase the risk of late fibrosis. If immediate oncoplastic reconstruction results in increased surgical scar tissue, cosmesis after radiotherapy could be compromised. However, because many women who undergo oncoplastic reconstruction may have otherwise required mastectomy or would have had greater asymmetry without the oncoplastic procedures, it is likely that the overall cosmetic outcome will be more satisfactory for these patients.

The cosmetic appearance of the treated breast after whole-breast irradiation is typically recorded by the physician at each follow-up visit. Radiation oncologists use a four-point cosmetic scoring system to compare the treated and untreated breast. The appearance of the treated breast can be scored as “excellent” (nearly identical to the untreated breast), “good” (slight difference of less than 25% asymmetry between breasts), “fair” (obvious differences between breasts), or “poor” (marked distortion of the treated breast).^{18,19} Traditionally, excellent or good cosmetic outcomes have been noted in more than 70% of women with long-term follow-up. A series from Fowble et al¹⁸ evaluated 697 women with stage I/II disease treated with BCT and with 58-month follow-up, a 93% rate of excellent or good cosmesis was noted. An analysis from Wazer et al¹⁹ found that factors associated with adverse cosmetic outcomes included the volume of breast tissue resected. Oncoplastic techniques would be able to help with this by reducing the tissue deficit in the area around the lumpectomy cavity. Additionally, previous studies have documented inferior outcomes with the use of reexcision, the placement of the excision scar, the volume of skin excised, older patient age, a larger tumor size, the use of radiotherapy and medial or inferior tumors, which is often a result of less tissue and more-visible defects.¹⁹⁻²¹

However, oncoplastic techniques exist specifically for this region to optimize cosmesis.¹⁷ A more homogeneous dose of radiotherapy is associated with better long-term cosmesis; therefore the use of compensators or dose modulation to achieve a homogeneous dose is

critical. Likewise, the total dose to the whole breast, the total dose of the tumor bed boost, and the dose per fraction may affect overall cosmesis. Whole-breast doses of less than or equal to 50 Gy in daily dose fractions of less than or equal to 2.6 Gy are typically used, and the total tumor bed dose is generally less than or equal to 66 Gy.

Large breast size has been consistently associated with inferior cosmetic outcomes following traditional radiotherapy; the rationale for increased toxicity and inferior cosmesis is based on larger skin folds, which can create an autobolus effect, exacerbating skin toxicity and also the potential for increased inhomogeneity with larger breast volumes.

Gray et al²² evaluated 257 women undergoing BCT and found significantly higher rates of asymmetry and breast retraction in a large-breasted cohort compared with a small-breasted cohort. Similar findings were noted by Moody et al²³; they reported that 39% of women with large breasts had late radiation changes, compared with 6% of women with small breasts. A recent study from William Beaumont Hospital found that these outcomes persisted with standard and hypofractionated radiotherapy and that acute and chronic toxicities were increased in large-breasted patients.²⁴

In theory, oncoplastic techniques resulting in a smaller breast volume may improve homogeneity and cosmesis after irradiation; however, this has not been studied and must be balanced against the potential increase in surgical complications or by the impact of more extensive surgery compared with lumpectomy alone.

Boost radiotherapy is an additional dose given to the lumpectomy cavity over several fractions. Multiple randomized studies have demonstrated a consistent reduction in local recurrence with the addition of boost to whole-breast irradiation.^{25,26} However, the addition of the boost also increases the potential for toxicity, including telangiectasias, and fibrosis.^{26,27} One concern regarding boost therapy and oncoplastic surgery is the delineation of the lumpectomy cavity.

Precise delineation of the tumor bed is critical for adequate targeting for both the whole-breast portion and for the tumor bed boost, which is given in most patients.

It is common for surgeons to place radiopaque clips in the periphery of the tumor bed to mark the lateral, inferior, superior, deep, and anterior extent of the resection bed. This technique improves the ability of the radiation oncologist to accurately define the region of resection, which is also the target for the boost. This target volume should include the marking clips as well as any visible postoperative seroma or other tissue changes seen on the CT scan that was obtained during treatment planning. A three-dimensional reconstruction of this target volume is created for the whole-breast and boost portions of the radiotherapy treatments to ensure adequate dose coverage. Some surgeons have concerns about the stability of the clips' placement in the breast tissue, knowing that they may shift when the tissue is brought together for closure. Although these are valid concerns, the presence of clips is still preferable, especially in patients who will receive chemotherapy before radiotherapy. In these patients, the postoperative seroma may have completely resolved by the time they present for radiotherapy planning, leaving no visible target volume on the CT scan. Clip placement may be particularly critical in patients undergoing oncoplastic reconstructions. In these patients, the surgical scars may be relatively unrelated to the tumor location, and other areas of postoperative tissue changes that result from the reconstruction will be present in the breast parenchyma.

A study from the Institut Curie evaluated 31 patients (13 had undergone standard lumpectomy, and 18 had received oncoplastic therapy). The investigators found that three or more clips were needed to enhance and increase the consistency of the boost volume definition.²⁸ Similar results were seen in a series of 25 patients presented by Pezner et al²⁹; in those patients with a minimum of four clips, 73% had a final tumor bed that extended beyond the original quadrant or into a different region with 27% of cases having the treatment volumes separated into two or three regions of the breast. A larger series of 86 patients undergoing oncoplastic reduction mammoplasty at Emory University reported that clips were found outside the primary tumor quadrant in 43% of patients, with boost doses delivered beyond the primary quadrant more frequently than inside the primary tumor quadrant.³⁰ This does raise concerns, because the omission of boost therapy increases the potential for local recurrence, while the expansion of boost targets increases the potential for toxicity, particularly fibrosis and telangiectasias.

OUTCOMES WITH RADIOTHERAPY AND ONCOPLASTIC SURGERY

Over the past few years, increasing data have become available regarding outcomes in patients treated with breast conservation and oncoplastic surgery; however, prospective data with long-term follow-up remain limited at this time.

Table 10-1 Outcomes With Oncoplastic Surgery and Radiotherapy

Institution	Year Published	Number of Patients	Follow-up (mo)	Oncoplastic Technique	Outcomes
Tepecik Training and Research Hospital ³¹	2015	82	121	Reduction mammoplasty	10-yr LR: 8.7%; early/late complications: 12.2%/14.6%
Emory University ³⁰	2014	86	54	Reduction mammoplasty	5-yr IBTR: 7%/9% invasive carcinoma/DCIS; 43% of clips outside primary tumor quadrant
Coastal Carolina Radiation Oncology ³²	2015	79	35	Predominantly inferior pedicle mastopexy	LC 100%; excellent/good cosmesis: 3%/94%
Institut Curie ²⁸	2003	101	44	Variable	5-yr LR: 9.4%; favorable cosmesis: 82%
University of Chicago ³³	2012	45	38	—	No local recurrences; 14% positive margins with immediate procedure, lower complications with immediate procedure
University of California, San Francisco ³⁶	2014	37	33	Mammoplasty	Increased complications with mastectomy and reconstruction compared with oncoplastic mammoplasty: unplanned interventions (2.7% versus 37.5%), skin necrosis (10.8% versus 29.7%), infection (16.2% versus 35.9%)
University of Kansas ³⁷	2014	58	—	—	Immediate complications similar to non-oncoplastic, except increased nonhealing (8.6% versus 1.2%) with oncoplastic, increased fat necrosis with oncoplastic (25.9% versus 9.5%)
Institute Verbeeten ⁴⁰	2015	125 (26% onco-plastic)	—	—	No difference in cosmetic results compared with conventional lumpectomy, conventional lumpectomy associated with improved objective cosmetic outcomes

DCIS, Ductal carcinoma in situ; IBTR, ipsilateral breast tumor recurrence; LC, local control; LR, local recurrence.

In a series from Turkey with 10-year follow-up, 82 patients who underwent oncoplastic reduction mammoplasty between 1996 and 2011 were retrospectively reviewed. At 10 years the rate of local recurrence was 8.7%, and overall survival was 82%. The rates of early or late complications were 12.2% and 14.6%, respectively.³¹ Similar results were reported in the retrospective analysis of 86 patients from Emory that found the 5-year IBTR rates to be 7% and 9% for invasive carcinomas and DCIS, respectively.³⁰ A retrospective review of 79 patients treated with oncoplastic surgery identified an 18% rate of preradiotherapy, postsurgical toxicity, with 6% of patients developing toxicity with radiation.³² Cosmesis was excellent in 3% and good in 94% of patients, leading to high rates of patient satisfaction. No local failures were documented at 3 years. Consistent results have been noted in several other series.³³⁻³⁵

A comparison of oncoplastic mammoplasty and mastectomy with immediate reconstruction in patients undergoing radiotherapy was performed by Peled et al.³⁶ Oncoplastic patients were compared with 64 mastectomy and reconstruction patients with reduced complications, unplanned operative interventions, flap necrosis, and infection noted in the oncoplastic cohort. Overall, complications were 45% in the mastectomy group compared with 19% for the oncoplastic patients.³⁶

A comparison of oncoplastic and nononcoplastic lumpectomies found similar complication rates and cosmetic outcomes with higher rates of fat necrosis with oncoplastic procedures, though a larger percentage of oncoplastic patients did receive radiation.³⁷ An analysis from the University of Southern California evaluated 66 patients undergoing “extreme oncoplasty” in cases that would typically require mastectomy compared with 245 normal cases. All oncoplasty patients received adjuvant radiation with tumor bed boost. Ninety-four percent of extreme patients were able to complete surgery with negative margins (6.1% converted to mastectomy) and with 2-year follow-up the local recurrence rate was 1.5% compared with 1.2% for the standard cohort.³⁸

One issue that has emerged is the timing of procedures with radiotherapy as options include immediate, delayed-immediate, and delayed techniques. Egro et al³⁹ evaluated timing and found that complications were reduced with immediate reduction mammoplasty (20.5% versus 33.0% versus 60.0%) as was asymmetry with fewer total procedures required. No significant difference was noted in patient satisfaction or cosmesis. Similar results were seen in a study from the University of Chicago which found higher rates of toxicity with delayed techniques compared with immediate reconstruction techniques.³³

Several studies have evaluated cosmetic and quality of life outcomes in those undergoing oncoplastic procedures. A study from Lansu et al⁴⁰ evaluated 125 patients treated with BCT retrospectively and found that oncoplastic patients had worse objective cosmetic outcomes and were associated with worse quality of life outcomes; it should be noted that this study included a heterogeneous mix of radiation schedules and techniques. However, a study comparing 64 patients treated with standard techniques and 32 with oncoplastic found excellent cosmetic outcomes with oncoplastic techniques.⁴¹

While most series evaluating oncoplastic techniques and radiation have used whole breast irradiation, a study from Roth et al⁴² retrospectively evaluated 134 patients treated with interstitial accelerated partial breast irradiation with either high-dose rate or pulsed-dose rate treatment. With a median follow-up of 39 months, 3 breast failures were noted with low rates of fibrosis, telangiectasias, and hyperpigmentation. Data has also demonstrated the feasibility of intraoperative radiotherapy with oncoplastic techniques.³⁹

CONCLUSIONS AND FUTURE DIRECTIONS

Moving forward, the role of oncoplastic surgery as part of standard breast cancer care continues to expand and it is increasingly being used. Prospective and retrospective data to date are promising, demonstrating improved cosmesis and quality of life with no difference in clinical outcomes to date. However, at this time there is a lack of large prospective studies with long-term follow-up comparing clinical outcomes, toxicity, quality of life, and cosmesis with traditional surgical techniques. Data are needed regarding which patients are ideal candidates for oncoplastic techniques, including patient characteristics, tumor size and location, and the adjuvant treatment⁵ to be used. Although this can be based on previous data evaluating toxicity and cosmetic outcomes in patients undergoing standard BCT, it is imperative that these factors be prospectively evaluated.^{43,44}

Further work is also needed regarding the implications of oncoplastic techniques on radiotherapy. Accelerated partial breast irradiation with interstitial brachytherapy has been evaluated, but using brachytherapy applicators or external beam techniques would remain difficult with some oncoplastic techniques and requires a discussion with the patient preoperatively to identify whether they prefer an oncoplastic approach or one where the cavity remains to deliver APBI. Furthermore, with difficulty noted in cavity delineation and clip identification, techniques should be developed to better identify the lumpectomy cavity to assist with radiotherapy boost delivery so that the benefits of oncoplastics are not reduced by creating a large cavity. With increasing numbers of patients receiving neoadjuvant chemotherapy, the role of oncoplastic techniques in these patients remains unanswered, with the potential for tumor shrinkage having an impact on surgical and reconstruction decisions.⁴⁵⁻⁴⁷

Finally, cost-effectiveness studies should be performed comparing standard techniques and outcomes with oncoplastic techniques based on cosmetic and quality of life outcomes, since no difference in clinical outcomes would be expected. However, data exist supporting lower rates of positive margins with oncoplastic compared with standard techniques offering a potential cost savings.^{48,49} Additionally, comparison to mastectomy with immediate reconstruction may highlight the cost-effectiveness of oncoplastic techniques when factoring in the potential for increased complications among those receiving postmastectomy radiotherapy.³⁴ However, in the interim, oncoplastic techniques should continue to be used and evaluated as an option to improve cosmetic outcomes and potentially increase the number of patients eligible for breast conservation.

Critical Issues

- Over the past two decades, radiotherapy techniques to deliver adjuvant radiation after breast-conserving surgery have evolved to reduce the rates of acute and chronic toxicities.
- Despite advances in radiotherapy planning, subsets of patients (for example, large-breasted women) still remain at high risk for toxicity associated with radiotherapy.
- Oncoplastic surgery is not a single technique but rather a collection of techniques, with the choice driven by patient-specific and tumor location-specific factors.
- Radiation oncologists must be aware of oncoplastic techniques used.
- Initial studies evaluating women undergoing oncoplastic techniques have provided favorable outcomes, though further study and longer follow-up is required.
- Future studies are required that compare oncoplastic techniques with traditional therapies with respect to oncologic outcomes, toxicity/cosmetic outcomes, and cost efficacy.

References

1. Fisher B, Anderson S, Bryant J, et al. Twenty-year follow-up of a randomized trial comparing total mastectomy, lumpectomy, and lumpectomy plus irradiation for the treatment of invasive breast cancer. *N Engl J Med* 347:1233, 2002.
2. Veronesi U, Cascinelli N, Mariani L, et al. Twenty-year follow-up of a randomized study comparing breast-conserving surgery with radical mastectomy for early breast cancer. *N Engl J Med* 347:1227, 2002.
3. Litière S, Werutsky G, Fentiman IS, et al. Breast conserving therapy versus mastectomy for stage I-II breast cancer: 20 year follow-up of the EORTC 10801 phase 3 randomised trial. *Lancet Oncol* 13:412, 2012.
4. Jacobson JA, Danforth DN, Cowan KH, et al. Ten-year results of a comparison of conservation with mastectomy in the treatment of stage I and II breast cancer. *N Engl J Med* 332:907, 1995.
5. Solin LJ, Fourquet A, Vicini FA, et al. Long-term outcome after breast-conservation treatment with radiation for mammographically detected ductal carcinoma in situ of the breast. *Cancer* 103:1137, 2005.
6. Darby S, McGale P, Correa C, et al. Effect of radiotherapy after breast-conserving surgery on 10-year recurrence and 15-year breast cancer death: meta-analysis of individual patient data for 10,801 women in 17 randomised trials. *Lancet* 378:1707, 2011.
7. Correa C, McGale P, Taylor C, et al. Overview of the randomized trials of radiotherapy in ductal carcinoma in situ of the breast. *J Natl Cancer Inst Monogr* 2010:162, 2010.
8. Jagsi R, Li Y, Morrow M, et al. Patient-reported quality of life and satisfaction with cosmetic outcomes after breast conservation and mastectomy with and without reconstruction: results of a survey of breast cancer survivors. *Ann Surg* 261:1198, 2015.

9. Munshi A, Dutta D, Kakkar S, et al. Comparison of early quality of life in patients treated with radiotherapy following mastectomy or breast conservation therapy: a prospective study. *Radiother Oncol* 97:288, 2010.
10. Hille-Betz U, Vaske B, Bremer M, et al. Late radiation side effects, cosmetic outcomes, and pain in breast cancer patients after breast-conserving surgery and three-dimensional conformal radiotherapy: risk-modifying factors. *Strahlenther Onkol* 192:8, 2016.
11. Mery B, Vallard A, Trone JC, et al. Correlation between anthropometric parameters and acute skin toxicity in breast cancer radiotherapy patients: a pilot assessment study. *Br J Radiol* 88:1055, 2015.
12. Munshi A, Pai RH, Phurailatpam R, et al. Do all patients of breast carcinoma need 3-dimensional CT based planning? A dosimetric study comparing different breast sizes. *Med Dosim* 34:140, 2009.
13. Barnett GC, Wilkinson JS, Moody AM, et al. Randomized controlled trial of forward-planned intensity modulated radiotherapy for early breast cancer: interim results at 2 years. *Int J Radiat Oncol Biol Phys* 82:715, 2012.
14. Pignol JP, Olivetto I, Rakovitch E, et al. A multicenter randomized trial of breast intensity-modulated radiation therapy to reduce acute radiation dermatitis. *J Clin Oncol* 26:2085, 2008.
15. Donovan E, Bleakley N, Denholm E, et al. Randomised trial of standard 2D radiotherapy (RT) versus intensity modulated radiotherapy (IMRT) in patients prescribed breast radiotherapy. *Radiother Oncol* 82:254, 2007.
16. Piper M, Peled AW, Sbitany H. Oncoplastic breast surgery: current strategies. *Gland Surg* 4:154, 2015.
17. Silverstein MF, Mai T, Savalia N, et al. Oncoplastic breast conservation surgery: the new paradigm. *J Surg Oncol* 110:82, 2014.
18. Fowble BL, Solin LJ, Schultz DJ, et al. Ten year results of conservative surgery and irradiation for stage I and II breast cancer. *Int J Radiat Oncol Biol Phys* 21:269, 1995.
19. Wazer DE, DiPetrillo T, Schmidt-Ullrich R, et al. Factors influencing cosmetic outcome and complication risk after conservative surgery and radiotherapy for early-stage breast carcinoma. *J Clin Oncol* 10:356, 1992.
20. Al-Ghazal SK, Blamey RW, Stewart J, et al. The cosmetic outcome in early breast cancer treated with breast conservation. *Eur J Surg Oncol* 25:566, 1999.
21. Van Limbergen E, Rijnders A, van der Schueren E, et al. Cosmetic evaluation of breast conserving treatment for mammary cancer. 2. A quantitative analysis of the influence of radiation dose, fractionation schedules and surgical treatment techniques on cosmetic results. *Radiother Oncol* 16:253, 1989.
22. Gray JR, McCormick B, Cox L, et al. Primary breast irradiation in large-breasted or heavy women: analysis of cosmetic outcome. *Int J Radiat Oncol Biol Phys* 21:347, 1991.
23. Moody AM, Mayles WP, Bliss JM, et al. The influence of breast size on late radiation effects and association with radiotherapy dose inhomogeneity. *Radiother Oncol* 33:106, 1994.
24. Shah C, Wobb J, Grills I, et al. Use of intensity modulated radiation therapy to reduce acute and chronic toxicities of breast cancer patients treated with traditional and accelerated whole breast irradiation. *Pract Radiat Oncol* 2:e45, 2012.
25. Poortman PM, Collette L, Bartelink H, et al. The addition of a boost dose on the primary tumour bed after lumpectomy in breast conserving treatment for breast cancer. A summary of the results of the EORTC 22881-10882 'boost versus no boost' trial. *Cancer Radiother* 12:565, 2008.
26. Romestaing P, Lehingue Y, Carrie C, et al. Role of a 10-Gy boost in the conservative treatment of early breast cancer: results of a randomized clinical trial in Lyon, France. *J Clin Oncol* 15:963, 1997.
27. Collette S, Collette L, Budiharto, et al. Predictors of the risk of fibrosis at 10 years after breast conserving therapy for early breast cancer: a study based on the EORTC Trial 22881-10882 'boost versus no boost.' *Eur J Cancer* 44:2587, 2008.
28. Furet E, Peurién D, Fournier-Bidoz N, et al. Plastic surgery for breast conservation therapy: how to define the volume of the tumor bed for the boost? *Eur J Surg Oncol* 40:830, 2014.

29. Pezner RD, Tan MC, Clancy SL, et al. Radiation therapy for breast cancer patients who undergo oncoplastic surgery: localization of the tumor bed for the local boost. *Am J Clin Oncol* 36:535, 2013.
30. Eaton BR, Losken A, Okwan-Duodu D, et al. Local recurrence patterns in breast cancer patients treated with oncoplastic reduction mammoplasty and radiotherapy. *Ann Surg Oncol* 21:93, 2014.
31. Emiroglu M, Salimoglu S, Karaali C, et al. Oncoplastic reduction mammoplasty for breast cancer in women with macromastia: oncological long-term outcomes. *Asian J Surg* 2015 Sep 7. [Epub ahead of print]
32. Maguire PD, Adams A, Nichols MA. Oncoplastic surgery and radiation therapy for breast conservation: early outcomes. *Am J Clin Oncol* 38:353, 2015.
33. Roughton MC, Shenaq D, Jaskowiak N, et al. Optimizing delivery of breast conservation therapy: a multidisciplinary approach to oncoplastic surgery. *Ann Plast Surg* 69:250, 2012.
34. Clough KB, Lewis JS, Couturaud B, et al. Oncoplastic techniques allow extensive resections for breast-conserving therapy of breast carcinomas. *Ann Surg* 237:26, 2003.
35. Hernanz F, Regaño S, Redondo-Figuero C, et al. Oncoplastic breast-conserving surgery: analysis of quadrantectomy and immediate reconstruction with latissimus dorsi flap. *World J Surg* 31:1934, 2007.
36. Peled AW, Sbitany H, Foster RD, et al. Oncoplastic mammoplasty as a strategy for reducing reconstructive complications associated with postmastectomy radiation therapy. *Breast J* 20:302, 2014.
37. Tenofsky PL, Dowell P, Topalovski T, et al. Surgical, oncologic, and cosmetic differences between oncoplastic and nononcoplastic breast conserving surgery in breast cancer patients. *Am J Surg* 207:398, 2014.
38. Silverstein MJ, Savalia N, Khan S, et al. Extreme oncoplasty: breast conservation for patients who need mastectomy. *Breast J* 21:52, 2015.
39. Egro FM, Pinell-White X, Hart AM, et al. The use of reduction mammoplasty with breast conservation therapy: an analysis of timing and outcomes. *Plast Reconstr Surg* 135:963e, 2015.
40. Lansu JT, Essers M, Voogd AC, et al. The influence of simultaneous integrated boost, hypofractionation, and oncoplastic surgery and cosmetic outcome and PROMs after breast conserving therapy. *Eur J Surg Oncol* 41:1411, 2015.
41. Massa M, Meszaros P, Baldelli I, et al. Aesthetic evaluation in oncoplastic and conservative breast surgery: a comparative analysis. *Plast Reconstr Surg Glob Open* 3:e339, 2015.
42. Roth AM, Kauer-Dorner D, Resch A, et al. Is oncoplastic surgery a contraindication for accelerated partial breast radiation using the interstitial multicatheter brachytherapy method? *Brachytherapy* 13:394, 2014.
43. Kelly DA, Wood BC, Knoll GM, et al. Outcome analysis of 541 women undergoing breast conservation therapy. *Ann Plast Surg* 68:435, 2012.
44. Waljee JF, Hu ES, Newman LA, et al. Predictors of breast asymmetry after breast-conserving operation for breast cancer. *J Am Coll Surg* 206:274, 2008.
45. Schwartz GF, Meltzer AJ, Lucarelli EA, et al. Breast conservation after neoadjuvant chemotherapy for stage II carcinoma of the breast. *J Am Coll Surg* 201:327, 2005.
46. Cance WG, Carey LA, Calvo BF, et al. Long-term outcome of neoadjuvant therapy for locally advanced breast carcinoma: effective clinical downstaging allows breast preservation and predicts outstanding local control and survival. *Ann Surg* 236:295, 2002.
47. Danforth DN Jr, Zukewski J, O'Shaughnessy J, et al. Selection of local therapy after neoadjuvant chemotherapy in patients with stage IIIA,B breast cancer. *Ann Surg Oncol* 5:150, 1998.
48. Giacalone PL, Roger P, Dubon O, et al. Comparative study of the accuracy of breast resection in oncoplastic surgery and quadrantectomy in breast cancer. *Ann Surg Oncol* 14:605, 2007.
49. Kaur N, Petit JY, Reijnders M, et al. Comparative study of surgical margins in oncoplastic surgery and quadrantectomy in breast cancer. *Ann Surg Oncol* 12:539, 2005.

11

Indications and Benefits of Oncoplastic Breast Surgery

Maurice Y. Nahabedian



ncoplastic surgery has become an accepted modality for the management of breast cancer.^{1,2} Breast surgeons throughout the world have incorporated oncoplastic techniques to optimally manage patients with tumors amenable to it. In its simplest form, oncoplastic surgery is defined as the total removal of the breast cancer and partial removal of the adjacent breast parenchyma, followed by immediate or staged-immediate reconstruction of the partial mastectomy defect. Oncoplastic techniques continue to expand as surgeons devise innovative methods that are safe, effective, and provide high patient satisfaction.

Oncoplastic breast surgery is not advocated to supersede skin-sparing mastectomy (SSM) and immediate reconstruction; rather, it is an alternative in the setting of an early-stage breast cancer that is easily resectable.

BENEFITS OF ONCOPLASTIC SURGERY

The benefits of oncoplastic surgery have been well described; the principle benefit is that total mastectomy can be avoided in properly selected patients. The oncoplastic approach also broadens the indications for BCT. Patients with small breasts or subareolar tumors are often poor candidates for BCT alone because of the severe distortion of breast tissues as a result of radiotherapy. Oncoplastic techniques may provide options using strategies of volume displacement and replacement to minimize distortion and avoid total mastectomy.

The psychological advantages of breast preservation in the management of breast cancer are well established. Patient satisfaction has been demonstrated to be superior compared with that of mastectomy in most cases.³⁻⁶ In many women the NAC is preserved, eliminat-

ing the need for nipple reconstruction. Oncoplastic surgery is advantageous compared with BCT, because parenchymal defects are immediately reconstructed and contour abnormalities of the breast are significantly minimized or eliminated altogether. It is expected that 5% to 40% of women who undergo breast conservation will have a contour abnormality.⁷ Typically, these defects are more difficult to correct because of the adverse effects on tissue vascularity and the fibrosis that occurs after radiotherapy. Secondary correction of these irradiated deformities sometimes results in delayed healing and poor aesthetic outcomes. With the current concepts regarding oncoplastic tumor resection and plastic surgical closure, immediate reconstruction has minimized the incidence of these contour abnormalities, has allowed a wider margin of tumor resection, and has decreased the number of subsequent operations required. All of these factors have improved oncologic and aesthetic outcomes.

The oncologic safety and efficacy of oncoplastic surgery are adequately discussed in Chapter 7. Although local recurrence rates may be increased compared with those of total mastectomies, the early detection and management of these tumors have not had an adverse influence on survival. It is recognized that local recurrence is closely correlated with the margin of resection—the wider the margin, the less likely the local recurrence. Studies have demonstrated that resection margins of 1 cm or more have a recurrence rate equal to that of mastectomy.⁸ With oncoplastic surgery, margins of 2 to 3 cm are not uncommon, because the resultant deformity is immediately corrected. Hence an additional benefit of the oncoplastic approach includes the ability to take wider resection margins. Although it is not the driving force behind choosing oncoplastic approaches, tissue sampling of the opposite breast may help to diagnose contralateral occult breast cancer when reduction techniques are applied. Others have suggested that reduction techniques provide further risk reduction by removing additional breast tissue; however, studies of this are limited.⁹

The oncologic feasibility of oncoplastic surgery is well appreciated.^{10,11} To best understand the safety and efficacy of this approach, comparison studies to SSM followed by immediate breast reconstruction have been performed. In a study of mastectomy and immediate reconstruction from the University of Texas MD Anderson Cancer Center, 1694 women were reviewed to determine the incidence of local recurrence.¹² A recurrence was documented in 39 women (2.3%). Of the women with recurrence, 28 cases (72%) involved the skin or subcutaneous tissues, and 11 (28%) involved the chest wall. Metastatic disease was documented in 57% of the women with superficial recurrences and in 91% of those with deep recurrences. Among the women who had a recurrence, the metastases-free survival was 52% at 2 years, 42% at 5 years in women who had a recurrence in the skin or subcutaneous layer, and 24% at 2 and 5 years in women who had a chest wall recurrence.

In contrast to mastectomy and immediate reconstruction, oncoplastic techniques result in similar survival and recurrence rates. Clough et al¹³ reviewed 101 women who underwent oncoplastic surgery in which a partial mastectomy was followed with immediate reduction mammoplasty. The margin of resection was at least 1 cm of normal tissue. The median follow-up was 46 months (range 7 to 168 months). The recurrence rate at 5 years was 9.4%. The 5-year actuarial survival was 95.7%, and the 5-year metastases-free survival was 82.8%.

Studies evaluating patient satisfaction have demonstrated that women report higher satisfaction scores after an oncoplastic approach than they do with a SSM and immediate breast

reconstruction.¹⁴ The reasons for this are mainly related to the preservation of the natural breast mound and NAC.

The importance of the nipple-areola complex in preserving a woman's body image and femininity cannot be underestimated.

In studies evaluating women's satisfaction after undergoing reconstruction of the NAC, total satisfaction based on projection, texture, color, and appearance was obtained in only 13% of patients.¹⁵

After oncoplastic surgery, the appearance and behavior of the NAC is usually retained, and this seems to lead to a higher degree of patient satisfaction. These satisfaction results are favorable regarding the various approaches to oncoplastic surgery, such as reduction mammoplasty and latissimus dorsi flap reconstruction.¹³⁻¹⁹

Table 11-1 Six Studies Reviewing Techniques, Morbidity, and Patient Satisfaction

Study	Technique	Number of Patients	Morbidity (%)	Patient Satisfaction (%)
Kat et al ¹⁶ (1999)	Latissimus dorsi	30	38 (seroma, infection)	100
Losken et al ¹⁷ (2002)	Reduction mammoplasty	20	30 (delayed healing)	100
Clough et al ¹³ (2003)	Reduction mammoplasty	101	20 (delayed healing, fibrosis)	88
Gendy et al ¹⁴ (2003)	Latissimus dorsi	47	8 (sensory changes, activities of daily living affected)	84
Spear et al ¹⁸ (2003)	Reduction mammoplasty	11	27 (fat necrosis)	100
Losken et al ¹⁹ (2004)	Latissimus dorsi	30	33 (recurrence, seroma)	NA

NA, Not assessed.

In six well-established studies in which latissimus dorsi reconstruction or reduction mammoplasty was performed, patient satisfaction ranged from 84% to 100%. In three of the six studies, the patient satisfaction was 100% following both techniques, despite a complication rate that ranged from 8% to 38%. These complications included seromas, infection, delayed healing, fat necrosis, sensory changes of the breast and NAC, disruption in activi-

ties of daily living, and fibrosis. In a recent meta-analysis comparing BCS alone (N = 5497) to the oncoplastic approach (N = 3165), the patient satisfaction was higher in the oncoplastic group (90% oncoplastic reduction and 92% oncoplastic flap) compared with 83% in the BCT-alone group ($p < 0.001$).

PATIENT SELECTION

Box 11-1 Indications for Oncoplastic Surgery

Cosmetic

- High tumor/breast ratio ($>20\%$)
- Tumor location is central, inferior, or medial
- Macromastia
- Large tumor
- Patient desires smaller breasts
- Significant ptosis or breast asymmetry
- An unfavorable result is anticipated

Oncologic

- Concern about clear margins
- Wide excision required
- Patient is a poor candidate for mastectomy and reconstruction (because of factors such as age or breast size)
- Patient desires BCT

As with all reconstructive procedures, patient selection is critical to the ability to predict and reproduce successful outcomes.

Perhaps the most important criteria are the patient's wish to preserve her breast and the agreement or recommendation of the oncologic or ablative surgeon that this is a viable option.

In general, oncoplastic surgery may be beneficial in women with the following:

- A strong desire to preserve the breast and nipple-areola complex
- BCT feasibility from an oncologic standpoint
- A medium-sized or large tumor in a large breast
- A small tumor in a small breast
- A unifocal tumor
- Stage I or II breast cancer
- No previous breast cancer or radiotherapy

Oncoplastic surgery may not be beneficial for women with the following:

- Recurrent breast cancer
- A multifocal tumor
- A large tumor in a small breast
- Locally advanced breast cancer
- A tumor measuring more than 5 cm
- Unsuccessful BCT or previous breast irradiation

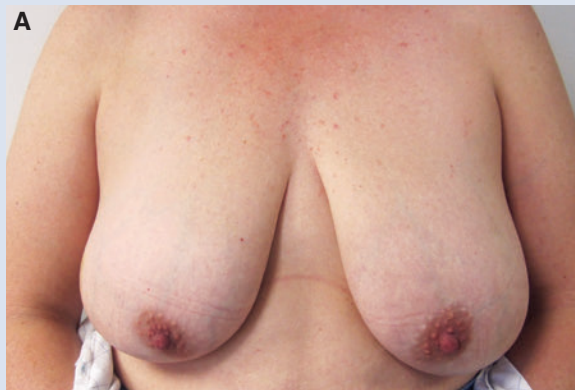The preoperative evaluation of the patient who is considering oncoplastic surgery is important. Attention should be directed toward the body habitus, breast size, degree of breast asymmetry, and breast contour. When considering a patient as a candidate for oncoplastic surgery, it is important to thoroughly evaluate the breast in terms of the tumor location, tumor size, and breast volume. Tumors that are localized or segmentally extended are usually amenable to oncoplastic resection; however, tumors that are irregularly extended are usually less amenable to oncoplastic resection.²⁰ In the analysis of these variables, several parameters related to breast volume should be assessed. These include the volume of breast to be removed, the volume of breast remaining, and the ratio of the two volumes. In women with large breasts, the tumor location is usually not a significant factor because of the various techniques that can be used to reconstruct a breast to achieve normal proportions and contour.

RECONSTRUCTION OF A PARTIAL MASTECTOMY DEFECT: GENERAL PRINCIPLES

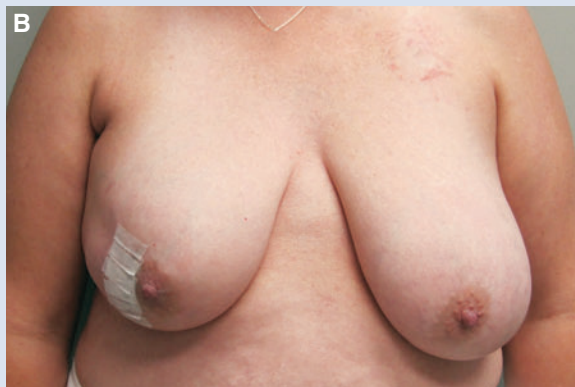The principles guiding the reconstructive options following oncoplastic surgery stem from proper patient selection. Various techniques have been described to correct the deformity after oncoplastic surgery. In general, the type of reconstruction selected depends on certain characteristics of the breast, including the estimated breast volume, the amount resected, and the amount remaining. These assessments allow surgeons to determine whether an oncoplastic approach will be beneficial and, if so, the optimal technique. These techniques are based on the principles of volume displacement and volume replacement. Volume displacement techniques include methods of tissue rearrangement, which can be as simple as parenchymal resection followed by undermining and closure, or they can be more complex procedures, such as reduction mammoplasty. These techniques are usually applied in women with moderate- to large-volume breasts in which the residual volume is sufficient to reconstruct a naturally contoured breast. Volume replacement techniques are usually considered when there is insufficient residual tissue for rearrangement; thus remote tissues are used to replace what was removed. This is more commonly used in women with a small preoperative breast volume and in women with a very large partial mastectomy. Novel techniques of oncoplastic surgery include incorporating volume displacement and replacement techniques simultaneously.^{21,22} In some women with smaller or ptotic breasts, a partial mastectomy defect may be corrected using adjacent parenchymal tissue rearrangement in conjunction with the placement of a small subpectoral tissue expander or implant. This technique has demonstrated success in properly selected patients.

Contralateral procedures are sometimes necessary to obtain symmetry.²³ As with all breast operations, breast surgeons must be aware of breast shaping at all times to ensure a natural contour and position. After parenchymal excision of any sort, it is important to consider reapproximation and closure of the defect to preserve shape.

PATIENT EXAMPLE

**Fig. 11-1, A**

This patient was diagnosed with a stage II right breast cancer (A). Sternal notch-to-nipple distance was 32 cm on the right and 34 cm on the left. The plan was to perform a partial mastectomy of the right lower quadrant and to delay the reduction mammoplasty until clear margins were confirmed.

**Fig. 11-1, B**

The patient underwent a lumpectomy of the right breast; the margins were clear. Two weeks after this partial mastectomy (B), she was scheduled for a staged-immediate oncoplastic reduction mammoplasty. The weight of the lumpectomy specimen was 125 g. The approach for the reduction mammoplasty was designed to be through an inverted-T technique.

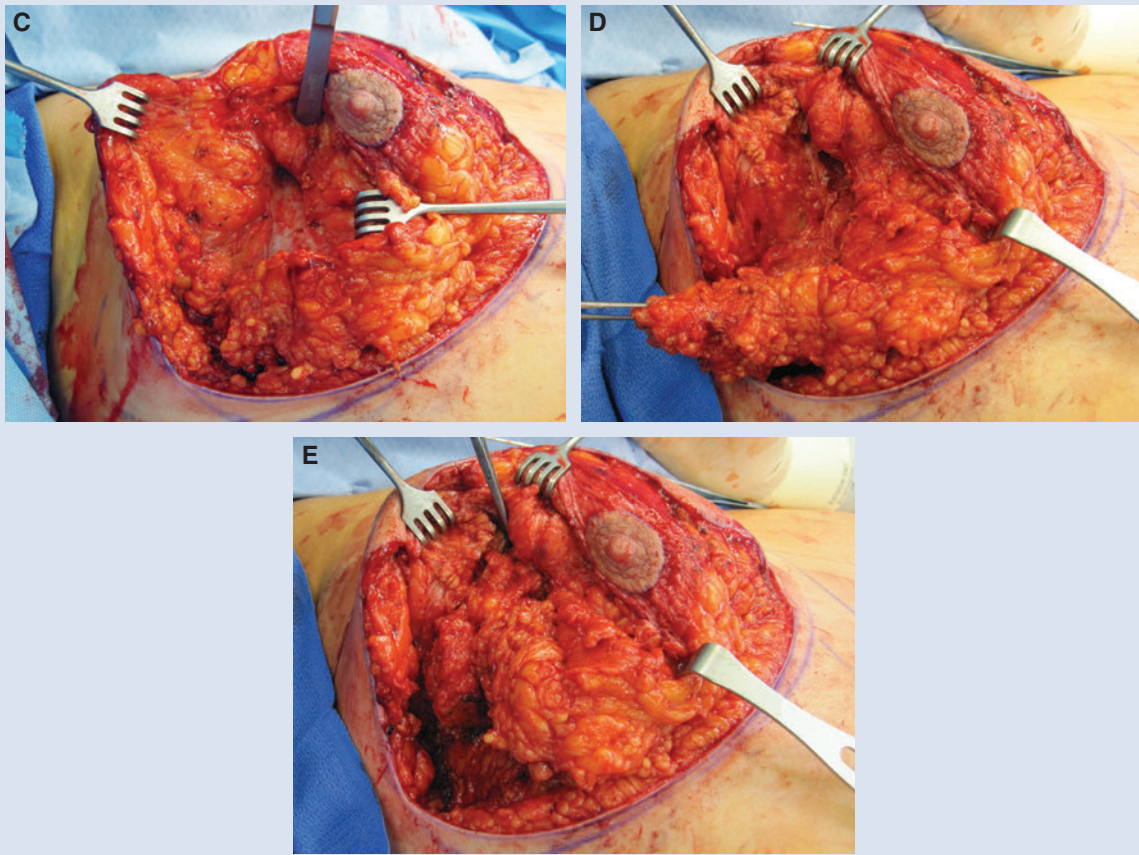


Fig. 11-1, C-E

The lumpectomy cavity was visualized and an additional layer of parenchyma was excised (C). An inferiorly based pedicle of parenchyma was created to be transposed into the defect (D), constituting a volume displacement procedure. The inferior pedicle of tissue was transposed into the breast defect to correct any contour abnormality (E). An additional 225 g of tissue was excised.

Continued

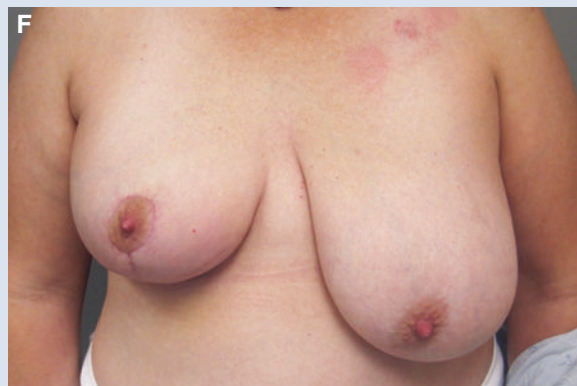

Fig. 11-1, F

This early postoperative photograph demonstrates a successful unilateral oncoplastic reduction (*F*). The patient recovered well and completion of radiotherapy was scheduled.

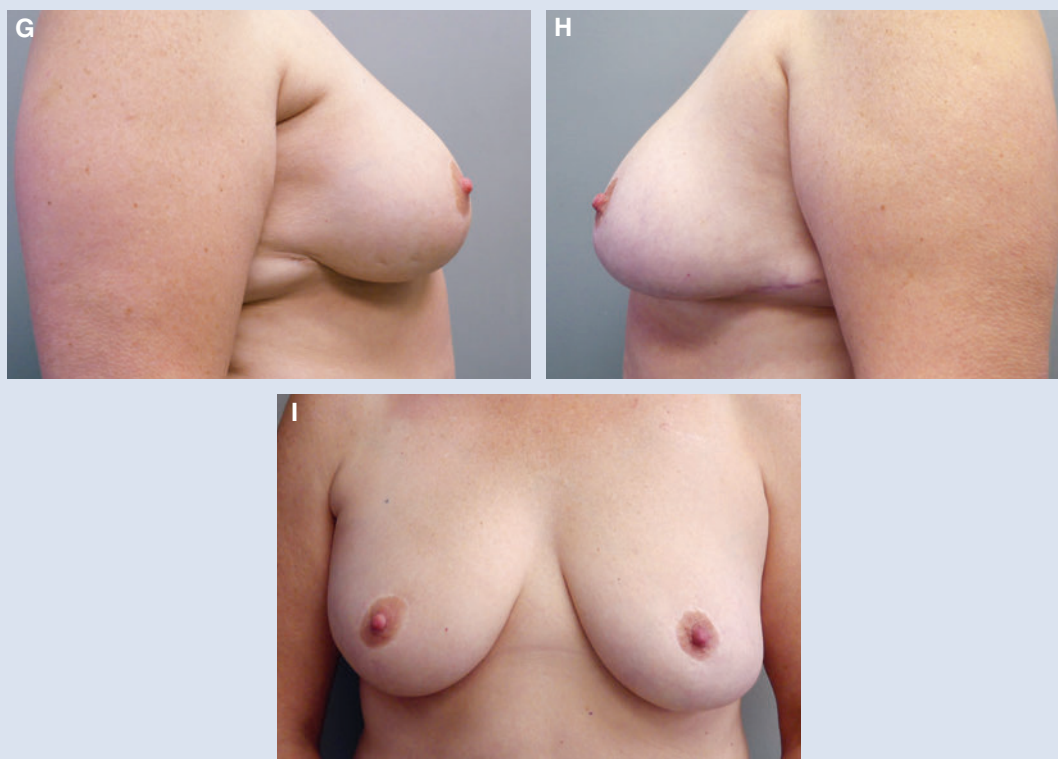


Fig. 11-1, G-I

A contralateral reduction mammoplasty was performed; the patient is seen 4 years postoperatively (*G* through *I*). The total amount of tissue excised from the right breast was 350 g. She has excellent volume, and both the irradiated right breast and the contralateral breast show excellent projection. The frontal view confirms her postoperative contour symmetry.

CONCLUSION

Oncoplastic surgery is becoming increasingly accepted as a safe and effective alternative. For successful outcomes, surgeons must demonstrate good judgment, exercise proper patient selection, adhere to oncologic principles, and follow the reconstructive ladder. The collaboration between ablative and reconstructive surgeons provides a solid foundation for patient safety. Although significant advancements in the management of breast cancer have been made, we must be careful not to cut corners and place patients at an increased risk of local recurrence and demise for the sake of maintaining breast aesthetics.

Critical Issues

- Oncoplastic techniques are indicated in patients who prefer breast conservation and who have the potential for poor aesthetic results.
- Additional indications include the need for wide resection; a high tumor/breast ratio; large and ptotic breasts; and central, inferior, or medial defects.
- Ablative and reconstructive surgeons must collaborate to optimize the patient's safety.
- Partial mastectomy defects may be reconstructed using volume replacement (flap) techniques and volume displacement (reduction) techniques.
- Benefits of oncoplastic surgery include the following:
 - The indications for BCT are broadened.
 - Tumor margins are wider.
 - The potential for poor cosmetic outcomes is minimized.
 - Contralateral tissues may be sampled during reduction techniques.
 - Reduction techniques may decrease the risk of recurrence by removing additional breast tissue.
 - Survival and recurrence rates are equivalent to those for total mastectomy.
 - The breast shape and size are preserved using flap techniques.

References

1. Losken A, Hamdi M. Partial breast reconstruction: current perspectives. *Plast Reconstr Surg* 124:722, 2009.
2. Munhoz AM, Montag E, Gemperli R. Oncoplastic breast surgery: indications, techniques and perspectives. *Gland Surg* 2:143, 2013.
3. Veiga DF, Veiga-Filho J, Ribeiro LM, et al. Quality-of-life and self-esteem outcomes after oncoplastic breast-conserving surgery. *Plast Reconstr Surg* 125:811, 2010.
4. Patel KM, Hannan C, Gatti M, et al. A head to head comparison of quality of life and aesthetic outcomes following immediate, staged-immediate, and delayed oncoplastic reduction mammoplasty. *Plast Reconstr Surg* 127:2167, 2011.

5. Rezai M, Knispel S, Kellersmann S, et al. Systematization of oncoplastic surgery: selection of surgical techniques and patient-reported outcome in a cohort of 1,035 patients. *Ann Surg Oncol* 22:3730, 2015.
6. Santos G, Urban C, Edelweiss MI, et al. Long-term comparison of aesthetical outcomes after oncoplastic surgery and lumpectomy in breast cancer patients. *Ann Surg Oncol* 22:2500, 2015.
7. Clough KB, Cuminet J, Fitoussi A, et al. Cosmetic sequelae after conservative treatment for breast cancer: classification and results of surgical correction. *Ann Plast Surg* 41:471, 1998.
8. Kaur N, Petit JY, Rietjens M, et al. Comparative study of surgical margins in oncoplastic surgery and quadrantectomy in breast cancer. *Ann Surg Oncol* 12:539, 2005.
9. Boice JD Jr, Persson I, Brinton LA, et al. Breast cancer following breast reduction surgery in Sweden. *Plast Reconstr Surg* 106:755, 2000.
10. Asgeirsson KS, Rasheed T, McCulley SJ, et al. Oncological and cosmetic outcomes of oncoplastic breast conserving surgery. *Eur J Surg Oncol* 31:817, 2005.
11. Munhoz AM, Montag E, Arruda EG, et al. Critical analysis of reduction mammoplasty techniques in combination with breast conservation surgery for early breast cancer treatment. *Plast Reconstr Surg* 117:1091, 2006.
12. Langstein HN, Cheng MH, Singletary SE, et al. Breast cancer recurrence after immediate reconstruction: patterns and significance. *Plast Reconstr Surg* 111:712, 2003.
13. Clough KB, Lewis JB, Couturaud B, et al. Oncoplastic techniques allow extensive resections for breast-conserving therapy of breast carcinomas. *Ann Surg* 237:26, 2003.
14. Gendy RK, Able JA, Rainsbury RM. Impact of skin-sparing mastectomy with immediate reconstruction and breast-sparing reconstruction with miniflaps on the outcomes of oncoplastic breast surgery. *Br J Surg* 90:433, 2003.
15. Jabor MA, Shayani P, Collins DR, et al. Nipple areola reconstruction: satisfaction and clinical determinants. *Plast Reconstr Surg* 110:457, 2002.
16. Kat CC, Darcy CM, O'Donoghue JM, et al. The use of the latissimus dorsi flap for the immediate correction of the deformity resulting from breast conserving therapy. *Br J Plast Surg* 52:99, 1999.
17. Losken A, Elwood ET, Styblo TM, et al. The role of reduction mammoplasty in correcting partial mastectomy defects. *Plast Reconstr Surg* 109:968, 2002.
18. Spear SL, Pelletiere CV, Wolfe AJ, et al. Experience with reduction mammoplasty combined with breast conservation therapy in the management of breast cancer. *Plast Reconstr Surg* 111:1102, 2003.
19. Losken A, Schaefer TG, Carlson GW, et al. Immediate endoscopic latissimus dorsi flap. *Ann Plast Surg* 53:1, 2004.
20. Anderson BO, Masetti R, Silverstein ML. Oncoplastic approaches to the partial mastectomy: an overview of volume displacement techniques. *Lancet Oncol* 6:145, 2005.
21. Nahabedian MY, Patel KM, Kaminsky AJ, et al. Biplanar oncoplastic surgery: a novel approach to breast conservation for small and medium sized breasts. *Plast Reconstr Surg* 132:1081, 2013.
22. Kaminsky AJ, Patel KM, Cocilovo C, et al. The biplanar oncoplastic technique case series: a 2-year review. *Gland Surg* 4:257, 2015.
23. Kaviani A, Safavi A. Immediate and delayed contralateral symmetrization in oncoplastic breast reduction: patients' choices and technique formulation. *Plast Reconstr Surg Glob Open* 3:e286, 2015.

12

Designing the Oncoplastic Operation

*Gianluca Franceschini, Marzia Salgarello,
Giuseppe Visconti, Liliana Barone Adesi,
Riccardo Masetti*



Careful patient selection and preoperative planning are key components to the success of any oncoplastic operation for breast cancer. An accurate preoperative evaluation of the clinical and biologic features of the tumor and the morphologic aspects of the breast allows the surgeon to determine whether a radical or conservative approach is preferable and to select the most effective surgical technique. The available options are discussed with the patient, highlighting the advantages, disadvantages, and technical challenges of each procedure.

Breast-conserving surgery (BCS) is our treatment of choice and is used in all patients who have a favorable tumor diameter/breast size ratio and when optimal local control can be achieved without compromising the cosmetic result.¹⁻³

Oncoplastic skills may be incorporated in the surgical planning in less favorable cases, when traditional breast-conserving techniques may expose them to a higher risk of local deformity. Total mastectomy is considered mandatory only for multicentric disease, T4 and inflammatory tumors, extensive malignant mammographic microcalcifications, or when clear surgical margins cannot be achieved without generating a significant risk of local deformity, even with the use of oncoplastic techniques.^{4,5} Oncoplastic skills are incorporated in the surgical planning for breast-conserving surgery and a total mastectomy.^{2,3,6}

PREOPERATIVE PLANNING FOR BREAST-CONSERVING ONCOPLASTIC PROCEDURES

When a breast-conserving approach is feasible, the selection of the most appropriate technique is guided mainly by the location of the tumor, the volume and shape of the breast, the size of the lesion, and the morphologic changes that the surgery is likely to cause. For cancers that are small (relative to the breast size) and do not require extensive parenchymal excisions, traditional techniques of BCS can be applied with excellent cosmetic results.

If more than 20% of the parenchymal volume is to be resected to achieve adequate local control, particularly for cancers located in the central, medial, or lower pole of the breast, using oncoplastic techniques helps to avoid the risk of an unpleasant cosmetic outcome.⁷⁻¹¹

The planning for oncoplastic BCS includes the following:

- Placing accurate preoperative skin markings according to the technique selected for parenchymal excision
- Evaluating the risk that the parenchymal excision may displace the NAC and adapting the skin drawings to ensure that it may be repositioned to the center of the breast mound, if significantly displaced
- Evaluating the most appropriate volume displacement or volume replacement technique to be used to reshape the defect after resection
- Evaluating the need for symmetrization of the contralateral breast and selecting the most appropriate technique

Planning for oncoplastic BCS includes selecting the most effective technique for parenchymal excision and placing accurate preoperative markings on the skin. The breast size and the patient's age, general health status, and personal wishes are also taken into account.

PLANNING THE ONCOPLASTIC APPROACH BY TUMOR LOCATION: VOLUME DISPLACEMENT TECHNIQUES

Table 12-1 Designing the Oncoplastic Procedure

Tumor Location	Choice of Procedure
Periareolar	Donut mastopexy (minimal ptosis) Batwing mastopexy (upper periareolar tumor, close to skin, no ptosis) Reduction mammoplasty (large or ptotic breasts)
Central	Mastopexy with Grisotti technique (minimal ptosis) Resection with purse-string (no to minimal ptosis) Reduction mammoplasty pattern (large and ptotic breasts)
Lower	Reduction mammoplasty techniques (vertical, L-scar techniques and inverted-T pattern) based on ptosis and breast size
Upper quadrant or any other resection including skin out of the inferior pole	Local flaps Pedicle flaps

Periareolar Lesions

Oncoplastic volume displacement techniques provide excellent outcomes in the treatment of periareolar lesions. For breasts with minimal or moderate ptosis, we prefer a donut mastopexy or a batwing mastopexy, and for breasts with severe ptosis or redundant skin we favor a reduction mammoplasty pattern.

PATIENT EXAMPLE

DONUT MASTOPEXY

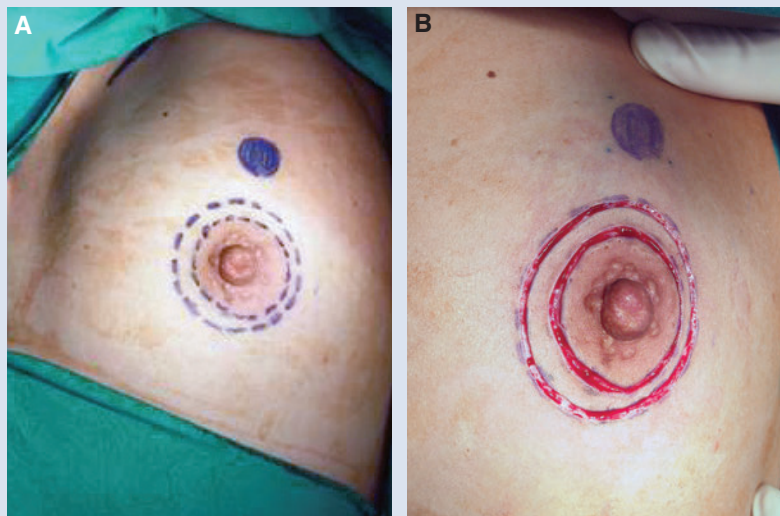


Fig. 12-1, A and B

The donut mastopexy approach provides comfortable access to any lesion in the periareolar region compared with traditional breast-conserving techniques. Two concentric circles with different diameters are designed around the nipple (A). The areolar skin is stretched only mildly when the inner circle is designed to avoid the potential for the final areolar diameter being too small. The diameter of the inner circle is usually from 4 to 4.5 cm, depending on the size of the breast. The diameter of the outer circle should not exceed the diameter of the original areola by more than 20 to 25 mm to prevent widening the circumareolar scar or excessive flattening of the breast.

The initial step is the incision of the inner circle, which will represent the new border of the areola (B).

Continued

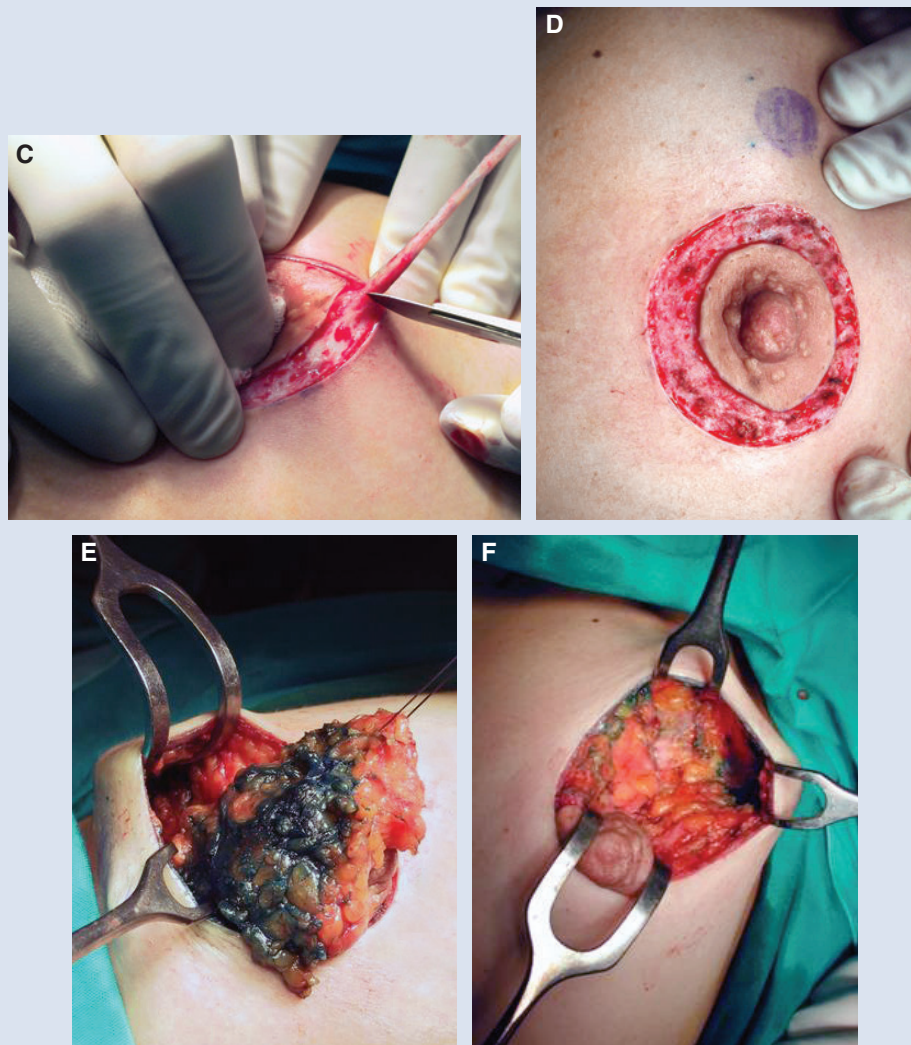


Fig. 12-1, C-F

The outer circle is incised, whereas the donut of skin between the two circles is excised. Through this incision, any periareolar lesion can be easily accessed (*C* and *D*). Quadrant resection of the breast parenchyma can be performed through a wider incision that extends to the pectoralis fascia, allowing better control of the tumor removal than when the resection is performed through conventional conservative skin incisions (*E* and *F*).

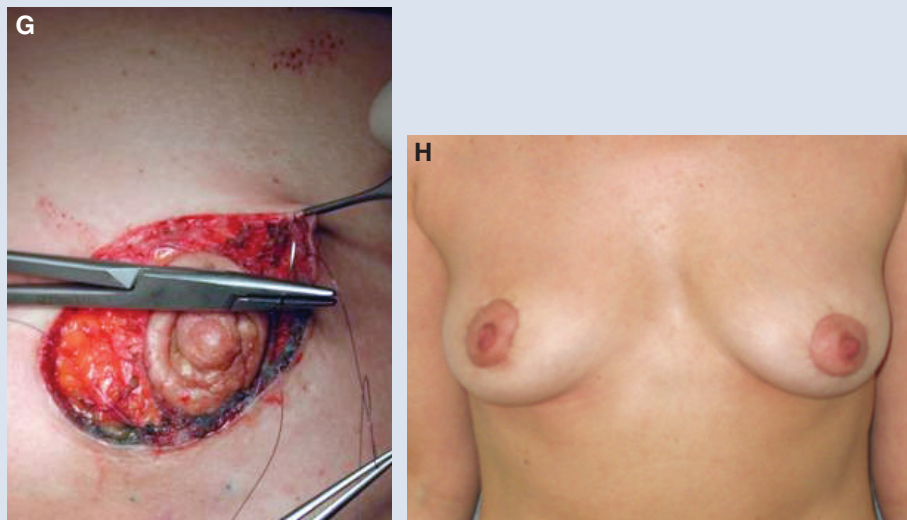


Fig. 12-1, G and H

The breast can be reshaped appropriately by displacing the residual gland. To do this, we normally separate the residual gland off of the pectoralis fascia using electrocautery, paying attention to limit the number of major perforating vessels that are sectioned to avoid interference with the blood supply to the residual glandular tissue. After hemostasis is achieved, the residual breast parenchyma is reapproximated to facilitate a natural-appearing breast. Sutures are placed in the deep portion of the residual gland, just above the fascia, to secure the posterior edges in their new position. We normally use 2-0 Vicryl sutures for this purpose and 4-0 absorbable sutures in the dermis to reapproximate the superficial portion of the breast. If needed, a purse-string suture is used to reduce the diameter of the larger circle and is then sutured to the new border of the areola, leaving only a periareolar scar at the end of the procedure (G). The patient is shown 6 months after surgery. Only a periareolar scar is visible (H).

Axillary dissection is usually performed through a separate incision, but occasionally through the same periareolar incision. If the two circles are concentric, the NAC is not elevated; if the outer circle is centered around a point located higher than the existing nipple, the nipple-areola complex can be elevated slightly as a consequence of the procedure. After the skin is closed, the thorax is wrapped in an elastic bandage to reduce the risk of hematoma formation.

PATIENT EXAMPLE

BATWING MASTOPEXY

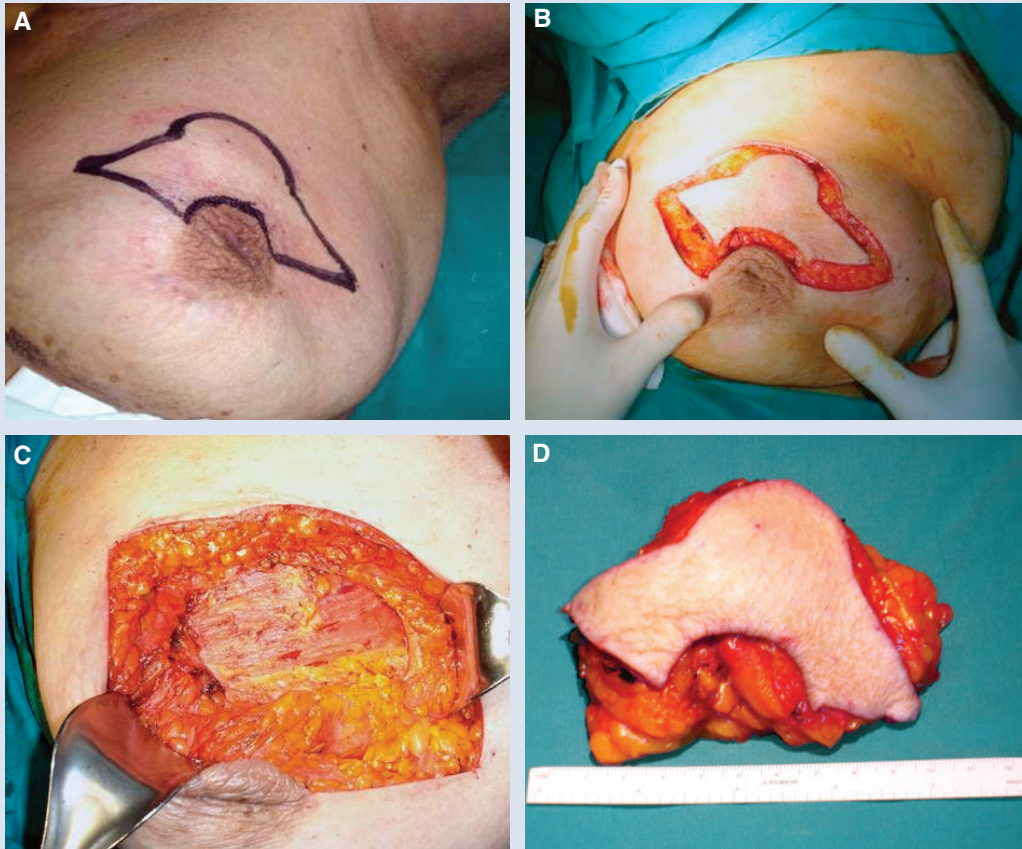


Fig. 12-2, A-D

The batwing mastopexy approach is ideal for cancers located in the upper periareolar region, particularly when the lesions are in close proximity to the skin. Two semicircles are designed, one on the border of the areola and one 20 to 25 mm above it, connected with angled wings on each side of the areola (A). The skin incisions should be designed with the patient sitting upright. The areolar semicircle is incised first, followed by the upper semicircle and the wings (B). A full-thickness lumpectomy is performed (C and D), and the residual gland is lifted off of the pectoralis fascia, allowing adequate tissue advancement and defect remodeling. Breast defect remodeling requires skills similar to those needed for the donut mastopexy.

The procedure allows ample removal of the skin overlying the lesion and therefore can increase the safety of the oncologic control of cancers located superficially. Some uplifting of the NAC may result at the end of the procedure, but normally this does not cause significant asymmetry.

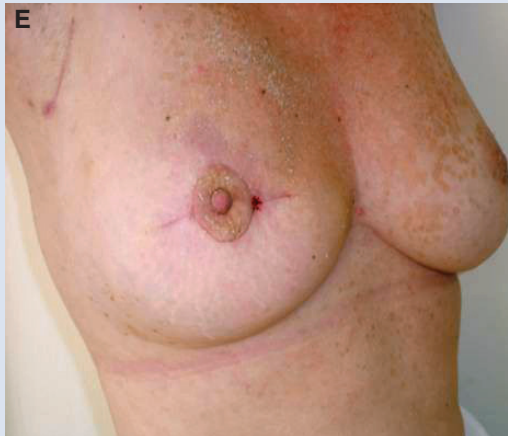

Fig. 12-2, E

The patient is shown 4 months after surgery (*E*).

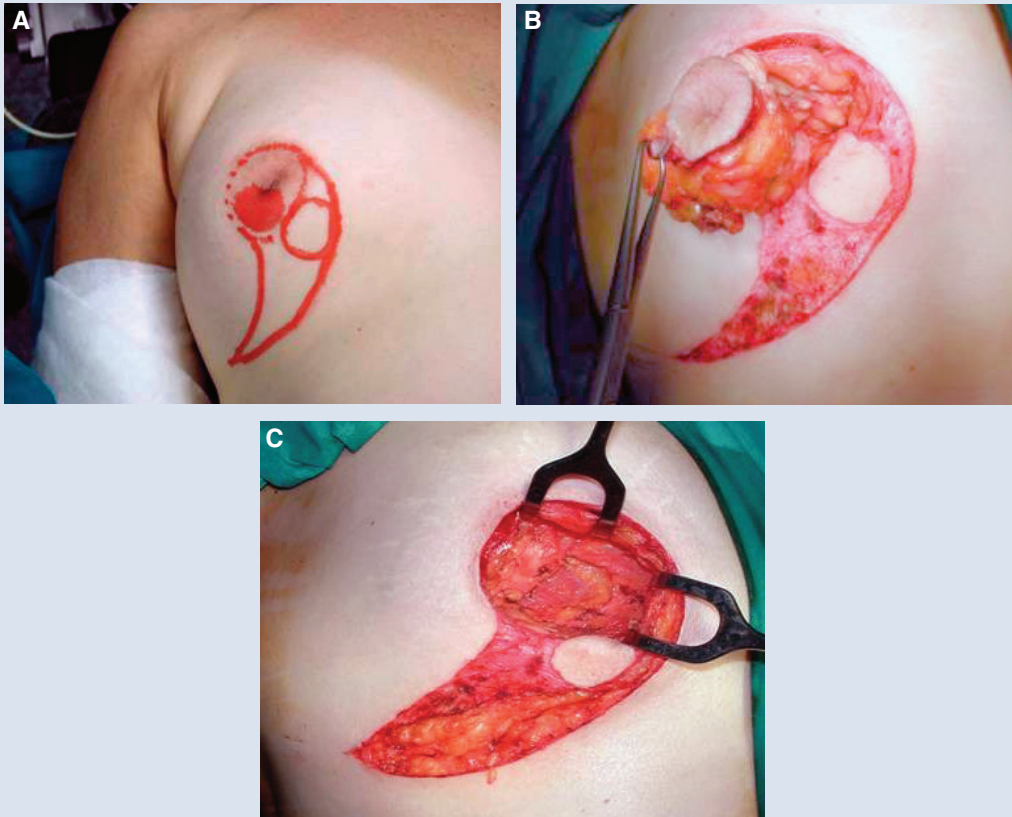
Reduction Mammoplasty

For patients with severe ptosis, reduction mammoplasty patterns may offer better results.

The resection of the tumor with wide macroscopically clear margins can be achieved easily in combination either with an inferior or superior pedicled flap to recreate a normally shaped breast and to shift the NAC to an appropriate position.

Central Retroareolar Lesions

For centrally located tumors involving the retroareolar region or for Paget disease, several breast-conserving oncoplastic procedures have been used in recent years as an alternative to a total mastectomy. All of these techniques include a complete excision of the tumor with the entire NAC and the corresponding underlying cylinder of parenchyma down to the pectoralis fascia. The central defect is restored with a simple purse-string suture, linear sutures, or skin-parenchyma flaps. We usually use the Grisotti technique,¹² because it is simple and offers excellent cosmetic results.

PATIENT EXAMPLE**GRISOTTI TECHNIQUE****Fig. 12-3, A-C**

With patient in the sitting position, a circle is drawn along the borders of the areola. Another circle is drawn below the areola, and lines from the medial and lateral sides of the upper circle are connected laterally on the inframammary fold (A). Incisions are made along the drawings, and the skin below the areola is excised, with the exception of the skin included in the lower circle. The NAC, with the underlying tumor, is completely excised down to the pectoralis fascia (B and C). The skin-gland flap, mobilized from the inferior lateral pole of the residual gland, is used to create the new areola. The flap is incised medially down to the pectoralis fascia and separated from the latter to allow adequate rotation and advancement. It is sutured to the gland stump superiorly to give adequate projection to the tip of the breast mound, and the circular area of preserved skin is sutured to replace the excised areola. Care should be taken to avoid excessive devascularization of the skin-gland flap to minimize the risk of ischemic injury to the neoareola. At the end of the procedure, the breast may be slightly smaller than the contralateral breast, but with preserved shape.

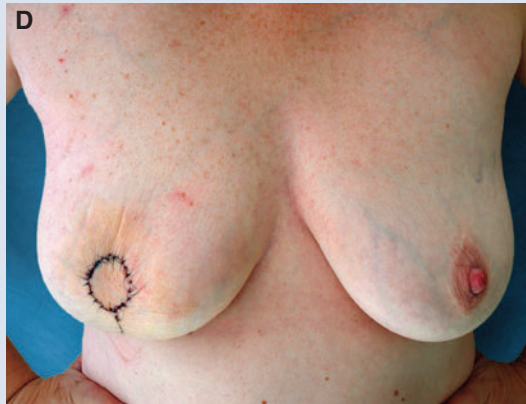

Fig. 12-3, D

The patient is shown 2 weeks after surgery (D). The nipple reconstruction can be performed immediately, if the patient prefers, or at a later stage, with tattooing of the areola. Contralateral breast remodeling is required if major asymmetry occurs.

Lesions Located in the Lower Quadrants

Cancers located in the lower region of the breast result in a higher risk of cosmetic failure if standard lumpectomy techniques are used.

Downturning of the NAC and/or introflexion of the lower pole is often seen with lesions of the lower quadrants. For these lesions, we tend to prefer a reduction mammoplasty pattern that may allow large amounts of breast tissue to be resected with excellent cosmetic outcomes and wide surgical margins, even in small breasts.

PATIENT EXAMPLES

REDUCTION MAMMAPLASTY

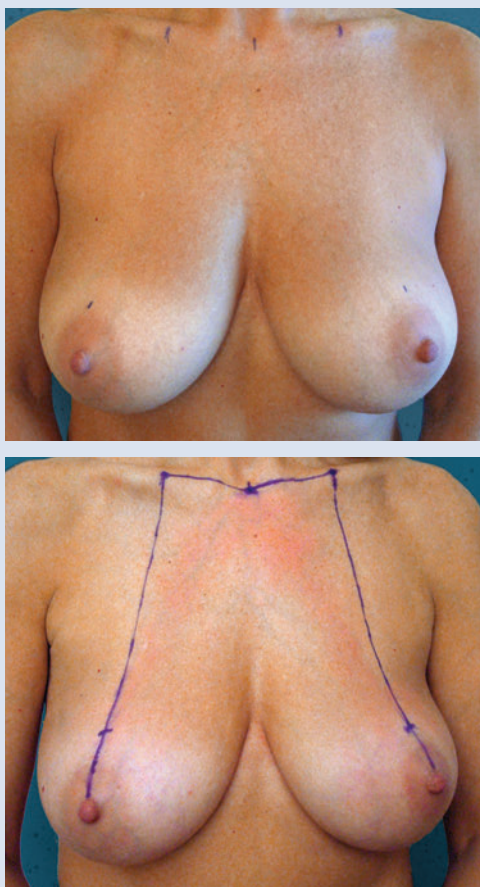


Fig. 12-4

A vertical pattern, an L-shaped pattern, or a keyhole pattern incision may be used. The reduction pattern choice is made based on the ptosis features and the amount of breast parenchyma to be resected. For symmetry, the same reduction pattern is performed contralaterally. For a vertical and an L-shaped pattern, we design the skin markings with the patient in a semisitting position. The midline is marked with methylene blue dye as well as the inframammary fold bilaterally. A line is then marked bilaterally, from the midclavicle of each side to the inframammary fold, dividing the breast in two halves. This line, also called the *hemimammary line*, usually but not always crosses the nipple (that is, when the nipple is medially or laterally located on the breast mound).

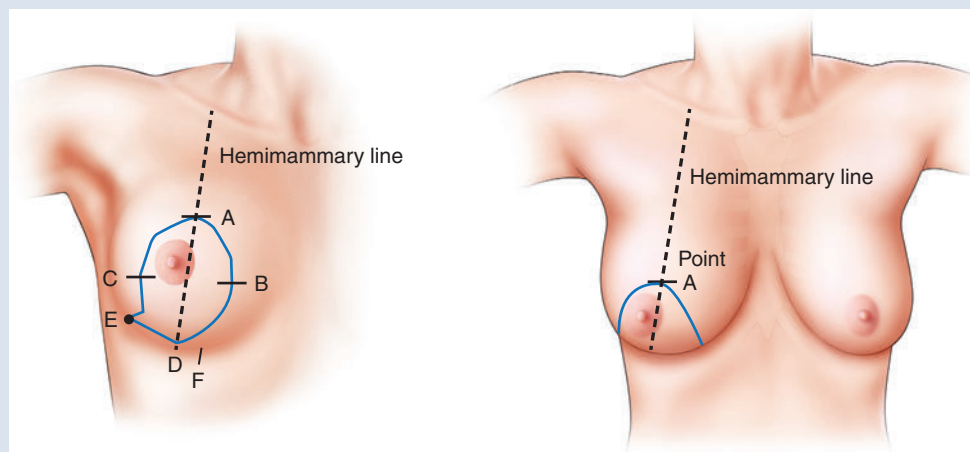


Fig. 12-5

At the level of the inframammary fold, the hemimammary line intersection defines point *F*. The symmetry of this line is checked by measuring the distance between the midline and point *F* on both breasts. By means of the Pitanguy maneuver, point *A* (the approximate new nipple position) is marked around 1 cm over the anterior projection of the IMF along the hemimammary line. By using a compass, a symmetrical *A* point is marked on the contralateral breast and called *A'*.

By pushing the breast laterally (the Biesemberger maneuver), point *B* is marked medially on the inferior breast pole aligned with the hemimammary line, point *A*, and point *F*. Point *B* determines the medial line of incision (line *AB*), which is drawn. By pushing the breast medially, point *C* is marked, aligned with the hemimammary line, points *A* and *F*. Point *C* determines the lateral line of incision (line *AC*), which is drawn. Then, keeping point *A* projected forward in a high position, the surgeon pinches the skin at points *B* and *C*, approximating them. The two segments *AB* and *AC* must coincide with the hemimammary line.

Approximately 1 cm over point *F*, point *D* is marked as well; this defines the lowermost limit of the J-scar skin pattern.

Line *AB* is then connected to point *D* as a straight line, then curves inferolaterally with an upward concavity approximately 3 cm above the IMF and 3 to 5 cm from the anterior axillary line in the inferolateral breast quadrant. The endpoint of this line is called point *E*.

The markings are completed by connecting point *C* downward and gently curving laterally with an upward concavity to reach point *E*.

While the assistant holds the breast from point *A* in an upward and forward position, the markings are double-checked by the surgeon by pinching the skin and bringing together lines *AB* and *AC*, as well as lines *BDE* and *CE*. The area *ABCDE* represents the resection skin pattern.

Continued

As on a compass, points B' , D' , and E' are symmetrically marked on the contralateral breast. Point C' is marked by using the Biesemberger maneuver on the contralateral breast to check whether the lateral margin of skin pattern resection is wider or smaller than the contralateral side. This marking method is not based on fixed measurements but on breast proportions. If breast asymmetry is present, the skin areas encircled by the markings will be different, wider on the bigger breast.

To ensure precise and fast skin closure, the lines BDE and CE , as well as $B'D'E'$ and $C'E'$ are divided into three parts of the same length and these points tattooed with methylene blue ink. At the end of the procedure, each of the longer segments of line BDE will be sutured to each of the shorter segment of line CE . By suturing these three key points, skin gathering is minimized.

The vertical or J-scar patterns is a very versatile pattern in the setting of breast ptosis. It is not only indicated for resection of a tumor located in the central lower quadrant for which a straightforward resection like the breast reduction technique is indicated.

A tumor located in the medial or lateral lower quadrant, as well as a tumor located in the upper quadrants can benefit from this pattern. In case of a tumor in the lower quadrant the resection is performed through the inferior quadrant incision and for a tumor in the upper quadrant the resection is performed through the periareolar incision. After resection, the lower quadrant pattern vertical or J-scar pattern designed is deepithelialized and an inferior based adipoglandular flap is raised and displaced at the level of the resection to improve the shape. The flap is usually suspended with one or two stitches of 0 Vicryl to the pectoralis major muscle and approximated with 2-0 Vicryl to the surrounding breast parenchyma.

PATIENT EXAMPLES

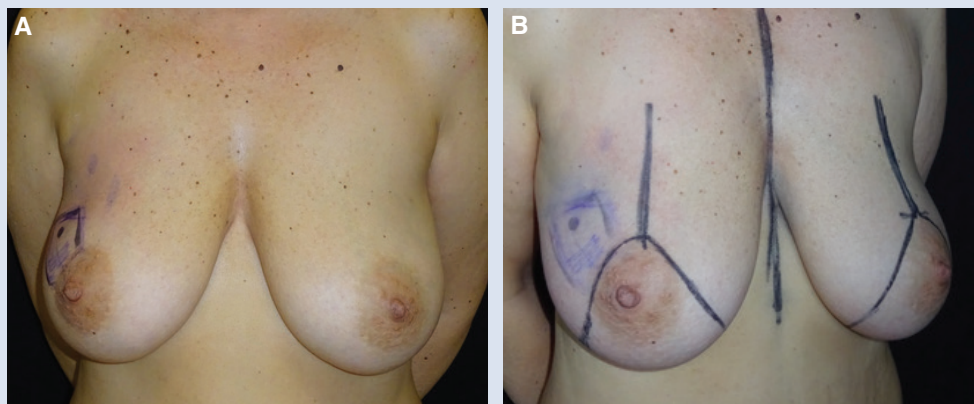


Fig. 12-6, A and B

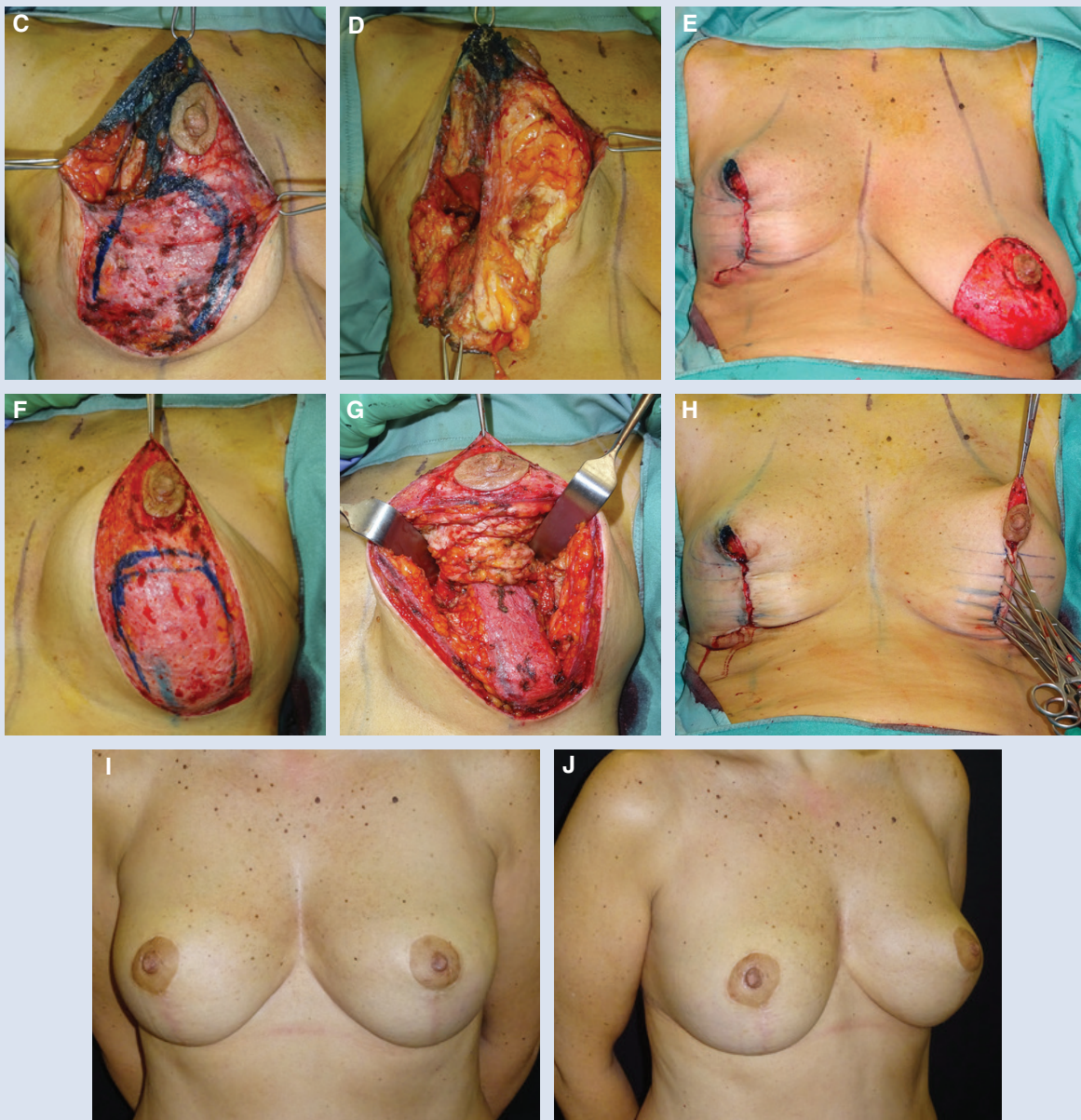

Fig. 12-6, C-J

This 45-year-old woman presented for right breast quadrantectomy in the upper lateral quadrant using J-scar oncoplastic technique with NAC superior pedicle and contralateral symmetrization (A and B). Intraoperative sequence of the oncoplastic procedure, after tumor resection (C), inferior pole flap dissected to fill the upper defect (D) and temporarily based (E). Contralateral symmetrization with inferior pole dermoglandular flap for auto-augmentation (F through H). The patient is shown 9 months after surgery (I and J).

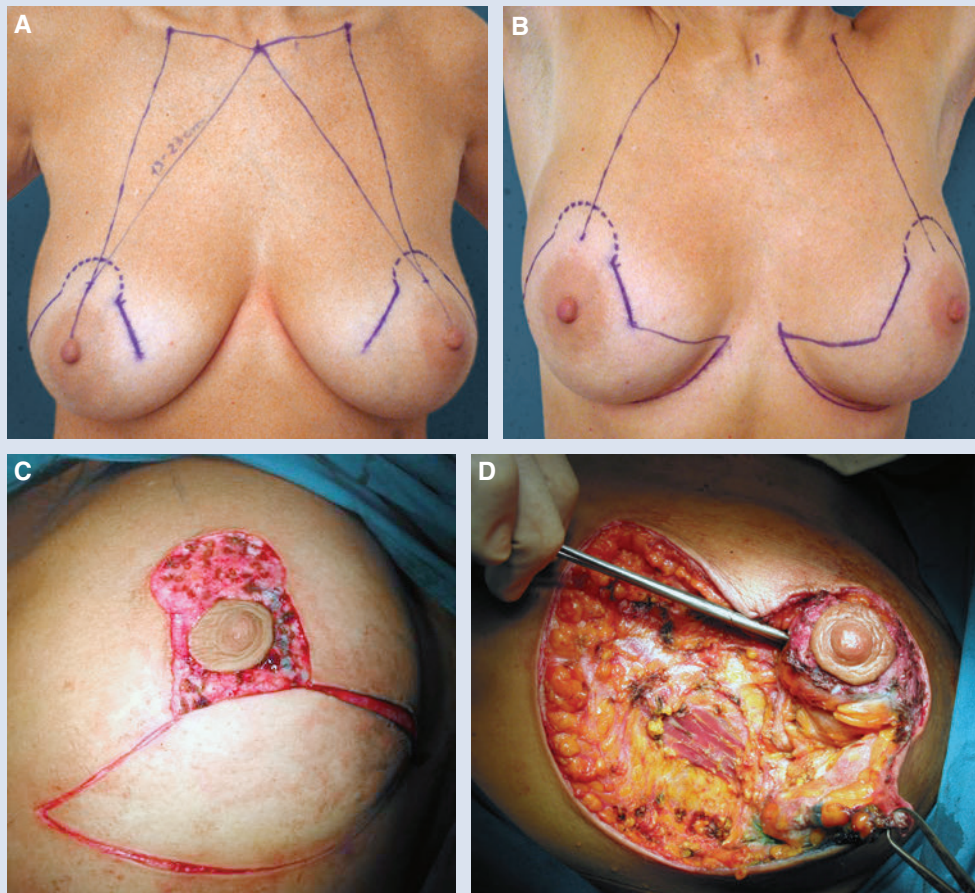


Fig. 12-7, A-D

As for the keyhole pattern, the skin marking are as follows. A mark is made in the center of the sternal notch; each clavicle is marked 6 cm laterally from this sternal mark (A). A straight line is drawn from each clavicular mark to the nipple of the breast below (B).

The center of the proposed nipple location is sited on this line, from 19 to 23 cm from the sternal notch mark, depending on the size of the patient (A). A semicircle with a 5 cm diameter is drawn, centered on the new nipple location. Radial lines 6 cm long are designed from the lower half of the circle and connected in straight lines to markings previously made on the inframammary creases (B). Medially, these lines should connect about 1 cm from the midline and should never reach the medial drawings of the contralateral breast. The lateral end of the inframammary crease is not marked on its natural ending (because it extends

too far laterally and too low), but rather is crossed superiorly on the midaxillary line to terminate 2 to 3 cm superior to the crease. This end is connected with a straight line to the inferior end of the lateral wing. The skin markings are progressively incised, and the lesion is completely excised with the overlying skin (C). The parenchymal excision is extended down to the fascia of the pectoralis major muscle, and a superior pedicle flap is created to mobilize the NAC (D).

For cancers located in the inferolateral or inferomedial quadrants, the parenchymal excision can be oriented to include more lateral or medial portions of the breast. This requires more extended undermining of either the medial or lateral flap. After completing the parenchymal excision, the medial and lateral flaps are sutured together to restore the normal shape of the breast mound, leaving a vertical, L-shaped, or typical inverted-T scar.

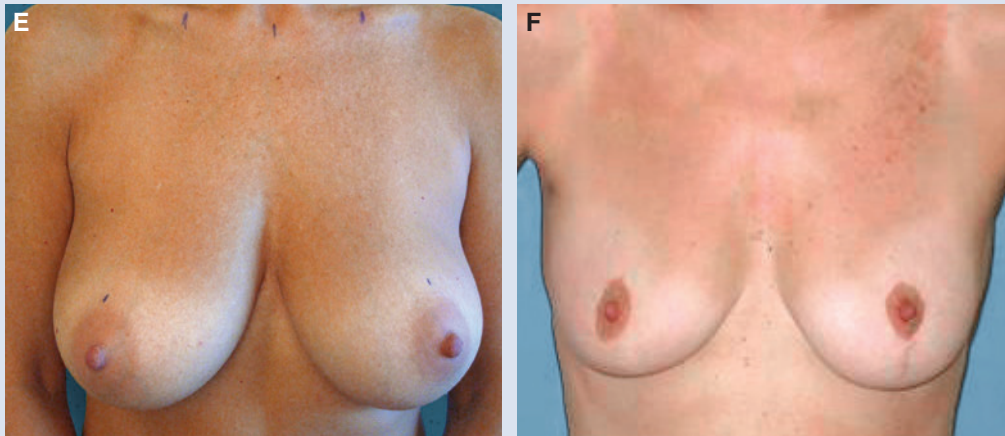


Fig. 12-7, E and F

The patient is shown preoperatively (E) and 6 months after surgery (F). The reduction mammoplasty approach is particularly convenient in women with very large and pendulous breasts, because it improves the cosmetic appearance of the breast and can facilitate the delivery of postoperative radiotherapy.¹³ Because of the size of the breast, consistent positioning for radiotherapy treatment may be quite difficult in these patients, resulting in dosing inhomogeneity, a higher percentage of unacceptable late radiation reactions, and overall inadequate local treatment. By reducing the size of the breast with a reduction mammoplasty approach, these risks may be avoided, without any significant interference with the clinical or radiologic follow-up.

Lesions Located in the Upper Quadrants

The excision of small tumors located in the upper outer quadrant often does not require any particular reconstruction, and adequate cosmetic results can be achieved simply by approximating the residual parenchyma in layers. When the tumor excision generates a larger defect, either in the upper outer or upper inner quadrants, some form of reconstruction is required. In the setting of a large and ptotic breast, a reduction pattern is useful as the tumor resection can be performed from the periareolar approach and the volume can be displaced by mobilizing up an inferior based adipoglandular flap from the lower quadrant.

Volume Replacement Techniques

When the breast is not large and ptotic and the resection is proportionally wider than the residual breast, volume displacement techniques have limited power to properly correct the defect. In this setting, volume replacement technique with the use of locoregional or distant flaps are often needed to properly reconstruct the defect.

As for the locoregional flap, many subtype of flaps can be constructed on the thoracodorsal artery pedicle (such as pedicled latissimus dorsi, muscle or myocutaneous flap), or pedicled adipocutaneous thoracodorsal artery perforator flap (TDAP).^{14,15}

As the volume is restored, symmetry is usually maintained and contralateral surgery is rarely required.

The cosmetic outcome is generally better when replacement techniques are used to restore a defect in the upper outer quadrant.

Procedures on the Contralateral Breast

Reshaping the contralateral breast may be included in the treatment planning to improve symmetry and the cosmetic outcome.^{5,16}

The option of a mastopexy or volume reduction of the contralateral breast should be discussed with the patient, particularly younger women and women with large and pendulous breasts.

If the oncoplastic procedure uses mammoplasty patterns, the same pattern should be used for the contralateral surgery.

PATIENT EXAMPLE

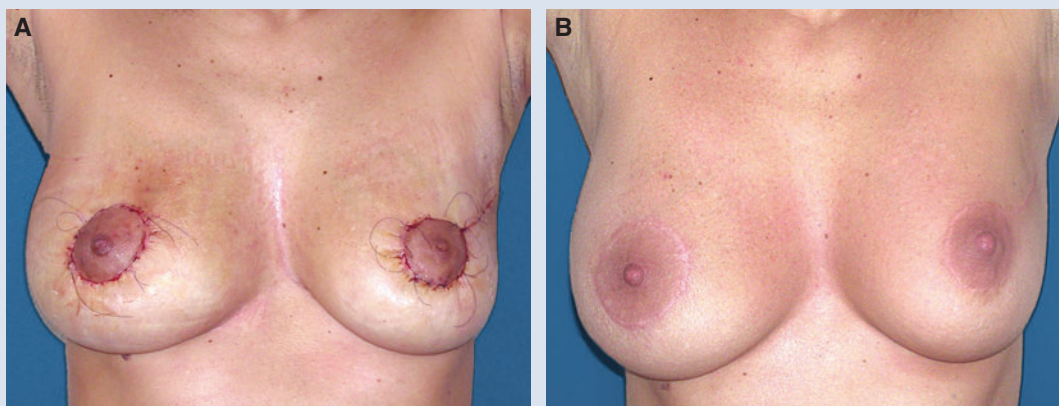


Fig. 12-8

If the difference between the two breasts is not excessive, we often use a periareolar mastopexy, because it is relatively simple and fast, and it allows the contralateral breast to be elevated a maximum of 2 cm. The decision to adopt this procedure can be made at the end of the oncologic procedure, while the patient is on the operating table. This patient is shown shortly after a periareolar mastopexy was performed on the right breast simultaneously with an oncoplastic upper external quadrantectomy of the left breast; it was completed to achieve symmetry (A). The final result is shown 6 months after surgery (B). The design for the concentric mastopexy can be made with the patient in the supine position. Reduction mammoplasty is more time consuming, but it allows more effective symmetrization, particularly when dealing with large, ptotic breasts that need major lifts. This procedure needs to be planned before surgery, because the markings have to be made with the patient in a standing or sitting position.

When performing symmetrization procedures, the surgeon should take the opportunity to remove any suspicious tissue in the contralateral breast that was seen on the preoperative mammogram. In many series, this has resulted in a 5% detection rate of contralateral subclinical cancers.⁴

In case of breast reduction on the affected breast, the contralateral breast can benefit from the same procedure with two plans: symmetrization and risk-reduction surgery and the adipoglandular tissue that is removed will be sent for histology evaluation in order to evaluate presence of any occult tumor in the contralateral breast.

CONCLUSION

Meticulous planning, patient selection, and surgical design are integral parts of the oncoplastic approach. Once the decision has been made that the patient requires partial reconstruction, the techniques are planned. Attention to the breast tumor location alone often determines the most appropriate reconstructive options, with the breast size and shape further narrowing the choice. Once the approach has been appropriately designed, resection and reconstruction are performed. Attention to the contralateral breast preserves symmetry in some cases.

Critical Issues

- Careful patient selection and preoperative planning are key components for the success of any oncoplastic operation for breast cancer.
- The location of the tumor within the breast is the main criterion that guides the selection of the most appropriate oncoplastic technique. The breast size and the patient's age, general status, and personal wishes are also taken into account.
- The donut and the batwing mastopexy are the techniques of choice for periareolar lesions, and a central quadrantectomy with the Grisotti technique is preferable for subareolar lesions.
- Reduction mammoplasty techniques offer excellent results, both in terms of local control and cosmetic outcome, particularly for lesions in pendulous breasts.
- The option of symmetrization of the contralateral breast should be presented to the patient, particularly to women with higher cosmetic expectations.

References

1. Brédart A, Petit JY. Partial mastectomy: a balance between oncology and aesthetics? *Lancet Oncol* 6:130, 2005.
2. Anderson BO, Masetti R, Silverstein MJ. Oncoplastic approaches to partial mastectomy: an overview of volume-displacement techniques. *Lancet Oncol* 6:145, 2005.
3. Masetti R, Pirulli PG, Magno S, et al. Oncoplastic techniques in the conservative surgical treatment of breast cancer. *Breast Cancer* 7:276, 2000.
4. Smith ML, Evans GR, Gürlek A, et al. Reduction mammoplasty: its role in breast conservation surgery for early-stage breast cancer. *Ann Plast Surg* 41:234, 1998.
5. Cody HS III. Current surgical management of breast cancer. *Curr Opin Obstet Gynecol* 14:45, 2002.
6. Masetti R, Di Leone A, Franceschini G, et al. Oncoplastic techniques in the conservative surgical treatment of breast cancer: an overview. *Breast J* 12(5 Suppl 2):S174, 2006.

7. Lanfrey E, Rietjens M, Garusi C, et al. [Mammoplasty for symmetry of the contralateral breast and its oncologic value] *Ann Chir Plast Esthet* 42:160, 1997.
8. Clough KB, Cuminet J, Fitoussi AD, et al. Cosmetic sequelae after conservative treatment for breast cancer: classification and results of surgical correction. *Ann Plast Surg* 41:471, 1998.
9. Clark J, Rosenman J, Cance W, et al. Extending the indications for breast-conserving treatment to patients with locally advanced breast cancer. *Int J Radiat Oncol Biol Phys* 42:345, 1998.
10. Clough KB, Lewis JS, Couturaud B, et al. Oncoplastic techniques allow extensive resection for breast-conserving therapy of breast carcinomas. *Ann Surg* 237:26, 2003.
11. Kaur N, Petit JY, Rietjens M, et al. Comparative study of surgical margins in oncoplastic surgery and quadrantectomy in breast cancer. *Ann Surg Oncol* 12:539, 2005.
12. Galimberti V, Zurrida S, Zanini V, et al. Central small size breast cancer: how to overcome the problem of nipple and areola involvement. *Eur J Cancer* 29A:1093, 1993.
13. Losken A, Styblo TM, Carlson GW, et al. Management algorithm and outcome evaluation of partial mastectomy defects treated using reduction or mastopexy techniques. *Ann Plast Surg* 59:235, 2007.
14. Hamdi M, Van Landuyt K, Monstrey S, et al. Pedicled perforator flaps in breast reconstruction: a new concept. *Br J Plast Surg* 57:531, 2004.
15. Hamdi M, Salgarello M, Barone-Adesi L, Van Landuyt K. Use of the thoracodorsal artery perforator (TDAP) flap with implant in breast reconstruction. *Ann Plast Surg* 61:143, 2008.
16. Salgarello M, Visconti G, Barone-Adesi L, et al. Contralateral breast symmetrisation in immediate prosthetic breast reconstruction after unilateral nipple-sparing mastectomy: the tailored reduction/augmentation mammoplasty. *Arch Plast Surg* 42:302, 2015.

13

Timing of the Oncoplastic Reconstruction: Immediate, Delayed, and Delayed-Immediate

Alexandre Mendonça Munhoz, Rolf Gemperli

Oncoplastic reconstruction may begin at the time of BCT/BCT (immediate), weeks (delayed-immediate), or months to years afterward (delayed).¹ Not every oncologic surgeon planning to perform BCT intends to use any type of oncoplastic procedure, and some patients are satisfied with the use of external breast prostheses worn under clothing. However, with immediate reconstruction, the surgical process is smooth, because both BCT and reconstruction can be completed in one operative setting. Additionally, the emotional benefit for the patient of having begun reconstruction at the time of the oncologic procedure may decrease the impact of the loss. Conversely, the surgical time can be lengthened and potential complications such as skin necrosis, dehiscence, or infection can unfavorably affect the outcome. Although the immediate approach permits wider excision of the tumor,²⁻⁵ the whole procedure can be compromised by positive histologic margins. In addition, some patients are so distressed by their cancer diagnosis that they are not capable of significantly participating in reconstructive considerations, and delayed reconstruction will defer the need to make a decision about it. On the other hand, delayed reconstructions can be technically difficult, since these patients have scarred breast tissue as a result of previous procedures and fibrosis from radiotherapy.^{1,2,5-7}

Despite these arguments for and against, surgical planning should include breast volume, tumor location, the extent of glandular tissue resected, and chiefly addressing individual reconstructive requirements, enabling each patient to receive an individual, custom reconstruction. Evaluation of BCT reconstruction must subsequently consider these important points and, only then should the proper technique at an appropriate time be chosen. In addition, an in-depth dialogue concerning alternatives for BCT reconstruction should be undertaken with the patient and her family, including the risks and positive aspects of the time of approach of reconstruction.

IMMEDIATE RECONSTRUCTION

The immediate application of oncoplastic techniques to BCT is an expected reaction to the realization that aesthetic outcome following BCT and radiotherapy is occasionally disappointing.⁸ The major advantage of the immediate approach is that BCT and reconstruction can be achieved in a one-stage surgery and the patient does not have to cope with a deformity following the operation. Because there is no glandular and skin scar tissue, breast reshaping is easier, and the cosmetic results are improved.^{1,3}

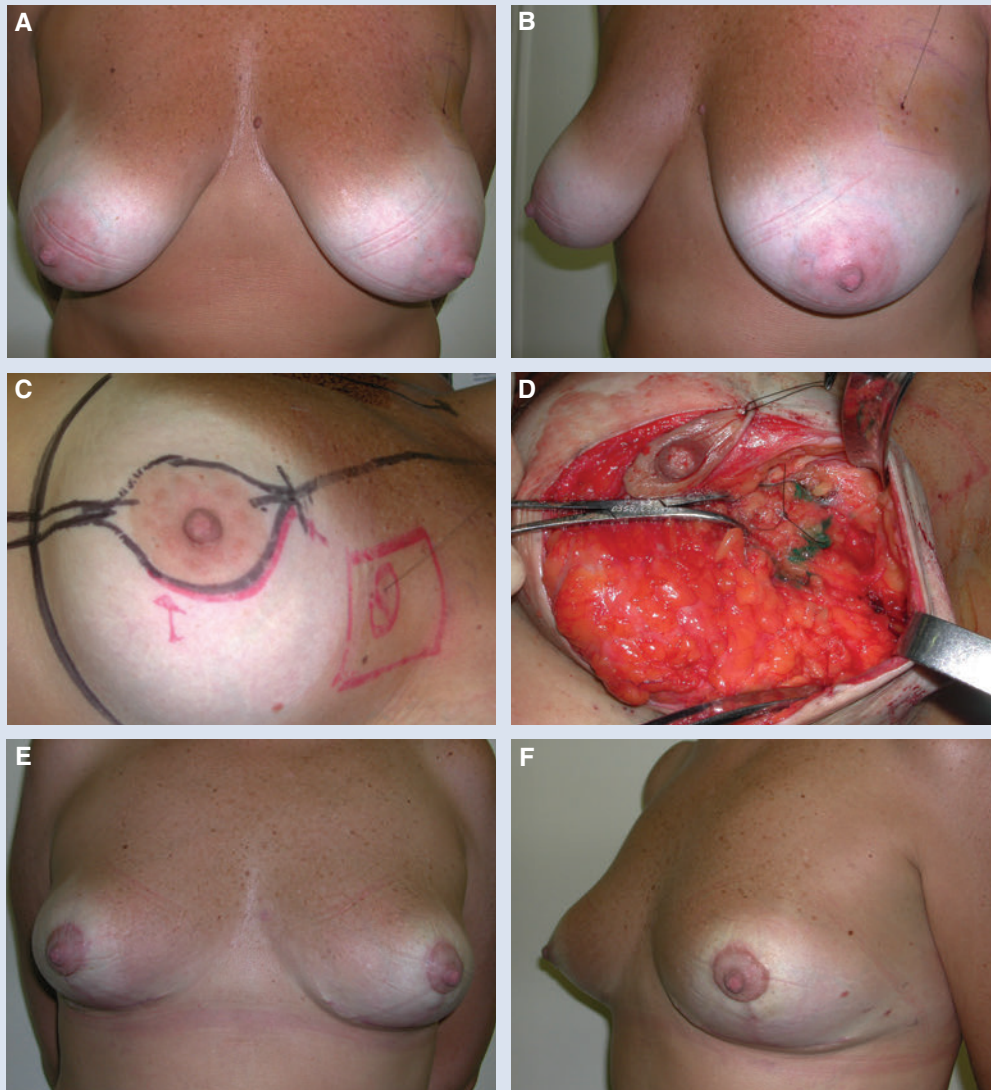
When the potential for a deformity exists preoperatively, immediate reconstruction is preferred; however, it should not jeopardize the oncologic outcome or delay radiotherapy.

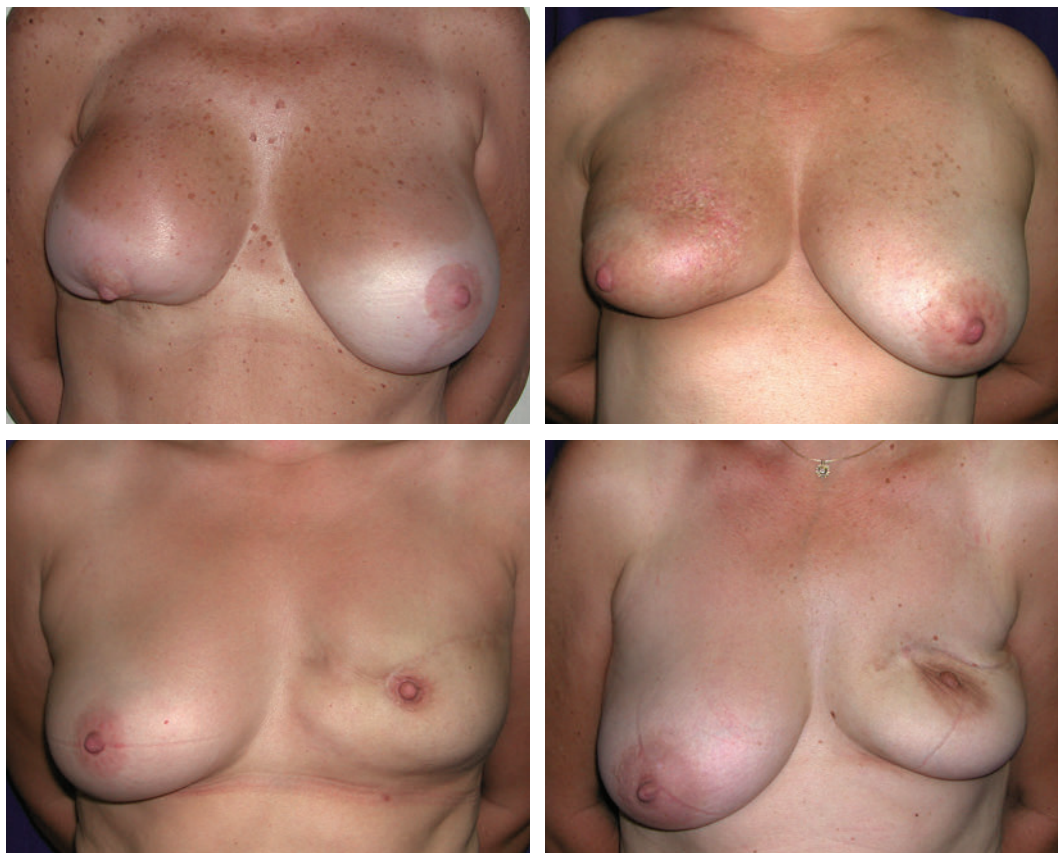

Fig. 13-1

These two patients have poor aesthetic outcomes following conservative breast surgery and radiotherapy without reconstruction.

PATIENT EXAMPLE

**Fig. 13-2**

This 48-year-old patient had a 1.9 cm invasive ductal carcinoma of the left breast (A and B). She underwent a left superolateral quadrantectomy and sentinel lymph node biopsy, immediately followed by a bilateral reduction mammoplasty reconstruction. A total of 125 g was removed from the left breast and 145 g from the right breast (C and D). She is shown 8 months postoperatively with a very good outcome after radiotherapy (E and F).

Thus it is advocated that the treatment of choice should be preventive by preoperative planning and immediate breast repair before adjuvant radiotherapy.^{1-3,8} Papp et al,⁹ in a comparative series of 40 immediate and delayed reconstructions, observed that the cosmetic results showed a higher success rate in the immediate repair group compared with the delayed reconstruction patients, of which 16% had poor ratings. Similarly, Kronowitz et al³ observed that delayed reconstruction usually required the use of autologous tissue to provide additional blood supply to assist with healing within the irradiated operative field. Despite the fact that radiotherapy has a negative impact on the cosmetic result, some authors suggest that the incidence of related complications varies, depending on the radiation technique used.^{2,6} The total radiation dose, the use of radiation boost, and the number of radiation fields are important related risk factors.^{10,11} Beadle et al¹⁰ did not observe radiotherapy complications in patients without radiation boost compared with 22% of complications in those treated with boost therapy. Correspondingly, Harris et al¹¹ observed that increasing the external irradiation dose (more than 60 Gy) was associated with a high incidence of skin fibrosis. In our previous studies,¹²⁻¹⁵ the maximum radiation dose used was 50 Gy to the remaining breast tissue and an additional boost of 10 Gy to the tumor site. In these studies, the majority of complications occurred in the initial postoperative period.

Outcomes

In our previous experience comparing the outcome following immediate and delayed reconstruction, we performed a retrospective review to compare complications, length of hospital stay, the need for revision surgeries, and satisfaction.¹⁶ In this series, the immediate approach was more advantageous because of the benefits of less psychological impairment. In addition, most of the complications were observed in the reconstructed breast and occurred in the initial postoperative period. One might surmise that previous oncologic manipulations and axillary dissection may be involved. However, there were no significant differences between patients who underwent axillary dissection and the sentinel lymph node biopsy in terms of complications. A total of 144 patients were followed for a mean of 47 months. Of the 106 patients in the immediate group, complications occurred in 24 (22.6%), skin necrosis was observed in 7.5%, fat necrosis in 5.6%, and 6.6% of patients developed local recurrence. The mean period of hospitalization was 1.89 days. Of

the 38 patients in the delayed group, complications occurred in 12 (31.5%), skin necrosis was observed in 7 (18.4%), fat necrosis in 4 (10.5%), and 5.2% of patients developed local recurrence. The mean period of hospitalization was 1.35 days. An increased length of hospital stay greater than 1 day ($p < 0.001$) and the number of revision surgeries ($p < 0.043$) were associated with the timing of the reconstruction. In univariate analysis, no difference between groups was found with respect to the incidence of complications ($p < 0.275$); however, after adjusting for other risk factors, the probability of complications tends to be higher for the delayed group (OR = 2.65; 95% confidence interval = 1.01 to 7.00; $p = 0.049$). In a recent series by Egro et al¹⁷ evaluating the timing of the reduction techniques, the complication rate and reoperation rate were significantly lower in the immediate group compared with the delayed group.

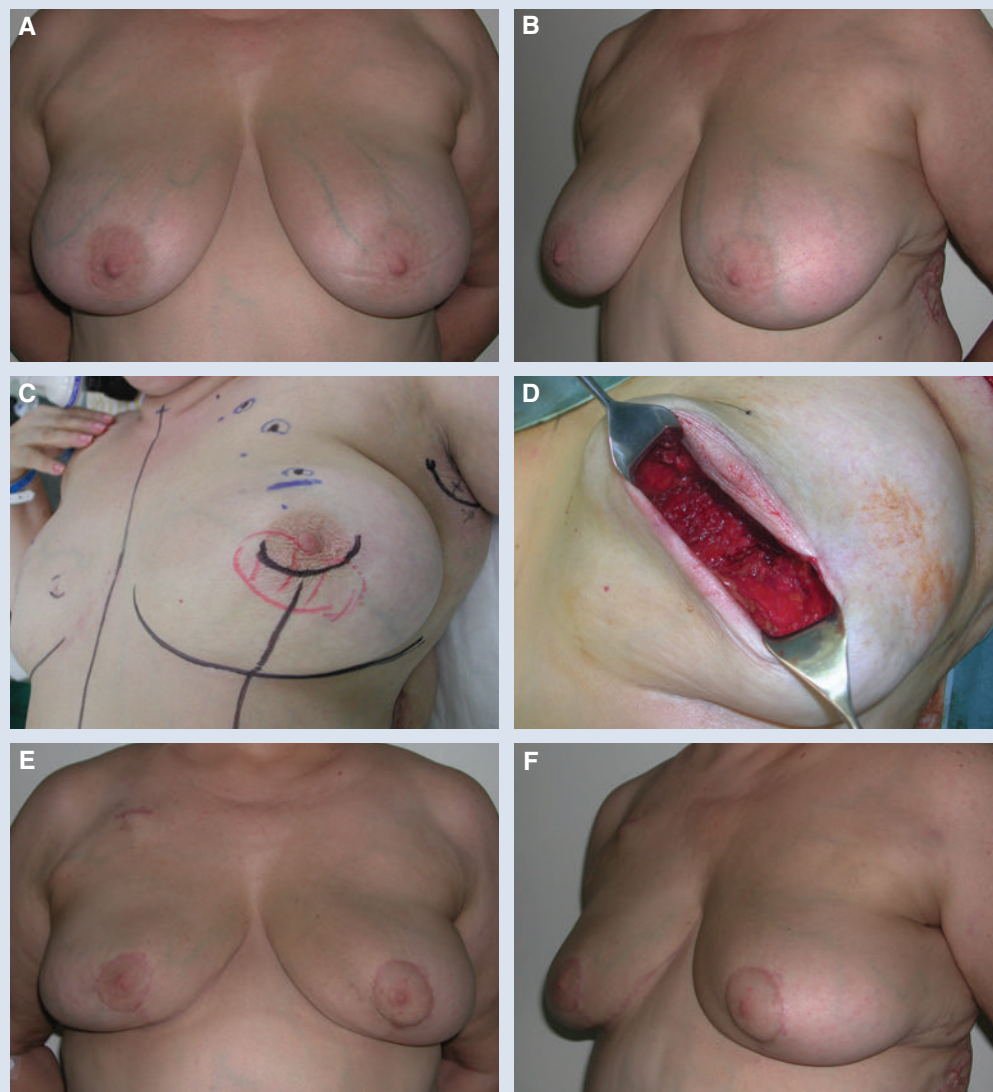Oncologic Advantages

Immediate reconstruction can provide beneficial oncologic advantages in some groups of patients. Some studies observed that patients with macromastia present more radiation-related complications than patients with normal volume breasts.^{10,11} Thus immediate breast reduction can increase the eligibility of large-breasted patients for BCT, since it can reduce the difficulty of providing radiotherapy to the remaining breast tissues.^{6,10,11,18-20} Brierley et al¹⁹ evaluated the correlation between late radiation reaction and brassiere size and demonstrated that late radiation fibrosis occurred 36% of the time in patients with larger breasts, compared with 3.6% for smaller breasts. Similarly, Gray et al²⁰ found that there was more retraction and asymmetry in the large-breasted versus the small-breasted group. Therefore it is common knowledge that the reduced size of the breast allows for more homogeneous delivery of radiation dose at lower levels, reducing late radiation complications.¹⁸⁻²⁰

Margin Issues

Another important factor in immediate reconstruction is the possibility of accomplishing a widely negative resection margin around the tumor. In fact, the immediate approach allows wider local tumor excision, potentially reducing the incidence of margin involvement and the development of local recurrence.^{1,3-5}

PATIENT EXAMPLE

**Fig. 13-3**

This 61-year-old patient was diagnosed with a 3.5 cm invasive ductal carcinoma of the left breast (A and B). The patient underwent a left central-inferior quadrantectomy and total axillary dissection, immediately followed by a bilateral reduction mammoplasty reconstruction. A total of 225 g was removed from the left breast and 235 g from the right breast (C and D). She is shown 1 year postoperatively with a good outcome after radiotherapy (E and F).

Kaur et al⁴ compared patients who underwent oncoplastic procedures and conventional quadrantectomy in terms of the volume of tissue excised and surgical margins. The immediate oncoplastic approaches permitted larger resections, with a superior mean volume of the specimen and negative margins. Losken et al⁷ demonstrated a significantly lower positive margin rate in a series of oncoplastic reduction patients compared with patients who underwent BCT alone, and this was also noted in a recent meta-analysis. The positive margin rate was 12.2% in the oncoplastic group and 20.6% in the BCT-alone group ($p < 0.001$). The translation of this to a long-term recurrence rate is unknown. Kronowitz et al³ reported a rate of local recurrence of 5% with breast reduction, compared with 13% for patients treated with the flap technique, in which no additional breast tissue is usually removed.

When immediate reconstruction is indicated, every attempt should be made to minimize the possibility of positive margins.

Although immediate BCT reconstruction does not represent a problem in routine postoperative cancer surveillance,^{5,7,12-15} it may lead to difficulty in establishing the location of a positive surgical margin postoperatively. Another important concern is postoperative scarring, which may mimic or obscure malignancy on mammography.^{6,14,15} Although these changes are well understood, and discrimination between tumor recurrence and fat necrosis can usually be differentiated in major cancer centers, we advocate careful surveillance and biopsy to elucidate a local recurrence.²¹ When a breast-reduction technique is performed, it is important to use one that employs safe flaps and has a low risk of fat necrosis.¹⁵

Scar tissue may mimic or obscure malignancy, and the appearance of a new mass can be similar to a normal scar on mammography.

All reconstructive techniques that involve rearrangement of glandular tissue make reexcision difficult and may jeopardize the oncologic treatment in cases in which close or positive margins are observed.¹³⁻¹⁵ This fact could make it difficult to locate the residual tumor and to perform margin reexcision. Additionally, intraoperative evaluation of surgical margins can present some limitations and as with any other test, there is an inherent false-positive and false-negative rate.²¹ Rietjens et al,⁵ in a recent study from a Milan group, reported an 8% positive or close margin involvement, which is lower than the 10% observed in the NSABP B-06 trial. Conversely, Kronowitz et al³ revealed that postoperative margins were positive in 15.7% of patients who underwent partial mastectomy without reconstruction. The authors emphasized that these patients had defect sizes four times smaller than the defects in the patients who underwent reconstruction. Larger defects in patients who undergo immediate reconstruction usually correlated with a lower incidence of positive postoperative tumor margins in this study.

If there are concerns about the margin status, the reconstruction should be deferred until final negative margins are obtained.

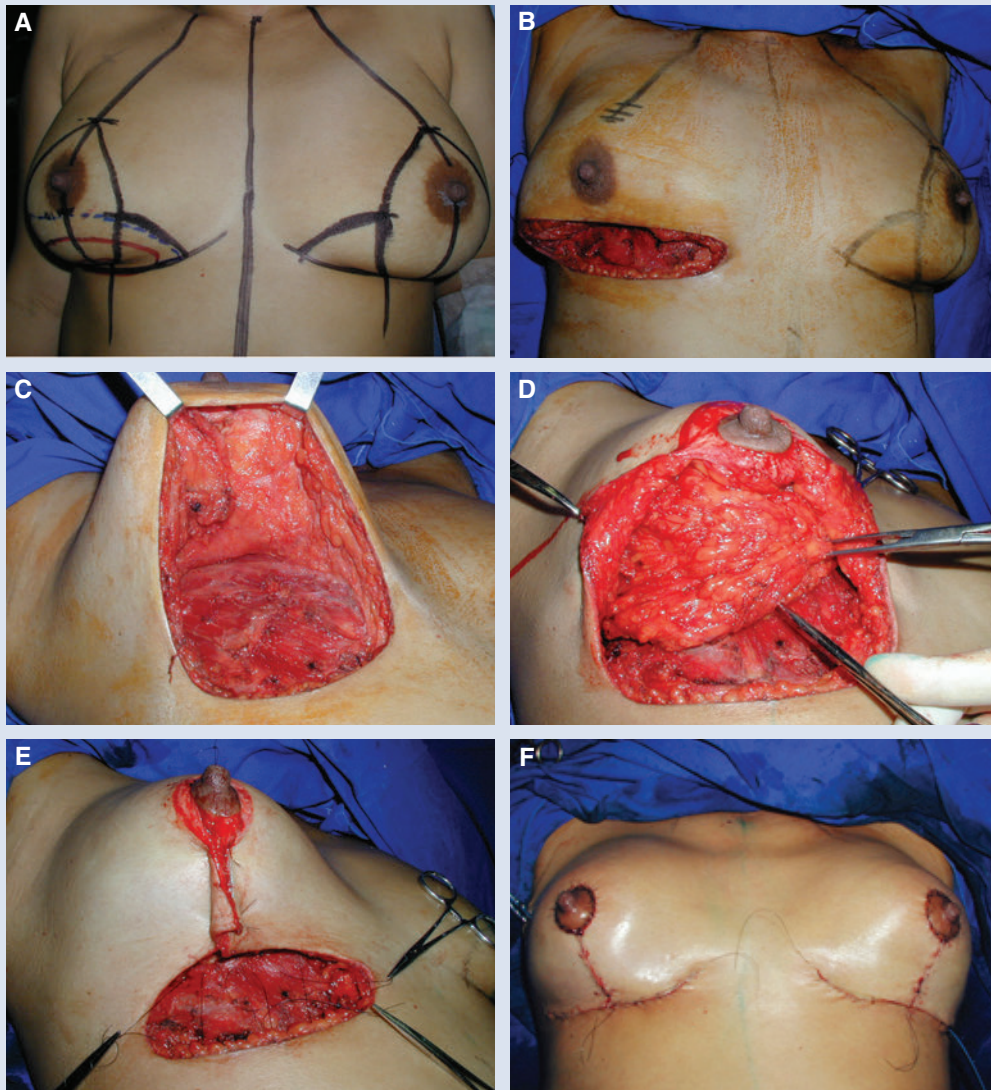
In our previous studies,¹²⁻¹⁵ surgical margins were assessed by intraoperative pathologic monitoring. This technique is based on radiologic, macroscopic, cytologic, and histologic examination of frozen sections of the breast specimens. Following surgical excision, the breast specimen is oriented with sutures by the surgeon and inked by the pathologist in different colors to retain orientation. The distance to the individual radial margins is estimated macroscopically by the pathologist and conveyed intraoperatively to the surgeon. A macroscopic tumor-margin distance of less than 10 mm and a microscopic tumor-margin distance of less than 2 lobular units is considered compromised. In both situations the margin or margins in question are then reexcised. In our previous experience, immediate reexcision was performed in 9.4% of cases and positive margins discovered on permanent pathology in previously negative-margin patients were observed in 5.7%.

Some investigators think that although meticulous microscopic evaluation can go a long way toward reducing errors related to sampling, errors cannot be totally eliminated, especially when dealing with large specimens for which freezing the entire lesion is not justified.²² Additionally, it has been our impression that interpretative errors may result from artifacts of the freezing procedure and/or inexperience on the part of the pathologist interpreting the slide. For this reason, careful and coordinated planning with the oncologic surgeon is important, since some techniques alter the normal architecture of the breast. We recommend orienting the glandular specimen and placing surgical clips at the tumor margins. In cases in which reexploration is performed, it is reasonable in conjunction with the plastic surgery team to attempt to identify the original tumor bed and to avoid injury to the nipple-areola complex pedicle. In some cases, preoperative MRI can help to clarify the extent of disease and may be helpful in planning the combined surgical treatment.

Another advantage of immediate reconstruction is the possibility of examining the opposite breast. Despite the low incidence of occult malignancy observed in aesthetic breast reductions, the risk undoubtedly increases in patients with previous breast cancer.²³⁻²⁵

In a study of 800 breast reductions including patients with breast hypertrophy, congenital breast asymmetry, and contralateral breast reduction in patients with known cancer, Colwell et al²⁵ observed a different incidence of occult carcinoma. Stratified by indication, the authors observed an inclination toward higher breast cancer detection rates in the reconstruction group (1.2%) compared with the breast hypertrophy patients (0.7%). In our previous study,²³ 4.3% of the patients who submitted to an immediate opposite mammoplasty were diagnosed with breast cancer. Although a diagnosis of occult carcinoma is not a reason to perform a contralateral breast reduction, some authors think that it can represent a potential benefit for high-risk patients.^{3,7}

PATIENT EXAMPLE

**Fig. 13-4**

This 36-year-old woman had a 2.7 cm invasive ductal carcinoma of the right breast (A). The patient underwent a right inferior quadrantectomy and sentinel lymph node biopsy, immediately followed by a bilateral reduction mammoplasty reconstruction; a total of 105 g was removed from the left breast and 95 g from the right breast (B through E). She is shown immediately postoperatively (F); there is a good bilateral result in terms of volume shape and symmetry.

The immediate approach has some disadvantages as well. In some situations it can be time consuming, technically demanding, and require specialist training (plastic or oncologic surgeon) to properly apply these techniques, which also have supplementary costs.^{1,8} Additionally, up to now the evidence in the literature of the oncologic and aesthetic outcomes was limited and based on a small number of studies where the selection criteria were not clear.¹ Comparison between these studies is complex, because the techniques and patients vary, both with regard to the oncoplastic procedures and aesthetic evaluation. Therefore there is a need for further evaluation of immediate BCT reconstruction. Despite these limitations, and although immediate reconstruction requires more preoperative planning and intraoperative care, we strongly believe that the concept can reduce deformities, favor the oncologic treatment and optimize the aesthetic outcome in most early stage cancer patients.^{8,12-15}

Box 13-1 Immediate Reconstruction: Pros and Cons

Pros

- Aesthetic benefit
- One-stage surgery/less psychological trauma
- Absence of scar tissue/radiation effects
- Fewer radiation-related complications (macromastia)
- Widely resected margins
- Opposite breast examination (occult malignancy)

Cons

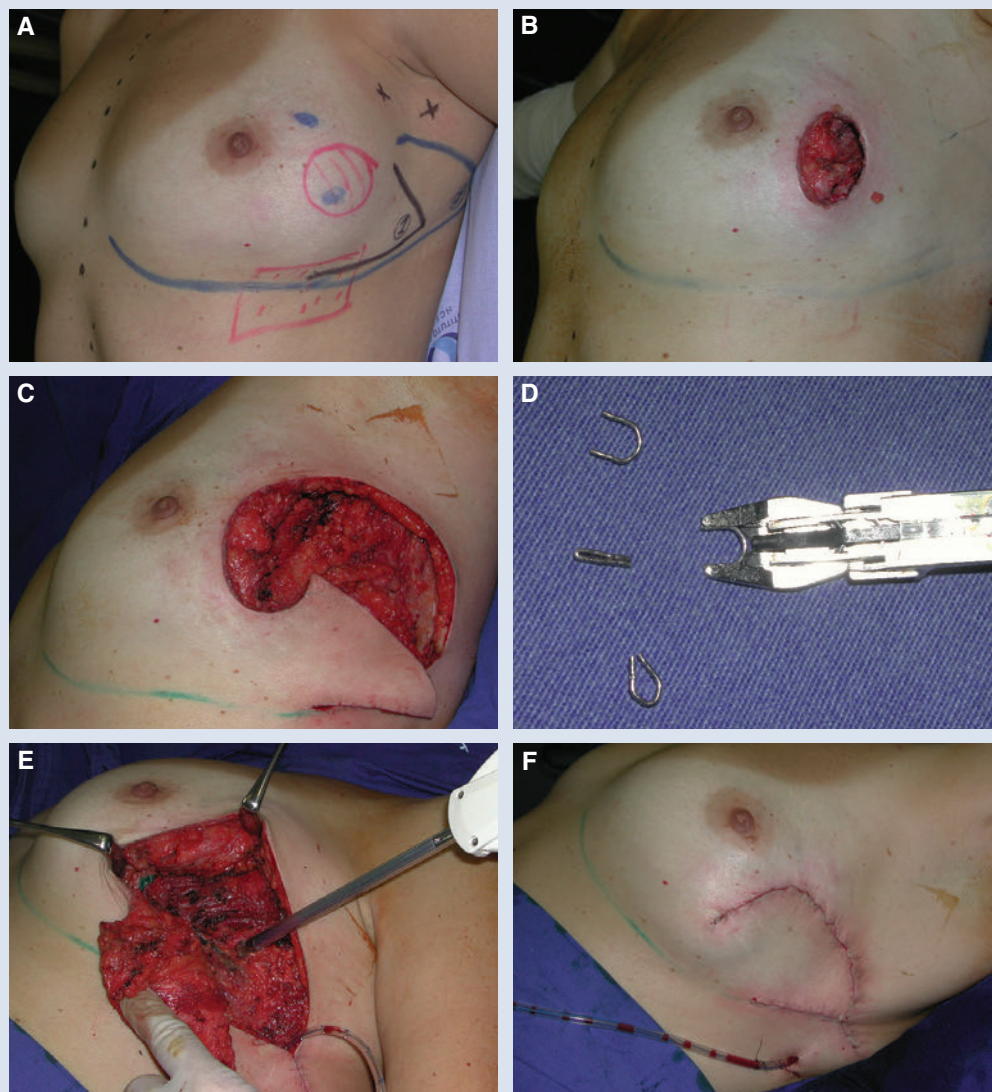
- Reexploration (positive margins)
- Surveillance (postoperative scarring/obscure malignancy)
- Time consuming, and technically demanding
- Cost and resource implications (community hospitals)

DELAYED RECONSTRUCTION

The advantage of performing a delayed reconstruction is frequently debated.^{1,2,6,9} With an immediate reconstruction, operative time is lengthened and the surgical process is more extensive than conventional breast-conserving surgery. One might surmise that these aspects can, in theory, jeopardize the adjuvant oncologic treatment. Additionally, some potential complications of the reconstruction techniques can unfavorably defer the adjuvant therapy. Our previous experience,^{12-15,23} and of other Europeans,^{2,5,26} has shown that immediate BCT reconstruction does not compromise the start of radiotherapy and chemotherapy in the overall treatment of breast cancer. In our previous study,²³ the mean time for initiation of adjuvant chemotherapy was 34.0 days in patients who underwent reduction mammoplasty and 33.6 days in patients who did not undergo the procedure.

Although immediate BCT reconstruction is ideal for many patients, there are two potential problems with this approach. One dilemma concerns postoperative radiation and specifically the boost therapy. The other potential problem is that postoperative radiation may adversely affect the aesthetic outcome of an immediate BCT reconstruction. Concerning the postoperative boost, all immediate reconstructive techniques that involve rearrangement of glandular tissue may jeopardize the boost radiation dose delivery, since the target area for the radiation is defined as the site of the tumor.^{13-15,27,28} For this reason, careful and coordinated planning with the multidisciplinary team is important, especially with the radiotherapy group, since some oncoplastic techniques alter the normal architecture of the breast.¹³⁻¹⁵ To locate the original tumor area, we recommend orienting the tumor site by skin markings (surgical ink) and placing surgical clips at the tumor margins. Identification of the original tumor bed based only on physical examination without precise imaging information can potentially lead to missing the primary tumor bed in a substantial percentage of patients undergoing breast reshaping techniques.^{27,28} Based on our experience, we recommend surgical clips that have not interfered with routine mammography and have actually helped recognize areas at high risk for recurrence.^{14,15} Additionally, no reports have indicated that clips have interfered with physical examination or cosmesis or have added to any morbidity related to the reconstructive procedure.

PATIENT EXAMPLE

**Fig. 13-5**

This 46-year-old woman with a 2.6 cm invasive ductal carcinoma of the left breast (A), underwent a left superolateral quadrantectomy and sentinel lymph node biopsy, immediately followed by a lateral thoracodorsal flap reconstruction. A total of 75 g was removed from the left breast (B and C). To locate the original tumor area, surgical clips were placed at the original tumor margins (D and E). Immediate postoperative appearance showing the final result with the lateral thoracodorsal flap reconstruction (F).

There is a potential risk that radiation will affect the aesthetic outcome of an immediate reconstruction. One might surmise that the final contour and symmetry of the breast cannot be predicted at the time of the immediate reconstruction. Additionally, it is well accepted that radiotherapy usually involves some degree of fibrosis, shrinkage, and fat necrosis. Because the breast shape continues to change and a skin radiation effect is a cause of secondary asymmetry, the cosmetic outcome can be hypothetically unpredictable. In our previous experience,¹³⁻¹⁵ the majority of complications occurred in the initial postoperative period. In the late period, the complications were related to skin disorders or fat necrosis, and radiation partially contributed to the aesthetic result. However, in a long-term analysis, the majority of patients presented good or very good breast shape and symmetry. Some patients (9.4%) developed fibrosis and asymmetry secondary to immediate complications and radiotherapy. Despite these facts, the majority of these cases were treated by a conservative approach or by small revision surgeries and an acceptable result was achieved in which 93.2% of patients were either very satisfied or satisfied, and none regretted the surgery. Other authors have described these aspects and observed that although the aesthetic outcome can be satisfactory in both breasts, the appearance of the irradiated breast is occasionally less pleasing than the nonirradiated one.^{10,13,17,18} Spear et al²¹ observed cases of fat necrosis and nipple hypopigmentation, but no significant cases. The authors mentioned that besides the differences observed in the normal healing process, the irradiated breast has longer induration and swelling than the contralateral breast. Again, although there has been no prospective study evaluating this important issue, it has been our impression that the incidence of radiotherapy effects diverges, depending on the radiation technique employed.^{10,11}

Another important issue is postoperative internal breast scarring resulting from immediate BCT reconstruction. This postoperative scarring may mimic or obscure malignancy, and the appearance of a new mass can be similar to the findings of a normal scar on mammography. The same dilemma applies to microcalcifications. Differential diagnosis in some situations can be complex, because such lesions near the scar could be caused by fibrosis (fat necrosis calcifications), not only to recurrence. Although these mammographic changes are well understood and discrimination between tumor recurrence and fat necrosis can be differentiated in major cancer centers, we advocate a careful surveillance and invasive diagnosis to elucidate a local recurrence.¹²⁻¹⁵

On the other hand, previous unplanned breast scars (of skin and glandular tissue) can jeopardize adequate surgical planning in a delayed reconstruction scenario. In theory, and depending on the incision, it is difficult to design an appropriate skin resection pattern for delayed reconstruction. According to Kronowitz et al,³ some scarring of glandular tissue can also disrupt the local blood supply and the ability to create a viable parenchymal pedicle. Therefore, although using mammaplasty for delayed reconstruction is technically viable, delayed reconstruction usually requires a latissimus dorsi flap, because it assists with fluid resorption and wound healing within the irradiated field. We agree that in some

cases it may be preferable to avoid delayed reconstruction with a flap. To preserve future reconstructive options, consideration should be given to performing a contralateral mammaplasty for symmetry or a mastectomy with total breast reconstruction, as suggested by Kronowitz et al.³ Additionally, delayed reconstructions with distant flaps can sometimes be associated with a less than optimal aesthetic outcome, because the distant skin stands out in sharp disparity with the previous irradiated skin, giving it a patchlike appearance.²⁴

Box 13-2 Delayed Reconstruction: Pros and Cons

Pros

Reexploration (positive margins)
Surveillance (postoperative scarring/obscure malignancy)

Cons

Two-stage surgery/more psychological trauma and higher costs
Presence of scar tissue/radiation effects

PATIENT EXAMPLES

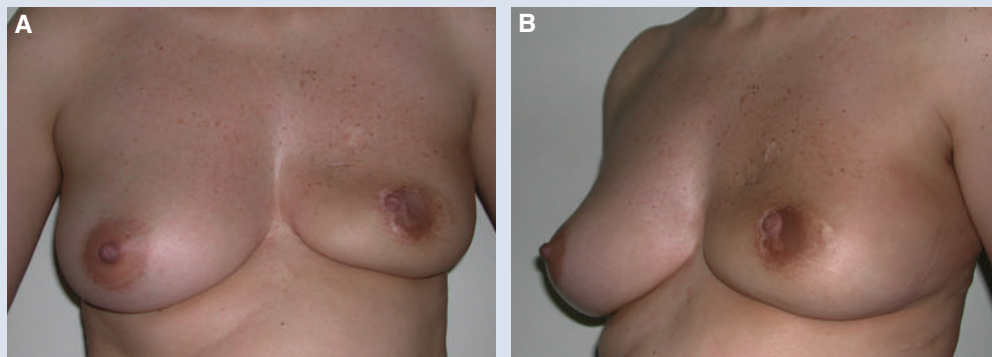


Fig. 13-6, A and B

This 40-year-old patient with a 2.5 cm invasive ductal carcinoma of the left breast had undergone a superomedial quadrantectomy and radiotherapy 2 years earlier (A and B).

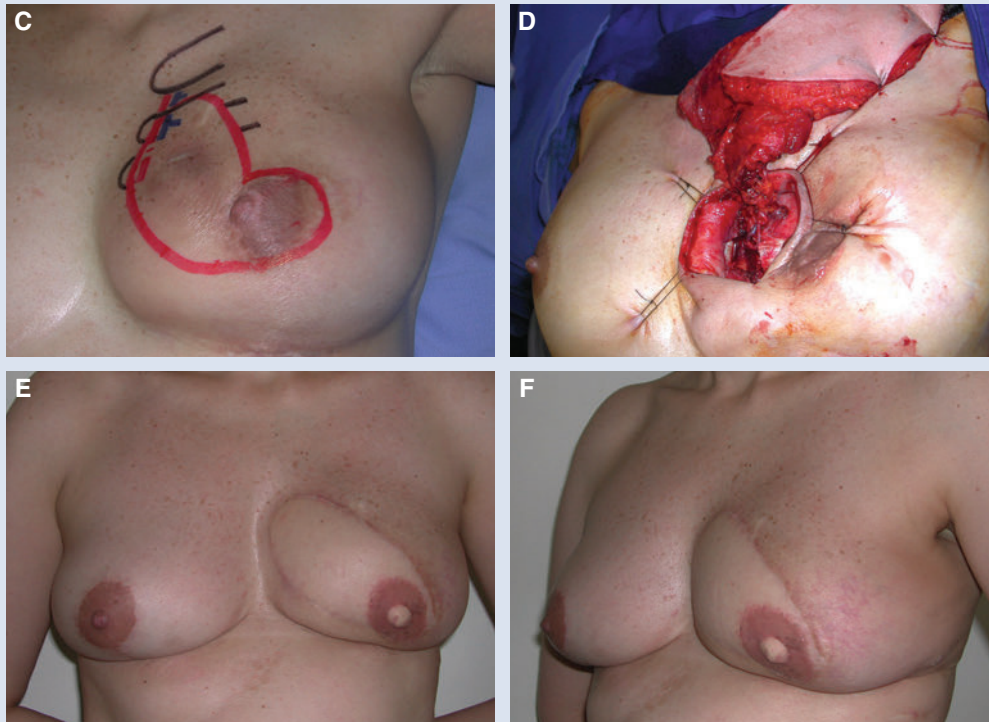
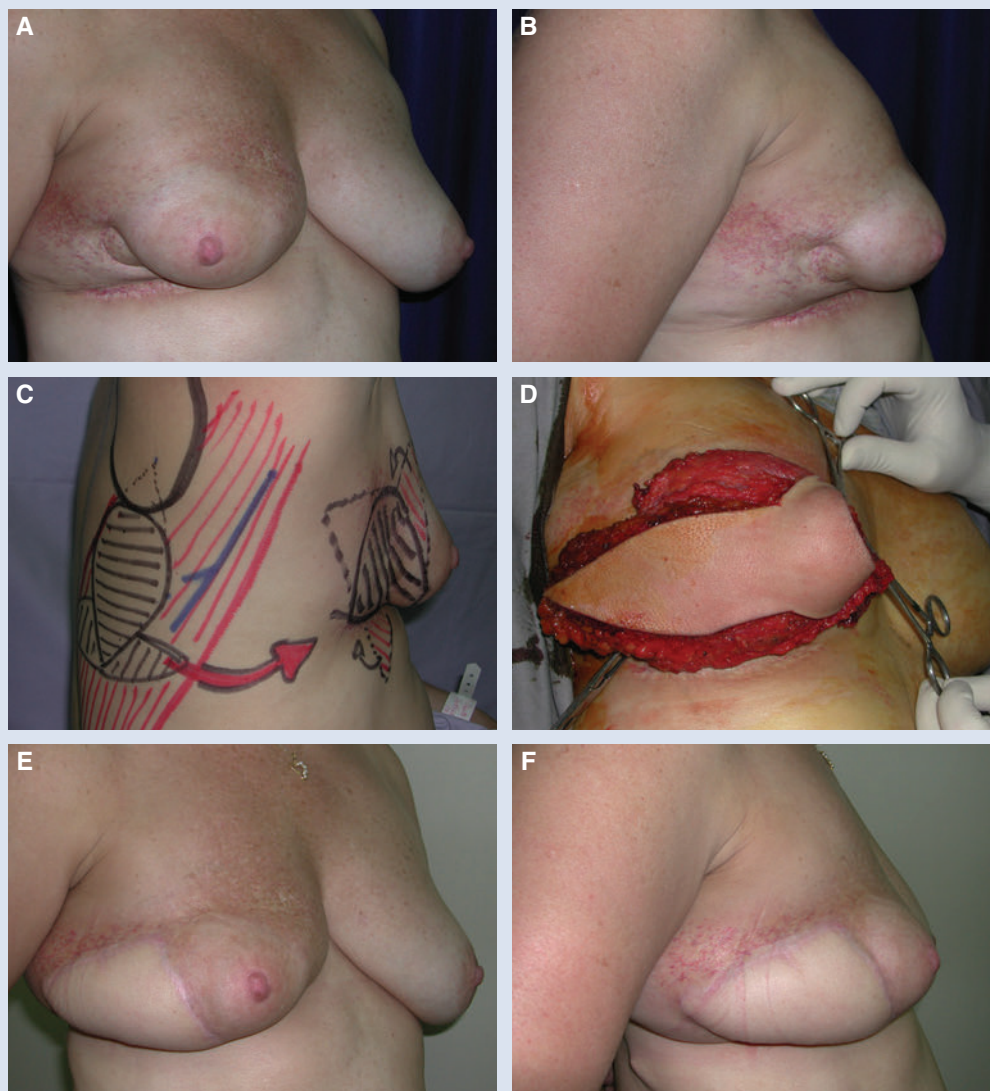


Fig. 13-6, C-F

Because of the severe scar tissue and radiotherapy skin effects that developed, she underwent a delayed reconstruction with a free latissimus dorsi myocutaneous flap (*C* and *D*). She is shown 11 months postoperatively with a very good outcome after nipple-areola complex reconstruction (*E* and *F*).

**Fig. 13-7**

After this 51-year-old woman was diagnosed with a 3.0 cm invasive ductal carcinoma of the right breast, she underwent an inferolateral quadrantectomy and radiotherapy (A and B). Three years later, because of the severe scar tissue and radiotherapy skin effects that developed, she presented for reconstruction and underwent a delayed procedure with a pedicled latissimus dorsi myocutaneous flap (C and D). Six months postoperatively, she is shown with a good outcome; however, there is a patchlike effect with the flap (E and F).

We think that the immediate approach is preferable to delayed reconstruction because fewer revision surgeries are required. In our experience, comparing immediate and delayed reconstructions, the immediate approach has also resulted in a higher satisfaction rate than delayed repair because of the use of glandular tissue without radiation effects.¹⁶ In our sample, almost 92.4% patients of the immediate group and 73.2% of the delayed group were either very satisfied or satisfied with their aesthetic result. Although the majority of patients achieved an improved breast shape and volume, almost 23% of patients in the delayed group were disappointed, because their reconstruction resulted in breast asymmetry, with the irradiated breast more retracted than the opposite breast.

DELAYED-IMMEDIATE RECONSTRUCTION

Recently, some authors have suggested delayed-immediate reconstruction for patients who are potential candidates for BCT and oncoplastic reconstruction.¹ By definition, two-stage procedures can be delayed-immediate (2 to 3 weeks later), with initial wide local excision, and then oncoplastic reconstruction with the appropriate technique when the histologic margin assessment has been performed. In this approach, it is possible to postpone immediate reconstruction until after the review of the final pathology report on the breast tissue specimen and the definitive surgical margins have been determined. If partial breast reconstruction is done at the time of BCT and the patient is found postoperatively to have surgical margin involvement, reexploration can be troublesome and may adversely affect the oncologic and aesthetic outcome. Thus the potential advantage of two-stage procedures relates to the possibility of accurate location of the original tumor site in cases in which close or positive margins are observed in the permanent pathology.

The delayed-immediate concept can be advantageous, in theory, when compared with immediate reconstruction. However, delayed-immediate reconstruction can present some limitations. The negative aspects are related to the technical difficulties of operating on a previously treated breast, such as recent scar tissue and fibrotic tissue. Additionally, the procedure can be time consuming and demands additional costs that may have additional resource implications for community hospitals.

This delay offers the benefit of immediate reconstruction with the luxury of confirmed negative margins.

As with breast remodeling procedures, uncertainties about surgical margin involvement have dictated whether a one- or two-stage approach is indicated. Some authors^{1,29} have defended a one-stage approach with immediate reconstruction in which tumor bed biopsies are taken after tumor resection and these samples are sent for frozen section analysis. The entire cavity is then reexcised as a continuous shaving, and this tissue is sent for formal histologic assessment. If any intraoperative biopsies are found to contain tumor, a further set of bed biopsies is taken following the reexcision of the tumor bed. If tumor is present in the second set of biopsies, this indicates the need for mastectomy. In our previous stud-

ies,¹³⁻¹⁵ intraoperative margin evaluation was assessed by pathologic monitoring, which is based on radiologic, macroscopic, cytologic, and histologic examination of frozen sections. If there are compromised margins, the margin or margins in question are then reexcised.

On the other hand, Dixon et al²⁹ first suggested the two-stage procedure. In the first step, a BCT and definite histologic margin analysis are performed. If the definite surgical margins are free, an oncoplastic reconstruction with the appropriate technique is usually indicated 2 weeks later. Similarly, Choi et al³⁰ recommended the early delayed latissimus dorsi muscle flap for reconstruction of large lumpectomy defects. This is performed approximately 1 week after lumpectomy, when the final pathology results are available.

One potential advantage of a two-stage procedure is knowing the location of the original tumor site preoperatively. This is especially important in cases in which close or positive margins are observed in the permanent pathology specimens.

With the delayed-immediate approach, patients who do not require secondary reexcision of surgical margins can achieve aesthetic outcomes similar to those of immediate reconstruction. Additionally, delayed-immediate reconstruction provides a further option that broadens patients' treatment choices and allows them to participate fully in treatment and reconstruction decisions. When there is no intraoperative pathology analysis, the delayed-immediate reconstruction concept can be advantageous. Again, this aspect stresses the importance of the multidisciplinary concept and the benefits of individual clinicians' abilities in the oncoplastic reconstruction, because the entire procedure could be compromised by positive histologic margins in a previously negative result.

Box 13-3 Delayed-Immediate Reconstruction: Pros and Cons

Pros

- Reexploration (positive margins)
- Two-stage surgery in short period of time/less psychological trauma
- Absence of radiation effects
- Opposite breast examination (occult malignancy)

Cons

- Presence of recent scar tissue
- Time consuming, technically demanding
- Cost and resource implications (community hospitals)

CONCLUSION

Oncoplastic techniques in association with BCT are not a new concept but are becoming increasingly accepted by oncologic breast surgeons. In selected patients, this approach has allowed surgeons to perform wide resections and to obtain good oncologic control with favorable aesthetic outcome. The majority of the complications have been immediate, minor, and comparable to those of other aesthetic reduction techniques. Although immediate reconstruction requires more preoperative planning and intraoperative care, the concept can reduce deformities, provide benefits for the oncologic treatment, and optimize the aesthetic outcome in most early stage cancer patients.

Critical Issues

- Meticulous preoperative assessment is crucial to the success of any conservative breast surgery reconstruction.
- The timing of partial BCT reconstruction is generally based on oncologic concerns.
- The immediate approach is preferable.
- Delayed-immediate reconstruction is safer, but requires two procedures.
- Adequate medical information must be provided to patients, and informed consent must be received from them.

References

1. Asgeirsson KS, Rasheed T, McCulley SJ, et al. Oncological and cosmetic outcomes of oncoplastic breast conserving surgery. *Eur J Surg Oncol* 31:817, 2005.
2. Clough KB, Thomas SS, Fitoussi AD, et al. Reconstruction after conservative treatment for breast cancer: cosmetic sequelae classification revisited. *Plast Reconstr Surg* 114:1743, 2004.
3. Kronowitz SJ, Feledy JA, Hunt KK, et al. Determining the optimal approach to breast reconstruction after partial mastectomy. *Plast Reconstr Surg* 117:1; discussion 12, 2006.
4. Kaur N, Petit JY, Rietjens M, et al. Comparative study of surgical margins in oncoplastic surgery and quadrantectomy in breast cancer. *Ann Surg Oncol* 12:539, 2005.
5. Rietjens M, Urban CA, Rey PC, et al. Long-term oncological results of breast conservative treatment with oncoplastic surgery. *Breast* 16:387, 2007.
6. Slavin SA, Halperin T. Reconstruction of the breast conservation deformity. *Semin Plast Surg* 18:89, 2004.
7. Losken A, Elwood ET, Styblo TM, Bostwick J III. The role of reduction mammoplasty in reconstructing partial mastectomy defects. *Plast Reconstr Surg* 109:968, 2002.
8. Munhoz AM, Aldrighi C, Ferreira MC. Paradigms in oncoplastic breast surgery: a careful assessment of the oncological need and aesthetic objective. *Breast J* 13:326, 2007.

9. Papp C, Wechselberger G, Schoeller T. Autologous breast reconstruction after breast-conserving cancer surgery. *Plast Reconstr Surg* 102:1932, 1998.
10. Beadle GF, Silver B, Botnick L. Cosmetic results following primary radiation therapy for early breast cancer. *Cancer* 54:2911, 1984.
11. Harris JR, Levene MB, Svensson G, et al. Analysis of cosmetic results following primary radiation therapy for stages I and II carcinoma of the breast. *Int J Radiat Oncol Biol Phys* 5:257, 1979.
12. Munhoz AM, Montag E, Arruda EG, et al. Outcome analysis of breast-conservation surgery and immediate latissimus dorsi flap reconstruction in patients with T1 to T2 breast cancer. *Plast Reconstr Surg* 116:741, 2005.
13. Munhoz AM, Montag E, Arruda EG, et al. The role of the lateral thoracodorsal fasciocutaneous flap in immediate conservative breast surgery reconstruction. *Plast Reconstr Surg* 117:1699, 2006.
14. Munhoz AM, Montag E, Fels KW, et al. Critical analysis of reduction mammoplasty techniques in combination with conservative breast surgery for early breast cancer treatment. *Plast Reconstr Surg* 117:1091, 2006.
15. Munhoz AM, Montag E, Arruda EG, et al. Superior-medial dermoglandular pedicle reduction mammoplasty for immediate conservative breast surgery reconstruction. *Ann Plast Surg* 57:502, 2006.
16. Munhoz AM, Aldrighi CM, Montag E, et al. Outcome analysis of immediate and delayed conservative breast surgery reconstruction with mastopexy and reduction mammoplasty techniques. *Ann Plast Surg* 67:220, 2011.
17. Egro FM, Pinell-White X, Hart AM, Losken A. The use of reduction mammoplasty with breast conservation therapy: an analysis of timing and outcomes. *Plast Reconstr Surg* 135:963e, 2015.
18. Chang E, Johnson N, Webber B, et al. Bilateral reduction mammoplasty in combination with lumpectomy for treatment of breast cancer in patients with macromastia. *Am J Surg* 187:647, 2004.
19. Brierley JD, Paterson IC, Lallemand RC, et al. The influence of breast size on late radiation reaction following excision and radiotherapy for early breast cancer. *Clin Oncol* 3:6, 1991.
20. Gray JR, McCormick B, Cox L, et al. Primary breast irradiation in large-breasted or heavy women: analysis of cosmetic outcome. *Int J Radiat Oncol Biol Phys* 21:347, 1991.
21. Spear SL, Pelletiere CV, Wolfe AJ, et al. Experience with reduction mammoplasty combined with breast conservation therapy in the treatment of breast cancer. *Plast Reconstr Surg* 111:1102, 2003.
22. Laucirica R. Intraoperative assessment of the breast: guidelines and potential pitfalls. *Arch Pathol Lab Med* 129:1565, 2005.
23. Ricci MD, Munhoz AM, Geribela A, et al. The influence of reduction mammoplasty techniques in synchronous breast cancer diagnosis and metachronous breast cancer prevention. *Ann Plast Surg* 57:125, 2006.
24. Boice JD, Harvey EB, Blettner M, et al. Cancer in the contralateral breast after radiotherapy for breast cancer. *N Engl J Med* 326:781, 1992.
25. Colwell AS, Kukreja J, Breuing KH, et al. Occult breast carcinoma in reduction mammoplasty specimens: 14-year experience. *Plast Reconstr Surg* 113:1984, 2004.
26. Petit JY, Rietjens M, Garusi M, et al. Integration of plastic surgery in the course of breast conserving surgery for cancer to improve cosmetic results and radicality of tumor excision. *Recent Results Cancer Res* 152:202, 1998.
27. Solin L, Danoff B, Schwartz G, et al. A practical technique for the localization of the tumor volume in definitive irradiation of the breast. *Int J Radiat Oncol Biol Phys* 11:1215, 1985.
28. Regine W, Ayyangar K, Komarnickv L, et al. Computer-CT planning of the electron boost in definitive breast irradiation. *Int J Radiat Oncol Biol Phys* 20:121, 1991.
29. Dixon JM, Venizelos B, Chan P. Latissimus dorsi mini-flap: a technique for extending breast conservation. *Breast* 11:58, 2002.
30. Choi JY, Alderman AK, Newman LA. Aesthetic and reconstruction considerations in oncologic breast surgery. *J Am Coll Surg* 202:943, 2006.

14

Psychosocial Aspects of Oncoplastic Breast Conservation

Diana Harcourt

The psychosocial consequences of breast cancer surgery can be profound, including a negative impact on a woman's sense of self and body image, as well as an impact on those people close to her. These effects have been documented in numerous research reports and moving, personal accounts. Recent developments in breast conservation and oncoplastic surgery have been driven, in part, by a desire to minimize these negative experiences and they have offered considerable benefits to many women who have lost one or both breasts.¹

This chapter considers the possible psychosocial implications of breast reconstruction after a full or partial mastectomy and reflects on the need to provide appropriate support for women who are faced with often complex and overwhelming decisions about oncoplastic and reconstructive surgery. Examples of recently developed interventions to support patient decision-making and areas for future research in this field are also discussed.

THE PSYCHOLOGICAL IMPACT OF BREAST RECONSTRUCTION

A large body of research in this field suggests that a breast cancer patient's psychosocial functioning (in terms of anxiety, depression, and quality of life) typically returns to pre-surgical levels approximately 1 year after diagnosis. Researchers have also explored the effect of treatment on patients' body image (defined here as their thoughts, feelings, and behaviors in relation to their physical appearance), sexuality, and self-esteem. Less-invasive surgical procedures typically have a more favorable impact on a patient's body image than radical operations² but any form of surgery may have lasting effects that can remain problematic when other psychosocial aspects have improved.³⁻⁵

Although reconstruction has proved beneficial for many women⁶ it is not a universal remedy for the challenges and distress associated with a mastectomy.⁷ Women often report being satisfied with their decision to undergo reconstruction,⁶⁻⁹ even though they may still have difficulty adjusting to their postsurgical appearance and body image because of scarring, the loss of sensation, and breast asymmetry.^{8,10}

The number of women who choose either a conservative surgical procedure or a mastectomy with reconstruction, instead of a mastectomy alone, illustrates the importance they place on their appearance and on preserving their body image and body integrity throughout their breast cancer treatment.⁹ Women often seek treatment that will make them feel “intact,” and developments in partial reconstruction are likely to appeal to many who undergo cancer surgery. However, although breast conservation and partial reconstructive techniques are less radical, there may still be a poor cosmetic result, causing patients to feel “less whole.”

To date, there has been limited research into the psychosocial impact of partial breast reconstruction. That which has been conducted has found that anxiety about residual cancer and concerns around breast self-examination were similar among women who had either a skin-sparing surgery or partial mastectomy with flap reconstruction.¹¹ Anxiety and depression were similar in the two surgical groups.

On the basis of the small amount of research in this area to date, it would be shortsighted to assume that partial breast reconstruction is a panacea for the body image concerns of patients who do not undergo a full mastectomy; they all face the challenge of assimilating the altered appearance, sensations, and texture of the reconstructed breast into their body image. This can be a difficult and slow process.

Conservative procedures will not suit all women, and it is important to reiterate that women who undergo less-radical procedures can also experience the difficulties and concerns associated with full reconstruction.

PATIENT SATISFACTION AND EXPECTATIONS OF SURGERY

Several studies have reported a high level of patient satisfaction with the outcome of breast reconstruction and with the decision to undergo the surgery. However, findings about patient satisfaction are inconsistent. In an audit of more than 15,000 women who underwent mastectomy in England,¹² which included more than 5,000 who chose to undergo breast reconstruction, a third of immediate reconstruction patients and almost a quarter (22%) of delayed reconstruction patients could not describe the outcome as “excellent” or “very good” 18 months after surgery. Forty percent of immediate reconstruction patients were unsatisfied with the appearance of their breast after surgery.

Patient satisfaction is a complex issue, and general reports of ‘overall satisfaction’ do not reveal whether patients are more or less satisfied with some aspects than with others.

Scarring (particularly at the donor site), asymmetry of the breasts, complications, and the need for additional procedures have all been identified as areas of dissatisfaction among patients who have undergone a full reconstruction.^{8,10,13,14} These factors are also likely to influence the satisfaction of women who have had partial procedures.

Interestingly, Roth et al¹⁵ examined the influence of presurgical psychological variables on patient satisfaction with outcome. Affect, depressive symptoms, and somatization (bodily complaints) all related to general and aesthetic satisfaction 1 year after surgery, raising the possibility that presurgical psychosocial support and interventions might influence post-surgical satisfaction.

A surgeon might think that postsurgical scarring could be improved through further intervention, yet the patient is happy with the aesthetic outcome as it stands.

When considering patient satisfaction, surgeons must recognize that this can vary over time and that a woman's subjective experience and report of satisfaction with the outcome of surgery may not agree with the objective ratings given by another person, such as her partner, or by the breast care team. Indeed, research and personal accounts have repeatedly shown that objective measures of an individual's appearance (for example, the extent of scarring) fail to predict psychosocial adjustment.¹⁶ Surgery can still affect a woman's body image and prove distressing, even if someone else would consider the results to be satisfactory or unnoticeable.

Very little research has focused on the psychological impact of complications after breast reconstruction and their affect on patient satisfaction. A study by Gopie et al¹⁷ found a discrepancy between patients' and surgeons' reports of complications after reconstructive surgery, with women reporting more complications than surgeons did. Women who thought they had had a complication reported higher levels of anxiety and depressive symptoms than those who did not. The psychosocial impact of complications after partial breast reconstruction warrants consideration, as does a more detailed understanding of women's experiences of complications of any sort and how this relates to patient satisfaction.

Expectations may be particularly high—possibly unrealistically so—if patients view partial reconstruction as a less radical and therefore simpler procedure that will have little impact on their body image and appearance.

Body image and appearance may be particularly salient issues for women who elect to have breast-conserving surgery rather than mastectomy alone. This may lead them to be particularly aware and critical of the aesthetic outcome of their surgery and is one of the reasons

that establishing each woman's motivations and presurgical expectations is so important. Because a reconstruction is not a true replacement, women who expect a reconstructed breast to look and feel the same as their natural breast are likely to be dissatisfied with the outcome of surgery.

DECISION-MAKING

Deciding whether to undergo breast reconstruction after a full mastectomy can be difficult and daunting.⁸ The numerous options regarding the type and timing of surgery are complex, and each option requires thoughtful consideration. Decision-making can be particularly difficult if the choices are presented soon after the cancer diagnosis. Furthermore, the patient may be influenced—consciously or unconsciously—by other people, including partners^{18,19} and health care professionals. Women's experiences of decision-making about partial breast reconstruction have yet to be researched, but such a decision is not likely to be any easier than choosing whether to undergo a full reconstruction. A challenge for any oncoplastic breast care team is how to help each woman to make the decision that is best for her as an individual, and to ensure that each patient has the information, support, and time she needs to make that choice.

The reasons for choosing either a full or partial breast reconstruction are likely to be very similar. Women who select either option may want to feel “normal”; to preserve their body's integrity, symmetry, and wholeness; and to maintain their self-confidence, self-esteem, and a sense of femininity. They might also hope to avoid any restrictions on clothing choices and lifestyle that they believe will be inevitable if they opt to have a full or partial external prosthesis. They will want to minimize any constant reminder of the disease and avoid the effects of a mastectomy on intimacy and relationships.^{8,18,20-23} Their choices may also be influenced by the need for any adjuvant treatment. One of the few studies to explore the psychosexual impact of partial or total reconstruction²⁴ found that expectations about improved body image and sexual well-being after surgery were not met. Nevertheless, women who underwent partial reconstruction reported greater improvement in body image satisfaction 1 year after surgery than those who underwent full mastectomy and reconstruction. This study supports others that have highlighted the importance of examining patients' presurgical expectations. However, sample size was small, and a study-specific questionnaire was used rather than a standardized patient reported outcome measure such as the Breast-Q²⁵ which would have allowed direct comparison with other studies.

Clarifying each woman's individual motivations, expectations, preferences, and values is essential if health care professionals are to support them through decision-making and surgery.

One of the reasons it may be particularly difficult to make decisions about breast reconstruction is that the options are “preference sensitive,”²⁶ meaning that the “right choice” depends on each woman’s personal preferences. However, there are few resources and interventions to help health care professionals promote realistic expectations. Support for patients facing this decision tends to focus on providing information. However, this does not necessarily help to elicit their expectations or address erroneous expectations, because it reinforces the patient’s role as a passive recipient²⁷ rather than an individual actively engaged in shared decision-making—a collaborative process that allows the patient and her providers to make health care decisions together, taking into account the best scientific evidence available, as well as the patient’s values and preferences.

Decision aids help patients make choices when they are presented with multiple treatment options. Often provided in the form of computer-based programs to supplement surgical consultations, these provide structured information and exercises to help patients determine which attributes are personally important to them, so they can use these salient aspects to make their decision on the basis of improved knowledge, a more realistic expectation of outcome, and their own values.²⁸ Such resources can help any patients faced with treatment decisions, particularly those finding decision-making very difficult.

The development of complex online decision-making tools for breast reconstruction has been a noticeable advance in recent years, yet some women will still find decision-making very difficult and distressing. In such situations it is advisable to put decisions about reconstruction on hold until there has been time to access the support of appropriate services, including psychologists and counselors, if necessary.¹⁵

PROVIDING INFORMATION

A successful oncoplastic service is one that facilitates patients’ access to information that meets their individual needs before and after surgery.

Patients’ expectations of surgery in any health context are influenced by the information available to them. However, patients vary considerably in the amount, details, and type of information they prefer; many patients make their decisions without seeking detailed information.⁸ Perhaps not surprisingly, the availability of information about breast reconstruction influences the decisions that women make about whether to undergo reconstruction, and if so, the type and timing of the procedure.²³ Providing clear, accurate, timely, and personally relevant information is an essential component of care and could reduce the likelihood of regret at a later date. Sheehan et al²⁹ found that women who were less satisfied with information were more likely to experience moderate to strong regret about their decision to undergo reconstruction.

Information should be available in a variety of formats, including leaflets, interactive computer programs, and audio recordings, and should address the possible physical (discomfort and the lack of sensation) and psychosocial (self-consciousness and the impact on intimacy) consequences of surgery. Information about the possible effect of surgery on donor sites also needs to be available.¹⁰ Ideally, patients should have access to a library of photographs of successful and less successful outcomes of different surgical procedures involving women of various ages, physiques, and ethnic backgrounds at various stages in their postsurgical recovery. However, not all women want to see detailed, graphic photographs, and some patients may find such images upsetting.³⁰ Furthermore, it may take some time to establish a portfolio of photographs of one surgeon's practice, necessitating the reliance on photographs from other sources, which may or may not reflect that surgeon's own outcomes.

PEER SUPPORT

Some aspects of reconstruction, such as physical sensations after surgery, are particularly difficult for health care professionals to predict or describe to those contemplating reconstruction. For example, what is considered to be "mild tingling" to one woman could be "persistent pain" to another.

Peer support can be a valuable resource in many health situations, and meeting other women who have previously undergone reconstruction can be an opportunity to discuss the situation with someone who is willing to share their personal experience, which may help with decision-making. However, this needs to be carefully managed so that women considering surgery are not overly swayed by others who are particularly enthusiastic or unhappy about their own surgical outcomes. Some support groups are available specifically for women who are contemplating or who have undergone breast reconstruction, such as Keeping Abreast (<http://www.keepingabreast.org.uk>). However, not all women will want to meet other patients personally, and it may not be easy to find women who are willing to discuss their own experiences, especially when surgical procedures are still relatively novel. It might also not be feasible to meet other patients face-to-face, so web-based resources such as the Healthtalk Online website (www.healthtalkonline.org) can make personal experiences readily available and accessible and may also help to remind the patient that she is not alone in her experience.

PSYCHOLOGICAL SUPPORT

Guidelines for the provision of oncoplastic surgery³¹ have outlined the importance of psychosocial support within a breast reconstruction service, and all members of the multidisciplinary team have a role to play. Wolf³⁰ reflected on the particular role specialist nurses play in supporting decision-making and providing information. She highlighted topics that should be routinely discussed, including fears, expectations, 'showing others,' emotional recovery, and practical issues, such as advice about bras and massage after surgery.

Decision-making about reconstruction and adjusting to the changes that take place during surgery is an ongoing, often challenging, process. Many women manage these challenges well, and the support of their families, friends, and a well-delivered oncoplastic service can be invaluable in this process. However, some may need specialist psychosocial support to help them before, during, and after surgery.³² Such support (including referral to a psychologist with expertise in this area, if needed) should therefore be ongoing and available to meet patients' evolving needs over time. Patients' partners may also benefit from having support available, because they are likely to play an important supportive role in a woman's experience of reconstructive surgery, yet still have their own needs and concerns about the surgery.^{19,33}

FURTHER RESEARCH

Despite growing interest in the psychosocial aspects of breast reconstruction, further research is needed into women's experiences before and after partial breast reconstruction. Longitudinal research, from diagnosis onward, is needed to explore the long- and short-term psychosocial impact of surgery in terms of decision-making, body image, well-being, sexual functioning, patient expectations and concerns, and satisfaction with outcome. Such research needs to use appropriate outcome measures that tap into the issues that are of importance to patients themselves. Until now, a variety of different patient reported outcome measures have been used in breast reconstruction research, which makes comparisons between studies difficult. The use of an agreed core set of outcomes in this field,³⁴ including breast-reconstruction specific *patient reported outcome measures* (PROMs) such as the Breast-Q,²⁵ could advance our knowledge in this area considerably.

Understanding more about the psychosocial factors that influence women's adjustment to a reconstructed breast would usefully inform the provision of care and the development of appropriate interventions for those having difficulty before and after surgery.

CONCLUSION

In summary, oncoplastic breast reconstruction offers the potential of psychosocial benefits for patients. However, meeting the information and support needs of women who are suitable candidates for these procedures and who are faced with complex decisions presents a number of challenges to the oncoplastic breast team. Although new ways of supporting patients' decision-making about breast reconstruction are being developed, further patient-centered research is still needed in this field to enable oncoplastic breast teams to provide comprehensive, evidence-based patient care.

Critical Issues

- Undergoing breast reconstruction of any kind is a major commitment, and both the physical and psychological outcomes of surgery are difficult to predict.
- Choosing to undergo reconstruction is a significant decision, one that some women may find difficult to make.
- Information that meets patients' individual needs and interventions that promote shared decision-making can support women through the challenges they face before and after surgery.
- The psychosocial impact of conservative oncoplastic surgery may be similar to that of reconstruction after a full mastectomy.
- Conservative oncoplastic surgery has the potential to offer psychosocial benefits to patients who prefer not to undergo a mastectomy and those who would otherwise be left with an unsatisfactory cosmetic outcome.
- There is still a pressing need for further research in this rapidly developing area.

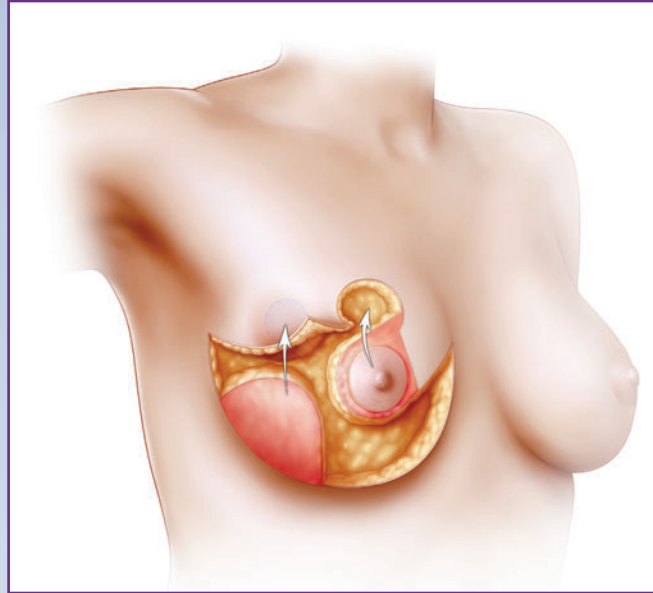
References

1. Watson M. Psychological issues in breast reconstruction. In della Rovere GQ, Benson JR, Breach N, et al, eds. *Oncoplastic and Reconstructive Surgery of the Breast*. London: Taylor & Francis/CRC Press, 2004.
2. Al-Ghazal SK, Fallowfield L, Blamey RW. Comparison of psychological aspects and patient satisfaction following breast conserving surgery, simple mastectomy and breast reconstruction. *Eur J cancer* 36:1938, 2000.
3. Wilkins EG, Cederna PS, Lowery JC, et al. Prospective analysis of psychosocial outcomes in breast reconstruction: one-year postoperative results from the Michigan Breast Reconstruction outcome study. *Plast Reconstr Surg* 106:1014, 2000.
4. Parker PA. Breast reconstruction and psychosocial adjustment: what have we learned and where do we go from here? *Semin Plast Surg* 18:131, 2004.
5. Harcourt D, Rumsey N, Ambler N, et al. The psychological impact of mastectomy with or without immediate breast reconstruction: a prospective, multicenter study. *Plast Reconstr Surg* 111:1060, 2003.
6. Al-Ghazal SK, Sully L, Fallowfield L. The psychological impact of immediate rather than delayed breast reconstruction. *Eur J Surg Oncol* 26:17, 2000.
7. Harcourt D, Rumsey N. Psychological aspects of breast reconstruction: a review of the literature. *J Adv Nurs* 35:477, 2001.
8. Harcourt D, Rumsey N. Mastectomy patients' decision-making for or against immediate breast reconstruction. *Psychooncology* 13:106, 2004.
9. Fung KW, Lau Y, Fielding R, et al. The impact of mastectomy, breast-conserving treatment and immediate breast reconstruction on the quality of life of Chinese women. *ANZ J Surg* 71:202, 2001.

10. Abu-Nab Z, Grunfeld EA. Satisfaction with outcome and attitudes towards scarring among women undergoing breast reconstructive surgery. *Patient Educ Couns* 66:243, 2007.
11. Gendy RK, Able JA, Rainsbury RM. Impact of skin-sparing mastectomy with immediate reconstruction and breast-sparing reconstruction with miniflaps on the outcomes of oncoplastic breast surgery. *Br J Surg* 90:433, 2003.
12. National Mastectomy & Breast Reconstruction Audit, 4th Annual Report. Leeds, UK: NHS Information Centre, 2011.
13. Schwartz MD. Contralateral prophylactic mastectomy: efficacy, satisfaction, and regret. *J Clin Oncol* 23:7777, 2005.
14. Frost MH, Slezak JM, Tran NV, et al. Satisfaction after contralateral prophylactic mastectomy: the significance of mastectomy type, reconstructive complications and body appearance. *J Clin Oncol* 23:7849, 2005.
15. Roth RS, Lowery JC, Davis J, et al. Psychological factors predict patient satisfaction with post-mastectomy breast reconstruction. *Plast Reconstr Surg* 119:2008, 2007.
16. Rumsey N, Harcourt D. *The psychology of appearance*. Buckingham, UK: Open University Press, 2005.
17. Gopie JP, Timman R, Hilhorst MT, et al. The short-term psychological impact of complications after breast reconstruction. *Psychooncology* 22:290, 2013.
18. Marshall C, Kiemle G. Breast reconstruction following cancer: its impact on patients' and partners' sexual functioning. *Sex Relat Ther* 20:155, 2005.
19. Sandham C, Harcourt D. Partner experiences of breast reconstruction post mastectomy. *Eur J Oncol Nurs* 11:66, 2007.
20. Reaby LL. Reasons why women who have mastectomy decide to have or not to have breast reconstruction. *Plast Reconstr Surg* 101:1810, 1998.
21. Reaby LL, Hort LK, Vandervord J. Body image, self-concept, and self-esteem in women who had a mastectomy and either wore an external breast prosthesis or had breast reconstruction and women who had not experienced mastectomy. *Health Care Women Int* 15:361, 1994.
22. Denford S, Harcourt D, Rubin L, et al. Understanding normality: a qualitative analysis of breast cancer patients' concepts of normality after mastectomy and reconstructive surgery. *Psychooncology* 20:553, 2011.
23. Alderman AK, Hawley ST, Morrow M, et al. Receipt of delayed breast reconstruction after mastectomy: do women revisit the decision? *Ann Surg Oncol* 18:1748, 2011.
24. Hart AM, Pinell-White X, Egro FM, Losken A. The psychosexual impact of partial and total breast reconstruction: a prospective one-year longitudinal study. *Ann Plast Surg* 75:281, 2015.
25. Pusic AL, Klassen A, Scott AM, et al. Development of a new patient-reported outcome measure for breast surgery: the BREAST-Q. *Plast Reconstr Surg* 124:345, 2009.
26. Lee CN, Hultman CS, Sepucha K. Do patients and providers agree about the most important facts and goals for breast reconstruction decisions? *Ann Plast Surg* 64:563, 2010.
27. Sherman KA, Harcourt DM, Lam TC, et al. BRECONDA: development and acceptability of an interactive decisional support tool for women considering breast reconstruction. *Psychooncology* 23:835, 2014.
28. O'Connor AM, Rostom A, Fiset V, et al. Decision aids for patients facing health treatment or screening decisions: systematic review. *BMJ* 319:731, 1999.
29. Sheehan J, Sherman KA, Lam T, et al. Association of information satisfaction, psychological distress and monitoring coping style with post-decision regret following breast reconstruction. *Psychooncology* 16:342, 2007.
30. Wolf L. The information needs of women who have undergone breast reconstruction. Part I: decision-making and sources of information. *Eur J Oncol Nurs* 8:211, 2004.

31. Association of Breast Surgery at BASO, Association of Breast Surgery at BAPRAS, Training Interface Group in Breast Surgery, et al. Oncoplastic breast surgery—a guide to good practice. *Eur J Surg Oncol* 33(Suppl 1):S1, 2007.
32. Fingeret MC, Nipomnick S, Guindani M, et al. Body image screening for cancer patients undergoing reconstructive surgery. *Psychooncology* 23:898, 2014.
33. Rowland E, Metcalfe A. A systematic review of men's experiences of their partner's mastectomy: coping with altered bodies. *Psychooncology* 23:963, 2014.
34. Potter S, Holcombe C, Ward JA, Blazeby JM; BRAVO Steering Group. Development of a core outcome set for research and audit studies in reconstructive breast surgery. *Br J Surg* 102:1360, 2015.

PART THREE



Immediate Partial Breast Reconstruction

15

Reduction Techniques to Optimize Results

Steven J. Kronowitz

Poor outcomes after breast-conserving therapy (BCT) are likely to be underestimated in the literature, because many patients with such outcomes are reluctant to seek additional surgical treatment. Breast preservation may provide sufficient psychological satisfaction for some women; however, others may fear additional operations or may not be aware of the reconstructive options available to them.¹ Many patients choose to undergo BCT to limit the extent of surgery. Therefore these women are not eager to undergo a major secondary reconstructive procedure, which may be necessary after radiotherapy.

Many patients wish to preserve their breasts, regardless of the anticipated cosmetic outcome. This has led to the more aggressive use of partial mastectomies and to more extensive local resections being classified as partial mastectomies.¹ As partial mastectomies become more extensive, the risk of suboptimal cosmetic results most likely will increase.² The importance of incorporating immediate reparative techniques in the multidisciplinary care of these patients has never been so critical.

THE DECISION-MAKING PROCESS

In addition to an improved cosmetic outcome, the immediate repair of partial mastectomy defects using the breast-reduction technique offers a number of potential advantages. It can facilitate the resection of wider margins around the tumor, which in turn has the potential to lower the rates of local recurrence of breast cancer.³ The immediate repair of partial mastectomy defects may also increase the eligibility of large-breasted patients for BCT. Some radiation oncologists are reluctant to treat large-breasted patients because of the potential for poor aesthetic outcomes. Because of the increased fat content, radiation delivered to a large breast can lead to increased fibrosis; it can also be difficult to duplicate the setup from one daily treatment to the next.⁴ A reduced breast size allows a more uniform radiation dose to be delivered at lower levels, thereby reducing unacceptable late radiation reactions.^{5,6} The immediate repair of a partial mastectomy defect using breast-reduction techniques represents an alternative for those patients who would otherwise not be considered candidates for BCT.

Immediate repair with the breast-reduction technique does not pose a problem with postoperative cancer surveillance,⁵ and it may provide some medical benefits.

A contralateral breast reduction is often required. Although this increases the potential for complications, it allows tissue from the contralateral breast to be sampled. Occult carcinomas have been found in approximately 4.5% of contralateral breast reduction specimens in patients undergoing a symmetry procedure for breast reconstruction.⁴ Although the detection of occult carcinoma is not itself a reason to perform a contralateral breast reduction, it may provide a benefit for high-risk patients. Breast-reduction surgery has also been shown to significantly reduce the risk of breast cancer, especially in women older than 40 years of age.⁷

This chapter introduces a management algorithm to guide the clinician in determining which patients are good candidates for having the breast-reduction technique to repair a partial mastectomy defect. It focuses on patient selection and presents new zone designations of the breast, with corresponding designs for dermoglandular pedicles based on the tumor location.

Table 15-1 Complication Rates by Timing of Reconstruction and Reconstructive Technique*

Timing of Reconstruction	Number of Reconstructions Associated With Complications (%)			
	All (N = 69)	LTR (n = 20)	BR (n = 41)	FLAP (n = 8)
All	21/69 (30)	6/20 (30)	12/41 (29)	3/8 (38)
Immediate (n = 50)	13/50 (26)	3/14 (21)	8/33 (24)	2/3 (67)
Delayed (n = 19)	8/19 (42)	3/6 (50)	4/8 (50)	1/5 (20)

*Complications include nipple necrosis, donor or recipient site seroma, wound dehiscence, infection, hematoma, fat necrosis, and mastectomy skin-flap necrosis.

BR, Breast reduction; FLAP, reconstruction with a latissimus dorsi myocutaneous or thoracoepigastric flap; LTR, local tissue rearrangement.

The results of our studies^{8,9} indicate that, in eligible patients, breast-reduction techniques result in the fewest complications.

Table 15-2 Cosmetic Outcomes by Timing of Reconstruction and Reconstructive Technique*

Reconstructive Technique	Aesthetic Outcome, Number of Patients (%)					
	All†		Immediate‡		Delayed§	
	Excellent or Good	Fair or Poor	Excellent or Good	Fair or Poor	Excellent or Good	Fair or Poor
LTR or BR	9 (64)	5 (36)	4 (57)	3 (43)	5 (71)	2 (29)
FLAP	3 (60)	2 (40)	1 (33)	2 (67)	2 (100)	0 (0)

*As opposed to the calculation of complication rates, which were based on each reconstructed breast, a cosmetic outcome score was determined for each patient. Cosmetic outcomes were evaluated for 10 patients who underwent immediate reconstruction and 9 patients who underwent delayed reconstruction.

†Mean intervals: from reconstruction to photograph, 10 months; from radiotherapy to photograph, 2 years 3 months. Mean defect size: 21%.

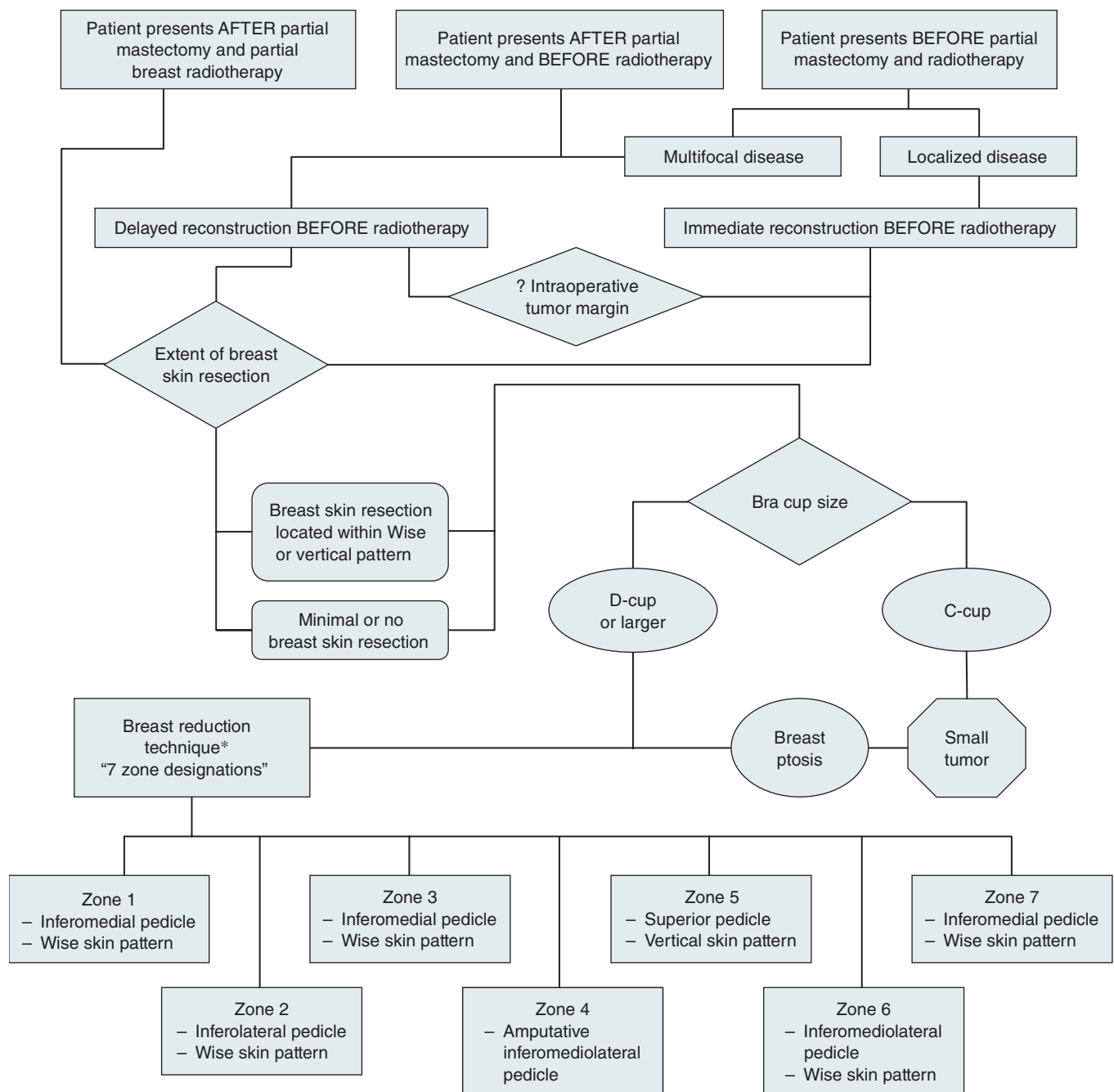
‡Mean intervals: from reconstruction to photograph, 12 months; from radiotherapy to photograph, 8 months. Mean defect size: 23%.

§Mean intervals: from reconstruction to photograph, 8 months; from radiotherapy to photograph, 4 years. Mean defect size: 19%.

BR, Breast reduction; FLAP, reconstruction with a latissimus dorsi myocutaneous or thoracoepigastric flap; LTR, local tissue rearrangement.

Breast-reduction techniques also yield the best cosmetic outcomes, because they use the remaining breast tissue to maintain the color and texture of the breast.

MANAGEMENT ALGORITHM



*Before radiotherapy, breast reduction is performed only on the ipsilateral involved breast. Six months or later, breast reduction is performed to achieve symmetry on the contralateral breast using the same pedicle design.

Fig. 15-1

Although no exact measures are available to determine which patients will benefit from repairing a partial mastectomy defect using the breast-reduction technique, the algorithm presented should prove useful in determining eligibility. This technique usually is limited to patients with large-sized breasts (D-cup bra size or larger). However, some patients with moderate-sized breasts (C-cup bra size), small tumors, and nipple ptosis may also be candidates for the breast-reduction technique. Ultimately it is up to the multidisciplinary breast team and the patient to determine the best approach.

Three groups of patients are presented in the algorithm. The first group includes patients who present *after* undergoing a partial mastectomy and partial breast radiotherapy; this group consists of an increasing number of women who, in the near future, may become the largest presenting population for the repair of partial mastectomy defects. Because the radiotherapy is delivered only to the tumor site, the remainder of the breast parenchyma can be rearranged in these patients without significant concerns of poor wound healing. Another advantage for patients in this group is that a negative margin has already been obtained and the tumor cavity does not need to be elucidated (with placement of surgical clips) for the radiation oncologist. The disadvantage is that an incision on the breast has already been made, which may interfere with the design of the skin resection pattern. The decision-making with these patients is based on the extent and location of the breast skin resection and the breast size. Patients with D-cup breasts and C-cup breasts with small tumors and breast ptosis are excellent candidates for the breast-reduction technique. The second group of patients, those who present *after* a partial mastectomy and *before* radiotherapy, also has an advantage and disadvantage in terms of the reconstruction. The advantage is that negative tumor margins have usually already been obtained in these patients. However, the disadvantage is that the specific location and extent of the tumor resection often are not known. This is especially important when determining whether an adequate blood supply from the underlying breast parenchyma remains for the NAC.

In patients who have undergone a central resection or, by examination, have evidence of a subareolar resection, the blood supply to the NAC should be explored before the surgeon commits to performing a breast-reduction technique.

Otherwise, when choosing the best technique for repairing a partial breast defect in these patients, consideration must be given to the location and extent of the tumor resection and to the breast size.

The third group of patients present before undergoing a partial mastectomy and radiotherapy. This scenario is ideal, because it allows the multidisciplinary approach of caring for the patient with breast cancer to be applied. However, several important considerations must be given to this patient population. Most patients who undergo a partial mastectomy have localized disease. However, if a woman presents with multiple foci of disease, she is probably better served with delayed repair; there is an increased risk of both a positive tumor margin and a severe breast deformity, and she would more likely benefit from a total mastectomy with immediate or delayed immediate breast reconstruction.

The most important consideration for these patients is the status of the tumor margin. The decision to either proceed with an immediate repair or to wait 1 or 2 weeks until a negative margin has been confirmed rests with the breast surgeon, the pathologist, and the reconstructive breast surgeon in consultation.

Although it may seem intuitive to delay the repair until after a negative tumor margin is confirmed, many patients are at a low risk and would require an additional surgery to perform the repair before radiotherapy. After these issues have been addressed, the location and extent of the skin resection and the breast/tumor ratio must be considered.

Timing of the Reconstruction

Waiting to repair a large partial mastectomy deformity until after whole breast radiotherapy usually necessitates a complex transfer of a large volume of autologous tissue, and many patients who undergo BCT are not willing to undergo this procedure. The difficulties associated with a secondary repair in an irradiated surgical field often limit the use of adjacent irradiated breast tissue, because complication rates are high and breast implants are not a preferred option. However, with the increasing use of partial breast irradiation instead of whole breast irradiation, using the remaining breast tissue (breast-reduction technique) may become a viable option for these patients. Although we usually prefer immediate repair, if an unexpected deformity results after a partial mastectomy or if the tumor margin status is unclear at the time of the partial mastectomy, reconstruction still can be performed before radiotherapy once the final margin status has been confirmed.

Tumor Margin Status

Attention must be given to the tumor margin status before rearranging the breast parenchyma. If there is ever any concern—either preoperatively or intraoperatively—about the ability to determine the adequacy of the tumor margins, the partial mastectomy wound is closed primarily, without any tissue rearrangement. After negative margins are confirmed on the permanent sections, the repair is performed within several weeks of the partial mastectomy; usually there is no delay in starting radiotherapy.

Table 15-3 Effect of the Timing of Reconstruction and Reconstructive Techniques on the Incidence of Positive Postoperative Tumor Margins and Local Recurrence of Breast Cancer

Factor	Positive Postoperative Tumor Margin* (n = 4) (%)	Local Recurrence of Breast Cancer† (n = 4) (%)
Timing of Reconstruction		
All	5	6
LTR	5	5
BR	6	5
FLAP	0	13
Reconstructive Technique		
Immediate	5	2
Delayed	—‡	16§

*Based on the initial 84 patients, before excluding patients who did not receive radiotherapy, because it did not affect the rate of positive postoperative tumor margins.

†Based on the 69 patients who received radiotherapy. Positive postoperative tumor margins are only pertinent to immediate reconstruction after partial mastectomy.

‡Borderline statistical significance ($p = 0.06$).

§Positive postoperative tumor margins are only pertinent to immediate reconstruction after partial mastectomy. BR, Breast reduction; FLAP, reconstruction with a latissimus dorsi myocutaneous or thoracoepigastric flap; LTR, local tissue rearrangement.

In our series,⁸ only 5% of patients had a positive tumor margin after undergoing immediate repair after partial mastectomy. This relatively low rate of positive tumor margins reflects the large defect sizes that are usually present in patients who undergo a partial mastectomy and require repair. This rate is lower than rates for positive margins in patients who do not undergo repair,¹⁰ because the defect sizes that are reported in patients who do not undergo repair are usually smaller.

The low rate of positive tumor margins alleviates concerns regarding the potentially awkward situation of trying to locate the position of a positive tumor margin after an immediate repair with the breast-reduction technique. In addition, our experience indicates that the majority of the patients who are scheduled for repair because of larger anticipated defects usually proceed to a completion mastectomy with immediate breast reconstruction and not additional reexcision. The relatively low incidence (5%) of the local recurrence of breast cancer⁸ is further evidence of its safety and should support the role of immediate

repair of partial mastectomy defects using the breast-reduction technique as a definitive method of breast reconstruction.

Technique Selection: Skin Defect Size and Location

The anticipated size and location of the skin defect are essential factors to consider when deciding on the most appropriate reparative technique.

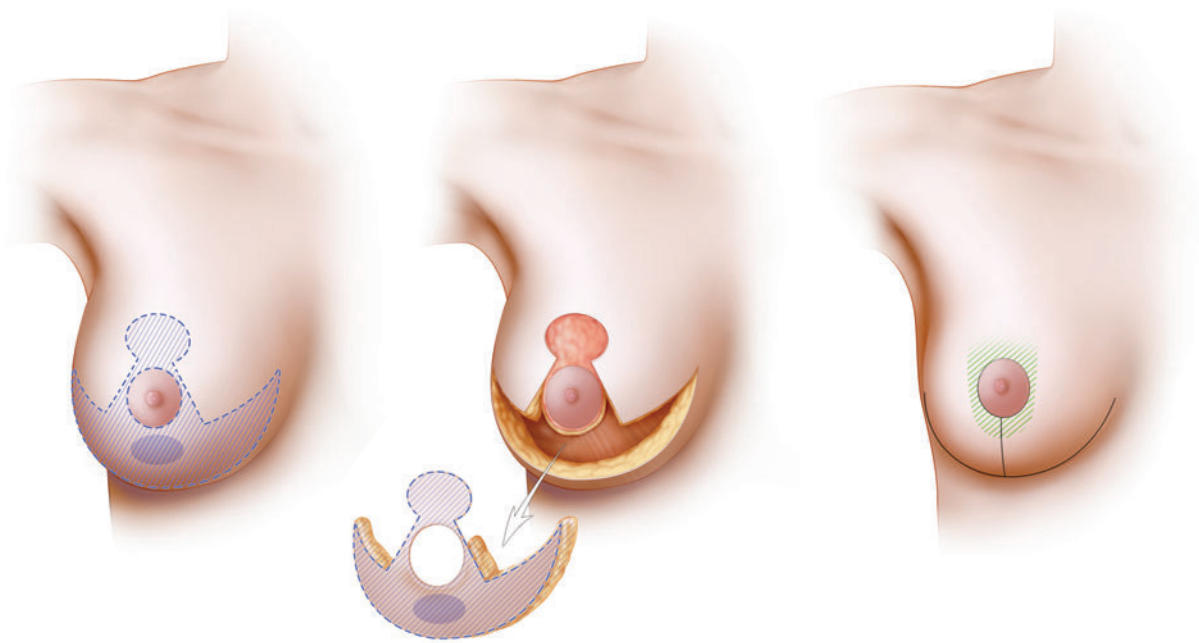


Fig. 15-2

When the breast skin resection (tumor extirpation) is located within the boundaries of the Wise pattern, the situation is ideal. Conversely, when the skin to be resected is located outside the Wise pattern, this can be problematic. In such situations, modifying the Wise skin pattern to incorporate the resected skin should be considered. If the skin to be resected involves only the reexcision of an existing biopsy site, and if there is an adequate skin bridge between the biopsy site and the Wise pattern, the biopsy site can be reexcised separately. The tumor extirpation can be performed through an access incision located along the superior or inferior limb of the Wise pattern. Although the appropriateness of a separate access incision for the tumor resection is determined by the breast surgeon, this approach can result in an optimal cosmetic outcome with minimal breast-shape distortion.

Technique Selection: Proximity of the Anticipated Defect to the Nipple-Areola Complex

Another important consideration regarding the use of the breast-reduction technique is the proximity of the anticipated breast parenchymal defect to the NAC. When the anticipated defect is centrally located (subareolar) within the breast, patients are advised preop-

eratively of the possibility that the only remaining blood supply to the NAC after resection will be from the skin attachments, potentially jeopardizing nipple viability. The options are discussed preoperatively, including the breast-reduction technique with a free nipple graft and the local rearrangement of the surrounding breast parenchyma without repositioning the NAC (local tissue rearrangement). Patients are advised that when the local tissue rearrangement technique is used in such circumstances, the contralateral breast is not reduced at the time of repair, because further recommendations are based on the cosmetic outcome.

SURGICAL TECHNIQUE

At MD Anderson Cancer Center, the majority of partial mastectomy defects are repaired with the breast-reduction technique.

Probably the most important factor in designing the dermoglandular pedicle is the location of the tumor.

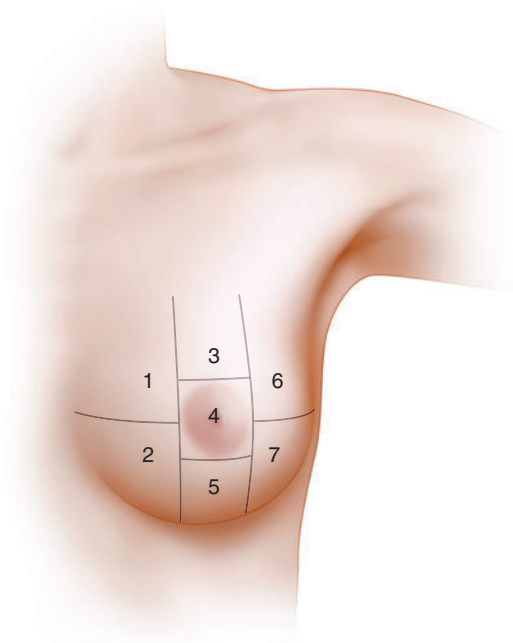


Fig. 15-3

We have formulated zone designations of the breast, which are based on the tumor location that can help design this pedicle when repairing a partial mastectomy defect using the breast-reduction technique.

Together, the plastic and breast surgeons preoperatively determine the location for the skin incisions to optimize the cosmetic outcomes and decrease the potential for complications. Often, the breast surgeon can access the tumor through a skin incision located along the Wise skin pattern, which we have found to be particularly useful for repairing partial mastectomy defects. This approach—with the use of a separate axillary incision through which a sentinel lymph node biopsy or a complete axillary node dissection is performed—can minimize the need to undermine the lateral Wise skin flap, which can decrease its blood supply.

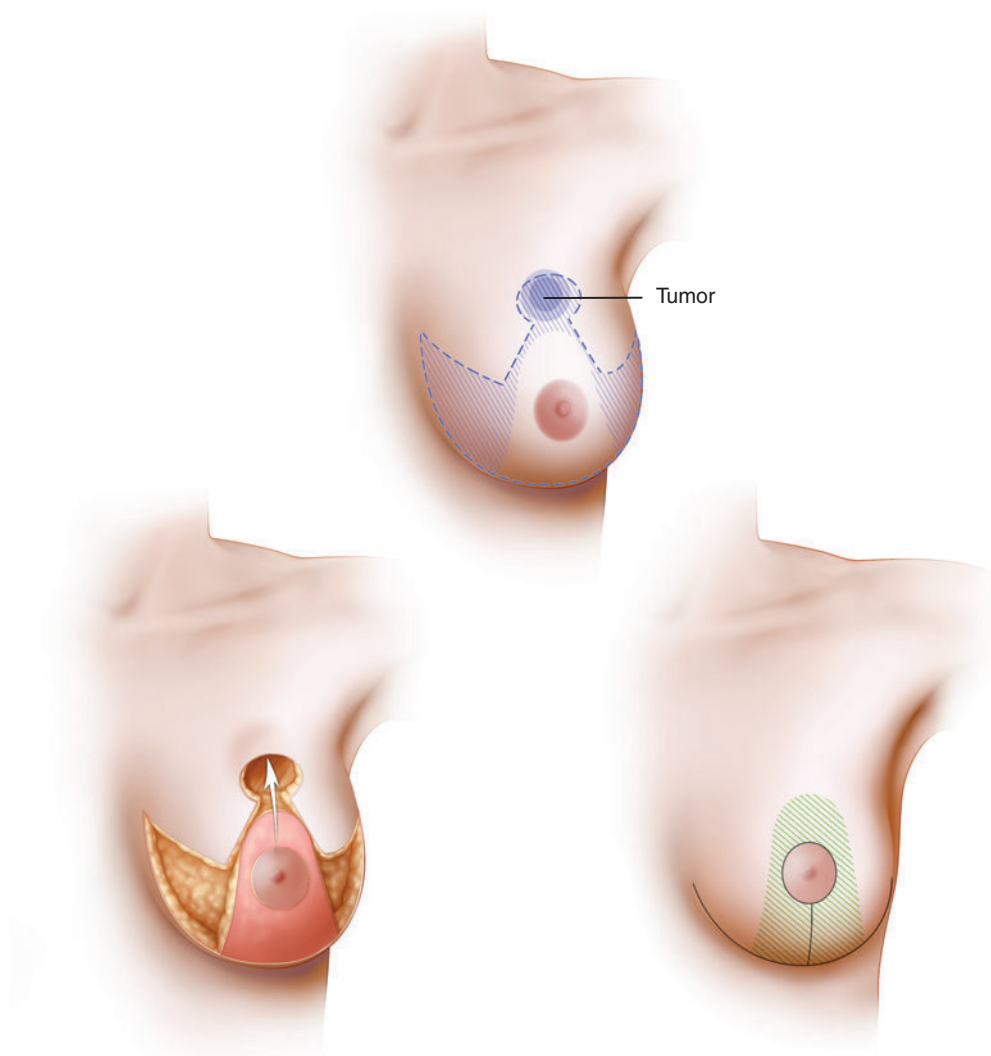


Fig. 15-4

Most commonly, we use an inferiorly based dermoglandular pedicle. The widespread use of the inferior pedicle to perform a standard reduction mammoplasty very likely has made our surgeons more comfortable with using and modifying this pedicle design, which is often required when repairing partial mastectomy defects.

Table 15-4 Effect of Parenchymal Pedicle Design and Tumor Location on Cosmetic Outcome*

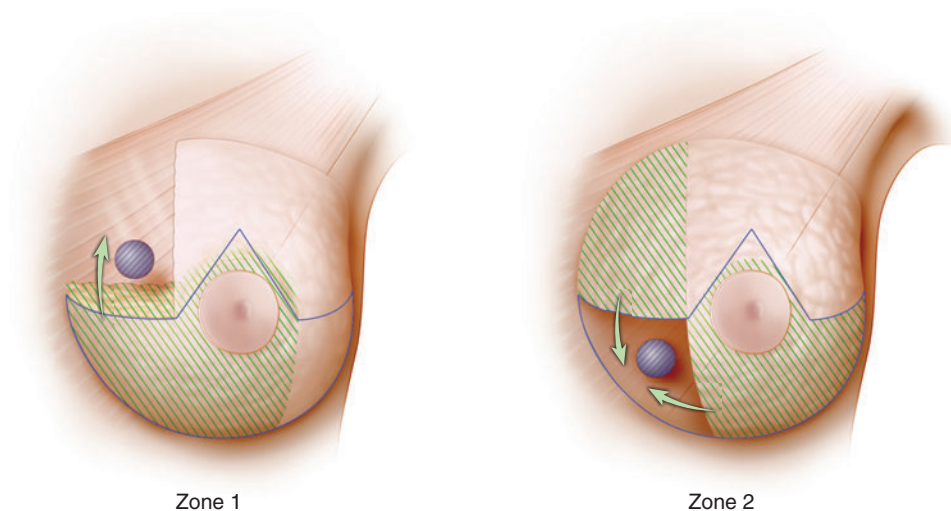
Characteristics	Cosmetic Outcomes (%)	
	Excellent or Good	Fair or Poor
All pedicle designs	4 (57)	3 (43)
Inferior	3 (75)	1 (25)
Superior	0 (0)	2 (100)
Central	1 (100)	0 (0)
Tumor Quadrant		
Upper outer	2 (67)	1 (33)
Upper inner	0 (0)	1 (100)
Lower inner	2 (67)	1 (33)
Mean defect size†	19%	17%

*Cosmetic outcomes were evaluated by reviewing postoperative photographs. A panel of 23 physician assistants, nurses, and plastic surgery fellows who did not participate in these reconstructions blindly evaluated the patients' photographs. Results were classified as excellent if the shape of the reconstructed breast and the symmetry between the treated breast and the contralateral breast were normal, good if the shape of the reconstructed breast was normal but some asymmetry with the contralateral breast was evident, fair if the shape of the reconstructed breast was abnormal but reasonably symmetric with the contralateral breast, and poor if the shape and symmetry were abnormal. Only 7 patients who underwent the breast-reduction technique had photographs available. The mean time intervals from radiotherapy to the photograph used for scoring were: overall, 23 months; excellent or good, 20 months; fair or poor, 27 months. The overall mean defect size was 18% of the initial breast volume. The mean resection weight was 245 g. The bra size was a C cup in 1 patient, D in 2 patients, and DD in 4 patients. Of these patients, 3 underwent immediate repair and 4 underwent delayed repair. Cosmetic outcomes for all modifications of the inferior pedicle were included within this group.

†Weight of the breast cancer resection specimen (g)/estimated initial breast weight (g), based on the initial bra cup size and the chest wall circumference. The relative proportions of glandular tissue and fat within the breast tissue and their respective densities indicate that the density of the breast tissue is 1 g/cm³ (also the density of water). Thus the volume of the breast tissue in cubic centimeters is equal to the weight of the breast tissue in grams. For this study, the volume of each breast resection specimen was determined by weighing the specimen. Similarly, the preoperative volume of the entire breast was determined by estimating the weight of the breast using the patient's bra cup size and chest wall circumference.

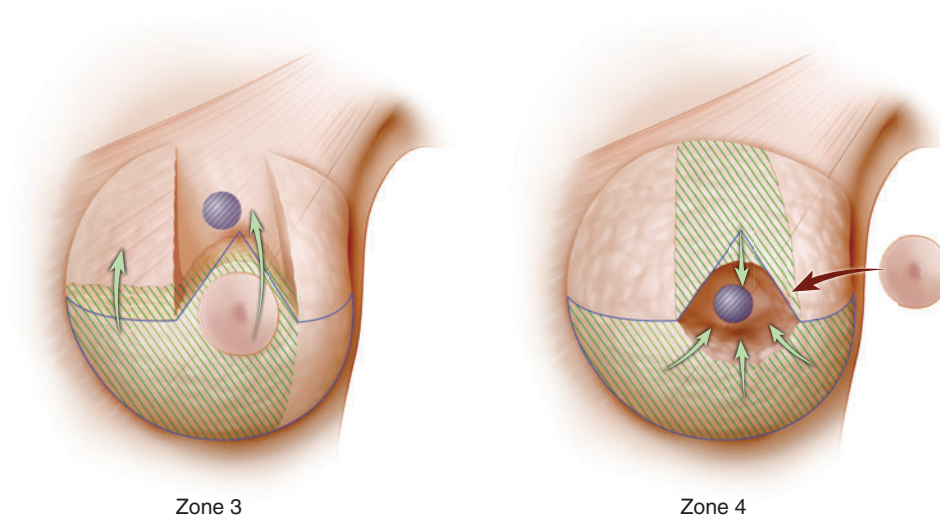
We tend to achieve more favorable cosmetic outcomes with an inferior pedicle,⁸ because it maintains an inferior pole projection and incorporates into the Wise skin-resection pattern. In addition, the inferior pedicle can be modified easily to accommodate a free nipple graft, if necessary.

We modify the standard inferior pedicle design when using an inferiorly based dermoglandular pedicle to repair a partial mastectomy defect.⁹ Some practical guidelines for designing the dermoglandular pedicle according to the tumor location have been developed. These can be applied to repair a partial mastectomy defect using the breast-reduction technique.

**Fig. 15-5**

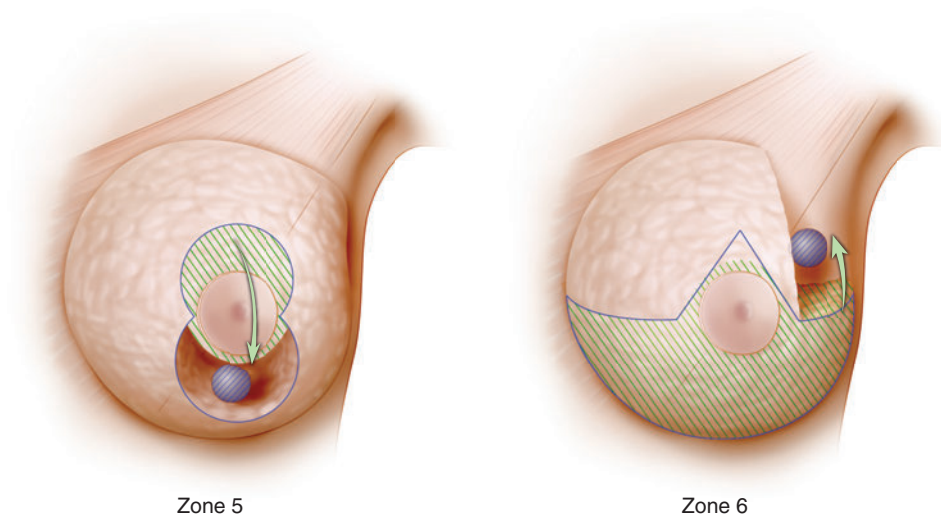
For defects in the upper inner quadrant (zone 1), an inferomedial pedicle should be used. The retained medial component fills the defect on closure of the Wise skin pattern and maintains the breast cleavage.

In the lower inner quadrant (zone 2), defects should be repaired with an inferolateral pedicle. The retained lateral component provides an additional blood supply to the NAC if the tumor resection encroaches on the inferior pedicle. A thick layer of subcutaneous tissue is maintained on the medial aspect of the Wise pattern skin flap to fill the defect on closure of the Wise skin pattern and to maintain the breast cleavage.

**Fig. 15-6**

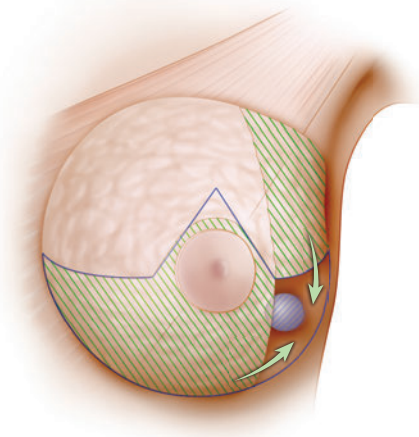
An inferomedial pedicle should be used in the upper central quadrant (zone 3). The retained medial component provides a cosmetic advantage and an additional blood supply to the NAC in patients with very large, ptotic breasts, possibly obviating the need for a free nipple graft.

This amputative design, located in the middle central quadrant (zone 4), has a free nipple graft and maintains a thick layer of subcutaneous tissue on the central aspect of the Wise pattern skin flap to fill the defect and improve contour.

**Fig. 15-7**

This vertical scar reduction mammaplasty is located in the lower central quadrant (zone 5).

An inferomediolateral pedicle is used in the upper outer quadrant (zone 6). The retained lateral component fills the defect on closure of the Wise skin pattern, and the retained medial component provides a cosmetic advantage.

**Fig. 15-8**

In the lower outer quadrant (zone 7), an inferomedial pedicle is used. The retained medial component provides a cosmetic advantage and an additional blood supply to the NAC if lateral resection encroaches on its blood supply. A thick layer of subcutaneous tissue is maintained on the lateral aspect of the Wise pattern skin flap to fill the defect.

The most common modification is the inferomedial pedicle. When compared with a standard inferior pedicle, it may provide an enhanced blood supply to the NAC, because it retains the medial wedge of breast tissue that usually is discarded with a standard inferior pedicle design. When a standard inferior pedicle is impinged on by the tumor resection, the pedicle is extended medially (the least frequent location for breast cancer) to increase

the blood supply (from the intercostals and internal mammary perforating blood vessels) and the volume of breast tissue available for repair.

Table 15-5 Effect of Timing of the Repair and Design of the Parenchymal Pedicle on Complication Rates*

Parenchymal Pedicle	All Repairs (%)		Immediate Repairs Before Radiotherapy (%)†		Delayed Repairs After Radiotherapy (%)‡	
	Number	Number of Complications	Number	Number of Complications	Number	Number of Complications
Inferior	27	8 (30)	21	5 (24)	6	3 (50)
Superior	5	3 (60)	4	2 (50)	1	1 (100)
Lateral	3	0 (0)	3	0 (0)	0	—
Central	1	0 (0)	0	—	1	0 (0)
McKissock bipedicle	1	0 (0)	1	0 (0)	0	—
Amputative with FNG or NR	4	1 (25)	4	1 (25)	0	—

*Complication rates were calculated per repair. Complications include nipple necrosis, seroma formation, wound dehiscence, infection, hematoma, fat necrosis of breast tissue, and mastectomy skin flap necrosis. The most frequently occurring complications were fat necrosis (5 of 41; 12%), seroma formation (3 of 41; 7%), breast skin necrosis (2 of 41; 5%), wound dehiscence (2 of 41; 5%), and infection (2 of 41; 5%). Thirty-eight percent (3 of 8) of the patients who underwent delayed repair developed a postoperative seroma compared with none of the patients who underwent immediate repair. Although the occurrence of postoperative fat necrosis was similar for immediate (4 of 32; 12.5%) and delayed (1 of 8; 13%) repair, both infection and wound dehiscence were more frequent with delayed repair (1 of 8; 12.5%) than with immediate repair (1 of 33; 3%). Only one case of nipple necrosis occurred, in a patient who underwent delayed repair with an inferior pedicle. However, 12% of immediate repairs and none of the delayed repairs required conversion to an amputative pedicle with a free nipple graft or nipple reconstruction, which may have selected out the patients at high risk for nipple necrosis.

†For immediate reconstruction, the mean time interval between the partial mastectomy with immediate reconstruction and radiotherapy was 3 months. The time interval did not differ between patients who had complications and those who did not.

‡For delayed reconstruction, the mean time interval between the partial mastectomy and after radiotherapy was 4 months. A shorter time interval was associated with a higher rate of complications, which may reflect less time for the remaining breast tissue to reestablish a local blood supply before the start of radiotherapy. The subsequent mean time interval between radiotherapy and reconstruction was 37 months.

FNG, Free nipple graft; NR, nipple reconstruction.

It is likely that the additional medial wedge of breast tissue retained with the inferomedial pedicle decreases the incidence of complications by decreasing the dead space. This is especially true in the repair of upper inner quadrant (zone 1) defects, which we found to be associated with a relatively high incidence of complications when the medial wedge was not retained.

Table 15-6 Effect of the Breast Tumor Location on Complications and the Requirement for Free Nipple Graft or Nipple Reconstruction*

Tumor Quadrant	Number	Number of Overall Complications (%)	NAC Viable† Number (%)	NAC Not Viable† (Required FNG or NR) Number (%)
Upper outer	23	8 (35)	22 (96)	1 (4)
Upper inner	7	2 (29)	6 (86)	1 (14)
Lower outer	2	0 (0)	1 (50)	1 (50)
Lower inner	7	2 (29)	7 (100)	0 (0)
Central	2	0 (0)	1 (50)	1 (50)

*The values in this table are reported as the number of repairs (percentage). Complications of repairing the partial mastectomy defects were nipple necrosis, seroma formation, wound dehiscence, infection, hematoma, fat necrosis of the breast tissue, and breast skin flap necrosis.

†The assessment was performed after completing the partial mastectomy at the time of repair. Ninety percent of the patients who underwent repair of a partial mastectomy defect with the breast reduction had a viable NAC and did not require an FNG or NR ($p = 0.05$).

FNG, Free nipple graft; NAC, nipple-areola complex; NR, nipple reconstruction.

In addition, in patients with very large breasts who have a long distance between the NAC and the inframammary fold, the additional blood supply provided by the inferomedial pedicle may improve the viability of the NAC and decrease the need for a conversion to a free nipple graft.

The wedge of medial breast tissue retained with the inferomedial pedicle can also provide significant cosmetic benefits, especially for repairs after the resection of tumors located in the upper inner quadrant (zone 1)—a notoriously challenging location from which it is difficult to obtain an adequate volume of tissue for repair. When compared with other dermoglandular pedicles, we found that the inferomedial pedicle also enhances the cosmetic outcomes of most repairs performed with the breast-reduction technique in the lower outer (zone 7) and upper central quadrants (zone 3) of the breast. For defects in the lower outer quadrant (zone 7), the cosmetic result can be improved further by retaining the thickness of breast tissue on the lateral Wise pattern skin flap. The retained medial wedge of breast tissue increases the fullness in the medial aspect of the repaired breast, which improves the flattened appearance that tends to occur with the use of a standard inferior pedicle. It also augments the breast cleavage and improves the cosmetic outcomes in large-breasted patients (in whom we perform the majority of partial mastectomy repairs).

In several quadrants of the breast, an inferomedial pedicle is not the preferred choice.⁹ For defects located in the lower inner quadrant (zone 2), we usually use an inferolateral pedicle and compensate for the loss of tissue by retaining the thickness of breast tissue on the medial Wise pattern skin flap. For defects located in the upper outer quadrant (zone 6), we

often use an inferomediolateral pedicle. The lateral component fills the defect; the medial component provides the aforementioned cosmetic advantages and enhances the blood supply to the NAC. For defects located in the direct vicinity of the inferior pedicle, along the breast meridian (lower central quadrant or zone 5), we often use a superior pedicle with a vertical skin-reduction pattern. This tends to be the only circumstance in which a Wise skin resection pattern is not preferred.

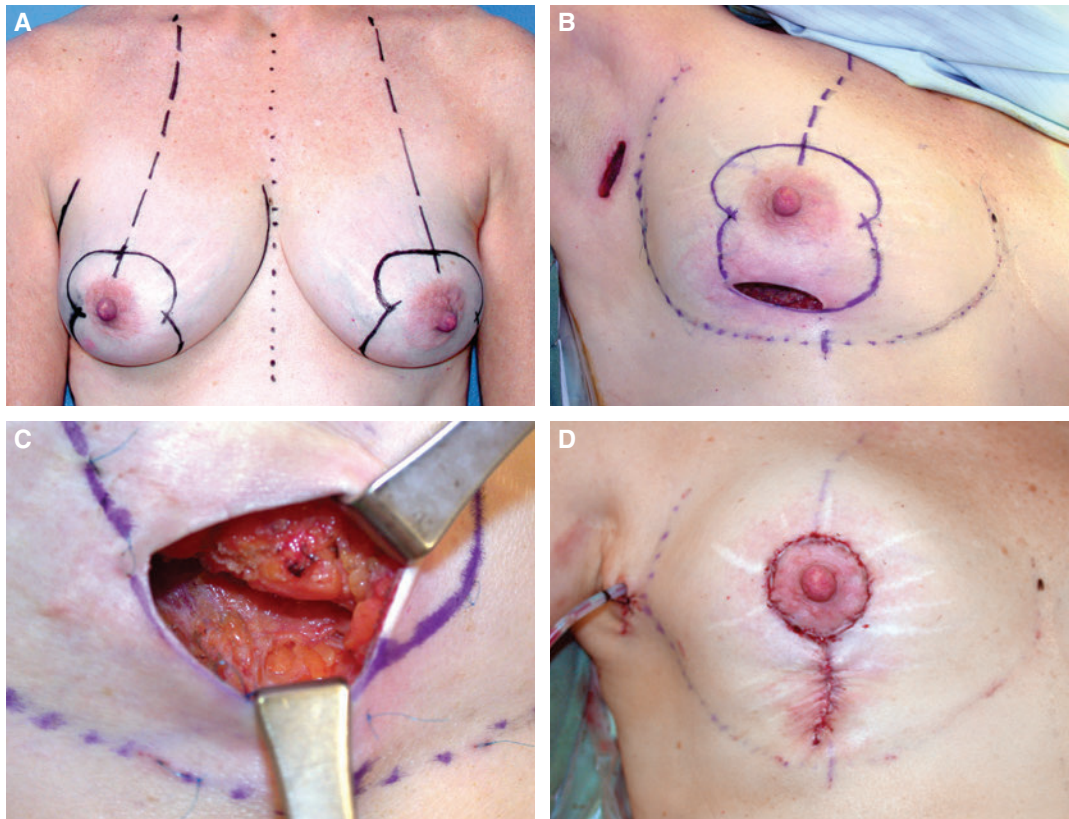


Fig. 15-9

The repair of a partial mastectomy defect is shown in a 52-year-old woman who presented with a T2 tumor (zone 5) of the right breast. Markings were made preoperatively with a vertical skin-reduction pattern (A). The defect (zone 5) and the access incision used by the breast surgeon to perform the tumor resection are shown intraoperatively (B and C). The repair was completed using a superior dermoglandular pedicle (D). Over the next several months, the fullness in the superior aspect of the repaired breast descended inferiorly to fill the lower pole.

When the anticipated defect is centrally located in the breast, underlying the NAC, we advise patients preoperatively that the only remaining blood supply to the NAC after the tumor resection may be from the skin attachments, which may preclude the use of the standard breast-reduction technique. In this setting, the surgical options are also discussed with the patient preoperatively. These include the breast-reduction technique (inferomediolateral pedicle) with a free nipple graft or local rearrangement of the surrounding, remaining breast parenchyma without repositioning the NAC. In cases involving local tissue rearrangement, the contralateral breast is not reduced at the time of the repair. Rather, if the cosmetic outcome is unacceptable, consideration is given to proceeding with a completion mastectomy with a total breast reconstruction, thereby avoiding the adverse effects of radiotherapy.

The Contralateral Breast

A contralateral breast reduction for symmetry is required in most patients (about 95%) who undergo repair of a partial mastectomy defect using the breast-reduction technique.⁸ We prefer to perform this procedure once radiotherapy has been completed.

When the contralateral breast reduction is performed before radiotherapy, the ipsilateral repaired breast may become larger (that is, chronically edematous from impaired lymphatic drainage) or smaller (from radiation-induced fat necrosis with subsequent atrophy) than the contralateral breast when it is reduced at the same time that the ipsilateral breast is repaired.⁹

However, the optimal timing for performing the contralateral breast reduction for symmetry varies according to the patient selection and surgeon's preference.^{9,11}

PATIENT EXAMPLES

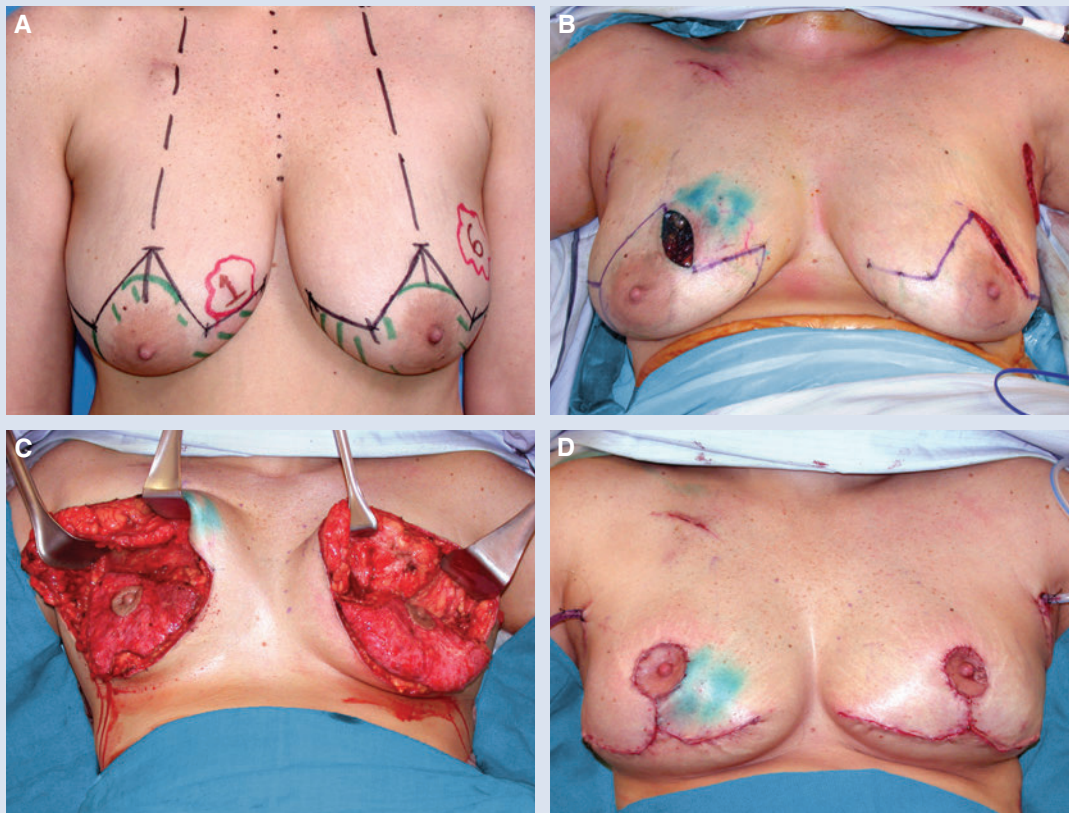


Fig. 15-10

This 39-year-old woman with D-cup breasts presented with a T2N3 tumor in the left breast and a T2N0 tumor in the right breast. She had neoadjuvant chemotherapy with an excellent response and wanted to undergo BCT. Preoperative markings for a tumor in the right breast (zone 1) and a tumor in the left breast (zone 6) were made (A). Markings were also made for access incisions through which the tumor resections, the right axillary sentinel lymph node biopsy, and the left levels I and II axillary lymph node dissection were to be performed (B). The intraoperative view after the tumor resection shows extirpative defects and dermoglandular pedicle designs (C). The defect in the right breast was repaired using an inferomedial pedicle, and an inferomediolateral pedicle was used to repair the left breast. The patient is shown intraoperatively, after the repairs are completed (D). Notice how the retained *medial* wedge of breast tissue fills the defect (zone 1) in the right breast; the retained *lateral* wedge fills the defect (zone 6) in the left breast.

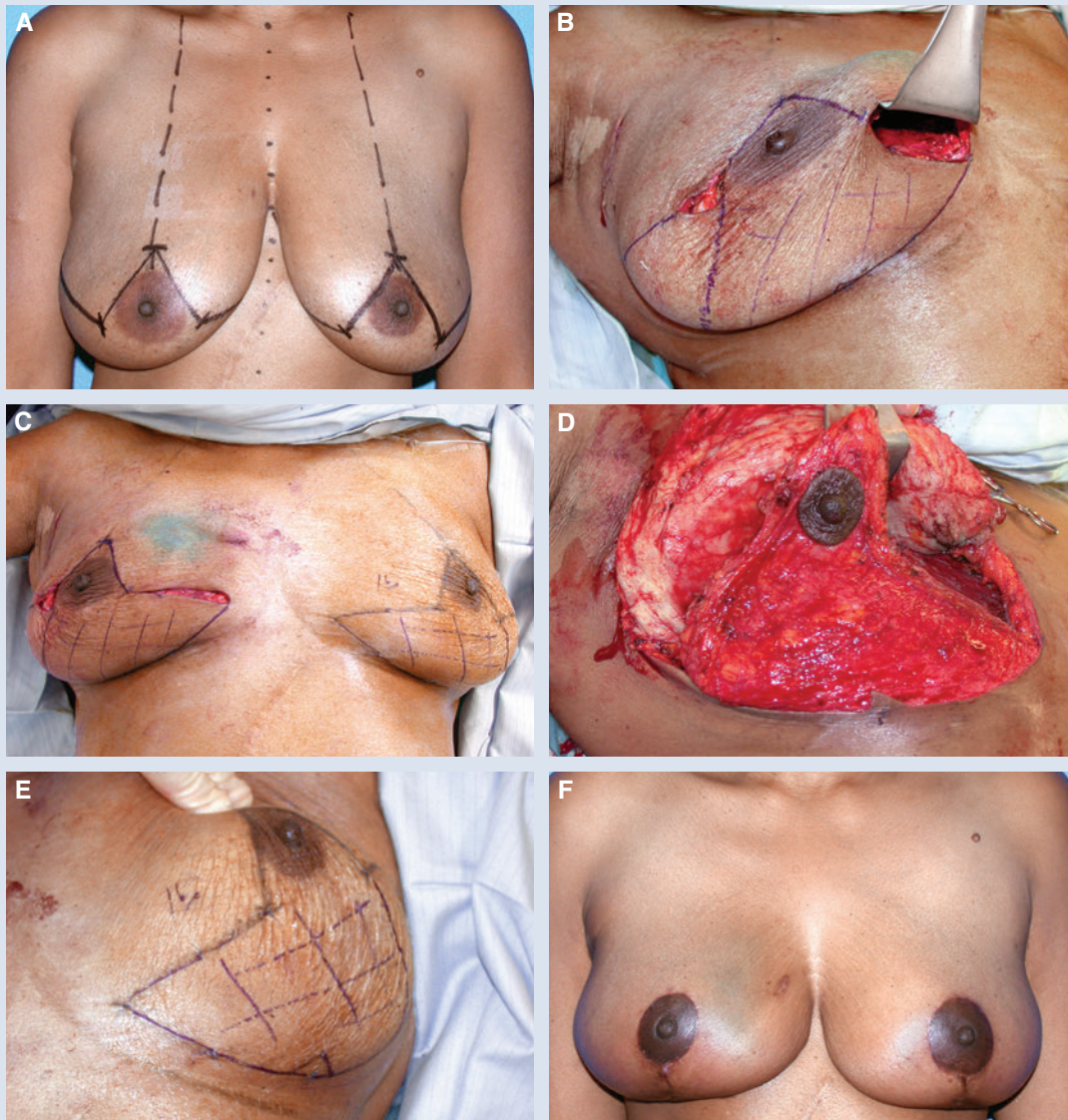
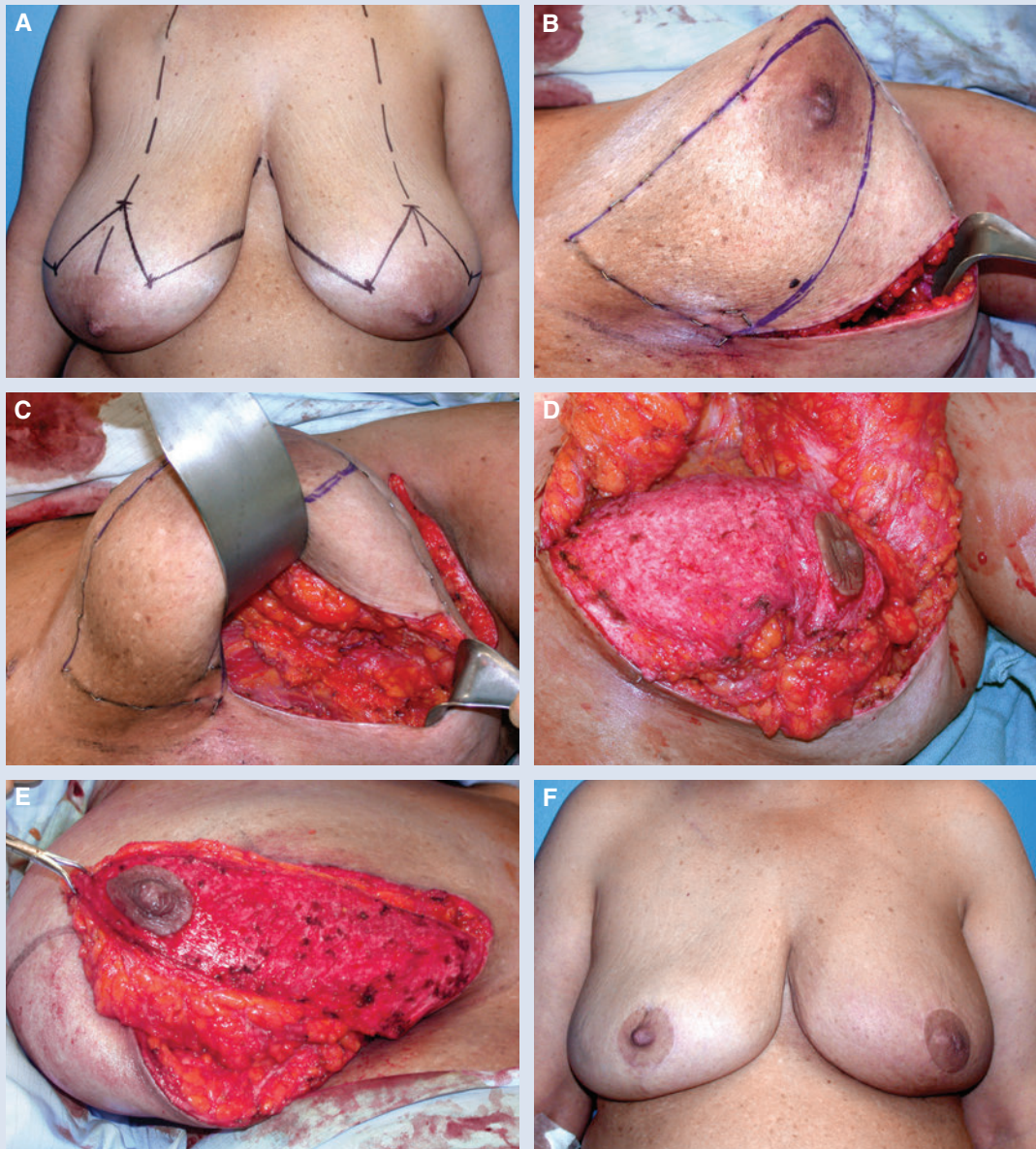
Fig. 15-11

This 46-year-old woman with a 38D bra size presented with a T1N0 (stage I) invasive ductal carcinoma in the upper inner quadrant of her right breast. She underwent immediate breast repair after a partial mastectomy. Wise pattern skin markings were made preoperatively in preparation for reconstruction with the breast-reduction technique (A). A partial mastectomy was performed. The resected specimen weighed 80 g. The breast defect (B) involved 7% of the initial breast volume (zone 1). A reexcision at the previous biopsy site was carried out separately from the tumor resection, which was performed through an access incision along the superior limb of the Wise pattern (C). The defect was repaired immediately, using an inferomedial pedicle (D). The additional tissue resected in the reconstruction weighed 60 g. A contralateral breast reduction was also performed to achieve symmetry (E). The tissue resected from the contralateral breast weighed 110 g. Six weeks after the repair, the retained medial wedge of breast tissue filled the defect in zone 1 (F). In addition, the reexcised biopsy site was barely noticeable and did not detract from the appearance of the breast.

**Fig. 15-12**

This 57-year-old woman with a 38DD bra size presented with a T3N1 (stage III) invasive ductal carcinoma of the left breast (zone 7). The patient received neoadjuvant chemotherapy, and the tumor responded well to the treatment. She underwent a partial mastectomy with breast reconstruction and radiotherapy. Wise pattern skin markings were made preoperatively (A). A partial mastectomy (resection weight of 252 g) and a left level I and II axillary node dissection were performed (B). The tumor resection was performed through an access incision along the inferior limb of the Wise pattern (C). The resultant defect, which corresponded to 18% of the initial breast volume, was immediately repaired with an inferomedial pedicle (D). The additional tissue resected in performing the repair weighed 325 g. The tumor resection encroached

on the inferior component of the pedicle; however, it preserved the blood supply to the medial aspect. Although it is not a classical technique in breast reduction, a similar inferomedial pedicle was also applied to the right breast at the same surgery (*E*). We currently delay the contralateral breast reduction until 6 months after radiotherapy. The tissue resected from the right breast weighed 635 g. The patient is shown 10 months after the repair and 8 months after radiotherapy (*F*). Note the fullness in the medial aspect of the breasts and the smooth contour of the reconstructed lower outer quadrant of the left breast.

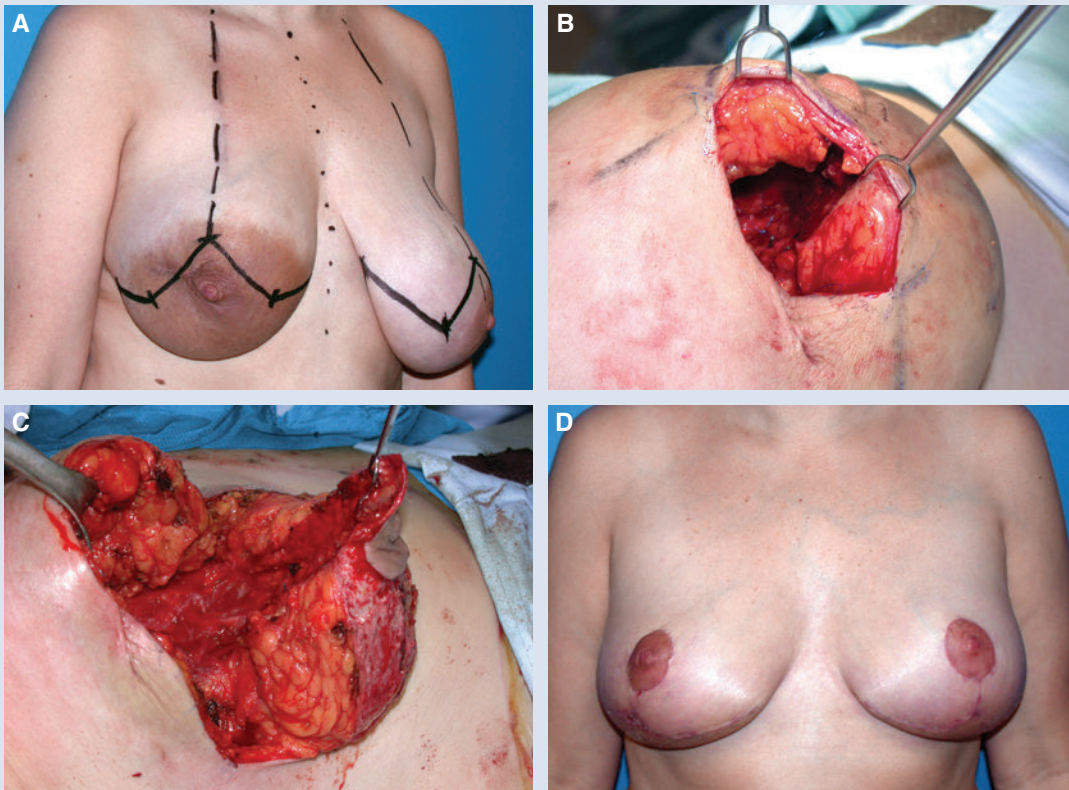


Fig. 15-13

This case demonstrates an unexpected deformity after a partial mastectomy that required a delayed repair before radiotherapy. This 41-year-old woman presented 2 weeks after undergoing a partial mastectomy for a central quadrant tumor. She was very dissatisfied with the result and understood that the cosmetic outcome also would be adversely affected by the radiotherapy. Wise pattern skin markings are shown preoperatively in preparation for a partial mastectomy repair with the breast-reduction technique (*A*). Because the extent and exact location of the central resection (presumed to be in zone 3) could not be determined preoperatively, the NAC was explored to assess the adequacy of the blood supply before beginning the breast-reduction technique (*B*). The blood supply retained by the NAC was adequate for repair with an inferomedial pedicle (*C*). The patient is shown 3 months after the repair (*D*). She is happy with the result, as is the breast surgeon.

CONCLUSION

We have found that optimal outcomes are achieved in patients who undergo repair of a partial mastectomy defect using the breast-reduction technique before radiotherapy.^{12,13} The breast-reduction technique is usually reserved for patients with D-cup or larger breasts. The use of an inferiorly based parenchymal pedicle for the breast-reduction technique is associated with an acceptable rate of complications and favorable aesthetic outcomes. In addition, most plastic surgeons are familiar with the use of this pedicle and are comfortable modifying its design, which is often required when it is used to repair partial mastectomy defects. We have found that this technique results in low rates of positive postoperative tumor margins and local recurrence of breast cancer.^{8,9} It is a useful addition to the reconstructive options available for women with breast cancer and macromastia who desire breast preservation.

Critical Issues

- It is important to coordinate the placement of the skin incision with the breast surgeon.
- The tumor is accessed for resection using a skin incision along the Wise skin pattern, vertical skin pattern, concentric skin pattern, or a prior biopsy site.
- A previous biopsy site is reexcised if it is located outside of the Wise skin pattern. Unless there is tumor involvement, it is not necessary to extend or modify the pattern.
- A separate axillary incision is recommended to perform the lymphadenectomy (axillary sentinel lymph node biopsy or complete axillary lymph node dissection) to avoid the need to undermine and subsequently decrease the blood supply to the lateral Wise skin flap.
- If there is a concern regarding the adequacy of the intraoperative tumor margin, the wound can be closed primarily and the defect subsequently repaired using the breast-reduction technique (within several weeks) after obtaining a negative margin on the permanent sections.
- If the tumor resection encroached on the blood supply to the NAC, the surgeon should consider delaying the blood supply to the NAC before the oncoplastic repair. Typically, 2 weeks is adequate time to upregulate the blood supply to the NAC and to permit oncoplastic repair with minimal risk of NAC necrosis.

- The type of reduction technique used and the design of the dermoglandular nipple pedicle depend mainly on the physician's preference, the skin defect, and the tumor location. Options include the Wise, vertical, or concentric skin resection patterns. The dermoglandular pedicle can be supplied from any location including inferiorly based, superiorly based, or the central mound.
- Avoid positioning the Wise skin resection pattern within the inframammary fold to prevent wound healing.
- Wound dehiscence and delayed wound healing at the T-junction on closure of the Wise skin pattern can be decreased by including a triangular piece of breast skin located within the Wise pattern along the inferior edge, located centrally within the breast meridian.
- It is important to include either the medial or lateral wedge of breast tissue as part of the inferiorly based dermoglandular pedicle to ensure an adequate blood supply to the NAC. Compared with cosmetic breast reduction, tumor resection can encroach on the blood supply to the NAC.
- Whenever feasible, the medial wedge should be included with the dermoglandular pedicle—excluding zone 2 defects—to optimize the cosmetic outcome by retaining the fullness in the medial aspect of the repaired breast.
- To optimize breast symmetry, (1) the contralateral breast reduction for symmetry should be deferred until radiotherapy is completed to allow adequate time for the repaired ipsilateral breast to assume its final size (radiation-induced fat necrosis with subsequent atrophy) and (2) the same dermoglandular pedicle design should be used for the contralateral breast symmetry procedure that was used for the repair of the partial mastectomy defect of the ipsilateral breast.

References

1. Slavin SA, Love SM, Sadowsky NL. Reconstruction of the radiated partial mastectomy defect with autogenous tissues. *Plast Reconstr Surg* 90:854, 1992.
2. Clough KB, Cuminet J, Fitoussi A, et al. Cosmetic sequelae after conservative treatment for breast cancer: classification and results of surgical correction. *Ann Plast Surg* 41:471, 1998.
3. Clough KB, Kroll SS, Audretsch W. An approach to repair of partial mastectomy defects. *Plast Reconstr Surg* 104:409, 1999.
4. Rietjens M, Petit JY, Contesso G, et al. The role of reduction mammoplasty in oncology. *Eur J Plast Surg* 20:246, 1997.
5. Losken A, Elwood ET, Styblo TM, et al. The role of reduction mammoplasty in reconstructing partial mastectomy defects. *Plast Reconstr Surg* 109:968, 2002.
6. Smith ML, Evans GR, Gurlek A, et al. Reduction mammoplasty: its role in breast conservation surgery for early-stage breast cancer. *Ann Plast Surg* 41:234, 1998.
7. Boice JD Jr, Persson I, Brinton LA, et al. Breast cancer following breast reduction surgery in Sweden. *Plast Reconstr Surg* 106:755, 2000.

8. Kronowitz SJ, Feledy JA, Hunt KK, et al. Determining the optimal approach to breast reconstruction after partial mastectomy. *Plast Reconstr Surg* 117:1, 2006.
9. Kronowitz SJ, Hunt KK, Kuerer HM, et al. Practical guidelines for repair of partial mastectomy defects using the breast reduction technique in patients undergoing breast conservation therapy. *Plast Reconstr Surg* 120:1755, 2007.
10. Pawlik TM, Perry A, Strom EA, et al. Potential applicability of balloon catheter-based accelerated partial breast irradiation after conservative surgery for breast carcinoma. *Cancer* 100:490, 2004.
11. Losken A, Styblo TM, Carlson GW, et al. Management algorithm and outcome evaluation of partial mastectomy defects treated using reduction or mastopexy techniques. *Ann Plast Surg* 59:235, 2007.
12. Kronowitz SJ, Kuerer HM, Buchholz TA, et al. A management algorithm and practical oncoplastic surgical techniques for repairing partial mastectomy defects. *Plast Reconstr Surg* 122:1631, 2008.
13. Kronowitz SJ. State of the art and science in postmastectomy breast reconstruction. *Plast Reconstr Surg* 135:755, 2015.

16

Reduction and Mastopexy Techniques With Parenchymal Autoaugmentation

*Albert Losken, Alexandra M. Hart,
James Walter Dutton, Jr.*



ammaplasty reduction techniques have become a popular option for the management of partial mastectomy defects, as described in Chapter 15. Plastic surgeons are familiar with these techniques, making the incorporation of this approach into their reconstructive practice an easy addition.¹⁻³ They are probably the most common oncoplastic techniques used by plastic surgeons in the United States. In Europe, they became popular for reconstructing quadrantectomy defects in the lower pole, improving the poor cosmetic results associated with defects in this location.⁴

In the United States, the popularity of this technique probably evolved out of the frustration of managing breast cancer patients with macromastia.⁵ Large, pendulous breasts are often more difficult to reconstruct after a total mastectomy because of the patient's body habitus, any associated morbidities, and the inherent difficulties associated with skin envelope reduction. These women are often deemed poor candidates for reconstruction because of the increased potential for complications and unfavorable cosmetic results. Breast-conserving therapy (BCT) was also seen as less desirable for women with large breasts. Macromastia initially was believed to be a relative contraindication to BCT because of poor cosmetic results and less effective radiotherapy.⁶ Radiation-induced fibrosis is a greater problem in women with larger breasts because of the dosing inhomogeneity.^{7,8} In addition, late-radiation fibrosis has been demonstrated in 36% of patients with larger breasts, compared with 3.6% of patients with smaller breasts.⁸ Higher doses of radiotherapy are often necessary in women with larger breasts, which contributes to morbidity and adversely affects the appearance of the breast.

For these reasons, reduction mammaplasty techniques were a welcome addition to the reconstructive armamentarium for partial mastectomy defects in patients with macromastia. Suddenly, BCT became a viable option for women with large breasts, simply by adding reduction techniques. These techniques are relatively easy to learn and produce predictable results for patients in whom a total mastectomy and reconstruction can be extremely challenging. This chapter expands on the use of simple reduction mammaplasty techniques for reconstructing partial mastectomy defects.

THE DECISION-MAKING PROCESS

Indications

The indications for oncoplastic techniques are covered in detail in Chapter 11. These techniques minimize the potential for a BCT deformity and broaden the indications for BCT in select patients. Traditionally, reduction techniques were used either in women with large breasts in whom sufficient breast tissue was available to reshape the breast using almost any pedicle type (glandular displacement) or in women in whom the partial mastectomy defect could be incorporated into the tissue being removed in a standard reduction technique. An example of the latter is the removal of a lower pole tumor with the dermatoglandular Wise pattern using a superior pedicle reduction. However, as familiarity with BCT grew, the indications for its use broadened.

This chapter demonstrates how glandular flaps or autoaugmentation from within the breast mound—together with standard reduction or mastopexy techniques—can be used to reconstruct lumpectomy defects in almost any location, as long as sufficient breast tissue remains after the resection. This technique suddenly becomes a reasonable option for women with smaller, ptotic breasts, even when the defect lies outside of the typical reduction specimen. When the defect is small enough, the indications have evolved into mastopexy-type techniques in women with moderate-sized or ptotic breasts.

UNDERSTANDING THE DEFECT

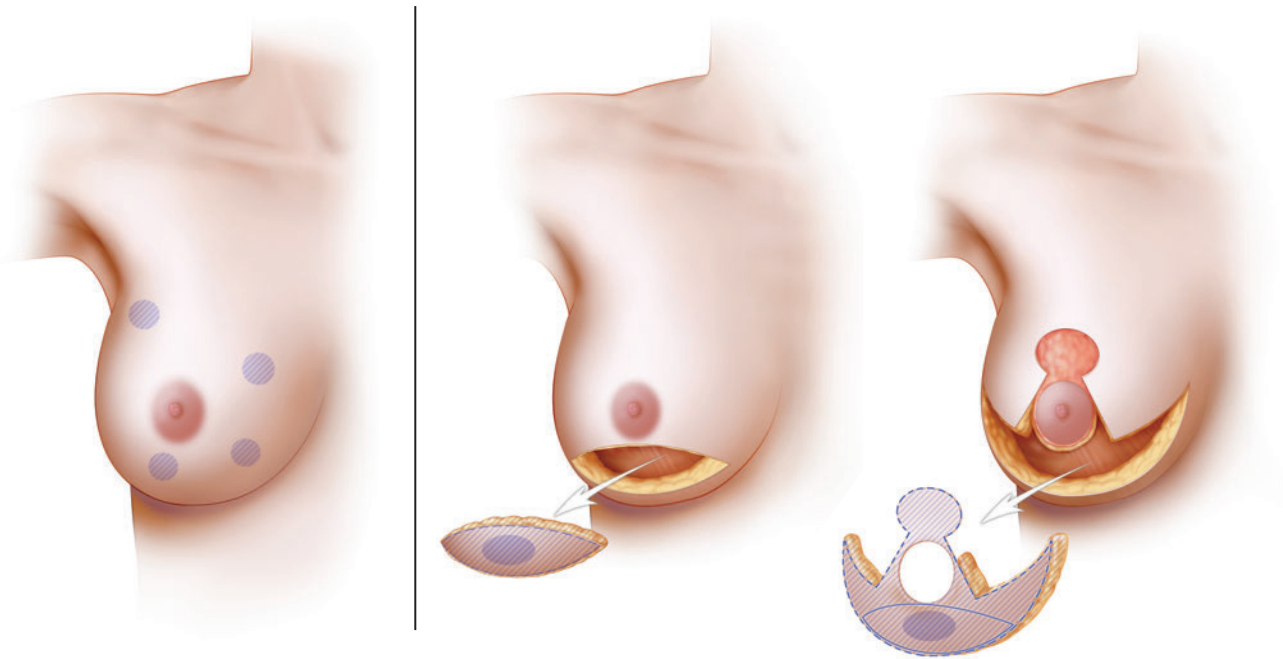


Fig. 16-1

The type of defect is important when considering the reduction technique. This approach is reasonable even for a quadrantectomy-type defect involving skin and parenchyma, but only when the skin resection is within the Wise pattern or vertical take-out pattern. In some situations, a medial or lateral resection is required outside the Wise pattern markings, either to resect some skin involvement or to resect a previous scar. In these cases, as long as the defect is low and small enough, it can be “plugged” with a small skin island from the deepithelialized dermatoglandular pedicle. Any skin defect in the upper half of the breast typically requires a flap reconstruction. Lumpectomy-type defects involving only parenchyma are easier to reconstruct, because the issue is mainly a volume void. In moderate or large breasts with or without ptosis, a lumpectomy defect in almost any location within the breast mound can be reconstructed using reduction or mastopexy techniques. This is especially true for larger breasts in which a simple reduction pattern is usually sufficient. In smaller breasts, when the defect is not in an area that would ordinarily have been resected with a standard mastopexy (that is, the lower pole), glandular flaps are required to fill the defect. One example is a medial defect in a cosmetically sensitive location in smaller-breasted women in whom the volume of the pedicle or remaining breast parenchyma is not sufficient to fill the defect without autoaugmentation. The remaining tumors discussed in the chapter are lumpectomy-type defects, unless otherwise specified.

No-Man's Land

Reduction and mastopexy techniques essentially involve creating a smaller breast mound and positioning the areola at the center of the mound. However, in some situations, mobilizing the flap carrying the areola to reshape the breast mound is limited by where the nipple needs to be positioned. For aesthetic reasons the nipple cannot be placed higher than 16 cm from the sternal notch or closer than 7 cm from the midline. A woman with smaller breasts and a tumor in this location—referred to as *no-man's land*—cannot rely on filling the defect with the nipple pedicle, and additional measures are required.⁹ However, reconstruction of these defects is now possible by using reduction techniques and either extended dermatoglandular or secondary pedicles.

SURGICAL TECHNIQUE

Surgical Plan

- The decision to proceed with the oncoplastic breast conservation is discussed with the team, and the choice between an immediate or delayed-immediate procedure is made.
- The patient is marked preoperatively.
- Wire is placed for tumor localization, if necessary.
- The resective and reconstructive surgeons discuss the final plan after the wire has been placed and the patient has been marked.
- The tumor is excised, with or without lymph node sampling.
- Mammographic confirmation with frozen section analysis is performed, if appropriate.
- Separate cavity sampling is performed.
- The cavity is clipped for orientation.
- The residual breast tissue and the size and location of the deformity are evaluated.
- The intraoperative reconstructive goals are as follows:
 - Preserve nipple viability and reposition the nipple on the breast mound.
 - Eliminate dead space.
 - Resect excess breast parenchyma and skin.
 - Reshape the breast mound to preserve its shape.
 - Perform a contralateral procedure for symmetry, if necessary.

As the indications for therapeutic mammoplasty become more liberal, we cannot forget the importance of patient selection for optimal cosmetic outcomes and oncologic safety.

Patient Selection

Patient selection is multifactorial; however, it is usually initiated by the resective surgeon, who is concerned either about a potential deformity or asymmetry using the standard excision or about not being able to obtain clear margins without a wide excision. This process may also begin with the patient's wish to have smaller breasts.

The ideal patient for this oncoplastic technique is one whose tumor can be widely excised within the reduction specimen and for whom a smaller breast is viewed as a positive outcome. The aim of this approach is threefold: a high survival rate, a good cosmetic outcome, and improved patient satisfaction. Patient selection is also critical in terms of margin status, because some women (younger patients with ductal carcinoma in situ [DCIS]) are at a higher risk for positive margins, which influences the timing of partial breast reconstruction.

Preoperative Planning

Once it is established that the patient is a candidate for BCT and would benefit from a simultaneous reduction, the preoperative planning phase can begin. If a two-team approach is used, communication between the teams is essential. The resective surgeon must understand the importance of the blood supply to the nipple, placement of skin incisions, and breast aesthetics. It is equally vital that the reconstructive surgeon understand the size and location of the tumor and the margin status and locoregional control. They should review the radiographic imaging and discuss the anticipated defect location and size, as well as whether the resection should include skin. This discussion helps to determine the most appropriate glandular pedicle to use to maintain nipple viability and to reshape the mound. There should always be a backup plan, because the defect occasionally is different from what was anticipated.

Preoperative Marking

Preoperative marking must be relatively conservative on both sides. If a Wise pattern is drawn, its vertical limbs are slightly longer than normal, and the angle is smaller to ensure minimal tension on the incisions and to reduce the incidence of healing problems. If radiographically placed wires are used for the lumpectomy, these should be examined and the radiographs reviewed.

The team should discuss possible access incisions on the mound for tumor resection. Poorly placed incisions could interfere with the viability of the skin flaps and lead to less than optimal results.

Tumor Resection

The tumor resection is performed in the usual fashion using safe and effective oncologic principles (see Chapter 5). The intraoperative margin assessment could include radiographic imaging, macroscopic assessment, frozen section analysis, or touch cytology. We have found that patient selection, cavity sampling, and generous resection further reduce the incidence of positive margins. The cavity is clipped for postoperative surveillance and guidance for radiation boosts to the tumor bed, if required.

Partial Mastectomy Reconstruction

Partial mastectomy reconstruction typically is performed before radiotherapy. It can be delayed until negative margins are confirmed in patients who are at an increased risk of having positive margins (that is, patients younger than 40 years of age and patients with extensive ductal carcinoma in situ [DCIS], lobular carcinoma in situ [LCIS], or prior chemotherapy). As with any oncoplastic procedure, the technique selection depends on the breast size and shape and the defect size and location. Numerous options exist, depending on these variables.

On examination of the partial mastectomy defect, we are faced with trying to determine the following:

1. How to keep the nipple viable and positioned appropriately on the mound
2. How to fill the dead space
3. Where to resect excess breast tissue when necessary
4. How to reshape the breast mound using the pedicles and remaining breast tissue

When deciding on reconstructive options, one aspect that is almost more important than the size of the defect is evaluating the remaining breast tissue and determining where it is in relation to the defect, the nipple, and the breast mound. The first decision that should be addressed is establishing how the nipple will be kept alive. Typically, the shortest pedicle maximizes the nipple viability and allows additional glandular manipulation, without compromising the nipple. Many options exist for nipple pedicles, and most surgeons have a favorite. For example, if the superomedial pedicle is the procedure of choice for standard breast reductions, then this technique could be used for most oncoplastic defects—provided the patient is a candidate and the defect location is not medial to the nipple. As a general rule, if the pedicle points to or can be rotated into the defect, it can be used. Occasionally, it is not possible to preserve the nipple because of the breast size or the tumor location. Options include amputation and a free nipple graft or nipple reconstruction at a later date.

Once the nipple preservation has been determined, the pedicle is deepithelialized and dissected using the cautery unit, enough to allow rotation into the proposed nipple position. A second decision is then made about how to fill the dead space. At this point, the glandular resection has not yet been performed. If the defect is removed as part of a reduction specimen and is adequately filled through glandular displacement with the pedicle and/or remaining glandular tissue, then autoaugmentation is not required. If it is believed that additional glandular flaps are required to fill the dead space, then a decision is made based on what tissue is available and where it is in relation to the nipple pedicle. If possible, filling the defect by rotating an extended portion of the original nipple pedicle is often the technique of choice. This single-pedicle autoaugmentation approach works well for smaller defects in women with small- or moderate-sized breasts or when tissue can be taken with the pedicle from a less cosmetically sensitive area and rotated to fill a defect.

PATIENT EXAMPLE

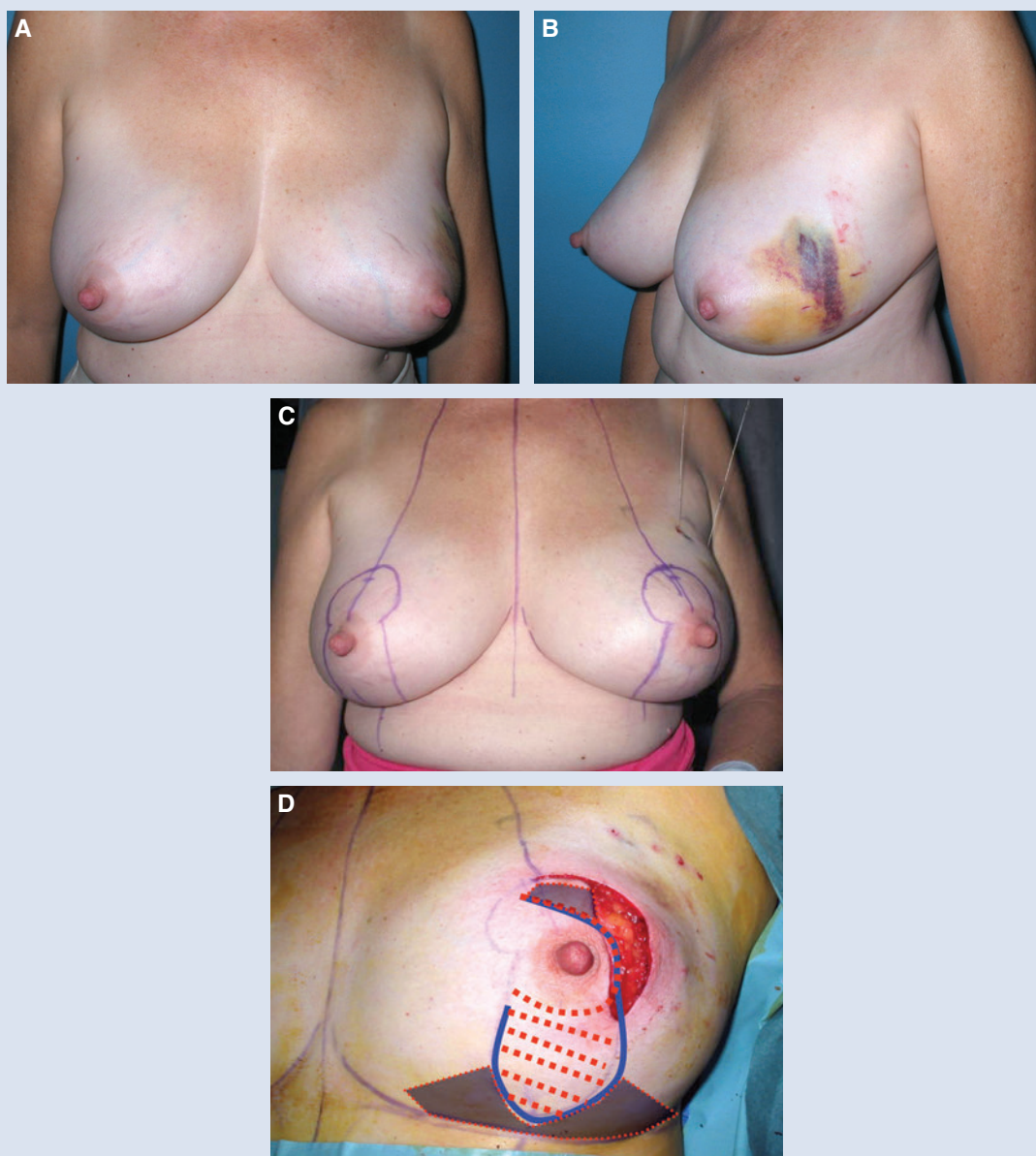


Fig. 16-2, A-D

This 42-year-old woman had moderate-sized breasts with minimal ptosis and some asymmetry (A and B). Her breasts were marked preoperatively (C). A 92 g DCIS was resected from the lateral aspect of her left breast, leaving a defect slightly above the proposed nipple position (D). This was filled with an extended superomedial dermatoglandular pedicle (*blue line*) that was rotated to fill the defect. An additional 22 g was resected from above the nipple and at the inframammary fold (*gray shading*).

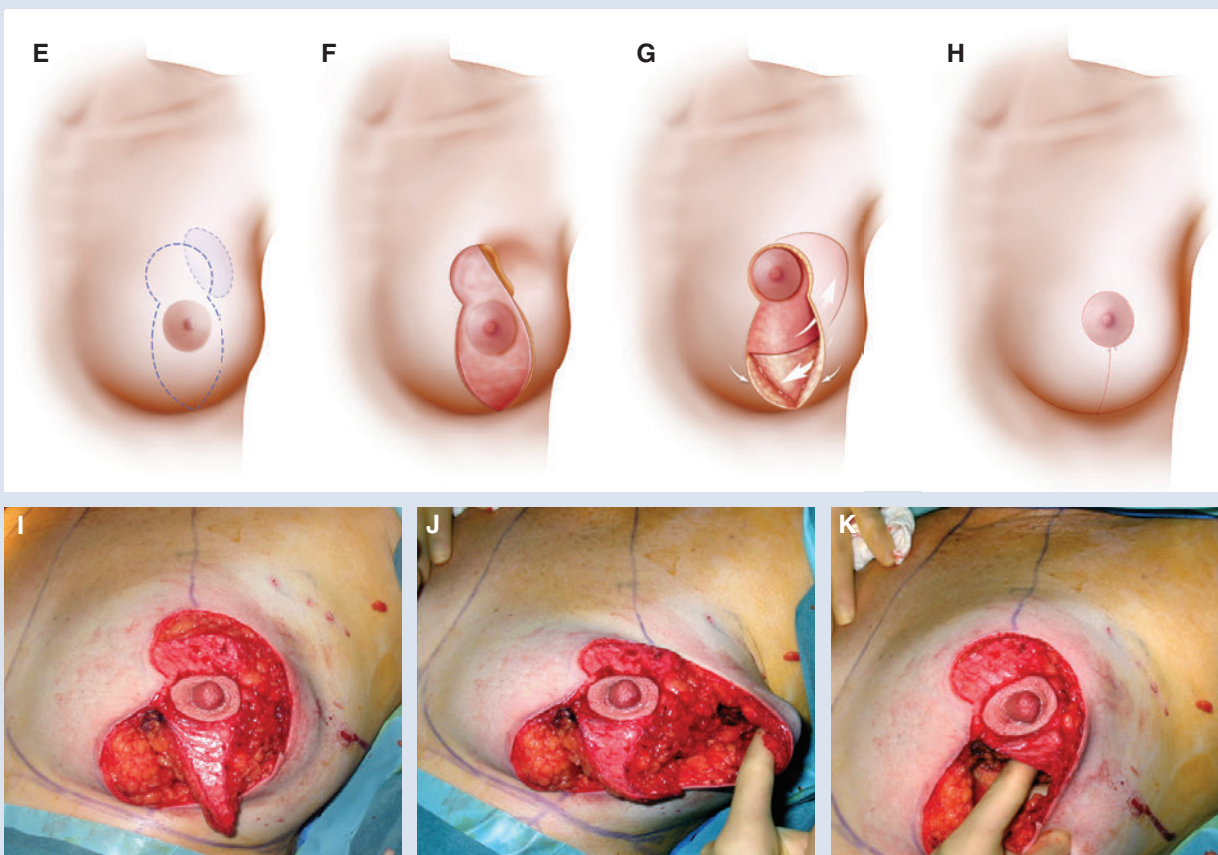


Fig. 16-2, E-K

The medial and lateral pillars were plicated in the usual vertical mastopexy fashion, and a contralateral symmetry procedure was performed (total resected 102 g) (*E* through *K*).

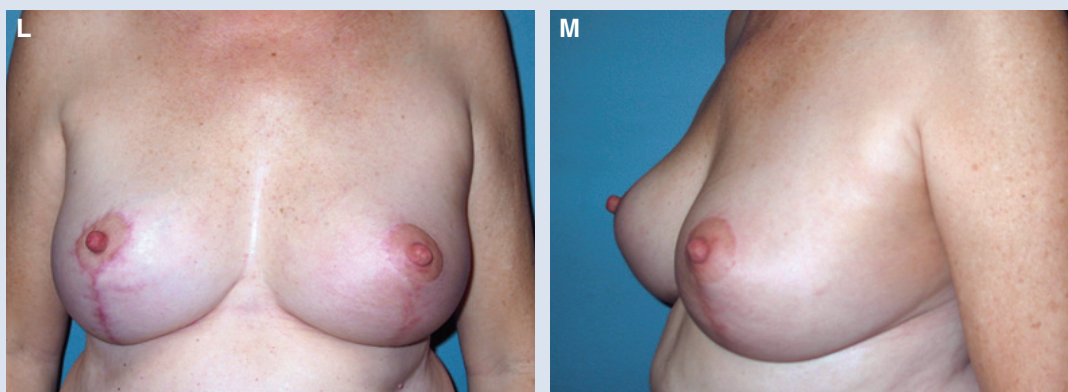


Fig. 16-2, L and M

She had good contour laterally 1 year after radiotherapy (*L* and *M*).

Another alternative for larger defects in women with large breasts is to fill the dead space using a secondary pedicle autoaugmentation approach if the primary pedicle or residual parenchyma is not sufficient.

Two pedicles are often safer and usually reduce the length of each respective pedicle, subsequently minimizing the potential for fat necrosis and maximizing the ability to safely manipulate the glandular flaps.

PATIENT EXAMPLE

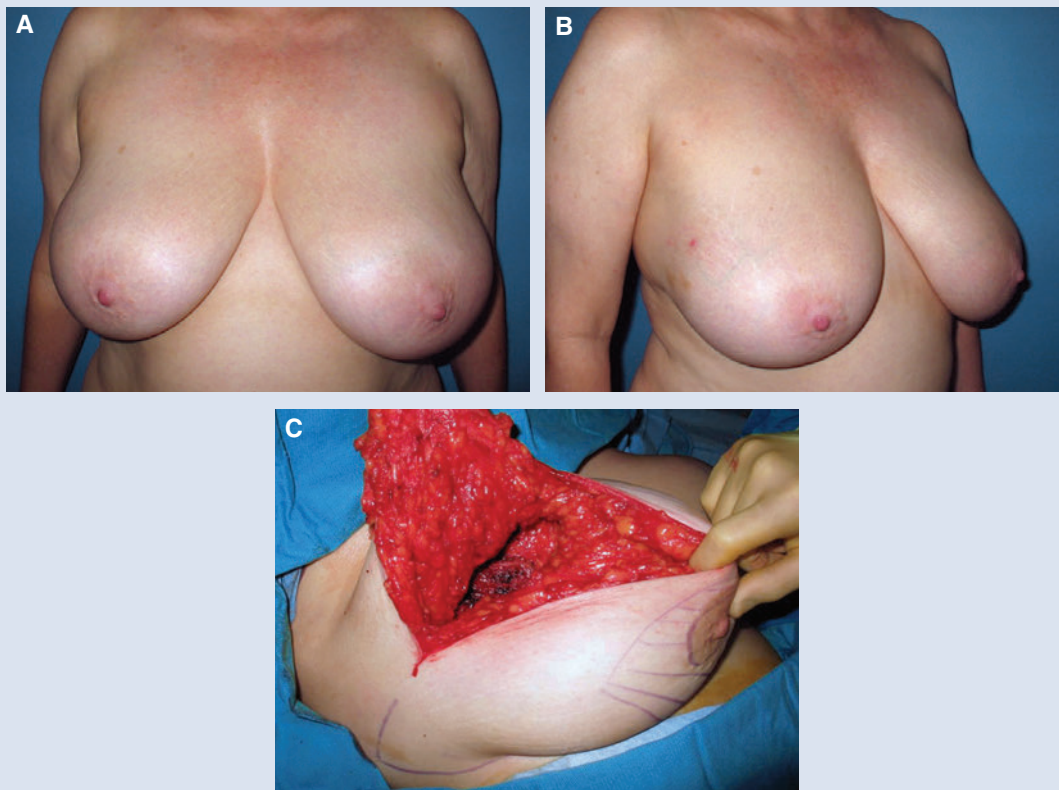
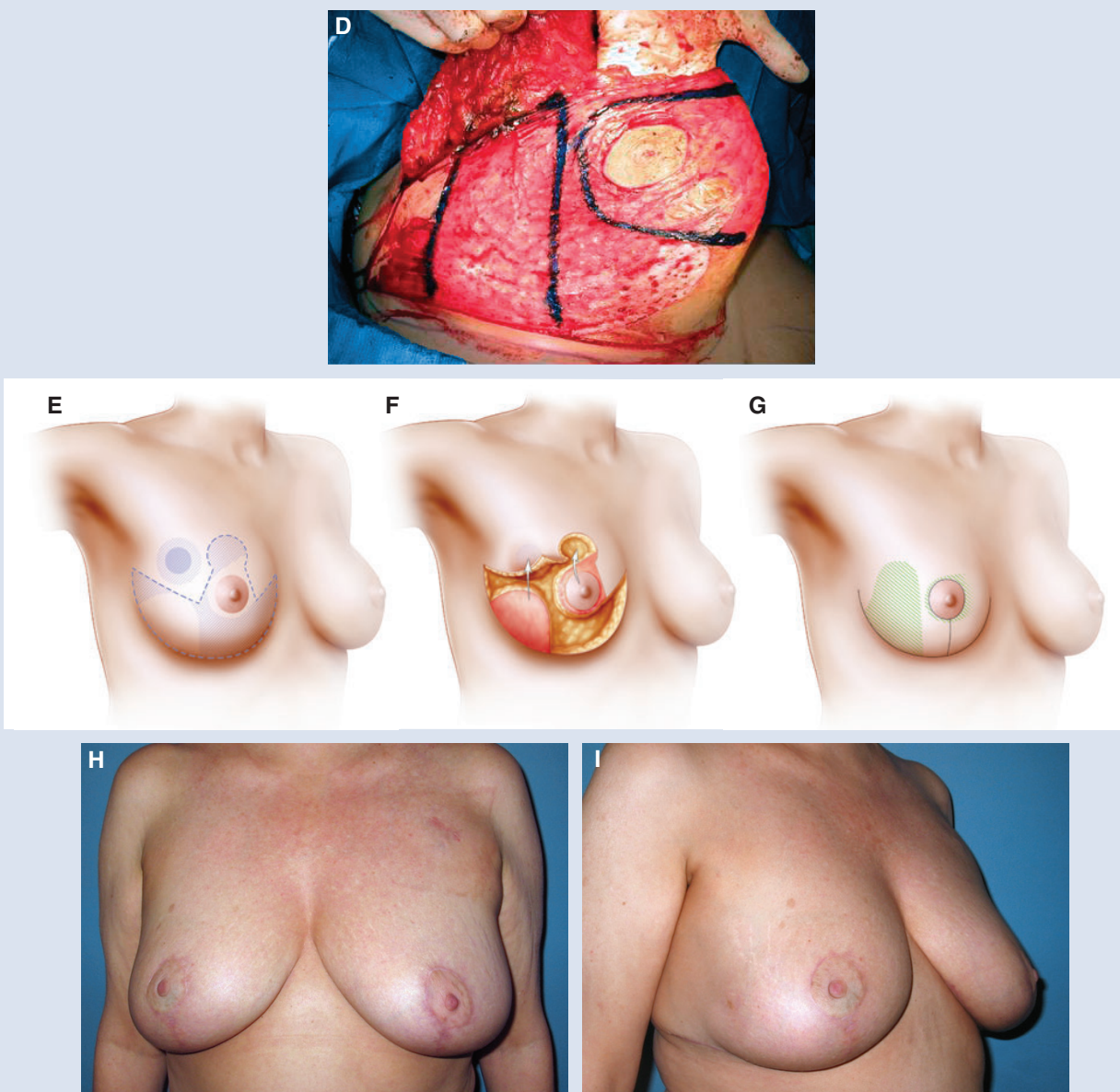


Fig. 16-3, A-C

This 40-year-old woman had a stage II infiltrating ductal carcinoma in her right breast and requested BCT (A and B). The oncologist anticipated a fairly large resection and, because of her breast size and the potential for a poor cosmetic result, we elected to perform an oncoplastic reduction. Her partial mastectomy specimen weighed 315 g, leaving a large upper outer quadrant defect down to the chest wall (C).

**Fig. 16-3, D-I**

The defect was lateral and above the level of the proposed nipple position. An inferior or central mound would have made it difficult to shape the breast mound and fill the dead space. We chose to use a superomedial pedicle for the nipple and a secondary dermatoglandular pedicle with lateral breast tissue to fill the defect (*D* through *G*). An additional 425 g was resected from the lower breast mound. Her contralateral breast was reduced by 812 g using a superomedial pedicle technique. She had good shape and symmetry 1 year after radiotherapy to the right side (*H* and *I*).

An additional pedicle is often useful because the primary nipple pedicle is limited in its range of motion, and the position of the nipple on the breast mound determines where that pedicle needs to be.

After it has been determined how to fill the dead space and reshape the breast mound, the excess dermatoglandular tissue can be resected. The weight of the specimen is added to this additional resection, and a total weight for that side is calculated. This is useful when trying to keep the ipsilateral breast larger. The breast mound is shaped using the glandular pedicles and the remaining breast tissue. Glandular shaping is performed using resorbable sutures where necessary, and the skin is redraped over the mound. Drains are used if the defect communicates with the axillary dissection.

Skin Pattern

Wise pattern markings are versatile and allow easy access to tumors located anywhere within the breast mound. The Wise pattern also gives more options for reconstructing the defect using glandular flaps. If it is unclear whether glandular flaps will be required to reconstruct the defect, standard Wise flaps about 1 inch thick can be elevated up to the chest wall without resecting any additional breast tissue or skin. There are numerous options for using either primary or secondary pedicles to keep the nipple alive or for filling the defect with the skin flaps that are redraped over the mound to complete the reconstruction. The vertical-type reduction or mastopexy is useful for smaller breasts when the defect is accessed easily through this approach.

Contralateral Breast

To maximize symmetry, the contralateral breast is typically managed using a technique similar to the one used on the ipsilateral breast. If an inferior pedicle was used on the involved breast, an inferior pedicle is often chosen for the contralateral side; however, this can vary. Because the ipsilateral side undergoes a procedure involving volume loss (partial mastectomy), a glandular resection is usually required on the opposite breast, even if a mastopexy technique was used for partial breast reconstruction.

The contralateral breast is kept about 10% smaller than the ipsilateral breast in anticipation of radiation fibrosis.

The procedure on the contralateral breast is usually performed simultaneously, but it can also be performed once radiotherapy is completed. My preference is to manipulate the contralateral breast at the time of resection. If minor changes in the shape and size of the

contralateral side are required years after radiotherapy, these fine-tuning procedures are easier and more predictable than a full reduction at that time, which might require additional revisions to maximize symmetry. A longer-term follow-up is required; however, revision rates to the opposite breast when the contralateral procedure is performed initially have been approximately 10%. Because of the 2% to 5% incidence of synchronous breast cancer diagnosed in women with breast cancer, it is important to send the contralateral breast tissue to the pathologist.^{2,3}

PATIENT EXAMPLE

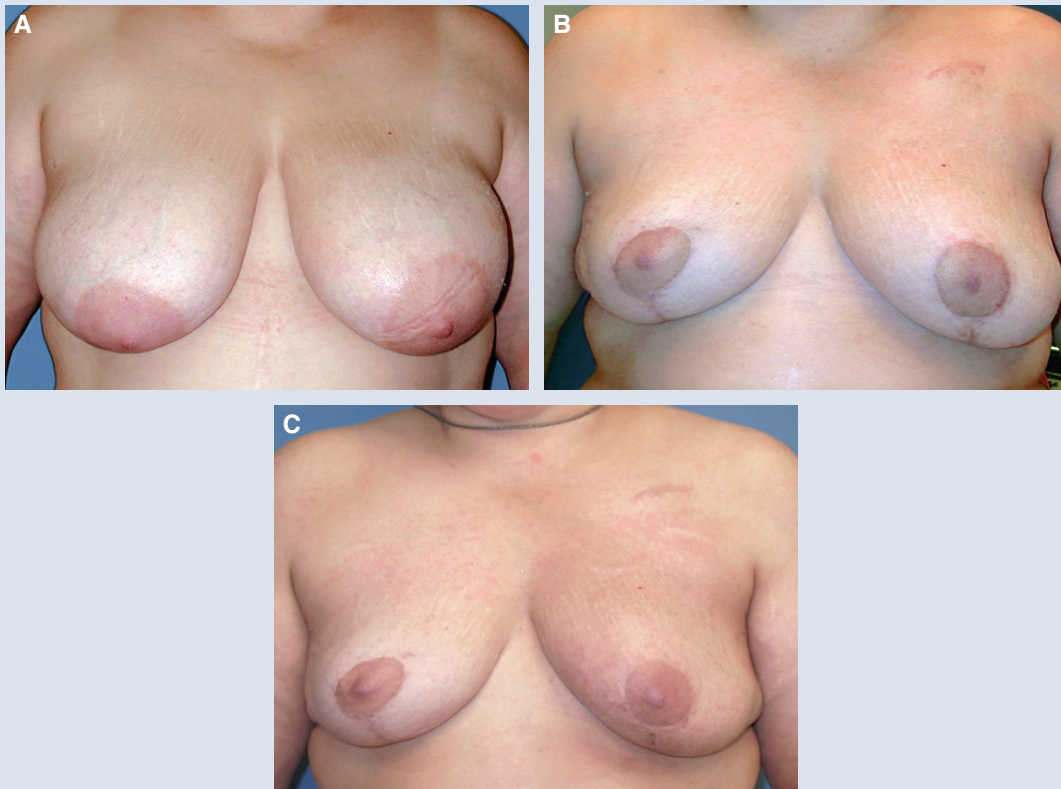


Fig. 16-4

This 49-year-old woman had a stage I ductal carcinoma in the medial portion of her left breast (A). She underwent a 195 g resection with immediate reduction reconstruction in which 502 g (including the lumpectomy) was removed from the left breast and 536 g was removed from the right. The left breast was larger postoperatively (B). However, it can be seen that symmetry was improved 2 years after radiotherapy (C).

DEFECT LOCATION

For simplicity, the defect location is described as central, medial, lateral, inner, or outer. The various adopted principles that use these techniques are essentially the same for every case. The differences are the nuances in the pedicle design and technique, which, except for the breast and tumor size, are determined mainly by the tumor location.

Upper Quadrant

Defects in the upper pole of the breast—in the area known as no-man's land—are often difficult to reconstruct. If the defect in the upper pole is below the level of the new nipple position, an inferior pedicle is sufficient. If the defect is higher and there is sufficient glandular tissue above the nipple, an inferior pedicle allows the nipple to be positioned adequately with augmentation of the defect using the primary pedicle. The difficult upper quadrant scenario occurs when the defect extends above the level of the proposed nipple location (that is, higher than 16 cm from the sternal notch). An inferior pedicle is insufficient to fill the void, because it can only be elevated as high as the new, desired nipple position. The nipple position limits how high the inferior pedicle can be lifted to fill the dead space. In this situation, glandular flaps are necessary. Medial and/or lateral glandular flaps can be undermined as needed to preserve as many chest wall perforators as possible. These flaps are rotated up to fill the upper pole defect. If sufficient glandular tissue is available above the nipple, simple glandular plication and closure of the defect is possible using interrupted sutures in addition to a mastopexy-type procedure in which the nipple is repositioned and the skin is redraped over the breast mound. In women with smaller breasts, the medial and lateral glandular flaps can be deepithelialized and rotated superiorly to maximize blood flow into those flaps. Another option is to use an extended superomedial or medial dermatoglandular pedicle. The superomedial pedicle is extended down to the chest wall and deepithelialized as one large pedicle that includes the nipple (now more proximally located). This is rotated superiorly to provide additional soft tissue above the proposed nipple position. The created medial and lateral parenchymal pillars are plicated, and the breast is reshaped.

PATIENT EXAMPLE

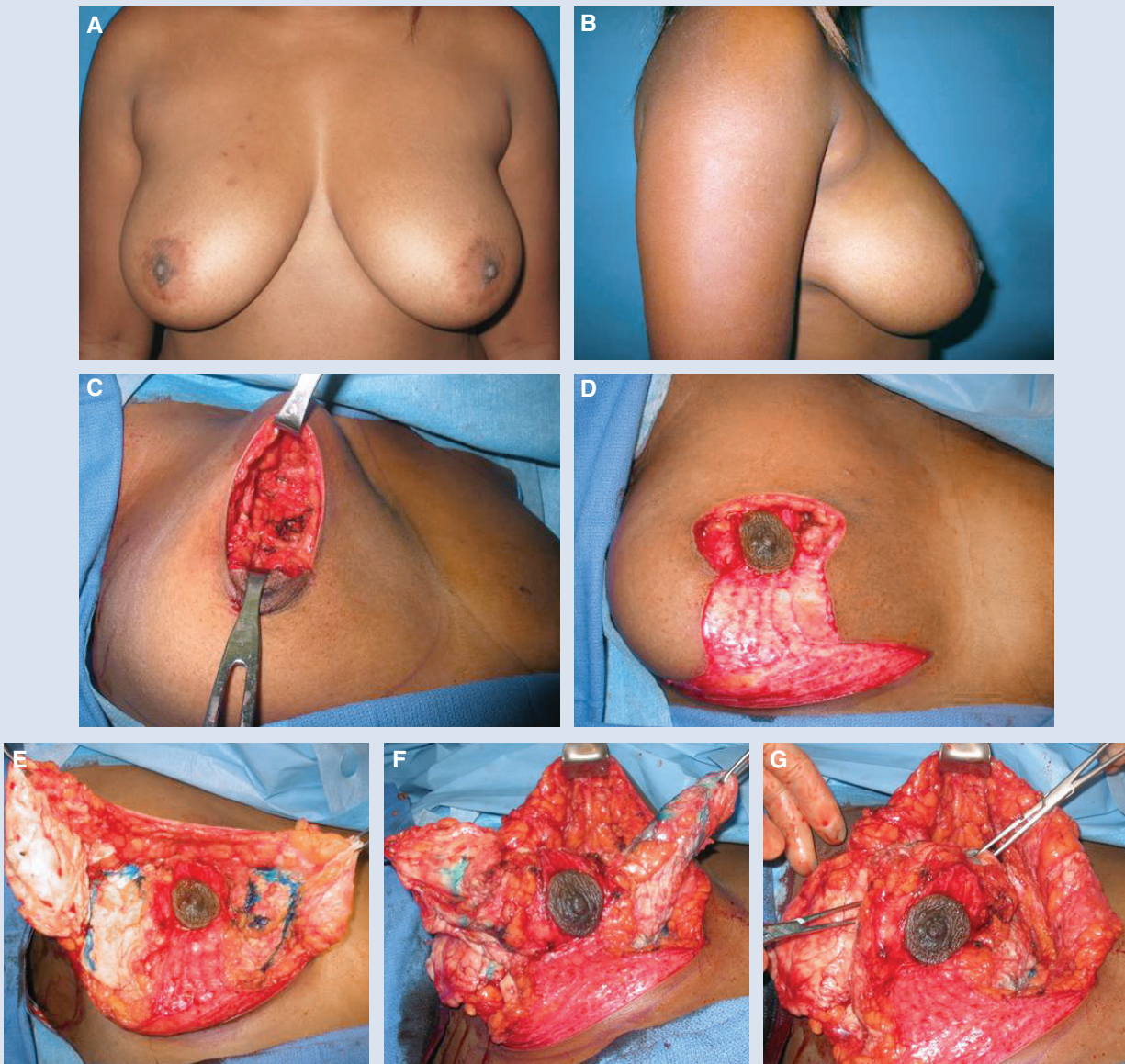


Fig. 16-5, A-G

This 39-year-old woman had an upper pole tumor (A and B). She had relatively small, ptotic breasts, with a significant potential for breast deformity after resection. The tumor required a 163 g resection, leaving a full-thickness defect above the location of the proposed nipple position (C). Insufficient glandular tissue was present above the nipple to fill the dead space using an inferior or central mound alone (D). This would have left a volume void above the nipple. We elected to rotate glandular flaps from the medial and lateral breast mound to fill the volume void above the nipple (E through G).

Continued

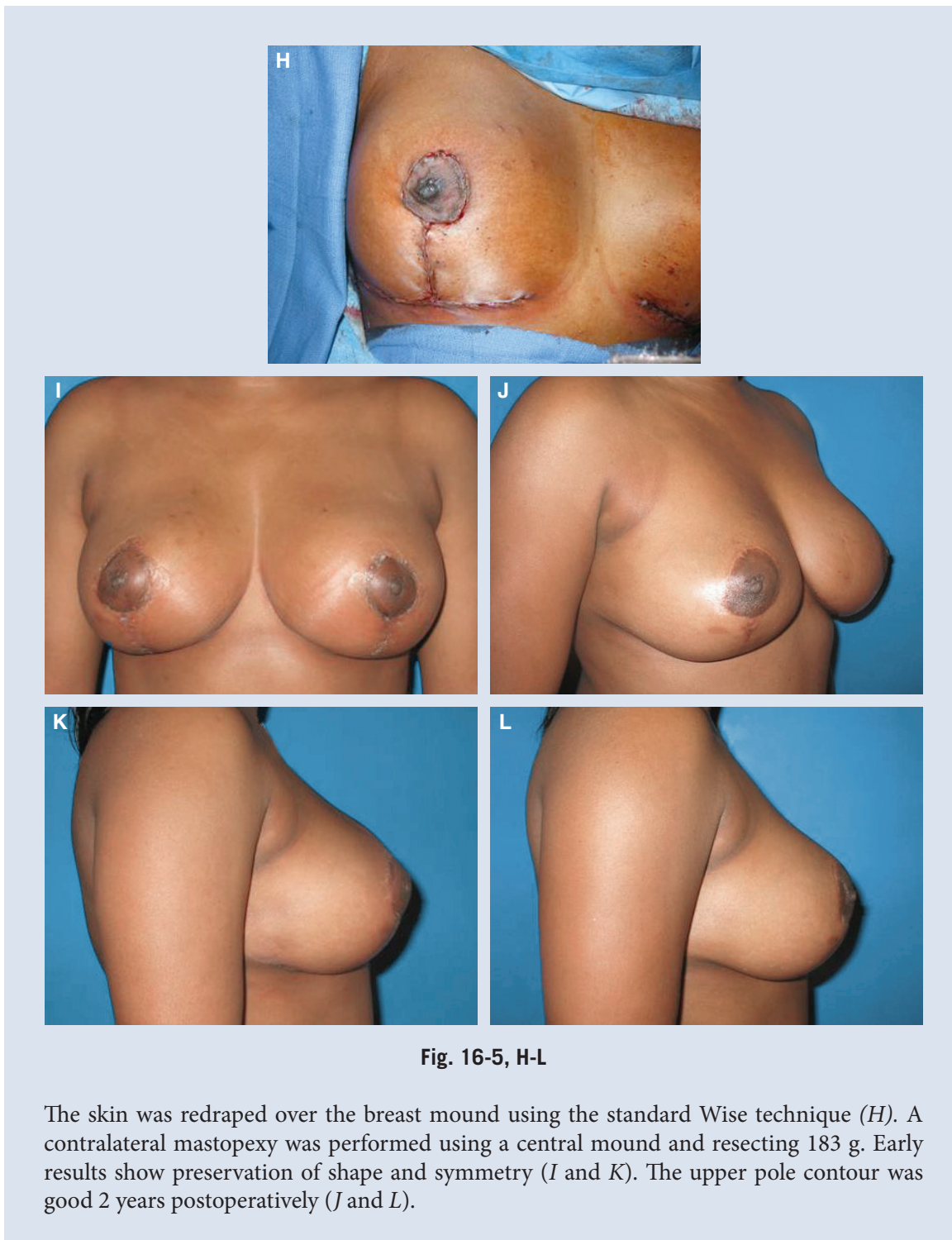


Fig. 16-5, H-L

The skin was redraped over the breast mound using the standard Wise technique (*H*). A contralateral mastopexy was performed using a central mound and resecting 183 g. Early results show preservation of shape and symmetry (*I* and *K*). The upper pole contour was good 2 years postoperatively (*J* and *L*).

Lateral Defects

Numerous options are available for defects in the lateral part of the breast mound. When the defect is below the level of the nipple or if the defect is relatively small, it can be filled with residual breast tissue using almost any pedicle or technique. If the breasts are small or moderately sized, an extended superomedial dermatoglandular pedicle can be rotated into the defect, closing the remaining breast in a vertical mastopexy fashion. For larger defects in women with moderate- to larger-sized breasts, additional tissue is often required, especially when the defect is above the new nipple position (upper outer quadrant). It is often safer to keep the superomedial pedicle short to ensure nipple viability and to minimize the potential for fat necrosis at the end of a long, extended dermatoglandular flap. In this situation, a lateral, inferiorly based dermatoglandular pedicle can be used as a secondary pedicle to fill the dead space. This allows accurate positioning of the nipple on the breast mound and of the secondary pedicle into the defect, without distorting the shape. When the defect is lateral without residual breast parenchyma in the upper or lower lateral location, tissue needs to be rotated from elsewhere to fill the defect. One alternative is to rotate tissue from the lower pole of the breast into the defect in women with moderately sized ptotic breasts.

PATIENT EXAMPLE

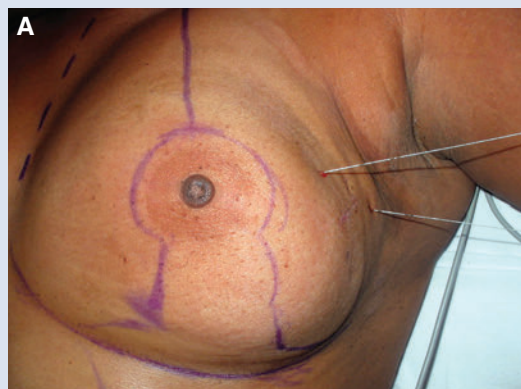

Fig. 16-6, A

This 44-year-old woman with a history of lateral DCIS underwent a 110 g partial mastectomy, leaving a lateral defect down to the chest wall (A). Her breast was moderately sized, with minimal ptosis. The defect, in relation to her breast mound, resulted in a lateral volume void.

Continued

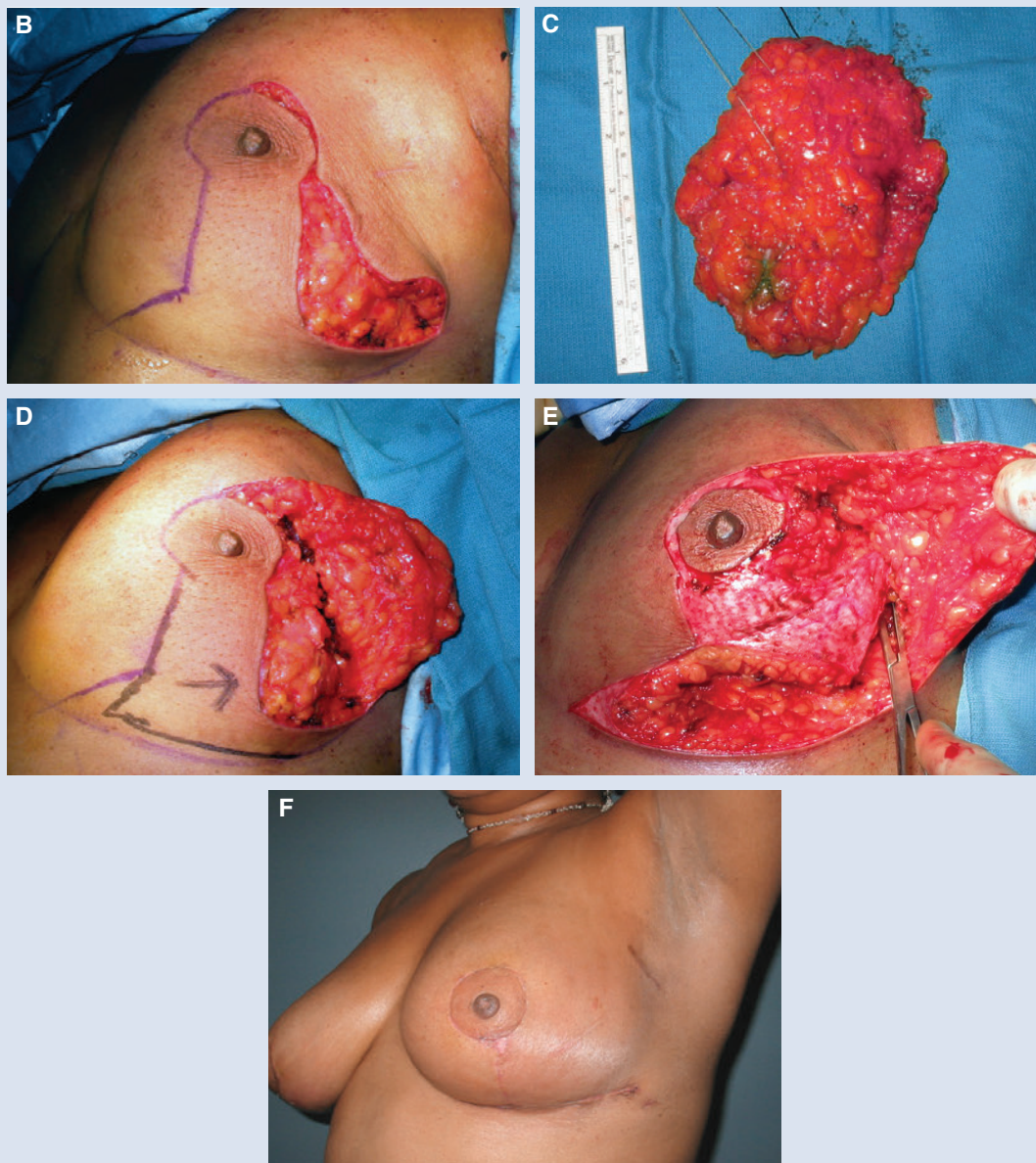


Fig. 16-6, B-F

The nipple was in a fairly good position, requiring only minimal elevation, and the remaining breast required a lower pole reduction to reshape the mound (*B* and *C*). There was no lateral tissue available to fill the defect. We elected to use a superomedial pedicle, rotating it as an extended autoaugmentation flap to move the nipple up, fill the lateral defect, and reshape the breast mound (*D* and *E*). This approach was determined after evaluating the defect and residual breast tissue in relation to the nipple position and the proposed nipple position. A 118 g superomedial mastopexy was performed on the contralateral side. The patient is shown 9 months postoperatively (*F*).

Medial Defects

The medial quadrant is a relatively sensitive area in terms of aesthetics, especially for larger defects or for women with relatively small breasts. If the defect is below the level of the proposed vertical limbs, glandular tissue above that point drops down to fill the defect when using a superiorly based pedicle. If the defect is relatively high, lower pole tissue is preserved medially to fill the volume void. When the defect involves the entire medial quadrant, then additional tissue is required as a glandular flap.

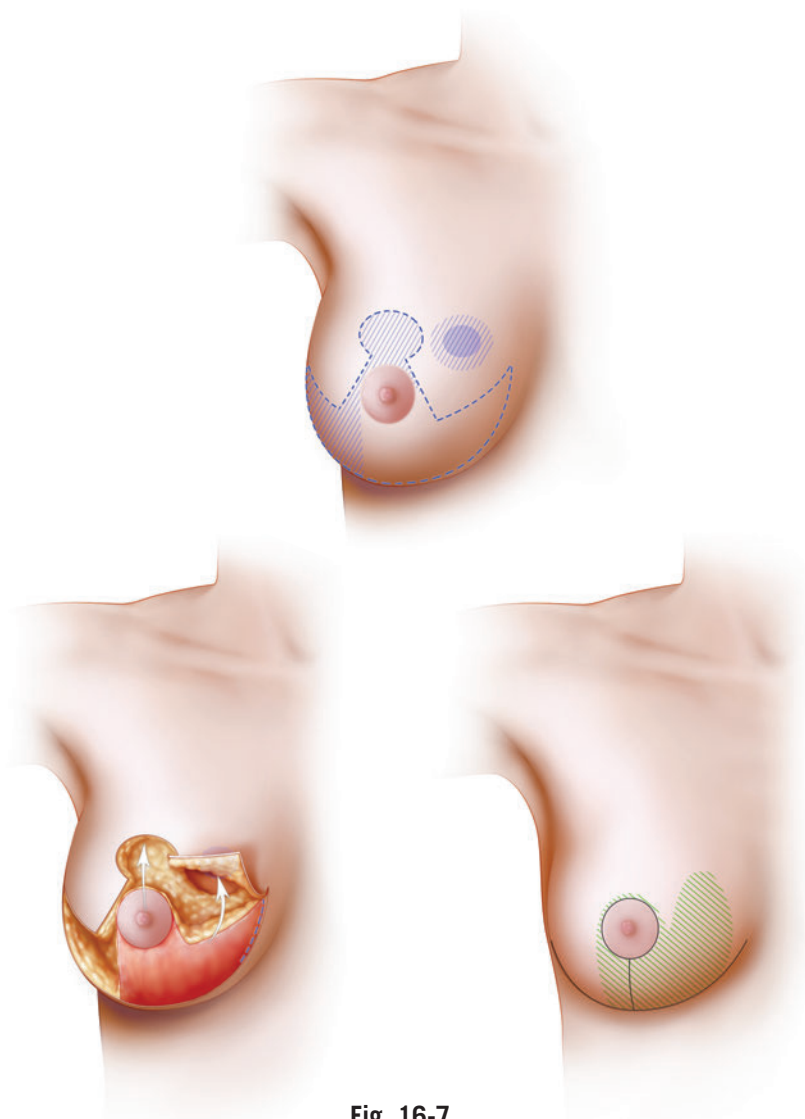


Fig. 16-7

If sufficient tissue remains, an inferiorly based pedicle could be used with a medial extension that is rotated up to fill the defect. If there is insufficient medial tissue, another option is to extend a laterally based pedicle to allow the nipple to rotate up and the dead space to be filled with the extended portion of the dermatoglandular pedicle.

Lower Defects

Lower quadrant defects are probably the easiest to reconstruct. In small- to moderate-sized breasts, if the defect is midline and below the level of the nipple, the nipple could be elevated using a superior pedicle, with the medial and lateral pillars plicated to close the dead space. In women with larger breasts or even larger defects, the superior pedicles allow generous resection from the entire lower quadrant, with the upper breast tissue dropped down to reshape the breasts.

PATIENT EXAMPLE

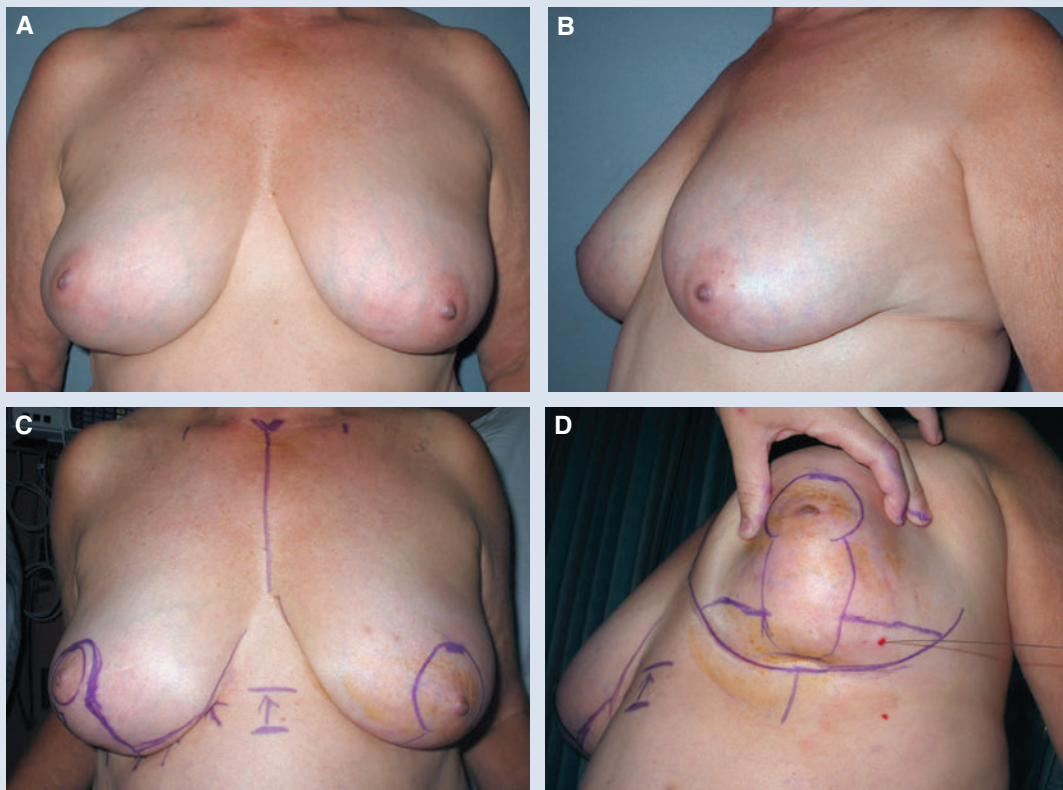


Fig. 16-8, A-D

This 58-year-old woman had a stage I infiltrating ductal carcinoma in the lower pole with skin dimpling (A and B). On the preoperative evaluation, breast asymmetry was noted, with her left inframammary fold about 2 to 3 cm higher than the right (C and D).

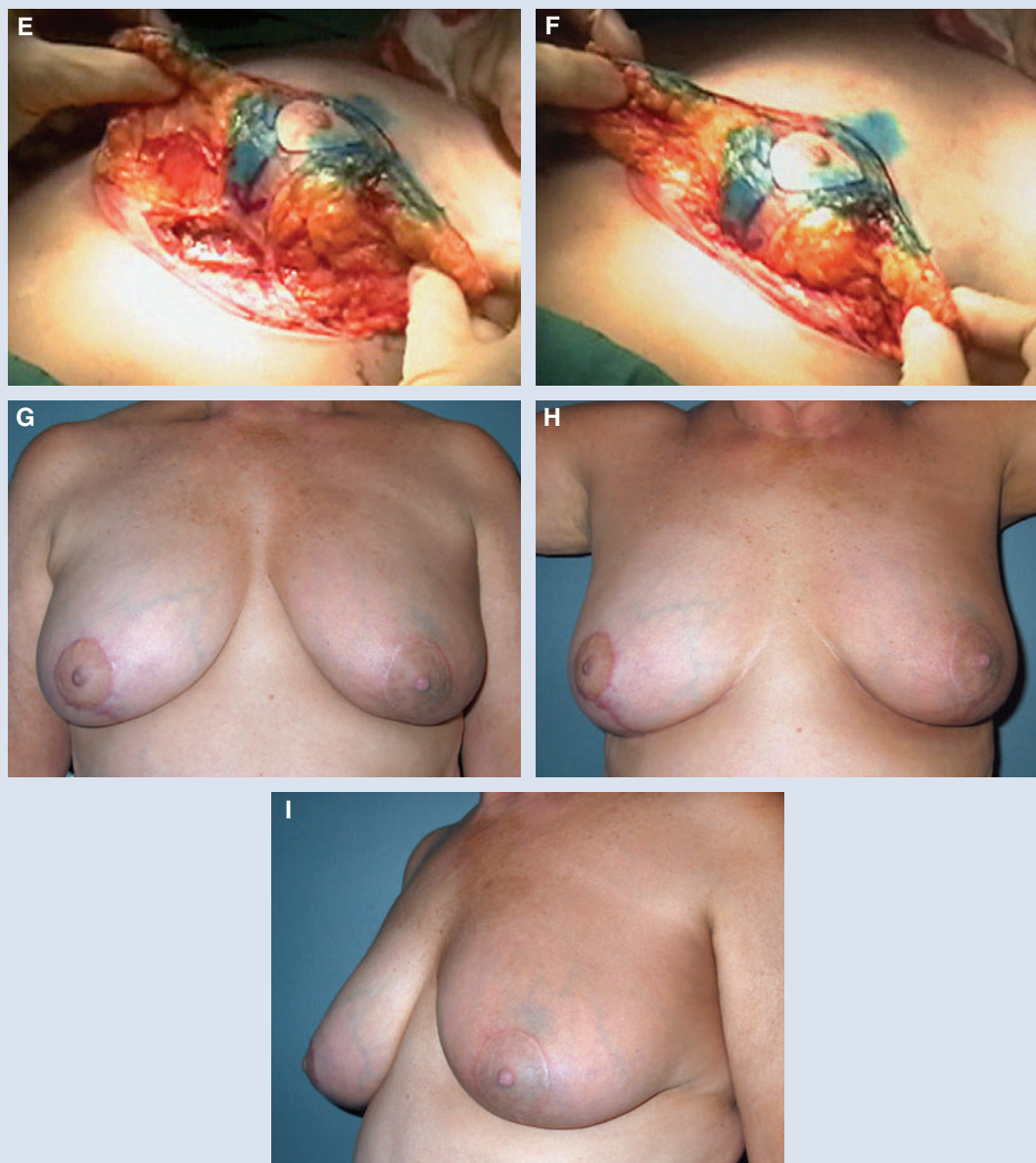


Fig. 16-8, E-I

She underwent a left lumpectomy (65 g) with immediate reconstruction using a deepithelialized superior central-type pedicle, with the dermatoglandular flap dropped into the defect to fill the dead space and to minimize the deformity (*E* and *F*). A Wise pattern was used to allow manipulation of the inframammary fold. A contralateral reduction (195 g) was performed using a superior pedicle. The inframammary fold was elevated 2 cm on the right. Six months after left breast irradiation, the shape and symmetry were good (*G* through *I*).

Central Defects

Central and subareolar defects are covered separately, in Chapter 17. In women with relatively small or ptotic breasts, defects below the nipple that lack sufficient local tissue occasionally require additional tissue to be brought in to provide adequate projection.

PATIENT EXAMPLE

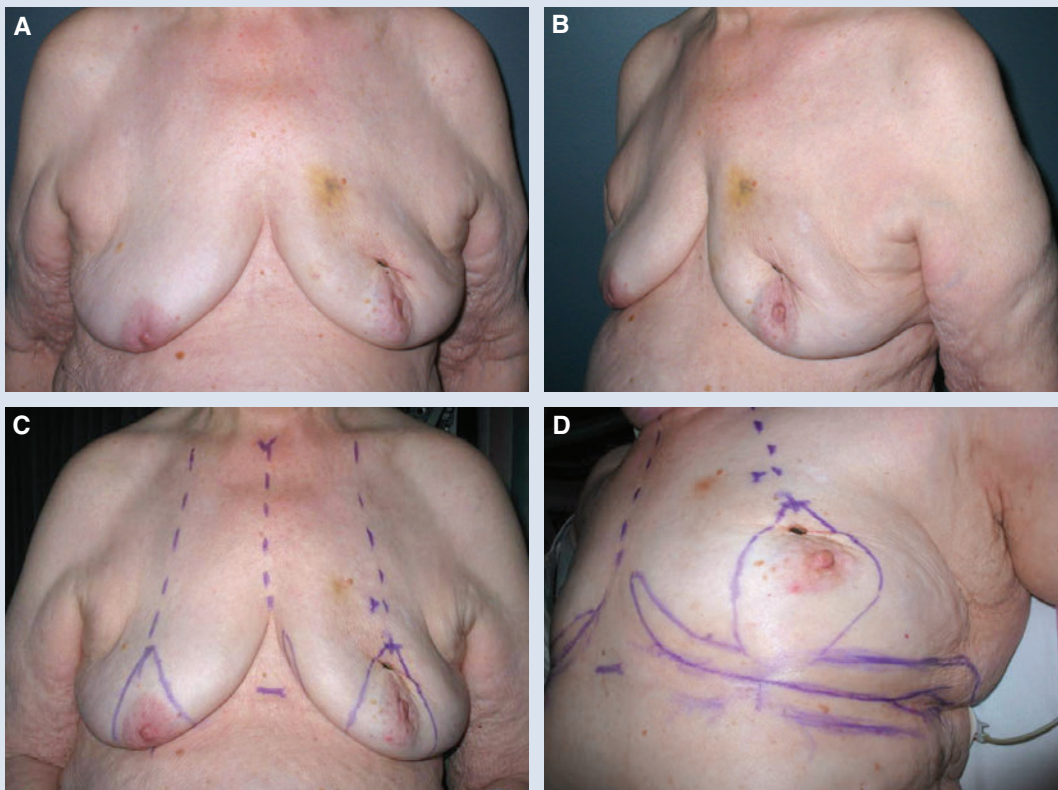


Fig. 16-9, A-D

This 80-year-old woman with small, ptotic breasts had a carcinoma arising in an adenomyoepithelioma (A and B). She previously had undergone a lumpectomy, with positive margins. The patient had a strong desire to preserve her breasts, despite her already having a deformity that needed additional resection. The skin was marked (C and D).

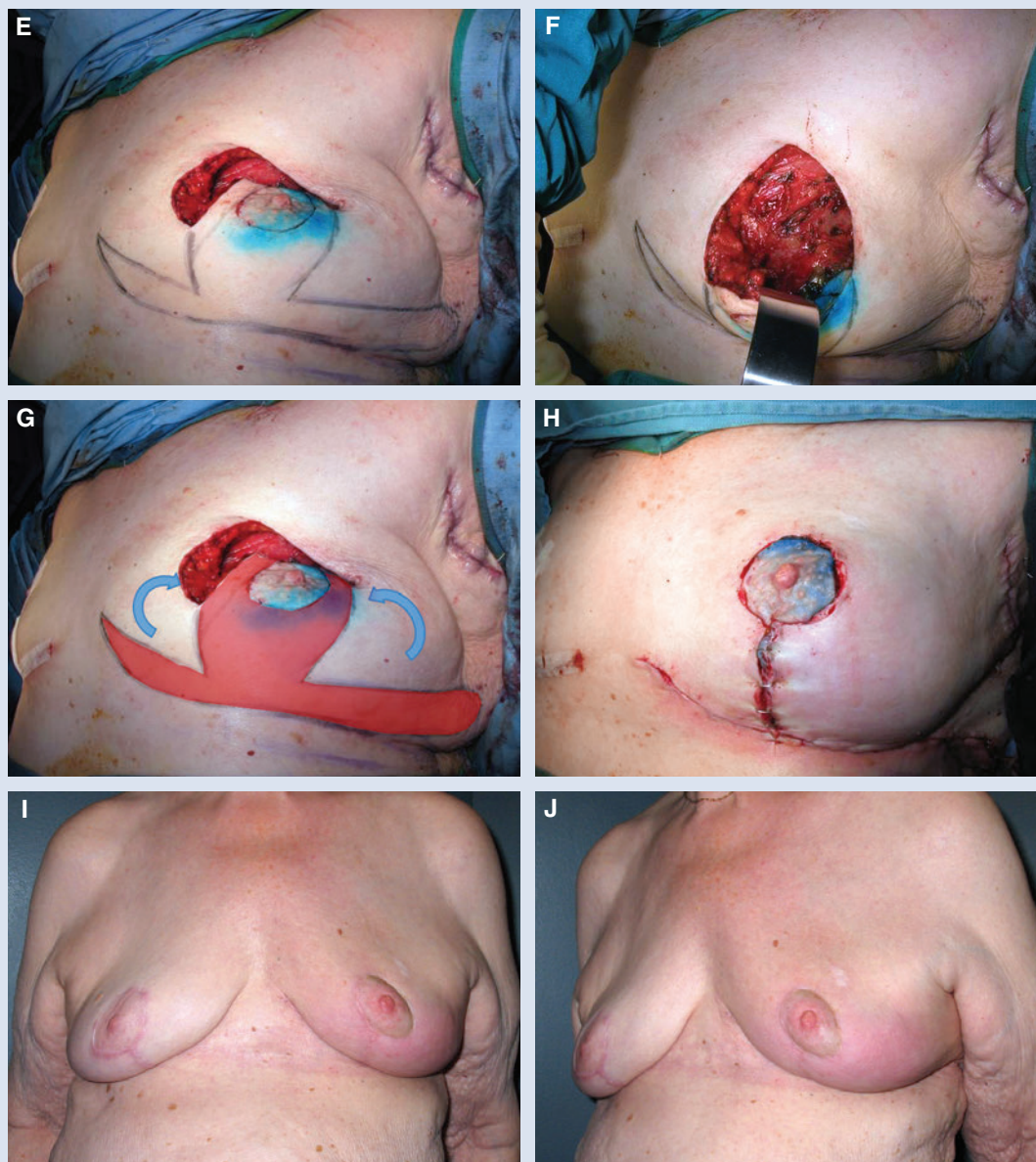


Fig. 16-9, E-J

A 60 g reexcision was performed, leaving a defect above and beneath the nipple (*E*). The nipple was essentially flat on the chest wall after the resection, with no tissue above to fill the void. We used the medial and lateral dermatoglandular flaps in a rotation fashion to place beneath and above the nipple (*F* and *G*). Immediately after surgery, the patient had good shape and nipple projection (*H*). The results are shown 1 year after radiotherapy (*I* and *J*).

Additional Tips

- Minimize undermining.
- Keep markings conservative to reduce skin tension and wound-healing difficulties.
- Do not resect tissue until a decision has been made about how to fill the dead space, rotate the nipple, and reshape the breast mound.

OUTCOME

Oncologic Safety

Other potential oncologic benefits of partial breast reconstruction include the following:

- Oncoplastic techniques allow larger resections (more than 200 g) than nononcoplastic techniques (40 to 50 g).
- Risk reduction is achieved with additional parenchymal resection.
- Contralateral procedures help to detect synchronous breast cancer and reduce metachronous breast cancer.
- The incidence of positive margins is lower.
- These techniques allow more effective radiotherapy.

Local recurrence is an important outcome measure; however, longer-term studies are required before any definitive conclusions can be made regarding tumor recurrence and survival. It has been proposed that local recurrence rates would be lower because of the ability to widely excise the tumor.

The rearrangement of breast tissue using reduction techniques is a concern because of the potential to alter the architecture and influence the pattern of recurrence or the ability to accurately screen the tissue.

Surgical clips at the tumor margin help to identify the tumor bed and assist with radiation boosts, postoperative surveillance, and reexploration if necessary. We have accurately followed these women using mammographic techniques and MRI when necessary.

Interval changes in mammographic readings are usually stabilized by about 21 months and are covered in more detail in Chapter 29. Additional tissue sampling (for example, a fine-needle aspiration and/or core biopsy) is often required because of the nature of these combined procedures and the importance of ruling out a tumor recurrence.

Local wound-healing complications include delayed healing, skin necrosis, infection, and wound dehiscence; however, these are usually minimal and do not delay the initiation of neoadjuvant therapy. Most series have demonstrated excellent patient and surgeon satisfaction with the cosmetic results using these techniques, and longer-term outcomes will be interesting, especially because of the persistent effects of radiation with time.

The breast shape is typically preserved with time, although some radiation fibrosis can occur. In these situations, it is now easier to further reduce the contralateral breast than to reconstruct a radiated deformity.

SPECIAL CONSIDERATIONS

The rotation of glandular tissue should be performed cautiously because of the oncologic concerns with the margin status. The reconstruction can always be deferred until the final margin status is confirmed in high-risk patients. The management of positive margins is detailed in Chapter 7; however, two main options exist—reexcision or completion mastectomy and reconstruction. If positive margins are found after oncoplastic-type resections, the extent of the patient's disease helps to determine which option to use.

Reconstruction after an oncoplastic reduction is now easier, because the breast is smaller and the skin envelope has already been reduced. The contralateral procedure has typically been performed, and no reconstructive options have been previously used. If the completion mastectomy is secondary to a recurrence, then managing the skin envelope is difficult because it has been irradiated and typically requires more skin replacement using autologous tissue reconstruction.

PATIENT EXAMPLE

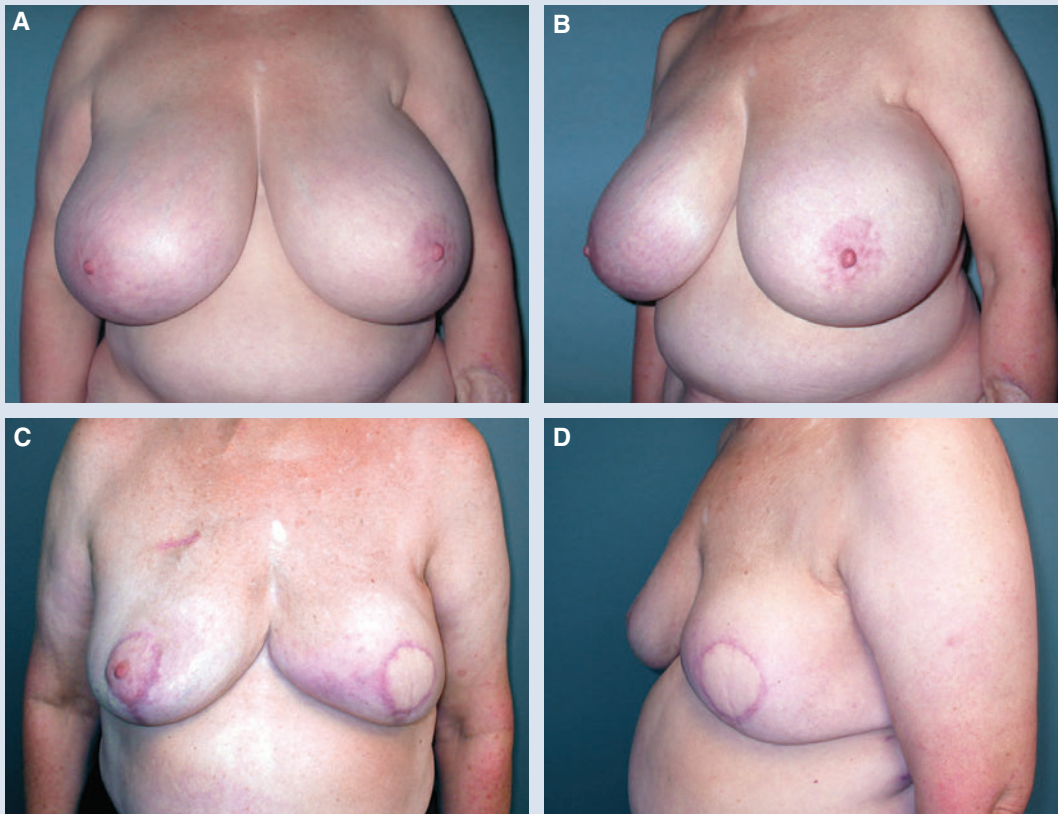


Fig. 16-10

This 64-year-old woman with infiltrating ductal carcinoma underwent a partial mastectomy in the upper outer quadrant (490 g), followed by a bilateral reduction mammoplasty (total 1010 g from the right breast, 1170 g from the left) (A and B). Despite intraoperative imaging and cavitary sampling, margins were positive for DCIS. She subsequently underwent a left completion mastectomy and latissimus dorsi reconstruction with an implant, and is shown postoperatively (C and D).

CONCLUSION

As the patient selection and surgical techniques are refined, the cosmetic results, patient satisfaction, and oncologic safety can only improve. The reduction mastopexy technique will continue to gain popularity as a safe and effective method of reconstructing partial mastectomy defects. Expanding this approach using autoaugmentation techniques will likely improve the versatility of these oncoplastic reduction techniques and provide better options for women with breast cancer who wish to preserve their breasts.

Critical Issues

- Reduction mammaplasty techniques may be used to reconstruct lumpectomy defects in any quadrant of the breast.
- In special situations, additional maneuvers are occasionally required to fill the defect when insufficient tissue is available locally.
- The nipple position often limits the ability of glandular pedicles to fill the dead space.
- Techniques such as extended dermatoglandular pedicle, autoaugmentation, and secondary dermatoglandular flaps can be used to transfer local tissue into areas of volume void when using reduction mammaplasty techniques.
- These techniques allow reconstruction of almost any parenchymal defect as long as sufficient breast tissue is available.

References

1. Clough KB, Lewis JS, Couturaud B, et al. Oncoplastic techniques allow extensive resections for breast-conserving therapy of breast carcinomas. *Ann Surg* 237:26, 2003.
2. Losken A, Styblo TM, Carlson GW, et al. Management algorithm and outcome evaluation of partial mastectomy defects treated using reduction or mastopexy techniques. *Ann Plast Surg* 59:235, 2007.
3. Munhoz AM, Montag E, Arruda EG, et al. Critical analysis of reduction mammaplasty techniques in combination with conservative breast surgery for early breast cancer treatment. *Plast Reconstr Surg* 117:1091, 2006.
4. Clough KB, Nos C, Salmon RJ, et al. Conservative treatment of breast cancers by mammaplasty and irradiation: a new approach to lower quadrant tumors. *Plast Reconstr Surg* 96:363, 1995.
5. Shestak KC, Johnson RR, Greco RJ, et al. Partial mastectomy and breast reduction as a valuable treatment option for patients with macromastia and carcinoma of the breast. *Surg Gynecol Obstet* 177:54, 1993.
6. Gray JR, McCormick B, Cox L, et al. Primary breast irradiation in large-breasted or heavy women: analysis of cosmetic outcome. *Int J Radiat Oncol Biol Phys* 21:347, 1991.
7. Zierhut D, Flentje M, Frank C, et al. Conservative treatment of breast cancer: modified irradiation technique for women with large breasts. *Radiother Oncol* 31:256, 1994.
8. Brierley JD, Paterson IC, Lallemand RC, et al. The influence of breast size on late radiation reaction following excision and radiotherapy for early breast cancer. *Clin Oncol (R Coll Radiol)* 3:6, 1991.
9. Grisotti A, Calabrese C. Conservative treatment of breast cancer: reconstructive issues. In Spear SL, ed. *Surgery of the Breast. Principles and Art*. Philadelphia: Lippincott Williams & Wilkins, 2005.

17

Central Defect Reconstruction

Stephen J. McCulley, R. Douglas Macmillan



ncoplastic approaches and principles are no better demonstrated than in the breast-conserving approaches to central breast tumors that require the removal of the nipple-areolar complex. These procedures represent less than 5% of patients with breast cancer; however, from a cosmetic outcome perspective, they have traditionally been regarded as a difficult group to treat.

PATIENT SELECTION AND PLANNING

The ideal oncoplastic procedure potentially improves the oncologic and cosmetic outcomes for a patient. Such techniques extend the role of breast conservation by allowing standard or even extended oncologic excisions in patients at high risk of a breast deformity. The techniques also reduce the need for reexcision especially in DCIS and with larger volume excisions. Patients benefiting from oncoplastic techniques include those who require an excision of a significant percentage of their breast¹ or who have tumors in sensitive areas such as the central part of the breast. The cosmetic outcomes for central tumors have been so poor traditionally that mastectomy was often regarded as the first line treatment. BCTs are now increasingly applied to central tumors when it is oncologically feasible to do so.² In some cases the balance between mastectomy and reconstruction and oncoplastic breast-conserving surgery may be a fine one, particularly in smaller breasts or large-percentage excisions. However, even with these patient groups, oncoplastic techniques can be applied with predictable outcomes, and women can be given a choice.^{3,4}

Important influences on the technique selection include degree of ptosis, breast size, any preexisting breast asymmetry, surgical risk factors, the desired margin of excision, the patient's preferences regarding breast size and willingness to undergo bilateral surgery, and to a lesser degree, her age. All of these factors need to be considered when discussing the options with the patient.

Therapeutic mammoplasty is our preferred term for the use of mammoplasty techniques for the primary treatment of breast tumors. It is an ideal option for women at risk of deformity after breast-conserving surgery (BCS), especially if they consider an uplifted or smaller breast to be a positive outcome.

For central tumors the surgical options include simple or modified ellipse excisions, round bloc purse-string excisions, therapeutic mammoplasty, and volume replacement techniques. Therapeutic mammoplasty can again be divided into either a reduction mammoplasty when significant volume is removed or mastopexy mammoplasty when the only volume excision is the wide local excision. For very large-breasted patients, almost regardless of the tumor size, the advantages of a smaller breast with regard to postoperative radiotherapy should be emphasized.^{5,6} For suitable cases, mammoplasty surgery is particularly safe and reliable, because there is no requirement for a pedicle to the nipple. In many situations, a nipple reconstruction can be performed primarily. This may be on a skin-bearing inferior pedicle with a mammoplasty,^{3,7} a skin-bearing local perforator flap, or may be performed on the remaining local skin after nipple areolar excision.

When bilateral surgery is neither favored by the patient nor thought to be required by the surgeon, unilateral surgery should be performed. Small excisions can be treated with simple ellipse excisions or Grisotti flap techniques. Larger excisions (those involving more than 15% of the breast volume) can be treated with a unilateral extended ellipse, a Grisotti flap, or a unilateral therapeutic mammoplasty. When there is insufficient ptosis or volume to consider a mammoplasty or no change in breast volume is required, volume replacement techniques are preferable. These are particularly used in the smaller breast.

SURGICAL TECHNIQUES

Box 17-1 Surgical Options for Centrally Located Tumors

- Simple excisions
 - Central ellipse
 - Round block
- Volume displacement techniques
 - Therapeutic mammoplasty wedge excisions
 - Therapeutic mammoplasty with parenchymal advancement
 - Grisotti flap
 - Therapeutic mammoplasty with parenchymal flaps
- Volume replacement procedures

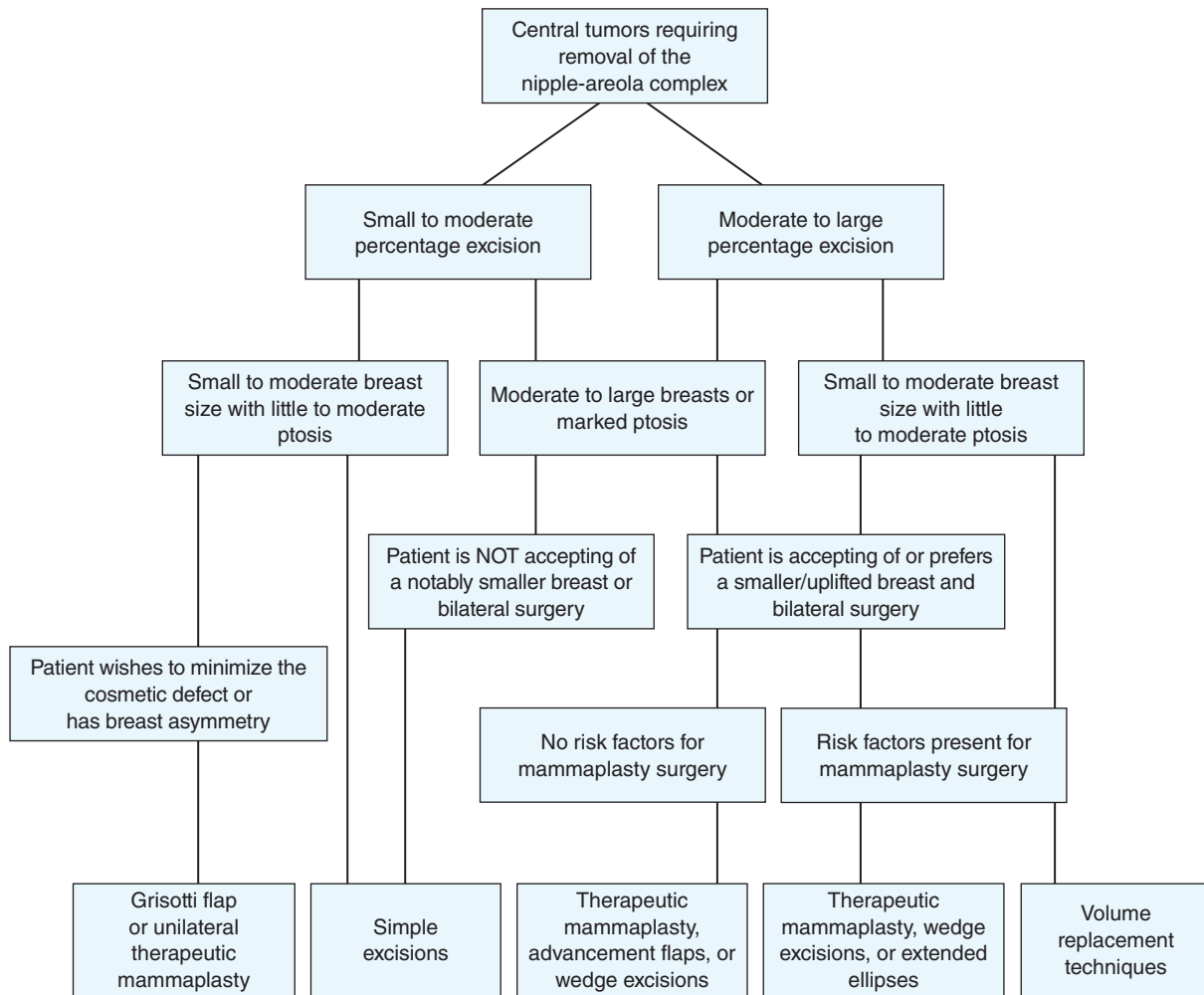


Fig. 17-1

Simple Excisions

Central Ellipse

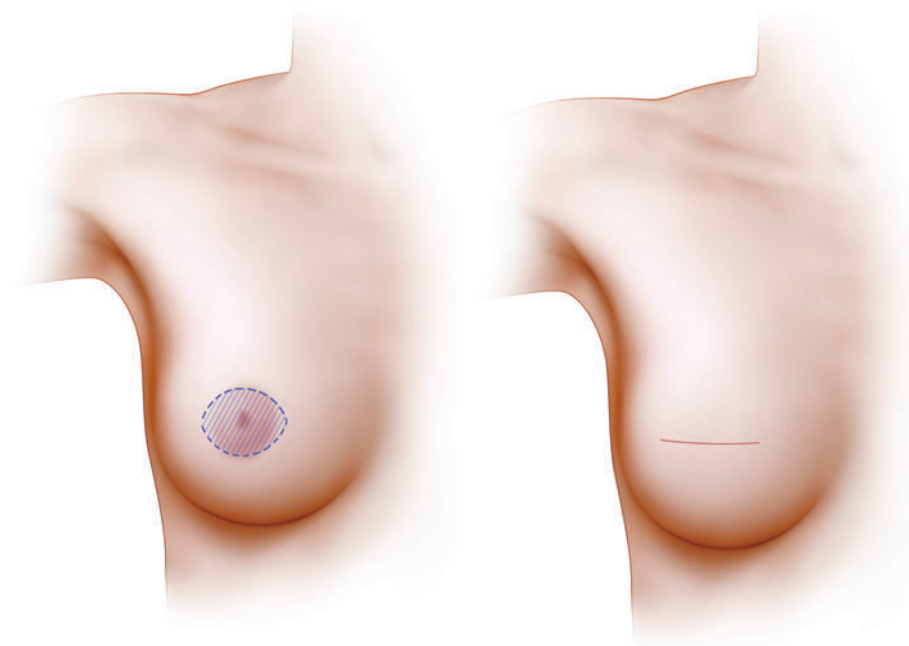


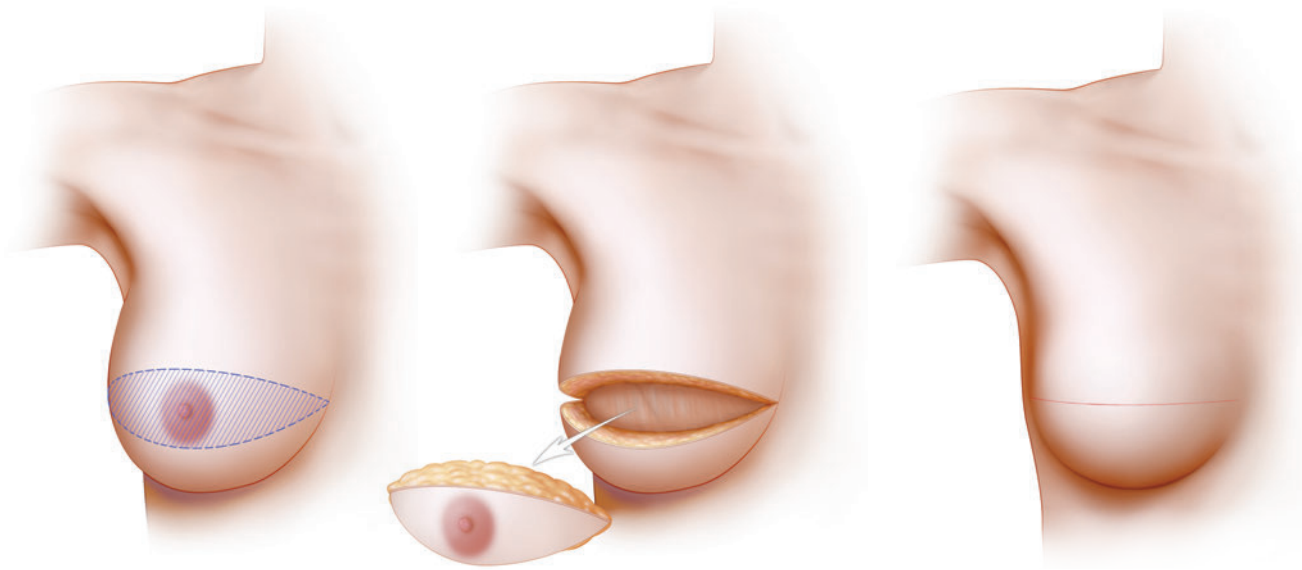
Fig. 17-2

Ellipse excisions are easy to perform, but they always flatten the breast apex, resulting in some asymmetry. Little or no skin undermining is required. This is a good option when a small volume is to be excised and/or a limited surgery is favored, regardless of the breast size or shape. Ellipse excisions are usually transversely oriented, but they may be rotated if necessary and are performed as a single excision of cutaneous and parenchymal tissue.

The wider the ellipse excision of the skin and areola, the greater the breast flattening. This effect can be limited by narrowing and shortening the excision.

One method of decreasing flattening is to remove the nipple and leave some areola, if oncologically feasible. In addition to limiting the flattening effect, the remaining areolar tissue may also add to the cosmetic outcome.

Alternatively, the ellipse may be made in a vertical direction with the superior extension limited. In principle, this becomes a vertical wedge mammoplasty, but it is almost as easy to perform as a horizontal ellipse. The vertical orientation tends to tighten or lift the breast and can often be performed in conjunction with a vertical mastopexy on the opposite breast. It is ideal in breasts with minor to moderate ptosis. As with the transverse ellipse, it is not necessary to remove all of the areola with this method.

**Fig. 17-3**

An extended ellipse, or melon slice excision is usually performed transversely but can be at an oblique angle if required. It is a simple method of simultaneously excising the tumor and nipple-areola complex and significantly reducing the breast size. It is a helpful technique if a wide margin is preferred, in reexcision cases, in patients with risk factors, in elderly patients for whom a quick, simple procedure may be preferable, and if the patient prefers a smaller breast or this facilitates postoperative radiotherapy.

Therapeutic mammoplasty achieves similar goals but is more complex. An extended central ellipse is preferred for patients with risk factors, since there is very little undermining of breast tissue or pillar creation as for mammoplasty surgery, minimizing the healing risks for patients who smoke, are obese, have diabetes, or those with very soft, oily parenchymal tissue.

Although the disadvantage of an extended ellipse is a long, transverse scar across the breast, the advantages include its simplicity, relative safety, and predictability. Preoperative markings are essential. The tumor is best marked with the patient lying down; the mammoplasty marks should be made with the patient standing. The resection needs to extend across the entire breast to minimize contour irregularities. The superior marking of the ellipse is placed at or just below the IMF and then a gentle curve is drawn medially to a chosen point on the medialmost aspect of the breast. The ellipse is concave inferiorly. The lateral markings should have a slightly wider or higher marking to create a somewhat wider excision laterally. This helps to narrow the breast. The inferior marking of the ellipse needs to retain 8 to 14 cm of central tissue above the IMF to create enough central bulk for the breast. At the breast meridian the ellipse is convex superiorly. It is possible to leave some additional tissue on either the superior or inferior aspect of the ellipse, depending on the tumor excision site. The tumor is excised first, and then the remaining excision and axillary surgery are performed. The superficial fascia is reapproximated to lift the breast and close the dead space.

PATIENT EXAMPLE

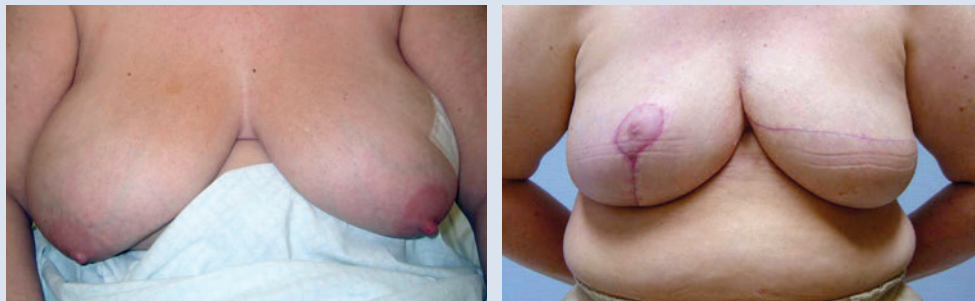

Fig. 17-4

This 52-year-old woman was diagnosed with a screening-detected invasive tumor in her left breast that measured 33 mm on imaging and required excision of the nipple-areola complex. It is important to note that the patient is overweight and diabetic. A left extended ellipse and a right Wise pattern reduction were performed. The patient is shown 4 months after surgery and radiotherapy.

Round Block

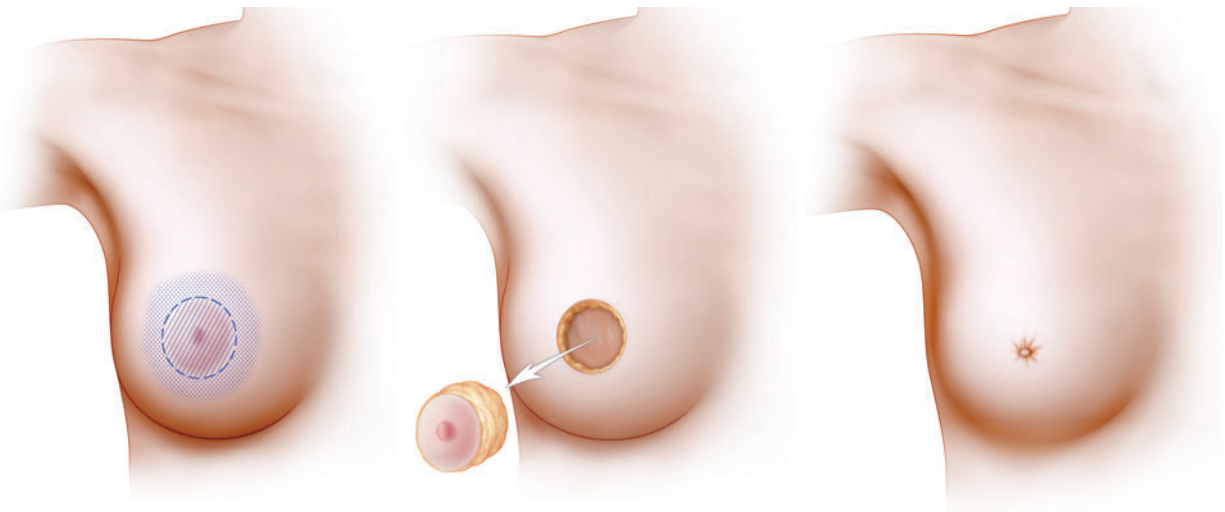


Fig. 17-5

The round block excision with a purse-string closure is an attractive option, because it results in a reduced scar length. The nipple and areola are excised with the underlying tumor, and the skin surrounding the excision is undermined. The parenchyma is approximated, and the skin is closed with a purse-string suture. However, although the scar is shorter, this

technique also produces flattening of the breast apex, and the scar has a tendency to stretch and is prone to healing problems. It is not always ideal for nipple reconstruction. However, this round block excision remains a simple option for small, unilateral cases.

Volume Displacement Techniques

Because of the relative simplicity of planning mammaplasty surgery in which the nipple-areola complex is to be excised, therapeutic mammaplasty is a very useful and reliable tool in patients with central tumors. Although modifications are required in mammaplasty techniques when applied to tumors throughout the breast, central tumors may be treated by one of two therapeutic mammaplasty methods. The first and simpler method is the wedge excision, in which the central tumor, nipple, and additional tissue are removed as required. These incisions are usually in the form of a vertical or inverted-T skin pattern. No pedicles are required for the nipple or to fill in the tumor defect. This simplifies the surgery and reduces the risk of complications.

The second group of techniques for central tumors uses an inferiorly based pedicle to fill the parenchymal and nipple-areola defect. A central skin island is created to replace the nipple-areola complex. The surgery is usually bilateral. These procedures are broadly based on the principles of the Grisotti flap, using an inferior pedicle that advances or rotates into the central defect.

Therapeutic Mammaplasty Wedge Excisions

Of all the therapeutic mammaplasty options, a wedge mammaplasty excision remains one of the easiest to perform; it is also ideal for managing central tumors in which the nipple-areola complex is to be removed.

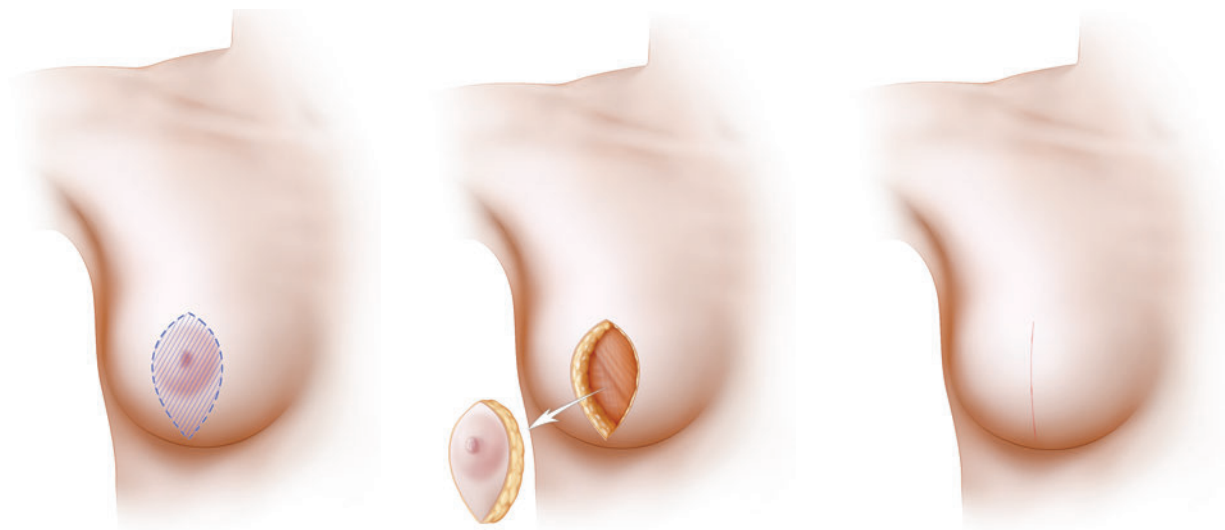


Fig. 17-6

It is usually planned as either a vertical or inverted-T pattern. The skin pattern is determined by the size of the breast and the degree of ptosis.

Because no pedicles are used, wedge excisions are a predictable procedure for patients with extremely large breasts or risk factors such as obesity, smoking, or diabetes. These procedures are ideal as a primary excision and in reexcision cases.

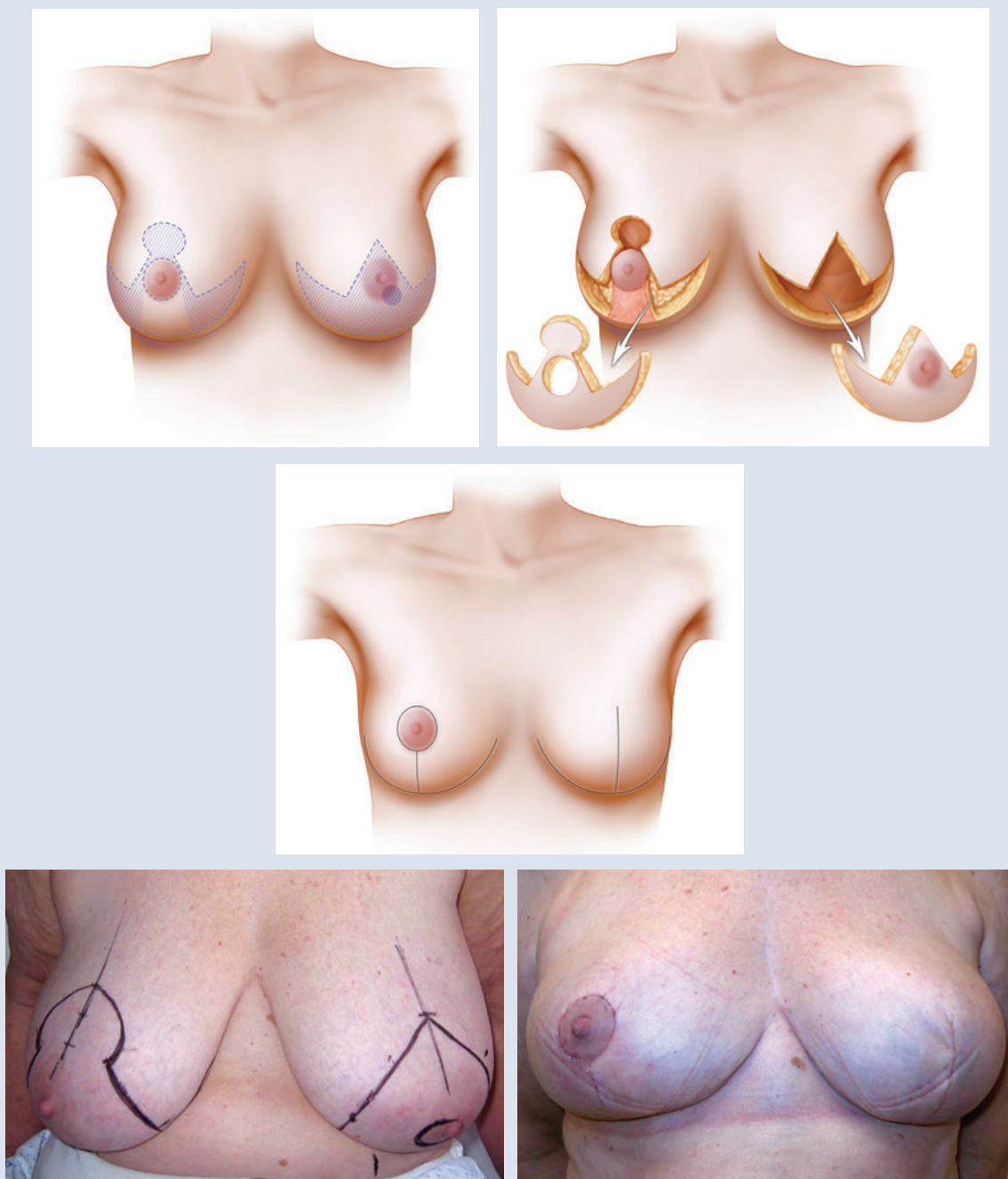
The vertical technique is preferred in women with smaller breasts or mild to moderate ptosis. However, a wide nipple-areola complex excision in smaller-breasted patients still blunts the breast apex. If oncologically feasible, some areolar tissue can be preserved. In patients with larger breasts or significant ptosis, the inverted-T wedge mammoplasty often allows a very wide central excision. In all cases, nipple-areola reconstruction may be performed later, if desired.

Because of the lack of a pedicle for the nipple-areola complex, the bulk of the breast is maintained in the pillars of the mammoplasty or by leaving some central parenchymal tissue to add to the projection as needed.

Overthinning the mammoplasty pillars should be avoided, because it creates an empty, nonprojecting breast.

The markings are similar to those for standard reduction mammoplasty, but care must be taken to avoid tension. The vertical marking should be made to allow a reasonably tension-free closure. The vertical component is usually 8 to 11 cm in length, depending on breast size. The horizontal marking if required can be as for a Wise pattern mammoplasty. It is important to leave some additional parenchymal tissue on the pillars of the mammoplasty for central bulk and projection. The tumor/nipple-areola complex and central tumor should be excised initially and then the remaining mammoplasty performed. As this is a volume reduction procedure, a contralateral symmetry procedure is most often required.

PATIENT EXAMPLE

**Fig. 17-7**

This 69-year-old woman had macromastia and was diagnosed with a 19 mm left retroareolar tumor, which was excised by an inverted-T wedge mammoplasty; a contralateral Wise pattern reduction was also performed. The patient is shown 4 months after surgery and radiotherapy.

Therapeutic Mammoplasty With Parenchymal Advancement *Grisotti Flap*

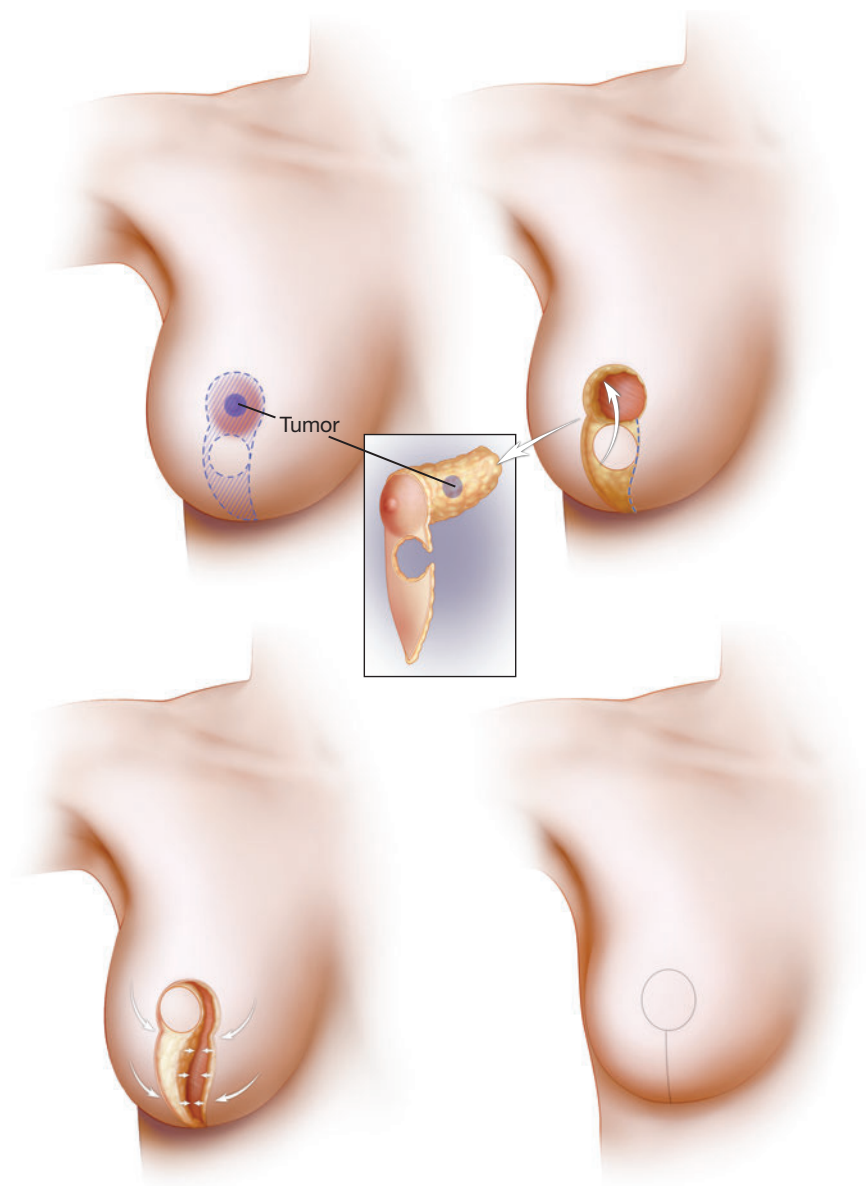


Fig. 17-8

The Grisotti flap⁸ was first described in 1993 for the treatment of central tumors. It uses rotation and advancement of inferiorly based tissue into the central defect and is described as a unilateral procedure.

The Grisotti flap is ideal when the central excision is not large in a moderate-sized breast with moderate ptosis. It minimizes the cosmetic impact on the breast without a significant change in the breast volume.

The principle of the flap can be adapted either to have a buried parenchymal flap or, more commonly, to carry a skin island into the nipple-areola complex defect.

The central excision is performed, and a dermoglandular flap is planned inferiorly. This flap curves into the IMF. A skin island is usually left to fill the nipple-areola defect. The flap has a broad attachment to the lateral breast tissue and is elevated off of the pectoral fascia to allow advancement and rotation into the defect. Although not originally described, it is feasible to perform an immediate nipple reconstruction on the skin island.

Therapeutic Mammoplasty With Advancement Pedicles

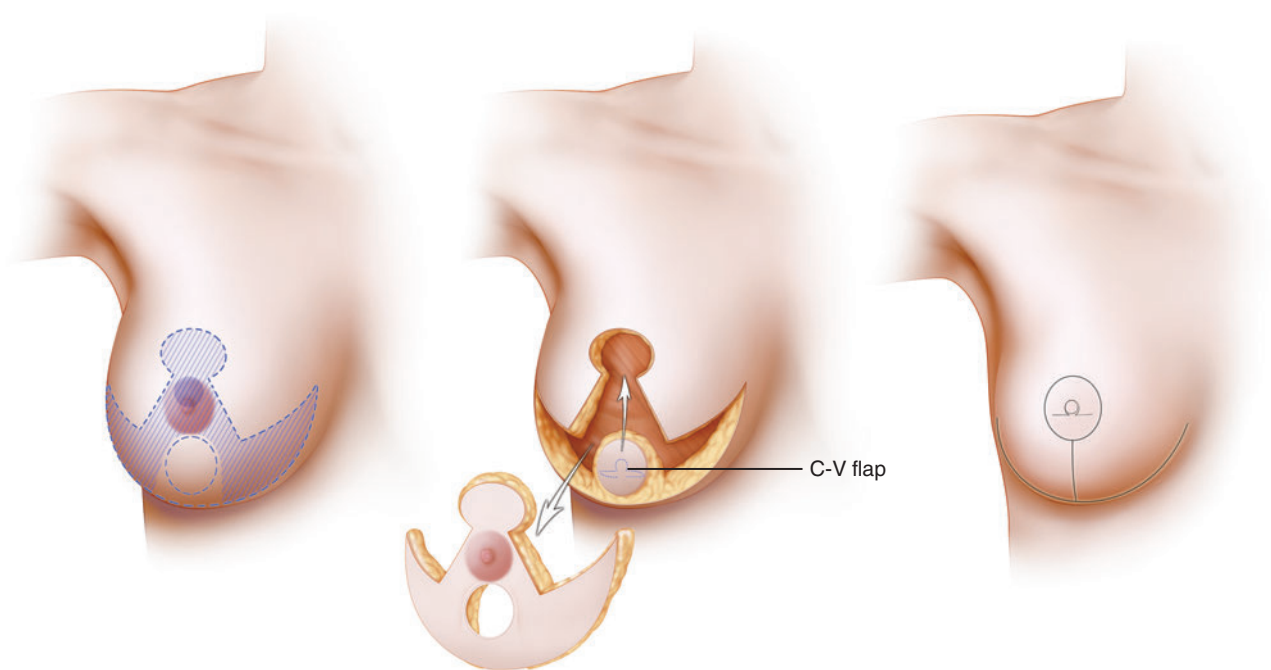


Fig. 17-9

The advancement pedicle used is usually a true inferior pedicle advanced directly into the defect. It has the advantage of carrying skin and parenchyma into the defect. The inferior pedicle allows projection to be well controlled with the size of the pedicle, and the addition of skin to replace the nipple-areola complex allays concerns about blunting of the breast apex in smaller-breasted patients. It is important that the skin island is not much less than 6 or 7 cm from the inframammary fold. An immediate nipple reconstruction can also be performed on the skin disk during the primary procedure. One advantage of immedi-

ate nipple reconstruction is that all the skin is available on the inferior pedicle, making it easier to create and/or reconstruct the required size nipple. This availability ensures that adequate nipple heights can be achieved without being limited later to the skin island. A similar inferior pedicle mammaplasty technique carrying the nipple-areola complex is usually performed on the opposite breast. The neo-nipple-areola complex may be tattooed to complete the reconstruction. The procedure is just as reliable as a standard inferior pedicle reduction mammaplasty.

PATIENT EXAMPLES

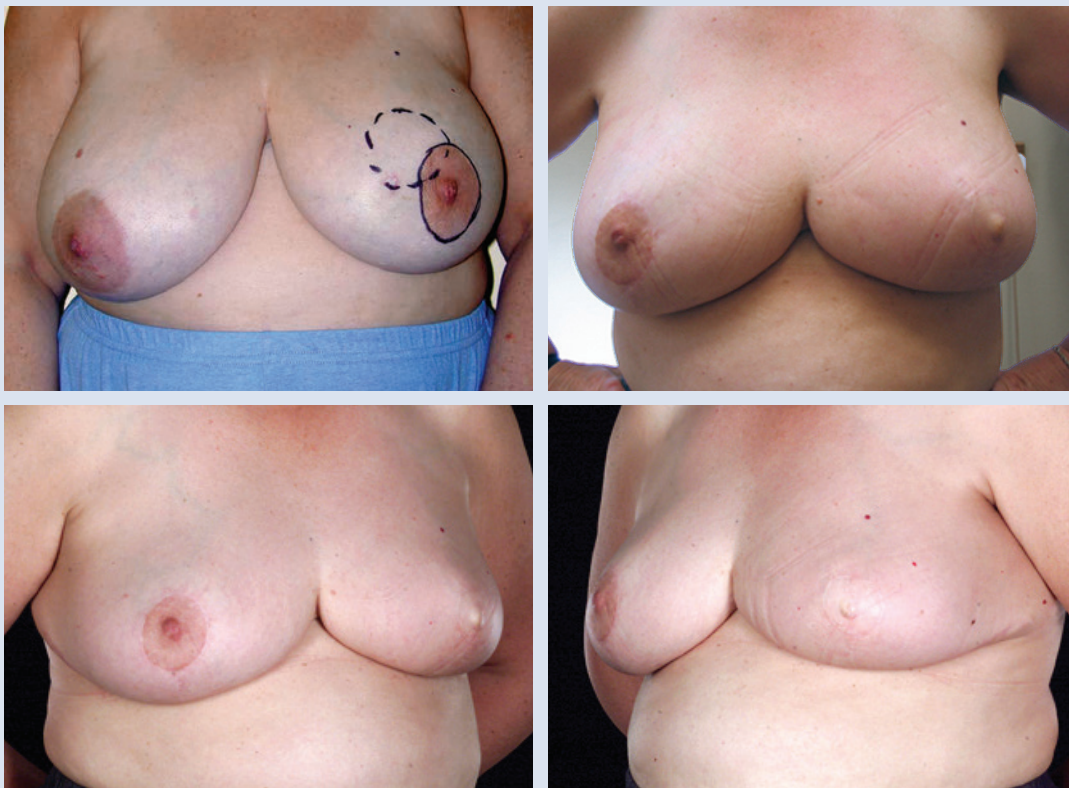


Fig. 17-10

This 58-year-old patient was diagnosed with a 31 mm grade 2 tumor in the left breast. A central tumor excision and reconstruction with an inferior advancement pedicle and immediate nipple reconstruction were planned. The breast was marked as for a standard Wise mammaplasty. An inferior pedicle was used, carrying skin from the inferior pole of the breast. Skin was maintained on the upper half of the pedicle. Once the nipple position was determined, the nipple was created with a C-V flap. The skin disk was created as needed around the nipple. The patient is shown 6 months after surgery and after radiotherapy, which was performed 18 months postoperatively.

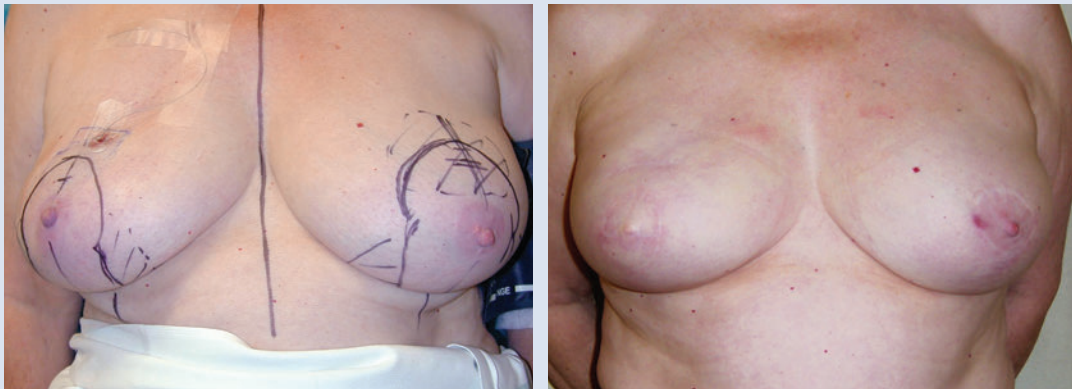


Fig. 17-11

This patient was diagnosed with screening-detected recurrent DCIS of the right breast, which required the removal of the nipple and areola. In addition, marker wire was required for localization. Treatment involved a vertical-pattern therapeutic mammoplasty with a medial parenchymal flap and nipple reconstruction with a C-V flap. The patient is shown preoperatively and 15 months after surgery and radiotherapy.

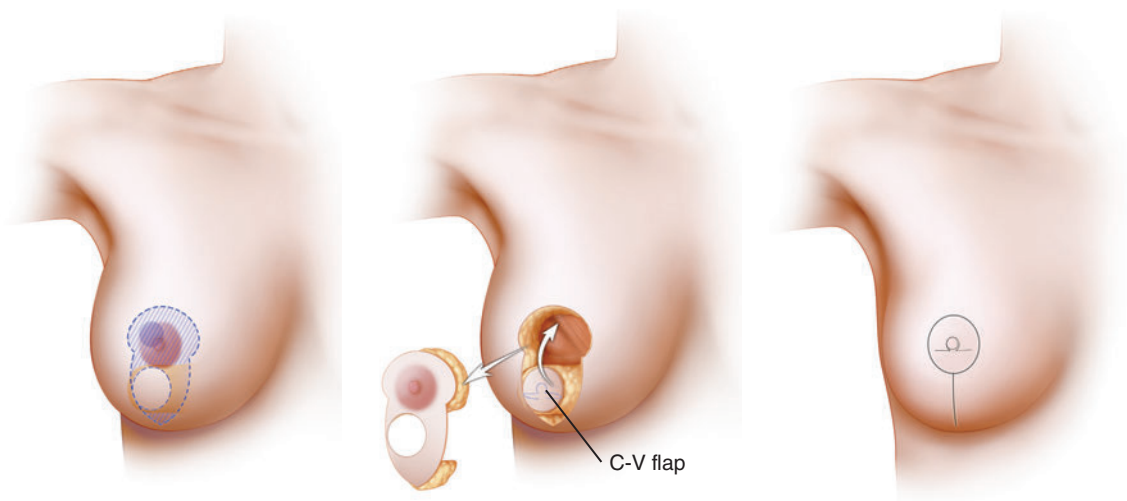


Fig. 17-12

With a vertical skin pattern, it is often easier to use a medial or lateral pedicle to fill the defect and carry the skin island. This allows excision of the inferior pole of breast tissue, frequently performed with a vertical reduction mammoplasty.

When performing a therapeutic mammoplasty, the surgeon must ensure that the skin closure is not too tight; this is especially true when an inferiorly based pedicle is used. Tension

is a common cause of wound-related problems, and these can be exacerbated by the presence of the bulk of the inferior pedicle. Markings for all mammaplasty procedures (reduction and therapeutic mammaplasties) should be made according to landmarks, not measurements. The breast should be gently pushed medially and laterally with respect to the breast meridian to define the position of the vertical markings. Similarly, the mammaplasty apex is planned at the inframammary crease. Nipple reconstruction is easily performed at a later stage, when not reconstructed immediately.

Volume Replacement Procedures

Many new perforator flaps have been described for use as volume replacement flaps, including intercostal perforators be they lateral (LICAP flap) or anterior (AICAP) and thoracodorsal artery perforator (TAP) flaps.⁹

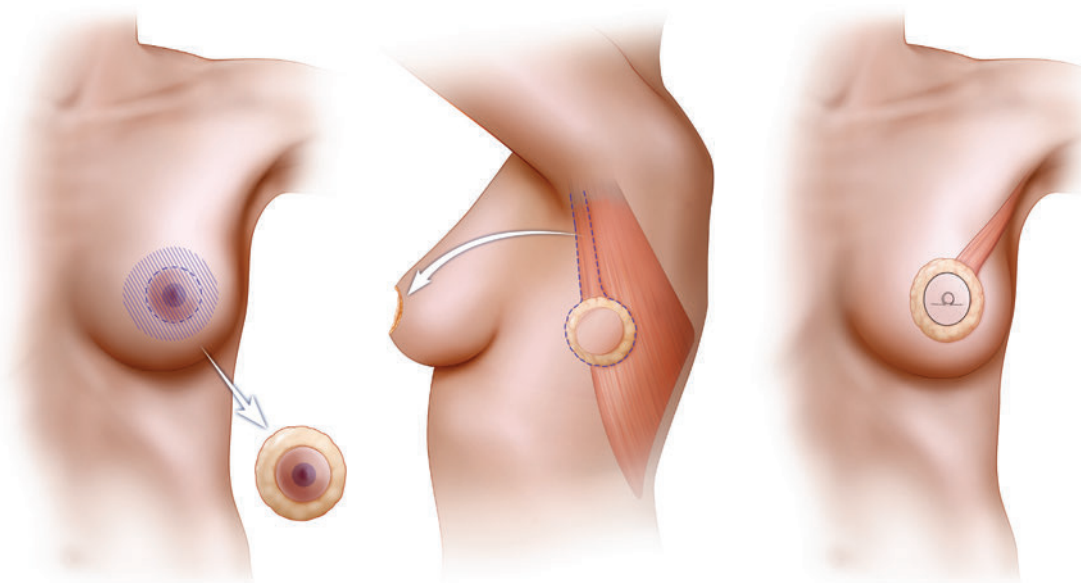


Fig. 17-13

For central tumors, the TAP flap or the traditional LD miniflap have better reach and are more valuable than the LICAP flaps. Anteriorly based perforators flaps have been described.¹⁰ The TAP flap and the muscle-sparing LD flap have mostly superseded the traditional LD miniflap, since the majority or all of the LD muscle is preserved, providing much better function and donor site. TAP flaps or muscle-sparing LD flaps are ideal for central defects and allow both reach and adequate volume while preserving the latissimus dorsi muscle function.

Also for most central tumors the flap volume required does not require muscle bulk.

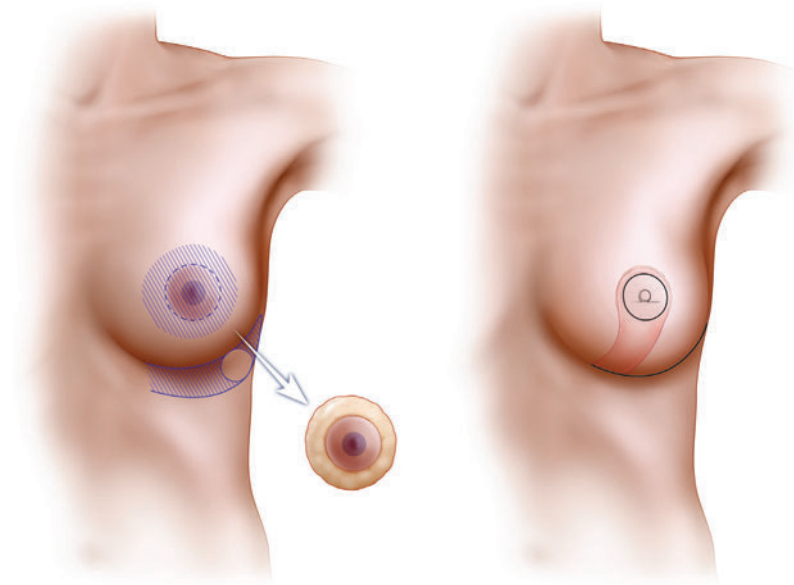


Fig. 17-14

The use of anterior intercostal perforator flaps can allow central filling in selected cases, keeping scars within the breast inframammary fold.

When choosing between the options, it is important to consider the reach of the flap and the volume required. Classically, the TAP flap will have its skin island based on the main perforator, which is usually 10 cm from the posterior axillary fold. Ensure that the reach into the central area is adequate. For breast volume replacement the TAP flap often needs to be based on more inferior perforators.

All these options can be performed as a single-stage procedure using frozen section or as a two-stage procedure, which is our preference.¹⁰ This approach is indicated in women with smaller breasts who wish to preserve breast volume, shape, and symmetry.

These techniques potentially allow very wide excisions of skin and parenchyma, limited only by the volume of skin island for TAP flaps that can be harvested. If it is performed as a single operation, a detailed frozen section analysis of the margins is required. Prior consent must be obtained from the patient before surgery to convert to a mastectomy (plus or minus reconstruction) if clear margins cannot be achieved. The rates of local recurrence are reported to be low, with no loss in mammogram sensitivity when the frozen sections are clear.^{11,12}

A two-stage procedure allows a routine margin assessment to be performed and the second procedure to be planned. A sentinel node biopsy at the first procedure also allows axillary node clearance to be performed, if appropriate, at the time of definitive flap raising. The slight disadvantage of a two-stage technique is that some form of skin closure needs to be temporally fashioned. However, closing the areolar excision as a short ellipse or with a purse-string suture allows a skin island to be set in with relative ease.

With either the one- or two-stage method, a tunnel of breast tissue is created toward the axilla to allow the pedicle to sit comfortably within the breast. The nipple reconstruction may be performed at the same time.

SURGICAL TREATMENT BY BREAST SIZE

Marked Macromastia

Patients with marked macromastia have a similar presentation to those who present for reduction mammoplasty of more than 500 g. Although these patients are still at risk for a significant cosmetic deformity and asymmetry after a central tumor excision, the impact of the surgery is likely to be minimal. However, postoperative radiotherapy can be very problematic in this group, causing edema, skin changes, or ulcerations.^{6,13-15} In addition, radiotherapy dosing inhomogeneity may occur in women with very large breasts and may overlap at the IMF. Total mastectomies and total reconstructions also have higher risk profiles for patients with very large breasts, making therapeutic mammoplasty an attractive treatment option.

Reduction mammoplasty procedures should be seriously considered as a first-line treatment in patients with significant macromastia.

Traditionally, these patients have been treated with a simple central ellipse excision. However, if the patient agrees to bilateral surgery and to having smaller breasts, treatment by extended central ellipses or therapeutic mammoplasty becomes preferable.

Moderate Macromastia and Ptosis

Patients with moderate macromastia and ptosis have a breast morphology that is similar to that of patients who present for a small to moderate reduction mammoplasty (100 to 500 g). They are at an increased risk of poor cosmetic outcomes and asymmetry, but at a lower risk of serious radiation-related problems that occur with larger-breasted patients. The options for treatment are broad and influenced strongly by the size of the planned excision, risk factors, and patient preferences. Therapeutic mammoplasty remains an ideal treatment for selected patients in whom large-percentage excisions are planned or those who have significant ptosis. However, simple ellipses are still a good option within this group when less involved or unilateral surgery is preferred. When a very large excision is required or the patient wishes to maintain her breast size, volume replacement techniques are preferable.

Small to Moderate Breast Size and Ptosis

Patients with small- to moderate-sized breasts and ptosis have a breast morphology similar to that of patients who present for a mastopexy. Although these women may not deem a smaller breast an advantage, very good therapeutic mammoplasty options are still available, depending on the size of the planned excision. Parenchymal redistribution is usually preferred over wedge-type excisions to maximize the use of the available parenchyma. Effectively, a mastopexy with a small reduction is performed. Once excisions become too large, volume replacement methods become more helpful. Unilateral treatment with Grisotti-type flaps are also helpful options.

Small to Moderate Breast Size and Little or No Ptosis

In patients with small- to moderate-sized breasts and little or no ptosis, the treatment method chosen depends on the percentage of tissue excised. Smaller central excisions may be managed with a unilateral simple excision or a Grisotti flap. Volume replacement methods allow complete freedom with respect to the size of the excision and are the preferred options for breast conservation in patients who undergo excision of a significant percentage of tissue. These methods also allow skin replacement as required.

NIPPLE RECONSTRUCTION

Nipple reconstruction can be performed at the primary setting in many cases or as a delayed reconstruction. When a skin island is used to fill the central defect, a primary reconstruction can be performed and may even be preferable. All of the skin on the inferior pedicle can be used in this primary setting to create the nipple of the required size (expecting it to shrink approximately 60% over time). The areolar disk can be cut from the remaining skin to create a circular disk. Our preference is to create a modified C-V flap on the skin island, with delayed tattooing of the reconstruction.

CONCLUSION

Traditionally, central tumors have been treated with a mastectomy for both oncologic and cosmetic reasons. It is now accepted that tumors up to 4 cm in size are amenable to treatment with breast conservation and radiotherapy.^{2,16,17} Established oncoplastic procedures and concepts¹⁸⁻²⁴ have become ideal in the treatment of these tumors. They allow the wide excision of the nipple-areola complex and tumor, and the cosmetic results appear to be consistently good. This result should be expected, because the complexity of preserving the nipple-areola complex is not required, and any pedicles used are reliable and commonly performed during a standard reduction mammoplasty. Because the periphery of the breast parenchyma is preserved, the breast shape tends to be well preserved, provided the cen-

tral defect is adequately filled. The outcomes for central tumors are, in many ways, more reliable than for tumors treated using oncoplastic procedures in some other areas of the breast. The use of oncoplastic procedures is transforming the options available to patients with centrally located tumors—a traditionally challenging group of patients to treat.

Critical Issues

- Therapeutic mammoplasty techniques truly broaden indications for breast-conserving therapy in patients with centrally located tumors.
- Numerous treatment options are available, depending on the breast size and shape.
- The scar should be extended when performing wedge excisions to obtain better breast shape.
- An inferolateral rotation flap (Grisotti flap) is indicated for patients with a small to moderate breast size.
- Parenchymal advancement flaps are used to replace central volume and to maintain projection.
- Nipple-areola reconstruction needs to be taken into consideration when planning surgery for patients with central breast tumors.
- Contralateral procedures are often required to maintain symmetry in larger resections.
- Grisotti flaps are indicated for small excisions in small or moderate breasts with mild ptosis.

References

1. Cochrane R, Valasiadou P, Wilson AR, et al. Cosmesis and satisfaction after breast-conserving surgery correlates with the percentage of breast volume excised. *Br J Surg* 90:1505, 2003.
2. Simmons RM, Brennan MB, Christos P, et al. Recurrence rates in patients with central or retroareolar breast cancers treated with mastectomy or lumpectomy. *Am J Surg* 182:325, 2001.
3. McCulley SJ, Durani P, Macmillan RD. Therapeutic mammoplasty for centrally located breast tumors. *Plast Reconstr Surg* 117:366, 2006.
4. Huemer GM, Schrenk P, Moser F, et al. Oncoplastic techniques allow breast-conserving treatment in centrally located breast cancers. *Plast Reconstr Surg* 120:390, 2007.

5. Gunilla C, Lawrence M, Curtis S, et al. Acute and late morbidity of using a breast positioning ring in woman with large/pendulous breasts. *Radiother Oncol* 50:277, 1999.
6. Moody AM, Mayles WP, Bliss JM, et al. The influence of breast size on late radiation effects and association with radiation dose inhomogeneity. *Radiother Oncol* 33:106, 1994.
7. Schoeller T, Huemer G. Immediate reconstruction of the nipple/areolar complex in oncoplastic surgery after central quadrantectomy. *Ann Plast Surg* 57:611, 2006.
8. Galimberti V, Zurrida S, Zanini V, et al. Central small size breast cancer: how to overcome the problem of nipple and areola involvement. *Eur J Cancer* 29:1093, 1993.
9. Hamdi M, Van Landuyt K, Monstrey S, et al. Pedicled perforator flaps in breast reconstruction: a new concept. *Br J Plast Surg* 57:531, 2004.
10. Carstensen L, Bigaard J. Management of central breast tumours with immediate reconstruction of the nipple-areola complex; a suggested guide. *Breast* 24:38, 2015.
11. Rainsbury R. Breast-sparing reconstruction with latissimus dorsi miniflaps. *Eur J Surg Oncol* 28:891, 2002.
12. Dixon JM, Venizelos B, Chan P. Latissimus dorsi mini-flap: a technique for extending breast conservation. *Breast* 11:58, 2002.
13. Al-Ghazal SK, Fallowfield L, Blamey RW. Does cosmetic outcome from treatment of primary breast cancer influence psychological morbidity? *Eur J Surg Oncol* 25:571, 1999.
14. Gray J, McCormick B, Cox L, et al. External irradiation in large-breasted or heavy woman: analysis of cosmetic outcome. *Int J Radiat Oncol Biol Phys* 21:347, 1991.
15. Moody AM, Mayles WP, Bliss JM, et al. The influence of breast size on late radiation effects and association with radiation dose inhomogeneity. *Radiother Oncol* 33:106, 1994.
16. Fisher B, Anderson S, Redmond C, et al. Reanalysis and results after 12 years of follow-up in a randomized clinical trial comparing total mastectomy with lumpectomy with or without irradiation in the treatment of breast cancer. *N Engl J Med* 333:1456, 1995.
17. Asgeirsson KS, McCulley SJ, Pinder SE, et al. Size of invasive breast cancer and risk of local recurrence after breast-conservation therapy. *Eur J Cancer* 39:2462, 2003.
18. Masetti R, Pirulli P, Magno S, et al. Oncoplastic techniques in the conservative surgical treatment of breast cancer. *Breast Cancer* 7:276, 2000.
19. Clough K, Lewis J, Couturand B, et al. Oncoplastic techniques allow extensive resections for breast-conserving therapy of breast carcinomas. *Ann Surg* 237:26, 2003.
20. Spear S, Pelletiere C, Wolfe A, et al. Experience with reduction mammoplasty combined with breast conservation therapy in the treatment of breast cancer. *Plast Reconstr Surg* 111:1102, 2003.
21. Garusi C, Petit JY, Rietjens M, et al. Role of plastic surgery in the conservative treatment of breast cancer. *Ann Chir Plast Esthet* 42:168, 1997.
22. Munhoz AM, Montag E, Arruda EG, et al. Critical analysis of reduction mammaplasty techniques in combination with conservative breast surgery for early breast cancer treatment. *Plast Reconstr Surg* 117:1091, 2006.
23. Losken A, Styblo TM, Carlson GW, et al. Management algorithm and outcome evaluation of partial mastectomy defects treated using reduction and mastopexy techniques. *Ann Plast Surg* 59:235, 2007.
24. Anderson BO, Masetti R, Silverstein MJ. Oncoplastic approaches to partial mastectomy: an overview of volume-displacement techniques. *Lancet Oncol* 6:145, 2005.

18

The Role of Local Flaps as Volume Replacement in Oncoplastic Reconstruction

Alexandre Mendonça Munhoz, Rolf Gemperli

Despite the recognition that most breast-conserving surgery (BCS) defects can be treated with primary closure, the aesthetic outcome may be unpredictable and occasionally can be complex to reconstruct.^{1,2} Recently increasing attention has been focused on reconstructive techniques.¹⁻¹³ Basically, two different groups of oncoplastic procedures exist, and the choice of which technique to perform depends on the volume of the excised breast tissue related to the total breast volume and degree of ptosis. One group of techniques is commonly defined as volume displacement procedures, which combines resection with a variety of different breast-reshaping and breast-reduction procedures; the other group is defined as the volume replacement procedure in which the volume of excised breast tissue is replaced with autologous tissue. In fact, these techniques can retain the volume and shape of the breast and avoid contralateral breast surgery. However, these techniques can be more complex and require a donor site and increased recovery time following flap harvesting.

Local flaps are relatively simple techniques that reconstruct with tissue of similar color and feel and can maintain the volume/shape of the breast, avoiding contralateral surgery.

Among the main technical options, local flaps,^{1,3,6,8} the latissimus dorsi myocutaneous flap,^{1,6,7} and reduction mammoplasty^{1-4,9-13} are the most commonly employed techniques with more favorable outcomes. Regardless of the fact that there is no consensus concerning the best approach, the decisive criteria is determined by the surgeon's experience and the size of the defect in relation to the size of the remaining breast.^{1,3,7-10} The main advantages of the technique utilized should include reproducibility, low interference with the onco-logic treatment and long-term results. Probably, all these goals are not achieved by any single procedure and each technique has advantages and limitations.⁹

In terms of aesthetic results and surgical morbidity, local flaps have some positive aspects. The skin texture and color are comparable, the technique is simpler, and the operative process is less aggressive.⁸ All these factors are important, because some patients will undergo adjuvant chemotherapy and radiotherapy. Local flaps have been described previously.^{3,8,14-17} Basically, the major part of the techniques have employed a rotation or transposition flap of skin and subaxillary fat for the breast defect.⁸

Initially described by Holmstrom and Lossing in 1986,¹⁸ the lateral thoracodorsal flap is a commonly performed procedure for delayed radical surgery reconstruction. The flap can be planned as a wedge-shaped transposition design located in the lateral aspect of the thorax. The axis is located in the lateral extensions of the submammary fold. Its major clinical application is in patients who refuse higher morbidity procedures or are not good candidates for more extensive reconstruction, particularly with myocutaneous flaps.^{8,18}

In spite of the simplicity of the technique, important technical steps must be considered beforehand. Operative planning should include tumor location and the extent of glandular tissue resected, essentially addressing individual reconstructive requirements. Thus enabling each patient to receive an individual “customized” reconstruction. The success of the procedure depends on patient selection, coordinated planning with the oncologic surgeon, and careful intraoperative management. In addition, an in-depth dialog concerning alternatives for BCS reconstruction should be undertaken with the multidisciplinary scenario, including the risks and positive aspects of the local flap reconstruction.

DELAYED-IMMEDIATE LOCAL FLAP RECONSTRUCTION

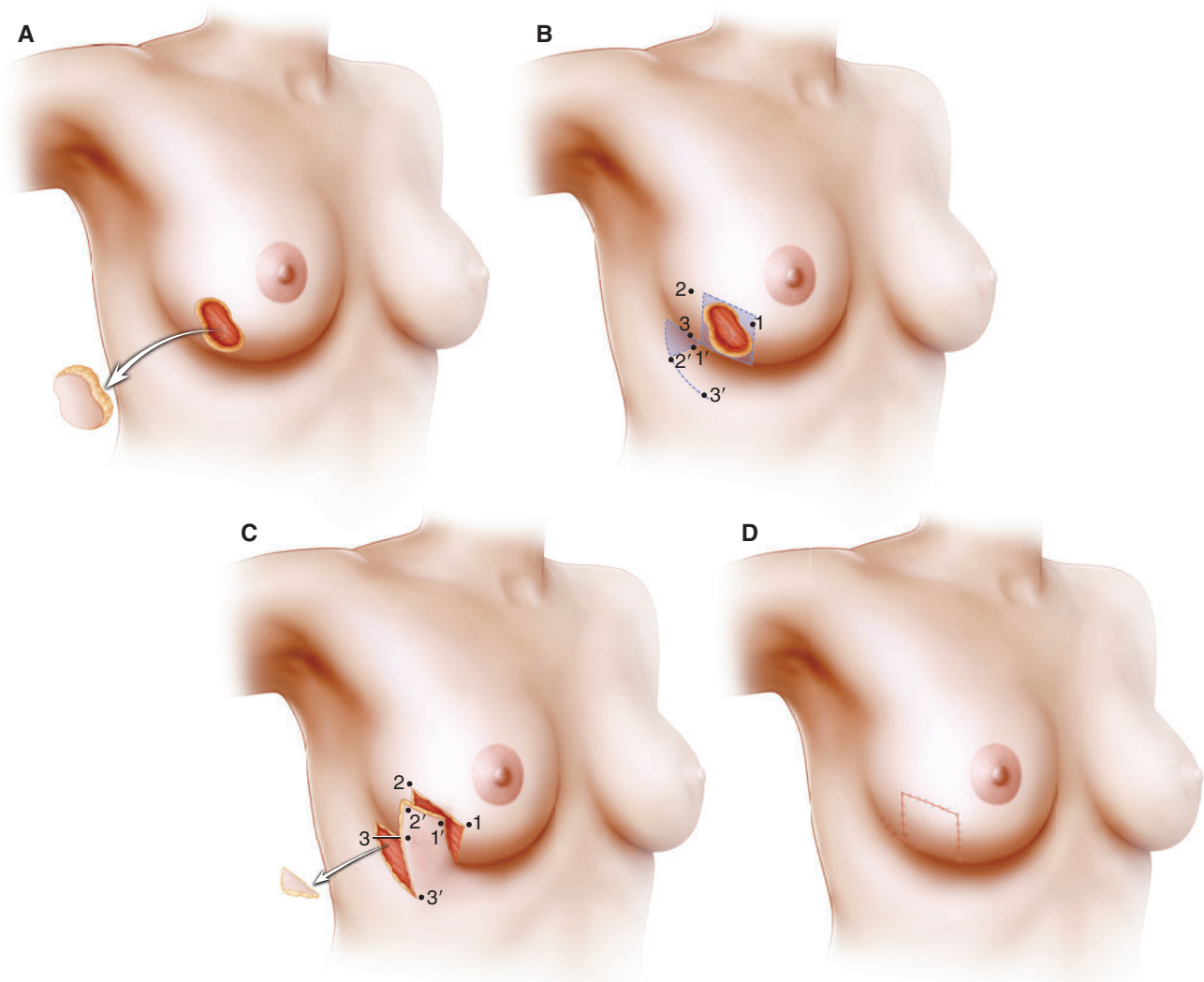
Volume replacement procedures and the use of local flaps can be indicated for immediate, delayed, and delayed-immediate reconstructions. The advantages of each approach are described in Chapter 13.

INDICATIONS FOR USE OF LOCAL FLAPS WITH ONCOPLASTIC TECHNIQUES

Partial breast defects represent an anatomic variety that ranges from small defects to large defects that involve skin, nipple-areola complex (NAC), and a significant amount of glandular tissue. Each defect has its own special reconstructive necessities and varying expectations for aesthetic outcome.

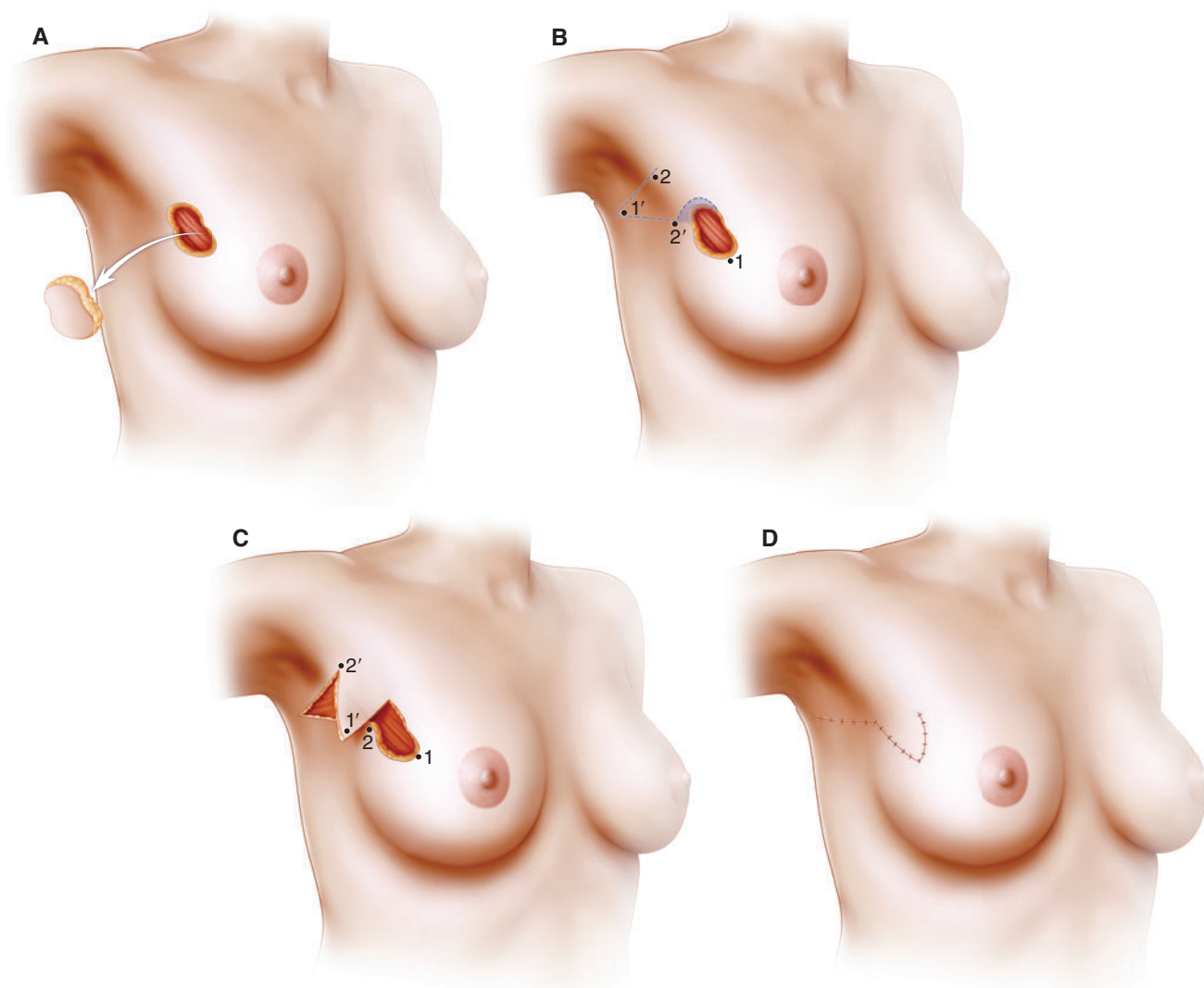
Although a number of reconstructive procedures are available, the surgeon and patient need to consider a number of factors when selecting the most appropriate approach. Adequate selection depends on a range of features, including breast size/ptosis, tumor location, timing of surgery, morbidity, and patient expectation. Volume replacement techniques can maintain the volume and shape of the breast, avoiding contralateral surgery to attain symmetry.^{7,19} However, these techniques can be more complex procedures associated with donor site and flap morbidity.^{6,7}

Volume replacement procedures is defined when the resection defect is reconstructed by replacing the volume of tissue removed with a similar volume of autologous tissue from an extramammary region.¹⁹ This restores the breast volume and avoids the need for contralateral surgery to achieve symmetry. As opposed to breast volume displacement techniques the concept of breast volume replacement using local flaps has some advantages. The main indication for local flaps is the absence of some remaining breast tissue.^{7,8} This is true primarily in patients with small-volume breasts with or without ptosis. It includes patients with moderate lateral defects where there is not enough breast tissue to perform the reconstruction by local glandular flaps or reduction mammoplasty techniques.⁸



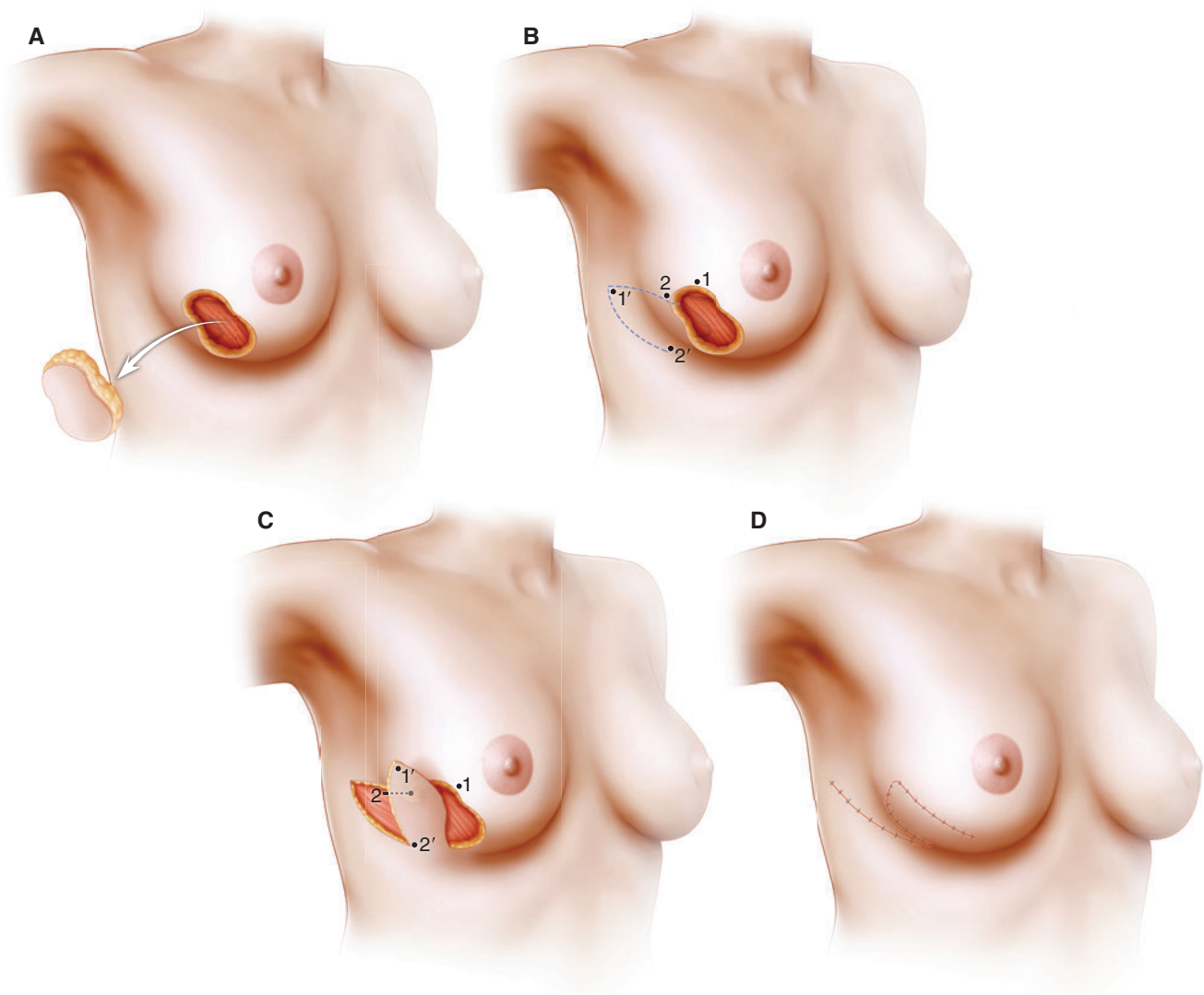
Rhomboid flap for small defects in inferolateral pole

Fig. 18-1



Subaxillary flap for defects in upper lateral pole

Fig. 18-2



Lateral thoracodorsal flap for defects in lower lateral pole

Fig. 18-3

Recently, different techniques of local flaps have been proposed for reconstruction after BCS.^{1,3,8,14-17} Fundamentally, these procedures all rely on rhomboid flaps, lateral thoracodorsal flaps, and subaxillary flaps. The majority of techniques involves the use of excess skin and subcutaneous tissue in the lateral thoracic region.⁸ When a large local flap is necessary a modification of the lateral thoracodorsal flap can be planned to harvest a flap carrying a large amount of skin and fat tissue. For this purpose a convex flap design, which provides a large amount of skin and makes the base narrower to avoid wound tension closure, is used. Since the axis is located in the lateral/dorsal extensions of the submammary fold, its major clinical application is in patients who refuse major morbidity procedures or are not good candidates for more extensive autologous tissue reconstruction.⁸

In spite of these positive aspects, local flaps present some limitations. Preoperative patient evaluation is crucial to determine the amount of tissue available and to allow optimal positioning of the tumor incisions to avoid an ischemic flap. Moreover, for the tumors located in the lower outer quadrants, a wide undermining below the inframammary sulcus during tumor resection may jeopardize flap vascularization and favor complications.⁸ For this reason, a coordinated planning with the oncologic surgeon is imperative with discussion of the surgical approach. Since some local flaps are not axial flaps, vascularization to the most distant parts is difficult to predict.^{1,8,20} This situation can predispose to partial necrosis (skin and fat) and an undesirable result.

Typically, lateral thoracodorsal flap reconstruction is most appropriate for women with small- or medium-sized breasts with large defects, who are not good candidates for volume displacement procedures.⁸ Other volume replacement techniques such as the subaxillary flap^{14,15} and the rhomboid flap are better indicated when reconstructing less extensive BCS defects.

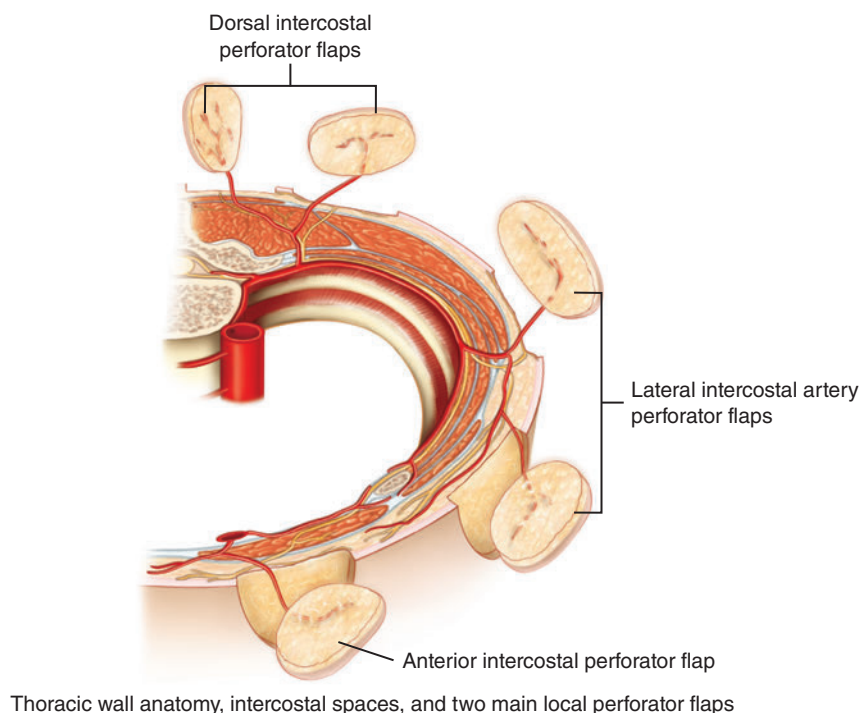


Fig. 18-4

Although presently BCS defect repair is the main objective, minimizing donor-site morbidity has now become an important point in surgical planning. For this purpose a number of local perforator flap techniques are available and the choice of procedure depends not only on an aesthetic outcome of the reconstructed defect but also on the reconstructive and functional requirements. Usually, the lateral thoracic area contributed to potential alternatives for perforator flaps. The use of the intercostal perforator vessels to supply a skin-muscle flap has been described and some authors divided the intercostal region into

four anatomical segments: vertebral, costal groove, intermuscular, and rectus.^{21,22,23} Thus based on the anatomy of the main perforator vessels, different perforator flaps can be harvested to repair partial breast defects without significant technical complications and with oncologic results comparable to other oncoplastic procedures. It has been our impression that the application of perforator concept to local flaps has greatly expanded the range of alternatives available. Therefore the present technique broadens the range of local flap applications and decreases donor-site morbidity. Variations of the local perforator flaps will become potential alternatives as reconstructive surgeons become more familiar with its anatomy, planning and clinical applications.

OPERATIVE TECHNIQUE

The Rhomboid Flap

Classically, a rhombus is defined as an oblique-angled parallelogram, whereas a rhomboid differs in that it has uneven adjacent sides. The expression rhomboid is commonly used in facial reconstruction to represent either rhombus-like defects or to illustrate one of the popular transposition flaps used to repair rhombus-shaped defects. Rhomboid flaps are helpful when the size or shape of a breast skin defect does not permit direct closure using a fusiform incision. In some BCS defects, attempting to close a wide lumpectomy defect primarily requires an ellipse with either long limbs or blunt angles. Lengthy limbs create long scars and remove healthy tissue unnecessarily, whereas blunt ends often create an unpleasant standing-cone or dog-ear appearance. Additionally, the lack of skin and breast tissue and the deviation or distortion of the NAC can be observed.

Surgical Planning and Technique

Considerations when designing any rhomboid flap include the diameter of the breast tissue/skin defect, the amount of normal skin that needs to be redundant, the scar orientation with respect to relaxed skin tension lines, the arc of skin rotation, and the vector of maximal tension after closure. When designing a flap, if possible match the skin color and thickness and respect boundaries of breast aesthetic units.²⁴ Rhomboid flaps have been used in reconstruction of the lateral and inferior breast pole defects (see Fig. 18-1, A). However, the aesthetic and mechanical properties of these flaps and especially the characteristics of the breast shape, make them particularly helpful for reconstruction of small BCS defects in the lateral quadrants. The flap and adjacent tissue are undermined in the subdermal plane after creating the rhombus defect (see Fig. 18-1, B and C). Rhomboid flaps are full-thickness local flaps with a random blood supply. Rather than depend on an axial blood vessel for nourishment, rhomboid flaps rely upon the dermal-subdermal plexus of blood vessels. If a large amount of tissue is necessary to fill the defect, the undermining can incorporate the surrounding breast tissue and fat. Lines of maximal extensibility lie perpendicular to skin creases. Tension is greatest at the closure point of the donor defect. The size and degree of undermining do not change the relative tensions of closure. It is important to place the line of maximum flap tension (the line of closure of the donor area) in a line of maximum extensibility of the breast. Primary tension of the closure must never displace a neighboring structure and the prominent landmarks, especially the NAC and the inframammary fold.

Complications

Most rhomboid flaps are closed under some degree of tension, and this tension is typically irregularly distributed along the flap's length. Areas of maximal tension are subject to widening and depression along the line of tension. Trapdoor deformities may occur and may be associated with insufficient incision of wound edges, incomplete undermining, or postoperative scar thickening. Flap failure is infrequent. However, partial necrosis of the distal tip of the flap can occur if the flap angle is excessively acute. More frequently, imperfections such as standing cones or widened scars result from transposition of such a flap. Standing cones are created when the rotation point of a rhomboid flap approaches 60 degrees, especially in young people or in patients with thick skin.

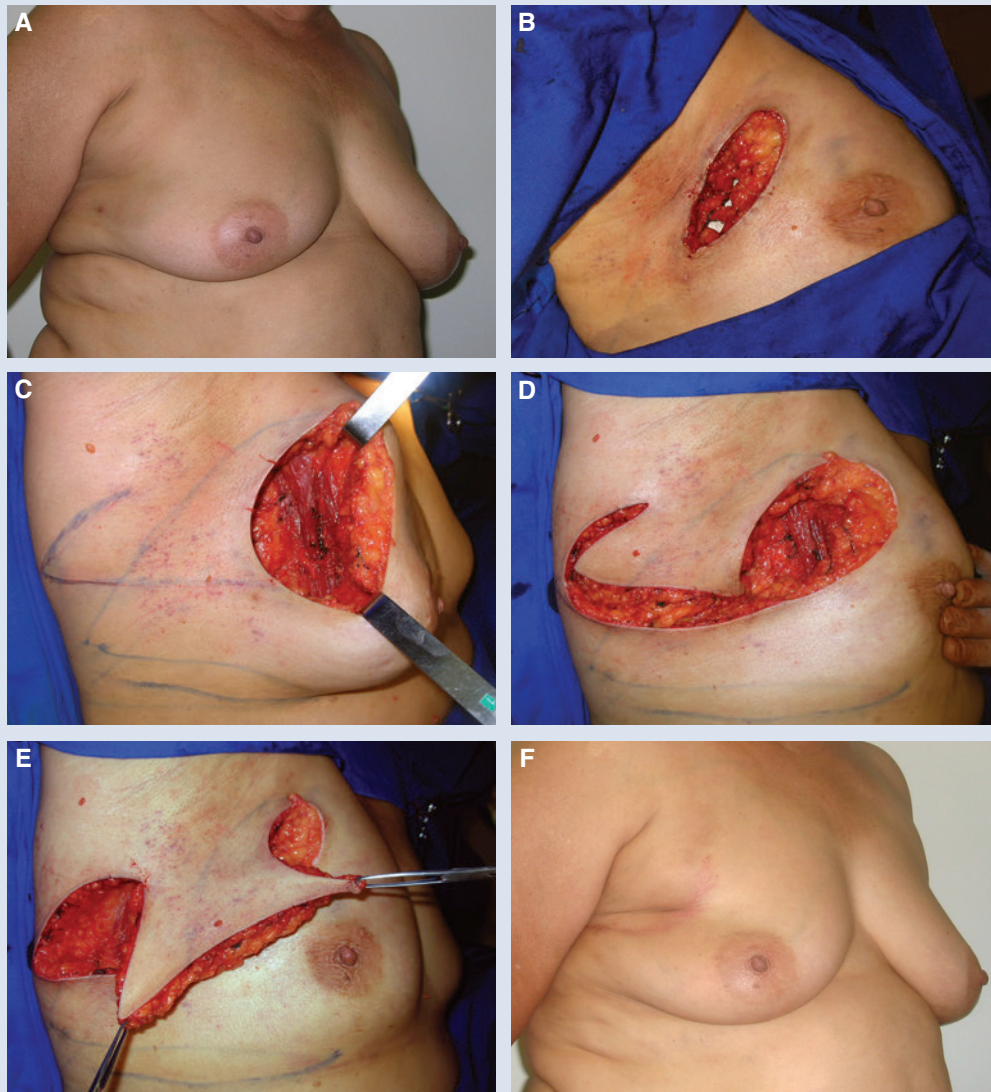
The Subaxillary Flap

First introduced by Kroll and Singletary¹⁴ the subaxillary flap uses local tissue as a rotation or transposition flap of subaxillary fat and skin or of a superiorly based composite flap of skin, subcutaneous fat, and upper-pole breast tissue. Usually this flap will consist of redundant skin and subcutaneous fat that is located just lateral to the breast.^{14,15} According to Clough et al,³ this technique is best indicated for medium-sized defect reconstruction in smaller breasts. One way to do this is to shift the defect into the subaxillary area by using a local flap, including skin and subcutaneous tissue. In this way the defect will be less noticeable and the overall cosmetic outcome improved. The authors advocated it despite some limitations to this flap in thin patients, where there may be insufficient tissue to replace all the breast tissue that has been removed but enough to reduce the deformity to an acceptable level.³

Surgical Planning and Technique

All patients with superolateral breast tumors are potential candidates for subaxillary flap reconstruction. It is important to evaluate the amount of subaxillary tissue available and to allow optimal positioning of the axillary incisions to avoid an ischemic flap. With the patient sitting, three skin markings are designed before the oncologic surgery; the inframammary sulcus, the anterior axillary line, and then a third line drawn posteriorly to form an approximately triangular area.¹⁵

PATIENT EXAMPLE

**Fig. 18-5**

This 49-year-old woman was diagnosed with invasive ductal carcinoma (2.9 cm) of the right breast (A). She underwent a right superolateral quadrantectomy and a sentinel lymph node biopsy; a total of 105 g was removed from the right breast (B and C). The patient underwent a reconstruction with a right subaxillary flap (D and E). She is shown 9 months postoperatively demonstrating a very good outcome after radiotherapy (F).

Usually a rhomboid or a wedge-shaped flap is designed on the subaxillary region and the amount of tissue available is determined by a pinch test. The flap axis is located in the axilla and the base is placed on a line extended from the anterior axillary line. For aesthetic purposes, the flap axis is drawn vertically, so that the final scar will be under the arm. Usually, the base of the flap varies 4 to 9 cm and the length varies 6 to 10 cm. For small defects the flap is planned as a triangle located exclusively on the axilla. For moderate and large breast defects, the distal limit can reach the whole lateral thoracic region and the inferior and superior limits are designed more obliquely with curved borders. Because of this large design, the skin, fat, and fascia of the anterior serratus and latissimus dorsi can be included in the flap.

The flap margin incision is carried down to the axilla and the underlying anterior serratus and latissimus dorsi muscles. The skin and the subcutaneous axilla fat are dissected from the underlying muscles in a medial direction. The donor site is closed in layers with nonabsorbable sutures and the flap is rotated to the superolateral breast defect. A nonabsorbable suture is used to bring the defect margins to the flap. The skin incisions are stapled temporarily, and the patient is positioned upright to assess flap molding and breast shape.

Complications

In general, reconstruction with the subaxillary flap is a simple and safe procedure; however, important points must be planned before the surgery. For tumors located in the upper outer quadrants, wide undermining near the axilla during tumor resection or even during axillary dissection may jeopardize flap vascularization and favor complications. For this reason, a coordinated planning with the oncologic surgeon is imperative with discussion of adequate undermining and surgical incisions. As observed in rhomboid flaps, regions of maximal tension are subject to widening and even partial flap necrosis.

Rhomboid and subaxillary flaps are better suited to less extensive defects. Adequate selection depends on a range of features, including breast size/ptosis, tumor location, morbidity, and patient expectation.

The Lateral Thoracodorsal Flap

Described as a fasciocutaneous flap in the 1980s,¹⁸ the lateral thoracodorsal flap is a well-studied procedure for late breast reconstruction following radical surgery.²⁰⁻²⁵ Although it is a consistent technique, little information has been available regarding clinical outcome after BCS reconstruction.^{8,17} Originally, the lateral thoracodorsal flap was a wedge-shaped transposition flap located in the lateral region of the thorax and it is a modification of the thoracoepigastric flap developed by Cronin et al.¹⁶ With the axis located in the lateral and dorsal extensions of the submammary fold, its major clinical application is in patients who refuse higher morbidity procedures or are not good candidates for more extensive autologous tissue transplantation.⁸ In our previous experience,⁸ this flap was indicated to reconstruct the lateral breast skin and glandular tissue resected during the BCS. In almost 60% of patients the tumors were located in the upper outer quadrants, which are the more

favorable locations. It is our impression that the main indication has been in patients with small- or medium-volume breasts without ptosis, which precludes the use of volume displacement techniques.⁸

PATIENT EXAMPLES

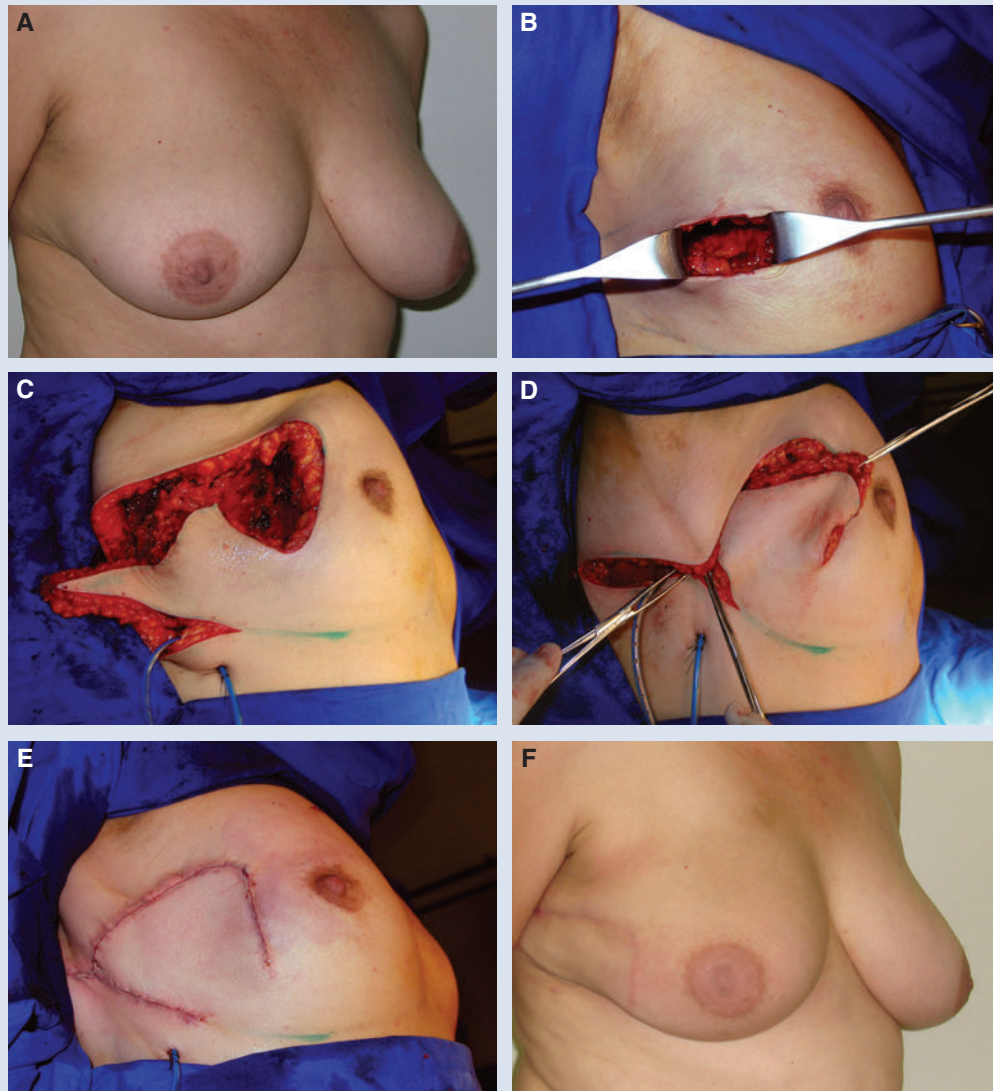
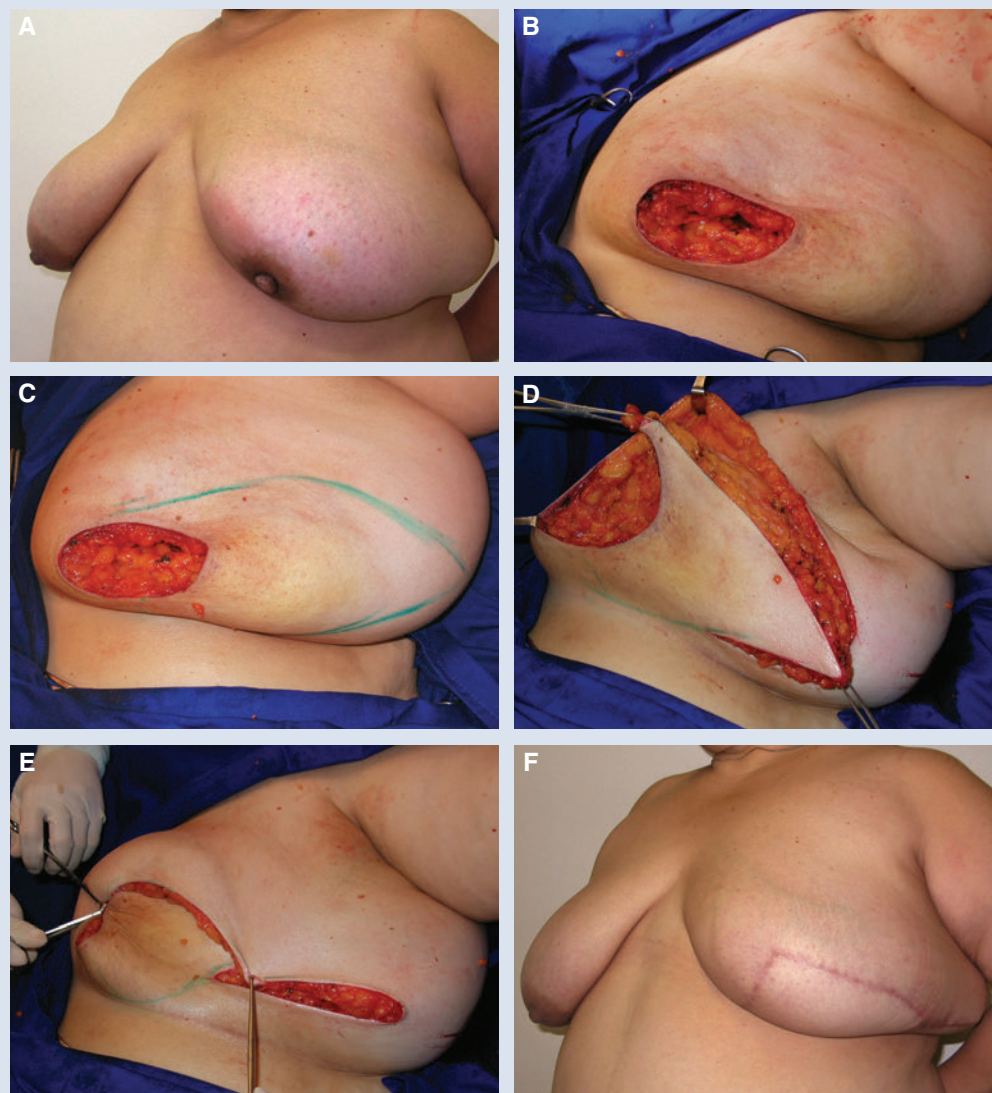
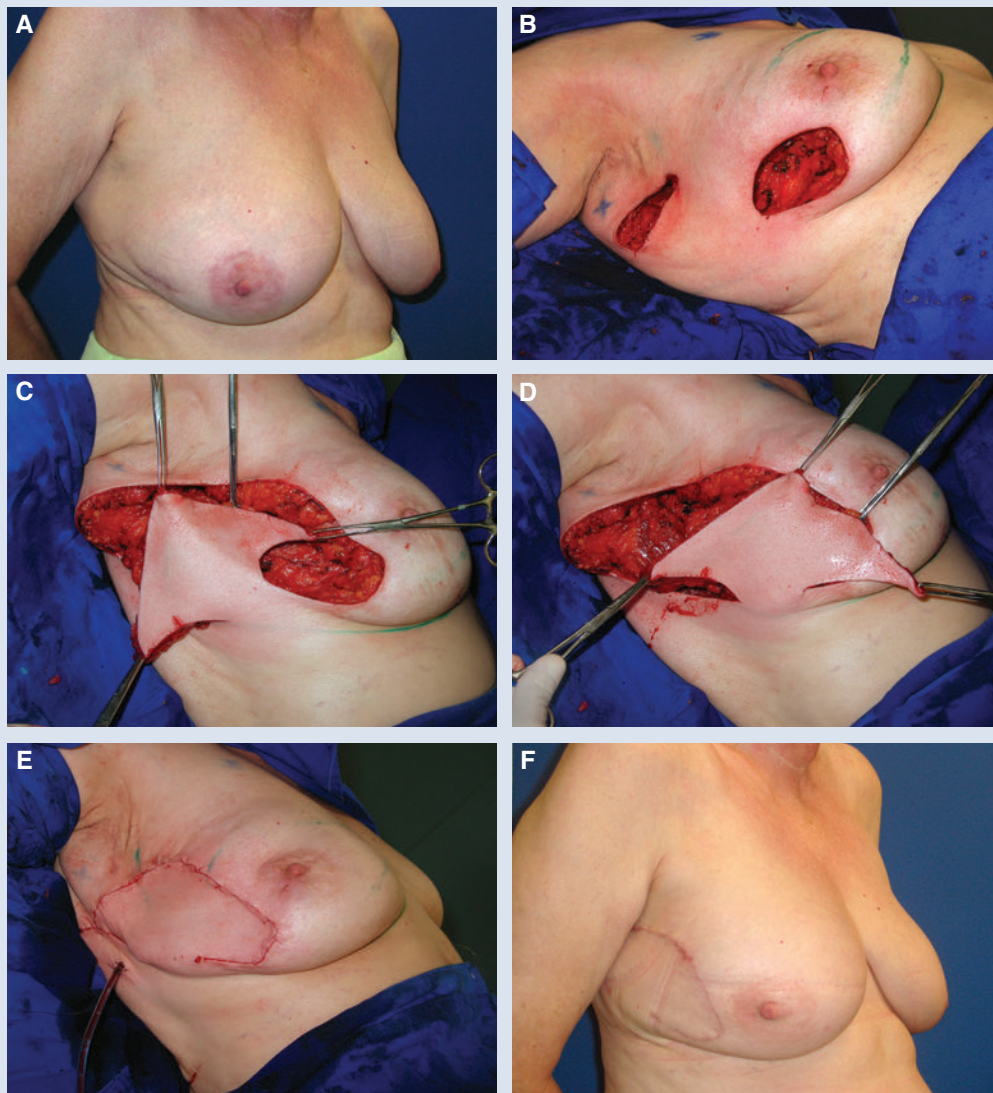


Fig. 18-6

This 44-year-old woman with invasive ductal carcinoma of the right breast (1.9 cm) (A) underwent a right inferolateral quadrantectomy and total axillary dissection; a total of 125 g was removed from the right breast (B). The patient underwent a reconstruction with a right lateral thoracodorsal flap (C through E). She is shown 1 year postoperatively with a very good outcome after radiotherapy (F).

**Fig. 18-7**

This 53-year-old patient with invasive ductal carcinoma of the left breast (3.4 cm) (A) underwent a left central and inferolateral quadrantectomy and total axillary dissection; a total of 225 g was removed from the left breast (B). The patient underwent a reconstruction with a left lateral thoracodorsal flap (C through E). Ten months postoperatively, she is shown with a very good outcome after radiotherapy (F).

**Fig. 18-8**

This 59-year-old woman had invasive ductal carcinoma of the right breast (3.1 cm) (A). She underwent a right inferolateral quadrantectomy and total axillary dissection; a total of 205 g was removed from the right breast (B). The patient underwent a reconstruction with a right lateral thoracodorsal flap (C through E). She is shown 9 months postoperatively with a very good outcome after radiotherapy (F).

Surgical Planning and Technique

All patients with lateral breast tumors are potential candidates for lateral thoracodorsal flap reconstruction. Obese patients with excess tissue on the lateral aspect of the thorax are the most suitable candidates for this procedure. This fact is important since the technique relies on the redundancy of skin and subcutaneous fat in this region. With the patient sitting, three skin markings are designed before the oncologic surgery; the inframammary sulcus, the central meridian of the breast, and the anterior axillary line. Preoperative patient evaluation is crucial to determine the amount of lateral tissue available and to allow optimal positioning of the tumor incisions to avoid an ischemic flap. Moreover, for the tumors located in the lower outer quadrants, a wide undermining below the inframammary sulcus may jeopardize flap vascularization and favor complications. Usually, the wedge-shaped flap is designed on the lateral thoracic region and the amount of tissue available is determined by a pinch test. The flap axis is located in the lateral and dorsal extensions of the inframammary sulcus and the base is placed on a line extending from the anterior axillary line. For aesthetic purposes, the flap axis is drawn following the inframammary sulcus, so that the final scar will be under the brassiere strap. Usually, the base of the flap varies 5 to 10 cm and the length varies 8 to 20 cm. For small defects the flap is planned as a triangle located exclusively on the lateral aspect of the thorax. For moderate and large breast defects, the distal limit can reach the posterior thoracic region and the inferior and superior limits are designed more obliquely with curved borders. This convex design provides a large amount of skin and subcutaneous fat and narrows the base in order to avoid tension to the lateral aspect of the breast. Because of this large design, the skin, fat, and fascia of the anterior serratus and latissimus dorsi can be included in the flap.

The flap margin incision is carried down to the underlying anterior serratus and latissimus dorsi muscles. The skin and the subcutaneous fat are dissected from the underlying muscles in a lateral to medial direction. Since the flap's vascular supply originates from the lateral intercostal perforators and the muscle fascia, care must be taken to include the fascia and avoid a wide undermining in the inframammary sulcus. The donor site is closed in layers with nonabsorbable sutures and the flap is rotated to the lateral breast defect. The skin incisions are stapled temporarily, and the patient is positioned upright to assess flap molding and breast shape.

Complications

The lateral thoracodorsal flap is a simple and consistent technique. In our previous experience,⁸ the majority of complications was predictable and did not extend hospital stay or interfere with the adjuvant treatment. Most of complications occur in the initial postoperative period and donor-site complications were considerably higher than flap complications. In spite of the fact that suction drains were used routinely in all patients, donor site seroma was observed in 20% of patients and represented more than 50% of all complications. One supposition for seroma formation is the disruption of the lymphatic channels in the

axillary dissection and the linkage of the axillary region to the flap donor site. Donor-site wound–related problems are a potential cause of a final unsatisfactory donor site scar. In these cases, a late lateral hypertrophic and depressed scar was observed in some patients. For this reason, care must be taken in flap planning since large flaps and wound tension closure may be involved. When a large flap is necessary, we suggest the convex flap design which allows a large amount of skin and makes the base narrower to avoid wound tension closure. Flap complications can occur and were mainly represented by small partial flap loss and fat necrosis. Flap vascularization to the most distant parts is difficult to predict since the flap is not an axial flap.^{9,18} This situation can predispose to partial necrosis. Care must be taken in high-risk patients such as smokers and patients with comorbid associated diseases. Additionally, it is practical to evaluate dermal bleeding in the tip of the flap and shorten it if necessary to avoid partial flap loss.²⁰

Lateral thoracodorsal flaps are better suited to patients with lateral breast tumors. Obese patients with excess tissue on the lateral aspect of the thorax are the most suitable candidates.

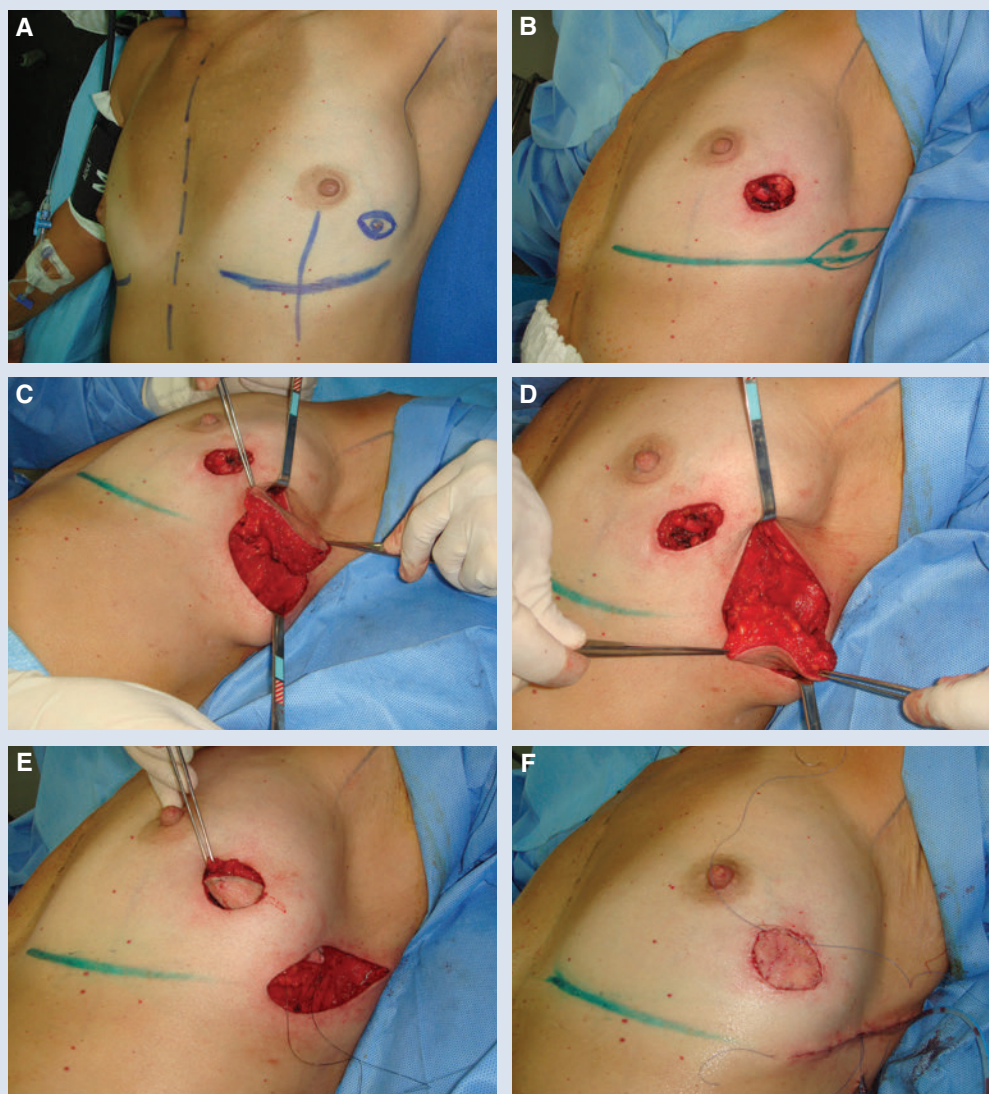
The Local Perforator Flaps

The introduction of free perforator flaps in total breast reconstruction has enabled surgeons to reduce donor-site morbidity.^{25,26} Recently, the same concept was applied in partial breast defects reconstruction with the thoracodorsal perforator flap (TDAP) where a similar skin territory to the latissimus dorsi myocutaneous flap (LDMF) is transferred into the CBS defect.²¹ Additionally, the intercostal artery perforator flap (ICAP) presented the advantages of sparing the underlying muscles and preserved the LDMF.^{21,27-30} Although CBS reconstruction with local flaps is a well-studied procedure and there are some previous series evaluating the outcome, there are few previous reports regarding the feasibility of the pedicled perforator flaps.

Surgical Planning and Technique

Compared with the lateral thoracic flap planned as a wedge-shaped design in the lateral aspect of the thorax, the island ICAP flap presents an arc of rotation that is more flexible, and the final scar does not extend over the breast skin.³⁰ For a better aesthetic outcome, the flap axis is usually planned to follow the inframammary sulcus, so that the final donor-site scar can be under the brassiere strap. For small lateral defects, the flap is planned as an ellipse located exclusively on the lateral aspect of the thorax. For large partial breast defects, a convex design allows a large amount of skin and subcutaneous tissue.

PATIENT EXAMPLE

**Fig. 18-9**

This 56-year-old patient was diagnosed with invasive ductal carcinoma of the left breast (0.9 cm) (A). She underwent a left inferolateral lumpectomy and sentinel lymph node biopsy; a total of 65 g was removed from the left breast (B). The patient underwent a reconstruction with a LICAP flap (C through F).

For this purpose, the distal limit can reach the posterior thoracic region and the inferior and superior limits are designed more obliquely with curved borders. In our sample, obese patients with inferolateral breast tumors with excess of tissue on the lateral thorax were the most convenient for this procedure. In spite of its benefits, the local perforator flap presents some technical limitations and patients with medial breast tumors are not good candidates because of its short vascular pedicle. Usually, the lateral ICAP pedicle presents 4 to 5 cm length and if a longer pedicle is necessary, is advocated an additional dissection of the perforator vessel within the costal groove or the indication of the TDAP flap. Thus it is important to design the skin-island flap according to the tumor location to avoid pedicle tension. For central breast tumors, the skin paddle can be designed more distally on the posterolateral thoracic region or even the anterior ICAP should be planned on the anterior thorax.

Complications

Our results have demonstrated that the majority of complications were immediate and minor and did not increase length of hospital stay or interfere with the adjuvant treatment. However, flap complications can be expected and can be mainly represented by partial flap loss and fat necrosis. For this reason care must be taken in high-risk patients such as smokers and patients with comorbid associated diseases. It is also practical to evaluate dermal bleeding in the tips of the flap and shorten it if necessary to avoid partial flap loss. In addition, a careful evaluation of the perforator vessels should be investigated on the lateral resections and axillary dissection. Thus a working relationship between the breast and the plastic surgeon is fundamental to preserve the main perforator and to minimize complications. It has been our experience that sometimes a perforator flap's donor site is closed under some degree of tension, and this tension is typically irregularly distributed along the flap's length. Areas of maximal tension are subject to widening and depression along the line of tension.

Local perforator flaps are better suited to patients with lateral and inferior breast tumors. Compared to the lateral thoracic flap, the ICAP flap presents an arc of rotation more flexible and the final scar does not extend over the breast skin.

ONCOLOGIC ASPECTS AND CANCER SURVEILLANCE

Compared with other volume displacement techniques that involve rearrangement of glandular tissue, the volume replacement procedure has some positive aspects in terms of oncologic safety. In some techniques such as reduction mammoplasty, postoperative boost radiation dose delivery may be jeopardized, because the target area for the additional dose of radiation is the site of the primary tumor.^{9,10} In theory, local flaps do not alter the normal architecture of the breast and the original tumor site location.⁸ Additionally, reconstructive techniques that involve relocation of glandular tissue make reexcision difficult in cases where close or positive margins are observed in the permanent pathology.^{1,8-10,19} In this sce-

nario, the use of local flaps is potentially beneficial since the techniques for the most part do not obscure the original lumpectomy space, as the margins of the flap and the lumpectomy are just closed at full thickness.⁸ Rainsbury and Paramanathan,¹⁹ in a survey of BCS reconstruction, observed that patients underwent volume replacement techniques were managed most commonly by reexcision, as opposed to patients who underwent volume displacement procedures, who were managed most commonly by mastectomy. According to the authors, this disparity may be an expression of the difficulties observed when attempting to locate the site of a positive margin after performing volume displacement techniques. Conversely, locating the positive margin following local flap reconstruction is a less demanding process. The reexcision process usually involves local flap displacement, excision of the relevant margin, followed by flap molding.¹⁹ Despite these advantages and the fact that local flap techniques do not obscure the original lumpectomy space, a careful and coordinated planning with the oncologic surgeon is crucial in the situation of reexploration. Similar to reduction mammoplasty reconstruction, we advocate orienting the glandular specimen and also placing surgical clips at the tumor margins. In cases of reexploration, it is reasonable to perform in conjunction with the plastic surgery team to identify the original tumor bed and to avoid injury to the flap pedicle.⁸⁻¹⁰ In patients with small volume breasts or in cases where it is not possible to identify the tumor bed, skin-sparing mastectomy can be performed and other reconstructive techniques are still available.

Another important issue is related to surveillance after BCS and flap reconstruction. All patients should be followed in the postoperative period by the oncologic surgeon and oncologist who indicated the appropriate surveillance method. Normally a physical examination and mammography should be performed 6 to 8 months postoperatively. Physical examination usually demonstrates mild thickening or areas of fibrosis near the flap margins and the residual breast tissue tending to stabilize by 6 months to 1 year after BCS. Prolonged skin-thickening, increased density, a spiculated mass, and fine calcifications that vary in size and shape should be carefully investigated, especially if these alterations develop in different quadrants from the initial tumor and a few years after the BCS.¹ In situations in which it is not possible to distinguish postsurgical changes and local recurrences, MRI should be indicated. In cases where imaging examinations demonstrate some suspicious lesions, a core biopsy should be performed to evaluate a potential recurrence.⁸⁻¹⁰

Critical Issues

- Local flaps can be taken from within the breast tissue (volume displacement) or from outside the breast (volume replacement).
- Local flaps are better indicated in the lateral or upper quadrant, where the defect involves both skin and volume loss and in patients with smaller breasts.
- Most flaps involve rotations or transposition of skin, parenchyma, and/or subaxillary fat to fill the defect.
- Adequate medical information must be provided to patients, and a signed informed consent must be received from them.

References

1. Slavin SA, Halperin T. Reconstruction of the breast conservation deformity. *Semin Plast Surg* 18:89, 2004.
2. Clough KB, Thomas SS, Fitoussi AD, et al. Reconstruction after conservative treatment for breast cancer: cosmetic sequelae classification revisited. *Plast Reconstr Surg* 114:1743, 2004.
3. Clough KB, Kroll SS, Audretsch W. An approach to the repair of partial mastectomy defects. *Plast Reconstr Surg* 104:409, 1999.
4. Kronowitz SJ, Feledy JA, Hunt KK, et al. Determining the optimal approach to breast reconstruction after partial mastectomy. *Plast Reconstr Surg* 117:1, 2006.
5. Munhoz AM, Aldrighi C, Ferreira MC. Paradigms in oncoplastic breast surgery: a careful assessment of the oncological need and aesthetic objective. *Breast J* 13:326, 2007.
6. Asgeirsson KS, Rasheed T, McCulley SJ, et al. Oncological and cosmetic outcomes of oncoplastic breast conserving surgery. *Eur J Surg Oncol* 31:817, 2005.
7. Munhoz AM, Montag E, Arruda EG, et al. Outcome analysis of breast-conservation surgery and immediate latissimus dorsi flap reconstruction in patients with T1 to T2 breast cancer. *Plast Reconstr Surg* 116:741, 2005.
8. Munhoz AM, Montag E, Arruda EG, et al. The role of the lateral thoracodorsal fasciocutaneous flap in immediate conservative breast surgery reconstruction. *Plast Reconstr Surg* 117:1699, 2006.
9. Munhoz AM, Montag E, Fels KW, et al. Critical analysis of reduction mammoplasty techniques in combination with conservative breast surgery for early breast cancer treatment. *Plast Reconstr Surg* 117:1091, 2006.
10. Munhoz AM, Montag E, Arruda EG, et al. Superior-medial dermoglandular pedicle reduction mammoplasty for immediate conservative breast surgery reconstruction. *Ann Plast Surg* 57:502, 2006.
11. Spear SL, Pelletiere CV, Wolfe AJ, et al. Experience with reduction mammoplasty combined with breast conservation therapy in the treatment of breast cancer. *Plast Reconstr Surg* 111:1102, 2003.
12. Chang E, Johnson N, Webber B, et al. Bilateral reduction mammoplasty in combination with lumpectomy for treatment of breast cancer in patients with macromastia. *Am J Surg* 187:647, 2004.
13. Losken A, Elwood ET, Styblo TM, Bostwick J III. The role of reduction mammoplasty in reconstructing partial mastectomy defects. *Plast Reconstr Surg* 109:968, 2002.
14. Kroll SS, Singletary SE. Repair of partial mastectomy defects. *Clin Plast Surg* 25:303, 1998.
15. Chaturvedi S. Subaxillary dermocutaneous fat flap for reconstruction of the upper outer quadrant of the breast following conservation surgery. *Br J Surg* 90:45, 2003.
16. Cronin TD, Upton J, McDonough JM. Reconstruction of the breast after mastectomy. *Plast Reconstr Surg* 59:1, 1977.
17. Garcia EB, Sabino M, Ferreira LM, et al. Retalho tóraco-axilar na reparação imediata da quadrantectomia supero-lateral da mama. *Rev Bras Mastol* 10:185, 2000.
18. Holmstrom H, Lossing C. The lateral thoracodorsal flap in breast reconstruction. *Plast Reconstr Surg* 77:933, 1986.
19. Rainsbury RM, Paramanathan N. UK survey of partial mastectomy and reconstruction. *Breast* 16:637, 2007.
20. Blomqvist L, Malm M. Clinical experience with the lateral thoracodorsal flap in breast reconstruction. *Ann Plast Surg* 43:7, 1999.
21. Hamdi M, Van Landuyt K, Monstrey S, et al. Pedicled perforator flaps in breast reconstruction: a new concept. *Br J Plast Surg* 57:531, 2004.
22. Dibbell DG. Use of a long island flap to bring sensation to the sacral area in young paraplegics. *Plast Reconstr Surg* 54:220, 1974.

23. Kerrigan CL, Daniel RK. The intercostal flap: an anatomical and hemodynamic approach. *Ann Plast Surg* 2:411, 1979.
24. Beahm E. Timing and key considerations in reconstruction for breast conserving therapy. In Nahabedian N, ed. *Oncoplastic Surgery of the Breast*. Philadelphia: Elsevier, 2009.
25. Koshima I, Inagawa K, Yamamoto M, et al. New microsurgical breast reconstruction using free paraumbilical perforator adiposal flaps. *Plast Reconstr Surg* 106:61, 2000.
26. Allen RJ, Treece P. Deep inferior epigastric perforator flap for breast reconstruction. *Ann Plast Surg* 32:32, 1994.
27. Levine JL, Soueid NE, Allen RJ. Algorithm for autologous breast reconstruction for partial mastectomy defects. *Plast Reconstr Surg* 116:762, 2005.
28. Hamdi M, Van Landuyt K. Pedicled perforator flaps. In Spear SL, Willey SC, Robb GL, eds. *Surgery of the Breast: Principles and Art*. Philadelphia: Lippincott Williams & Wilkins, 2006.
29. Hamdi M, Spano A, Van Landuyt K, et al. The lateral intercostal artery perforators: anatomical study and clinical application in breast surgery. *Plast Reconstr Surg* 121:389, 2008.
30. Munhoz AM, Montag E, Arruda E, et al. Immediate conservative breast surgery reconstruction with perforator flaps: new challenges in the era of partial mastectomy reconstruction? *Breast* 20:233, 2011.

19

Latissimus Dorsi Miniflap Reconstruction

Richard Myles Rainsbury

Until recently, breast-conserving surgery (BCS) and mastectomy have been the only two surgical choices for women with breast cancer. Survival rates from these techniques are similar,¹ although local recurrence rates are higher when the breast is conserved.² A meta-analysis by Clarke et al³ demonstrating the negative impact of local recurrence on long-term survival after BCS highlighted the importance of thorough local excision in preventing local recurrence.⁴

An extensive resection of parenchymal tissue around the tumor can reduce the risk of local recurrence but increases the risk of an unacceptable cosmetic result and the associated psychological distress.⁵ Recent data suggest that resecting much more than 15% or 20% of the breast volume, particularly from central, medial, or inferior locations, is likely to lead to a poor cosmetic result.⁶ Cosmetic failure can be caused by poor surgical technique, such as inappropriate incisions, or complications like hematoma formation, infection, and necrosis; however, volume loss underlies most of the more visible and distressing examples of poor cosmetic outcome.

Volume replacement methods using latissimus dorsi muscle can overcome volume loss by providing immediate volume replacement using living autologous tissue at the time of BCS. Although these techniques can be used to reconstruct resection defects in women with any breast size, they are best applied in women with small or medium breasts. This particular group of patients often cannot afford the loss of breast volume associated with therapeutic mammoplasty techniques, which are detailed in Chapters 15 and 17. Tissue replacement is also suitable for women with larger breasts who may prefer to avoid a breast reduction and the need for contralateral surgery to achieve asymmetry.

EVOLUTION OF THE TECHNIQUE

The latissimus dorsi muscle has been used regularly for breast reconstruction after a total mastectomy since the early 1970s, but in 1985 Pearl and Wisnicki⁷ were the first to describe how a myocutaneous flap can be used to reconstruct the breast to correct a deformity after a partial mastectomy and radiotherapy. The following year, Santi et al⁸ described using a myocutaneous latissimus dorsi flap for a technique to transpose the entire latissimus dorsi muscle through small incisions to correct a number of deformities, including those following a quadrantectomy. In 1988, deepithelialized flaps of latissimus dorsi were used by Papp et al⁹ to correct iatrogenic and congenital volume loss.

Noguchi et al¹⁰ were the first to describe immediate reconstruction of quadrantectomy defects with a myosubcutaneous latissimus dorsi flap in small-breasted Japanese women in 1990. In 1992 Slavin et al¹¹ used myocutaneous latissimus dorsi flaps as a secondary procedure to correct cosmetic deformities in a variety of breast locations after BCS. A year later, Zoetmulder et al¹² described the use of similar flaps for the immediate reconstruction of big resection defects resulting from the excision of large T2 and T3 breast cancers. In 1994 Rainsbury¹³ described a modification of Noguchi's technique and called this the *latissimus dorsi miniflap*. This technique allowed a quadrantectomy, axillary dissection, flap harvest, and reconstruction of the resection defect to be performed through a single lateral retro-mammmary incision, thereby avoiding a frontal scar. Eaves et al¹⁴ described an endoscopic latissimus dorsi flap harvest in 1995, and Audretsch et al¹⁵ played a central role in popularizing the use of the latissimus dorsi muscle in mainland Europe to reconstruct the partial mastectomy defect.

INDICATIONS AND ASSESSMENT

Table 19-1 Indications for Volume Replacement With Latissimus Dorsi Muscle

Patient Factors	Tumor Factors
Small or medium breast	Any breast location
20% to 70% volume loss	In situ disease
Mastectomy declined	Invasive disease
Contralateral surgery declined	Segmental disease
Radiotherapy anticipated	Not locally advanced
Limited comorbidity	Typically 100-350 g specimen
Functioning, intact latissimus dorsi muscle	Clear margins

Volume replacement with a latissimus dorsi flap is a very useful alternative to a wide excision or a mastectomy when a patient wishes to conserve her breast and preserve its

size and shape; it is also useful if an unfavorable cosmetic result with resection alone is a concern. A poor cosmetic outcome may result after resecting a 15 mm tumor from a small breast, whereas resecting a 45 mm tumor from a large, pendulous breast may result in little or no deformity.

Numerous factors must be considered before performing a volume replacement procedure. For example, the surgeon must determine the expected volume loss, which can be estimated in a number of ways. One simple technique that provides a good estimate of the percentage of breast tissue to be excised involves calculating the volume of the resection specimen (by assuming it is spherical and use the Pythagorean formula to find the volume of a sphere); this figure is then divided by the volume of the breast, which can be estimated from the craniocaudal mammogram.⁶

An estimated resection volume of 10% to 15% is unlikely to have an adverse aesthetic outcome, and the patient can be treated with conventional BCS.

Resecting a larger proportion of the breast, even up to 70%, requires reconstructing the resection defect to avoid an inevitable cosmetic deformity. Patients with tumors in upper inner, central, and lower locations where the estimated resection volume is greater than 20% are particularly vulnerable to these deformities and should be advised against BCS without reconstruction.⁶

An estimation of the tumor type and extent is an essential adjunct to the clinical evaluation. This is true for tumors in any location for in situ and invasive disease (see the table). By definition, to achieve the complete local excision of a breast cancer, the tumor in its entirety must be located within a breast segment and must be excised with tumor-free margins. The minimum preoperative workup should therefore include mammography and ultrasound, with MRI if a multifocal disease is suspected. In a small number of women with very large breasts, it may be impossible to harvest sufficient volume to reconstruct 300 to 400 g resection defects. In this clinical setting, either a therapeutic reduction mammoplasty or a total mastectomy and immediate breast reconstruction would be a more appropriate alternative.

THE DECISION-MAKING PROCESS

Treatment Decision

As with any relatively new and emerging technique, decisions about the patient selection, technique selection, and overall management undergo a continuous process of analysis and refinement. A partial mastectomy with immediate latissimus dorsi miniflap reconstruction was developed at the Winchester Breast Unit,¹⁶ and more than 270 patients have undergone this operation at this facility.

Drawing on this experience, the following four key questions should be answered to help assess if this approach is suitable for your patient:

1. Is a partial mastectomy with oncoplastic reconstruction a reasonable treatment option?
 - Will the patient lose more than 15% to 20% of her breast volume?
 - Is the tumor in the upper pole, the upper inner quadrant, the subareolar region, or the lower pole, thus increasing the risk of cosmetic failure?
 - Does imaging confirm suitability for resection by segmental resection?
 - Is the patient prepared to have adjuvant breast irradiation?
 - Is the patient prepared to accept the risks of the procedure?
2. Is volume replacement preferable to therapeutic mammoplasty?
 - Does the patient have small to medium breasts (150 to 500 g)?
 - Does the patient prefer that her breasts remain the same size?
 - Does the patient prefer to avoid contralateral surgery, even if she has a larger breast size?
 - Is the patient prepared for more complex surgery and a longer convalescence?
 - Is the patient aware of the potential complications?
 - If she subsequently needs a mastectomy, is the patient aware that one of her options for full reconstruction will have already been “spent”?
3. Should the operation be carried out in one or two stages?
 - If a one-stage procedure is selected:
 - Is the pathologist prepared to perform an intraoperative frozen section analysis?
 - Are you confident using this method of analysis?
 - Does your operative schedule allow for any delays related to waiting for the frozen section examination?
 - Is your patient fully informed about the risk of a false-negative report and the subsequent sequelae?
 - Is your patient prepared to lose her nipple in the event of a positive subareolar biopsy?
 - If a two-stage procedure is selected:
 - When will the second stage be scheduled?
 - Can you accommodate both procedures in your timetable?
 - Will you delay any axillary surgery as well?
 - If not, are you skilled at identifying the thoracodorsal trunk in a recently dissected axilla?

A two-stage procedure has certain advantages. When access to pathologists with sufficient experience in frozen section margin analysis is limited, a detailed examination of all specimens, including sentinel nodes (SNs), can be performed without the time constraints of intraoperative analysis. In our experience, it should be considered in those situations where rapid margin analysis may be difficult, even for the most experienced pathologist. Interpretation is particularly challenging in patients following neoadjuvant chemotherapy and previous radiotherapy (RT), and also when resecting lobular carcinoma and low/intermediate grade DCIS.

The benefits of postmastectomy RT in patients with one to three positive nodes¹⁷ and the significant risks of RT after postmastectomy reconstruction¹⁸ will influence decisions about the timing and type of reconstruction in this group of patients.

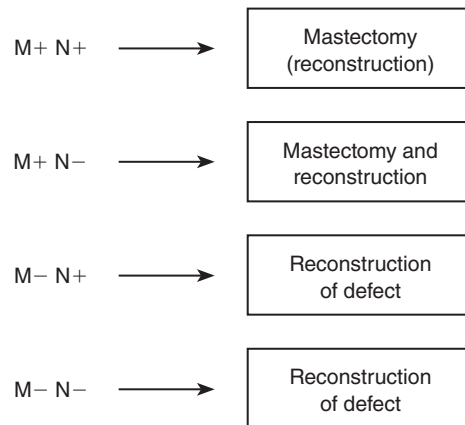


Fig. 19-1

Delayed margin analysis informs decision-making and generates a number of different scenarios, depending on the final nodal and margin status. (*M+*, positive margin; *M-*, negative margin; *N+*, positive sentinel node; *N-*, negative sentinel node.)

In our experience, patients fall into four broad groups. Group 1 consists of patients with extensive margin positivity and positive SNs: conversion to mastectomy is recommended, delaying reconstruction until completion of chest wall RT. Group 2 has extensively involved margins but negative SNs, without other pathologic features indicating the need for RT (such as multicentricity, close margins, and T3/T4 tumors). Again, conversion to mastectomy is recommended, combined with reconstruction if desired. If the margin involvement is limited, an early reexcision may achieve clear margins, allowing reconstruction of the defect in this group of patients. Patients in groups 3 and 4 have clear margins, with or without positive SNs. They can be advised that reconstruction of the partial mastectomy defect followed by RT is a safe option that will result in outcomes similar to WLE and RT.¹⁹

4. How are you going to manage the axilla? There is a range of alternatives based around the following three main options:
 - The SN is biopsied preoperatively, clearing the axilla at the time of reconstruction if positive or the area around the vascular pedicle if negative.
 - The SN is biopsied and assessed perioperatively, using the same approach that was followed for the preoperative SN biopsy specimen.
 - A “lateral” axillary clearance is undertaken, because the lateral aspect of the axilla has to be cleared anyway to identify and skeletonize the deep subscapular and thoracodorsal vascular pedicles.

RATIONALE FOR CHOOSING THE LATISSIMUS DORSI MINIFLAP

The main alternatives to volume replacement with latissimus dorsi miniflaps are discussed in detail in Chapter 18. The rationale for selecting this approach over other techniques can be summarized as follows:

- Use of implants to reconstruct resection defects has not been widely adopted.^{20,21} Problems include interference with mammographic surveillance and capsular contraction leading to pain and local distortion. These features are not reported after latissimus dorsi miniflap reconstruction.
- Lateral thoracic and other adipose tissue flaps have been reported mainly for the reconstruction of upper outer quadrant tumors.^{22,23} They provide a relatively limited amount of volume for reconstruction. The latissimus dorsi miniflap can be used to reconstruct any part of the breast, and it provides a very significant amount of tissue for volume replacement.
- Perforator flaps are more complex, and there are little data on their long-term performance. Experience using the pedicled latissimus dorsi flap is considerable and supports their reliability and durability.
- Therapeutic mammoplasty techniques offer an excellent alternative in patients with medium or large breasts, when volume loss associated with these techniques is acceptable or beneficial.^{24,25} There are potential problems with the margin orientation and analysis and with fat and parenchymal necrosis, which may delay or disrupt radiotherapy. Therapeutic mammoplasty excises tumors that are often situated in the center of a very large breast specimen. The surface area of this specimen is therefore extensive, increasing the time required for comprehensive pathologic examination.

PREOPERATIVE PLANNING

As with all oncoplastic and cosmetic breast surgeries, careful preoperative planning is vital to a good oncologic and cosmetic outcome. It should be carried out on the ward, with the patient relaxed and with good lighting. Before surgery, the patient must be made aware of the potential that a conversion to a completion mastectomy and reconstruction may prove necessary if negative margins are not achieved, and consent for this should be obtained in advance.

Choice of Incision

The choice of incisions on the breast, in the axilla, and over the latissimus dorsi muscle is influenced by oncologic considerations and by the type of latissimus dorsi miniflap selected for reconstruction.

Incisions on the Breast

There are four types of breast incisions that can be used: (1) a radial or circumferential incision over the tumor-bearing quadrant, (2) a circumareolar incision for subareolar and central tumors, (3) an elliptical incision, mainly for lower pole tumors, and (4) lateral S-shaped or inframammary fold incisions.

Axillary Incisions

The two choices of axillary incision are (1) a lateral S-shaped incision, which can be extended for access to the breast or the latissimus dorsi muscle and (2) a transverse incision, extending posteriorly for access to the latissimus dorsi muscle.

Incisions on the Back

The choice of incision on the back depends on whether a myocutaneous or myosubcutaneous (myofascial) latissimus dorsi miniflap has been selected. A myosubcutaneous latissimus dorsi miniflap is usually performed without a back incision, but a counterincision over the lower border of the flap has been described. A myocutaneous latissimus dorsi miniflap can be raised through an elliptical transverse or oblique incision, depending on the surgeon's preference.

Choice of Technique

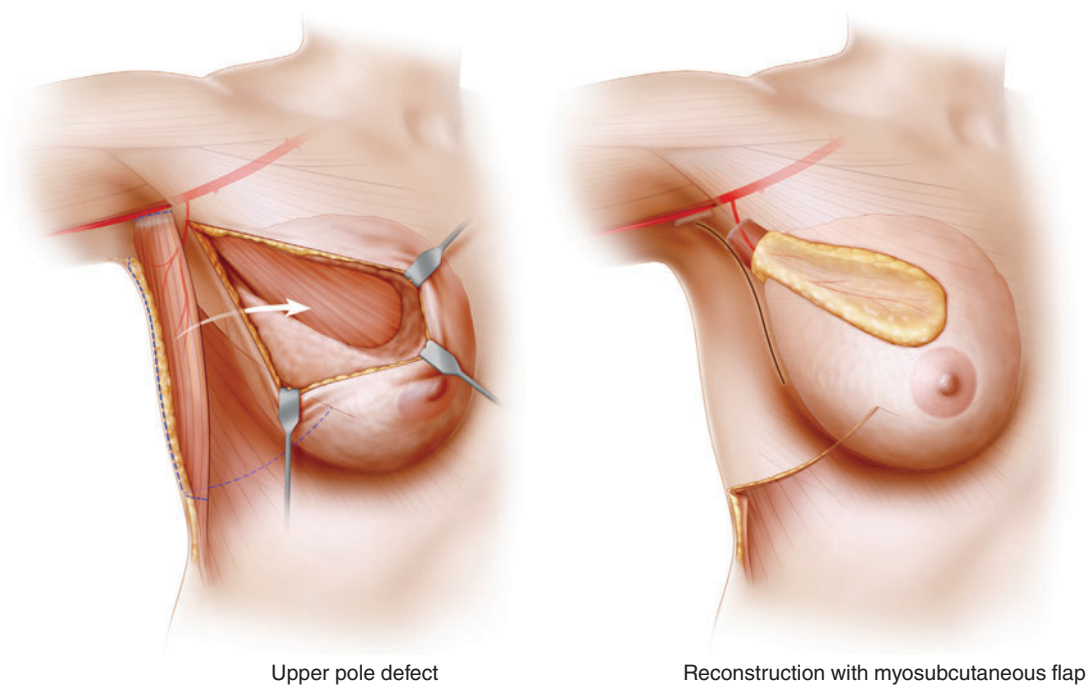


Fig. 19-2

Table 19-2 Factors Influencing the Type of Latissimus Dorsi Muscle Flap Selected for Reconstructing the Partial Mastectomy Defect

	Myocutaneous	Myosubcutaneous
Resection site	Central and lower pole	Central and upper pole
Volume loss	Up to 70%	Up to 50%
Weight of flap	Up to 350 g	Up to 250 g
Skin replacement	Yes*	No
Body habitus	Any	Average or above

*Including the nipple-areola complex.

When planning a partial mastectomy, either a myosubcutaneous or myocutaneous flap is chosen for the latissimus dorsi miniflap reconstruction. The myosubcutaneous flap is best suited for reconstructing resection defects in the center and upper half of the breast, where scarring and 20% to 50% volume loss can lead to major local deformity. Most subcutaneous flaps weigh 150 to 250 g, and a myocutaneous flap should be considered when more extensive volume replacement is anticipated.

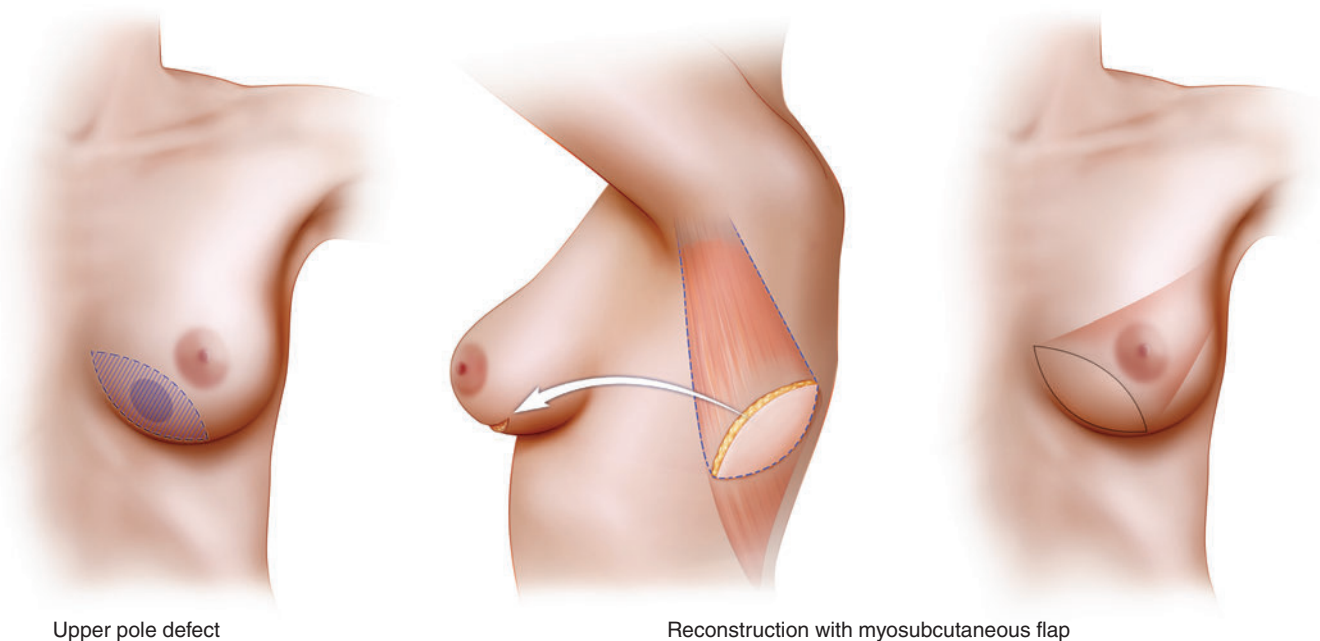


Fig. 19-3

Lower pole and central defects are most easily reconstructed with a myocutaneous flap. This approach overcomes the difficulties encountered in recruiting and transposing a sufficient volume of flap to reconstruct these more remote locations. It is most appropriate

when reconstructing large central and lower pole defects either by deepithelializing and burying the whole skin island and the flap, or by using a small island of skin to reconstruct the nipple-areola complex or the skin envelope of the lower pole of the breast. This approach is also useful in very slim patients in whom the volume of a myosubcutaneous flap is inadequate.

The added volume provided by the deepithelialized skin island allows volume replacement when 70% or even 80% of the breast is resected.

SURGICAL TECHNIQUE

Surgical Plan

- The positions of the tumor, the margin, the access tunnel, and the incision are carefully marked with an indelible ink pen.
- The patient is secured on the operating table with the arm abducted to 90 degrees.
- The subcutaneous tissues over the whole operative field are infiltrated with a dilute solution of epinephrine in normal saline solution (1 in 250,000).
- The tumor-bearing quadrant is separated from the subcutaneous tissue superficially and from the pectoralis major muscle deeply.
- The tumor is resected with a 1 to 2 cm palpable margin of normal breast tissue, and adequate excision is confirmed by frozen section examination of biopsy specimens taken from the cavity walls.
- An axillary dissection is performed according to local protocols, and the subscapular and thoracodorsal neurovascular pedicle is identified and preserved.
- Superficial and deep pockets are developed around the latissimus dorsi muscle, and the miniflap is harvested by dividing the muscle and its tendon around the perimeter of these pockets.
- The miniflap is transposed into the resection defect, and sutures are used to mold the shape of the muscle flap, securing it into place.
- The cavity and the incision are closed over a suction drain.

Surgical Technique for the Myosubcutaneous (Myofascial) Latissimus Dorsi Miniflap

Step One: Skin Markings

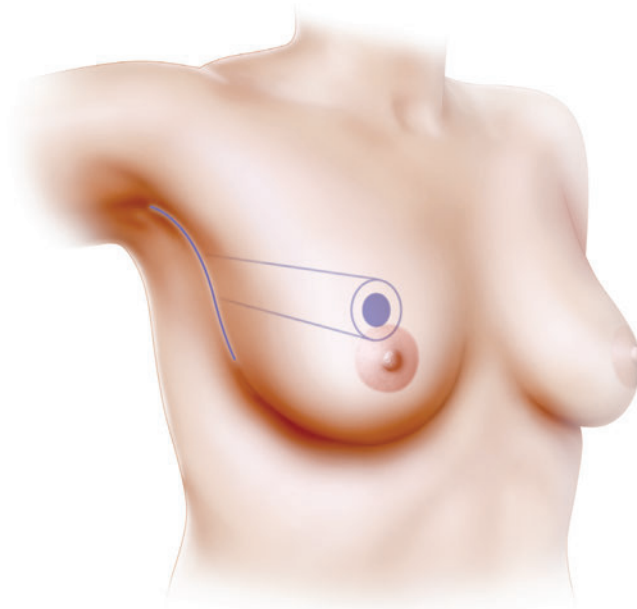
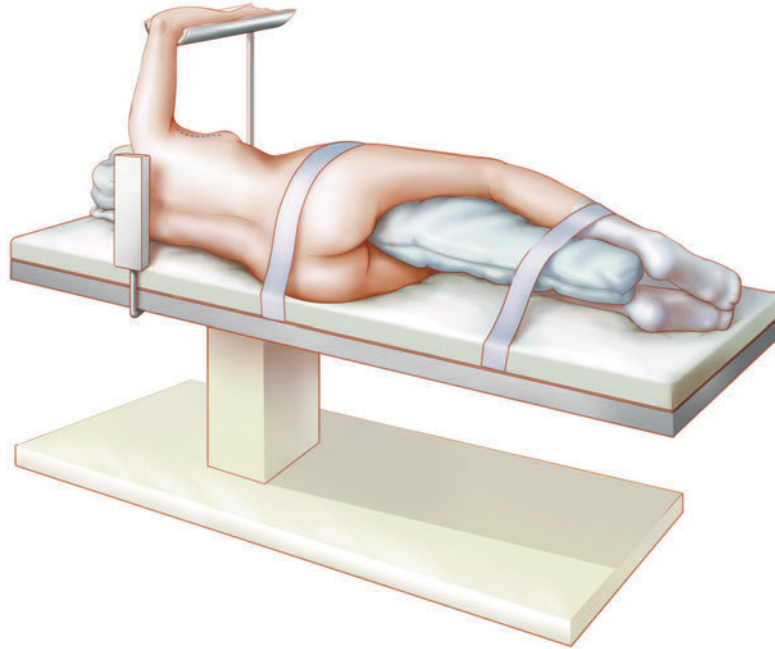


Fig. 19-4

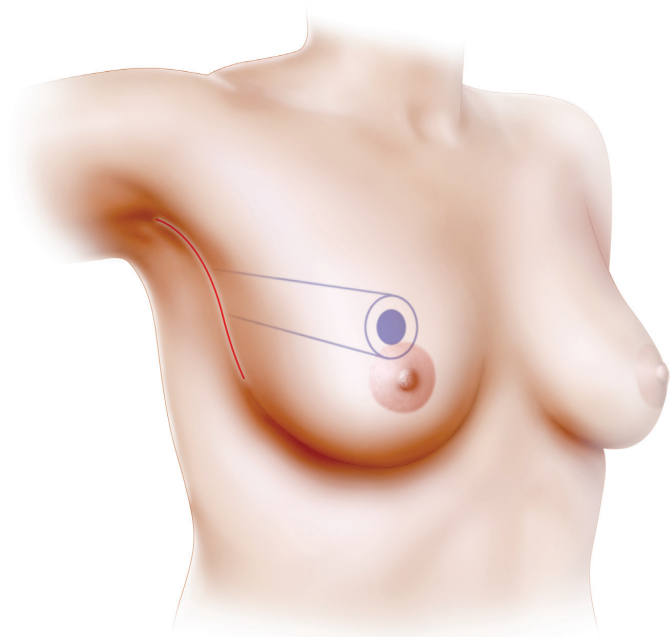
- The tumor and access tunnel are outlined on the skin.
- The outer margin of the tumor is continued laterally to delineate a short access tunnel (formed by resecting the underlying parenchymal tissue) to accommodate the tendinous part of the latissimus dorsi miniflap.
- An S-shaped incision is marked on the skin, running from the apex of the axilla along the lateral border of the breast to just above the inframammary fold. The line of this incision is often indicated by a fold that can be demonstrated with the patient sitting at 45 degrees while the breast is displaced laterally.
- The posterior axillary fold represents the anterior border of the latissimus dorsi muscle, which is marked as it passes from the humerus toward the iliac crest. It is accentuated by active adduction of the shoulder.

Step Two: Patient Positioning**Fig. 19-5**

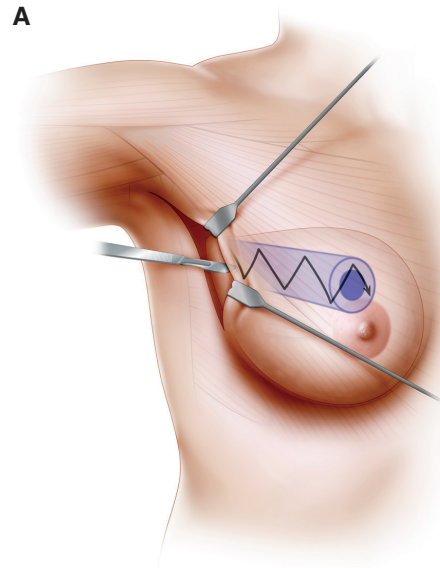
The patient is positioned carefully in the lateral decubitus position. The use of a vacuum-molded support mattress and fixation of the hips and knees to the table with straps help to maintain the lateral position throughout the procedure. The ipsilateral shoulder is supported at 90 degrees of abduction in the gutter of a lithotomy stirrup, and a padded support is placed behind the scapula. These maneuvers help to prevent brachial plexus traction injuries by avoiding inadvertent overabduction or traction of the shoulder joint. Antiembolism stockings or mechanical calf compression boots are applied.

Step Three: Incision

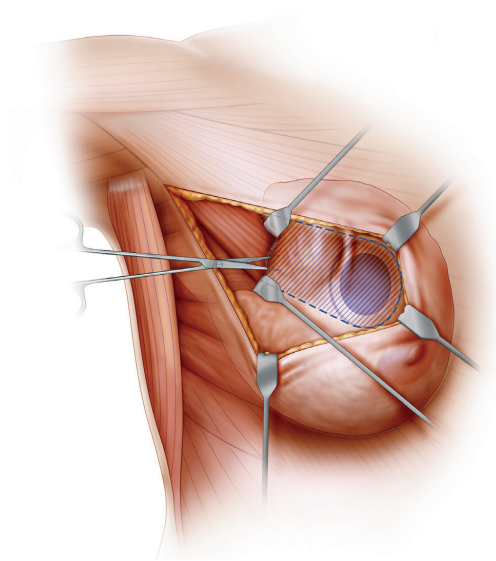
The procedure is simplified by the liberal use of a dilute solution of epinephrine in normal saline solution (1:250,000), which is infiltrated in the subcutaneous tissue over the entire operative field. An incision is made along the previously marked S-shaped line as shown (*in red*), at least as far as the meridian of the breast. This is deepened to identify the lateral border of the pectoralis major muscle in the upper part of the wound.

**Fig. 19-6****Step Four: Mobilization of the Breast**

The breast disk is separated from the overlying skin envelope by introducing a broad-bladed scalpel into the subcutaneous fat layer through the medial edge of the S-shaped incision. With the blade lying parallel to the skin, it is swept over the tumor-bearing quadrant of the breast, thereby freeing it from the overlying tissues. The previously marked outline of the tumor and the resection margin help to define the limits of this dissection.

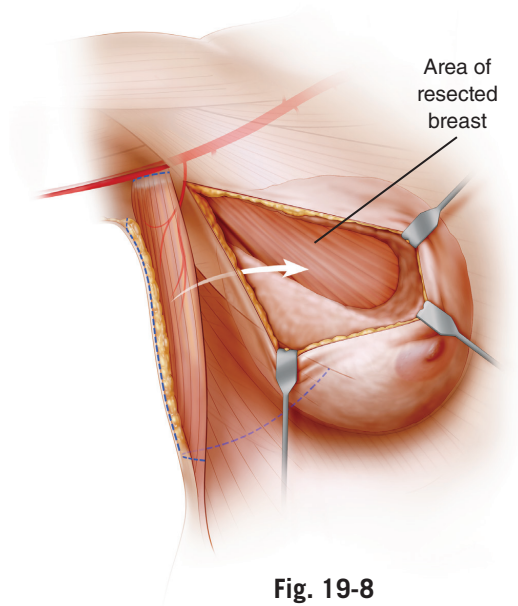
**Fig. 19-7, A**

The dissection is extended medially, behind pectoralis fascia and the tumor-bearing quadrant of the breast. This maneuver opens up a deep retromammary space between the breast and the underlying pectoralis muscle, which is developed to a point about 2 cm medial to the border of the tumor, as marked on the skin.

B**Fig. 19-7, B**

Step Five: Partial Mastectomy

At this point, the tumor-bearing quadrant of the breast has been separated completely from the deep and superficial tissues, but the tumor remains attached circumferentially to the breast parenchyma. The tumor is grasped between the fingers and thumb and, using the skin marking as a guide, it is resected with a 1 to 2 cm margin of palpably normal breast tissue. The specimen is oriented and marked with clips before being sent for a radiologic assessment. At this point, the latissimus dorsi muscle can be identified in the lateral aspect of the operative field.

**Fig. 19-8**

Step Six: Margin Analysis

Bed biopsies are taken from the medial, lateral, superior, and inferior aspects of the wall of the resection cavity. Areas where the surgeon is suspicious of residual tumor are targeted. These are sent for frozen section analysis, and the cavity wall is inked in situ with methylene blue, which helps to identify the surface adjacent to the resection specimen. The cavity wall is excised as two continuous “shavings,” one from the inferior hemisphere and the other from the superior hemisphere. Each specimen has a blue inner surface and an undyed outer surface to facilitate orientation for the pathologist. If any of the bed biopsies is reported as positive, another biopsy is taken from the same position on the new cavity wall created by cavity shaving. If the second bed biopsy specimen is positive, the process may be repeated. If multiple, repeated biopsy specimens are positive, and consent has been given, a mastectomy and immediate reconstruction can be carried out.

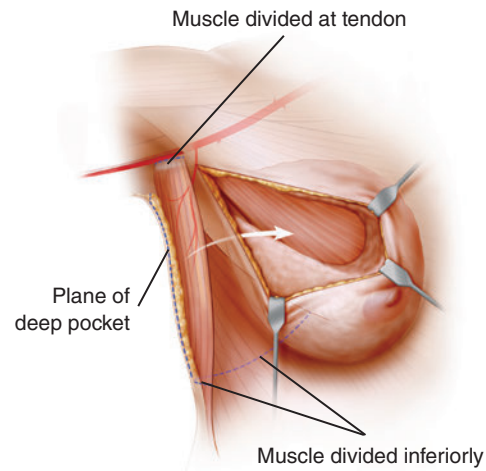
Step Seven: Axillary Dissection

If a decision has been made to perform a full axillary dissection, the axillary vessel and nerves are identified. They usually appear to lie more superficially when performing this procedure with the patient in the lateral position. Failure to recognize the axillary vein, which is often collapsed when the patient is in this position, may lead to inadvertent damage.

Step Eight: Miniflap Harvest

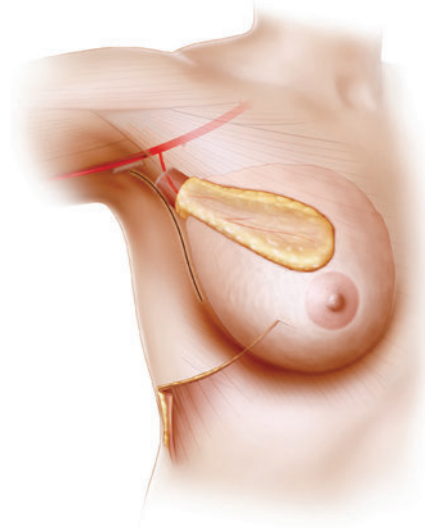
By the time the axilla is dissected and the pedicle is prepared, frozen section analysis results are available and a decision to go ahead can be made. Similar to the steps leading to a partial mastectomy, a miniflap harvest has three components: the development of a superficial pocket around the muscle, the development of a deep pocket around the muscle, and the separation of the flap from the remaining muscle and tendinous attachments. The superficial pocket is developed by separating the overlying subcutaneous fat from the underlying deeper fat layer, which is attached to the superficial surface of the muscle. This is achieved by dissecting just underneath the superficial fascia to create a rectangular space that extends from the anterior border of latissimus dorsi muscle toward the lumbosacral fascia posteriorly and to the level of the costal margin inferiorly. To reconstruct larger resection defects, the volume of the flap can be increased by extending the posterior and inferior limits of the dissection.

The deep pocket is developed between the latissimus dorsi and serratus anterior muscles to produce a space that mirrors the superficial pocket. The miniflap is completely mobilized by dividing the muscle all around the perimeter of the dissection pockets and, finally, by dividing the tendon. This last step maximizes the mobility of the flap, which is now attached only by its neurovascular pedicle.

**Fig. 19-9**

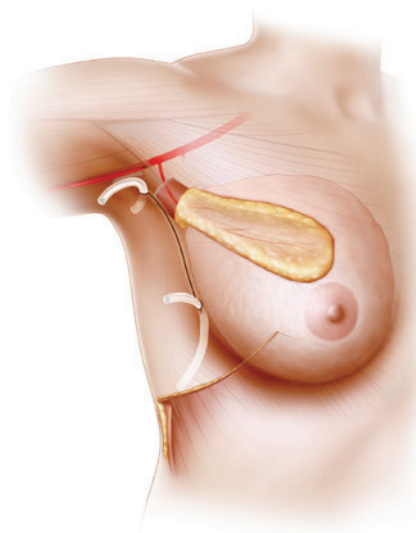
Step Nine: Reconstruction of the Resection Defect

The transposed tendon of the muscle is sutured to the lateral border of pectoralis major muscle to stabilize the flap and to protect the pedicle from traction injury. Several absorbable interrupted sutures are placed between the margins of the resection defect and the flap, and the flap is molded by folding it to produce a shape that matches the shape of the resection defect.

**Fig. 19-10**

Step Ten: Closure

Two suction drains are placed, one at the lower border of the latissimus dorsi muscle donor cavity and the other in the axilla. The use of “quilting” sutures between the subcutaneous fat and the chest wall can help to reduce the quantity of seroma fluid in the postoperative period. The wound is closed with interrupted absorbable sutures.

**Fig. 19-11**

Apart from the general complications of surgery, the surgical team should check for three specific problems in the first 24 hours:

1. *Check the flap's viability.* This can be confirmed by asking the patient to actively adduct her shoulder by pushing her hand on her hip. As the flap is innervated, this movement produces contraction of a viable muscle in the resection defect, and this is visible under the skin. Viability can be confirmed by direct inspection if a skin paddle has been used.
2. *Check for an expanding hematoma in the breast.* A moderate hematoma may occur, but progressive swelling requires a return to the operative theater and reexploration.
3. *Check for bleeding into the latissimus dorsi muscle donor defect.* As the patient leans forward in a sitting position, inspect her back. A moderate collection usually discharges through the drain, but an expanding hematoma requires reexploration.

Variation in Surgical Technique for the Myocutaneous Latissimus Dorsi Miniflap

When using a myocutaneous latissimus dorsi miniflap, the steps for positioning, the partial mastectomy, margin analysis, axillary dissection, and closure are very similar to the steps described for the myosubcutaneous latissimus dorsi reconstruction; however, the following steps are different:

Step One: Skin Markings

Using this approach, the tumor is removed together with overlying skin. This includes the skin of the nipple-areola complex for central tumors and a paddle of skin overlying the lower pole of the breast for inferiorly placed tumors. Sometimes an island of deepithelialized skin is used to add volume to the flap when no skin has been excised from the breast. The area of skin to be excised is designed according to the oncologic requirements for adequate tumor excision and is clearly marked on the breast. In the myocutaneous latissimus dorsi procedure, skin removed from the breast must be replaced by a skin island taken from the back and carried by the flap into the resection defect. The shape of this skin island mimics the skin island excised from the breast, and it is marked over the latissimus dorsi muscle. This can usually be fashioned out of an ellipse of skin placed under the line of the bra strap, with its long axis running transversely.

Step Three: Incisions

In addition to the S-shaped axillary incision used to form the access tunnel to carry out the axillary dissection and to prepare the vascular pedicle, a periareolar incision or elliptical incision in the lower pole of the breast is used to mobilize and resect the tumor with a clear margin. The cavity that remains communicates with the axilla through the access tunnel, which accommodates the transposed tendon. The incision on the back is made down to the level of the deep surface of the superficial fascia before mobilizing the flap.

Step Five: Partial Mastectomy

The partial mastectomy is carried out through the predetermined skin incision using an anterior approach. The resection may produce a large central defect or may involve removing the entire lower pole of the breast.

Step Eight: Miniflap Harvest

Most of the latissimus dorsi myocutaneous flap harvest is performed using a conventional posterior approach, unlike the myosubcutaneous flap harvest, which is carried out through a lateral incision.

Step Nine: Reconstruction of the Resection Defect

After the flap is transposed, the muscle is molded and the skin island is trimmed to match the skin aperture and to reconstruct the underlying defect. Finally, unlike reconstruction with a myosubcutaneous flap, it is easier to position and suture the myocutaneous flap accurately into the resection defect if the patient is turned to the supine position. This is optional. With both flap types, the resection volume is overreplaced by about 10% to 20% to compensate for the small degree of postoperative flap atrophy that may take place.

Tips and Tricks

The following aspects of this approach are emphasized:

- This approach is well indicated when a poor cosmetic outcome is a concern with conventional BCS.
- Be familiar with conventional latissimus dorsi muscle reconstruction after a total mastectomy before offering these techniques.
- Careful preoperative marking is the key to successful resection, flap harvest, and reconstruction.
- Spend time positioning the patient firmly and correctly on the table.
- Ensure excellent illumination and visualization, preferably with a high-quality headlight, lighted retractors, and good electrical cutting and coagulation equipment.
- Infiltration helps dissection, reduces hemorrhage, and prevents tissue dehydration.
- Avoid overabduction of the shoulder, because a traction injury of the brachial plexus can take 4 to 6 months to resolve.
- Begin with a two-stage approach to build up confidence in your technique and in your pathologist.
- Divide the tendon of the latissimus dorsi muscle to optimize the amount of muscle you can transpose into the resection defect.
- Harvest a flap that is about 10% to 20% larger than the resection defect to compensate for any postoperative flap atrophy.

OUTCOMES AND EVALUATION

The outcomes after volume replacement with latissimus dorsi muscle miniflaps fall into two groups: early outcomes and later oncologic and clinical outcomes.

Early Outcomes

Reexcision Rates

Studies using intraoperative frozen section margin analysis report significant reductions in margin positivity and subsequent reexcision rates.

Table 19-3 Margin Assessment: The Use of Frozen Section Margin Analysis and Margin Reexcision Rates: Comparison of the National Surgical Quality Improvement Program (NSQIP)²⁶ With Mayo Clinic²⁷ and Winchester²⁸ Data

	NSQIP	Mayo	Winchester	<i>p</i> value
Number	24,217	306	139	
Reexcision (%)	13.2	3.6	2.2	<.001

The Mayo Clinic showed a threefold reduction in reexcision rates after breast-conserving surgery following the introduction of frozen section margin analysis, achieving rates one third of those reported by the U.S. National Surgical Quality Improvement Program.^{26,27} We have reported similar benefits of frozen section during oncoplastic resections, achieving negative margins in 97.8% of patients.²⁸

Complications

Complications following this type of surgery are similar to those occurring after other breast-conserving procedures, with the added complications associated with flap reconstruction. The early postoperative complication rate from 1991 to 1997 in the Winchester series was 11% and included infection (4), hematoma (1), flap necrosis (1), and transient brachial plexopathy (1).²⁹ There have been no subsequent cases of flap necrosis, and the overall complication rate in this center has fallen subsequently to 8%.³⁰

Late Oncologic Outcomes

Data from seven small retrospective studies (total 189 patients) of volume replacement using the latissimus dorsi muscle have been published.³¹ Local recurrence rates of 0% to 5% and cosmetic failure rates of 0% to 9% with a median follow-up of around 3 years have been reported.

Table 19-4 Local Recurrence After Volume Replacement Using the Latissimus Dorsi Muscle With or Without Frozen Section

	With Frozen Section ³²	Without Frozen Section ²⁸
Procedures	110	72
Follow-up (mo)	51	58
Local recurrence (%)	1 (0.9)	2 (2.8)

In our own series of 182 patients who received radiotherapy, the use of intraoperative frozen section margin analysis has reduced local recurrence rates from 2.8% at 58 months²⁸ to 0.9% at 51 months.³²

A recent meta-analysis confirmed the long-term oncologic benefits of oncoplastic breast conserving surgery (OBCS). Comparing 3165 OBCS (volume replacement and displacement) procedures with 5494 breast-conserving (BCS) procedures, Losken et al³³ reported a highly significant reduction in rates of reexcision and local recurrence in the OBCS group (volume replacement versus BCS, reexcision rate 5.7% versus 14.6%, local recurrence rate 3.6% versus 7.0%, $p < 0.0001$).

Clinical Outcomes

Table 19-5 Clinical Outcomes Comparing the Latissimus Dorsi Miniflap With Skin-sparing Mastectomy and Immediate Reconstruction

	Latissimus Dorsi Miniflap (%)	Skin-sparing Mastectomy and Immediate Reconstruction (%)
Postoperative complications	8	14
Subsequent interventions	12	79
Nipple sensory loss	2	98
Restricted activities	54	73
Cosmetic assessment*	3.8	2.9
Total number of patients	49	57

*Score used by panel: 1 = gross deformity; 5 = no deformity.

The outcomes of patients who underwent volume replacement and latissimus dorsi miniflap reconstruction were compared with outcomes of patients who underwent a skin-sparing mastectomy and immediate latissimus dorsi reconstruction. Those who were treated with the volume replacement technique had significantly better outcomes.³⁰ Compared with volume replacement and reconstruction, the need for additional procedures after a skin-sparing mastectomy and immediate reconstruction is striking. These procedures include an implant exchange, capsulectomy, nipple reconstruction, and injection port removal. Moreover, the area of sensory loss after a total mastectomy is much greater than after a partial mastectomy, with altered sensation involving 65% of the surface of the reconstructed breast, compared with only 10% of the surface after partial mastectomy.³⁰

Patient-reported Outcomes

Very little has been published about patient-reported outcomes after OBCS procedures, including volume replacement with latissimus dorsi miniflaps. We have recently completed a study of 333 patients treated by OBCS between 1995-2014, based on the BREAST-Q

questionnaire developed and validated by Pusic et al.³⁴ The study included 221 patients who had undergone latissimus dorsi miniflaps (mean age 50 years; mean follow-up 112 months).

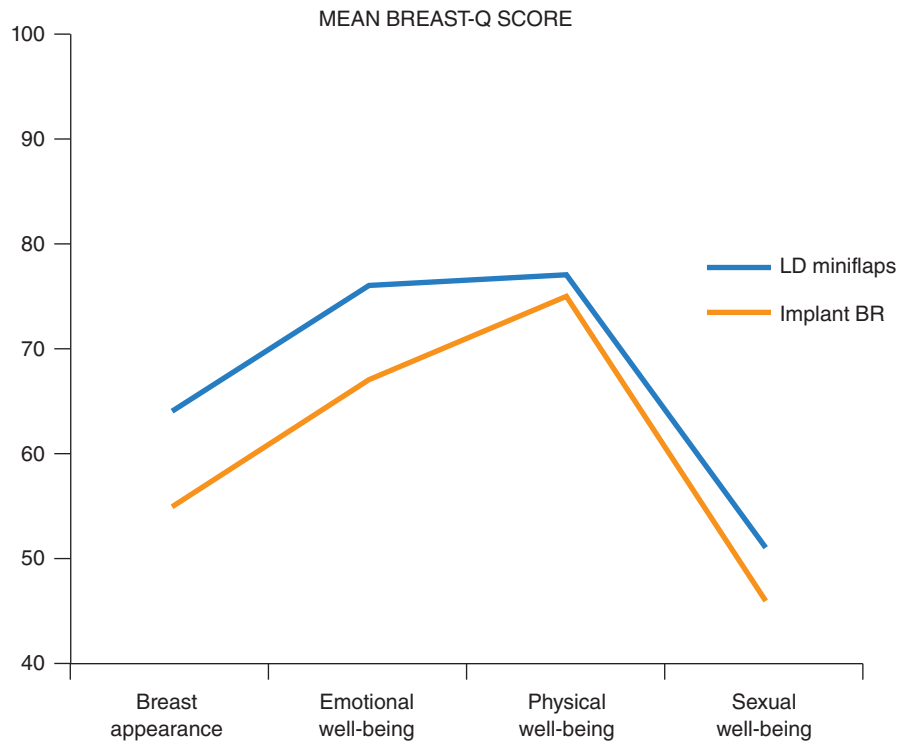


Fig. 19-12

Patients were asked to score outcomes in four domains: breast appearance, and emotional, physical, and sexual well-being. These scores were compared with the scores returned by patients 18 months after more than 1000 implant-based reconstructions taking part in the U.K. National Mastectomy and Breast Reconstruction Audit of more than 5000 reconstructions.³⁵ The audit used the same validated scoring system, and the scores in each domain returned by the miniflap group were comparable to or better than those returned by women after implant-based procedures. The figure shows Breast-Q scores in four domains following LD miniflap reconstruction (mean assessment interval 112 months) versus mastectomy and implant-based reconstruction (mean assessment interval 18 months).

The delay between surgery and assessment of outcome was very different between the two groups, therefore a further analysis of 4 cohorts undergoing OBCS procedures at different times was carried out. This showed that BREAST-Q scores were largely unaffected by the delay between surgery and assessment, with the exception of a small number (18 patients) who had undergone OBCS more than 15 years before the assessment was carried out.

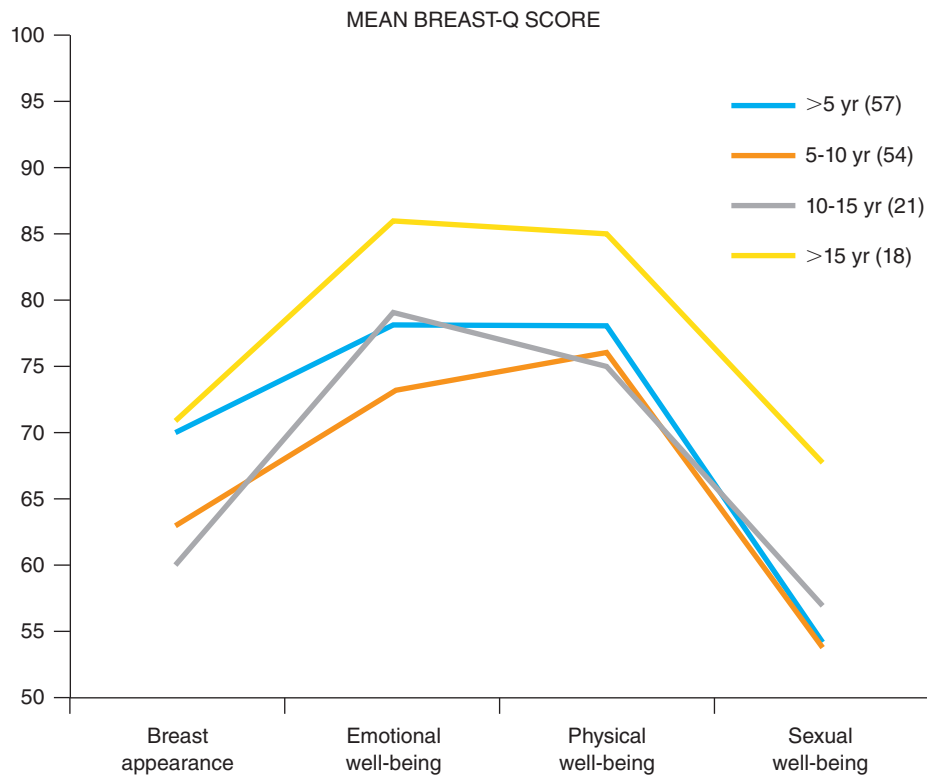


Fig. 19-13

This figure shows BREAST-Q scores at four different time intervals after OBCS, based on 150 returns from 92 LD miniflap and 58 therapeutic mammoplasty patients (numbers in each cohort shown in parentheses).

Radiologic and Volumetric Outcomes

The radiologic outcomes following volume replacement procedures compare favorably with those after BCS without reconstruction. Flaps are often isodense and may be indistinguishable from the surrounding breast tissue.

Distorting, stellate scars are common after BCS but are avoided when volume replacement procedures are used, facilitating the early detection of local recurrence. These findings have been reported by others.³⁶

Finally, we compared the breast volume loss in patients after conventional BCS and after volume replacement with latissimus dorsi muscle miniflaps. Similar changes in volume were observed up to 6 years after surgery, although the volume resected in patients with latissimus dorsi miniflaps was twice the volume resected in the BCS group.¹⁹

PATIENT EXAMPLES

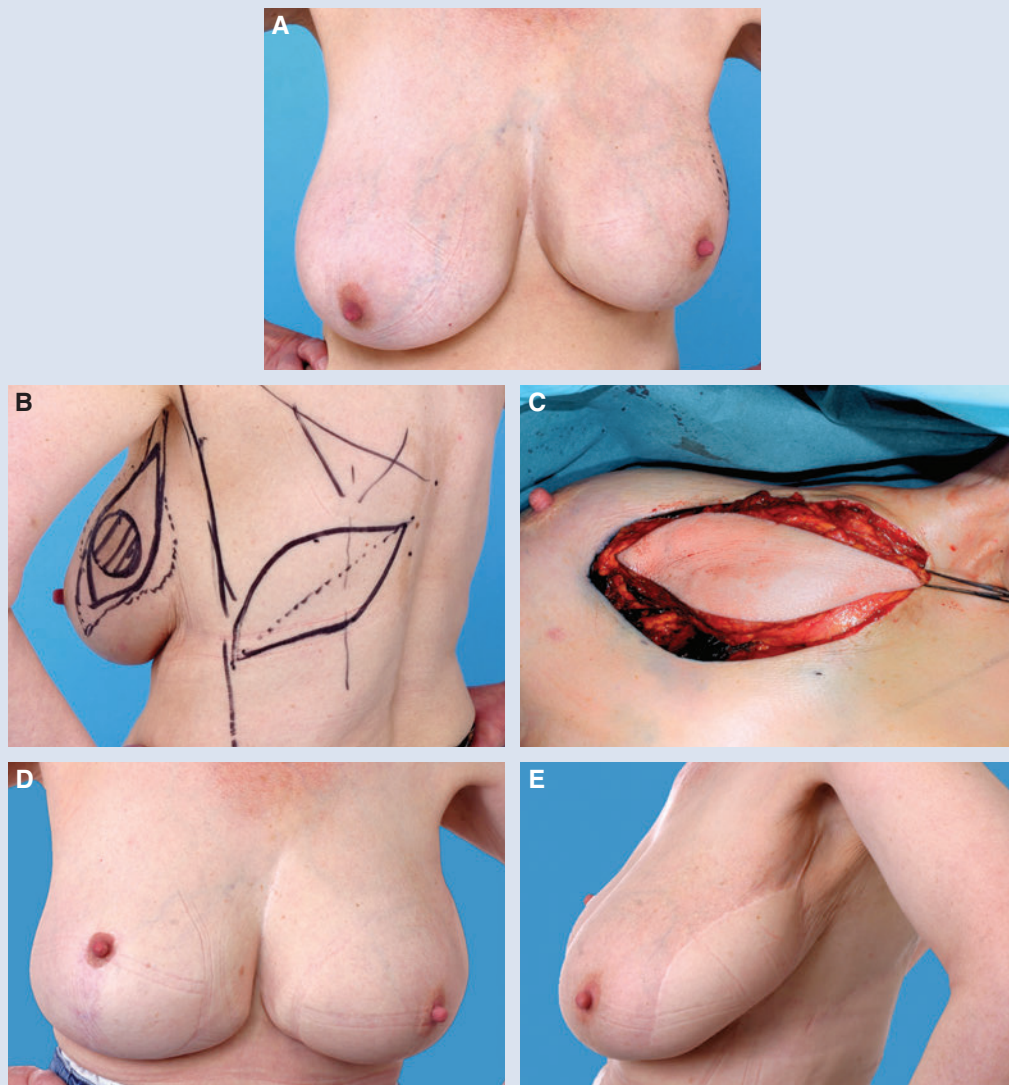
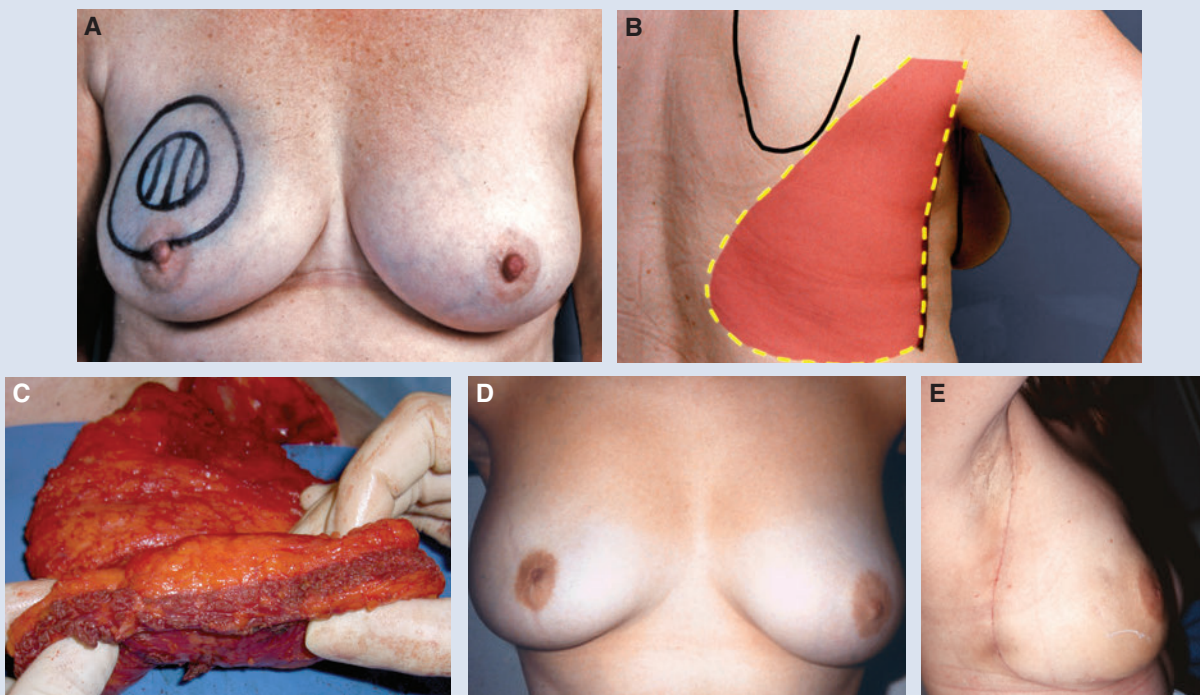


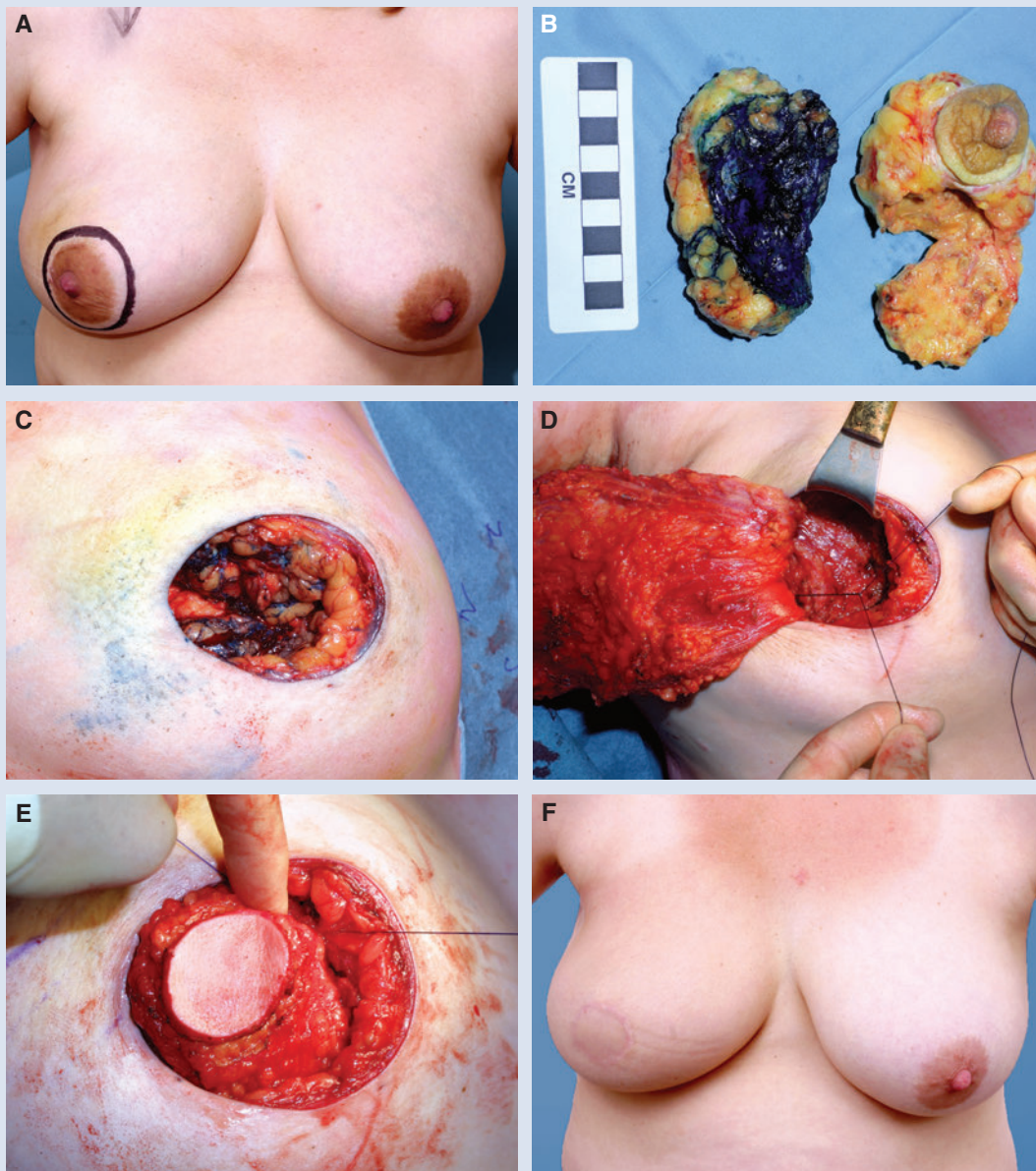Fig. 19-14

This 60-year-old patient presented with a 35 mm grade 2 invasive ductal carcinoma in the upper outer quadrant of her left breast (A). Seventeen years earlier, she underwent a wide local excision and radiotherapy for a 30 mm grade 2 node-negative invasive ductal carcinoma in the same quadrant. The patient declined a mastectomy and requested further local excision of this bulky local recurrence. She also declined contralateral surgery and wished to retain her ptotic shape. A loss of volume in her left breast and the degree of ptosis of both breasts was evident preoperatively. Markings were made preoperatively and included the tumor, the segment of breast to be removed, and the latissimus dorsi myocutaneous miniflap, which was to be used to reconstruct the resection defect (B). To produce a specimen with clear tumor-free margins, 300 g of tissue were resected, and the flap was transposed to the defect (C).

The patient is shown 4 years postoperatively (D). She has had a contralateral reduction and is awaiting repositioning of the left nipple. Her breasts are symmetrical, and the left breast has a natural, ptotic appearance (E).

**Fig. 19-15**

This 40-year-old patient presented with a 38 mm grade 3 invasive ductal carcinoma in the upper pole of her right breast (A). The border of the tumor and the resection margin were clearly marked on the skin. The outline of the extent of miniflap harvest is shown (B). A typical miniflap has a significant layer of fat on the superficial surface of the flap and a thinner layer on the deep surface (C). The patient is shown postoperatively (D and E). Note the single lateral S-shaped incision following resection, axillary dissection, flap harvest, and reconstruction.

**Fig. 19-16**

This 33-year-old patient presented with a 28 mm grade 3 invasive ductal carcinoma surrounded by high-grade ductal carcinoma in situ with a total diameter of 50 mm in the subareolar region (A). The tumor was excised, including the nipple-areola complex (B). The specimen and the reexcision margin were resected, leaving a central defect that measured 9 cm in diameter (C). The specimen weighed 410 g. The latissimus dorsi myocutaneous miniflap was sutured into the resection defect, and the skin island was positioned in the central aperture (D and E). The patient is shown 2 years postoperatively, after completing adjuvant chemotherapy and radiotherapy (F).

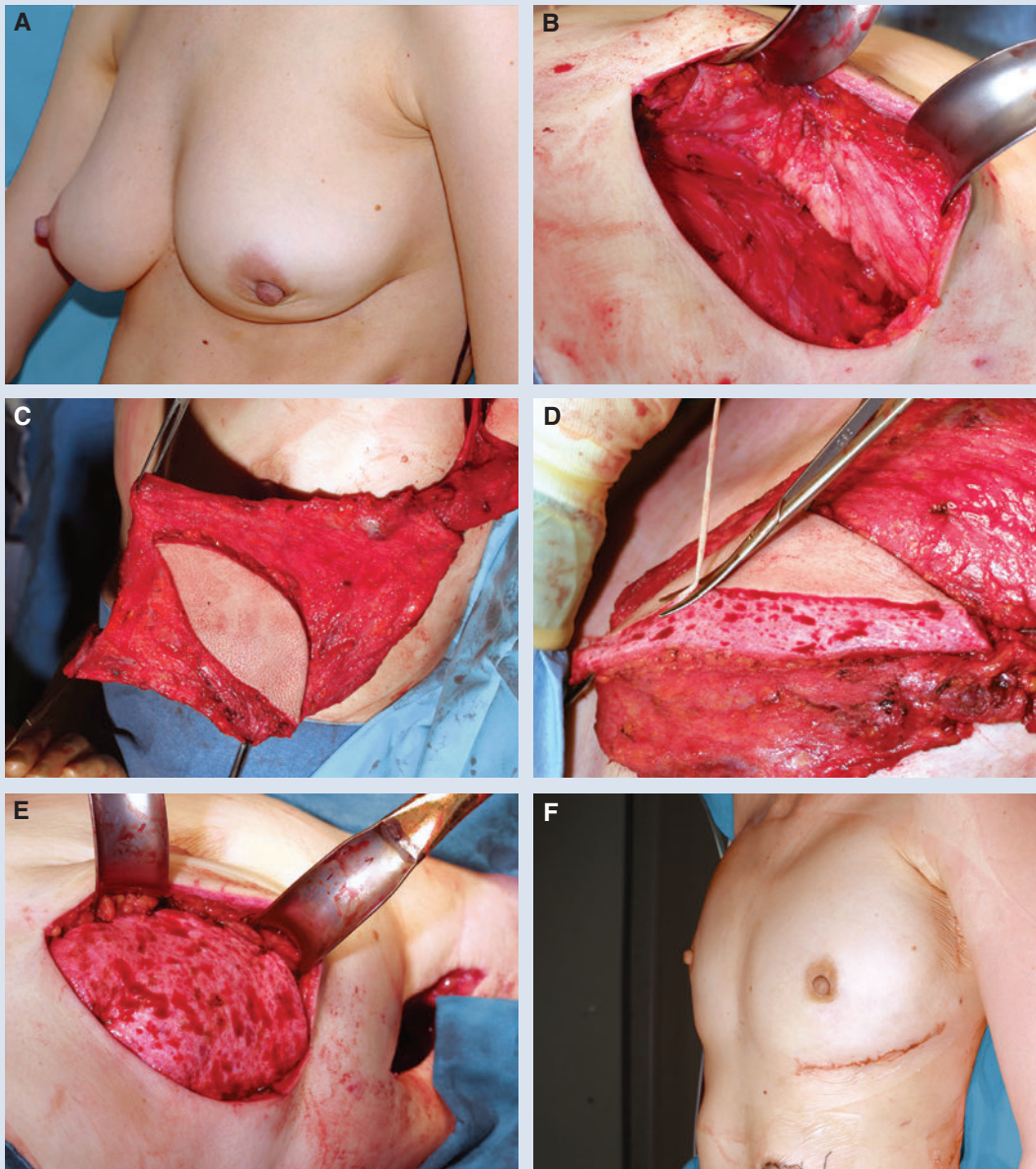


Fig. 19-17

This 38-year-old patient presented with three small, invasive ductal carcinomas in the lower pole of her left breast. These were resected by excising the entire lower pole of the breast (190 g) through an inframammary incision. She is shown before reconstruction of the lower pole (*A*), and after reexploration and preparation of the resection defect, which took place several days later (*B*). Reconstruction was performed using a myocutaneous latissimus dorsi miniflap (*C*). The skin island was deepithelialized (*D*), and the flap was positioned in the resection defect (*E*). The inframammary incision was closed, and the patient is shown at the end of the procedure (*F*).

CONCLUSION

Volume replacement with latissimus dorsi miniflaps provides an exciting alternative to BCS or mastectomy for patients with breast cancer. Emerging data confirm the clinical utility of these techniques in the management of a group of patients traditionally treated with a mastectomy. Early reports of favorable physical and oncologic outcomes require a more detailed, prospective evaluation before they are more widely adopted in clinical practice. Greater availability of these procedures in the future will depend on the closer alignment of the skills of the general and the plastic surgeons with an interest in breast surgery.

Critical Issues

- The quality of surgery affects local recurrence and survival after BCS.
- Volume replacement with latissimus dorsi miniflaps extends the role of BCS without compromising complete tumor excision.
- This approach has evolved over 20 years and allows resection and reconstruction of up to 70% of the breast.
- Volume replacement is most appropriate for patients with small or medium breasts.
- A careful preoperative assessment, markings, and technique selection ensure good outcomes.
- Volume replacement can be carried out in one or two stages.
- Intraoperative margin assessment is effective at ensuring complete excision and subsequent local control.
- The position and size of the resection defect determine the type of reconstruction.
- Oncologic outcomes are similar to those reported after BCS.
- Physical outcomes are better than those reported after skin-sparing mastectomy and immediate reconstruction.

References

1. Abrams J, Chen T, Giusti R. Survival of the breast sparing surgery versus mastectomy. *J Natl Cancer Inst* 86:2, 1994.
2. Veronesi U, Saccozzi R, Del Vecchio M, et al. Comparing radical mastectomy with quadrantectomy, axillary dissection, and radiotherapy in patients with small cancers of the breast. *N Eng J Med* 305:6, 1981.
3. Clarke M, Collins R, Darby S, et al; Early Breast Cancer Trialists' Collaborative Group. Effects of radiotherapy and of differences in the extent of surgery for early breast cancer on local recurrence and 15-year survival: an overview of the randomised trials. *Lancet* 366:2087, 2005.

4. Veronesi U, Voltarrani F, Louini A, et al. Quadrantectomy versus lumpectomy for small size breast cancer. *Eur J Cancer* 26:671, 1990.
5. Al-Ghazal SK, Fallowfield L, Blamey RW. Does cosmetic outcome from treatment of primary breast cancer influence psychological morbidity? *Eur J Surg Oncol* 25:571, 1999.
6. Cochrane RA, Valasiadou P, Wilson ARM, et al. Cosmesis and satisfaction after breast-conserving surgery correlates to the percentage of breast volume excised. *Br J Surg* 90:1505, 2003.
7. Pearl R, Wisnicki J. Breast reconstruction following lumpectomy and irradiation. *Plast Reconstr Surg* 76:83, 1985.
8. Santi P, Berrino P, Galli A, et al. Anterior transposition of the latissimus dorsi muscle through minimum incisions. *Scand J Reconstr Surg* 20:89, 1986.
9. Papp C, Zanon E, McCraw J. Breast volume replacement using the de-epithelialised latissimus dorsi myocutaneous flap. *Eur J Plast Surg* 11:120, 1988.
10. Noguchi M, Taniya T, Miyazaki I, et al. Immediate transposition of a latissimus dorsi muscle for correcting a postquadrantectomy breast deformity in Japanese patients. *Int Surg* 75:166, 1990.
11. Slavin S, Love S, Sadowsky N. Reconstruction of the irradiated partial mastectomy defect with autogenous tissues. *Plast Reconstr Surg* 90:854, 1992.
12. Zoetmulder FA, Borger JH, Rutgers EJ, et al. Breast conserving therapy in patients with relatively large (T2, T3) breast cancers by preoperative irradiation and myocutaneous LD flap reconstruction. A new technique in breast conservation. *Eur J Cancer* 29A:957, 1993.
13. Rainsbury R. Breast conservation with latissimus dorsi miniflap: a new technique. *Eur J Surg Oncol* 20:102, 1994.
14. Eaves F, Bostwick J, Nahai F, et al. Endoscopic techniques in aesthetic breast surgery. *Clin Plast Surg* 22:683, 1995.
15. Audretsch W, Rezai M, Kolotas C, et al. Tumour-specific immediate reconstruction (TSIR) in breast cancer patients. *Perspect Plast Surg* 11:71, 1998.
16. Raja M, Straker V, Rainsbury R. Extending the role of breast-conserving surgery by immediate volume replacement. *Br J Surg* 84:101, 1997.
17. Early Breast Cancer Trialists' Collaborative Group. Effect of radiotherapy after mastectomy and axillary dissection on 10-year recurrence and 20-year breast cancer mortality: a meta-analysis of individual patient data for 8135 women in 22 randomised trials. *Lancet* 383:2127, 2014.
18. Momoh AO, Ahmed R, Kelley BP, et al. A systematic review of complications of implant-based breast reconstruction with prereconstruction and postreconstruction radiotherapy. *Ann Surg Oncol* 21:118, 2014.
19. Laws S, Cheetham J, Rainsbury R. Temporal changes in breast volume after surgery for cancer and the implications for volume replacement with a latissimus dorsi miniflap. *Eur J Surg Oncol* 27:761, 2001.
20. Thomas P. Use of silicone implants after wide local excision of the breast. *Br J Surg* 80:858, 1993.
21. Elton C, Jones SE, Jones PA. Initial experience of intramammary prosthesis in breast conservation surgery. *Eur J Surg Oncol* 25:138, 1999.
22. Chaturvedi S. Subaxillary dermocutaneous fat flap for reconstruction of the upper outer quadrant of the breast following conservation surgery. *Br J Surg* 91:69, 2004.
23. Ohuchi N, Harada Y, Ishida T, et al. Breast-conserving surgery for primary breast cancer. Immediate volume replacement using lateral tissue flap. *Breast Cancer* 4:135, 1997.
24. Clough K, Lewis J, Couturaud B, et al. Oncoplastic techniques allow extensive resections for breast-conserving therapy of breast carcinomas. *Am Surg* 237:26, 2003.
25. McCulley S, Macmillan R. Planning and use of therapeutic mammoplasty—Nottingham approach. *Br J Plast Surg* 58:889, 2005.
26. Khuri SF, Daley J, Henderson W, et al. The Department of Veterans Affairs NSQIP: the first national, validated, outcome-based, risk-adjusted, and peer-controlled program for the measurement and enhancement of the quality of surgical care. National VA Surgical Quality Improvement program. *Ann Surg* 228:491, 1998.

27. Boughey JC, Hieken TJ, Jakub JW, et al. Impact of analysis of frozen section margin on reoperation rates in women undergoing lumpectomy for breast cancer: evaluation of the National Surgical Quality Improvement Program data. *Surgery* 156:190, 2014.
28. Rusby JE, Paramanathan N, Laws SA, Rainsbury RM. Immediate latissimus dorsi miniflap volume replacement for partial mastectomy: use of intra-operative frozen sections to confirm negative margins. *Am J Surg* 196:512, 2008.
29. Rainsbury R, Paramanathan N. Recent progress in breast-conserving volume replacement using latissimus dorsi miniflaps in UK patients. *Breast Cancer* 5:139, 1998.
30. Gendy R, Abel J, Rainsbury R. Impact of skin-sparing mastectomy with immediate reconstruction and breast-sparing reconstruction with miniflaps on the outcomes of oncoplastic breast surgery. *Br J Surg* 90:433, 2003.
31. Rainsbury R. Surgery insight: oncoplastic breast-conserving reconstruction—indications, benefits, choices and outcomes. *Nat Clin Pract Oncol* 4:657, 2007.
32. Banerjee D, Paramanathan N, Summerhayes C, et al. Local recurrence following skin-sparing oncoplastic techniques: 10-year Winchester experience. Presented at the Eighth Nottingham International Breast Cancer Conference, Nottingham, UK, Sept 2003.
33. Losken A, Dugal CS, Styblo TM, et al. A meta-analysis comparing breast conservation therapy alone to the oncoplastic technique. *Ann Plast Surg* 72:145, 2014.
34. Pusic AL, Klassen AF, Scott AM, et al. Development of a new patient reported outcome measure for breast surgery. The BREAST-Q. *Plast Reconstr Surg* 124:345, 2009.
35. Jeevan R, Cromwell DA, Browne JP, et al. Findings of a national comparative audit of mastectomy and breast reconstruction surgery in England. *J Plast Reconstr Aesthet Surg* 67:1333, 2014.
36. Monticciolo DL, Ross D, Bostwick J III, et al. Autologous breast reconstruction with endoscopic latissimus dorsi musculocutaneous flaps in patients choosing breast-conserving therapy: mammographic appearance. *AJR Am J Roentgenol* 167:385, 1996.

20

Endoscopic Latissimus Dorsi Flap Reconstruction

Albert Losken

T

he introduction of minimally invasive techniques in aesthetic plastic surgery in the 1990s has proved to be an extremely useful addition; however, reconstructive surgery has been slower to incorporate these techniques. The harvesting of the latissimus dorsi muscle for pedicled and free flaps is one area in which minimally invasive approaches have been used with some frequency; this technique reduces scarring and potentially decreases donor site morbidity.

When compared directly with traditional harvesting techniques for microvascular reconstruction, the endoscopically assisted harvest of the latissimus dorsi muscle results in improved postoperative pain, better ipsilateral upper extremity activity, and significant improvement in patient scarring and patient satisfaction.¹

In 1993 Friedlander and Sundin² reported using the endoscope for harvesting the latissimus dorsi muscle in cadaver and porcine models. Clinical uses were later reported mainly for lower extremity defects.^{3,4} John Bostwick⁵ popularized the use of this technique to fill partial mastectomy defects.

PATIENT SELECTION

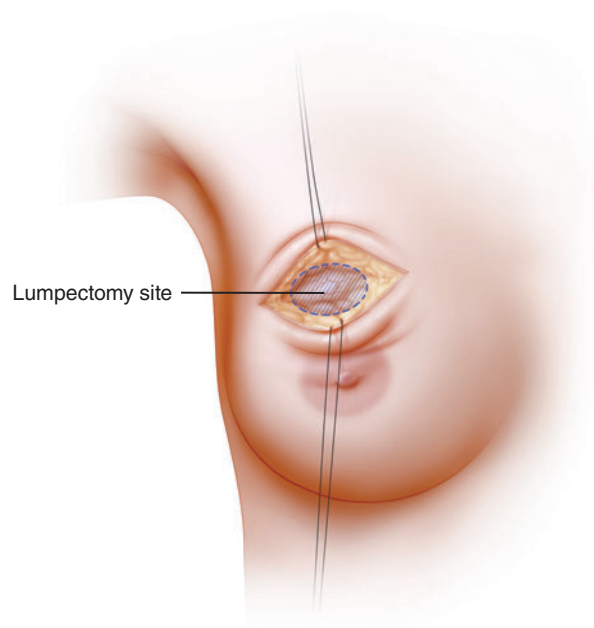


Fig. 20-1

If a patient has small breasts or insufficient residual breast tissue for remodeling procedures or wishes to maintain her breast size and shape without altering the opposite breast, the endoscopically assisted technique is very useful. It is more commonly used for immediate reconstruction of partial mastectomy defects when volume only is required. An endoscopically harvested latissimus dorsi flap can be used for defects in almost any location; however, its use becomes more difficult for correction of medial quadrant defects. This illustration shows an upper pole lumpectomy defect with volume loss above the nipple, with no deficiency in skin coverage. If closed primarily, this defect could result in contour irregularities after radiotherapy.

THE DECISION-MAKING PROCESS

After deciding that the latissimus dorsi flap is required for immediate volume replacement of the partial mastectomy defect, the most appropriate timing for the reconstruction must be established. It is often safer to confirm clear margins before proceeding with the flap reconstruction.

Because positive tumor margins on final pathologic evaluation could potentially compromise the reconstruction, it is imperative that this confirmation be obtained before the flap reconstruction.

SURGICAL PLAN TO ASSESS THE TISSUE DEFICIENCY AFTER THE QUADRANTECTOMY

- Confirm negative margins (delayed-immediate reconstruction).
- Harvest the latissimus dorsi muscle and subcutaneous tissue.
- Minimally extend the axillary dissection incision and incise along the lateral portion of the latissimus dorsi muscle for access.
- Infiltrate the wetting solution and pretunnel to reduce bleeding.
- Undermine the skin below the subdermal plexus.
- Elevate the flap and divide along the lateral edge of the latissimus dorsi muscle and inferiorly.
- Separate the flap from the teres major muscle to the tip of the scapula and divide the medial aspect of the latissimus dorsi muscle.
- Identify the pedicle.
- Release the insertion and rotate and inset the flap.
- Place drains and close the donor site.

OPERATING ROOM SETUP AND PATIENT POSITIONING

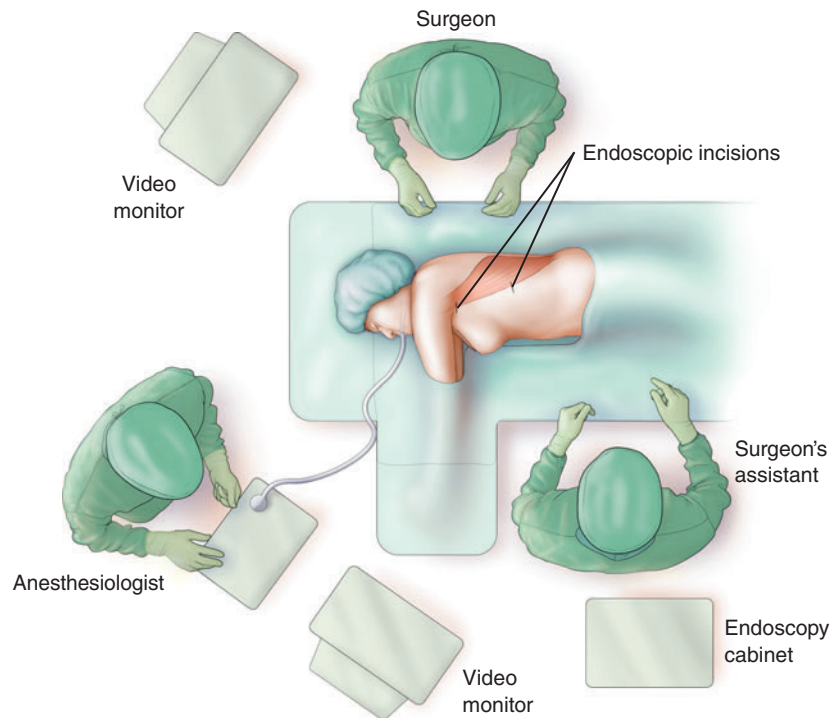


Fig. 20-2

The operating room setup and patient positioning are the same for harvesting either a pedicled or a free latissimus dorsi muscle. As illustrated, the patient is placed in the preferred lateral position, with the ipsilateral arm prepared widely to allow repositioning during the pedicle dissection and tendon division. This position allows optimal exposure, visualization, and orientation for the surgeon and assistant. Occasionally, for smaller defects that require a relatively small portion of the flap, the patient can be placed in the supine position for segmental harvest of the anterior section of muscle.

MARKINGS AND TECHNIQUE

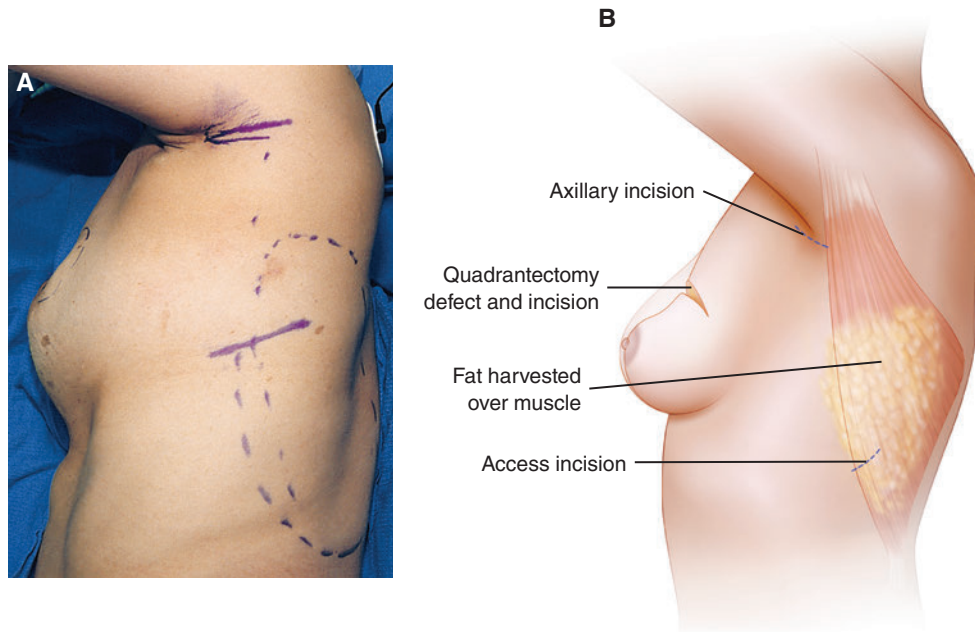
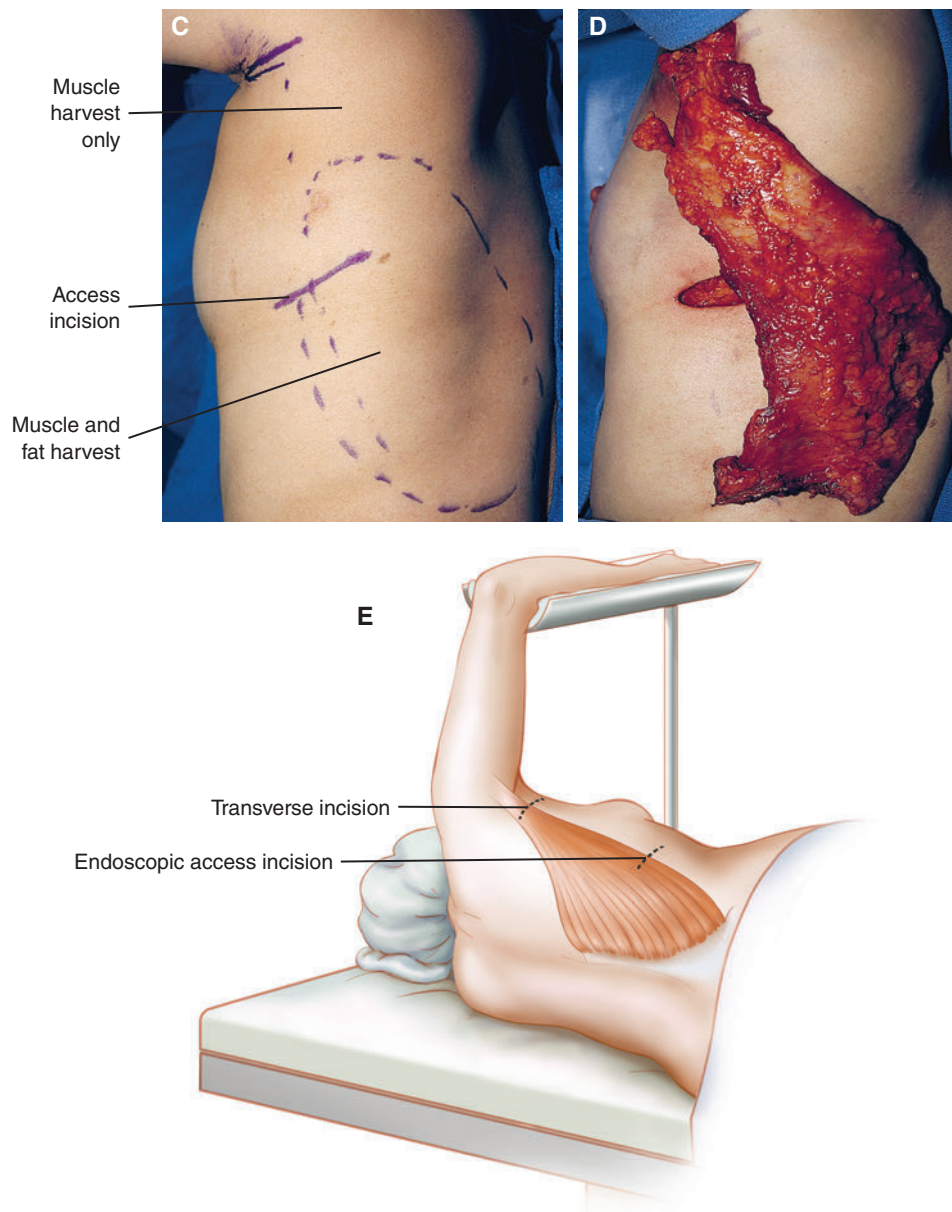


Fig. 20-3, A and B

The patient is marked preoperatively in the standing position (A). The amount of volume required is anticipated by evaluating the films and the size of the defect and by communicating with the respective surgeon. The borders of the muscle are drawn out and the proposed incisions are marked. Axillary and lateral chest incisions are used for muscle access (B). Wetting solution is infiltrated in the subcutaneous tissue overlying the latissimus dorsi muscle. Occasionally, a single 5 to 7 cm access incision can be positioned about 5 cm caudal to the axillary fossa at the posterior axillary line, anterior to the lateral border of the latissimus dorsi muscle. This is often possible if the muscle length is less than about 20 cm. The entire flap can be harvested through this incision. The two-incision approach is preferred and allows smaller incisions to be used; it also allows accurate identification and protects the pedicle. A small axillary incision is often already there from the nodal dissection, and it can be used for the harvest.

**Fig. 20-3, C-E**

The latissimus dorsi muscle is harvested along with the overlying subcutaneous tissue, which is pretunneled over the entire extent of the muscle. The top of the axilla is dissected to minimize the bulk of the muscle itself and of the lateral breast tunnel (C and D). As on this patient, the flap is dissected in the subcutaneous plane, and the lateral margin of the latissimus dorsi muscle is identified. The latissimus dorsi muscle is elevated off the serratus anterior muscle. The thoracodorsal vessels are dissected under direct visualization through the axillary incision to ensure safety of the pedicle before its dissection off the chest wall. The dissection is initiated with direct visualization. The endoscope is inserted through the axillary incision, and the lateral margin of the latissimus dorsi muscle is dissected almost to the extent of the endoscopic incision inferiorly (E). The interval between the latissimus

dorsi and teres major muscles is identified using the endoscope, and the dissection is extended down to the tip of the scapula. The endoscope is then positioned through the lateral incision, and the dissection proceeds to the interval between the serratus anterior and latissimus dorsi muscles, separating these structures and preserving the crossing branch on top of the serratus anterior muscle.

It is important to maintain the dissected optical cavity to allow visualization, often with the aid of a Deaver or an Emory endoscopic retractor with an endoscope, which is attached to a video monitor. Submuscular dissection can be performed bluntly; however, any perforating vessels off the chest wall should be clipped and transected. The extended Bovie electrocautery unit is used with a bent tip or specially designed endoscopic scissors with electrocautery. A third small incision is occasionally required along the upper medial border of the muscle if adequate visualization of the instrumentation is not possible because of the chest wall curvature. The dissection of the optical cavity should extend beyond the marked recipient defect to facilitate hemostasis after division of the distal muscle. The latissimus dorsi muscle is then divided inferiorly and medially using electrocautery and endoscopic assistance.

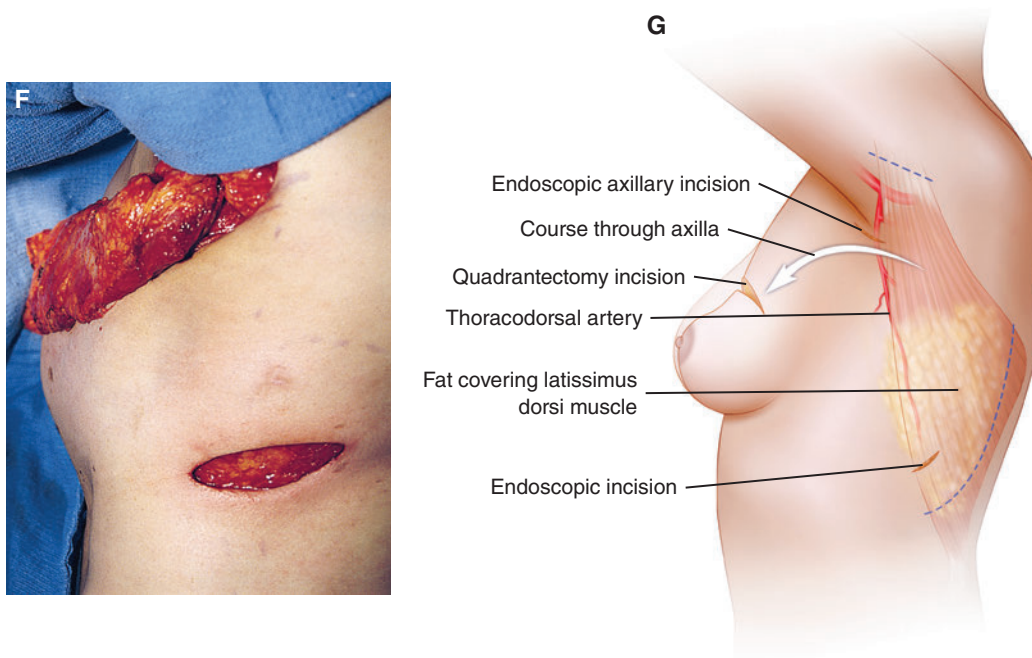
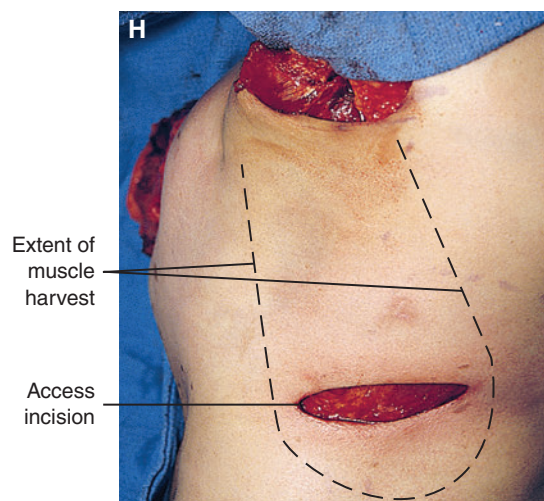
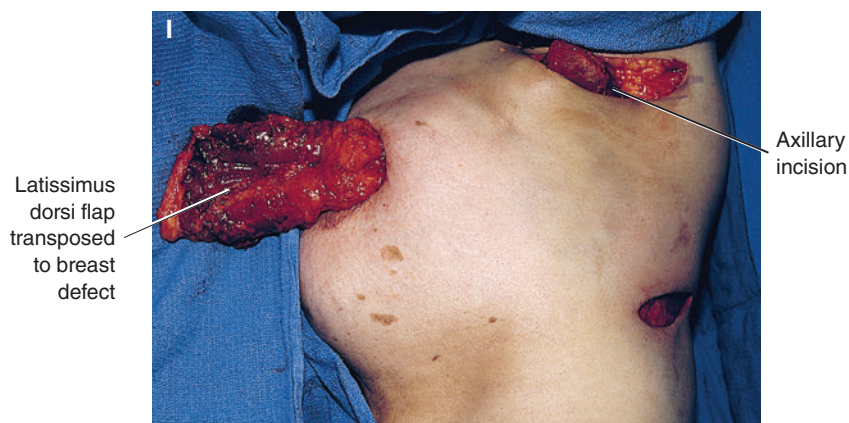

Fig. 20-3, F and G

The latissimus dorsi is dissected completely on its vascular pedicle and passed through the subcutaneous tunnel into the axillary incision (*F* and *G*).

**Fig. 20-3, H**

The humeral insertion of the latissimus dorsi muscle is divided to facilitate flap movement into the breast and to minimize any postoperative animation. Muscular denervation is typically not performed, because this causes additional atrophy. The flap is passed from the axillary incision into the partial mastectomy defect (*H*).

**Fig. 20-3, I**

The latissimus dorsi muscle is brought out of the breast through the quadrantectomy incision (*I*).

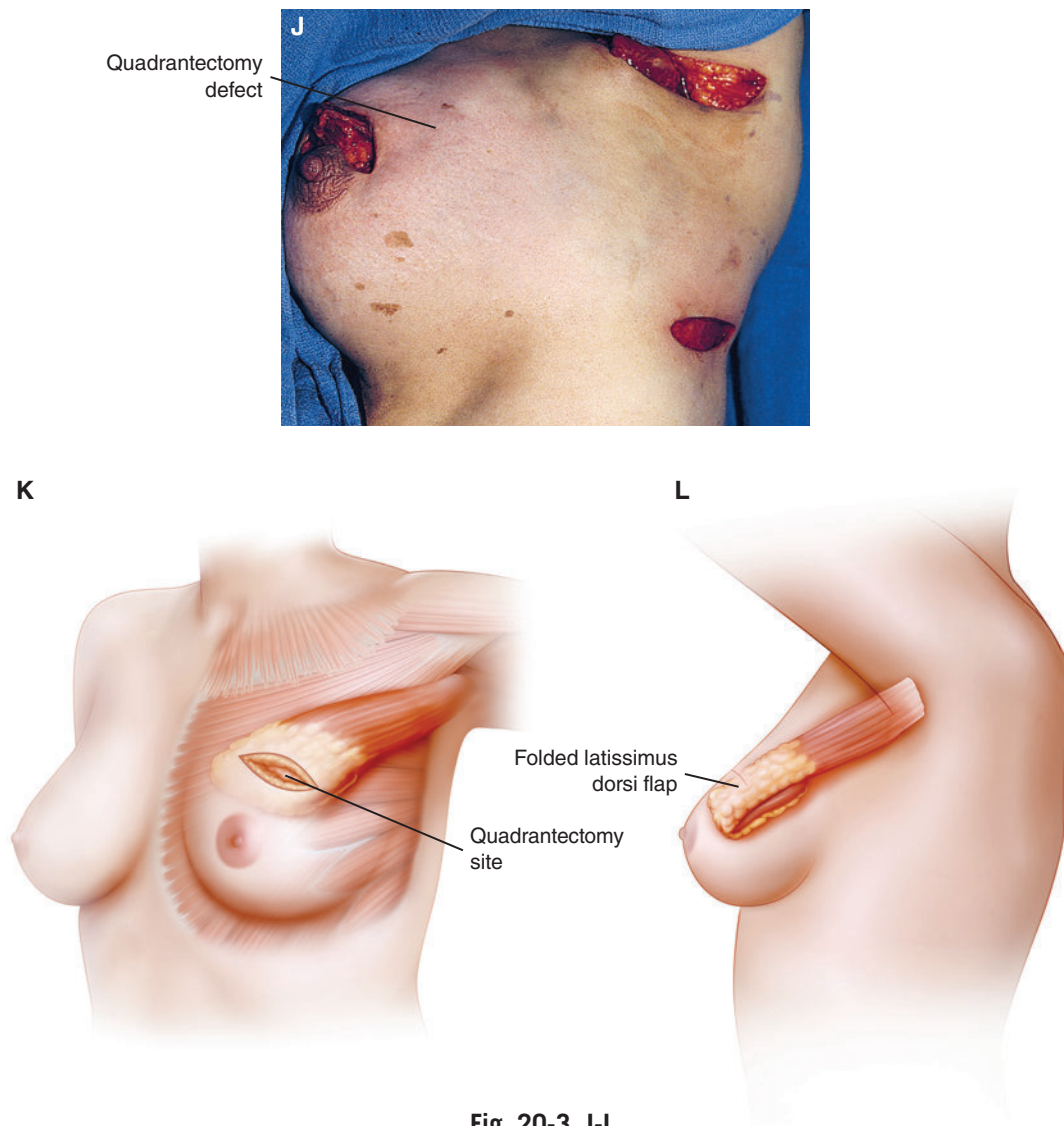


Fig. 20-3, J-L

The muscle is folded on itself to add bulk, then is positioned to fill the defect and provide good contour for shape preservation and symmetry (*J* through *L*).

PATIENT EXAMPLE

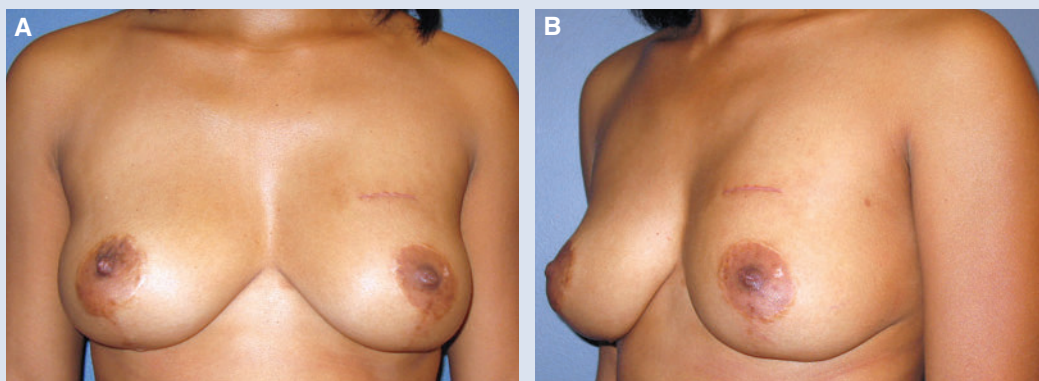


Fig. 20-4, A and B

This 34-year-old woman previously had a breast reduction and presented to the surgical oncologist with left-sided breast cancer at the 12 o'clock position (A and B). The patient preferred to preserve her breasts and opted for a partial mastectomy. A moderate resection was performed; however, margins remained involved. The surgeon and patient discussed the possibilities of undergoing a mastectomy or attempting further reexcision. The patient still desired breast conservation, and she expressed concerns about further contour distortion with additional resection.

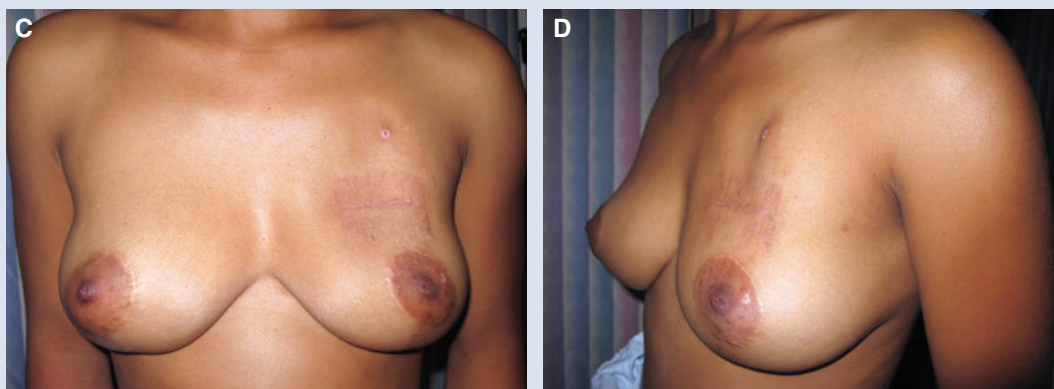
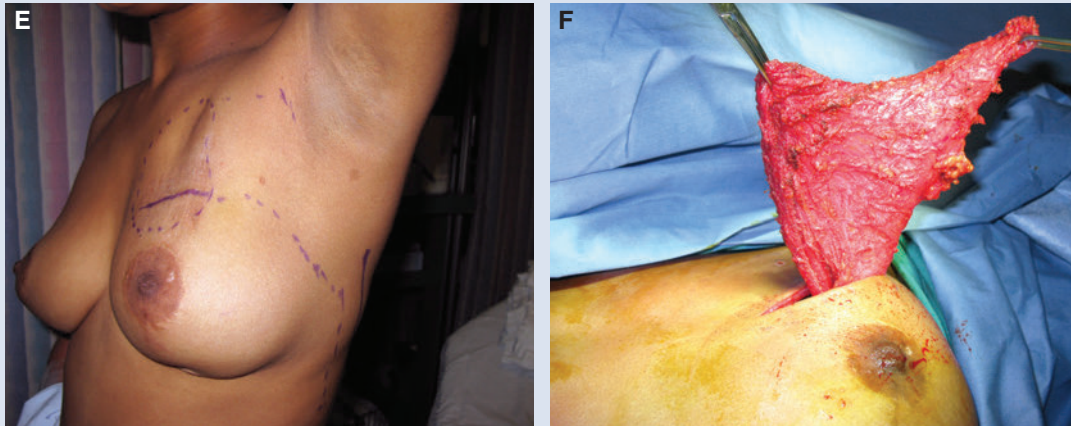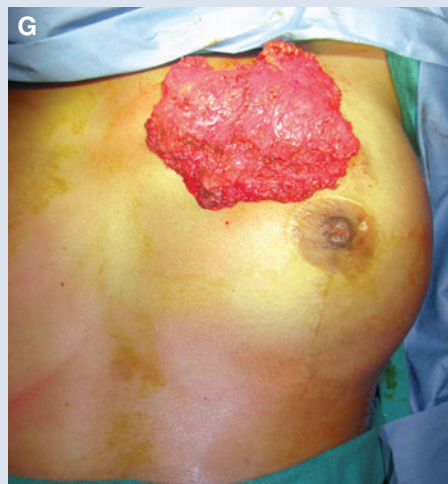


Fig. 20-4, C and D

To allow a generous resection that would also ensure negative margins and preserve breast shape, the patient was referred for partial breast reconstruction. She presented with decent shape, although she had a scar in the upper pole (C and D). It was believed that an additional resection would further compromise her shape and result in a BCT deformity. To prevent this outcome, additional volume was required. There was no skin lost with the resection, and the deformity was not a complication from radiotherapy. Therefore skin was not required with the reconstruction, only volume. The patient was concerned about scars, and the decision was made to harvest a latissimus dorsi flap using an endoscope.

**Fig. 20-4, E and F**

Because flap reconstructions can be compromised if the new margins are still positive, the reconstruction was deferred until her margin status was confirmed. A generous reexcision was performed that resulted in an upper pole contour deformity, despite being filled with seroma fluid (*E* and *F*). The patient's margins were clear after reexcision, and she was taken back to the operating room for reconstruction of the partial mastectomy defect. In the decubitus position, an endoscope was used to harvest the latissimus dorsi muscle through two small access incisions. The humeral insertion was taken down, and the flap was transferred to the upper pole.

**Fig. 20-4, G**

The donor incisions were then closed over drain suction, and she was prepped again in the supine position. The latissimus dorsi myofascial flap provides vascularized tissue with sufficient bulk, under no tension, before it is inset (*G*). The flap is then contoured and inset with precision to correct the volume and preserve the shape of the upper pole. The cavity is clipped for postoperative surveillance. The volume is typically overcorrected in anticipation of potential radiation fibrosis.

Continued

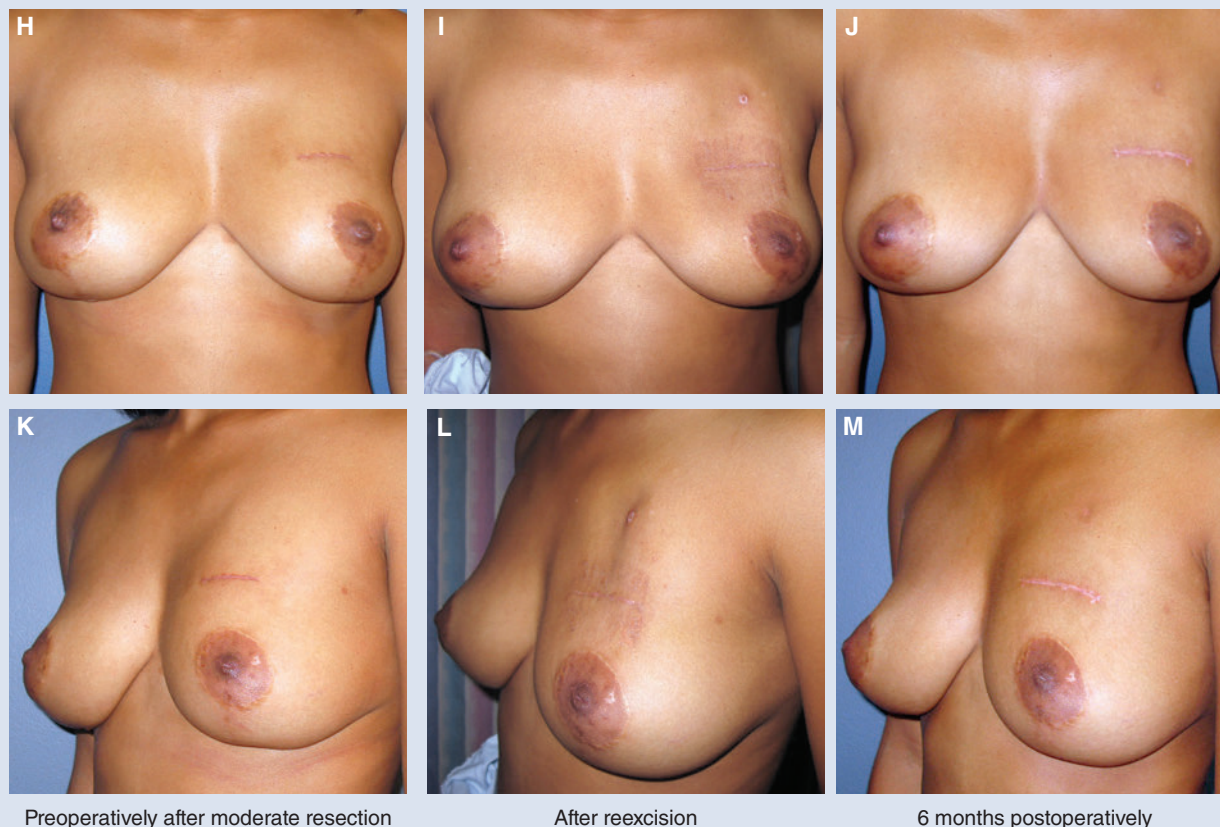


Fig. 20-4, H-M

The patient is shown in all stages of her treatment: preoperatively after moderate resection (*H* and *K*), after reexcision (*I* and *L*), and 6 months after surgery (*J* and *M*). Her final outcome is good—the shape and symmetry of her breast have been preserved, and there is improvement in the contour of the upper pole.

OUTCOMES

The actual data on endoscopic latissimus dorsi reconstruction in the literature are sparse. However, the endoscopic approach to harvesting the latissimus dorsi muscle has minimal donor site morbidity, and patients have less postoperative pain, an earlier recovery, and improved cosmesis with regard to donor site. The risk of seroma is likely related to the actual muscle dissection and is believed to be similar in the open and endoscopic techniques. We reviewed the results of 39 patients at Emory who underwent this technique for the immediate reconstruction of partial mastectomy defects. The average follow-up was 3.7 years, and the most common donor site complication was a seroma in 7% of the patients. Nine percent of the patients were found to have positive or close margins on final pathologic findings (DCIS and invasive ductal carcinoma), requiring either a completion mastectomy and reconstruction or reexcision with confirmation of negative margins and radiotherapy. The recur-

rence rate in this series was 15% (two local and four distant recurrences).⁶ Based on these data and the few patients whose positive margins resulted in the loss of a useful muscle flap, it is now our preference to delay the reconstruction until negative margins are confirmed. With this approach, the muscle can still be used with confidence as an autologous filler—without compromising oncologic principles. This is important, because a recurrence is still possible.

Given the potential for a compromised reconstruction if margins are positive, we prefer to delay the reconstruction until negative margins are confirmed. With this approach, the muscle can still be used as an autologous filler, without compromising oncologic or reconstruction principles.

LIMITATIONS

The main limitations of this technique are the difficulties with instrumentation, visualization, and achieving the optimal optical cavity. Various methods have been suggested for creating the optical cavity, such as the use of a retractor device,³ retraction sutures,⁴ balloon dissectors, and insufflation⁷; the manual retractor technique seems to be the most reliable and popular method.⁸ Dissecting with the endoscope does require some familiarity with these techniques, and there is a learning curve. Although it may be easier to dissect directly on the muscle, keeping the subscarpal fat is an important component for volume replacement, because it is not likely to atrophy. The other limitation is the potential use of a reconstructive option if the endoscopic approach does not end up being the definitive surgical procedure. This concern can be addressed by the surgeon being discerning about patient selection and intraoperative margin assessment or by using delayed-immediate reconstruction. Delayed reconstruction of BCT deformities often requires skin, limiting the usefulness of this technique in those situations.

Critical Issues

- Endoscopically assisted harvest of the latissimus dorsi flap greatly improves recovery and minimizes donor site morbidity.
- This technique can be used to fill partial mastectomy defects in almost any location when sufficient local tissue is unavailable or when the patient wishes to preserve size and shape.
- Prone harvest is realistic for hemiflap transfer (smaller defects).
- Subscarpal fat is kept on top of the muscle for added volume.
- Familiarity with instrumentation and endoscopic techniques is required.
- It is safer to confirm a negative margin status before reconstruction.

References

1. Lin C, Wei FC, Levin SL, et al. Donor site morbidity comparison between endoscopically assisted and traditional harvest for free latissimus dorsi muscle flap. *Plast Reconstr Surg* 104:1070, 1999.
2. Friedlander L, Sundin J. Minimally invasive harvesting of the latissimus dorsi. *Plast Reconstr Surg* 94:881, 1993.
3. Cho BC, Lee JH, Ramasastry SS, et al. Free latissimus dorsi muscle transfer using endoscopic techniques. *Ann Plast Surg* 38:586, 1995.
4. Fine NA, Orgill DP, Pribaz JJ. Early clinical experience in endoscopic-assisted muscle flap harvest. *Ann Plast Surg* 33:465, 1994.
5. Bostwick J III. *Plastic & Reconstructive Breast Surgery*, ed 2. St Louis: Quality Medical Publishing, 1999.
6. Losken A, Schaefer TG, Carlson GW. Immediate endoscopic latissimus dorsi flap: risk or benefit in reconstructing the partial mastectomy defect. *Ann Plast Surg* 53:1, 2004.
7. Karp NS, Bass LS, Kasabian AK, et al. Balloon assisted endoscopic harvest of the latissimus dorsi muscle. *Plast Reconstr Surg* 100:1061, 1997.
8. Bostwick J III, Eaves FF, Nahai F. *Endoscopic Plastic Surgery*. St Louis: Quality Medical Publishing, 1996.

21

Omental Flap Reconstruction

Hisamitsu Zaha



ncoplastic surgery encompasses unique approaches and focuses on tumor resection and breast aesthetics through partial breast reconstruction techniques that minimize potential breast deformity, as described by Audretsch.¹ Volume replacement technique is often needed for smaller breasts or for patients with a small breast-to-tumor ratio.

They often consist of partial breast reconstruction with pedicled distant flap. The latissimus dorsi (LD) flap has played a main role in volume replacement, but has the disadvantages of donor-site morbidity and deformity, such as seroma formation and an obvious scar on the back.² An ideal flap for volume replacement should have (1) less donor-site morbidity and deformity, (2) strength against radiotherapy, (3) applicability to any quadrants of the breast, (4) preservation of total reconstructive options, (5) at least equal or better cosmetic outcome than that of total reconstruction, and (6) more simplicity than that of total reconstruction. No single flap can meet all the conditions described above. Surgeons must select the appropriate technique for the appropriate patients.

For example, lateral chest wall perforator flaps, including the thoracodorsal artery perforator (TDAP) flap and the lateral intercostal artery perforator (LICAP) flap have been well developed to minimize the donor-site morbidity.³ However, it is generally difficult to utilize these perforator flaps in partial breast reconstruction for lower medial located tumors because adequate mobilization and a longer pedicle are needed to reach and replace the distant defect of the breast tissue.⁴

Defects in the lower medial quadrant can be addressed using the abdominal adipofascial flap^{5,6} and the anterior intercostal artery perforator (AICAP) flap.⁷ However, it is still difficult to utilize these flaps for the upper medial quadrant, which constitutes a major part of a no-man's land of the breast.

The omental flap is unique but not a newly developed flap. Historically, many applications for the omentum have been reported because of its protective and beneficial roles against infection and regenerative properties of ischemia.⁸ Nevertheless, the omental flap could not obtain widespread popularity because of its severe laparotomy-associated donor-site morbidities and deformity such as ventral hernia and bowel obstruction.⁹ However, rapid advances in endoscopic surgery have allowed laparoscopic harvesting of the omental flap with minimal donor-site deformity and morbidity, which has made the omental flap revive and more attractive.¹⁰

The omental flap can be harvested laparoscopically with minimal donor-site deformity and morbidity.

It was not until 1993 that Salz et al¹¹ published a case of a laparoscopically harvested omental free flap. Since then, there have been several case series in which the omental flap was used for breast and/or chest wall reconstruction.^{12,13} Taking both the advantages and the disadvantages of this flap into account, the best indication of the omental flap is immediate partial breast reconstruction after breast-conserving surgery (BCS).^{14,15}

PATIENT SELECTION

The omental flap is usually used when a 20% or wider region of the breast tissue is resected or the cosmetic result is poor because of the location of the tumor in the medial quadrants. When the patient's breast size is small, even a 10% resection of the breast tissue in the lower medial quadrant might cause cosmetic disaster.

The biggest advantage of this flap is minimal donor-site deformity. To obtain this advantage, patients must be carefully selected based on a combination of factors.

Factors Related to the Tumor

When a large amount of skin over the tumor needs to be resected, this procedure is not appropriate because the omental flap cannot replace the skin.

Factors Related to the Size of the Defect

One of the disadvantages of this procedure is an inability for preoperative estimation of the volume of the omentum. Some patients have a large omentum which weighs more than 500 g and can easily accomplish total reconstruction, but some patients have only 100 g of the omentum. Patients who are large or obese tend to have a larger omentum, but estimation only by body size does not always fit. Our limited data, derived from only Japanese patients, suggest that it should be cautious when the volume of the defect ex-

ceeds 100 g for the very thin patients, and for the large patient, care must be taken when the volume of the defect exceeds 200 g.

It is difficult to estimate the accurate volume of the omental flap preoperatively. Care has to be taken when more than a quadrant of resection is necessary.

Factors Related to the Location of the Defect

The omental flap can reach any quadrants, however, the lower medial quadrant is the most suitable defect because of its anatomic advantage. The upper medial and the lower lateral quadrant are also comfortable locations. For the upper lateral quadrant, a long subglandular tunnel must be created under the breast tissue for the omental flap to pass and reach the defect, just like for the LD flap to replace the lower medial quadrant. So it is usually more complicated to apply the omental flap for the upper lateral quadrant than for the other quadrants.

The omental flap is most suitable for the medial quadrants, which are difficult to reconstruct for the other pedicled flaps.

Factors Related to the Patient

Patients who have either a history of intraabdominal malignancy or upper abdominal laparotomy are excluded. However, a history of laparoscopic surgery (such as laparoscopic cholecystectomy) and a history of lower abdominal surgery (such as cesarean section) do not necessarily have to be excluded, because intraabdominal adhesions tend to be mild in such cases. Patients who wish to be pregnant in the future are also indicated.

Although obese patients are not contraindicated, our current practice basically excludes patients with a body mass index (BMI) of 35 or more, because it is difficult to extract a huge amount of the pedicled omental flap without making a mini-laparotomy incision on the upper abdomen, which prevents minimization of the donor-site scar.

The omental flap is most appropriate for small- or medium-sized breasts.

PREOPERATIVE PLANNING

The IMFs and midline on the sternum are marked in the standing position. The choice of incision on the breast is influenced mainly by the location of the tumor. An inframammary incision for the lower quadrants is the preferable choice for the omental flap. For the upper quadrants, many types of incisions, such as circumareolar and lateral S-shaped, can be adapted, depending on the surgeon's preference or oncologic consideration. A separate small incision on the medial IMF to extract the omental flap as well as a skin incision for partial mastectomy are also necessary.

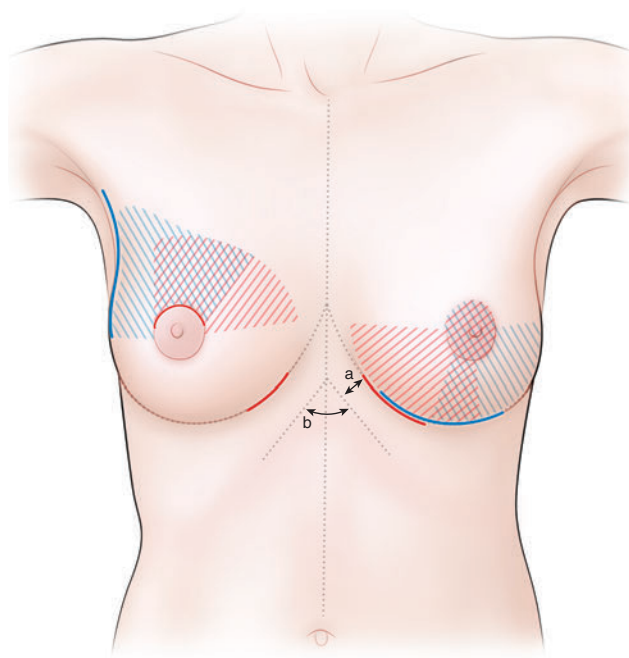


Fig. 21-1

A length between the IMF and the costal margin is also checked in the supine position to make a plan to create a subcutaneous tunnel (*arrow a*). The tumor and resection margins are outlined on the skin of the breast.

SURGICAL TECHNIQUE

Surgery is performed with the patient in the supine position with both arms abducted at 90 degrees. A general anesthetic is administered.

Partial Mastectomy

Lower Quadrants

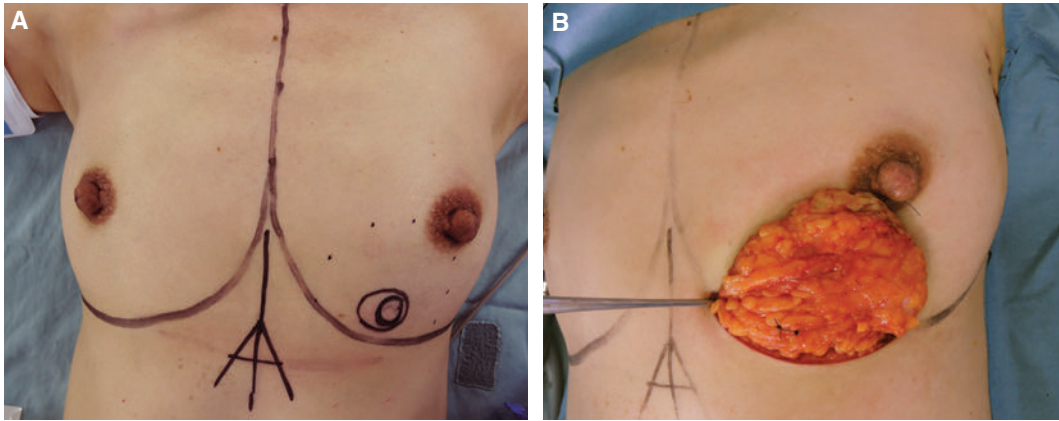


Fig. 21-2

Dye mixed with lidocaine is injected around the planned resection margins to make appropriate resection. The injection markings should reach the pectoralis fascia. An incision is made along the IMF.

An inframammary incision is always preferable for the partial mastectomy in the lower quadrants because it is invisible and gives easy access to the abdominal cavity.

For the tumor in the lower medial quadrant, a 6 to 7 cm skin incision is made on the medial IMF (*red line on the left IMF in Figs. 21-1 and 21-2, B*). For the tumor in the lower outer quadrant, a medial end of the incision is placed at the closest point to the lower pole of the xiphoid process and an approximately 10 cm long incision is made on the IMF laterally (*blue line on the left IMF in Fig. 21-1*). The dissection is extended above or behind pectoralis fascia depending on oncologic consideration. The previously dye-marked outline of the resection margins on the pectoralis fascia help to define the area of this dissection. It is better to avoid unnecessary dissection from the pectoralis fascia for subsequent reconstruction. Then the subcutaneous dissection is performed, also depending on the marked outline. Thus the tumor-bearing quadrant has been separated completely from the deep and superficial tissue, and a partial mastectomy is completed by grasping the dissected breast tissue.

Upper Quadrants

A circumareolar incision is the preferable choice for partial mastectomy (*red line on the right breast in Fig. 21-1*). A lateral S-shaped incision is also applied for the tumor in the upper outer quadrant (*blue line on the right breast in Fig. 21-1*).

A separate 3 to 4 cm long incision on the medial IMF as well as an incision on the breast is also necessary for the tumor located in the upper quadrants to extract the omental flap (*red line on the right IMF in Fig. 21-1*).

Laparoscopic Harvesting of the Omental Flap

The principles of laparoscopic surgery are followed.¹³ Surgery continues with the patient in the same position. Three ports are usually used.

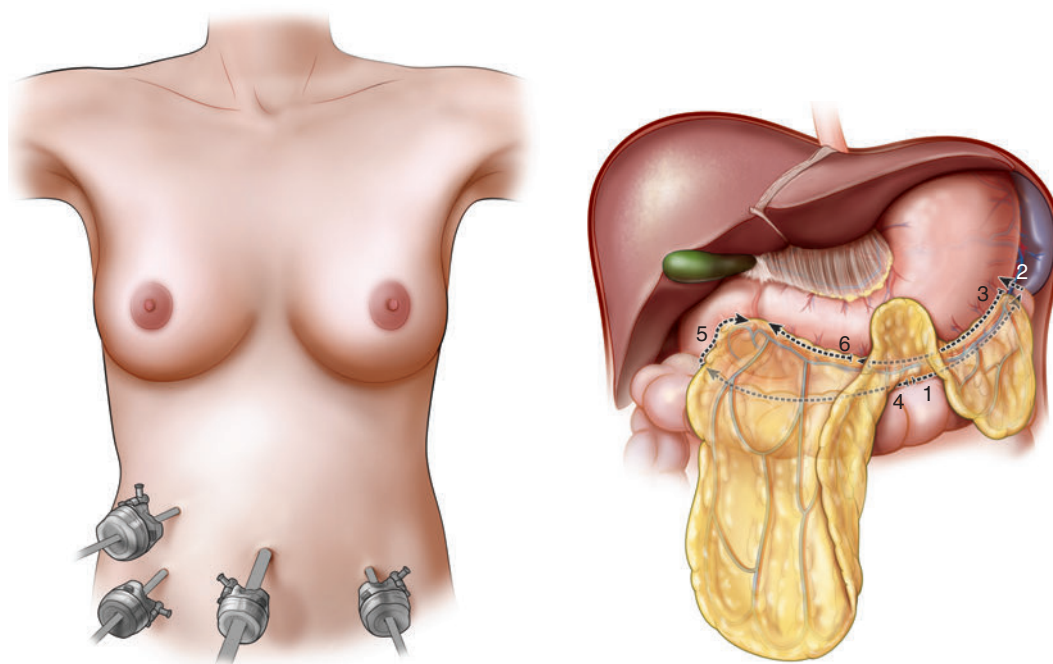


Fig. 21-3

The omentum is first dissected from the left side of the transverse colon, followed by ligation of the left gastroepiploic vessels. The second step is to separate the omentum from the stomach to reach the right side from the omentum.

After complete dissection from the transverse colon, dissection from the stomach is advanced across the pyloric ring. Very careful dissection is required at this point, because the gastroepiploic artery and vein (GEAV) run close to the wall of the stomach and the proximal duodenum, and the branches tend to bleed easily.

It is better to resect as much fatty tissue around the root of the GEAV as possible for the long, thin pedicle of the flap to avoid a ventral hernia.

One of the epiploic vessels that descends on the right side of the omentum sometimes must be resected to make the longer pedicle. Then a pedicled omental flap is completed.

Partial Breast Reconstruction After Breast-Conserving Therapy

Lower Quadrants

An inframammary skin incision used for partial mastectomy can be used to extract the omental flap. A subcutaneous tunnel approximately two fingerbreadths wide is prepared from the medial side of the inframammary incision toward the xiphoid process over the anterior sheath of the rectus muscle, and when it reaches the white line, a two fingerbreadths wide longitudinal incision is made to communicate with the abdominal cavity. This was facilitated by intraabdominal resection of the white line with an LCS. For reconstruction of the right breast, the right side of the falciform ligament was resected to communicate with the tunnel, and vice versa. The surgeon's fingers are inserted into the abdominal cavity and the pedicled omental flap is carefully withdrawn, avoiding twisting.

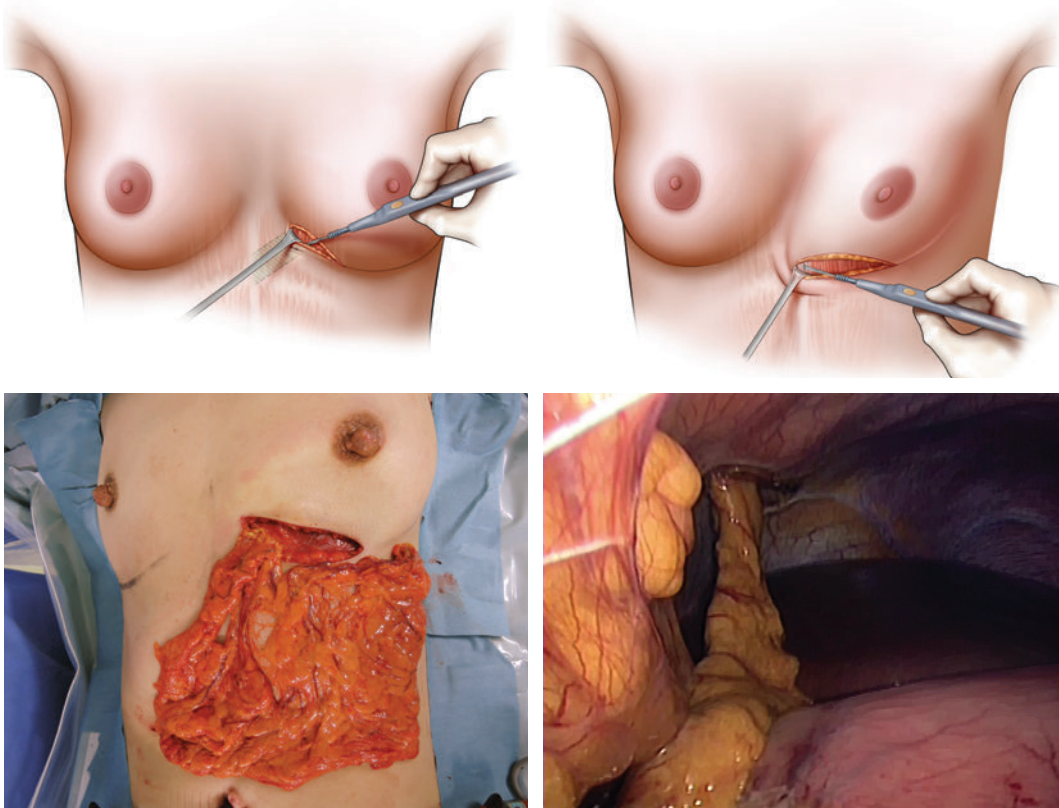


Fig. 21-4

The length between the IMF and the white line and the infrasternal angle (*angle b* in Fig. 21-1) are quite different. When the former length is long and the latter angle is narrow, it is relatively difficult to extract the omental flap through the subcutaneous tunnel. And of course, the size of the omental flap also has an influence on difficulty of this step. In such cases, it is better to add a wider longitudinal incision on the white line and/or a small transverse resection of the rectus muscles. The xiphoid process sometimes has to be resected to make an abdominal longitudinal incision wider. When the incision is wider than two fingers, semiclosure of the incision on the white line is necessary after the flap is pulled out to avoid incisional hernia. Hemostasis is carefully confirmed and vascularity of the flap

is checked. If the volume of the omentum is too large to fill the defect of the breast, the flap is partially resected in the peripheral part.

Subcutaneous fat around the tunnel and fat tissue around the pedicle are resected to avoid subcutaneous bulging because of the pedicle, with care taken to avoid injury to the gastroepiploic vessels.

After extraction of the flap, tension of the pedicle should be checked intraabdominally with a laparoscopy. A straight pedicle with strong tension might cause gastric outlet obstruction at the pyloric ring by the root of the pedicle.

The cephalad and lateral cut margins of residual breast tissue is fixed with the original position on the pectoralis major muscle to avoid movement of the omental flap. It is important to make the width of the pedicle and an entrance of the subcutaneous tunnel small (less than 2 cm) for appropriate re-creation of the IMF, and for avoidance of subcutaneous bulging. Finally, the omental flap is placed over the pectoralis major muscle to fill the defect in the breast tissue. Fixation of the omental flap to the chest wall is usually unnecessary.

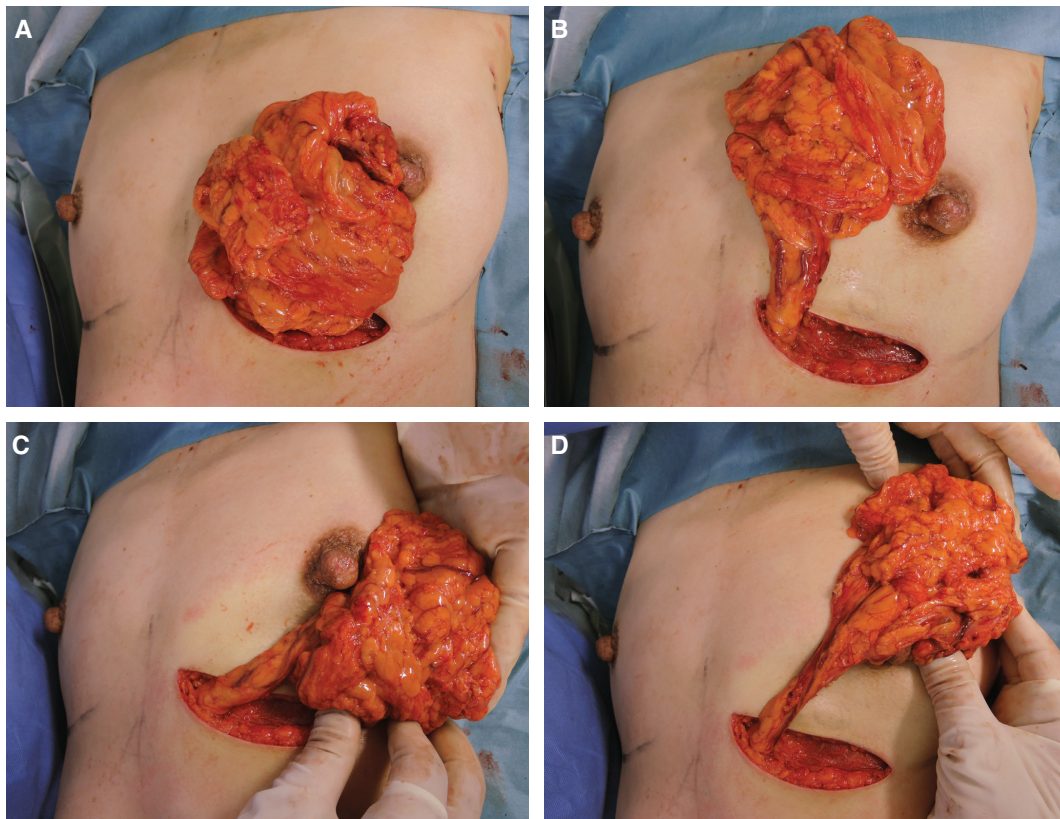


Fig. 21-5, A-D

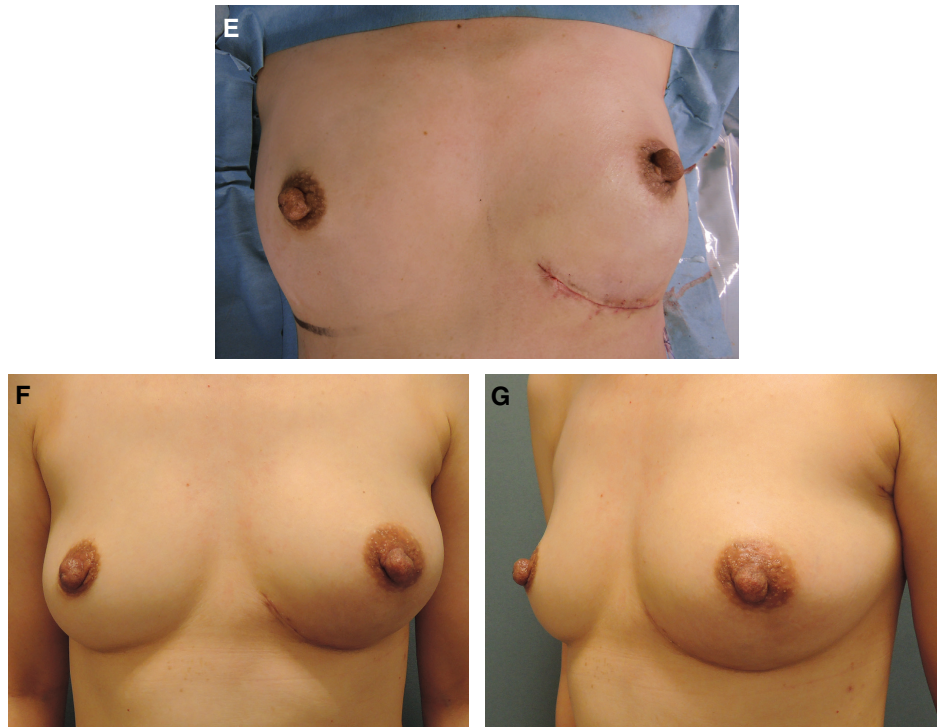


Fig. 21-5, E-G

The omental flap can reach and fill any quadrants of the breast. In this patient a closed suction drain was inserted over the omental flap and the wound is closed in layers with care to recreate an original, natural and curved IMF. The patient is shown 1 year after surgery. An inframammary incision and donor-site scars are almost invisible.

Upper Quadrants

After partial mastectomy, an additional small, 3 to 4 cm long incision is made on the medial IMF to extract the omental flap (*red line on the right IMF* in Fig. 21-1). Then a subglandular tunnel that passes under the lower quadrants is also created between the inframammary incision and the partial mastectomy defect in the upper quadrants. The omental flap is very soft and can fill the partial mastectomy defect, even through a small circumareolar incision because of its pliability. After filling the defect in the upper quadrants, the flap is fixed at the upper portion of the pectoris muscle with one or two stitches to avoid caudal movement.

When bulging in the lower medial quadrant is obvious because of the pedicle of the flap that passes the subglandular tunnel, it is better to resect the breast tissue around the subglandular tunnel. When the volume of the flap is too large and/or the patient is obese, it is difficult to extract the omental flap through the medial inframammary incision via the subcutaneous tunnel, even if the incision on the white line is created wider than two fingerbreadths wide. In such a situation, a direct upper midline skin incision sometimes has to be made to approach the abdominal cavity to extract the omental flap. However, the author tries to avoid this approach, because the biggest advantage of the omental flap

is minimal donor-site scars. That's why our indication is limited to patients with a BMI of less than 35. For obese patients, the free omental flap is another good option, because the large amount of the flap can be easily taken out through the umbilical or lower abdominal incision.¹⁶

PATIENT EXAMPLES

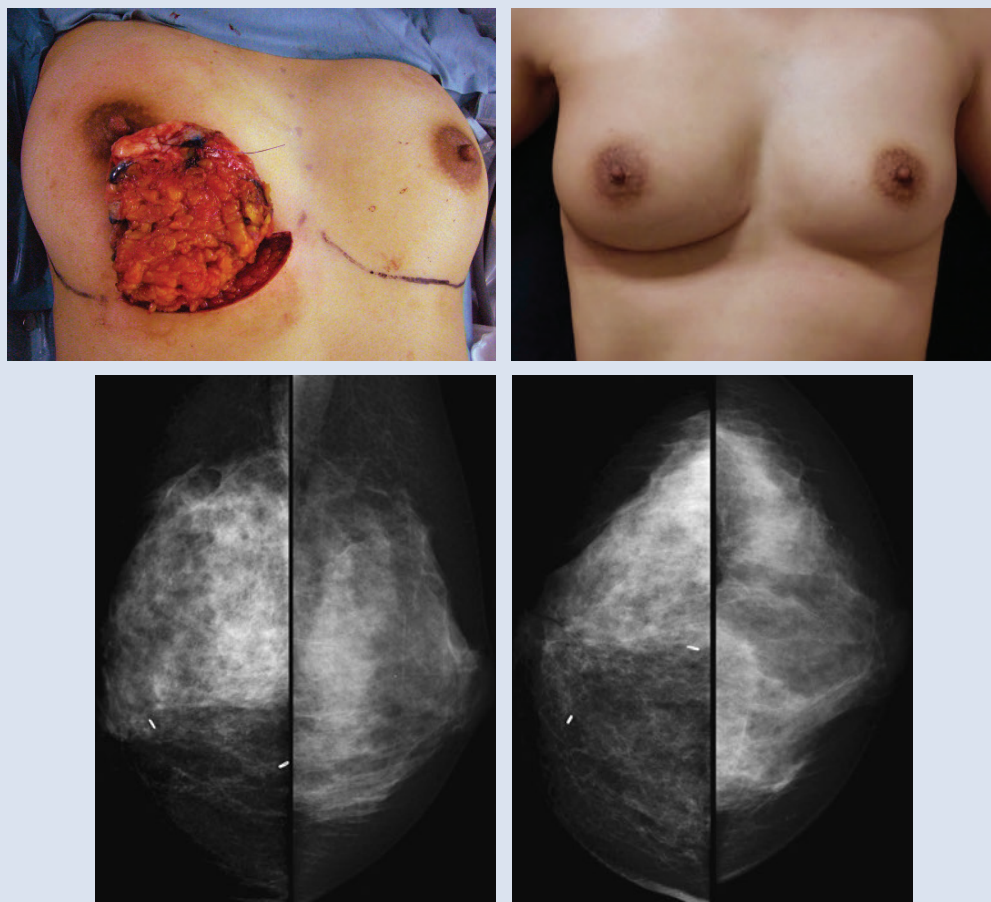
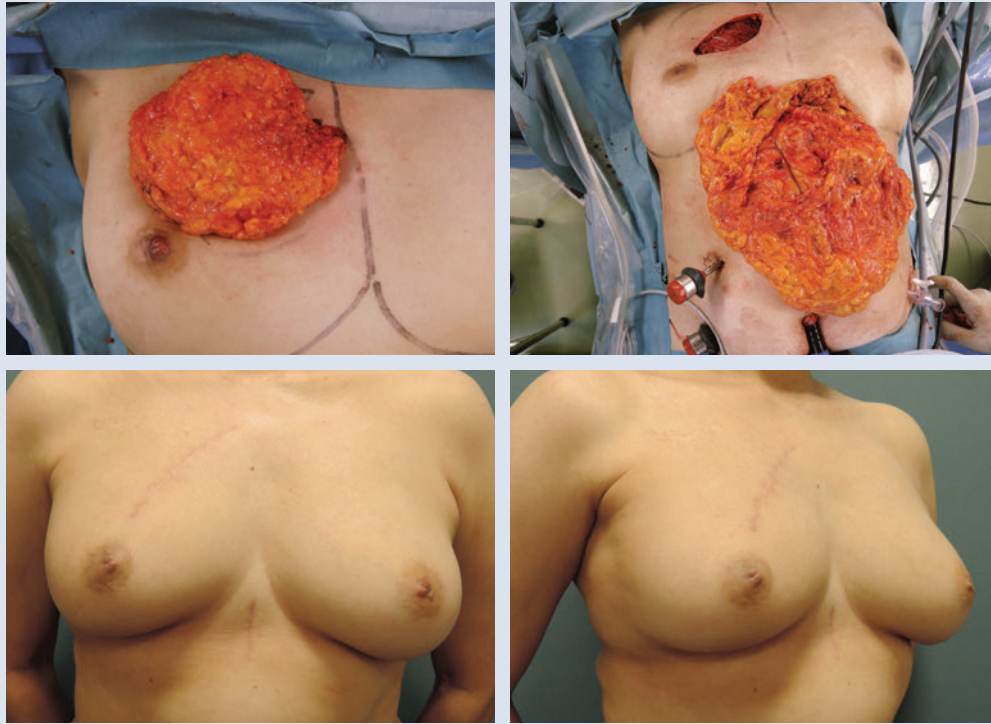


Fig. 21-6

This 29-year-old patient had a T2 ductal carcinoma in the left lower medial quadrant, and underwent a 90 g resection with partial reconstruction with the omental flap. The patient is shown 1 year after postoperative radiotherapy. Postoperative mammograms are notable for a marked radiolucent area in the reconstructed breast.

**Fig. 21-7**

This 49-year-old patient had a T3 ductal carcinoma with a suspicious parasternal lymph-node metastasis in the upper medial quadrant. She underwent a 250 g resection and axillary dissection after preoperative chemotherapy. A long radial scar had to be chosen to excise overlying skin and a parasternal lymph node. The volume of the omental flap was too large to extract through a small medial IMF incision; a direct longitudinal upper abdominal incision had to be made. The patient is shown 1 year after postoperative radiotherapy. Although the shape and size of the reconstructed breast is good, the scars on the breast and donor site are obvious.

OUTCOMES

Table 21-1 Operative Data on Omental Flap Reconstruction in 190 Patients	
Successful rate of harvesting the omental flap	202 (125-665)*
Resection volume	185 g (40-770)*
Radiotherapy in breast-conserving surgery	72.6% (106/146)

*Values are median.

The omental flap was used for breast reconstruction in 190 breast cancer patients between April 2002 and June 2015 in our single institution. The median follow-up period reached 78 months. The average age was 49 years (range 25 to 69 years). Tumor size was 2.8 cm in average with a range of 1 to 4.2 cm. Although 44 cases of nipple-sparing mastectomy or skin-sparing mastectomy were included, most patients underwent partial breast reconstruction after BCT.

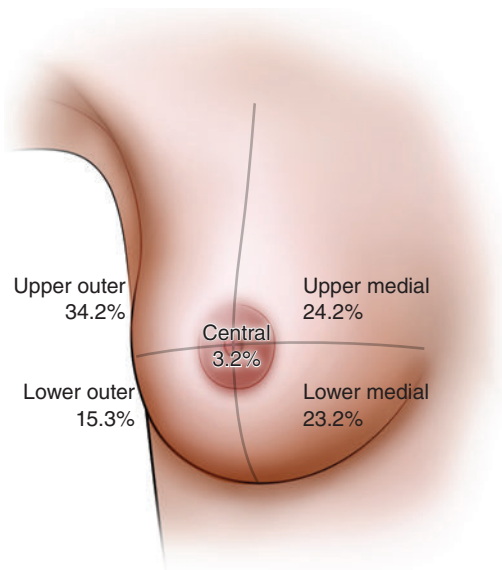


Fig. 21-8

Approximately 50% of the patients had tumors in the medial quadrants, a characteristic associated with use of the omental flap. The successful rate of laparoscopically harvesting the omental flap was 99.5% (189 out of 190). Usually it took about 1 hour to harvest the omental flap laparoscopically. The omentum was typically transferred to the breast as a pedicled flap; however, free transfer was done in 5.3% of the cases.

Radiotherapy was performed in 72.6% of the patients after BCT. The reasons for omission of radiotherapy were patient refusal or a large extent of resection (more than 70% of breast tissue).

COMPLICATIONS

Table 21-2 Complications in Omental Flap Reconstruction in 190 Patients

	Number (%)
Total complications	21 (12.6)
Complications associated with laparoscopy	4 (2.1)
Vascular injury	1 (1.1)
Vascular hernia	1 (1.1)
Complications associated with the breast	20 (10.5)
Partial graft necrosis	10 (5.3)
Partial skin flap necrosis	5 (2.6)
Hemorrhage	2 (1.1)
Infection	2 (1.1)
Other (chylous leakage)	1 (0.5)

The rate of complications was 12.6%. Donor-site complications occurred in 4 cases (2.1%). One major vascular injury to the main trunk of the GEA converted to the LD flap reconstruction. The other vascular injury in the peripheral part of the GEA could be treated with hemostasis but resulted in large volume loss of the flap. Late complications include two ventral hernias in the infraxiphoid area which needed surgery to repair. There was no other intraabdominal complication such as small bowel obstruction. Six patients underwent abdominal surgeries for other diseases, including 1 sigmoidectomy, 2 hysterosalpingo-oophorectomies, and 3 cholecystectomies several years after omental flap surgery, all of which were completed without difficulties.

Our study showed that the rate of laparoscopically associated complications is low (2.1%), which suggests that harvesting an omental flap laparoscopically is a safe procedure.

Regarding complications in the reconstructed breasts in our series, partial necrosis occurred in 10 cases, all of which were treated conservatively with prolonged drainage and debridement, but ultimately resulted in volume loss of the flap.

Oncologic Outcomes From Complications

Table 21-3 Oncologic Outcomes in Omental Flap Reconstruction in 190 Patients

	Number (%)
Positive margin	13 (6.8)
Local recurrence	2* (1.1)

*One recurrence in the other quadrant after breast-conserving surgery; one in the nipple after nipple-sparing mastectomy.

The rate of positive margins, defined as “ink on invasive carcinoma or ductal carcinoma in-site,” was 6.8%. Eight of 13 cases of positive margins were treated with reexcision to obtain free margins. The rest were treated with radiotherapy only.

Radiologic evaluation with mammography after partial reconstruction with the omental flap is very impressive because of its radiolucent nature compared with that of the surrounding breast parenchyma. It might be one of the advantages of this procedure to follow the patients after BCT. Local recurrence occurred in 2 cases (1.1%) during a medial follow-up period of 78 months. One recurrence was found in another quadrant after BCT, and the other occurred in the nipple after a nipple-sparing mastectomy. Neither patient underwent postoperative radiotherapy, but they maintained disease-free survival after salvage surgery.

Volumetric and Cosmetic Outcomes From Complications

Table 21-4 Cosmetic Outcomes of Omental Flap Reconstruction in 190 Patients

Panel Assessment: Number (%)	
Cosmetic Score	
Excellent	113 (59.5)
Good	39 (20.5)
Fair	19 (10.0)
Poor	19 (10.0)
Main Causes of Cosmetic Failure	
Insufficient volume	24/190 (12.6)
BCS	9/145 (6.2)
NSM or SSM	15/45 (33.3)
Fat necrosis	11/190 (5.8)

In our series, the range of resection volume was very wide (25 to 770 g), because even a small defect in very thin Japanese patients often needs volume replacement to avoid a miserable cosmetic outcome, especially for the lower medial quadrant.

In 24 patients (12.6%), the volume of the flap was insufficient. When applied to nipple-sparing mastectomy or skin-sparing mastectomy, volume insufficiency occurred in 33.3% of patients, and the LD mini-flap or tissue expander was combined to the omental flap. The median resection volume was 256 g (75 to 770 g) among patients in which the volume of the omental flap was insufficient. Cosmetic outcome was mostly satisfactory. Approximately 80% of patients scored good or excellent when evaluated with a 4-point scale by three health professionals. Very soft and natural tactile feelings are characteristic of this flap.

The size of the reconstructed breast basically did not change, even after radiotherapy.

Significant size reduction of the reconstructed breast was observed in only 2 patients. Of note, the reconstructed breasts became larger than the original size a few years after surgery in 6 patients. In 11 patients (5.8%), hard nodules or indurations were formed in the reconstructed breasts, which may have been caused by fat necrosis.

Donor-site scars were almost negligible just like those of laparoscopic cholecystectomy. Postoperative pain is minimal and recovery is fast. Our length of hospital stay was influenced by the duration of axillary drainage, but when combined with negative sentinel node biopsy, a 1-night stay after surgery may be enough.

In the main, the inframammary incision for extracting the flap was invisible; however, an upper abdominal incision was needed in several patients because the size of the flap was too large to pull out through the inframammary incision and the subcutaneous tunnel.

ADVANTAGES OF THE OMENTAL FLAP IN PARTIAL BREAST RECONSTRUCTION

The major advantages of the omental flap are minimal donor-site deformity and morbidity.^{10,13-16} Donor-site scars produced by laparoscopic harvesting of the omental flap are negligible, and our short- and long-term donor-site complication rate (2.1%) was much less than that of previous reports.⁹

Another unique advantage of the omental flap in partial breast reconstruction is its applicability to the medial quadrants, which are difficult to reach for reconstruction with other autologous flaps. Our experiences suggest that the omental flap might be the best flap for the lower medial quadrant and may be a very good option for the upper medial and the lower lateral quadrant.

Because the omentum consists of abundant fatty tissue, the flap is very soft and is less atrophic, even after radiotherapy, compared with the muscle flap. Preservation of the LD flap as an option for a total reconstruction is also an important consideration in partial reconstruction.

Limitation

The biggest disadvantage of the omental flap is the inability to estimate the volume of the flap preoperatively. In our series, 12.6% of the patients fell into insufficient volume of the flap. Although most of them occurred in nipple-sparing mastectomy (NSM) or skin-sparing mastectomy (SSM) cases, it could happen in BCT cases when the resection volume exceeds 200 g. When the patient is very thin, the volume of the omentum could be less than 100 g.

Our limited data were derived from only Japanese patients. Compared with Western women, East Asian women are basically small and thin, and the volume of the omental flap can be quite different. Khater reported successful omental reconstruction with mini-laparotomy for large-sized breasts.¹⁷ There is one attractive preliminary report from the United Kingdom suggesting that the volume of the omental flap could be accurately estimated by CT scan and three-dimensional segmentation software, and the medial volume in their study was 270 g.¹⁸

Although our median follow-up period has reached more than 6 years, there are only a few other case series of laparoscopically harvested omental flaps in partial breast reconstruction to reach a conclusion about the true efficacy and oncologic safety of the procedure.¹⁹

CONCLUSION

The laparoscopically harvested omental flap has minimal donor-site morbidity and deformity. If adapted in carefully selected patients, the omental flap is an attractive option in partial breast reconstruction, especially for tumors of the medial quadrant.

Critical Issues

- The omental flap can be laparoscopically harvested with minimal donor-site morbidity and deformity.
- Preoperative accurate volume estimation of the omental flap is not possible; thus appropriate patient selection is imperative, with careful consideration of the resection volume and body habitus of the patient.
- The right GEAV should always be selected as a pedicle of the flap. The root of the pedicle should be as thin and long as possible to be extracted from the abdominal cavity.
- The omental flap can reach any quadrants of the breast; however, the medial quadrants and lower outer quadrant are most suitable.
- The omental flap should be extracted from the abdominal cavity with gentle maneuver to prevent mechanical injuries to the flap, which strongly influences the quality of the flap.
- When the laparotomy incision on the white line is wider than two fingerbreadths, the wound should be semiclosed after extracting the flap to avoid possible late-occurring ventral hernia.
- Our study suggests that oncologic outcomes are similar to those reported after BCS, and cosmetic outcomes are satisfactory with minimal donor-site scars.
- The omental flap can preserve both the LD flap and the lower abdominal wall flaps such as the TRAM or the DIEP flap for future total reconstructive options.

References

1. Audretsch WP. Fundamentals of oncoplastic breast surgery. In Loskin A, Hamdi M, eds. Partial Breast Reconstruction. St Louis: Quality Medical Publishing, 2009.
2. Munhoz AM, Motag E, Fels KM, et al. Outcome analysis of breast-conservation surgery and immediate latissimus dorsi flap reconstruction in patients with T1 to T2 breast cancer. *Plast Reconstr Surg* 116:741, 2004.
3. Hamdi M, Landuyt KV, Monstrey S, et al. Pedicled perforator flaps in breast reconstruction: a new concept. *Br J Plast Surg* 57:531, 2004.
4. Kronowitz SJ, Feledy JA, Hunt KK, et al. Determining the optimal approach to breast reconstruction after partial mastectomy. *Plast Reconstr Surg* 117:1, 2006.

5. Ogawa T, Hanamura N, Yamashita M, et al. Usefulness of breast-volume replacement using an inframammary adipofascial flap after breast-conservation therapy. *Am J Surg* 193:514, 2007.
6. Kijima Y, Yoshinaka H, Owaki T, et al. Immediate reconstruction using inframammary adipofascial flap of the anterior rectus sheath after partial mastectomy. *Am J Surg* 193:789, 2007.
7. Hamdi M, Van Landuyt K, de Frene B, et al. The versatility of the inter-costal artery perforator (ICAP) flaps. *J Plast Reconstr Aesthet Surg* 59:644, 2006.
8. Kiricuta I. [The use of the great omentum in the surgery of breast cancer] *Press Med* 71:15, 1963.
9. van Garderen JA, Wiggers TH, van Geel AN. Complications of the pedicled omentoplasty. *Neth J Surg* 43:1171, 1991.
10. Zaha H, Inamine S. Laparoscopically harvested omental flap: results for 96 patients. *Surg Endosc* 24:103, 2006.
11. Salz R, Stowers R, Smith M, et al. Laparoscopically harvested omental free flap to cover a large soft tissue defect. *Ann Surg* 217:542, 1993.
12. Cothier-Savey I, Tamtawi B, Dohnt F, et al. Immediate breast reconstruction using laparoscopically harvested omental flap. *Plast Reconstr Surg* 107:1156, 2001.
13. Zaha H, Inamine S, Naito T, et al. Laparoscopically harvested omental flap for immediate breast reconstruction. *Am J Surg* 192:556, 2006.
14. Zaha H, Sunagawa H, Kawakami K, et al. Partial breast reconstruction for an inferomedial breast carcinoma using an omental flap. *World J Surg* 34:1782, 2010.
15. Zaha H. Oncoplastic volume replacement technique for the upper inner quadrant using the omental flap. *Gland Surg* 4:263, 2015.
16. Zaha H, Onomura M, Nomura H, et al. Free omental flap for partial breast reconstruction after breast-conserving surgery. *Plast Reconstr Surg* 129:583, 2012.
17. Khater A. Evaluation of pedicled omental flap delivered through a minilaparotomy for immediate breast reconstruction in obese patients. *Aesthetic Plast Surg* 37:1140, 2013.
18. Westbroek D, Nizak R, Karunanithy N, et al. Volume assessment of the greater omentum for autologous breast reconstruction planning. *Eur J Surg Oncol* 39:474, 2013.
19. Claro F Jr, Sarian LO, Pinto-Neto AM. Omentum for mammary disorders: a 30-year systematic review. *Ann Surg Oncol* 22:2540, 2015.

22

Pedicled Perforator Flap Reconstruction

Moustapha Hamdi

Breast-conserving therapy (BCT), a combination of tumor resection and postoperative radiotherapy, has become the preferred treatment for early stage invasive breast cancer.¹⁻³ Although partial mastectomies (lumpectomy or quadrantectomy) conserve the nipple-areola complex, 20% to 30% of patients are dissatisfied with the aesthetic result after BCT.⁴⁻⁷ There are many possible causes of aesthetic failure. The tumor resection can produce distortion, retraction, and noticeable volume changes in the breast. Changes to the position of the nipple-areola complex can accentuate asymmetry. Radiation can also have a profound effect on the breast. Initially, radiation causes generalized breast edema and skin erythema. Long-term effects of radiation to the breast skin include hyperpigmentation, hypopigmentation, telangiectasia, and atrophy. In the breast parenchyma, radiation causes fibrosis and retraction. For most patients, radiation-induced changes plateau 1 to 3 years after treatment. Unfortunately, it is difficult to predict which individuals will develop the most severe postradiation changes.⁷⁻⁹

Most of the poor outcomes result from one of the significant surgical dilemmas that are related to breast cancer treatment—choosing between making wider excisions to attain clear margins and better local control of the disease and sparing as much breast tissue as possible to adequately close the defect and optimize the aesthetic outcome.^{10,11} Therefore we prefer to perform immediate reconstruction whenever it is indicated and feasible, because operating on irradiated breasts has high complication rates with frequently poor aesthetic results. In small- to moderate-sized breasts, tissue replacement techniques using pedicled flaps are required to restore the breast shape and size. Although the thoracodorsal and intercostal vessels provide many perforators to the region of the back, only the latissimus dorsi flap is described for partial breast reconstruction; it requires sacrificing the largest muscle in the body. As the perforator flap concept has gained acceptance, many previously described myocutaneous flaps have been harvested as perforator flaps. Harvesting the flap without sacrificing the muscle or nerve is essential in this technique.

Therefore the donor-site morbidity is reduced to the absolute minimum. In 1995 Angri-giani et al¹² first described the use of a cutaneous island of the latissimus dorsi flap without the muscle based on one thoracodorsal cutaneous perforator as a free flap transferred for cervical burn contracture. However, the use of pedicled perforator flaps in partial breast reconstruction is a relatively new concept and it was first described by Hamdi et al.¹³⁻¹⁷ Nevertheless, they have become an integral part of the armamentarium of oncoplastic techniques available for partial breast reconstruction.

DECISION-MAKING PROCESS

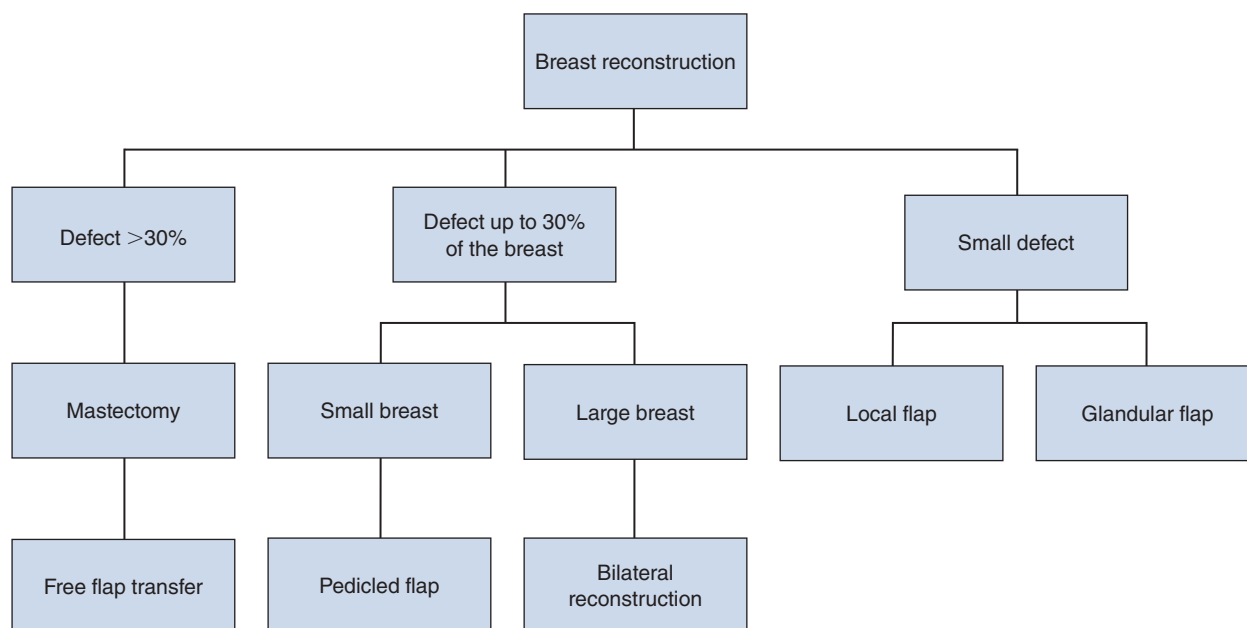


Fig. 22-1

The ultimate goal when using pedicled perforator flaps in oncoplastic surgery is to reduce donor-site morbidity.¹⁸ The major indications for this flap are defects estimated to be up to 30% of the breast size, or any case in which the tumor resection will result in an unacceptable aesthetic result.^{19,20} The clinical application of pedicled perforator flaps in partial breast reconstruction is based on a combination of factors.

Factors Related to the Tumor

As for any conservative breast therapy, the safest treatment for tumors up to 3 cm in diameter is a quadrantectomy with postoperative radiotherapy; mastectomy is still the first choice for larger tumors. However, the introduction of more efficient protocols of neoadjuvant chemotherapy may allow a more conservative local approach to advanced tumors.²¹⁻²²

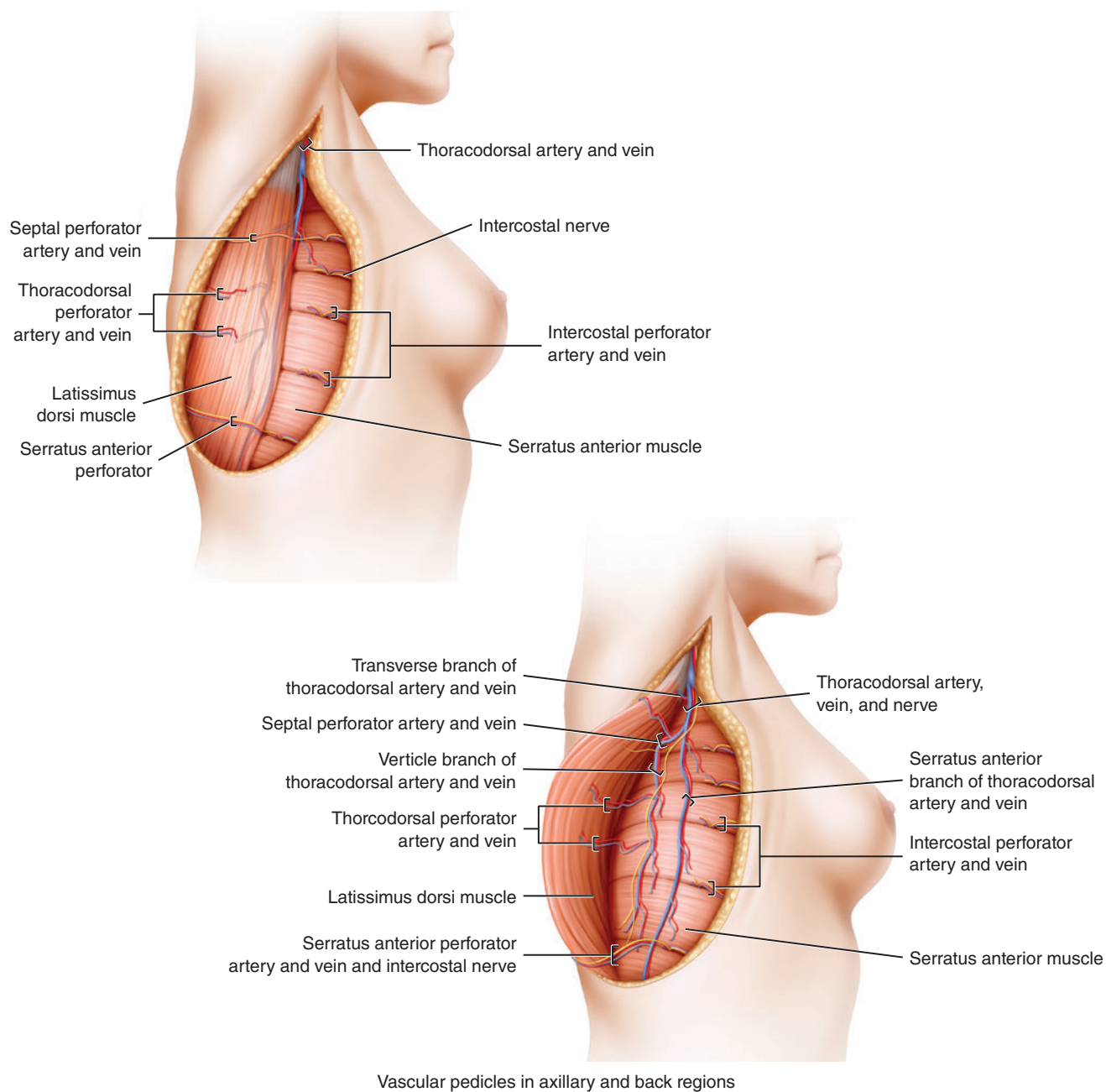
Any immediate partial reconstruction should be delayed if the surgeon is uncertain about the margins or tumor extension, despite the preoperative radiologic assessment. A delayed-immediate reconstruction can still be performed within a few days after the definitive margin status is known.²³

Factors Related to the Size of the Breast

Many surgeons have suggested incorporating a reduction mammoplasty-type procedure during the tumor resection in patients with large breasts.¹⁶⁻²¹ However, one of the relative anatomic contraindications for rearrangement breast surgery is a large tumor/breast ratio. Smaller breasts require different methods of reconstruction. If a significant postoperative deformity is expected because of a large-volume tumor resection in a smaller breast, the recruitment of nonbreast tissue is required. Depending on the location and the size of the breast defect, a variety of pedicled perforator flaps can be used for partial mastectomy reconstruction.^{13,19,20,24}

Factors Related to the Location of the Defect

Almost all postquadrantectomy defects can be reconstructed with a pedicled perforator flap. However, depending on the pedicle length, some flaps are more suitable for certain defects. Defects located at the inferomedial quadrant of the breast are difficult to reach using a pedicled perforator flap raised on the thoracodorsal or intercostal vascular pedicle axis. However, some defects can still be considered for reconstruction with pedicled flaps based on the anterior thoracic vessels, such as the intercostal or superior epigastric vessels.^{15,17}

**Fig. 22-2**

Based on the thoracodorsal-serratus, intercostal, or superior epigastric vessels, several pedicled flaps can be raised on perforators, either in the axillary and back regions or the anterior thoracic and upper abdominal regions.

The pedicled perforator flaps commonly used for breast reconstruction are the thoracodorsal artery perforator (TDAP) flap, the intercostal artery perforator (ICAP) flap, the serratus anterior artery perforator (SAAP) flap, and the superior epigastric artery perforator (SEAP) flap.

TDAP Flap

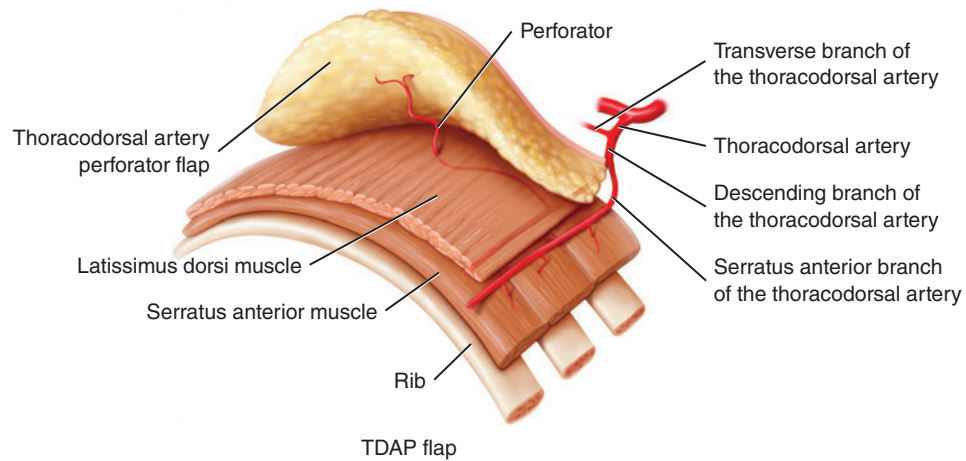


Fig. 22-3

The TDAP flap is based on perforators raised from the descending or horizontal branches of the thoracodorsal vessels.^{22,25} However, a segment of latissimus dorsi muscle can be included in the flap because of anatomic variations, thus creating one of the types of muscle-sparing latissimus dorsi TDAP flaps described in the following text^{13,16}:

- **Muscle-sparing latissimus dorsi TDAP I flap**: A small piece of latissimus dorsi muscle (4 cm by 2 cm) is incorporated in the flap.
- **Muscle-sparing latissimus dorsi TDAP II flap**: A larger segment (up to 5 cm wide) is designed along the anterior border of the latissimus dorsi muscle.

ICAP Flap

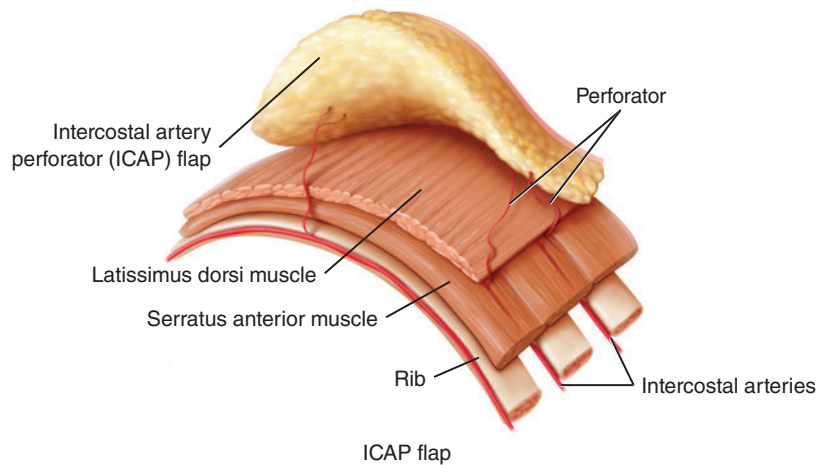


Fig. 22-4

The ICAP flaps are classified as follows¹⁴:

- Dorsal intercostal artery perforator (DICAP) flap. The flap is based on perforators arising from the vertebral segment of the intercostal vessels.
- Lateral intercostal artery perforator (LICAP) flap. The flap is based on perforators originating from the costal segment.
- Anterior intercostal artery perforator (AICAP) flap. The flap is based on perforators originating from the muscular segment.

SAAP Flap

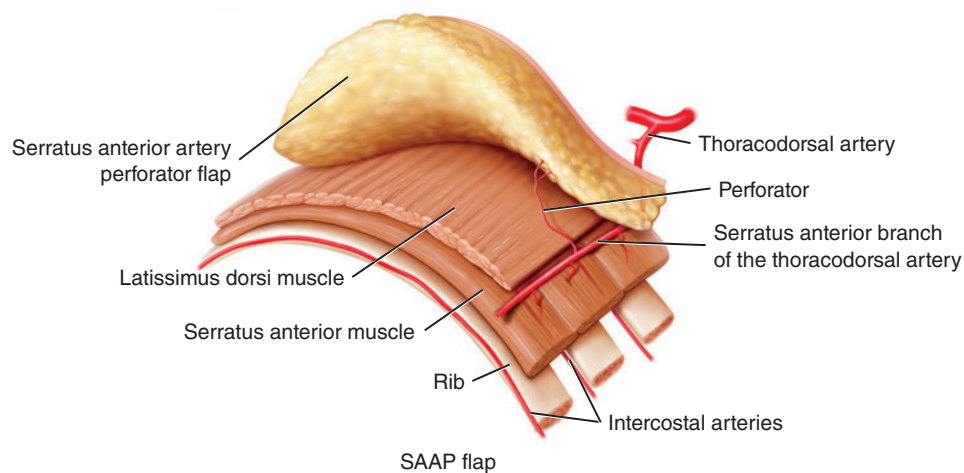


Fig. 22-5

The SAAP flap is based on the connection between the serratus branch of the thoracodorsal artery and the intercostal perforators. This connection is found in 21% of cases.¹⁷

SEAP Flap

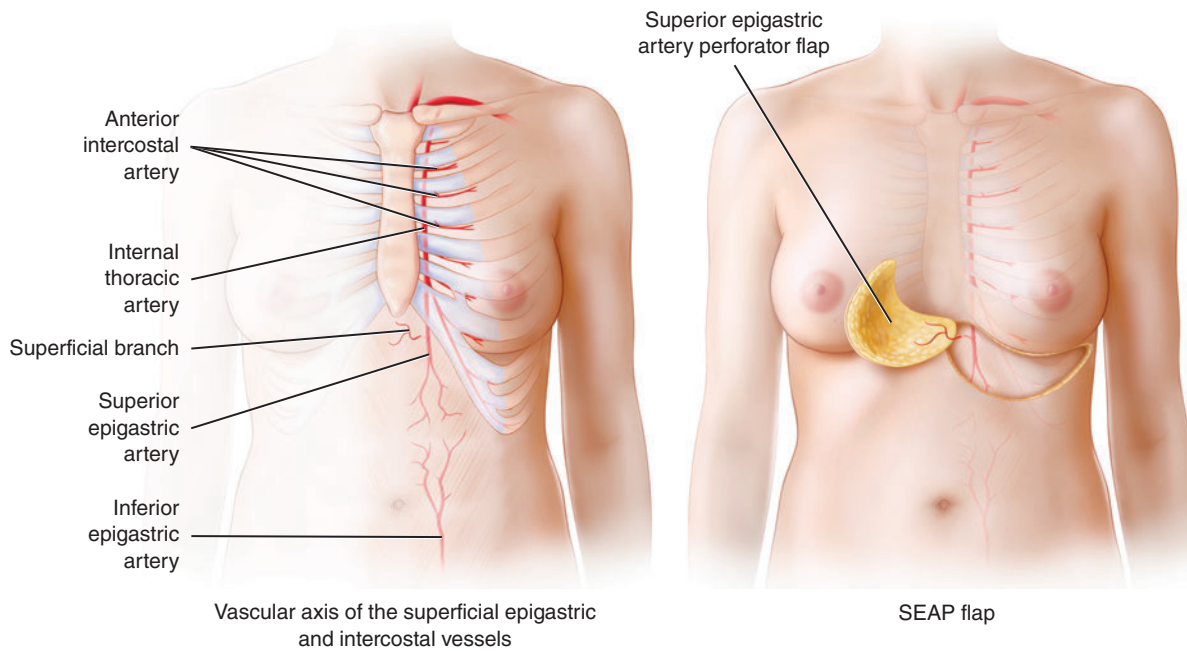


Fig. 22-6

The SEAP flaps are based on perforators originating from either the superficial or the deep branch of the superior epigastric artery and are classified as follows¹⁵:

- Superficial superior epigastric artery perforator (SSEAP) flap
- Deep superior epigastric artery perforator (DSEAP) flap

PREOPERATIVE PLANNING

The patient is marked the day before surgery. The incision of the tumor resection is planned with the breast surgeon to provide the best access for resection and the best aesthetic result.

Preoperative Perforator Mapping

It is essential to locate the perforators preoperatively. Careful perforator mapping is a decisive step for choosing a pedicled perforator flap and reduces the operative time and complication rate significantly. Unidirectional Doppler (8 Hz) ultrasonography is used to locate potential perforators on which the flap is designed. Based on previous anatomic studies and our clinical experience,^{16,25} we look for perforators in a region 8 to 10 cm below the axillary crease and within 5 cm of the anterior border of the latissimus dorsi muscle.

A possible pitfall of using unidirectional Doppler ultrasonography to identify the thoracodorsal perforators is the background signal from the main thoracodorsal pedicle. To avoid this, the patient is positioned for perforator marking in the same position she will be in during surgery—a lateral decubitus position with 90 degrees of shoulder abduction and 90 degrees of elbow flexion.

This positioning places the skin under tension, causing the perforators to enter the skin with a more perpendicular orientation, which makes their Doppler signal more distinct. In this orientation, the Doppler unit detects the signal from the discrete end of the perforator rather than along its length. This allows one to differentiate between the signal from the perforator and the longitudinally oriented thoracodorsal pedicle. True perforator tones can be distinguished from the thoracodorsal artery by moving the Doppler probe proximally and distally. If the signal disappears, it belongs to a perforator; signals from the thoracodorsal vessels are present continuously along the length of the latissimus dorsi muscle. When the perforator is located in front of the anterior border of the latissimus dorsi muscle, a direct (septal) perforator from the thoracodorsal artery can be expected.

Intercostal or superior epigastric perforators are mapped while the patient is in the supine position. In difficult cases, a duplex examination is performed.²⁶ More recently, the multi-detector CT has been introduced to preoperatively localize various perforators.²⁷⁻²⁹

Choice of Technique

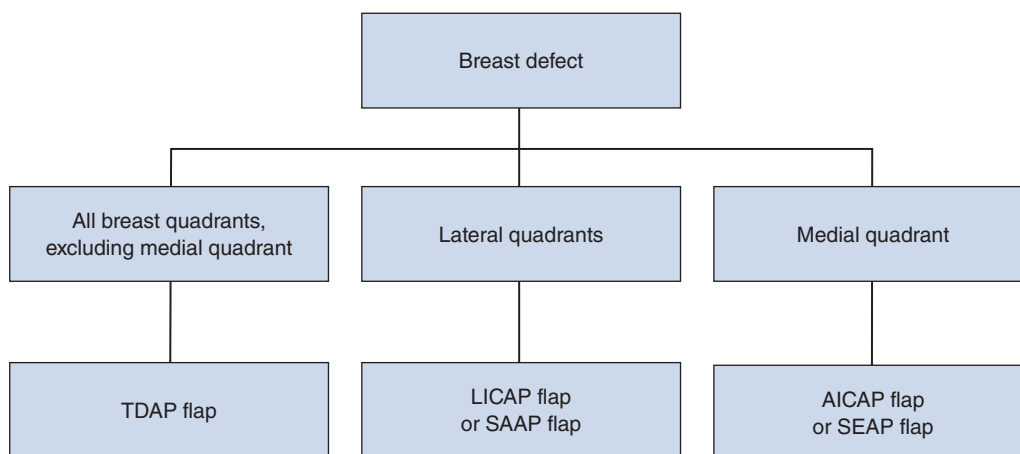


Fig. 22-7

Defects Located in the Lateral, Superolateral, or Superomedial Quadrants

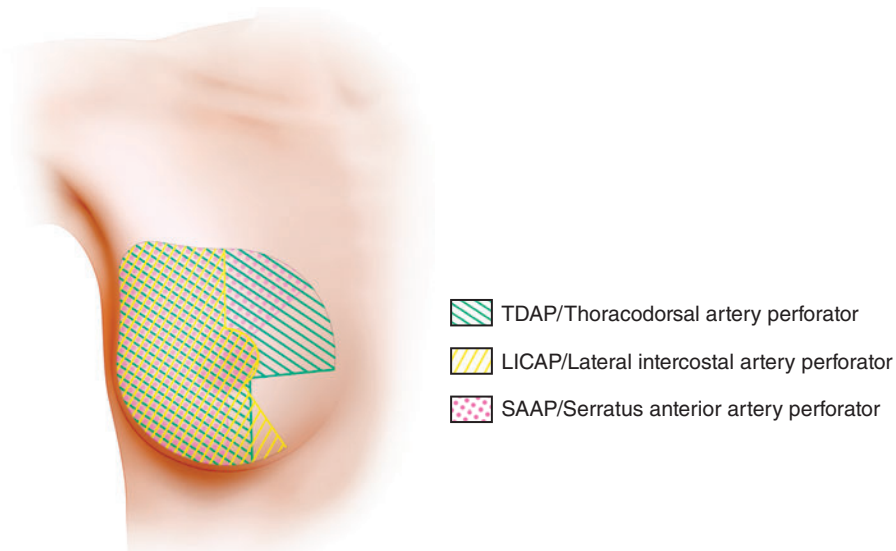


Fig. 22-8

Defects located in the lateral, superolateral, or superomedial quadrants are usually reconstructed with either the TDAP or the LICAP flap. The skin marking begins with the patient in an upright position. The anterior border of the latissimus dorsi muscle is palpated and marked. The patient is asked to lie down on her side, similar to the intraoperative position. The width of the TDAP flap is determined based on the expected breast defect and the possibility for primary donor-site closure. The excess of skin and fat of the back is determined using the pinch test. The average flap size is 20 by 8 cm (range 16 to 25 cm long and 6 to 10 cm wide). The flap paddle is oriented parallel to the skin lines. The island can also be horizontally designed, according to the wishes of the patient. It is always extended over the anterior border of the latissimus dorsi muscle to include the premuscular perforators, if they can be found. The length of the skin paddle depends on the location of the defect. When the defect is located in the lateral or superolateral quadrants, the skin paddle is designed over the lateral thoracic area. The proximal edge of the flap reaches the inframammary fold. For more medially located defects, the skin paddle is designed more distally, toward the back.

PATIENT EXAMPLES

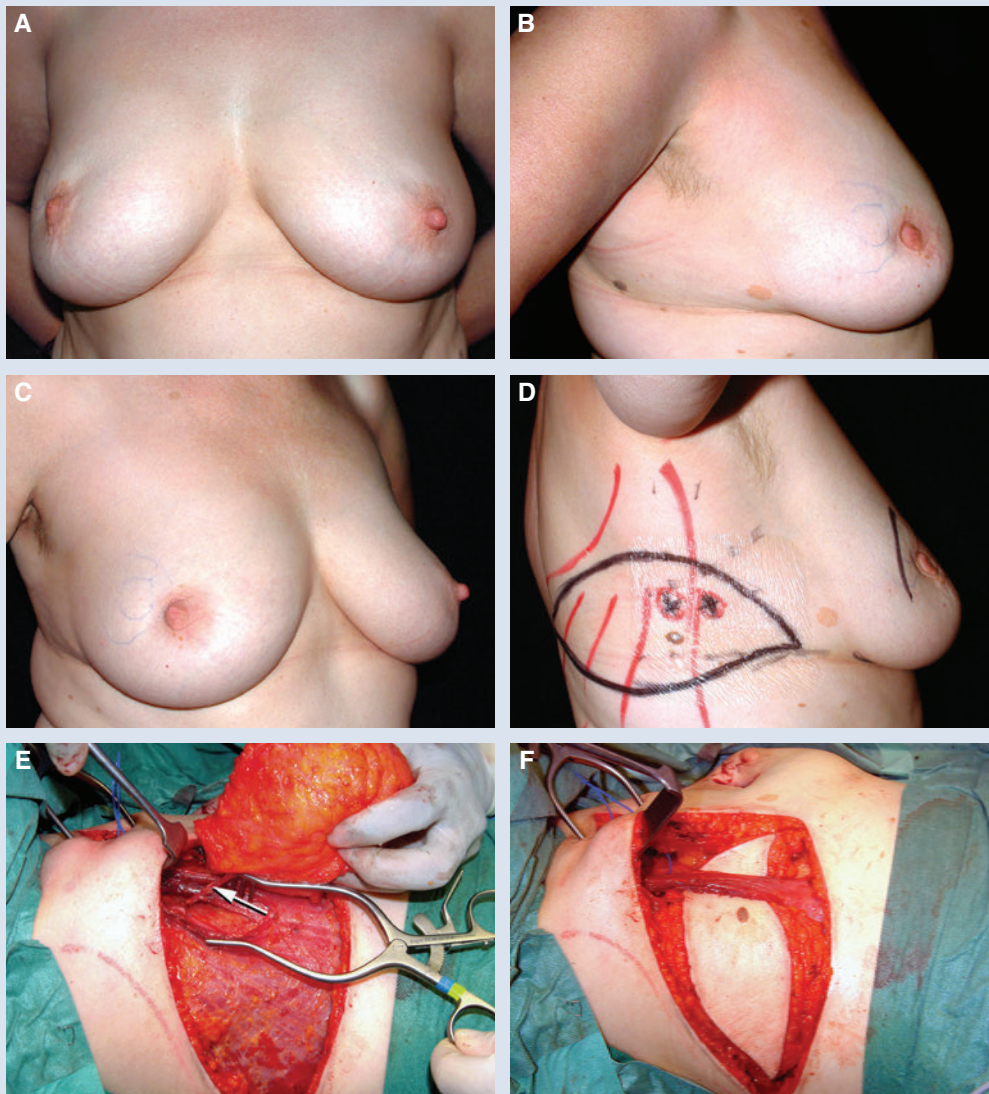


Fig. 22-9, A-F

This 53-year-old patient had a tumor (invasive ductal carcinoma) located in the right superolateral quadrant (A through C). A pedicled (21 by 8 cm) TDAP flap was designed with a horizontal orientation over the lateral thoracic region, with two perforators detected using a unidirectional Doppler probe (D). The intraoperative view shows the dissection of one perforator (*arrow*) through the split latissimus dorsi muscle (E). The thoracodorsal nerve branches to the latissimus dorsi muscle were spared. The flap was passed through the split latissimus dorsi muscle (F).

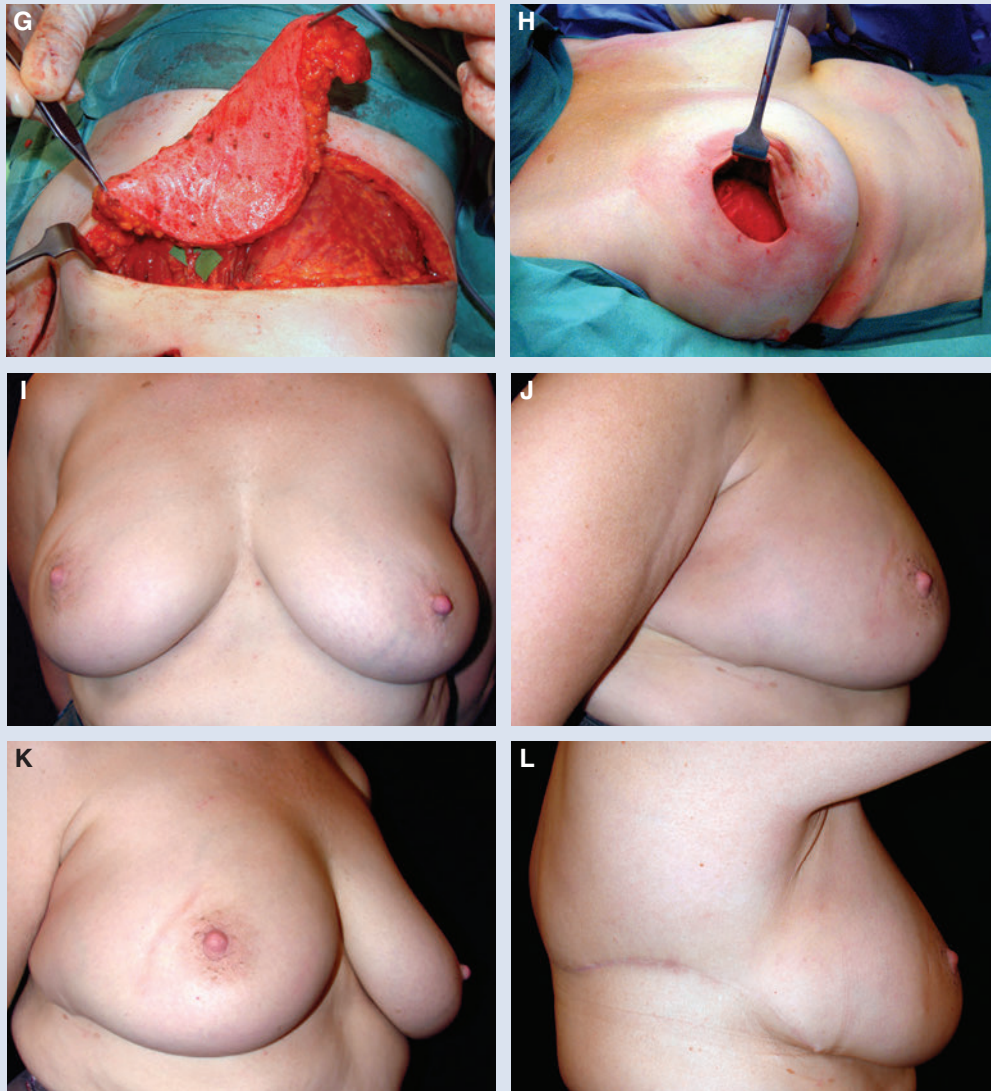


Fig. 22-9, G-L

The flap was completely deepithelialized (G). The flap was set into the postquadrantectomy defect (specimen weight 98 g) (H). The patient is shown 18 months postoperatively (I through K). The donor site also is shown 18 months postoperatively (L).

The LICAP flap is designed in a similar way. According to our anatomic study,¹⁷ the largest perforators that may be used for breast surgery are located between the fourth and sixth intercostal spaces. Their distances to the anterior border of the latissimus dorsi muscle are between 0.8 and 3 cm. Therefore they are more suitable for defects in the lateral and inferior quadrants. The flap is designed over the lateral thoracic region at the level of the inframammary fold.

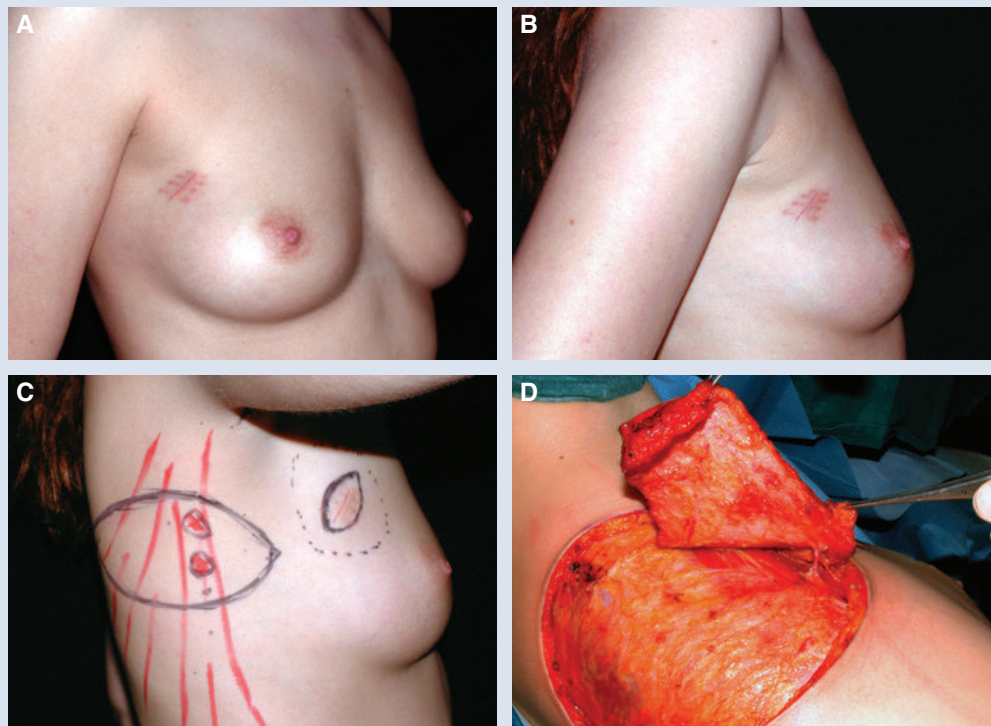


Fig. 22-10, A-D

This 32-year-old patient has already had a tumor excised (invasive ductal carcinoma) from the superolateral quadrant of the right breast (*A* and *B*). The margins were involved, and the patient was scheduled for further excision. The breast size was small, and any further excision without reconstruction would result in a major breast deformity. Partial breast reconstruction with a pedicled perforator flap was planned. The flap was designed to include the perforators located very close to the anterior border of the latissimus dorsi muscle (*C*). The flap was raised on an intercostal perforator without jeopardizing the latissimus dorsi muscle or its blood supply (*D*).

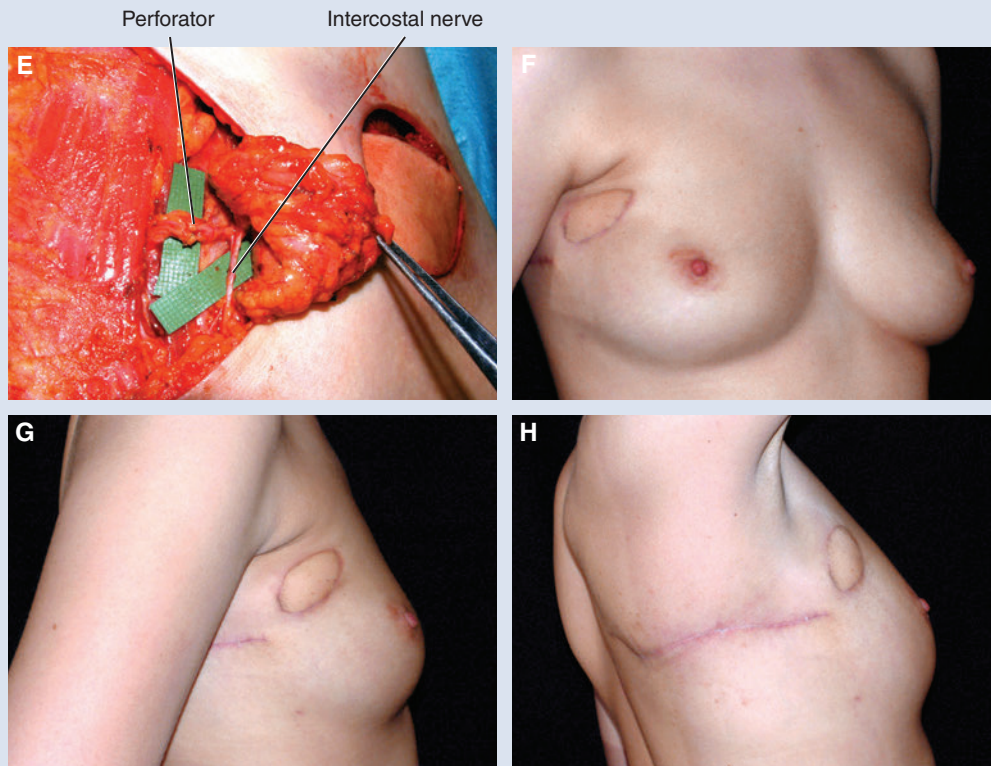


Fig. 22-10, E-H

The flap was rotated 180 degrees to fill the defect (*E*). The patient is shown postoperatively (*F* and *G*). The donor site also is shown postoperatively (*H*). Raising an SAAP flap can only be performed when the vascular connection between the serratus branch and an intercostal perforator is found intraoperatively. The flap can reach the superior and inferior lateral quadrants.

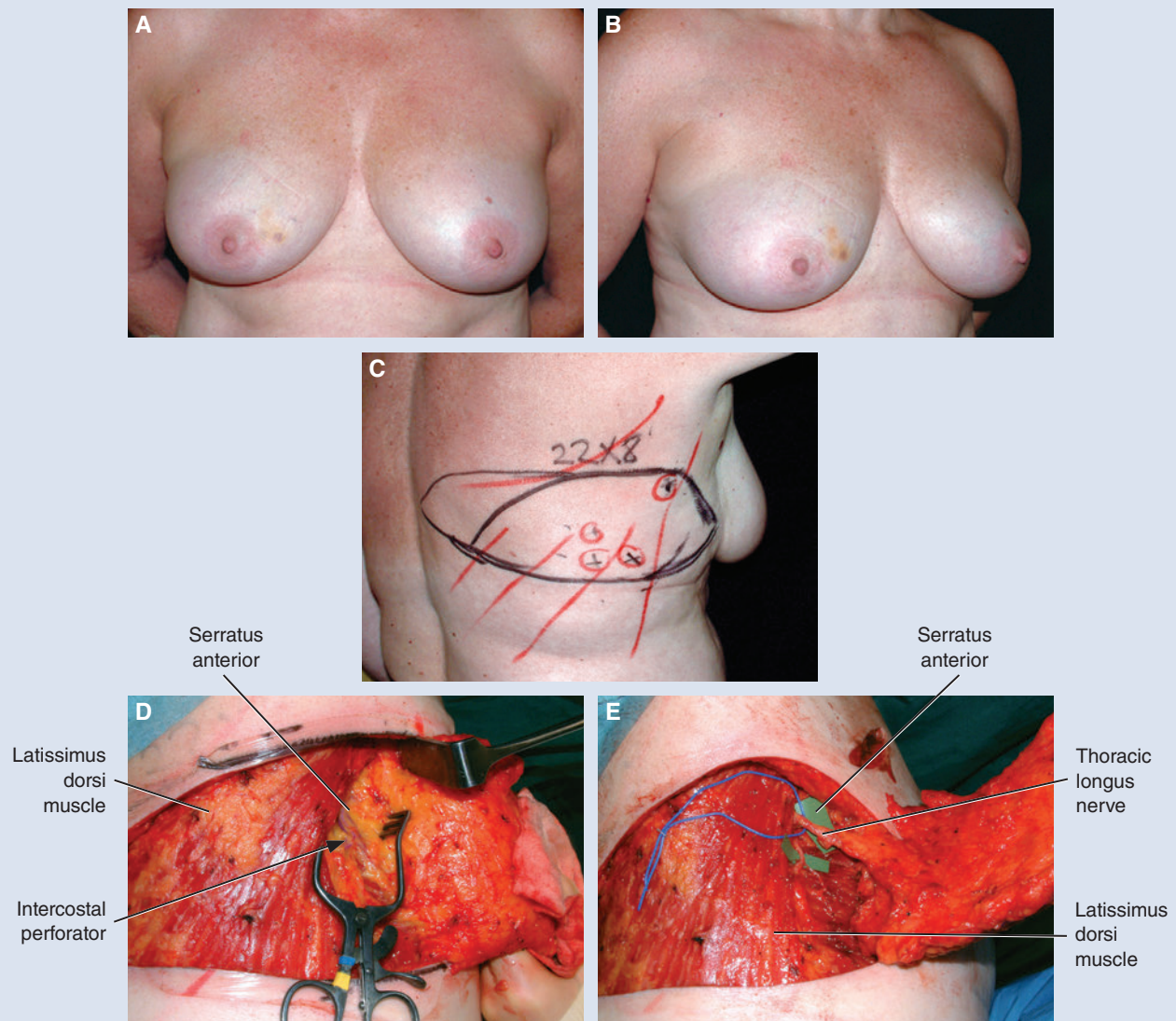


Fig. 22-11, A-E

This 65-year-old patient underwent a partial right breast reconstruction with a pedicled SAAP flap (A and B). A 22 by 8 cm flap was designed and the perforators were marked (C). The flap was based on the communication between the serratus anterior muscle and the intercostal perforator (*arrow*) (D). The connection between the intercostal perforator and serratus anterior muscle was clipped and the flap harvested, based on the serratus anterior vessels and without sacrificing the motor nerve (E).

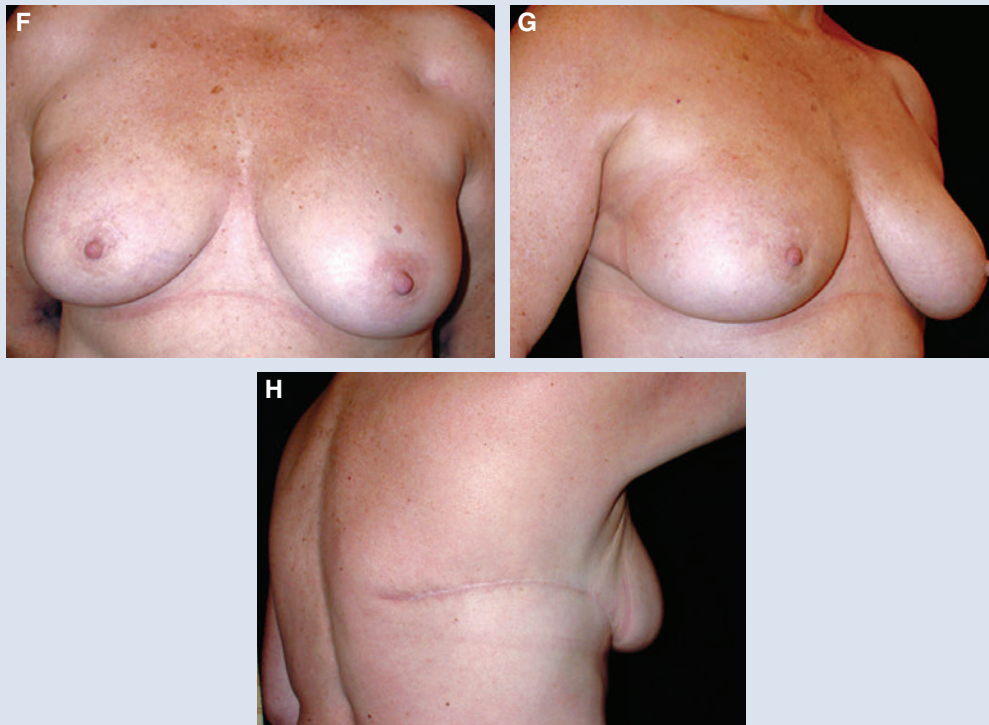




Fig. 22-11, F-H

The patient is shown postoperatively (*F* and *G*). The donor site also is shown postoperatively (*H*).

Defects Located in the Inferomedial Quadrants

-  AICAP/Anterior intercostal artery perforator
-  SEAP/Superior epigastric artery perforator

Defects in the inferomedial quadrant are difficult to reach with pedicled perforator flaps based on the thoracodorsal pedicle. However, the AICAP or SEAP flaps can be used in select cases. The patient is placed in the supine position and marked. The flap is designed over the inframammary region. The flap width is estimated using the pinch test (up to 6 cm). A larger flap can be harvested, and the donor site is closed as a reversed abdominoplasty.

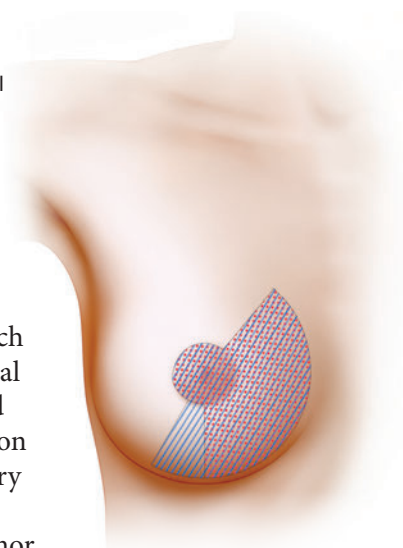


Fig. 22-12

PATIENT EXAMPLE

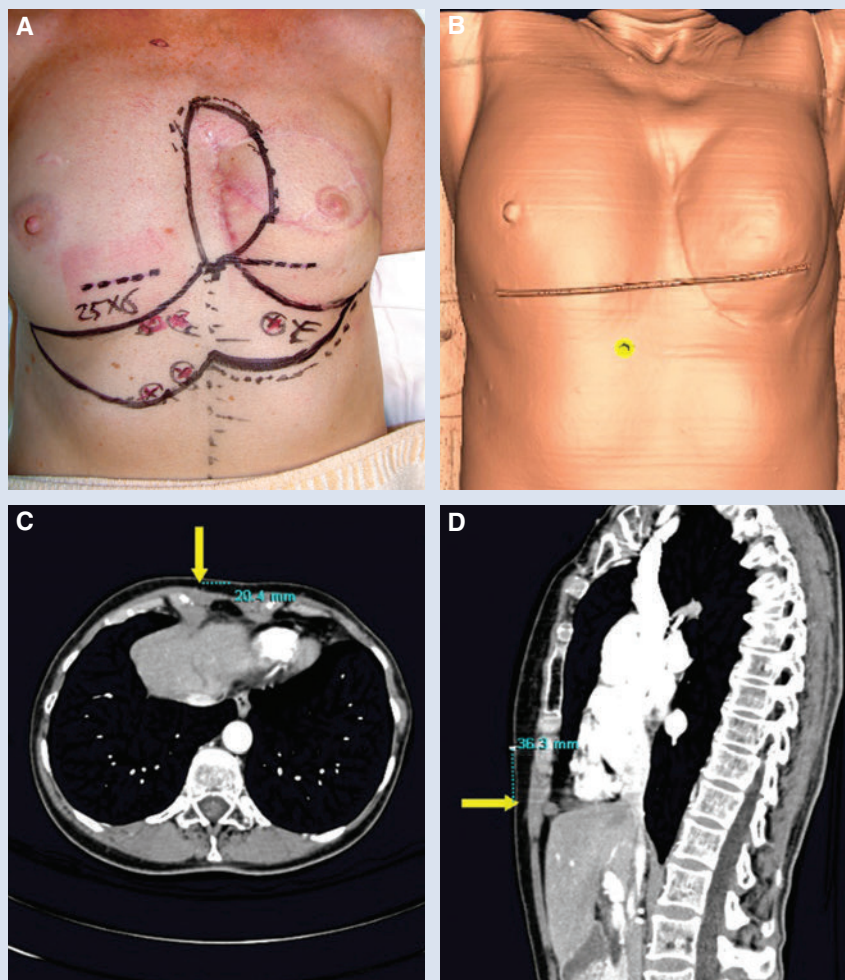


Fig. 22-13, A-D

This 51-year-old patient had recurrent breast cancer in the medial quadrant that extended over the sternum (A). The perforators were mapped preoperatively and an SEAP flap was designed. The multidetector CT showed the superficial branch of the superficial epigastric artery (arrow) (B through D).

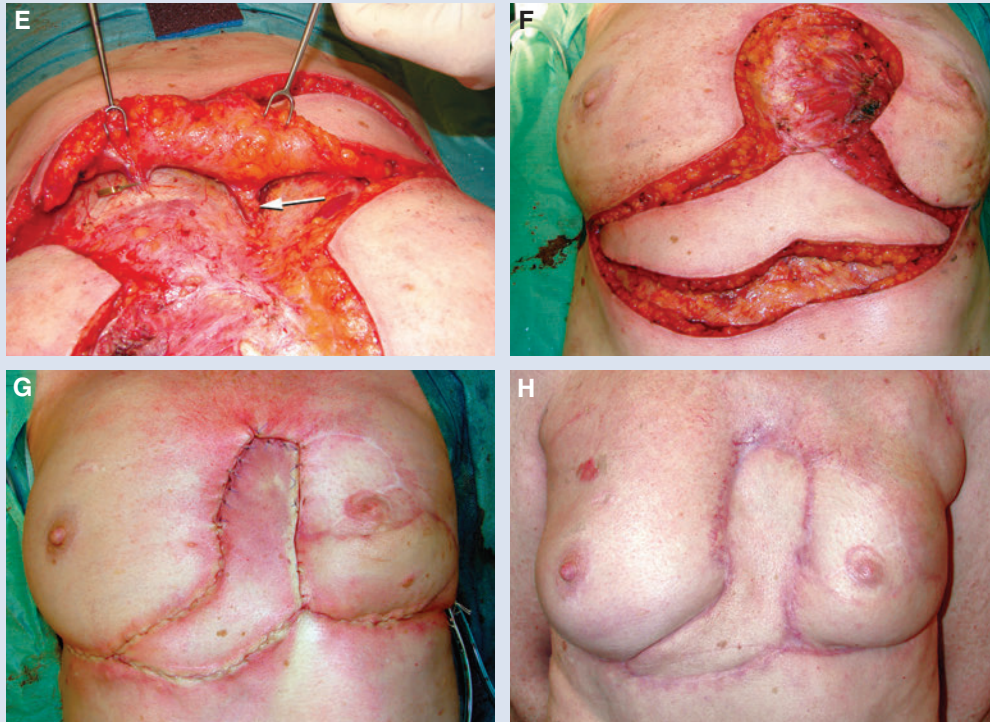


Fig. 22-13, E-H

The flap (cranial view) was based on the superficial branch (*arrow*) after clamping the perforator (*E*). The resulting defect and flap harvesting are shown intraoperatively (*F*). The flap was rotated upward 90 degrees to cover the defect (*G*). The patient is shown 6 months postoperatively (*H*).

SURGICAL TECHNIQUE

Surgical Plan

- The tumor is resected and clips are placed.
- The patient is placed in lateral recumbency, and subcutaneous tissues are incised to the muscle fascia.
- Using loupe magnification, the flap is dissected and elevated.
- An adequately sized perforator is dissected to its origin from the main pedicle.
- The skin paddle is raised from the latissimus dorsi muscle and passed into the breast area under the skin bridge between the axilla and the thoracic region.
- The flap is secured onto the anterior axillary line, and the donor site is closed.
- With the patient supine, the flap is shaped and deepithelialized, if necessary.
- The flap is positioned and sutured, and a drain is placed.

With the patient supine, the quadrantectomy or tumorectomy and the axillary surgery are performed. The resected tumor specimen is oriented and weighed. Surgical clips are always left around the tumor bed in the breast as a guide for postoperative radiotherapy. The incisions are covered with a sterile OpSite drape, and the patient is turned to a lateral position. The arm is abducted 90 degrees. The skin and subcutaneous tissue are incised to the muscle fascia. The dissection must be beveled to include a maximum amount of fat.

Regardless of the type of flap dissected, the following general considerations are applied for every pedicled perforator flap. Under loupe magnification, the flap is dissected. The flap is elevated from distal to proximal and from medial to lateral at the level just above the latissimus dorsi muscle fascia until the perforator is identified with a Doppler unit or until another good-sized perforator is found. If the caliber and the quality of the perforator are satisfactory, it is completely dissected.

Perforators must be pulsating and have a good diameter (more than 0.5 mm) if a flap is to be harvested.

The muscle is split and the perforator is dissected cranially. All side branches are clipped or coagulated using microbipolar electrocautery to ensure a bloodless field. Nerve branches are dissected away from the vessels and preserved. The perforator is dissected proximally to its origin from the main pedicle to provide a long pedicle. When the vessels are completely dissected, the skin paddle can be raised from the latissimus dorsi muscle. The skin paddle is passed into the breast area, under the skin bridge between the axilla and the thoracic region. Extreme care should be taken at this point to avoid damaging the perforator during the passage of the flap. The flap is secured to the anterior axillary line with several sutures. The donor site is closed over a suction drain. The patient is turned to the supine position, and the flap is reshaped. The flap is folded, if necessary, and any redundant part is discarded; however, an overcorrection is always performed. Depending on the defect, the flap is deepithelialized. The skin paddle is left only when breast skin is initially resected

above the tumor. The flap is positioned without kinking the perforator and is sutured to the pectoralis fascia. Another suction drain is placed between the flap and the breast skin.

Converting a TDAP Flap to a Muscle-Sparing Latissimus Dorsi Flap

When tiny but pulsating perforators are found, a muscle-sparing latissimus dorsi TDAP I flap technique is used to harvest the flap, along with a piece of latissimus dorsi muscle that is 2 cm wide. In this case, the perforators are “deroofed” within the split muscle. In other words, the posterior side of the perforator remains attached to the muscular part, which is included in the flap. This requires including the muscle under direct visualization of the perforators to avoid damaging them when harvesting the muscular segment. Only a small nerve branch to the muscle is sacrificed. This technique also can be used when the flap is planned to reach more medial defects in the breast. By keeping the perforator attached to the muscle segment, safer flap inseting can be obtained without direct traction on the perforator.

If the perforators are very tiny and nonpulsating, then the flap should be converted to a muscle-sparing latissimus dorsi TDAP II flap to incorporate the maximum number of perforators within the flap. The nerve that innervates the rest of the latissimus dorsi muscle is always preserved. In these specific cases, the muscle-sparing latissimus dorsi TDAP I or II flap allows a safer flap harvest. Special considerations for harvesting TDAP flaps are listed in the box.

Box 22-1 Special Considerations for Harvesting TDAP Flaps

- A perforator arising from the descending branch of the thoracodorsal artery is usually dissected, because it has a shorter intramuscular course.
- Regular irrigation of the perforator with saline and delicate manipulation is recommended to avoid spasm. If spasm persists, topical papaverine irrigation can be used.
- Failure of spasms to resolve typically indicates intraluminal damage to the perforator intima from excessive traction during dissection, usually resulting in flap failure.
- We recommend keeping the posterior aspect of the perforator attached to the latissimus dorsi muscle, where the perforator enters the skin, until just before flap transfer.
- When dissecting the thoracodorsal pedicle, more proximal branches to the muscle are left intact to maintain the blood supply to the proximal part of the latissimus dorsi muscle. This precaution allows a latissimus dorsi flap to be raised later, if needed.
- Passing the TDAP flap through the split latissimus dorsi muscle provides a longer pedicle and, consequently, less tension on the perforator.
- The septal perforator can be injured during the axillary lymph node dissection; therefore it is imperative to first verify that it is still pulsating and not coagulated or ligated proximally.
- Damage to the thoracodorsal pedicle (for example, resulting from axillary clearance) is an absolute contraindication to raising a TDAP flap, because it is needed for a traditional latissimus dorsi flap. In this case, however, a perforator flap based on intercostal vessels may still be harvested for lateral breast defects.
- The serratus branch should not be systematically ligated. To elongate the pedicle, simple dissection and mobilization of the serratus branch is sufficient in many cases.

PATIENT EXAMPLE

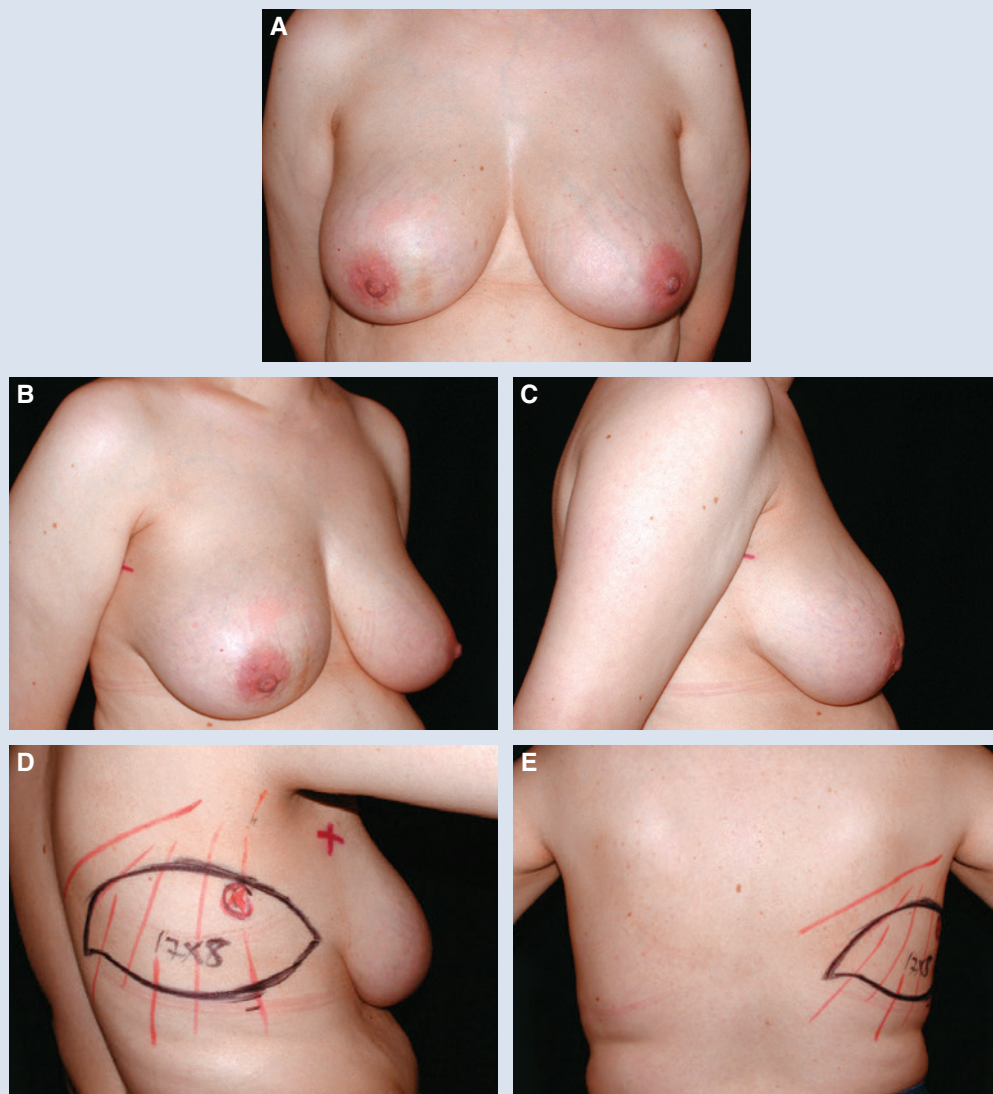


Fig. 22-14, A-E

This 39-year-old patient presented with a 3 cm tumor located in the superomedial quadrant of her right breast (A through C). A perforator was identified using Doppler ultrasonography, and the flap was designed (D and E).

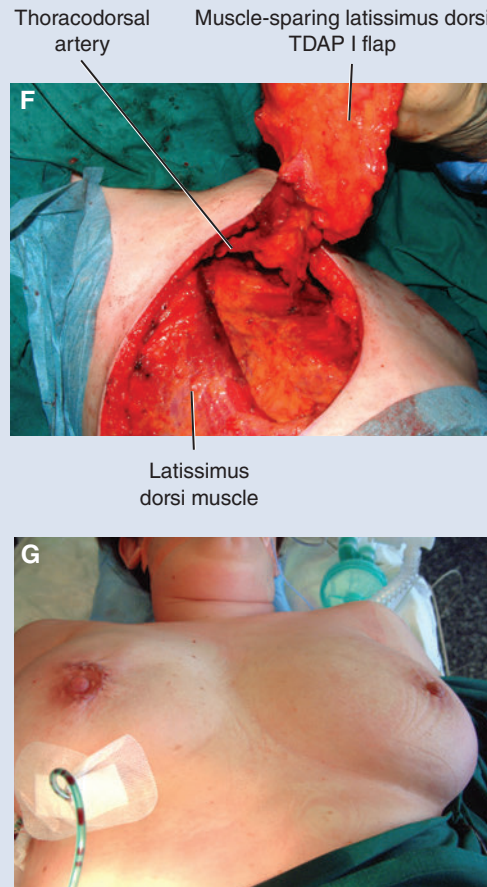


Fig. 22-14, F and G

A muscle-sparing latissimus dorsi TDAP I flap was harvested to include a 2 cm width of muscle behind the perforator (*F*). The *black outline* shows the missing part of the latissimus dorsi muscle. The flap was transferred to the superomedial breast defect. The tumorectomy incision, which was designed in the periareolar line, was closed (*G*).

Continued

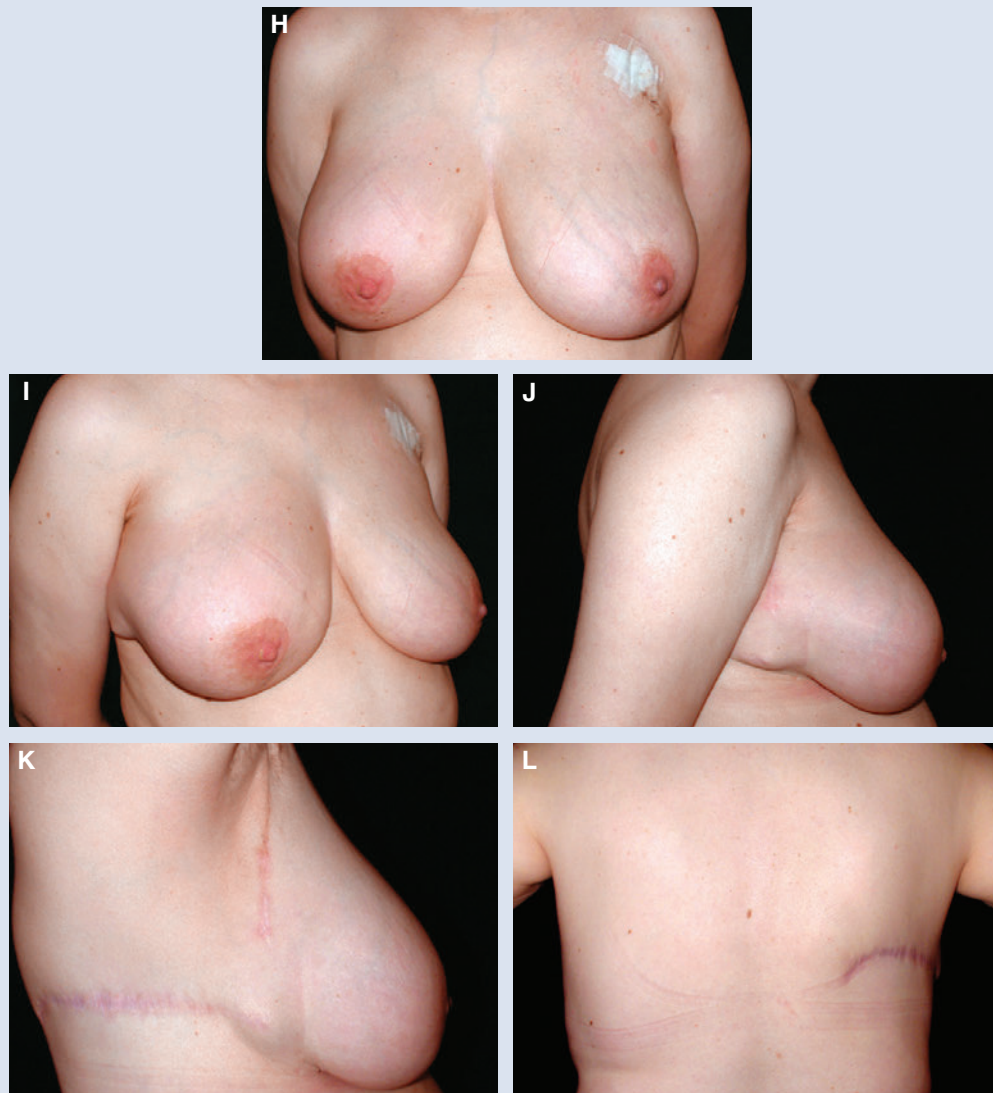


Fig. 22-14, H-L

The patient is shown 1 year postoperatively (*H* through *L*). The healed donor site is also shown.

ADVANTAGES OF PEDICLED PERFORATOR FLAPS FOR PARTIAL BREAST RECONSTRUCTION

The major advantage of harvesting a perforator flap is the significant reduction in the incidence of seroma formation in the donor site, which has been reported to be as high as 60% after harvesting a latissimus dorsi muscle flap.³⁰ In addition, shorter postoperative recovery and less pain at the donor site have also been reported after harvesting other perforator flaps.^{18,31} Alternatively, latissimus dorsi muscle preservation has the obvious benefit of less contour deformity of the donor site than a latissimus dorsi harvest; however, functional studies are still necessary to confirm the objective functional benefits of latissimus dorsi muscle-sparing techniques.

Although non-thoracodorsal-based perforator flaps, such as the intercostal, serratus, or superior epigastric flaps, do not harm the latissimus dorsi muscle, the effect on shoulder function after dissecting a TDAP flap was not clear. We conducted a functional study to evaluate shoulder strength, range of motion, and the thickness of the latissimus dorsi muscle after harvesting a pedicled TDAP flap.¹⁹ Our study clearly showed that muscle strength was not affected by harvesting a pedicled TDAP flap for breast reconstruction. Moreover, the range of motion of the shoulder seemed to recover, despite the initial decrease in forward elevation and passive abduction.

Abduction and forward elevation are not directly related to latissimus dorsi muscle function; initial deficits in these movements could be related to the tightening caused by scar tissue.

Indeed, it is difficult to estimate the resulting decrease in shoulder motion as related to tumorectomy/quadrantectomy, sentinel/axilla lymph node dissection, and flap harvesting.

OUTCOMES WITH EVALUATION OF RESULTS

We published our results in 119 patients who underwent oncoplastic surgery.³² Bilateral breast remodeling (displacement techniques) and pedicled flaps (replacement techniques) were used in 26 and 93 patients, respectively. In three cases (2.5%), margins were involved with the tumor: two cases after pedicled TDAP flap and one case after remodeling techniques. Wider excision was done in two cases, and a skin-sparing mastectomy was required in the third patient, because all margins were involved with the tumor. Postoperative complications were limited to wound healing (4%), infection (2%), and hematoma (2%). When pedicled flaps were used, seroma in the donor site was found in only six cases of MS TDAP II flaps (5.5%). No perforator flaps were complicated with seroma in the donor site.³²

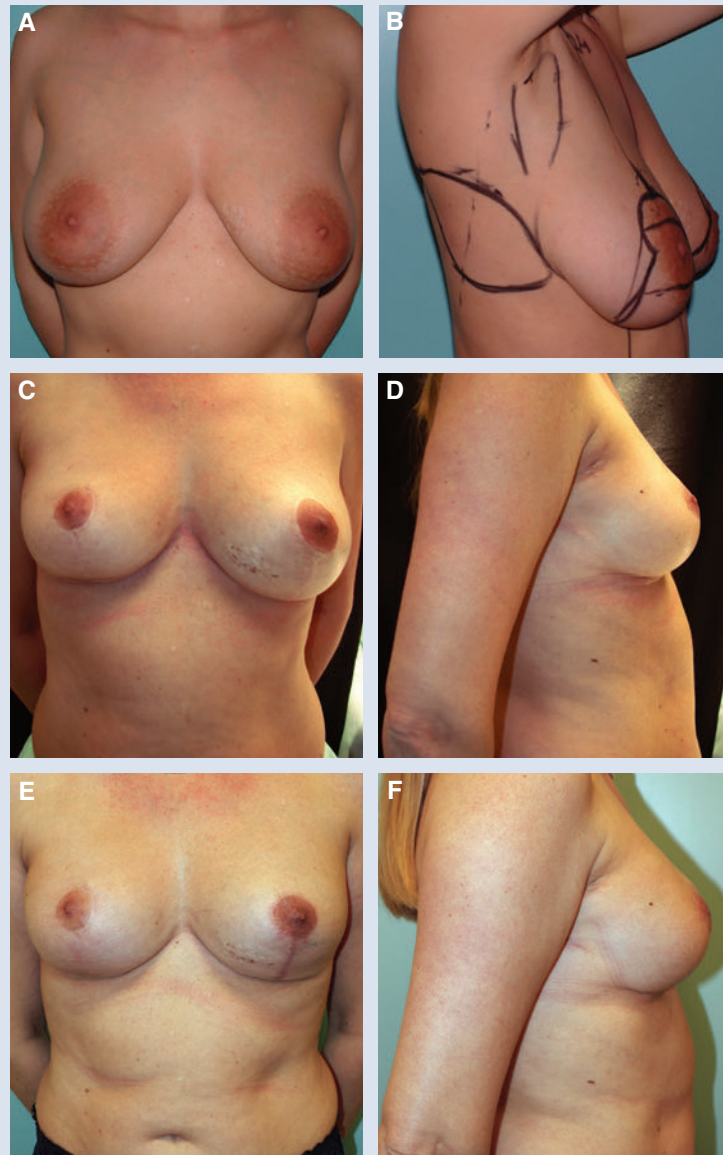
Because postoperative radiation is a part of the therapy, the long-term outcome of using pedicled perforator flaps may be unpredictable. Actually, postoperative radiotherapy of any flap is a major concern. The largest series investigating irradiated flap reconstruction in a total mastectomy showed no statistically significant increase in complications when the patient received postoperative radiotherapy, compared with no radiation. However, both series revealed significant increases in delayed flap contracture, pigmentation changes, and volume loss. Because these changes can dramatically lower the final aesthetic outcome, most surgeons delay the total mastectomy reconstruction until radiotherapy has been completed.³²⁻³⁸

Presently there are no large, long-term outcome studies comparing immediate flap reconstruction in irradiated and nonirradiated partial mastectomy patients. Because most of the breast tissue is spared, including dermal/gland connections and breast ligaments, radiation would be expected to have less detrimental aesthetic effects on partial mastectomy patients than on total mastectomy patients. Theoretically, irradiating the flap and conserving breast tissue should produce a more homogeneous appearance than the “plugged-in” appearance of nonirradiated flaps after delayed reconstruction. Stable results with a 4-year or shorter follow-up were reported in a few studies.^{5,32-38}

With an average follow-up of 4 years (range 6 months to 10 years), seven flaps (6.3%) were complicated with palpable fat necrosis.³² Further surgeries were required in three patients. In one of these patients, excision of fat necrosis was performed with primary closure. The other two patients required a wide excision and reconstruction with pedicled skin flaps. However, mastectomy was required in the second patient because of the extended fat necrosis, and a free DIEP flap was then used for the breast reconstruction. In the group of breast remodeling patients, one patient underwent fat necrosis excision (3.8%). Local recurrence was found in two patients (1.7%). Both patients were treated with a mastectomy.

Our experience showed a stable result in the long term. However, one may expect breast asymmetry because of the differential “aging” process between the two breasts. The nonirradiated side may become more ptotic compared with the irradiated one. On the other hand, the irradiated side may show signs of total breast atrophy. When the breast asymmetry becomes obvious, fat grafting is indicated, alone or with contralateral breast remodeling. The use of fat grafting is gaining great popularity, either alone or more commonly, in combination with other reconstruction options for the treatment of breast defects after tumor resection.³⁸⁻⁴¹ Despite concerns in the past, fat grafting of the breast has proved to be a safe, reliable, lasting method for the transposition of autologous fatty tissue to restore contour-deformed areas of the breast.³⁸⁻⁴¹

PATIENT EXAMPLE

**Fig. 22-15**

This 42-year-old patient had right breast cancer in the upper lateral quadrant that extended over the breast meridian (A). A pedicled TDAP flap was planned for partial breast reconstruction, together with bilateral mastopexy (B). Her results are shown 8 years postoperatively demonstrating a nice reconstructed right breast with stable form. However, the (non-irradiated) left breast had more ptosis, which resulted in breast asymmetry (C and D). A simple repeat mastopexy restored symmetry; nothing was done to the reconstructed breast (E and F).

CONCLUSION

Pedicated perforator flaps are additional tools at the disposal of breast reconstructive surgeons. We have shown that the donor-site morbidity after harvesting a TDAP flap was reduced to a minimum. We encourage using perforator flaps whenever adequate perforators can be identified and safely dissected.

Critical Issues

- The use of perforator flaps is a new and promising concept in oncoplastic surgery.
- The TDAP flap is the workhorse of this technique.
- Preoperative perforator mapping is essential in planning for this flap.
- A meticulous technique is required when harvesting perforator flaps.
- A bloodless field and wide exposure are the major factors leading to a successful perforator dissection.
- Converting the TDAP flap to a muscle-sparing version is mandatory when the perforator size is inadequate.
- The LICAP flap is mainly indicated for laterally located breast defects.
- For defects located in the inferomedial quadrant, partial breast reconstruction using a SEAP flap provides an alternative to a mastectomy.

References

1. Winchester DP, Cox JD. Standards for diagnosis and management of invasive breast carcinoma. American College of Radiology. American College of Surgeons. College of American Pathologists. Society of Surgical Oncology. CA Cancer J Clin 48:83, 1998.
2. Veronesi U, Cascinelli N, Mariani L, et al. Twenty-year follow-up of a randomized study comparing breast-conserving surgery with radical mastectomy for early breast cancer. N Engl J Med 347:1227, 2002.
3. Fisher B, Anderson S, Bryant J, et al. Twenty-year follow-up of a randomized trial comparing total mastectomy, lumpectomy, and lumpectomy plus irradiation for the treatment of invasive breast cancer. N Engl J Med 347:1233, 2002.
4. Berrino P, Campora E, Santi P. Postquadrantectomy breast deformities; classification and techniques of surgical correction. Plast Reconstr Surg 79:567, 1987.
5. Clough KB, Kroll SS, Audretsch W. An approach to the repair of partial mastectomy defects. Plast Reconstr Surg 104:409, 1999.
6. Clough KB, Cuminet J, Fitoussi A, et al. Cosmetic sequelae after conservative treatment for breast cancer: classification and results of surgical correction. Ann Plast Surg 41:471, 1998.

7. Bajaj AK, Kon PS, Oberg KC, et al. Aesthetic outcomes in patients undergoing breast conservation therapy for the treatment of localized breast cancer. *Plast Reconstr Surg* 114:1442, 2004.
8. Fehlauser F, Tribius S, Höller U, et al. Long-term radiation sequelae after breast-conserving therapy in women with early-stage breast cancer: an observational study using the LENT-SOMA scoring system. *Int J Radiat Oncol Biol Phys* 55:651, 2003.
9. Slavin SA, Love SM, Padousky NL. Reconstruction of the radiated partial mastectomy defect with autogenous tissue. *Plast Reconstr Surg* 90:854, 1992.
10. Dillon MF, Hill AD, Quinn CM, et al. A pathologic assessment of adequate margin status in breast-conserving therapy. *Ann Surg Oncol* 13:333, 2006.
11. Audretsch WP. Reconstruction of the partial mastectomy defect: classification and method. In Spear SL, Willey SC, Robb GL, eds. *Surgery of the Breast: Principles and Art*. Philadelphia: Lippincott Williams & Wilkins, 2006.
12. Angrigiani C, Grilli D, Siebert J. Latissimus dorsi musculocutaneous flap without muscle. *Plast Reconstr Surg* 96:1608, 1995.
13. Hamdi M, Van Landuyt K, Monstrey S, et al. Pedicled perforator flaps in breast reconstruction: a new concept. *Br J Plast Surg* 57:531, 2004.
14. Hamdi M, Van Landuyt K, de Frene B, et al. The versatility of the inter-costal artery perforator (ICAP) flaps. *J Plast Reconstr Aesthet Surg* 59:644, 2006.
15. Hamdi M, Van Landuyt K, Ulens S, et al. The superior epigastric artery perforator (SEAP) flap: a clinical experience and anatomical study with multi-detector CT (MDCT). *J Plast Reconstr Aesthet Surg* 62:1127, 2009.
16. Hamdi M, Van Landuyt K, Hijjawi JB, et al. Surgical technique in pedicled thoracodorsal artery perforator flaps: a clinical experience with 99 patients. *Plast Reconstr Surg* 121:1632, 2008.
17. Hamdi M, Spano A, Van Landuyt K, et al. The lateral intercostal artery perforators: anatomical study and clinical application in breast surgery. *Plast Reconstr Surg* 121:389, 2008.
18. Hamdi M, Decorte T, Demuyneck M, et al. Functional evaluation of the donor site morbidity after harvesting a thoracodorsal artery perforator flap. *Plast Reconstr Surg* 122:1111, 2008.
19. Hamdi M, Wolfli J, Van Landuyt K. Partial mastectomy reconstruction. *Clin Plast Surg* 34:51, 2007.
20. Losken A, Hamdi M. Partial breast reconstruction: current perspectives. *Plast Reconstr Surg* 124:722, 2009.
21. Cance W, Garey L, Calvo B, et al. Long-term outcome of neoadjuvant therapy for locally advanced breast cancer. *Ann Surg* 236:295, 2002.
22. Shen J, Valero V, Buchholz T, et al. Effective local control and long survival in patients with T4 locally advanced breast cancer treated with breast conservation therapy. *Ann Surg Oncol* 11:854, 2004.
23. Kronowitz SJ, Hunt KK, Kuerer HM, et al. Delayed-immediate breast reconstruction. *Plast Reconstr Surg* 113:1617, 2004.
24. Losken A, Styblo TM, Carlson GW, et al. Management algorithm and outcome evaluation of partial mastectomy defects treated using reduction or mastopexy techniques. *Ann Plast Surg* 59:235, 2007.
25. Guerra AB, Metzinger SE, Lund KM, et al. The thoracodorsal artery perforator flap: clinical experience and anatomic study with emphasis on harvest techniques. *Plast Reconstr Surg* 114:32, 2004.
26. Hallock GG. Doppler sonography and color duplex imaging for planning a perforator flap. *Clin Plast Surg* 30:347, 2003.
27. Masia J, Clavero JA, Larranaga JR, et al. Multidetector-row computed tomography in the planning of abdominal perforator flaps. *J Plast Reconstr Aesthet Surg* 59:594, 2006.
28. Hamdi M, Van Landuyt K, Van Hedent E, et al. Advances in autogenous breast reconstruction: the role of preoperative perforator mapping. *Ann Plast Surg* 58:18, 2007.

29. Offodile AC II, Chatterjee A, Vallejo S, et al. A cost-utility analysis of the use of preoperative computed tomographic angiography in abdomen-based perforator flap breast reconstruction. *Plast Reconstr Surg* 135:662e, 2015.
30. Randolph LC, Barone J, Angelats J, et al. Prediction of postoperative seroma after latissimus dorsi breast reconstruction. *Plast Reconstr Surg* 116:1287, 2005.
31. Kroll SS, Sharma S, Koutz C, et al. Postoperative morphine requirements of free TRAM and DIEP flaps. *Plast Reconstr Surg* 107:338, 2001.
32. Hamdi M. Oncoplastic and reconstructive surgery of the breast. *Breast* 22 Suppl 2:S100, 2013.
33. Kat CC, Darcy CM, O'Donoghue JM, et al. The use of the latissimus dorsi musculocutaneous flap for immediate correction of the deformity resulting from breast conservation surgery. *Br J Plast Surg* 52:99, 1999.
34. Rainsbury RM. Breast-sparing reconstruction with latissimus dorsi miniflaps. *Eur J Surg Oncol* 28:891, 2002.
35. Losken A, Schaefer TG, Carlson GW, et al. Immediate endoscopic latissimus dorsi flap: risk or benefit in reconstructing partial mastectomy defects. *Ann Plast Surg* 53:1, 2004.
36. Munhoz AM, Montag E, Fels KW, et al. Outcome analysis of breast-conservation surgery and immediate latissimus dorsi flap reconstruction in patients with T1 to T2 breast cancer. *Plast Reconstr Surg* 116:741, 2005.
37. Navin C, Agrawal A, Kolar KM. The use of latissimus dorsi miniflap for reconstruction following breast-conserving surgery: experience of a small breast unit in a district hospital. *World J Surg* 31:46, 2007.
38. Agha R, Fowler A, Herlin C, et al. Use of autologous fat grafting for breast reconstruction: a systematic review with meta-analysis of oncological outcomes. *J Plast Reconstr Aesthet Surg* 68:143, 2015.
39. Brenelli F, Rietjens M, De Lorenzi F, et al. Oncological safety of autologous fat grafting after breast conservative treatment: a prospective evaluation. *Breast J* 20:159, 2014.
40. Khouri RK, Rigotti G, Khouri RK Jr, et al. Tissue-engineered breast reconstruction with Brava-assisted fat grafting: a 7-year, 488-patient, multicenter experience. *Plast Reconstr Surg* 135:643, 2015.
41. Goldman BE. Micro fat grafting for post lumpectomy and breast reconstruction deformities: pearls for success. *Plast Reconstr Surg* 136(4 Suppl):101, 2015.

23

Partial Breast Reconstruction Using Distant Flaps

Aldona J. Spiegel, Sarosh Zafar

Surgical options for the treatment of breast cancer have evolved to incur less morbidity while optimizing breast aesthetics.¹ Recent advances in imaging and adjuvant therapy have led to detection at earlier stages and have increased the number of patients who are candidates for breast-conserving therapy (BCT).^{2,3} BCT leaves the patient with more overall native breast tissue than mastectomy; however, patients may be left with a significant tissue deficit or deformity, and reconstructive surgeons face a larger subset of patients who have complex partial breast deformities.⁴ The reconstructive options for these deformities fall into two general groups. Since the breast is a paired organ, one way to achieve balance when tissue is removed from one breast is to rearrange the remaining tissue and to reduce the contralateral side. If this is not indicated, additional tissue needs to be transferred to the affected breast with either local or distant flaps. For some of these patients, the best option for breast reconstruction will be a distant flap. In those cases, we prefer to use muscle-preserving abdominal flaps, either the superficial inferior epigastric artery (SIEA) flap, or the deep inferior epigastric perforator (DIEP) flap.

PATIENT ASSESSMENT AND INDICATIONS

With BCT, the NAC and its sensation are usually preserved, but a significant number of women will have resulting deformity and asymmetry that ultimately affect breast cosmesis.⁴ The percentage of patients who require reconstruction after BCT varies widely in the literature. This is probably because of limitations in the length of follow-up, differences in the proportion of breast size versus tissue excised, and variations in postoperative radiotherapy.⁵ In one prospective study by Clough et al,⁶ the median time between the initial breast conservation surgery and correction of cosmetic sequelae was 7 years. In this cohort, they reported that 20% to 30% of patients who underwent BCT developed significant deformity that could warrant reconstruction; others have reported rates as high as 60%.⁷

For many women, preservation of the NAC is an important aspect of breast reconstruction. In the past, this was achieved with BCT. However, in the past 10 years surgeons have been performing an increasing number of nipple-sparing mastectomies, preserving the NAC. Consequently, in the senior author's practice (A.S.), the rate of BCT has decreased, whereas that of nipple-sparing mastectomy has increased. Over time, there may be an evolving trend toward nipple-sparing mastectomy and away from BCT.⁸

TIMING OF RECONSTRUCTION

To date, there is no reliable prognostic classification of defects from BCT. The reconstructive surgeon should discuss the anticipated defect with the breast surgeon and radiation oncologist.

We prefer to allow the breast surgeon to perform the lumpectomy and primary closure. After final pathologic clear margins are verified 1 to 2 weeks later, we reconstruct the defect in a second-stage procedure. This prevents positive margins requiring reresection with local tissue rearrangement. The other consideration in immediate partial reconstruction is the need for adjuvant radiotherapy. Although it is well accepted that breast reconstruction after total mastectomy should be delayed after radiotherapy, we have found that adjuvant radiation dosage in BCT is administered at a lower dose and therefore causes significantly less deleterious effects on the affected tissue.⁹ Radiotherapy protocols differ among institutions, and discussion regarding local protocols may help with preoperative planning of the reconstruction.

IMMEDIATE RECONSTRUCTION

The availability of a large amount of tissue allowed by the transfer of a free flap, especially in locations not amenable to local tissue flaps, such as the medial breast, allows the breast surgeon's patient to undergo a wide local excision. This improves the patient's oncologic care, because positive surgical margins and ipsilateral breast tumor recurrence are associated with an increased risk of systemic recurrence and decreased disease-specific survival.^{10,11} Furthermore, various reports in the literature have recognized that there is a trend toward lower rates of local recurrence, with an increase in the peritumor free margin width.¹²⁻¹⁴

Immediate reconstruction is most often favored by the patient, because this means she has no residual defect rather than "living with a deformity" for several years. If a patient initially presents to a multidisciplinary BCT team, then once the final pathology has demonstrated clear margins of resection, immediate reconstruction should be considered to improve the eventual aesthetic outcome. A well-perfused flap prevents cavitation and skin shrinkage in the lumpectomy site by providing well-vascularized tissue when radiotherapy is planned. We have seen evidence of excellent results in these patients, and usually there is little to no delay in initiating radiotherapy.

DELAYED RECONSTRUCTION

Often the reconstructive surgeon does not have the luxury of evaluating the patient before the initial excision. Some patients present to the surgeon months or even years after BCT. These patients often have a scarred and tethered defect from past irradiation of the breast. This is caused when the breast parenchyma has not been approximated and a seroma formed that was subsequently replaced by fibrosis. This in turn is further affected by irradiation of the tissue, which increases the volume loss, distortion, and fibrosis.^{15,16} Reconstruction in these patients involves release of this contracture, which often leads to re-creation of a rather large defect. The reconstructive surgeon should be aware that these patients often have an unexpectedly large tissue deficit that is more likely to require a free tissue transfer for adequate volume replacement.

The need cannot be overstated for a thorough physical examination and imaging to confirm the absence of residual disease or recurrence before reconstruction.

PATIENT SELECTION

Certain tumor locations, such as medial quadrants of the breast, are deficient in surrounding breast tissue to fill the resultant dead space, leading to excessive undermining of the adjacent tissues.¹⁷ Rearrangement of local tissue from the back or from the area inferior to the breast is the next option. Local island perforator flaps, the thoracodorsal artery perforator (TDAP) flap and the intercostal artery perforator (ICAP) flap, are excellent choices. However, the location and volume of the defect, as well as limitations in the arc of rotation of these local perforator flaps, may reduce these options. The latissimus dorsi myocutaneous flap is another choice for a local flap because of its ability to fill in large deficits and reach the lateral breast, but it is not easily transposed to the medial quadrants.¹⁸

Distant flaps represent a solution for patients with partial breast deformities that are not amenable to local flaps because of location, defect size, or patient preference.

When discussing the option of a local versus a distant flap, the patient's expectations and willingness to undergo treatment should be explored. Patients with a significant deformity and a strong desire for BCT are candidates for free tissue transfer of a muscle-preserving flap. Patients view the opportunity to improve their overall appearance as an overwhelming benefit of the abdominal perforator free flap surgery. This is accomplished through the concurrent flattening of the abdominal contour at the donor site. Furthermore, in lieu of a local flap that creates an extended incision adjacent to the breast, this surgery allows a less

conspicuous scar location, which may even overlie an old cesarean scar. Published reports have demonstrated high patient satisfaction with their abdominal contour after lower abdominal perforator harvest for breast reconstruction.^{19,20} Even on relatively slim patients who have had a full-term pregnancy, there is usually a small amount of excess abdominal tissue that is adequate for a mini-SIEA or a mini-DIEP flap.

TREATMENT DECISIONS

The patient with a large breast defect who is considering BCT and reconstruction rather than a complete mastectomy must be informed about the possibility of recurrence and demonstrate the means and motivation to continue with follow-up breast cancer surveillance. These patients should be informed that screening may be obscured by scarring as a result of autologous reconstruction. Free tissue transfer may be complicated by fat necrosis, which must be differentiated from recurrent breast cancer, often by imaging and occasionally by biopsy. However, the incidence of fat necrosis in these small flaps is rare, and improving radiologic imaging has improved monitoring in these patients.

The reconstructive surgeon should inform the patient of prognostic factors affecting her outcome. Healthy patients with adequate abdominal tissue who do not have severe comorbidities such as diabetes mellitus or coronary arterial disease are generally suitable candidates. Some patients may have other relative contraindications, such as age greater than 60 years, obesity defined as a BMI of 30 or more, prior abdominal surgery with extensive scarring, extensive prior abdominal liposuction, an active smoking history, or a coagulation disorder. Therefore each patient should be evaluated on a case-by-case basis.

PREOPERATIVE PLANNING

The choice of donor site for reconstruction warrants discussion. Although critics state that sacrificing the lower abdominal tissue for only a partial breast defect is contraindicated, there are many women who choose to undergo a cosmetic abdominoplasty, knowing that the average woman's chances of developing breast cancer is at least 13%. The chances of local recurrence vary from 9% to 15%, so if the same logic applies to spare the abdominal tissue in the case of breast cancer, then should the average woman be counseled against having an elective abdominoplasty? We contend that there are now many described reconstructive options for autologous breast reconstruction that also offer minimal patient morbidity if a patient later requires total breast reconstruction because of a recurrence. These include the superior and inferior gluteal perforator (SGAP and IGAP) flaps, in addition to the transverse upper gracilis (TUG) flap and the anterior lateral thigh flap (ALT), which may be suitable even for large-volume breast reconstruction.²¹

We prefer to preserve the thoracodorsal vessels to preserve the latissimus dorsi myocutaneous flap as a salvage option for patients when microsurgical tissue transfer is unsuccessful.

Surgical Plan

- Preoperative CTA evaluation of abdominal wall vasculature
- Doppler assessment of the SIEA, SIEV, and DIEP vasculature
- Preoperative markings
- Re-creation of the BCT defect
- Harvest of recipient vessels
- Creation of a defect template
- Lower abdominal incision
- Assessment of the SIEA and SIEV
- Superior abdominal incision
- Examination of perforators
- A decision regarding SIEA versus DIEP flap harvest
- Examination of the flap for any zones of vascular congestion
- Ligation of vessels
- Orientation and securing of the flap at the breast defect
- Microsurgical anastomosis
- Flap deepithelialization and inseting
- Closure

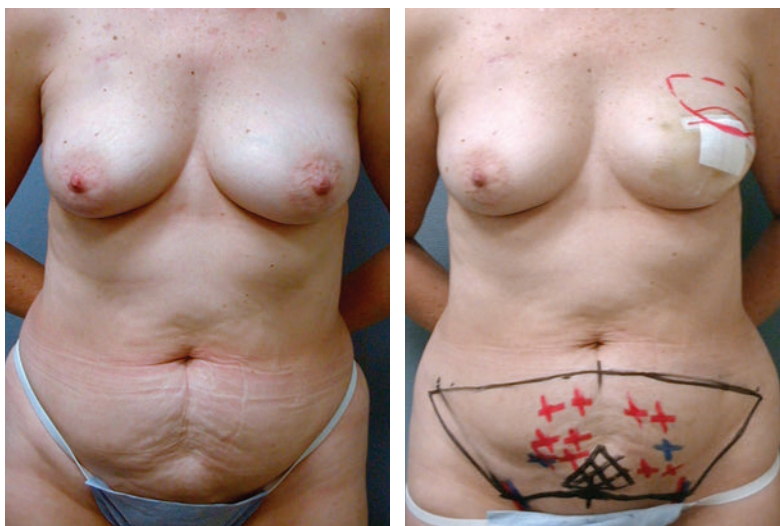


Fig. 23-1

This 50-year-old woman presented with T2N0M0 invasive ductal carcinoma and underwent a left upper pole partial mastectomy after completing neoadjuvant chemotherapy. Given the size and location of the defect with relation to the remaining breast tissue, it was determined that the patient would benefit most from immediate reconstruction. After the final margin status was confirmed, she was scheduled and marked for mini-SIEA flap reconstruction before radiotherapy.

SURGICAL TECHNIQUE

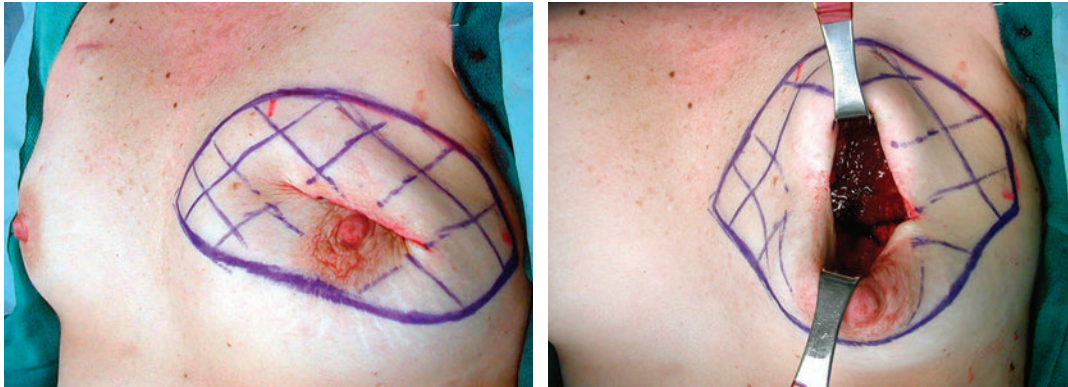


Fig. 23-2

Preoperatively, a handheld duplex Doppler is used to assess the quality and quantity of perforators, verifying the exact location of the SIEA along with the main perforators of the medial and lateral branches of the DIEA; these are all marked. Ultrasound localization of perforators is especially useful for women with a large body habitus or for those who have had previous abdominal operations.²²

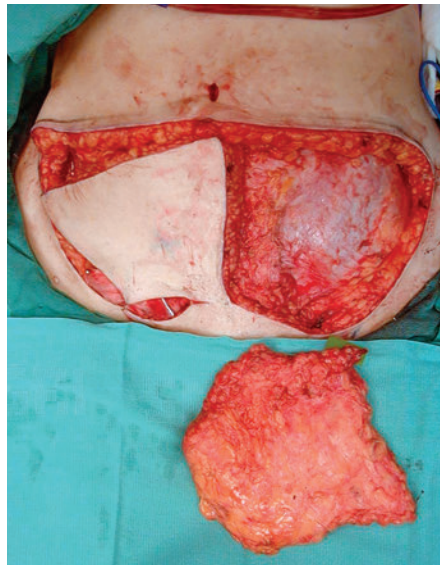
We use preoperative CTA to visualize perforator patterns of dominance and size; this provides a roadmap of the most favorable perforators.

The number of DIEP perforators per side with a caliber greater than 0.8 mm ranges from one to three. The majority of perforators are located within 8 cm of the umbilicus. The mini-SIEA flap is based on the SIEA, which is a branch off the common femoral artery. The anatomy of these vessels is quite variable²³; in one study of 100 cadaver dissections, the artery was found to be present in 72% of dissected groins, with an average size of 1.6 mm (range 0.75 to 3.5 mm).²⁴ The vessels are marked, and the flap is outlined with the patient in the supine position. The midline is marked as is the inframammary crease on both sides.

General anesthesia is administered, and the patient is prepped and draped from the chin to the upper thighs. The ipsilateral arm should be prepped and included in the field for lateral defects to give access to the serratus arterial branches; for medial defects, the arms may be

tucked. The breast defect is first re-created, removing scar tissue from the prior excision site. This facilitates determining the flap size required.

The abdominal skin incisions should be planned while keeping in mind that although the SIEA flap is the first choice for breast reconstruction, the vessels are often absent or too small in diameter to use in the reconstruction. If this is the case, reconstruction will instead be performed with the DIEP flap. Therefore the preoperative flap design must consider both types of flap. In BCT defects the amount of tissue that needs to be transferred is much smaller than in total mastectomy reconstruction, which allows a conservative or mini-flap design.



Immediate partial breast reconstruction

Fig. 23-3

Attention should initially focus on re-creating the partial mastectomy defect. It is crucial that the defect is re-created to its fullest extent by removing and releasing all scar tissue. During this dissection, the surgeon should take great care not to injure any adjacent perforator vessels that might serve as potential recipient vessels.

The lower abdominal incision is performed at the level just superior to the pubic hairline, extending laterally with a gentle curve and superiorly to the iliac spine. This lower incision maximizes the possibility of using the SIEA. The superior incision is adjusted according to the tissue laxity; in slimmer patients it will be below the umbilicus at the midline. This lower incision is made first to allow for evaluation of the SIEA and the superficial inferior epigastric vein (SIEV), to determine whether they are of adequate size and character on either side since ipsilateral or contralateral flaps may be used.

Arterial size is the rate-limiting factor; 1.5 mm arterial size is a critical cutoff criterion for using the SIEA flap.²⁵ However, because of the smaller size of this flap type and the preference for smaller recipient vessels in BCT reconstruction, we accept 1.3 mm as the critical diameter at the entry point into the flap.

The SIEV is also dissected as a second option for venous drainage. However, we prefer to use the venae comitantes, because their proximity to the artery results in a better length match. The dissection of the SIEA should be performed with clips in the adjacent tissue to minimize the risk of a seroma developing.

The SIEA is evaluated, and if its size is not adequate or it does not have a visible and palpable pulse, the DIEP flap is dissected. However, caution is necessary to identify adequate perforators within the flap design before making the superior incision. Since these flaps are smaller in size than their total mastectomy reconstruction counterparts, a smaller perforator vessel size is tolerated.

To accomplish this, the anterior rectus sheath is opened in a longitudinal fashion around the DIEP perforators, and the vessels are carefully dissected through the rectus muscle to the DIEA and DIEV, taking care to spread in the direction of the muscle fibers. Because of the smaller size of the inferior perforators, we prefer to use two perforators for the mini-DIEP. High-powered loupe magnification and precise microsurgical technique are essential during this dissection.²⁶ Any intercostal nerves innervating the medial aspect of the muscle are carefully identified, since these might cross the pedicle. Dissection continues until the pedicle is of sufficient length, typically 8 to 10 cm long, and the vessels are of adequate caliber to match the recipient vessels in the chest.

During the dissection of the recipient vessels, we try to save the internal mammary artery (IMA), because it may be necessary for any future reconstructions or for use in revascularization after coronary surgery.

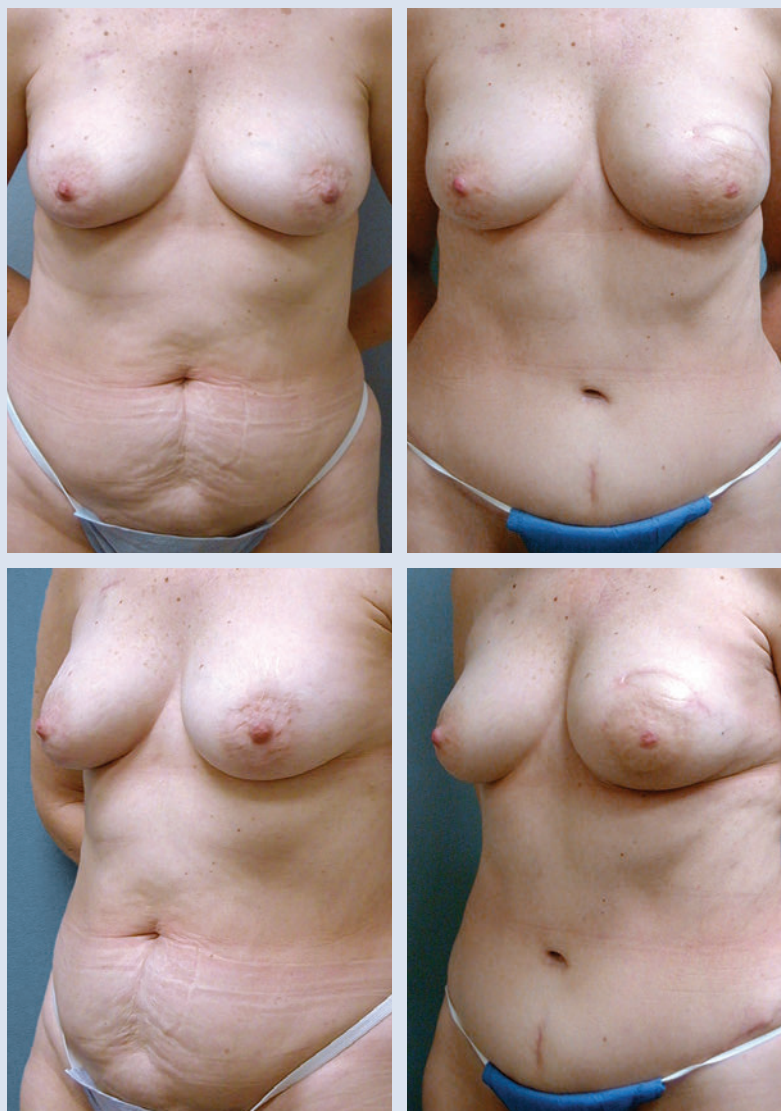
The first choice is a perforator that closely matches the donor vessel caliber. Depending on the location of the defect, this will be a branch of either the internal mammary, serratus, thoracoacromial, or thoracodorsal vessels. The next choice is to expose the IMA vessels between two rib cartilages (either the second or third interspace). The last option is to remove the third costal cartilage. A template of the defect is then created and the vessel orientation is drawn. The template is brought to the flap and the best design is outlined, keeping in mind that any peripheral tissue that shows poor perfusion will be excised. Once harvested, the flap is weighed, and the venous and arterial anastomoses are performed with the operating microscope. We use the anastomotic coupler for the vein and 9-0 nylon interrupted suture anastomosis for the artery.

After anastomosis, the flap is shaped and deepithelialized to match the excised tumor cavity. This is facilitated by using the template design of the defect. The flap is secured in position with surgical staples, and the patient is placed in a seated position to assess the breasts for symmetry. Doppler signals are verified with the flap in its inset position to confirm perfusion. A venous internal Doppler device is especially useful, because inseting the flap often includes squeezing it through a small incision. The signal quality and volume are carefully noted before and after inset to ensure that the vessels are not kinked, because direct vessel visualization is often impossible.

Once the surgeon is satisfied with the shape and size, the flap is inset over drains with the buried portion deepithelialized. The drains should be placed to avoid contact with the pedicle.²⁷ If a DIEP flap is performed, the fascia of the abdomen is closed using nonabsorbable sutures. If rectus diastasis or umbilical hernia is present, these may be repaired in the manner of a cosmetic abdominoplasty.²⁸ Umbilical hernia repair is best performed with an inferior midline incision and internal suturing, which does not compromise the peri-umbilical blood flow.²⁹ The soft tissue of the abdomen is closed overlying two 15 Fr Blake drains.³⁰

The resulting abdominal scar is low on the abdomen, which patients find pleasing. Occasionally there is a small vertical scar as a result of transposition of the umbilicus. In a very small subset of patients with a high waistline and lax abdominal tissue, the umbilicus does not need to be transposed as in a mini abdominoplasty.

PATIENT EXAMPLE

**Fig. 23-4**

This 50-year-old woman presented with T2N0M0 invasive ductal carcinoma of her left breast. She completed neoadjuvant chemotherapy, and we performed immediate partial breast reconstruction with a mini-SIEA flap. Her results are shown 1 year after the completion of radiotherapy, with preservation of shape and symmetry after reconstruction of her left partial mastectomy defect.

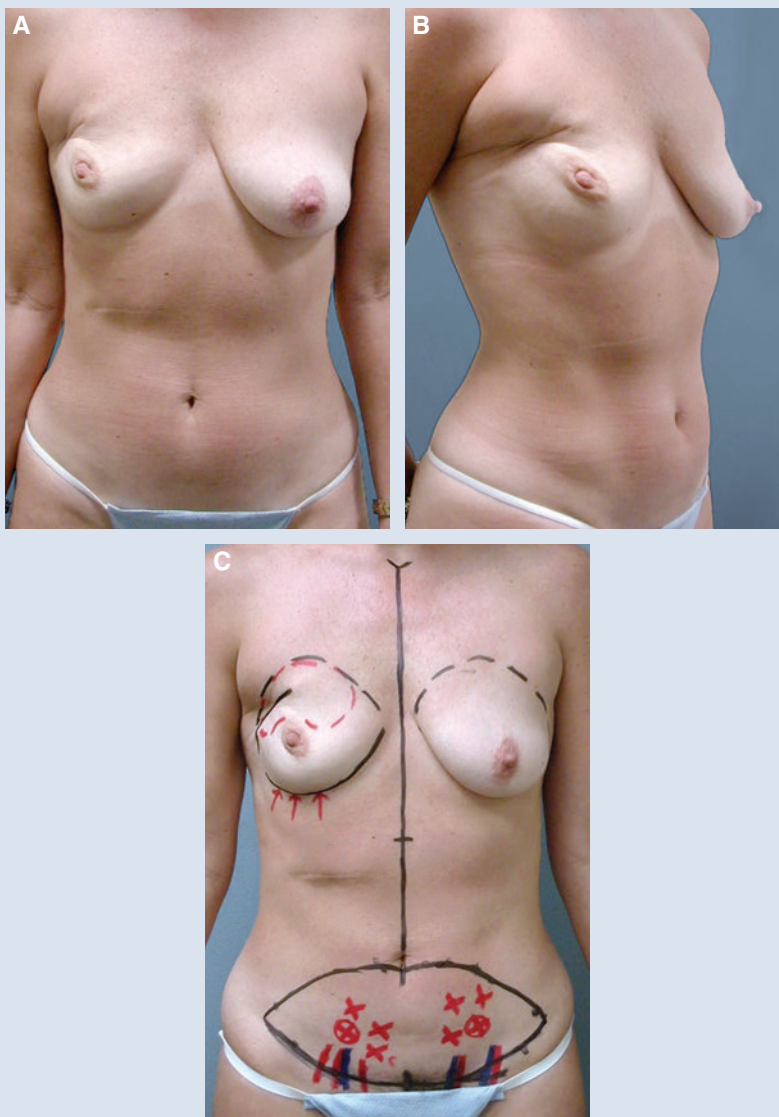
OUTCOMES

We studied patients who had immediate and delayed partial breast reconstructions with an abdominal muscle-preserving flap at our institution, and we have seen excellent results. The immediate reconstructions were performed approximately one week after the ablative surgery, once the final pathology report was back and indicated generous negative margins. The flap volume used was slightly overcorrected to anticipate for shrinkage after radiotherapy, but this was not as significant as expected. The flaps were soft without evidence of fat necrosis either immediately after irradiation or long term. We recommend caution when shaping these flaps, because they do not have as much tolerance for liposuction as nonirradiated flaps. Overall, patients had high satisfaction scores, and most decided not to undergo a small outpatient procedure for flap shaping and resection of the skin paddle.

As with any advanced procedure, success is tied with volume. With experience in abdominal perforator flap anatomy and technique, morbidity such as total flap necrosis, partial flap necrosis, fat necrosis, and venous congestion are rare. While arterial insufficiency and venous congestion are some of the more common complications of larger flaps used for total breast reconstruction, these occur less frequently in partial breast reconstruction as the amount of tissue supplied by the microanastomosis is less, allowing for fewer problems with circulatory imbalances.

In general, aesthetic and functional results after mini-SIEA and mini-DIEP reconstruction are excellent. Because the size of the flap needed for a partial breast deficit is much smaller than that for a total breast reconstruction, there is a high ratio of blood flow to tissue weight, decreasing the likelihood of flap morbidity. In cases in which the oncologic resection does not involve skin removal, the small skin paddle that is placed for postoperative flap monitoring may be excised at a later date, leaving only a linear incision overlying the breast.

PATIENT EXAMPLE

**Fig. 23-5, A-C**

This 42-year-old woman presented 2½ years after a lumpectomy for T1N0M0 invasive ductal carcinoma. She requested reconstruction for her significant breast asymmetry after BCT (A and B). She did not want any back scars and was most interested in an abdominal flap. Before surgery, the vessels were marked, and the flap was outlined (C).

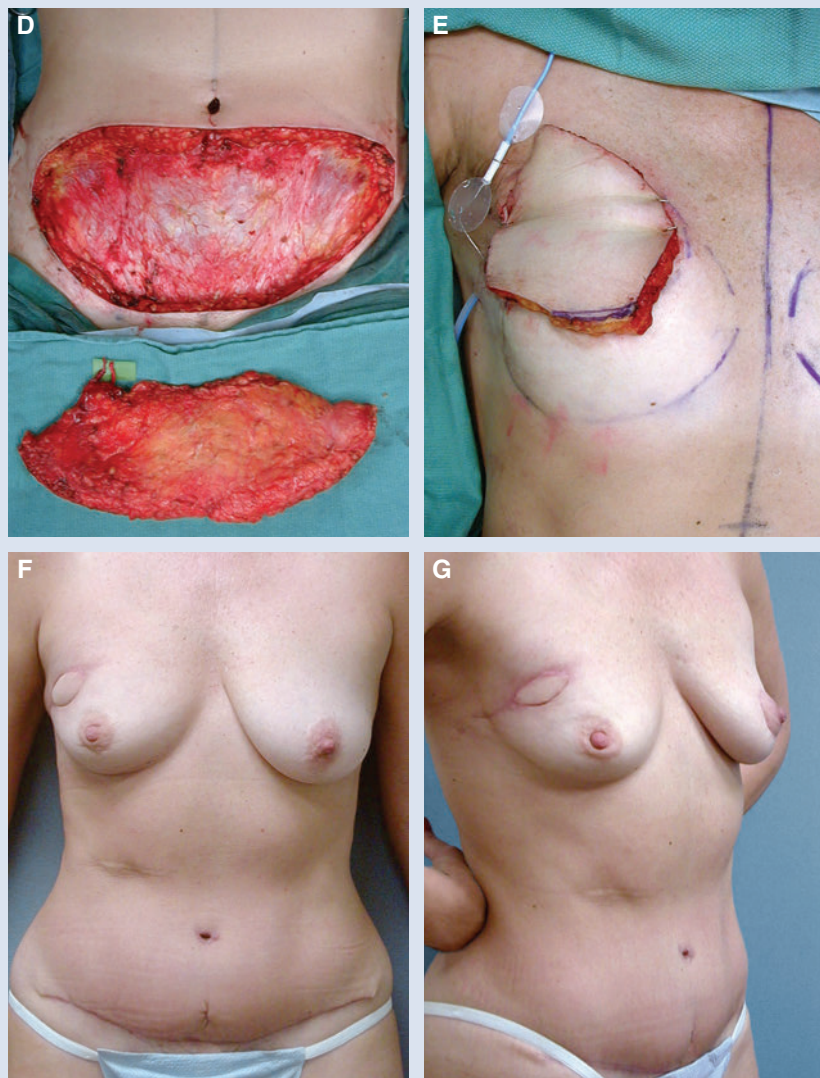


Fig. 23-5, D-G

A mini-SIEA flap was harvested from the abdomen (*D*), and the flap was placed in the right breast (*E*). She is shown 12 months after surgery (*F* and *G*).

CONCLUSION

An ideal breast flap is one that accurately replicates the original tissue to match its shape, size, consistency, mobility, and sensation. The muscle-preserving abdominal free flap provides a transverse paddle of abdominal skin and fat which remains unmatched in quality and texture for breast reconstruction. The decision to use a mini-SIEA or a mini-DIEP flap is made on the basis of preoperative and intraoperative factors. This technique includes cosmetic advantages at the donor site without functional compromise. The mini-SIEA and mini-DIEP flaps have firmly established themselves as reliable flaps for partial breast reconstruction because of their low donor-site morbidity and high patient satisfaction.

Critical Issues

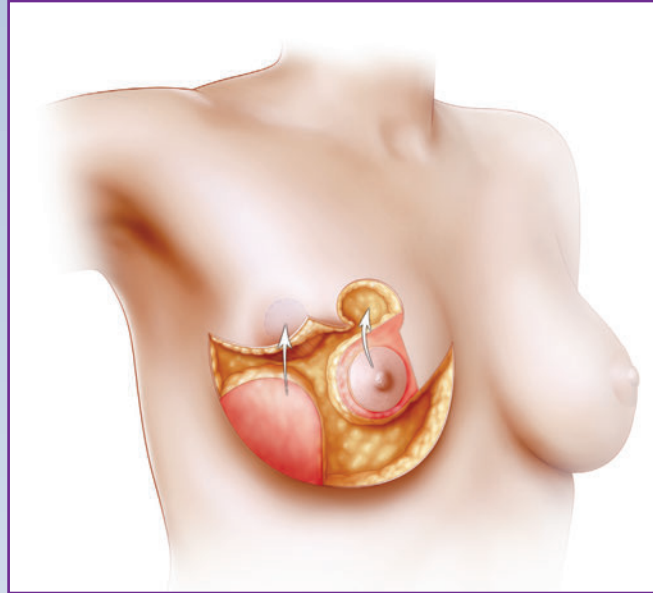
- The patient's desire for distant flap reconstruction rather than local flap BCT must be discussed in the first consultation.
- A more conservative flap design may be possible using a distant flap.
- A breast defect template is invaluable in determining the best flap design.
- Smaller and variable recipient blood vessels may be chosen, based on the defect location.
- The decision to employ a mini-SIEA versus a mini-DIEP flap is made intraoperatively.

References

1. Zurrida S, Bassi F, Arnone P, et al. The changing face of mastectomy (from mutilation to aid to breast reconstruction). *Int J Surg Oncol* 2011;980158, 2011.
2. Holmes DR, Schooler W, Smith R. Oncoplastic approaches to breast conservation. *Int J Breast Cancer* 2011;303879, 2011.
3. Chen AM, Meric-Bernstam F, Hunt KK, et al. Breast conservation after neoadjuvant chemotherapy. *Cancer* 103:689, 2005.
4. Khansa I, Colakoglu S, Curtis MS, et al. Postmastectomy breast reconstruction after previous lumpectomy and radiation therapy: analysis of complications and satisfaction. *Ann Plast Surg* 66:444, 2011.
5. Haloua MH, Krekel NM, Winters HA, et al. A systematic review of oncoplastic breast-conserving surgery: current weaknesses and future prospects. *Ann Surg* 257:609, 2013.
6. Clough KB, Thomas SS, Fitoussi AD, et al. Reconstruction after conservative treatment for breast cancer: cosmetic sequelae classification revisited. *Plast Reconstr Surg* 114:1743, 2004.
7. Munhoz AM, Aldrighi CM. Determining the optimal approach to breast reconstruction after partial mastectomy. *Plast Reconstr Surg* 118:813; author reply 814, 2006.
8. Spear SL, Hannan CM, Willey SC, et al. Nipple-sparing mastectomy. *Plast Reconstr Surg* 123:1665, 2009.

9. Borger JH, Kemperman H, Smitt HS, et al. Dose and volume effects on fibrosis after breast conservation therapy. *Int Radiat Oncol Biol Phys* 30:1073, 1994.
10. Park CC, Mitsumori M, Nixon A, et al. Outcome at 8 years after breast-conserving surgery and radiation therapy for invasive breast cancer: influence of margin status and systemic therapy on local recurrence. *J Clin Oncol* 18:1668, 2000.
11. Meric F, Mirza NQ, Vlastos G, et al. Positive surgical margins and ipsilateral breast tumor recurrence predict disease-specific survival after breast-conserving therapy. *Cancer* 97:926, 2003.
12. Peterson ME, Schultz DJ, Reynolds C, et al. Outcomes in breast cancer patients relative to margin status after treatment with breast-conserving surgery and radiation therapy: the University of Pennsylvania experience. *Int J Radiat Oncol Biol Phys* 43:1029, 1999.
13. Freedman G, Fowble B, Hanlon A, et al. Patients with early stage invasive cancer with close or positive margins treated with conservative surgery and radiation have an increased risk of breast recurrence that is delayed by adjuvant systemic therapy. *Int J Radiat Oncol Biol Phys* 44:1005, 1999.
14. Smitt MC, Nowels KW, Zdeblick MJ, et al. The importance of the lumpectomy surgical margin status in long-term results of breast conservation. *Cancer* 76:259, 1995.
15. Gray JR, McCormick B, Cox L, et al. Primary breast irradiation in large-breasted or heavy women: analysis of cosmetic outcome. *Int J Radiat Oncol Biol Phys* 21:347, 1991.
16. Matory WE Jr, Werthheimer M, Fitzgerald, TJ, et al. Aesthetic results following partial mastectomy and radiation therapy. *Plast Reconstr Surg* 85:739, 1990.
17. Kronowitz SJ, Hunt KK, Kuerer HM, et al. Practical guidelines for repair of partial mastectomy defects using the breast reduction technique in patients undergoing breast conservation therapy. *Plast Reconstr Surg* 120:1755, 2007.
18. Kronowitz SJ, Feledy JA, Hunt KK, et al. Determining the optimal approach to breast reconstruction after partial mastectomy. *Plast Reconstr Surg* 117:1; discussion 12, 2006.
19. Nahabedian MY, Tsangaris T, Momen B. Breast reconstruction with the DIEP flap or the muscle-sparing (MS-2) free TRAM flap: is there a difference? *Plast Reconstr Surg* 115:436; discussion 445, 2005.
20. Wolfram D, Schoeller T, Hussl H, et al. The superficial inferior epigastric artery (SIEA) flap: indications for breast reconstruction. *Ann Plast Surg* 57:593, 2006.
21. Rosenberg JJ, Chandawarkar R, Ross MI, et al. Bilateral anterolateral thigh flaps for large-volume breast reconstruction. *Microsurgery* 24:281, 2004.
22. Blondeel PN, Beyens G, Verhaeghe R, et al. Doppler flowmetry in the planning of perforator flaps. *Br J Plast Surg* 51:202, 1998.
23. Rizzuto RP, Allen RJ. Reconstruction of a partial mastectomy defect with the superficial inferior epigastric artery (SIEA) flap. *J Reconstr Microsurg* 20:441, 2004.
24. Taylor GI, Daniel RK. The anatomy of several free flap donor sites. *Plast Reconstr Surg* 56:243, 1975.
25. Spiegel AJ, Khan FN. An intraoperative algorithm for use of the SIEA flap for breast reconstruction. *Plast Reconstr Surg* 120:1450, 2007.
26. Granzow JW, Levine JL, Chiu ES. Breast reconstruction using perforator flaps. *J Surg Oncol* 94:441, 2006.
27. Hamdi M, Rebecca A. The deep inferior epigastric artery perforator flap (DIEAP) in breast reconstruction. *Semin Plast Surg* 20:95, 2006.
28. Munhoz AM, Sturtz G, Montag E, et al. Clinical outcome of abdominal wall after DIEP flap harvesting and immediate application of abdominoplasty techniques. *Plast Reconstr Surg* 116:1881, 2005.
29. Bruner TW, Salazar-Reyes H, Friedman JD. Umbilical hernia repair in conjunction with abdominoplasty: a surgical technique to maintain umbilical blood supply. *Aesthet Surg J* 29:333, 2009.
30. Scevola S, Youssef A, Kroll SS, et al. Drains and seromas in TRAM flap breast reconstruction. *Ann Plast Surg* 48:511, 2002.

PART FOUR



**Correction of the
Breast-Conserving
Therapy Deformity:
Delayed Partial Breast
Reconstruction**

24

Classification and Analysis of the Breast-Conserving Therapy Deformity

Krishna B. Clough, Isabelle Sarfati, Sunil S. Thomas, Claude Nos

Ideally, BCT should result in a breast with a normal appearance, without any major asymmetry or deformity. Unfortunately this is not always the case and subsequent deformities are not uncommon. An estimated 20% to 40% of women who undergo BCT have a residual deformity or breast asymmetry.¹⁻³ Some of these patients are referred to a plastic surgeon for reconstruction to improve the appearance of the treated breast; such reconstruction may take place many years after the initial treatment is completed.⁴ A growing number of plastic surgeons are faced with requests for the correction of complex sequelae of BCT; these surgeons also face the technical problems related to managing an irradiated breast.

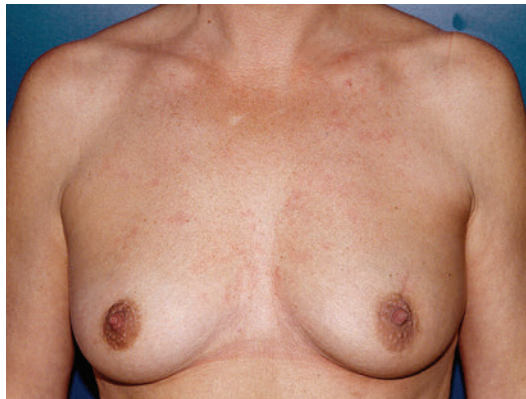

Fig. 24-1

In 1998 and 2004, we published a classification of cosmetic sequelae after conservative treatment based on two series of patients.^{5,6} This classification was proposed as a guide to help surgeons identify cosmetic sequelae and to plan reconstruction.

PATIENTS AND METHODS

BCT protocols can be schematically classified into two groups. The first group includes patients with small tumors (less than 3 to 4 cm), treated with BCS and postoperative radiotherapy, with or without adjuvant therapy (chemotherapy and endocrine therapy).⁷⁻⁹ The second group comprises patients with larger tumors, treated with preoperative therapy (chemotherapy, endocrine therapy, or even radiotherapy, separately or in combination) to reduce the tumor volume and to allow BCS in patients responding to this treatment.¹⁰ In all BCT patients, the combination of conservative surgery and radiotherapy can induce both skin and glandular sequelae. Various combinations of these sequelae are observed, and the possible asymmetry with the untreated breast always presents a complex problem for the plastic surgeon. We classify these cosmetic sequelae into the following three types to simplify the surgical approach.^{5,6}

Type 1 Cosmetic Sequelae

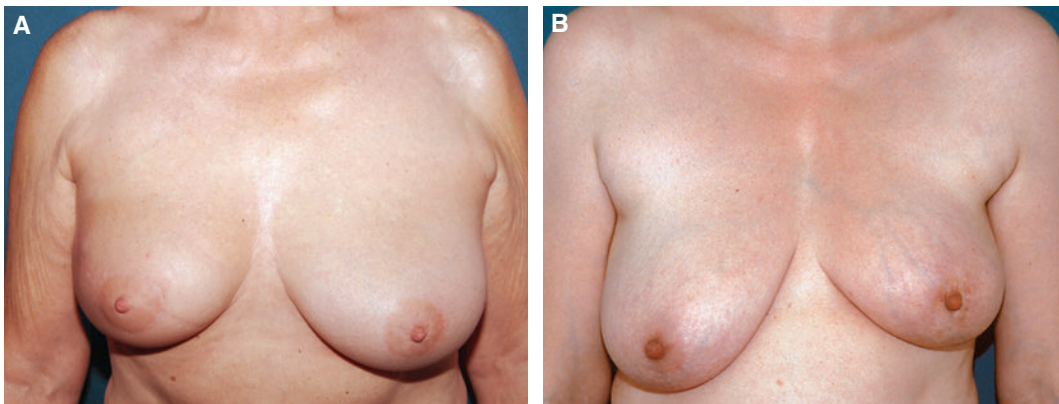


Fig. 24-2

The overall shape of the treated breast is maintained, because there is no deformity. The major abnormality is an asymmetry in the shape and volume between the two breasts (A and B), which can be repaired by conserving the irradiated breast and symmetrizing the contralateral breast.

Type 2 Cosmetic Sequelae

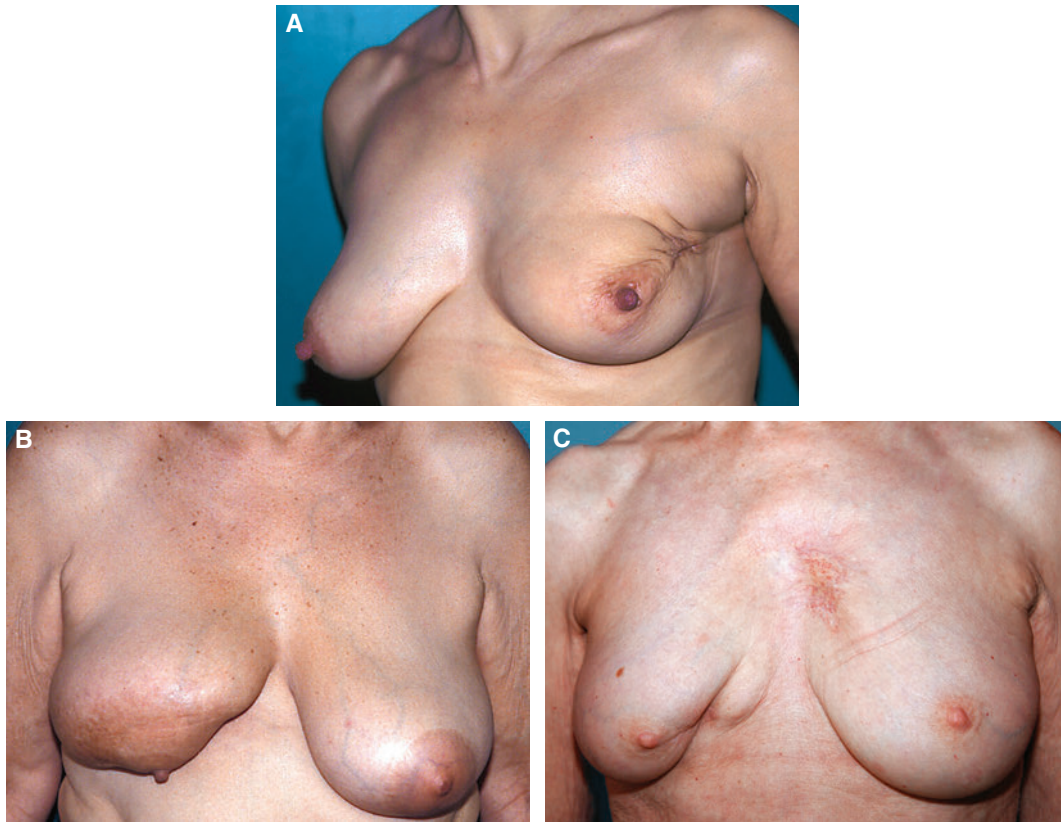


Fig. 24-3

There is an obvious deformity of the treated breast associated with breast asymmetry, often resulting from the resection of an upper outer quadrant tumor (*A*), a lower quadrant tumor (*B*), or an inner quadrant tumor (*C*). A mastectomy is not required. For these patients, reconstruction is compatible with breast conservation.

Type 3 Cosmetic Sequelae

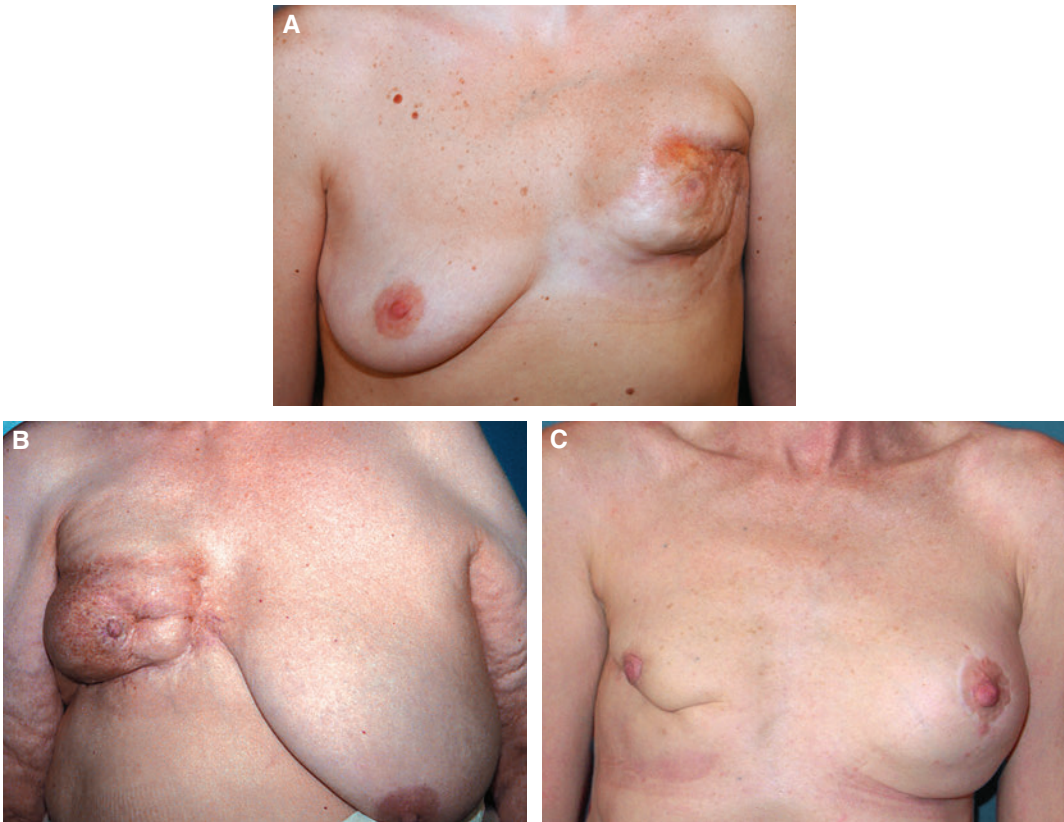

Fig. 24-4

There is a massive retractile fibrosis of the entire breast (also called marble breast) (A and B) and/or a major postoperative deformity of the breast (C), making partial reconstruction impossible. The breast is so severely deformed that it cannot be conserved. A mastectomy with immediate reconstruction is the only possible option for restoring the normal breast shape and contour.

Table 24-1 Ipsilateral and Contralateral Procedures for the Correction of Cosmetic Sequelae in 85 Patients

Type of Surgery	Type of Cosmetic Sequelae			Total (%) (n = 85)
	Type 1 (n = 48)	Type 2 (n = 33)	Type 3 (n = 4)	
Ipsilateral	25	30	4	59 (68.2)
Contralateral	46	27	2	75 (88.2)

NB: Most patients were treated with a combination of ipsilateral and contralateral procedures.

Table 24-2 Detailed Operative Techniques for Each Type of Cosmetic Sequelae in 85 Patients

Type of Cosmetic Sequelae	Ipsilateral Surgery (n = 58)	Contralateral Surgery (n = 75)
Type 1 (n = 48)	NAC repositioning: 6 Breast augmentation: 6 Mammoplasty: 6 Other: 7	Breast reduction: 39 Breast augmentation: 5 Other: 2
Type 2 (n = 33)	Myocutaneous flap: 15 Mammoplasty: 15 NAC repositioning: 13 Breast augmentation: 6 Other: 3	Breast reduction: 20 Breast augmentation: 4 Other: 3
Type 3 (n = 4)	Mastectomy plus immediate breast reconstruction with a myocutaneous flap: 4	Breast reduction: 2

NB: Several procedures were performed in some patients to obtain an optimal result. Other procedures include excision of fat necrosis, liposuction, and scar revision.

NAC, Nipple-areola complex.

We have operated on more than 150 patients with cosmetic sequelae. A systematic prospective analysis of the first 85 consecutive patients was published in 2004.⁶

After reconstruction, patients were followed during the immediate postoperative period and every 6 months thereafter. The median follow-up after reconstruction was 33 months (range 6 to 132 months). At each breast cancer follow-up visit, the cosmetic result of reconstruction was quantified and recorded. The cosmetic result after reconstruction for cosmetic sequelae was evaluated using the following scoring system: 1 (excellent), 2 (good), 3 (average), 4 (below average), and 5 (poor). These scores were described in our previous publications^{5,6,11} and represent the mean of the individual scores given by a panel of three individuals—the surgeon, his or her nurse, and his or her assistant. Scores of 1, 2, and 3 were broadly categorized as good, and scores of 4 and 5 were categorized as poor.

RESULTS AND ANALYSIS OF THE INITIAL 85 CASES

The mean patient age was 44 years (range 27 to 68 years). The interval between the initial BCT and reconstruction of cosmetic sequelae ranged from 10 to 318 months (26.5 years), with a median of 87 months (7.3 years).

UICC Classification

Patients were classified according to the 1998 UICC classification,¹² with the exception of seven patients (Tx, or those with an unknown tumor stage) who were initially treated by another team and subsequently referred to us for cosmetic sequelae with no detailed docu-

mentation of their cancer stage. The tumors for the 85 patients were given the following classifications: 13 T0, 25 T1, 35 T2, 5 T3, and 7 Tx.

Cosmetic Sequelae Classification

All sequelae were graded according to our classification, as shown in the tables. Forty-eight patients (56.5%) had type 1 sequelae, 33 (38.8%) had type 2 sequelae, and 4 (4.7%) had type 3 sequelae.

Tumor Site

Most tumors were in the upper outer quadrant (45 cases), 15 were in the upper inner quadrant, 13 in the lower outer quadrant, 7 in the lower inner quadrant, and 5 in the central region. Lower quadrant tumors more frequently involved type 2 sequelae (33% of the cases) than type 1 sequelae (16.6%).

Initial Local Therapy (BCT)

A lumpectomy and radiotherapy were proposed in 81 patients (95.3%). Three (3.5%) patients chose not to undergo postoperative irradiation. Four patients (4.7%) were treated with radiotherapy alone.

Reconstruction of Type 1 Cosmetic Sequelae

Forty-eight patients had type 1 cosmetic sequelae after BCT (see Tables 24-1 and 24-2).

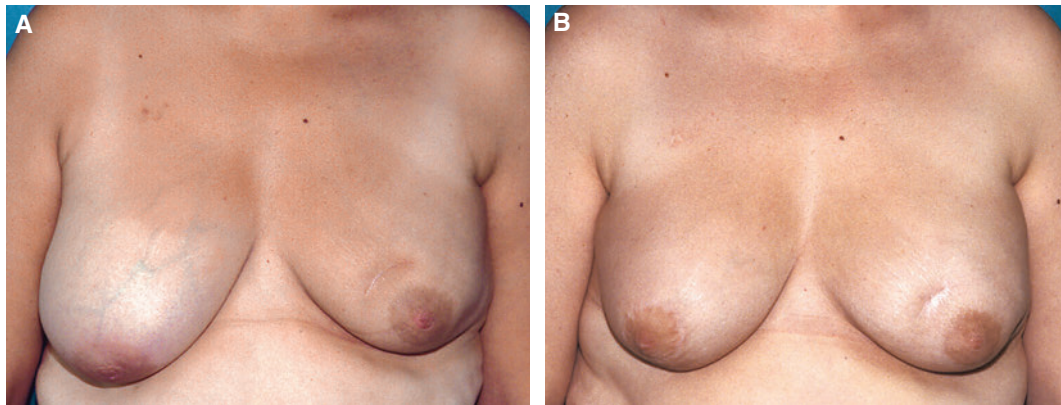


Fig. 24-5

This patient had cancer in the upper inner quadrant of the left breast. Preoperatively, the breast had a normal shape but was asymmetrical with the contralateral breast (A). The asymmetry was treated with a contralateral mammoplasty (B). No procedures were performed on the irradiated breast.

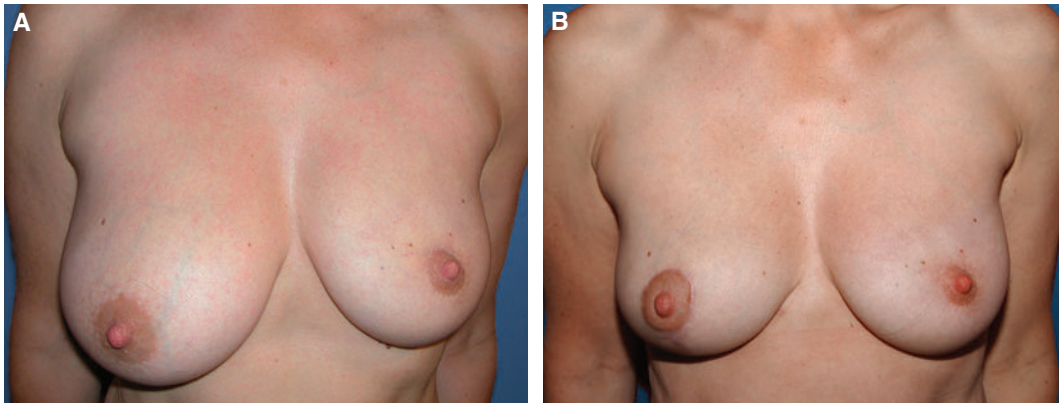


Fig. 24-6

This patient had a tumor located at the junction of the upper quadrants of the left breast. The patient is shown preoperatively (A). A right breast reduction was performed (B).

Treatment of the Irradiated Breast

Twenty-five patients (52.1%) had ipsilateral surgery. Of these, only 6 had mammoplasty, because we try to avoid glandular undermining on an irradiated breast.^{9,10,13} Six other patients had breast augmentation with a submuscular implant. The remaining 13 patients had minor procedures, such as NAC repositioning, minimal resection of a fibrous zone, scar revision, or localized liposuction.

Treatment of the Contralateral Breast

Contralateral symmetrization was performed in 46 of these 48 patients. Reduction mammoplasties were performed in 39 patients, breast augmentation in 5 patients, and other procedures in 2 patients; 23 patients (47.9%) were treated solely with a contralateral procedure.

Number of Operations

Thirteen patients (27.1%) had a second operation to further improve their cosmetic sequelae.

Reconstruction of Type 2 Cosmetic Sequelae

Thirty-three patients were treated for type 2 cosmetic sequelae (see Tables 24-1 and 24-2).

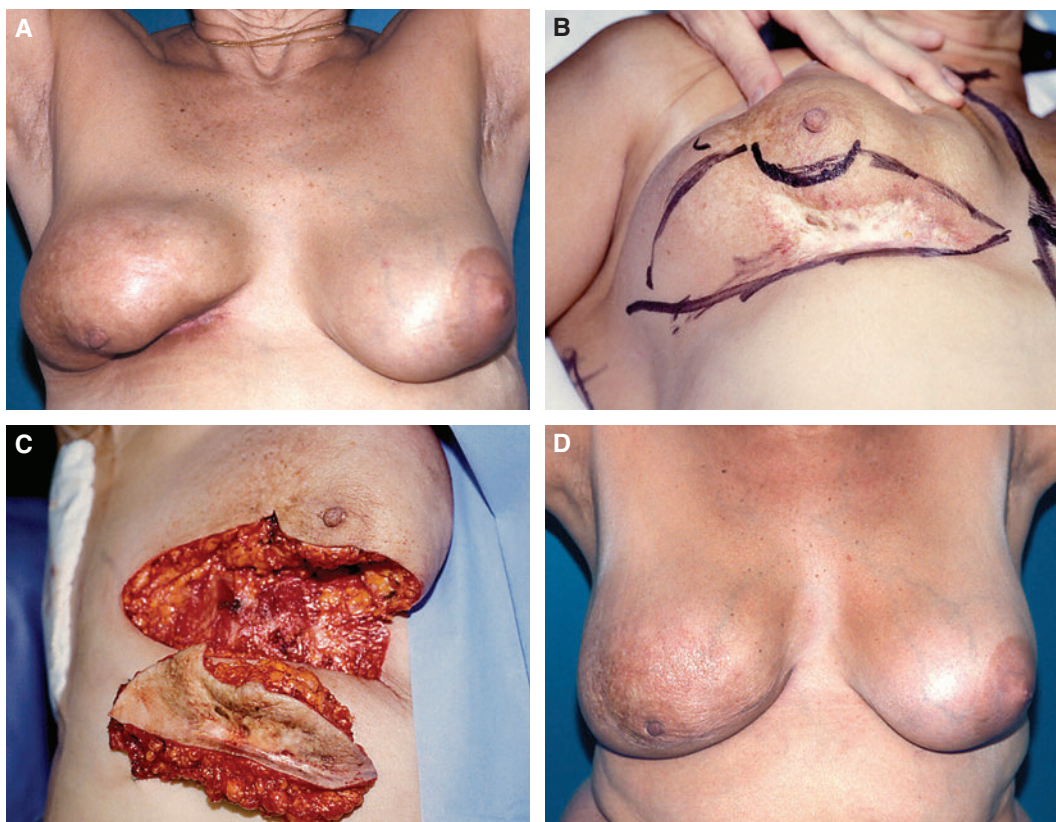
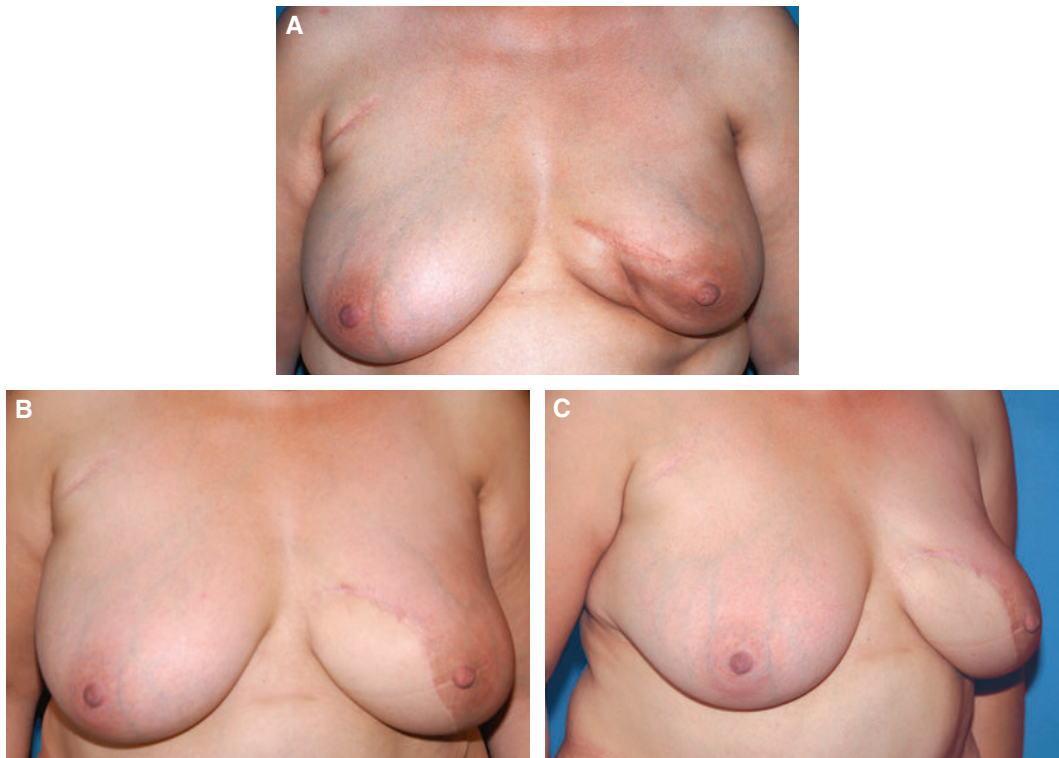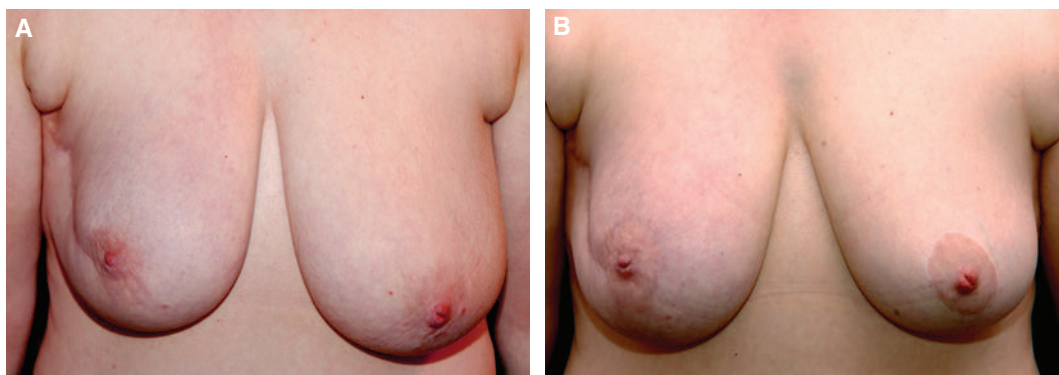


Fig. 24-7

Preoperatively, this patient had breast retraction, pain, and skin ulceration (A). A partial reconstruction of the lower quadrants with a latissimus dorsi flap was performed (B and C). The surgical plan included resection away from the fibronecrotic zones. The patient is shown 3 years postoperatively (D).

**Fig. 24-8**

This patient had type 2 cosmetic sequelae affecting the lower inner quadrant. Preoperatively, she had a major retraction of the quadrant with skin adhesions to the chest wall (A). A partial breast reconstruction with a latissimus dorsi flap was performed. She is shown 2 years postoperatively (B and C).

**Fig. 24-9**

This patient had type 2 cosmetic sequelae affecting the upper outer quadrant. Preoperatively, the quadrant was retracted, causing volume asymmetry (A). Partial breast reconstruction with fat grafting was performed. The patient is shown 1 year postoperatively (B). In addition to fat grafting, scar revision and a contralateral breast reduction were performed.

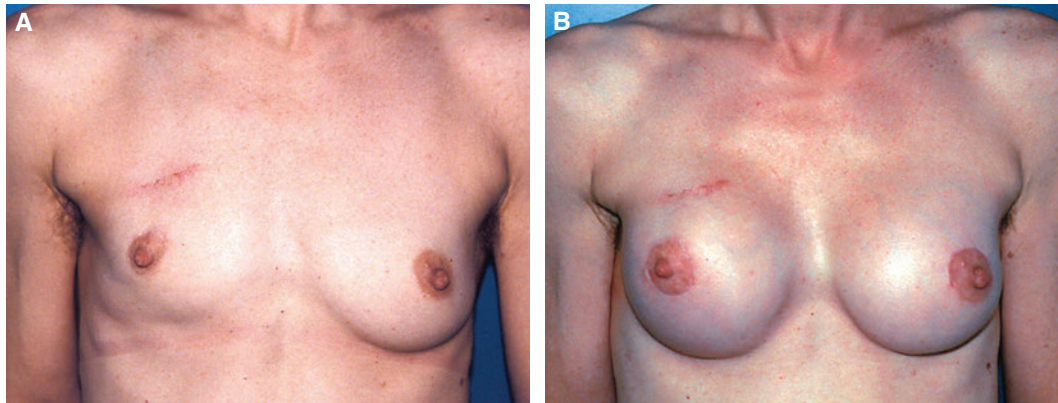


Fig. 24-10

Preoperatively, this patient had major volume asymmetry, postradiotherapy fibrosis of the upper quadrants, and nipple-areola complex deviation (A). Partial breast reconstruction with a submuscular implant was performed, and both NACs were repositioned. She is shown 1 year postoperatively (B).

Because the predominant sequela in these patients was a major breast deformity, a corrective procedure on the irradiated breast was performed in almost all of these patients: 30 of 33 (91%). A partial breast reconstruction with a myocutaneous flap was performed in 15 patients, or 45.5% (latissimus dorsi in 14 cases and transverse rectus abdominis [TRAM] flap in 1 case). Another 15 patients were treated using an atypical mammoplasty, limiting undermining. This mammoplasty usually consisted of an en bloc resection of the distorted zone of the breast and overlying skin, with a direct glandular suture and recentralization of the NAC. Other procedures were performed, either alone or in combination with a flap or a mammoplasty: NAC repositioning in 13 cases (39.4%), implant augmentation in 6 cases (18.2%), and other techniques in 3 cases (18.2%).

Treatment of the Contralateral Breast

A symmetrizing procedure was performed in 27 patients (81.8%) with type 2 cosmetic sequelae. Breast reduction was performed in 20 patients, breast augmentation in 4 patients, and a minor procedure in 3 patients.

Number of Operations

A second reconstruction procedure was performed in 12 patients (36.4%).

Reconstruction of Type 3 Cosmetic Sequelae

Four patients had type 3 cosmetic sequelae (see Tables 24-1 and 24-2).

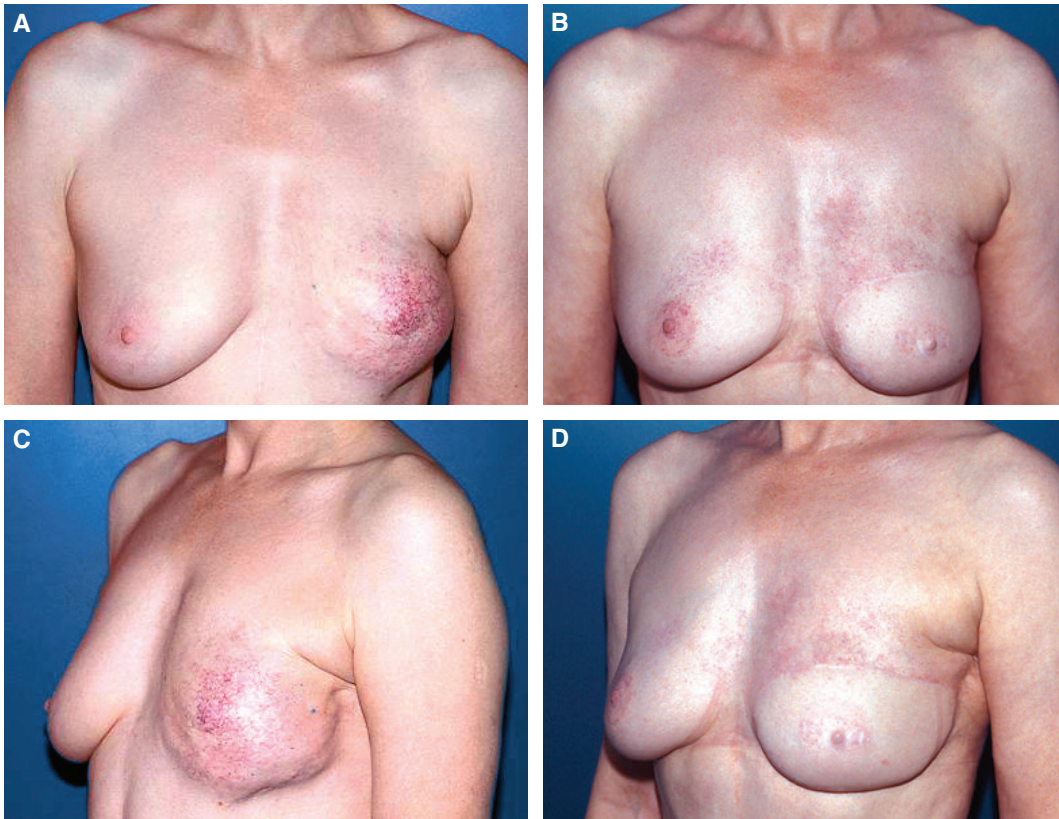


Fig. 24-11

Preoperatively, this patient had postradiotherapy fibrosis with marble breast, disabling pain, and preulcerative skin (A and C). The surgical plan included a mastectomy and immediate TRAM flap reconstruction. She is shown 6 years postoperatively (B and D). Cancer of the right breast was diagnosed 4 years after this operation and was treated with BCT.

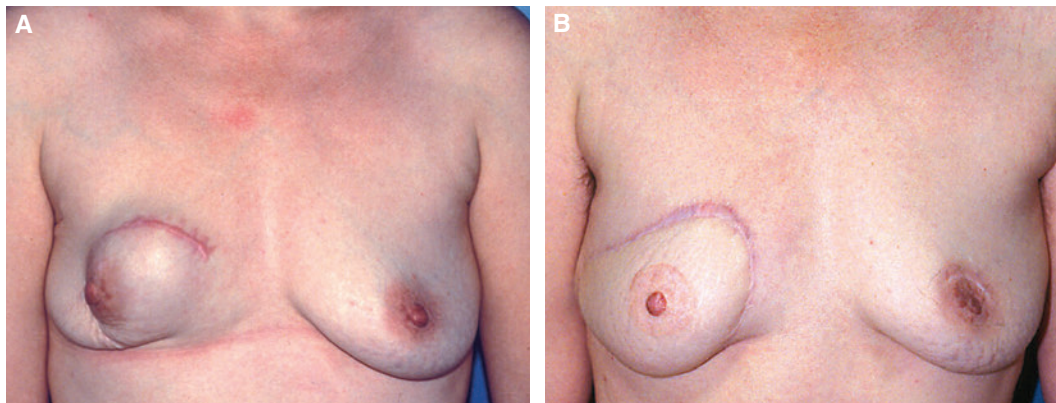


Fig. 24-12

This patient developed type 3 cosmetic sequelae after a partial subcutaneous mastectomy, placement of a subcutaneous implant, and radiotherapy. Preoperatively, the patient had significant capsular contracture, radiation-induced fibrosis, and distorted breast size and shape (A). The treatment included a mastectomy with implant removal and immediate TRAM flap reconstruction. She is shown 2 years postoperatively (B).

Treatment of the Irradiated Breast

All patients were treated with a total mastectomy and immediate flap reconstruction.

Treatment of the Contralateral Breast

A symmetrizing procedure with breast reduction was performed in two patients.

Number of Operations

A second reconstruction procedure was performed in 3 patients.

COMPLICATIONS AFTER COSMETIC SEQUELAE CORRECTION

Early Complications

Sixteen patients (18.8%) developed a complication during the first 2 months after the operation: 15 local complications (17.7%) and one systemic complication (chest infection). The complication rate was not significantly different according to the type of cosmetic sequelae: 16.6% for type 1 and 21.2% for type 2. No complications were observed in patients with type 3 cosmetic sequelae.

Late Complications

Three patients developed late complications that persisted for more than 2 months after the operation. All three were patients with major postradiotherapy sequelae who chose not to have a mastectomy. They developed progressive skin and glandular fibrosis with limited necrosis, which was treated with repeated local care, or conservative wound treatment, in three cases.

EVALUATION OF COSMETIC RESULTS AFTER COSMETIC SEQUELAE CORRECTION

Overall, 90.5% of patients obtained either an excellent, good, or average result (scores 1, 2, or 3) at 2 years. The cosmetic result was better for type 1 cosmetic sequelae (97.6%) than for type 2 cosmetic sequelae (82.7%). The 4 patients treated for type 3 cosmetic sequelae obtained a good result.

CANCER RECURRENCE

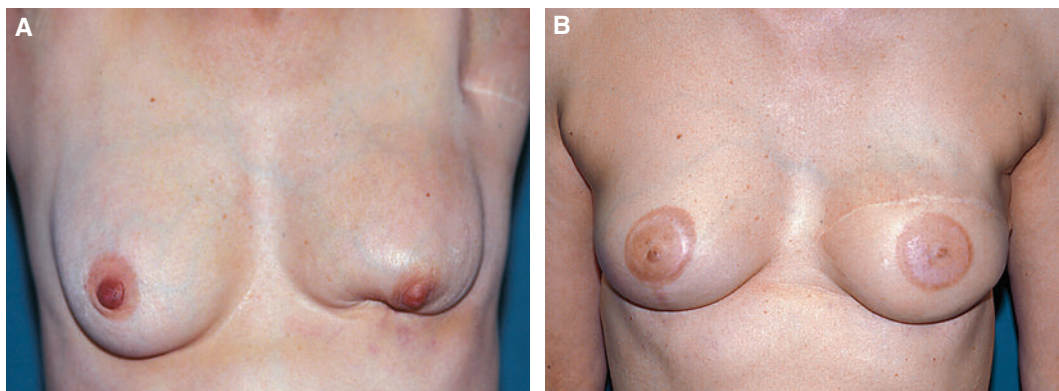


Fig. 24-13

Preoperatively, this patient's lower pole retracted after a lumpectomy, masking a recurrence (A). A mastectomy and immediate breast reconstruction with a latissimus dorsi flap and implant placement were performed. The patient is shown 2 years postoperatively (B).

During the course of this study, another 13 patients who were referred to us for cosmetic sequelae had a clinical or subclinical breast recurrence. The first group consisted of seven patients who were referred for surgical correction of cosmetic sequelae caused by an underlying recurrence, which was suspected on clinical examination and confirmed with a fine-needle aspiration or a core biopsy. All of these patients were treated with a mastectomy and were excluded from the study.

DISCUSSION

Sixty percent to 70% of patients with breast cancer are currently treated with BCT, and 20% to 30% of patients present major sequelae after lumpectomy and radiotherapy.^{1,2,11,13-15}

The combination of the increasing incidence of breast cancer and the increasing rate of BCT accounts for the growing number of patients consulting for cosmetic sequelae.

Cosmetic sequelae after treatment for breast cancer is a relatively new issue for most plastic surgeons, but one that is becoming increasingly common. To address the complex reconstruction problems raised by these patients and to facilitate their management, we published our cosmetic sequelae classification in 1988 and revised it in 2004.^{5,6} Various authors have proposed other classifications.^{4,13,15}

Of the more than 150 patients we have treated for cosmetic sequelae after BCT, most presented with type 2 sequelae and were more concerned with their breast deformity than their breast asymmetry. However, after having been informed of the available reconstructive options, many patients with type 2 sequelae decided not to undergo the proposed procedures unless they had a major disability related to their breast. Many of these patients required flap reconstruction to repair the defect. Alternatively, patients with type 1 cosmetic sequelae were fairly easily convinced of the benefit of a simple contralateral breast reduction to restore breast symmetry. Most patients therefore consulted for type 2 cosmetic sequelae, but half of the operated patients had type 1 sequelae, and about one third had type 2 sequelae. Patients with major type 3 cosmetic sequelae are much rarer.

No classification system is all-inclusive. However, although it is schematic and imperfect, our classification has many advantages. It is simple, does not require a complex classification or measurement system, is reproducible between observers, and constitutes a valuable tool to guide treatment decisions for the planning of breast reconstruction in patients with cosmetic sequelae.

Type 1 Cosmetic Sequelae

In our patients with type 1 cosmetic sequelae, the overall contour and shape of the treated breast were maintained, but the patients were concerned with asymmetry in volume and shape compared with the untreated breast. In some cases, this asymmetry was related to the treatment, resulting from glandular resectioning during the lumpectomy and from postradiotherapy retraction. It was visible soon after surgery.

Asymmetry can also be observed later, if it is related to weight gain.

Although the untreated breast changes with age and increases in size with weight gain, the irradiated breast remains stable as a result of radiotherapy. This late asymmetry further worsens the initial asymmetry caused by surgery and radiotherapy.

The main treatment for type 1 cosmetic sequelae is a contralateral mammoplasty to symmetrize the breasts, using the irradiated breast as the “model” for contralateral reshaping.

In our first series of patients treated for cosmetic sequelae,⁵ we recommended avoiding any surgery on the treated breast because of the presence of fibrosis and a decreased blood supply to the breast, which resulted from the combined effects of radiotherapy and surgi-

cal undermining. In the second series,⁶ a procedure on the treated breast was performed in 25 patients with type 1 cosmetic sequelae; however, only 6 of these operations really concerned the breast parenchyma, because most ipsilateral operations (13 of 25) consisted of minor skin procedures.

This conservative approach to leave the irradiated breast untreated can only be envisaged when the residual volume is sufficient to allow reduction of the contralateral breast to the same size. When this is not the case, the patient frequently requests breast augmentation; this request should be carefully evaluated and often discouraged because of the history of breast irradiation. In our second series, a breast augmentation implant was used in five patients with type 1 cosmetic sequelae. They were always placed in a submuscular position to avoid any sectioning or undermining of the irradiated breast.

Bilateral breast augmentation is a rare treatment option for carefully selected patients with soft, hypoplastic breasts and asymmetry that can be corrected with two submuscular implants, with a larger implant on the irradiated side. These patients must be warned about the risk of more marked asymmetry that could occur over time between the irradiated breast and the contralateral breast.

The complication rate is much higher in this population than in patients with nonirradiated breasts.

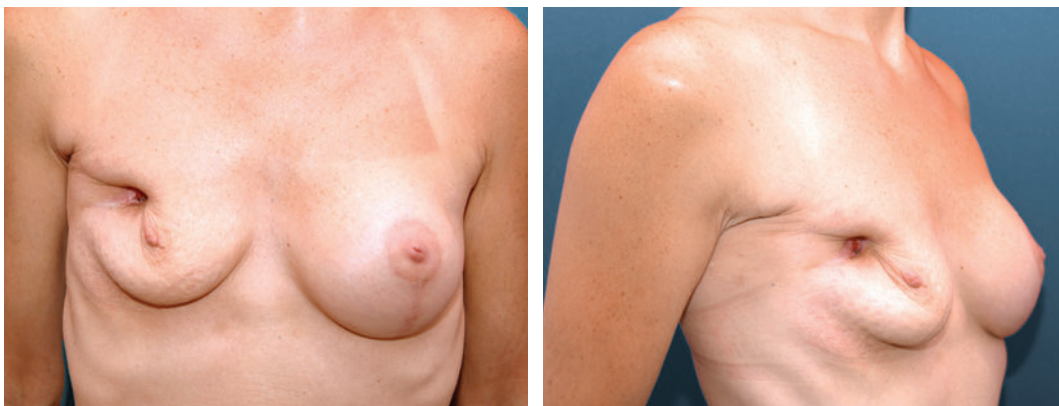

Fig. 24-14

We managed several cases of glandular and skin necrosis in patients initially treated for bilateral augmentation after BCT for breast cancer. This patient was referred 4 years after undergoing bilateral breast augmentation with implants for a right-sided breast cancer deformity. The complications included extensive skin and glandular necrosis of the upper outer quadrant of the irradiated breast, requiring removal of the implant. She is shown after delayed healing that lasted 1 year. Implant augmentation after BCT for breast can-

cer must therefore be considered a high-risk procedure to be reserved for rare, carefully selected cases (see Chapter 31).

Fat grafting¹⁶⁻¹⁸ or lipofilling¹⁹⁻²⁴ of the irradiated breast is another solution for major hypotrophy after BCT associated with type 1 cosmetic sequelae. Lipofilling can increase the volume of the breast with fat, thereby avoiding the risks related to implants in an irradiated area. This is an innovative and fascinating line of research that requires further evaluation.²⁴ Fat grafting must not interfere with subsequent radiologic follow-ups in these patients, because the risk of local recurrence is high. (The lifetime risk is about 1% per year.)

Generally, the surgeon managing these patients must learn to limit his or her goal of achieving “perfection” in terms of breast morphology. Many patients with type 1 cosmetic sequelae wish to have bilateral surgery, but we try to convince them to limit the procedures to only the irradiated breast. This very conservative approach requires a lot of explanations and counseling but nevertheless achieves excellent symmetry and good cosmetic results (97% at 2 years) for type 1 cosmetic sequelae, with a very low complication rate.

Type 2 Cosmetic Sequelae

Type 2 cosmetic sequelae are by far the most difficult to manage, as reflected by the wide range of surgical techniques proposed. In these cases, the breast shape is influenced by a localized defect and/or a major breast retraction, inducing deformity and asymmetry. A glandular defect is always present, usually associated with skin sequelae and NAC deviation. These type 2 sequelae are related to surgery because of the large volume of breast tissue resected and/or the lack of immediate breast reshaping at the time of the cancer resection. Rarer causes are complications such as hematoma, infection, and glandular or fat necrosis. Unlike type 3 cosmetic sequelae, type 2 sequelae can be corrected by conserving the treated breast, but these partial reconstructions raise numerous problems related to radiation sequelae and preexisting scars.

A partial reconstruction of the treated breast was recommended to all patients in this series; however, three patients were not treated on the irradiated side because of their formal refusal of any surgery to the treated breast. An ipsilateral procedure was therefore performed in 30 patients (91%). For patients with type 2 cosmetic sequelae, the goals are to correct the breast deformity and to restore normal shape and symmetry. The ipsilateral procedure is complex. The defect can be theoretically filled by displacing the irradiated gland^{14,15} and inseting a myocutaneous flap,^{16,17} fat grafting, or placing an implant. Other adjunctive procedures, such as NAC repositioning and Z-plasties, can be used to complement the main corrective operation.

Our goal is to avoid displacing the irradiated breast to limit the risk of complications. A myocutaneous flap can be used to fill the defect and to transfer vascularized tissues to this irradiated area. This was theoretically the ideal solution, one that we proposed in a large number of cases; however, many patients chose not to undergo this procedure, because

they considered it to be excessively invasive after BCT. It should be noted that most patients seeking reconstructive surgery for cosmetic sequelae are young women (with a mean age of 44 years in our series) who are traumatized by the appearance of their breasts. However, unlike women who have undergone a mastectomy, they are often reluctant to accept the harvesting of a flap, which explains why only 15 flaps (45.5%) were performed for partial reconstruction in this group. When a glandular defect is associated with a skin defect, flap harvesting is essential. The skin of the flap contrasts markedly with the irradiated skin, sometimes resulting in a patch effect. The flap must be positioned to preserve the cosmetic appearance of the breast (in the inframammary fold for lower quadrant defects or in the lateral fold of the breast for outer quadrant defects). This sometimes requires supplementary breast skin excision.

Despite our efforts and the wide range of techniques used, the cosmetic results of partial breast reconstructions for type 2 cosmetic sequelae were disappointing: 17.3% of patients had a poor result (versus 2.4% for type 1 cosmetic sequelae). The reoperation rate was also higher for type 2 (36.4%) than for type 1 (27.1%) sequelae, but this difference was not significant. A standard treatment strategy cannot be defined, and the surgeon is continually faced with the following dilemma of treating an irradiated breast: additional scars for a patient already severely traumatized by the cosmetic appearance of her breast versus the benefit of a myocutaneous flap in terms of shape and softness.

Fat grafting is an attractive solution to repair the defect, and satisfactory results have been obtained in some cases of type 2 cosmetic sequelae.²¹⁻²⁴ Fat grafting might advantageously replace myocutaneous flaps in minor or moderate defects, with no associated skin defect. Although quite promising, this is a recent technique, and the published results are based on a very small number of patients with a short follow-up in terms of cosmetic and oncologic results. No data are currently available concerning the cancer risk related to possible reinjection of stem cells into a breast treated for cancer. More data are needed to confirm the initial results and the safety of this technique.

Type 2 cosmetic sequelae are difficult to manage, requiring tissue transfers with unpredictable cosmetic results. Most of these deformities are postoperative sequelae that could have been avoided had the breast been reshaped immediately, at the time of the initial surgery. Breast cancer surgeons play an essential role in the reduction of type 2 and 3 cosmetic sequelae. Preventing these sequelae is infinitely more effective than treating them. Oncoplastic surgery is based on integrating plastic surgery techniques during the primary tumor resection to reduce surgical sequelae of BCT and extend the BCT possibilities by allowing extensive glandular resections. This approach was first proposed in Europe^{7,25-34} and is now widely used. Together with the sentinel node technique, it is one of the most innovative aspects of breast cancer surgery. Similar to other teams in Europe, our team⁷ has demonstrated that this approach does not modify the multidisciplinary approach to treatment and that radiotherapy and chemotherapy can be performed using the usual modalities and timescale.^{4,7} Furthermore, this approach extends the possibilities of BCT by allowing a more extensive resection than that allowed with a conventional lumpectomy.^{7,32-34}

An oncoplastic procedure must be proposed to all patients with a high risk of breast deformity following a conventional lumpectomy.^{25,26,28,29} This includes some lower pole or upper inner quadrant cancers, all other tumor sites with a resected volume exceeding 20% of the breast volume, and cases in which the skin resection must be combined with extensive glandular resection.

As for mastectomies with immediate breast reconstruction, an oncoplastic procedure can be performed using a two-team approach or, as in more and more specialized breast units, by dual-trained oncoplastic breast surgeons who are able to address the oncologic and aesthetic reconstructive problem at the very outset of planning the primary procedure. Patient selection is an essential feature of oncoplastic procedures.

The following two errors should be avoided: failure to ever use these techniques and, at the other extreme, excessive use of oncoplastic procedures for tumors that can be effectively treated without a mammoplasty.

At the Paris Breast Center, immediate mammoplasties (oncoplastic surgery in our classification) are performed during the initial lumpectomy in about 15% of all BCT patients.

Type 3 Cosmetic Sequelae

Type 3 cosmetic sequelae are characterized by a major breast deformity that cannot be corrected with a partial reconstruction. The incidence of these cosmetic sequelae is rare, although with the increasing use of BCT, it may increase if patients are inappropriately selected. The only possible reconstruction for these patients is a mastectomy with immediate breast reconstruction. A myocutaneous flap is essential in these cases, because of the extent of the deformity and the sequelae observed after the initial radiotherapy.

Unlike type 2 cosmetic sequelae that are mostly related to the initial surgery, these major sequelae of massive skin and glandular fibrosis are mainly the result of radiotherapy. In the most extreme cases, this results in a so-called marble breast, with all of the breast retracted by a stonelike fibrosis. This fibrosis can cause disabling pain, leading the patient to require surgery. These type 3 cosmetic sequelae can also result from extensive surgical resection of more than 50% of the breast volume, without remodeling at the time of resection.

Few patients now present with type 3 cosmetic sequelae for two reasons. First, the incidence of this type of sequela is extremely low, almost always corresponding to patients

treated 20 to 30 years ago, when surgical techniques and especially irradiation could leave major sequelae; such effects are rarely seen today. Second, most of these patients prefer to keep their deformed breasts rather than undergo mastectomy. At the time of our last publication in 2004, we had operated on 4 patients with type 3 cosmetic sequelae of this nature.¹¹ The number of patients with post-BCT deformities has now more than doubled. We always find it extremely difficult to convince these patients to accept a mastectomy, because it represents a major failure of BCT for patients who initially chose this treatment option with the hope of conserving their breast.

CONCLUSION

More and more patients are requesting advice for cosmetic sequelae after BCT. Our classification of cosmetic sequelae into three groups is a simple tool designed to guide surgeons in the management of these patients. It is simple, easy to remember, and does not require any complex measurements. It serves as a practical guide to propose a tailored treatment for each of these three groups of cosmetic sequelae.

For type 1 cosmetic sequelae, the simplest and safest solution when the residual volume of the treated breast is satisfactory is a contralateral breast reduction. It is recommended to avoid surgery to the irradiated breast, although various minor procedures can be proposed in very carefully selected patients.

Type 2 cosmetic sequelae are the most frequently seen—but are the most difficult to treat. A standard solution cannot be proposed for all patients, and a partial flap reconstruction is one of the major options that should be discussed with the patient; however, even after the inset of a flap into the defect, the result is not always optimal, and patients may be disappointed. Fat grafting may help to solve some of the technical difficulties, but more data on fat grafting are needed regarding the late cosmetic results and the oncologic follow-up.

Type 3 cosmetic sequelae are by far the most severe. They require a mastectomy and immediate reconstruction with a flap. From the patient's perspective, this is a devastating failure, because they expected that BCT would allow them to retain their breast. These patients require a lot of patience and repeated consultations to convince them that no cosmetic benefit is achieved by retaining their breast and that a mastectomy with immediate reconstruction is the only reasonable option.

Based on our experience managing these patients over the past 15 years, we strongly believe that the main solution to these problems is based on preventive measures and not on a cure. For a long time, breast cancer surgeons underestimated the importance of breast reshaping at the time of the initial surgery. Fortunately, more breast cancer surgeons are now trained in oncoplastic techniques. Closer collaboration between surgeons specialized in breast cancer surgery and surgeons specialized in plastic and reconstructive surgery in a multidisciplinary framework is essential to reduce the incidence of cosmetic sequelae after BCT.

Critical Issues

- BCT deformities can be broken down into three cosmetic sequelae.
- Classification of the BCT deformity will depend on the breast size, shape, contour, symmetry, and quality of the skin envelope.
- These deformities are often difficult to treat and are best avoided by using oncoplastic techniques before breast irradiation.
- Type 1 sequelae have preservation of shape, and symmetry is improved by a contralateral procedure only.
- Type 2 sequelae demonstrate differences in both shape and symmetry, and will often require reconstruction using a myocutaneous flap or mammaplasty techniques.
- Type 3 sequelae demonstrate significant distortion that is best managed by completion mastectomy and reconstruction.
- Extreme caution should be taken when manipulating the involved breast, given the history of radiotherapy and the increased risk of complications.

References

1. Clarke D, Martinez A, Cox RS. Analysis of cosmetic results and complications in patients with stage I and II breast cancer treated by biopsy and irradiation. *Int J Radiat Oncol Biol Phys* 9:1807, 1983.
2. Pearl RM, Wisnicki J. Breast reconstruction following lumpectomy and irradiation. *Plast Reconstr Surg* 76:83, 1985.
3. Matory WE Jr, Wertheimer MD, Fitzgerald TJ, et al. Aesthetic results following partial mastectomy and radiation therapy. *Plast Reconstr Surg* 85:739, 1990.
4. Bostwick J III, Paletta C, Hartrampf CR. Conservative treatment for breast cancer. Complications requiring reconstructive surgery. *Ann Surg* 203:481, 1986.
5. Clough KB, Cuminet J, Fitoussi A, et al. Cosmetic sequelae after conservative treatment of breast cancer: classification and results of surgical correction. *Ann Plast Surg* 41:471, 1998.
6. Clough KB, Thomas SS, Fitoussi AD, et al. Reconstruction after conservative treatment for breast cancer: cosmetic sequelae classification revisited. *Plast Reconstr Surg* 114:1743, 2004.
7. Fisher B, Anderson S, Bryant J, et al. Twenty-year follow-up of a randomized trial comparing total mastectomy, lumpectomy, and lumpectomy plus irradiation for the treatment of invasive breast cancer. *N Engl J Med* 347:1233, 2002.
8. Veronesi U, Cascinelli N, Mariani L, et al. Twenty-year follow-up of a randomized study comparing breast-conserving surgery with radical mastectomy for early breast cancer. *N Engl J Med* 347:1227, 2002.
9. Jacobson JA, Danforth DN, Cowan KH, et al. Ten-year results of a comparison of conservation with mastectomy in the treatment of stage I and II breast cancer. *N Engl J Med* 332:907, 1995.
10. Scholl SM, Forquet A, Asselain B, et al. Neoadjuvant versus adjuvant chemotherapy in premenopausal patients with tumours considered too large for breast conserving surgery: preliminary results of a randomised trial: S6. *Eur J Cancer* 30A:645, 1994.

11. Clough KB, Lewis JS, Couturaud B, et al. Oncoplastic techniques allow extensive resections for breast conserving therapy of breast carcinomas. *Ann Surg* 237:26, 2003.
12. Sobin LH, Wittekind C. Breast tumours. In Brierley JD, Wittekind C, eds. *TNM Classification of Malignant Tumours*, ed 5. New York: Wiley-Liss, 1997.
13. Berrino P, Campora E, Santi P. Postquadrantectomy breast deformities: classification and techniques of surgical correction. *Plast Reconstr Surg* 79:567, 1987.
14. Petit JY, Rietjens M, Garusi C, et al. Integration of plastic surgery in the course of breast-conserving surgery for cancer to improve cosmetic results and radicality of tumour excision. *Recent Results Cancer Res* 152:202, 1998.
15. Berrino P, Campora E, Leone S, et al. Correction of type II breast deformities following conservative cancer surgery. *Plast Reconstr Surg* 90:846, 1992.
16. Rigotti G, Marchi A, Galie M, et al. Clinical treatment of radiotherapy tissue damage by lipoaspirate transplant: a healing process mediated by adipose derived adult stem cells. *Plast Reconstr Surg* 119:1409, 2007.
17. Coleman SR, Saboeiro AP. Fat grafting to the breast revisited: safety and efficacy. *Plast Reconstr Surg* 119:775, 2007.
18. Missana MC, Laurent I, Barreau L, et al. Autologous fat transfer in reconstructive breast surgery: indications, technique and results. *Eur J Surg Oncol* 33:685, 2007.
19. Delay E, Gosset J, Toussoun G, et al. Efficacy of lipomodelling for the management of sequelae of breast cancer conservative treatment. *Ann Chir Plast Esthet* 53:153, 2008.
20. Gosset J, Flageul G, Toussoun G, et al. Lipomodelling for correction of breast conservative treatment sequelae. *Medicolegal aspects. Expert opinion on five problematic clinical cases. Ann Chir Plast Esthet* 53:190, 2008.
21. Slavin SA, Love SM, Sadowsky NL. Reconstruction of the radiated partial mastectomy defect with autogenous tissues. *Plast Reconstr Surg* 90:854, 1992.
22. Papp C, Wechselberger G, Schoeller T. Autologous breast reconstruction after breast conserving cancer surgery. *Plast Reconstr Surg* 102:1932; discussion 1937, 1998.
23. Paolucci R, Rusca M, Cattelani L, et al. Centroinferior hemimastectomy. *Br J Surg* 80:44, 1993.
24. Schondorf NK. The technique of B-, S-, or W-reduction mammoplasty in the conservative therapy of breast carcinomas: experiences with a new surgical technique. *Breast* 10:501, 2001.
25. Clough KB, Nos C, Fitoussi A. Oncoplastic conservative surgery for breast cancer. *Oper Tech Plast Reconstr Surg* 6:50, 1999.
26. Clough KB, Nos C, Salmon RJ, et al. Conservative treatment of breast cancers by mammoplasty and irradiation: a new approach to lower quadrant tumours. *Plast Reconstr Surg* 96:363, 1995.
27. Clough KB, Kroll SS, Audretsch W. An approach to the repair of partial mastectomy defects. *Plast Reconstr Surg* 104:409, 1999.
28. Nos C, Fitoussi A, Bourgeois D, et al. Conservative treatment of lower pole breast cancers by bilateral mammoplasty and radiotherapy. *Eur J Surg Oncol* 24:508, 1998.
29. Audretsch WP, Rezai M, Kolotas C, et al. Tumor specific immediate reconstruction in breast cancer patients. *Perspect Plast Surg* 11:71, 1998.
30. Kaur N, Petit JY, Maffini F, et al. Comparative study of surgical margins in oncoplastic surgery and quadrantectomy in breast cancer. *Ann Surg Oncol* 12:539, 2005.
31. Kat CC, Darcy CM, O'Donoghue JM, et al. The use of latissimus dorsi myocutaneous flap for immediate correction of the deformity resulting from breast conservation surgery. *Br J Plast Surg* 52:99, 1999.
32. Bailldam AD. Oncoplastic surgery of the breast. *Br J Surg* 89:532, 2002.
33. Rietjens M, Urban CA, Rey PC, et al. Long-term oncological results of breast conservative treatment with oncoplastic surgery. *Breast* 16:387, 2007.
34. Rainsbury RM. Surgery insight: oncoplastic breast-conserving reconstruction—indications, benefits, choices and outcomes. *Nat Clin Pract Oncol* 4:657, 2007.

25

Rearrangement Surgery

Dennis C. Hammond, Kuylhee Kim

M

any variables are used to describe the appearance of the breast. Anatomic features include volume, fat content, parenchymal content, breast position, skin envelope surface area, skin elasticity, volume-to-skin envelope ratio, nipple position, asymmetry, height, and weight. These characteristics are combined in numerous ways to describe different breast sizes and shapes. Even without the confounding effect of one-sided surgery such as lumpectomy with or without radiation, the challenge of surgically altering the breast to create symmetry requires a well-thought-out and expertly executed surgical plan. It is easy to understand why reconstruction of the lumpectomy defect can be such a difficult undertaking.

Approximately 10% to 30% of patients are dissatisfied with the aesthetic result after a partial mastectomy with radiotherapy.¹⁻⁷ There are many possible causes of aesthetic failure. Tumor resection can produce distortion, retraction, and noticeable volume change in the breast. Changes to the position of the NAC can accentuate asymmetry. Radiation also can have a profound effect on the native breast.

The nature of each deformity depends on the magnitude and location of the lumpectomy. In addition, radiotherapy has a significant deleterious effect on the remaining breast tissue, which limits the extent to which the breast can be safely reconstructed. All of these factors make reconstruction using simple rearrangement surgery one of the most challenging surgical problems in plastic surgery of the breast.

THE DECISION-MAKING PROCESS

When choosing the most suitable technique to reconstruct a partial mastectomy defect, several factors should be considered; the longevity of the follow-up, the oncologic status, the severity of the deformity, and the patient's wishes.

Edema, which occurs most commonly during the first year after surgery, and the effects of the radiotherapy may mask some volume loss. Therefore major correction procedures should be delayed until at least 1 year after radiotherapy. Radiation injuries typically resolve in 6 to 12 months after the last treatment.

A clean oncologic evaluation is required before planning any surgical procedure in one or both breasts. A careful analysis of the problem is the key to a successful outcome. When evaluating a patient for possible rearrangement surgery for reconstruction after a lumpectomy, certain conditions must be present for this approach to be effective. Before any technique is performed, the effects of radiotherapy on the breast to be reconstructed must have stabilized. Typically, the radiation injury initially manifests as an intense, dull red color of the skin in the irradiated field. The skin texture is edematous and firm. With a severe radiation injury, superficial epidermolysis also may be present, particularly in areas of skin folding. These postradiation changes must be allowed to settle before the breast can be operated on effectively. By allowing the swelling in the breast to resolve, the extent of the deformity can be better understood and surgical decision-making can proceed with greater accuracy. Rearranging the tissues is easier if they are as soft and pliable as possible. Once the skin has softened and the erythema has resolved, surgical rearrangement can be considered.

Several classification schemes have been developed to characterize delayed breast deformities and suggest reconstructive options^{2,8-10} (see Chapter 23). The tumor's original location is important. For example, tumors located within the superolateral quadrant cause a lateral distortion of the breast gland and/or the NAC, and tumors located centrally or superiorly lead to retraction and an upward dislocation of the whole breast.

As with any reconstructive method, reoperative breast surgery has to be very carefully planned and executed for each patient. Before surgery, the surgeon should review records of previous procedures and treatments. The clinical evaluation should include all components of the defect. Skin deficiency may not always be obvious, but some kind of skin correction is needed, because skin retraction and scar tissue occur in almost every case. Any postradiation skin alterations should be noted, because they reflect the degree of parenchymal damage. It is difficult, however, to estimate the required amount of skin tissue needed to repair the defect. Nevertheless, severe NAC distortion is an indication that a large skin component is needed.

Patients presenting for rearrangement surgery must have enough tissue left in the treated breast to mold onto an acceptable breast mound. If this is not the case, volume replacement techniques must be employed to obtain an acceptable result. These include a breast implant, but an autologous latissimus dorsi myocutaneous flap or a transverse rectus abdominis myocutaneous (TRAM) flap is preferred. In cases of significant breast asymmetry in which the unaffected breast is larger than the treated breast, reducing the opposite breast may restore enough symmetry to allow rearrangement surgery to be considered as a viable technique. Alternatively, if a persistent size asymmetry is acceptable to the patient, simple reshaping of the affected breast with correction of scar contracture may provide a reasonable result. Whatever the circumstance, the patient must understand that simple rearrangement surgery is a difficult undertaking and the chance for developing a complication is significant.

OPERATIVE STRATEGY

Contralateral Reduction

Many patients who have undergone a lumpectomy with radiation can actually present with an aesthetic breast mound with the NAC properly positioned and thus do not require surgical alteration of the treated breast. Typically, such patients will have some degree of preexisting macromastia that minimizes the magnitude of the distortion created by the lumpectomy. However, it is very common for such patients to have a significant size asymmetry, with the opposite untreated breast being much bigger than the cancer-affected breast. This size discrepancy is a result of both the volume loss created by the lumpectomy as well as the soft tissue atrophy that is often associated with radiation. The magnitude of volume difference and any discrepancy in the level of the inframammary fold can cause the patient to feel self-conscious about her appearance, and it can be difficult to find clothing that does not emphasize this discrepancy. In these patients, a simple unilateral reduction can restore breast symmetry and make it easier for the patient to function socially.

If opposite breast reduction is indicated as a part of the overall reconstructive strategy, it is highly recommended that it be performed after the full effect of the lumpectomy and radiation has become evident.

Often it is not possible to predict how small or how misshapen the treated breast will become in the postoperative period after a lumpectomy. When these changes are allowed to stabilize, a more accurate opposite breast reduction can be performed to maximize the symmetry.

Technique

Essentially, any technique for breast reduction can be used to reduce the volume of the larger breast. However, several modifications in the surgical approach may be required to optimize symmetry.

Nipple-Areola Complex

In general, patients who present for unilateral breast reduction after lumpectomy and radiation had larger breasts preoperatively and therefore a larger areolar diameter. When applying a breast-reduction technique to such patients, it must be recognized that most skin envelope management strategies have a significant areolar reduction component built into the operative plan. However, areolar reduction rarely results from simple lumpectomy alone, and blind application of a normal reduction pattern can create an areolar diameter on the reduced side that is too small when compared to the diameter of the areola on the lumpectomy side. Therefore, when marking the pattern for the opposite sided breast reduction, an alteration in the pattern is often required to create an areolar diameter that is symmetrical with the previously treated breast.

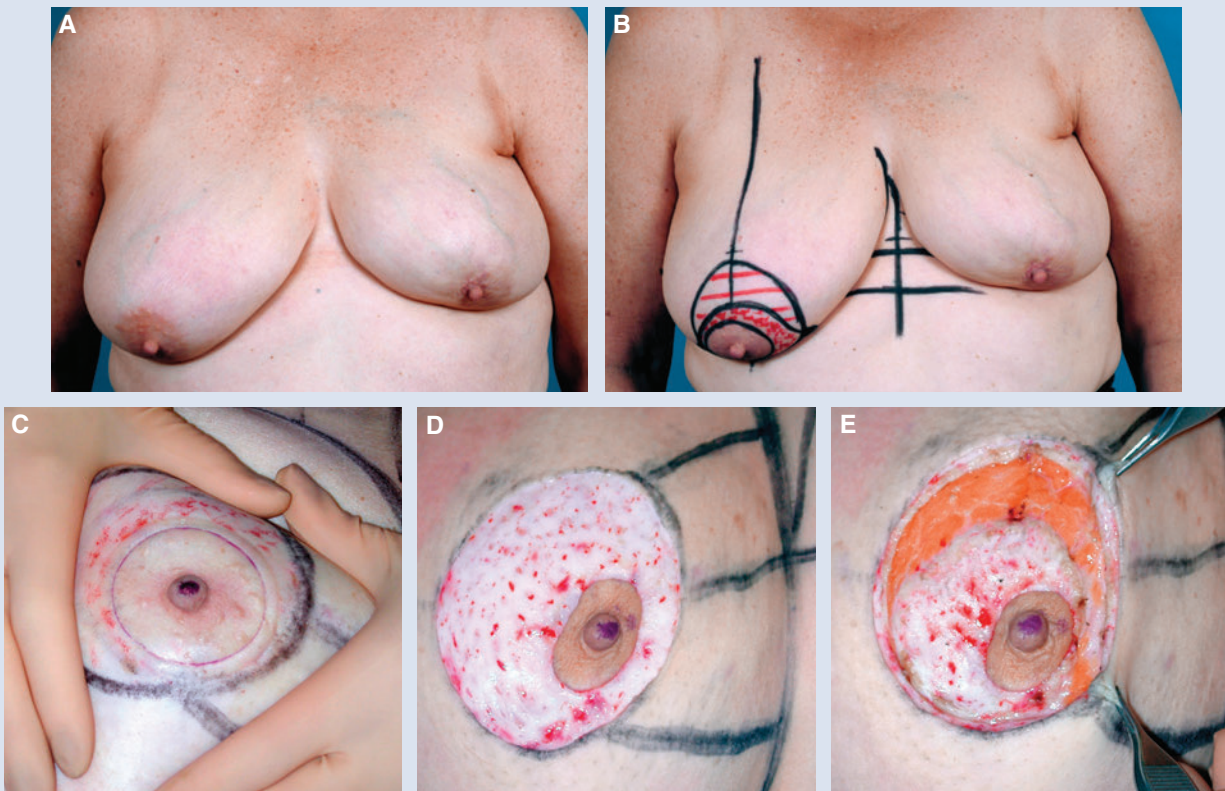
Although the affected breast may have a reasonable aesthetic result after lumpectomy and radiotherapy, it is often positioned slightly lower on the chest wall than it would be after a standard reduction. The location of the NAC can also be lower than is typically seen after breast reduction. Because the affected breast is not being changed, it becomes necessary to alter the marking strategy used for the breast reduction to ensure symmetry.

Therefore, when planning the reduction of the unaffected breast, it is often necessary to mark the NAC position lower than it would be under normal circumstances. In addition, a more conservative volume and skin resection is commonly performed to match the affected breast. By altering the standard reduction approach in this fashion, better symmetry can be obtained.

Shape

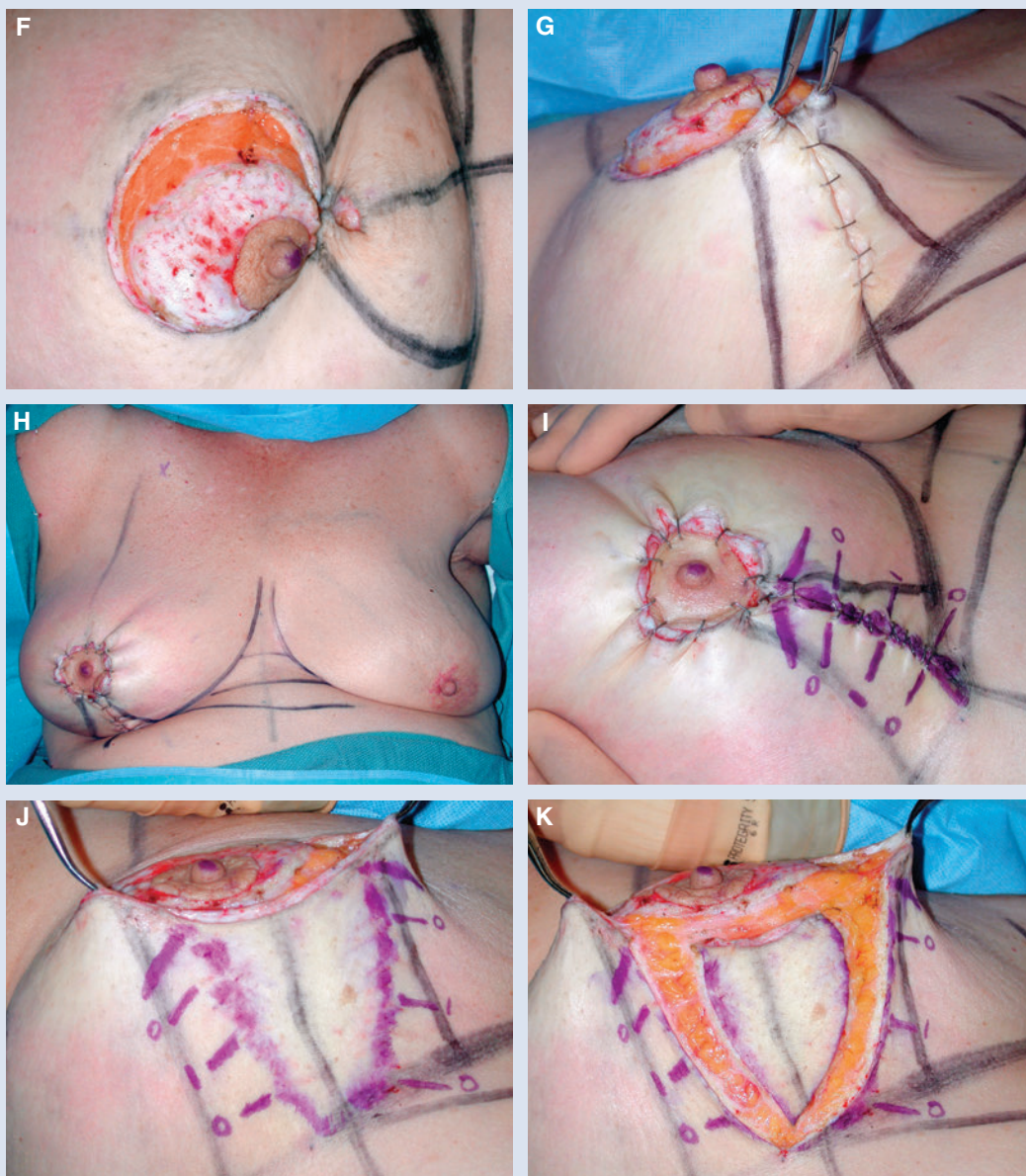
It is very common for the affected breast to have a rounded contour after a lumpectomy and radiotherapy. Unfortunately, it can be difficult to match this breast shape using the standard inverted-T breast reduction pattern. A better option may be to use some variant of a circumvertical reduction strategy,^{1-4,11,12} because these techniques tend to create a rounder breast contour than the inverted-T approach.

PATIENT EXAMPLES

**Fig. 25-1, A-E**

This 63-year-old woman had undergone a lumpectomy of the left breast with postoperative radiotherapy 16 years previously (A). As a result of the significant volume asymmetry, she found it difficult to wear clothes comfortably and complained of neck and back strain from unilateral macromastia. Although the left breast was ptotic and the NAC was low, she requested only a reduction of the right breast. The right breast was marked preoperatively for reduction using a circumvertical technique (B). Since the left side was not to be treated, the pattern was adjusted to avoid raising the NAC too high. The areolar diameter was stretched maximally to match the diameter of the opposite breast (C). The skin between the two incisions was deepithelialized (D). The dermis was divided, leaving a small dermal cuff to support the eventual purse-string suture (E).

Continued

**Fig, 25-1, F-K**

The redundant skin of the lower pole was plicated with staples (*F* through *H*). The plication pattern was begun by stapling the estimated limits of the skin redundancy along the vertical axis of the breast until the shape was reasonably symmetrical with the left breast. Once the plication pattern was set, the margins were marked with a surgical pen, and orientation lines were placed to facilitate the eventual closure of the vertical incision (*I*). After the staples were removed, the margins of the vertical pattern could be seen (*J*). The skin was incised (*K*).

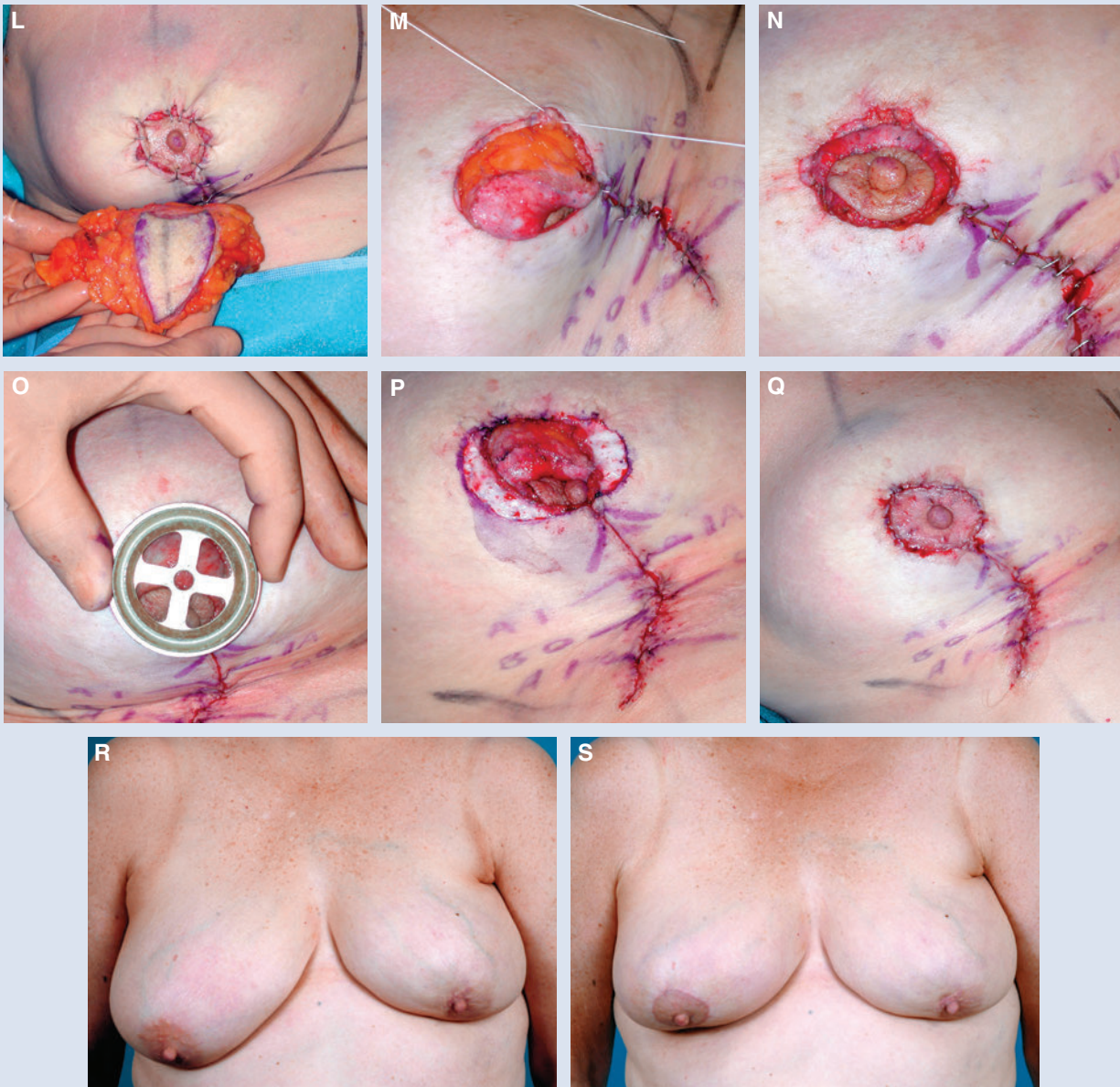


Fig. 25-1, L-S

A small wedge from the inferior pole of the breast was removed (total 114 g) (L). A purse-string suture was applied to the periareolar defect and cinched down to the desired diameter (M and N). The irregular periareolar defect was rounded off by marking a circular pattern with a nipple marker, and additional skin was deepithelialized as needed (O through Q). The patient is shown again preoperatively (R). Postoperatively, she has symmetrical breast volume, shape, and contour (S). Although the NAC position is low, its position and size are symmetrical with the opposite side.

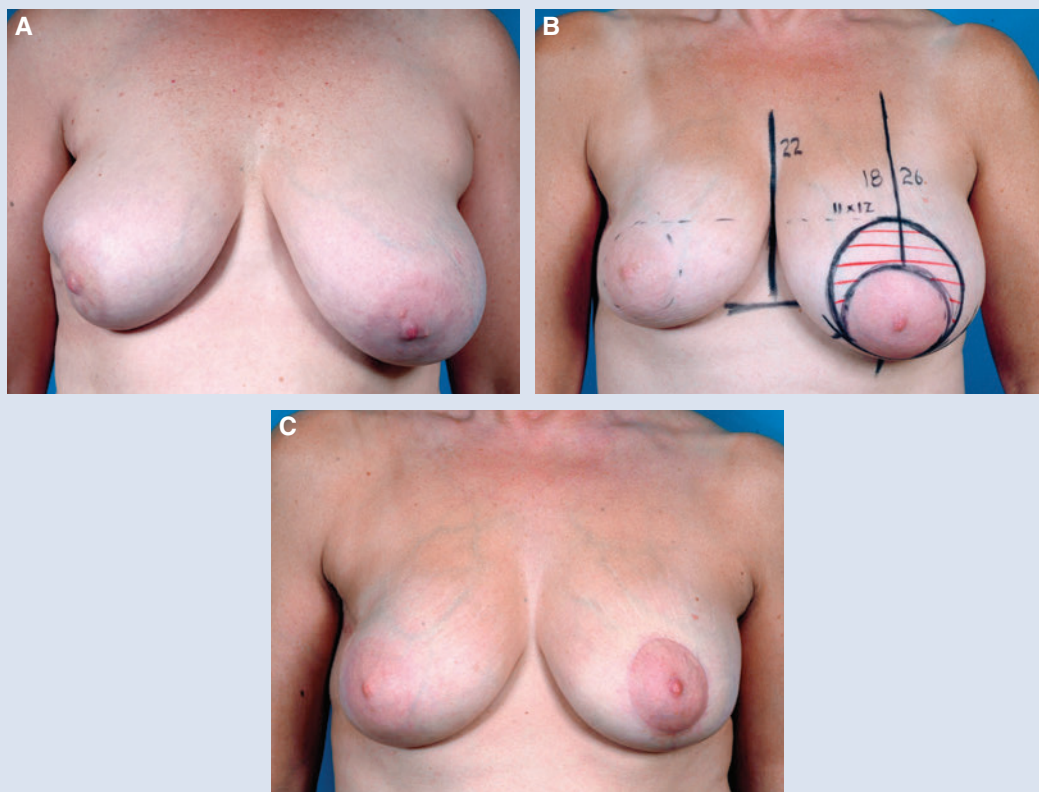


Fig. 25-2

The 55-year-old woman had undergone a right-sided lumpectomy with radiotherapy 8 years previously (A). She was marked preoperatively for reduction of the left breast using the short-scar periareolar inferior pedicle reduction (SPAIR) technique (B). She is seen 6 months postoperatively with better symmetry in the size and shape of her breasts (C). Note that the areolar diameter was intentionally left wide to match the areolar diameter of the untreated side.

CHOICE OF TECHNIQUE

Table 25-1 Pedicle Options Based on the Location of the Defect

Location of the Defect	Choice of Pedicle
Inferior, inferomedial, or inferolateral	Superior, superomedial, or superolateral pedicle
Superior	Inferior or centroinferior pedicle
Superomedial	Superolateral pedicle with an inferocentral component to fill the defect
Superolateral	Superomedial pedicle with an inferocentral component to fill the defect
Central	Inferior pedicle

For patients who are likely to have any degree of deformity after a lumpectomy, it may be advantageous to rearrange the remaining breast parenchyma and fat using standard techniques of breast reshaping, as discussed in previous chapters.

SURGICAL TECHNIQUE

When mild radiation sequelae are observed, a bilateral matching procedure can be performed. Mammoplasty techniques should be adapted for each situation.

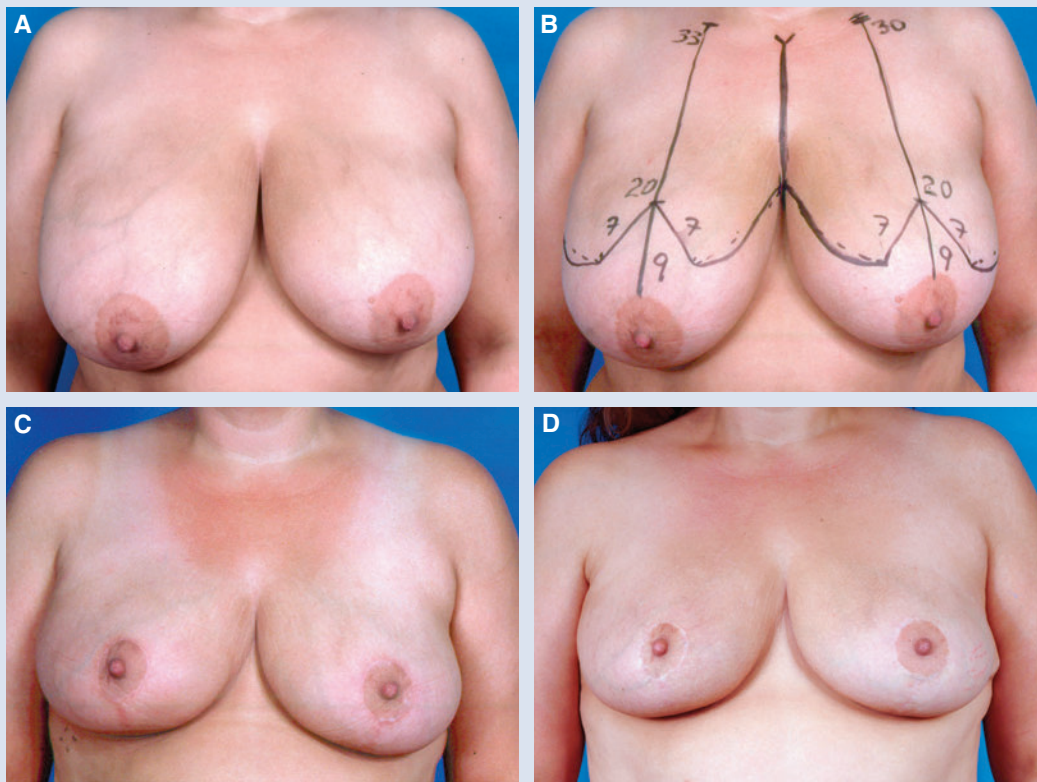
Surgical Plan

- Mark the skin preoperatively with the patient standing.
- Excise the scar tissue and remnant seroma cavity completely.
- Limit gland dissection.
- Consider using a wide-based glandular flap.
- Use the superficial and deep fascia for closure.
- Avoid placing a tight dressing on the wound site.

Skin Markings

With the patient standing, the skin is marked preoperatively. The nipple elevation should be very conservative, and the high-riding nipple position should be avoided. The nipple-areola gland flap is less malleable and less vascularized because of the irradiation; therefore long flaps are not recommended. The flap carrying the NAC is made wider than usual to maximize its blood supply. Conservative skin and gland excision should be planned to avoid closing skin or gland flaps under tension, which may lead to further ischemia and wound dehiscence. The contralateral breast is marked to reduce its volume and to modify its form; however, the definitive amount of gland resection should not be determined before the irradiated breast has remolded.

PATIENT EXAMPLE

**Fig. 25-3**

This 43-year-old woman was diagnosed with adenocarcinoma of the right breast. She underwent preoperative chemotherapy, and postoperative radiotherapy was planned (A). Preoperatively she had shoulder pain, back pain, and submammary intertrigo associated with her large breast size. To provide symmetry and to give her a better chance at postoperative comfort, a bilateral inferior pedicled breast reduction was planned. She was marked preoperatively using a standard T pattern (B). She is shown 6 months after removal of 987 g of tissue from the right breast and 867 g from left breast (C). Six years postoperatively, good symmetry in the size and shape of her breasts have been maintained (D).

Delayed Reconstruction

When a delayed reconstruction is planned, the same surgical strategy with the same surgical plan is employed. However, additional considerations must be kept in mind. After the breast has been irradiated, the skin, fat, and parenchyma are less able to tolerate the relative ischemia created by surgical rearrangement. For this reason, conservative undermining of flaps and pedicles with a wide base is required. When techniques of aggressive undermining or extended pedicle creation are used in an irradiated breast, the potential is high for the development of fat necrosis.

Technically, the initial goal is to re-create the lumpectomy defect. The remnant of the seroma cavity often remains after the initial tissue resection. This must be removed, along with any tethering scar bands that formed during the healing process and that were modified by the effects of radiation. Often the dimensions of the cavity that results can be surprisingly large, and the surgical plan must include filling in this significant defect.

It can be very helpful to plan a contralateral breast reduction to provide a certain degree of latitude on the reconstructive side with regard to breast volume and shape. By coordinating these two procedures effectively, reasonable symmetry can be obtained by resecting the scar and reshaping the breast on the affected side and then reducing and symmetrically reshaping the larger breast. Unlike primary reconstruction, the pedicle that carries the NAC is generally less released from the surrounding breast flaps and therefore cannot easily be rotated into a remote postlumpectomy defect.

Once the breast is reassembled, very few sutures, if any, are used to approximate the gland. They are usually placed in the superficial fascia and deep dermis for closure. A drain is always placed. Tight dressings or garments should be avoided postoperatively in anticipation of postoperative edema and to avoid further skin or gland ischemia.

PATIENT EXAMPLE

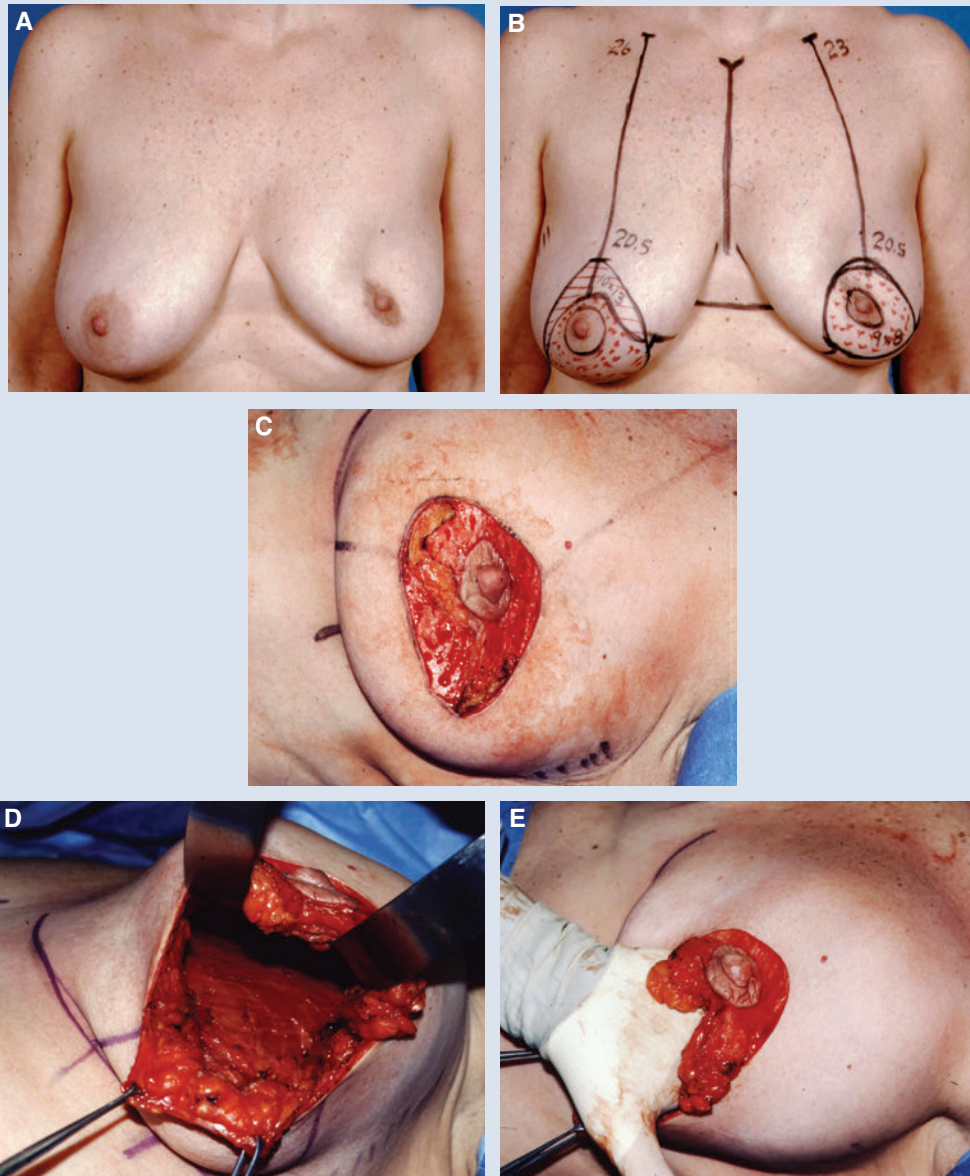


Fig. 25-4, A-E

This 45-year-old woman had scarring and shape distortion after undergoing a lumpectomy of her left breast 6 months earlier. Note that her left nipple-areola complex was depressed because of the removal of breast cancer mass which was located in the central core (A). She was marked preoperatively in preparation for a left breast tissue rearrangement with a circumvertical pattern using an inferiorly based parenchymal flap and a right breast reduction mammoplasty using the SPAIR technique (B). On the left breast, the periareolar marking and the mark around the periphery of the breast to outline the periareolar pattern were incised. The intervening skin was also deepithelialized (C). The old lumpectomy defect was resected and the scar excised (D and E).

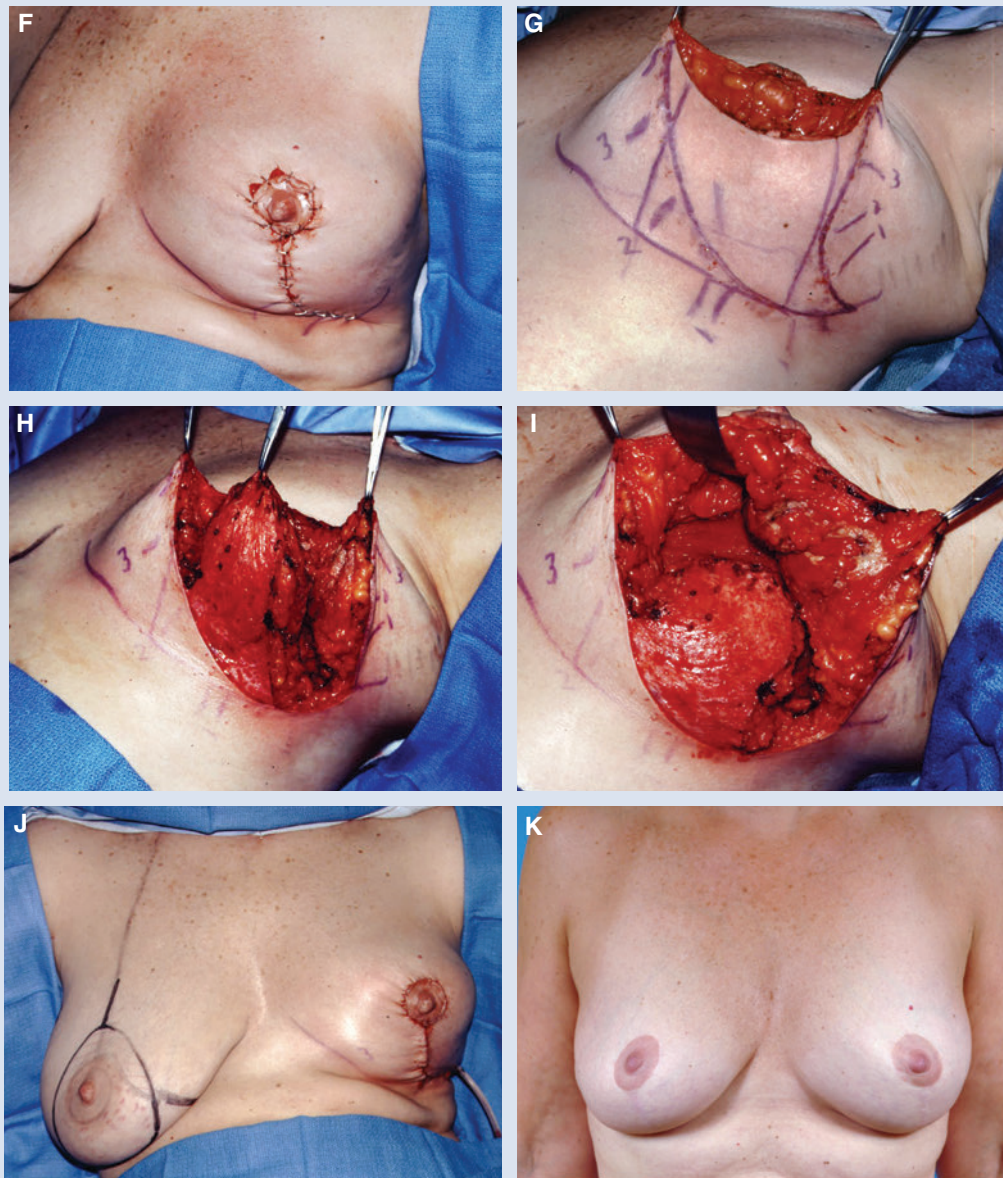


Fig. 25-4, F-K

The plication pattern was started by stapling the estimated limits of the skin redundancy along the vertical axis of the breast (*F*). After the staples were removed and the skin was deepithelialized, the inferior pedicle flap was developed (*G* and *H*). The medial and lateral pillars were dissected as had been outlined in the dermis previously, and the entire breast was undermined medially, superiorly, and laterally (*I*). The pillars were sutured together in several locations to support the nipple-areola complex (*J*). Ten years postoperatively, she has good symmetry in the shape, size of breast and nipple-areola complex (*K*).

CONCLUSION

The strategic use of internal breast shaping maneuvers and retailoring of the skin envelope helps to mold the breast parenchyma that remains after a lumpectomy—with or without radiotherapy—into a pleasing breast shape. Breast reduction or mastopexy on the opposite breast can be performed as needed to optimize the symmetry. For patients who have undergone conservative surgical management of breast cancer, these techniques provide an excellent option for reconstruction without the need for an additional donor site.

Critical Issues

- The tumor location and the severity of the deformity are the key factors to consider when planning the surgical technique for delayed partial breast reconstruction.
- Careful analysis and planning are crucial to avoid further complications.
- A contralateral breast reduction can correct many cases of volume asymmetry after breast-conserving therapy.
- Ipsilateral rearrangement procedures alone may be appropriate for patients with mild deformities and adequate residual breast gland.
- Patients with more severe deformities require mammoplasty techniques in both breasts to achieve symmetry.
- Mammoplasty techniques should be modified to accommodate the decreased tissue elasticity and vascularization caused by irradiation and previous surgery.

References

1. Audretsch WP. Reconstruction of the partial mastectomy defect: classification and method. In Spear SL, Willey SC, Robb GL, Hammond DC, Nahabedian MY, eds. *Surgery of the Breast: Principles and Art*, ed 2. Philadelphia: Lippincott Williams & Wilkins, 2006.
2. Clough KB, Cuminet J, Fitoussi A, et al. Cosmetic sequelae after conservative treatment for breast cancer: classification and results of surgical correction. *Ann Plast Surg* 41:471, 1998.
3. Kronowitz SJ, Feledy JA, Hunt KK, et al. Determining the optimal approach to breast reconstruction after partial mastectomy. *Plast Reconstr Surg* 117:1, 2006.
4. McCulley SJ, Macmillan RD. Therapeutic mammoplasty—analysis of 50 consecutive cases. *Br J Plast Surg* 58:902, 2005.
5. Spear LS, Pelletiere CV, Wolfe AJ, et al. Experience with reduction mammoplasty combined with breast conservation therapy in the treatment of breast cancer. *Plast Reconstr Surg* 111:1102, 2003.

6. Munhoz AM, Montang E, Arruda EG, et al. Critical analysis of reduction mammoplasty techniques in combination with conservation breast surgery for early breast cancer treatment. *Plast Reconstr Surg* 117:1091, 2006.
7. Patel KM, Hannan CM, Gatti ME, et al. A head-to-head comparison of quality of life and aesthetic outcomes following immediate, staged-immediate, and delayed oncoplastic reduction mammoplasty. *Plast Reconstr Surg* 127:2167, 2011.
8. Kronowitz SJ, Hunt KK, Kuerer HM, et al. Practical guidelines for repair of partial mastectomy defects using the breast reduction technique in patients undergoing breast conservation therapy. *Plast Reconstr Surg* 120:1755, 2007.
9. Kronowitz SJ, Kuerer HM, Buchholz TA, et al. A management algorithm and practical oncoplastic surgical techniques for repairing partial mastectomy defects. *Plast Reconstr Surg* 122:1631, 2008.
10. Losken A, Hamdi M. Partial breast reconstruction: current perspectives. *Plast Reconstr Surg* 124:722, 2009.
11. Hammond DC, Loffredo M. Breast reduction. *Plast Reconstr Surg* 129:829e, 2012.
12. Hammond DC, Khuthaila DK, Kim J. The interlocking Gore-Tex suture for control of areolar diameter and shape. *Plast Reconstr Surg* 119:804, 2007.

26

Correction of the Breast-Conserving Therapy Deformity Using Local Flaps

Albert Losken, Katrina Abuabara, Sumner A. Slavin

Local flaps are often the procedure of choice for the correction of breast-conserving therapy (BCT) deformities. Because these defects are irradiated and tend to have both a skin and volume component,¹ nonirradiated, vascularized tissue is typically transferred to provide bulk and coverage. The secondary correction of these deformities using local flaps became popular in the 1990s because of the dissatisfaction with aesthetic results following breast preservation and radiotherapy.²⁻⁴ Although these patients often choose BCT to minimize the amount of surgery and preserve their breasts, they often require more extensive procedures to correct the deformity if one develops. Local flaps remains an excellent option for correcting BCT deformities after radiotherapy.

ADVANTAGES OF USING LOCAL FLAPS

Timing

Reconstruction is best performed before radiotherapy; however, there are some advantages to performing delayed autologous tissue reconstruction a few years after the completion of radiotherapy. The main advantages are that the margin status has been determined, and the potential for compromised margins and the loss of a reconstructive option (that is, a flap) is less likely.⁵ Another advantage of delayed reconstruction is that the patient has had several years of cancer surveillance and a documented disease-free status; however, she is not completely without risk of local recurrence.

Technique

The use of autologous tissue offers several advantages. It provides well-vascularized flaps consisting of muscle and fat for volume and skin for coverage when necessary. These flaps often assist with fluid reabsorption and wound healing within an irradiated and often compromised field. Numerous options are available for local flaps that are outside of the irradiated field, including the latissimus dorsi myocutaneous flap, chest wall perforator flaps, and abdominal flaps.

DISADVANTAGES OF USING LOCAL FLAPS

Timing

Delayed reconstruction of BCT deformities requires an additional surgical procedure that is often extensive, with more recovery time than the original resection. In addition, the breast tissue has significant scarring and radiation-induced changes that include fibrosis, edema, and compromised wound-healing ability.

Technique

The disadvantages of using autologous tissue techniques include the potential for donor-site morbidity, further flap-related complications, and local recurrence. In addition, a local reconstructive option will have to be used should completion mastectomy and reconstruction be necessary.

CLASSIFICATION OF BCT DEFORMITIES

Box 26-1 Classification of Breast Deformity After Conservative Surgery and Radiotherapy

Type I	Mild to moderate skin and parenchymal defect, nipple-areola complex undisturbed
Type II	Severe skin and parenchymal disturbance, some nipple-areola complex distortion
Type III	Combined cutaneous, parenchymal, and nipple-areola complex deformity

BCT deformities have a spectrum of severity, depending on the amount and type of tissue resected, the location of the defect, and the local effects of radiation at the wound site.⁶ Numerous classification systems have been designed to correlate the deformity type with treatment options. In a recent review of all BCT deformities using the complexity-based, multitiered Fitoussi classification,¹ 83% of all grade IV deformities required a myocutaneous reconstruction.⁷

INDICATIONS FOR FLAP RECONSTRUCTION

Numerous options are available for reconstructing BCT deformities, including fat grafting, parenchymal remodeling, implants, a local breast flap, and distant flaps. Most reconstructive surgeons prefer to use autologous tissues to correct these deformities,³ because they tend to be more reliable and appropriately address the problem. The surgeon must critically examine breast deformities and determine what tissues are absent or injured. Although skin is often not removed as part of a partial mastectomy, there is invariably a relative skin loss that requires correction.

PATIENT EXAMPLE

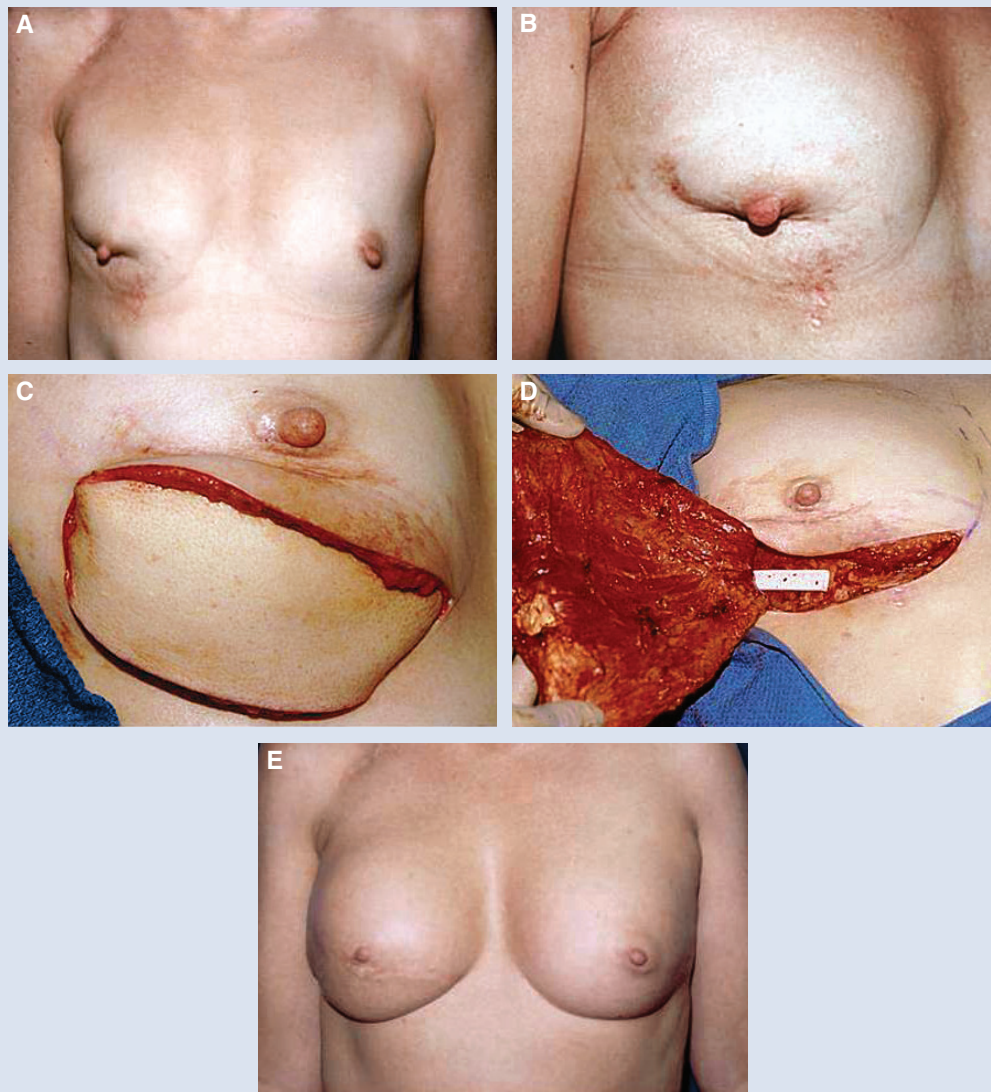


Fig 26-1

This patient presented with a retracted nipple-areola complex (NAC) 2 years after a lumpectomy and radiotherapy. Radiation changes to the skin included local hypopigmentation and telangiectasia (A and B). These changes necessitated a wide excision with release of the nipple-areola complex and resection of the damaged skin (C). A latissimus dorsi flap with a large cutaneous island was used to reconstruct the lower pole defect (D). Subpectoral implants were placed for symmetry. The size and shape are maintained 4 years after the flap transfer (E).

A thorough evaluation of the skin quality, including texture and surface abnormalities, helps determine the flap requirements. A contracted scar often distorts the breast contour and nipple position, requiring release and replacement with vascularized (nonirradiated) tissue. Once the tethered skin is released, the resultant defect and soft tissue requirement are often greater than anticipated. This possibility needs to be considered in the planning phase.

Breasts with significant skin envelope fibrosis and significant radiation changes always require flap reconstruction, regardless of the location of the defect. In addition to skin and contour analysis, breast symmetry should be assessed for volume differences, which will indicate the need for additional bulk with the flap. Most defects require skin and volume.

Every patient who has undergone BCT has a parenchymal deficit and requires volume augmentation in addition to skin coverage. Occasionally, volume is required without the need for skin coverage.

Unfavorable defects in almost any breast location can be reconstructed with local flaps. Larger medial defects often require options other than the latissimus dorsi flap. The main indication for correcting any BCT deformity is patient dissatisfaction with the cosmetic result after BCT.

TIMING OF RECONSTRUCTION

Unfortunately, the effects of radiation damage to the breast persist and need to be considered when planning reconstruction. During the reconstruction, it is critical to understand ongoing changes and anticipate future ones to optimize the aesthetic outcome. Appropriate preoperative cancer screening is crucial before reconstruction.

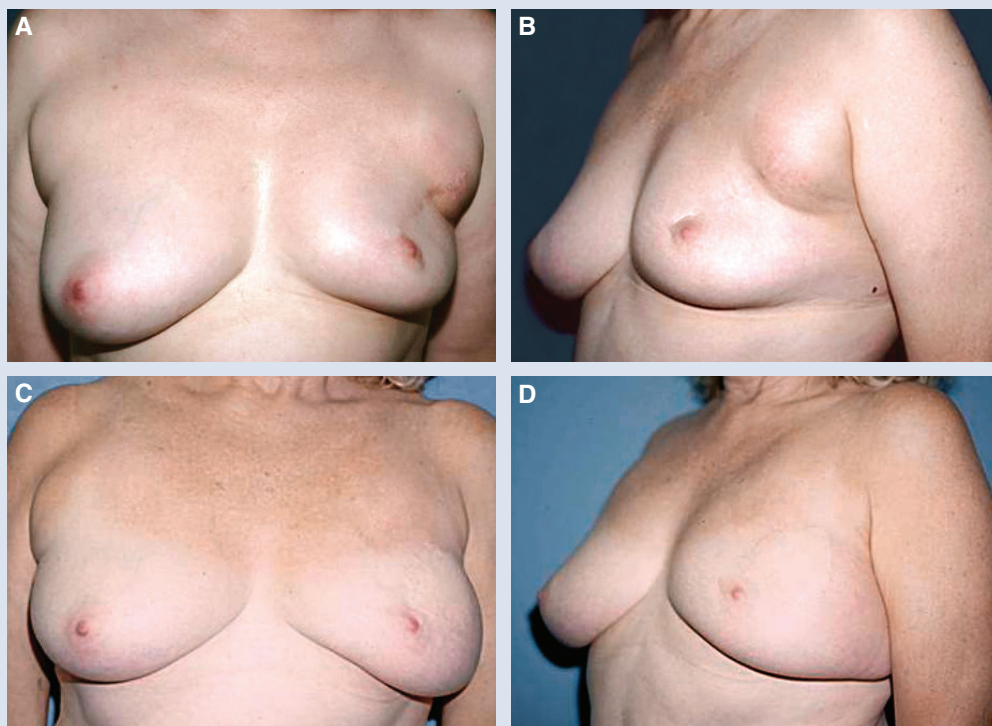
Following BCT, the breast undergoes early alternating changes of edema and retraction, so it is important to wait long enough after radiotherapy to schedule reconstruction to ensure that the breast's shape and cosmesis have stabilized. A delay of 1 to 3 years is recommended.

FLAP SELECTION

The most appropriate flap choice depends on the location and size of the defect and the required tissue components. The surgeon must also consider the patient's individual needs and lifestyle issues before selecting the flap. For many patients, donor-site morbidity is a critical factor, and limiting donor-site complications or functional issues helps to determine the most appropriate flap option. The latissimus dorsi and rectus muscles provide reliable and versatile units of soft tissue; however, the latissimus dorsi flap is the safer of the two in terms of donor-site morbidity. Other considerations regarding flap selection include patient risk factors, body habitus, and preservation of another reconstructive option (most commonly, the transverse rectus abdominis myocutaneous [TRAM] flap) if a completion mastectomy and reconstruction are required. In higher-risk patients (patients who are obese, diabetic, or who smoke), the latissimus dorsi flap tends to be the workhorse for most BCT deformities.

The latissimus dorsi flap is generally better for small- to medium-sized breasts. Larger defects, especially those in the medial portion of the breast, that require a significant amount of skin or volume often benefit from TRAM flap reconstruction.

PATIENT EXAMPLES

**Fig. 26-2**

This 43-year-old woman presented with a superolateral breast deformity 1½ years after BCT. There is evident volume loss and lateral depression on the left side (*A* and *B*).

The scar was released and some skin was resected. The latissimus dorsi muscle, with an attached skin island, was transposed into the defect. This flap is a good option for lateral defects. The patient has improved shape and symmetry, and the lateral contour remains 5 years after surgery (*C* and *D*).

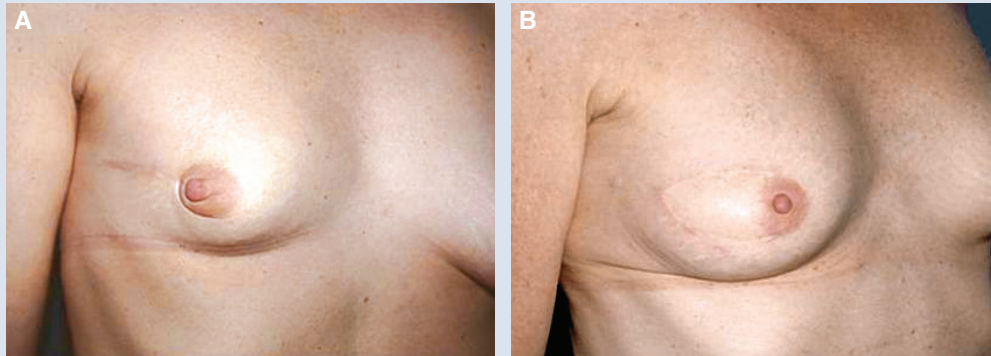


Fig. 26-3

After BCT, this patient had a lateral breast deformity (type III) with fibrosis, skin and parenchymal loss, and nipple-areola dislocation (A). A latissimus dorsi flap was transferred into the defect. Two years after surgery, the lateral breast contour and the position of the nipple-areola complex are improved (B).

The location of the deformity also influences flap selection. Defects in the lateral, superior, superolateral, and superomedial locations are very amenable to latissimus dorsi reconstruction. The rectus flap is often bulky and results in unfavorable results when it traverses the breast parenchyma to reach the deformity. Inferior defects can be treated with either the latissimus dorsi or rectus flap, with comparable aesthetic results. Central defects can be reconstructed with either flap; however, the latissimus dorsi flap tends to provide more support for nipple-areola depression types of deformities.

The endoscopic approach is of limited value for secondary correction of BCT deformities, because skin is usually required. We prefer to use the latissimus dorsi flap for partial mastectomy deformities because of its versatility and decreased donor-site morbidity. If a completion mastectomy is required at a later date, the TRAM flap is still available and is often the desired procedure.

SURGICAL TECHNIQUE: LATISSIMUS DORSI FLAP RECONSTRUCTION

Surgical Plan

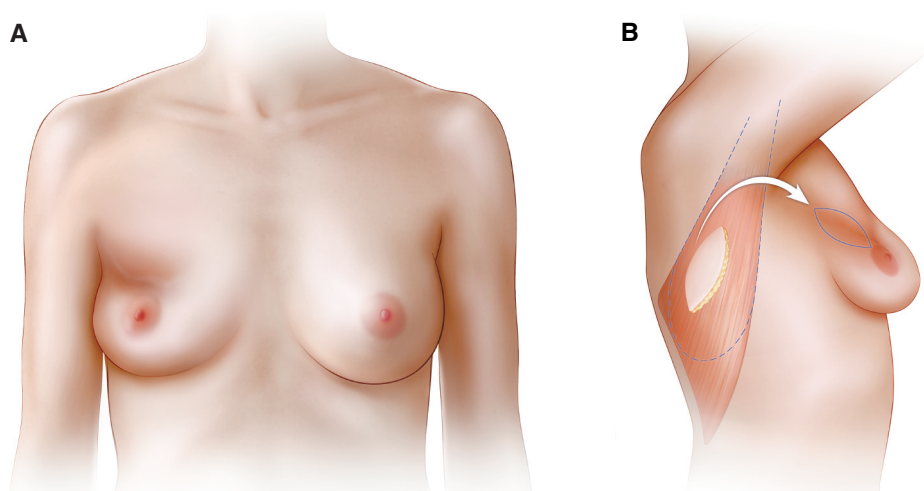


Fig. 26-4, A and B

- The most appropriate flap for the particular defect is determined.
- The patient is marked preoperatively. The proposed defect shape and location determine the orientation and location of the skin island at an equal distance from the vascular pedicle.

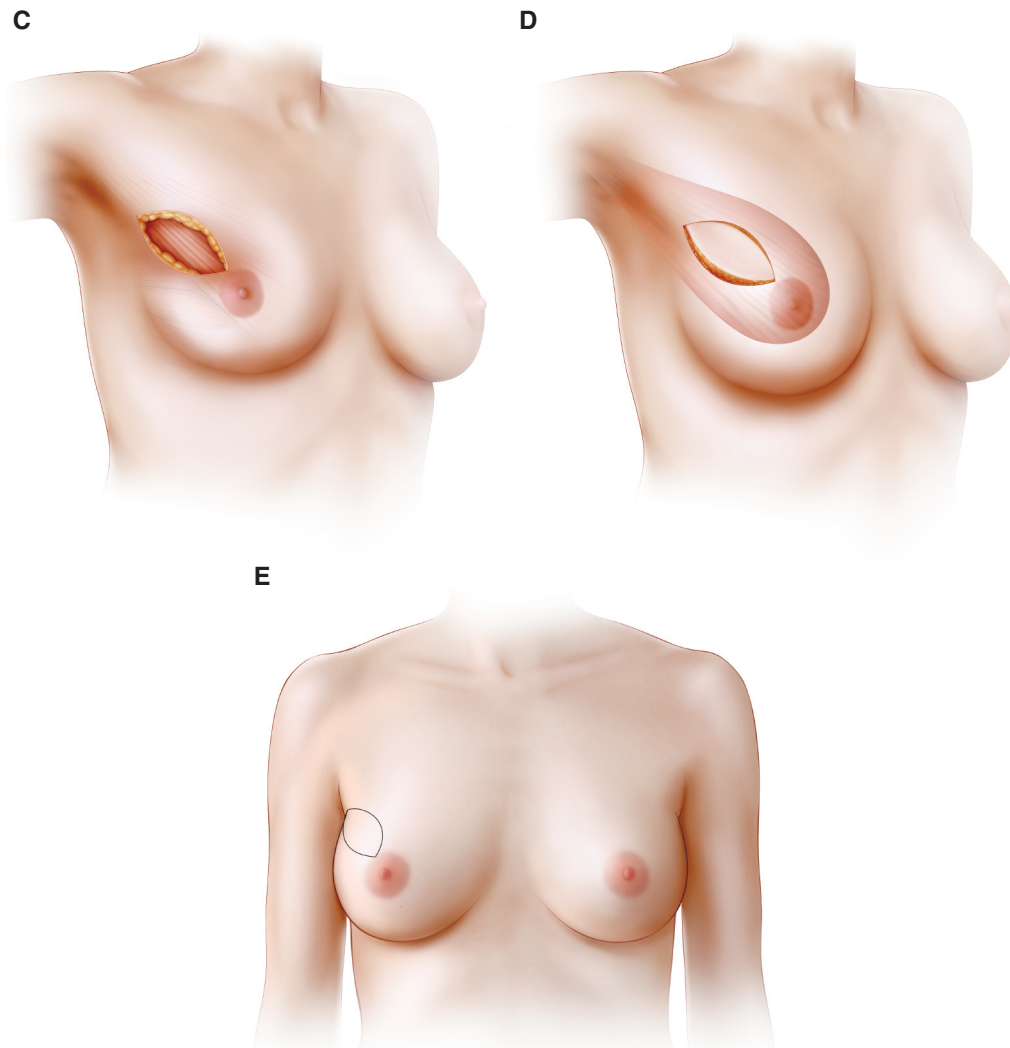


Fig. 26-4, C-E

- The irradiated scar and contracted skin are excised (re-creating the defect).
- Tissue requirements are assessed and the measurements are recorded.
- The skin island is incised and the flap is harvested.
- The pedicle is identified and the humeral insertion is released.
- A communication with the defect is created.
- The flap is rotated into the resected defect.
- The donor site is closed.
- Autologous tissue is positioned and inset to fill the defect and obtain symmetry.

Markings are always made with the patient in the upright position. The tip of the scapula and the borders of the latissimus dorsi muscle are marked. The proposed defect is designed, taking the degree of irradiated skin into account when determining the extent of resection. The orientation of the skin island is determined and drawn on top of the latissimus dorsi muscle. This orientation depends on the amount and location of desired soft tissue augmentation, the arc of rotation from the pedicle, and natural skin tension lines on the back.

The skin island is typically designed larger than needed, in anticipation of skin edge retraction once the tethering is released.

Because the defect is always dissected and prepared first, the design and dimensions of this cutaneous island can be altered and customized to fit the defect during the procedure. The fat preservation is drawn on top of the latissimus dorsi muscle and depends on where bulk is required in relation to the skin defect. The skin orientation of superior or lateral defects is relatively versatile, because the humeral insertion is released. The skin island is located more distally on the muscle for medial or upper quadrant defects, and lateral breast defects can be designed more proximally or anteriorly on the muscle.

The patient is placed in the supine or decubitus position, prepped and draped. The defect is surgically released through the original scar, and the dissection is continued into the subcutaneous and intraparenchymal planes. The defect is essentially re-created, and any tight, irradiated skin is resected. The dissection is extended down to the level of the pectoralis muscle fascia, if this is the location of the original resection. The tissue is sent to the pathologist for routine evaluation. The clinical detection of residual tumor foci is difficult to determine grossly; however, suspicious areas should be analyzed intraoperatively. If the margin status is a concern, reconstruction should be deferred until negative margins are confirmed.

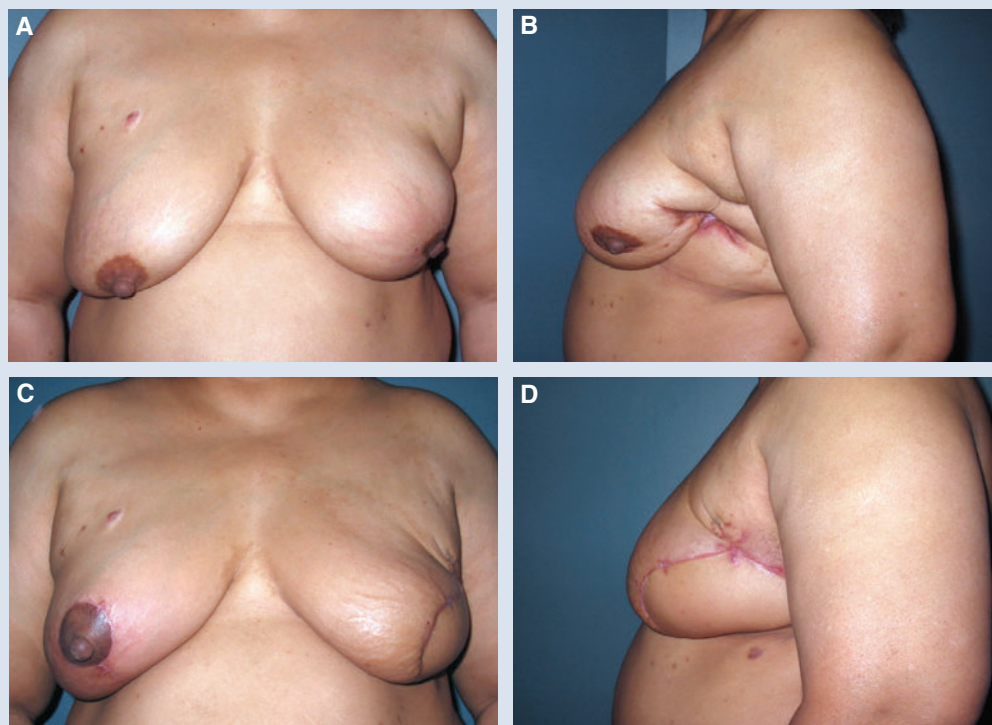
The skin island is incised and the latissimus dorsi muscle is exposed. Fat is preserved on the muscle as needed. Although a smaller skin island often results in a better donor site, it could restrict exposure. The use of a lighted retractor or endoscope can facilitate dissection in these situations. The muscle thickness varies, and harvesting a larger portion is often safer, because it can be trimmed to fit the defect. This ensures that the entire dead space is filled within the recipient site, minimizing wound contraction that could produce irregularities in breast contour months or years later. The dissection is extended directly on top of the muscle up into the axilla to minimize bulk in that location once transferred. The thoracodorsal vessels are identified and protected. A tunnel is created from the defect laterally to the axilla, where the latissimus dorsi muscle is identified. The vessels can be dissected from the defect anteriorly and from the skin island incision laterally. Keeping the tunnel high in the axilla prevents lateral contour distortion during pedicle rotation. Once the desired amount of latissimus dorsi muscle is harvested, it is elevated off the chest wall in the usual fashion. The humeral insertion is taken down, and the flap is transferred through the tunnel into the defect. The donor site is closed over a closed drain.

During the flap inset, the muscle is often folded to provide further bulk, which is well tolerated. The muscle is usually trimmed to custom-fit the defect. With absorbable sutures, the flap is secured to the deepest portion of the wound. This helps to withstand early muscle contractions that may occur because the thoracodorsal nerve has been preserved.

The final part of the reconstruction is precise alignment of the skin island with the adjacent wound edges. Debridement of the irradiated skin edges and subsequent reconstruction of the defect as an aesthetic unit are often more desirable and minimize the patchlike appearance of the flap. Debridement in aesthetic breast units also maximizes the final appearance and minimizes the flap prominence and contrast. Skin tension is determined to provide the most natural contour, and the flap is inset. If tension is too tight, scar widening and contraction might occur; if it is too loose, redundant skin edges affect the final contour. Buried deepithelialized dermis is often useful to add volume and renourish skin edges.

The potential color mismatch and patchlike appearance that the latissimus dorsi skin island occasionally produces need to be considered preoperatively. Reconstructing the defect as part of a breast aesthetic unit might also minimize this color contrast. Drains are typically kept in the donor site and breast defect until output is minimal. Every attempt is made to preserve the nipple-areola complex; however, occasionally the defect is significant enough to warrant resection of the nipple with the deformity and reconstruction of the nipple in the appropriate location at a later stage. This is often safer and minimizes morbidity while maximizing shape and symmetry.

PATIENT EXAMPLE

**Fig. 26-5**

Occasionally, a patient's lateral defect is severe enough to cause significant displacement of the NAC, causing pain and tightness in the breast, as in this woman who presented 3 years after BCT (A and B). The scar was completely resected, along with the nipple-areola complex, and the breast was reconstructed with a large latissimus dorsi cutaneous island. A contralateral reduction was performed for symmetry. In this patient, it was easier to plan for a nipple reconstruction at a later stage than to try to mobilize the dislocated NAC. The patient is shown 6 months after surgery (C and D).

OUTCOME

Aesthetic improvements in contour and size have been noted after flap reconstruction of BCT deformities. Patients with tethering or dislocation of the NAC and severe contour irregularities often have the most improvement in contour and nipple position after scar release and flap transfer. Defects in the lateral and lower poles of the breast have similarly been found to have consistent improvement in breast aesthetics. Breast complications are minimal, and patients are pleased with the preserved breast skin sensation and improved symmetry. Replacing the tight scar tissue with a vascularized flap ensures that the breast feels as soft and natural as possible. Flap and breast edema usually subsides 6 to 12 months after the reconstruction, and cosmetic results improve over the first year, generally stabilizing after this time. Donor-site morbidity does occur and is similar to the morbidity that occurs after flap harvest for total breast reconstruction. Back seromas following latissimus dorsi harvest are the most common complication and respond well to aspiration in an outpatient setting in almost every instance. Postoperative cancer surveillance is not affected by flap reconstruction of the BCT deformity.⁸

PATIENT EXAMPLE

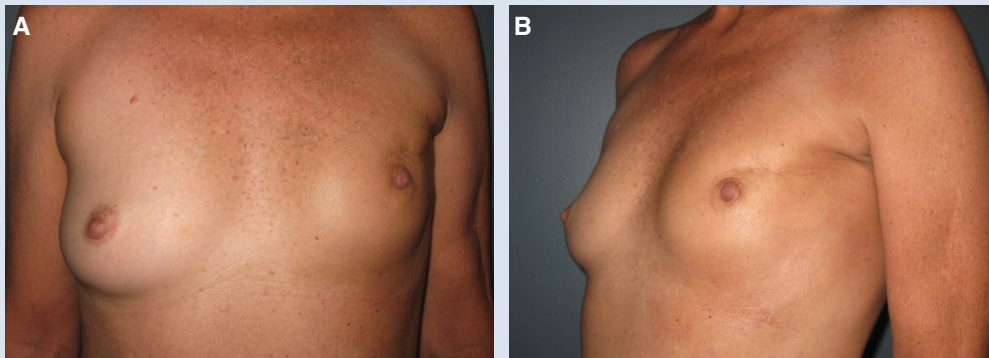


Fig. 26-6, A and B

Occasionally, multiple modalities are required to correct a complex deformity. This 48-year-old woman presented 5 years after left BCT. She had obvious volume asymmetry, blunting of the IMF, and dislocation of the NAC.

Continued

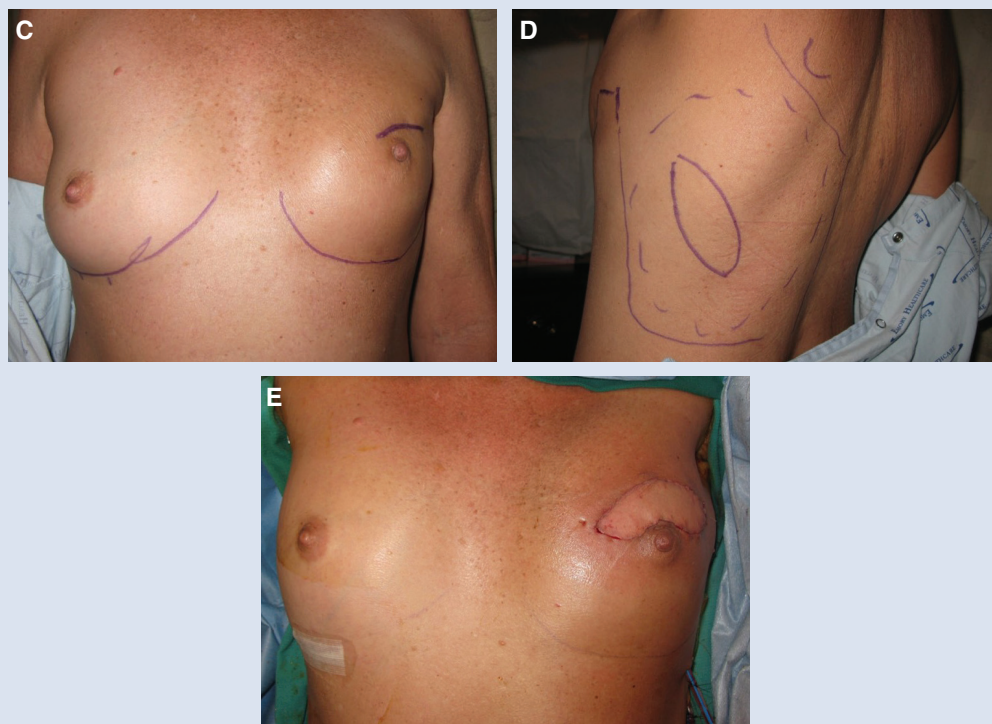


Fig. 26-6, C-E

In her initial procedure, the defect was re-created and a latissimus dorsi myocutaneous flap was transferred to help reposition the NAC. A contralateral augmentation was performed for symmetry.

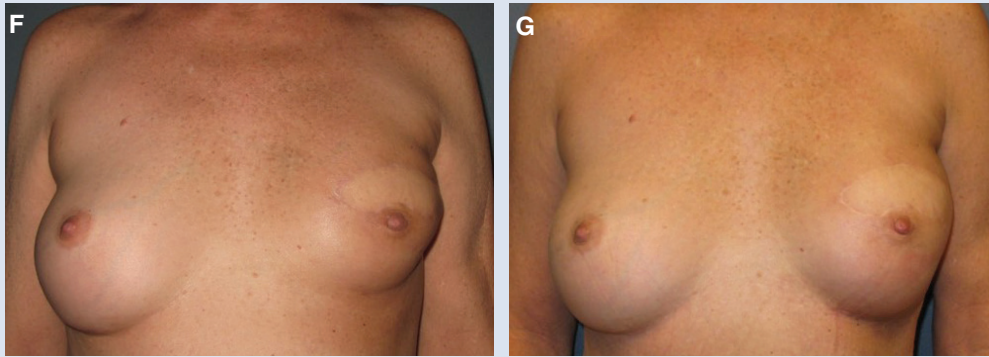


Fig. 26-6, F and G

Although her nipple position was corrected, she still had volume and IMF asymmetry. An implant was placed in the left breast to assist with volume and IMF positioning.

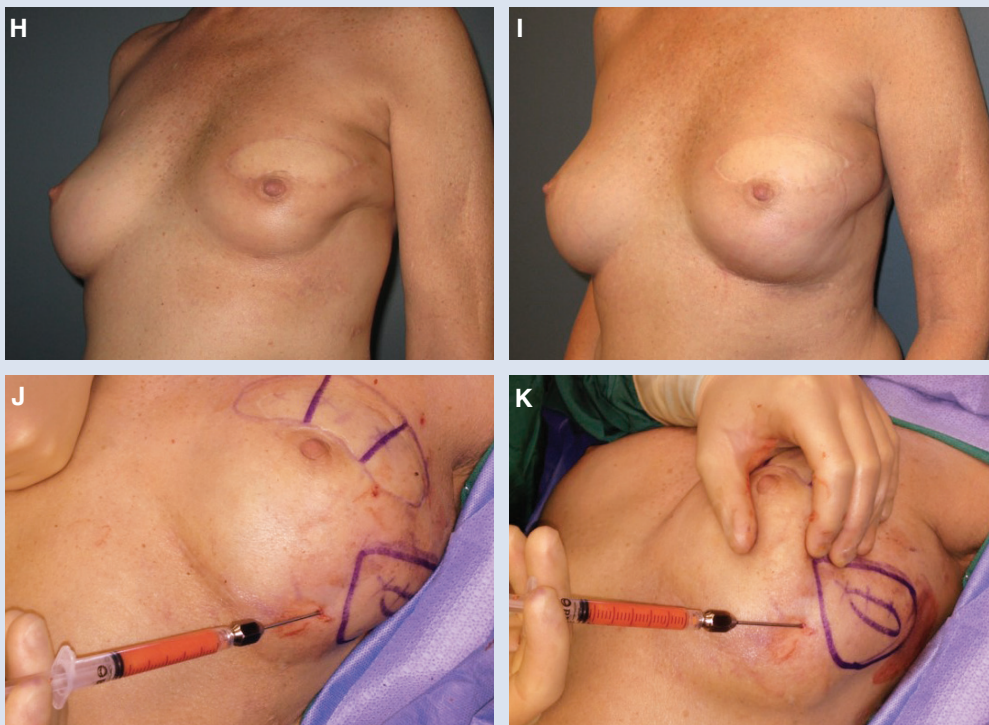


Fig. 26-6, H-K

After healing from implant placement, she still had contour irregularity laterally, so she was taken back to the operating room for autologous fat grafting.

Continued

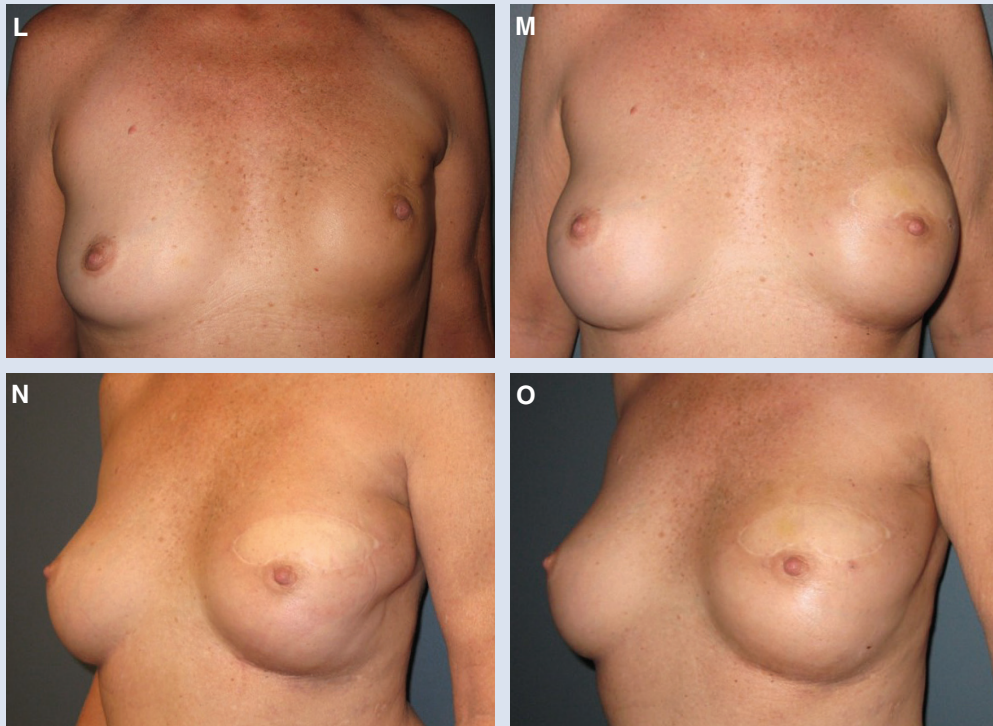


Fig. 26-6, L-O

She is shown 2 years after her multistage, multimodality correction of a complex BCT deformity.

Surgical Sequence

- Latissimus dorsi muscle flap To lower the nipple
- Implant placement To lower the nipple and adjust breast size to match the contralateral breast
- Fat grafting To improve the breast's lateral contour

Critical Issues

- It is important to understand the deformity and determine the components that need to be replaced.
- Deficiencies in the skin, parenchyma, and nipple-areola position must be addressed.
- Most BCT deformities benefit from local flap reconstruction using vascularized, nonirradiated tissue.
- Skin and volume are typically required to reconstruct the deformity.
- Recreate the deformity as an aesthetic unit when possible.
- Dislocation of the nipple-areola complex is often corrected by scar release and flap interposition.
- The latissimus dorsi flap can be used to reconstruct most BCT deformities.
- Smaller defects, particularly those in the superior, lateral, and inferior portion of the breast, are best treated with the latissimus dorsi flap.
- Larger defects, particularly those in the medial portion of the breast, are often more amenable to a TRAM flap.
- TRAM flap reconstruction is used with caution for the BCT deformity, because it may be needed for total breast reconstruction.

References

1. Clough KB, Cuminet J, Fitoussi A, et al. Cosmetic sequelae after conservative treatment for breast cancer: classification and results of surgical correction. *Ann Plast Surg* 41:471, 1998.
2. Berrino P, Campora E, Santi P. Postquadrantectomy breast deformities: classification and techniques of surgical correction. *Plast Reconstr Surg* 79:567, 1987.
3. Slavin SA, Love SM, Sadowsky NL. Reconstruction of the radiated partial mastectomy defect with autogenous tissues. *Plast Reconstr Surg* 90:854, 1992.
4. Clough KB, Kroll SS, Audretsch W. An approach to the repair of partial mastectomy defects. *Plast Reconstr Surg* 104:409, 1999.
5. Losken A, Schaefer TG, Jones GE, et al. Endoscopic latissimus flap: risk or benefit in reconstructing partial mastectomy defects. *Ann Plast Surg* 53:1, 2004.
6. Matatory WE Jr, Wertheimer M, Fitzgerald TJ, et al. Aesthetic results following partial mastectomy and radiation. *Plast Reconstr Surg* 85:739, 1990.
7. Losken A, Pinell-White X, Hodges M, et al. Evaluating outcomes after correction of the breast conservation therapy deformity. *Ann Plast Surg* 74 Suppl 4:S209, 2015.
8. Monticello DL, Ross D, Bostwick J III, et al. Autologous breast reconstruction with endoscopic latissimus dorsi musculocutaneous flaps in patients choosing breast-conserving therapy: mammographic appearance. *AJR Am J Roentgenol* 167:385, 1996.

27

Perforator Flap Reconstruction of Breast-Conserving Therapy Deformities

Moustapha Hamdi



he treatment of early stage breast cancer by partial mastectomy followed by postoperative radiotherapy, often referred to as breast conservation therapy (BCT), may be considered as an oncologic equivalent to mastectomy in selected cases.^{1,2}

After partial mastectomies (lumpectomies and quadrantectomies) that preserve the nipple-areola complex (NAC) and a large portion of the native breast tissue, up to 31% of the patients indicate an unsatisfactory appearance after BCT.³⁻⁵ Most conditions that lead to the described poor aesthetic outcome following BCT are a result of the surgical dilemma in the treatment of breast cancer. This dilemma arises because wider excision is necessary to provide clear margins and better local control of breast cancer on the one hand, and because of the concerns about sparing as much tissue as possible for defect closure and the resulting aesthetic outcome on the other hand.⁶⁻⁸

Our preference is to perform immediate reconstruction when it is feasible and indicated. To obtain a satisfactory aesthetic result, the created cavity should be filled with local or distant tissues before starting the irradiation, because operating on irradiated breasts has high complication rates and often poor aesthetic results. During immediate reconstruction, the breast can be manipulated before irradiation, this could lower the complication rate and improve the outcome.⁷⁻¹⁰

The clinical outcomes and expert impressions support our approach.⁸⁻¹⁵ They suggest that surgical factors are more important than radiation-induced injury and fibrosis in the development of post-BCT breast deformity. When immediate reconstruction is not performed in cases with unfavorable resection defects, significant breast deformities will likely manifest following completion of the BCT regimen. There are many reasons for aesthetic failure:

- Tumor resection can produce distortion, retraction, or volume changes in the breast.
- Changes in the nipple-areola complex can exaggerate asymmetry.
- Irradiation can have a profound effect on the remaining breast tissue; however, it is very difficult to predict who will develop those severe postradiation changes.^{7,16} Radiotherapy generally “exaggerates” the surgically created deformity.¹⁷

Several classification scales have been developed to characterize delayed breast deformities, and they suggest reconstructive options. Berrino et al¹⁵ were the first to classify post-BCT deformities. Their morphologic classification system underscores the importance of analyzing the etiologic factors of the deformity.^{15,16} They described the following four deformity types, which are based on the presence of one or more: nipple malposition, localized breast defect, generalized breast contracture, or severely total damaged breast.¹⁵

Clough et al¹³ have altered this classification, based on response to reconstruction.

In clinical application, these classifications help to clarify the deformities, which typically result when BCT is performed under suboptimal conditions. The classification schema also guides us in reconstruction by emphasis on identifying what is missing or disordered and on seeking a reasonable match between the two breasts. In this chapter, we will focus on post-BCT deformity which required surgical procedures (mainly flap surgery) to the irradiated breast.

CLINICAL APPROACH TO BCT DEFORMITIES

As for all reconstructive procedures, reoperative breast surgery should be carefully planned on an individual base. Before considering any treatment, relapse of cancer should be ruled out.

In the approach to BCT deformities two major points should be considered:

1. Fewer local options of repair methods and techniques are available in breasts previously treated with BCT because of reduced breast volume, scarring, distorted anatomy, and disturbed vascularity.
2. Postradiation changes make corrections more technically difficult, and results and complications are highly unpredictable.

Therefore an extensive surgical procedure of the breast after BCT should be carefully planned, because of the high complication rate, including wound dehiscence, fat necrosis, skin necrosis, and nipple necrosis.^{8,13} Studies have estimated the complication rate to be as high as 50%⁷ and the final aesthetic result to be poor when extensive tissue rearrangement is performed in a previously irradiated breast.^{13,18}

Preoperative Analysis of the Deformity

Delayed partial breast reconstruction should be considered when post-BCT deformities occur. However, the patient's expectations for the cosmetic outcome are often much higher than during the primary cancer treatment phase. Therefore thorough preoperative analysis of the problem and the patient's expectations should be explored during several outpatient visits. Careful surgical planning and clear patient consent is essential, as in every reoperative surgery.

The clinical examination should encompass the patient's general condition and any risk factors such as obesity, smoking history, or any concurrent disease, such as diabetes mellitus or arterial hypertension. A high BMI and smoking history are major risk factors that adversely affect wound healing, compounding the vulnerability of the tissue as a result of irradiation. Patients should be instructed to quit smoking at least 3 months before surgery.

A thorough oncologic checkup is essential before planning a surgical procedure in patients after BCT deformity. Because these patients have a greater risk of local recurrence than mastectomy patients do, clear documentation of initial tumor therapy and margin status is essential.

Local physical examination includes both breasts and the surrounding tissue, such as the axillary region, shoulder, and back. Any limitation of the ipsilateral breast function should be documented. Although correction of irradiated breast tissue by removing scar tissue and adding “healthy” flap tissue may improve the locoregional aspect and function, functional deterioration may result if a major flap-related complication occurs.

When the irradiated breast is analyzed, several points should be considered:

1. Breast volume and position
2. NAC position
3. The number of affected quadrants
4. The general quality of the breast

Depending on the resultant deformity, one or more surgical options can be performed. Regardless of the reconstructive method that is required for the irradiated breast, a contralateral breast remodeling may still be necessary to achieve better breast symmetry. Therefore the contralateral breast is almost a part of the surgical strategy and should be discussed with the patient.

Reconstructive Methods for BCT Deformities

The ultimate goal of the treatment is to achieve breast symmetry. We consider the treatments of BCT deformities to be salvage procedures. The currently available methods in reconstructive surgery cannot re-create the initial anatomy status of the breast, which is irreversibly damaged by previous surgery and irradiation. This last point must be emphasized to the patient during the preoperative visit.

The available surgical methods for BCT deformities are divided into three groups. Nevertheless, the definitive surgical plan may still include more than one option.

Techniques That Improve Breast Volume and Position

When there is no major deformity in the irradiated breast, procedures on the contralateral breast to adjust symmetry are ideal options. However, BCT often results in a smaller and higher position of the breast. In these cases, either a breast fat grafting procedure¹⁹ or contralateral breast remodeling or a combination of both is the optimal treatment. The contralateral breast is often larger and more ptotic.

Techniques That Improve NAC Position

The techniques described may be adequate to correct the asymmetry in the NAC position. However, when a horizontal displacement of the NAC is found, additional repositioning is required. Mild lateral or medial NAC shift can be corrected with elliptic deepithelialization or with a circumferential or round bloc mastopexy.¹⁴ When mild radiation sequelae are observed, a bilateral matching procedure can be done.^{8,12,16} Nevertheless, techniques in mammoplasty should be adapted to this specific situation. A minimal skin undermining with a short and wide pedicle must be used.⁸ When a major NAC malposition is caused by a large breast defect or a generalized severe irradiation sequela, flap surgery is indicated.

As an alternative to flap surgery, fat grafting plus the application of a negative pressure tissue expansion device was successfully used to treat BCT deformities.¹⁹⁻²¹

Techniques That Correct Breast Defects

Box 27-1 General Guidelines for Perforator Flap Reconstruction After BCT

- Excision lines have to be designed within the reconstructive approach.
- The breast tissue should be opened like scar release after burn contracture.
- Fibrosis and scar tissue is removed without undermining of the breast tissue.
- Frozen section examination can be requested if recurrence is suspected within the excised tissue.
- Flaps should only be incised after releasing the breast for better evaluation of the breast defect.

The main indication for perforator flap reconstruction is a localized breast defect with no major postradiotherapy fibrosis. Nevertheless, the key step for success in these cases of delayed reconstruction involves the radical excision and release of scar tissue. Different methods can be performed, depending on the severity and the location of the defect.

Rearrangement Procedures

Similar to the procedures described for immediate reconstruction, rearrangement techniques using skin and glandular flaps or glandular flaps based on breast tissue can be done.^{8,12,13,15} This is only indicated when the following absolute requirements are encountered:

1. Minimal postradiotherapy sequelae
2. 10% to 20% localized defect in relatively moderate to large breast
3. Respecting the principles of no tissue undermining and no-tension closure

Tissue Recruitment Techniques: Flap Surgery

Tissue recruitment techniques are indicated when there is:

1. Inadequate breast volume for a local reshaping procedure
2. Moderate to severe irradiation sequelae
3. A major deformity extended on more than two quadrants (greater than 20% of initial breast size)
4. Generalized severe fibrotic breast

FLAP SURGERY

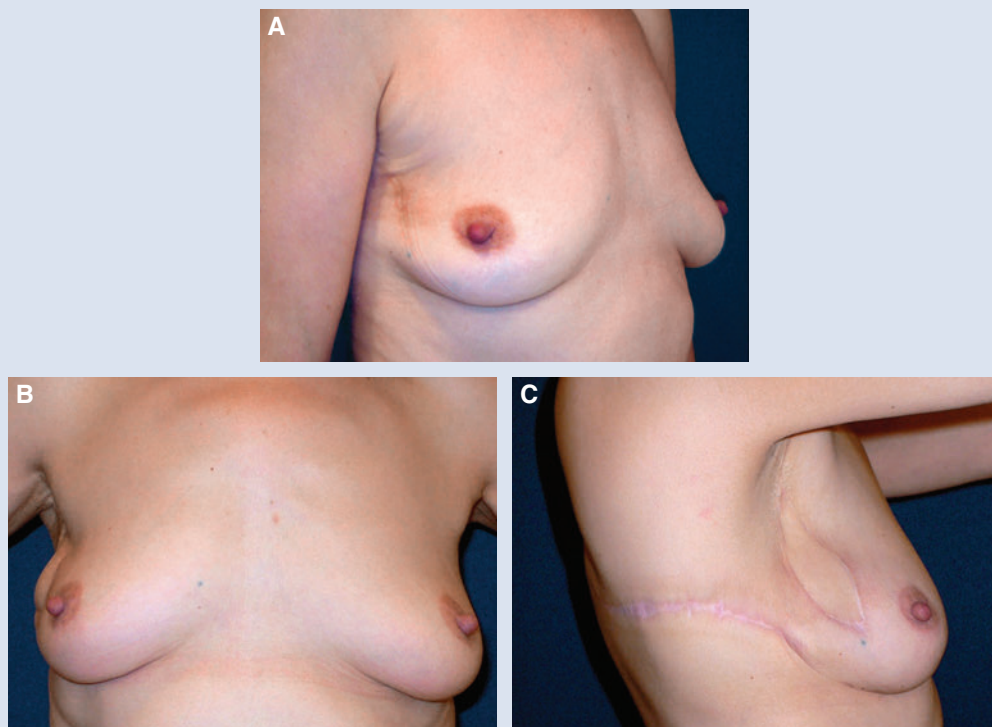
Pedicled Flaps

Pedicled flaps are our first choice for distant tissues for partial breast reconstruction. Pedicled flaps include the latissimus dorsi (LD) muscle or myocutaneous flap and the transverse rectus abdominis myocutaneous (TRAM) flap.^{10,18,22} With the development of pedicled perforator flaps for partial breast reconstruction, more options and potentially lower donor-site morbidity are now available.^{8,24,25} Pedicled perforator flap options include the thoracodorsal artery perforator (TDAP) and the lateral intercostal artery perforator (LICAP) flaps.²³⁻²⁵

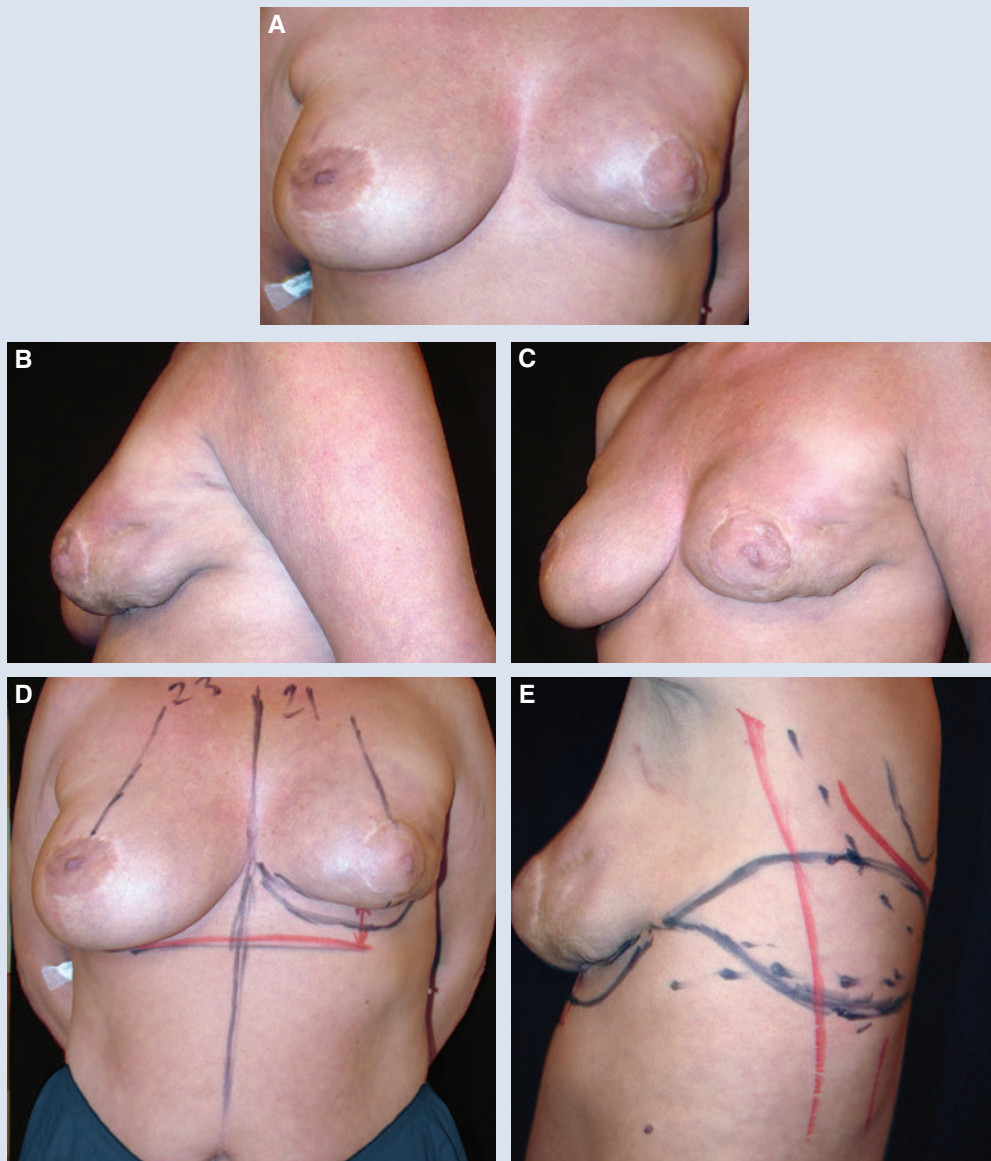
Previous surgery or radiotherapy can damage the thoracodorsal vessels, and therefore the vessels should first be checked. Location of the deformity does influence the choice of flaps. Laterally based pedicled flaps (LD, LICAP, TDAP, lateral thoracic) generally are not suitable for reconstruction of large defects of the medial breast quadrants due to insufficient reach.

However the pedicled superior epigastric artery perforator (SEAP) flap can be used in selected cases with a small-sized defect.²⁶ Surgical techniques for perforator flap harvesting are presented in Chapter 22.

PATIENT EXAMPLES

**Fig. 27-1**

This 48-year-old woman had undergone BCT 3 years earlier. She presented with a localized defect in her right breast located at the superolateral quadrant, with NAC displacement (A). The rest of the breast was supple. A fat grafting procedure in the superolateral quadrant of the right breast may restore the defect. Additionally, the asymmetry in NAC level could be corrected by a matching procedure in the left breast. However, the patient did not want to operate on the left breast, so a pedicled TDAP flap was performed to reconstruct the missing part and to reposition the nipple. The patient is shown 2 years postoperatively with good breast symmetry (B). The TDAP flap and the donor site (C).

**Fig. 27-2, A-E**

This 54-year-old woman had undergone a tumorectomy and radiotherapy for left breast cancer. She had had a mastopexy with implant breast augmentation 2 years before. The implant was ultimately removed from the left side, and two surgical corrections were performed. She maintained breast asymmetry (A through C). She was then referred to our department for further correction. We found that there was asymmetry in breast volume and NAC placement. There was a large breast defect over the inferior quadrants, in addition to extended fibrosis at the lateral quadrant. The patient is a heavy smoker. A pedicled muscle-sparing latissimus dorsi (MS-LD) TDAP flap was planned to re-create the inframammary fold and partially reconstruct the breast. A segment of 5 cm LD muscle was included in the TDAP flap to add extra volume (D and E).

Continued

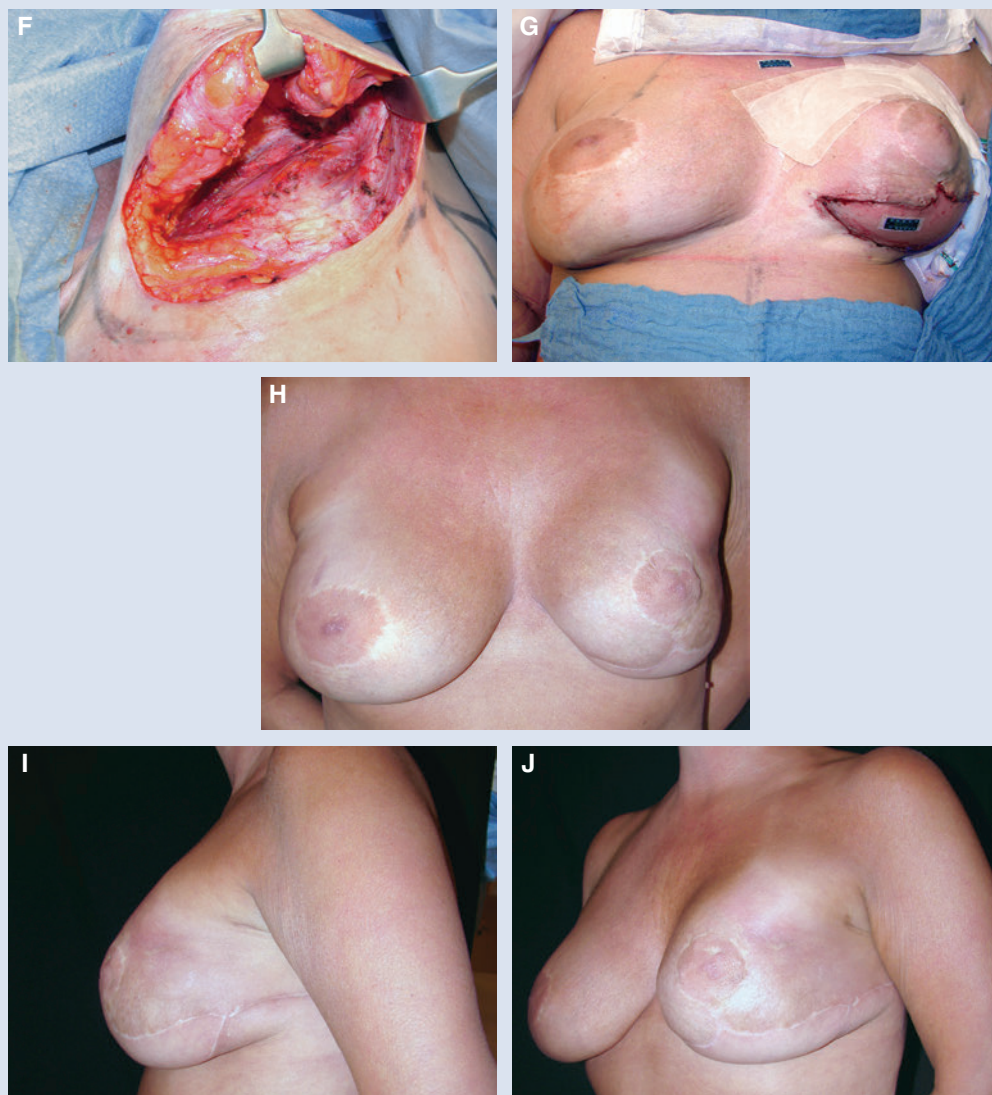


Fig. 27-2, F-J

The scar tissue was removed (*F*), and the flap was inset in the inferior quadrants (*G*). The results are shown 6 months postoperatively (*H* through *J*).

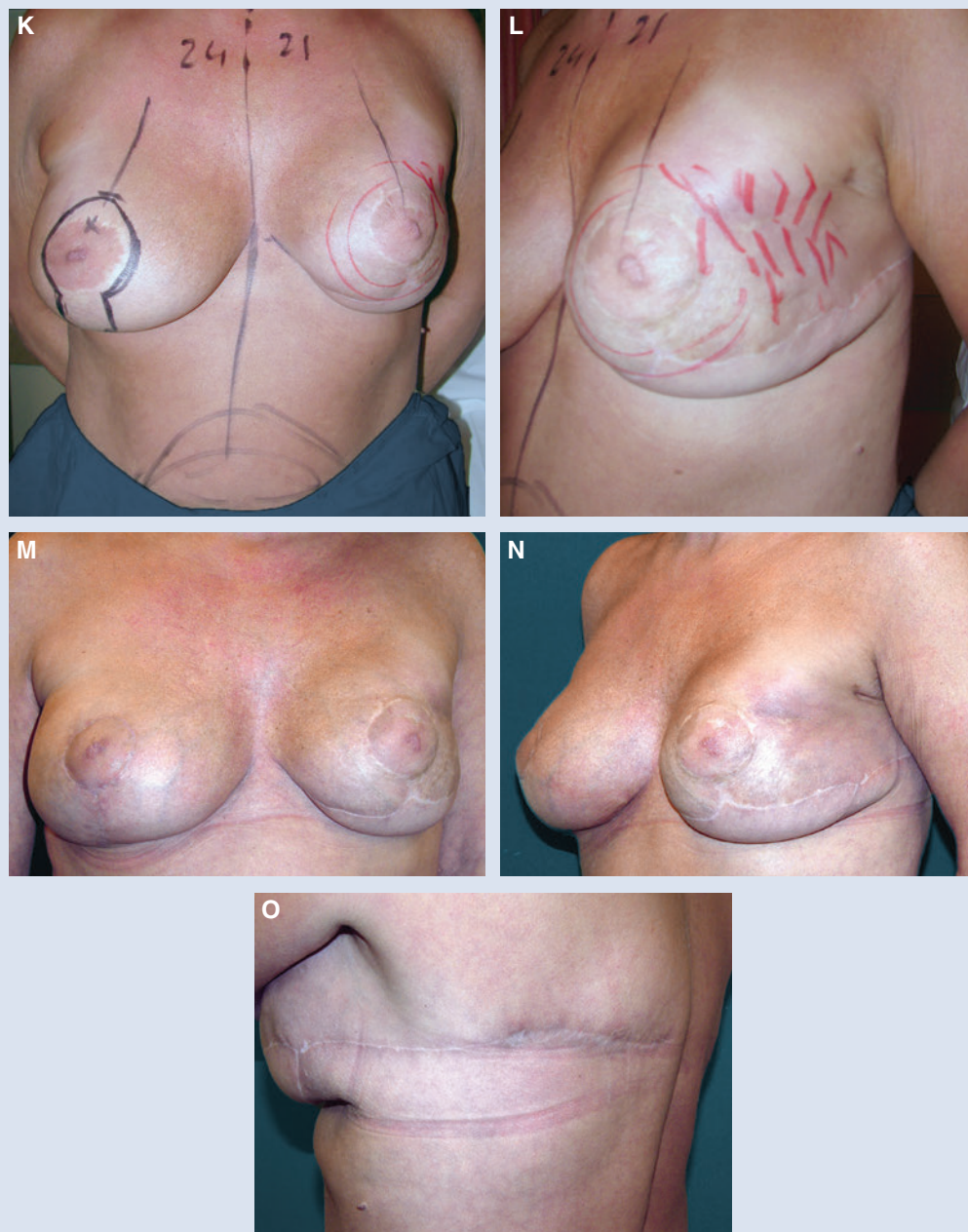


Fig. 27-2, K-O

The second procedure consisted of remodeling of the right breast and fat grafting in the left side (preoperative views, *K* and *L*). The results are shown 3 months after the second surgery (*M* and *N*). The donor site of the MD-LD TDAP is shown (*O*).

Free Flaps

Only when pedicled flaps are insufficient or unavailable are free flaps chosen.²⁵ However, the use of a free flap for partial breast reconstruction generally must be discouraged, because this eliminates the use of the abdominal wall flap for a local recurrence or a new tumor in the contralateral breast, as discussed previously. When a free flap is indicated, it is better to complete the mastectomy, followed by the autologous reconstruction. In my experience, indications are real but limited for delayed free flap reconstruction of partial mastectomy defects:

1. For severe breast deformity or major glandular fibrosis after irradiation
2. For large breast deformity in the medial quadrants
3. In conjunction with completion mastectomy for difficult tumor control
4. As part of treatment consisting of contralateral mastectomy (therapeutic or prophylactic) and correction of ipsilateral post-BCT deformity

PATIENT EXAMPLE

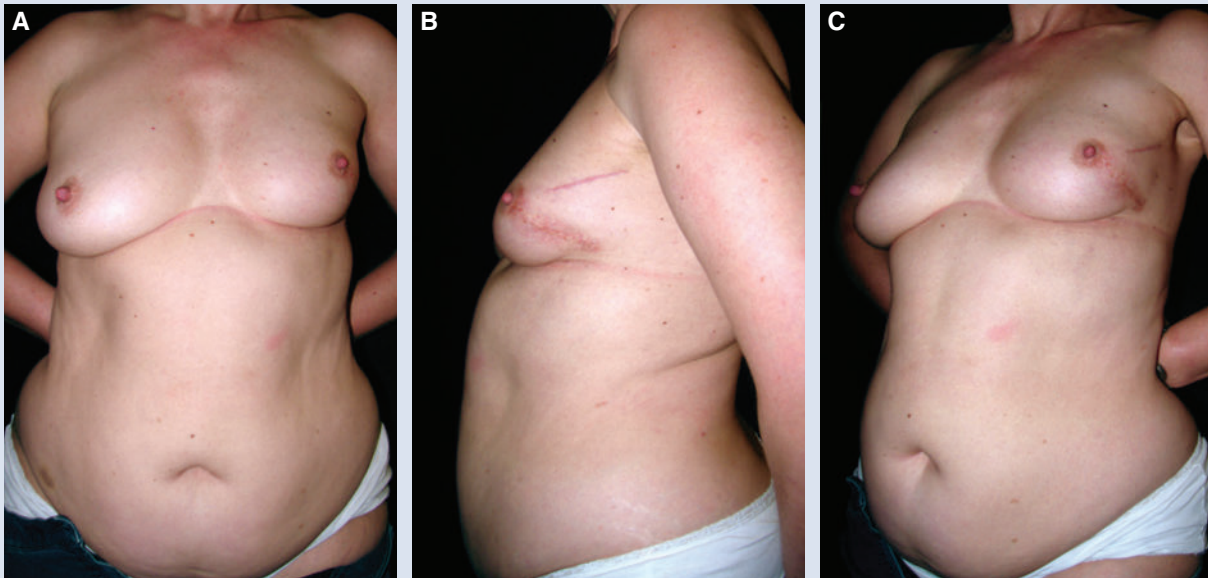
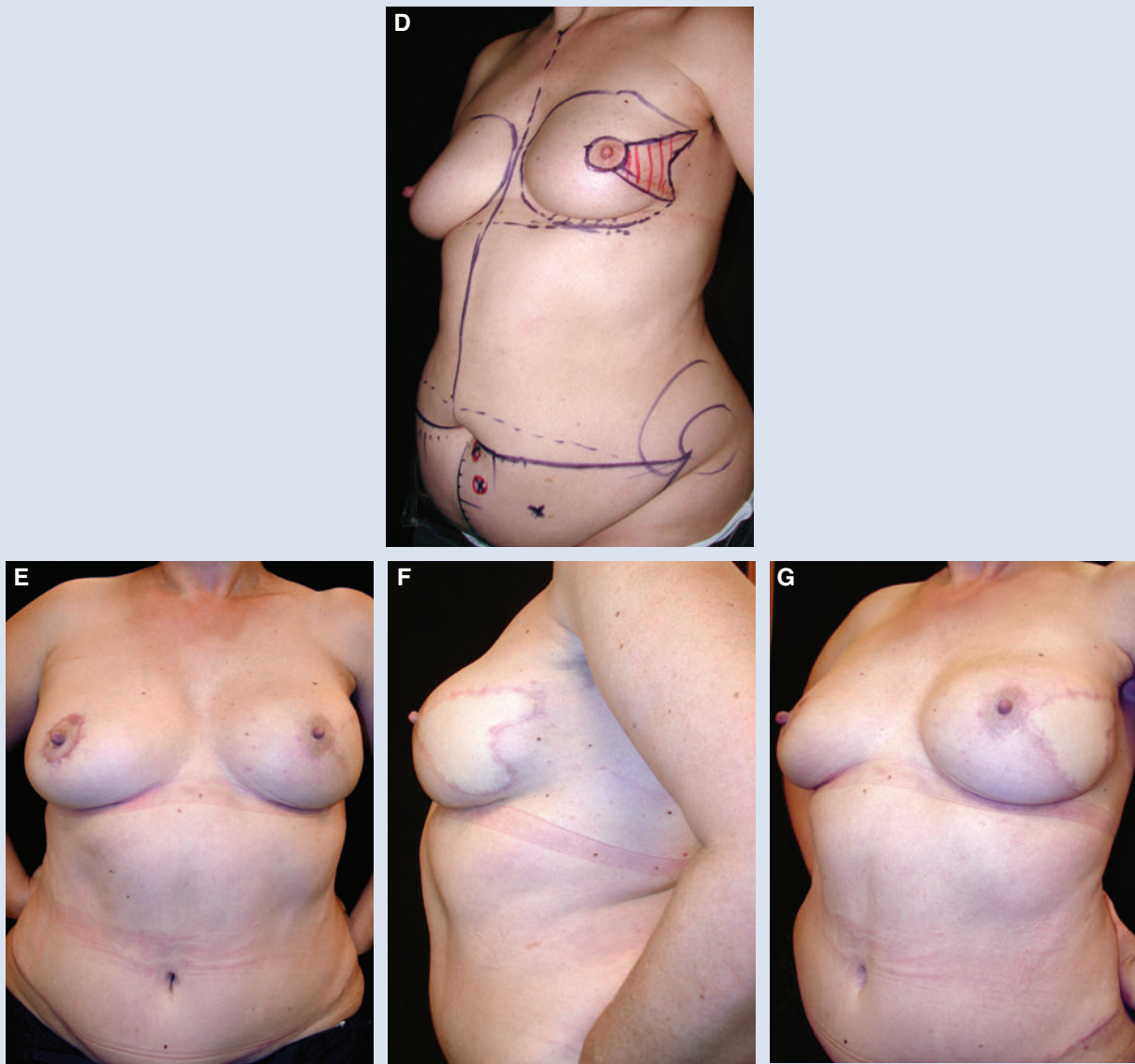


Fig. 27-3, A-C

This 50-year-old woman presented with a post-BCT deformity of the left breast (A). A defect was located at the junction of the lateral quadrant with NAC malposition, and two scars were located in the lateral quadrants (B and C).

**Fig. 27-3, D-G**

The breast was supple, and a pedicled TDAP or LICAP would have corrected her breast asymmetry. However, she asked for a completing mastectomy because breast control was difficult after the conservative therapy and fine-needle puncture and excision-biopsy were necessary to roll out a recurrence several times. In addition, the patient complained of a severe tightening under her left axillary region as a result of scar tissue. We performed a completing mastectomy with removal of the skin of the lateral quadrant, including the two scars. We lowered the inframammary fold and performed a periareolar mastopexy and breast reconstruction with a DIEAP flap. The results of her reconstruction are seen 6 months postoperatively.

A completion subcutaneous mastectomy is usually performed; thicker skin flaps are developed, with preservation of internal mammary perforators to the medial breast tissues. This maximizes vascularity and thereby minimizes ischemic slough of the previously irradiated skin. We think that by performing a completion subcutaneous mastectomy, a significant reduction in the cancer recurrence rate and a more complete release of the postirradiation parenchymal fibrosis can be achieved.

The recipient vessels should be carefully prepared if irradiation was targeted specifically to the selected region. We prefer the internal mammary vessels, because these usually have less damage after BCT compared to the thoracodorsal vessels. In addition, sparing the thoracodorsal vessels allows future use of a pedicled TDAP or LD flap for breast salvage in the event of free flap failure or cancer recurrence. Of our flap options, we consider perforator free flaps to be the gold standard for reconstruction because of their low donor-site morbidity. Our first choice is the deep inferior epigastric artery perforator (DIEAP) flap, because it provides an ample amount of soft tissue with a good match of color and consistency.^{27,28} The superficial inferior epigastric artery (SIEA) flap is a good alternative to the DIEAP flap whenever the direct cutaneous SIE vessels are available and suitable in diameter to perform microanastomoses.^{28,29} The transverse myocutaneous gracilis (TMG) flap has become a valuable alternative to abdominal flaps.³⁰⁻³²

After harvesting the free flap and performing the microanastomoses, flap inset is completed with a larger skin paddle than the original breast skin deficiency. The flap skin paddle ideally replaces an entire breast aesthetic subunit, rather than leaving a small and poorly concealed patch that is very conspicuous when viewed alongside the native breast skin.

AESTHETIC AND FUNCTIONAL RESULTS

When the above measures are incorporated into clinical practice, minimal complication rates can be expected. We have not experienced increased flap failure rates in post-BCT free flap cases. Some patients may develop reactive breast edema, which subsides after 6 to 12 months. Therefore, if further correction is needed, it should be postponed for at least 6 months after the reconstruction in order to allow these reactive changes to dissipate. A stable aesthetic outcome is usually achieved one year after reconstruction. We would expect better long-term evolution in patients treated with completion subcutaneous mastectomy and free flap replacement, when compared to patients treated with limited partial reconstruction by pedicled flaps, because most of the irradiated tissue has been eliminated.

The number of flap surgeries I perform for postlumpectomy deformity has significantly decreased in the last few years because of the introduction of fat grafting techniques. Recent publications have confirmed the safety and efficacy of fat grafting to treat radiotherapy sequelae.³³⁻³⁵

In a recent evaluation of patients after correcting a BCT deformity, local scar correction with or without fat grafting was most common in grade I or II deformities; grades III and VI were usually treated with flap surgery.³⁶ Complications occurred in 34.9%, with no significant variation across the different modes of reconstruction. There was a trend toward higher complication rates with increasing defect severity (0% for grade I, 32% for grade II, 39% for grade III, and 50% for grade IV). Patients required an average of 1.3 procedures (range 1 to 3), at an average follow-up of 2½ years. Eighty percent of patients had only one reconstructive operation, 14% required a second procedure, and 6% a third.³⁶

Surprisingly, many patients express gratitude regarding the functional outcome after delayed free flap reconstruction after BCT. They subjectively experience less tightening sensations in their chest wall and reduced arm edema or heaviness following microvascular flap transfer to the thorax. We postulate that releasing postirradiation scar tissue and importing healthy nonirradiated tissue may be responsible for this subjective improvement.

In the Losken study,³⁶ patient satisfaction was generally high; the mean aesthetic rating was 5 of 7 and trended downward with the extent of the deformity. Patients who underwent contralateral reduction-only had the highest aesthetic scores (5.8 of 7).

Patient surveillance proceeds on a regular basis, in the same manner as before the surgical correction. Good communication between the plastic surgeon, oncologist, and radiologist is essential for following these patients properly. The characteristics of the transferred tissue (fat alone, or muscle and fat combined) and the residual breast tissue (position and amount of retained parenchyma) should be communicated, as well as any areas of fat necrosis that are identified on postoperative follow-up.

CONCLUSION

Post-BCT deformity is addressed in a graded manner, depending on the degree of deformity, the oncologic requirements, and the patient's wishes. Careful patient selection, surgical planning, and technical execution are essential to the success of the surgical treatment. If there is no breast defect, minor revisional surgery with or without a contralateral breast remodeling procedure is often adequate to correct breast asymmetry. Flap surgery is necessary when a breast deformity is encountered. Pedicled flaps should be the first choice to correct breast defects. Free tissue transfer is an important option for treatment of severe post-BCT deformities. Although the indications are limited, when used appropriately, perforator flap procedures offer superior cosmetic and functional results over other techniques. The surgeon must remember that the abdominal tissue is the optimal choice for reconstruction of a future recurrence or new tumors and must not be wasted.

Critical Issues

- Postlumpectomy deformity is a challenging problem.
- Surgery on an irradiated breast has been associated with high complication rates.
- Preoperative oncologic checkup for locoregional recurrence is mandatory.
- Careful assessment of the defect and general condition of the breast is required to choose the surgical option.
- Local pedicled flaps are indicated in severe but limited deformity.
- Mastectomy is indicated in cases of extensive breast fibrosis or major deformity.
- Fat grafting is a new and efficient tool to correct postlumpectomy deformity.
- Multiple sessions might be required to correct the irradiated breast deformity regardless the reconstructive technique.

References

1. Veronesi U, Cascinelli N, Mariani L, et al. Twenty-year follow-up of a randomized study comparing breast-conserving surgery with radical mastectomy for early breast cancer. *N Engl J Med* 347:1227, 2002.
2. Fisher B, Anderson S, Bryant J, et al. Twenty-year follow-up of a randomized trial comparing total mastectomy, lumpectomy, and lumpectomy plus irradiation for the treatment of invasive breast cancer. *N Engl J Med* 347:1233, 2002.
3. Amichetti M, Busana L, Caffo O. Long-term cosmetic outcome and toxicity in patients treated with quadrantectomy and radiation therapy for early-stage breast cancer. *Oncology* 52:177, 1995.
4. Rose MA, Olivotto I, Cady B, et al. Conservative surgery and radiation therapy for early breast cancer. Long-term cosmetic results. *Arch Surg* 124:153, 1989.
5. Taylor ME, Perez CA, Halverson KJ, et al. Factors influencing cosmetic results after conservation therapy for breast cancer. *Int J Radiat Oncol Biol Phys* 31:753, 1995.
6. Spear SL, Davison SP. Aesthetic subunits of the breast. *Plast Reconstr Surg* 112:440, 2003.
7. Kronowitz SJ, Feledy JA, Hunt KK, et al. Determining the optimal approach to breast reconstruction after partial mastectomy. *Plast Reconstr Surg* 117:1, 2006.
8. Hamdi M, Wolfli J, Van Landuyt K. Partial mastectomy reconstruction. *Clin Plast Surg* 34:51, 2007.
9. Matory WE, Wertheimer M, Fitzgerald TJ, et al. Aesthetic results following partial mastectomy and radiation therapy. *Plast Reconstr Surg* 85:739, 1990.
10. Kroll SS, Schusterman MA, Reece GP, et al. Breast reconstruction with myocutaneous flaps in previously irradiated patients. *Plast Reconstr Surg* 93:460, 1994.
11. Olivotto IA, Rose MA, Osteen RT, et al. Late cosmetic outcome after conservative surgery and radiotherapy: analysis of causes of cosmetic failure. *Int J Radiat Oncol Biol Phys* 17:747, 1989.
12. Clough KB, Kroll SS, Audretsch W. An approach to the repair of partial mastectomy defects. *Plast Reconstr Surg* 104:409, 1999.
13. Clough KB, Cuminet J, Fitoussi A, et al. Cosmetic sequelae after conservative treatment for breast cancer: classification and results of surgical correction. *Ann Plast Surg* 41:471, 1998.

14. Kroll SS, Singletary E. Repair of partial mastectomy defects. *Clin Plast Surg* 25:303, 1998.
15. Berrino P, Campora E, Santi P. Postquadrantectomy breast deformities: classification and techniques of surgical correction. *Plast Reconstr Surg* 79:567, 1987.
16. Berrino P, Campora E, Leone S, et al. Correction of type II breast deformities following conservative cancer surgery. *Plast Reconstr Surg* 90:846, 1992.
17. Bold RJ, Kroll SS, Baldwin BJ, et al. Local rotational flaps for breast conservation therapy as an alternative to mastectomy. *Ann Surg Oncol* 4:540, 1997.
18. Slavin SA, Love SM, Sadowsky NL. Reconstruction of the radiated partial mastectomy defect with autogenous tissues. *Plast Reconstr Surg* 90:854, 1992.
19. Rigotti G, Marchi A, Galiè G, et al. Clinical treatment of radiotherapy tissue damage by lipoaspirate transplant: a healing process mediated by adipose-derived adult stem cells. *Plast Reconstr Surg* 119:1409, 2007.
20. Khouri RK, Smit JM, Cardoso E, et al. Percutaneous aponeurotomy and lipofilling: a regenerative alternative to flap reconstruction? *Plast Reconstr Surg* 132:1280, 2013.
21. Khouri RK, Rigotti G, Khouri RK Jr, et al. Tissue-engineered breast reconstruction with Brava-assisted fat grafting: a 7-year, 488-patient, multicenter experience. *Plast Reconstr Surg* 135:643, 2015.
22. Kroll SS, Doores S. Nipple centralization for the correction of breast deformity from segmental mastectomy. *Ann Plast Surg* 24:271, 1990.
23. Hamdi M, Van Landuyt K, Monstrey S, et al. Pedicled perforator flaps in breast reconstruction: a new concept. *Br J Plast Surg* 57:531, 2004.
24. Levine JL, Soueid NE, Allen RJ. Algorithm for autologous breast reconstruction for partial mastectomy defects. *Plast Reconstr Surg* 116:762, 2005.
25. Hamdi M, Spano A, Van Landuyt K, et al. The lateral intercostal artery perforators: anatomical study and clinical applications in breast surgery. *Plast Reconstr Surg* 121:389, 2008.
26. Hamdi M, Van Landuyt K, Ulens S, et al. The role of the multi-detector CT scan images in pre-operative perforator mapping and clinical applications of the superior epigastric artery perforators flaps. *J Plast Reconstr Aesthet Surg* 62:1127, 2009.
27. Hamdi M, Weiler-Mithoff E, Webster M. Deep inferior epigastric perforator flap in breast reconstruction: experience with the first 50 flaps. *Plast Reconstr Surg* 103:86, 1999.
28. Granzow JW, Levine JL, Chiu ES, et al. Breast reconstruction with the deep inferior epigastric perforator flap: history and an update on current technique. *J Plast Reconstr Aesthet* 59:571, 2006.
29. Rizzuto RP, Allen RJ. Reconstruction of a partial mastectomy defect with the superficial inferior epigastric artery (SIEA) flap. *J Reconstr Microsurg* 20:441, 2004.
30. Arnez ZM, Pogorelec D, Planinsek F, et al. Breast reconstruction by the free transverse gracilis (TUG) flap. *Br J Plast Surg* 57:20, 2004.
31. Schoeller T, Huemer GM, Wechselberger G. The transverse musculocutaneous gracilis flap for breast reconstruction: guidelines for flap and patient selection. *Plast Reconstr Surg* 122:29, 2008.
32. Craggs B, Vanmierlo B, Zeltzer A, et al. Donor-site morbidity following harvest of the transverse myocutaneous gracilis flap for breast reconstruction. *Plast Reconstr Surg* 134:682e, 2014.
33. Rigotti G, Marchi A, Micciolo R, et al. Autologous fat grafting in breast cancer patients. *Breast* 21:690, 2012.
34. Rigotti G, Marchi A, Micciolo PR, et al. On the safety of autologous fat grafting for breast reconstruction. *Plast Reconstr Surg* 130:206e, 2012.
35. Delay E, Gosset J, Toussoun G, et al. [Efficacy of lipomodelling for the management of sequelae of breast cancer conservative treatment] *Ann Chir Plast Esthet* 53:153, 2008.
36. Losken A, Pinell-White X, Hodges M, et al. Evaluating outcomes after correction of the breast conservation therapy deformity. *Ann Plast Surg* 74 Suppl 4:S209, 2015.

28

Local Perforator Flaps in Oncoplastic Breast-Conserving Surgery: The Nottingham Experience

*R. Douglas Macmillan, Lena F. Carstensen,
Veronique K. Tan, Stephen J. McCulley*

Fasciocutaneous chest wall perforator flaps such as the lateral intercostal artery perforator (LICAP), the lateral thoracic artery perforator (LTAP) flap, and the thoracodorsal artery perforator (TDAP) flap have been described for reconstruction of partial breast defects in breast-conserving surgery/breast-conserving therapy (BCS/BCT) for breast cancer and also have a role in postmastectomy reconstruction.¹⁻⁴ In this chapter we present our approach to using these flaps in BCT and present surgical and patient-reported outcomes.

Local perforator flaps harvested from the chest wall adjacent to the breast have inherent advantages. The lax lateral chest wall subcutaneous tissue acts as an ideal filler to replace volume in breast defects. In addition, the resultant scarring from harvesting tissue lateral or inferior to the breast can usually be hidden in the bra line and full function of the latissimus dorsi (LD) muscle is preserved, keeping donor-site morbidity to a minimum.

Harvested without associated muscle bulk, they have homogeneous flap thickness. They may also be raised on a solitary vascular pedicle and can safely be oriented 90 degrees to the axis of the vascular pedicle, maximizing use of the frequently available axillary skin fold for good volume and skin transfer if required. Similarly, they can quickly be raised on a small mesentery of tissue including perhaps two or three perforators and turned over into the lateral or lower regions of the breast. These characteristics, and their close proximity to the breast, enable these flaps to be used for a wide variety of indications in primary cancer excisions and breast reconstructive surgery.

NOTTINGHAM EXPERIENCE

The experience presented in this chapter relates to all local perforator flap surgeries performed for BCT at the Nottingham Breast Institute (Nottingham, UK) from 2007 to 2015. Patients were closely followed after surgery, and outcomes and complications were identified prospectively. Routine cancer surveillance was performed annually by means of clinical examination and mammography.

Patient satisfaction was assessed at 1 year after surgery by a self-rated questionnaire consisting of two parts; the first was the validated Hopwood Body Image Score⁵ that assessed the patient's affective, behavioral, and cognitive response to treatment; the second part consisted of questions formulated to elicit feedback specifically on local perforator flap surgery.

Indications for Local Perforator Flaps in Breast-Conserving Surgery

Local perforator flaps were primarily performed in the same procedure with tumor resection, the volume of which would otherwise have resulted in a poor cosmetic outcome.

Typically, women in our series had nonptotic breasts, a degree of lateral chest wall laxity with adequate subcutaneous volume, and a tumor situated in the lateral third or lower pole of the breast. Such cases would usually be thought of as ideal for a local perforator flap, and this group of women represented our most common indication for this surgery. However, in women with breasts of similar morphology and a suitable donor site, a local perforator flap would be considered a defect in any location if the scar resulting from flap harvest was acceptable.

The key selection criteria were the degree of lateral chest wall laxity and adequate subcutaneous tissue volume. In most cases flaps would be replacing more than 20% of breast volume, but the range is estimated to be 5% to 50%, reflecting the fact that flap size varied greatly, depending on clinical need and the volume of available donor tissue.

As our experience grew with the LICAP and LTAP flaps, the indications for a TDAP flap in BCT became much less common and more specific.

The specific elements of TDAP flap design and dissection are described separately.

Principles of LICAP and LTAP Flap Design

By using the appropriate chest wall perforator located around the periphery of the breast, a flap can be raised to permit reach into any breast defect location in any woman who is a suitable candidate.

Characterizing the position of the perforating vessels used for these flaps was initially based on clinical experience, using preoperative handheld Doppler (8 MHz) mapping and intraoperative observation. A detailed study using anatomic dissections and a clinical series of Doppler observations assisted in confirming and better defining the anatomic basis of the flaps most commonly used. Other good anatomic descriptions of chest wall perforator locations exist, but these have been mainly defined in terms of their proximity to the anatomic landmark of the anterior border of the latissimus dorsi muscle or axillary fold. The aim of our studies was to define the location of the perforators in terms of their proximity to the breast. In so doing, we identified consistent perforator locations, which reinforced our clinical experience that local perforator flaps could be raised based on perforators lying very close to the breast periphery, giving them easy and potentially long reach within the breast. In addition, identification of these perforator locations allowed scar placement to be within the bra line in most cases.

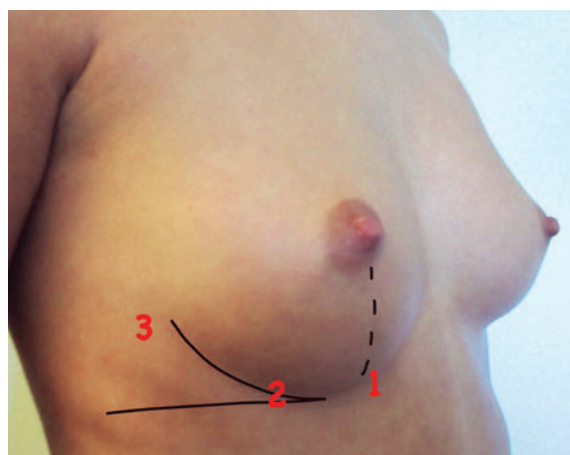
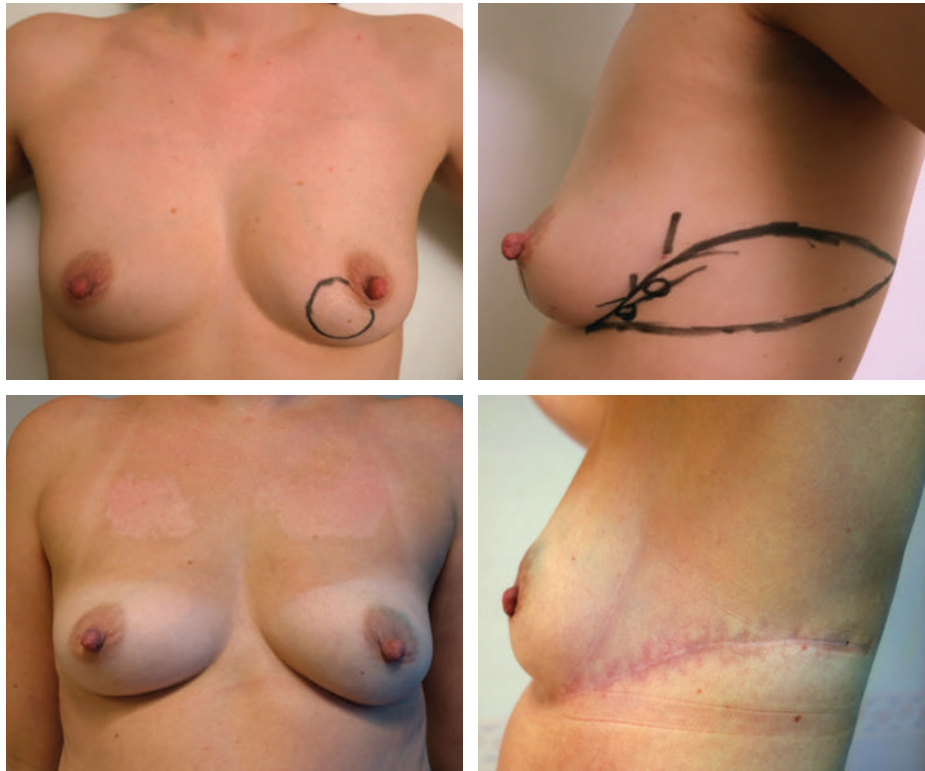
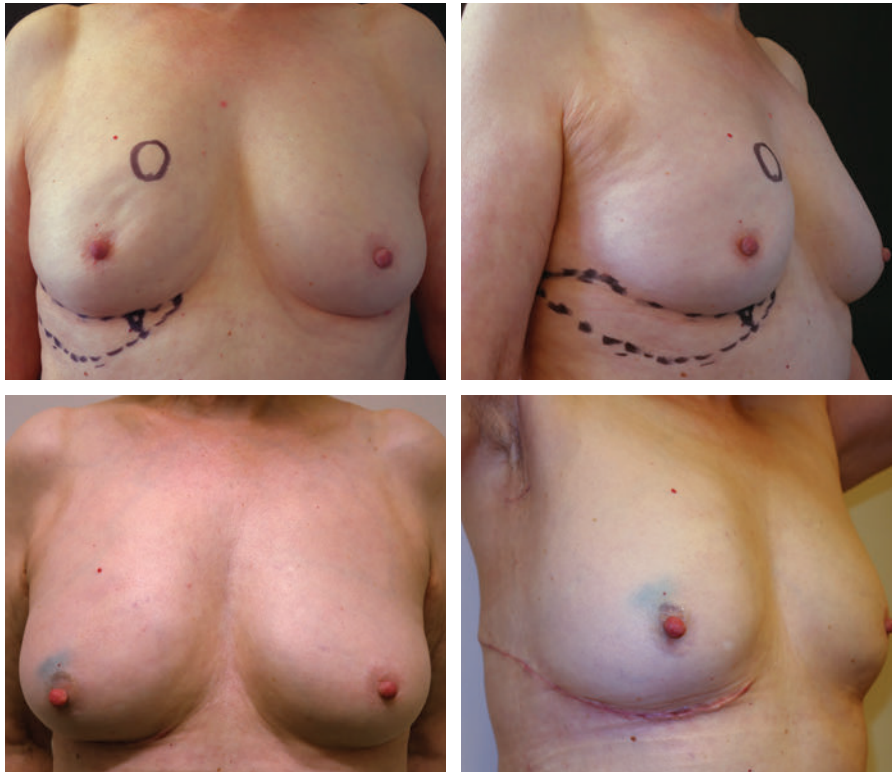


Fig. 28-1

The vascular basis of the vast majority of local perforator flaps used in our series is illustrated. Although considerable anatomic variation exists in the precise location of individual perforators, the figure shows a simplification of where perforators are initially looked for preoperatively. The consistency of these sites is such that it is exceptional for perforators not to be found in close proximity to these landmarks. The most commonly used and consistent LICAP perforators are indicated: located close to the point where the breast meridian crosses the IMF (1); located in the angle between the lateral breast curve and a horizontal line level with the IMF (2); and located just lateral to the lateral breast curve (3).

**Fig. 28-2**

The flap is planned to include one or more perforators near to the breast then varied according to the distribution of skin laxity, and the volume and reach of tissue required. Flap design followed a typical pattern in most cases, the guiding principles of which are as follows; the inferior border of the flap is based on a lateral upwardly curving extension of the inframammary fold (IMF). The superior border is then mapped according to skin laxity, perforator location, and natural skin tension lines. Potential tension on wound closure is avoided and the flap incorporates existing skin laxity so that the resulting closure does not displace the breast laterally. The flap design typically forms a leaf pattern, as shown for a typical LICAP case.

**Fig. 28-3**

For women with skin laxity below the IMF, a crescent-shaped flap is used that may be extended laterally, if required. A flap based on an inframammary perforator may be used for a wide excision of a cancer in the upper inner quadrant.

LICAP and LTAP Flap Dissection

General anesthesia is administered, and the patient is positioned supine with an inflatable 3 L pressure bag below the ipsilateral hemithorax to tilt the torso. This provides good access to the lateral chest wall and breast, and deflation of the pressure bag after flap harvest and closure of the wound posteriorly allows inset with the patient supine, or sitting up if necessary. Local anesthetic with epinephrine is infiltrated around the planned wide local excision and is used as a means of hydrodissection of the subcutaneous tissue overlying the cancer. It is also infiltrated around the flap, carefully avoiding the marked LICAP perforators and the potential LTAP territory.

For most breast defect locations, the LICAP flap is based on a perforator located at the junction of the IMF and lateral breast fold. In most cases, an additional perforator located above this could also be included and a mesentery of tissue between the two is preserved. In addition to the LICAP perforators, we found intraoperatively that a high percentage of LICAP flaps could be either converted into or supplemented by LTAP vessels.

In many cases, an LTAP vessel had been suspected preoperatively on Doppler during planning of the flap, but in an equal number it was sought and found intraoperatively, and the course and size of the vessel was such that it became the serendipitous source of flap perfusion. In some cases, anatomic variants of the chest wall vessels, such as a long subcutaneous branch of the thoracodorsal vessels, the serratus branch of the thoracodorsal vessels, or a subcutaneous branch of a vessel accompanying the long thoracic nerve was used. In many such cases, preserving both LTAP (or a variant vessel) and LICAP vessels did not compromise the mobility of the flap, whereas in others the flap was rationalized to the largest and most clinically well-located source. In such situations this was usually the LTAP vessels because of their larger caliber and the surgeon's ability to convert the flap into one with a longer pedicle, enabling greater reach and more flexibility of orientation and means of transposition.

For breast defects in the lower pole or medial half of the breast, perforators along the IMF are used, creating the anterior and medial intercostal artery perforator flaps (AICAP or MICAP). The most constant of these is located at the point at which the breast meridian crosses the IMF or just lateral or medial to this point. This allows a flap to be designed along the IMF, extending for the required distance along the bra line, and to be transposed into a defect, which could even lie in the upper inner quadrant. Similarly, a skin-bearing flap can be used to replace the nipple when a central excision is indicated.

Because of the rich diversity of options available to vascularize a chest wall flap, the learning curve for this operation includes developing a sense of when one ideal source of vascularization has been identified so that others can be sacrificed.

The flap can then be made as mobile as possible and the operation completed in a reasonable time frame. In this regard, any visibly pulsatile vascular bundle was considered adequate. If this could easily be supplemented with other contributory vessels without compromising flap mobility, that would be our preference and describes the most common scenario in our practice. The main indication for isolating a flap on a single perforator was the requirement to propeller a skin-bearing flap into a defect that required skin replacement.

For BCS, the operative sequence is to perform wide excision of the cancer first through the upper anterior marking of the flap design. Care is obviously required to avoid damage to any identified LICAP vessels while the wide local excision is performed. As with all oncoplastic BCS, a generous margin of excision is planned to maximize the likelihood of achieving clear histologic margins. Care is taken not to extend subcutaneous or submammary dissection beyond the defect created by the wide local excision, the principle being to create a hand-in-glove scenario when the defect is filled with the flap.

The large majority of local perforator flaps are performed simultaneous with cancer excision.

In a few cases, where the extent of disease was less predictable and margin involvement more likely (such as a large area of DCIS), the operation was planned for two stages. In this situation, an initial wide local excision was performed and the defect filled with sterile water. Once clear margins of excision had been confirmed histologically, the flap was performed as a second procedure, usually 2 to 3 weeks later. For such cases it is important to freshen up the margins of the cavity to prevent encapsulation of the flap.

The sequence for raising the flap could be varied, but was usually started with initial circumferential dissection down to the muscular fascial plane. During this, the dissection could be beveled away from the flap slightly to increase volume, particularly deep to the Scarpa fascia. The flap can be raised completely posterior to anterior, which is most common with experience, or anterior to posterior initially to identify the likely LICAP or LTAP perforators and then posterior to anterior to meet the identified perforators to complete the dissection. In the superior aspect of flap dissection, the longitudinal branches of the LTAP vessels or other anatomic variants are identified. If they are found and clearly consist of an artery and vein, a decision may be made to isolate the entire flap on these vessels at this stage, expediting any further dissection. If they are not found or not deemed adequate (sometimes only a vein is identified), the flap dissection would proceed by raising the flap from posterior to anterior. Because the fallback vascular source of the LICAP flap is usually the TDAP vessels, or converting the flap to a more random one based on the inferior dermal attachments (in turn derived from more caudally located perforators), both of these areas are worth some consideration during their respective parts of the dissection. As the surgeon gains experience, if LICAP perforators are clearly identified preoperatively, these fallback options are sacrificed early in the dissection. Early in the learning curve, the surgeon may preserve them until he or she is satisfied that more suitable flap perfusion options are present. Once the flap is elevated anterior to the border of the LD, dissection continues on a much more cautious basis. This may be achieved with cutting diathermy on a low setting (our preference) or with fine scissors, and bipolar diathermy as required. The level of dissection is just superficial to the serratus fascia. Perforating vessels are readily identified and preserved according to their suitability to be part of the overall flap design and plan for transposition.

In a common scenario we encountered, the flap reached the degree of mobility required to turn over into the defect without formally exposing the perforator that was planned for it. As such, in many cases, the flap was based on a mesentery of tissue that included one or more LICAPs at the border of the breast. As the flap turns over, the lateral curvature and breast shape is naturally reconstructed. For the flap to achieve this orientation comfortably, it is often necessary to remove most of the remaining breast tissue between the base of the flap and the breast defect, with awareness of the actual or likely perforator position and arborization. In some situations the flap is more easily transposed into the defect.

Axillary surgery was performed in all cases through the LICAP incision. It was usually found easier to raise the flap before performing a sentinel node biopsy or axillary node clearance due to the access that is then afforded. As an axillary dissection usually involves division of the lateral thoracic vessels, planning an LTAP flap in this setting is a less suitable option, although if desired the LTAP vessels can be dissected through the axilla. However, this is time consuming because of the multiple branches encountered.

The breast cavity is then washed thoroughly, a drain is placed, and the flap is inserted into the defect.

A principle of flap deployment is that it is sutured to prevent the flap from falling out of the defect rather than being sutured in.

Thus if any sutures are necessary to maintain flap position they are usually placed between the flap and deep subcutaneous or breast tissue at the very peripheral part of the breast. The wound is then closed in layers with sutures to the deep fascia, deep dermis, and subcutis.

In most cases the operation was performed as an outpatient procedure and the drain is removed 1 to 5 days later. Pain was not a significant problem with this operation. Return to full normal activities is usually with a few days and temporary shoulder restriction was only seen in those who had an axillary node clearance.

The TDAP Flap in Breast-Conserving Surgery

As stated earlier, the indications for a TDAP flap in BCT are few. They are indicated primarily for a large-volume flap to reconstruct medial defects and for delayed partial breast reconstruction after radiotherapy.

Our preference is always to perform a LICAP or LTAP flap in preference to a TDAP flap, if both options are available.

If performed as a primary volume replacement after wide local excision, a two-stage approach is used. An initial wide local excision of the cancer and sentinel node biopsy is performed and the breast defect filled with water. Once a clear histologic margin is confirmed, a second operation is performed to fill the defect with a TDAP flap, similar to the two-stage LICAP procedure described earlier. If axillary node clearance becomes indicated, this would be performed at the second stage. This staged approach avoids the scenario in which the total breast reconstruction option of an LD flap is compromised if a completion mastectomy is required for involved margins.

Classically, the TDAP flap is planned around the primary perforator located approximately 10 cm below the posterior axillary fold.⁶ However, for most of our indications, this would restrict reach. More caudal perforators are readily found, but because of the extra length of dissection, the flap harvest is modified in most cases using the technique described next, which greatly reduces operative time.

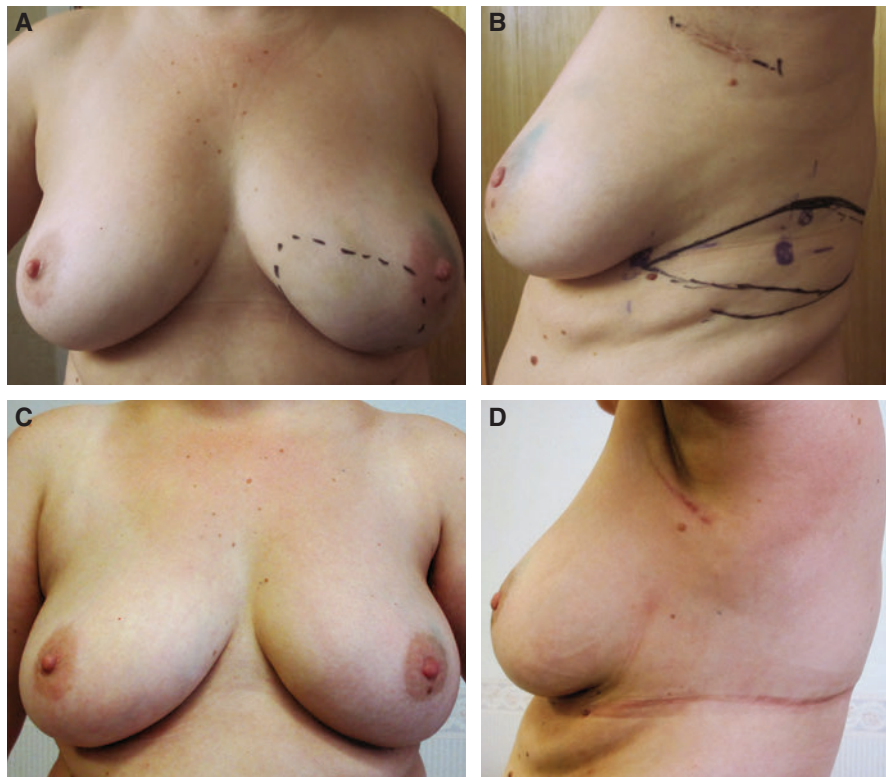

Fig. 28-4

A TDAP flap is usually designed around perforators located in the bra strap line, because the indication usually dictates that a long pedicle is required, and the resulting scar can be hidden. In this patient's two-stage TDAP flap, an initial wide local excision and sentinel node biopsy were performed (A) and clear margins confirmed. The TDAP flap was designed in the bra strap line (B). The patient is seen 1 year postoperatively (C and D).

TDAP Flap Dissection

General anesthesia is administered, and the patient is placed in the lateral decubitus position with the arm flexed to 90 degrees. In some cases the flap dissection can be completed with the patient supine with an inflatable 3 L pressure bag below the ipsilateral hemithorax to tilt the torso, as for the LICAP flap. Local anesthetic with epinephrine is infiltrated around the flap.

The TDAP flap is dissected circumferentially down to LD and serratus fascia, beveling outward to increase volume, particularly deep to Scarpa fascia. The anterior flap is then raised to the anterior border of the LD, which is in turn elevated for a few centimeters from the underlying serratus and chest wall such that the undersurface of the lateral border of LD is visualized. In almost all cases, an anterior branch of the descending branch of the thoracodorsal vessels is identified and this (and its undissected perforators) is used as the basis of the flap. If there is uncertainty regarding the quality and location of the perforators, these may be identified by careful dissection anteriorly over the lateral border of LD.

A myotomy is then created just medial to this anterior branch of the descending thoracodorsal vessel and continued caudally along the width of the flap. The flap is then raised medial to lateral to this level, and the distal end of the vessels are ligated and the overlying muscle divided. The anterior branch is then dissected proximally until the main descending branch of the thoracodorsal vessels is encountered. At this point the distal continuation of the descending branch is ligated and the thoracodorsal nerve preserved. Also at this point, the overlying muscle is divided, thus isolating the flap on its perforators protected by a small patch of muscle, usually measuring approximately 2 or 3 cm by 6 or 8 cm. The vessels are then dissected proximally according to the length of pedicle required. In most patients who have undergone BCT, this would include division of the transverse branch of the thoracodorsal vessels. The flap is then tunneled into the breast defect and the wound closed in layers with a drain.

The TDAP flap is thus raised with a muscle patch, eliminating the need for perforator dissection through the muscle and allowing the flap to be based on more than one perforator. This technique was found to greatly reduce dissection time. Whether purists would term this a TDAP flap, as it is traditionally known, is debatable.

RESULTS

Between June 2007 and June 2015, we performed 124 local perforator flap surgeries for primary volume replacement in association with BCT; 12 were TDAP flaps and 112 were LICAP and/or LTAP flaps. All patients underwent postoperative radiotherapy. The average patient age was 54 years (range 30 to 85 years), and all were women. Overall, the mean preoperative tumor size (largest reported dimension on any breast imaging for invasive plus

DCIS: mammography, ultrasonography or MRI) was 25.9 mm (range 12 to 60 mm)—a mean specimen weight of wide local excision (WLE) 74.6 g (range 25 to 226 g) for LICAP/LTAP flaps and 100.1 g (range 34 to 173 g) for TDAP flaps. Tumors were located in the lateral one third or lower pole of the breast in 95% of LICAP/LTAP flaps, and were evenly distributed throughout the breast in patients who had TDAP flap reconstruction.

The average total hospital stay for all 124 cases was 1.3 days (median 1 day). Twelve (9.7%) surgical complications were encountered. These included minor wound problems and seromas or hematomas that required an aspiration. There were no flap losses. Two hematomas required a return to the operating room. One patient underwent reexploration for a presumed postoperative infection but was found to have sterile fat necrosis. This was debrided with subsequent successful flap preservation. One patient had a contralateral breast reduction 4 years after the initial chest wall perforator flap surgery for symmetrization.

Patient Satisfaction

Of 68 patients who were at least 1 year after CWPF surgery and thus eligible for an audit of patient satisfaction, 52 responded, giving an overall response rate of 75%.

Box 28-1 Hopwood Body Image Score

What do you think of the appearance of your breast compared with before surgery?

Better	4 (7.8%)
Same	25 (49%)
Slightly worse	22 (43.1%)
Much worse	0

Does your scar bother you?

Not at all	37 (72.5%)
Slightly	11 (21.6%)
Quite a bit	2 (3.9%)
A lot	2 (3.9%)

The mean Hopwood Body Image Score was 3.09 (range 0 to 15). Patients were asked what they thought of the appearance of their breast compared with its appearance before surgery: 4 patients (7.8%) thought their breasts were better, 25 (49%) considered their breast to be the same, 22 (43.1%) were of the opinion that their breasts were slightly worse after surgery, and none felt their breast was much worse. When asked how they felt about their scar, 37 (72.5%) said it did not bother them at all, 11 (21.6%) said it bothered them slightly, 2 (3.9%) said it bothered them quite a bit, and 2 (3.9%) said it bothered them a lot.

DISCUSSION

The location and consistency of tissue from the lateral chest wall makes it ideal for various aspects of breast reconstruction. In this chapter we have presented our experience using local perforator flaps for primary reconstruction of defects after breast-conserving surgery. Local perforator flaps fill a breast cavity with breastlike subcutaneous adipose tissue and can provide a good-sized skin island if required.

When evaluating a patient and planning for surgery, patients are considered to belong to one of two categories: having a local flap based on a LICAP/LTAP vessel, or one based on the TDAP vessel. A good spatial appreciation of surgical options is therefore useful and knowledge of the anatomy of these perforators is critical to a good outcome.

Immediate postsurgery recovery was generally rapid, and most patients were managed as day cases or discharged the day after surgery. The findings of a self-reported questionnaire on satisfaction showed a low Body Image Score of 3.09, which fares well in comparison to reported mean scores of 14.22 after a simple mastectomy and 4.27 after a standard wide local excision.⁵ Although no indicative threshold exists for a good body image, a lower score corresponds to better body image.

Among the additional questions that were included it is of interest that 95% of women were either “not at all” or only “a little” dissatisfied with the scar along the lateral chest wall.

This offers reassurance to surgeons who may consider the longer incision a disadvantage. Also, more than half (56.8%) of our patients who underwent a volume replacement (VR) BCT felt that their breasts were better or the same compared with their breasts before surgery, and none felt their breasts to be much worse—itself a remarkable finding, considering that these patients have had ablative surgery with large-percentage breast excision and radiotherapy to treat breast cancer.

CONCLUSION

Chest wall perforator flaps are versatile and may be employed for various indications in breast reconstruction. When used as volume replacement in BCT, they effectively extend the option of breast conservation to many patients who would otherwise be denied. Overall patient satisfaction is high.

Critical Issues

- The lateral chest wall and inframammary region provide ideal sites for local flap harvest.
- The position of intercostal perforators around the periphery of the breast is largely predictable.
- Local perforator flaps are usually based on more than one perforator.
- The lateral thoracic vessels can often be used to at least supplement the vascularity of a flap.
- The TDAP flap has only a few and quite specific indications in breast-conserving surgery.
- Resulting scars are very acceptable.

References

1. Hamdi M, Van Landuyt K, de Frene B, Roche N, Blondeel P, Monstrey S. The versatility of the inter-costal artery perforator (ICAP) flaps. *J Plast Reconstr Aesthet Surg* 59:644, 2006.
2. McCulley SJ, Schaverien MV, Tan VK, Macmillan RD. Lateral thoracic artery perforator (LTAP) flap in partial breast reconstruction. *J Plast Reconstr Aesthet Surg* 68:686, 2015.
3. Hamdi M, Van Landuyt K, Hijjawi JB, Roche N, Blondeel P, Monstrey S. Surgical technique in pedicled thoracodorsal artery perforator flaps: a clinical experience with 99 patients. *Plast Reconstr Surg* 121:1632, 2008.
4. Hamdi M, Van Landuyt K, Monstrey S, Blondeel P. Pedicled perforator flaps in breast reconstruction: a new concept. *Br J Plast Surg* 57:531, 2004.
5. Hopwood P, Fletcher I, Lee A, et al. A body image scale for use with cancer patients. *Eur J Cancer* 37:189, 2001.
6. Heitmann C, Guerra A, Metzinger SW, et al. The thoracodorsal artery perforator flap: anatomic basis and clinical application. *Ann Plast Surg* 51:23, 2003.

29

Breast Lumpectomy Reconstruction With External Vacuum Expansion and Autologous Fat Grafting

Daniel Calva, Roger K. Khouri

M

ore than 1.5 million women worldwide are diagnosed with breast cancer every year, and in the United States, approximately 231,840 women are diagnosed annually.^{1,2} Although about 35% to 40% of these women will undergo total mastectomy,³⁻⁵ the majority of patients (60% to 65%) are offered the option of breast-conserving therapy (BCT) with partial mastectomy and radiation. Of women who undergo mastectomy, 25.8% elect to have their breast reconstructed with an implant-based technique and 12% with autologous flap reconstruction.⁶ However, most women who opt for BCT and radiation do so in hopes of avoiding reconstruction surgery. Unfortunately, many partial mastectomy surgeries produce significant deformities that still require reconstruction.

In this chapter we describe the workup, patient selection, and techniques for reconstructing the breast after lumpectomy using external tissue expansion (ETE) to prepare the recipient area and fat grafting to replace the missing tissue. We also elaborate on the principles and techniques of large-volume autologous fat grafting, especially those pertinent to grafting scarred and irradiated tissue. We review the ideal patient for lumpectomy reconstruction using ETE and fat grafting.

Minimally invasive fat grafting is another option to reconstruct partial defects, and to optimize its success, the defect should be prepared with ETE.

ETE stretches the scar and increases its vascularity to generate a favorable recipient fibrovascular scaffold for fat grafting.

Within a few days to several weeks, under the effect of cyclic mechanical forces, ETE creates a three-dimensional, vascularized, fibrous scaffold. The skin envelope, subcutaneous fat, residual parenchymal tissue, and—to a lesser extent, because it is stiffer—the scar tissue expand to generate new stromal, connective, and vascular tissue.⁷⁻¹³ This is effectively tissue engineering. ETE induces the in situ creation of a vascularized biologic scaffold that is optimized to be seeded with microdroplets of judiciously transferred fat grafts.¹⁴

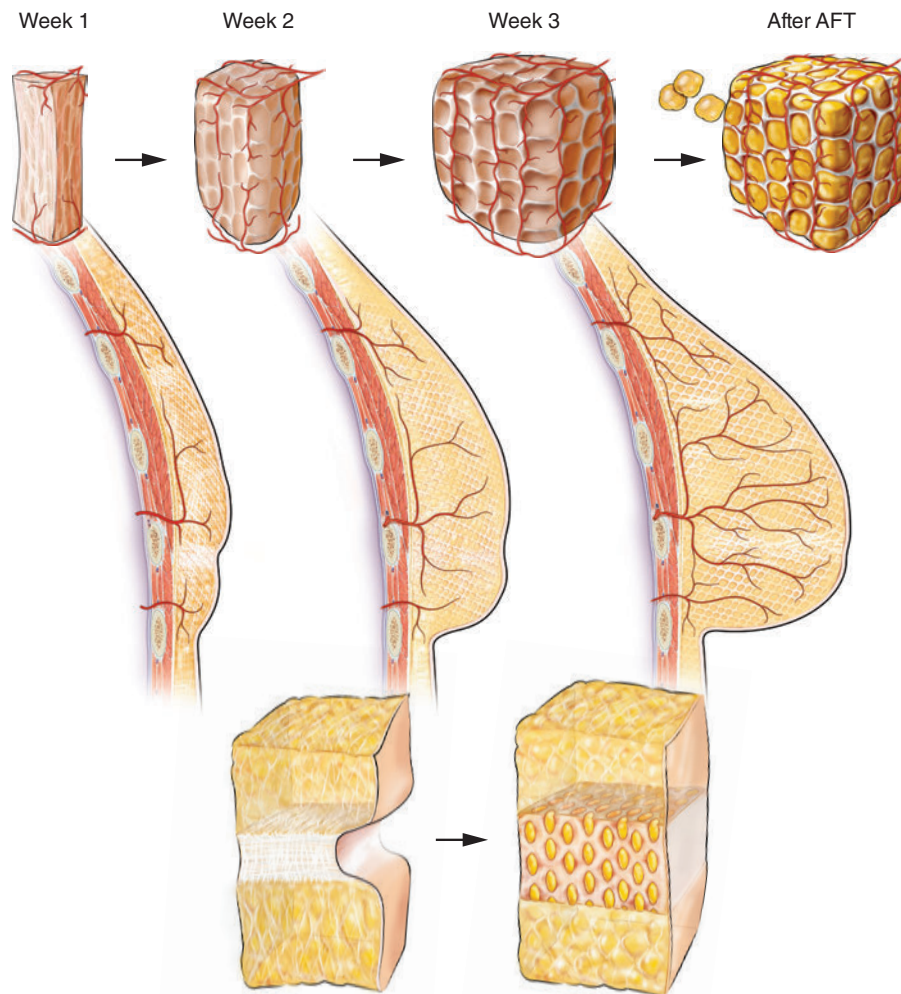


Fig. 29-1

These images show how the tissue scaffold is created with ETE, showing the generation of new stromal and vascularized tissues. Notice how after fat grafting the small holes that are made in the expanded scaffold percutaneously are filled with small droplets of grafted fat. The grafted fat particles occupy the small spaces created and undergo revascularization. Ultimately, when the graft “takes,” the volume deficit and contour irregularities are corrected.

The combination of ETE and fat grafting has been shown to be a safe, effective, and minimally invasive outpatient method for reconstructing the breast after a partial breast mastectomy.¹⁵⁻¹⁷

PRINCIPLES OF FAT GRAFT SURVIVAL

There are two fundamental factors that can limit the survival of free fat grafts: (1) restoration of the blood supply, and (2) adequate recipient site capacity.

Restoration of the Blood Supply

No free graft can survive without a blood supply. Angiogenesis, the process responsible for neovascularization, can only cause growth of vessels about 1 mm inside the grafted tissue before the deeper parts die from ischemia. Stem cells in the graft are most resistant to ischemia and are able to survive at that depth to regenerate cells to replace the more superficial fat cells lost to ischemia.¹⁸ Restoration of the blood supply therefore depends on a graft-to-recipient interface that cannot be much wider than 1 mm. Cells positioned farther from the blood supply are doomed to necrose from ischemia. Multiple experimental models have confirmed that free grafts larger than 2 mm across (1 mm per side), even pure stem cell grafts, will invariably have a central necrotic focus. This means fat droplets larger than 10 μ l will invariably have some central necrosis and for a 1 cc droplet, only its outermost 40% shell will survive. Fortunately, the body is able to scavenge the central necrotic debris, leaving only the larger necrotic cysts to persist after a few months. Therefore, ideally, grafted fat should be delivered as a fine mist of tiny 10 μ l droplets or 2 mm wide microribbons that remain separated by recipient tissue and that do not coalesce into larger blobs.¹³

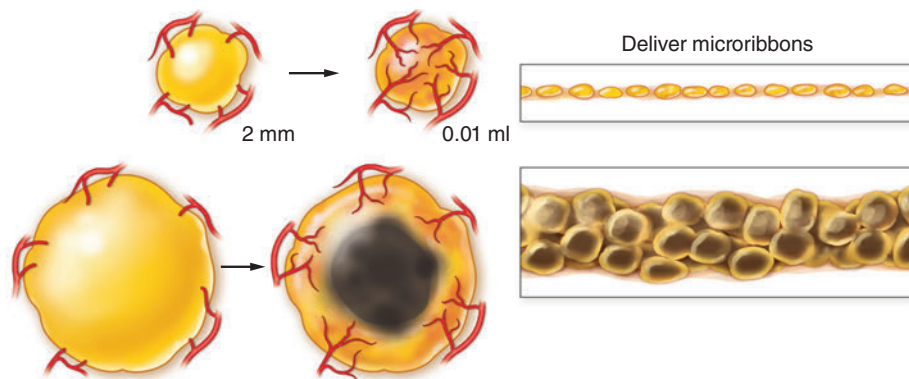


Fig. 29-2

Large-volume three-dimensional avascular graft survival is shown in terms of the fundamental principle of the graft-to-recipient interface, and the droplet size restriction principle. It is important to evenly spray 0.01 ml microdroplets that do not coalesce into large lakes of fat that will ultimately undergo fat necrosis.

Recipient Site Capacity

As the surgeon inserts tiny individual droplets (or microribbons) into the recipient site, the area has to expand to accommodate the added tissue. However, even if these droplets are meticulously inserted without any coalescence, there is a limit to how much the recipient site is capable of expanding before the filling pressure increases to levels that choke capillary circulation. Beyond this limit, grafting is counterproductive, and more grafting will lead to more significant necrosis. This limit to expansion is determined by the mechanical compliance of the recipient site.

The lumpectomy site must be prepared to best accept the amount of fat graft required for the reconstruction.

Normal subcutaneous fat is the body's natural buffer for excess fluid and is the most compliant recipient tissue. Studies have shown that it can accommodate up to a 20% volume change without a significant pressure increase. From 20% to 30%, every percentage point leads to 0.5 mm Hg pressure rise in interstitial tissue pressure, a tolerable increase. With a 30% to 40% volume increase, every percentage point results in a 1 mm Hg pressure rise, an increase that is somewhat less tolerable. Then from 40% to 50%, the pressure increment becomes steeper, and unless the tissue of the site has been preexpanded, no recipient site can accommodate more than a 50% volume increase. The compliance curve is not linear; as fatty tissue is added, compliance becomes stiffer and stiffer, and smaller increments lead to a major pressure increase. It is important to avoid grafting beyond that last drop that can tilt the pressure to the necrosis zone. Unfortunately, partial mastectomy defects, especially regions that have been irradiated, are much less compliant and much less tolerant of overgrafting. In practical terms, the recipient site volume and its mechanical compliance determine the amount of graft that can be tolerated.¹³

The pressure compliance curve of various tissue recipient beds is shown. Noncompliant, moderate, and compliant beds show how the percent volume change can increase with minimal increases in pressure gradients in more compliant recipient sites. In this chart, the more compliant curve reflects breast preexpansion using an external tissue expansion system.

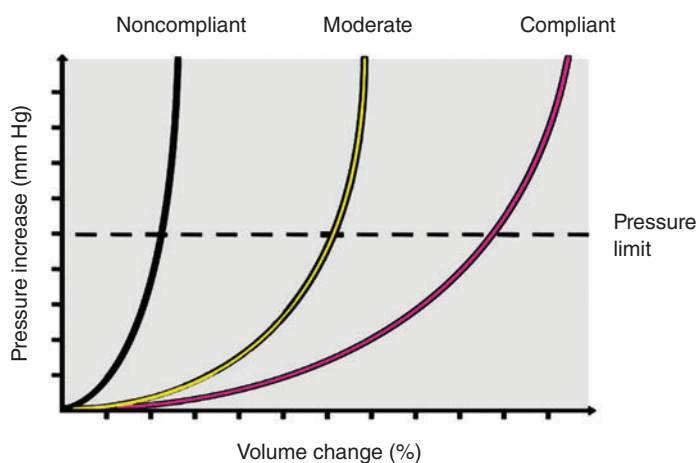


Fig. 29-3

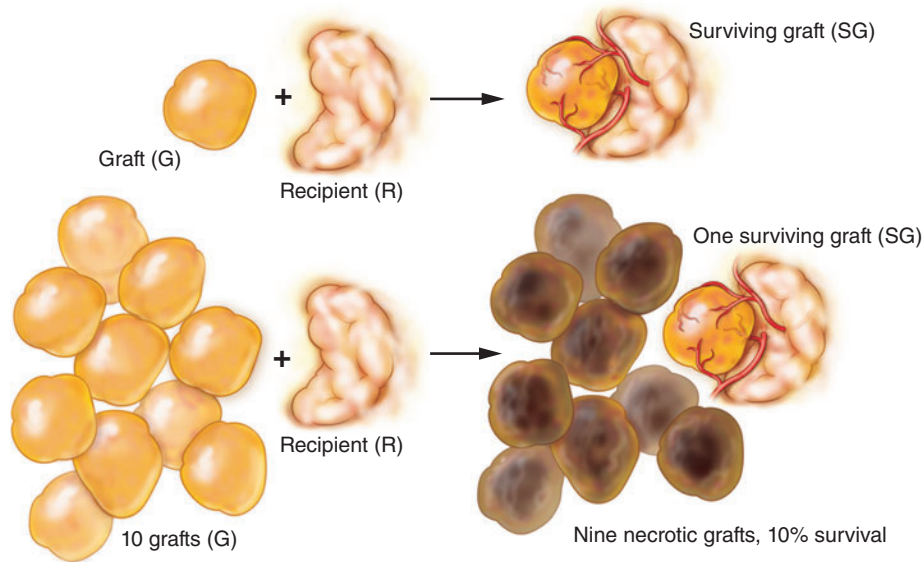


Fig. 29-4

It is also important to recognize the stoichiometry of graft-to-recipient interaction, where 1 graft (G) plus 1 recipient site (R) leads to 100% survival; however, if we place 10 grafts to 1 recipient site, we end up with 1 surviving graft (SG) and 9 necrotic grafts, for a 10% survival rate.

Every graft G (the smallest fat droplet unit) needs to interact with a specific recipient site R (the smallest unit of the fibrovascular network) to yield a surviving GR complex. Adding more G s in the face of a fixed number of R s is counterproductive. It will not result in more GR s—only more necrotic R s; not more augmentation, only a lower *percentage graft survival*. Herein lies the fallacy of percentage graft survival.

Assuming an ideal grafting technique and that every G successfully reacts with an R , grafting 10 G s when there are only 5 R s will at the very best lead to 5 GR s; the remaining G s will eventually die, for a 50% graft survival. Similarly, grafting only 5 G could lead to a 100% survival; this constitutes the same effective augmentation, but double the percentage survival with less necrosis. On the other hand, brutally grafting 20 G of the same graft in the same 5 G recipient bed will probably not lead to 25% survival, but total necrosis, because the compliance of the recipient site would be unable to accommodate the grafted tissue.

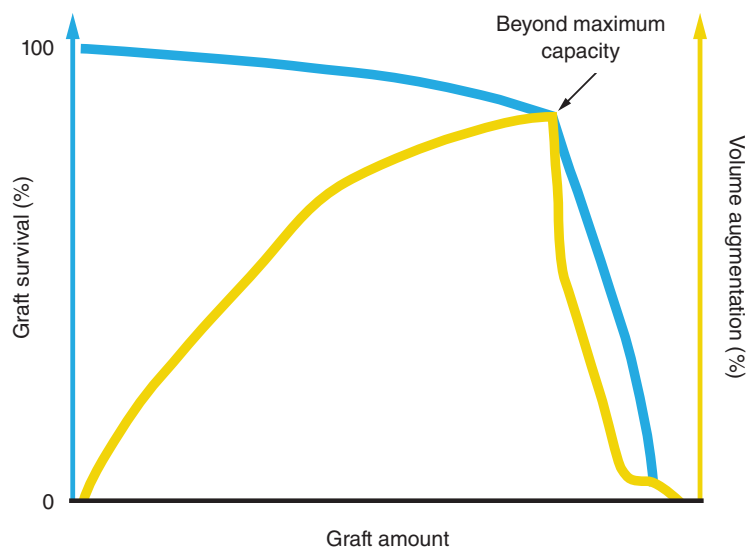


Fig. 29-5

These two superimposed graphs show graft survival (*light blue curve*) versus volume augmentation (*yellow curve*) compared with the grafted amount (x axis). The most difficult question is to know when to stop grafting, since the last-drop effect dictates that one cannot graft more than what the recipient tissue bed can tolerate. This point is called the “point beyond max capacity” (*black arrow*), where the volume augmented and graft survival are optimized compared with the amount grafted. This is the point at which the more grafts, the worse the results will be.

Therefore percentage graft survival, the most commonly used yardstick of success in fat grafting, is only a reflection of the tendency to overgraft. Since the ultimate goal is tissue augmentation, a more relevant measure of success should be the *percentage augmentation* of that recipient area, regardless of whatever amount of fat preparation is grafted. The upper limit of percentage augmentation is determined by the amount of Rs present in the recipient and not by the amount of added Gs. Grafting beyond the point where all available Rs interact with Gs is counterproductive. Of course, the craftsmanship of the surgeon in ensuring that Gs are delivered in optimal-sized packages that do not coalesce and that every G is inserted in close proximity to a recipient R remains a critical step.

Because fat grafting is done to add volume to a mastectomy defect, the final percentage volume augmentation obviously should be one of the most relevant measures of success. Assuming we are using the very best graft tissue, augmentation is still limited by (1) the stoichiometry, or the ratio of graft to recipient, (2) the craftsmanship of graft delivery, and (3) the recipient site's capacity to accommodate the graft. We reviewed the literature and performed some calculations to derive this often unreported number; this revealed that augmentation is limited to 40% in the best-documented reports and in nonirradiated recipient tissues.¹⁹ It is only after preexpansion of the tissue of the recipient site (and thus increasing the Rs and compliance) that percentage augmentation reaches the 80% to 90% range.^{7,8,13-17}

Thus in practice, achieving success of large-volume fat grafting is a complex, multifactorial process. Focusing on a single factor or a single step in the series of events leading to graft survival is a common but erroneous oversimplification. The ultimate survival of the grafts depends on a number of individual factors and steps that are chain-linked in series. Regardless of the strength of the other links, it is the weakest link that seals the outcome. The following analogy of a farmer optimizing his crop nicely illustrates this multistep process.

The four Ss of a successful crop are:

1. The “seeds”: These must be gently harvested—viable, fine fat tissue droplets.
2. The “soil”: The recipient site, which needs to be large enough, well ploughed, and fertilized to accept the large number of “seeds” required for the necessary crop.
3. The “sowing”: The fat grafting technique must skillfully distribute the “seeds,” one at a time, over the entire field to maximize their individual chance of taking root.
4. The “support”: After grafting, the area must be immobilized to protect the “seedlings” from stamping, drying, and shaking as they engraft.

Most of the scientific literature focuses on the graft, the method of harvesting and preparation, the selection of better seeds, such as stem cells, and the addition of growth-promoting factors. However, even the very best seeds with the best additives will not yield much if they are crammed in a tiny and rocky plot. The success of large graft amounts is most often limited by the fact they are used to enlarge small hostile (irradiated) recipient sites. Injected fat is not a tissue expander; grafted seeds/fat droplets are not capable of significantly stretching the recipient site and also surviving. They will do better when they are comfortably seeded in an already stretched recipient site. Furthermore, the sowing technique is unfortunately the least studied and the most variable operator factor. Even the best seeds in an ideal recipient field will not yield much if they are dumped all together in a clump. The ideal seeding technique should disperse a fine mist of fat droplets instead of a “caulking gun” stream. Skillful dispensing is a critical factor that requires time and craftsmanship to gain mastery.

Microvascular surgeons know that free flaps can fail despite a perfect anastomosis, because success and failure depend on many factors besides the anastomosis. Similarly, perfect grafting materials, such as adipose-derived stem cells, do not guarantee success, because there may be other bottleneck rate-limiting factors that can lead to a poor result. An appropriate analogy in this case is that of a moped and a Ferrari competing in heavy traffic—adding horsepower is fruitless when traffic is the rate-limiting factor.

For practical purposes, the farmer analogy still stands; all four Ss need to be optimized, and struggling to improve a non-rate-limiting factor is futile, because the remaining bottleneck will still limit the outcome.

This brief overview is still incomplete, since we still do not fully understand the intricate biology of fat grafting and the multitude of additional cytokines and factors involved in the sequence of events leading to successful fat graft survival. But again, farmers knew what it takes to feed our civilization for centuries, long before they understood the complex biologic processes that led them to reap successful crops. Further investigations will allow us to achieve ever-better results in breast reconstruction after lumpectomy.

CHALLENGES PARTICULAR TO THE IRRADIATED PARTIAL MASTECTOMY

Considering the principles stated previously, an irradiated partial mastectomy represents a formidable challenge for the surgeon performing fat grafting. It is a recipient site with limited capacity, poor mechanical compliance, and poor in vascular receptor units (*Rs*). Irradiated tissue is a hostile site for grafting that can initially accept very little graft. Over-grafting should be avoided at all costs as the resultant scar from fat necrosis will worsen an already poor situation. Most of the complications encountered by the senior author (R.K.K.) can be blamed for grafting beyond the capacity of the recipient to accept the larger amounts of graft. A less-experienced surgeon should realize that these defects are rarely reconstructed with only one procedure. It is safer to undergraft and acknowledge the need for multiple procedures than to overgraft and run the risk of tissue loss and necrosis.

Probably the most important contribution to the field of fat grafting in patients who have undergone radiotherapy is by Rigotti and colleagues,²⁰ who have shown that serial fat grafting can reverse the deleterious effects of irradiation. If practically possible, it is best to treat these defects with multiple small, safer grafting sessions with the use of local anesthetic (with some sedation) than to try to reduce the number of grafting sessions by pushing the limit of graft tolerance.

In the first grafting session for an irradiated partial mastectomy, less is more. This session primarily serves to repopulate the arid irradiated tissue with healthy cells and does little to augment the defect. The amount grafted should be modest, and patient expectations need to be tempered. Subsequent grafting sessions can then be performed in tissue that is more and more healthy (higher *R* concentration and better compliance), leading to progressively better augmentation ratios.

ETE in combination with three-dimensional percutaneous mesh expansion (also called Rigottomies) can transform an irradiated cicatrix into a recipient matrix for fat grafts.

Radiation damage varies from patient to patient, depending on the radiation dose, its method of delivery, and the individual patient tolerance. Fibrotic, irradiated tissue has to be loosened up to accommodate the graft. Both the jackhammer technique of creating tunnels to loosen the scar with the grafting cannula and the Rigottomy percutaneous needle three-dimensional meshing technique expand the cicatrix to become a matrix for fat grafts. The goal is to generate a fine mesh, not a coarse, cavernous structure. It is safer to remain conservative with the needling technique, because overzealous release will turn the cicatrix into a cavity; a cavity is the enemy of fat grafts and should be avoided at all costs.

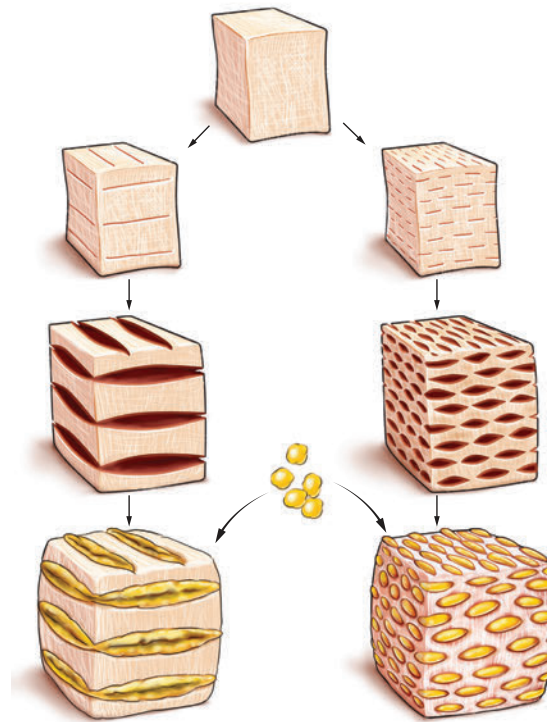


Fig. 29-6

Three-dimensional Rigottomies create a volumetric mesh expansion within the cicatrix of the contracted recipient bed. In essence, the surgeon creates a percutaneous three-dimensional mesh, releasing the dense tethering of the cicatrix, into a matrix that is expanded and ready to receive fat grafts.

In an irradiated partial mastectomy, the greatest challenge is tethered scar pits. They are often three-dimensional, with vertical adhesions to the chest wall and omega-type fibers that run horizontally to reinforce the folds side to side. The irradiated skin over these scars derives its tenuous blood supply from these fibers. Their complete release is treacherous; not only will it lead to a cavity where the fat will die, but it will also compromise the circulation of the overlying skin.

Scarred pits of the irradiated partial mastectomy contracture present at least four challenges:

1. A volume deficiency and therefore limited recipient room for the graft. Even if the site is adequately prepared by ETE, fat grafting can at the very best only double the original thickness of the recipient tissue with live healthy tissue.
2. A three-dimensional scaffold of fibers that tether the tissue down. These fibers need to be released by staggered percutaneous nicks. Expanding these fibers beyond 50% destroys the capillary network that perfuses the skin.
3. A deficient capillary network, because radiation is known to reduce capillary density. Irradiated and scarred tissue is partially ischemic and has limited tolerance for surgical manipulation. It also has a reduced number of Rs to revascularize the grafted Gs.
4. Poor mechanical compliance of the recipient tissue.

ETE provides a remedy for these problems. Mechanical forces enlarge the biologic scaffold, stimulating the genesis of new stromal and vascular elements, making room for more grafts to have a better chance of surviving.¹⁴ And although ETE does not stretch the tough, irradiated fibers as much as the rest of the tissues, it still expands them enough to allow more effective mesh release. ETE is angiogenic and increases the capillary density. This increases the amount of recipient Gs, and the richer vascular network makes it possible to perform a more aggressive mesh release while still preserving enough tissue perfusion capillaries.

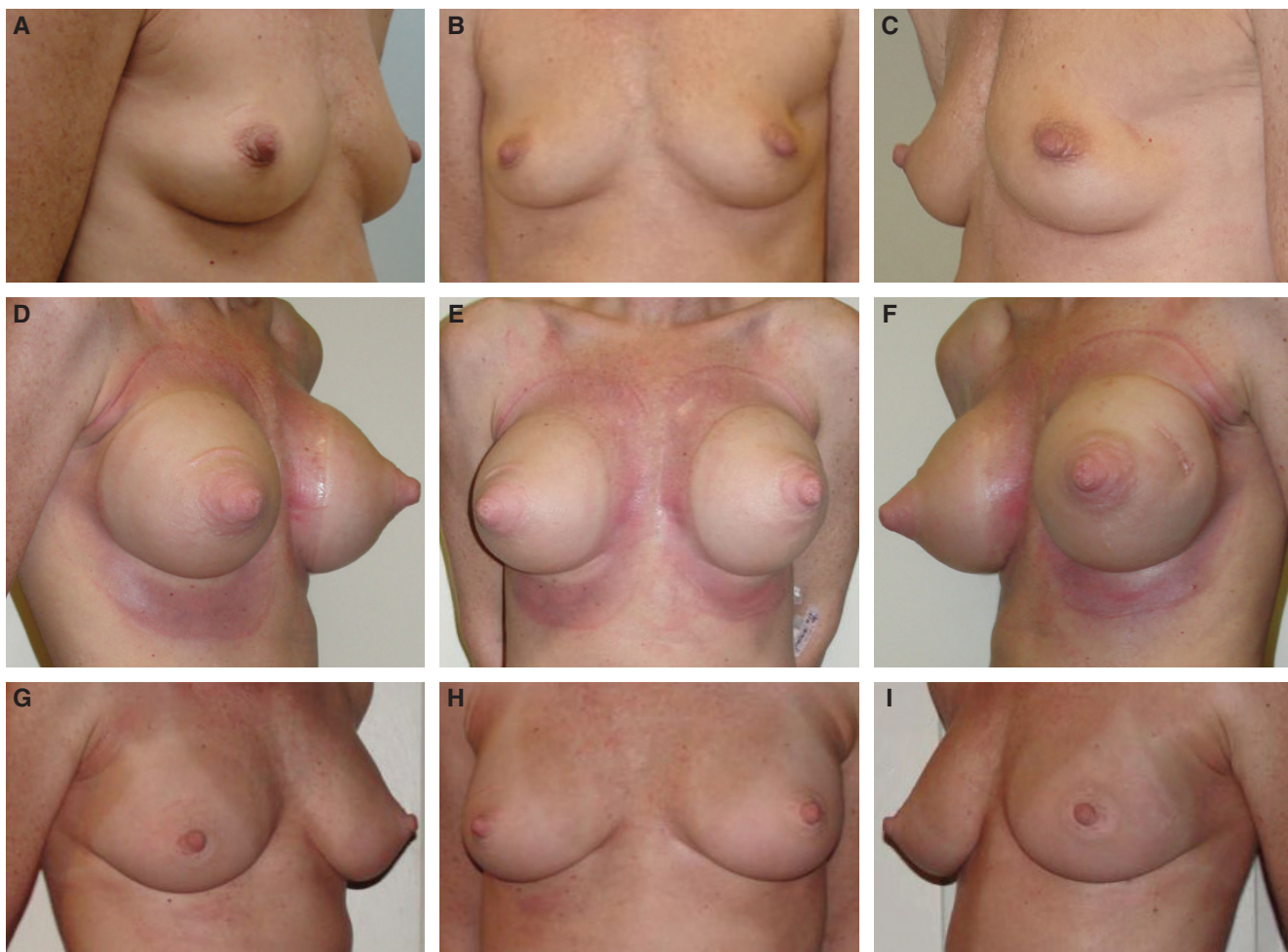


Fig. 29-7

This patient, who was scheduled to undergo grafting of her lumpectomy site, is shown before ETE (A through C). After the expansion process, 300 cc of fat was grafted to her left breast; she is shown at her 1-week postoperative follow-up (D through F). Her final results are shown at 1-year follow-up after two ETE and fat grafting procedures (G through I).

Tissue engineering generates new tissue by seeding scaffolds with cells. The reconstruction of mastectomy defects with ETE, Rigottomy, and fat grafting is a good example of in vivo tissue engineering. The scaffold is prepared through a combination of mechanical stretch and mesh release of the scar, while the lipoaspirate provides the cells.

PATIENT SELECTION AND PREPARATION

The ideal patient has moderate fat deposits to harvest and has realistic expectations. She should be able to tolerate a 20-minute trial of external expansion in the office as the nurse teaches her placement of the device and activates it. She should also understand that her compliance with wearing the device is crucial to successful expansion. Exclusion criteria include smoking, bleeding disorders, skin conditions that lead to deepithelialization (such as epidermolysis bullosa and pemphigus), an active skin infection at the location where the device will be placed, and having unrealistic expectations. Patients with a low BMI are still good candidates for the procedure, and unless they had previous liposuction, we have rarely turned away patients for being too thin. However, harvesting enough fat from patients with no localized fat deposits requires significantly more effort, care, time, and expertise.

We recommend obtaining a baseline MRI with contrast in all patients who are seen more than 3 months after their partial mastectomy and radiotherapy. This not only provides the best possible three-dimensional evaluation of the recipient site architecture, but it also helps ensure that there are no tumor foci that need to be addressed before ETE and fat grafting. Patients should also have a repeat MRI study about 6 months after we complete the reconstruction, which serves as a baseline reference for future follow-up studies.

In contrast to conventional practice, it is best to perform the first grafting session immediately after the last radiation dose. This is when the tissues are still inflamed and before fibrosis has set in. As a matter of fact, the goal is to interpose healthy fat in an attempt to prevent fibrosis. For this first grafting session, which is very limited in amount, we do not use ETE. Our experience with this early intervention has been very promising; patients report a soothing effect from the early fat grafting session, and it seems to reduce radiation scarring.

ETE is required to best prepare the recipient for the subsequent sessions, or often for the first session when the patient is seen late after her radiation. We currently recommend a therapeutic dose of 200 hours of active expansion over the 15 days immediately preceding fat grafting. The vacuum pump is set to deliver intermittent pressures of 60 to 0 mm Hg that cycle for 3 minutes on and 1 minute off for at least 10 hours per day.

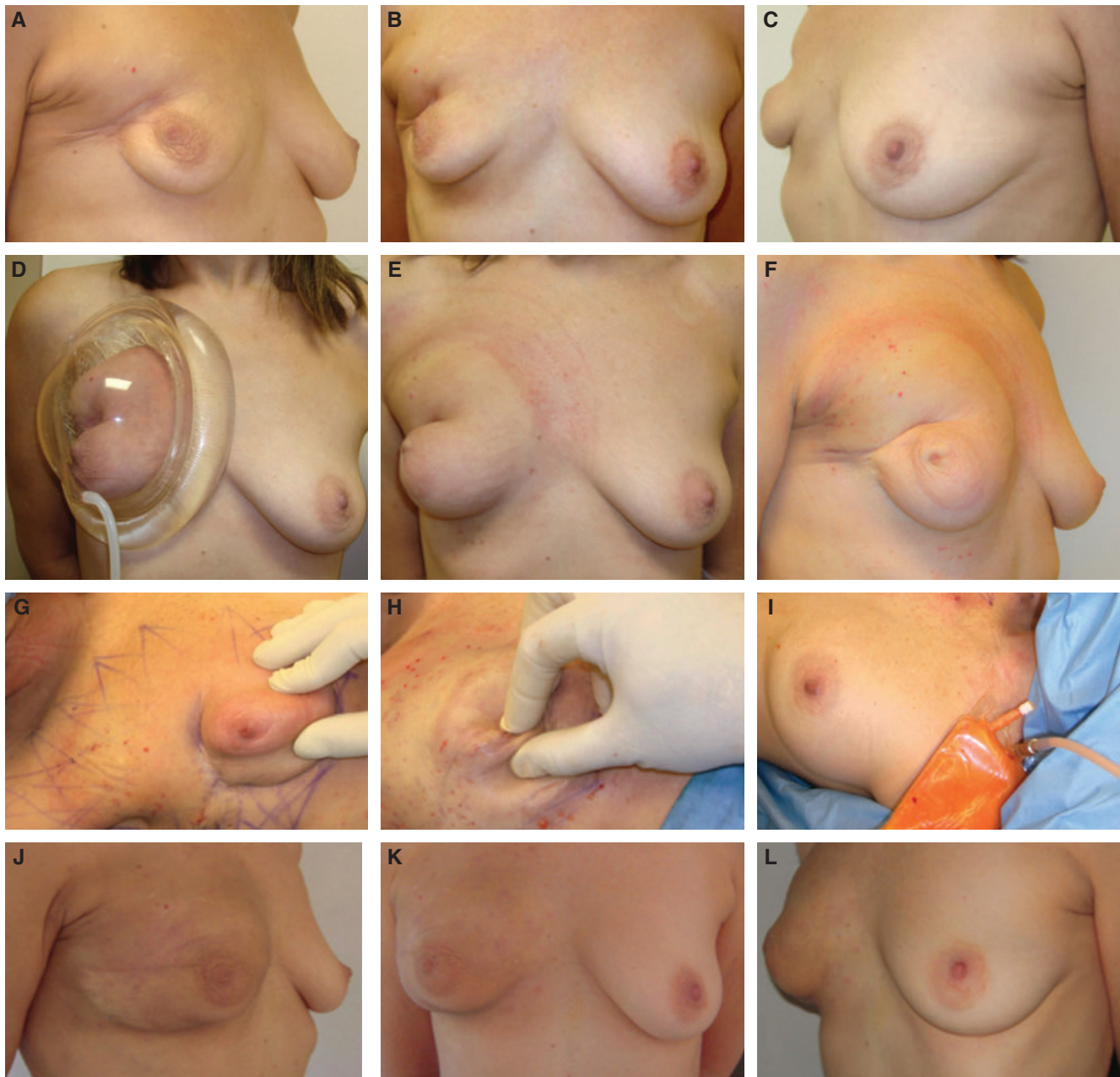

Fig. 29-8, A-L

This patient is seen before use of the ETE device (A through C). The external tissue expansion device is placed on the patient (D), and the multiple vectors that are used to deposit the fat graft into the expanded scaffold percutaneously are shown (E and F).

The expanded breast scaffold is shown, demonstrating how the lumpectomy site looks after expansion and before grafting (G through I). Notice how the defect contour is effaced compared with this patient's preexpansion photographs (A through C). Her results are shown at 1-year follow-up (J through L).

Patients are ready for fat grafting if their breast mound volume is at least 2.5 times greater than their preexpansion volume, and if the lumpectomy site has effaced compared with its preexpansion state. The patient must understand that she is an important part of her ultimate results and plays an active role in her reconstructive process. The more expanded the breast tissue, the more fat that can be grafted and survive within the scaffold, and the better the ultimate results in volume and contour.

SURGICAL TECHNIQUE

Harvesting of Fat

Harvesting of lipoaspirate is carefully planned, and the patient is marked preoperatively while she is standing. Typical donor sites are the flanks, abdomen, and inner thighs. We prefer to harvest fat from stable deposit areas that are least likely to fluctuate with weight gain or loss; these vary from patient to patient. The tumescent solution must contain epinephrine for its vasoconstrictive effect. The soft tissues are tumesced until they are tense, and typically we infuse 1 to 2 L per area to be harvested.

In patients with a low BMI and no localized fat deposits, an even layer should be harvested out of a wide expanse. This is achieved by crisscrossing centripetal strokes with a fine cannula inserted through 8 to 10 needle punctures all around the periphery of the donor area. Contrary to conventional liposuction, which can only be harvested through a few hidden incisions, we use multiple entry sites, which results in more even harvesting because the 14-gauge needle punctures used for cannula insertion leave minimal scars. We call this technique the *sprinkler method*. This same sprinkler principle is repeated for fat grafting. Sprinkling a fine mist through many “sprinkler heads” achieves evenness through randomness.

In patients with a low BMI, fat is precious, and we only harvest what is needed for each grafting session. This is determined by estimating the recipient capacity of the recipient site. This is an obvious approximation as we determine the recipient volume ($\text{Surface area} \times \text{Thickness}$) and its compliance, which will determine its capacity to expand. Stiff, irradiated, scarred tissues that are being grafted for the first time will not safely expand more than 20% to 35%, even after preoperative ETE, but as tissue quality and ETE effect improves with repeat grafting,²¹ this could increase to 50% to 60%. In practical terms, the surface area of a partial mastectomy defect is approximately 200 cm², ranging from 100 to 400 cm², depending on the patient's body habitus. If the average tissue thickness from ribs to skin is approximately 5 cm, ranging from 3 to 8 cm, the average amount we typically harvest for the first graft is 20% of 1000 cc recipient volume = 200 cc. However, with subsequent grafting sessions, this might double to 400 cc of loose, uncentrifuged fat in suspension.

The Lipografter system (Lipocosm, Key Biscayne, FL), is a simple, practical, and efficient device that facilitates gentle harvesting, collection, preparation, and grafting of the fat in a closed system with minimal manipulation of the lipoaspirate. It uses a very efficient 12-hole, 12-gauge (2.7 mm) harvesting cannula connected to the K-VAC syringe (Lipocosm).

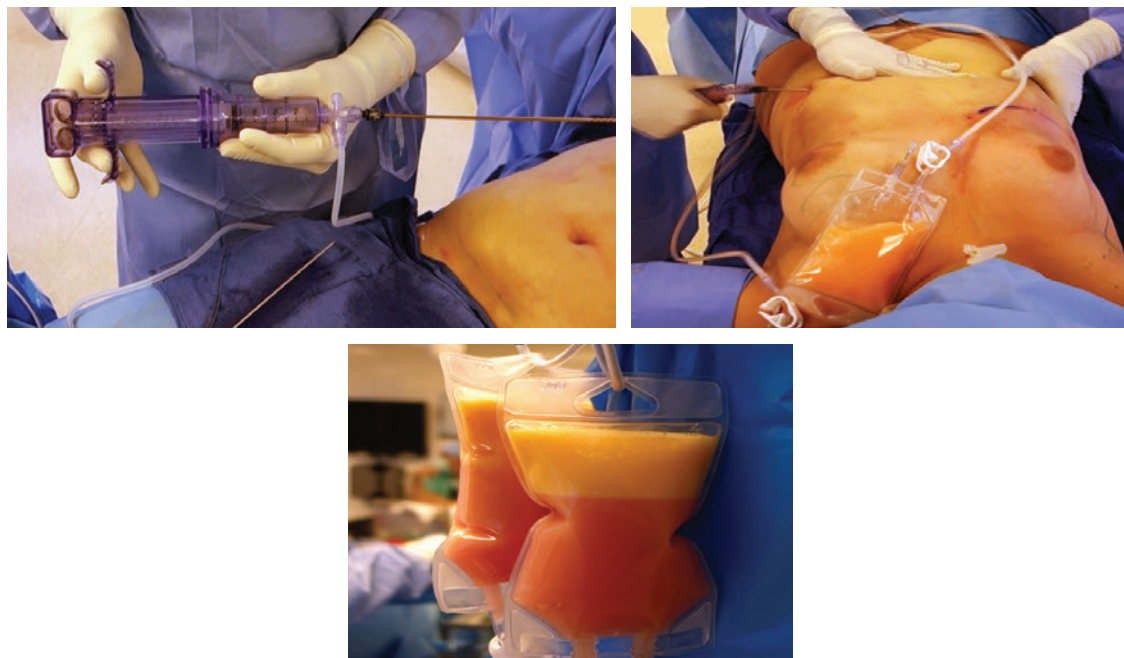


Fig. 29-9

The Lipografter, K-VAC syringe, and AT-Valve allow the fat to be harvested and kept in a closed system. The viable fat is allowed to separate from the tumescent fluid by gravity for 15 minutes. The system contains a pair of ribbon springs calibrated to deliver a constant 300 mm Hg vacuum pressure along the entire excursion of the syringe plunger. Once the syringe fills with lipoaspirate, the surgeon pulls back the plunger to recock the spring and to automatically send the fluid to the collection bag through a four-way atraumatic AT-Valve (Lipocosm).¹⁴ This system saves time by eliminating the need to switch syringes. The harvested lipoaspirate is always kept in a closed system, which minimizes its exposure to the environment. And while mechanical pumps can also be dialed down to deliver a low, atraumatic suction pressure, they still have a high airflow that can desiccate the fat in the necessarily long tubing.

Preparation of the Lipoaspirate

The collection bags have a 200 cc capacity. Once filled, the scrub nurse replaces the bag with an empty one as the team continues filling bags with K-VAC-suctioned lipoaspirate. The full bag can either be centrifuged at 15 g for 1 minute in a blood bank bag centrifuge, or it is simply allowed to separate by gravity (1 g) for 15 minutes by hanging on a simple IV stand covered with a sterile drape. With the Lipografter system, there is almost no free oil noted; the infranatant fluid is simply drained out of the bag, preserving the collected supernatant fat for grafting.

Most surgeons who perform large-volume fat grafting have abandoned the standard 1200 g centrifugation of the harvested lipoaspirate. It has been demonstrated that graft-to-recipient contact is better achieved with a loose suspension of fat than with a compacted paste. Furthermore, we prefer to graft back essentially most of the harvested lipoaspirate, manipulating

it as little as possible. Lipoaspirate is not “dirty,” and it does not need to be washed or purified. Quite the contrary; there are many beneficial elements (such as platelets and plasma) in the lipoaspirate that should not be discarded. Dilute fat will lipotumescence the recipient site, putting the scar bands under tension, and its epinephrine content will provide vasoconstriction to facilitate the release of the scar bands.

Fat Grafting

To maximize revascularization and survival, the graft has to be carefully and diffusely dispersed as a fine mist of microdroplets using the sprinkler principle. The plan is to lay down microribbons that are no wider than 2 mm through contiguous radial passes that do not coalesce into larger blobs. We repeat this process through 8 to 12 circummammary 14-gauge (2.3 mm) puncture holes that act as “sprinkler heads.” Depending on the thickness of the recipient tissue, the mastectomy defect is conceptually divided into a number of planes 0.5 to 1 cm thick. We usually start with the most superficial, most subdermal plane, proceeding to the second plane of grafting a few millimeters deeper. The third plane is often the deepest and prethoracic, and we then continue grafting as many in-between planes as possible so that the graft is laid down in layers as evenly and diffusely as possible. The key is to avoid delivering large droplets that will coalesce into lakes of fat, ultimately leading to either fat necrosis or lipid cysts.¹³⁻¹⁷

We use a single 1 by 2 mm hole, 14-gauge (2.3 mm) spatulated-tip curved cannula that gently glides through the breast tissues and the contours of the natural breast curvature. The tip is always kept pointing upward to prevent an inadvertent puncture into the chest wall.

We recommend using a 2.5 cc syringe connected to a 20 cm cannula. This provides the controlled precision needed to deliver 0.1 cc for every centimeter of cannula retraction as these leave behind the optimal 2 mm ribbons. Larger syringes are incapable of this degree of precision. The AT-Valve of the Lipografter device automatically draws fat from the bag to refill the syringe and makes it practical to use a small syringe. This also saves time, avoiding the wasted motion of switching syringes.

Postoperative Care

The patient is allowed to recover for 4 or 5 days. She is instructed not to put any pressure on her breasts and not to wear a bra or other compression garment. At postoperative day 5 to 7, the patient will either resume using ETE at a very low constant pressure about 10 hours a day for 6 to 8 weeks or will have her grafted breast placed in an immobilizing, conforming, adhesive, and rigid splint that maintains the expanded grafted state and prevents it from deflating. This places the tissues under constant tension as they are held up and prevented from their natural tendency to recoil to their previous dimensions. The splint is worn for 6 to 8 weeks; the chronic edema it induces tends to be adipogenic also. Most defects will require another procedure to complete the reconstruction. Therefore, 10 weeks after the grafting session, the patient resumes ETE for 2 weeks before the next graft, and the cycle is repeated as necessary until the goal of a satisfactory breast mound is achieved.

CLINICAL EXPERIENCE

Whereas nonirradiated defects can be corrected in one to three sessions, most patients require two to four grafting sessions 3 months apart to reverse the radiation damage and restore normal contour and symmetry. The grafted breasts become soft and they tend to recover the sensation lost after mastectomy. The procedure has a high satisfaction rate, with 90% of patients achieving their expected volume, contour, symmetry, and general feel of their breasts. Essentially all patients returned to their normal daily activities within 5 to 7 days after fat grafting.

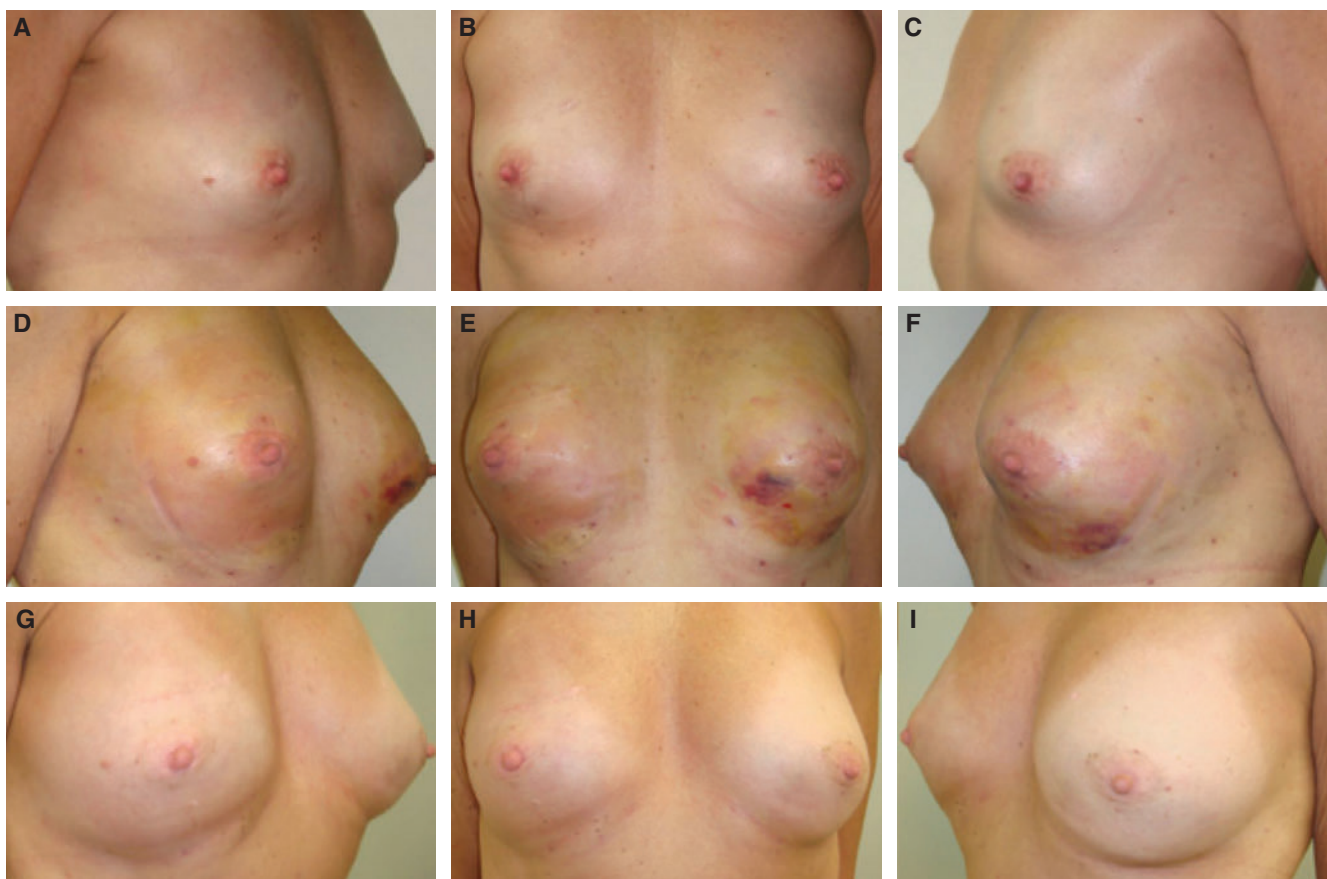


Fig. 29-10

These photos show the process of breast lumpectomy reconstruction using ETE and fat grafting. The patient is shown before external tissue expansion (A through C), after ETE (D through F), and her final results at 1-year follow-up after a total of two sessions of ETE and fat grafting (G through I).

Overall, our postoperative complication rate is 3%. Despite being careful not to puncture the thoracic cavity, we still have a 1% incidence of pneumothorax. Fortunately, we have had no incidence of air leak, since these are easily handled with simple reinflation of the

lung. We also have a 2% incidence of skin necrosis, which in all instances were traced to an aggressive Rigotomy or to overgrafting. Despite our best care in minimizing fat necrosis, about 18% of patients end up with radiologically benign palpable masses. At an average follow-up of 3½ years, two patients out of the 115 partial mastectomy patients reconstructed with ETE plus fat grafting were diagnosed with either recurrent carcinoma or a second primary tumor in the same breast. This is slightly below the expected recurrence rate and confirms recent studies that found no increased incidence of cancer recurrence after fat grafting reconstruction.²²

CONCLUSION

Reconstruction of the partial mastectomy with ETE plus fat grafting plus Rigotomy is a safe and minimally invasive method of in vivo tissue engineering. External expansion creates a three-dimensional biologic scaffold with a new capillary bed that can be seeded with grafted fat droplets. The Rigotomies transform the irradiated cicatrix into a matrix for fat grafts. By adhering to the fundamental principles of fat grafting, scars can be released, graft survival can be maximized, defects can be optimally augmented, and an aesthetically pleasing contour can be restored to the breast. This outpatient incisionless procedure restores the natural properties of the breast. It becomes soft, sensate, and feels normal again to the patient.

A drawback is the need for multiple procedures and the necessity of having the patient comply with wearing a relatively uncomfortable but painless external expander for a few weeks. Nevertheless, ETE plus fat grafting is very well accepted, with high satisfaction rates for the reconstruction of partial mastectomy defects.^{8,14,16}

Critical Issues

- Partial mastectomy surgeries can produce significant deformities that require reconstruction.
- ETE is used to generate a favorable recipient fibrovascular scaffold for fat grafting.
- Fundamental factors that can limit the survival of free fat grafts are restoration of the blood supply and adequate recipient site capacity.
- The lumpectomy site must be prepared to best accept the amount of fat graft required for reconstruction.
- ETE combined with three-dimensional percutaneous mesh expansion can transform an irradiated cicatrix into a recipient matrix for fat grafts.
- The ideal patient has moderate fat deposits to harvest and has realistic expectations.
- To maximize revascularization and survival, the graft has to be carefully and diffusely dispersed as a fine mist of microdroplets using the sprinkler principle.

References

1. World Health Organization. Globocan 2008, estimated cancer incidence, mortality, prevalence and disability-adjusted life years (DALYs) worldwide in 2008. Available at <http://globocan.iarc.fr>.
2. American Cancer Society. Breast reconstruction after mastectomy. Available at <http://www.cancer.org/acs/groups/cid/documents/webcontent/002992.pdf>.
3. Nano MT, Gill PG, Kollias J, et al. Psychological impact and cosmetic outcome of surgical breast cancer strategies. *ANZ J Surg* 75:940, 2005.
4. Wilkins EG, Cederna PS, Lowery JC, et al. Prospective analysis of psychosocial outcomes in breast reconstruction: one-year postoperative results from the Michigan Breast Reconstruction Outcomes Study. *Plast Reconstr Surg* 106:1014; discussion 1026, 2000.
5. Atisha D, Alderman AK, Lowery JC, et al. Prospective analysis of long-term psychosocial outcomes in breast reconstruction: two-year postoperative results from the Michigan Breast Reconstruction Outcomes Study. *Ann Surg* 247:1019, 2008.
6. Albornoz CR, Bach PB, Mehrara BJ, et al. A paradigm shift in U.S. breast reconstruction: increasing implant rates. *Plast Reconstr Surg* 131:15, 2013.
7. Khouri RK, Schlenz I, Murphy BJ, et al. Nonsurgical breast enlargement using an external soft-tissue expansion system. *Plast Reconstr Surg* 105:2500, 2000.
8. Khouri RK, Del Vecchio D. Breast reconstruction and augmentation using pre-expansion and autologous fat transplantation. *Clin Plast Surg* 36:269, 2009.
9. Chin MS, Ogawa R, Lancerotto L, et al. In vivo acceleration of skin growth using a servo-controlled stretching device. *Tissue Eng Part C Methods* 16:397, 2010.
10. Liu PH, Lew DH, Mayer H, et al. Micro-mechanical forces as a potent stimulator of wound healing. *J Am Coll Surg* 199:57, 2004.
11. Heit YI, Lancerotto L, Mesteri I, et al. External volume expansion increases subcutaneous thickness, cell proliferation, and vascular remodeling in a murine model. *Plast Reconstr Surg* 130:1, 2012.
12. Lancerotto L, Chin MS, Freniere B, et al. Mechanisms of action of external volume expansion devices. *Plast Reconstr Surg* 132:569, 2013.
13. Khouri RK, Rigotti G, Cardoso E, Khouri RK Jr, Biggs TM. Megavolume autologous fat transfer: part I. Theory and principles. *Plast Reconstr Surg* 133:550, 2014.
14. Khouri RK, Rigotti G, Cardoso E, Khouri RK Jr, Biggs TM. Megavolume autologous fat transfer: part II. Practice and techniques. *Plast Reconstr Surg* 133:1369, 2014.
15. Khouri RK, Eisenmann-Klein M, Cardoso E, et al. Brava and autologous fat transfer is a safe and effective breast augmentation alternative: results of a 6-year, 81-patient, prospective multicenter study. *Plast Reconstr Surg* 129:1173, 2012.
16. Khouri RK, Khouri RK Jr, Rigotti G, et al. Aesthetic applications of Brava-assisted megavolume fat grafting to the breasts: a 9-year, 476-patient, multicenter experience. *Plast Reconstr Surg* 133:796, 2014.
17. Khouri RK, Rigotti G, Khouri RK Jr, et al. Tissue-engineered breast reconstruction with Brava-assisted fat grafting: a 7-year, 488-patient, multicenter experience. *Plast Reconstr Surg* 135:643, 2015.
18. Doi K, Ogata F, Eto H, et al. Differential contributions of graft-derived and host-derived cells in tissue regeneration/remodeling after fat grafting. *Plast Reconstr Surg* 135:1607, 2015.
19. Spear SL, Pittman T. A prospective study on lipoaugmentation of the breast. *Aesthet Surg J* 34:400, 2014.

20. Rigotti G, Marchi A, Galie M, et al. Clinical treatment of radiotherapy tissue damage by lipoaspirate transplant: a healing process mediated by adipose-derived adult stem cells. *Plast Reconstr Surg* 119:1409, 2007.
21. Mojallal A, Lequeux C, Shipkov C, et al. Improvement of skin quality after fat grafting: clinical observation and an animal study. *Plast Reconstr Surg* 124:765, 2009.
22. Kuerer HM, Smith B, Garvey P, et al. Lipofilling of the breast does not increase the risk of recurrence of breast cancer: a matched controlled study. *Plast Reconstr Surg* 137:385, 2016.

Gino Rigotti, Alessandra Marchi, Guido Baroni

Breast-conserving therapy (BCT) offers patients with early-stage breast cancer a valuable option for local control of the tumor and potentially acceptable cosmetic results. Several studies have shown that the oncologic safety of a lumpectomy or quadrantectomy followed by radiotherapy is comparable to that of a mastectomy, with the advantage of being less mutilating.¹⁻⁶ In recent years, however, disappointing cosmetic results have increased because of poor attention to cosmesis and the widespread use of BCT for women with large breasts or for those who require large excisions for tumor removal. Despite the development of oncoplastic techniques,^{7,8} more unsatisfied patients present to plastic surgeons for further reconstruction because of persistent deformities. BCT deformities have been classified according to Berrino et al⁹ as postquadrantectomy deformities and have been reclassified by Clough et al¹⁰ as types I through III (see Chapter 24). The conventional approach to the correction of BCT deformities is surgery; however, this often requires complex flap procedures, which are further complicated by the poor response of irradiated tissue to surgery, leading to a relatively low success rate.

It is important to consider the two main causes of BCT deformities and what is required to correct them: (1) shape modifications caused by fibrosis, scar contracture, and radiotherapy and (2) volume modifications resulting from the resection of glandular and subcutaneous tissue.

When these two causes are considered, the therapeutic approach to BCT deformities should also involve the concept of tissue regeneration. Shape modifications can be resolved if fibrotic tissue is restored to normal tissue; volume modifications can be achieved by adding volume and creating new, healthy tissue at the site where the tumor and appropriate margins were surgically excised.

ADIPOSE TISSUE: REGENERATIVE FACTORS

The use of adipose tissue as a filler material in plastic surgery has a long history. Since the nineteenth century, fat grafting has been described and proposed for therapeutic and cosmetic purposes.¹¹ Only recently has progress in molecular and cell biology allowed further insight into the scientific basis of fat transfer and the emerging evidence of the regenerative potential of fat grafts.¹²⁻¹⁵ Although still controversial, strong evidence suggests that adipose tissue plasticity is attributable to multipotent stromal cell populations capable of differentiating into mature adipocytes with multilineage properties. Recent studies have shown that the adipose stromal vascular cell fraction (SVF) contains regenerative precursor cells with proangiogenic capabilities.¹⁶⁻¹⁸ Adipose stromal cells were reported to secrete angiogenic and antiapoptotic factors^{19,20} that allow differentiation into endothelial cells and their incorporation into vessels,²¹ thus promoting neovascularization in ischemic tissues.

Transplanted adipose tissue (lipoaspirate) offers the potential to restore volume after BCT because of its ability to promote the generation of mature adipocytes. In addition, the observed neoangiogenic properties of the stromal cell fraction contained in lipoaspirates provide neovascularization factors in fibrotic tissue to promote shape recovery.

CYTOLOGIC CHARACTERIZATION OF LIPOASPIRATES

In a recent clinical pilot study,²² we reported striking results with repeated fat grafts for the treatment of chronic radiation-induced lesions. To understand the mechanisms responsible for such impressive regeneration capabilities of fat injection, we applied cytologic techniques to characterized lipoaspirates to quantitatively assess the presence and density of the mesenchymal stem cell (MSC) fraction in the transplanted tissue and to evaluate differentiation potentialities. The analysis was performed according to current standard methods and procedures.

Phase One: Isolation of the Stromal Vascular Cell Fraction

Sterile Hanks' balanced salt solution was used to wash 40 cc of lipoaspirate. After washing, the extracellular matrix was digested at 37° C in the same salt solution with 1 mg/ml collagenase type I and 2% bovine serum albumin (BSA). After incubation, the digestion enzyme was neutralized, and centrifugation at 1200 rpm for 10 minutes was performed to obtain a high-density SVF pellet. This was resuspended in 160 mM NH₄Cl and incubated at room temperature for 10 minutes to lyse contaminating red blood cells. After incubation, the SVF was collected by centrifugation and filtered through a 70 µm nylon mesh to remove cellular debris.

Phase Two: MSC Expansion

To obtain a homogeneous MSC population, the SVF was incubated for 72 hours at a concentration of 1×10^5 cells/cm² with a high glucose concentration, GlutaMAX-I, 15% heat-inactivated fetal calf serum (FCS), 100 U/ml penicillin, and 100 µg/ml streptomycin. The cells underwent a second incubation period of 2 to 3 weeks in specific flasks (BD Falcon). Cells were cultured at a temperature of 37° C in a 5% CO₂ atmosphere.

Phase Three: MSC Immunophenotypic Analysis

MSCs were identified according to their immunophenotype using monoclonal antibodies specific for CD105 (endoglin), CD73, CD106 (VCAM-1), CD29, CD44, and CD90. In addition, we assessed the lack of endothelial cell (with anti-CD31 antibodies) and hematopoietic cell (with anti-CD45, anti-CD14, anti-CD11c, and anti-CD34 antibodies) marker expression. The immunophenotypic analysis was performed by incubating 100 cc of cell suspension with the specific antibody for 30 minutes. At least 10,000 events were analyzed using flow cytometry. The results showed that the immunophenotype of adipose tissue-derived and in vitro-expanded MSCs were positive for surface CD105, CD73, CD29, CD44, and CD90, and therefore were similar to bone marrow-derived stem cells. They were negative for endothelial (CD31) and hematopoietic (CD45, CD14, and CD34) markers. A significant quantity of clonogenic CD105-positive cells was documented (1.02×10^3 CFU-F [colony forming units–fibroblast]) could be obtained with a single lipoaspirate.

Phase Four: MSC Differentiation Assay

MSCs were tested for their ability to differentiate into adipocytes, osteoblasts, and chondrocytes. Differentiation was obtained after culturing MSCs with specific media (adipogenic, osteogenic, or chondrogenic, depending on how the cells were to be processed) for 2 weeks. More than 90% of the cells differentiated, depending on the time left in culture with the differentiating agent.

CLINICAL RESULTS OF FAT GRAFTING

This clinical pilot study focused on the treatment of radiolesions and showed very significant improvements in all 20 participants.²² The clinical evaluation was associated with ultrastructural analysis of the tissue within the pathologic site, with up to 36 months of follow-up. The analysis showed clear signs of gradual tissue regeneration. The final results showed very well-hydrated tissue, a significant density of mature and normal adipocytes, and newly formed microvascular networks with normal ultrastructure. These results encouraged us to evaluate the use of lipoaspirate autologous transplant for the treatment of BCT deformities, with the hypothesis that the promotion of tissue regeneration processes and neovascularization would lead to increased volume expansion and a more normal shape, respectively.

SURGICAL TECHNIQUE

Surgical Plan

- Harvest the lipoaspirate.
- Purify the lipoaspirate.
- Place the lipoaspirate.

No specific patient preparation or surgical planning procedures are required. It is preferable to wait at least 1 year after breast irradiation before initiating reconstruction. The deformity may range from a minor contour irregularity with healthy skin coverage (preferable) to significant fibrosis with scar contracture (more difficult). More complex deformities require more procedures, which need to be discussed preoperatively with the patient. Preoperative cancer surveillance and breast imaging are important before reconstructing any BCT deformity.

The targeted area, the number and location of entry points, and the direction of tissue injection tunnels are defined preoperatively. The goals are to achieve maximum uniformity of distribution and to limit significant overlaps and gaps in tissue deposition.

Fat grafting surgery has three main phases: harvest, purification, and placement of the graft.

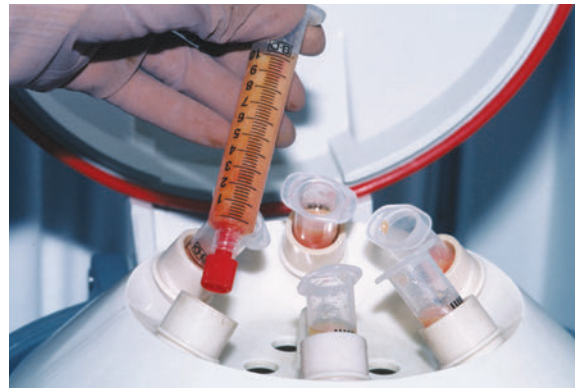Phase One: Harvesting the Lipoaspirate

The lipoaspirate is harvested while the patient is deeply sedated. An antibiotic agent is administered 20 minutes before surgery. Lipoaspirate is typically harvested from the medial area of the knee, the abdominal region, or the trochanteric region. Before beginning the procedure, the identified donor area is infiltrated with a local anesthetic consisting of a cold saline solution with 1:400,000 epinephrine and 20 ml lidocaine 0.5% to total 500 ml.

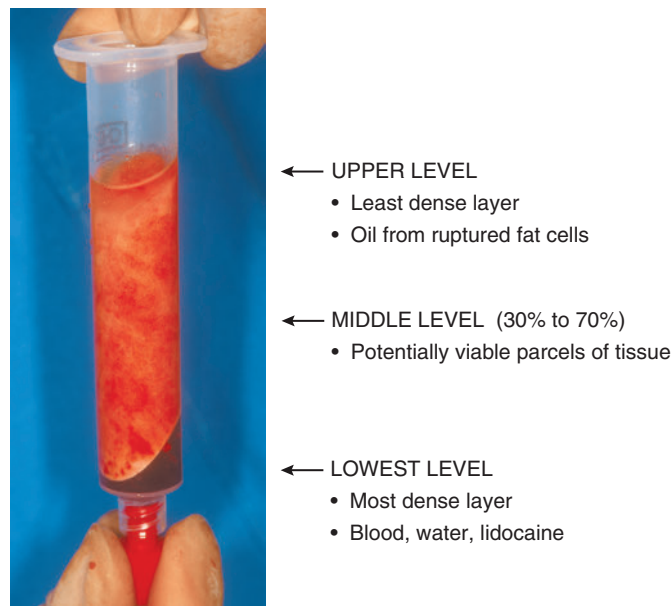
**Fig. 30-1**

Lipoaspirate is harvested using a 2 mm diameter cannula with a blunt tip and dull distal opening. It is connected to a Luer-Lok 10 cc syringe. Excessive negative pressure is avoided.

Phase Two: Lipoaspirate Purification

**Fig. 30-2**


The lipoaspirate purification procedure is designed to rapidly remove a large volume of the triglyceride stored in the tissue after injection. At the end of the harvest, the cannula is removed from the syringe and replaced with a plug. The plunger is removed, and the syringe is placed directly into a centrifuge.

**Fig. 30-3**

Purification is achieved by centrifuging the syringes at 3000 rpm for 3 minutes to separate the tissue from its water content and from the oil produced by the destruction of damaged adipocytes. The centrifugation produces three evident layers within the syringe: the upper level contains oil from ruptured adipocytes; the middle level contains the useful fatty tissue; and the lowest level contains blood, saline solution, and residual epinephrine and lidocaine. The upper and lower levels are discarded (by using neuropads and opening the plug, respectively), and the remaining purified lipoaspirate is transferred to a 2 cc syringe for injection.

Phase Three: Lipoaspirate Placement

While the patient is deeply sedated, the predefined target area in the breast is infiltrated with the same local anesthetic solution used for harvest. The purified fat is injected using a blunt needle to avoid perforating veins and arteries and causing hematomas.

**Fig. 30-4**

The instruments used for fat grafting (especially in irradiated tissue) are Coleman style III and V dissectors.

Two main issues to consider when performing fat grafting are (1) the quantity of lipoaspirate to administer and (2) the homogeneity of the deposition.

The quantity of fat to be injected is patient specific. The stiffness of the subcutaneous and glandular tissues and skin contraction are crucial factors. It is important to avoid applying too much pressure when injecting the fat graft to preserve some elasticity within the treated area.

Homogeneity of the distribution of fatty tissue in the targeted area maximizes the contact of the fat with the host tissue and greatly increases the quality of the final result. Computer-assisted surgical planning and intraoperative guidance help to optimize the uniformity of fatty tissue distribution. This technology employs patient photographs and images of a defined set of boundaries to pinpoint the numbers and initial positions of entry points and tunnels, peak angular values of feasible insertion pathways, and eventual inaccessible or untreatable areas.²²

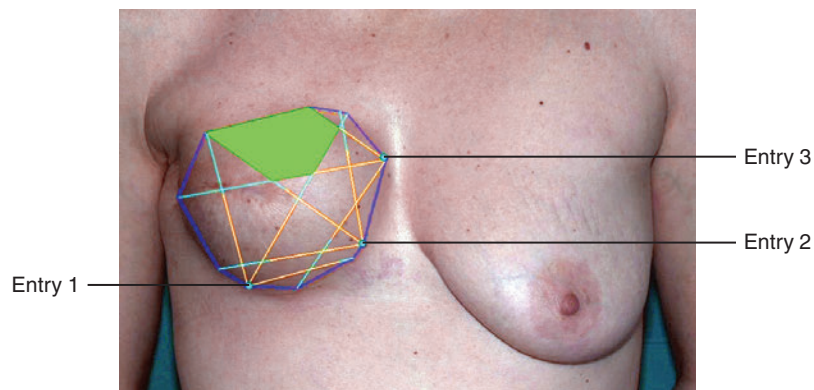


Fig. 30-5

This computer-assisted image shows three entry points, each with three paths of insertion. The green region is the largest area without contact with the lipoaspirate and represents the quantity to be minimized by the automatic optimization procedure.

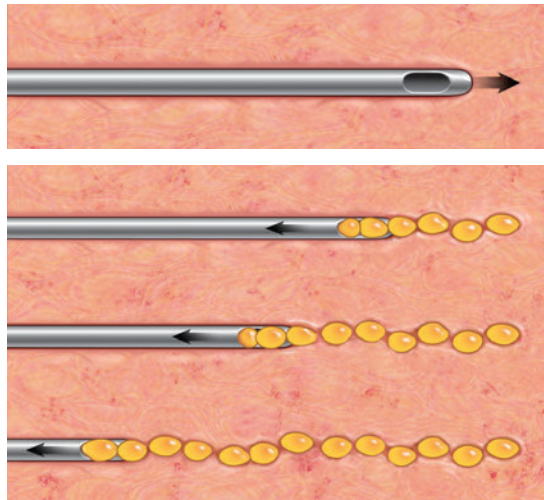


Fig. 30-6

As a general rule, the placement of miniscule quantities of purified fat tissue for each insertion path is the key to obtaining remarkable results.

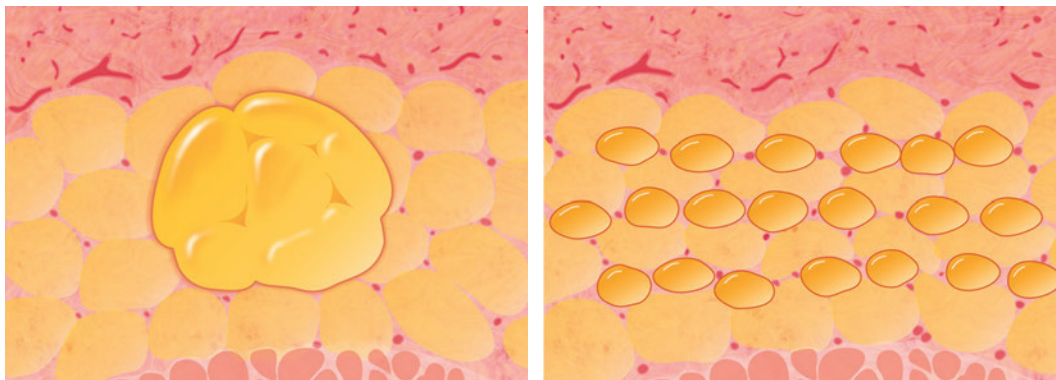


Fig. 30-7

In most cases, injecting bulky quantities of tissue results in oil cysts and/or macrocalcifications. *The injection must be performed while withdrawing the cannula* to minimize the risk of arterial or venous embolization.

The number of treatments depends on the initial clinical picture and the patient-specific response to cell therapy. Three to six treatments were sufficient for all of our patients; however, no evidence of any contraindication to additional administrations of lipoaspirate has been reported.

PATIENT EXAMPLES

To support fat grafting as a particularly promising therapy for the treatment of BCT deformities, we report on six patients who underwent a quadrantectomy and radiotherapy and who later gave their informed consent to receive lipoaspirate cell therapy. The number of fat grafting procedures varied from three to six sessions. The average amount of purified fatty tissue administered at each session varied from 80 to 130 cc.

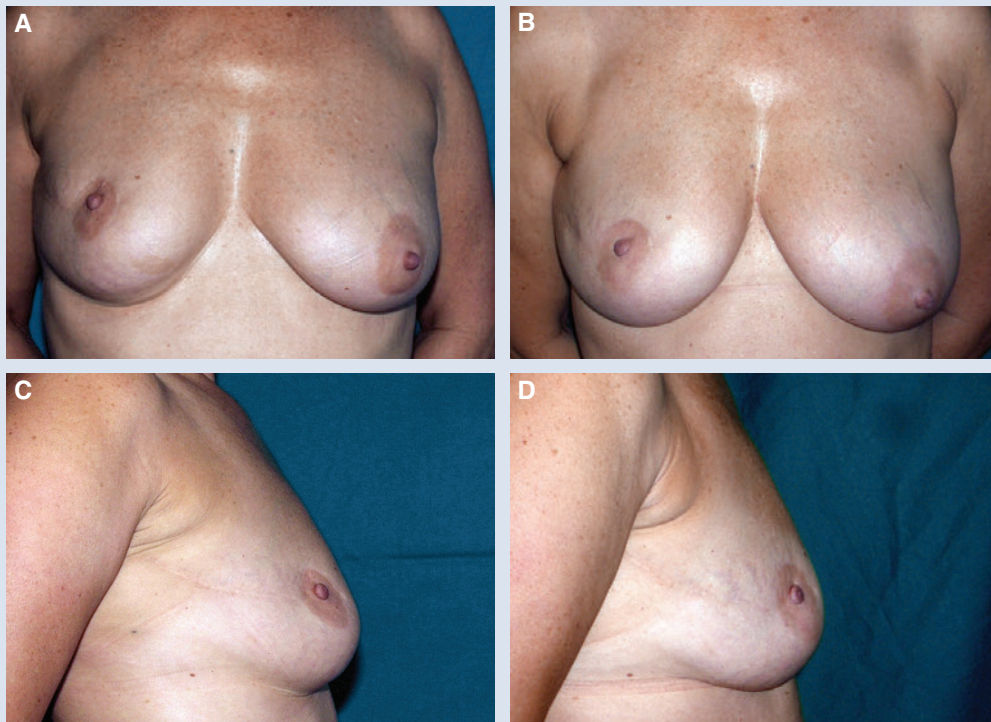


Fig. 30-8

This patient presented with a deformity following a quadrantectomy and radiotherapy to the upper external quadrant of her right breast (A and C). Upper displacement of the glandular tissue reduced ptosis and elevated the inframammary fold. A uniform distribution of three fat grafts in the subcutaneous and retroglandular tissue allowed us to obtain a volume increase and a lower displacement of the glandular tissue. This displacement restored ptosis, the proper position of the inframammary fold, and the desired lower NAC. The final cosmetic result shows great improvement (B and D).

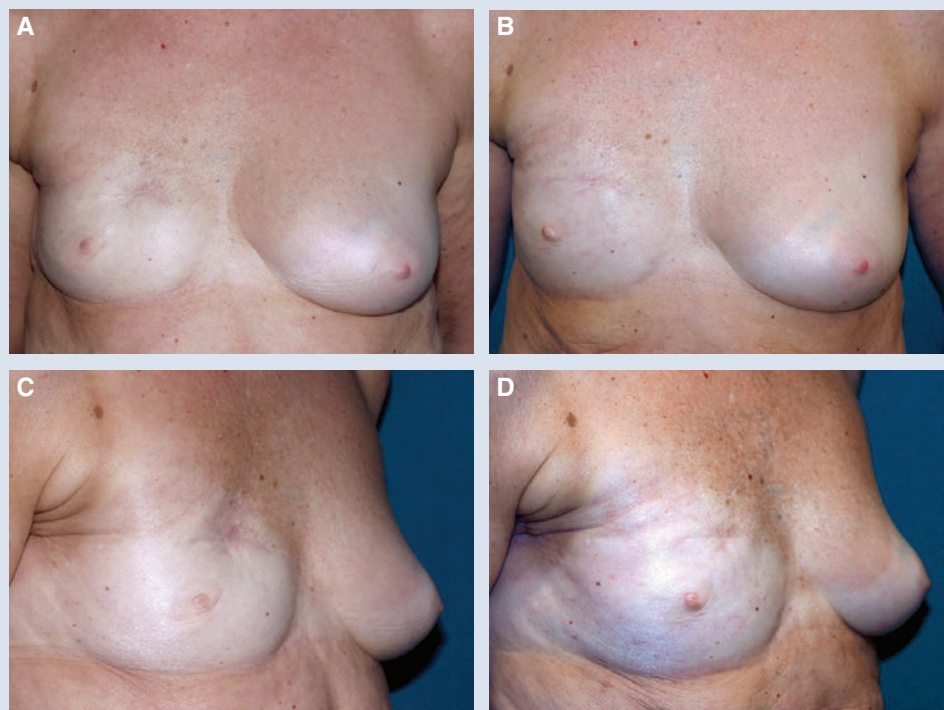


Fig. 30-9

This patient presented with a deformity of volume and shape that was worsened by scar retraction after radiotherapy (A and C). Therapy was administered in four sessions with 3- to 4-month intervals. Lipoaspirate was uniformly distributed in the upper medial quadrant and the subcutaneous and retroglandular tissue of all the remaining quadrants. After therapy, significant volume and shape were recovered (B and D).

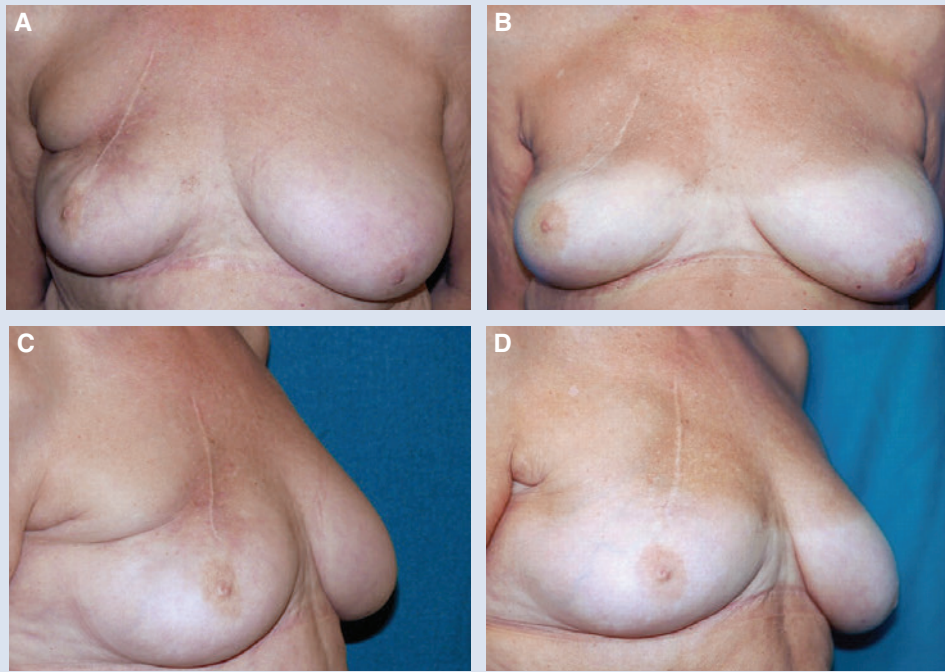
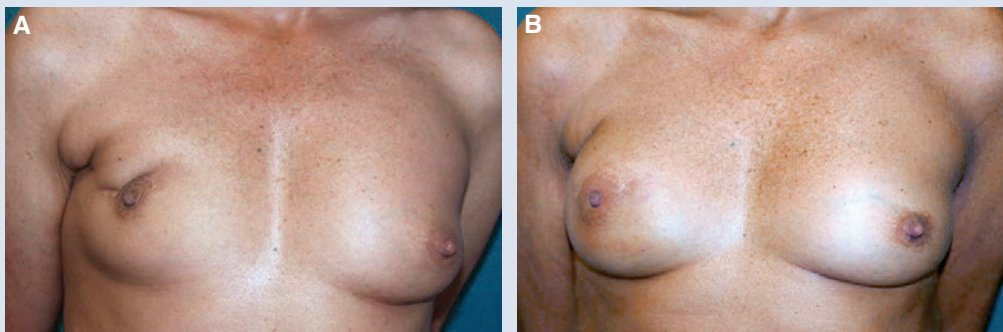
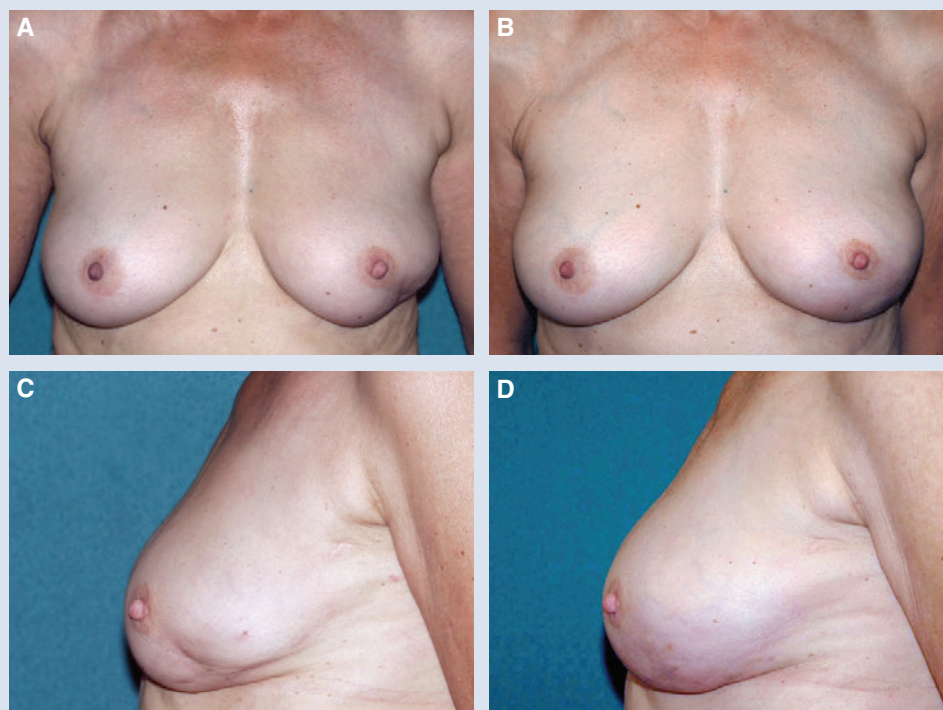


Fig. 30-10

This patient presented with three problems: retraction of the long vertical scar between the two superior quadrants, adhesion to the rib plane with upper retraction of the residual glandular tissue of the upper external quadrant, and significant ptosis reduction with a volume deficit (A and C). Cell therapy comprised four fat grafts with 3- to 4-month intervals, targeting the vertical scar, the subcutaneous adipose, and the retroglandular tissue of the upper quadrants and the whole breast. After therapy, the vertical scar is lengthened and the NAC is lower. The upper quadrants are fuller, with increased subcutaneous adipose and retroglandular tissue, and the transverse fold of the upper external quadrant is no longer present. The increased subcutaneous adipose and retroglandular tissue of the whole breast have restored the volume and ptosis (B and D).

**Fig. 30-11**

This patient underwent a quadrantectomy and radiotherapy focused on the upper external quadrant and partially on the central quadrant. The shape deformity was worsened by adhesion of the NAC to the rib cage plane (A). Six fat grafts were required. They were mainly administered in the central and upper external quadrants to regenerate the adipose layer and to raise the NAC. After therapy, the glandular tissue is fuller in the outer quadrant and lower pole, and the inframammary fold is restored (B).

**Fig. 30-12**

This patient presented with a nearly complete absence of the lower external quadrant (A and C). She had no mammary gland tissue in this quadrant, and the insufficiency of the cutane-

ous envelope was worsened by scar retraction after radiotherapy. Fortunately, the residual mammary gland was not retracted upward. Three fat grafts were needed to resolve cutaneous retraction and to regenerate tissue resected during the quadrantectomy. After therapy, the shape of the lower lateral quadrant has been restored (*B* and *D*).

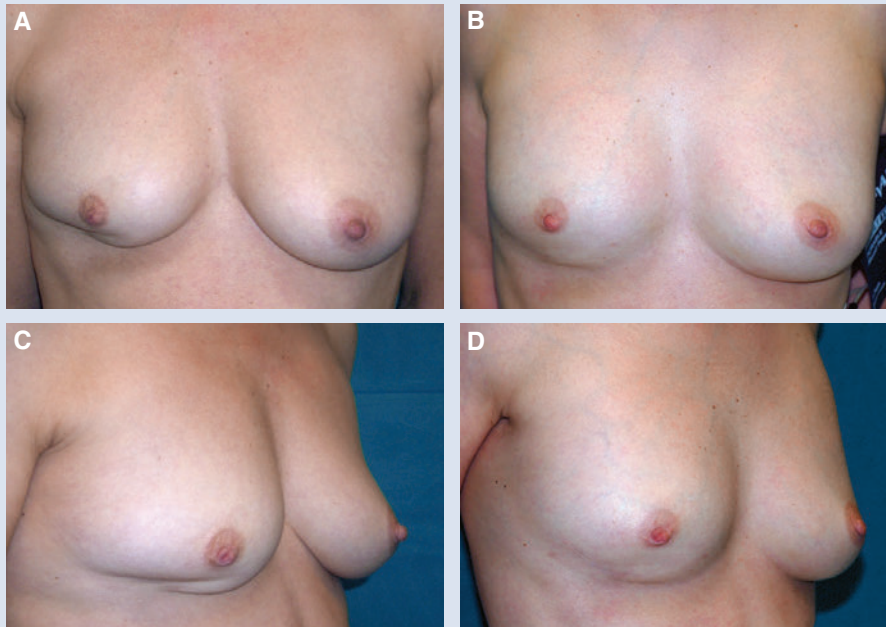


Fig. 30-13

Similar to the previous patient, this woman's lower external quadrant was almost completely absent at presentation (*A* and *C*). There was no mammary gland tissue in this quadrant, and the cutaneous envelope was insufficient and worsened considerably by scar retraction after radiotherapy. The inframammary sulcus was linearized by combining the cutaneous retraction and radiation-induced retraction. Four fat grafts were performed within the subcutaneous adipose layer of the lower external quadrant and in the space between the pectoral muscle and the lower external quadrant of the mammary glandule to restore the inframammary sulcus (*B* and *D*).

CONCLUSION

Based on reported experiences and clinical outcomes, fat grafting is a particularly promising technique for the treatment of deformities after BCT. The main advantage is that fatty tissue represents an elective source of stem cells: It is abundant in the body and easily accessible using minimally invasive procedures. Immediate and late complications are rare and limited to postoperative ecchymoses and small hematomas in the donor area that disappear in a few weeks. Scarring has never been a problem after fat grafting. On the contrary, fibrosis is normally diminished in control cases. Regarding postoperative surveillance, recent clinical data suggest that the number of calcifications after BCT, including radiotherapy, is lower in patients who received fat grafts than in those who did not. In addition, calcifications were never found to be predictive of local cancer recurrence. Infections after fat grafting are very uncommon, but a prophylactic intravenous injection of an antibiotic agent before surgery is strongly recommended. Although rare, small areas of liponecrosis could develop, typically in oil cysts. These are easily identified with ultrasound scanning and are eliminated through aspiration. This described technique is simple, easily transferable in clinical situations, and extremely powerful for volume and shape restoration. Contraindications to fat grafting are limited to the availability of fat tissue in the donor areas. As a general rule, the therapy can be administered only after excluding the local residual or recurrent oncologic disease.

Critical Issues

- Fat transfer allows volume restoration and shape recovery in BCT deformities.
- This therapy appears to nourish the irradiated skin and improves cosmesis.
- Attention to meticulous fat harvest, tissue purification, and injection is essential.
- Homogeneity of the fat transplant maximizes the duration of the result and optimizes shape.
- The need for numerous fat grafts is not uncommon, especially in patients who have significant deformities with larger volume requirements.
- Strict protocols for postoperative cancer surveillance must be established.

References

1. Recht A, Connolly JL, Schnitt SJ, et al. Conservative surgery and radiation therapy for early breast cancer: results, controversies, and unsolved problems. *Semin Oncol* 13:434, 1986.
2. Clark RM, Wilkinson RH, Miceli PN, et al. Breast cancer. Experiences with conservative therapy. *Am J Clin Oncol* 10:461, 1987.
3. Veronesi U, Banfi A, Salvadori B, et al. Breast conservation is the treatment of choice in small breast cancer: long-term results of a randomized trial. *Eur J Cancer* 26:668, 1990.
4. Veronesi U, Luini A, Vecchio MD, et al. Radiotherapy after breast-conserving surgery in women with localized cancer of the breast. *N Engl J Med* 328:1587, 1993.
5. Veronesi U, Cascinelli N, Mariani L, et al. Twenty-year follow-up of a randomized study comparing breast-conserving surgery with radical mastectomy for early breast cancer. *N Engl J Med* 347:1227, 2002.
6. Doridot V, Nos C, Aucouturier JS, et al. [Breast-conserving therapy of breast cancer] *Cancer Radiother* 8:21, 2004.
7. Audretsch W, Rezaei M, Kolotas C, et al. Tumor-specific immediate reconstruction in breast cancer patients. *Perspect Plast Surg* 11:71, 1998.
8. Clough KB, Lewis JS, Couturaud B, et al. Oncoplastic techniques allow extensive resections for breast-conserving therapy of breast carcinomas. *Ann Surg* 237:26, 2003.
9. Berrino P, Campora E, Santi P. Postquadrantectomy breast deformities: classification and techniques of surgical correction. *Plast Reconstr Surg* 79:567, 1987.
10. Clough KB, Cuminet J, Fitoussi A, et al. Cosmetic sequelae after conservative treatment for breast cancer: classification and results of surgical correction. *Ann Plast Surg* 41:471, 1998.
11. Neuber F. Fat transplantation. *Chir Kongr Verhandl Deutsch Gesellsch Chir* 22:66, 1893.
12. Tzikas TL. Lipografting: autologous fat grafting for total facial rejuvenation. *Facial Plast Surg* 20:135, 2004.
13. Trepsat F. Periorbital rejuvenation combining fat grafting and blepharoplasties. *Aesthetic Plast Surg* 27:243, 2003.
14. Berman M. Rejuvenation of the upper eyelid complex with autologous fat transplantation. *Dermatol Surg* 26:1113, 2000.
15. Coleman SR. Hand rejuvenation with structural fat grafting. *Plast Reconstr Surg* 110:1731, 2002.
16. Rafii S, Lyden D. Therapeutic stem and progenitor cell transplantation for organ vascularization and regeneration. *Nat Med* 9:702, 2003.
17. De Ugarte DA, Morizono K, Elbarbary A, et al. Comparison of multi-lineage cells from human adipose tissue and bone marrow. *Cells Tissues Organs* 174:101, 2003.
18. Rydén M, Dicker A, Götherström C, et al. Functional characterization of human mesenchymal stem cell-derived adipocytes. *Biochem Biophys Res Commun* 311:391, 2003.
19. Gimble J, Guilak F. Adipose-derived adult stem cells: isolation, characterization, differentiation potential. *Cytotherapy* 5:362, 2003.
20. Rehman J, Traktuev D, Li J, et al. Secretion of angiogenic and antiapoptotic factors by human adipose stromal cells. *Circulation* 109:1292, 2004.
21. Cao Y, Sun Z, Liao L, et al. Human adipose tissue-derived stem cells differentiate into endothelial cells in vitro and improve postnatal neovascularization in vivo. *Biochem Biophys Res Commun* 332:370, 2005.
22. Rigotti G, Marchi A, Galiè M, et al. Clinical treatment of radiotherapy tissue damage by lipoaspirate transplant: a healing process mediated by adipose-derived adult stem cells. *Plast Reconstr Surg* 119:1409, 2007.

31

Can Implants Correct a Breast-Conserving Therapy Deformity?

Albert Losken, Allen Gabriel

T

he old notion that breast implants and radiotherapy do not mix still holds true most of the time. With the exception of fat injections, all of the techniques described in previous chapters have focused on using well-vascularized tissue in the form of local or distant flaps to reconstruct BCT deformities. This concept is one of the basic principles in reconstructive surgery when it comes to irradiated wounds—namely, that they require adequate debridement and coverage with vascularized tissue.

This chapter addresses whether there is any role for reconstruction with implants after BCT in a scarred, irradiated breast. Based on our experience with breast reconstruction after a skin-sparing mastectomy (SSM) in previously irradiated breasts, it can be assumed that reconstruction using implants is less desirable. The complication rates are higher and cosmetic results are worse when expanders are used after an SSM in breasts that previously have been irradiated. These patients often require autologous tissue to achieve the desired outcome.

Using implants in previously irradiated breasts is always a concern. Although the irradiated skin envelope encountered when correcting the BCT deformity is often more favorable than random mastectomy skin flaps in patients with a failed BCT, extreme caution should still be used.

Although the general impression is that implants are not good options for correcting BCT deformities in women with irradiated breasts, there may be exceptions. However, available literature on this topic is essentially nonexistent.

PATIENT SELECTION

When evaluating a patient who has a poor cosmetic result after BCT, the surgeon must confirm that at least 1 year has passed since the completion of radiotherapy, that the patient has been adequately screened for any potential recurrence, and that a mammogram of the contralateral breast has been obtained.

Although the incidence of unfavorable cosmetic results after BCT is lower in women with smaller breasts than in women with large breasts, a certain percentage of patients opt for delayed reconstruction to have the deformity corrected. Their wishes and goals might include correction of their asymmetry, correction of the actual deformity, shape improvement, and breast enlargement. These patients are potential candidates for reconstruction of their BCT deformity with implants. However, the patient's wishes are not enough to determine her eligibility; the breast evaluation is the main factor.

The physical examination should include classification of the deformity, with close attention paid to the size of the breasts, breast symmetry, the location of the deformity, and the amount of skin retraction and volume loss. In addition, the quality of the skin envelope should be assessed; this is likely the most important factor for correction with implants. If breast skin has edema, tightness, or hyperpigmentation with a leathery feel—all evidence of significant radiation damage—then that patient is not a good candidate for implants.

The ideal patient has smaller breasts and minimal to no ptosis, with minor residual changes to the skin and breast from radiotherapy. The breast mound should be relatively soft, the skin retraction minimal, and the nipples symmetrical.

If a contour deformity is present, the breast mound needs to be soft for the implant to correct or improve the deformity. If the mound is firm or significantly fibrosed, an implant will not allow the remaining breast tissue to fill out or improve the deformity. The result will be a larger breast with a persistent contour irregularity, which may be even more pronounced because of the size enhancement. It is probably preferable to correct the deformity as long as possible after radiotherapy, because its effects persist.

Although it is often easier to achieve symmetry by placing implants bilaterally, some patients have a fairly significant size discrepancy and require only an ipsilateral implant. Generally, however, if a patient has extensive radiation fibrosis, she will not be an ideal candidate for using implant placement to correct a BCT defect.

Autologous fat grafting to the breast can be used in conjunction with placing a smaller implant, which might improve minor contour deformities and minimize implant-related complications.¹

The use of implants to correct BCT deformities in well-selected patients allows rectification of parenchymal loss by replacing volume and minor skin deficiencies and contour irregularities by stretching the skin.

A number of classification systems are used to describe the BCT deformity. The Clough classification system, presented in Chapter 24, has classifications that range from a breast with preserved shape, no deformity, and some asymmetry in volume (type 1), to a breast with severe retractile fibrosis of the entire breast (type 3). Another useful morphologic classification of partial deformities was described by Berrino et al² and is described in the following text.

Reasonable candidates for reconstruction of BCT deformities with implants should have the following:

- A wish for some size enhancement
- Clough type 1 or 2 cosmetic sequelae (see Chapter 24)
- Small to medium breasts
- No or minimal ptosis
- Good nipple symmetry
- A healthy skin envelope
- Minimal skin retraction or volume void
- A soft, supple breast mound

Contraindications to this type of correction include the following:

- Clough type 3 or 4 cosmetic sequelae
- Significant deformity
- A thick, tight skin envelope with persistent radiation changes
- Marked breast fibrosis
- A firm breast mound
- Large or ptotic breasts
- Significant nipple retraction or asymmetry

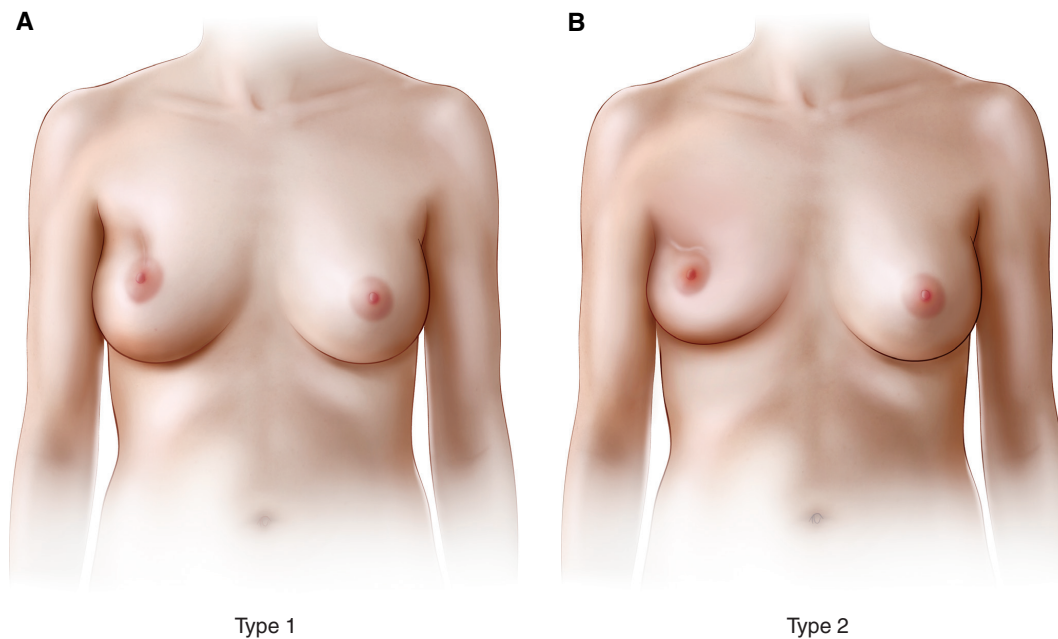


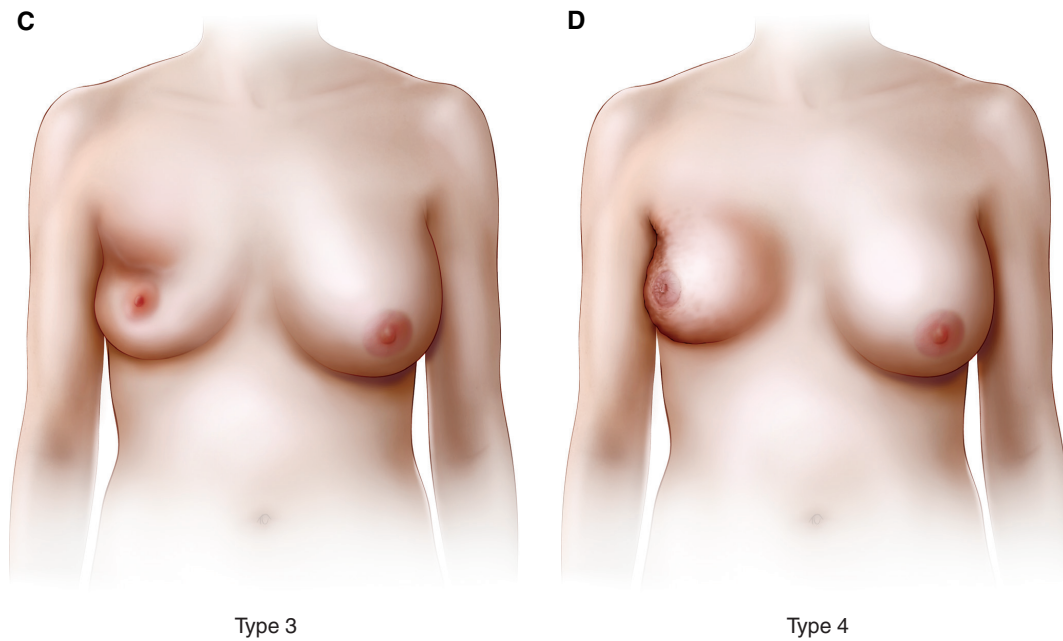
Fig. 31-1, A and B

Type 1 Deformity: Localized Breast Distortion

In a type 1 deformity the NAC is distorted or displaced, mainly from fibrosis and scar contracture. The asymmetry and displacement of the NAC can be mild to severe, depending on the amount of tissue that has been removed; it may also lose its round contour and natural location at the apex of the breast mound.

Type 2 Deformity: Localized Tissue Deficiency

Type 2 deformity is characterized by localized tissue insufficiency, which can be caused by skin deficiency (2a), subcutaneous tissue deficiency (2b), or both, depending on the kind of resection performed. The resultant form is dictated by the ratio of skin and subcutaneous resection. This can vary considerably, and collaboration with the oncologic surgeon preoperatively can minimize skin resection and maximize the reconstructive efforts. This deformity is more frequent in patients with smaller breasts.

**Fig. 31-1, C and D**

Type 3 Deformity: Breast Retraction

The type 3 deformity is generally caused by shrinkage of the breast parenchyma after radiotherapy. However, it is sometimes caused by the extensive resection of glandular tissue. Adjuvant chemotherapy also can increase postoperative shrinkage. The skin has a normal appearance, and asymmetry is severe. This deformity is more frequently seen in patients with large, ptotic breasts.

Type 4 Deformity: Heavily Irradiated Breast

The type 4 deformity is characterized by significant retraction and distortion of the breast; the parenchyma is dense and fibrotic. The skin is thickened, inelastic, and presents with radiodermatitis. In addition, the NAC is often displaced, the nipple is stiff and dry, and the size of the areola is reduced.

SURGICAL TECHNIQUE

Surgical Plan

- Complete preoperative markings on the intramuscular fat (IMF) and soft tissue deformity.
- Make the access incision through the IMF.
- Perform a soft tissue scar contracture release (recreate the deformity).
- Autologous fat grafting if indicated.
- Create the implant pocket.
- Use implant sizers to select the appropriate implant shape and size.
- Place the permanent prosthesis.
- Raise the patient to assess for symmetry.
- Adjust the implant position and perform soft tissue release, if necessary.
- Complete the skin closure.

The surgical technique for correction of BCT deformities with implants does differ slightly from that of regular breast augmentation surgery. The general principles are the same and are covered extensively elsewhere. The patient is marked preoperatively, with close attention given to the level of the inframammary fold, the nipple position, and the location of the deformity. Any variation in the level of the inframammary fold can be changed intraoperatively. When the asymmetry is mainly one of size and the shape is preserved, a simple augmentation with different volumes should suffice. Minor contour irregularities are often filled and improved with an implant placement. It is important to address any significant contour irregularity, because it might be even more noticeable with larger breasts. These irregularities might require release of contractures or scars and/or fat grafting in addition to implant placement. It is also important to adequately counsel the patient preoperatively and inform her that the contour irregularity might not be completely corrected with an implant, although it may become less prominent and subsequently less noticeable.

Given the unpredictable interaction between the irradiated breast mound and the breast implant, reconstructive surgeons are often hesitant to use implants for correcting BCT deformities.

The two main concerns with using implants to correct BCT deformities are the following:

1. The potentially higher rate of capsular contracture
2. Skin envelope retraction and possible shape compromise over time

Access

It is probably better to use an access incision in an area off the breast, one with good exposure (for example, the inframammary fold or axilla). Periareolar incisions require dissection through the breast mound with skin undermining and should be avoided if possible. The periareolar approach could be used if that is where the deformity is located and if contracture release is required in that location to recreate the deformity.

Location

It makes intuitive sense that submuscular implant placement would be preferable, especially in upper pole defects, because it provides another layer of vascularity above the implant. The only potential disadvantage of submuscular implant placement (especially with upper pole defects) is that the release of a scar contracture band is occasionally required at the time of implant placement to improve contour. Subglandular placement might be more beneficial for these patients.

Implant

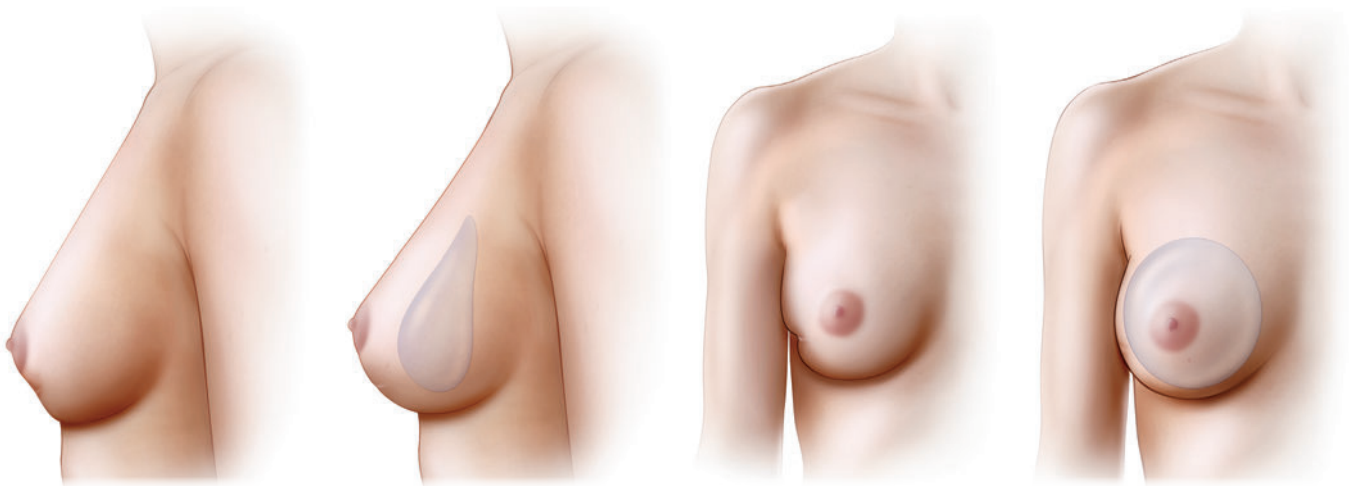
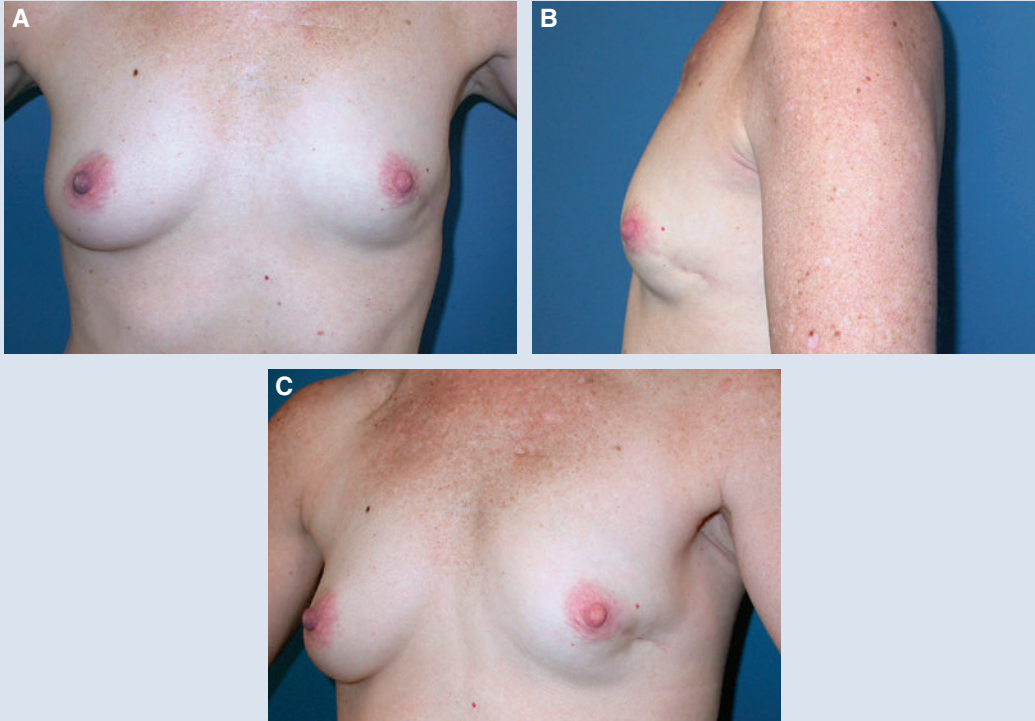


Fig. 31-2

Silicone gel implants often result in a more natural-appearing and natural-feeling breast mound; however, saline does have one advantage in this situation. It is easier to make minor volume adjustments with saline, which may be necessary if small implant volume asymmetries are expected. Choosing the most appropriate implant should be based on the patient's breast shape and width (measuring the contralateral side). Smaller implants are probably safer if the breast has previously been irradiated. Anatomic implants might be more useful for lower pole deformities.

PATIENT EXAMPLES

BILATERAL SUBMUSCULAR AUGMENTATION

**Fig. 31-3, A-C**

This 46-year-old woman presented with an unfavorable result 4 years after a left lumpectomy and radiotherapy (A through C). She was concerned with the size and shape of her breast, and she expressed an interest in having larger breasts, if possible. Her left breast had some volume loss, a fairly significant contour distortion, and scarring on the lateral aspect (Clough type 2 cosmetic sequelae). Apart from the scarring, her skin was otherwise soft and appeared healthy, and her nipples were fairly symmetrical.

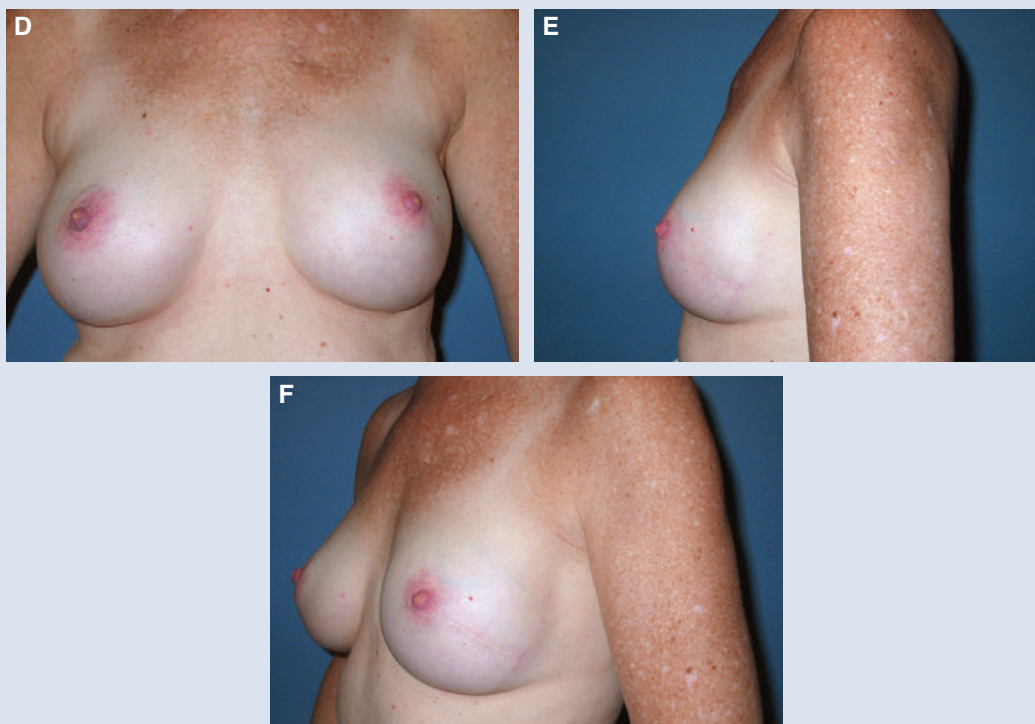


Fig. 31-3, D-F

After discussing her options, she elected to undergo bilateral implant augmentation. A sub-pectoral pocket was created through an inframammary fold incision, and 250 cc smooth, round saline implants were inserted into each breast. Her implants were filled to 250 cc on the left and 260 cc on the right. A small amount of scar release was performed on the left side. She is shown 3 years postoperatively with good symmetry, improved contour, and soft breasts (*D* through *F*). There is no evidence of capsular contracture.

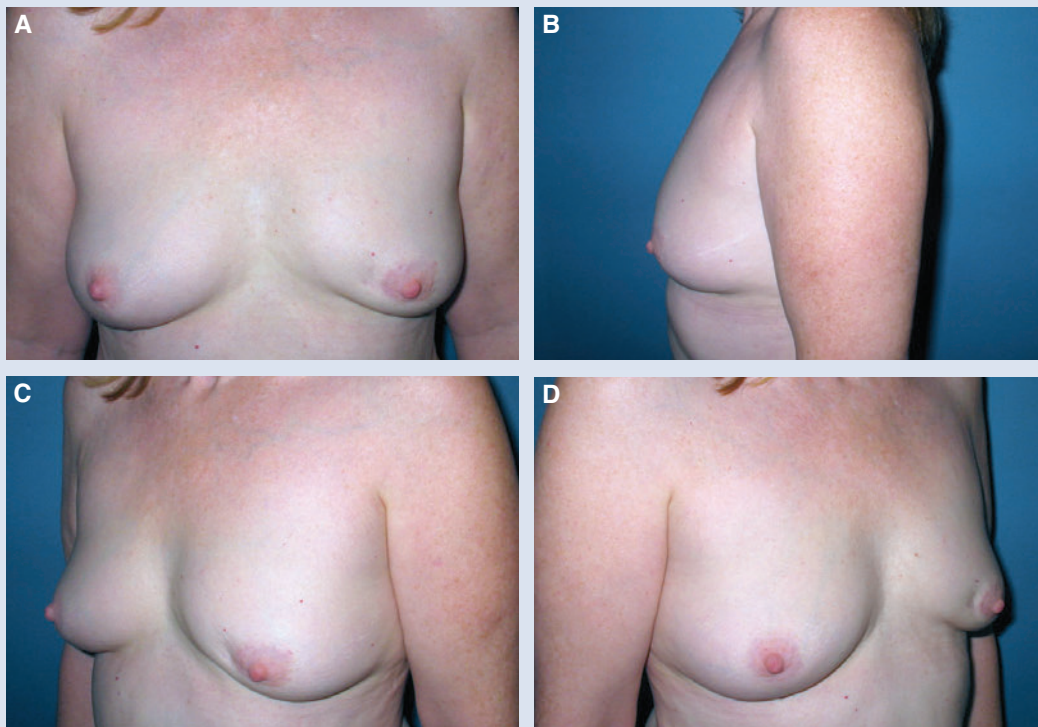


Fig. 31-4, A-D

This 50-year-old woman had numerous biopsies from her left breast and presented with deformities about 3 years after BCT (*A* through *D*). She had minor volume differences and some fairly prominent contour irregularities beneath and medial to her nipple on the left side (Clough type 2 cosmetic sequelae). Her skin envelope was otherwise relatively healthy in appearance, without evidence of unfavorable radiation changes.

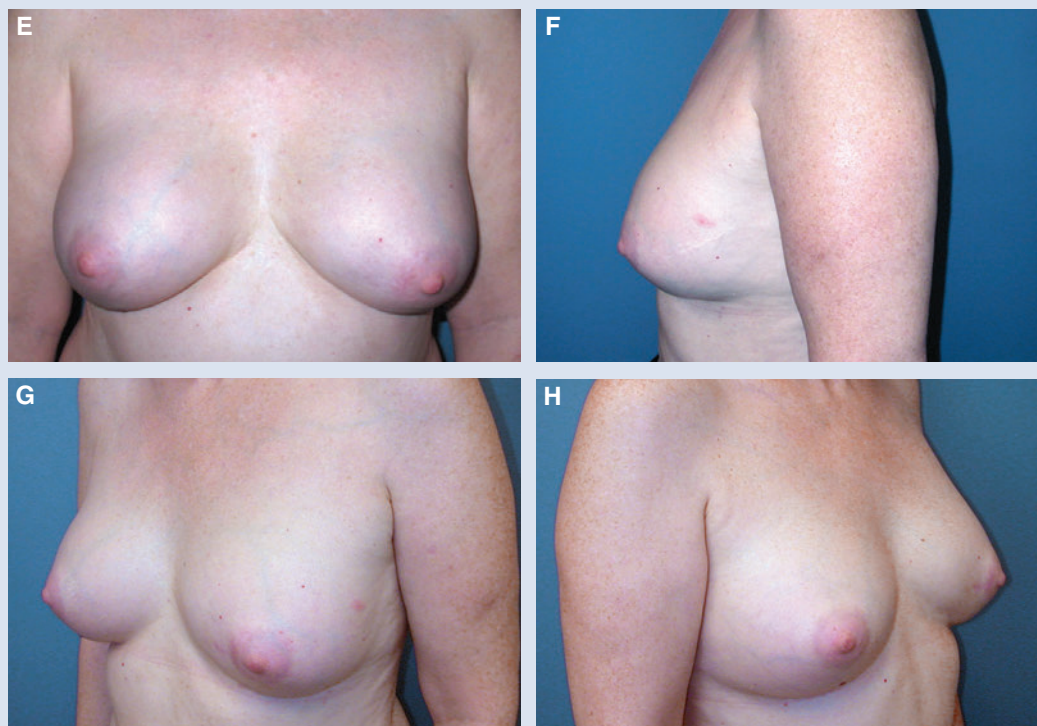
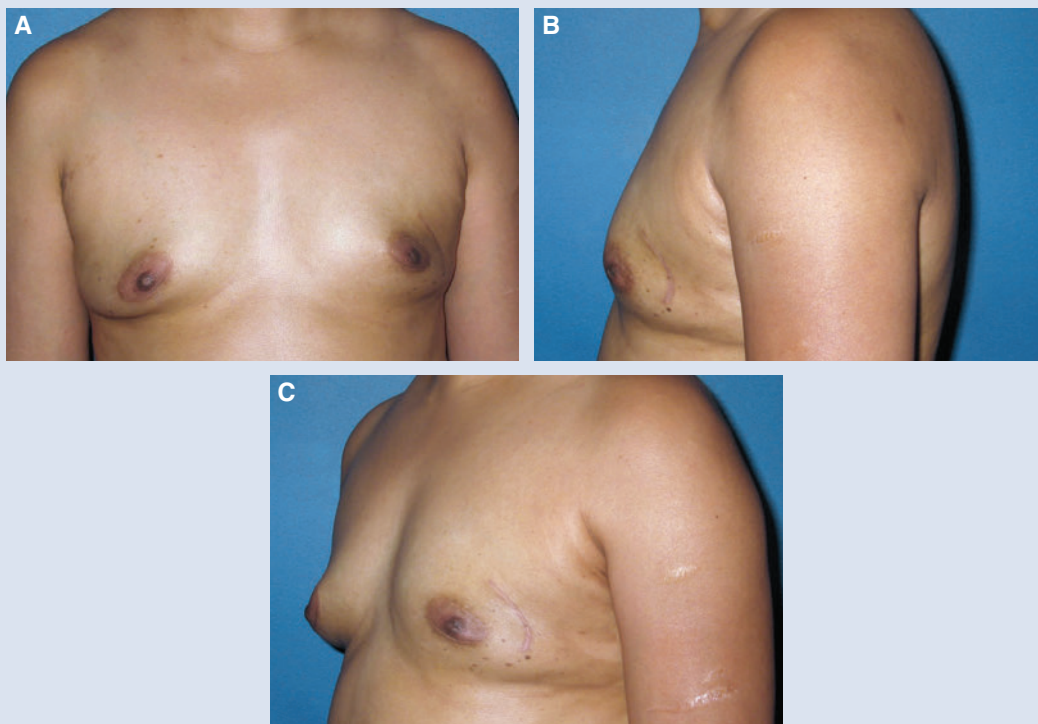


Fig. 31-4, E-H

The patient elected to undergo bilateral implant augmentation. Bilateral subglandular implants (225 cc smooth, round saline implants) were placed through inframammary incisions. The implants were inflated to 215 cc on the left and 200 cc on the right. Multiple radial scoring incisions were made in the lower pole parenchyma to release some of the tethering of her scars to the skin for contour improvement. This decision was made intraoperatively, after the implant was placed and the deformity persisted. She has good shape and symmetry 1 year after implant placement. Note the modest improvement—not complete resolution—of her medial contour irregularity (*E* through *H*).

BILATERAL SUBGLANDULAR AUGMENTATION**Fig. 31-5, A-C**

This 41-year-old woman presented with some breast asymmetry (Clough type 1) after undergoing a left lumpectomy for a fibroadenoma (A through C). She did not have radiotherapy and expressed an interest in having larger breasts. We performed a bilateral submuscular implant augmentation with 250 cc smooth, round saline implants, both filled to 250 cc.

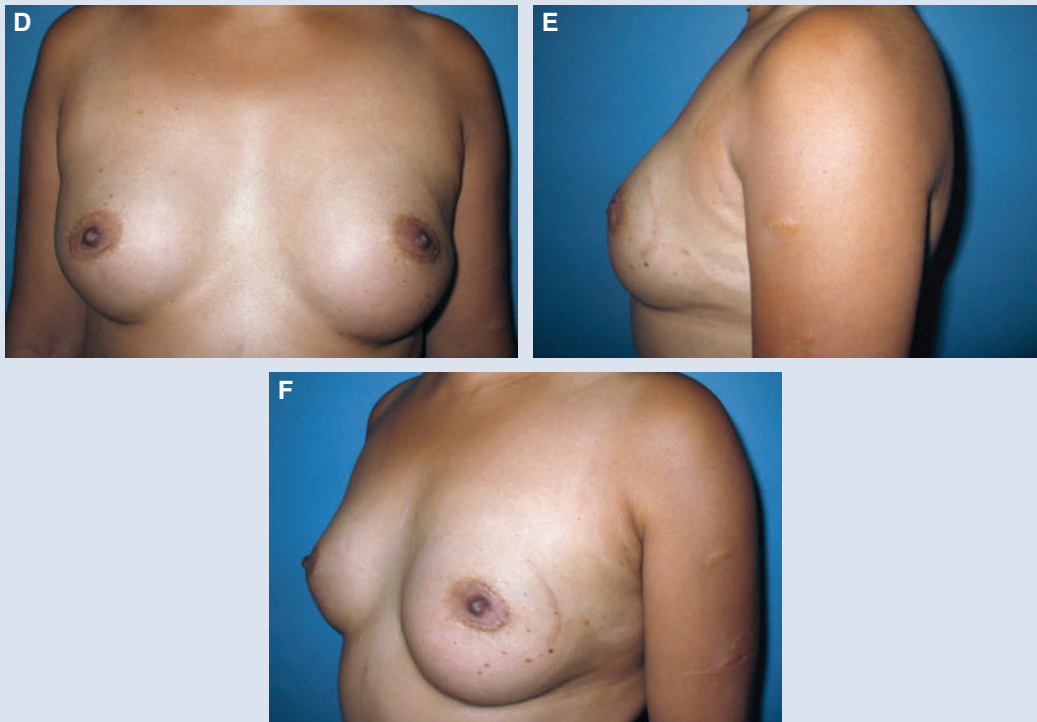


Fig. 31-5, D-F

One year postoperatively, she has improved shape (*D* through *F*); her implants are soft and breast symmetry is good.

CONCLUSION

The use of implants to correct a BCT deformity is always risky, given the long-term effects of breast irradiation. Theoretically, there is a higher chance of capsular contraction and breast fibrosis in these patients; however, good results can be obtained. The key to success using this approach is appropriate patient selection. Few patients with BCT deformities are good candidates for implants. The ideal patient has relatively small, nonptotic breasts, with good nipple position, a soft breast mound, and a normal-appearing skin envelope. Asymmetries in shape and volume can be corrected using standard augmentation techniques with some minor variations. Because the effects of radiation persist, aesthetic results require a long-term, critical evaluation, and patients need to be aware of the possibility for further shape compromise.

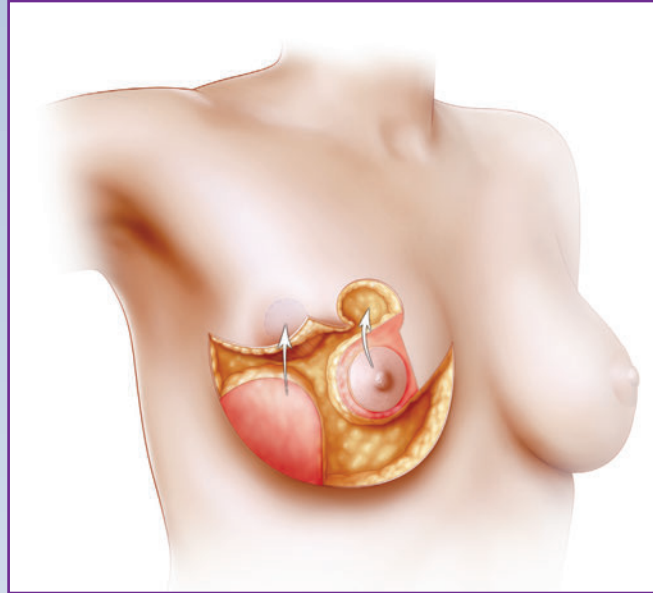
Critical Issues

- Implants can correct BCT deformities in carefully selected patients.
- Reconstruction with implants should be performed at least 1 year (preferably longer) after radiotherapy.
- Good candidates should have minimal radiation-related changes to the skin and breast mound.
- The ideal candidate has size asymmetry, shape preservation, a soft, supple breast mound, normal-appearing skin, and symmetrical nipples.
- The technique should vary, depending on the deformity.
- Expect increased rates of complications, capsular contracture, and variations in the long-term shape.
- Recreate the deformity with scar contracture release before implant placement.
- Implants are a reasonable option for the right patients; however, they must be used cautiously.
- Patients need to be aware that implant failures can occur; alternative reconstructive techniques may be required to correct the deformity.

References

1. Losken A, Pinell-White X, Hodges M, et al. Evaluating outcomes after correction of the breast conservation therapy deformity. *Ann Plast Surg* 74 Suppl 4:S209, 2015.
2. Berrino P, Campora E, Santi P. Postquadrantectomy breast deformities: classification and techniques of surgical correction. *Plast Reconstr Surg* 79:567, 1987.

PART FIVE



Outcomes and Future Directions

Albert Losken, Mary S. Newell

Partial breast reconstruction has been shown to improve cosmetic outcomes after BCT, and the indications for its use have broadened. However, many surgeons are concerned that these reconstructive procedures—whether through parenchymal rearrangement or flap reconstruction—alter the architecture and affect patterns of local recurrence. Because BCT does preserve the majority of breast tissue, the importance of accurate surveillance for recurrent cancer cannot be underestimated. The recurrence rate after these oncoplastic techniques has been discussed in previous chapters. The all-important question is: “Does partial breast reconstruction impair our ability to accurately screen for breast cancer recurrence in these patients?” It is safe to say that for a reconstructive procedure to be accepted by the medical community or by patients we need to demonstrate that it does not in any way impede the detection of a recurrent lesion. Despite the impact this information has on the acceptance of oncoplastic-type techniques, the actual data are limited.

The advantages of partial breast reconstruction are limited in terms of postoperative surveillance. One potential advantage is that the physical examination and mammography might be easier after oncoplastic reduction techniques, because the size of the breast is smaller. The potential difficulty associated with partial breast reconstruction is that additional surgeries might cause scarring, fat necrosis, inclusion cysts, or other findings, which could be misinterpreted as a recurrence on radiologic imaging or a physical examination. Changes caused by radiation further confound the situation. All of this information needs to be considered when managing these patients postoperatively.

One main concern with partial breast reconstruction is that it could change the patterns of recurrence or impair screening of the actual tumor bed. It is helpful for the medical team to be aware of what was done to the reconstructed breast so that they know where to look and what anatomic changes can be expected in that location. Another helpful addition is to place metal clips in the tumor bed to facilitate its identification during postoperative screenings. The team needs to be educated on the differences that might be present and develop an effective surveillance protocol.

SURVEILLANCE OPTIONS

The tools available for postoperative surveillance include the physical examination, radiologic imaging, and tissue sampling. About 30% to 50% of local recurrence is detected by mammography alone or a combination of mammography and the physical examination. Clinical and mammographic surveillance are complementary in helping to detect a local recurrence following BCT. When a local recurrence is detected, it is usually in the form of a mass, calcifications, or both. The tumor recurrence is typically found at the lumpectomy bed (true recurrence), adjacent to it (marginal miss), or elsewhere in the treated breast.¹ The greatest emphasis on surveillance is in the first 5 years, because the risk of recurrence is the highest during this time; however, the risk persists.

Physical Examination

It is important that the patient and physician are familiar with the various changes that might occur after partial breast reconstruction, and that both have an understanding of the reconstructive procedure performed. Regardless of which reconstructive technique was used, there is a potential for scarring, fat necrosis, partial flap loss, or radiation fibrosis, which might present as a palpable mass or thickening within the breast. Breast swelling, skin edema, and areas of firmness are considered normal in the early postoperative period. These should be followed closely and be accurately documented. They often improve with time as the swelling resolves and the breast takes on a more natural appearance and feel. Epidermal inclusion cysts and areas of fat necrosis may occur after reduction mammoplasty and need to be addressed.² Areas of firmness that persist are most likely fat necrosis or surgical scarring. However, it is safer to obtain a tissue diagnosis to rule out a recurrence. New masses need to be worked up appropriately. The patient needs to be educated on breast self-examination and report any suspicious findings or changes to the team.

Physical Examination Postoperative Surveillance

The physical examination should continue postoperatively as follows:

- The patient needs to perform a monthly breast self-examination.
- The physician needs to record the history and perform a physical examination every 3 to 6 months for the first 3 years; every 6 to 12 months for years 4 and 5; and annually thereafter.

Radiologic Imaging

Currently, no consensus is available regarding appropriate imaging protocols after oncoplastic procedures. Regardless of the imaging modality used, the main objectives are to (1) exclude residual disease, (2) rule out a recurrence, (3) establish a new baseline, and (4) evaluate for metachronous disease—all while minimizing misinterpretation. For non-palpable lesions, imaging-directed preoperative localization is indicated.

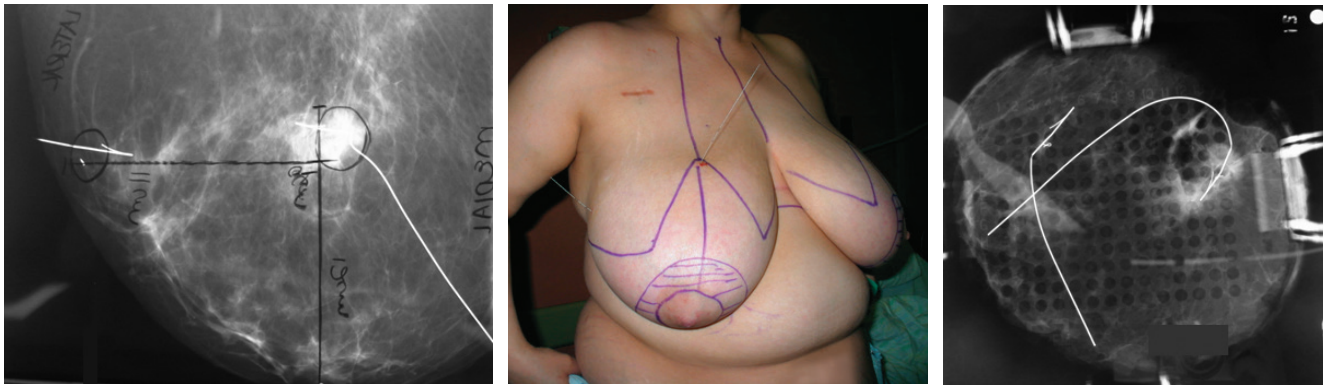


Fig. 32-1

Specimen radiography can ensure the removal of the target lesion, confirm that the specimen includes calcifications, and aid in assessing the margin status.³ Using a prearranged system of orienting the submitted specimen often allows the radiologist to not only comment on the apparent closeness of a margin, but to specify which margin is affected and to communicate this to the surgeon while the patient is still anesthetized, thus allowing reexcision of that margin.

Assessment of the margins remains a pathologic determination. If there is any question regarding the involvement of margins, the reconstruction should be delayed until the final margin status is determined to prevent having to address this issue after reconstruction.

If malignant calcifications are a component of the lesion, magnification mammography of the surgical bed can be performed a few weeks after surgery, before initiating radiotherapy, to establish a new baseline and to exclude residual malignant calcifications. Ill-defined masses or asymmetries, often seen when lobular carcinoma is the target lesion, may require full-breast mammography and breast MRI to ensure complete removal.

Mammography is less sensitive in the treated breast; it is about 55% to 68% accurate in patients who have undergone BCT.⁴⁻⁷ The surveillance data on combined procedures are limited; however, we do have a reasonable understanding of the radiographic appearance of the conservatively treated breast. Mendelson⁹ followed the mammographic changes over time in patients who underwent BCT, and the most frequent findings were skin thickening and breast edema, which occurred in almost 100% of the patients. Six months after treatment, other findings included scarring and fibrosis (50%), fluid collections/seromas (40%), and dystrophic calcifications (10%). Skin thickening, edema, and seromas tend to resolve with time. These probably represent the changes associated with radiation dermatitis and often peak about 6 months after radiotherapy and resolve over 2 to 3 years in most patients.

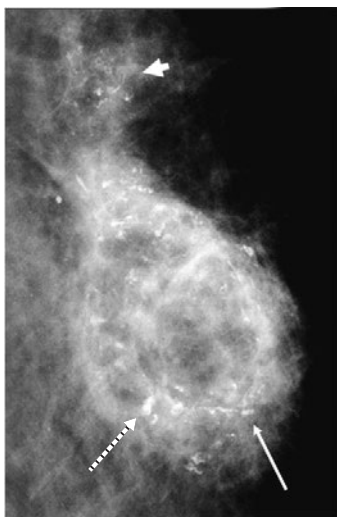


Fig. 32-2

The true nature of calcifications is at times difficult to determine. Magnification of the mediolateral view of the left breast shows rim and lucent-centered calcifications (*long arrows*) around a low-density area of tissue superior to the lumpectomy site (surgical clip, *dashed arrow*). These changes are characteristic of evolving fat necrosis. Adjacent, more suspicious, linear and pleomorphic calcifications (*arrowhead*) required a core biopsy to exclude a recurrent ductal carcinoma in situ. The pathology results indicated fat necrosis with dystrophic calcifications.

Typical findings after breast-reduction surgery are displaced parenchyma, architectural distortion, skin thickening, and dystrophic calcifications. We wanted to determine whether additional surgery (that is, reduction mammoplasty) at the time of a lumpectomy delayed mammographic stabilization or reduced the sensitivity of this screening tool.⁸ The concept of mammographic stability was described by Mendelson⁹ and is defined as the time when there is no significant change between two successive mammograms. We evaluated our patients at Emory University Hospital who underwent oncoplastic reduction procedures and compared them with a cohort of risk-matched women who underwent BCT without reconstruction.¹⁰ The average follow-up was about 6 years. The mammographic findings were similar between the groups and included architectural distortion, cysts, and calcifications. There was a slight trend toward longer times to mammographic stabilization in the study group (21.2 months for the BCT group versus 25.6 months for the oncoplastic group, $p = 0.23$), which is expected given the additional scarring, inflammation, and parenchymal alteration associated with the reconstruction. The time to mammographic stability in the oncoplastic group demonstrated a 95% confidence interval between 20 and 30 months.

To confirm stability, we feel that, based on these data, biannual mammographic screening should be extended until the third postoperative year in patients who undergo partial breast reconstruction.

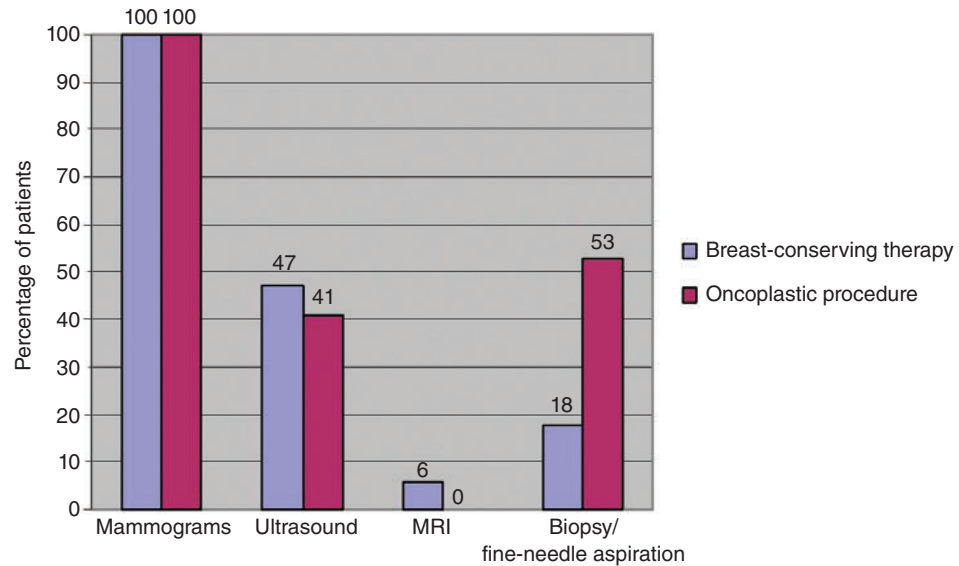


Fig. 32-3

We also performed a greater number of postoperative mammograms and ultrasounds in the oncoplastic group when indexed per each follow-up year. The oncoplastic group averaged 1.28 mammograms per follow-up year, and the BCT-only group averaged 1.21 mammograms per follow-up year ($p = 0.38$). The oncoplastic group averaged 0.17 ultrasounds per follow-up year compared with 0.09 ultrasounds per follow-up year ($p = 0.29$) in the BCT-only group. A breast ultrasound examination was performed in around 45% of patients in both groups. The breast density, measured as a percentage (fatty to extremely dense), was used to equate the sensitivity of the test. A sensitivity value from 1 to 4 was assigned (4 = least sensitive in an extremely dense breast: parenchyma content 75% or greater). The average sensitivity value for the group that underwent BCT was 2.67, and for the group that also had reconstruction it was 2.36, showing that the reconstruction did not seem to reduce the sensitivity of a mammographic evaluation.

Surgical manipulation of the breast may also result in a hematoma or seroma, which may resorb with time and be replaced by a fibrotic scar (especially after radiotherapy). This process may result in an area of increased density with irregular and spiculated margins that may also mimic malignancy. The presence of entrapped fat, which often occurs with scar formation, can be evaluated based on clinical suspicion and serial imaging, which may help distinguish these changes from those of cancer.

Calcifications after breast conservation and reconstruction are relatively common and occur in one fourth to one third of patients.^{9,11} Although the majority of these are benign, some represent a disease recurrence.

PATIENT EXAMPLES

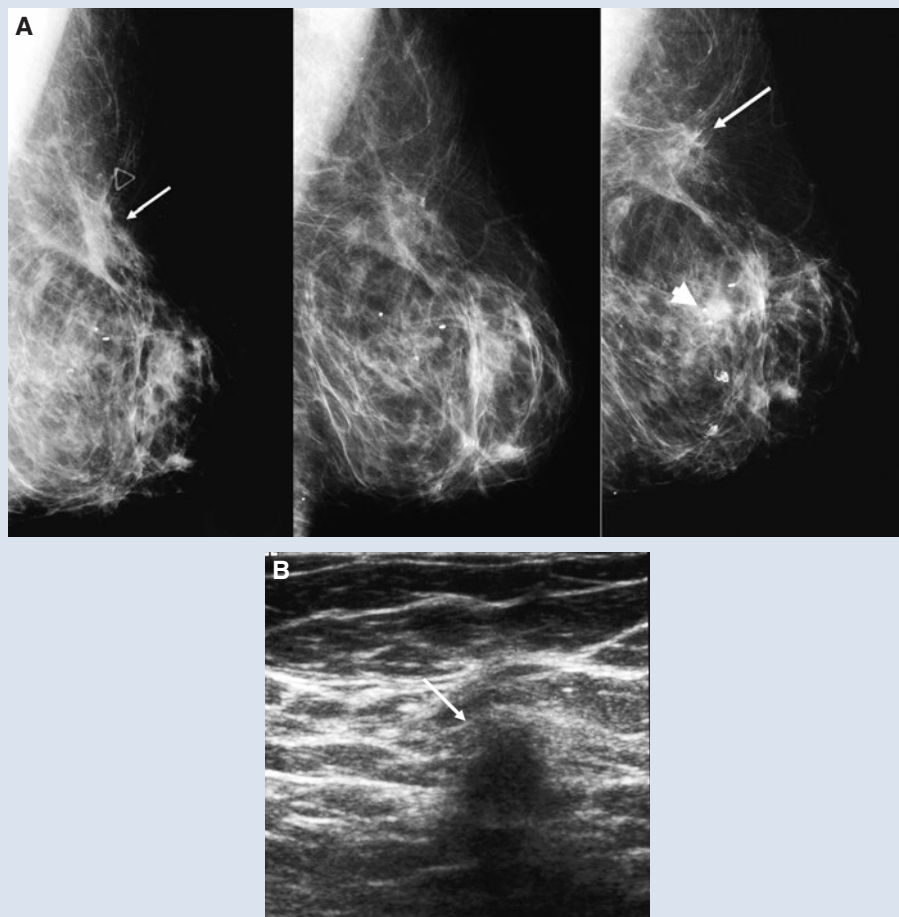
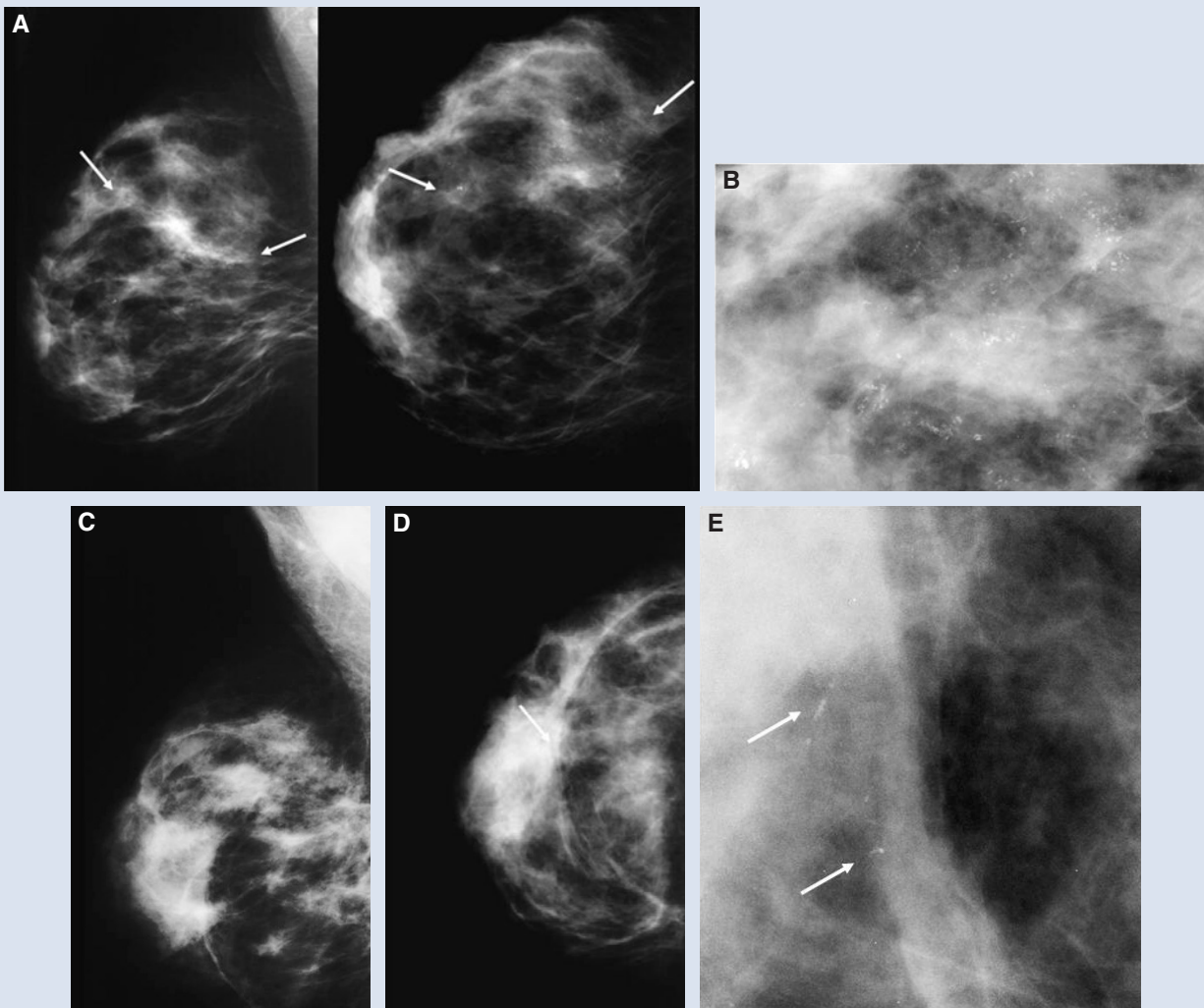


Fig. 32-4

In this 76-year-old woman there was progression of her postsurgical changes over time, with recurrence, after she underwent the oncoplastic removal of a left infiltrating ductal carcinoma. Left mediolateral oblique views were obtained from 3 consecutive years (A). The examination performed 1 year postoperatively (*left*) shows the lumpectomy site with the initial density and distortion (*arrows*) in the upper breast. This was less conspicuous in the views from the 2-year (*center*) and 3-year (*right*) examinations. Three years postoperatively (*right*), a 1 cm new focal asymmetry was present (*arrowhead*). This lesion was a solid, shadowing mass on ultrasound and was confirmed to be an infiltrating ductal carcinoma on the core biopsy (B).

**Fig. 32-5**

There is a subtle recurrence of ductal carcinoma in situ after an oncoplastic procedure. Medi-lateral oblique (*left*) and craniocaudal (*right*) views of the right breast show segmentally distributed linear and pleomorphic calcifications in the upper, outer right breast (*between the arrows*) (A). Their highly suspicious nature was confirmed on a magnified craniocaudal view (B). A postsurgical mammogram obtained 1 year later shows postoncoplastic changes (decreased breast size, mild distortion, and scarring) and a few subtle calcifications (C and D; *arrow*). A magnified craniocaudal view shows the calcifications (*arrows*) (E). Ductal carcinoma in situ was confirmed on a core biopsy.

Calcifications do not follow a predictable time course, making surveillance more difficult. If any are found at the site of the initial partial mastectomy, they should be evaluated with the same criteria used for diagnosing a primary breast cancer.

The overlying density from edema or fibrosis complicates the workup. Spot compression images with magnification techniques help in the evaluation to best define the character of the individual calcifications. Calcifications with features typical of fat necrosis (coarse dystrophic or rimlike calcifications associated with oil cysts) are easily identified and often do not need to be removed.¹² However, as these calcifications evolve, they may present a very confusing picture, often appearing classically malignant in their infancy.

The mammographic appearance of the breast after a myocutaneous flap reconstruction has been demonstrated.^{13,14} Most flaps show areas of radiolucency, consistent with the fibrofatty component. Microcalcifications are easily identified, as are areas of fat necrosis and new lesion formation.

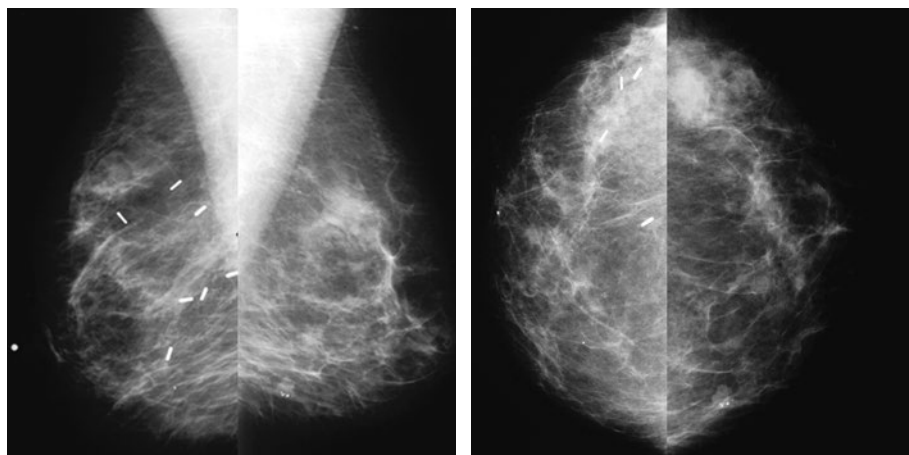


Fig. 32-6

Mediolateral oblique and craniocaudal mammographic views were obtained after a lumpectomy and latissimus dorsi myocutaneous flap reconstruction. Both views show clips that indicate the exact location of the lumpectomy and flap.

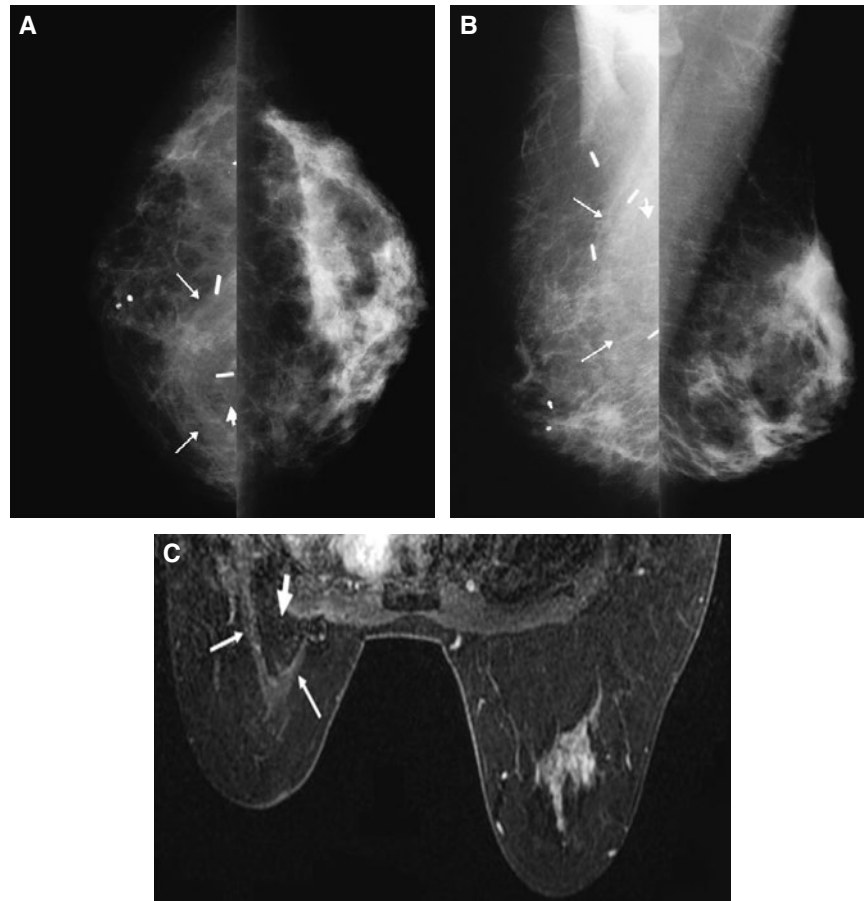


Fig. 32-7

These mammographic views were obtained after a lumpectomy and latissimus dorsi flap reconstruction. Craniocaudal and mediolateral oblique views of both breasts show the characteristic appearance of the flap, with the striated, curved orientation of the muscle (*arrows*) and the accompanying fat (*short arrows*) (A and B). Clips are present at the surgical site. Note the symmetrical size of the breasts despite the prior lumpectomy. An MRI of the same patient shows the site of the lumpectomy and reconstruction (C). An axial postcontrast fat-saturated T1 image shows the muscle (*arrows*) and fatty (*short arrow*) components of the flap.

Well-vascularized flaps do not show increased density, and, in some patients, the fibrotic architecture within the breast is actually diminished. This suggests improved blood flow, especially in an irradiated field.

Qualitative mammographic changes in patients who have undergone oncoplastic procedures are similar to those seen after BCT alone, and mammography remains a sensitive tool. However, specific findings that change somewhat predictably over time do exist. An accurate interpretation requires familiarity with these temporal changes. Changes that occur after treatment should be followed until they are stable. Establishing a new baseline is important and avoids unnecessary biopsies, because many of the posttreatment mammographic findings can mimic radiographic signs of malignancy. Serial screening mammograms are obtained annually thereafter as surveillance for recurrence. It is possible to accurately distinguish between recurrence and postsurgical changes based on the characteristic appearance of the posttreatment sequelae on serial mammograms and by understanding the concept of stabilization. The concept of stability is important; any mammographic changes that occur after obtaining two consecutive unchanged mammograms may indicate a recurrence, and further evaluation or a biopsy is needed. A heightened awareness of the need for close mammographic surveillance allows the detection of subtle mammographic changes that can herald a local recurrence.¹⁵ Additional radiographic imaging is used for confirmation or when mammographic findings are equivocal. These include targeted breast sonography and MRI studies. Magnetic resonance mammography has been shown to be a sensitive method to differentiate a recurrence from posttreatment changes at the lumpectomy site following BCT and will likely prove beneficial after the oncoplastic approach as well.¹⁶ The high negative predictive value of this test will hopefully help to avoid unnecessary biopsies. MRI is indicated after partial breast reconstruction when it is not possible to distinguish normal postsurgical changes and local recurrence using mammography.

The importance of temporal changes cannot be overemphasized, and mammograms should be compared over time.

Fat Necrosis Versus Recurrence

One of the biggest issues in imaging the postsurgical breast is distinguishing a recurrence from fat necrosis. Fat necrosis can produce a wide spectrum of imaging findings, depending on its chronicity and the degree to which either liquefied fat or a fibrotic/inflammatory response predominates.¹⁷⁻¹⁹ Mammographically, the classic radiolucent oil cyst, with or without associated rim calcifications, may appear if no significant inflammatory response accompanies the process. With an increasing fibrotic response, the area of necrosis may appear masslike, often with architectural distortion and spiculation, indistinguishable from neoplasm.

Although the calcifications that can form at sites of fat necrosis are often pathognomonically benign (rim or eggshell), occasionally they have a malignant-appearing, amorphous, or pleomorphic morphology.²⁰

The sonographic findings of fat necrosis are similarly variable. At one extreme, it may resemble either a simple or complicated cyst; at the other, more troubling extreme, it may appear as a solid, irregular mass with posterior shadowing, suggestive of a tumor recurrence. Other potential presentations include heterogeneous hyperechogenicity of regional fat (resulting from edema),²¹ a cystic mass with a fat-fluid level or mural nodule, or a mass with an intensely echogenic anterior margin and posterior shadowing (related to rim calcification).^{17,19}

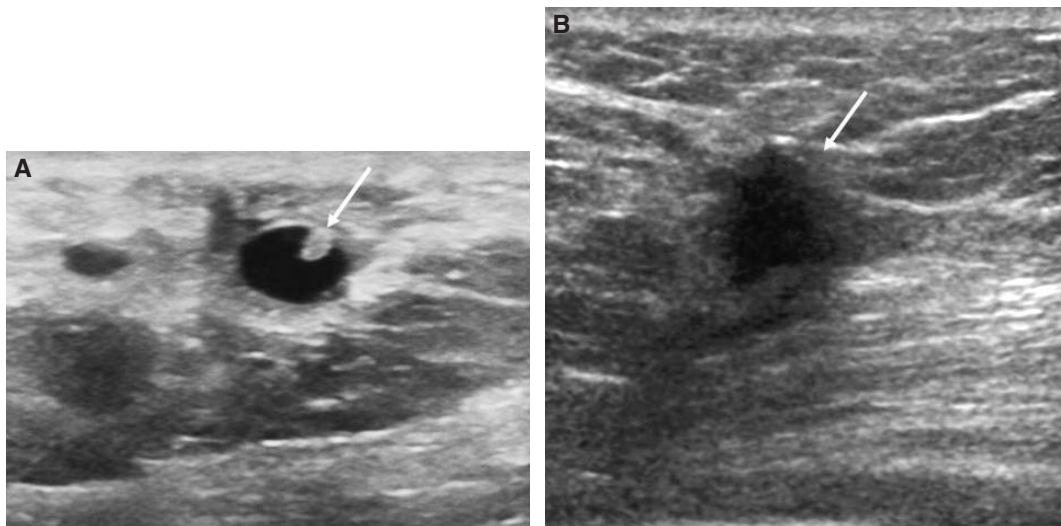


Fig. 32-8

Ultrasound can be used as a problem-solving tool. This targeted sonography of a new, palpable breast lump in the region of prior oncoplastic reduction shows a cystic mass with a possible mural nodule (*arrow*), which proved mobile on further scanning, indicating debris such as an oil cyst (*A*). This ultrasound revealed a hypoechoic irregular mass (*arrow*) at the site of the prior lumpectomy and increasing mammographic asymmetry, which could be scar tissue or a recurrent tumor (*B*). The core biopsy showed scar tissue.

MRI is emerging as a robust tool in evaluating breast pathology. Its efficacy in evaluating fat necrosis versus recurrence has not been fully determined. As with the other modalities, the imaging features of fat necrosis as detected on MRI are variable, related to the relative degrees of necrotic fat, inflammatory tissue, and evolving fibrosis. The fibrotic and inflammatory portions of the lesion may display a low, intermediate, high, or heterogeneous signal on T1-weighted fat-saturated images. The enhancement pattern is unpredictable, with all patterns and distribution of enhancement described. Lesions may present with thick, irregular peripheral enhancement, similar to recurrent/residual cancer.²² Chala et al¹⁷ describe a relatively specific feature of fat necrosis on MRI that consists of a central nonenhancing area of tissue that behaves like fat on T1-weighted images, but that tends to have a slightly lower signal on fat-saturated T1 images compared with fat elsewhere in the breast.

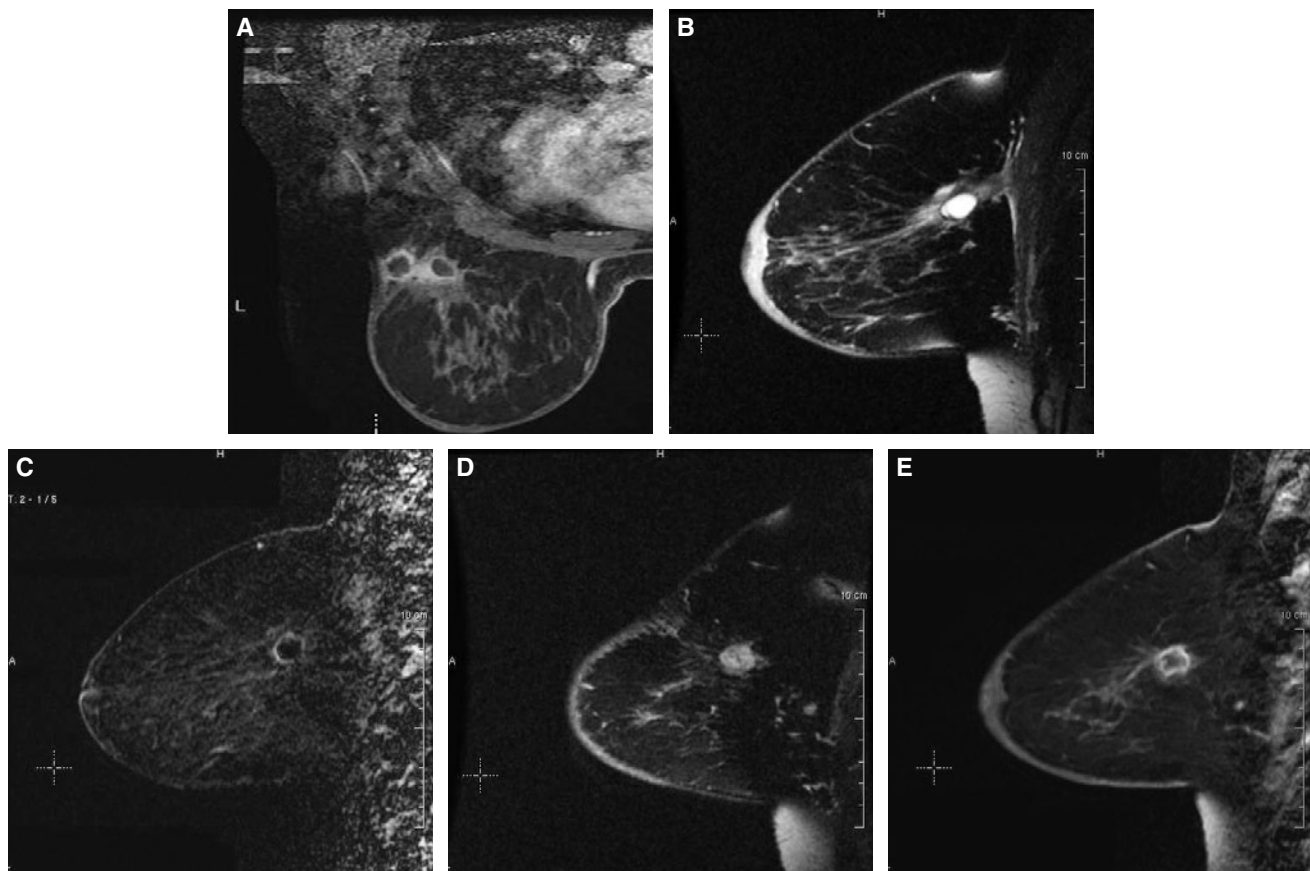


Fig. 32-9

MRI is also a problem-solving tool for the breast. This MRI, performed 1½ years after an oncoplastic procedure for infiltrating ductal carcinoma, shows two masses near the site of the prior cancer. Neither mass shows internal enhancement (A). The more medial mass shows T2 hyperintensity, indicating a fluid content (B). A lack of significant marginal enhancement is evident on postcontrast subtraction images (C). The more lateral mass is isointense on T2, indicating its solid nature (D). The lateral mass also displays an irregular rim enhancement. The medial mass is a seroma, and the lateral mass is a recurrent tumor (E).

At times, the nature of fat necrosis can be gleaned from close correlation among its mammographic, sonographic, and MRI features. However, because of its nonspecific clinical presentation and imaging appearance, tissue sampling may be necessary to establish the correct diagnosis in some cases.

Radiographic Postoperative Surveillance

The following imaging techniques are recommended after breast-conserving surgery (BCS):

- A mammogram should be obtained in the immediate postoperative period, before radiotherapy, if malignant calcifications were a component of the cancer.
- A mammogram should be obtained every 6 months for the first 3 years and then annually (magnification views are at the discretion of the interpreting mammographer).²³
- Ultrasound is not recommended for routine breast cancer surveillance.
- Per the American Cancer Society's recent recommendations, there is no definitive evidence either for or against the use of breast MRI in surveillance of the postoperative breast.²⁴ However, it may prove very useful as a problem-solving tool.

Tissue Diagnosis

Routine tissue sampling is not recommended for surveillance. If an area of abnormality is identified on a physical examination or by radiographic imaging, the lesion must be appropriately sampled and examined by a pathologist. Palpable lesions are amenable to fine-needle aspiration. Other methods used for tissue diagnosis include core needle biopsies and surgical biopsies. Mammographic imaging or ultrasound guidance can be used to locate the area of abnormality if it is nonpalpable. Partial breast reconstruction, whether using local flaps or parenchymal modification, can be associated with fat necrosis, scarring, or a partial flap loss, which might present as a palpable mass or an area of firmness. Because the index of suspicion is high in patients who have undergone BCT, the threshold for obtaining a tissue diagnosis to rule out recurrence is high. Although these are often amenable to accurate radiographic imaging and surveillance, the physician and patient often require confirmation. In our series comparing patients after BCS with patients after BCT and reconstruction, we demonstrated a statistically significant increased rate of tissue sampling in the study group compared with the cohort group (18% in the BCT group, and 53% in the oncoplastic group). This equated to one biopsy every 4 follow-up years when reconstruction was performed, compared with one biopsy every 33 follow-up years for only BCT ($p = 0.015$).¹⁰ In another study, 26% of patients who underwent an oncoplastic reduction ($N = 53$) required a fine-needle aspirate, core biopsy, or excisional biopsy.²⁵ Although the vast majority of these are benign, it is critical that those local recurrences be diagnosed and managed appropriately. Patients who undergo partial breast reconstruction need to be informed of the increased incidence of tissue sampling.

Histologic Postoperative Surveillance

Routine histologic postoperative surveillance is not recommended; however, it should be performed on suspicious areas to confirm a diagnosis.

CONCLUSION

Appropriate surveillance and detection of local recurrence is critical following BCT, and partial reconstruction must not impair the accuracy of these protocols. Given the complexities associated with increased surgical manipulation, certain modifications must be made to maintain sensitivity. Safe and effective patient care is ensured by maintaining a heightened awareness of the potential posttreatment findings (physical and radiographic), understanding the concept of stabilization, and strictly adhering to a multispecialty approach. It is important that both the team members and the patient are aware of this information and of the inherent difficulties that might be associated with surveillance after partial breast reconstruction. The prompt detection and treatment of a local recurrence after BCT may improve the patient's survival. Longer-term studies are required to determine the accuracy of such surveillance protocols; however, so far the addition of the oncoplastic approach to BCT has not impaired the ability to screen for or diagnose recurrence.

Critical Issues

- Appropriate surveillance and detection of local recurrence are critical after BCT, and partial reconstruction must not affect the accuracy of these protocols.
- The placement of clips in the tumor bed facilitates surveillance. Other postoperative surveillance tools include the physical examination, radiologic imaging, and tissue sampling.
- Mammography is still a sensitive tool for imaging the breast after partial reconstruction.
- Qualitative changes observed after oncoplastic procedures are similar to those observed after BCT alone; however, there is a slightly longer time to mammographic stabilization.
- Patients should be instructed on the proper technique of breast self-examination and on the importance of reporting any suspicious findings or changes.
- It is important to evaluate calcifications that occur at the site of the initial partial mastectomy with the same criteria used for primary tumors.
- Changes that occur after treatment should be followed until they are stable.

References

1. Recht A, Silen W, Schnitt SJ, et al. Time-course of local recurrence following conservative surgery and radiotherapy for early stage breast cancer. *Int J Radiat Oncol Biol Phys* 15:255, 1988.
2. Fajardo LL, Bessen SC. Epidermal inclusion cyst after reduction mammoplasty. *Radiology* 186:103, 1993.
3. Graham RA, Homer MJ, Sigler CJ, et al. The efficacy of specimen radiography in evaluating surgical margins of impalpable breast carcinoma. *AJR Am J Roentgenol* 162:33, 1994.
4. Orel SG, Troupin RH, Patterson EA, et al. Breast cancer recurrence after lumpectomy and irradiation: role of mammography in detection. *Radiology* 183:201, 1992.
5. Hassell PR, Olivotto IA, Mueller HA, et al. Early breast cancer: detection of recurrence after conservative surgery and radiation therapy. *Radiology* 176:731, 1990.
6. Dershaw DD, McCormick B, Osborne MP. Detection of local recurrence after conservative therapy for breast carcinoma. *Cancer* 70:493, 1992.
7. Stomper PC, Recht A, Berenberg AL, et al. Mammographic detection of recurrent cancer in the irradiated breast. *AJR Am J Roentgenol* 48:39, 1987.
8. Miller CL, Feig SA, Fox JW. Mammographic changes after reduction mammoplasty. *AJR Am J Roentgenol* 149:35, 1987.
9. Mendelson EB. Evaluation of the postoperative breast. *Radiol Clin North Am* 30:107, 1992.
10. Schaefer T, Losken A, Newell M, et al. The impact of partial breast reconstruction using reduction techniques on postoperative cancer surveillance. *Plast Reconstr Surg* 124:9, 2009.
11. Rebner M, Pennes DR, Adler DD, et al. Breast microcalcifications after lumpectomy and radiation therapy. *Radiology* 170:691, 1989.
12. Madorin CA, Styblo TM. Follow up after breast surgery for primary breast cancer. In Spear S, ed. *Surgery of the Breast: Principles and Art*, ed 2. Philadelphia: Lippincott Williams & Wilkins, 2006.
13. Slavin S, Love SM, Sadowsky NL. Reconstruction of the radiated partial mastectomy defect with autologous tissue. *Plast Reconstr Surg* 90:854, 1992.
14. Monticciolo DL, Ross D, Bostwick J III, et al. Autologous breast reconstruction with endoscopic latissimus dorsi musculocutaneous flaps in patients choosing breast-conserving therapy: mammographic appearance. *AJR Am J Roentgenol* 167:385, 1996.
15. Geiss CS, Keating DM, Osborne MP, et al. Local tumor recurrence following breast-conservation therapy: correlation of histopathologic findings with detection method and mammographic findings. *Radiology* 212:829, 1999.
16. Preda L, Villa G, Rizzo S, et al. Magnetic resonance mammography in the evaluation of recurrence at the prior lumpectomy site after conservative surgery and radiotherapy. *Breast Cancer Res* 8:R53, 2006.
17. Chala LF, de Barros N, de Camargo Moraes P, et al. Fat necrosis of the breast: mammographic, sonographic, computed tomography, and magnetic resonance imaging findings. *Curr Probl Diagn Radiol* 33:106, 2004.
18. Bassett LW, Gold RH, Cove HC, et al. Mammographic spectrum of traumatic fat necrosis: the fallibility of "pathognomonic" signs of breast cancer. *AJR Am J Roentgenol* 130:119, 1978.
19. Bilgen IG, Usten EE, Memis A, et al. Fat necrosis of the breast: clinical, mammographic, and sonographic features. *Eur J Radiol* 39:92, 2001.
20. Hogge JP, Robinson RE, Magnant CM, et al. The mammographic spectrum of fat necrosis of the breast. *Radiographics* 15:1347, 1995.

21. Stavros AT. Breast Ultrasound. Philadelphia: Lippincott Williams & Wilkins, 2004.
22. Kinoshita T, Yashiro N, Yoshigi J, et al. Fat necrosis of breast: a potential pitfall in breast MRI. *Clin Imaging* 26:250, 2002.
23. American Society of Clinical Oncology. Recommended Guidelines. Alexandria, VA: The Society, 2006.
24. Saslow D, Boetes C, Burke W, et al. American Cancer Society guidelines for breast screening with MRI as an adjunct mammography. *CA Cancer J Clin* 57:75, 2007.
25. Losken A, Styblo TM, Carlson GW, et al. Management algorithm and outcome evaluation of partial mastectomy defects treated using reduction or mastopexy techniques. *Ann Plast Surg* 59:235, 2007.

33

Complications and Outcomes After Immediate Partial Breast Reconstruction

Moustapha Hamdi, Albert Losken

Partial breast reconstruction at the time of lumpectomy often adds additional procedures with their own inherent increased risk of complications. Moreover, postoperative irradiation for breast cancer is an integral part of breast-conserving therapy (BCT), additional complications or accentuation of surgical complications may also arise. When oncoplastic techniques are employed, it is important that complications do not interfere with the initiation of adjuvant therapy, whether chemotherapy or radiotherapy.

In this chapter, we discuss immediate and delayed complications. Cosmetic outcome is also considered, and we present guidelines to reduce complication rates and improve aesthetic results.

IMMEDIATE COMPLICATIONS

Displacement Techniques

Different methods of parenchymal redistribution have been described to fill small and moderate defects in the breast.

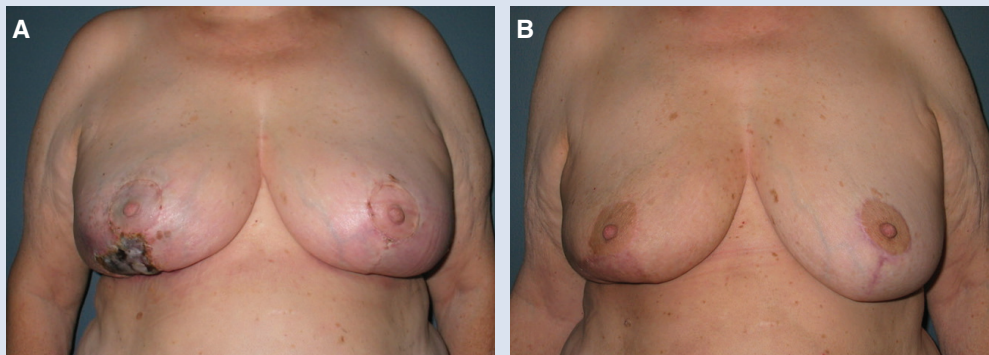
Looking at aesthetic surgery as a whole, breast reduction surgery in the United States is second only to rhinoplasty in the number of malpractice claims filed over the past 10 years.¹ Most of these malpractice cases are related to complications.

Table 33-1 Overall Complication Rate in Oncoplastic Mammoplasty

Authors	Number of Patients	NAC Loss/ NAC Free Graft or Reconstruction	Wound Healing	Hematoma/ Seroma	Infection	Fat Necrosis
Losken et al ⁶	63	3 (5%)	9 (14%)	1 (1.5%)	2 (3%)	7 (11%)
Kronowitz et al ⁷	41	4 (10%)	2 (5%)	3 (7%)	2 (5%)	5 (12%)
Munhoz et al ²	109	10 (9.2%)	4 (3.7%)	NA	3 (2.75%)	4 (3.7%)

The incidence of complications is generally related to the surgeon's learning curve and/or the patient's body mass index (BMI), breast size, smoking history, and skin management. Oncoplastic surgeons should never forget the complexity of the procedure when two different procedures are done in one stage, which may accumulate the complications of both. Therefore complications may occur more frequently in oncoplastic breast reduction than in classic breast reduction procedures. The defect often has undermined areas that would not ordinarily have been undermined and skin flaps are often thinner than expected as a result of tumor resection. This all needs to be taken into consideration when planning the oncoplastic procedure and techniques changed to avoid adverse outcomes.

PATIENT EXAMPLES

**Fig. 33-1, A and B**

This 45-year-old woman had a superficial tumor resected from the right lower quadrant with an oncoplastic reduction to reconstruct the deformity. She unfortunately had full-thickness skin necrosis, necessitating debridement and split-thickness skin grafting before radiotherapy.

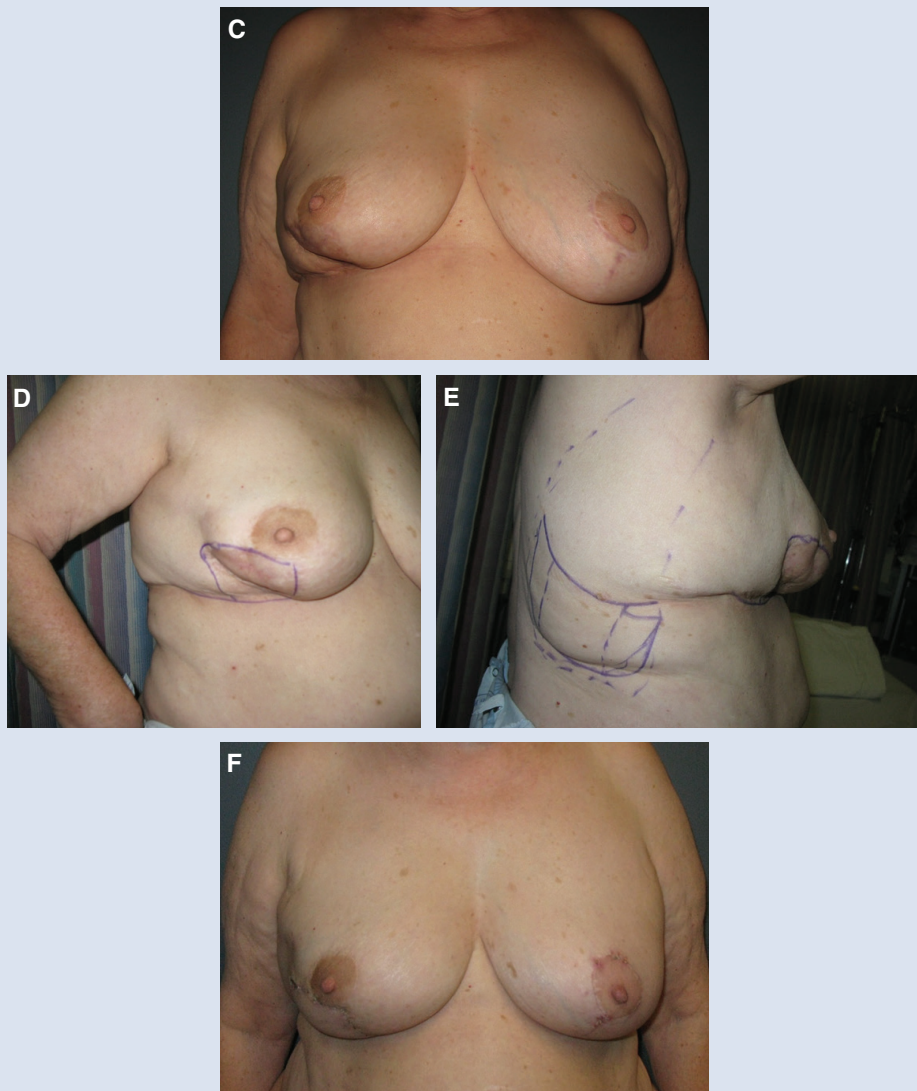


Fig. 33-1, C-F

One year after completion of radiotherapy she had a significant deformity. This was reconstructed by excision of the contracted skin graft and placement of a latissimus dorsi flap.

Although her result was good after reconstruction with the latissimus dorsi flap, she required an unplanned reoperation as a result of a complication from skin flap necrosis.

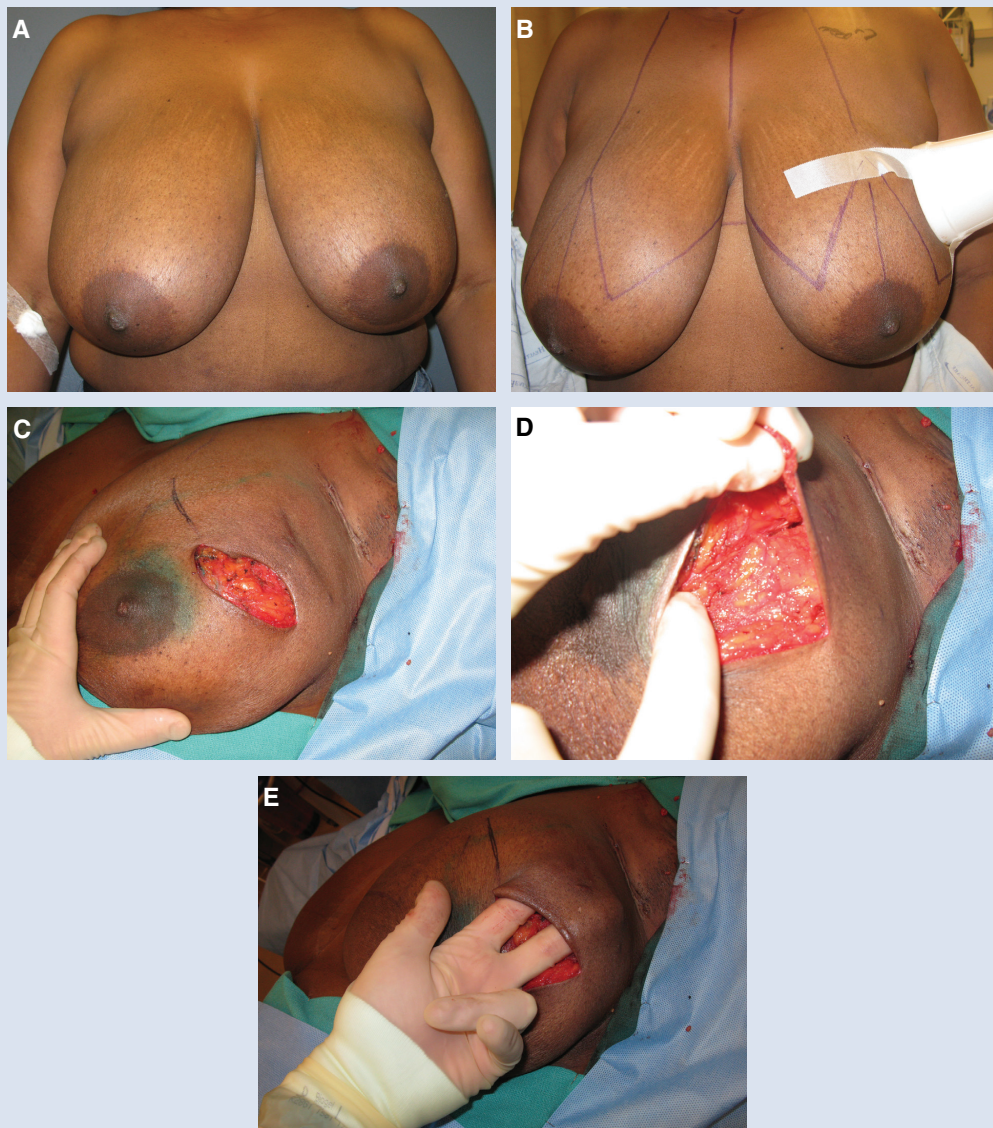

Fig. 33-2, A-E

This 52-year-old woman had a superficial left lateral invasive ductal carcinoma. She underwent tumor resection, and on examination of the defect, her skin flaps were found to be very thin. This was concerning for the development of skin necrosis (as described for Fig. 33-1).

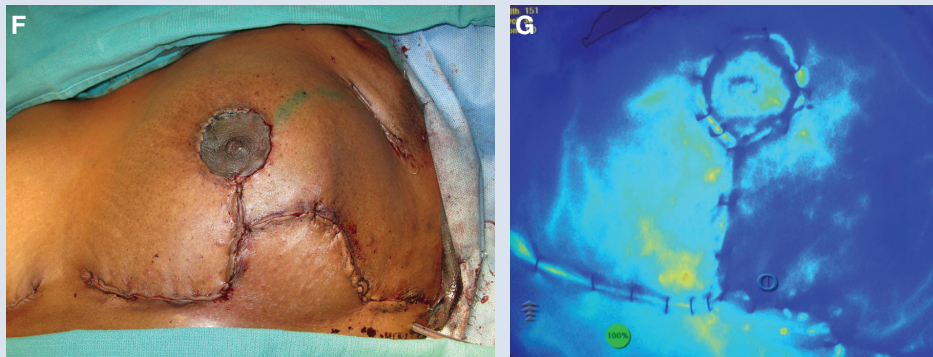


Fig. 33-2, F and G

An immediate oncoplastic reduction was performed using a superomedial pedicle, and the skin was closed temporarily. Intraoperative angiography confirmed poor perfusion in the area of concern, subsequently predicting skin necrosis.

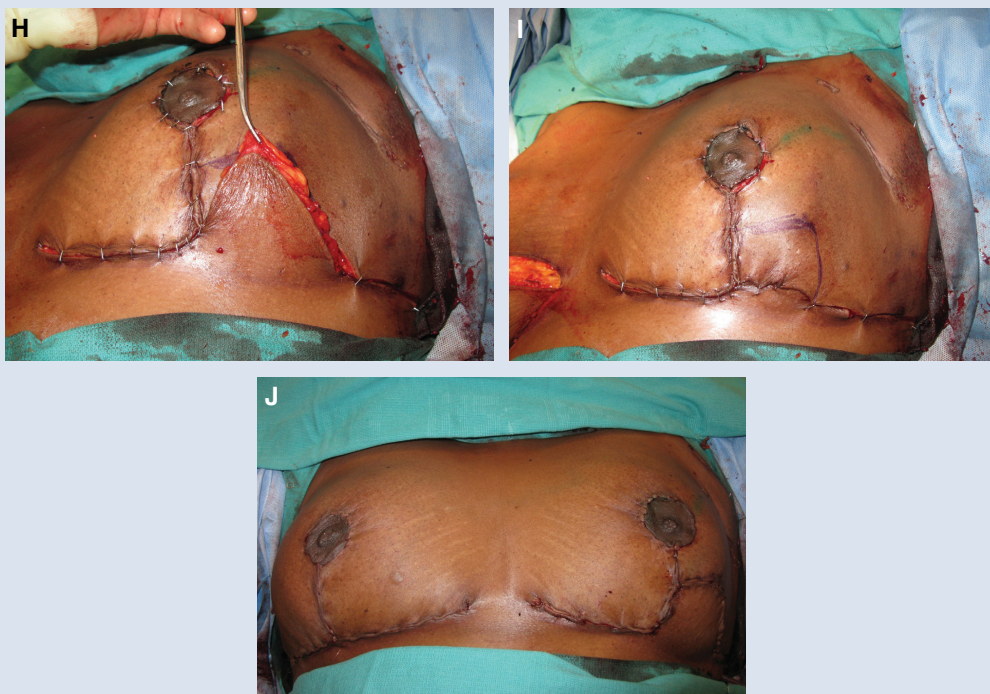

Fig. 33-2, H-J

An inferiorly based flap was preserved because of a suspicion that skin ischemia might occur, and this was used to reconstruct the defect once the thin skin was removed.

Continued

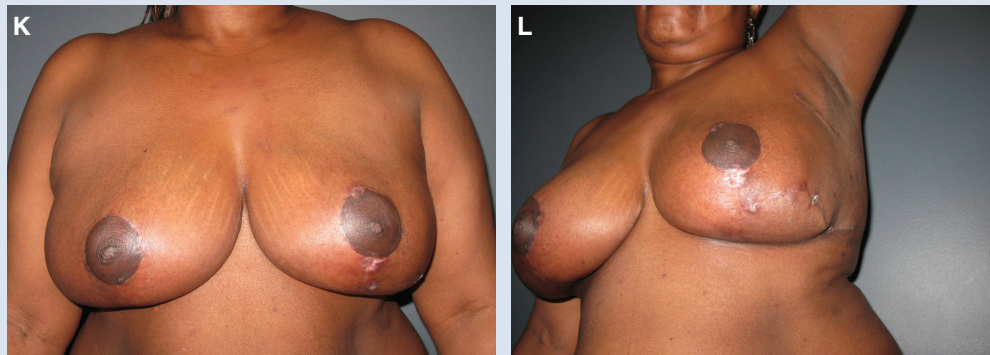


Fig. 33-2, K and L

Her result is shown 1 month after oncoplastic reduction with a well-healed skin envelope that will tolerate radiotherapy better than thin skin flaps or a skin graft.

Ischemia of glandular or dermoglandular flaps may lead to fat necrosis when a large glandular flap with large skin undermining or separation from the muscles is done to close remote or large breast defects (see Fig. 33-1). Partial or total nipple-areola complex (NAC) necrosis can also occur. Most likely, unanticipated extension of the tumor resection into the subareolar region in an attempt to obtain a negative intraoperative tumor margin may result in a compromising of blood supply to the NAC (see Fig. 33-2). Wound dehiscence can occur either in the NAC or at the junction of an inverted-T scar. Incidence of other complications such as hematoma, seroma and infection is usually not different from the classical breast reduction. Nevertheless, overall complication rates after oncoplastic breast reduction was reported by Nogushi et al⁸ to be as high as 24%. However, the authors found that some techniques (delayed corrections) performed in irradiated breasts have 50% complication rates. They also found that tumor location is a factor in the incidence of complications.

Tumors located within the upper outer quadrants tend to have the highest rate of complications followed by the inner quadrants of the breast.

One of the explanations is that resection performed in the upper outer quadrant is adjacent to the axillary lymphatic system, which can be traumatized intraoperatively and increase the potential for fluid-related complications. Another reason may be that the excessive length of a glandular flap that should be harvested and rotated upward to reach the most

upper outer area in the defect which may end up with fat necrosis. The inner quadrants of the breast are also prone to complications because of the deficiency of surrounding breast tissue to fill the resultant defect.

Most of the repairs were done for tumors within the inferior quadrants, which reflects a particular experience of the surgeon with this technique. However, this may result in a less optimal outcome when the surgeon uses one technique for tumors with different locations. Munhoz et al² reported a larger series with 209 immediate breast-conserving reconstructions. However, only 141 of their patients underwent displacement procedures: 32 breast advancement flaps and 109 mastopexy or breast-reduction procedures. In the first group, fat necrosis occurred in 2 cases (6.25%). The authors reported a lower fat necrosis rate after mastopexy and breast-reduction techniques. They used lateral thoracic flaps or LD flaps for upper outer defects.

Adopting an algorithm for selecting the appropriate technique should reduce the complication rate and improve cosmetic outcomes. A recent comparison of timing of the oncoplastic reduction procedure demonstrated an overall complication rate of 21% when the reduction was done at the time of mastectomy, compared with 57% in delayed reconstruction.³ Complications were higher in the delayed group as a result of the scarring and radiotherapy and more likely higher in the immediate delayed group because of the inflamed environment in which the reduction was being performed. The incidence of fat necrosis was 1% in the immediate reduction group and 14% in the delayed reduction group ($p < 0.001$). Nipple necrosis was also significantly higher in the delayed reduction group (5% versus 0%, $p = 0.01$).

A recent meta-analysis compared 1773 oncoplastic reductions, 1392 oncoplastic flap reconstructions, and 5494 BCT-alone patients.⁶ The average complication rate in the oncoplastic reduction group was 16%, and in the oncoplastic flap reconstruction group was 14%; however, there was no delay in the initiation of adjuvant therapy. Early complication rates were not routinely reported in the BCT-alone group; however, were on average 25.9% ($n = 201:775$), compared to 15.5% (386:2482) in the oncoplastic group. Satisfaction with the aesthetic outcome was significantly higher in the oncoplastic group 89.5% (1148:1283) versus 82.9% (1590:1916), ($p < 0.0001$) in the BCT-alone group.

In a large oncoplastic series with 540 patients, Fitoussi et al⁴ reported a complication rate of 16%. Complications are rarely recorded in BCT-only reports; however, in a series of 714 patients with BCT alone, Waljee et al⁵ reported a complication rate of 24%. Such complications, especially in BCT-only patients, are often managed conservatively. The severity of the complications in the oncoplastic groups is different, with the need for surgical intervention being roughly 3%. It does not appear that complications in the oncoplastic groups, although potentially higher, have any negative impact on patient care from an oncologic standpoint. The reoperation rate is relatively low and does not appear to interfere with appropriate management. Safety is further confirmed by the lack of any adverse effects on cancer surveillance in both the oncoplastic reduction and flap reconstruction groups. Late complications requiring additional surgery are usually related to aesthetic outcome, radiation changes, or recurrence.

Box 33-1 Surgical Guidelines for Displacement Techniques

- Careful preoperative assessment of the tumor resection and anticipation of the resultant defect are essential.
- Surgical protocols and algorithm should be employed in selecting the appropriate reconstructive technique.
- Any unnecessary glandular flap and or skin undermining must be avoided.
- Skin-glandular flaps or perforator-based glandular flaps should be selected.
- Excise ischemic or less vascularized parts of the flap, mainly the distal portions.
- Meticulous hemostasis must be ensured.
- A drain should be placed.
- Dead space must be avoided.
- A separate incision should be considered for axillary lymphatic dissection.
- Tight skin closure must be prevented.

Replacement Techniques

Table 33-2 Overall Complications After Immediate Partial Breast Reconstruction With a Latissimus Dorsi Flap

Authors	Number	Overall Complications (%)
Hernanz et al ⁹	28	39
Rainsbury et al ¹⁰	49	8
Nano et al ¹¹	18	77
Kat et al ¹²	32	19
Gendy et al ¹³	49	8
Losken et al ¹⁴	39	31
Munhoz et al ¹⁵	48	33

A significant number of authors have reported their experience using volume replacement techniques for the immediate correction of the partial mastectomy defect. This approach restores the breast volume using autologous extramammary tissue as the frequently used latissimus dorsi flap. Noguchi et al⁸ first described using the LD myocutaneous flap for partial breast reconstruction.

One major difference in flap techniques when compared with volume displacement techniques is the addition of donor-site complications. This increases the overall complication rate for flap techniques and ranges from 2% to 77%.⁹⁻¹⁵ In most situations, the donor-site complication rate is higher than the flap complication rate, likely because of high seroma

rates. Flap-related complications consist of total or partial flap loss, fat necrosis, hematoma, wound dehiscence, and infections, whereas donor-site-related complications include seroma formation, hematoma, wound dehiscence, and infection.

Munhoz et al¹⁵ recently reported a 33% complication rate using the latissimus dorsi technique for partial mastectomy defects; 65% of these were related to the donor site. The most common complication was dorsal seroma, which occurred in 20% of their patients (that is, 50% of their complications). However, when they compared obese to nonobese patients, seroma formation was significantly higher in the first group.

Wound dehiscence should be less frequent when a smaller skin island is harvested.

Seroma formation can be decreased by sacrificing less LD muscle and by adding sutures between the skin and the underlying muscles to eliminate large dead space at the donor site.

Table 33-3 Immediate Complications in Pedicled Flaps for Immediate Partial Mastectomy Reconstruction

Flap		Flap-Related Complications			Donor-Site–Related Complications				
Complication	Number	Total Flap Loss	Partial Flap Loss	Fat Necrosis	Wound Dehiscence, Breast	Infection	Wound Dehiscence, Back	Seroma, Donor Site	Infection
LD myocutaneous flap (Munhoz et al ¹⁵)	48	1 (3.3%)	3 (6.2%)	NR	3 (6.2%)	2 (2.4%)	3 (6.2%)	10 (20.8%)	1 (2.9%)
LTHD Fasciocutaneous flap (Munhoz et al ²⁰)	34	0 (0%)	3 (8.8%)	2 (5.8%)	0 (0%)	3 (8.8%)	5 (14.7%)	3 (8.8%)	
TDAP flap (Hamdi et al ¹⁸)	61	0 (0%)	2 (3.27%)	1 (1.63%)	1 (1.63%)	1 (1.63%)	0	1 (1.63%)	0 (0%)

LD, Latissimus dorsi; LTHD, lateral thoracodorsal; TDAP, thoracodorsal artery perforator.

Pedicled perforator flaps were recently reported for partial breast reconstruction.¹⁶⁻¹⁸ The thoracodorsal artery perforator flap is mostly used.^{16,18} However, pedicled flaps based on the lateral intercostal artery perforators are also indicated for lateral breast defects.¹⁷ The major advantage of harvesting a perforator flap is a significant reduction in the incidence of seroma formation at the donor site, which has been reported to be as high as 60% after harvesting an LD muscle flap.¹⁹ In addition, shorter postoperative recovery time and less pain at the donor site have been reported with the use of perforator flaps. On the other hand, preservation of the LD muscle results in less body contour deformity at the donor site than with an LD harvest.²⁰

Table 33-4 Other Techniques for Immediate Reconstruction of Partial Mastectomy Defects

Authors	Technique	Number	Limitations
Zaha et al ²¹	Omental flap (laparoscopic harvest)	28	Limited volume, hernia
Kijima et al ²²	IMF adipofascial flap	2	None
Ogawa et al ²³	IMF adipofascial flaps	4	Inferior pole defects

Other flap techniques and procedures have been described for the correction of partial mastectomy defects. Although these have been small case report series, they do demonstrate favorable outcomes with limited morbidity.

Box 33-2 Surgical Guidelines for Replacement Techniques

- Careful planning (markings, orientation, and width of skin paddle) for flap surgery is essential.
- The right flap must be used for the right indication (depending on the surgeon's experience and the tumor location).
- A muscle-sparing technique should be considered to avoid donor-site morbidity.
- Dead spaces should be avoided both in the donor site and in the breast.
- Complications must be treated immediately to avoid delay of adjuvant therapy.

DELAYED COMPLICATIONS AND OUTCOMES

Despite the surge of published reports on oncoplastic surgical techniques for the management of early breast cancer, most have been small series with midrange follow-up. Additionally, it is difficult to measure and evaluate the relative outcomes because of a lack of standardization of reporting. The published data would be most helpful if it were standardized, allowing more critical evaluation and more accurate comparisons. Local recurrence and survival rates are often not mentioned, and patient satisfaction or cosmetic results data are variable in presentation, making comparisons difficult. The most frequently reported delayed complication after volume displacement techniques is fat necrosis. However, fat necrosis is insignificant when it is clinically nonpalpable or undetectable. The second most common complication is breast asymmetry; the incidence appears to increase with longer follow-up.

When volume replacement techniques are performed, postoperative radiotherapy of any flap is a major concern. A significant increase in delayed flap contracture, pigmentation

changes, and volume loss can be seen. At present there are no large long-term outcome studies that compare immediate flap reconstruction in irradiated and nonirradiated partial mastectomy patients. Because most of the breast tissue includes dermal and gland connections and the breast ligaments are spared, one would expect radiation to have less detrimental aesthetic influences on partial mastectomy patients than on total mastectomy patients. Theoretically, irradiating both the flap and the conserved breast tissue should produce a more homogeneous appearance than the “plugged-in” appearance of nonirradiated flaps after delayed reconstruction.

Table 33-5 Outcomes of Breast-Conserving Reconstruction by Technique Used

	Volume Displacement	Volume Replacement
Total number of studies	11 ^{26,27-32}	7 ^{11-14,32-36}
Total number of patients	433	189
Median follow-up (mo)	21-54	24-53
Cosmetic failure (%)	0-18	0-9

Two similar papers on oncoplastic displacement and replacement techniques^{24,25} evaluating multiple studies from various centers were from the Nottingham Breast Institute. They found that cosmetic failure rates ranged from 0% to 18% on intermediate follow-up (up to 4½ years).

In one of the largest published studies, by Clough et al,³⁷ 101 patients underwent breast reduction procedures for partial breast reconstruction. The majority of the techniques used were a superior pedicle flap (83%), and 91% of the tumors were located in the lower pole or center of the breast. The authors reported fair and excellent results in 88% and 82%, respectively, at 2- and 5-year follow-up using a grading system. In a similar study from Milan by Petit et al,³⁸ a series of 111 patients were treated with either breast-reduction techniques or latissimus dorsi flaps. Analysis of the results after a mean follow-up of 21 months showed good, fair, and poor results in 77%, 17%, and 5%, respectively. There was no statistical difference between tumors at different locations. However, good results were obtained in 100% with the round bloc technique and Grisotti flap, 87% with an inferior pedicle, 77% with a superior pedicle, and 67% with a latissimus dorsi flap. Noguchi et al³⁹ reported 67% excellent or good results in 51 patients who had immediate breast reconstruction with transposition of adipose tissue with the LD muscle. One of the major problems they encountered was LD muscle atrophy after irradiation. This made it imperative that sufficient volume of adipose tissue be transposed into the defect rather than the LD muscle. In addition, they reduced the radiation dosage from 5000 centigrays. The authors concluded that the cosmetic improvement was related to the transposition of an increased volume of adipose tissue.

MANAGEMENT OF POOR OUTCOME IN ONCOPLASTIC SURGERY

Analysis of post-BCT breast deformity should be undertaken in cases with poor results after oncoplastic breast surgery (see Chapters 25 through 27).

Failure to establish breast symmetry through oncoplastic surgery can be classified as:

- Asymmetry caused by distortion, retraction, or volume changes in the breast
- Asymmetry in nipple-areola complex location, size, form, or color
- Asymmetry from radiotherapy sequelae

The aim of surgical correction is to achieve symmetry between both breasts. Since the surgeon must deal with irradiated tissue, the general principles and surgical guidelines associated with the characteristics of this tissue must be considered. In contrast with immediate complications following oncoplastic surgery, which must be treated as soon as possible to avoid any delay in initiating adjuvant therapy, delayed complications should be managed when the final outcome or status has been obtained and the acute effect of radiotherapy has subsided. However, irradiation effects on tissue may take a long time to settle, and there is a long-term evolution that is difficult to assess during the initial 2 years after radiotherapy. Nevertheless, surgical correction of an irradiated breast, when indicated, can be planned for 1 year after the end of the radiotherapy. When poor breast contour or insufficient breast volume results in breast asymmetry, it is better to wait at least 2 years after radiotherapy before any decision is made on surgical management, because the deformity may become worse in the long term, and a different surgical approach might be necessary.

PATIENT EXAMPLE

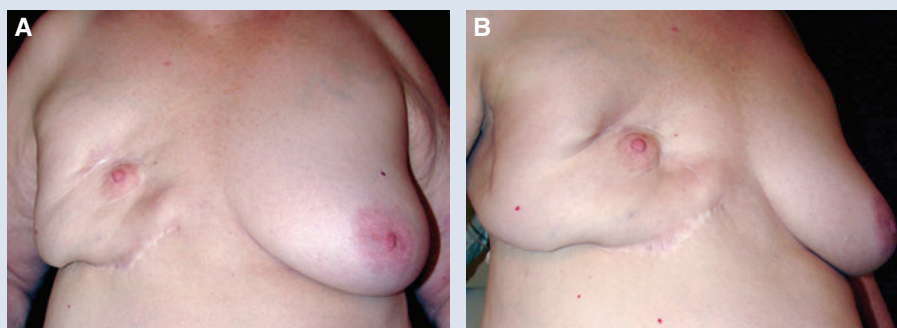
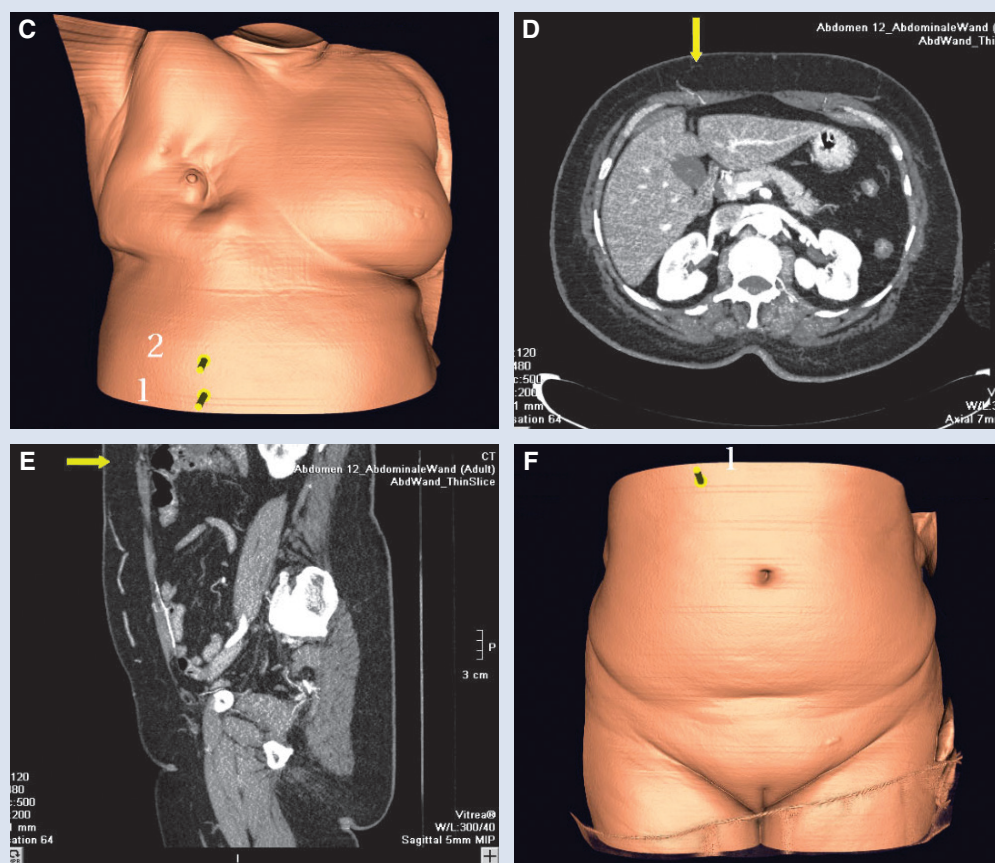


Fig. 33-3, A and B

This 73-year-old woman had undergone immediate breast reconstruction 3 years earlier with a pedicled LD flap for the right breast. She had major partial necrosis as a result of postoperative hematoma, and after radiotherapy she presented at our clinic with painful and extended fat necrosis. The preoperative views show major fat necrosis with breast contour deformity (A and B).

**Fig. 33-3, C-F**

Although the resultant breast deformity was severe, the patient refused major surgery (completing mastectomy with free DIEP flap breast reconstruction). A pedicled superficial epigastric artery perforator flap (SEAP) was then planned to salvage the situation.⁴⁰ A multidetector CT (MDCT) was done and showed the SEA perforators (C through F).

Continued

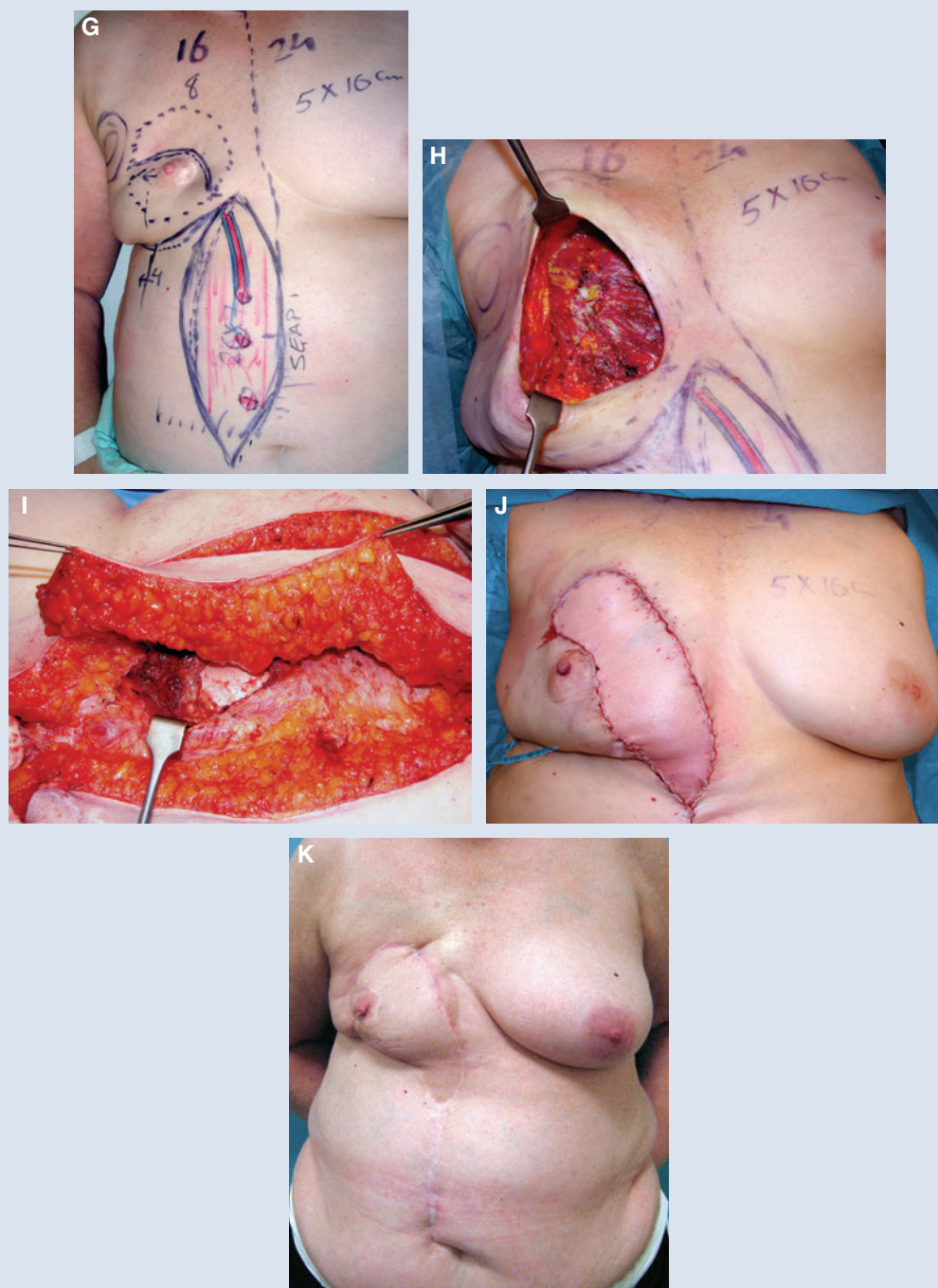


Fig. 33-3, G-K

The SEAP flap was designed with a vertical skin paddle (G). The defect after large debridement of the fat necrosis (H). An intraoperative view shows the SEAP flap is isolated on one perforator (I). The flap was rotated 180 degrees to cover the defect (J). The result is shown at 30 months postoperatively (K).

When patients complain of major fat necrosis or pain, earlier surgical correction is indicated once the immediate radiotherapy sequelae have subsided (6 to 9 months after radiotherapy). However, if the poor result is caused by a major fat necrosis or complication, most cases of breast asymmetry can still be treated with minimal procedures such as NAC reposition, scar revisions, or fat grafting. Procedures of the contralateral breast may be also indicated/required. When major fat necrosis or severe postirradiation sequelae occurs, large debridement is performed and the residual defect should be covered with living, healthy tissue, most commonly transferred from remote areas. Either a pedicled flap (see Fig. 33-3), away from the irradiation field, can be used or most often free flaps (see Fig. 33-4). Pedicled flaps may not be available if they have already been used for partial breast reconstruction or if their vascular pedicles were damaged or compromised during previous surgery or irradiation.

PATIENT EXAMPLE

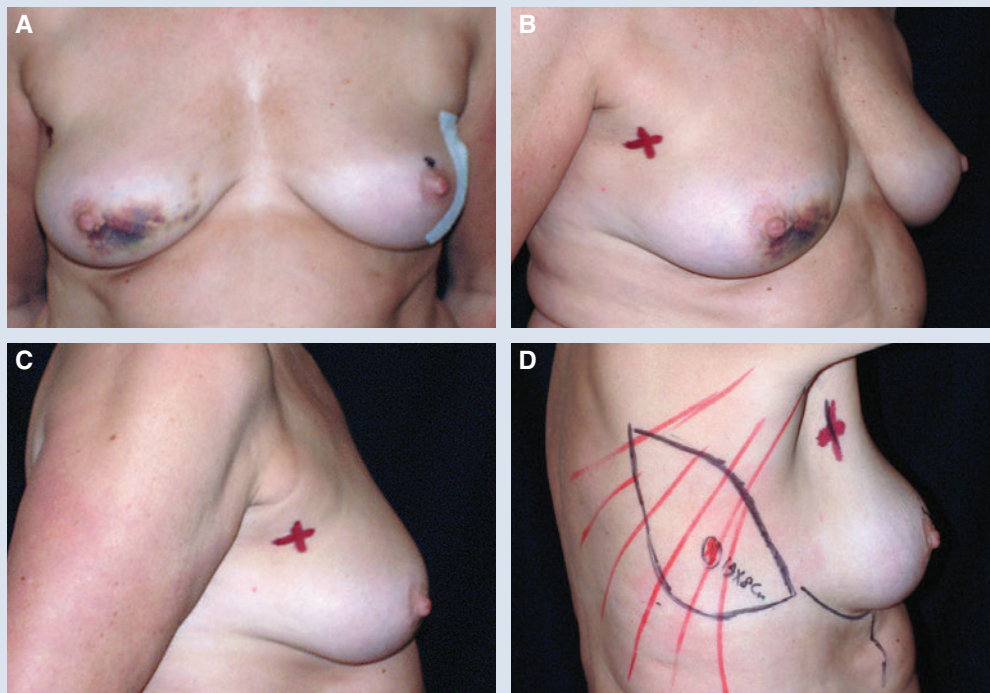


Fig. 33-4, A-D

For this 49-year-old woman, oncoplastic surgery was planned using a pedicled TDAP flap for immediate partial breast reconstruction. The tumor was in the medial quadrant of her right breast. Postoperative follow-up was uneventful, and she was able to begin adjuvant therapy. The patient was lost to follow-up; however, she returned to our clinic 2 years later with major fat necrosis. Since the breast deformity was large in such a moderate-sized breast, a completing mastectomy with immediate breast reconstruction with a free DIEP flap was performed to salvage the breast (A through C). Postoperative views show the patient before the oncoplastic surgery. A TDAP flap was planned (D).

Continued

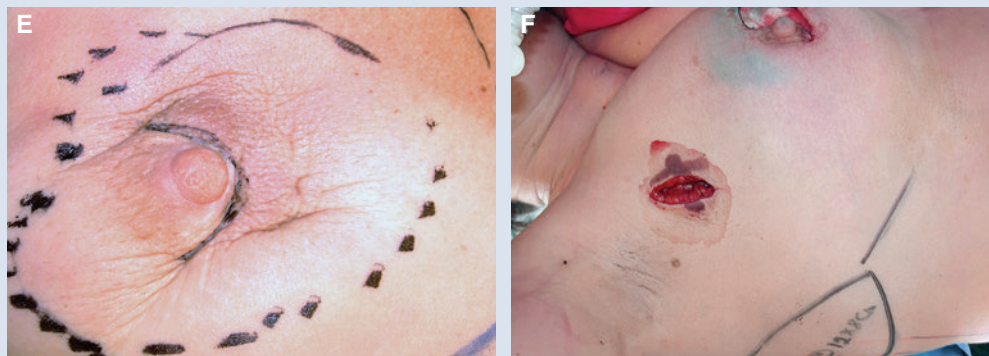

Fig. 33-4, E and F

A quadrantectomy with sentinel lymph node dissection was performed (*E*). The TDAP flap passed into the defect (*F*).

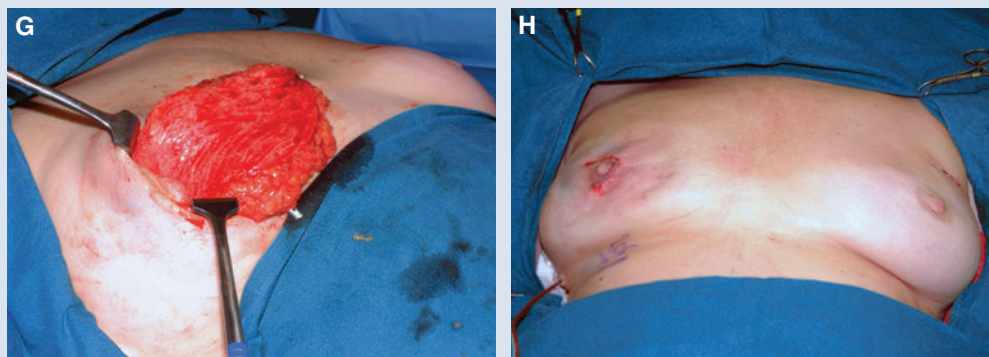


Fig. 33-4, G and H

The breast is shown at the end of surgery (*G*) and 2 years later (*H*).

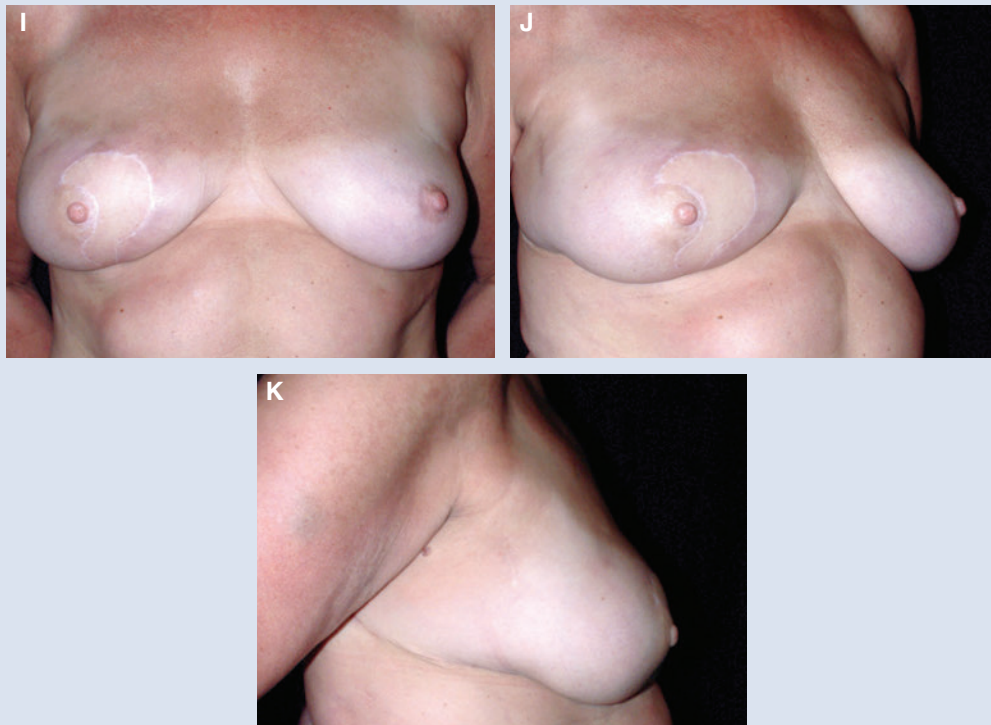


Fig. 33-4, I-K

A major fat necrosis of the flap. The results of a completing mastectomy and breast reconstruction with a DIEP flap are shown (*I* through *K*).

Table 33-6 Summary of Solutions to Problems Resulting in Poor Outcome

Problem	Grade of Severity	Treatment
Breast volume asymmetry	Mild/moderate	Fat injection \pm contralateral breast remodeling/mastopexy
	Severe	Convert to mastectomy and autologous reconstruction (Implant in selected cases)
Residual breast defect	Mild	Fat injection
	Moderate	Repeated fat injection or Pedicled local flap
	Severe	Mastectomy and autologous reconstruction (DIEP/SGAP/TRAM)
NAC asymmetry	Horizontal position	NAC repositioning with elliptical deepithelialization
	Vertical position or size	Round bloc technique, or matching technique with contralateral breast
	Depigmentation	Unilateral or bilateral tattoo
Radiotherapy sequelae	Skin changes	Fat injection
	General gland atrophy or retraction	Fat injection
		Complete mastectomy and flap reconstruction

DIEP, Deep inferior epigastric artery perforator flap; *SGAP*, superior gluteal artery perforator flap; *TRAM*, transverse rectus abdominis flap.

CONCLUSION

Oncoplastic breast surgery is a rather new field in reconstructive breast surgery. Because the discipline combines two surgical procedures with oncologic resection and reconstruction, a higher complication rate may be expected. However, the available studies in the oncoplastic surgery literature show a complication rate comparable to those of classic breast reduction (without radiotherapy). The complication rate can be decreased through an understanding of the underlying causes, familiarity with the technique, and appropriate patient and technique selection.

Longer follow-up of patients may reveal more or unexpected complications as a result of the combination of ablative/reconstructive surgery and irradiation. Control of the disease and breast symmetry are our ultimate goal; however, aesthetic outcome can be difficult to maintain over the long-term follow-up. The difference in surgical technique between the two breasts and the delivery of radiotherapy on one side may always result in different evolution of the breasts and consequently some degree of asymmetry.

Critical Issues

- Partial breast reconstruction may result in additional morbidity.
- Volume displacement techniques can result in local breast complications.
- Flap reconstruction techniques have the potential for donor-site morbidity.
- Upper quadrant tumors tend to have higher complication rates.
- Late complications can occur and are often exacerbated by the effects of radiotherapy.
- Minor asymmetry can occur long term, and various options exist for its correction.
- Because the effects of radiotherapy persist, cosmetic results must be evaluated in the long term.
- It is important that complications do not interfere with or delay postoperative cancer treatments.
- Appropriate patient selection will reduce complications and improve cosmetic outcomes.
- Attention to detail and safe surgical principles minimize the risk of unfavorable outcomes.
- Patient satisfaction with partial breast reconstruction is high.
- Larger, longer-term studies are required.

References

1. Gorney M. Ten years' experience in aesthetic surgery malpractice claims. *Aesthet Plast Surg* 21:569, 2000.
2. Munhoz AM, Montag A, Arruda E. Assessment of immediate conservative breast surgery reconstruction: a classification system of defects revisited and an algorithm for selecting the appropriate technique. *Plast Reconstr Surg* 121:716, 2008.
3. Egro FM, Pinell-White XA, Hart AM, Losken A. The use of reduction mammoplasty with breast conservation therapy: an analysis of timing and outcomes. *Plast Reconstr Surg* 135:963, 2015.
4. Fitoussi AD, Berry MG, Famà F, et al. Oncoplastic breast surgery for cancer: analysis of 540 consecutive cases [outcomes article]. *Plast Reconstr Surg* 125:454, 2010.
5. Waljee JF, Hu ES, Newman LA, et al. Correlates of patient satisfaction and provider trust after breast-conserving surgery. *Cancer* 112:1679, 2008.
6. Losken A, Styblo TM, Carlson GW, et al. Management algorithm and outcome evaluation of partial mastectomy defects treated using reduction or mastopexy techniques. *Ann Plast Surg* 59:235, 2007.

7. Kronowitz SJ, Feledy JA, Hunt KK. Determining the optimal approach to breast reconstruction after partial mastectomy. *Plast Reconstr Surg* 118:813, 2006.
8. Noguchi M, Taniya T, Miyazaki I, et al. Immediate transposition of a latissimus dorsi muscle for correcting a postquadrantectomy breast deformity in Japanese patients. *Int Surg* 75:166, 1990.
9. Hernanz F, Regano S, Redondo-Figuero C, et al. Oncoplastic breast-conserving surgery: analysis of quadrantectomy and immediate reconstruction with latissimus dorsi flap. *World J Surg* 31:1934, 2007.
10. Rainsbury RM, Paramanathan N, Straker V, et al. The effect of immediate volume replacement with latissimus dorsi mini flaps on the outcome of breast-conserving surgery. *Euro J Cancer* 34:S47, 1998.
11. Nano MT, Gill PG, Kollias J, et al. Breast volume replacement using the latissimus dorsi miniflap. *ANZ J Surg* 74:98, 2004.
12. Kat CC, Darcy CM, O'Donoghue JM, et al. The use of the latissimus dorsi musculocutaneous flap for immediate correction of the deformity resulting from breast conservation surgery. *Br J Plast Surg* 52:99, 1999.
13. Gendy RK, Able JA, Rainsbury RM. Impact of skin sparing mastectomy with immediate reconstruction and breast sparing reconstruction with miniflaps on outcomes of oncoplastic breast surgery. *Br J Plast Surg* 90:433, 2003.
14. Losken A, Schaefer TG, Carlson GW, et al. Immediate endoscopic latissimus dorsi flap: risk or benefit in reconstructing partial mastectomy defects. *Ann Plast Surg* 53:1, 2004.
15. Munhoz AM, Montag E, Arruda E, et al. Outcome analysis of breast-conservation surgery and immediate latissimus dorsi flap reconstruction in patients with T1 to T2 breast cancer. *Plast Reconstr Surg* 116:741, 2005.
16. Hamdi M, Van Landuyt K, Monstrey S, et al. Pedicled perforator flaps in breast reconstruction: a new concept. *Br J Plast Surg* 57:531, 2004.
17. Hamdi M, Spano A, Van Landuyt K, et al. The lateral intercostal artery perforators: anatomical study and clinical applications in breast surgery. *Plast Reconstr Surg* 121:389, 2008.
18. Hamdi M, Van Landuyt K, Hijjawi J, et al. Surgical technique in pedicled thoracodorsal artery perforator flaps: a clinical experience with 99 patients. *Plast Reconstr Surg* 121:1632, 2008.
19. Randolph LC, Barone J, Angelats J, et al. Prediction of postoperative seroma after latissimus dorsi breast reconstruction. *Plast Reconstr Surg* 116:1287, 2005.
20. Munhoz AM, Montag E, Arruda E, et al. The role of the lateral thoracodorsal fasciocutaneous flap in immediate conservative breast surgery reconstruction. *Plast Reconstr Surg* 117:1699, 2006.
21. Zaha H, Inamine S, Naito T, et al. Laparoscopically harvested omental flap for immediate breast reconstruction. *Am J Surg* 192:556, 2006.
22. Kijima Y, Yoshinaka H, Owaki T, et al. Immediate reconstruction using inframammary adipofascial flap of the anterior rectus sheath after partial mastectomy. *Am J Surg* 193:789, 2007.
23. Ogawa T, Hanamura N, Yamashita M, et al. Usefulness of breast-volume replacement using an inframammary adipofascial flap after breast-conservation therapy. *Am J Surg* 193:514, 2007.
24. Asgeirsson KS, Rasheed R, McCulley SJ, et al. Oncological and cosmetic outcomes of oncoplastic breast conserving surgery. *Eur J Surg Oncol* 31:817, 2005.
25. Rainsbury RM. Surgery insight: oncoplastic breast-conserving reconstruction—indications, benefits, choices and outcomes. *Nat Clin Pract Oncol* 4:657, 2007.
26. Clough KB, Kroll SS, Audretsch W. An approach to the repair of partial mastectomy defects. *Plast Reconstr Surg* 104:409, 1999.
27. Spear SL, Pelletiere CV, Wolfe AJ, et al. Experience with reduction mammoplasty combined with conservative breast therapy in the treatment of breast cancer. *Plast Reconstr Surg* 111:1102, 2003.

28. Nos C, Fitoussi A, Bourgeois D, et al. Conservative treatment of lower pole breast cancers by bilateral mammoplasty and radiotherapy. *Eur J Surg Oncol* 24:508, 1998.
29. Masetti R, Pirulli PG, Magno S, et al. Oncoplastic techniques in the conservative surgical treatment of breast cancer. *Breast Cancer* 7:276, 2000.
30. Chang E, Johnson N, Webber B, et al. Bilateral reduction mammoplasty in combination with lumpectomy for treatment of breast cancer in patients with macromastia. *Am J Surg* 187:647, 2004.
31. Petit JY, Rietjens M, Garusi C. Breast reconstructive techniques in cancer patients: which ones, when to apply, which immediate and long term risks? *Crit Rev Oncol Hematol* 38:231, 2001.
32. Papp C, Zanon E, McCraw J. Breast volume replacement using the deepithelialized latissimus dorsi myocutaneous flap. *Eur J Plast Surg* 11:120, 1988.
33. Zoetmulder FA, Borger JH, Rutgers EJ, et al. Breast conserving therapy in patients with relatively large (T2, T3) breast cancers by preoperative irradiation and myocutaneous LD flap reconstruction. A new technique in breast conservation. *Eur J Cancer* 29A:957, 1993.
34. Raja MA, Straker VF, Rainsbury RM. Extending the role of breast-conserving surgery by immediate volume replacement. *Br J Surg* 84:101, 1997.
35. Dixon JM, Venizelos B, Chan P. Latissimus dorsi miniflap: a new technique for extending breast conservation. *Breast* 11:58, 2002.
36. Navin C, Agrawal A, Kolar KM. The use of latissimus dorsi miniflap for reconstruction following breast-conserving surgery: experience of a small breast unit in a district hospital. *World J Surg* 31:46, 2007.
37. Clough K, Fitoussi A, Bourgeois D, et al. Reconstruction after conservative treatment for breast cancer: cosmetic sequelae classification revisited. *Plast Reconstr Surg* 114:1743, 2004.
38. Petit JY, Garusi C, Greuse M, et al. One hundred and eleven cases of breast conservation treatment with simultaneous reconstruction at the European Institute of Oncology (Milan). *Tumori* 88:41, 2002.
39. Noguchi M, Minami M, Earashi M, et al. Oncologic and cosmetic outcome in patients with breast cancer treated with wide excision, transposition of adipose tissue with latissimus dorsi muscle, and axillary dissection followed by radiotherapy. *Breast Cancer Res Treat* 35:163, 1995.
40. Hamdi M, Van Landuyt K, Ulens S, et al. Clinical applications of the superior epigastric artery perforator (SEAP) flaps: anatomical studies and preoperative perforator mapping with the multi-detector CT. *J Plast Reconstr Aesthet Surg* 62:1127, 2009.

34

Outcomes and Tumor Recurrence After Oncoplastic Surgery of the Breast: Eighteen-Year Follow-up

Cristina Garusi, Santos Soto



ncoplastic surgery may allow more-extensive resections and good aesthetic outcomes in some patients, minimizing the deformity and expanding the indications for breast-conserving therapy (BCT).¹ Although numerous series have documented acceptable cosmetic outcomes using these techniques, the available data on local recurrence and distant metastasis following oncoplastic surgery are limited. Most series are small, with a relatively short follow-up.

In this chapter we first review our experience with 148 consecutive patients who underwent oncoplastic surgery consisting of BCT and concomitant bilateral plastic remodeling. We also present an updated follow-up of our cohort, 18 years after the original procedure. Local recurrence, metastases, and death rates are reported. Related complications and cosmetic outcomes are also discussed. All patients are reclassified according to the Revision of the American Joint Committee on Cancer staging system for breast cancer.²

SURGICAL APPROACH

The oncoplastic procedures were performed with the patients under general anesthesia. Using a two-team approach, oncologic and plastic surgeons worked on both breasts simultaneously.

The tumor resection included at least 1 cm of macroscopically safe margin.

If the lesion was close to the resection margins, further resection was performed. The deep and superficial surfaces of the remaining breast tissue were evaluated bimanually for occult lesions.^{3,4} The mammaplasty techniques used to reconstruct the involved breast were superior pedicle (Lejour or Pitanguy techniques), inferior pedicle, round block, latissimus dorsi, or definitive silicone implants.⁵⁻⁷ The contralateral mammaplasty was performed concomitantly in all cases of this series, with a technique similar to that used in the breast with the tumor to achieve the best symmetry. A complete axillary dissection or sentinel node biopsy was performed in all clinically indicated cases, independent of the oncoplastic technique. When the sentinel node was positive after an extensive frozen section analysis, a complete axillary dissection was performed according to our previously described protocol.⁸

HISTOPATHOLOGIC EXAMINATION

Specimens were weighed and well oriented in the operating room to allow the pathologist to evaluate the margins grossly or microscopically to determine the need for further treatment and eventual reexcision. The volume of each specimen was calculated by multiplying the length, width, and height.⁹ They were inked and formalin fixed, and paraffin-embedded sections were stained with hematoxylin and eosin for routine examination.

For consistency with the literature, we used a 2 mm surgical margin as the cutoff point for negative margins.

Positive margins were defined as those with tumor cells at the cut edge of the specimen. *Close margins* were defined as those with tumor cells between the cut edge of the specimen and the boundary defined as negative (less than or equal to 2 mm).

A complete axillary dissection or sentinel node biopsy was performed in all clinically indicated cases, independent of the oncoplastic technique. When the sentinel node was positive after an extensive frozen section analysis, a complete axillary dissection was performed according to our previously described protocol.⁸

ADJUVANT TREATMENT

The decision-making process to use adjuvant systemic therapy (hormone therapy or chemotherapy) was based on the clinical and pathologic statuses, and the therapy followed our standard protocols, without modification. All chemotherapy regimens began 15 to 45 days after surgery. We followed four chemotherapy schedules in this series of patients:

1. Cyclophosphamide, methotrexate, and fluorouracil (CMF)
2. Anthracycline plus cyclophosphamide (AC)
3. Four cycles of AC and three cycles of CMF (AC and CMF)
4. High-dose chemotherapy with autologous stem cell transplantation rescue.

Anthracycline regimens or high-dose chemotherapy with autologous stem cell transplantation rescue were indicated for patients with more aggressive disease, including women with more than three positive lymph nodes and those who were premenopausal or estrogen- and progesterone-receptor (ER and PgR) negative.

Radiotherapy was delivered to the breast at a dose of 50 Gy plus a boost of 10 Gy after the conclusion of chemotherapy or at least 30 days after surgery, when chemotherapy was not indicated.

FOLLOW-UP

For the first 5 years after the surgery, the patients were seen at the clinic every 6 months by the clinical oncologist, breast surgeon, and/or plastic surgeon. In addition, the patients underwent a complete clinical checkup every year, which included blood examinations, chest radiography, liver ultrasonography, gynecologic ultrasonography (only in patients undergoing adjuvant therapy with tamoxifen), and mammography. Bone scans were performed only when indicated by blood examination or clinical symptoms. The patients were subsequently seen once a year, and all had annual mammography examinations. Our last follow-up was performed 18 years after the first surgical intervention. All of the patient charts were retrieved and updated in our database. We contacted patients by telephone interviews or through family members in the case of deceased individuals.

STATISTICAL ANALYSIS

The estimated crude cumulative incidence of tumor recurrence in the same breast after oncoplastic surgery, contralateral breast carcinomas, regional or distant metastasis, and other primary tumors was calculated according to a framework described by Marubini and Valsocchi.¹⁰ The time to the occurrence of these events was computed from the date of surgery. The overall survival curves were obtained using the Kaplan-Meier method, and competing risk methods were used to assess the cumulative incidence of local recurrence and distant metastasis, depending on which event occurred first. Finally, the multivariate Cox proportional regression model was used to assess the effects of the independent prognostic value of the selected tumor and patient's characteristics on the development of local recurrence, distant metastasis, or death. A statistical analysis was performed using SAS software. All tests were two sided.

RESULTS

The average patient age was 50 years (range 31 to 71 years). Ninety-one patients (61.5%) were premenopausal, and 28 (18.9%) had grade I or grade II breast cancer in their family history. In 71 patients (48%) the tumor was in the right breast. A superolateral quadrant was involved in 47 patients (32%), a superomedial quadrant in 22 (15%), a union of superior quadrants in 17 (11%), an inferolateral quadrant in 17 (11%), an inferomedial quadrant in 16 (11%), a union of inferior quadrants in 15 (10%), a central quadrant in 15 (10%), a union of lateral quadrants in 2 (1%), and a union of medial quadrants in 1 (0.7%). In four patients (3%), we found tumors in two quadrants. One hundred thirty-seven patients (93%) had invasive tumors, and 11 (7 %) had ductal carcinoma in situ (DCIS). The average size of the tumor determined in the pathologic analysis was 22 mm (range 3 to 100 mm), and 31 (21%) tumors were multifocal, with more than one lesion on the same quadrant. The mean weight of breast tissue from the breast containing the tumor was 198 g (range 20 to 2100 g).

Complete axillary dissections were performed in 129 patients (87%), and a sentinel node biopsy was done in 7 (5%); 12 (8%) did not receive any axillary treatment. Seventy-six patients (51%) had axillary metastasis. There were early complications (less than 2 months after surgery) in 16 patients (11%): wound infection in 7 (5%), hematoma in 4 (3%), partial nipple-areola necrosis in 2 (1%), breast seroma in 1 (0.7%), hypertrophic wound in 1 (0.7%), and partial wound dehiscence in 1 (0.7%). These complications did not delay the beginning of systemic and local adjuvant treatments.

An assessment of the excision margins showed complete excision of the tumor in 135 patients (91%), focally involved margins with DCIS in 8 patients (5.5%), and close margins (less than 2 mm) in 5 patients (3%). One patient with focally involved margins with DCIS underwent a total mastectomy and developed a local recurrence. Distant metastasis was subsequently detected, and she died 48 months after the first surgery. Other patients with focally involved margins received a boost in the tumor bed, similar to the patients with negative margins.

Table 34-1 Characteristics of the Women Who Underwent Oncoplastic Breast Surgery

Characteristic	Cases (N = 148)	Characteristic	Cases (N = 148)
Age (yr)		Hormone Receptor Status	
<40	18	ER or PgR positive	106
40-49	57	ER and PgR negative	35
50-59	50	ER and PgR missing	7
60-69	21		
>70	2		
Tumor Size (mm)*		Ki67	
1-10	18	16	57
11-20	65	>16	81
21-30	42	Unknown	10
>30	19		
Grading		Axilla	
I	34	NX	12
II	60	N0	60
III	48	Nlmi	8
Unknown	6	N1a	44
		N2a	13
		N3a	11
Vascular Invasion		Adjuvant Chemotherapy*	
Yes	54	Yes	89
No	94	No	58
Multifocal Tumors		Adjuvant Hormone Therapy*	
Yes	31	Yes	108
No	117	No	39
Surgical Margins		Complementary Radiotherapy*	
Negative	135	Yes	141
Positive	8		
Close (<2 mm)	5		

*Data were not available for all patients in these four categories.

All patients received some form of adjuvant systemic therapy. Seventy-one (48%) received the CMF regimen, 47 (32%) received the AC regimen, 31 (21%) followed the AC and CMF regimen, 2 (1%) had high-dose chemotherapy with autologous stem cell transplantation rescue as part of a study protocol, and 58 (39%) received no chemotherapy. Adjuvant hormone therapy with tamoxifen was indicated in 108 patients (73%). One hundred forty-one patients (95%) received adjuvant radiotherapy.

Local Recurrences and Distant Metastases

Table 34-2 Distribution of Local Recurrence and Distant Metastasis According to Baseline Characteristics in Women Who Underwent Oncoplastic Breast Surgery

Characteristic	Local Recurrence		Distant Metastasis	
	Number of Patients	<i>p</i> Value	Number of Patients	<i>p</i> Value
Overall	5		19	
Menopausal status		0.388		0.731
Premenopause	4		11	
Postmenopause	1		8	
Diameter of Primary Tumor		0.009		<0.0001
1-20 mm	5		3	
>21 mm	0		16	
Histologic Grading		0.248		0.029
G1	0		1	
G2 and G3	5		18	
ER/PgR		0.363		0.060
+	3		11	
—	2		8	

The median follow-up was 74 months (range 10 to 108 months), and only three patients (2%) of this group were lost to follow-up. Five patients developed an ipsilateral breast cancer recurrence (3%) in an average of 23 months (range 12 to 36 months) after the first surgery. Four patients had a recurrence in the tumor bed and one patient had a recurrence in the axilla. In the univariate analysis, the probability of local recurrence was significantly higher in the group of patients with tumors larger than 2 cm ($p = 0.009$), and

Table 34-2 (continued)

Characteristic	Local Recurrence		Distant Metastasis	
	Number of Patients	<i>p</i> Value	Number of Patients	<i>p</i> Value
Ki67		0.066		0.007
16	0		2	
>16	5		17	
Vascular Invasion		0.401		0.292
Present	1		9	
Absent	4		10	
Plurifocality		0.303		0.188
Yes	0		2	
No	5		17	
Margins		0.372		0.480
Close or positive	1		1	
Negative	4		18	
Axillary Nodes		0.265		0.237
Involved	4		6	
Not involved	1		13	

in patients with Ki67 greater than 16 was closed up to significance ($p = 0.06$). Nineteen patients (13%) developed distant metastasis in an average time of 33 months (range 1 to 65 months) after the first surgery. The metastasis sites were: bone (13), liver (10), lung (7), brain (5), supraclavicular area (5), internal mammary chain (2), and skin (1). The risk of distant metastasis was significantly higher in the group of patients with tumors larger than 2 cm ($p < 0.0001$), Ki67 greater than 16 ($p = 0.007$), and histologic grading G2 and G3 ($p = 0.029$).

Table 34-3 Long-Term Oncologic Results in Oncoplastic Breast Surgery

Stage	Patients	Relapse	Metastases	Death
pTis	11	0	0	0
pT1a-1b	14	0	0	0
pT1c	63	0	4	1
pT2-3	57	5	15	10

Three patients were lost to follow-up.

Table 34-4 Characteristics of Patients With a Local Relapse

	pT	pN	Age	ER/PgR	Ki67	Others
First patient	2	1a	41	+	60	
Second patient	2	3a	56	—	33	
Third patient	2	1a	39	—	18	PVI+
Fourth patient	2	0	35	—	70	Margin+
Fifth patient	2	1a	33	—	40	

PVI, Peritumoral vascular invasion.

Table 34-5 Prognostic Factors for the Development of Local Recurrence, Distant Metastasis, and Death in 57 pT2-3 Oncoplastic Breast Cancer Patients

	Local Recurrence HR (CI) (5 events)	Distant Metastases HR (CI) (16 events)	Death HR (CI) (10 events)
Age <45 years	22.5 (1.37-370) $p = 0.029$	6.35 (1.77-22.8) $p = 0.005$	12.5 (1.72-90.9) $p = 0.013$
ER or PgR	4.68 (0.41-53.7) NS	4.86 (1.31-18.0) $p = 0.018$	8.91 (1.07-74.3) $p = 0.043$
Two or more positive nodes	5.04 (0.26-97.6) NS	9.59 (2.62-35.1) $p = 0.0006$	20.7 (2.74-156) $p = 0.003$

The hazard ratio (HR), 95% confidence intervals (CI), and p value were obtained from the multivariate Cox proportional hazards regression model. (No association was found with the tumor grade, plurifocality, PVI, or Ki67.) NS, Not significant.

The sequence of events in 59 patients with pT2-3 tumors shows that 43 (73%) are free of disease, 5 (8%) had a local relapse (all developed distant metastases, and 4 died from the disease), and 11 (19%) developed distant metastases (6 died).

Other Events and the Contralateral Breast

Table 34-6 Oncoplastic Remodeling and Histologic Findings in the Contralateral Breast

Oncoplastic Remodeling of the Contralateral Breast	Cases (N = 148)
Reductive mammoplasty	135
Mastopexy	9
Definitive silicone implant	4
Histologic Findings in Reduction Specimen	Cases (N = 135)
Normal breast tissue	40
Fibrocystic disease	31
Proliferative fibrocystic disease	53
Proliferative disease with atypia	2
Ductal carcinoma in situ	6
Lobular carcinoma in situ	2
Invasive ductal carcinoma	1

Four patients underwent a quadrantectomy, four underwent a total mastectomy, and one had a modified radical mastectomy in the contralateral breast, because a second breast tumor was diagnosed in the follow-up.

Mortality

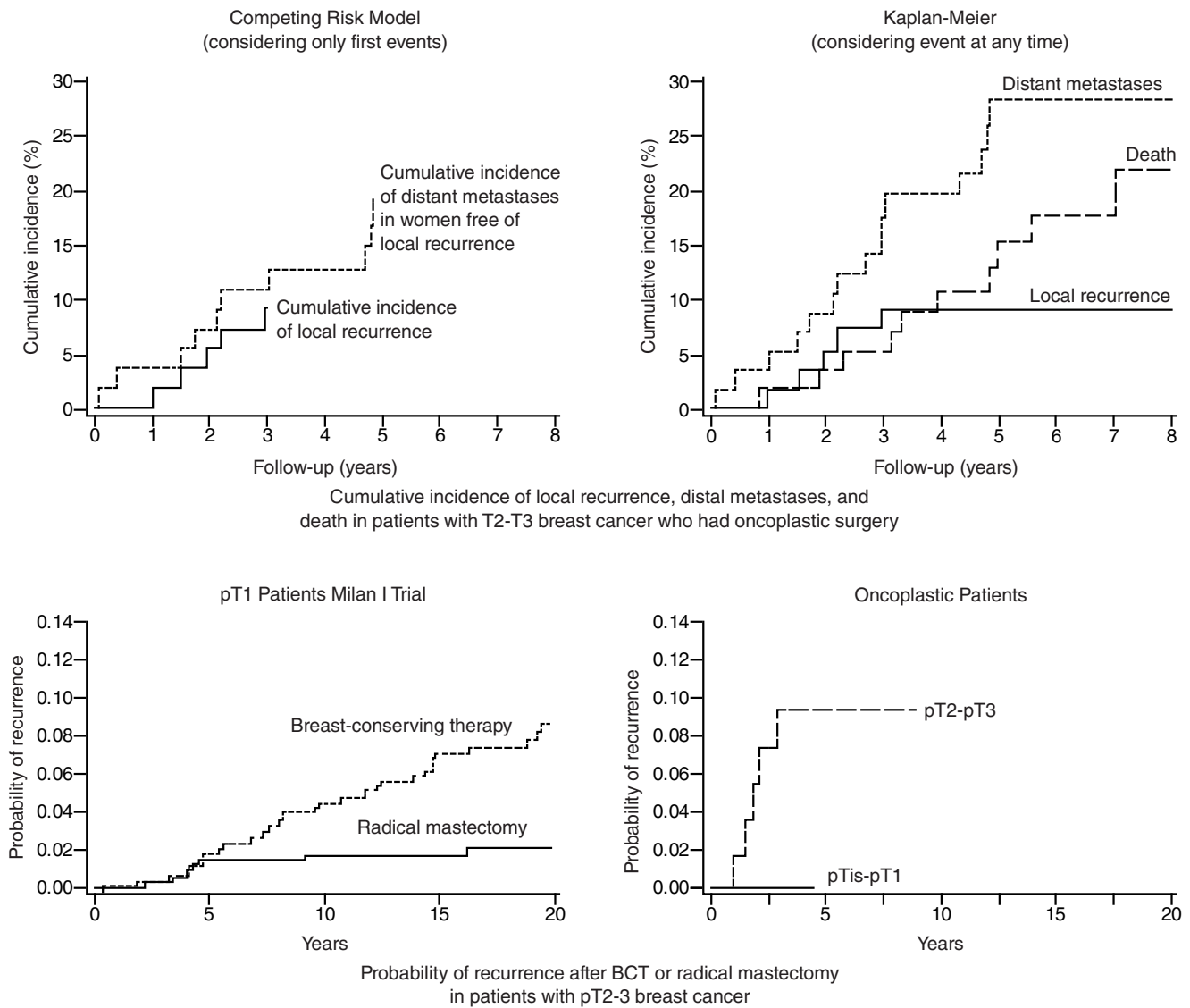


Fig. 34-1

Eleven patients (7.4%) died of breast cancer at a median of 45 months after the first surgery. Ten patients had T2 tumors, 7 had a histologic grade of G3, 6 were ER/PgR negative, and 7 had positive axillary lymph nodes. (For the long-term oncologic results in oncoplastic surgery of the breast, see Table 34-3.) No events were registered in the DCIS group.

Eighteen-Year Follow-up Assessment

In the secondary follow-up 18 years after the beginning of our study, 32 (21.6%) patients were excluded because of unavailable data in our hospital records and patient noncompliance. The remaining charts were updated regarding the current medical status of the disease until August 2015. Adequate follow-up was possible in 116 patients (78.4%) who were contacted by phone or through a family member and were the only ones considered in our updated analysis. The mean time of follow-up was 18 years (16 to 21 years), and the patient's average age was 67 years (46 to 87 years).

There were a total of 35 (30.1%) deaths related to breast cancer and 4 (3.4%) associated with other malignancies or cardiovascular events. Eleven deaths (9.5%) corresponded to our first 6-year study period, and 24 patients (20.7%) were deceased during our second follow-up 12 years later. No evidence of disease (NED) was confirmed in 69 patients (59.5%) who had a recent visit to the physician no more than 12 months before, and showed a negative clinical and imaging examination. There were 5 (4.3%) new local recurrences, all of them being good candidates for a second surgical intervention with either mastectomy or further breast-conserving treatment. All of the patients who presented with local relapse are alive. Distant metastasis was shown in 3 (2.6%) new patients who were also alive and under treatment with chemotherapy in a palliative setting. These 3 metastatic patients were very young at diagnosis; they were 21, 30, and 37 years of age when included in our study, and they subsequently developed distant metastases 17, 19, and 20 years later, respectively. Four patients (3.5%) reported some degree of breast asymmetry or contracture following whole-breast radiotherapy. Three of these patients had no evidence of disease at the time of the interview regarding their cosmetic outcome. The fourth patient had distant metastasis when she was asked about her cosmetic result, which she judged to be poor. In 73 (62.9%) patients, cosmetic outcome was reported as good and acceptable, and patients seemed to be happy with their aesthetic result.

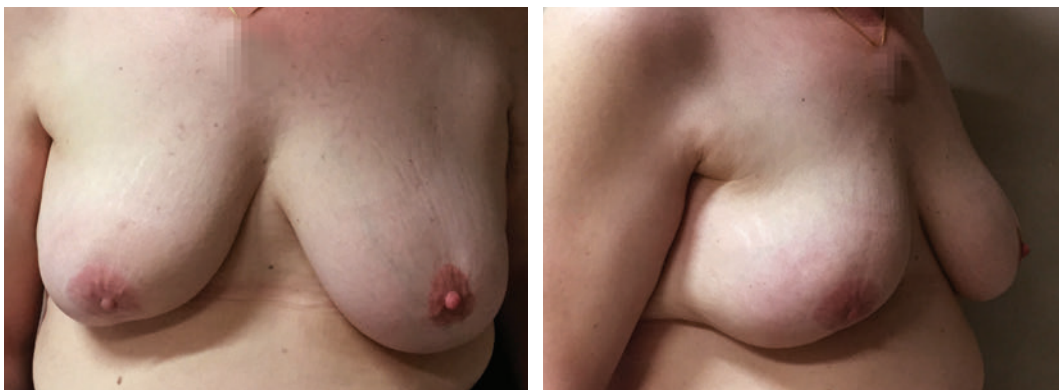

Fig. 34-2

These are current views of a 61-year-old patient who in 1997 underwent a tumor-adapted oncoplastic inferior quadrantectomy on the left breast for a T1c infiltrating ductal carcinoma. Axillary clearance was performed because of a metastatic sentinel lymph node biopsy, together with oncoplastic remodeling of the left defect and a reduction mammoplasty on

the right breast. Following surgery the patient received adjuvant radiochemotherapy. After 18 years of follow-up, the patient remains asymptomatic, free of disease, and satisfied with her cosmetic outcome.

DISCUSSION

The overall survival, disease-free survival, and the determination of risk factors for local and distant recurrences after BCT have been widely studied; however, the literature discussing oncoplastic techniques is limited. Our series of 148 patients began in 1994, and almost all patients received the current accepted complementary radiotherapy and systemic adjuvant therapy after BCT.¹¹ Recently we performed an updated analysis of our patient cohort up to August 2015, with a mean follow-up of 18 years. We were able to obtain data regarding local relapse, distant metastasis, death rate, and associated surgical complications and patients' degree of satisfaction with the cosmetic results. We compared the results with our previous 2006 analysis.

Traditionally, breast preservation has been associated with a lower local control and higher rates of positive margins than mastectomy. The reported rates of positive margins in the final excision specimens range from 10% in the National Surgical Adjuvant Breast and Bowel Project (NSABP B-06) trial to 48% in the European Organization for Research and Treatment of Cancer (EORTC) trial.^{12,13} Nonrandomized studies have found similar results of close (2 mm) or positive margins.¹⁴ In final resection specimens, both of these results are associated with an increased risk of local recurrence, and all efforts to avoid reexcision with more aggressive adjuvant treatments have failed.¹⁴⁻¹⁶

Nevertheless, new concepts in margin control have been introduced in routine practice. Based on serious meta-analysis, it has been demonstrated that differences between 1, 2, or 5 mm margins does not have an impact in local recurrence. Currently the definition of pathologic negative margin of no ink on tumor has become generally accepted as the standard, and advances in radiotherapy delivery and systemic therapy, result in an approximately 50% reduction in the rates of local recurrence for patients who undergo BCT with an oncoplastic approach.¹⁷⁻¹⁹ In 2005 Kaur et al²⁰ reported the safety and efficacy of surgical margins when an oncoplastic approach was performed at our Institution (European Institute of Oncology, Milan), and found that when compared with classic quadrantectomy, negative margins had significantly higher rates in the group of patients with an oncoplastic approach. This study showed an average surgical margin of 8.5 mm in the oncoplastic group compared with 6.5 mm with classic quadrantectomy. A recent meta-analysis by Losken et al²¹ confirmed these data by comparing positive margin rates between oncoplastic (12%) and nononcoplastic BCT (21%). This low rate of pathologic positive margins can be extrapolated to understand the low reexcision rates of 2.4% to 4% among the oncoplastic group of patients when compared with 14.5% reexcision rates reported in the nononcoplastic BCT group.²²

Although clear surgical margins are fundamental in BCT, wide excision of tumors may involve removing up to 20% of the breast volume and must be followed by radiotherapy

Poor aesthetic outcomes may not be limited to mastectomy patients,²³ because the volume of resected breast has been shown to directly correlate with ultimate cosmetic outcomes.²⁴ Consequently, after BCT without oncoplastic techniques and radiotherapy, up to 30% of patients are expected to require a surgical correction of the residual deformity.²⁵

Oncoplastic surgery was conceived to address anatomic concerns related to unfavorable tumor size and tumor site, in an effort to obtain local control and cosmesis, and optimize sequencing of surgery and radiation.²⁶ Currently, oncoplastic surgery is indicated for patients with large tumors when a standard BCT is not suitable and for patients with a high risk of gross deformity after BCT.¹ In our series, 40% of the patients had tumors larger than 2 cm, and the mean weight of the resection specimen was 198 g, which is about four times the volume of a standard quadrantectomy in our institution. Our rate of negative margins was subsequently higher than that for most series of BCT alone.

A major difference between our series and the randomized BCT trials was the inclusion criteria. The NSABP trial excluded tumors greater than 4 cm, and the Milan I trial excluded tumors greater than 2 cm, which in our series represent 11% and 42% of the cases, respectively. The National Cancer Institute (NCI) trial allowed patients with T1c and T2 tumors in a proportion that was similar to that of our group. At the 18-year follow-up of this trial, 22% of the patients had ipsilateral in-breast events.²⁷ We reported in the other two BCT landmark trials, the overall rate of ipsilateral failure was 14.3% (NSABP) and 8.8% (Milan trial). The recently published data from the Institute Curie of 101 patients who underwent an oncoplastic procedure with a mean follow-up of 3.8 years show an actuarial 5-year local recurrence rate of 9.4%.¹ These results correlate with our 8.6% local recurrence rate in our cohort of 116 patients who underwent an oncoplastic procedure and were followed during a period of 18 years. Also, our 3% of local recurrence rate at 24-month follow-up is consistent with the report of Losken et al,²¹ who observed a local recurrence rate of 4% at 37 months' follow-up. Similar to the Milan II trial, which compared quadrantectomy with tumorectomy and showed that the more extensive local surgery resulted in more than a threefold reduction in local failures, we believe that the low rate of local failure in our series (3% during the first 24 months of follow-up and 8.6% at 18 years) may be attributed, in part, to a more radical surgery.²⁸ In addition, the importance of effective local and systemic adjuvant treatments for node-positive and node-negative patients cannot be ignored.

In our series, the observed recurrence peak in a T2 patient is in a higher level, but parallels the curve observed after mastectomy in the Milan I trial in patients with tumors less than 2 cm, as shown in Fig. 34-1. This finding suggests that this early local recurrence is not a random event, but arises from occult micrometastatic foci of an aggressive tumor and is not related to a partial or inadequate surgical resection. All of these patients developed distant metastases, and almost all of them died from the disease. In our 18-year follow-up analysis, distant metastasis was observed in 3 patients, all of them very young at the time of diagnosis, with an average age of 30 years and currently alive with some type of palliative chemotherapy.²² Following this hypothesis, it could be assumed that radical local treatment, in association with complementary radiotherapy and adjuvant systemic therapy, is important to decrease the risk of local failure after BCT. However, this treatment is not enough to “cure” breast cancer and avoid systemic metastasis leading to death, as observed after mastectomy in which local recurrences represent a component of widespread relapse and are rarely an isolated event.²⁹

The most established risk factors for local recurrence after BCT are young age, positive resection margins, multicentric disease, and vascular invasion. These factors seem to have less prognostic value for local recurrences after oncoplastic surgery, because a tumor diameter greater than 2 cm was the only statistically significant prognostic factor in our series (see Table 34-2).

The low incidence of local recurrence after oncoplastic surgery is similar to that observed after a skin-sparing mastectomy. In a consecutive series of 176 patients with a median follow-up of 73 months, Medina-Franco et al³⁰ showed a 4.5% rate of local recurrence after a skin-sparing mastectomy. As in our group, they found the size to be one of the most significant predictors of local recurrence after this procedure.

The symmetry procedure in the contralateral breast allows a good examination of the glandular tissue at the time of breast remodeling. This is important even if a tumor is not evident on preoperative examinations.^{3,31}

In seven patients (5%), we found clinically and radiologically occult contralateral cancers in the reduction specimen. In two patients (1%), we found fibrocystic disease with atypia, which is a unilateral predictor of breast cancer risk³² (see Table 34-6). These results show that there is an occult subgroup of patients with a high risk of contralateral cancer who must be closely followed after treating the contralateral breast tumor. No consistent data are available on the positive effects of reductive surgery in lowering the breast cancer risk in this group of patients or in patients with proliferative fibrocystic disease.

All efforts to expand the eligibility of patients for BCT and to decrease its associated morbidity have been focused on improving the patient's quality of life.³³ Until recently, the safety of oncoplastic surgery was not tested in specific trials because of technical and ethical difficulties with designing them.

Using this approach, we have shown low rates of local failure, even in patients with large tumors, and with consistency throughout 18 years of follow-up. Oncoplastic surgery or tumor-specific immediate reconstruction as it was described by Audretsch²⁶ and Bostwick has proved to be an oncologically safe procedure, with results similar to those of mastectomy concerning effectiveness and local control of the disease.

Critical Issues

- Long-term oncologic outcomes of oncoplastic surgery have proven it to be safe.
- Local recurrence and survival following oncoplastic procedures are low and comparable to nononcoplastic BCT or mastectomy.
- Patients degree of cosmetic satisfaction is high when they undergo an oncoplastic approach.
- Careful patient selection and attention to margin status should minimize local recurrence rates when combined with tailored systemic therapy and radiotherapy.
- The risk of local and distant recurrence was higher in patients with tumors greater than 2 cm in diameter.

References

1. Clough KB, Lewis JS, Fitoussi A, et al. Oncoplastic techniques allow extensive resections for breast-conserving therapy of breast carcinomas. *Ann Surg* 237:26, 2003.
2. Singletary SE, Alfred C, Ashley P, et al. Revision of the American Joint Committee on Cancer staging system for breast cancer. *J Clin Oncol* 20:3628, 2002.
3. Rietjens M, Petit JY, Contesso G, et al. The role of reduction mammoplasty in oncology. *Eur J Plast Surg* 20:245, 1997.
4. Petit JY, Garusi C, Greuse M, et al. One hundred and eleven cases of breast conservation treatment with simultaneous reconstruction at the European Institute of Oncology (Milan). *Tumori* 88:41, 2002.
5. Pitanguy I. Surgical treatment of breast hypertrophy. *Br J Plast Surg* 20:78, 1967.
6. Lejour M. Vertical mammoplasty and liposuction of the breast. *Plast Reconstr Surg* 94:100, 1994.
7. Benelli L. A new periareolar mammoplasty: the “round block” technique. *Aesthetic Plast Surg* 14:93, 1990.
8. Viale G, Bosari S, Mazzarol G, et al. Intraoperative examination of axillary sentinel lymph nodes in breast carcinoma patients. *Cancer* 85:2433, 1999.
9. Graham RA, Homer MJ, Katz J, et al. The pancake phenomenon contributes to the inaccuracy of margin assessment in patients with breast cancer. *Am J Surg* 184:89, 2002.
10. Marubini E, Valsecchi MG. *Analyzing Survival Data From Clinical Trials and Observational Studies*. Chichester, UK: John Wiley & Sons, 1995.
11. Goldhirsch A, Wood WC, Gelber RD, et al. Meeting highlights: updated international expert consensus on the primary therapy of early breast cancer. *J Clin Oncol* 21:3357, 2003.

12. Fisher B, Anderson S, Bryant J, et al. Twenty-year follow-up of a randomized trial comparing total mastectomy, lumpectomy, and lumpectomy plus irradiation for the treatment of invasive breast cancer. *N Engl J Med* 347:1233, 2003.
13. van Dongen JA, Voogd AC, Fentiman IS, et al. Long-term results of a randomized trial comparing breast-conserving therapy with mastectomy: European Organization for Research and Treatment of Cancer 10801 trial. *J Natl Cancer Inst* 92:1143, 2000.
14. Neuschatz AC, DiPetrillo T, Safaii H, et al. Long-term follow-up of a prospective policy of margin-directed radiation dose escalation in breast-conserving therapy. *Cancer* 97:30, 2003.
15. Roukos DH, Kappas AM, Agnantis NJ. Perspectives and risks of breast-conservation therapy for breast cancer. *Ann Surg Oncol* 10:718, 2003.
16. Smitt MC, Nowels KW, Zdeblick MJ, et al. The importance of the lumpectomy surgical margins status in long-term results of breast conservation. *Cancer* 76:259, 1995.
17. Houssami N, Macaskill P, Marinovich ML, Morrow M. The association of surgical margins and local recurrence in women with early-stage invasive breast cancer treated with breast-conserving therapy: a meta-analysis. *Ann Surg Oncol* 21:717, 2014.
18. Houssami N, Morrow M. Margins in breast conservation: a clinician's perspective and what the literature tells us. *J Surg Oncol* 110:2, 2014.
19. Early Breast Cancer Trialists' Collaborative Group. Effect of radiotherapy after breast-conserving surgery on 10-year recurrence and 15-year breast cancer death: meta-analysis of individual patient data for 10,801 women in 17 randomised trials. *Lancet* 378(9804):1707, 2011.
20. Kaur N, Petit JY, Rietjens M, et al. Comparative study of surgical margins in oncoplastic surgery and quadrantectomy in breast cancer. *Ann Surg Oncol* 12:539, 2005.
21. Losken A, Pinell-White X, Hart AM, et al. The oncoplastic reduction approach to breast conservation therapy: benefits for margin control. *Aesthet Surg J* 34:1185, 2014.
22. Losken A, Dugal CS, Styblo TM, et al. A meta-analysis comparing breast conservation therapy alone to the oncoplastic technique. *Aesthet Surg J* 34:1185, 2014.
23. Baildam AD. Oncoplastic surgery of the breast. *Br J Surg* 89:532, 2002.
24. Wazer DE, DiPetrillo T, Schmidt-Ullrich R, et al. Factors influencing cosmetic outcome and complication risk after conservative surgery and radiotherapy for early-stage breast carcinoma. *J Clin Oncol* 10:356, 1992.
25. Clough KB, Cuminet J, Fitoussi A, et al. Cosmetic sequelae after conservative treatment for breast cancer: classification and results of surgical correction. *Ann Plast Surg* 41:471, 1998.
26. Audretsch W. Commentary on: The oncoplastic reduction approach to breast conservation therapy: benefits for margin control. *Aesthet Surg J* 34:1192, 2014.
27. Poggi MM, Danforth DN, Sciuto LC, et al. Eighteen-year results in the treatment of early breast carcinoma with mastectomy versus breast conservation therapy: the National Cancer Institute Randomized Trial. *Cancer* 98:697, 2003.
28. Veronesi U, Volterrani F, Luini A, et al. Quadrantectomy versus lumpectomy for small size breast cancer. *Eur J Cancer* 26:671, 1990.
29. Carlson GH. Local recurrence after skin-sparing mastectomy: a manifestation of tumor biology or surgical conservatism? *Ann Surg Oncol* 5:571, 1998.
30. Medina-Franco H, Vasconez LO, Fix RJ, et al. Factors associated with local recurrence after skin-sparing mastectomy and immediate breast reconstruction for invasive breast cancer. *Ann Surg* 235:814, 2002.
31. Petit JY, Rietjens M, Contesso G, et al. Contralateral mastoplasty for breast reconstruction: a good opportunity for glandular exploration and occult carcinomas diagnosis. *Ann Surg Oncol* 4:511, 1997.
32. Page DL, Schuyler PA, Dupont W, et al. Atypical lobular hyperplasia as a unilateral predictor of breast cancer risk: a retrospective cohort study. *Lancet* 361(9352):125, 2003.
33. Morrow M. Rational local therapy for breast cancer. *N Engl J Med* 347:1270, 2002.

CREDITS

CHAPTER 12

Fig. 12-1, B and G From Anderson BO, Masetti R, Silverstein MJ. Oncoplastic approaches to partial mastectomy: an overview of volume-displacement techniques. *Lancet Oncol* 6:145, 2005.

CHAPTER 15

Figs. 15-11, 15-12, B-E, 15-13 From Kronowitz SJ, Hunt KK, Kuerer HM, et al. Practical guidelines for repair of partial mastectomy defects using the breast reduction technique in patients undergoing breast conservation therapy. *Plast Reconstr Surg* 120:1755, 2007.

Fig. 15-12, A and F From Kronowitz SJ, Feledy JA, Hunt KK, et al. Determining the optimal approach to breast reconstruction after partial mastectomy. *Plast Reconstr Surg* 117:1, 2006.

Tables 15-1 through 15-3 From Kronowitz SJ, Feledy JA, Hunt KK, et al. Determining the optimal approach to breast reconstruction after partial mastectomy. *Plast Reconstr Surg* 117:1, 2006.

Tables 15-4 through 15-6 From Kronowitz SJ, Hunt KK, Kuerer HM, et al. Practical guidelines for repair of partial mastectomy defects using the breast reduction technique in patients undergoing breast conservation therapy. *Plast Reconstr Surg* 120:1755, 2007.

CHAPTER 16

Fig. 16-4 From Losken A, Styblo TM, Carlson GW, et al. Management algorithm and outcome evaluation of partial mastectomy defects treated using reduction or mastopexy techniques. *Ann Plast Surg* 59:235, 2007.

CHAPTER 22

Fig. 22-11 From Hamdi M, Spano A, Van Landuyt K, et al. The lateral intercostal artery perforators: anatomical study and clinical application in breast surgery. *Plast Reconstr Surg* 121:389, 2008.

Fig. 22-13 From Hamdi M, Van Landuyt K, Ulens S, et al. Clinical applications of the superior epigastric artery perforator (SEAP) flap: anatomical studies and preoperative perforator mapping with multidetector CT. *J Plast Reconstr Aesthet Surg* 62:1127, 2009.

CHAPTER 24

Fig. 24-1, 24-2 From Clough KB, Cuminet J, Fitoussi A, Nos C, et al. Cosmetic sequelae after conservative treatment for breast cancer: classification and results of surgical correction. *Ann Plast Surg* 41:471, 1998.

Figs. 24-3 through 24-12 From Clough KB, Nos C, Fitoussi A, et al. Séquelles esthétiques du traitement conservateur des cancers du sein: une classification pour les reconstructions après tumorectomie. *Annales de Chirurgie Plastique Esthétique* 53:88, 2008.

Tables 24-1, 24-2 Data from Clough KB, Thomas SS, Fitoussi AD, et al. Reconstruction after conservative treatment for breast cancer: cosmetic sequelae classification revisited. *Plast Reconstr Surg* 114:1743, 2004.

CHAPTER 26

Figs. 26-1, 26-3 From Slavin SA, Love SM, Sadowsky NL. Reconstruction of the radiated partial mastectomy defect with autogenous tissues. *Plast Reconstr Surg* 90:854, 1992.

Fig. 26-2 From Slavin SA. Reconstruction of the breast conservation patient. In Spear SL, Willey SC, Robb GL, et al, eds. *Surgery of the Breast: Principles and Art*, ed 2. Philadelphia: Lippincott Williams & Wilkins, 2006.

Box 26-1 Data from Slavin SA. Reconstruction of the breast conservation patient. In Spear SL, Willey SC, Robb GL, et al, eds. *Surgery of the Breast: Principles and Art*, ed 2. Philadelphia: Lippincott Williams & Wilkins, 2006.

INDEX

A

Ablative surgeon, perspective of, 39-41
 Accelerated partial breast irradiation (APBI), 94
 Adipose tissue regeneration, 540; *see also* Fat grafting
 Adjuvant chemotherapy
 in breast-conserving therapy management, 96
 operative complications and delay of, 117
 recurrence and, 611
 Advancement flaps
 breast tissue, in partial mastectomy deformity management, 127-128, 131
 dermoglandular, in partial mastectomy deformity management, 128-129, 131, 132-133, 136-137
 Advancement pedicles
 with central defects, 295-298, 296-298
 patient example, 296-298
 Aesthetic diagnostic round-block technique, 4
 Aesthetics
 patient example, 68
 principles of, 63-66
 scars in, 66
 shape in, 64-65
 size in, 63
 symmetry in, 65-66
 Aesthetic subunits, 66-67
 AICAP; *see* Anterior intercostal artery perforator flap (AICAP)
 American experience, 30-34

American Society of Breast Surgeons (ASBS), 43
 American Society of Plastic Surgeons (ASPS), 43
 Anatomic classification, 4-5; *see also* Breast composition
 Anatomic landmarks, in radiotherapy, 158
 Angiogenesis, 521
 Angiography, in distant flaps for partial mastectomy deformity, 420
 Anterior intercostal artery perforator flap (AICAP)
 in central defects, 298
 dissection in, 510
 Anterolateral intercostal nerves, 59, 60
 neuromas with, 60
 Anterolateral intercostal perforator, 57, 58
 Anteromedial intercostal nerves, 59, 60
 Anteromedial intercostal perforator, 57
 APBI; *see* Accelerated partial breast irradiation (APBI)
 ASBS; *see* American Society of Breast Surgeons (ASBS)
 ASPS; *see* American Society of Plastic Surgeons (ASPS)
 Assessment, 69-70
 in latissimus dorsi miniflap, 326-327
 in partial mastectomy deformity, 121-123
 patient example, 68
 principles in, 63-66
 ptosis in, 64
 results evaluation in, 70-71

scars in, 66
 shape in, 64-65
 size in, 63
 symmetry in, 65-66
 Association of Breast Surgery, 26
 Asymmetry; *see also* Symmetry
 avoidance of, 5
 congenital, 50
 in cosmetic sequelae classification, 435-437
 in latissimus dorsi myocutaneous flap, 10
 opposite breast management in, 17-18
 in quadrantectomy defect management, 142
 Atherosclerosis, 57
 Augmentation mammoplasty, thoracoacromial artery in, 58; *see also* Implant(s)
 Axilla, in breast-conserving therapy, 78-79

B

Backup options, in planning, 14-15
 Bacteria, ductal system and, 52
 Batwing mastopexy, 186-187
 BCS; *see* Breast-conserving surgery (BCS)
 BCT; *see* Breast-conserving therapy (BCT)
 Biesemberger maneuver, 191
 Blood supply
 in breast composition, 56-59
 in fat grafting, 521
 to muscles, 55
 skin and, 51
 Body image, 221, 223-224
 Boost radiotherapy, 162
 Bostwick, John, 355

- Bracketing wires, 114-115
- BRCA mutations, 76
- Breast bud, 50
- Breast composition, 51-63
 - blood supply in, 56-59
 - connective tissue in, 53-55
 - fat in, 53
 - glandular parenchyma in, 52
 - lymphatic system in, 62-63
 - muscles in, 55
 - nerve supply in, 59-60
 - skin in, 51-52
 - Würinger septum in, 60-62
- Breast-conserving surgery (BCS)
 - alternatives to, 18
 - appeal of, 89-90
 - failure to deliver promise of, 90-91
 - preoperative planning in, 181-182
 - selection criteria for, 121
 - spread of, 24
 - thoracodorsal artery perforator flaps in, 512-513
- Breast-conserving therapy (BCT)
 - axilla in, 78-79
 - clinical approach in, 490-493
 - contraindications for, 76
 - dead space in, 92-94
 - delayed management of unfavorable outcomes in, 99-101
 - in ductal carcinoma in situ, 157
 - equivalence with mastectomy, 157
 - goals of, 89-90
 - history of, 75
 - imaging in, 96
 - indications for, 76
 - mastectomy versus, outcomes with, 80
 - oncological significance of, 109-111
 - oncoplastic surgery and, 81-83
 - outcomes in, 80-81
 - patient expectations and, 91
 - patient selection for, 76
 - prediction of poor aesthetic result in, 92-94
 - preoperative analysis in, 490-491
 - radiotherapy in, 79-80
 - reconstructive methods in, 491-493
 - sentinel node in, 78-79
 - technique, 77-80
 - tumor resection in, 78
- Breast development, 49-50
- Breast embryology, 49-50
- Breast functionality, 90
- Breast implant, in matrix rotation, 7-9
- Breast lobules, 52
- Breast subunits, 51
- C**
- Cancer, determining extent of, 111-113
- Cancer recurrence, fat grafting and, 100
- Case study; *see* Patient example(s)
- Cavity shave margins, 116
- Central lesion
 - advancement pedicles with, 295-298, 296-298
 - algorithm for, 287
 - anterior intercostal perforator flaps in, 298
 - breast size and, 300-301
 - choice of technique with, 126, 182
 - dermoglandular advancement flaps in, 128-129
 - ellipse excision of, 288-290
 - Grisotti technique with, 182, 188-189, 294-295
 - in immediate versus delayed reconstruction, 246
 - lateral intercostal perforator flaps in, 298
 - latissimus dorsi muscle flap in, 332
 - in macromastia, 300
 - melon slice excision of, 289
 - nipple reconstruction in, 301
 - in parenchymal autoaugmentation, 278
 - patient examples, 187-189, 290, 293, 296-298
 - patient selection with, 285-286
 - pedicle design and, 243
 - procedure choice and, 182
 - ptosis and, 300-301
 - in rearrangement surgery, 463
 - retroareolar, 187
 - round block excision in, 290
 - scarring and, 78
 - simple excision of, 288-290
 - surgical techniques with, 286-300
 - volume displacement techniques with, 291-293
 - volume replacement procedures with, 298-300
 - wedge excisions with, 291-293
- Central pedicle, 246
- Central tumor reduction, 4
- Cervical plexus, 60
- Chemotherapy, neoadjuvant
 - in breast-conserving therapy management, 96
 - operative complications and delay of, 117
 - recurrence and, 611
- Circumareolar incision, in quadrantectomy defect management, 143
- Clips
 - cosmesis and, 163
 - in delayed reconstruction, 211, 212
 - perimeter, intraoperative placement of, 116
- Close margins, defined, 610
- Coastal Carolina Radiation Oncology, 164
- Collagen vascular disease, 57
- Compensation methods, in radiotherapy, 159
- Complications
 - adjuvant treatment delay and, 117
 - delayed, 596-597
 - in displacement techniques, 587-594
 - early, 444
 - with fat grafting, 534-535
 - immediate, 587-596
 - late, 444
 - with lateral intercostal perforator flap, 321
 - with lateral thoracodorsal flap, 318-319
 - with latissimus dorsi miniflap, 343
 - in lower defects, 592-593
 - with omental flap reconstruction, 381-383
 - overall rates, 588
 - parenchymal pedicle design and, 246
 - patient examples, 588-592, 598-603
 - in pedicled perforator flaps, 595
 - in perforator flaps, 595
 - psychological impact of, 223
 - rates of, by timing and technique, 235
 - in replacement techniques, 594-596
 - with rhomboid flap, 312

with subaxillary flap, 314
 tumor location and, 247
 in upper quadrant lesions, 592-593

Computed tomography angiography (CTA), in distant flaps for partial mastectomy deformity, 420

Congenital breast asymmetry, 50

Connective tissue, in breast composition, 53-55

Contralateral breast, 17-18
 asymmetry and, 5
 in cosmetic sequelae classification, 436-437
 immediate timing and, 208, 234
 mammaplasty in, 196-197
 occult carcinomas in, 234
 in parenchymal autoaugmentation, 265, 268-269
 in rearrangement surgery, 457-458
 recurrence and, 617
 in reduction mammaplasty, 249-254
 symmetry and, 147-148

Cooper ligament in breast composition, 54-55

Cosmesis
 defect locations and, 82
 periareolar incisions and, 125
 with radiotherapy, 94, 161-163
 resection volume and, 122

Cosmetic indications, for oncoplastic surgery, 174

Cosmetic quadrantectomy, 4
 defined, 6
 surgical sequence for, 6

Cosmetic sequelae, types of, 434-437, 446-451

Council of the British Association of Plastic Surgeons, 26

CTA; *see* Computed tomography angiography (CTA)

Cytology, in fat grafting, 540-541

D

DCIS; *see* Ductal carcinoma in situ (DCIS)

Dead space, 92-94

Decision-making
 in endoscopic latissimus dorsi flap reconstruction, 357

in immediate breast reconstruction, 234-235

in latissimus dorsi miniflap, 327-329

in pedicled perforator flap reconstruction, 388-393

psychological impact and, 224-225

in rearrangement surgery, 456-457

shared, with patient, 95-96

in team versus individual approach, 30

Deep inferior epigastric artery flap (DIEA), 420-425

Deep superior epigastric artery perforator (DSEAP), 393

Deformity classification and analysis
 cosmetic sequelae types in, 434-437, 446-451

implants and, 558-559

methods of, 434-437

tumor site in, 438

UICC classification in, 437-438

Deformity location; *see also specific locations*
 in classification, 438

complications and, 247

cosmesis and, 82

in local flap reconstruction, 477

in parenchymal autoaugmentation, 270-280

in pedicled perforator flap reconstruction, 389-390, 394-395

preoperative planning and, 182-197

in rearrangement surgery, 463

Delayed complications, 596-597

Delayed-immediate reconstruction, 214-215

Delayed reconstruction
 advantage of, 211

after quadrantectomy, 215-216

clips in, 211, 212

complication rates in, 235

in distant flaps for partial mastectomy deformity, 417

immediate versus, 211, 216

latissimus dorsi myocutaneous flap in, 215

patient example, 212, 214-216

pros and cons, 214

in rearrangement surgery, 465

in volume replacement with local flaps, 306

Dermatoglandular pedicle, in parenchymal autoaugmentation, 264

Dermoglandular advancement flaps, in partial mastectomy deformity management, 128-129, 131, 132-133, 136-137

Dermoglandular pedicle, in reduction mammaplasty, 241, 242

Development, breast, 49-50

Diabetes, 57

Differential inking techniques, 115-116

Donut mastopexy
 incision in, 183-184

nipple-areola complex in, 185

patient example, 183-185

in periareolar lesion, 183-185

residual gland displacement in, 185

sutures in, 185

Dosing, in radiotherapy, 94, 161-162

DSEAP; *see* Deep superior epigastric artery perforator (DSEAP)

Ductal carcinoma in situ (DCIS)
 breast-conserving therapy in, 157

in mammography, 112

margins with, 107

in ultrasonography, 112

Ductal system, bacteria and, 52-53

E

Ectoderm, 49

Edema, 62, 142, 249, 456

Education
 ablative surgeon, tools for, 41

patient
 psychological impact and, 225-226

tools for, 39

reconstructive surgeon, tools for, 42

for referring physicians, 42

Ellipse excision, for central defects, 288-290

Embryology, breast, 49-50

Emory University, 164

Endoscopic latissimus dorsi flap reconstruction
 decision-making process with, 357

harvesting in, 360

history of, 355

Endoscopic latissimus dorsi flap reconstruction—cont'd
 incisions in, 359
 limitations of, 367
 markings in, 359-360
 operating room setup for, 358
 outcomes with, 366-367
 patient examples, 364-366
 patient positioning for, 358
 patient selection for, 356
 surgical plan with, 357
 technique in, 359-363

EORTC; *see* European Organization for the Research and Treatment of Cancer (EORTC)

ETE; *see* External tissue expansion (ETE)

European experience, 23-28

European Organization for the Research and Treatment of Cancer (EORTC), 80

Expectation management, 95-96

Expectations, patient, 32, 91, 222-224

External mammary artery, 57

External mammary nodes, 62

External oblique

blood supply to, 55

insertion of, 55

nerve supply to, 55

origin of, 55

External tissue expansion (ETE); *see also* Fat grafting

clinical experience with, 534-535

mechanism of, 520

patient selection for, 529-531

postoperative care in, 533

scaffold creation with, 520

scarring and, 527-529

surgical technique, 531-533

F

Fascia, in breast composition, 53-54

Fat, in breast composition, 53

Fat grafting

adipose tissue regeneration and, 540

angiogenesis in, 521

blood supply restoration in, 521

cancer recurrence and, 100

clinical experience with, 534-535

complications in, 534-535

cytology in, 540-541

differentiation assay in, 541

graft survival principles in, 521-525

harvesting in, 531-532, 542-543

homogeneity of deposition in, 545

immunophenotypic analysis in, 541

implants and, 557

injection technique with, 546

mesenchymal stem cell fraction in, 540, 541

outcomes with, 541

patient examples, 547-551

patient selection for, 529-531

placement in, 544-546

planning in, 542

postoperative care in, 533

preparation of lipoaspirate in, 532-533

pressure increases with, 522

purification in, 543-544

radiotherapy and, 526-529

recipient site capacity in, 522-525

recurrence and, 100

scaffolding for, 520

scarring and, 527-529

stromal vascular cell fraction in, 540

surgical technique, 531-533, 542-546

surveillance and, 99

Fat necrosis

excision of, 410

incidence of, 164

ischemia and, 592

in lateral thoracodorsal flap, 319

in omental flap, 382

in oncoplastic versus nononcoplastic lumpectomies, 165

in partial mastectomy reconstruction, 266

in perforator flaps, 321

in quadrantectomy, 146

radiotherapy and, 213

recurrence versus, 207, 580-581

in reduction mammoplasty, 173

risk factors for, 53

undermining and, 58

volume displacement and, 83

Fetal breast development, 49

Fibrosis

in cosmetic sequelae classification, 436-437

implants and, 557

in radiotherapy, 161, 257

Flaps

anterior intercostal artery perforator, 592, 588-592

in central defects, 298

dissection in, 510

breast tissue advancement, in partial mastectomy deformity management, 127-128, 131

deep inferior epigastric artery, 420-425

deep superior epigastric artery, 393

dermoglandular advancement, in partial mastectomy deformity management, 128-129, 131, 132-133, 136-137

endoscopic latissimus dorsi muscle

decision-making process with, 357

evolution of technique, 326

harvesting in, 360

history of, 355

incisions in, 359

limitations of, 367

markings in, 359-360

operating room setup for, 358

outcomes with, 366-367

patient examples, 364-366

patient positioning for, 358

patient selection for, 356

surgical plan with, 357

technique in, 359-363

in upper quadrant lesions, 196

glandular, in quadrantectomy defect management, 153

Grisotti, for central lesion, 182, 188-189, 294-295

intercostal artery perforator complications, 321

pedicled, 392

planning, 319

technique, 319

in volume replacement, 319-321

lateral intercostal perforator, 493

in central defects, 298

design principles, 507-509

dissection in, 509-512

indications for, 506

patient example, 319, 397

in volume replacement, 319

- lateral thoracic artery perforator
 - design principles, 507-509
 - dissection in, 509-512
 - indications for, 506
- lateral thoracodorsal
 - complications, 318-319
 - patient example, 315-317
 - planning, 318
 - technique, 318
 - in volume replacement, 309, 310, 314-319
- latissimus dorsi miniflap
 - assessment in, 326-327
 - axillary dissection in, 338
 - axillary incisions in, 331
 - back incisions in, 331
 - breast incisions in, 331
 - breast mobilization in, 336-337
 - closure in, 340
 - complications with, 343
 - decision-making with, 327-329
 - defect reconstruction in, 339
 - donor site bleeding in, 340
 - evolution of technique, 326
 - harvest in, 338-339
 - hematoma in, 340
 - implant versus, 330
 - incisions in, 330-331, 336
 - indications for, 326-327
 - margin analysis in, 338
 - markings in, 334
 - myocutaneous, 341-342
 - myosubcutaneous, 332, 334-340
 - oncologic outcomes with, 343-344
 - outcomes with, 342-346
 - partial mastectomy in, 337
 - patient examples, 347-350
 - patient positioning for, 335
 - preoperative planning with, 330-333
 - radiotherapy and, 329
 - rationale for choice of, 330
 - reexcision rates with, 342-343
 - surgical plan in, 333
 - surgical technique for, 333-342
 - technique choice in, 331-333
 - treatment decision in, 327-329
 - and two-stage procedures, 328
 - viability check in, 340
- latissimus dorsi myocutaneous
 - in central defects, 298
 - in delayed reconstruction, 215
 - indications for, 10
- markings in, 480
- outcomes with, 483
- patient example, 11, 473, 476-477, 482-486
- planning, 12-13, 477
- in study, 173
- surgical sequence, 10
- technique, 478-486
- in upper quadrant lesions, 196
- latissimus dorsi pedicle
 - conversion of, to thoracodorsal artery perforator flap, 405
 - in upper quadrant lesions, 196
- local
 - advantages of, 471
 - deformity location and, 477
 - disadvantages of, 472
 - flap selection in, 475
 - indications for, 472
 - outcomes with, 483
 - patient example, 7-9, 473, 476-477, 482-486
- perforator
 - design principles, 507-509
 - dissection in, 509-512, 514
 - harvesting of, 505
 - indications for, 506
 - at Nottingham Breast Institute, 506-516
 - outcomes with, 514-515
 - patient satisfaction with, 515
- skin quality in, 474
- surgical sequence, 9
- timing with, 471, 472
- in volume replacement
 - immediate versus delayed timing of, 306
 - indications for, 306-311
 - intercostal artery perforator flaps in, 319-321
 - lateral thoracodorsal flap in, 309, 314-319
 - limitations of, 310
 - oncologic aspects in, 321-322
 - patient example, 313, 315-317
 - rhomboid flaps in, 307, 311-312
 - subaxillary flap in, 308, 312-314
 - surveillance and, 321-322
- medial intercostal artery perforator, 510
- omental
 - advantages of, 383-384
- complications with, 381-383
- cosmetic outcomes with, 382
- defect location factors in, 371
- defect size factors in, 370-371
- harvesting in, 370, 374
- history of, 370
- limitations of, 384
- lower quadrant, 373, 375-377
- in obese patients, 371
- oncologic outcomes with, 382
- outcomes with, 380-381
- in partial breast reconstruction, 375-378, 383-384
- partial mastectomy in, 373-374
- patient examples, 378-379
- patient factors in, 371
- patient positioning for, 372
- patient selection in, 370-371
- preoperative planning for, 372
- technique for, 372-378
- tumor factors in, 370
- upper quadrant, 373-374, 377-378
- volumetric outcomes with, 382
- pedicled perforator flap, 493-497
 - advantages of, 409
 - anatomy in, 390
 - breast size in, 389
 - complications with, 595
 - decision-making process for, 388-393
 - defect location and, 389-390
 - goal of, 388
 - inferomedial defects in, 401-403
 - mapping in, 393-394
 - outcomes with, 409-410
 - patient examples, 396-401, 402-403, 406-408, 411, 494-497
 - perforators in, 390
 - planning in, 404-405
 - preoperative planning for, 393-403
 - radiotherapy and, 410
 - technique choice in, 394-395
 - technique for, 404-405
 - tumor factors in, 389
- perforator
 - aesthetic results with, 500-501
 - clinical approach in, 490-493
 - complications with, 595
 - free, 498-500
 - functional results with, 500-501
 - general guidelines for, 492

Flaps—cont'd

perforator—cont'd

local

- design principles, 507-509
- dissection in, 509-512, 514
- harvesting of, 505
- indications for, 506
- at Nottingham Breast Institute, 506-516
- outcomes with, 514-515
- patient satisfaction with, 515
- patient examples, 494-497, 499-500

in rearrangement surgery, 457

rhomboid

- complications, 312
- planning for, 311
- technique, 311
- in volume replacement, 307

serratus anterior artery perforator, 392, 399, 400-401

subaxillary

- complications with, 314
- patient example, 313
- planning for, 312
- technique, 312
- in volume replacement, 308, 312-314

superficial superior epigastric artery, 393

superior epigastric artery, 393, 402-403, 493

superior inferior epigastric artery, 420-425

thoracodorsal artery perforator, 493

- in breast-conserving surgery, 512-513
- in central defects, 298
- converting to muscle-sparing latissimus dorsi flap, 405
- dissection in, 514
- harvesting, 405
- indications for, 506
- patient example, 396-397, 406-408, 411, 494, 495-497
- pedicled, 391
- in upper quadrant lesions, 196
- transverse rectus abdominis musculocutaneous, 493
- in rearrangement surgery, 457
- selection of, 475

Functional breasts, 90

G

Glandular flap, in quadrantectomy defect management, 153

Glandular parenchyma, in breast composition, 52

Glandular tissue, protrusion of, 51

Grafting; *see* Fat grafting

Grisotti technique, for central lesion, 182, 188-189, 294-295

H

Halsted, William, 75

Hemimammary line, 191

Hopwood Body Image Score, 506

Hypofractionated whole-irradiation, 94

I

IBR; *see* Immediate breast reconstruction (IBR)ICAP; *see* Intercostal artery perforator flap (ICAP)IMA; *see* Internal mammary artery (IMA)

Imaging

- in breast-conserving therapy management, 96
- in determination of extent of disease, 111-113
- differential inking techniques in, 115-116
- in distant flaps for partial mastectomy deformity, 420
- in localization of lesions, 113
- perimeter clips in, 116
- in surveillance, 572-575

IMF; *see* Inframammary fold (IMF)

Immediate breast reconstruction (IBR), 4

- complication rates in, 235
- contralateral breast and, 208
- decision-making in, 234-235
- defect size and location in, 240
- delayed, 214-215
- delayed versus, 211, 216
- disadvantages of, 210, 211
- in distant flaps for partial mastectomy deformity, 416
- management algorithm in, 236-241
- margin issues and, 205, 207-208
- margin status and, 238-240
- nipple-areola complex proximity in, 240-241

oncologic advantages of, 205

outcomes with, 204-205

patient example, 203, 206, 209, 250-253

positive margins and, 207

and preoperative deformity potential, 202

pros and cons, 210

radiotherapy and, 213

reduction technique in, 241-254

scarring and, 207, 213

surveillance and, 207

technique selection for, 240-241

in volume replacement with local flaps, 306

Immediate complications, 587-596

Implant(s)

- access in placement of, 561
- breast mound and, 557
- in breast retraction, 559
- contraindications for, 557
- fat grafting and, 557
- fibrosis and, 557
- indications for, 557
- latissimus dorsi miniflap versus, 330
- in localized distortion, 558
- location in placement of, 561
- materials, 561
- in matrix rotation, 7-9
- patient examples, 562-567
- patient selection for, 556-559
- planning with, 560
- radiotherapy and, 555, 559
- saline, 561
- silicone, 561
- subglandular, 566-567
- submuscular, 562-565
- technique, 560-567
- in tissue deficiency, 558

Incisions

- in batwing mastopexy, 186
- in donut mastopexy, 183-184
- in endoscopic latissimus dorsi flap reconstruction, 359
- in Grisotti technique, 188
- in latissimus dorsi miniflap, 330-331, 336
- in partial mastectomy deformity management, 125-126
- in quadrantectomy defect management, 142, 144
- in reduction mammoplasty, 190, 242

Infant, breast milk secretion in, 50
 Infection; *see* Wound infection
 Inferior pedicle, 56, 246
 Inferolateral defects
 in rearrangement surgery, 463
 Inferomedial defects
 in pedicled perforator flap reconstruction, 401-403
 in rearrangement surgery, 463
 Inferomedial pedicle, in reduction mammoplasty, 244-246, 247-248
 Information access, 225-226
 Inframammary fold (IMF)
 clothing and, 91
 in functional breasts, 90
 in melon slice excision, 289
 in quadrantectomy defect management, 145
 Inframammary fold incision, in partial mastectomy deformity management, 126
 Inking techniques, differential, 115-116
 Institute Curie, 164
 Institute Verbeeten, 164
 Intercostal artery, 57
 Intercostal artery perforator flap (ICAP); *see also* Pedicled perforator flap reconstruction
 pedicled, 392
 planning for, 319
 technique, 319
 in volume replacement, 319-321
 Intercostal perforators, 57, 58, 390
 Intercostobrachial nerve, 59
 "Interface" Breast-Plastic Surgery Training Group, 26
 Internal mammary artery (IMA), 57, 422-423
 Internal mammary nodes, 62
 Internal mammary perforator, 57
 Inverted-T pattern
 in lower lesion, 182
 in rearrangement surgery, 458

J

J-scar pattern, 192

K

Keyhole pattern, in reduction mammoplasty, 194

L

Landmarks, in radiotherapy, 158
 Large resections, 96-98
 Lateral defect
 in parenchymal autoaugmentation, 273
 in pedicled perforator flap reconstruction, 394-395
 Lateral intercostal nerves, 59
 Lateral intercostal perforator flap (LICAP), 493; *see also* Pedicled perforator flap reconstruction; Perforator flaps
 in central defects, 298
 complications, 321
 design principles, 507-509
 dissection in, 509-512
 indications for, 506
 patient example, 319, 397
 in volume replacement, 319
 Lateral pedicle, 246
 Lateral thoracic artery perforator flap (LTAP)
 design principles, 507-509
 dissection in, 509-512
 indications for, 506
 Lateral thoracodorsal flap
 complications, 318-319
 patient example, 315-317
 planning, 318
 technique, 318
 in volume replacement, 309, 310, 314-319
 Latissimus dorsi miniflap
 assessment in, 326-327
 axillary dissection in, 338
 axillary incision in, 331
 back incisions in, 331
 breast incisions in, 331
 breast mobilization in, 336-337
 closure in, 340
 complications with, 343
 decision-making in, 327-329
 defect reconstruction in, 339
 donor site bleeding in, 340
 evolution of technique, 326
 harvest in, 338-339
 hematoma in, 340
 implants versus, 330
 incision for, 330-331, 336
 indications for, 326-327
 margin analysis in, 338
 markings for, 334

myocutaneous, 341-342
 myosubcutaneous, 332, 334-340
 oncologic outcomes with, 343-344
 outcomes with, 342-346
 partial mastectomy in, 337
 patient examples, 347-350
 patient positioning for, 335
 preoperative planning for, 330-333
 radiotherapy and, 329
 rationale for choice of, 330
 reexcision rates with, 342-343
 surgical plan for, 333
 surgical technique for, 333-342
 technique choice in, 331-333
 treatment decision in, 327-329
 and two-stage procedures, 328
 viability check in, 340
 Latissimus dorsi muscle flap, endoscopic
 decision-making process with, 357
 evolution of technique, 326
 harvesting in, 360
 history of, 355
 incisions in, 359
 limitations of, 367
 markings in, 359-360
 operating room setup for, 358
 outcomes with, 366-367
 patient examples, 364-366
 patient positioning for, 358
 patient selection for, 356
 surgical plan with, 357
 technique in, 359-363
 in upper quadrant lesions, 196
 Latissimus dorsi myocutaneous flap
 in central defects, 298
 in delayed reconstruction, 215
 indications for, 10
 markings in, 480
 outcomes with, 483
 patient example, 11, 473, 476, 477, 482-486
 planning, 12-13, 478-481
 in study, 173
 surgical sequence, 10
 technique, 478-486
 in upper quadrant lesions, 196
 Latissimus dorsi pedicle flap
 conversion of thoracodorsal artery perforator flap to, 405
 in upper quadrant lesions, 196
 Lejour technique, 152

LICAP; *see* Lateral intercostal perforator flap (LICAP)

Lipoaspirate; *see* Fat grafting

Lipograft, 531-532

Lobules, 52

Local flap reconstruction; *see also specific flaps*

- advantages of, 471
- deformity location and, 477
- disadvantages of, 472
- flap selection, 475
- indications for, 472
- outcomes with, 483
- patient example, 7-9, 473, 476, 477, 482-486

perforator

- design principles, 507-509
- dissection in, 509-512, 514
- harvesting of, 505
- indications for, 506
- at Nottingham Breast Institute, 506-516
- outcomes with, 514-515
- patient satisfaction with, 515
- skin quality in, 474
- surgical sequence, 9
- timing with, 471, 472, 474

in volume replacement

- immediate versus delayed timing of, 306
- indications for, 306-311
- intercostal artery perforator flaps in, 319-321
- lateral thoracodorsal flap in, 309, 314-319
- limitations of, 310
- oncologic aspects in, 321-322
- patient example, 313, 315-317
- rhomboid flaps in, 307, 311-312
- subaxillary flap in, 308, 312-314
- surveillance and, 321-322

Localization

- bracketing wires for, of extent of resection, 114-115
- of lesions, 113

Location of deformity; *see also specific locations*

- in classification, 438
- complications and, 247
- cosmesis and, 82
- in local flap reconstruction, 477
- in parenchymal autoaugmentation, 270-280

- in pedicled perforator flap reconstruction, 389-390, 394-395
- preoperative planning and, 182-197
- in rearrangement surgery, 463

Lower lesion

- complications with, 592-593
- cosmesis and, 82
- in omental flap reconstruction, 373, 375-377
- in parenchymal autoaugmentation, 276
- patient examples, 189-195, 190-195
- pedicle design and, 243, 244-248
- in pedicled perforator flap reconstruction, 401-403
- planning for, 189-195
- procedure choice and, 182
- in rearrangement surgery, 463
- reduction mammoplasty in, 190-195

Low pole tumor reduction mammoplasty, 4

L-scar technique, in lower lesion, 182

LTAP; *see* Lateral thoracic artery perforator flap (LTAP)

Lymphatic system, in breast composition, 62-63

Lymphedema, 62; *see also* Edema

M

Macromastia, 257; *see also* Size

Magnetic resonance imaging (MRI)

- in determination of extent of disease, 112-113
- in localization of lesions, 113
- in surveillance, 581-582

Mammaplasty; *see also* Flaps

- augmentation, thoracoacromial artery in, 58
- reduction

 - Biesemberger maneuver in, 191
 - contralateral breast in, 249-254
 - cosmetic outcomes in, 243
 - dermoglandular pedicle in, 241, 242
 - evolution of popularity of, 257
 - in immediate breast reconstruction, 241-254
 - incisions in, 190, 242
 - inferomedial pedicle in, 244-246, 247-248
 - J-scar pattern in, 192

- keyhole pattern in, 194
- in lower lesions, 182, 190-195
- nipple-areola complex in, 193
- as oncoplastic technique, 160-161
- in periareolar lesion, 187
- in study, 173
- sutures in, 192

Mammographic surveillance, 98, 573-575, 578-580

Mammography, in determination of extent of disease, 111-112

Markings, preoperative

- in endoscopic latissimus dorsi flap reconstruction, 359-360
- in latissimus dorsi miniflap, 334
- in latissimus dorsi myocutaneous flap, 480
- in omental flap reconstruction, 372
- in parenchymal autoaugmentation, 262
- in quadrantectomy defect management, 141-145
- in rearrangement surgery, 463
- in wedge excision, 292

Mastectomy; *see also* Partial mastectomy deformity management

- equivalence with breast-conserving therapy, 157
- partial, deformity management

 - assessment in, 121-123
 - breast advancement flaps in, 127-128, 131
 - decision-making in, 123-127
 - dermoglandular advancement flaps in, 128-129, 131, 132-133, 136-137
 - excision magnitude in, 121
 - general principles of, 175
 - incision choice in, 125-126
 - indications for, 121
 - inferior tumors in, 122, 123
 - inframammary fold incision in, 126
 - medial tumors in, 122
 - patient examples, 132-137, 176-178
 - periareolar incisions in, 125
 - periareolar mastopexy in, 130
 - positive margins in, 124-125
 - preoperative planning in, 124-127

- resection volume to breast volume ratio in, 122
 - “snoopy nose deformity” in, 123
 - technique choice in, 126-127
 - Mastopexy; *see also* Parenchymal autoaugmentation
 - batwing, 186-187
 - in central lesions, 182
 - donut
 - incision in, 183-184
 - nipple-areola complex in, 185
 - patient example, 183-185
 - in periareolar lesion, 183-185
 - residual gland displacement in, 185
 - sutures in, 185
 - as oncoplastic technique, 160
 - periareolar
 - in contralateral breast, 197
 - in partial mastectomy deformity management, 130
 - Matrix rotation
 - patient example, 7-9
 - surgical sequence, 9
 - McKissock bipedicle, 246
 - MD Anderson Cancer Center, 172
 - Medial defect
 - incisions for, 78
 - parenchymal autoaugmentation in, 259, 275
 - Medial intercostal artery perforator flap (MICAP), 510
 - Melon slice excision, with central defects, 289
 - Menopause
 - blood supply and, 56
 - fat in, 53
 - Mesenchymal stem cell (MSC) fraction, in fat grafting, 540, 541
 - Mesh expansion, 526-527
 - Metastatic disease, 614-616
 - MICAP; *see* Medial intercostal artery perforator flap (MICAP)
 - Midbreast line, 69
 - Milan Cancer Institute, 80
 - Milk ridge, 49, 50
 - “Mirror tumorectomy” technique, 149
 - MLC; *see* Multileaf collimation (MLC)
 - Mortality, 618
 - MRI; *see* Magnetic resonance imaging (MRI)
 - MSC; *see* Mesenchymal stem cell (MSC) fraction
 - Multidisciplinary team
 - members, 31
 - patterns of care from, 33-34
 - Multileaf collimation (MLC), in radiotherapy, 160
 - Muscles, in breast composition, 55
- N**
- NAC; *see* Nipple-areola complex (NAC)
 - National Cancer Institute (NCI), 80
 - National Surgical Adjuvant Breast Project (NSABP), 80, 109, 620, 621
 - NCI; *see* National Cancer Institute (NCI)
 - Necrosis
 - fat
 - excision of, 410
 - incidence of, 164
 - ischemia and, 592
 - in lateral thoracodorsal flap, 319
 - in omental flap, 382
 - in oncoplastic versus nononcoplastic lumpectomies, 165
 - in partial mastectomy reconstruction, 266
 - in perforator flaps, 321
 - in quadrantectomy, 146
 - radiotherapy and, 213
 - recurrence versus, 207, 580-581
 - in reduction mammoplasty, 173
 - risk factors for, 53
 - undermining and, 58
 - volume displacement and, 83
 - skin
 - in distant flaps, 425
 - incidence of, 204-205
 - in mammoplasty, 164
 - in omental flaps, 381
 - in subaxillary flap, 314
 - undermining and, 52
 - Neoadjuvant chemotherapy
 - in breast-conserving therapy management, 96
 - operative complications and delay of, 117
 - recurrence and, 611
 - Nerves
 - in breast composition, 59-60
 - in muscles, 55
 - skin and, 51
 - Neuromas, 60
 - Nipple, in assessment, 69-70
 - Nipple-areola complex (NAC)
 - in anatomic classification, 5
 - in assessment, 69
 - in batwing mastopexy, 187
 - central defects and, 301
 - in donut mastopexy, 185
 - in ellipse excision, 288
 - in Grisotti technique, 188
 - in immediate reconstruction, proximity of, 240-241
 - necrosis, 592
 - in periareolar mastopexy, 130
 - preservation of, 171-172
 - in quadrantectomy defect management, 148-149
 - in rearrangement surgery, 458, 459, 461
 - in reduction mammoplasty, 193
 - resection size and, 93
 - in “snoopy nose deformity,” 123
 - techniques for, 492
 - width, 69
 - wound dehiscence in, 592
 - Nipple height, 69
 - Nipples, supernumerary, 50
 - Nipple tilt, 70
 - No-man’s land
 - defined, 9
 - in parenchymal autoaugmentation, 260
 - Nottingham Breast Institute, 506-516
 - NSABP; *see* National Surgical Adjuvant Breast Project (NSABP)
- O**
- Obese patients
 - challenges of, 70
 - in omental flap reconstruction, 371
 - Omental flap reconstruction
 - advantages of, 383-384
 - complications with, 381-383
 - cosmetic outcomes with, 382
 - defect location factors in, 371
 - defect size factors in, 370-371
 - harvesting in, 370, 374
 - history of, 370
 - limitations of, 384
 - lower quadrant, 373, 375-377
 - in obese patients, 371

Omental flap reconstruction—cont'd
 oncologic outcomes with, 382
 outcomes with, 380-381
 in partial breast reconstruction, 375-378, 383-384
 partial mastectomy in, 373-374
 patient examples, 378-379
 patient factors in, 371
 patient positioning for, 372
 patient selection in, 370-371
 preoperative planning for, 372
 technique for, 372-378
 tumor factors in, 370
 upper quadrant, 373-374, 377-378
 volumetric outcomes with, 382

Oncological safety
 in parenchymal autoaugmentation, 280-281
 “scoop and run” approach and, 107

Oncoplastic surgery
 ablative surgeons; perspective in, 39-41
 anatomic classification in, 4-5
 beneficiaries of, 38-44
 benefits of, 171-174
 breast-conserving therapy and, 81-83
 choice of techniques in, 83
 cosmetic indications or, 174
 evolution of, 23
 initial focus of, 3
 large resections in, 96-98
 milestones in history of, 24
 models, 27-28
 origin of, 3-4
 origin of term, 3, 23
 outcomes, 163-166
 patient perspective in, 38-39
 patient selection for, 174-175
 single versus team approach in, 37
 tumor-specific immediate reconstruction and, 4
 two-surgeon model and, 24

Oncoplastic techniques, 160-161

Operating room time issues, 40

Opposite breast management, 17-18

Outcomes
 in breast-conserving therapy, 80-81
 with endoscopic latissimus dorsi flap reconstruction, 366-367
 with fat grafting, 541

with immediate breast reconstruction, 204-205
 with latissimus dorsi mini flap, 342-346
 with latissimus dorsi myocutaneous flap, 483
 with local flap reconstruction, 483
 with omental flap reconstruction, 380-381
 in parenchymal autoaugmentation, 280-281
 poor, management of, 598-604
 radiotherapy, 163-166
 in reduction mammoplasty, 243

P

Parenchymal autoaugmentation
 central defects in, 278
 contralateral breast in, 265, 268-269
 decision-making process in, 258
 defect in, 259-260
 defect location in, 270-280
 dermatoglandular pedicle in, 264
 indications for, 258
 lateral defect in, 273
 lower defect in, 276
 medial defect in, 259, 275
 no-man's land in, 260
 oncologic safety in, 280-281
 outcomes in, 280-281
 partial mastectomy reconstruction in, 262-263
 patient examples, 264-267, 269, 273-274, 276-277, 278-279, 282
 patient selection for, 261
 preoperative marking in, 262
 preoperative planning in, 261
 quadrantectomy defect in, 259
 reconstructive goals in, 260
 secondary pedicle in, 266, 267
 skin pattern in, 268
 special considerations with, 281-282
 surgical plan in, 260
 surgical technique in, 260-269
 tumor resection in, 262
 upper defect in, 259, 270
 Wise pattern in, 268

Partial mastectomy deformity management
 assessment in, 121-123

breast advancement flaps in, 127-128, 131
 decision-making in, 123-127
 dermoglandular advancement flaps in, 128-129, 131, 132-133, 136-137
 distant flaps in
 assessment in, 415-416
 deep inferior epigastric artery flap in, 420-425
 delayed, 417
 immediate, 416
 indications for, 415-416
 outcomes in, 425
 patient example, 424, 426-427
 patient selection for, 417-418
 preoperative planning for, 418-419
 superior inferior epigastric artery flap in, 420-425
 surgical planning in, 419
 technique for, 420-423
 timing of, 416
 treatment decisions in, 418
 excision magnitude in, 121
 failure in, aesthetic, 455
 general principles of, 175
 incision choice in, 125-126
 indications for, 121
 inferior tumors in, 122, 123
 inframammary fold incision in, 126
 latissimus dorsi mini flap and, 337
 medial tumors in, 122
 omental flap reconstruction and, 373-374, 375-378, 383-384
 in parenchymal autoaugmentation, 262-263
 patient examples, 132-137, 176-178
 periareolar incisions in, 125
 periareolar mastopexy in, 130
 positive margins in, 124-125
 preoperative planning in, 124-127
 resection volume to breast volume ratio in, 122
 “snoopy nose deformity” in, 123
 technique choice in, 126-127

Partial reconstruction, 4

Patient decision-making, shared, 95-96
 wedge excision, 293

Patient education
 psychological impact and, 225-226
 tools for, 39

- Patient example(s)
 advancement pedicle, 296-298
 aesthetics, 68
 assessment, 68
 central lesion, 187-189, 290, 292, 296-298
 complications, 588-592, 598-603
 contralateral breast, 197
 delayed reconstruction, 212, 214-216
 distant flaps in partial reconstruction, 424, 426-427
 donut mastopexy, 183-185
 endoscopic latissimus dorsi flap reconstruction, 364-366
 fat grafting, 547-551
 Grisotti technique, 188-189
 immediate timing, 203, 206, 209, 250-253
 implants, 562-567
 lateral intercostal perforator flap, 319, 397
 lateral thoracodorsal flap, 315-317
 latissimus dorsi miniflap, 347-350
 latissimus dorsi myocutaneous flap, 11, 473, 476, 477, 482-486
 local flap reconstruction, 7-9, 473, 476, 477, 482-486
 lower lesion, 189-195
 matrix rotation, 7-9
 melon slice excision, 289
 omental flap reconstruction, 378-379
 parenchymal autoaugmentation, 264-267, 269, 273-274, 276-277, 278-279, 282
 partial mastectomy deformity management, 132-137, 176-178
 pedicled perforator flap reconstruction, 396-401, 402-403, 406-408, 411, 494-497
 periareolar lesion, 183-189
 periareolar mastopexy, 197
 planning, 12-13, 15-16
 quadrantectomy defect management, 149-153
 rearrangement surgery, 459-462, 464, 466-467
 reduction mammoplasty, 190-195
 skin-sparing mastectomy, 15
 "smile" mastectomy, 15-16
 superior epigastric artery flap, 402-403
 surveillance, 576-577
 thoracodorsal artery perforator flap, 396-397, 406-408, 494, 495-497
 upper quadrant lesions, 8, 9, 16, 186, 188, 193
 volume replacement, 313, 315-317
 Patient expectation management, 95-96
 Patient expectations, 32, 91, 222-224
 Patient perspective, 38-39
 Patient positioning
 for endoscopic latissimus dorsi flap reconstruction, 358
 for latissimus dorsi miniflap, 335
 for omental flap reconstruction, 372
 Patient satisfaction
 expectations and, 222-224
 in local perforator flaps, 515
 in mastectomy versus oncoplastic surgery, 171, 172-173
 in partial mastectomy, 455
 Patient selection
 for breast-conserving surgery, 121
 for breast-conserving therapy, 76
 with central defects, 285-286
 in distant flaps for partial mastectomy deformity, 417-418
 in endoscopic latissimus dorsi flap reconstruction, 356
 for external tissue expansion, 529-531
 for fat grafting, 529-531
 for implants, 556-559
 in omental flap reconstruction, 370-371
 for oncoplastic surgery, 174-175
 for parenchymal autoaugmentation, 261
 Pectoralis major
 blood supply to, 55, 57-58
 insertion of, 55
 nerve supply to, 55
 origin of, 55
 Pectoralis minor
 blood supply to, 55
 insertion of, 55
 nerve supply to, 55
 origin of, 55
 Pedicled perforator flap reconstruction, 493-497
 advantages of, 409
 anatomy in, 390
 breast size in, 389
 complications with, 595
 decision-making process for, 388-393
 defect location and, 389-390
 goal of, 388
 inferomedial defects in, 401-403
 mapping in, 393-394
 outcomes with, 409-410
 patient examples, 396-401, 402-403, 406-408, 411, 494-497
 perforators in, 390
 planning in, 404-405
 preoperative planning for, 393-403
 radiotherapy and, 410
 technique for, 404-405
 tumor factors in, 389
 Peer support, 226
 Percutaneous mesh expansion, 526-527
 Perforator flaps; *see also specific flaps*
 aesthetic results with, 500-501
 clinical approach in, 490-493
 complications with, 595
 free, 498-500
 functional results with, 500-501
 general guidelines for, 492
 local
 design principles, 507-509
 dissection in, 509-512, 514
 harvesting of, 505
 indications for, 506
 at Nottingham Breast Institute, 506-516
 outcomes with, 514-515
 patient satisfaction with, 515
 patient examples, 494-497, 499-500
 preoperative deformity analysis in, 490-491
 Periareolar incision
 in partial mastectomy deformity management, 125
 in quadrantectomy defect management, 144
 Periareolar lesion
 batwing mastopexy in, 186-187
 patient example, 183-189
 procedure choice and, 182
 reduction mammoplasty in, 187

Periareolar mastopexy
 in contralateral breast, 197
 in partial mastectomy deformity management, 130

Perimeter clips, intraoperative placement of, 116

Phipp chart, 14

Planning
 backup options and, 14-15
 with central defects, 285-286
 in endoscopic latissimus dorsi flap reconstruction, 357
 in fat grafting, 542
 with implants, 560
 in parenchymal autoaugmentation, 260
 patient example, 12-13, 15-16
 in pedicled perforator flap reconstruction, 404-405

Phipp chart in, 14

preoperative, 12
 in breast-conserving surgery, 181-182
 in distant flaps for partial mastectomy deformity, 418-419
 in latissimus dorsi miniflap, 330-333
 in parenchymal autoaugmentation, 261
 in partial mastectomy deformity management, 124-127
 in pedicled perforator flap reconstruction, 393-403
 tumor location and, 182-197

procedures in, 12

in rearrangement surgery, 456, 463

Positioning, patient
 for endoscopic latissimus dorsi flap reconstruction, 358
 for latissimus dorsi miniflap, 335
 for omental flap reconstruction, 372

Positive margins, defined, 610

Preference sensitivity, 225

Preoperative markings
 in endoscopic latissimus dorsi flap reconstruction, 359-360
 in latissimus dorsi miniflap, 334
 in latissimus dorsi myocutaneous flap, 480
 in omental flap reconstruction, 372
 in parenchymal autoaugmentation, 262

in quadrantectomy defect management, 141-145
 in rearrangement surgery, 463
 in wedge excision, 292

Preoperative planning, 12
 in breast-conserving surgery, 181-182
 in distant flaps for partial mastectomy deformity, 418-419
 in latissimus dorsi miniflap, 330-333
 in parenchymal autoaugmentation, 261
 in partial mastectomy deformity management, 124-127
 in pedicled perforator flap reconstruction, 393-403
 tumor location and, 182-197

Pseudoptosis, defined, 64

Psychological impact of breast reconstruction, 221-222
 body image and, 223-224
 complications and, 223
 decision-making and, 224-225
 information access and, 225-226
 patient expectations and, 222-224
 patient satisfaction and, 222-224
 peer support and, 226
 preference sensitivity and, 225
 psychological support and, 226-227

Psychological support, 226-227

Ptosis
 central defects and, 300-301
 classification of, 64

Puberty, breast development in, 50

Q

Quadrantectomy
 defined, 77
 delayed reconstruction after, 215-216
 fat necrosis in, 146
 technique, in quadrantectomy defect management, 146-147

Quadrantectomy defect management
 asymmetry in, 142
 breast size and, 142
 circumareolar incision in, 143
 glandular flap in, 153
 glandular plane approximation in, 151
 incisions in, 142, 144

inframammary fold in, 145
 Lejour technique in, 152
 “mirror tumorectomy” technique in, 149
 nipple-areola malposition in, 148-149
 parenchymal autoaugmentation in, 259
 patient examples, 149-153
 periareolar deepithelialization in, 151
 periareolar incision in, 144
 preoperative markings in, 141-145
 quadrantectomy technique in, 146-147
 scar positioning in, 143
 symmetry improvement in, 147-149
 Z-plasty in, 149

R

Radiotherapy
 accelerated partial breast irradiation in, 94
 anatomic landmarks in, 158
 anticipating impact of, 94-95
 avoidance of, 95
 boost, 162
 in breast-conserving therapy, 79-80
 breast size and, 162, 257
 clips in, 163
 compensation methods in, 159
 cosmesis with, 94, 161-163
 dosing in, 94
 edema and, 456
 fat grafting and, 526-529
 fat necrosis and, 213
 fibrosis in, 161, 257
 hypofractionated whole-breast irradiation in, 94
 immediate reconstruction and, 213
 implants and, 555, 559
 latissimus dorsi miniflaps and, 329
 multileaf collimation in, 160
 outcomes, 163-166
 pedicled perforator flap reconstruction and, 410
 skin-sparing mastectomy and, 18
 tangent beam in, 158
 toxicity, 160, 161-163
 wedge compensators in, 159
 whole-breast irradiation in, 157

- Rearrangement surgery
 - contralateral reduction in, 457-458
 - decision-making in, 456-457
 - defect location in, 463
 - delayed, 465
 - nipple-areola complex in, 458, 459, 461
 - operative strategy in, 457-458
 - patient examples, 459-462, 464, 466-467
 - planning in, 456, 463
 - preoperative markings in, 463
 - shape in, 458
 - short-scar periareolar inferior pedicle reduction in, 462, 466-467
 - skin in, 456
 - technique choice in, 463
 - technique in, 463-467
 - transverse rectus abdominis musculocutaneous in, 457
- Reconstructive surgeon perspective, 41-43
- Rectus abdominis
 - blood supply to, 55
 - insertion of, 55
 - nerve supply to, 55
 - origin of, 55
- Recurrence
 - contralateral breast and, 617
 - fat grafting and, 100
 - fat necrosis versus, 207, 580-581
 - follow-up in, 611
 - histopathologic examination in, 610-611
 - metastatic disease and, 614-616
 - mortality and, 618
 - partial breast reconstruction and, 571
 - patient characteristics in, 615
 - prognostic factors in, 616
 - in statistical analysis, 612
 - in surgical approach, 610
- Reduction mammoplasty; *see also* Parenchymal autoaugmentation
 - Biesemberger maneuver in, 191
 - contralateral breast in, 249-254
 - cosmetic outcomes in, 243
 - dermoglandular pedicle in, 241, 242
 - evolution of popularity of, 257
 - in immediate breast reconstruction, 241-254
 - incisions in, 190, 242
 - inferomedial pedicle in, 244-246, 247-248
 - J-scar pattern in, 192
 - keyhole pattern in, 194
 - in lower lesions, 182, 190-195
 - nipple-areola complex in, 193
 - as oncoplastic technique, 160-161
 - in periareolar lesion, 187
 - in study, 173
 - sutures in, 192
 - Wise skin pattern in, 242
- Reexcision, for positive margins, 117
- Referring physicians, educational seminars for, 42
- Reimbursement issues, 40
- Relaxed skin tension lines (RSTL), 125
- Resection
 - bracketing wires to localize extent of, 114-115
 - size, 93
 - large, 96-98
- Rhomboid flap
 - complications, 312
 - planning for, 311
 - technique, 311
 - in volume replacement, 307, 311-312
- Rigotomies, 526-527
- Round block excision, in central defects, 290
- RSTL; *see* Relaxed skin tension lines (RSTL)
- S**
- SAAP; *see* Serratus anterior artery perforator flap (SAAP)
- Safety, oncological
 - in parenchymal autoaugmentation, 280-281
 - “scoop and run” approach and, 107
- Saline implants, 561; *see also* Implant(s)
- Satisfaction, patient
 - expectations and, 222-224
 - in local perforator flaps, 515
 - in mastectomy versus oncoplastic surgery, 171, 172-173
 - in partial mastectomy, 455
- Scar positioning, in quadrantectomy defect management, 143
- Scars
 - in breast aesthetics and assessment, 66
 - central lesions and, 78
 - fat grafting and, 527-529
 - in immediate reconstruction, 213
 - immediate timing and, 207
 - in melon slice excision, 289
 - tissue expansion and, 527-529
 - “Scoop and run” approach, 107
- SEAP; *see* Superior epigastric artery flap (SEAP)
- Secondary internal mammary perforator, 57, 58
- Selection, patient
 - for breast-conserving surgery, 121
 - for breast-conserving therapy, 76
 - with central defects, 285-286
 - in distant flaps for partial mastectomy deformity, 417-418
 - in endoscopic latissimus dorsi flap reconstruction, 356
 - for external tissue expansion, 529-531
 - for fat grafting, 529-531
 - for implants, 556-559
 - in omental flap reconstruction, 370-371
 - for oncoplastic surgery, 174-175
 - for parenchymal autoaugmentation, 261
- Sentinel nodes, 62
 - in breast-conserving therapy, 78-79
- Septal perforators, 390
- Seroma, 595
- Serratus anterior
 - blood supply to, 55
 - insertion of, 55
 - nerve supply to, 55
 - origin of, 55
- Serratus anterior artery perforator flap (SAAP), 392, 399, 400-401
- Serratus anterior perforator, 390
- Shape
 - in breast aesthetics and assessment, 64-65
 - in cosmetic sequelae classification, 434-437
 - in rearrangement surgery, 458
- Short-scar periareolar inferior pedicle reduction (SPAIR), 462, 466-467

- Silicone implants, 561; *see also* Implant(s)
- Single-surgeon approach, 37
- Size
- in breast aesthetics and assessment, 63
 - central defects and, 300-301
 - as contraindication to breast conserving therapy, 257
 - in pedicled perforator flap reconstruction, 389
 - in quadrantectomy defect management, 142
 - radiotherapy and, 162, 257
 - resection, 93, 96-98
- Skin
- blood supply and, 51
 - in breast composition, 51-52
 - factors in quality of, 51
 - glandular tissue protrusion and, 51
 - innervation, 51
 - in local flap reconstruction, 474
 - in rearrangement surgery, 456
 - tension lines, 125
 - thickness, 51
 - types, 51
- Skin necrosis
- in distant flaps, 425
 - incidence of, 204-205
 - in mammaplasty, 164
 - in omental flaps, 381
 - in subaxillary flap, 314
 - undermining and, 52
- Skin-sparing mastectomy (SSM)
- anatomic classification and, 4
 - breast conservation and, 18
 - omental flap and, 384
 - patient example, 15
 - Phipp chart and, 14
 - radiotherapy and, 18
- “Smile” mastectomy, patient example, 15-16
- Smoking, 57
- “Snoopy nose deformity,” 123
- Sonography, 581
- SPAIR; *see* Short-scar periareolar inferior pedicle reduction (SPAIR)
- Specialist Advisory Committee, 26
- Specialties, territorial divides with, 25
- SSM; *see* Skin-sparing mastectomy (SSM)
- Staphylococcus epidermidis*, in ductal system, 52
- Stem cells; *see* Mesenchymal stem cell (MSC) fraction
- Stromal vascular cell fraction (SVF), 540
- Subaxillary flap
- complications with, 314
 - patient example, 313
 - planning for, 312
 - technique, 312
 - in volume replacement, 308, 312-314
- Subclavicular nodes, 62
- Subdermal plexus, 51, 59
- Superficial superior epigastric artery perforator flap (SSEAP), 393
- Superior defect; *see* Upper quadrant lesions
- Superior epigastric artery flap (SEAP), 393, 402-403, 493
- Superior inferior epigastric artery flap (SIEA), 420-425
- Superior inferior epigastric vein (SIEV), 422
- Superior pedicle, 246
- Supernumerary breasts, 50
- Supernumerary nipples, 50
- Superolateral defect
- in pedicled perforator flap reconstruction, 394-395
 - in rearrangement surgery, 463
- Superomedial defect
- in pedicled perforator flap reconstruction, 394-395
 - in rearrangement surgery, 463
- Superomedial pedicle, 56
- Supraclavicular nodes, 62
- Surgeons
- ablative, perspective of, 39-41
 - reconstructive, perspective of, 41-43
 - skill base of, 26
 - territorial divides among, 25
 - training of oncologic, 5-6
 - in two-surgeon model, 24
- Surveillance
- calcifications in, 573, 574, 578
 - fat grafting and, 99
 - histologic postoperative, 583
 - imaging in, 572-575
 - immediate reconstruction and, 207
 - magnetic resonance imaging in, 581-582
 - mammographic, 98, 573-575, 578-580
 - options, 572-575
 - partial mastectomy reconstruction and, 40
 - patient example, 576-577
 - physical examination in, 572
 - postoperative, 583
 - sonography in, 581
 - tissue diagnosis in, 583
 - ultrasound in, 581
 - volume replacement with local flaps and, 321-322
- Suspensory ligaments of Cooper, in breast composition, 54-55
- Sutures
- in donut mastopexy, 185
 - in reduction mammaplasty, 192
- SVF; *see* Stromal vascular cell fraction (SVF)
- Symmetry; *see also* Asymmetry
- in breast aesthetics and assessment, 65-66
 - in cosmetic sequelae classification, 435-437
 - mastopexy and, 160
 - in quadrantectomy defect management, 147-149
- ## T
- Tangent beam, 158
- TDAP; *see* Thoracodorsal artery perforator flap (TDAP)
- Team approach, 30-32
- Tension lines, 125
- Tepecik Training and Research Hospital, 164
- Territorial divides, 25
- Third internal mammary perforator, 57, 58
- Thoracoacromial artery, 58
- Thoracodorsal artery perforator flap (TDAP), 493; *see also* Pedicled perforator flap reconstruction; Perforator flaps
- in breast-conserving surgery, 512-513
 - in central defects, 298
 - converting to muscle-sparing latissimus dorsi flap, 405
 - dissection in, 514

- harvesting, 405
- indications for, 506
- patient example, 396-397, 406-408, 411, 494, 495-497
- pedicled, 391
- in upper quadrant lesions, 196
- Thoracodorsal perforators, 390
- Three-dimensional percutaneous mesh expansion, 526-527
- Timing
 - delayed
 - advantage of, 211
 - after quadrantectomy, 215-216
 - clips in, 211, 212
 - complication rates in, 235
 - in distant flaps for partial mastectomy deformity, 417
 - immediate versus, 211, 216
 - latissimus dorsi myocutaneous flap in, 215
 - patient example, 212, 214-216
 - pros and cons, 214
 - in rearrangement surgery, 465
 - in volume replacement with local flaps, 306
 - delayed-immediate, 214-215
 - in distant flaps for partial mastectomy deformity, 416
 - immediate
 - complication rates in, 235
 - contralateral breast and, 208
 - decision-making in, 234-235
 - defect size and location in, 240
 - delayed, 214-215
 - delayed versus, 211
 - disadvantages of, 210, 211
 - in distant flaps for partial mastectomy deformity, 417
 - management algorithm in, 236-241
 - margin issues and, 205, 207-208
 - margin status and, 238-240
 - nipple-areola complex proximity in, 240-241
 - oncologic advantages of, 205
 - outcomes with, 204-205
 - patient example, 203, 206, 209, 250-253
 - positive margins and, 207
 - and preoperative deformity potential, 202
 - pros and cons, 210
 - radiotherapy and, 213
 - reduction technique in, 241-254
 - scarring and, 207, 213
 - surveillance and, 207
 - technique selection for, 240-241
 - in volume replacement with local flaps, 306
 - with local flaps, 471, 472, 474
 - outcomes and, 165
 - recurrence and, 239
- Tissue expansion; *see* External tissue expansion (ETE); Three-dimensional percutaneous mesh expansion
- Toxicity, in radiotherapy, 160, 161-163
- Training
 - of oncoplastic surgeons, 5-6
 - and two-surgeon model, 24
- Transverse rectus abdominis musculocutaneous (TRAM) flap, 493
 - in rearrangement surgery, 457
 - selection of, 475
- TSIR; *see* Tumor-specific immediate reconstruction (TSIR)
- Tuberous breasts, 51
- Tubular breasts, 51
- Tumor/breast ratio, 4, 5
- Tumor resection, in breast-conserving therapy, 78
- Tumor-specific immediate reconstruction (TSIR), 4
- Turkey, 164
- Two-surgeon model, 24, 37
- U**
- UICC classification, 437-438
- Ultrasonography
 - in determination of extent of disease, 111-112
 - in surveillance, 581
- United States experience, 30-34
- University of California, San Francisco, 164
- University of Chicago, 164
- University of Kansas, 164
- Upper quadrant lesions
 - complications with, 592-593
 - innervation in, 51, 59
 - in omental flap reconstruction, 373-374, 377-378
 - parenchymal autoaugmentation in, 259, 270
 - patient examples, 8, 9, 16, 186, 188, 193
 - pedicle design and, 243, 244-245, 247-248
 - radial scar in, 144
 - in rearrangement surgery, 463
 - volume replacement for, 196
- V**
- Vacuum expansion; *see* External tissue expansion (ETE)
- Venous drainage, 59
- Volume displacement techniques, with central defects, 291-293
- Volume replacement procedures
 - with central defects, 298-300
 - defined, 307
 - intercostal artery perforator flap in, 319-321
 - lateral thoracodorsal flap in, 309, 310, 314-319
 - oncologic aspects of, 321-322
 - patient example, 313, 315-317
 - rhomboid flaps in, 307, 311-312
 - subaxillary flap in, 308, 312-314
 - surveillance and, 321-322
- W**
- Wedge compensators, in radiotherapy, 159
- Wedge excisions, with central defects, 291-293
- Whole-breast irradiation, 157
- Wise pattern, 242, 268
- Wound dehiscence, 592, 595
- Wound infection, ductal system and, 52
- Würinger septum, 60-62
- Z**
- Z-plasty, in quadrantectomy defect management, 149