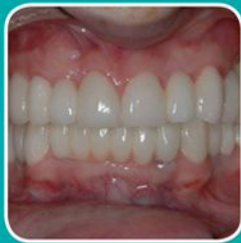
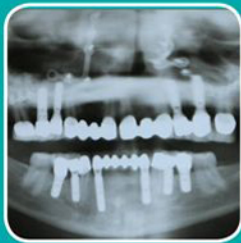
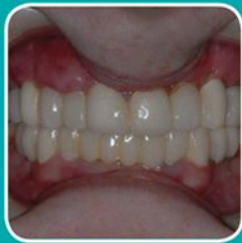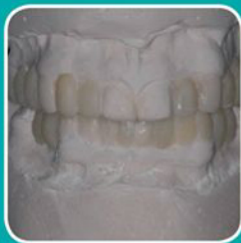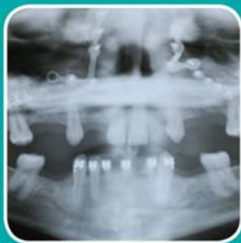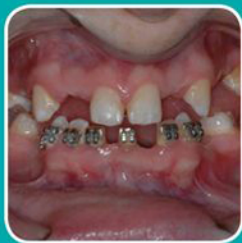CLINICAL CASES SERIES

Clinical Cases in Restorative and Reconstructive Dentistry

Gregory J. Tarantola



**Clinical Cases in
Restorative &
Reconstructive Dentistry**

 CLINICAL CASES SERIES

Clinical Cases in

Restorative & Reconstructive Dentistry

Gregory J. Tarantola, D.D.S

 **WILEY-BLACKWELL**

A John Wiley & Sons, Inc., Publication

Edition first published 2010
© 2010 Blackwell Publishing Ltd.

Blackwell Publishing was acquired by John Wiley & Sons in February 2007. Blackwell's publishing program has been merged with Wiley's global Scientific, Technical, and Medical business to form Wiley-Blackwell.

Editorial Office
2121 State Avenue, Ames, Iowa 50014-8300, USA

For details of our global editorial offices, for customer services, and for information about how to apply for permission to reuse the copyright material in this book, please see our Website at www.wiley.com/wiley-blackwell.

Authorization to photocopy items for internal or personal use, or the internal or personal use of specific clients, is granted by Blackwell Publishing, provided that the base fee is paid directly to the Copyright Clearance Center, 222 Rosewood Drive, Danvers, MA 01923. For those organizations that have been granted a photocopy license by CCC, a separate system of payments has been arranged. The fee code for users of the Transactional Reporting Service is ISBN-13: 978-0-8138-1564-0/2010.

Designations used by companies to distinguish their products are often claimed as trademarks. All brand names and product names used in this book are trade names, service marks, trademarks or registered trademarks of their respective owners. The publisher is not associated with any product or vendor mentioned in this book. This publication is designed to provide accurate and authoritative information in regard to the subject matter covered. It is sold on the understanding that the publisher is not engaged in rendering professional services. If professional advice or other expert assistance is required, the services of a competent professional should be sought.

Library of Congress Cataloging-in-Publication Data

Tarantola, Gregory J.

Clinical cases in restorative & reconstructive dentistry / Gregory J. Tarantola.

p. ; cm. – (Clinical cases)

Other title: Clinical cases in restorative and reconstructive dentistry

Includes bibliographical references and index.

ISBN 978-0-8138-1564-0 (pbk. : alk. paper)

1. Dentistry, Operative--Case studies. 2. Dental implants--Case studies. I. Title. II. Title: Clinical cases in restorative and reconstructive dentistry. III. Series: Clinical cases (Ames, Iowa) [DNLM: 1. Dental Prosthesis--methods--Case Reports. 2. Oral Surgical Procedures--methods--Case Reports. 3. Reconstructive Surgical Procedures--methods--Case Reports. 4. Stomatognathic System--Case Reports. WU 500 T176c 2010] RK501.5.T37 2010 617.6'05--dc22

2010013916

A catalog record for this book is available from the U.S. Library of Congress.

Set in 10/13pt Univers Light by Toppan Best-set Premedia Limited
Printed in Singapore

1 2010

CONTENTS

Author	xi
Contributors to Appendices	xi
Acknowledgments	xiii
Introduction	xv

Part 1 Didactics **3**

Chapter 1 Fundamental Principles of the Comprehensive Approach	5
The Case for the Four-Part Comprehensive Evaluation	5
The Details of the Four-Part Comprehensive Evaluation	5
The Initial Conversation	6
The Clinical System–Based Masticatory System Examination	8
Imaging	22
Articulated Diagnostic Casts	25
Chapter 2 The People Side of Dentistry	27
The Importance of Behavioral and Communication Skills	27
The All-Important 5 Questions	27
The Codiscovery Process	29
Which Approach Is Best—The 4 Quadrants	33
Dentistry: A Blend of Technical, Emotional, and Intellectual Skills	33
Chapter 3 The 4 Essential Skills of the Comprehensive Dentist	37
Section A Bite Splint Therapy	38
Section B Definitive Occlusal Therapy: Equilibration	45
Section C The Diagnostic Blueprint—Wax-Up	50
Section D Provisionalization	55
Chapter 4 The 10 Decisions	63
Section A TMJ Diagnosis and Condylar Position	64
Section B Vertical Dimension	66
Section C Lower Incisal Edge Position	74
Section D Upper Incisal Edge Position	77
Section E Centric Stop Design	86
Section F Anterior Guidance	91
Section G Curve of Spee	98

Section H	Curve of Wilson	101
Section I	Cusp to Fossa Angle	102
Section J	The Aesthetic Occlusal Plane	105

Part 2 Case Studies 109

Chapter 5	Nonremovable Implant Restoration with Natural Teeth	111
Case 1	Nonremovable maxillary implant restorations with natural teeth restorations including crowns, veneers, and fixed partial dentures	112
Case 2	Transitioning a maxillary tooth-supported fixed partial denture to an implant-supported fixed partial denture along with other single crowns and tooth-supported fixed partial dentures	121
Case 3	Lower reconstruction with lower left being implant-supported, important neutral zone consideration affecting design; upper reconstruction landmarks acceptable; temporomandibular disorder managed	129
Case 4	Maxillary fixed partial denture supported by both teeth and implants along with other maxillary and mandibular implant-supported crowns and tooth-supported crowns and fixed partial dentures	133
Case 5	Maxillary extractions, periodontal surgery, orthodontics, veneers, and fixed partial dentures on teeth; mandibular extractions, implants, fixed partial dentures on teeth and implants	139
Case 6	Multiple congenitally missing teeth, past orthognathics/orthodontics, tooth position inconsistencies handled restoratively, multiple implants, tooth-supported crowns and fixed partial dentures, implant-supported crowns and fixed partial dentures	143
	See also: Chapter 6 Case 1	148
	Chapter 7 Case 7	216
	Chapter 14 Case 4	342
Chapter 6	TM Disorders Followed by Reconstruction	147
Case 1	Osteoarthritis of the left TMJ managed with bite splint therapy followed by implant-supported restorations and tooth-supported restorations	148
Case 2	Intracapsular and muscular components of a temporomandibular disorder managed with bite splint therapy followed by occlusal therapy and a full reconstruction.	152
Case 3	Intracapsular and muscle disorder resolved with bite splint therapy followed by occlusal reconstruction with maxillary lingual porcelain veneers	157
Case 4	Intracapsular and muscle disorder with resultant occlusal plane asymmetry resolved with bite splint therapy and followed by occlusal therapy with restoration only on the lower left.	162
Case 5	Past condylar replacement due to avascular necrosis followed by posterior occlusal reconstruction.	166

Case 6	Temporomandibular disorder resolved with bite splint therapy followed by definitive occlusal therapy including a maxillary reconstruction and mandibular functional changes with composite	171
Case 7	Past mandibular orthognathic surgery to correct maxillary to mandibular malrelationship caused by condylar degeneration; intracapsular and muscle pain resolved with bite splint therapy followed by definitive occlusal therapy with posterior reconstruction and anterior composites.	178
	See also: Chapter 15 case 1	350
	Chapter 16 case 1	360
Chapter 7	Restorations to Achieve Aesthetic and Functional Changes	183
Case 1	Restoration of anterior aesthetics and anterior guidance in a deep overbite damaged by bruxism with upper and lower anterior reconstruction	184
Case 2	Posterior reconstruction with severe interferences to the centric arc of closure	189
Case 3	Restoration of aesthetics and anterior guidance damaged by wear by increasing overbite with upper and lower anterior crowns	195
Case 4	Maxillary reconstruction at open vertical dimension to improve aesthetics, length, buccal profiles, and functional landmarks; mandibular restorations only recontoured	199
Case 5	Maxillary and mandibular aesthetic and functional reconstruction with lab-processed composite restorations to treat amelogenesis imperfecta	204
Case 6	Restorations maxillary bicuspid-to-bicuspid done first as part of a comprehensive plan; maxillary left central incisor implant and other functional discrepancies corrected with reshaping and equilibration	210
Case 7	Maxillary and mandibular dental reconstruction including 4 dental implants replacing unrestorable teeth; impaired aesthetics due to recession handled with grafts and all porcelain restorations	216
	See also: Chapter 16 case 1	360
Chapter 8	Complete Implant-Supported Restorations	221
Case 1	Complete implant-supported maxillary reconstruction—transitioning the anterior teeth from tooth-supported to implant-supported	222
Case 2	Complete maxillary nonremovable restoration supported by 6 implants converted from a completed removable restoration on 4 implants	226
Case 3	Complete implant-supported nonremovable maxillary and mandibular reconstructions; transitioning from natural teeth that were not predictably restorable	231

Case 4	Maxillary extractions, immediate implant placement, immediate loading, and complete nonremovable zirconia restoration with pink porcelain	237
Case 5	Mandibular implant bar–supported full removable denture converted to a nonremovable restoration to improve comfort of the neutral zone and phonetics.	240
Chapter 9	Orthognathics	245
Case 1	Severe anterior open bite corrected with maxillary-only orthognathics and occlusal therapy with upper incisor restorations	246
Case 2	Mandibular orthognathic surgery and chin implant; managing a temporomandibular disorder during treatment; posterior restorative dentistry including implants	250
Case 3	Maxillary and mandibular orthognathic surgery with chin advancement; preresorative occlusal therapy with equilibration and composite additions.	256
	See also: Chapter 16 Case 1	360
Chapter 10	Bruxism and Wear Reconstruction	261
Case 1	Restoration of worn lower anterior teeth in a deep bite without changing other restorations	262
Case 2	Severe wear from parafunctional habits restored with a complete reconstruction at an increased vertical dimension of occlusion	266
	See also: Chapter 16 Case 2	366
Chapter 11	Perioprosthesis	275
Case 1	Full maxillary periodontal-restorative reconstruction improving aesthetics and function; lower posterior reconstruction following conventional surgery, bone and soft tissue grafts, covering recession.	276
Case 2	Posterior reconstruction in conjunction with conventional periodontal surgery; root resection, pocket elimination.	282
Chapter 12	Implants in the Aesthetic Zone	289
Case 1	Hopeless maxillary central incisor transitioned to an implant-supported restoration (delayed placement and delayed loading) with crowns on the remaining incisors along with occlusal therapy	290
Case 2	Extraction and immediate implant placement, delayed loading, and restoration maxillary central incisors; pink porcelain to simulate papilla	296
Case 3	Congenitally missing maxillary lateral incisors, orthodontics to open lateral incisor space, dental implants, and other aesthetic improvements.	302
Case 4	Congenitally missing upper right cuspid; upper right lateral incisor lost in an accident; implant placed in cuspid position with 2-unit cantilever restoration, pink porcelain to simulate gingival	307
Case 5	Maxillary central incisor extracted and replaced with a dental implant, delayed placement, and delayed loading	311
	See also Chapter 7 case 6	210

Chapter 13	Removable Implant-Supported Restoration with Natural Teeth	313
Case 1	Maxillary implant-supported bar-retained removable partial denture along with tooth-supported restorations to reconstruct occlusion and vertical dimension	314
Case 2	Combination mandibular fixed anterior–removable posterior reconstruction with Locator attachments	319
	See also: Chapter 14 Case 4	342
Chapter 14	Combination Fixed-Removable Restoration on Natural Teeth	323
Case 1	Maxillary bar–supported removable partial denture; lower crowns with semiprecision removable partial denture	324
Case 2	Maxillary fixed partial dentures with precision removable partial denture; mandibular bar–supported complete denture	331
Case 3	Maxillary telescope case: alumina copings on natural teeth and removable overstructure; mandibular telescope case: Galvano copings on natural teeth and nonremovable overstructures	337
Case 4	Mandibular anterior fixed partial denture and posterior removable partial denture with implants and Locator attachments for added support and retention; maxillary reconstruction, telescope case with 1 dental implant included along with 6 teeth	342
Chapter 15	Implant-Supported Complete Dentures	349
Case 1	Maxillary extensive bone graft followed by implant-supported bars and bar-supported overdenture after managing a temporomandibular disorder; flange needed for lip support necessitating a removable rather than a nonremovable approach	350
Case 2	Severe maxillary and mandibular resorption; maxillary bone grafting; maxillary and mandibular implant-supported bar and bar-supported dentures; flange needed for lip and cheek support necessitating a removable rather than a nonremovable approach	355
Chapter 16	Reconstructions on All Natural Teeth	359
Case 1	Severe anterior overjet handled with occlusal/restorative treatment in lieu of orthognathics; muscular component of a temporomandibular disorder also managed	360
Case 2	Failed multiple reconstructions; original deep overbite with current condition in provisionals with an opened vertical dimension and anterior overjet; managed with a new reconstruction harmonizing a physiologic deep overbite	366
Case 3	Maxillary reconstruction combined with extractions and periodontal surgery to improve periodontal architecture; landmarks of lower acceptable with minor modification	373
Case 4	Full mouth reconstruction utilizing crown-lengthening surgery, extractions, single crowns, veneers, and a fixed partial denture sequenced over 2 years.	379

CONTENTS

Case 5	Maxillary complete fixed partial denture on 9 Galvano telescopic copings; mandibular anterior fixed partial denture on 4 Galvano copings	385
	See also: Chapter 6 Case 6	171
	Chapter 14 Case 3	337
	Chapter 14 Case 4	342
Appendix 1	Definitive Occlusal Therapy Using the T-Scan III, by Robert B. Kerstein, D.M.D.	391
Appendix 2	What Your Laboratory Technician Needs to Provide Excellence, by Jerry Ulaszek, C.D.T.	433
Index.	449

Author

Gregory J. Tarantola, D.D.S., is former clinical director of the Department of Education at The Pankey Institute for Advanced Dental Education in Key Biscayne, Florida. In January of 2002, he opened a full-time restorative practice and now lives and practices in Jacksonville, Florida. He also continues to lecture around the country and around the world on comprehensive, masticatory system dentistry in a relationship-based setting.

Contributors to Appendices

Robert B. Kerstein, D.M.D., maintains a private practice limited to prosthodontics and myofascial pain in Boston Massachusetts. Dr. Kerstein has taught at Tufts University School of Dental Medicine and has lectured extensively on various topics in restorative dentistry.

Jerry Ulaszek, C.D.T, is president of Artistic Dental Studio, a full-service dental laboratory in Bolingbrook, Illinois. A graduate of Southern Illinois University with a B.A. in Dental Technology, he is a certified dental technician in Crown & Bridge and Ceramics. He is also a founding member of several occlusion-related study clubs and the author of numerous articles for dental journals.

Acknowledgments

As Sir Isaac Newton has said, “If I have seen further it is only by standing on the shoulders of giants.” I have been blessed to have had many giants’ shoulders to stand on.

My two biggest influences, both professionally and personally, have been the Pankey Institute and Dr. Peter Dawson. It is from them that I learned very early in my career that dentistry is about a lot more than “fixing teeth, getting paid, and moving on.” If one’s goal is happiness and fulfillment in dentistry, we must clarify our own vision; and they helped me do that. I owe a debt of gratitude to my dental school friend, Dr. John Gordon, who in December of 1983 told me I “just had” to attend the Pankey Institute.

I would like to thank Dr. Irwin Becker, past Chairman, and Mr. Chris Sager, past Director, of the Pankey Institute for giving me the opportunity to become Clinical Director of the Pankey Institute and

for bringing my career to places not possible were it not for that opportunity; Dr. Peter Dawson whose passion for masticatory system dentistry has hopefully rubbed off on me at least a bit; the dozens of Visiting Faculty of the Pankey Institute for their friendship and encouragement; the thousands of dentists from around the world whom I met at Pankey and whose lives and stories have touched and influenced me; my friend and dental consultant, Mr. Kirk Behrendt, who has helped me and scores of dentists on their journey of happiness and fulfillment in dentistry and life; my patients who have trusted me with their masticatory systems; and my parents who encouraged me to be happy no matter what I did and who, even though they had very little, made my education possible.

Most importantly, I thank my family for their love, support, and encouragement in all of my decisions.

Introduction

It is with great pleasure and honor that I embrace the opportunity to write this book. After more than 25 years of practice, clinical observation, and case documentation, you get excited about what works and what does not work. The case study format is an excellent way to share this knowledge. All the cases are presented in a systematic format illustrating examination, diagnosis, diagnostic wax-up, treatment plan, treatment sequence, provisionalization, and the finished case.

A key observation has been that there are certain universal, fundamental principles that apply to each and every case. Making the commitment to apply these principles to each situation enables you to add tremendously to the predictability of a particular case. Shortcutting these principles, even though a case might seem simple and straightforward, can diminish that predictability. Because of that diminished predictability, expectations may not be met. As the dentist, we may not get the results that we expect and, more importantly, the patient may not get the results that he or she anticipated. This can result in costly remakes, hurt feelings, loss of trust, and possibly even a tarnished reputation.

Today is truly a remarkable time in dentistry. Technology has elevated heights the goals that we are able to accomplish for our patients to amazing. We can bond with predictability and longevity to both enamel and dentin. Composite and porcelain restorations can be virtually undetectable from natural tooth structure. With modern surgical techniques we are able to put bone and soft tissue where it has been lost or perhaps never present. With the science of dental implants we are able to give our patients a tertiary nonremovable dentition. To accomplish this often requires a significant investment of time, energy, effort, and finances. Allowing us to literally take a patient's mouth apart and put it back together again requires an incredible

amount of trust. We must give that trust the respect it deserves by putting forth our best efforts in all aspects of the patient's care and by involving the patient in every step of the process.

The failures and disappointments we all experience in dentistry at times is analogous to being hit by a train. I recall as a child growing up Kansas City; that trains were commonplace and having to cross the railroad tracks was a frequent occurrence. Our teachers in school constantly warned us to "Stop, look, and listen" before crossing the tracks. I found that to be wise advice then and also now as a dentist. Dentists are eager to begin treatment for our patients—the treatment that we know and believe will be in their best interest. However, before we begin it would be wise to remember that early advice.

Stop. Ponder, think, and reflect prior to beginning treatment. Have we done a complete masticatory system examination? Have we thought through a reasonable diagnosis? Have we done the work on the articulated diagnostic casts? Do we have a solid rationale for the treatment we are proposing for our patient? One of my favorite quotes is from Abraham Lincoln who said, "It is indispensable to develop a habit of observation and reflection." As dentists we are often too anxious to begin treatment for our patient. After 25 years I still firmly believe that any time we spend thinking, pondering, and reflecting will never be wasted time and can only enhance the results we've worked so hard to achieve.

Look. Before beginning treatment, have we taken the time to step back and "look" beyond just the area we are treating and "look" at the entire masticatory system. How does the treatment we are recommending for a particular area of the mouth fit in to the big picture? Does it complement and enhance it? Is it a

INTRODUCTION

step along the way toward the overall optimal treatment plan?

Listen. Have we truly listened to our patient? Have we not only listened to the words, but do we also *understand* our patients and their concerns, desires, and expectations? Have *they* heard *us*? Do they truly grasp and understand the nature and scope of the treatment we are proposing and the responsibility that goes along with moving forward

with this treatment? The biggest fallacy about communication is simply assuming that it has been accomplished.

My desire is that this book will help the dentist use the tools that have been given to me by my teachers and mentors, and that I pass these along in a way that will result in the happiness, satisfaction, and fulfillment that is possible by helping patients in this truly wonderful profession of dentistry.

**Clinical Cases in
Restorative &
Reconstructive Dentistry**

Part 1

Didactics

Fundamental Principles of the Comprehensive Approach

The foundation of a comprehensive practice is a four-part comprehensive evaluation. Dentists often say that they will do a comprehensive evaluation, diagnosis, and treatment plan if the patient is “having a problem” or if it appears to be “a big case.” First, how do you know whether there is a problem unless the complete exam is done? You can base it on the patient report of symptoms, or lack of symptoms, but there can be significant changes or issues with components of the masticatory system without manifestation of symptoms. These symptom-free issues, also known as *signs*, can have a significant impact on a treatment plan and the stability of the results. Second, how do you know whether it will be a “big case” unless a complete exam is done? Without the exam, the evaluation is usually based just on an obvious deterioration of teeth or missing teeth and the presence of crowns, bridges, or implants—and if these obvious issues are not present, it is deemed not to be a “big case.”

Part of the problem is with the term *big case*. It is usually synonymous with needing many units of crowns or bridges. An even bigger problem is falsely assuming that a *comprehensive case* implies a *big case*. Even a simple restorative case—that is, some simple restorations on just a few teeth, with concurrent occlusal management for predictability of the restorative result and for long-term health of the patient’s temporomandibular joints and neuromuscular system—should be a comprehensive case.

The Case for the Four-Part Comprehensive Evaluation

What is the rationale of a four-part comprehensive evaluation for patients who have healthy teeth and periodontium, are not complaining of pain or dysfunction, and are not in need of any significant restorative dentistry? Simply put, it serves as a baseline for future comparison. We may not see issues that are immediately in need of treatment, but there are often issues that are not ideal but still do not warrant treatment. These are described as *observations* and not *problems*. Examples include slight wear, gingival recession, erosion, and abrasion, etc. If we do a complete baseline examination, at some future point we can repeat this examination and compare it to the baseline. If nothing has changed, we can assure the patient. If any of these issues has gotten worse, we now have the baseline to compare to and have a more valid rationale for suggesting treatment. It is easy for the patient to see the progression especially when comparing photographs and diagnostic casts. Our role as dentists is not just to repair what is broken but to prevent future breakdown and maintain optimal health.

The Details of the Four-Part Comprehensive Evaluation

Figure 1.1 illustrates all the components of the four-part comprehensive evaluation. With the initial interview, clinical examination, necessary imaging, and articulated diagnostic casts completed, we have all the information needed to make a diagnosis and formulate an appropriate treatment plan and treatment sequence. With this complete information about our patients and their masticatory systems, they can “be in our office” even after they have left. Now we can invest some thinking time to sort through all the information. What

The 4-Part Comprehensive Evaluation

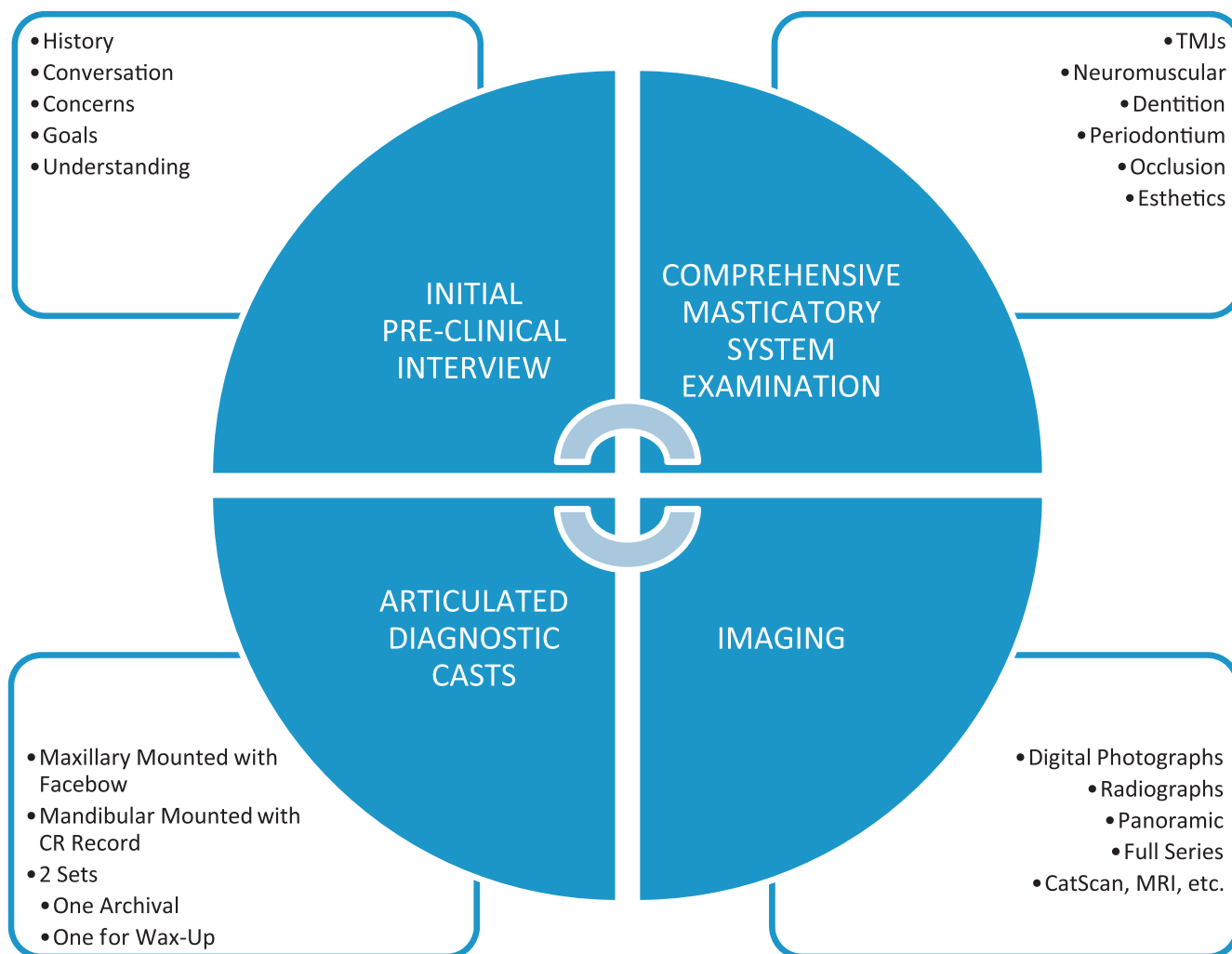


Figure 1.1. The four-part comprehensive evaluation gives us a complete picture of the patient's masticatory system—the starting point for diagnosis and treatment planning.

a valuable service for our patients! This is behind-the-scenes work that we are investing on behalf of our patients. Be sure that you and your team communicate to your patients that you are investing this time on their behalf. If they do not know that you are investing the time, they cannot value and appreciate that effort. Their perception is reality, so be sure that their perception is correct.

The Initial Conversation

Figure 1.2 illustrates all components of the complete clinical masticatory system examination. After the patient calls the practice, has an initial conversation with the administrative assistant, and is appointed, the process should continue with a one-on-one conversation with the dentist. The purpose of this conversation

is for the dentist to get to know the patient, and vice versa, and basically to get the process started on a personal level. The medical and dental history is reviewed and an attempt is made by the dentist to understand the patient's concerns, desires, and expectations. It is a time for the patient to do most of the talking and for the dentist to do most of the listening. Talking on the part of the dentist should be mainly in the form of questions to help better understand what the patient is trying to convey. Many times, dentists do too much talking during this initial conversation—telling the patient about ourselves, our practices, and the services that we provide for our patients. There certainly is a need to talk about these things, but this initial conversation is not the proper time. As we listen to the patient's conversation we

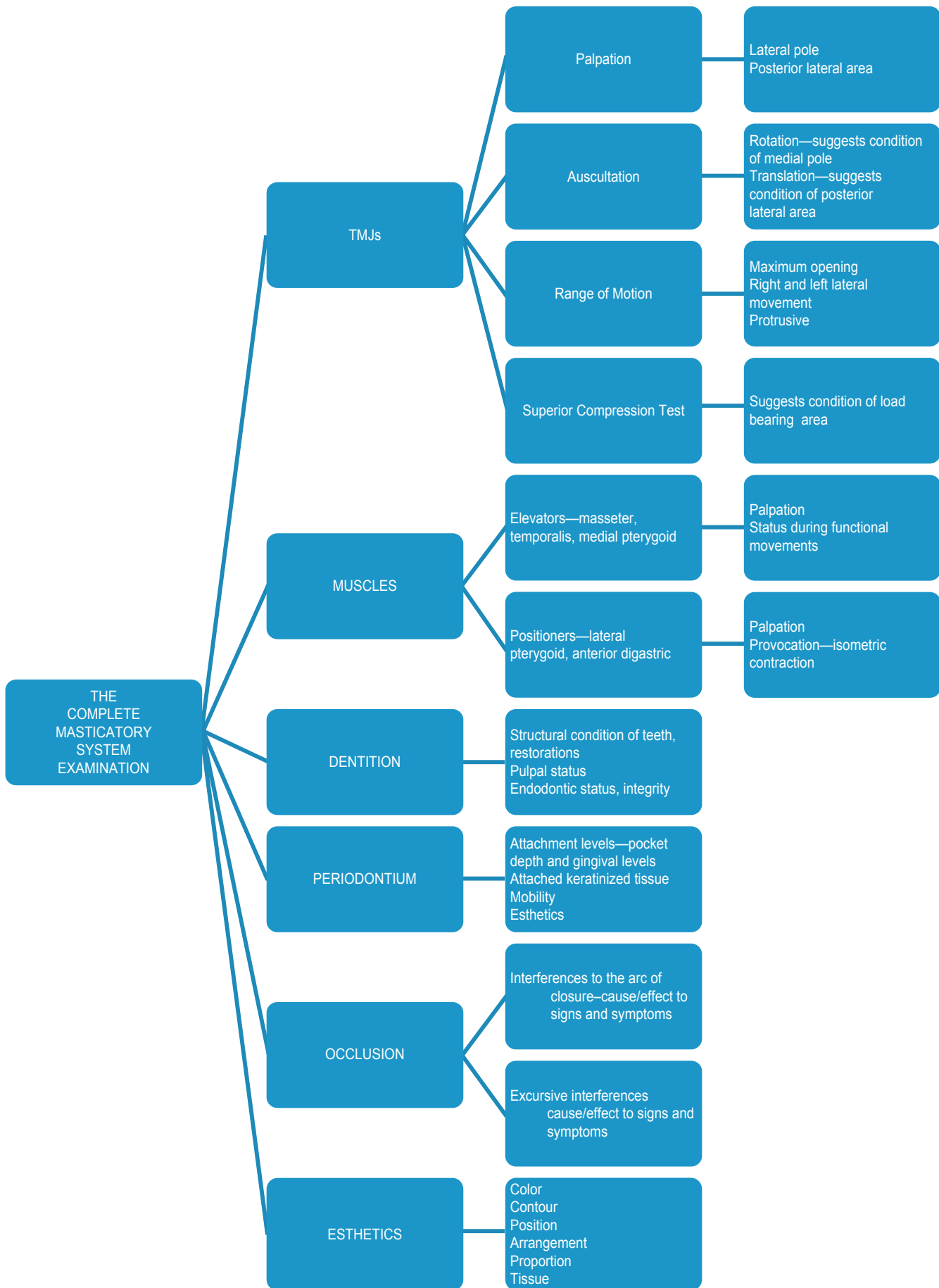


Figure 1.2. The clinical examination of the masticatory system follows this protocol so that nothing is overlooked. It is a pragmatic, step-by-step, systemwide approach rather than just a symptom-based approach.

need to control the urge to offer an answer or a solution; rather we should think of the right question to ask to help us better understand what the patient is trying to tell us. This initial conversation can set the tone for the entire relationship that follows. We want patients to leave this conversation feeling that it is about them and that their best interests are at the top of the list. Once we have listened and truly understand the concerns of the patient, it is a very natural transition to the complete masticatory system examination.

The Clinical System-Based Masticatory System Examination

The second step is a clinical examination of all components of the masticatory system (refer to Figure 1.1). It is important to say that this is a system-based examination and not just a symptom-based examination. It needs to be a systematic, step-by-step evaluation. A lack of symptoms is not a reason to not complete a

certain aspect of the clinical evaluation. For example, just because the patient may not complain of temporomandibular joint symptoms does not mean that we should not do a thorough temporomandibular joint examination. There can be significant intracapsular changes with no report of symptoms, and these changes can have significant implications on the long-term stability of our restorative and occlusal results. Knowing and understanding this at the beginning of the case is much better than being unprepared if it becomes an issue after we begin the case. If we know about it ahead of time it's called a *diagnosis*. If we find out about it after we began the case because of some issue or problem that arises, we find ourselves making excuses and explanations. An after-the-fact excuse is never going to satisfy the patient. It will always seem to be an oversight on the part of the dentist.

Figure 1.3 illustrates all the parts of a comprehensive clinical masticatory system evaluation. Each part

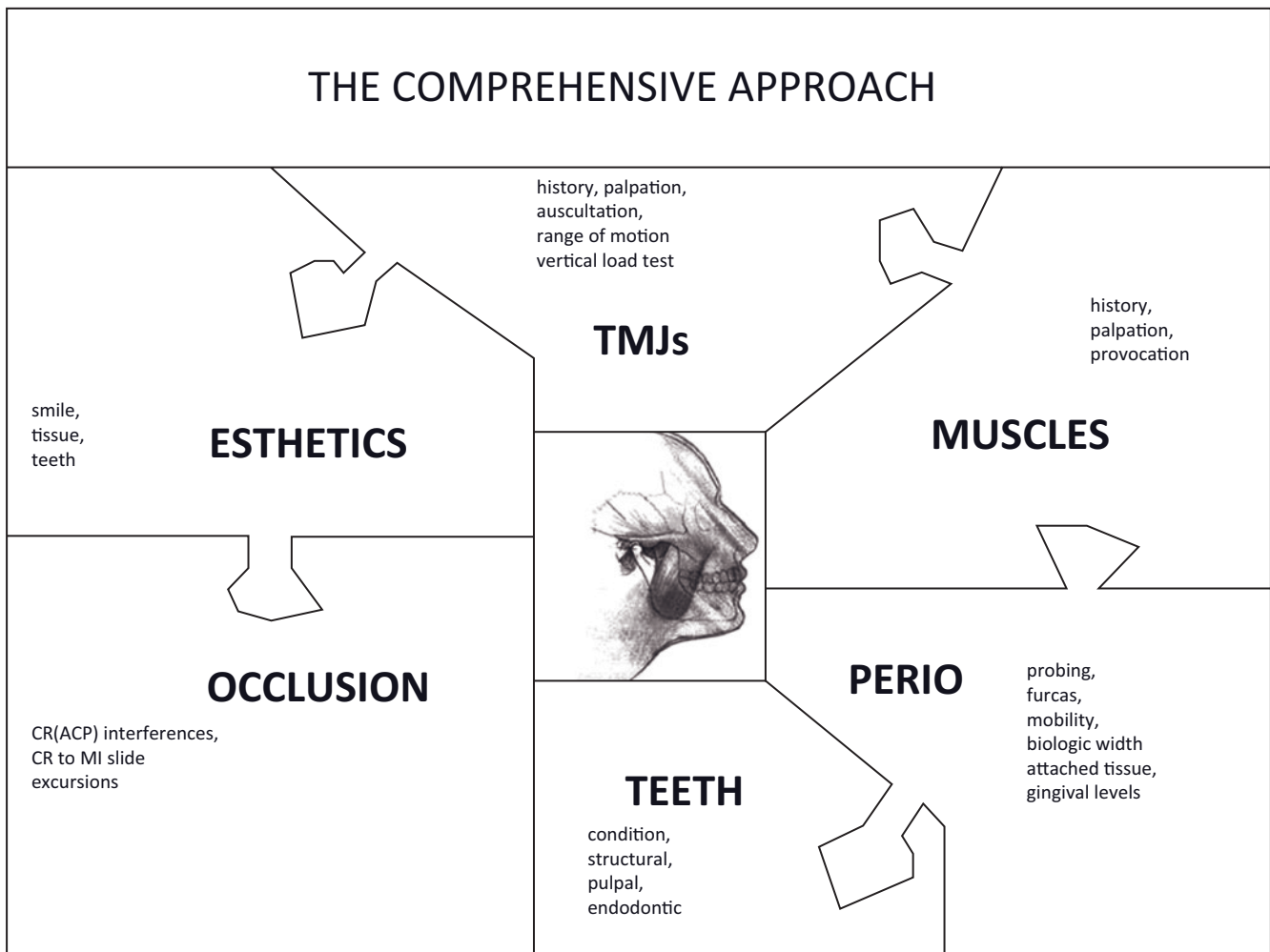


Figure 1.3. The complete masticatory system examination supplies all the pieces of the puzzle to get a complete picture.

of the examination is like a piece of the puzzle. As we complete all parts of the examination we then have all the pieces of the puzzle to accurately visualize the current status of the patient's masticatory system. Being thorough and complete with the examination goes a long way toward eliminating oversights and mistakes in the future.

We need to have a systematic, step-by-step pragmatic approach to the evaluation of all the components of the masticatory system, but we need to be flexible in how we begin and go through the various parts, primarily with the behavioral aspects of a comprehensive evaluation, which are covered in more depth and detail in Chapter 2. Basically we want to use the information that we gather during the initial conversation with the patient to guide us through the various parts of the clinical evaluation. For example, if the patient reports a temporomandibular joint problem, the logical place to start is the temporomandibular joint examination. If the patient reports headaches and muscle tension, we consider beginning with the muscle palpation part of the examination. Doing the examination in this way illustrates to patients that we have not forgotten about their chief concerns. You will find patients are more interested and receptive during the examination when it is about them. We don't want the examination to be something that we do "to" patients but rather something that is done with the active participation of patients.

The Four-Part TMJ Examination

The temporomandibular joint examination consists of four parts: palpation; auscultation; range of motion tests; and superior compression test, also known as a *vertical load test*. This four-part test, along with any necessary imaging, will suggest to us the condition of the components of the temporomandibular joint.

Figure 1.4 illustrates palpation of the temporomandibular joints. With the mandible closed we can palpate the lateral pole and associated structures. With the mandible opened widely and the condyles translated down and forward along the articular eminence, we can palpate the posterior aspects of the temporomandibular joints. Healthy structures should not be uncomfortable or painful to palpation. Gently touch the patient's shoulder and explain that this represents simply the pressure of the touch. On a scale of 1 to 5, the pressure of the touch is zero. If patient feels more than just a pressure of the touch, ask them to rate the discomfort on a scale of 1 to 5. Tenderness or discomfort to palpation suggests edema or inflammation in

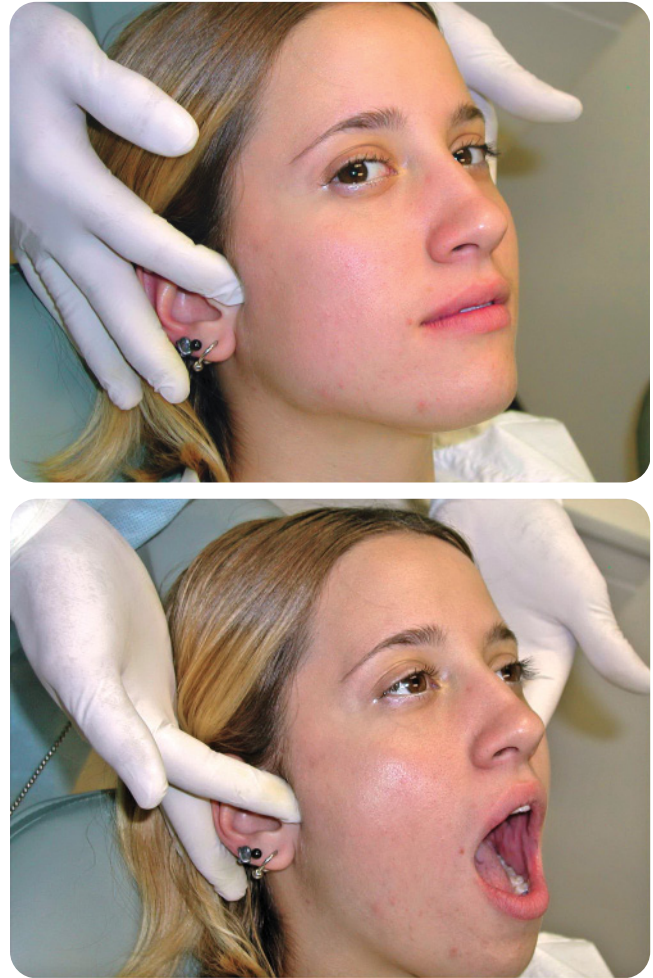

Figure 1.4. Palpation of the lateral pole with mandible closed and posterior-lateral area with the mandible open.

those structures. Discomfort to palpation on the lateral pole suggests issues with the lateral aspect of the disc or capsule. Discomfort to palpation of the posterior aspect of the condyles suggests edema or inflammation in the retrodiscal tissues.

Temporomandibular joint issues often have trauma as a contributing factor. It may be microtrauma such as bruxism or macrotrauma such as an accident. Talk to the patient about any past history of trauma, as insignificant as it may seem. A bump to the chin or a sporting accident as a teenager may have been a significant event in the adult patient's current temporomandibular joint condition.

Figure 1.5 illustrates one aspect of the range of motion tests. Maximum opening and full movement to the left, right, and protrusive are measured. These should be pain-free movements. Ask the patient whether any discomfort is felt during these range-of-motion tests and, if so, to specifically point to the area

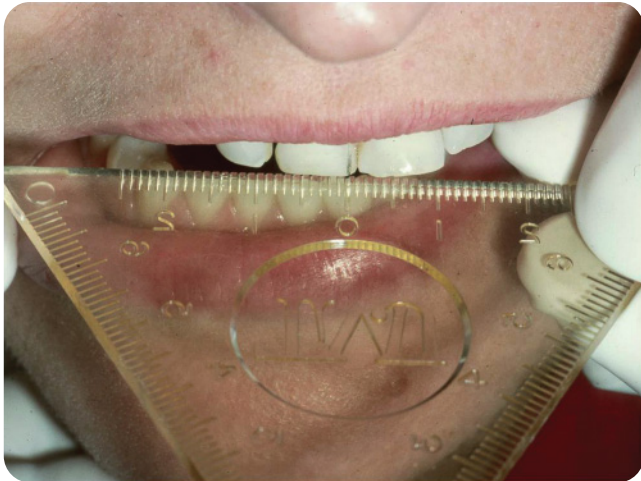


Figure 1.5. Measuring right lateral excursive movements with a millimeter ruler. Maximum opening, left lateral excursions, and protrusive are also measured.

of discomfort. It may be muscles, joints, or both. This not only gets the patient involved but it also helps you get a sense of condylar movements and muscular coordination. Maximum opening averages 45–55mm, excursive movements average 9–12mm. These averages represent approximately a 4:1 ratio between maximum opening and excursions. Deviations from these averages or this ratio might suggest problems with intracapsular structures or muscle coordination. Smaller ranges may not necessarily be a problem; they may be normal for that patient if movement is pain free, if the patient functions well and has no distress, and if those movements are symmetrical and fall within the 4:1 ratio.

Figure 1.6 illustrates auscultation with Doppler ultrasonography. One advantage of the Doppler is that the sound is magnified, which not only helps the dentist in diagnosis but it also helps patients to understand the current condition of their temporomandibular joints. Bear in mind that a meniscus that is normal in condition and position between the condyles and the fossa produces no sound during auscultation. The surface of the normal fibrocartilage disc is smooth, and this already smooth surface is lubricated by synovial fluid. Movement across these surfaces is very quiet. Noises such as crepitation and clicks suggest changes in condition and/or position of the disc, whether or not there is pain. If the disc, either all or part, is displaced anteriorly, the functional surface now becomes the retrodiscal tissues, which are not as smooth a surface and will produce crepitation. This retrodiscal tissue has the capacity to adapt and form a “pseudodisc,” which

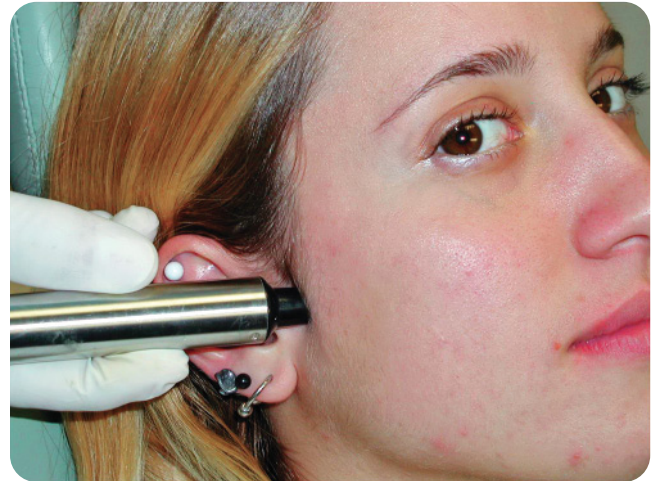

Figure 1.6. Use of Doppler ultrasonography is an effective way to auscultate the temporomandibular joints. Auscultation in hinge rotation gives information regarding the medial pole. Auscultation in translation gives information regarding the superior-lateral aspect of the temporomandibular joints.

is a rougher, more fibrotic surface resulting in a higher degree of crepitation. Perforations can occur in this retrodiscal tissue in some patients, resulting in an even coarser crepitation. Functioning bone-to-bone over time can result in a hardening, or eburnation, of those surfaces, resulting in less crepitation. So a careful history is important. The patient may report that they experienced noise for a long time that eventually went away.

The implication of changes in position or condition, even without pain is instability. Instability of joint structures correlates to instability of the occlusion, an issue that both dentists and patients need to be aware of, especially if definitive occlusal and/or reconstructive dentistry is going to be part of the treatment plan.

Bear in mind that the temporomandibular joint is a ginglymo-arthrodial joint, meaning that it both hinges and translates. Structures on the medial aspect of the joint are compressed and under function during hinge rotation; therefore, auscultation during hinge rotation suggests the condition of the structures on the medial aspect of the joint. Structures on the superior and lateral aspects of the joint are compressed and under function during translation; therefore, auscultation during translation suggests the condition of the structures on the superior lateral aspect of the joint. These translation movements can be opening past 15mm or excursive movements. Lateral pole changes are rather common, which is understandable because bruxism, which is very common, loads the superior and lateral aspects of the joints. Medial pole changes are less

common but more serious because the medial pole supports the condyle in centric hinging. Future lateral pole changes may result in more excursive interferences, whereas medial pole changes result in centric occlusion changes. Bear that in mind when designing occlusal schemes for your patient (see discussion in Chapter 4).

Figure 1.7 illustrates the superior compression test, also known as the vertical load test. This is a valid orthopedic test that suggests the load-bearing status and capacity of joint structures. The temporomandibular joints are designed to withstand firm loads without any sign of tension or tenderness.¹ Be sure to ask the patient to point with one finger to the specific location where he/she feels tension or tenderness. We want to differentiate whether that pain is coming from intracapsular structures or surrounding structures. If the discomfort is indeed coming from intracapsular structures, the patient will usually point to a spot over the temporomandibular joint area. If the patient reports tension during the superior compression tests, that may suggest hypercontraction of the lateral pterygoid muscle. Hypercontraction of lateral pterygoid pulls the condyles down and forward along the articular eminence. As the condyle is compressed vertically the lateral pterygoid is being stretched and causing a symptom of tension. If the patient reports tenderness during the superior compression tests, that may suggest edema or inflammation in or near the load-bearing areas. Either of these signs represents a condition of the temporomandibular joints that both

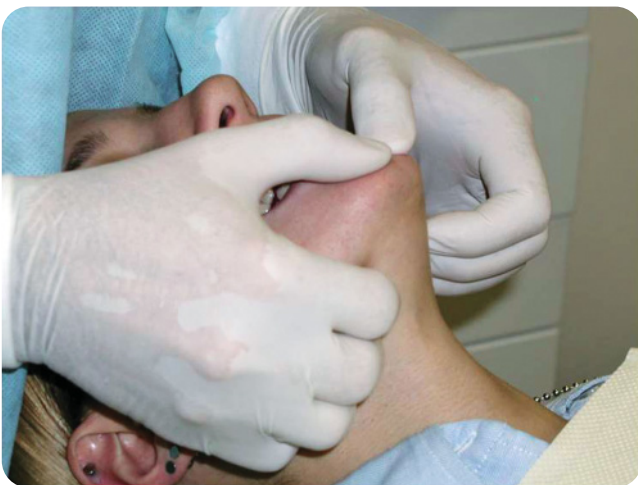

Figure 1.7. Use of bimanual guidance to superiorly compress the condyles within the fossa and test the load-bearing capacity of the temporomandibular joints.

the dentist and patient need to be aware of and that needs to be addressed before definitive treatment.

The temporomandibular joints can be superiorly compressed in a number of different ways. One very common way is with bimanual guidance as illustrated in Figure 1.7.¹ With proper placement of the hands on the patient's mandible, a superiorly directed vector of force is created, thereby vertically compressing the condyles in the fossa. Care must be taken with hand position so that a posteriorly directed vector of force is not created. This mistake pushes the condyles posteriorly into the retrodiscal tissues and causes discomfort even if those tissues are healthy, thereby giving a false-positive result. Another method of superiorly compressing the condyles within the fossa is by having the patient bite on cotton rolls placed across the bicuspids. The contraction of the elevator muscles compresses the condyles within the fossa. Once again the patient is asked whether this produces any sign of tension or tenderness within the temporomandibular joints. A variety of premade anterior deprogrammers are available that can be used for this test. The device is fitted over the upper central incisors so that the lower central incisors strike the anterior deprogrammer at 90 degrees to its horizontal platform. Once again the contraction of the elevator muscles vertically compresses the condyles within the fossa.

After the complete examination of the TMJs, the joints are classified according to Dr. Mark Piper's classification system.² Piper 1 indicates a normal joint. Piper 2 indicates a joint with early changes. There may be intermittent clicking from ligament laxity and nighttime bruxism. A very mild crepitation may be heard in excursions because the lateral aspects of the disc may have signs of roughening or fibrillation. Piper 3A suggests more advanced change on the lateral pole. The lateral pole may be displacing anteriorly and recapturing and therefore there will be clicking. With Doppler, there will be crepitation if the disc is anterior; if it has moved back in to place it will be quiet. Piper 3B suggests locking of the disc anteriorly at the lateral pole. The Doppler reveals a moderate crepitation in excursions, a very common finding. Piper 4A suggests medial pole changes. The medial aspect of the disc may be displacing anteriorly and recapturing. In this case there is crepitation in hinge rotation when the disc is forward and it is quiet when the disc is in the correct position. If the medial pole is anteriorly displaced and does not recapture, it is classified as Piper 4B. There is crepitation in hinge rotation revealed by the Doppler. The author finds medial pole changes to

be rather infrequent. Piper 5A suggests a perforation and is acute and painful. Piper 5B suggests a perforation, has adapted, and is not painful. This is indicated by a rather coarse crepitation upon Doppler auscultation. A more detailed description of these stages can be found at Dr. Mark Piper's website.²

If the results of the temporomandibular joint examination just described suggest problems or issues, these must be addressed before undertaking a definitive treatment plan. The key point to remember is that the implication of intracapsular issues is instability over time, whether or not there are symptoms. Both the dentist and the patient need to know that instability within the joint is going to affect stability of the occlusion. Chapter 3 addresses bite splint therapy and equilibration as a way to manage these intracapsular issues.

IS THE DIAGNOSIS CENTRIC RELATION, ADAPTED CENTRIC POSTURE, OR NEITHER?

After this temporomandibular joint exam, we can make the diagnosis of either centric relation (CR) or adapted centric posture.³ Centric relation describes a joint that is normal in structure and in which the disc is normal in shape and position on both the medial and lateral poles. This joint is quiet during auscultation and exhibits no signs of tension or tenderness during the superior compression test. Adapted centric posture describes a joint that has undergone structural changes. The condition and/or position of the disc may be altered on either the medial or lateral pole or both. This joint is generally *not* totally quiet during the auscultation exam. However, to make the diagnosis of adapted centric posture, this joint should pass the superior compression test. In other words there should be no sign of tension or tenderness during that aspect of the examination.

There are some important implications of the diagnosis of adapted centric posture as compared to centric relation. Since centric relation describes a normal joint, that joint will be much more stable over time; with joint stability comes occlusal stability. Since adapted centric posture describes a joint that is disordered, this joint typically may not be as stable over time; with joint instability comes occlusal instability. Therefore, this is a diagnosis that we need to be aware of prior to treatment, and we need to help patients understand their diagnosis and condition and the implications. With the diagnosis of adapted centric posture both dentist and patient need to know that future occlusal refinements will be necessary. If this

diagnosis is not clear, future occlusal changes may be looked upon as a mistake rather than an expectation based on the diagnosis. Remember: diagnoses not excuses, and inform before you perform.

Whether or not there are structural changes within the joint, if the temporomandibular joints cannot be vertically compressed with no sign of tension or tenderness, the diagnosis can be neither centric relation nor adapted centric posture. In that case we diagnose it as a *treatment position* from which to begin treatment to resolve the intracapsular problems. The goal of therapy is to achieve either centric relation or adapted centric posture. If the joint is normal in structure and the pain (or tension) is simply from a hypercontracted lateral pterygoid or trauma that has not caused irreversible damage, centric relation is achievable. If it is a structurally disordered joint with intracapsular issues, centric relation may not be attainable, but adapted centric posture may be.

In the case of intracapsular changes, the goals of therapy are healing, remodeling, and adaptation of connective tissue and fibrocartilage as well as muscle improvement. These goals require more time than just muscle improvement, often as much as 9–12 months. Experience has shown that beginning definitive therapy too soon in a patient with intracapsular disorders can result in occlusal instability with the definitive therapy. Make sure you can achieve 2–3 months of occlusal stability on a bite splint or long-term provisionals before going to finish. A cardinal rule is to never begin definitive or irreversible therapy if the temporomandibular joints cannot be superiorly compressed without tension or tenderness.

Cases will occur in which there have been changes within the temporomandibular joints to a degree that these joints may never be able to be superiorly compressed without tension or tenderness despite the most conscientious of various treatment modalities. If this is the case, the dentist and the patient need to know at the outset about any definitive or irreversible treatment that may be needed, that total comfort may not be possible, and that long-term stability will be compromised; and both the dentist and patient need to be ready to accept the consequences.

The Muscle Examination

Muscle palpation and testing is another important aspect of masticatory system examination. Healthy, properly functioning muscles should not exhibit tenderness to palpation. Discomfort to palpation suggests issues within that muscle such as hypercontraction or

incoordination. Lactic acid buildup within the muscle could be a cause that discomfort.

There are several aspects to the muscle examination. It generally involves palpation, patient report of status of the muscles during functional movements, and—in the case of the lateral pterygoid—isometric contraction. The latter is also known as the *provocation test*. Muscle discomfort can have a variety of causes, such as medical conditions, musculoskeletal disorders, biochemical issues, etc. Occlusal interferences, especially when coupled with bruxism, can be a factor in muscle discomfort. We know from many studies^{4,5} that interferences on posterior teeth during excursive movements hyperactivate the elevator muscles. Therefore, tenderness to palpation in the masseter, temporalis, and medial pterygoid suggests

that excursive interferences may be a cause. We also know that interferences to the centric relation arc of closure cause a hyperactivity of the lateral pterygoid muscle. Therefore, tenderness to lateral pterygoid palpation or provocation suggests centric relation interferences.

Figure 1.8 illustrates palpation of the extraoral closing muscles. Generally, the extraoral muscles are palpated first, gloves are changed, and then the intraoral muscles are palpated. These muscle palpation tests are another good way of getting patients involved in the examination. Have patients precisely point, along with your palpation, to where the muscle discomfort occurs. Quite often only a small portion of the muscle may be painful, rather than the entire muscle. During a range of motion tests, be sure to ask

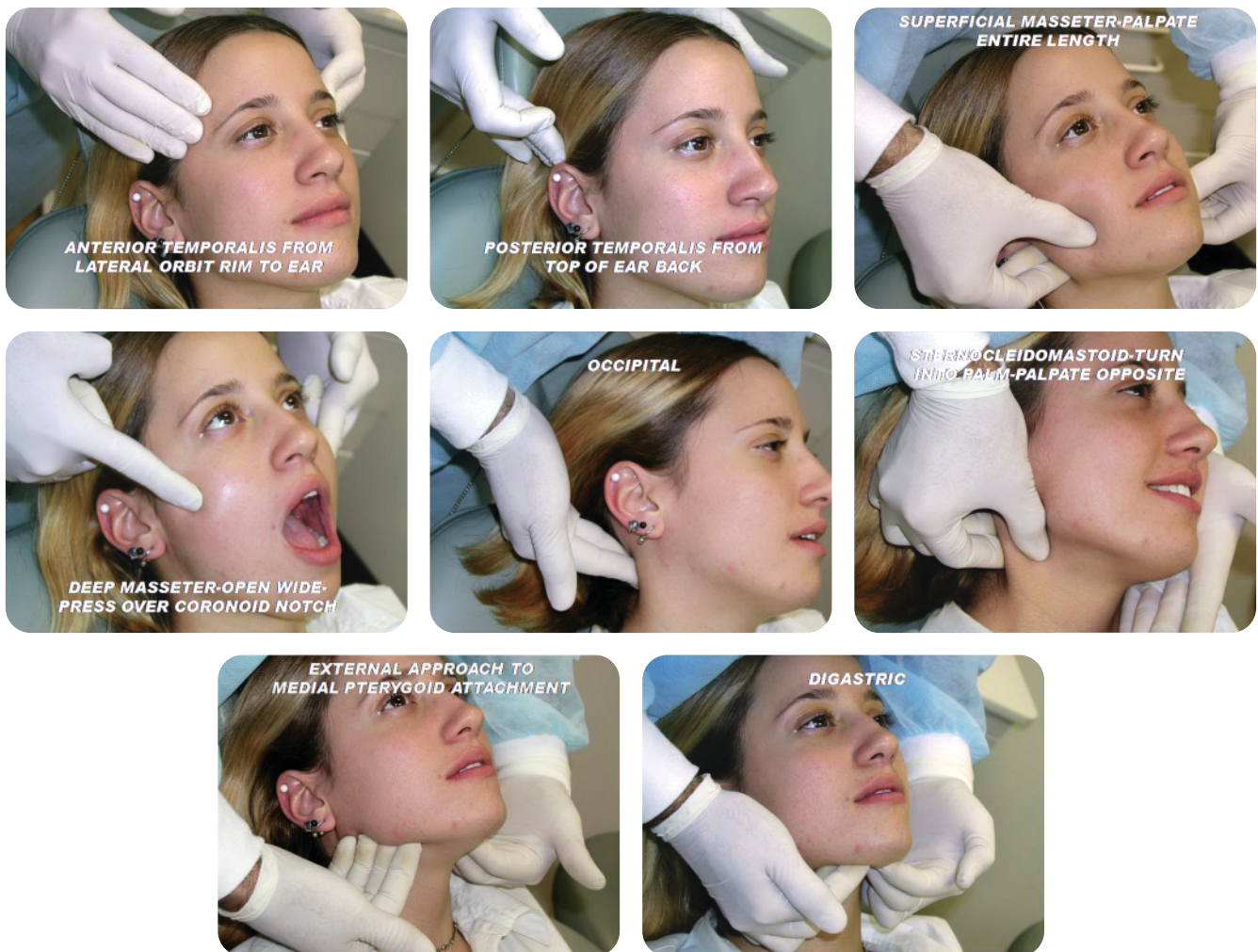

Figure 1.8. Composite picture illustrating palpation of the extraoral masticatory muscles. Using a scale of 1 to 5, ask the patient to rate any discomfort. Gently touch the patient’s shoulder as a reference to compare. The pressure of a light touch will be zero.

patients to report any discomfort they may be feeling during these functional movements. Ask them to point to precisely where they feel the discomfort because it may be in muscles or joints.

Figure 1.9 illustrates palpation of the area around the lateral pterygoid muscle. The area palpated is superior and medial to the maxillary tuberosity. The

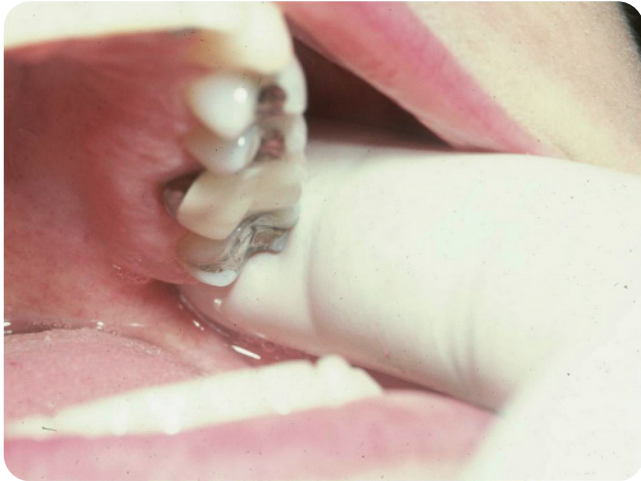


Figure 1.9. Palpation of the lateral pterygoid area is superior and medial to the maxillary tuberosity. This area is very often quite tender even to a light touch. The lateral pterygoid is commonly in a state of hypercontraction due to centric relation interferences.

muscle is too high up and back to palpate directly, but information from palpation in this area is helpful and diagnostic. After occlusal bite splint therapy, for example, this area becomes much less tender to palpation. It is not uncommon for this muscle to be uncomfortable in a big percentage of patients. Most patients have centric relation interferences, so it stands to reason that this muscle may be in a state of hypercontraction. Whether or not the patient has symptoms is another issue. Patient host resistance and adaptive capacity are factors in whether any sign will result in outward symptoms. Figure 1.10 illustrates the relationship between occlusal stressors and adaptive capacity. As occlusal stressors intensify, the chances of those stressors exceeding adaptive capacity increase, as do the chances of having outward symptoms. Bruxism can increase the intensity of occlusal stress. If the patient “doesn’t do much” with those occlusal interferences, the chances of symptoms are less. Changing a patient’s maximum intercuspation without a definitive end point can intensify occlusal stress. All dentists have experienced doing some simple restorations on a symptom-free patient that seem to cause a whole cycle of signs and symptoms. Occlusal stressors are not the only thing that can fluctuate. The patient’s adaptive capacity can also fluctuate, as shown in Figure 1.11. If the adaptive

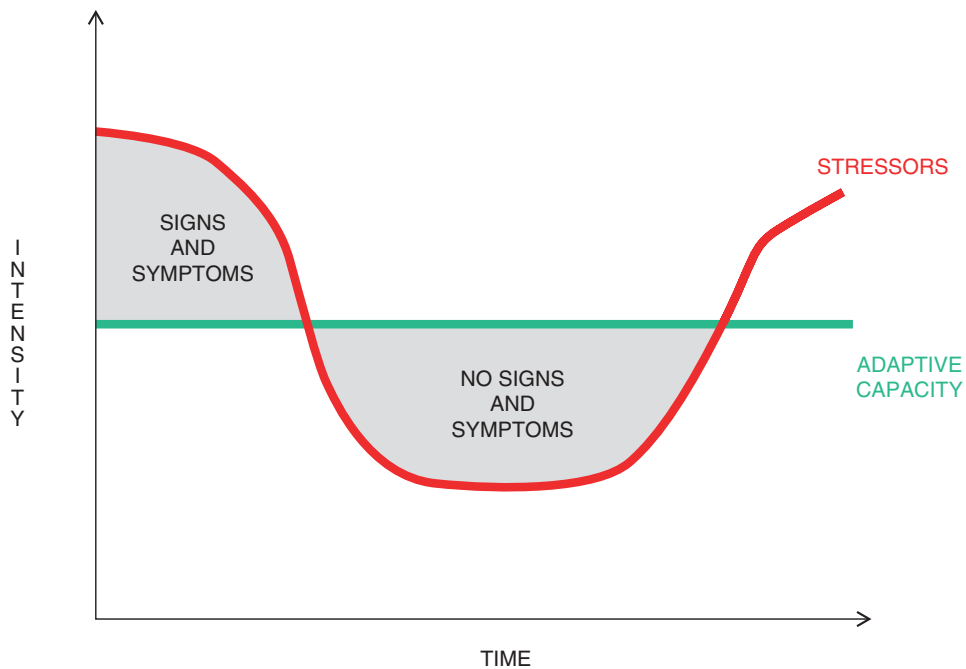


Figure 1.10. Intensity of occlusal stressors can fluctuate. If it exceeds the patient’s adaptive capacity, the likelihood of symptoms is high. If it is below the patient’s adaptive capacity, the likelihood of symptoms is less.

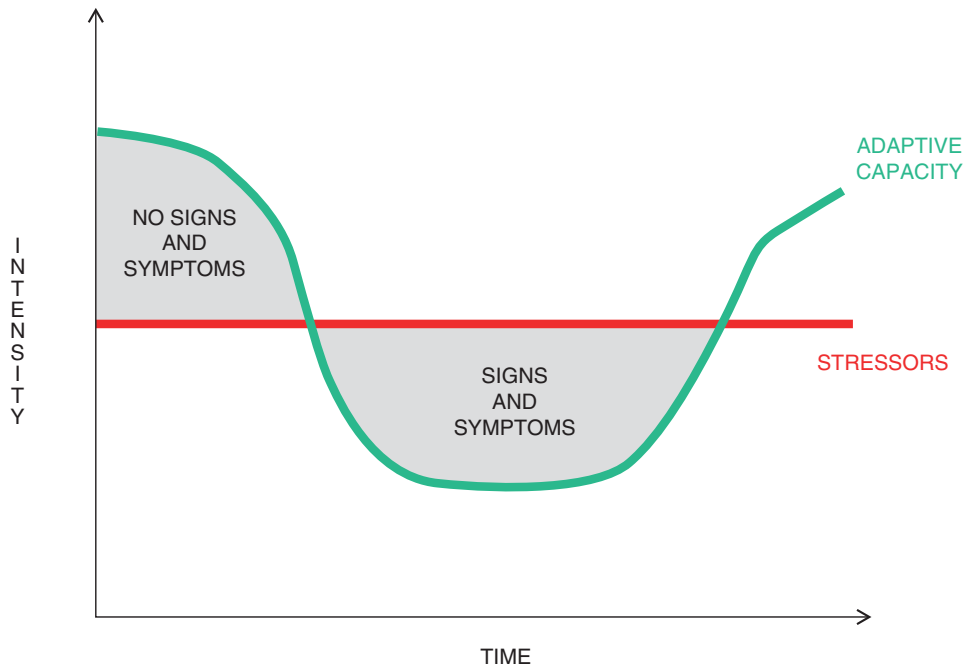


Figure 1.11. The patient’s adaptive capacity can also fluctuate. If the patient’s adaptive capacity is low, there may be symptoms. If the patient’s adaptive capacity is high, the likelihood of symptoms is less.

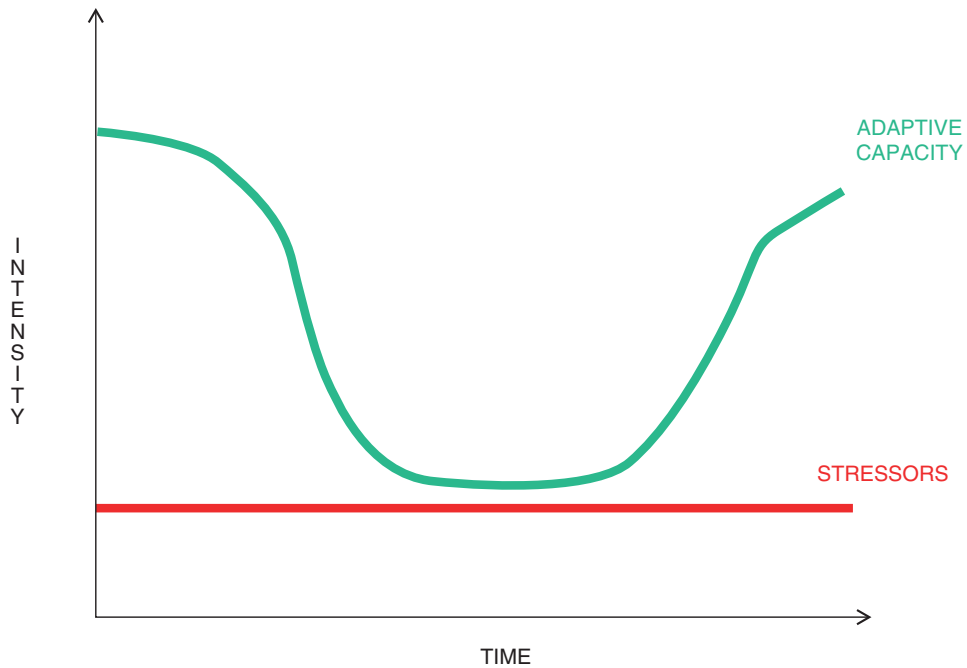


Figure 1.12. Definitive occlusal therapy can keep the occlusal stressors low enough so their level will be below the patient’s adaptive capacity. The likelihood of symptoms therefore is diminished.

capacity decreases, the occlusal stressors may now exceed that adaptive capacity and the patient may be more prone to outward symptoms. There are many things that can decrease adaptive capacity. The life events that a patient experiences may be a factor as can medical conditions and illnesses. The benefit of

definitive occlusal therapy is that it keeps occlusal stresses as low as possible and below the patient’s adaptive capacity, as illustrated in Figure 1.12. Stable occlusal contacts in the centric relation/adapted centric posture arc of closure with simultaneous, equal intensity forces, anterior guidance on anterior teeth

with immediate posterior disclusion has been shown to achieve this. We are putting the masticatory system at a mechanical *disadvantage* and we are minimizing destructive occlusal forces.

Palpation with much less pressure than was used for the other muscles often exhibits a response that is quite painful. Many patients think that this area is uncomfortable only because it may be a tender part of the mouth, so it requires some conversation and explanation from the dentist. Figure 1.13 shows the Denar TMJ Tutor, which is an excellent communication and educational tool. Patients can easily visualize occlusal interferences, how the lateral pterygoid must contract to get the mandible to maximum intercuspation, and therefore why it may be uncomfortable to touch. The Tutor also shows how occlusal interferences can cause joint displacement, disc issues, and teeth and periodontium problems. This is just one example of how the examination should be much more than data collection; it should be an interactive process that involves the patient. An interested and involved patient is much more open to hearing our suggestions for treatment at the time of the consultation.

Figure 1.14 illustrates palpation of the medial pterygoid muscle. The reference is the pterygomandibular raphe. Palpation is medial to the raphe and the finger is moved superiorly and inferiorly to palpate as much of the length of the muscle as possible. This is another muscle that is often tender to palpation and is usually the response to posterior excursive interferences.




Figure 1.13. The Denar TMJ Tutor, or a similar patient education tool, is effective at helping the patient understand the status of his/her masticatory system.

Figure 1.15 illustrates the lateral pterygoid provocation test. Since the lateral pterygoid cannot be directly palpated like the other muscles can, this additional test is done to gain more information about the status of the muscle. When the lateral pterygoid contracts, it pulls the condyle down and forward along the articular eminence to protrude the mandible. Positioned in front of the patient, the thumb is gently placed on the chin and the patient is asked to protrude his/her mandible forward. As it protrudes, more resistance is applied with the thumb so that the effect is to isometrically contract the lateral pterygoid. This position is held for

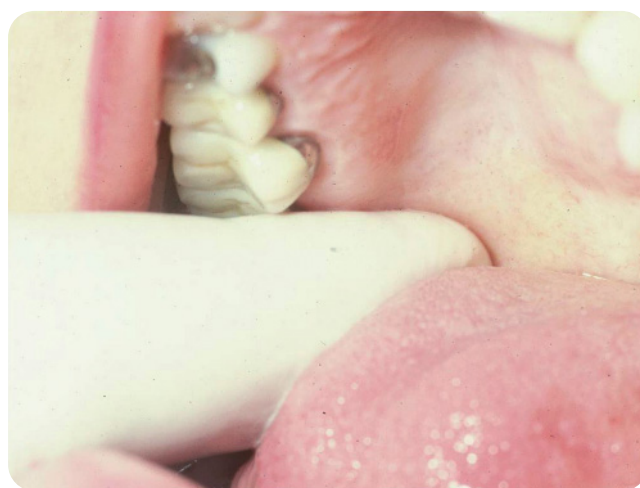


Figure 1.14. By placing the fingertip medial to the pterygomandibular raphe, we can palpate the medial pterygoid.

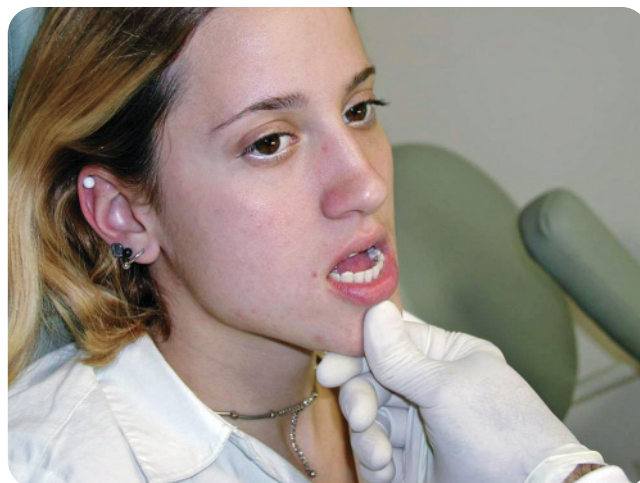


Figure 1.15. Technique for the lateral pterygoid provocation test to isometrically contract the muscle. **NOTE: THIS IS NOT CR MANIPULATION.**

10–15 seconds and the patient is asked to report any painful or burning sensation that may be felt in the area anterior to the condyle. A muscle that is in a state of continued hypercontraction will have lactic acid buildup and become painful during this isometric contraction.⁶ Any muscle, even a healthy one, becomes painful due to lactic acid buildup after an extended time of isometric contraction. Clinical experience shows that a 10–15 second test duration is enough to gain diagnostic information. It is important to note that Figure 1.15 should *not* be mistaken for the older, incorrect method of positioning the condyles to centric relation. Using this method will push the condyles down and back and into the retrodiscal tissues, which is *not* the physiologic centric relation position.

It is important to explain the rationale of the muscle palpation examination. If a patient is complaining of pain, headaches, muscle fatigue, and/or dysfunction, the rationale seems obvious. In making a diagnosis, the status of the muscles needs to be determined to rule in or out the role of muscles in the pain/dysfunction symptomatology. But what about the pain-free patient? The answer lies in what their overall treatment plan will be. If the patient is not in need of any restorative dentistry and is showing no other signs of breakdown or deterioration, this palpation exam serves as a baseline for future comparison. If the patient is in need of restorative dentistry, understanding the muscular status and bringing it to a state of health and stability will add to the predictability of the restorative result. If muscles are in a state of incoordination, even if without symptoms, it can affect the position of the condyle in the fossa. This will not be a stable, predictable, repeatable position. As a result, the position may change during the course of treatment and affect the occlusion of the restorations. All dentists have had the experience of placing the definitive restorations and being frustrated at the amount of occlusal adjustment needed. Therefore, managing temporomandibular joints, muscles, and occlusion will increase predictability and minimize frustration.

The Dental Examination

The next item in the examination is an evaluation of the status of the dentition (refer to Figure 1.2). Decay, status of restorations, structural integrity of the teeth, pulpal status, periapical status, integrity of past endodontic therapy, and integrity of posts are all noted. Digital photography is a valuable addition to the dental evaluation because it allows us to visualize tooth

surfaces that are sometimes difficult clinically and to review confidently at a later time. Figure 1.16 is an example of the form used for the dental evaluation. It has a simple tooth grid to note restorations and decay, and there is space to make notes about any other significant observations.

The Periodontal Examination

Figure 1.17 is an example of the form used for the periodontal examination. Digital photography augments the periodontal examination, especially in terms of evaluating gingival levels, attached keratinized tissue, and overall symmetry and aesthetics of the gingival tissues. By assessing gingival levels as well as crevice/pocket depth, we are able to calculate the attachment level of that particular tooth. In terms of evaluating current restorations, we want to assess their gingival margins and possible recurrent decay in relation to the biologic attachment. We often need to consider gingival/osseous surgery to re-create a normal physiologic architecture and create an environment for the new restorations that is healthy, cleanable, and aesthetically pleasing.

The Occlusal Examination

The detailed occlusal examination is a very important aspect of the complete masticatory system evaluation. The purpose is not only to identify interferences but more importantly to determine whether these occlusal interferences are part of a cause-effect relationship with other signs and/or symptoms discovered during the examination. Figure 1.18 lists the signs and symptoms that are commonly observed with which occlusal interferences can be implicated. Determining this is part of the thinking and reflection that must occur after the examination. The results of the clinical exam, photographs, radiographs, and articulated diagnostic casts are studied when making this determination.

Figure 1.19 shows an example of an interference to the centric relation arc of closure. It is interesting to note that the tooth with the interference, the upper left second molar, was sensitive, had more mobility than the surrounding teeth, and had a crack on the mesial marginal ridge. Since the interference is on the facial incline of the mesiolingual cusp, the mandible must shift to the left to arrive at maximum intercuspation. It is also interesting to note that the right lateral pterygoid was more tender to palpation because that muscle had to contract more to achieve this maximum intercuspation.

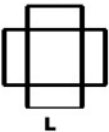
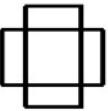
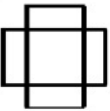
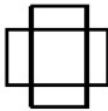
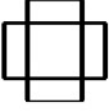
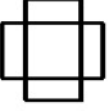
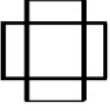
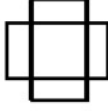
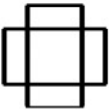
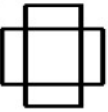
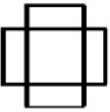
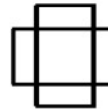
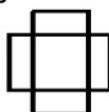
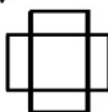
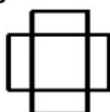
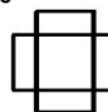
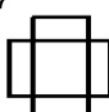
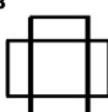
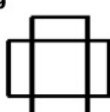
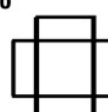
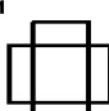
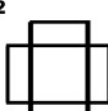
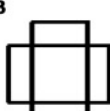
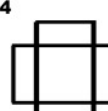
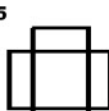
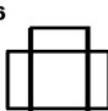
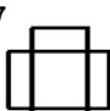
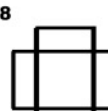



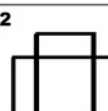
NAME _____		DATE _____	
SOFT TISSUE EVALUATION			
HARD PALATE		TORI	
SOFT PALATE		PHARYNX:	POSTERIOR
CHEEKS		LATERAL PILLARS	
LIPS		SALIVARY DUCTS:	PAROTID
TONGUE:	TOP	LYMPH NODES:	SUBMANDIBULAR
	LATERAL		CERVICAL
	UNDERSIDE		SUBMANDIBULAR
FLOOR OF MOUTH		ORAL CANCER EXAM	
BLOOD PRESSURE		COLOR	
DENTAL and RADIOGRAPHIC EVALUATION			
1 B  L	2 	3 	4 
5 	6 	7 	8 
9 	10 	11 	12 
13 	14 	15 	16 
17 	18 	19 	20 
21 	22 	23 	24 
25 	26 	27 	28 
29 	30 	31 	32 

Figure 1.16. Example of a form used to chart condition of the dentition. An area is available in which to make notes in addition to marking restorations and decay on the grid.

PERIODONTAL EXAM

NAME _____ DATE _____

POCKET DEPTH									DMM M	MD								B U C C A L
DISTAL FURCA																		
BUCCAL FURCA																		
KERAT TISSUE																		
GING LEVEL																		
TOOTH NUMBER	1	2	3	4	5	6	7	8	9	10	11	12	13	14	15	16		L I N G U A L
GING LEVEL																		
MESIAL FURCA																		
MOBIL																		
POCKET DEPTH									DMM M	MD								

POCKET DEPTH									DMM M	M	D							L I N G U A L
LING FURCA																		
MOBIL																		
KERAT TISSUE																		
GING LEVEL																		
TOOTH NUMBER	32	31	30	29	28	27	26	25	24	23	22	21	20	19	18	17		B U C C A L
GING LEVEL																		
KERAT TISSUE																		
BUCCAL FURCA																		
POCKET DEPTH									DMM M	M	D							

Figure 1.17. Example of a periodontal examination form.

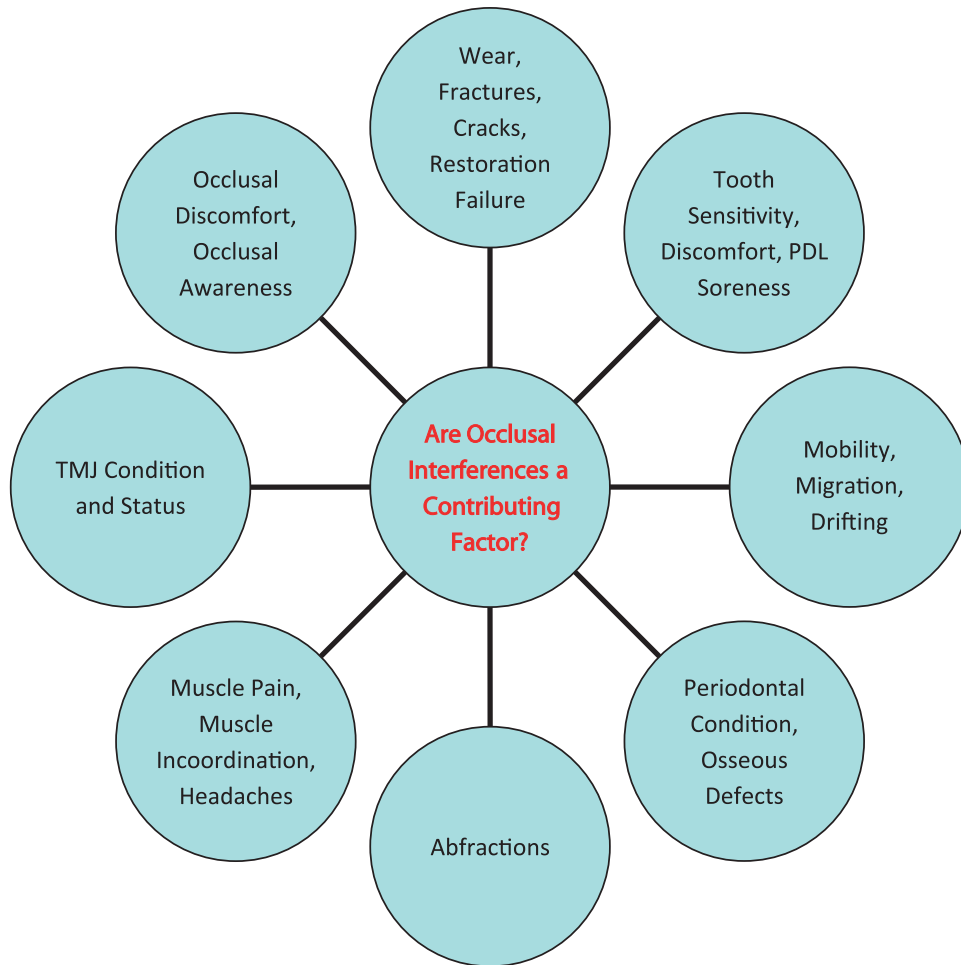

Figure 1.18. The purpose of the occlusal examination is not only to identify interferences but also to determine whether those occlusal interferences may be a contributing factor in other signs and/or symptoms of breakdown identified during the rest of the examination.

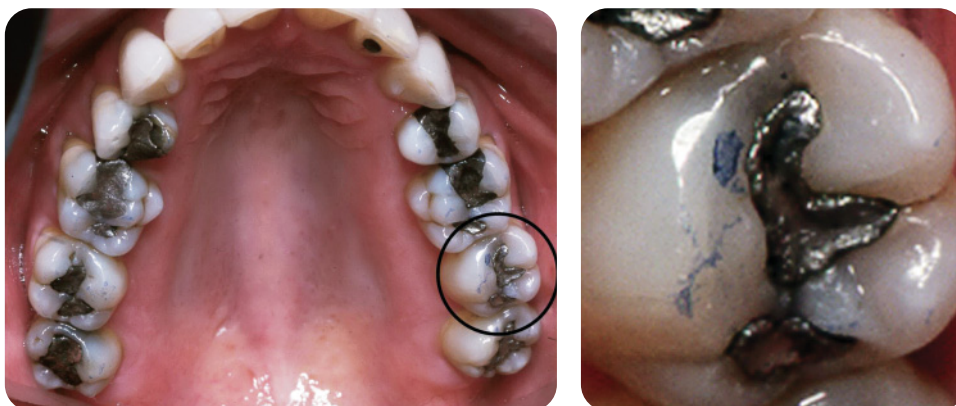

Figure 1.19. Identification of an occlusal interference to the centric relation arc of closure. Identify the interference with marking paper but also give patients an opportunity to verbalize what they feel and identify it themselves.

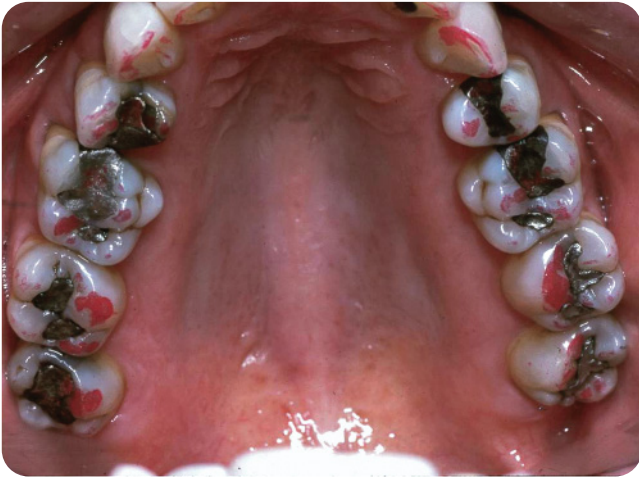

Figure 1.20. With red ribbon, excursive interferences can be identified by having patients rub from side to side. Give patients an opportunity to verbalize what they feel as they rub and engage these interferences.

Figure 1.20 illustrates excursive interferences on the posterior teeth. These interferences were a contributing factor in this patient's overall mobility patterns and medial pterygoid tenderness to palpation.

The occlusal examination is another opportunity to involve the patient in the overall process. Just identifying the interferences and noting it in the patient record does nothing to elevate the patient's awareness and understanding. As these interferences are identified, patients are given an opportunity to verbalize what they feel as these interferences are engaged. Ask them to point to the area they feel contacting first. Ask them to verbalize what they feel as they contract the muscles and shift to maximum intercuspation. What about when they rub from side to side—do they feel soreness in teeth or muscles or temporomandibular joints? It does indeed take some time to slow down and allow this interaction to occur, but it goes a long way toward involving the patient, making the examination more interesting, and differentiating you and your practice from past dental experiences the patient might have had. Your attention to detail and explanations may be the determining factors that help patients decide to choose you and your practice. A visual aid such as the previously described Denar TMJ Tutor also makes these explanations much more meaningful.

A technological aid that helps with the occlusal exam and subsequent definitive therapy is the T-Scan III (Figure 1.21). Its 100 micron sensor records occlusal forces from the first contact to full closure into maximum intercuspation. The software calculates the net vector of force in real time and displays it as a

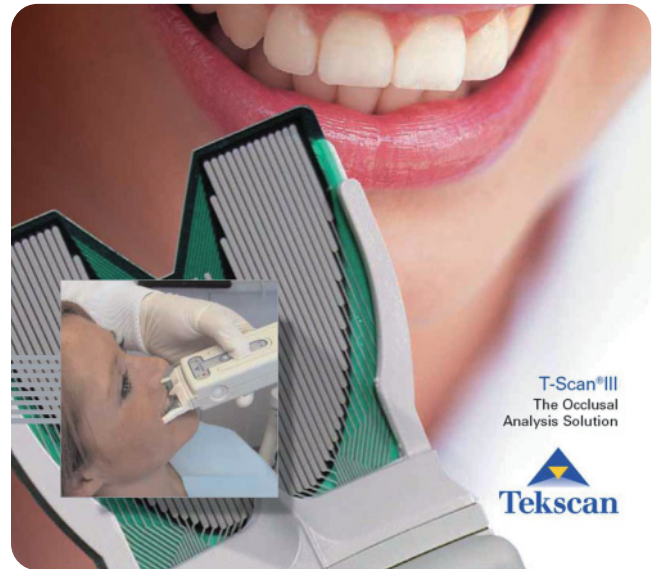

Figure 1.21. The T-Scan III is a computerized device that allows precise mapping of occlusal forces during the entire timing of closure from first contact to maximum intercuspation.

percentage right and left. The visuals displayed also allow visualization tooth by tooth along the entire time span. Figure 1.22 is a screen shot that shows one moment in time in this process. One can then correlate this visual to signs and symptoms as previously described. It is an easy-to-understand visual display for both dentists and patients. It confirms what you discovered clinically and what the patient felt and verbalized during the examination. With this kind of occlusal evaluation and patient discussion, patients will rarely object to definitive occlusal therapy. In general, if patients understand the problem and the implications of that problem, they are much more receptive during our conversations explaining various treatment options. An informed patient is a receptive patient.

The Aesthetic Examination

The last piece of the puzzle in the complete masticatory examination is the aesthetic evaluation. Aesthetics plays a role in virtually everything we do in dentistry. Aesthetics is not a separate area or specialty in dentistry but rather an integral part of the comprehensive approach. The restorations not only need to be technically, functionally, and biologically correct, they also need to be aesthetically pleasing and appropriate for that particular patient. We need to pay attention not only to the aesthetics of the individual teeth and areas that we are treating and restoring; we also need to pay attention to how the aesthetics fits into the

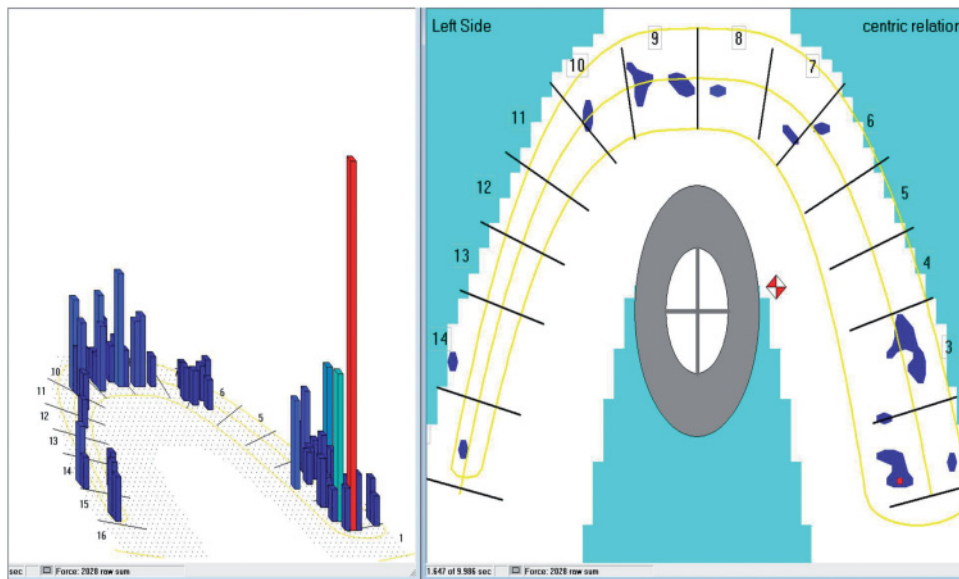


Figure 1.22. Screenshot of a T-Scan III recording.

frame of the lips and face. In other words, we need to step back and get a broader perspective. Figure 1.23 is the aesthetic evaluation form used in our practice. Parts of this evaluation can be done during the actual clinical exam. Other parts are done afterward when evaluating photographs and articulated diagnostic casts. The results of the aesthetic exam will give us important information when planning the definitive restorations in terms of incisal edge position, contours, proportions, and arrangement.

Imaging

The third component of the complete examination is imaging (refer to Figure 1.1). In this category of imaging is digital photography and radiographs, which typically are the panoramic and full mouth series. Other types of imaging may be indicated depending on the rest of the clinical examination. Questions that cannot be answered with the clinical examination, photographs, and radiographs need additional forms of imaging. For example, CAT scans allow accurate visualization of osseous architecture for dental implant treatment planning. MRIs allow visualization of both hard and soft tissues of the temporomandibular joints.

The complete digital photography series is a vital part of the complete examination and should not be overlooked. The benefits are many. You cannot diagnose what you cannot see. Digital photography helps us see better so that we can make more complete diagnoses. Photography helps patients learn about and

understand their condition in a way that a handheld mirror and verbal explanations cannot. It is quite remarkable to sit in front of a computer monitor with your patients and, at the end of the examination appointment right before they leave, hand them a laser pointer as you view their photographs and then just sit back and listen! They typically will make many observations and ask many questions. Make it a point to just talk about what you see and not about treatment options. They are just beginning to learn and understand their condition—it is too soon to talk about treatment options. It is generally too overwhelming for them at this point. Give both your patients and yourself time to think, ponder, and reflect. The photographs of their teeth are the last thing they see at that first appointment. It typically makes an impact and motivates them to want to find out more. I don't agree with consultants who say you need to give patients the treatment plan at that first visit because otherwise they might not come back. Following the suggestions outlined, it is rare that patients are not interested enough to return for the consultation.

The photographic series also makes it much easier to communicate with your specialists and laboratory technicians.

It is beyond the scope of this textbook to go into the details of dental photography, techniques, and equipment. There are many good sources available for this. However Figure 1.24 shows the individual views that comprise the complete photographic series and Figure 1.25 lists the various categories and views.


AESTHETIC EVALUATION (CLINICAL OBSERVATION, PHOTOGRAPHS AND STUDY CASTS)					
NAME			DATE		
INCISAL EDGE AT REST	UPPER _____ mm		LOWER _____ mm		DISPLAYED
SMILE (E-SOUND)	UPPER EDGES ARE _____ BETWEEN UPPER AND LOWER LIP				
	UPPER LIP POSITION:		BELOW TIP OF PAPILLA		AT TIP OF PAPILLA
				AT GINGIVAL MARGIN	
	LOWER LIP POSITION		BELOW UPPER EDGES		AT UPPER EDGES
			ABOVE UPPER EDGES		FOLLOWS SMILE LINE
LIP FULLY RAISED	AMOUNT OF GINGIVA DISPLAYED _____ mm				
MIDLINE OF UPPER CENTRAL INCISORS	CENTERED TO FACE?		YES		NO _____ mm TO L / R OF CENTER
	ORIENTATION		SLANTED		VERTICAL
	DRAW MIDLINE AND UPPER INCISAL PLANE RELATED TO FACE IS IT AN OBVIOUS AESTHETIC DISTRACTION? Y N IS PATIENT AWARE AND UNHAPPY? Y N				
UPPER INCISAL PLANE	LEVEL?		YES		NO, SLOPES UP TO PATIENTS R L
	REL TO UP OCCL PL		HIGHER		EVEN LOWER
	ARE LATS SHORTER		YES		NO
F / V SOUND	UPPER INCISAL EDGE POSITION		AT WET / DRY BORDER		
			IN FRONT OF WET / DRY BORDER		
			BEHIND WET / DRY BORDER		
LOWER INCISAL PLANE	LEVEL?		YES		NO, SLOPES UP TO PATIENTS R L
	REL TO LOW OCC PL		HIGHER		EVEN LOWER
UPPER GINGIVAL LINE	LEVEL?		YES		NO
	ARE POSTERIOBS, CUSPIDS AND CENTRALS ON SAME PLANE WITH LATERALS LOWER?				
			YES		NO
	INDIVIDUAL GINGIVAL MARGINS				
			CURVED		FLAT CORRECT ZENITH
TOOTH FORM	CENTRAL INCISOR LENGTH _____ mm				
	LENGTH WIDTH PROPORTION OK?		YES		NO
	GOLDEN PROPORTION OK?		YES		NO
	INCISAL EMBRASURES OK?		YES		NO
	CONTOUR RIDGES OK?		YES		NO
	LONG AXES ALIGNMENT OK?		YES		NO
FRONTAL AND LATERAL PORTRAIT EVALUATION	ASYMMETRY				
	CHIN				
	MANDIBULAR PLANE				
	MIDFACE				
	LIPS REL TO NOSE AND CHIN				
	NEUTRAL ZONE, LIP TONICITY				
OTHER COMMENTS OR OBSERVATIONS, E.G., PATIENT CONCERNS, DESIRES AND EXPECTATIONS					

Figure 1.23. Example of a form to evaluate aesthetic parameters.

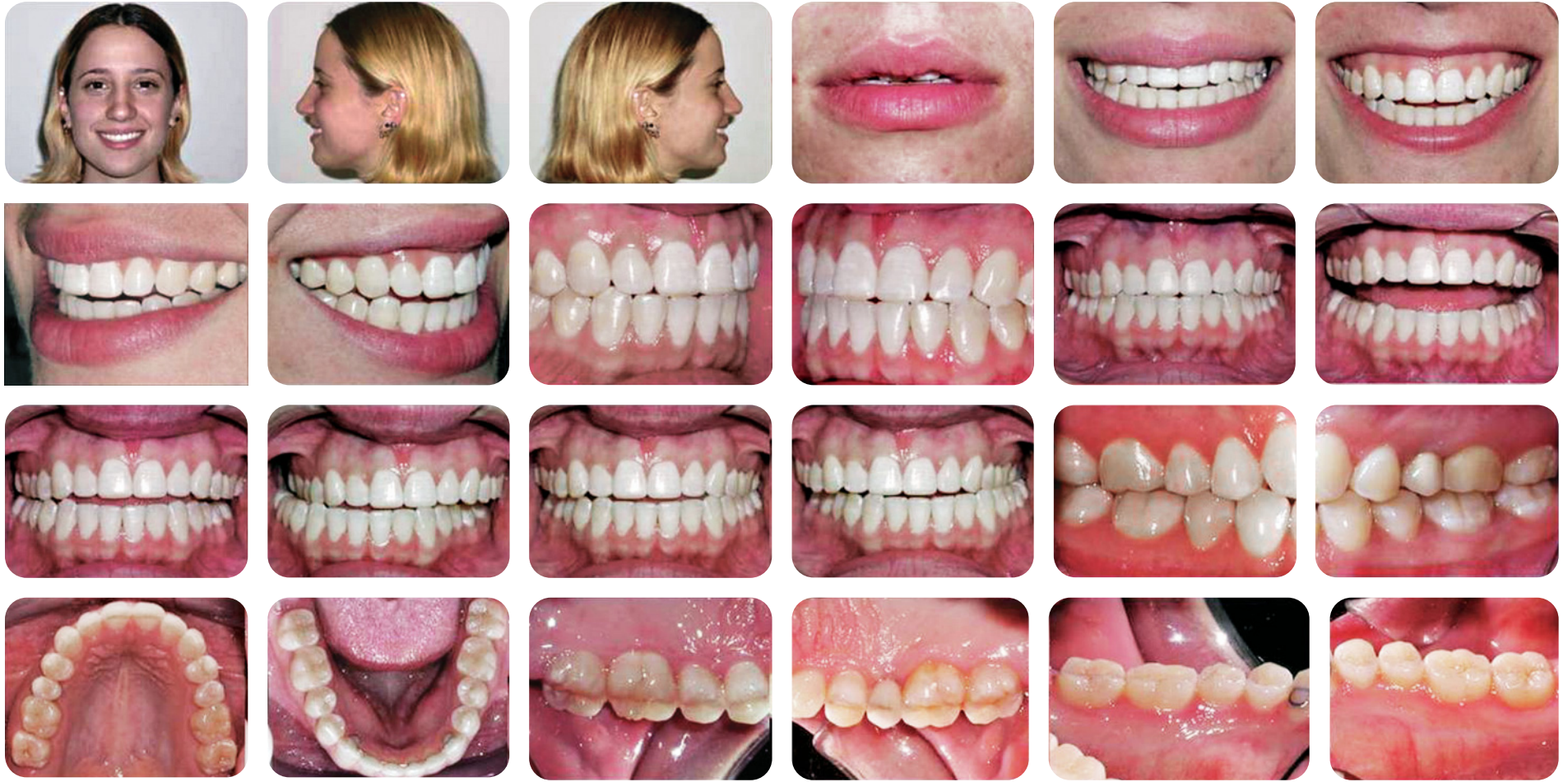

Figure 1.24. Composite of all views of a complete photographic examination. Photography allows us to see things that can be missed clinically. It allows us to go back and review at any point in the diagnosis and treatment planning process.

Category	Views
Full Face	Frontal Profile
Close-up Smile	Lip at rest Smile (E-sound) Lip fully raised Lateral smile
Retracted	Frontal in occlusion Frontal teeth apart Lateral anterior Right and left excursions Right and left crossover
Mirror Views	Buccal occluded Full arch occlusal Posterior lingual

Figure 1.25. Summary of the various views completed during a complete photographic examination.

It is a skill that the dentist and dental team can learn to seamlessly integrate into the practice.

Articulated Diagnostic Casts

The final component of the comprehensive evaluation is articulated diagnostic casts (refer to Figure 1.1). Articulated diagnostic casts give us the opportunity to visualize the maxillary-to-mandibular jaw-to-jaw and tooth-to-tooth relationships in the centric relation arc of closure. We can visualize the three-dimensional dynamics of the slide from the first contact in centric relation to maximum intercuspation as well as tooth contacts and interferences in excursive movements of the mandible. This allows us to further investigate any cause and effect relationships that may occur between various occlusal interferences and signs and/or symptoms uncovered during the clinical examination.

On a duplicate set of articulated diagnostic casts we are able to create a diagnostic blueprint, also referred to as a *diagnostic wax-up*. Any changes in form and/or function are previewed on a duplicate set of articulated diagnostic casts, and thereby you always have an original, archival set of casts to refer to as necessary.

The maxillary cast is mounted on the articulator by way of a facebow transfer. The mandibular cast is mounted on the articulator by way of a centric relation bite record (Figure 1.26). The centric relation bite record is made using bimanual guidance and at a slightly open vertical dimension, just short of the first point of contact and with the condyles fully seated into the fossa. Inspection of the articulated diagnostic casts should reveal the same first point of contact that was identified in the mouth during the occlusal examination. Inspection should also reveal the same hit and slide to maximum intercuspation that was identified during the occlusal examination. The articulated casts should slide to the same maximum intercuspation as observed with the casts held together by hand off the articulator. If not, this is a sign of an inaccurate CR record or an inaccurate mounting. A common error is observing a posterior open bite when attempting to slide the casts to maximum intercuspation. This usually is the result of the CR record capturing a slightly protruded position rather than with the condyles fully seated. The most common reason for this is a posteriorly directed force during bimanual guidance, which results in the patient resisting, contracting the lateral pterygoids, and posturing slightly forward.

The digital photographs of the various excursive movements help to set the condylar inclination on the articulator. The condylar inclination is adjusted so that the various excursive movements on the articulator look the same as the various excursive movements

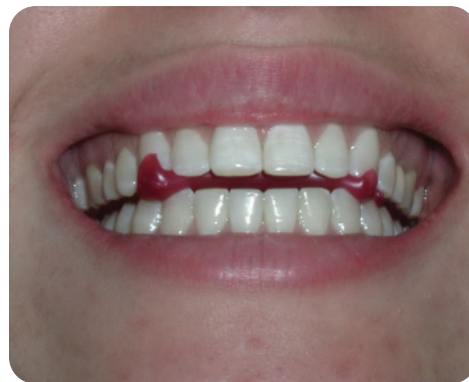
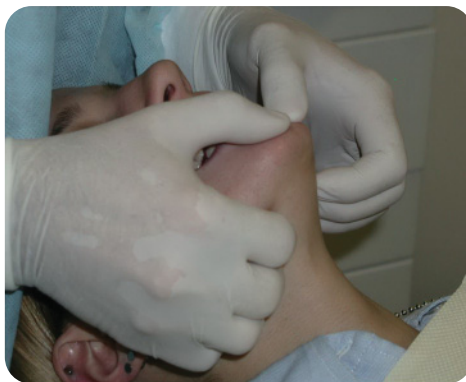
Figure 1.26. Bimanual guidance is used to make a centric relation bite record. The condyles are seated and the record made at an open vertical, short of the first point of contact.

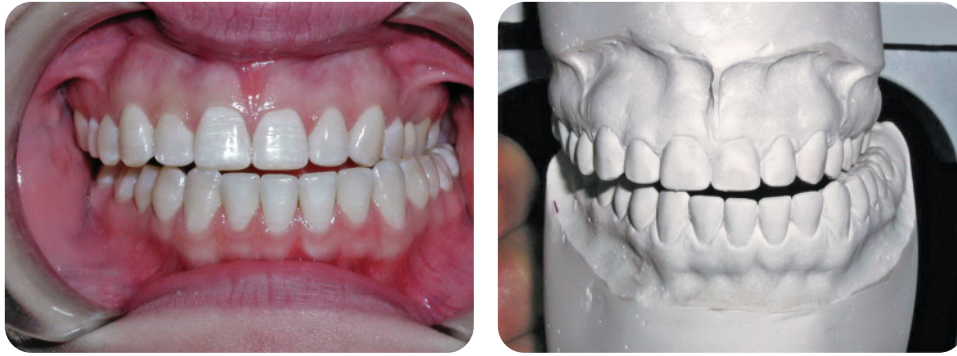

Figure 1.27. Photographs of mandibular excursions help in setting condylar inclination of the articulator. Simply adjust the inclination so that the casts look just like the mouth in the various movements.

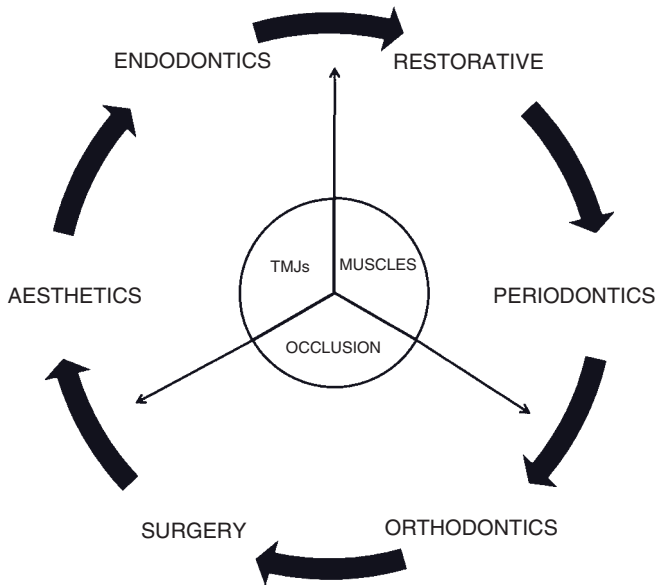


Figure 1.28. Achieving equilibrium between the TMJs, muscles, and occlusion allows more predictability with all the various types of dentistry we may be doing.

observed clinically and recorded with the digital photographs. This is illustrated in Figure 1.27. In other words, if there was a balancing interference on the left second molars during a right excursive movement, the left condylar inclination on the articulator needed to be adjusted so that this same balancing interference occurred on the articulated diagnostic casts.

A final note regarding the rationale for this comprehensive evaluation and complete masticatory system examination: By embracing this philosophy we are able to restore our patient's dentitions, both from an aesthetic and functional point of view, so that these restorations are in harmony and balance with all the components of the masticatory system. We want to design a minimal stress/minimal adaptation occlusal scheme so that we can obtain a predictable restor-

ative/occlusal/aesthetic result that has both stability and longevity. Figure 1.28 illustrates this concept. By achieving harmony and balance between the temporomandibular joints, neuromuscular system, and occlusion, the results we get with the various disciplines in dentistry are more predictable and less frustrating. Our aesthetic and restorative dentistry lasts longer because we are controlling and directing occlusal forces. Our orthodontic and orthognathic results are more predictable because we are moving teeth and/or jaw segments with the condyles seated. Endodontic therapy and periodontal therapy heals more predictably and without significant events because we have eliminated occlusal trauma. As we broaden our scope and look beyond just fixing teeth or replacing missing teeth and begin to look at ourselves as physicians of the masticatory system, as so frequently and eloquently taught by Dr. Peter E. Dawson,^{1,3} we enjoy much more happiness and fulfillment in the practice of dentistry.

References

1. Dawson PE. Evaluation, Diagnosis and Treatment of Occlusal Problems, 1974. Mosby, Inc., St. Louis, MO.
2. Dr. Mark Piper, www.tmjsurgery.com.
3. Dawson PE. New definition for relating occlusion to varying conditions of the temporomandibular joint. *J Prosthet Dent.* 1995 Dec;74(6):619–627.
4. Gibbs CH, Mahan PE, Wilkinson TM, Mauderli A. EMG activity of the superior belly of the lateral pterygoid muscle in relation to other jaw muscles. *J Prosthet Dent.* 1984 May;51(5):691–702.
5. Manns A, Chan C, Miralles R. Influence of group function and canine guidance on electromyographic activity of elevator muscles. *J Prosthet Dent.* 1987 Apr;57(4):494–501.
6. Roth, SM, professor in the department of kinesiology at the University of Maryland. Why does lactic acid build up in muscles? Why does it cause soreness? *Health, Scientific American*, www.SciAm.com, 1-23-06.

2

The People Side of Dentistry

After 27 years in dentistry, I am still amazed at the trust it takes for many patients to say yes to their treatment plan and embark on a journey that has a price of time, energy, effort, and finances, and from their perspective can have many unknowns. In many situations, we literally take their mouth completely apart and put it back together again. They may have teeth removed, bone and soft tissue removed and/or augmented, titanium screwed in, braces put on, pulps removed, and porcelain applied. It is a trust that we must honor and respect at every juncture and do everything we can not only to safeguard that trust but also to strengthen it.

How does a dentist build a practice that routinely does comprehensive cases as opposed to a practice that primarily just fixes teeth? First and foremost, as I heard Dr. L. D. Pankey say many times in the 1980s, you have to have it “on the shelf.” In other words, if a dentist wants to do comprehensive, masticatory system dentistry, he/she needs to get the training and become proficient at the technical aspects of this type of dentistry. A universal law says that what you do today you will do more of tomorrow. If a dentist makes the commitment to do this kind of dentistry and practices it daily, that is the reputation that will emerge; and as time goes on, more and more patients seeking that kind of dentistry will find the practice. Likewise, if a practice is merely fixing teeth, it will be doing the same tomorrow; that practice also will often be frustrated and wonder why nothing ever seems to change.

Clinical Cases in Restorative & Reconstructive Dentistry,
Gregory J. Tarantola, © 2010 Blackwell Publishing Ltd.

As the reputation of the practice—the “face” of the practice—is being created, happy satisfied patients will refer others, and specialists you work with will also refer patients that need your expertise. It is a natural phenomenon. The patients that find your practice, however it may be, seem to know already what you do and how you do it. So it seems to take less effort to “sell” patients on what you do.

The Importance of Behavioral and Communication Skills

The other essential criteria, in addition to the technical expertise, are the behavioral and communication skills that guide patients to enthusiastically say yes. They say yes for the right reasons, because they believe they are making a decision that is in their best interest. Even though you may find that as time goes on, more and more “quality” patients are finding your practice, the need for these communication and behavioral skills does not diminish. We still need to make sure that patients fully understand the nature and scope of their problem and the nature and scope of the solution. This does not happen by itself—it takes time, effort, and communication. The beauty of these skills is that patients who may not even be aware of the scope of their needs are brought into this interactive process, and it brings them to a place that they can begin to understand and where they can eventually say yes to a more comprehensive approach rather than being stuck in the “cleaning and check-up” cycle.

The All-Important 5 Questions

Figure 2.1 lists the 5 questions that one must answer prior to making a decision to say yes and feel that that decision is in their best interest with no regrets. Question 1 is “What is the problem?” In other words,

5 Questions That Must Be Answered Prior to Making a Decision

- What is the problem?
- What is the solution?
- Are you the right person to provide the solution?
- Is the time right for me?
- Is the cost right for me?

Figure 2.1. The thought process one must go through in making an important purchase decision.

do I understand the need? This question begins to be answered during the codiscovery examination. Codiscovery means that the examination is done with the active participation of the patient rather than at the exclusion of the patient. It is more than just data collection. As the data is collected, patients are involved when the dentist asks questions, invites comments, asks for patients' input, etc. It is an interesting learning experience that not only captures patients' attention but shows them that your approach is quite different from what they might have experienced. There should be two-way communication rather than the dentist merely speaking the data for a chair-side assistant to record in a patient's chart.

Only after this initial conversation can Question 2 be asked and answered: "What is the solution?" Patients cannot really understand the solution and how this solution benefits them unless they first understand the need and nature of the problem. My observation has been that as dentists we begin to answer this question too soon in the process. We try to explain the solutions before patients really understand the need. We try to describe crowns, veneers, implants, etc., and all too often this comes across as if we are trying to sell the patients something rather than trying to help solve a problem or fulfill a need that they might have. I make it a point never to talk about the definitive treatment plan during the exam. It really is not fair to us to try to design a treatment plan on the spot. We need time to think, ponder, and reflect. If we, or a team member, come up with a plan on the spot, it usually is a tooth-by-tooth restorative plan rather than a comprehensive one. It also is not fair to patients to expect them to digest this overwhelming amount of information. "I really don't know the answer at this point. I need to sort through all this information, study and analyze it, and come up with a plan that is most appropriate for you," can be a powerful statement. Patients appreciate your honesty and are impressed that you actually are putting forth this extra effort on their behalf.

Once patients begin to understand the nature of the problem and how the solution can help them, they

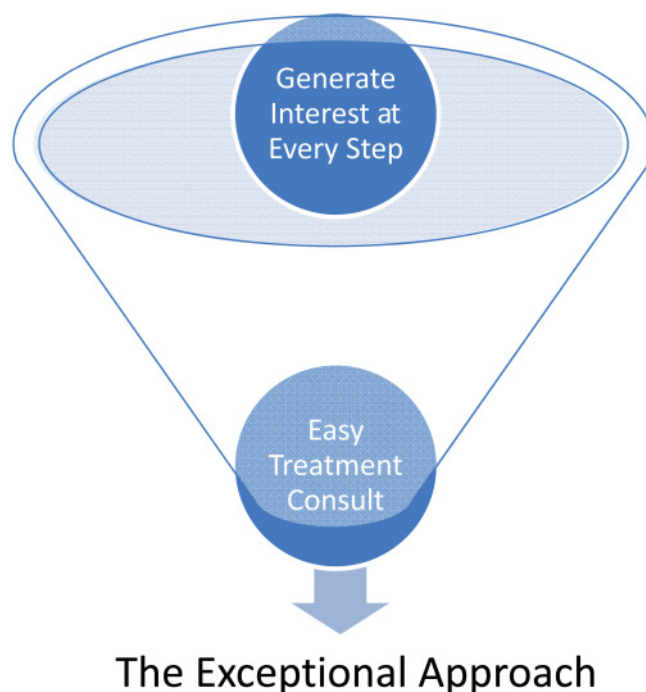


Figure 2.2. An approach that involves the patient with active participation throughout the examination process leads to more effective consultation.

need to feel that they are in the right hands. This brings us to Question 3: "Are you the right person to provide the solution?" In other words, is the trust in place? Do patients feel they are in the right office, with the right dentist and the right team? Many things must happen correctly for this trust to begin to develop. How was the whole process handled beginning with the very first phone call? Were they seen on time? Did they feel rushed? Was there time for questions and conversation? Did they sense that the whole process was only about their best interest and nothing else?

Once these first three questions are answered, then patients can consider Questions 4 and 5—whether the time and the fee are right. In other words, is this the right time in their life to begin this project and give it the attention it needs, and do they feel that this solution is enough of a benefit to them that they see the value and can pay the fee with gratitude and appreciation?

There is much written about how we and our dental teams can better answer that second question. There are many excellent patient communication tools, models, and computer programs that offer great help with the process. However, we should not use these tools in lieu of the time needed for the codiscovery process to answer the first question. Figure 2.2

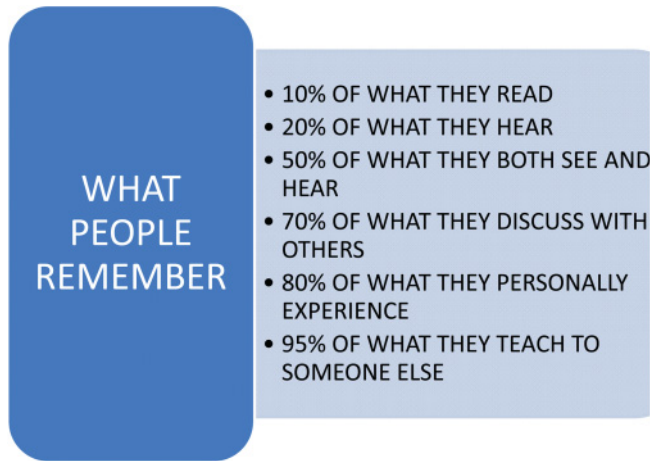
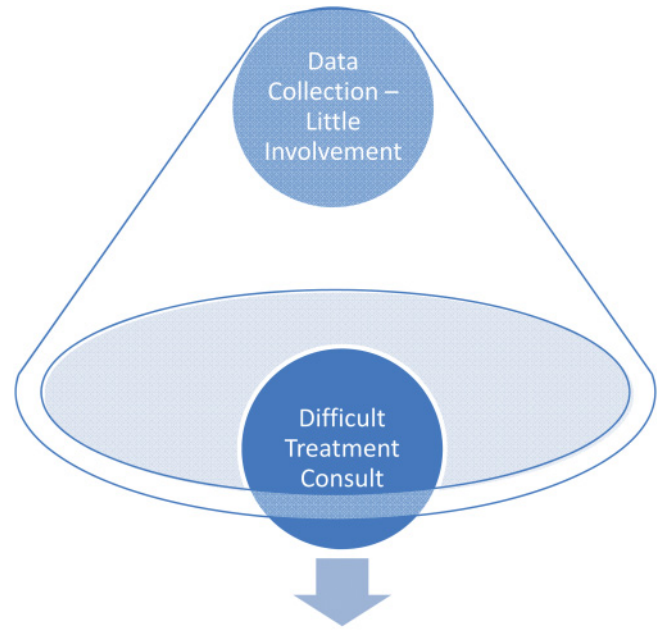


Figure 2.3. People remember more information when they actively participate.

illustrates this. If we use the analogy of a funnel, the wide end of the funnel would be on top and represent the time we spend in the codiscovery process. We want to invest all the time necessary to involve patients and generate interest during the examination by asking questions and inviting active participation. By doing it this way, we find that the time, energy, and effort needed during the consultation appointment is much less and thus represented by the small end of the funnel. Figure 2.3 lists the ways people remember. If we discuss the issues with them in a conversation, rather than just tell them, and if we engage their participation in a codiscovery examination process, they will remember 70–80%. Then a discussion about the treatment plan will make more sense to them and they will feel more connected to it.

Figure 2.4 illustrates an occurrence that happens all too often. It is represented by the upside-down funnel. In this case the small end of the funnel represents the examination. It may be a rather quick examination, more a data collection than a codiscovery process. It may be done more at the exclusion of the patient rather than with the active participation of the patient. It may be a very good technical examination, but patients may feel as if they are a little in the dark and unaware of the true nature of their conditions. In other words, Question 1 may not be fully answered for them. Therefore a lot of time, energy, and effort must be devoted to the consultation appointment, which is represented by the wide end of the funnel. These are the situations where we may see that blank look on our patients' faces. We go through the process of explaining the treatment but we know and feel in our hearts that they will most likely say no. I can speak



The Frustrating Approach

Figure 2.4. An approach where the examination process is rushed and does not promote active participation leads to less effective consultations.

from personal experience and observation that this is a very frustrating approach. The time we invest in an interactive, codiscovery examination process that involves the patient every step of the way will never be wasted time. An excellent resource that illustrates the process is the book *Question-Based Selling* by Tom Freece.

The Codiscovery Process

Let's look at this in more detail. Figure 2.5 lists the 6 goals of this process. As a rule of thumb, we like to fulfill these 6 goals prior to the treatment consultation appointment. Fulfilling these goals paves the way for an effective treatment consultation that helps patients move forward with a decision that is in their best interest. Accomplishing these goals may happen rather quickly, sometimes in one appointment if it is a well-referred and well-informed patient. Often it may take several appointments over an extended period of time. We need to meet each patient at his/her own level and be aware that how each patient progresses is a very individualized thing.

Understand Their Concerns

Goal 1 is to understand their concerns. What is on their mind, what have they been concerned with, what

SIX GOALS OF THE CODISCOVERY EXAMINATION

- * Understanding the patients' concerns should be a top priority.
- * Address their concern in a positive way.
- * Orchestrate the exam so the patient learns about their condition.
- * Speak comprehensively about the inter-relationships between teeth, perio, TMJs, muscles and occlusion.
- * Relate their concerns to these inter-relationships and the implications.
- * Invite a response / continue the dialogue / negotiate a plan.

Figure 2.5. The codiscovery examination has 6 goals that should be achieved prior to expecting to have an effective consultation.

are *their* goals, their fears, etc? As we converse with our patients we may find that these issues bring us to nondental places. That's fine, even desirable. Our job is to listen nonjudgmentally. As we listen, we have to make sure we truly understand. We need to not only hear the words but try to understand what is behind those words, the meanings and implications. Thoughts and information are brought out that may not initially seem important but may play a very big role in the treatment plan and sequence. The environment in which this happens is critically important. If the whole process seems rushed, mechanical, and just a process to get information, the patient most likely won't feel comfortable enough to open up to us.

As we listen, we must be careful at this point to not offer an answer, solution, or suggestion. It is too soon in most cases. We don't have all the information, both technical and emotional, to offer an appropriate solution. Let me offer a communication skill that we as dentists and our teams can consciously practice until we are comfortable with it. When patients express a concern, issue, or problem, do *not* reply with an answer. Rather, reflect for a moment on what was said and *ask an appropriate question* that will help you better understand their concern or issue. Asking questions is powerful. It not only helps you better understand, but it helps the those you ask begin to formulate answers on their own; they must ponder

and reflect as they answer your thoughtful questions. It is a powerful thing. As we finish this initial conversation, I summarize what I heard and ask patients whether I understand correctly. If their concerns are rather involved, I often ask patients to list their priorities. They must think about that and it helps me determine how closely aligned we might be in our thinking. Does it take time to do this, time that we often might feel we do not have in our busy schedule? Yes indeed! But how this initial conversation transpires sets the tone for the entire future relationship with your patients. So whatever time it takes is worth it.

Address Their Concerns Appropriately

Goal 2 is to address patients' concerns in a positive way. This does not necessarily mean offering a definitive solution. If their concerns present a long problem list, it may simply be something like, "I think I am beginning to understand your concerns. As we do the examination, we will leave no stone unturned in figuring out your current status, determining why it may be this way, and designing an appropriate solution." If their concerns initially seem to be something simple and straightforward, such as a small chip on an incisal angle, a small composite restoration may be the best way to address it—not at the expense of a complete examination but as a way to move toward the complete examination. If they are concerned about the appearance of this tooth because of an upcoming event, and we overlook that, how in tune will they be during the complete examination?

Customize and Orchestrate the Exam for Each Patient

The preceding now sets the stage for the Goal 3, which is to orchestrate the examination in a way that patients learn about their condition. How do we begin the actual examination? The word "orchestrate" implies that every examination may be a little different. Every dentist and team has a routine and protocol based on his/her office systems. It is important to have systems, but these systems need to "assist rather than insist." This means we need to be able to flex based on the individual we have just come to know a little better. Figure 2.6 illustrates this. I look at the masticatory system examination as a circular process. In other words, we will eventually collect the data, but where we enter this process can vary. The best place to enter the process may be determined by what you learned in the preceding conversation. If

THE CODISCOVERY APPROACH

Where to begin the examination

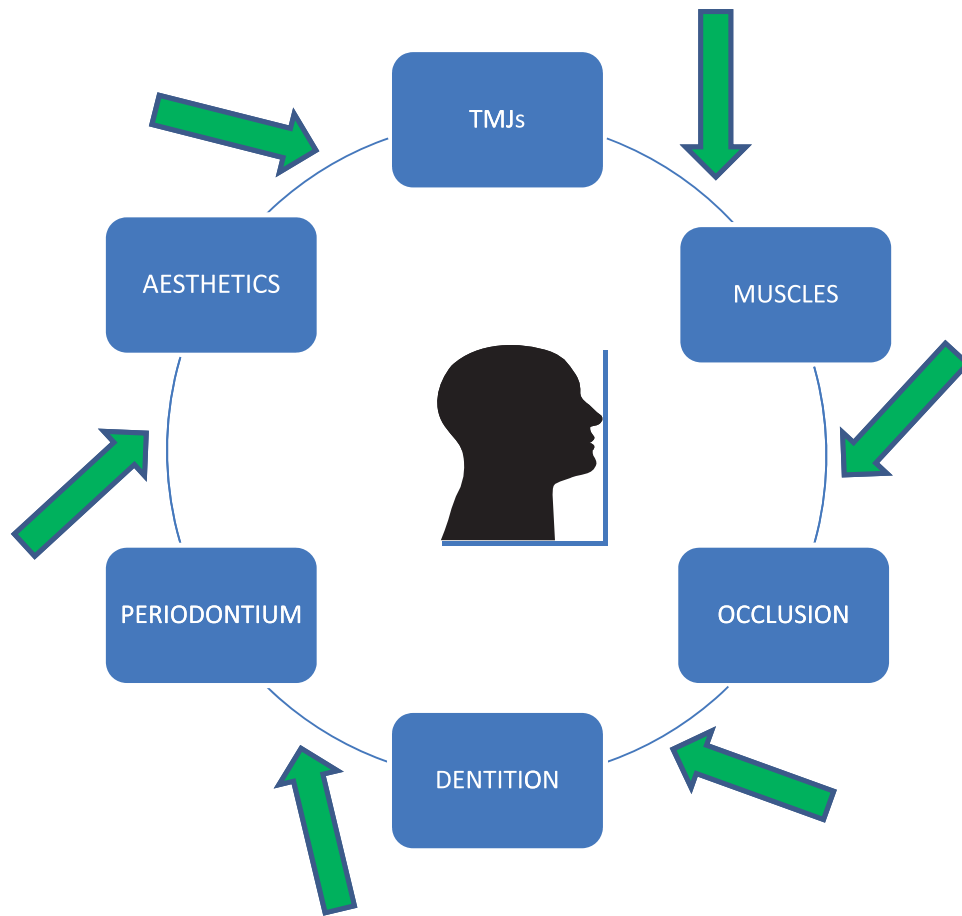


Figure 2.6. Although the clinical examination has several components, it is best to be flexible enough to begin the examination at a point that best addresses the patient's primary concerns.

their concern is TMJ in nature, you begin with the TMJ exam. If their concern is aesthetic in nature, you begin with the aesthetic exam. If they are concerned about daily headaches, you begin with the muscle exam, and so on. Keeping their concerns at the forefront is powerful. It keeps them more interested and attentive because it once again shows that this whole process is about *them* and not about some other agenda.

Just as in the initial conversation we look for ways to ask questions to help us better understand, we follow the same approach during this clinical codiscovery examination. This is especially true during the occlusal examination. As we discover occlusal interferences, just identifying and recording these inter-

ferences may be helpful to us, but what does it mean to the patient? Ask your patient to point to the interference. Ask questions such as the following: What do you feel when I press on this interference? Does the tooth feel sore? Do you feel discomfort somewhere else? Where? Ask the patient to point to the other location of discomfort. There are many junctures throughout the complete examination that give us this opportunity. It makes the entire process more interesting, fun, and personalized, and the patient will better remember the information most interesting to him or her. Once again, I feel it is important to resist the urge to talk about treatment during the examination. It is too early to speak about definitive treatment. Just talk about what you see.

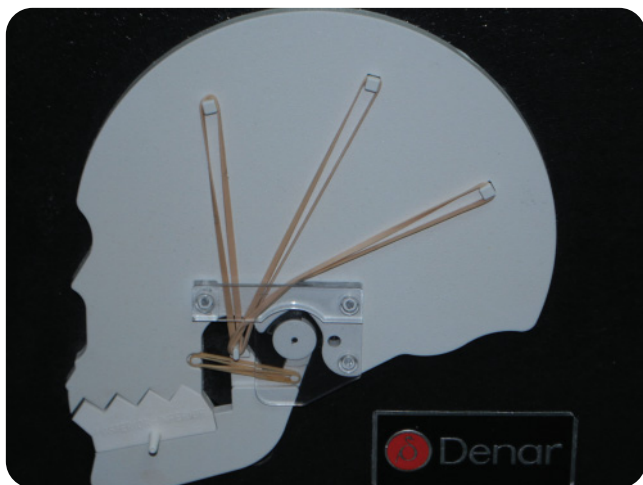


Figure 2.7. A visual educational tool such as the TMJ Tutor helps the patients see the big picture and where their current condition fits.

Tie It All Together—Help Them See the Big Picture

As you complete the actual clinical examination, it is important to tie it all together, which brings us to Goal 4: speak comprehensively about the interrelationships of all the parts you just examined together. A visual aid such as the TMJ tutor by Denar helps accomplish this (Figure 2.7). It helps patients see how occlusal interferences can affect TMJs, muscles, teeth, and periodontium. We like to see all the teeth fit when the joint fits. However, what we see happening is that when the joint fits, the teeth *don't* fit. And when the muscles accommodate to get the teeth to fit, the joints don't fit. This discrepancy can be the source of many issues. Patients may have problems in any or all of these areas or they may not. But it helps them see the big picture. If they are having problems in a particular area, it helps them to begin to understand why. If they are not having problems in a particular area, celebrate that fact! Remember that the purpose of the examination is to assess the status of their masticatory system, and not just to find problems with it.

Relate the Exam Findings Back to Their Concerns

This brings us to Goal 5, which is to relate patients' own individual concerns to the things you just found and discussed. If their concern is the unaesthetic appearance of their front teeth, you may be able to relate occlusal misengineering and imbalance to these concerns. If their concern is TMJ noise and pain, they

begin to see why, and so on. This is another reason it is so important to grasp and understand their concerns. It becomes the anchor for the rest of the process. It is the anchor that makes it about them and not about the dentist. It is the anchor that keeps them interested. Everyone wants to be listened to and understood. They hope that somehow, some way their concerns will be addressed. If we don't really understand what those concerns are, we are missing a critical opportunity.

Continue Appropriately

This now leads us to Goal 6, which is to invite a response/continue the dialogue/negotiate a plan. Ask whether they have questions or concerns. Ask whether they feel they understand. This is now a great opportunity to reinforce the need for radiographs, photographs, and articulated diagnostic casts, as necessary, for you to thoroughly study the concerns you found clinically. Think of it as tests that the physician orders to be able to make the correct diagnosis. You need the same tests to make the right diagnosis and to devise the right treatment plan and most appropriate treatment sequence.

Concluding this examination appointment in the right way is very important. It will be the last experience before they leave and therefore most likely the one they will remember the most. I conclude that appointment with my patients by reviewing their clinical photographs on the computer monitor with them. I hand patients a laser pointer, show them how to use it, and ask them to point to anything they want to comment on or ask a question about. As I sequence through the photographs, I review and talk about what we found and discovered during the examination and ask once again for their input and questions. I resist the inclination to talk about treatment options and talk only about what we see and how I will be spending more time evaluating the information after they leave, working on their behalf analyzing and studying to come up with the right diagnosis, treatment plan, and treatment sequence. They will never know that you are going to invest this time on their behalf unless you and your team communicate this to them. Patient perception is reality so be sure that the perception is correct. In addition, patients can only place value in what they know to be reality and not just perception. How can patients place value in the time, energy, and effort that you will be investing on their behalf unless they know what you will actually be doing for them? This is a powerful way to end the appointment, and it

gives them a reason and motivation to want to come back for the consultation appointment. To further reinforce the value of their appointment that day and the value of your continued work on their behalf, give them a note, as shown in Figure 2.8, that lists everything that was done and that you will be doing. This is another step that reinforces their decision to choose you and your practice for their dentistry.

Which Approach Is Best—The 4 Quadrants

After the patient leaves, invest the time to ponder, reflect, and design a treatment plan and sequence for your patient. What will be the most appropriate approach for a given patient? It depends on the patient's individual circumstances (Figure 2.9). Quadrant 1 represents a patient who values optimal health and has the circumstances to move forward in a timely manner. How do we recognize patients who value optimal health? They are well-referred. If they were not directly referred, they may have found your practice after researching the Internet and your website, so they already have a sense of what you are all about. They are on time. They come to the visit prepared. They are interested, ask questions, and want to be involved. They are friendly and respectful to the team. What illustrates no limitations to treatment? Their circumstances are such that they have the time and finances to proceed with a project of a scope needed to fulfill the goals.

In Quadrant 2, we still have a patient who values optimal health but the circumstances require sequencing. What circumstances might those be? The patient's time and/or finances are such that a big project cannot be tackled all at once. We have to figure out a way to sequence it over a period of time that fits in their life circumstances. It is important to say that it is not a compromise treatment plan but rather the same optimal plan just sequenced into smaller segments. When we have a diagnostic wax-up/blueprint, we can often figure creative ways to sequence their dentistry. If there are form and function changes that need to be made, they can often be done with direct composite additions so that the segment in which we do the definitive dentistry has correct landmarks to be built against. The key is creative thinking and planning, which by all means is easier with a diagnostic wax-up in front of us. Remember, the diagnostic wax-up does not dictate the specific dentistry we must do. It just tells us what the dentistry we do, whatever it may be, must look like.

Quadrant 3 is a patient who does not yet value optimal health, but we and our teams sense that with some TLC, this patient will eventually come to learn and understand what is in his/her best interest. How do we recognize these patients? They may be untrusting, possibly because of past dental experiences. They have a limited focus, put limitations on what we suggest, and may not be as interested as a Quadrant 1 or 2. As time goes on, we may see their trust deepen, we may see their level of interest increase, and we may see an overall improvement in their demeanor when they come to visit. These are the patients that may not be ready to hear an entire comprehensive plan right away. We still need to do a complete exam to understand their baseline status and diagnosis but the dentistry we do may be more basic in nature, that is, basic periodontal care, restorative care, possibly bite splint therapy to address a TMJ, and/or muscle need. If we pay attention and make sure they don't get stuck in the "recall rut," we will recognize when they are ready for something more. A good way to recognize this is to periodically schedule an appointment with the dentist, separate from a maintenance appointment, to review, reexamine, and converse. There typically is not enough time, nor is it the right environment, to do this at the end of a maintenance appointment.

Quadrant 4 is characterized as the crisis patient who does not desire, and may not ever desire, the benefits of good dentistry, whatever the circumstances may be. These patients may have the time and finances, but it just may not be important to them. Everyone is entitled to his/her own decisions. These are the patients for whom I will do the most limited of dentistry, just to minimally address their immediate concerns. They may not ever see the benefit of a comprehensive exam and may not ever return to the practice, or they may return for another crisis event. It is up to each individual dentist and his/her own vision and philosophy as to what the future holds for Quadrant 4 individuals. There is no right or wrong answer.

Dentistry: A Blend of Technical, Emotional, and Intellectual Skills

One of the important points to make in these beginning chapters, before we get into the actual clinical cases, is that dentistry is much more than a technical endeavor (Figure 2.10). For us to be successful in masticatory system dentistry and enjoy the happiness and fulfillment that is possible, we also need to develop our emotional/behavioral/communication skills

YOUR INITIAL EVALUATION

The following was completed during your initial evaluation:

- Reviewing your medical and dental history
- Clarifying your concerns, expectations and/or problems
- Ora cancer examination
- Dental examination evaluating condition of teeth and/or restorations
- Periodontal examination of your gums
- Temporomandibular joint examination
- M muscle examination
- Occlusal (bite) examination
 - Computerized Analysis
- R radiographs
- Full mouth series
- Bi bitewings only
- Panoramic, showing entire upper and lower jaw
- Diagnostic study casts and bite records
- Photographs for diagnostic purposes

Other:

- Dental prophylaxis (cleaning) with self-care coaching
- Whi whitening kit
- Dec preventing toothpaste: MI Paste, other fluoride toothpaste

Dr. Tarantola will take the time to evaluate all the above information carefully, consult with any specialists, if indicated, make a specific diagnosis for your current condition and design a blueprint for your care with the diagnostic casts. An individualized long-term treatment program will be designed and discussed with you fully at a future appointment. Above all, we want you to be informed and involved and feel that the decisions you make are in your best interest.

Dr. Tarantola and Staff

Figure 2.8. A letter that summarizes all that was done during the patient's clinical evaluation helps to build the value for that process.

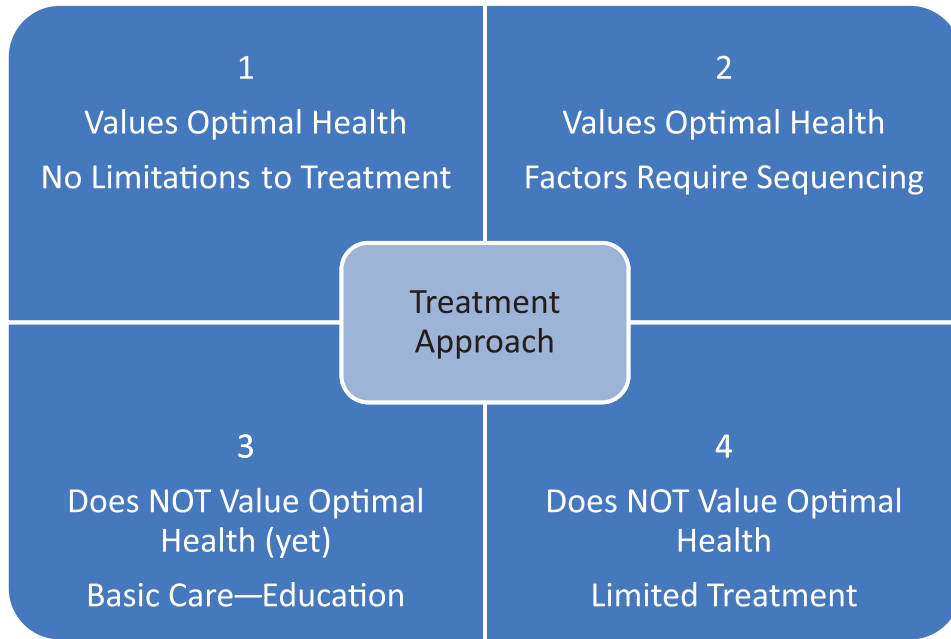


Figure 2.9. The patient’s individual circumstances are important factors in determining the best individualized approach.

SKILLS WE NEED TO DEVELOP

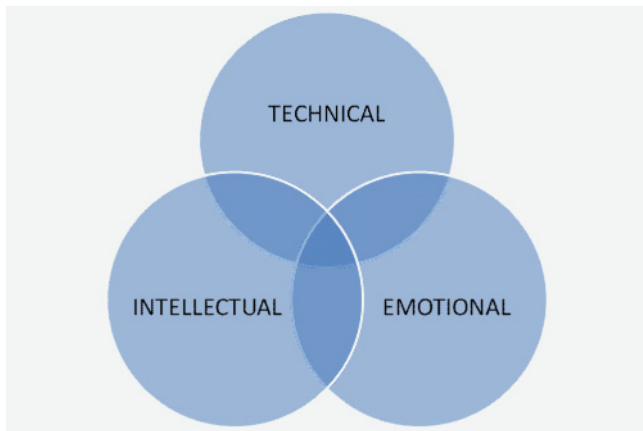


Figure 2.10. Dentistry is much more than technical skills. We must be good communicators and allow time to think.

and be committed to investing the intellectual time to ponder, reflect, and think. One of my favorite quotes is from Abraham Lincoln, who said “It is indispensable to develop a habit of observation and reflection.” This is not meant to minimize in any way the importance of exquisite technical dentistry and the need for us to continually improve those skills. Poor technical quality leads to disappointments and failures. But if we are an excellent technical/clinical dentist but can’t help our patients learn and discover the benefits of what we have to offer, we may not have all the opportunities we would like to be able to use those skills. If we don’t devote the time for the intellectual component, we may find our technical time at the chair may be inefficient, and we may find ourselves wasting time doing things over when thorough planning would have resulted in more efficiency and in predictable success.

3

The 4 Essential Skills of the Comprehensive Dentist

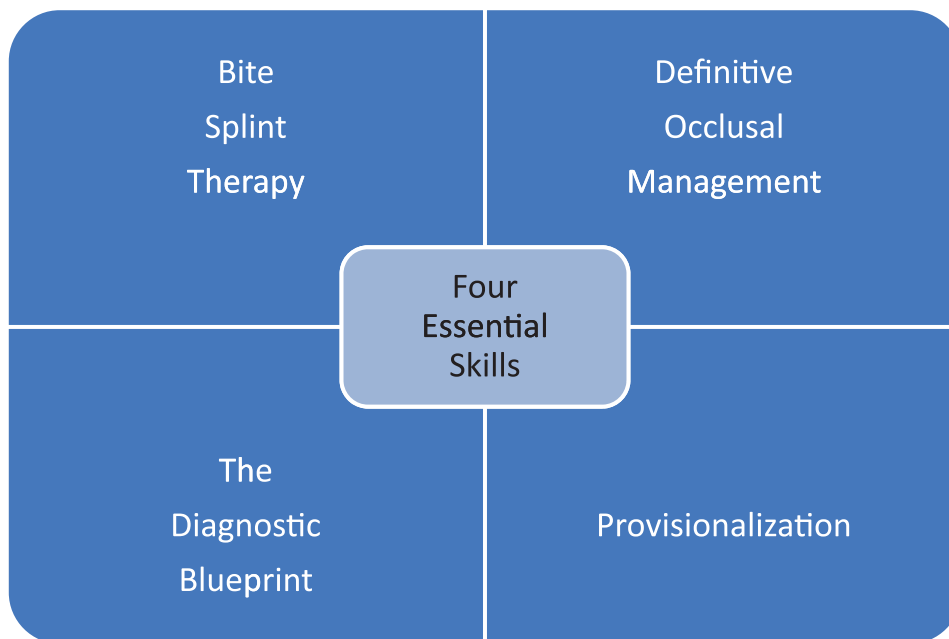


Figure 3.1. The 4 Essential Skills needed by the masticatory system restorative dentist.

Comprehensive dentistry is much more than just fixing teeth, in small or large quantities, or just improving cosmetics (Figure 3.1). It is understanding the masticatory system, recognizing problems, and addressing problems of any of the components of the system. A valuable tool in addressing issues with the temporomandibular joints and/or the neuromuscular system is

bite splint therapy. The masticatory system dentist needs to be proficient in its use. Once these components are in harmony, health, and balance, the occlusion needs to be definitively managed. Before the dentistry begins, a diagnostic blueprint is created on a second set of articulated diagnostic casts so an appropriate plan and sequence can be created. When aesthetic and functional changes are made, it is best to test these changes prior to finalization, so the dentist needs to be proficient in a technique of provisionalization.

Clinical Cases in Restorative & Reconstructive Dentistry,
Gregory J. Tarantola, © 2010 Blackwell Publishing Ltd.

3A

Bite Splint Therapy

One of the important factors that plays a role in the longevity and stability of restorative and reconstructive result is the status of the temporomandibular joints and neuromuscular system. If the status and condition of the temporomandibular joint structures is altered, that joint may not be as stable over time as a normal joint. Changes within the temporomandibular joint will result in occlusal changes, which may be a factor in problems with restorative result. If the neuromuscular system is not in a state of equilibrium, that also could be a reason for occlusal changes, so the temporomandibular joints and neuromuscular system must be examined on all of our patients. If there are issues with these systems they must be diagnosed and addressed prior to finalizing the restorative result. Quite often with appropriate therapy we can bring the structures to a state of health and stability, which makes the restorative result more predictable. If the condition of these systems has been altered to the point that there are irreversible structural changes that cannot be returned to a state of normalcy even with appropriate therapy, the dentist and patient must be fully aware of this diagnosis and accept the implications and consequences even though the patient may be without pain and/or other symptoms.

Bite splint therapy can be an effective way to manage the signs and symptoms of a temporoman-

dibular disorder, both intracapsular issues and neuromuscular issues.¹⁻⁶ There must be a logical rationale for the use of bite splint therapy. After a complete masticatory system evaluation, it is determined whether occlusal interferences may be a factor in these signs and symptoms. If they are determined to be a factor, bite splint therapy is indicated. If they are not determined to be a factor, the rationale for bite splint therapy may be questioned (Figure 3.A.1). The splint is simply a device to give the patient a good occlusion; and with wear over time, we can assess the effect this good occlusion has on the signs and symptoms. If our examination was thorough and complete and our diagnosis accurate, the results will be predictable. "Let's try a bite splint and see what happens" is not a valid rationale.

Other issues may also be a factor in these signs and symptoms, such as trauma, musculoskeletal disorders such as fibromyalgia, other medical conditions, etc. It is not within the scope of this text to delve into these other issues other than to point out that they may be an issue and thus may indicate a referral to the appropriate health care professional.

If It's Not Centric Relation or Adapted Centric Posture, Bite Splint Therapy Is Started from a Treatment Position

If the TMJs cannot be superiorly compressed without tension or tenderness, the diagnosis cannot be centric

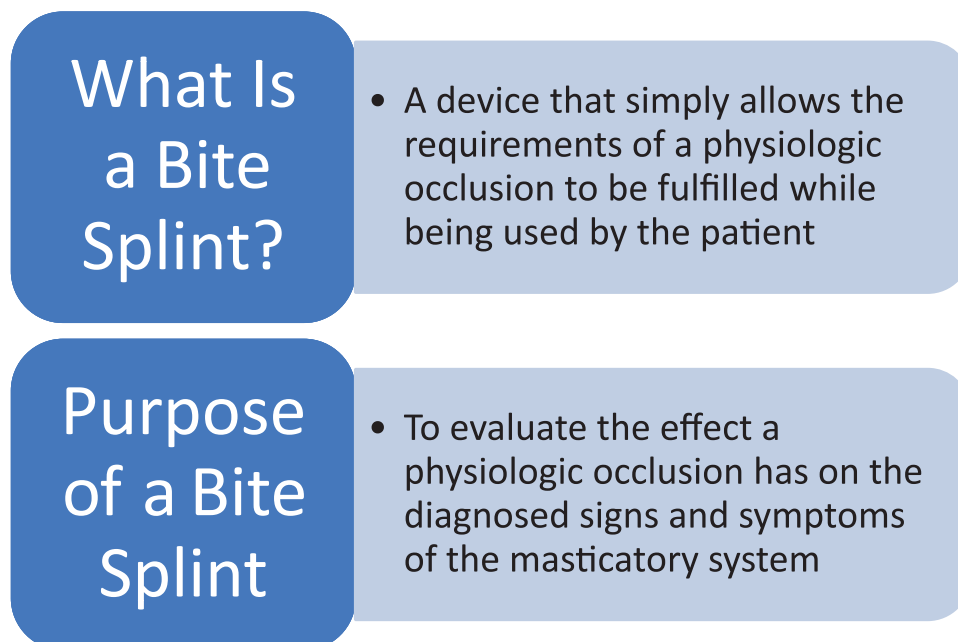


Figure 3.A.1. A bite splint is a device that helps us preview the effects of a physiologic occlusion.

relation or adapted centric but rather a “treatment position” from which to begin treatment. The eventual goal is centric relation or adapted centric posture. The purpose of bite splint therapy is to allow healing, remodeling, and adaptation of joint structures by controlling forces to the TMJs with proper bite splint design. Experience has shown that this process of healing, remodeling, and adaptation of fibrocartilage and bone can take several months. There are two goals we want to achieve (Figure 3.A.2): 1) the elimination, or at least the improvement of, patient symptoms and 2) stability of occlusion on the splint for at least 2–3 months. This means that once we get to the point that occlusal adjustments on the splint are no longer necessary because there is no change from appointment to appointment, we like to see that there are no further changes for an additional 2–3 months. Experience has shown that if this assessment step is rushed and the definitive treatment started too soon, the disappointment of occlusal changes in the definitive dentistry is more likely.

Bite splint therapy is an effective tool even in the patient with structural alterations *without* pain or other symptoms, in particular, the patient in whom we have diagnosed adapted centric posture. It will give us further indication of stability of these altered joint structures as this splint is monitored and adjusted over a period of time. When major amounts of restorative dentistry are needed, an extended period of time in

provisionals may also be prudent. It will give us another opportunity to make occlusal changes in the restorative design if indeed there are TMJ changes.

To get predictable results with bite splint therapy it must be properly designed, fitted to the arch, and adjusted. My preference is a hard acrylic material. This allows for precise fit and adjustment. A soft material does not allow this kind of precise adjustment. A hard bite splint with a soft liner also has some disadvantages. With a soft liner, the base of the splint has some “give,” which may allow some movement that is like an occlusal change due to instability. Since the base is soft, experience has shown that the hard outer shell can also develop cracks and crazes. With two different materials, repair is difficult. Often during bite splint therapy we may do some restorative dentistry such as composites for caries management. A hard acrylic splint is easy to grind out and relin, extending the useful life of the splint and preventing an entire remake. This type of modification is difficult with a hard splint with a soft liner.

Maxillar or Mandibular Arch?

Since the purpose of the splint is simply to create a physiologic occlusion while the splint is being used, this purpose can be fulfilled with either a maxillary or mandibular bite splint. The decision of which arch to choose should be determined simply by deciding which arch will allow for the most efficient design. For

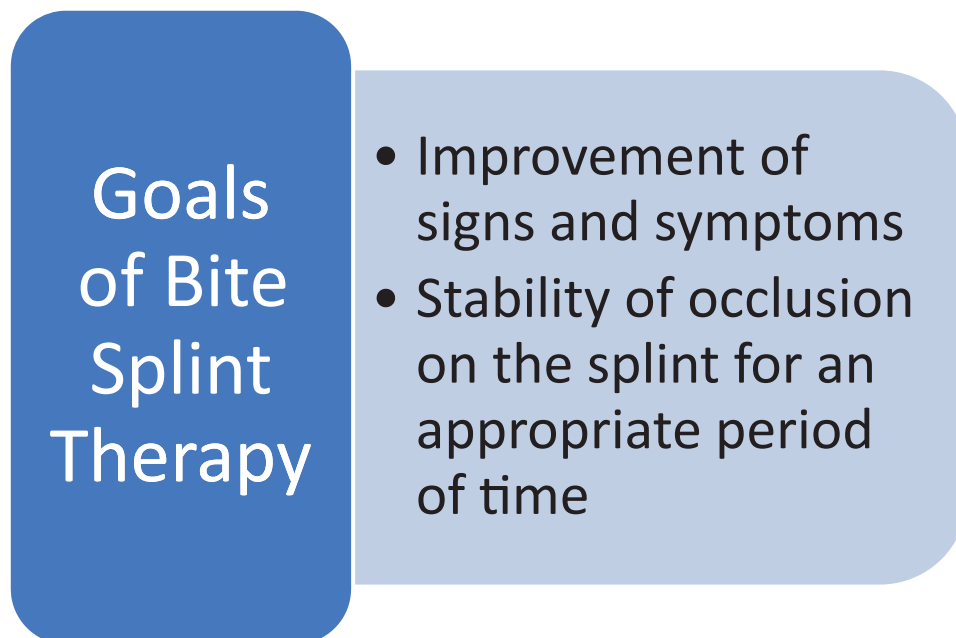


Figure 3.A.2. Two specific goals are achieved with the use of a bite splint.

example, if the lower anterior teeth have uneven incisal edges but the upper anterior teeth have fairly even incisal edges, a lower bite splint is indicated because it will be easier to refine anterior guidance with even incisal edges. Experience has shown that patients generally prefer a lower bite splint. There are several reasons for this. A lower bite splint is more easily camouflaged by the lower lip. A lower bite splint interferes less with the tongue during speech. A lower bite splint engages the natural undercuts on the lingual of the lower posterior teeth, allowing for adequate retention even with a design that does not cover the buccal surfaces and making it more comfortable to wear. An upper bite splint typically covers the buccal surfaces of the posterior teeth for retention or has to have some sort of clasp design. Whichever arch you choose, be sure every aspect of the design takes patient comfort into consideration. A comfortable splint will help ensure better patient compliance.

The Anatomy and Physiology of the Masticatory System Determines the Design of the Splint

Because the purpose of the bite splint is to improve anatomic relationships within the temporomandibular joints and to improve the physiology of the neuromuscular system, we should take the anatomy and physiology of the masticatory system into consideration when we design the bite splint. Figure 3.A.3 lists some important anatomic and physiologic considerations and also describes how that anatomic or physiologic principle would affect the design of the bite splint.

Condyles in the Most Superior Position

Figure 3.A.4 illustrates the condyle/disc assembly. Note the smooth functional surface of the fibrocartilage disc. Figure 3.A.5 illustrates the glenoid fossa. Note that the fossa and eminence are covered by smooth fibrocartilage. Bear in mind that these functional surfaces are lubricated by synovial fluid, which has a very low coefficient of friction. Understanding these anatomic conditions helps explain why the condyles should be in the most superior position within the fossa. If the condyle is down and forward along the steep, slippery eminence, it must be held there by the lateral pterygoid muscles. Condyles in a down and backward position would impinge upon the retrodiscal tissues, which are highly innervated and vascular. The condyles cannot be in any other position. They cannot be hanging down away from any part of

the glenoid fossa because all the muscles pull the condyles toward these surfaces. This brings us to principle number one in the splint design illustration, which states that the condyles are in the most superior position. Because this is the goal, the splint should be designed in a way that will most efficiently allow this to happen. Therefore, the splint is designed with a flat surface that will, over time and with correct adjustment, allow the condyles to seat in the most superior position. A splint with occlusal indentations that engage cusps will be more directive in nature and, like interfering inclines of maximum intercuspation, may cause the condyles to posture forward. Once we have verified that the condyles are fully seated and stable, we make the diagnosis of either centric relation or adapted centric posture. If the temporomandibular joints are painful and cannot be superiorly compressed at the beginning of bite splint therapy, we should identify it as a treatment position and not centric relation or adapted centric posture.

Interferences to the Arc of Closure Hyperactivate Positioning Muscles

The second principle states that occlusal interferences to the arc of closure with the condyles seated will hyperactivate the positioning muscles, in particular the lateral pterygoid. Understanding this principle helps us understand how the bite splint must be adjusted to get this condylar seating and decrease activity of the lateral pterygoid muscles. Bimanual guidance, as previously discussed, allows us to keep the condyles seated as we are adjusting the bite splint. If we are beginning with a treatment position—that is, temporomandibular joints that cannot be compressed without discomfort—it may be prudent to initially avoid firm superior compression with bimanual guidance. In this case we want to begin adjusting the splint to a position that is as comfortable as possible, which allows healing remodeling and adaptation with the goal of eventual firm superior seating. Once the condyles can be compressed comfortably, adjusting the bite splint to the patient's own unguided closure may actually adjust the bite splint to a condylar position, which may be down and forward. Recall that the only way the condyles can be held down and forward is by contraction of the lateral pterygoid muscles. The goal is to get the lateral pterygoid in as relaxed a state as possible. If there is contraction of the lateral pterygoid, it will be stretched upon superior compression, resulting in possible discomfort or a sign of tension reported by the patient. If the condyle is fully seated to the medial

ANATOMIC-PHYSIOLOGIC PRINCIPLE	• RESULTANT EFFECT ON SPLINT DESIGN
Condyles in the Most Superior Position	• Splint is flat in design allowing the condyle to seat with adjustments over time.
Interferences to the Arc of Closure Hyperactivate Positioning Muscles	• Bimanual guidance, or similar technique, is used to adjust the splint.
Posterior Excursive Interferences Hyperactivate Closing Muscles.	• Anterior guidance on anterior teeth • Immediate posterior disclusion
Steep Guidance Ramp = More Energy Used	• Keep anterior guidance shallow, flat, and smooth.
Muscles Hyperactivate to 30 micron Interferences	• Stable fit • Adequate retention • Precise adjustment
Curve of Wilson Facilitates Working Side Disclusion	• Incorporate the correct Curve of Wilson.
Retrodiscal Tissues Are Innervated and Vascular.	• No retrusive inclines to diatalize condyles

Figure 3.A.3. The anatomy and physiology of the masticatory system helps determine the design of the bite splint.

pole brace, the lateral pterygoid cannot be stretched any further (Figure 3.A.6).

Posterior Excursive Interferences Hyperactivate Elevator Muscles

The third physiologic principle states that posterior excursive interferences hyperactivate the elevator

muscles—that is the masseters, temporalis and medial pterygoid. Therefore, we eliminate all working side, balancing side, and protrusive interferences by designing a guidance that functions on the anterior teeth, ideally from cuspid to cuspid. This leads us to the fourth principle, which addresses the steepness of the anterior guidance.

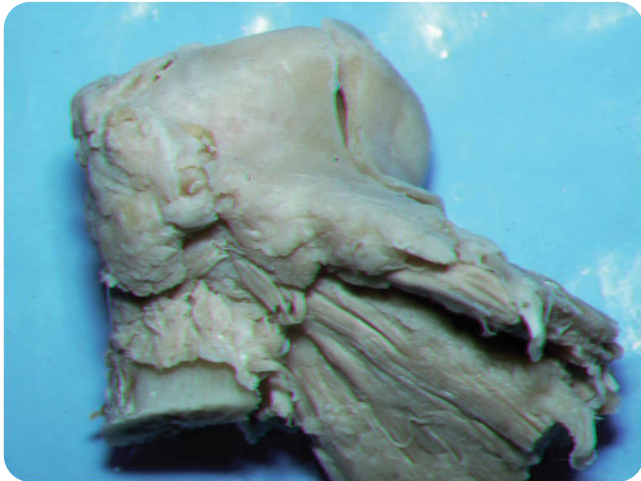


Figure 3.A.4. A dissected condyle disc assembly with the lateral pterygoids attached.

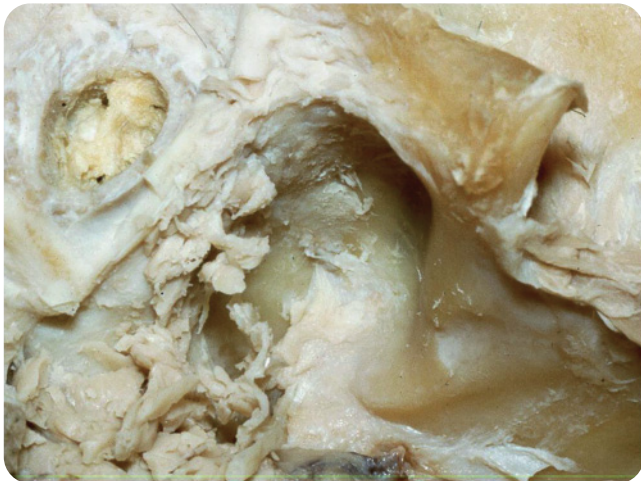

Figure 3.A.5. The glenoid fossa with the condyle disc assembly removed showing the medial wall and posterior slope of the articular eminence.

Anterior Guidance Platform Should Be Shallow, Flat, and Smooth

An anterior guidance platform that has a steep incline will naturally take more energy output from the muscles to guide along this steep ramp. Many patients for whom we prescribed bite splint therapy are already having muscle discomfort or muscle incoordination. So we do everything we can to allow the muscles to heal and recover as quickly as possible. One way to do this is to create an anterior guidance platform that is as flat and shallow as possible—in other words, one that will just disclude the posterior teeth. It will take less energy for the muscles to move the mandible on the shallow, flat anterior guidance platform, allowing them

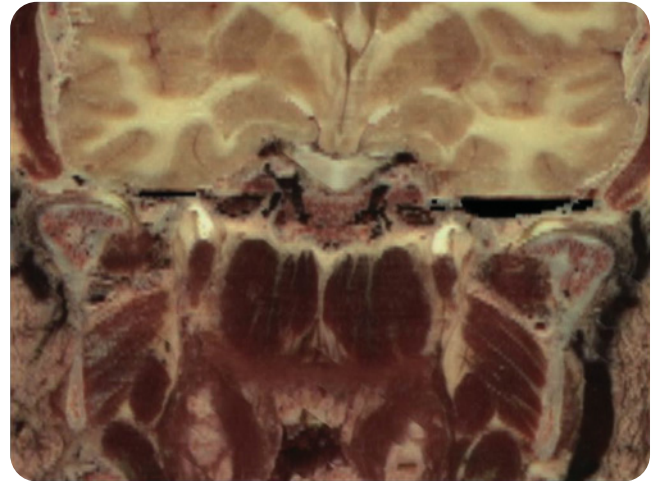


Figure 3.A.6. Frontal dissection slice showing the condyle-fossa relationship and pterygoid muscles.

to heal and recover quickly. When evaluating the movement of the anterior teeth on the anterior guidance platform of the bite splint, you must evaluate throughout the entire range of movement on the bite splint. In other words, you evaluate these movements not only in the functional range but also in the para-functional range—that is, beyond that point where the cuspids would be in an edge-to-edge position. As the mandible transitions beyond that position, we ideally like to see a very smooth transition from the cuspids to the incisors; as the mandible moves back toward centric we like to see a smooth transition from the incisors back to the cuspids (Figure 3.A.7). If there is a point or points along this pathway that are not smooth or that cause a jerky or rough movement, the muscles may not achieve maximum improvement.

The Bite Splint Should Have a Stable, Retentive Fit

The next principle addresses the degree of precision that is necessary to affect a positive result with bite splint therapy. It has been shown that an occlusal interference as small as .5mm can disrupt harmonious muscle coordination.⁷ Therefore, we must take all necessary steps to assure that we can achieve an adequate degree of precision. First, the bite splint must be absolutely stable in the way it fits on the teeth. Even a very slight movement, or “squish,” can prevent us from adjusting to that .5mm degree of precision. As we try the bite splint in the patient’s mouth, we must verify this stability by pressing the bite splint from front to back and verifying that there is no movement. If we detect movement, the best way

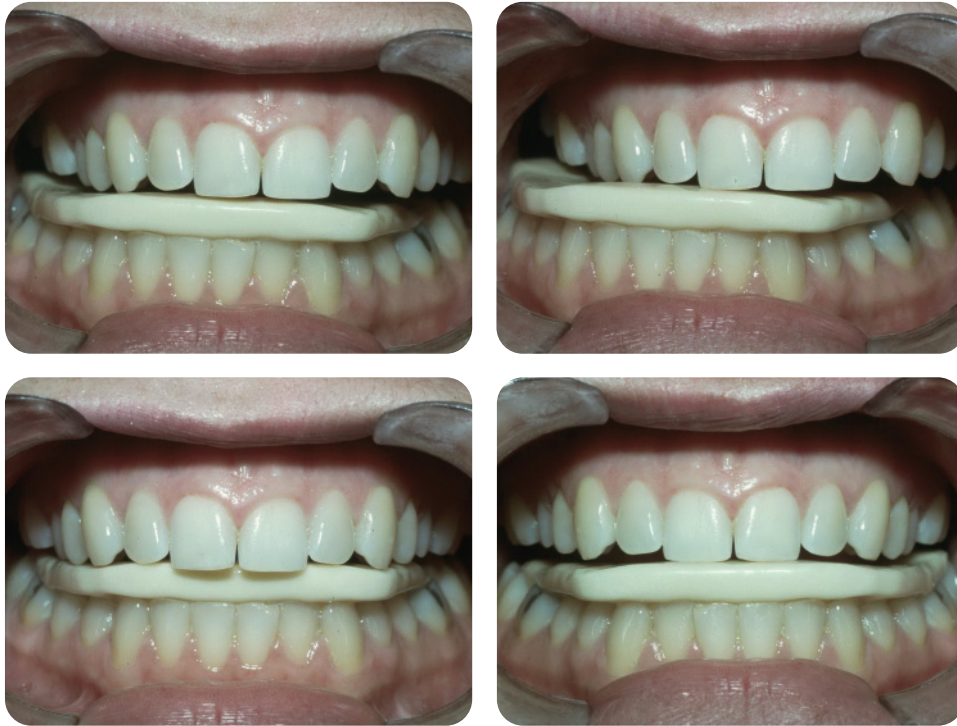

Figure 3.A.7. Mandibular bite splint with a shallow, flat anterior guidance platform, which allows the mandible to slide smoothly throughout the range of motion.

to correct this is my relining the bite splint directly in the patient's mouth. We must now verify that the bite splint has adequate retention by determining whether the splint can be removed from its seated position on the teeth rather easily by the patient's tongue. The retention of a mandibular bite splint is typically adequate because of the natural slight lingual inclination of the posterior teeth, which provides natural retention. In patients with short clinical crowns and minimal undercuts, additional retention such as clasps may be necessary. However, experience has shown that this is a rare occurrence. Once we have verified the stability and retention, we now have a stable platform upon which we can precisely adjust the occlusion on the bite splint. A few extra minutes spent on precise refinement with rubber wheels can mean the difference between success and failure of bite splint therapy. Figure 3.A.8 is a photo of a splint being refined on the articulator. One centric stop per tooth is all that is necessary. The red marks on the front of the splint show the lateral guidance on the cuspids and the protrusive guidance on the incisors. Use of the T-Scan III, which was discussed earlier, can significantly add to the predictability of precise bite splint refinement.

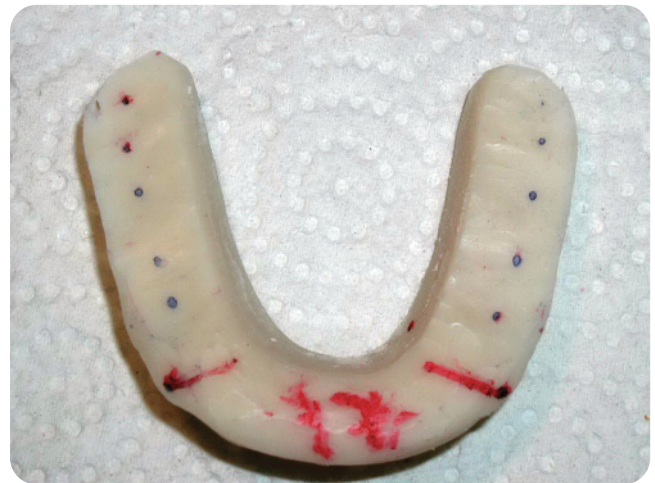

Figure 3.A.8. Bite splint during laboratory refinement showing one centric stop point per tooth and smooth uninterrupted red stripes illustrating the anterior guidance.

The Curve of Wilson Facilitates Working Side Disclusion

The next anatomic principle to consider in the design of the bite splint is the Curve of Wilson. The functional benefit the Curve of Wilson provides is that of disclusion of the posterior teeth on the working side.

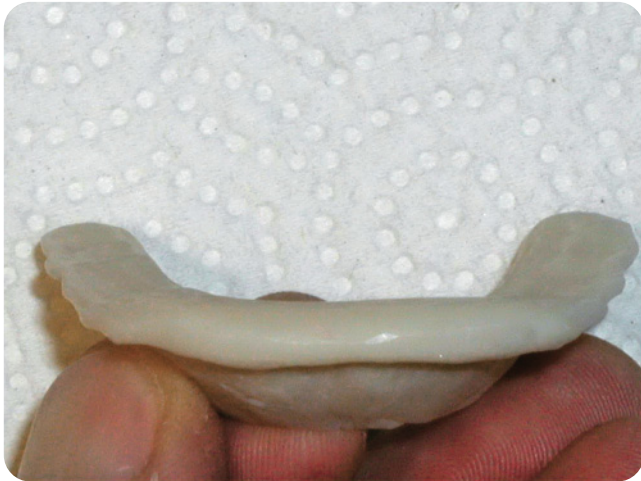

Figure 3.A.9. A refined, polished bite splint without fossa and any sharp angles that would restrict smooth mandibular movements.

Because of the Curve of Wilson, the lower lingual cusps are slightly shorter than the lower buccal cusps; this provides that disclusion. If the lower lingual cusps are too tall, they introduce working side interferences. Therefore, this anatomy must be provided in the design of the bite splint. As we view the occlusal plane of the bite splint from an anterior perspective, we should be able to view that Curve of Wilson. Because the anterior guidance on the bite splint is already fairly shallow, the correct Curve of Wilson plays an even more important role in assuring posterior disclusion on the working side. Figure 3.A.9 shows the Curve of Wilson and overall smooth design.

No Retrusive Inclines That May Distalize the Condyles

The last anatomic principle to discuss is that of the retrodiscal tissues, which are highly innervated and vascular. If these tissues are impinged upon, pain and discomfort may result. Therefore, we must verify that there is no component of the bite splint that may introduce a distalizing vector of force. An example of this may be a very steep anterior guidance platform ramp that occludes prematurely or with more force than the posterior teeth. Upon clenching in this position the mandible, and therefore the condyles, may be distalized. Another factor to consider is the technique of bimanual guidance itself. Care must be taken to assure that no distalizing vectors are introduced.

Bite splint therapy plays an important role in the restorative and reconstructive dental practice.

However, it must be given the same level of importance and degree of precision as any other technical procedure in the dental practice. By making this commitment we can minimize frustrations and disappointments.

Bite Splint Therapy Has Behavioral Benefits

In addition to the occlusal, anatomic, and physiologic benefits that bite splint therapy can provide, there are also behavioral benefits. As patients wear their bite splints they begin to experience the benefits of a physiologic occlusion. They become more comfortable. They begin to understand the cause and effect relationship between their occlusal interferences and the signs and symptoms that they may have. They begin to understand the importance of definitive occlusal therapy in their own dentition. They also begin to experience the care and concern of the dentist and dental team. If they have a good experience with bite splint therapy, it may be the motivating factor that convinces them to understand and believe that your dental practice is the right dental practice for them.

References

1. Conti PC, dos Santos CN, Kogawa EM, de Castro Ferreira Conti AC, de Araujo Cdos R. The treatment of painful temporomandibular joint clicking with oral splints: A randomized clinical trial. *J Am Dent Assoc.* 2006 Aug;137(8):1108–1114.
2. Ekberg E, Vallon D, Nilner M. Treatment outcome of headache after occlusal appliance therapy in a randomized controlled trial among patients with temporomandibular disorders of mainly arthrogenous origin. *Swed Dent J.* 2002 26(3):115–124.
3. Williamson EH, Lundquist DO. Anterior guidance: Its effect on electromyographic activity of the temporal and masseter muscles. *J Prosthet Dent.* 1983 Jun; 49(6):816–824.
4. Manns A, Chan C, Miralles R. Influence of group function and canine guidance on electromyographic activity of elevator muscles. *J Prosthet Dent.* 1987 Apr; 57(4):494–501.
5. Kreiner M, Betancor E, Clark GT. Occlusal stabilization appliances. Evidence of their efficacy. *J Am Dent Assoc.* 2001 Jun;132(6):770–777.
6. Curtis DA, Nielsen I, Kapila S, Miller AJ. Adaptability of the adult primate craniofacial complex to asymmetrical lateral forces. *Am J Orthod Dentofacial Orthop.* 1991 Sep;100(3):266–273.
7. Sheikholeslam A, Riise C. Influence of experimental interfering occlusal contacts on the activity of the anterior temporal and masseter muscles during submaximal and maximal bite in the intercuspal position. *J Oral Rehabil.* 1983 May;10(3):207–214.

3B

Definitive Occlusal Therapy—Equilibration

Definitively managing the patient's occlusion in either his/her natural dentition or restored dentition, whether it is a full or partial restoration, is an essential skill in the complete masticatory system dental practice. The goal with definitive occlusal therapy is to engineer a maximum intercuspation that occurs in the arc of closure with the condyles fully seated—that is, either centric relation or adapted centric posture (Figure 3.B.1). The *Glossary of Prosthodontic Terms* defines centric relation occlusion and centric occlusion as the occlusion of opposing teeth when the condyles are in centric relation, which may or may not coincide with maximum intercuspation. These terms are synonymous with one another. Definitive occlusal therapy takes this definition one step further by saying that maximum intercuspation should occur when the condyles are fully seated.

Maximum intercuspation occurring when the condyles are fully seated is not typically a naturally occurring occlusion. Occlusal interferences are a common finding. Therefore, centric relation occlusion is a therapeutic occlusion that we prescribe to solve a particular problem with the masticatory system in which we have diagnosed occlusal interferences to be a contributing factor.

When Should Definitive Occlusal Therapy Be Considered?

What are the indications for definitive occlusal therapy? When the signs and symptoms of a temporomandibular disorder have been resolved by bite splint therapy, definitive occlusal therapy is generally the next step in the treatment sequence. If a physiologic

CENTRIC RELATION OCCLUSION

- A therapeutic occlusion prescribed to solve diagnosed and confirmed problems with the components of the masticatory system
- All teeth maximally intercuspate in the centric arc of closure without deflection of teeth or the mandible

Figure 3.B.1. The goal of definitive occlusal therapy is centric relation occlusion.

occlusion has proven to be beneficial on the bite splint, the same physiologic occlusion can be designed into its own occlusion.¹⁻⁴ Another indication for definitive occlusal therapy is whether the patient for whom definitive restorations is planned has signs and/or symptoms of a temporomandibular disorder. The rationale in this case is for predictable restorative results. By engineering a physiologic occlusion and controlling occlusal forces, we are designing a minimal stress, minimal adaptation occlusion that will enhance the stability and longevity of the restorative result. This means fewer problems and less frustration during and after the restorative plan and sequence.

The Goal Is to Fulfill the Requirements of a Physiologic Occlusion

Figure 3.B.2 illustrates the principles of a physiologic occlusion that are fulfilled with definitive occlusal therapy. First is simultaneous equal intensity contact on all teeth in the centric arc of closure. These should be nondeflective, nonincline centric contacts. When the patient contracts his/her elevator muscles and squeezes firmly into maximum intercuspation, there should be no deflection or movement of individual teeth or the mandible itself. In other words, we want

REQUIREMENTS OF A PHYSIOLOGIC OCCLUSION

Simultaneous, equal intensity, nondeflective centric stops on all teeth in the centric arc of closure

A smooth anterior guidance as far forward as possible, ideally the anterior teeth

Immediate disclusion of the posterior teeth in all excursions

Figure 3.B.2. The purpose of definitive occlusal therapy is to fulfill the requirements of a physiologic occlusion for that particular patient.

simultaneous, equal intensity contacts in both light and firm closure.

The second requirement of a physiologic occlusion involves the anterior guidance. Ideally, we like lateral guidance on the cuspids and protrusive guidance on the central incisors. When evaluating with articulating paper, we should observe a smooth, uninterrupted streak on those preferred tooth surfaces. As the mandible moves beyond the functional range of cuspids being in an edge-to-edge position into the parafunctional range or crossover position, we like to see a smooth transition from the cuspid to the central incisor. This has been termed an *inside-out movement*; in other words, from centric out to an excursive position. We also want to evaluate the *outside-in movement*, which would be a movement from an excursive position inward toward centric. These are generally considered the movements that occur during mastication. The lateral pterygoids are the main muscles involved in the inside-out movement, and the closing muscles are the main muscles involved in the outside-in movement; therefore, the pathways may be slightly different, resulting in different tooth surfaces potentially contacting or interfering. Because the more powerful elevator muscles are involved in the outside-in movement, more force can be applied in this pathway. Tooth surfaces should be evaluated visually, tactilely by placing our fingertip over those surfaces and feeling for potential fremitus, and also with a red articulating ribbon. Any sharp surfaces or sharp line angles that get in the way of a smooth movement should be carefully identified and polished.

There may be situations where we have determined that the cuspid alone is not stable enough to withstand the entire force of a lateral guidance movement. It may be a periodontally weak tooth, it may be structurally weak with a large post and core, or it may be a less-than-ideal implant situation, such as a less than ideal length or less than ideal bone. In this case we can engineer an anterior group function—in other words, have the lateral guidance shared among multiple teeth. Ideally we want to share this lateral guidance with the teeth anterior to the cuspids—that is, the lateral and central incisors—rather than with teeth posterior to the cuspids. If we extend the lateral guidance posteriorly we know that we will be hyperactivating the elevator muscles and introducing an elevated level of force to the system.

The third requirement of a physiologic occlusion is immediate posterior disclusion in all excursions—in other words, no working, balancing, or protrusive

interferences on any posterior teeth. We know from the studies referred to previously that immediate posterior disclusion results in less activity of the elevator muscles and therefore reduced forces to the system. Predictable immediate posterior disclusion involves designing the correct Curve of Spee, Curve of Wilson, and cusp tip to fossa angle. These issues are discussed in Chapter 4.

Treatment Modalities for Definitive Occlusal Therapy

Figure 3.B.3 illustrates how we can incorporate these principles of a physiologic occlusion clinically. One way is with modification of occlusal form and morphology, generally referred to as *equilibration*. This may involve reshaping and recontouring the patient's existing dentition and/or restorations. It may also involve rebuilding or restoring deficient areas with a wide variety of restorative materials from direct composites to laboratory-processed restorations. Figure 3.B.4 illustrates definitive occlusal therapy that was completed totally with reshaping and recontouring of the occlusal form of the patient's existing dentition. The upper left photograph shows the centric relation interference on the upper left second molar. The lower left photograph shows the excursive interferences occurring on the posterior teeth. The upper right picture is after the equilibration, showing the refined centric stops. The lower right picture shows a close-up detail of the anterior guidance. Figure 3.B.5 illustrates definitive occlusal therapy that was completed with a combination of modifying occlusal form by reshaping/recontouring and restoring deficient areas with direct bonded composites. This is a prerestorative equilibra-

DEFINITIVE OCCLUSAL THERAPY

- Modification of occlusal form—equilibration
 - Reshape, recontour existing natural tooth structure or restorations
 - Restore with a variety of materials
- Movement of teeth
 - Orthodontics
- Movement of jaws or jaw segments
 - Orthognathics

Figure 3.B.3. The techniques and procedures required to fulfill the requirements of a physiologic occlusion need to be determined on an individual basis.

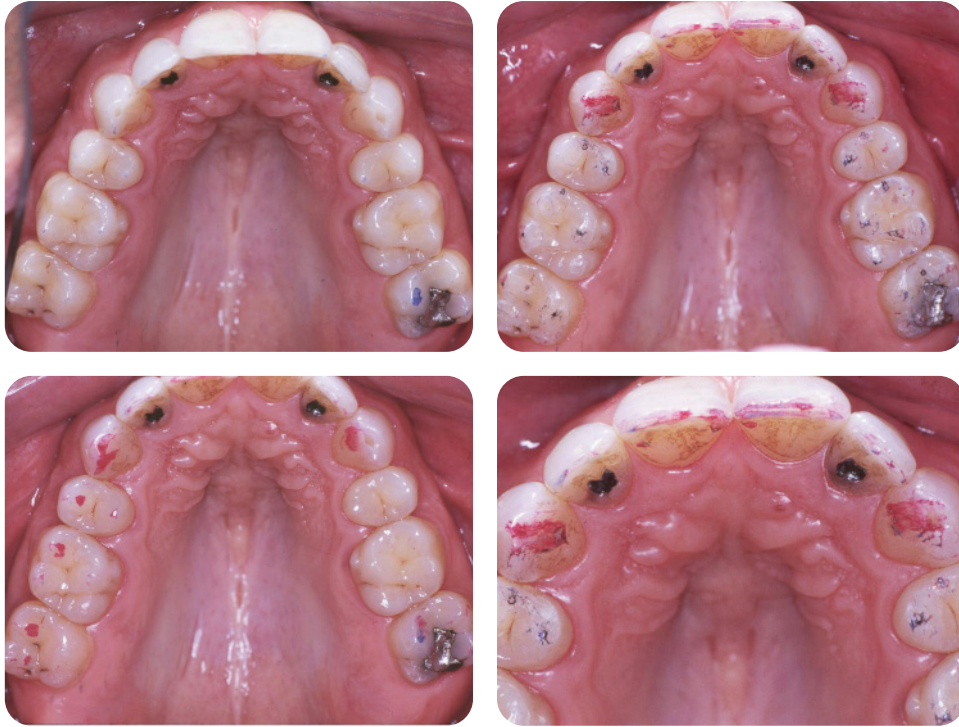


Figure 3.B.4. Clinical example of definitive occlusal therapy that was completed by modifying occlusal form with reshaping only.

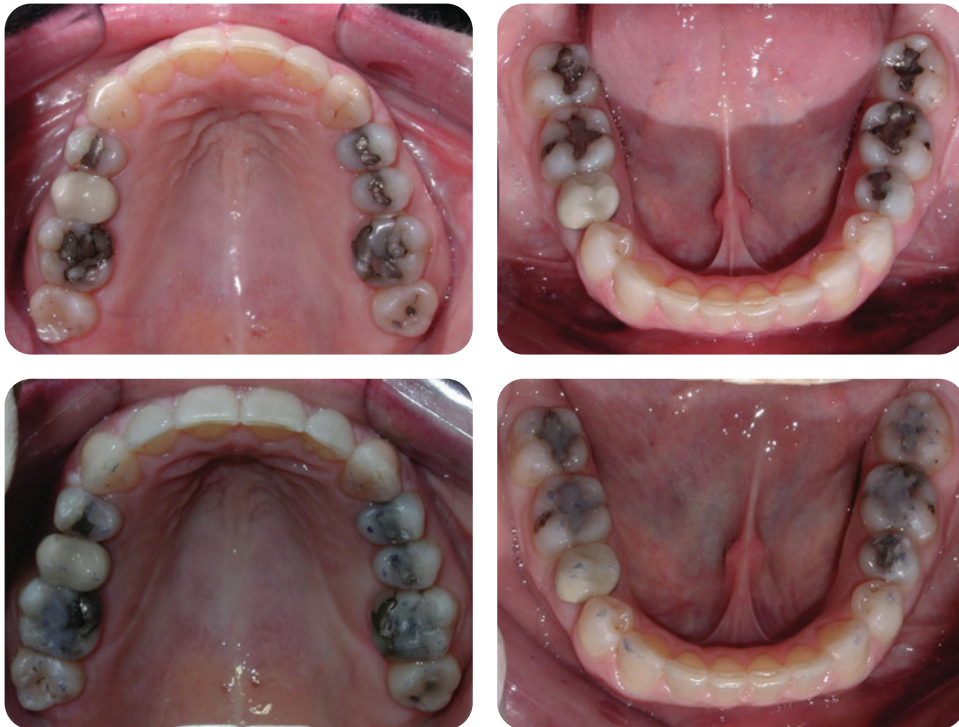

Figure 3.B.5. Clinical example of definitive occlusal therapy that was completed by modifying occlusal form with both reshaping and restoration with direct bonded composites. This is prerestorative definitive occlusal therapy, and composites are only temporary until restorations can be done.

tion done prior to the patient's posterior teeth being restored with laboratory-processed restorations. Because of deficiencies in occlusal form, reshaping and recontouring alone was not enough to fulfill the requirements of a physiologic occlusion. These deficient areas, in particular the central fossa of several of the posterior teeth, were built up and enhanced with directly bonded composites, as shown in the bottom two photographs. This composite is bonded over enamel and restorations. A prerestorative equilibration such as this helps stabilize the components of the masticatory system prior to the restorative procedures, thereby making the restorative procedures more predictable.

Another modality of definitive occlusal therapy is orthodontics and/or orthognathics (refer to Figure 3.B.3). If modification of occlusal form by reshaping/recontouring and/or restorations does not fulfill the requirements of a physiologic occlusion because of tooth position issues, we must consider movement of the teeth by orthodontics or movement of the maxillary and/or mandibular jaws, either segmentally or completely, by orthognathics to put teeth in more idealized positions so that reshaping/recontouring and/or minor restorations can fulfill the requirements of a physiologic occlusion. How do we know which of these treatment modalities is correct for that particular patient? The only way to know for sure is to make the anticipated modifications on an articulated set of diagnostic casts to see whether your vision is possible in the patient's mouth. First, it is important to visualize these modifications on articulated diagnostic casts. It is very difficult, if not impossible, to precisely visualize the jaw-to-jaw and tooth-to-tooth relationship in the centric arc of closure at the vertical dimension of maximum intercuspation without deflective interferences. If the anticipated modifications fall short of

fulfilling the requirements of a physiologic occlusion and additional procedures may be needed, it is best to find this out on articulated diagnostic casts rather than the patient's dentition. Clinical experience has shown that the results of trial corrections on articulated diagnostic casts precisely replicates the actual results of the corrections done in the patient's mouth.

Morphological Design of Posterior and Anterior Centric Stops

The final three figures illustrate the desired morphology and how it affects the nature and character of centric stops of both the anterior and posterior teeth. Figure 3.B.6 illustrates the desired posterior centric stop design, described as a definitive cusp tip occluding with an opposing flat, noninclined receiving area as opposed to a broad cusp occluding with the triangular ridges of an opposing fossa. There are several reasons that clinical experience has shown this type of centric stop design to be desirable. It is a practical, relatively easy clinical procedure to accomplish during definitive occlusal therapy. The form and morphology of the centric holding cusps are altered by reshaping, recontouring, and sculpting so that no inclines are contacting and the desired definitively shaped cusp tip is formed. The opposing centric stop seating area for this cusp tip is formed by creating a flat "landing pad" approximately 1 mm in diameter for occlusion with the opposing cusp tip. Once these centric stops have been created, achieving immediate posterior disclusion in all excursions is a straightforward process because the potentially interfering inclines have already been removed. As seen in Figure 3.B.6, there is some space, or freedom, between the cusp inclines, making immediate disclusion in excursions easier to accomplish.

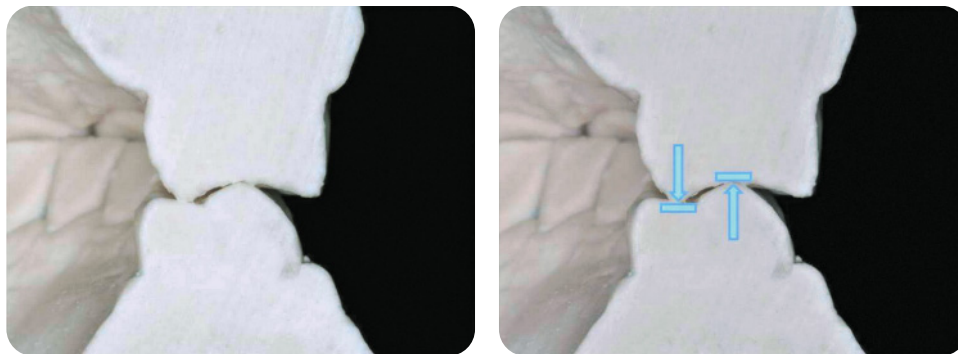


Figure 3.B.6. Illustration of the desired posterior centric stop design, which is a definitive centric holding cusp tip occluding with an opposing small flat receiving area.

Another advantage of this design is the ease of maintenance over time. In cases of adapted centric posture where we expect some joint changes, we would also expect some occlusal changes. As these changes occur, the additional recontouring potentially needed to regain simultaneous equal intensity contacts is generally relatively minor.

Figure 3.B.7 illustrates the desired morphology of the anterior centric holding contacts. The lower anterior teeth have definitive incisal edges. The labial incisal line angle of the incisal edge occludes with the marginal ridge on the lingual surface of the upper

anterior teeth. The surfaces incisal to these centric holding contacts become the surfaces upon which the anterior guidance functions. If the lower anterior tooth does not have a definitive incisal edge, it is difficult, if not impossible, to design stable centric holding contacts. If stable anterior centric holding contacts are not achieved the teeth may migrate, potentially disrupting the equilibrium desired with definitive occlusal therapy.

Figure 3.B.8 illustrates the occlusal morphology that incorporates the receiving area or landing pad on the central fossa that will occlude with the opposing cusp tip. The desired area of contact is flat with the

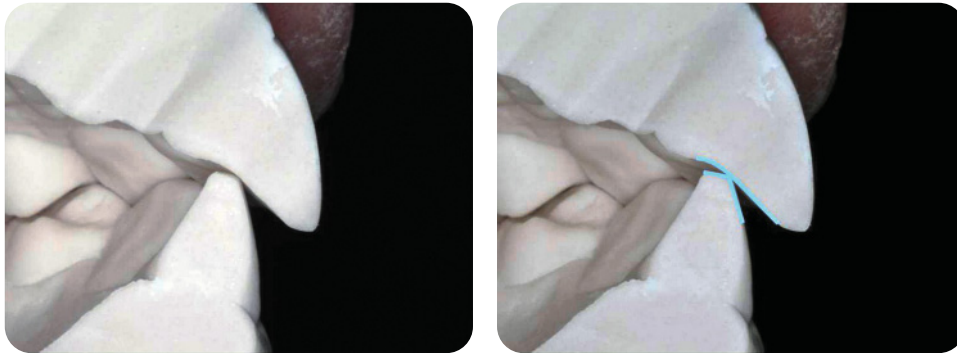

Figure 3.B.7. Illustration of the desired anterior centric stop design, which is the labial incisal line angle of the lower anterior tooth occluding with the lingual surface of the upper anterior tooth.

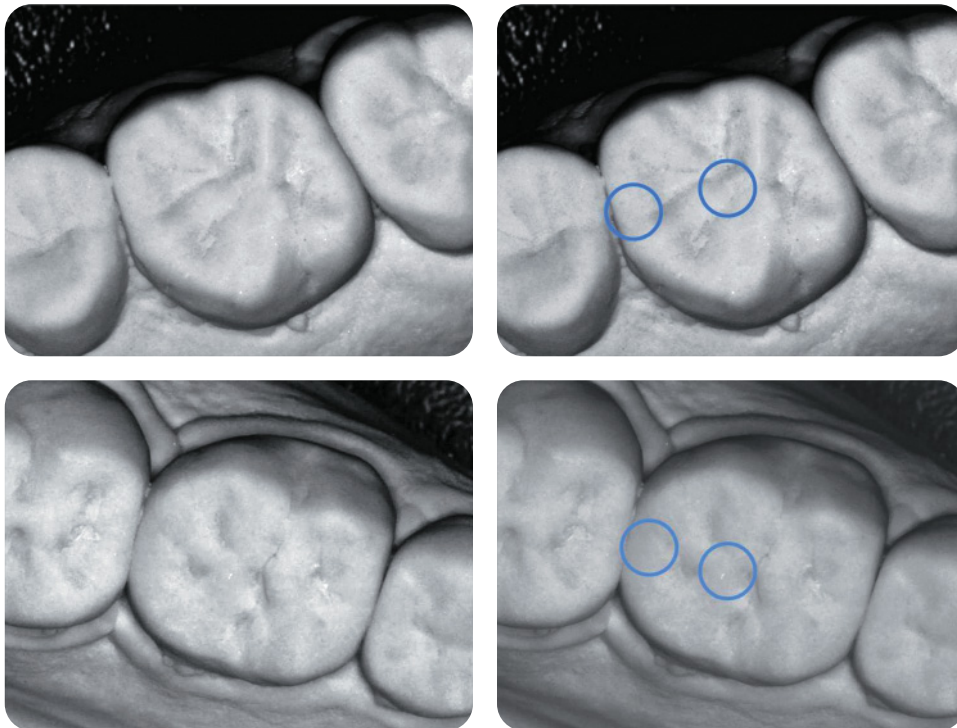


Figure 3.B.8. Illustration of the small flat receiving area designed into the occlusal surface of a definitive restoration. The other nonfunctional areas on the occlusal surface can be designed aesthetically to the desires of the dentist.

secondary anatomy of the occlusal surface beginning just beyond this receiving area.

Definitive occlusal therapy is an essential component of the complete masticatory system dental practice that routinely does restorative and reconstructive dentistry. By controlling and redirecting occlusal forces by definitive occlusal therapy we create a minimal-stress, minimal-adaptation type of occlusion that is essential for stability and longevity of all components of the masticatory system. This is also essential in designing restorative and reconstructive dentistry that results in optimal comfort, good function, health, and aesthetics for our patients.

References

1. Koriath TW, Hannam AG. Effect of bilateral asymmetric tooth clenching on load distribution at the mandibular condyles. *J Prosthet Dent.* 1990 Jul;64(1):62–73.
2. Karjalainen M, Le Bell Y, Jämsä T, Karjalainen S. Prevention of temporomandibular disorder–related signs and symptoms in orthodontically treated adolescents. A 3-year follow-up of a prospective randomized trial. *Acta Odontol Scand.* 1997 Oct;55(5):319–324.
3. Tarantola GJ, Becker IM, Gremillion H, Pink F. The effectiveness of equilibration in the improvement of signs and symptoms in the stomatognathic system. *Int J Periodontics Restorative Dent.* 1998 Dec;18(6):594–603.
4. Di Paolo C, Panti F, Crocitto P, De Luca M. Long term follow-up of patients affected by temporomandibular joint dysfunction treated with orthodontic and/or prosthetic occlusal therapy. *Minerva Stomatol.* 2004 Oct;53(10):555–570.

3C

The Diagnostic Blueprint (Wax-Up)

If there is one thing that has added tremendously to the predictability of both occlusal and restorative results in my 27 years of dental practice, it would definitely be the diagnostic wax-up or the diagnostic blueprint. A *blueprint* is defined as a model or prototype. It is also defined as something intended as a guide for making something else. As seen in Figure 3.C.1, a *diagnostic blueprint* is defined as an opportunity to visualize the anticipated changes in form and function prior to beginning the case. It gives the dentist and the patient an opportunity to visualize these changes in three dimensions. Since the diagnosis is done on articulated diagnostic casts, it also gives us an opportunity to preview the effects of these changes on both the static and dynamic aspects of occlusion. I believe that the diagnostic blueprint should

THE DIAGNOSTIC WAX-UP (BLUEPRINT)

- An opportunity to visualize the anticipated form and function prior to beginning the case

Figure 3.C.1. Definition and description of the diagnostic blueprint, which is also called the *diagnostic wax-up*.

be considered as routine a process in the dental practice as radiographs and photographs.

The diagnostic blueprint usually implies a wax-up done by a dental laboratory. Although that is certainly a good way to complete a diagnostic blueprint, it is not necessarily the most practical. It is a procedure that is usually completed only for a few selected cases, such as larger restorative cases or aesthetic cases that require many veneers. I like to think of the diagnostic blueprint as an everyday procedure, so it should be a procedure that is easily integrated into the routine dental practice activities—that is, it needs to be a procedure that is time-efficient and cost-effective. Although a diagnostic blueprint done by a dental laboratory can be showcase quality, that type of blueprint is not always necessary or practical for common everyday procedures. All it needs to be is a working blueprint that proves to you that the dentistry you have in mind is indeed the correct approach and one that shows the possibilities to the patient. That said, it is important to have two sets of articulated diagnostic casts, one that will not be changed and another that will be used for the anticipated corrections.

A Technique for the Diagnostic Blueprint

Figures 3.C.2 and 3.C.3 illustrate techniques that can be practical in even a busy dental practice. When only small corrections or changes need to be made, flowable composite works very well. It bonds nicely to the casts and can be easily contoured and shaped. When larger areas need to be corrected, such as missing

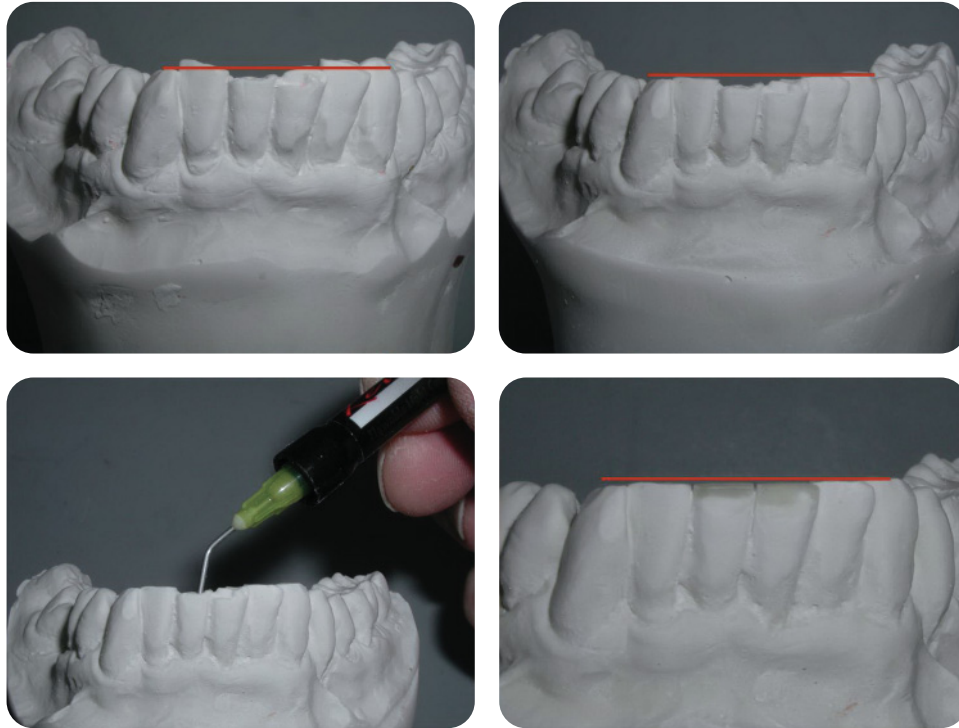


Figure 3.C.2. Areas that require only a small amount of material to achieve ideal form can be easily managed with a flowable composite.

teeth, bulk composite such as triad works well. Even old outdated composite that is no longer used clinically can be used for the diagnostic blueprint. Place some flowable composite on the cast first as a bonding medium, place the bulk composite over this, get the anticipated shape fairly close by molding it with your favorite dental instrument, cure it with a dental curing light, and then do the refinement with a dental hand-piece. As seen in Figure 3.C.3, it is easy to identify areas that have additions. This makes it easier to visualize clinically where the changes need to be made. In a diagnostic wax-up where the entire tooth is changed with wax or composite, it is more difficult to visualize where the precise changes have to occur even if you refer back to an uncorrected set of casts. It may not be of showcase quality but it gives us the information we need to come up with a correct treatment plan.

I also believe that the diagnostic blueprint should be done by the dentist. By doing it yourself, you become familiar with all the details of the case. You discover precisely what needs to be changed and what does not need to be changed. You understand the subtleties of the case, such as occlusal refinements, subtle contour changes for optimal aesthetics, subtle line

angle changes for optimal anterior guidance, etc. Becoming familiar with the subtle details allows you to complete these changes clinically in a much more efficient manner because you have already completed it once before on the articulated diagnostic casts. I have been doing diagnostic blueprints for over 20 years and have found it to be a practice that is easily learned, can be done in a relatively short period of time, and, with some efficient scheduling, can be done during the workday at specified times. For it to be done in this manner, an efficient area is designated in the lab with all the necessary materials and instruments readily available. As the dental assistant prepares the treatment room for the upcoming procedures, he/she should also prepare the designated area in the lab in the same manner so that the dentist can efficiently sit down and get to work. However, in this case it will be on the articulated diagnostic casts of the patient and not the actual patient. Throughout the years, in speaking with many dentists who have made a commitment to integrate the diagnostic blueprint into their practice, most all have said that the benefits of these procedures have far outweighed the initial stress and frustration of learning to integrate the procedure into their practice.

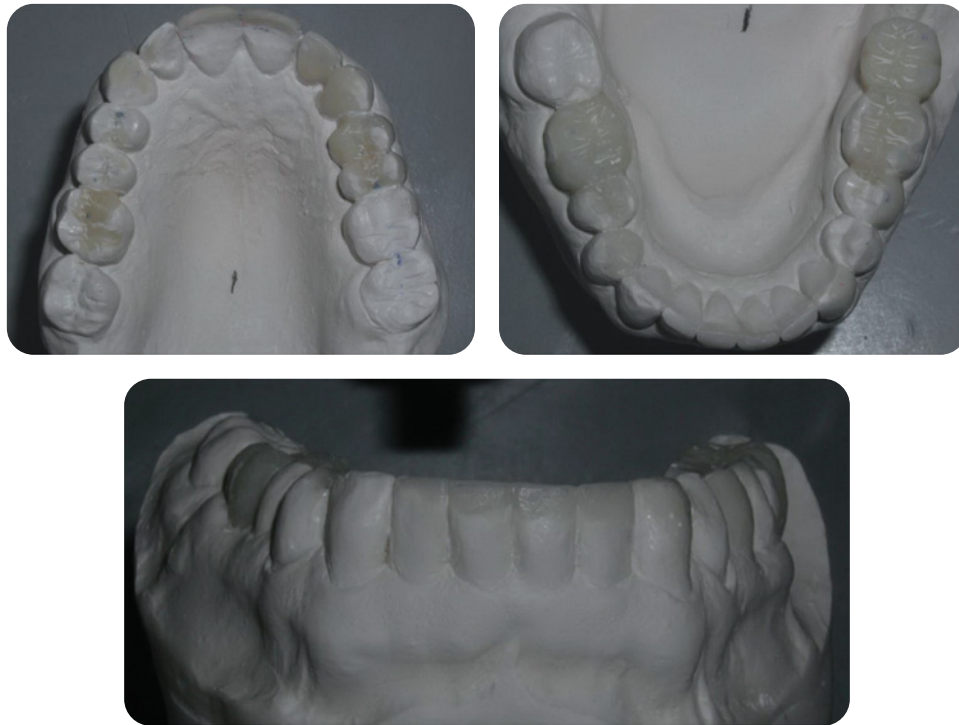

Figure 3.C.3. Areas that require a larger amount of material to achieve ideal form can be managed with a light-cured composite material designed for provisional restorations, such as Triad.

Setting the Condylar Inclination of the Articulator

Set a condylar inclination on the articulator so that the excursive movements of the casts closely replicate the excursive movements occurring in the patient's mouth. Figure 3.C.4 shows a method of setting the condylar inclination. It simply involves "reading" the wear facets and adjusting the condylar inclination so that as the casts go through their excursive pathways these wear facets will glide across one another. For example, if there is a balancing side wear facet on a second molar, we know that the balancing side condylar inclination needs to be such that in that excursive movement those balancing side wear facets rub across one another. If that balancing side condylar inclination is too steep, those balancing side wear facets might disclude rather than touch. If the balancing side condylar inclination is too shallow, those balancing interferences may become so severe that the teeth on the working side will not be able to touch. If there are no wear facets, it means either one of two things: 1) Patients may have balancing interferences, but they may not be parafunctioning to the point that it is causing wear of tooth structure. 2) There are no balancing interferences, and those teeth are simply discluding rather than interfering. In either

case there are no wear facets to "read," so the condylar inclination can be set by simply clinically observing the maxillary or mandibular tooth-to-tooth relationship during various excursive movements. Having digital photographs of these various excursive pathways becomes very helpful. These photos can be referenced as the articulated casts are analyzed in excursions and the condylar inclination adjusted and customized so that the relationships of the teeth on the articulated diagnostic casts are similar to the relationships of the teeth clinically during these excursive movements.

Benefits of the Diagnostic Blueprint

Figure 3.C.5 outlines some of the many benefits of the diagnostic blueprint. As stated earlier, it allows the dentist to visualize what the possibilities are for that particular patient. If any of the parameters of what we know to be physiologic and correct in terms of form and function are not right, we are able to see what it takes to improve those issues. It is important to say that just because a parameter is not ideal does not necessarily mean that it needs to be corrected. We need to decide whether that non-ideal parameter is simply an observation or is a problem. If it is simply an observation and not causing any problems, it does not

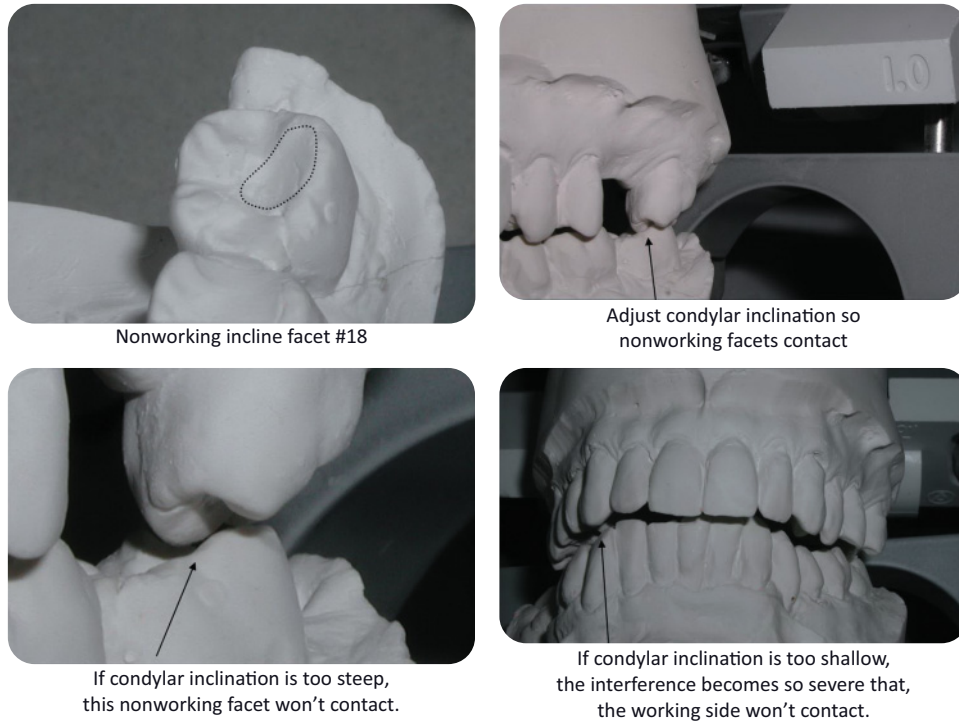


Figure 3.C.4. The condylar inclination on the articulator can be accurately adjusted by verifying that wear facets on the teeth match up during excursive movements on the articulator.

**BENEFITS
OF THE
DIAGNOSTIC
BLUEPRINT**

- Visualization of what is possible
- Prescription of the most appropriate material, technique or procedure
- Patient, specialist, technician communication
- Provisional matrices
- Confidence at case explanation
- More efficiency at the chair
- Diagnoses, not excuses

Figure 3.C.5. There are many benefits to completing a diagnostic blueprint that have a positive impact on both the technical and communication aspects of the dental practice.

necessarily need to be changed. If it is a problem or a contributing factor in a problem, we have a rationale for prescribing some type of treatment. An example might be a non-ideal Curve of Spee. If it is discluded in all excursions, if it poses no aesthetic issue, if the teeth are easily cleanable and healthy despite their non-idealized positions, then no treatment may be indicated. However, if that non-ideal Curve of Spee is

the cause of posterior excursive interferences or is a distraction to the patient’s smile, or has some other biologic health issue, then it might be considered to be a problem and we have a rationale to change it. My approach through the years has been this: if I feel some parameter of form and/or function needs to be changed in the patient’s mouth, I will always make those changes first on articulated diagnostic casts to verify that my initial assumption was correct. It takes only a few minutes to make these changes; and if the result is not what I expected, I would rather find that out on the articulated diagnostic casts of patients and not in their own dentition.

Visualize Form and Function First, and Then the Treatment Plan

Once we have the anticipated changes in form and function visualized on the articulated diagnostic casts, we can now prescribe the most appropriate material, technique, or procedure that will best effect those changes. This is especially true in those types of cases where we will be replacing multiple missing teeth with implants and implant-supported restorations. The diagnostic blueprint tells us where the teeth need to be for ideal form and function. From there we can determine, often with the help of our surgeon,

whether it will be a straightforward implant placement or bone and/or soft tissue may need to be augmented either prior to or along with the placement of the dental implants.

Facilitate the Communication Process

The diagnostic blueprint is a valuable tool in facilitating the communication process. As we consult with our patient about the treatment possibilities, having various visual aids to help the patient better understand is desirable. Articulated diagnostic casts that have been corrected give patients a three-dimensional viewpoint of what their mouth and teeth will look like after the suggested treatment. If the initial examination was a codiscovery process that helped them understand their current condition, augmenting that with the uncorrected set of articulated diagnostic casts enables them to see a beginning point as well as an end point; this helps them grasp all the steps necessary to move from point A to point B.

If a specialist member of our interdisciplinary team is going to be an integral part of the case, the corrected articulated diagnostic casts facilitate the communication process between the restorative dentist and a specialist. With the diagnostic blueprint we can precisely communicate our desires and expectations in terms of the form and function. Once specialists see the diagnostic blueprint, they can better communicate to us their suggestions and recommendations as to how their area of expertise can help achieve an ideal result. In this way we are developing a solid rationale for all aspects of the proposed treatment and not coming up with a particular treatment because it “just seems like the correct approach.”

The diagnostic blueprint can also help us in our initial conversations with the dental technician. As we discuss the patient’s current condition and the anticipated changes in form and function illustrated with the diagnostic blueprint, we can get the technician’s input regarding material choices, tooth preparation considerations, sequencing, etc. These discussions are especially helpful with the more involved interdisciplinary implant cases. We can get input from the technician regarding implant abutment selection and restoration design. We also can get the technician’s fee estimate, which will be important in calculating the total case fee for the patient’s complete dentistry.

Make Matrices for Provisionals

The diagnostic blueprint also allows us to fabricate provisional matrices. We can then construct a provi-

sional restoration that incorporates all the details of the diagnostic blueprint and allows us to subsequently test these changes in the patient’s mouth. We can then determine whether these changes fit within the parameters of the patient’s masticatory system and, if not, allow us to modify the provisional as needed. We want to create a provisional restoration that previews what is desired and expected in the definitive restoration in terms of form and function. The only difference is that it is in acrylic rather than porcelain.

There is no doubt that helping patients grasp and understand the nature and scope of their treatment plan is a critically important task. Without this understanding they may never make the decision to move forward with the dentistry that we know is correct and in their best interest. We not only want them to say yes but we want them to say yes for the right reasons—that is, because they know that they are making a decision that is in their best interest and not because we as the dentist said so. This process begins with the codiscovery examination as they begin to grasp and understand their current condition and continues through the consultation appointment. How this consultation appointment transpires is therefore critically important. If it comes across as just a sales pitch, truly discriminating patients may see through this and it might be the reason they decide not to proceed. Many of these uncertainties are overcome when the dentist is intimately involved in the diagnostic wax-up. As we think, ponder, and reflect while doing the diagnostic wax-up, we get to the point that we believe without a doubt that the proposed treatment is the correct treatment and in our patients’ best interest. As we consult with patients we come across with believability and conviction. Our patients see it in our face, hear it in our voice, and feel it in our body language. They know they are not just getting a sales pitch but they are consulting with their dentist who has their best interest as a top priority. If the dental technician completes the diagnostic blueprint and the dentist has not been intimately involved in the process, this believability and conviction does not come across as strongly.

Perform the Clinical Procedures More Efficiently

The more involved restorative and reconstructive interdisciplinary cases can be clinically and technically demanding. It is important to learn to work efficiently at the chair to minimize stress and frustration. One of the keys to accomplishing this is to be fully prepared.

The diagnostic blueprint helps us accomplish this. If we are fully involved in the diagnostic blueprint process we begin to learn about every aspect of the case. For example, in terms of tooth preparation we must understand that certain teeth may need more reduction in some areas and less reduction in others. In terms of anterior guidance, we must understand the subtle contours that are necessary to get a smooth, nontraumatic movement throughout the functional and parafunctional range of motion. All this allows us to work more efficiently and confidently at the chair. In a way, it is really a second time we've done the case, the first time being the diagnostic blueprint. It is almost like a practice session before the big game. One of the biggest profitability killers is excessive chair time—that is, extra appointments for repeat procedures. My experience after 25 years of putting these principles into practice on a daily basis has shown time and time again that even the more complicated cases can be done in an efficient manner with a minimal number of appointments.

Make “Diagnoses, Not Excuses”

Expectations that have not been met and unexpected eventualities as we progress through the case can be extremely frustrating for us and our patients and can erode away at the happiness and fulfillment that we know is possible when completing these kinds of cases. Doing a comprehensive masticatory system examination, formulating a correct diagnosis, completing a diagnostic blueprint, and from there formulating the most appropriate treatment plan and treatment sequence allows us to uncover the potential hazards and eventualities that may indeed arise throughout the case. Knowing this ahead of time gives us the opportunity to speak with patients about these things before we actually begin the case, and then, if these potential issues arise, they are not unexpected eventualities. If we do not go through this reflective process, when these types of things happen, no matter how we try to explain it to patients, the explanation often comes across as an excuse. This can erode the trust we've worked so hard to develop with our patients.

The dentistry we do for our patients, especially the more complicated interdisciplinary cases, can be life-changing experiences for them and be the source of great happiness and fulfillment for us and our team. As the dentist, our excitement with these possibilities sometimes triggers us to start a case without investing the time and energy in thought and reflection prior to beginning the case. Making the commitment

routinely to do the diagnostic blueprint forces us to make this investment and then achieve the predictable success that makes dentistry so rewarding and fulfilling.

3D

Provisionalization

The *Glossary of Prosthodontic Terms* defines a provisional restoration as a “fixed or removable dental prosthesis designed to enhance aesthetics, stabilization and/or function for a limited period of time, after which it is to be replaced by a definitive dental prosthesis. Often such prostheses are used to assist in determination of the therapeutic effectiveness of a specific treatment plan or the form and function of the planned definitive prosthesis.” The provisional restoration therefore should be constructed carefully enough so that it fulfills these objectives. Having a provisional technique in the restorative and reconstructive practice that allows the efficient fabrication and modification of these provisional restorations is extremely important. The provisionals need to be trouble-free so that the dentist and the patient do not feel rushed to complete the definitive restoration. If the provisional restoration comes uncemented, breaks, or is otherwise unaesthetic, the dentist or patient feels compelled to get through this phase as quickly as possible and complete the definitive restoration. In reality if the provisional comes uncemented or breaks, the correct thing to do is to actually *slow down* the process, figure out why the provisionals are problematic, address those factors, and once again test those changes with the modified, corrected provisionals. Once the provisionals meet the expectations of the dentist and patient an articulated cast of these provisionals becomes an excellent communication tool for the laboratory technician.

There are a number of ways to fabricate excellent provisionals. One way is to provide the technician a set of articulated diagnostic blueprint casts and have the technician fabricate a provisional shell that will be subsequently relined in the patient's mouth over the prepared teeth. Another way is to make a silicone putty matrix that can be used to fabricate a provisional directly in the patient's mouth with a variety of excellent materials that are available today. The final way, which I prefer, is to fabricate the provisional indirectly on a stone cast of the actual tooth preparations using a silicone putty matrix made from the diagnostic blueprint. Fabricating a provisional indirectly has many advantages. It is easier on the patient because these

somewhat time-consuming procedures are done outside the mouth, giving the patient an opportunity to rest and relax with his/her mouth closed. It is easier for the dentist to fabricate a provisional on a cast where all aspects are easily viewed and evaluated. Margins typically fit very precisely because the acrylic can set to completion undisturbed on the cast rather than having to tease the setting acrylic on and off the teeth to prevent it from locking on. Heat from the exothermic setting of the acrylic is not an issue since it is not setting on the teeth. If the provisional is fabricated on a cast that is articulated, all aspects of static and dynamic occlusal parameters can be refined more precisely, especially when various aspects of form and function, such as the occlusal plane, have to be changed from the initial condition. Experience has shown that whatever time it takes to fabricate the initial provisional to a high level of excellence and precision that results in a minimum of frustration and problems is time well invested. Subsequent time spent repairing provisionals or otherwise dealing with problems is not only frustrating and costly but is also a major inconvenience for the patient; if that happens frequently enough, this can begin to erode the trust we have worked so hard to develop.

The top two photos in Figure 3.D.1 illustrate the putty index that is fabricated on the diagnostic blueprint. The putty index captures all the detail of the diagnostic blueprint and needs to be extended beyond the teeth to a land area that will provide a vertical stop when seating the index on the cast of the prepared teeth. The bottom left is an impression that captures all of the detail that would be expected in any definitive impression, using whatever your preferred impression material might be. The bottom right is a cast made with a fast-setting stone, such as Modern Materials StatStone, which can be removed from the impression in 5–6 minutes.

Once the cast has been removed from the impression the putty index is placed on the cast of the preparations and verified for precise fit using the land areas as reference points (Figure 3.D.2). Once the fit has been verified, a pencil line is drawn where the putty index meets the cast. This will be a seating reference once the putty index, which has been filled with acrylic, is placed back upon the cast.

The cast upon which the provisional will be fabricated needs to be prepared prior to the application of the acrylic (Figure 3.D.3). First a cement spacer needs to be applied. A material such as George Taub Rubber

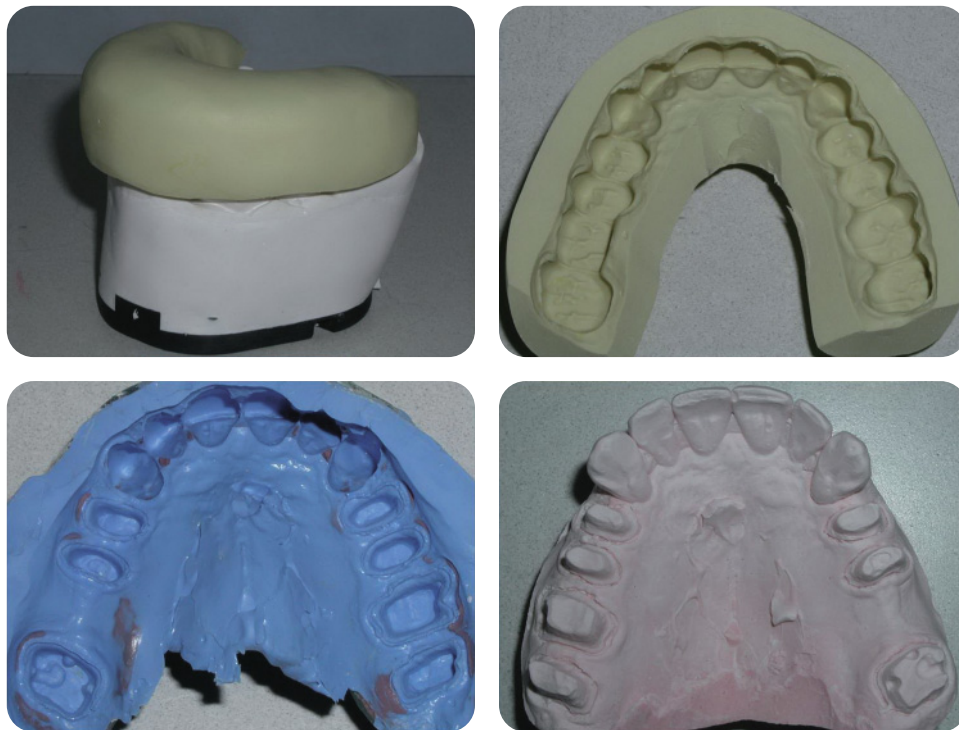

Figure 3.D.1. A putty index is made over the diagnostic blueprint, and the edges are trimmed to a square surface. An accurate, definitive impression is made of the tooth preparations, and a quick-setting cast is made.




Figure 3.D.2. The putty index is verified for an accurate, fully seated fit on the cast of the tooth preparations, and a vertical and horizontal seating line is drawn to help orientation upon reseating with the acrylic-filled putty index.

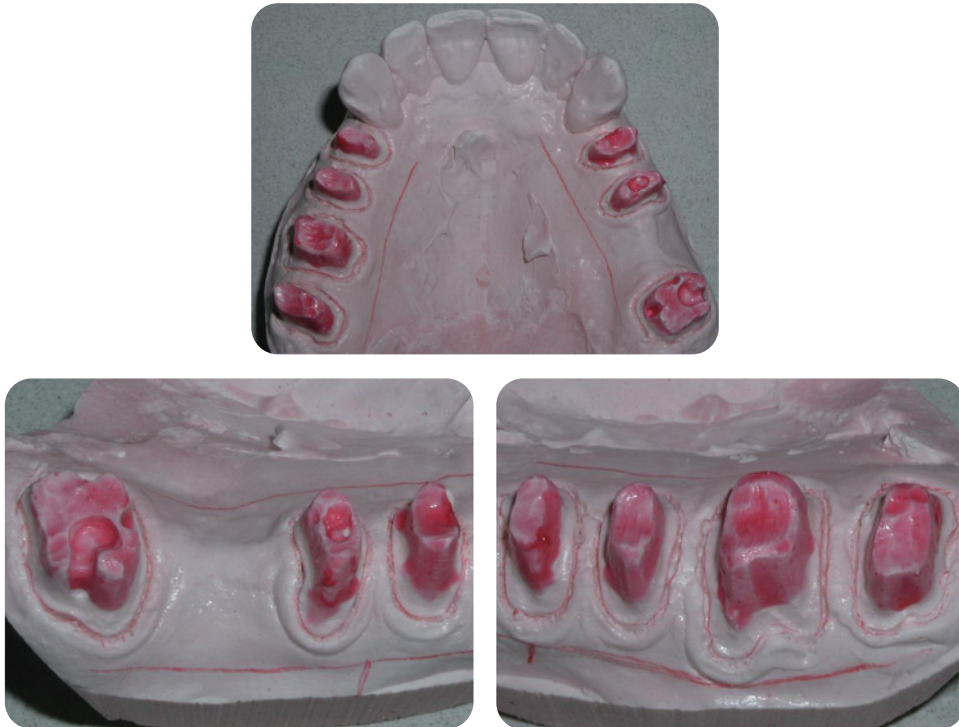

Figure 3.D.3. The tooth preparations are painted with George Taub Rubber Sep as a cement spacer and then Modern Materials as an acrylic separator.

Sep works very well. It is similar to a rubberized latex paint, paints easily on the preparations, and sets quickly with the heat from a hair dryer. This spacer should be kept short of the finish lines approximately 1.5 mm. An acrylic separator such as Buffalo Foil Cote is applied next and keeps the acrylic from adhering to the stone cast. It is applied liberally with a brush, blown thin with compressed air and dried with the heat from a hair dryer. The cast is now ready to accept the acrylic.

There are many excellent materials to use for the actual fabrication of the provisional. I prefer cold-cured methylmethacrylate acrylic resin because of its resil-

ency and toughness especially with longer span provisionals. It also withstands removal and recementation that is often necessary in longer-term interdisciplinary cases without fracture or other problems. There are many excellent cold-cure acrylic resins but this author prefers ColdPac by the Motloid Company (Figure 3.D.4). It has an extended working time in the doughy stage, which is necessary for this technique. You have plenty of time to place the doughy acrylic into the putty matrix and to seat it precisely on the cast prior to the setting of the material. This material also has excellent color stability, which is obviously very important for longer-term provisionals. The



Figure 3.D.4. Motloid ColdPac is mixed in a rubber dappen dish until it reaches a doughy consistency, at which point it can be kneaded with the sides of the dish to further improve the mix.

powder and liquid material is mixed in a rubber dappen dish until a creamy consistency is achieved. The material is left to continue its set undisturbed until it reaches a doughy consistency, at which time the material can be kneaded by pushing the sides of the dappen dish into the mass of acrylic thereby improving the mix of the acrylic. At this point the sides of the dappen dish will not stick to the acrylic, which indicates that the material can be removed cleanly and easily from the dappen dish.

As illustrated in Figure 3.D.5, the doughy mass of acrylic can now be placed into the putty matrix. The acrylic filled matrix is now seated to place on the cast using the previously drawn pencil lines as a reference point, stabilized with rubber bands, and allowed to set undisturbed to completion. Once the acrylic has completely set, the putty index is removed, leaving the acrylic provisional on the cast. Upon removal from the cast one can observe a precise adaptation of the acrylic onto the tooth preparation and a precise fit of the margin of the provisional to the finish line of the tooth preparation. The provisional is now ready for finishing and polishing with the dentist's favorite technique (Figure 3.D.6). At this point, if the cast has been articulated, the occlusion can be precisely refined. Figure 3.D.7 shows the provisionals after they

had been seated in the patient's mouth with a minimum adjustment needed.

In the long-term, extended interdisciplinary cases, a reinforced provisional is very beneficial. In these kinds of cases the provisional not only has to have a useful life of many months but it must also be able to withstand being manipulated in various ways throughout the treatment process. The provisional may need to be removed and recemented, or it may need to be removed, relined, or otherwise modified prior to recementing it. This is especially common in cases where teeth may be removed and implants placed. The provisional technique previously described can be used with Ribbond reinforcement, which results in a provisional that will withstand the various manipulations in these extended cases. Figure 3.D.8 illustrates Ribbond reinforcement in an implant case; the top left picture is an implant level impression, the top right picture is the implant cast with the implant abutments attached and modified. The bottom left picture is a direct impression of the implant cast with the modified abutments; the bottom right picture shows the stone cast made from that impression. Following the provisional technique described, the rubber-sep and acrylic separator have been applied. Figure 3.D.9 illustrates the Ribbond reinforcement scaffolding in place and the

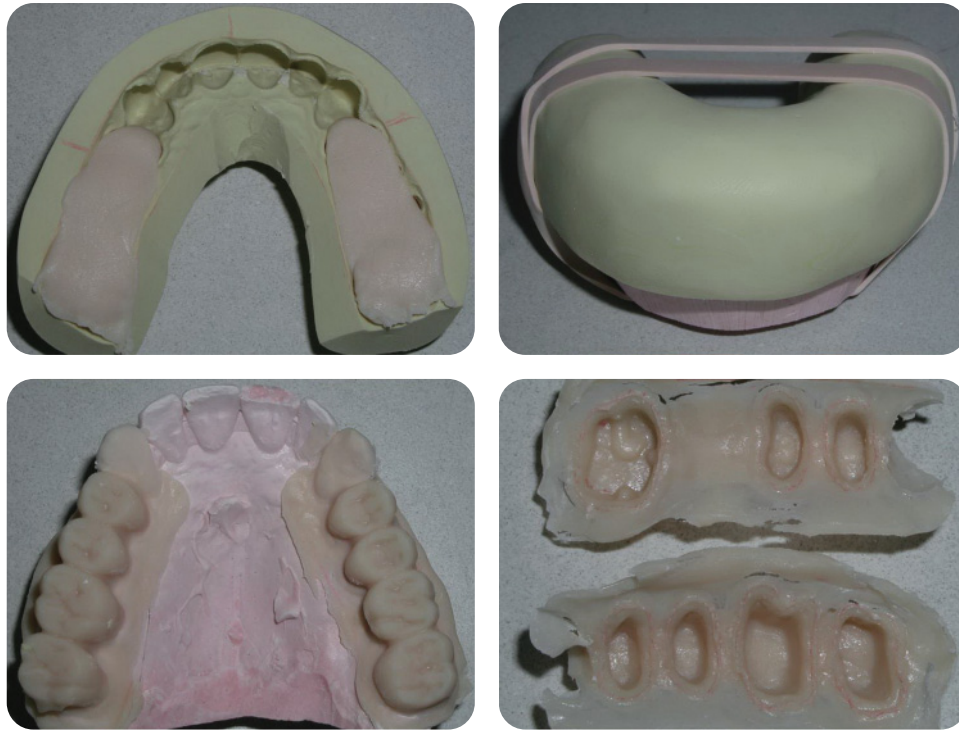

Figure 3.D.5. The doughy acrylic is placed into the putty matrix and seated back onto the cast of the preparations until it is properly oriented to the previously drawn seating lines and stabilized with rubber bands; when completely set, the matrix and provisionals can be removed from the cast.

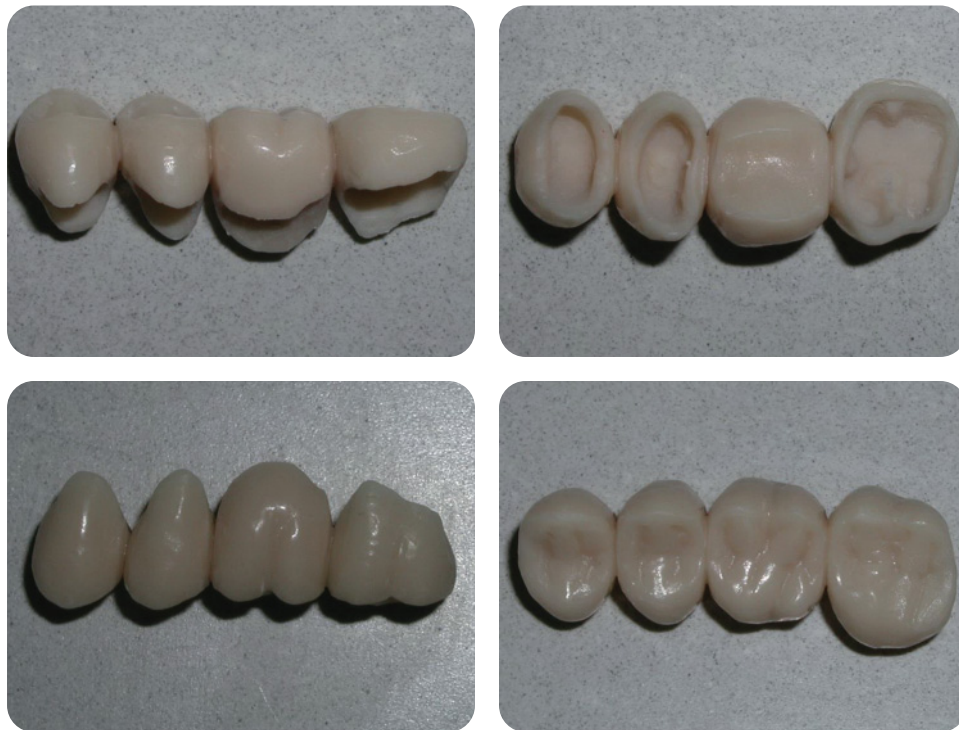

Figure 3.D.6. The provisionals can be trimmed, finished, and polished with the dentist's favorite technique.

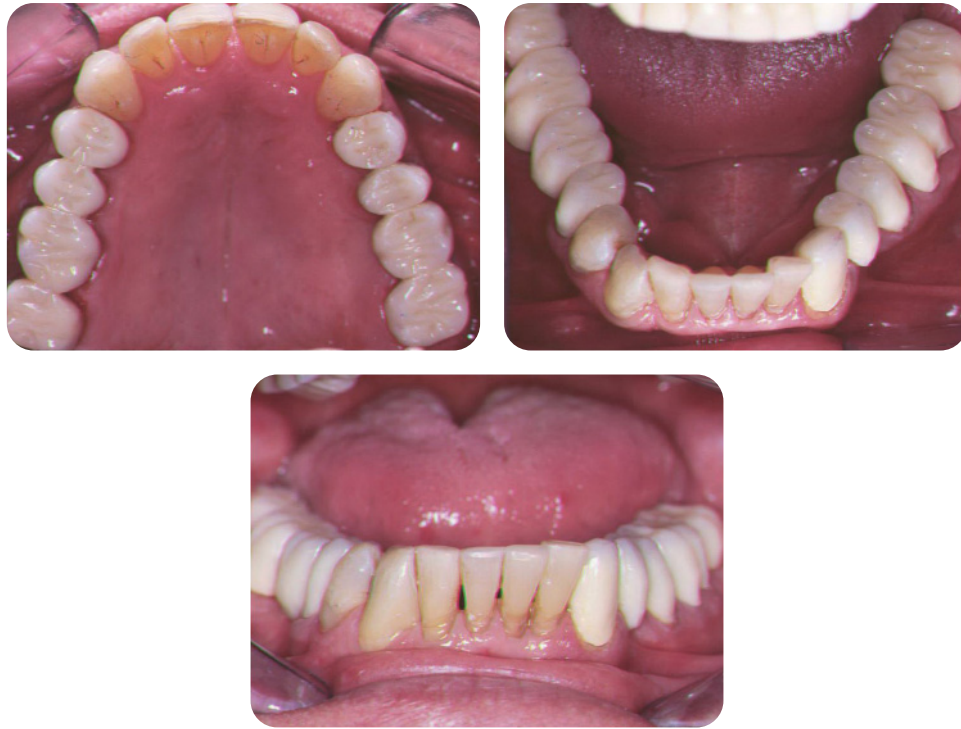

Figure 3.D.7. The provisionals are placed in the mouth with a minimum amount of extra work needed. The finish lines of the provisionals fit the margins of the tooth preparations precisely.

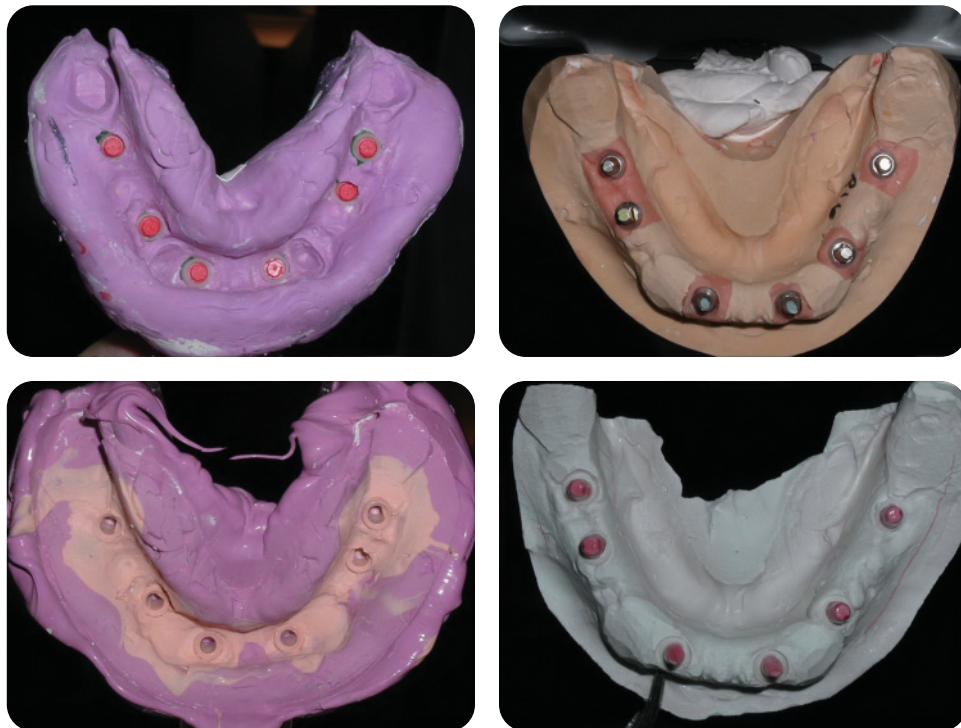


Figure 3.D.8. In implant cases, an implant model is made and implant abutments placed and modified. An impression is made of the implant model and cast in stone. This cast is prepared the same way as previously described.

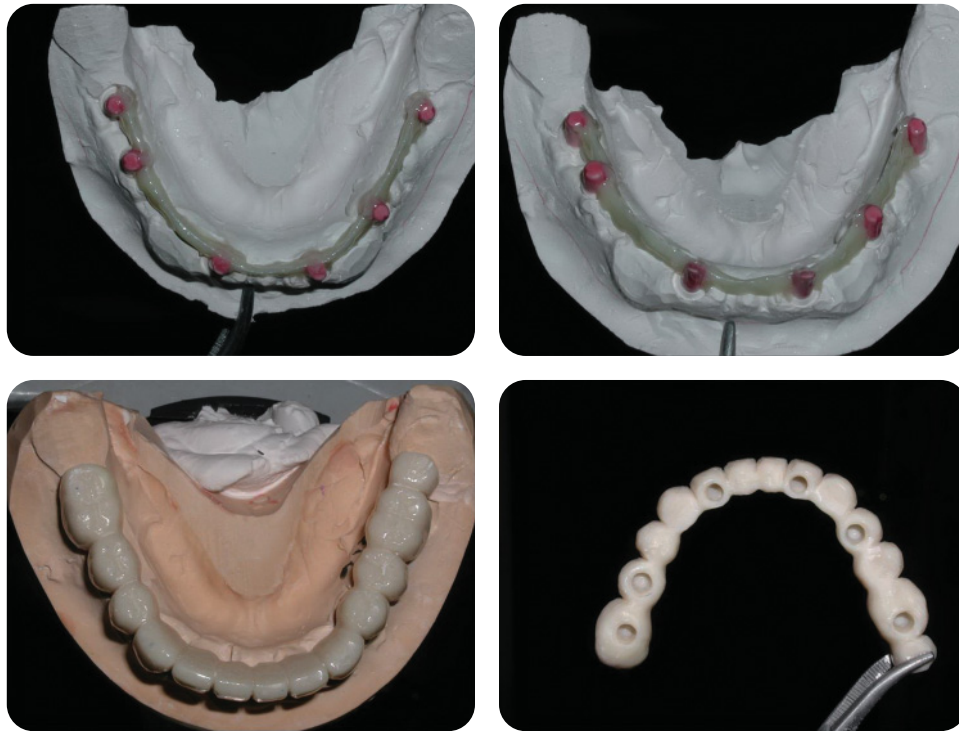

Figure 3.D.9. Ribbon fiber mesh is added to the abutments and across the edentulous areas and further stabilized with flowable composite. All areas of the Ribbon must be covered as well as any space between the Ribbon and edentulous ridges.

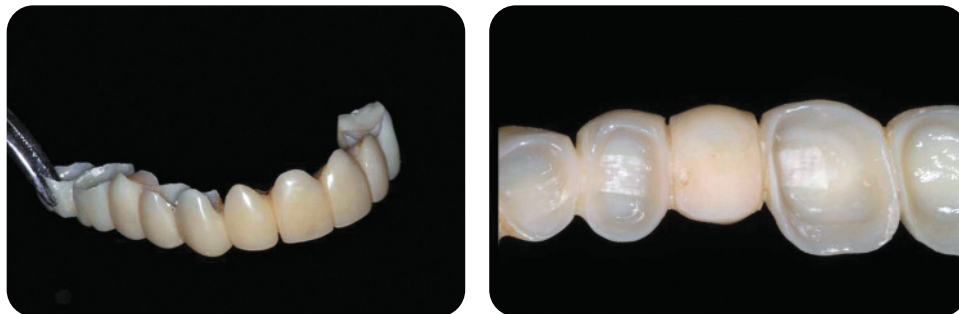


Figure 3.D.10. Clinical example of a provisional that has been functioning in the mouth for a period of 9 months. Note the Ribbon reinforcement that can be seen on the inner surface of the abutments.

Ribbon reinforced provisional. As shown in the top two pictures, the Ribbon is extended from abutment to abutment and across the edentulous spaces and is reinforced with flowable composite. All the exposed surfaces of the Ribbon must be covered with the flowable composite and any space between the Ribbon and edentulous ridge as it spans the space must also be filled in with Ribbon. From this point that fabrication of the provisional is handled as previously described in Figure 3.D.5. Figure 3.D.10 illustrates a provisional that has been in the mouth for more than 9 months. You can see how well it held up. When removed at various steps along the way it is simply repolished and it assumes an appearance

almost as nice as the day it was initially fabricated. The right picture shows the internal aspects of the abutments, and you can see how the Ribbon is encapsulated in the acrylic.

This is a proven technique that I have used for many years. As mentioned earlier, having relatively trouble-free provisionals can certainly minimize the stress and frustration, especially in longer-term interdisciplinary cases. It keeps the patient comfortable and happy, minimizes interruptions in the daily schedule because of fewer provisional problems, and allows the technician to take his/her time in fabricating a definitive restoration that meets the expectation of the dentist and the patient in all regards.

Materials and Manufacturers

Buffalo Foil Cote
800-828-0203
www.buffalodental.com

George Taub Rubber Sep
800-828-2634
www.taubdental.com

Ivoclar Sil-Tech Putty
800-533-6825
www.ivoclarvivadent.us.com

Modern Materials StatStone
800-431-1785
www.heraeus-kulzer.com

Motloid ColdPac
800-622-5021
www.yates-motloid.com

Ribbon provisional reinforcement
800-624-4554
www.ribbon.com

Triad Light Cured Provisional Material for diagnostic
blueprint
800-532-2855
www.dentsply.com

4

The 10 Decisions

As we examine, diagnose, plan, and complete our restorative and reconstructive cases our goal is to end up with as ideal a result as possible. When the result has an ideal form and function we can be more assured that we can achieve a comfortable result that works well, looks good, and promotes and maintains health of all components of the masticatory system. We can also be confident that the results will be stable over a reasonable length of time. The commitment of our patient in terms of time, energy, effort, and finances deserves nothing less than this.

Achieving predictable results requires not only paying attention to a lot of details but also being able to step back and look at the big picture. The details need to look right but the big picture also needs to look reasonable. Seeing the big picture necessitates us stepping back from the details every now and then and looking at the case from a broader perspective. I recall watching a landscaping program on Home and Garden TV. The show's host was illustrating all the fine details of the project in terms of outlining the landscape borders, choosing the correct plants, putting the plants in the right position, proper groundcover, irrigation, etc. As these details were close to being finalized he offered wise advice. He suggested walking across the street to the neighbor's yard, turning around and looking at this project from this broader perspective, and asking yourself, "Does this look reasonable?" And the same goes for our case planning and diagnostic blueprint. A wise bit of advice would be to set the diagnostic blueprint on the benchtop, look at it from arm's length away, and ask yourself the same question.

We need a system that is specific enough to keep us on track and give us the details we need to be sure

nothing is missed, and yet flexible enough to allow us to step back, look at the big picture, and make any refinements that give us not only an ideal result but also a reasonable result. The rest of this chapter is dedicated to just that system, which requires that we make decisions in 10 important areas regarding form and function (Figure 4.1). We may find that in one or more of these areas nothing really needs to be changed. Even if that is the case we can rest assured

The 10 Decisions

- TMJ diagnosis and condylar position
- Vertical dimension
- Lower anteriors
- Upper anteriors
- Centric stops
- Anterior guidance
- Curve of Spee
- Curve of Wilson
- Cusp-fossa angle
- Aesthetic plane

Figure 4.1. The 10 parameters that must be examined, diagnosed, and addressed when planning restorative and reconstructive cases.

that that parameter was looked at and that a decision was made only after some thought. We may also find that an area that we initially thought was not going to need any changes does indeed need to be changed to get the ideal result. It is important to say that the changes being referred to are not necessarily always major restorative changes. It may be something as simple as recontouring, reshaping, or polishing. The rest of this chapter is dedicated to describing each of these decisions in detail, and all of the subsequent case studies will have all of these 10 decisions discussed and illustrated.

4A

TMJ Diagnosis and Condylar Position

It is interesting to think that all the decisions we need to make regarding the front end of the system (that is, the teeth) really begin with the decisions we need to make regarding the back end of the system (that is, the temporomandibular joints and muscles) as illustrated in Figure 4.A.1. We need to assess the status of the temporomandibular joints and muscles and be sure that their condition will add to the predictability and longevity of the restorative result. If there is some question about this, that question must be addressed with appropriate therapy such as bite splint therapy. We then need to make a specific diagnosis of either centric relation or adapted centric posture. If the diagnosis is centric relation we know that long-term

stability is more predictable because the structures are normal. If the diagnosis is adapted centric posture we know that long-term stability may be somewhat compromised because of the altered condition of the temporomandibular joint structures. Figure 4.A.2 illustrates such a scenario. Although a panoramic radiograph is not diagnostic of exact joint condition, it is certainly suggestive of joint condition, especially when coupled with the clinical examination previously described, which entails palpation, auscultation, range of motion tests, and superior compression tests. The condylar changes and asymmetry noted in this panoramic x-ray plus the clinical tests help us make the diagnosis of adapted centric posture.

We need to be aware of this diagnosis, we need to make sure that the patient understands the implications of this diagnosis, and we need to build safeguards into our restorative result that will make it easier to deal with future changes. These safeguards may be things such as a shallower and flatter Curve of Spee, a shallower cusp tip to fossa angle of the posterior teeth, tooth preparations and materials that allow us to more easily make future changes as needed, etc. For example, a minimal reduction bonded porcelain onlay on a second molar may not be the restoration of choice in these kinds of cases. Other safeguards may be a commitment to long-term bite splint therapy use, a commitment to more frequent occlusal engineering checks at continuing care appointments, and an understanding that some aspects of the

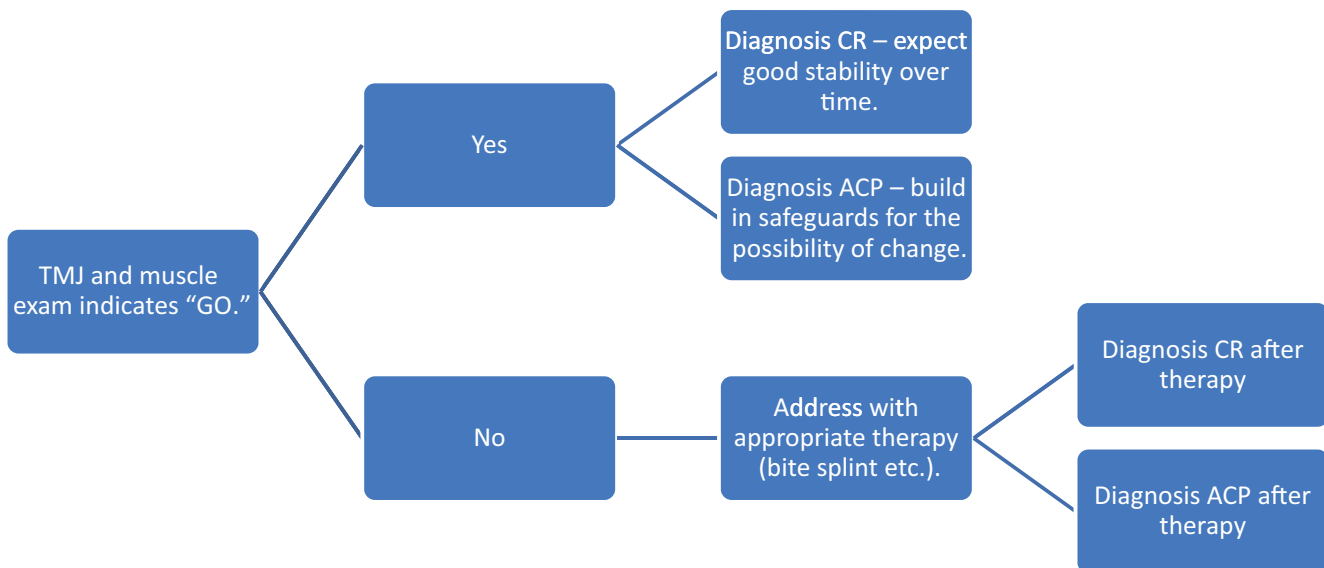


Figure 4.A.1. Thought process and decision tree when examining the temporomandibular joints and factoring that diagnosis into the overall treatment plan.

restorative dentistry may need to be changed in the future.

The diagnosis of centric relation or adapted centric posture implies that the condyles are in the most superior position within the glenoid fossa. Figure 4.A.3 illustrates articulated diagnostic casts and the jaw-to-jaw and tooth-to-tooth relationship in centric and also in maximum intercuspation. When the condyles are fully seated in the glenoid fossa, as seen in the upper

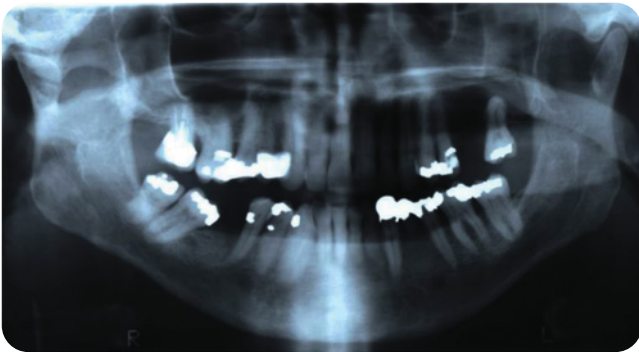


Figure 4.A.2. A panoramic radiograph in addition to the clinical TMJ exam and history can add important information to the diagnosis and treatment plan.

left picture, the teeth do not maximally intercuspate as seen in the upper right picture. This picture illustrates the centric interferences that prevent maximum intercuspation from occurring in the centric arc of closure. When the mandible postures to a position where the teeth maximally intercuspate, as seen in the bottom right picture, the condyles must be displaced downward and forward from their fully seated position in centric to allow maximum intercuspation to occur. When the condyles fit, the teeth don't fit; and when the teeth fit, the condyles don't fit. So there is a constant "war" between where the joint should fit and the teeth should fit, and the "casualties" of this war could be any of the various signs and symptoms we have uncovered in the complete masticatory system examination.

We have an important decision to make. Do we want to somehow try to maintain maximum intercuspation at the expense of never really knowing the position of the condyles—and, if so, accept the fact that it will be a muscle-braced position with all the potential resultant consequences and problems? Or do we choose to treat the case with the condyles in the most superior position and then figure out how to get the teeth to maximally intercuspate with the condyles

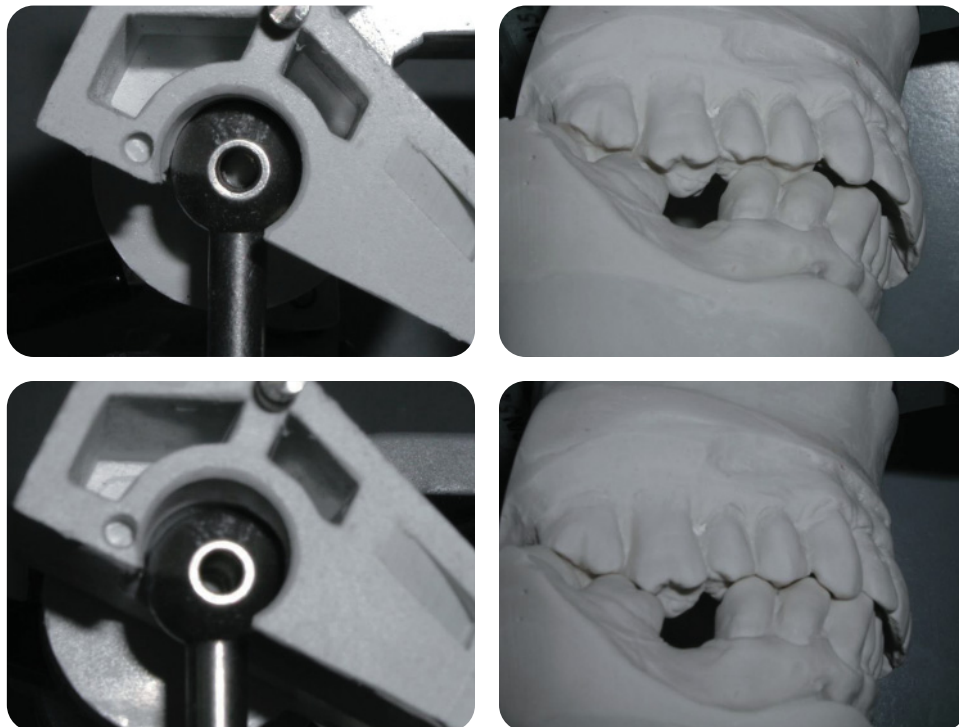


Figure 4.A.3. Articulated diagnostic casts allow us to see jaw-to-jaw and tooth-to-tooth relationships when the condyles are fully seated to centric. They also allow us to see the effect posturing the mandible to maximum intercuspation has on the position of the condyle in the fossa.

in this position? My view is that the most predictable, satisfying, and long-lasting results are achieved with the latter. My firm belief is that this decision is never made without a complete masticatory system examination and diagnosis, as described in previous chapters.

4B

Vertical Dimension

Once we have made the temporomandibular joint diagnosis and are assured that the condyles are in the most superior position within the glenoid fossa, either centric relation or adapted centric posture, we can now make some decisions regarding the vertical dimension that we need to treat the case. Vertical dimension has been a somewhat confusing subject in dentistry. We may hear advice that says we should never change the vertical dimension of occlusion for fear that it may cause a temporomandibular disorder. On the other extreme we may hear advice that says we can arbitrarily increase the vertical dimension of occlusion without any fear of problems because of predictable patient adaptability. As usual I believe that the answer lies somewhere between these two extremes.

First let's discuss what actually determines the vertical dimension of the maxilla to the mandible. This

vertical dimension is determined by the repetitive contracted length of the elevator muscles. The elevator muscles have a repetitive contracted length that holds the maxilla and mandible at a repeatable vertical dimension that is unique to each patient. During growth and development the teeth continue to erupt until they occlude at that vertical dimension determined by the muscles. This vertical dimension remains relatively consistent throughout life. So when we make a decision to open the vertical dimension of occlusion with our restorative dentistry we not only need to think of the effect on the teeth but we also need to think about the effect on the muscles (Figure 4.B.1).

We must remember that the condyle is a joint that not only rotates but also slides. Hinge rotation occurs up to approximately a 15mm opening. Once the mandible opens past 15mm the condyle begins to translate down the eminence. During hinge rotation the condyle simply rotates around its medial pole hinge axis as illustrated by the green dot in Figure 4.B.1. So opening or closing the vertical dimension of occlusion within hinge rotation causes only no change in condylar position. There is no danger of distalizing the condyle and pushing it into the neurovascular bundle. This is not to say that we have free rein to open the vertical dimension of occlusion up to 15mm. In my experience our restorative and aesthetic goals

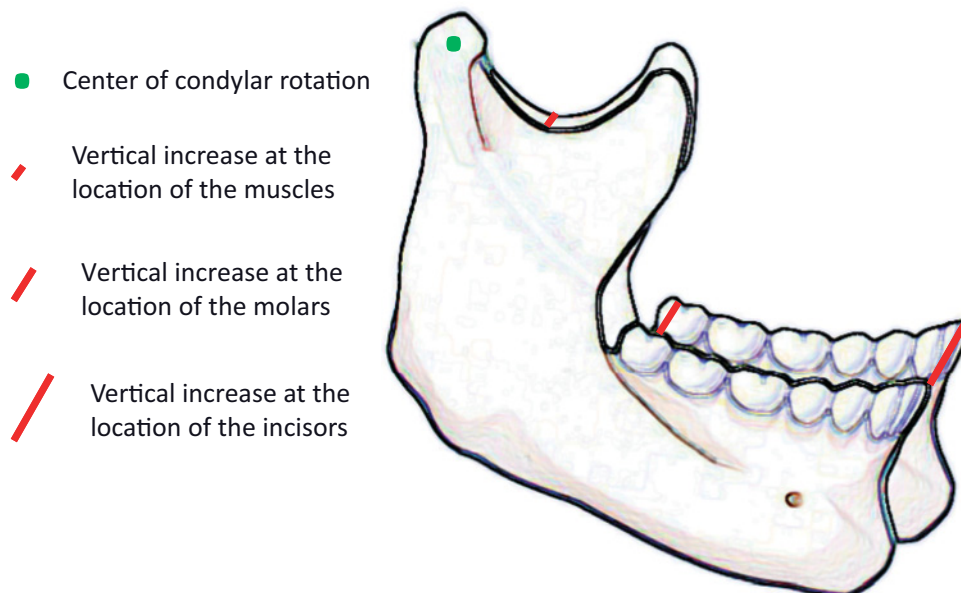


Figure 4.B.1. Because the mandible rotates on an arc around the condylar axis, the effect of vertical dimension changes lessens from anterior to posterior, with the least effect being at the location of the muscle attachments.

can be accomplished either at the patient’s current vertical dimension of occlusion or by opening it just a few millimeters. Figure 4.B.2 itemizes the thought process regarding the changes in the vertical dimension of occlusion.

We must also remember that the mandible opens on an arc and not in a straight line. Because of the arc of rotation the amount of opening lessens as we move posteriorly (refer to Figure 4.B.1). If we open the vertical dimension of occlusion 3mm at the position of the central incisors, because of the arc of rotation the posterior teeth will open only 1–1.5mm. And because the insertion of the muscles are even closer to the hinge axis of rotation than the posterior teeth, the effect of a 3mm vertical opening at the incisors results in less than a 1 mm opening at the level of the muscles.

We must also take into consideration the vertical difference of the condylar position in maximum intercuspation as compared to its fully seated, most superior position. As the condyle changes its position in maximum intercuspation to its most superior

position, this movement upward actually results in a slight shortening of muscle length. Figure 4.B.3 illustrates the three-dimensional dynamics. The upper left photo shows the patient’s maximum intercuspation. There was quite a discrepancy between centric relation and maximum intercuspation, which resulted in an approximate 2mm down and forward displacement of the condyle. A measurement is made from the upper to lower member of the articulator at the approximate position of the elevator muscles, which is posterior to the last molar. The upper right picture shows that this measurement was 108.5mm. The lower left picture shows the diagnostic wax-up. Because of the severe wear of this particular case, the vertical dimension of occlusion needed to be open approximately 4–5mm at the incisors. This can be seen by the careful comparison of the two left figures. As seen in the lower right photo, this opening of the vertical dimension of occlusion, coupled with the condylar seating from maximum intercuspation to centric relation, resulted in only a .5mm increase in vertical dimension of the elevator muscles. As can be

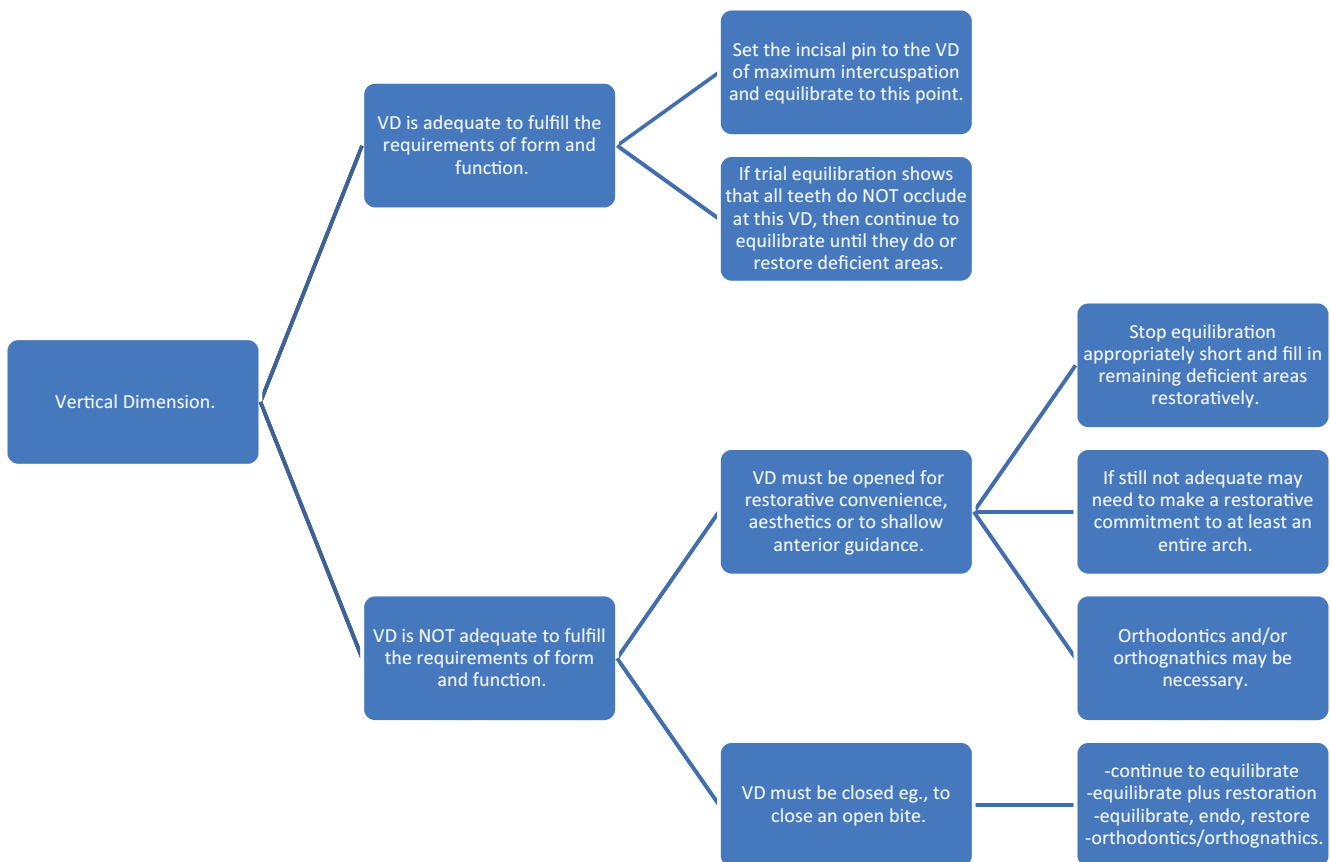


Figure 4.B.2. Thought process and decision tree regarding changes made to the vertical dimension of occlusion.

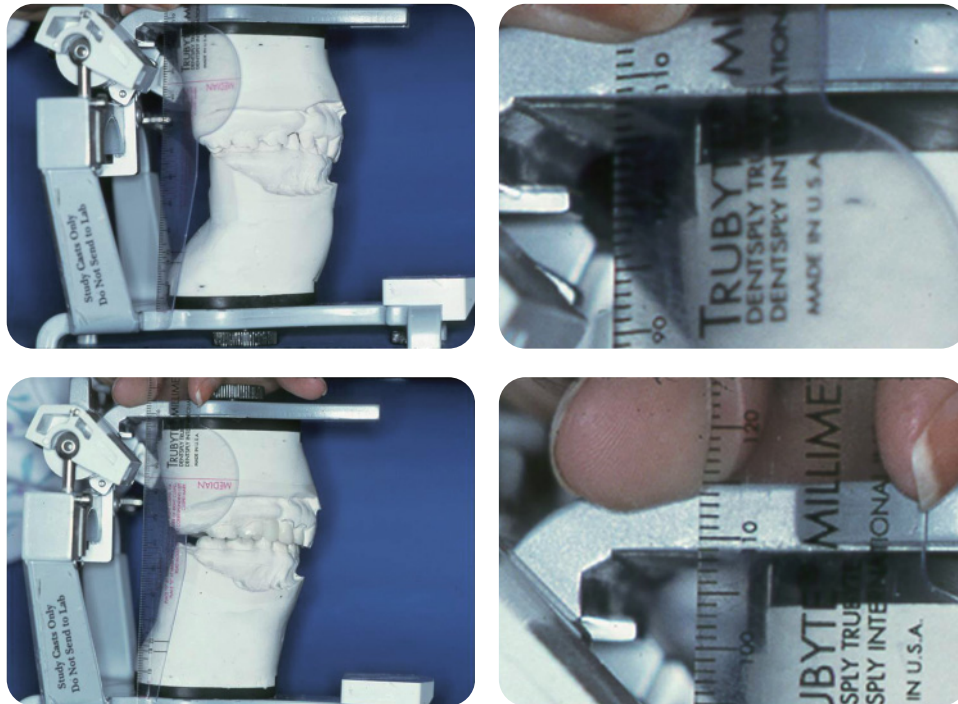


Figure 4.B.3. The effect of vertical dimension changes on muscle length between the vertical dimension of maximum intercuspation and the vertical dimension of the diagnostic blueprint can be measured on the articulator at a point of the approximate attachment of the muscles, which is posterior to the teeth.

seen in the lower right photo, the measurement is at 109mm.

Just as important as determining the vertical dimension of occlusion is fulfilling all the requirements of a physiologic occlusion at whatever vertical dimension is chosen. It is very important to develop simultaneous, equal intensity contact on all teeth in the centric relation arc of closure at the vertical dimension that is chosen. There should be no incline contact that could result in deflection or movement of either teeth or mandible when the patient squeezes firmly.

The flowchart in Figure 4.B.2 illustrates a thought process to consider when making decisions regarding vertical dimension of occlusion changes. The primary question to ask is whether the patient's current vertical dimension of occlusion is adequate to fulfill the requirements of form and function. In other words, will the resultant anatomic form be aesthetically acceptable and can all the requirements of a physiologic occlusion be adequately fulfilled—that is, stable centric holding contacts, an adequate anterior guidance of the correct steepness, and immediate posterior disclusion in both the functional and parafunctional range of motion. In terms of clinical crown length we need to determine whether it is adequate enough for proper resistance and retention form of the tooth preparations.

If the current vertical dimension of occlusion is assumed to be adequate, the incisal pin on the articulator is set to the vertical dimension of maximum intercuspation by unlocking the centric lock and squeezing the casts into maximum intercuspation. The centric lock is once again engaged, the casts are closed to the vertical dimension of the interferences, and the incisal pin is observed to be off the incisal table. As the trial equilibration is done, the goal is to refine the occlusion by removing interferences in the centric arc of closure until the pin is back to the incisal table. Once the pin is back to the incisal table but it is observed that all the tooth-to-tooth centric holding contacts are not adequate, a decision needs to be made. If it is just a small amount, we might consider continuing the equilibration until all the desired tooth-to-tooth holding contacts are achieved. Obviously good clinical judgment needs to rule. If it can be done without removing excessive tooth structure, this indeed may be a reasonable approach. An alternative approach is to restore deficient areas with the most appropriate material to achieve the centric holding contacts that still may be lacking. If the areas of deficiency are on teeth that need to be restored anyway, the restorative approach may be the most appropriate. Each decision needs to be made on a

case-by-case, individualized approach, and testing each decision requires sound clinical judgment. We must always ask ourselves whether the approach we are considering is reasonable and whether it fulfills our objectives in the most conservative way.

In our analysis we may determine that the patient's current vertical dimension of occlusion is not adequate to fulfill all the requirements of form and function. We may decide that it needs to be increased for aesthetic reasons, or for restorative convenience to achieve better resistance and retention form in the tooth preparation, or to gain room to make the anterior guidance less steep. As the vertical dimension of occlusion is opened, the lower anterior incisal edge moves down and back, thereby allowing more space on the lingual of the upper anterior teeth to create a shallower anterior guidance platform.

We must analyze the amount of vertical opening at the first point of centric interference and determine whether this space is adequate for our restorative and occlusal goals, whether it is too much, or whether it is not enough. If it is adequate, we may consider completing a diagnostic blueprint at the vertical dimension of the first point of centric interference. If the space is too much for our restorative and occlusal goals, we may consider a partial equilibration, which closes the vertical dimension from the first point of centric interference but not all the way to the vertical dimension of maximum intercuspation. As the centric interferences are equilibrated, the resultant vertical opening is constantly assessed until we reach a point where the remaining space can be adequately restored to our desired occlusal and restorative goals. With this approach we actually open the vertical dimension of occlusion but do it with less than a full arch of restorations. If at the first point of centric interference we determine that there is not enough space to fulfill our goals of form and function, we may determine that the vertical dimension of occlusion will need to be opened with restorations on at least the entire arch. If this is the case, we open the vertical dimension of occlusion the minimum amount necessary to fulfill our requirements of form and function and complete a diagnostic blueprint at that vertical dimension.

In our analysis we may determine that restorations required to restore the desired form and function are not reasonable or are needed on structurally intact teeth; if so, we may need to consider orthodontics or orthognathics as part of the treatment plan to achieve the desired goals.

There are clinical situations where we may decide to decrease the vertical dimension of occlusion from the patient's current maximum intercuspation. The patient may present with an anterior open bite that we would like to close to achieve better anterior tooth-to-tooth relationships for improved centric stops and for improved anterior guidance. Another situation may occur in which we need to improve the crown-to-root ratio of the posterior teeth in a periodontal case. These cases require careful correction on articulated diagnostic casts to determine the amount of tooth removal necessary to achieve our vertical dimension goal. As always, good clinical judgment must prevail. As we correct and analyze on articulated diagnostic casts, we may determine that continued equilibration alone will close the vertical dimension of occlusion adequately enough to fulfill our goals without irreversible tooth damage. Other scenarios may reveal that the tooth structure removal necessary to gain our vertical dimension goals will necessitate restorations. If these teeth are already in need of restorations because of their current structural condition, this may be a reasonable approach. Our analysis may reveal that the tooth structure removal needed to achieve our vertical dimension goals will necessitate not only restorations but also endodontic procedures. If the teeth are structurally intact, this obviously is not a reasonable approach. However, if the teeth are already structurally compromised to the point that endodontic therapy may need to be considered anyway, this approach of managing the vertical dimension of occlusion is more reasonable. In cases in which restorations are simply not needed because the teeth are structurally intact, orthodontics and/or orthognathics may be considered as the most reasonable approach to achieve our vertical dimension goals. None of these decisions can be made without analysis and trial corrections done on articulated diagnostic casts.

Figure 4.B.4 illustrates a wear case in which the vertical dimension of occlusion needs to be opened in order to better fulfill our aesthetic and functional goals. Figure 4.B.5 illustrates the articulated diagnostic casts. This represents the vertical dimension at the first point of occlusal interference in the centric arc of closure. Since we have already determined that we will be increasing the vertical dimension of occlusion, we now need to decide how much. The amount of vertical opening at the first point of occlusal interference resulted in more space between the rest of the teeth than was needed to create restorations that fulfilled our goals of form and function. Therefore, the occlusal

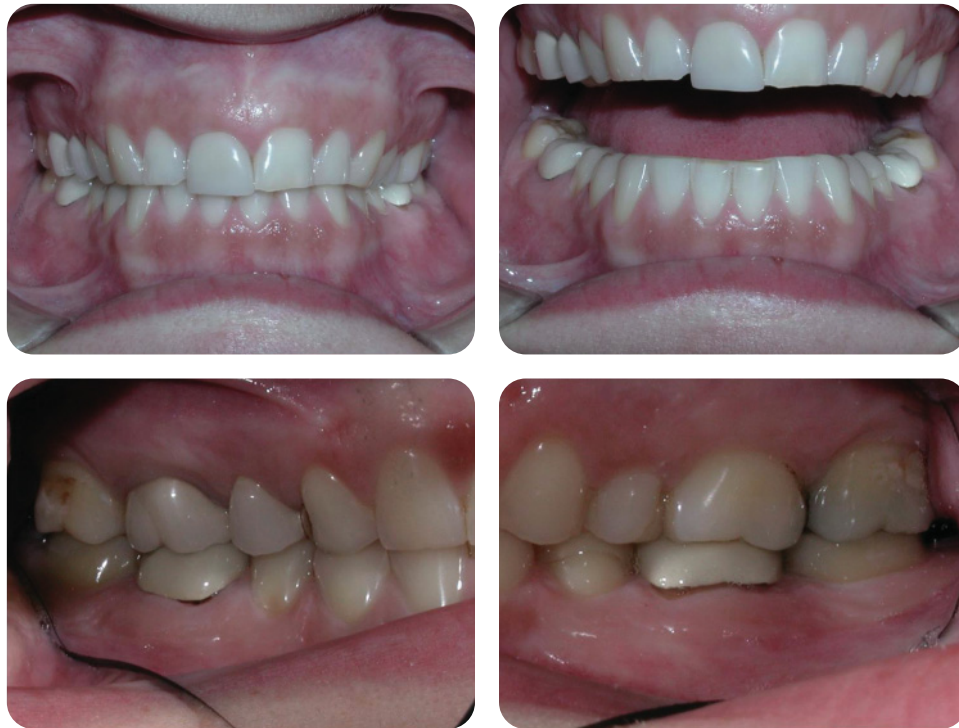

Figure 4.B.4. A rather severe wear case in which a vertical dimension of occlusion needed to be opened for the restorations.

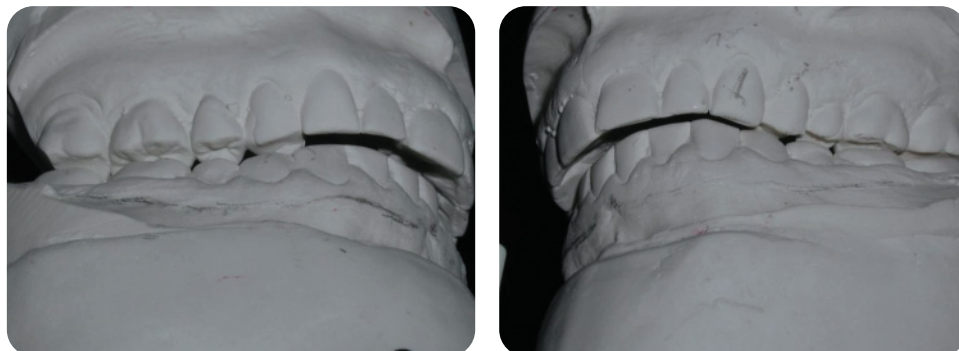


Figure 4.B.5. Articulated diagnostic casts of the wear case in Figure 4.B.4 showing the amount of vertical opening at the first point of occlusal interference in the centric arc of closure. All or part of the space can be used for the restorations.

interferences in the centric arc of closure were equilibrated and the vertical dimension closed slightly until we had the amount of space allowing us to create reasonably contoured restorations that fulfilled our goal of form and function. Figure 4.B.6 illustrates the diagnostic wax-up that was done at that predetermined vertical dimension of occlusion. Because of the current structural condition of the teeth, we knew that restorations were needed on all teeth; therefore, we had the opportunity to design ideal form and function. Figure 4.B.7 illustrates the completed restorative result. The vertical dimension of occlusion that was determined in the diagnostic blueprint was used in the

patient's mouth with provisional restorations, and this vertical dimension of occlusion was tested over a period of time. Articulated diagnostic casts of these verified provisionals were used as precise laboratory communication. Bite records for the restorative dentistry were made at the working vertical dimension of occlusion by keeping a section of the provisional in place while bite records were made over the repaired teeth at the working vertical dimension of occlusion.

Figure 4.B.8 illustrates the case in which the vertical dimension of occlusion was closed. The patient presented with an anterior open bite. The complete

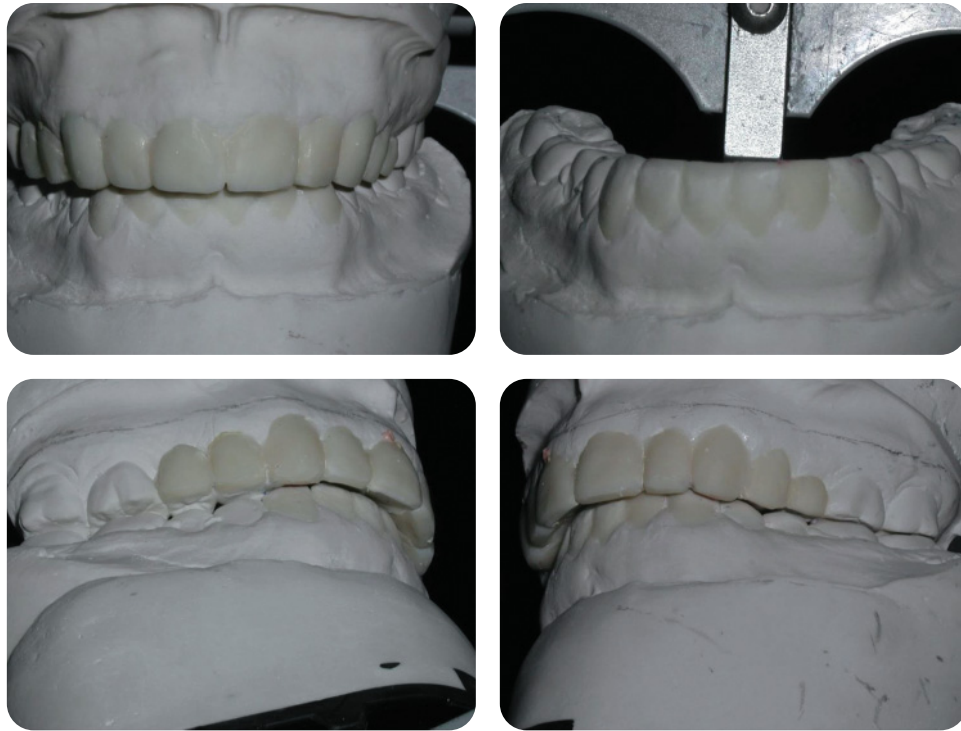


Figure 4.B.6. After a slight equilibration of the occlusal interferences, which results in a slight closure of the vertical dimension at the first point of occlusal interference, the diagnostic blueprint is done to fulfill the rest of the occlusal and aesthetic parameters.

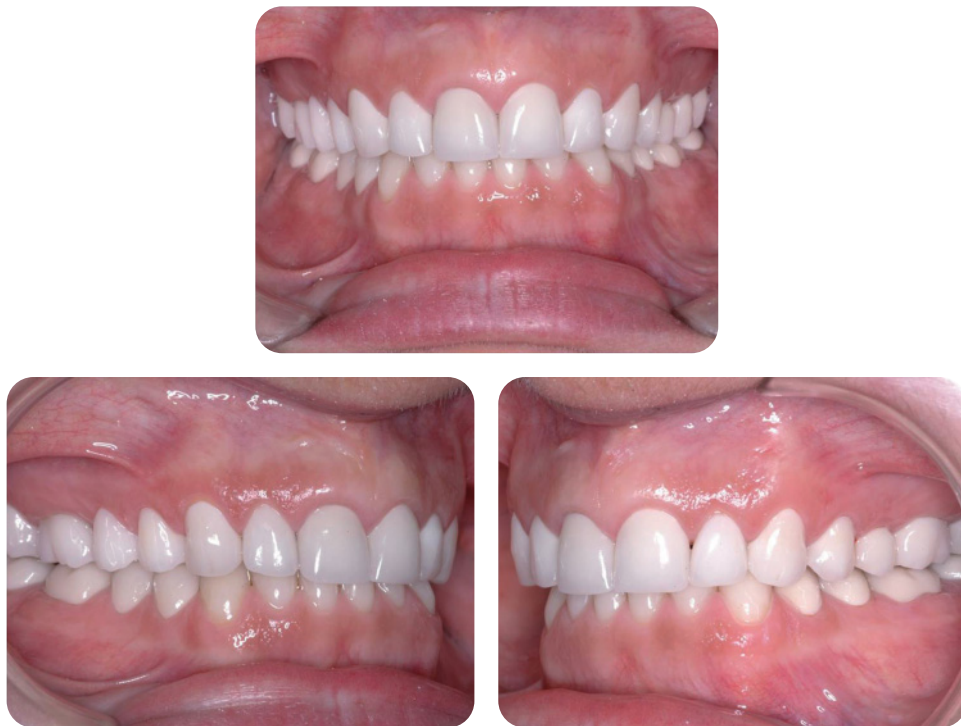

Figure 4.B.7. The restored case has the vertical dimension of occlusion opened the minimum amount to fulfill the requirements of aesthetics and function.

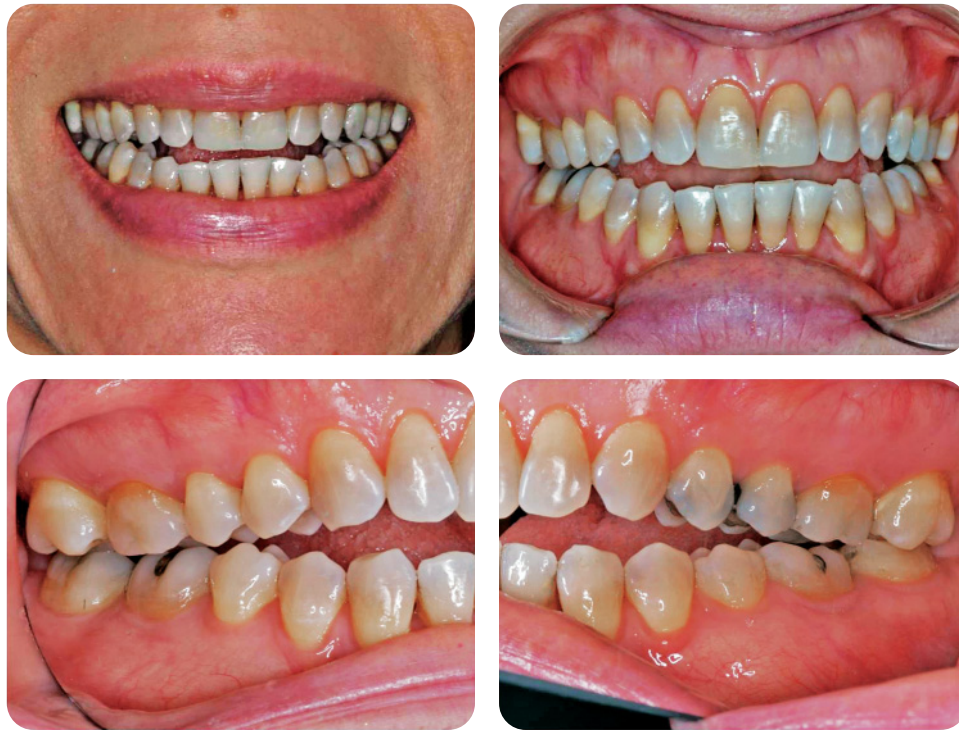

Figure 4.B.8. An anterior open bite case in which the patient refused orthodontics and orthognathics.

temporomandibular joint exam showed that this open bite was not due to a condylar degeneration. Clinical examination also suggested that this anterior open bite was not due to a tongue thrust. Reviewing the photos, it can be seen that the tongue is not filling the space created by the anterior open bite. Although this type of occlusal misengineering can result in a variety of signs and symptoms, these signs and symptoms were not prevalent in this particular patient. Her main concern was the aesthetics of the anterior open bite and her inability to incise food. We therefore had a rationale for a treatment plan to close the anterior open bite. A variety of treatment options were discussed with the patient, the primary one being orthodontics/orthognathics. Upon pondering the pros and cons of this approach, the patient decided against this treatment alternative. The approach of closing the vertical dimension of occlusion by shortening the interfering teeth and restoring as needed was agreeable to the patient. Figure 4.B.9 illustrates restorations on most all of the posterior teeth that were in varying degrees of structural breakdown; therefore, the thought of closing the vertical dimension of occlusion with this approach was pursued on the articulated diagnostic casts and seen in Figure 4.B.10. By shortening and equilibrating the posterior teeth, the anterior teeth came into a reasonable tooth-to-tooth relationship as the vertical dimen-

sion closed on the centric arc of rotation. The left cuspids were restored with conservative direct bonded composites restorations to achieve a tooth-to-tooth relationship that equilibration alone did not achieve. A careful analysis was done by comparing the corrected articulated diagnostic casts to the original untouched set of articulated diagnostic casts, and an estimate of the amount of tooth structure removal was determined. Analysis of the radiographs revealed that the pulp chambers had receded to a point that this tooth reduction could be done without pulp exposure, although this latter possibility was certainly discussed with the patient. Areas of dentin exposed by the tooth reduction were to be restored with bonded composites restorations because the axial surfaces of the teeth were structurally sound. Although this may seem to be a nonconventional approach to treatment, analysis of the corrected articulated diagnostic casts after a complete masticatory system examination set forth a valid rationale for this approach. Figure 4.B.11 illustrates the complete treatment result. The functional result achieved clinically was precisely the same as a result achieved on the articulated diagnostic casts. Endodontic treatment was not needed.

It has been my experience that the results achieved by correcting the articulated diagnostic casts is a very

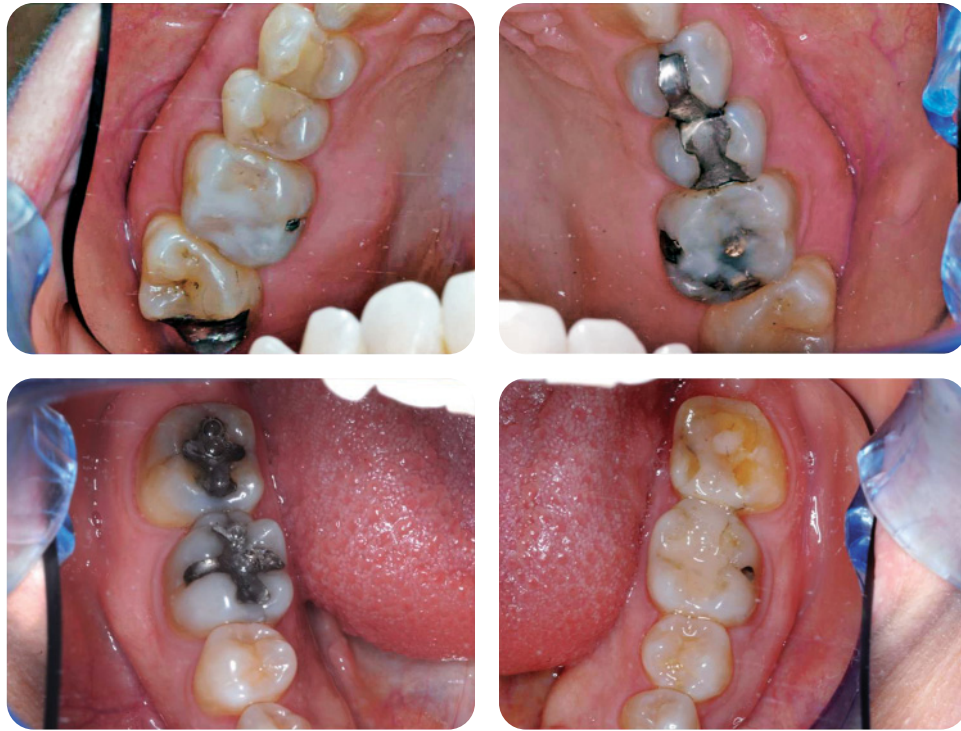

Figure 4.B.9. Nearly all of the posterior teeth needed some type of restorations, giving us the opportunity to close the vertical dimension of occlusion by shortening and equilibrating the posterior teeth.

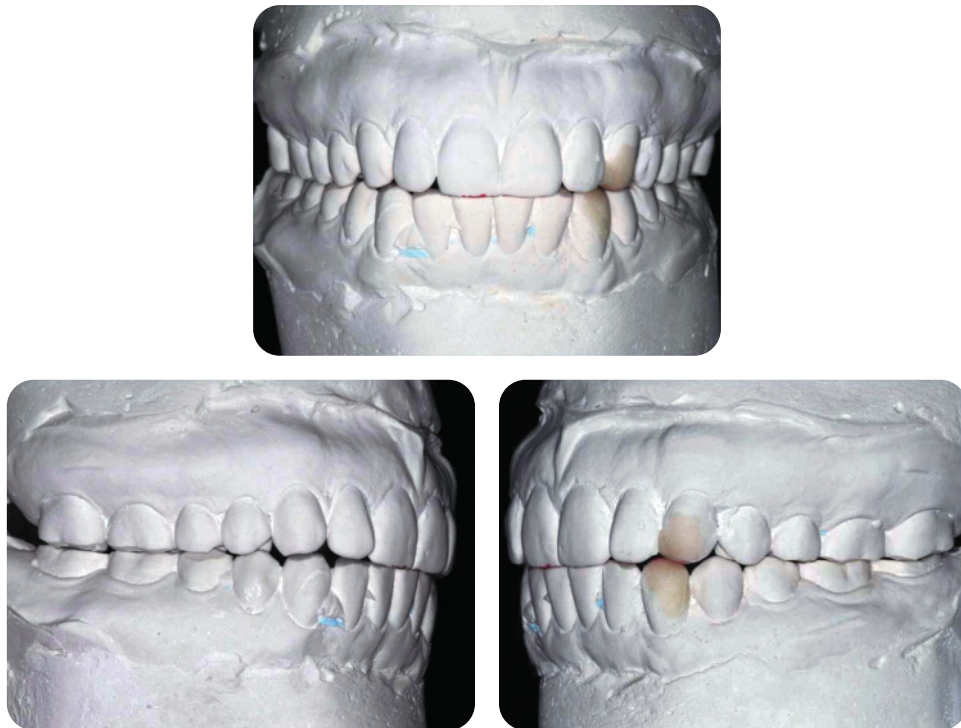

Figure 4.B.10. The diagnostic blueprint, which involved shortening and equilibrating the posterior teeth and simple direct composites restorations on the left cuspids, showed us that the desired result we envisioned was indeed possible.

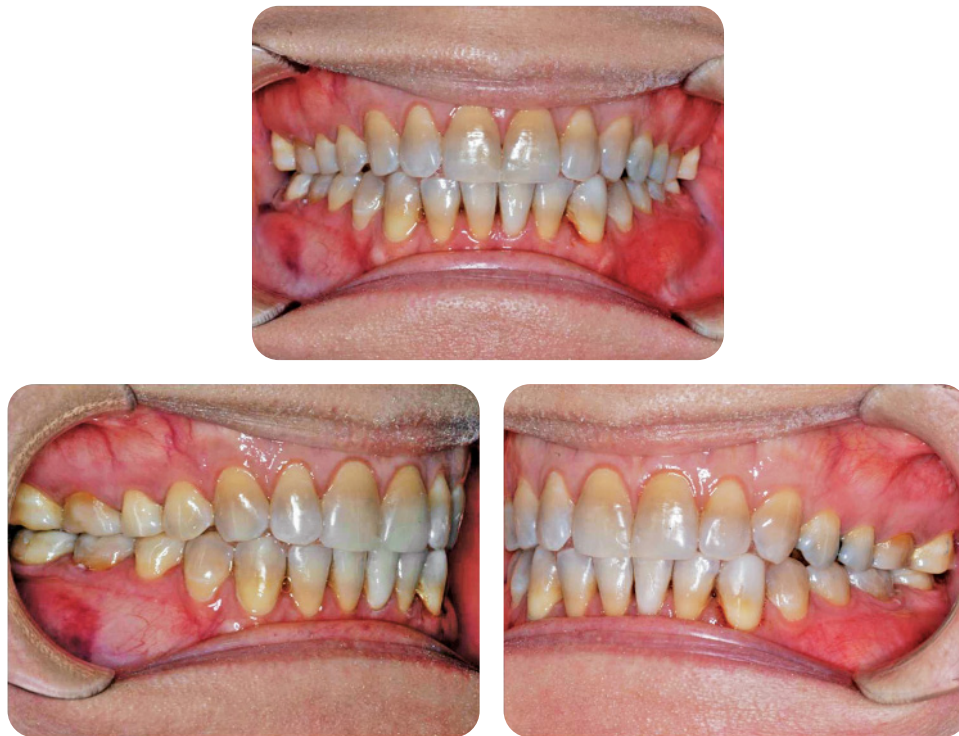

Figure 4.B.11. The clinical result is nearly identical to the result of the diagnostic blueprint.

precise indication of what can be achieved clinically. I never attempt a treatment approach such as this or *any* treatment approach, without a complete masticatory system examination and without making any anticipated corrections on a duplicate set of articulated diagnostic casts. Once this is done the clinician can then determine the validity of that anticipated treatment.

4C

Lower Incisal Edge Position

Once we have examined and diagnosed the temporomandibular joints and have verified that the condyles are in the most superior position with no sign of tension or tenderness and have an idea regarding the vertical dimension of occlusion that will be used in the restoration, we can focus our attention on the details of form and function of the teeth. We begin our discussion with the lower anterior teeth.

Figure 4.C.1 illustrates the anatomic form and position of the lower anterior teeth both individually and collectively. Each individual lower anterior tooth should have a definitive labial incisal line angle and a definitive incisal edge. The labial incisal edge is the functional surface upon which a centric stop is created on the lingual of the upper anterior tooth. A definitive

labial incisal line angle will create a stable centric holding contact with the lingual of the upper. If the labial incisal is not an angle but rather a rounded or sloped surface as seen in Figure 4.C.2, this will make it difficult if not impossible to create a stable centric holding contact. The purpose of a stable centric holding contact is to keep the tooth in a stable position and prevent movement or migration. If the centric stop is a sloped surface against a sloped surface, or does not make definitive contact with the lingual of the upper whether or not it has the correct anatomic form, stability is compromised and the tooth may migrate over time as seen in Figure 4.C.3. The reason the lower anterior teeth may migrate and the anterior teeth stay in a stable position even without a stable centric holding contact is because of the lip musculature being the entity holding the upper anterior tooth in a stable position.

Referring back to Figure 4.C.1, you see that each lower anterior tooth should also have a definitive incisal edge. The incisal edge is a surface created by the labial incisal and lingual incisal line angle. The functional purpose of the lower incisal edge is to create a flat platform that occludes with a definitive incisal edge of the upper anterior teeth at the end of a protrusive movement or a lateral crossover movement from the cuspids onto the anterior teeth. Figure 4.C.4

LOWER INCISAL EDGE ANATOMY AND POSITION

- Each Tooth Has a Definitive Labio-Incisal Line angle
- Each Tooth Has a Definitive Incisal Edge
- The Collective Plane Is Level and Horizontal
- Display Is Age Appropriate

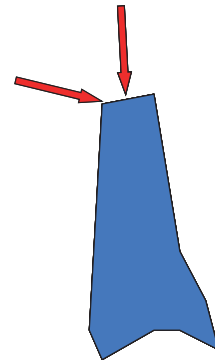


Figure 4.C.1. Illustration of the anatomic and functional landmarks necessary for lower anterior teeth.

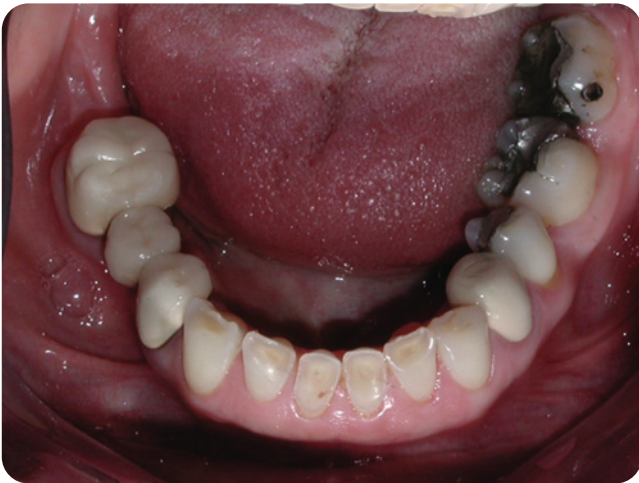

Figure 4.C.2. Clinical example of lower anterior teeth that had been worn to create undesirable lower anterior anatomic form. Note there is no labial incisal line angle or incisal edge.

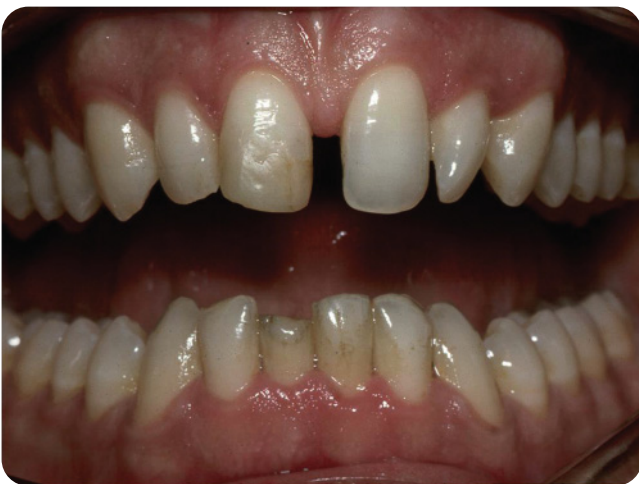

Figure 4.C.3. Lower anterior teeth that do not have stable centric holding contacts can migrate.

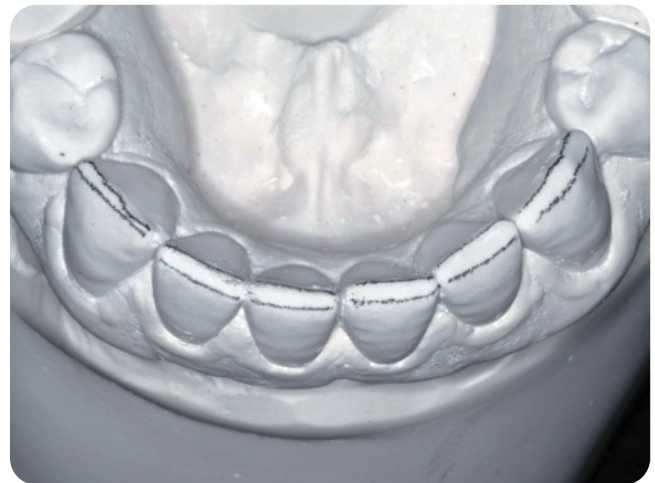

Figure 4.C.4. Anatomic form of lower anterior restorations showing an incisal edge outlined by the lingual incisal line angle and a labial incisal line angle.

shows a restored case that identifies these anatomic landmarks. When evaluating lower anterior teeth to determine whether these anatomic guidelines are being met, a good way to visualize the anatomy is to trace the line angles with the edge of a pencil lead to see whether indeed these definitive line angles are present.

The next criteria is evaluation of the lower anterior teeth collectively to determine whether they create a plane from left to right that is level and horizontal (refer to Figure 4.C.1). The lower anterior teeth can collectively be viewed as a blade, so to speak, that will function on the lingual of the upper anterior teeth during anterior guidance movements. A blade that is level and horizontal functions more smoothly and less

traumatically on the lingual of the upper anterior teeth than a blade that is jagged or not even. Figure 4.C.5 illustrates this concept. The top picture shows a lower anterior plane that is not level and even. The bottom picture shows the restored case, which resulted in more idealized individual lower anterior tooth anatomic form and an incisal plane that is level and even. Also note that after the restoration the anterior incisal plane is more level and consistent with the posterior occlusal plane.

The last factor to consider when evaluating lower anterior teeth is the amount of display with the lip at rest. Age must be taken into consideration when evaluating this aesthetic aspect. Generally speaking, as we age we display more of the lower anterior teeth and less of the upper anterior teeth.

Figure 4.C.6 lists some of the treatment options to consider when our examination and evaluation show that the lower anterior anatomic and functional parameters are not correct. If the discrepancies are minor and those discrepancies present as excessive contours rather than deficient contours, simple reshaping and polishing may be all that is necessary. As reshaping is

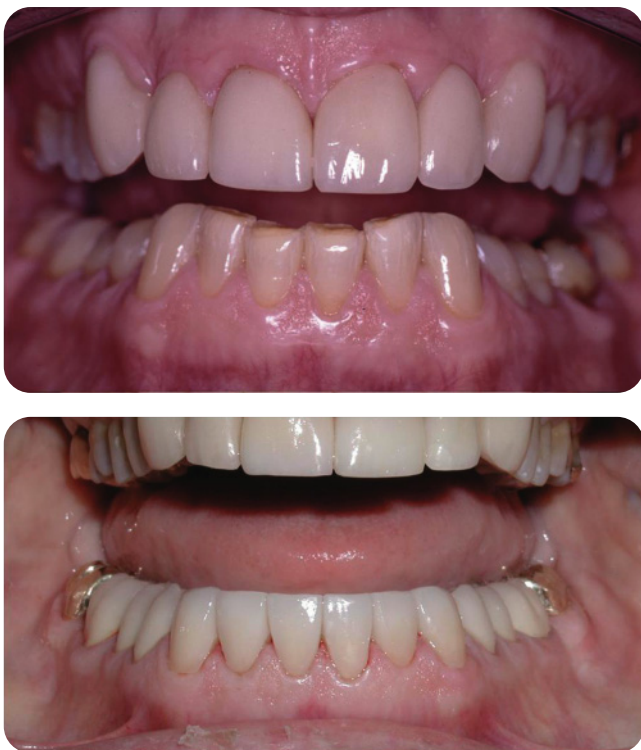

Figure 4.C.5. Uneven and irregular lower anterior incisal plane restored to more idealized forms individually and collectively with porcelain veneers. Note that the anterior incisal plane is more consistent with the posterior occlusal plane.

done, be sure to create a definitive incisal edge and a definitive labial incisal line angle by creating a facial surface plane and an incisal edge plane rather than just rounding or excessively angling that surface.

If the contours are deficient as well as excessive, the corrections may involve some simple restorations as well as reshaping and recontouring. If it is a rather small restoration, direct composites bonding works well and is a very conservative option. Experience has shown that if all the details of a physiologic occlusion are implemented and if the anterior guidance presents itself as a smooth, nontraumatic functional movement in both the functional and parafunctional range of motion, direct bonded composites can also be a fairly long-lasting restoration. Occlusal engineering is the primary consideration. The choice of restorative material is obviously also an important decision but really a secondary one after the occlusion has been definitively addressed. Because direct composite bonding is such a conservative procedure, it can be easily refreshed if the time comes when it may be necessary.

There are certainly situations where the structural condition of the lower anterior teeth—whether it be due to wear, fracture, decay, and/or restorations—is such that a laboratory-processed restoration such as a veneer or crown may be the best treatment choice. We must take into consideration tooth preparation and reduction in the correct areas so that our laboratory technician has the space to create a restoration that provides the desired anatomic form.

Finally, the patient may present with a situation such that reshaping, simple restorations, or even laboratory-processed restorations will not result in the correct anatomic form and position because the teeth may be in locations where that is just not possible. In these scenarios we may need to consider orthodontics and/or orthognathics to move the teeth and/or jaw segments so that the anatomic form will be idealized with these procedures alone or, after completed, with some simple conservative restorations.

Lower anterior teeth tend to be overlooked when planning restorative cases especially if the teeth are structurally intact. They play such an important role in stability, longevity, and function of upper anterior teeth and restorations that they should routinely be considered in the overall plan. Experience has shown that the majority of times the lower anterior teeth can be addressed with reshaping and simple restorations. Correct lower anterior teeth are the starting point for correct anterior guidance.

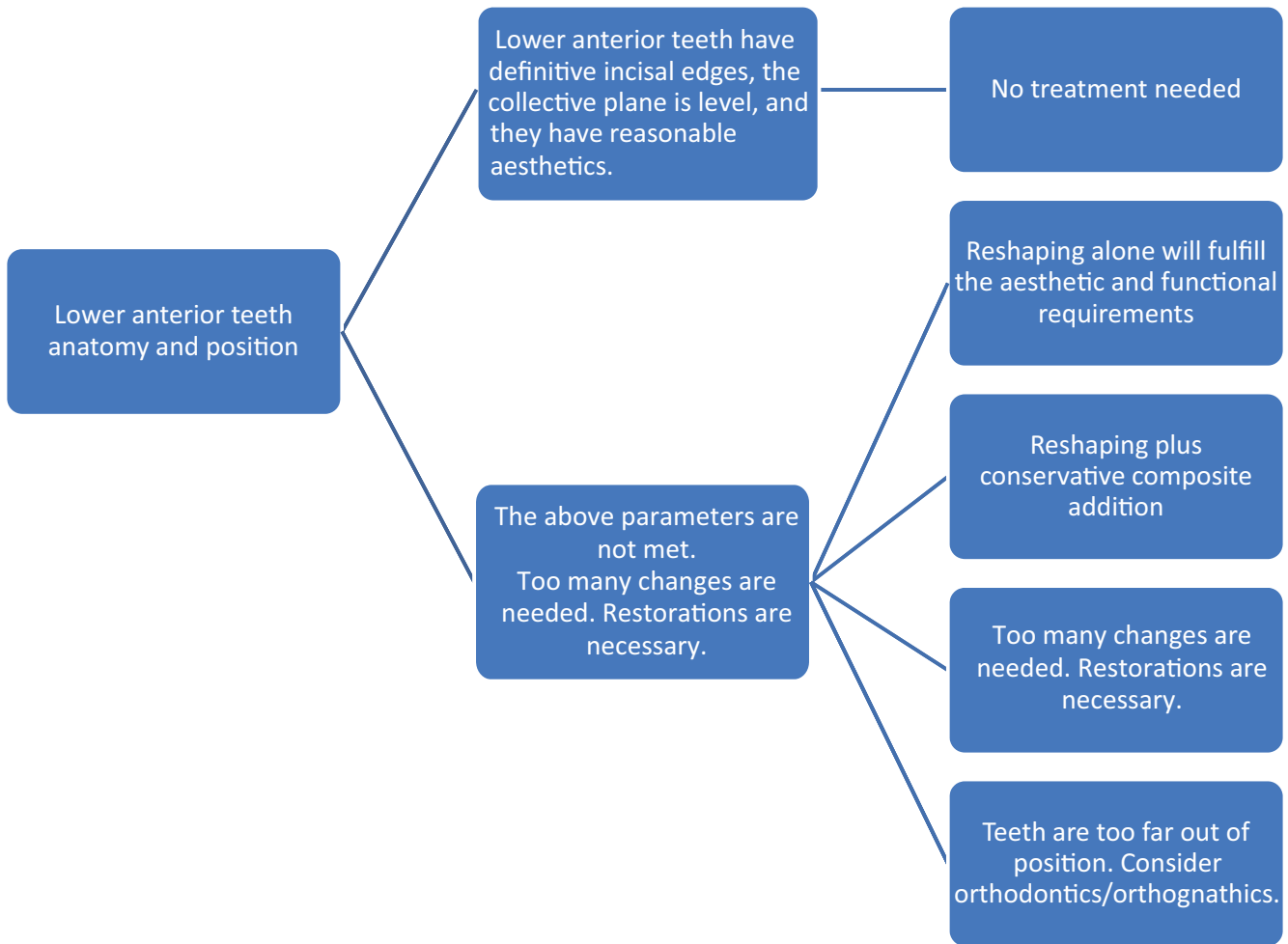


Figure 4.C.6. Thought process and decision tree regarding different treatment options for lower anterior teeth that do not meet the requirements of form and function.

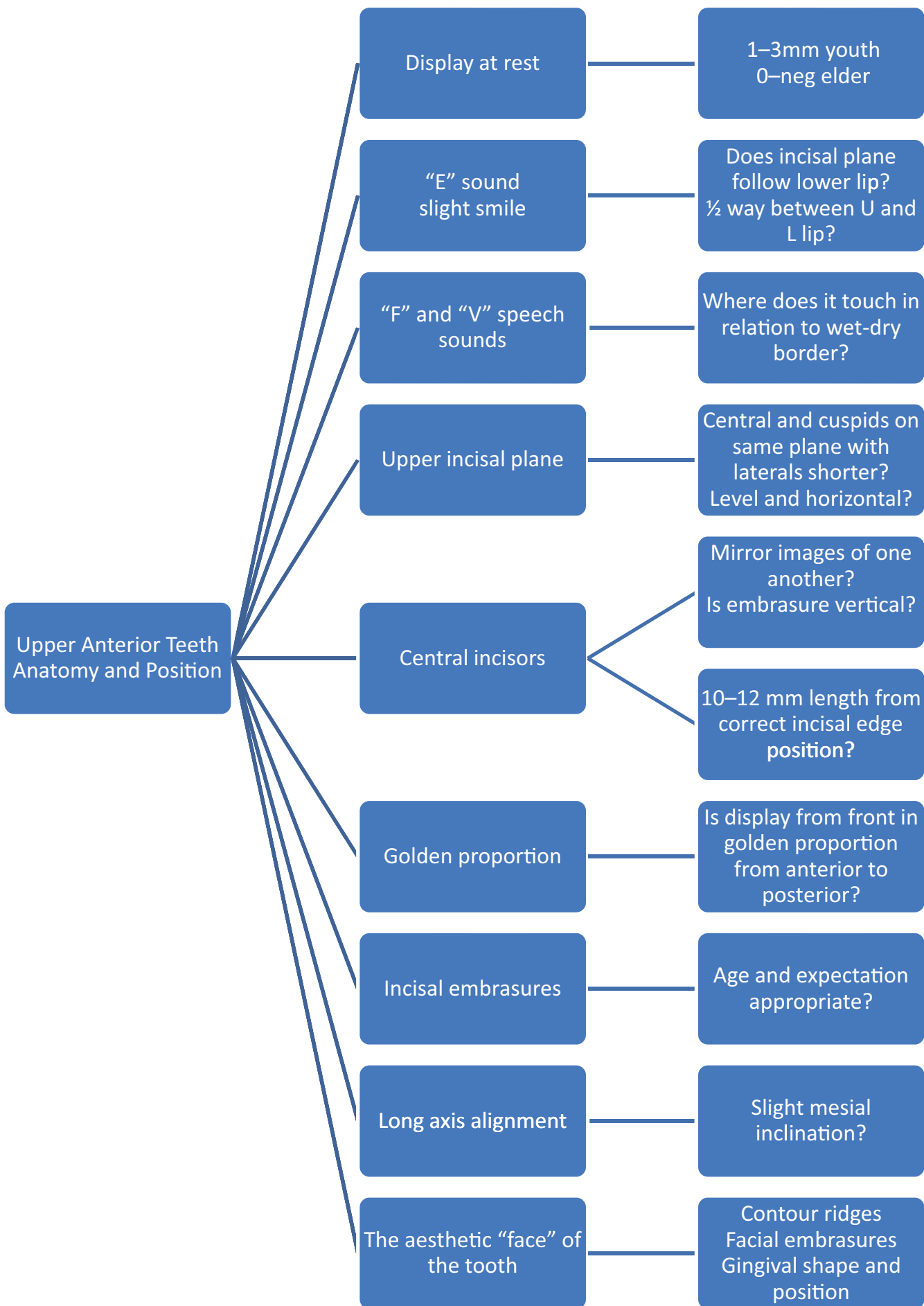
4D

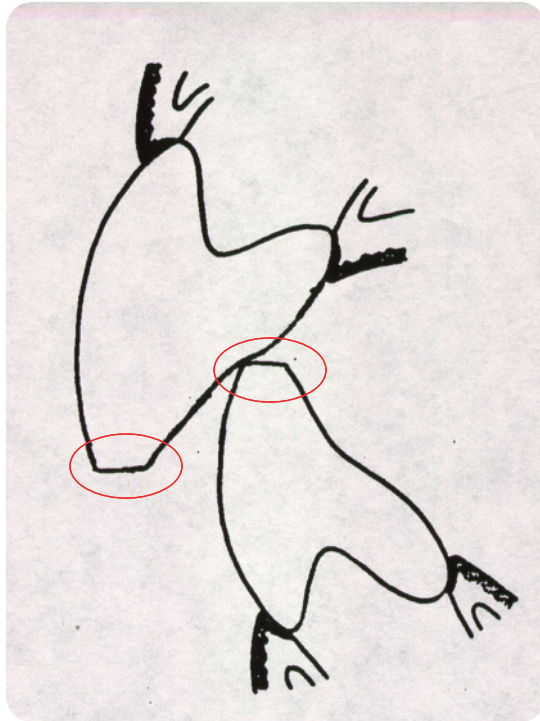
Upper Incisal Edge Position

The upper anterior teeth present some of the most exciting opportunities for us in dentistry. Being the major component of the smile we are able to make a major impact on our patient with upper anterior dentistry. Some of the most gratifying and fulfilling successes we have in dentistry are with our anterior restorative cases. The fact that it is the fourth decision we need to make in no way diminishes its importance. Many schools of thought place the upper anterior teeth as the primary decision that needs to be made and the rest of the case is built around that decision. The fact is, none of these 10 factors are independent decisions in and of themselves. They are all interrelated and one plays upon another, so we simply need to have a thought process or some guidelines to be

sure that we have addressed all the important factors. Even if no changes or treatments are needed, we still need to look, evaluate, and decide. In our excitement to provide some beautiful dentistry for our patient, especially when it is upper anterior restorations, we may overlook some of the other factors, which may not seem to be critical at first but which may play an important role in those upper anterior restorations down the line. For example, an irregular lower anterior incisal plane may be a reason for some porcelain to chip on the upper anteriors. One of the major themes of this book is to train our eye and mind to look at the big picture, despite our excitement and enthusiasm, and focus on one section that our patient has given us the opportunity to treat.

Figure 4.D.1 outlines the important criteria to observe, evaluate, and change if necessary as we address upper anterior restorations.





THE KEY TO ANTERIOR GUIDANCE

- Lower Incisal Edge Anatomy and Position
- Upper Incisal Edge Position

Figure 4.D.2. Determining the upper central incisal edge position is a key factor in designing the correct anterior guidance. The details of anterior guidance are discussed in Section 4G.

The primary criterion is the position of the upper central incisal edge in all dimensions, that is length and facial-lingual position. Once we have the upper central incisal edge determined, all the other factors involving form and function can be better determined.

We have several criteria that help us evaluate upper central incisal edge position to determine whether it is correct and, if not, to give us some parameters within which we can make changes and be sure that they will be correct for that particular patient. One important criterion is the amount of upper central incisal edge display with the lip at rest. This criterion not only is important for natural-looking aesthetics but also for designing correct function, that is, the anterior guidance performance platform. Figure 4.D.2 illustrates that the key to designing this correct anterior guidance function is correct upper and lower incisal edge position. These two points mark the limits of the anterior guidance performance platform, that is, its beginning point and end point. From these two points the performance platform contours can be precisely determined for that particular patient's envelope of

function. This is discussed in more detail in Section 4G.

In evaluating upper incisal edge position, patients are asked to moisten their lips, let their lips and face totally relax, and close until their lips barely touch one another and then once again, without moving the lips, open the mandible slightly and observe the amount of edge display, if any. This particular position is an important view in the complete digital photographic series. It can be referenced when completing a diagnostic blueprint at a future point.¹ In youth with the lip at rest, approximately 1–3mm and sometimes more of the upper central incisal edge is displayed. As we age, less of the upper central incisal edge is displayed and more of the lower anterior teeth are displayed. If the lip drapes in such a way that none of the central incisal edge is displayed, a ruler can be placed on the incisal edge, and the amount of lip drape over that incisal edge can be measured. This then can give us some parameters if we decide increasing upper central incisal edge length is appropriate for that particular patient.

Figure 4.D.1. Decision tree regarding the various issues that need to be addressed when evaluating upper anterior teeth.

Another parameter that gives us guidelines on the upper anterior incisal edge position is the amount of the incisal edge display in a slight smile, such as when the patient subtly says the “E” sound. In this slight smile, we like to see a smile line created by the upper anterior teeth that generally follows the contour of the lower lip. We also like to see the upper anterior incisal edge displayed at least halfway between the upper and lower lip. If it is closer to the upper lip, less tooth is displayed and presents a less attractive smile.

Figure 4.D.3 illustrates these concepts. In the upper left picture it can be seen that this patient in her twenties displays none of the upper anterior incisal edges with the lip at rest. When measuring the position of the upper anterior incisal edge that is covered by the lip we can see a 3mm measurement. The guideline this information gives us is that if we do indeed decide to increase the length of the upper anterior teeth that we may do so 3–4 mm or more. The bottom left picture illustrates the patient in a slight smile, that is, saying the letter “E.” It can be observed that the upper anterior incisal edges are not displayed halfway between the upper and lower lip but are closer to the upper lip. It can also be observed that the smile line of the teeth does not follow the contour of the lower lip. These criteria, in addition to the mea-

surement made with the lip at rest, validates a rationale for increasing the length of the upper anterior teeth at least 3–4 mm. The bottom right picture illustrates the completed restoration in which the upper anterior teeth were indeed increased in length approximately 4 mm. It is prudent to test these changes in a reversible way prior to completing the definitive restoration. Temporarily applying direct bonded composites resin can be a good take-home test to evaluate these changes. We also want the provisional restorations to incorporate the precise upper anterior incisal edge position so it can be tested and verified. An articulated cast of the verified, corrected provisionals becomes an important communication tool to the laboratory technician.

Once the upper anterior incisal edge position has been determined, it can be further verified with phonetics, in particular the words that have the “F” and “V” sounds. The previously described parameters help us determine upper anterior incisal edge length; phonetics helps us verify the upper anterior incisal edge position in a buccal-lingual dimension. When we say words with the “F” and “V” sound, the upper anterior incisal edge should touch the wet/dry border of the lower lip. Figure 4.D.4 illustrates a patient during speech, and upon close observation one can see how

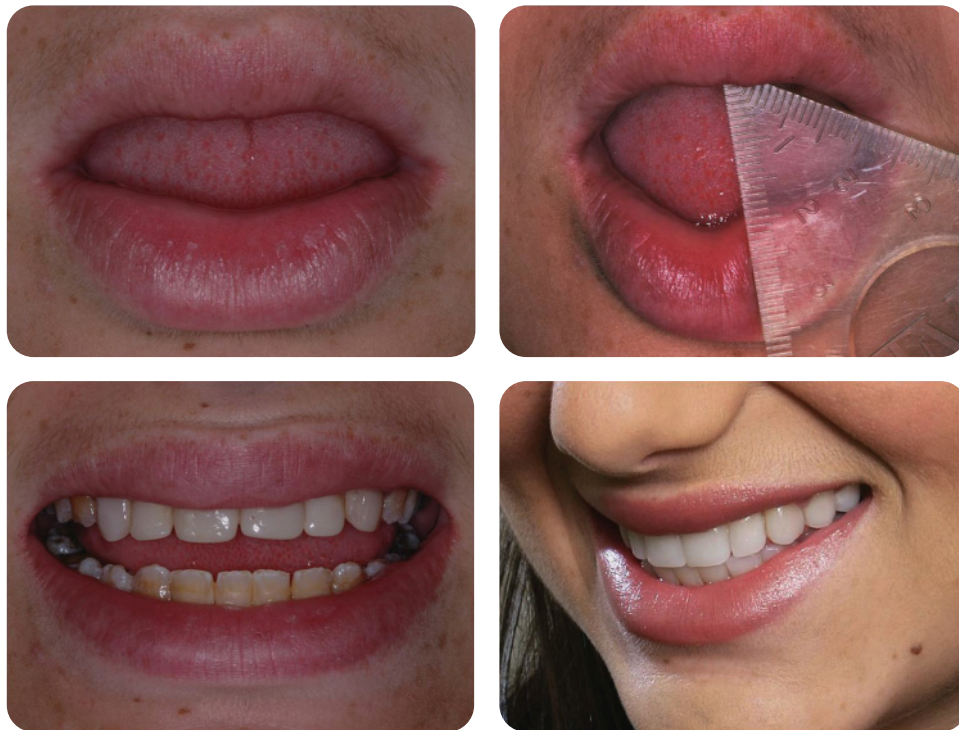

Figure 4.D.3. The amount of upper central incisal edge displayed, or not displayed, with the lip at rest is an important starting point for determining precise incisal edge position.

the upper anterior incisal edge relates to the lower lip. Figure 4.D.5 illustrates an upper anterior incisal edge that is too far to the buccal and during phonetics touches forward on the dry part of the lower lip. The patient's chief concern was an awkward feeling during phonetics and speech that did not sound natural for her. The awkward feeling is due to a violation of the neutral zone. The neutral zone is the area of neutrality between the lip and tongue musculature. For the restorations to be comfortable and stable, the contours must be within the limits of the neutral zone. When these contours are changed for whatever reason deemed necessary, it should always be tested provisionally to be sure it is within the patient's adaptive capacity. The right photo was taken after her current restorations were removed and provisional restorations

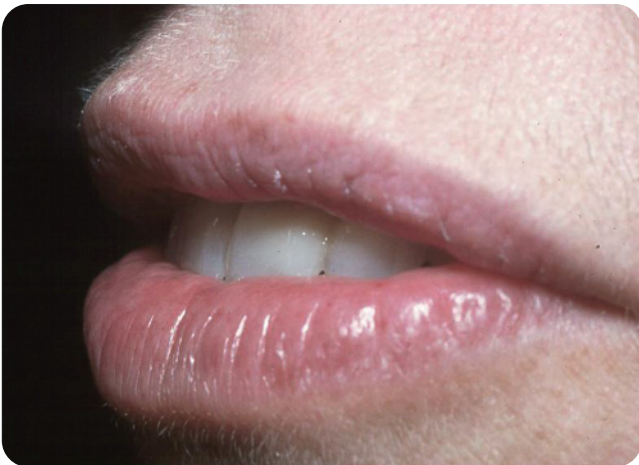

Figure 4.D.4. During phonetic sounds "F" and "V," the incisal edge should touch the wet/dry border of the lower lip.

fabricated. We diagnosed the problem from the history and examination and knew the incisal edge needed to be moved lingually. Those corrections were made on the diagnostic blueprint, and a putty index was made to verify proper tooth reduction in all dimensions necessary to accommodate the new incisal edge position in the restoration. Figure 4.D.6 illustrates this concept from another perspective. We typically look at teeth from an anterior perspective. More information can be gathered when viewed from an occlusal perspective, both digital intraoral photos and diagnostic casts. The alignment and position of the incisal edges, contours of the facial surfaces, and facial embrasures can be analyzed. When a patient has unrestored teeth that are aesthetically pleasing, comfortable, and correct phonetically, we have an excellent reference point for teeth that need to be restored. It is obvious in the bottom photo that the restored tooth's incisal edge and facial surface is buccal to the unrestored tooth. Using this perspective during tooth preparation, along with a putty reduction guide, assures enough reduction in all dimensions so that the technician has enough room to create a restoration with the proper contours.

Once the upper anterior central incisal edge has been determined, we can now look at the incisal plane of all the upper anterior teeth collectively, which is the next criterion (refer to Figure 4.D.1). In general for an aesthetically pleasing smile, the cuspids and central incisors are on the same horizontal plane, with the lateral incisors slightly shorter. When evaluating the upper anterior incisal plane we want to see it relatively level and horizontal. An upper anterior incisal plane that slopes uphill to one side or another can be very distracting aesthetically. In addition, achieving a

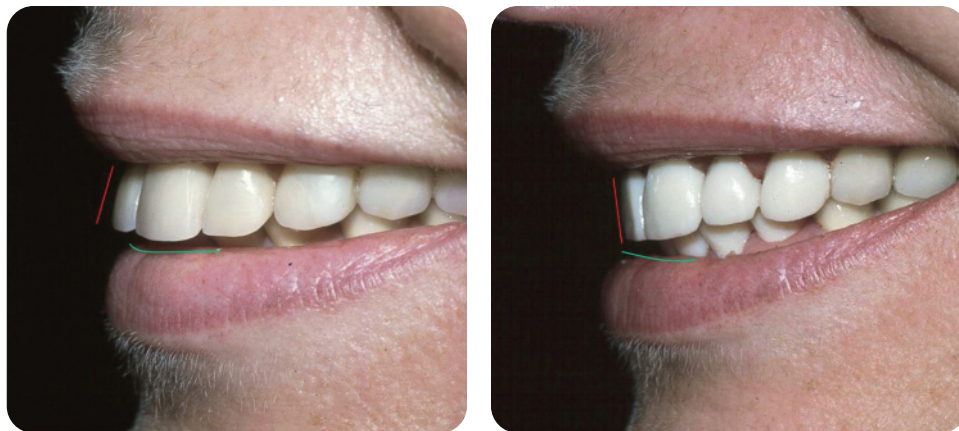

Figure 4.D.5. An incisal edge too far forward will touch the dry part of the lip during phonetics. Changes should be tested with provisional restorations to make sure that the goals have been met.

smooth anterior guidance in both the functional and parafunctional range is difficult, if not impossible. Therefore, this is an important criterion to evaluate during the initial examination. Digital photographs become an important record for future reference. Full face, unretracted and retracted anterior photos should be done with the camera held horizontally so that the smile line can be accurately evaluated. When the facebow transfer is made, it is important to hold the facebow horizontally so that the upper cast sets in the

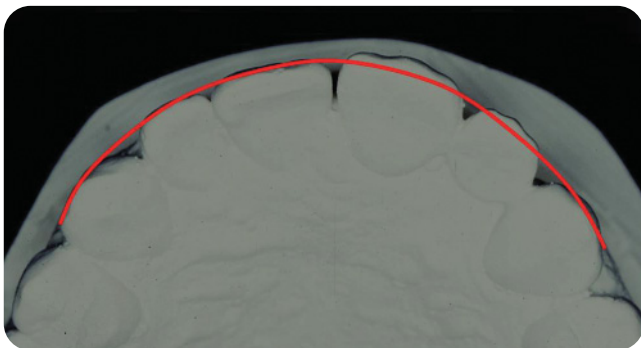
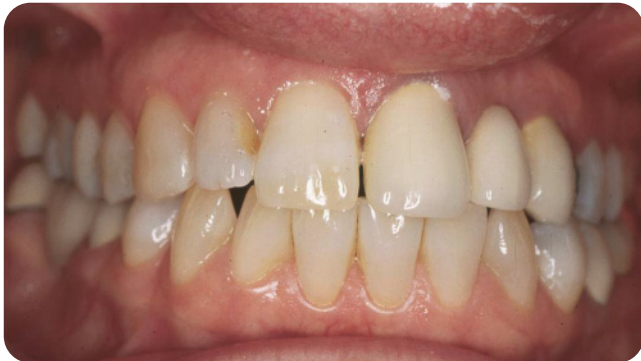

Figure 4.D.6. An unrestored natural tooth that is correctly positioned is an ideal reference point. The restoration should fit within the limits of the neutral zone.

articulator the same way the patient’s maxilla relates to the face and the horizontal plane. With an accurate representation of the patient’s current condition we can more confidently make alterations that we know will be correct for that particular patient.

We can now focus on the aesthetic appearance of the upper central incisors. Two of the most important criteria for best aesthetics are to have the central incisors as close to mirror images to one another as possible and to have the central incisor embrasure vertical and not slanted. Figure 4.D.7 illustrates this point. Due to relatively advanced periodontal disease of this young patient and therefore a very guarded prognosis, orthodontics as a treatment option was ruled out. A restorative plan was considered and to make it as conservative as possible, cosmetic reshaping and direct bonded composite was determined to be the best choice. Cosmetic reshaping made the central incisor embrasure as vertical as possible, and direct composites bonding improved the form of the teeth and made them as close to mirror images of one another as possible.

Anatomic averages tell us that the upper central incisors are generally 10–12mm in length. Once the upper anterior central incisal edge is determined to be correct in length and buccal-lingual position, a measurement apically from the incisal edge can be made. If the incisal edge position is correct and the central incisors are determined to be too short, the increase in length needs to come from apically positioning the gingival tissues. Other factors need to be considered when making this decision, such as the amount of tooth and/or gingival tissues displayed and the patient’s desires and expectations in terms of aesthetics.

The next criterion is the golden proportion, which generally implies a relationship between a larger and a

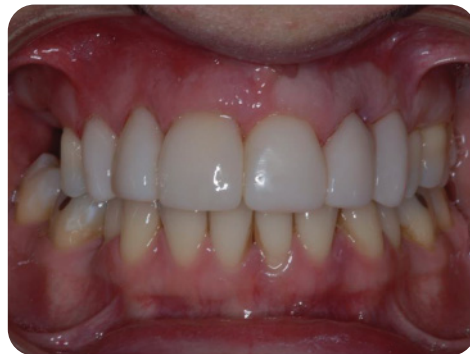
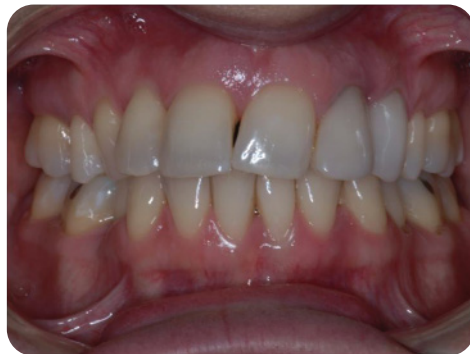
Figure 4.D.7. The embrasure between the upper central incisors should be vertical, and the two central incisors should be mirror images of one another.

smaller object (refer to Figure 4.D.1). The smaller object is generally .618 of the size of the larger object. In evaluating a smile, this proportion refers to the perceived width from central incisor posteriorly as viewed from the front and not the actual measurement of the width (Figure 4.D.8). There are commercially available gauges and grids to help apply the golden proportion to teeth, but the best test is your aesthetic eye. When viewing a photo or a diagnostic blueprint, view it from a broader perspective and ask your mind's eye whether it looks aesthetically pleasing. If it does, it is probably close to the golden proportion. If not, identify the offending tooth or teeth and make the appropriate changes.

The next topic of discussion listed in Figure 4.D.1 involves the incisal embrasures. A flat incisal plane with very little if any incisal embrasure generally conveys a worn, older aesthetic appearance as illustrated in the left photo in Figure 4.D.9. Ideally, the incisal embrasure between the central incisors is the smallest, with the size increasing between the central

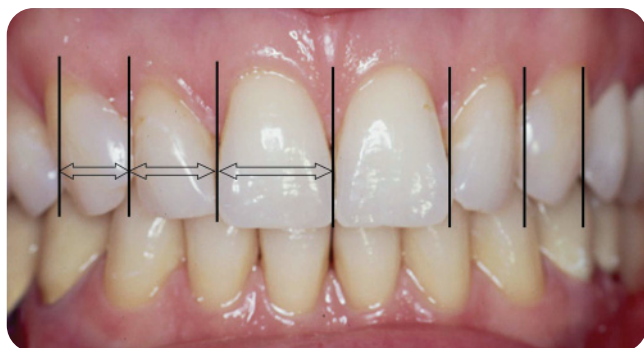

Figure 4.D.8. The perceived width of the upper anterior teeth from anterior to posterior when viewed from front generally fit the Golden proportion; that is, each tooth is approximately .618 of the width of the tooth anterior to it.

and lateral incisors and the biggest being between the lateral incisor and cuspid. The incisal embrasure should be formed by symmetrical curves of the proximal-incisal curves of the adjacent teeth. The right photo illustrates the changes that were made in the definitive restorations.

Another factor that affects the overall appearance of the smile is the long axis alignment of the anterior teeth (Figure 4.D.10). The long axis of the central incisors is fairly vertical, the long axis of the lateral incisors has a slight mesial inclination, and the long axis of the cuspids has a bit more. The left photo in Figure 4.D.11 illustrates a violation of these principles, along with other principles already discussed. Recall that in correcting discrepancies we have many options available to us from simple cosmetic recontouring, restorations from simple composites to porcelain, and orthodontics/orthognathics. In this particular case a combination of orthodontics, recontouring, and direct composites was used.

The discussion to this point has focused primarily on the position and alignment of the upper anterior teeth. Once these criteria have been evaluated and corrected, if necessary, we can focus our attention on the pure aesthetic appearance of the facial surface or "face" of the tooth, which is the last item in Figure 4.D.1.

As illustrated in Figure 4.D.12, the face of the tooth is formed by the mesial and distal proximal line angles or contour ridges. Proximal to these line angles is the facial embrasure, and between these line angles is the facial surface. The tooth can be given the illusion of being wider by making these line angles farther apart. The tooth can be given the illusion of being narrower by making these line angles closer together. Note that the mesial line angle curves to the distal with the gingival extent being slightly to the distal of center. As

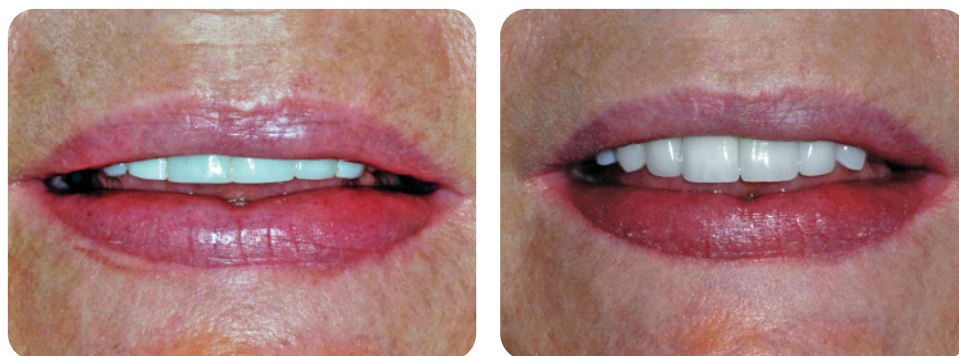

Figure 4.D.9. Properly designed incisal embrasures are important for ideal aesthetics.

seen in Figure 4.D.13, this results in the gingival contour having its peak slightly to the distal of center. Referring back to Figure 4.D.12, note that the surface between the line angles is relatively flat with some subtle concavities. A common mistake is to make this

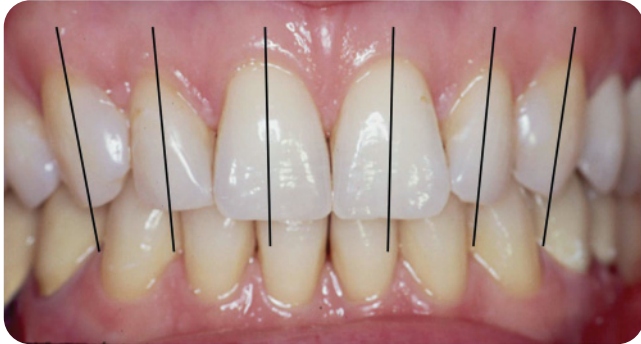


Figure 4.D.10. The upper anterior teeth have a slightly increasing mesial angulation from the central incisor to the cuspid.

surface too convex. When light reflects off the surface, the outline of the line angles is seen. If the surface is too convex, the light is reflected back as a point. Finally as we observe the gingival levels, the central incisors and cuspids are on the same horizontal plane, with the gingival margin of the lateral incisors being slightly incisal to the line of the central incisors and cuspids (Figure 4.D.14).

Figure 4.D.15 summarizes the concepts just discussed. The details of the lingual surface are discussed in detail in Section 4G.

The emergence contour should be appropriately designed for each individual case. It should be flat to convex to support the gingival tissues and be easily cleanable. It should also be designed so that it leads the way to the correctly designed face of the tooth. This is especially true in implant restorations. The implant abutment does not have the contours of a natural tooth, so the emergence contours need to be creatively designed so that the aesthetics of the

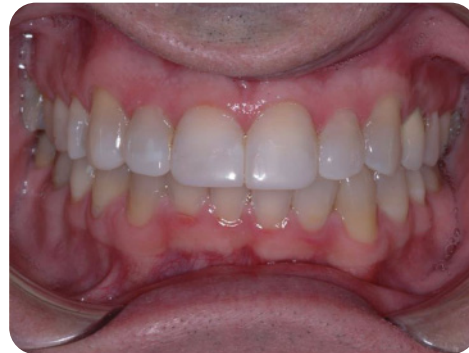
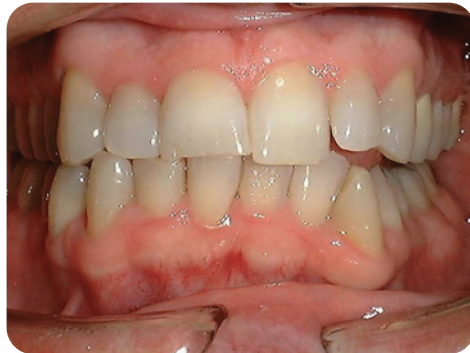
Figure 4.D.11. Example of the angulation and other issues improved with orthodontics, cosmetic recon contouring, and direct bonded composites restorations.

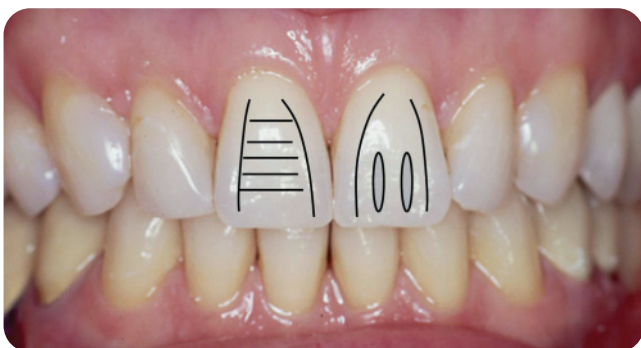

Figure 4.D.12. The “face” of the upper central incisors created by the mesial and distal line angles. The surface between the line angles is relatively flat with subtle concavities.

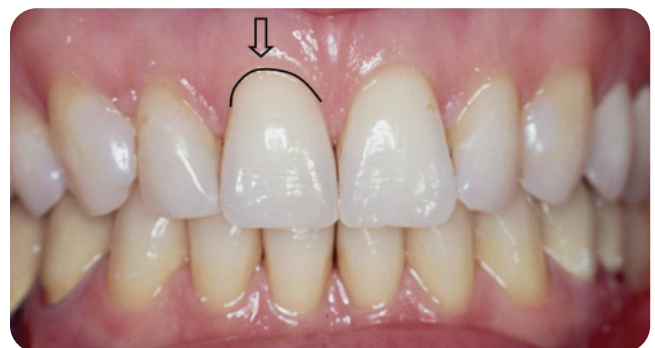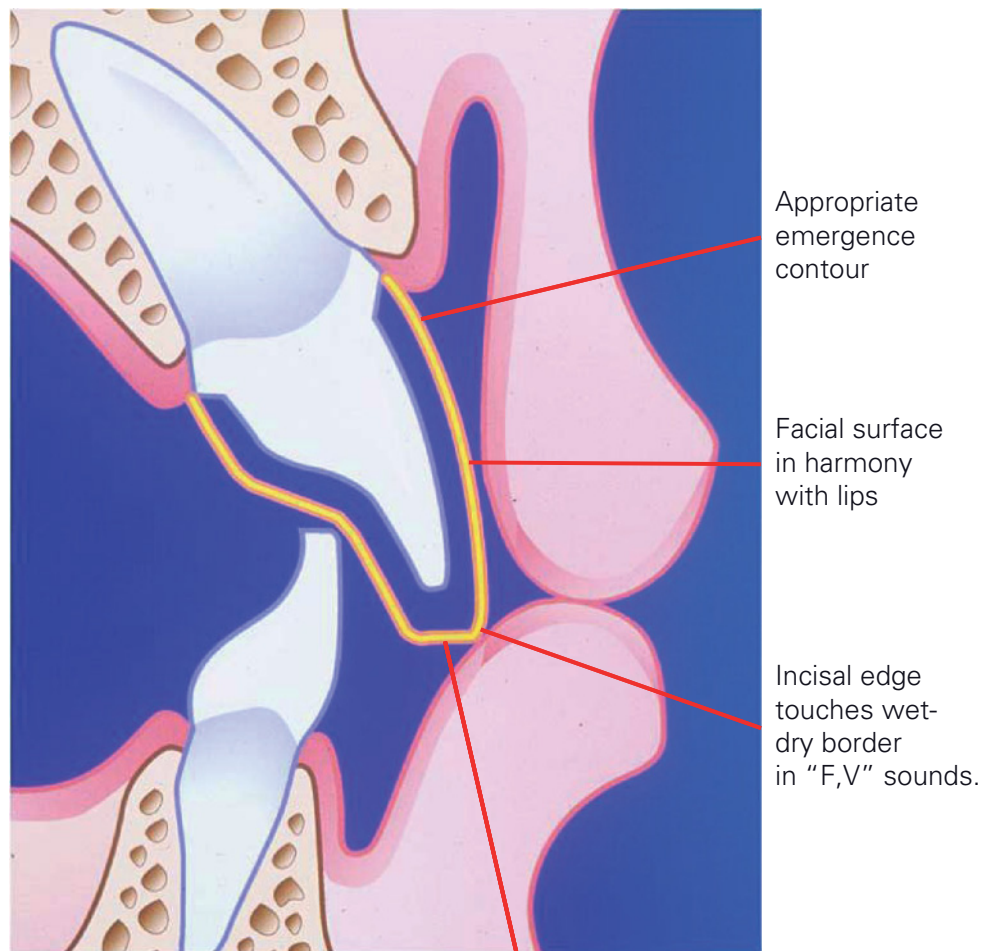


Figure 4.D.13. The peak of the gingival curvature is slightly to the distal of center.

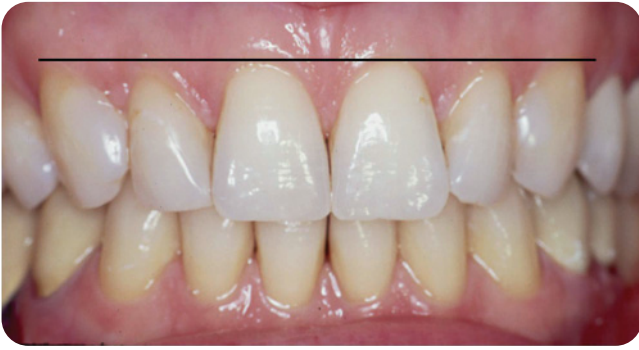

Figure 4.D.14. The gingival margins of the central incisors and cuspids are on the same horizontal line with the gingival margins of the lateral incisors being slightly incisal.

face—that is, what we see—is correct. This is illustrated in Figure 4.D.16, which is a provisional for an implant restoration. The upper right and lower left photos show a facial surface that is as close to being symmetrical to the adjacent unrestored natural tooth as possible. The lower right photo shows the gingival contours that were necessary to allow the correct facial contours. Figure 4.D.17 shows the finished restoration. No doubt restoring a single central incisor implant restoration can be one of the most challenging things we do. When patients are pleased with the appearance of their surrounding teeth, and we have determined that it fits functionally within their physiologic parameters, we have to respect their wishes not to restore the adjacent teeth even though some



Upper incisal edge length is correct aesthetically.

Figure 4.D.15. Composite drawing illustrating the previously described concepts.

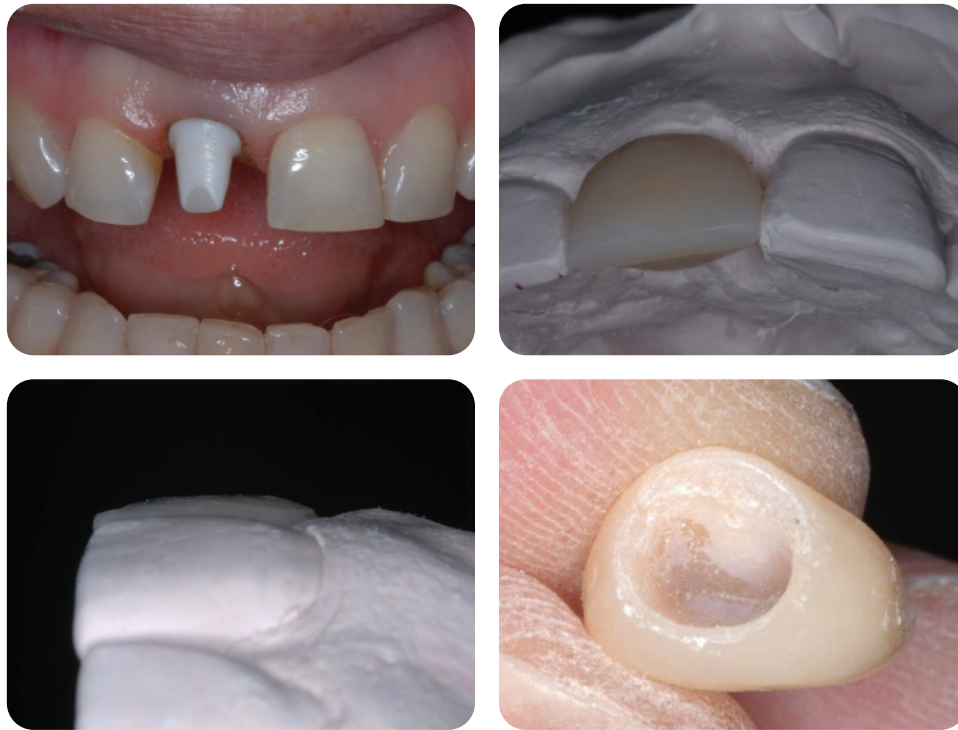

Figure 4.D.16. Manipulation of the gingival emergence profile contours is necessary for tissue support, for cleanability, and to lead the way to properly designed facial contours.

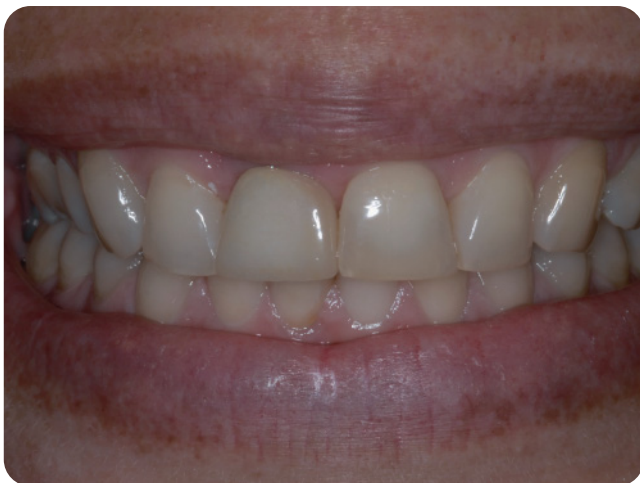

Figure 4.D.17. Completed upper right central incisor implant restoration whose contours closely resemble the natural unrestored upper left central incisor by way of correctly contouring the emergence profile.

changes may make our job with the definitive restorations a little easier. Following the principles outlined in this section should make the results more predictable.

Reference

¹Vig RG, Brundo GC. The kinetics of anterior tooth display. *J Prosthet Dent.* 1978 May;39(5):502–504.

4E

Centric Stop Design

The Glossary of Prosthodontic Terms defines centric stops as opposing cuspal/fossae contacts that maintain the occlusal vertical dimension between the opposing arches. Mesial-distal stability is maintained by proper interproximal contacts, and buccal-lingual stability is maintained by the neutral zone, that is, the zone of equilibrium between buccal and lingual musculature. To achieve this desired stability, the centric stops must be properly designed so that deflection or migration will not occur. Figure 4.E.1 illustrates an idealized occlusal scheme where each posterior tooth has each of its cusp tips occluding with an opposing fossa/receiving area and each anterior tooth has a centric stop. In a class 1 orthodontic relationship with an ideal overbite relationship, this ideal scheme can be achieved. However, variations of this ideal are often necessary and can work well if the basic principles are adhered to. The Case Studies illustrate many of these variations. These centric stops should have simultaneous, equal intensity contact in light and firm closure. Upon muscle contraction from light to firm closure, there should be no shift of either the mandible or individual teeth. This simultaneous, equal intensity

PRINCIPLES OF A PHYSIOLOGIC OCCLUSION

STABLE STOPS ON ALL
TEETH IN C.R.
with simultaneous,
equal intensity contact

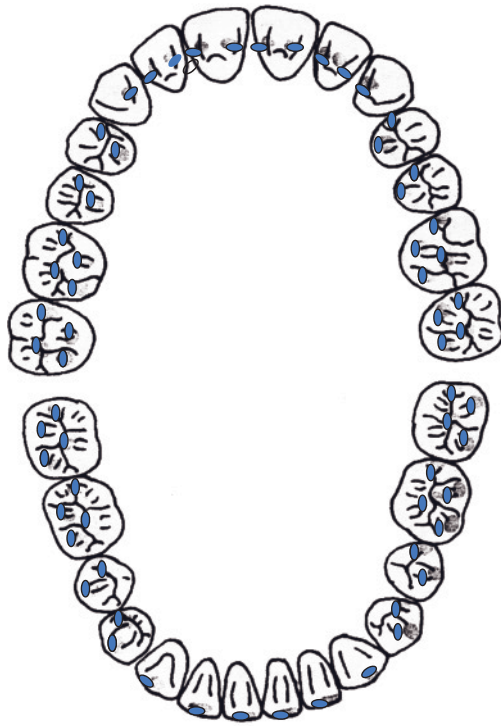


Figure 4.E.1. Illustration of ideal anterior and posterior centric stop locations.

contact is best refined with the use of the T-scan III computerized force measurement device (see Appendix 1).

Each anterior tooth should have a centric holding contact unless the patient presents with a stable anterior open bite Figure 4.E.2. A stable open bite is one that has been present for years and has not changed. An increasing open bite may be the result of a degenerating condylar situation. As the condyle degenerates, the bite anteriorly will open. But if that open bite has been consistent for years, and there are no signs of instability or breakdown, it may be correct and appropriate for that particular patient, and, for the most part, it should be maintained because some other factor such as tongue or lip is maintaining the open bite. The challenging decision is how to design the most appropriate anterior guidance. This is discussed in Part 2, the Case Studies section. If the patient has anterior centric holding contacts, this should be maintained after definitive therapy. If the vertical dimension of occlusion is increased resulting in the down and back movement of the lower anteriors, care should be taken in the anterior centric stop design to maintain contact. Not maintaining anterior centric stops in a patient who previously had them may result in tooth position instability, anterior guidance difficulties, and/or speech difficulties.

Figure 4.E.3 illustrates the desired anterior centric stop design. The ideal scenario is the labial-incisal line angle of the lower anterior tooth contacting the cingulum or marginal ridge of the upper anterior tooth. This design is very important because it assures stability and maintains a position ready to start correct anterior guidance (refer to Section 4C). Figure 4.E.4 illustrates a clinical example of correct centric stops on the lingual of the upper anteriors. A commonly held misconception is that a deep overbite is more prone to TMJ problems. One study shows that higher or lower overbite or overjet jaw relationships, even extreme values, are not risk factors for TMJ sounds as assessed by clinical examination.¹ The difficulty that is encountered with deep overbites is achieving stable anterior centric holding contacts. Figure 4.E.5 illustrates a sequela of anterior centric stops that are not of a stable configuration, that is, migration of the lower anteriors. Note that the two-step occlusal plane and gingival discrepancy anterior to posterior is evidence of this. The upper anterior teeth did not super-erupt because the neutral zone of the upper and lower lip held them in a stable position. Figure 4.E.6 illustrates a more stable anterior tooth-to-tooth contact design in a deep overbite situation. The left figure illustrates the common scenario with a deep overbite, that is, a slope-to-slope contact that is not stable. The right

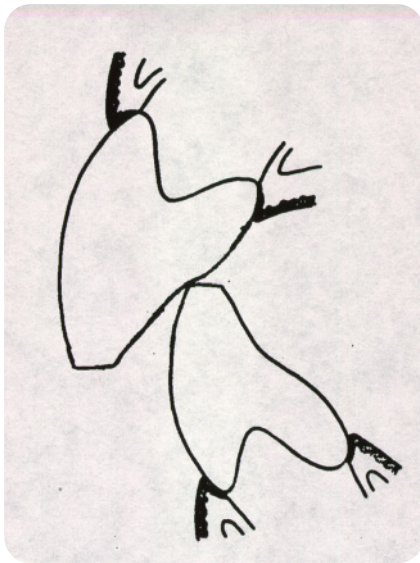
ANTERIOR CENTRIC STOPS

Each anterior tooth should have a definitive centric holding contact...

...unless the patient presents with a "STABLE" anterior open bite.

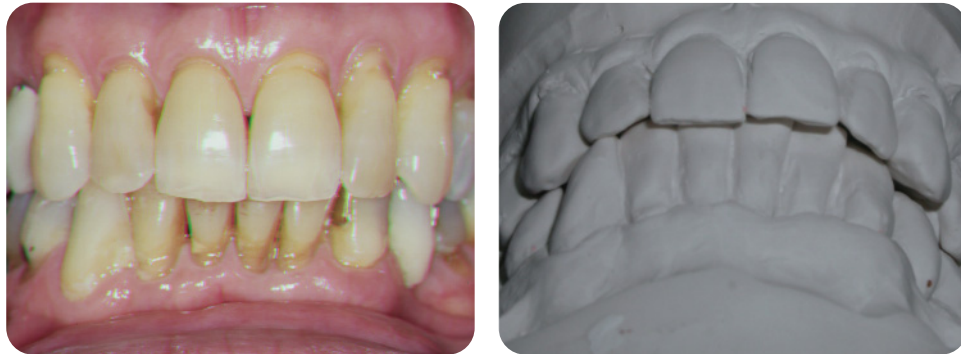

Figure 4.E.2. Anterior centric stops, if present in maximum intercuspation, should be maintained in the treated case. If an anterior open bite is present, it should also be maintained.



ANTERIOR
CENTRIC
STOPS

LABIAL-
INCISAL
LINE ANGLE
OF LOWER
CONTACTING
MARGINAL
RIDGES OF
UPPER

Figure 4.E.3. Correct anatomy of upper and lower anterior teeth, lower incisal edges in particular, allow idealized anterior centric stops.

figure illustrates the ideal scenario. As a rule, the deeper the overbite, the more the need for a more horizontal stop area on the lingual of the upper. Figure 4.E.7 is a clinical example of this situation, which is the treatment result of the case in Figure 4.E.5.

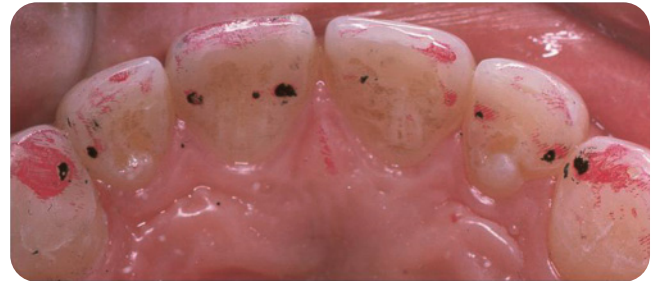


Figure 4.E.4. Clinical example of anterior centric stops on the lingual of upper anteriors, ideally on marginal ridges.

Figure 4.E.8 illustrates the ideal posterior occlusal scheme, which consists of a definitively shaped cusp tip contacting an opposing fossa/receiving area. It is important to clarify the nature and character of the fossa/receiving area. It is not a pit or deep concave area that contacts but rather a small flat landing pad for the opposing cusp tip to contact. This was discussed in Chapter 3, Section 3B and illustrated by Figures 3.B.6 and 3.B.8. This design is easy to achieve by the clinician during occlusal refinement and by the technician during restoration fabrication. It allows for easy disclusion during excursive movements of the mandible by a correctly designed anterior guidance. this design also can be easily maintained over time in

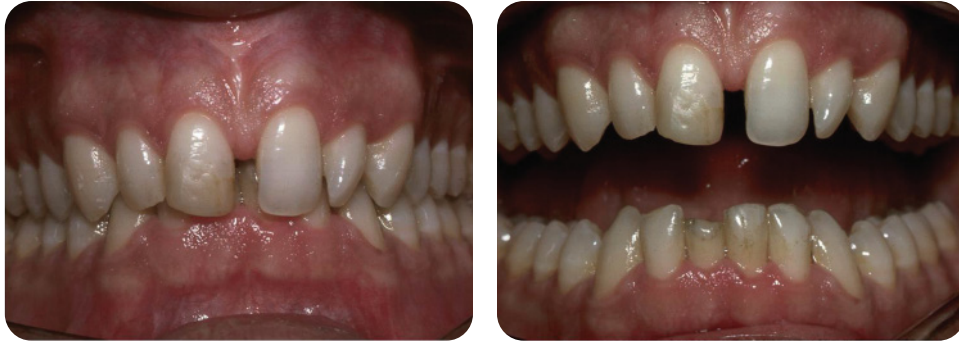

Figure 4.E.5. Clinical example of anterior centric stops that are *not* of a stable design, allowing eruption of the lower anterior segment. Upper anteriors may not erupt because of the neutral zone.



THE DEEPER THE OVERBITE
THE GREATER THE NEED FOR A MORE
DEFINITIVE HORIZONTAL HOLDING AREA

Figure 4.E.6. Illustration of centric stop design in deep bite situations. Slope-to-slope contact is not stable, and a more distinct and horizontal upper lingual centric stop design for the lower incisal edge is ideal.

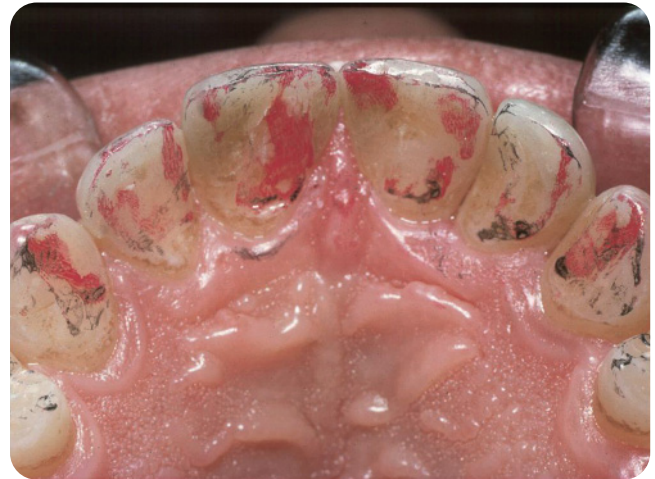

Figure 4.E.7. Treated case in Figure 4.E.5. The lower incisal edges were reshaped/restored and the upper cingulum reshaped to a more horizontal design for definitive centric holding contacts.

POSTERIOR CENTRIC STOPS

What defines a stable posterior centric holding contact?

1. Number per tooth
 - every cusp and fossa is ideal
 - 2 is practical
 - 1 may suffice
2. Location
 - non-incline contact
 - create flat receiving area
 - create definitive cusp tip

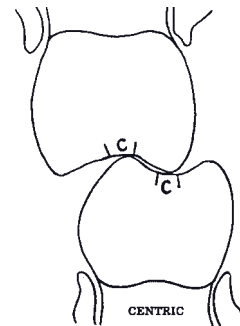


Figure 4.E.8. Illustration of idealized posterior centric holding contacts.

patients for whom we have diagnosed adapted centric posture and expect to see some joint changes, which in turn will necessitate some occlusal refinement. It is ideal to have every cusp tip in occlusion (refer to Figure 4.E.8). This may not always be possible or practical; and in those cases, having a lower buccal and upper lingual cusp in occlusion may suffice. There are times where one may be all that is possible, as is commonly observed with first bicuspid. As already discussed, having nonincline contact is important for nondeflective stability of the posterior teeth.

Non-Axial Forces vs. Axial Forces

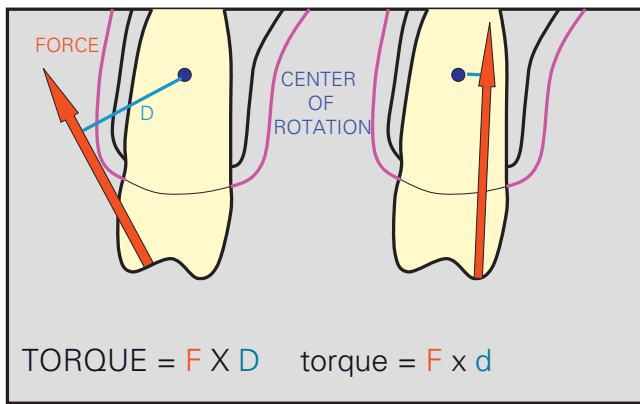


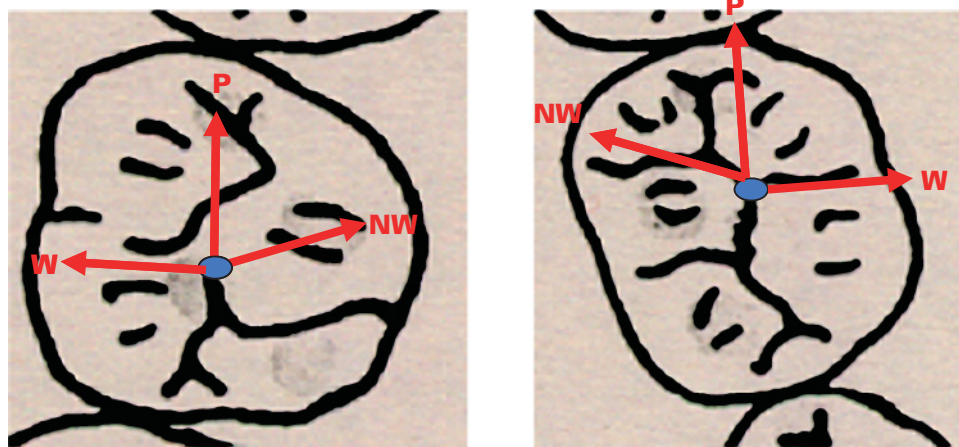
Figure 4.E.9. Effect of axially directed and nonaxially directed forces from centric stops on torque.

Nonincline contacts result in axially directed forces, whereas incline contacts result in nonaxially directed forces (Figure 4.E.9). Nonaxially directed forces increase torque to the tooth and surrounding supporting structures because the distance from the line of force to the center of the tooth is much greater than axially directed forces. Torque can be calculated by multiplying the amount of force the tooth is subjected to by the distance from the center of the tooth. As can be seen, even though the amount of force may

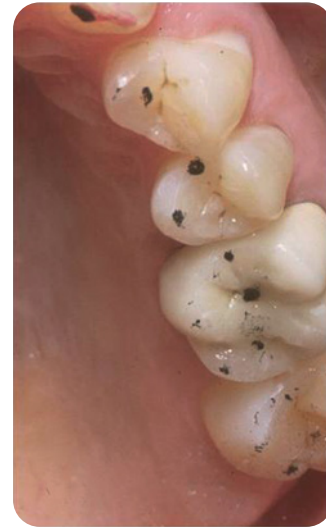

Figure 4.E.10. Clinical example of idealized posterior centric stops on a restoration and a natural tooth.

Cusp pathways during excursions follow general ridge and groove direction



NW = Non-Working
 W = Working
 P = Protrusive

Figure 4.E.11. As the mandible moves through excursions, the pathway that the opposing cusp follows is illustrated by the red arrows. Proper cusp placement allows disclusion through anatomic grooves.

actually be the same, the torque is significantly less in axially directed centric stops. Figure 4.E.10 illustrates this concept of posterior centric stops on a full crown restoration and a natural tooth.

It is also interesting to observe the location of posterior centric stops and how they relate to cusp movement pathways during excursive movements of the mandible (Figure 4.E.11). In a protrusive movement, the lower buccal cusp tip moves forward through the upper central fossa, and the upper lingual cusp moves posteriorly through the lower central fossa. In a working movement, the lower buccal cusp tip moves laterally through the upper buccal groove, and the upper lingual cusp tip moves laterally through the lower lingual groove. In a nonworking movement, the lower buccal cusp tip moves medially and obliquely through the upper distolingual groove, and the upper lingual cusp tip moves laterally and obliquely through the distobuccal groove of the lower molar.

To review, proper centric stop design is important for stability of tooth position, for management of forces generated to teeth and supporting structures and for disclusion during excursive movements. When an entire reconstruction is planned, idealized centric stops can be easily designed. In partial reconstructions, the opposing teeth need to be carefully evaluated, even if they are not in immediate need of structural help, to decide whether their anatomic form is such that a correct opposing restoration can be made. If not, consider judicious reshaping of excessive areas and composite additions to deficient areas to create a more idealized opposing morphology.

Reference

¹Hirsch C, John MT, Drangsholt MT, Mancl LA. Relationship between overbite/overjet and clicking or crepitus of the temporomandibular joint. *J Orofac Pain*. 2005 Summer;19(3):218–225.

4F

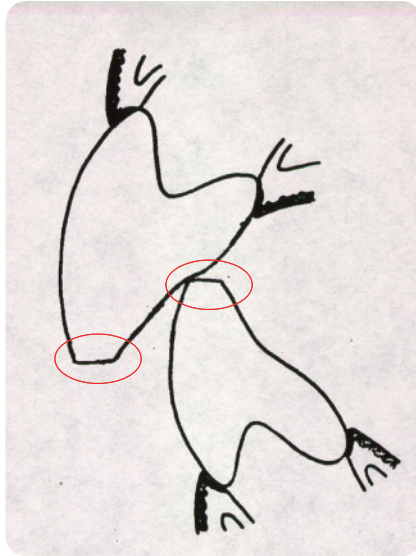
Anterior Guidance

Occlusion has both a static and a dynamic component. To this point we have discussed the static aspects of occlusion in terms of tooth anatomic landmarks and centric stops. Anterior guidance describes the dynamic aspect of occlusion, that is, what happens when the mandible starts to move into its excursive pathways. The *Glossary of Prosthodontic Terms* defines anterior guidance as the influence of the contacting surfaces of anterior teeth on tooth-limiting mandibular movements. A good or ideal anterior guidance is one in which only

the anterior teeth guide during excursive movements with immediate disclusion of all the posterior teeth in both the functional and parafunctional range of motion. In more global terms, anterior guidance can be described as any tooth contacts that are involved in excursive movements. If a severe balancing interference on a second molar is the only tooth contact at some point in excursions, that is the anterior guidance at that moment in time. So anterior guidance needs to be evaluated throughout the entire range of movement because it can move around from tooth to tooth. It may start on a cuspid, move to a bicuspid, move to a balancing molar, and then move back to the cuspid. The posterior guidance is the movement of the condyles along the eminence. Anterior guidance, although it ideally should be anterior teeth, can be on any teeth anterior to the condyles, which are the posterior guidance.

As illustrated in Figure 4.F.1, the functional anterior guidance surface starts where the lower anterior incisal edge contacts on the lingual of the upper anteriors and ends at the incisal edge of the upper anteriors. The movement can go beyond the edge-to-edge position into the crossover or parafunctional position, but these movements are also influenced by upper and lower incisal edges. That is why the details of upper and lower incisal edges have been previously discussed; they are the key determinants of anterior guidance and must be verified to be correct first by evaluating aesthetics, phonetics, and neutral zone.

The precise contours of this functional surface have to be determined on a patient-by-patient basis. The contour of this surface is determined by the patient's envelope of function, which is the three-dimensional space contained within the envelope of motion that defines mandibular movement during masticatory function and/or phonation. Some patients have a relatively vertical envelope of function, and others have a more horizontal component to the envelope. It is a variable feature that is particular to that patient. These contours must not interfere with these movements. Figure 4.F.2 illustrates how this lingual anterior guidance performance platform contour fits with all the rest of the contours of the anterior teeth. It is interesting to note how all the contours of the upper anterior teeth have a precise determinant that influences that contour. Figure 4.F.3 illustrates a lingual contour that does not interfere with that particular patient's envelope of function. This contour gives that patient the freedom to masticate and speak without interference of the anterior teeth. Figure 4.F.4 illustrates a lingual



THE KEY TO ANTERIOR GUIDANCE

- Lower Incisal Edge Anatomy and Position
- Upper Incisal Edge Position

Figure 4.F.1. Once the upper and lower incisal edges have been determined and verified to be correct aesthetically and functionally, the contours between these two points, the anterior guidance performance platform angle, can be determined.

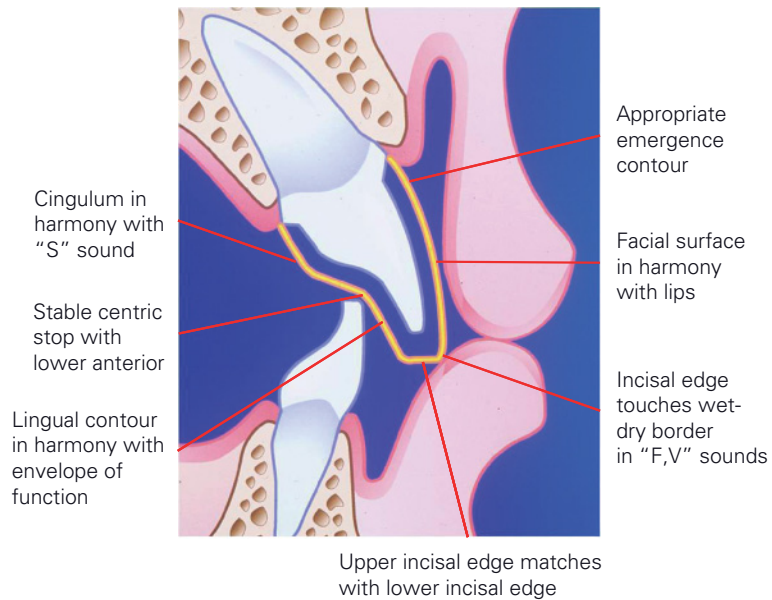



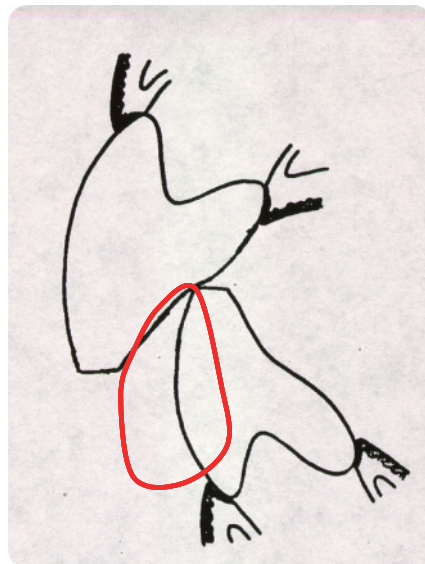
Figure 4.F.2. Anterior guidance contour is one of several parameters of the anterior teeth that needs to be carefully determined.



ENVELOPE
OF FUNCTION
=
CHEWING PATH
=
PHONETIC PATH

TOOTH
CONTOURS
MUST NOT
INTERFERE

Figure 4.F.3. The anterior guidance contours must not interfere with the patient's own unique envelope of function.



ENVELOPE
OF FUNCTION

IF TOOTH
CONTOURS
INTERFERE,
THERE MAY
BE SIGNS AND
SYMPTOMS.

Figure 4.F.4. This anterior guidance contour interferes with the patient's envelope of function making it susceptible to a variety of signs and symptoms.

contour that *does* interfere with that particular patient's envelope of function. This contour interferes with normal function and mastication and does *not* give the patient the freedom to function without interference of the anterior teeth. Figure 4.F.5 lists the signs and symptoms we may see when the lingual contours do interfere with the patient's envelope of

SIGNS AND SYMPTOMS OF ENVELOPE OF FUNCTION VIOLATION

- Wear
- Mobility
- Migration
- Fremitus
- Sensitivity
- Fracture
- De-cementation
- Speech Difficulties
- Contact during Function

Figure 4.F.5. Some of the signs and symptoms that may be manifested if the lingual anterior guidance contours interfere with the patient's envelope of function.

function. It is important to realize that an envelope of function interference can occur even when the occlusion is in perfect harmony with centric relation or adapted centric posture. It may simply be a case of the contours *anterior* to centric relation not being correct for that particular patient. This list of possible signs and symptoms is particularly useful when changes are being made to this lingual anterior guidance contour, especially when this contour is *steepened*, which has more implications than *shallowing* this contour. In this steepening of the guidance, it is prudent to make these changes in a reversible way prior to the definitive restorations, such as with direct bonded composites or the provisional restorations. In this way, these signs and symptoms can be evaluated and the contours corrected prior to the definitive restorations.

It is also important to understand that the angle of the anterior guidance is not related to the angle of the condylar guidance.¹ These are independent entities. Condylar guidance is an anatomic determinant of osseous and soft tissue joint structures that is determined during growth and development and may change as a result of functional and/or parafunctional overloading. Figure 4.F.6 illustrates this concept. The upper left photo illustrates a typical anterior guidance

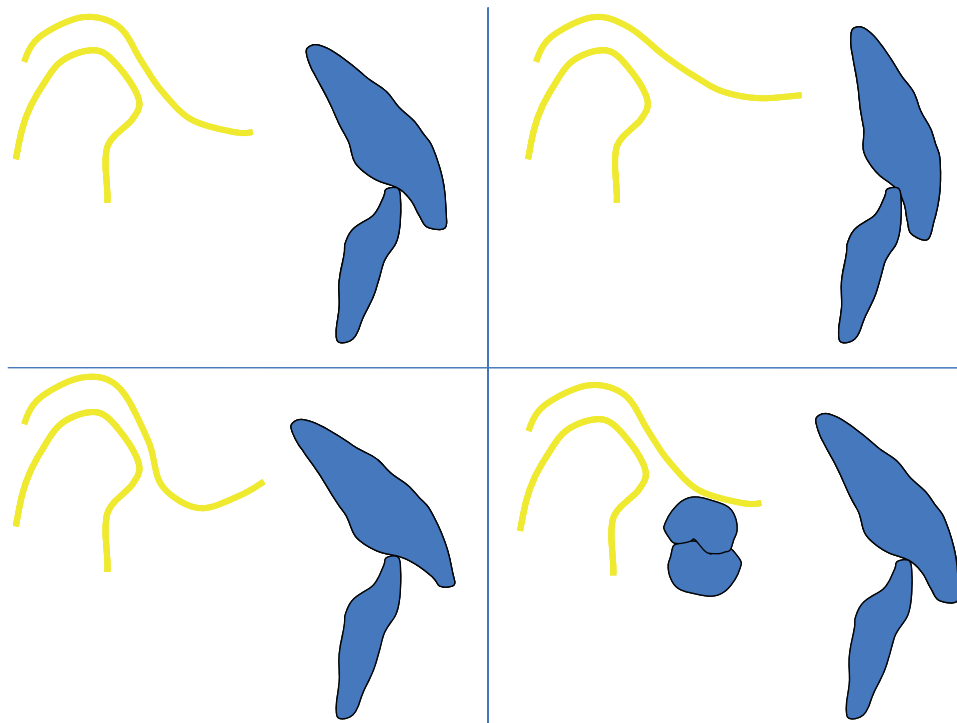


Figure 4.F.6. The anterior guidance angle is not mathematically related to the eminence angle. Any combination may be seen and can function without signs or symptoms.

relationship and angle and a typical condylar guidance angle. The upper right photo shows a flatter condylar guidance angle and a steeper anterior guidance angle, which we may assume is in harmony with that patient's relative verticalized envelope of function. The lower left photo shows a much steeper condylar guidance angle and a flatter, shallower anterior guidance angle, again assumed to be correct for that patient's envelope of function. Any of these combinations, or anything in between is possible and can function normally and without pathology or distress for that particular patient. The primary implication, as illustrated in the lower right photo, is that the functional relationships of the posterior teeth must be such that they are discluded in all excursions by the condylar guidance that the patient anatomically presents with and the anterior guidance that the patient presents with and we have diagnosed to be acceptable, or the anterior guidance that we may have prescribed in their definitive treatment plan.

We may decide that the anterior guidance needs to be made shallower for a particular patient. There are a

number of ways this can be accomplished. It is important to remember that this is done *after* maximum intercuspation has been refined to be harmonious with centric relation or adapted centric posture. The refinement or shallowing of the anterior guidance is done on the platform anterior to the centric contacts.

If it is a small amount, it can be done by adjusting alone, if there is sufficient tooth structure available. To get a shallower platform, the adjusting must be done all the way to the incisal edge. Care must be taken not to thin the incisal edge too much.

If this is not possible, restorations are considered. Figure 4.F.7 illustrates the goal to achieve. By enhancing the lingual contours, the anterior guidance angle is actually made shallower or less steep. This can be accomplished in a couple of ways. If there is enough tooth structure on the lower anteriors, they can be shortened to create space for the illustrated enhancement. Obviously, an analysis must be made to assure that shortening the lower incisal edges does not cause other issues, such as compromised aesthetics,

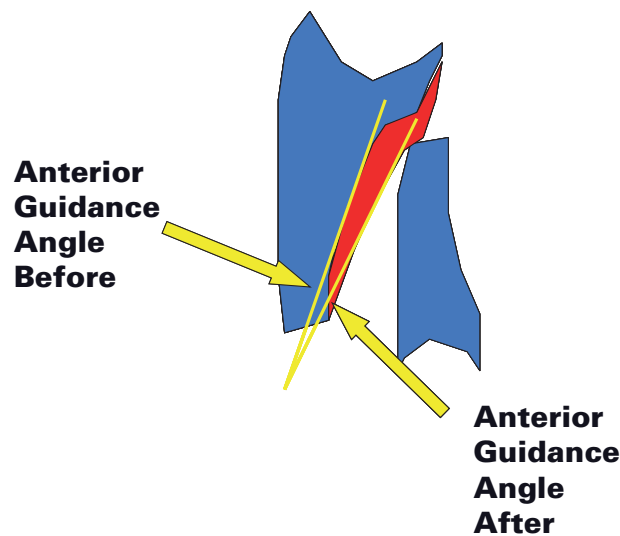


Figure 4.F.7. Illustration of how the anterior guidance angle can be made less steep (shallower) by lowering the lower incisal edges either by reshaping or opening the vertical dimension of occlusion.

sensitivity, etc. If this is not possible, the other consideration is to increase the vertical dimension of occlusion with an entire arch of restorations or a combination of equilibration stopped at an open vertical and restorations on the rest of the teeth, as discussed in Section 4B. This opening causes the lower incisors to move down and back, creating room for the contours necessary to shallow the anterior guidance. As always, careful analysis must be done on articulated diagnostic casts to evaluate the tooth-to-tooth relationships at this increased vertical dimension; we must be sure that stable centric stops can be achieved. Figure 4.F.8 illustrates such a case. The top photo shows the lingual surfaces of upper provisionals that had a steep, vertical anterior guidance. The provisionals kept coming uncemented, indicating that

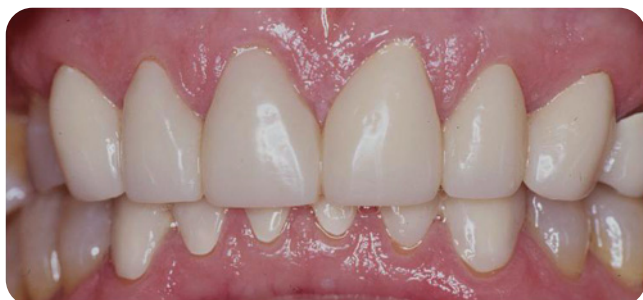
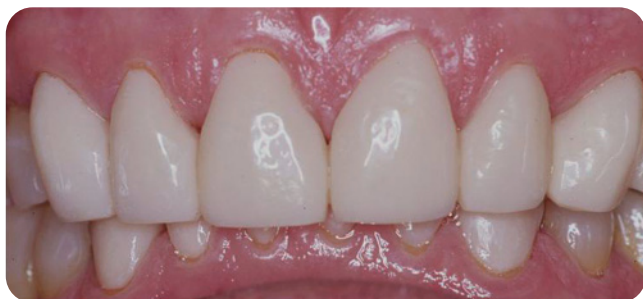
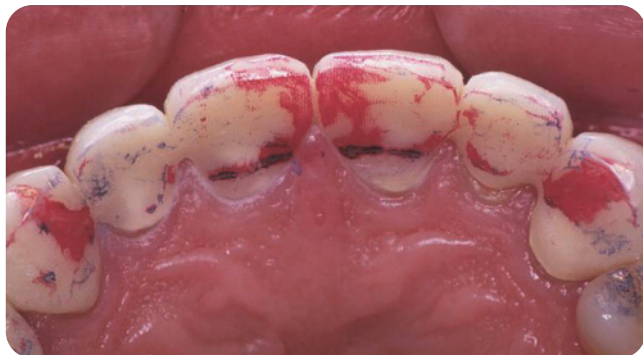Figure 4.F.8. Clinical example of making the anterior guidance shallower by opening the vertical dimension of occlusion. The amount of opening can be seen by observing the upper incisal edge as it relates to the lower.

the anterior guidance angle was not in harmony with the envelope of function and needed to be made less steep or shallower. The middle photo gives you an idea of the vertical dimension of occlusion. The vertical dimension was opened in the provisionals; the incisal edges in the bottom photo give you an idea of the increase in vertical dimension of occlusion, approximately 1.5mm. This created the space on the lingual of the upper anteriors to make the changes illustrated in Figure 4.F.8. Figure 4.F.9 shows those changes on the lingual surfaces; you can see that the angle of anterior guidance performance platform is less steep. This solved the problem of the provisionals coming uncemented, confirming that the changes were now in harmony with the envelope of function.

At the end point of a protrusive movement, the upper and lower incisal edges approximate one another. As seen in Figure 4.F.10, ideally the edges of both central incisors should contact simultaneously in a straight protrusive position (upper left photo). Forces are equally distributed between both centrals, the lateral pterygoids work harmoniously to get to this position, and both condyles are loaded equally. If in this position, only one central contact is seen in the upper right photo; that central incisor may be occlusally overloaded. Because the length from that point of contact back to each condyle is not equal, the forces to the condyles are not equalized. In an attempt to get both centrals to contact, the patient may have to move the mandible laterally to get a point of equal contact (lower left photo). In this case the lateral pterygoids must contract asymmetrically to get to this position. The lower right photo illustrates a clinical case that has the incisal edges in an edge-to-edge position refined equally.

The last detail of the lingual surfaces of the upper anterior teeth in this discussion is the surface apical to

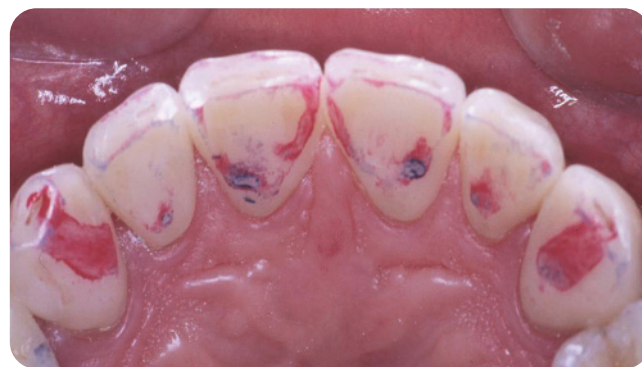

Figure 4.F.9. Lingual surfaces of the case illustrated in Figure 4.F.8.

THE IMPORTANCE OF REFINING THE “EDGE-TO-EDGE” POSITION

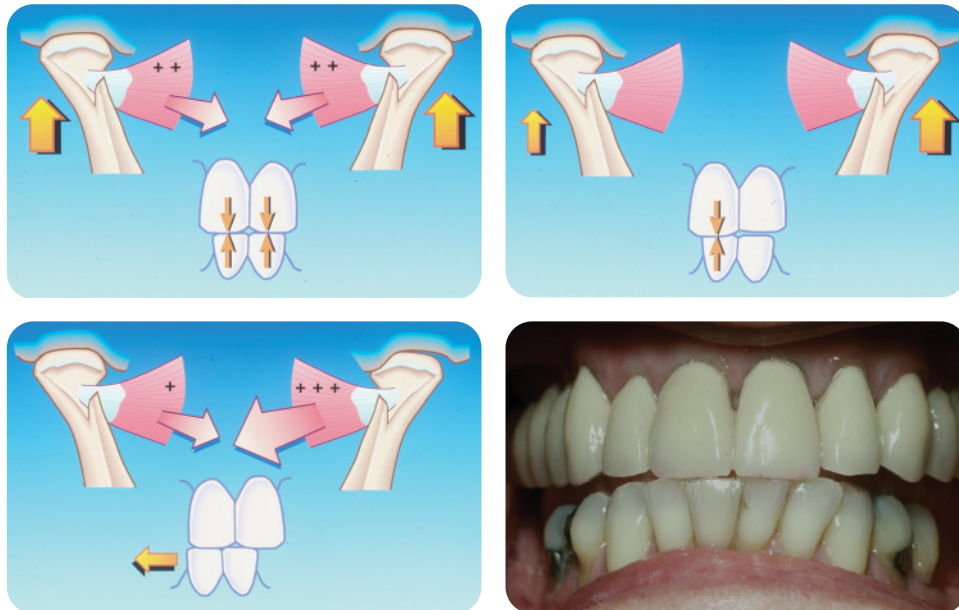

Figure 4.F.10. The importance of upper and lower incisal edge relationships in the protruded edge-to-edge position. Upper left is ideal—even edge contact, equal joint loading, and harmonious lateral pterygoid contraction. Upper right shows only one incisor contacting, resulting in unequal joint loading. Lower left shows mandible moving to the right to get even contact, resulting in unequal lateral pterygoid contraction. Lower right is a clinical example.

the centric stop. This contour is related to the “T, D, and S” sounds. As illustrated in Figure 4.F.11, when these sounds are made the tongue approximates this surface to shape a sheet of air as it comes forward to make that particular sound. If the patient has difficulty with these sounds in the provisionals—such as lisping, which indicates excessive contour or whistling that indicates deficient contours—these contours can be modified until phonetics are correct and comfortable. The author has observed quite a range of patient adaptability to these contours. Some patients are very sensitive to contour changes in this area, whereas the majority seem not to be.

Once these issues have been confirmed to be correct for a patient, an impression of the verified provisionals is made and the cast articulated along with the die and solid cast as a communication to the laboratory technician.

Reference

¹Pelletier LB, Campbell SD. Evaluation of the relationship between anterior and posterior functionally disclusive angles. Part II: Study of a population. *J Prosthet Dent.* 1990 May;63(5):536–540.

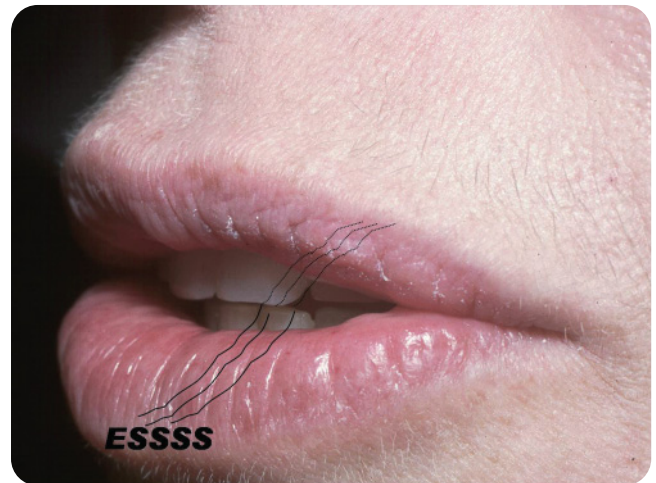

Figure 4.F.11. “T, D, and S” sounds are made by a sheet of air forced forward between the tongue and the lingual contours of the upper anteriors.

4G

Curve of Spee

One of the requirements of a physiologic occlusion is disclusion of all the posterior teeth during excursive movements in both the functional and parafunctional range of motion. Movement of the mandible is determined by both the anterior guidance and the movement of the condyles down the articular eminence. Therefore disclusion of the posterior teeth is determined by correctly designed Curve of Spee, Curve of Wilson, and cusp to fossa angle that will be discluded by these determinants. Curve of Spee, Curve of Wilson, and cusp to fossa angle are all designed together; however, for the sake of discussion these three criteria will be explored in separate sections.

The Curve of Spee is defined as the anatomic curve established by the occlusal alignment of the teeth, as projected onto the median plane: beginning with the cusp tip of the mandibular canine and following the buccal cusp tips of the premolar and molar teeth, continuing through the anterior border of the mandibular ramus, and ending with the anterior most portion of the mandibular condyle. It was first described by Ferdinand Graf Spee, German anatomist, in 1890. The Curve of Spee is illustrated in Figure 4.G.1, and is often referred to with regards to the maxillary arch. When describing the Curve of Spee on the maxillary, it is defined by the central fossa of the upper posterior teeth, in particular where the lower buccal cusp tips occlude (Figure 4.G.2). It is *not* defined by the upper

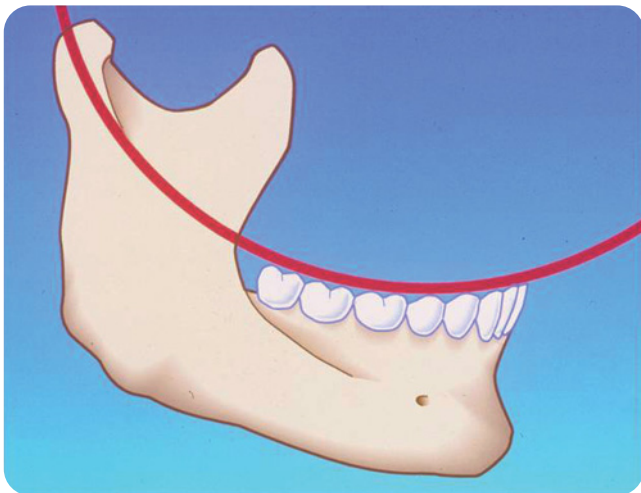


Figure 4.G.1. The Curve of Spee generally fits a 4-inch radius. It is defined by the lower buccal cusp tips, the anterior border of the ramus, and the condyle.

buccal cusp tips. The upper buccal cusp tips define the aesthetic plane, which is discussed in Section 4J.

Figure 4.G.3 is a clinical illustration of this curve. If the functional requirements of the Curve of Spee are met, it generally is pleasing aesthetically—that is, it has a gentle, pleasing curve anterior to posterior and is symmetrical and horizontal from side to side, within the anatomic limits of the patient.

As with all aspects of the design of the masticatory system, there is an interrelationship between form and

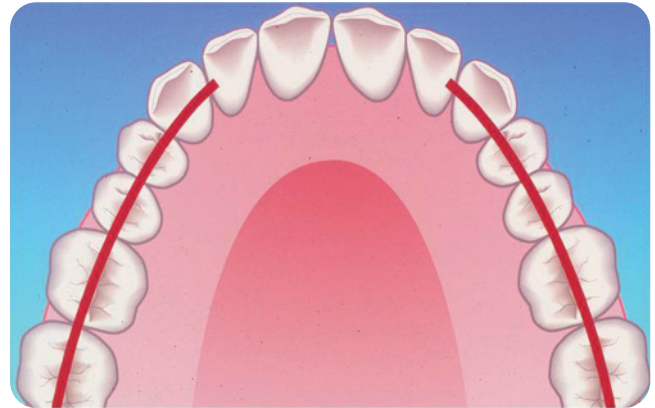


Figure 4.G.2. The Curve of Spee is defined by the central fossa of the upper posterior teeth, not the buccal cusp tips.

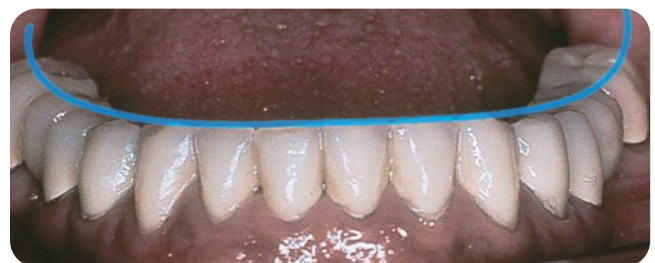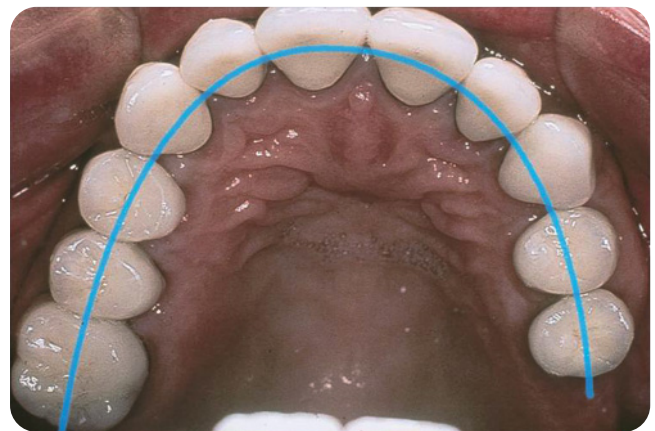


Figure 4.G.3. Clinical example of idealized Curve of Spee.

function. The described form of the Curve of Spee provides several functional benefits. Because the Curve of Spee passes through the condyle and the curve is a relatively shallow 4-inch radius, disclusion predictably occurs when the mandible moves forward in protrusive. The condyles translate down the eminence at a steeper angle than the Curve of Spee. This disclusion also occurs on the balancing side as the balancing side condyle translates down the eminence, so disclusion of the posterior teeth on the balancing side and in protrusive is a combination of anterior guidance, condylar eminence inclination, and the Curve of Spee. This applies to movements in the functional and parafunctional range of motion. The other factor that accounts for disclusion of the posterior teeth is obviously the anterior guidance. If the anterior guidance is relatively steep, the Curve of Spee becomes less important in disclusion, unless it is excessively curved. As the anterior guidance becomes shallower and flatter, the Curve of Spee plays a more important role in disclusion and must be designed to be shallower for disclusion to occur. The Curve of Wilson and the cusp to fossa angle also play roles in disclusion and are discussed in Sections 4H and 4I. If the Curve of Spee passes in front of the condyle as in a high mandibular plane angle case, disclusion can be difficult if not impossible to attain with just equilibration and/or restorative procedures, and orthodontics and possibly orthognathics may be considered to make the Curve of Spee less inclined anteroposteriorly. A Curve of Spee that passes posterior to the condyle as with a low

mandibular plane angle case is easier to disclude.

Figure 4.G.4 illustrates the consequences of an incorrect Curve of Spee. An observation of the photo shows a steeply inclined Curve of Spee in the area of the lower right second molar. This inclination was too steep to be discluded by the patient's lateral anterior guidance and right side condylar guidance; therefore, a balancing interference in the functional range occurred as well as the parafunctional range, which this photo captured. This patient had a long history of a temporomandibular disorder, which has many contributing factors. However, this kind of balancing interference in the parafunctional range imposes tremendous stresses on the joints as it changes from a class III lever to a class I lever. A class I lever can do more work and therefore cause more damage.

Another functional benefit of the Curve of Spee is that forces are directed down the long axes of the teeth upon closure into maximum intercuspation. Each tooth has its own arc of closure around the condylar axis, and since the Curve of Spee would ideally pass through the condyle, the axial alignment of each posterior tooth is generally parallel to its own individual arc of closure around the condyle. There, upon closure, forces are directed axially.

The Curve of Spee is best viewed from a broader perspective. Set the articulated diagnostic casts on the benchtop in front of you, view the Curve of Spee at eye level and determine what appears to be incorrect as in Figure 4.G.5. In this case, in addition to the incisal plane being uneven, the Curve of Spee is excessive on the left, excessive and uneven on the

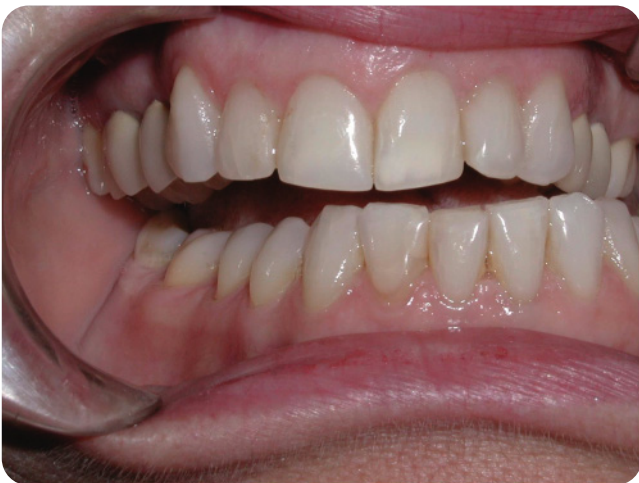

Figure 4.G.4. The excessive Curve of Spee at the location of the lower right second molar caused a balancing side interference in both the functional and parafunctional range of motion.

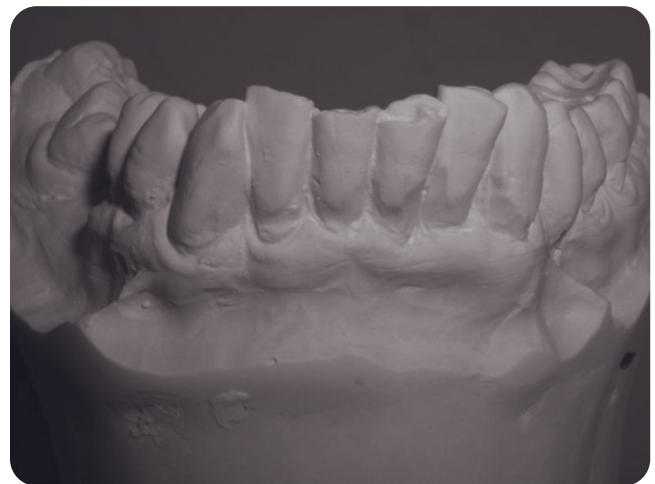


Figure 4.G.5. Study cast illustrating many incorrect aspects of the presenting Curve of Spee.

right, and higher on the right posterior than the left. Figure 4.G.6 illustrates the corrections in the diagnostic wax-up, and Figure 4.G.7 illustrates the changes in the definitive dentistry.

When planning the definitive dentistry, it is important to note the areas and extent of the changes necessary. If a tooth or teeth are reduced on the

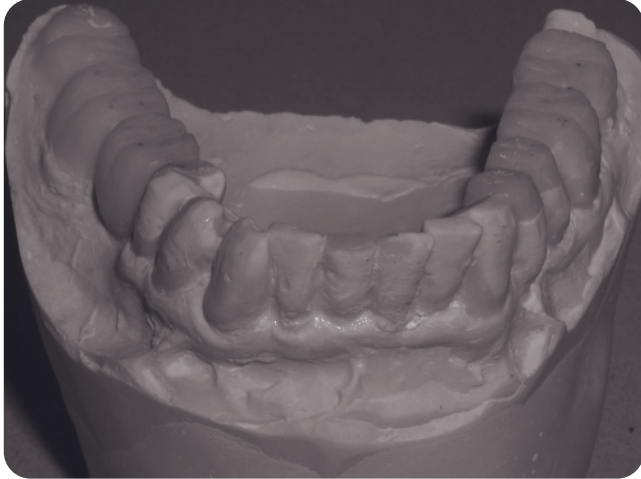


Figure 4.G.6. Diagnostic corrections of the case shown in Figure 4.G.4. View the cast from a broader perspective to evaluate the expected improved parameters.

diagnostic blueprint because of an excessive Curve of Spee or a reverse Curve of Wilson, these teeth will require additional reduction at the time of tooth preparation to allow for enough room for the changes to be made in the definitive restorations. If teeth contours are enhanced because of a deficient curve, that tooth will require less reduction at the time of tooth preparation. Occlusal clearance with the oppos-

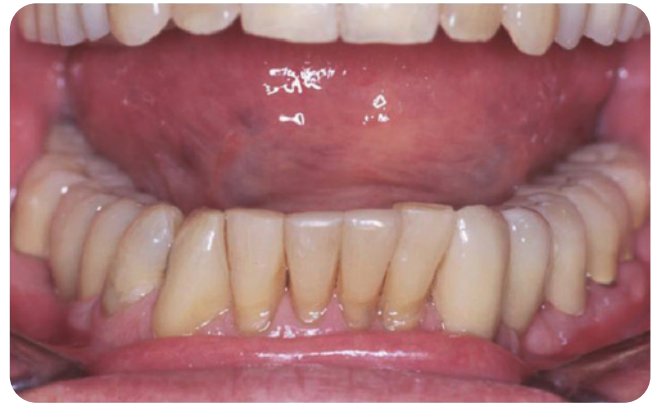

Figure 4.G.7. Final corrections of the Curve of Spee in the definitive dentistry.

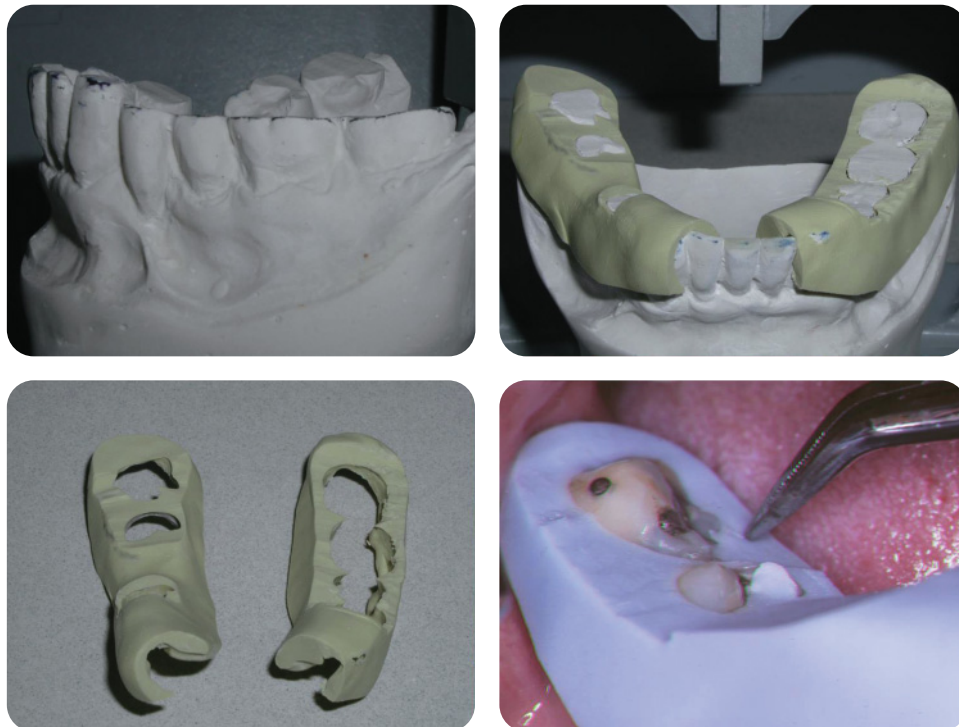

Figure 4.G.8. Upper left: occlusal reduction on diagnostic cast, which will accommodate occlusal plane changes. Upper right: putty reduction guide trimmed to the occlusal reduction surfaces. Lower left: reduction guides ready for use intraorally at time of tooth preparation. Lower right: reduction guide in place showing what needs to be reduced.

ing dentition is a common landmark when assessing the amount of occlusal reduction with tooth preparations. These landmarks are adequate if the Curves of Spee and Wilson are correct but are not adequate when changes are being made to the occlusal plane. In these kinds of cases, some type of occlusal reduction guide will help the dentist at the time of tooth preparation. An example is illustrated in Figure 4.G.8. The top left photo shows the occlusal reduction necessary for tooth preparation, which will allow the reconstruction of the correct occlusal plane. The upper right photo illustrates a silicone putty reduction guide fabricated on the diagnostic cast. The top of the reduction guide is cut back to the point of the occlusal reduction on the diagnostic cast. The lower left photo illustrates the completed reduction guides, and the lower right photo illustrates the reduction guide in place intraorally at time of tooth preparation. It is now evident what needs to be reduced and what does not need to be reduced to allow for the anticipated functional changes.

4H

Curve of Wilson

The Curve of Wilson, or the mediolateral curvature is the curvature of the cusps as projected on the frontal plane expressed in both arches; the curve in the lower arch is concave and the one in the upper arch is convex. The curvature in the lower arch is affected by an equal lingual inclination of the right and left molars so that the tip points of the corresponding cross-aligned cusps can be placed into the circumferences of a circle with a 4-inch radius. The transverse cuspal curvature of the upper teeth is affected by the equal buccal inclinations of their long axes.

Figure 4.H.1 illustrates the Curve of Wilson and the fact that the lower lingual cusps are shorter than the lower buccal cusps as viewed from the front. There are several functional benefits of a correct Curve of Wilson. One benefit is that it allows the masticatory process to be more efficient. Because the lower lingual cusps are shorter than the buccal cusps the tongue is able to move the bolus of food more easily onto the occlusal table. Because the upper buccal cusps are slightly shorter than the lingual cusps the buccinator muscle is able to squeeze and push the bolus of food onto the occlusal table more efficiently.

The primary benefit of the Curve of Wilson is disclusion of the posterior teeth on the working side during lateral excursions (Figure 4.H.2). Recall that

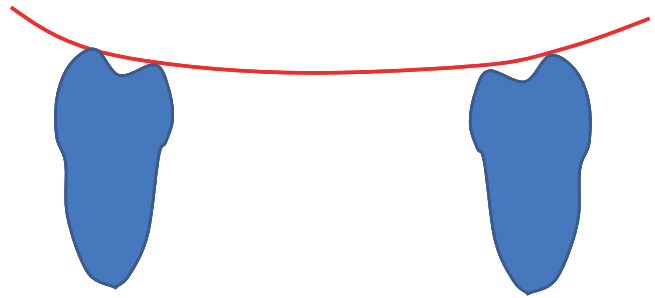


Figure 4.H.1. The Curve of Wilson is defined by the lower lingual cusps being shorter than the lower buccal cusps. The curved line that connects the buccal and lingual cusps on the right and left sides generally follows the curvature of a sphere with a 4-inch radius.

during a lateral excursion the condyle on the working side does not translate down the eminence; therefore, the working side condyle does not help with disclusion of the posterior teeth on the working side. The balancing side condyle does translate down the eminence; therefore, that movement does help with disclusion of the posterior teeth on the balancing side. On the working side disclusion of the posterior teeth is attained by a combination of the lateral anterior guidance and the Curve of Wilson. As the lateral anterior guidance becomes shallower and flatter, the Curve of Wilson becomes more important. A steeper lateral anterior guidance may disclude even an incorrect Curve of Wilson. If the Curve of Wilson is incorrect there may be working side interferences on the upper buccal and lower lingual cusps in both the functional and parafunctional range of motion. In the functional range the interferences may be the outer incline of the lower buccal cusp against the inner incline of the upper buccal cusp or it may be the outer incline of the lower lingual cusps against the inner incline of the upper lingual cusp. In the parafunctional range it may be the lower lingual cusps against the upper lingual cusps. This can be seen in Figure 4.H.3. The lower molar with the gold onlay has an incorrect Curve of Wilson as seen by the long mesiolingual cusp. As the patient moved into an extreme left lateral excursion position, that is, into the parafunctional range, the long lower mesiolingual cusp interfered with the upper mesiobuccal cusp. The problem this caused in this case is a fracture of the mesial buccal cusp of the upper left first molar porcelain restoration and a perforation in the mesiolingual cusp of the gold restoration on the lower left first molar.

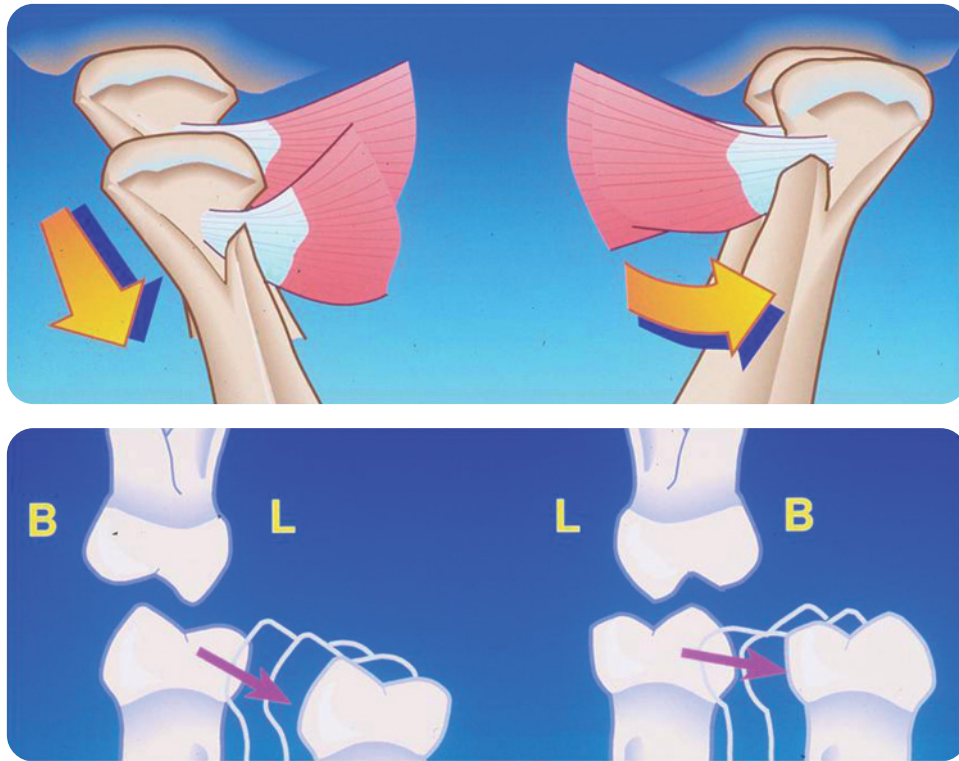


Figure 4.H.2. The Curve of Wilson facilitates disclusion of the posterior teeth on the working side in both the functional and parafunctional range of motion. Because the working side condyle only rotates and does not translate it does not help with disclusion as does the balancing side condyle.

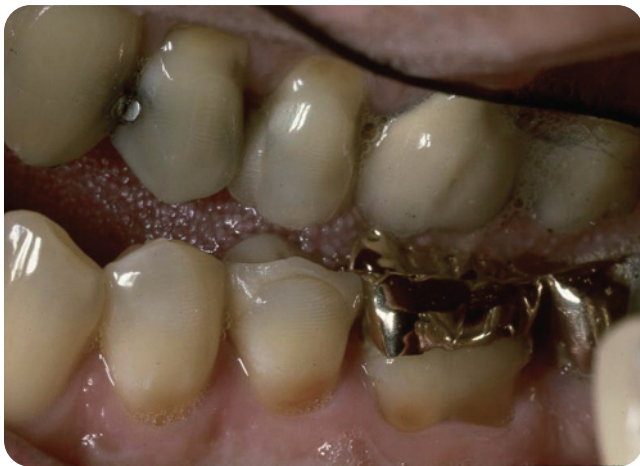

Figure 4.H.3. In an extreme left lateral parafunctional movement the long mesiobuccal cusp of the upper left first molar interferes with the long mesiolingual cusp of the lower left first molar—the result of an incorrect Curve of Wilson. Note that the porcelain fracture of the upper left first molar matches up with the lower left molar, suggesting that the patient does indeed parafunction in this position.

4I

Cusp to Fossa Angle

For the sake of discussion the cusp to fossa angle is defined in this section as the angle a line from the lower buccal cusp tip to the centric stop on the central fossa makes with a horizontal line (Figure 4.I.1). The steepness of this angle can be better determined after the Curve of Spee, that is the lower buccal cusps, and the Curve of Wilson, that is the lower lingual cusps have been determined to be functionally correct. For this angle to be predictably discluded, it must be shallower than the angle of the lateral anterior guidance, that is, the cuspid guidance. Figure 4.I.2 illustrates the role the lateral anterior guidance plays in determining the cusp to fossa angle of the posterior teeth. The left lateral guidance is illustrated by the green line next to the left cuspid. That movement affects the working inclines on the left molars and the nonworking inclines on the right molars. The right lateral guidance is illustrated by the purple line next to the right cuspid. That movement affects the working inclines on the right molars and the nonworking inclines on the left molars. These two movements

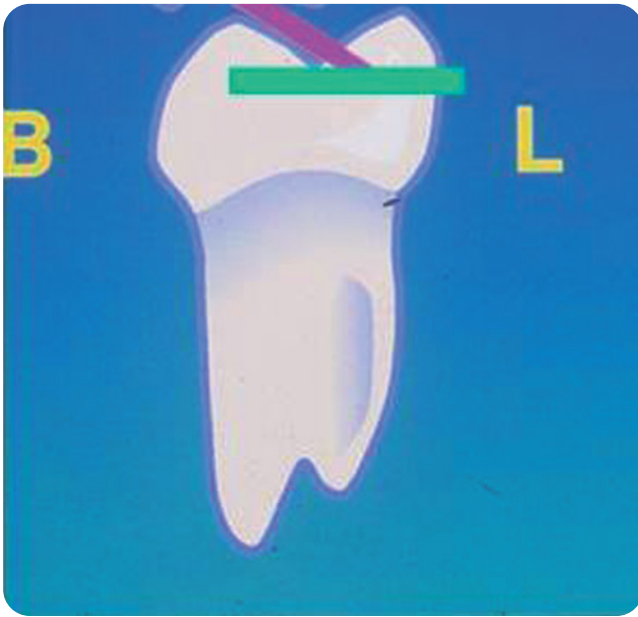

Figure 4.1.1. The cusp to fossa angle is the angle a line from the centric stop on the cusp tip to the centric stop on the central fossa makes with a horizontal line.

together determine the cusp to fossa angle of the posterior teeth. That angle must be less steep, or shallower, than the lateral anterior guidance for disclusion to occur.

As a general rule the cusp to fossa angle gets shallower from first bicuspid back to second molar because the more posterior teeth are farther away from the effect of the lateral anterior guidance and closer to the fulcrum, that is, the condyle (Figure 4.1.3). There are other factors to take into consideration when determining the cusp to fossa angle. If the joint diagnosis is adapted centric posture and we know future changes may occur, it may be prudent to make this cusp to fossa angle even shallower to assure future disclusion if indeed these joint changes do occur. Another consideration is the patient who has proven to be a habitual bruxer. Having a shallower cusp to fossa angle minimizes the possibility of engaging excursive interferences during these bruxing movements. It is the author's opinion that these habitual bruxism patients should also have the protection of a bite splint.

Figure 4.1.4 illustrates one of the effects of the cusp to fossa angle not being shallower than the lateral anterior guidance. The lower right second molar has essentially no wear because the cusp to fossa angle is

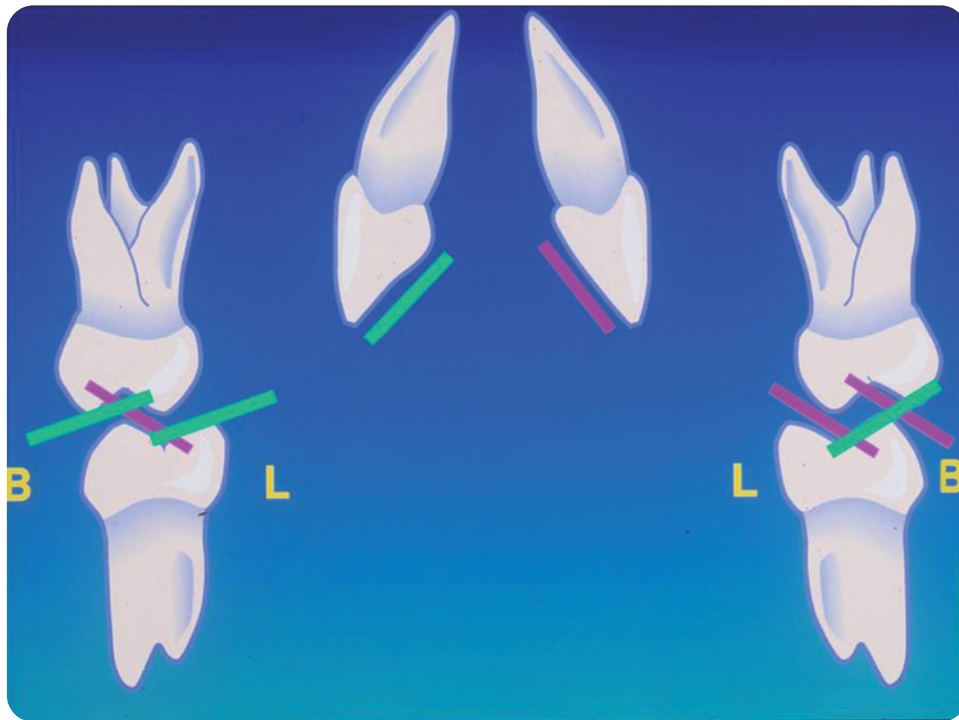


Figure 4.1.2. The cusp tip to fossa angle of the posterior teeth must be shallower than the lateral anterior guidance disclusion angle for disclusion to occur.

shallower than the lateral anterior guidance. Note that the lower left second molar has a rather severe wear facet on the inner incline of the distal buccal cusp because of a balancing interference in a right lateral excursive movement. The cusp to fossa angle is not shallower than the right lateral anterior guidance

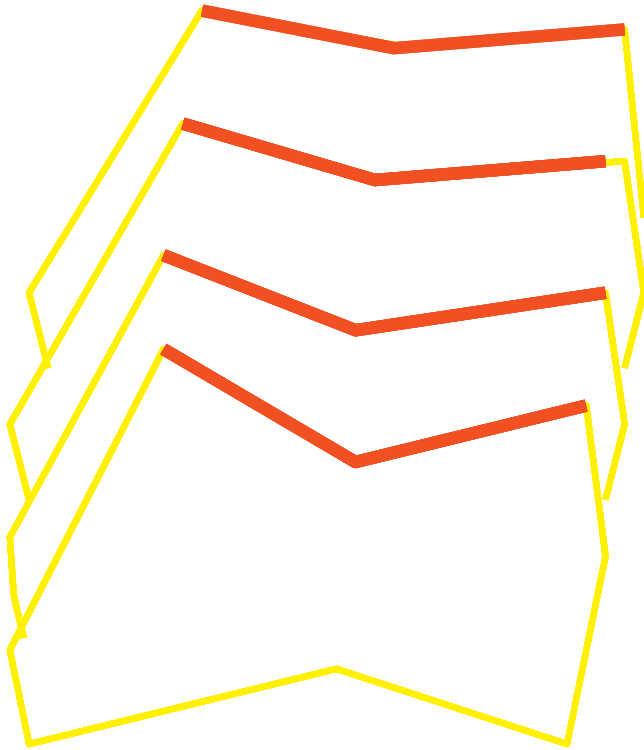


Figure 4.1.3. The cusp tip to fossa angle generally gets shallower (less steep) from first bicuspid to second molar because the second molar is farther from the affect of the lateral anterior guidance and closer to the fulcrum.

because of an overcarved amalgam restoration. Figure 4.1.5 illustrates another example, as illustrated by multiple balancing incline wear facets on the gold restoration on the lower right second molar. These interferences are due to an excessive Curve of Spee as well as the cusp to fossa angle being steeper than the lateral anterior guidance.

When planning a case on articulated diagnostic casts, the cusp to fossa angle relationship to the lateral anterior guidance can be observed and evaluated by viewing the casts from a broader frontal perspective (Figure 4.1.6). The red and green lines represent the lateral anterior guidance. These angles can be viewed in relationship to the lower molars. The

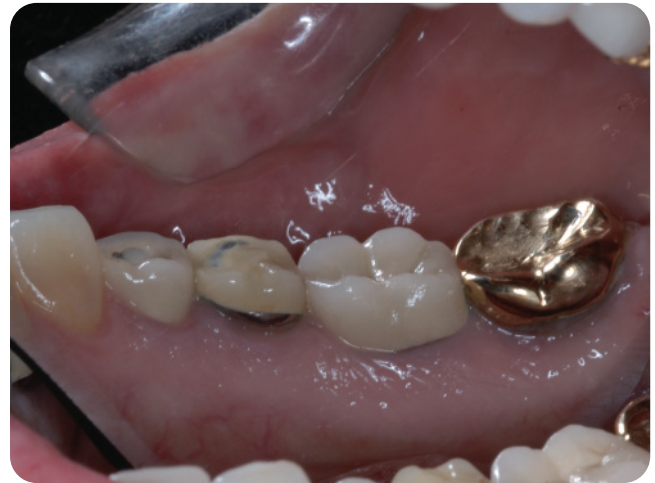

Figure 4.1.5. Wear facets on the inner incline of the gold restoration on the lower right second molar. The cusp tip to fossa angle is too steep and there is an excessive Curve of Spee in the distobuccal cusp area.

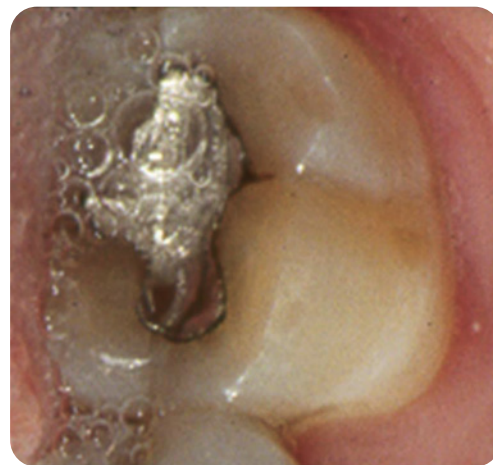
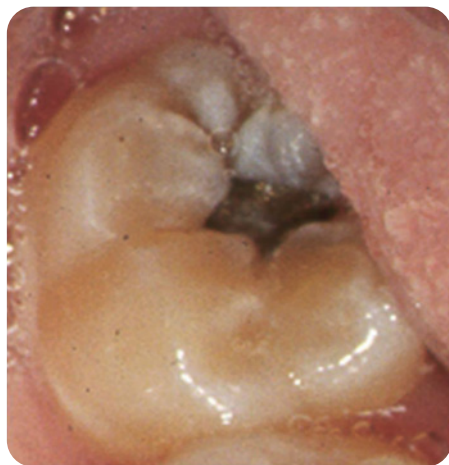
Figure 4.1.4. Wear facet on the inner incline of the distobuccal cusp of the lower left second molar due to a balancing interference. The cusp tip to fossa angle is steeper than the lateral anterior guidance.

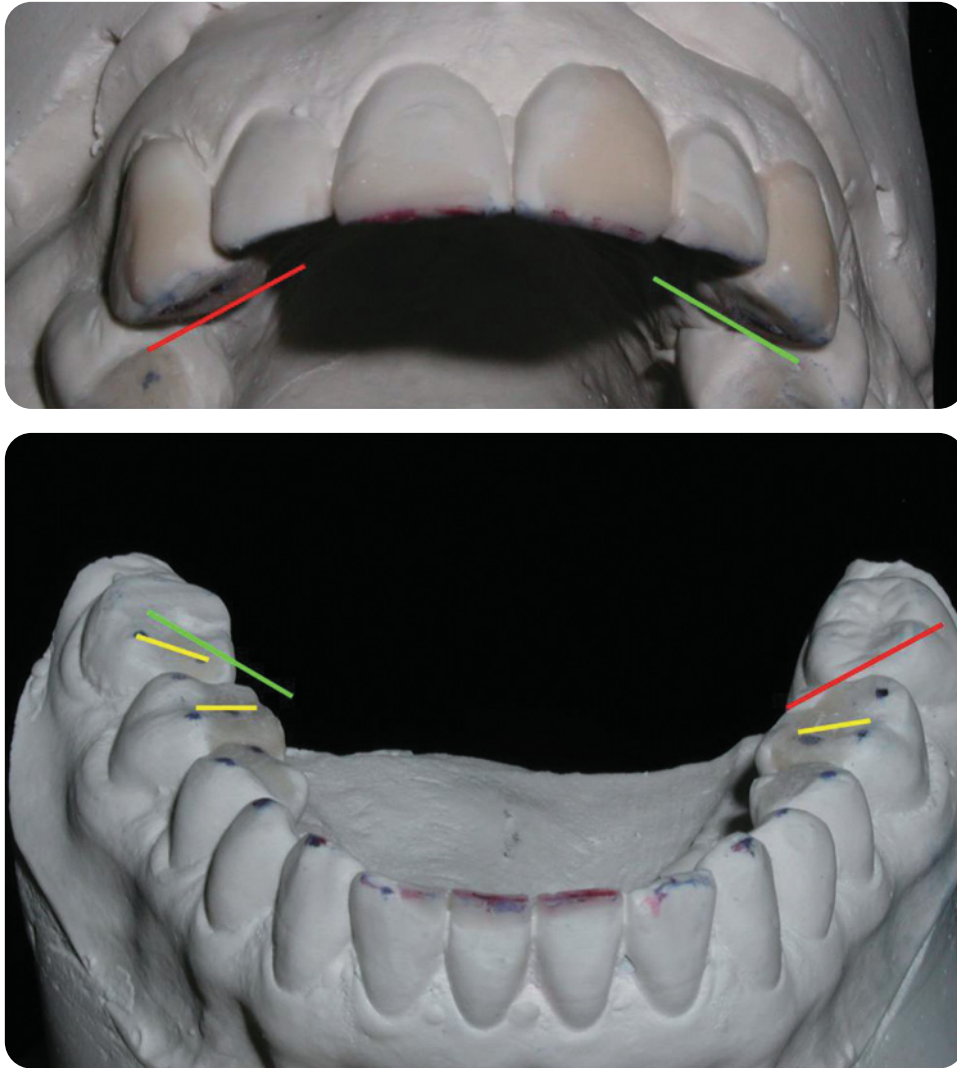


Figure 4.1.6. The relationship of the cusp tip to fossa angles to the lateral anterior guidance on a diagnostic blueprint can be viewed from a broader frontal perspective.

yellow lines represent the cusp to fossa angle from the centric stop at the cusp tip to the centric stop in the fossa. This can be observed as the blue dots on the diagnostic blueprint. The cusp to fossa angle of the molars is shallower than the lateral anterior guidance, so disclusion will predictably occur. The anatomy in areas other than the functional centric stop areas can be deeper if desired. This can give the tooth a more artistic and natural-looking appearance and not interfere with function.

General anatomic form and groove placement also plays a role in disclusion of the posterior teeth during excursive movements. Section 4E discusses this concept (refer to Figure 4.E.11).

4J

The Aesthetic Occlusal Plane

The aesthetic occlusal plane is generally referred to as that plane that is visible and displayed in the smile. Its anatomic landmarks are the incisal edges of the upper anterior teeth and the buccal cusp tips of the upper posterior teeth. The line connecting these landmarks should be level and symmetrical for the best appearance. An aesthetic occlusal plane that is uneven or that slopes can be distracting to the smile. Because the upper incisal edges have been previously determined and verified, they can be the starting points for the rest of the aesthetic plane as it extends

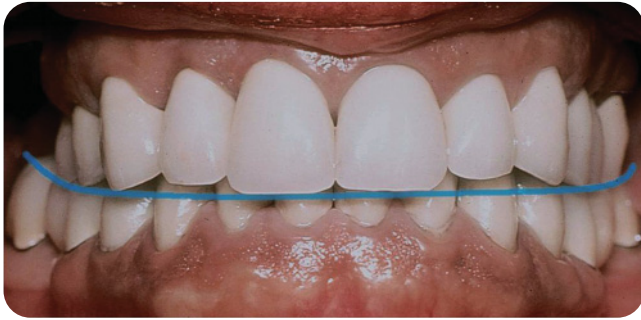

Figure 4.J.1. The aesthetic occlusal plane is formed by the incisal edges of the upper anterior teeth and the buccal cusp tips of the upper posterior teeth. This plane should be symmetrical, even, and aesthetically pleasing.

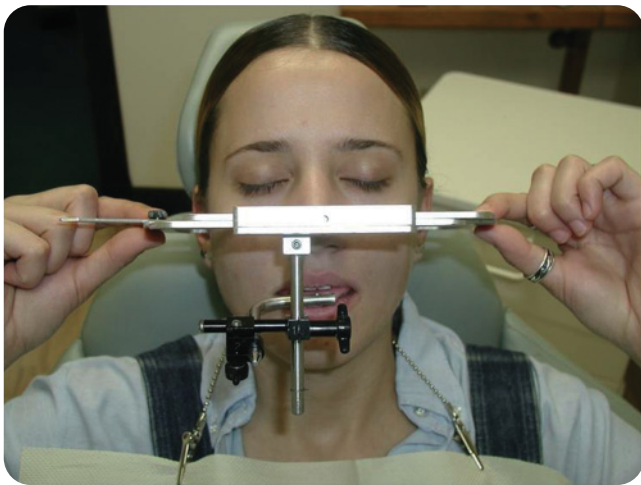


Figure 4.J.2. The facebow should be held horizontally, that is, parallel to the floor, to capture the correct orientation of the maxilla. The cast will be mounted on the articulator in the same orientation.

posteriorly. Figure 4.J.1 illustrates the desired goal of the aesthetic occlusal plane.

For proper planning and for predictable results with the definitive restorations, it is important that the maxillary cast be properly mounted on the articulator with a properly done facebow transfer. As illustrated in Figure 4.J.2, the facebow should be held horizontally, that is, parallel to the floor. In this way a maxillary cast will be mounted on the articulator in the same orientation as the patient's maxilla is oriented to his/her skull and face. Therefore, when corrections are made on the diagnostic blueprint or when definitive restorations are inserted they will be aesthetically correct for that particular patient.

The top photo in Figure 4.J.3 illustrates an uneven aesthetic occlusal plane. There is a reverse anterior smile line as well as an irregular posterior aesthetic

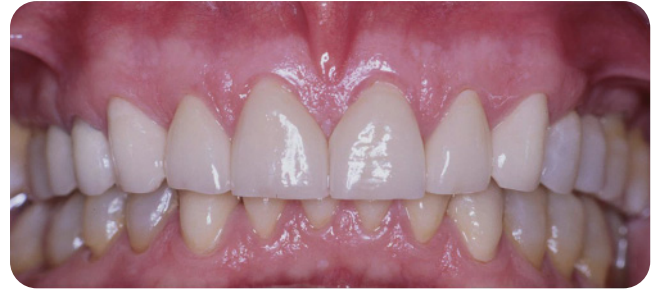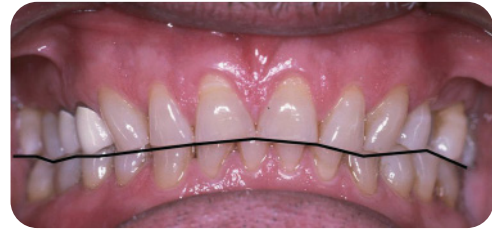


Figure 4.J.3. Clinical example of an aesthetic occlusal plane that is uneven and irregular and the corrections made with the definitive restorations.

plane. The bottom photo illustrates the corrections made with the definitive restorations. Just as with the Curve of Spee and Curve of Wilson, the aesthetic plane is best observed from a broader frontal perspective. In this way it is easier to observe the aesthetic plane and its orientation in its entirety.

The aesthetic occlusal plane not only pertains to the line connecting the incisal edges and buccal cusp tips but also pertains to the alignment of the facial surfaces of the teeth from anterior to posterior. The profiles of the facial surfaces should be relatively parallel to one another from anterior to posterior, and the amount of display from a frontal perspective should be similar from tooth to tooth and from side to side. An observation of the top photo in Figure 4.J.4 shows the irregular and uneven profiles of the facial surfaces of the upper posterior teeth. Figure 4.J.5 illustrates the corrections that were made on the articulated diagnostic casts. Some contours required reduction and other contours required enhancement. The bottom photo of Figure 4.J.4 shows the corrections made with the definitive restorations. The details of the corrections that were necessary are important when planning the actual tooth preparations. If a tooth is displaced too far to the facial, additional reduction facially will be necessary to give the technician enough room to create a properly contoured definitive restoration. If the tooth is displaced to the lingual, not as much reduction may be necessary. Having an uncorrected set of articulated diagnostic casts to refer to when studying the

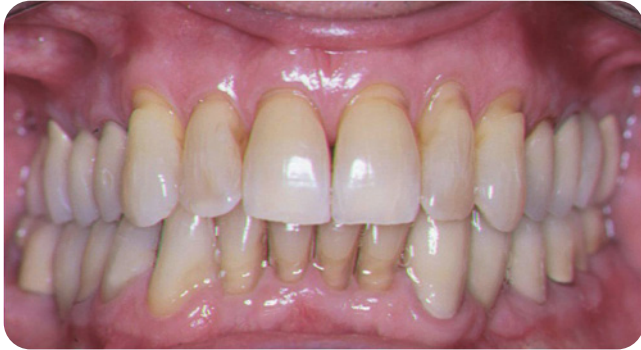
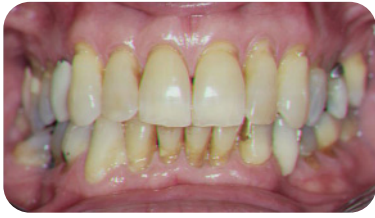
Figure 4.J.4. Clinical example of uneven and asymmetrical profiles of the facial surfaces of the upper posterior teeth and the corrections made with the definitive restorations.

diagnostic blueprint and making a note of these kinds of changes is important in the planning process.

There are cases where the changes made to the upper incisal edge position, the aesthetic occlusal plane, and the profiles of the upper posterior teeth are significant enough that a removable diagnostic template with the proposed corrections should be utilized by the patient before the commitment to the definitive dentistry is made (Figure 4.J.6). The patient desired a fuller smile, that is, an enhancement of the facial profiles of the upper posterior teeth. She also desired an increase in the length of the upper anterior teeth. During the diagnostic phase it was determined that an increase in vertical dimension of occlusion was also required to not only make these aesthetic changes but to also make functional improvements. All these anticipated changes were initially made with a removable diagnostic template, as illustrated in Figure 4.J.7. It was designed to fit over her unaltered current dentition to allow her to visualize and feel the

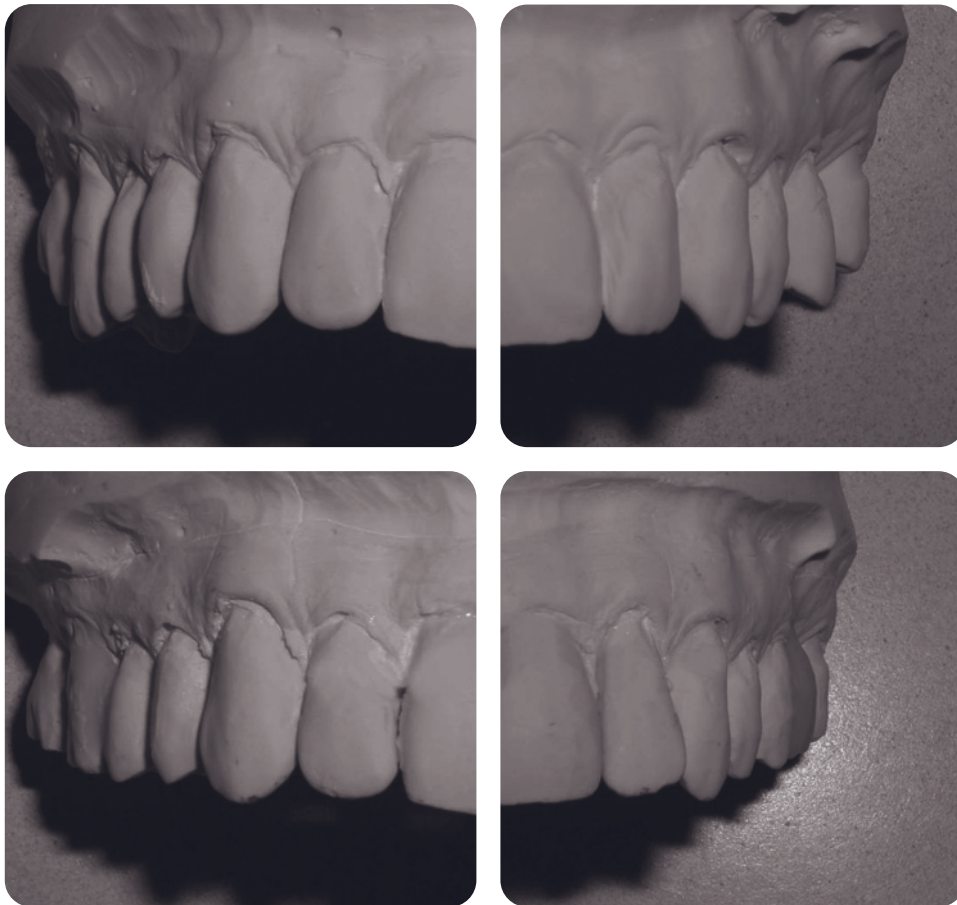


Figure 4.J.5. Diagnostic corrections made on articulated diagnostic casts of the clinical case in Figure 4.J.4. Making a note of the location and type of changes made, either reduction or addition, will help at the time of tooth preparation.

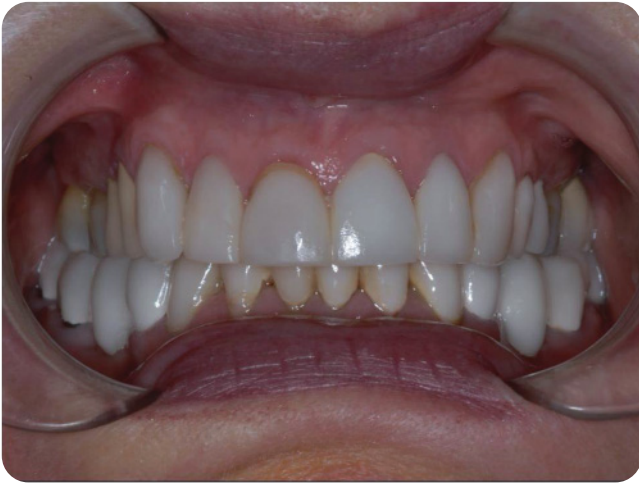

Figure 4.J.6. Clinical case requiring significant changes in upper incisal edge length, upper aesthetic plane, and profiles of the posterior teeth and vertical dimension of occlusion.

aesthetic changes as well as the functional changes in a totally reversible fashion. Having the patient use this device away from the dental practice for several days gives both the dentist and the patient important information regarding the appropriateness of the changes made. There are a variety of excellent materials and techniques available for the fabrication of this type of device. Your laboratory technician is an excellent resource for this information. Once the changes have been approved, often after some modification of the diagnostic template, a definitive diagnostic blueprint can be done and the changes incorporated into provisional restorations. This will allow for more precise evaluation and modification of the aesthetic and functional changes.

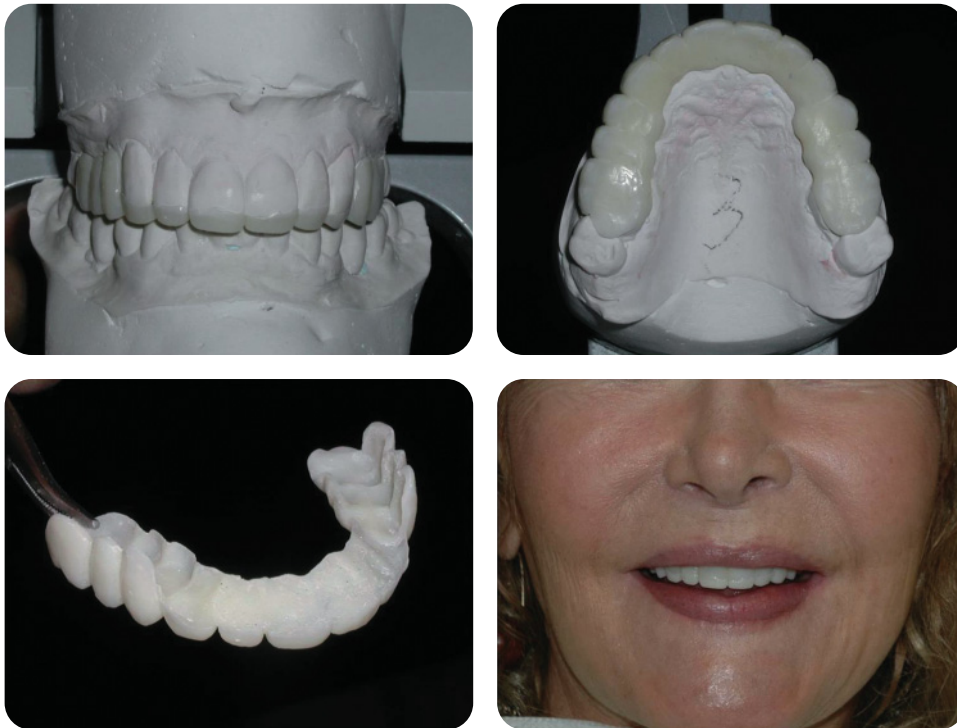

Figure 4.J.7. Upper left: changes to incisal edges and buccal cusps and facial profiles. Upper right: changes to vertical dimension. Lower left: device removed from cast. Lower right: device in place for dentist and patient to evaluate.

Part 2

Case Studies

The second part of the book is case studies of 50 patients. All patients have been treated by the author. These case studies illustrate the principles and practices discussed in the first part of the book. A wide variety of cases are presented, and they are organized by general type of case. Many of the cases were completed many years ago before dental implants were as common as they are today, but they illustrate the principle that the end result should look the same in terms of form and function landmarks no matter

what materials, techniques, or procedures are used. It is my hope that, as you review these case presentations, they will add to your understanding of the principles and practices outlined in the first part of this book. I also hope that as you develop treatment plans for your own cases and come across one that may be a bit perplexing, you will find a similar case in these presentations that will help you finalize your own treatment plan.

5

Nonremovable Implant Restoration with Natural Teeth

Case 1 Nonremovable maxillary implant restorations with natural teeth restorations including crowns, veneers, and fixed partial dentures

Case 2 Transitioning a maxillary tooth-supported fixed partial denture to an implant-supported fixed partial denture along with other single crowns and tooth-supported fixed partial dentures

Case 3 Lower reconstruction with lower left being implant-supported, important neutral zone consideration affecting design; upper reconstruction landmarks acceptable; temporomandibular disorder managed

Case 4 Maxillary fixed partial denture supported by both teeth and implants along with other maxillary and mandibular implant-supported crowns and tooth-supported crowns and fixed partial dentures

Case 5 Maxillary extractions, periodontal surgery, orthodontics, veneers, and fixed partial dentures on teeth; mandibular extractions, implants, fixed partial dentures on teeth and implants

Case 6 Multiple congenitally missing teeth, past orthognathics/orthodontics, tooth position inconsistencies handled restoratively, multiple implants, tooth-supported crowns and fixed partial dentures, implant-supported crowns and fixed partial dentures.

See also:

Chapter 6 Case 1 Osteoarthritis of the left TMJ managed with bite splint therapy followed by implant-supported restorations and tooth-supported restorations.

Chapter 7 Case 7 Maxillary and mandibular dental reconstruction including 4 dental implants replacing unrestorable teeth. Impaired aesthetics due to recession handled with grafts and all porcelain restorations.

Chapter 14 Case 4 Mandibular anterior fixed partial denture and posterior removable partial denture with implants and Locator attachments for added support and retention; maxillary reconstruction, telescope case with one dental implant included along with 6 teeth.

Chapter 5 Case 1

Nonremovable maxillary implant restorations with natural teeth restorations including crowns, veneers, and fixed partial dentures

A common reconstruction today is one in which there are missing teeth, the remaining natural teeth are in need of restorations due to structural inadequacies, and the edentulous areas are restored with implant supported restorations. In this case, the maxillary edentulous areas are restored with implants and the mandibular with fixed partial dentures. Clinical judgment will help the dentist decide whether the edentulous areas should be restored with dental implants or tooth-supported fixed partial dentures. Attached keratinized tissue needs to be augmented in several areas. The case was provisionalized prior to the periodontal surgery and dental implant placement.

This patient is an out-of-town physician who had to wait until retirement to complete his dentistry. He had holding pattern type dentistry done to get him by. He

SUMMARY OF EXAMINATION AND DIAGNOSIS

Dentition

All teeth are structurally weak or worn but all appear to be predictably restorable.

Malpositioning of lower teeth

Periodontium

Generalized recession but healthy

No pockets over 3 mm

Areas of minimal attached keratinized tissue

TMJs

Piper 3B right and left

Both can be superiorly compressed without discomfort.

Muscles

Slight lateral pterygoid palpation tenderness

Occlusion

Loss of posterior support

Aesthetics

Upper incisal edge position short

Aesthetic form of teeth unacceptable

has no difficulties in terms of pain or dysfunction.

Aesthetics is not a primary concern. He knows he has a deteriorating dentition and needs extensive dentistry to restore form and function.

THE 10 DECISIONS

1. TMJ Diagnosis

Adapted centric posture

2. Vertical Dimension

Maintain or open slightly as needed.

3. Lower Incisal Edge

Use corrected 22 as a reference. Develop definitive edges and keep plane level using 22.

4. Upper Incisal Edge

Increase length of 8 and 9 approx. 1 mm. Develop the rest of the upper plane from this reference.

5. Centric Stops

All teeth will have definitive centric holding contacts.

6. Anterior Guidance

Anterior guidance will be slightly shallower from preoperative condition because vertical dimension will be slightly opened.

7. Curve of Spee

Idealize, follow 4-inch radius, consistent with anterior incisal plane.

8. Curve of Wilson

Verify that upper buccal and lower lingual cusps do not interfere in the functional and parafunctional range of motion.

9. Cusp/Fossa Angle

Angle will be shallower than anterior guidance angle.

10. Aesthetic Plane

Create an upper posterior aesthetic plane that is consistent with the upper incisal edge position and with pleasing buccal profiles.

SUMMARY OF TREATMENT PLAN

Dentition

- Veneers 22–27
- Crowns on all remaining teeth
- Implants upper edentulous areas
- Fixed partial dentures for lower edentulous areas

Periodontium

Grafts for areas with minimal attached keratinized tissue

TMJs

No treatment is needed other than correct occlusal engineering.

Muscles

No treatment is needed other than correct occlusal engineering.

Occlusion

Simultaneous, equal intensity centric stops in the adapted centric posture arc of closure on tooth and implant-supported restoration and anterior guidance on anterior teeth

Aesthetics

- Lengthen upper incisal edge 1–2 mm.
- “Straighten” lower teeth with restorations.
- Idealize tooth contours.

SUMMARY OF TREATMENT SEQUENCE

Appointment	Treatment Completed
1	Provisionalize 6–14. Provisionalize lower posteriors. Provisionalize lower anterior with composite.
2	To periodontist for grafts and dental implants
3	Healing and integration
4	Monitor and maintain provisionals.
5	Impressions for lower posterior crowns/bridges and anterior veneers
6	Place crowns/bridges. Bond lower anterior veneers.
7	Place upper implant abutments. Abutment preparations and impressions. Implants handled like teeth New provisionals
8	Place upper restorations.

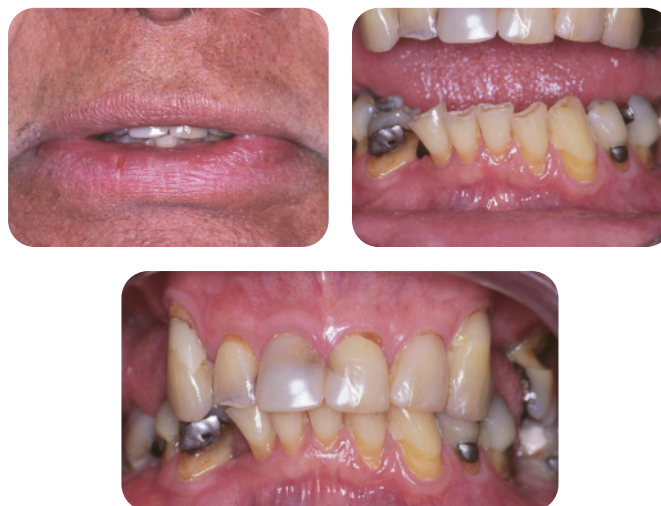

Figure 5.1.1. Preoperative condition, frontal view.

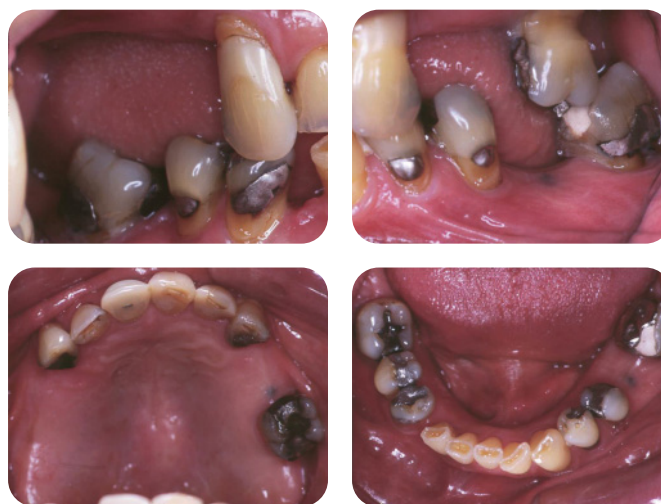

Figure 5.1.2. Preoperative condition, buccal and occlusal views.

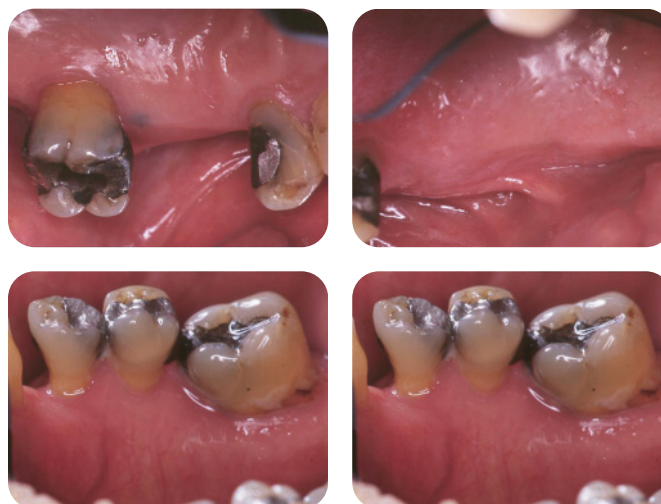

Figure 5.1.3. Preoperative condition, lingual views.

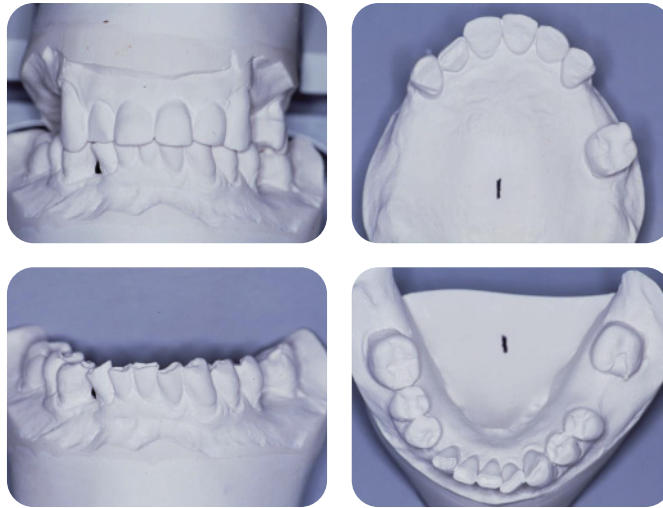


Figure 5.1.4. Preoperative articulated diagnostic casts.

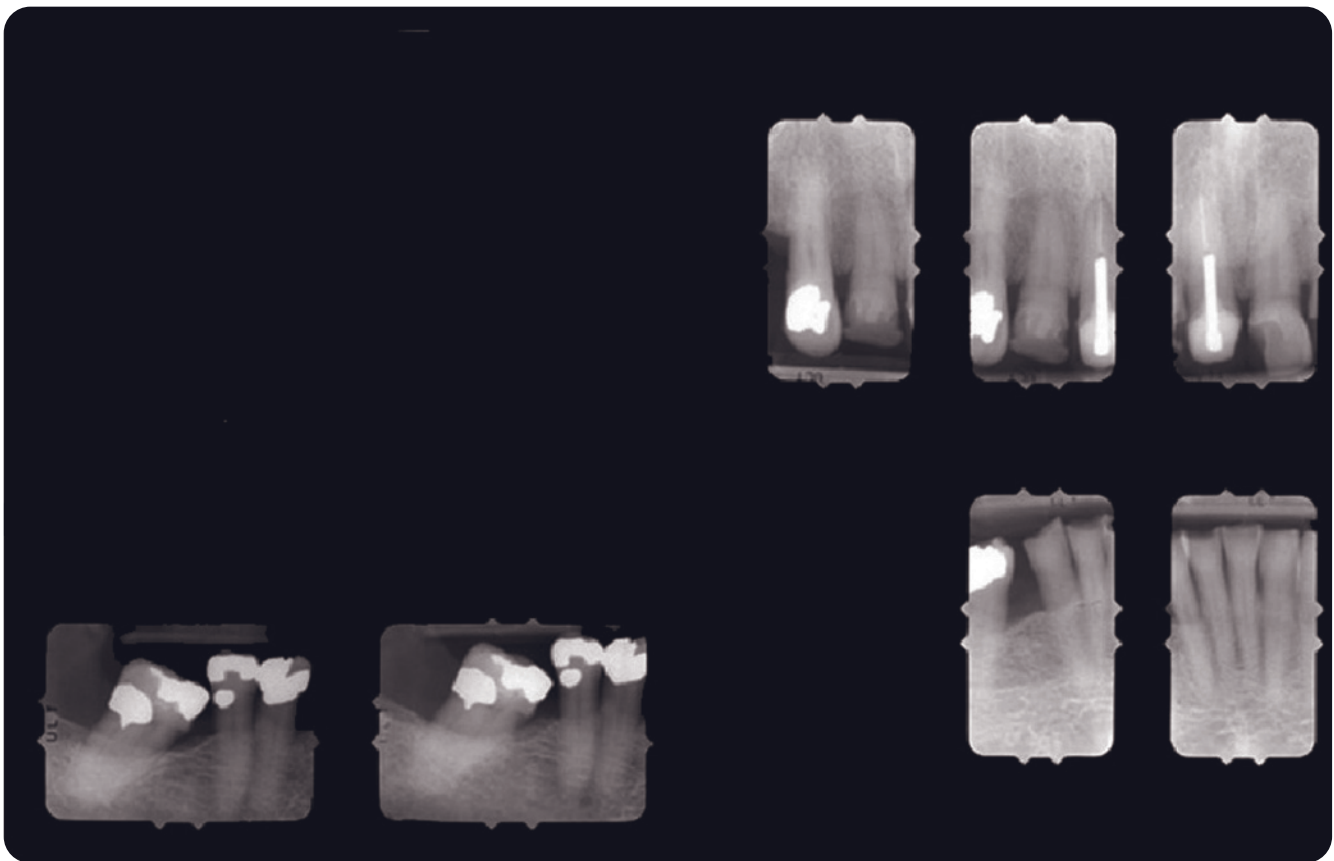


Figure 5.1.5. Preoperative radiographs, right side.

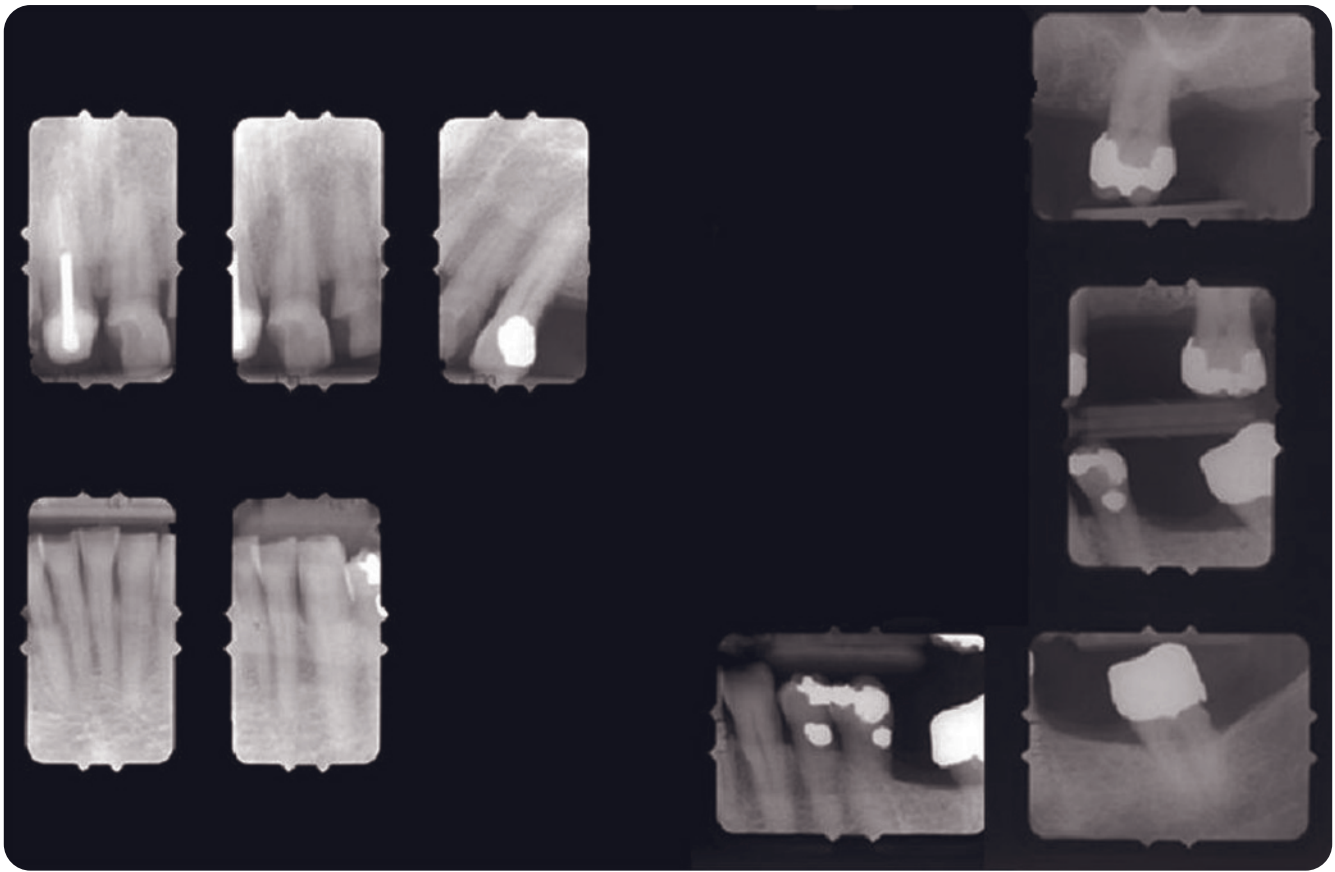


Figure 5.1.6. Preoperative radiographs, left side.

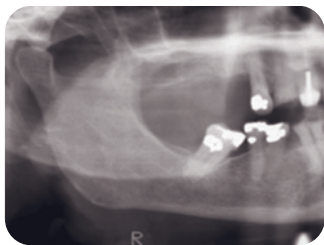

Figure 5.1.7. Preoperative panoramic radiograph, right side, showing condition of the right temporomandibular joint.

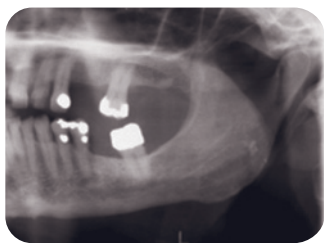

Figure 5.1.8. Preoperative panoramic radiograph, left side, showing condition of the left temporomandibular joint.

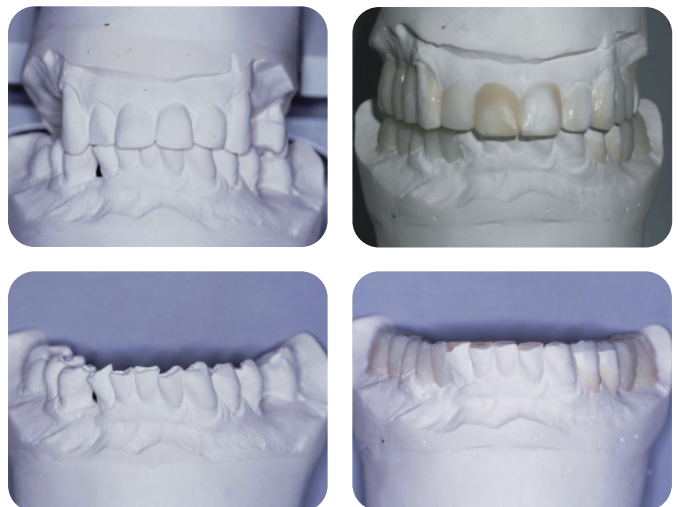


Figure 5.1.9. Diagnostic blueprint, frontal view.

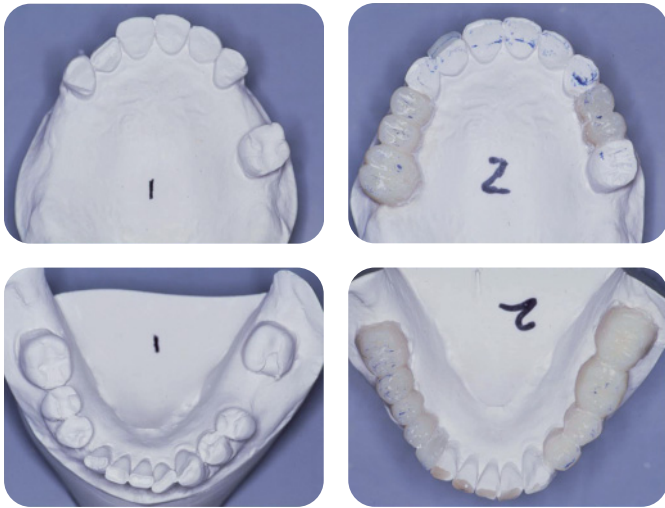


Figure 5.1.10. Diagnostic blueprint, occlusal view. The tipped molars were prepared for full crowns on the cast to “upright” them and get a better idea of the edentulous space between the abutments. The lower, right cuspid is replaced with a mesial cantilever pontic.

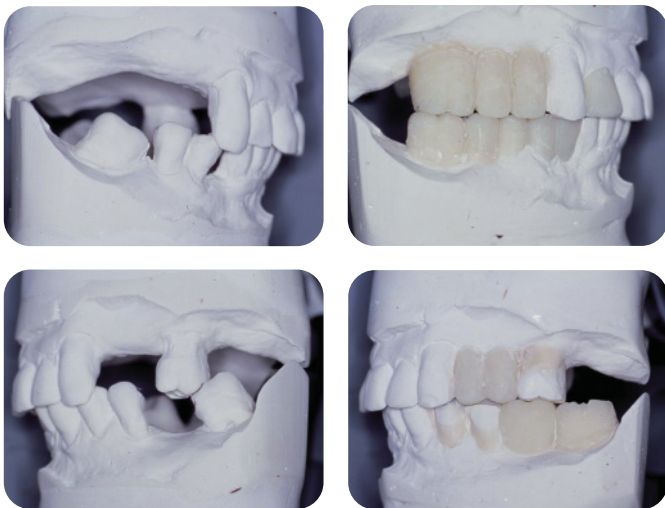


Figure 5.1.11. Diagnostic blueprint, buccal views. The “uprighted” molar abutments are seen more easily in these views.

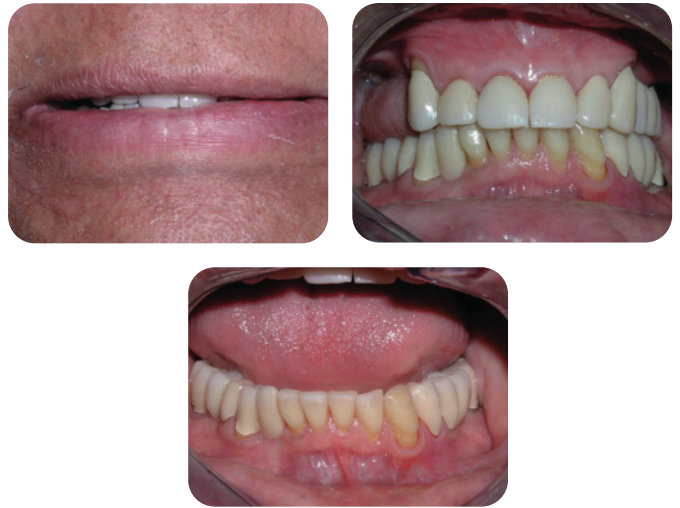

Figure 5.1.12. Provisional restorations prior to periodontal surgery and implant placement.

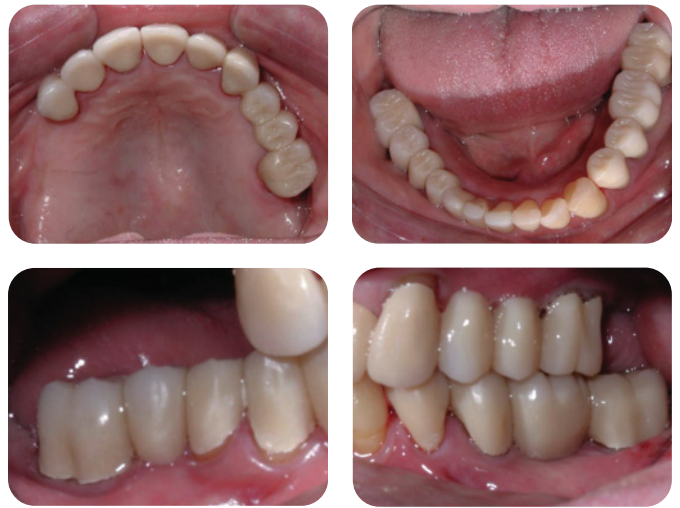

Figure 5.1.13. Provisional restorations, occlusal and buccal views.

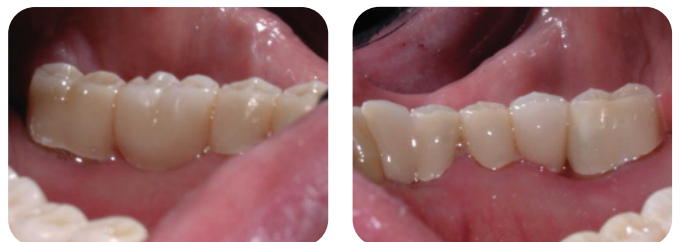
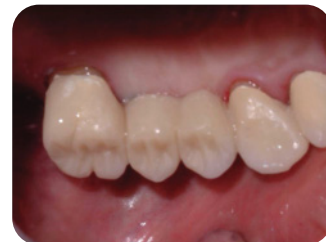
Figure 5.1.14. Provisional restorations, lingual views.

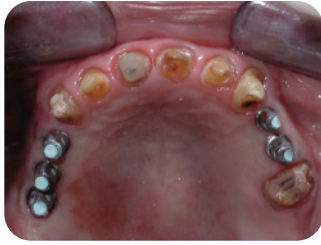

Figure 5.1.15. Occlusal view after periodontal surgery and dental implant placement.

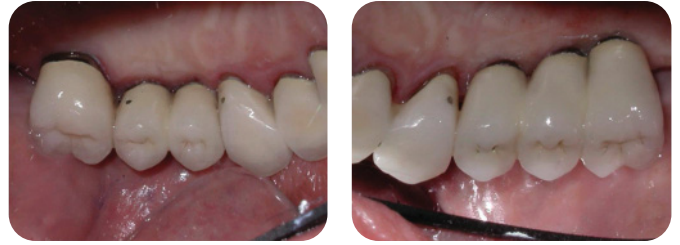

Figure 5.1.18. Posttreatment photographs, lingual views.

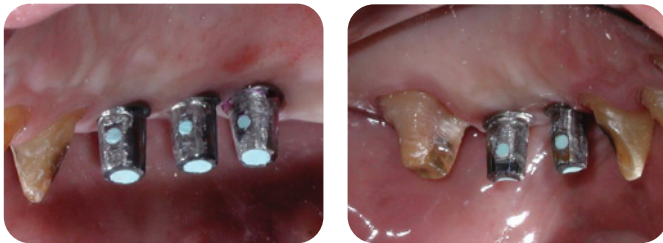
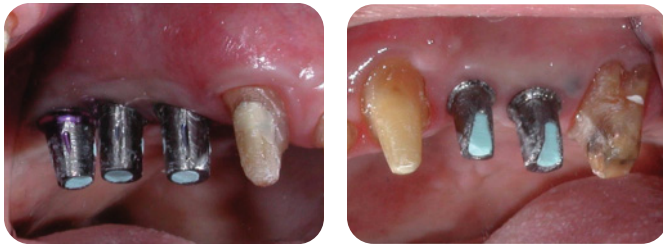
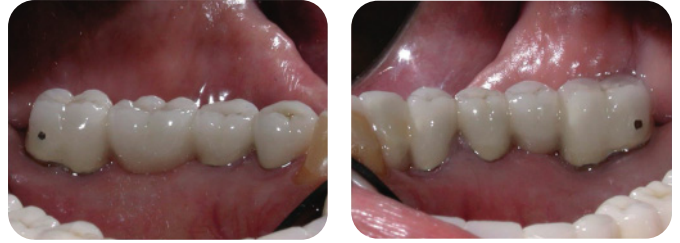Figure 5.1.16. Buccal and lingual views after periodontal surgery and dental implant placement.

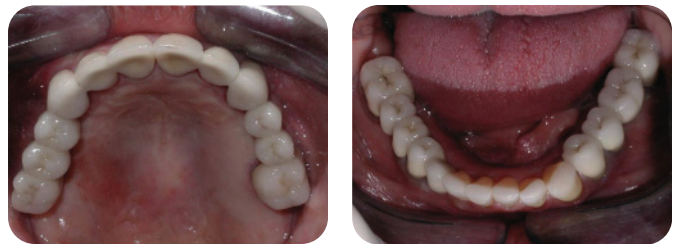
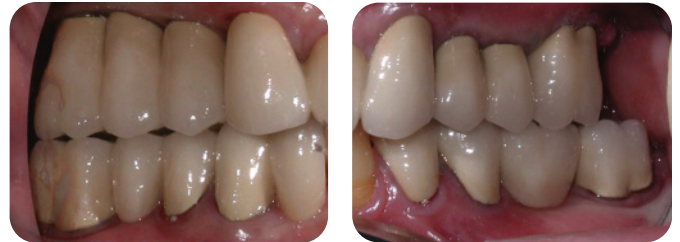
Figure 5.1.19. Posttreatment photographs, buccal and occlusal views.

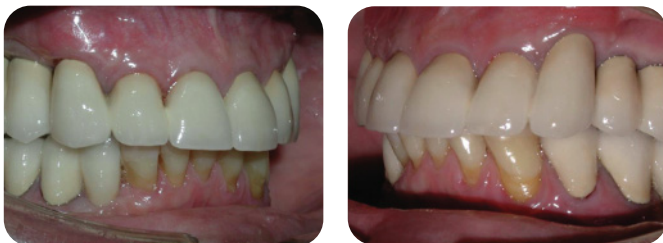
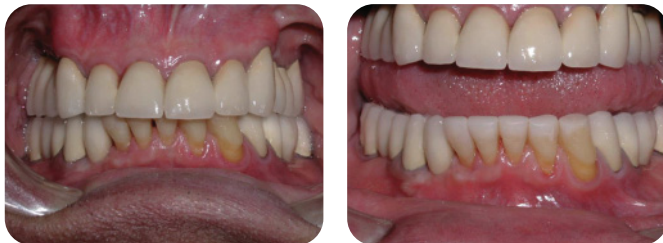
Figure 5.1.17. Posttreatment photographs, frontal views.

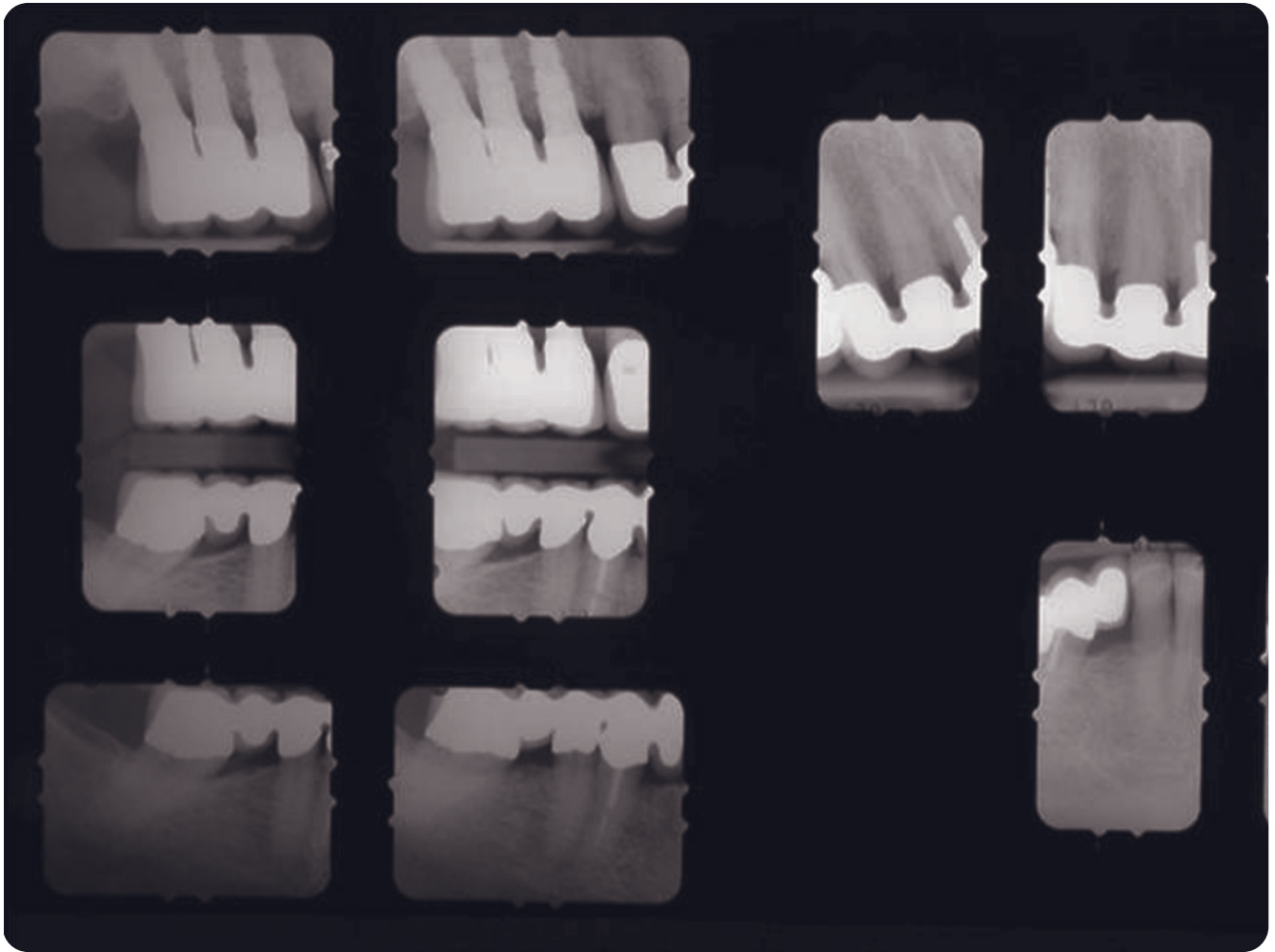


Figure 5.1.20. Posttreatment radiographs, right posterior.

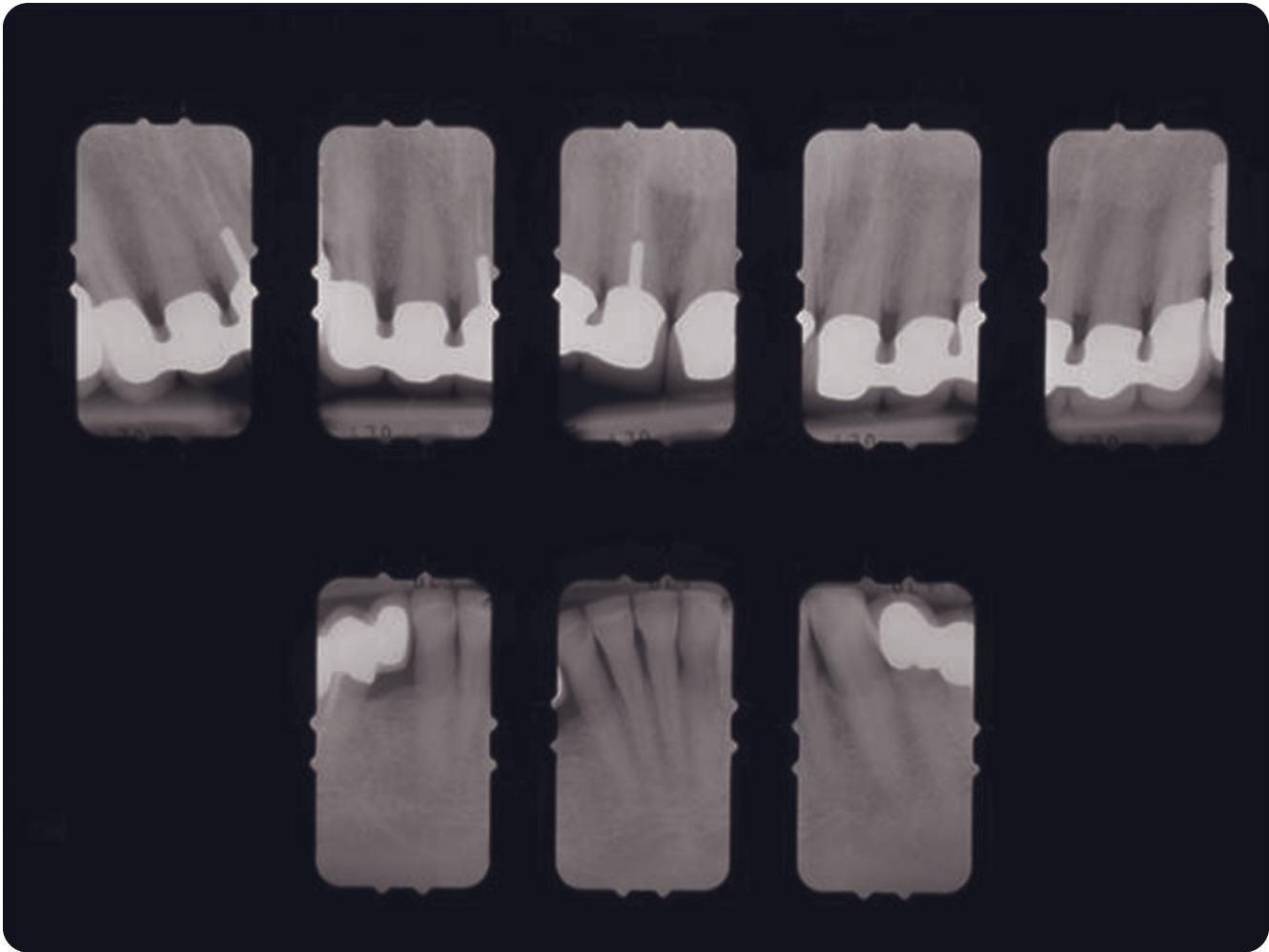


Figure 5.1.21. Posttreatment radiographs, anterior.

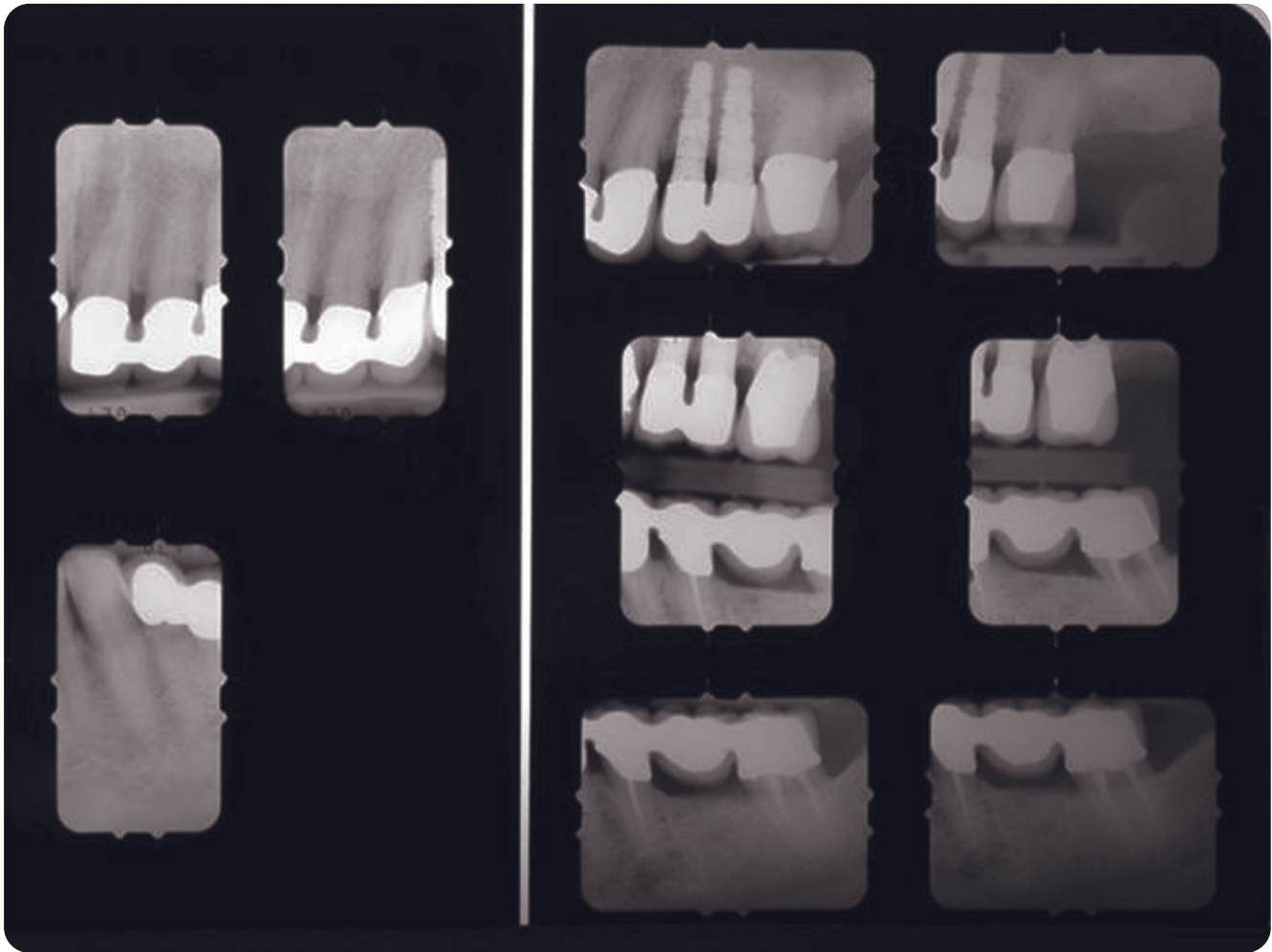


Figure 5.1.22. Posttreatment radiographs, left posterior.

CHAPTER 5 CASE 1 KEY POINTS

- Prepare tipped teeth on the diagnostic casts to get a true sense of proportions between the teeth and edentulous areas.
- A level, even mandibular anterior incisal plane is essential for a proper anterior guidance.

Chapter 5 Case 2

Transitioning a maxillary tooth-supported fixed partial denture to an implant-supported fixed partial denture along with other single crowns and tooth-supported fixed partial dentures

It is often necessary to transition from a tooth-supported fixed partial denture to an implant-supported approach. This may be necessary because key abutments may have a questionable long-term prognosis. The difficulty lies in making a nonremovable provisional throughout the process because a removable provisional may be unacceptable to the patient.

This patient had a full reconstruction done in another country. He is not happy with the result, dislikes the aesthetics, feels his upper lip is too concave, and does not have a comfortable bite. In addition there are structural and marginal fit inadequacies, which necessitate changing all the dentistry. There are several missing teeth and a key abutment,

SUMMARY OF EXAMINATION AND DIAGNOSIS

Dentition

Failing restorations

Key abutment upper right cuspid has a poor prognosis.

Periodontium

Healthy

TMJs

Both right and left normal, Piper 1

Both quiet to auscultation and can be superiorly compressed without discomfort

Muscles

Lateral pterygoids slight tenderness to palpation, 1 on a scale of 5; no symptoms

Occlusion

Interferences and slide from a guided CR position to maximum intercuspation; very little overbite

Aesthetics

Tooth size, proportions, contours unacceptable

Slanted aesthetic plane, right side low

Not enough lip support, concave upper lip

the upper right cuspid, has a poor prognosis.

Therefore, a treatment plan involving bone augmentation followed by implant placement was developed with the oral surgeon.

THE 10 DECISIONS

1. TMJ Diagnosis

Guided, verifiable CR

2. Vertical Dimension

Keep current vertical dimension of occlusion.

3. Lower Incisal Edge

Keep height the same, make plane level from right to left, create definitive incisal edges.

4. Upper Incisal Edge

Move forward 1.5–2 mm, increase in length 1.5–2 mm, thereby increasing overbite slightly.

5. Centric Stops

All teeth will have stable centric holding contacts centric relation arc of closure.

6. Anterior Guidance

Increasing the overbite increases the anterior guidance performance platform angle.

7. Curve of Spee

Keep relatively shallow and flat because of shallow anterior guidance.

8. Curve of Wilson

Verify that the upper buccal and lower lingual cusps do not interfere in either the parafunctional or functional range of motion.

9. Cusp/Fossa Angle

Angle will be shallower than the anterior guidance angle.

10. Aesthetic Plane

Verify that the upper buccal cusps follow the general plane of the anterior incisal edges and are level from side to side. Verify that the buccal profiles are symmetrical and pleasing.

SUMMARY OF TREATMENT PLAN

Dentition

Change all restorations.
 Endodontics as needed
 Implants 4, 5, 7, 8, 9, 10; 6 will be a pontic in the implant-supported fixed partial denture.
 Other edentulous areas will be pontics of a tooth-supported fixed partial denture.

Periodontium

No treatment is needed other than implants.

TMJs

No treatment is needed other than correct occlusal engineering.

Muscles

No treatment is needed other than correct occlusal engineering.

Occlusion

Simultaneous, equal intensity centric stops in the centric relation arc of closure
 Increase overbite by 1.5mm.

Aesthetics

Bone/soft tissue augmentation to increase lip support as well as a foundation for implants
 Improve contour, proportions with restorations.
 Improve aesthetic plane, level from right to left.

SUMMARY OF TREATMENT SEQUENCE

Appointment	Treatment Completed
1	Provisionalize all teeth, 2 appointments over 2 consecutive days.
2	Bone grafts done by the oral surgeon in areas that will be receiving implants
3	Monitor and modify provisionals as needed.
4	Endodontics and endodontic retreatment as needed
5	Finalize lower restorations.
6	Place implants in areas 4, 5, 7, 8, 9, 10. Keep tooth 6 as a provisional abutment.
7	Time for healing and integration Monitor and maintain provisionals.
8	Place implant abutments, surgeon to remove 6, new provisional restoration supported by implants.
9	Time for healing of extraction site
10	Definitive upper restorations: single units 2 and 3; implant-supported fixed partial denture 4–10 with 6 being a pontic; tooth-supported fixed partial denture 11–15

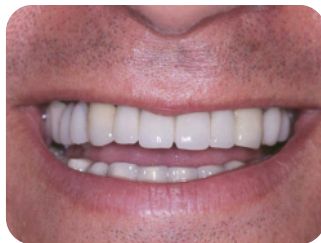
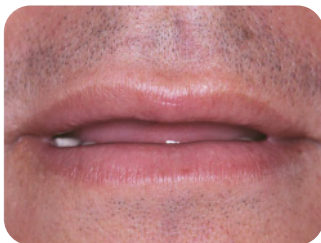
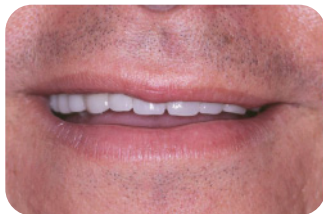Figure 5.2.1. Pretreatment smile photographs. With the lip at rest no incisal edge is displayed, and therefore the length of the upper anteriors can be increased slightly. In a full smile the upper papilla and facial gingival tissues are not displayed.

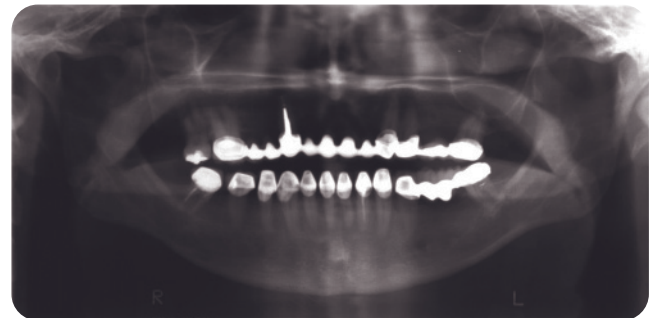
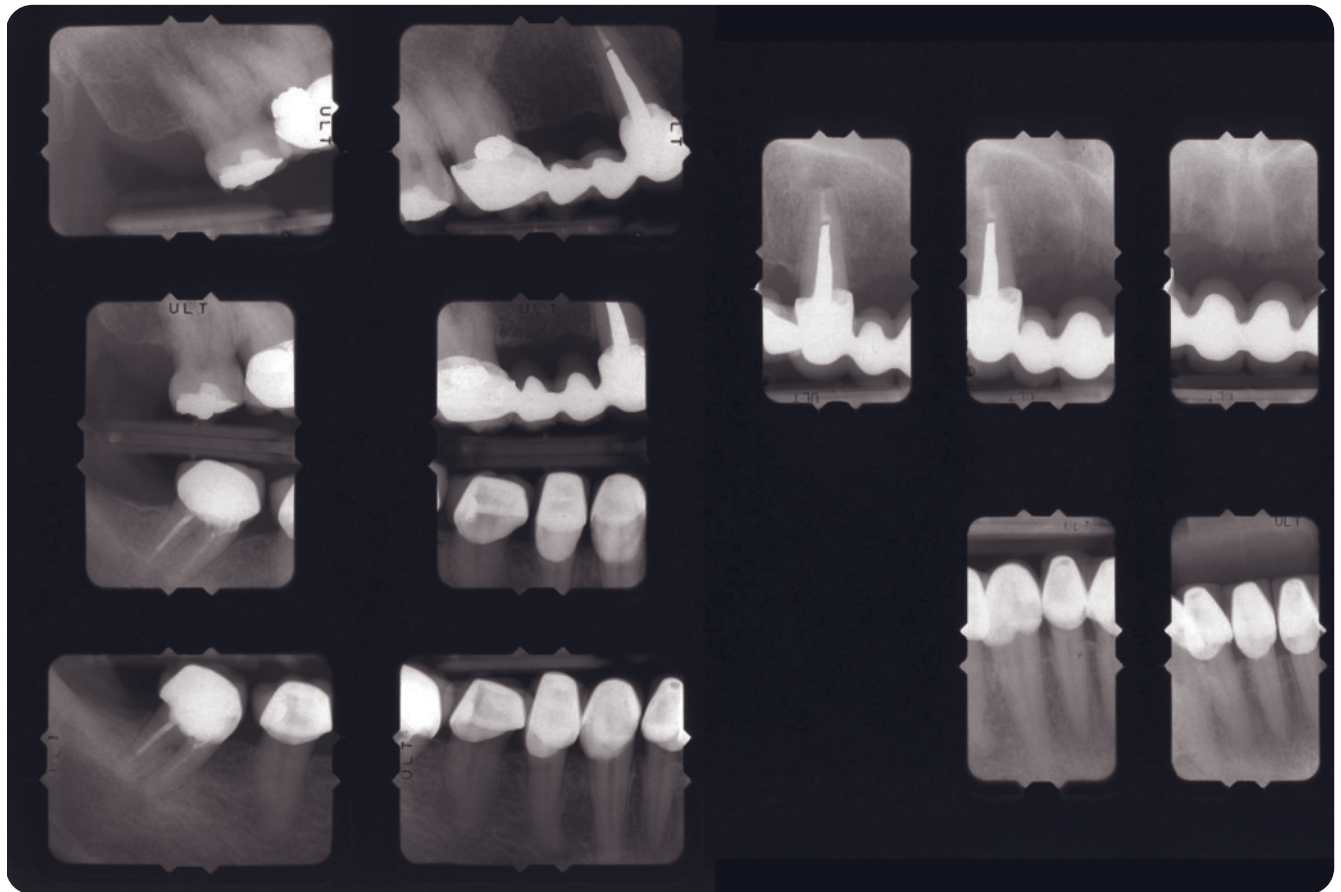
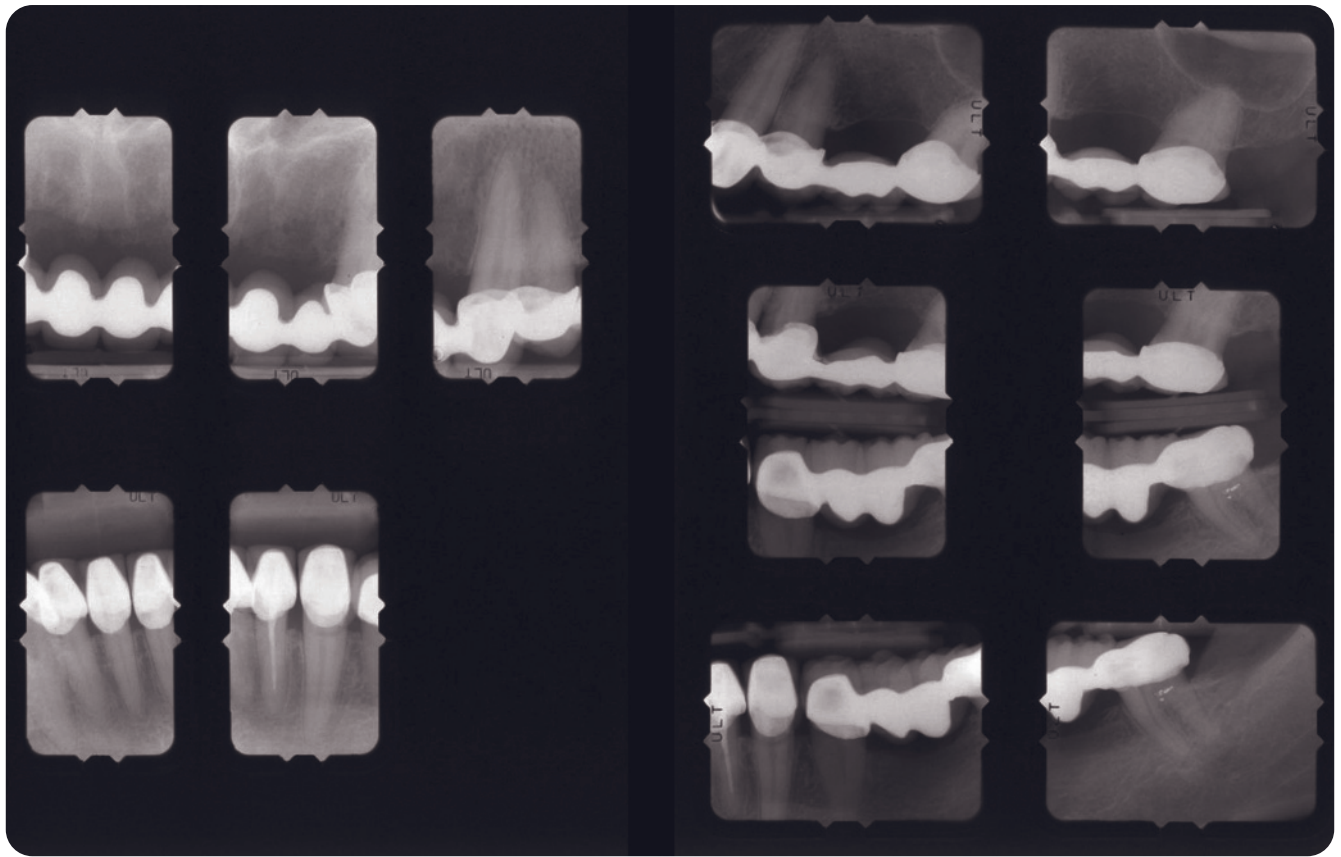


Figure 5.2.2. Pretreatment panoramic radiograph. Fixed partial denture abutment number 6 has a poor prognosis due to a large post and core and a suspicious periapical lesion.



Figures 5.2.3 and 5.2.4. Pretreatment full mouth series radiographs.

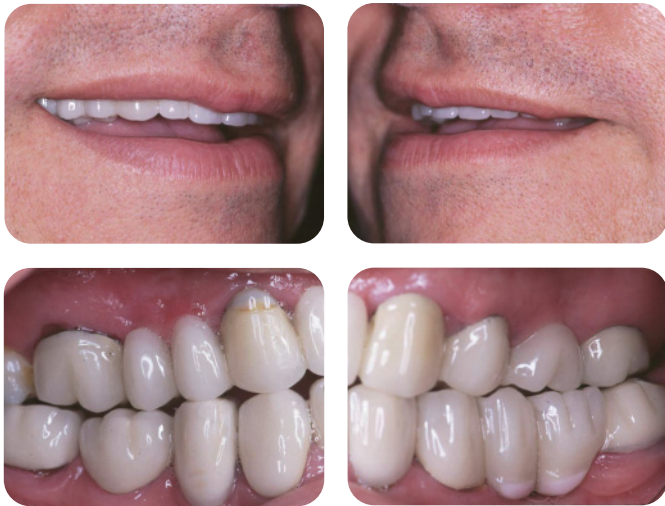

Figure 5.2.5. Preoperative lateral smile photographs suggesting a concave upper lip needing more support and preoperative buccal occluded views showing an irregular occlusal plane. The end-to-end posterior tooth-to-tooth relationship is not problematic from a functional point of view and can be acceptable if aesthetics is correct.

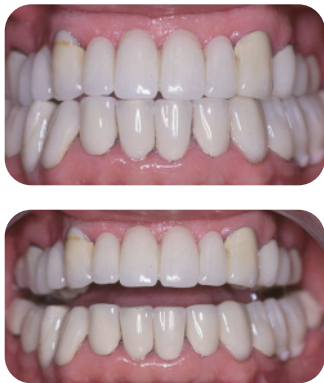

Figure 5.2.6. Preoperative anterior retracted photographs with teeth in maximum intercuspation and with teeth slightly apart suggesting the end-to-end anterior tooth-to-tooth relationship and the somewhat irregular lower incisal and occlusal planes.

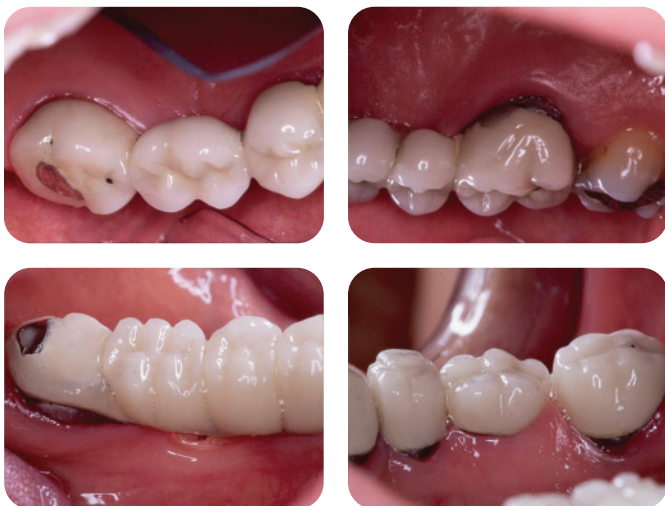

Figure 5.2.7. Preoperative lingual photographs suggesting inadequate contours and inadequate marginal adaptation of the restorations.

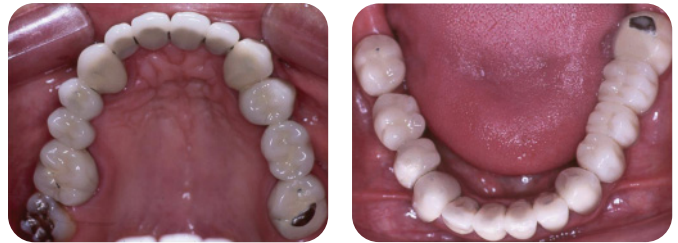

Figure 5.2.8. Preoperative maxillary and mandibular occlusal photographs suggesting occlusal issues, tooth size and proportion issues, and tooth contour issues.

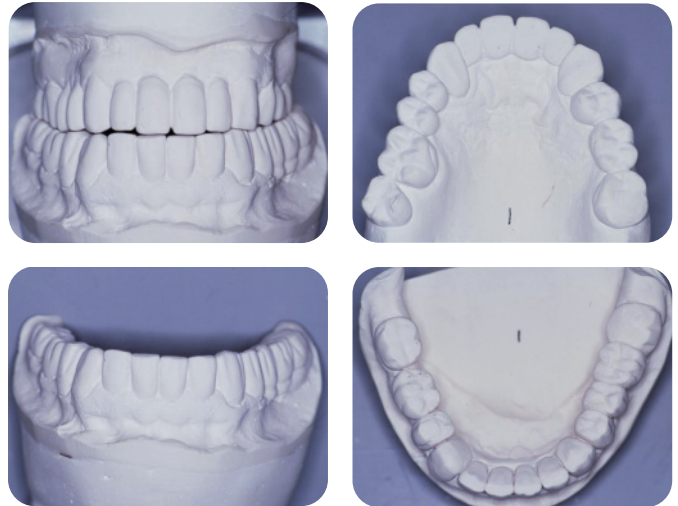


Figure 5.2.9. Preoperative articulated diagnostic casts.

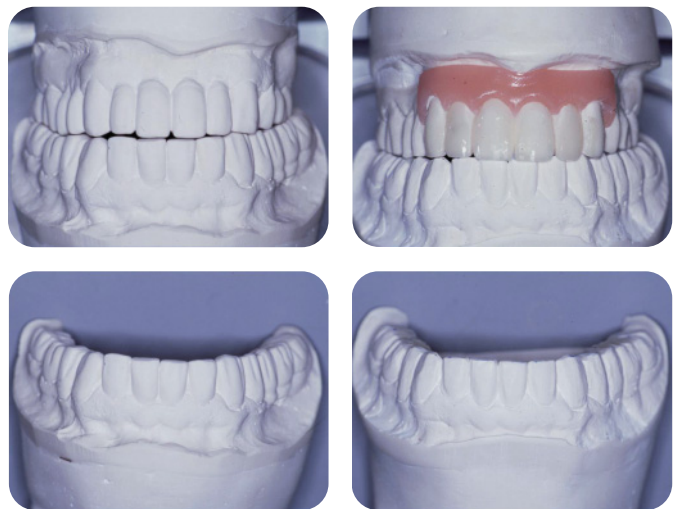


Figure 5.2.10. Diagnostic blueprint illustrating improvements in the mandibular incisal and occlusal planes, improvement of the contours and proportions of upper anterior teeth, and enhancement of the upper anterior gingival tissues. This addressed the need for increased lip support and also to bring the alveolar bone facially so that the implants could be placed in the correct position anterior-posteriorly.

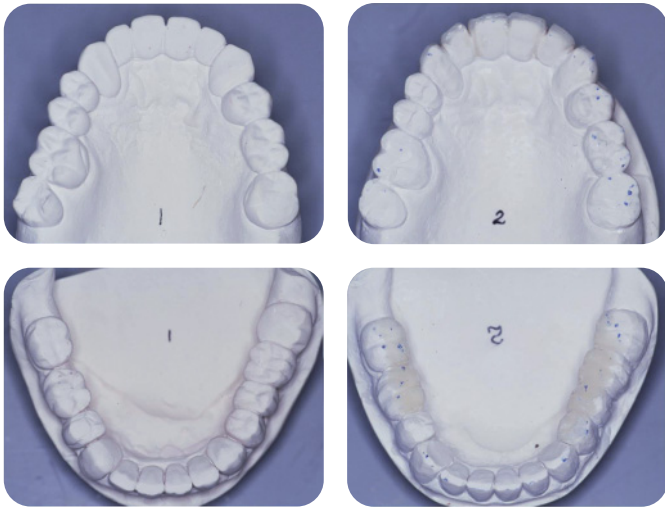


Figure 5.2.11. Occlusal view of the diagnostic blueprint illustrating improvements in occlusion, tooth proportions, and tooth contours.

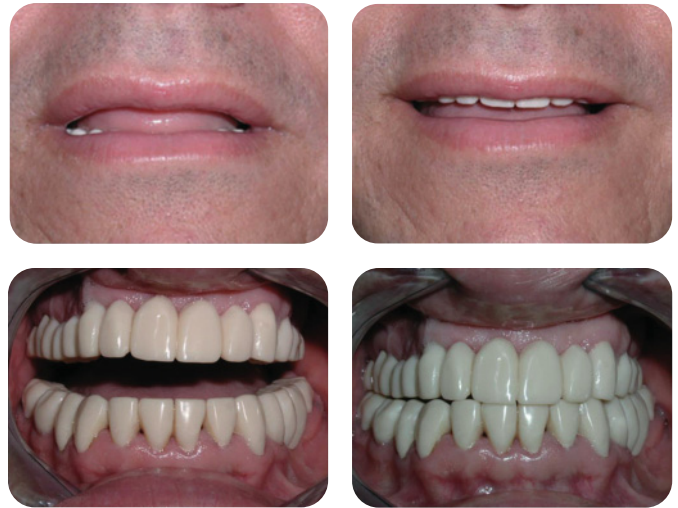

Figure 5.2.13. First phase of treatment with provisional restorations on all maxillary and mandibular teeth.

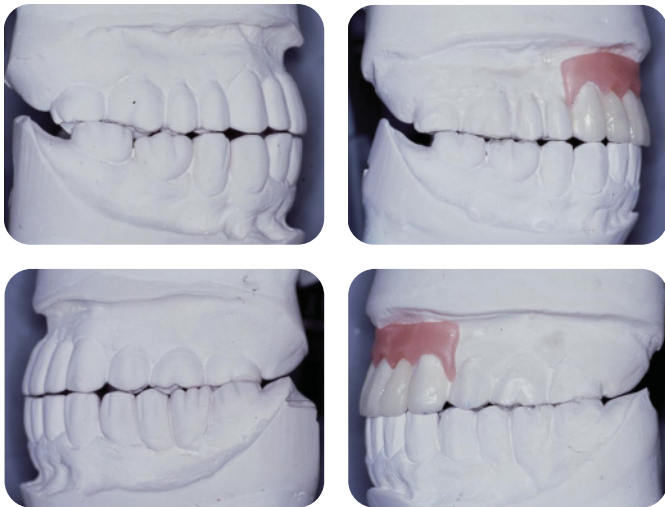


Figure 5.2.12. Lateral views of the diagnostic blueprint illustrating the increase in overbite and the more anterior position of the upper anterior teeth and gingival tissues. The gingival tissue on the diagnostic blueprint is a removable pink triad façade, which helps the patient understand the need and rationale for enhancing bone and soft tissue.

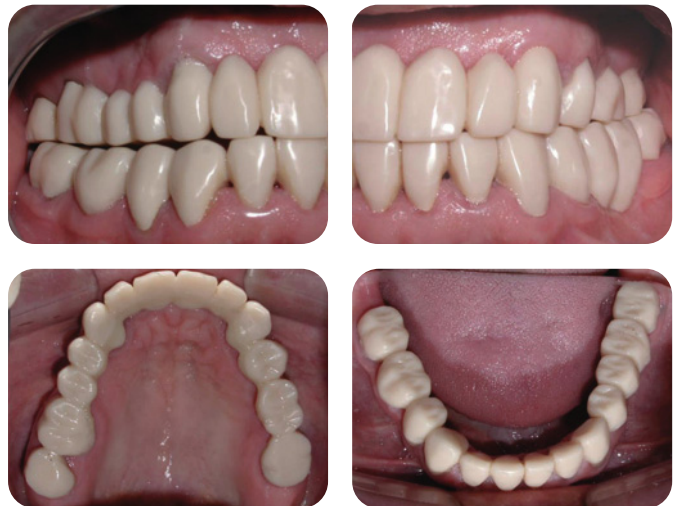

Figure 5.2.14. Lateral and occlusal views of the provisional restorations showing a close similarity to the diagnostic blueprint.

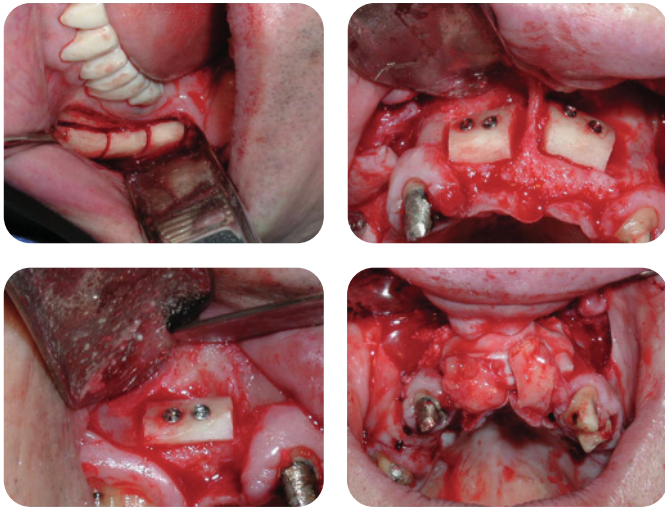


Figure 5.2.15. Surgical photographs taken at the oral surgeon's office illustrating the bone donor site at the lower left posterior mandible, the bone segments secured in place in the upper right bicuspid and upper anterior areas, and initial soft tissue enhancement.

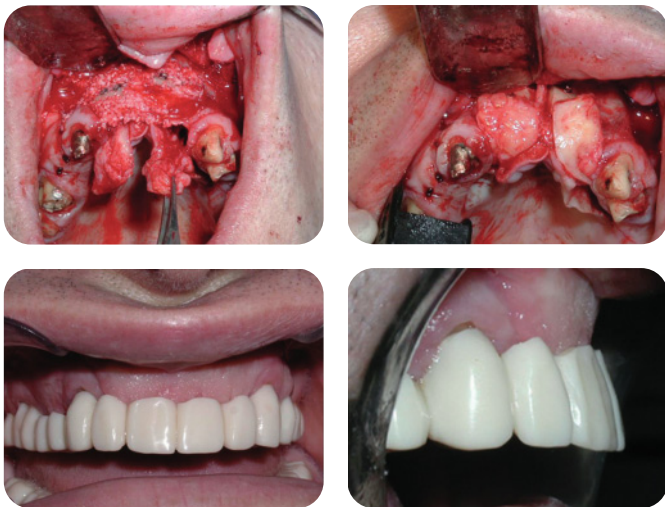

Figure 5.2.16. The top photos are additional views of the soft tissue augmentation procedures, and the bottom photos are several weeks posttreatment with the provisionals modified illustrating the soft tissue enhancement.

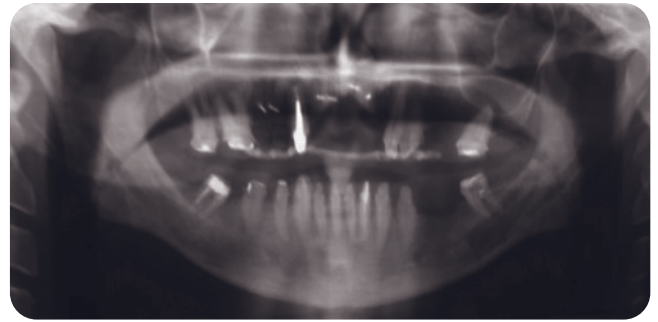


Figure 5.2.17. Interim treatment panoramic radiograph illustrating the bone augmentation segments being held in place with bone screws.

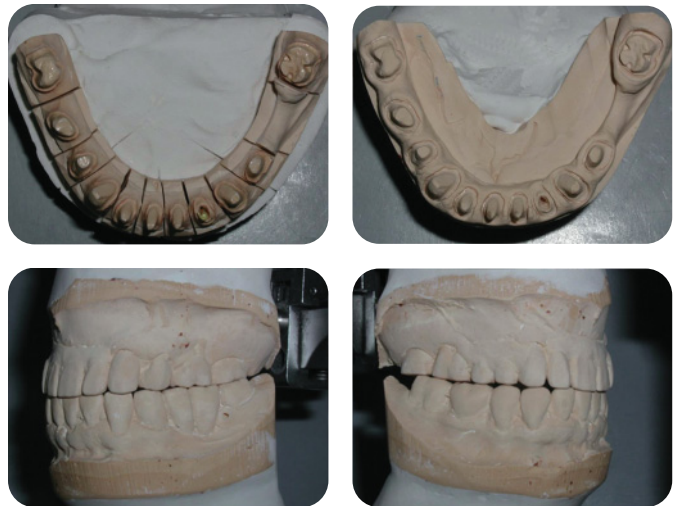

Figure 5.2.18. While the upper surgery is healing the lower definitive dentistry is completed. The top two photos illustrate the pinned die model and the solid cast, which will be used for interproximal contact refinement and for visualization of the soft tissue. The bottom two photos are articulated casts of the provisional restorations.

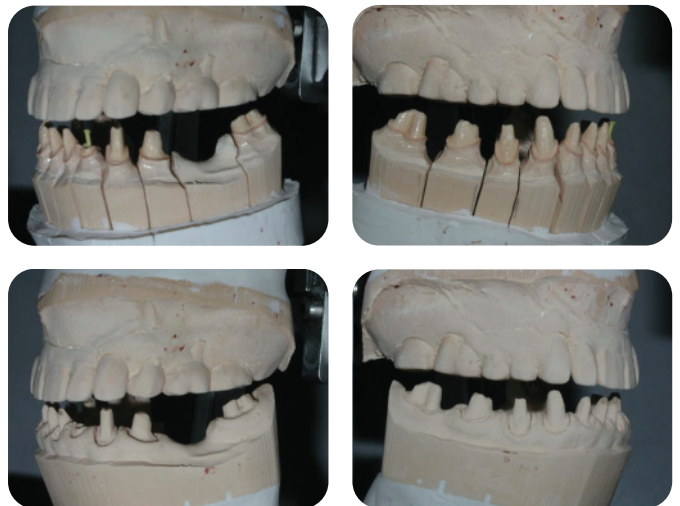


Figure 5.2.19. Both the pinned die model and the solid cast are articulated against the upper model of the provisional restoration.

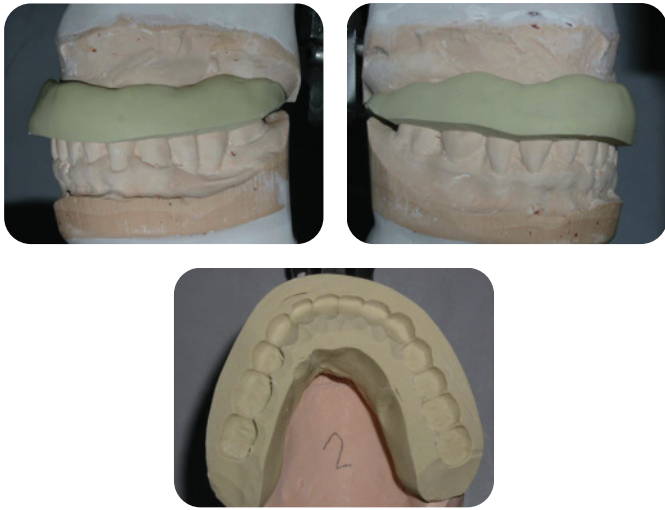

Figure 5.2.20. A putty index capturing the incisal edges and occlusal surfaces of the lower provisional restorations is attached to the upper member of the articulator.

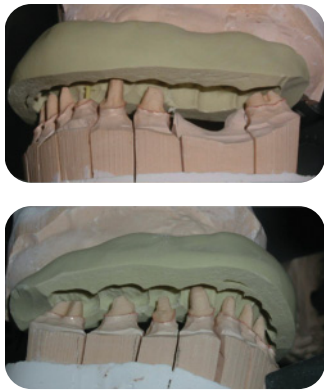


Figure 5.2.21. This putty index can be used by the technician when the lower pinned die model and solid model are on the articulator as a precise guide for lower incisal edge and occlusal surface configuration.

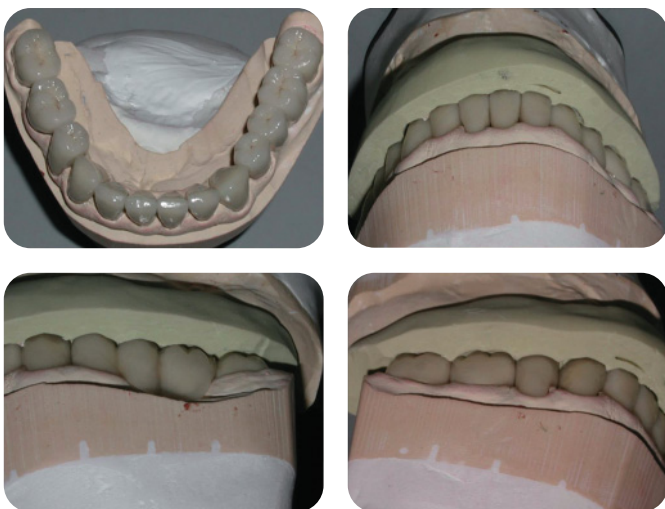


Figure 5.2.22. The completed lower restorations must not only look correct on the lower solid model as the upper left photo illustrates, but they should also fit precisely into the putty index as a verification of incisal edge and occlusal surface position and configuration.

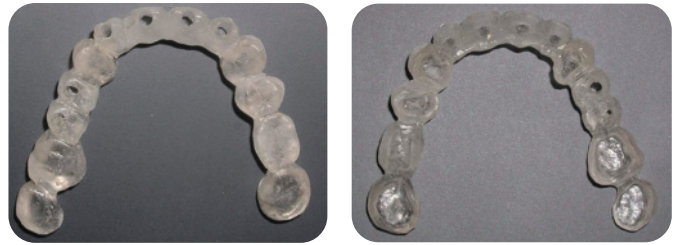


Figure 5.2.23. The maxillary arch is now ready for implant placement by the oral surgeon. A surgical stent is fabricated that fits on the upper tooth preparations and has guide channels to help the surgeon with correct placement and orientation of the upper implants.

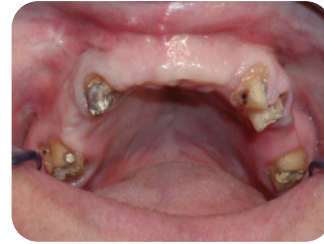

Figure 5.2.24. The top photo was taken immediately after removal of the provisional restoration. The bottom left photo was taken after the flap had been reflected showing the bone screws that were subsequently removed, and the bottom right photo shows the surgical stent in place.

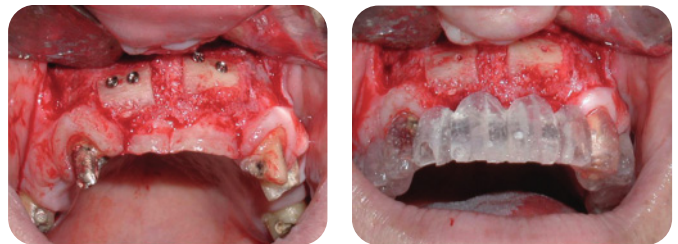


Figure 5.2.25. This photo was taken immediately after implant placement and closure of the gingival tissues.

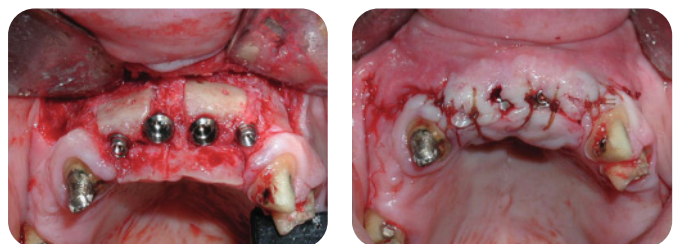

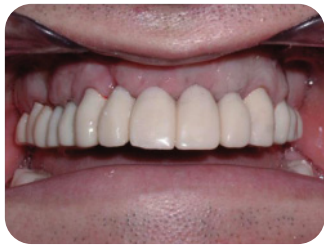


Figure 5.2.26. The provisional restoration is relined and otherwise modified to accommodate the changes just made during implant placement.

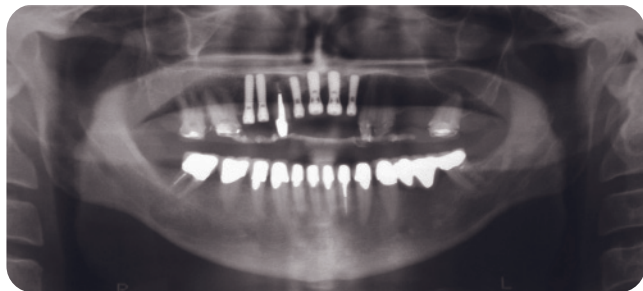


Figure 5.2.27. Interim panoramic radiograph illustrating the placement of the implants. Tooth 6 is still present and being utilized as a provisional abutment until the implants have integrated and can be used to support a new provisional.

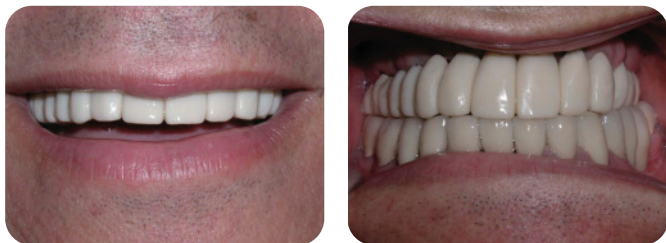

Figure 5.2.28. Anterior smile and retracted photographs of the new implant-supported provisional restoration. At this point number 6 has been extracted and is now a pontic in the implant-supported provisional.

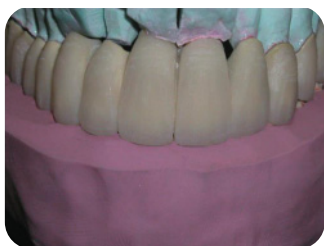

Figure 5.2.29. Direct impressions are made of the modified implant abutments and tooth preparations. The same communication is supplied to the technician and with the lower dentistry. This photo illustrates verification with the putty index.

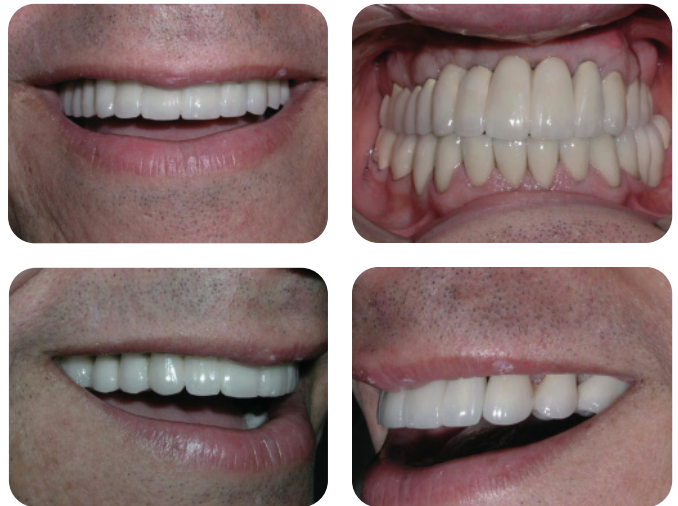

Figure 5.2.30. Photos of the completed upper restoration—frontal and lateral smile views and retracted view. Note the improved support of the upper lip and the improved overbite relationship of the anterior teeth.

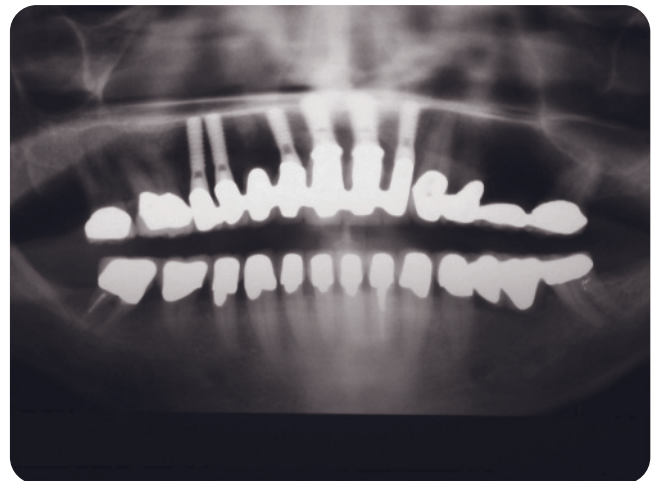


Figure 5.2.31. Panoramic radiograph 5 years posttreatment.

CHAPTER 5 CASE 2 KEY POINTS

- Create visuals on the diagnostic casts specific to the case to help the patient understand the rationale and scope of the treatment, such as anterior tissue augmentation.
- Coordinate appointments with yourself and the specialists to make each appointment as efficient as possible, minimizing the number of appointments.

Chapter 5 Case 3

Lower reconstruction with lower left being implant-supported, important neutral zone consideration affecting design; upper reconstruction landmarks acceptable; temporomandibular disorder managed

The patient in this case study had the upper reconstruction done 3 years prior and is currently in pain in TMJs and muscles. She feels she has to clench hard to get teeth together. Bridge lower right and bicuspid were built up with composite to “open the bite and relieve the pain.” However, the anterior teeth were left out of occlusion, thereby making the anterior

guidance function on posterior teeth. The lower right bridge is now loose. Her desire is to feel more comfortable, and to have her teeth on the lower left replaced. She reported having a 4-unit fixed partial denture for years; however, the molar abutment was lost and the pontic was sectioned from the bicuspid, leaving the cuspid and bicuspid splinted.

SUMMARY OF EXAMINATION AND DIAGNOSIS

Dentition

Many concerns with all upper teeth
Large post and cores, implant connected to natural tooth.

Restorations appear adequate in terms of fit but have very deep restorative margins.

Many concerns with lower teeth: wear; post and cores; inadequate fit of restorations

Periodontium

Grade 1 mobility of many maxillary teeth, painful to palpation—seems to be coming from inflamed tissue due to biologic width violation
Lowers not as problematic as uppers

TMJs

Right side Piper 3B coarse crepitation
Left side Piper 3B coarse crepitation
Neither can be superiorly compressed comfortably.

Palpation tenderness

Range of motion normal but painful in TMJs and muscles

Muscles

Lateral and medial pterygoids very tender to palpation, neck, and face

Occlusion

Right side contact only; upper landmarks acceptable; anterior end-to-end relationship

Aesthetics

Acceptable

THE 10 DECISIONS

1. TMJ Diagnosis

Bite splint—start in treatment position because TMJs are uncomfortable.

Definitive—treat to a guided verifiable adapted centric posture.

2. Vertical Dimension

Open slightly to increase overjet in the anterior tooth-to-tooth relationship.

3. Lower Incisal Edge

Restore and raise to contact upper anterior teeth at new vertical dimension.

4. Upper Incisal Edge

Maintain.

5. Centric Stops

Simultaneous, equal intensity centric stops in the ACP arc of closure

Both anterior and posterior will tend to an end-to-end tooth-to-tooth relationship.

6. Anterior Guidance

Shallow, performance platform will be incisal edges and not lingual surfaces.

7. Curve of Spee

Match to upper, which is acceptable.

8. Curve of Wilson

Match to upper, which is acceptable.

9. Cusp/Fossa Angle

Angle will be shallower and flatter than anterior guidance disclusion angle.

10. Aesthetic Plane

Acceptable; upper does not need changing.

SUMMARY OF TREATMENT PLAN

Dentition

Upper condition does not lend itself to treatment other than extractions and replacements with implant (which patient does not want to do), so it will be maintained as well as possible since functional landmarks are acceptable.

Lower will be treated with full crowns: lower left replaced with implant-supported crowns.

Endodontics/endodontic retreatment as needed, lower

Periodontium

Maintenance and self care

Crown lengthening lower left and right

TMJs

Bite splint therapy followed by definitive occlusal therapy

Muscles

Bite splint therapy followed by definitive occlusal therapy

Occlusion

Build to upper landmarks but at an increased vertical dimension of occlusion.

Anterior will be end-to-end tooth-to-tooth relationship with flat anterior guidance disclusion angle, so posterior anatomy will need to be flat.

Aesthetics

Acceptable

SUMMARY OF TREATMENT SEQUENCE

Appointment

Treatment Completed

- | Appointment | Treatment Completed |
|-------------|---|
| 1 | Bite splint and physical therapist as needed with typical goal of comfort; improve signs and occlusal stability |
| 2 | Provisionalize lower left second bicuspid to lower right molar; provisional removable partial denture for lower left to see whether patient can tolerate; if not, then implants |
| 3 | Periodontal surgery lower left and right |
| 4 | Finalize lower left first bicuspid to lower right molar; patient decided to have implants, did not like removable partial denture |
| 5 | Place 3 implants lower left. |
| 6 | Finalize restorations on implants. |
| 7 | Posttreatment bite splint |

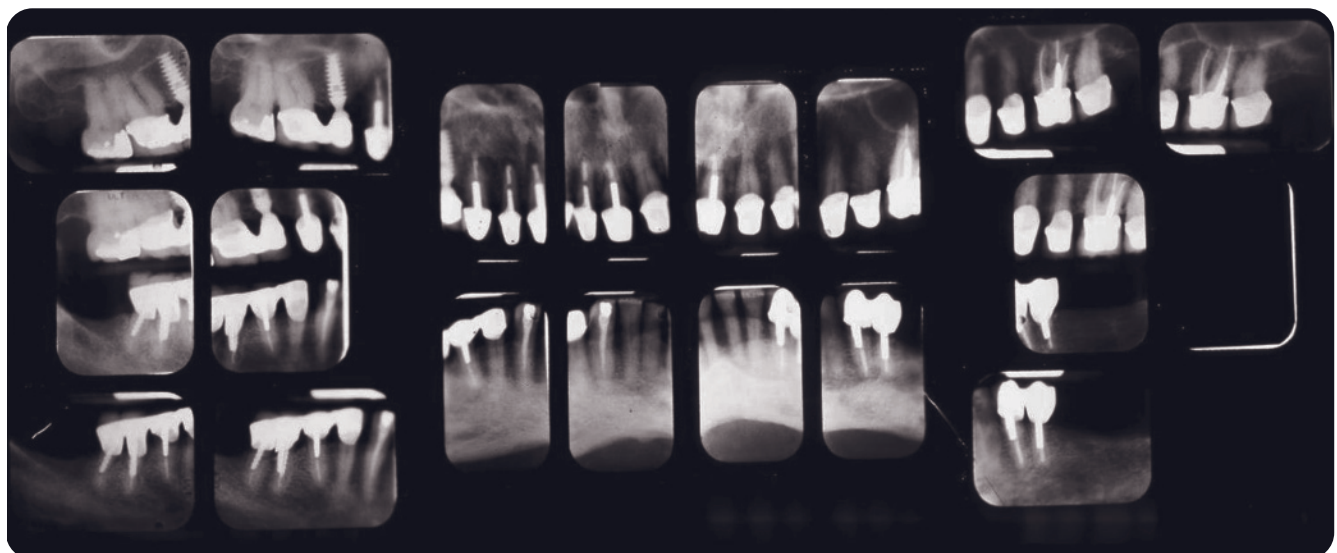


Figure 5.3.1. Pretreatment radiographs suggesting many guarded teeth due to large posts and cores.

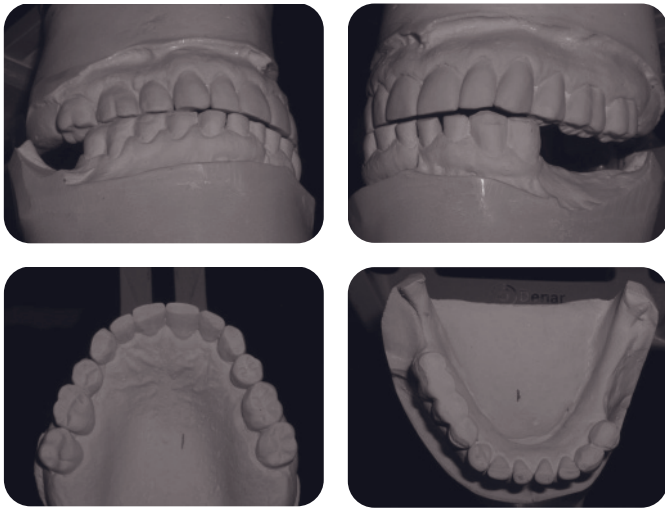


Figure 5.3.2. Pretreatment articulated diagnostic casts illustrating premature occlusal contacts on the right side and suggesting the strain these interferences can place on joints and muscles.

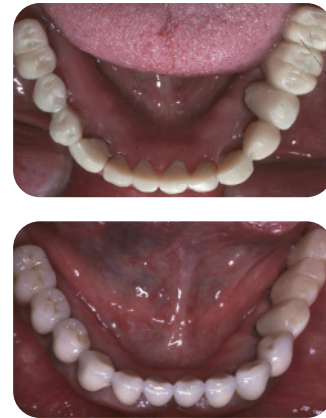

Figure 5.3.4. Photographs of provisionals on implants. Top photo is the first attempt, which was very uncomfortable to the tongue. The implants were lingually placed and therefore implant restorations encroached on the neutral zone. In the bottom photo, the definitive restorations from lower left first bicuspid to lower right first molar are placed. The implant provisionals are thinned even more from the lingual necessitating further reduction of the implant abutments on the lingual.

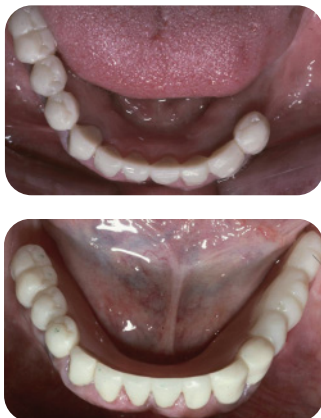

Figure 5.3.3. Lower provisional restorations. Notice the tongue, arch form, and residual ridge lower left suggesting a large tongue space was required. She also has a low tongue posture, so lower arch is wide and therefore has an end-to-end occlusal relationship with the upper. Because of this, she did not tolerate the lower provisional removable partial denture even though it was thinned from the lingual considerably. She decided to have implants and a fixed restoration.

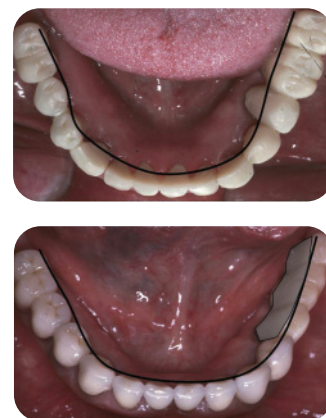

Figure 5.3.5. To eliminate the impingement on the neutral zone that the shaded area suggests, the implants needed to be placed more to the buccal. However, lack of bone in that area made this impossible. The correct approach would have been bone grafting first and then implants placed in a more physiologic position.

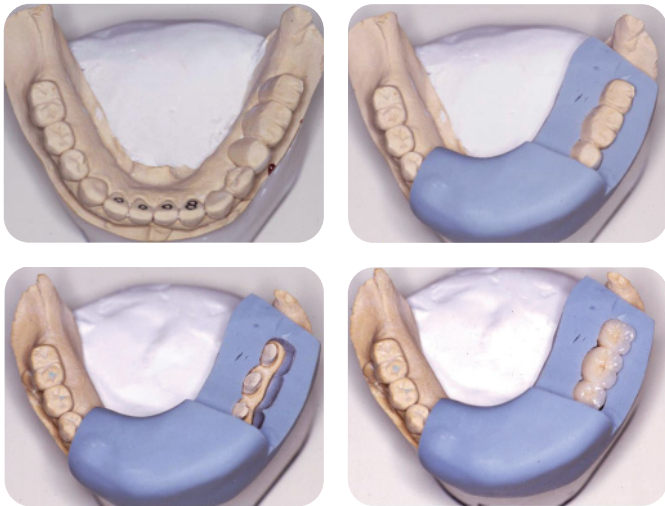


Figure 5.3.6. Photographs of the communication to the technician to assure duplication of provisional contours. Top left: articulated cast of the provisionals. Top right: putty index capturing provisional contours and trimmed to visualize provisionals. Bottom left: putty index on solid cast of implant abutment preparations suggesting minimal clearance on the lingual. Abutments were maximally contoured. Bottom right: contour of the definitive restoration verified with putty index.

CHAPTER 5 CASE 3 KEY POINTS

- Arch form gives information about the neutral zone.
- Verify that implants can be placed within the limits of the neutral zone; if not, consider bone augmentation.

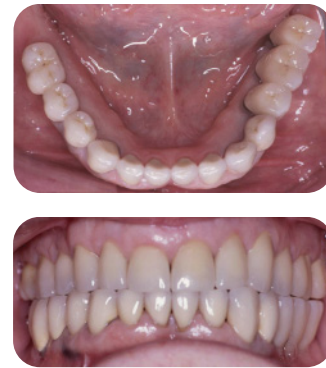

Figure 5.3.7. Occlusal and anterior retracted photographs of the completed restorations. Observe the lower buccal posterior contours left compared to right. Because the implants were placed too far to the lingual, the buccal contours slanted occlusally making food collection an issue because the buccinator could not push the food up. The lack of soft tissue to the buccal also made cantilevering the buccal contours at the gumline impossible. The patient eventually adapted to the contours to a large degree but not 100%.

Chapter 5 Case 4

Maxillary fixed partial denture supported by both teeth and implants along with other maxillary and mandibular implant-supported crowns and tooth-supported crowns and fixed partial dentures

When implants are included with natural teeth, the first choice is to place enough implants so that the implant-supported restorations are independent of the tooth-supported restorations. Sometimes this is not possible, as this case study illustrates, and the resulting fixed partial denture has implant-supported abutments as well as tooth-supported abutments.

This patient had an upper removable partial denture that she disliked. She recently lost tooth number 3 and

the new removable partial denture was intolerable. She tried to wear a lower removable partial denture but was unsuccessful and wants a fixed restoration. She is also unhappy with her smile, which has a reverse curvature. She reports no tooth pain, TMJ, muscle pain, or headaches.

SUMMARY OF EXAMINATION AND DIAGNOSIS

Dentition

Several missing, several heavily restored, but all remaining teeth lend themselves well to restorative procedures.

Removable partial dentures tried unsuccessfully.

Periodontium

Generalized attachment loss but nothing probes over 3.

Minimal attached keratinized tissue, in particular lower bicuspids

Generalized grade 1 mobility

TMJs

Right side Piper 2

Left side Piper 2

Both can be superiorly compressed comfortably.

No palpation tenderness

Range of motion acceptable

Muscles

Lateral pterygoids slight tenderness to palpation

Occlusion

No posterior centric holding contacts

Anterior tooth-to-tooth relationship needs improvement.

Aesthetics

Tooth form, proportion, position

Reverse smile

THE 10 DECISIONS

1. TMJ Diagnosis

Treat to a guided, verifiable adapted centric posture.

2. Vertical Dimension

Acceptable

3. Lower Incisal Edge

Maintain; just smooth and polish.

4. Upper Incisal Edge

Lengthen centrals 1 mm; shorten cuspids 1 mm to achieve a pleasant curve.

5. Centric Stops

Simultaneous, equal intensity contact on all teeth

6. Anterior Guidance

Shallow with restoration because of compromised periodontal support; there is enough tooth structure to do this at current VDO.

7. Curve of Spee

Orient so that upper molars are shortened slightly to improve crown/root ratio.

8. Curve of Wilson

Verify that the upper buccal and lower lingual cusps do not interfere in either the parafunctional or functional range of motion.

9. Cusp/Fossa Angle

Angle will be shallower than anterior guidance.

10. Aesthetic Plane

Verify that the upper buccal cusps follow the general plane of the anterior incisal edges and are level from side to side. Verify that the buccal profiles are symmetrical and pleasing.

SUMMARY OF TREATMENT PLAN

Dentition

Implants 3, 4, 5, 18, 19, 30, 31
 Restore all upper and lower posterior

Periodontium

Simultaneous sinus graft and implant placement
 4, 5

Delayed implant placement 3

Connective tissue grafts lower right and left
 bicuspid area

TMJs

No treatment is needed other than correct
 occlusal engineering.

Muscles

No treatment is needed other than correct
 occlusal engineering.

Occlusion

All parameters of occlusion can be fulfilled in
 reconstruction; simultaneous, equal intensity
 centric stops in the adapted centric posture arc
 of closure with anterior guidance on anterior
 teeth.

Aesthetics

Idealize proportion, contours, and form.
 Improve reverse smile.

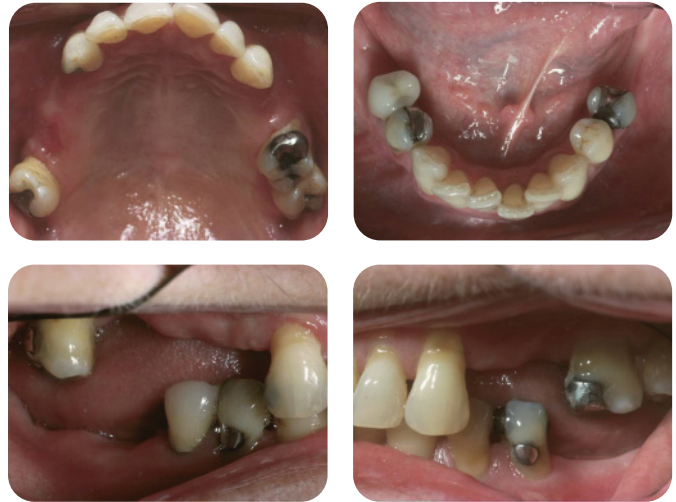

Figure 5.4.1. Preoperative occlusal and buccal photographs.

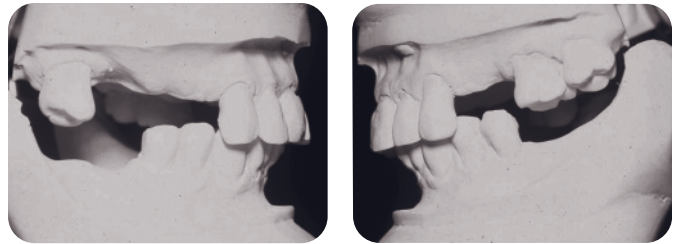


Figure 5.4.2. Preoperative articulated diagnostic casts suggesting occlusal plane issues.

SUMMARY OF TREATMENT SEQUENCE

Appointment	Treatment Completed
1	Provisionalize 2–15.
2	Sinus lift/graft UR Immediate implant placement 4, 5—primary stability possible
3	Connective tissue graft lower left and right
4	Implant placement 18, 19, 30, 31
5	Implant placement 3
6	Finalize lower left and lower right.
7	Finalize 2–15.

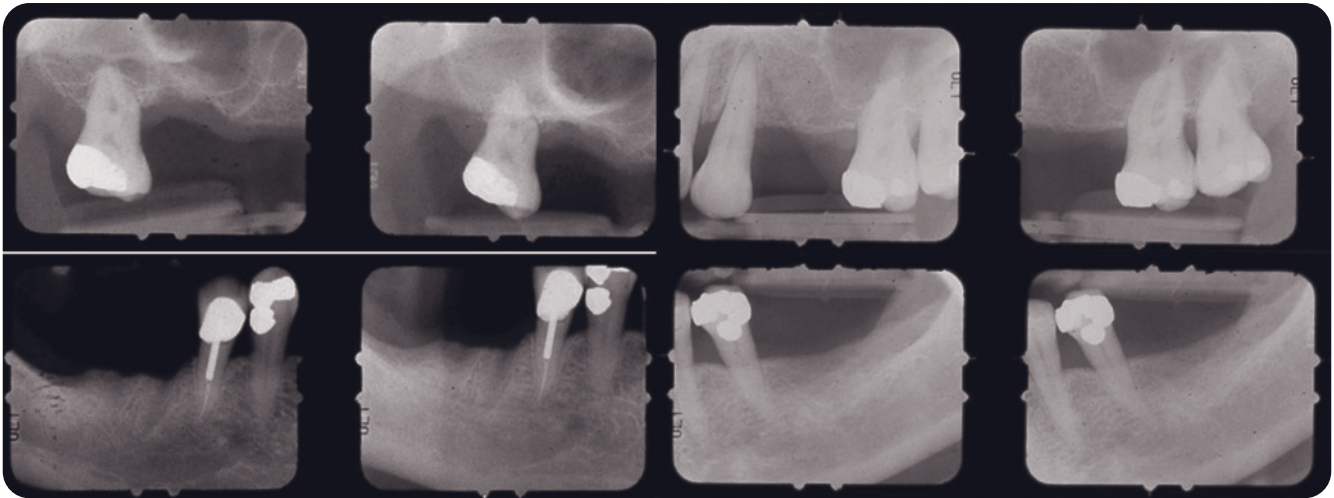


Figure 5.4.3. Preoperative posterior radiographs. The periodontium, although reduced, is maintainably healthy. There is generalized grade 1 mobility. Note sinus anatomy upper right.

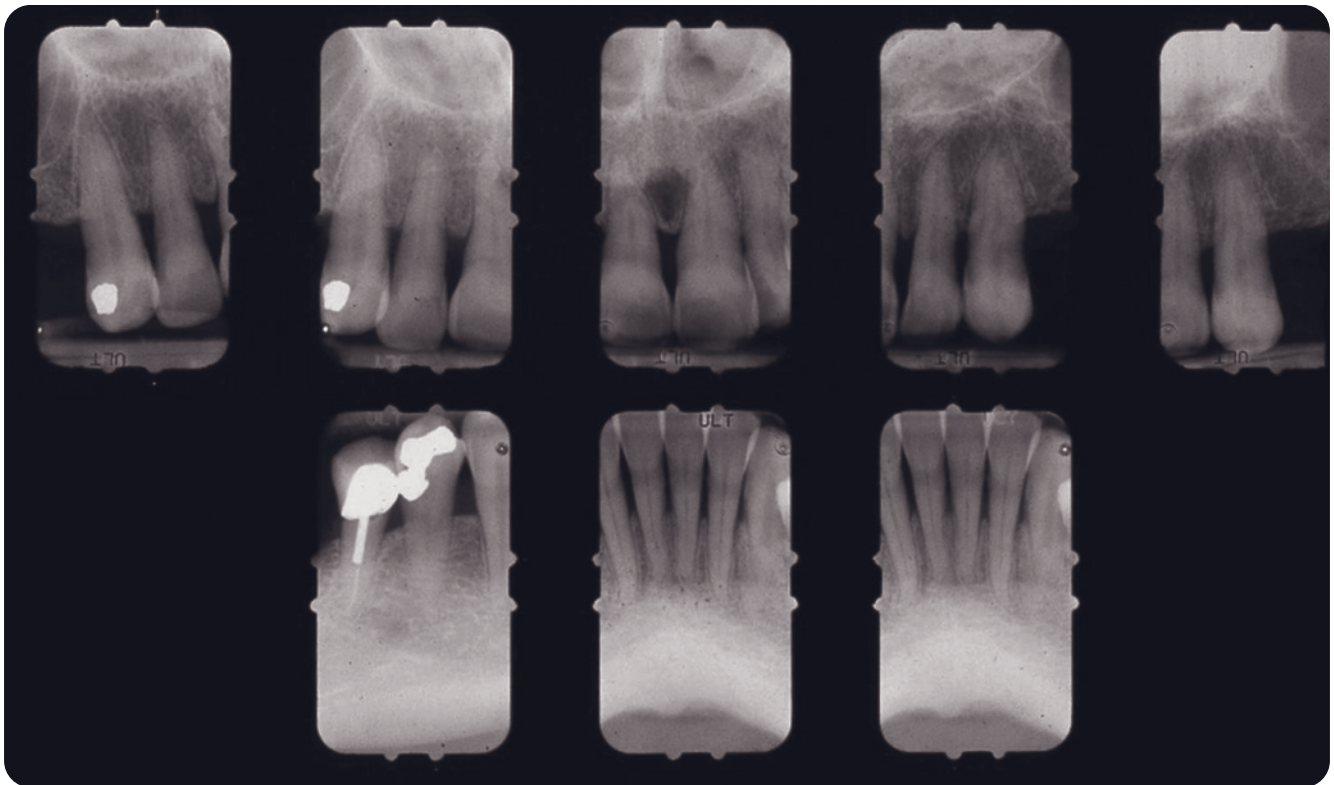


Figure 5.4.4. Preoperative anterior radiographs. The periodontium, although reduced, is maintainably healthy. There is generalized grade 1 mobility.

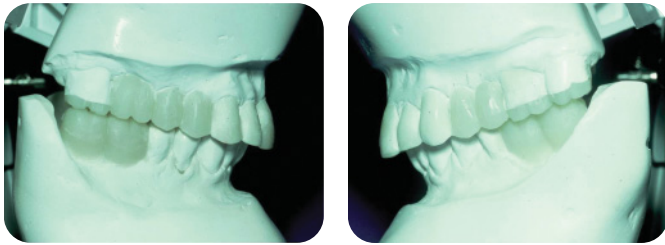


Figure 5.4.5. Diagnostic blueprint. Note occlusal plane changes and increase in length of central incisors.

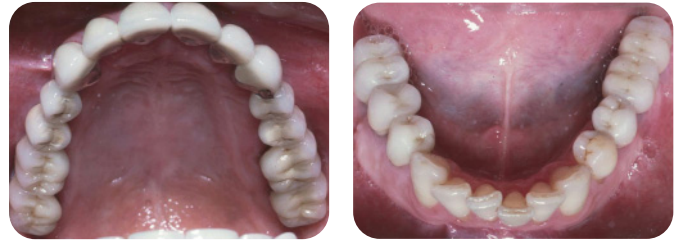

Figure 5.4.8. Photographs of completed upper and lower restorations. Note implant 31 was lost prior to abutment placement and was not redone.

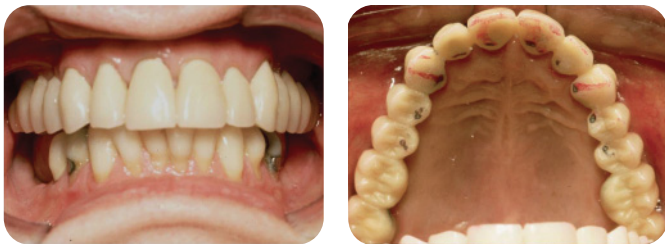

Figure 5.4.6. Anterior retracted and occlusal photos of first provisional restoration. Note definitive centric stops anteriorly and on bicuspid as well as anterior guidance on anterior teeth.

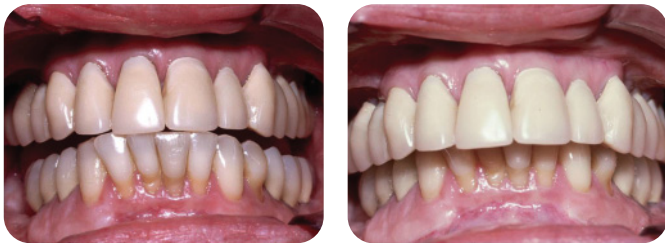

Figure 5.4.7. Protrusive end-to-end photograph and anterior retracted photograph after provisional modification from upper surgery. Note lower bicuspid's connective tissue grafts done. Lower definitive restorations have been completed.

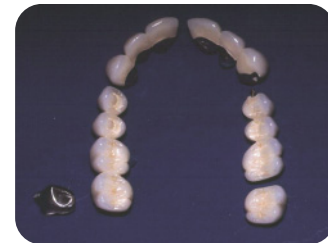

Figure 5.4.9. Photograph of the design of the upper restoration. Implant 3 was not placed at the patient's request and the restoration was finalized as a fixed partial denture from tooth 2 to implants 4 and 5, with 3 being a pontic. A coping was definitively cemented on tooth 2 and the fixed partial denture placed from coping 2 to implant 4, 5 with a retrievable cement. Upper cuspid-lateral-central were splinted to control mobility. All 6 were not splinted because splinting 3 teeth controlled the mobility. A precision attachment was placed between the upper left cuspid abutment and pontic bicuspid to prevent overreduction of teeth to get a line of draw. Restoration 15 was a single unit because mobility was not an issue.

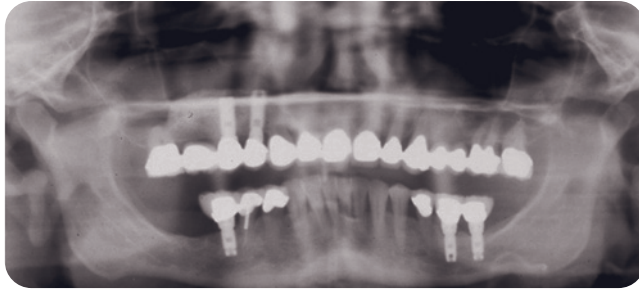


Figure 5.4.10. Posttreatment panoramic radiograph. Note sinus graft upper right.

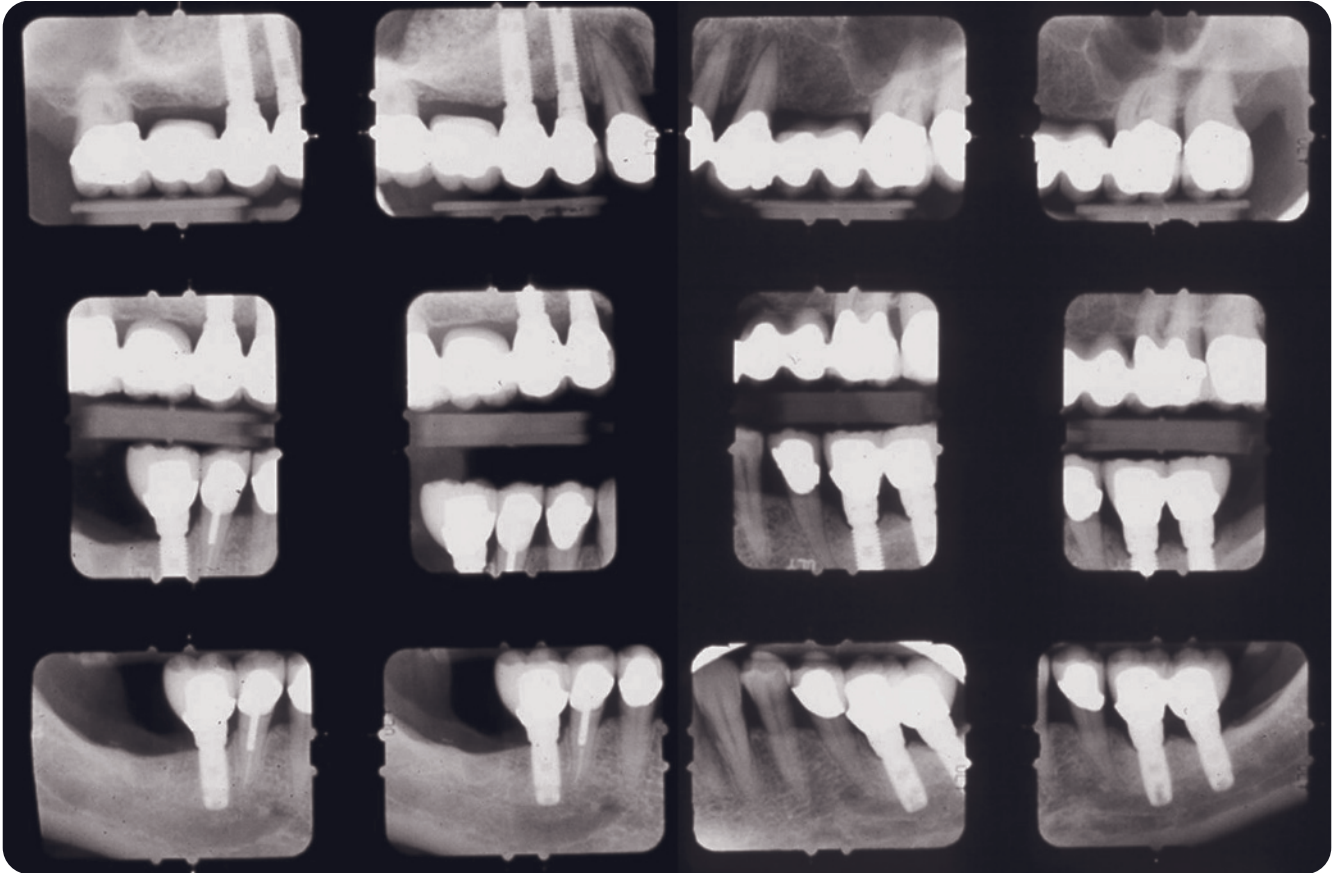


Figure 5.4.11. Posttreatment periapicals.

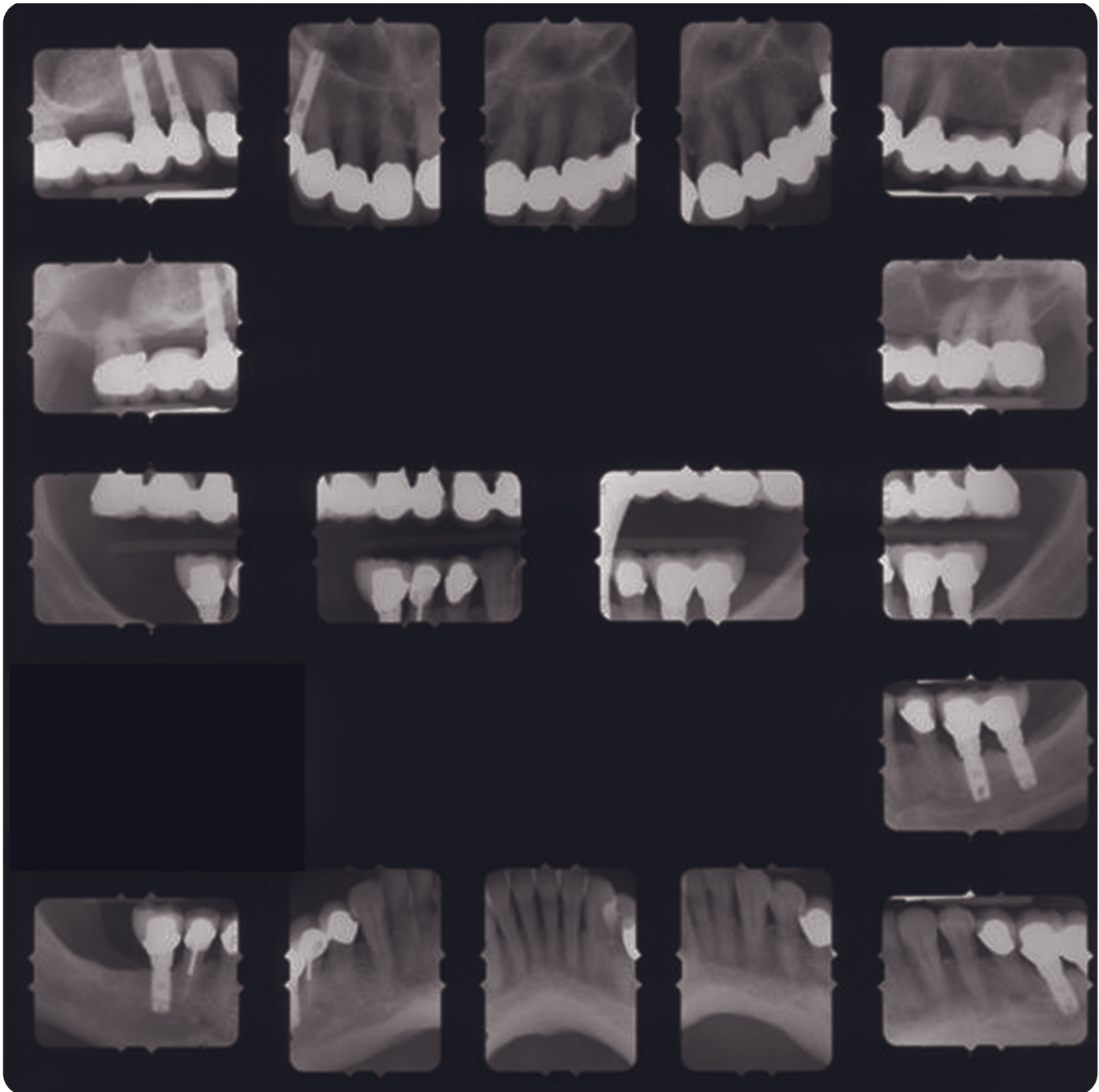


Figure 5.4.12. Seven-year follow-up radiographs. Note bone levels have stayed consistent, as have mobilities.

CHAPTER 5 CASE 4 KEY POINTS

- In complex treatment plans, patients sometimes change course despite our best efforts at communication.
- If implant restorations must be splinted to natural tooth restorations, consider telescope copings on the natural teeth.

Chapter 5 Case 5

Maxillary extractions, periodontal surgery, orthodontics, veneers, and fixed partial dentures on teeth; mandibular extractions, implants, fixed partial dentures on teeth and implants

The patient in this case study had a myriad of dental and periodontal problems that caused a loss of teeth, loss of vertical dimension, and flaring of the anterior teeth. Each patient's motivation to begin a reconstruction is a unique, individual thing. This patient's dentition had deteriorated to the point that it affected his appearance, comfort, and function. His reconstruction resulted in a fixed dentition on natural teeth and dental implants.

SUMMARY OF EXAMINATION AND DIAGNOSIS

Dentition

Failing restorations, wear, migration

Periodontium

Periodontal disease characterized by 6+ mm pockets

TMJs

Right side Piper 1

Left side Piper 1

Both can be compressed without discomfort.

Muscles

Test normally

Occlusion

Loss of posterior support, loss of vertical dimension

Aesthetics

Color, contour, proportion, position

THE 10 DECISIONS

1. TMJ Diagnosis

Treat to a guided centric relation.

2. Vertical Dimension

Open 4 mm to gain space to orthodontically retract the maxillary incisors.

3. Lower Incisal Edge

Use the position of the lower left cuspid as a guide.

4. Upper Incisal Edge

Use the position of the upper right cuspid as a guide.

5. Centric Stops

Simultaneous, equal intensity centric stops in the centric relation arc of closure

6. Anterior Guidance

This is determined by final maxillary and mandibular incisal edge position, restoratively and orthodontically; it will be steeper than original.

7. Curve of Spee

Idealize with implant restoration, using cuspids as an anterior reference.

8. Curve of Wilson

Verify that the upper buccal and lower lingual cusps do not interfere in either the functional or parafunctional ranges of motion.

9. Cusp/Fossa Angle

Angle will be shallower than the anterior guidance.

10. Aesthetic Plane

Upper left needs to be raised several millimeters. Create an upper posterior aesthetic plane that is consistent with the upper incisal edge position and with pleasing buccal profiles.

SUMMARY OF TREATMENT PLAN**Dentition**

Fixed partial dentures from maxillary cuspids back

Maxillary incisor veneers

Mandibular anterior fixed partial denture

Mandibular posterior implant-supported fixed partial dentures

Periodontium

Extract hopeless maxillary right first bicuspid, mandibular right first bicuspid, and mandibular incisors.

Periodontal surgery all areas

Dental implants mandibular posterior

TMJs

No treatment is needed other than correct occlusal engineering.

Muscles

No treatment is needed other than correct occlusal engineering.

Occlusion

Simultaneous, equal intensity centric stops in the centric relation arc of closure; anterior guidance on anterior teeth

Aesthetics

Improve position with orthodontics.

Improve color, contour, proportion with veneers.

Improve aesthetic plane with fixed partial dentures.

SUMMARY OF TREATMENT SEQUENCE**Appointment****Treatment Completed**

1	Prepare teeth for provisionals. Directly to the periodontist for extractions, periodontal surgery, two implants lower left, two implants lower right, bone graft lower right first bicuspid Back to office for provisional and mandibular removable partial denture placement
2	Begin orthodontics to retract maxillary incisors.
3	Place implant lower right first bicuspid.
4	Continue and finish orthodontics.
5	Place mandibular implant abutments and provisionals. Splint maxillary incisors with Ribbond.
6	Impressions for lower anterior fixed partial denture and lower posterior implant fixed partial dentures
7	Place lower definitive restorations. Minimal preparation maxillary incisor veneers Impressions for maxillary definitive restorations
8	Place maxillary definitive restorations.
9	Ongoing periodontal maintenance

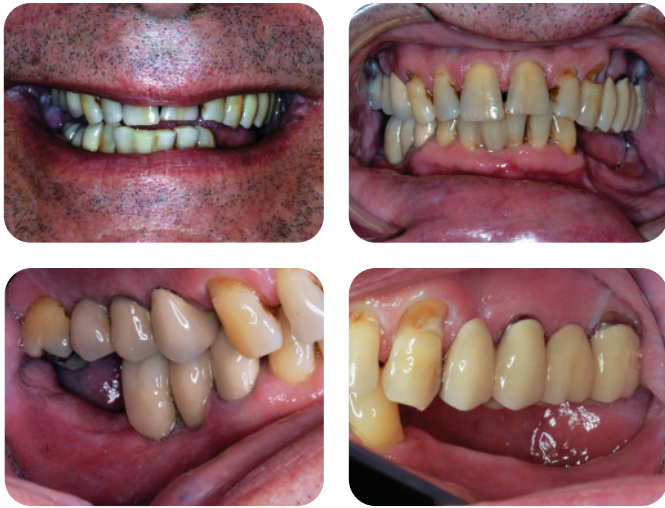

Figure 5.5.1. Pretreatment photographs illustrating a multitude of problems. Issues have been addressed nondefinitively just to keep the situation patched together. There can be many reasons that patients postpone treatment for a problem that they know is obvious. One big reason is finding a dentist and office with whom they feel comfortable and can trust with their care. Another reason can be that patients cannot visualize the outcome. This patient reported never having a complete exam or detailed diagnosis and treatment plan. Options were explained in a limited fashion. A complete examination and diagnostic blueprint with photographs of patients treated with similar problems helps a patient visualize the outcome and at the same time goes a long way toward building trust.

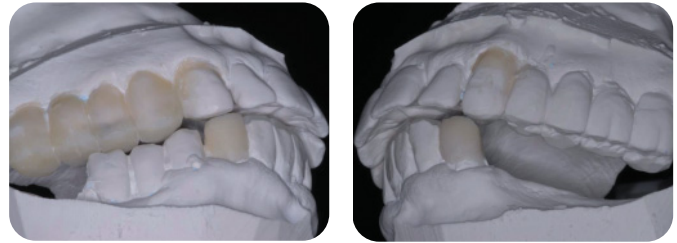
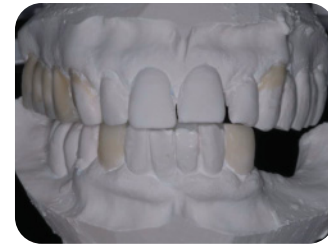

Figure 5.5.3. Initial diagnostic wax-up. The functional landmarks were corrected and the vertical dimension opened by creating definitive centric holding contacts on the cuspids. The lingual of the maxillary cuspids was enhanced horizontally to create the definitive stop. These cuspid stops by themselves will support the vertical dimension of occlusion. Note the space on the lingual of the maxillary incisors for orthodontic retraction. The lower right posterior teeth, though present on the cast, will be removed. The transitional removable partial denture will help with mastication and is not needed to support the vertical dimension.

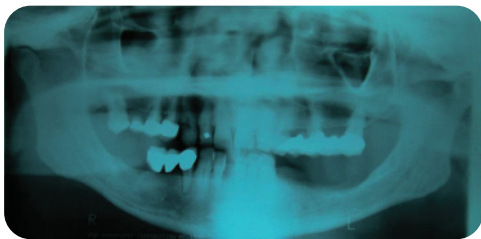
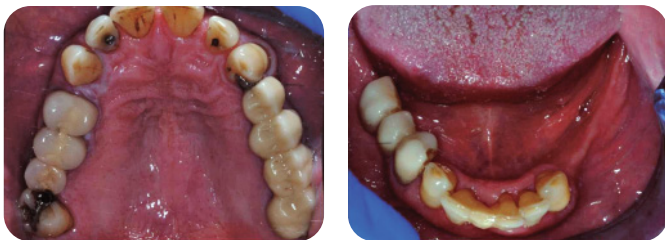
Figure 5.5.2. Pretreatment occlusal photographs and panoramic radiograph. An avulsed lower incisor was bonded to the surrounding tooth and a hopeless abutment extracted leaving a double cantilever on a first bicuspid.

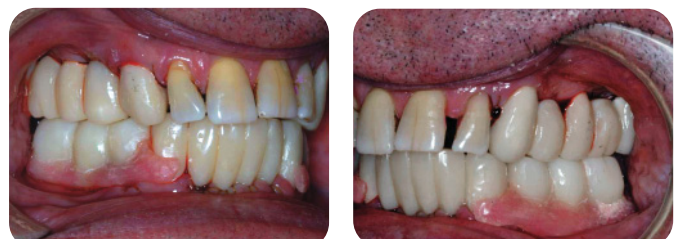
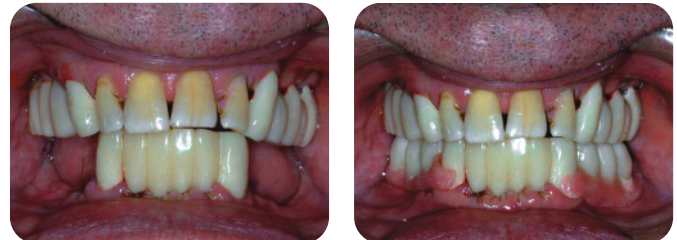
Figure 5.5.4. Photographs immediately after the first phase. The patient returned from the periodontist for placement of the provisionals. The mandibular removable partial denture provisional is fabricated in the office and used short-term. Impressions were made of the cemented fixed provisionals and a laboratory-processed provisional partial denture was made. As stated previously, the cuspid-to-cuspid centric holding contacts hold the vertical dimension at a position that creates room to retract the maxillary incisors.

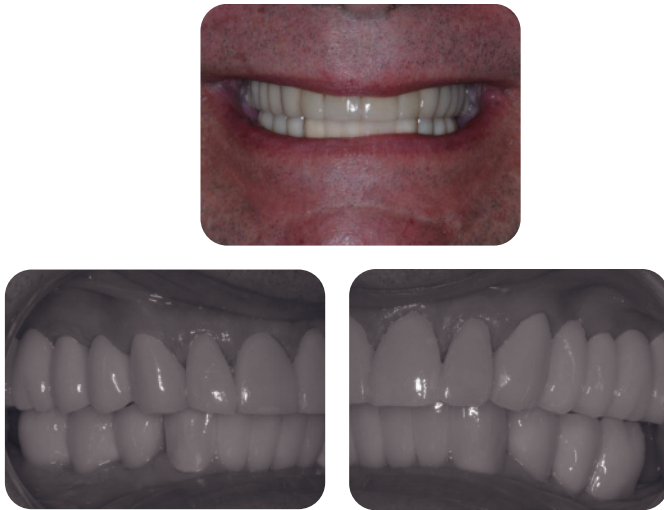

Figure 5.5.5. Smile and retracted photographs of the completed dentistry.

CHAPTER 5 CASE 5 KEY POINTS

- With missing posterior teeth, the anterior tooth-to-tooth centric stop design has to be such that it alone supports the vertical dimension.
- Limited, problem-specific orthodontics can improve landmarks significantly.

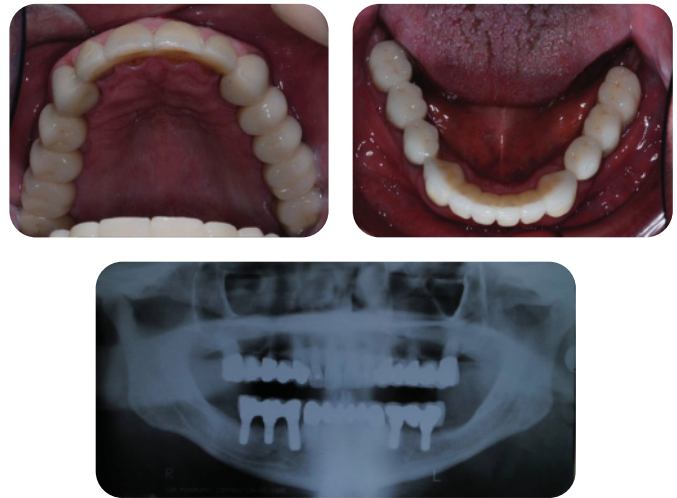

Figure 5.5.6. Occlusal photographs of the completed dentistry and posttreatment panoramic radiograph. The maxillary incisors are splinted with Ribbond reinforced composite and then restored with veneers. This approach was utilized as a more conservative option compared to full crown preparations, which would have been extensive due to the gingival recession. The patient also desired an approach that did not involve cutting down the incisors for crowns, if possible. The patient was very pleased with the aesthetic and functional result. In addition, he commented that he feels much healthier not only orally and dentally but also in general.

Chapter 5 Case 6

Multiple congenitally missing teeth, past orthognathics/orthodontics, tooth position inconsistencies handled restoratively, multiple implants, tooth-supported crowns and fixed partial dentures, implant-supported crowns and fixed partial dentures

The young lady in this case study had spent most of her life in some sort of dental treatment to handle her dental issues. Prior to referral, she had recently completed orthognathics, orthodontics, and bone grafting and was “ready to go” with the implant reconstruction. The patient and parents were troubled because no comprehensive treatment plan was formulated with a clear visualization of the outcome. This prompted them to seek care elsewhere and they were referred to our practice. The complete examination, diagnostic blueprint, and close communication with the oral surgeon gave them the confidence and trust to move forward.

SUMMARY OF EXAMINATION AND DIAGNOSIS

Dentition

The remaining natural teeth except the mandibular incisors are predictably restorable. Anterior tooth positions are not ideal for correct proportions of restorations.

Periodontium

No issues with remaining savable natural teeth
Recently completed grafts for implant placement

TMJs

Right side Piper 3B
Left side Piper 3B
Neither can be compressed without discomfort.
Discomfort upon palpation and range of motion tests

Muscles

Many painful to testing

Occlusion

The only contacts in the arc of closure and maximum intercuspation are right molars.

Aesthetics

Position, contours, proportions

THE 10 DECISIONS

1. TMJ Diagnosis

Initial; treatment position

Managed with provisionals rather than bite splint
Reconstruction completed in adapted centric posture

2. Vertical Dimension

Closed 1 mm from first contact on right molars

3. Lower Incisal Edge

Use height of lower right cuspid as a reference; lower the rest of the plane to that level.

4. Upper Incisal Edge

Use maxillary right central incisor as a reference; right cuspid will be shortened 2 mm and left cuspid will be lengthened 1 mm to that reference.

5. Centric Stops

Simultaneous, equal intensity centric stops in the adapted centric posture arc of closure

6. Anterior Guidance

This is determined by final upper and lower incisal edge position; the goal is a 3 mm overbite.

7. Curve of Spee

Mandibular molars are on the same horizontal plane and will be the reference. Maxillary right will be shortened and maxillary left will be lengthened.

8. Curve of Wilson

Verify that upper buccal and lower lingual cusps do not interfere in the functional and parafunctional range of motion.

9. Cusp/Fossa Angle

Angle will be shallower than the anterior guidance disclusive angle.

10. Aesthetic Plane

Create an upper posterior aesthetic plane that is consistent with the upper incisal edge position, making the changes outlined in the Curve of Spee decision above and with pleasing buccal profiles.

SUMMARY OF TREATMENT PLAN**Dentition**

Remove mandibular incisors.
 4 maxillary implants
 6 mandibular implants
 Crowns and fixed partial dentures using remaining natural teeth except the mandibular molars, which are in the correct functional position
 Tooth position and proportion managed restoratively: center maxillary midline; 2 pontics between maxillary right central incisor and cuspid; "close" maxillary left lateral incisor space; 6 teeth between mandibular cuspids due to excessively wide space

Periodontium

Bone grafting previously completed
 Soft tissue grafting needed in all implant sites and maxillary anterior edentulous areas
 Level tissue on maxillary right central and cuspid to maxillary left
 Crown lengthening maxillary right molar

TMJs

Managed with occlusal management in provisionals rather than a bite splint
 Definitive occlusal management with the reconstruction

Muscles

Managed with occlusal management in provisionals rather than a bite splint
 Definitive occlusal management with the reconstruction

Occlusion

Simultaneous, equal intensity centric stops in the adapted centric posture arc of closure with anterior guidance on anterior teeth with immediate posterior disclusion

Aesthetics

Color, contours, position, and proportions idealized with the restorations

SUMMARY OF TREATMENT SEQUENCE

Appointment	Treatment Completed
1	Prepare natural teeth for provisionals, except mandibular molars. Directly to surgeon for extractions, placement of all implants and soft tissue grafts Back to the office for provisional placement Provisionals are not attached to any implants; mandibular premolar pontics are cantilevers resting on the healing caps.
2	Manage provisionals. Monitor and adjust occlusion on the provisionals utilized like a bite splint.
3	Remove provisionals and check implants.
4	Place mandibular implant abutments. Finalize preparations and impressions. Modify provisionals.
5	Place definitive mandibular restorations. Place maxillary implant abutments. Finalize preparations and impressions. Modify provisionals.
6	Place all definitive maxillary restorations.

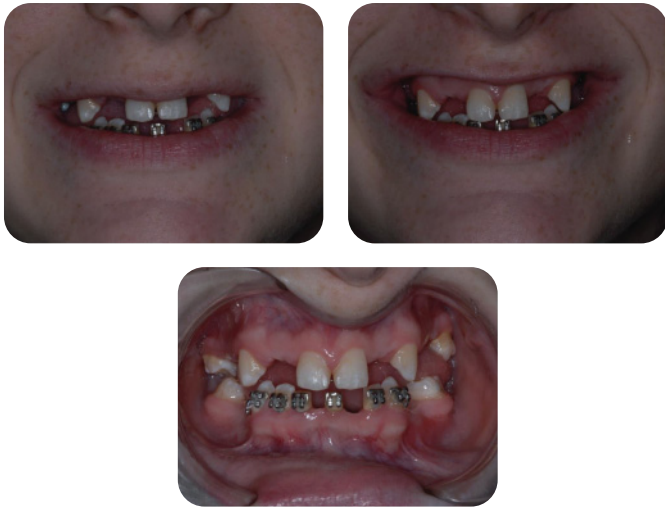

Figure 5.6.1. Pretreatment smile and retracted photographs. Note the canted maxillary and mandibular incisal planes, the canted maxillary occlusal plane, uneven gingival levels, maxillary midline to the right of center, and excessive edentulous space maxillary right incisor area. The mandibular molars interestingly are on the same horizontal plane and therefore can be used as a correct reference.

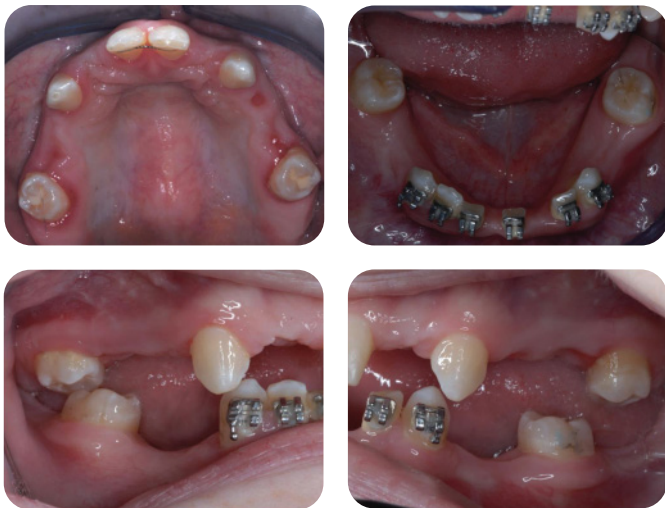

Figure 5.6.2. Pretreatment occlusal and buccal occluded photographs. The maxillary right molars are the only contacting teeth in the arc of closure and maximum intercuspation. This will be a vertical dimension reference.

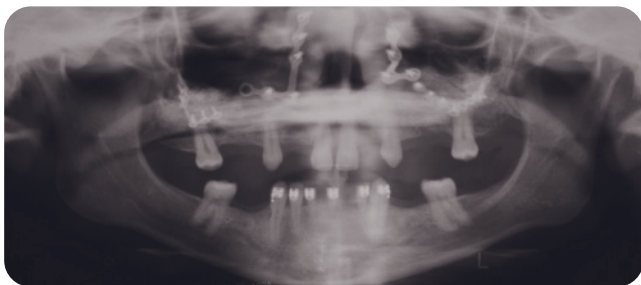


Figure 5.6.3. Pretreatment panoramic radiographs illustrating past orthognathic surgery and bone grafts.

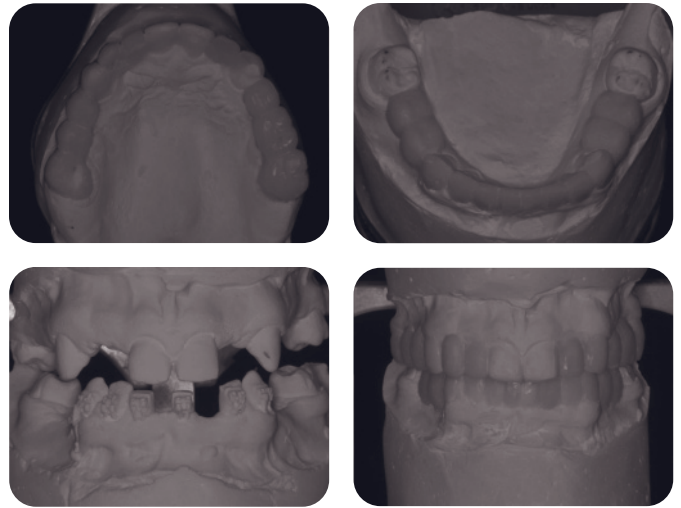


Figure 5.6.4. Diagnostic wax-up photographs. The incisal and occlusal planes were leveled. The maxillary midline was moved to the left making more room for two pontics in the maxillary right anterior edentulous area. The maxillary left cuspid was moved mesially decreasing the space for the left lateral incisor pontic. It was obvious from the wax-up that a soft tissue graft was needed to create a cuspid prominence for the maxillary right cuspid pontic. Although the presenting scenario may reveal positional shortcomings, the truth can always be discovered with the diagnostic wax-up. If an acceptable solution can be designed, both dentist and patient can move forward. If an acceptable solution cannot be found, we would know that more orthodontics would have been necessary. This is just another example of the benefits of the dentist being intimately involved with every step of the wax-up, either personally or with the technician.

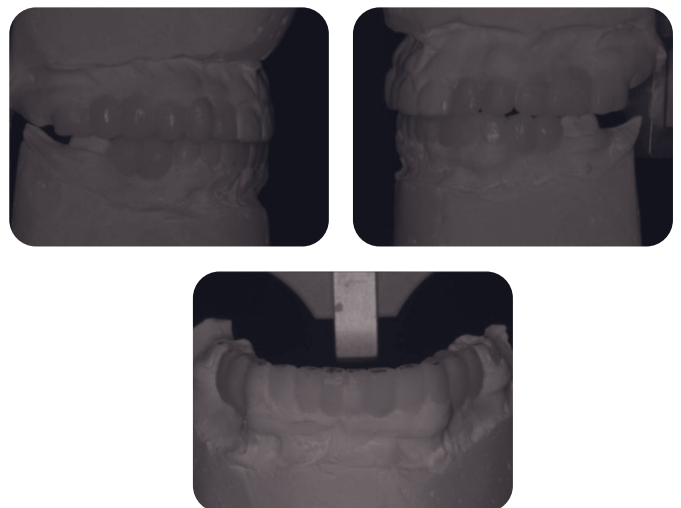


Figure 5.6.5. Diagnostic wax-up photographs. The mandibular molars are correctly positioned functionally, and therefore they are not changed and are used as a reference for functional landmarks for the rest of the teeth. The maxillary left posterior teeth are visually longer occlusogingivally but need to be this way to create a level maxillary aesthetic and functional plane.

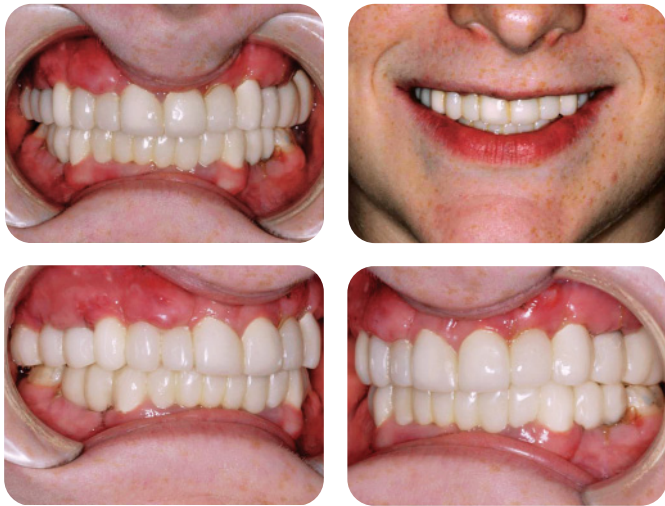

Figure 5.6.6. Provisional photographs 2 weeks after the first phase. Based on the CAT-scan diagnosis and the diagnostic wax-up, all surgical treatment was completed in one surgical appointment. These provisionals were utilized as a bite splint to help resolve the intracapsular and muscular component of the temporomandibular disorder. The patient was anxious to begin treatment, so a separate bite splint phase was forgone, using the provisionals. Three to four months was needed for healing and integration of the implants, so the provisionals not only restored form and function, giving a tremendous emotional lift to the patient, but also allowed the opportunity for resolution of the temporomandibular disorder.

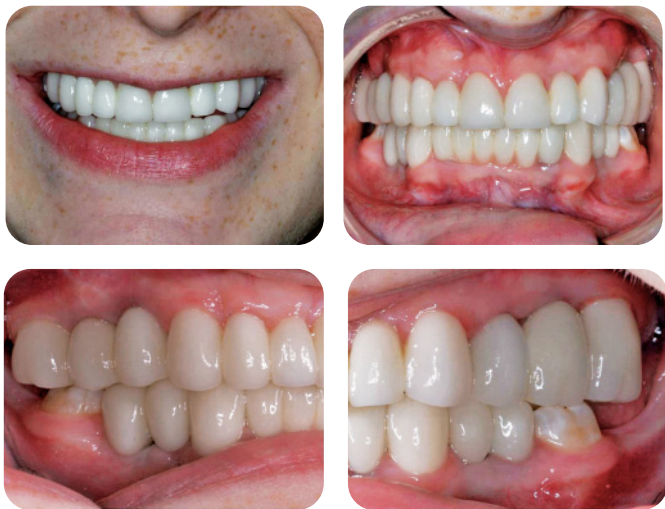

Figure 5.6.7. Photographs of the finished restorations. Pink porcelain was used to simulate mandibular anterior papilla. Although the anterior teeth proportions are not ideal, they are certainly acceptable and far exceeded the patient's expectations. The only other option was additional orthodontics, which the patient would not have been able to tolerate emotionally.

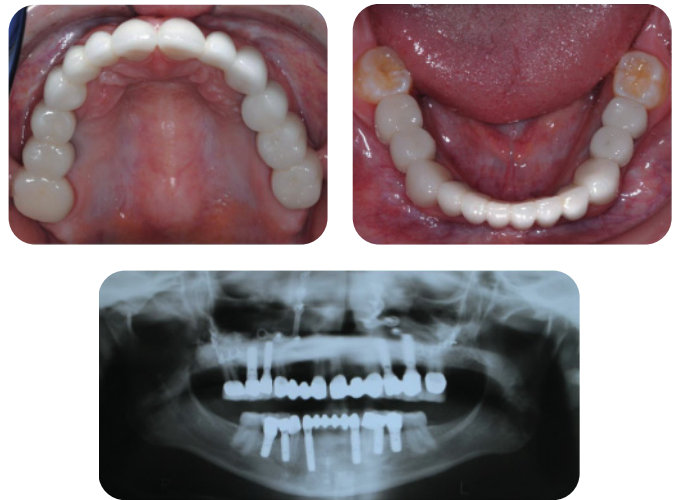

Figure 5.6.8. Occlusal photographs of the finished restorations and posttreatment panoramic radiograph. All posterior implant restorations were splinted at the request of the surgeon because some had a narrow diameter and additional bone grafting was needed. Occlusal anatomy was kept shallow to minimize any possibility of lateral excursive incline interferences.

CHAPTER 5 CASE 6 KEY POINTS

- Careful planning and coordination of appointments with the surgeon allows even complex care to be delivered in a timely manner.
- Correct posterior functional landmarks, such as a level occlusal plane, take precedence over occlusal-gingival length.

6

TM Disorders Followed by Reconstruction

Case 1 Osteoarthritis of the left TMJ managed with bite splint therapy followed by implant-supported restorations and tooth-supported restorations

Case 2 Intracapsular and muscular components of a temporomandibular disorder managed with bite splint therapy followed by occlusal therapy and a full reconstruction

Case 3 Intracapsular and muscle disorder resolved with bite splint therapy followed by occlusal reconstruction with maxillary lingual porcelain veneers

Case 4 Intracapsular and muscle disorder with resultant occlusal plane asymmetry resolved with bite splint therapy and followed by occlusal therapy with restoration only on the lower left

Case 5 Past condylar replacement due to avascular necrosis followed by posterior occlusal reconstruction

Case 6 Temporomandibular disorder resolved with bite splint therapy followed by definitive occlusal therapy including a maxillary reconstruction and mandibular functional changes with composite

Case 7 Past mandibular orthognathic surgery to correct maxillary to mandibular malrelationship caused by condylar degeneration; intracapsular and muscle pain resolved with bite splint therapy followed by definitive occlusal therapy with posterior reconstruction and anterior composites

See also:

Chapter 15 Case 1 Maxillary extensive bone graft followed by implant-supported bars and bar-supported overdenture after managing a temporomandibular disorder; flange needed for lip support necessitating a removable rather than a nonremovable approach

Chapter 16 Case 1 Severe anterior overjet handled with occlusal/restorative treatment in lieu of orthognathics; muscular component of a temporomandibular disorder also managed

Chapter 6 Case 1

Osteoarthritis of the left TMJ managed with bite splint therapy followed by implant-supported restorations and tooth-supported restorations

Often our patients in need of restorative dentistry also have temporomandibular joint concerns. This patient had severe osteoarthritis of the left condyle. It was pain-free, but its instability and resultant occlusal instability was a contributing factor in the failure of his current restorative dentistry. The rationale for bite splint therefore was not to control pain but rather to assess the stability of the joints. Lack of stability of occlusion on the splint suggests lack of TMJ stability. It takes time for stabilization to occur because bone, connective tissue, and fibrocartilage must heal, remodel, and adapt. Even when our goals are

achieved, we cannot expect this joint to stay absolutely stable over time. So we and our patient must accept and be ready for ongoing occlusal refinements.

SUMMARY OF EXAMINATION AND DIAGNOSIS

Dentition

Failing restorations
Endodontic concerns
All teeth restorable
Edentulous in all quadrants

Periodontium

Biologic width concerns
Crown length concerns—resistance and retention

TMJs

Severe degenerative osteoarthritis, left side
R Piper 3B
L Piper 4B
No symptoms other than “stiffness” left side
Both can be superiorly compressed.
Big question is stability

Muscles

Lateral pterygoids tender to palpation

Occlusion

Interferences and slide from seated condylar posture
Occlusal plane issues, excursive interferences

Aesthetics

Length, proportion, and gingival levels need to be improved.
Occlusal plane, upper left, too low

THE 10 DECISIONS

1. TMJ Diagnosis

Bite splint therapy—start in a treatment position with the goal of stability of the occlusion on the bite splint for a period of four consecutive months.

Postsplint therapy, treat to a bimanually guided adapted centric posture.

2. Vertical Dimension

Acceptable; there is no need to change it.

3. Lower Incisal Edge

Position is acceptable; just smooth and polish.

4. Upper Incisal Edge

Increase the length of the central incisors 1 mm. Use that as a starting point for the rest of the upper anterior teeth.

5. Centric Stops

Design stable tooth-to-tooth holding contacts on anterior and posterior teeth with the condyles in adapted centric posture and anterior guidance on anterior teeth.

6. Anterior Guidance

Shallow performance platform slightly—this is possible at the current vertical dimension of occlusion.

7. Curve of Spee

Keep the curve and shallow end flat as possible because of TMJ condition.

8. Curve of Wilson

Verify no interference on the upper buccal and lower lingual cusps in any excursive movement.

9. Cusp/Fossa Angle

Shallower than the anterior guidance angle

10. Aesthetic Plane

Upper right is acceptable, upper left needs to be raised; use anterior plane as a guide.

SUMMARY OF TREATMENT PLAN

Dentition

New restorations all uppers and lower posteriors
 Implants 11, 12, 13, and 19
 Endodontics and endodontic retreatment as needed

Periodontium

Scaling and home care instructions
 Crown lengthening surgery as needed
 Dental implant placement

TMJs

Bite splint therapy: The goal is four months of occlusal stability on the bite splint.
 Follow with appropriate occlusal engineering of the definitive restorations.

Muscles

Bite splint therapy followed by appropriate occlusal engineering of the definitive restorations

Occlusion

All parameters of a physiologic occlusion can be fulfilled.

Aesthetics

Idealized form, proportions, and contours in the definitive restorations

SUMMARY OF TREATMENT SEQUENCE

Appointment	Treatment Completed
1	Bite splint therapy
2	Periodontal maintenance
3	Provisionalize all uppers and lower posteriors in one restorative appointment.
4	Endodontics as needed while in the provisional restorations
5	Periodontal surgery Dental implant placement
6	Monitor and maintain provisionals.
7	Finalize lower restorations against the upper provisionals.
8	Finalize upper restorations. Posttreatment bite splint
9	Expected long-term maintenance of occlusion due to condylar diagnosis and prognosis

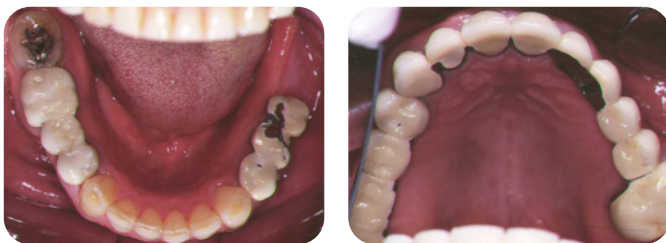
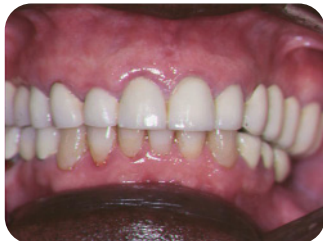
Figure 6.1.1. Preoperative condition of failing reconstruction.

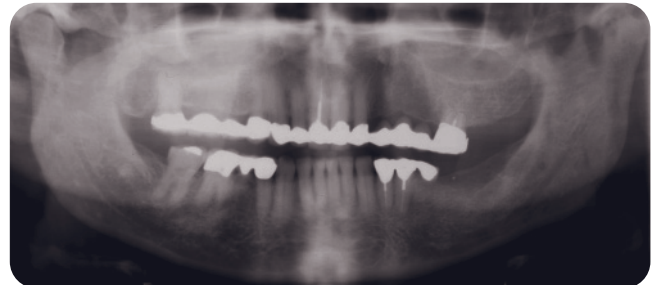


Figure 6.1.2. Panoramic radiograph showing suspicious left condyle in a pain-free patient.

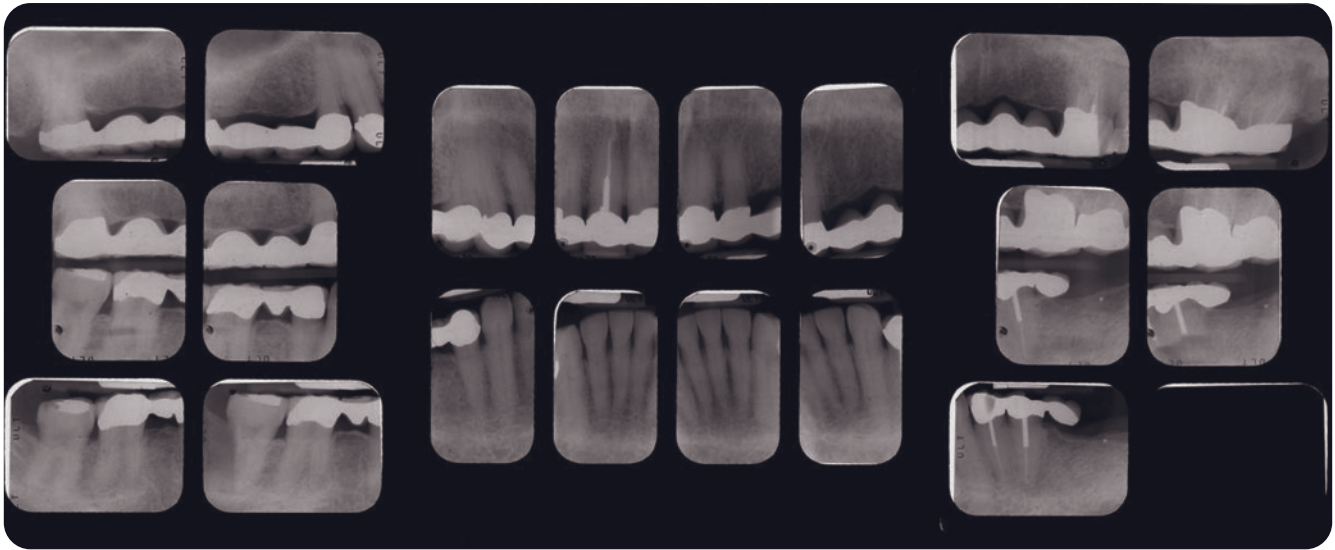


Figure 6.1.3. Preoperative full mouth radiographic series.

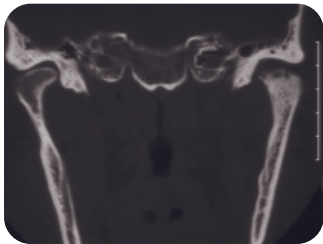


Figure 6.1.4. Frontal CAT-scan view showing the osseous changes and breakdown in the left condyle.

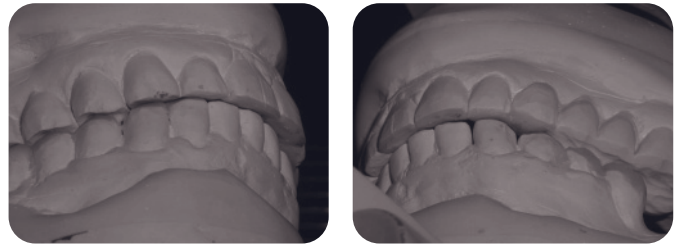


Figure 6.1.6. Diagnostic blueprint illustrating improvements in form and function.

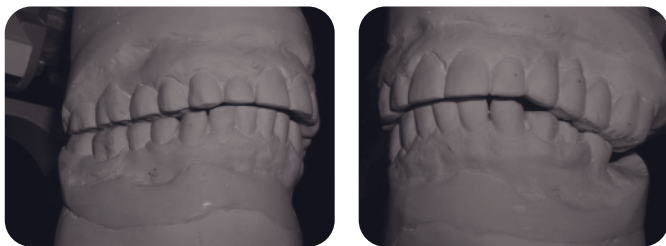


Figure 6.1.5. Preoperative articulated diagnostic casts done after bite splint therapy goals have been accomplished.

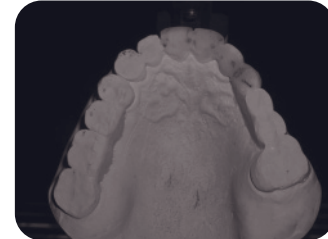


Figure 6.1.7. Diagnostic blueprint showing improvements with the occlusal plane. Anatomic limitations sometimes preclude absolutely ideal results.

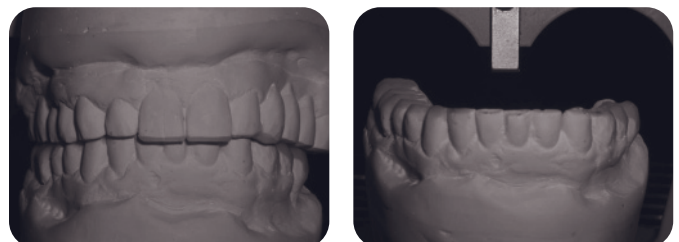
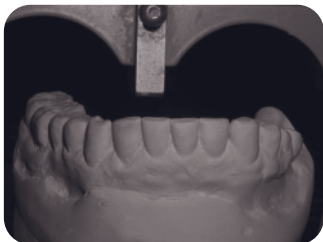
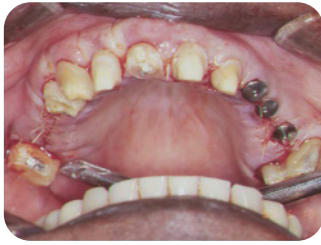



Figure 6.1.8. Photo taken immediately after surgery, which involved crown lengthening of all upper teeth and the placement of three dental implants. The upper right was handled with a fixed partial denture because all abutments appeared acceptable. The upper left molar was not a good abutment. This case was done approximately 10 years ago. Today, we would certainly consider implants for the upper right.

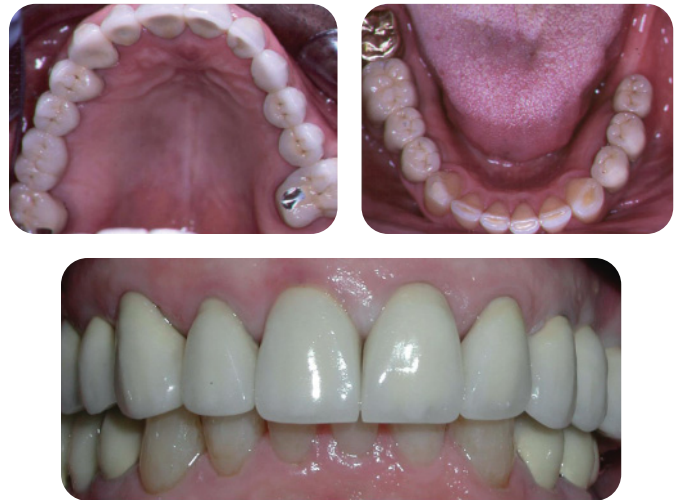

Figure 6.1.9. Posttreatment restorative result.

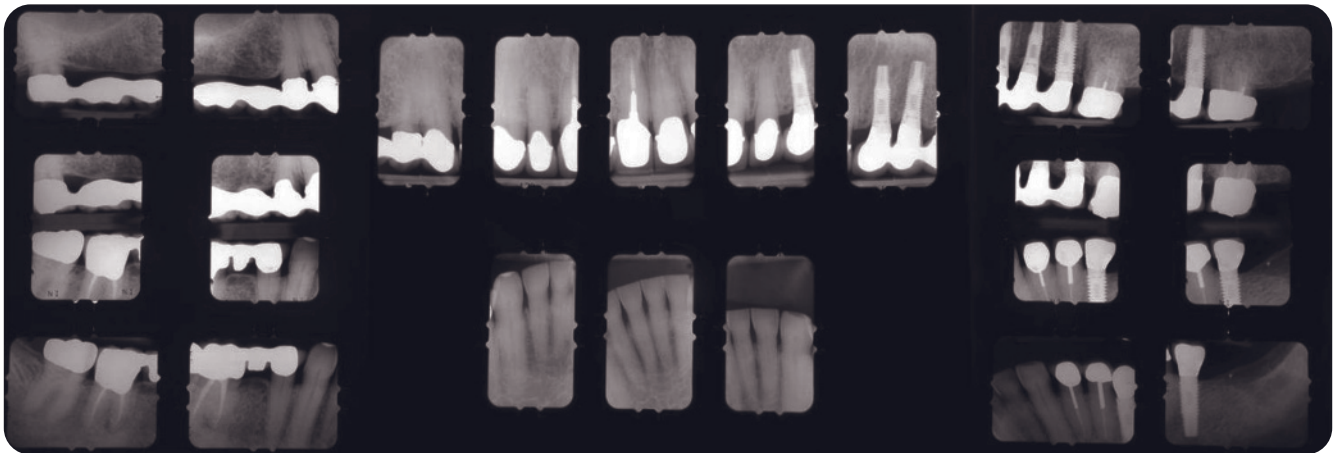


Figure 6.1.10. Posttreatment full mouth radiographs.

CHAPTER 6 CASE 1 KEY POINTS

- When the temporomandibular joints have structural changes, test for stability with a bite split for an appropriate period of time.
- Splinting multiple natural teeth can be problematic; use implants to eliminate multiple splints or at least fewer teeth.
- Keep implant restorations separate from tooth restorations.

Chapter 6 Case 2

Intracapsular and muscular components of a temporomandibular disorder managed with bite splint therapy followed by occlusal therapy and a full reconstruction

This patient was in her thirties and has suffered for many years with both an intracapsular and muscle component of a temporomandibular disorder. She had various occlusal treatments through the years, but none was entirely effective. The TM disorder component obviously had to be addressed first before her teeth could be restored. Bruxism was a contributing factor and had caused wear and tear on the teeth to the degree that she was unhappy with her smile. Because of time constraints with the activities of three young children, she preferred to extend the treatment over a period of time, with several shorter appointments rather than fewer longer appointments.

A posttreatment bite splint was fabricated to protect the dentistry and to minimize the effects of her continued bruxism on the components of the masticatory system. Because the TMJ diagnosis was adapted centric posture, we expect some degree of instability and therefore occlusal changes. Yearly occlusal refinements have been necessary but not unexpected by either the author or the patient.

SUMMARY OF EXAMINATION AND DIAGNOSIS

Dentition

Wear, structural, and restorative concerns on nearly all teeth

Periodontium

Healthy, aesthetic issues of uneven gingival levels

TMJs

Right side Piper 3A with intracapsular pain

Left side Piper 3A with intracapsular pain

Neither can be load-tested comfortably.

Palpation tenderness

ROM limited in all excursions

Muscles

Lateral/medial pterygoids very tender to palpation

Occlusion

Interferences and slide when condyles seated

Excursive interferences

Aesthetics

Edge of 8 acceptable, others short

Gingival level 9, 13 low

Form, proportions, and symmetry of teeth unacceptable

THE 10 DECISIONS**1. TMJ Diagnosis**

Bite splint starting point is a treatment position with the goal of CR or ACP.

Definitive restorative treatment to a verified postsplint position of CR or ACP

2. Vertical Dimension

Equilibrate the posterior teeth in the ACP arc of closure until there is approximately 2mm of space between the lingual of the upper anteriors and incisal edges of the lower anteriors.

3. Lower Incisal Edge

Idealize with veneers. Use the height of the cuspids as a guide for the height of the incisors.

4. Upper Incisal Edge

Incisal edge position of 8 appears to be correct. Use that as a guide for the rest of the upper anteriors.

5. Centric Stops

All teeth will have stable centric holding contacts in the ACP arc of closure.

6. Anterior Guidance

Increasing the vertical dimension of occlusion will allow the anterior guidance performance platform to be shallowed slightly.

7. Curve of Spee

Increase the radius slightly by decreasing the height of the lower second molars.

8. Curve of Wilson

Idealize so that the lower lingual and upper buccal cusps will not interfere in excursions in both the functional and parafunctional range of motion.

9. Cusp/Fossa Angle

Shallower than the anterior guidance angle

10. Aesthetic Plane

Plane of the upper buccal cusps should continue the plane of the upper incisal edges. The facial profiles of the upper bicuspids will be enhanced.

SUMMARY OF TREATMENT PLAN**Dentition**

Definitive restorations, all teeth, after TMD issues resolved

Periodontium

Aesthetic crown lengthening only

TMJs

Bite splint therapy will be followed by definitive occlusal/restorative treatment. Goal: adapted centric posture

Muscles

Bite splint therapy followed by definitive occlusal/restorative treatment

Occlusion

Complete reconstruction idealizing all parameters of occlusion Simultaneous, equal intensity centric stops in the adapted centric posture arc of closure and anterior guidance on anterior teeth.

Aesthetics

Idealize contours and proportions with restorations.

SUMMARY OF TREATMENT SEQUENCE

Appointment	Treatment Completed
1	Bite splint therapy with the goal of improving muscle symptoms and allowing intracapsular structures to heal, remodel, and adapt—3–4 months of occlusal stability on the bite splint.
2	Veneers 22–27. Equilibrate the posterior teeth to the adapted centric posture arc of closure until there is 2 mm of space anteriorly, which will allow room to restore the linguals of the upper anteriors and the incisal edges of the lower anteriors. Once the provisionals are finalized, composite will be added to the linguals of the upper anteriors to gain centric stops with the lower anterior provisionals and the anterior guidance refined on this performance platform.
3	Porcelain crowns on 6–11
4	Porcelain crowns on 18–21 and 28–31
5	Porcelain crowns and fixed partial denture on 2–5 and 12–15
6	Posttreatment bite splint
7	Ongoing occlusal refinement and bite splint refinement to keep up the changes of adapted centric posture

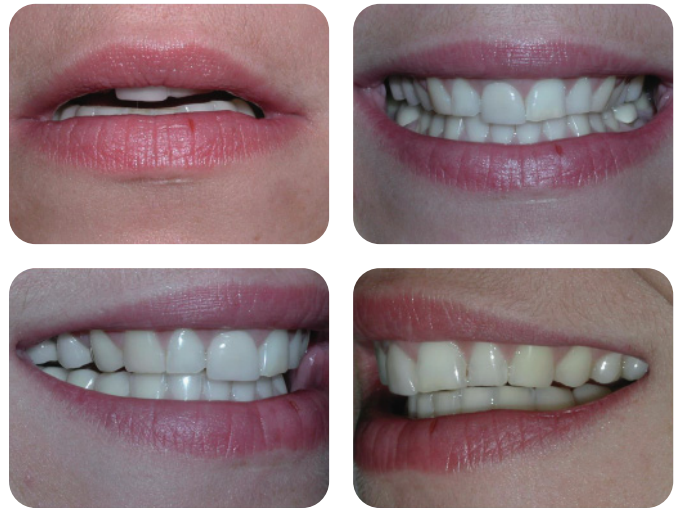

Figure 6.2.1. Preoperative frontal and smile photos suggesting wear from bruxism. Uneven and unattractive incisal plane is also observed.

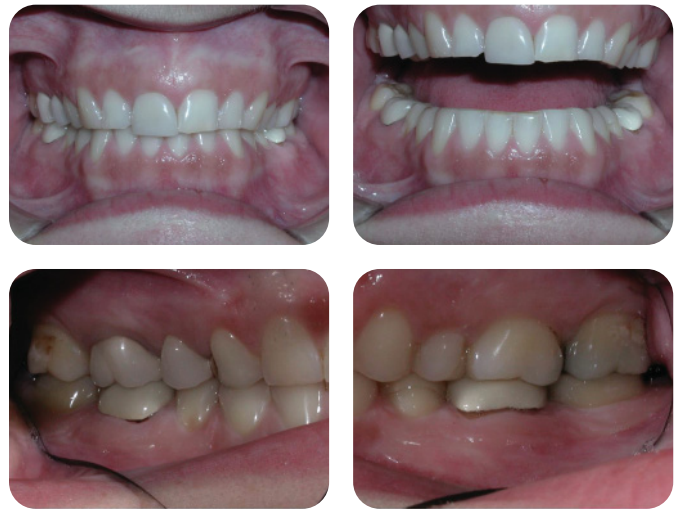

Figure 6.2.2. Preoperative retracted anterior and buccal views suggesting excessive lower Curve of Wilson and weak facial contours and profiles of the upper bicuspids.

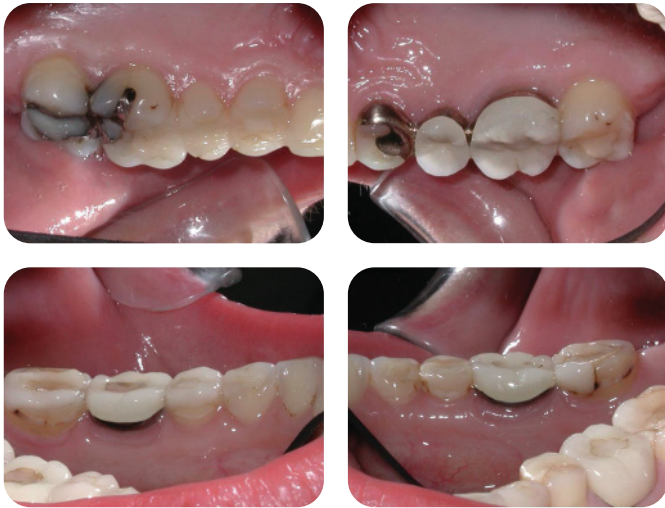

Figure 6.2.3. Preoperative lingual views of all quadrants.

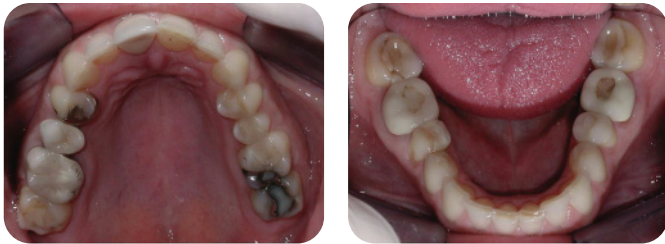

Figure 6.2.4. Preoperative maxillary and mandibular occlusal views suggesting the wear and tear on both teeth and restorations. Composite was added to the occlusal surfaces of several posterior teeth by the previous dentist in an attempt to improve the occlusion. This can be a valid rationale for an interim type of treatment, but it was done without regard to condylar condition and position.

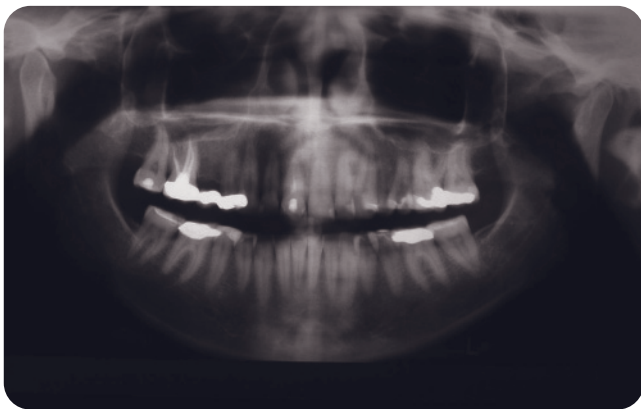


Figure 6.2.5. Preoperative panoramic radiograph suggesting condylar osseous changes. This radiograph suggests more advanced changes in the left condyle, which happened to be the more symptomatic joint.

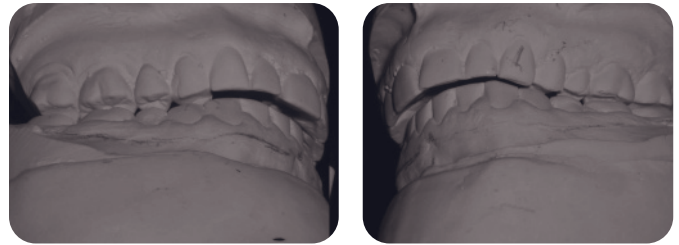


Figure 6.2.6. Articulated diagnostic casts after the goals of bite splint therapy have been accomplished. This view represents the first contact in the ACP arc of closure. Note the amount of vertical opening at this first point of contact. This space can be utilized well for designing the restorations to an optimal occlusal scheme.

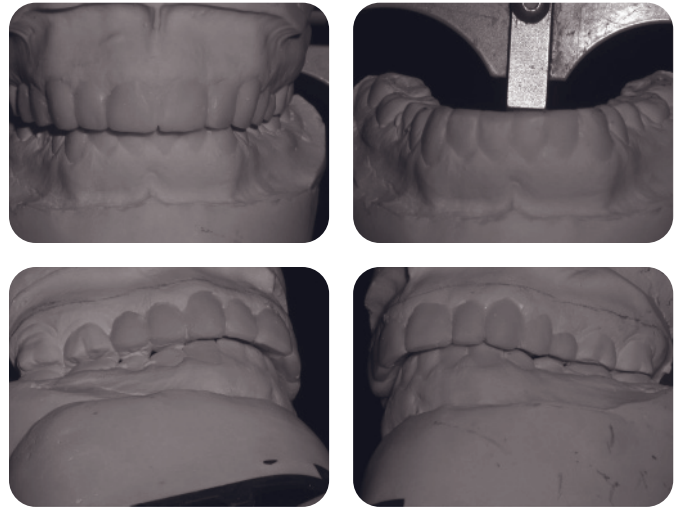


Figure 6.2.7. The casts were trial equilibrated and the vertical dimension closed slightly from the first point of contact until there was approximately 2mm of space anteriorly. This allowed room to restore the lower incisal edges and lingual surfaces of the upper anterior teeth. Aesthetic and functional parameters were further optimized.

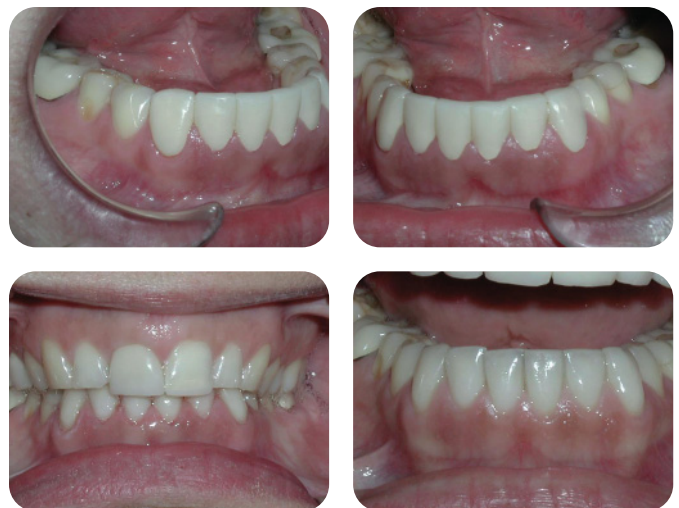

Figure 6.2.8. Photos of the lower anterior provisionals and definitive restorations. At this point composite was added to the linguals of the upper anteriors, and the length of 9 increased to match that of 8. This provided anterior centric stops and an anterior guidance performance platform prior to the definitive upper anterior restorations.

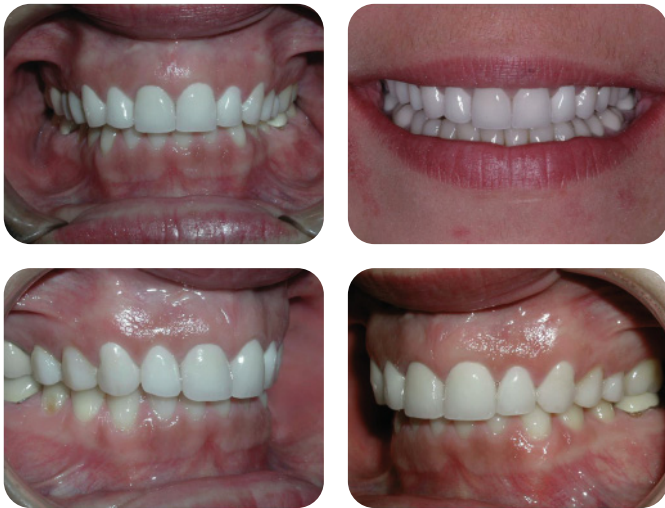

Figure 6.2.9. The next phase was completion of the upper anterior crowns. The buccal surfaces of the upper bicuspids were enhanced with direct composite additions as a preview of what was to be accomplished with the upper posterior definitive restorations.

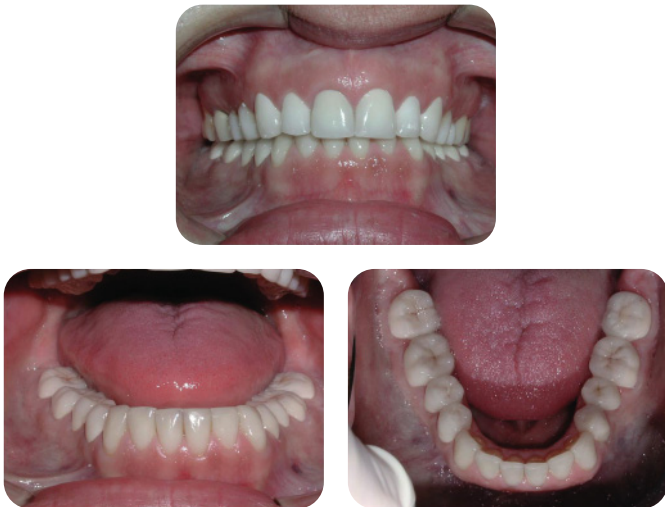

Figure 6.2.10. Completed lower posterior restorations with the Curve of Spee flattened to the degree allowed by anatomic limitations.

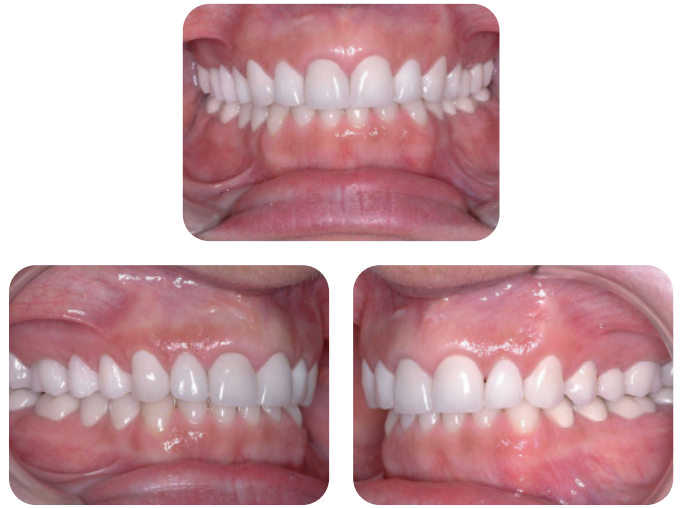

Figure 6.2.11. The upper posteriors were completed in the last step of the treatment plan.

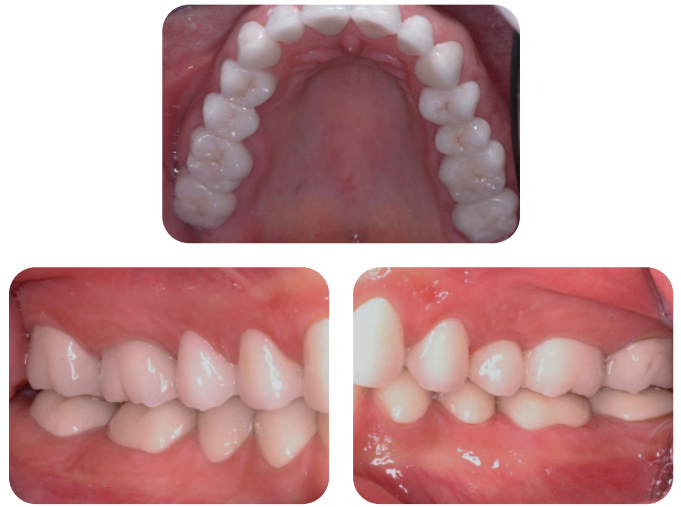

Figure 6.2.12. Posttreatment maxillary occlusal view and buccal occluded views.

CHAPTER 6 CASE 2 KEY POINTS

- Allow plenty of time in the bite splint to verify stability.
- When sequencing a treatment plan, improve landmarks in the mouth with composite so that each section is idealized as it is completed.
- Use a bite splint technique that allows easy modification as different segments are completed.

Chapter 6 Case 3

Intracapsular and muscle disorder resolved with bite splint therapy followed by occlusal reconstruction with maxillary lingual porcelain veneers

This case study illustrates a patient with a long-standing temporomandibular disorder with both an intracapsular component and a muscle component. She has suffered with this disorder for over 15 years and has had two dental reconstructions in an attempt to improve her signs and symptoms, but both provided minimal benefit. Her last dentist said that the lower dentistry was done incorrectly and that by changing it correctly, her problem would be solved. You will see as the case is discussed that it was actually the upper dentistry that needed to be changed. She was not unhappy with the lower removable partial denture and did not want to go through the surgeries it would take for mandibular posterior dental implants.

SUMMARY OF EXAMINATION AND DIAGNOSIS

Dentition

Integrity of the lower fixed partial denture is acceptable although the bicuspid abutments have past endodontic treatment and short roots giving them a guarded prognosis.

Lower removable partial denture is acceptable.

Upper anterior teeth are structurally sound.

Periodontium

Minimal attached keratinized tissue on the lower bicuspids, otherwise acceptable

TMJs

Right side Piper 4B

Left side Piper 4B

Cannot be superiorly compressed without pain

Limited range of motion

Muscles

Lateral and medial pterygoid extremely painful to palpation, 5 on a scale of 5

Muscle pain nearly all the time especially when masticating

Occlusion

No posterior teeth to support the occlusion

Sloped wear of lower anterior teeth coupled with a deep overbite, which precludes to a distalizing vector of force

Aesthetics

Patient is pleased with aesthetics.

THE 10 DECISIONS

1. TMJ Diagnosis

Begin bite splint therapy in a treatment position with the goal being adapted centric posture.

Definitive treatment in adapted centric posture.

2. Vertical Dimension

Increase vertical dimension of occlusion to minimize anterior overbite relationship and to create nondistalizing anterior centric holding contacts with as shallow an anterior guidance as possible.

3. Lower Incisal Edge

Keep height of current lower anteriors.

Reshape fixed partial denture to create definitive incisal edges and a level horizontal plane.

4. Upper Incisal Edge

No changes are necessary.

5. Centric Stops

Nondistalizing anterior centric stops with lowers contacting a horizontal area on the lingual of the uppers; simultaneous equal intensity contact on all posterior teeth in the adapted centric posture arc of closure

6. Anterior Guidance

Bite splint proved that anterior guidance must be shallow and flat.

7. Curve of Spee

Shallow and flat for easy disclusion

8. Curve of Wilson

Verify that the upper buccal and lower lingual cusps do not interfere in the functional or parafunctional range of motion.

9. Cusp/Fossa Angle

Must be shallow because of shallow anterior guidance

10. Aesthetic Plane

Verify that the aesthetic plane of the new upper right restorative dentistry is symmetrical and consistent with the acceptable upper left restorative dentistry.

SUMMARY OF TREATMENT PLAN**Dentition**

Restore teeth 6–11 with lingual porcelain veneers at an increased vertical dimension of occlusion and creating a flat, horizontal, nondistalizing anterior tooth-to-tooth centric stop relationship.

New teeth on lower removable partial denture at new vertical dimension of occlusion

Fixed partial denture from 2–4 and a single crown on 5

Periodontium

Soft tissue grafts lower bicuspid

TMJs

Maxillary flat plane, nondistalizing bite splint followed by definitive occlusal therapy

Muscles

Maxillary flat plane, nondistalizing bite splint followed by definitive occlusal therapy

Occlusion

Significant changes to include increased vertical dimension of occlusion and lower anteriors occluding against restored, horizontal, nondistalizing veneers on the lingual of the upper anterior teeth

Aesthetics

No changes are necessary.

SUMMARY OF TREATMENT SEQUENCE**Appointment****Treatment Completed**

1	Maxillary bite splint with a flat, horizontal, nondistalizing anterior centric stop design and shallow anterior guidance
2	Monitor and adjust bite splint.
3	Composite additions on the lingual of the upper anterior teeth to test new occlusal scheme along with additions to the lower partial denture
4	Lingual porcelain veneers upper anterior teeth New teeth, lower removable partial denture
5	Soft tissue grafts to be done by periodontist
6	Fixed partial denture teeth 2–4 and single crown
7	Posttreatment bite splint
8	Ongoing maintenance and adjustment expected due to diagnosis of the temporomandibular joints and the resulting prognosis

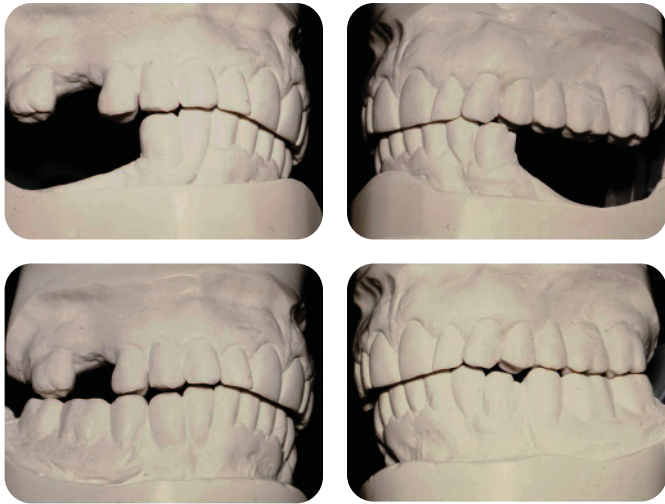


Figure 6.3.1. Pretreatment articulated diagnostic casts. Upper photos are without the lower partial dentures. Lack of posterior support and an anterior tooth-to-tooth relationship, which is a steep slope of the lower contacting a steep slope of the upper, creating a distalizing vector of force. The lower photos are with the lower partial dentures. There are posterior interferences in the arc of closure. In a case with missing posterior support, a partial denture cannot be expected to support the vertical dimension. Correctly designed, nondistalizing anterior centric stops must support the vertical dimension.

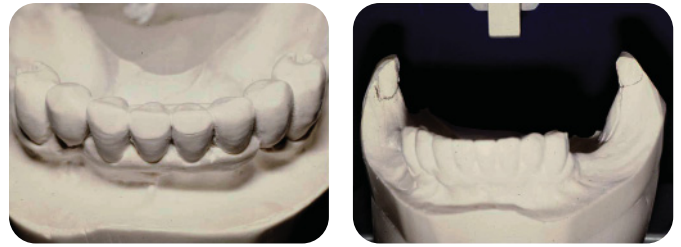

Figure 6.3.2. The left photo illustrates the slanted wear on the lower anterior teeth precluding to distalizing the mandible. The right photo illustrates an incisal plane that slopes up to the left.

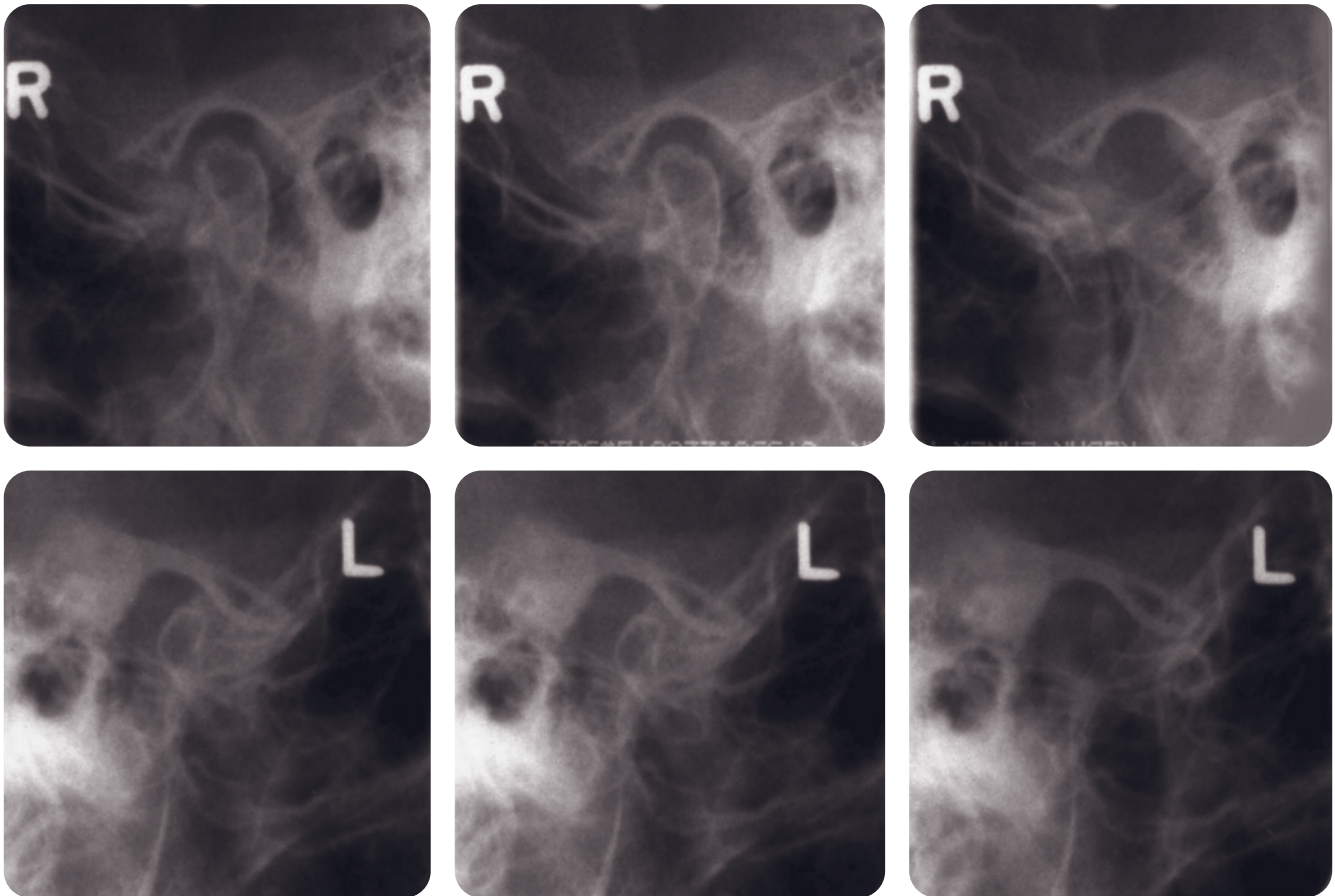


Figure 6.3.3. Pretreatment transcranial radiographs. Note that the left condyle is significantly smaller than the right condyle. This anatomic observation correlates to the lower incisal plane sloping up to the left, the side of the smaller condyle.

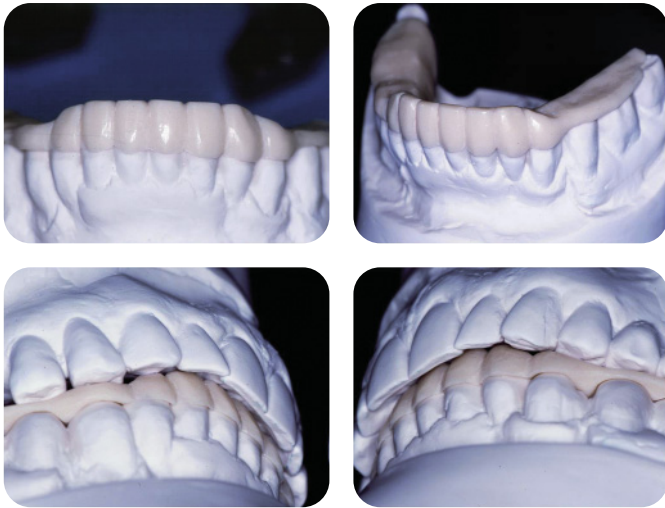


Figure 6.3.4. A significant improvement in signs and symptoms quickly occurred with the maxillary bite splint. The patient was convinced that her lower dentistry needed to be changed and that this change would give her the same comfort as the maxillary bite splint. The problem with changing the lower and not the upper is that non-distalizing centric stops cannot be created because the lingual of the upper anteriors would not be changed. To prove this to her, a lower bite splint was made with the anterior segment closely resembling anterior teeth. This closely replicates what a new lower anterior bridge would accomplish. This bite splint, as expected, did not give her the comfort she experienced with the upper bite splint. She was now convinced that the upper dentistry needed to be done and not the lower dentistry.

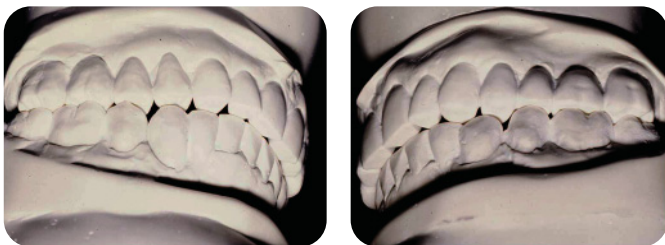


Figure 6.3.5. Posttreatment articulated diagnostic casts. Note the increase in the vertical dimension of occlusion, the decrease of the anterior overbite relationship, and the shallow anterior guidance performance platform. This occlusal scheme very closely resembled the occlusal scheme of the maxillary bite splint. Note that this anterior tooth-to-tooth relationship cannot distalize the condyle.




Figure 6.3.6. Diagram illustrating the maxillary to mandibular anterior tooth-to-tooth relationship changes that were made. The left illustration shows a deep overbite without stable centric holding contacts but rather a steep slope contacting a steep slope. This precludes distalization of the mandible. The right illustration shows the changes made to the incisal edges of the lower anteriors and the lingual surfaces of the upper anteriors as well as an increase in vertical dimension of occlusion. This creates nondistalizing anterior centric holding contacts. This tooth-to-tooth relationship supports the vertical dimension regardless of whether there are posterior teeth present. The posterior teeth of a removable partial denture cannot be expected to support the vertical dimension of occlusion.

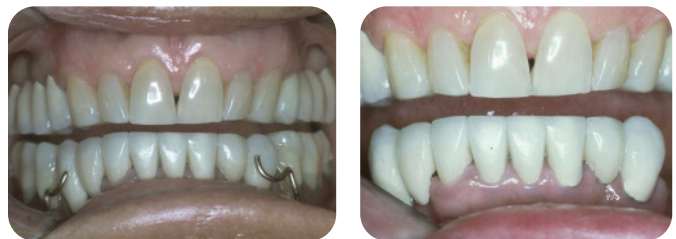

Figure 6.3.7. Posttreatment photograph of the recontoured and reshaped lower anterior fixed partial denture. Note that the original slope up to the left has been made more horizontal and that each individual lower anterior tooth has a definitive incisal edge and not a slope.

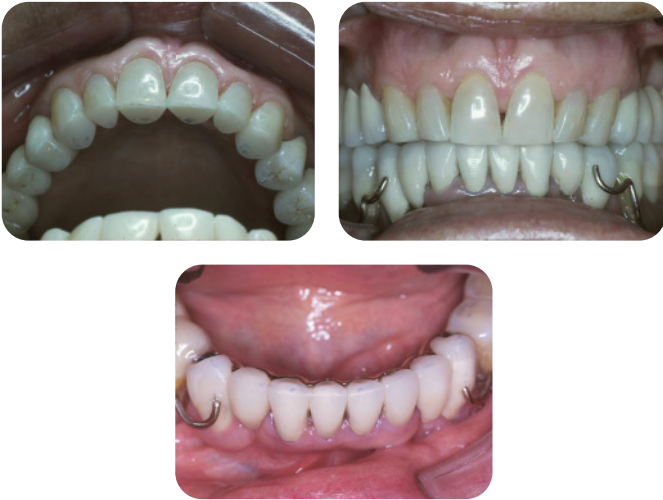

Figure 6.3.8. Posttreatment photographs. The upper left is an occlusal view illustrating the maxillary anterior lingual porcelain veneers. The upper right illustrates the new occlusal relationship. The lower photo illustrates the changes made by recontouring and reshaping alone to her current lower fixed partial denture.

CHAPTER 6 CASE 3 KEY POINTS

- Use the bite splint creatively designing it to closely resemble the definitive plan so as to preview its effect.
- In posterior edentulous situations, design the anterior centric holding contacts with a more horizontal receiving area to support the vertical dimension on its own without relying on a removable partial denture.

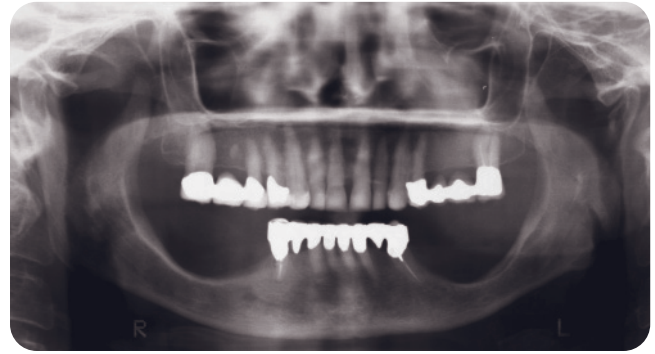

Figure 6.3.9. Posttreatment panoramic radiograph. The lower anterior fixed partial denture was not changed other than reshaping and recontouring. The lower removable partial denture was not changed other than new prosthetic teeth. The new dentistry done was only on the maxillary. At the time of this writing the patient has been followed for approximately 15 years and has stayed very comfortable.

Chapter 6 Case 4

Intracapsular and muscle disorder with resultant occlusal plane asymmetry resolved with bite splint therapy and followed by occlusal therapy with restoration only on the lower left

This case study is a patient who has suffered for many years with the signs and symptoms of a temporomandibular disorder. There were both intracapsular signs and symptoms as well as muscular signs and symptoms. She reported falling into an empty swimming pool as a youngster, so macrotrauma is certainly a factor. As the affected condyle changed, so did the occlusion, which then became an additional factor in the disorder.

After examination and diagnosis, the first step is to treat the temporomandibular disorder, which in this case was bite splint therapy. In cases with an intracapsular structural disorder, we can expect future changes; so managing these changes needs to be part of the long-term plan. Her dentistry, which she needed anyway, had to be designed with an optimal occlusal scheme.

SUMMARY OF EXAMINATION AND DIAGNOSIS

Dentition

Missing 19 and 20, patient desires replacement
History of endodontic failure (fractures) possibly related to the changes in the left condyle and resultant occlusal trauma to that side

Periodontium

Localized pockets and angular bone loss upper left, possibly related to occlusal trauma from condylar changes; 15 and 18 grade 1 mobility

TMJs

Right side Piper 3B

Left side Piper 3B

Left cannot be superiorly compressed without pain.

Range of motion to the right is limited, due to factors in the left TMJ.

Muscles

Lateral and medial pterygoids very tender to palpation

Occlusion

Interferences and slide in the guided arc of closure

Left side balancing interferences due to steepened occlusal plane from left side condylar changes

Aesthetics

Upper lateral incisor shape and position

Lower anterior spacing

Occlusal plane slopes up to left.

THE 10 DECISIONS**1. TMJ Diagnosis**

Bite splint therapy in a treatment position with adapted centric posture as a goal
Definitive occlusal and restorative treatment in adapted centric posture

2. Vertical Dimension

Vertical dimension of maximum intercuspation is acceptable.

3. Lower Incisal Edge

Slight reshaping and aesthetic bonding; general position is acceptable.

4. Upper Incisal Edge

Centrals are acceptable; reshape laterals.

5. Centric Stops

Simultaneous equal intensity, nonincline contact in the ACP arc of closure with equilibration and restoration

6. Anterior Guidance

Current anterior guidance is acceptable; just smooth and refine.

7. Curve of Spee

Right is acceptable.

Left slopes excessively up to the left because of condylar condition. Flatten as much as possible and reshape upper to the corrected lower.

8. Curve of Wilson

Verify that upper buccal and lower lingual cusps do not interfere in the functional and parafunctional range of motion.

9. Cusp/Fossa Angle

When equilibrating, shorten cusp tips rather than deepen fossa. Keep cusp to fossa angle of FPD shallow for easy disclusion.

10. Aesthetic Plane

Reshape upper buccal cusps for an ideal aesthetic plane.

SUMMARY OF TREATMENT PLAN**Dentition**

Fixed partial denture 18–21

Periodontium

Periodontal surgery upper left and lower left

TMJs

Bite splint therapy followed by correct bite engineering

Muscles

Bite splint therapy followed by correct bite engineering

Occlusion

Equilibration and design correct occlusal plane into lower left bridge; correct upper left by reshaping to the corrected lower left.

Aesthetics

Reshape #7 and #10.

Bond lower anteriors to close spaces.

Reshape upper left buccal cusps to create an even and consistent aesthetic plane.

SUMMARY OF TREATMENT SEQUENCE**Appointment****Treatment Completed**

1	Bite splint therapy until the goals of sign and symptom improvement and stability of the occlusion on the splint have been met
2	Bite splint follow-ups
3	Periodontal surgery
4	Equilibration and provisional lower left
5	Monitor provisional and abutments; possible endodontic therapy because of reduction is needed to correct the Curve of Spee.
6	Finalize lower left bridge. Reshape #7 and #10. Bond lower anteriors.
7	Posttreatment bite splint
8	Ongoing occlusal evaluation and refinement based on TMJ diagnosis and prognosis

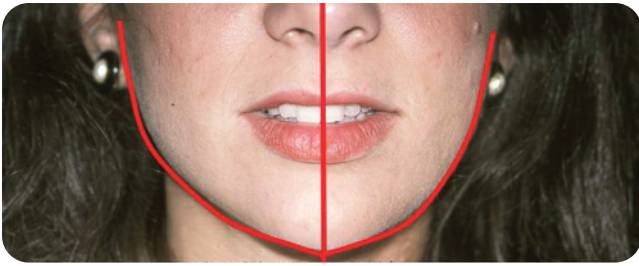

Figure 6.4.1. Pretreatment photos illustrating facial asymmetry and aesthetic plane sloping up to her left.

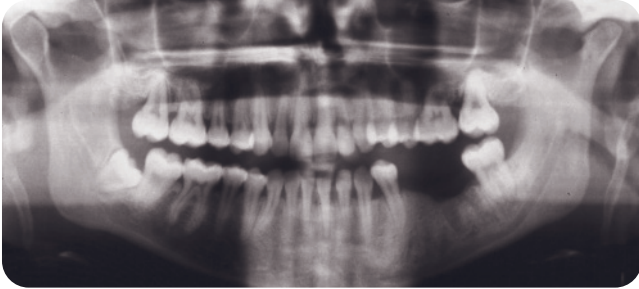


Figure 6.4.2. Pretreatment panoramic radiograph suggesting left condylar changes, shortened condyle-ramus height left side, tooth loss lower left, interproximal bone loss upper left. Note bone right side appears within more normal limits.

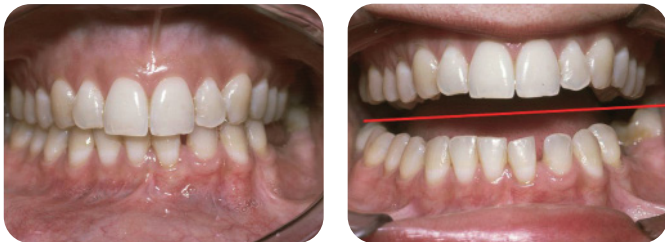

Figure 6.4.3. Pretreatment retracted anterior photographs suggesting the sloping occlusal plane. Note that the left posterior teeth are more end to end, a result of left condylar shortening.

Schellhaus K, Piper M, Omlie M
Facial Skeleton Remodelling Due to TMJ Degeneration: An Imaging Study of 100 Patients

J Craniomandib Pract, 1992; 10(3): 248-259

Schellhaus K, Keck R
Disorders of Skeletal Occlusion and TMJ Disease

Northwest Dentistry, 1989, 68(1): 35-42

Figure 6.4.4. These two studies found a very high degree of correlation between facial asymmetries, occlusal asymmetries, and TMJ changes.

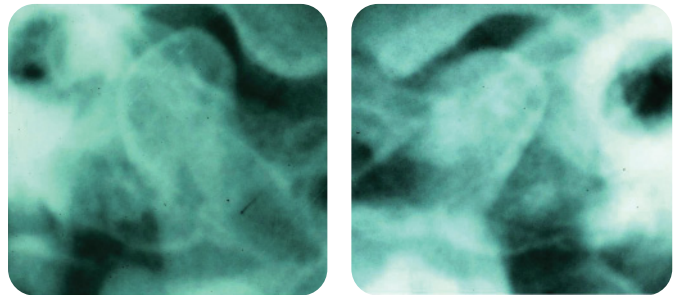


Figure 6.4.5. Pretreatment transcranial radiograph suggests left side alterations and significant asymmetry with the right side.

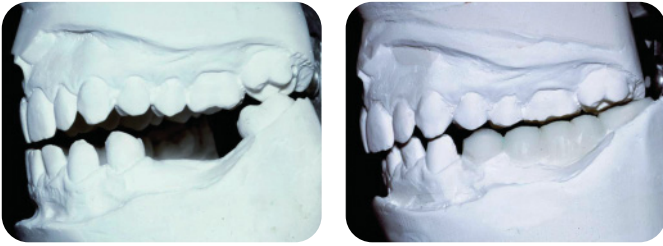


Figure 6.4.6. Left photograph: pretreatment articulated diagnostic casts suggest severe left side balancing interference in a right lateral excursion. Right photograph: articulated diagnostic casts corrected with equilibration and correcting lower left Curve of Spee, with wax-up resulting in disclusion in excursions.

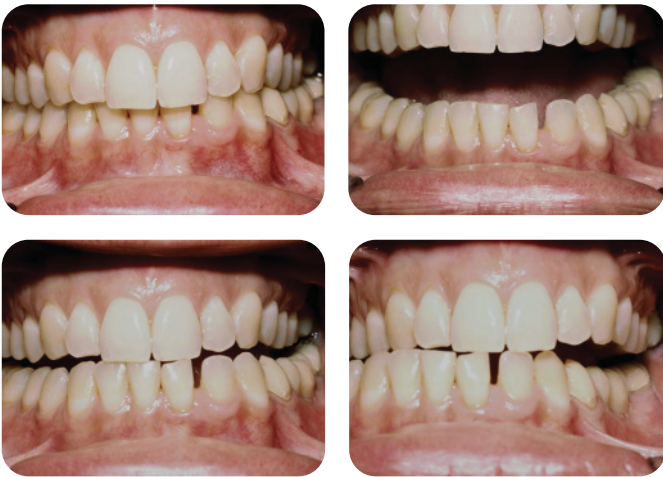

Figure 6.4.7. Photos of the provisional restoration suggesting improved Curve of Spee and disclusion in protrusive and right lateral excursion.

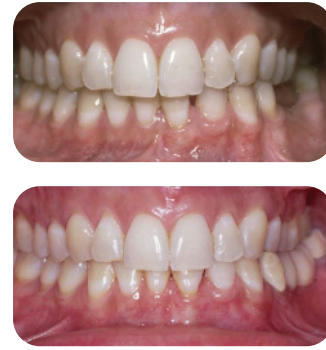

Figure 6.4.8. Pre- and posttreatment photographs. Upper lateral incisors have been reshaped and bonding done to close lower spaces. Patient continues to use bite splint, and occlusion needs periodic refinements as expected.

CHAPTER 6 CASE 4 KEY POINTS

- Skeletal and occlusal asymmetries indicate condylar changes.
- Correlate those changes and resulting interferences to other signs and symptoms of breakdown.

Chapter 6 Case 5

Past condylar replacement due to avascular necrosis followed by posterior occlusal reconstruction

The patient in this case study reported past maxillary and mandibular orthognathic surgery. It was diagnosed that this surgery compromised the blood supply to the right condyle, causing avascular necrosis. A titanium condyle was placed 2 years prior to the author examining her. She reported only mild temporomandibular joint discomfort and mild to moderate muscle discomfort at the time of the examination. Her occlusion as a result of the temporomandibular joint surgery was now open on the right posterior, making it difficult for her to masticate. Her posterior teeth needed to be restored anyway for structural reasons, thereby also presenting the opportunity to design an occlusion that was in harmony with the new jaw-to-jaw relationship resulting from the joint prosthesis.

Conclusion: This case was included not to illustrate surgical techniques of condylar replacement surgery but rather to illustrate that occlusal management follows the same fundamental, physiologic principles. As a reference, an article by R. E. Marx et al. comments on the outcome of this kind of surgery (Outcome analysis of mandibular condylar replacements in tumor and trauma reconstruction: A prospective analysis of 131 cases with long-term follow-up, *J Oral Maxillofac Surg*, 2008 Dec;66(12):2515–2523).

Conclusion: Alloplastic replacement of the mandibular condyle with a metallic condyle on a rigid reconstruction plate functioning against a natural disc or a soft tissue graft in the temporal fossa after disarticulation for pathology or trauma provides long-term stability with minimal complications (a total complication incidence of 10.6%).

SUMMARY OF EXAMINATION AND DIAGNOSIS

Dentition

Most all posterior teeth have restorations with some degree of breakdown.

Periodontium

Localized recession

No mobility

No measurements over 3mm

TMJs

Right side titanium implant

Left side Piper 3B coarse crepitation

Can be load-tested comfortably with light pressure only

No palpation tenderness

ROM limited to the left

Protrusive deviates to the right and also deviates to the right on maximum opening, which is 35mm

Muscles

Lateral and medial pterygoids tender to palpation

Occlusion

Posterior open bite right side due to surgery

Left side has interferences to the arc of closure.

Aesthetics

Acceptable; however, the upper right cuspid is in linguo-version.

THE 10 DECISIONS**1. TMJ Diagnosis**

Bite splint—start with a treatment position.

Postsplint—treat to a guided “artificial” adapted centric posture right side and typical adapted centric posture left side.

2. Vertical Dimension

Determined by equilibration to obtain contacts of upper right cuspid to upper left second molar

3. Lower Incisal Edge

Acceptable; just smooth and polish.

4. Upper Incisal Edge

Bring incisal edge of the upper right cuspid facially 2 mm.

5. Centric Stops

Simultaneous, equal intensity centric stops in the adapted centric posture arc of closure

6. Anterior Guidance

Current is acceptable. Guidance on the upper right cuspid will be lengthened at the same angle with the veneer.

7. Curve of Spee

Idealize with equilibration and restoration; lower right will be restored to the same height as the lower left, resulting in symmetry right to left.

8. Curve of Wilson

Verify that upper buccal and lower lingual cusps do not interfere in the functional and parafunctional range of motion.

9. Cusp/Fossa Angle

Keep shallower than the anterior guidance.

10. Aesthetic Plane

Create an upper posterior aesthetic plane that is consistent with the upper incisal edge position.

SUMMARY OF TREATMENT PLAN**Dentition**

First, composite add-ons to test occlusal scheme
Then, gold restorations on all posterior teeth plus a veneer on the upper right cuspid

Gold chosen as the material of choice as long-term adjustments are expected

Periodontium

Ongoing maintenance and self care

Soft tissue grafts lower left and right cuspids

TMJs

Bite splint therapy followed by definitive occlusal management

Muscles

Bite splint therapy followed by definitive occlusal management

Occlusion

Reconstruction per diagnostic blueprint

Posterior reconstruction

Design lower right occlusal plane to be on same horizontal plane as lower left

Aesthetics

A veneer upper right cuspid will improve aesthetics as well as function.

SUMMARY OF TREATMENT SEQUENCE**Appointment****Treatment Completed**

- | | |
|---|--|
| 1 | Bite splint to test stability and achieve muscle comfort |
| 2 | Composite additions to open bite areas, equilibrate |
| 3 | Provisionalize one quadrant at a time so the compromised masticatory system is not overstressed. The ability to do this occurs as step 2 above results in the desired occlusion. |
| 4 | Finalize one quadrant at a time. |
| 5 | Posttreatment bite splint |
| 6 | Ongoing occlusal management because long-term stability of the joint structures cannot be expected |

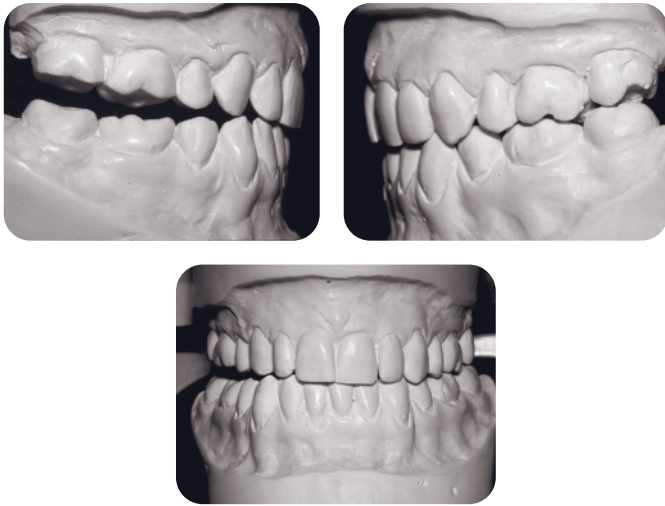

Figure 6.5.1. Pretreatment photographs of the articulated diagnostic casts at time of the examination approximately 2 years after the surgery to place a prosthetic condyle and ramus on the right side. The surgery restored the condyle ramus height that was lost by the avascular necrosis, resulting in the posterior open bite on the right side. As the condyle shortened by the avascular necrosis, the alveolar processes remodeled allowing all the teeth to maintain occlusion. If the alveolar process did not remodel, the bite would have opened on the left side as the condyle shortened.

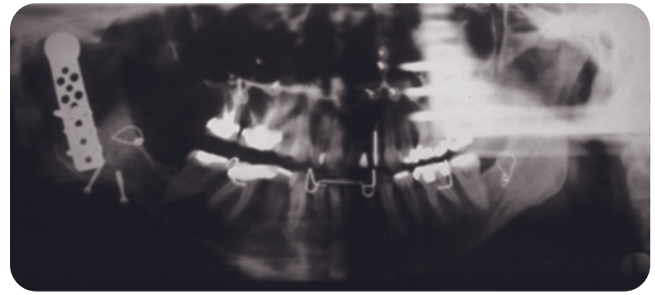


Figure 6.5.2. Pretreatment panoramic radiograph illustrating the condyle-ramus prosthesis and the bone plates and wires from prior orthognathic surgery.

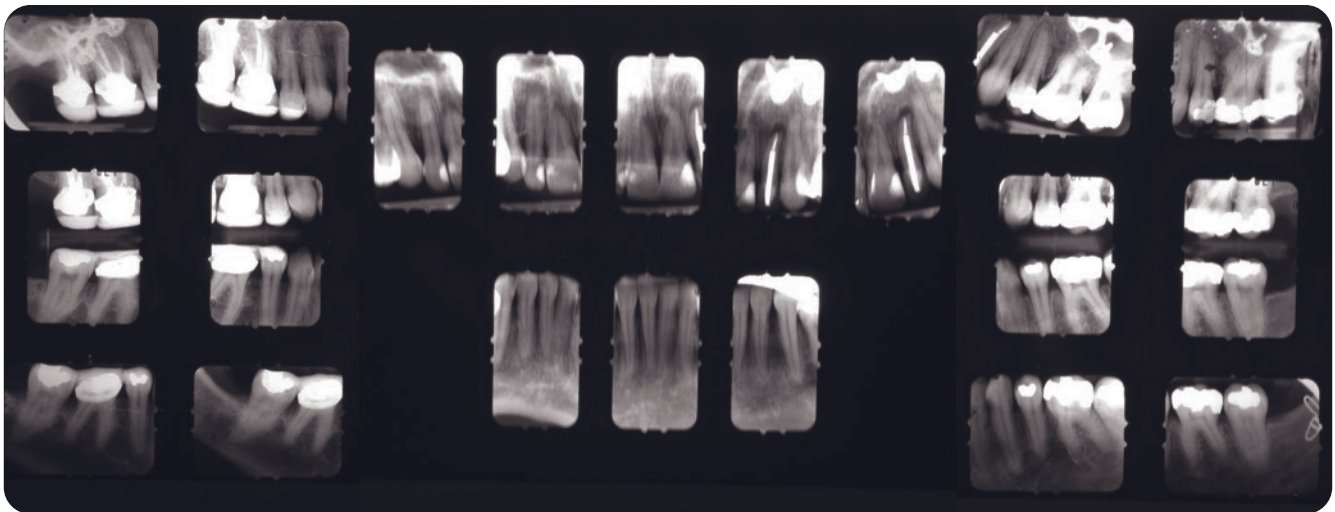


Figure 6.5.3. Full mouth series taken after bite splint therapy and initial occlusal management, which involved equilibration and composite additions to the teeth on the right side out of occlusion. Composite overlays can be seen on the right posterior teeth.

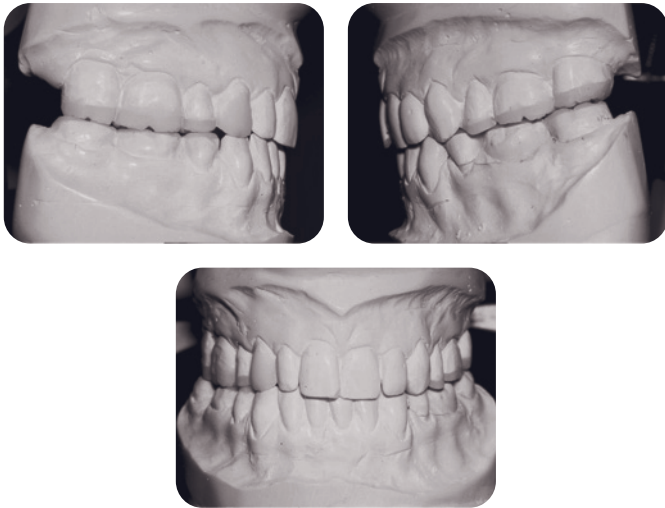


Figure 6.5.4. Photographs of the diagnostic wax-up. The goal was to keep the occlusal plane on the right side on the same horizontal plane as the left side. This involved lengthening the upper right posterior teeth more than the lower right posterior teeth. As the right condyle shortened by avascular necrosis, the right posterior occlusal plane raised along with it. The condylar prosthesis then lowered the right side occlusal plane close to its original position.

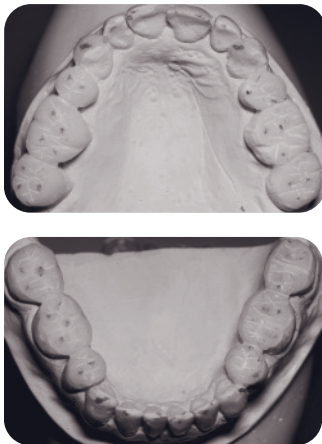


Figure 6.5.5. Occlusal photographs of the diagnostic wax-up suggesting the shallow cusp to fossa angles. Also note that the upper right cuspid restoration will create a centric stop and an anterior guidance performance platform.

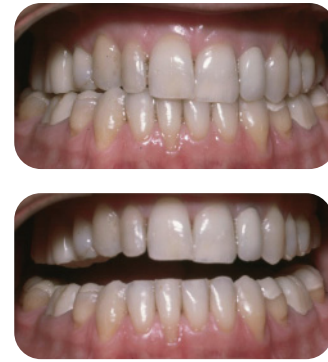

Figure 6.5.6. Anterior retracted photographs of the provisionals. Keeping the occlusal plane low will minimize the chances of excursive interferences. Even though the right condyle is a prosthesis, there is a small amount of translation. There is more range of motion to the right, as expected, making correct management of the occlusal plane important.

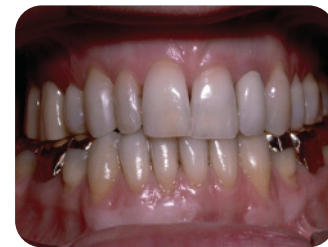

Figure 6.5.7. Anterior retracted view of the lower completed restorations against the upper provisionals. Staging the finalization like this allows further evaluation and modification of the occlusion prior to completion of all restorations.

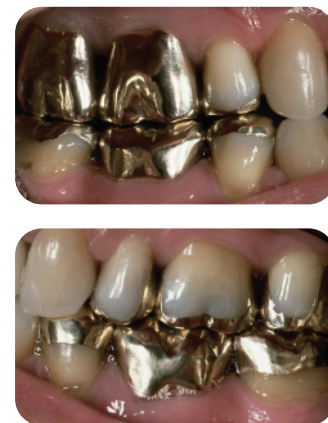

Figure 6.5.8. Buccal retracted photographs of all the completed restorations. Gold will allow easier occlusal modification as time goes on. Note improved right side cuspid occlusal relationship with the upper right cuspid veneer.

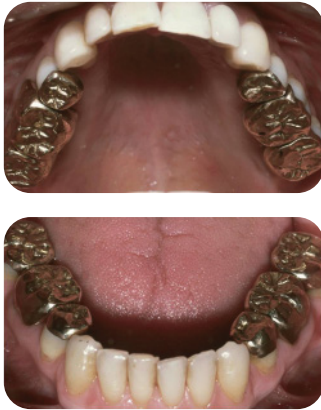

Figure 6.5.9. Maxillary and mandibular occlusal photographs of the completed dentistry.

CHAPTER 6 CASE 5 KEY POINTS

- Apply the 10 decisions even to the most unusual of situations.
- If future change is expected, choose materials and techniques that allow these changes to be made as easily as possible.

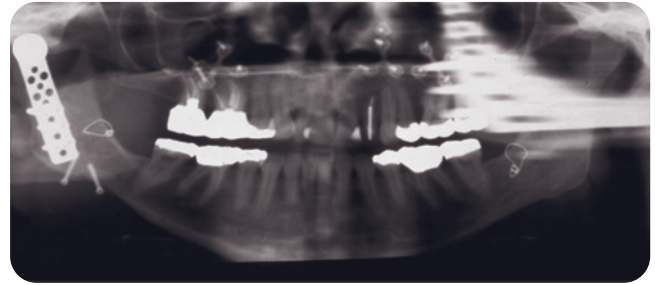


Figure 6.5.10. Posttreatment panoramic radiograph. The patient was followed for several years posttreatment. Periodic occlusal refinement was necessary as expected. Most likely, remodeling of the fossa occurred in response to the titanium condyle.

Chapter 6 Case 6

Temporomandibular disorder resolved with bite splint therapy followed by definitive occlusal therapy including a maxillary reconstruction and mandibular functional changes with composite

The patient in this case study has suffered with the signs and symptoms of a temporomandibular disorder for 20 years. The signs and symptoms were both muscular and intracapsular in nature. She has had various treatments through the years, including occlusal treatments, but with unacceptable results. In recent years, the cause of her pain was placed in a psychological category; the patient did not agree with this conclusion. She always felt there was a biological and functional factor that had not been diagnosed. Throughout more recent months, undiagnosed pulpal pathology contributed to the overall pain symptomatology. She also reported that she has always desired aesthetic improvement of her teeth but, knowing that it would involve restorative dentistry, has postponed that treatment fearing that it would exacerbate her pain symptoms.

SUMMARY OF EXAMINATION AND DIAGNOSIS

Dentition

Old restorations, endodontic concerns, all teeth restorable, slight rotations upper anterior teeth, wear of lower incisal plane

Periodontium

No concerns

Gingival level of upper right cuspid is high but not a concern to the patient.

TMJs

Degenerative changes radiographically

Right side Piper 3B

Left side Piper 3B

Neither can be superiorly compressed without pain.

Muscles

Medial and lateral pterygoids very painful to testing

Occlusion

Interferences and slide to maximum intercuspation

Occlusal plane issues; balancing interference right second molars severe enough to keep anterior teeth from contacting in that excursion

Aesthetics

Patient desires longer front teeth.

THE 10 DECISIONS**1. TMJ Diagnosis**

Bite splint—start in treatment position; the goal is stability and comfort with adapted centric posture.

Postsplint—treat to a guided verifiable adapted centric posture.

2. Vertical Dimension

Open 1 mm at incisors to gain room for restorative material.

3. Lower Incisal Edge

Reshape and direct composite additions to achieve an even plane.

4. Upper Incisal Edge

Increase length 1 mm.

5. Centric Stops

Simultaneous, equal intensity centric stops on all teeth in the adapted centric posture arc of closure

6. Anterior Guidance

Slightly shallower due to increase in vertical dimension of occlusion

Increasing length of maxillary and mandibular incisors will help with disclusion of right second molars.

7. Curve of Spee

Flatten mandibular second molars to facilitate disclusion.

8. Curve of Wilson

Verify that upper buccal and lower lingual cusps do not interfere in the functional and parafunctional range of motion.

9. Cusp/Fossa Angle

Shallower than anterior guidance disclusive angle
Selected mandibular fossa need to be shallowed with direct composite additions.

10. Aesthetic Plane

Create an upper posterior aesthetic plane that is consistent with the upper incisal edge position and with pleasing buccal profiles.

SUMMARY OF TREATMENT PLAN**Dentition**

Restore all maxillary teeth.

Endodontics as needed

Composite lower incisors and selected lower central fossa until definitive restorations are appropriate.

Periodontium

Ongoing maintenance and self care

TMJs

Bite splint therapy followed by definitive occlusal therapy

Muscles

Bite splint therapy followed by definitive occlusal therapy

Occlusion

Simultaneous, equal intensity centric stops in the adapted centric posture arc of closure with anterior guidance on anterior teeth

Aesthetics

Idealize form and contours with restorations.

“Straighten” upper anterior teeth with restorations.

SUMMARY OF TREATMENT SEQUENCE

Appointment	Treatment Completed
1	Bite splint therapy
2	Bite splint follow-up until goals of comfort and occlusal stability are achieved
3	Periodontal maintenance
4	Endodontics as needed
5	Equilibration with composite additions as a test step prior to restorative treatment
6	Prepare and provisionalize maxillary anteriors.
7	Prepare and provisionalize maxillary left.
8	Prepare and provisionalize maxillary right.
9	Once again, test comfort and stability.
10	Definitive maxillary impressions
11	Place definitive restorations. Place new bite splint.
12	Ongoing occlusal management as needed and expected

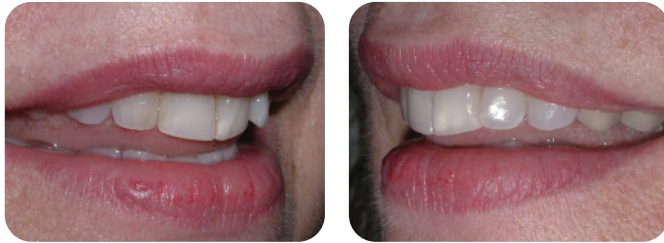
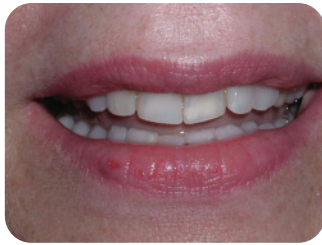
Figure 6.6.1. Pretreatment anterior and lateral smile photographs illustrating rotations of maxillary anterior teeth. The position and display of the mesioincisal angles of the maxillary central incisors is pleasing to the patient.

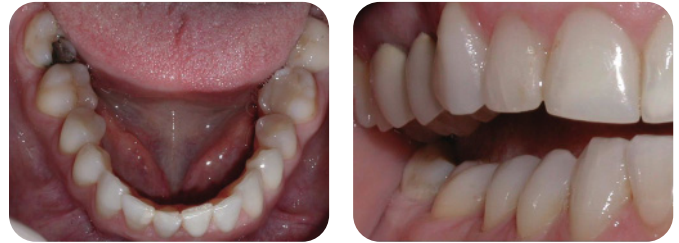
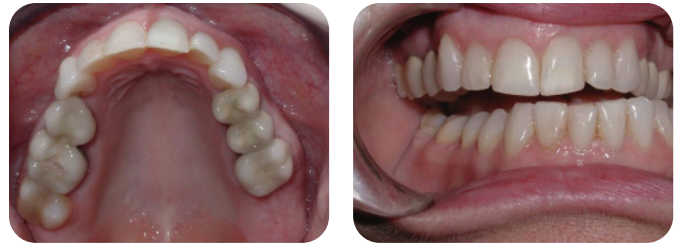
Figure 6.6.3. Pretreatment occlusal photographs. The right photographs illustrate a left lateral excursive movement where the right second molars are the only contacting teeth. This severe balancing interference places extreme stress on the joints and hyperactivates the muscles. Her past occlusal treatments had not addressed this issue—a possible reason for lack of success. This, coupled with interferences to the arc of closure, was a main factor in her signs and symptoms. Correctly designed and executed bite splint therapy resulted in rapid improvement of signs and symptoms. It took several months to gain stability of occlusion on the splint because remodeling of connective tissue and fibrocartilage takes time.

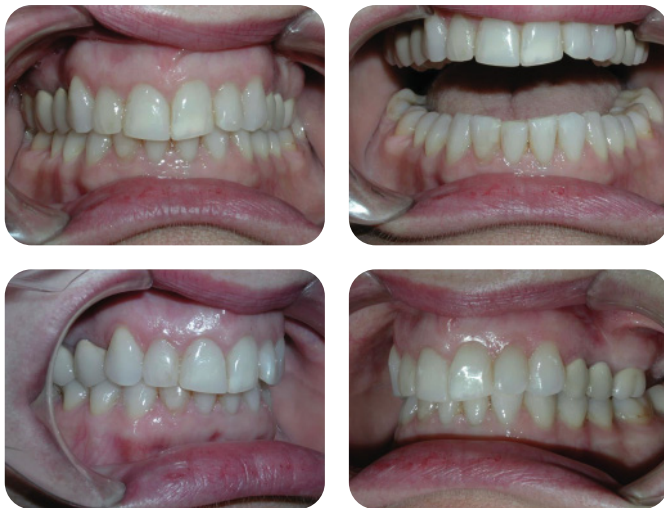

Figure 6.6.2. Pretreatment anterior and lateral retracted photographs illustrating a reverse curve of the mandibular anterior plane and a severe Curve of Spee at the mandibular second molars.

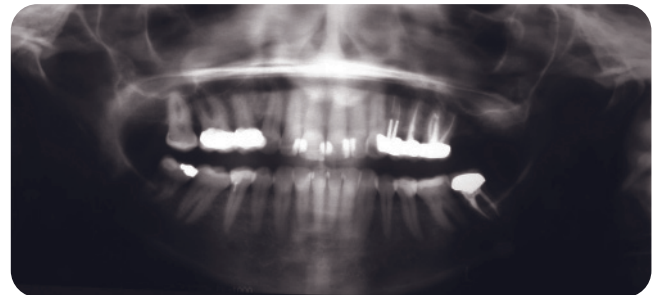


Figure 6.6.4. Pretreatment panoramic radiograph.

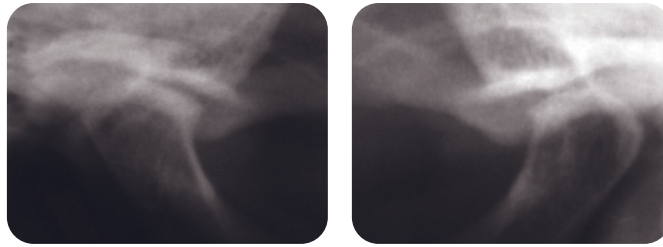


Figure 6.6.5. Radiographs illustrating significant alteration of the condyles, more so on the right as compared to the left. The right side was more symptomatic, and more interferences occurred on the right side of the bite splint over time as that condyle healed, remodeled, and adapted.

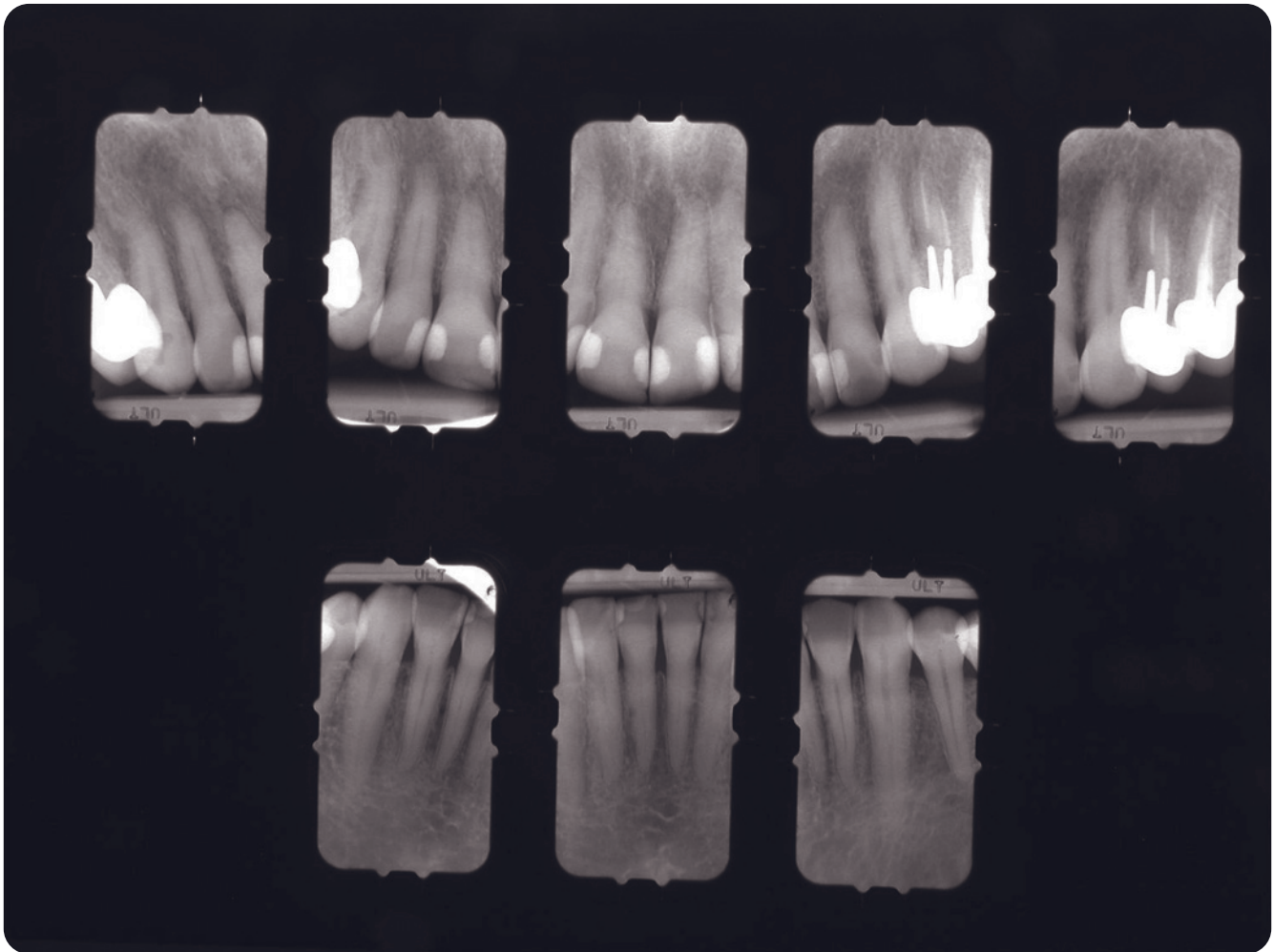


Figure 6.6.6. Pretreatment anterior radiographs illustrating heavily restored maxillary anterior teeth.

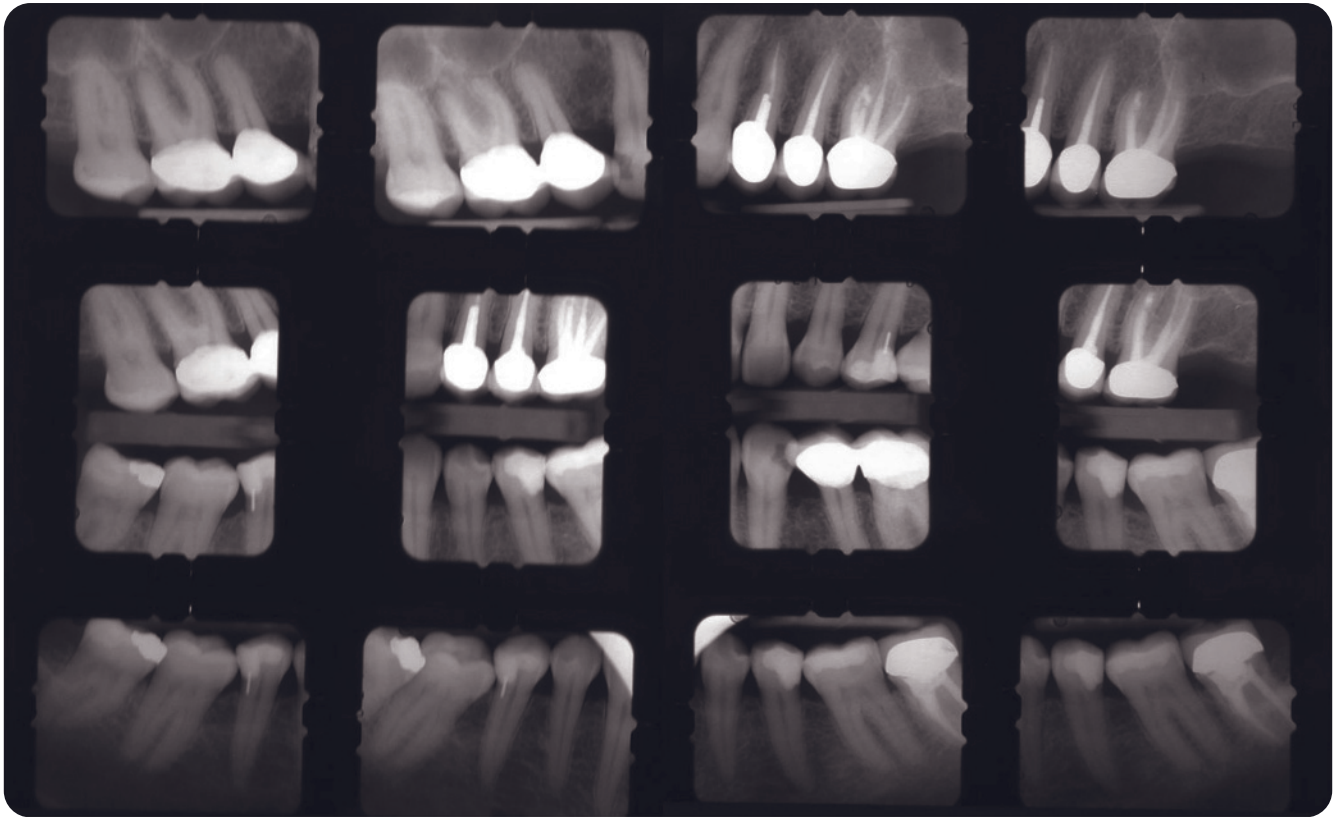


Figure 6.6.7. Pretreatment posterior radiographs illustrating heavily restored posterior teeth. The endodontist diagnosed irreversible pulpitis of the maxillary right first and second molars, possibly a contributing factor in her overall pain symptomatology.

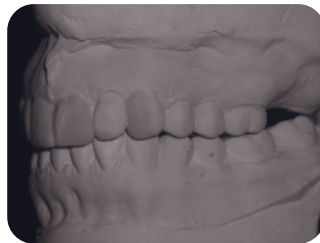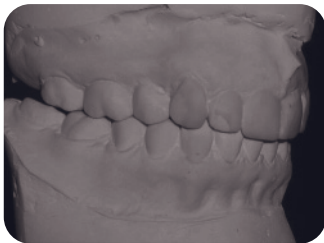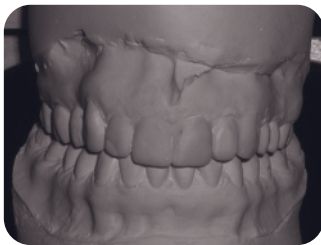


Figure 6.6.8. Photographs of the diagnostic wax-up illustrating aesthetic improvements. These articulated diagnostic casts were fabricated after bite splint therapy was completed.

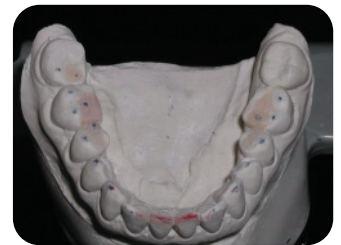
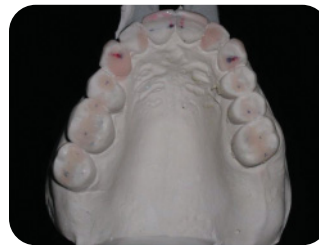
Figure 6.6.9. Occlusal photographs of the functional changes made on the articulated diagnostic casts. Note that the central fossae were filled in to create a shallower cusp to fossa angle. The maxillary changes will be made with the restorative dentistry. The mandibular changes will be made with direct bonded composite additions because the definitive restorations will not be completed at this time.

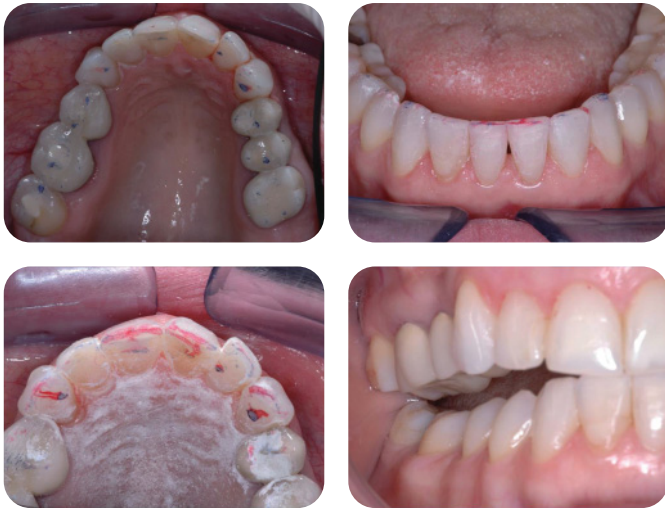

Figure 6.6.10. Because of the patient's long-standing temporomandibular disorder, the definitive treatment was completed in multiple shorter appointments rather than fewer longer appointments so as not to stress her susceptible temporomandibular joint condition. These photographs illustrate the first phase, which included composite additions on all teeth prescribed by the diagnostic wax-up and definitive equilibration. The lower right photograph illustrates that the second molars now completely disclude in left lateral excursions.

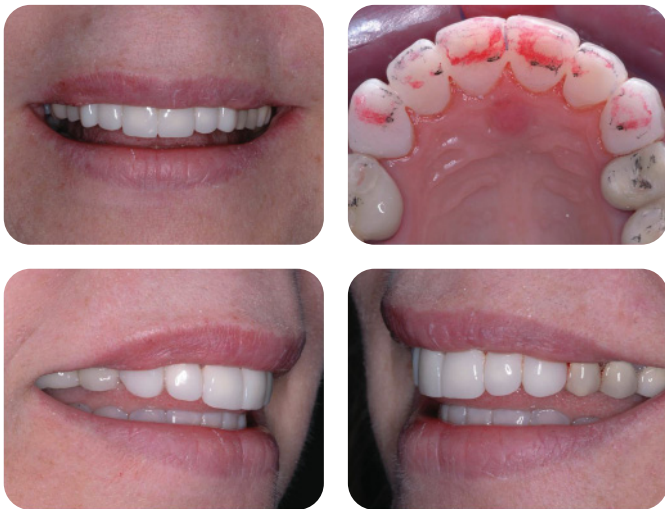

Figure 6.6.11. Photographs of the second phase of the definitive treatment, which was provisionalization of the maxillary anterior teeth. The alignment of the teeth and anterior guidance could now be refined to a higher degree.

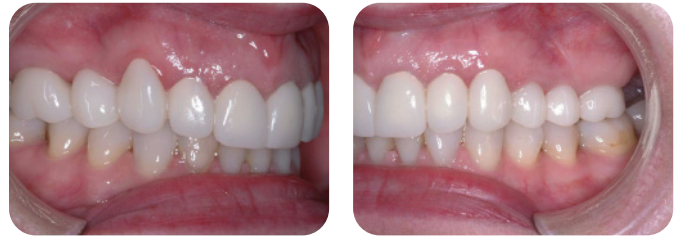
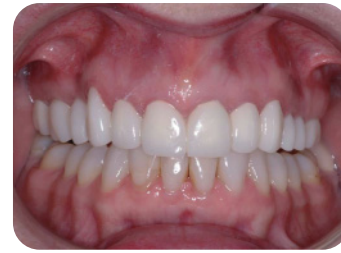
Figure 6.6.12. Photographs of the third and fourth phase of the treatment plan, which was provisionalization of the maxillary right and left posterior teeth. Throughout these phases, the original bite splint was modified so the patient could continue to use it throughout all phases of treatment.

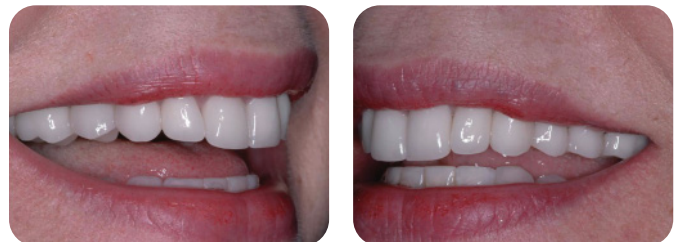
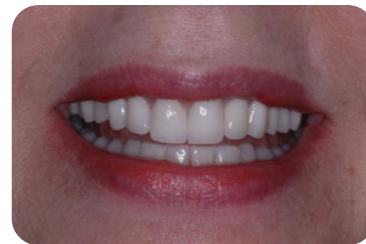
Figure 6.6.13. Anterior and lateral smile photographs of the completed restorations.

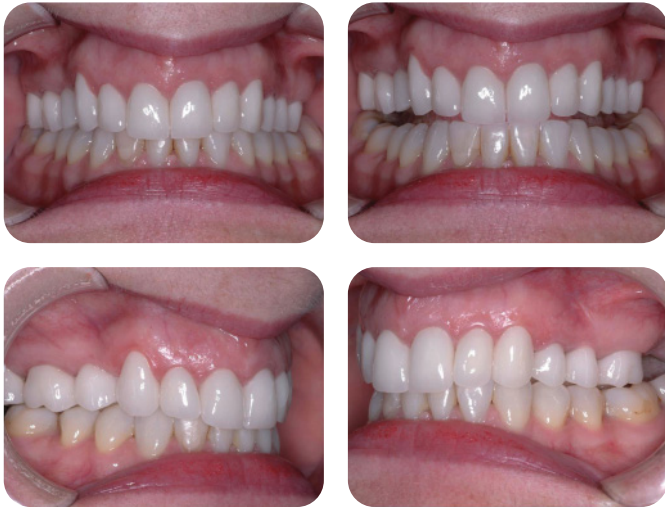

Figure 6.6.14. Anterior and lateral retracted photographs of the completed restorations. All functional changes on the mandibular teeth are still with composite restorations. The form and function is correct so that when the time comes that the patient is ready to complete the definitive restorations, this form and function simply needs to be duplicated in the new restoration.

CHAPTER 6 CASE 6 KEY POINTS

- Diligently investigate all biologic and mechanical causes of signs and symptoms. Do not be too quick to call it a psychological issue.
- Sequence treatment in smaller segments in patients with chronic, possibly fragile temporomandibular structures.
- Extreme parafunctional movements can have severe interferences related to occlusal plane and incisal plane issues.

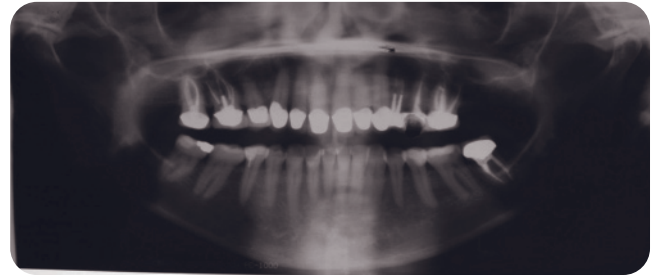


Figure 6.6.15. Posttreatment panoramic radiograph. Endodontic therapy on the maxillary right first and second molars was completed prior to provisionalization. Patient has remained comfortable and symptom-free. Her long-term treatment plan includes twice yearly occlusal refinements. With her adapted centric posture diagnosis and degree of osseous changes, continued subtle remodeling is to be expected. The twice yearly refinements have needed less and less adjusting over the 4 years of posttreatment follow-up. The original tooth preparations included extra occlusal reduction so there would be enough thickness for these refinements.

Chapter 6 Case 7

Past mandibular orthognathic surgery to correct maxillary to mandibular malrelationship caused by condylar degeneration; intracapsular and muscle pain resolved with bite splint therapy followed by definitive occlusal therapy with posterior reconstruction and anterior composites

The patient in this case study traveled from South America for her treatment. Initially, her treatment was for orthodontics and orthognathic surgery. She had suffered from the signs and symptoms of a temporomandibular disorder for several years. Those signs and symptoms included intracapsular as well as muscular pain. The treating oral surgeon made the referral for

treatment. Several months of bite splint therapy were needed to improve signs and symptoms and to allow structures to heal, remodel, and adapt. Once stability was achieved, definitive occlusal therapy followed by reconstruction was undertaken. Her joint diagnosis predicts that future joint changes are expected with resultant necessary occlusal refinements.

SUMMARY OF EXAMINATION AND DIAGNOSIS

Dentition

Failing posterior restorations
All teeth restorable

Periodontium

Within normal limits

TMJs

Right side Piper 3B
Left side Piper 4B (medial pole changes)
Pain in the left TMJ—cannot be superiorly compressed comfortably

Muscles

Several uncomfortable to testing; headaches; facial pain

Occlusion

Interferences and slide when condyles seated
Occlusal plane issues
Anterior open bite precludes good anterior guidance
Arch malrelationship due to condylar changes

Aesthetics

No aesthetic concerns; however, maxillary incisors can be longer (which will help anterior guidance in the parafunctional range).

THE 10 DECISIONS**1. TMJ Diagnosis**

Bite splint—start in treatment position; the goal is stability and comfort and remodeling, healing, and adaptation of TMJ structures.

Postsplint—treat to a manipulated verifiable ACP.

2. Vertical Dimension

Close a bit to get improved anterior tooth-to-tooth relationships.

3. Lower Incisal Edge

Acceptable; just smooth and polish.

4. Upper Incisal Edge

Increase length centrals 1–1.5 mm to improve disclusion in edge-to-edge and crossover; aesthetically they can be longer.

5. Centric Stops

Simultaneous, equal intensity centric stops in the adapted centric posture arc of closure

6. Anterior Guidance

This is determined by upper and lower incisal edge position; it will be shallow.

7. Curve of Spee

Flatten as much as possible with restoration for easier disclusion.

8. Curve of Wilson

Verify that upper buccal and lower lingual cusps do not interfere in the functional and parafunctional range of motion.

9. Cusp/Fossa Angle

Shallower than the anterior guidance disclusion angle. Do not deepen with equilibration. Make shallower with restorations.

10. Aesthetic Plane

Create an upper posterior aesthetic plane that is consistent with the upper incisal edge position and with pleasing buccal profiles.

SUMMARY OF TREATMENT PLAN**Dentition**

New restorations upper molars, second bicuspids, and lower molars

Periodontium

Ongoing self care and professional maintenance

TMJs

Bite splint therapy: The goal is improvement of signs and symptoms with occlusal stability 4 months.

Follow with definitive occlusal/restorative therapy.

Muscles

Bite splint therapy: The goal is improvement of signs and symptoms.

Follow with definitive occlusal/restorative therapy.

Occlusion

Simultaneous, equal intensity centric stops in the adapted centric posture arc of closure and anterior guidance on anterior teeth with equilibration, posterior restorations, and anterior composites

Aesthetics

Increase length of maxillary incisors with composite

SUMMARY OF TREATMENT SEQUENCE**Appointment****Treatment Completed**

1	Bite splint therapy
2	Bite splint therapy follow-ups
3	Adjunctive therapy (physical therapy) as needed
4	Four months of stability of occlusion on the splint is a requirement to move forward.
5	Prerestorative equilibration; reshape posterior teeth; composite additions anterior teeth
6	Continue with bite splint.
7	Definitive posterior reconstruction
8	Insertion and posttreatment bite splint
9	Ongoing occlusal management as needed and expected

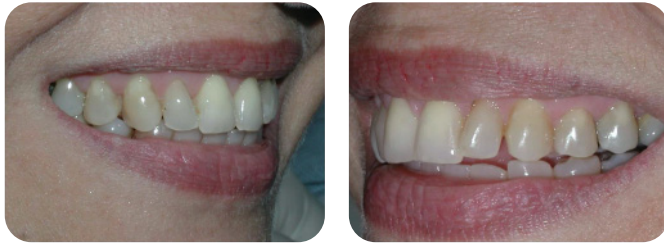
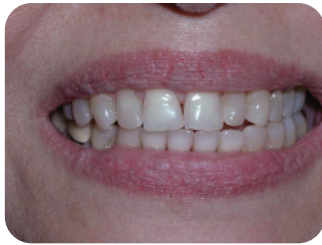
Figure 6.7.1. Pretreatment anterior and lateral smile photographs suggesting subtle reverse anterior smile line.

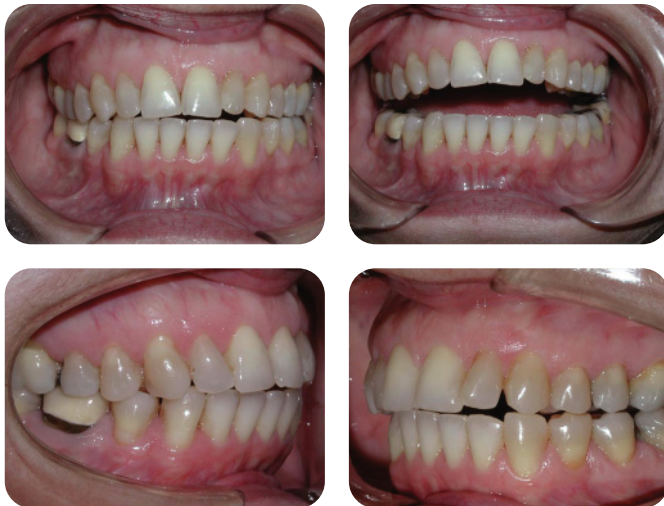

Figure 6.7.2. Pretreatment anterior and lateral retracted photographs suggesting incomplete anterior coupling, especially on the left side, resulting in an anterior guidance that does not disclude the posterior teeth.

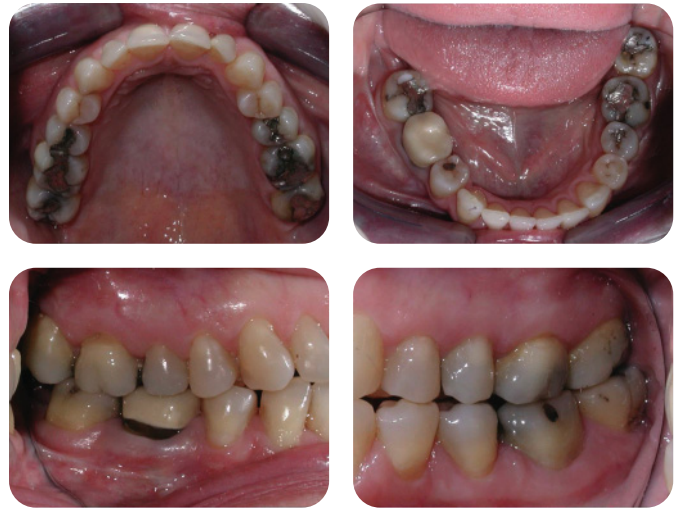

Figure 6.7.3. Pretreatment occlusal and buccal occluded photographs suggesting incomplete coupling on the left side. Most posterior teeth are in need of restorations, allowing an occlusal reconstruction that fulfills the requirements of a physiologic occlusion.

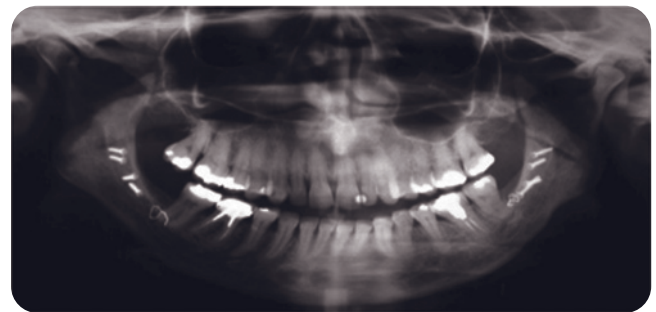


Figure 6.7.4. Pretreatment panoramic radiograph suggesting significant remodeling and asymmetry in the left condyle.

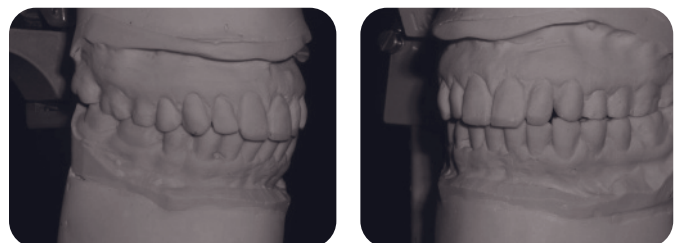
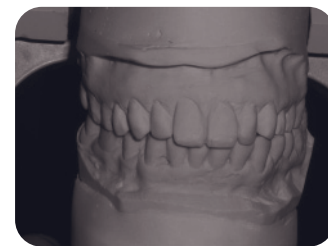

Figure 6.7.5. Photographs of trial equilibration and diagnostic wax-up illustrating improved maxillary to mandibular occlusal relationships. Maxillary incisor length was increased.

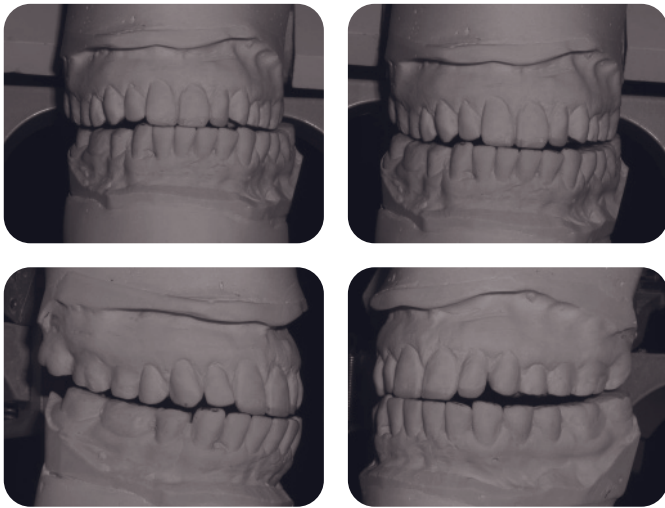


Figure 6.7.6. Photographs of diagnostic wax-up through various excursions. Disclusion now occurs following equilibration, shallowing cusp to fossa angles, flattening the Curve of Spee, and increasing maxillary incisor length.

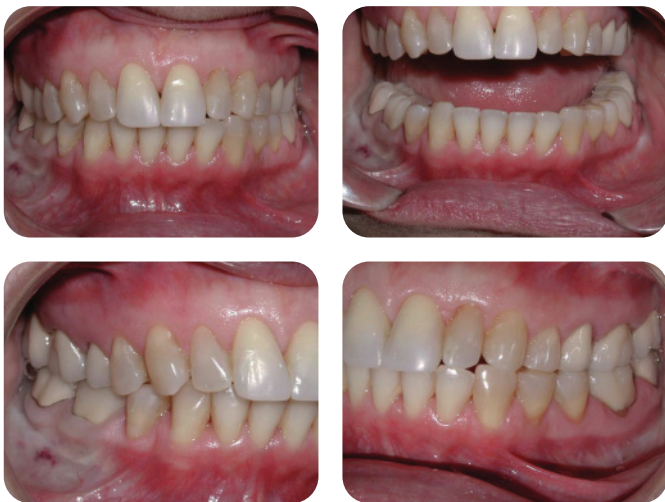

Figure 6.7.7. Photographs of completed equilibration, posterior restorations, and anterior composites.

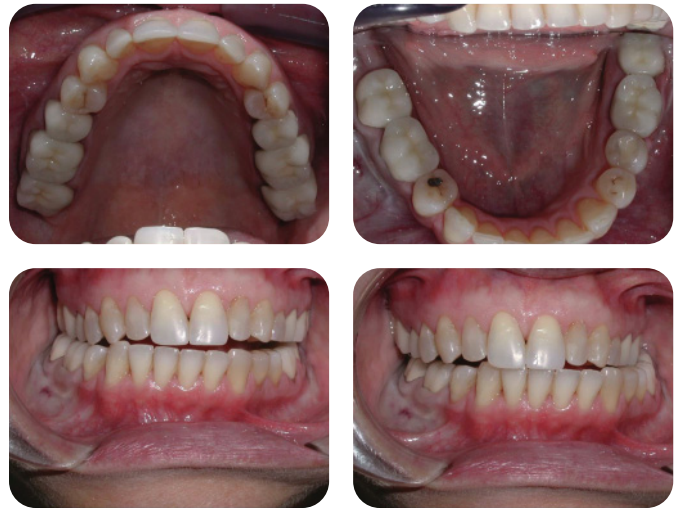

Figure 6.7.8. Occlusal photographs of completed dentistry. Right lateral range of motion is limited just the cuspid edge to edge position, and not beyond, due to significant left condylar changes. There is posterior disclusion. Left lateral range of motion is more normal, and this movement gets to the incisal edges. There is posterior disclusion. Patient continues to use bite splint, and yearly occlusal refinements are necessary as expected by the TMJ diagnosis and resultant prognosis.

CHAPTER 6 CASE 7 KEY POINTS

- Incisal edges of anterior teeth are important not only for good aesthetics but also to help clear excursive interferences in parafunctional positions.
- Correlate condylar changes to occlusal, arch, and skeletal changes.

7

Restorations to Achieve Aesthetic and Functional Changes

Case 1 Restoration of anterior aesthetics and anterior guidance in a deep overbite damaged by bruxism with upper and lower anterior reconstruction

Case 2 Posterior reconstruction with severe interferences to the centric arc of closure

Case 3 Restoration of aesthetics and anterior guidance damaged by wear by increasing overbite with upper and lower anterior crowns

Case 4 Maxillary reconstruction at open vertical dimension to improve aesthetics, length, buccal profiles, and functional landmarks; mandibular restorations only recontoured

Case 5 Maxillary and mandibular aesthetic and functional reconstruction with lab-processed composite restorations to treat amelogenesis imperfecta

Case 6 Restorations maxillary bicuspid-to-bicuspid done first as part of a comprehensive plan; maxillary left central incisor implant and other functional discrepancies corrected with reshaping and equilibration

Case 7 Maxillary and mandibular dental reconstruction including 4 dental implants replacing unrestorable teeth. Impaired aesthetics due to recession handled with grafts and all porcelain restorations

See also:

Chapter 16 Case 1 Severe anterior overjet handled with occlusal/restorative treatment in lieu of orthognathics; muscular component of a temporomandibular disorder also managed

Chapter 7 Case 1

Restoration of anterior aesthetics and anterior guidance in a deep overbite damaged by bruxism with upper and lower anterior reconstruction

Bruxism and parafunctional habits are a common observation with our patients. Some have symptoms and some do not. Whether or not they have symptoms, we commonly find signs of breakdown that have these habits and occlusal interferences as a contributing factor. These signs can be wear and tear on teeth, periodontal issues, subsequent aesthetic issues, etc.

This patient had significant wear and tear on his teeth, and he was becoming self-conscious about the appearance of his teeth and his smile. There were muscle signs and symptoms but no TMJ symptoms.

SUMMARY OF EXAMINATION AND DIAGNOSIS

Dentition

Wear on all teeth especially anteriors
Aesthetic concerns, appearance of teeth and smile

Subosseous root fracture 31, asymptomatic

Periodontium

Periodontitis posteriorly

TMJs

Right side Piper 3B

Left side Piper 3B

Both can be superiorly compressed with no tenderness.

Somewhat limited range of motion due to elevator muscle hypertrophy

Muscles

Lateral and medial pterygoids tender to palpation

Occlusion

Slight slide, has been equilibrated

Aesthetics

Tooth form, proportions, incisal edge position need to be changed.

The restoration necessitated increasing the length of his anterior teeth along with steepening of the anterior guidance.

THE 10 DECISIONS

1. TMJ Diagnosis

Bite splint—guided ACP (muscle problem only)

Definitive treatment—guided ACP

2. Vertical Dimension

May need to increase to shallow anterior guidance performance platform if provisionals made at current VDO show signs of instability

3. Lower Incisal Edge

Height okay, just make even and level.

4. Upper Incisal Edge

Increase length 2 mm.

5. Centric Stops

Tooth-to-tooth centric holding contacts on all teeth in the adapted centric posture arc of closure

6. Anterior Guidance

Do not steepen guidance even though lengthening incisors; may need to shallow by increasing VDO with lower posterior restorations.

7. Curve of Spee

Acceptable

8. Curve of Wilson

Acceptable

9. Cusp/Fossa Angle

Shallower than anterior guidance

10. Aesthetic Plane

Use corrected upper central incisal edges as a guide. Enhance facial surface profiles of upper bicuspids.

SUMMARY OF TREATMENT PLAN

Dentition

Porcelain crowns 6–11, 22–27, veneers 4, 5, 12, 13 to enhance aesthetic plane

Periodontium

Scaling and root planning/surgery as needed at periodontal specialist

TMJs

No treatment is needed other than correct occlusal engineering.

Muscles

Bite splint therapy followed by correct occlusal engineering

Occlusion

Simultaneous, equal intensity centric stops in the adapted centric posture arc of closure with anterior reconstruction, posterior equilibration; may need to open VDO with lower posterior onlays to shallow the anterior guidance performance platform

Aesthetics

Increase central incisor length by 2mm. Idealize form, proportion, contour, and texture.

SUMMARY OF TREATMENT SEQUENCE

Appointment

Treatment Completed

- | | |
|---|--|
| 1 | Bite splint therapy for muscles |
| 2 | Periodontal maintenance and surgery at specialist |
| 3 | Provisionalize 6–11 and 22–27. |
| 4 | Test provisionals for 4–6 weeks since significant anterior guidance changes were made. If necessary, increase VDO to shallow anterior guidance performance platform. |
| 5 | Lower posterior occlusal onlays to increase VDO
Add to linguals of 6–11 to shallow guidance. |
| 6 | Finalize 22–27. |
| 7 | Finalize 6–11.
Veneers 4, 5, 12, 13 to enhance aesthetic plane |
| 8 | Finalize lower posterior onlays. |
| 9 | Posttreatment protective bite splint |

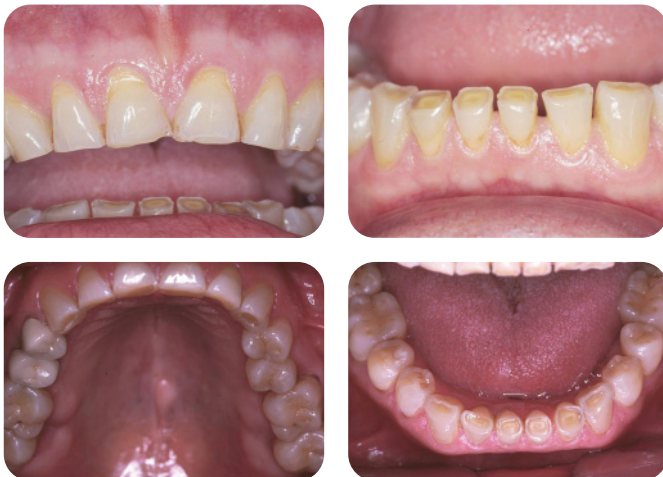

Figure 7.1.1. Pretreatment photographs suggesting wear and aesthetic issues.

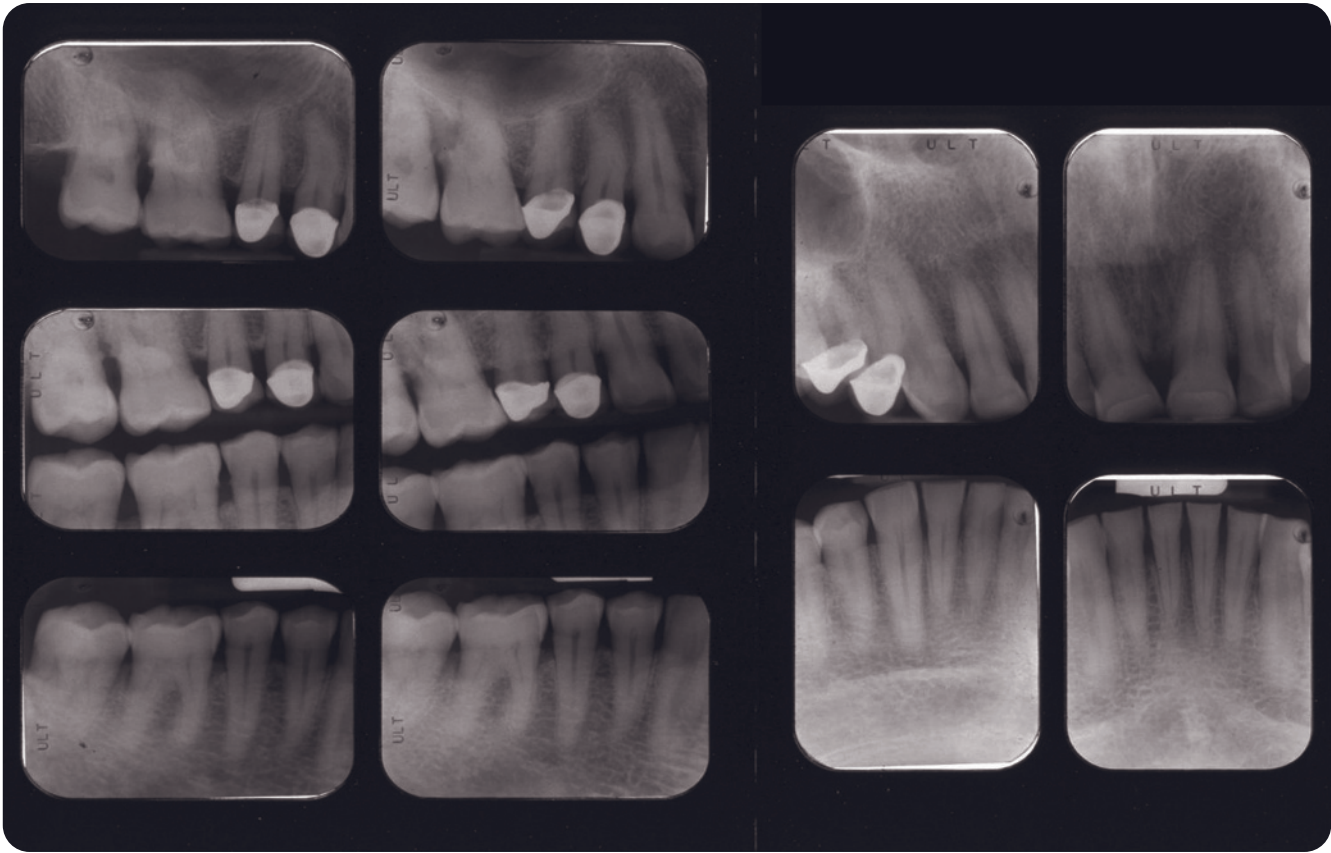


Figure 7.1.2. Pretreatment radiographs, right side.

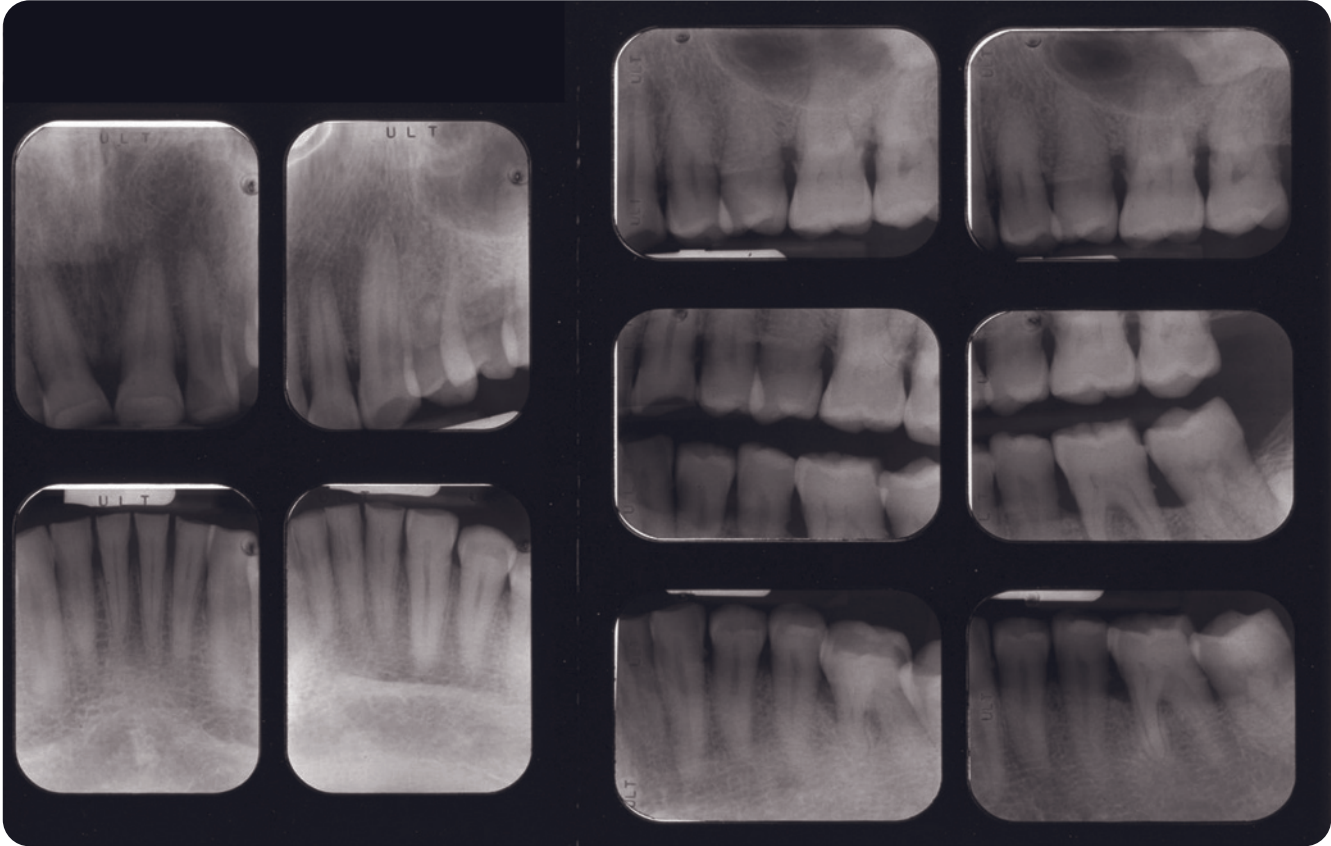


Figure 7.1.3. Pretreatment radiographs, left side.

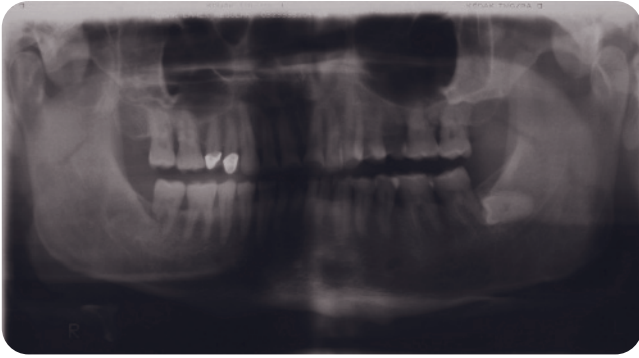


Figure 7.1.4. Pretreatment panoramic radiograph.

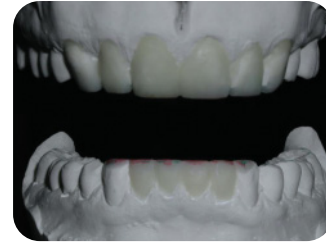

Figure 7.1.7. Diagnostic wax-up illustrating aesthetic changes.

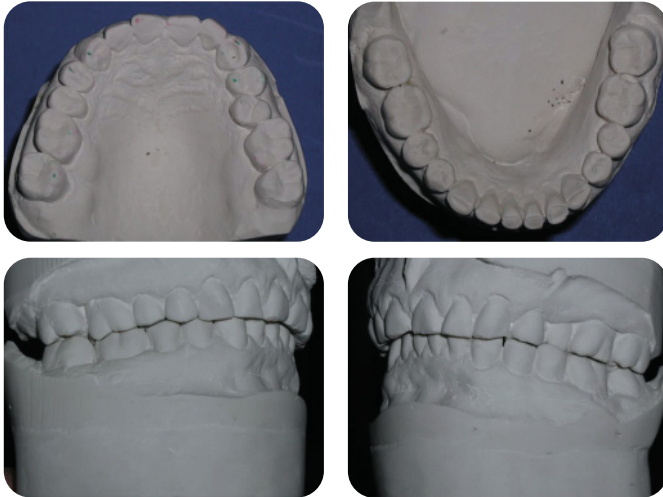

Figure 7.1.5. Pretreatment articulated diagnostic casts. Only slight interferences present because of previous equilibration. It would have been preferable to stop the equilibration short of the original vertical dimension of occlusion to gain space anteriorly for restorations. See Chapter 6, Case 2 for an explanation of the concept.

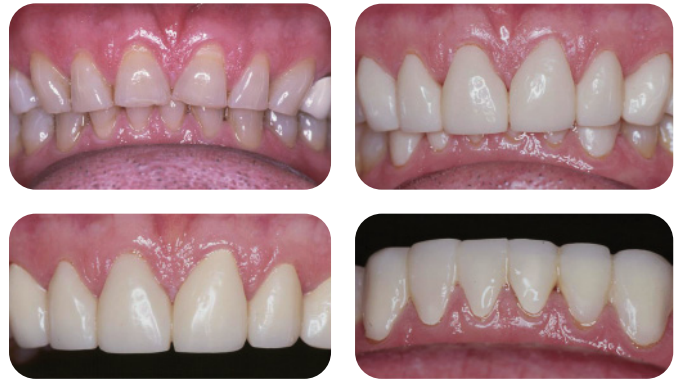

Figure 7.1.8. Photographs of upper and lower anterior provisionals at the current vertical dimension of occlusion, after occlusal refinement.

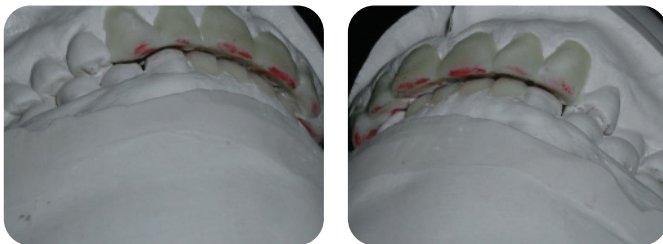
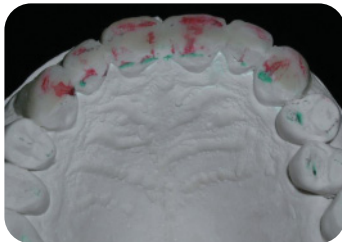

Figure 7.1.6. Diagnostic wax-up illustrating anterior functional relationship changes. Anterior guidance is very steep and needs to be tested with the provisionals. Anterior guidance performance may need to be made less steep by opening the vertical dimension of occlusion and shallowing the lingual performance platform.

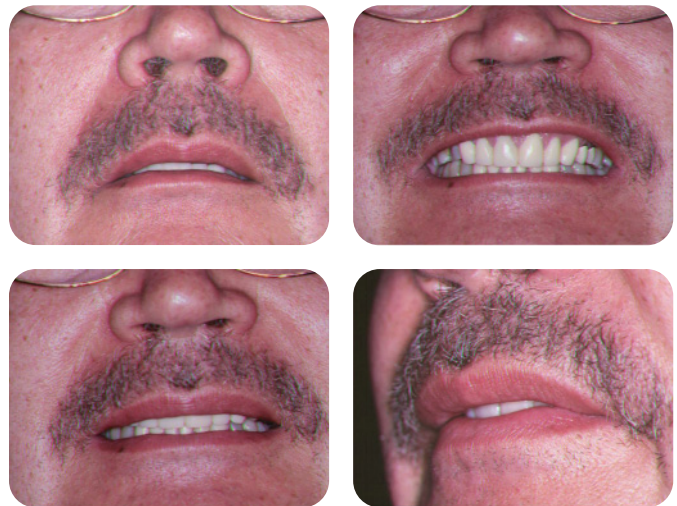

Figure 7.1.9. Photographs of verification of changes made with the provisionals. Upper left, lip at rest, no incisal edge display, but other parameters are acceptable. Upper right: lip fully raised. Lower left: "E" sound, good display of incisal edge. Lower right, "F" sound, incisal edge touches the wet-dry border of the lip. Patient was happy and comfortable. Steepened anterior guidance performance platform was tolerated by the envelope of function; no signs or symptoms of nonaccommodation.

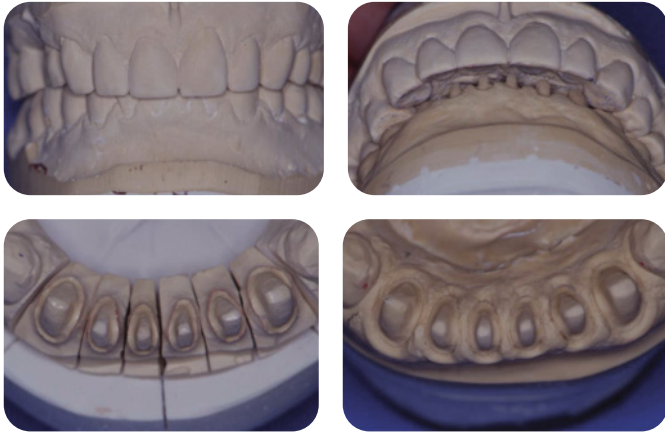

Figure 7.1.10. Lower restorations were finalized first. Communication to the technician included articulated casts of the provisionals, articulated pinned dies, and articulated solid cast.

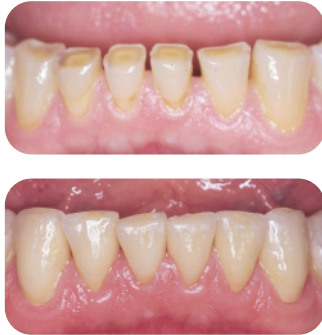

Figure 7.1.11. Definitive lower anterior restorations. Patient desired a less perfect look. The functional labial-incisal line angles were still level and horizontal.

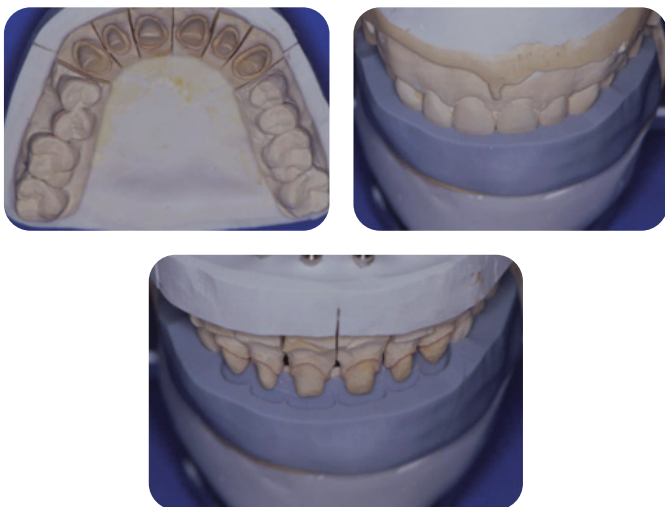


Figure 7.1.12. Communication to the technician to complete the upper restorations included an articulated putty index of the provisionals that captured the incisal edges and lingual contours. Facial veneers were fabricated for the upper bicuspids to improve the aesthetic plane.

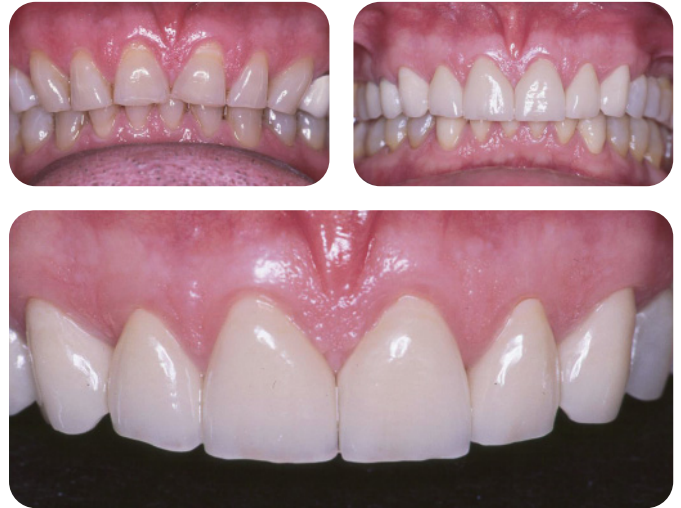

Figure 7.1.13. Photographs of the upper definitive restorations.

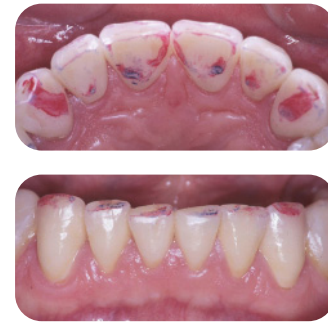

Figure 7.1.14. Photographs of the centric stops (blue) and anterior guidance (red) functional markings of the definitive restorations.

CHAPTER 7 CASE 1 KEY POINTS

- Test an increase in the steepness of the anterior guidance with provisionals for an appropriate period of time.
- Increasing the vertical dimension of occlusion may be necessary to shallow the guidance. Make sure this possibility is discussed.

Chapter 7 Case 2

Posterior reconstruction with severe interferences to the centric arc of closure

This case study illustrates the importance of evaluating our patients in the centric relation (or adapted centric posture) arc of closure. What appears to be an acceptable occlusion when evaluating maximum intercuspation may look totally different when evaluating the maxillary to mandibular occlusal relationships with the condyles seated. The patient in this case study has had his posterior teeth repaired many times over the past several years. He had no tooth sensitivity or temporomandibular joint or muscular symptoms. His main concern was why his posterior restorations have never lasted very long. As we investigate his occlusion with the condyles seated, you will see why.

SUMMARY OF EXAMINATION AND DIAGNOSIS

Dentition

Posterior teeth have structural concerns including cracks and failing restorations.

Periodontium

Stable, already under the care of a periodontist

TMJs

Right side Piper 3B

Left side Piper 3B

Both condyles can be superiorly compressed with no sign of tension or tenderness.

Muscles

Lateral pterygoids slightly tender to palpation

Occlusion

Interferences to the adapted centric posture arc of closure results in a 4–5mm opening anteriorly.

Aesthetics

All parameters are acceptable to the patient.

THE 10 DECISIONS

1. TMJ Diagnosis

Treat to a guided adapted centric posture.

2. Vertical Dimension

Equilibrate interferences in the centric arc of closure to the original vertical dimension of maximum intercuspation.

3. Lower Incisal Edge

Acceptable; just smooth and polish.

4. Upper Incisal Edge

Acceptable; just smooth and polish.

5. Centric Stops

Simultaneous equal intensity contact on all teeth in the centric arc of closure

6. Anterior Guidance

Keep as is; just smooth and polish.

7. Curve of Spee

Keep low and flat.

8. Curve of Wilson

Verify that upper buccal and lower lingual cusps do not interfere in the functional and parafunctional range of motion.

9. CUSP/FOSSA ANGLE

Shallower than the angle of the anterior guidance performance platform

10. Aesthetic Plane

Verify that the aesthetic plane of the upper buccal cusps is level and symmetrical and that the facial profiles of the upper posterior teeth are aligned correctly.

SUMMARY OF TREATMENT PLAN

Dentition

Molars restored with full crowns, upper left first and second bicuspids restored with porcelain inlays

Periodontium

Ongoing maintenance and self care

TMJs

No treatment is needed other than correct occlusal engineering.

Muscles

No treatment is needed other than correct occlusal engineering.

Occlusion

Because posterior teeth need to be restored anyway, they can be reduced enough to gain anterior centric stops in the adapted centric posture arc of closure along with equilibration of the bicuspids.

Aesthetics

Idealize with restorations.

SUMMARY OF TREATMENT SEQUENCE

Appointment

Treatment Completed

- | | |
|---|--|
| 1 | Provisionalization of all molars; Prep lowers first using reduction guide from blueprint and make lower molar provisionals. Equilibrate upper molars to idealized lower provisionals, do occlusal reduction of upper molars from this corrected vertical reference, and then prepare and provisionalize. |
| 2 | Time to test results |
| 3 | Finalize lower restorations. |
| 4 | Continued time to test with lower definitive restorations against upper provisionals |
| 5 | Finalize upper restorations. |

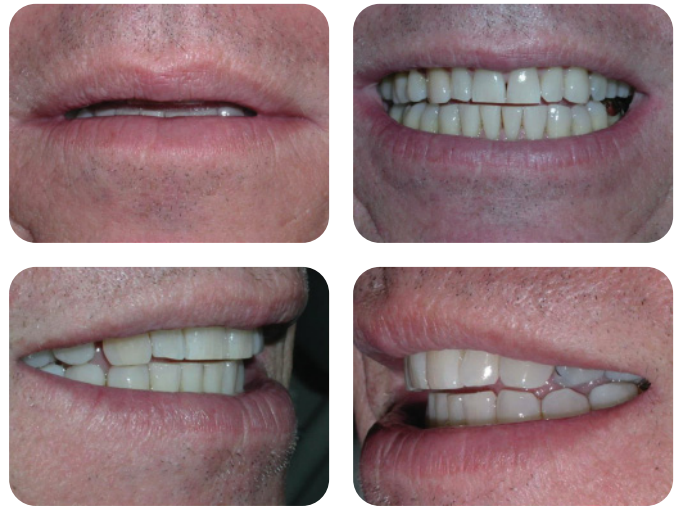

Figure 7.2.1. Pretreatment photographs with lips at rest, a slight smile, and lateral smile views suggesting that the aesthetic parameters are acceptable.

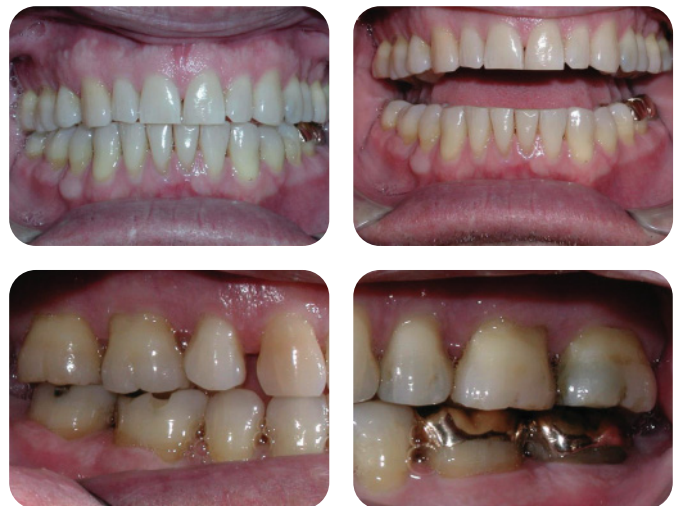

Figure 7.2.2. Retracted anterior and buccal photographs suggesting that occlusion seems acceptable. This is an evaluation of maximum intercuspation only at this point.

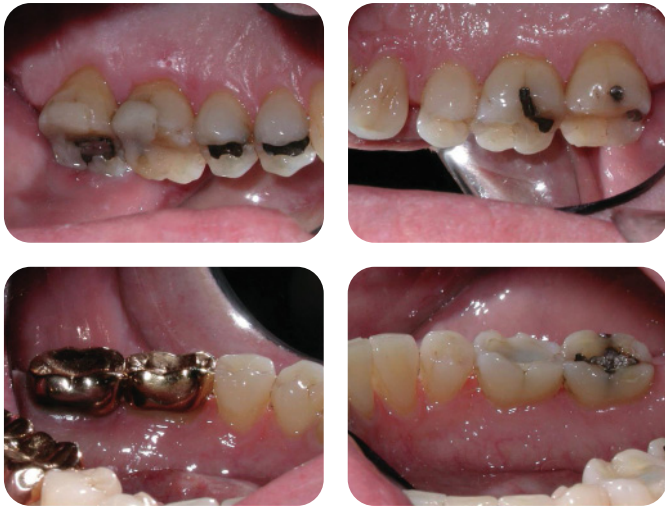

Figure 7.2.3. Pretreatment lingual photographs suggesting wear and tear on most all of the posterior teeth.

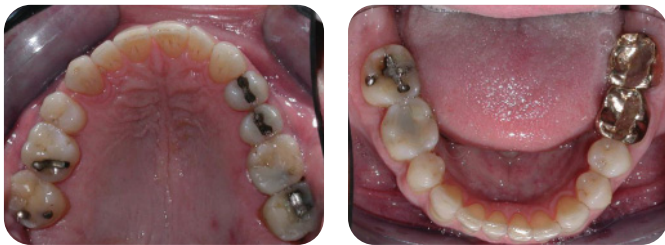

Figure 7.2.4. Pretreatment maxillary and mandibular occlusal photographs.

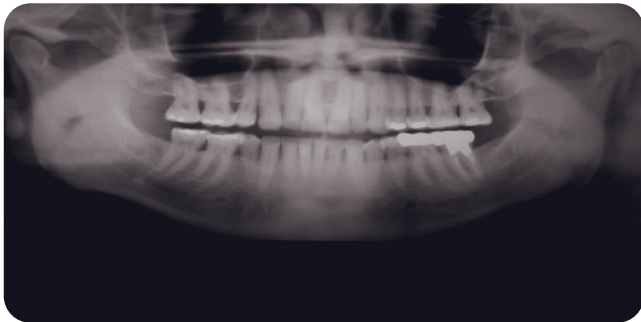


Figure 7.2.5. Pretreatment panoramic radiograph.

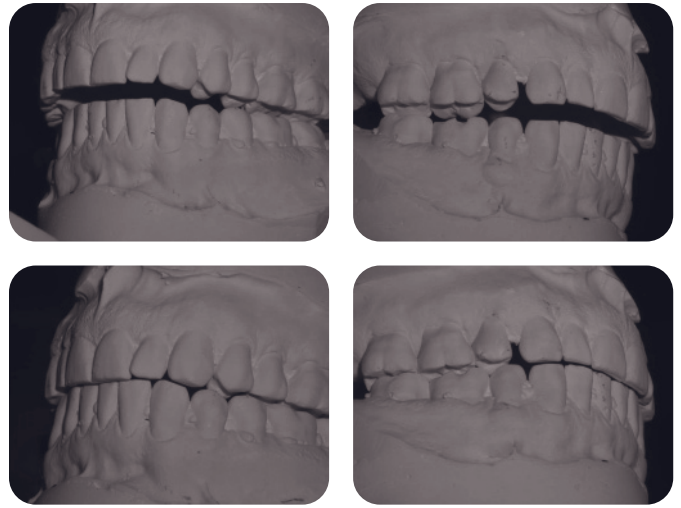


Figure 7.2.6. The top photographs are of the articulated diagnostic casts closed to the first point of contact in the adapted centric posture arc of closure illustrating the severe opening anteriorly at this position. The bottom photographs are maximum intercuspation. Imagine the position of the condyle when the teeth are in maximum intercuspation, which is down and forward somewhere along the articular eminence. Unless this case is treated with the condyles seated, the posterior restorations will be problematic.

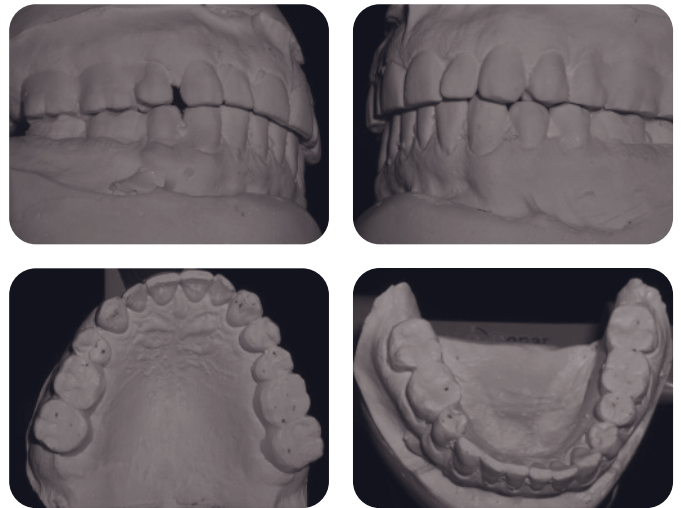


Figure 7.2.7. Photographs of a second set of articulated diagnostic casts trial equilibrated in the adapted centric posture arc of closure to the vertical dimension of the cuspids contacting. At this point, maximum intercuspation will be in harmony with the seated condyles. Although it required a significant amount of reduction of the posterior teeth, it was within physiologic limits and did not appear as if elective endodontics would be necessary.

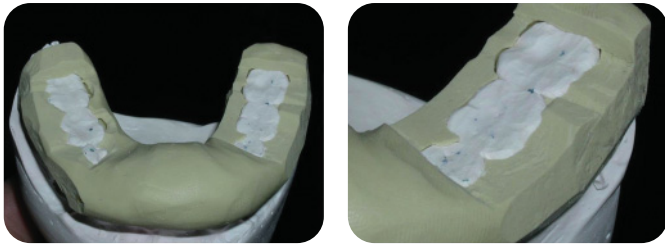

Figure 7.2.8. Photographs of silicone putty reduction guides. These guides represent the height that the occlusal surfaces need to be. When used intraorally, these guides can be a reference to verify that the occlusal reduction of the crown preparations is adequate.

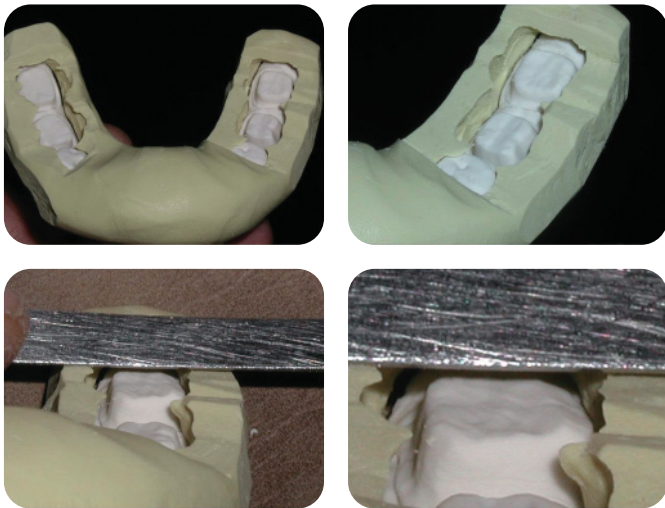

Figure 7.2.9. Photographs of the occlusal reduction guides seated on a cast of the tooth preparations. A straight edge spanning the buccal and lingual edges of the reduction guide allows visualization of the reduction of the occlusal surfaces. The reduction guides are used in a similar manner intraorally.

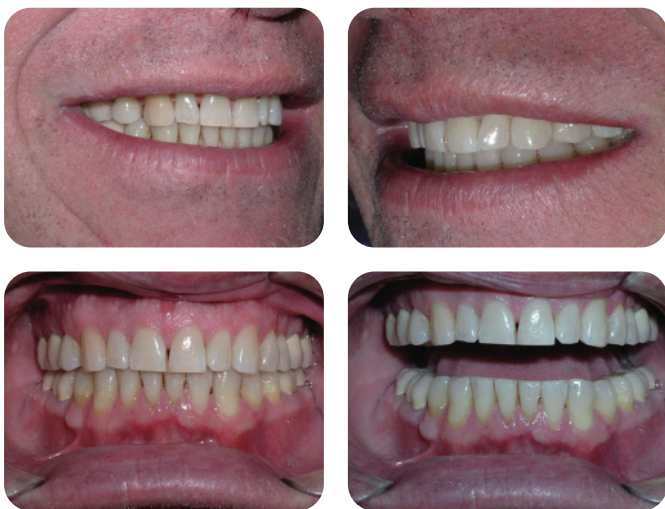

Figure 7.2.10. Lateral smile and retracted photographs of the completed restorations.

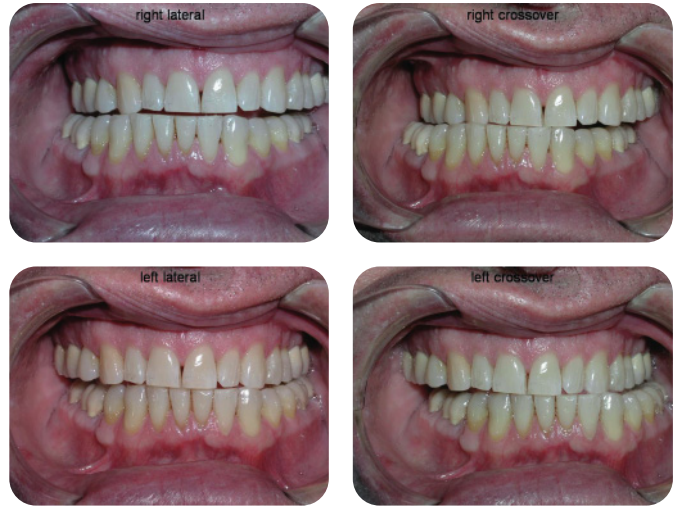

Figure 7.2.11. Photographs of various excursive movements illustrating disclusion of the posterior teeth.

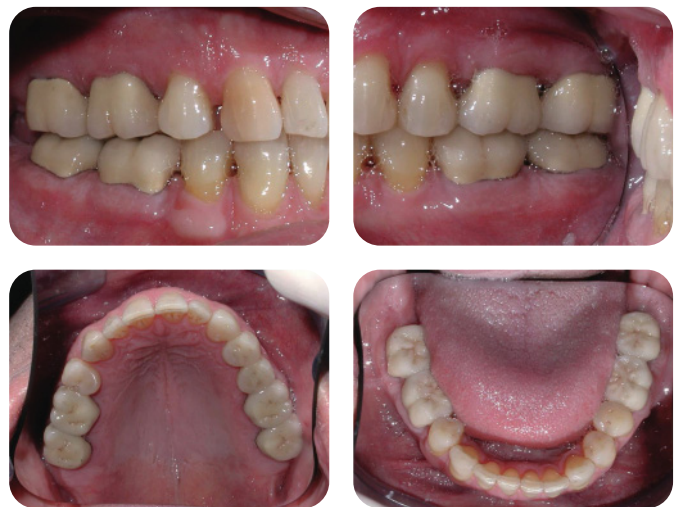

Figure 7.2.12. Buccal occluded photographs and maxillary and mandibular occlusal photographs of the completed restorations.

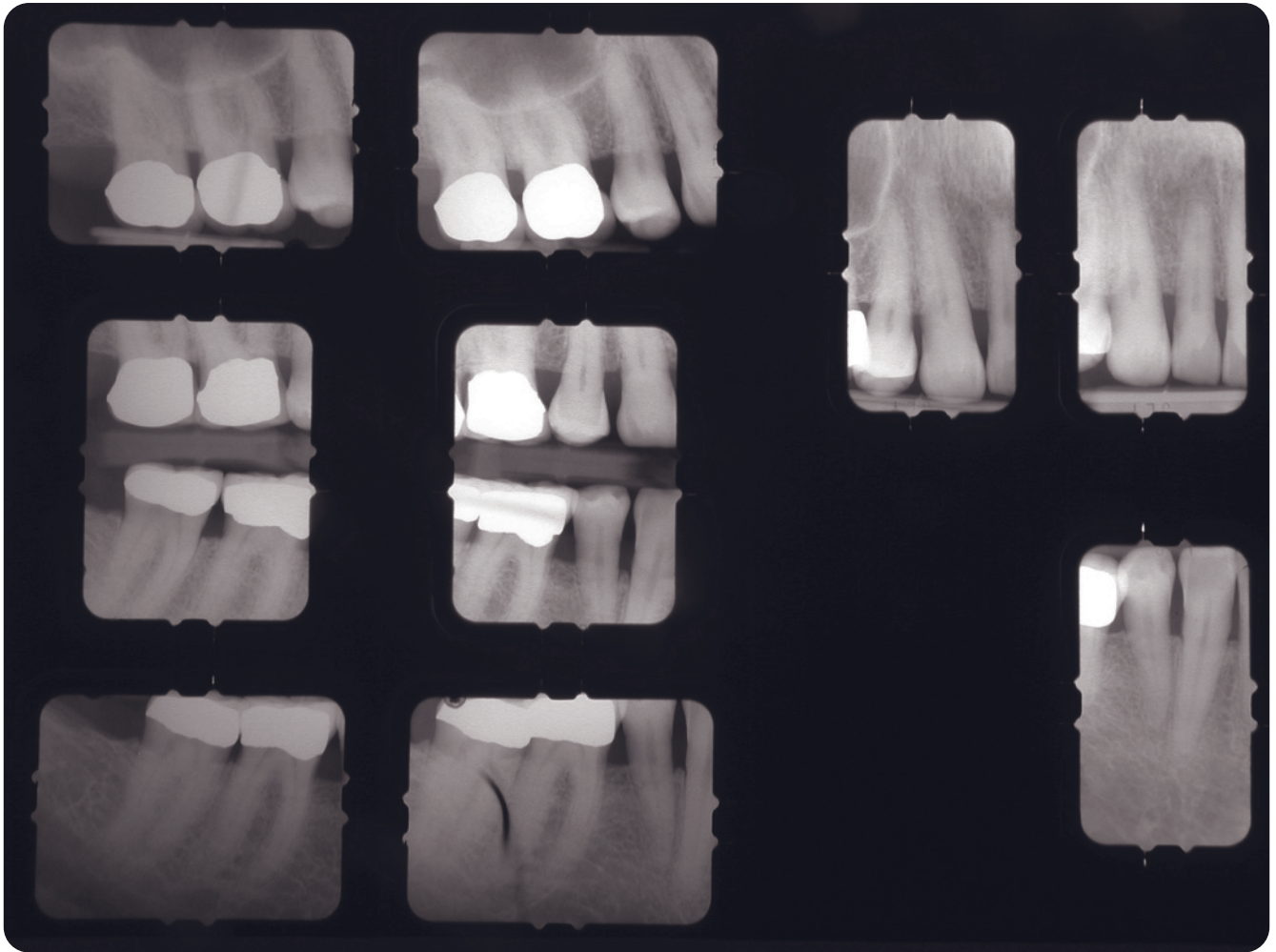


Figure 7.2.13. Posttreatment radiographs of the completed restorations, right side.

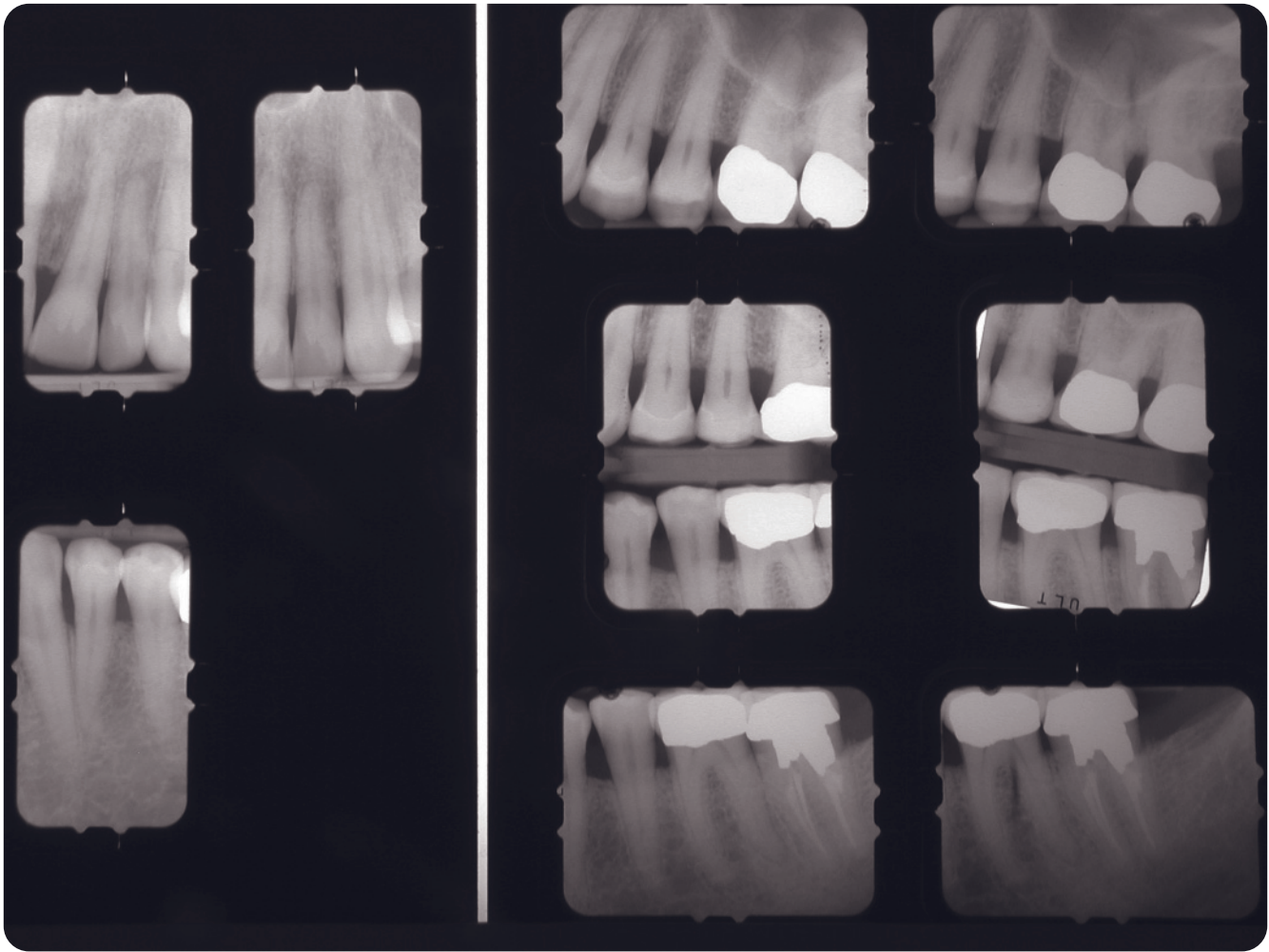


Figure 7.2.14. Posttreatment radiographs of the completed restoration, left side. Despite the occlusal reduction that was necessary on all molars to gain an occlusion that was in harmony with adapted centric posture, none of the teeth required endodontic therapy.

CHAPTER 7 CASE 2 KEY POINTS

- Always analyze the occlusion on articulated diagnostic casts mounted with the condyles seated, even in the seemingly simple cases or those with no symptoms.
- Plan occlusal reduction on articulated casts, make occlusal reduction guides when necessary.

Chapter 7 Case 3

Restoration of aesthetics and anterior guidance damaged by wear by increasing overbite with upper and lower anterior crowns

The main motivation for the patient in this case study was to improve the appearance of her smile. There was wear and tear on the teeth resulting in an uneven incisal plane. Although she was having no TMJ or muscle symptoms, occlusal misengineering was evident; and that, in addition to a tendency to brux, led to the occlusal and incisal wear.

The aesthetic and functional improvements required an increase in the length of the teeth and a slight increase in overbite. It is prudent to test these kinds of changes for an extended period of time in provisionals that incorporate all the functional and aesthetic

SUMMARY OF EXAMINATION AND DIAGNOSIS

Dentition

Wear, especially the anterior teeth, structural concerns as well as endodontic concerns

Periodontium

Localized recession, no pockets over 3 mm, no mobility

TMJs

Right side Piper 3B, coarse crepitation

Left side Piper 3B, coarse crepitation

Both can be comfortably compressed.

No palpation tenderness

Range of motion normal

Muscles

Lateral and medial pterygoids are painful to palpation.

Occlusion

Interferences to the adapted centric posture arc of closure with a slide to maximum intercuspation.

Anterior tooth-to-tooth relationship is end-to-end with severe excursive interferences.

Aesthetics

Position, form, proportion, incisal edges, and color are all inadequate.

changes desired in the definitive dentistry. In this way, alterations can be made and once again verified until the patient is happy, the dentist is happy, and there are no signs of any of the changes exceeding the adaptive capacity of the masticatory system.

THE 10 DECISIONS

1. TMJ Diagnosis

Treat to a verified adapted centric posture.

2. Vertical Dimension

Equilibrate to second bicuspid contact. First bicuspid will occlude in restoration; this will provide room anteriorly for restorations.

3. Lower Incisal Edge

Use height of lower right cuspid as a reference.

4. Upper Incisal Edge

Increase length 1–1.5 mm.

5. Centric Stops

Simultaneous, equal intensity centric stops in the ACP arc of closure

6. Anterior Guidance

Will be steepened by increasing overbite to about 3 mm; will need to be tested in provisionals

7. Curve of Spee

Shallow and flatten with equilibration.

8. Curve of Wilson

Verify that upper buccal and lower lingual cusps do not interfere in the functional and parafunctional range of motion.

9. Cusp/Fossa Angle

Keep shallow; do not deepen fossa when equilibrating.

10. Aesthetic Plane

Create an upper posterior aesthetic plane that is consistent with the upper incisal edge position and with pleasing buccal profiles with veneers and reshaping.

SUMMARY OF TREATMENT PLAN

Dentition

Empress crowns 6–12, 22–27
 Onlay/veneers 5, 21, 28
 Endo evaluation
 Posttreatment splint as a protective device

Periodontium

Ongoing maintenance and self-care
 Soft tissue grafts 6 and 22–27

TMJs

No treatment is needed other than correct occlusal engineering.

Muscles

No treatment is needed other than correct occlusal engineering.

Occlusion

Reconstruction per diagnostic blueprint
 Anterior reconstruction to steepen guidance,
 posterior equilibration with the goal of flattening
 Curve of Spee, Curve of Wilson, and cusp-fossa
 angle in the process

Aesthetics

Idealize form and proportions with restorations;
 increase length of incisors 1 mm.

SUMMARY OF TREATMENT SEQUENCE

Appointment	Treatment Completed
1	Soft tissue grafts done by the periodontist
2	Provisionalize 6–11, 22–27 along with equilibration to achieve simultaneous, equal intensity contacts on all teeth.
3	Test anterior guidance since it was steepened and modify as needed by evaluating provisionals.
4	Final preparations and impressions lower to include onlay/veneers 21, 28
5	Deliver lower restorations.
6	Final preparations and impressions 6–11 to include veneer 5
7	Deliver restorations and protective bite splint.
8	Posterior restoration at a sequence agreeable to patient

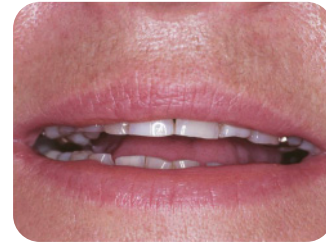

Figure 7.3.1. Pretreatment smile photograph suggesting aesthetic and functional concerns.

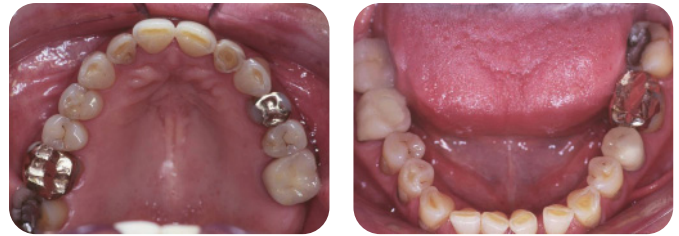


Figure 7.3.2. Pretreatment maxillary and mandibular photographs suggesting wear from bruxism and possibly other causes such as habits.

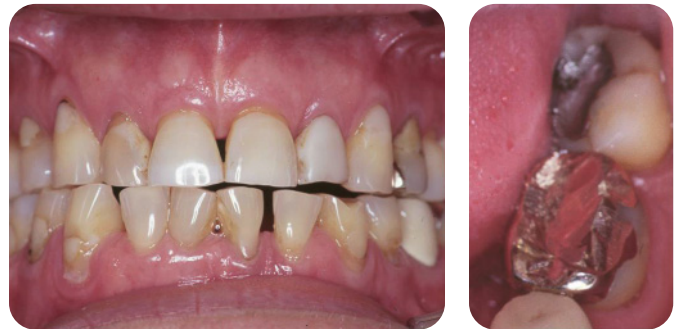

Figure 7.3.3. Pretreatment retracted anterior photograph suggesting anterior end-to-end functional relationship. The left lateral and cuspid display wear facets that do not match up in any functional or parafunctional position suggest loss of tooth structure from other causes. Also note the severe balancing interference wear facet on the gold restoration of the lower left first molar.

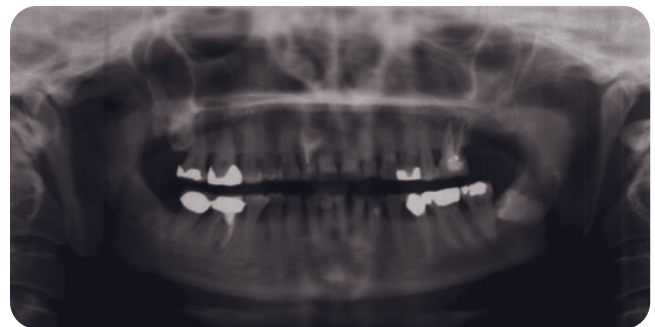

Figure 7.3.4. Pretreatment panoramic radiograph suggesting endodontic concerns.

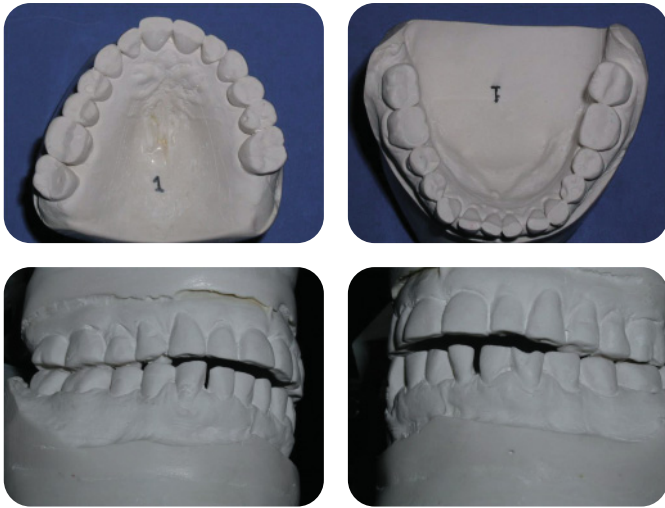


Figure 7.3.5. Pretreatment articulated diagnostic casts photographed at the first contact in the adapted centric posture arc of closure. Note the anterior tooth-to-tooth relationship at this position suggesting that room to restore the anterior teeth can be gained.

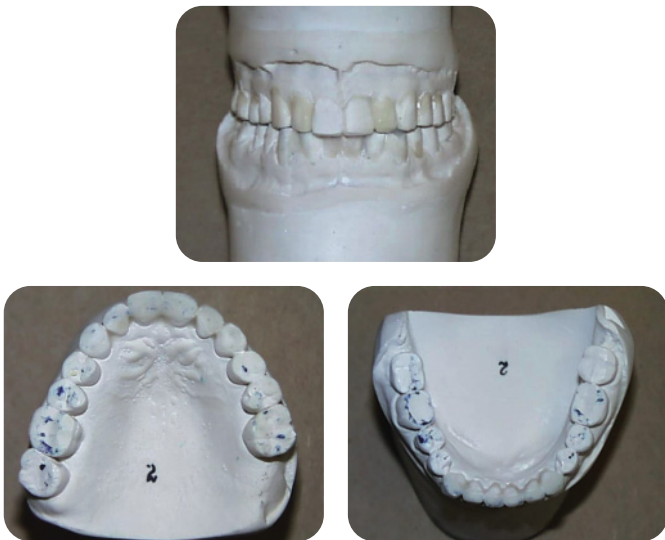

Figure 7.3.6. The trial equilibration was done until bicuspids coupled. The goal was to shorten cusp tips rather than deepen fossa since it is a low anterior guidance disclusion case. This left room anteriorly to redesign the anterior guidance. The lower anteriors were "moved" lingually with the wax-up, and the upper incisors were lengthened approximately 1 mm. with the goal of slightly increasing the overbite relationship. It was possible to equilibrate the posterior teeth effectively so restorations do not need to be changed for structural reasons. When changed in the future (for aesthetic and/or structural reasons), they simply need to be coordinated into this acceptable scheme.

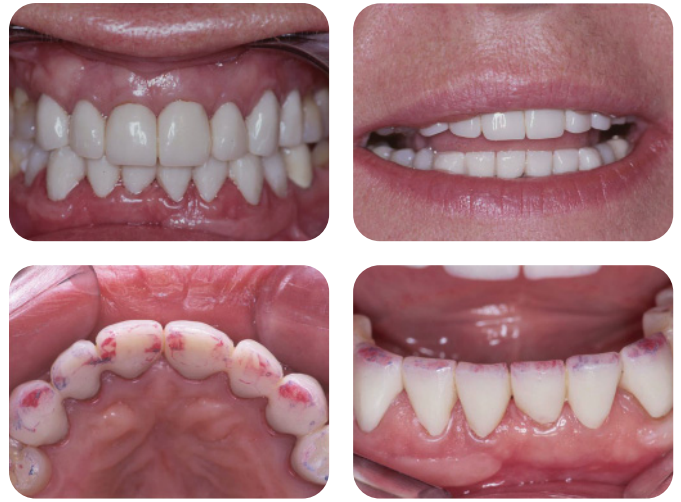

Figure 7.3.7. Photographs after provisionalization suggesting an improved overbite relationship, improved incisal edge display at rest, and functional anterior guidance marks on the appropriate teeth in excursions.

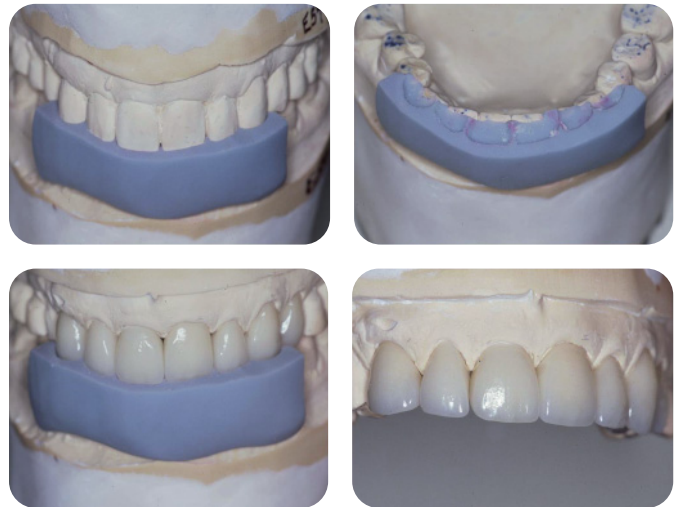

Figure 7.3.8. The lower restorations were completed first. This photograph illustrates the putty index made from the articulated casts of the provisionals and the definitive restorations fitting precisely into the index, thereby accurately duplicating incisal edges and lingual surfaces.

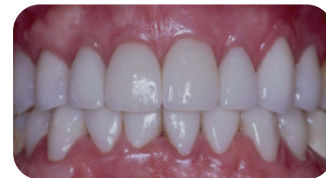

Figure 7.3.9. Close-up anterior retracted photograph of the completed restorations.

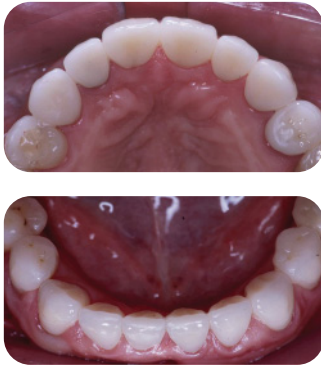

Figure 7.3.10. Close-up occlusal photographs of the completed restorations.

CHAPTER 7 CASE 3 KEY POINTS

- Use putty indices to communicate landmarks to the technician.
- Equilibrate the posterior teeth when doing only anterior restorations. Use the anterior guidance steepness to decide whether to shorten cusp tips or deepen fossa.

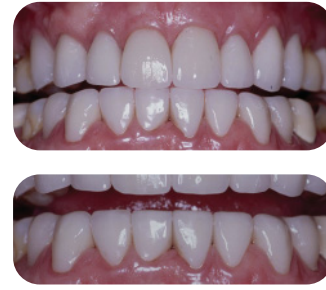

Figure 7.3.11. Close-up anterior retracted photographs of the completed restorations with the mandible protruded to an anterior end-to-end relationship suggesting good edge-to-edge contacts with no posterior interferences. The lower photograph illustrates an improved lower incisal plane, an important component for good anterior guidance.

Chapter 7 Case 4

Maxillary reconstruction at open vertical dimension to improve aesthetics, length, buccal profiles, and functional landmarks; mandibular restorations only recontoured

The patient in this case study had the mandibular reconstruction done many years ago and the maxillary reconstruction just recently. She is unhappy with the aesthetic result sensing they are too short and too flat and the smile too narrow. She is also discouraged that the maxillary anterior veneers have chipped and come off multiple times.

SUMMARY OF EXAMINATION AND DIAGNOSIS

Dentition

Failing maxillary restorations
Mandibular posterior restorations acceptable
Mandibular anterior restorations serviceable for a limited time

Periodontium

Within normal limits

TMJs

Right side Piper 1, quiet to auscultation
Left side Piper 1, quiet to auscultation
Both can be superiorly compressed comfortably.

Muscles

Lateral pterygoids only slight discomfort to testing

Occlusion

Interferences in the arc of closure to maximum intercuspation

Aesthetics

Inadequate display of incisal edges, buccal corridors narrow, flat incisal embrasures, color, and proportions

THE 10 DECISIONS

1. TMJ Diagnosis

Treat to centric relation (normal joints).

2. Vertical Dimension

Increase 2 mm to improve functional landmarks and aesthetics.

3. Lower Incisal Edge

Smooth and polish.

4. Upper Incisal Edge

Increase length 2 mm.

5. Centric Stops

Simultaneous, equal intensity centric stops in the centric relation arc of closure

6. Anterior Guidance

Shallower since vertical dimension is increased

7. Curve of Spee

Reshape mandibular restorations to lessen curve at second molars.

8. Curve of Wilson

Verify that upper buccal and lower lingual cusps do not interfere in the functional and parafunctional range of motion.

9. Cusp/Fossa Angle

Shallower than anterior guidance

10. Aesthetic Plane

Verify that the aesthetic plane of the upper buccal cusps is level, symmetrical, and consistent with correct anterior teeth and that the facial profiles of the upper posterior teeth are enhanced and aligned correctly.

SUMMARY OF TREATMENT PLAN

Dentition

Maxillary reconstruction

Periodontium

Ongoing self care and professional maintenance

TMJs

No treatment is needed other than correct occlusal engineering.

Muscles

No treatment is needed other than correct occlusal engineering.

Occlusion

Simultaneous, equal intensity centric stops in the centric relation arc of closure at an increased vertical dimension and anterior guidance on anterior teeth

Aesthetics

Increase length, widen buccal corridor, enhance embrasures.

SUMMARY OF TREATMENT SEQUENCE

Appointment

Treatment Completed

- | | |
|---|--|
| 1 | Removable diagnostic provisional to test length, aesthetics, buccal corridor, and neutral zone accommodation |
| 2 | Diagnostic wax-up based on results of step 1 |
| 3 | Prepare and provisionalize all maxillary teeth. Reshape mandibular teeth minimally. |
| 4 | Review restorations together at technician's lab. |
| 5 | Place definitive restorations. |

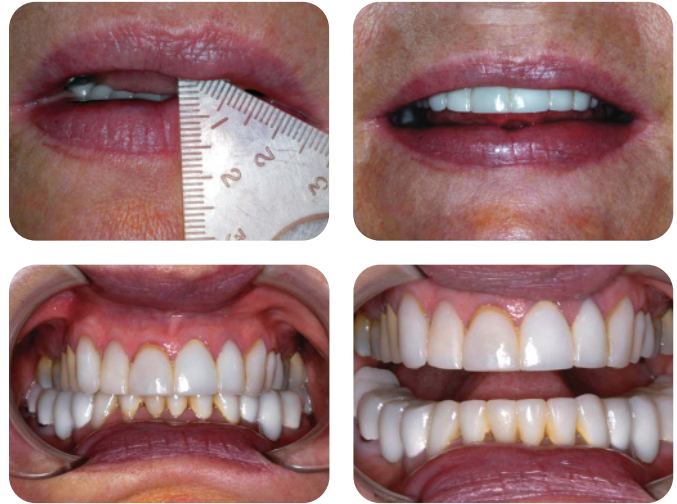

Figure 7.4.1. Pretreatment smile and retracted photographs. With lip at rest, the maxillary edges are covered by 3mm suggesting that the length can be increased. Also note flat incisal embrasures and narrow buccal profiles of the posterior teeth. The lower right occlusal plane has a reverse Curve of Wilson and a severe Curve of Spee.

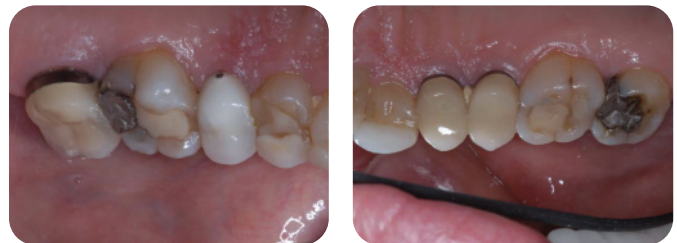
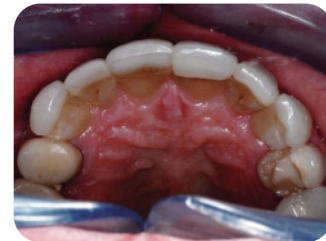
Figure 7.4.2. Mirror photographs of the maxillary teeth, which have failing restorations. The patient was surprised at the condition of her teeth, thinking everything was okay. The photographs were an eye-opening experience for her. Since the teeth need new restorations anyway, an opportunity to improve aesthetics and function is available.

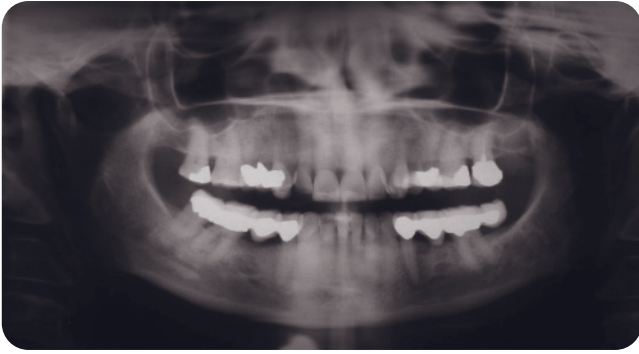

Figure 7.4.3. Pretreatment panoramic radiograph suggesting that mandibular teeth are structurally acceptable. The joints are quiet in both hinging and excursions, not a common finding in the author's experience. This could truly be called a normal centric relation. The occlusion has been stable and needed no adjustments posttreatment as is often seen in adapted centric posture.

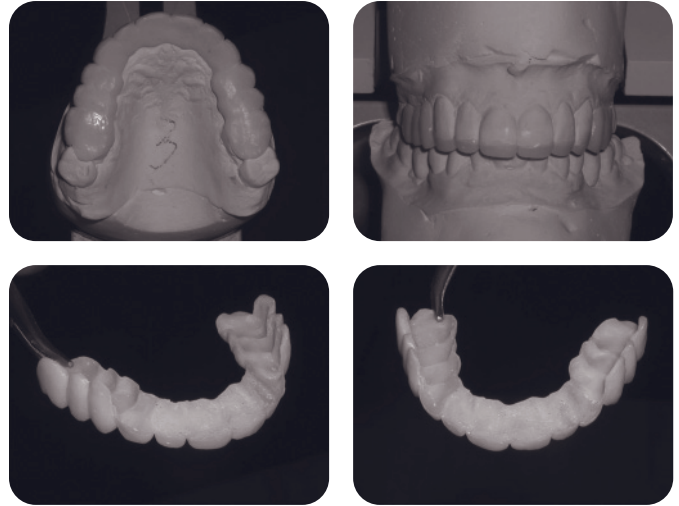


Figure 7.4.4. Photograph of a removable diagnostic provisional made over an unaltered maxillary cast. This diagnostic provisional has all the components of the treatment plan, such as increased vertical dimension, increased anterior length, and enhanced buccal profiles. This type of diagnostic provisional is possible when all changes are "add-on" rather than "takeaway." The patient can take it home and live with the changes and help decide whether this is a project to undertake. Better to find out now than after teeth are prepared.

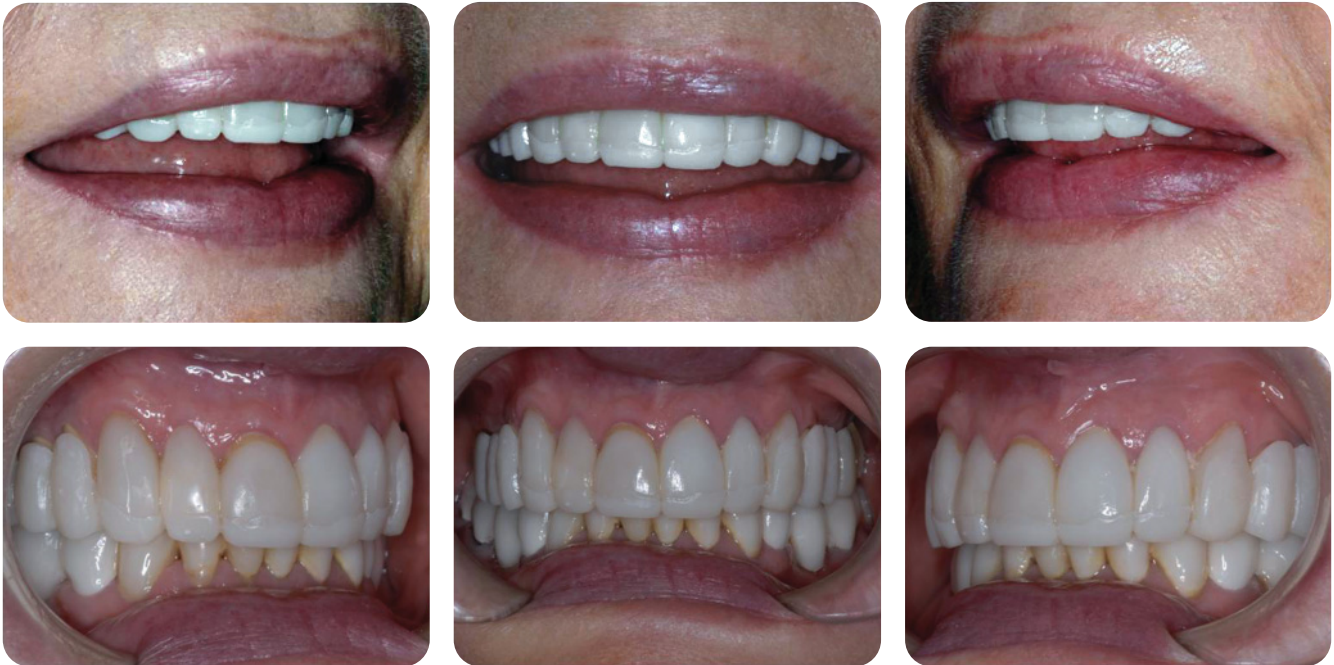

Figure 7.4.5. Smile and retracted photographs of the diagnostic provisional in place. She was very pleased with all the proposed changes and excited to begin the treatment plan.

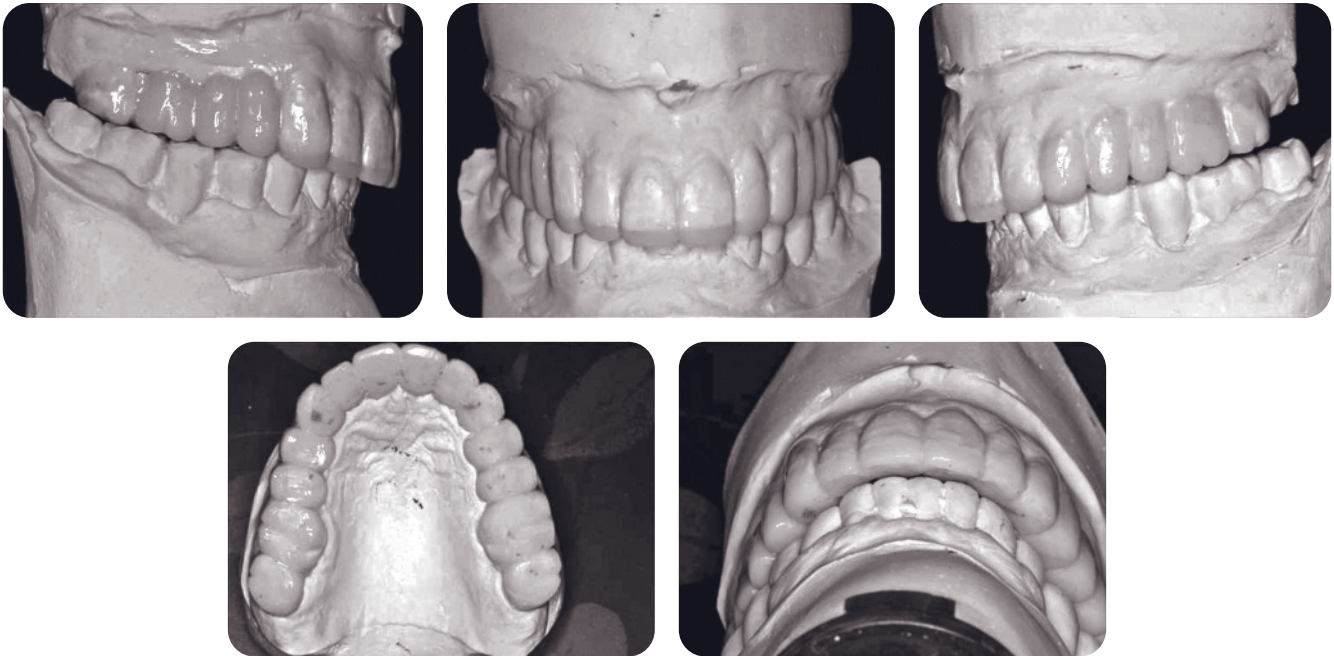


Figure 7.4.6. Photographs of the diagnostic wax-up incorporating the aesthetic and functional changes approved with the previous step. Particular attention is paid to the lingual surfaces of the maxillary anterior teeth to design stable centric holding contacts and a smooth anterior guidance performance platform. Mandibular landmarks have been refined by reshaping.

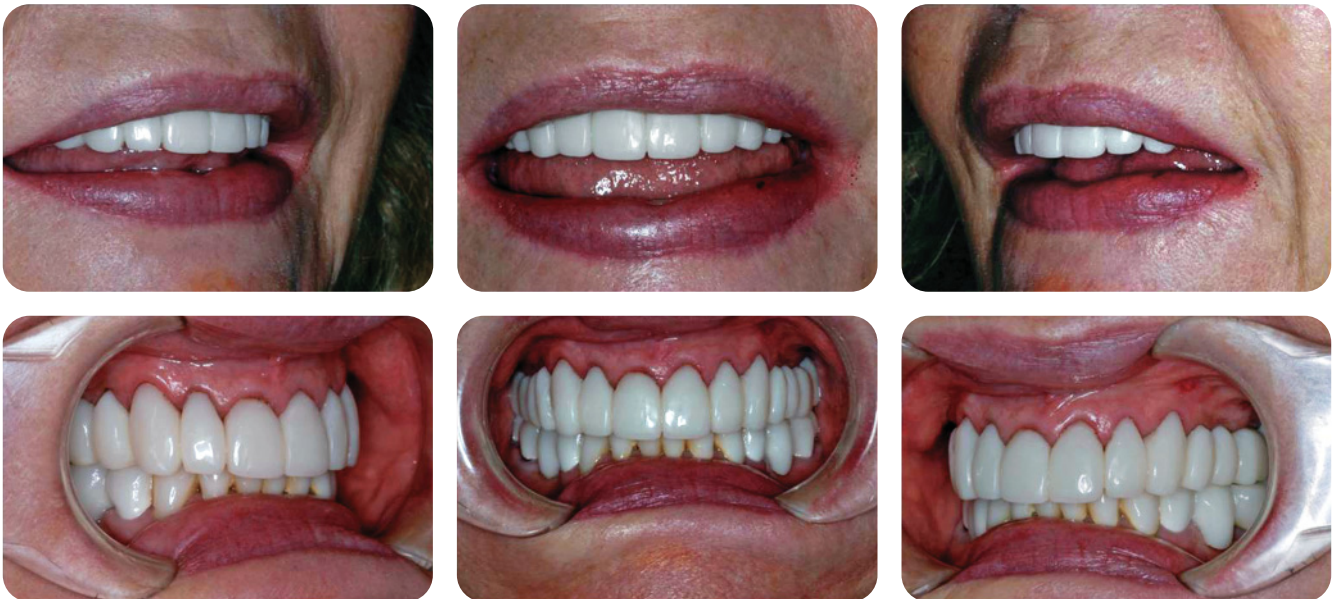

Figure 7.4.7. Smile and retracted photographs of the provisional restorations. Note similarity to the diagnostic provisional. As described in detail in other case studies, articulated casts of the provisionals along with putty landmark guides are used by the technician.

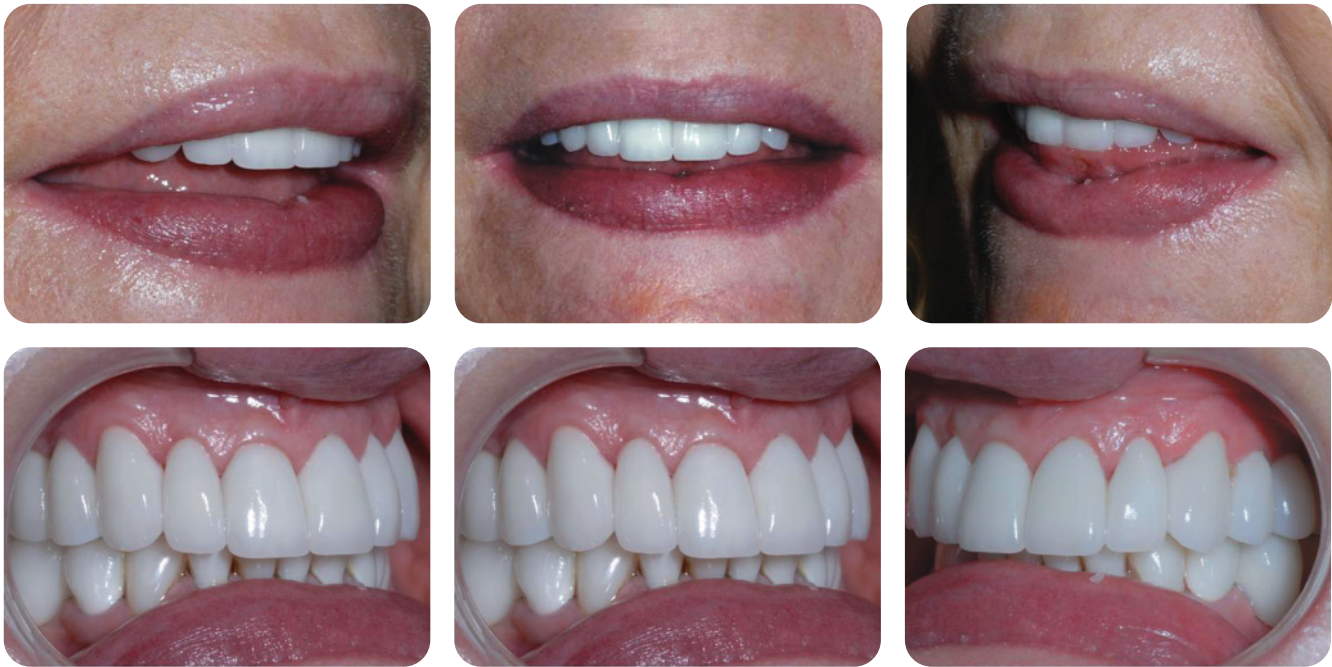

Figure 7.4.8. Smile and retracted photographs of the definitive dentistry.

CHAPTER 7 CASE 4 KEY POINTS

- A removable “takeaway” diagnostic provisional allows the patient to visualize the proposed changes and “live with it” for a while.
- When only one arch is treated, always evaluate the opposing arch and modify by reshaping as necessary to improve landmarks.

Chapter 7 Case 5

Maxillary and mandibular aesthetic and functional reconstruction with lab-processed composite restorations to treat amelogenesis imperfecta

The young lady in this case study has never been happy with her smile. Her condition was managed in a way consistent with her age and development. She recently completed orthodontics and is ready to begin a reconstruction.

SUMMARY OF EXAMINATION AND DIAGNOSIS

Dentition

All teeth are structurally deficient but restorable.

Periodontium

Gingivitis

TMJs

Right side Piper 2

Left side Piper 2

Both can be superiorly compressed comfortably.

Muscles

No issues to testing

Occlusion

Interferences in the arc of closure to maximum intercuspation

Aesthetics

Position, color, contours, proportions

THE 10 DECISIONS

1. TMJ Diagnosis

Treat to centric relation.

2. Vertical Dimension

Open 2 mm at the incisors.

3. Lower Incisal Edge

Keep height the same but move the incisal edges facially 1 mm.

4. Upper Incisal Edge

Increase length of central incisors 2 mm.

5. Centric Stops

Simultaneous, equal intensity centric stops in the centric relation arc of closure

6. Anterior Guidance

Determined by finalized upper and lower incisal edge positions. Will be shallower because vertical dimension is being opened

7. Curve of Spee

No major changes are needed.

8. Curve of Wilson

Verify that upper buccal and lower lingual cusps do not interfere in the functional and parafunctional range of motion.

9. Cusp/Fossa Angle

Shallower than the anterior guidance disclusion angle

10. Aesthetic Plane

Create an upper posterior aesthetic plane that is consistent with the upper incisal edge position and with pleasing buccal profiles.

SUMMARY OF TREATMENT PLAN**Dentition**

Restore all teeth with laboratory processed composite crowns.

Periodontium

Ongoing professional maintenance and self care

TMJs

No treatment is needed other than correct occlusal engineering.

Muscles

No treatment is needed other than correct occlusal engineering.

Occlusion

Simultaneous, equal intensity centric stops in the centric relation arc of closure with anterior guidance on the anterior teeth

Aesthetics

Idealize form, color, contours, and proportions with restorations.

SUMMARY OF TREATMENT SEQUENCE**Appointment Treatment Completed**

1–4: All pre-arranged with the technician

1	Prepare mandibular first bicuspid to first bicuspid and place the same day.
2 (next day)	Prepare maxillary first bicuspid to first bicuspid and place the same day.
3 (next day)	Prepare remaining mandibular teeth and place the same day.
4 (next day)	Prepare remaining maxillary teeth and place the same day.
5	Maxillary bite splint

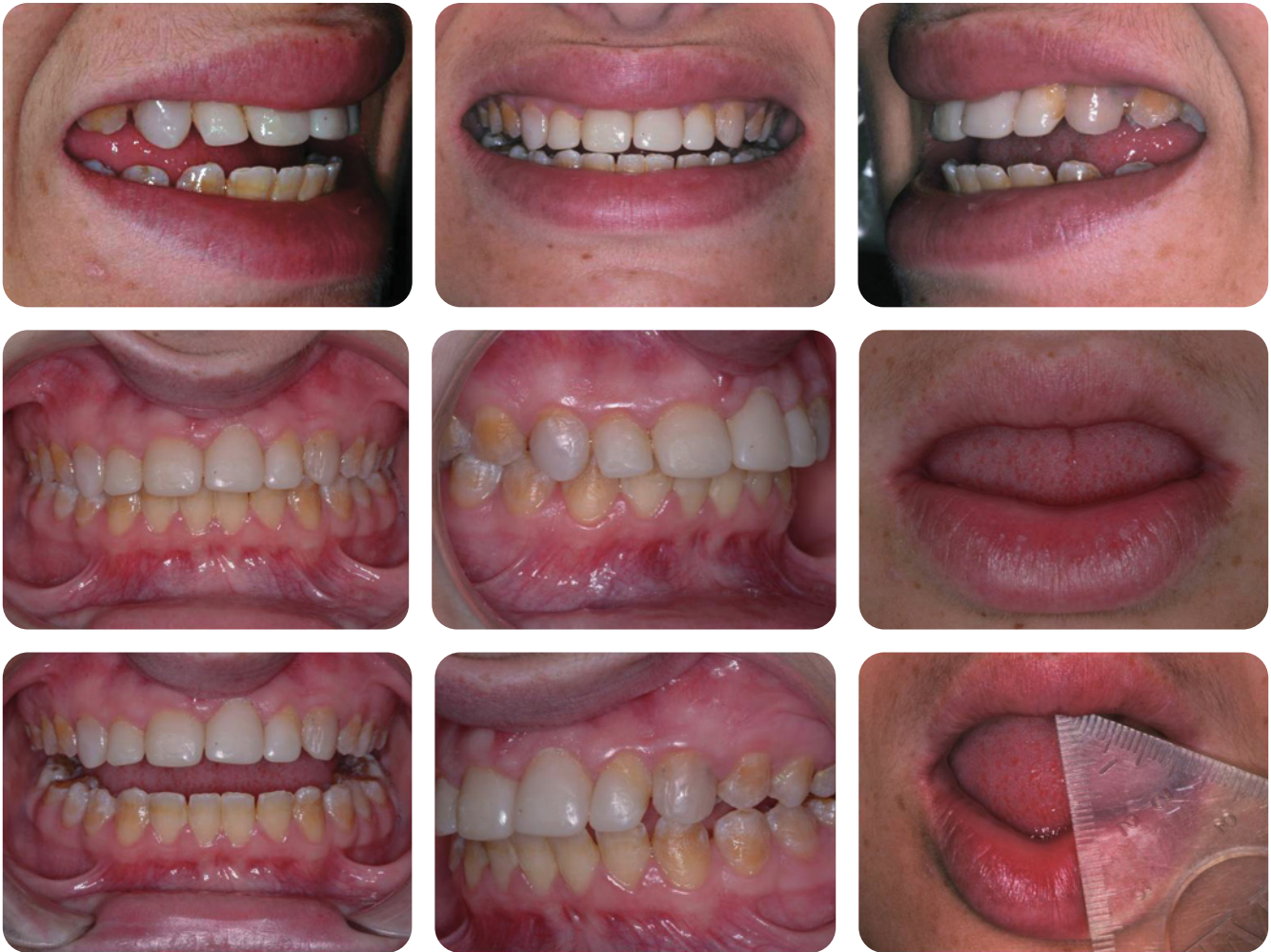

Figure 7.5.1. Pretreatment photographs illustrating the condition of the teeth and the unattractive smile. The maxillary anterior teeth appear to be angled facially. With the lip at rest, the lip covers the maxillary incisal edges by 2 mm suggesting that the length can be increased.

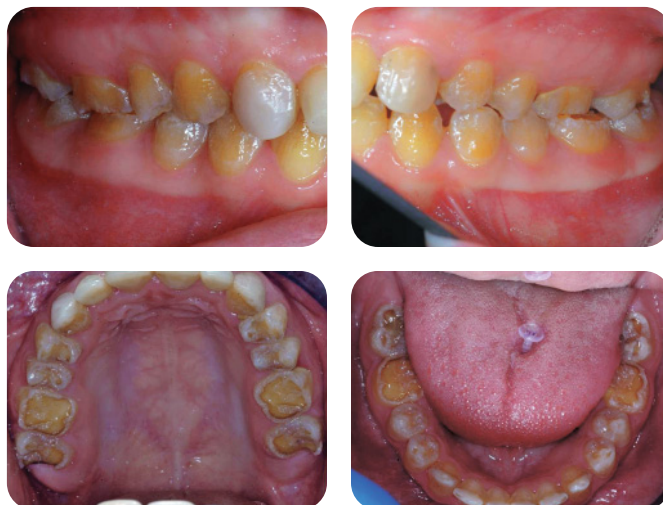

Figure 7.5.2. Pretreatment buccal occluded and occlusal photographs.

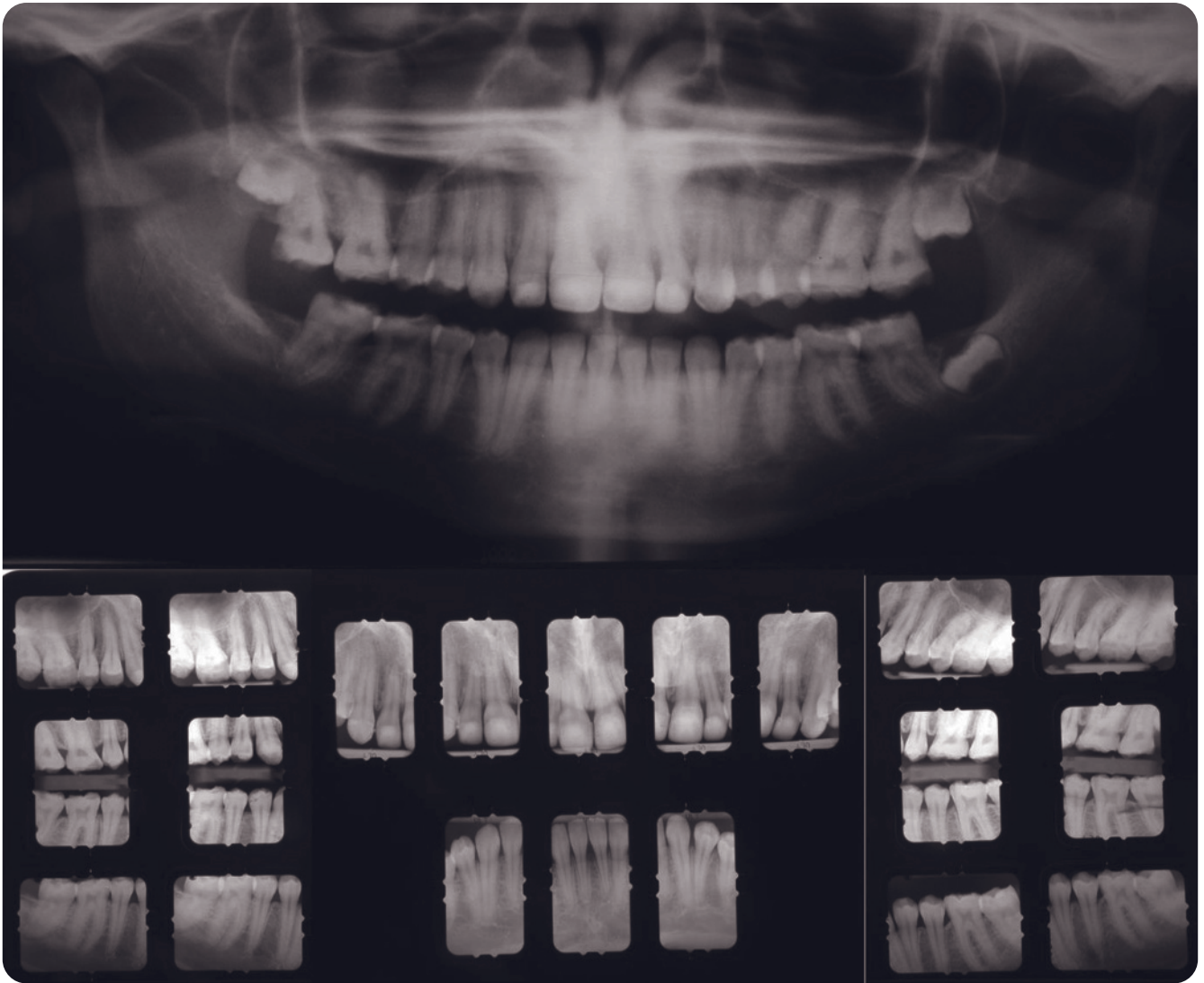


Figure 7.5.3. Pretreatment panoramic and periapical radiographs suggesting normal dentin, root anatomy, and bone despite the defective enamel.

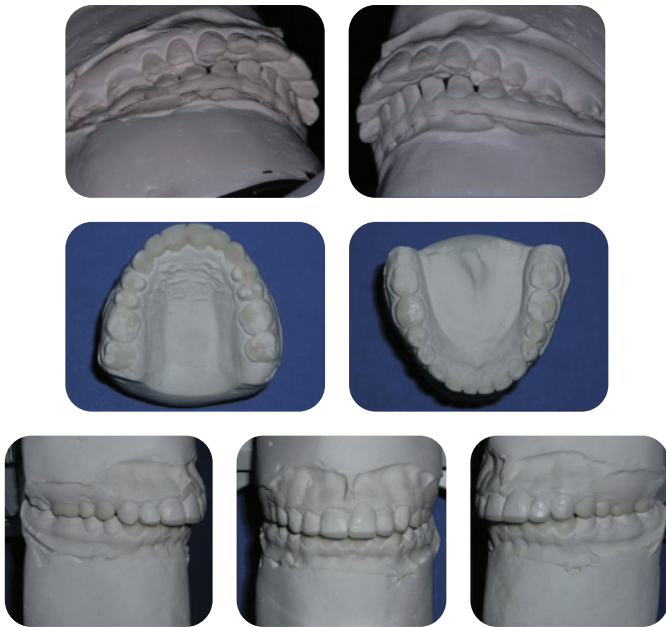

Figure 7.5.4. Pretreatment articulated diagnostic casts and diagnostic wax-up. The top photographs are at the first contact in the centric relation arc of closure. Note the anterior tooth-to-tooth relationship at this position. There is space to create contours that will result in stable tooth-to-tooth centric holding contacts. The bottom five photographs are of the diagnostic wax-up. The maxillary anterior teeth were lengthened and uprighted. The mandibular anterior teeth had their incisal edges moved facially. The lingual surfaces of the maxillary anterior teeth were contoured to create stable centric holding contacts and a proper anterior guidance performance platform. These anterior tooth aesthetic and functional changes helped determine the vertical dimension. The posterior teeth were then recontoured/corrected to that vertical dimension.

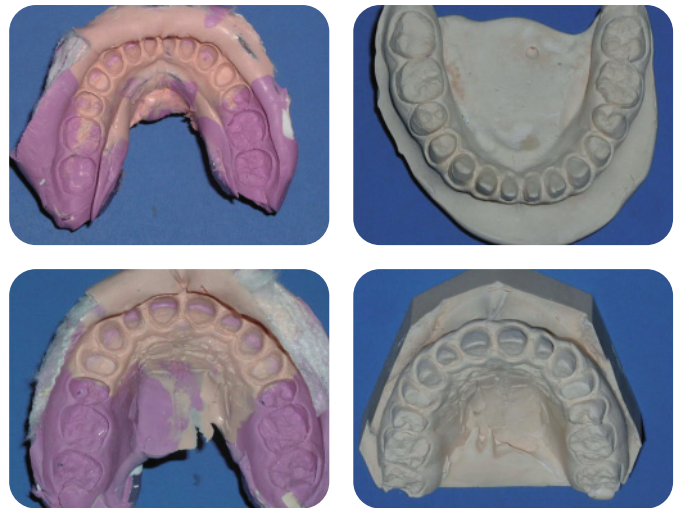


Figure 7.5.5. Top: Photographs of the mandibular impression and cast completed on day 1. Bottom: Photographs of the maxillary impression and cast completed on day 2. The restorations were bonded the same day as the preparations. This required preplanning with the local technician. The advantage of this technique was to save time and allow a more affordable fee. The restorations were bonded to freshly cut, noncontaminated dentin. Composite preparations can be more conservative than porcelain preparations. Composite can be more easily refreshed as needed than porcelain. No need to make provisionals. The disadvantage of this no-provisional approach is that aesthetic and functional changes cannot be tested prior to finalization. Therefore a well-thought-out diagnostic wax-up after a complete examination and diagnosis is essential.

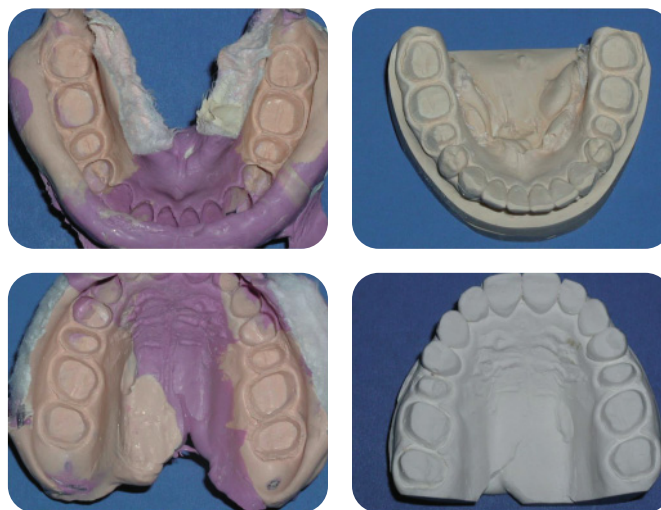


Figure 7.5.6. Maxillary and mandibular posterior impressions and casts managed the same as the anterior restorations completed on days 3 and 4.

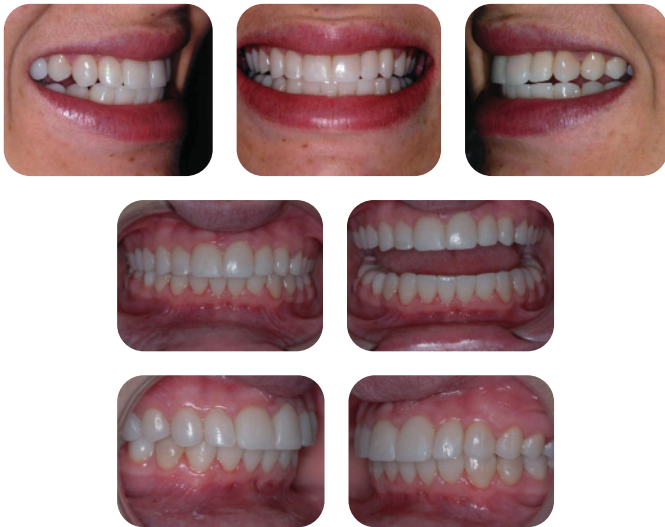

Figure 7.5.7. Smile and retracted anterior photographs of the completed restorations.

CHAPTER 7 CASE 5 KEY POINTS

- One-visit indirect laboratory-processed composite restorations are a good alternative in young patients.
- Prearranging appointments with the technician will allow timely delivery of the restorations.

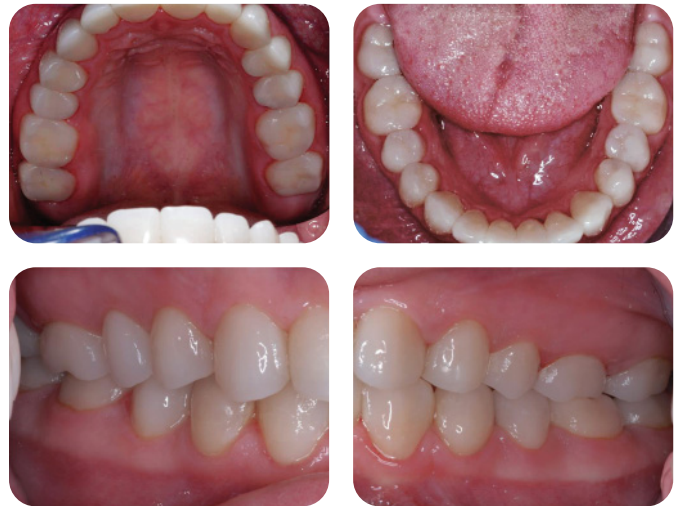

Figure 7.5.8. Occlusal and buccal occluded photographs of the completed restorations.

Chapter 7 Case 6

Restorations maxillary bicuspid-to-bicuspid done first as part of a comprehensive plan; maxillary left central incisor implant and other functional discrepancies corrected with reshaping and equilibration

The patient in this case study was referred to the office by an out-of-town treating periodontist; the patient had recently lost the maxillary left central incisor and an implant placed. The surrounding teeth had aesthetic shortcomings and the occlusion was traumatic; so even though he initially expected just one restoration, he was counseled to approach his treatment comprehensively.

SUMMARY OF EXAMINATION AND DIAGNOSIS

Dentition

Missing upper right first molar
Posterior teeth and old restorations in need of treatment
Wear and attrition

Periodontium

Acceptable; under the care of a periodontist

TMJs

Right side Piper 3B
Left side Piper 3B
Both can be compressed without discomfort.

Muscles

All test normal.

Occlusion

Interferences in the arc of closure to maximum intercuspation; 3mm slide

Aesthetics

Color, exposed margins, proportions, aesthetic plane uneven

THE 10 DECISIONS

1. TMJ Diagnostics

Treat to a guided, verified adapted centric posture.

2. Vertical Dimension

Open slightly by stopping the equilibration short of anterior coupling.

3. Lower Incisal Edge

Using the mandibular left cuspid as a reference, shorten the remaining anterior teeth to this level.

4. Upper Incisal Edge

Maxillary right central incisor is acceptable; use as a reference.

5. Centric Stops

Simultaneous, equal intensity centric stops in the adapted centric posture arc of closure up to the second bicuspid with equilibration; remaining centric stops in restorations

6. Anterior Guidance

Determined by final upper and lower incisal edge position; will be shallower than initial because vertical dimension is opened and the mandibular anterior plane is shortened

7. Curve of Spee

Slight correction needed; done with equilibration

8. Curve of Wilson

Slight correction needed; done with equilibration; verify that upper buccal and lower lingual cusps do not interfere in the functional and parafunctional range of motion

9. Cusp/Fossa Angle

Shallower than anterior guidance disclusion angle, do not deepen with equilibration

10. Aesthetic Plane

Create an upper posterior aesthetic plane that is consistent with the upper incisal edge position and with pleasing buccal profiles; cuspids need to be lengthened and enhanced facially; upper left first bicuspid needs to be shortened.

SUMMARY OF TREATMENT PLAN

Dentition

Initial phase: restore maxillary first bicuspid-to-bicuspid with porcelain crowns

Second phase: posterior teeth crowns and fixed partial denture

Periodontium

Ongoing self care and professional maintenance

TMJs

No treatment is needed other than correct occlusal engineering.

Muscles

No treatment is needed other than correct occlusal engineering.

Occlusion

Equilibration plus restorations to attain simultaneous, equal intensity centric stops in the adapted centric posture arc of closure

Aesthetics

Improve aesthetic plane and buccal/facial profiles with restorations.

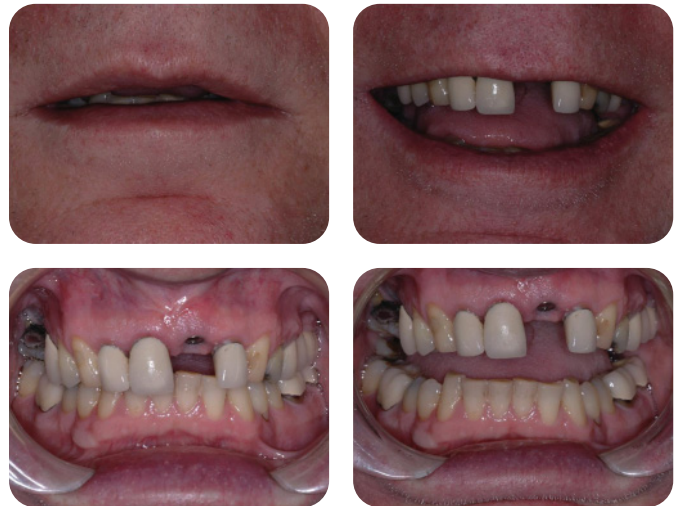

Figure 7.6.1. Pretreatment smile and retracted photographs. Patient was referred with implant already placed. Note the uneven upper and lower anterior planes as well as the deficient maxillary cuspid facial profiles.

SUMMARY OF TREATMENT SEQUENCE

Appointment

Treatment Completed

- | | |
|---|--|
| 1 | Place implant abutment.
Prepare maxillary first bicuspid to first bicuspid.
Equilibration
Reshape mandibular anteriors.
Shorten maxillary right second bicuspid. |
| 2 | Place restorations. |
| 3 | Phase maxillary and mandibular posterior restoration to fit patient circumstances. |

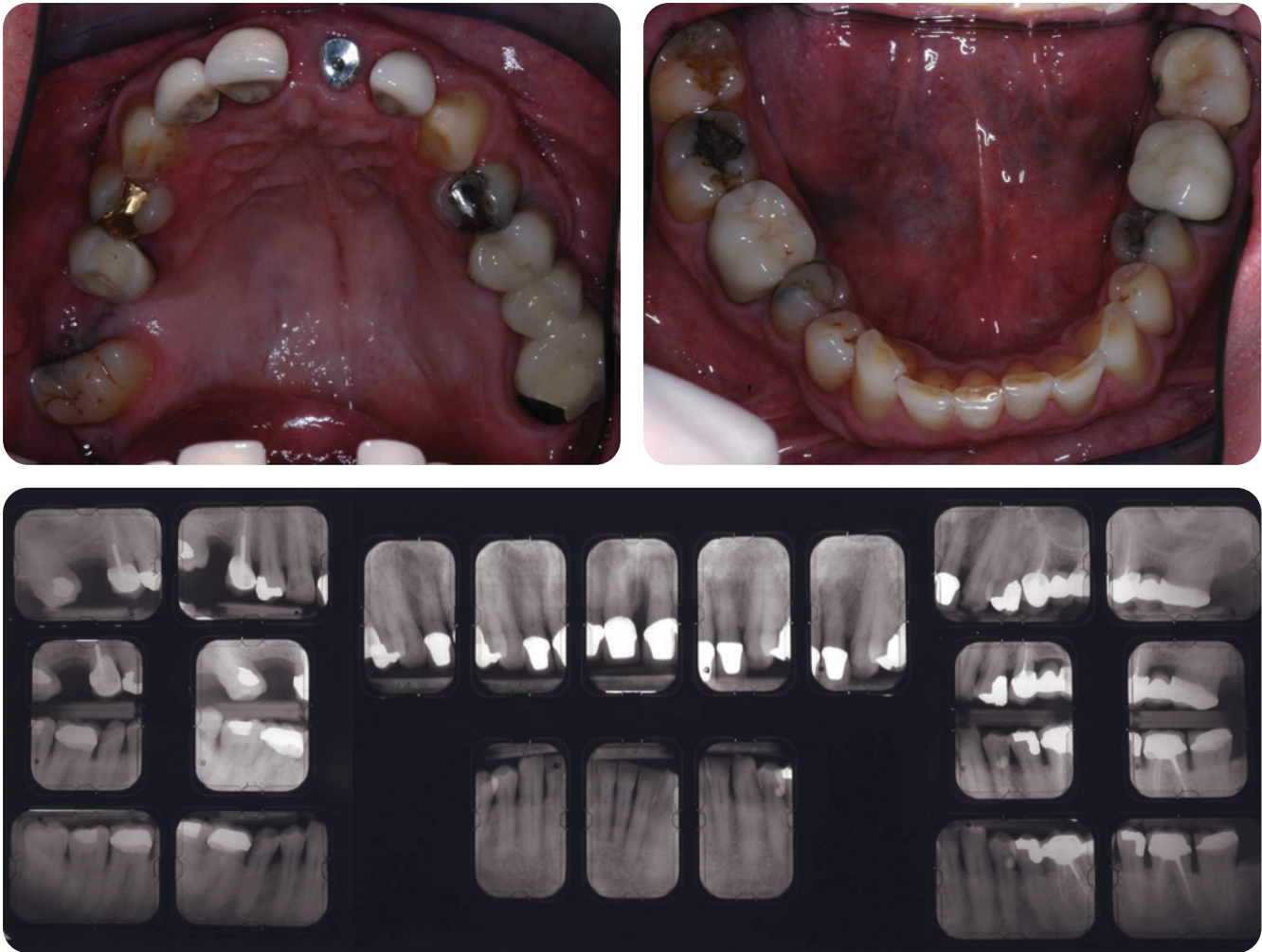


Figure 7.6.2. Pretreatment occlusal photographs and initial radiographs supplied by the treating periodontist. Posterior teeth need attention but will be phased appropriately for patient circumstances. Initial restorations will include maxillary first bicuspid to first bicuspid.

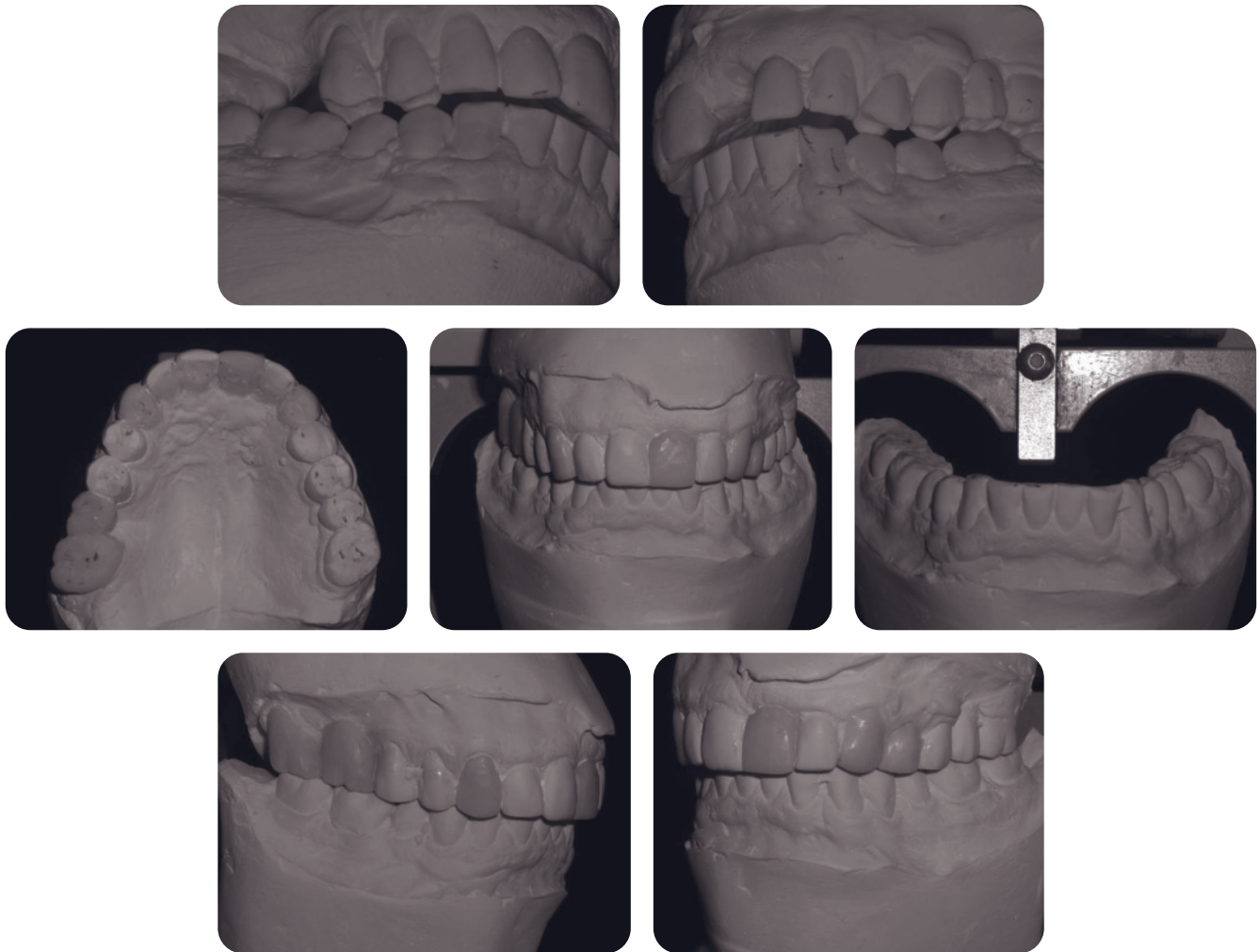


Figure 7.6.3. Top photographs illustrate the first contact in the adapted centric posture arc of closure and the amount of anterior opening at that point. The slide to maximum intercuspation included anterior contact. One wonders if that hit and slide may have been a factor in the loss of the central incisor. Note the high mesioincisal angle of the mandibular left central incisor that may have traumatized that tooth. The case is equilibrated until second bicuspids occlude and the rest is “filled in” with the diagnostic wax-up. Note the changes to the maxillary cuspid length and facial profiles. The mandibular anterior teeth were leveled to the height of the left cuspid. Although the initial phase included only the maxillary first bicuspid to first bicuspid, the entire case was waxed up. It is always important to visualize the entire case even though the initial treatment may be just a part of it. It is interesting to note that the patient’s initial concern was just a restoration on the implant. Once all the photographs were reviewed together along with the diagnostic wax-up, he understood the prudence in looking beyond just the one tooth.

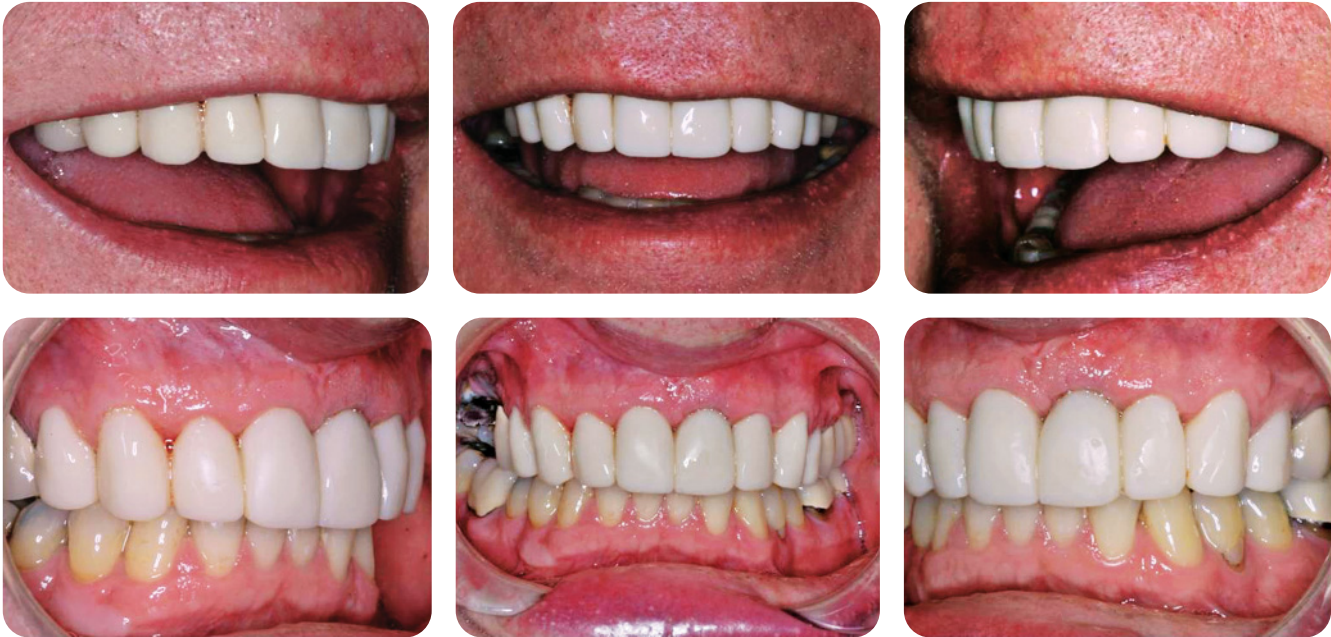
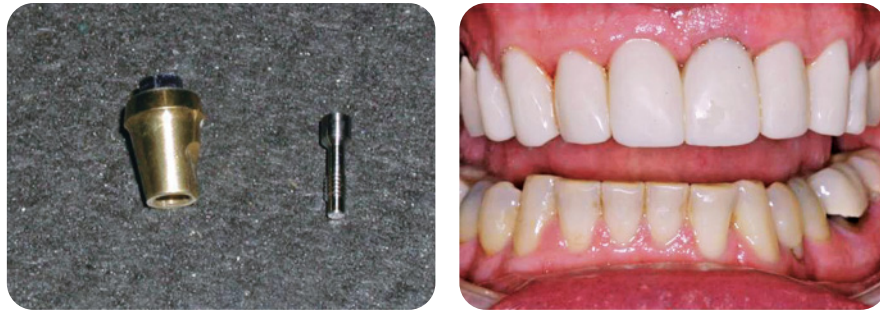
Figure 7.6.4. Provisional photographs. Note the similarity of the diagnostic wax-up and provisionals. The implant abutment and screw were supplied by the periodontist. Once placed, it was prepared just like a tooth with a regular crown and bridge impression made of it and the rest of the preparations.

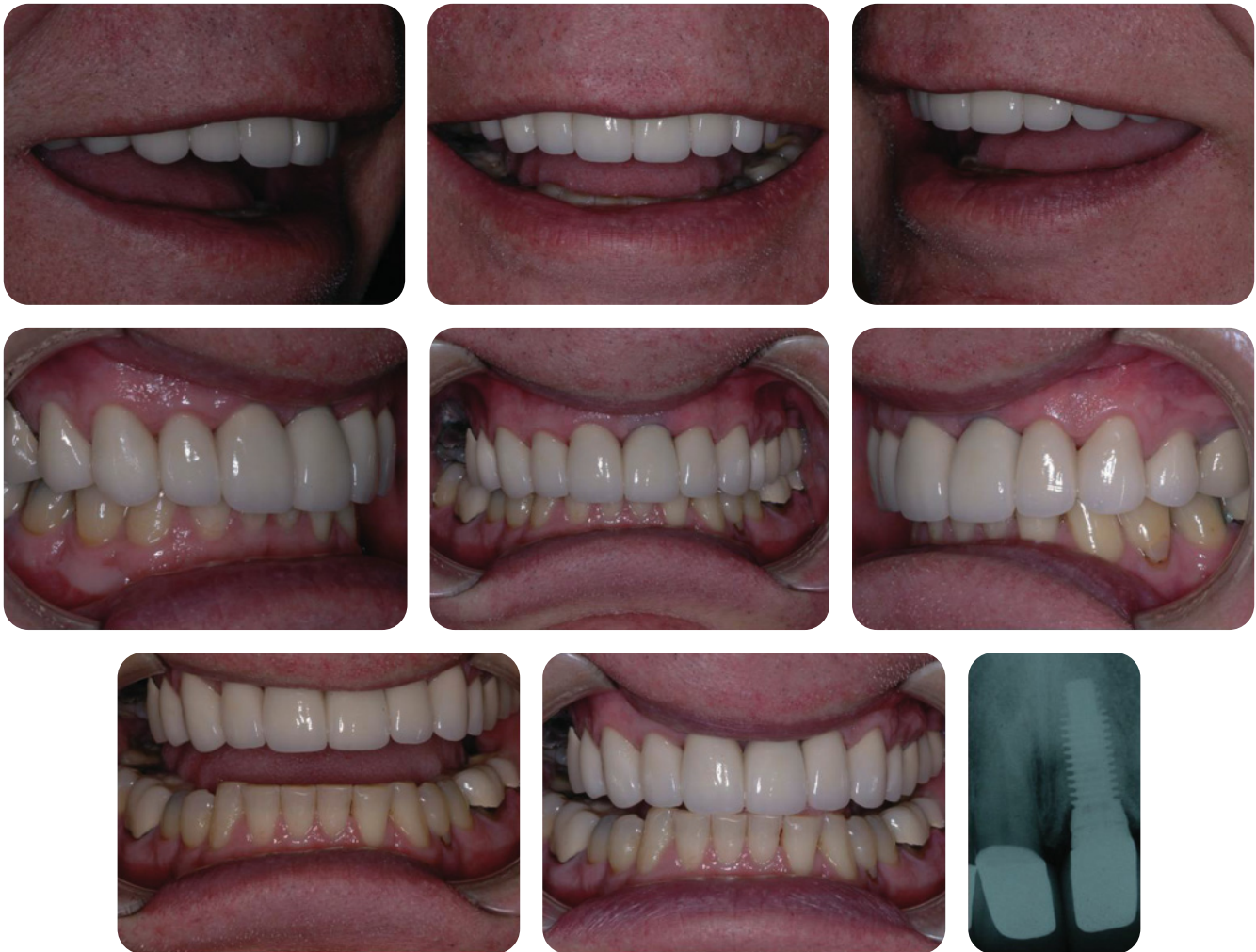

Figure 7.6.5. Photographs of the completed dentistry. Putty indices were made of the articulated casts of the provisionals, as described in other case studies. When the patient is ready to continue treatment in the posterior segments, no further functional changes will need to be made because the entire case was “set up” properly in this phase. Any further dentistry is simply integrated into the current scheme. This is another example of the importance of treatment planning and visualizing the entire case at the start, even though only a portion may be initially completed.

CHAPTER 7 CASE 6 KEY POINTS

- Even though all teeth needing attention may not be initially treated, make a treatment plan for the entire case.
- The mandibular anterior plane is essential for anterior guidance function and quite often can be improved significantly with reshaping only.

Chapter 7 Case 7

Maxillary and mandibular dental reconstruction including 4 dental implants replacing unrestorable teeth; impaired aesthetics due to recession handled with grafts and all porcelain restorations

The patient in this case study has had her current restorations for 20 years and has never been happy with the appearance or “feel” to her lips. She delayed having the problem addressed due to fear of the unknown and fear of the discomfort involved in attaining a new reconstruction. Pain in the upper left requiring endodontic therapy finally prompted her to seek care. A good experience throughout that process motivated her to continue with the rest of her care.

SUMMARY OF EXAMINATION AND DIAGNOSIS

Dentition

Restorations have exposed margins—many with recurrent decay, some unrestorable
Maxillary anteriors have always felt thick and protruded to the lip

Periodontium

Recession, minimal attached keratinized tissue in areas, but maintainably healthy

TMJs

Right side Piper 3B
Left side Piper 3B
Both can be compressed without discomfort.

Muscles

All test normally.

Occlusion

Interferences in the arc of closure to maximum intercuspation
Anterior centric stops are lacking; therefore, anterior guidance starts on posterior teeth.

Aesthetics

Recession, uneven gingival levels, contours, proportion, buccal profiles

THE 10 DECISIONS

1. TMJ Diagnosis

Treat to a guided, verifiable adapted centric posture.

2. Vertical Dimension

Close slightly with equilibration to gain anterior coupling.

3. Lower Incisal Edge

Level and even with a combination of reshaping and addition with composite.

4. Upper Incisal Edge

Shorten 1 mm and move lingually to approach the wet-dry border of the lower lip.

5. Centric Stops

Simultaneous, equal intensity centric stops in the adapted centric posture arc of closure

6. Anterior Guidance

Determined by finalized maxillary and mandibular incisal edge position. Guidance will be entirely on anterior teeth whereas before it started on posterior teeth.

7. Curve of Spee

Shallow left side in last molar area.

8. Curve of Wilson

Correct the reverse Curve of Wilson. Verify that upper buccal and lower lingual cusps do not interfere in the functional and parafunctional range of motion.

9. Cusp/Fossa Angle

Shallower than the anterior guidance disclusion angle

10. Aesthetic Plane

Create an upper posterior aesthetic plane that is consistent with the upper incisal edge position and with pleasing buccal profiles.

SUMMARY OF TREATMENT PLAN

Dentition

New restorations, all teeth except mandibular anteriors
 Maxillary anterior fixed partial dentures
 Posterior missing teeth replaced with implants
 Endodontics as needed

Periodontium

Grafts maxillary anterior to cover recession
 Posterior dental implants

TMJs

No treatment is needed other than correct occlusal engineering.

Muscles

No treatment is needed other than correct occlusal engineering.

Occlusion

Simultaneous, equal intensity centric stops in the adapted centric posture arc of closure
 Establish stable anterior centric holding contacts with anterior guidance on anterior teeth.

Aesthetics

Close gingival embrasures.
 Improve proportions.
 Verify that the aesthetic plane of the upper buccal cusps is level and symmetrical and that the facial profiles of the upper posterior teeth are aligned correctly.

SUMMARY OF TREATMENT SEQUENCE

Appointment	Treatment Completed
1	Equilibration Level mandibular anterior plane with reshaping and composite additions This step was added because the plan was to provisionalize in segments rather than all at once for patient comfort. This occlusal treatment allows each segment to be easily integrated.
2	Provisionalize maxillary anterior.
3	Gingival grafts maxillary anterior
4	Provisionalize lower right.
5	Extract .first molar Implant placement, other surgery as needed
6	Provisionalize lower left.
7	Implant placement, other surgery as needed
8	Provisionalize upper right.
9	Implant placement
10	Endodontics as needed
11	Finalize maxillary anterior and right posterior.
12	Finalize mandibular posterior.
13	Prepare upper left.
14	Place upper left.

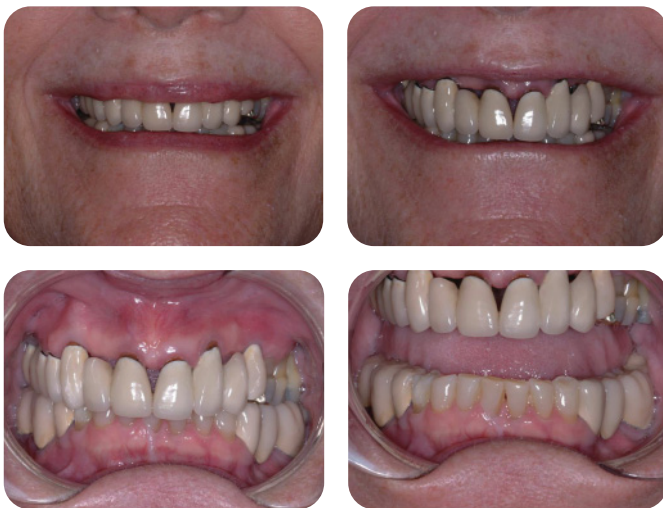

Figure 7.7.1. Pretreatment smile and retracted photographs illustrating recession, uneven gingival levels, uneven mandibular incisal plane, and reverse Curve of Wilson. Patient reported that the maxillary anterior teeth have always felt bulky and protruded. Note how maxillary incisal edges contact the dry part of the lip.

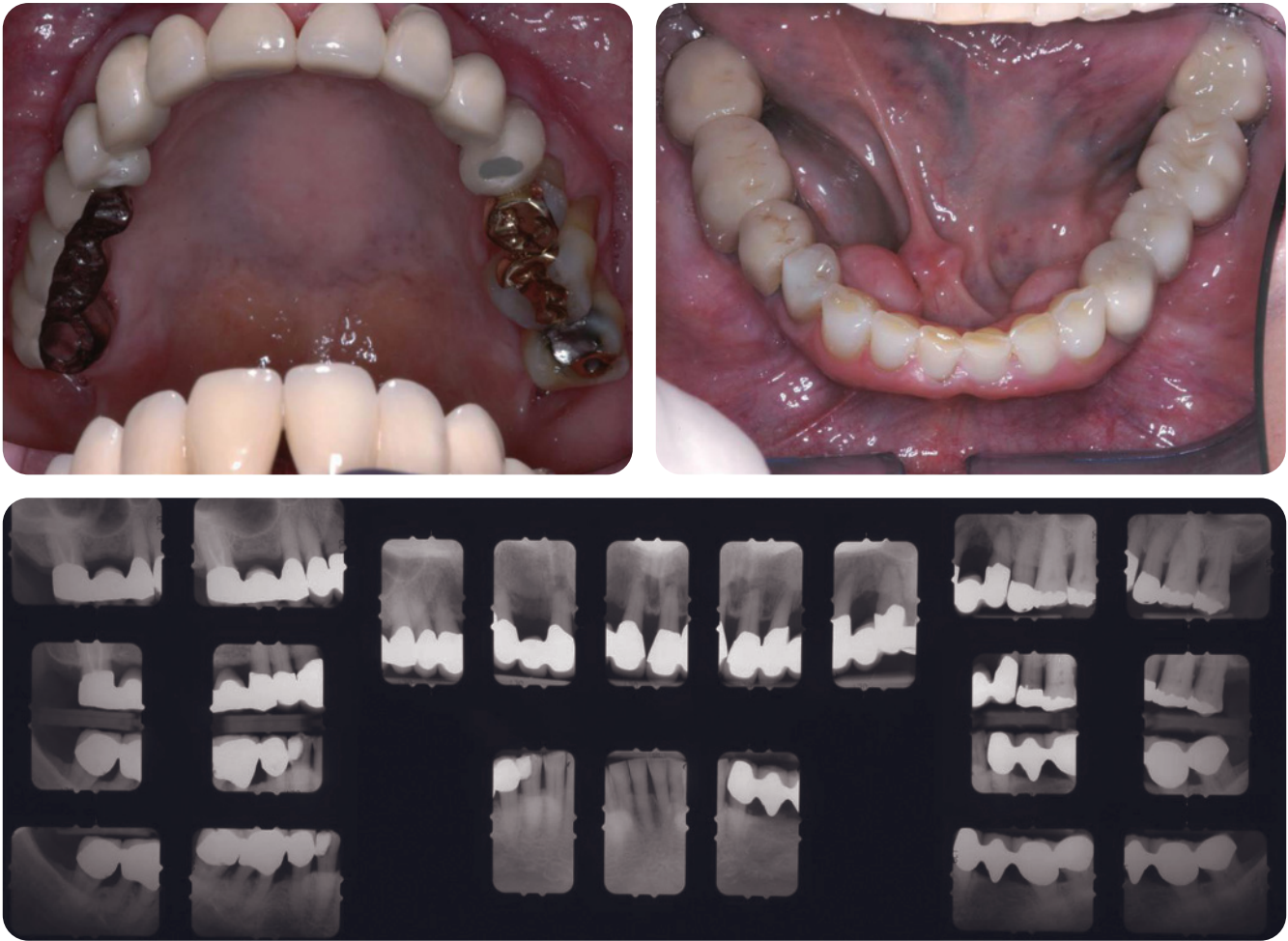


Figure 7.7.2. Pretreatment occlusal photographs and full mouth radiographic series.

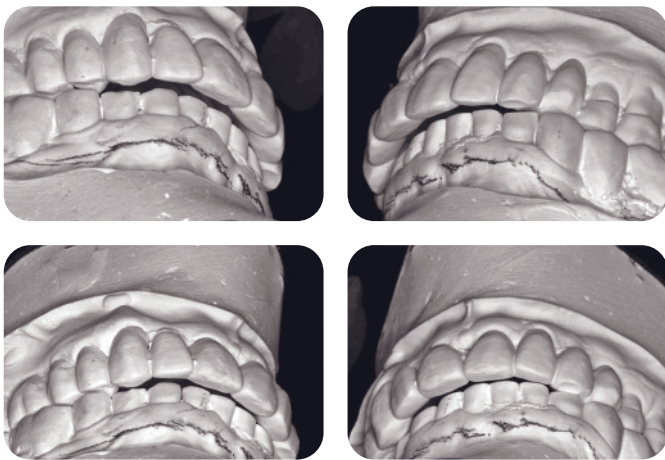

Figure 7.7.3. Pretreatment articulated diagnostic casts. Top photographs are at the first contact in the arc of closure. The bottom photographs are after the hit and slide to maximum intercuspation. Note the incomplete anterior centric stops indicating that the anterior guidance must start on posterior teeth.

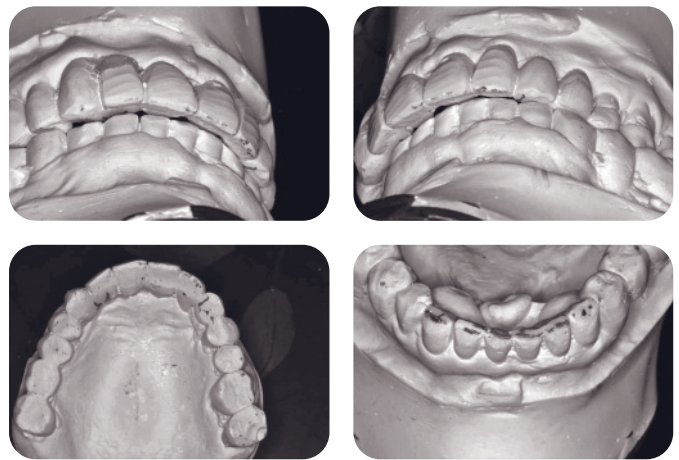


Figure 7.7.4. Photographs of the trial equilibration/diagnostic wax-up. The mandibular anterior incisal plane was leveled with reshaping and composite additions. The cingulum of the maxillary anteriors was enhanced to gain stable holding contacts. The facial surfaces of the maxillary anteriors were reduced to be more in harmony with the neutral zone.

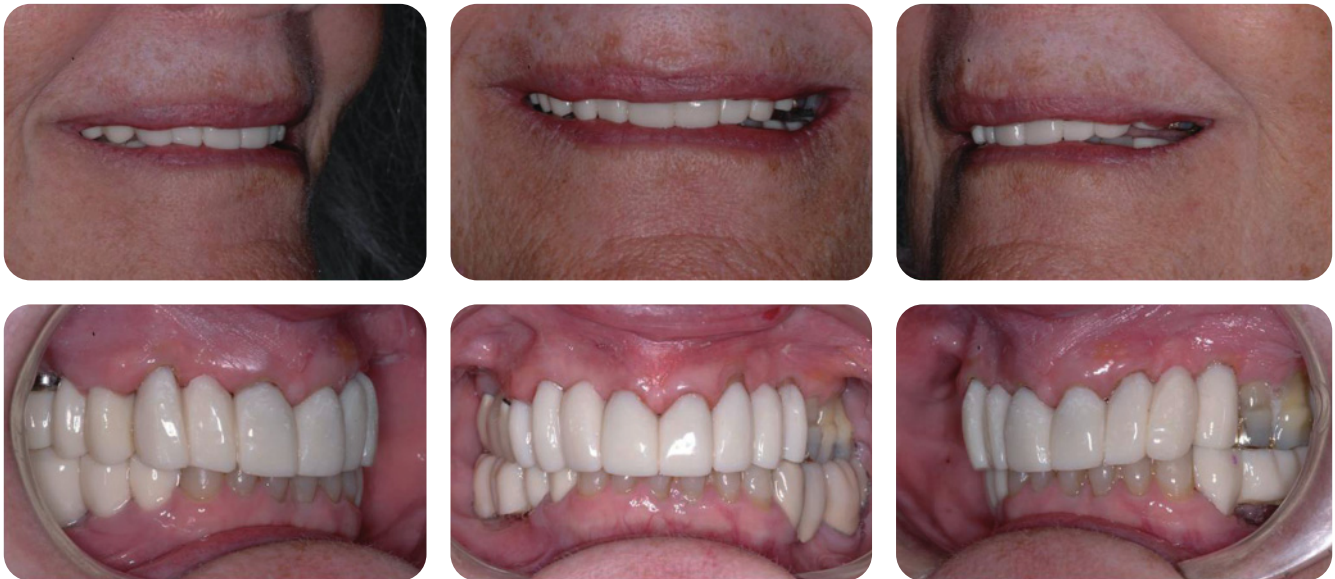

Figure 7.7.5. Photographs of various stages of provisionalization, implant placement, and grafting.

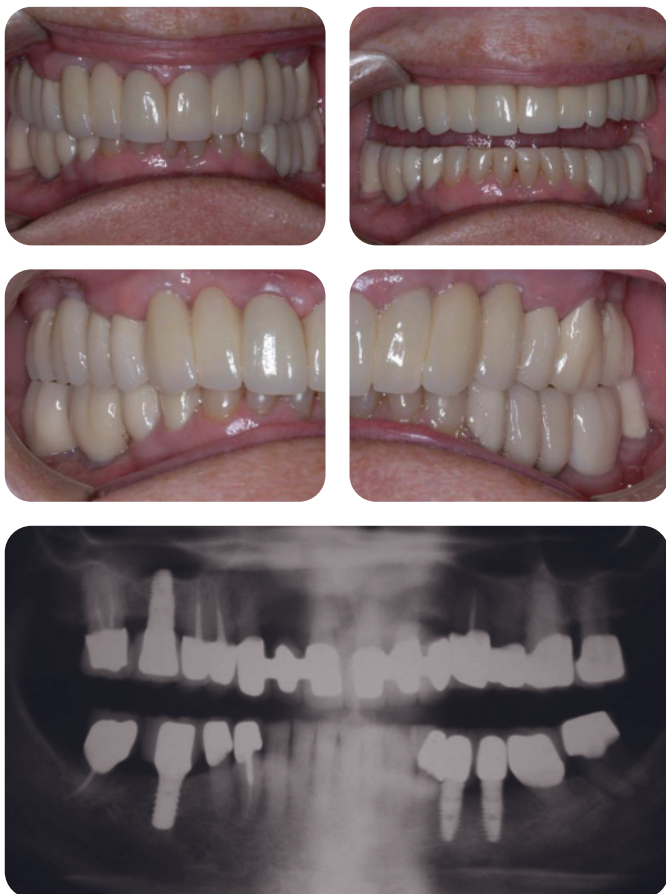

Figure 7.7.6. Photographs of the completed dentistry and posttreatment panoramic radiograph. Five endodontic therapies were done in provisionals because of pain that developed. The mandibular left last molar developed a periapical lesion after placement of the definitive dentistry and was subsequently treated. All restorations are porcelain to zirconia. The case is 3 years postcompletion and gingival levels have remained stable. I believe the recession was due to ill-fitting margins and traumatic occlusion.

CHAPTER 7 CASE 7 KEY POINTS

- The patient may never accommodate to maxillary incisal edges that interfere with the neutral zone; take a careful history and photographs.
- When the case must be phased, make all functional corrections initially with equilibration and composite additions.

8

Complete Implant-Supported Restorations

Case 1 Complete implant-supported maxillary reconstruction—transitioning the anterior teeth from tooth-supported to implant-supported

Case 2 Complete maxillary nonremovable restoration supported by 6 implants converted from a complete removable restoration on 4 implants

Case 3 Complete implant-supported nonremovable maxillary and mandibular reconstructions; transitioning from natural teeth that were not predictably restorable

Case 4 Maxillary extractions, immediate implant placement, immediate loading, and complete nonremovable zirconia restoration with pink porcelain

Case 5 Mandibular implant bar-supported full removable denture converted to a nonremovable restoration to improve comfort of the neutral zone and phonetics

Chapter 8 Case 1

Complete implant-supported maxillary reconstruction—transitioning the anterior teeth from tooth-supported to implant-supported

Today's dentistry gives us the opportunity to transition a failing tooth-supported restoration to an implant-supported solution. Patient circumstances often necessitate a segmental approach rather than changing everything at once. Before we make this decision, we must evaluate thoroughly and verify that the form and function of what will not be changed is acceptable or can be made acceptable with equilibration and reshaping alone.

This patient has had a posterior screw-retained implant-supported restoration for many years. Although a much better looking restoration could be done, the one she had was acceptable to her, it was healthy,

and it functioned well. The upper anterior teeth supporting a fixed restoration were hopeless and the plan was to transition to an implant-supported restoration. The lower anterior teeth supporting a fixed restoration have a guarded prognosis but will be maintained for as long as possible. The functional landmarks were acceptable, so there was no occlusal compromise.

SUMMARY OF EXAMINATION AND DIAGNOSIS

Dentition

Endodontic and structural failure 6, 7, 10, 11
Guarded but maintainable condition of lower anterior teeth

Posterior implants and restorations are acceptable and do not need to be changed.

Periodontium

Stable

TMJs

Right Piper 3B

Left Piper 3B

Both can be superiorly compressed with no sign of tension or tenderness.

Muscles

Slight lateral and medial pterygoid palpation discomfort

Occlusion

Interferences and slide when condyles are in ACP

Aesthetics

Reverse smile of upper anteriors

THE 10 DECISIONS

1. TMJ Diagnosis

Treat to a guided adapted centric posture.

2. Vertical Dimension

Acceptable; maintain.

3. Lower Incisal Edge

Acceptable; just smooth and polish.

4. Upper Incisal Edge

Lengthen upper central incisors 1.5–2.0 mm.

5. Centric Stops

Definitive centric stops posteriorly with equilibration

Definitive centric stops anteriorly with restoration

6. Anterior Guidance

Acceptable, it will steepen slightly with new incisal edge position.

7. Curve of Spee

Acceptable

8. Curve of Wilson

Slight reverse Curve of Wilson. Correct as much as possible with reshaping. It discludes completely even though not "ideal looking."

9. Cusp/Fossa Angle

Acceptable

10. Aesthetic Plane

Improve reverse anterior smile line.

Posterior aesthetic plane is acceptable.

SUMMARY OF TREATMENT PLAN

Dentition

Remove 6, 7, 10, 11.
 Immediate implant placement
 Delayed restoration

Periodontium

Professional maintenance

TMJs

No treatment is needed other than correct bite engineering.

Muscles

No treatment is needed other than correct bite engineering.

Occlusion

Equilibrate posteriorly; improve anterior guidance with new restoration.

Aesthetics

Correct reverse smile of upper anterior, increase length of centrals

SUMMARY OF TREATMENT SEQUENCE

Appointment	Treatment Completed
1	Surgeon to remove 6, 7, 10, 11 Immediate implant placement Removable provisional immediately placed
2	Time to heal and integrate
3	Equilibrate posterior teeth to eliminate slide Implant level impressions
4	Place custom abutments and fixed provisional. Evaluate changes in form and function.
5	Impressions of abutments
6	Place definitive restoration.

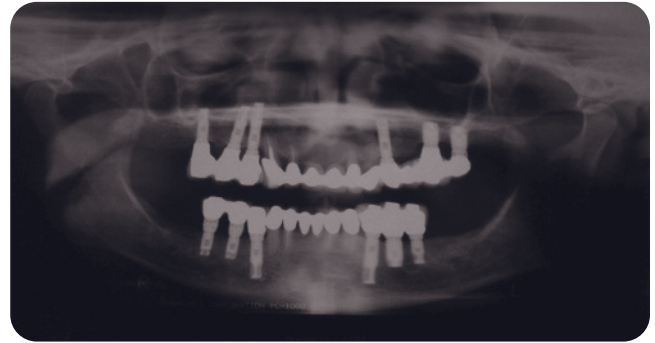


Figure 8.1.1. Preoperative panoramic. Upper anterior teeth are hopeless. Lower anterior teeth guarded but maintainable for the short term. Posterior implants and restorations acceptable.

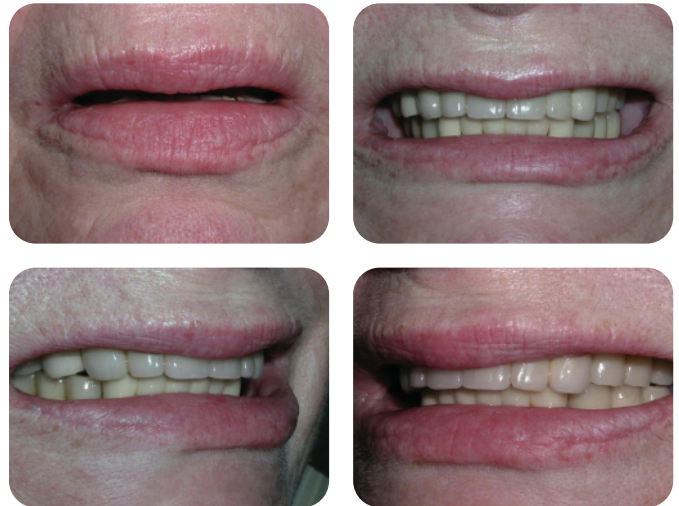

Figure 8.1.2. Preoperative smile photograph, reverse smile evident.

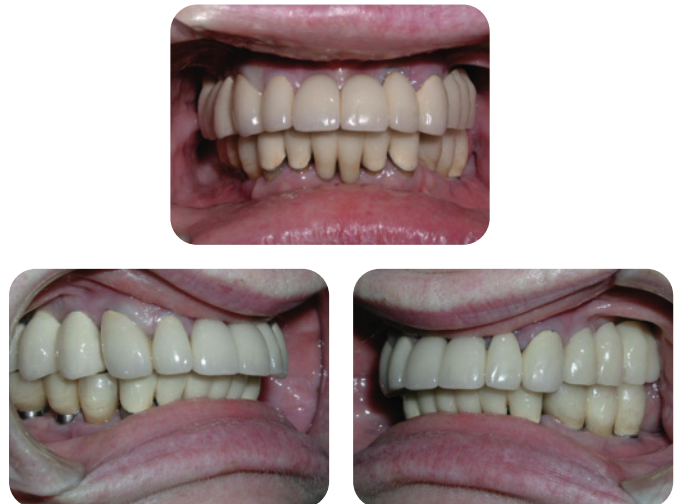

Figure 8.1.3. Preoperative retracted views.

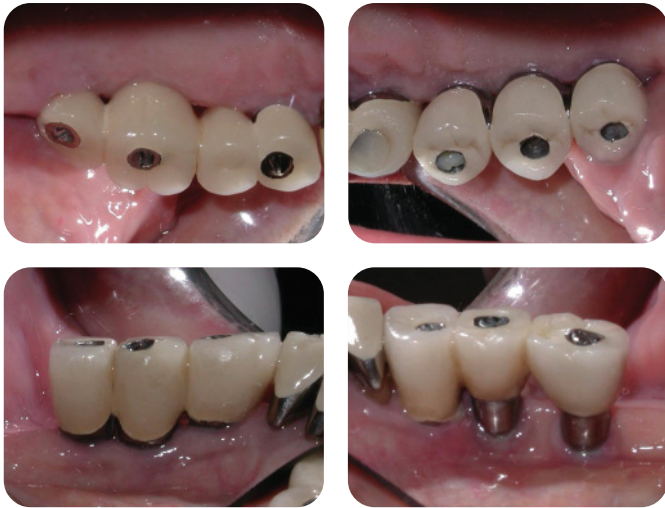

Figure 8.1.4. Preoperative lingual views. Old but acceptable screw-retained posterior implant-supported restorations. They have been in place over 10 years.

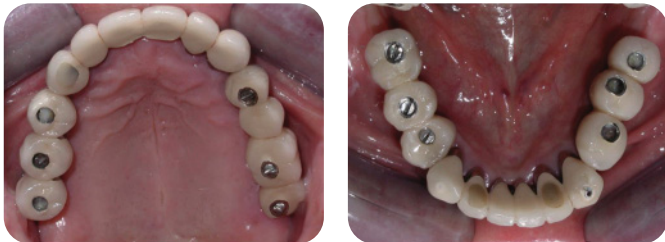

Figure 8.1.5. Preoperative occlusal view.

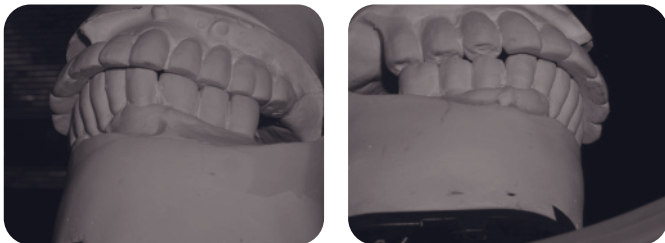


Figure 8.1.6. Trial equilibrated articulated diagnostic casts. All parameters of static and dynamic occlusion can be fulfilled. Maxillary anterior teeth will be lengthened.

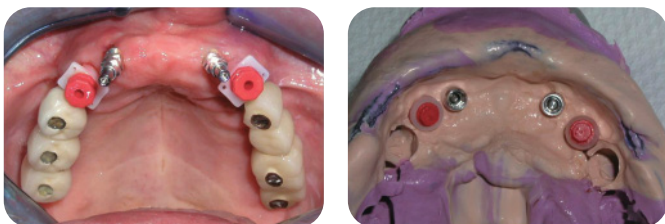


Figure 8.1.7. Implant level impressions.

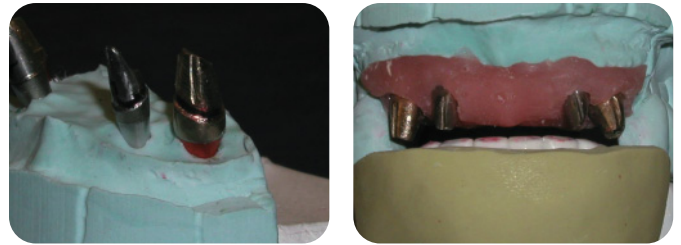


Figure 8.1.8. Custom abutments and soft tissue cast. Implants are deep subgingivally. Custom abutment brings restoration finish line to tissue level.

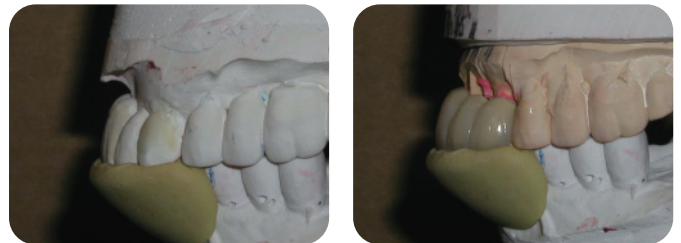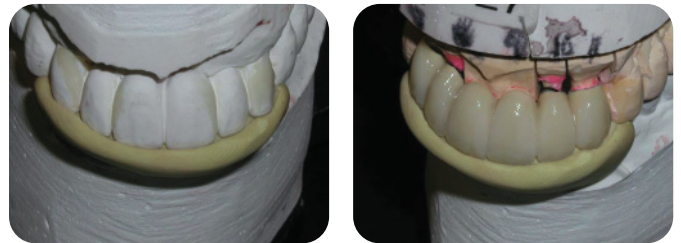


Figure 8.1.9. Putty index of verified provisionals and definitive restoration verified.

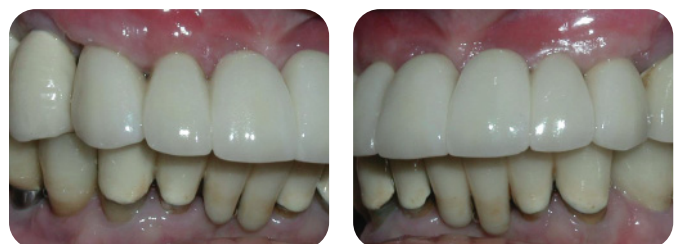
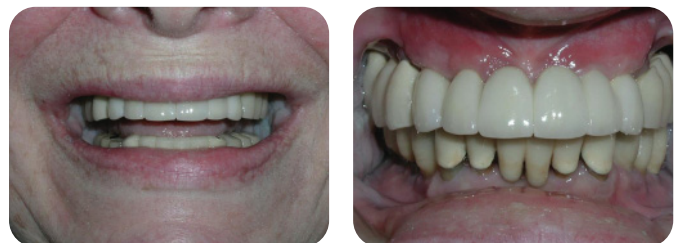
Figure 8.1.10. Finished result, reverse smile improved.

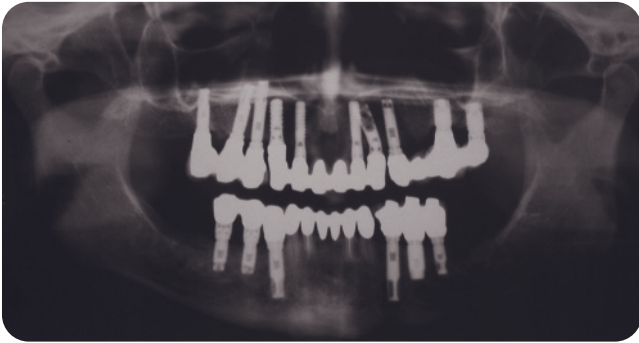


Figure 8.1.11. Posttreatment panoramic radiograph. Lower anteriors still maintained as of 8 years posttreatment completion of upper anterior.

CHAPTER 8 CASE 1 KEY POINTS

- If the top of the implant is very deep, use a two-piece or custom abutment to bring the finish line of the restoration closer to the free margin of the tissue.
- Consider cemented restorations as the treatment of choice over screw-retained restorations.

Chapter 8 Case 2

Complete maxillary nonremovable restoration supported by 6 implants converted from a completed removable restoration on 4 implants

The patient in this case study had recently completed a restoration from another dentist but she was not pleased. She had expected a nonremovable restoration but the definitive dentistry was a removable denture supported by 4 implants. She had some very specific ideas about the aesthetics she desired, so additional time was spent before any treatment was initiated to confirm that her expectations could be met.

SUMMARY OF EXAMINATION AND DIAGNOSIS

Dentition

4 upper implants, unacceptable denture
Lower teeth have many restorations, recently completed orthodontics.

Periodontium

Lower is guarded to hopeless.

TMJs

Right side Piper 2
Left side Piper 2
Both can be superiorly compressed comfortably.

Muscles

Lateral pterygoids uncomfortable to palpation

Occlusion

Lower functional landmarks are acceptable or easily modifiable.

Aesthetics

Incisal edge position is acceptable but size, proportion, and color are not.

THE 10 DECISIONS

1. TMJ Diagnosis

Treat to a guided, verifiable adapted centric posture.

2. Vertical Dimension

Determined by traditional denture techniques with 2mm of freeway space

3. Lower Incisal Edge

Acceptable; just smooth and polish.

4. Upper Incisal Edge

Current restoration is acceptable.

5. Centric Stops

Simultaneous, equal intensity centric stops in the adapted centric posture arc of closure

6. Anterior Guidance

Determined by finalized upper and lower incisal edge position

7. Curve of Spee

Lower needs minor reshaping to improve.

8. Curve of Wilson

Lower needs minor reshaping to improve.

9. Cusp/Fossa Angle

Shallower than the anterior guidance disclusive angle

10. Aesthetic Plane

Create an upper posterior aesthetic plane that is consistent with the upper incisal edge position and with pleasing buccal profiles.

SUMMARY OF TREATMENT PLAN

Dentition

Place 2 more implants.
Nonremovable implant-supported restoration

Periodontium

Maintain lower by periodontist until patient is able to proceed with an implant solution.

TMJs

No treatment is needed other than to correct occlusal engineering.

Muscles

No treatment is needed other than correct occlusal engineering.

Occlusion

Simultaneous equal intensity contacts in centric relation and anterior guidance on anterior teeth

Aesthetics

Idealize form, contour, and proportions. Gingiva will be simulated with pink porcelain.

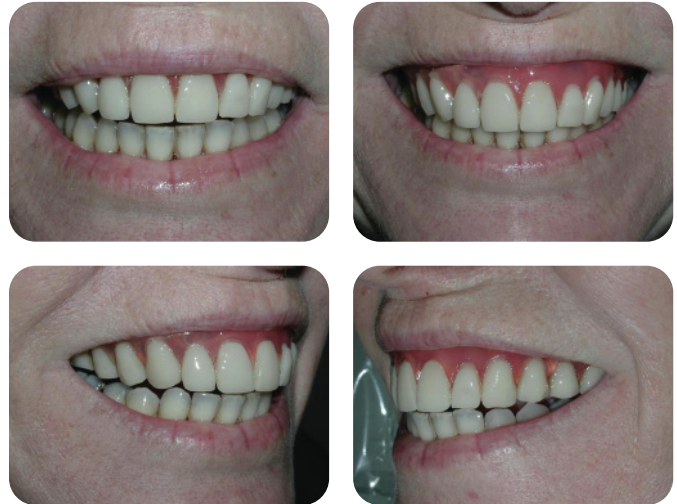

Figure 8.2.1. Pretreatment anterior and lateral smile photographs. Restoration is a removable complete implant-retained denture. She desires a nonremovable solution. Incisal edge position is acceptable but she feels teeth are too large. A nonacrylic denture material was used (Valplast) because of a suspected acrylic allergy.

SUMMARY OF TREATMENT SEQUENCE

Appointment

Treatment Completed

- | | |
|---|--|
| 1 | Removable provisional to be used as a diagnostic wax-up to verify that expectations can be met |
| 2 | Once (and if) approved, place 2 more posterior implants. |
| 3 | Heal and integrate. |
| 4 | Implant level impressions for custom abutments |
| 5 | Place abutments and retrofit previously approved provisional. |
| 6 | Evaluate and modify provisional. |
| 7 | Definitive impression and bite records |
| 8 | Place upper definitive restoration. |
| 9 | Plan lower when appropriate. |

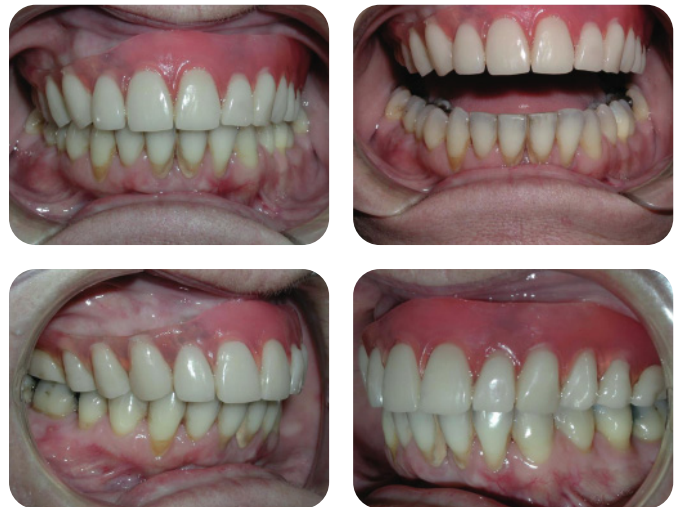

Figure 8.2.2. Pretreatment anterior and lateral retracted photographs. The denture flange was shortened because of path of insertion problems due to facially angulated anterior implant placement. Orthodontics was completed on the mandibular resulting in acceptable functional landmarks. This will allow upper dentistry to be completed without treating lower at this point. Patient circumstances necessitated lower treatment being delayed.

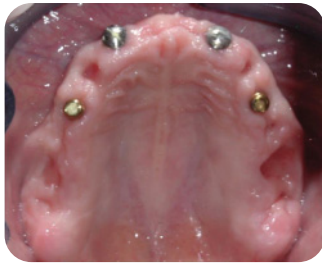

Figure 8.2.3. Pretreatment maxillary occlusal photographs. The two most posterior implants have Locator abutments for denture retention. The two most anterior implants have healing caps because severe angulation prevented their use as an abutment. Several other teeth were recently extracted.

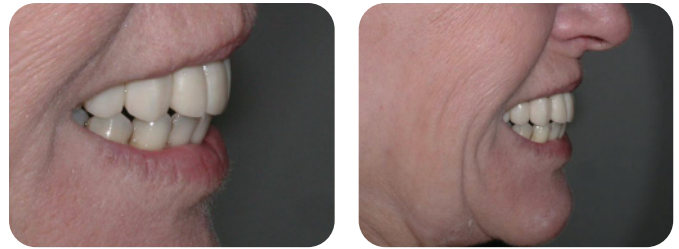

Figure 8.2.6. Lateral smile photographs of the provisional in Figure 8.2.5. Lip support was acceptable, verifying that a denture flange is not necessary and that a nonremovable approach is possible.

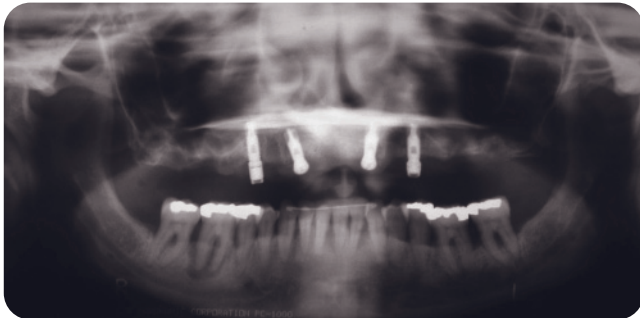


Figure 8.2.4. Pretreatment panoramic radiograph illustrating major periodontal issues with the mandibular teeth. Patient is fully aware of the diagnosis.

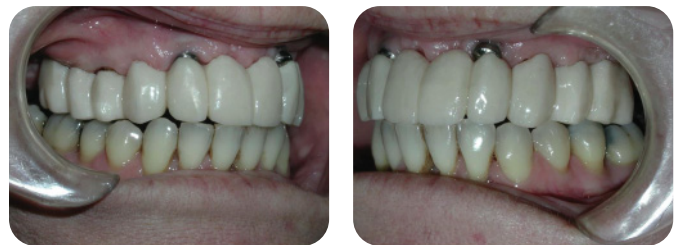
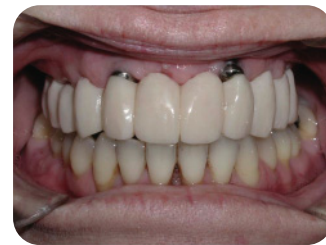
Figure 8.2.7. Anterior and lateral retracted photographs of the provisional in Figure 8.2.5. It simply sets on the current abutment situation for diagnostic evaluation.

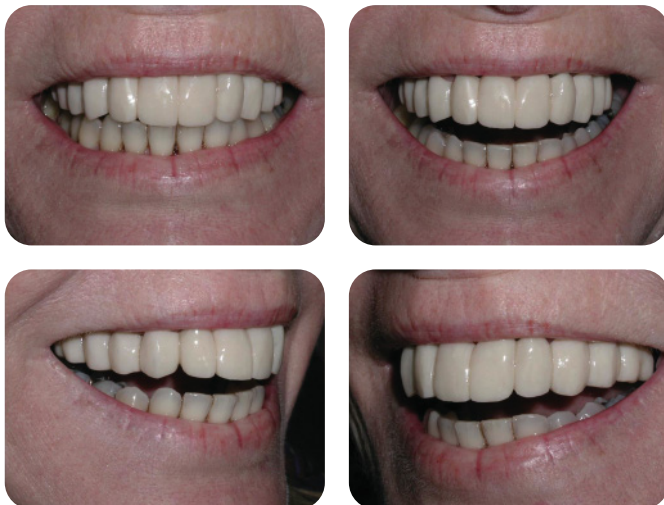

Figure 8.2.5. Photographs of a diagnostic provisional made on the initial articulated diagnostic casts. This is not attached to the implants but sets on the current abutments and is stable and retentive enough for evaluation. Although incisal edge position was acceptable, the patient did not like the width and incisal-gingival length of the teeth.

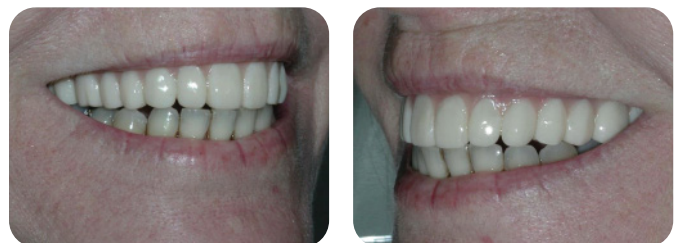
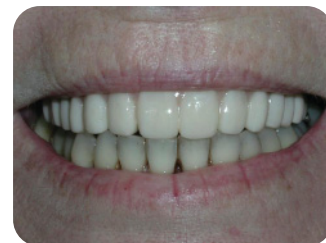
Figure 8.2.8. Anterior and lateral smile photographs of a second attempt at a diagnostic provisional. Patient comments about first diagnostic provisional were incorporated into this second attempt. The teeth were made narrower mesiodistally, and pink acrylic was used to make the teeth appear smaller incisogingivally. This fulfilled her aesthetic expectations.

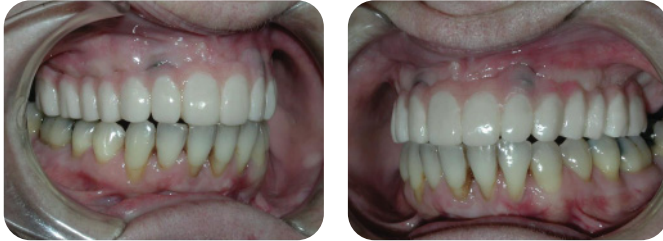
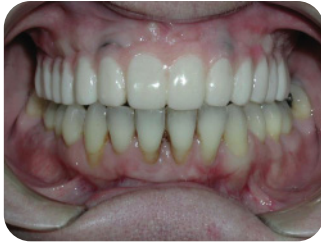
Figure 8.2.9. Anterior and lateral retracted photographs of the second diagnostic provisional. Current mesiodistal implant position aligned favorably with the maxillary lateral incisors. The pink acrylic fits to the edentulous ridge like a pontic; there is not a denture flange. Since this was acceptable to the patient, the plan of a nonremovable restoration was indeed possible and would achieve acceptable results. Two more posterior implants were needed for the support necessary to make a nonremovable restoration. All this was done prior to making any irreversible changes to the patient. She simply continued to wear her current removable prosthesis. It was extra work but well worth the effort in gaining assurance that patient expectations could be met.

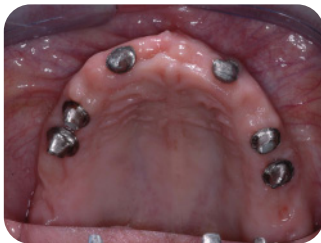

Figure 8.2.10. Maxillary occlusal photograph after placement of two more implants and finalized abutments. The two anterior abutments are 8mm solid healing abutments prepped and used as final abutments. A two-piece abutment could not be used because the screw head would have been totally obliterated to gain a path of insertion in the facially inclined implants. This creative solution allowed these implants to be used as abutments.

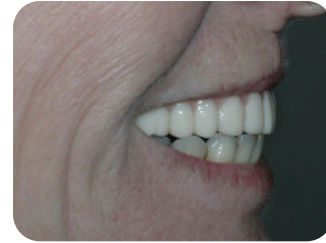

Figure 8.2.11. Lateral smile photograph of the second provisional confirming acceptable lip support.

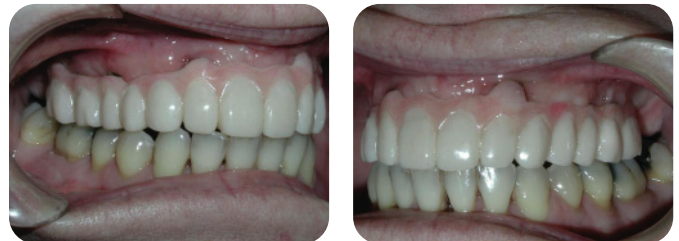
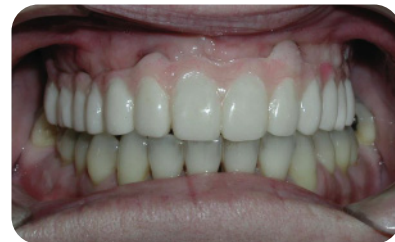
Figure 8.2.12. Anterior and lateral retracted photographs of the cemented nonremovable provisional. The second diagnostic provisional was used as a definitive fixed provisional over the final abutments.

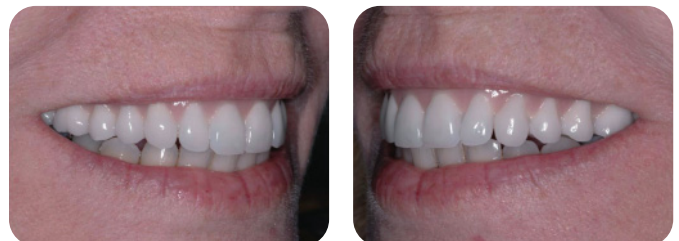
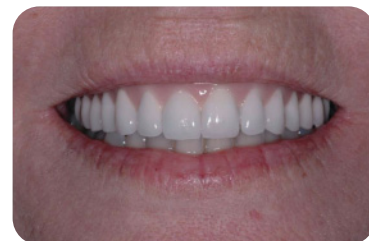
Figure 8.2.13. Anterior and lateral smile photographs of the definitive restoration using pink porcelain to simulate the gingival. Note similarities with the provisional restoration.

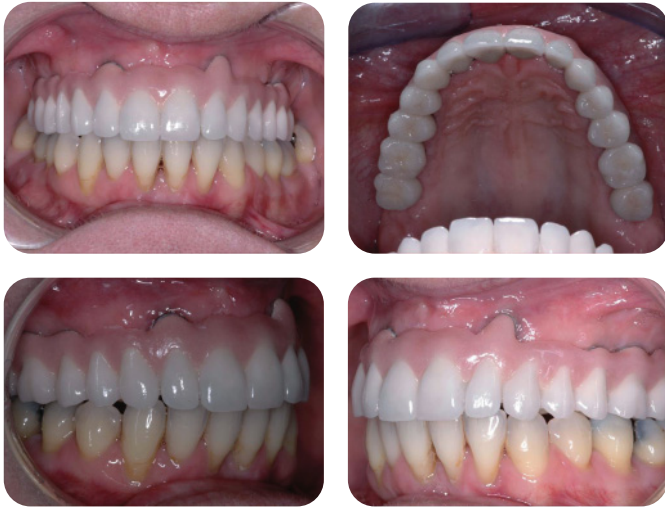

Figure 8.2.14. Anterior and lateral retracted photographs of the cemented definitive restoration. The second molars are cantilevers. The entire restoration is supported by the six implants. The patient was pleased with the final result and very happy to have a nonremovable restoration—her primary desire and expectation.

CHAPTER 8 CASE 2 KEY POINTS

- In totally edentulous cases, a nonremovable restoration is possible if a flange is not needed for lip support.
- Time spent at the diagnostic phase making even multiple “preview” restorations is never wasted time.
- Even if the opposing arch may not be treated right away, make needed functional or landmark changes with reshaping and composite additions as needed.

Chapter 8 Case 3

Complete implant-supported nonremovable maxillary and mandibular reconstructions; transitioning from natural teeth that were not predictably restorable

The gentleman in this case study had teeth that were not predictably restorable, and he understood and was willing to go through the project of transitioning from his natural secondary dentition to a nonremovable implant-supported reconstruction. The key is to save enough strategically placed natural teeth to support a nonremovable provisional. This gives the patient a better representation of the final result and also eliminates any pressure that a removable provisional might pose on the surgical sites.

SUMMARY OF EXAMINATION AND DIAGNOSIS

Dentition

Not predictably restorable

Periodontium

No major disease

TMJs

Right side Piper 2

Left side Piper 2

Both can be compressed without discomfort.

Muscles

Lateral pterygoids are uncomfortable to testing.

Occlusion

Interferences in the arc of closure to maximum intercuspation

End-to-end anterior tooth-to-tooth relationship does not disclude posterior teeth.

Aesthetics

Position, proportion, contour.

THE 10 DECISIONS

1. TMJ Diagnosis

Treat to a guided, verifiable centric relation.

2. Vertical Dimension

Open slightly.

3. Lower Incisal Edge

Maintain incisal edge position.

4. Upper Incisal Edge

Increase length and move facially to improve overbite and overjet relationship.

5. Centric Stops

Simultaneous, equal intensity centric stops in the centric relation arc of closure

6. Anterior Guidance

Shallow due to minimal overbite.

7. Curve of Spee

Shallow and flat due to shallow anterior guidance

8. Curve of Wilson

Verify that upper buccal and lower lingual cusps do not interfere in the functional and parafunctional range of motion.

9. Cusp/Fossa Angle

Shallower than the anterior guidance disclusion angle

10. Aesthetic Plane

Create an upper posterior aesthetic plane that is consistent with the upper incisal edge position and with pleasing buccal profiles.

SUMMARY OF TREATMENT PLAN**Dentition**

Remove all natural teeth.
 8 implants upper
 6 implants lower
 Maxillary and mandibular nonremovable reconstructions

Periodontium

Grafting as needed in conjunction with implant placement

TMJs

No treatment is needed other than to correct occlusal engineering.

Muscles

No treatment is needed other than to correct occlusal engineering.

Occlusion

Simultaneous, equal intensity centric stops in the centric relation arc of closure, 2mm overbite with anterior guidance on anterior teeth

Aesthetics

Idealize form, contour, proportion.
 Use pink porcelain on maxillary reconstruction for more ideal length of teeth.

SUMMARY OF TREATMENT SEQUENCE**Appointment****Treatment Completed**

1	Prepare lower third molars and cuspids for provisional abutments. Prepare maxillary second molars and left central incisor for provisional abutments. To surgeon for lower extractions and implant placement, maxillary extractions, and bone grafts
2	Mandibular implant level impression CAT scan with radiopaque maxillary surgical stent
3	Surgeon to extract 4 remaining lower teeth Surgeon to place 8 maxillary implants To restorative dentist to place mandibular abutments and new provisional Reline and recement upper provisional.
4	Maxillary implant level impressions Mandibular impressions of abutments for definitive restoration
5	To surgeon to extract remaining maxillary teeth To restorative dentist to place definitive mandibular restoration Place maxillary abutments and new provisional.
6	Impressions for definitive maxillary restoration
7	Place maxillary restoration.
8	Follow-up and bite splint

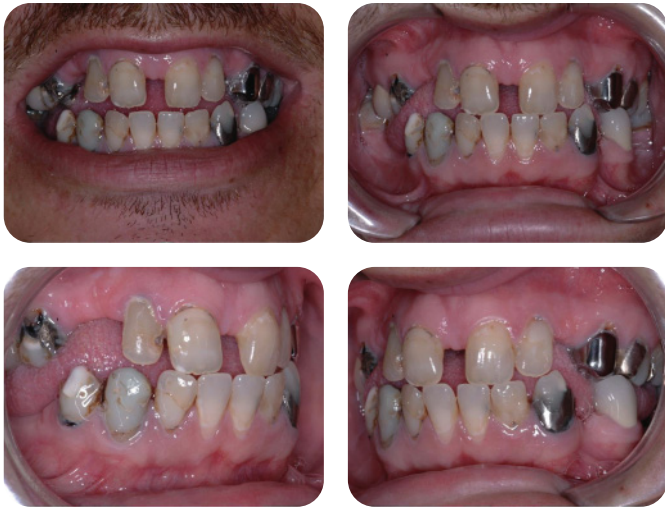

Figure 8.3.1. Pretreatment smile and retracted photographs suggesting a multitude of problems.

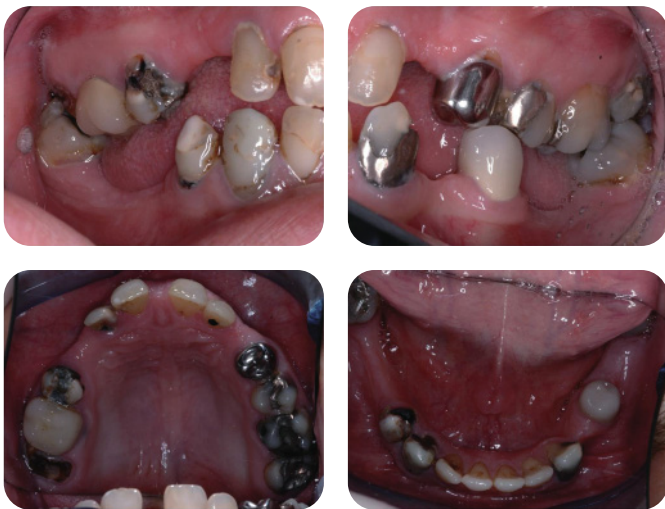

Figure 8.3.2. Pretreatment buccal occluded and occlusal photographs suggesting functional occlusal plane problems, anterior guidance problems, and structural problems.

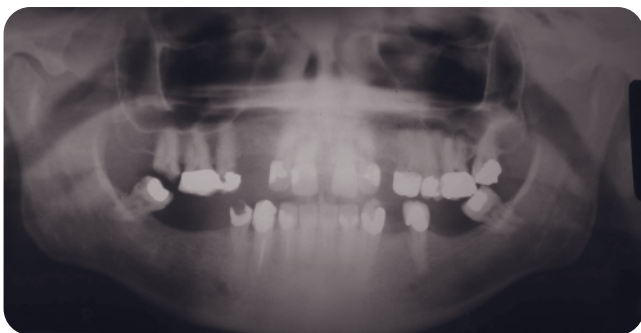

Figure 8.3.3. Pretreatment panoramic radiograph. The very few teeth that might be savable do not lend themselves to a comprehensive plan. In fact if they were kept, they would compromise the result, adding uncertainty to the longevity.

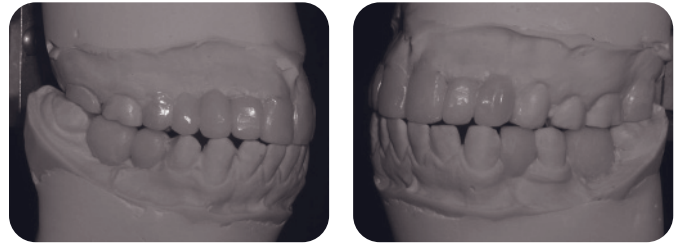
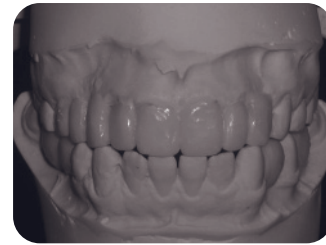

Figure 8.3.4. Photographs of the initial diagnostic wax-up illustrating functional and aesthetic changes. This could be considered a "starting point" wax-up because there will be time and multiple provisionals to make modifications and refinements.

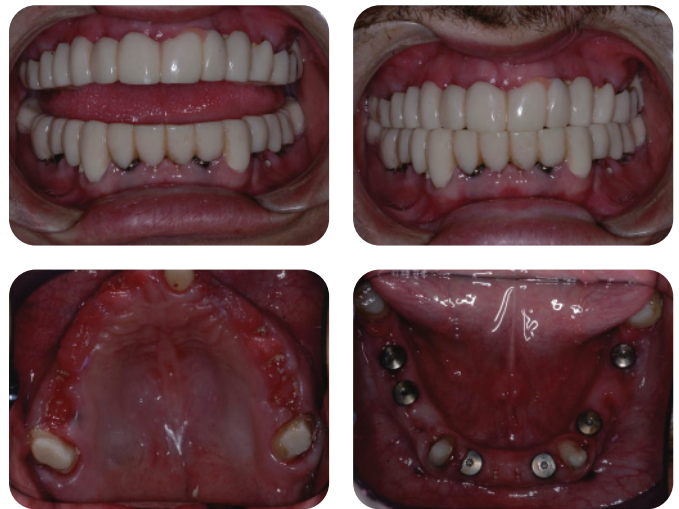

Figure 8.3.5. Posttreatment photographs after the first phase of treatment. The maxillary second molars and left central incisor support a provisional restoration. Even though these abutments will eventually be lost, they are carefully built up with foundation restorations and prepared. The maxillary implants could not be immediately placed, so extractions and bone grafts were done. The mandibular third molars and cuspids retain a provisional. The implants were immediately placed but not loaded. Note how the maxillary central incisors were "moved" to close the diastema. The maxillary left central incisor abutment is actually between the maxillary left central and lateral incisors. Pink acrylic was used to simulate a papilla and give the illusion of correctly placed teeth. Doing this will allow for correct placement of the implant in the maxillary right central incisor position.

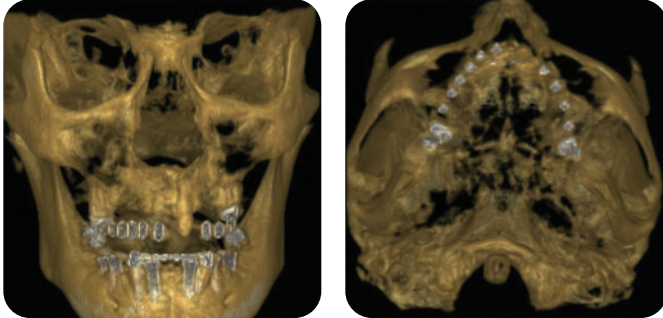
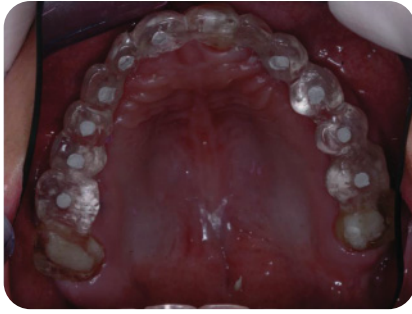

Figure 8.3.6. Planning for the second phase. A surgical stent with gutta percha is used for a CAT scan analysis so that the surgeon could evaluate which sites would work best for implants to be placed in positions correct for the end result tooth position. Eight sites were chosen.

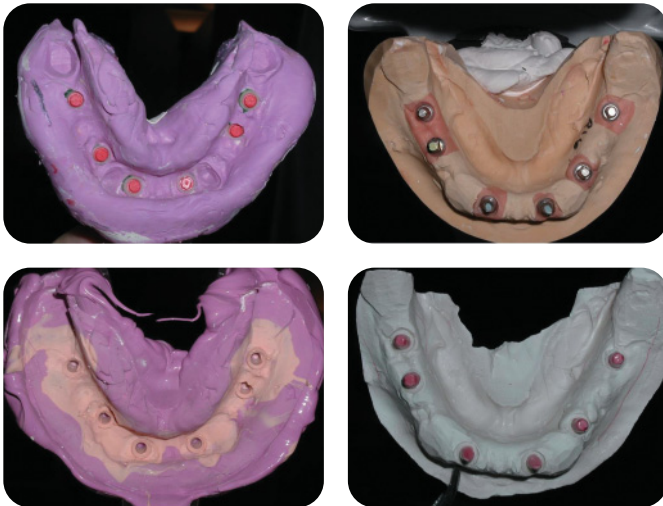


Figure 8.3.7. The planning for the second phase included a mandibular implant level impression, top left. The correct abutments were selected and prepared on an implant cast, top right. An impression was made of this implant cast, lower left, and another all stone cast prepared, lower right. This cast will be used to fabricate a provisional.

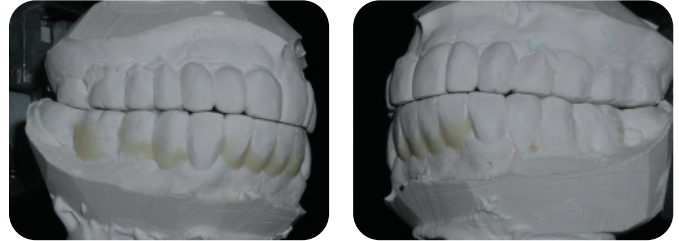
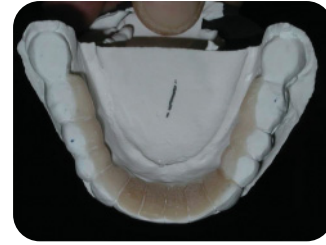

Figure 8.3.8. Articulated diagnostic casts were made of the first provisional and modifications were made to the contours of the mandibular in preparation for a new provisional.

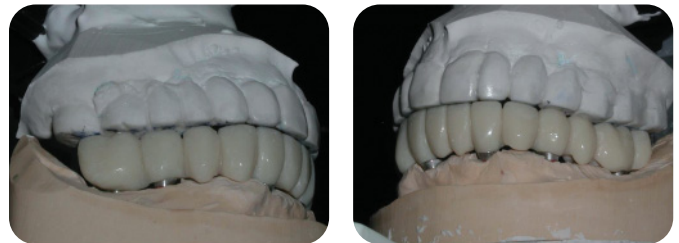
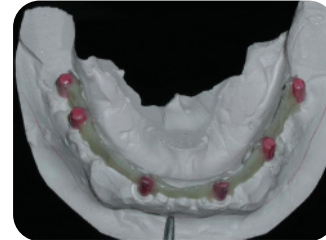

Figure 8.3.9. Top: photograph of a Ribbond scaffolding attached to the preparations with light-cured flowable composite resin. The acrylic is processed over this scaffolding, and a final check is made on the articulated implant cast (bottom).

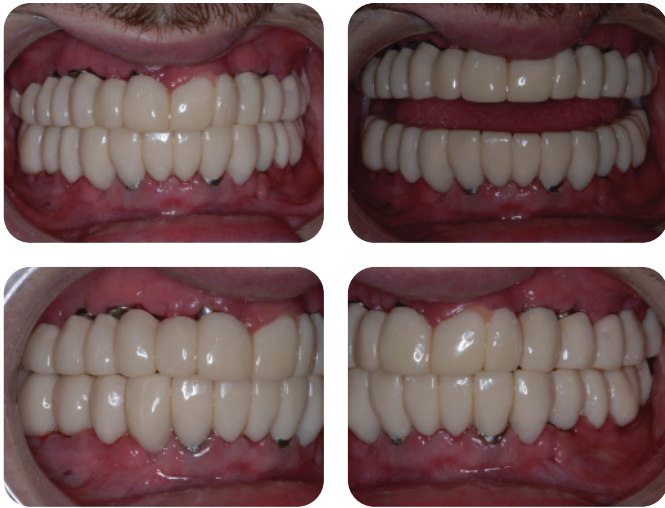

Figure 8.3.10. Photographs after the second phase. The patient appoints with the surgeon first to place the 8 maxillary implants and extract the 4 remaining mandibular teeth. The patient returned immediately to the office to place the mandibular abutments and new provisional and to refit the maxillary provisional over the implant healing caps. The implants were not immediately loaded.

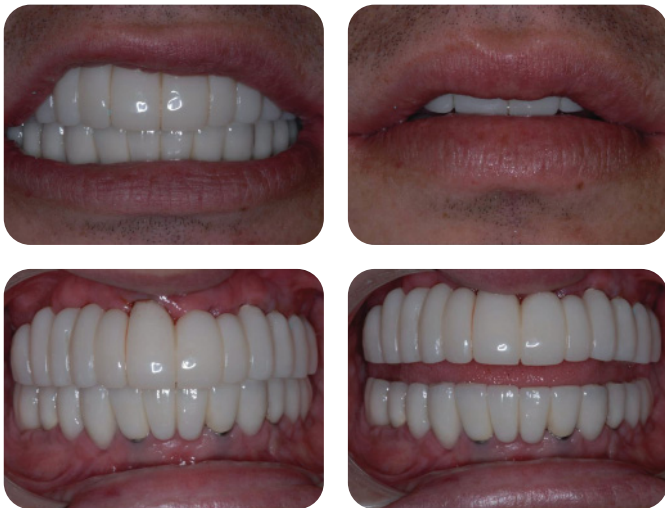

Figure 8.3.11. After time for complete healing, the next phase was begun. A maxillary implant level impression was made along with a mandibular impression of the implant abutments. Maxillary implant abutments were selected and a new provisional was made, following the same procedure as for the mandibular. The mandibular definitive casts were sent to the technician for fabrication. These photographs illustrate the new maxillary provisional on the implant abutments and the definitive mandibular implant-supported restoration.

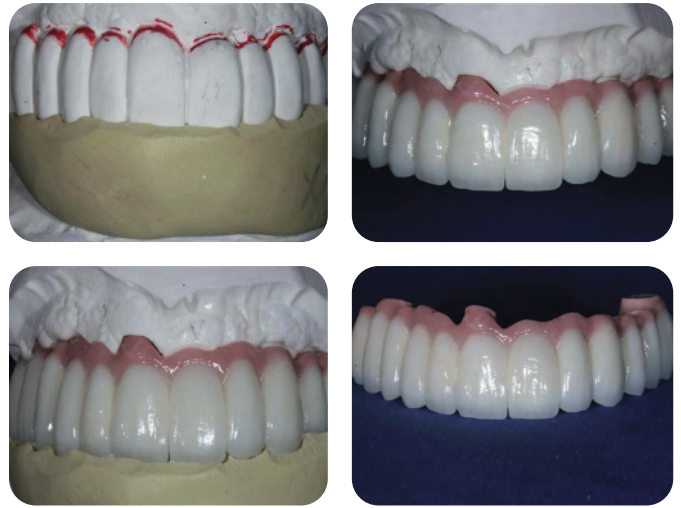

Figure 8.3.12. After enough time for healing of the 3 remaining maxillary extractions, impressions were made for the definitive maxillary implant-supported restoration. Top left: photograph of the maxillary provisional restoration with incisal edge/aesthetic plane putty index. Areas planned for pink porcelain are also outlined. Bottom left: the definitive restoration checked with the putty index. Top right: the definitive restoration on the solid cast to verify tissue contours. Bottom right: all concavities emerging from the implant abutment finish lines are filled in to create straight-to-convex contours for tissue support and cleanability.

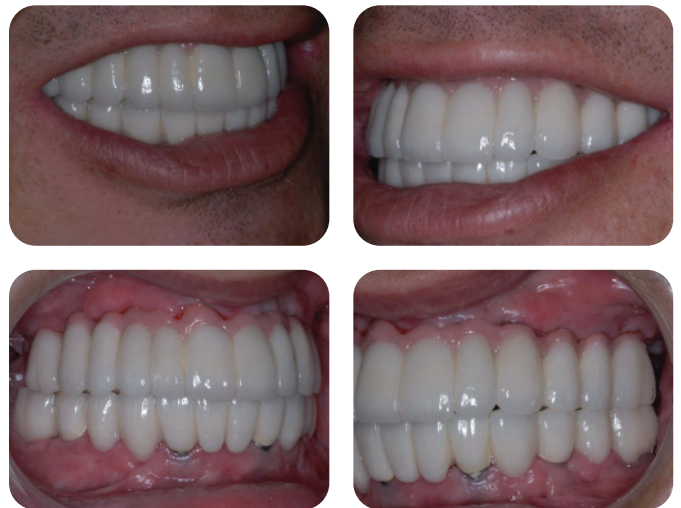

Figure 8.3.13. Lateral smile and retracted photographs of the definitive restoration. Overbite/overjet was increased to approximately 2 mm.

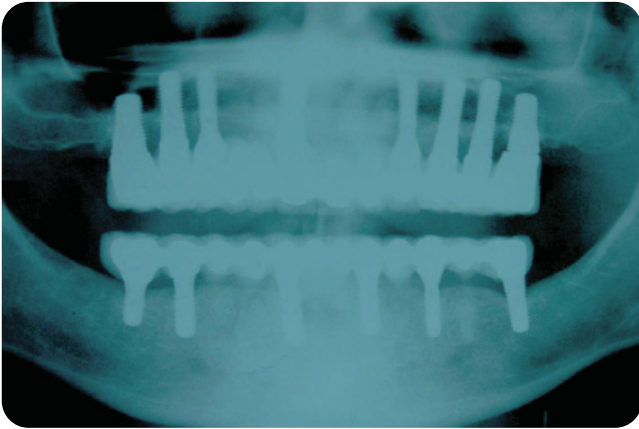


Figure 8.3.14. Panoramic radiograph of the completed maxillary and mandibular restorations. The slight marginal gap on the maxillary left last abutment was deemed to be clinically acceptable.

CHAPTER 8 CASE 3 KEY POINTS

- When using natural teeth for provisional abutments, carefully prepare and build up abutments and use a straight finish line for maximum resistance and retention form.
- Ribbond reinforced provisionals are extremely durable for long term provisionals.

Chapter 8 Case 4

Maxillary extractions, immediate implant placement, immediate loading, and complete nonremovable zirconia restoration with pink porcelain

The patient in this case study has a failing maxillary and mandibular reconstruction with both dental implant and natural tooth abutments. The maxillary is the more urgent arch because there are currently no maxillary right posterior teeth. The patient desires a nonremovable implant-supported reconstruction. The mandibular dentition is hopeless and needs the same treatment; however, her circumstances dictate that only the maxillary will be addressed at this time. The mandibular functional landmarks can be modified for a good result.

SUMMARY OF EXAMINATION AND DIAGNOSIS

Dentition

Maxillary and mandibular are hopeless.

Periodontium

Maxillary and mandibular are hopeless.

TMJs

Right side Piper 2

Left side Piper 2

Both can be compressed without discomfort.

Muscles

Slight lateral pterygoid discomfort to testing

Occlusion

Interferences in the arc of closure to maximum intercuspation

Excessive Curve of Spee

Aesthetics

Form, contour, proportion, excessive length

THE 10 DECISIONS

1. TMJ Diagnosis

Treat to a guided, verified centric relation.

2. Vertical Dimension

No need to change

3. Lower Incisal Edge

Smooth and polish for an even plane.

4. Upper Incisal Edge

No need to change

5. Centric Stops

Simultaneous, equal intensity centric stops in the centric relation arc of closure

6. Anterior Guidance

Determined by finalized upper and lower incisal edge position.

7. Curve of Spee

Reshape mandibular to flatten and idealize.

8. Curve of Wilson

Verify that upper buccal and lower lingual cusps do not interfere in the functional and parafunctional range of motion.

9. Cusp/Fossa Angle

Shallower than the anterior guidance disclusive angle

10. Aesthetic Plane

Create an upper posterior aesthetic plane that is consistent with the upper incisal edge position and with pleasing buccal profiles.

SUMMARY OF TREATMENT PLAN

Dentition

Maxillary extractions
 Immediate implant placement
 Utilize 2 current implants upper left.
 Immediate placement of 8 implants
 Immediate provisional with temporary abutments

Periodontium

Transition to implants

TMJs

No treatment is needed other than correct occlusal engineering.

Muscles

No treatment is needed other than correct occlusal engineering.

Occlusion

Simultaneous, equal intensity centric stops in the centric relation arc of closure
 Correct Curve of Spee.
 Anterior guidance on anterior teeth

Aesthetics

Improve color, size, proportion.
 Use pink porcelain to control tooth length.

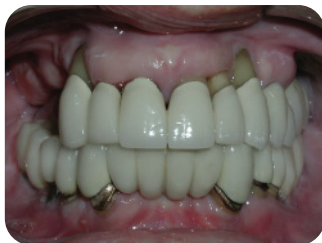

Figure 8.4.1. Pretreatment photograph illustrating a hopeless maxillary and mandibular dentition.

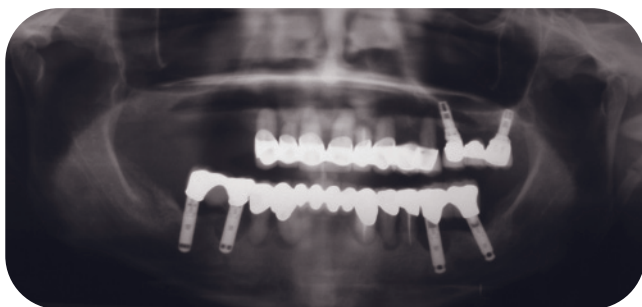

Figure 8.4.2. Pretreatment panoramic radiograph. The two maxillary left implants and the two most posterior mandibular implants are serviceable.

SUMMARY OF TREATMENT SEQUENCE

Appointment Treatment Completed

- | | |
|---|--|
| 1 | Maxillary extractions
Immediate placement of 8 implants
Place 8 temporary abutments.
Use 2 implants currently in place.
Nonremovable provisional |
| 2 | Heal and integrate. |
| 3 | Implant level impression |
| 4 | Place definitive abutments and new provisional.
Definitive impressions |
| 5 | Place definitive maxillary reconstruction. |
| 6 | Begin mandibular treatment as circumstances permit. |

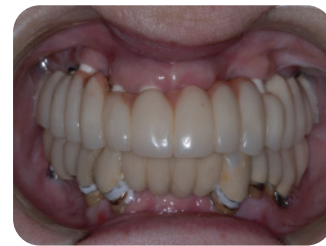

Figure 8.4.3. Anterior retracted photograph approximately 1 month postsurgery. The maxillary teeth were extracted and 8 dental implants immediately placed. This decision was made by the oral surgeon based on analysis of the CAT scan. Temporary plastic implant abutments were placed and prepared and an alginate impression was made. The prefabricated provisional was relined over the cast of the temporary implant abutment preparations and then refined intraorally. The mandibular restorations were reshaped and contoured to create a more ideal incisal plane, Curve of Spee, and Curve of Wilson.

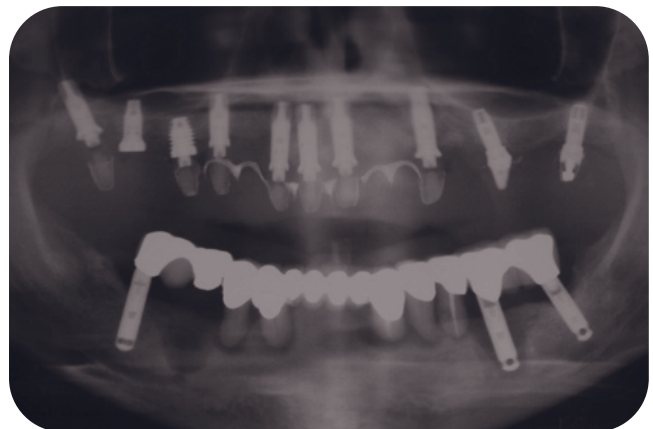

Figure 8.4.4. Postsurgery panoramic radiograph of the maxillary dental implants and temporary abutments.

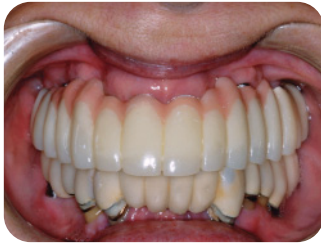

Figure 8.4.5. Photograph of the new provisional after the definitive implant abutments were placed. An implant level impression was made, the implant abutments were modified, and the provisional was fabricated as illustrated in Figures 8.3.7–8.3.9.

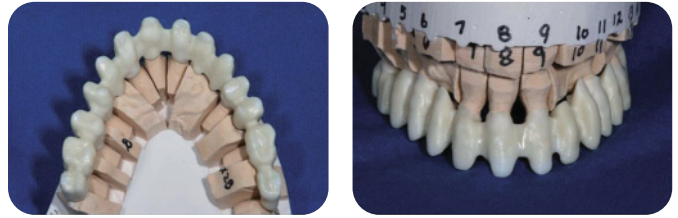


Figure 8.4.6. Definitive impressions were made of the implant abutments after they were secured in place. From this point, the case was handled just like a crown and bridge case. These photographs illustrate the 14-unit Zirconia framework.

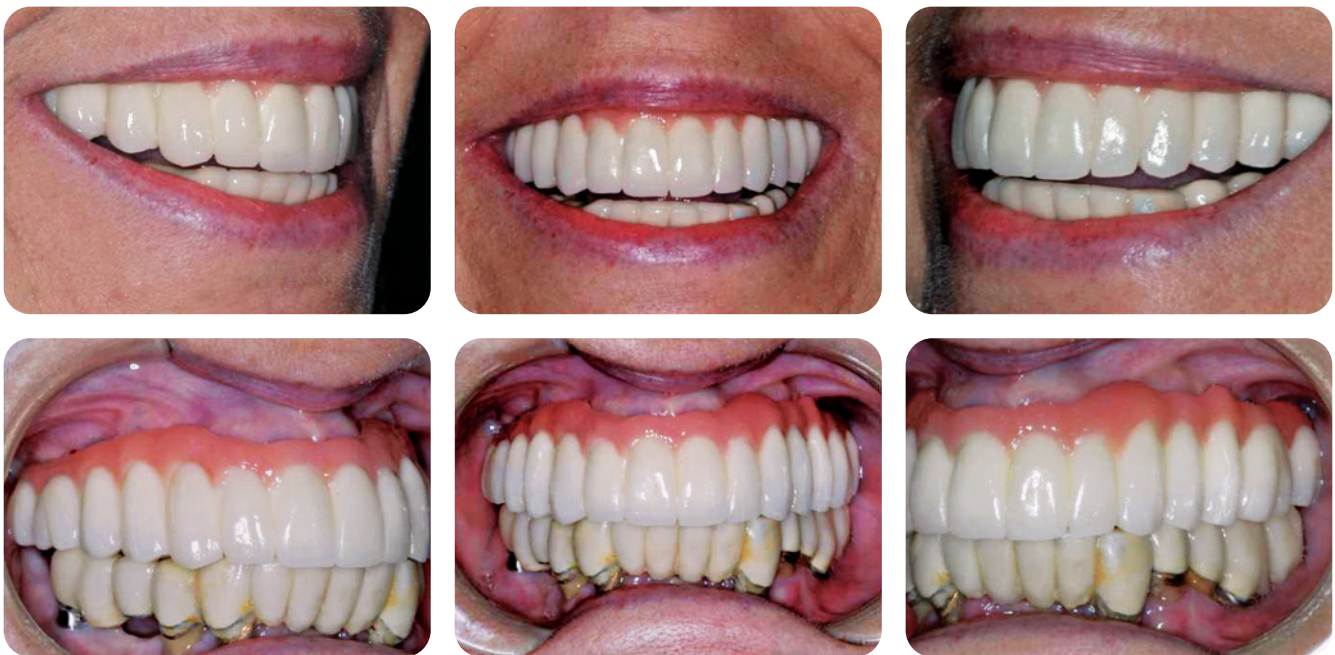

Figure 8.4.7. Anterior and lateral smile photographs and anterior and lateral retracted photographs of the completed restoration. All areas are easily cleanable with brushes and floss. The restoration is placed with a soft, retrievable cement.

CHAPTER 8 CASE 4 KEY POINTS

- Immediately loaded dental implants can be a predictable approach in select circumstances.
- Pink porcelain can be used to simulate tissue if a flange is not needed for lip support.
- Zirconia can be used for an extensive fixed framework.

Chapter 8 Case 5

Mandibular implant bar–supported full removable denture converted to a nonremovable restoration to improve comfort of the neutral zone and phonetics

The patient in this case study recently had her implant bar–supported restoration completed on 4 implants. The fit and stability was acceptable, but the restoration felt bulky and interfered with the tongue during phonetics. With the placement of 2 more implants, a new nonremovable restoration was completed.

SUMMARY OF EXAMINATION AND DIAGNOSIS

Dentition

Unacceptable mandibular implant bar–supported full denture on 4 implants

Periodontium

Current implants are healthy.

TMJs

Right side Piper 3B

Left side Piper 3B

Both can be compressed without discomfort.

Muscles

No discomfort to testing

Occlusion

Denture occlusion is not coincident to the arc of closure.

Aesthetics

Insufficient maxillary incisor display

Lower denture interferes with neutral zone.

THE 10 DECISIONS

1. TMJ Diagnosis

Treat to a guided, verifiable adapted centric posture.

2. Vertical Dimension

Acceptable for the facial aesthetics of a full denture patient

3. Lower Incisal Edge

Acceptable

4. Upper Incisal Edge

Increase length 1.5 mm.

5. Centric Stops

Simultaneous, equal intensity centric stops on the posterior teeth in the adapted centric posture arc of closure; anterior teeth slightly out of occlusion

6. Anterior Guidance

Typical full denture anterior guidance; starts on posterior teeth and transitions to a shallow, flat, smooth anterior tooth disclusion angle

7. Curve of Spee

Anterior reference—cuspid

Posterior reference—halfway on retromolar pad

8. Curve of Wilson

Verify that upper buccal and lower lingual cusps do not interfere in the functional and parafunctional range of motion.

9. Cusp/Fossa Angle

Approximately the same as the anterior guidance disclusion angle

10. Aesthetic Plane

Create an upper posterior aesthetic plane that is consistent with the upper incisal edge position and with pleasing buccal profiles.

SUMMARY OF TREATMENT PLAN**Dentition**

Place 2 more implants.
Fabricate a nonremovable 12-unit restoration.

Periodontium

Place 2 implants.
No additional treatment is needed.

TMJs

No treatment is needed other than correct occlusal engineering.

Muscles

No treatment is needed other than correct occlusal engineering.

Occlusion

Simultaneous, equal intensity centric stops on the posterior in the adapted centric posture arc of closure; anterior teeth slightly out of occlusion; anterior guidance starts on posterior teeth and then transitions to anterior teeth—typical full denture anterior guidance.

Aesthetics

Create an upper posterior aesthetic plane that is consistent with the upper incisal edge position and with pleasing buccal profiles.

SUMMARY OF TREATMENT SEQUENCE**Appointment****Treatment Completed**

1	Remove bar. To surgeon for 2 more implants Back to office to modify underside of bar and replace—use as provisional during healing
2	Remove current abutments. Implant level impression Fabricate implant cast in office. Modify stock abutments. Fabricate provisional on duplicate of implant cast. Place abutments intraorally. Definitive impressions Upper full denture impression and bite records. A duplicate of her current maxillary denture was used as an impression tray and bite record because it was acceptable other than increasing maxillary incisor length 1.5 mm. Place nonremovable provisional. NOTE: Patient traveled 4 hours, so this lengthy appointment was carefully planned and prearranged.
3	Place definitive mandibular nonremovable restoration. Place new maxillary denture.
4	Future: plan for implant-supported maxillary full denture.

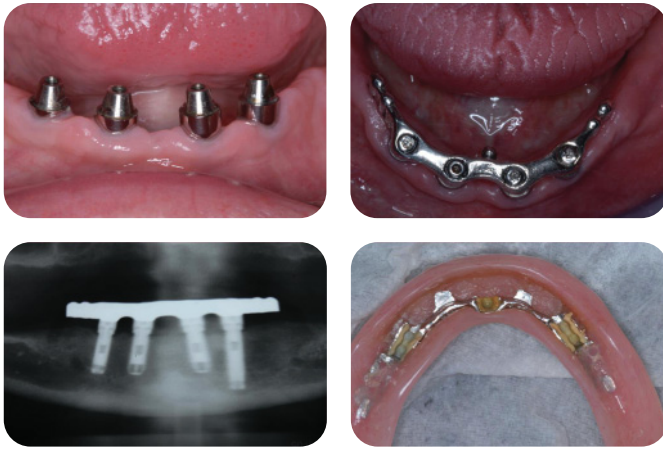

Figure 8.5.1. Pretreatment condition. Top left: implants with abutments for screw-retained bar. Top right: implant-supported bar screwed in place on the implant abutments. Bottom left: pretreatment radiograph of implants and bar suggesting well integrated implants. Bottom right: underside of removable prosthesis with metal reinforcement and attachments on distal extension bar and lingual button. The patient disliked the bulkiness of the prosthesis, which interfered with phonetics. Her desire was to have a nonremovable restoration as close to natural teeth as possible. The oral surgeon, after CAT scan analysis reported that 2 more implants could be placed distally and that these 6 implants could support a nonremovable restoration. A diagnostic wax-up revealed that teeth and pontics lined up well over the implants as they are currently positioned.

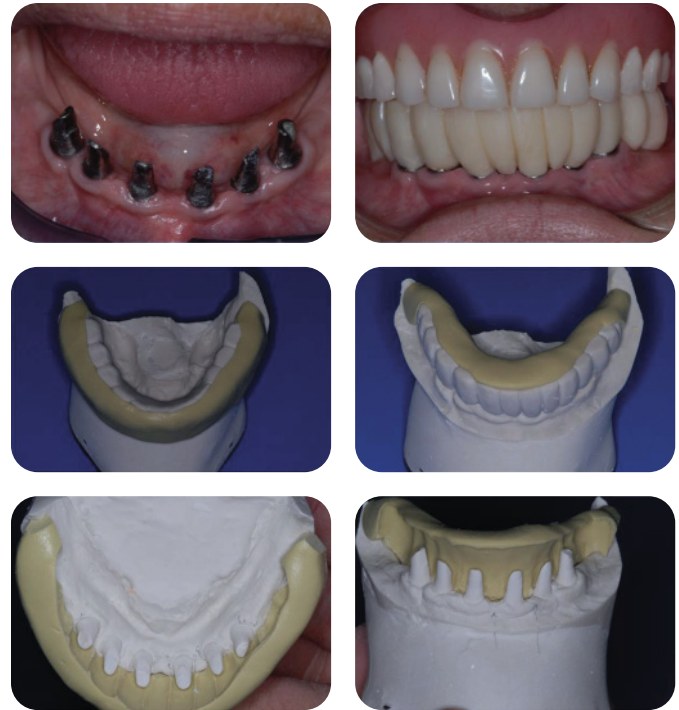

Figure 8.5.2. Top left: photograph after the 2 additional implants were placed and new abutments prepared for a nonremovable restoration. Top right: provisional nonremovable restoration in place. It is always desirable to make a provisional as close to the definitive as possible. This minimizes unmet expectations. Middle photographs: buccal and lingual putty indices made over the articulated cast of the provisional restoration. Bottom photographs: putty indices in place on the solid cast of the definitive implant abutments. This laboratory communication will guide the technician to make a definitive restoration as close to the provisional restoration as possible, which the patient approved in terms of contours, aesthetics, phonetics, comfort, and function.

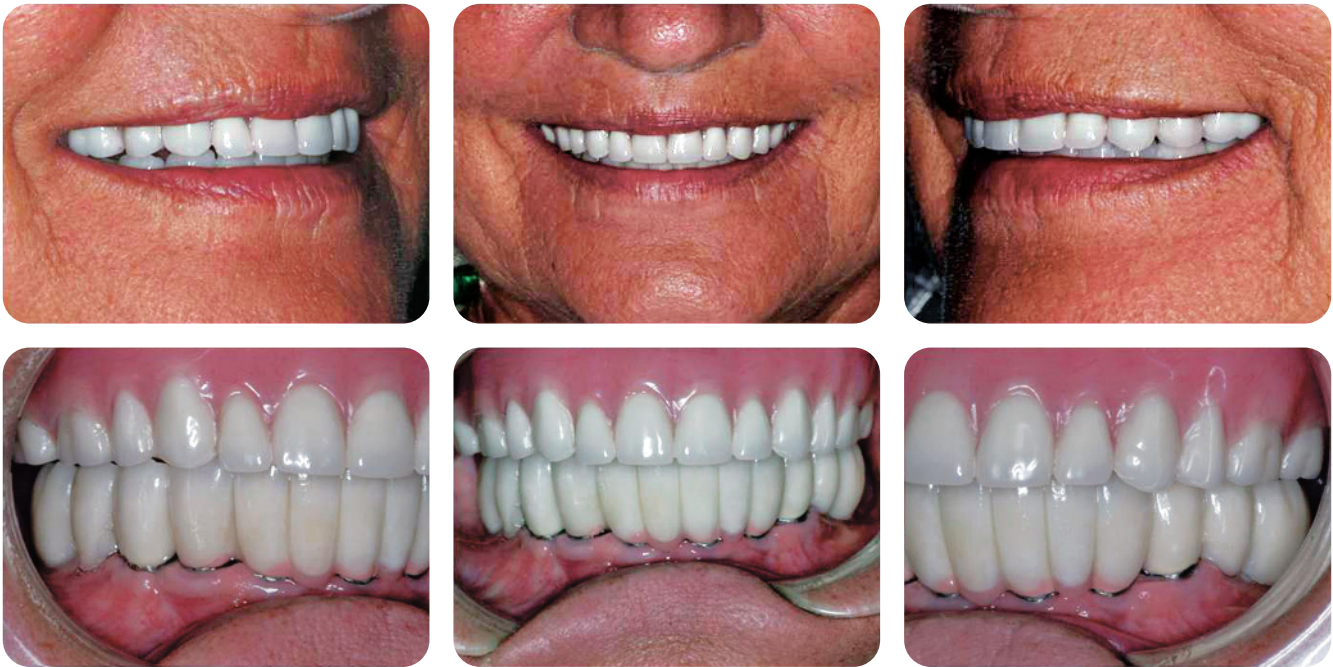

Figure 8.5.3. Smile and retracted photographs of the completed restoration; a new maxillary complete removable denture and a mandibular 12-unit nonremovable implant-supported restoration.

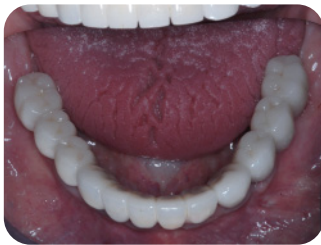

Figure 8.5.4. Occlusal photograph of the completed mandibular restoration suggesting natural size, contours, and position. The patient's expectations were exceeded. When her circumstances permit, she will begin a treatment plan for an implant-retained maxillary denture.

CHAPTER 8 CASE 5 KEY POINTS

- Full denture patients get the same complete examination with articulated diagnostic casts that the dentate patient gets.
- The diagnostic wax-up will confirm how desired tooth position relates to current implant position.

9

Orthognathics

Case 1 Severe anterior open bite corrected with maxillary-only orthognathics and occlusal therapy with upper incisor restorations

Case 2 Mandibular orthognathic surgery and chin implant; managing a temporomandibular disorder during treatment; posterior restorative dentistry including implants

Case 3 Maxillary and mandibular orthognathic surgery with chin advancement; prerestorative occlusal therapy with equilibration and composite additions

See also:

Chapter 16 Case 1 Severe anterior overjet handled with occlusal/restorative treatment in lieu of orthognathics; muscular component of a temporomandibular disorder also managed

Chapter 9 Case 1

Severe anterior open bite corrected with maxillary-only orthognathics and occlusal therapy with upper incisor restorations

This patient has had an open bite as long as he can remember. He has no muscular or TMJ symptoms and has no difficulty chewing. Interestingly, he has no aesthetic concerns and is happy with the appearance of his teeth and smile. Some teeth are sensitive to temperature. He knows he has periodontal problems and that his bite is a factor, and he does not want to lose any more teeth—this is his main motivator.

There are significant condylar changes but no signs or symptoms. The main issue is to determine stability, which will help us make a prognosis of occlusal stability. This will be accomplished with a bite splint. Then we can proceed with orthodontics, orthognathics, and definitive occlusal/restorative treatment.

SUMMARY OF EXAMINATION AND DIAGNOSIS

Dentition

Severe wear
Recession, erosion, tooth sensitivity to temperature
Fit and structure of upper anterior crowns unacceptable

Periodontium

Failing, but most areas are treatable and maintainable.
Lower right second molar needs to be removed. Although there is rather extensive bone loss, teeth exhibit minimal mobility.
Analysis of past radiographs shows that bone levels have been relatively stable for several years.

TMJs

Right Piper 4B
Left Piper 4B
Significant osseous changes are visible on panoramic radiograph.
Both can be superiorly compressed comfortably.
Range of motion is normal.
The big question is stability over time.

Muscles

Medial and lateral pterygoid have slight tenderness to palpation.

Occlusion

Severe anterior open bite from last molars forward

Aesthetics

Upper aesthetic plane landmarks are acceptable.
Aesthetics of upper anterior crowns are unacceptable.

THE 10 DECISIONS**1. TMJ Diagnosis**

Bite splint—adjust to guided ACP, the purpose is to test stability for 3 months, not to treat symptoms.

Treat with orthognathics/orthodontics to guided ACP.

Definitive occlusal treatment and restorative treatment to guided ACP.

2. Vertical Dimension

Closed by maxillary impaction (keeping incisal edge where it is and impacting by elevating posteriorly around the incisal edge) and mandibular autorotation

3. Lower Incisal Edge

Idealize with orthodontics.

4. Upper Incisal Edge

Display with lip at rest is acceptable even pretreatment; therefore, maintain this throughout treatment.

5. Centric Stops

Posttreatment goal is equal contacts on all teeth, anterior and posterior with condyles in ACP.

6. Anterior Guidance

To be determined by final relationship of upper to lower incisal edge—goal is 3–4 mm overbite.

7. Curve of Spee

Idealize with orthodontics.

8. Curve of Wilson

Idealize with orthodontics.

9. Cusp/Fossa Angle

Keep shallow and flat due to TMJ diagnosis.

10. Aesthetic Plane

Using upper incisal edge position as a reference, idealize plane and profiles.

SUMMARY OF TREATMENT PLAN**Dentition**

Remove lower right second molar.

Implant and restoration of lower left first molar

Restoration as needed post-ortho

Periodontium

Periodontal maintenance

Connective tissue grafts as needed

TMJs

Bite splint therapy to test stability over time

No symptoms to treat

Muscles

Bite splint therapy followed by definitive occlusal management

Occlusion

Orthodontics, orthognathics, equilibration, restorations as needed to achieve simultaneous, equal intensity centric stops in the adapted centric posture arc of closure

Aesthetics

Maintain upper incisal edge position.

Improve restoration aesthetics with new crowns 7–10.

SUMMARY OF TREATMENT SEQUENCE

Appointment	Treatment Completed
1	Bite splint to test stability of altered joints, not to treat symptoms
2	Bite splint follow-up for 4 months
3	To periodontist for treatment: remove lower right second molar; scaling; grafts
4	Preorthognathic orthodontics
5	Orthognathics
6	Postorthognathic orthodontics
7	Equilibration
8	Implant lower left first molar.
9	Equilibration follow-up
10	Restore maxillary incisors and lower left first molar implant.
11	Yearly bite engineering evaluation and refinement

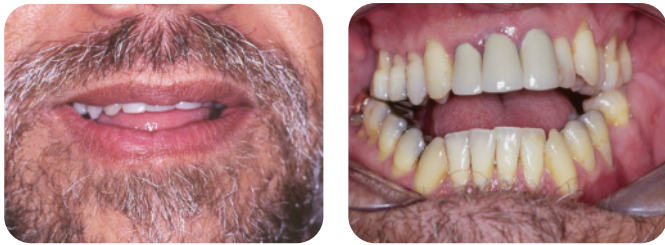

Figure 9.1.1. Preoperative smile and retracted view. Despite the open bite, he is quite happy with his smile.

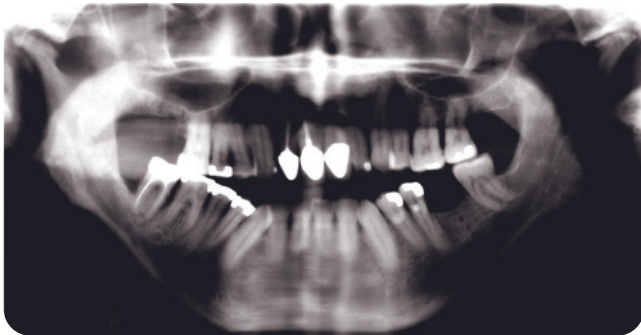


Figure 9.1.2. Preoperative panoramic radiograph shows significant condylar changes. Signs and symptoms are none to minimal. Stability is the big question.

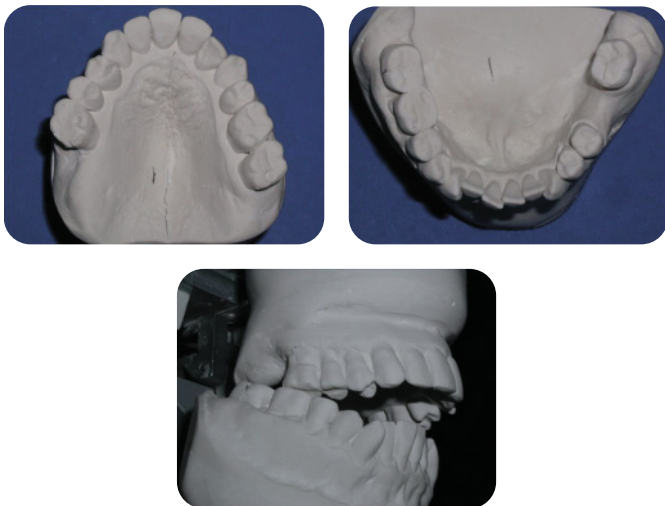

Figure 9.1.3. Preoperative articulated diagnostic casts.

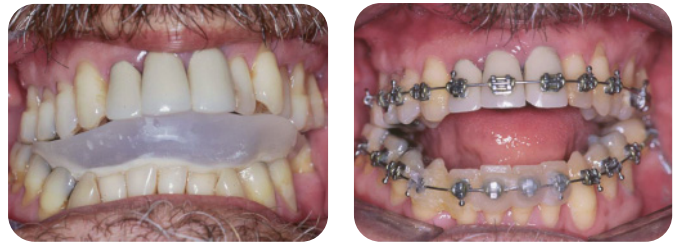

Figure 9.1.4. Bite splint in full occlusal contact worn for 4 months to assess stability. Occlusion changed very little, if at all, suggesting TMJ stability. Orthodontics was started after the bite splint.

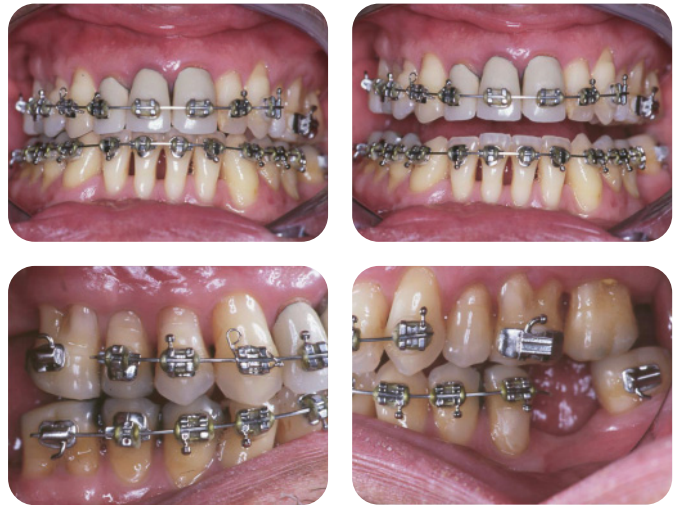

Figure 9.1.5. Postorthognathic surgery and orthodontic refinement to couple all teeth.

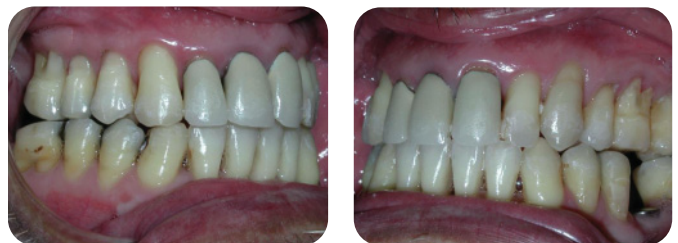
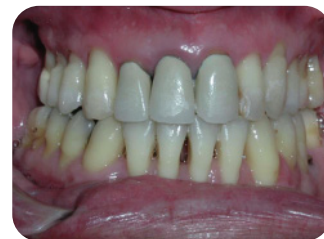
Figure 9.1.6. Postorthodontic equilibration fulfilled all requirements of a physiologic occlusion.

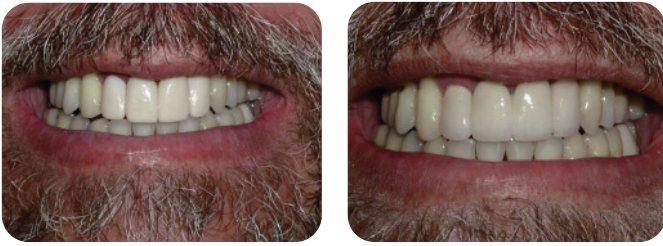

Figure 9.1.7. Provisionals followed by crowns 7–10. The crowns were splinted to act as an orthodontic retainer.

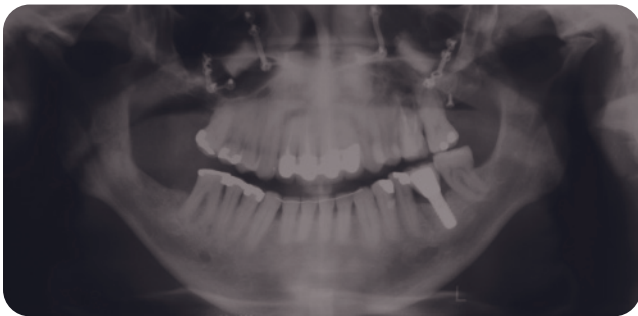


Figure 9.1.8. Twelve years posttreatment. Occlusion does need to be refined yearly, as expected, based on TMJ diagnosis. Relatively stable considering the condition of his condyles.

CHAPTER 9 CASE 1 KEY POINTS

- Test stability of altered joint structures with a bite splint even if the patient is symptom-free.
- Verify the patient's main concern for seeking treatment—it may not be what we initially assume it to be.

Chapter 9 Case 2

Mandibular orthognathic surgery and chin implant; managing a temporomandibular disorder during treatment; posterior restorative dentistry including implants

The patient in this case study has had her current dentistry for 20 years. She wanted it changed and was open to a discussion about dental implants instead of the fixed partial dentures. In addition, she also wanted to address her bite issues, concurrent temporomandibular disorder, and the aesthetic appearance of a retruded jaw and chin.

SUMMARY OF EXAMINATION AND DIAGNOSIS

Dentition

Posterior teeth are in need of restorative attention.

Periodontium

Healthy

TMJs

Right side Piper 3B

Left side Piper 3B

Neither can be compressed comfortably.

Muscles

Medial and lateral pterygoids are painful to palpation.

Occlusion

Interferences in the arc of closure to maximum intercuspation

Inadequate anterior centric stops due to Class 2 jaw relationship

Aesthetics

Protrusive position of upper anterior teeth

Retruded mandible and chin

THE 10 DECISIONS

1. TMJ Diagnosis

Begin bite splint therapy in a treatment position with the goal of adapted centric posture.

2. Vertical Dimension

Open with orthodontics as occlusal plane is leveled.

3. Lower Incisal Edge

Move down and forward with orthodontics and orthognathics.

4. Upper Incisal Edge

Move lingually with orthodontics.

5. Centric Stops

Simultaneous, equal intensity centric stops in the adapted centric posture arc of closure

6. Anterior Guidance

Determined by final lower and upper incisal edge position and an idealized 4mm overbite

7. Curve of Spee

Flatten.

8. Curve of Wilson

Verify that upper buccal and lower lingual cusps do not interfere in the functional and parafunctional range of motion.

9. Cusp/Fossa Angle

Shallower than the anterior guidance disclusive angle

10. Aesthetic Plane

Create an upper posterior aesthetic plane with orthodontics and restorations that is consistent with the upper incisal edge position and with pleasing buccal profiles.

SUMMARY OF TREATMENT PLAN

Dentition

Orthodontics and orthognathics
Implants and posterior restorations

Periodontium

Ongoing self care and professional maintenance

TMJs

Bite splint therapy followed by definitive occlusal therapy

Muscles

Bite splint therapy followed by definitive occlusal therapy

Occlusion

Orthodontics and orthognathics
Equilibration
Posterior reconstruction

Aesthetics

Orthodontics and orthognathics followed by restorations

SUMMARY OF TREATMENT SEQUENCE

Appointment	Treatment Completed
1	Bite splint therapy
2	Diagnostics on articulated diagnostic casts
3	Orthodontics
4	Manage temporomandibular disorder signs and symptoms throughout orthodontics.
5	Orthognathics
6	Equilibration and lower posterior provisional bridges Bite splint
7	Bone graft for mandibular first molar edentulous areas
8	Dental implants
9	Complete upper posterior restorations. Modify bite splint.
10	Complete lower posterior restorations. New bite splint

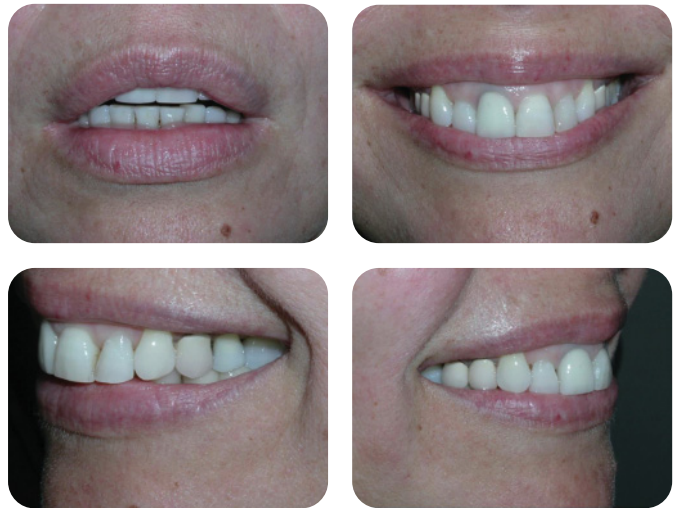

Figure 9.2.1. Pretreatment anterior and lateral smile photographs suggesting protruded maxillary anterior teeth (incisal edges on the dry border of the lower lip)—also due to retruded mandible.

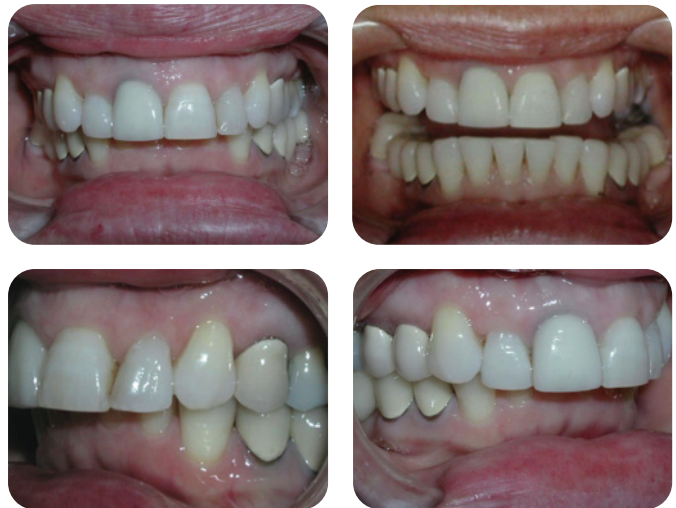

Figure 9.2.2. Pretreatment anterior and lateral retracted photographs suggesting class 2 orthodontic relationship with excessive overjet.

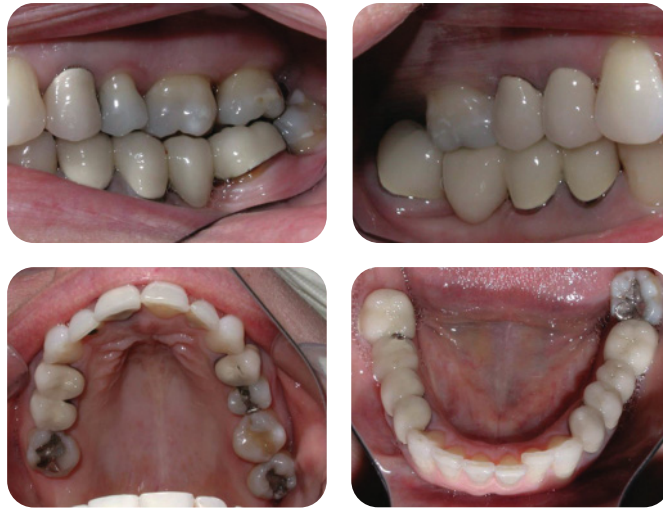

Figure 9.2.3. Pretreatment buccal occluded and occlusal photographs.

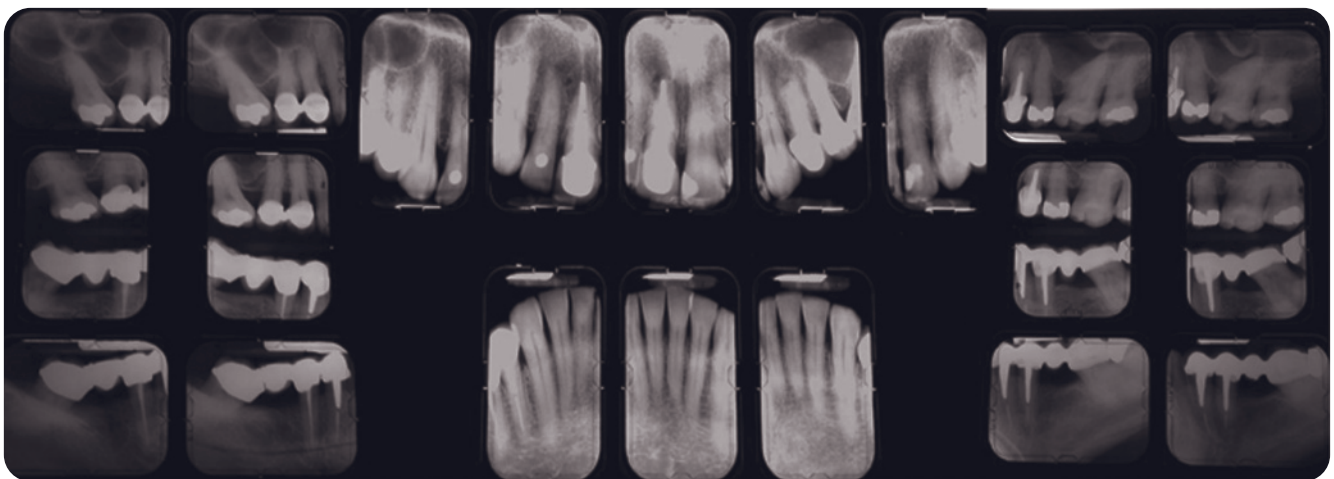
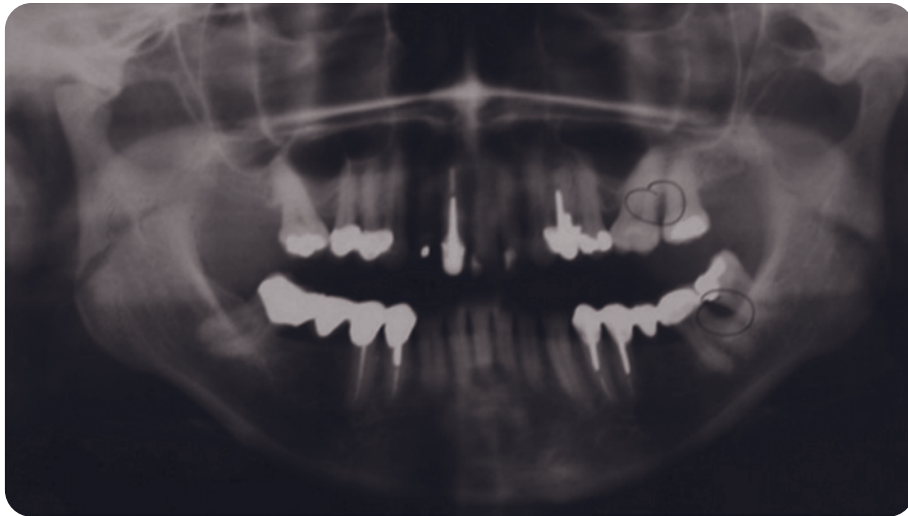


Figure 9.2.4. Pretreatment panoramic and periapical radiographs illustrating condylar changes, tipped molars, multiple restorations, and endodontic therapy with large posts.

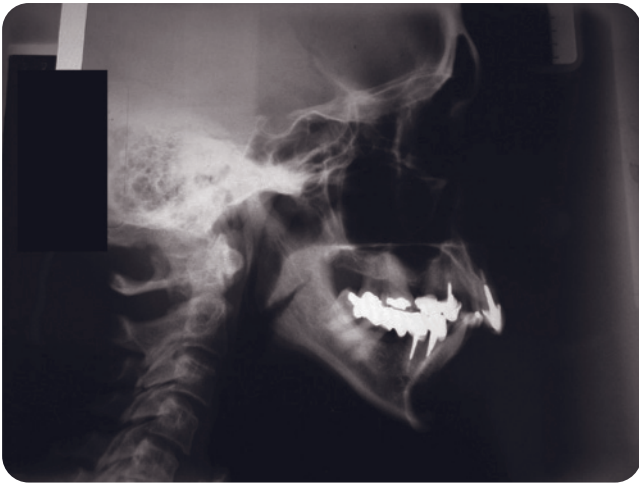

Figure 9.2.5. Pretreatment cephalometric radiograph suggesting protruded maxillary incisors and steep mandibular plane angle.



Figure 9.2.6. Equilibrated articulated diagnostic casts suggesting an anterior tooth-to-tooth relationship with no centric holding contacts.

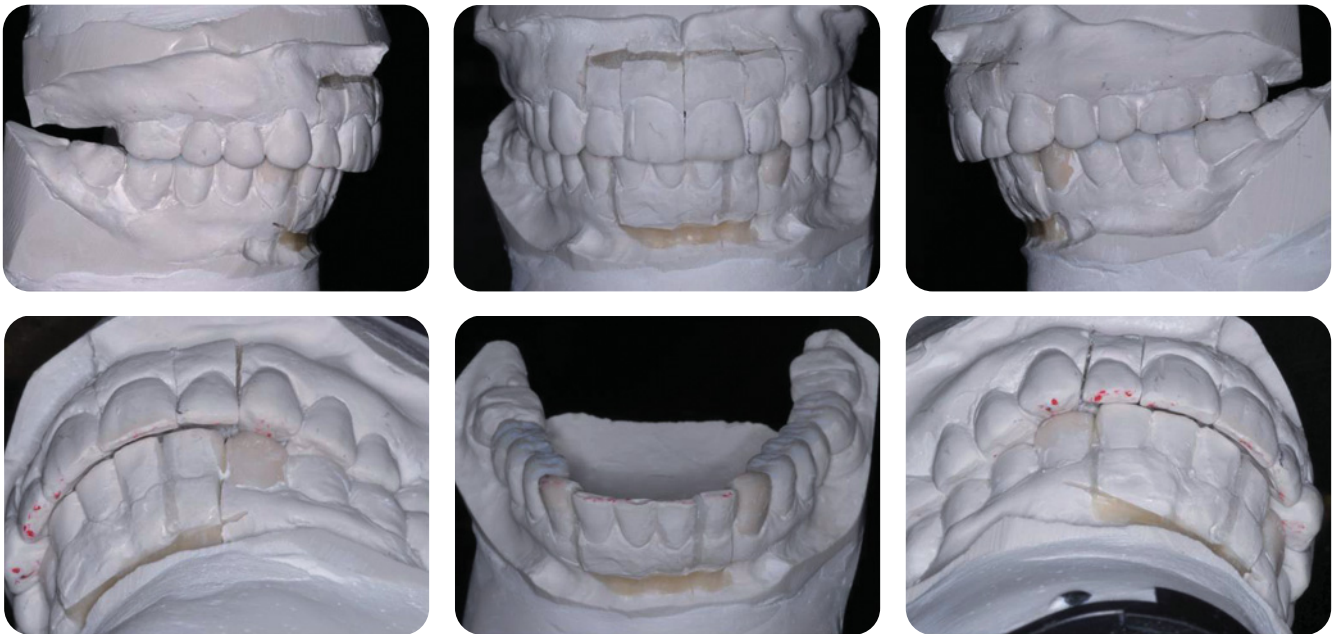


Figure 9.2.7. The patient had been advised in the past regarding orthognathic surgery and wanted more information about a nonsurgical approach. Therefore, additional diagnostic corrections were done on the articulated diagnostic casts, including moving the anterior teeth on the casts to obtain centric holding contacts, correcting the occlusal plane with restorations, and also restoring the lower cuspids to gain centric stops. The patient could see that functional improvements could be done without orthognathics. She was still very concerned about the appearance of her retruded jaw and chin and was counseled that although functional improvements could be made with orthodontics and restorations, her desired aesthetic appearance could not improve with just a restorative approach. She appreciated the time and effort of this additional diagnostic work and was convinced that orthognathic surgery was necessary to achieve her goals. This additional work was well worth the effort.

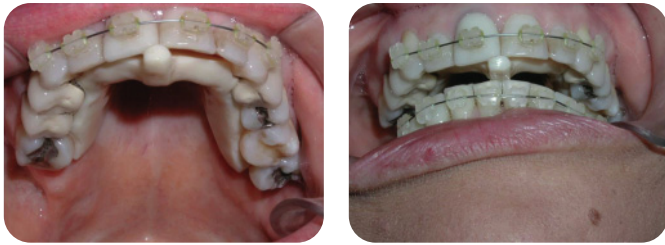

Figure 9.2.8. The temporomandibular disorder was resolved early on; however, she developed muscle pain during orthodontics. The photographs illustrate a very useful type of anterior deprogrammer splint that is used during orthodontics. It will not interfere with orthodontic tooth movement and is easily modified.

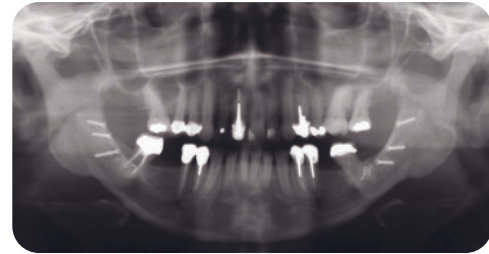
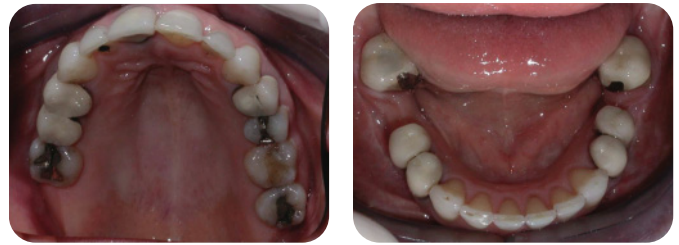

Figure 9.2.11. Postorthognathic occlusal photographs and panoramic radiograph.

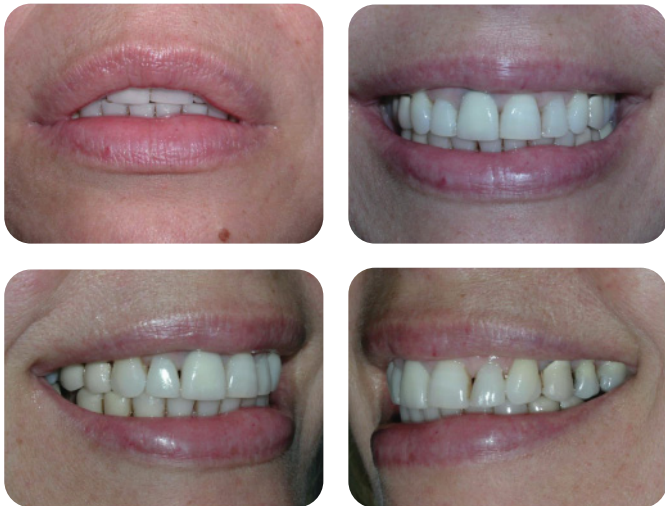

Figure 9.2.9. Postorthognathic anterior and lateral smile photographs illustrating a much more aesthetic maxillary anterior tooth-to-lower lip relationship.

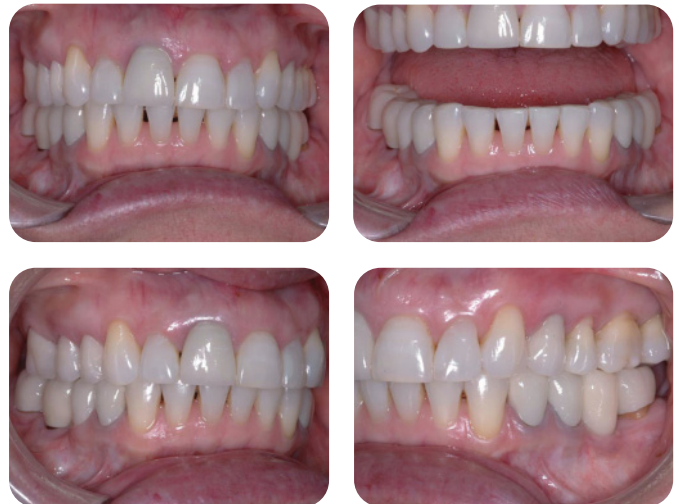

Figure 9.2.12. Postrestorative anterior and lateral retracted photographs illustrating ideal aesthetics and functional relationships. The patient continues to use a maxillary splint, which functions as an orthodontic retainer and therapeutic bite splint.

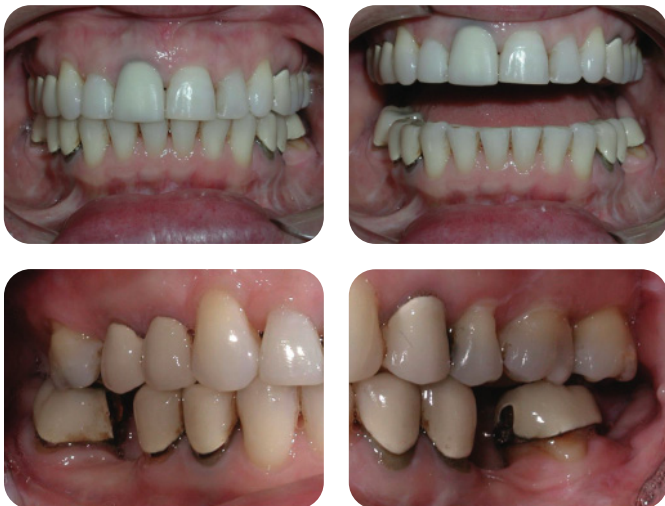

Figure 9.2.10. Postorthognathic treatment anterior and lateral retracted photographs illustrating ideal maxillary to mandibular anterior tooth-to-tooth relationship, uprighted molars, improved occlusal plane, and adequate space for dental implants.

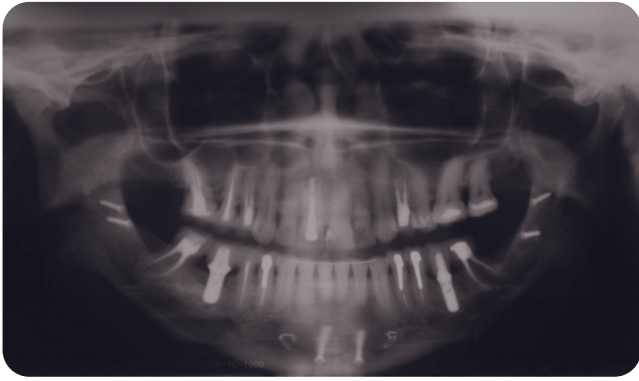


Figure 9.2.13. Posttreatment panoramic radiograph. The maxillary anterior teeth were restored with direct bonded composite and a new crown on the central incisor. The maxillary posterior teeth were a combination of porcelain crowns and onlays. The mandibular posterior teeth were individual porcelain crowns on natural teeth and 2 dental implants. Endodontics was completed on the maxillary right bicuspid and molar and the lower molars because of symptoms prior to finalization. The maxillary left bicuspid endodontics was retreated due to questionable appearance. The lower bicuspid posts were not disturbed. The patient was counseled regarding the potentially weak nature of longstanding endodontics with large posts. A chin implant and advancement was also done.

CHAPTER 9 CASE 2 KEY POINTS

- Sectioning and moving teeth on articulated casts will tell you and the patient what orthodontics will and will not do.
- The signs and symptoms of a temporomandibular disorder can be managed during orthodontics with an anterior deprogrammer retained with a simple lingual flange.

Chapter 9 Case 3

Maxillary and mandibular orthognathic surgery with chin advancement; preresorative occlusal therapy with equilibration and composite additions

The patient in this case study wanted to improve her smile and function and was open to a discussion about whatever it would take to achieve an ideal result. Her teeth also needed restorations because of structural issues, and she wanted to approach that project in a way to get a predictable restorative result. She embraced the idea of orthodontics but was apprehensive about orthognathics. As the case was analyzed, it became obvious that orthognathics was essential to achieve the desired expectations.

SUMMARY OF EXAMINATION AND DIAGNOSIS

Dentition

Posterior teeth have structural weaknesses due to old restorations.

Periodontium

Within normal limits

TMJs

Right side Piper 3B

Left side Piper 3B

Neither can be compressed comfortably.

Palpation discomfort

Muscles

Medial and lateral pterygoids are uncomfortable to palpation.

Occlusion

Class 2 jaw relationship

Interferences to maximum intercuspation in the centric arc of closure

Anterior teeth couple in maximum intercuspation but not after trial equilibration, indicating a significant horizontal component to the condylar shift from maximum intercuspation to adapted centric posture.

Aesthetics

Excessive maxillary incisal edge and gingival display

Retrusive jaw and chin

THE 10 DECISIONS

1. TMJ Diagnosis

Bite splint therapy started in a treatment position with a goal of adapted centric posture

2. Vertical Dimension

Idealize with orthodontics and orthognathics by establishing ideal maxillary incisal edge position, ideal occlusal plane, and class 1 jaw relationship.

3. Lower Incisal Edge

Acceptable

4. Upper Incisal Edge

Excessive tooth and gingival display will be lessened with maxillary orthognathics.

5. Centric Stops

Simultaneous, equal intensity centric stops in the adapted centric posture arc of closure in a class 1 jaw relationship are achieved with mandibular orthognathics.

6. Anterior Guidance

Determined by final upper and lower incisal edge position with an idealized 4 mm overbite

7. Curve of Spee

Idealize with orthodontics.

8. Curve of Wilson

Idealize with orthodontics.

9. Cusp/Fossa Angle

Shallower than the anterior guidance disclusion angle

10. Aesthetic Plane

Create an upper posterior aesthetic plane with orthodontics and restorations that is consistent with the upper incisal edge position and with pleasing buccal profiles.

SUMMARY OF TREATMENT PLAN

Dentition

Restorations posterior teeth
Anterior cosmetic reshaping

Periodontium

Ongoing self care and professional maintenance

TMJs

Bite splint therapy

Muscles

Bite splint therapy

Occlusion

Orthodontics, orthognathics followed by definitive occlusal therapy and restorations

Aesthetics

Orthodontics, orthognathics, and chin advancement

SUMMARY OF TREATMENT SEQUENCE

Appointment	Treatment Completed
1	Bite splint therapy
2	Preorthognathic orthodontics
3	Maxillary orthognathics, mandibular orthognathics, chin advancement
4	Postorthognathic orthodontic refinement
5	Posttreatment bite splint
6	Prerestorative occlusal therapy to include equilibration and composite additions to improve functional landmarks
7	Restorations at a pace and sequence to fit patient expectations and circumstances

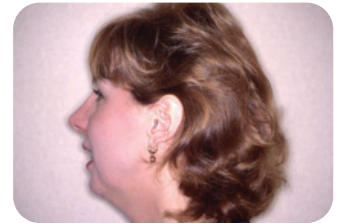
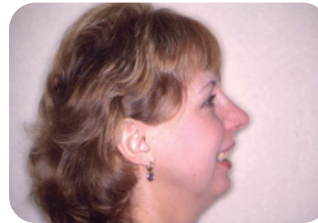

Figure 9.3.1. Pretreatment frontal and lateral smile photographs illustrating excessive tooth and gingival display and retruded chin.

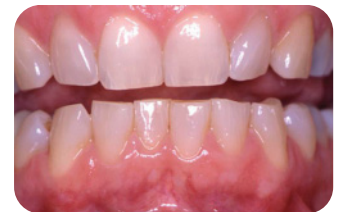
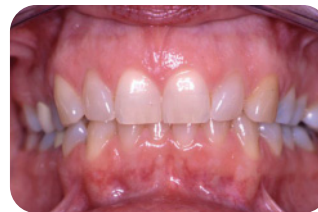
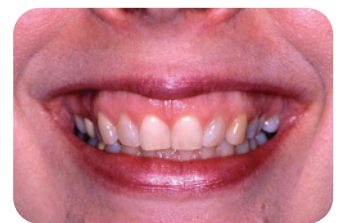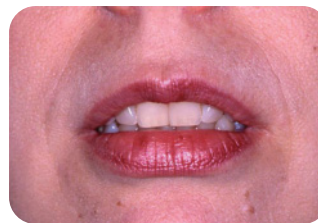Figure 9.3.2. Top left: pretreatment photograph of relaxed lip illustrating 8mm of tooth display. Top right: smile photograph illustrating 5mm of gingival display. Bottom left: maximum intercuspation looks acceptable at first glance. Bottom right: evidence of wear from bruxism.

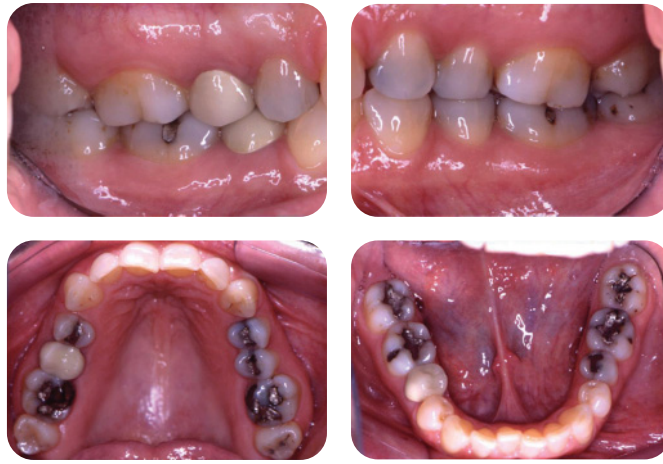

Figure 9.3.3. Top left: buccal occluded nearly an orthodontic class 1. Top right: buccal occluded an orthodontic class 2. Bottom occlusal photographs illustrate old restorations on almost all posterior teeth needing attention eventually. The patient wanted to take the necessary steps to assure that these restorations would have the most predictable long-term result; and that necessitated orthodontics, orthognathics, and definitive occlusal therapy.

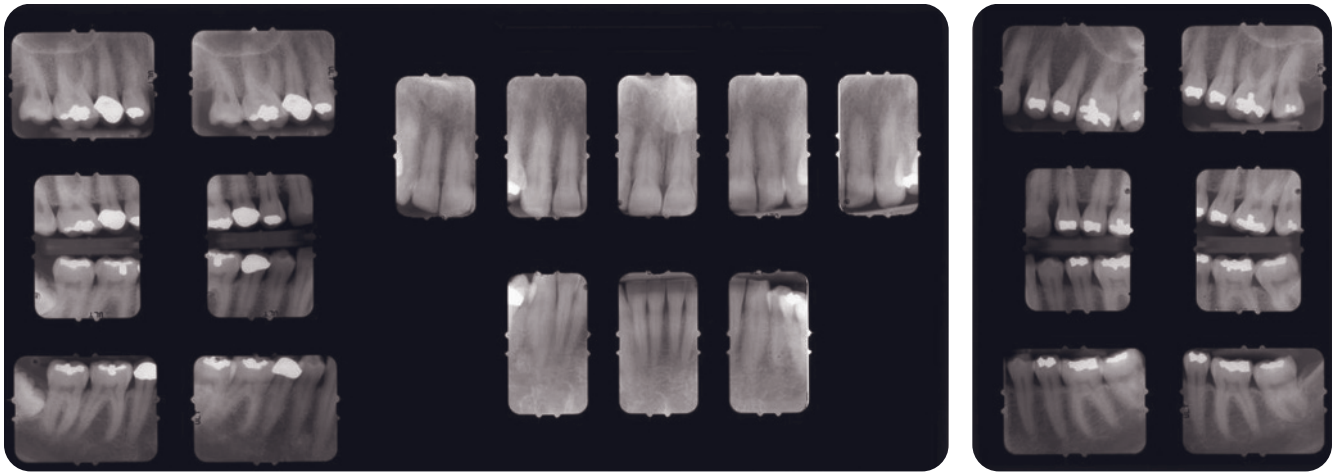


Figure 9.3.4. Pretreatment full mouth radiographic series.

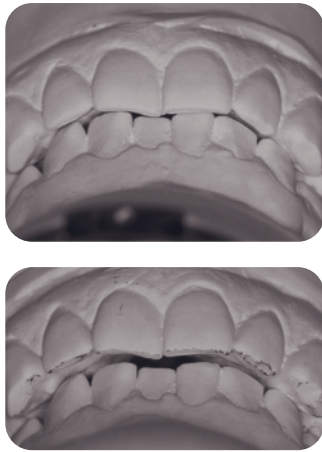


Figure 9.3.5. Top photograph illustrates the articulated diagnostic casts in maximum intercuspation after the slide from the interferences in the centric arc of closure. Note there is coupling of the anterior teeth. The bottom photograph illustrates the tooth-to-tooth relationship after a trial equilibration. The pin, which was set at the original vertical dimension of occlusion, was back on the incisal table. Note that the anterior teeth now have 2–3mm of overjet. There was a significant horizontal component to the condylar displacement from centric to maximum intercuspation. This trial equilibration proves that this is not a case for equilibration alone. Orthodontics alone could not move the teeth to gain acceptable anterior coupling and to satisfy the aesthetic concerns of the retruded jaw and excessive gingival display. Orthognathics was essential. This analysis helped the patient understand the rationale of orthognathics, along with her desire for a less gummy smile and less retruded jaw and chin.

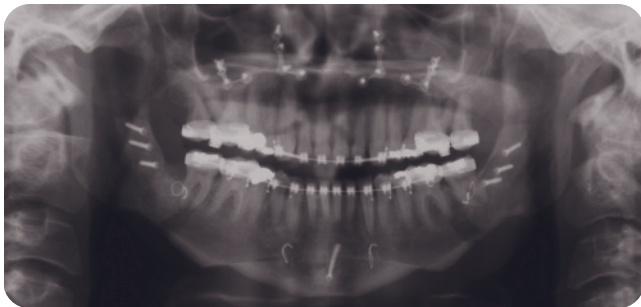


Figure 9.3.6. Postorthognathic panoramic radiograph.

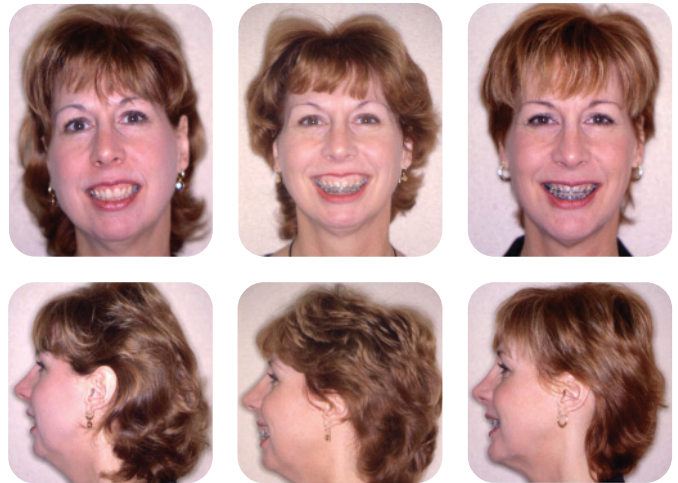

Figure 9.3.7. Left photographs: pretreatment. Middle photographs: postorthodontics illustrating even more of a gummy smile as arches were leveled and aligned. Right photographs: postorthognathics illustrating improved incisal edge display, lessened gummy display, and a more pleasing profile.

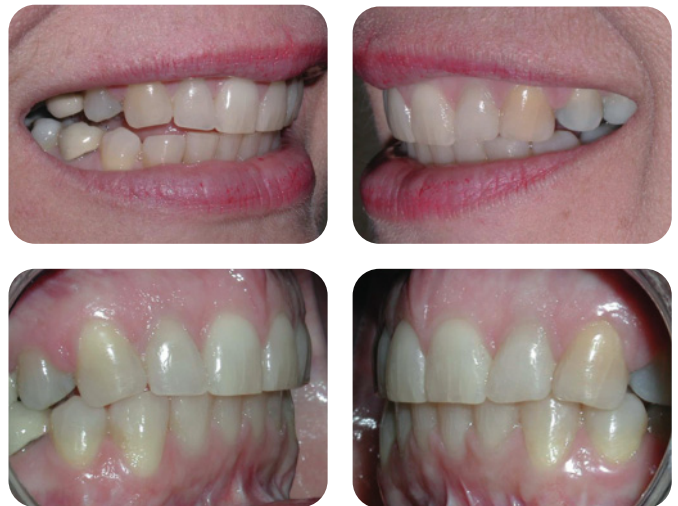

Figure 9.3.8. Top photographs illustrate the upper lip at the free margin of the gingival in a smile. Bottom photographs illustrate a class 1 anterior occlusal relationship. There is very little interference on the arc of closure to maximum intercuspation.

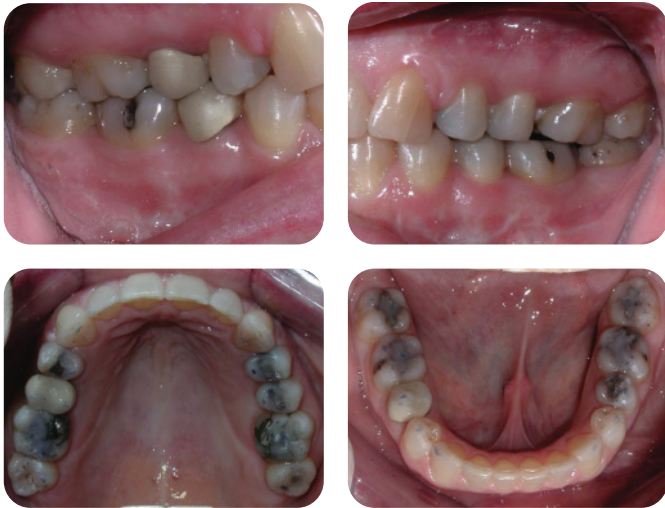

Figure 9.3.9. Buccal occluded photographs illustrate a class 1 posterior occlusal relationship. This makes the definitive occlusal and restorative treatment much easier and more predictable. The occlusal photographs are after preresorative definitive occlusal therapy, which involved equilibration and composite additions to the central fossa. The cusp to fossa angles were steeper than the new anterior guidance and needed to be shallowed to get stable holding contacts that discluded immediately in all excursions. The “system” is now set up for predictable aesthetic and restorative dentistry.

CHAPTER 9 CASE 3 KEY POINTS

- The maxillary-to-mandibular tooth-to-tooth relationship must be evaluated with a trial equilibration at the correct vertical dimension in the centric arc of closure.
- Occlusal therapy with equilibration and composite additions is a beneficial preresorative procedure.

10

Bruxism and Wear Reconstruction

Case 1 Restoration of worn lower anterior teeth in a deep bite without changing other restorations

Case 2 Severe wear from parafunctional habits restored with a complete reconstruction at an increased vertical dimension of occlusion

See also:

Chapter 16 Case 2 Failed multiple reconstructions; original deep overbite with current condition in provisionals with an opened vertical dimension and anterior overjet; managed with a new reconstruction harmonizing a physiologic deep overbite

Chapter 10 Case 1

Restoration of worn lower anterior teeth in a deep bite without changing other restorations

Not every patient we see can have a complete reconstruction because of his/her circumstances, objectives, and temperament. We have to decide whether the limited treatment each patient desires can be made to work correctly with the landmarks and parameters that are presented. Patients may not be able to change the dentistry but we may be able to modify it by recontouring, reshaping, and judicious composite additions.

This patient has had her dentistry for many years. It shows signs of inadequacies but is acceptable in terms of marginal fit and lack of decay. Her primary concern is the excessive wear on the lower anterior teeth. This wear has occurred not just because the upper anterior teeth are porcelain restorations but because there is a slide from the first point of contact to maximum intercuspation. The end point of the slide is the anterior teeth. The contours of lingual surfaces of the upper anterior restorations also are flat to convex rather than concave.

The beauty of articulated diagnostic casts is that we can preview the end result of the limited treatment to determine whether it fits the parameters of acceptable form and function. It was determined in this case that equilibrating in the centric relation arc of closure gave us the needed space to restore the lower anterior teeth.

SUMMARY OF EXAMINATION AND DIAGNOSIS

Dentition

Severe wear on the lower anterior teeth
Structural and restorative concerns on most all the remaining posterior teeth but not an urgency
Inadequate endodontic therapy and periapical lesion tooth 28

Periodontium

Healthy, uneven gingival levels but not an aesthetic concern to the patient

TMJs

Right side Piper 3B

Left side Piper 3B

TMJs can be superiorly compressed comfortably.

No palpation tenderness

Range of motion within normal limits

Muscles

Lateral and medial pterygoids have slight tenderness to palpation, 2 on a scale of 5

Symptoms of muscle tightness and fatigue

Occlusion

Interferences to the ACP arc of closure with a slide to maximum intercuspation

Aesthetics

Form, contour, color, and proportions of upper anterior restorations are not ideal; however, they are acceptable to the patient.

THE 10 DECISIONS**1. TMJ Diagnosis**

Bite splint–adapted centric posture; the goal is improvement of muscles.

Definitive occlusal and restorative treatment–guided adapted centric posture

2. Vertical Dimension

Equilibrate in the adapted centric posture arc of closure until there is 2 mm of space anteriorly for the restorations. This will involve reshaping the molars and small composite additions to the bicuspid.

3. Lower Incisal Edge

Use the height of the lower cuspids as a reference for the entire incisal plane. Create definitive incisal edges with the restorations.

4. Upper Incisal Edge

No change at this time

5. Centric Stops

Simultaneous equal intensity contact with equilibration and bicuspid composite additions. The lingual surfaces of the upper anterior teeth need to be reshaped to create a definitive centric holding contact for the lower anterior incisal edges.

6. Anterior Guidance

Reshape the lingual surfaces of the upper anterior teeth to create a slightly concave performance platform

7. Curve of Spee

Idealize as much as possible with equilibration.

8. Curve of Wilson

Idealize as much as possible with equilibration.

9. Cusp/Fossa Angle

Do not deepen with equilibration.

10. Aesthetic Plane

No immediate changes are necessary.

SUMMARY OF TREATMENT PLAN**Dentition**

Porcelain crowns on mandibular anterior teeth
Maintain current dentistry for now with the plan of changing it in the future.

Endodontic retreatment mandibular right first bicuspid

Periodontium

Professional maintenance

TMJs

No treatment is needed other than correct occlusal engineering.

Muscles

Bite splint therapy followed by definitive occlusal and restorative dentistry

Occlusion

Equilibrate to a vertical dimension of occlusion that allows room to restore the lower anterior teeth. This will require small composite additions on the bicuspid

Aesthetics

Idealized form of the lower anterior teeth with the porcelain crowns
When the rest of the dentistry can be changed, idealize gingival heights and contours and idealize the aesthetics of the teeth with the new restorations.

SUMMARY OF TREATMENT SEQUENCE**Appointment****Treatment Completed**

- | | |
|---|---|
| 1 | Bite splint therapy with the goal of improving muscle physiology |
| 2 | Equilibrate to the adapted centric posture arc of closure until simultaneous contacts on molars
Small composite additions on the bicuspid to gain centric stops
Prepare the lower anterior teeth or porcelain crowns. |
| 3 | Posttreatment bite splint |
| 4 | Change remaining dentistry as patient's circumstances and objectives permit. |
| 5 | Endodontic retreatment mandibular right first bicuspid |

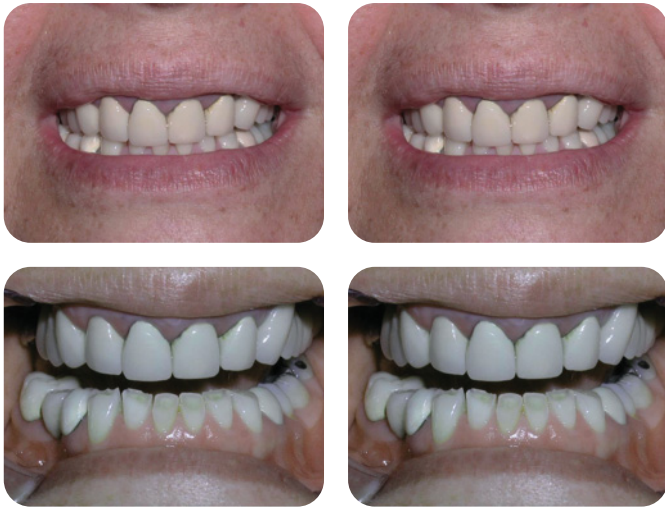

Figure 10.1.1. Preoperative retracted and smile photos suggesting the excessive wear on the lower anterior teeth.

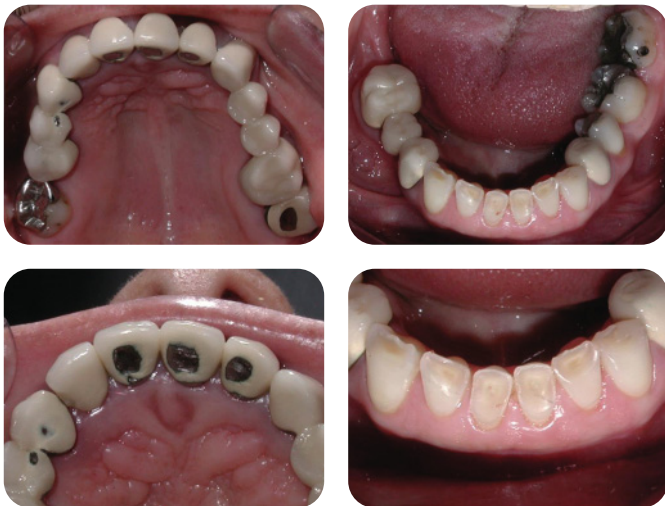

Figure 10.1.2. Preoperative occlusal photos suggesting the flat to convex surfaces on the lingual of the upper anterior teeth as a contributing factor to the wear of the lower anterior teeth.

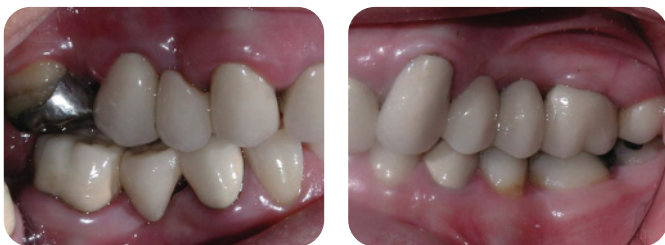

Figure 10.1.3. Preoperative buccal occluded views.

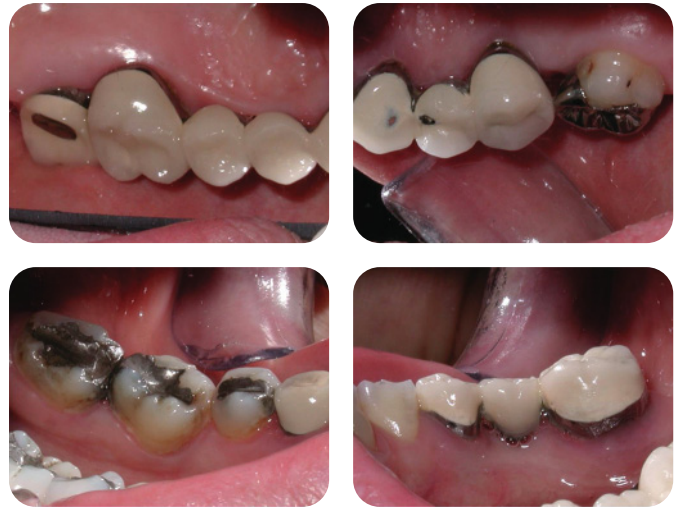

Figure 10.1.4. Preoperative lingual views suggesting a rather severe Curve of Spee. However, it can be discluded by the rather steep anterior guidance.

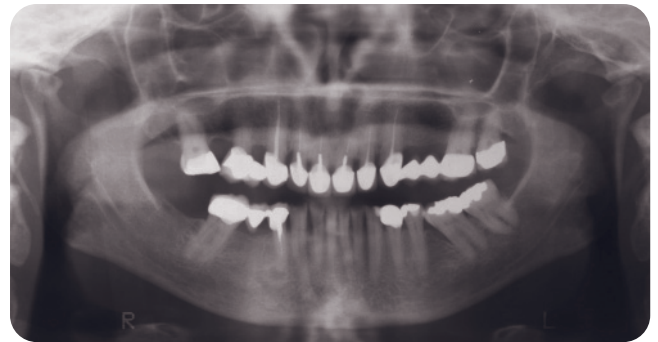


Figure 10.1.5. Preoperative panoramic radiograph. Note flattening of both condyles suggesting adapted centric posture because both joints can be superiorly compressed without any sign of tension or tenderness after bite splint therapy.

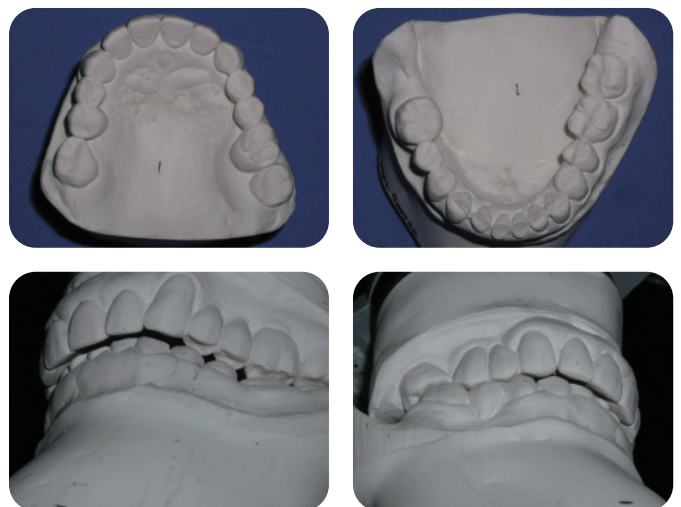


Figure 10.1.6. Preoperative articulated diagnostic casts at the first point of contact in the adapted centric posture arc of closure suggesting enough space anteriorly to restore the lower anterior teeth.

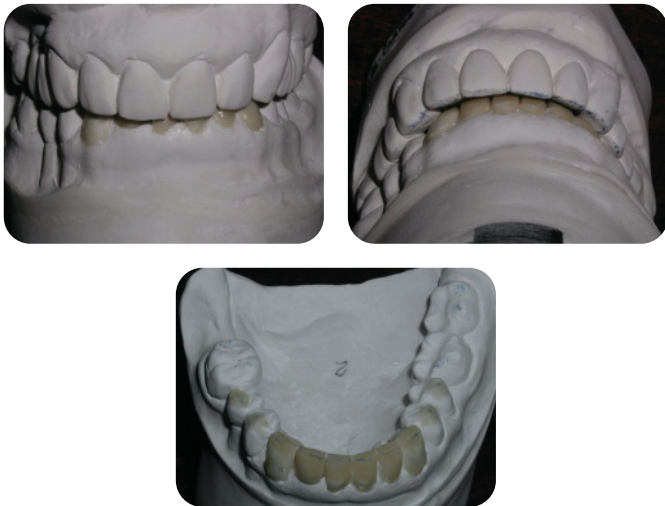

Figure 10.1.7. Diagnostic blueprint. The molars have been equilibrated to simultaneous, equal intensity contact. This left space from the bicuspid anteriorly. Composite was added to the bicuspid to gain centric stops, and the lower anterior teeth were waxed up to simulate the anticipated porcelain crowns.

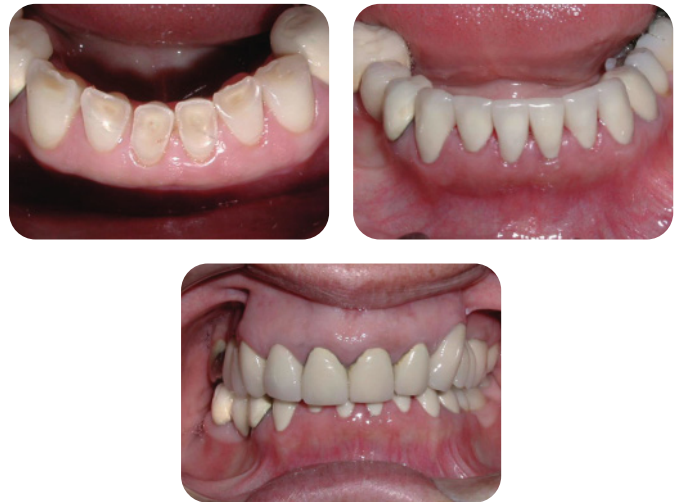

Figure 10.1.9. The final lower anterior restorations. Teeth were prepared without pulp exposure or the need for endodontic therapy because of the space gained from the equilibration in the adapted centric posture arc of closure.

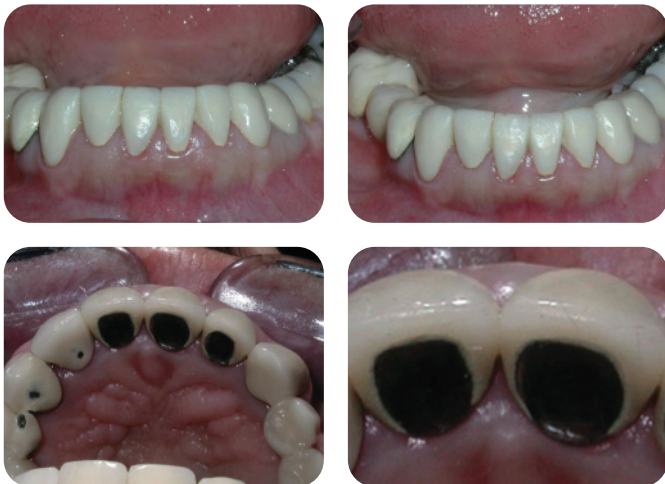

Figure 10.1.8. The lower anterior provisional restorations and the linguals of the current upper anterior dentistry recontoured to create definitive centric holding contacts for the lower anterior restorations and a slightly concave anterior guidance performance platform.

CHAPTER 10 CASE 1 KEY POINTS

- Even if the patient cannot do the entire case as needed, do some creative analysis on articulated casts to see whether the segment they want to do can be done without a compromise. If so, it can be looked at as a step along the way rather than an end point of treatment.
- With worn lower anterior teeth in deep overbite cases, carefully analyze on articulated casts mounted in CR. As the condyle seats up and back, space may be gained.
- Make sure the lingual of the upper anterior is concave with a definitive centric holding contact.

Chapter 10 Case 2

Severe wear from parafunctional habits restored with a complete reconstruction at an increased vertical dimension of occlusion

Bruxism along with other parafunctional habits can result in incredible wear and tear on the teeth. It can affect supporting structures, TMJ structures, and muscles. Controlling the habit can be difficult and restoring the effects can be challenging.

This patient had the habit of chewing on pencil erasers and continuing to rub on the grit. She has controlled the habit with appropriate counseling. The wear on the teeth has affected the aesthetics and has made chewing difficult for her. Soft tissue impingement from sharp edges results in discomfort. Interestingly, she had no tooth pain or sensitivity and no muscle or TMJ symptoms. She is ready to undertake a reconstruction project.

SUMMARY OF EXAMINATION AND DIAGNOSIS

Dentition

Severe wear on all teeth

Pulpal concerns on most teeth because of the extent of the wear; however, no pain or sensitivity at the present time

Periodontium

Healthy, no mobility

Aesthetic concerns of uneven gingival levels

TMJs

Right side Piper 2

Left side Piper 2

Both TMJs can be superiorly compressed with no sign of tension or tenderness; diagnosis is CR.

Muscles

Lateral and medial pterygoid very slight tenderness to palpation, 1 on a scale of 5

Occlusion

Interferences and a significant slide from the first contact in CR to maximum intercuspation

Aesthetics

Tooth form, proportions, contours, symmetry and gingival levels are all concerns

THE 10 DECISIONS

1. TMJ Diagnosis

Definitive restorative and occlusal treatment completed to a verifiable guided centric relation position

2. Vertical Dimension

Open to a point that all landmarks can be fulfilled, there is room for restorative materials and resistance/retention form of the tooth preparations (after crown lengthening).

3. Lower Incisal Edge

Cuspid height reference—build to ideal anatomic form and build lower incisal plane to this level creating definitive incisal edges.

4. Upper Incisal Edge

The distal incisal line angle of tooth 8 appears to be appropriate when evaluating the lip at rest. Create definitive cingulum for definitive centric holding contacts with lower incisal edges.

5. Centric Stops

Definitive centric holding contacts on all teeth with particular attention to designing anterior stable centric holding contacts

6. Anterior Guidance

Increasing the vertical dimension of occlusion will allow the anterior guidance performance platform to be shallowed.

7. Curve of Spee

Idealized with the reconstruction keeping right and left sides on the same horizontal plane

8. Curve of Wilson

Idealized with the reconstruction confirming no interferences on the upper buccal or lower lingual cusps in either the functional or parafunctional range of motion

9. Cusp/Fossa Angle

Keep shallower than the anterior guidance.

10. Aesthetic Plane

Create an upper posterior aesthetic plane that is consistent with the upper incisal edge position and with pleasing buccal profiles.

SUMMARY OF TREATMENT PLAN**Dentition**

Extract tooth 1.

Restore all teeth: fixed partial dentures to replace upper first bicuspid; empess crowns on upper and lower incisors; porcelain fused to metal crowns and all other areas

Periodontium

Crown lengthening to improve resistance and retention form and to even the gingival levels

TMJs

No treatment is needed other than correct occlusal engineering.

Muscles

No treatment is needed other than correct occlusal engineering.

Occlusion

Reconstruction at increased vertical dimension of occlusion

All occlusal parameters can be fulfilled with the reconstruction.

Deep overbite can be managed with enhanced cingulum on the lingual of the upper anterior teeth to assure stable centric holding contacts.

Aesthetics

Idealize with the reconstruction.

SUMMARY OF TREATMENT SEQUENCE**Appointment****Treatment Completed**

1	Extract tooth 1. Periodontal surgery prior to provisionalization to gain more tooth structure for correct resistance and retention form of tooth preparations Aesthetic crown lengthening upper anterior Elective endodontics on lower bicuspid because of severe super eruption
2	Provisionalize all teeth, mandibular on day 1 and maxillary the following day.
3	Monitor and maintain provisionals. Make any aesthetic and/or functional changes. Assess pulpal integrity and endodontic therapy as needed.
4	Finalize 22–27.
5	Finalize 7–10; 6 and 11 will not be finalized in this phase because these teeth will be abutments or fixed partial dentures replacing the upper first bicuspid.
6	Finalize 18–21 and 28–31.
7	Finalize 2–6 and 11–15.
8	Posttreatment bite splint as a protective device

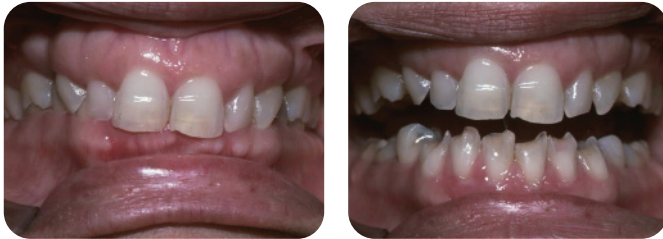
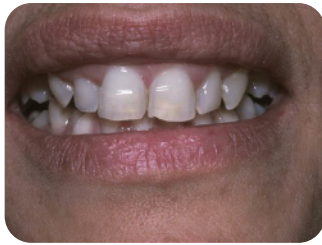
Figure 10.2.1. Preoperative smile and retracted photos suggesting the extent of the wear, the aesthetic issues, and the deep overbite impinging upon gingival tissues.

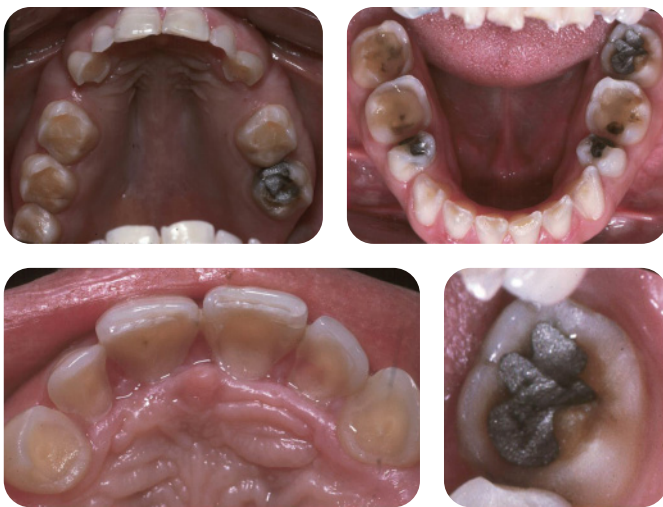

Figure 10.2.2. Preoperative occlusal photos suggesting extent of the wear and its proximity to the pulps. Note the sharp edges on the lingual of the upper anterior teeth; note also that the amalgam restoration on the lower left second molar is worn level with the surrounding tooth structure. These observations suggest wear from bruxism and parafunctional habits and not erosion from a gastrointestinal disorder.

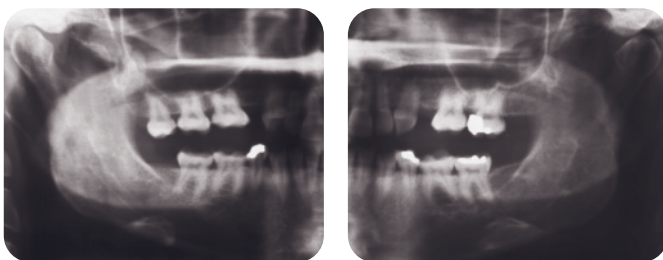


Figure 10.2.3. Preoperative panoramic radiograph suggests normal condylar anatomy. Even though the crown:root ratio seems somewhat compromised, there is no mobility present.

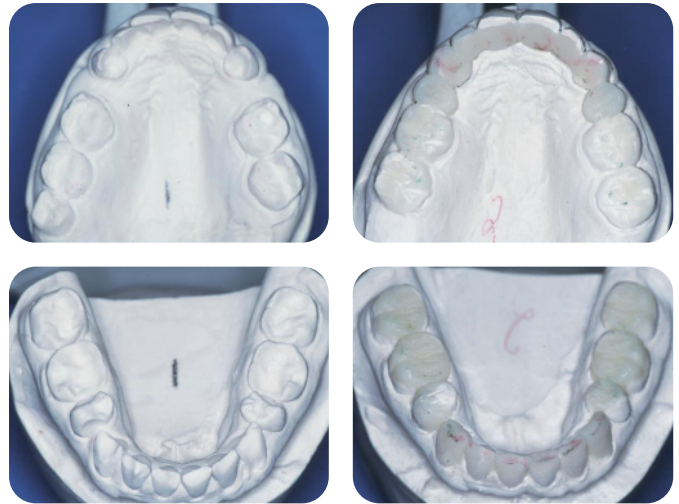


Figure 10.2.4. Preoperative articulated diagnostic casts and diagnostic wax-up. Note the definitive lower anterior incisal edges and the design of the upper anterior cingulum to obtain stable anterior centric holding contacts.

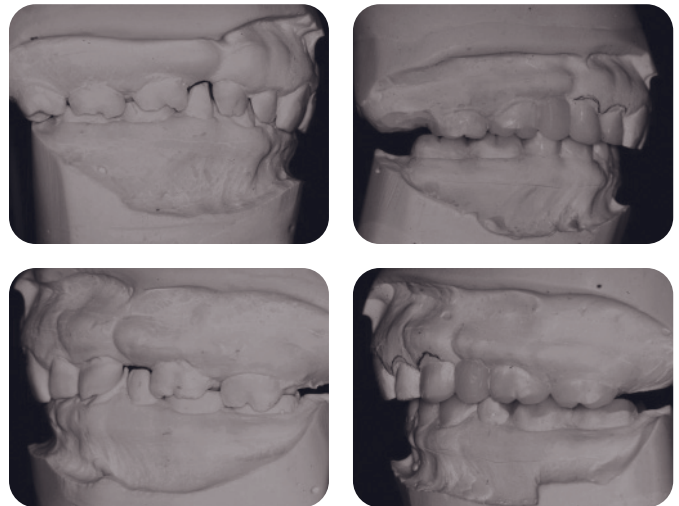


Figure 10.2.5. Buccal view of preoperative articulated diagnostic casts and diagnostic wax-up. Note the increase in the vertical dimension of occlusion. The upper anterior teeth are very vertically inclined; however, this results in an upper incisal edge position that is correct for her neutral zone.

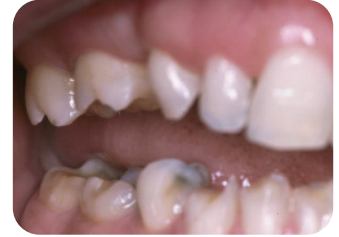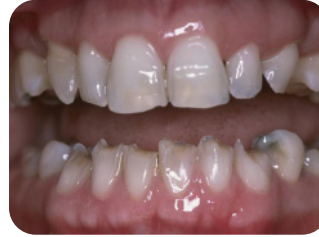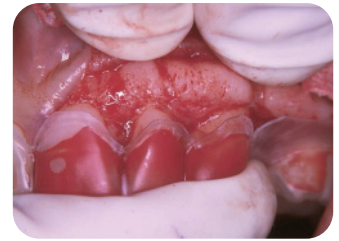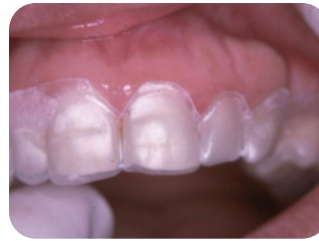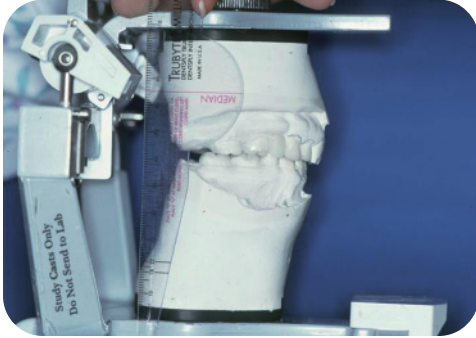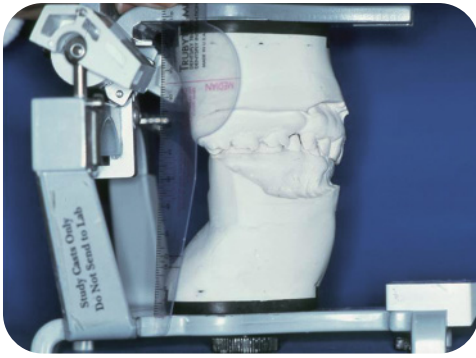


Figure 10.2.7. Prerestorative crown-lengthening surgery. The two upper photos illustrate the surgical stent used by the periodontist during crown lengthening. The surgical stent indicates the desired clinical crown length. The periodontist then assesses this position with the bone levels to determine how much bone to remove to allow for the reestablishment of the biologic width. Crown lengthening was done posteriorly to gain crown length and better resistance and retention form of the tooth preparations.

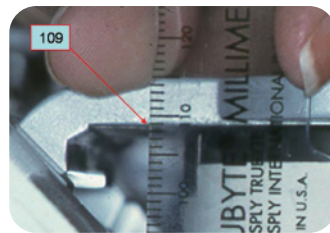
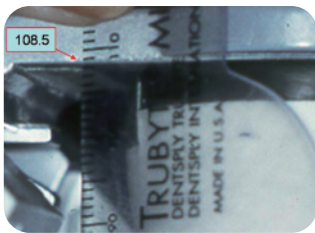

Figure 10.2.6. This photo illustrates the minimal effect that opening the vertical dimension of occlusion has on muscle length. The left pictures illustrate measuring muscle length at two fixed points on the articulator at the approximate origin and insertion points, which are between the last molars and the TMJs. This measurement prior to the diagnostic wax-up and at the vertical dimension of maximum intercuspation was 108.5mm. The measurement after the diagnostic wax-up at an increased vertical dimension of occlusion was 109mm. So even though the vertical dimension of occlusion was opened several millimeters at the location of the incisors, the effect on muscle length was minimal, only .5mm.

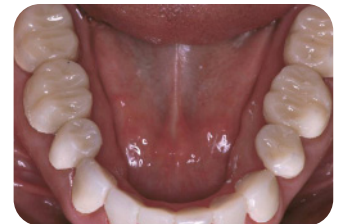
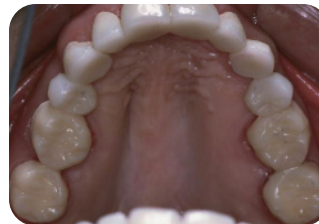
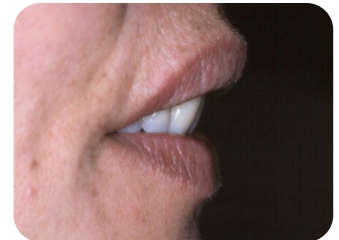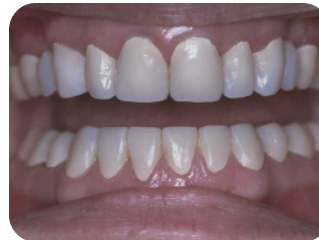Figure 10.2.8. Provisionalization completed. Note that even though the upper anterior teeth are vertically inclined, the incisal edges relate to the lower lip correctly. Both the author and the patient were fully prepared to deal with wear and tear on the provisionals based on the observations of the preoperative condition. To the surprise of both the author and the patient, wear and tear on the provisionals was not an issue.

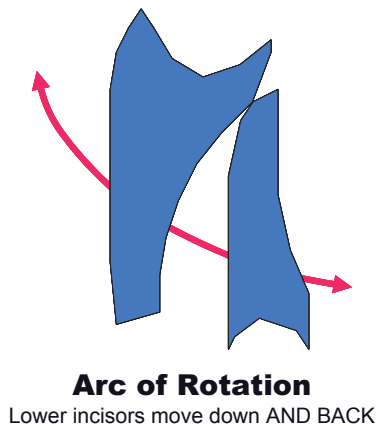


Figure 10.2.9. This figure illustrates an anterior tooth-to-tooth relationship that does not lend itself to stable centric holding contacts. The lower incisal edge is sloped rather than definitive. Two contacting sloped surfaces cannot be stable. Also note that as the vertical dimension of occlusion is increased, the lower incisal edge not only moves down but also back, making it potentially more difficult to gain a stable centric holding contact.

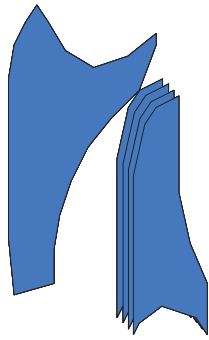


Figure 10.2.10. This figure illustrates the down and back movement of the lower incisors as the vertical dimension of occlusion is opened and its resultant relationship to the upper anterior teeth.

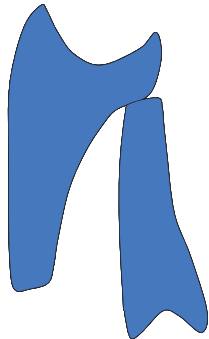


Figure 10.2.11. This figure illustrates the desired design of the anterior tooth-to-tooth relationship in deep overbite situations. Note the definitive lower incisal edge and the enhanced cingulum of the upper anteriors. This creates definitive centric holding contacts, which will prevent the continued super eruption of the anterior teeth.

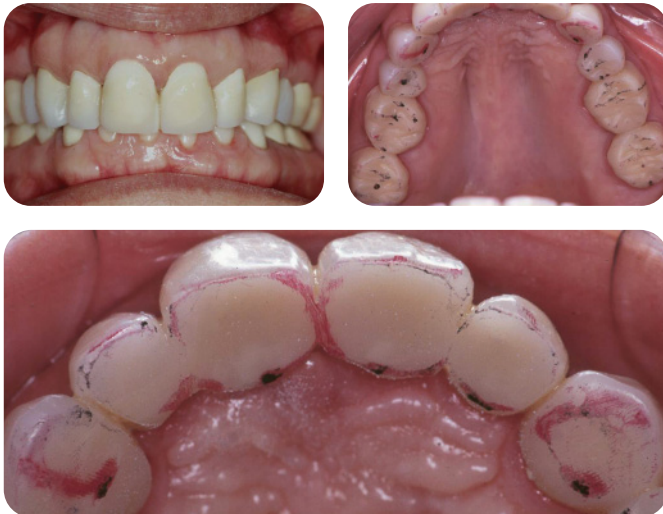

Figure 10.2.12. Note the enhanced cingulum on the lingual of the upper anterior teeth, which provides a definitive centric holding contact for the lower incisal edges. The axial contours gingival to this cingulum are physiologically cleanable. If this design was not possible with the restorative dentistry, which was previewed with the diagnostic wax-up, orthodontics would have been necessary to move the teeth into positions such that stable anterior centric holding contacts were possible.

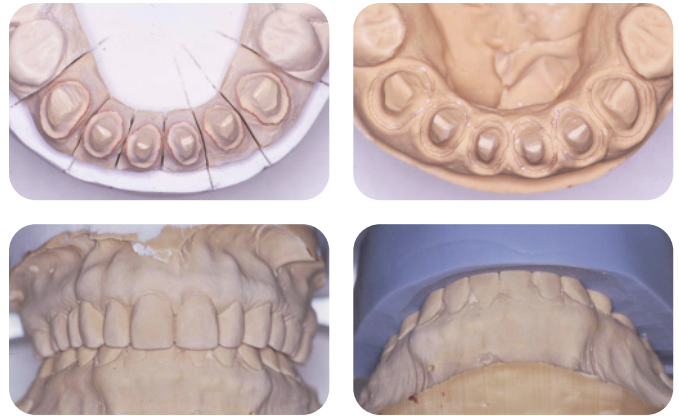


Figure 10.2.13. The lower anterior teeth are completed first. This photo illustrates the communication to the laboratory technician that is necessary for predictable results. The upper left photo illustrates the pinned dies. The upper right photo illustrates the solid cast for interproximal contacts refinement and for soft tissue. The lower left picture shows articulated casts of the verified provisionals. This gives the technician a 3D picture of the desired result. The lower right picture illustrates a putty index, which captures the lower incisal edge position of the verified provisionals.

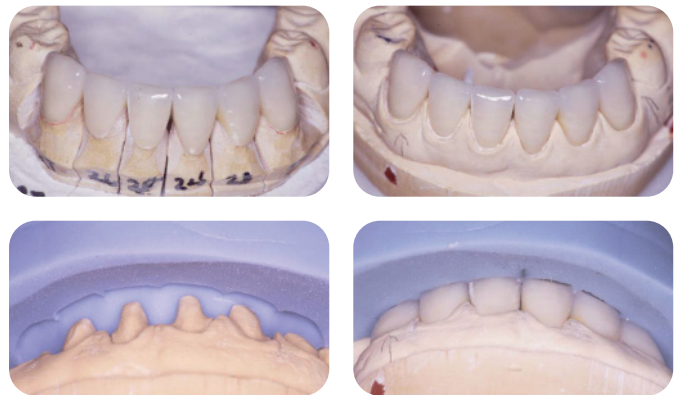


Figure 10.2.14. This figure illustrates the verification of the restorations on both the pinned cast and the solid cast. The bottom left picture illustrates the putty index seated on the solid cast, which is the technician communication for the lower incisal edge position. The lower right picture shows the verification of the lower incisal edge as it seats into the putty index.

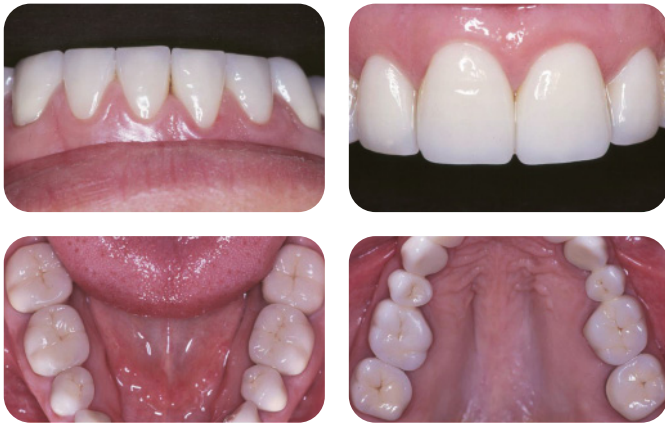

Figure 10.2.15. The upper left photo illustrates the completed lower anteriors. The upper right illustrates the completion of the next phase, the upper incisors. The lower left illustrates the completion of the third phase, the lower posteriors. The lower right photo illustrates the completion of the fourth phase, the upper posteriors along with the upper cuspids which were fixed partial denture abutments for the missing bicuspid pontics.

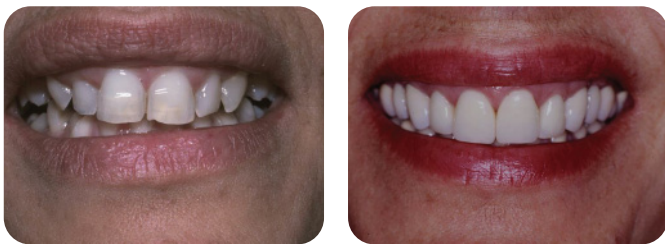

Figure 10.2.16. Pre- and posttreatment smile photos.

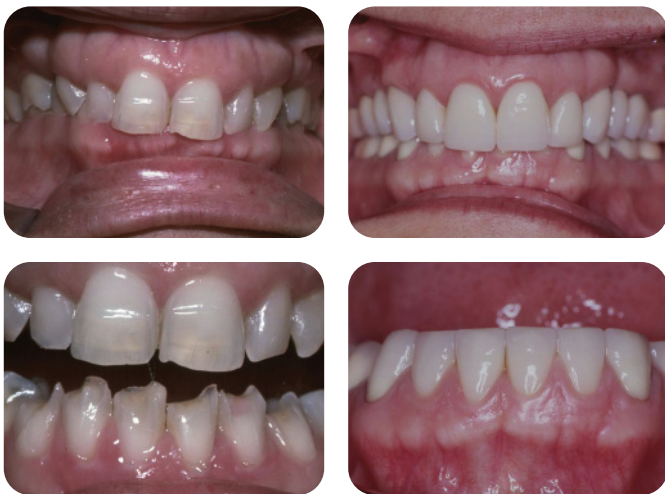

Figure 10.2.17. Pre- and posttreatment retracted photos.

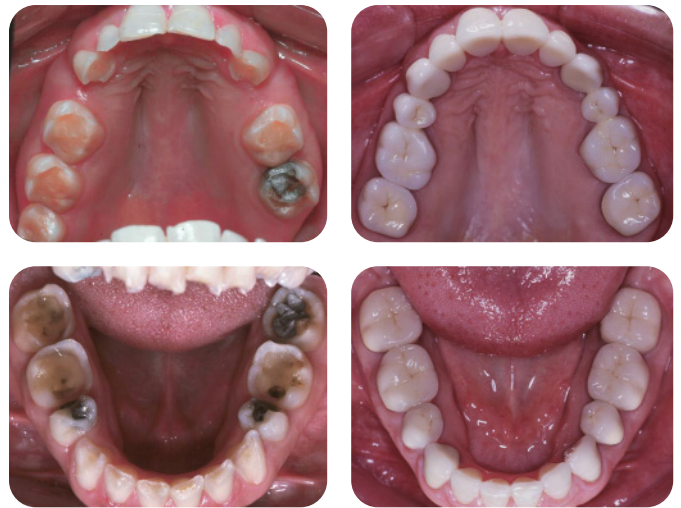

Figure 10.2.18. Pre- and posttreatment occlusal photos.

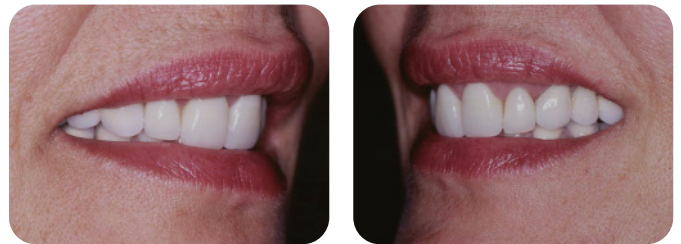

Figure 10.2.19. Posttreatment photos showing relationship of the upper incisal edges to the lower lip.

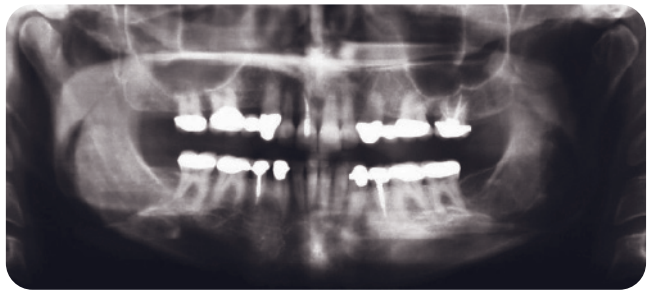
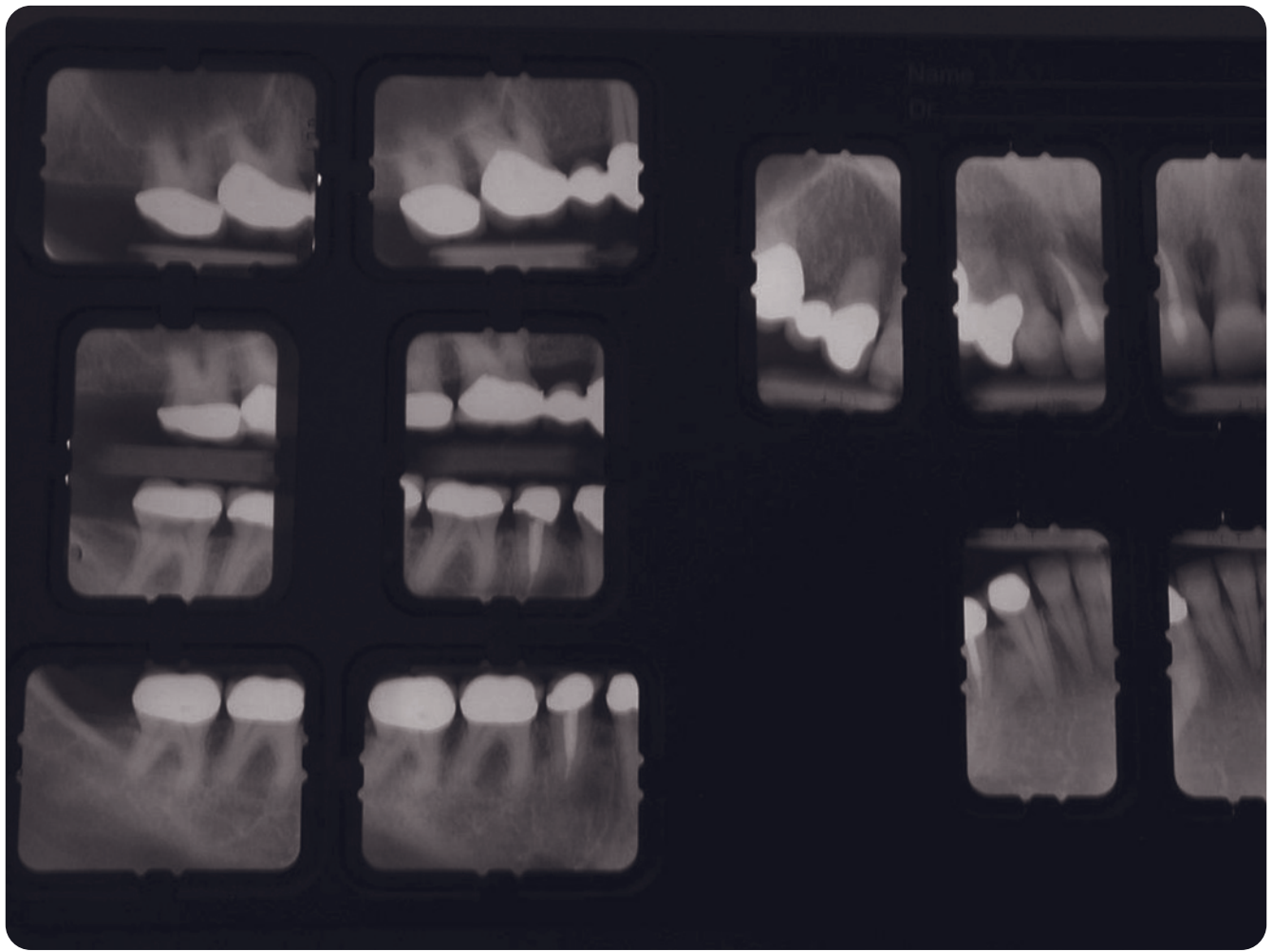
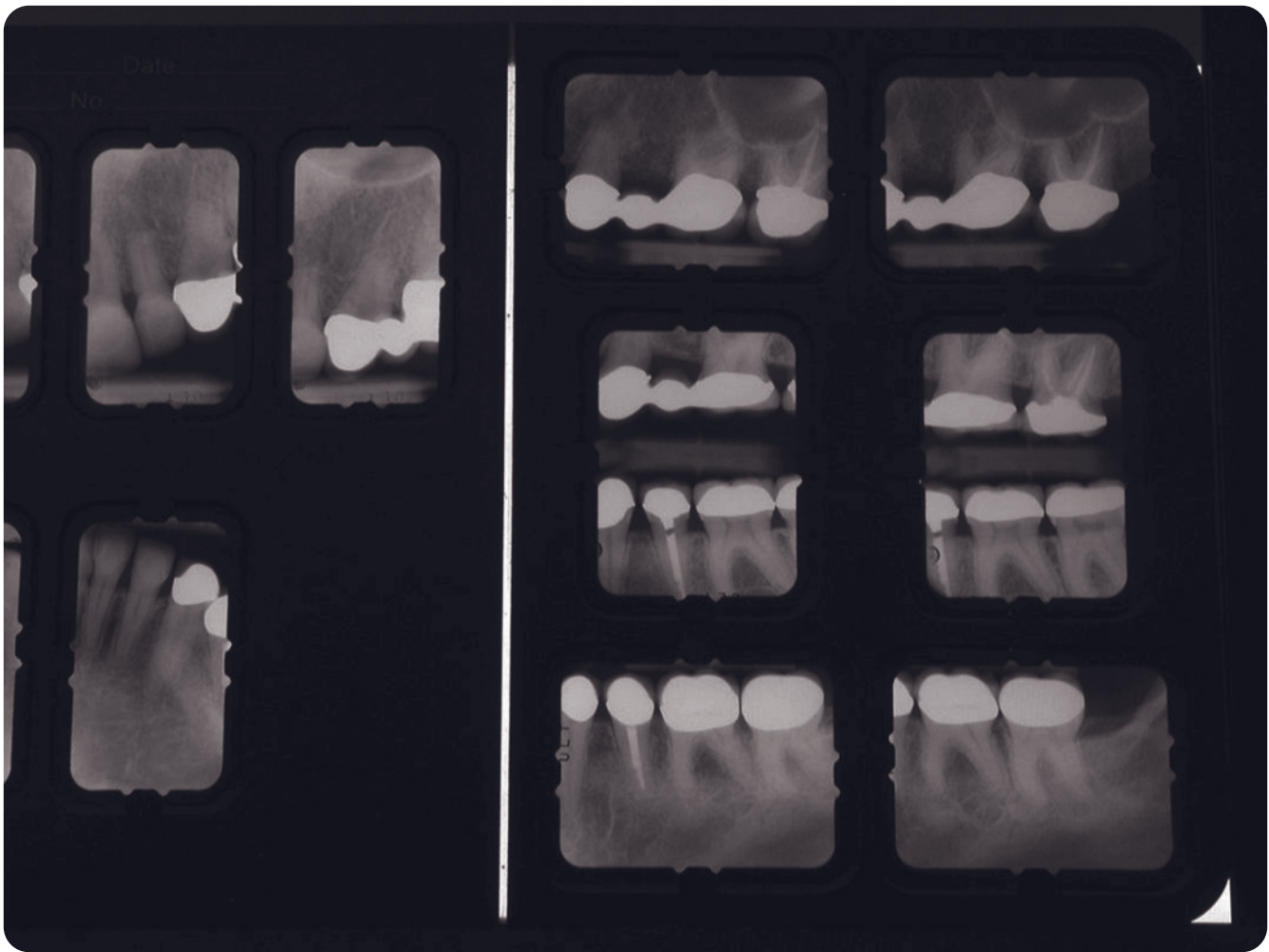


Figure 10.2.20. Posttreatment panoramic radiograph. Elective endodontics was done on the lower bicuspid. Endodontics was necessary during provisionalization on 8 and 15 because of irreversible pulpitis.



Figures 10.2.21 and 10.2.22. Posttreatment full mouth series 10 years after completion.



Figures 10.2.21 and 10.2.22. *Continued*

CHAPTER 10 CASE 2 KEY POINTS

- Investigate etiology of wear, erosion, and abrasion. Wear facets that match up and that have sharp angles are most likely from bruxism and not erosion.
- Analyze opening of the vertical dimension of occlusion at the level of the muscle attachments.
- When opening the vertical dimension of occlusion, be aware that the lower incisal edges go back as well as down, making centric stops more difficult.

11

Perioprosthesis

Case 1 Full maxillary periodontal-restorative reconstruction improving aesthetics and function; lower posterior reconstruction following conventional surgery, bone and soft tissue grafts, covering recession

Case 2 Posterior reconstruction in conjunction with conventional periodontal surgery; root resection, pocket elimination

Chapter 11 Case 1

Full maxillary periodontal-restorative reconstruction improving aesthetics and function; lower posterior reconstruction following conventional surgery, bone and soft tissue grafts, covering recession

Although dental implants can be a wonderful treatment option, not every patient is willing to go through the procedures that it takes to make dental implants a reality. In these cases we need to carefully evaluate the prognosis of each individual tooth that we hope to keep and choose the appropriate “traditional” treatment option that will enhance that prognosis. The patient in this case study had previous dentistry whose periodontal support was failing. Interferences to the centric relation arc of closure as well as excursive interferences were contributing factors.

SUMMARY OF EXAMINATION AND DIAGNOSIS

Dentition

Teeth 2 and 12 and mesial root of 19 are hopeless periodontally. All of the teeth are treatable.

Periodontium

Recession upper anterior and severe resorption edentulous area upper right

TMJs

Right side Piper 2

Left side Piper 2

Both TMJs can be superiorly compressed comfortably.

Muscles

Lateral and medial pterygoid slight tenderness to palpation, 1 on a scale of 5

Occlusion

Interferences to the centric relation arc of closure as well as excursive interferences, a major contributing factor in the periodontal bone loss of 2 and 12

Aesthetics

Alignment, proportions, and contours need to be changed as well as recession and resorption of the ridge.

THE 10 DECISIONS

1. TMJ Diagnosis

Treat to a guided, verifiable centric relation.

2. Vertical Dimension

Decrease slightly to improve crown:root ratio.

3. Lower Incisal Edge

Shorten slightly with recontouring, reshaping, and polishing.

4. Upper Incisal Edge

Use the incisal edge position of 9 as a reference for the upper incisal plane. “Straighten” upper anterior teeth with restorative dentistry.

5. Centric Stops

Simultaneous equal intensity contacts on all teeth in the centric relation arc of closure

6. Anterior Guidance

Increase steepness of anterior guidance slightly as a result of slight closure of the vertical dimension of occlusion and slight increase in the anterior overbite relationship.

7. Curve of Spee

Shallower and flatter in the area of the lower second molars

8. Curve of Wilson

Verify that upper buccal and lower lingual cusps do not interfere in the functional or parafunctional range of motion.

9. Cusp/Fossa Angle

Shallower than the angle of the anterior guidance platform

10. Aesthetic Plane

Verify that the aesthetic plane of the upper buccal cusps is level and symmetrical and that the facial profiles of the upper posterior teeth are aligned correctly.

SUMMARY OF TREATMENT PLAN

Dentition

Remove 2, 12, and mesial root of 19. Upper restorative reconstruction. Lower fixed partial dentures to replace missing 19 and 30.

Periodontium

Bone and soft tissue grafting to enhance ridge upper anterior
 Grafts to cover the recession upper anterior
 Root resection upper left first molar

TMJs

No treatment is needed other than correct occlusal engineering.

Muscles

No treatment is needed other than correct occlusal engineering.

Occlusion

Fulfill all requirements of a physiologic occlusion in the reconstruction.

Aesthetics

Idealize alignment, contours, and proportions in the restorative dentistry. Use above periodontal procedures to enhance tissue aesthetics.

SUMMARY OF TREATMENT SEQUENCE

Appointment	Treatment Completed
1	Provisionalize maxillary arch. Keep margins short of tissue for grafting.
2	Periodontist to remove 2, 12, mesial root 19 Bone/soft tissue graft upper edentulous ridge Soft tissue graft upper anterior Distobuccal root resection 14
3	New provisionals
4	Finalize upper.
5	Finalize lower.

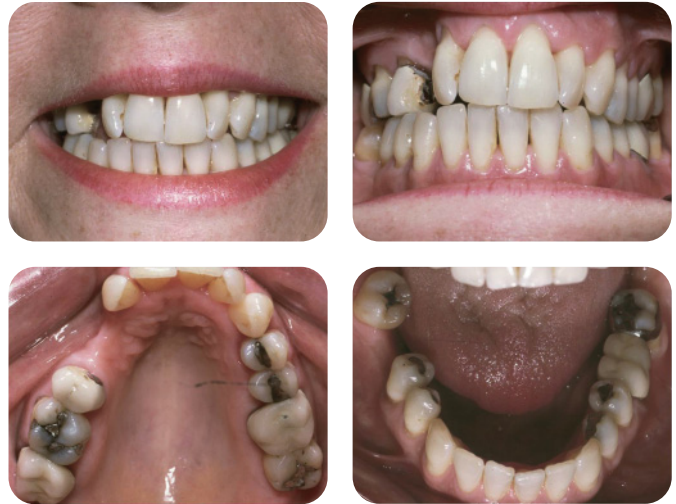

Figure 11.1.1. Pretreatment photographs illustrating malalignment of the teeth, recession of the upper anteriors, and resorption of the edentulous ridge in the upper right.

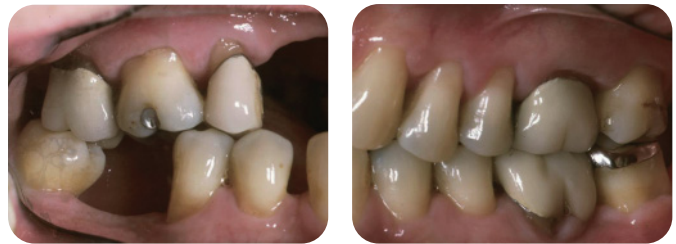

Figure 11.1.2. Pretreatment buccal occluded photographs. Note the occlusal relationships, in particular teeth 2 and 12, and visualize how the excursive interferences on these teeth were a contributing factor in their periodontal condition.

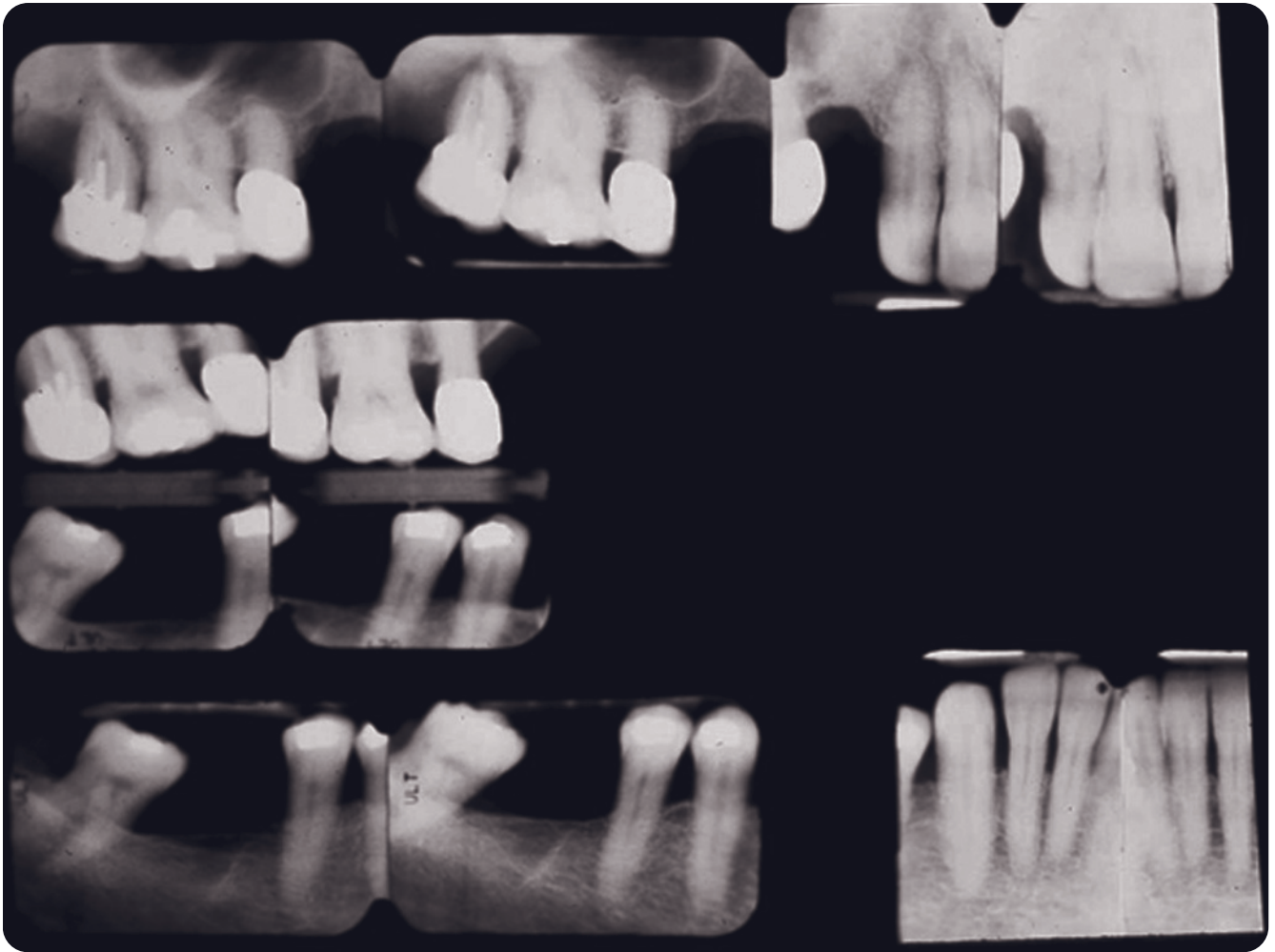


Figure 11.1.3. Pretreatment radiographs, right side. Note the extensive bone loss on tooth 2.

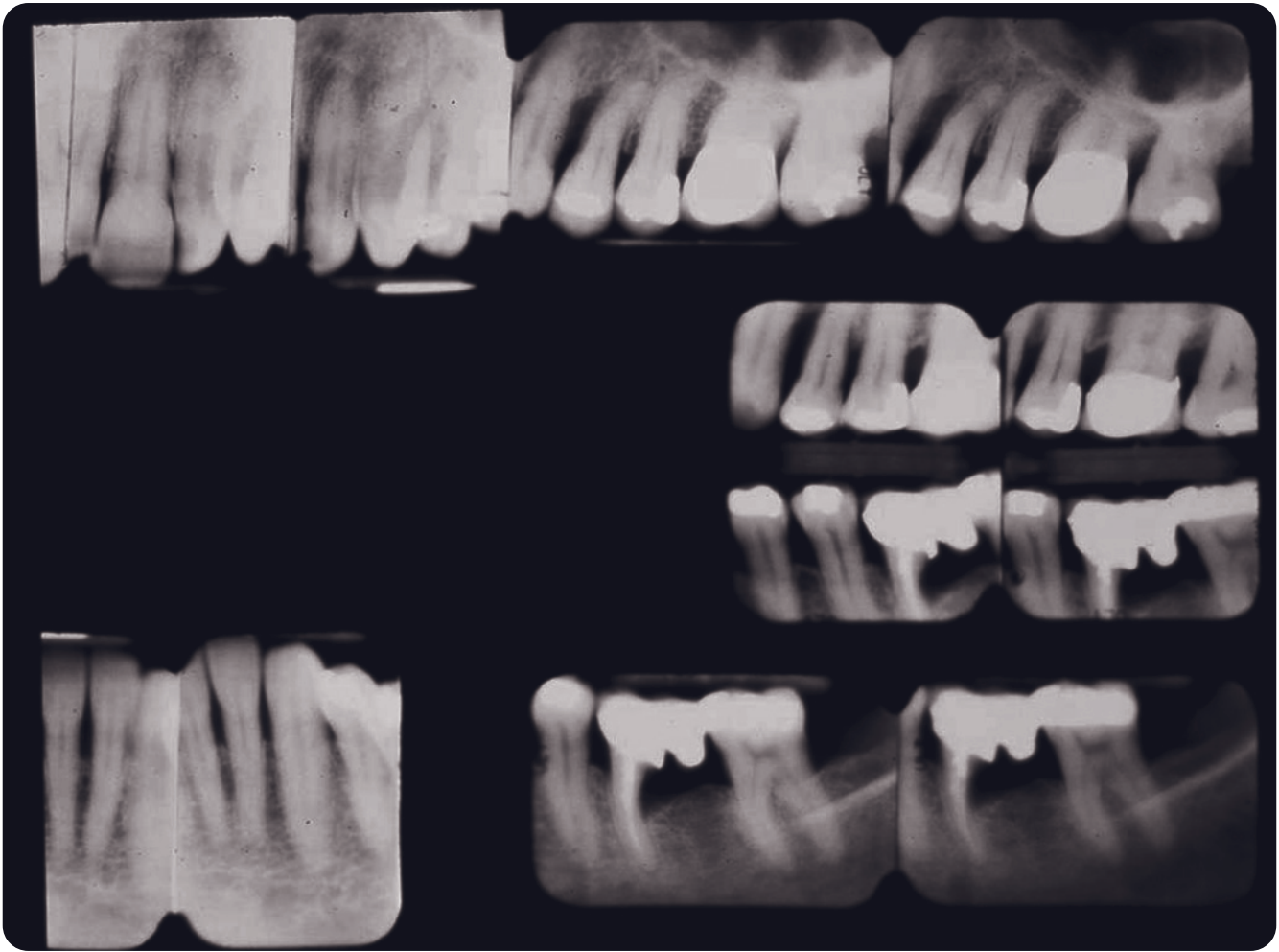


Figure 11.1.4. Pretreatment radiographs, left side. Note the extensive bone loss on tooth 12.

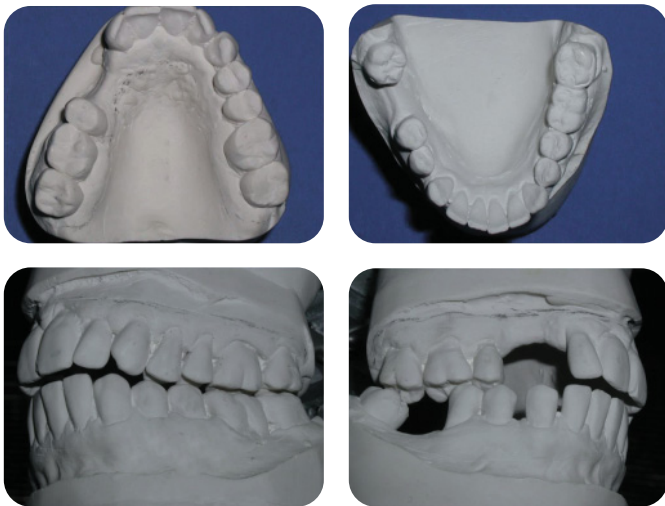


Figure 11.1.5. Pretreatment articulated diagnostic casts. Note that the interferences in the centric relation arc of closure are the second molars. Visualize how these interferences in addition to the excursive interferences were a contributing factor to the periodontal condition.

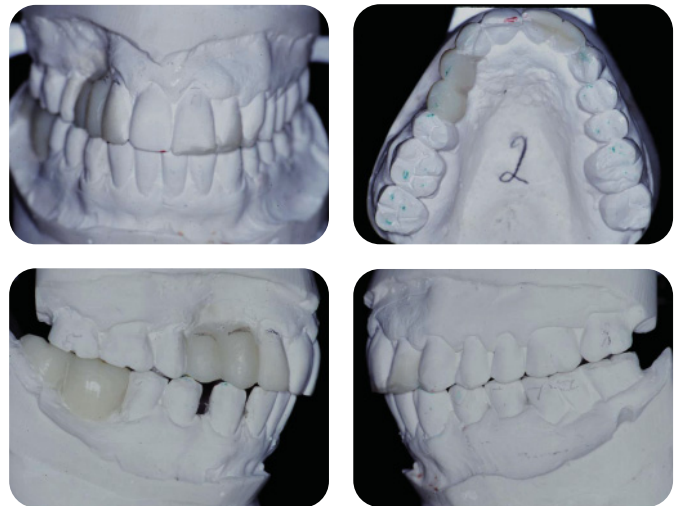


Figure 11.1.6. Diagnostic blueprint. Note resorption in the edentulous areas of 5 and 6. Anterior tooth-to-tooth relationship and anterior guidance have been improved.

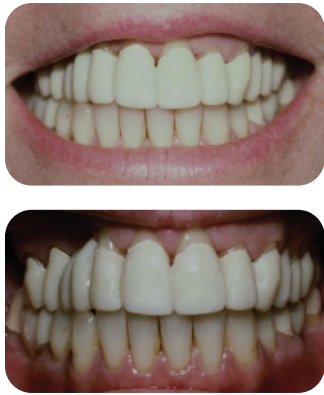

Figure 11.1.7. First set of provisionals with finish lines well short of the gingival tissues, giving a periodontist room to graft the receded areas.

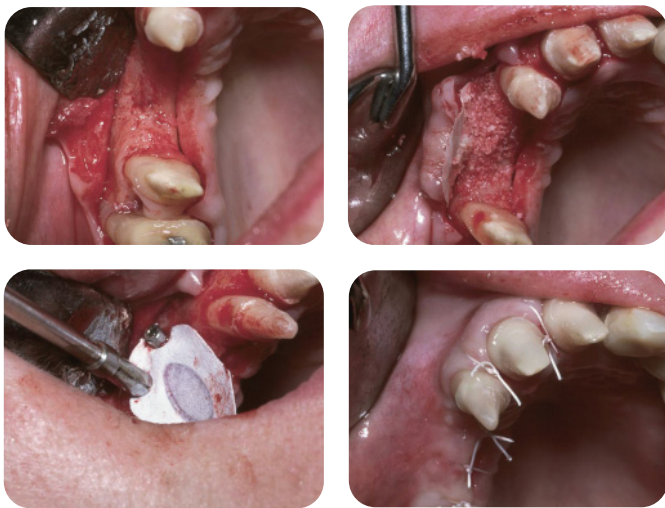

Figure 11.1.8. Photos taken at the periodontist's office illustrating the bone graft of the resorbed ridge upper right. At a subsequent procedure after healing of the bone graft, the soft tissue grafting will be done.

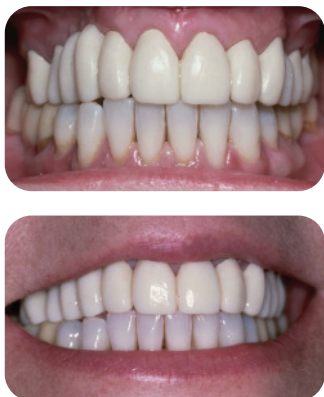

Figure 11.1.9. Second maxillary provisional done after healing of all surgical procedures.

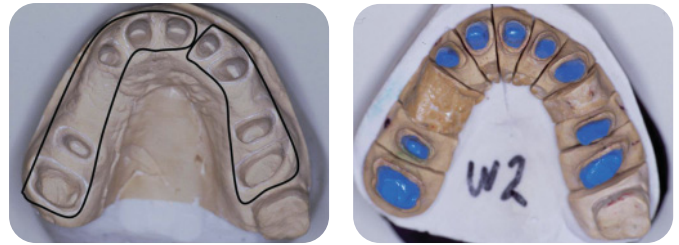

Figure 11.1.10. Photos of the solid cast and in die cast sent to the technician. The definitive restoration will be a fixed partial denture from teeth 3–9 and a fixed partial denture from teeth 10–14. It was not necessary to do a full arch splint.

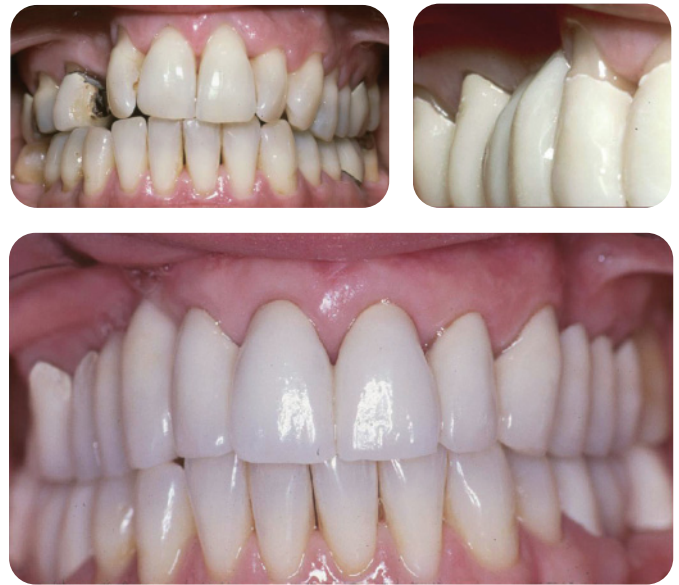

Figure 11.1.11. Photos showing ridge resorption from pretreatment to first provisional to the definitive restoration. Note the improved symmetry of the gingival tissues from pontics 6–11.

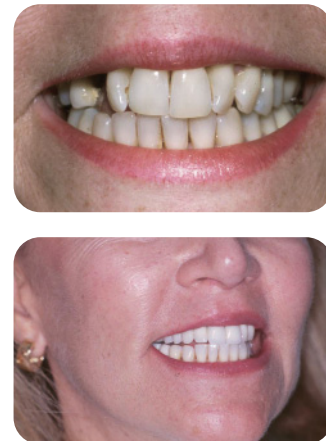

Figure 11.1.12. Before and after smile photos.

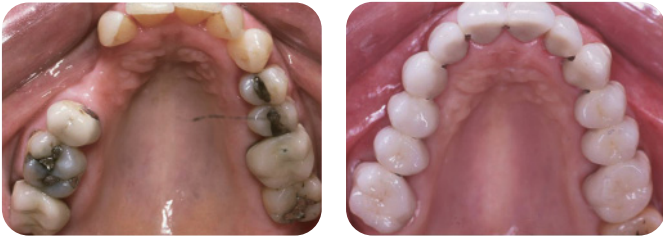

Figure 11.1.13. Before and after maxillary occlusal photos.

CHAPTER 11 CASE 1 KEY POINTS

- Even with the success of implants, a traditional periorestorative approach can be an excellent solution.
- Splint the minimal number of teeth to minimize future restorative problems yet manage mobility effectively.

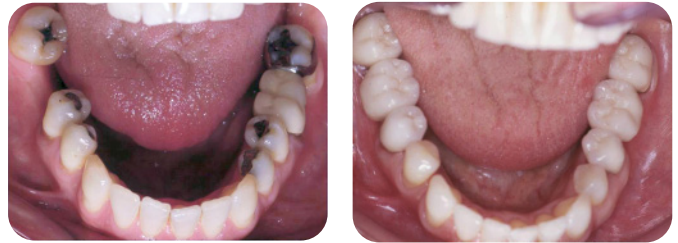

Figure 11.1.14. Before and after mandibular occlusal photos.

Chapter 11 Case 2

Posterior reconstruction in conjunction with conventional periodontal surgery; root resection, pocket elimination

This case study is another example of saving teeth with periodontal surgery and restorative procedures. There are many patients who do not want to lose their teeth and would like to avoid implants for a variety of reasons. One can make a good argument for keeping the teeth; another could make a good argument for extracting the teeth and placing implants. We must use good clinical judgment after examination and diagnosis and get the patient involved in the decision-making process.

SUMMARY OF EXAMINATION AND DIAGNOSIS

Dentition

Posterior teeth are in need of restorations; anterior teeth are structurally sound.

Periodontium

Moderate to advanced periodontal disease posteriorly.

TMJs

Right side Piper 3B

Left side Piper 3B

Both can be superiorly compressed without discomfort.

Muscles

Lateral pterygoids are very slightly tender to palpation.

Occlusion

Slight (.5mm) slide from first point of contact in adapted centric posture to maximum intercuspation

Aesthetics

Acceptable

THE 10 DECISIONS

1. TMJ Diagnosis

Treat to a guided, verifiable adapted centric posture.

2. Vertical Dimension

Acceptable; no need to change.

3. Lower Incisal Edge

Higher than the posterior occlusal plane, but acceptable aesthetically and functionally

4. Upper Incisal Edge

Acceptable; no need to change.

5. Centric Stops

Anterior teeth will have natural tooth-to-tooth centric stops.

Posterior restorations will have simultaneous, equal intensity, nonincline contact in the adapted centric posture arc of closure.

6. Anterior Guidance

Current anterior guidance is acceptable; just smooth, refine, and polish.

7. Curve of Spee

Relatively shallow and flat

8. Curve of Wilson

Verify that the upper buccal and lower lingual cusps do not interfere in the functional and parafunctional range of motion.

9. Cusp/Fossa Angle

Relatively shallow and flat due to periodontal condition

10. Aesthetic Plane

Verify that upper buccal cusps and facial profiles follow an acceptable aesthetic plane.

SUMMARY OF TREATMENT PLAN

Dentition

Posterior reconstruction

Periodontium

Remove 3, periodontal surgery all quadrants

TMJs

No treatment is needed other than correct occlusal engineering.

Muscles

No treatment is needed other than correct occlusal engineering.

Occlusion

Equilibrate anterior teeth; refine anterior guidance.

Build restorations in harmony with ACP.

Aesthetics

Porcelain restorations

SUMMARY OF TREATMENT SEQUENCE

Appointment	Treatment Completed
1	Provisionalize UL and LL; equilibrate remaining dentition.
2	Periodontal surgery UL and LL
3	Healing
4	Reprep, reline provisionals, impressions
5	Place definitive restorations.
6	Provisionalize UR and LR.
7	Periodontal surgery UR and LR; remove 3.
8	Healing
9	Reprep, reline provisionals, impressions.
10	Place definitive restorations.

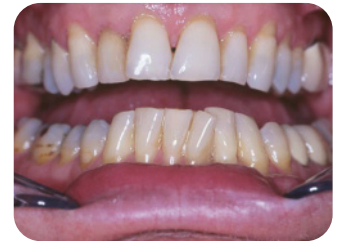
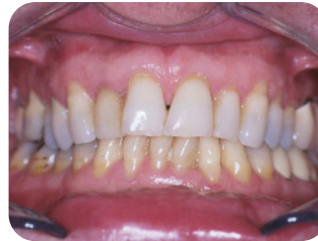
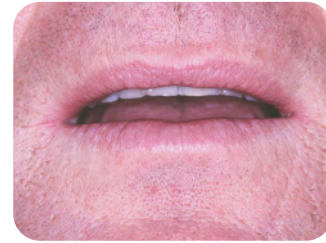Figure 11.2.1. Pretreatment photographs of the smile with lip at rest and retracted anterior views. Upper incisal edge display with lip at rest is acceptable. Anterior teeth show slight wear, but no treatment is needed other than shaping and polishing.

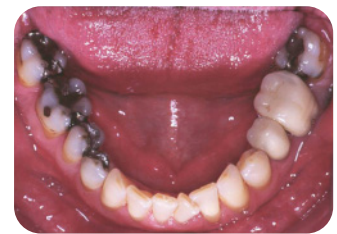
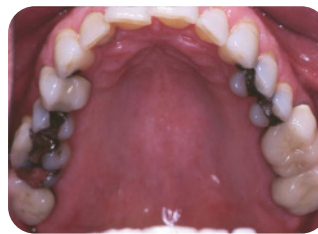
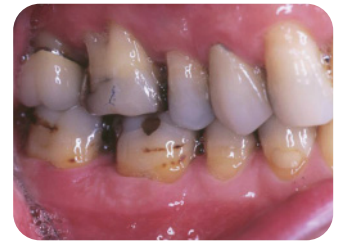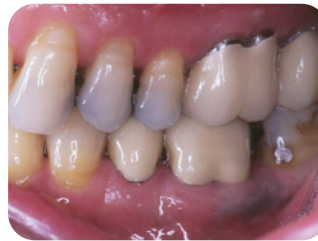Figure 11.2.2. Pretreatment buccal occluded photos and maxillary and mandibular occlusal photo suggesting the poor structural condition of the posterior teeth.

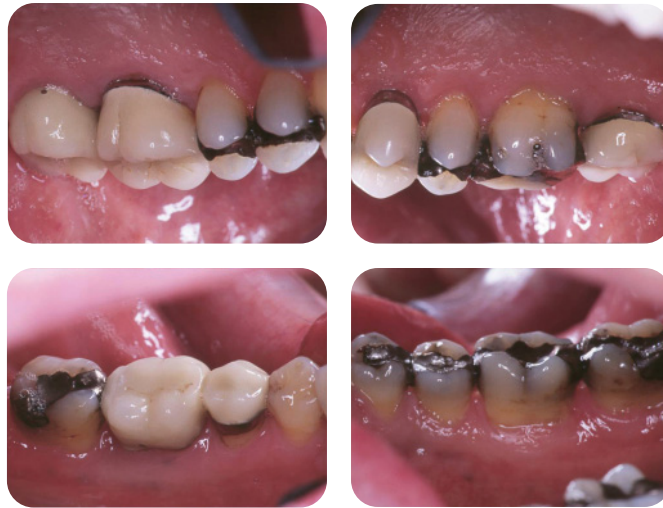

Figure 11.2.3. Pretreatment lingual photos. Although there is some recession, the superficial gingival tissues appear fairly healthy; but this is not an indicator of the underlying bone.

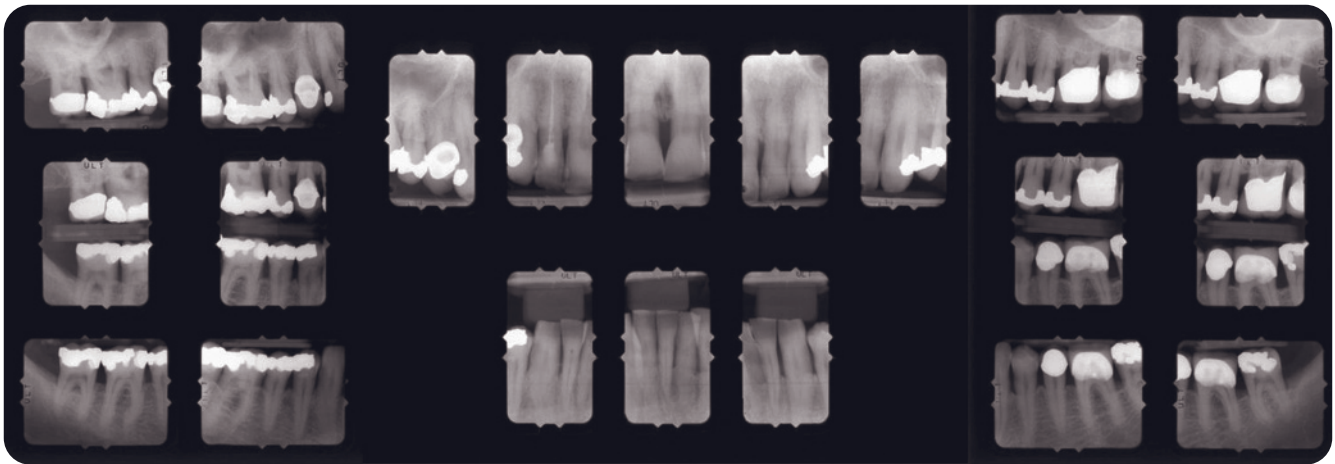


Figure 11.2.4. Pretreatment full mouth radiographic series suggesting structural condition of the posterior teeth and the poor condition of the supporting osseous structures.

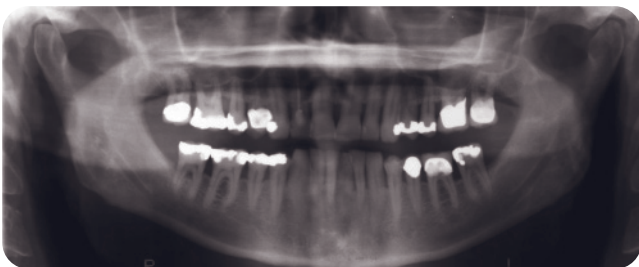


Figure 11.2.5. Pretreatment panoramic radiograph. Surprisingly there is very little, if any, mobility on any of the teeth.

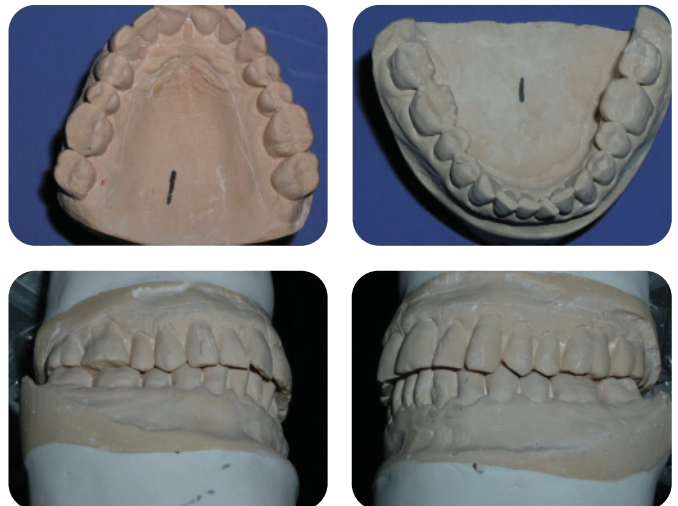

Figure 11.2.6. Pretreatment articulated diagnostic casts.

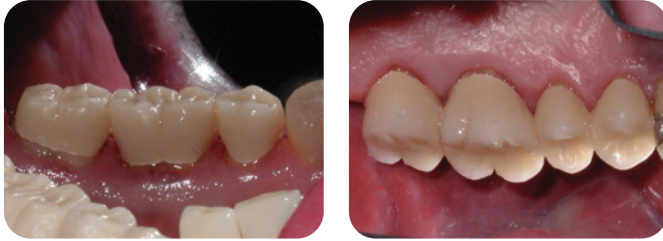
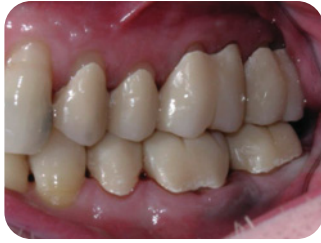
Figure 11.2.7. Initial provisionalization of the upper and lower left posterior quadrants.

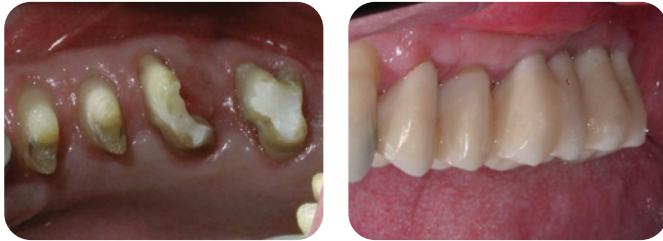

Figure 11.2.8. Healing of the periodontal surgery of the upper left quadrant which included a distobuccal root resection on tooth 14. The right photo illustrates the relined provisionals after the teeth had been prepared again to follow the new periodontal architecture. The same was done on the lower left quadrant.

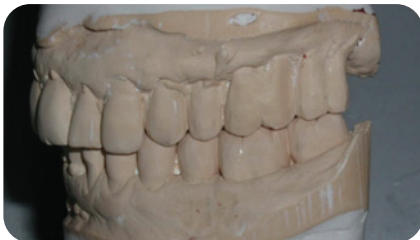
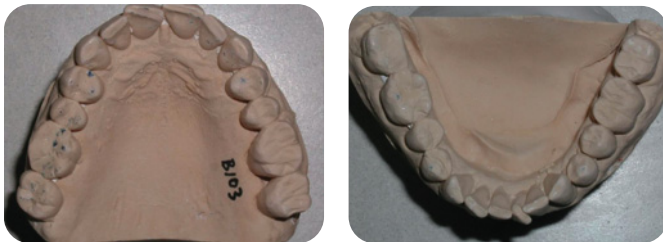
Figure 11.2.9. Photos of the articulated diagnostic casts of the provisional restorations as a communication to the laboratory technician.

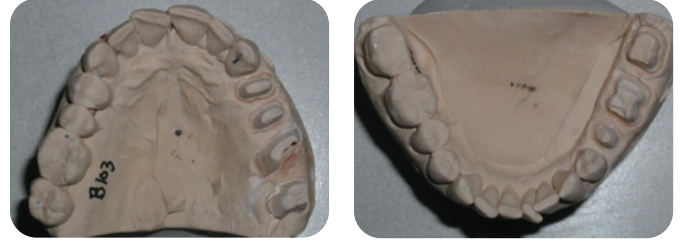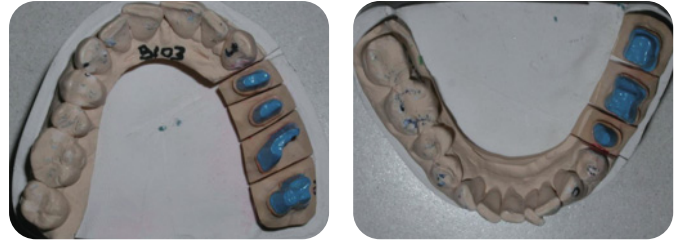


Figure 11.2.10. Photos of the articulated pinned die cast and solid cast. The solid cast serves as a soft tissue cast as well as a verification of interproximal contacts.

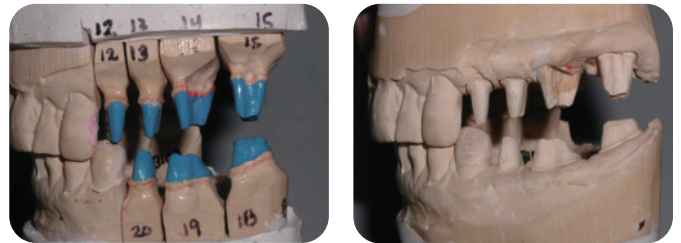
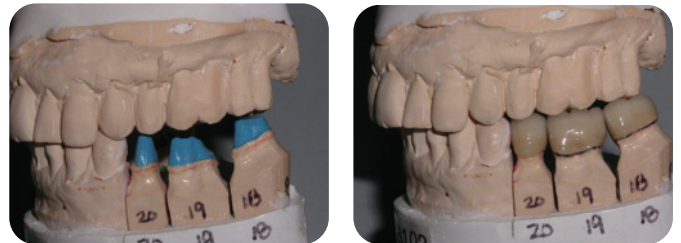


Figure 11.2.11. Since the casts of the provisionals are mounted along with the casts of the dies, the technician will fabricate the lower restorations first against the upper cast of the provisionals, thereby incorporating the correct functional landmarks. When upper and lower opposing dies are sent to the technician precise communication such as this is essential so that the correct functional landmarks are built into the restorations.

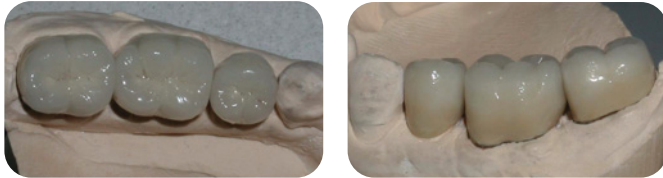
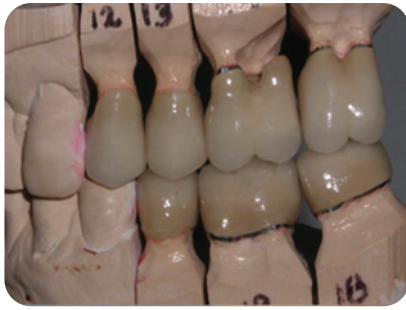
Figure 11.2.12. Photos of completed restoration on the die casts as well as the solid casts.

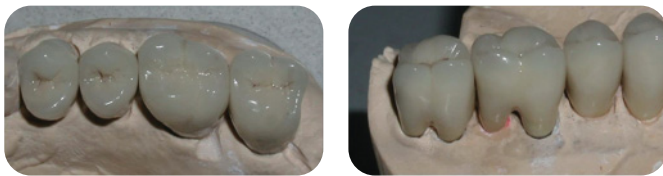
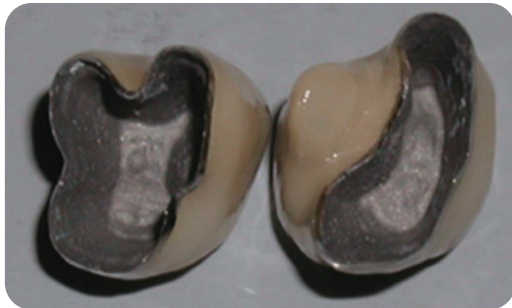

Figure 11.2.13. The margins of the restorations must carefully follow the finish lines of the preparations, and the axial contours must be barreled into the concavities of the furcations to create a cleanable environment. The distobuccal root of the upper left first molar is now a pontic. A cleanable area from the midbuccal to the distolingual must be created.

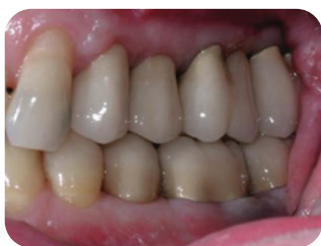

Figure 11.2.14. Photos of the definitive restorations upper left and lower left.

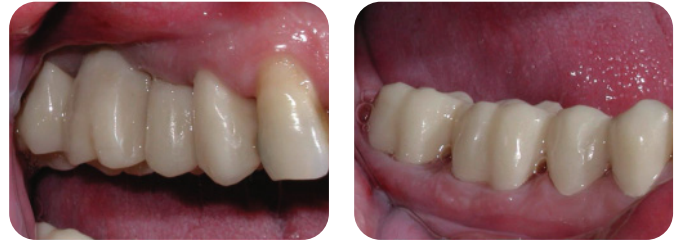
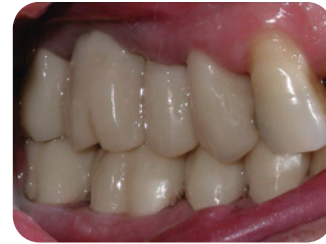
Figure 11.2.15. The same process was completed on the right side. These photos are of the relined provisionals after healing of the surgery. The upper right first molar was extracted.

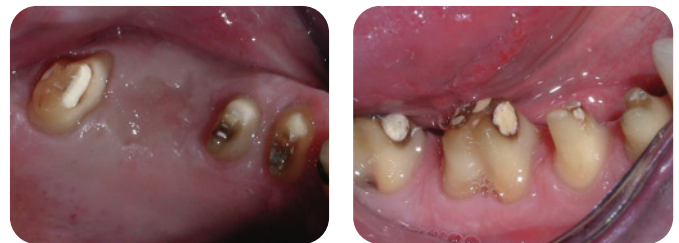
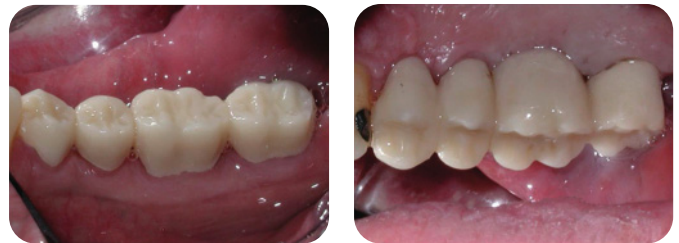

Figure 11.2.16. Lingual photos of the relined provisionals and refined tooth preparations. Note how the finish lines of the tooth preparations follow the axial contours of the tooth in the furcal areas.

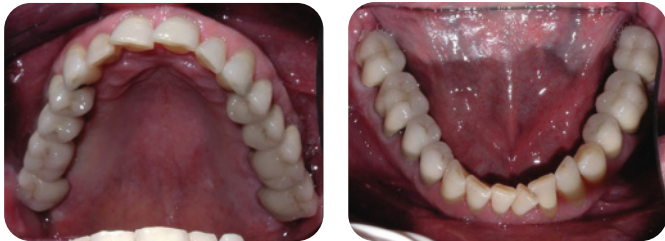
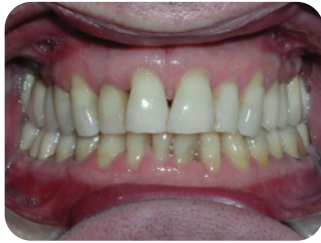

Figure 11.2.17. Anterior retracted photos as well as maxillary and mandibular occlusal photos of the completed dentistry.

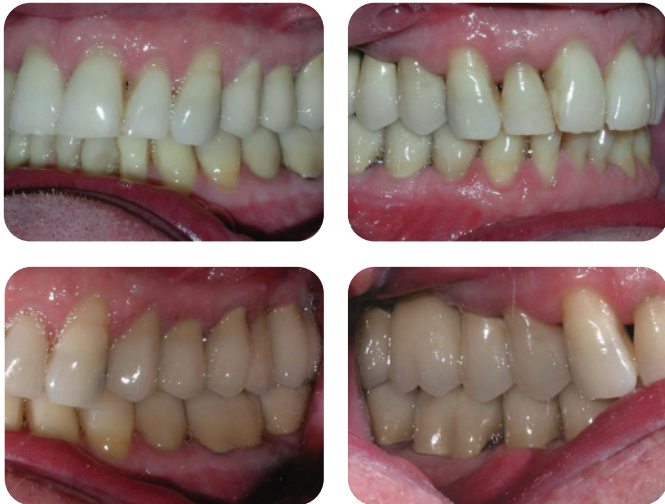

Figure 11.2.18. Right and left buccal views of the completed dentistry.

CHAPTER 11 CASE 2 KEY POINTS

- Even with the success of implants, a traditional periorestorative approach can be an excellent solution.
- Create a physiologic, cleanable architecture around furcations and resected teeth.

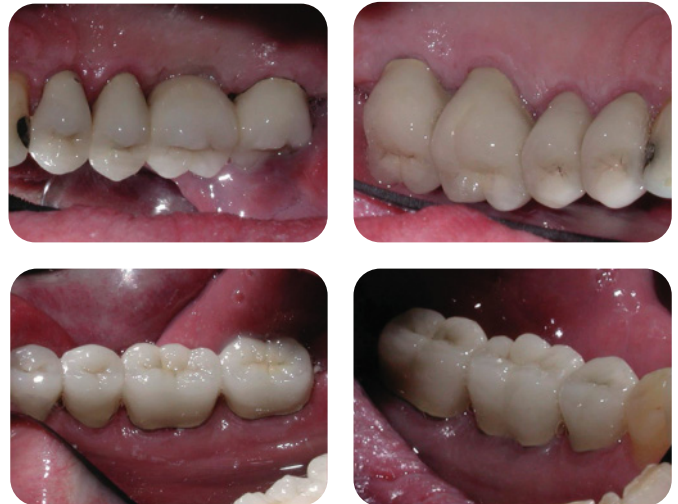

Figure 11.2.19. Lingual photos of the completed dentistry.

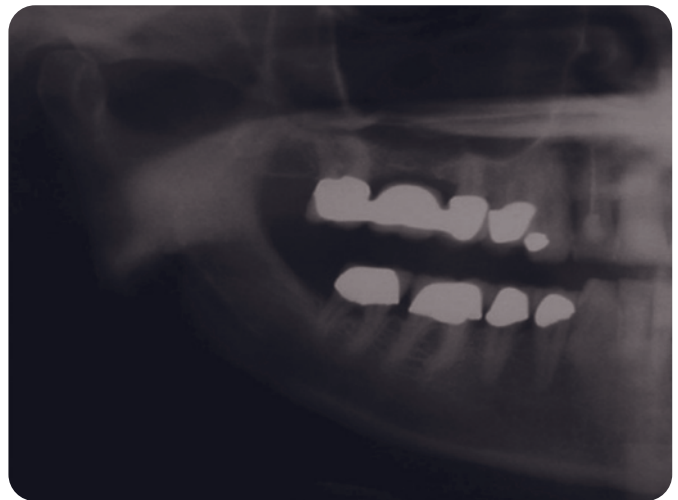

Figure 11.2.20. Posttreatment panoramic radiograph, right side.

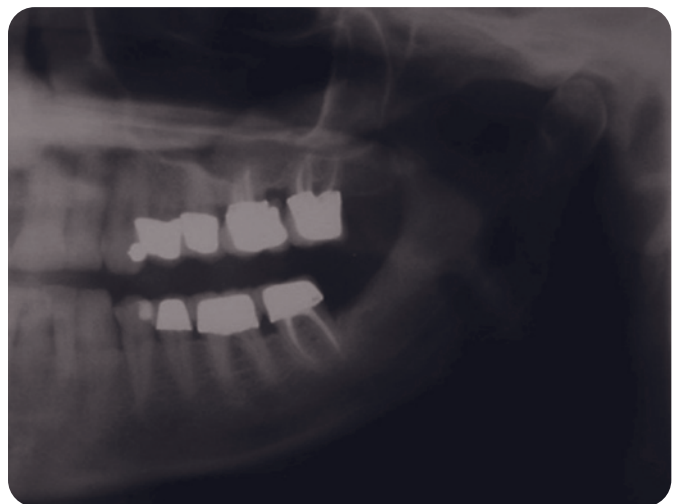

Figure 11.2.21. Posttreatment panoramic radiograph, left side.

12

Implants in the Aesthetic Zone

Case 1 Hopeless maxillary central incisor transitioned to an implant-supported restoration (delayed placement and delayed loading) with crowns on the remaining incisors along with occlusal therapy

Case 2 Extraction and immediate implant placement, delayed loading, and restoration maxillary central incisors; pink porcelain to simulate papilla

Case 3 Congenitally missing maxillary lateral incisors, orthodontics to open lateral incisor space, dental implants, and other aesthetic improvements

Case 4 Congenitally missing upper right cuspid; upper right lateral incisor lost in an accident; implant placed in cuspid position with 2-unit cantilever restoration, pink porcelain to simulate gingival

Case 5 Maxillary central incisor extracted and replaced with a dental implant, delayed placement, and delayed loading

See also:

Chapter 7 Case 6 Restorations maxillary bicuspid-to-bicuspid done first as part of a comprehensive plan; maxillary left central incisor implant and other functional discrepancies corrected with reshaping and equilibration

Chapter 12 Case 1

Hopeless maxillary central incisor transitioned to an implant-supported restoration (delayed placement and delayed loading) with crowns on the remaining incisors along with occlusal therapy

A failing tooth in the aesthetic zone poses a particular challenge to us. The implant and definitive implant restoration must not only look aesthetically pleasing, but we have to keep the patient together aesthetically and functionally during the transition from tooth to implant—especially if the implant cannot be immediately placed. Even though the focus may be the failing tooth and treatment plan at hand, we must still do a complete examination and diagnosis and address the entire masticatory system.

The patient in this case study had a hopeless tooth 9 that was replaced with an implant. He was in a serious car accident 6 years prior; 8 and 9 were restored as a result, with orthodontics prior to that. He had not been happy with anterior aesthetics, that is, asymmetry between 8 and 9. He has noticed 9 migrating facially since the restoration; 9 subsequently needed endodontic therapy 2 weeks after a definitive crown was placed. He is aware of grinding; however, he has no TMJ symptoms but does report muscle tension and fatigue especially in the morning, typically a result of nighttime bruxism. There were also occlusal issues and wear and tear from bruxism that needed to be addressed as part of the comprehensive plan.

SUMMARY OF EXAMINATION AND DIAGNOSIS

Dentition

Failing tooth 9
Significant generalized wear for someone in midtwenties

Periodontium

Gingivitis
Uneven gingival levels

TMJs

Right side Piper 2
Left side Piper 2
Both can be superiorly compressed comfortably.

Muscles

Lateral and medial pterygoids tender to testing, 1 on a scale of 5

Occlusion

Interferences and slide to maximum intercuspation in the centric arc of closure
Excursive interferences

Aesthetics

Tooth size, form, proportion, and gingival asymmetry

THE 10 DECISIONS

1. TMJ Diagnosis

Treat to a guided, verifiable CR.

2. Vertical Dimension

Equilibrate to bicuspid contact in CR; this will gain space anteriorly for restorations.

3. Lower Incisal Edge

Use height of idealized cuspids as a reference. Restore 23–26 with composite to that height.

4. Upper Incisal Edge

Current lengths of 8 and 9 are acceptable.

5. Centric Stops

Simultaneous, equal intensity contacts on all teeth in CR with equilibration and restorations

6. Anterior Guidance

Because vertical dimension will be “opened” slightly with equilibration (see above comment in “Vertical Dimension”), the anterior guidance performance platform angle will be shallower.

7. Curve of Spee

Acceptable

8. Curve of Wilson

Verify that upper buccal and lower lingual cusps do not interfere in the functional and parafunctional range of motion.

9. Cusp/Fossa Angle

When equilibrating, shorten cusps rather than deepen fossa.

10. Aesthetic Plane

Verify that the aesthetic plane of the upper buccal cusps is level and symmetrical and that the facial profiles of the upper posterior teeth are aligned correctly.

Reshape upper buccal cusps for an even, consistent plane.

SUMMARY OF TREATMENT PLAN

Dentition

Remove 9, socket preservation
 Delayed implant placement
 Delayed implant loading
 Definitive restorations 7–10
 Composite restorations lower anterior and 6, 11—a conservative approach that will eventually need porcelain

Periodontium

Implant and concurrent surgeries

TMJs

No treatment is needed other than correct occlusal engineering.

Muscles

No treatment is needed other than correct occlusal engineering.

Occlusion

Simultaneous, equal intensity centric stops in the centric arc of closure fulfilled with equilibration and restorations
 Bite splint for bruxism protection

Aesthetics

Tissue augmentation along with implant
 Idealize contours, form, and proportion of restorations.

SUMMARY OF TREATMENT SEQUENCE

Appointment

Treatment Completed

1	Equilibration Composites 6 and 11, 22–27 for functional reasons Provisionalize 7–10. Bite splint for bruxism protection
2	Periodontist to remove 9, bone preservation Modify provisional at time of surgery.
3	Heal; monitor provisional.
4	Implant placement; modify provisional.
5	Monitor provisional; do additional grafting as needed.
6	Custom abutment 9; new provisionals
7	Monitor provisional.
8	Finalize 7–10.
9	New posttreatment bite splint Refresh composites and occlusal refinement as needed.
10	Eventually change composite to porcelain.

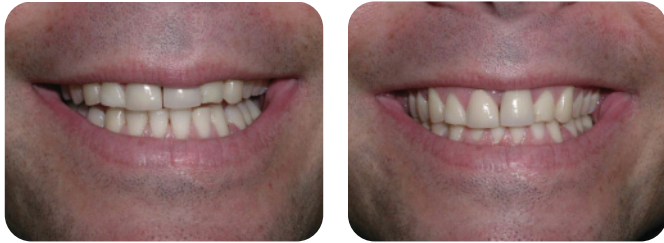
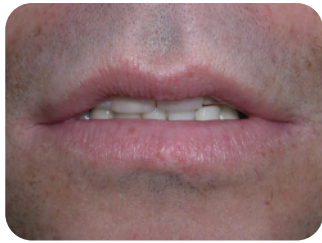
Figure 12.1.1. Pretreatment photographs with lip at rest, slight smile, and high smile. With the lip at rest, an acceptable amount of the upper incisal edges are displayed. In a high smile the lip is approximately at the free margin of the gingival with the interdental papillae exposed.

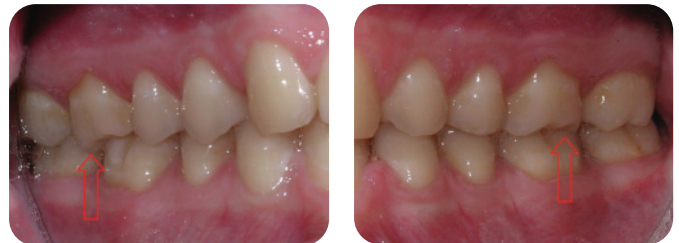
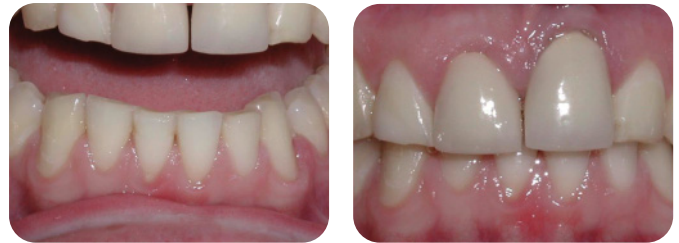
Figure 12.1.3. Close up photographs illustrating wear and uneven incisal edges. The bottom two photos illustrate rather severe wear on the buccal cusps of the upper first molars due to working interferences in both the functional and parafunctional range of motion.

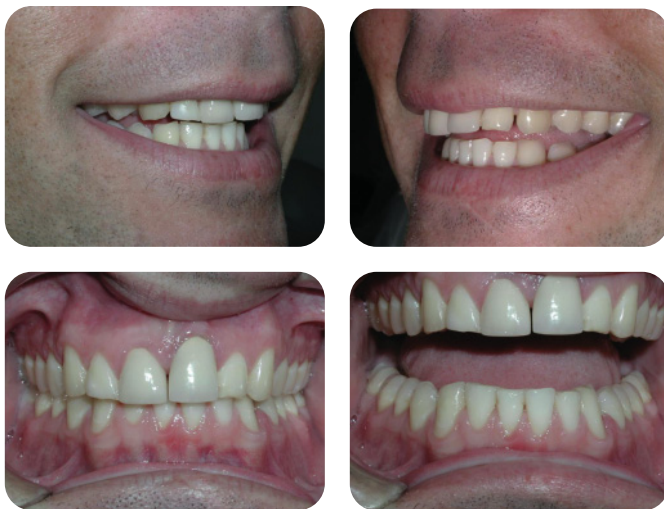

Figure 12.1.2. Lateral smile photographs and retracted anterior photographs suggesting uneven incisal edges due to wear from bruxism. Asymmetry of teeth 8 and 9 is also evident.

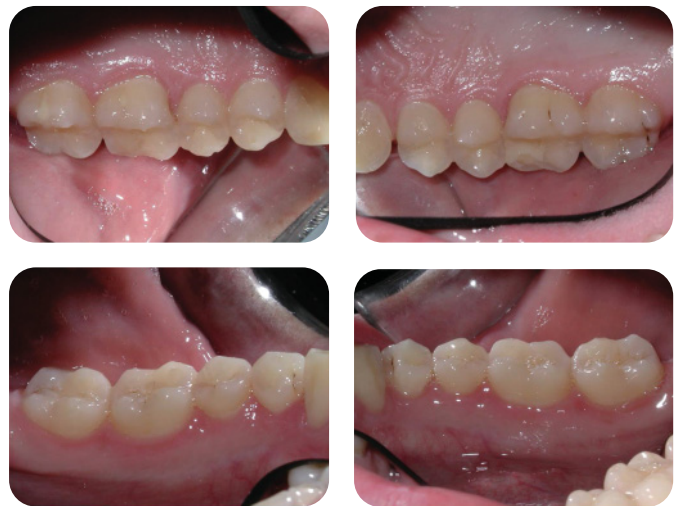

Figure 12.1.4. Pretreatment photographs of the lingual surfaces of the posterior teeth.

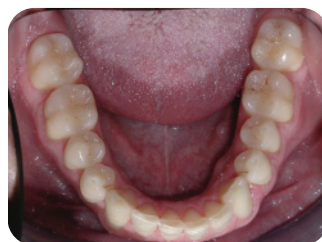

Figure 12.1.5. Pretreatment mandibular occlusal photograph illustrating wear on the lower anterior incisal edges into the dentin.

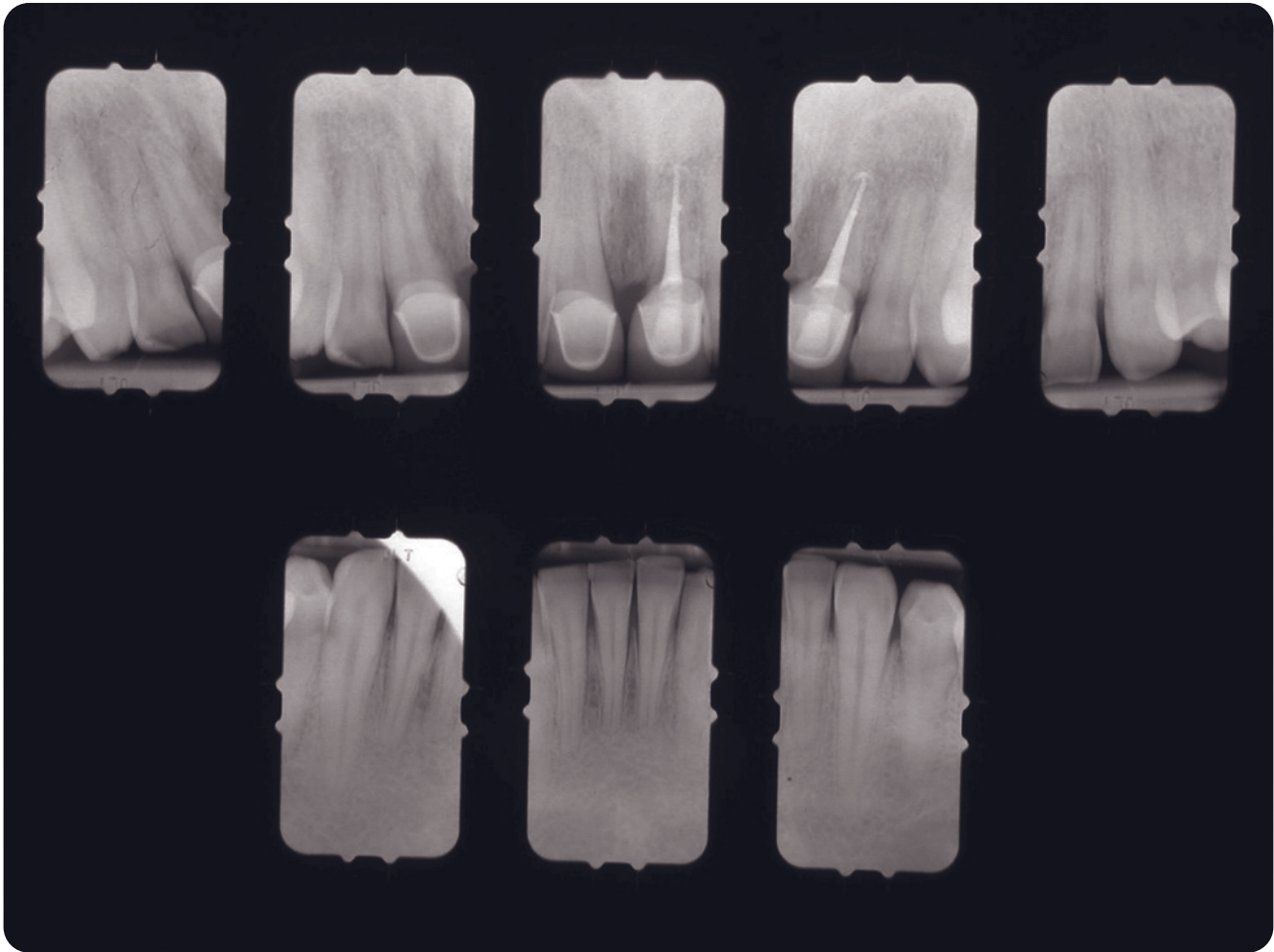


Figure 12.1.6. Pretreatment radiographs of the anterior teeth suggesting compromised root integrity of tooth 9.

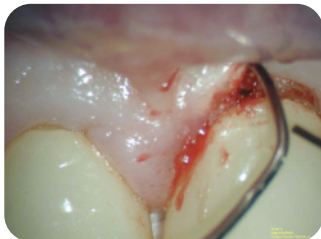


Figure 12.1.7. Pretreatment microscope view photograph of the compromised facial root surface provided by the endodontist who diagnosed the tooth as untreatable.

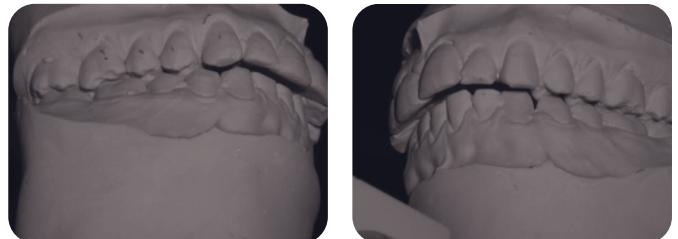


Figure 12.1.8. Pretreatment articulated diagnostic casts mounted in centric relation and closed to the first point of contact suggesting the amount of vertical opening at the position.

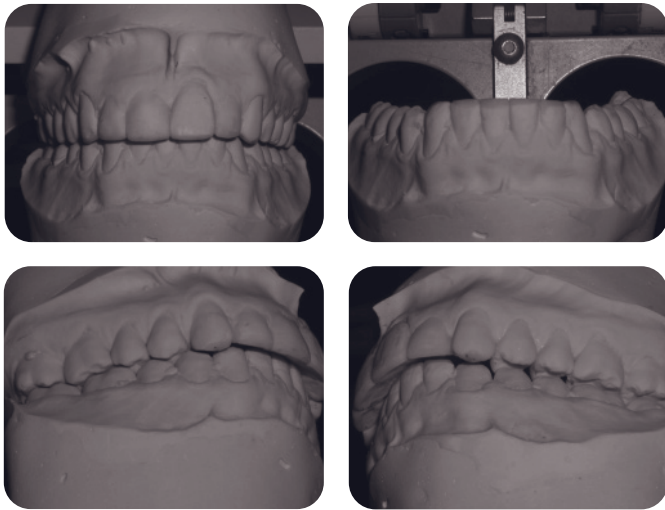


Figure 12.1.9. A second set of articulated diagnostic casts were equilibrated in the centric relation arc of closure until there were centric stops up to the bicuspids. This left space anteriorly to make room for restorative materials to rebuild proper form and function of the lower anterior teeth and anterior guidance performance platform of the upper anterior teeth. These changes were made on the articulated diagnostic casts with composite.

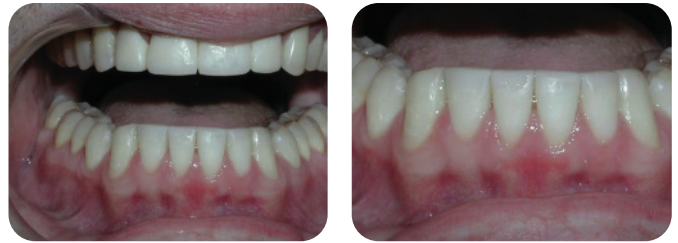

Figure 12.1.11. Close-up photographs of these changes made to the lower anterior teeth.

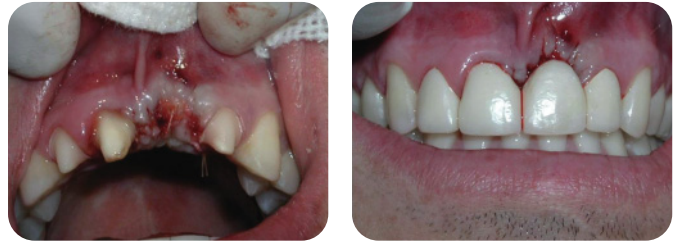

Figure 12.1.12. Photograph at the end of the first surgical appointment at the periodontist's office. The provisional was modified at that time by converting tooth 9 to a pontic and creating a convex tissue surface.

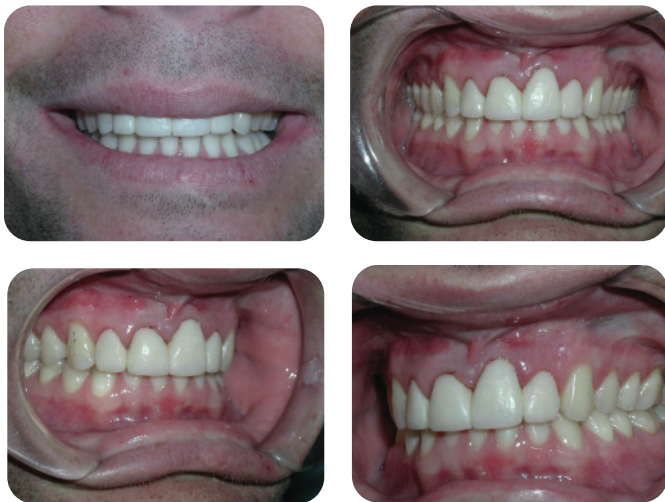

Figure 12.1.10. Photographs following the first treatment appointment which involved equilibration, composite restorations on the lower anterior teeth and the upper cuspids, provisionals on teeth 7–10, and a mandibular bite splint.

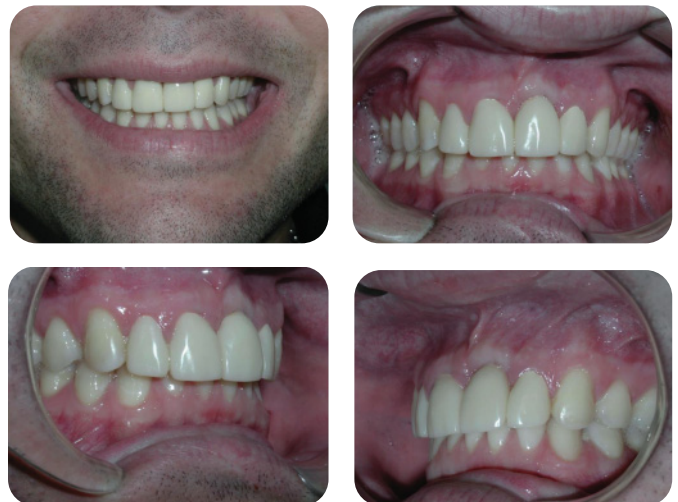

Figure 12.1.13. Photographs of the new provisionals after the implant abutment for 9 was placed.

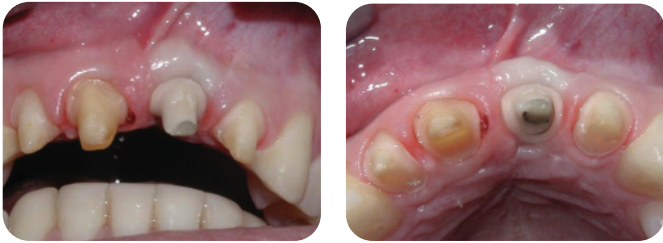

Figure 12.1.14. Photographs of the preparations of teeth 7, 8, and 10 and the custom abutment for implant number 9.

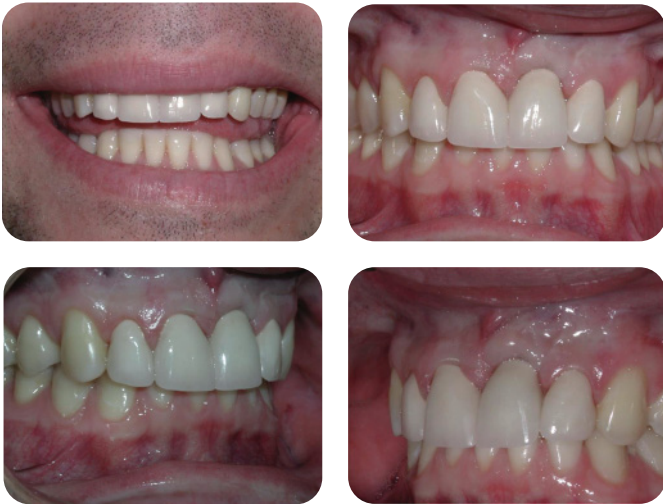

Figure 12.1.15. Posttreatment photographs of the definitive restorations for teeth 7, 8, 9, and 10 suggesting much improved gingival tissues symmetry.

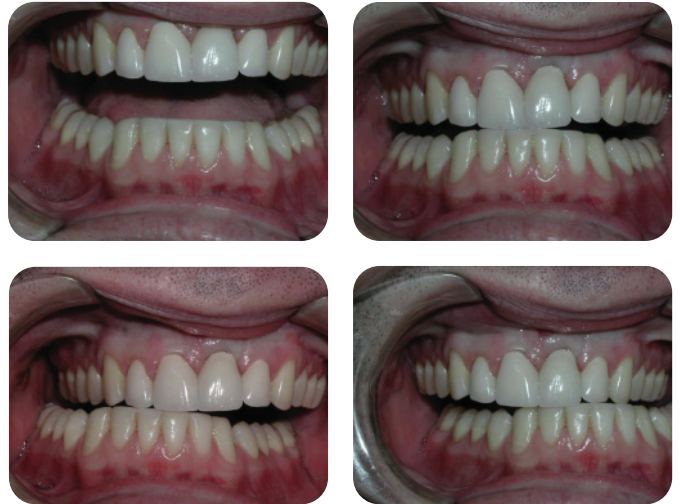

Figure 12.1.16. Posttreatment photographs with the teeth apart and also a protrusive edge-to-edge position and right and left crossover positions suggesting smooth, nontraumatic movement across the edges throughout these excursions.

CHAPTER 12 CASE 1 KEY POINTS

- Address the entire masticatory system even if the focus is just the front teeth.
- Much is gained, technically and behaviorally, if you can be present at the surgeon's office during the surgery.

Chapter 12 Case 2

Extraction and immediate implant placement, delayed loading, and restoration maxillary central incisors; pink porcelain to simulate papilla

The maxillary central incisors have been problematic for the patient in this case study for many years. They were traumatized many years ago and had endodontic therapy and composite restorations. After several episodes of fracturing, the previous dentist placed veneers, which continued to have fracturing issues. Core buildups and complete crowns were considered as an option, but the questionable radiographic appear-

ance of the endodontic treatment necessitated retreatment for predictability even though the teeth were symptom-free. The patient had a favorable experience with implant therapy to replace another tooth and was open to considering that as an option for the maxillary central incisors. Considering what it would take to save the natural teeth and still with a guarded prognosis, he chose the implant approach.

SUMMARY OF EXAMINATION AND DIAGNOSIS

Dentition

History of problems with root canals and restorations, maxillary central incisors

Upper right first bicuspid was replaced with an implant; patient had a good experience with the process.

Mesiobuccal cusp upper right first molar fractured

Evidence of bruxism

Minimal restorations elsewhere

Periodontium

Healthy, being maintained at a periodontist

Has had gingival grafting upper left bicuspid

TMJs

Right side Piper 3B

Left side Piper 3B

No symptoms

Both can be superiorly compressed comfortably.

Muscles

Lateral pterygoids slight discomfort

Occlusion

Minimal interferences to the arc of closure

Aesthetics

Length, proportion, gingival levels acceptable

Some embrasure spaces anteriorly but not an aesthetic concern

Diastema between central incisors, recently closed with veneers at previous dentist

THE 10 DECISIONS

1. TMJ Diagnosis

Treat to adapted centric posture.

2. Vertical Dimension

No need to change

3. Lower Incisal Edge

Smooth and polish.

4. Upper Incisal Edge

Smooth and polish; shorten upper right cuspid.

5. Centric Stops

Simultaneous, equal intensity centric stops in the ACP arc of closure

6. Anterior Guidance

Refine lateral guidance.

Protrusive guidance will be on maxillary central incisors.

7. Curve of Spee

No need to change

8. Curve of Wilson

Verify that upper buccal and lower lingual cusps do not interfere in the functional and parafunctional range of motion.

9. Cusp/Fossa Angle

Do not deepen with equilibration.

10. Aesthetic Plane

Cosmetic shaping

SUMMARY OF TREATMENT PLAN

Dentition

Immediate implants/delayed restoration maxillary central incisors

Crown upper right first molar

Periodontium

Professional maintenance and self care

TMJs

No treatment is needed other than correct occlusal engineering.

Muscles

No treatment is needed other than correct occlusal engineering.

Occlusion

Simultaneous, equal intensity centric stops in the adapted centric posture arc of closure with equilibration by reshaping

Aesthetics

Idealize form and contours with restorations.

SUMMARY OF TREATMENT SEQUENCE

Appointment

Treatment Completed

- | | |
|---|---|
| 1 | Remove maxillary central incisors; immediate implant placement; place removable Essex type provisional. |
| 2 | Maintain provisional during healing. |
| 3 | Uncover implant; do additional soft tissue grafting as needed. |
| 4 | Implant level impression for custom abutment |
| 5 | Place abutments and provisional, equilibrate. |
| 6 | Refine provisional as needed. |
| 7 | Impressions |
| 8 | Place definitive restorations. |

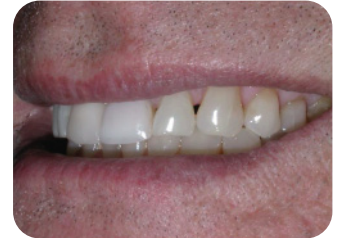
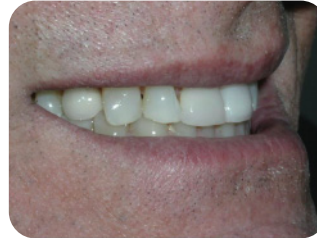
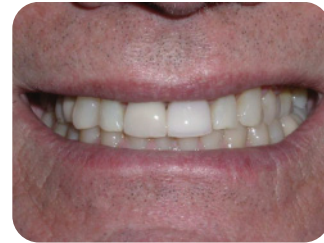Figure 12.2.1. Pretreatment anterior and lateral smile photographs. Restorations on central incisors have fractured multiple times.

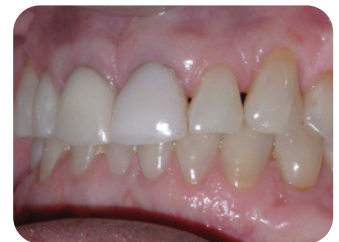
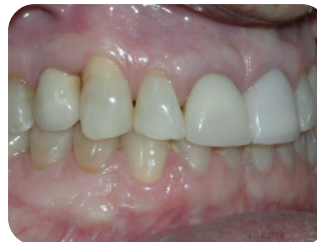
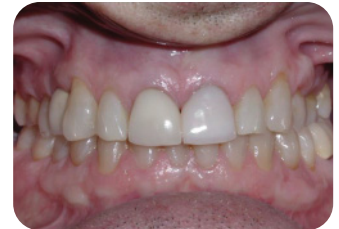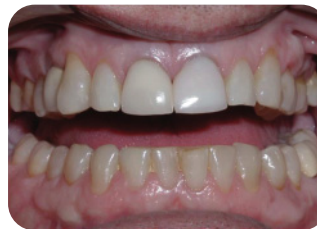Figure 12.2.2. Pretreatment anterior and lateral retracted photographs.

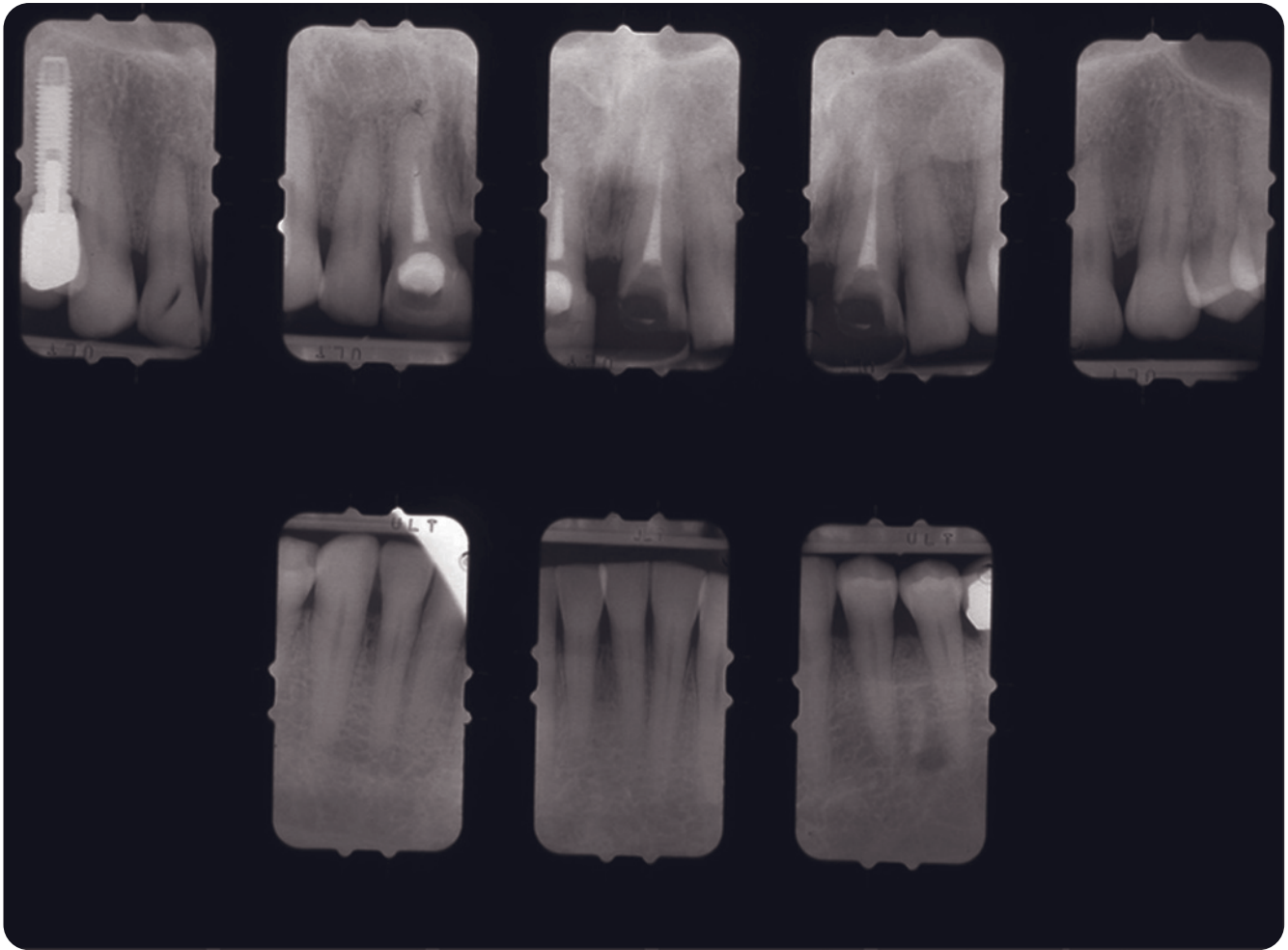


Figure 12.2.3. Pretreatment anterior radiographs. Note short endodontic fills on the maxillary central incisors.

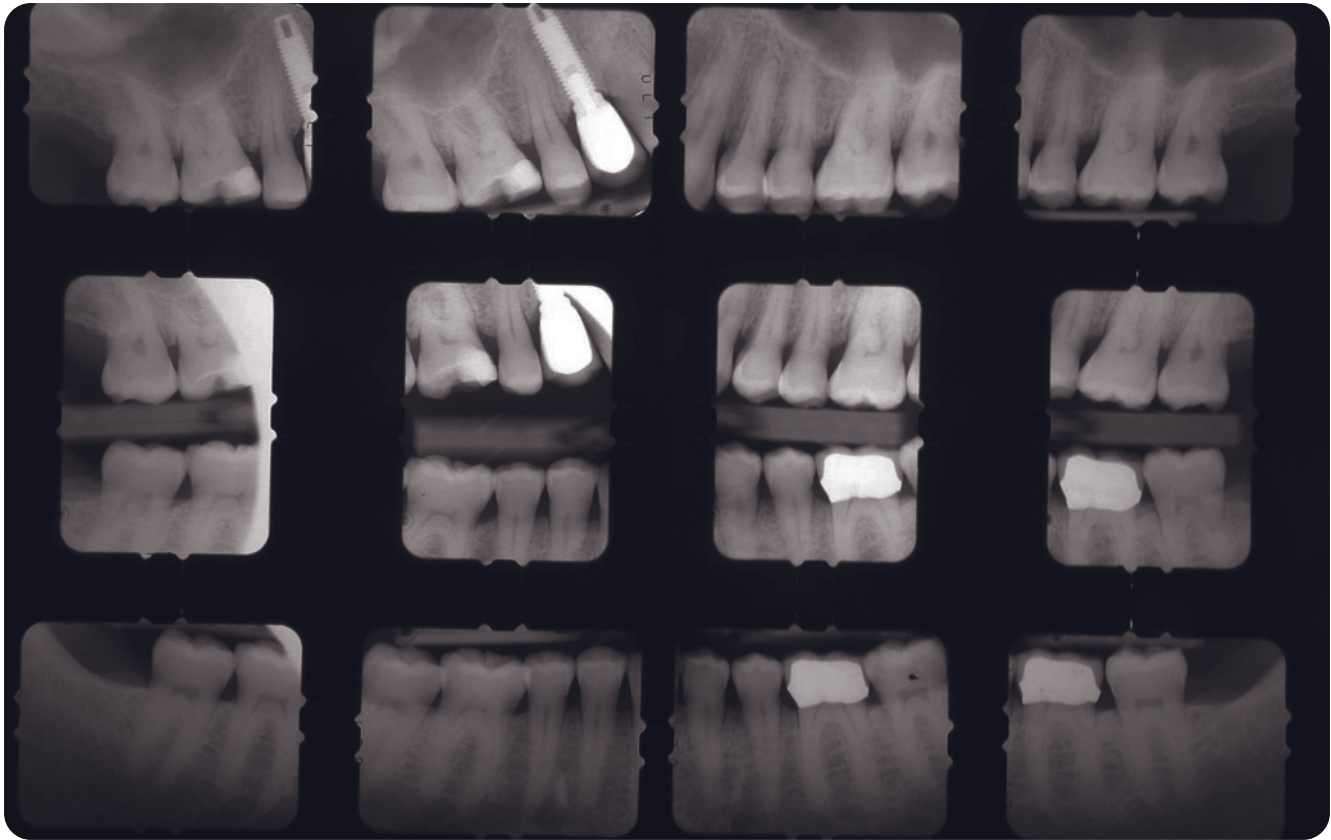


Figure 12.2.4. Pretreatment posterior radiographs. Success of the upper right implant was a big factor in his accepting an implant treatment plan for the central incisors.

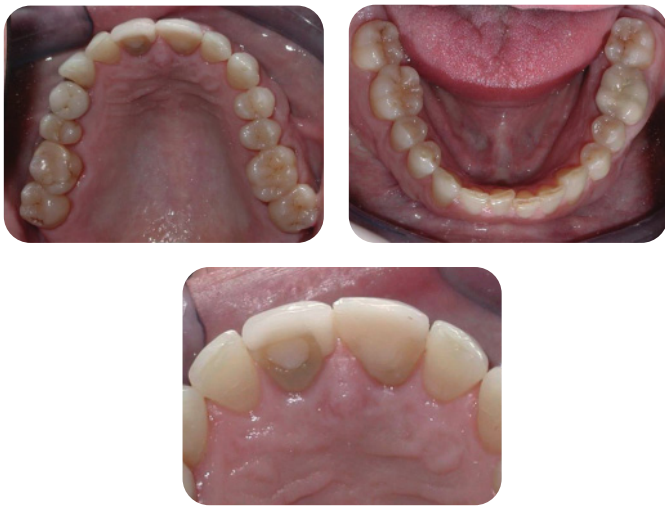

Figure 12.2.5. Maxillary and mandibular occlusal photographs. Implant and restoration was done by the previous dentist. The provisional was a Maryland bridge type of approach, which required preparation of the adjacent teeth as seen in the photographs making the implant restoration wider mesiodistally. This would not have been acceptable for maxillary central provisionals.

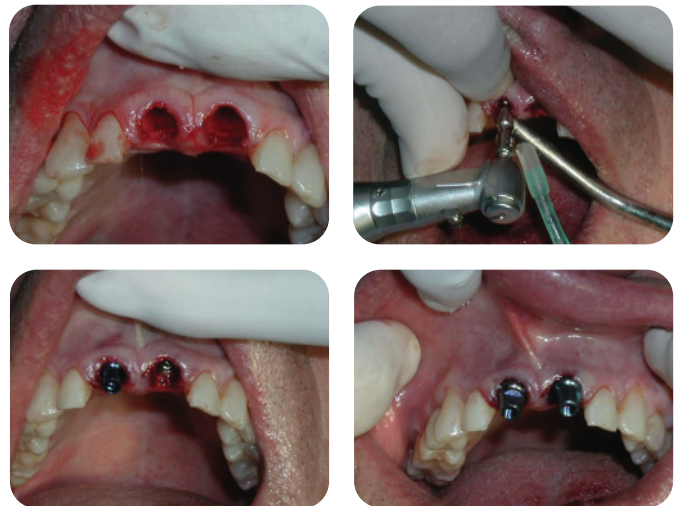

Figure 12.2.6. Photographs taken at the periodontist's office illustrating immediate implant placement.

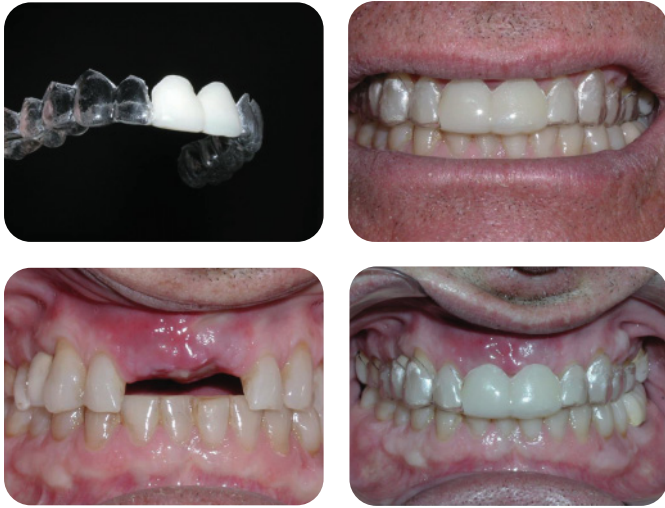

Figure 12.2.7. Photographs of the Essex provisional. His comment was that it was just for a few months so he could tolerate a somewhat cumbersome removable provisional. His motivation was the outcome, and it did not require altering the adjacent teeth.

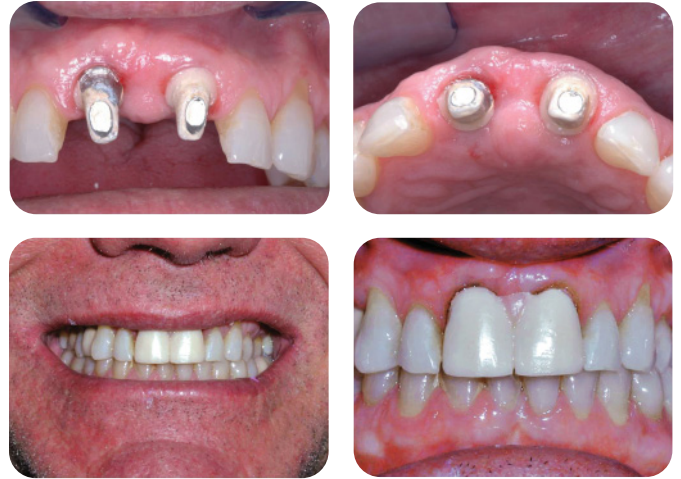

Figure 12.2.9. Photographs after soft tissue grafting, implant abutment refinement, and new provisionals.

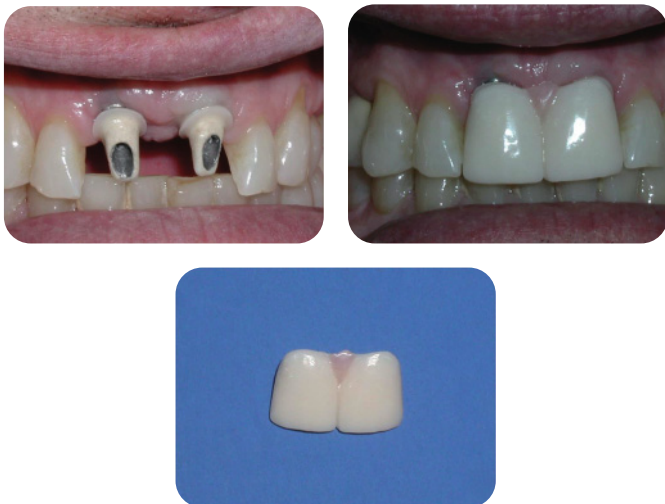

Figure 12.2.8. Photographs of custom abutments and provisionals with pink acrylic to simulate the interdental papilla. Implants were too far apart and not placed deeply enough. The top of the implant was close to the crest of tissue. The tissue over the right implant was thin and required soft tissue grafting. A better approach would have been to extract and bone graft then place the implants later. The implants could have been placed a little closer and the depth managed better.

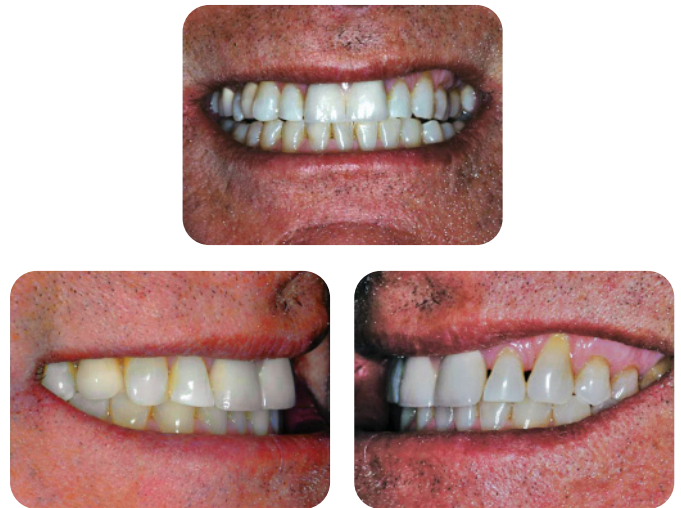

Figure 12.2.10. Anterior and lateral smile photographs of the definitive restorations. Subtle cosmetic reshaping completed.

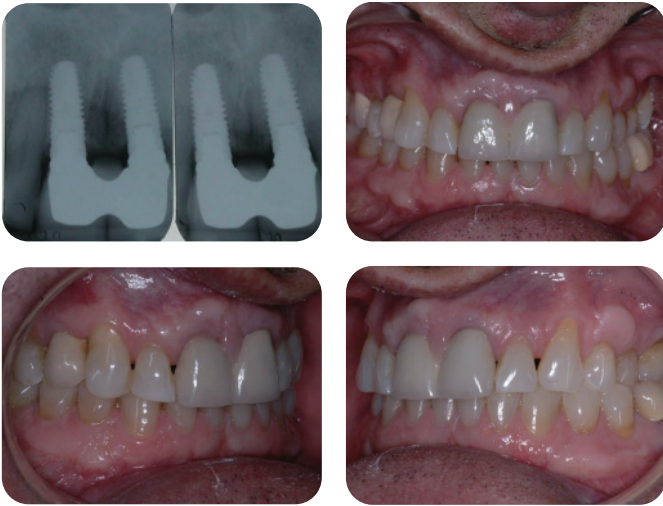

Figure 12.2.11. Anterior and lateral retracted photographs of the definitive restorations as well as posttreatment radiographs. The restorations were splinted for ease of addition of the pink porcelain.

CHAPTER 12 CASE 2 KEY POINTS

- A removable Essex-type provisional eliminates the need to prep good adjacent teeth. Make sure the patient understands fully.
- When anterior implants are not deep enough, there may not be enough “running room” to create proper contours. Pink porcelain can work well.

Chapter 12 Case 3

Congenitally missing maxillary lateral incisors, orthodontics to open lateral incisor space, dental implants, and other aesthetic improvements

Congenitally missing maxillary lateral incisors are a rather common occurrence. If not managed early orthodontically, the surrounding teeth will drift, often posing a treatment-planning dilemma.

The patient in this case study was a young lady who faced such a dilemma. The first choice whenever possible is to orthodontically move the teeth to their correct positions and then replace the missing teeth with dental implants. Good communication at the beginning and throughout treatment with all the specialists involved is critically important in getting the results expected by the dentist and patient.

SUMMARY OF EXAMINATION AND DIAGNOSIS

Dentition

Congenitally missing maxillary lateral incisors
Surrounding teeth drifted

Periodontium

Excessive tissue and maxillary frenum

TMJs

Right side Piper 2

Left side Piper 2

Both can be superiorly compressed comfortably.

Muscles

Lateral pterygoids are uncomfortable.

Occlusion

Interferences to the arc of closure

Aesthetics

Length, proportion, shape, and position of teeth;
gingival levels

THE 10 DECISIONS

1. TMJ Diagnosis

Treat to guided, verifiable centric relation.

2. Vertical Dimension

Use vertical dimension achieved with orthodontics.

3. Lower Incisal Edge

Idealize with orthodontics.

4. Upper Incisal Edge

Increase display 1–2 mm with orthodontics.

5. Centric Stops

Simultaneous, equal intensity centric stops in the CR arc of closure postorthodontics with equilibration

6. Anterior Guidance

Determined by idealized maxillary and mandibular incisal edge positions

7. Curve of Spee

Acceptable

8. Curve of Wilson

Acceptable

9. Cusp/Fossa Angle

Unrestored teeth; the correct anterior tooth-to-tooth relationship and guidance will disclude; do not deepen fossa with equilibration.

10. Aesthetic Plane

Verify that the aesthetic plane of the upper buccal cusps is level and symmetrical and that the facial profiles of the upper posterior teeth are aligned correctly with orthodontics and refined with equilibration.

SUMMARY OF TREATMENT PLAN

Dentition

Orthodontics to idealize position
 Implants for maxillary lateral incisors
 Improve shape of maxillary central incisors with composite.

Periodontium

Frenectomy, gingivoplasty

TMJs

No treatment is needed other than correct occlusal engineering.

Muscles

No treatment is needed other than correct occlusal engineering.

Occlusion

Orthodontics followed by equilibration

Aesthetics

Idealize position with orthodontics.
 Idealize form and contours with restorations.

SUMMARY OF TREATMENT SEQUENCE

Appointment	Treatment Completed
1	Orthodontics
2	Periodontal maintenance
3	Articulated diagnostic casts prior to debanding
4	Equilibration Maxillary retainer with prosthetic lateral incisors
5	Wax-up and surgical stent
6	Implant placement
7	Abutments and provisionals
8	Definitive impressions
9	Place restorations.

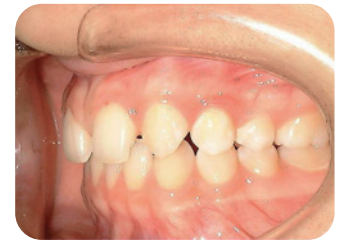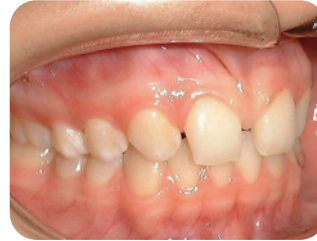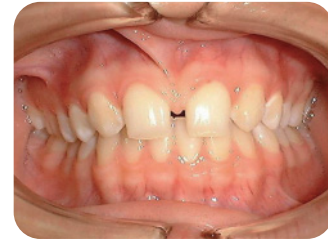


Figure 12.3.1. Pretreatment retracted anterior and lateral photographs illustrating missing maxillary lateral incisors, interfering frenum, and drifting of teeth.

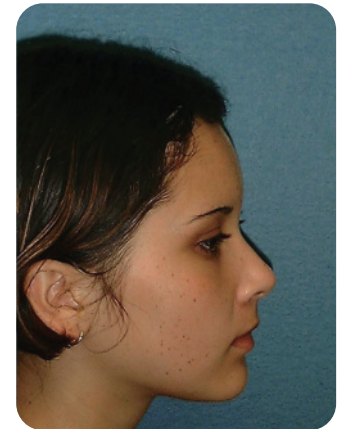


Figure 12.3.2. Frontal and lateral full face photos.

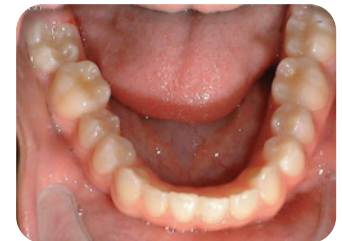
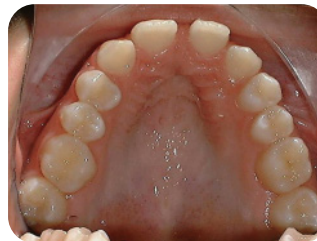
Figure 12.3.3. Pretreatment maxillary and mandibular occlusal photographs.

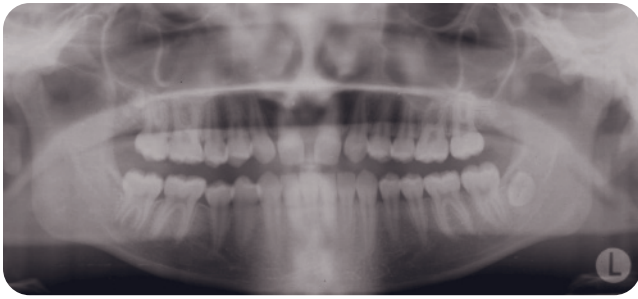


Figure 12.3.4. Pretreatment panoramic radiograph.

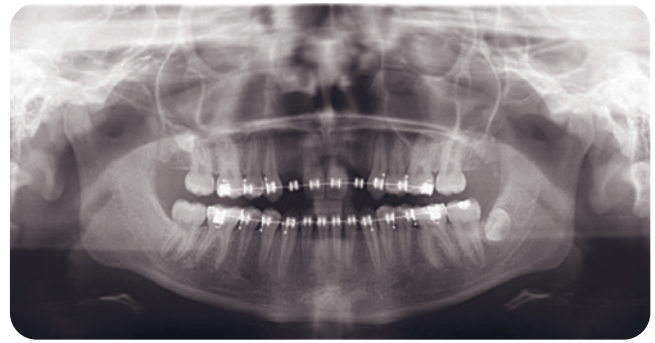

Figure 12.3.7. Progress panoramic provided by the orthodontist to verify correct root angulations and proper spacing for dental implants. Note that the maxillary first bicuspids were removed to gain space for distalizing the maxillary cuspids.

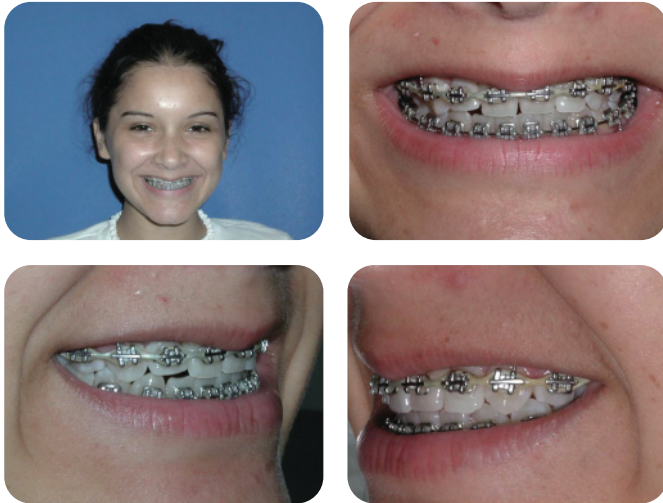

Figure 12.3.5. Photographs near the end of orthodontic treatment. The maxillary lateral incisors are pontics attached to the orthodontic arch wire. The maxillary central incisors need to display more of the incisal edge for improved smile aesthetics.

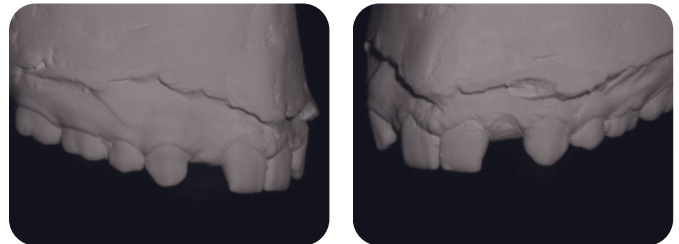
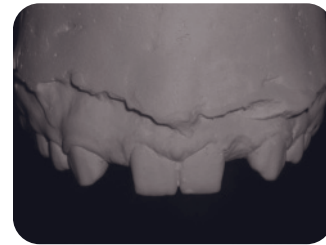


Figure 12.3.8. Postorthodontic casts illustrating wedge-shaped maxillary central incisors, bulky interdental papilla, and low maxillary frenum attachment.

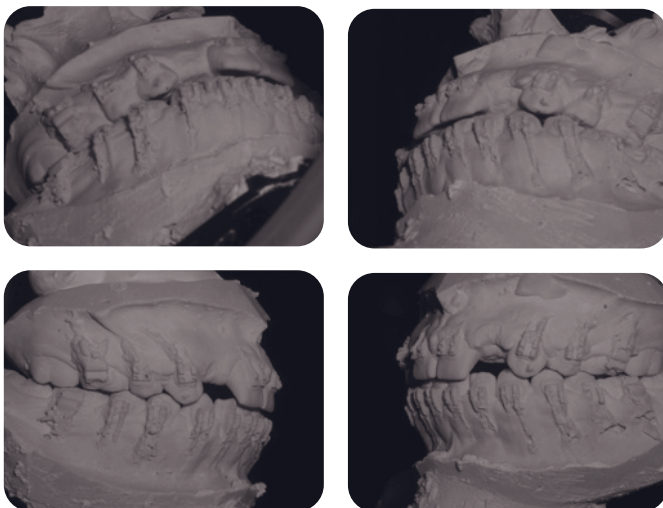


Figure 12.3.6. Photographs of articulated diagnostic casts prior to debanding done by the restorative dentist. A trial equilibration is done to verify that all the requirements of form and function can be achieved with current tooth positions. The results of this diagnosis are communicated to the orthodontist. This protocol, done prior to debanding, allows the opportunity for refinements, if need be, and is routine in the author's practice.

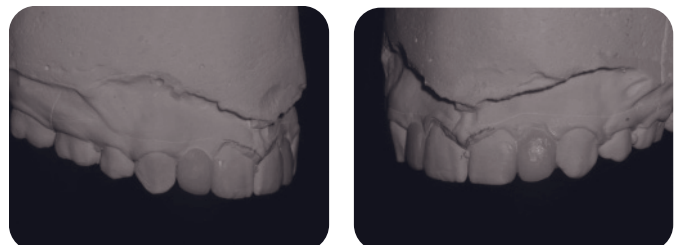
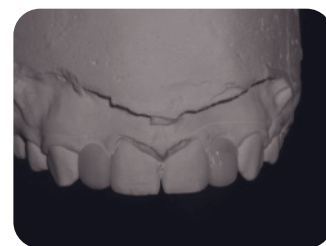


Figure 12.3.9. Diagnostic corrections completed by adding to the distal surfaces of the maxillary central incisors, adding maxillary lateral incisors and outlining correct gingival margins of the maxillary central incisors.

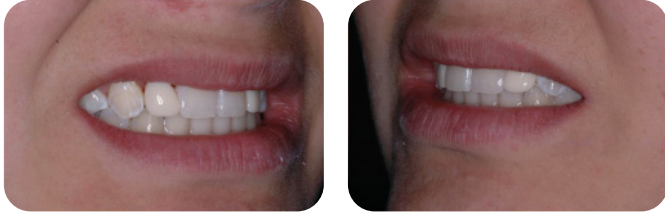
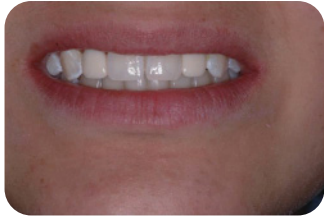
Figure 12.3.10. Anterior and lateral smile photographs with maxillary lateral incisor provisionals on implant abutments and composite corrections made to maxillary central incisors.

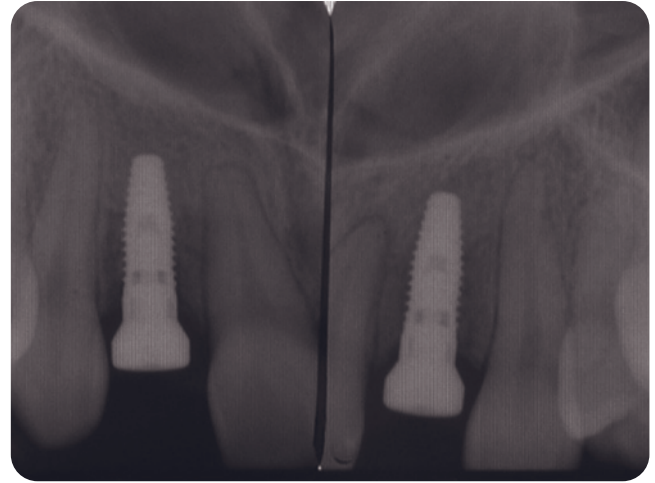


Figure 12.3.13. Posttreatment radiographs of integrated implants.

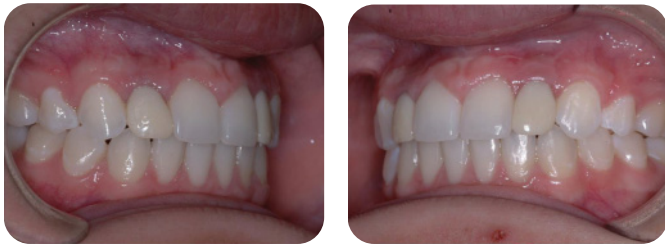
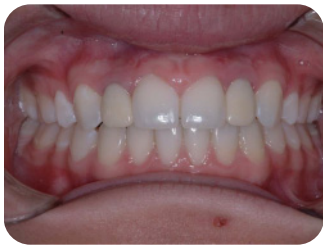
Figure 12.3.11. Retracted anterior and lateral photographs of the maxillary lateral provisional restorations. Whitening procedures were done as suggested by color difference of provisionals and natural teeth.

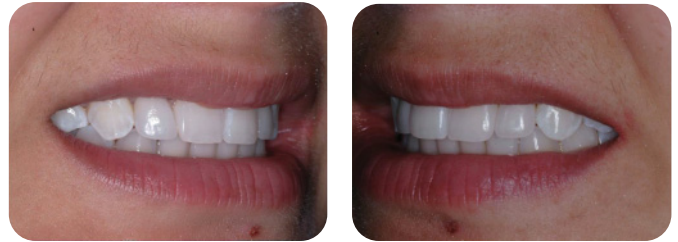
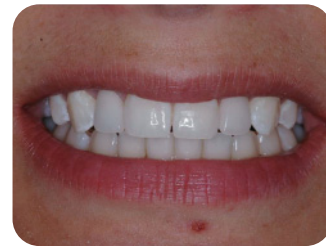
Figure 12.3.14. Posttreatment anterior and lateral smile photographs of the definitive restorations.

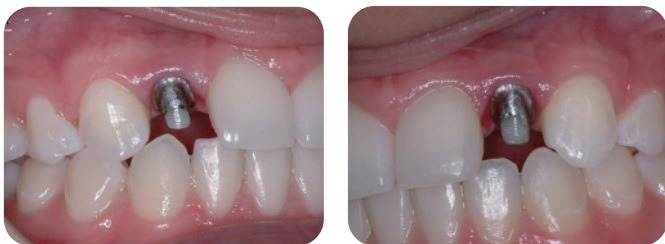

Figure 12.3.12. Photographs of stock abutments prepared extraorally and refined intraorally with composite placed in the screw access chamber. From this point, the abutments are managed just like teeth. This case was done before the use of Zirconia abutments.

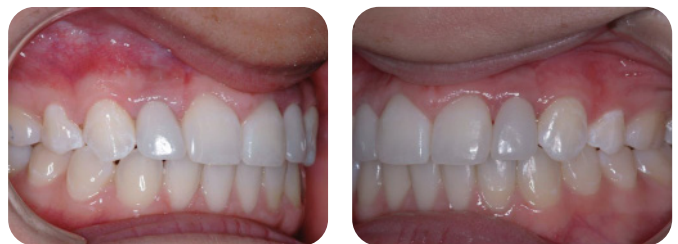
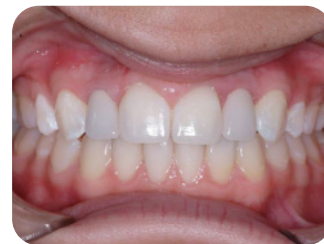
Figure 12.3.15. Posttreatment anterior and lateral retracted photographs of the completed zirconia restorations.



Figure 12.3.16. Full face photograph, approximately 1 year posttreatment.

CHAPTER 12 CASE 3 KEY POINTS

- When lateral incisors are missing, the first choice is to put the maxillary cuspids in the correct position.
- Articulated diagnostic casts with a trial equilibration and diagnostic wax-up prior to debanding assures the desired results.

Chapter 12 Case 4

Congenitally missing upper right cuspid; upper right lateral incisor lost in an accident; implant placed in cuspid position with 2-unit cantilever restoration, pink porcelain to simulate gingival

The patient in this case study moved to the area from out of the state while in the midst of orthodontic treatment. Records needed to be updated to verify that all requirements of form and function could be properly incorporated into the implant restoration. The restorative dentist needs to play an active role in the transfer to the new orthodontist.

SUMMARY OF EXAMINATION AND DIAGNOSIS

Dentition

Congenitally missing upper right cuspid
Traumatic loss of upper right lateral incisor

Periodontium

Gingivitis

TMJs

Right side Piper 2

Left side Piper 2

Both can be comfortably compressed.

No symptoms

Muscles

Several are tender to palpation.

Temporal headaches

Occlusion

Interferences to the arc of closure with slide to maximum intercuspation

Aesthetics

Color, minor wear, minor chipping

THE 10 DECISIONS

1. TMJ Diagnosis

Treat to a guided, verifiable centric relation.

2. Vertical Dimension

No need to change

3. Lower Incisal Edge

Smooth and polish.

4. Upper Incisal Edge

Smooth and polish.

5. Centric Stops

Simultaneous, equal intensity centric stops in the centric relation arc of closure achieved with equilibration.

6. Anterior Guidance

Lateral guidance of restoration is similar to the other side.

7. Curve of Spee

Acceptable

8. Curve of Wilson

Acceptable

9. Cusp/Fossa Angle

Do not deepen with equilibration.

10. Aesthetic Plane

Reshape maxillary buccal cusps as needed.

SUMMARY OF TREATMENT PLAN

Dentition

Orthodontic transfer; refer and finalize the treatment plan.
 Extrude upper right cuspid to bring bone.
 Implant upper right cuspid.
 Implant restoration cuspid with lateral cantilever.

Periodontium

Ongoing professional maintenance and self care
 Soft tissue grafting at implant site as needed

TMJs

No treatment is needed other than correct occlusal engineering.

Muscles

Bite splint therapy (anterior deprogrammer) as needed during orthodontics
 Followed by definitive occlusal/restorative therapy

Occlusion

Equilibration along with implant restoration

Aesthetics

Make implant restoration symmetrical to upper left cuspid and lateral incisor.

SUMMARY OF TREATMENT SEQUENCE

Appointment	Treatment Completed
1	Finish orthodontics. Anterior deprogrammer as needed
2	Articulated diagnostic casts by restorative dentist to verify that all landmarks are correct
3	Postorthodontic equilibration
4	Surgical stent, periodontist to place implant as soft tissue graft
5	Healing; orthodontic retainer with pontic
6	Place abutment, provisional, and impression.
7	Place definitive restoration. Posttreatment vacuum-formed retainer

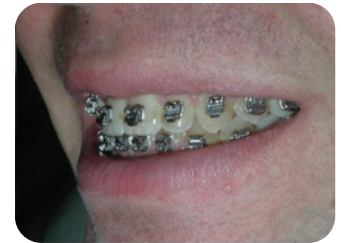
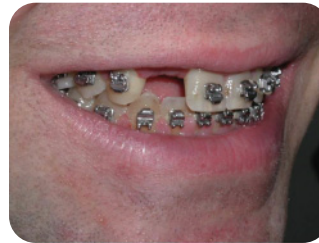
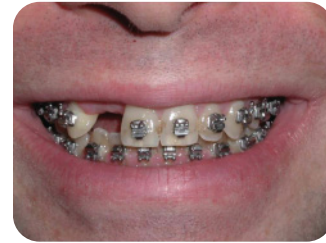Figure 12.4.1. Pretreatment anterior and lateral smile photographs.

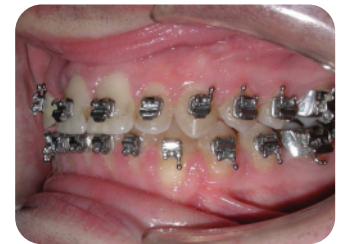
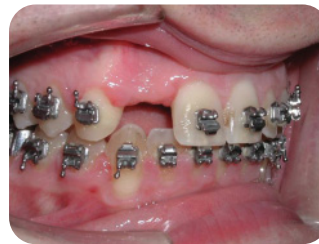
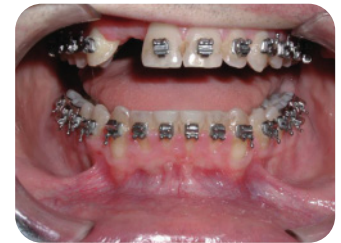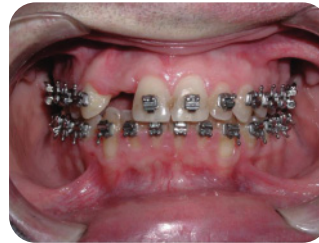Figure 12.4.2. Pretreatment anterior and lateral retracted photographs. Papilla on the distal of the maxillary right central incisor is gingival to the papilla between the maxillary left central and lateral incisor. Pink porcelain will be needed.

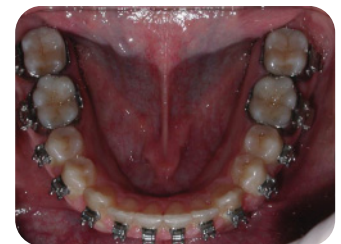
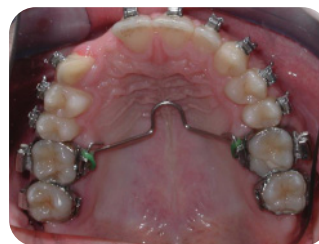
Figure 12.4.3. Pretreatment occlusal photographs.

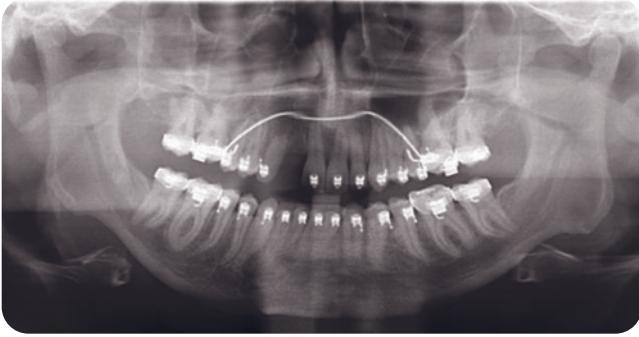


Figure 12.4.4. Pretreatment panoramic radiograph.

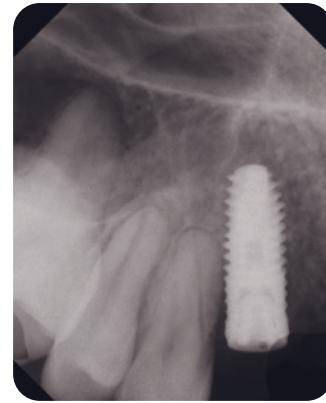


Figure 12.4.7. Radiograph of implant placed in maxillary right cuspid position.

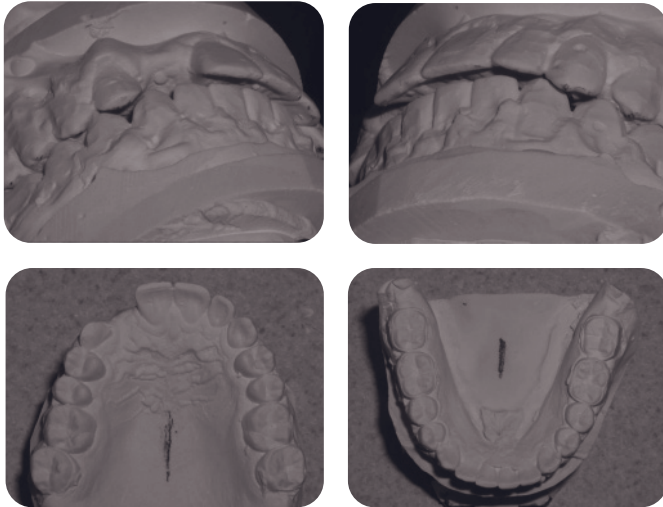


Figure 12.4.5. Articulated diagnostic casts done by the restorative dentist prior to debanding. A trial equilibration is done to verify that all functional requirements can be met. If not, the orthodontist can still refine positions. In this case, the maxillary centrals and lateral needed to be lingualized a bit more.

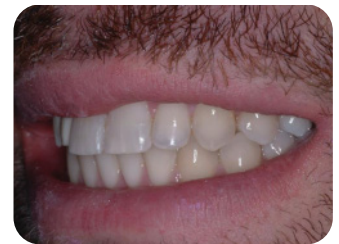
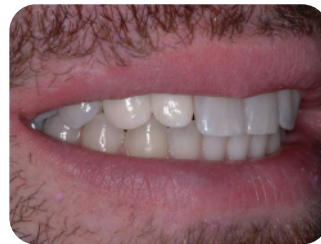
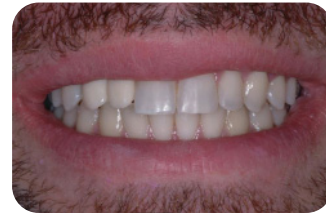Figure 12.4.8. Anterior and lateral photographs of the provisional restoration.

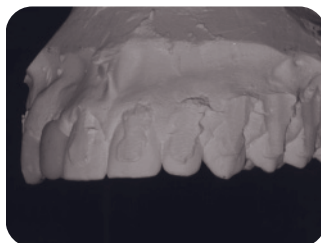
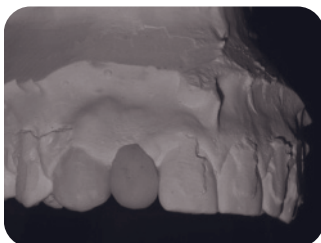
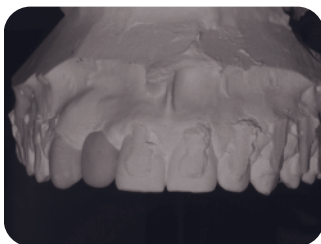


Figure 12.4.6. Photographs of diagnostic wax-up are also taken to verify that proportions of the restorations will be acceptable. This wax-up yields an acceptable result and is used to fabricate a surgical stent for the periodontist.

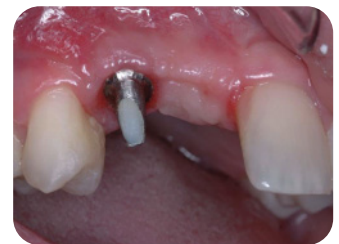
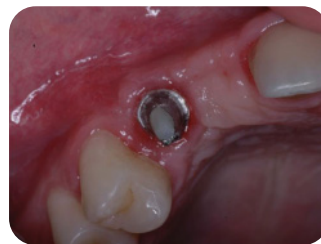
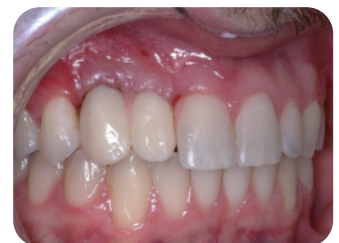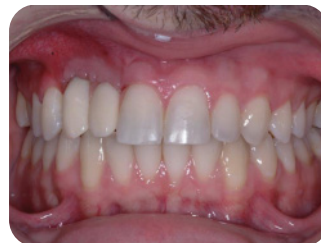Figure 12.4.9. Retracted photographs of the provisional and the modified implant abutment. Pink composite is added to the distal of the upper right maxillary central incisor to simulate the papilla. Pink composite is also used to simulate the papilla between the abutment and pontic. The tissue levels are not level to right and will be handled with pink porcelain in the definitive restoration.

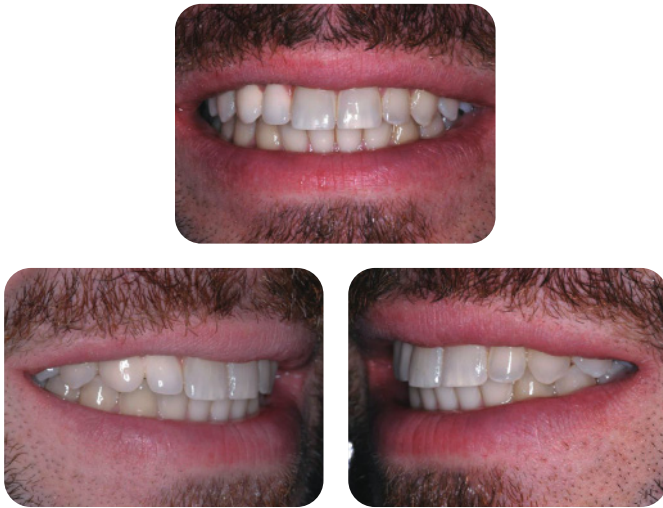

Figure 12.4.10. Anterior and lateral photographs of the definitive restorations. Pink porcelain is used to simulate not only the papilla but also the marginal gingival so the clinical crown length is similar to the left cuspid and lateral. The pink porcelain on the mesial of the lateral incisor butts up to the pink composite on the distal of the central incisor. Incisal embrasures are similar to the left side. Even though the deciduous cuspid was moved, the alveolar bone level was still more gingival in position to the left side. Patient does not have a high smile line, so it was decided not to raise the tissue levels on the maxillary anterior teeth.

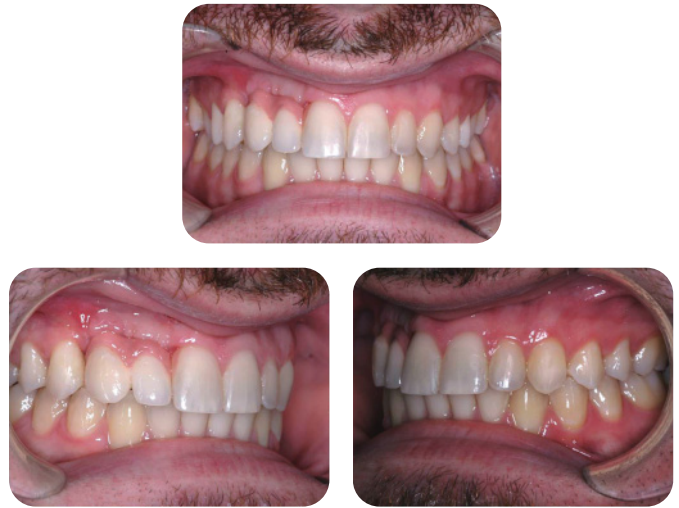

Figure 12.4.11.

CHAPTER 12 CASE 4 KEY POINTS

- Articulated diagnostic casts with a trial equilibration and diagnostic wax-up prior to debanding assures the desired results.
- Pink porcelain is an important adjunct in some implant cases.

Chapter 12 Case 5

Maxillary central incisor extracted and replaced with a dental implant, delayed placement, and delayed loading

The patient in this case study had a maxillary central incisor endodontically treated several years prior due to internal resorption. With the multiple problems and very guarded prognosis, it was decided to extract the tooth. The patient was happy with the appearance of her remaining teeth, so the treatment was focused on the maxillary central incisor.

SUMMARY OF EXAMINATION AND DIAGNOSIS

Dentition

All are acceptable except the maxillary right central incisor.

Periodontium

Normal and healthy

TMJs

Right side Piper 3B

Left side Piper 3B

Both can be compressed with no discomfort.

Muscles

Slight lateral pterygoid discomfort to testing

Occlusion

Very slight interference in the arc of closure to maximum intercuspation

Aesthetics

Central incisors can be lengthened 1 mm, but patient is happy with aesthetics.

THE 10 DECISIONS

1. TMJ Diagnosis

Treat to guided, verifiable adapted centric posture.

2. Vertical Dimension

No need to change

3. Lower Incisal Edge

Maintain; just smooth and polish.

4. Upper Incisal Edge

Maxillary left central incisor can be lengthened 1 mm, but patient is happy with current condition. Maintain; just smooth and polish.

5. Centric Stops

Refine with equilibration.

6. Anterior Guidance

Just smooth, polish, and refine.

7. Curve of Spee

No need to change

8. Curve of Wilson

No need to change

9. Cusp/Fossa Angle

Do not deepen with equilibration.

10. Aesthetic Plane

No need to change

SUMMARY OF TREATMENT PLAN

Dentition

Replace maxillary right central incisor with a dental implant.

Periodontium

Ongoing self care and professional maintenance

TMJs

No treatment is needed other than correct occlusal engineering.

Muscles

No treatment is needed other than correct occlusal engineering.

Occlusion

Only slight equilibration is needed.

Aesthetics

Match implant restoration to maxillary left central incisor.

SUMMARY OF TREATMENT SEQUENCE

Appointment	Treatment Completed
1	Extraction of maxillary right central incisor and bone graft Essix provisional
2	Implant placement
3	Place ceramic abutment, provisional, and impression.
4	Place definitive implant-supported restoration
5	Posttreatment protective bite splint at patient's request

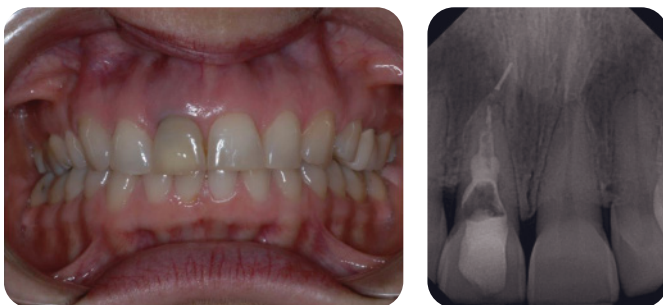

Figure 12.5.1. Pretreatment retracted photograph and radiograph. The buccal plate of bone was very thin, so the periodontist decided to place a bone graft and delay implant placement. The patient used an Essex type provisional, as illustrated in Figure 12.2.7.

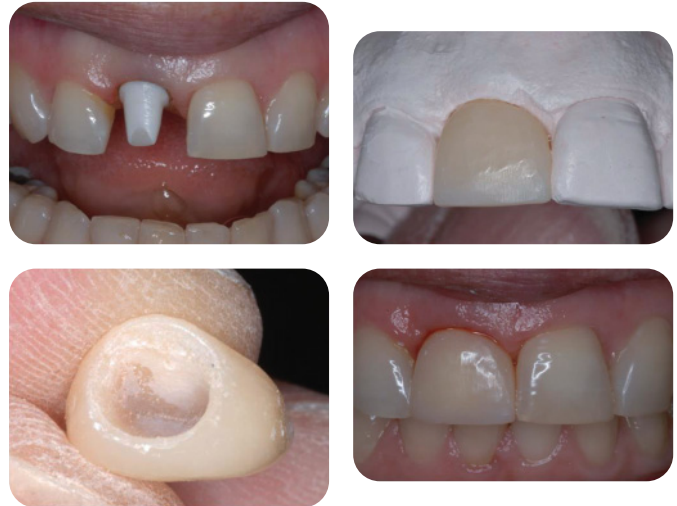

Figure 12.5.2. Top left: photograph of the prepared ceramic implant abutment. Top right: the provisional is made on a cast made from an impression of the implant abutment. The tissue on the cast is trimmed to be as symmetrical to the maxillary left central incisor as possible, so the provisional contours are as symmetrical as possible. Bottom left: the mesial contours are extended laterally so that a mesial contour ridge can be created resulting in symmetry with the left central. The tissue surface is slightly convex. Bottom right: immediately after provisional cementation. The mesial contour ridge needs to extend vertically another 2mm to match the left central.

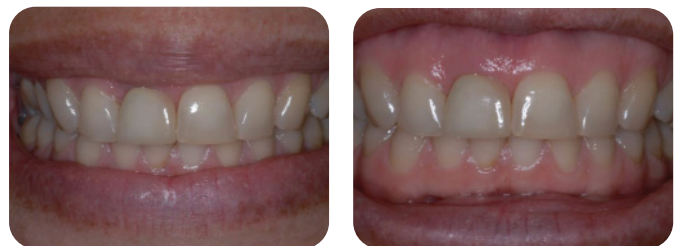

Figure 12.5.3. Smile and retracted photograph of the completed restoration. Note that the mesial contour ridges of the 2 central incisors are very nearly mirror images. The patient liked the color of her teeth and wanted to maintain it, making the porcelain color match rather difficult..

CHAPTER 12 CASE 5 KEY POINT

- Understand the patient's aesthetic desires. Not all patients want white and bright.

13

Removable Implant-Supported Restoration with Natural Teeth

Case 1 Maxillary implant-supported bar-retained removable partial denture along with tooth-supported restorations to reconstruct occlusion and vertical dimension

Case 2 Combination mandibular fixed anterior—removable posterior reconstruction with Locator attachments

See also:

Chapter 14 Case 4 Mandibular anterior fixed partial denture and posterior removable partial denture with implants and Locator attachments for added support and retention; maxillary reconstruction, telescope case with 1 dental implant included along with 6 teeth

Chapter 13 Case 1

Maxillary implant-supported bar-retained removable partial denture along with tooth-supported restorations to reconstruct occlusion and vertical dimension

The patient in this case study lost teeth 2–10 in a bad car accident and has had a combination fixed-removable prosthesis. The fixed part has semiprecision attachments, and the removable part covers the palate with a palatal strap. It is not stable and she dislikes the palatal coverage. Additionally, her bite is not comfortable and she complains of muscle tension and difficulty chewing. Crowns 11–15 and onlays 18–20 were done in conjunction with a removable partial denture. The upper teeth are symptomatic. She would like a nonremovable treatment option if feasible.

SUMMARY OF EXAMINATION AND DIAGNOSIS

Dentition

Restorations 11–15 are structurally adequate; however, there is pulpal pain.

Restorations 18–20 are structurally adequate; however, vertical dimension and occlusal plane are inadequate.

Periodontium

Supporting structures are healthy.

Sinus anatomy and buccal width of the ridge is inadequate.

TMJs

Right side Piper 2

Left side Piper 2

Both can be superiorly compressed without tension or tenderness.

Muscles

Lateral and medial pterygoids are tender to palpation.

Occlusion

Vertical dimension appears to be closed.

Lower left occlusal plane “steps down” from incisal plane.

Minimal interocclusal space right side

Interferences to the arc of closure

Inadequate centric stop design on left cuspids

Aesthetics

Anterior prosthetic teeth appear small although incisal edge position is adequate.

THE 10 DECISIONS

1. TMJ Diagnosis

Treat to a guided adapted centric posture.

2. Vertical Dimension

Open vertical dimension using an idealized left cuspid-to-cuspid relationship as a guide.

3. Lower Incisal Edge

23–27 are acceptable.

Move the incisal edge of 22 incisally to the same height as 23–27 and facially to develop a stable centric holding contact with 11.

4. Upper Incisal Edge

Use incisal edge of 11 as a reference.

5. Centric Stops

Simultaneous, equal intensity contacts

The linguals of prosthetic teeth 6–10 will need to be modified to gain stable centric holding contacts.

6. Anterior Guidance

Opening the vertical dimension will result in a shallower, flatter anterior guidance performance platform.

7. Curve of Spee

Left side needs to be raised so that anterior aspect is level with the cuspid.

Lower right distal aspect needs to be shortened.

8. Curve of Wilson

Verify that upper buccal and lower lingual cusps do not interfere in the functional and parafunctional range of motion.

9. Cusp/Fossa Angle

Shallower than anterior guidance

10. Aesthetic Plane

Create an upper posterior aesthetic plane that is consistent with the upper incisal edge position and with pleasing buccal profiles.

SUMMARY OF TREATMENT PLAN

Dentition

Keep restorations 11–15.
 Endodontic treatment as needed
 Restore 18–22 to correct occlusal plane and correct cuspid-to-cuspid centric stop.
 5 upper implants are needed to support a removable, palateless partial denture; nonremovable is not possible.

Periodontium

Ongoing self care and professional maintenance

TMJs

No treatment is needed other than correct bite engineering.

Muscles

No treatment is needed other than correct bite engineering.

Occlusion

Open VDO, correct lower left occlusal plane to achieve simultaneous, equal intensity centric stops in the adapted centric posture arc of closure.

Aesthetics

Maintain incisal edges, and increase length gingivally.

SUMMARY OF TREATMENT SEQUENCE

Appointment	Treatment Completed
1	Restore 18–22 at correct vertical dimension. Adjust upper left to improved occlusal plane. Add to 2–10 of current RPD as a provisional.
2	Endodontics as needed
3	Oral surgeon to place implants and graft Modify current provisional RPD.
4	Time for healing/integration
5	Definitive prosthesis bar-retained segmental removable partial denture
6	Maintain as necessary.

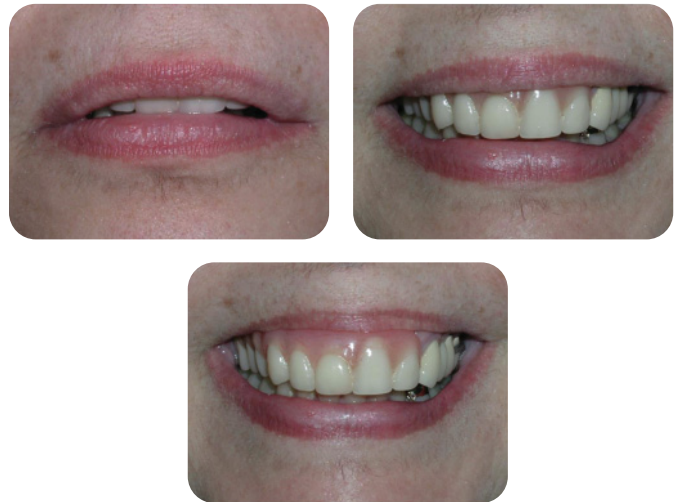

Figure 13.1.1. Pretreatment smile photographs. Incisal edge position is acceptable; however, the incisal-gingival length is too short, and gingival needs to be raised.

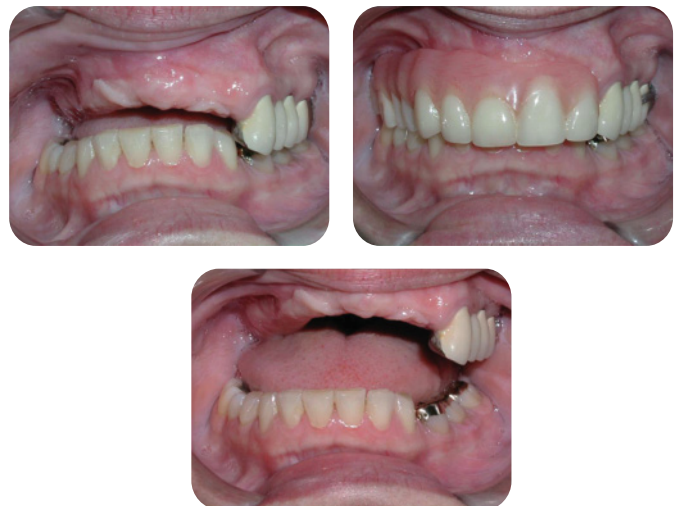

Figure 13.1.2. Pretreatment retracted photographs suggesting lack of interocclusal space, unstable left cuspid-to-cuspid relationship and lower left occlusal plane that is too low anteriorly. Note also the position of prosthetic teeth as it relates to underlying ridge. This is discussed in more depth in upcoming figures.

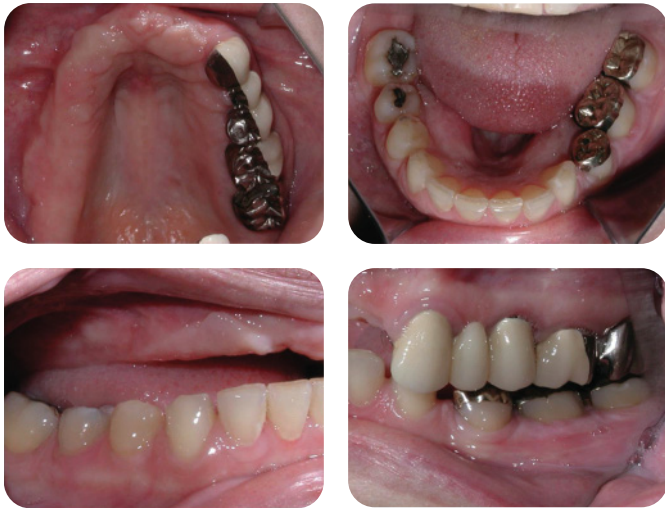

Figure 13.1.3. Pretreatment occlusal and buccal photographs. Note the excessive Curve of Spee on the distal aspect of the lower right molar.

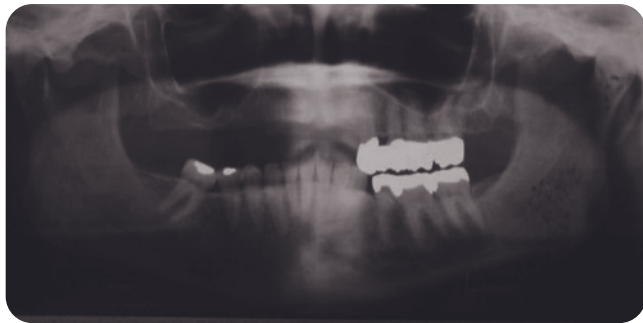

Figure 13.1.4. Pretreatment panoramic radiograph.

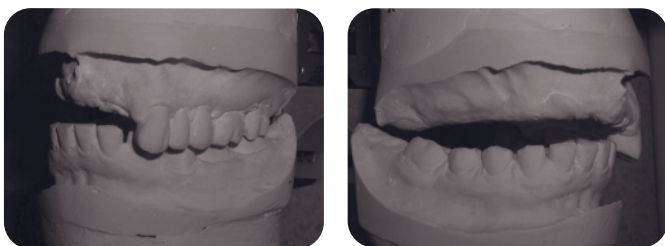
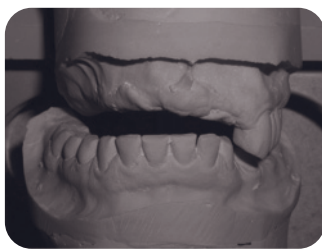

Figure 13.1.5. Pretreatment articulated diagnostic casts at the vertical dimension of the first contact in the adapted centric posture arc of closure. Note unstable cuspid relationship and inadequate interocclusal space, especially at the right second molar.

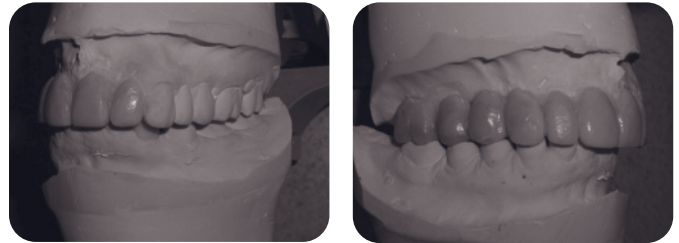
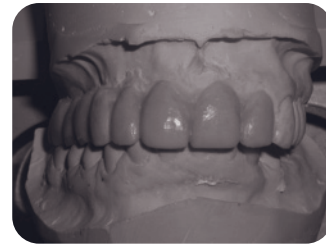

Figure 13.1.6. Initial diagnostic wax-up with the intent of a nonremovable restoration. Note position of teeth to the ridge.

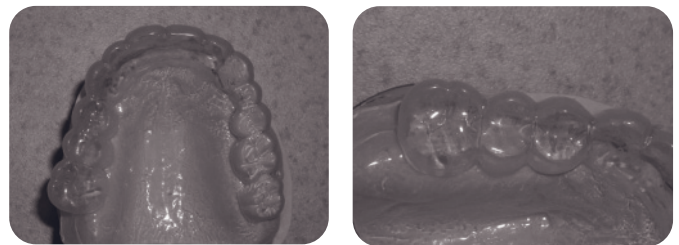
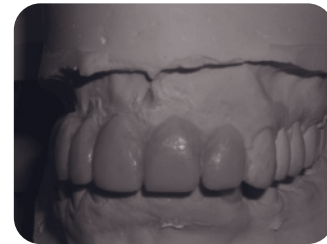

Figure 13.1.7. Note position of anterior teeth to the ridge: A flange is needed. Also note the position of the ridge through the vacuum formed index: The teeth are several millimeters buccal to the ridge. The patient did not want to pursue extensive bone grafting procedures.

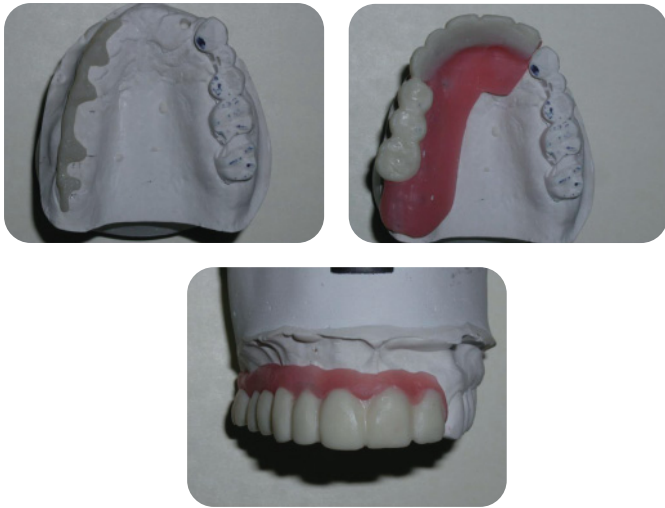

Figure 13.1.8. Second diagnostic wax-up illustrating the removable approach. This illustrates the nonremovable bar and the removable prosthetics. Creating a blueprint that accurately allows the patient to “see” the end result assures that the patient understands what the end result will actually be. This extra effort at the planning stage minimizes patient disappointments with the end result.

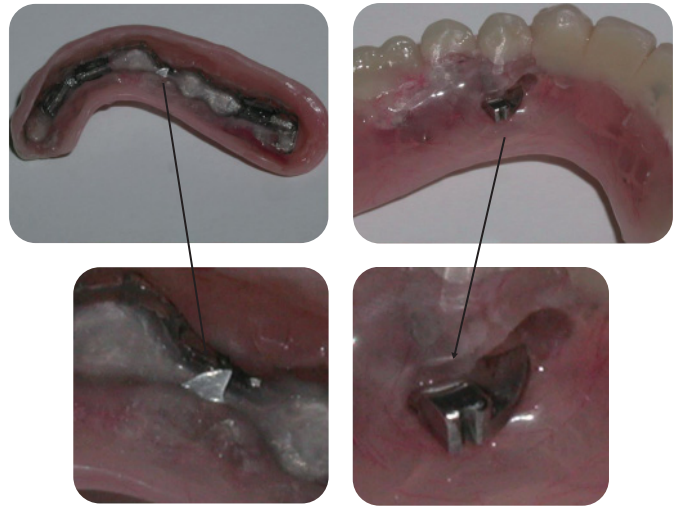


Figure 13.1.11. The bar gives the partial denture lateral and vertical stability but not retention. The retention comes from the locking mechanism, which the patient swings open to unlock and remove the partial denture and swings closed so that the lock engages into a slot in the bar. This is a Swivel-Loc attachment. For more information, see www.attachments.com.

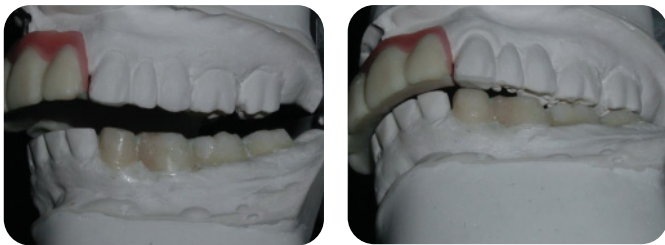

Figure 13.1.9. Buccal view of second diagnostic wax-up illustrating improved occlusal plane, improved cuspid tooth-to-tooth relationship and the design of the lingual of the upper anteriors necessary to gain centric stops.

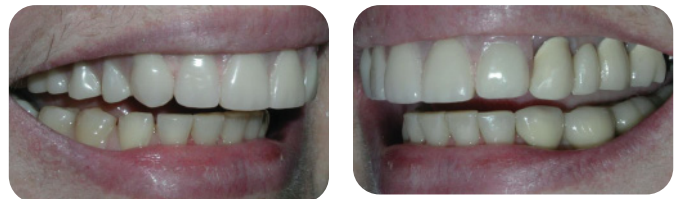
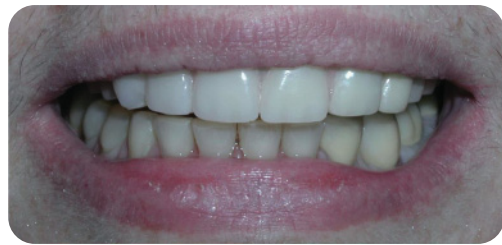
Figure 13.1.12. Posttreatment anterior and lateral smile photographs.

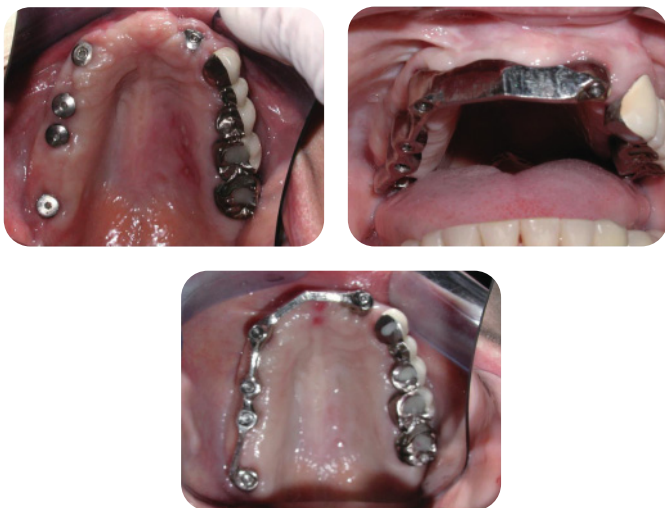

Figure 13.1.10. Photograph of integrated implants and nonremovable laser-welded bar, which will support a removable, segmental partial denture.

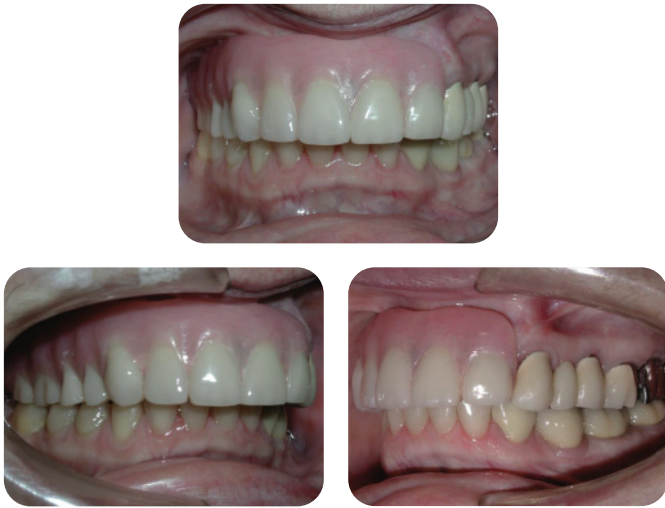

Figure 13.1.13. Posttreatment anterior and lateral retracted photographs suggesting improved vertical dimension and improved incisal-lingual length of the prosthetic teeth.

CHAPTER 13 CASE 1 KEY POINTS

- Determine how the desired tooth position aesthetically and functionally relates to the available bone to determine whether a non-removable approach is an option.
- Create visual 3D diagnostic blueprints so the patient fully understands what you are proposing. It minimizes disappointments and frustrations.

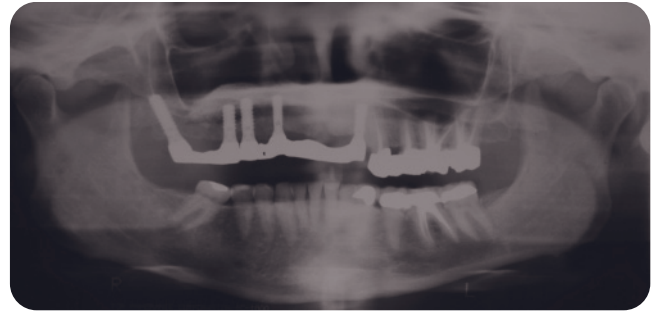

Figure 13.1.14. Five-year posttreatment panoramic radiograph.

Chapter 13 Case 2

Combination mandibular fixed anterior—removable posterior reconstruction with Locator attachments

The patient in this case study also would have preferred a nonremovable solution but the grafting necessary to achieve this was more than the patient wanted to pursue. Implants were utilized to provide additional support and retention for a removable partial denture. Both arches need to be treated; however, the lower arch was the more problematic arch and was the one where the patient wanted to begin treatment. The upper arch was to be sequenced at a future time. The landmarks on the upper arch were acceptable, or easily modifiable, making the sequencing he desired possible without compromise.

SUMMARY OF EXAMINATION AND DIAGNOSIS

Dentition

All restorations are failing to some degree. All teeth on the lower except 22, 23, 27, 28 are not predictably restorable.

Periodontium

Periodontal support is hopeless on all lowers except 22, 23, 27, 28.

TMJs

Right side Piper 3B

Left side Piper 3B

Both can be superiorly compressed without discomfort.

Muscles

Lateral pterygoids are slightly tender to palpation.

Occlusion

All important landmarks are acceptable; there is very slight discrepancy to the arc of closure.

Aesthetics

Color, proportion, and position need slight changes.

THE 10 DECISIONS

1. TMJ Diagnosis

Treat to a guided adapted centric posture.

2. Vertical Dimension

Maintain current VDO.

3. Lower Incisal Edge

Shorten incisors to the level of the cuspids.

4. Upper Incisal Edge

Increase incisors 1 mm, shorten cuspids 1 mm.

5. Centric Stops

Simultaneous, equal intensity centric stops in the ACP arc of closure

6. Anterior Guidance

Acceptable; just smooth and refine.

7. Curve of Spee

Use cuspids as an anterior reference.

Use mesiobuccal cusp of second molar as posterior reference.

Keep right and left on same horizontal plane.

Modify upper occlusal plane by adjusting/adding to current removable partial denture.

8. Curve of Wilson

Verify that upper buccal and lower lingual cusps do not interfere in the functional and parafunctional range of motion.

9. Cusp/Fossa Angle

Shallower than anterior guidance; because lower will be done first, flatten angles on upper by reshaping.

10. Aesthetic Plane

Create an upper posterior aesthetic plane that is consistent with the upper incisal edge position and with pleasing buccal profiles.

SUMMARY OF TREATMENT PLAN

Dentition

Lower, remove all but 22, 23, 27, 28.
 Endodontic therapy or endodontic retreatment therapy as needed
 One implant LL posterior and one implant LR posterior
 Fixed partial denture 22–28
 Implant with Locator attachments and tooth-supported lower removable partial denture
 Upper, remove 3 and 11
 One implant UL
 Fixed partial denture 3–10
 Implant and tooth-supported upper removable partial denture

Periodontium

Maintenance and surgery on remaining teeth
 Implants

TMJs

No treatment is needed other than to correct occlusal engineering.

Muscles

No treatment is needed other than to correct occlusal engineering.

Occlusion

Idealize centric stops with restoration to achieve Simultaneous, equal intensity centric stops in the adapted centric posture arc of closure and anterior guidance on anterior teeth.

Aesthetics

Idealize with restorations.

SUMMARY OF TREATMENT SEQUENCE

Appointment	Treatment Completed
1	Prepare 22, 23, 27, 28. To surgeon for extractions and implant placement Back to office for provisional placement
2	Heal and integrate.
3	Monitor and maintain provisionals.
4	Finalize lower.
5	Same sequence on upper when ready to proceed

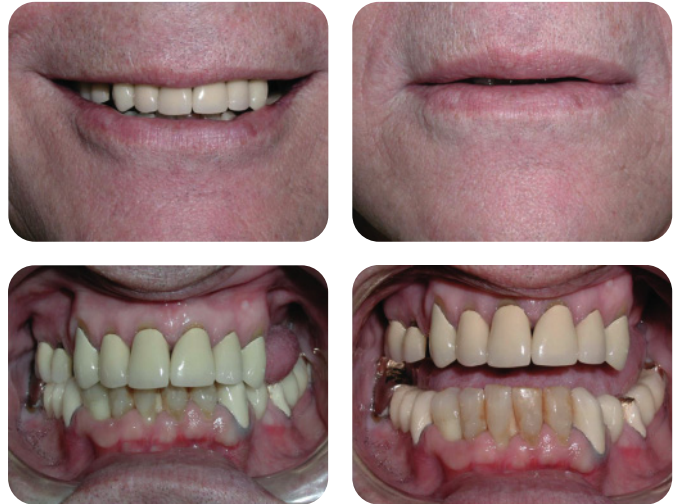

Figure 13.2.1. Pretreatment smile and retracted photographs suggesting lower occlusal plane issues.

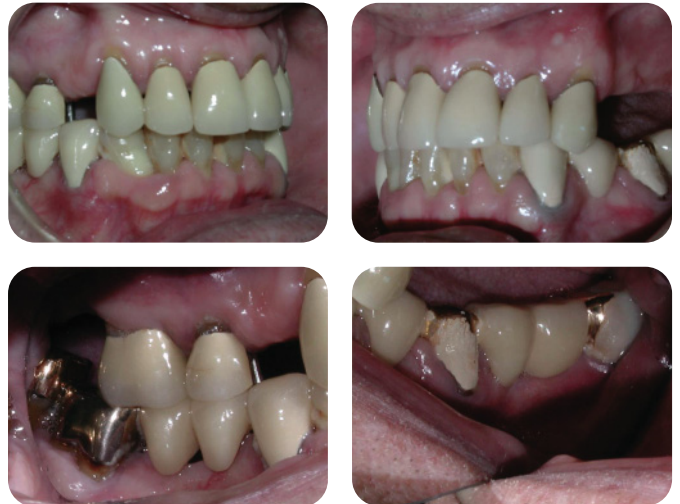

Figure 13.2.2. Pretreatment lateral anterior and buccal posterior photographs. Although both arches have problems, the more urgent arch is the mandibular. The upper can be delayed per patient's desire.

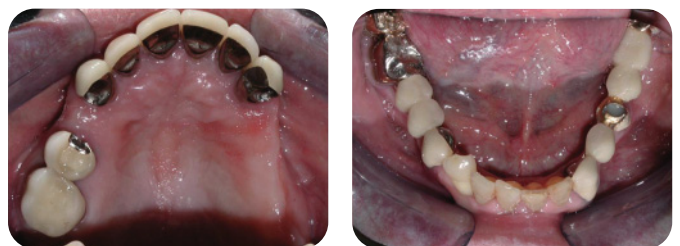


Figure 13.2.3. Pretreatment maxillary and mandibular photographs suggesting severe resorption of the residual ridges making the placement of multiple implants for a nonremovable restoration impossible without extensive grafting.

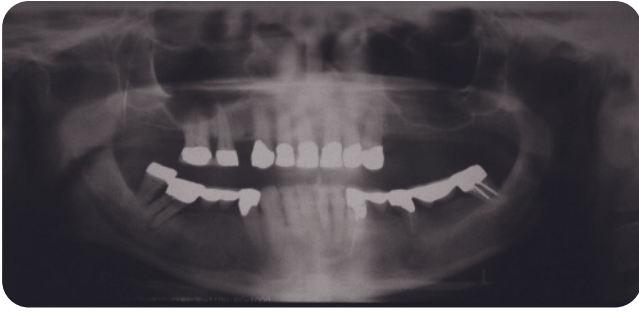

Figure 13.2.4. Pretreatment panoramic radiograph. The lower edentulous areas have acceptable vertical height for implant placement but inadequate buccal-lingual width. Also note the size of the maxillary sinus.

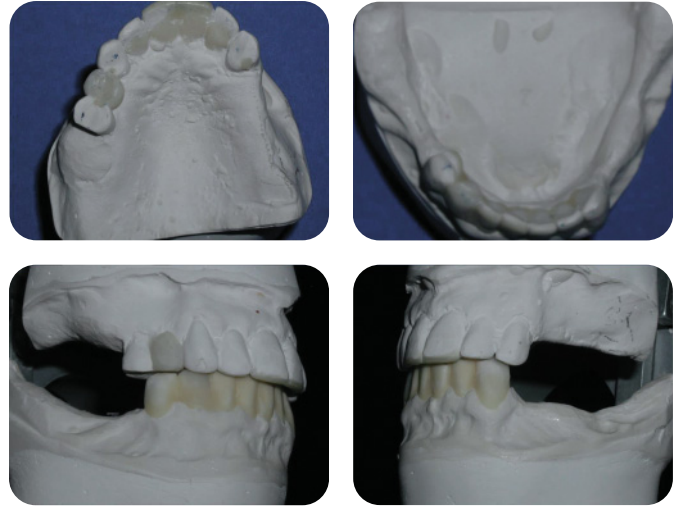


Figure 13.2.6. Diagnostic wax-up of the nonremovable part of the restoration. Right and left cuspid tooth-to-tooth relationship acceptable with current upper cuspid position. The lingual of the upper anteriors were modified to accommodate the changes to the lower incisors but were slight and could be postponed until the restoration is done. The lower incisors will not erupt because they will be part of the fixed partial denture. The upper incisors will not erupt because they are stabilized by the neutral zone.

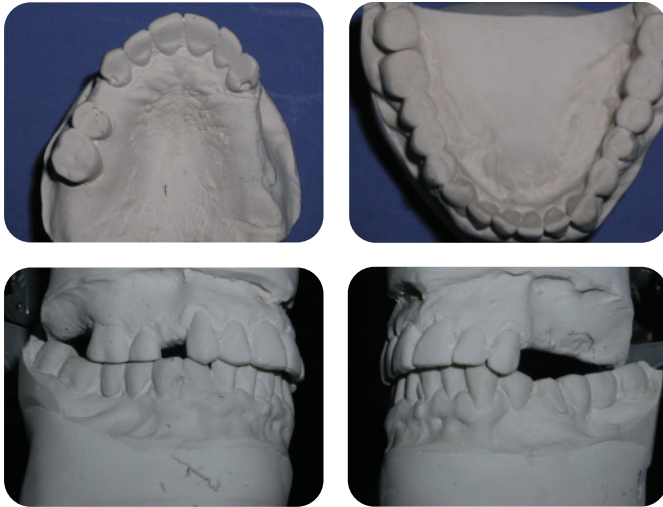


Figure 13.2.5. Pretreatment articulated diagnostic casts. There are slight interferences to the adapted centric posture arc of closure.

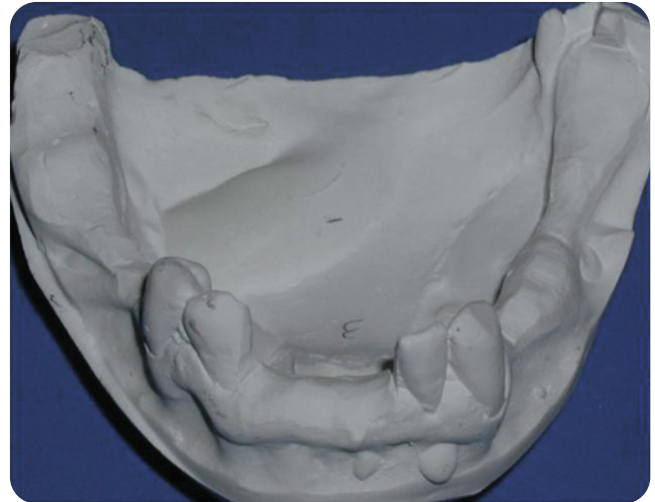


Figure 13.2.7. Patient misunderstandings are always a potential hazard, especially when explaining an involved treatment plan that will involve multiple extractions. This lower diagnostic cast has all the teeth removed except the ones to be saved. This provides the patient an opportunity to actually "see" what will be done and what the lower will look like when the involved teeth are removed.

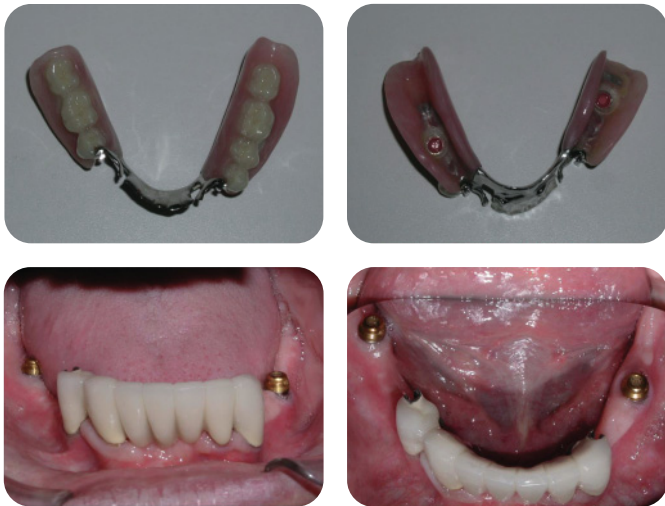

Figure 13.2.8. Posttreatment photographs. The removable partial denture has one implant retained Locator abutment on each side to stabilize and better retain the partial. The fixed part of the restoration has distal semiprecision PD (partial denture) attachments that provides the RPD lateral and vertical stabilization. The retention anteriorly is with a lingual retentive arm.

CHAPTER 13 CASE 2 KEY POINTS

- Determine how the desired tooth position aesthetically and functionally relates to the available bone to determine whether a non-removable approach is an option.
- Locator abutments are ideal for added support and retention for removable partial dentures.
- Always cover the retromolar pad, as in any removable full or partial denture, for added stability.
- Even if treating just one arch, evaluate opposing landmarks and change by reshaping and composite additions.

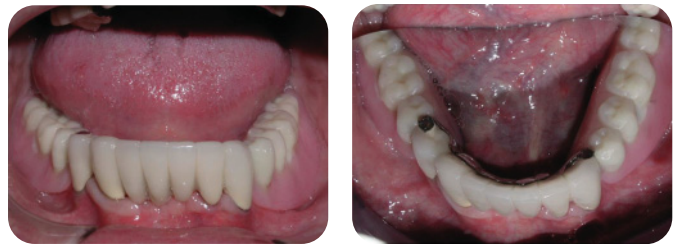

Figure 13.2.9. Posttreatment photographs with the removable partial denture in place. Note that from a facial perspective no metal is visible. The distal extension of the partial denture covers the retromolar pad for added stability. To date, 5 years after completion of the lower, the upper dentistry has not been done. The upper old dentistry and remaining teeth, even though the prognosis is poor, are still present. As stated before, since the upper functional landmarks were acceptable (or easily modifiable), the plan could be sequenced as expected.

14

Combination Fixed-Removable Restoration on Natural Teeth

Case 1 Maxillary bar-supported removable partial denture; lower crowns with semiprecision removable partial denture.

Case 2 Maxillary fixed partial dentures with precision removable partial denture; mandibular bar-supported complete denture.

Case 3 Maxillary telescope case: alumina copings on natural teeth and removable overstructure; mandibular telescope case: Galvano copings on natural teeth and nonremovable overstructures.

Case 4 Mandibular anterior fixed partial denture and posterior removable partial denture with implants and Locator attachments for added support and retention; maxillary reconstruction, telescope case with 1 dental implant included along with 6 teeth.

Chapter 14 Case 1

Maxillary bar-supported removable partial denture; lower crowns with semiprecision removable partial denture

A well-designed fixed-removable reconstruction on natural teeth can be a well-functioning, long-lasting, aesthetic solution for many patients. For many valid reasons, not all patients can, or want, to undergo the procedures to have an implant-supported restoration.

The patient in this case study had a problematic removable reconstruction. It was uncomfortable and the anterior prosthetic teeth kept fracturing. He did not mind that it was removable, only that it was problematic. He had been through some other medical procedures; and although he understood dental implants, he did not want them.

The same fundamental principles of examination, diagnosis, diagnostic blueprint, and treatment planning

apply. The parameters of form and function should “look” the same, whether it is an implant-supported, nonremovable reconstruction or a combination fixed-removable with natural teeth.

SUMMARY OF EXAMINATION AND DIAGNOSIS

Dentition

Many are missing.

Recent crowns are structurally intact but functionally incorrect.

Removable prosthetics are loose and uncomfortable.

Periodontium

Although there is attachment loss, there are no pockets over 5 mm and no mobility.

TMJs

Right side Piper 3B

Left side Piper 3B

Both can be superiorly compressed comfortably.

Muscles

Lateral pterygoids slight tenderness

Occlusion

Interferences and slide to the seated arc of closure; appears to be overclosed

Aesthetics

Current prosthetic teeth unacceptable; uneven aesthetic occlusal plane; maxillary dental midline is not in center of face—3 mm to the left—but this is not an issue to the patient.

THE 10 DECISIONS

1. TMJ Diagnosis

Treat to a verifiable ACP.

2. Vertical Dimension

Open VDO in ACP. Reference points will be corrected, lower anterior plane, with 27 in good centric stop relationship with corrected 6.

3. Lower Incisal Edge

Use 22 as a reference; build others up to this point.

4. Upper Incisal Edge

Use corrected edge of 6 as a reference.

5. Centric Stops

Anterior: customized linguals of prosthetic teeth in ACP

Posterior: restorations and RPD in ACP

6. Anterior Guidance

Opening VDO will shallow the anterior guidance performance platform.

7. Curve of Spee

Left: corrected with crowns; RPD retainer on 18 will even the occlusal plane.

Right: use a point on the same horizontal plane as the corrected 18 as the posterior survey point.

8. Curve of Wilson

Verify that upper buccal and lower lingual cusps do not interfere in the functional and parafunctional range of motion.

9. Cusp/Fossa Angle

Shallower than anterior guidance

10. Aesthetic Plane

Create an upper posterior aesthetic plane that is consistent with the upper incisal edge position and with pleasing buccal profiles.

SUMMARY OF TREATMENT PLAN

Dentition

New splinted crowns 5–6–12 with a bar; 20–21, 27–28; new RPDs

Composites 25, 26 to level the incisal plane

Periodontium

Ongoing maintenance and self care

TMJs

No treatment is needed other than correct occlusal engineering.

Muscles

No treatment is needed other than correct occlusal engineering.

Occlusion

Reconstruction per diagnostic blueprint; open VDO, correct the occlusal and incisal planes, fashion a creative design of linguals 6–11 to gain stops and create a good anterior guidance at the increased VDO.

Aesthetics

Verify that the aesthetic plane of the upper buccal cusps is level and symmetrical and that the facial profiles of the upper posterior teeth are aligned correctly.

Dental midline will still be off center. Keep it vertical.

SUMMARY OF TREATMENT SEQUENCE

Appointment	Treatment Completed
1	Prepare teeth for fixed and removable impressions. Bite records: prep vs. prep; prov vs. prov; lower prov vs. upper prep Insert fixed/removable provisionals
2	Communication with lab tech at all steps
3	Insert all dentistry.
4	Ongoing follow-ups

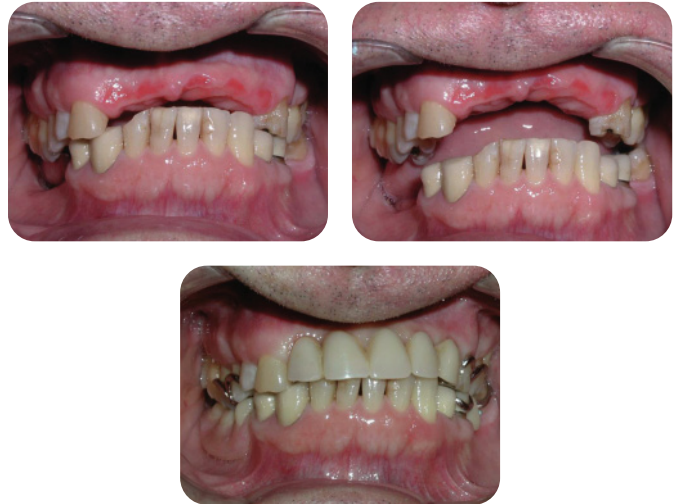

Figure 14.1.1. Pretreatment photographs retracted anterior in maximum intercuspation and teeth separated, as well as maximum intercuspation with current removable partial dentures. Note incisal and occlusal planes.

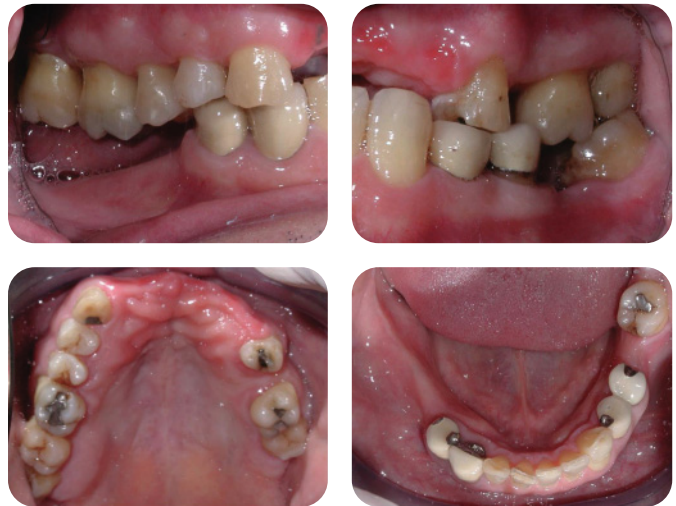

Figure 14.1.2. Pretreatment photographs buccal occluded and maxillary and mandibular occlusal. Lower crowns and RPDs were recently completed.

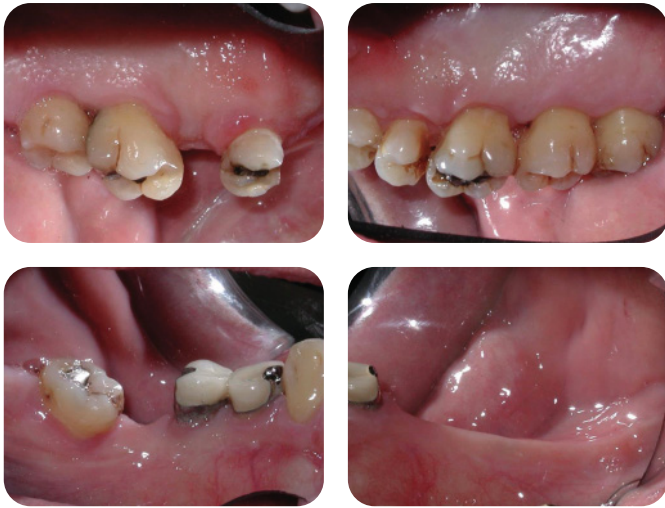

Figure 14.1.3. Pretreatment lingual photographs.

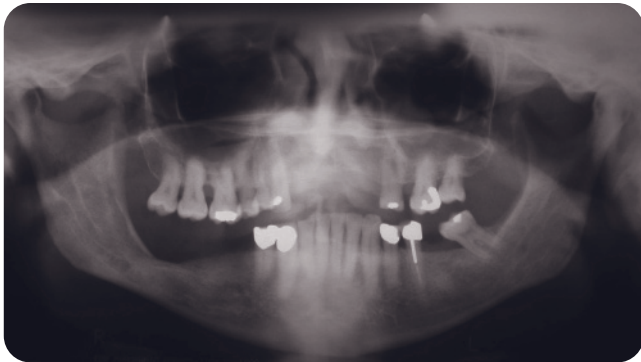

Figure 14.1.4. Pretreatment panoramic radiographs. Patient reported surgery to remove benign lesion lower right posterior 20 years prior.

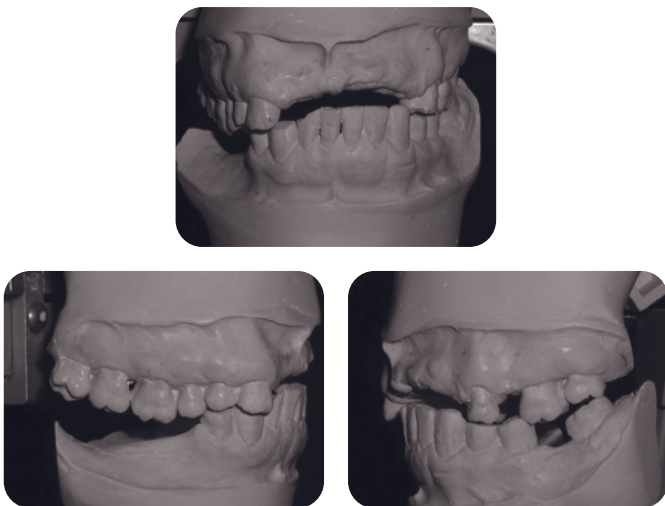


Figure 14.1.5. Pretreatment articulated diagnostic casts mounted in the adapted centric posture arc of closure and photographed at the first contact. Note incline, deflective contacts.

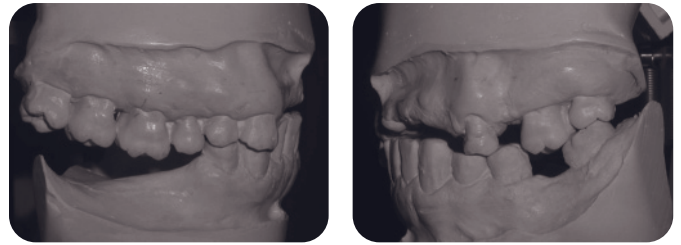


Figure 14.1.6. Pretreatment articulated diagnostic casts photographed in maximum intercuspation. Visualize the slide to get from the first contact in centric to maximum intercuspation.

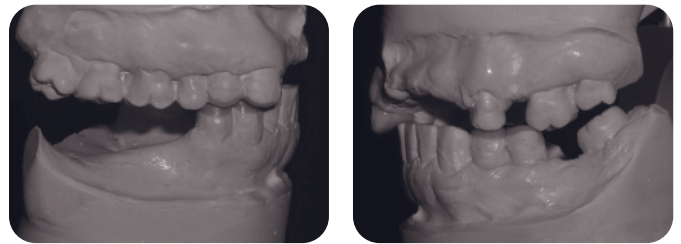
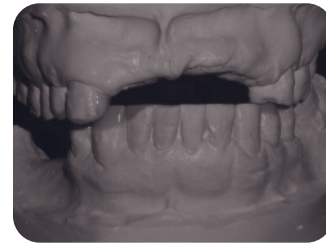

Figure 14.1.7. Diagnostic blueprint. The corrected lower incisal plane in correct occlusion with the upper right cuspid helped determine the treatment vertical dimension of occlusion.

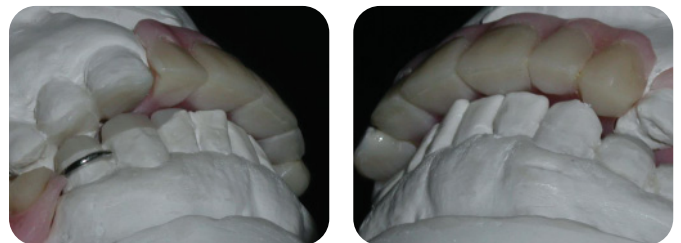
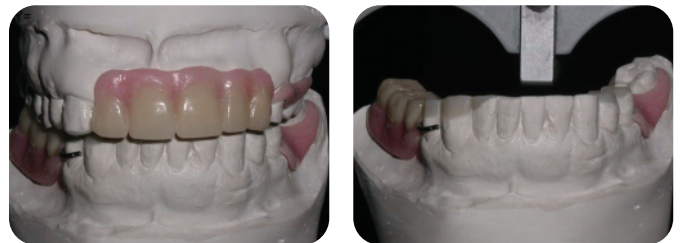

Figure 14.1.8. Diagnostic blueprint with the provisional removable partial dentures illustrating the lingual surfaces customized for accurate centric holding contacts and anterior guidance performance platform.

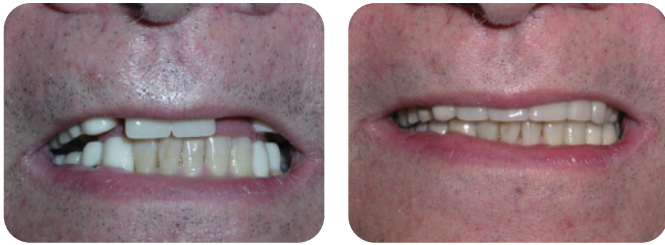

Figure 14.1.9. Photograph of a trial "façade" with the central incisors in the center of the face. This created surrounding space that was too small for a lateral incisor on the patient's right and a space too wide on the patient's left. It was decided to use a setup that had tooth proportions more normal despite the dental midline to the left of the center of the face.

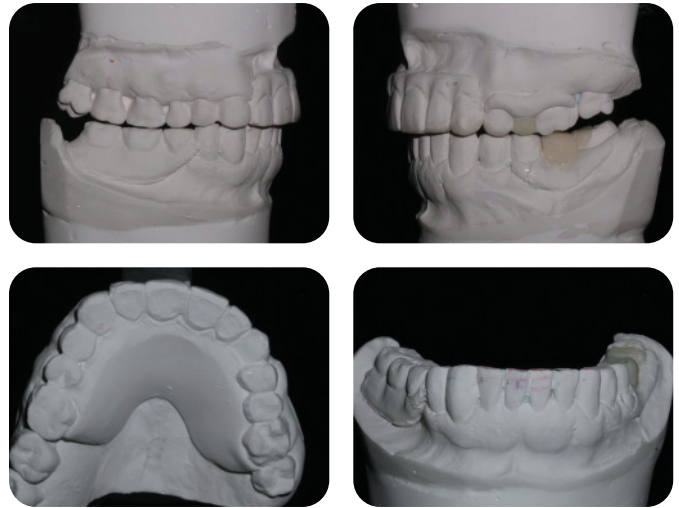


Figure 14.1.11. Articulated casts of the provisionals, both fixed and removable. If further refinements need to be made to better communicate aesthetic and functional landmarks to the technician, these changes can be made with light cured composite or wax, as illustrated on the left bicuspid and molar areas.

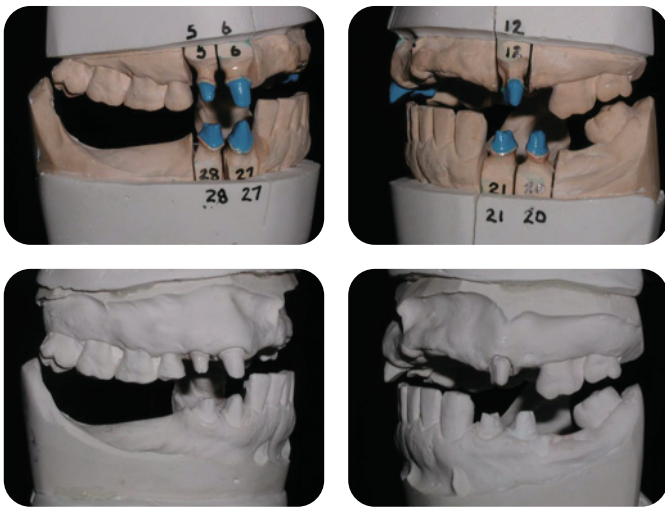


Figure 14.1.10. Photographs of articulated casts of maxillary preparations against mandibular preparations. With the removable provisionals in place, a bite record was made over the preps at the correct vertical dimension of occlusion. With the provisional partial dentures removed, the bite records over the preparations maintained the VDO and the rest of the bite record was made.

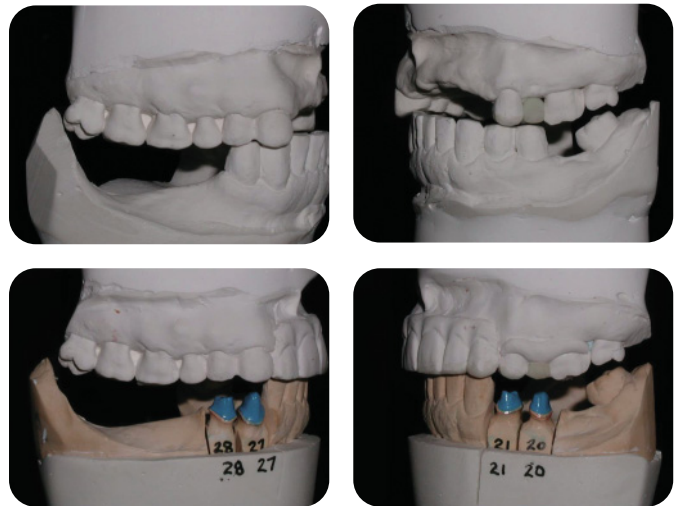


Figure 14.1.12. Articulated casts of the provisionals without the removable partial dentures and articulated casts of the lower preparations against the upper fixed and removable provisionals. This will allow the technician to create the lower restorations first and thereby incorporate the correct functional landmarks into these restorations.

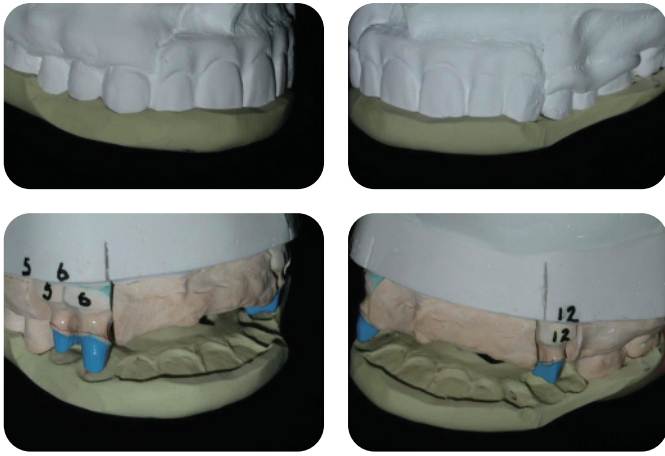


Figure 14.1.13. Putty index made on the maxillary cast of the provisionals, which then transfers to the casts of the preparations. This helps the technician create the aesthetic and functional landmarks of the provisionals into the definitive restorations.

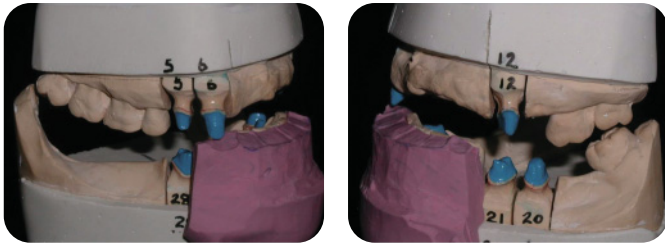


Figure 14.1.14. A putty index made of the upper incisal edges and lingual surface made with the casts in occlusion. With this index on the lower cast, the technician can accurately reproduce the lingual contours of the provisionals into the definitive restorations.

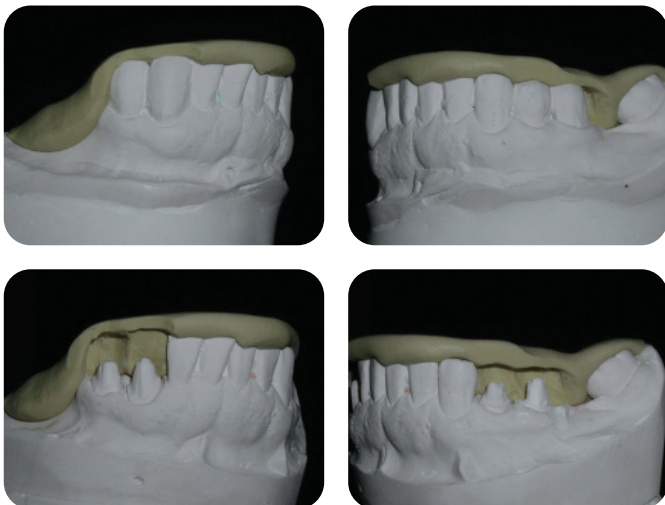


Figure 14.1.15. Mandibular putty index made on the cast of the lower fixed provisionals without the removable provisionals. This will help the technician accurately re-create the lower functional landmarks.

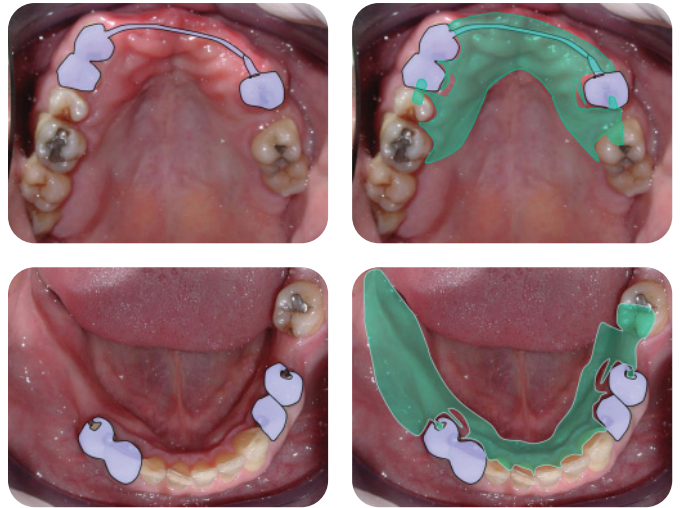


Figure 14.1.16. Drawing on maxillary and mandibular photographs communicating the desired design of the fixed and removable aspects to the technician. The upper fixed restoration will have a bar between the abutments. The removable aspect will fit over the bar for vertical and horizontal stabilization. Retention will come from lingual retentive arms on the bicuspids. The mandibular design will be splinted crowns with distal semiprecision slots for vertical and lateral stability. Retention will come from lingual retentive arms on the most distal abutments.

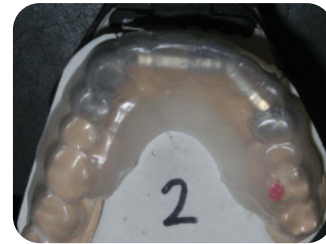

Figure 14.1.17. Photograph of a vacuum-formed index made on the cast of the upper fixed and removable provisionals. This fits over the cast of the preps, which helps the technician design a bar that will not interfere with the placement of the prosthetic teeth.

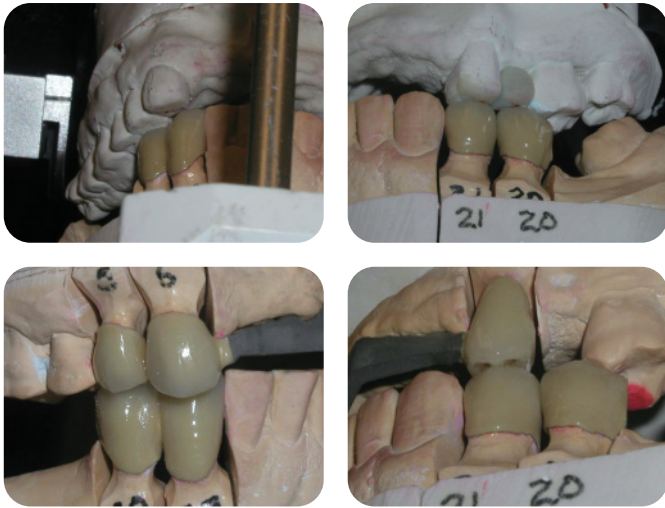

Figure 14.1.18. The top photograph shows the mandibular fixed restorations against the upper cast of the fixed provisionals. Because these are made first, the aesthetic and functional landmarks are incorporated correctly into the lower restorations. The upper fixed aspect is then fabricated against the already completed lower restorations, as illustrated in the bottom photographs.

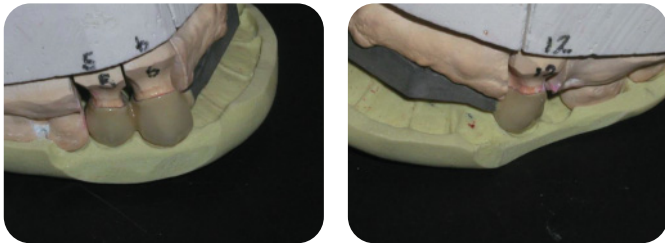


Figure 14.1.19. Photograph of the maxillary fixed portion being checked with the putty index of the maxillary provisional restorations. Areas of deficient contours can be seen and further modified by the technician.

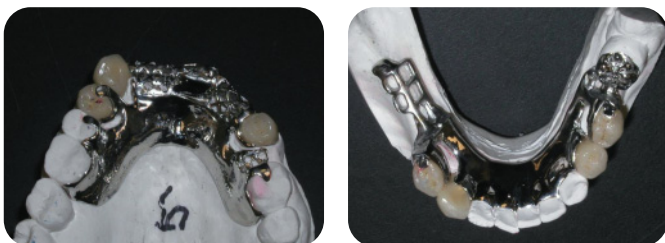

Figure 14.1.20. Photograph of the maxillary and mandibular removable frameworks prior to placement of the prosthetic teeth.

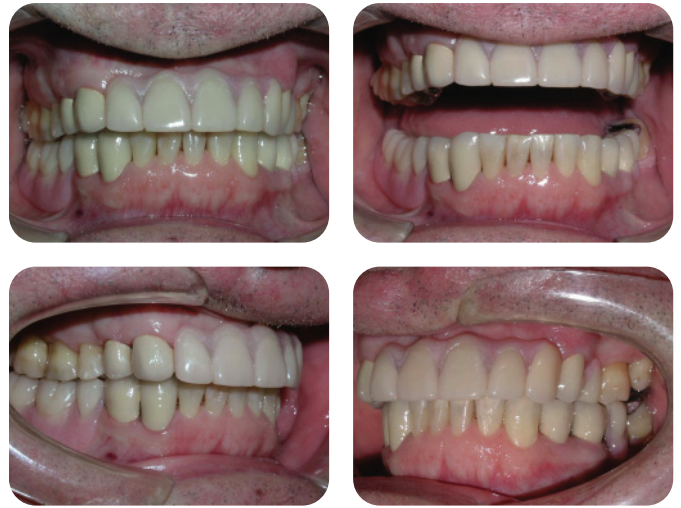

Figure 14.1.21. Photographs of the maxillary and mandibular completed fixed and removable dentistry. This was placed on the next appointment after the preparations. With accurate impressions, bite records, and technician communication, this type of predictability is routinely achievable.

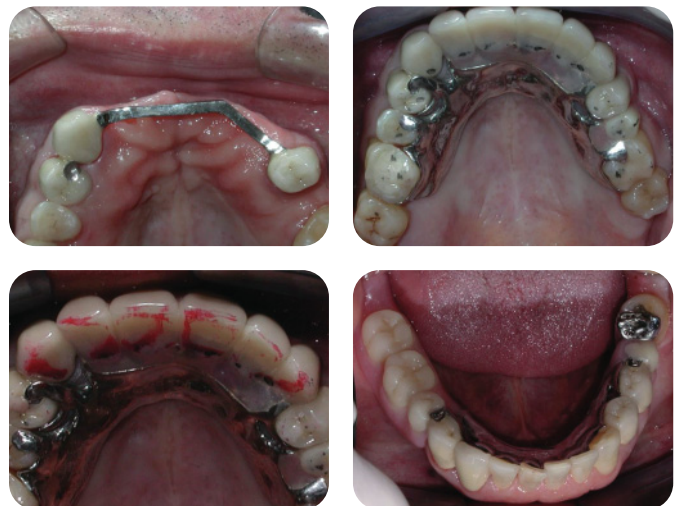

Figure 14.1.22. Occlusal photographs of the maxillary and mandibular completed dentistry. The top left photograph illustrates the design of the bar. The top right photograph illustrates the maxillary removable partial denture with centric stops marked. Note the design of the lingual surfaces of the upper anterior teeth, which is laboratory processed composite resin over the denture teeth. The bottom left photograph illustrates the anterior guidance functional movements—protrusive guidance on the incisors and lateral guidance on the cuspids. The bottom right photograph illustrates the lower completed dentistry. The large occlusal rest on the lower left second molar completes the correct occlusal plane of the tipped molar. As of the date of this text, this dentistry is 7 years old and has required minimal to no maintenance.

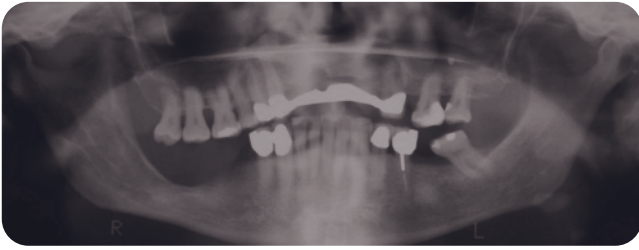


Figure 14.1.23. Posttreatment panoramic radiograph.

CHAPTER 14 CASE 1 KEY POINTS

- Removable cases need the same complete exam, articulated diagnostic casts, and diagnostic wax-up as any reconstruction case.
- A bar in an edentulous space provides maximal vertical and horizontal stabilization, needing only retention from a lingual clasp—simple and very aesthetic.
- Communicate desired tooth position to the technician before designing the bar so that it does not interfere with proper tooth placement.
- The better the communication to the technician with putty indices and casts of provisionals, the better the result.

Chapter 14 Case 2

Maxillary fixed partial dentures with precision removable partial denture; mandibular bar-supported complete denture

The patient in this case study had struggled with upper and lower removable partial dentures for many years. A comprehensive approach was offered many times in the past by her previous dentist but, for various reasons, it was never pursued. She has a wide variety of medical problems that make treatment very difficult and uncomfortable and she is apprehensive.

Intracapsular and muscular signs and symptoms of a temporomandibular disorder were present. Her condition has deteriorated to the point that she feels she has no choice but to move forward with a comprehensive plan. Her previous dentist has suggested orthognathics but she did not want this approach because of her medical conditions and fear of postoperative problems.

A broken clasp on her lower removable partial denture brought her in as a new patient. As we spoke, she asked some very good questions: Should I get this fixed? Should I get a new one? If I don't get it fixed, will it damage the surrounding teeth? What are my other options?

Obviously, there is no way to give an answer right on the spot. It is unfair to the dentist and the patient to try to do so. It was explained that these things could be figured out with some thought, but a complete exam needed to be done first. We talked about what that entailed, and she would not leave that day until the complete exam was done.

At first, she had difficulty understanding the approach of her treatment plan. She was a very visual person and we used some creative methods of communicating the outcome to help her fully understand.

SUMMARY OF EXAMINATION AND DIAGNOSIS

Dentition

Many missing teeth
Current restorations failing

Periodontium

Fragile, significant attachment loss, grade 1 mobility
Lower left bicuspid is not maintainably healthy; the rest of the teeth are maintainably healthy.

TMJs

Right side Piper 3B
Left side Piper 3B
Both have tenderness to superior compression and to palpation.

Muscles

Pterygoids are rather tender to palpation.

Occlusion

Maxillary-to-mandibular tooth-to-tooth malrelationship
Overclosed due to lack of posterior support

Aesthetics

Appears overclosed
Dental midline not centered

THE 10 DECISIONS**1. TMJ Diagnosis**

Start provisionals in a treatment position because TMJs cannot be superiorly compressed comfortably. The goal is adapted centric posture.

2. Vertical Dimension

Open to the vertical dimension that positions the anterior teeth at about 3mm overbite.

3. Lower Incisal Edge

27 needs to be brought 4–5mm facial of current position, making a crown and bridge approach difficult. Preparing the teeth for copings and making an overdenture will allow ideal placement. Verify height with wax try-in using slight display with relaxed lower lip as a guide.

4. Upper Incisal Edge

Use corrected upper right cuspid as a reference.

5. Centric Stops

Simultaneous, equal intensity centric stops in the ACP arc of closure

6. Anterior Guidance

Opening the vertical dimension of occlusion will make the anterior guidance performance platform shallower and flatter.

7. Curve of Spee

Idealize with lower prosthetic teeth.

8. Curve of Wilson

Verify that upper buccal and lower lingual cusps do not interfere in the functional and parafunctional range of motion.

9. Cusp/Fossa Angle

Shallower than the anterior guidance performance platform

10. Aesthetic Plane

Verify that the aesthetic plane of the upper buccal cusps is level and symmetrical and that the facial profiles of the upper posterior teeth are aligned correctly.

SUMMARY OF TREATMENT PLAN**Dentition**

FPD 2–6, 12–15, and precision RPD for maxillary Gold copings splinted 22–27–28 with bar and overdenture for mandibular

Periodontium

Ongoing maintenance and self-care
Connective tissue grafting

TMJs

No treatment is needed other than correct occlusal engineering.

Muscles

No treatment is needed other than correct occlusal engineering.

Occlusion

Reconstruction per diagnostic blueprint; open vertical dimension of occlusion; correct the occlusal and incisal planes. Lower landmarks are so far off, the overdenture approach was chosen. It gave the most leeway to position teeth to fulfill these landmarks.

Aesthetics

Open vertical dimension of occlusion; arrange upper anterior prosthetic teeth to ideal. Maxillary dental midline will be off center.

SUMMARY OF TREATMENT SEQUENCE**Appointment****Treatment Completed**

1	Prepare 22, 27, 28 for gold copings splinted with a bar and overdenture.
2	Deliver lower, modify upper by reshaping and composite additions to accommodate corrected lower.
3	Prepare upper right, provisionalize, and modify her current all-acrylic RPD.
4	Prepare upper left, provisionalize, and modify her current RPD; make impressions and bite records.
5	Deliver upper definitive dentistry.

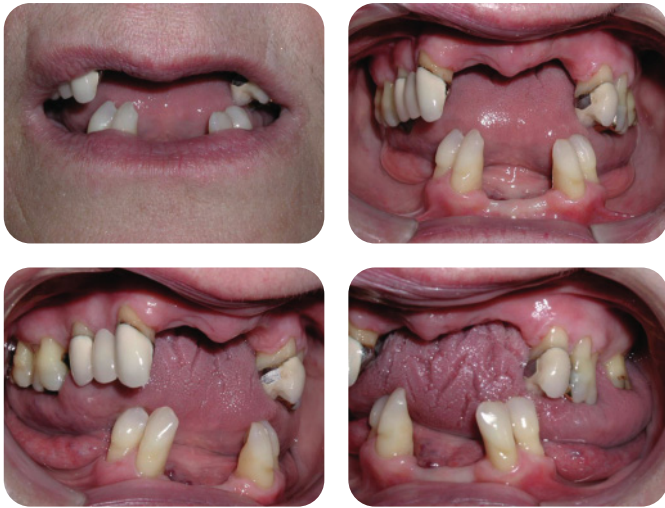

Figure 14.2.1. Pretreatment smile and retracted photographs suggesting lower incisal plane issues in both a vertical and horizontal dimension. The lower right cuspid and bicuspid are elongated and lingually displaced.

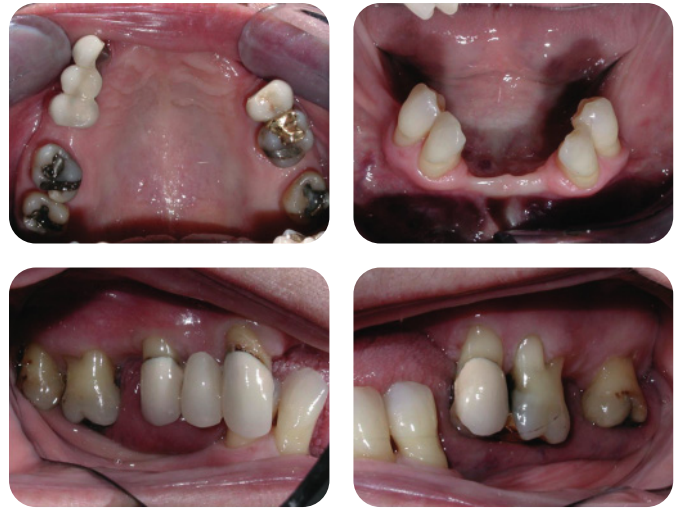

Figure 14.2.3. Pretreatment occlusal and buccal photographs suggesting vertical dimension issues and lower tooth position issues.

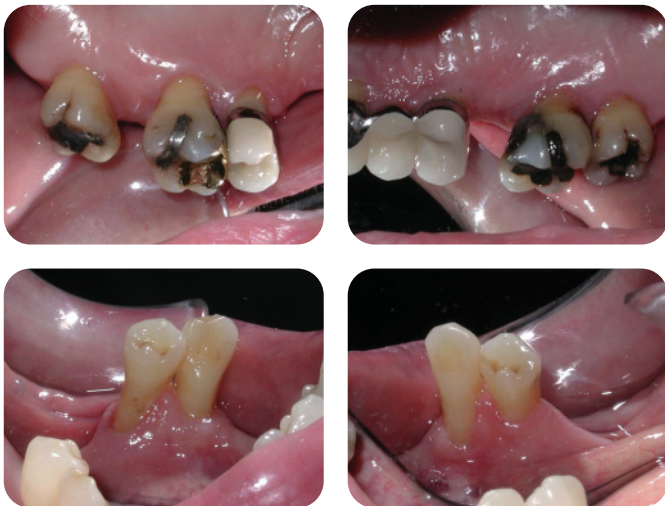

Figure 14.2.2. Pretreatment lingual photographs suggesting failing upper restorations.

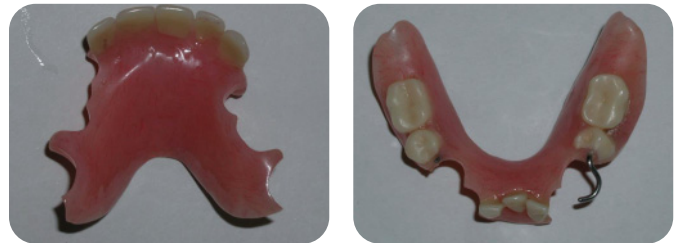

Figure 14.2.4. Photographs of patient's current upper and lower all-acrylic removable partial dentures. The fractured clasp on the lower prosthesis is what initiated the appointment.

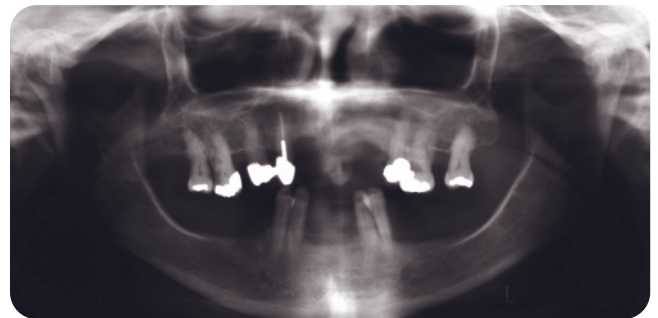


Figure 14.2.5. Pretreatment panoramic radiograph. Although there may have been enough bone for straightforward placement of implants, the patient had no desire to pursue this approach.

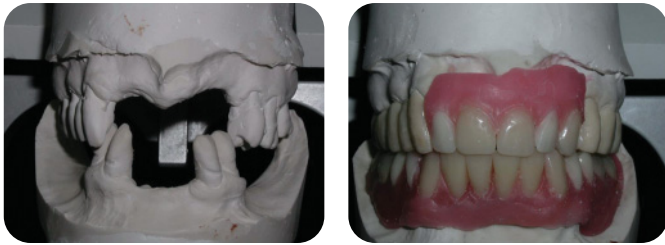


Figure 14.2.6. Photograph of pretreatment articulated diagnostic casts and diagnostic blueprint. The diagnostic blueprint shows the fixed and removable aspects of the treatment plan for better patient communication.

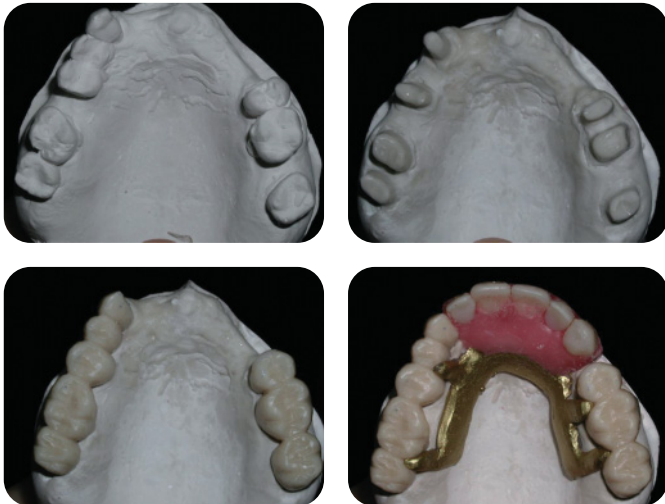


Figure 14.2.7. Photographs of the detailed maxillary diagnostic blueprint illustrating tooth preparations, provisional fixed restorations, and a prototype of the removable partial denture.

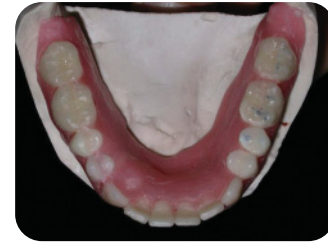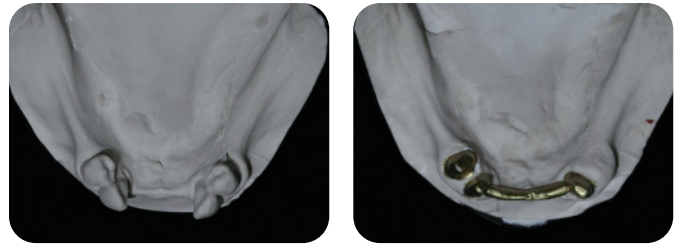


Figure 14.2.8. Photographs of the detailed mandibular diagnostic blueprint illustrating the gold copings and bar on the remaining three teeth and the removable overdenture. The overdenture approach allowed the lower anterior teeth to be positioned ideally for proper centric holding contacts with the upper anterior teeth. These prototypes were made because the patient was having a difficult time understanding the nature and scope of the treatment plan. Photos and verbal discussions helped but she still was not clear until these prototypes were made. Once she saw these, she proceeded immediately to begin treatment.

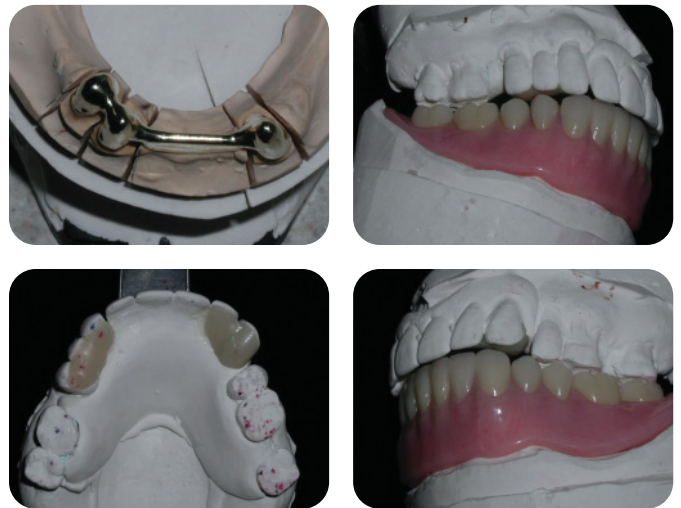

Figure 14.2.9. Photographs of the lower definitive restorations. The lower complete denture has a clip on the inside that attaches to the gold bar to provide retention. The treatment was staged into smaller segments to accommodate her difficulty in tolerating dental procedures. Since the lower was completed prior to the upper being provisionalized, the upper landmarks were improved with reshaping and composite additions on the maxillary cast to give the technician precise communication. When the lower dentistry was delivered, these same changes were made to her maxillary dentition by the same method.

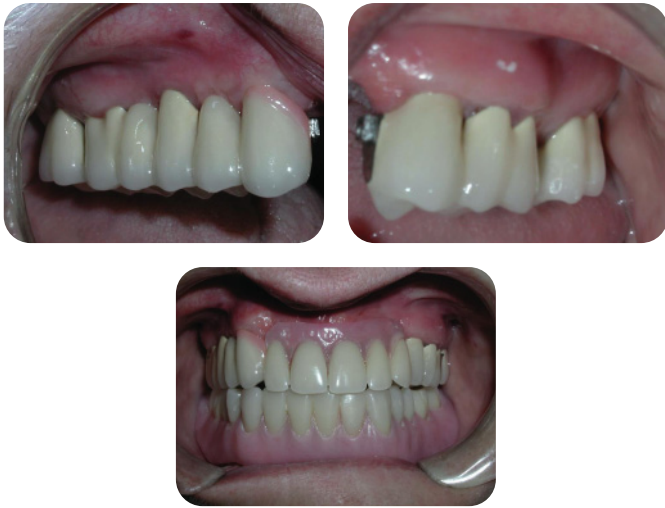

Figure 14.2.10. Photographs of the definitive maxillary fixed partial dentures and maxillary and mandibular removable restoration. The bottom photograph is prior to occlusal refinement.

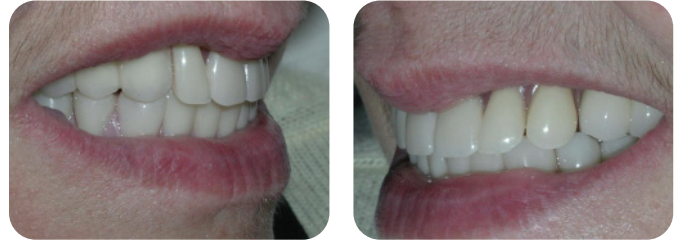
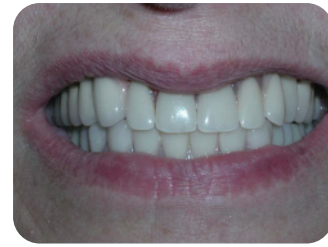
Figure 14.2.12. Anterior and lateral smile photographs of the definitive dentistry. Occlusion has been refined.

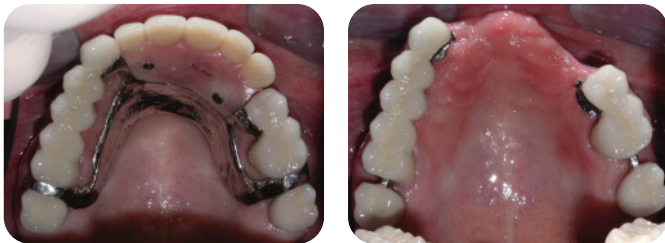

Figure 14.2.11. Photographs of the completed maxillary dentistry with and without the removable partial denture. Retention is provided by two plunger-type attachments in the removable portion that engage the extracoronal attachment on the mesial of the fixed partial dentures. This is the Dawson D 2.7 attachment. The distal connectors on the removable partial denture fit over the small bars between the molars on the fixed partial dentures. This adds lateral and vertical stability and not retention.

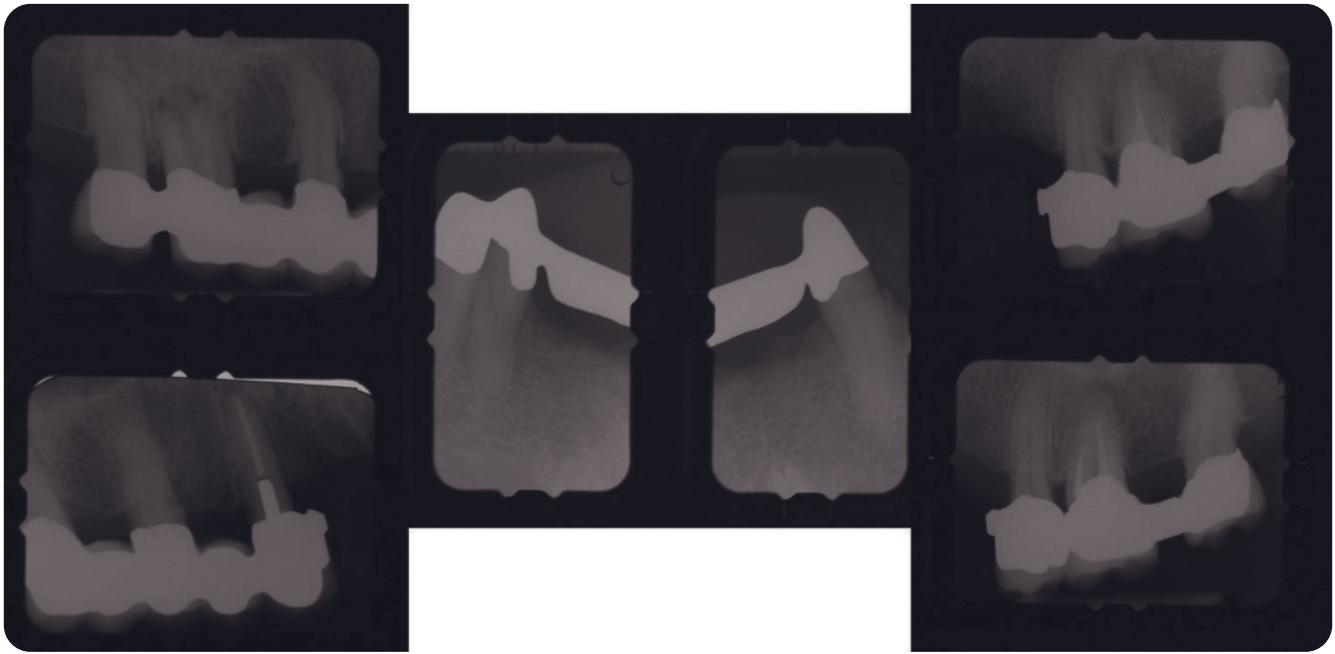


Figure 14.2.13. Posttreatment radiographs. Endodontics by a specialist was completed on the maxillary left first molar prior to provisionalization. The maxillary right first molar developed a periapical lesion 2 years after completion of the dentistry and was treated by the endodontist. This case has been mechanically problem-free as of this writing, 5 years posttreatment.

CHAPTER 14 CASE 2 KEY POINTS

- Removable cases need the same complete exam, articulated diagnostic casts, and diagnostic wax-up as any reconstruction case.
- Be creative in communicating with provisional mock-ups. The better the patient understands, the less confused he/she will be. Confused patients don't say yes.
- When sequencing a case, modify the opposing landmarks as necessary with reshaping and composite additions. You might also need to do this on the articulated working casts.

Chapter 14 Case 3

Maxillary telescope case: alumina copings on natural teeth and removable overstructure; mandibular telescope case: Galvano copings on natural teeth and nonremovable overstructures

The patient in this case study had failing maxillary and mandibular restorations, which included uncomfortable and unstable removable partial dentures. There was recurrent decay that was deep pulpally and subgingivally in areas. There were also endodontic concerns. She did not want to lose any teeth unless it was absolutely necessary, and although she understood the benefits of dental implants, she decided to pursue a nonimplant approach. Removable partial dentures were acceptable to her if they were comfortable and stable.

SUMMARY OF EXAMINATION AND DIAGNOSIS

Dentition

Failing restorations
Endodontic concerns; upper left lateral incisor has a guarded prognosis
All teeth restorable

Periodontium

Biologic width concerns due to recurrent decay
Crown length concerns

TMJs

Right side Piper 3B
Left side Piper 3B
Both can be superiorly compressed comfortably

Muscles

Lateral pterygoids uncomfortable to testing

Occlusion

Appear overclosed
Curve of Spee excessive

Aesthetics

Inadequate upper incisal edge display
Reverse anterior smile line
Maxillary anteriors appear to be facially inclined
Gingival levels uneven

THE 10 DECISIONS

1. TMJ Diagnosis

Treat to adapted centric posture.

2. Vertical Dimension

Open to increase interocclusal space posteriorly and improve anterior tooth-to-tooth relationship

3. Lower Incisal Edge

Use the height of the cuspids as a reference; shorten incisors.

4. Upper Incisal Edge

Increase length centrals 2 mm and move edge/facial surface lingually to accommodate lower lip closure path.

5. Centric Stops

Simultaneous, equal intensity centric stops in the adapted centric posture arc of closure

6. Anterior Guidance

Shallower because of increased VDO, determined by final lower and upper edges

7. Curve of Spee

Flatten excessive curve in lower second molar area.

8. Curve of Wilson

Verify that upper buccal and lower lingual cusps do not interfere in the functional and parafunctional range of motion.

9. Cusp/Fossa Angle

Shallower than anterior guidance disclusive angle

10. Aesthetic Plane

Create an upper posterior aesthetic plane that is consistent with the upper incisal edge position and with pleasing buccal profiles.

SUMMARY OF TREATMENT PLAN

Dentition

Remove upper left lateral incisor.
 Retreat endodontics upper right cuspid
 Upper fixed removable on alumina telescope copings
 Lower fixed on Galvano telescope copings

Periodontium

Crown lengthening surgery to improve biologic width issues and to even gingival levels

TMJs

No treatment is needed other than correct occlusal engineering.

Muscles

No treatment is needed other than correct occlusal engineering.

Occlusion

Improve anterior tooth-to-tooth centric stops.
 Simultaneous, equal intensity centric stops in the adapted centric posture arc of closure

Aesthetics

Increase length; bring facial surfaces lingually; improve contours and proportions.

SUMMARY OF TREATMENT SEQUENCE

Appointment	Treatment Completed
1	Provisionalize all upper and lower. Utilize current maxillary removable partial denture as a provisional.
2	Periodontist to perform crown-lengthening surgery and remove upper left lateral incisor
3	Retreat endodontics upper right cuspid and any others as needed.
4	Finalize lower.
5	Finalize upper.

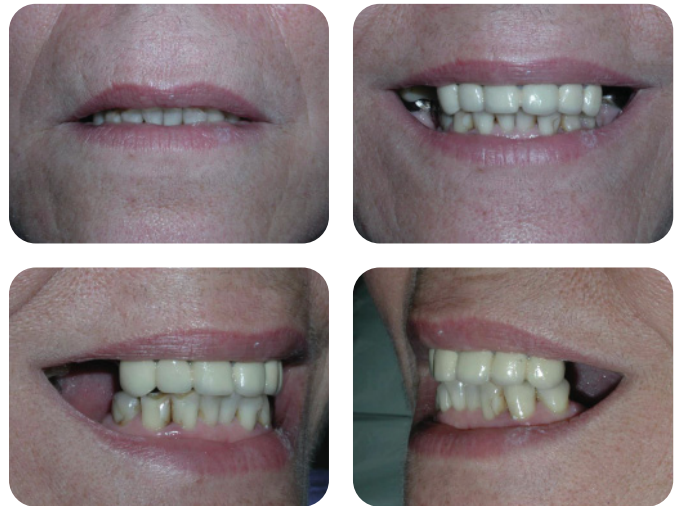

Figure 14.3.1. Pretreatment anterior and lateral smile photographs. Upper left photograph is with lip at rest showing none of the maxillary incisal edges. Also note the reverse smile line. Patient would like to display more of the maxillary anterior teeth and also feels the teeth are too protruded.

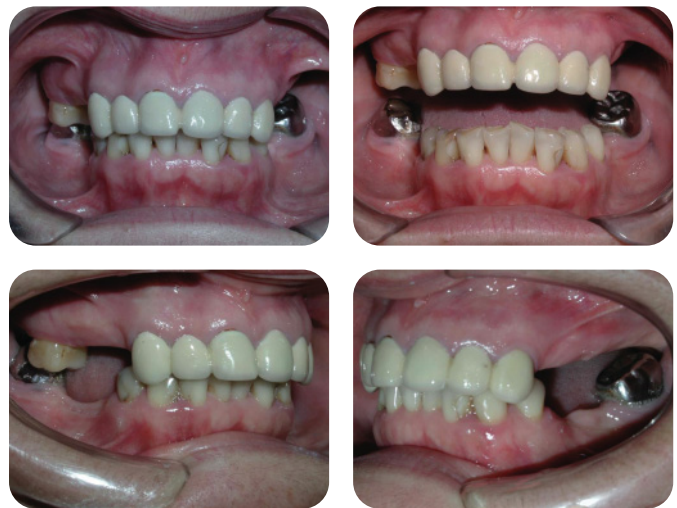

Figure 14.3.2. Pretreatment anterior and lateral retracted photographs suggesting uneven gingival levels, severe Curve of Spee, uneven lower incisal plane, minimal interocclusal space, and unattractive maxillary anterior contours and proportions.

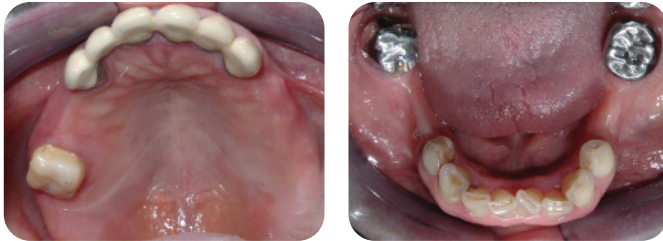
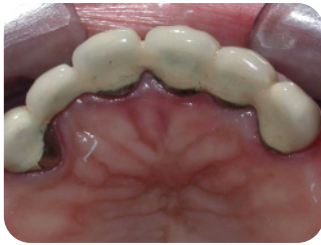

Figure 14.3.3. Pretreatment maxillary and mandibular occlusal photographs.

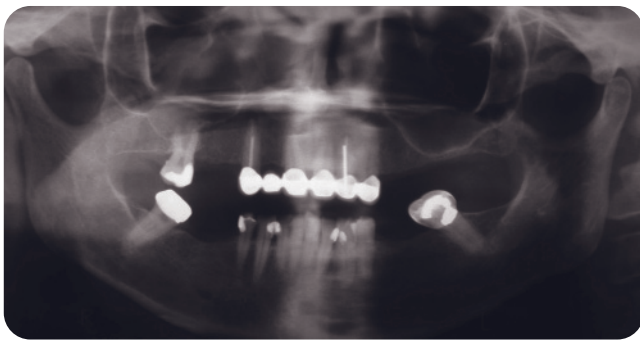


Figure 14.3.4. Pretreatment panoramic radiograph suggesting endodontic concerns and several deep restorations. Bone levels are acceptable and there is no significant mobility.

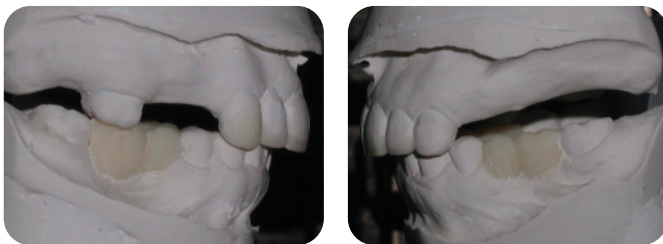
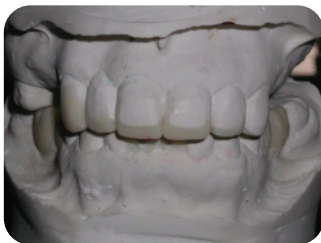

Figure 14.3.5. Anterior and lateral photographs of the diagnostic blueprint suggesting an increase in the vertical dimension of occlusion, flattening of the Curve of Spee, increase in maxillary anterior length, improvement in maxillary anterior proportions and contours, and decreasing the protrusive inclination of the maxillary anterior teeth. The facial surfaces are now perpendicular to the occlusal plane.

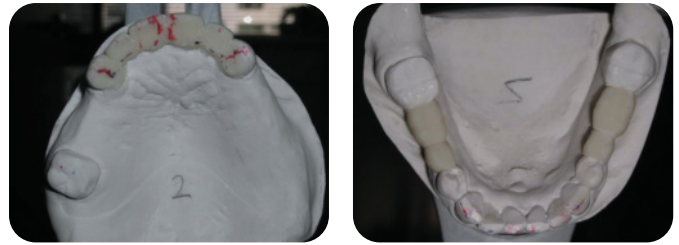


Figure 14.3.6. Occlusal photographs of the diagnostic wax-up illustrating enhanced maxillary cingulum for improved stability of anterior tooth-to-tooth contacts and a more idealized anterior guidance performance platform.

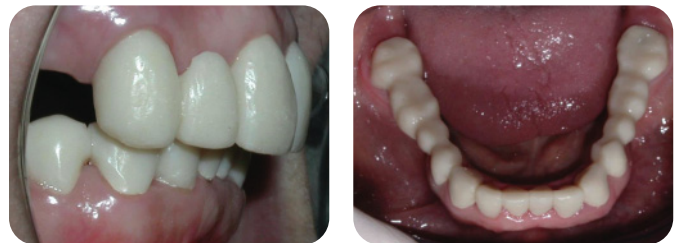
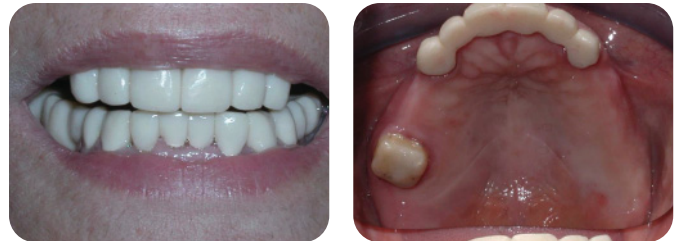
Figure 14.3.7. Two-week postoperative photographs of the provisional restorations suggesting a close resemblance to the diagnostic wax-up. The upper right second molar was acceptable and was not changed. The patient was very pleased with the aesthetics, the feel to the lips, and phonetics.

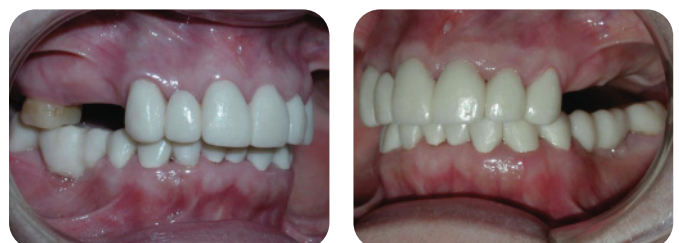
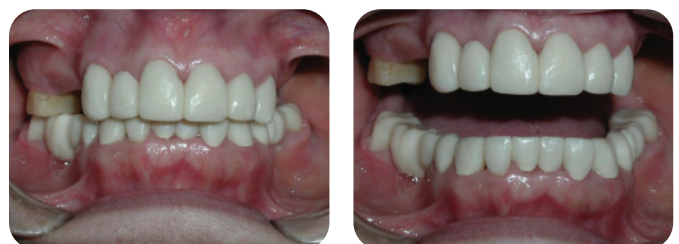
Figure 14.3.8. Anterior and lateral retracted photographs of the provisionals suggesting improved Curve of Spee, incisal planes, vertical dimension, and anterior tooth-to-tooth relationships.

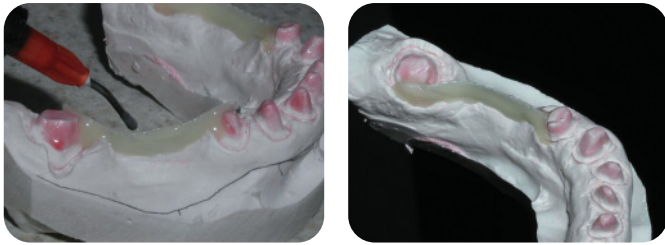

Figure 14.3.9. The lower posterior long-span provisionals are reinforced with Ribbond for increased durability, considering the increased duration of use during healing of the periodontal surgery. The Ribbond is attached to the cast and reinforced with flowable composite prior to processing the acrylic over the Ribbond scaffold.

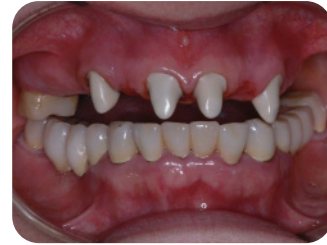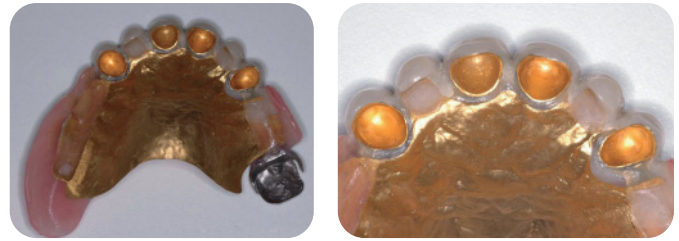


Figure 14.3.11. Photographs of the maxillary definitive dentistry. The copings on the maxillary anteriors are alumina rather than Galvano simply so that the patient does not display gold when the removable partial denture is removed. The removable portion has Galvano copings incorporated and composite processed over these copings, which fits over the natural teeth. The intimate fit of the Galvano copings provides good retention. The major connector is electroplated Galvano material for a very precise, intimate fit onto the palate. The unrestored maxillary right second molar has a typical partial denture clasp. The rationale for this approach was retrievability if additional endodontic treatment may be needed, precision of fit, aesthetics, and no metal display.

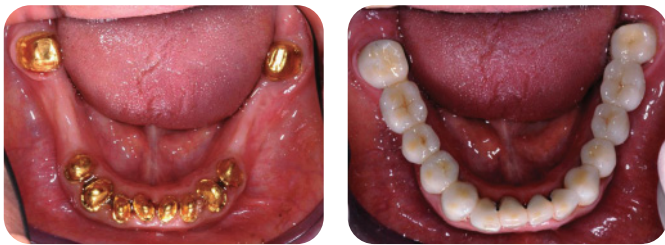
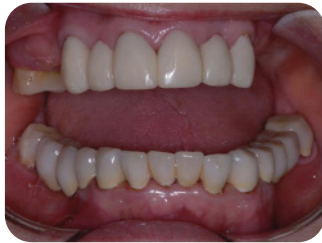
Figure 14.3.10. Completed mandibular dentistry. Galvano copings are cemented on the teeth with a definitive cement, and the fixed partial dentures and anterior 4-unit splint were cemented with a softer cement allowing retrievability. The rationale for this approach was for ease of future endodontic therapy if needed. None of the teeth were symptomatic despite the large previous restorations. Elective endodontic therapy was suggested but the patient refused and decided to deal with endodontic therapy if and as needed. The lower incisors were splinted for ease of managing the overstructure. The Galvano copings are .2mm in thickness allowing for properly contoured crowns and ease of cleanability. The upper anterior has also had the periodontal surgery completed, illustrating improved gingival contours and symmetry.

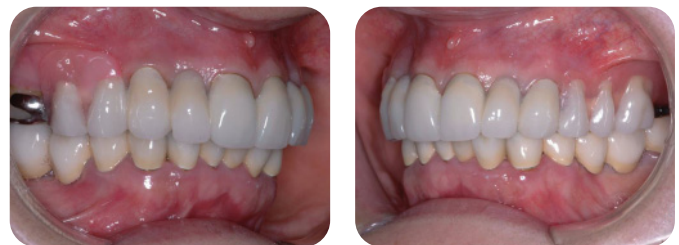
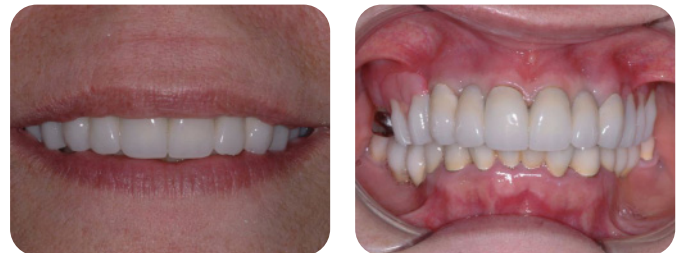
Figure 14.3.12. Photographs of the completed maxillary and mandibular dentistry.

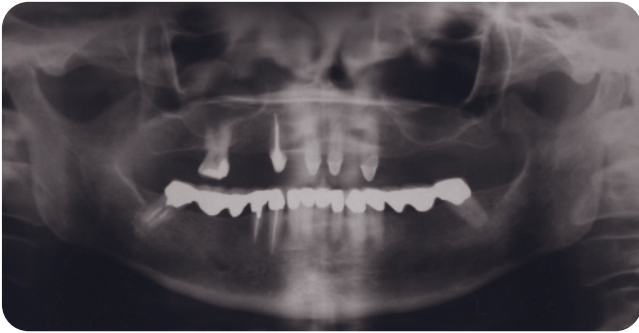

Figure 14.3.13. Posttreatment panoramic radiograph. Endodontic therapy was completed on the lower right cuspid, first bicuspid, and molar prior to placement of the definitive dentistry, as was the retreatment on the upper right cuspid. Note the periapical lesion on the lower left lateral incisor. The overstructure was removed, the endodontic therapy completed, and the overstructure recemented uneventfully.

CHAPTER 14 CASE 3 KEY POINTS

- Telescopic copings for a nonremovable prosthesis are a good option when future retrievability is desirable.
- Telescopic copings for a removable prosthesis, especially very precise Galvano copings, are a good option for both stability and clasplless retention, due to the intimate fit.

Chapter 14 Case 4

Mandibular anterior fixed partial denture and posterior removable partial denture with implants and Locator attachments for added support and retention; maxillary reconstruction, telescope case with 1 dental implant included along with 6 teeth

The patient in this case study presented with a failing maxillary fixed reconstruction and a failing mandibular fixed-removable reconstruction. Several teeth had recurrent decay to the point of nonrestorability. She was not pleased with the aesthetics, had difficulty functioning due to an unstable mandibular removable partial denture, and reported not having a comfortable bite. Her circumstances necessitated phasing the comprehensive treatment plan over approximately 24 months.

SUMMARY OF EXAMINATION AND DIAGNOSIS

Dentition

Failing restorations

Endodontic concerns

Lower right first and second bicuspid are not restorable.

Implant in upper left first bicuspid area is not in the best location but is usable.

Periodontium

Minimal attached keratinized tissue

Upper left first molar hopeless

TMJs

Right side Piper 3B

Left side Piper 3B

Both can be compressed comfortably.

Muscles

Lateral pterygoids are uncomfortable to testing.

Occlusion

Anterior teeth (the only contacting teeth) do not touch simultaneously.

Incisal and occlusal plane asymmetry

Aesthetics

Length, proportion problems

Canted planes unaesthetic

THE 10 DECISIONS

1. TMJ Diagnosis

Treat to adapted centric posture.

2. Vertical Dimension

Acceptable; no need for major changes

3. Lower Incisal Edge

Using lower left cuspid as a reference, shorten all others to that point.

4. Upper Incisal Edge

Increase length of central incisors 1.5 mm.

5. Centric Stops

Simultaneous, equal intensity centric stops in the adapted centric posture arc of closure; design anterior centric stops to hold the vertical dimension of occlusion.

6. Anterior Guidance

Determined by new upper and lower incisal edge position

7. Curve of Spee

Level and symmetrical using a point halfway up the retromolar pad as a posterior reference
Will require raising the upper left posterior

8. Curve of Wilson

Verify that upper buccal and lower lingual cusps do not interfere in the functional and parafunctional range of motion.

9. Cusp/Fossa Angle

Shallower than the anterior guidance disclusive angle

10. Aesthetic Plane

Create an upper posterior aesthetic plane that is consistent with the upper incisal edge position and with pleasing buccal profiles

SUMMARY OF TREATMENT PLAN

Dentition

Remove lower right bicuspid and upper left first molar.

Telescope copings on 6 remaining upper teeth, 14-unit fixed partial denture on 6 teeth and 1 implant

6-unit mandibular anterior fixed partial denture

Implants in lower first bicuspid position with Locator attachment for removable partial denture retention, to relieve stress on mandibular anteriors

Mandibular posterior implants are not easily possible.

Periodontium

Soft tissue grafts as needed

TMJs

No treatment is needed other than correct occlusal engineering.

Muscles

No treatment is needed other than correct occlusal engineering.

Occlusion

Simultaneous, equal intensity centric stops in the adapted centric posture arc of closure with anterior guidance on anterior teeth

Aesthetics

Idealize form, proportions, and incisal/occlusal planes.

SUMMARY OF TREATMENT SEQUENCE

Appointment	Treatment Completed
1	Remove all restorations, preparations, impressions for provisionals both fixed and removable. Periodontist same day for extractions and implants Return for provisional placement.
2	Monitor and maintain provisionals throughout healing.
3	Impressions for lower fixed-removable
4	Deliver lower, attach Locator abutments intraorally.
5	Reprep maxillary teeth, reline provisional, impressions for telescope copings.
6	Place copings with definitive cement; fabricate new provisional.
7	Maxillary impression of teeth with copings and implant to fabricate fixed partial denture
8	Place maxillary fixed partial denture with a retrievable cement.
9	Ongoing maintenance

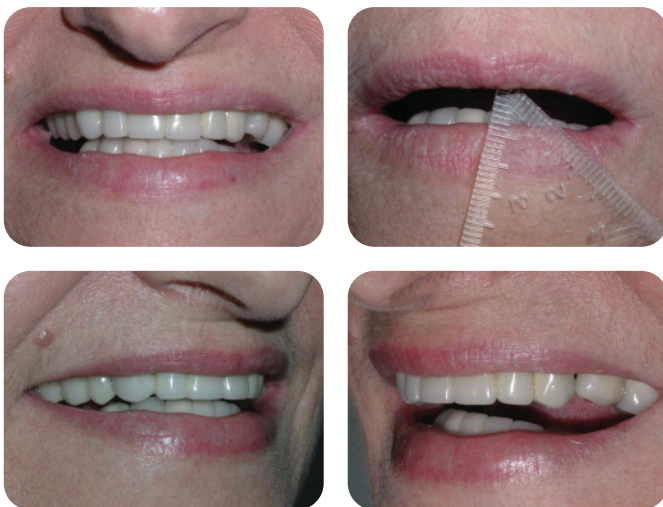

Figure 14.4.1. Pretreatment anterior and lateral smile photographs. With the upper lip at rest, the maxillary incisal edges are covered by 2mm suggesting that length can be increased. Patient has a very short upper lip and does not display any gingival tissues.

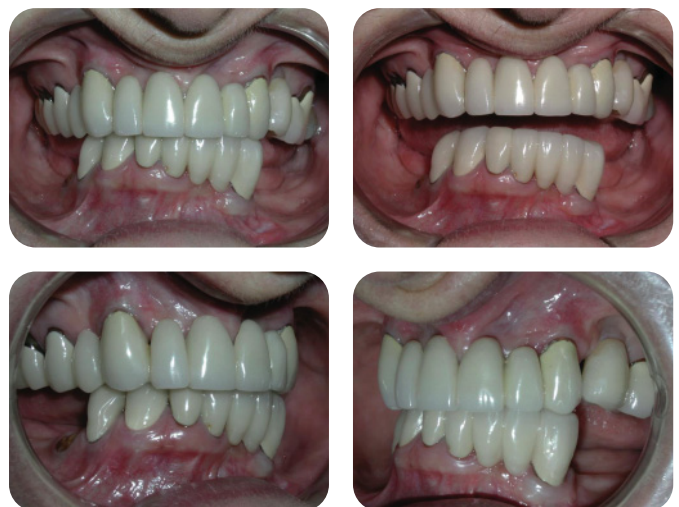

Figure 14.4.2. Pretreatment anterior and lateral retracted photographs illustrating a canted lower incisal plane as well as upper posterior aesthetic plane. Note the thin but healthy gingival tissues with minimal attached keratinized tissue.

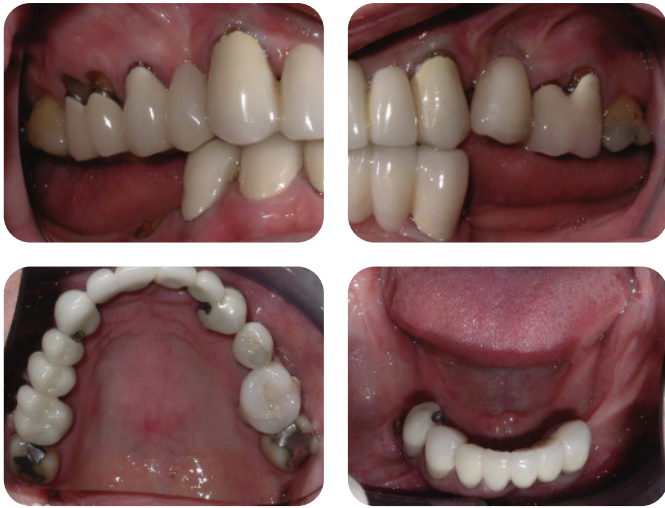

Figure 14.4.3. Pretreatment buccal occluded and occlusal photographs. The upper left bicuspid is a free-standing implant restoration. The lower right bicuspids are not restorable.

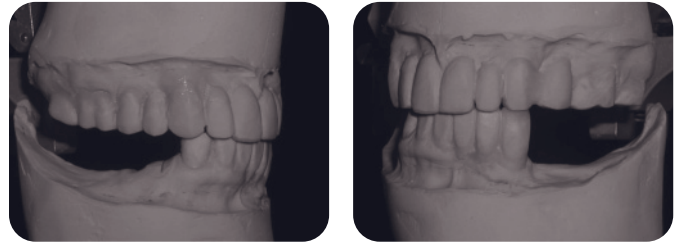
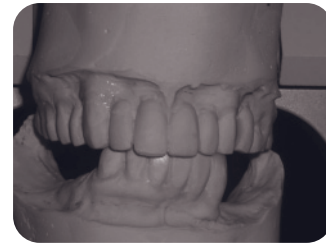

Figure 14.4.6. Photographs of corrections made on articulated diagnostic casts. The maxillary occlusal plane is leveled, facial contours are improved, and incisor length increased by 1 mm.

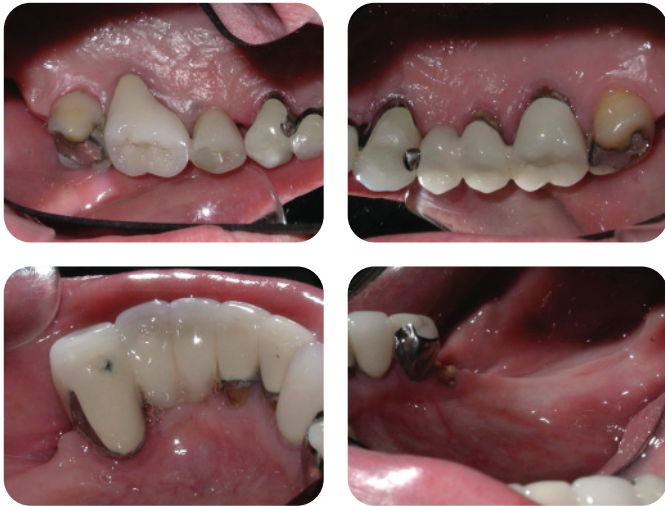

Figure 14.4.4. Pretreatment lingual mirror photographs.

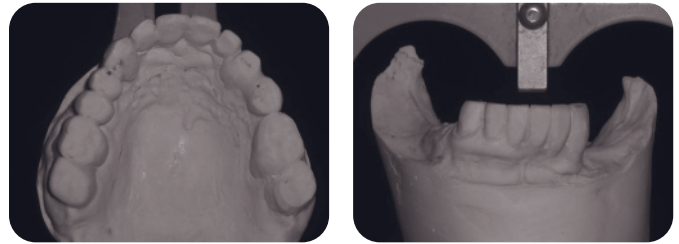


Figure 14.4.7. Photographs of corrections made on articulated diagnostic casts. The lower incisal plane is leveled to the height of the lower left cuspid. This information is important when preparing teeth for adequate reduction. Lower anterior incisal edges are made more definitive to create stable centric holding contacts on the lingual of the upper anterior teeth. Anterior centric stops must be designed to hold the vertical dimension of occlusion even without the mandibular removable partial denture. Mandibular transitional removable partial denture is fabricated on these casts.

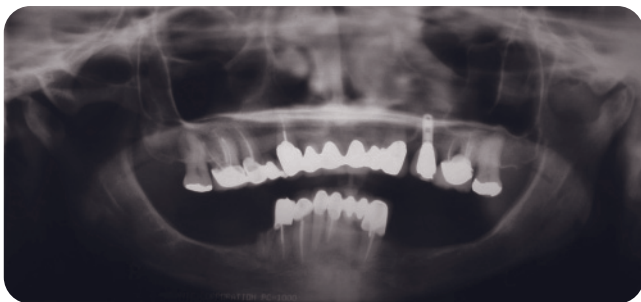

Figure 14.4.5. Pretreatment panoramic radiograph.

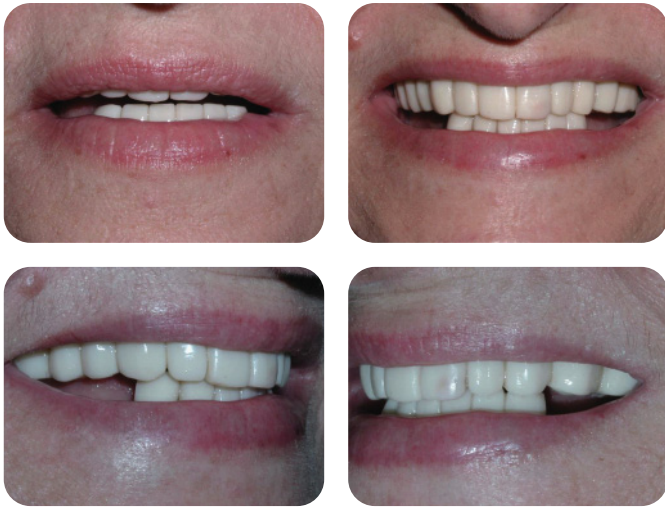

Figure 14.4.8. Photographs 2 weeks after initial provisionalization. More of the maxillary incisal edge is displayed, and the maxillary occlusal plane is level and symmetrical.

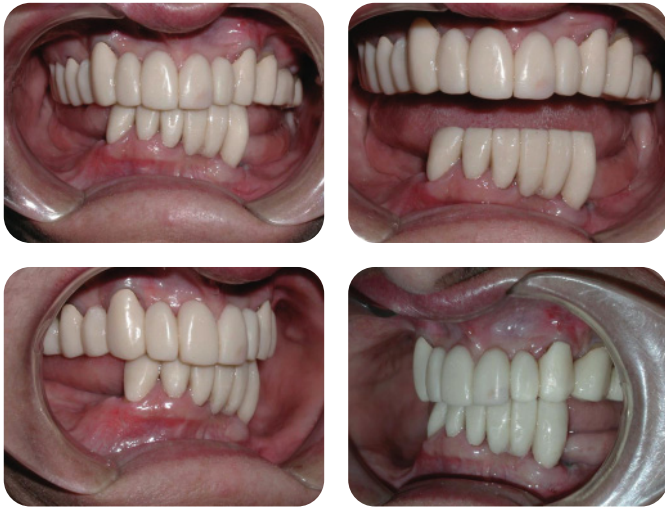

Figure 14.4.9. Anterior and lateral retracted photographs of the provisionals. Note the level mandibular incisal plane. Incisal edges and plane must be level even though the gingival levels are quite asymmetrical, which is not an aesthetic issue. Implants in the mandibular first bicuspids have been placed.

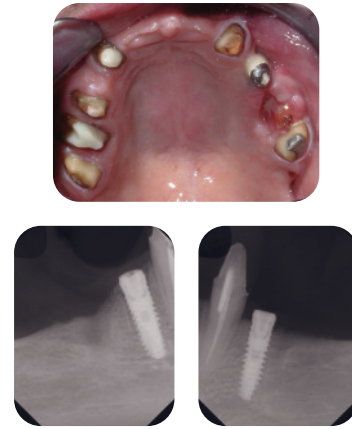


Figure 14.4.10. Maxillary occlusal photograph of preparations and radiographs of mandibular implants approximately 3 weeks postop. The implant crown on the upper left bicuspid was prepared just like a tooth and handled just like a tooth from that point in terms of impressions, provisionals, etc.

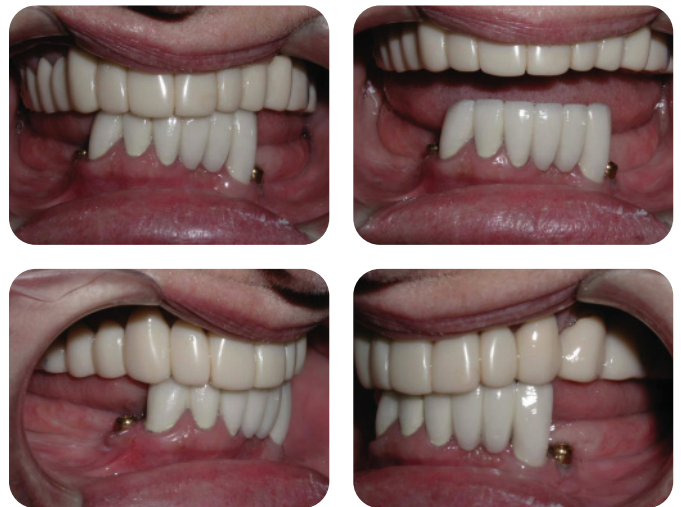

Figure 14.4.11. Photographs of the mandibular anterior definitive fixed partial denture and Locator abutments attached to the implants along with initial maxillary provisional.

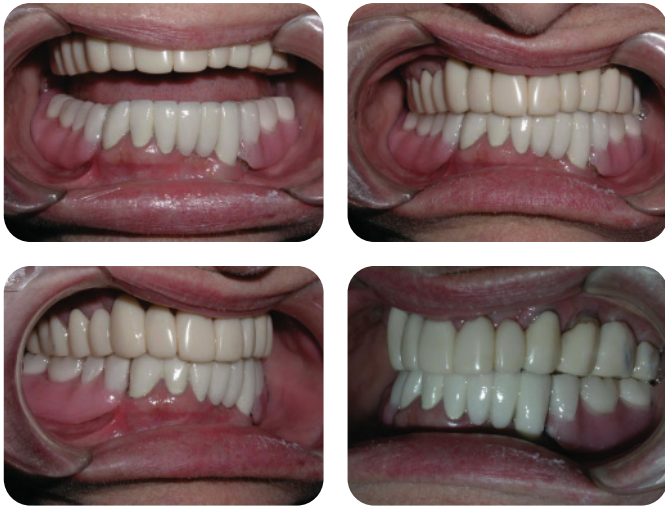

Figure 14.4.12. Photographs of the mandibular removable partial denture in place attached to the Locator abutments.



Figure 14.4.13. Maxillary cast with telescope copings on 6 natural teeth. The upper left bicuspid is the prepared implant crown, which does not need a telescope coping. This was done approximately 6 months after the mandibular dentistry was completed. The right photograph is the mandibular removable partial denture with the Locator attachments in place. The major connector has two semiprecision attachments that fit into slots on the lingual of the mandibular anterior fixed partial denture. This is simply to help guide the partial denture into place over the Locator attachments. The retention, lateral, and horizontal stabilization comes from the Locator abutments.

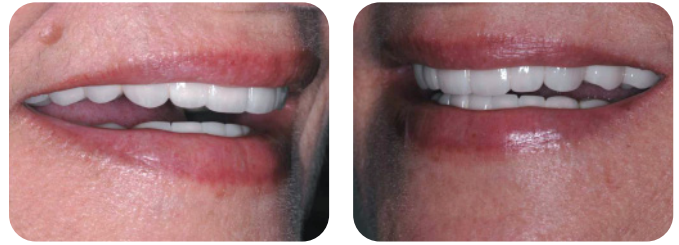
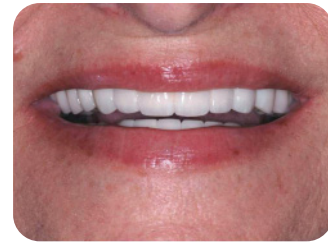
Figure 14.4.14. Anterior and lateral smile photographs maxillary definitive dentistry over the cemented telescope copings.

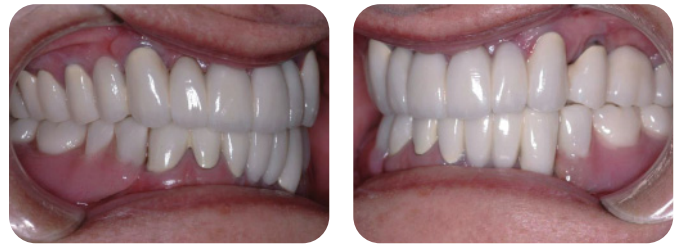
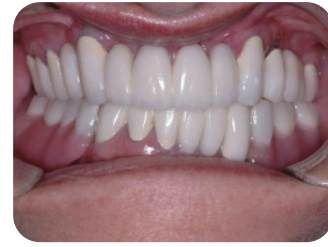
Figure 14.4.15. Anterior and lateral retracted photographs of the definitive dentistry.

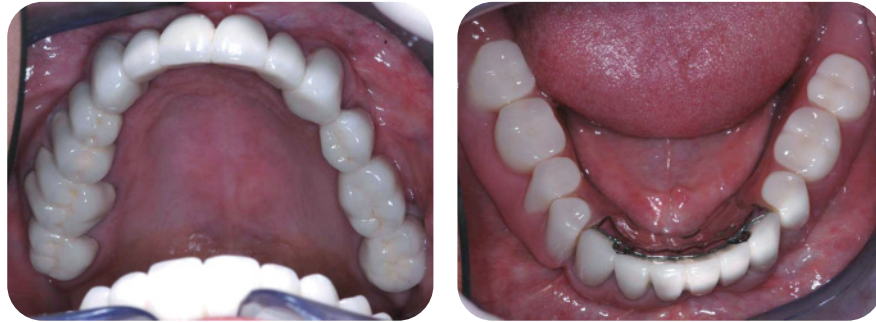

Figure 14.4.16. Occlusal photographs of the definitive dentistry. The maxillary dentistry is cemented over the telescope copings and lone implant crown with a retrievable cement. This allows for easy future management. The right photographs illustrate the slots that guide the removable partial denture over the fixed partial denture onto the Locator attachments.

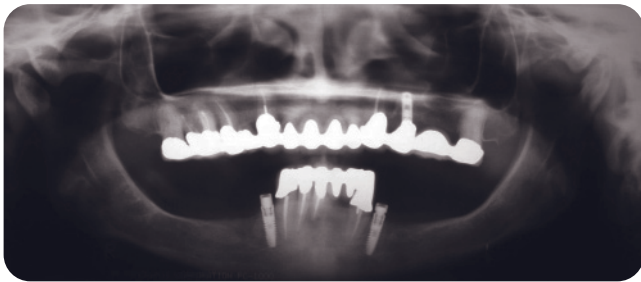


Figure 14.4.17. Posttreatment panoramic radiograph. The lower right lateral incisor was endodontically treated while in the provisional restoration. The lower right central incisor developed a periapical lesion with pain after placement of the definitive dentistry and was treated with an apicectomy and retrofill and has been asymptomatic.

CHAPTER 14 CASE 4 KEY POINTS

- Telescopic copings on natural teeth are a good option when the prosthesis includes an implant abutment(s).
- Create level planes even if the tissues are assymetrical. If the tissue is an aesthetic concern, correct the tissue.

15

Implant-Supported Complete Dentures

Case 1 Maxillary extensive bone graft followed by implant-supported bars and bar-supported overdenture after managing a temporomandibular disorder; flange needed for lip support necessitating a removable rather than a nonremovable approach.

Case 2 Severe maxillary and mandibular resorption; maxillary bone grafting; maxillary and mandibular implant-supported bar and bar-supported dentures; flange needed for lip and cheek support necessitating a removable rather than a nonremovable approach.

Chapter 15 Case 1

Maxillary extensive bone graft followed by implant-supported bars and bar-supported overdenture after managing a temporomandibular disorder; flange needed for lip support necessitating a removable rather than a nonremovable approach

The patient in this case study reported poor dental care as a young man, resulting in loss of many teeth. After years of progression, he ended up with a full upper denture and lower fixed-removable restoration. He complained of pain in pre-maxilla. Implants were placed in the maxillary tuberosity but with no prosthetic plan, so he lost confidence and eventually lost the implants. As a busy physician he found it difficult to find the time for major procedures and had to suffer with difficulty chewing and resultant pain in intraoral tissues. Throughout this history he developed intracapsular and muscle symptoms. When condyles are seated and the mandible is arced closed, the first contact is the posterior (as it typically is) and there is a slide up and forward into the anterior teeth, thereby traumatizing the pre-maxilla. His treatment plan was staged over a number of years because of his schedule as a physician. The bone grafting and implants were not done until he retired from active practice.

SUMMARY OF EXAMINATION AND DIAGNOSIS

Dentition

Many teeth are missing. Current lower restorations are structurally acceptable but not functionally acceptable.

Severe resorption lower posterior and entire maxilla

Periodontium

Moderate attachment loss but no mobility
5–6 mm pockets lower

TMJs

Right side Piper 3B

Left side Piper 3B

Neither TMJ can be compressed comfortably.

Palpation tenderness

Range of motion is within normal limits.

Muscles

Lateral and medial pterygoid is very painful to palpation.

Occlusion

Posterior interferences to the arc of closure with an anterior and vertical slide into maximum intercuspation, which traumatizes the anterior ridge

Aesthetics

Does not display maxillary anterior teeth, most likely kept short because of resorbed pre-maxilla

THE 10 DECISIONS**1. TMJ Diagnosis**

Begin bite splint in treatment position with the goal being adapted centric posture.

2. Vertical Dimension

Current vertical dimension of occlusion appears adequate.

3. Lower Incisal Edge

Reshape 22–26 to be level.

4. Upper Incisal Edge

Condition of upper pre-maxilla bony support does not lend itself to making anterior display longer. The display can be increased when an implant-supported prosthesis is done.

5. Centric Stops

Only on posterior teeth until upper implants can be done

6. Anterior Guidance

Design a bilateral balanced denture occlusion. Guidance will transition to a shallow, flat anterior guidance on anterior teeth. When implants are placed, anterior guidance can be fully on anterior teeth.

7. Curve of Spee

Idealize with new dentistry.

8. Curve of Wilson

Idealize with new dentistry.

9. Cusp/Fossa Angle

Design a lingualized denture-type occlusion.

10. Aesthetic Plane

Verify that the aesthetic plane of the upper buccal cusps is level and symmetrical and that the facial profiles of the upper posterior teeth are aligned correctly. When implants are done on the upper, the display can be increased.

SUMMARY OF TREATMENT PLAN**Dentition***Phase 1*

Change 20–21 and 27–29 to improve occlusal plane.

New lower removable partial denture

New upper denture

Phase 2

Bone graft maxilla

8 implants supporting a bar

Bar-supported overdenture

Phase 3

Remove remaining lower teeth and transition to an implant bar-supported overdenture.

Implants posterior mandible are not possible.

Periodontium

Ongoing maintenance and self care

Corrective surgery lower teeth

TMJs

Bite splint therapy followed by definitive occlusal reconstruction

Muscles

Bite splint therapy followed by definitive occlusal reconstruction

Occlusion

Create prosthetics in harmony with adapted centric posture. Anterior teeth are slightly out of contact in centric. Anterior guidance will start on bicuspid until a shallow anterior guidance performance platform of the upper anterior comes into function. Once upper implants are placed, anterior centric stops and anterior guidance will be immediately possible on anterior teeth.

Aesthetics

Once upper implants are placed, more of the upper teeth can be displayed.

SUMMARY OF TREATMENT SEQUENCE

Appointment	Treatment Completed
1	Mandibular bite splint until goals of comfort and occlusal stability are met
2	Prepare and provisionalize 20–21, 27–29, reshape 22–26; do impressions/records for new maxillary full denture and lower-fixed removable partial denture.
3	Try-in
4	Insert
5	Posttreatment bite splint if tendency to brux continues
6	Maxillary bone graft
7	8 maxillary implants
8	Implant-supported bars; bar-supported full denture
9	Future: remove remaining lower teeth and transition to implants and implant-supported denture.

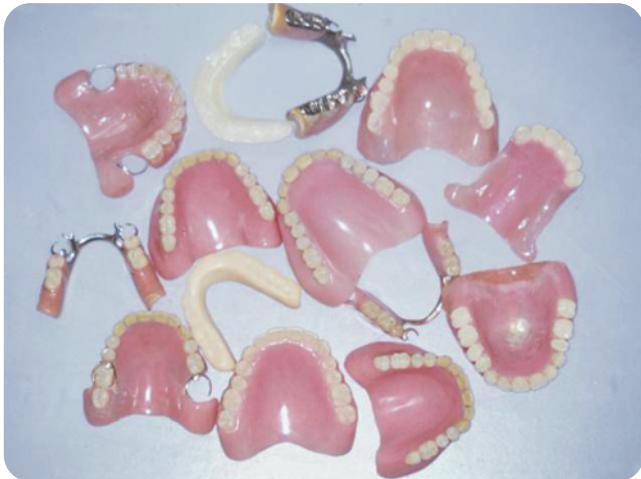

Figure 15.1.1. Photograph of the results of years of dentistry trying to deal with loss of teeth, loss of supporting bone, and progressively worsening temporomandibular disorder.

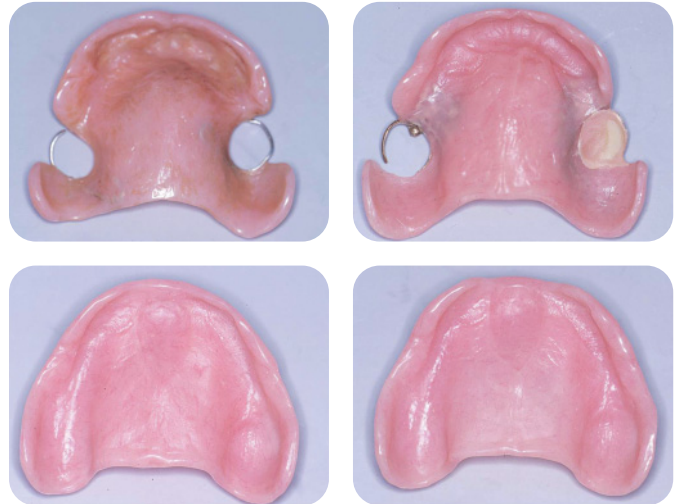


Figure 15.1.2. Photograph of the 4 most recent maxillary prostheses, suggesting the loss of support in the pre-maxilla region.

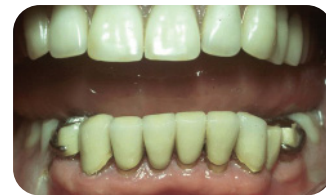

Figure 15.1.3. Anterior retracted photograph suggesting uneven incisal plane that is higher vertically than the posterior occlusal plane.

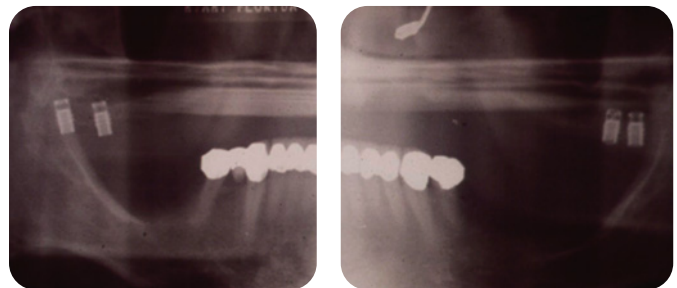


Figure 15.1.4. Pretreatment panoramic radiograph. Implants were placed a few years prior but never utilized for a prosthesis. Patient reported that he was unaware of the overall plan. The implants were not integrated and the patient was very discouraged.

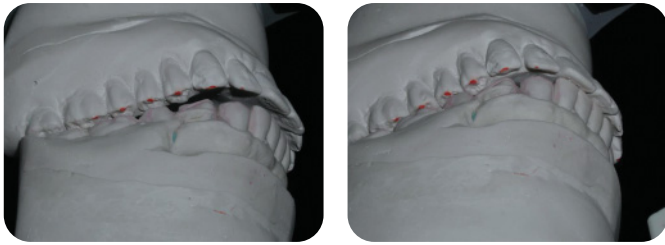


Figure 15.1.5. Pretreatment articulated diagnostic casts. The left photograph is after bite splint therapy and at the vertical dimension of the first contact in the adapted centric posture arc of closure suggesting the anterior opening at this interference. The right photograph is in maximum intercuspation after the hit and slide suggesting trauma into the anterior teeth and underlying supporting structures.

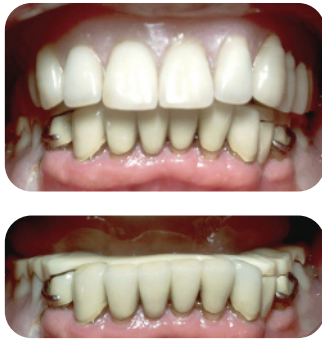

Figure 15.1.6. A mandibular bite splint was made and adjusted over time in the arc of closure with the condyles seated. There was simultaneous, equal intensity contact on all posterior teeth, with the anterior teeth slightly out of centric contact. In excursive movements, the posterior teeth initiated the guidance with a quick transition to the anterior teeth. The anterior guidance was smoothed and refined until the upper denture did not dislodge in excursions. His signs and symptoms improved significantly, 75% in his own description. He said that with the severity of his condition he did not expect 100% improvement.

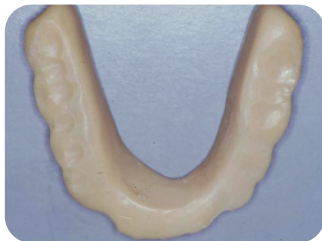

Figure 15.1.7. Observation of the bite splint over time is very informative about parafunctional habits. Even with the decreased bite force of an upper denture, significant wear facets can be observed on the splint. The upper denture teeth were acrylic and not porcelain.

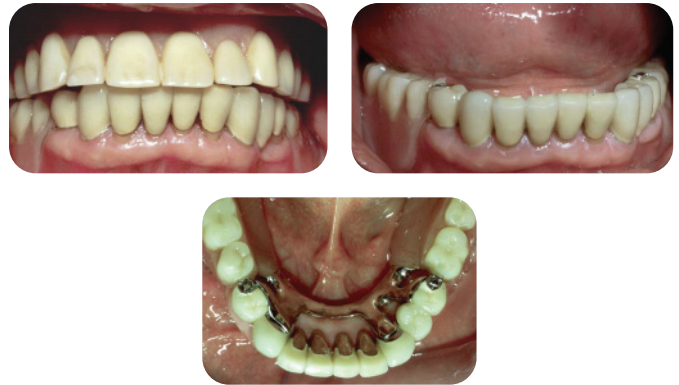

Figure 15.1.8. Photograph of the completed lower fixed-removable and upper complete denture. The lower incisors were only recontoured. While in the bite splint, the patient reported that if new upper and lower prostheses could be designed so that he had the same comfort as when wearing the bite splint, he would be agreeable to beginning treatment. Note the similarity to the occlusion on the bite splint.

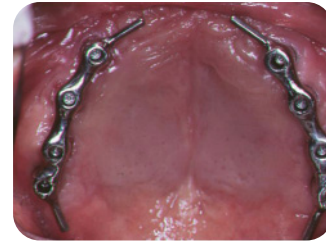


Figure 15.1.9. In the next phase of treatment, several years later, upper bone grafts using the hip as donor bone were done in the posterior maxilla, followed by 8 implants. It is preferable to keep the implants posterior to the lateral incisors so as not to interfere with the correct aesthetic and phonetic placement of the upper incisors.

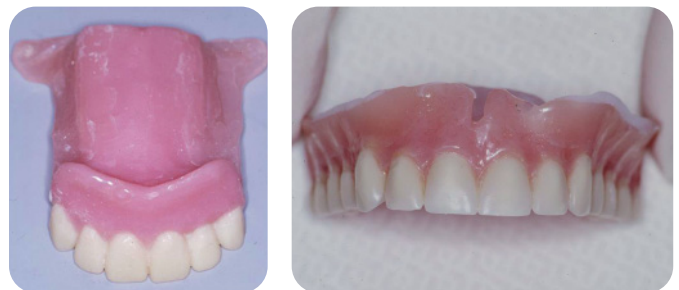

Figure 15.1.10. Approximately 6 weeks after the bone grafts, an upper anterior "façade" was made for aesthetics only. It covered only the midpalate so as to totally avoid the surgical site. Several weeks later, the original maxillary denture was soft relined until full healing had occurred.

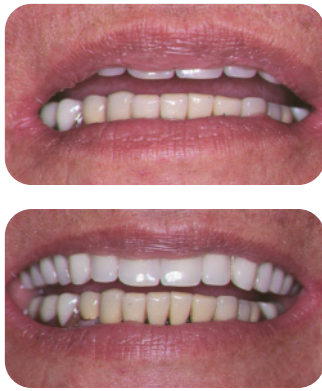

Figure 15.1.11. Photographs of the completed implant bar-supported maxillary complete denture. Teeth are now displayed with the lip at rest for improved aesthetics.

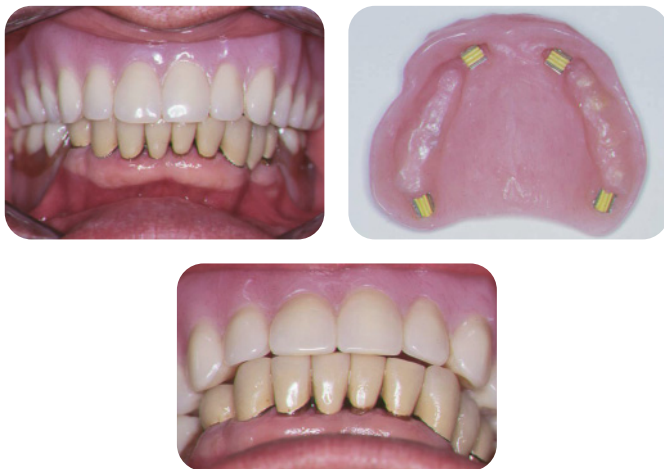

Figure 15.1.12. Photographs of the completed prosthesis. The denture is retained onto the implant bar with 4 Hader clips (www.Preat.com). Because the implants are in grafted bone, a full palatal coverage denture was made for added support and stability. The lower picture suggests a much improved anterior tooth-to-tooth functional relationship. Because of the support of the implant bar, anterior guidance can begin immediately on the anterior teeth.

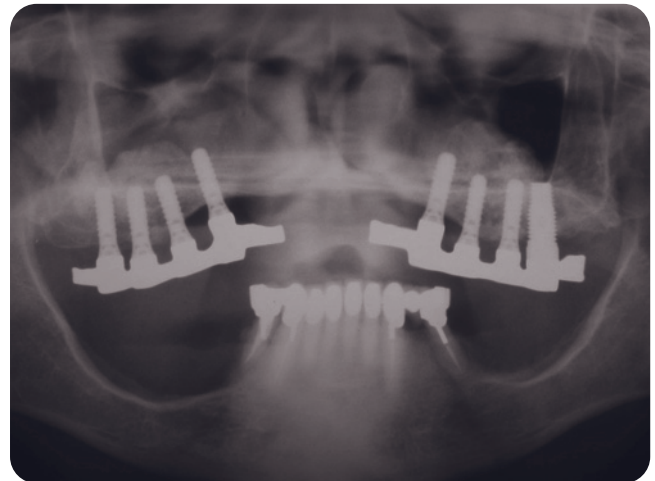


Figure 15.1.13. Posttreatment panoramic radiograph suggesting the precision fit of a laser-welded bar. Note the severe resorption of the posterior mandible. The 4 most posterior abutments needed endodontic therapy. The next phase will be transitioning the lower to an implant-supported restoration. As of this writing, the patient has not initiated this phase of treatment.

CHAPTER 15 CASE 1 KEY POINTS

- When there is significant maxillary anterior resorption, keep implants and bars distal to the maxillary lateral incisors so as not to interfere with tooth placement and phonetics.
- Resolve temporomandibular disorders first, just as with any patient.
- When a maxillary denture is stabilized by implants and lower anterior natural teeth are present, a typical dentulous anterior guidance can be utilized.

Chapter 15 Case 2

Severe maxillary and mandibular resorption; maxillary bone grafting; maxillary and mandibular implant-supported bar and bar-supported dentures; flange needed for lip and cheek support necessitating a removable rather than a nonremovable approach

The patient in this case study is 45 years old and has been edentulous for 25 years. Supporting structures have resorbed to the point that she is in constant discomfort, is not able to masticate efficiently, and is self-conscious about her condition. She is in a management position but has arranged to schedule extended time off to go through the surgeries and recovery period to get the treatment done.

SUMMARY OF EXAMINATION AND DIAGNOSIS

Dentition

Full maxillary and mandibular complete dentures

Periodontium

Maxillary and mandibular bony support are severely compromised.

TMJs

Right side Piper 3B

Left side Piper 3B

Both can be compressed comfortably.

Range of motion is normal.

Muscles

Lateral and medial pterygoids are tight and uncomfortable to palpation.

Occlusion

Impossible to evaluate because of instability of denture bases

Aesthetics

Tooth position is acceptable; however, lip and facial support is lacking.

THE 10 DECISIONS

1. TMJ Diagnosis

Treat to a guided, verified adapted centric posture.

2. Vertical Dimension

Restore with prosthetics to allow 2 mm freeway space.

3. Lower Incisal Edge

Acceptable with current denture

4. Upper Incisal Edge

Acceptable with current denture

5. Centric Stops

Simultaneous, equal intensity centric stops on all teeth in the ACP arc of closure

6. Anterior Guidance

Determined by verified upper and lower incisal edge position

Because dentures will be implant-supported, anterior guidance can be on anterior teeth.

7. Curve of Spee

Idealize with dentures,

8. Curve of Wilson

Verify that upper buccal and lower lingual cusps do not interfere in the functional and parafunctional range of motion.

9. Cusp/Fossa Angle

Slightly shallower than the anterior guidance angle

10. Aesthetic Plane

Create an upper posterior aesthetic plane that is consistent with the upper incisal edge position and with pleasing buccal profiles.

SUMMARY OF TREATMENT PLAN

Dentition

Maxillary and mandibular implant-supported bars and bar-supported complete removable dentures

Periodontium

Maxillary supporting structures are augmented with hip bone.

TMJs

No treatment is needed other than correct occlusal engineering.

Muscles

No treatment is needed other than correct occlusal engineering.

Occlusion

Because dentures will be implant-supported, an ideal occlusion can be established: simultaneous, equal intensity contacts in the arc of closure; anterior guidance on anterior teeth; immediate posterior disclusion.

Aesthetics

Maintain incisal edge position.
Improve lip and facial support.

SUMMARY OF TREATMENT SEQUENCE

Appointment	Treatment Completed
1	Verified wax set-up is converted to clear surgical stents.
2	Hospital procedure to place lower implants and upper bone graft, using hip as donor site because of the volume of bone needed
3	Per oral surgeon, patient must be totally without teeth for 8 weeks, anterior stayplate with 6–11 for aesthetics only after that.
4	Place 8 upper implants; office procedure at oral surgeon.
5	Soft-reline her current dentures.
6	Implant level impressions and jaw relation records
7	Try-in bars Wax try-in; verify aesthetics and occlusion.
8	Deliver definitive case.

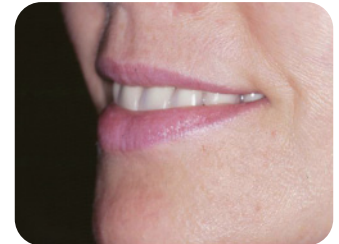
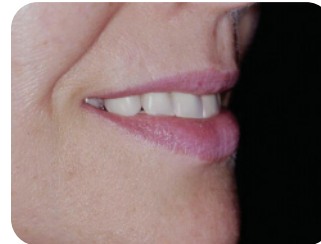
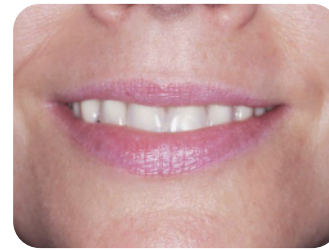Figure 15.2.1. Pretreatment anterior and lateral smile photographs. Patient is pleased with display of anterior teeth but desires improved lip and facial support.

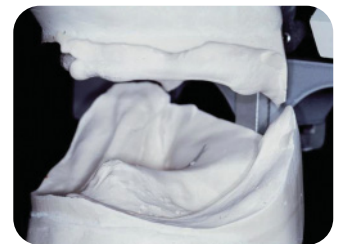
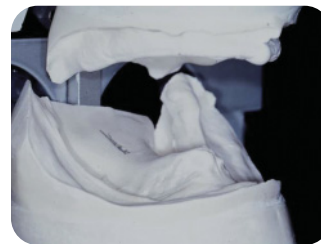
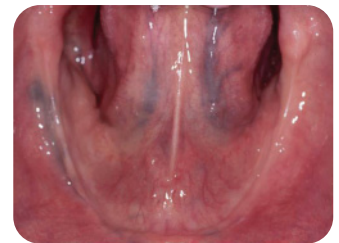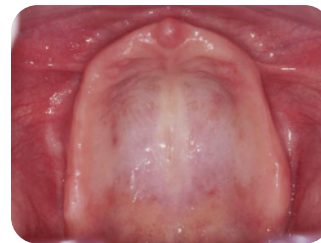Figure 15.2.2. Pretreatment maxillary and mandibular occlusal photos and pretreatment articulated diagnostic casts suggesting severe resorption of supporting structures. The interarch space is excessive, making a nonremovable approach impossible. Articulated diagnostic casts are just as important with fully edentulous patients as they are with patients with all or part of their dentition.

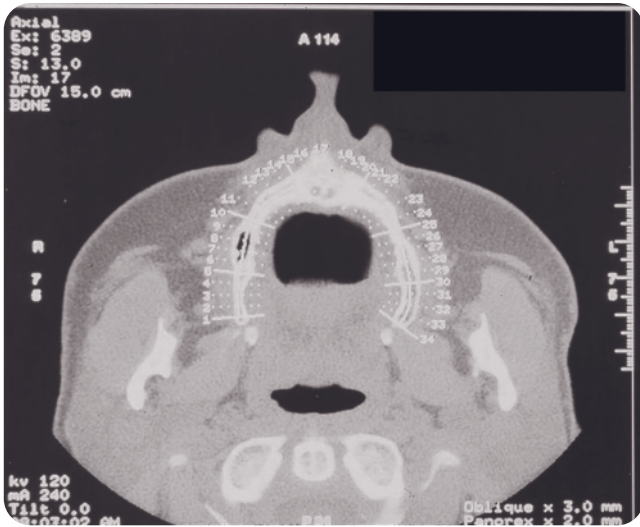

Figure 15.2.3. Pretreatment maxillary CAT scan suggesting very narrow maxillary alveolar process and close proximity to maxillary sinus.

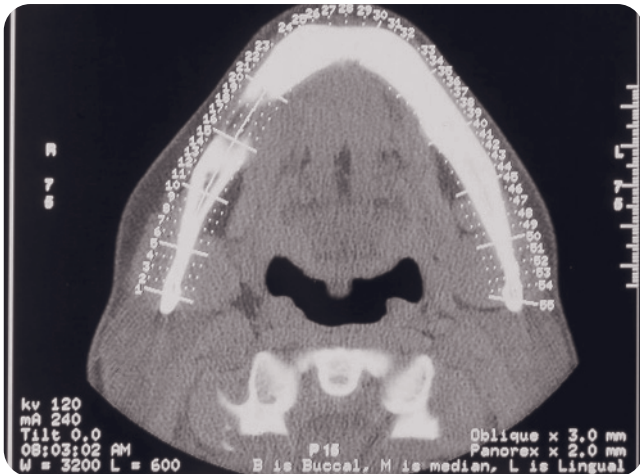

Figure 15.2.4. Pretreatment mandibular CAT scan suggesting adequate bone in anterior mandible but deficient bone in posterior mandible and proximity to mandibular canal.

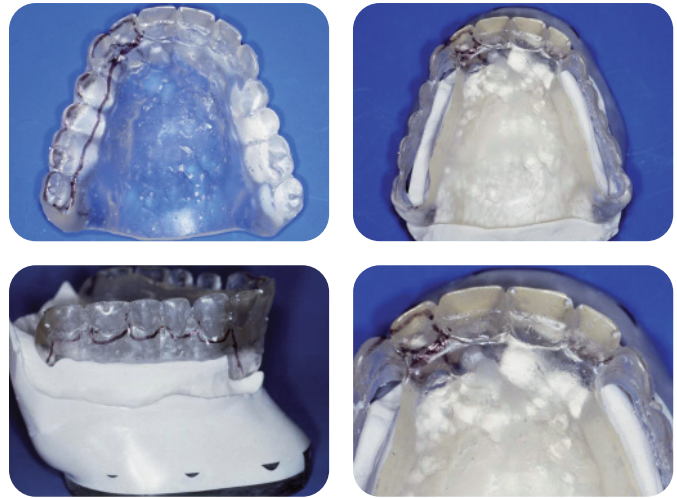


Figure 15.2.5. Clear surgical maxillary stent, which is a duplicate of an approved diagnostic set-up. Occlusal and buccal windows are made, leaving the facial surfaces and part of the occlusal surfaces of the posterior teeth intact. The surgeon will use this both in the bone graft surgery and implant placement surgery to verify that placement of bone and implants are correct for final tooth position. The bottom right photo illustrates how far forward the anterior teeth are in relation to the underlying maxillary anterior bone. Implants are avoided in the anterior region because they would be too far lingual. The denture base would then be too thick in this area, interfering with phonetics.

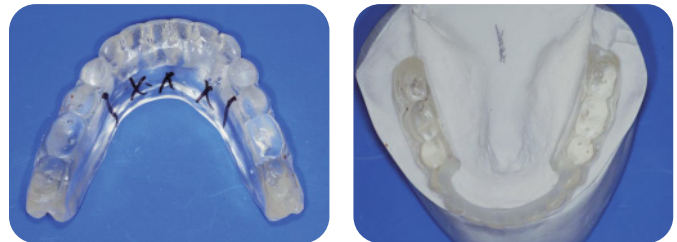

Figure 15.2.6. Clear surgical mandibular stent, which is a duplicate of an approved diagnostic setup. The stent is ground away from cuspid to cuspid, leaving the facial surfaces intact and giving the surgeon a guide to implant placement. Implant placement in the anterior mandible does not cause as much of a phonetic problem in many patients as do implants in the anterior maxillary, because the tongue does not function in the mandibular anterior region during phonetics.

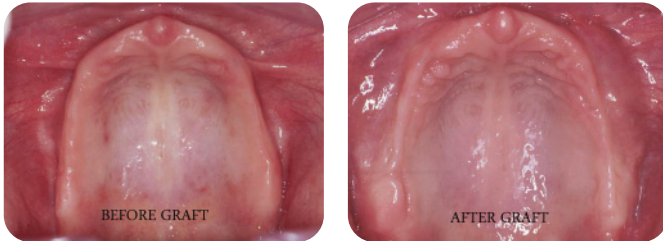
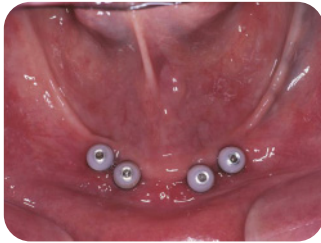


Figure 15.2.7. Photographs after first surgery. The bottom two photographs illustrate the maxillary bone augmentation, which was lateral to the crest of the ridges and posterior to the lateral incisor region.

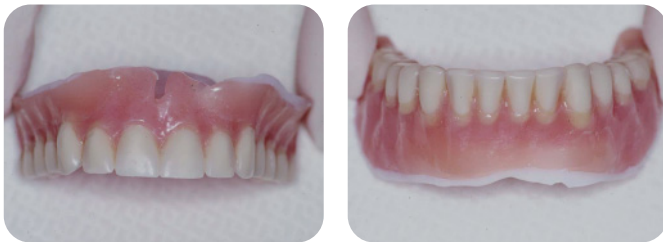

Figure 15.2.8. Photographs of the soft relined dentures done after adequate healing of the first surgery. After the second surgery of placing maxillary implants, the upper denture was once again soft relined.

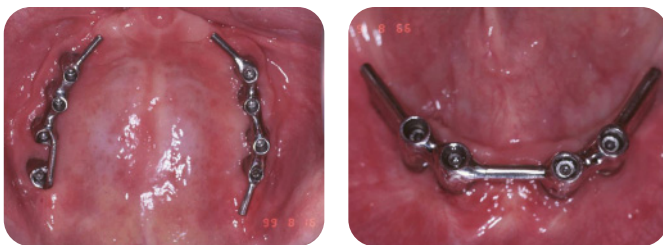


Figure 15.2.9. Photographs of the completed maxillary and mandibular implant-supported bars illustrating the maxillary anterior uncovered for unimpeded placement of the prosthetic teeth.

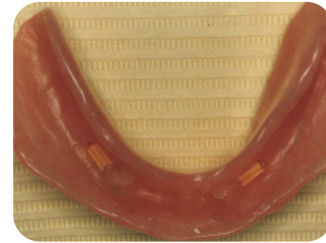


Figure 15.2.10. Dentures are retained with plastic Hader clips (www.Preat.com). They provide excellent retention and are easy to change and maintain as needed. It is important to extend the mandibular denture base to cover the retromolar pad, as in any full mandibular denture, to provide added stability and minimize front-to-back rocking.

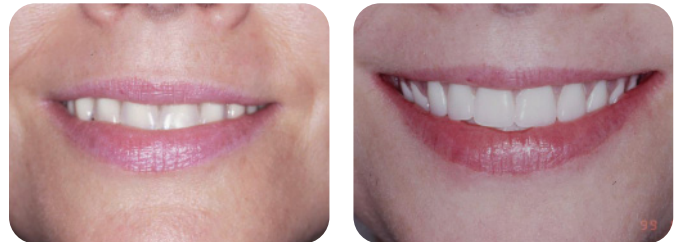

Figure 15.2.11. Before and after smile photos. Although tooth position was not drastically changed, there is improved lip and face support. The stability of implant support gave her tremendously improved comfort and function.

CHAPTER 15 CASE 2 KEY POINTS

- When there is significant maxillary anterior resorption, keep implants and bars distal to the maxillary lateral incisors so as not to interfere with tooth placement and phonetics.
- Totally edentulous patients require a complete exam and articulated diagnostic casts just like any other patient.

Reconstructions on All Natural Teeth

Case 1 Severe anterior overjet handled with occlusal/restorative treatment in lieu of orthognathics; muscular component of a temporomandibular disorder also managed

Case 2 Failed multiple reconstructions; original deep overbite with current condition in provisionals with an opened vertical dimension and anterior overjet; managed with a new reconstruction harmonizing a physiologic deep overbite

Case 3 Maxillary reconstruction combined with extractions and periodontal surgery to improve periodontal architecture; landmarks of lower acceptable with minor modification

Case 4 Full mouth reconstruction utilizing crown-lengthening surgery, extractions, single crowns, veneers, and a fixed partial denture sequenced over 2 years

Case 5 Maxillary complete fixed partial denture on 9 Galvano telescopic copings; mandibular anterior fixed partial denture on 4 Galvano copings

See also:

Chapter 6 Case 6 Temporomandibular disorder resolved with bite splint therapy followed by definitive occlusal therapy including a maxillary reconstruction and mandibular functional changes with composite

Chapter 14 Case 3 Maxillary telescope case: alumina copings on natural teeth and removable overstructure; mandibular telescope case: Galvano copings on natural teeth and nonremovable overstructures

Chapter 14 Case 4 Mandibular anterior fixed partial denture and posterior removable partial denture with implants and Locator attachments for added support and retention; maxillary reconstruction, telescope case with 1 dental implant included along with 6 teeth

Chapter 16 Case 1

Severe anterior overjet handled with occlusal/restorative treatment in lieu of orthognathics; muscular component of a temporomandibular disorder also managed

The patient in this case study completed a full upper and lower left reconstruction 2 years prior to seeing the author for an examination. Six years before that, the patient had undergone her first reconstruction. Both were done to resolve a muscular component of a temporomandibular and neither succeeded at accomplishing that. The upper molars were temperature-sensitive at the time of initial examination. The reconstruction was a full splint 2–15 and the molars appeared to be decemented. The patient reported muscle fatigue and pain, especially during mastication. She also reported joint noise but no joint pain. Another complaint was lip (neutral zone) impingement in the upper bicuspid-to-bicuspid region manifested as a “stretched” feeling, which was not present before the reconstruction. She was very upset and disappointed that the previous reconstructions did not resolve the problem she had hoped that they would address. Because any further treatment would have involved another major reconstruction, a lot of time was invested in bite splint therapy, not only addressing a muscle component but also gaining and developing her trust.

SUMMARY OF EXAMINATION AND DIAGNOSIS

Dentition

Full upper fixed partial denture on 9 abutments
Evidence of decementation from molars
Gingival embrasures not cleanable

Periodontium

Mild to moderate disease upper molars

TMJs

Right side Piper 3B
Left side Piper 3B
Coarse crepitation
Both can be compressed comfortably.
Range of motion is normal.

Muscles

Lateral and medial pterygoids are painful to palpation.
Muscles feel very hard and tight to palpation.
This was patient’s main complaint.

Occlusion

Interferences to the arc of closure
Because of overjet, anterior guidance starts on molars.
Because of severe Curve of Spee lower left, there are very severe balancing interferences.

Aesthetics

Anterior open bite, but aesthetics is acceptable to patient; however, restoration impinges on neutral zone of the lips.

THE 10 DECISIONS**1. TMJ Diagnosis**

Bite splint and definitive treatment to a verifiable, guided adapted centric posture

2. Vertical Dimension

Determined by centric stops, lower cuspids to upper first bicuspid because of severe Class 2 jaw relationship

3. Lower Incisal Edge

Acceptable; just smooth and polish.

4. Upper Incisal Edge

Move edge and facial surface lingually 2–3 mm to relieve impingement on neutral zone. Abutments already have endodontics so there is room to do this.

5. Centric Stops

Simultaneous, equal intensity contact in adapted centric posture up to upper first bicuspid with lower cuspids; open anterior to that; patient reports lifelong anterior open bite, therefore assumed stable

6. Anterior Guidance

Shallow and flat

Start lower cuspids and upper bicuspid until upper cuspids take over.

7. Curve of Spee

Flatten lower left with new restoration.

Flatten lower right by reshaping.

8. Curve of Wilson

Verify that upper buccal and lower lingual cusps do not interfere in the functional and parafunctional ranges of motion.

9. Cusp/Fossa Angle

Shallower and flatter than anterior guidance

10. Aesthetic Plane

Create an upper posterior aesthetic plane that is consistent with the upper incisal edge position and with pleasing buccal profiles

SUMMARY OF TREATMENT PLAN**Dentition**

Replace upper reconstruction in as small segments as possible based on mobility issues rather than a full splint.

Bring contours from upper bicuspid to bicuspid lingually 2–3 mm.

New fixed partial denture lower left second molar to first bicuspid, flattening Curve of Spee
Endodontics as needed

Periodontium

Maintenance and self-care

Surgery upper left, upper right, and lower left

TMJs

Definitive occlusal/restorative treatment

Muscles

Bite splint therapy followed by definitive occlusal/restorative treatment

Occlusion

Occlusal reconstruction with main goal of stable centric stops in the ACP arc of closure and redesigning the anterior guidance so that lower cuspids begin the anterior guidance on the upper bicuspid until the cuspids come into function; also must flatten lower left Curve of Spee

Aesthetics

Idealize proportions and contours with new restorations.

SUMMARY OF TREATMENT SEQUENCE

Appointment	Treatment Completed
1	Lower bite splint to improve muscle function. Start with centric stops and anterior guidance cuspid to cuspid until signs and symptoms improve, and then convert to guidance on bicuspids to test muscle reaction and preview the restorative goals.
2	Bite splint follow-ups as needed until goals of comfort and stability are achieved
3	Provisionalize upper in three segments rather than a full splint to test mobility. Provisionalize lower left.
4	Periodontal surgery to improve architecture
5	Endodontics if and as needed
6	Finalize lower left.
7	Finalize upper.
8	Posttreatment bite splint
9	Follow-ups as needed and expected

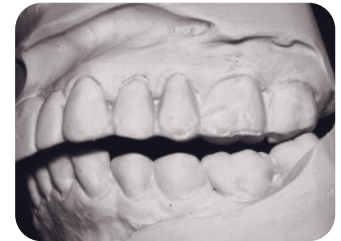
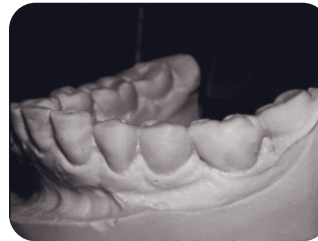
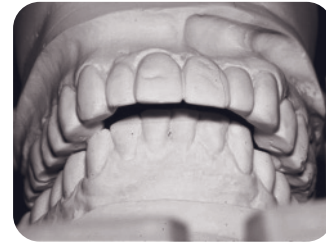Figure 16.1.1. Pretreatment articulated diagnostic casts suggesting a severe overjet. Because of the left maxillary-to-mandibular tooth-to-tooth relationship, the lateral guidance begins on the first molars. Because of the severe Curve of Spee on the lower left, as seen in the lower left photograph, there is a severe balancing interference on the left in a right lateral movement, as seen in the lower right photograph. Orthodontics/orthognathics would be the first choice to improve the maxillary-to-mandibular jaw-to-jaw and tooth-to-tooth relationships; however, the patient did not desire that approach. There is nothing to lose by trying to correct another set of articulated diagnostic casts to determine whether a restorative approach would yield acceptable results.

Bite splint therapy took several months because muscle relaxation was a slow process. The mandibular splint started with upper cuspid contact to help with muscle relaxation and then was converted/adjusted to have just bicuspid contact to preview the possibilities of the definitive dentistry.

The length of time was also needed to gain trust for her to feel comfortable to move forward with another big restorative project and believe her expectations would be met. We did not proceed until she asked to begin the definitive phase.

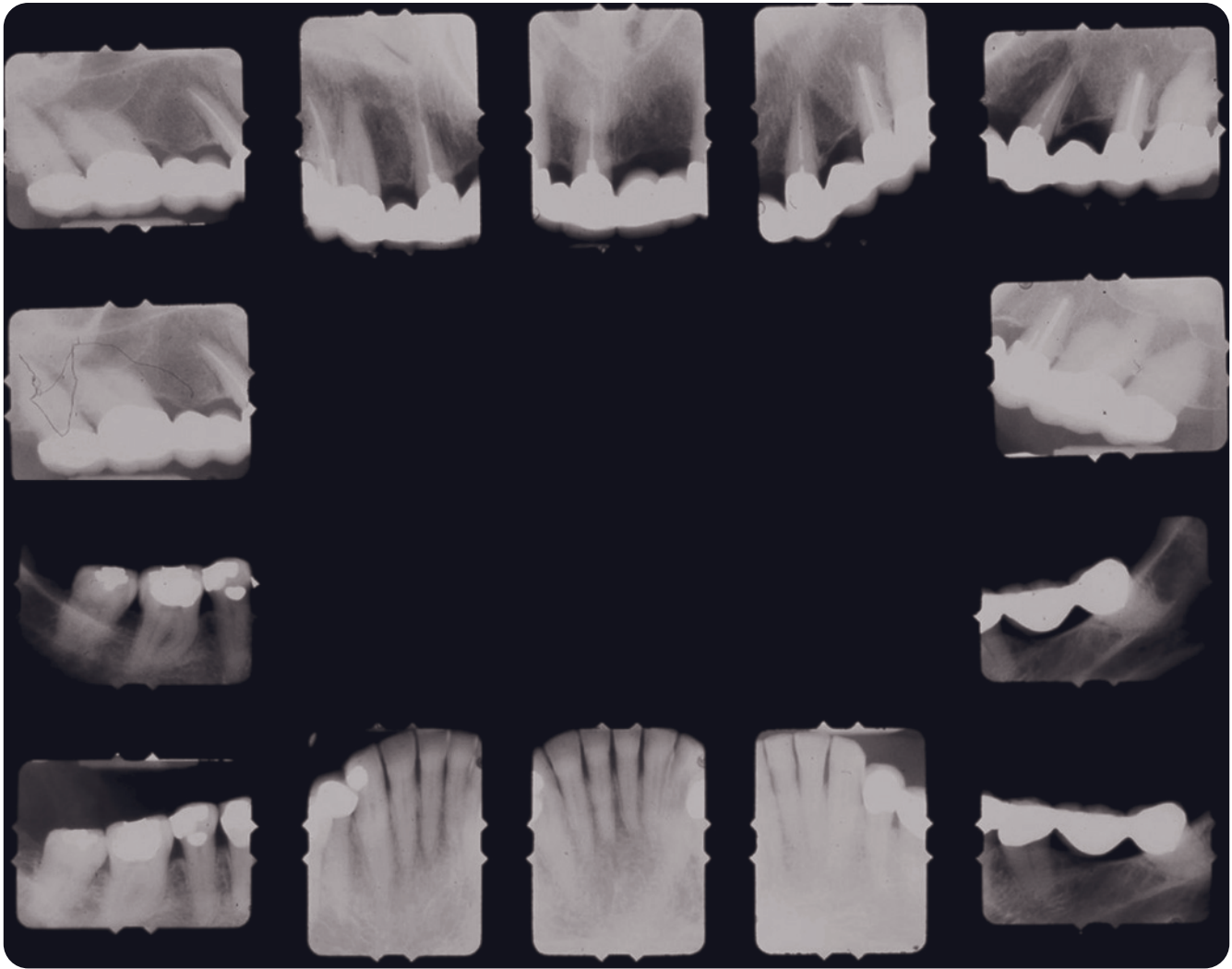


Figure 16.1.2. Pretreatment radiographs. Multiple endodontics on anterior teeth with narrow, tapered roots can make structural prognosis somewhat guarded.

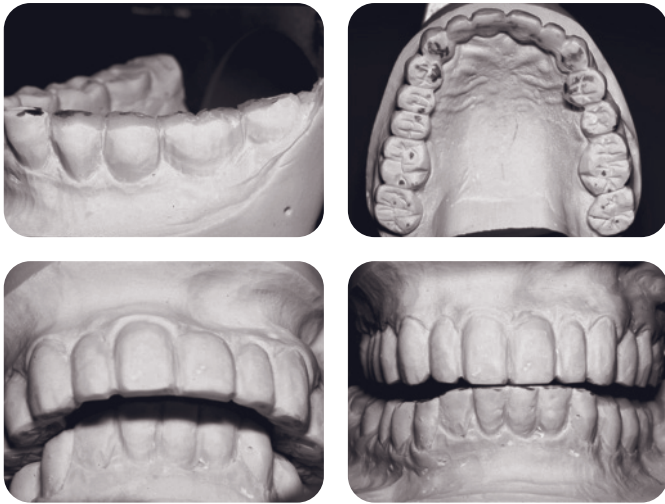

Figure 16.1.3. Photographs of the diagnostic wax-up suggest several issues: the lower left Curve of Spee was improved significantly by flattening the curve and lowering the second molar; the upper left first bicuspid was extended lingually to gain a centric stop with the lower cuspid; the lateral guidance starts on the upper first bicuspid and then transitions to the cuspids with immediate disclusion posterior to that; the facial surfaces from bicuspid to bicuspid were reduced; there is an acceptable edge-to-edge position with posterior disclusion in an end-to-end position. Since orthodontics/orthognathics will not be done, this will be an acceptable solution.

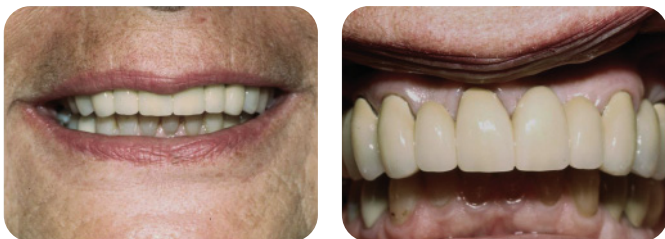

Figure 16.1.4. Anterior smile and retracted photographs of the finished dentistry. The patient's lips are much more comfortable and the restorative dentistry duplicated the same level of comfort attained with the bite splint.

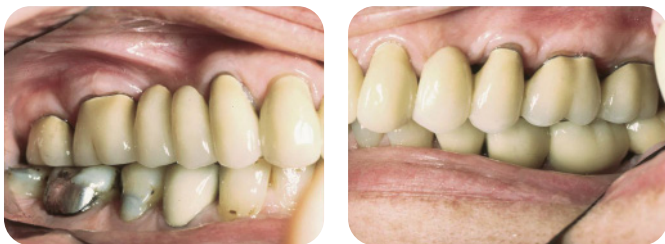

Figure 16.1.5. Posttreatment buccal photographs. Periodontium is healthy, all areas are now cleanable. The functional landmarks of the lower right molars were acceptable after reshaping. There are large old restorations that may need to be addressed in the future, but no functional parameters will need to be changed.

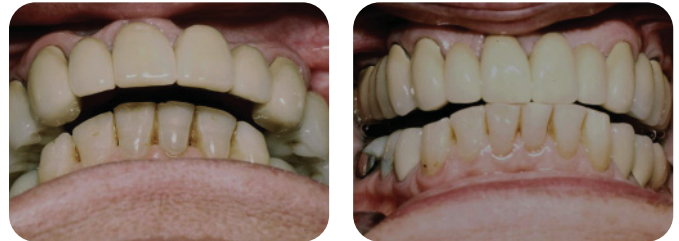
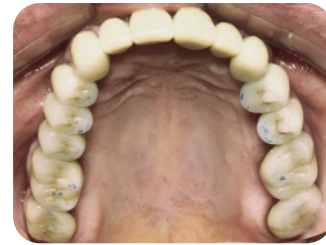
Figure 16.1.6. The top photograph illustrates the centric stops in the adapted centric posture arc of closure. The contacts on the first bicuspid are from the distal inclines of the lower cuspid. The bottom left photograph illustrates the amount of overjet and also suggests the distance that the lower cuspid must travel on the upper first bicuspid before the upper cuspid comes into function. The lower right photograph illustrates the protrusive end-to-end position with posterior disclusion. In anterior open bites, if a protrusive end-to-end position achieves posterior disclusion, the results can be stable and successful as compared to a case where the posterior teeth cannot be discluded.

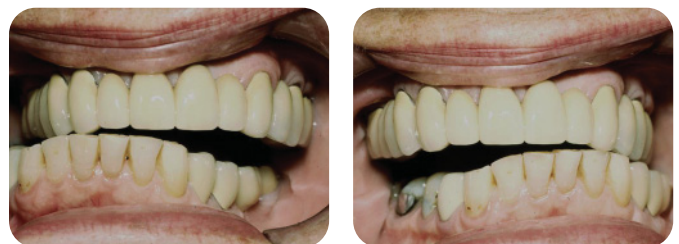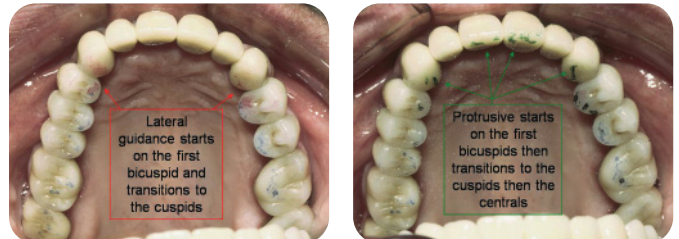


Figure 16.1.7. The red marks on the top left photo illustrate the lateral guidance starting on the first bicuspid and transitioning to the cuspid. The green marks on the top right photograph illustrate protrusive that starts on the upper first bicuspid and then transitions to the cuspids and then the incisors. The bottom photographs illustrate full range of motion right and left. It would be better to get incisor contact in this position, but there was too much overjet.

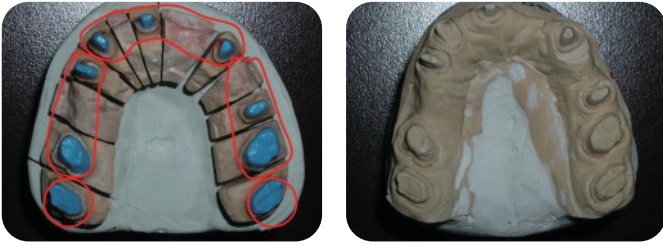

Figure 16.1.8. These photographs illustrate how the definitive restoration was designed as smaller fixed partial dentures and single units rather than a full arch splint. There was no mobility, so there was no reason to splint further. There was a precision attachment between the upper left cuspid abutment and upper left bicuspid pontic. Using smaller sections makes the dentistry much easier.

CHAPTER 16 CASE 1 KEY POINTS

- When the end result will be an anterior open bite, make sure the anterior guidance transitions across teeth very smoothly.
- When an anterior open bite case can reach the incisal edges with no posterior interferences, good results can be expected.
- If it is also a temporomandibular disorder case, test the anticipated occlusion, such as this open bite, with a modified bite splint to preview the response of the masticatory system.

Chapter 16 Case 2

Failed multiple reconstructions; original deep overbite with current condition in provisionals with an opened vertical dimension and anterior overjet; managed with a new reconstruction harmonizing a physiologic deep overbite

When the patient in this case study was seen for initial examination, it was his third reconstruction. He reported having a very deep overbite originally, and the lower anteriors were impinging on the palate. His first reconstruction, done when he was in his thirties, was a posterior reconstruction to open the vertical dimension of occlusion. The anterior teeth were left out of occlusion and continued to erupt into the palate. In addition he fractured some posterior teeth. Parts of the reconstruction were done over, this time to include anterior teeth, and that failed too. He recently had these provisionals placed. The bite was opened to the degree that he has anterior overjet. He is now very uncomfortable with speech. He feels the anterior teeth are too bulky and long and feels impingement on the neutral zone of the lips. Although not a problem in the past, he now is having symptoms of a temporomandibular disorder, both muscular and intracapsular. Needless to say, he is very unhappy, distraught, and distrustful. He mentions that he “just wants to get this completed and over with as quickly as possible.” To complicate matters more, there were some undiagnosed advanced periodontal problems. This case is included because of how the anterior tooth-to-tooth relationship was managed and because of the behavioral challenge, as well as the technical challenge.

SUMMARY OF EXAMINATION AND DIAGNOSIS

Dentition

All are currently in provisionals except 23–26; 7 has very large post/core but no pathology; 6 has no clinical crown.

Periodontium

Localized moderate to advanced disease upper left and lower left

TMJs

Right side Piper 3B

Left side Piper 3B

Both can be superiorly compressed comfortably but both are uncomfortable to palpation, suggesting inflammation.

Range of motion is normal.

Muscles

Lateral and medial pterygoids are painful.

Occlusion

Interferences to the arc of closure, slides to maximum intercuspation; anterior open bite, which patient reports was not there naturally but created with reconstructions

Aesthetics

Upper edges are too long and too far facial.

THE 10 DECISIONS**1. TMJ Diagnosis**

Adjust current provisionals (instead of bite splint) in a treatment position with the goal of adapted centric posture.

Definitive treatment done in a guided, verified adapted centric posture

2. Vertical Dimension

Close current vertical dimension of occlusion in the adapted centric posture arc of closure until anterior teeth contact.

3. Lower Incisal Edge

Use current height but create definitive incisal edges.

4. Upper Incisal Edge

Shorten 1–2 mm and move lingually 1–2 mm based on diagnosis of violation of the neutral zone and phonetics.

5. Centric Stops

Simultaneous, equal intensity centric stops in the ACP arc of closure

6. Anterior Guidance

Will be steepened because gaining anterior centric stops will create approximately 5 mm overbite; this is supposedly returning to his natural condition.

7. Curve of Spee

Make the left side on the same horizontal plane as the right side.

8. Curve of Wilson

Verify that upper buccal and lower lingual cusps do not interfere in the functional and parafunctional range of motion.

9. Cusp/Fossa Angle

Shallower than the anterior guidance

10. Aesthetic Plane

Create an upper posterior aesthetic plane that is consistent with the upper incisal edge position and with pleasing buccal profiles

SUMMARY OF TREATMENT PLAN**Dentition**

Upper reconstruction

Lower reconstruction from cuspids posterior to second molars, lower incisors will be composite
Endodontics and endodontic retreatment as needed

Periodontium

Localized definitive periodontal surgery

TMJs

Use provisionals as a bite splint to accomplish goals of comfort and stability followed by definitive occlusal therapy.

Muscles

Use provisionals as a bite splint to achieve muscle comfort followed by definitive occlusal therapy.

Occlusion

Correct upper incisal edges and lower occlusal plane; close the vertical dimension of occlusion until anterior teeth have stable centric holding contacts.

Aesthetics

Shorten upper incisal edges and improve contours and proportions in the new restorations.

SUMMARY OF TREATMENT SEQUENCE**Appointment****Treatment Completed**

1	Reline and recontour current provisionals; correct lower occlusal plane; close vertical dimension to anterior contact; refine equilibration.
2	Monitor results.
3	Get restorative commitment.
4	New provisionals; refine more precisely because metal framework of original provisional got in the way
5	Definitive periodontal surgery upper and lower left
6	Monitor results.
7	Endodontics as needed
8	Finalize lower.
9	Monitor lower definitive against upper provisional.
10	Finalize upper.

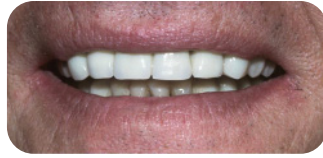

Figure 16.2.1. Pretreatment smile photograph. The patient reported that the anterior teeth were too long, felt bulky (violated the neutral zone), and were problematic phonetically.

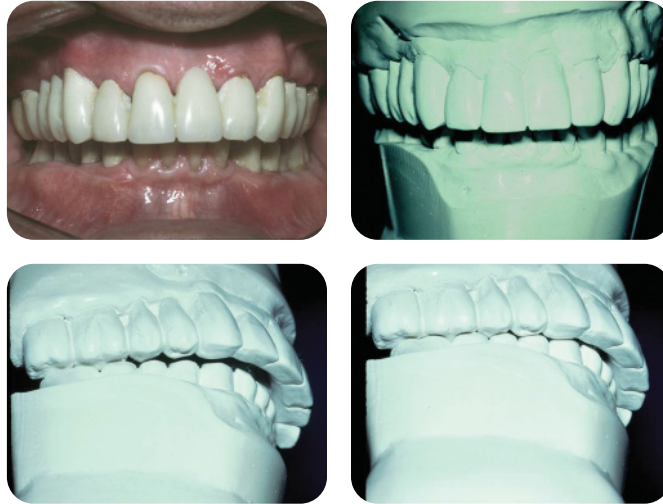

Figure 16.2.2. Top photos: pretreatment anterior retracted photographs and pretreatment articulated diagnostic casts. Bottom left: articulated diagnostic casts closed to the first contact in the adapted centric posture arc of closure. Note the anterior overjet despite the thick upper anterior teeth. Bottom right: after the hit and slide to maximum intercuspation. Note that there is still anterior overjet. The patient reported having a deep bite with anterior tooth-to-tooth contacts with his natural teeth. The initial problem was super-eruption into the soft tissue. The answer was not to create an open bite but rather to create stable anterior tooth-to-tooth centric holding contacts in the arc of closure at the proper vertical dimension of occlusion.

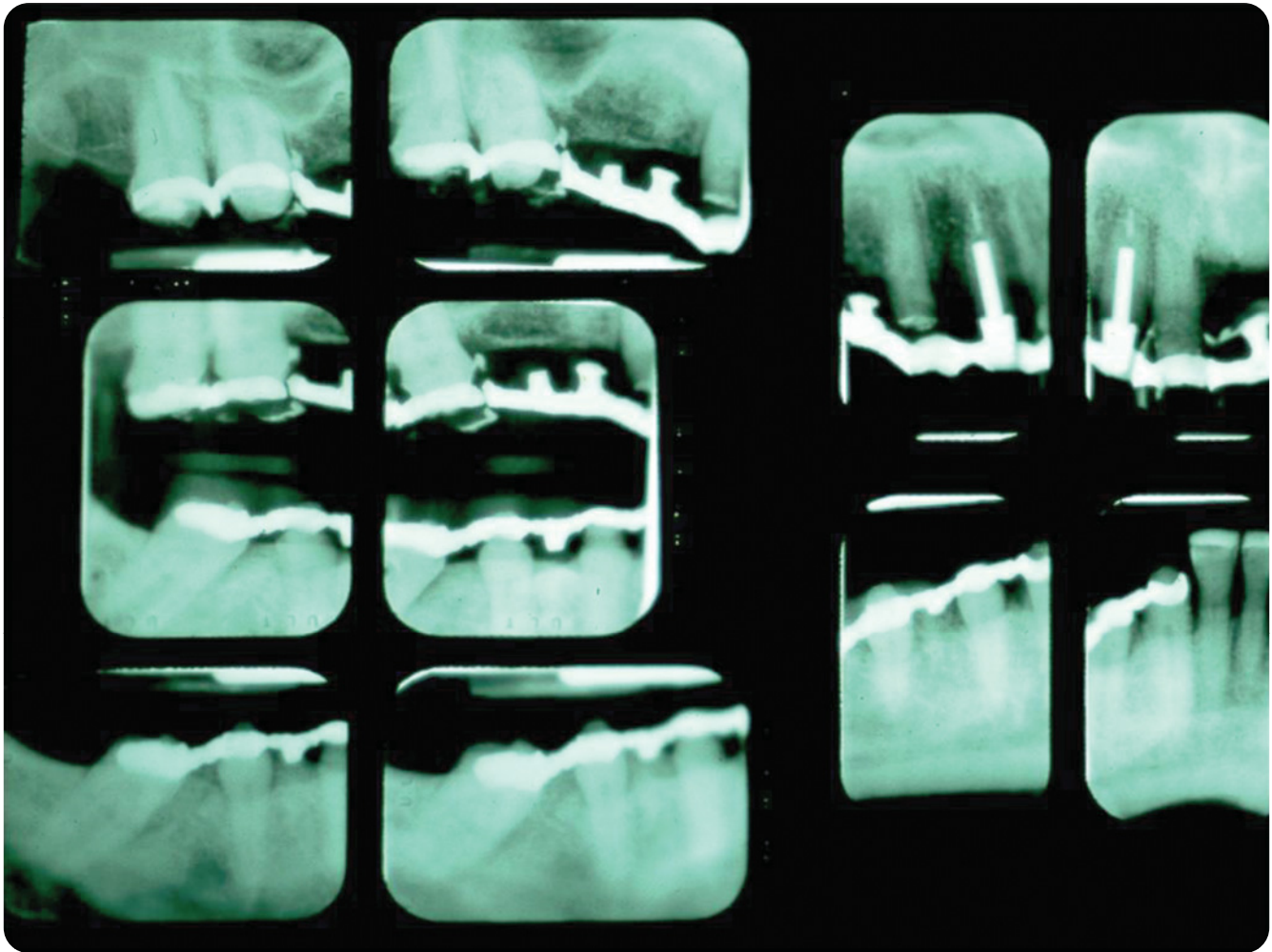


Figure 16.2.3. Pretreatment radiographs, right side. Note excessively large post in upper right lateral incisor and no clinical crown on upper right cuspid.

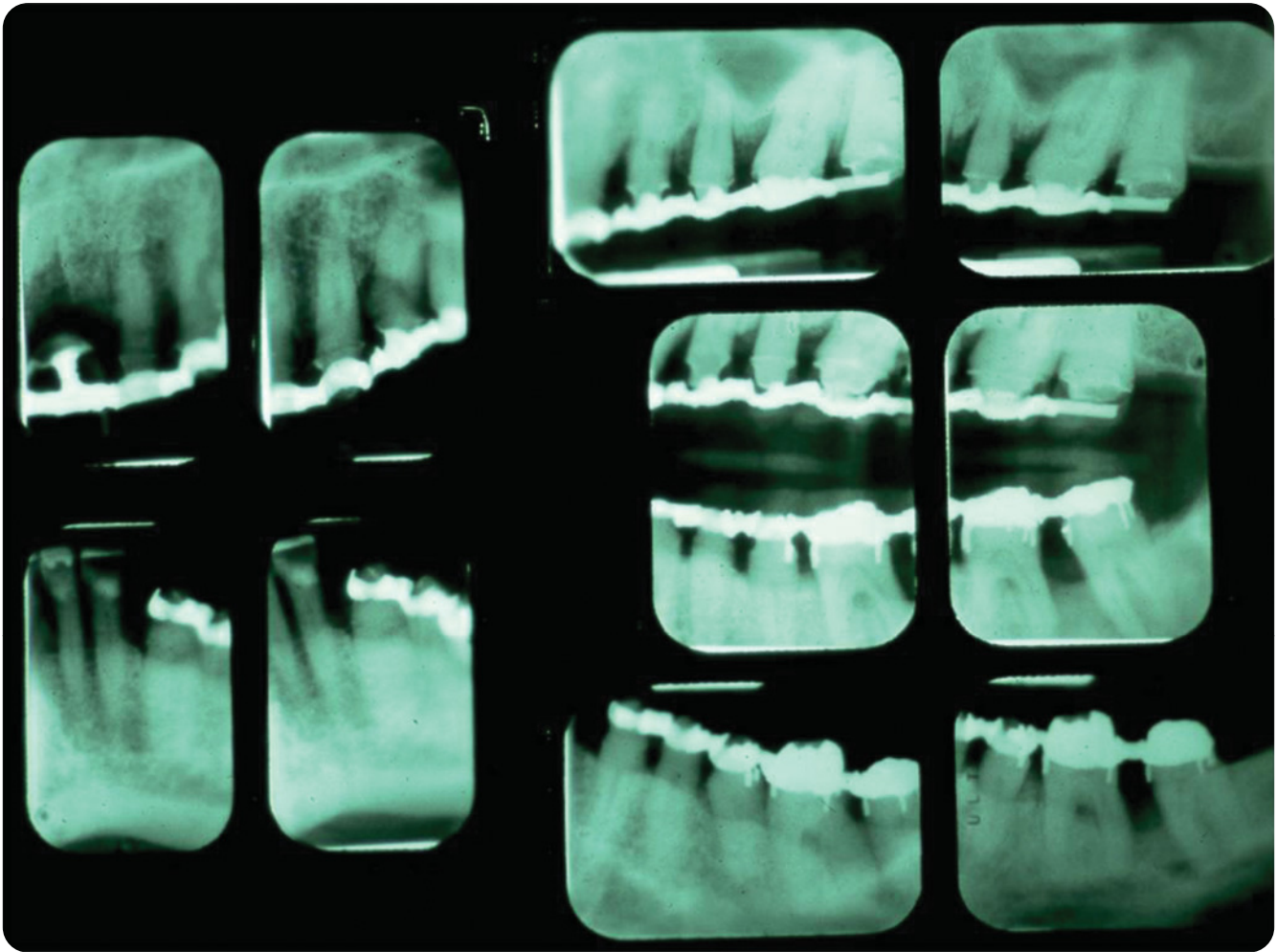


Figure 16.2.4. Pretreatment radiographs left side. Note severe bony defects upper and lower left.

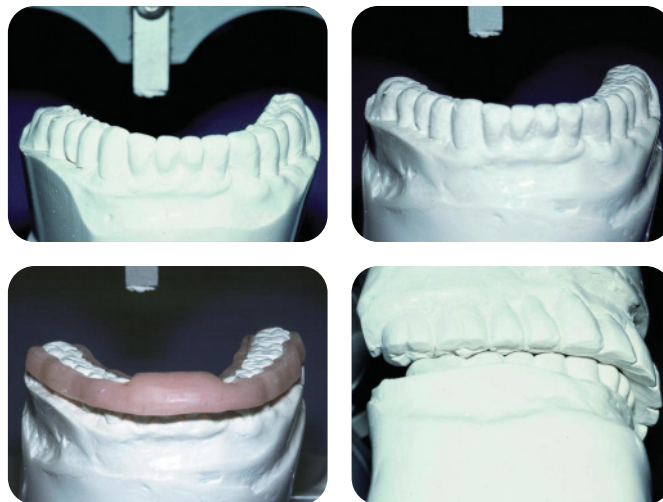


Figure 16.2.5. Top left: pretreatment mandibular arch suggesting reverse Curve of Wilson right side and uneven plane right to left. Top right: corrected cast of mandibular arch suggesting improved occlusal plane. Bottom left: reduction guide made out of acrylic used to help correct the lower current provisional intraorally. Bottom right: the upper cast is equilibrated to the corrected lower cast until the anterior teeth achieve centric holding contacts.

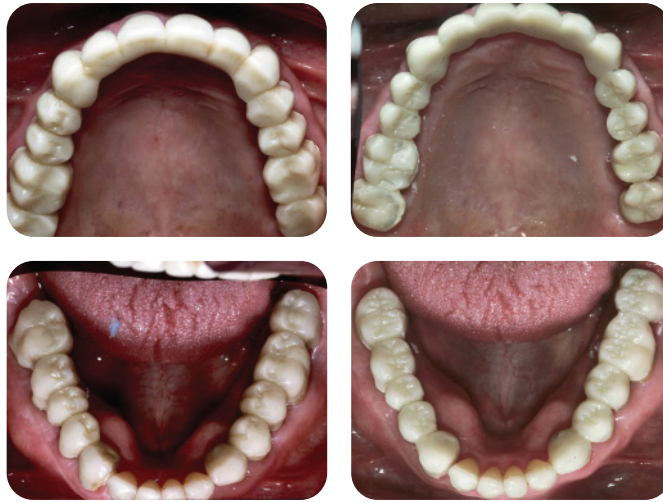


Figure 16.2.6. The corrections made on the casts were then made intraorally on the provisionals. Left photographs: original provisionals. Right photographs: corrected provisionals suggesting less bulk of the upper anterior teeth.

Why were his initial provisionals corrected rather than just making new ones? It was more a behavioral decision than a technical one. Here is a patient who has had some very bad past experiences. He is distrustful and said he never really felt that he had been listened to in the past when he expressed his concerns. To say that we need to take these provisionals off and essentially throw them away and start over again may lead him to believe that he made another bad decision by choosing that dentist and treatment. The key is to take our time, listen nonjudgmentally and go slow ... even though he wants to go fast. He would be happy to take final impressions today and just make the definitive dentistry. But that would be impossible; there are too many issues that need to be worked out and changed. Saying that we can modify these initial provisionals and make them better, and *addressing his concerns in the process*, accomplishes a lot. But it must be done gently. It was shown on the casts that all the parameters and landmarks can be corrected, proving that they can be corrected intraorally.

After these were improved, his whole demeanor changed. He became more comfortable. His speech improved, and he was happier with the appearance. Refinements needed to be made, as expected, just as with a bite splint. He knew this; there were no surprises. As the provisionals were refined—in particular, when the linguals of the upper were hollowed to make room for his envelope of function—the metal framework got in the way, and the acrylic started to deteriorate. Then something interesting happened: *he* asked whether we could make a new set of provisionals—remember, this is a patient who just wanted to get it over with fast. He started to have hope, and we were well on our way to a great relationship—and he agreed that he needed to pay a visit to the periodontist.

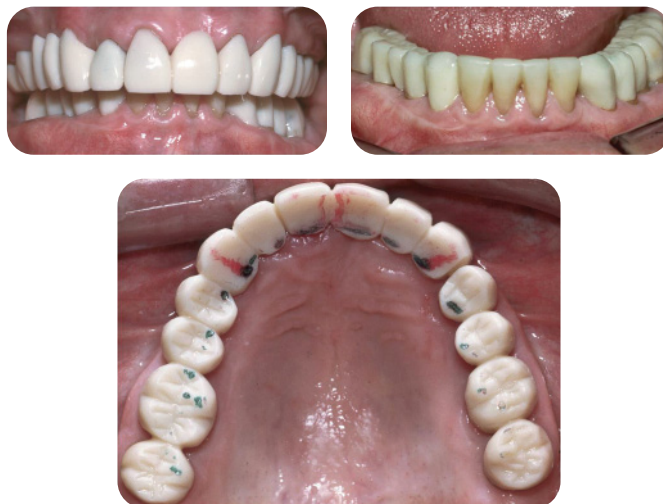

Figure 16.2.7. Photographs of new provisionals and composite buildups of the lower incisors suggesting very definitive anterior centric holding contacts. These types of centric stops assure that the teeth will not super-erupt. He preferred not to have his lower incisors crowned, and he felt these were his last remaining unprepared teeth and wanted to keep it that way. He understood that composite would need to be refreshed periodically.

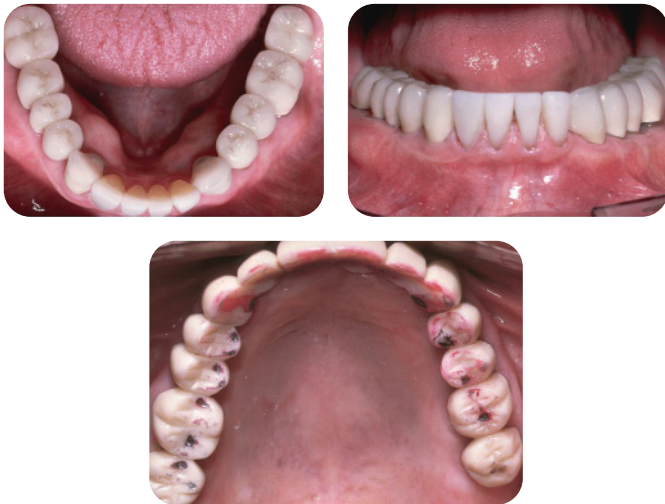

Figure 16.2.8. Photographs of the completed definitive lower dentistry refined against the same upper provisional.

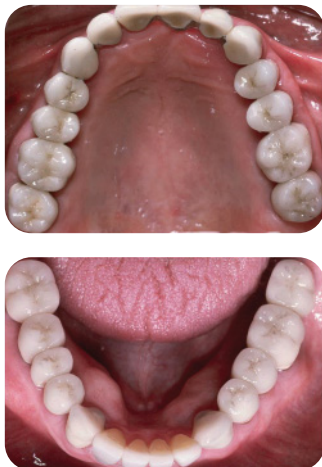

Figure 16.2.9. Photographs of the completed upper definitive dentistry suggesting a natural lingual concavity on the upper anterior teeth with natural contours and proportions. These teeth were now in harmony with his neutral zone and envelope of function and he enjoyed comfort, good function, and improved aesthetics.

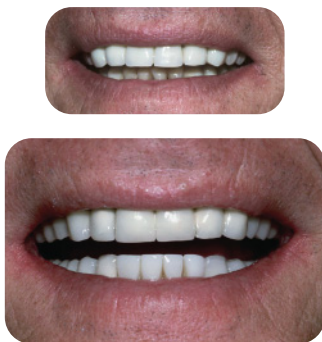

Figure 16.2.10. Before and after smile photographs suggesting a more natural, less strained upper lip.

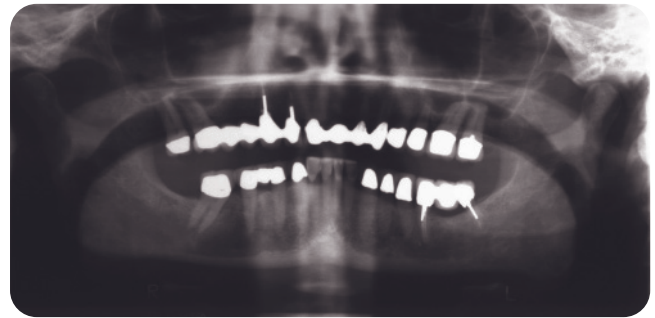

Figure 16.2.11. Posttreatment panoramic radiograph. Note that the definitive dentistry is small fixed partial dentures and single units rather than a full arch splint. Mobility was not an issue, so they did not need to be splinted. Smaller fixed partial dentures are much easier and more predictable in the long term.

CHAPTER 16 CASE 2 KEY POINTS

- An open bite cannot be expected to be stable and functional if the teeth once had centric contacts. Opening a deep bite and leaving the anterior teeth out of contact can be problematic.
- The deeper the overbite, the more the need for an enhanced cingulum on the maxillary anteriors for tooth-to-tooth stability.
- A deep overbite can be a problem-free scenario if all teeth have stable centric holding contacts in the centric arc of closure.

Chapter 16 Case 3

Maxillary reconstruction combined with extractions and periodontal surgery to improve periodontal architecture; landmarks of lower acceptable with minor modification

In this case study the patient was prompted to seek treatment because of an accident that resulted in the fracture of several maxillary anterior teeth. She resided in a Caribbean country and her dentist there performed emergency-type treatment and referred her for comprehensive restorative care.

SUMMARY OF EXAMINATION AND DIAGNOSIS

Dentition

Maxillary anterior teeth fractures and other failing restorations, endodontic concerns, maxillary left central incisor not restorable

Lower reconstruction, though not ideal, has functional landmarks that can be acceptably modified.

Periodontium

Biologic width concerns; periodontal attachment loss concerns; maxillary right first molar questionable—root proximity issues

TMJs

Right side Piper 3B

Left side Piper 3B

Both can be compressed comfortably.

Osseous irregularity right condyle

Muscles

Lateral pterygoids are uncomfortable to testing.

Occlusion

Interferences and slide to maximum intercuspatation when condyles seated

Occlusal plane issues

Unstable anterior tooth-to-tooth relationship due to overjet from a class 2 orthodontic relationship

Aesthetics

Length, proportion, gingival excess, narrow maxillary posterior aesthetic profiles

THE 10 DECISIONS

1. TMJ Diagnosis

Treat to adapted centric posture.

2. Vertical Dimension

Open 1–2 mm at the incisors to improve tooth-to-tooth functional relationships.

3. Lower Incisal Edge

Smooth and polish: “move” lower right lateral incisor anteriorly with composite and shorten.

4. Upper Incisal Edge

Shorten 1.5 mm.

5. Centric Stops

Enhance cingulum of maxillary anteriors to obtain stable tooth-to-tooth holding contacts.

Simultaneous, equal intensity centric stops in the ACP arc of closure

6. Anterior Guidance

Shallower as a result of opening the vertical dimension of occlusion and corrected upper and lower incisal edges

7. Curve of Spee

Reshape last molars to flatten plane.

Add composite to lower right first bicuspid and first molar to further lessen the curve.

8. Curve of Wilson

Idealize by reshaping.

9. Cusp/Fossa Angle

Keep shallow for easy disclusion because of the shallower anterior guidance.

10. Aesthetic Plane

Keep upper plane level.

Enhance facial contours of all posteriors.

SUMMARY OF TREATMENT PLAN

Dentition

Remove maxillary right third and first molar and left central incisor.

Maxillary reconstruction

Endodontics as needed

Periodontium

Crown-lengthening surgery and osseous surgery to improve periodontal architecture

TMJs

No treatment is needed other than correct occlusal engineering.

Muscles

No treatment is needed other than correct occlusal engineering.

Occlusion

Maxillary reconstruction, minor mandibular modifications to improve landmarks

Aesthetics

Idealize form, buccal corridor, and contours with restorations.

SUMMARY OF TREATMENT SEQUENCE

Appointment

Treatment Completed

- | | |
|---|--|
| 1 | Reshape lower anteriors; composite 26.
Reshape and add composite to lower dentistry per the diagnostic blueprint to improve landmarks. Prepare upper teeth; impression for provisional.
To periodontist while provisional is fabricated
Back to office to place provisional |
| 2 | Monitor and maintain provisional. |
| 3 | Endodontics as needed
Time for healing, maturation of tissues |
| 4 | Modify preparations and new provisionals. |
| 5 | Finalize preparations, definitive impressions. |
| 6 | Place definitive dentistry. |

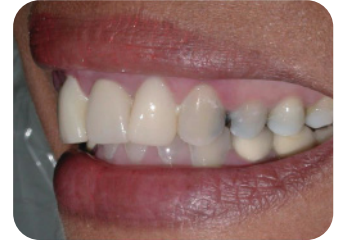
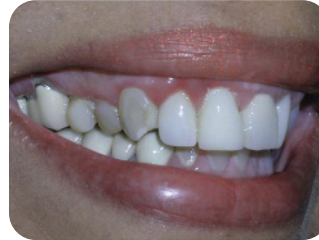
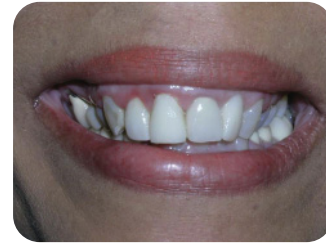Figure 16.3.1. Pretreatment anterior and lateral smile photographs illustrating fractures and a variety of aesthetic issues, both dental and gingival. She presented with maxillary right central and left lateral provisionals.

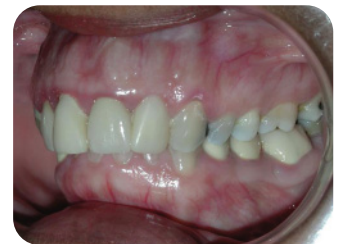
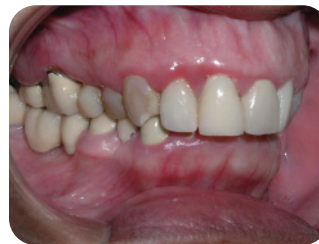
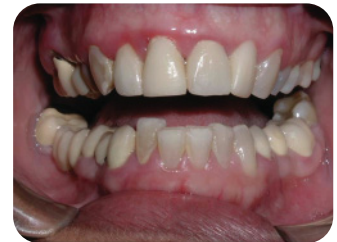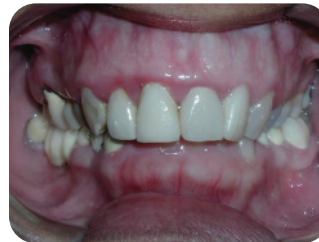Figure 16.3.2. Pretreatment anterior and lateral retracted photographs.

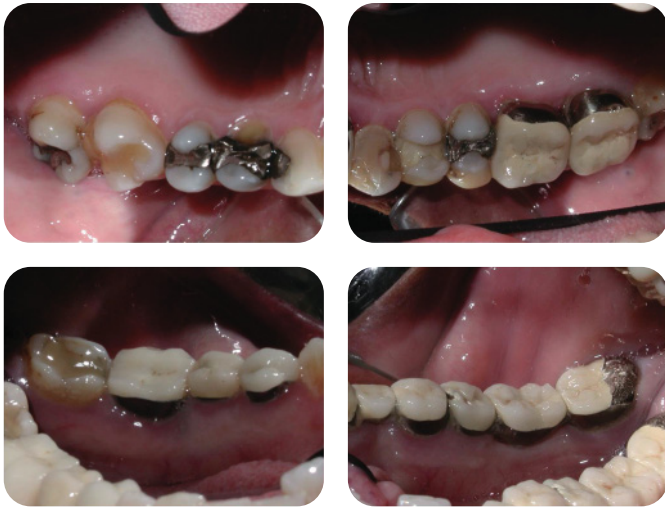

Figure 16.3.3. Pretreatment lingual photographs illustrating a variety of other problems on the maxillary posterior teeth. The mandibular restorations, though not ideal, are serviceable with minor modifications.

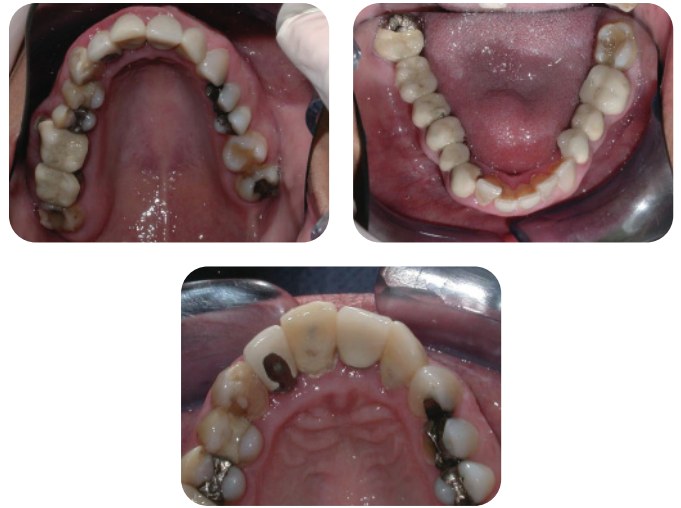

Figure 16.3.4. Pretreatment maxillary and mandibular occlusal photographs.

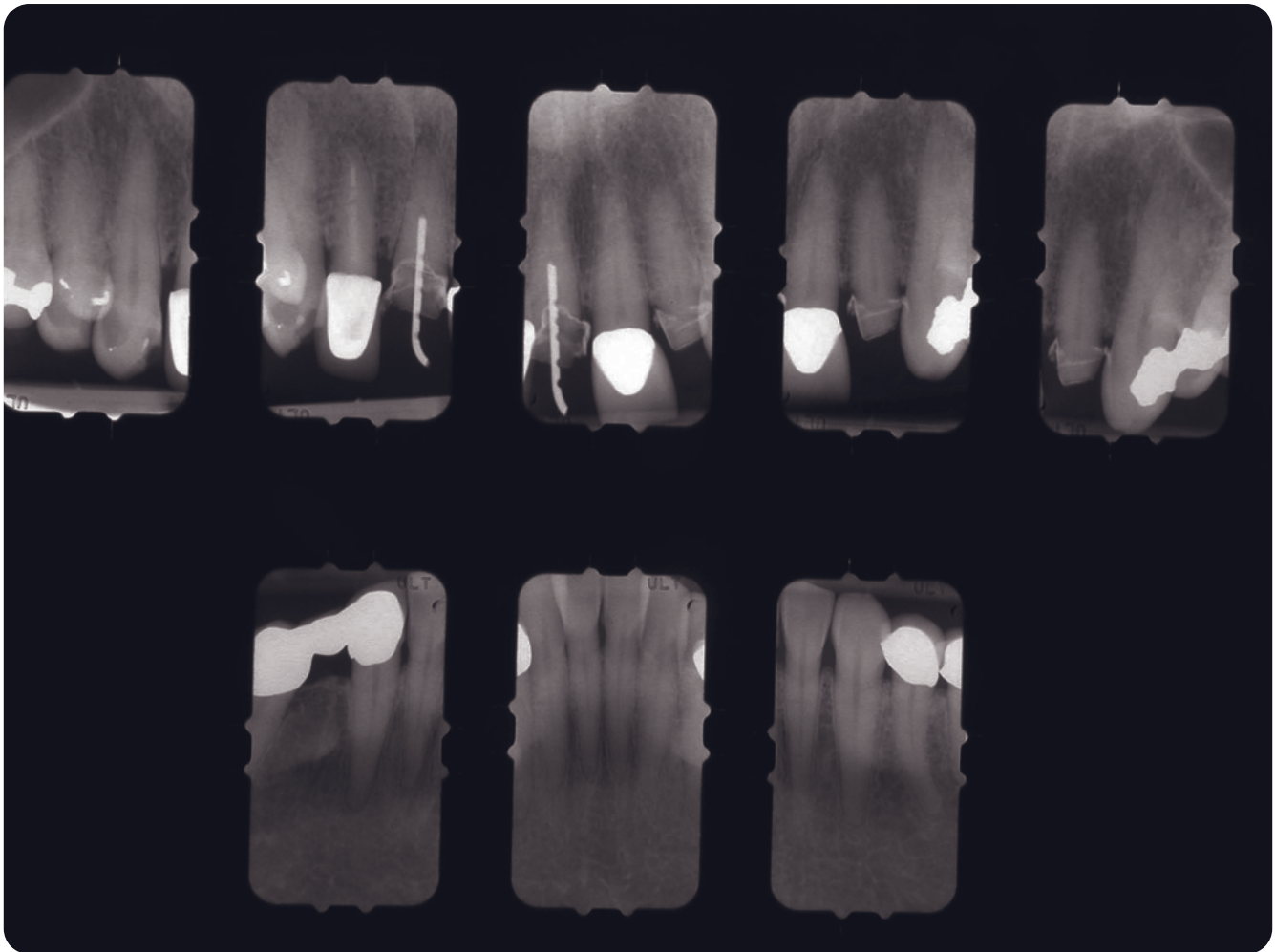


Figure 16.3.5. Pretreatment anterior radiographs illustrating endodontic and dental concerns.

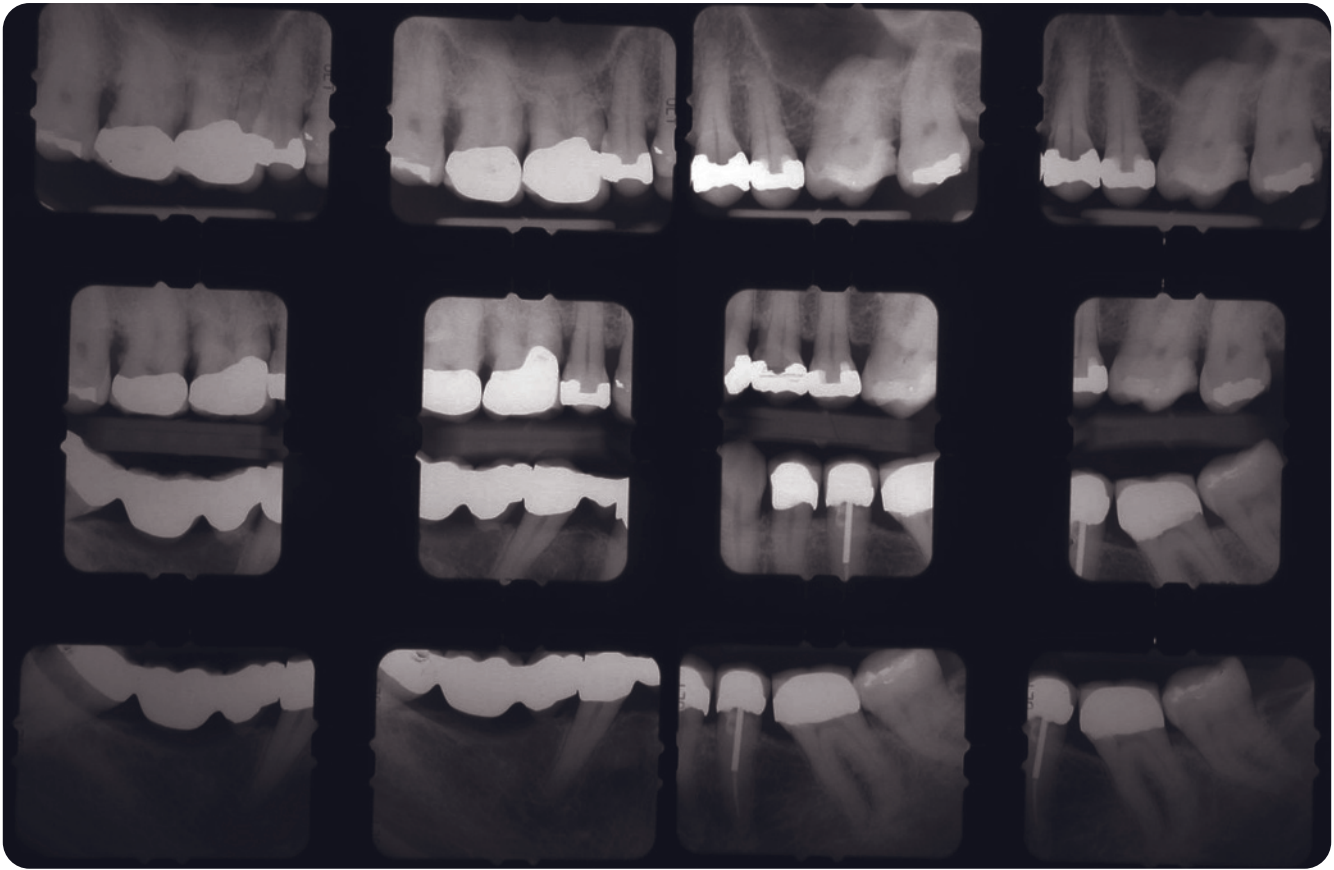


Figure 16.3.6. Pretreatment posterior radiographs. Note root proximity issues of maxillary right first molar. Structurally the mandibular teeth are maintainable.

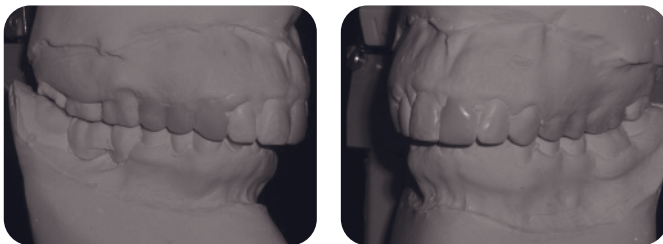
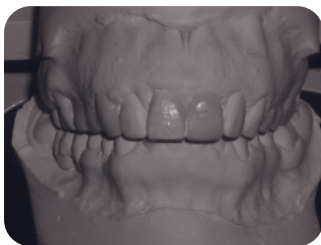


Figure 16.3.7. Diagnostic wax-up photographs illustrating aesthetic and buccal profile changes.

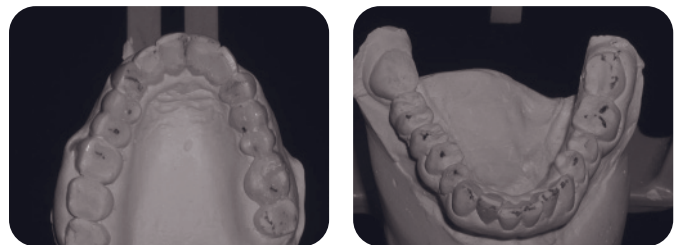


Figure 16.3.8. Occlusal photographs of the diagnostic wax-up illustrating occlusal improvements and maxillary anterior cingulum improvements for better centric stops. It was decided to correct the lower right lateral incisor by reshaping and composite rather than using orthodontics due to the patient residing out of the country. The tooth super-erupted because it did not have a stable holding contact.

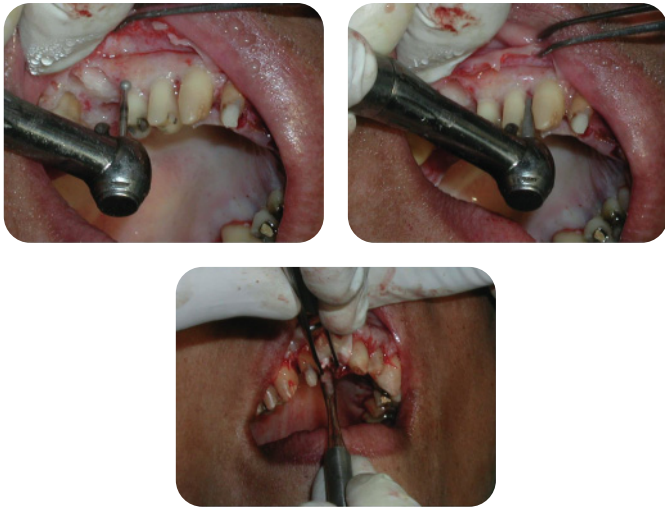

Figure 16.3.9. Photographs taken at the periodontist's office. The root-alveolar interface was improved by odontoplasty and alveoplasty.

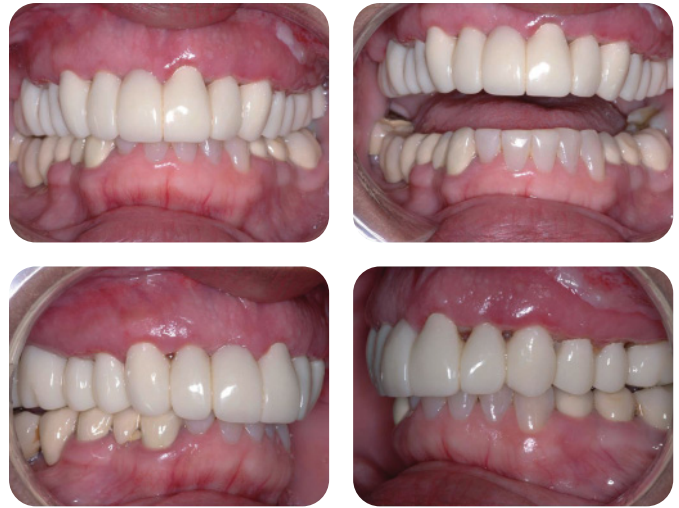

Figure 16.3.12. Anterior and lateral retracted photographs. Tissues are improving. At this point, the patient got back on track with home care and follow-ups.

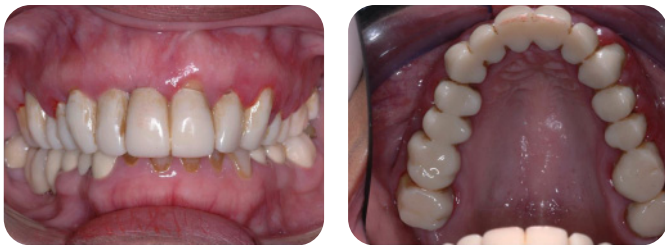

Figure 16.3.10. Photographs 3 months postperiodontal surgery. Although the importance of follow-ups was emphasized, she did not return as prescribed. That, coupled with poor home care, resulted in unfavorable healing.

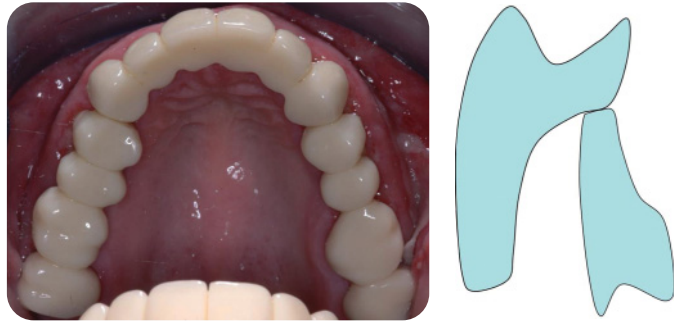


Figure 16.3.13. Maxillary occlusal photograph of provisional along with an illustration of the cingulum design necessary for stable anterior centric holding contacts. Phonetics was not affected.

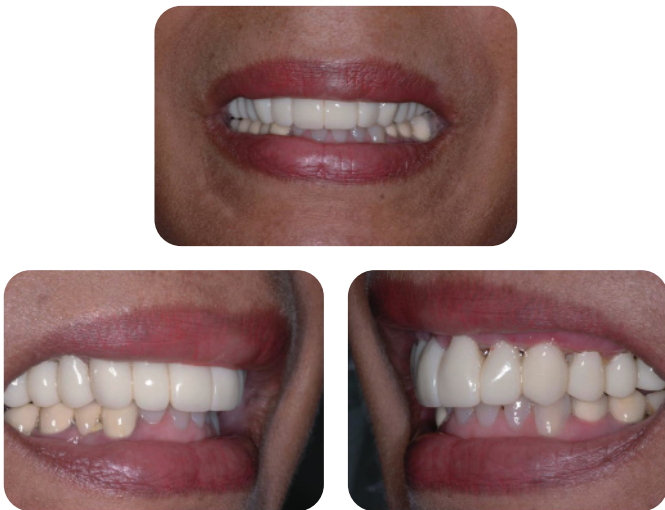

Figure 16.3.11. Anterior and lateral smile photographs 1 week after gingivoplasty/gingivectomy of the hyperplastic tissue and new provisionals restorations.

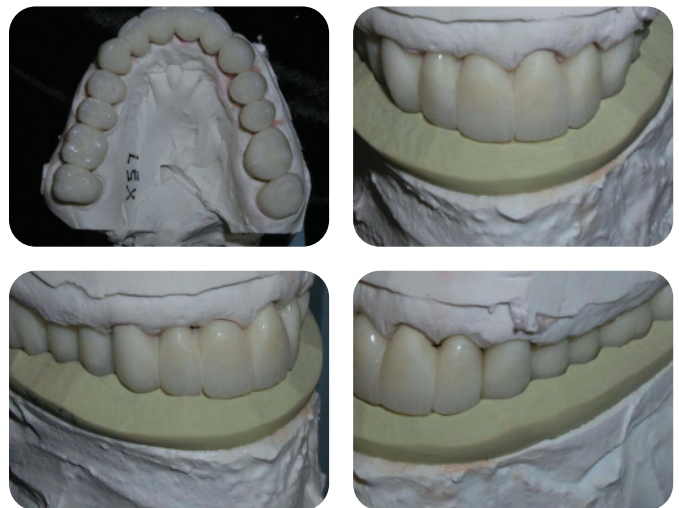

Figure 16.3.14. Photographs from the laboratory technician verifying the contours of the restorations with the putty index made from the provisional restorations.

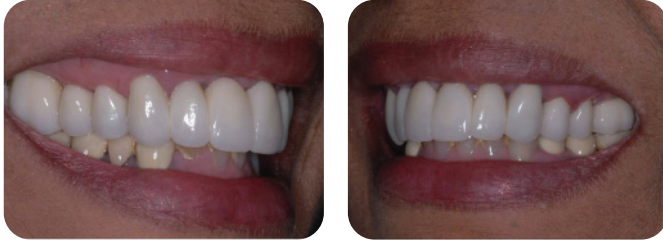
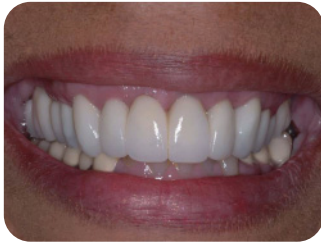
Figure 16.3.15. Anterior and lateral smile photographs of the completed restorations suggesting improved buccal profiles of the aesthetic plane.

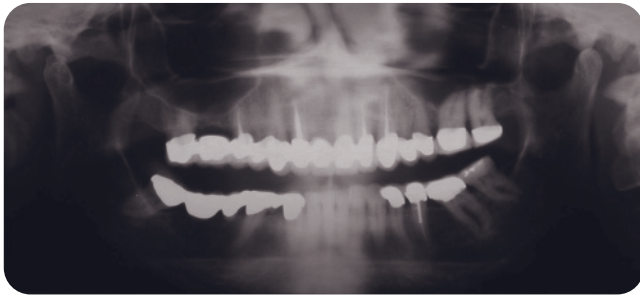

Figure 16.3.16. Posttreatment panoramic radiograph of the completed maxillary reconstruction done with zirconia restorations.

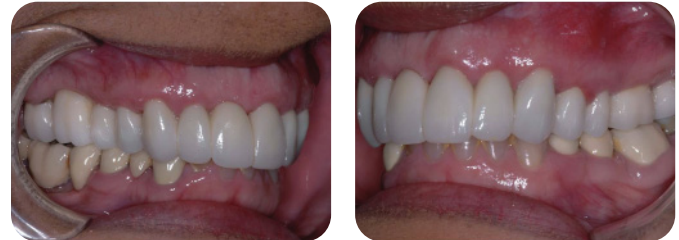
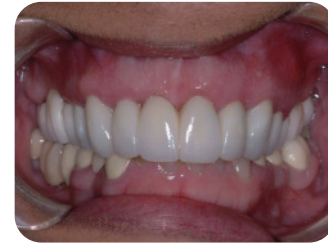
Figure 16.3.17. Posttreatment anterior and lateral retracted photographs of the completed maxillary reconstruction. There is still some inflammation between the maxillary left bicuspids but a good recovery overall from the disappointing 3-month postsurgery condition.

CHAPTER 16 CASE 3 KEY POINTS

- If only one arch will be treated due to patient circumstances, the opposing arch must be evaluated and modified by reshaping and composite additions as necessary.
- Periodontal surgery in conjunction with restorative dentistry carries a lot of responsibility on the part of the dentist and patient.
- Patients who travel great distances for treatment must understand the responsibilities.

Chapter 16 Case 4

Full mouth reconstruction utilizing crown-lengthening surgery, extractions, single crowns, veneers, and a fixed partial denture sequenced over 2 years

Years of neglect, some unfavorable past experiences, and the resulting embarrassment kept the patient in this case study from seeking care for many years. A referral from a trusted friend finally motivated him to begin treatment. The scope of the project was large and his circumstances necessitated staging the treatment.

SUMMARY OF EXAMINATION AND DIAGNOSIS

Dentition

Failed restorations, endodontic concerns, lower right second bicuspid and first molar not restorable, wear and erosion

Periodontium

Biologic width concerns posteriorly; gingival aesthetic issues anteriorly

TMJs

Right side Piper 3B

Left side Piper 3B

Both can be superiorly compressed comfortably.

Muscles

Medial and lateral pterygoids are uncomfortable to testing.

Occlusion

Interferences to maximum intercuspation in the arc of closure

Traumatic anterior guidance due to uneven edges

Aesthetics

Length, proportion, contours, gingival levels

THE 10 DECISIONS

1. TMJ Diagnosis

Treat to a guided, verifiable adapted centric posture.

2. Vertical Dimension

Open slightly to make room for anterior restorations.

3. Lower Incisal Edge

Polish cuspids; move edge of lower left cuspid facially to get a better stop with upper left cuspid; restore incisors to this level.

4. Upper Incisal Edge

Increase length of central incisors 1 mm.

5. Centric Stops

Simultaneous, equal intensity centric stops on all teeth in the adapted centric posture arc of closure

6. Anterior Guidance

Slightly shallower due to increased vertical dimension of occlusion; determined by verified upper and lower anterior incisal edge position

7. Curve of Spee

Idealize with restorations.

Shorten super-erupted maxillary left second molar.

8. Curve of Wilson

Verify that upper buccal and lower lingual cusps do not interfere in the functional and parafunctional range of motion.

9. Cusp/Fossa Angle

Shallower than the anterior guidance disclusive angle

10. Aesthetic Plane

Create an upper posterior aesthetic plane that is consistent with the upper incisal edge position and with pleasing buccal profiles

SUMMARY OF TREATMENT PLAN**Dentition**

Crowns all maxillary teeth
 Crowns lower left posterior
 Remove lower right second bicuspid and first molar
 Fixed partial denture lower right
 Veneers lower anterior
 Plan for implant lower left second molar

Periodontium

Crown lengthening maxillary posterior due to biologic width issues
 Crown lengthening maxillary anterior for aesthetic reasons

TMJs

No treatment is needed other than correct occlusal engineering.

Muscles

No treatment is needed other than correct occlusal engineering.

Occlusion

Simultaneous, equal intensity centric stops in the adapted centric posture arc of closure
 Anterior guidance on anterior teeth

Aesthetics

Idealize contours and proportions with restorations.
 Patient desires a natural color, not bright and white.

SUMMARY OF TREATMENT SEQUENCE**Appointment****Treatment Completed**

1	Composite buildups (as long-term provisionals) lower anterior Provisional restorations lower left and right
2	Composite build-ups (as long-term provisionals) upper anterior Provisional restorations upper left and right
3	Evaluate, monitor, and modify aesthetic and functional changes as needed.
4	Finalize lower posteriors.
5	Crown lengthening upper posteriors
6	Reprep, new provisionals, maxillary posterior
7	Healing time
8	Crown lengthening maxillary anterior
9	Healing time
10	Impressions maxillary posterior
11	Place maxillary posterior definitive restorations. New provisionals maxillary anterior
12	Preparation and provisionalized veneers mandibular anterior
13	Place mandibular anterior veneers.
14	Impressions maxillary anterior
15	Place maxillary anterior restorations.
16	Plan for dental implant lower left second molar

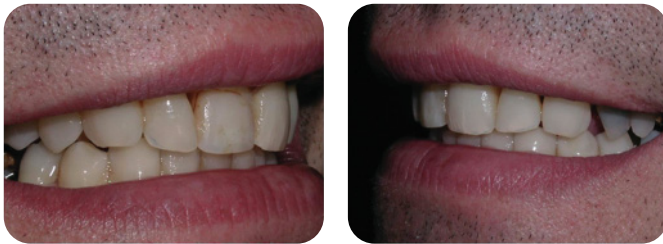
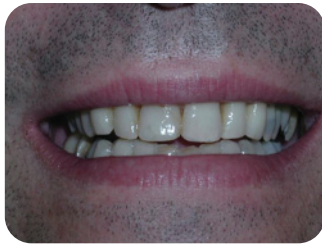
Figure 16.4.1. Pretreatment anterior and lateral smile photographs suggesting structural, functional, and aesthetic issues.

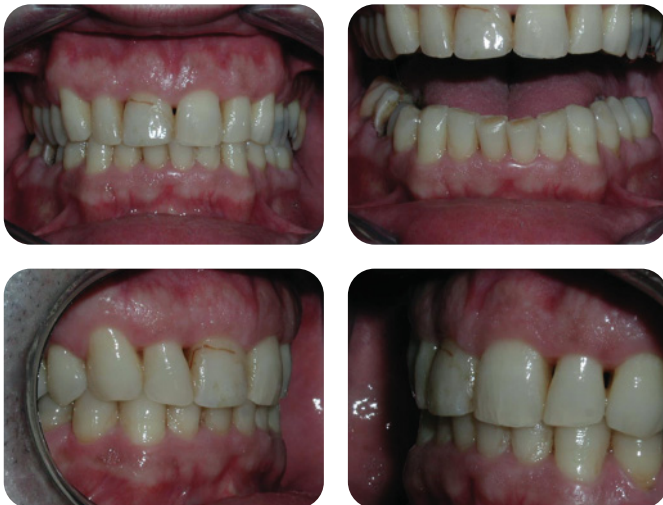

Figure 16.4.2. Pretreatment anterior and lateral retracted photographs illustrating uneven upper and lower anterior incisal edges, resulting in traumatic anterior guidance movements in the functional and parafunctional range of motion.

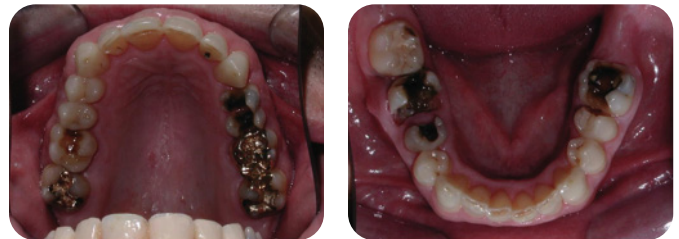
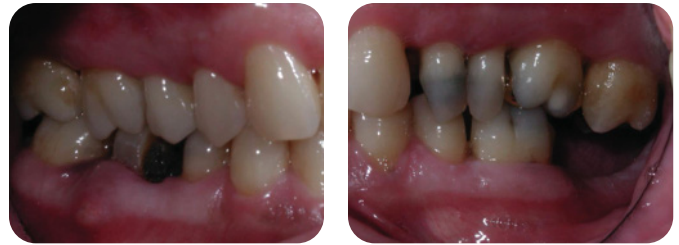
Figure 16.4.3. Pretreatment buccal occluded and occlusal photographs. The posterior teeth with missing restorations were gold inlays and onlays. The patient reported that the restorations were done in a rather hurried environment with not a lot of attention being paid to the functional occlusion. He reported that the bite never felt right as the gold restorations were completed.

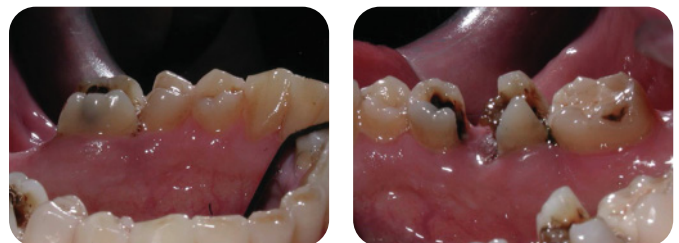
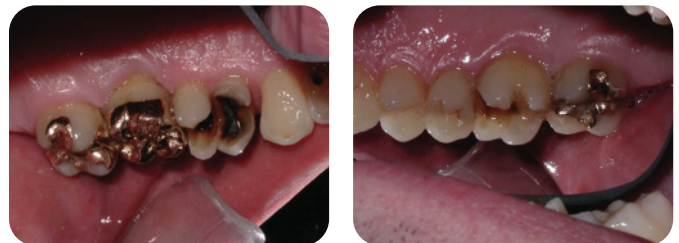

Figure 16.4.4. Pretreatment lingual photographs suggesting extensive recurrent decay, biologic width violation interproximally, and drifting of teeth as interproximal contacts were lost. The lower right second bicuspid and first molars are not restorable. The patient desires a fixed partial denture and not dental implants.

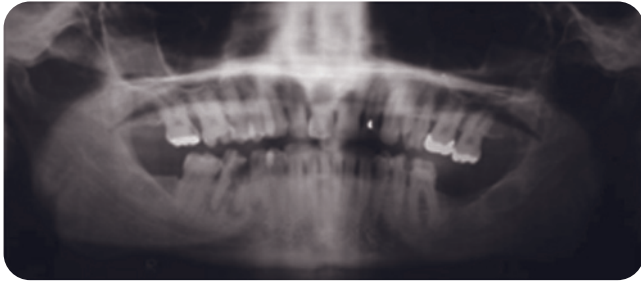


Figure 16.4.5. Pretreatment panoramic radiograph.

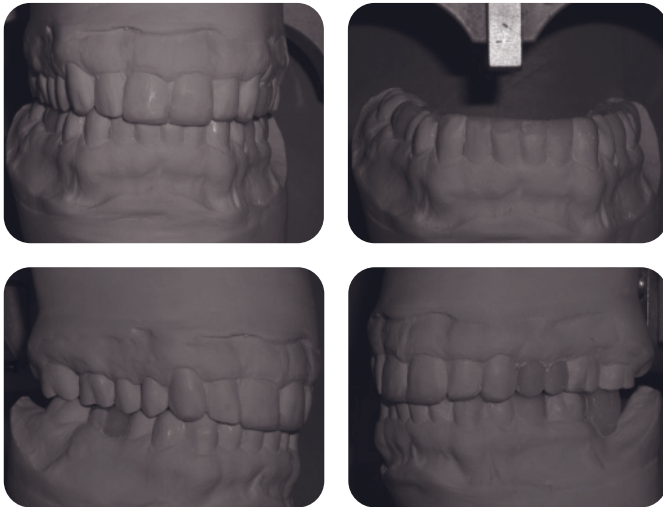


Figure 16.4.6. Diagnostic wax-up photographs illustrating incisal edge changes, contour improvements, and occlusal plane corrections. The lower left cuspids needed to be "moved" facially to obtain a stable centric stop with the upper left cuspid. Although the lower left second molar implant will not be immediately done, the wax-up was done to guide the correction of the super-erupted upper left second molar.

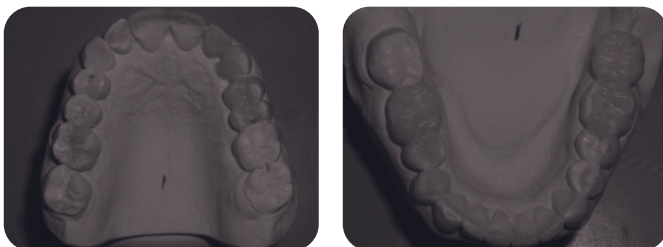


Figure 16.4.7. Occlusal photographs of the diagnostic wax-up illustrating the functional changes.

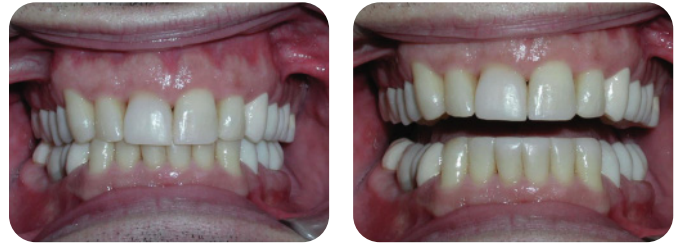
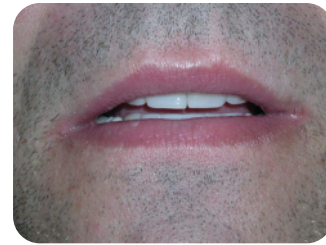
Figure 16.4.8. Photographs of the first phase of provisionalization. Because the definitive treatment needed to be staged over a period of time due to patient circumstances, the maxillary and mandibular anterior teeth were provisionalized with direct bonded composite to avoid the potential hazards of long-term temporarily cemented provisionals.

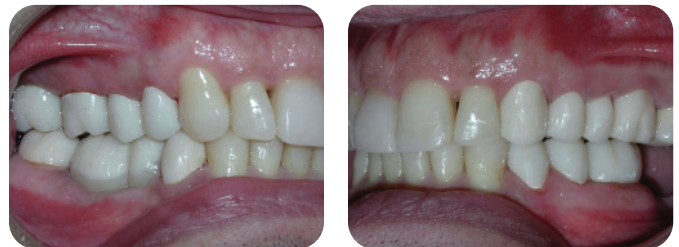

Figure 16.4.9. Buccal occluded photographs of the provisional restorations. The lower right fixed partial denture provisional is Ribbond reinforced. The gingival aspect of the pontics are light-cured composite Ribbond reinforcement, accounting for the color difference. The mandibular posterior teeth will be finalized because surgery is not needed. The maxillary posterior teeth are ready for crown-lengthening surgery.

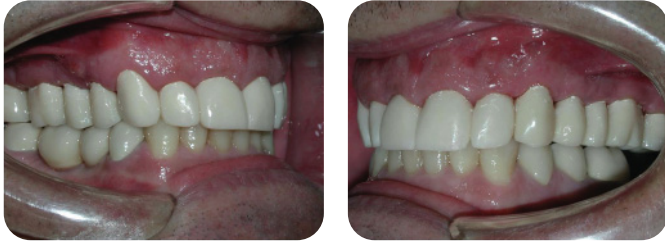
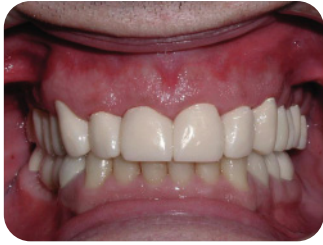
Figure 16.4.10. Photographs of the mandibular posterior definitive restorations and the maxillary anterior teeth provisionalized.

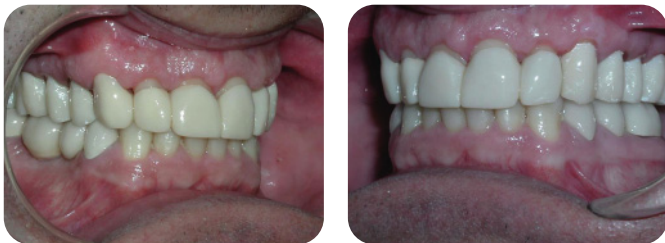
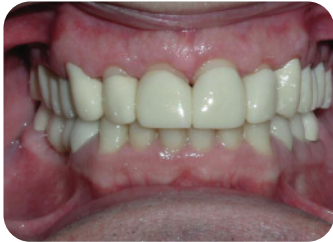
Figure 16.4.11. Photographs after maxillary posterior crown-lengthening surgery has been completed, the teeth repped, and the provisionals relined. Maxillary anterior surgery has been completed, but the teeth are not yet repped and relined.

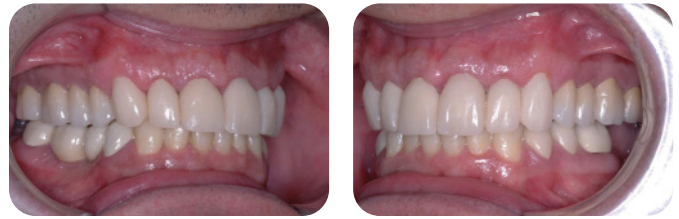
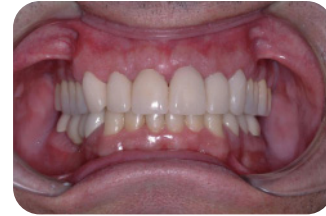
Figure 16.4.12. Photographs of the completed maxillary posterior definitive restorations and new maxillary anterior provisionals after repping several weeks after crown-lengthening surgery. The upper left first and second molar restorations were splinted so that the upper left second molar would not super-erupt in the time that the lower left second molar dental implant would be done.

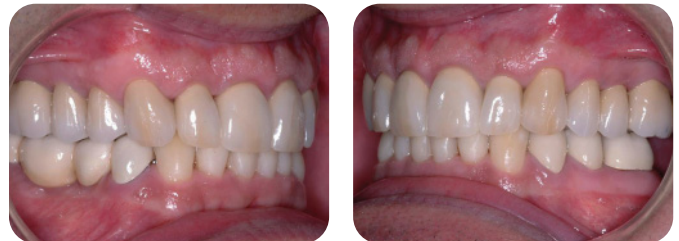
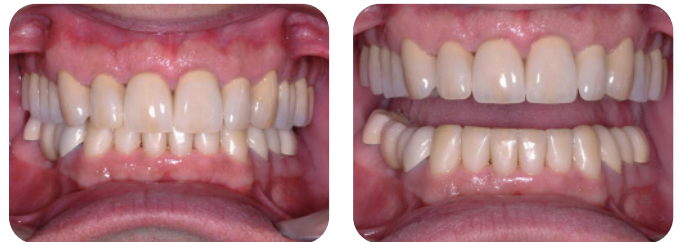
Figure 16.4.13. Photographs of all the completed definitive restorations. The lower anterior teeth are porcelain veneers. The patient desired the natural coloration seen in the photographs rather than a whiter color.

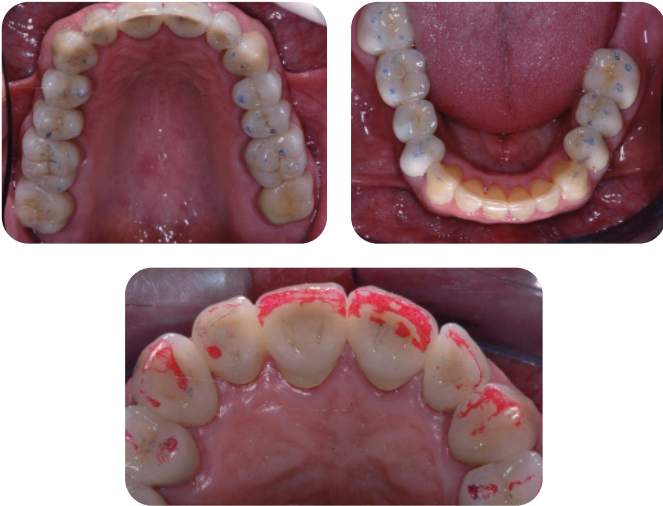

Figure 16.4.14. Photographs of the completed dentistry with the centric stops marked and the anterior guidance functional movements also marked.

CHAPTER 16 CASE 4 KEY POINTS

- When a treatment plan is accepted but must be sequenced over an extended period of time, consider direct composite buildups as provisional when possible.
- When sequencing the various segments, modify the opposing landmarks intraorally and on the working casts as necessary to get the most ideal results in the section being finalized.
- Understand that cases involving periodontal surgery in conjunction with the restorative dentistry will need added appointments for reprepping, relining provisionals, and often new provisionals. Build this into the treatment sequence.

Chapter 16 Case 5

Maxillary complete fixed partial denture on 9 Galvano telescopic copings; mandibular anterior fixed partial denture on 4 Galvano copings

The patient in this case study had her current reconstruction done 20+ years ago and has been maintained by her periodontist. The blade implant on the lower left has been problem-free. The reconstruction has been maintained also by repairing marginal recurrent decay. It reached the point that two of the abutments were diagnosed as unrestorable and the patient was referred. The maxillary anterior segment was connected to the posterior segments with a precision attachment and was mobile as an entire unit due to tooth mobility and not decementation. Occlusion was a

primary factor for the mobility. She traveled from another country, so efficient sequencing and timely execution were very important.

SUMMARY OF EXAMINATION AND DIAGNOSIS

Dentition

Maxillary reconstruction past the point of maintainability

Upper right cuspid and upper left first bicuspid are not restorable.

Mandibular posterior reconstruction is maintainable; anterior has endodontic and periodontal problems, lower left lateral incisor.

Periodontium

Upper anterior segment grade 2 mobility despite precision attachment to posterior

Lower left lateral incisor untreatable pockets

TMJs

Right side Piper 3B

Left side Piper 3B

Both can be compressed comfortably.

Muscles

Lateral pterygoids slight tenderness

Occlusion

Interferences in the arc of closure to maximum intercuspation

End point of the slide is the anterior segment.

High incisal plane exacerbates this trauma.

Excessive Curve of Spee

Aesthetics

Proportions of teeth can be improved.

THE 10 DECISIONS

1. TMJ Diagnosis

Treat to a guided verifiable adapted centric posture.

2. Vertical Dimension

No need to change

3. Lower Incisal Edge

Lower the plane by 2.5 mm to be consistent with posterior plane.

4. Upper Incisal Edge

Maintain; just improve proportions.

5. Centric Stops

Simultaneous, equal intensity centric stops on all teeth in the adapted centric posture arc of closure; no slide to maximum intercuspation

6. Anterior Guidance

Determined by verified upper and lower incisal edge position

7. Curve of Spee

Flatten lower curve by reshaping current dentistry.

8. Curve of Wilson

Reshape current lower dentistry; verify that upper buccal and lower lingual cusps do not interfere in the functional and parafunctional range of motion.

9. Cusp/Fossa Angle

Shallower than the anterior guidance disclusive angle; when reshaping the lower, do not deepen fossa.

10. Aesthetic Plane

Verify that the aesthetic plane of the upper buccal cusps is level and symmetrical and that the facial profiles of the upper posterior teeth are aligned correctly.

SUMMARY OF TREATMENT PLAN

Dentition

Remove upper right cuspid and upper left first bicuspid.
 Galvano telescopic copings on 9 remaining teeth and a 13-unit fixed partial denture
 Section lower left cuspid abutment from posterior segment.
 Remove lower left central incisor.
 5-unit fixed partial denture lower left cuspid to lower right lateral incisor on 4 Galvano telescopic copings
 Rationale for telescopic copings: although all remaining teeth are restorable and have no present problems, they do have a potential for problems (endodontic reinfection. etc). The telescopic approach allows retrievability and easier treatment if needed.

Periodontium

Surgery along with extractions

TMJs

No treatment is needed other than correct occlusal engineering.

Muscles

No treatment is needed other than correct occlusal engineering.

Occlusion

Simultaneous, equal intensity centric stops in the adapted centric posture arc of closure and an anterior guidance on anterior teeth

Aesthetics

Improve proportions and create a good aesthetic plane.

SUMMARY OF TREATMENT SEQUENCE

Appointment	Treatment Completed
1	Prepare lower left cuspid to lower right lateral incisor. Remove lower left central incisor. Periodontal surgery Provisional
2	Prepare all maxillary teeth. Remove upper right cuspid and upper left first bicuspid Periodontal surgery Provisional
3	Heal; maintain provisional.
4	Impressions for all dentistry
5	Place definitive dentistry; telescopic copings with definitive cement, fixed partial dentures with retrievable cement.

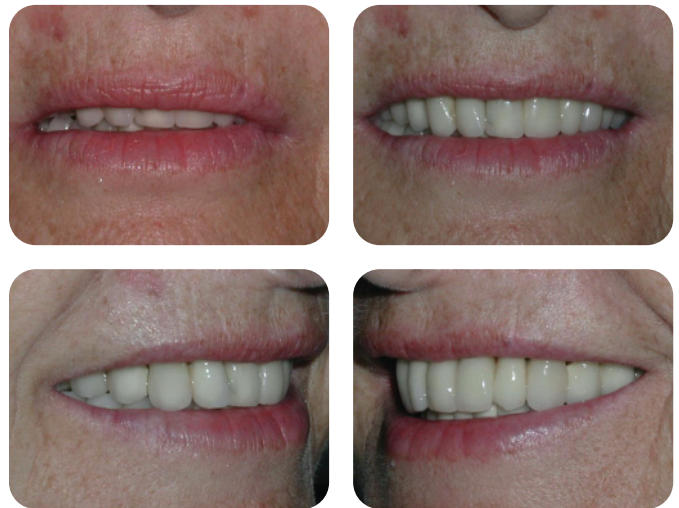

Figure 16.5.1. Pretreatment anterior and lateral smile photographs suggesting unaesthetic proportions of the anterior teeth.

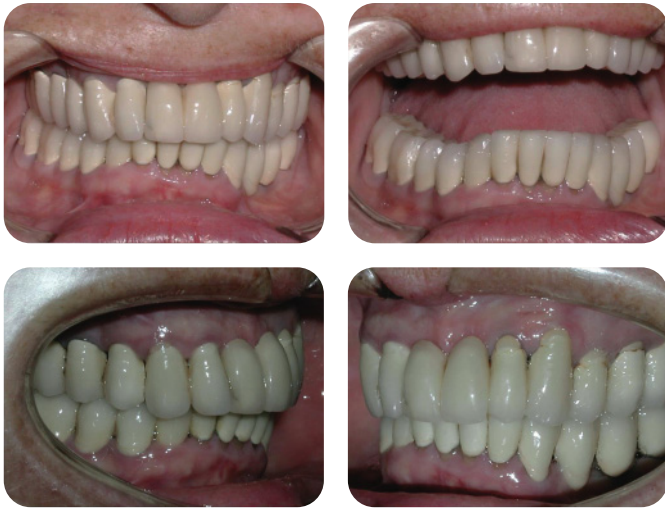

Figure 16.5.2. Anterior and lateral retracted photographs illustrating the facial margin decay repair. Decay onto root surfaces is always worrisome regarding the issue of restorability. Note also the excessively high lower anterior incisal plane.

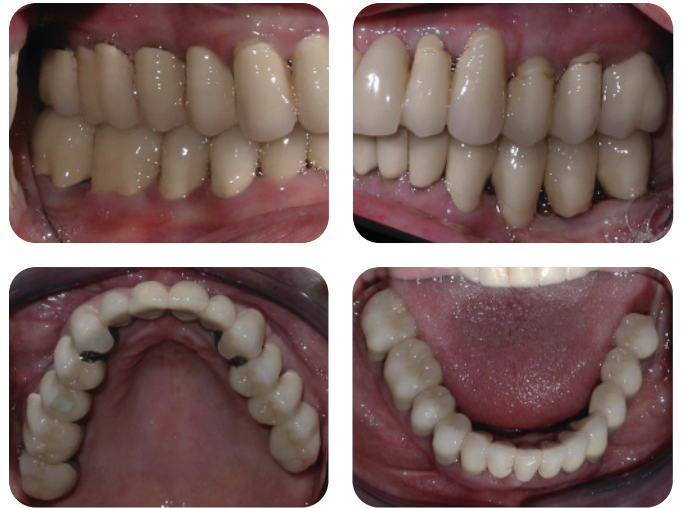

Figure 16.5.3. Buccal occluded and occlusal photographs. Note that the upper anterior segment is attached to the posterior segments with precision attachments. The anterior segment had grade 2 mobility despite the attachment. It was primary occlusal trauma, the teeth tightened as treatment progressed.

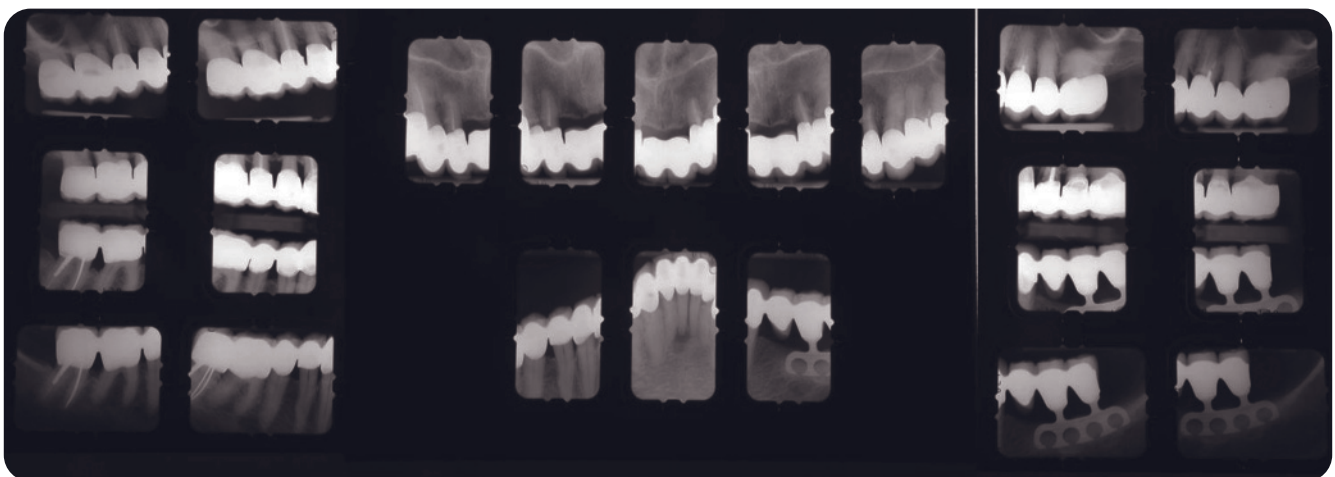
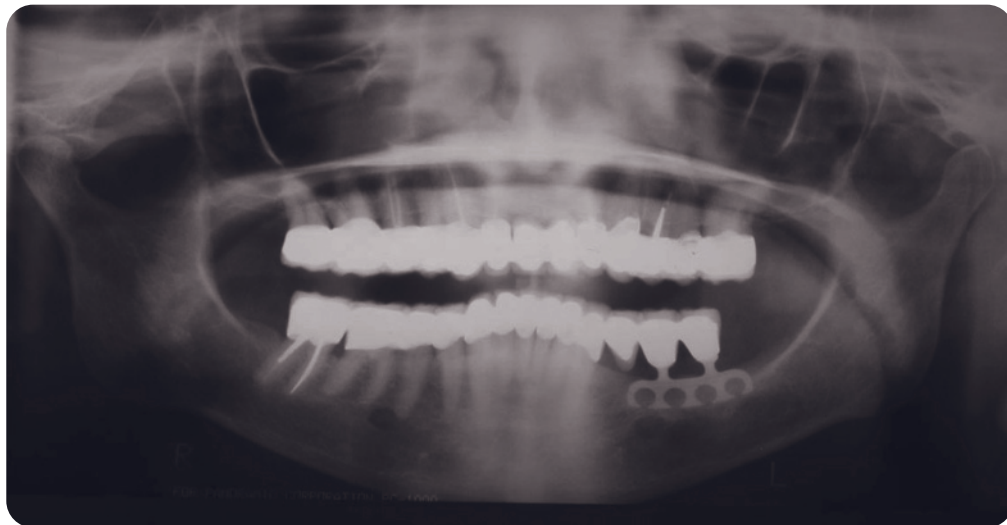


Figure 16.5.4. Pretreatment radiographs. The blade implant and restoration is 20+ years old and has been, and is currently, problem-free. The lower prosthesis is a fixed partial denture from the lower left last molar to the lower right lateral incisor. The prosthesis was sectioned between the lower left first bicuspid and cuspid. The lower left 4-tooth fixed partial denture remained.

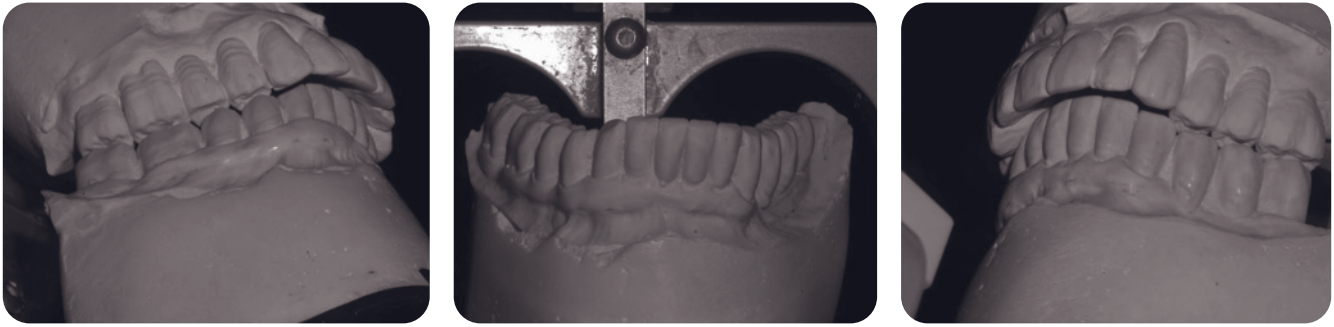

Figure 16.5.5. Pretreatment articulated diagnostic casts closed to the first contact in the adapted centric posture arc of closure, which were the posterior teeth. Note the anterior opening at this position. The mandible slid up and forward to maximum intercuspation and the end point of the slide was the anterior teeth causing the mobility.

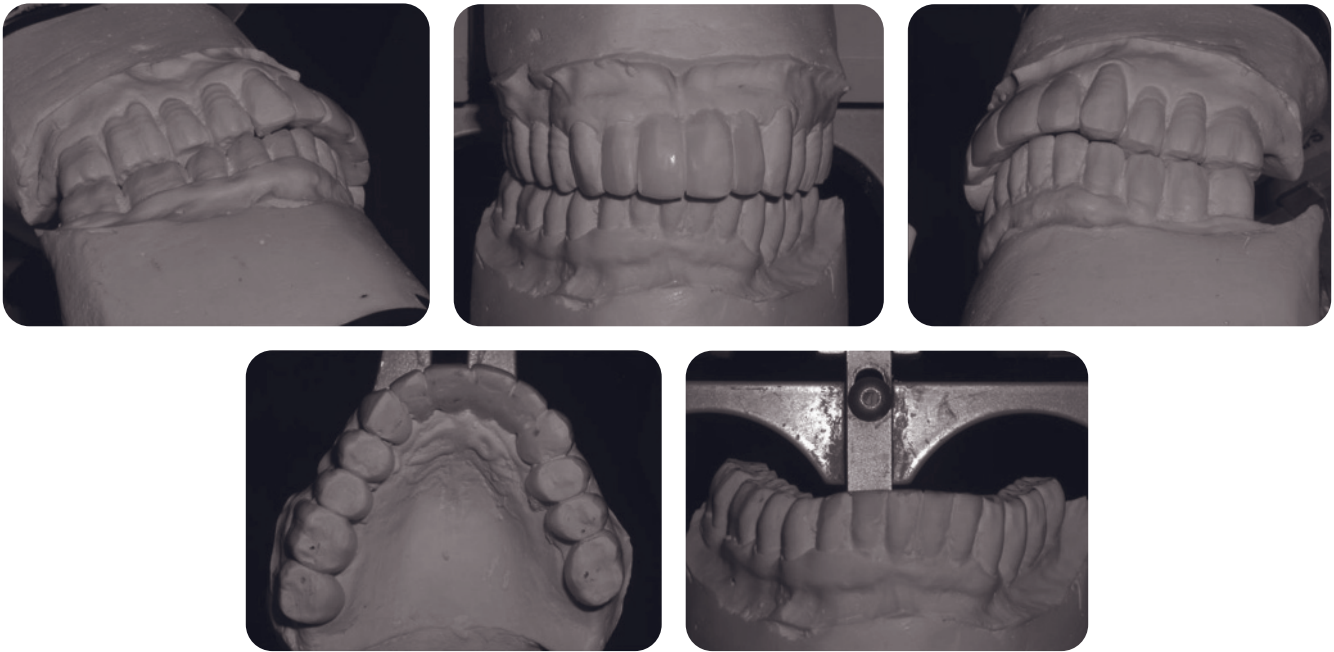


Figure 16.5.6. Trial equilibration and diagnostic wax-up. The slide was eliminated, the excessive plane lessened and the lingual cingulum of the maxillary anterior teeth enhanced to gain stable centric holding contacts and a smooth anterior guidance performance platform. The proportions of the maxillary anterior teeth were also improved.

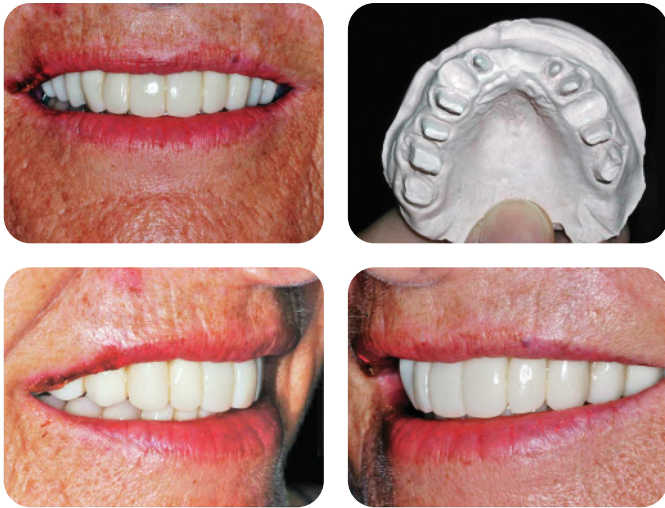

Figure 16.5.7. Anterior and lateral smile photographs of the provisional restorations. The provisional was made indirectly on the cast of the tooth preparations. The teeth to be extracted were removed from the cast and made into pontics.

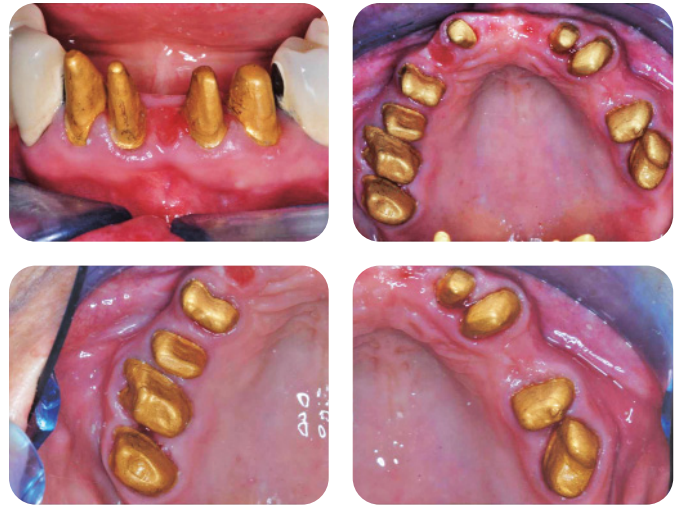

Figure 16.5.9. Photographs of the Galvano telescopic copings cemented with a definitive cement.

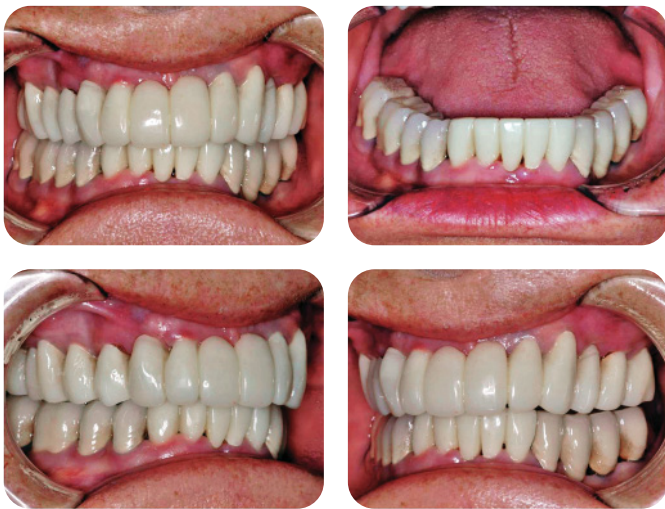

Figure 16.5.8. Anterior and lateral retracted photographs of the provisional restorations illustrating the improved mandibular occlusal plane.

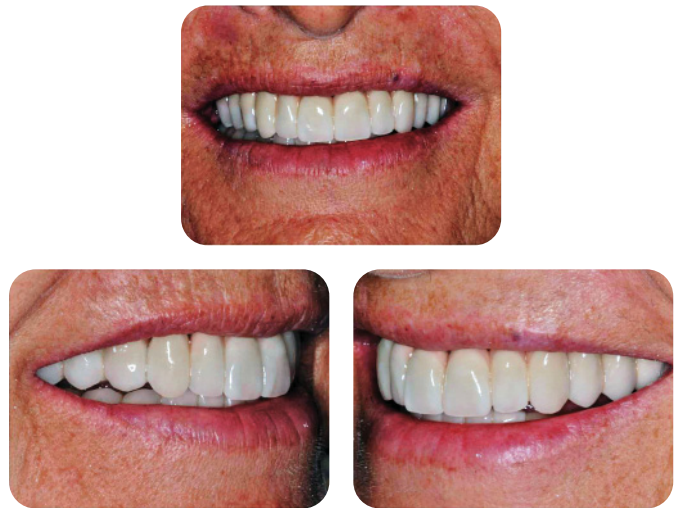

Figure 16.5.10. Anterior and lateral photographs of the definitive dentistry illustrating improved proportions of the anterior teeth and a maxillary posterior aesthetic plane consistent with the anterior incisal plane.

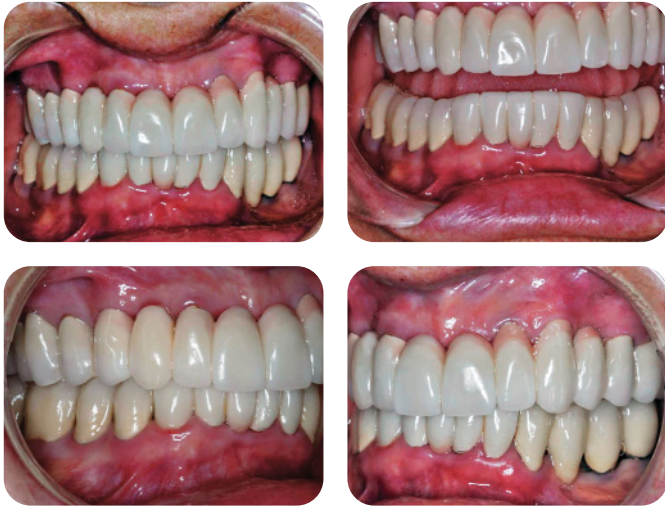

Figure 16.5.11. Anterior and lateral retracted photographs of the definitive dentistry. Note that the precise, very thin Galvano telescopic copings do not require bulk in the fixed partial denture overstructure. Even though the patient did not have a high smile line, the subtle use of pink porcelain created the illusion of a more consistent incisal-gingival length from side to side.

CHAPTER 16 CASE 5 KEY POINTS

- The end point of a hit and slide (anterior teeth), especially with a high lower incisal plane, can be a reason for mobility—primary occlusal trauma.
- Telescopic copings add retrievability to a case.
- Dealing with root decay is difficult.

Appendix 1

Definitive Occlusal Therapy Using the T-Scan III

Robert B. Kerstein, D.M.D.

Computerized Occlusal Analysis technology (T-Scan III for Windows®, Version 6.0, Tekscan, Inc., S. Boston, MA) records and displays occlusal contact relative occlusal force and tooth contact timing data that occur during functional mandibular movements (Figures A1.1 and A1.2).¹⁻⁴ These functional movements are recorded intraorally with an ultrathin, electronically charged, mylar-encased sensor that is connected to a computer via a USB interface. The desktop software then displays the tooth contact sequences in .003sec increments with their changing occlusal forces as a percentage of the maximum occlusal force obtained within the recording (Figure A1.3).

The T-Scan III Occlusal Analysis System can be employed by an operator clinically to

- Precisely balance an unbalanced occlusal force distribution, in either an operator-guided, bimanual-manipulated centric relation closure,⁴ or in a patient self-intercuspatation.
- Isolate and treat prolonged excursive interferences that are transitory during mandibular excursive movements made to the right, left, or protrusively from a fully intercuspatated position, or from centric relation occlusion.
- Determine the location of closure time-premature contacts and occlusal force excesses, which can occur on natural teeth, dental prostheses, dental implant prostheses, and combinations of all of these. Excess force regions can be measurably lessened to preserve long-term occlusal integrity and minimize potential long-term damage to teeth, the

periodontium, the endosseous implants, and various dental prostheses.

Measuring relative occlusal forces and time-premature contacts with the T-Scan III System is a vastly superior method of assessing occlusal function over other occlusal indicators that are routinely employed by clinicians (articulating paper, shim stock, artist foil, occlusal wax, silicone impressions, and mounted stone dental casts). None of these dental materials is “technology-based” such that they cannot record or reproduce, dynamic occlusal contact data. Instead, these other indicators produce static occlusal contact “representations,” which demonstrate no real-time or relative force measurement capacity.

No published study has shown that these static dental materials possess the ability to measure relative occlusal force or sequentially order tooth contacts. Additionally, all of these materials require operator subjective interpretation of their appearance characteristics to attempt determinations of the presence of occlusal force excesses and tooth contact time abnormalities.

The most commonly employed occlusal indicator is dental *articulating paper*. This widely used occlusal indicator has never been shown in any published study of its potential performance effectiveness, to reliably represent occlusal forces.⁵⁻¹¹ In the most comprehensive articulating paper mark size/force correlation study performed to date (600 paper marks created on intercuspatated epoxy dental casts across 0–500 newtons applied occlusal load), it was shown that only 21% of the marks were able to represent the applied occlusal load (79% of the marks did not reliably predict the applied load).⁸ Alternatively, a recently published performance study of the currently available, 4th

Clinical Cases in Restorative & Reconstructive Dentistry, Gregory J. Tarantola, © 2010 Blackwell Publishing Ltd.



Figure A1.1. T-Scan III Recording Handle with USB plug and sensor. Reprinted with permission from Tekscan, Inc. www.tekscan.com/dental.

generation high definition (HD) recording sensor of the T-Scan III System (Figure A1.4) showed that the HD sensor demonstrated consistent force reproduction across 30 different test sensors in at least 20 in-laboratory trial crushing cycles.¹²

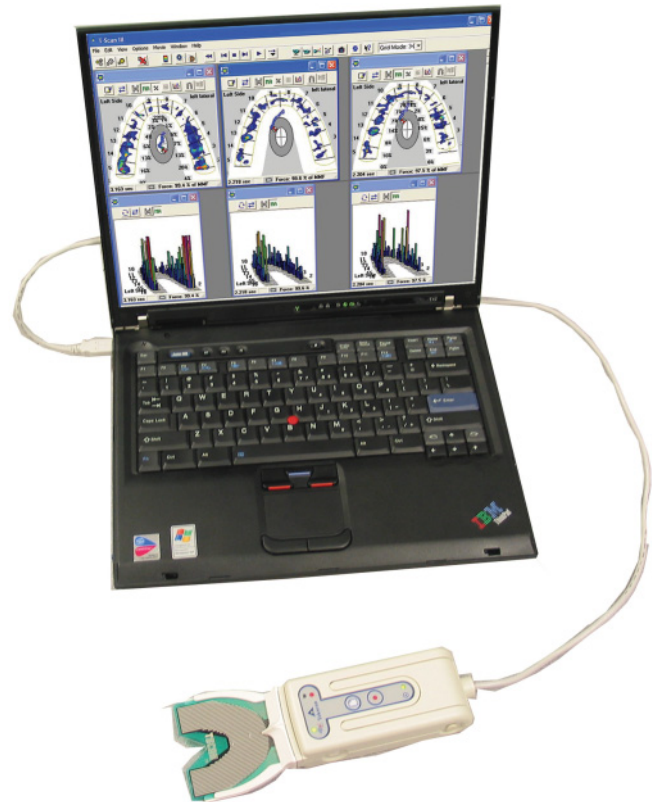

Figure A1.2. T-Scan III Recording Handle with USB plug and sensor connected to a PC with occlusal data on the desktop. Reprinted with permission from Tekscan, Inc. www.tekscan.com/dental.

HD Sensor Structural Components and Design

The HD sensor's structural design consists of two layers of Mylar encasing a grid of resistive ink rows and columns printed between them (Figure A1.5). The high definition design has both larger sensels (Tekscan's proprietary force recording element within each sensor) and less space between the sensels than all of the previous T-Scan I and II sensor designs. The HD design increases the total amount of recording surface area for teeth to occlude upon over the three previous T-scan sensor designs, while minimizing the amount of inactive (nonrecording) area between the sensels.

Occlusal Contact Time and Force Data Acquisition

A recording sensor is placed intraorally within a recording handle that locks the sensor in place. The sensor support orients the sensor between the two central incisor teeth within their shared mesial facial embrasure (see Figure A1.1).

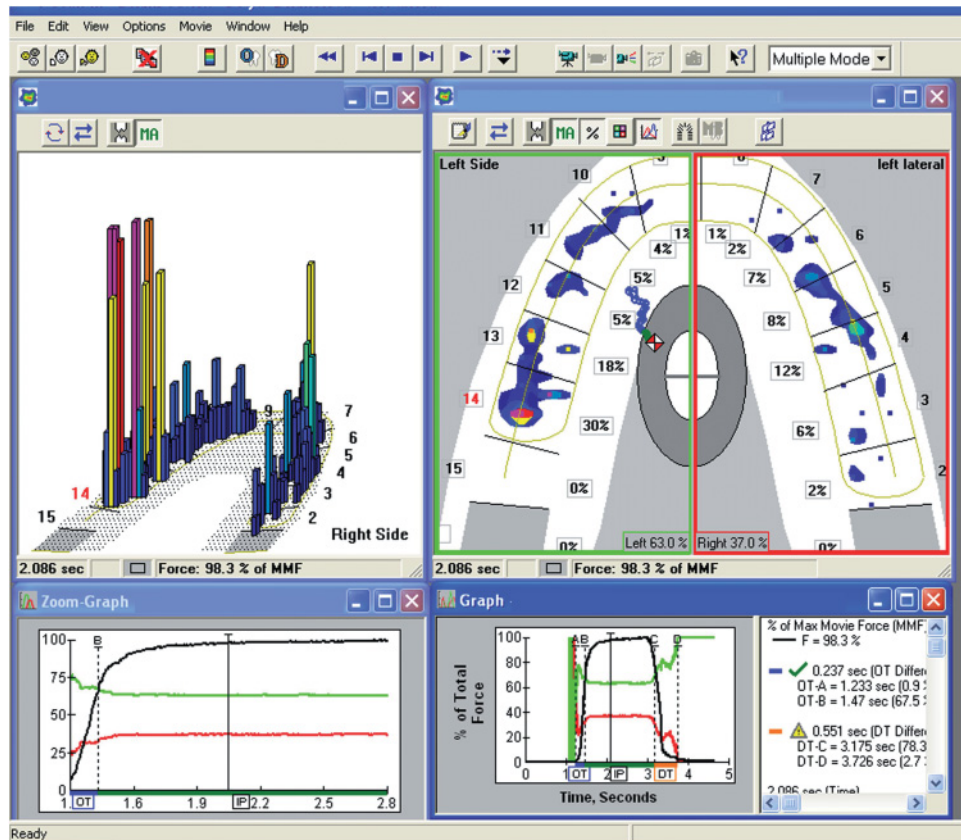


Figure A1.3. T-Scan III desktop.



Figure A1.4. T-Scan III Sensor Schematic. Reprinted with permission from Tekscan, Inc. www.tekscan.com/dental.

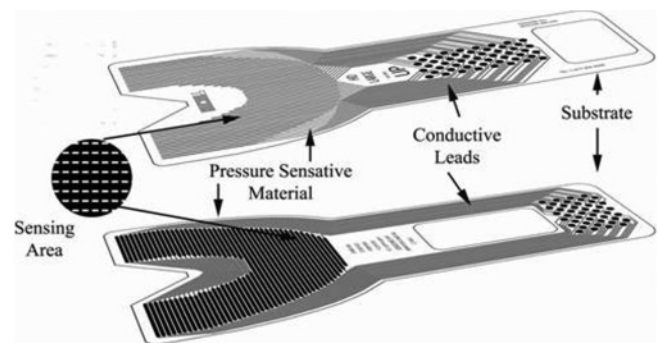


Figure A1.5. High definition (HD) sensor. Reprinted with permission from Tekscan, Inc. www.tekscan.com/dental.

The recording handle excites the sensor by applying voltage to each column of sensels. When the sensor is occluded upon, a change in the applied force at various tooth contacts results in a change in the resistance of the resistive ink near each of the contacted sensels such that higher forces produce larger resistance changes and lower occlusal forces produce smaller resistance changes.

This resistance change is measured by the T-Scan III System's hardware electronics as a change in *digital output voltage (DO)*. Higher forces on contacting teeth

result in larger decreases in the resistance of the loaded sensels, and therefore, a higher measured output voltage. The greater the applied force to the contacting teeth, the higher the output voltage that is measured from that tooth contact.

Occlusal Contact Time and Force Data Electronic Processing

Next, the electronics in the recording handle reads the output voltage of each row of sensels, and then it conditions and converts the output voltage to an 8-bit digital value so that the measured resistance change is proportional to the force applied to each sensel with a range between 0 and 255 raw counts. The software receives the stream of changing sensel digital output voltage values and displays them to the operator in the same orientation pattern that the sensels make within the sensor matrix.

Occlusal Contact Time and Force Data Display

A legend with color spectrum (Figure A1.6) depicts a scale of relative occlusal forces. Darker, cooler colors represent lower forces. Brighter, warmer colors indicate higher occlusal contact forces. Pink indicates that a sensel has saturated and reached its maximum digital output.

In 2 or 3 dimensions, the occlusal contact timing sequence can be played forward or backward continuously, in either .01 sec increments when recorded in non-Turbo Mode, or in .003 sec increments when recorded in Turbo Mode (high-speed data acquisition). In the 3-Dimensional (3-D) playback window the force columns change both their height and color designation. In the 2-Dimensional (2-D) contour view, the color-coded force concentration zones change size, shape, and color as occlusal forces change (see Figure A1.3).

In addition to the playback windows, there are several software features that enhance the operator's ability to interpret the recorded occlusal force and time data.

Center of Force Trajectory (COF)

The history of changing total occlusal force summation evolves over the passage of time as more teeth reach or leave occlusion. This is graphically represented in the 2-D playback window by a red-and-white diamond icon and its red, blue, and orange line trailer (Figure A1.7).

A poorly positioned COF trajectory, as can be seen in Figure A1.7 (left 2-D window), can be manipulated into an ideally positioned COF trajectory by employing computer-guided occlusal adjustments that alter the

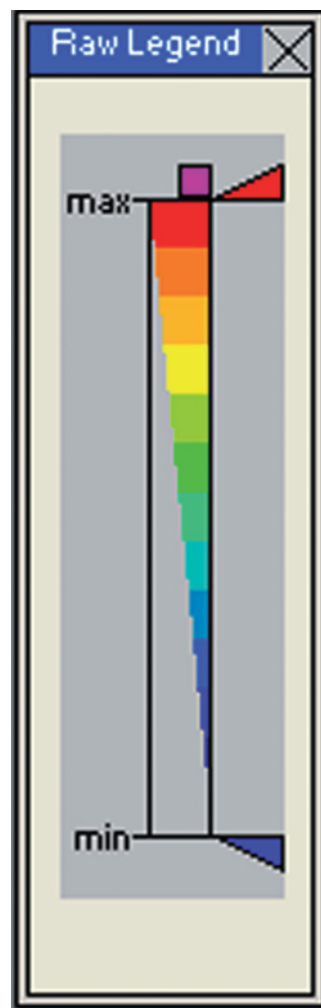


Figure A1.6. Force legend with color spectrum.

COF position within the arch-halves, its direction of movement, and its overall length (Figure A1.7, right 2-D window). These COF trajectory *reorienting* computer-guided occlusal adjustments are accomplished on both regions of occlusal force excess and on locations of time-premature tooth contact.

Force Percentage per Tooth

During both recording and playback, the changing percentage of occlusal forces on each tooth in a given mandibular functional movement is displayed next to each tooth in the 2-D view window.

Force % per tooth describes the changing, unequal, or equal, individual tooth-loading percentages between arch-half occlusal counterparts. Computer-guided corrective occlusal adjustments can be employed to equalize force percentages per tooth discrepancies, which are based upon the right percentage per tooth comparison to its left percentage per tooth counterpart (i.e., % 1st molar right-% 1st molar left).

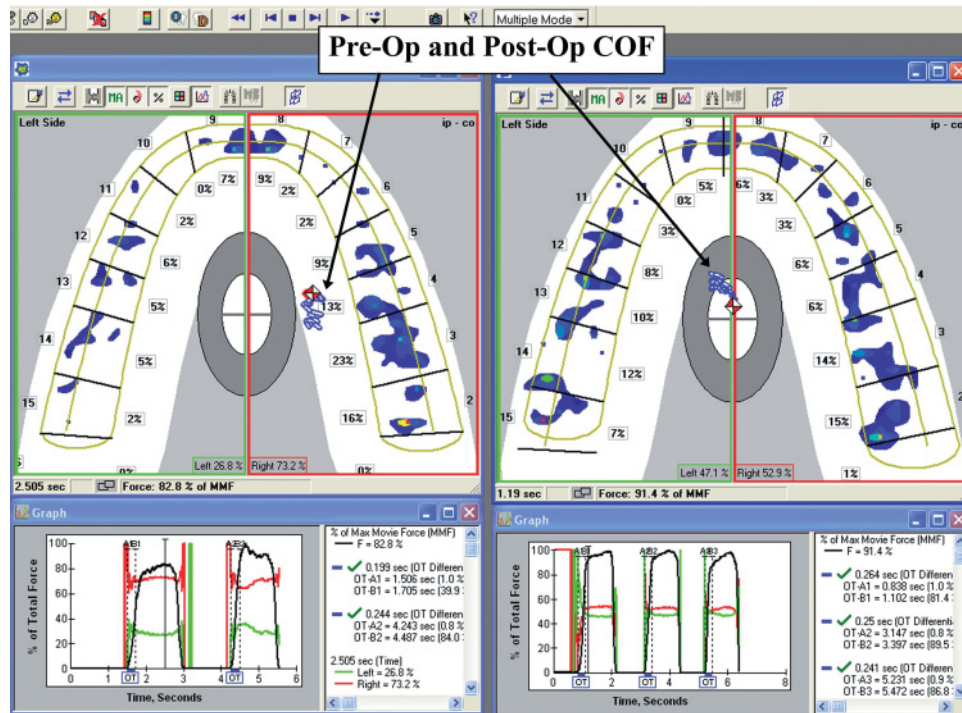


Figure A1.7. Poorly positioned and ideally positioned COF trajectories.

A Note about the Remaining Chapter Figures

Most of the remaining figures illustrate evolving occlusal forces as time elapses within a recorded Movie. As such, many figures contain 3 or 4 T-Scan III Movie frames that are denoted together (i.e., Figure A1.17a–d, later in this appendix). The Movie frames are shown in a sequence that describes the occlusal force differences that result with the passage of time. It is important to note that the shown figure frames are not sequenced frame-after-frame but are instead chosen frames from within the many that, in total, comprise the entire recorded Movie. The selected frames detail key occlusal contact force moments and critical occlusal surface engagement periods that occur within a functional movement’s dynamic continuum. The selected frames are displayed in proper order relative to each other by alphabetically naming their sequence from a–c or a–d. Finally, some figures may be accompanied by clinical photographs of the recorded functional movement.

Figures A1.8a–c illustrates the differing force percentages per tooth being displayed in a Movie of a patient self-closure into static intercuspation. These 3 sequential 2-D Movie frames map the changing force percentage per tooth of the occlusal forces on all 14 individual teeth that make occlusal contact. Note that the COF trajectory moves toward the teeth with the most force percentage as more time elapses.

Force vs. Time Graphing

Each recorded Movie is represented in a *Force vs. Time graph* that shows the changing force percentages by arch-half or quadrant throughout the entire recorded mandibular movement (Figures A1.9–12). Within a graph there is 1 vertical black *time line*, and 3 colored nonvertical lines (red, green, and black) that describe changing occlusal forces as the functional movement unfolds:

- A total force % line—black nonvertical line
- A Right arch-half % line—red nonvertical line
- A Left arch-half % line—green nonvertical line

There are four distinct graph types that illustrate three different mandibular movements that can be recorded from a patient’s occlusal scheme:

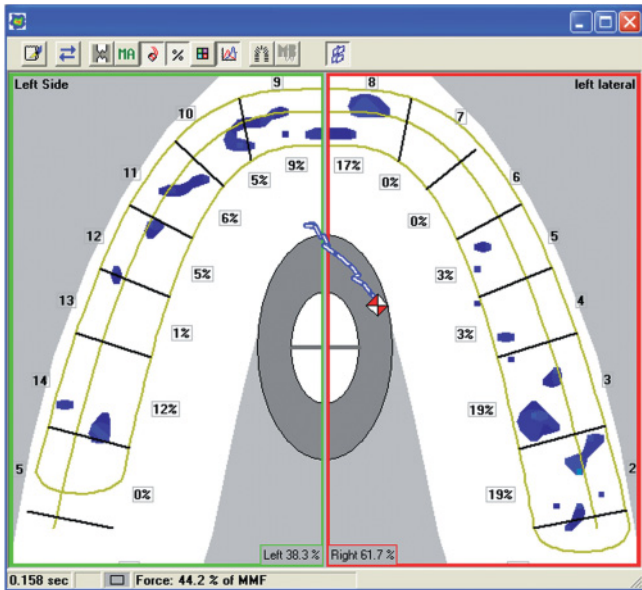


Figure A1.8a. Early closure contacts force % per tooth.

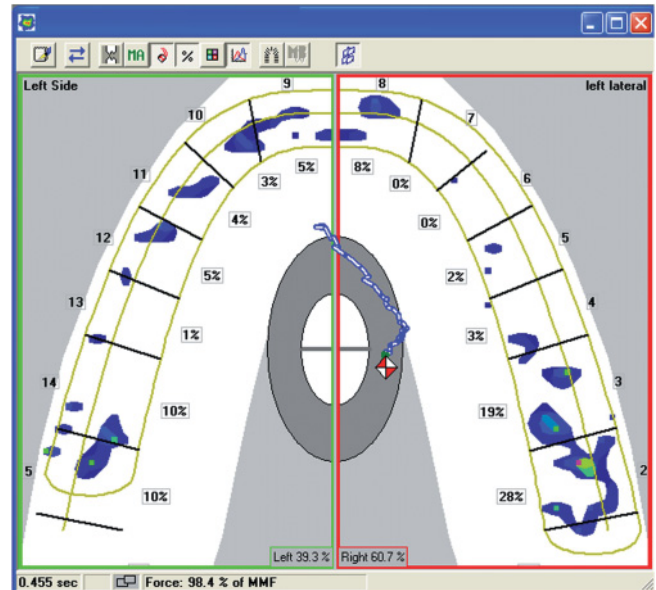


Figure A1.8c. Late closure contacts force % per tooth.

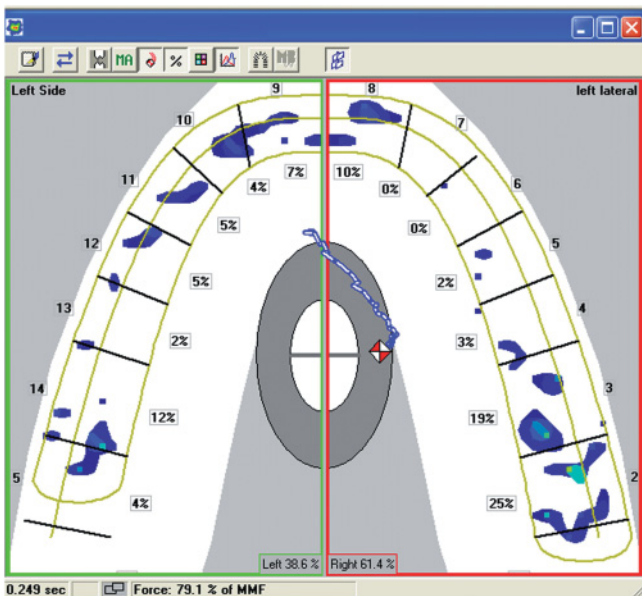


Figure A1.8b. Midclosure contacts force % per tooth.

Centric Relation Manipulated Closure Graph

This graph represents when a patient is “operator-guided” into the centric relation (CR) position through the recording sensor until the CR occlusal contacts occur and stop further guided closure. Patients can either open from the CR contact

position to disarticulate the CR contacts, or self-slide their jaw forward into maximum intercuspation (Figure A1.9).

Patient Self-Closure Graph

This graph represents a patient occluding into complete tooth intercuspation without operator manipulation, holding the teeth together firmly and fully intercusated for 1–3 seconds, and then opening to disarticulate their teeth completely (Figure A1.10).

The CR manipulated closure graph is different in appearance from a patient self-closure graph. During a CR recording, the operator-manipulated closure is a slow closure event because the speed of closure is controlled by the operator, not by the patient. Operator mandibular manipulation creates a slow rise of occlusal forces that results in a nearly horizontal, low-force, total force line (Figure A1.9; from 2.0–4.3 seconds). This is often followed by a more rapid force rise when the patient self-squeezes the teeth together after the operator manipulation ends (Figure A1.9; after 4.3 seconds).

In a patient self-closure recording, the occlusal forces quickly rise because there is no operator manipulation controlling the closure speed of the mandible. Within the graph, this results in a more vertical total force line with little horizontal component present (Figure A1.10; 1.426–1.697 seconds).

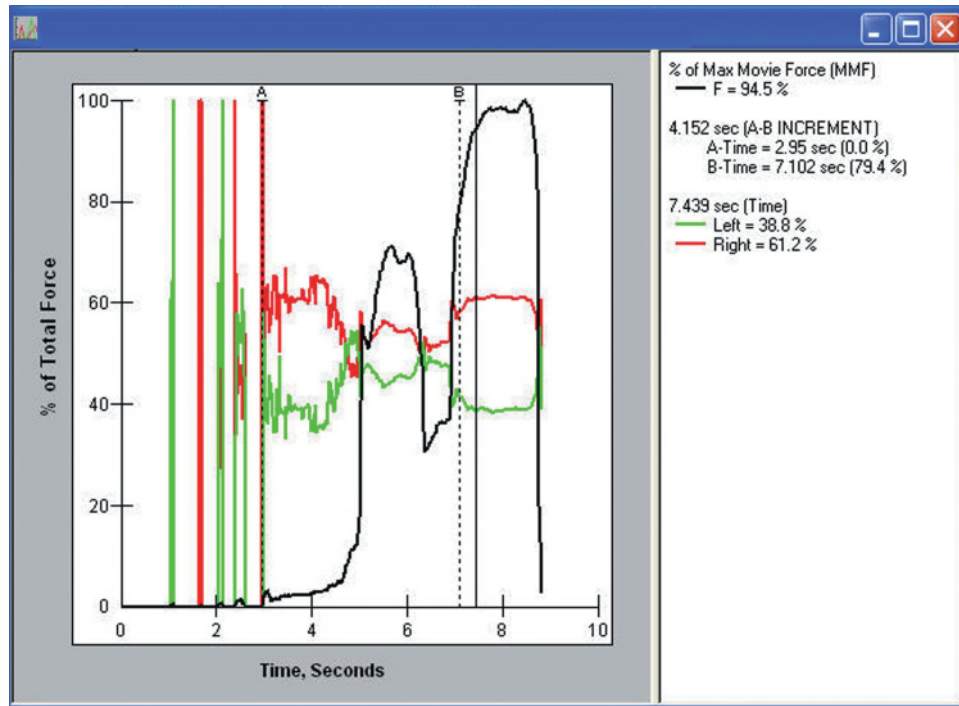


Figure A1.9. Centric relation manipulated closure graph.

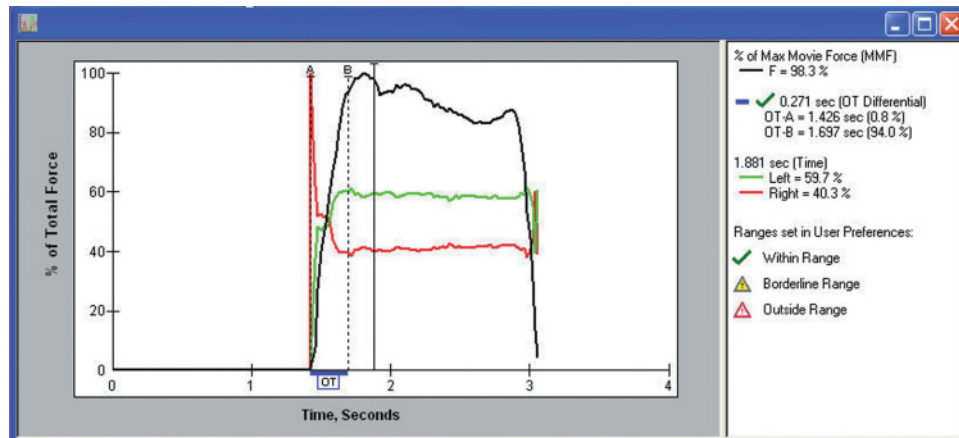


Figure A1.10. Patient self-closure graph.

Multi-Bite Graph

This graph represents when a patient occludes into maximum intercuspation, holds the teeth together firmly together for 1–3 seconds, then opens to disarticulate their teeth, recloses the teeth together again into maximum intercuspation, holds the teeth together once again for 1–3 seconds, and then reopens to disarticulate all occluding teeth. This can be repeated numerous times in one recording (Figure A1.11a).

A Multi-Bite recording generates multiple patient self-closure data that is averaged and presented to the

operator for analysis in tabular form. The *Multi-Bite Table* describes the elapsed time from first tooth contact through to static intercuspation (the Occlusion Time, OT)¹³ of each patient self-closure made within 1 Movie.

Figure A1.11b shows the Multi-Bite Table data of the 2 patient self-closures of Figure A1.11a. The OT of the 2 closures are calculated as individuals and then averaged. This OT average of .157 seconds duration is deemed physiologic (≤ 2 sec) with a green check mark.

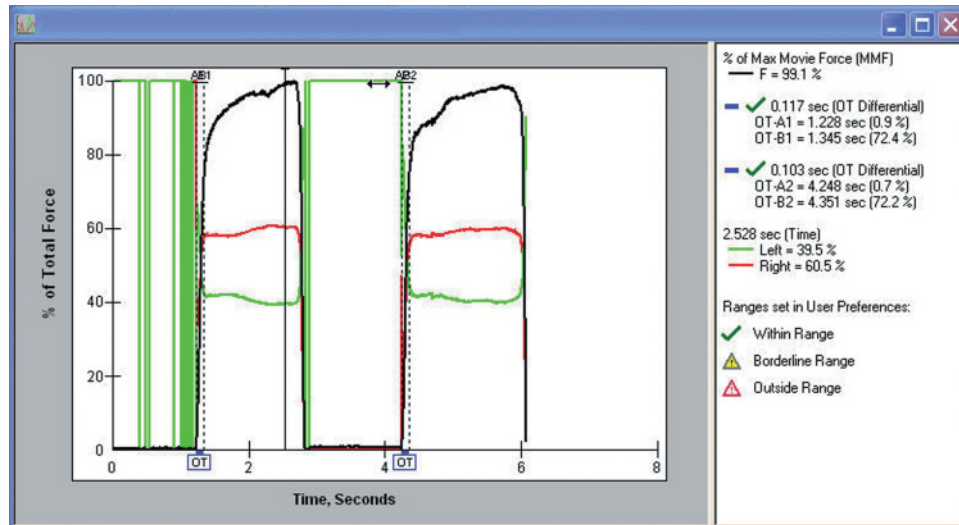


Figure A1.11a. Multi-Bite graph of 2 patient self-closures.

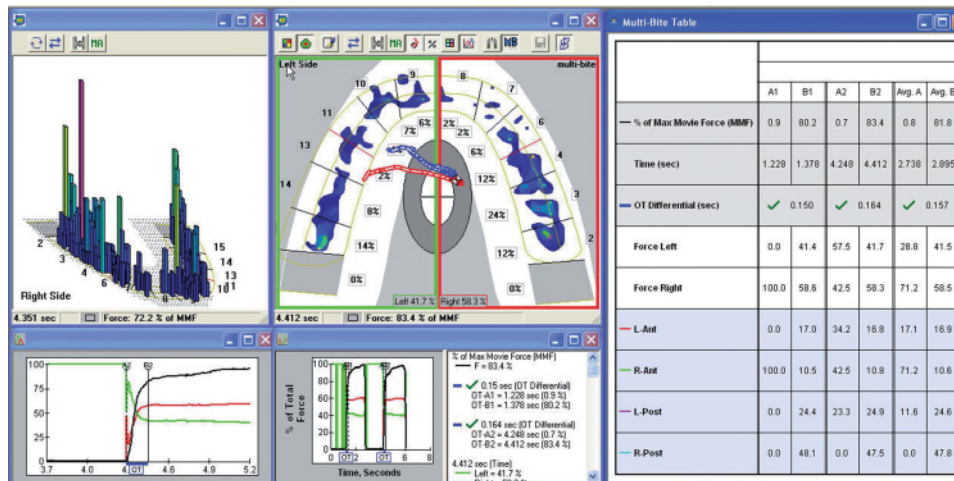


Figure A1.11b. Multi-Bite Table generated from the 2 patient self-closures from Figure A1.11a.

Excursive Graph

This graph represents force changes from when a patient occludes into maximum intercuspation, holds the teeth firmly together for 1–3 seconds, and then slides the lower teeth across and over the maxillary teeth to the left, right, or forward until only the anterior teeth are in contact (Figure A1.12a).

An excursive graph is formed in a 2-D window by dividing the arch-halves into quadrants at the distal of the canines so as to separate the anterior guidance from the posterior teeth. This is accomplished by clicking on the *Quadrant Tool* button on the 2-D window toolbar (Figure A1.12b). This tool definitively isolates the anterior quadrants from the presence of posterior lateral interferences that occur during an

excursion. The quadrant division creates 2 new graph lines within the Force vs. Time graph:

- A posterior right quadrant % line—nonvertical purple line
- A posterior left quadrant % line—nonvertical aqua line

The red line now represents force percentage in the right anterior quadrant, and the green line now represents force percentage in the left anterior quadrant.

A recorded mandibular movement contains *Time-Regions* within the Force vs. Time graph that depict different parts of a mandibular movement. *Time-Regions* are defined within the graph by an additional 4

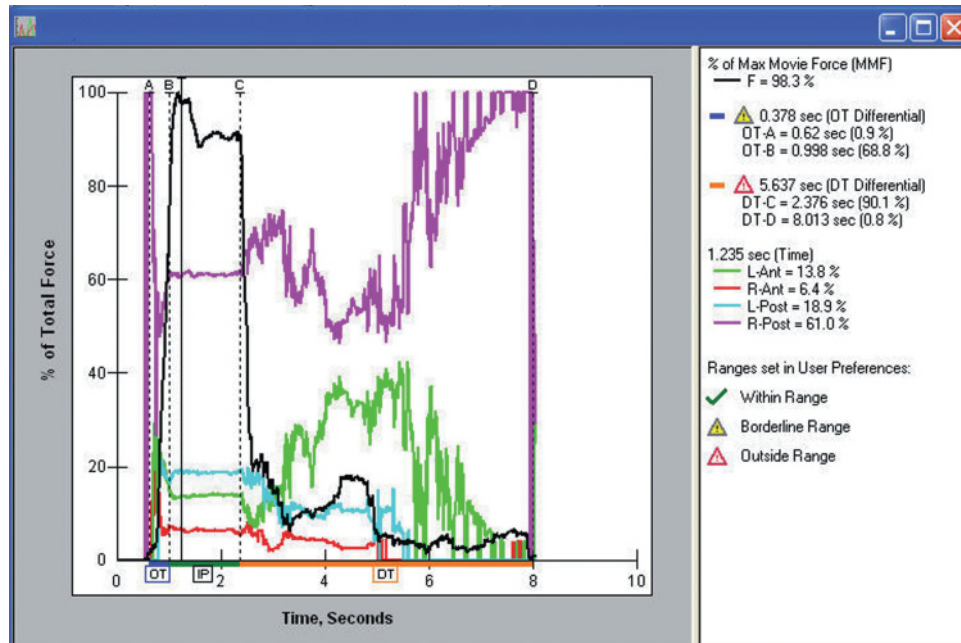


Figure A1.12a. Excursive graph resultant from dividing the 2-D window into four quadrants.

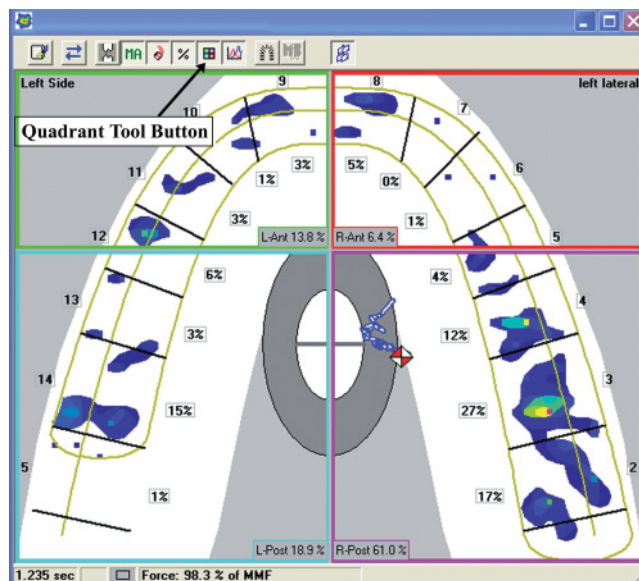


Figure A1.12b. Quadrant division tool button.

movable, vertical, hyphenated time-position lines, whereby the horizontal distances between these lines calculate certain time durations of different parts of a recorded mandibular movement.

The A-B line separation can be used to calculate the *Occlusion Time*¹³ in a patient self-closure graph. Occlusion Time is defined as the elapsed time from first tooth contact through until static intercuspation is reached (not maximum intercuspation; static intercuspation always precedes maximum intercuspation).

The C-D line separation can be used to calculate the *Disclosure Time*¹⁴ in an excursive graph.

Disclosure Time (DT) is defined as the elapsed time required for a patient to exit his/her maximum intercuspated position and move the mandible either right, left, or forward, so as to measurably (not visually) disclude all posterior teeth, including and behind the 1st premolar tooth, so that only canines and/or incisors are the guiding tooth contacts.

The separation between the A-B and C-D line pairs is color-coded along the x-axis of the Force vs. Time

graph. The OT (Occlusion Time, A-B increment) is denoted in blue; the IP (intercuspsation period, B-C increment), where teeth are held firmly together in a clenched relationship, is denoted in green; and the DT (Disclusion Time, C-D increment) is denoted in orange (Figure A1.12a).

Individual Patient Arch Customization

When you enter new patients into the T-Scan III patient database, their maxillary dental arch can be individually customized to represent their true clinical presentation (Figure A1.13). Missing teeth can be removed, pontic spaces denoted, implants located, crowns denoted, and arch size can be adjusted to fit a patient’s occlusal contact distribution.

The arch in Figure A1.13a has been altered in Figure A1.13b to represent the patient’s actual clinical presentation. This arch customization was accomplished by removing a 1st premolar that was clinically absent (tooth 13), properly shrinking a pontic space in the 14 region, denoting 2 single implants in teeth 4 and 5 regions, and expanding the arch so that teeth 2 and 15 force concentration zones are properly contained just within the distal limit of the yellow arch grid (there are no 3rd molars present). The yellow arch grid outlines the force concentration zones buccolingually and anteroposteriorly by the software after the sensor is contacted by all occluding teeth.

Arch model customization simplifies correlating problematic force concentration zones to the

articulating paper mark locations of the occlusal contacts that demonstrate the problematic forces. When employing computer-guided occlusal adjustments, arch model customization makes it possible for the operator to accurately select the correct contact locations on occlusally overloaded or time-premature teeth.

T-SCAN III Occlusal Analysis System’s Role in Occlusal Diagnoses; The T-SCAN III Occlusal Examination

The T-Scan III Occlusal Analysis System can be employed in a clinical occlusal examination to assess various occlusal force and time parameters that describe arch-half occlusal force imbalances,^{13,15} occlusal contact timing nonsimultaneity,^{13,16} centric relation prematurity isolation,⁴ and prolonged posterior disclusion in excursive function.¹⁴ Some of these force and time diagnostic measurements can often be contributory to Myofascial Pain Dysfunction Syndrome (MPDS) symptomatology,^{14,17–22} occlusal wear, abfraction formation, periodontal tissue loss, cracks and craze lines in enamel, and tooth mobility.²³

Measurements of .01–.003 second real-time occlusal contact recording and .01–.003 second incremental playback of the tooth contact timing data can illustrate the exact sequential order of tooth contacts, as well as their evolving and changing forces. The combination of contact order, contact duration that precedes the next

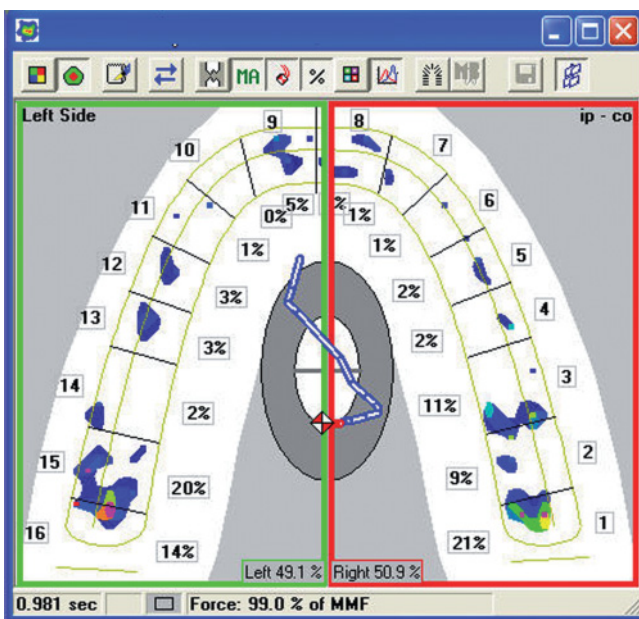


Figure A1.13a. Noncustomized patient arch.

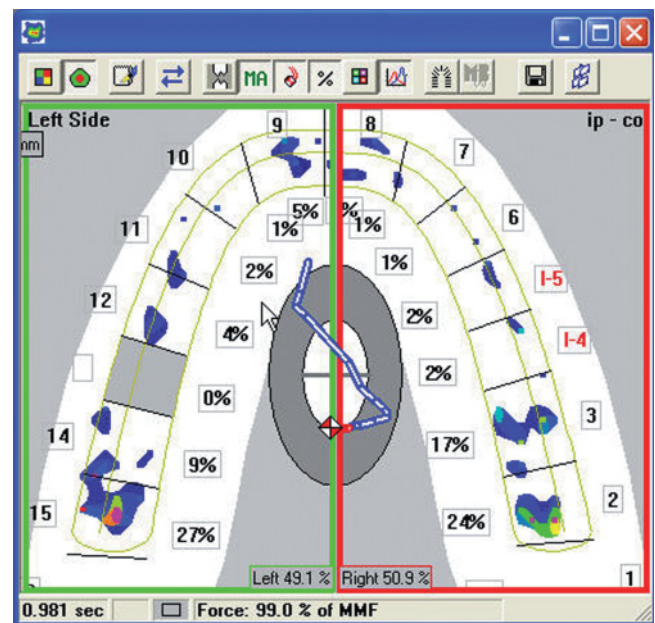


Figure A1.13b. Customized patient arch.

occlusal contact, contact location within the arch, and contact force content determine the degree of the overall occlusal force balance that is present in a particular occlusal scheme.

A T-Scan III occlusal examination can include some, or all, of the Movie recordings in the following sections.

4-Handed Centric Relation Recording

This recording determines the true (not patient-perceived) first tooth premature contact in the operator-manipulated centric relation position.⁴ To accomplish this recording, the operator guides the mandible to the centric relation position into and through the recording sensor using the Bi-Manual Manipulation technique as outlined by Dawson²⁴, while the chair side assistant holds and controls the T-Scan III recording handle (Figure A1.14).

Patient Self-Closure into Maximum Intercuspatation

This recording determines the right arch-half to left arch-half force percentage imbalance, the Occlusion Time, and the changing history of the Center of Force. This recording can be accomplished as a single patient self-closure into and through the recording sensor, or as multiple patient self-closures, where the patient firmly occludes the teeth together repeatedly. Recording multiple repeated patient self-closures in one Movie generates a Multi-Bite recording.

Excursive Movement Recording

Right, left, and protrusive excursive movement recordings made from centric relation occlusion or maximum

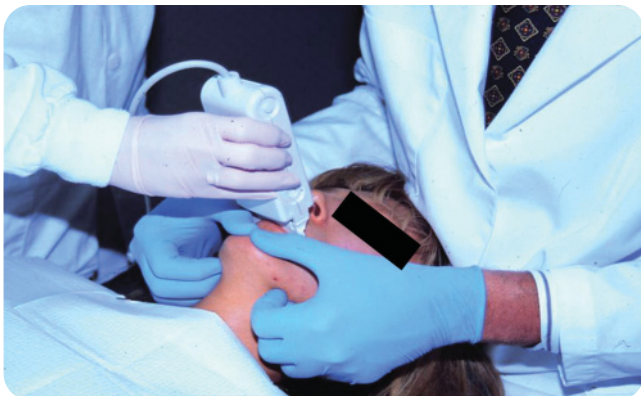

Figure A1.14. 4-handed centric relation recording technique.

intercuspatation illustrate anterior guidance effectiveness (or lack thereof) as measured by the posterior Disclusion Time.

Excursive movements are best recorded by having a patient occlude into complete tooth intercuspatation, hold the teeth firmly and fully intercuspatated for 1–3 seconds, and then slide the lower teeth across and over the maxillary teeth to the left, right, or forward, by leaving their complete intercuspatated position, until the patient reaches and translates across solely the anterior teeth.

When long Disclusion Time (>.4 seconds per excursion)^{14,22} is present within a patient's excursive functional movements, the occlusal surfaces of opposing posterior teeth mill and mesh against each other for prolonged periods of time, thereby compressing their periodontal ligaments for long periods of time. This milling action can create damaging friction between opposing occlusal surfaces, and lateral flexural stresses on the involved posterior teeth. This can lead to wear and occlusal attrition, as well as abfraction formation.

Additionally, it has been shown that Long Disclusion Time elevates the amount of contractile muscle activity present in the masseter and temporalis muscles due to prolonged periodontal ligament compressions "overfiring" the masticatory musculature.^{14,21,22} This hyperfunction of the masticatory musculature is the direct result of the unique central nervous system feedback mechanism within the periodontal ligament mechanoreceptors of the molar teeth. These mechanoreceptors synapse directly with the Trigeminal Motor Nucleus of the Trigeminal Nerve²⁵ to create add-on muscle contractions within the masticatory musculature that are above the individual muscle's baseline firing required to move the mandible functionally. This elevated contractile muscle activity resultant from prolonged excursive posterior occlusal contact can create lactic acid buildup in the muscles of mastication leading to clinical appearance of MPDS symptomatology. Therefore, Long Disclusion Time has been deemed to be partially etiologic for MPDS symptomatology in dentate-susceptible patients.^{14,17,18,21,26}

Alternatively, correcting prolonged Disclusion Time with T-Scan III computer-guided occlusal adjustments resulting in Short Disclusion Time (<.4 seconds per excursion, which is considered optimal so as to reduce long periods of tooth interaction friction, and lessen masticatory muscle hyperactivity), has been shown to minimize MPDS symptomatology.^{14,17–20,22,26}

Habitual Force Pattern (HFP) Recording

HFP recordings illustrate which teeth are repetitively overloaded within the patient's chewing cycle. Often, the HFP patterns lead to the clinical observance of locations of excessive wear, cracked teeth, abfraction formation, and supportive periodontal tissue loss. An HFP is best recorded by instructing the patient to swallow into a recording sensor, squeeze the teeth together into maximum intercuspation, open to disarticulate the teeth, and then lightly reocclude the teeth back together into near intercuspation by repeatedly tapping their teeth together.²³

When the stomatognathic system functions, a sequence of force that has an origin, direction, and intensity is generated on the occlusal surface. Force distribution in the dental arch will isolate to repetitive regions with each compression and decompression. The recording and subsequent mapping of this repetitive force distribution produces a unique signature known as a *habitual force pattern* (HFP).²³ Each HFP illustrates how force is transferred through the occlusion in cycles of compression and decompression.

Some occlusal dynamics will concentrate the stresses in the posterior, anterior, left side, right side, or in combination of some of these arch regions (such as anterior-right). In an HFP, the COF trajectory repeats itself as the patient taps the teeth together repeatedly, leaving many overlapping COF trajectories by which a pattern of force transmission within the arches can be observed.

It has been reported that there are 6 different HFP force distributions (Figures A1.15a–f).²³ Although the 6 patterns differ from each other, each pattern illustrates force location predominance within the dental arch that often correlates with areas of stomatognathic system breakdown.

Representative Occlusal Examination Findings Significant Centric Relation Prematurity

In this bimanually manipulated centric relation (CR) recording, the earliest forceful tooth contact appears in the 3-D window on tooth 2 at 2.2% of total force (Figure A1.16a). The COF icon is not yet present because there is so little overall force summation at this earliest part of the recorded Movie (The COF appears at 5% of total force). This CR contact is "time-premature," whereby it stops the mandibular closure from complete condylar seating into centric relation as it also stops the intercuspation of additional tooth contacts. Within the Force vs. Time graph, the Red and Green Lines stay horizontal, and the total

force line is nearly horizontal (see Figure A1.9), which indicates a period of static occlusal contact at 2.2% of total force from 3.008 seconds until 4.816 seconds (1.808 seconds time-premature).

Then, the operator further manipulates the mandible past this contact blockage so as to more closely approach the centric relation position while at the same time occluding more teeth into contact. Here, more teeth are sequentially making occlusal contact, which increases total force from 2.2% up to 10.8%. The COF icon appears left of center with a force imbalance of 52.6% left–47.4% right (Figure A.16b).

Later at 5.341 seconds into the guided closure, the total force increases to 60% of maximum and the COF trajectory moves toward the middle of the arches demonstrating a reversed 54.1% right–45.9% left overall force imbalance of the centric relation position (Figure A1.16c). The elapsed time to reach 60% of total force of the operator-guided closure was 5.341 sec – 3.008 sec. = 2.423 sec.

Significant Unbalanced Occlusion in a Patient Self-Closure

Figure A1.17a is a facial view of an unbalanced occlusion. Note that when completely intercuspated, the teeth appear to fit together very well, but they do not give any hint as to what the measured occlusal imbalance actually is.

Figures A1.17b–d illustrate an excessive force imbalance evolving to the patient's right side as more and more teeth sequentially occlude during a patient's self-closure movement. The COF trajectory and icon show that the earliest contacts demonstrate early occlusal balance (Figure A1.17b). But, as more teeth reach occlusal contact, the occlusal forces quickly rise in the right half of the arch. Here the COF moves out of the middle of the arches to the right arch-half (Figure A1.17c). Later in the self-closure, the left side makes more occlusal contact than is seen in Figure A1.17c. This force increase pulls the COF back slightly left toward the centering target (Figure A1.17d). The COF stays on the right half of the arch at static intercuspation, which indicates the presence of a significant force imbalance to the right arch-half (80.7% right–19.3% left). The COF trajectory is blue, indicating that a closure movement has been recorded.

Within the Force vs. Time graph, the OT duration (Occlusion Time) is prolonged at .306 seconds. This is noted as "near physiologic" in the Graph Data Box by a yellow warning triangle (physiologic is \leq .2 seconds).

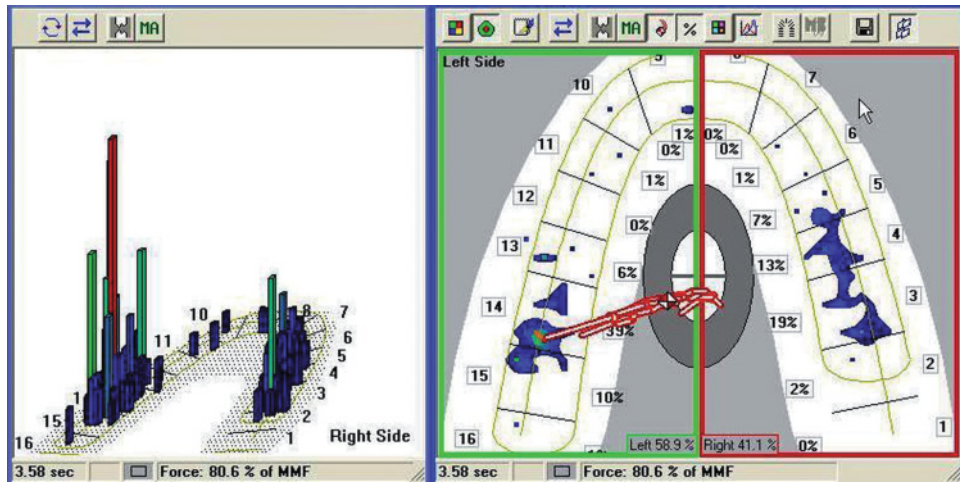


Figure A1.15a. HFP Pattern 1.

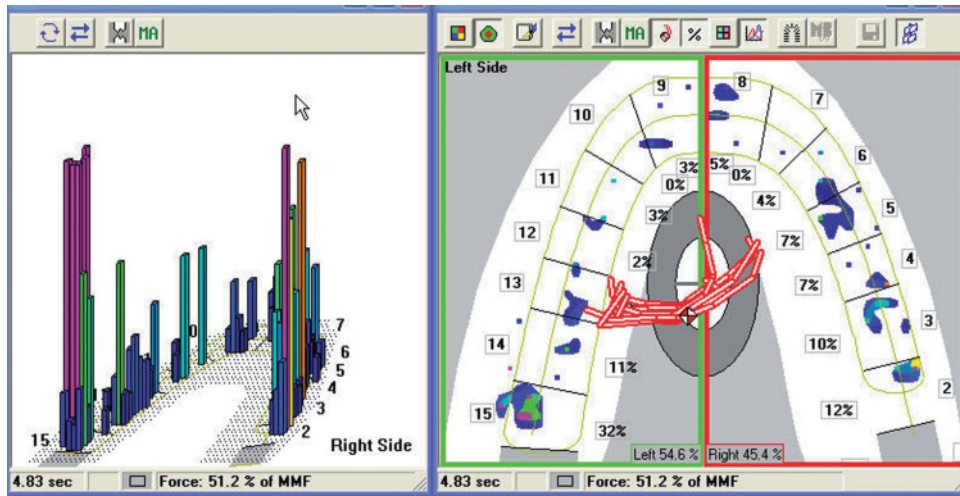


Figure A1.15b. HFP Pattern 2.

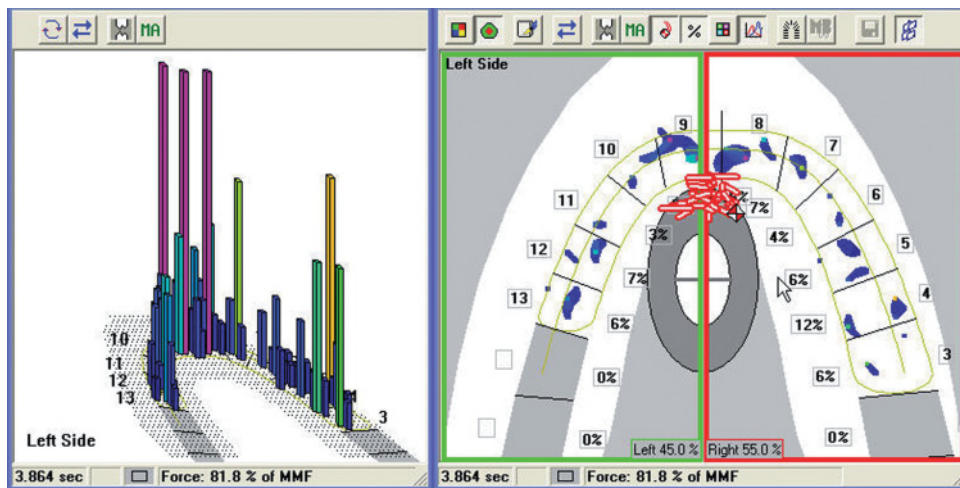


Figure A1.15c. HFP Pattern 3.

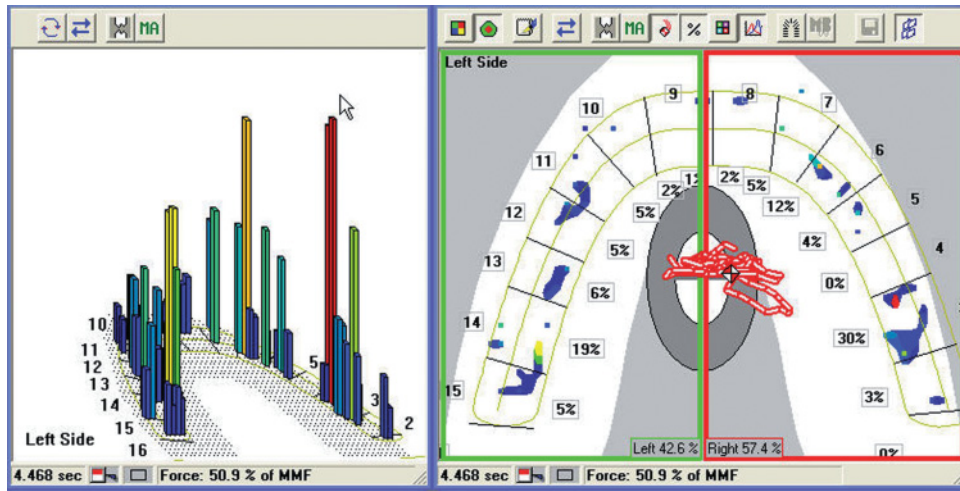


Figure A1.15d. HFP Pattern 4.

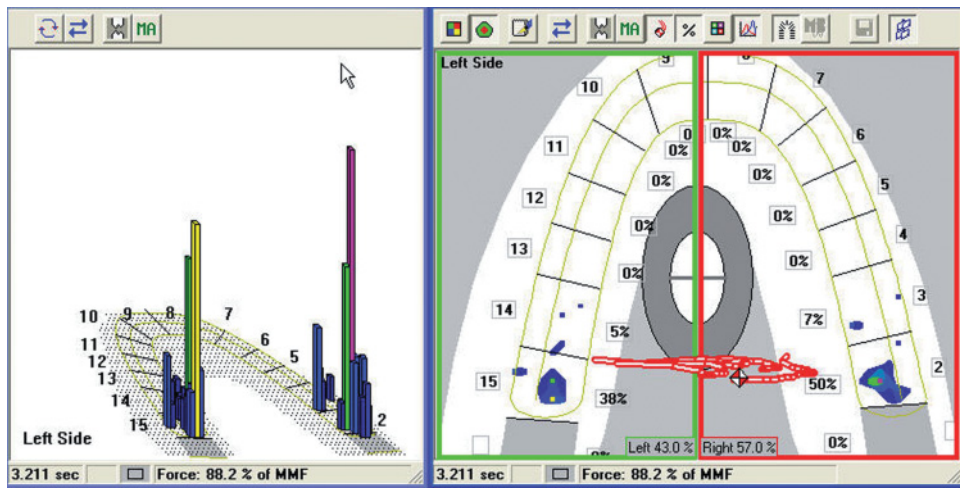


Figure A1.15e. HFP Pattern 5.

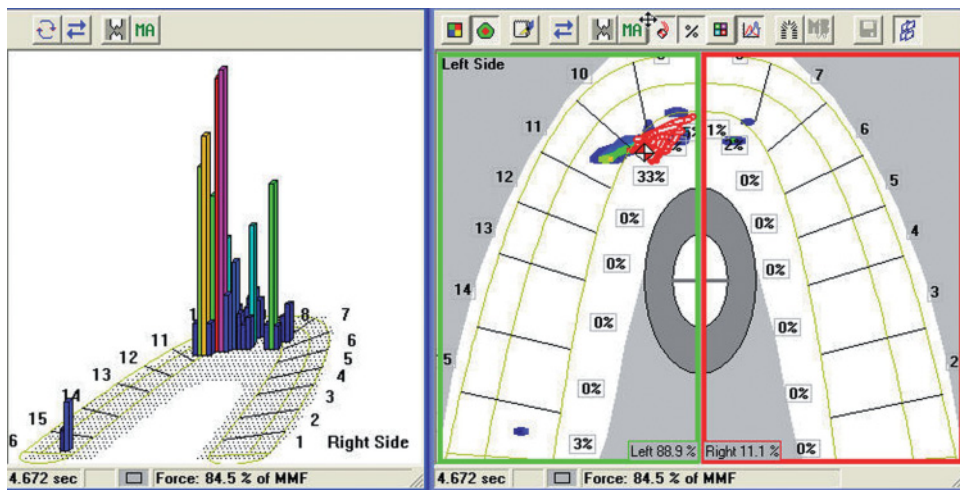


Figure A1.15f. HFP Pattern 6.

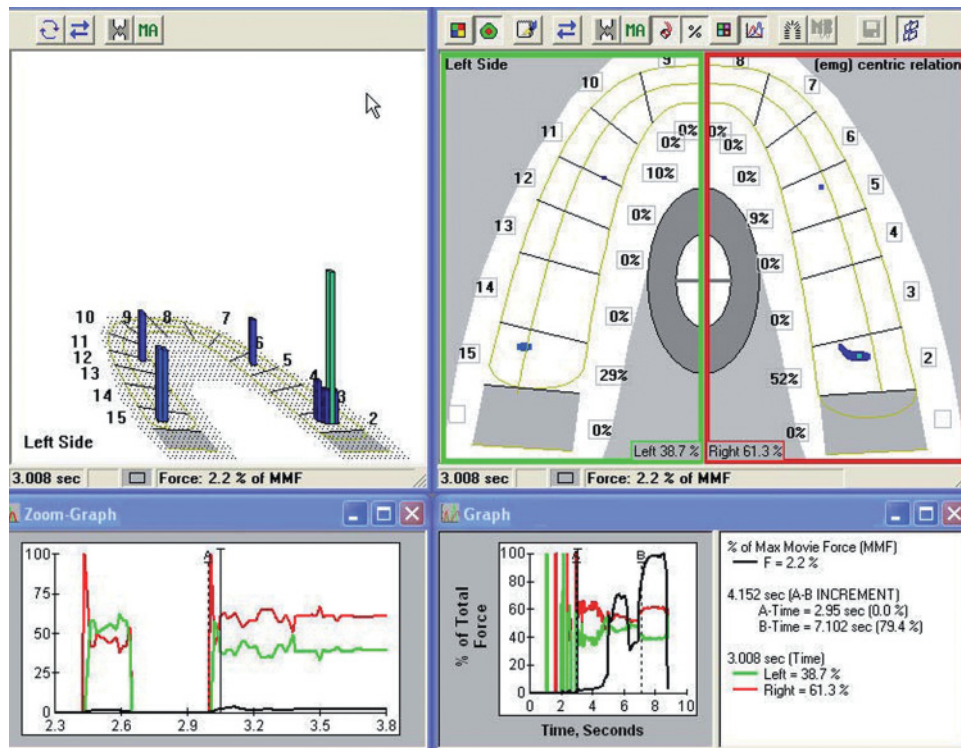


Figure A1.16a. Early centric relation contacts at 2.2% total force.

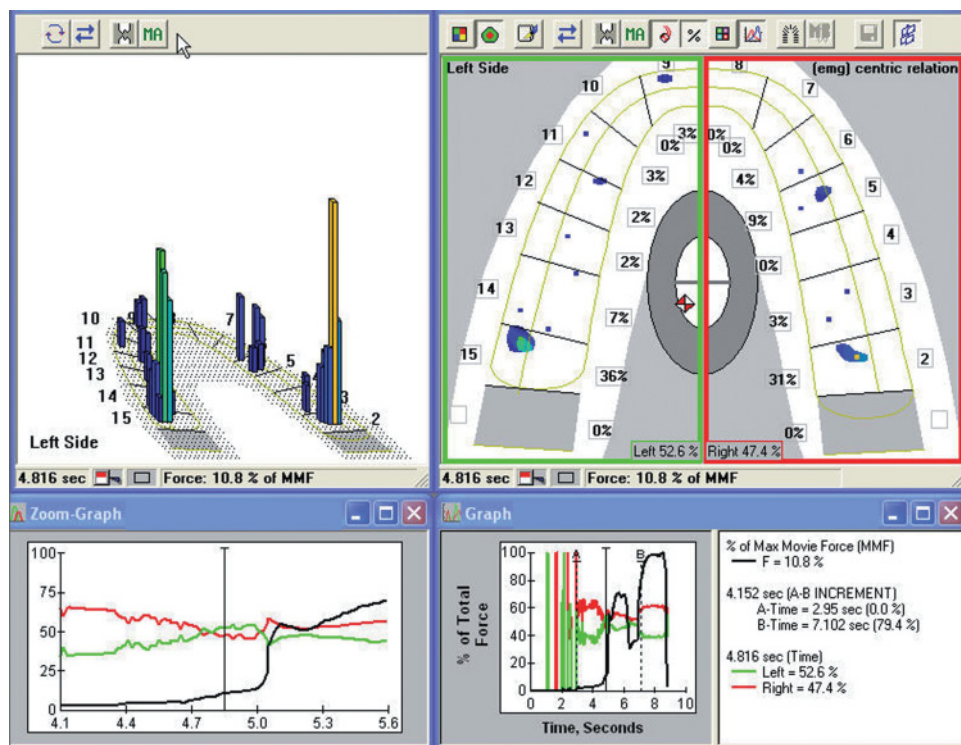


Figure A1.16b. Centric relation contacts at 10.8% total force.

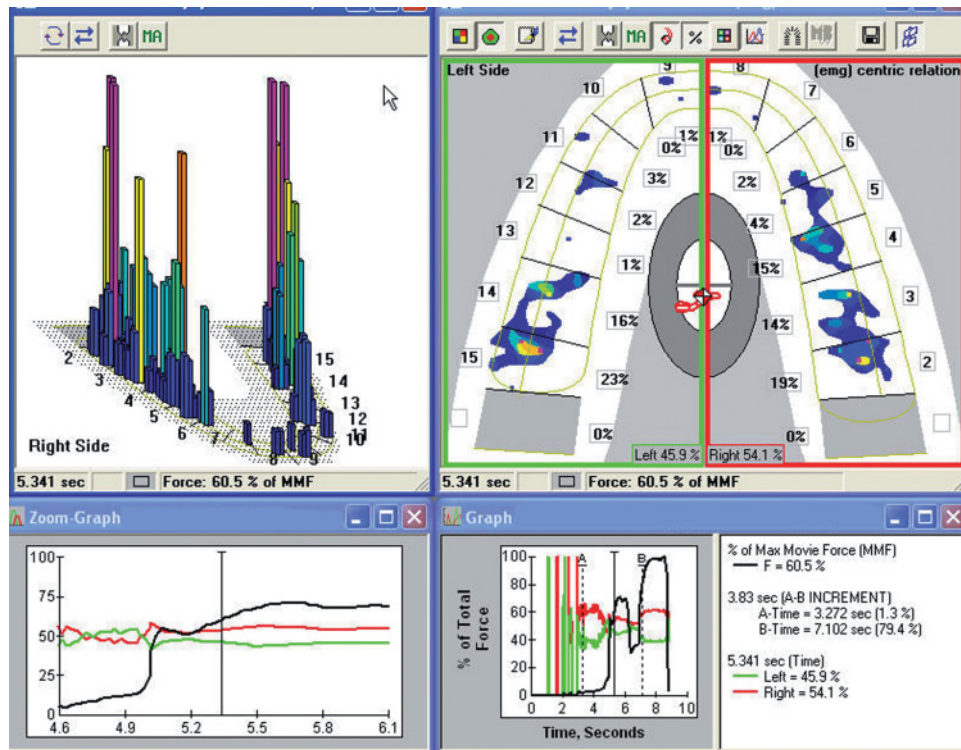


Figure A1.16c. Centric relation contacts at 60.5% total force.

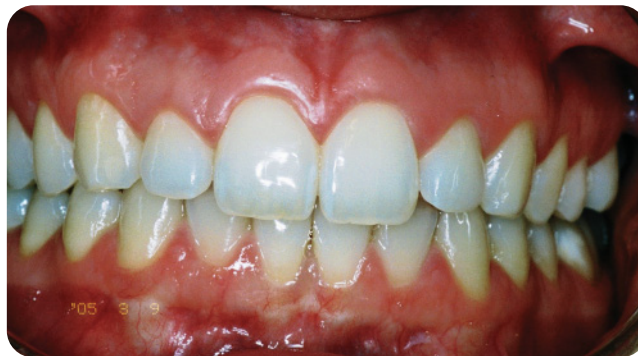

Figure A1.17a. Facial view of an unbalanced occlusion. Note how the teeth appear to intercusate very well but there is no indication as to what the measured occlusal imbalance actually is.

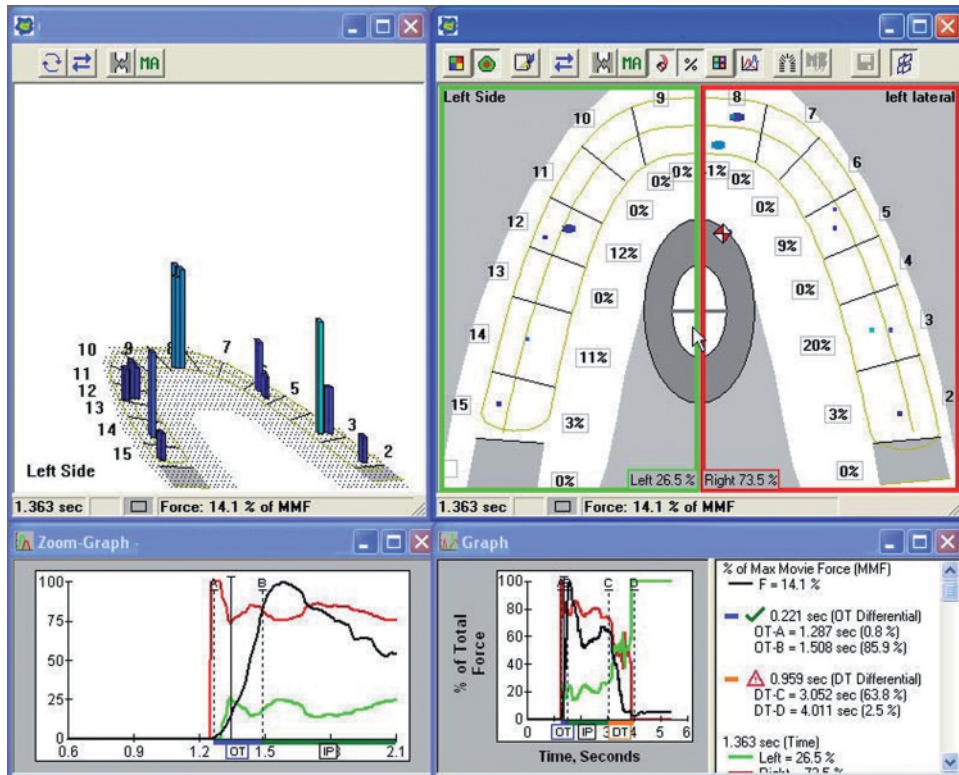


Figure A1.17b. Unbalanced patient self-closure at 14.1%.

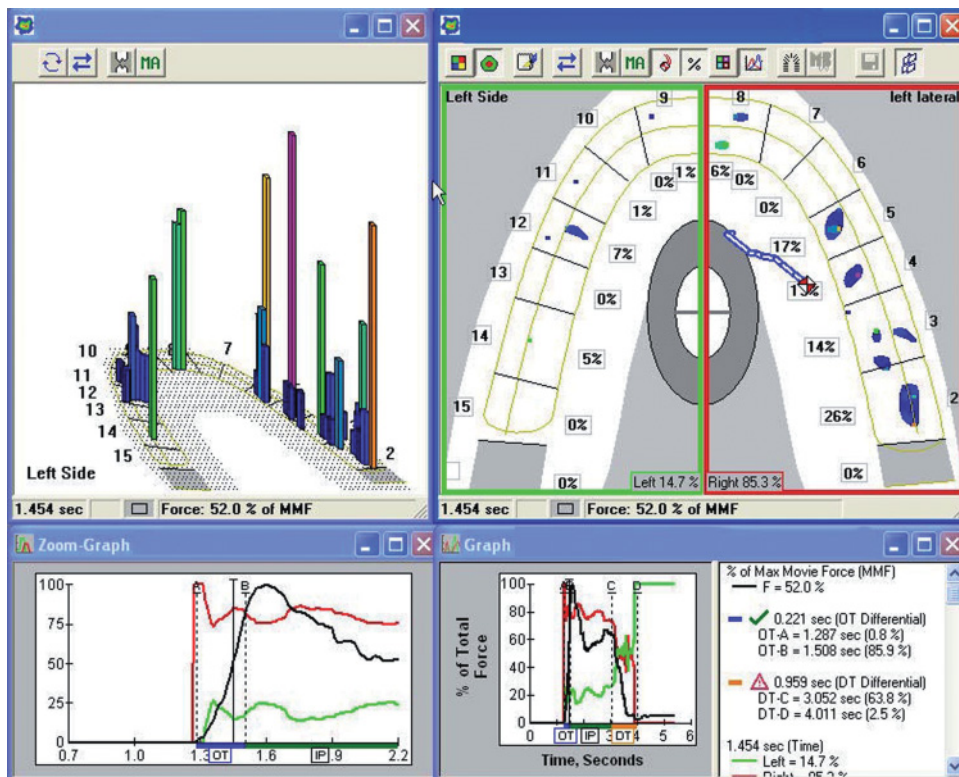


Figure A1.17c. Unbalanced patient self-closure at 52.0%.

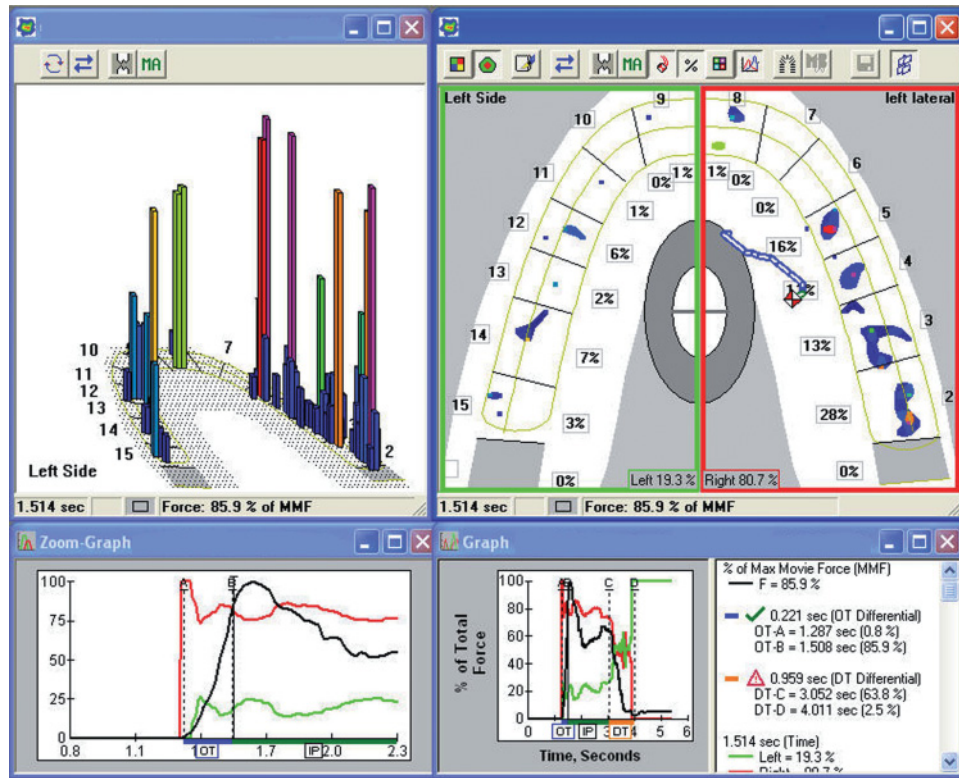


Figure A1.17d. Unbalanced patient self-closure at 85.9%.

Problematic Lateral Excursion with Long Disclusion Time

Figure A1.18a shows a left excursive movement where many posterior teeth are in contact throughout the excursion. Figures A1.18b–d illustrate the sequential contacts involved in the excursive function. Here the 2-D window is divided into quadrants at the distal of the canines to separate the anterior guidance from the posterior teeth.

Within the Force vs. Time graph from A-B-C, the patient self-closes (A-B) and then statically intercuspatates (B-C). At C, the patient commences moving left out of intercuspatation, so within the 2-D window the COF begins to track to the left toward the 1st molar region (Figure A1.18b). Here the total force line sharply declines because there is a major force drop when a patient disarticulates the teeth to commence moving excursively. In the 3-D window, the left posterior quadrant rises in force as the opposing teeth in that quadrant mesh their occlusal surfaces together while the mandible moves left. The aqua line within the graph rises and falls but stays elevated above 0% through the entire duration of the lateral movement (Figure A1.18c). This indicates the presence of a

working side posterior group function that occurs prior to, and then later with, the anterior guidance function. The aqua and green lines rise and fall while crossing each other as the excursion unfolds (Figure A1.18d). The group function persists within the excursion and is never completely discluded. The excursion ends at D (5.251 seconds). Note that the COF trajectory is L-shaped because it first moves left and then turns anteriorly as the anterior teeth attempt to unsuccessfully disclude the posterior teeth. An L-Shaped COF trajectory indicates the presence of a posterior Group Function within an excursive movement. The COF trajectory is orange during the excursion, indicating that a lateral excursive movement has been recorded.

Within the Force vs. Time graph, the DT period is marked with a long orange period on the x-axis. The total Disclusion Time = [5.251 seconds (D – end of excursion) – 3.4 seconds (C – Excursive Commencement)] = 1.851 seconds Disclusion Time.

This Disclusion Time (DT) is marked in the Graph Data Box as “a non physiologic” by a pink warning triangle because the DT is much longer than .4 seconds in duration.

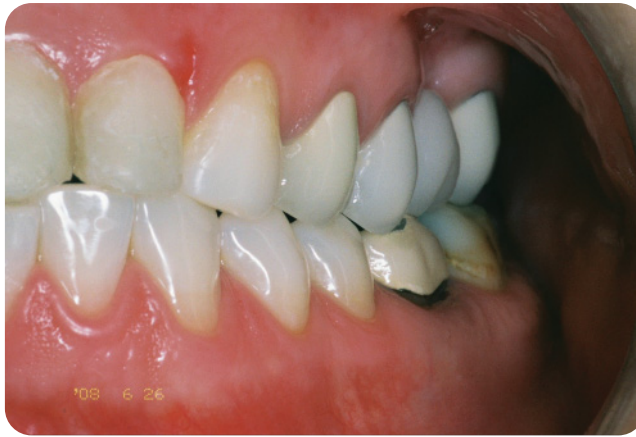

Figure A1.18a. Left excursion with visible group function demonstrating long Disclusion Time.

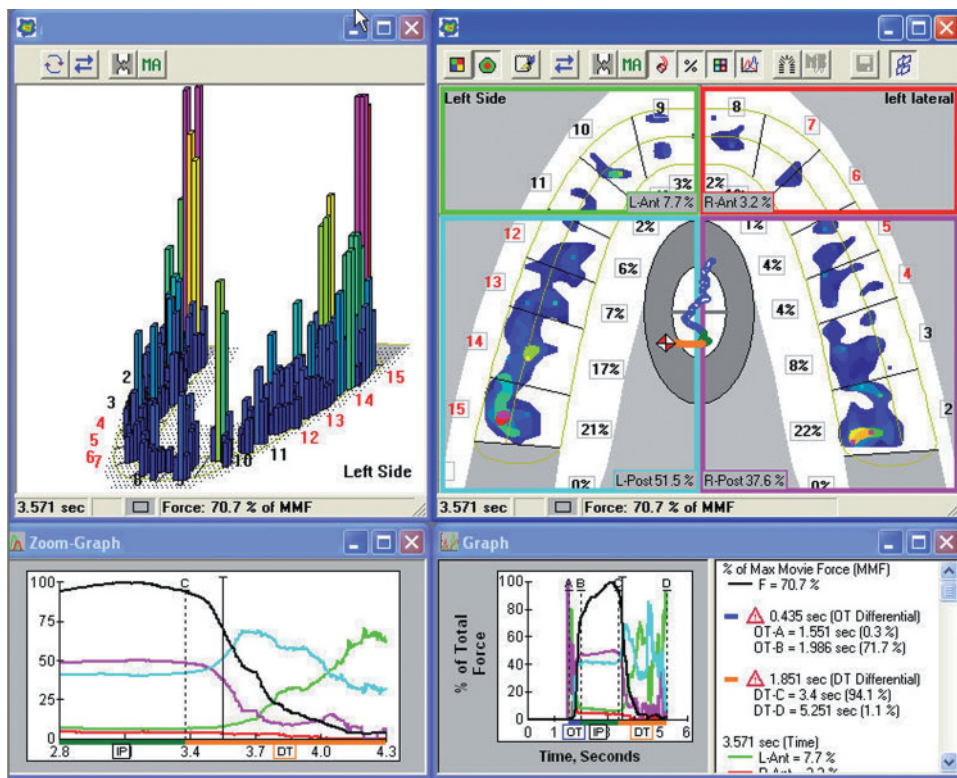


Figure A1.18b. Problematic left excursion at excursive commencement.

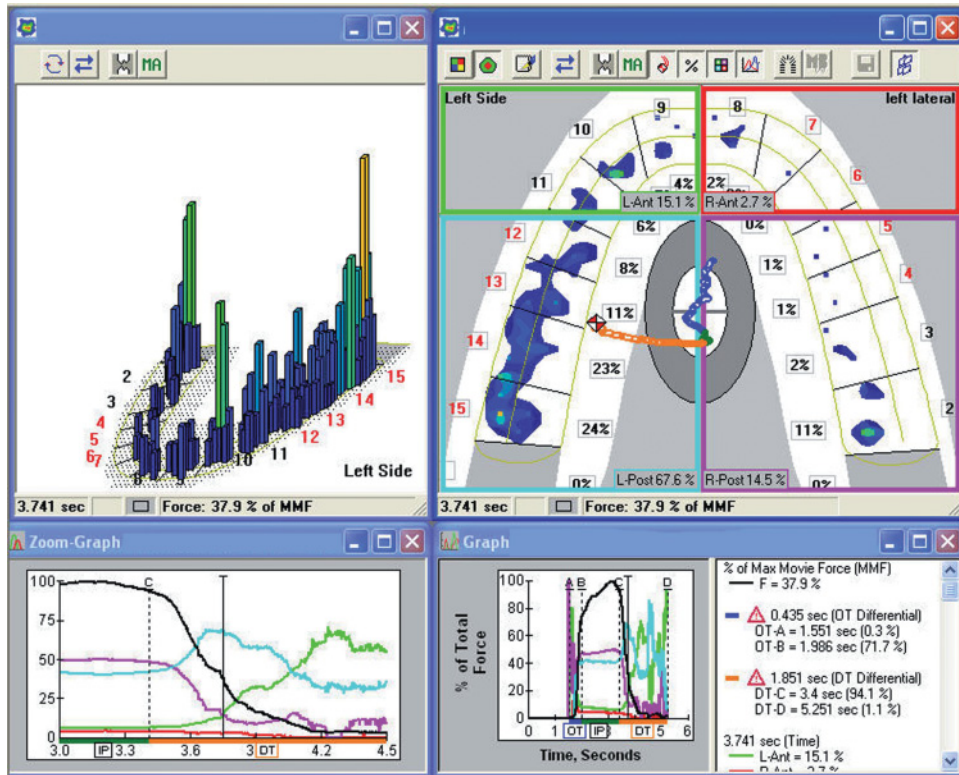


Figure A1.18c. Problematic left excursion during ongoing group function. Note, as well, that the balancing side is not excluded.

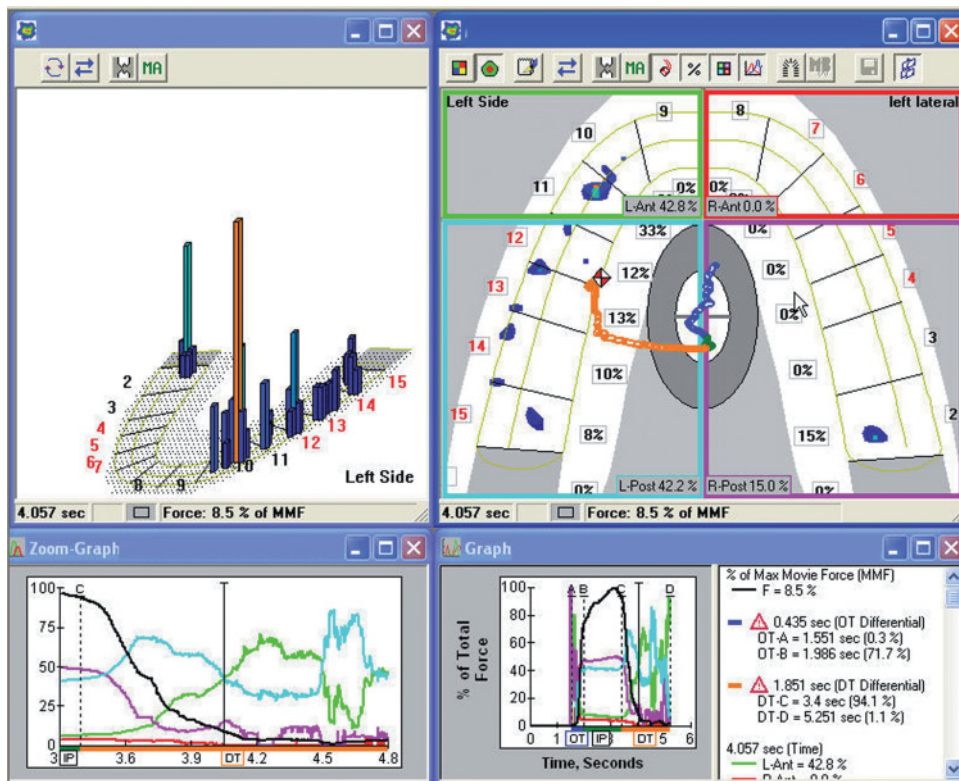


Figure A1.18d. Problematic left excursion late into group function.

Clinical Computer-Guided Occlusal Adjustments Performed upon Natural Teeth and Prosthodontic Reconstruction

There are numerous researched and published clinical applications of the T-Scan III Occlusal Analysis System in Dental Medicine.^{1,3,4,13,14,16–18,22,27–32} The following applications are discussed:

1. Occlusal equilibration end point control
2. Disclusion Time reduction therapy to treat MPDS symptomatology WITHOUT splints, nightguards, deprogrammers, or orthotic devices
3. Understanding the force levels and timing sequences that are poorly represented by all forms of articulating paper markings
4. Developing measurable bilateral simultaneous occlusal contacts
5. Isolating which part of a sore tooth is the correct occlusally activated portion
6. Crown and bridge, adhesive, CAD-CAM milled, complete denture and partial denture prosthodontic case-finishing at prosthesis insertion
7. Provisional restoration occlusal design evaluation
8. Implant-supported prosthesis occlusal force control
9. Occluding implant prostheses after teeth by fractions of seconds to minimize occlusal overload when they reside together in the same arch
10. TMD splint/orthotic occlusal force centering and balancing
11. Long-term permanent record of patient occlusal histories; all T-Scan III recordings can be saved by date and time so an operator can track occlusal changes that occur over time and treat any potentially injurious changes so as to minimize damage and improve long-term occlusal health
12. Legal documentation of both diagnostic conditions and occlusal treatment end results

Occlusal adjustment procedures performed upon nonrestored natural teeth, restored natural teeth, differing dental prostheses, and implant-supported prostheses can be guided by computer analysis to accomplish precise, ideal, measurable occlusal end points.^{13,17–20,22,29,31}

Because the T-Scan III System records the elapsed time and changing occlusal contact force evolution that occurs during any recorded occlusal event, it is possible to manipulate the sequence of the timing of closure and/or excursive contacts, while simultaneously controlling damaging occlusal force excesses. Since 1990, published clinical reports and research

have revealed that computer-guided occlusal adjustments can measurably optimize an occlusal scheme.^{3,4,6,13,19,20,29,31}

In order to measurably optimize a natural tooth occlusal scheme or control forces on a dental or implant prosthesis, preliminary diagnostic closure, multi-bite, HFP, and/or excursive Movies are recorded by the operator, to determine which occlusal contacts throughout the arches initially require occlusal force and time corrections. After the initial occlusal adjustments are accomplished based upon where the force and timing aberrations are located within the 1st diagnostic recording, a 2nd recording is then required to determine the new force and time aberrations that resulted from the 1st Movie's required corrective adjustments. The 2nd Movie then guides further occlusal adjustments based upon the aberrations isolated within the 2nd Movie. This process of recording followed by computer-guided occlusal adjustments repeats, as needed, until ideal occlusal force and timing end points are measurably achieved.

For brevity within the following examples of clinical computer-guided occlusal scheme end point optimization, only the preoperative condition and the final ideal occlusal result will be described. However, it is important to understand that each illustrated end point optimization procedure required between 4 and 10 recording and adjustment sequences to successfully achieve the final depicted ideal occlusal end point.

Examples of Clinical Occlusal Scheme End Point Optimization Using Computer-Guided Occlusal Adjustments

Centric Relation Prematurity

Redirecting a poor preoperative centric relation COF trajectory can be seen in Figures A1.19 and A1.20. Figure A1.19a shows that the pretreatment centric relation time prematurity is located on teeth 2 (and 31) 1.924 seconds into the recording. In Figure A1.19b, at 4.274 seconds, teeth 2 and 3 comprise 81% of the total force in both arch-halves, such that the COF icon appears nearest to those 2 teeth. Then, at 7.021 seconds (Figure A1.19c), the patient's left side begins to make significant contact, which moves the COF trajectory away from the posterior right teeth toward the anterior-left region. Finally at 9.244 seconds, centric relation occlusion is reached with the COF trajectory still on the right arch-half. The pretreatment condition demonstrates a 63% right–47% left arch-half force imbalance (Figure A1.19d). Additionally, the pre-treatment COF trajectory is long and noncentered,

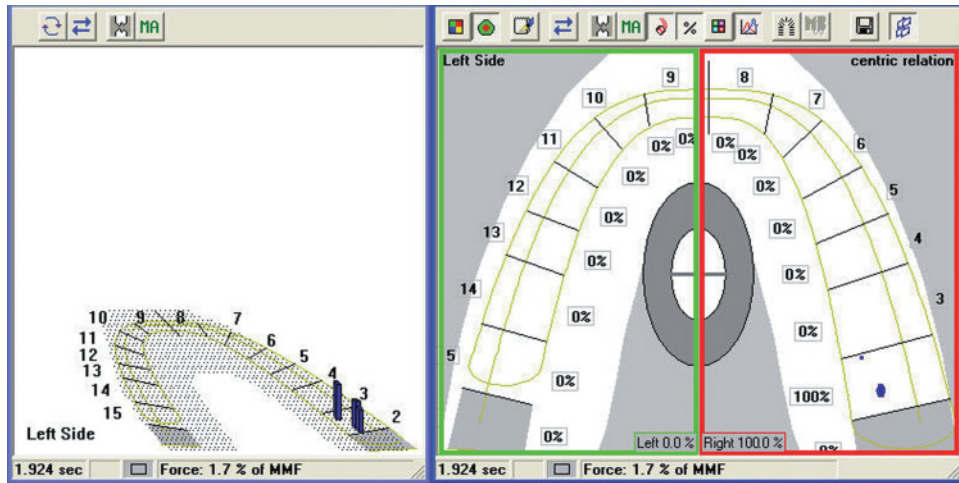


Figure A1.19a. Preoperative centric relation contacts at 1.7% total force.

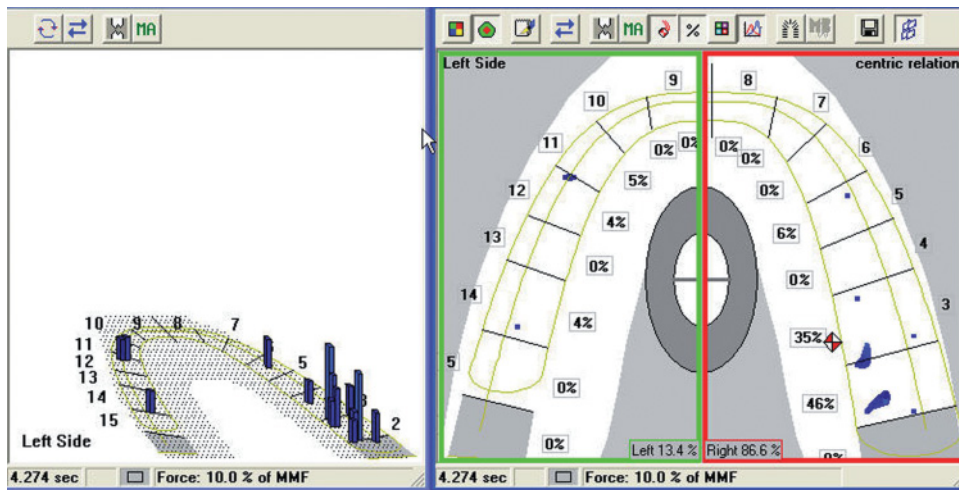


Figure A1.19b. Preoperative centric relation contacts at 10.0% total force.

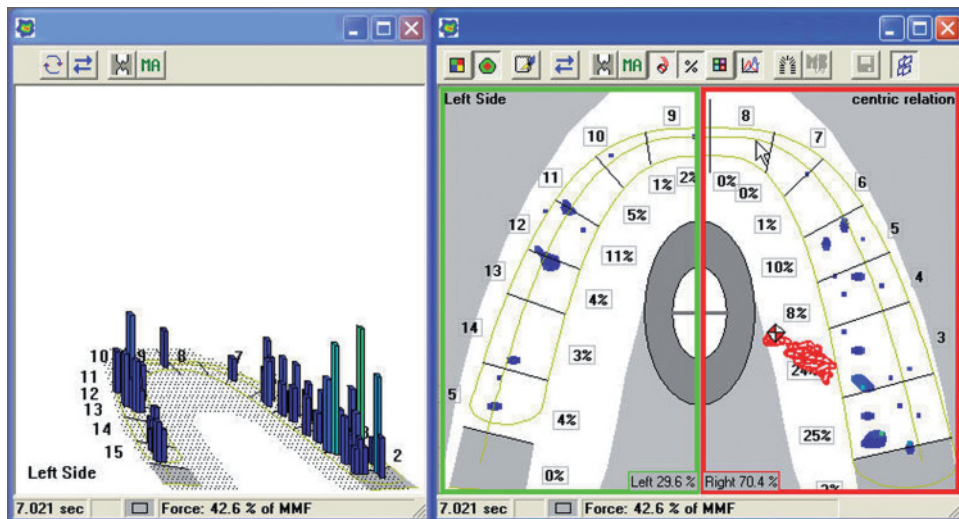


Figure A1.19c. Preoperative centric relation contacts at 42.46% total force.

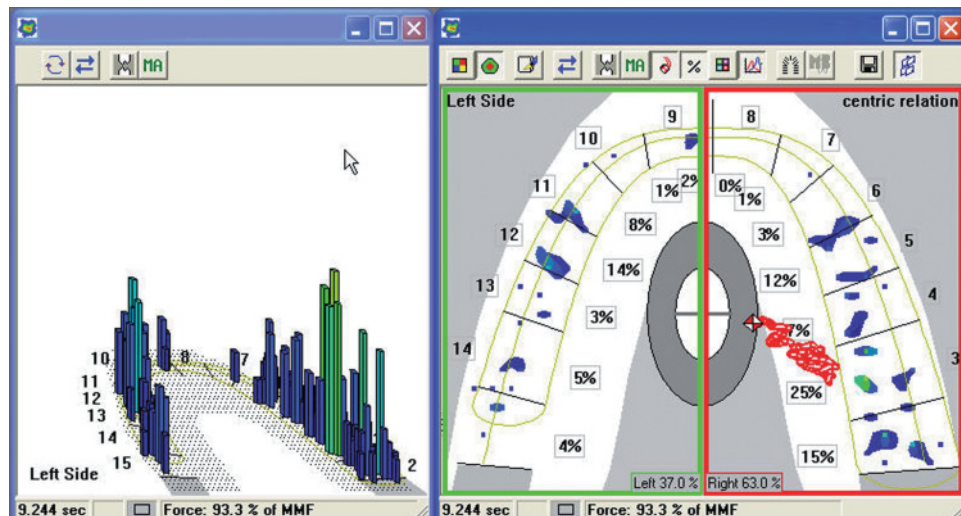


Figure A1.19d. Preoperative centric relation contacts at 93.3 % total force.

indicating excessive nonsimultaneity of an unbalanced centric relation occlusal scheme.

After initial adjustments were made to the early contacts on teeth 2 and 3, as well as to the predominantly right-sided occlusal force summation, a series of 5 more recording and adjustment sequences were performed. The final COF trajectory (Figures A1.20a–c) is centered, and short in length, indicating improved overall force summation and bilateral contact time simultaneity. At 2.233 seconds, the earliest low force contacts can be seen as widespread and uniform because the COF trajectory starts near the middle of the arch with only a 5% force imbalance to the right (Figure A1.20a). Later at 3.393 seconds, moderate forces are demonstrated bilaterally and the COF hovers near the center of the arch. The force imbalance is now only a 2.1% difference between the right and left arch-halves at 71% of total force (Figure A1.20b). At complete centric relation occlusion (99.9% total force), the COF icon settles on the right arch-half with a final 7% imbalance to the right (Figure A1.20c).

Establishing Measurable Bilateral Simultaneous Contacts

Balancing an unbalanced patient self-closure to improve the degree of bilateral simultaneity involves centering a pretreatment noncentered COF trajectory through corrections made to the early timing order of a tooth contact sequence. The earliest contacts that demonstrate unmatched occlusal force rise will drag the COF toward the earlier side of the arch. By employing the .003 sec incremental playback of the

contact sequence, the contact sequence becomes discernible so that adjustments can be made to the position of the COF trajectory. Successive recording and adjusting sequences will establish measurable bilateral simultaneous contacts where all teeth occlude during a patient self-closure in $\leq .2$ sec with nearly 50% right to 50% left arch half equality from first contact to last.²⁹ This is represented by a COF trajectory that travels close to the playback window midline while containing very few legs (each leg = .003 sec).

Recall that Figures A1.8a–c illustrate a noncentered COF trajectory during a patient self-closure into static intercuspation. The COF travels to the right through most of the closure and then is pulled back slightly to the left at static intercuspation as the left side increases in force late in the closure. The arch-half force imbalance at intercuspation is 60.7% right–39.3% left.

After 5 recording and adjustment sequences, the postoperative balanced COF trajectory can be seen in Figures A.21a–c. At 21.7% of total force, the COF trajectory is located just to the left of the midline (Figure A1.21a). The arch-half imbalance at the beginning of patient self-closure is 53.3% left–46.7% right.

As the patient self-closure advances to 52.4 % of total force .019 sec later, the COF has traveled backward and right, where it rests on the midline of the 2-D window (Figure A1.21b). The arch-half imbalance midclosure is 52.1% left–47.9% right.

At 94.6 % of total force (near maximum intercuspation), the COF finishes slightly left of the midline with a final arch-half force imbalance of 54.0% left–46.0%

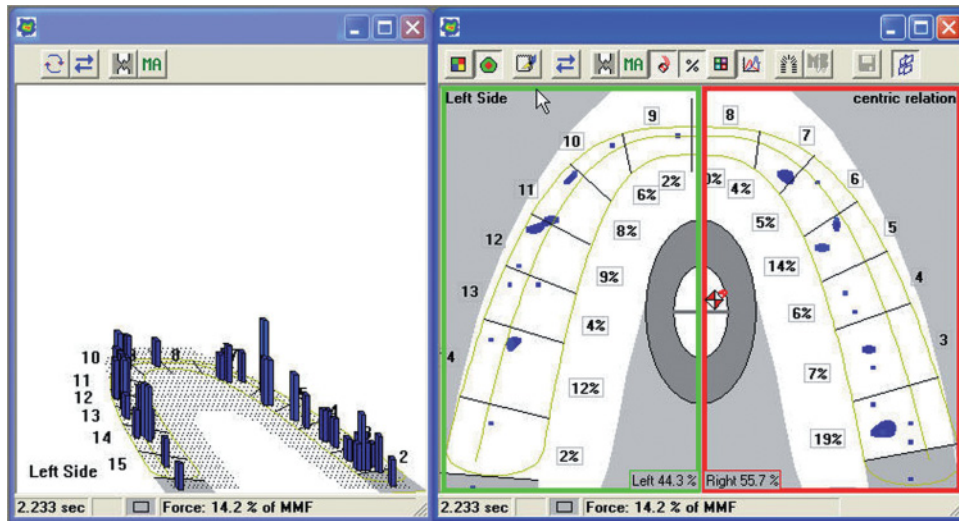


Figure A1.20a. Postoperative corrected centric relation occlusion at 14.2% total force.

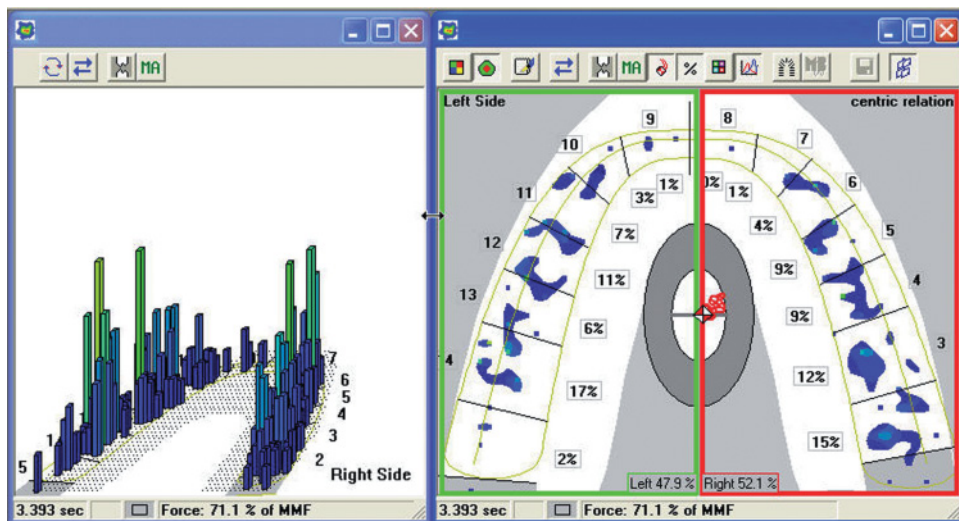


Figure A1.20b. Postoperative corrected centric relation occlusion at 71% total force.

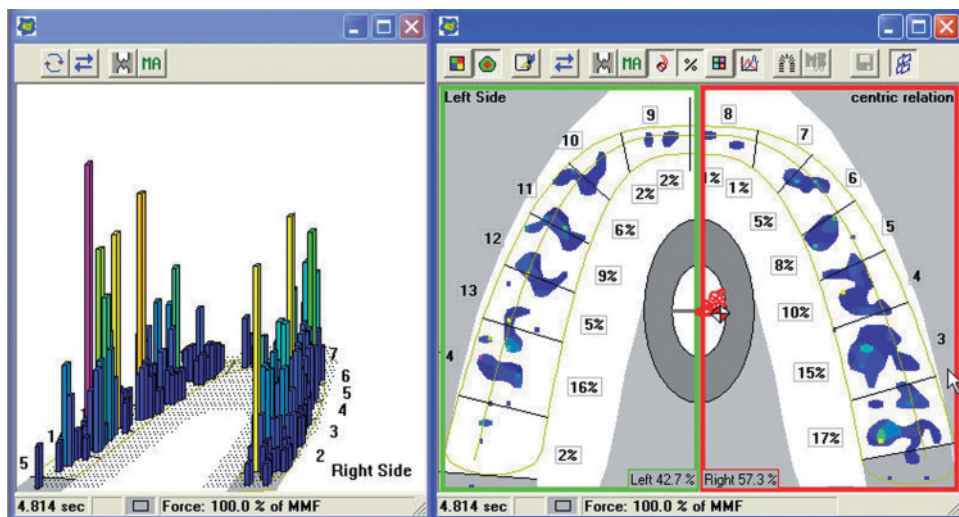


Figure A1.20c. Postoperative corrected centric relation occlusion at 100% total force.

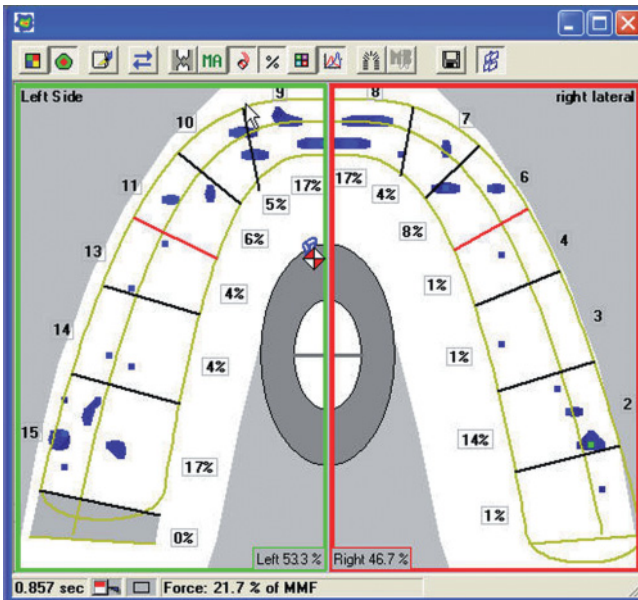


Figure A1.21a. Postoperative (corrections to Figures A1.8a–c) balanced COF trajectory; early contacts.

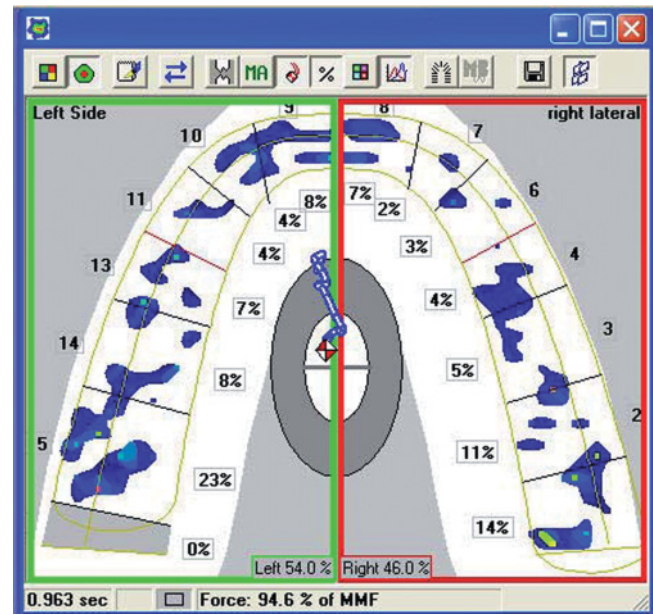


Figure A1.21c. Postoperative (corrections to Figures A1.8a–c) balanced COF trajectory; near maximum intercuspation.

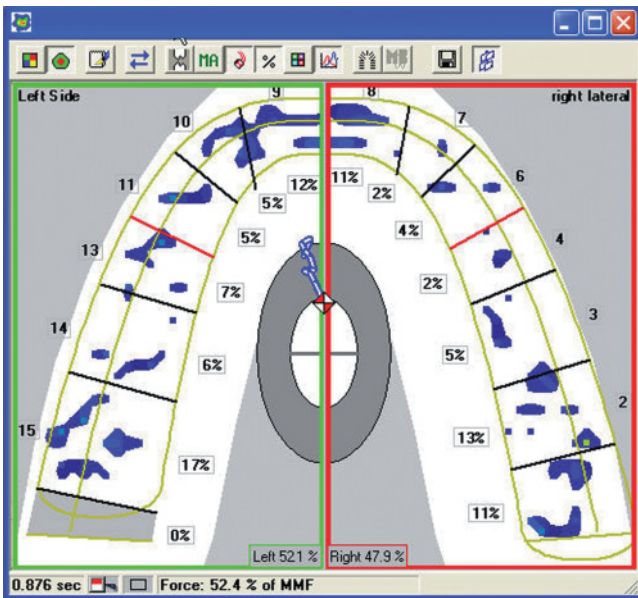


Figure A1.21b. Postoperative (corrections to Figures A1.8a–c) balanced COF trajectory; midclosure contacts.

right (Figure A1.21c). Comparing Figures A1.8c to Figure A1.21c, the postoperative COF trajectory illustrates measurable occlusal balance throughout the entire closure sequence. There is consistent, near 50% left–50% right arch-half force equality as the patient’s self-closure contacts evolve from earliest to maximum.

Maxillary and Mandibular Implant Hybrid Force Management

Although implant 5-year survival rates are very high,^{33,34,35} it has been shown that occlusal dental material damage, and superstructure breakage, can compromise the longevity of an implant-supported prostheses. In one published study involving 76 implant restorations, within 3.25 years of intraoral service, 70% (n = 56) of the delivered prostheses sustained documented dental material damage or breakage.³⁶ These poor longevity results are due to the lack of the periodontal ligament “cushioning effect” that is missing from dental implants, combined with “articulating paper–only” delivery occlusal adjustments made during the insertion of these prostheses.

Because there is no shock absorber within the bone surrounding dental implants, potentially damaging occlusal forces rise very quickly on an implant prosthesis’ occlusal surface. And, because the proper locations of any occlusal force excess is not quantifiably and reliably described to the operator by the articulating paper markings,^{5–11} there is no predictable occlusal force control when insertion occlusal adjustments are performed without a *measurement* of the occlusion. Therefore, the regions of occlusal force excess are often not removed during the insertion occlusal adjustment procedures. Hence, rapid occlusal surface dental material breakage is often clinically observed.³⁶

Mitigating occlusal force excess while improving the overall occlusal balance on implant-supported prostheses can be readily achieved with measurement of the overall occlusal force distribution. An example of how the T-Scan III can detect implant prosthesis occlusal force excess and guide its correction can be seen in Figures A1.22–A1.27.

Figure A1.22 shows two 20-year-old opposing hybrid restorations sitting on 6 abutments each (Figure A1.23). These hybrids have recently been resurfaced with new teeth and pink acrylic, and their occlusion is to be finished with T-Scan III guided occlusal adjusting. Figure A1.24 (maxillary occlusal view matched to T-Scan III 2-D window) and Figure A1.25 detail the articulating paper markings resultant from preliminarily occlusal adjustments made to the hybrid prostheses at insertion. At this point in the insertion process, there are more paper markings through the left side than are present on the right side and the largest paper markings are present in the left canine and central incisor regions.

Not seen within the paper mark distribution is the moving occlusal force summation (COF trajectory) that begins near the left upper canine area (Figure A1.26a), crosses slightly anteriorly (Figure A1.26b), and then moves posteriorly to finish in the left anterior quadrant with an overall force imbalance of 60.8% left–39.2% right (Figure A1.26c). This poorly directed occlusal force summation, if not corrected, will, during occlusal function, repeatedly torque the prosthesis through its lifespan by overly depressing the left anterior region while simultaneously lifting the right posterior region.

Note that at the end of the preoperative closure sequence (Figure A1.26c) there are very large forces present on teeth 3 and 4, despite the fact that there

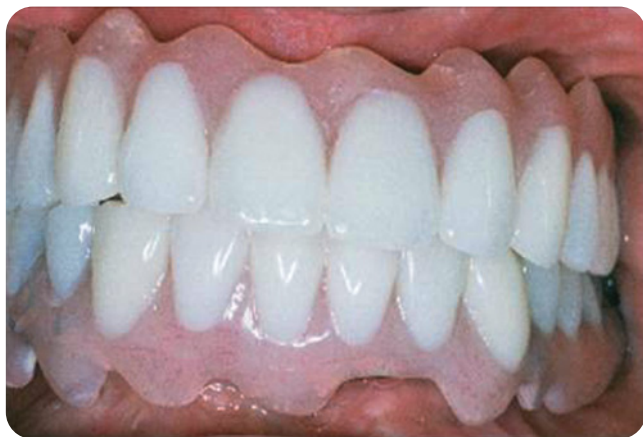

Figure A1.22. Twenty-year-old implant hybrid prostheses after resurfacing with new teeth and acrylic.

are very small paper marks on these same teeth observed in Figure A1.24. This is a clear example of how both large articulating paper marks (like those on teeth 11 and 9; Figure A1.24) and very small marks (like those on teeth 3 and 4) even though there are

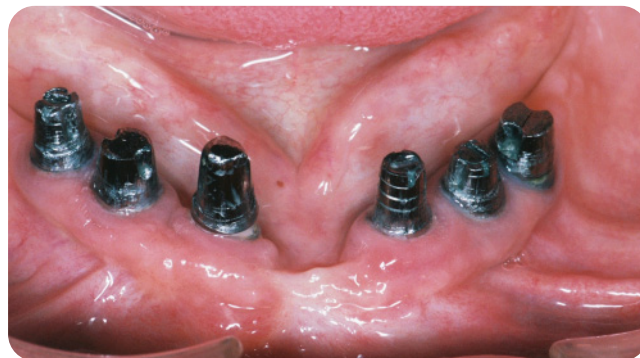

Figure A1.23. Mandibular implant abutments supporting mandibular hybrid prosthesis.

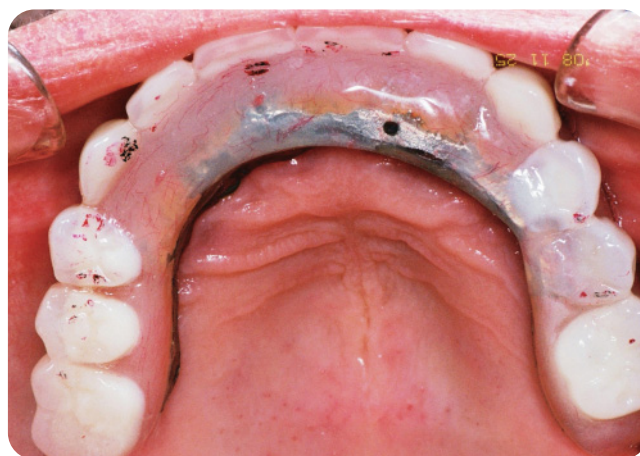

Figure A1.24. Maxillary articulating paper marks at insertion.

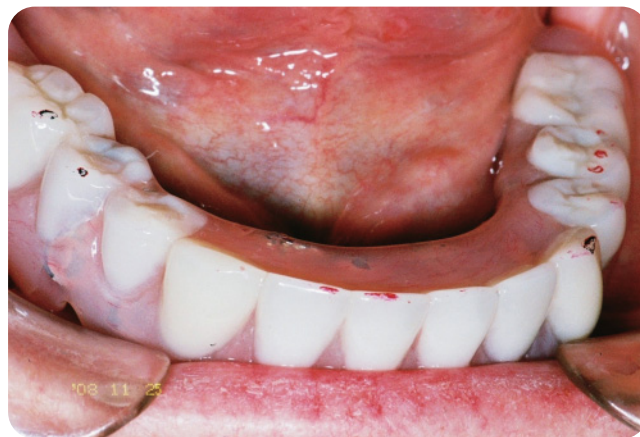

Figure A1.25. Mandibular articulating paper marks at insertion.

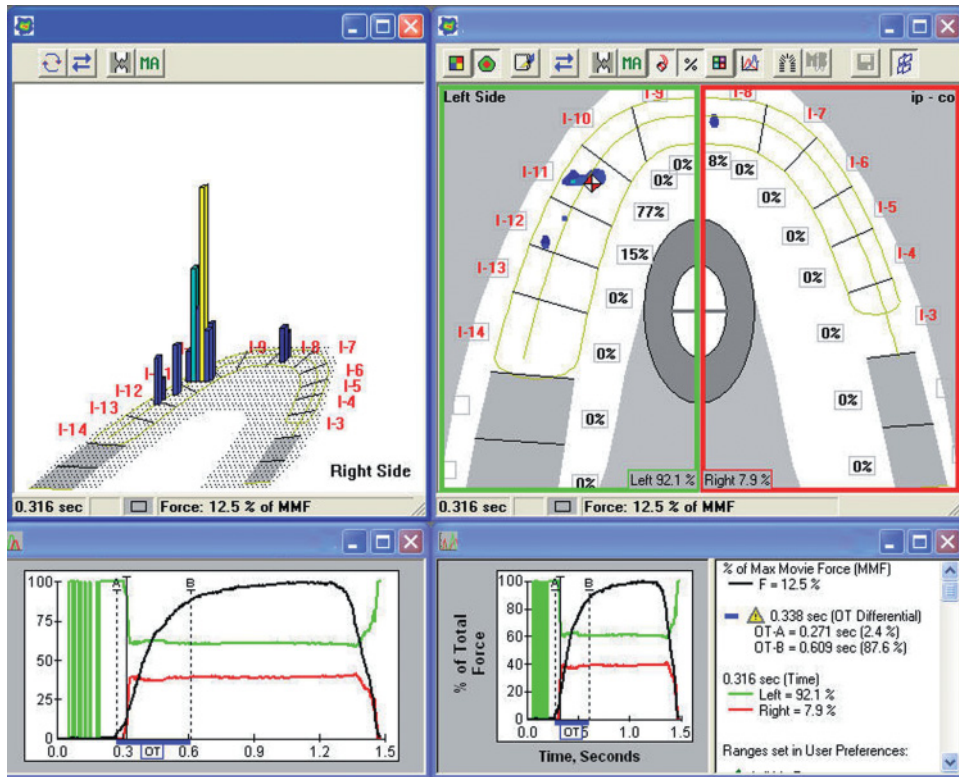


Figure A1.26a. Implant hybrid pretreatment early closure contacts.

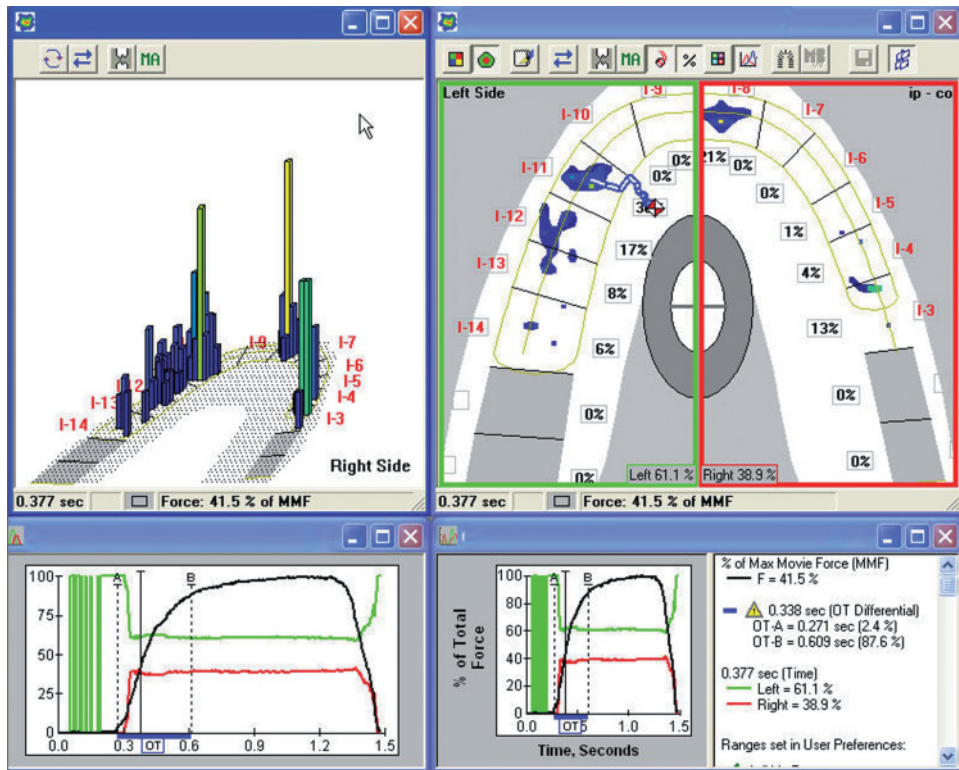


Figure A1.26b. Implant hybrid pretreatment midclosure contacts.

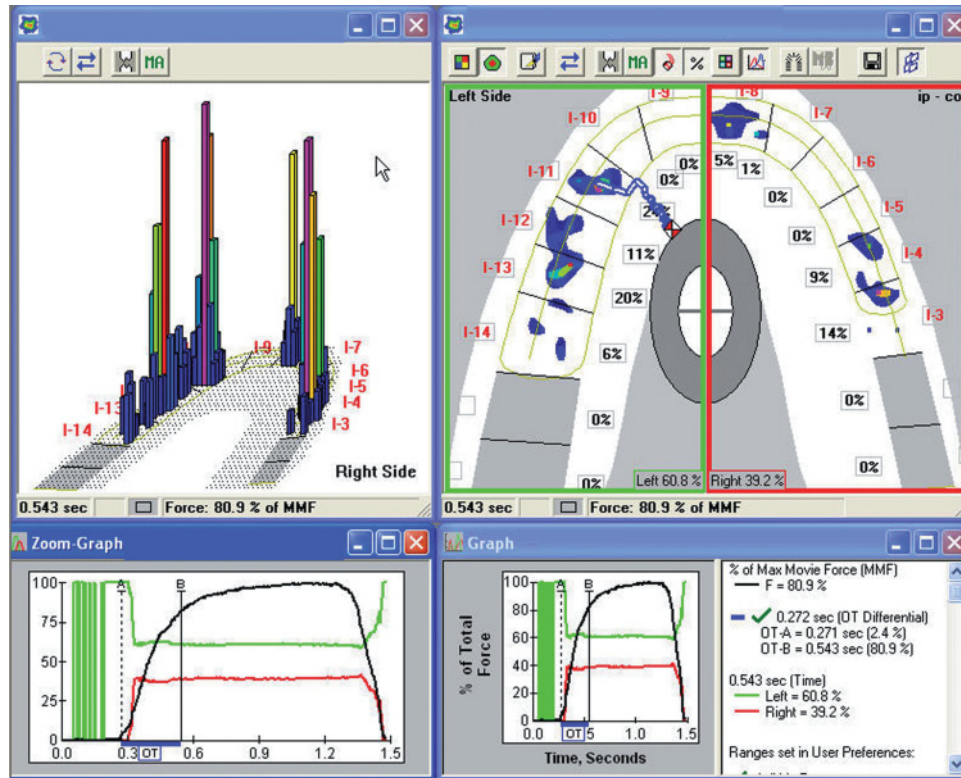


Figure A1.26c. Implant hybrid pretreatment end of closure contacts.

very small articulating paper marks present on those same teeth. Small paper markings can often contain high occlusal forces.

Figures A1.27a–c show the T-Scan III corrected end point obtained after 10 recording and adjustment sequences. Postoperatively, the COF trajectory starts just left of the center of the prostheses (Figure A1.27a), travels to the right across the midline (Figure A1.27b), and moves to the posterior slightly where its movement ends near the midline. The corrected right to left force imbalance is now only .2% (50.8% right–49.2% left) (Figure A1.27c).

After the completion of computer-guided occlusal adjustments, under functional occlusal loading instead of being repeatedly torqued to the left anterior, the prostheses will be seated upward into the center of the palate and downward into the floor of the mouth. Through their lifespan, this occlusal end point will be far more preservational of all the components of these prostheses, thereby improving the longevity of the implants, the metal substructures, and the acrylic denture teeth.

The Distal Extension Implant Prosthesis

Natural teeth move vertically and horizontally significantly more than implants because of the resiliency

of the periodontal ligament.^{37,38} In mixed implant–natural tooth occlusal schemes, this discrepancy in movement results in a force transmission difference whereby an implant prosthesis, which moves significantly less, can stop the natural teeth nearby from completely depressing into their periodontal ligaments. Because the implant prosthesis is the least mobile element when compared to its neighboring natural teeth, the implant prosthesis will absorb more of the occlusal forces than its neighboring natural teeth, making it more prone to breakage or deosseointegration.

Therefore, in mixed implant–natural tooth occlusal schemes, the optimal clinical scenario is where the implant prosthesis occludes *after* the natural teeth by enough elapsed time for the teeth to depress partway into their periodontal ligament fibers. This is when the teeth will begin to meet resistance by the surrounding alveolar housing. Ideally, the natural teeth will physiologically move in response to the applied occlusal load before the implant prosthesis commences occluding.¹⁶

The clinical benefits of applying the *time delay principle* were reported by Stevens,³⁰ who demonstrated that by delaying the loading on a long-standing distal extension implant prosthesis that had previously

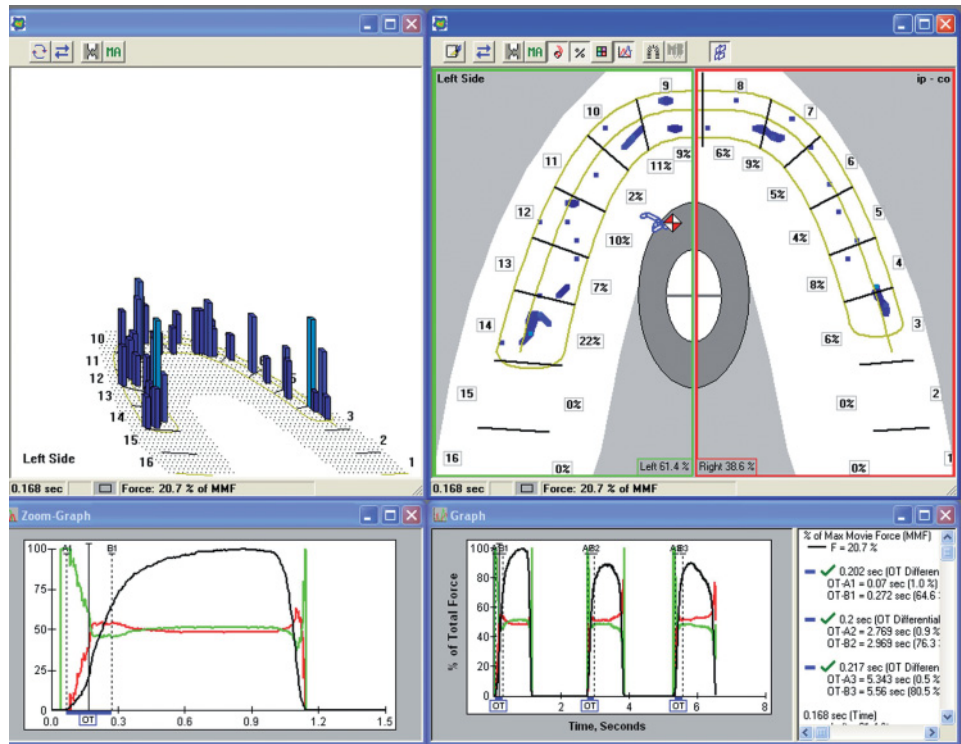


Figure A1.27a. Implant hybrid posttreatment early closure contacts.

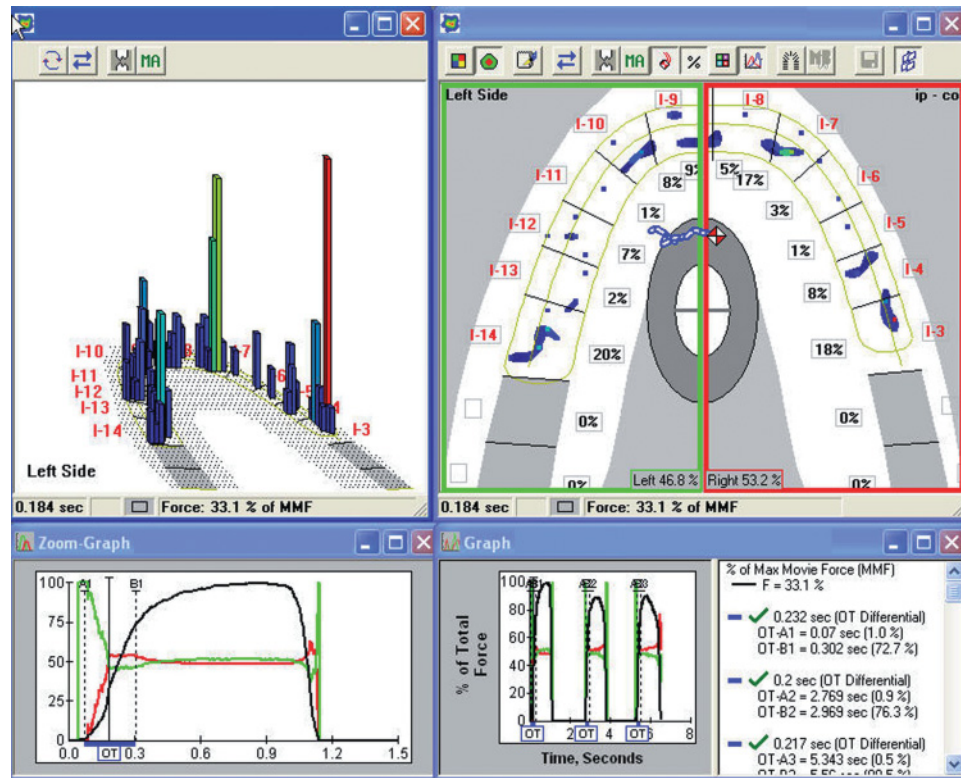


Figure A1.27b. Implant hybrid posttreatment midclosure contacts.

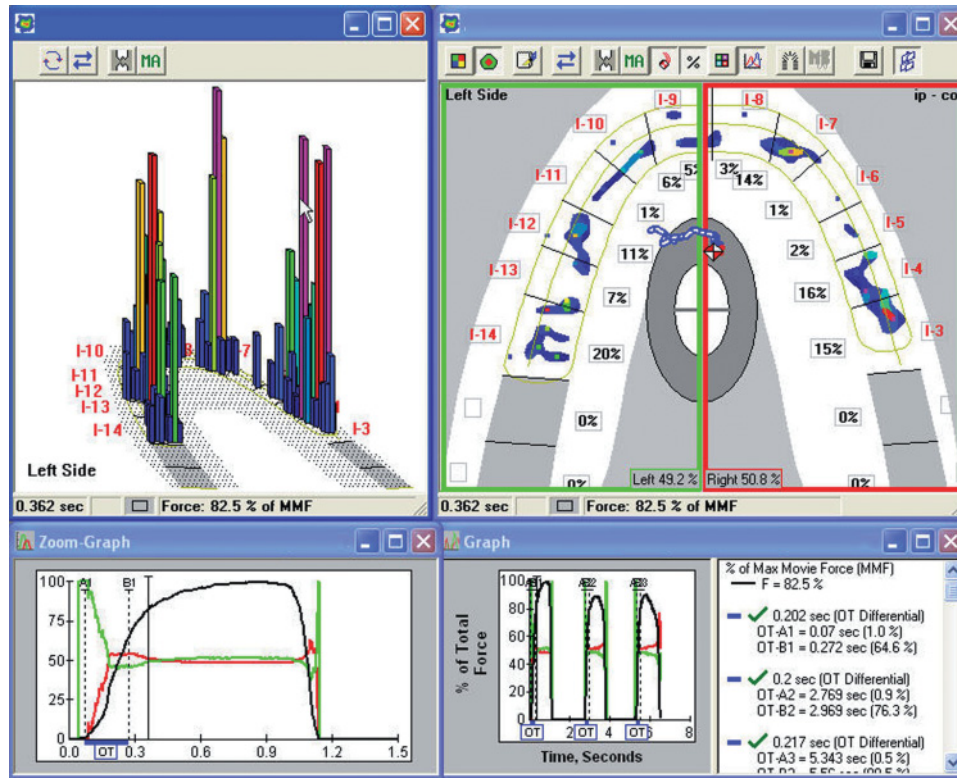


Figure A1.27c. Implant hybrid posttreatment end closure contacts.

lost significant bone support around the supporting implants, the lost bone was regenerated.

Establishing a Time Delay is a precise occlusal adjustment that requires time measurement to successfully accomplish. The operator should first establish implant prosthesis—natural tooth contact time simultaneity in patient self-closure—by improving the COF trajectory position and length, as has been previously described. It should be a short, nearly straight line that is centered along the arch-half midline, and the Occlusion Time for the entire arch in self-closure is ≤ 2 sec from first to last contact.

Then, to delay the implant prosthesis during subsequent patient self-closures, the closure occlusal contacts on the implant prosthesis need to be gently “shaved” so that only a small amount of occlusal material is removed during subsequent adjustment sequences.¹⁶ This shaving is accomplished by brushing the occlusal surface with a medium course round-diamond bur.

The following time delay example required 4 recording and adjustment sequences after measurable simultaneity was established to hold back the loading of 3 different implant prostheses. There are opposing 3- and 4-unit distal extension implant prostheses in the posterior right quadrants, and another 2-unit distal

extension prosthesis located in the lower left posterior quadrant that opposes upper previously crowned natural teeth. The remaining anterior teeth are non-restored (Figures A1.28a–c). Note how the articulating paper marks (Figure A1.28c) on the installed maxillary prosthesis, although widespread, do not measure or describe the contact timing sequence for the operator.

The posttreatment computer-guided occlusal result is depicted in Figures A1.29a–d, which depict 4 sequential Movie frames that illustrate the established delay. At 2.869 sec, there are light-force (blue) early contacts present on all of the natural teeth that are anterior to the implant prostheses, while no contacts are present on the implant prostheses. The COF trajectory starts anteriorly near the right anterior teeth as they are the first occluders (Figure A1.29a).

At 2.947 sec (Figure A1.29b), the right 4-unit implant prosthesis begins to make light force contact (blue) while the anterior natural teeth are contacting more forcefully than previously (light green, yellow, light blue).

At 3.044 sec (Figure A1.29c), all the anterior teeth are making moderately forceful contact just as the middle left posterior teeth begin to rise in force. There are light blue columns present on teeth 11 and 12, while at the same time, the right posterior implant

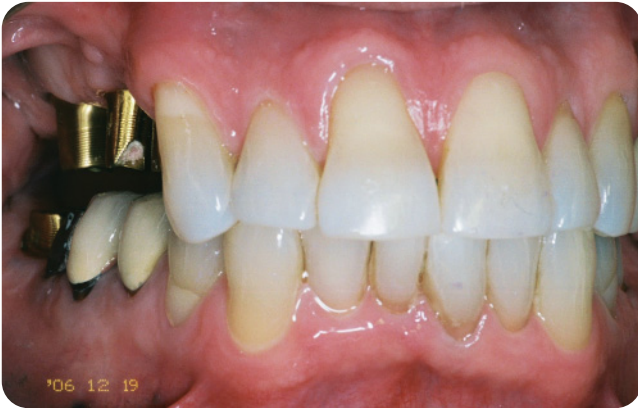

Figure A1.28a. Opposing maxillary distal extension implant prostheses requiring a “time delay” when restored with crowns.

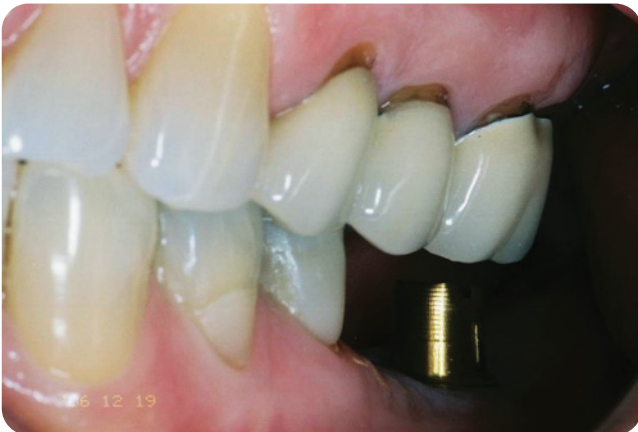

Figure A1.28b. Mandibular left implant abutments opposing upper crowns.

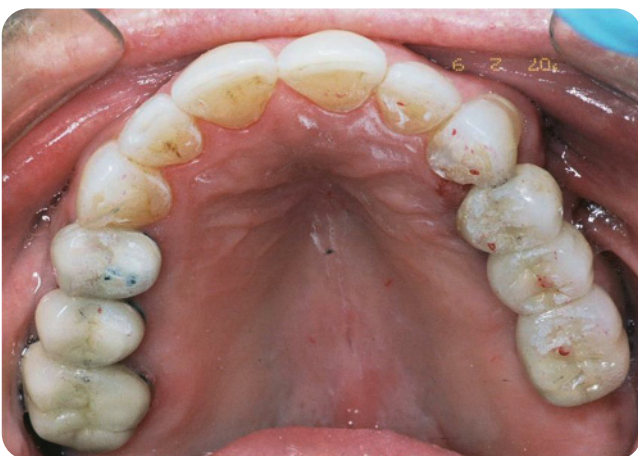

Figure A1.28c. Articulating paper marks on the installed maxillary prostheses; note how there is no timing or contact sequence discernible to the operator.

prosthesis is demonstrating mostly low force (blue) contacts. At this point in the patient self-closure, the left posterior 2-unit implant prosthesis has not yet begun to make contact. Finally, at 3.417 sec (Figure A1.29d), both the right and left posterior implant prostheses rise to low-moderate force levels (light blue) and maintain these reduced force levels into static intercuspation. The desired end point has been achieved as the anterior natural teeth reach near maximal occlusal forces prior to the initial force rise on the 3 different implant prostheses.

The definitive time delay is (3.417 sec [Static Intercuspation] – 3.081 sec [both implant prostheses in low-force contact]) = .336 sec.

Disclusion Time Reduction with Synchronized Electromyography to Physiologically Lessen Masticatory Muscle Hyperactivity during Excursive Function

The T-Scan III system can be linked through software integration with the BioPAK Electromyography System (BioResearch, Assoc., Milwaukee, WI) (Figure A1.30).²¹ The *T-Scan III/ BioEMG Integration Module* uniquely combines the simultaneous recording and display of tooth contact timing order and changing occlusal contact forces with masticatory muscle activity of up to 8 head and neck muscles. The synchronization of these two differing diagnostic and treatment computer programs allows the operator to record and play back their separate occluso-muscular data simultaneously.

Together, these two technologies allow the operator to analyze and correlate specific occlusal functional contact time and force moments to specific electromyographic changes that result from these same functional occlusal moments. Their combined desktops can be seen in Figure A1.31, which places the recorded occlusal function data beside the recorded electromyographic data.

The Time Line in the T-Scan III Force vs. Time graph is synchronized with a *Time Cursor* in the EMG playback window (vertical gray line) such that the displayed occlusal data and displayed electromyographic data are time-stamped exactly. Also the T-Scan III's Time Region Lines (the A, B, C, and D hyphenated lines) are superimposed over the corresponding EMG data so that an operator can ascertain the relationship of the changing muscle activity levels resultant from the key time regions within any mandibular functional occlusal movement.

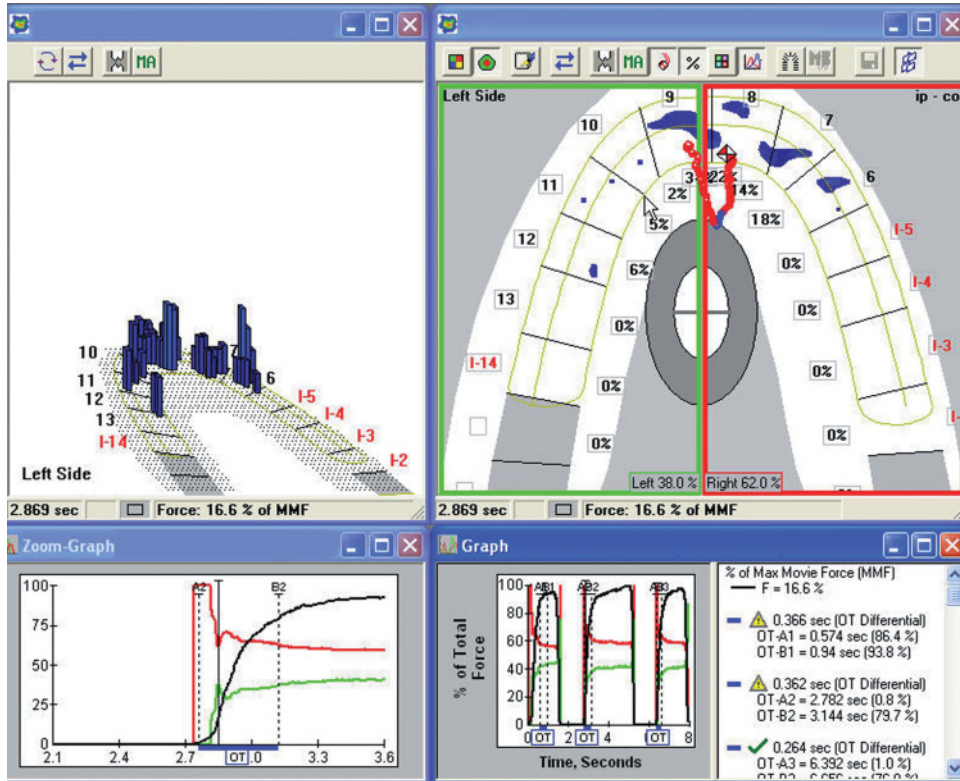


Figure A1.29a. Early closure contacts on only natural teeth.

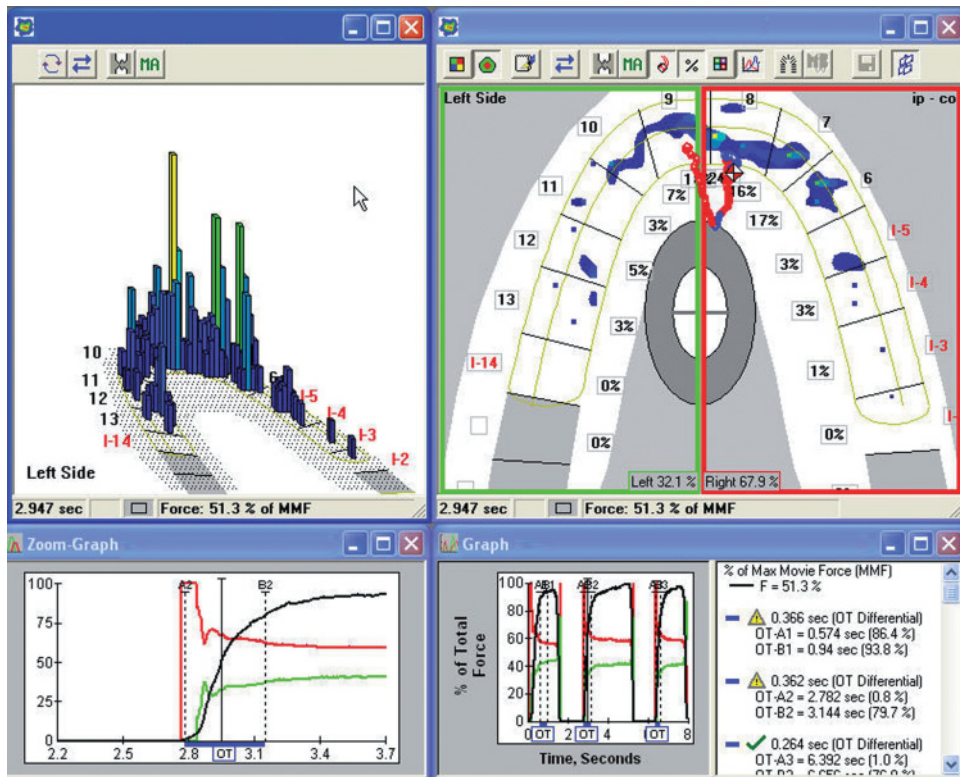


Figure A1.29b. Natural teeth reach near maximal contacts.

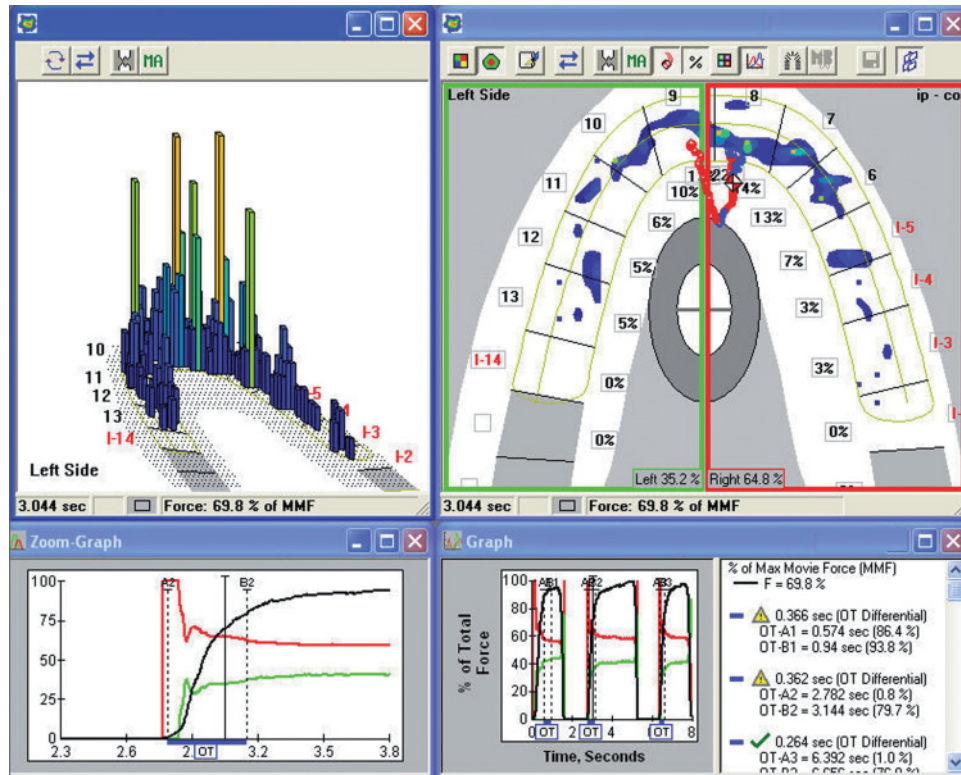


Figure A1.29c. Implant prosthesis begins to make low-force contact.

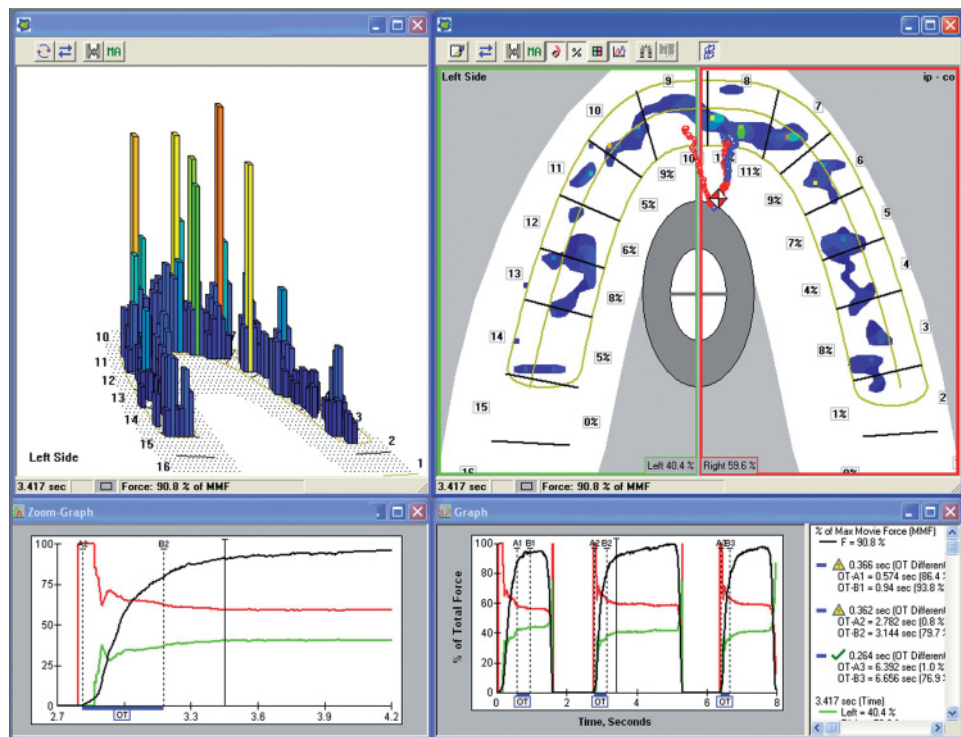


Figure A1.29d. Implant prosthesis in full contact at low—moderate force well after natural teeth reach near maximal contact.

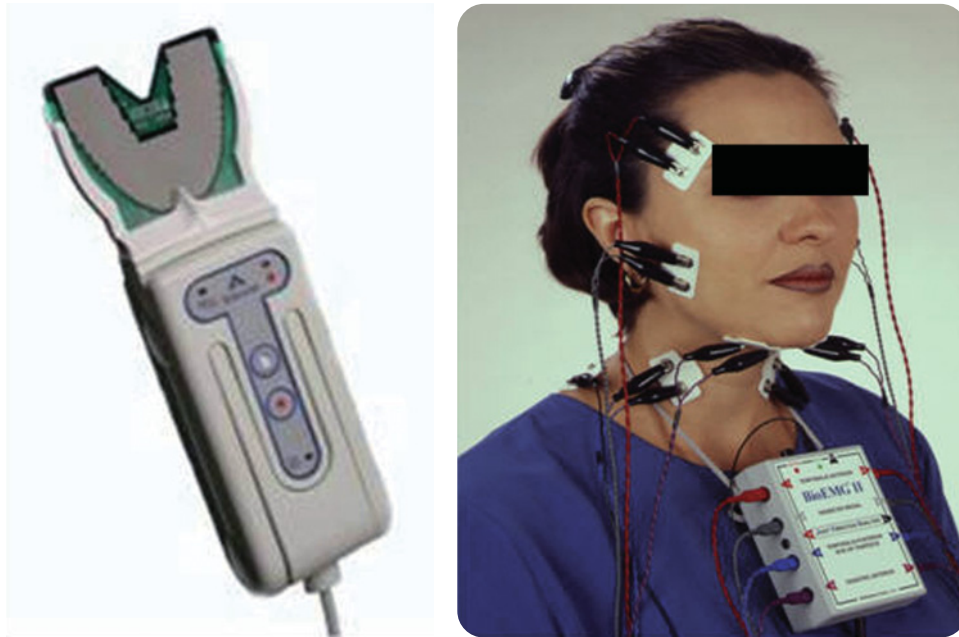

Figure A1.30. Patient with EMG leads placed on 8 head and neck muscles. The BioPAK EMG is synchronized with the T-Scan III such that their individual data is recorded simultaneously.

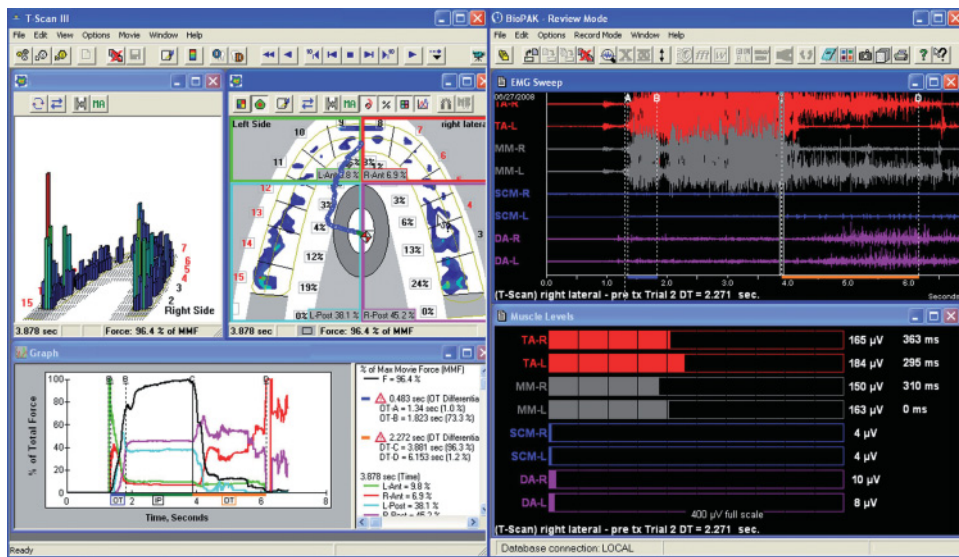


Figure A1.31. T-Scan III/BioEMG desktop.

BioPAK Electromyography System

The BioPAK electromyography system records electrical (biopotential) activity from eight muscles simultaneously. Bilaterally, the anterior temporalis, masseter, digastric, and sternocleidomastoid muscles, can be

measured. The operator can choose which muscle combinations are to be analyzed.

Surface EMG measurements are obtained by means of conductive adhesive gel-based bipolar electrodes. The electrodes are attached to the skin, over the

palpated main bulk of the contracted muscle, and oriented parallel to the general direction of the muscle fibers (see Figure A1.30). An IBM/PC-compatible computer (or Macintosh with Intel Processor) samples the individual muscular activity level signals sequentially through a USB interface at the rate of 1000–6000 samples per sec (with a resolution of 12 or 16 bits).

The T-Scan III system initiates the acquisition of both types of data when its recording function is activated. At the exact moment the T-Scan has begun recording, the BioPAK recording begins. While tooth contact sequences evolve and occlusal force data fluctuates, they are being recorded simultaneously with the changing muscle activity levels that measure the muscular response to the ongoing functional movement.²¹

In the Biopak EMG playback windows, the recorded electromyography data is displayed as a real-time EMG Movie that is time-stamped to the T-Scan III Movie. Two EMG playback windows are present: one that shows the recorded muscle activity in waveform (above) with a vertical time cursor that moves through the waveforms forward or backward. The other window below is a horizontal bar graph, which contains fluctuating bar lengths that illustrate the changing quantitative muscle activity levels in microvolts. Both the waveform and bar graphs can be played forward and backward continuously, or as .01 sec frames (non-Turbo Mode) or .003 sec frames (Turbo Mode), in stop-action, at the same time, and in the same manner as the T-Scan III Movie plays back.

An example of the combined use of the T-Scan III/ BioPAK EMG synchronization module can be seen in Figures A1.32 and A1.33. Figure A1.32a shows a complete group function present within a right excursion. Figures A1.32b–d illustrates the preoperative T-Scan/EMG data of a patient who demonstrates a right excursive movement with a prolonged Disclusion Time of 2.271 sec duration. This 32-year-old female patient has experienced chronic MPDS symptomatology over the past 10 years resultant from this prolonged disclusion (facial muscle pain, chewing fatigue, temporal headache, clenching and bruxing habits, morning jaw tightness, and pain).

Within the EMG data of Figure A1.32b, just to the direct right of C where the right excursion commences at the vertical Time Cursor, there is excursive muscle hyperactivity in the right temporalis and left masseter muscles while the left temporalis and right masseter

muscles demonstrate near resting levels of muscle activity (resting is <10 microvolts).

The observed elevated muscle activity in the right temporalis and left masseter muscles is caused by prolonged tooth socket compressions that occur when the patient's teeth stay in occlusal contact for too long as the excursion progresses. The longer the Disclusion Time, the longer the opposing occluding posterior teeth compress each other into their respective tooth sockets.³¹ Because of the unique neuroanatomy of the molar periodontal mechanoreceptors, which synapse directly with the muscles of mastication via afferents from the trigeminal motor nucleus,²⁵ prolonged tooth socket compressions can trigger an equally prolonged duration of elevated masticatory muscle contraction.³¹

Pretreatment, 1.024 sec into the right excursion after C (Figure A1.32c), the lack of disclusion continues to compress posterior teeth and contract the right temporalis and left masseter muscles. Both muscles here exhibit elevated activity levels that are well above resting state levels (140 uv and 110 uv, respectively). Later, just after D only the right canine is in contact. At this point 2.271 sec has passed since excursive commencement. Here the microvolt levels of the right temporalis and left masseter muscles begin to drop down to less than 40 microvolts (Figure A1.32d).

There is a long orange region along the x-axes of both the T-Scan graph and the waveform EMG data, indicating the presence of long preoperative Disclusion Time. As the excursion evolves with prolonged

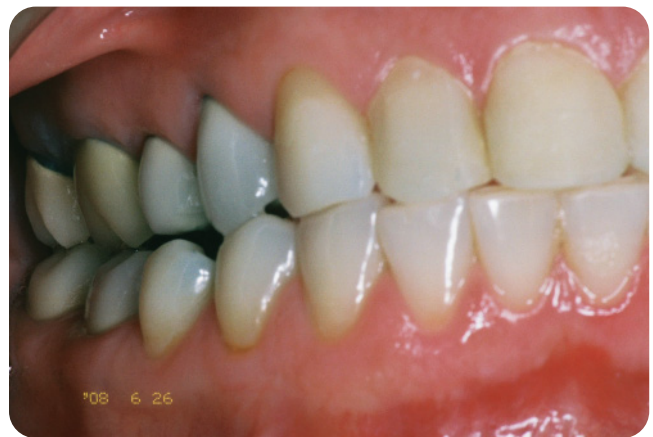

Figure A1.32a. Group function during right excursion.

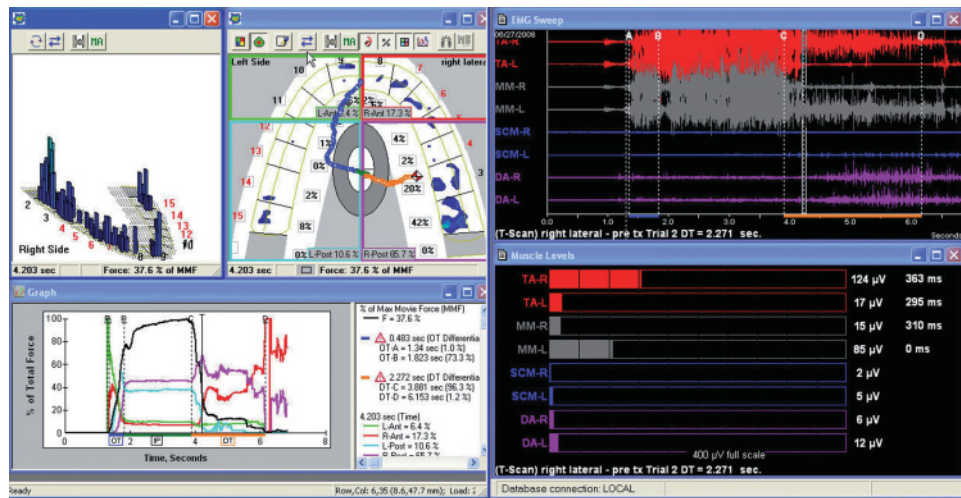


Figure A1.32b. T-Scan III/BioEMG desktop illustrating the presence of muscular hyperactivity when a right excursive movement is commenced by the patient presenting with prolonged Disclusion Time.

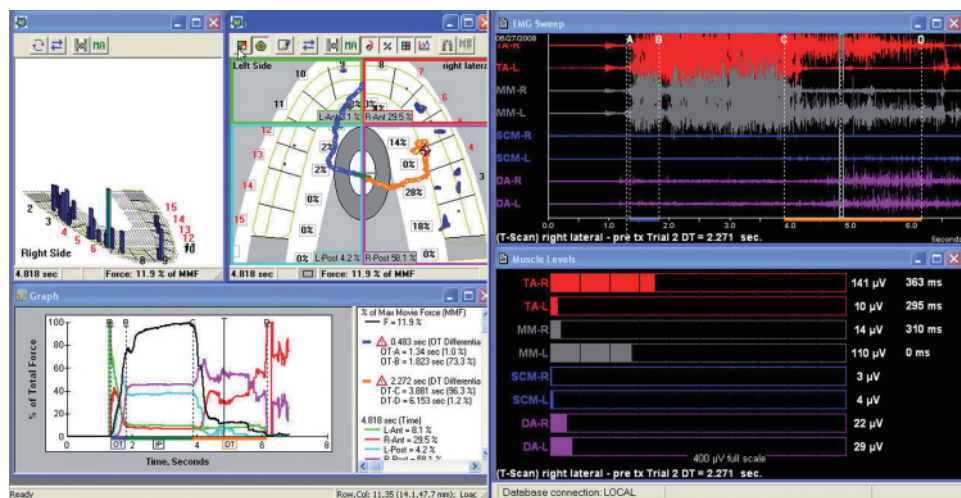


Figure A1.32c. T-Scan III/BioEMG desktop illustrating the presence of muscular hyperactivity during a right excursive movement.

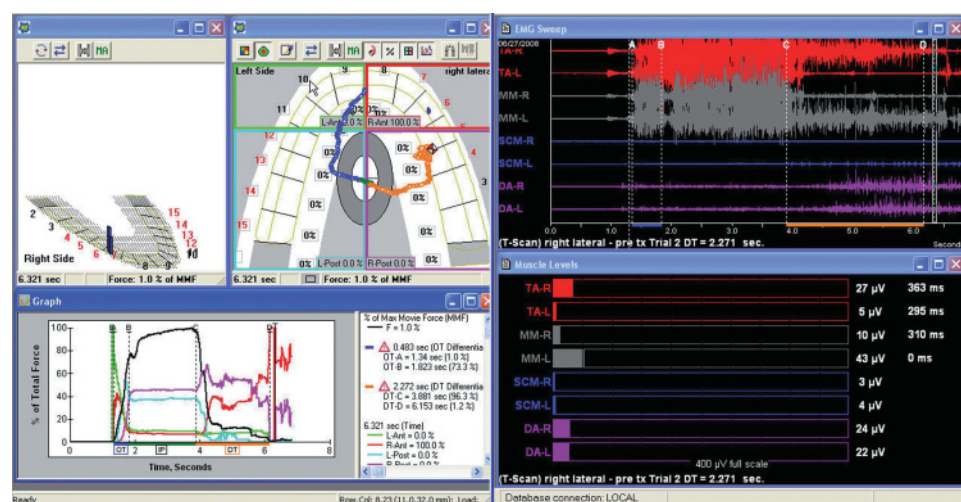


Figure A1.32d. T-Scan III/BioEMG desktop illustrating the lessening of muscular hyperactivity at the end of a right excursive movement when posterior teeth are finally discluded, leaving only canine contact.

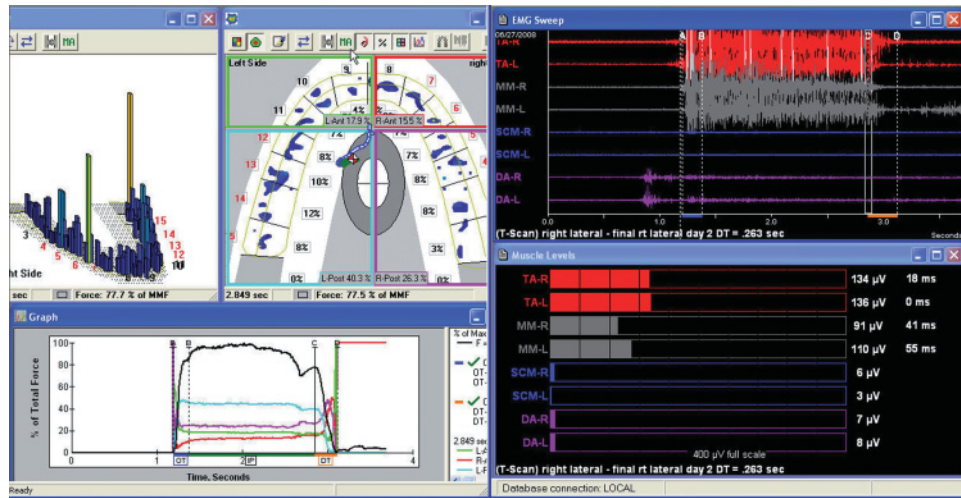


Figure A1.33a. T-Scan III/BioEMG data after preoperative long Disclusion Time has been shortened to .263 seconds; intercuspation ends and the right excursion commences at C.

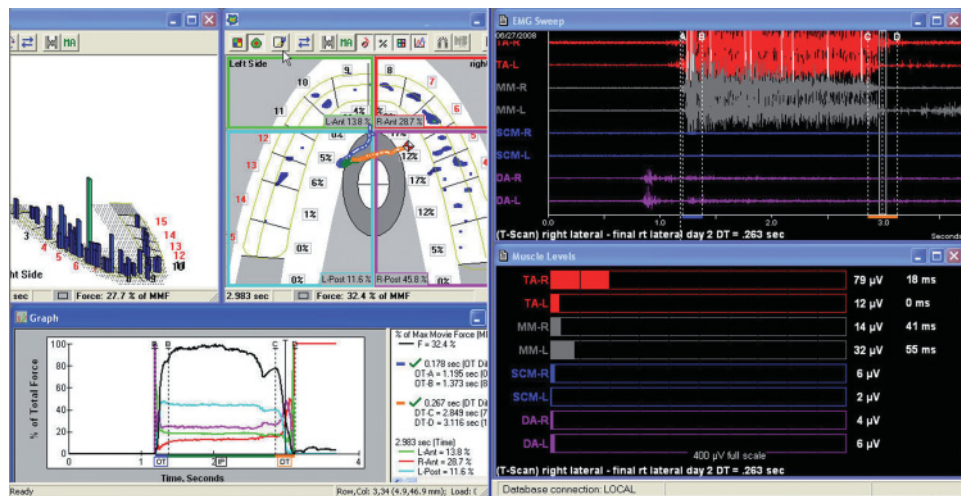


Figure A1.33b. T-Scan III/BioEMG data after preoperative long Disclusion Time has been shortened to .263 seconds; midright excursion after .127 seconds.

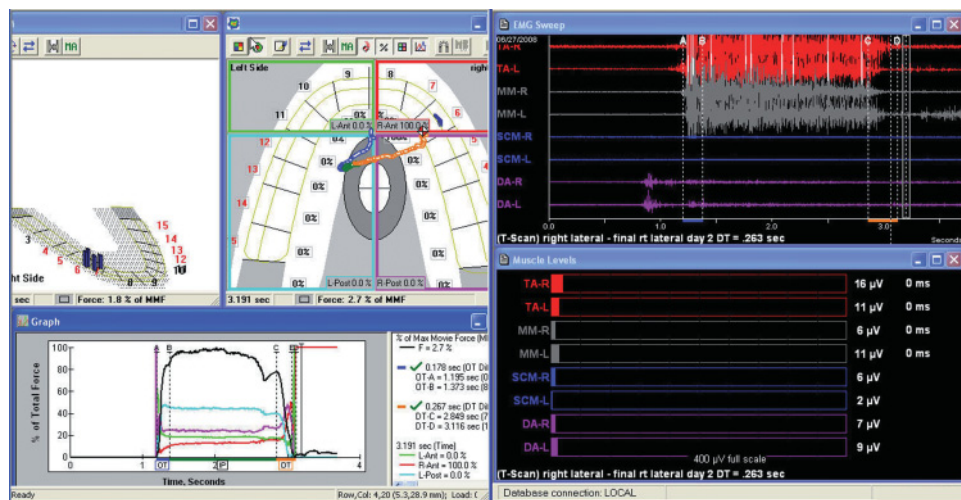


Figure A1.33c. T-Scan III/BioEMG data after preoperative long Disclusion Time has been shortened to .263 seconds; after D at muscle shutdown.

disclusion between C and D, the digastric muscles also contract above the resting state (22 uv and 29 uv). Much of this observed excursive muscle hyperactivity can be physiologically minimized by shortening the Disclusion Time, which directly shortens the posterior tooth socket compression time during the excursion, which in turn stops the periodontal ligament mechanoreceptors from firing the masticatory muscles for prolonged periods of time.

Shortening prolonged Disclusion Time is accomplished by performing the *Immediate Complete Anterior Guidance Development* enameloplasty procedure (ICAGD).^{14,17,29,31} The ICAGD enameloplasty primarily treats excursive tooth contacts present within the right, left, and protrusive movements that are commenced from a static intercuspatated patient self-closure. Only after the patient is measurably discluded (not visually) in all 3 directions ($DT \leq .4 \text{ sec/}$ excursion) are patient self-closure contacts adjusted and optimized by centering the COF and shortening its trajectory.^{29,31} ICAGD is not operator-guided because patients make all excursive movements from their intercuspal position, with their own speed and mandibular motion patterns. These significant procedural differences make ICAGD a very different occlusal adjustment procedure than is *Occlusal Equilibration*.^{4,24,31}

Figures A1.33a–c illustrates the shortened postoperative Disclusion Time of .263sec duration. Figure A1.33a shows the muscle activity levels at the end of patient self-intercuspatation just prior to commencing the excursion to the right. Figure A1.33b illustrates the early muscle activity level drops that occur after .127sec has elapsed within the corrected right excursion. Note that comparing Figure A1.33b to Figure A1.32b, in Figure A1.32b after 1.024sec into the excursion (10 times longer time-frame than is observed in Figure A1.33b) there are still very high muscle activity levels observed in the right temporalis and left masseter muscles. In Figure A1.33b, the muscle activity levels are significantly less in a time frame that is 10 times shorter. Finally, Figure A1.33c shows the muscle activity shutdown just after D in .335sec from excursive commencement. There is a drastically shorter C-D period than pretreatment depicted by a very short orange segment along the x-axes of both the T-Scan graph and waveform EMG data. Note that there is no elevated digastric muscle activity present within the excursion posttreatment.

Postoperatively, just to the right of the vertical EMG Time Cursor posttreatment at D (2.866sec), the right temporalis and left masseter muscles “flatline,” indicating very low resting state levels are reached rapidly resultant from the short Disclusion Time. This observed muscular effect occurs because of the dramatically shortened compression time of the posterior tooth sockets of the treated contacting opposing posterior teeth. Rapid muscle shutdown during excursive functional movements is the therapeutic action of shortening the pretreatment prolonged Disclusion Time to $<.4 \text{ sec}$.¹⁴

Treating a Problematic HFP Pattern with Computer-Guided Force Corrections

In an HFP recording, as the patient taps the teeth together repeatedly, the COF trajectory repeats itself. This creates an overlapping trail of many COF trajectories by which a repetitive pattern of force transmission within the arches can be observed.

Corrections to these repetitive patterns will decompress the repeatedly overloaded involved teeth and share forces over more teeth, thereby reducing the potential for long-term occlusal force damage. These corrections are guided by the 3-D columnar force data that correlates to the repeating COF trajectories within the 2-D window.

Figures A1.34a and b show a patient who demonstrates excessive wear on the lower right 1st and 2nd molars resultant from a long-standing preoperative repeating posterior right HFP pattern (Figure A1.35). This preoperative COF repeatedly favors the midposterior right quadrant while the 3-D columnar window illustrates that the 1st and 2nd molar teeth repeatedly demonstrate high force concentrations. The 2-D window shows that the 1st and 2nd molars contain 34% and 28% of the right side total force, respectively, with an HFP arch-half force imbalance of 81% right–19% left.

The corrected postoperative HFP required 6 recording and adjustment sequences to complete. Figure A1.36 shows a repeatedly shared bilateral force pattern where the COF stays centered between the right and left arch-halves and travels anteroposteriorly along the midline of the 2-D window. This corrected pattern of force transmission shares forces between both arch-halves, is spread out over many more teeth, and demonstrates a very small .5% HFP arch-half force imbalance of 49.5% right–50.5% left.

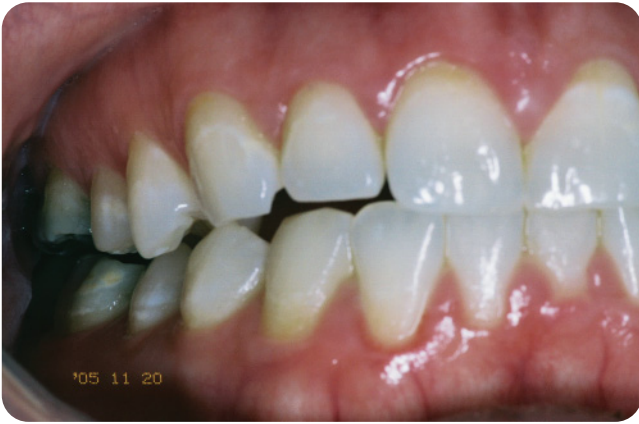

Figure A1.34a. Facial view of HFP patient.

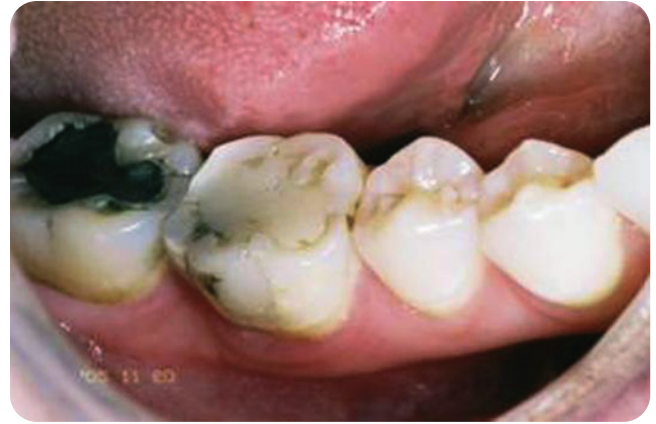

Figure A1.34b. Observable wear on the mandibular right teeth affected by the noncentered right posterior HFP pattern.

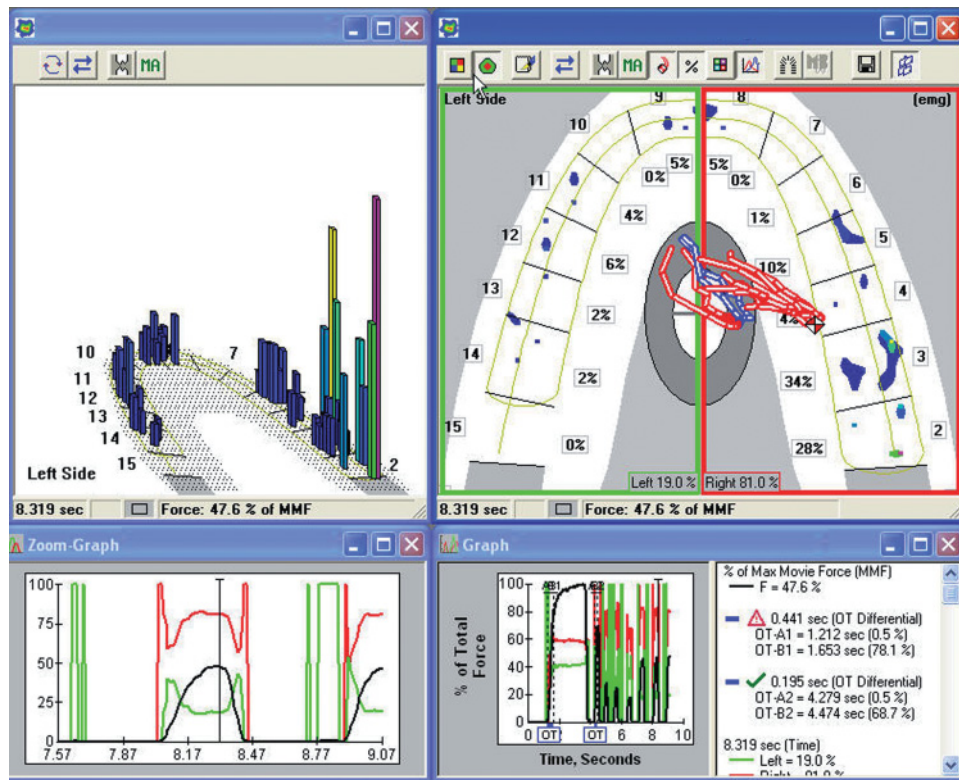


Figure A1.35. Noncentered posterior right HFP pattern with 3-D view showing excessive force in the 1st and 2nd molar region.

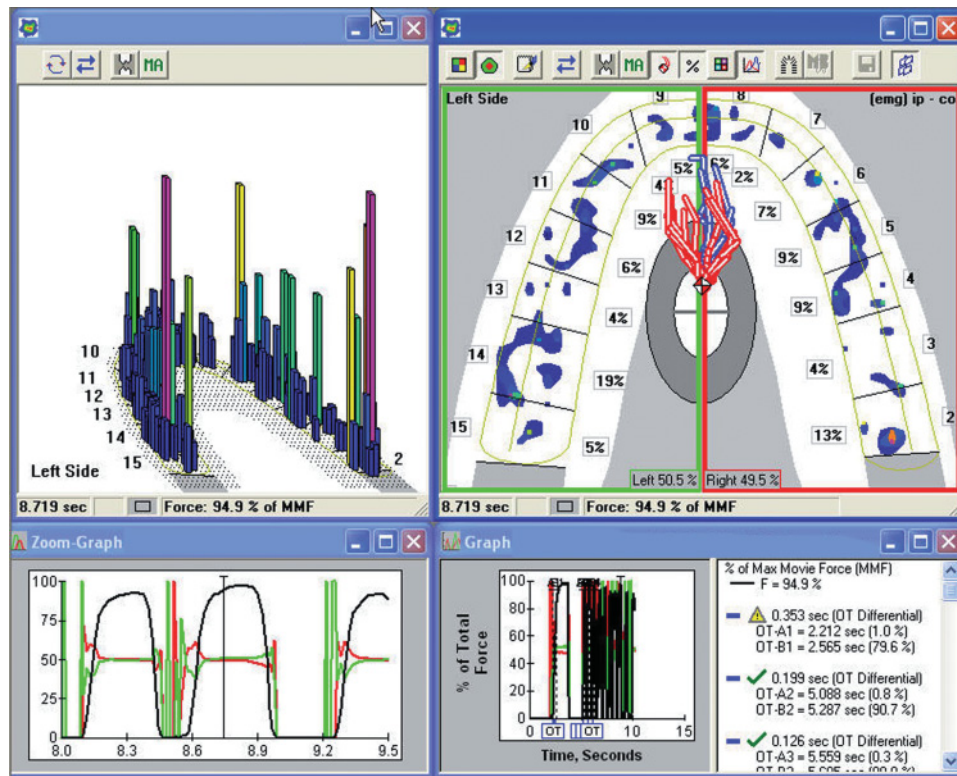


Figure A1.36. Postoperative corrected and centered HFP pattern.

Summary

Computerized occlusal analysis technology displays for clinical interpretation, tooth contact timing order in .003sec increments, while simultaneously measuring and displaying each tooth contact's fluctuating relative occlusal force levels that occur during functional jaw movements. The displayed occlusal time sequence and force data aids in the examination and treatment of occlusal abnormalities on natural teeth, dental prostheses, and dental implant prostheses. Time- and force-based computer-guided occlusal corrections can measurably optimize an occlusal scheme to known physiologic occlusal end points that can enhance patient occlusal comfort, improve occlusal force characteristics throughout the dental arches, and aid in dental material and dental implant longevity.

Numerous clinical applications of computerized occlusal analysis have been detailed in the dental literature since 1990. Those that have been described within this chapter are the computer-guided occlusal management of Centric Relation, overall occlusal force balance and arch-half force equality, mandibular excursive function, dental implant force and timing control, and patient habitual occlusal force pattern improvements.

Additionally, computerized occlusal analysis software can be linked to electromyography software so that together, they can simultaneously record the occlusal function and the muscular response to that occlusal function of up to eight head and neck muscles. This combination of measured occlusal contact force and time data, when paired with functional muscular electromyographic data, illustrates to an operator detailed, precise, and unparalleled diagnostic and treatment information with which to treat many differing clinical occlusal conditions and dysfunctional pathologies.

References

1. Kerstein RB. Current applications of computerized occlusal analysis in dental medicine. *Gen Dentistry*. 2001 49(5):521–530.
2. Maness WL. Computerized occlusal analysis, Hi-Tech, Hi-Care. *Dentistry J*. 1993. August Vol. 59, No. 8.
3. Montgomery M, Kerstein RB. Mapping occlusal forces on rebuilt anterior guidance. *Contemporary Esthetics* 2000 4(4):68–72.
4. Kerstein RB, Wilkerson D. Locating the centric relation prematurity with a computerized occlusal analysis system. *Compend Contin Educ Dent*. 2001 22(6):525–532.

5. Saad MN, Weiner S, Ehrenberg D, et al. Effects of load and indicator type upon occlusal contact markings. *J Biomed Mater Res B Appl Biomater.* 2008 85(1):18–22.
6. Millstein P, Maya A. An evaluation of occlusal contact marking indicators descriptive quantitative method. *J Am Dent Assoc.* 2001 132(9):1280–1286.
7. Reiber T, Fuhr K, Hartmann H, et al. Recording pattern of occlusal indicators, influence of indicator thickness, pressure, and surface morphology. *Dtsch Zahnarztl Z.* 1989 44(2):90–93.
8. Carey J, Craig M, Kerstein RB, Radke J. Determining a relationship between applied occlusal load and articulation paper mark area. *Open Dentistry J.* 2007 1:1–7.
9. Carossa S, Lojaco A, Schierano G, Pera P. Evaluation of occlusal contacts in the dental laboratory: Influence of strip thickness and operator experience. *Int J Prosthodont.* 2000 13(3):201–204.
10. Saraço lu A, Ozpinar BJ. In vivo and in vitro evaluation of occlusal indicator sensitivity. *J Prosthet Dent.* 2002 88(5):522–526.
11. Gazit E, Fitzig S, Lieberman MA. Reproducibility of occlusal marking techniques. *J Prosthet Dent.* 1986 55(4):505–596.
12. Kerstein RB, Lowe M, Harty M, Radke J. A Force reproduction analysis of two recording sensors of a computerized occlusal analysis system. *J Craniomandibular Pract.* 2006 24(1):15–24.
13. Kerstein RB, Grundset, K. Obtaining Bilateral simultaneous occlusal contacts with computer analyzed and guided occlusal adjustments. *Quintessence Int.* 2001 32:7–18.
14. Kerstein RB, Wright, N. An electromyographic and computer analysis of patients suffering from chronic Myofascial Pain Dysfunction Syndrome; pre- and post-treatment with immediate complete anterior guidance development. *J Prosthet Dent.* 1991 66(5):677–686.
15. Kerstein RB. Computerized occlusal management of a fixed/detachable implant prosthesis. *Pract Periodontol Aesthet Dent.* 1999 11(9):1093–1102.
16. Kerstein RB. Nonsimultaneous tooth contact in combined implant and natural tooth occlusal schemes. *Pract Periodontol Aesthet Dent* 2002 13(9):751–756.
17. Kerstein RB, Chapman R, Klein, M. A comparison of ICAGD (Immediate Complete Anterior Guidance Development) to mock ICAGD for symptom reductions in chronic Myofascial Pain Dysfunction Syndrome patient. *J Craniomandibular Pract.* 1997 5(1):21–37.
18. Kerstein RB. Treatment of Myofascial Pain Dysfunction Syndrome with occlusal therapy to reduce lengthy Disclusion Time—A recall study. *J Craniomandibular Pract.* 1995 13(2):105–115.
19. Kerstein RB. Disclusion Time measurement studies: Stability of Disclusion Time. A 1-year follow-up study. *J Prosthet Dent.* 1994 72(2):164–168.
20. Kerstein RB. Disclusion Time measurement studies; Part 2: A comparison of Disclusion Time length of 49 chronic Myofascial Pain Dysfunction Syndrome patients to 40 non-patients. A population analysis. *J Prosthet Dent.* 1994 72(5):473–480.
21. Kerstein RB. Combining technologies: A computerized occlusal analysis system synchronized with a computerized electromyography system, *J Craniomandibular Pract.* 2004 22(2):96–109.
22. Kerstein RB, Radke J. The effect of Disclusion Time reduction on maximal clench muscle activity level. *J Craniomandibular Pract.* 2006 24(3):156–165.
23. Kerstein RB. Bruxism (Maciel Roberto Nascimento) Tek Scan—Computerized Occlusal Analysis. The T-Scan System. Brasil, SP: Editor Artes Médicas. 2010. Chapter 11:295–322.
24. Dawson, PE. *Functional Occlusion: From TMJ to Smile Design.* Vol. 1. 2007. Mosby, Inc., St. Louis, MO.
25. Haines DE. *Neuroanatomy; An Atlas of Structures, Sections, and Systems.* 5th Ed. 2000. Lippincott, William and Wilkins, Baltimore, MD. pp. 175, 193.
26. Kerstein RB, DuPont, G. Anterior guidance and muscle function. *Contemporary Esthetics.* 2001 8(2):96–109.
27. Makofsky, HW. The influence of forward head posture on dental occlusion, *J Craniomandibular Pract* 2001 18(1):30–39.
28. Kerstein RB. Adhesive aesthetic occlusal case finishing employing computerized occlusal analysis. *AACD Monograph.* 2005 2:17–22.
29. Kerstein RB. Disocclusion time-reduction therapy with immediate complete anterior guidance development to treat chronic myofascial pain-dysfunction syndrome. *Quintessence Int.* 1992 23(11):735–747.
30. Stevens, C. Computerized occlusal implant management with the T-Scan II System. *Dentistry Today.* 2006 25(2):88–91.
31. Kerstein RB. A comparison of traditional occlusal equilibration and immediate complete anterior guidance development. *J Craniomandibular Pract.* 1993 11(2):126–140.
32. Kerstein RB. Computerized occlusal analysis technology and Cerec case finishing. *Int J Computerized Dent.* 2008 11(1):51–62.
33. Koldslund OC, Scheie AA, Aass AM. Prevalence of implant loss and the influence of associated factors. *J Periodontol.* 2009 80(7):1069–1075.
34. Astrand P, Ahlqvist J, Gunne J, Nilson H. Implant treatment of patients with edentulous jaws: A 20-year follow-up. *Clin Implant Dent Relat Res.* 2008 10(4):207–217.
35. Nixon KC, Chen ST, Ivanovski S. A retrospective analysis of 1,000 consecutively placed implants in private practice. *Aust Dent J.* 2009 54(2):123–129.
36. Kaptein MLA, DePutter C, Delange GL, Blijdorp, PA. A clinical evaluation of 76 implant supported superstructures in the composite grafted maxilla. *J Oral Rehab.* 1999 26:619–623.
37. Kurashima, K., Viscoelastic properties of periodontal tissue. *Bull Tokyo Med Dent Univ.* 1965 12:240.
38. Sekine H. Mobility Characteristics and tactile sensitivity of osseointegrated fixture-supporting systems. In Van Steenberg D, ed. *Tissue Integration in Oral Maxillofacial Reconstruction.* Elsevier, Amsterdam. 1986: 306–332.

Appendix 2

What Your Laboratory Technician Needs to Provide Excellence

Jerry Ulaszek, C.D.T.

The relationship necessary between the dentist and the dental laboratory is dependent upon the level of dentistry to be performed. If the dental office is performing single-tooth dentistry, the dental laboratory relationship needs only to be a commodity restoration provider, a low-cost, fast-turnaround producer. In this type of practice the dentist's fees are usually dictated by a third party and the laboratory restorations need to meet a minimum standard in both price and quality for the profession. These dental practices are usually based on high patient volume with little relationship between the doctor and patient. Many patients will leave the dental office if their insurance plan is no longer accepted.

In the late 1960s dental insurance allowed \$2,000 per year for patient dental coverage. Fifty years later dental insurers allow the same coverage, and many offer less. This type of dental insurance coverage will only allow for dentists to provide commodity dental restorations. If you make your choice of dental laboratories based upon a restoration costing less, you made a decision on the level of your practice. The question you need to ask yourself is "are you truly happy with the dentistry you provide and the business model of your practice?" It is your practice—is this how you want to work?

If you aspire to reach a higher standard for yourself and the dental care being provided to your patients, you need to be able to make choices that will allow you to deliver that higher standard. The dental laboratory you choose is an integral part of your team. Your laboratory needs to be able to perform at the same

level as you, your staff, and your team of specialists. The more comprehensive the dental practice, the higher the level of skill sets and communication the teams need to function well.

There are differences in skill levels in all specialties, but continuing education and communication can overcome many of our deficiencies. If we know what we are trying to achieve, it is a lot easier to identify roadblocks to our success and ultimately to quality patient treatment and satisfaction. At the L.D. Pankey Institute and from Dr. Peter Dawson, I learned that our dental career is a journey. If we always want to improve ourselves, we can never be totally satisfied with our current level of dentistry. This profession has treated me and many of the dentists I work with very well.

The Relationship between the Dentist and Dental Laboratories

The explosion of material choices, increased technology, and a shrinking pool of formally trained dental technicians have forced all dentists to work with larger laboratories or multiple smaller specialty laboratories—and many times on the same case—if they want to offer cutting-edge restorations. There are very few laboratories that can afford all the new technologies available today. The smaller the laboratory, the more that lab will need to outsource a portion of your restorations to be able to fill your prescription. It is my opinion that your choice of dental laboratories and your relationship with them will be a deciding factor in how much you enjoy dentistry. Your dental laboratory will have a bigger impact, positively or negatively, on your practice than all the other dental specialists you utilize.

I know of many dental laboratories that are afraid to call the dentist and explain why the case they received

will be compromised if the restoration is constructed on the models/impression received. I have had dentists respond with “send everything back, I’ll send it to another lab.” This scenario sets us up for frustration, failure, and a blocked path to high-level dentistry. The dentist and laboratory need to be able to communicate without fear. In doing so we learn from each other as to what is needed to reach top-tier dentistry. Dentists need to explain why there are biological limitations and roadblocks to perfection. The laboratory needs to explain what the consequences of those limitations are to the overall appearance or function of the case. No matter how skilled the dentist or laboratory, our success will be limited unless we both are on the same journey to top-tier dentistry. Once we get on the same path and both work for the same goal with mutual expectations and respect, our success rate will be extremely high, and dentistry will become very rewarding.

The Dentist’s Role in Predictable Dental Restorations

In this chapter I explain what you need to provide to your dental laboratory so that they can provide you with predictable functioning dental restorations—no matter how simple or complex the case.

The main point that you need to remember is that most laboratory technicians will not meet your patient. You are asking them to fabricate a dental appliance for a patient who may have a significant emotional opinion about the final restorative aesthetic outcome. It is the dentist’s responsibility to provide the laboratory the information needed to complete the final restoration and meet the expectations of the dentist and patient. The dentist must identify the patient’s desire for perfection and develop the treatment plan accordingly. There are times that what may seem like a simple change request may result in the laboratory having to scrap the restoration and start over. One example may be changing the incisal edge position to a more lingual position. The dental laboratory deals in tenths of millimeters. All of our materials’ optical properties are layered in very small increments. The substructure to support the porcelain was designed to be in a precise position. Moving the incisal edge position lingually will result in the thinning of the veneering material, violating the optical light-scattering properties of the ceramic material and thus result in a nonvital restoration. In this scenario, to achieve the desired shade, the veneering material will need to be removed, the substructure modified, and the veneering material reapplied.

Depending upon the size of the restoration and complexity of the restoration, this procedure may require the dental technician days to complete.

One of the frustrations/disappointments facing the dentist-dental technician team is seeing detailed craftsmanship adjusted away. How many times have we wondered why this happened? There are as many reasons why restorations need adjustment as there are different mouths and occlusal schemes. After over 30 years as a dental technician, I am still amazed that most restorations fit with minor to no alterations. Four shape transfers utilizing five different materials, transforming the restoration process from positive to negative shapes prior to the porcelain application—each one of these materials has its own expansion and contraction percentages along with precise handling characteristics.

When all of these steps are performed correctly, there remains one more critical step: *placing the restoration in the mouth*. This last step defines what we do. It really doesn’t matter how well the restoration fits and functions on the articulator. What really matters is how it fits and functions in the mouth. So now the restoration is seated, and the margins and interproximal contacts are checked and fit with precision. We have one more step: asking the patient to close into intercuspation. The larger the restorative case, the more anxiety there is with this step. The result of this last step, the occlusion/function step, is the culmination of all our communication and training.

Impression Materials

All the impressions we receive today for fabrication of dental restorations are taken in either vinyl polysiloxane or polyether impression material. Both of these materials perform extremely well when instructions are followed correctly. Many of the problems with impressions come from the handling of these materials in the dental office. As a means toward making the impression-taking procedure as comfortable to the patient as possible, many dental offices choose a fast-setting impression material. Although this choice may shorten the amount of time the patient has the impression material and tray in their mouth, it also shortens the amount of working time the dentist has available to seat the impression prior to the setting property of the material beginning. In most situations this may cause no effect. However, there are many situations where atmospheric conditions alter the setting times, and the office may not adjust to correspond to those conditions.

SEASONAL CHANGE AND MATERIAL STORAGE

Room temperature fluctuations can be caused by seasonal changes. If your impression material is stored in a cabinet that is attached to the outside wall of your building, the impression material stored inside that cabinet will be affected by seasonal changes. If the cabinet's temperature is higher than your normal operator's working temperature, the setting time of the impression material will be shortened. This situation causes everyone to rush the impression-taking procedure. If you notice that the impression material is beginning to set up, it is too late to use it. I have never read in any impression material instructions the statement, "if the impression material begins to set up, work faster!"

If the temperature of the cabinet is lower than your normal operator working temperature, there will be a delayed setting time due to the impression material being cooler than normal. This situation could cause the impression to be removed prior to its final and stable set. Summer to winter temperature changes will cause the cabinet's temperature to change and effect the setting time.

TIME-OF-DAY EFFECTS

If the wall that the cabinet is mounted on is in direct sunlight in the morning, the morning temperature/setting time will be different than the afternoon. Does the temperature in your operator or the area where your impression material is stored change during the day by a noticeable amount? Temperature change will have an effect on the setting times. If you alter the office temperature during the evening and weekends in an effort to conserve energy, the impression material may be cooler or warmer depending upon the season.

If the impression material becomes distorted due to one of these factors, there is no way you can visually determine that the impression is distorted. My suggestion is to maintain as constant a temperature as possible with all your impression materials. Placing the impression material in the refrigerator during warm months will increase your working time. I also suggest using a timer so that you or the dental assistant does not remove the impression earlier than the instructions state.

THE IMPRESSION TRAY "HAND-OFF"

This is a technique that has ruined and distorted more impressions than all other errors. After placing the impression, many dentists hand off the holding proce-

sure to the dental assistant or even the patient during the setting period. No two people will place the same amount of pressure in the same area of the tray every time. Any change in pressure will cause the impression tray to move. Movement and change of pressure during the setting period will cause distortions in the impression.

For more accurate impressions, try these tips:

1. Control the oral fluids. This is the most important step.
2. Use a light-body syringable material with a heavy body tray impression material combination.
3. Choose an impression material with a longer setting time.
4. Use a timer to ensure that you consistently follow the manufacturer's recommended setting time.
5. If your operator becomes warm during periods of the year, store your impression material in the refrigerator; this slows the setting time.
6. Do not transfer the holding of the tray during the setting period.

Bite Records

Be very aware of the accuracy of the bite relationships records sent with the case. Bite records are probably one of the most overlooked steps in the restorative process. A slight deviation in the arch-to-arch relationship can have devastating consequences. There are a number of anatomic features that technicians can use to aid them in setting the bite relationship, but the most important anatomical feature technicians never have is the patient's condyles. That simple hinge movement that the mandible makes with fully seated condyles does not exist in the laboratory. Dental technicians have two casts that can fit together in a multitude of ways. Without condyles, technicians cannot orient casts as easily as the dentist manipulates dental arches. The solid bite that the patient demonstrates to you has the benefit of all the remaining teeth and two condyles. The technician sometimes has only two posterior quadrant models with one or more of the teeth prepped. If the bite record we receive is incorrect and we can determine it is incorrect, how is the laboratory going to establish the tooth-to-tooth and arch-to-arch relationship?

When taking jaw relationship records you need to use only enough bite material to allow yourself and the laboratory to stabilize the models for articulation. We need to be able to visually determine whether the jaw relationship is incorrect prior to the patient leaving and

affixing the casts to an articulator. If too much bite registration material is used, you cannot visually determine whether the patient has correctly closed into maximum intercuspation. Too much bite registration material will cover the facial surfaces and obscure your view.

The reverse is also true: too little bite registration material may be insufficient to stabilize the casts for accurate mounting.

So, what is the correct amount of bite registration material? It varies with each patient. You need to use the following criteria to determine the appropriate amount (Figure A2.1). Ask yourself these questions:

1. How many teeth will be in the impression or present on the casts? The more teeth present, the less bite material needed.
2. How many teeth are prepared for restorations? Prepped teeth do not occlude, so these teeth need bite registration material on them.
3. What is the condition of the remaining unprepped teeth? Broken-down teeth give us less information to use in determining jaw relationships.
4. What is the reason for mounting the casts? Are we mounting in centric relation or maximum intercuspation?

Use only enough bite material to allow yourself and the laboratory to stabilize the models for articulation.

The bite record material needs to be noncompressible. If the casts do not have a solid terminal stop, the bite record could be compressed during articulation and cause the models to be rocked on the remaining solid cast area.

Shade Selection

The selection of a tooth shade can often confuse many dental offices. On many occasions the shade the office originally selected and matched by the dental laboratory is discovered to be incorrect when the restoration is placed in the mouth. There are many reasons why this error may have occurred; the reasons vary from office to office. Something as simple as the color of the scrubs worn during the shade selection process can affect the final outcome.

When we talk about selection of tooth shades, we are actually discussing color perception and color communication. You may be able to pick a perfect shade, but if you are unable to accurately communicate that shade to the laboratory, your results will be compromised. The laboratory I own is located in Illinois. In our state, laboratory technicians are able to have the patient come to the laboratory with a pre-

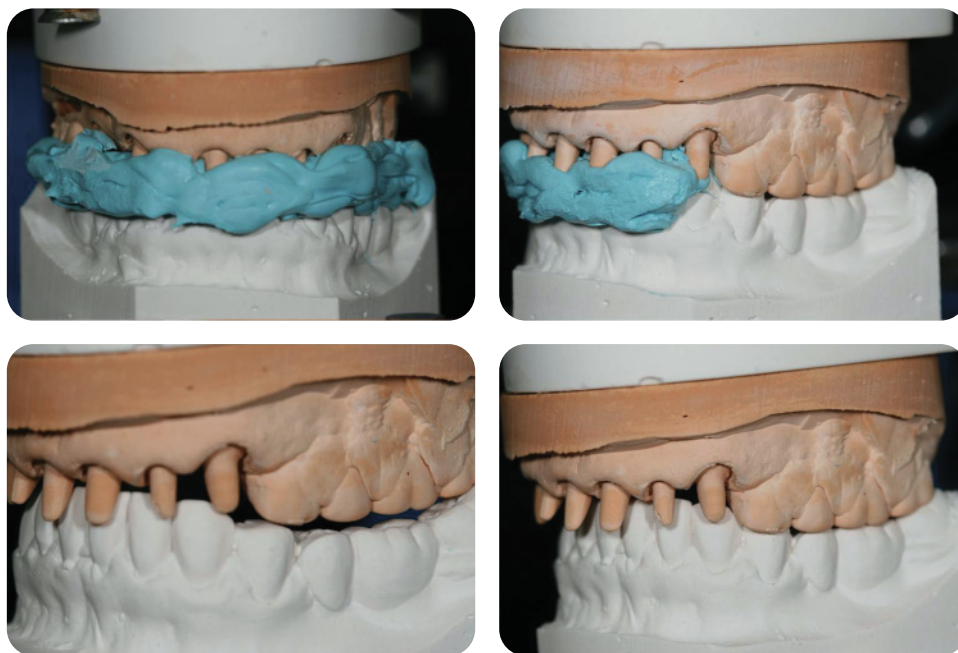


Figure A2.1. When too much bite registration material is used, you cannot verify that the patient is biting in the correct position. In the bottom left photo, the patient was biting in a left lateral protrusive position, but you are unable to notice this because of the excessive bite registration material. While watching key anterior and/or posterior reference points, have the patient close to the MI position. Then use only enough bite registration material necessary to record the bite. While the patient is closing onto the bite registration material, be sure he/she closes to the same MI position using your reference points.

scription from a licensed dentist for shade selection. Our shade selection procedure uses multiple methods of communication (I discuss these later) and multi-trained, color-tested technicians. Our selection process takes 45 minutes. After the restoration is completed and prior to the patient going to the dental office for delivery, we ask the patient to come back to the lab for a final shade check, and then we perform any additional shade adjustments.

I do not know of any dental office that goes through as rigorous a routine for shade selection. Many times the shade selection is a last-minute procedure. If you are going to reach for a higher level of success, your shade selection procedure needs to be as detailed and precise as all your other procedures.

THE INFLUENCE OF THE ENVIRONMENT ON SHADE SELECTION

Color recognition is the result of light reflecting off an object. The objects in our field are teeth. It stands to reason that any color introduced into the environment where the teeth are being color selected will have an effect on the final outcome. There are many operatories that have a dominant color. For example, walls or wall coverings that have a red, orange, green, or any other color where a strong chroma is present will influence the color of the object being viewed. How the tooth is affected is a process called a *matameric effect*. Simply stated, an object's color changes in different environments where the lighting and colors present are different.

COLOR OF CLOTHING, GLOVES, AND PATIENT BIBS

The color of the scrubs you and your staff wear and the color of the patient bibs will influence the shade selection process (Figure A2.2). Because color is the reflected light, any color present in the operatory,

including those worn by you and your staff, will have an influence on the perceived color. If on the day of shade selection you wear maroon scrubs and the day of delivery you wear yellow scrubs, you create a matameric effect on the restoration. This restoration will not be an exact match. You and your staff's colored clothing may have an aesthetic appeal to the patients. However, these colors need to be neutralized prior to selecting a tooth shade.

TIME-OF-DAY EFFECTS

The amount of light and angle of the sunlight in the operatory will also have an effect. Have you ever taken a shade when there was too much light? The effect is the same as using too much flash in a photo—the colors wash out. Indirect sunlight at 6500 degrees Kelvin is the best for shade selection. It is not practical to use a light meter and adjust the lighting at every shade appointment to reach 6500 degrees. To get the most natural daylight on the tooth, use color-corrected bulbs with a color rendering index (CRI) number above 90. A CRI number of 90 is a rating indicating that the bulb's illumination is 90% of natural daylight facing north at noon in Washington D.C. I have found that most operatories do not have enough lighting or the correct lighting.

SHADE-TAKING ABILITY

Have you and your staff been tested for shade perception? Women are much better at matching shades than men. Many men have a weakness in shade perception, with the color red being the most common. There are many tools available that test a person's ability to recognize shades. Patients' aesthetic demands have risen to an almost unachievable expectation. Matching a single central incisor has always been difficult, but now it is extremely demand-

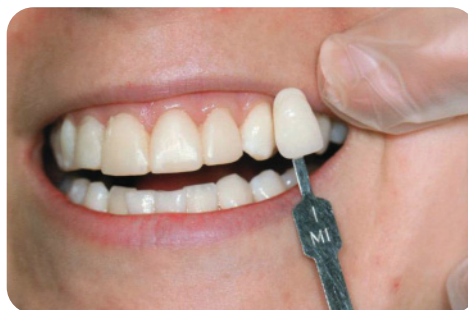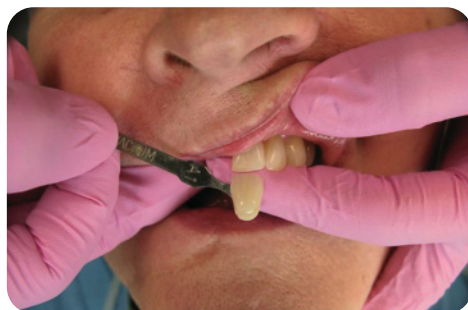


Figure A2.2. Environmental effect: The pink gloves surrounding the tooth and held directly behind the tooth alter the selection process. There is no way that you can predictably select a shade with this method. The photo with the clear or neutral glove does not alter the tooth being matched.

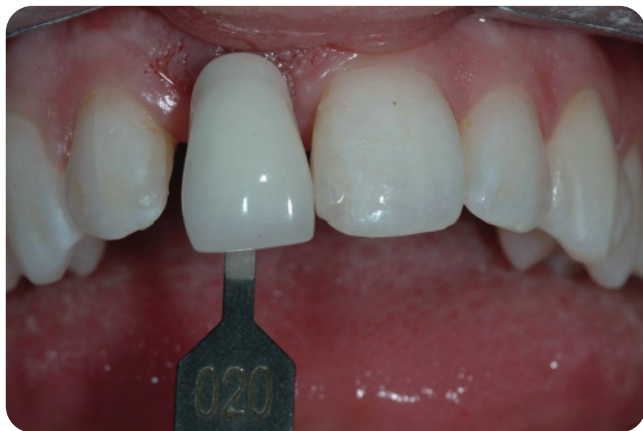

Figure A2.3. Very good shade photo: The shade tab is on the same plane as the tooth being matched, with the numbers and letters visible. The dental ceramist can make a comparison between the natural tooth and the shade tab and adjust the build-up technique.

ing. If you or someone on your staff selects the shades, you should conduct a color perception test so you know that you are starting the procedure with someone who can see color correctly (Figure A2.3).

COMPONENTS OF COLOR

Hundreds of books have been written about color. As mentioned earlier, there are three basic components of color: hue, chroma, and value. *Hue* is the actual color: red, blue, yellow, and so forth. *Chroma* is the intensity of the color; dark blue has a higher chroma than light blue. *Value* is the lightness and darkness; white has a higher value than gray. The value level is the most important component of color. At a conversational distance, the color and its saturation are not noticeable. It is only when we get very close to a tooth that we are able to see colors. With all the teeth bleaching taking place, a large percentage of teeth are very light with almost no color. I have had multiple situations where patients continued to bleach their teeth after their shade was selected and this resulted in an incorrect shade of the restoration. Vita has developed a new shade guide called the Leanear Shade Guide. This guide uses a shade selection process that is based first upon value and then on hue and chroma.

TIP: If you have a patient bleaching his/her teeth, take the tray away from the patient at least 2 weeks prior to selecting a shade.

VIEWING THE OBJECT

You want to view the tooth with the patient seated in a 45-degree angle in your dental chair. Your goal is to

allow as much color-corrected light to reach the tooth as possible. If the patient is sitting in a vertical position, the patient's lip will block any ceiling light and shadow the tooth.

COLOR MAPPING

Color mapping is simply a paper sketch of the tooth, identifying areas and the associated colors. Included in this drawing are chroma intensities, amount of translucency, maverick colors, and any characteristics that will help the ceramist provide an accurately shaded restoration.

PHOTOS

The old adage "a picture is worth a thousand words" is especially true in shade selection (Figure A2.4). The American Academy of Cosmetic Dentistry has a well-documented color pamphlet that is a great resource: *A Guide to Accreditation Photography*. Use the examples in the book as a guide, making sure to do the following:

1. Take only the pictures you need to communicate color to the laboratory.
2. When taking the photos, be sure to have the shade tab number visible in the photo (Figure A2.5). Although the photos will not be color correct, the lab can use the photo to make a comparison between the tooth and the tab. For example, the tooth may be slightly darker than the shade tab, but we can judge how much darker. The laboratory also can see whether the shade of the tooth is darker in chroma or value.

SHADE-TAKING DEVICES

There are several shade-taking devices on the market today. If you are going to invest in one of these, I recommend you select one that views the entire tooth and allows you to perform a virtual try-in. A virtual try-in occurs when the finished restoration is scanned and placed next to the original tooth scan and then compared using the components of color that I described earlier.

The Shade Selection Process We Follow When a Patient Is Sent to the Lab

Our shade selection process can be summarized in the following steps:

1. The environment in our shade operatory is one with no dominant color. Basically the room is light

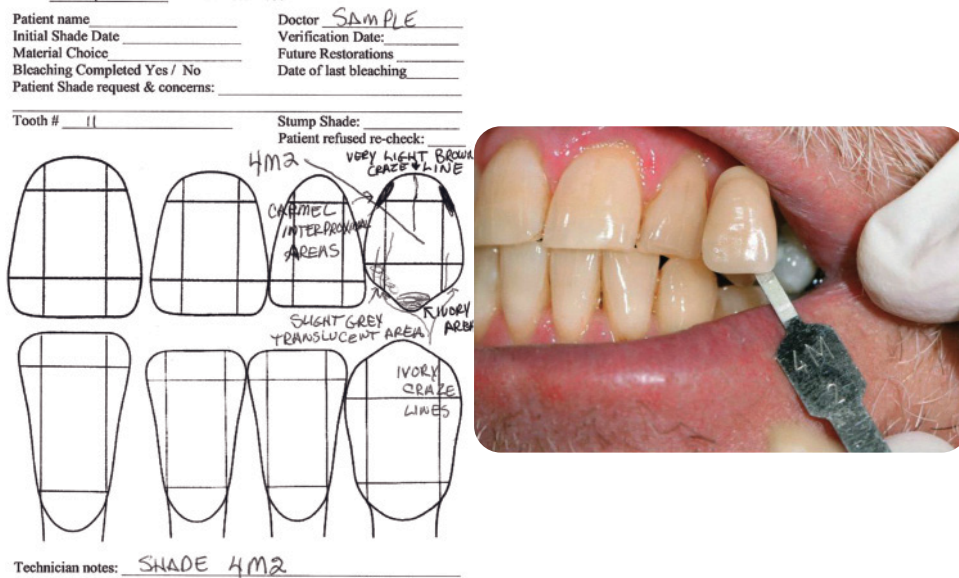


Figure A2.4. Shade mapping with an accompanying photo is a great aid to the dental ceramist. There are many subtle characteristics that can be depicted on a shade map that may not show on the photograph. Give the ceramist as much information as possible to develop the proper shade.

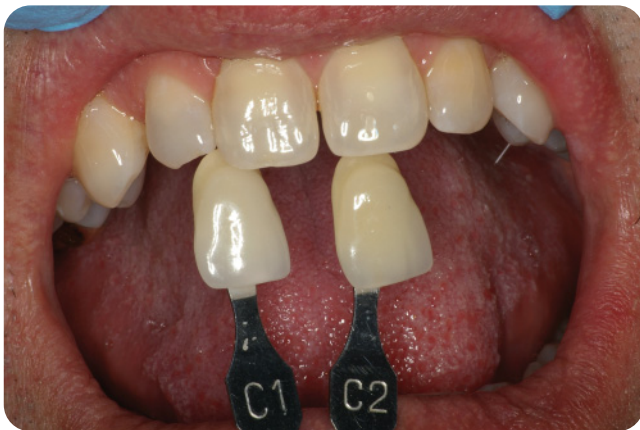

Figure A2.5. This is a very good photo showing multiple shade tabs with the tooth being matched. The shade tabs are aligned on the same plane as the natural tooth with the correct amount of light. The ceramist can use this photo to make a comparison with the shade of the restoration and either adjust the build-up technique and/or adjust the final shade prior to sending to the dentist.

beige. However, a light gray or light blue will also work.

2. All colored clothing is covered with a neutral patient bib. Any lipstick is removed. The technicians wear white lab coats.
3. Our shade operatory faces the west, so afternoon shades may be affected by too much light or reflected light. In these situations we close the window blinds that are a neutral gray color.

4. The technicians have been tested for color blindness and weakness.
5. Patients are seated with their back at approximately a 45-degree angle.
6. *Step one:* A color map of the teeth is drawn.
7. *Step two:* Photos are taken with and without shade tabs. With the use of digital cameras, you can take as many photos as desired and simply delete those that are not clear. We also set our flash and exposure settings so the histogram of the photo is correct.
8. *Step three:* We use a shade selection device called Shade Vision by X-rite to help select shades.
9. After these three steps and while the patient is still at the lab, the photos and Shade Vision mappings are printed. Once these are printed and laid out in the operatory, a ceramist rechecks the shade map and verifies the photos.
10. *Step four:* The patient returns to the laboratory so that we can verify that the final restoration matches correctly prior to the patient seeing the dentist; at this time, we can adjust the shade if necessary.

Diagnostic Wax-Ups and Study Casts

The diagnostic wax-up and study cast are probably the most valuable tools a dentist can supply to a laboratory. They give us guidance as to how to design the restorations not only for shape, but also for proper support of the restorative material. These diagnostic

tools define expectations and identify the patient's desire for perfection. Once this is understood and developed, the treatment can be planned accordingly.

I like to instruct dentists to tell their patients that we are going to make each patient's case three times. The first time they are going to design the case in wax to determine what can be accomplished with the remaining teeth and supporting structures. The diagnostic wax-up will tell us what can and cannot be accomplished with the teeth and oral structures in their current locations. The wax-up also will tell us whether other dental specialists will be needed to accomplish the desired results.

The second time we make the case it will be made in plastic. These are the provisionals that we will use to test to see whether the patient can function and speak correctly. The provisional will also tell us whether the patient approves of the aesthetics you have developed for them. This provisional stage, in my opinion, is the most important stage in the process. When patients are in provisionals, they have a chance to see the final outcome. Many times patients' aesthetic awareness increases and they are more critical and want to make additional changes. Making changes

at this stage is much easier and does not require much time or money. This is the stage that is too often rushed. By taking the necessary time, both you and the patient can review the changes with a fresh outlook. Once patients confirm that they will be satisfied if the final restorations look and function like the provisionals, a new set of study casts are made and sent to the laboratory to follow exactly. This new set of study models is referred to as *approved provisional models*.

The third time we make the case, it is in a more durable material. This material can be all porcelain, porcelain on metal, or any other material choices available.

Figures A2.6 and A2.7 show how a diagnostic denture setup is used as the blueprint for the implant-supported fixed restorations.

Remember a few key points regarding approved provisional models: Do not send instructions that state "follow study casts exactly" unless you really mean it. Usually provisionals are not of the contour quality you want your lab to follow for the final restorations. For example, incisal embrasures, facial contours, long axis alignment, and cervical embrasures usually need to be

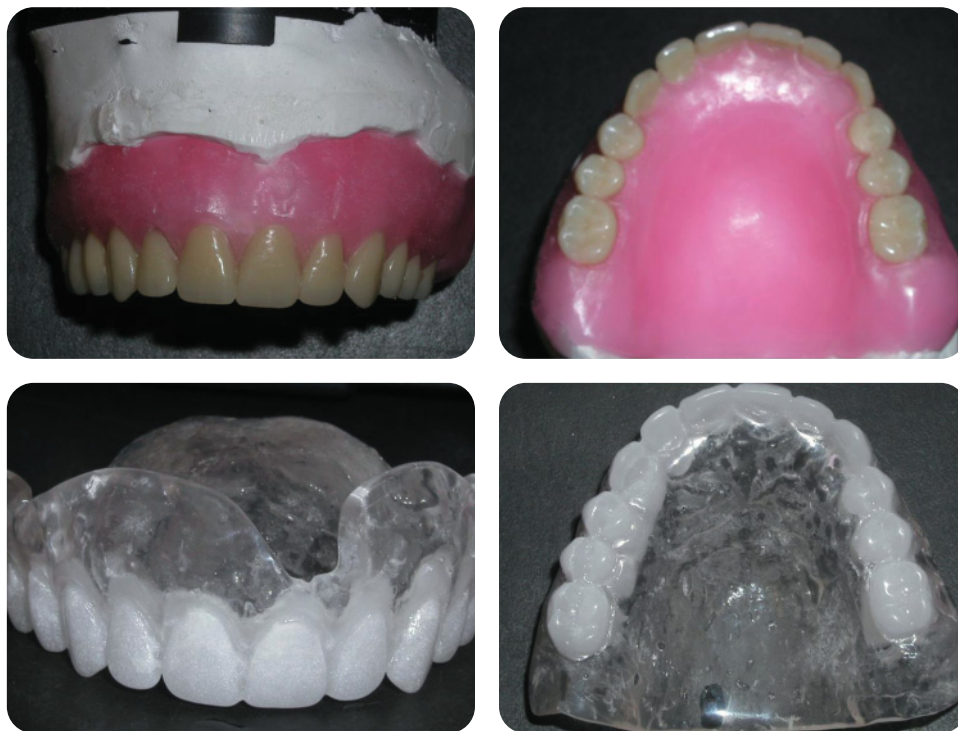

Figure A2.6. Diagnostic wax-up does not always need to be waxed directly to a cast. The diagnostic wax-up can also be in the form of a denture for try-in when dental implants are being planned. This wax-up was processed and used as a treatment appliance during the implant healing phase. The surgical stent for CT scan and implant placement were fabricated with barium using the treatment denture as a guide.

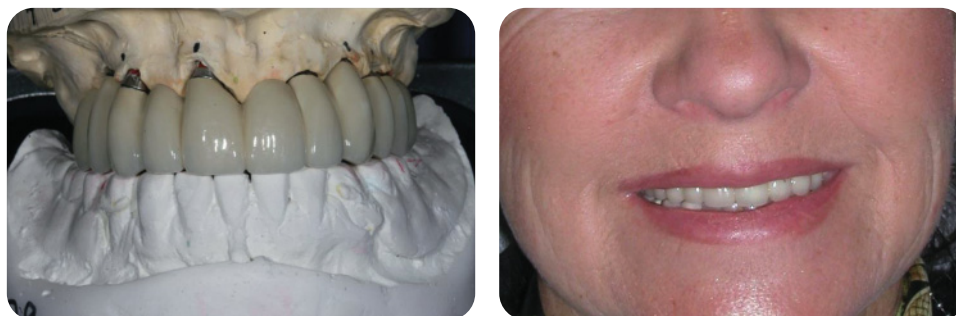

Figure A2.7. Final implant-retained restorations on the model and the patient's mouth: The patient was extremely pleased with the outcome. This result was predictable because we determined where the teeth needed to be to satisfy the patient at the very onset of treatment planning. Then we developed a treatment plan to reach the desired outcome. The patient was able to test the position and aesthetics of these teeth prior to fabrication of the final restorations.

refined. To be sure you get the aesthetics you expect, look at your provisional study casts with a critical eye. If your provisionals need contour improvements, you will want to instruct your lab to "follow incisal edge position, anterior guidance, and occlusion, but improve upon contours."

Another area to look at closely is the thickness of the final provisional material. Many times the provisional material has been thinned beyond the limits of the final restorative material. This happens when the patient and doctor decide to alter the shape of the provisional material to a more desirable shape and not reevaluate the position of the prepared tooth to the new position of the provisional. Many times additional reduction will be necessary.

Articulators

The choice of articulators can be as simple as a disposable plastic type to a semiadjustable model. I have worked with all of the semiadjustable articulators on the market today. They basically all function the same. Their differences are mainly features that allow us to accomplish certain procedures easier than others, but they all work. If you have a semiadjustable articulator in good working order, use the one you have. Your lab will need to have the same type and model or you will need to send yours with the case. Most articulators will not transfer casts exactly. So if you want us to check the occlusion of the final case with extremely thin articulating ribbon, you need to send your articulator with the case.

Materials Selection

The explosion of material choices is the most wonderful occurrence that has happened in the dental field in the last 10 years. The number of ceramic choices that are

available for dental restorations has increased dramatically. The material leader and workhorse of the industry is still the porcelain-to-metal crown. It is safe to say that 70% of the restorations we fabricate contain metal. And why not? Porcelain-to-metal crowns have been perfected over the last 60 years for durability and aesthetics, so it is the likely choice for predictability.

Currently, almost all of the technical and intraoral use problems and limitations have been eliminated or at least are understood regarding the PFM system. So why use anything but a PFM? In a word: *aesthetics*. Aesthetics in the anterior region is easier to obtain with all-ceramic restorations than porcelain-to-metal restorations. The metal substructure of the PFM limits the amount of light transmission through the restoration and into the surrounding tissues. This lack of light transmission through the PFM gives it the dreaded opaque appearance in the cervical half of these restorations and creates a graying of the surrounding tissue. Placing a porcelain butt joint on the facial of a PFM allows light to illuminate the tissue, and the absence of metal allows for more translucencies. This is the functional reason for using a porcelain butt joint. However, a PFM, even with a porcelain butt joint, does have aesthetic limitations.

With all restorations, we accept a certain amount of risk. This risk may be either aesthetic or function failure due to materials used. So what amount of risk are the patient, doctor, and lab willing to undertake to achieve the aesthetic and functional results required? Please note that I am asking you to define both aesthetic and functional demands with a risk of failure quotient. There is an aesthetic failure vs. functional failure trade-off. The more posterior we move in the mouth, the less visible the restoration (less aesthetically demanding) and the more occlusal forces are

applied (more functionally demanding). Although the patient may have a very high aesthetic demand, the functional demands may limit our material choices and aesthetic results. As the degree of aesthetics increases, so does the amount of risk of material failure. Why place a porcelain butt joint on a 1st or 2nd mandibular molar? The only person who will see this area is the dentist. We could argue about porcelain attracting less plaque, but then why did we design PFMs with metal lingual collars?

Table A2.1 lists restoration materials in the order of least to most risky. Also note that as aesthetic risk decreases, functional risk increases. We have to decide what type and amount of risk is acceptable for every patient. I have listed the zirconia restorations as moderate risk of failure due to the amount of time that zirconia has been in use. We have had very minimal porcelain fractures and no substructure failures. But zirconia is a new dental restorative material. We do not have 20 years of data on this material at this time.

Impressions, Related Bite Records, Shades, Study Casts, and Tools Necessary to Restore Different Types of Cases for Aesthetic and Functional Success

You need to approach every case you are restoring based upon its level of difficulty. The more you are going to be changing the patient’s appearance, occlusion, jaw relationship, or current restorations from the way they presented to you, the more information you need to provide to the laboratory and your specialists. When making major changes you also should increase the amount of time the patient wears the provisionals

to test the aesthetics and function you have developed.

My first choice is the one that is the best choice for aesthetic and functional success. Here are my recommendations for first choices for the following different restorative schemes:

1. Full arch impressions using a heavy body/light body one-step impression technique with a rigid tray. This technique gives the laboratory the most information of all the impression choices. The laboratory has all the remaining teeth the patient has present and can use them for determining occlusion, disclusion, contours, and mounting accuracy.
2. The bite record for jaw-to-jaw relationship should be stable and hold the casts while not being compressible.
3. Shade selection information is determined by the location in the arch where the restoration is being placed.
 - a. Anterior teeth require a shade map.
 - b. Photos of the patient and prepped teeth with shade guides
 - c. Digital shade scan if available
4. Approved provisional models
5. Facebow transfer
6. Patient’s chief concerns listed

How to Achieve Aesthetic and Functional Success with Providing Less than the Optimal Information

With my recommendation being stated, I will describe what I believe to be the minimum information needed

Table A2.1. Materials and risk of failure

Material	% Blockout	Risk of Function Failure		Risk of Aesthetic Failure	
		Anterior	Posterior	Anterior	Posterior
PFM	100	Low	Low	Moderate	Low
Captak	100	Low	High	Moderate	Low
Zirconia	80	Moderate	Moderate	Low	Moderate
Alumina	60	Moderate	High	Low	Low
Spinell	50	Moderate	High	Low	Low
Emax	20–70	Moderate	High	Low	Low
Empress	20–50	Moderate	N/A	Low	Low
Feldspathic	10–40	Moderate	High	Low	Low

Important: The more translucent the material, the more limited its use and the higher the risk of failure.

for predictable functional and aesthetic success in the different scenarios. I will also explain what errors may occur, which can make the case unpredictable if information is missing.

For single and multiple posterior teeth in the same quadrant with solid occlusal contact both anterior and posterior to the prepared teeth:

- *Second best choice:* Three-quarter arch impression including all the posterior teeth on the side of the restoration and up to the canine on the opposite side using the same material choice as above. These impressions still provide me with cross-arch stabilization for articulation and disclusion. No bite record is necessary if the remaining teeth are in good condition and exhibit good maximum intercuspation. A disposable articulator is acceptable to use. The occlusal movements will be guided by the teeth present on the casts. If the restoration is in the smile zone, you need to include the shade selection information that I listed earlier. If the tooth is out of the smile zone, state the shade tab selected and include photos with the shade tab next to the adjacent teeth.
- *Third choice:* Quadrant impressions using the same material choice as above. In this technique you have not provided cross-arch stabilization of the casts and lateral disclusion from the side that is missing; this missing lateral movement can cause a posterior interference. An occlusal bite record is necessary on the prepared teeth to ensure that the models are not tipped side to side. Tipping of the cast to the buccal or lingual will raise the buccal or lingual cusps and cause high occlusion when placed in the mouth. A disposable articulator is acceptable to use. Shade selection information is the same as above.
- *Fourth choice:* The double arch tray is the most technique-sensitive due to the selection of tray and material combinations. Too flexible a tray or impression material that is too viscous may cause the tray to flex and you get distortion. Your lab needs to be careful when pouring this type of tray. The weight of the stone can flex the tray and distort the impression. During maximum intercuspation, the fabric webbing that holds the impression material in the tray is exposed and distorts the occlusal surfaces of the models. I still receive many impressions using this technique and restore with excellent success. The double arch technique is the most technique-sensitive of all your choices. A bite record is not necessary. The double arch tray provides the occlu-

sal bite record if you ensure that the patient bites into MI. A disposable articulator is acceptable to use. Shade selection information is the same as above.

For a single anterior tooth with a solid occlusal contact both anterior and posterior to the prepared tooth:

- *Second best choice:* Three-quarter arch impression including all the anterior teeth and up to the second bicuspid on both sides of the arch using the same material choice as above. These impressions still provide me with cross-arch stabilization for articulation and anterior disclusion movements. No bite record is necessary if the remaining teeth are in good condition and exhibit good maximum intercuspation. A disposable articulator is acceptable to use. The occlusal movements will be guided by the remaining anterior teeth present on the casts. When the tooth is in the smile zone, you need to provide all the recommended shade selection information stated above that you have available. The single anterior tooth is the most difficult shade to match; do not skip any shade information that was recommended.
- *Third choice:* Anterior quadrant impressions using the same material choice as above. In all anterior cases, the contralateral anterior tooth must be included in the impression if we are going to match the contours and build in proper disclusion. In this technique you have not provided anterior to posterior stabilization of the casts. An occlusal bite record is necessary on the prepared tooth to ensure that the models are not tipped anterior to posterior. Tipping of the cast to the anterior will change the guidance, and tipping of the casts to the posterior will cause the occlusion to be high when placed in the mouth. A disposable articulator is acceptable to use.
- *Fourth choice:* The double arch tray is the most technique-sensitive due to the selection of tray and materials combinations, with the same errors as stated earlier. I still receive many impressions using this technique and restore with excellent success. A bite record is not necessary. The double arch tray provides the occlusal bite record if you ensure that the patient bites into MI. A disposable articulator is acceptable to use.

TIP: In the case of anterior teeth the contralateral anterior tooth must be included in the impression if we are to match the contour and disclusion.

For multiple posterior teeth with no solid posterior stop:

- With these types of restorations your bite record becomes the critical element.
- *Second best choice:* Three-quarter arch impression including all the posterior teeth on the side of the restoration and up to the canine on the opposite side using the same material choice as above. These impressions still provide me with cross-arch stabilization for articulation and disclusion. A bite record is necessary only on the prepared teeth if the remaining teeth are in good condition and exhibit good maximum intercuspation. A rigid brass or semiadjustable articulator must be used. A flexible-type disposable articulator will not provide posterior support. You need to use a bite registration material that cannot easily compress and will not distort or fracture during use. Be sure to verify that the teeth intercuspate the same with or without the bite registration in place. The occlusal movements will be guided by the teeth present on the casts. Your shade selection information is the same as above, with the smile zone the deciding factor on how inclusive the shade information needs to be.
- *Third choice:* Quadrant and double arch impressions are not acceptable impression choices. There are too few teeth that intercuspate to predictably restore these restorations with any degree of accuracy.

TIP: A rigid articulator is necessary to maintain an accurate interocclusal relationship. With no posterior stop present on the casts, models articulated on a malleable articulator can be moved out of position.

For multiple anterior teeth: When you are restoring multiple anterior teeth, aesthetics, anterior guidance, and tooth form are factors that must be seriously considered. Your impression choices are limited to a full arch or three-quarter arch impressions. A full arch is your impression of choice with a facebow transfer.

- *Second best choice:* A three-quarter arch impression is your only other impression choice besides a full arch impression.
- An occlusal bite record is recommended only on the prepared teeth. You must use a registration material that cannot easily compress and will not distort or fracture during use. Be sure to verify that the teeth intercuspate the same with or without the bite registration material in place.

- *Shade selection:* With fewer than all 6 anterior teeth being restored, your shade selection is as critical as restoring a single anterior tooth and should follow the same protocol. Shade selection may become easier if all 6 anterior teeth are being restored. The technician will need all the recommended shade selection materials stated earlier. However, your color map for an all-six case could be more limited to basic color and the amount of incisal translucency. Your photos become the most important tools available in this type of case. We need photos from multiple angles with the provisionals in place. Photos of the prepared teeth become an absolute necessity when an all-ceramic restoration is being requested. Technicians adjust the opacity of the porcelain for all-ceramic restorations based upon the amount of color shift from the prepped tooth to the final restoration. The materials selected for the restorations may change due to the shade of the prepared teeth.
- An approved provisional model of the tested provisionals is a vital necessity. The approved provisional models provide not only contours but also provide incisal edge position, anterior guidance including crossover, incisal embrasures, and cervical fullness. A technician can only guess what the dentist and patient desire the contours to be without this tool.
- A semiadjustable high-hinged articulator will be your instrument of choice in this situation to maintain accurate anterior guidance and posterior disclusion.
- A facebow transfer is necessary. If previously facebow-mounted models have been provided, we could use those models to cross-mount the working models.

Posterior quadrants on the same arch and posterior quadrants opposing each other: Your impression choice is limited to a full arch impression with a facebow transfer. In order to ensure posterior disclusion during jaw movements, you need to provide anterior teeth in your impression. The occlusal bite records and articulation requirements have changed.

- Occlusal bite records are recommended only on the prepared teeth. You need to use a material that you cannot easily compress and that will not distort or fracture during use. Be sure to verify that the teeth intercuspate in the same manner with or without the bite registration material. If you impress both posterior quadrants on the same arch, keep the provisionals in place when recording the bite record on the

opposite side. Then replace the provisionals on those teeth and remove the provisionals on the opposite side and take the bite record on those teeth. It is critical that you verify that the patient bites in MI while taking these bite records.

- A rigid articulator is necessary to maintain an accurate interocclusal relationship. However, a rigid articulator that does not mimic the movements of the jaw will not guide the casts in a correct manner. With no posterior stop present on the casts, models articulated on a malleable articulator can be moved out of position. A semiadjustable high-hinged articulator will be your instrument of choice in this situation to maintain an accurate anterior guidance and determine posterior disclusion.
- Facebow transfer or a previously facebow-mounted model can be used to cross-mount the casts to provide proper disclusion.

Note: There are only two determinants of disclusion of teeth: anterior guidance and angle of eminence. The amount of disclusion from the anterior teeth is determined by a combination of the vertical steepness of the anterior teeth and the amount of overbite. The angle of eminence determines how much the posterior teeth move in a downward direction as the teeth move in an anterior direction. It is the combination of these two conditions that determines anterior guidance and posterior disclusion. Your provisionals test the position that you want the final restorations to be in and the amount of stress the patient will place on them during use. As the restorative case becomes more complex, it becomes more important that the determinants of disclusion have an instrument that can duplicate the movements of the jaw.

When one entire arch is being restored: Your impression choice is limited to a full arch impression with a facebow transfer. Follow the guidelines I recommended earlier. Here your bite records and approved provisional models are your keys to predictability.

- When taking the full arch impressions of both your approved provisionals and final impressions, capture as many anatomical landmarks as possible. With a maxillary impression be sure to capture the palate. With a mandibular impression capture the retromolar pads and vestibules. There are many occasions where I have used these landmarks from the provisional models to assist me in articulating the working casts. I use laboratory putty with a Shore-A

hardness of 90 or higher. I verify bite records by comparing mounted provisional models with working casts.

- Bite records are very important. I recommend segmental bite records. If the provisionals can be removed in sections, remove one segment and take a bite record of the prepared teeth only. Then replace the provisionals and remove a different segment and take a bite record on those teeth. Continue the process until all the segments are recorded. During this process pay very close attention to the remaining provisionals to ensure they close to MI each time.
- The shade selection process should include photos of the opposing arch teeth with shade tabs, if you are matching those teeth; photos of the prepared teeth with shade tabs; and photos of the provisionals from different angles.
- A facebow is necessary unless a facebow-mounted model is provided so that we can cross-mount the facebow recording to a semiadjustable articulator.

When both arches are being restored: This is the situation where if the bite record or articulation is slightly off, the restorations may require significant adjustment. If you are at this point in the restorative process, you have “skin in the game.” By now diagnostic wax-ups have been fabricated, provisionals have been placed, and modified (possibly multiple sets) and other dental specialties have been utilized. ***Don't be in a hurry now!*** I would think you would want to deliver an entire arch of restorations without any adjustments. If you agree, just impress one of the prepared arches and the opposing arch of seated provisionals. If your final restorations are going to differ much from your final provisionals, in my opinion, you are going too fast in treatment. You and the patient still do not know exactly how the final restorations will look and function. Use the bite registration technique stated above for multiple quadrant bite records. When the restorations return, and if the bite is slightly off, adjust the opposing provisionals of the prepped teeth and not the final restorations.

If you are still intent on restoring both arches at the same time:

- Follow the same procedure regarding impressions stated in the earlier example.
- If you are going to restore both arches at the same time, bite records are extremely important. I recommend segmental bite records. One set of bite

records of prepared teeth to the provisionals (either arch) and a second set of bite records, prep-to-prep. When taking these bite records keep in place as many provisionals as possible and place bite registration material only on the prepared teeth, verifying that the remaining provisionalized teeth return to MI with the bite record in place. If the provisionals can be removed in sections, remove one segment and take a bite record of the prepared teeth only. Then replace the provisionals and remove a different segment and take a bite record on those teeth. Continue the process until all the segments are recorded. During this process pay very close attention to the remaining provisionals to ensure that they close to MI each time.

- Shade selection process should include photos of the opposing arch with shade tabs, photos of the prepared teeth with shade tabs, and photos of the provisionals from different angles.
- A facebow is necessary unless a face-bow-mounted model is provided so that we can cross-mount the facebow recording to a semiadjustable articulator.

Digital impressions: I have to include digital impressions. This technique is relatively new to the dental market and there are only three systems currently being used with any regularity: Cadent, COS, and Cerec. I have worked with all of these systems and have had very good results. Still, they are currently not suited for all impression situations and are also limited in the size of the impressed area. Also, if the dentist cannot control oral fluids, which is the source of most impression problems we currently receive, the digital impression will be compromised as well.

The digital impressions are sent over the Internet to a model fabrication facility where the model is milled out of a block of resin with removable dies. The models are fabricated so that they can be articulated on a system specific articulator. Although these current systems are not perfect, this is the way future impressions and restorations will be fabricated.

Changing a person from a full denture to an implant-supported fixed or fixed removable case: Implants are a rapidly growing treatment option in dentistry. The majority of all implants that I restore are replacing a single tooth. However, many patients are selecting extensive treatment options that will replace their dentures with a screw- or cement-retained implant appliance. The patient's confidence and ability to masticate food are huge benefits for them, but before you begin to restore one of these cases, there

is a very important factor that you must evaluate other than the amount of bone that remains to support the implants. Most patients who have been wearing dentures for a number of years have lost a significant amount of bone. This loss of bone is replaced with the acrylic flanges of the removable appliance or denture. If you restore a patient with an implant-retained restoration that does not contain flanges and do not evaluate the amount of facial support that these flanges provide, you may have an aesthetic situation that you might not be able to solve with the treatment-planned appliance.

To gain an understanding as to what the final aesthetic outcome of a flangeless appliance will be in the treatment-planning phase, there are two relatively inexpensive diagnostic tools available to you. The first step that you need to perform is asking patients whether they would be satisfied with the arrangement and position of their current denture's teeth in the new final restoration. If their answer is yes, follow step one; if they want more than minor changes to their existing denture, follow step two:

1. This step is the least expensive and requires minimal chair time. We ask the dentist to send the patient or the patient's denture to the laboratory so that we can duplicate the denture in clear acrylic. If the patient is going to have a radiographic scan performed for bone position evaluation, we duplicate the denture with the acrylic containing barium sulfide and you now have a radiographic stent also. If the patient comes to the lab, we need the denture for only approximately 1 hour. After the denture is duplicated, we remove the facial flanges from the duplicated denture. By removing the facial flanges but maintaining the palate or lingual flanges, the appliance is able to be worn for facial support evaluation. If you and the patient conclude that there is insufficient facial support without the denture flanges, your treatment options have just changed.
2. If more than minor changes are requested or needed from the current denture, you need to have a denture wax try-in to get agreement on the aesthetic and functional desired outcome. In one method, you can perform the traditional steps of a denture wax try-in and then remove the facial flanges. A second method is the easiest, most accurate, and fastest method I have found: use the patient's current denture as a guide and perform a little lab work in your office:

- a. Using the patient's current denture as a substitute for a custom tray, simply take a reline impression and pour in a dental model stone.
- b. Take an opposing arch alginate impression and pour in a dental model stone.
- c. Prior to separating the denture from the model, articulate the casts on a semiadjustable articulator that has an anterior pin.
- d. If you are restoring the maxillary arch, using lab putty with a Shore-A hardness of at least 80, fabricate an incisal edge matrix of the denture. This matrix needs to have a solid seat on the mandibular cast. I recommend carrying the putty into the labial vestibules of the opposing model.
- e. Record the articulator's anterior pin setting.
- f. Remove the denture from the articulated model and take an alginate impression of the denture to be used as a study cast.

Once you have completed the model work, remove the impression material and the denture can be returned to the patient. The model pouring and articulation usually takes approximately 1-1/2 hours. Instruct the lab as to the changes you would like to see in a denture wax-up based upon the original study model and mounting. For example, you could ask to open the VDO 2mm and maintain the same overbite. This request would lengthen the amount of tooth display but not change the occlusion. You will also want to request that the lab remove the facial flanges to evaluate the need for facial support.

By using this technique, you have eliminated a custom tray, a bite rim, and records appointment, and proceeded directly to a wax try-in. You now can make as many changes to VDO and tooth position as you need in wax. Once you determine the approved final position of the teeth at the wax try-in stage, you can evaluate the appliance for facial tissue support. The appliance can now be processed in acrylic to be used as a radiographic stent or surgical guide.

Laboratory soft tissue models: I have limited the use of the rubbery soft tissue models for almost all

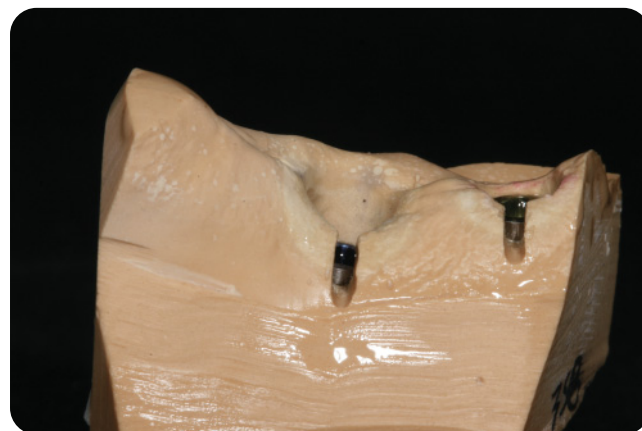

Figure A2.8. When the implant platform is subgingival, placing a narrow slot on the lingual of the stone model allows you to verify proper seating of the implant abutment to the analog and restoration to the implant abutment.

models. There are a few situations where you need the soft tissue area of the model to be able to be removed and replaced. I have found that the rubbery gaskets either are too difficult to use and prevent the restoration from seating correctly on the dental cast.

I prefer to use a solid stone dental cast for all soft tissue, interproximal, and implant models. With a solid stone model I could shape the cervical and emergence profile of the model to be able to aid in the contour of the restorations. The rubbery gaskets are not easily modified and never allow the restoration to be seated and evaluated while they are in place.

With dental implant models, many times the implant is subgingival; with a solid stone model you are not able to evaluate the seating of the implant abutment to the analog. I place a "viewing slot" on the lingual of the implant site (Figure A2.8). This slot allows me to determine whether further abutment modification is necessary. When implant models are going to be scanned for implant location and subsequent implant abutment or bar designing and milling, depending on the type of model scanner, a removable soft tissue model may be necessary.

Index

Note: Italicized page locators indicate a figure/photo.

A

- Abrasion, investigating etiology of, 273
- Adapted centric posture, bite splint therapy and goal of, 39
- Adaptive capacity
 - decrease in, 15
 - fluctuations in, 15
 - occlusal stressors and, 14, 14
- Aesthetic dentistry, harmony between temporomandibular joints, muscles, occlusion and, 26
- Aesthetic examination, 21–26
- Aesthetic failure vs. functional failure trade-off, 441
- Aesthetic occlusal plane, 105–108
 - changes to incisal edges and buccal cusps and facial profiles, 108
 - changes to vertical dimension, 108
 - defined, 105
 - desired goal of, 106
 - device in place for dentist and patient evaluation, 108
 - device removed from cast, 108
 - diagnostic corrections made on articulated diagnostic casts, 107
 - fabrication of, 108
 - sequencing patient evaluation and approval of changes, 107–108, 108
 - significant changes in upper incisal edge length, upper aesthetic plane, and profiles of posterior teeth, 108
 - uneven and asymmetrical profiles of facial surfaces of upper posterior teeth and corrections made with restorations, 106, 107
 - uneven and irregular, corrections made with definitive restorations, 106, 106
 - viewing from broader frontal perspective, 106
- Aesthetics
 - clinical examination of masticatory system and, 7, 8
 - as co-discovery approach, 31
 - as integral part of comprehensive approach, 21–22
- Aesthetics and anterior guidance restoration
 - close-up anterior retracted photograph of completed restorations, 197
 - close-up anterior retracted photographs of completed restorations with mandible protruded to anterior end-to-end relationship, 198
 - close-up occlusal photographs of completed restorations, 198
 - damage by wear with increasing overbite with upper and lower anterior crowns, 195–198
 - key points about case, 198
 - photographs after provisionalization suggesting improved overbite relationship, incisal edge display at rest and functional anterior guidance marks, 197
 - pretreatment articulated diagnostic casts showing anterior tooth-to-tooth relationship, 197
 - pretreatment panoramic radiograph suggesting endodontic concerns, 196
 - pretreatment retracted anterior photograph suggesting anterior and end-to-end functional relationship, 196
 - pretreatment smile photograph suggesting concerns, 196
 - putty index made from articulated casts of provisionals and definitive restorations fitting precisely into index, 197
 - summary of examination and diagnosis, 195
 - summary of treatment plan, 196
 - summary of treatment sequence, 196
 - 10 decisions, 195
 - trial equilibration done until bicuspid coupled, 197
- Aesthetics and functional changes
 - maxillary and mandibular aesthetic and functional reconstruction with lab-processed composite restorations, 204–209
 - maxillary and mandibular dental reconstruction including 4 dental implants replacing unrestorable teeth, 216–219
 - maxillary reconstruction at open vertical dimension to improve aesthetics, length, buccal profiles and functional landmarks, 199–203
 - posterior reconstruction with severe interferences to centric arc of closure, 189–194
 - restoration of aesthetics and anterior guidance damaged by wear, 195–198
 - restoration of anterior aesthetics and anterior guidance in deep overbite damaged by bruxism with upper and lower anterior reconstruction, 184–188
 - restorations maxillary bicuspid-to-bicuspid done first as part of comprehensive plan, 210–215
- Aesthetics and functional success
 - achieving with providing less than optimal information, 442–447
 - for both arches being restored, 445–446
 - changing a person from a full denture to implant-supported fixed or fixed removable case, 446–447
 - for digital impressions, 446
 - for entire arch being restored, 445
 - for laboratory soft tissue models, 447
 - for multiple anterior teeth, 444
 - for multiple posterior teeth with no solid posterior stop, 444
 - posterior quadrants on same arch and posterior quadrants opposing each other, 444–445
 - for single and multiple posterior teeth in same quadrant with solid occlusal contact both anterior and posterior to prepared teeth, 443
 - for single anterior tooth with solid occlusal contact both anterior and posterior to prepared tooth, 443

- impressions, related bite records, shades, study casts, and tools for restoring different types of cases for, 442
- Aesthetic zone. *See also* Implants in aesthetic zone
- Alumina copings on natural teeth and removable overstructure, maxillary telescope case, 337–341
- Amelogenesis imperfecta
 - disadvantage with no-provisional approach, 208
 - key points about case, 209
 - mandibular impression and cast completed on day 1, 208
 - maxillary and mandibular aesthetic and functional reconstruction with lab-processed composite restorations for treating, 204–209
 - maxillary and mandibular posterior impressions and casts, 208
 - occlusal and buccal occluded photographs of completed restorations, 209
 - pretreatment articulated diagnostic casts and wax-up, 208
 - pretreatment buccal occluded and occlusal photographs, 206
 - pretreatment panoramic radiograph, 207
 - pretreatment photographs showing condition of teeth and unattractive smile, 206
 - restorations bonded same day as preparations, 208
 - smile and retracted anterior photographs of completed restorations, 209
 - summary of examination and diagnosis, 204
 - summary of treatment plan, 205
 - summary treatment sequence, 205
 - 10 decisions, 204
- American Academy of Cosmetic Dentistry, 438
- Anterior aesthetics and anterior guidance
 - articulated putty index of provisionals that captured incisal edges and lingual contours, 188
 - centric stops and anterior guidance functional markings of definitive restorations, 188
 - definitive lower anterior restorations, 188
 - facial veneers fabricated for upper bicuspids to improve aesthetic plane, 188
 - key points about case, 188
 - lower restorations finalized first, 188
 - photographs of upper and lower provisionals at current vertical dimension of occlusion, after occlusal refinement, 187
 - photographs verifying changes made with provisionals, 187
 - pretreatment articulated diagnostic casts, 187
 - pretreatment panoramic radiograph, 187
 - pretreatment photographs suggesting wear and aesthetic issues, 185
 - pretreatment radiographs, left side, 186
 - pretreatment radiographs, right side, 186
 - restoration of, in deep overbite damaged by bruxism with upper and lower anterior reconstruction, 184–188
 - summary of examination and diagnosis, 184
 - summary of treatment plan, 185
 - summary of treatment sequence, 185
 - 10 decisions, 184
 - upper definitive restorations, 188
 - wax-up illustrating anterior functional relationship changes, 187
 - wax-up showing aesthetic changes, 187
- Anterior centric holding contacts
 - deep overbites and, 87
 - desired morphology of, 49, 49
- Anterior centric stops
 - ideal locations for, 87
 - labial-incisal line angle of lower contacting marginal ridges of upper, 88
 - on lingual of upper anteriors, ideally on marginal ridges, 87, 88
 - maintaining, if present in maximum intercuspation, 88
 - morphological design of, 48, 48
 - not of a stable design, allowing eruption of lower anterior segment, 89
- Anterior guidance, 91–97. *See also* Anterior aesthetics and anterior guidance
 - angle of condylar guidance vs. angle of, 94–95
 - defined, 91
 - envelope of function, tooth contours interfering with signs and symptoms and, 93
 - good or ideal, 91
 - key to, 79
 - lower incisal edge anatomy/position and upper incisal edge position, 91, 92
 - lingual surfaces in shallowing case which opened vertical dimension of occlusion, 96
 - physiologic occlusion and, 46
 - refining “edge-to-edge” position and, 96, 97
 - restoration of damage caused by wear with increasing overbite with upper and lower anterior crowns, 195–198
 - shallowing, by opening vertical dimension of occlusion, 96, 96
 - unique envelope of function, chewing path, phonetic path and, 93
 - various contours of functional surface on patient-by-patient basis and, 91, 92
- Anterior guidance angle, shallowing, before and after comparisons, 95
- Anterior open bite case, vertical dimension of occlusion, 70, 72, 72
- Anterior overjet, severe, handled with occlusal/restorative treatment in lieu of orthognathics
 - anterior smile and retracted photographs of finished dentistry, 364
 - definitive restoration designed as smaller fixed partial dentures and single units rather than a full arch splint, 365
 - diagnostic wax-up showing several issues, 364
 - green marks illustrating protrusive that starts on upper first bicuspid and transitions to cuspids and incisors, 364
 - key points about case, 365
 - photos illustrating centric stops in adapted centric posture arc of closure, 364
 - posttreatment buccal photographs, 364
 - pretreatment articulated diagnostic casts suggesting severe overjet, 362
 - pretreatment radiographs, 363
 - red marks illustrating lateral guidance starting on first bicuspid and transitioning to cuspid, 364
 - severe Curve of Spee, 362
 - summary of examination and diagnosis, 360
 - summary of treatment plan, 361
 - summary of treatment sequence, 362
 - 10 decisions, 361
- Anterior teeth, upper and lower, correct anatomy of, 88
- Arch customization
 - for individual patients, T-Scan III Occlusal Analysis System and, 400
 - customized patient arch, 400
 - noncustomized patient arch, 400
- Arc of closure, bite splint and interferences to, hyperactivating positioning muscles, 40–41
- Arc of rotation, mandible and, 67
- Articulated diagnostic casts, 5, 6, 26–27. *See also* Diagnostic casts; Wax-ups
 - facilitating communication process and, 54
 - inspection of, 26

- purpose of, 26
for severe wear case, 70
- Articulating paper, 391
- Articulators
choice of, 441
wax-up and, setting condylar inclination on, 52
- Auscultation
Doppler sonography in temporomandibular joint examination, 10, 10
temporomandibular joint examination and, 9
- Avascular necrosis, past condylar replacement due to, followed by posterior occlusal reconstruction, 166–170
- Axial forces, non-axial forces vs., 90
- B**
- Balancing interferences, diagnostic blueprint (wax-up) and, 52
- Bar in edentulous space, purpose of, 330
- Behavioral decisions, technical decisions, vs., some reasons for, 371
- Behavioral skills, importance of, 27
- Bibs, tooth shade selection and, 437
- Big case, comprehensive case vs., 5
- Big picture
seeing, 32
10 decisions and, 63
training eye and mind for, 77
- Bilateral simultaneous contacts, measurable, computer-guided occlusal adjustments and, 413, 415
- Bimanual guidance
centric relation bite record and use of, 26, 26
condyles, bite splint adjustment and, 40
to superiorly compress the condyles within fossa and test load-bearing status of TMJ, 11, 11
- Bi-Manual Manipulation technique, 4-handed centric relation recording with T-Scan III and, 401
- BioPAK electromyography system (T-Scan III), 424–425, 428 desktop, 424
illustrating lessening of muscular hyperactivity at end of right excursive movement when posterior teeth are finally discluded, leaving only canine contact, 426
illustrating presence of muscular hyperactivity during right excursive movement, 426
illustrating presence of muscular hyperactivity when right excursive movement commenced by patient presenting with prolonged Disclusion Time, 426
group function during right excursion, 425
patient with EMG leads placed on 8 head and neck muscles, 424
- Bite records
accuracy of, 435–436
aesthetic and functional success and, 442
- Bite registration material, correct amount of, 436, 436
- Bite splints/bite splint therapy, 37, 38–44, 362
anatomy/physiology of masticatory system and design of, 41
behavioral benefits with, 44
bruxism, cusp to fossa angle and, 103
Curve of Wilson facilitates working side disclusion, 43–44
defined and purpose of, 38
goals of, 39
intracapsular and muscle disorder resolved with, 157–161
intracapsular and muscle disorder with resultant occlusal plane asymmetry resolved with, 162–165
intracapsular and muscle pain resolved with, followed by definitive occlusal therapy with posterior reconstruction and anterior composites, 178–181
during laboratory refinement, 43
logical rationale for use of, 38
lower vs. upper, 40
materials for, 39
maxillar or mandibular arch?, 39–40
with no retrusive inclines distalizing condyles, 44
refined, polished, 44
shallow, flat, smooth anterior guidance platform for, 42
splint design and anatomy of masticatory system, 40–44, 41
anterior guidance platform: shallow, flat, and smooth, 42
condyles in most superior position, 40
Curve of Wilson facilitates working side disclusion, 43–44
interferences to arc of closure hyperactivate positioning muscles, 40–41
no retrusive inclines that distalize condyles, 44
posterior exclusive interferences hyperactivate elevator muscles, 41
stable, retentive fit for, 42–43
starting from treatment position, 38–39
temporomandibular disorder resolved with, followed by definitive occlusal therapy, 171–177
- Bleaching teeth, restoration shade issues and, 438
- Blueprint, defined, 50
- Bone loss, denture wear and, 446
- Breakage
distal extension implant prosthesis and, 418
maxillary and mandibular implant hybrid force management and, 415
- Bruxism, 13
cusp to fossa angle and, 103
fatigue typical with, 290
incredible wear and tear on teeth due to, 266
intracapsular and muscular components of TMJ disorder and, 152, 154
occlusal stress and, 14
restoration of anterior aesthetics and anterior guidance in deep overbite damaged by, with upper and lower anterior reconstruction, 184–188
- Bruxism and wear reconstruction, 261–273
restoration of worn lower anterior teeth in deep bite without changing other restorations, 262–265
severe wear from parafunctional habits restored with complete reconstruction at increased vertical dimension of occlusion, 266–273
- Buccal-lingual stability, centric stops and maintenance of, 86
- Buffalo Foil Cote
applying to provisional, 57
phone and website, 62
- C**
- Casts. *See also* Articulated diagnostic casts
for implant model, 60
putty index and, 56, 56
- CAT scans, 22
- Center of force trajectory
computer-guided occlusal adjustments and, 413, 415
postoperative balanced, early contacts, 415
poorly positioned and ideally positioned, 396
postoperative balanced, midclosure contacts, 415
postoperative balanced, near maximum intercuspation, 415
T-Scan III Occlusal Analysis System and, 394
- Central fossa, occlusal morphology incorporating receiving area or landing pad on, 49, 49

- Central incisors and cuspids, gingival margins of, 85
- Centric arc of closure
 posterior reconstruction with severe interferences to, 189–194
 problem-free deep overbite if all teeth have stable centric holding contacts in, 372
- Centric holding contacts, lower incisal edges reshaped/restored and upper cingulum reshaped, 89
- Centric relation, 12
 bite splint therapy and goal of, 39
- Centric relation arc of closure, identification of occlusal interference to, 20
- Centric relation bite record, making, bimanual guidance used in, 26, 26
- Centric relation contacts
 T-Scan III analysis
 contacts at 10.8% total force, 405
 contacts at 60.5% total force, 406
 early contacts at 2.2% total force, 405
- Centric relation manipulated closure graph, T-Scan III Occlusal Analysis System, 396, 397
- Centric relation occlusion, definitive occlusal therapy and goal of, 45
- Centric relation prematurity
 computer-guided occlusal adjustments and, 411, 413
 postoperative corrected centric relation occlusion at 14.2% total force, 414
 postoperative corrected centric relation occlusion at 71% total force, 414
 postoperative corrected centric relation occlusion at 100% total force, 414
 preoperative centric relation at 10% total force, 412
 preoperative centric relation contacts at 1.7% total force, 412
 preoperative centric relation contacts at 42.46% total force, 412
 preoperative centric relation contacts at 93.3% total force, 413
 significant, T-Scan III analysis and, 402
- Centric stops
 defined, 86
 design of, 86–91
 cusp pathways during excursions following general ridge and groove direction, 90
 in deep bite situations, 89
 proper, goal of, 91
 non-axial forces vs. axial forces and, 90
 stable stops in all teeth in, 87
- Ceramic choices, increase in, 441
- Change requests, dental laboratories and, 434
- Chewing cycle, habitual force pattern recording with T-Scan III and, 402
- Chin advancement, maxillary and mandibular orthognathic surgery with, 256–260
- Chin implant, mandibular orthognathic surgery and, 250–255
- Chroma, 438
- Clinical examination, 5
- Clinical system-based masticatory system examination, complete picture afforded by, 8
- Closing muscles, outside-in movement and, 46
- Clothing color, tooth shade selection and, 437
- Codiscovery, defined, 28
- Codiscovery process, 29–33, 31
 addressing patient concerns appropriately, 30
 continuing appropriately, 32–33
 customizing and orchestrating exam for each patient, 30–31
 goals in, 30
- relating exam findings back to patient concerns, 32
 seeing the big picture, 32
 understanding patient concerns, 29–30
- COF. *See* Center of force trajectory
- Cold-cure acrylic resins, for fabricating provisionals, 57
- ColdPac (Motloid Company), for fabricating provisionals, 57, 58
- Color, components of, 438
- Color mapping, 438
- Color recognition, defined, 437
- Color rendering index, 437
- Combination fixed-removable restoration on natural teeth, 322–347
 mandibular anterior fixed partial denture and posterior removable partial denture with implants and Locator attachments for added support; maxillary reconstruction, telescope case with 1 dental implant, 342–347
 maxillary bar-supported removable partial denture; lower crowns with semiprecision removable partial denture, 324–330
 maxillary fixed partial dentures with precision removable partial denture; mandibular bar-supported complete denture, 331–336
 maxillary telescope case: alumina copings on natural teeth and removable overstructure; mandibular telescope case: Galvano copings on natural teeth and nonremovable overstructures, 337–341
- Commodity dental restorations, dental insurance and, 433
- Communication process
 facilitating, diagnostic blueprint and, 54
 tooth shade selection and, 437
- Communication skills, importance of, 27
- Complete implant-supported maxillary reconstruction
 custom abutments and soft tissue cast, 224
 finished result, reverse smile improved, 224
 implant level impressions, 224
 key points about case, 225
 posttreatment panoramic radiograph, 225
 preoperative lingual views showing old but acceptable screw-retained posterior implant-supported restorations, 224
 preoperative occlusal view, 224
 preoperative panoramic: upper anterior teeth hopeless; lower anterior teeth guarded, 223
 preoperative retracted views, 223
 preoperative smile photograph showing reverse smile, 223
 putty index of verified provisionals and definitive restoration verified, 224
 summary of examination and diagnosis, 222
 summary of treatment plan, 223
 summary of treatment sequence, 223
 10 decisions, 222
 transitioning upper anterior teeth from tooth-supported to implant-supported, 222–225
 trial equilibrated articulated diagnostic casts, 224
- Complete implant-supported nonremovable maxillary and mandibular reconstructions
 acrylic processed over scaffolding and final check made on articulated implant cast, 234
 after complete healing, next phase begins, showing new maxillary impression on implant abutments and definitive mandibular implant-supported restoration, 235
 articulated diagnostic casts made of first provisional and modifications made to contours of mandibular, 234
 concavities emerging from implant abutment finish lines filled in to create straight-to-convex contours for tissue support and cleanability, 235

- definitive restoration checked with putty index, 235
- definitive restoration on solid cast to verify tissue contours, 235
- impressions made for definitive maxillary implant-supported restoration, 235
- key points about case, 236
- lateral smile and retracted photographs of definitive restoration; overbite increased to approximately 2 mm, 235
- maxillary provisional restoration with incisal edge/aesthetic lane putty index, 235
- panoramic radiograph of completed maxillary and mandibular restorations, 236
- photographs after second phase, 235
- photographs of initial diagnostic wax-up illustrating functional and aesthetic changes, 233
- planning for second phase: surgical stent with gutta percha used for CAT scan analysis, 234
- planning for second phase includes mandibular implant level impression, 234
- posttreatment photographs after first phase of treatment, 233
- pretreatment buccal occluded and occlusal photographs suggesting functional occlusal plane, anterior guidance, and structural problems, 233
- pretreatment panoramic radiograph, 233
- pretreatment smile and retracted photographs suggesting multitude of problems, 233
- Ribbon scaffolding attached to preparations with light-cured flowable composite resin, 234
- summary of examination and diagnosis, 231
- summary of treatment plan, 232
- summary of treatment sequence, 232
- 10 decisions, 231
- transitioning from natural teeth that were not predictably restorable, 231–236
- Complete implant-supported restorations, 221–243
- complete implant-supported maxillary reconstruction, 222–225
- complete implant-supported nonremovable maxillary and mandibular reconstructions, 231–236
- complete maxillary nonremovable restoration supported by 6 implants, 226–230
- mandibular implant-supported full removable denture converted to nonremovable restoration, 240–243
- maxillary extractions, immediate implant placement, immediate loading, and complete nonremovable zirconia restoration with pink porcelain, 237–239
- Complete masticatory system examination, 8
- aesthetic examination, 21–26
- articulated diagnostic casts, 26–27
- dental examination, 17
- four-part TMJ examination, 9–12
- imaging, 22, 25
- muscle examination, 12–17
- occlusal examination, 17, 21
- periodontal examination, 17
- Complete maxillary nonremovable restoration
- anterior and lateral retracted photographs of cemented definitive restoration, 230
- anterior and lateral retracted photographs of cemented nonremovable provisional, 229
- anterior and lateral retracted photographs of provisional, 228
- anterior and lateral retracted photographs of second diagnostic provisional, 229
- anterior and lateral smile photographs of definitive restoration using pink porcelain to simulate the gingival, 229
- anterior and lateral smile photographs of second attempt at diagnostic provisional, 228
- key points about case, 230
- lateral smile photograph of the second provisional confirming acceptable to support, 229
- lateral smile photographs of provisional, with acceptable lip support, 228
- maxillary occlusal photograph after placement of two more implants and finalized abutments, 229
- photographs of diagnostic provisional made on initial articulated diagnostic casts, 228
- pretreatment anterior and lateral retracted photographs, 227
- pretreatment anterior and lateral smile photographs; Valplast used because of suspected acrylic allergy, 227
- pretreatment maxillary occlusal photographs showing anterior and posterior implants; several teeth recently extracted, 228
- summary of examination and diagnosis, 226
- summary of treatment plan, 227
- summary of treatment sequence, 227
- supports for, by 6 implants converted from completed removable restoration on 4 implants, 226–230
- 10 decisions, 226
- Comprehensive approach. *See also* Four-part comprehensive evaluation
- complete masticatory system examination, 8
- fundamental principles of, 5–26
- Comprehensive case, big case vs., 5
- Comprehensive dentistry, scope of, 37
- Comprehensive evaluation, overall rationale for, 26
- Computerized occlusal analysis software, linking of, to electromyography software, 421, 425, 430
- Computerized occlusal analysis technology
- arch-half force equality and, 430
- capabilities and function of, 391
- centric relation management and, 402, 405–406, 411, 412–413, 414, 430
- dental implant force and timing control and, 430
- habitual occlusal force pattern improvements with, 402, 403–404, 428, 430, 430
- mandibular excursive function and, 398–400, 430
- overall occlusal force balance and, 430
- Concerns of patients
- addressing appropriately, 30
- relating exam findings back to, 32
- understanding, 29–30
- Concluding examination appointment, in appropriate way, 32–33
- Condylar axis, mandible rotating around, 66
- Condylar changes, skeletal and occlusal asymmetries and, 165
- Condylar guidance, angle of anterior guidance vs. angle of, 94–95
- Condylar inclination of articulator
- accurately adjusting by verifying wear facets on teeth match up during excursive movements of articulator, 53
- wax-up, setting, 52
- Condylar position, TMJ diagnosis and, 64–66
- Condylar replacement in past
- anterior retracted photographs of provisionals, 169
- anterior retracted view of lower completed restorations against upper provisionals, 169
- articulated diagnostic casts at time of exam approximately two years after surgery to place a prosthetic condyle and ramus on right side, 168
- buccal retracted photographs of completed restorations (gold will allow easier occlusal modification as times goes on), 169

- diagnostic wax-up: goal is to keep occlusal plane on right on same horizontal plane as left side, 169
- diagnostic wax-up suggesting shallow cusp to fossa angles, 169
- due to avascular necrosis followed by posterior occlusal reconstruction, 166–170
- full mouth series taken after bite splint therapy and occlusal management, 168
- key points about case, 170
- maxillary and mandibular occlusal photographs of completed dentistry, 170
- posttreatment panoramic radiograph, 170
- pretreatment panoramic radiograph showing condyle-ramus prosthesis and bone plates and wires from prior orthognathic surgery, 168
- summary of examination and diagnosis, 166
- summary of treatment plan, 167
- summary of treatment sequence, 167
- 10 decisions, 167
- Condyle disc assembly, dissected, with lateral pterygoids attached, 42
- Condyle-fossa, pterygoid muscles relationship to, 42
- Condyles. *See also* Osteoarthritis of left TMJ
- accuracy of bite records and, 435
- Curve of Spee and, 98, 98, 99
- Curve of Wilson and, 101
- in most superior position, bite splint and, 40
- rotation and sliding motion of, 66
- Congenitally missing maxillary lateral incisors
- anterior and lateral smile photographs with maxillary lateral incisor provisionals on implant abutments and composite corrections made to maxillary central incisors, 305
- articulated diagnostic casts prior to debanding done by restorative dentist, 304
- commonplace occurrence of, 302
- diagnostic corrections completed by adding to distal surfaces of maxillary central incisors, 304
- frontal and lateral full face photos, 303
- full face photograph, approximately 1 year posttreatment, 306
- key points about case, 306
- with orthodontics to open lateral incisor space, dental implants and other aesthetic improvements, 302–306
- photographs near end of orthodontic treatment, 304
- postorthodontic casts illustrating wedge-shaped maxillary central incisors, bulky interdental papilla, and low maxillary frenum attachment, 304
- posttreatment anterior and lateral retracted photographs of completed zirconia restorations, 305
- posttreatment anterior and lateral smile photographs of definitive restorations, 305
- posttreatment radiographs of integrated implants, 305
- pretreatment maxillary and mandibular occlusal photographs, 303
- pretreatment panoramic radiograph, 304
- pretreatment retracted anterior and lateral photographs, 303
- progress panoramic provided by orthodontist to verify correct root angulations and proper spacing for dental implants, 304
- retracted anterior and lateral photographs of maxillary lateral provisional restorations, 305
- stock abutments prepared extraorally and refined intraorally with composite placed in screw access chamber, 305
- summary of examination and diagnosis, 302
- summary of treatment plan, 303
- summary of treatment sequence, 303
- 10 decisions, 302
- Congenitally missing teeth, past orthognathics/orthodontics, tooth position inconsistencies, implants, crowns, fixed partial dentures, implant-supported crowns, 143–146
- benefits of dentist being intimately involved with every step of wax-up, 145
- diagnostic wax-up photographs, 145
- finished restorations; pink porcelain used to simulate mandibular and anterior papilla, 146
- key points about case, 146
- occlusal photographs of finished restorations and posttreatment panoramic radiograph, 146
- pretreatment occlusal and buccal occluded photographs, 145
- pretreatment panoramic radiographs showing past orthognathic surgery and bone grafts, 145
- pretreatment smile and retracted photographs, 145
- provisional photographs 2 weeks after first phase, treatment completed in one surgical appointment, 146
- summary of examination and diagnosis, 143
- summary of treatment plan, 144
- summary of treatment sequence, 144
- 10 decisions, 143
- Congenitally missing upper right cuspid
- anterior and lateral photographs of definitive restorations; pink porcelain used to simulate not only papilla but also marginal gingival, 310
- anterior and lateral photographs of provisional restoration, 309
- articulated diagnostic casts done by restorative dentist prior to debanding, 309
- diagnostic wax-up taken to verify acceptability of proportions of restorations, 309
- key points about case, 310
- pretreatment anterior and lateral retracted photographs; pink porcelain will be needed on papilla, 308
- pretreatment anterior and lateral smile photographs, 308
- pretreatment occlusal photographs, 308
- pretreatment panoramic radiograph, 309
- radiograph of implant placed in maxillary right cuspid position, 309
- retracted photographs of provisional and modified implant abutment; pink composite added to distal of upper right maxillary central incisor and to simulate papilla between abutment and pontic, 309
- summary of examination and diagnosis, 307
- summary of treatment plan, 308
- summary of treatment sequence, 308
- 10 decisions, 307
- upper right lateral incisor lost in accident; implant placed in cuspid position, pink porcelain to simulate gingival, 307–310
- Continuing education, 433
- Cosmetic recontouring, angulation and other issues improved with, 84
- Craftsmanship, dentist-dental technician team and, 434
- Crepitation, temporomandibular joints and, 10, 11
- CRI. *See* Color rendering index
- Crowns, lower anterior teeth and choice of, 76
- Cup to fossa angle, lateral anterior guidance and, 102, 103
- Curve of Spee, 46, 64, 98–101
- defined, 98, 98
- disclusion of posterior teeth and design of, 98
- excessive, at location of lower right second molar, 99, 99
- final corrections of, in definitive dentistry, 100, 100
- form of, 98–99
- idealized, 98

- intracapsular and muscular components of TMJ disorder and flattening of, to degree allowed by anatomic limitations, 156
 non-ideal, 53
 occlusal reduction guides and, 100, 101
 study cast illustrating many incorrect aspects of, 99
 viewing from broader perspective, 99–100, 100
- Curve of Wilson, 46, 101–102
 bite splint and working side disclusion facilitated by, 43–44
 bite splint design and, 41
 defined, 101, 101
 disclusion of posterior teeth and design of, 98
 efficiency of masticatory process and primary benefit of, 101
 excessive, intracapsular and muscular components of TMJ disorder and, 154
 facilitation of disclusion of posterior teeth on working side in both functional and parafunctional range of motion, 101, 102
 incorrect, working side interferences on upper buccal and lower lingual cusps in functional and parafunctional range of motion, 101, 102
- Cusp pathways, during excursions following general ridge and groove direction, 90, 91
- Cusp to fossa angle, 46, 102–105
 defined, 102, 103
 determining, 103
 disclusion of posterior teeth and design of, 98
 shallower appearance of, from first bicuspid to second molar, 103, 104
 wear facet on inner incline of distobuccal cusp of lower left second molar due to balancing interference, 104, 104
 wear facets on inner incline of gold restoration on lower right second molar, 104, 104
- D**
- Dappen dish, 58, 58
- Dawson, Peter E., 26, 433
- Deep bite
 opening, and leaving anterior teeth out of contact, problematic issue with, 372
 restoration of worn lower anterior teeth in, without changing other restorations, 262–265
- Deep overbites
 anterior centric holding contacts and, 87
 more definitive horizontal holding areas needed for, 89
- Definitive occlusal therapy. *See also* T-Scan III Occlusal Analysis System
 benefit with, 15
 modifying occlusal form with reshaping only, and restoration with direct bonded composites, 47
 occlusal stressors and, 15
- Definitive occlusal therapy-equilibration, 45–50
 centric relation occlusion, goal of, 45
 fulfilling requirements of physiologic occlusion, 45–46
 indicators for, 45
 individualized approach to, 46
 purpose of, 45
 treatment modalities for, 46
 morphological design of posterior and anterior centric stops, 48–50
- Denar TMJ Tutor, 16, 16, 21, 32, 32
- Dental articulating paper, 391
- Dental career, as a journey, 433
- Dental examination, 17
- Dental history, reviewing, 6
- Dental implants, patient willingness and issues with, 276
- Dental insurance, coverage with, 433
- Dental laboratory(ies)
 prescriptions brought to, 436–437
 relationship between dentist and level of dentistry and, 433
 shared goals and, 433–434
 shade selection process for when patient sent to, 438–439
 wax-up done by, 50
- Dental restorations, predictable, dentist's role in, 434
- Dentistry. *See* People side of dentistry
 technical, emotional, and intellectual skills in, 33, 35, 35
- Dentists. *See also* Four essential skills of comprehensive dentists
 relationship between dental laboratories and level of dentistry and, 433
 shared goals and, 433–434
 role of, in predictable dental restorations, 434
- Dentition
 charting condition of, 18
 clinical examination of masticatory system and, 7, 8
 co-discovery approach and, 31
- Dentures. *See also* Fixed partial dentures; Implant-supported complete dentures; Mandibular implant bar-supported full removable denture; Partial dentures; Removable partial dentures
 bone loss and, 446
 full, changing person from, to implant-supported fixed or fixed removable case, 446–447
- Design of definitive restoration, as smaller fixed partial dentures and single units rather than a full arch splint, 365
- Diagnosis, 8
- Diagnostic blueprints (wax-up), 50–55
 benefits of, 52–55, 53
 facilitating communication process, 54
 performing clinical procedures efficiently, 54–55
 visualize form and function first, and then treatment plan, 53–54
 big picture and, 63
 cusp to fossa angle relationship to lateral anterior guidance on, 104–105, 105
 defined, 50, 50
 flowable composite for, 51, 51
 make “diagnoses, not excuses,” 55
 materials and manufacturers, 62
 putty index made over, 56, 56
 setting condylar inclination of articulator, 52
 subtle details with, 51
 technique for, 50–51
 Triad, 52
- Diagnostic casts, 5, 439–441, 440
 approved provisional models, key points about, 440–441
 articulated, 26–27
 importance of, 439
 thickness of provisional material, 441
 three versions of, 440
- Dialogue with patient, continuing, 32
- Digital impressions, 446
- Digital output voltage, T-Scan III System and, 393
- Digital photographs
 complete series, 22
 upper incisal edge position and, 82
 of various excursive pathways, diagnostic casts and, 52
- Digital photography, periodontal examination and, 17

- Direct bonded composite restorations, angulation and other issues improved with, 84
- Direct composite buildups, treatment plans sequenced over extended period of time and, 384
- Disclusion Time
defined, 399
long, problematic lateral excursion with, 408
prolonged, shortening, 428
- “Disorders of Skeletal Occlusion and TMJ Disease” (Schellhaus and Keck), 164
- Distal extension implant prosthesis
T-Scan III analysis and, 418, 420–421
articulating paper marks on installed maxillary prostheses, 421
early closure contacts on only natural teeth, 422
implant prosthesis begins to make low-force contact, 423
implant prosthesis in full contact at low-moderate force well after natural teeth reach near maximal contact, 423
mandibular left implant abutments opposing upper crowns, 421
natural teeth reach near maximal contacts, 422
opposing maxillary distal extension implant prostheses requiring “time delay” when restored with crowns, 421
- Distal proximal line angles, face of upper central incisors and, 83, 84
- Distrust issues, listening nonjudgmentally and, 371
- DO. *See* Digital output voltage
- Doppler ultrasonography, auscultation of temporomandibular joints with, 10, 10
- Double arch tray, 443
- “D” sounds, making, 97, 97
- DT. *See* Disclusion Time
- E**
- Electromyography software, computerized occlusal analysis software linked to, 421, 425, 430
- Elevator muscles, bite splint, posterior excursive interferences and hyperactivation of, 41
- Emergence contour, upper central incisors and, 84
- Eminence angle, anterior guidance angle not mathematically related to, 94
- Emotional skills, in dentistry, 33, 35
- Endodontics, harmony between temporomandibular joints, muscles, occlusion and, 26
- Envelope of function
anterior guidance and signs/symptoms of violation of, 94, 94
anterior guidance contour and, 93
chewing path, phonetic path, anterior guidance contours and, 93
- Equal intensity contact, centric stops and, 86–87
- Equilibration, definitive occlusal therapy and, 46
- Erosion, investigating etiology of, 273
- Esthetic evaluation form, 23. *See also* Aesthetics
- Excellence, laboratory technician and providing of, 433–447
- Exceptional approach, 28
- Excursive graph
T-Scan III Occlusal Analysis System, 398–400
quadrant division tool button, 399
resulting from dividing 2-D window into four quadrants, 399
- Excursive interferences, identifying with red ribbon, 21
- Excursive movement recording, T-Scan III and, 401
- Extraction and immediate implant placement
anterior and lateral retracted photographs of definitive restorations as well as posttreatment radiographs, 301
anterior and lateral smile photographs of definitive restorations, 300
- delayed loading, restoration maxillary central incisors, pink porcelain to simulate papilla, 296–301
- key point about case, 301
- maxillary and mandibular occlusal photographs; provisional was Maryland bridge type of approach, 299
- photographs after soft tissue grafting, implant abutment refinement, and new provisionals, 300
- photographs of custom abutments and provisionals with pink acrylic to simulate interdental papilla, 300
- photographs of Essex provisional, 300
- photographs taken at periodontist’s office showing immediate implant placement, 299
- pretreatment anterior and lateral retracted photographs, 297
- pretreatment anterior and lateral smile photographs, 297
- pretreatment anterior radiographs, 298
- pretreatment posterior radiographs, 299
- summary of examination and diagnosis, 296
- summary of treatment plan, 297
- summary of treatment sequence, 297
- 10 decisions, 296
- Extraoral closing muscles, palpation of, 13
- Extraoral masticatory muscles, palpation of, 13
- F**
- Facebow, holding horizontally, to capture correct orientation of maxilla, 106
- Facebow transfer, 26, 442, 444, 445, 446
- Facial embrasure, 83
- “Facial Skeleton Remodeling Due to TMJ degeneration: An Imaging Study of 100 Patients” (Schellhaus, Piper, and Omlie), 164
- Facial surfaces of teeth, 83
anterior to posterior, aesthetic occlusal plane and, 106
- Failed multiple reconstructions
after hit and slide to maximum intercuspation, 368
before and after smile photographs, with more natural, less strained upper lip, 372
articulated diagnostic casts closed to first contact in adapted centric posture arc of closure, 368
completed definitive lower dentistry refined against same upper provisional, 372
corrected cast of mandibular arch suggesting improved occlusal plane, 370
corrected provisionals suggesting less bulk of upper anterior teeth, 371
key points about case, 372
new provisionals and composite buildups of lower incisors suggesting very definitive anterior centric holding contacts, 371
original deep overbite with current condition in provisionals with opened vertical dimension and anterior overjet, 366–372
original provisionals, 371
photographs of completed upper definitive dentistry showing teeth now in harmony and with good aesthetics, 372
posttreatment panoramic radiograph, 372
pretreatment anterior retracted photographs and pretreatment articulated diagnostic casts, 368
pretreatment mandibular arch suggesting reverse Curve of Wilson, 370
pretreatment radiographs, left side, 370
pretreatment radiographs, right side, 369
pretreatment smile photograph, 368
reduction guide made out of acrylic to help correct lower current provisional intraorally, 370

- summary of examination and diagnosis, 366
 summary of treatment plan, 367
 summary of treatment sequence, 367
 10 decisions, 367
 upper cast equilibrated to corrected lower cast until anterior teeth achieve centric holding contacts, 370
- Fatigue, bruxism and, 290
- Fibromyalgia, 38
- Fixed partial dentures. *See* Mandibular anterior fixed partial denture and posterior removable partial denture with implants and Locator attachments; Maxillary complete fixed partial denture on 9 Galvano telescopic copings; Maxillary fixed partial denture supported by both teeth and implants
- Fixed partial dentures with precision removable partial denture, maxillary; mandibular bar-supported complete denture, 331–336
- Fixed-removable reconstruction on natural teeth, well-designed, as long-lasting and aesthetic solution, 324
- Flowable composite, for diagnostic blueprint (wax-up), 51, 51
- Force percentage of tooth, T-Scan III and, 394–395
- Force vs. time graphing, T-Scan III and, 396
- 4-handed centric relation recording, T-Scan III and, 401, 401
- Four-part comprehensive evaluation
 case for, 5
 clinical system-based masticatory system examination, 6, 8–9
 complete picture in, 6
 details of, 5–6
 initial conversation, 6, 8
- 4 quadrants, for treatment plan, 33, 35
- Four skills of comprehensive dentists, 37–62
 bite splint therapy, 37, 38–44
 definitive occlusal management, 37, 45–50
 diagnostic blueprint (wax-up), 37, 50–55
 provisionalization, 37, 55–62
- Freece, Tom, 29
- Frustrating approach, 29
- Full mouth reconstruction
 buccal occluded photographs of provisional restorations; lower right fixed partial denture provisional is Ribbond reinforced, 382
 completed definitive restorations, 383
 completed dentistry with centric stops marked and anterior guidance functional movements marked, 384
 completed maxillary posterior definitive restorations and new maxillary anterior provisionals after repreppling several weeks after crown-lengthening surgery, 383
 with crown-lengthening surgery, extractions, single crowns, veneers, and fixed partial denture, 379–384
 diagnostic wax-up photos showing incisal edge changes, contour improvements, and occlusal plane corrections, 382
 first phase of provisionalization, 382
 key points about case, 384
 mandibular posterior definitive restorations and maxillary anterior teeth provisionalized, 383
 occlusal photographs of diagnostic wax-up, 382
 photographs after maxillary posterior crown-lengthening surgery completed, 383
 pretreatment anterior and lateral retracted photos showing uneven upper and lower anterior incisal edges, resulting in traumatic anterior guidance movements, 381
 pretreatment anterior and lateral smile, 381
 pretreatment buccal occluded and occlusal photographs, 381
 pretreatment lingual photographs suggesting extensive recurrent decay, biologic width violation and drifting of teeth, 381
 pretreatment panoramic radiograph, 382
 summary of examination and diagnosis, 379
 summary of treatment plan, 380
 summary of treatment sequence, 380
 10 decisions, 379
 Full range of motion, right and left, 364
 Future breakdown of teeth and periodontium, preventing, 5
- ## G
- Galvano copings. *See also* Maxillary complete fixed partial denture on 9 Galvano telescopic copings
 intimate fit of, stability and clasplless retention with, 341
 on natural teeth and nonremovable overstructures, mandibular telescope case, 337–341
- Gender, shade-taking ability and, 437
- George Taub Rubber Sep, 56–57
 phone and website, 62
 tooth preparations painted with, 57, 57
- Gingival curvature, peak of, slightly to distal of center, 84, 84
- Gingival emergence profile, manipulation of, for tissue support, cleanability and to lead way to properly designed facial contours, 86
- Gingival margins, of central incisors and cuspids, 85
- Ginglymo-arthroal joints, 10
- Glenoid fossa
 with condyle disc assembly removed, showing medial wall and posterior slope of articular eminence, 42
 TMJ diagnosis and condyles in most superior position within, 65, 66
- Glossary of Prosthodontic Terms*, 45, 55, 86, 91
- Goals, of co-discovery examination, 30
- Golden proportion, upper central incisors and, 82–83, 83
- Guide to Accreditation Photography, A*, 438
- ## H
- Habitual Force Pattern (HFP)
 Number 1, 403
 Number 2, 403
 Number 3, 403
 Number 4, 404
 Number 5, 404
 Number 6, 404
 problematic, treating with computer-guided force corrections, 428
 facial view of patient, 429
 noncentered posterior right HFP pattern with 3-D view showing excessive force in 1st and 2nd molar region, 429
 observable wear on mandibular right teeth affected by noncentered right posterior HFP, 429
 postoperative corrected and centered HFP pattern, 430
 recording with T-Scan III, 402
- Hinge rotation, condyle and, 66
- Hope, patient arriving at place of, 371
- Hue, 438
- ## I
- Imaging, 5, 6, 22, 25
- Immediate Complete Anterior Guidance Development (ICAGD)
 enameloplasty procedure
 shortening prolonged Disclusion Time with, 428
 to .263 seconds; after D at muscle shutdown, 427

- to .263 seconds, intercuspatation ends and right excursion commences at C, 427
- to .263 seconds; midright excursion after .127 seconds, 427
- Immediate posterior disclusion, physiologic occlusion and, 46
- Implant cases, Ribbond reinforcement in, 58, 60
- Implant model, provisionals and, 60
- Implant platform, subgingival, “viewing slot” on lingual of implant site, 447
- Implant restorations. *See also* Complete implant-supported restorations
 - emergence contour and, 84–85
- Implant-retained restorations, final, on model and in patient’s mouth, 441
- Implants. *See also* Dentures; Extraction and immediate implant placement; Implant-supported complete dentures; Nonremovable maxillary implant restorations; Removable implant-supported restoration with natural teeth
 - longevity results for, 415
- Implants in aesthetic zone, 289–312
 - congenitally missing maxillary lateral incisors, orthodontics to open lateral incisor space, dental implants, 302–306
 - congenitally missing upper right cuspid; upper right lateral incisor lost in accident; implant placed in cuspid position, pink porcelain to simulate gingival, 307–310
 - extraction and immediate implant placement, delayed loading, restoration maxillary central incisors; pink porcelain to simulate papilla, 296–301
 - hopeless maxillary central incisor transitioned to implant-supported restorations with crowns on remaining incisors along with occlusal therapy, 290–295
 - maxillary central incisor extracted and replaced with dental implant, delayed placement, and delayed loading, 311–312
- Implant-supported complete dentures, 349–358
 - maxillary extensive bone graft followed by implant-supported bars and bar-supported overdenture; flange needed for lip support, 350–354
 - severe maxillary and mandibular resorption; maxillary bone grafting; maxillary and mandibular implant-supported bar and bar-supported dentures, 355–358
- Implant-supported restoration, patient not wishing to undergo, 324
- Implant survival rates, 5-year, 415
- Impression materials, 434–435
 - seasonal change and material storage, 435
 - time-of-day effects on, 435
- Impression tray “hand off,” tips for, 435
- Impressions, aesthetic and functional success and, 442
- Incisal embrasures
 - formation of, 83
 - properly designed, 83
- Initial conversation, purpose of, 6
- Initial evaluation letter, 34
- Initial interview, 5
- Initial pre-clinical interview, in four-part comprehensive evaluation, 6, 6, 8
- Inside-out movement, 46
- Instability, temporomandibular joints and, 10
- Intellectual skills, in dentistry, 33, 35
- Interferences, excursive, identifying with red ribbon, 21
- Intracapsular and muscle disorder
 - diagram illustrating maxillary to mandibular anterior tooth-to-tooth relationship showing changes made, 160
 - incisal plane sloping to the left, 159
 - key points about case, 161
 - maxillary anterior lingual porcelain veneers, 161
 - posttreatment articulated diagnostic casts, 160
 - posttreatment panoramic radiograph, 161
 - pretreatment articulated diagnostic casts, 159
 - pretreatment transcranial radiographs showing left condyle being significantly smaller than right condyle, 159
 - recontoured and reshaped lower anterior fixed partial denture, 160
 - resolution with bite splint therapy and occlusal reconstruction with maxillary lingual porcelain veneers, 157–161
 - significant improvement in signs and symptoms quickly occurring with maxillary bite splint, 160
 - slanted wear on lower anterior teeth precluding to distalizing mandible, 159
 - summary of examination and diagnosis, 157
 - summary of treatment plan, 158
 - summary of treatment sequence, 158
 - 10 decisions, 157
- Intracapsular and muscle disorder with resultant occlusal plane asymmetry
 - articulated diagnostic casts corrected with equilibration and correcting lower left Curve of Spee, 164
 - key points about case, 165
 - photos of provisional restoration suggesting improved Curve of Spee and disclusion in protrusive and right lateral excursion, 164
 - pre- and posttreatment photographs showing reshaping of upper lateral incisors and bonding done to close lower spaces, 165
 - pretreatment articulated casts suggesting severe left side balancing interference in right lateral excursion, 164
 - pretreatment panoramic radiograph showing left condylar changes, 164
 - pretreatment photos illustrating facial asymmetry and aesthetic plane sloping to left, 164
 - pretreatment retracted anterior photographs suggesting sloping occlusal plane, 164
 - pretreatment transcranial radiograph suggesting left side alterations and significant asymmetry with right side, 164
 - resolved with bite splint therapy and occlusal therapy with restoration on lower left, 162–165
 - studies finding very high degree of correlation between facial asymmetries, occlusal asymmetries, and TMJ changes, 164
 - summary of examination and diagnosis, 162
 - summary of treatment plan, 163
 - summary of treatment sequence, 163
 - 10 decisions, 163
- Intracapsular and muscular components of TMJ disorder
 - articulated diagnostic casts after goals of bite splint therapy accomplished, 155
 - bite splint therapy followed by occlusal therapy and full reconstruction for, 162–166
 - casts trial equilibrated and vertical dimension closed slightly from first point of contact, 155
 - key points in case, 156
 - lower anterior provisionals and definitive restorations, 155
 - lower posterior restorations with Curve of Spee flattened to degree allowed by anatomic limitations, 156
 - posttreatment maxillary occlusal view and buccal occluded views, 156
 - preoperative frontal and smile photos suggesting wear from bruxism, 154
 - preoperative lingual views of all quadrants, 155

preoperative maxillary and mandibular occlusal views suggesting wear and tear on teeth and restorations, 155
 preoperative panoramic radiograph suggesting condylar osseous changes, 155
 preoperative retracted anterior and buccal views, suggesting excessive lower curve of Wilson, 152, 154
 summary of examination and diagnosis, 152
 summary of treatment plan, 153
 summary of treatment sequence, 154
 10 decisions, 153
 upper anterior crowns completed, 156
 upper posteriors completed in last step of treatment plan, 156
 Intracapsular issues, temporomandibular joints and, 11–12
 Ivoclar Sil-Tech Putty, phone and website, 62

J

Jaw relationship records, making, 435–436
 Jaw-to-jaw relationships, articulated diagnostic casts and, 65

K

Keck, R., 164

L

L. D. Pankey Institute, 433
 Laboratory soft tissue models, 447
 Lactic acid buildup, 13, 17
 Lateral anterior guidance
 cusp tip to fossa angle steeper than, 104
 cusp to fossa angle and role of, 102, 103
 cusp to fossa angle relationship to, viewing casts from broader frontal perspective, 104–105, 105
 Lateral excursions
 problematic with long Disclusion Time
 at excursive commencement, 409
 late into group function, 410
 left excursion with visible group function, 409
 during ongoing group function, 410
 Lateral incisors, missing, first choice with, 306
 Lateral pole
 changes in temporomandibular joints, 10, 11
 palpation of, TMJ examination, 9, 9
 Lateral pterygoid area, palpation of, 14, 14
 Lateral pterygoid provocation test, 16, 16
 Lateral pterygoids
 attached to condyle disc assembly, 42
 bite splint adjustment and, 40
 inside-out movement and, 46
 Leanear Shade Guide, 438
 Left lateral excursive movements, measuring, 10
 Limited treatment, decisions related to, 262, 265
 Lincoln, Abraham, 35
 Lingual anterior guidance contours, signs and symptoms of envelope of function violation and, 94, 94
 Lipping, 97
 Listening, nonjudgmentally, 30, 371
 Load-bearing capacity, of temporomandibular joints, 11, 11
 Locator abutments, for added support and retention for removable partial dentures, 321
 Locator attachments, combination mandibular fixed anterior-removable posterior reconstruction with, 319–322
 Long axis of central incisors, smile and, 83
 Long Disclusion Time, excursive movement recording with T-Scan III and, 401

Longevity results, for implants, 415
 Lower anterior incisal plane, uneven and irregular, restored to more idealized forms with porcelain veneers, 76
 Lower anterior restorations, anatomic form of, showing incisal edge outlined by lingual incisal line angle and labial incisal line angle, 75
 Lower anterior teeth
 amount of display, with lip at rest, 76
 anatomic and functional landmarks for, 75
 collective evaluation of, 75–76
 migration of, reason for, 74
 reshaping and simple restorations for, 76
 thought process and decision tree regarding treatment options for, 77
 without stable centric holding contacts, 75
 worn, to create undesirable lower anterior or anatomic form, 75
 Lower bite splint, 40
 Lower incisal edges
 anatomy and position, 75
 as key determinants of anterior guidance, 91
 position of, 74–76
 protruded edge-to-edge position in anterior guidance, 96, 97
 Lower reconstruction with lower left being implant-supported;
 temporomandibular disorder managed, 129–132
 articulated cast of provisionals, 132
 contour of definitive restoration verified with putty index, 132
 to eliminate impingement on neutral zone, implants needed to be placed more to the buccal, 130
 important neutral zone consideration affecting design; upper reconstruction landmarks acceptable, 129–132
 key points about case, 132
 lower provisional restorations, 130
 occlusal and anterior retracted photographs of completed restorations, 132
 photographs of provisionals on implants, 130
 pretreatment articulated diagnostic casts showing premature occlusal contacts on right side, 130
 pretreatment radiographs suggesting many guarded teeth due to large posts and cores, 130
 putty index capturing provisional contours and trimmed to visualize provisionals, 132
 putty index on solid cast of implant abutment preparations suggesting minimal clearance on lingual, 132
 summary of examination and diagnosis, 129
 summary of treatment plan, 130
 summary of treatment sequences, 130
 10 decisions, 129

M

Magnetic resonance imaging, 22
 Mandible
 Curve of Spee and movement of, 98
 cusp movement pathways during excursive movements of, 90, 91
 opening of, in an arc, 67
 Mandibular anterior fixed partial denture and posterior removable partial denture with implants and Locator attachments
 anterior and lateral retracted photographs of definitive dentistry, 346
 anterior and lateral retracted photographs of provisionals, 345
 anterior and lateral smile photographs maxillary definitive dentistry over cemented telescope copings, 346
 key points about case, 347

- mandibular anterior definitive fixed partial denture and Locator abutments attached to implants along with initial maxillary provisional, 345
- mandibular removable partial denture in place attached to Locator abutments, 346
- mandibular removable partial denture with Locator attachments in place, 346
- maxillary cast with telescope copings on 6 natural teeth, 346
- maxillary occlusal photograph of preparations and radiographs of mandibular implants 3 weeks postop, 345
- maxillary reconstruction, telescope case with 1 dental implant included with 6 teeth, 342–347
- occlusal photos of definitive dentistry with maxillary dentistry cemented over telescope copings and lone implant crown with retrievable cement, 346
- photographs of corrections made on articulated diagnostic casts, 344
- photographs two weeks after initial provisionalization, 345
- posttreatment panoramic radiograph, 347
- pretreatment anterior and lateral retracted photos showing canted lower incisal plane and upper posterior aesthetic plane, 343
- pretreatment anterior and lateral smile, 343
- pretreatment buccal occluded and occlusal photographs, 344
- pretreatment lingual mirror photographs, 344
- pretreatment panoramic radiograph, 344
- summary of examination and diagnosis, 342
- summary of treatment plan, 343
- summary of treatment sequence, 343
- 10 decisions, 342
- Mandibular arch, bite splint for, 39–40
- Mandibular bar-supported complete denture, maxillary fixed partial dentures with precision removable partial denture, 331–336
- Mandibular cast, 26
- Mandibular excursions, setting condylar inclination of articulator and, 26, 26
- Mandibular fixed anterior-removable posterior reconstruction combined with Locator attachments, 319–322
 - diagnostic wax-up of nonremovable part of restoration, 321
 - key points about case, 321
 - lower diagnostic cast for patient to see, with all teeth removed except ones to be saved, 321
 - posttreatment photographs showing removable partial denture with one implant retained Locator abutment on each side to stabilize and better retain the partial, 321
 - posttreatment photographs with removable partial denture in place, 321
 - pretreatment articulated diagnostic casts, 321
 - pretreatment lateral anterior and buccal posterior photographs, 320
 - pretreatment maxillary and mandibular photographs suggesting severe resorption of residual ridges, 320
 - pretreatment panoramic radiograph, 321
 - pretreatment smile and retracted photographs suggesting lower occlusal plane issues, 320
 - summary of examination and diagnosis, 319
 - summary of treatment plan, 320
 - summary of treatment sequence, 320
 - 10 decisions, 319
- Mandibular implant bar-supported full removable denture conversion of, to nonremovable restoration to improve comfort of neutral zone and phonetics, 240–243
- implant-supported bar screwed to place on implant abutments, 242
- implants with abutments for screw-retained bar, 242
- key points about case, 243
- occlusal photograph of completed mandibular restoration suggesting natural size, contours, and position, 243
- photograph after two additional implants placed and new abutments prepared for nonremovable restoration, 242
- pretreatment condition, 242
- pretreatment radiograph of implants and bar, 242
- provisional nonremovable restoration in place, 242
- putty indices in place on solid cast of definitive implant abutments, 242
- smile and retracted photographs of completed restoration, 243
- summary of examination and diagnosis, 240
- summary of treatment plan, 241
- summary of treatment sequence, 241
- 10 decisions, 240
- underside of removable prosthesis with metal reinforcement and attachments on distal extension bar and lingual button, 242
- Mandibular orthognathic surgery and chin implant
 - additional diagnostic corrections done on articulated diagnostic casts, 253
 - key points about case, 255
 - postorthognathic anterior and lateral smile photographs showing more aesthetic maxillary anterior tooth-to-lower lip relationship, 254
 - postorthognathic occlusal photographs and panoramic radiograph, 254
 - postorthognathic treatment anterior and lateral retracted photographs showing ideal maxillary to mandibular anterior tooth-to-tooth relationship, 254
 - postrestorative anterior and lateral retracted photographs showing ideal aesthetics and functional relationships, 254
 - posttreatment panoramic radiograph; crowns, endodontics, chin implant, 255
 - pretreatment anterior and lateral retracted photographs suggesting class 2 orthodontic relationship with excessive overjet, 251
 - pretreatment anterior and lateral smile suggesting protruded maxillary anterior teeth due to retruded mandible, 251
 - pretreatment buccal occluded and occlusal photographs, 252
 - pretreatment cephalometric radiograph suggesting protruded maxillary incisors and steep mandibular plane angle, 253
 - pretreatment panoramic and periapical radiographs illustrating condylar changes, tipped molars, multiple restorations, and endodontic therapy with large posts, 252
 - summary of examination and diagnosis, 250
 - summary of treatment plan, 251
 - summary of treatment sequence, 251
 - 10 decisions, 250
 - TMJ disorder managed during treatment; posterior restorative dentistry including implants, 250–255
 - TMJ resolved early on; useful type of anterior deprogrammer splint used during orthodontics, 254
- Mandibular orthognathic surgery in past
 - completed equilibration, posterior restorations, and anterior composites, 181
 - to correct maxillary to mandibular malrelationship caused by condylar degeneration, 178–181
 - diagnostic wax-up through various excursions, 181
 - key points about case, 181
 - occlusal photographs of completed dentistry, 181
 - pretreatment anterior and lateral retracted photographs suggesting incomplete anterior coupling, 180
 - pretreatment anterior and lateral smile photographs suggesting subtle anterior smile line, 180

- pretreatment occlusal and buccal occluded photographs suggesting incomplete coupling on left side, 180
- pretreatment panoramic radiograph suggesting significant remodeling and asymmetry on left condyle, 180
- summary of examination and diagnosis, 178
- summary of treatment plan, 179
- summary of treatment sequence, 179
- 10 decisions, 179
- trial equilibration and diagnostic wax-up showing improved maxillary to mandibular occlusal relationships, 180
- Mandibular splint, with shallow, flat anterior guidance platform, 43
- Marx, R. E., 166
- Masticatory system
- bite splint design and anatomy/physiology of, 41
 - examination of
 - as circular process, 30–31
 - clinical, 7
 - comprehensive, 6
- Masticatory system restorative dentist, 4 essential skills needed by, 37
- Matameric effect, 437
- Material choices, explosion in, 433
- Materials, risk of failure with, 441–442, 442t
- Materials selection, 441–442
- Maxillary arch, bite splint for, 39–40
- Maxillary and mandibular dental reconstruction
- with four dental implants replacing unrestorable teeth; impaired aesthetics due to recession handled with grafts and all porcelain restorations, 216–219
 - key points about case, 219
 - photographs of completed dentistry showing porcelain to zirconia restorations; and posttreatment panoramic radiograph, 219
 - photographs of trial equilibration/diagnostic wax-up, 218
 - pretreatment articulated diagnostic casts showing first contact in arc of closure and after hit and slide to maximum intercuspation, 218
 - pretreatment occlusal photographs and full mouth radiograph series, 218
 - pretreatment smile and retracted photographs showing recession, uneven gingival levels, uneven mandibular incisal plane, and reverse Curve of Wilson, 217
 - summary of examination and diagnosis, 216
 - summary of treatment plan, 217
 - summary of treatment sequence, 217
 - 10 decisions, 216
 - various stages of provisionalization, implant placement, and grafting, 219
- Maxillary and mandibular implant hybrid force management
- T-Scan III and, 415–416, 418
- implant hybrid posttreatment early closure contacts, 419
 - implant hybrid posttreatment end closure contacts, 420
 - implant hybrid posttreatment midclosure contact, 419
 - implant hybrid pretreatment early closure contacts, 417
 - implant hybrid pretreatment end closure contacts, 418
 - implant hybrid pretreatment midclosure contacts, 417
 - mandibular articulating paper marks at insertion, 416
 - mandibular implant abutments supporting mandibular hybrid prosthesis, 416
 - twenty-year-old implant hybrid prostheses after resurfacing with new teeth and acrylic, 416
- Maxillary and mandibular orthognathic surgery
- articulated diagnostic casts in maximum intercuspation after slide from interferences in centric arc of closure, 259
 - buccal occluded nearly an orthodontic class 1, 258
 - buccal occluded photographs showing class 1 posterior occlusal relationship, 260
 - with chin advancement; preresorative occlusal therapy with equilibration and composite additions, 256–260
 - class 1 anterior occlusal relationship, 259
 - evidence of wear from bruxism, 257
 - key points about case, 260
 - maximum intercuspation looking acceptable at first glance, 257
 - occlusal photographs showing old restorations on most all posterior teeth, 258
 - postorthodontics showing even more of a gummy smile as arches were leveled and aligned, 259
 - postorthognathic panoramic radiograph, 259
 - postorthognathics showing improved incisal edge display, lessened gummy display, and more pleasing profile, 259
 - pretreatment frontal and lateral smile photographs showing excessive tooth and gingival display and retruded chin, 257
 - pretreatment full mouth radiographic series, 258
 - pretreatment photograph of relaxed lip showing 8 mm of tooth display, 257
 - pretreatment photographs, 259
 - smile photograph showing 5 mm of gingival display, 257
 - summary of examination, 256
 - summary of treatment plan, 257
 - summary of treatment sequence, 257
 - 10 decisions, 256
 - tooth-to-tooth relationship after trial equilibration, 259
 - upper lip at free margin of gingival in a smile, 259
- Maxillary and mandibular resorption, severe
- before and after smile photos, 358
 - clear surgical mandibular stent, which is duplicate of approved diagnostic setup, 357
 - clear surgical maxillary stent, which is a duplicate of approved diagnostic setup, 357
 - completed maxillary and mandibular implant-supported bars illustrating maxillary anterior uncovered for unimpeded placement of prosthetic teeth, 358
 - dentures retained with plastic Hader clips, 358
 - key points about case, 358
 - maxillary bone grafting; maxillary and mandibular implant-supported bar and bar-supported dentures with flanges needed for lip and cheek support, 355–358
 - photographs after first surgery showing maxillary bone augmentation, 358
 - pretreatment maxillary CAT scan suggesting very narrow maxillary alveolar process and close proximity to maxillary sinus, 357
 - pretreatment anterior and lateral smile photographs, 356
 - pretreatment mandibular CAT scan suggesting adequate bone in anterior mandible but deficient bone in posterior mandible, 357
 - pretreatment maxillary and mandibular occlusal photos and pretreatment articulated diagnostic casts, 356
 - soft relined dentures, 358
 - summary of examination and diagnosis, 355
 - summary of treatment plan, 356
 - summary of treatment sequence, 356
 - 10 decisions, 355
- Maxillary anterior resorption
- significant, keep implants and bars distal to maxillary lateral incisors, 358

- significant, keep implants and bars distal to maxillary lateral incisors so as not to interfere with tooth placement and phonetics, 354
- Maxillary bar-supported removable partial denture
 anterior guidance functional movements, 329
 articulated casts of maxillary preparations against mandibular preparations, 327
 articulated casts of provisionals, both fixed and removable, 327
 articulated casts of provisionals without the removable partial dentures and articulated casts of lower preparations against upper fixed and removable provisionals, 327
 design of bar, 329
 diagnostic blueprint with corrected lower incisal plane in correct occlusion with upper right cuspid, 326
 diagnostic blueprint with provisional removable partial dentures, 326
 drawing on maxillary and mandibular photographs communicating desired design of fixed and removable aspects to technician, 328
 key points about case, 330
 lower completed dentistry, 329
 lower crowns with semiprecision removable partial denture and, 324–330
 mandibular fixed restorations against upper cast of fixed provisionals, 329
 mandibular putty index made on cast of lower fixed provisionals without removable provisionals, 328
 maxillary and mandibular completed fixed and removable dentistry showing type of predictability routinely achievable, 329
 maxillary and mandibular removable frameworks prior to placement of prosthetic teeth, 329
 maxillary fixed portion being checked with putty index of maxillary provisional restorations, 329
 maxillary removable partial denture with centric stops marked, 329
 occlusal photographs of maxillary and mandibular completed dentistry, 329
 photograph of trial “facade” with central incisors in center of face, 327
 photograph of vacuum-formed index made on cast of upper fixed and removable provisionals, 328
 posttreatment panoramic radiograph, 330
 pretreatment articulated diagnostic casts mounted in adapted centric posture arc of closure, 326
 pretreatment articulated diagnostic casts photographed in maximum intercuspation, 326
 pretreatment lingual photographs, 326
 pretreatment panoramic radiographs, 326
 pretreatment photographs of buccal occluded and maxillary and mandibular occlusal, 325
 pretreatment photographs of retracted anterior in maximum intercuspation and teeth separated, as well as maximum intercuspation with current removable partial dentures, 325
 putty index made of upper incisal edges and lingual surface made with casts in occlusion, 328
 putty index made on maxillary cast of provisionals, which then transfers to casts of preparations, 328
 summary of examination and diagnosis, 324
 summary of treatment plan, 325
 summary of treatment sequence, 325
 10 decisions, 324
 upper fixed aspect then fabricated against already completed lower restorations, 329
- Maxillary bicuspid-to-bicuspid restorations
 completed dentistry photographs, 215
 first contact in adapted centric posture arc of closure and amount of anterior opening at that point, 213
 as first part of comprehensive plan, with maxillary left central incisor implant and other discrepancies corrected with reshaping and equilibration, 210–215
 key points about case, 215
 pretreatment occlusal photographs and initial radiographs, 212
 pretreatment smile and retracted photographs, 211
 provisional photographs showing similarity of diagnostic wax-up and provisionals, 214
 summary of examination and diagnosis, 210
 summary of treatment plan, 211
 summary of treatment sequence, 211
 10 decisions, 210
- Maxillary cast, 26
 facebow mounting and, 106, 106
- Maxillary central incisor
 challenges with failing tooth in aesthetic zone, 290
 close-up photographs of changes made to lower anterior teeth, 294
 close up photographs of wear and uneven incisal edges, 292
 hopeless, transitioned to implant-supported restoration with crowns on remaining incisors along with occlusal therapy, 290–295
 key points about case, 295
 lateral smile photographs and retracted anterior photographs suggesting uneven incisal edges due to bruxism, 292
 photograph at end of first surgical appointment at periodontist office, 294
 photograph of new provisionals after implant abutment for 9 was placed, 294
 photographs following first treatment appointment which involved equilibration, composite restorations on lower anterior teeth and upper cuspids, provisionals on teeth 7-10, mandibular bite splint, 294
 photographs of preparations of teeth 7, 8, 10, and custom abutment for implant number 9, 295
 posttreatment photographs of definitive restorations for teeth 7, 8, 9, and 10 suggesting much improved gingival tissues symmetry, 295
 posttreatment photographs with teeth apart and also protrusive edge-to-edge position and right and left crossover positions, 295
 pretreatment articulated diagnostic casts, 293
 pretreatment mandibular occlusal photograph illustrating wear on lower anterior incisal edges, 292
 pretreatment microscope view photograph of compromised facial root surface, 293
 pretreatment photographs of lingual surfaces of posterior teeth, 292
 pretreatment photographs with lip at rest, slight smile, and high smile, 292
 pretreatment radiographs of anterior teeth suggesting compromised root integrity of tooth 9, 293
 second set of articulated diagnostic casts equilibrated in centric relation arc of closure until there were centric stops to bicuspid, 294
 summary of examination and diagnosis, 290
 summary of treatment plan, 291
 summary of treatment sequence, 291
 10 decisions, 291

- Maxillary central incisor extracted and replaced with dental implant
 delayed placement and loading with, 311–312
 immediately after provisional cementation, mesial contour ridge
 needs to extend vertically another 2mm to match left
 central, 312
 key points about case, 312
 mesial contours are extended laterally, 312
 photograph of the prepared ceramic implant abutment, 312
 pretreatment retracted photograph and radiograph; Essex type
 provisional used, 312
 provisional made on cast made from impression of implant
 abutment, 312
 smile and retracted photograph of completed restoration, 312
 summary of examination and diagnosis, 311
 summary of treatment plan, 312
 summary of treatment sequence, 312
 10 decisions, 311
- Maxillary complete fixed partial denture on 9 Galvano telescopic
 copings
 anterior and lateral photographs of definitive dentistry, 389
 anterior and lateral retracted photographs illustrating facia margin
 decay repair, 387
 anterior and lateral retracted photographs of definitive dentistry;
 precise, very thin Galvano telescopic copings do not require
 bulk in fixed partial denture overstructure; subtle use of
 pink porcelain, 390
 anterior and lateral retracted photographs of provisional
 restorations, 389
 anterior and lateral smile photographs of provisional restorations,
 389
 buccal occluded and occlusal photographs, 387
 Galvano telescopic copings cemented with definitive cement,
 389
 key points about case, 390
 with mandibular anterior fixed partial denture on 4 Galvano
 copings, 385–390
 pretreatment anterior and lateral smile, 386
 pretreatment articulated diagnostic casts closed to first contact in
 adapted centric posture arc of closure, 388
 pretreatment radiographs; blade implant and restoration is 20+
 years old, 387
 summary of examination and diagnosis, 385
 summary of treatment plan, 386
 summary of treatment sequence, 386
 10 decisions, 385
 trial equilibration and diagnostic wax-up, 388
- Maxillary extensive bone graft followed by implant-supported bar and
 bar-supported overdenture
 after bite splint therapy and at vertical dimension of first contact in
 adapted centric posture arc of closure, 353
 anterior retracted photo suggesting uneven incisal plane higher
 vertically than posterior occlusal plane, 352
 completed implant bar-supported maxillary complete denture,
 354
 completed lower fixed-removable and upper complete denture,
 353
 denture retained onto implant bar with 4 Hader clips, 354
 flange needed for lip support, 350–354
 four most recent maxillary prostheses, 352
 key points about case, 354
 mandibular bite splint made and adjusted over time in arc of
 closure with condyles seated, 353
 maximum intercuspation after hit and slide, 353
 much improved anterior tooth-to-tooth functional relationship, 354
 observation of bite splint over time is informative about
 parafunctional habits, 353
 photograph of results of years of dentistry trying to deal with loss
 of teeth, loss of supporting bone and worsening TMJ
 disorder, 352
 posttreatment panoramic radiograph, 354
 pretreatment articulated diagnostic casts, 353
 pretreatment panoramic radiograph, 352
 six weeks after bone grafts, upper anterior “facade” made for
 aesthetics only, 353
 summary of examination and diagnosis, 350
 summary of treatment plan, 351
 summary of treatment sequence, 352
 10 decisions, 351
 upper bone grafts using hip as donor bone were done in posterior
 maxilla followed by 8 implants, 353
- Maxillary extractions, immediate implant placement, and immediate
 loading
 anterior and lateral smile photographs and anterior and lateral
 photographs of completed restoration, 239
 anterior retracted photograph about one month postsurgery,
 238
 with complete nonremovable zirconia restoration with pink
 porcelain, 237–239
 definitive impressions made of implant abutments after they were
 secured to place; illustration of 14-unit zirconia framework,
 239
 key points about case, 239
 new provisional after definitive implant abutments were placed,
 239
 postsurgery panoramic radiograph of maxillary dental implants and
 temporary abutments, 238
 pretreatment panoramic radiograph, 238
 pretreatment photograph illustrating hopeless maxillary and
 mandibular dentition, 238
 summary of examination and diagnosis, 237
 summary of treatment plan, 238
 summary of treatment sequence, 238
 10 decisions, 237
- Maxillary fixed partial denture supported by both teeth and implants
 along with other maxillary and mandibular implant-supported
 crowns and tooth-supported crowns and fixed partial
 dentures, 132–137
 anterior retracted and occlusal photos of first provisional
 restoration, 136
 completed upper and lower restorations, 136
 design of upper restoration, 136
 diagnostic blueprint showing occlusal plane changes and increase
 in length of central incisors, 136
 key points about case, 138
 periodontium as maintainably healthy with generalized grade 1
 mobility, 135
 posttreatment panoramic radiograph showing sinus graft, 137
 posttreatment periapicals, 137
 preoperative articulated diagnostic casts suggesting occlusal plane
 issues, 134
 preoperative occlusal and buccal photographs, 134
 preoperative posterior radiographs showing generalized grade 1
 mobility and sinus anatomy, 135
 protrusive end-to-end photograph and anterior retracted
 photograph after provisional modification from upper
 surgery, 136

- seven-year follow-up radiographs, 138
- summary of examination and diagnosis, 132
- summary of treatment sequence, 134
- summary treatment plan, 134
- 10 decisions, 132
- Maxillary fixed partial dentures with precision removable partial denture; mandibular bar-supported complete denture, 331–336
 - anterior and lateral smile photographs of definitive dentistry showing refined occlusion, 335
 - completed maxillary dentistry with and without removable partial denture; retention provided with Dawson D 2.7 attachment, 335
 - definitive maxillary fixed partial dentures and maxillary and mandibular removable restoration, 335
 - detailed mandibular diagnostic blueprint showing gold copings and bar on remaining three teeth and removable overdenture, 334
 - detailed maxillary diagnostic blueprint illustrating tooth preparations, provisional fixed restorations and prototype of removable partial denture, 334
 - key points about case, 336
 - lower definitive restorations, 334
 - patient's current upper and lower all-acrylic removable partial dentures, 333
 - posttreatment radiographs, 336
 - pretreatment articulated diagnostic casts and diagnostic blueprint, 334
 - pretreatment lingual photographs suggesting failing upper restorations, 333
 - pretreatment occlusal and buccal photographs suggesting vertical dimension and lower tooth position, 333
 - pretreatment panoramic radiograph, 333
 - pretreatment smile and retracted photographs suggesting lower incisal plane issues in both vertical and horizontal dimension, 333
 - summary of examination and diagnosis, 331
 - summary of treatment plan, 332
 - summary of treatment sequence, 332
 - 10 decisions, 332
- Maxillary implant-supported bar-retained removable partial denture along with tooth-supported restorations to reconstruct occlusion and vertical dimension, 314–318
 - bar giving partial denture lateral and vertical stability but not retention; this is a Swivel-Loc attachment, 317
 - buccal view of second diagnostic wax-up, 317
 - five-year posttreatment panoramic radiograph, 318
 - flange needed relative to position of anterior teeth to ridge; also position of ridge through vacuum formed index, 316
 - initial diagnostic wax-up with intent of a nonremovable restoration, 316
 - key points about case, 318
 - photograph of integrated implants and nonremovable laser-welded bar, 317
 - posttreatment anterior and lateral retracted photographs suggesting improved vertical dimension and improved incisal-gingival length of prosthetic teeth, 318
 - posttreatment anterior and lateral smile photographs, 317
 - pretreatment articulated diagnostic casts at vertical dimension of first contact in adapted centric posture arc of closure, 316
 - pretreatment occlusal and buccal photographs, 316
 - pretreatment panoramic radiograph, 316
 - pretreatment retracted photographs suggesting lack of interocclusal space, unstable left cuspid-to-cuspid relationship and lower left occlusal plane that is too low anteriorly, 315
 - pretreatment smile photographs, 315
 - second diagnostic wax-up illustrating removable approach showing nonremovable bar and removable prosthetics, 317
 - summary of examination and diagnosis, 314
 - summary of treatment plan, 315
 - summary of treatment sequence, 315
 - 10 decisions, 314
- Maxillary periodontal-restorative reconstruction improving aesthetics and function
 - before and after mandibular occlusal photos, 281
 - before and after maxillary occlusal photos, 281
 - before and after smile photos, 280
 - diagnostic blueprint showing resorption in edentulous areas of 5 and 6, 279
 - first set of provisionals with finish lines well short of gingival tissues, 280
 - key points about case, 281
 - with lower posterior reconstruction following conventional surgery, bone and soft tissue grafts, covering recession, 276–281
 - photos showing progression from pretreatment to first provisional to definitive restoration, 280
 - photos taken at periodontist office showing bone graft of resorbed ridge upper right, 280
 - pretreatment articulated diagnostic casts, 279
 - pretreatment buccal occluded photographs, 277
 - pretreatment photographs showing malalignment of teeth, recession of upper anteriors, and resorption of edentulous ridge in upper right, 277
 - pretreatment radiographs, left side, 279
 - pretreatment radiographs, right side, 278
 - second maxillary provisional done after healing of all surgical procedures, 280
 - solid case and die cast sent to technician, 280
 - summary of examination and diagnosis, 276
 - summary of treatment plan, 277
 - summary of treatment sequence, 277
 - 10 decisions, 276
- Maxillary reconstruction at open vertical dimension
 - diagnostic wax-up incorporating aesthetic and functional changes approved with previous step, 202
 - to improve aesthetics, length, buccal profiles, and functional landmarks, 199–203
 - key points about case, 203
 - mirror photographs of maxillary teeth with failing restorations, 200
 - pretreatment panoramic radiograph suggesting mandibular teeth are structurally acceptable, 201
 - pretreatment smile and retracted photographs, showing reverse Curve of Wilson and severe Curve of Spee, 200
 - removable diagnostic provisional made over unaltered maxillary cast, 201
 - smile and retracted photographs of definitive dentistry, 203
 - smile and retracted photographs of diagnostic provisional in place, 201
 - smile and retracted photographs of provisional restorations, 202
 - summary of examination and diagnosis, 199
 - summary of treatment plan, 200
 - summary of treatment sequence, 200
 - 10 decisions, 199

- Maxillary reconstruction combined with extractions and periodontal surgery
- anterior and lateral photographs showing tissue improvement, 377
 - anterior and lateral smile photographs of completed restorations, 378
 - anterior and lateral smile photographs one week after gingivoplasty/gingivectomy of hyperplastic tissue, 377
 - diagnostic wax-up photos showing aesthetic and buccal profile changes, 376
 - key points about case, 378
 - maxillary occlusal photograph of provisional and illustration of cingulum design necessary for stable anterior centric holding contacts, 377
 - occlusal photographs of diagnostic wax-up showing occlusal improvements and maxillary anterior cingulum improvements for better centric stops, 376
 - periodontal architecture improved with, 373–378
 - periodontist office photographs, 377
 - photographs from lab tech verifying contours of restorations with putty index made from provisionals, 377
 - posttreatment anterior and lateral retracted photographs of completed maxillary reconstruction, 378
 - posttreatment panoramic radiograph of completed maxillary reconstruction done with zirconia restorations, 378
 - pretreatment anterior and lateral retracted photographs, 374
 - pretreatment anterior and lateral smile showing fractures and aesthetic issues, 374
 - pretreatment anterior radiographs showing endodontic and dental concerns, 375
 - pretreatment lingual photographs showing various other problems on maxillary posterior teeth, 375
 - pretreatment maxillary and mandibular occlusal photographs, 375
 - pretreatment posterior radiographs, showing root proximity issues of maxillary right first molar, 376
 - summary of examination and diagnosis, 373
 - summary of treatment plan, 374
 - summary of treatment sequence, 374
 - 10 decisions, 373
 - three months postperiodontal surgery, 377
- Maxillary telescope case: alumina copings on natural teeth and removable overstructure
- in addition mandibular telescope case: Galvano copings on natural teeth and nonremovable overstructures, 337–341
 - anterior and lateral photographs of diagnostic blueprint, 339
 - anterior and lateral retracted photographs of provisionals, suggesting improved Curve of Spee, incisal planes, vertical dimension, and anterior tooth-to-tooth relationships, 339
 - completed mandibular dentistry showing Galvano copings cemented on teeth with definitive cement, 340
 - key points about case, 341
 - lower posterior long-span provisionals reinforced with Ribbond for increasing durability, 340
 - maxillary definitive dentistry; alumina copings on maxillary anteriors, 340
 - occlusal photographs of diagnostic wax-up illustrating enhanced maxillary cingulum for improved tooth stability, 339
 - photographs of completed maxillary and mandibular dentistry, 340
 - posttreatment panoramic radiograph; endodontic therapy completed, 341
 - pretreatment anterior and lateral retracted photographs suggesting uneven gingival levels, severe Curve of Spee and other conditions, 338
 - pretreatment anterior and lateral smile photographs, 338
 - pretreatment maxillary and mandibular occlusal photographs, 339
 - pretreatment radiograph suggesting endodontic concerns and several deep restorations, 339
 - summary of examination and diagnosis, 337
 - summary of treatment plan, 338
 - summary of treatment sequence, 338
 - decisions, 337
 - two-week postoperative photographs of provisional restorations, 339
- Maxillary to mandibular malrelationship caused by condylar degeneration, past mandibular orthognathic surgery for correction of, 178–181
- Medial pole changes, in temporomandibular joints, 10–11
- Medial pterygoid muscle, palpation of, 16, 16
- Medical history, reviewing, 6
- Men, shade-taking ability and, 437
- Mesial-distal stability, centric stops and maintenance of, 86
- Mesial line angles, face of upper central incisors and, 83, 84
- Methylmethacrylate acrylic resin, cold-cured, for fabricating provisionals, 57
- Modern Materials StatStone, 56
- phone and website, 62
- Motloid ColdPac, phone and website, 62
- Motloid Company, 57
- Movie frames, T-Scan III Occlusal Analysis System, note about, 395
- MPDS. *See* Myofascial Pain Dysfunction Syndrome
- MRI. *See* Magnetic resonance imaging
- Multi-bite graphs, T-Scan III Occlusal Analysis System, 397
- Muscles
- achieving equilibrium between temporomandibular joints, occlusion and, 26, 26
 - clinical examination of masticatory system and, 7, 8
 - co-discovery approach and, 31
 - examination of, 12–17
- Muscular component of TMJ disorder managed, 360–365
- Myofascial Pain Dysfunction Syndrome
- BioPAK electromyography system (T-Scan III) analysis of, 425, 426–427, 428
 - Long Disclusion Time and, 401
 - T-Scan III and, 400
- Myriad of dental and periodontal problems causing tooth loss, vertical dimension loss, and flaring of anterior teeth, 139–146, 140
- cuspid-to-cuspid stops supporting vertical dimension of occlusion, 141
 - initial diagnostic wax-up, 141
 - key points about case, 142
 - maxillary incisors splinted with Ribbond reinforced composite and then restored with veneers, 142
 - maxillary & mandibular extractions, periodontal surgery, orthodontics, veneers, fixed partial dentures, implants, 139
 - photographs immediately after first phase, 141
 - pretreatment occlusal photographs and panoramic radiograph, 141
 - pretreatment photographs showing multitude of problems, 141
 - smile and retracted photographs of completed dentistry, 142
 - summary of examination and diagnosis, 139
 - summary of treatment plan, 140
 - summary of treatment sequence, 140
 - 10 decisions, 139

- N**
- Natural teeth. *See* Combination fixed-removable restoration on natural teeth; Reconstructions on all natural teeth
 clinical computer-guided occlusal adjustments performed upon, 411
 for provisional abutments, careful preparation and build up of abutments, and straight line used for maximum resistance and retention form, 236
 vertical and horizontal movement of, 418
- Neutral zone
 defined, 81
 mandibular implant bar-supported full removable denture converted to nonremovable restoration for improving comfort of, 240–243
 restorations fitting within limits of, 82
- Non-axial forces, axial forces *vs.*, 90
- Noncompressible bite record material, 436
- Nonincline contact, nondeflective stability of posterior teeth and, 90
- Nonremovable maxillary implant restorations
 buccal and lingual views after periodontal surgery and dental implant placement, 117
 diagnostic blueprint, buccal views, 116
 diagnostic blueprint, frontal view, 115
 diagnostic blueprint, occlusal view, 116
 key points about case, 120
 with natural teeth restorations: crowns, veneers, and fixed partial dentures, 112–120
 occlusal view after periodontal surgery and dental implant placement, 117
 posttreatment photographs, buccal and occlusal views, 117
 posttreatment photographs, frontal views, 117
 posttreatment radiographs, anterior, 119
 posttreatment radiographs, left posterior, 120
 posttreatment radiographs, right posterior, 118
 posttreatment photographs, lingual views, 117
 preoperative articulated diagnostic casts, 114
 preoperative condition, buccal and occlusal views, 113
 preoperative condition, frontal view, 113
 preoperative condition, lingual views, 113
 preoperative panoramic radiograph, right side, showing condition of right TMJ, 115
 preoperative panoramic radiographic, left side, showing condition of left TMJ, 115
 preoperative radiographs, left side, 115
 preoperative radiographs, right side, 114
 provisional restorations, occlusal and buccal views, 116
 provisional restorations prior to periodontal surgery and implant placement, 116
 provisional restorations, lingual views, 116
 summary of examination and diagnosis, 112
 summary of treatment plan, 113
 summary of treatment sequence, 113
 10 decisions, 112
- Non-Turbo Mode, BioPAK electromyography system (T-Scan III), 425
- O**
- Observations, 5
- Occlusal dental material damage, 415
- Occlusal examination, 17, 21
 purpose of, 20
- Occlusal examination with T-Scan III, 400–411
 excursive movement recording, 401
 4-handed centric relation recording, 401, 401
- habitual force pattern (HFP) recording, 401
 patient self-closure into maximum intercuspation, 401
 representative findings
 representative lateral excursion with long Disclusion Time, 408
 significant centric relation prematurity, 402
 significant unbalanced occlusion in patient self-closure, 402
- Occlusal interferences
 to centric relation arc of closure, 20
 definitive occlusal therapy and, 45
- Occlusal reduction guides, tooth preparation, Curve of Spee and, 100, 101
- Occlusal stressors
 definitive occlusal therapy and, 15
 intensity of, fluctuation in, 14, 14
- Occlusal therapy
 desired anterior centric stop design, 49
 small flat receiving area designed into occlusal surface of definitive restoration, 49
- Occlusion
 achieving equilibrium between occlusion, temporomandibular joints and, 26, 26
 clinical examination of masticatory system and, 7, 8
 co-discovery approach and, 31
 static and dynamic components in, 91
- Omlie, M., 164
- Open bite. *See* Severe anterior open bite
- Opposing landmarks, modifying, when sequencing a case, 336
- Optimal health
 maintaining, 5
 patients who place value on, 33, 35
- Orthodontics
 angulation and other issues improved with, 84
 definitive occlusal therapy and, 48
 harmony between temporomandibular joints, muscles, occlusion and, 26
- Orthognathics, 245–260
 definitive occlusal therapy and, 48
 mandibular orthognathic surgery and chin implant; managing TMJ disorder during treatment; posterior restorative dentistry including implants, 250–255
 maxillary and mandibular orthognathic surgery with chin advancement; preresorative occlusal therapy with equilibration and composite additions, 256–260
 severe anterior open bite corrected with maxillary-only orthognathics and occlusal therapy with upper incisor restorations, 246–249
 severe anterior overjet handled with occlusal/restorative treatment in lieu of, 360–365
- Osteoarthritis of left TMJ
 bite splint therapy for, plus implant-supported and tooth-supported restorations, 148–151
 diagnostic blueprint illustrating improvements in form/function, 150
 diagnostic blueprint showing improvements with occlusal plane, 150
 frontal CAT-scan view showing osseous changes and breakdown in left condyle, 150
 key points about case, 151
 panoramic radiograph showing suspicious left condyle in pain-free patient, 149
 photos taken immediately after surgery, showing crown lengthening of all upper teeth and dental implant placement, 151
 posttreatment full mouth radiographs, 151

posttreatment restorative result, 151
 preoperative articulated diagnostic casts after bite splint therapy
 goals accomplished, 150
 preoperative condition of failing reconstruction, 149
 preoperative full mouth radiographic series, 150
 severe, of left condyle, 148
 summary of examination and diagnosis, 148
 summary of treatment plan, 149
 summary of treatment sequence, 149
 10 decisions, 148
 “Outcome analysis of mandibular condylar replacements in tumor
 and trauma reconstruction: A prospective analysis of 131
 cases with long-term follow-up” (Marx), 166
 Outside-in movement, 46
 Overbite, deep, harmonizing with new reconstruction, 366–372

P

Palpation
 of lateral pterygoid area, 14, 14
 of medial pterygoid muscle, 16, 16
 muscle examination and, 13, 13–16
 temporomandibular joint examination and, 9
 Pankey, L. D., 27
 Parafunctional habits. *See also* Severe wear from parafunctional
 habits
 bruxism and, 184
 incredible wear and tear on teeth due to, 266
 observation of bite splint over time informative about, 353
 Partial dentures. *See* Combination fixed-removable restoration on
 natural teeth; Dentures; Maxillary bar-supported removable
 partial denture; Partial denture with implants and Locator
 attachments; Removable partial dentures
 Patient desires, identifying, treatment plan and dentist’s role in, 434
 Patient gloves, tooth shade selection and, 437
 Patients
 appropriately addressing concerns of, 30
 customizing and orchestrating exam for, 30–31
 relating exam findings back to concerns of, 32
 safeguarding trust given by, 27
 seeing big picture with, 32
 understanding concerns of, 29–30
 “your initial evaluation” letter to, 34
 Patient self-closure into maximum intercuspation, T-Scan III and,
 401
 People side of dentistry, 27–35
 all-important 5 questions, 27–29
 approach choice—the 4 quadrants, 33
 behavioral and communication skills, 27
 best individualized approach, 35
 codiscovery process, 29–36, 31
 address their concerns appropriately, 30
 continuing appropriately, 32–33
 customize and orchestrate exam for each patient, 30–31
 relating exam findings back to patient concerns, 32
 seeing the big picture, 32
 understand patient concerns, 29–30
 exceptional approach, 28
 frustrating approach, 29
 what people remember, 29
 Periodontal examination, 17
 Periodontal examination form, 19
 Periodontics, harmony between temporomandibular joints, muscles,
 occlusion and, 26

Periodontium
 clinical examination of masticatory system and, 7, 8
 co-discovery approach and, 31
 Perioprosthesis, 275–287
 full maxillary periodontal-restorative reconstruction improving
 aesthetics and function, 276–281
 posterior reconstruction in conjunction with conventional
 periodontal surgery; root resection; pocket elimination,
 282–287
 Phonetics
 mandibular implant bar-supported full removable denture
 converted to nonremovable restoration for improvement of,
 240–243
 significant maxillary anterior resorption, implant and bar placement
 so as not to interfere with, 358
 Photographic examination
 composite of all views in, 24
 summary of various views completed during, 25
 Photos
 of multiple shade tabs, 439
 shade mapping with, 439
 shade selection and, 438
 Physiologic occlusion, requirements of, 45, 45–46
 Pink porcelain
 as important adjunct in some implant cases, 310
 maxillary extractions, immediate implant placement, immediate
 loading, and complete nonremovable zirconia restoration
 with, 237–239
 for simulating tissue if flange not needed for lip support, 239
 Piper, Mark, 11, 164
 Piper’s classification system, for temporomandibular joints, 11–12
 Polyether impression material, 434
 Porcelain butt joint, 441, 442
 Porcelain-to-metal crown, 441
 Porcelain veneers, uneven and irregular lower anterior incisal plane,
 restored to more idealized forms with, 76
 Posterior centric holding contacts, idealized, 89
 Posterior centric stops
 idealized, on restoration and a natural tooth, 90
 locations of, 87
 morphological design of, 48, 48
 Posterior guidance, defined, 91
 Posterior-lateral area, palpation of, TMJ examination, 9, 9
 Posterior reconstruction in conjunction with conventional
 periodontal surgery; root resection; pocket elimination,
 282–287
 anterior retracted photos as well as maxillary and mandibular
 occlusal photos of completed dentistry, 287
 articulated diagnostic casts of provisional restorations, 285
 articulated pinned die cast and solid cast, 285
 completed restoration on die casts and solid casts, 286
 definitive restorations upper left and lower left, 286
 healing of periodontal surgery of upper left quadrant, 285
 initial provisionalization of upper and lower left posterior quadrants,
 285
 key points about case, 287
 lingual photos of completed dentistry, 287
 lingual photos of relined provisionals and refined tooth
 preparations, 286
 margins of restorations must carefully follow finish lines of
 preparations, 286
 posttreatment panoramic radiograph, left, 287
 posttreatment panoramic radiograph, right, 287

- precise communication with technician who will facilitate lower restorations first against upper cast of provisionals, 285
- pretreatment articulated diagnostic casts, 284
- pretreatment buccal occluded photos and maxillary and mandibular occlusal photo, 283
- pretreatment full mouth radiographic series, 284
- pretreatment lingual photos, 284
- pretreatment panoramic radiograph, 284
- pretreatment photographs of smile with lip at rest and retracted anterior views, 283
- refined provisionals after teeth had been prepared again to follow new periodontal architecture, 285
- relined provisionals after healing of surgery; upper right first molar was extracted, 286
- right and left buccal views of completed dentistry, 287
- summary of examination and diagnosis, 282
- summary of treatment plan, 283
- summary of treatment sequence, 283
- 10 decisions, 282
- Posterior reconstruction with severe interferences to centric arc of closure
- articulated diagnostic casts closed to first point of contact in adapted centric posture arc of closure, 191
 - buccal occluded photographs and maxillary and mandibular occlusal photographs of completed restorations, 192
 - key points about case, 194
 - lateral smile and retracted photographs of completed restorations, 192
 - maximum intercuspation, 191
 - occlusal reduction guides seated on cast of tooth preparations, 192
 - photographs of various excursive movements illustrating disclusion of posterior teeth, 192
 - posttreatment radiographs of completed restoration, left side, 194
 - posttreatment radiographs of completed restorations, right side, 193
 - pretreatment lingual photographs suggesting wear and tear on most all posterior teeth, 191
 - pretreatment maxillary and mandibular occlusal photographs, 191
 - pretreatment panoramic radiograph, 191
 - pretreatment photographs with lips at rest, a slight smile, and lateral smile views, 190
 - retracted anterior and buccal photographs suggesting occlusion seems acceptable, 190
 - second set of articulated diagnostic casts trial equilibrated in adapted centric posture arc of closure to vertical dimension of cuspids contacting, 191
 - silicone putty reduction guides, 192
 - summary of examination and diagnosis, 189
 - summary of treatment plan, 190
 - summary of treatment sequence, 190
 - 10 decisions, 189
- Posterior teeth, disclusion of, and correctly designed Curve of Spee, Curve of Wilson, and cusp to fossa angle, 98
- Prescriptions, dental laboratories and, 436–437
- Problems, articulating, 27–28
- Prostheses, provisional restorations and, 55
- Prosthodontic reconstruction, clinical computer-guided occlusal adjustments performed upon natural teeth and, 411
- Provisionalization, 37, 55–62
- Provisional mock-ups, creative communication relative to, 336
- Provisional restorations/provisionals
- acrylic for fabrication of, 56–58
 - defined, 55
 - doughy acrylic placed into putty matrix, 58, 59
 - fabricating, 55–56
 - matrices made for, 54
 - in mouth for 9 months, Ribbond reinforcement shown, 61, 61
 - placement of, in mouth with minimum of any extra work needed, 60
 - reinforcement of, 58, 61
 - Ribbond fiber mesh added to abutments and across edentulous areas, further stabilizing with flowable composite, 61
 - trimming, finishing, and polishing, 59
 - uncemented issue, vertical dimension opened in shallower anterior guidance case, 96, 96
 - upper anterior incisal edge position and, 80, 81, 81
- Provocation test, 13
- Pterygoid muscles, condyle-fossa relationship to, 42
- Purchase decision, thought process in 5 questions related to, 27–28, 28
- Putty index
- provisionals and, 56, 56
 - verifying for accuracy, 57
- Putty matrix, doughy acrylic placed into, 58, 59
- Q**
- Question-Based Selling* (Freece), 29
- R**
- Radiographs, 22
- Range of motion tests, temporomandibular joint examination and, 9, 9–10
- Reconstructions on all natural teeth, 359–390
- failed multiple reconstructions; original deep overbite with current condition in provisionals with opened vertical dimension and anterior overjet, 366–372
 - full mouth reconstruction utilizing crown-lengthening surgery, extractions, single crowns, veneers, and fixed partial denture, 379–384
 - maxillary complete fixed partial denture on 9 Galvano telescopic copings, 385–390
 - maxillary reconstruction combined with extractions and periodontal surgery to improve periodontal architecture, 373–378
 - severe anterior overjet handled with occlusal/restorative treatment in lieu of orthognathics, 360–365
- Referrals, for patients who place value on optimal health, 33, 35
- Reflection, 30
- Relative occlusal force, measuring with T-Scan III Occlusal Analysis System, 391
- Remembering, active participation and, 29
- Removable cases, same procedures done for, as with reconstruction cases, 336
- Removable implant-supported restoration with natural teeth, 313–322
- combination mandibular fixed anterior-removable posterior reconstruction with Locator attachments, 319–322
 - maxillary implant-supported bar-retained removable partial denture along with tooth-supported restorations to reconstruct occlusion and vertical dimension, 314–318
- Removable partial dentures
- Locator abutments ideal for added support and retention for, 321
 - maxillary bar-supported; lower crowns with semiprecision removable partial denture, 324–330

- maxillary implant-supported bar-retained, along with tooth-supported restorations to reconstruct occlusion and vertical dimension, 314–318
- no metal visible from a facial perspective, 322
- with one implant retained Locator abutment on each side for stabilizing and retention of, 322
- Reshaping and equilibration, maxillary bicuspid-to-bicuspid restorations as first part of comprehensive plan with left central incisor implant and other discrepancies corrected with, 210–215
- Restoration, critical step of placing in the mouth, 434
- Restorative dentistry, harmony between temporomandibular joints, muscles, occlusion and, 26
- Retrodiscal tissues
- bite splint with no retrusive inclines distalizing condyles and, 44
 - temporomandibular joints and, 10
- Retromolar pad, covering, for added stability, 321
- Ribbon provisional reinforcement
- durability of, for long term provisionals, 236
 - phone and website, 62
- Ribbon reinforcement, 58
- in provisional in mouth for 9 months, 61, 61
- Right lateral excursive movements, measuring, 10
- Root decay, difficulty in dealing with, 387, 390
- Rubbery soft tissue models, 447
- S**
- Schellhaus, K., 164
- Scrubs color, tooth shade selection and, 437
- Self-closure graphs, patient, T-Scan III Occlusal Analysis System, 396, 397
- Semiprecision removable partial denture, maxillary bar-supported removable partial denture; lower crowns with, 324–330
- Severe anterior open bite
- bite splint in full occlusal contact worn for 4 months to assess stability, 248
 - correction of, with maxillary-only orthognathics and occlusal therapy with upper incisor restorations, 246–249
 - key points about case, 249
 - postorthodontic equilibration fulfilled all requirements of physiologic occlusion, 248
 - postorthognathic surgery and orthodontic refinement to couple all teeth, 248
 - preoperative articulated diagnostic casts, 248
 - preoperative panoramic radiograph showing significant condylar changes, 248
 - preoperative smile and retracted view, 248
 - provisionals followed by crowns 7-10; crowns splinted to act as orthodontic retainer, 249
 - summary of examination and diagnosis, 246
 - summary of treatment plan, 247
 - summary of treatment sequence, 247
 - 10 decisions, 247
 - twelve years posttreatment, 249
- Severe wear from parafunctional habits
- anterior tooth-to-tooth relationship that does not lend itself to stable centric holding contacts, 269
 - articulated casts of verified provisionals, 270
 - buccal view of preoperative articulated diagnostic casts and wax-up, 268
 - completed lower anteriors, 271
 - desired design of anterior tooth-to-tooth relationship in deep overbite situations, 270
 - down and back movement of lower incisors as vertical dimension of occlusion is opened with resultant relationship to upper anterior teeth, 270
 - enhanced cingulum on lingual of upper anterior teeth, 270
 - key points about case, 273
 - lower anterior teeth completed first, 270
 - lower posteriors completed, 271
 - minimal effect that opening vertical dimension of occlusion has on muscle length, 269
 - pinned dies, 270
 - posttreatment of full mouth series 10 years after completion, 272–273
 - posttreatment panoramic radiograph, 271
 - posttreatment photos showing relationship of upper incisal edges to lower lip, 271
 - pre- and posttreatment occlusal photos, 271
 - pre- and posttreatment smile photos, 271
 - pre- and posttreatment retracted photos, 271
 - preoperative articulated diagnostic casts and wax-up, 268
 - preoperative occlusal photos suggesting extent of wear and its proximity to the pulps, 268
 - preoperative panoramic radiograph suggesting normal condylar anatomy, 268
 - preoperative smile and retracted photos, 268
 - prerestorative crown-lengthening surgery, 269
 - provisionalization completed, 269
 - putty index, which captures incisal edge position of verified provisionals, 270
 - putty index seated on solid cast, 270
 - restoration of, with complete reconstruction at increased vertical dimension of occlusion, 266–273
 - solid cast for interproximal contacts refinement and for soft tissue, 270
 - summary of examination and diagnosis, 266
 - summary of treatment plan, 267
 - summary of treatment sequence, 267
 - 10 decisions, 266
 - upper incisor completed, 271
 - upper posteriors completed, 271
 - verification of lower incisal edge as it seats into putty index, 270
 - verification of restorations on both pinned cast and solid cast, 270
- Shade mapping, with accompanying photo, 439
- Shades, aesthetic and functional success with, 442
- Shade selection, 436–437
- color mapping, 438
 - color of clothing, patient gloves, patient bibs, 437
 - components of color, 438
 - environment's effect on, 437, 437
 - for multiple anterior teeth, 444
 - photos, 438, 438
 - process used when patient sent to lab, 438–439
 - for restoring both arches at same time, 446
 - shade-taking ability, 437–438
 - shade-taking devices, 438
 - time-of-day effects on, 437
 - viewing the object, 438
- Shade tab, 438
- Shallowing anterior guidance contours, envelope of function and, 94, 95, 95
- Signs, 5
- Silicone putty matrix, provisionals and, 55

INDEX

Smile

- aesthetic occlusal plane and, 105
- long axis of central incisors and, 83

Soft tissue models, 447

Solutions, understanding, 28

Spee, Ferdinand Graf, 98

“S” sounds, making, 97, 97

Stable centric holding contract, purpose of, 74

Stable open bites, defined, 87

Steepened anterior guidance contours, envelope of function and, 94

Storage, of impression materials, 435

Superior compression tests, for temporomandibular joints, 9, 11, 11

Superstructure breakage, 415

Swivel-Loc attachment, web site for, 317

T

“Take home” diagnostic provisionals, 203

Technical decisions, behavioral decisions vs., some reasons for, 371

Technical skills, in dentistry, 33, 35

Technician, communicating desired tooth position to, 330

Technology, new, dental laboratories and, 433

Telescopic copings. *See also* Galvano copings

future retrievability and, 341

on natural teeth, as good option when prosthesis includes implant abutments, 347

retrievability added to case with, 390

Temperature, impression material storage and, 435

Temporomandibular joint diagnosis and condylar position, 64–66

articulated diagnostic casts and, 65

panoramic radiograph helpful in, 65

thought process and decision tree relative to, 64

Temporomandibular joint disorder resolved with bite splint therapy

anterior and lateral retracted photographs of completed restorations, 177

anterior and lateral smile photographs of completed restorations, 175

diagnostic wax-up showing aesthetic improvements, 175

first phase photographs including composite additions on all teeth prescribed by wax-up and definitive equilibration, 175

followed by definitive occlusal therapy including maxillary reconstruction and mandibular functional changes with composite, 171–177

key points about case, 177

occlusal photographs of functional changes made on articulated diagnostic casts, 175

posttreatment panoramic radiograph, 177

pretreatment anterior and lateral retracted photographs showing reverse curve of mandibular anterior plane and severe Curve of Spee at mandibular second molars, 173

pretreatment anterior and lateral smile photographs showing rotations of maxillary anterior teeth, 173

pretreatment anterior radiographs showing heavily restored maxillary anterior teeth, 174

pretreatment occlusal photographs, 173

pretreatment panoramic radiograph, 173

pretreatment posterior radiographs showing heavily restored posterior teeth, 175

radiographs showing significant alteration of condyles, 174

second phase of definitive treatment with provisionalization of maxillary anterior teeth, 175

summary of examination and diagnosis, 171

summary of treatment plan, 172

summary of treatment sequence, 172

10 decisions, 172

third and fourth phases, with provisionalization of maxillary right and left posterior teeth, 175

Temporomandibular joint disorders. *See also* Bite splints/bite splint therapy; Bruxism; Bruxism and wear reconstruction;

Intracapsular and muscular components of TMJ

definitive occlusal therapy and, 45

intracapsular and muscle disorder with resultant occlusal plane asymmetry resolved with bite splint therapy and occlusal therapy with restoration on lower left, 162–165

intracapsular and muscular components of, managed with bite splint therapy, occlusal therapy and full reconstruction, 152–156

managing muscular component of, 360–365

mandibular orthognathic surgery and chin implant and management of, 250–255

maxillary extensive bone graft followed by implant-supported bars and bar-supported overdenture after management of, 350–354

past condylar replacement due to avascular necrosis followed by posterior occlusal reconstruction, 166–170

past mandibular orthognathic surgery to correct maxillary to mandibular malrelationship caused by condylar degeneration, 178–181

resolving intracapsular and muscle disorder, with bite splint therapy and occlusal reconstruction with maxillary lingual porcelain veneers, 157–161

Temporomandibular joints

achieving equilibrium between muscles, occlusion and, 26, 26

bite splint therapy and occlusal changes in, 38

centric relation, adapted centric posture, or neither?, 12

clinical examination of masticatory system and, 7, 8

co-discovery approach and, 31

deep overbites and, 87

examination of

auscultation and, 9

Doppler sonography in, 10, 10

four-part, 9–12

palpation of lateral pole with mandible closed and posterior-lateral area with mandible open, 9

range of motion tests, 9, 9–10

osteoarthritis of left, managed with bite splint therapy, implant-supported restorations and tooth-supported restorations, 148–151

testing load-bearing capacity of, 11, 11

thought process and decision tree for examination of, 64

10 decisions, 63–108

aesthetic occlusal plane, 63, 105–108

anterior guidance, 63, 91–97

centric stop design, 86–91

Curve of Spee, 63, 98–101

Curve of Wilson, 63, 101

cuspid-fossa angle, 63, 102–105

lower incised edge position, 74–76

TMJ diagnosis and condylar position, 63, 64–66

upper incisal edge position, 77, 79–86

vertical dimension, 63, 66–74

3D diagnostic blueprints, minimizing patient disappointments and frustrations with use of, 318

Three-quarter arch impressions, 443, 444

Time Cursor, Time Line in T-Scan III Force vs. Time graph synchronized with, 421

Time Delay, establishing, 420

- Time delay principle, clinical benefits of applying, distal extension implant prosthesis and, 418, 420
- Time Line, in T-Scan III Force vs. Time graph, synchronizing with Time Cursor, 421
- Time-of-day effects
impression material storage and, 435
on tooth shade selection, 437
- Time Region Lines, T-Scan III, superimposition of, over corresponding EMG data, 421
- TMJ Tutor (Denar), 16, 16, 21, 32, 32
- Tooth shade selection, 436–437
- Tooth-supported fixed partial denture transitioned to implant-supported fixed partial denture, 121–128
after flap reflected showing bone screws that were subsequently removed, 127
along with single crowns and tooth-supported fixed partial dentures, 121–128
anterior smile and retracted photographs of new implant-supported provisional restoration, 128
completed upper restoration—frontal and lateral views and retracted view, 128
diagnostic blueprint showing improvements in mandibular incisal and occlusal planes, 124
direct impressions made of modified implant abutments and tooth preparations, 128
first phase of treatment with provisional restorations on all maxillary and mandibular teeth, 125
immediately after implant placement and closure of gingival tissues, 127
immediately after removal of provisional restoration, 127
interim panoramic radiograph showing placement of implants, 128
interim treatment panoramic radiograph showing bone augmentation segments held in place with bone screws, 126
key points about case, 128
lateral and occlusal views of provisional restorations, 125
lateral views of diagnostic blueprint showing increase in overbite, 125
lower restorations fitting precisely into putty index as verification of incisal edge and occlusal surface position, 127
maxillary arch ready for implant placement, 127
necessity behind, 121
occlusal view of diagnostic blueprint showing improvements in occlusion, tooth proportion and contours, 125
panoramic radiograph 5 years posttreatment, 128
pinned die model and solid cast articulated against upper model of provisional restoration, 126
preoperative anterior retracted photographs with teeth in maximum intercuspation and slightly apart, 124
preoperative articulated diagnostic casts, 124
preoperative lateral smile photographs suggesting concave upper lip, 124
preoperative lingual photographs suggesting inadequate contours and inadequate marginal adaptation, 124
preoperative maxillary and mandibular occlusal photographs, 124
pretreatment full mouth series radiographs, 123
pretreatment panoramic radiograph, 122
pretreatment smile photographs, 122
provisional restoration is relined, 128
putty index capturing incisal edges and occlusal surfaces of lower provisional restorations, 127
putty index used as precise guide for lower incisal edge and occlusal surface configuration, 127
- soft tissue augmentation procedures and several weeks posttreatment with provisionals modified, 126
- summary of examination and diagnosis, 121
- summary of treatment sequence, 122
- surgical photographs showing bone donor site at lower left posterior mandible, 126
- surgical stent in place, 127
- 10 decisions, 121
- while upper surgery is healing, lower definitive dentistry completed, 126
- Tooth-to-tooth relationships, articulated diagnostic casts and, 65
- Torque
in axially directed centric stops, 91
calculating, 90
- Totally edentulous patients, complete exam and articulated casts for, as for any patient, 358
- Transfer to new orthodontist, active role of restorative dentist and, 307
- Trauma, temporomandibular joint issues and, 9
- Travel distances, great, patient understanding of responsibilities and, 378
- Treatment plan
dentist's identification of patient's desires and, 434
4 quadrants for, 33, 35
negotiating, 32
visualizing form and function before, 53–54
- Treatment position, temporomandibular joints and, 12
- Triad, 52
- Triad Light Cured Provisional Material, phone and website, 62
- Trigeminal nerve, excursive movement recording with T-Scan III and, 401
- Trust, safeguarding, 27
- T-Scan III/BioEMG Integration Module, 421
- T-scan III computerized force measurement device, centric stops and, 87
- T-Scan III Occlusal Analysis System, 21, 21
BioPAK electromyography system, 424–425, 428
data after preoperative long Disclusion Time has been shortened to .263 seconds, 427
data after preoperative long Disclusion Time has been shortened to .263 seconds; midright excursion after .127 seconds, 427
desktop, 393, 424
desktop illustrating lessening of muscular hyperactivity at end of right excursive movement, 426
desktop illustrating presence of muscular hyperactivity during right excursive movement, 426
desktop illustrating presence of muscular hyperactivity when right excursive movement is commenced, 426
group function during right excursion, 425
patient with EMG leads placed on 8 head and neck muscles, 424
- clinical computer-guided occlusal adjustments performed on natural teeth and prosthodontic reconstruction, 411
- clinical uses for, 391
- examples of clinical occlusal scheme end point optimization
articulating paper marks on installed maxillary prostheses, 421
centric relation prematurity, 411, 413
disclusion time reduction with synchronized electromyography to lessen masticatory muscle hyperactivity during excursive function, 421
- distal extension implant prosthesis, 418, 420–421
- early closure contacts on only natural teeth, 422

- establishing measurable bilateral simultaneous contacts, 413, 415
- implant hybrid posttreatment early closure contacts, 419
- implant hybrid posttreatment end closure contacts, 420
- implant hybrid posttreatment midclosure contacts, 419
- implant hybrid pretreatment early closure contacts, 417
- implant hybrid pretreatment end closure contacts, 418
- implant hybrid pretreatment midclosure contacts, 417
- implant prostheses begins to make low-force contact, 423
- implant prostheses in full contact at low-moderate force well after natural teeth reach near maximal contact, 423
- mandibular articulating paper marks at insertion, 416
- mandibular implant abutments supporting mandibular hybrid prostheses, 416
- mandibular left implant abutments opposing upper crowns, 421
- maxillary and mandibular implant hybrid force management, 415–416, 418
- maxillary articulating paper marks at insertion, 416
- natural teeth reach near maximal contacts, 422
- opposing maxillary distal extension implant prostheses requiring a “time delay” when restored with crowns, 421
- postoperative balanced COF trajectory; early contacts, 415
- postoperative balanced COF trajectory; midclosure contacts, 415
- postoperative COF trajectory; near maximum intercuspation, 415
- postoperative corrected centric relation occlusion at 14.2% total force, 414
- postoperative corrected centric relation occlusion at 71% total force, 414
- postoperative corrected centric relation occlusion at 100% total force, 414
- preoperative centric relation contacts at 1.7% total force, 412
- preoperative centric relation contacts at 10% total force, 412
- preoperative centric relation contacts at 42.46% total force, 412
- preoperative centric relation contacts at 93.3% total force, 413
- twenty-year-old implant hybrid prostheses after resurfacing with new teeth and acrylic, 416
- force legend with color spectrum, 394
- HD sensor, 393
- HD sensor structural components and design, 392
- occlusal contact time and force data acquisition, 392–394
- occlusal contact time and force data display, 394
- center of force trajectory, 394
- poorly positioned and ideally positioned, 395
- centric relation manipulated closure graph, 396, 397
- customized patient arch, 400
- early closure contacts force % per tooth, 396
- excursive graph, 398–400
- excursive graph resultant from dividing 2-D window into four quadrants, 399
- force percentage by tooth, 394–395
- force vs. time graphing, 395
- individual patient arch customization, 400–401
- late closure contacts force % per tooth, 396
- midclosure contacts force % per tooth, 396
- Movie frames note, 395
- multi-bite graph, 397
- multi-bite graph of 2 patient self-closures, 399
- multi-bite table generated from 2 patient self-closures, 399
- noncustomized patient arch, 400
- patient self-closure graph, 396, 397
- quadrant division tool button, 399
- occlusal contact time and force data electronic processing, 394
- recording with, 22
- representative occlusal examination findings
- centric relation contacts at 10.8% total force, 405
- centric relation contacts at 60.5% total force, 406
- early centric relation contacts at 2.2% total force, 405
- facial view of unbalanced occlusion, 406
- HFP pattern 1, 403
- HFP pattern 2, 403
- HFP pattern 3, 403
- HFP pattern 4, 404
- HFP pattern 5, 404
- HFP pattern 6, 404
- left excursion with visible group function demonstrating long Disclusion Time, 409
- problematic lateral excursion with long Disclusion Time, 408
- problematic left excursion at excursive commencement, 408
- problematic left excursion during ongoing group function, 410
- problematic left excursion late into group function, 410
- significant centric relations prematurity, 402
- significant unbalanced occlusion in a patient self-closure, 402
- unbalanced patient self-closure at 14.1%, 407
- unbalanced patient self-closure at 52.0%, 407
- unbalanced patient self-closure at 85.9%, 408
- researched and published clinical applications of, 411
- role of, in occlusal diagnoses; occlusal examination, 400–402
- excursive movement recording, 401
- 4-handed centric relation recording, 401, 401
- habitual force pattern recording, 402
- patient self-closure into maximum intercuspation, 401
- sensor schematic, 393
- treating problematic HFP pattern with computer-guided force corrections, 428
- facial view of HFP patient, 429
- noncentered posterior right HFP pattern with 3-D view showing excessive force in 1st and 2nd molar region, 429
- observable wear on mandibular right teeth affected by noncentered right posterior HFP pattern, 429
- postoperative corrected and centered HFP pattern, 430
- T-Scan III Recording Handle with USB plug and sensor, 392
- “T” sounds, making, 97, 97
- Turbo Mode, BioPAK electromyography system (T-Scan III), 425
- ## U
- Unbalanced occlusion in patient self-closure
- at 85.9%, 408
- facial view of, 406
- at 52.0%, 407
- at 14.1%, 407
- significant, T-Scan III analysis and, 402
- Understanding patient, 30
- Upper anterior incisal edge position
- “F” and “V” sounds and, 80, 81
- provisional restorations and, 80, 81, 81
- saying letter “E” and, 80, 80
- Upper anterior incisal plane, relatively level and horizontal appearance desired for, 81–82
- Upper anterior teeth
- decision tree regarding issues in evaluation of, 78
- exciting opportunities available for, 77
- slightly increasing mesial angulation from central incisor to cuspid, 84
- Upper bite splint, 40
- Upper central incisal edges, anterior guidance and position of, 79, 79

- Upper central incisors
 aesthetic appearance of, 82
 “face” of, created by mesial and distal line angles, 84
 golden proportion and, 82–83, 83
- Upper incisal edge length, aesthetic correctness of, 85
- Upper incisal edge position, 77–86
 evaluating, 79, 80
 vertical embrasure between upper central incisors and two central incisors as mirror images of one another, 82
- Upper incisal edges
 as key determinants of anterior guidance, 91
 protruded edge-to-edge position in anterior guidance, 96, 97
- Upper right central incisor implant restoration, completed, 86
- V**
- Value, of color, 438
- Veneers, lower anterior teeth and choice of, 76
- Vertical dimension
 maxillary implant-supported bar-retained removable partial denture along with tooth-supported restorations for reconstruction of, 314–318
 opening in provisionals, in shallower anterior guidance case, 96, 96
- Vertical dimension of occlusion, 63, 66–74
 analysis related to treatment plan, 69
 anterior open bite case in which patient refused orthodontics and orthognathics, 70, 72, 72
 articulated diagnostic casts of wear case, 70
 clinical result nearly identical to result of diagnostic blueprint, 74
 closing, by shortening and equilibrating posterior teeth, 73
 diagnostic blueprint done to fulfill rest of occlusal and aesthetic parameters, 71
 diagnostic blueprint involving shortening and equilibrating posterior teeth, 73
 effect of changes in, on muscle length, 67, 68
 opening, analysis of, 273
 restored case, opening minimum amount to fulfill requirements of aesthetics and function, 71
 severe wear case, 70
 thought process and decision tree regarding changes made to, 67
- Vertical load test, 9, 11
- Virtual try-ins, 438
- Vynal polysiloxane impression material, 434
- W**
- Wax-ups, 26, 50. *See also* Articulated diagnostic casts; Diagnostic blueprints (wax-up)
 dental laboratory and value of, 439–441
 processed and used as treatment appliance during implant healing phase, 440
- Wear, investigating etiology of, 273
- Women, shade-taking ability and, 437
- Worn lower anterior teeth
 diagnostic blueprint, 265
 final lower anterior restorations, 265
 key points about case, 265
 lower anterior provisional restorations and recontouring of linguals of current upper anterior dentistry, 265
 preoperative articulated diagnostic casts of first point of contact in adapted centric posture arc of closure, 264
 preoperative buccal occluded views, 264
 preoperative lingual views suggesting rather severe Curve of Spee, 264
 preoperative occlusal photos suggesting flat to convex surfaces on lingual of upper anterior teeth, 264
 preoperative panoramic radiograph, 264
 preoperative retracted and smile photos, 264
 restoration of, in deep bite without changing other restorations, 262–265
 summary of examination and diagnosis, 262
 summary of treatment plan, 263
 summary of treatment sequence, 263
 10 decisions, 263
- Y**
- “Your initial evaluation” letter, 34
- Z**
- Zirconia, for extensive fixed framework, 239
- Zirconia restoration with pink porcelain, complete nonremovable, maxillary extractions, immediate implant placement, immediate loading and, 237–239

Keep up with critical fields

Would you like to receive up-to-date information on our books, journals and databases in the areas that interest you, direct to your mailbox?

Join the **Wiley e-mail service** - a convenient way to receive updates and exclusive discount offers on products from us.

Simply visit www.wiley.com/email and register online

We won't bombard you with emails and we'll only email you with information that's relevant to you. We will ALWAYS respect your e-mail privacy and NEVER sell, rent, or exchange your e-mail address to any outside company. Full details on our privacy policy can be found online.



www.wiley.com/email