

Essentials in Ophthalmology
Series Editor: Arun D. Singh

Ahmad A. Aref
Rohit Varma *Editors*

Advanced Glaucoma Surgery



 Springer

Essentials in Ophthalmology

Series editor

Arun D. Singh

More information about this series at <http://www.springer.com/series/5332>

Ahmad A. Aref • Rohit Varma
Editors

Advanced Glaucoma Surgery

Editors

Ahmad A. Aref, MD
Illinois Eye & Ear Infirmary
University of Illinois at Chicago
School of Medicine
Chicago, IL, USA

Rohit Varma, MD, MPH
USC Eye Institute
Department of Ophthalmology
University of Southern California
Los Angeles, CA, USA

Additional material to this book can be downloaded from <http://extras.springer.com>.

ISSN 1612-3212 ISSN 2196-890X (electronic)
Essentials in Ophthalmology
ISBN 978-3-319-18059-5 ISBN 978-3-319-18060-1 (eBook)
DOI 10.1007/978-3-319-18060-1

Library of Congress Control Number: 2015946238

Springer Cham Heidelberg New York Dordrecht London

© Springer International Publishing Switzerland 2015

This work is subject to copyright. All rights are reserved by the Publisher, whether the whole or part of the material is concerned, specifically the rights of translation, reprinting, reuse of illustrations, recitation, broadcasting, reproduction on microfilms or in any other physical way, and transmission or information storage and retrieval, electronic adaptation, computer software, or by similar or dissimilar methodology now known or hereafter developed.

The use of general descriptive names, registered names, trademarks, service marks, etc. in this publication does not imply, even in the absence of a specific statement, that such names are exempt from the relevant protective laws and regulations and therefore free for general use.

The publisher, the authors and the editors are safe to assume that the advice and information in this book are believed to be true and accurate at the date of publication. Neither the publisher nor the authors or the editors give a warranty, express or implied, with respect to the material contained herein or for any errors or omissions that may have been made.

Printed on acid-free paper

Springer International Publishing AG Switzerland is part of Springer Science+Business Media (www.springer.com)

Contents

1	Advanced Glaucoma Surgery: An Overview	1
	Ahmad A. Aref and Rohit Varma	
2	Trabecular Micro-Bypass Stent for the Treatment of Coexistent Cataract and Mild Open-Angle Glaucomas.....	5
	Wanda D. Hu and Marlene R. Moster	
3	Trabectome-Mediated Ab Interno Trabeculectomy for Secondary Glaucoma or as a Secondary Procedure	15
	Kevin Kaplowitz and Nils A. Loewen	
4	Lens Extraction in Angle Closure Glaucoma	31
	Sameer Trikha, Shamira A. Perera, Rahat Husain, and Tin Aung	
5	Gonioscopy Assisted Transluminal Trabeculotomy (GATT) for the Treatment of Adult and Developmental Glaucomas	41
	Davinder S. Grover and Ronald L. Fellman	
6	Ab-Interno Subconjunctival Glaucoma Implant for Advanced Open-Angle Glaucomas.....	51
	Alena Reznik and Rohit Varma	
7	Nonpenetrating Glaucoma Surgery	57
	Ziad Khoueir and Tarek M. Shaarawy	
8	Endoscopic Cyclophotocoagulation in the Treatment of Plateau Iris and Angle-Closure Glaucomas	73
	Robert Noecker and Shiyong Roh	
9	Ex-PRESS Miniature Glaucoma Shunt for the Treatment of Uveitic Glaucomas	77
	Evan Allan and Steven R. Sarkisian Jr.	
10	Surgical Management of Normal Tension Glaucoma.....	87
	Sarah S. Khodadadeh and James C. Tsai	
11	Glaucoma Drainage Implant Surgery Combined with Pars Plana Vitrectomy and KPro Implantation	99
	Thasarat S. Vajaranant and Ahmad A. Aref	

12	The Modified Schocket Procedure	107
	Luis E. Vazquez and Steven J. Gedde	
13	Ab-interno Bleb Needling.....	113
	Paul F. Palmberg	
14	Drainage of Choroidal Effusions	117
	Kyla M. Teramoto and Troy M. Tanji	
15	Surgical Management of Malignant Glaucoma	125
	Devesh K. Varma and Iqbal Ike K. Ahmed	
	Index.....	135

Contributors

Iqbal Ike K. Ahmed, M.D., F.R.C.S.C. Department of Ophthalmology and Vision Sciences, The University of Toronto, Toronto, ON, Canada
Trillium Health Partners, Mississauga, ON, Canada
Credit Valley Eyecare, Mississauga, ON, Canada

Evan Allan, M.D. Dean McGee Eye Institute, Oklahoma City, OK, USA

Ahmad A. Aref, M.D. Illinois Eye and Ear Infirmary, University of Illinois at Chicago School of Medicine, Chicago, IL, USA

Tin Aung, F.R.C.Ophth., Ph.D. Singapore Eye Research Institute and Singapore National Eye Centre, Singapore, Singapore
Yong Loo Lin School of Medicine, National University of Singapore, Singapore, Singapore

Ronald L. Fellman, M.D. Glaucoma Associates of Texas, Dallas, TX, USA

Steven J. Gedde, M.D. Bascom Palmer Eye Institute, University of Miami, Miami, FL, USA

Davinder S. Grover, M.D., M.P.H. Glaucoma Associates of Texas, Dallas, TX, USA

Wanda D. Hu, M.D. Miramar Eye Specialists Medical Group, Ventura, CA, USA

Rahat Husain, M.D. Res., F.R.C.Ophth. Singapore Eye Research Institute and Singapore National Eye Centre, Singapore, Singapore

Kevin Kaplowitz, M.D. Department of Ophthalmology, Stony Brook University Hospital Medical Center, Stony Brook, NY, USA

Sarah S. Khodadadeh, M.D. Center for Advanced Eye Care, Vero Beach, FL, USA

Ziad Khoueir, M.D., M.S.Ed. Department of Glaucoma, Beirut Eye Specialist Hospital, Beirut, Lebanon

Nils A. Loewen, M.D., Ph.D. Department of Ophthalmology, University of Pittsburgh, Pittsburgh, PA, USA

Marlene R. Moster, M.D. Glaucoma Division, Wills Eye Hospital, Philadelphia, PA, USA

Robert Noecker, M.D., M.B.A. Ophthalmic Consultants of Connecticut, Fairfield, CT, USA

Paul F. Palmberg, M.D., Ph.D. Bascom Palmer Eye Institute, University of Miami, Miami, FL, USA

Shamira A. Perera, B.Sc. (Hons). F.R.C.Ophth. Singapore Eye Research Institute and Singapore National Eye Centre, Singapore, Singapore

Alena Reznik, M.D. Department of Ophthalmology, USC Eye Institute, University of Southern California, Los Angeles, CA, USA

Shiyoung Roh, M.D. Lahey Clinic, Peabody, MA

Steven R. Sarkisian Jr., M.D. Dean McGee Eye Institute, Oklahoma City, OK, USA

Tarek M. Shaarawy, M.D., M.Sc. Department of Clinical Neurosciences, Ophthalmology Service, University of Geneva, Geneva, Switzerland

Troy M. Tanji, M.D. University of Hawaii John A. Burns School of Medicine, Honolulu, HI, USA

Kyla M. Teramoto, M.D. University of Hawaii John A. Burns School of Medicine, Honolulu, HI, USA

Sameer Trikha, B.Sc. (Hons), F.R.C.Ophth. Singapore Eye Research Institute and Singapore National Eye Centre, Singapore, Singapore

James C. Tsai, M.D., M.B.A. New York Eye and Ear Infirmary of Mount Sinai, New York, NY, USA

Thasarat S. Vajaranant, M.D. Illinois Eye and Ear Infirmary, University of Illinois at Chicago School of Medicine, Chicago, IL, USA

Devesh K. Varma, M.D., F.R.C.S.C. Department of Ophthalmology and Vision Sciences, The University of Toronto, Toronto, ON, Canada

Trillium Health Partners, Mississauga, ON, Canada

Credit Valley Eyecare, Mississauga, ON, Canada

Rohit Varma, M.D., M.P.H. Department of Ophthalmology, USC Eye Institute, University of Southern California, Los Angeles, CA, USA

Luis E. Vazquez, M.D. Bascom Palmer Eye Institute, University of Miami, Miami, FL, USA

About the Authors

Ahmad A. Aref, M.D. graduated from the Feinberg School of Medicine, Northwestern University, Chicago, IL, in 2006 and subsequently completed a residency at the Penn State Hershey Eye Center, Penn State University College of Medicine, and a fellowship in Glaucoma at Bascom Palmer Eye Institute, Miller School of Medicine, University of Miami. Since 2011, he has been Assistant Professor of Ophthalmology and Chief Quality Officer at Illinois Eye and Ear Infirmary, University of Illinois at Chicago School of Medicine. He is board certified by the American Board of Ophthalmology and the Royal College of Physicians and Surgeons of Canada. In 2011, Dr. Aref received an American Glaucoma Society MAPS Award, and he currently sits on the society's Multimedia Committee. He has published 25 articles in peer-reviewed journals and is a reviewer for a number of journals, including *Ophthalmology*, *JAMA Ophthalmology*, and *American Journal of Ophthalmology*.

Rohit Varma, M.D., M.P.H. graduated from Maulana Azad Medical College, University of Delhi, India, and completed fellowships in the Glaucoma Services of Wills Eye Hospital, Philadelphia, and the Doheny Eye Institute, University of Southern California School of Medicine. In 2005, he was appointed Professor (tenured) at the Department of Ophthalmology and Preventive Medicine, University of Southern California, Keck School of Medicine, Los Angeles. Since 2014, Dr. Varma has been Professor and Chairman, Department of Ophthalmology, USC Eye Institute, Keck School of Medicine, Los Angeles. During his distinguished career he has been the recipient of various honors, including the American Academy of Ophthalmology Honor Award (1998) and Senior Achievement Award (2006) and the President's Award from the Glaucoma Research Foundation (2009). Dr. Varma served on the Editorial Advisory Board of *Ophthalmology* from 1999 until 2013 and since 2010 has been an Examiner for the American Board of Ophthalmology Oral Examinations. He has published approximately 220 articles in peer-reviewed journals and edited/co-edited two books: *Essentials of Eye Care: The Johns Hopkins Wilmer Handbook* (Lippincott Raven, 1997) and *The Optic Nerve in Glaucoma* (Lippincott 1992).

Ahmad A. Aref and Rohit Varma

The current era has been described as a “Renaissance Period” in glaucoma surgical care. Our care has been revolutionized with innovative techniques and devices designed to enhance physiologic aqueous outflow pathways in patients with mild stages of glaucomatous optic neuropathy. Although these techniques in this specific patient population have deservedly taken the spotlight with regard to advancing glaucoma treatment paradigms, it is important to note similarly transformative treatment strategies for patients with late stages of the disease as well as those experiencing persistent complications in the postoperative period. This textbook aims to shed light on these strategies for a host of complex entities that may present to the glaucoma surgical consultant.

Drs. Hu and Moster describe use of a novel trabecular micro-bypass stent to access and enhance physiologic aqueous outflow pathways for the treatment of mild glaucomatous optic neuropathy (Chap. 2). In its current iteration, a

single micro-bypass stent (iStent, Glaukos Corp.) is attached to a disposable inserter. The device is currently approved for insertion in conjunction with cataract surgery. Upgrades in stent design are currently under study and will allow for multiple stents to be placed with a single inserter. Current evidence supports multiple stent insertion for enhanced aqueous outflow [1]. In addition, targeted stenting may increase rates of success by increasing chances of accessing functioning trabecular collector systems.

Drs. Kaplowitz and Loewen describe the use of the trabectome procedure (Neomedix, Inc.) for the treatment of complex angle-closure glaucomas (Chap. 3). Although typically categorized as a minimally invasive procedure with typical indications, the authors describe a technique with encouraging results for the reversal of peripheral anterior synechiae. In addition, the authors describe the use of the device after failed conventional glaucoma filtering procedures [2]. Supplemental video of the technique as performed by Dr. Nils Loewen provides invaluable instruction.

The conventional treatment paradigm for angle-closure glaucomas is currently under investigation, with lens extraction becoming a prime consideration in earlier stages of the disease. Drs. Tripathi, Perera, Husain, and Aung provide convincing evidence from anterior segment imaging studies to support this approach (Chap. 4) [3]. Indeed, the high-quality pre- and postoperative figures in this chapter reveal a marked improvement

A.A. Aref, M.D. (✉)
Illinois Eye and Ear Infirmary, University of Illinois
at Chicago School of Medicine, Chicago, IL, USA
e-mail: ahmadaref@gmail.com; aaref@uic.edu

R. Varma, M.D., M.P.H.
Department of Ophthalmology, USC Eye Institute,
University of Southern California,
Los Angeles, CA, USA
e-mail: rvarma@usc.edu

in angle crowding with presumed enhancement in trabecular outflow. The authors provide guidance for the performance safe cataract removal under challenging preexisting conditions of a shallow anterior chamber with angle closure.

Drs. Grover and Fellman describe a truly innovative technique, Gonioscopy-Assisted Transluminal Trabeculotomy (GATT) (Chap. 5). The technique involves use of the iTrack microcatheter for performance of ab-interno trabeculotomy for the treatment of adult and developmental glaucomas. Advantages of this technique include sparing of the conjunctiva and the ability to visualize safe cannulation of Schlemm's canal. The group recently reported a 39.8 and 52.7 % decrease in IOP with this technique in primary and secondary open angle glaucomas, respectively, after 12 months of follow-up [4].

Drs. Reznik and Varma describe a novel microinvasive procedure for bypass of physiologic outflow pathways (Chap. 6). The procedure is performed via an ab-interno approach, utilizing a porcine gelatin tube (XEN Gel Stent) to access the subconjunctival space. Three lumen sizes are available, with the degree of aqueous flow determined by the Hagen–Poiseuille equation. A multicentered randomized controlled clinical trial investigating the safety and efficacy of the device is currently underway.

Drs. Khoueir and Shaarawy describe non-penetrating glaucoma surgical procedures (Chap. 7). The authors note a relatively long learning curve with these techniques when compared to conventional glaucoma filtering surgeries. This learning curve may have slowed the adoption of these techniques which offer a superior safety profile when compared to trabeculectomy surgery [5]. Step-by-step instruction and supplemental video provided by the authors help to soften this learning curve for the novice while providing invaluable pearls for the experienced surgeon.

Dr. Noecker describes the use of endoscopic cyclophotocoagulation for the treatment of plateau iris and angle-closure glaucomas (Chap. 8). In a modification of the technique typically employed for open angle glaucomas, Dr. Noecker describes

treatment of the posterior aspect of the ciliary processes. This allows for pulling of the anterior processes away from the iris with subsequent angle opening. This technique, termed endocycloplasty, represents an important advance as angle-closure associated with plateau iris may persist after laser iridoplasty and/or lens extraction [6, 7].

Drs. Allan and Sarkisian describe surgical pearls for Ex-Press Mini-Glaucoma Device (Alcon Laboratories, Inc.) implantation for the treatment of complex glaucomas, including uveitic glaucoma (Chap. 9). The device may offer an advantage over conventional trabeculectomy in uveitic diseases as it is typically associated with less postoperative inflammation and anterior chamber shallowing. Supplemental surgical video by Dr. Sarkisian demonstrates key steps of the procedure.

Normal-tension glaucoma represents a challenging entity as it is often difficult to achieve significant intraocular pressure lowering from apparently moderate baseline levels. Drs. Khodadadeh and Tsai describe trabeculectomy pearls for safe achievement of these target levels (Chap. 10). The surgeons also describe their preferred topical anesthetic technique so as to reduce the risks for retrobulbar anesthesia.

The Boston Keratoprosthesis represents a landmark achievement in the treatment of corneal blindness. Unfortunately, postoperative glaucoma represents an important and vision-threatening complication after KPro implantation. Drs. Vajaranant and Aref describe a technique for combined glaucoma, pars plana vitrectomy, and KPro surgery (Chap. 11). The technique allows for posterior placement of the glaucoma implant tube in order to allow for optimal contact lens fitting and decreased risk of tube erosion. Addressing the preexisting (and likely future) glaucoma at the time of KPro implantation minimizes the risk of irreversible glaucomatous visual field loss. A recent report by the authors supports this strategy with a relatively low risk of postoperative complications [8].

Postoperative glaucoma may also develop after retinal detachment surgery. The presence of a scleral buckle makes surgical management of the condition somewhat challenging. Drs.

Vazquez and Gedde describe the Modified Schocket Procedure to manage this condition (Chap. 12). A supplemental surgical video by Dr. Aref demonstrates the procedure in an infant suffering traumatic glaucoma after prior scleral buckling surgery.

Dr. Palmberg describes an ab-interno technique for trabeculectomy revision once episcleral fibrosis has limited aqueous outflow (Chap. 13). The technique offers logistical, financial, and psychological advantages over conventional transconjunctival bleb needling. Preliminary results of the technique, as performed by Dr. Palmberg, are encouraging.

Ms. Teramoto and Dr. Tanji describe complex pathophysiology of choroidal effusions and hemorrhage (Chap. 14). The development of a postoperative choroidal hemorrhage may represent a devastating complication of ophthalmic surgery. However, appropriate management, as outlined by the authors, may allow for a successful outcome.

Drs. Varma and Ahmed describe the pathophysiology and management of malignant glaucoma (Chap. 15). Surgical techniques offer definitive therapy and include anterior or posterior iridodilatorotomy and anterior chamber reformation with intraocular lens pushback. It is important to note that core vitrectomy is not an effective stand-alone treatment. Exceptional figures in this chapter guide the reader through the appropriate surgical techniques.

Each section of the current text may serve as a stand-alone chapter for rapid reference by the practitioner during stages of surgical planning. In that regard, the text is meant to guide and assist the clinician in important surgical decision-making for complex ophthalmic conditions. At the same time, the text offers concise, clear explanations of these conditions while addressing advantages and disadvantages to various treatment strategies.

In this regard, the text serves as a valuable reference for experienced and novice ophthalmic surgeons alike.

Acknowledgements Conflicts of Interest: Dr. Aref—Consultant for New World Medical, Inc., Speaker for Alcon Laboratories, Speaker for Carl Zeiss Meditec.

Animal Studies: No animal or human studies were carried out by the authors for this article.

Informed Consent: Informed consent was not applicable for this article.

References

1. Belovay GW, Naqi A, Chan BJ, Rateb M, Ahmed IIK. Using multiple trabecular micro-bypass stents in cataract patients to treat open-angle glaucoma. *J Cataract Refract Surg.* 2012;38(11):1911–7.
2. Bussell II, Kaplowitz K, Schuman JS, Loewen NA, Trabectome Study Group. Outcomes of ab interno trabeculectomy with the trabectome after failed trabeculectomy. *Br J Ophthalmol.* 2015;99(2):258–62. doi:10.1136/bjophthalmol-2013-304717.
3. Tham CC, Leung DY, Kwong YY, Li FC, Lai JS, Lam DS. Effects of phacoemulsification versus combined phaco-trabeculectomy on drainage angle status in primary angle closure glaucoma (PACG). *J Glaucoma.* 2010;19(2):119–23.
4. Grover DS, Godfrey DG, Smith O, Feuer WJ, Montes de Oca I, Fellman RL. Gonioscopy-assisted transluminal trabeculectomy, ab interno trabeculectomy: technique report and preliminary results. *Ophthalmology.* 2014;121(4):855–61.
5. El Sayyad F, Helal M, El-Kholify H, Khalil M, El-Maghraby A. Nonpenetrating deep sclerectomy versus trabeculectomy in bilateral primary open-angle glaucoma. *Ophthalmology.* 2000;107(9):1671–4.
6. Ritch R, Tham CC, Lam DS. Long-term success of argon laser peripheral iridoplasty in the management of plateau iris syndrome. *Ophthalmology.* 2004; 111(1):104–8.
7. Tran HV, Liebmann JM, Ritch R. Iridoplasty apposition in plateau iris syndrome persists after cataract extraction. *Am J Ophthalmol.* 2003;135(1):40–3.
8. Huh ES, Aref AA, Vajaranant TS, de la Cruz J, Chau FY, Cortina MS. Outcomes of pars plana glaucoma drainage implant in Boston type 1 keratoprosthesis surgery. *J Glaucoma.* 2014;23:e39–44.

Trabecular Micro-Bypass Stent for the Treatment of Coexistent Cataract and Mild Open-Angle Glaucomas

2

Wanda D. Hu and Marlene R. Moster

2.1 Introduction

In the past few years, there has been an increasing interest in microinvasive glaucoma surgery (MIGS) procedures as they may play a novel role in the glaucoma treatment algorithm. More traditional ab externo glaucoma procedures such as trabeculectomies and glaucoma drainage devices are known to very effectively reduce intraocular pressure (IOP), but are also associated with numerous sight-threatening complications that may occur even years after surgery (e.g., bleb leak, bleb-related endophthalmitis, hypotony) [1,2]. Because of the relatively high complication rates associated with filtration procedures, practitioners often turn to medications and/or laser trabeculoplasty as first-line therapies to reduce IOP [3]. However, many patients struggle with compliance and ocular surface issues with medications [4,5], and laser trabeculoplasty may only have a limited and modest effect [6,7]. The hope is that MIGS procedures

will bridge the gap between medications and more invasive procedures for patients with mild to moderate glaucoma.

MIGS procedures utilize an ab interno approach, sparing the conjunctiva to allow for future glaucoma surgical procedures if necessary, and offer a much higher safety profile with smaller incisions and less distortion of the normal anatomy [8]. Compared to traditional filtering procedures, these procedures are often easier to adopt with fewer postoperative complications and therefore, can be utilized by both glaucoma specialists and comprehensive ophthalmologists in their armamentarium against this potentially blinding disease. Currently, there are several MIGS devices/procedures that may decrease IOP through either (1) improving trabecular outflow to Schlemm's canal (trabectome, Neomedix, Inc.; iStent, Glaukos, Corp.; Hydrus microstent, Ivantis, Inc.), (2) improving outflow through the suprachoroidal space (Cypass, Transcend Medical, Inc.; iStent Supra, Glaukos, Corp.), or (3) creating an alternative outflow pathway through the subconjunctival space (Xen Gel Stent; Aquesys, Inc.).

It is thought that the primary site of outflow resistance in primary open angle glaucoma (POAG) occurs at the juxtacanalicular component of the trabecular meshwork and the endothelial lining of the inner wall of Schlemm's canal [9–11]. A trabecular bypass stent bypasses the region of highest outflow resistance and creates a

W.D. Hu, M.D. (✉)
Miramar Eye Specialists Medical Group,
Ventura, CA 93003, USA
e-mail: wandahu@gmail.com

M.R. Moster, M.D.
Glaucoma Division, Wills Eye Hospital,
Philadelphia, PA 19107, USA
e-mail: marlenemoster@gmail.com;
marlenemoster@aol.com

direct pathway between the aqueous and Schlemm's canal. However, one study demonstrated that about one third of the outflow resistance occurs distal to Schlemm's canal and therefore, bypassing the trabecular meshwork may not reduce the IOP enough for all glaucomatous eyes [12].

The first trabecular bypass stent was first described by Speigel and Kobuch [13], who implanted a silicone trabecular bypass tube shunt via an ab externo approach in six eyes, with a significant reduction in IOP and glaucoma medications from preoperative levels. The implant was successfully implanted in five out of six eyes. All eyes showed no loss of visual acuity and a reduction of IOP or glaucoma medication use. Two of these eyes developed low diffuse filtering blebs through this ab externo approach.

The Glaukos iStent® trabecular micro-bypass stent (Glaukos Corporation, Laguna Hills, California) also bypasses the trabecular meshwork by connecting the anterior chamber to Schlemm's canal to enhance physiologic outflow, but through a titanium L-shaped stent and an ab interno approach. This device was approved by the FDA in June 2012 and is the first FDA-approved MIGS device to treat mild to moderate open angle glaucoma in conjunction with cataract surgery. Several clinical studies have been published since the first pilot study in 2007 [14], demonstrating the efficacy and safety of this device for treatment of mild to moderate glaucoma.

2.2 Anatomical Basis

2.2.1 First-Generation iStent

The iStent is a heparin-coated titanium single piece L-shaped device that measures 1.0 mm in length, 0.33 mm in high, and has a snorkel length of 0.25 mm. The snorkel diameter measures 120 μm . The iStent is the smallest medical device to be implanted in the human body and is nonferromagnetic. The canal portion is an open half-pipe body with the "closed" side lying against the

inner wall of the canal and the "open" side against the outer wall where the collector channels reside. Three retention arches fixate the device to the inner wall of Schlemm's canal. The "snorkel" sits in the anterior chamber and acts as a conduit for the aqueous to bypass the trabecular meshwork into Schlemm's canal (Fig. 2.1a). The stent comes attached to the end of a disposable inserter and is sterilized by gamma irradiation. Should the stent become dislodged into the anterior chamber during implantation, the inserter is capable of recovering the device.

The two models GTS100R and GTS100L are identical except the body faces opposite directions to assist with nasal stent placement. The GTS100R is designed for the right eye and GTS100L is designed for the left eye. The inferonasal quadrant is the preferred site for insertion as it is thought to be the area with the highest density of collector channels [15]. There are about 20–30 collector channels surrounding the globe that drain aqueous from Schlemm's canal to aqueous and episcleral veins [16].

2.2.2 Second-Generation iStent Inject®

Glaukos has recently developed a second-generation trabecular bypass stent, the iStent inject® (GTS400), which is currently CE (Conformité Européenne) marked in Europe and is undergoing clinical trials in the United States (Fig. 2.1b). This device is also a single-piece, heparin-coated, titanium device. This device is smaller than the first-generation device, measuring 360 μm in length and the conical head measuring 230 μm in width. The conical head sits in Schlemm's canal with four flow outlets, each measuring 50 μm in diameter. The trabecular meshwork holds the thinner thorax region and the flange contains an inlet orifice measuring 80 μm in diameter. Since this device is symmetrically designed, it can be used in either eye. The iStent inject is preloaded on the G2-M-IS injector which houses two stents, enabling insertion of two devices with one injector.

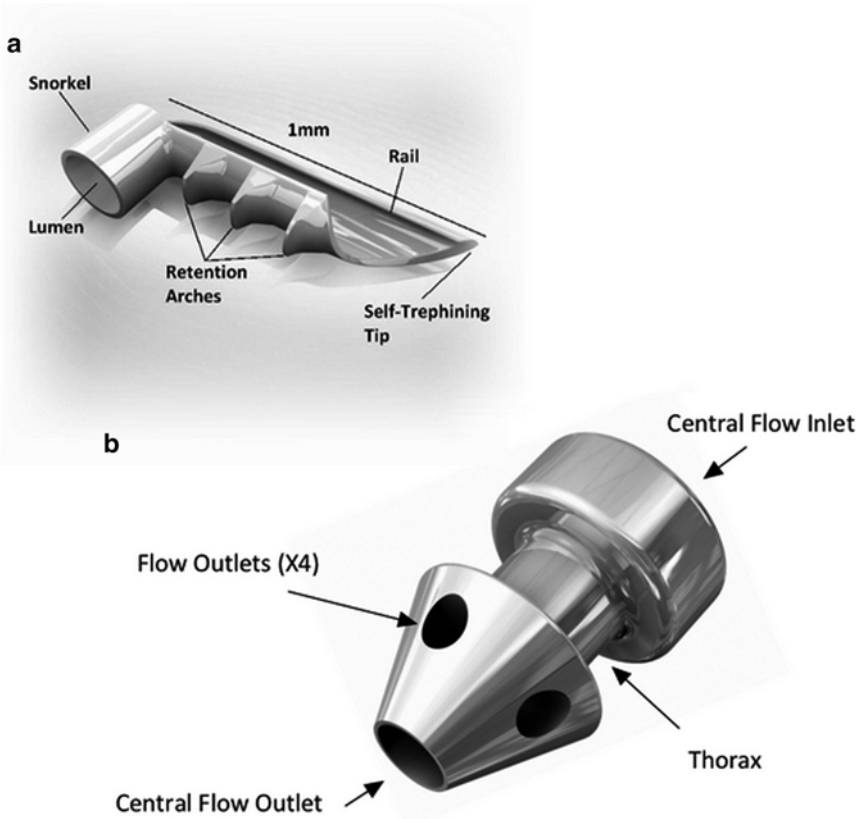


Fig. 2.1 (a) First-generation iStent®. (b) Second-generation iStent inject®. *Image Courtesy of Glaukos*

2.3 Indications

The iStent® trabecular micro-bypass stent is currently FDA approved to be used in conjunction with cataract surgery for the reduction of IOP in open angle glaucoma. Approximately 1 in 5 patients with a visually significant cataract is on at least one ocular hypotensive medication for glaucoma or ocular hypertension [17]. However, the appropriate patient should have mild to moderate glaucoma, demonstrating less than -12 dB MD on their visual field. A patient who has uncontrolled glaucoma, who is on three or more ocular hypotensive medications, or who requires very low IOPs (below episcleral venous pressure) would likely benefit from the more traditional combined phacoemulsification/trabeculectomy or tube shunt procedure, which provides better control for IOP in more advanced glaucoma.

FDA approval guidelines require that the iStent be implanted concurrently with phacoemulsification. There is often better visualization of the angle structures after the cataract is removed. Furthermore, cataract surgery alone has been shown in multiple studies to lower the IOP [18–20]. It is thought that the IOP lowers because there is a reversal of the compression of the ciliary body, Schlemm’s canal and trabecular meshwork complex after the enlarged cataractous lens is removed. The conventional wisdom is that the IOP lowers an average about 2–4 mmHg after cataract surgery [21]. Recent studies have shown IOP can lower as much as 8 mmHg especially when starting with a higher preoperative IOP [22]. By creating a bypass through the trabecular meshwork, the iStent can work in conjunction with cataract extraction to enhance the natural physiologic outflow system.

This device has been successfully implanted in eyes with POAG and secondary open angle glaucoma such as pseudoexfoliation and pigmentary glaucoma. Preoperative gonioscopy should rule out peripheral anterior synechiae (PAS), rubeosis, or other angle abnormalities that may make proper placement difficult. A more pigmented trabecular meshwork will also ease proper placement of the device, but is not necessary as identification of Schlemm's canal can be seen with blood reflux into the episcleral venous system during periods of transient intraoperative hypotony. With experience, one can consider implanting the device in eyes with a slightly narrow angle that is expected subsequently to deepen after phacoemulsification.

2.4 Contraindications

This device is contraindicated in eyes with primary or secondary angle closure glaucoma, as access to the trabecular meshwork is restricted. This device is also contraindicated in patients with pathology that may cause increased episcleral venous pressure such as thyroid eye disease or Sturge–Weber Syndrome. In these cases, the cause of increased IOP is not secondary to resistance in the juxtacanalicular meshwork and so the iStent would not be expected improve IOP. Lastly, one should be cautious while implanting this device in patients with corneal haze or opacities due to limitations in visualization of the angle structures.

2.5 Surgical Procedure

1. Preoperatively, one should carefully examine the angle gonioscopically to ensure that the angle structures, in particular the trabecular meshwork, are clearly visible. There should be no evidence of angle closure, rubeosis, angle recession, trauma, or other angle abnormalities that may make implantation of the iStent difficult.
2. It is advisable to perform phacoemulsification in the standard technique through a temporal clear corneal incision or limbal approach.

This will allow implantation of the iStent nasally.

3. After implantation of the intraocular lens (IOL), if the pupil is extremely dilated, an intracameral miotic can be instilled.
4. After irrigation/aspiration, the anterior chamber should be filled with additional cohesive viscoelastic to maintain the anterior chamber.
5. Position the microscope for better gonioscopic viewing of the angle. Rotate the patient's head 35° away from you and rotate the microscope 35° towards you. An intraoperative gonio prism is placed on the cornea to adequately view the trabecular meshwork. To ensure a clear view, a light touch is required to prevent striae induced from the gonio prism.
6. The iStent can then be inserted through the same temporal incision for cataract surgery (use the GTS100R for the right eye and the GTS100L for the left eye).
7. Traverse the anterior chamber with the inserter with the implant on the tip of the inserter.
8. View the angle under high magnification and approach the upper third of the nasal TM at a 15° angle with the tip pointed inferiorly (Fig. 2.2). If it is difficult to visualize the trabecular meshwork, transient hypotony can help cause blood reflux into Schlemm's canal for better visualization. Schlemm's canal is located just posterior to the TM.
9. Engage the TM and advance the iStent into Schlemm's canal. The device should be

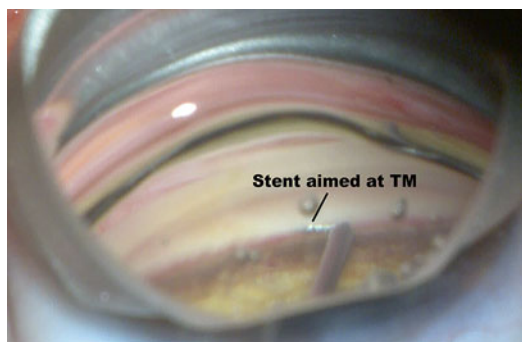


Fig. 2.2 iStent® aimed 15° into the trabecular meshwork (TM) under high magnification. Blood reflux from Schlemm's canal with hypotony can improve visualization of TM

placed close to areas of heavier pigmentation as the collector channels are expected to be nearby. Proper placement into Schlemm's canal typically demonstrates a small reflux of blood; however, this does not always occur even with proper placement.

10. The device is released by pushing the button on the inserter. Tap the snorkel on the side to ensure it is placed securely.
11. If there is resistance on insertion, one can try again a half clock hour more inferiorly.
12. Irrigate the anterior chamber with irrigation/aspiration to remove all viscoelastic to achieve physiologic pressure at the end of surgery.
13. Some surgeons prefer to perform phacoemulsification after implantation of the iStent device. The advantage to this is that there may be less corneal edema and one can use a smaller corneal incision, which may help with anterior chamber stability during implantation of the device. Furthermore, the extra viscoelastic needed to implant the iStent if performed after the cataract surgery is not necessary. However, the advantage of placing the iStent after phacoemulsification is that the angle will be deeper after the lens is removed, aiding visualization of angle structures.
14. Routine postoperative management after phacoemulsification should be used after cataract surgery with iStent placement. If the patient was on only one preoperative ocular hypotensive drop, one can consider stopping this postoperatively and resume it if necessary. Some surgeons use loteprednol instead of prednisolone acetate postoperatively to avoid a steroid response.

reduction of 4.4 ± 4.5 mmHg after 12 months of follow-up, with 50 % of subjects achieving adequate IOP control off of medications (Table 2.1). Fea [25], was the first published double-masked randomized controlled trial comparing IOP reduction between phacoemulsification alone (control) and phacoemulsification combined with iStent implantation. After a wash-out of all postoperative medications at 15 months follow-up, the mean IOP difference was almost 2.5 mmHg between the two groups with the combined group having the lower mean IOP. Furthermore, after a 15-month follow-up, 67 % of the combined group no longer required glaucoma medications compared to only 24 % in the control group, demonstrating that the iStent is an effective way to reduce the medication burden in patients with concomitant cataracts with mild to moderate glaucoma.

Samuelson et al. [26] reported on the largest multicenter randomized controlled trial to date, which demonstrated a significant IOP and medication reduction in the combined group (phacoemulsification+iStent) compared to the control group (phacoemulsification alone). This study included 240 eyes with IOP controlled on 1–3 medications preoperatively, with 111 eyes receiving the iStent. At all times points up to 2 years, there was a higher proportion of subjects in the combined group who achieved both the primary and secondary end points. The primary end point was an IOP ≤ 21 mmHg without medications and the secondary end point with an IOP reduction ≥ 20 % without medications at 1-year follow-up. Those in the control group (phacoemulsification only) had a substantially higher level of glaucoma medication use and restarted medications sooner postoperatively compared to the group that had the iStent implanted. Using the same study group, Craven et al. [27] showed that IOP was stable in the iStent group for a longer follow-up duration, between 12 and 24 months of follow-up. Mean IOP and medication use was still lower in the combined iStent and cataract extraction group compared to cataract extraction alone after 24 months of follow-up ($p=0.36$).

Most importantly, the safety profile was excellent in the combined group in this large cohort of

2.6 Outcomes

2.6.1 First-Generation iStent Prospective Studies

Initial studies by Spiegel et al. [23,24] first demonstrated the successful implantation of the iStent with phacoemulsification. Their prospective noncomparative studies demonstrated an IOP

Table 2.1 Results after Glaukos iStent® implantation

Study	Number of iStents	Combined with phaco?	Number of eyes	Follow-up (months)	Mean IOP reduction (mmHg)	Mean reduction in medications
Spiegel et al. [23]	1	Yes	48	6	5.7 ± 3.8	1.5 ± 0.7 vs. 0.5 ± 0.8^a
Spiegel et al. [24]	1	Yes	42	12	4.4 ± 4.5	1.2 ± 0.7
Fea [25]	1	Yes	12	15	3.2 ± 3.0	2.0 ± 0.9 vs. 0.4 ± 0.7
Samuelson et al. [26]	1	Yes	109	12	1.5 ± 3.0	1.4 ± 0.8
Craven et al. [27]	1	Yes	98	24	18.6 ± 3.4 vs. 17.1 ± 2.9^a	1.6 ± 0.8 vs. 0.3 ± 0.6
Arriola-Villalobos et al. [28]	1	Yes	19	54 ± 9.3	3.2 ± 3.9	0.5 ± 1.0
Fernández-Barrientos et al. [29]	2	Yes	17	12	6.6 ± 3.0	1.1 ± 0.5 vs. 0^a
Belovay et al. [30]	2 to 3	Yes	53	12	18.0 ± 4.0 vs. 14.3 ± 2.9	2.0 ± 1.4
Ahmed et al. [31]	2	No	39	18	22.2 ± 2.0 vs. $11.8 \pm 2.1^{a,b}$	N/A ^b
Arriola-Villalobos et al. [32]	2 (iStent inject® GTS-400)	Yes	20	12	3.2 ± 3.8	1.0 ± 0.8
Fea et al. [33]	2 (iStent inject® GTS-400)	No	94	12	8.1 ± 2.6	^c
Voskanyan et al. [34]	(iStent inject® GTS-400)	No	99	12	10.4 ± 3.2	^c

IOP intraocular pressure

^aData not available (mean pre-op vs. mean post-op shown)

^bNot applicable; all subjects required to be on at least travoprost postoperatively

^cData not available

patients. The most frequent adverse events occurred with similar frequencies in both groups. The only stent-related adverse events were stent obstruction (iris, fibrin, blood, etc.), which occurred in 4 % of eyes, and stent malposition which occurred in 3 % of eyes. Three of the malpositioned stents were repositioned and one was removed and replaced. Levels of iritis were similar between both groups. These stent-related events occurred early in the postoperative course and were much less serious compared to the complications that can occur with more traditional surgeries such as trabeculectomies and tube shunt implantation. The only severe adverse event was deemed not related to the ophthalmic surgery, in which one patient experienced a stroke and retinal ischemia from carotid artery stenosis. In another prospective study with a longer mean follow-up of 54 months, there were no late-onset complications, such as endophthalmitis or tube shunt exposure, which can occur with more traditional incisional glaucoma procedures [28].

2.6.2 Implantation of Multiple Stents and the iStent Inject®

All the initial studies with the iStent used one device only for a moderate but significant IOP reduction in conjunction with phacoemulsification. Recent studies have investigated the efficacy and safety of multiple iStent implantations. Investigation into the efficacy of multiple stent placement began with in vitro studies with cultured anterior segments from normal human eyes obtained at autopsy [35]. This study demonstrated that although one stent produces the greatest IOP reduction, additional stents may further lower IOP.

In a clinical study, Belovay et al. [30] demonstrated that implantation of two or three iStents with phacoemulsification results in a significant reduction in IOP and medication use. Furthermore, the three-stent group was on significantly fewer postoperative glaucoma medications than the two-stent group. In a comparative

study between implantation of two stents with cataract surgery to cataract surgery alone, the combined group with two stents demonstrated increased trabecular outflow facility and a reduction in IOP and medications at 1-year follow-up compared to the cataract only group [29]. This study deduced an increase in outflow facility of 157 % after 1 year of follow-up through two stents alone.

Recently, a few studies have been published describing the implantation of the iStent without concurrent phacoemulsification. Ahmed et al. [31] recently demonstrated that IOP is reduced from 25.3 ± 1.8 mmHg to 17.1 ± 2.2 mmHg at 13 months postoperatively with two iStent implantation after washout. At 12 months, 100 % of patients had achieved an IOP reduction of 20 % or more, an IOP of 18 mmHg or less, and a reduction of one glaucoma medication. Phacoemulsification was not performed during these surgeries. There were no intraoperative adverse events with multiple stent placements. The most common postoperative event was a progression of cataract over the 18-month period, which occurred in 4 out of 39 eyes. This study demonstrates that implantation of multiple stents even without phacoemulsification is safe and will lower IOP significantly with a reduction in medications.

Lastly, a few preliminary studies regarding the efficacy and safety of the iStent inject® have recently been published [32–34] (Table 1.1). This device is currently CE marked in Europe. All three studies demonstrated a favorable safety profile. Fea et al. [33] demonstrated a mean IOP decrease of 8.1 ± 2.6 mmHg after 12 months of follow-up and Voskanyan et al. [34] demonstrated a similar IOP reduction of 10.4 ± 3.2 mmHg. These recent studies show promise that the second-generation iStent may have the ability to reduce IOP and medication use even further.

2.6.3 The ICE Procedure

There has also been a recent interest in the triple procedure called ICE, which stands for iStent, cataract extraction, and endocyclophotocoagulation. Endoscopic cyclophotocoagulation (ECP) has been used to reduce IOP in conjunction with

phacoemulsification [36]. ECP ablates the ciliary body, thereby decreasing aqueous production and reducing IOP. In the “ICE” procedure, ECP decreases “inflow” and iStent implantation increases “outflow,” thereby targeting two methods of IOP reduction. In a retrospective noncomparative series of 24 eyes that underwent the “ICE” procedure, Radcliffe et al. [37] demonstrated a reduction of IOP from 19.1 ± 6.3 mmHg to 15.5 ± 3.9 mmHg with a reduction in glaucoma medications. No adverse events or hypotony occurred. Further prospective studies are warranted to investigate the efficacy and safety of this combined procedure.

2.7 Conclusion

With the advent of MIGS procedures, there is hope for a new set of glaucoma surgical procedures that can effectively control IOP in a safe manner and reduce the medication burden in those with mild to moderate glaucoma. The iStent trabecular micro-bypass stent has demonstrated in several prospective randomized controlled trials to reduce IOP and glaucoma medications in conjunction with cataract surgery for those with mild to moderate open angle glaucoma. Further studies are needed on the second-generation iStent, iStent implantation without phacoemulsification, and iStent placement with other MIGS procedures. Overall, this is an exciting time for the field of glaucoma with the myriad of tools and procedures we have available to battle this progressive and potentially blinding disease.

Acknowledgements Conflicts of Interest: Wanda D. Hu declares that she has no conflict of interest. Marlene R. Moster is a consultant for Glaukos.

Animal Studies: No animal or human studies were carried out by the authors for this article.

Informed Consent: Informed consent was not applicable for this article.

References

1. Gedde SJ, Herndon LW, Brandt JD, Budenz DL, Feuer WJ, Schiffman JC, Group TVTS. Postoperative complications in the Tube Versus Trabeculectomy (TVT) study during five years of follow-up. Am J

- Ophthalmol. 2012;153(5):804–14. doi:[10.1016/j.ajo.2011.10.024](https://doi.org/10.1016/j.ajo.2011.10.024).
2. DeBry PW, Perkins TW, Heatley G, Kaufman P, Brumback LC. Incidence of late-onset bleb-related complications following trabeculectomy with mitomycin. *Arch Ophthalmol*. 2002;120(3):297–300.
3. McIlraith I, Strasfeld M, Colev G, Hutnik CML. Selective laser trabeculoplasty as initial and adjunctive treatment for open-angle glaucoma. *J Glaucoma*. 2006;15(2):124–30.
4. Anwar Z, Wellik SR, Galor A. Glaucoma therapy and ocular surface disease: current literature and recommendations. *Curr Opin Ophthalmol*. 2013;24(2):136–43. doi:[10.1097/ICU.0b013e32835c8aba](https://doi.org/10.1097/ICU.0b013e32835c8aba).
5. Tsai JC. A comprehensive perspective on patient adherence to topical glaucoma therapy. *Ophthalmology*. 2009;116(11 Suppl):S30–6. doi:[10.1016/j.opthta.2009.06.024](https://doi.org/10.1016/j.opthta.2009.06.024).
6. Wong MO, Lee JW, Choy BN, Chan JC, Lai JS. Systematic review and meta-analysis on the efficacy of selective laser trabeculoplasty in open-angle glaucoma. *Surv Ophthalmol*. 2015;60(1):36–50. doi:[10.1016/j.survophthal.2014.06.006](https://doi.org/10.1016/j.survophthal.2014.06.006).
7. Realini T. Selective laser trabeculoplasty: a review. *J Glaucoma*. 2008;17(6):497–502. doi:[10.1097/IJG.0b013e32817d2386](https://doi.org/10.1097/IJG.0b013e32817d2386).
8. Saheb H, Ahmed IIK. Micro-invasive glaucoma surgery: current perspectives and future directions. *Curr Opin Ophthalmol*. 2012;23(2):96–104. doi:[10.1097/ICU.0b013e32834ff1e7](https://doi.org/10.1097/ICU.0b013e32834ff1e7).
9. Grant W. Experimental aqueous perfusion in enucleated human eyes. *Arch Ophthalmol*. 1963;69:783–801.
10. Rosenquist R, Epstein D, Melamed S, Johnson M, Grant WM. Outflow resistance of enucleated human eyes at two different perfusion pressures and different extents of trabeculotomy. *Curr Eye Res*. 1989;8(12):1233–40.
11. Johnson MC, Kamm RD. The role of Schlemm's canal in aqueous outflow from the human eye. *Invest Ophthalmol Vis Sci*. 1983;24(3):320–5.
12. Schuman JS, Chang W, Wang N, de Kater AW, Allingham RR. Excimer laser effects on outflow facility and outflow pathway morphology. *Invest Ophthalmol Visual Sci*. 1999;40(8):1676–80.
13. Spiegel D, Kobuch K. Trabecular meshwork bypass tube shunt: initial case series. *Br J Ophthalmol*. 2002;86(11):1228–31.
14. Spiegel D, Wetzel W, Haffner DS, Hill RA. Initial clinical experience with the trabecular micro-bypass stent in patients with glaucoma. *Adv Ther*. 2007;24(1):161–70.
15. Ascher K. The aqueous veins, American lecture series, no. 403. Springfield, IL: Charles C. Thomas; 1961.
16. Dvorak-Theobald G. Schlemm's canal: its anastomoses and anatomic relations. *Trans Am Ophthalmol Soc*. 1934;32:574–95.
17. 2002–2007 Medicare Standard Analytical File. Centers for Medicare and Medicaid Services, US Dept of Health and Human Services; 2007.
18. Tennen DG, Masket S. Short-and long-term effect of clear corneal incisions on intraocular pressure. *J Cataract Refract Surg*. 1996;22(5):568–70.
19. Shingleton BJ, Pasternack JJ, Hung JW, O'Donoghue MW. Three and five year changes in intraocular pressures after clear corneal phacoemulsification in open angle glaucoma patients, glaucoma suspects, and normal patients. *J Glaucoma*. 2006;15(6):494–8. doi:[10.1097/01.ijg.0000212294.31411.92](https://doi.org/10.1097/01.ijg.0000212294.31411.92).
20. Kim DD, Doyle JW, Smith MF. Intraocular pressure reduction following phacoemulsification cataract extraction with posterior chamber lens implantation in glaucoma patients. *Ophthalmic Surg Lasers*. 1999;30(1):37–40.
21. Friedman DS, Jampel HD, Lubomski LH, Kempen JH, Quigley H, Congdon N, Levkovitch-Verbin H, Robinson KA, Bass EB. Surgical strategies for coexisting glaucoma and cataract: an evidence-based update. *Ophthalmology*. 2002;109(10):1902–13.
22. Poley BJ, Lindstrom RL, Samuelson TW, Schulze R. Intraocular pressure reduction after phacoemulsification with intraocular lens implantation in glaucomatous and nonglaucomatous eyes: evaluation of a causal relationship between the natural lens and open-angle glaucoma. *J Cataract Refract Surg*. 2009;35(11):1946–55. doi:[10.1016/j.jcrs.2009.05.061](https://doi.org/10.1016/j.jcrs.2009.05.061).
23. Spiegel D, García-Feijoó J, García-Sánchez J, Lamielle H. Coexistent primary open-angle glaucoma and cataract: preliminary analysis of treatment by cataract surgery and the iStent trabecular micro-bypass stent. *Adv Ther*. 2008;25(5):453–64. doi:[10.1007/s12325-008-0062-6](https://doi.org/10.1007/s12325-008-0062-6).
24. Spiegel D, Wetzel W, Neuhaan T, Stuermer J, Hoeh H, Garcia-Feijoo J, Martinez-De-La-Casa JM, Garcia-Sanchez J. Coexistent primary open-angle glaucoma and cataract: interim analysis of a trabecular micro-bypass stent and concurrent cataract surgery. *Eur J Ophthalmol*. 2009;19(3):393–9.
25. Fea AM. Phacoemulsification versus phacoemulsification with micro-bypass stent implantation in primary open-angle glaucoma: randomized double-masked clinical trial. *J Cataract Refract Surg*. 2010;36(3):407–12. doi:[10.1016/j.jcrs.2009.10.031](https://doi.org/10.1016/j.jcrs.2009.10.031).
26. Samuelson TW, Katz LJ, Wells JM, Duh Y-J, Giamporcaro JE, Group UiS. Randomized evaluation of the trabecular micro-bypass stent with phacoemulsification in patients with glaucoma and cataract. *Ophthalmology*. 2011;118(3):459–67. doi:[10.1016/j.opthta.2010.07.007](https://doi.org/10.1016/j.opthta.2010.07.007).
27. Craven ER, Katz LJ, Wells JM, Giamporcaro JE, Group iS. Cataract surgery with trabecular micro-bypass stent implantation in patients with mild-to-moderate open-angle glaucoma and cataract: two-year follow-up. *J Cataract Refract Surg*. 2012;38(8):1339–45. doi:[10.1016/j.jcrs.2012.03.025](https://doi.org/10.1016/j.jcrs.2012.03.025).
28. Arriola-Villalobos P, Martínez-de-la-Casa JM, Díaz-Valle D, Fernández-Pérez C, García-Sánchez J, García-Feijoó J. Combined iStent trabecular micro-bypass stent implantation and phacoemulsification for coexistent open-angle glaucoma and cataract:

- a long-term study. *Br J Ophthalmol*. 2012;96(5):645–9. doi:[10.1136/bjophthalmol-2011-300218](https://doi.org/10.1136/bjophthalmol-2011-300218).
29. Fernández-Barrientos Y, García-Feijoó J, Martínez-de-la-Casa JM, Pablo LE, Fernández-Pérez C, García Sánchez J. Fluorophotometric study of the effect of the glaukos trabecular microbypass stent on aqueous humor dynamics. *Invest Ophthalmol Vis Sci*. 2010;51(7):3327–32. doi:[10.1167/iov.09-3972](https://doi.org/10.1167/iov.09-3972).
 30. Belovay GW, Naqi A, Chan BJ, Rateb M, Ahmed IIK. Using multiple trabecular micro-bypass stents in cataract patients to treat open-angle glaucoma. *J Cataract Refract Surg*. 2012;38(11):1911–7. doi:[10.1016/j.jcrs.2012.07.017](https://doi.org/10.1016/j.jcrs.2012.07.017).
 31. Ahmed IIK, Katz LJ, Chang DF, Donnenfeld ED, Solomon KD, Voskanyan L, Samuelson TW. Prospective evaluation of microinvasive glaucoma surgery with trabecular microbypass stents and prostaglandin in open-angle glaucoma. *J Cataract Refract Surg*. 2014;40(8):1295–300. doi:[10.1016/j.jcrs.2014.07.004](https://doi.org/10.1016/j.jcrs.2014.07.004).
 32. Arriola-Villalobos P, Martínez-de-la-Casa JM, Díaz-Valle D, García-Vidal SE, Fernández-Pérez C, García-Sánchez J, García-Feijoó J. Mid-term evaluation of the new Glaukos iStent with phacoemulsification in coexistent open-angle glaucoma or ocular hypertension and cataract. *Br J Ophthalmol*. 2013;97(10):1250–5. doi:[10.1136/bjophthalmol-2012-302394](https://doi.org/10.1136/bjophthalmol-2012-302394).
 33. Fea AM, Belda JJ, Rekas M, Jünemann A, Chang L, Pablo L, Voskanyan L, Katz LJ. Prospective unmasked randomized evaluation of the iStent inject (®) versus two ocular hypotensive agents in patients with primary open-angle glaucoma. *Clin Ophthalmol*. 2014;8:875–82. doi:[10.2147/oph.s59932](https://doi.org/10.2147/oph.s59932).
 34. Voskanyan L, García-Feijoó J, Belda JJ, Fea A, Jünemann A, Baudouin C, Group SS. Prospective, unmasked evaluation of the iStent® inject system for open-angle glaucoma: synergy trial. *Adv Ther*. 2014;31(2):189–201. doi:[10.1007/s12325-014-0095-y](https://doi.org/10.1007/s12325-014-0095-y).
 35. Bahler CK, Smedley GT, Zhou J, Johnson DH. Trabecular bypass stents decrease intraocular pressure in cultured human anterior segments. *Am J Ophthalmol*. 2004;138(6):988–94. doi:[10.1016/j.ajo.2004.07.035](https://doi.org/10.1016/j.ajo.2004.07.035).
 36. Kahoek MY, Lathrop KL, Noecker RJ. One-site versus two-site endoscopic cyclophotocoagulation. *J Glaucoma*. 2007;16(6):527–30. doi:[10.1097/IJG.0b013e3180575215](https://doi.org/10.1097/IJG.0b013e3180575215).
 37. Radcliffe NM, Parekh PD, Noecker RJ, Sarkisian S, Chapman KO (2014) ICE surgical technique outcomes: MIGS implantation of trabecular bypass stent, cataract extraction, and endoscopic cyclophotocoagulation. Paper presented at the 2014 American Glaucoma Society Annual Meeting, Washington, DC.

Trabectome-Mediated Ab Interno Trabeculectomy for Secondary Glaucoma or as a Secondary Procedure

Kevin Kaplowitz and Nils A. Loewen

3.1 Introduction

Ab interno trabeculectomy (AIT) with the trabectome handpiece (Neomedix, Tustin, CA) is a glaucoma surgery that the Food and Drug Administration (FDA) approved in February 2004 [1, 2] as a “micro-incisional glaucoma surgery for adult and infantile glaucomas.” The FDA definition of a micro-incisional surgery requires the incision to be below 2 mm and the keratome used in AIT is 1.8 mm wide. Trabectome surgery belongs to the family of “minimally invasive glaucoma surgeries (MIGS)” several of which do not meet the micro-incisional criterion, for instance endocyclophotocoagulation [3] and the suprachoroidal gold shunt [4]. Trabectome surgery was originally described as a plasma surgery method with a bipolar 550 kHz electrode tip that ablates 30–60° of

trabecular meshwork (TM) but can be extended to 180° using one incision or 360° using two. Over 10 years of growing trabectome use, the name has become synonymous with AIT although Ab interno trabeculectomy has been done with other instruments that were less successful due to more extensive trauma to the outer wall of Schlemm’s canal and considerable TM remnants [5–7]. The aim of this chapter is to briefly review the surgical technique, indications, results, and complications of trabectome surgery, focusing specifically on outcomes in secondary glaucomas.

3.2 Indications

Trabectome was first described for use in open angle glaucomas with an angle open more than 20° and uncontrolled intraocular pressure (IOP) on maximally tolerated medical therapy; however, its role has now considerably expanded [2]. The most important exclusion criteria are poor visualization of the TM and neovascular glaucoma. Additionally, the patient must be able to rotate either the neck or the entire axial core in order to assure an adequate gonioscopic view. In our experience with more than 600 trabectome surgeries, we have found that a wide range of glaucoma types and stages can be operated on using a modified surgical technique described below. We find that only active neovascular glaucoma, elevated episcleral venous pressure,

Electronic supplementary material The online version of this chapter (doi:[10.1007/978-3-319-18060-1_3](https://doi.org/10.1007/978-3-319-18060-1_3)) contains supplementary material, which is available to authorized users. Videos can also be accessed at http://link.springer.com/book/10.1007/978-3-319-18060-1_3.

K. Kaplowitz, M.D. (✉)
Department of Ophthalmology, Stony Brook
University Hospital Medical Center, Stony Brook,
NY, USA
e-mail: kevin.kaplowitz@stonybrookmedicine.edu

N.A. Loewen, M.D., Ph.D.
Department of Ophthalmology, University of
Pittsburgh, Pittsburgh, PA, USA

more than moderately active uveitis, and angle dysgenesis represent contraindications and now routinely operate on cases with narrow angles, trauma, scleral buckle, and uveitis.

3.3 Surgical Technique

3.3.1 Trabectome-Mediated AIT

The key steps to a successful surgery will be briefly reviewed, which we believe provide better chances of achieving the desired target pressure. The surgeon sits temporally. The irrigation bottle should be raised near maximum height if deemed safe for the stage of glaucoma because it will help deepen the angle and improve the view. If the case is combined with phacoemulsification, the trabectome part should be done first. No viscoelastic should be used to avoid optical interfaces and the trapping of ablation gas bubbles.

The main incision, 1.6 mm iris-parallel and uniplanar, is fashioned 2 mm anterior to the limbus to help prevent iris prolapse. Pressurizing the anterior chamber with BSS or preservative-free lidocaine from the paracentesis aids in constructing the main incision with minimal or no countertraction and without damaging the anterior capsule. The internal, left and right aspects of the incision are flared to maximize mobility of the handpiece within the wound. The uniplanar, short wound provides better visualization by reducing corneal striae from torque. For patients who may have significant difficulty rotating the neck, the microscope tilt can be increased or the patient's entire axial core may be rotated; although this can make the hand positioning and stability more challenging.

Under gonioscopic view, the TM is approached with the tip at a 45° angle at the level of the scleral spur. The upward angle eases the engagement of TM over the instrument tip (Fig. 3.1b). It is important

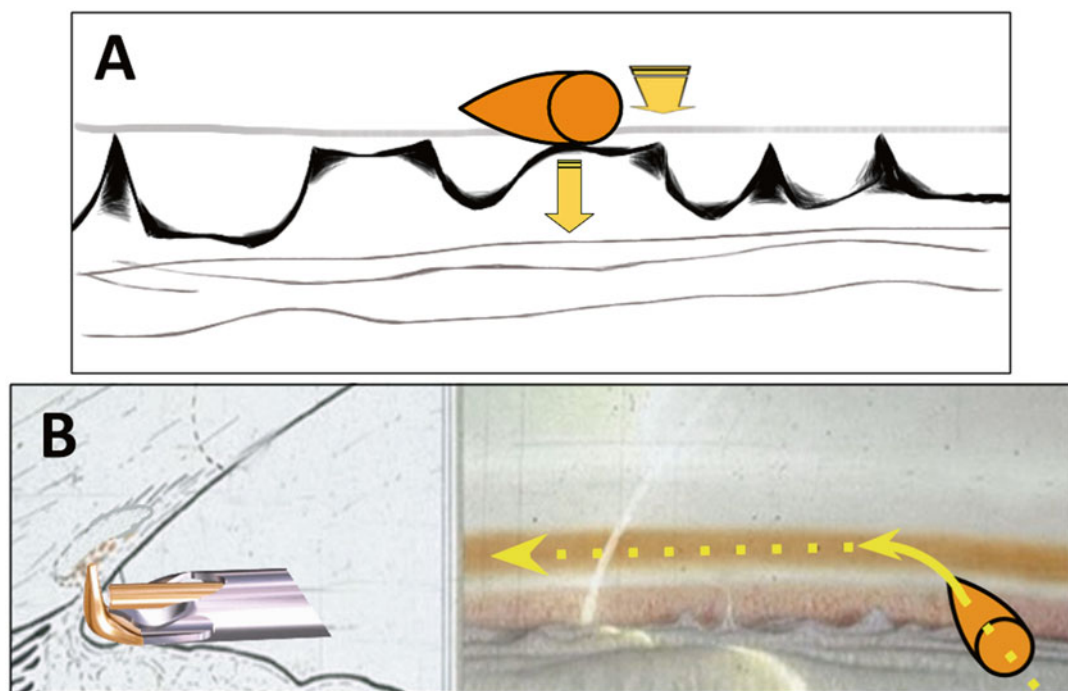


Fig. 3.1 Goniosynechiolysis technique with the trabectome tip. (a) The footplate (golden oval) is placed anterior to the tip of the peripheral anterior synechiae and gently pushed outward and down. (b) After access to the trabecular

meshwork is achieved, the tip is inserted into Schlemm's canal with a 45° upward and left movement and plasma-mediated ablation is initiated

to exert a slight inward pull during ablation to counteract the natural tendency to push outward, especially since the eye's curvature is not easily appreciated during gonioscopic view. Otherwise, excessive force will be directed against the outer wall of Schlemm's canal that can damage the collector channel orifices. Rather than starting ablation directly opposite to the main wound, it is easier to engage the TM towards the left since this offers a more acute angle of contact between the pointed tip and the TM (Fig. 3.1b).

The ablation is started at 0.8 mW and titrated up. The first 60° can usually be ablated continuously without many adjustments and up to 90° can be achieved by experienced surgeons. The tip is disengaged, rotated downward 180° (away from the cornea), and the ablation is started in the other direction. Again, the goal is to ablate for 90° in both directions. A total of 180° ablation will achieve near 240° of total outflow because a single opening through the TM typically provides access to about 60° of Schlemm's canal [8]. Once ablation is complete, a viscoadaptive substance can be injected to fill about 20 % of the anterior chamber in order to leave a crescent of tamponading viscoelastic over the ablation arc to minimize postoperative hyphema from flowback. Preservative-free dexamethasone (100 µL, 10 mg/mL) is injected under the viscoelastic shell into the capsular sac. We used the described technique in a consecutive series of 192 patients. After 1 year, 81 % of patients had an IOP ≤ 18, while 52 % of patients had an IOP ≤ 15, and 27 % had an IOP ≤ 12 [9].

All glaucoma medications can be discontinued on the day of surgery. The patient is seen on postoperative day 1, week 1, month 1, 2, and 3. The postoperative regimen for the first week consists of a topical fluoroquinolone, prednisolone acetate 1 %, and pilocarpine 2 %, all of which are started four times daily on the day of surgery. The fluoroquinolone is continued for 7 days and prednisolone is tapered over 2–4 weeks. Pilocarpine can be maintained at four times daily for 4 weeks, then three times per day for 4 more weeks. Flattening the peripheral iris using pilocarpine is thought to reduce the chance of forming peripheral anterior synechiae (PAS) [10].

3.3.2 Goniosynechiolysis

In narrow angles with synechiae, the smooth base plate of the trabectome handpiece serves as an excellent instrument for goniosynechiolysis. Video 3.1 shows an example of goniosynechiolysis and trabectome surgery in an eye with two failed tube shunts in a patient who had pressures around 25 mmHg and had a postoperative IOP of about 15 mmHg and needed one medication less at 1-year follow-up. For loosely connected synechiae, gentle posterior and outward pushing and sweeping motions with the base plate is often sufficient to displace them (Fig. 3.1). The pointed tip does not have to be used but more adherent synechiae can also be engaged directly between the tip and the baseplate and gently peeled away. Caution must be exercised to not injure the ciliary body band or create a cyclodialysis. The continuous irrigation under gonioscopic view offers direct visualization of the procedure while debris or blood is flushed away or actively aspirated and the anterior chamber stays well formed and pressurized, minimizing corneal striae.

3.4 Results

3.4.1 Overall Results

The initial clinical description of the trabectome was extended to 101 patients and demonstrated a 40 % IOP decrease [11]. Only 11 of those patients had follow-up for 30 months and that small group sustained a 33 % mean IOP decrease. The published results of trabectome surgery are divided into standalone trabectome cases below in Table 3.1 and combined phaco-trabectome in Table 3.2. Those results show that trabectome can be expected to decrease the IOP by an overall average of 8 mmHg (33 %) while concurrently lowering the number of medications by two. There are no published randomized trials involving trabectome. The largest case series, dating back to the first case, had 1,878 trabectome cases (alone or with phacoemulsification) recorded as of 2010 [24]. There was data on 5 patients who had been evaluated a full 6 years

Table 3.1 Outcomes for trabectome as the only procedure

Study	Type of study	Number of subjects	Mean baseline IOP (mmHg)	Mean final IOP (mmHg)	% IOP decrease	Mean # decrease in medication	Length of study (months)
Minckler et al. [2]	Prospective	37	28	16	45	1.1	13
Minckler et al. [11]	Prospective	101	28	16	41	Not reported	30
Minckler et al. [12]	Prospective	738	26	18	32	2.43	60
POAG of Ting et al. [13]	Prospective	450	26	17	34	0.57	12
PXG of Ting et al. [13]	Prospective	67	29	16	44	0.88	12
Jea et al. [14]	Retrospective	115	28	17	41	1	30
Minckler et al. [15]	Prospective	1,151	26	17	36	1.7	60
Mosaed et al. [16]	Prospective	538	26	17	37	0.79	12
Ahuja et al. [17]	Retrospective	88	26	13	50	0.3	48
Maeda et al. [18]	Prospective	80	27	18	33	1.7	12

Table 3.2 Combined phaco-trabectome outcomes

Authors	Type of study	Total n	Mean pre-op IOP (mmHg)	Mean final IOP (mmHg)	% IOP decrease	Mean # decrease in medication	Length of study (months)
Minckler et al. [12]	Retrospective	366	20	17	18	0.93	30
Francis et al. [19]	Prospective	304	20	17	17	1.22	21
POAG of Ting et al. [13]	Prospective	263	20	16	22	0.75	12
PXG of Ting et al. [13]	Prospective	45	22	14	35	0.96	12
Minckler et al. [15]	Prospective	681	20	16	21	0.87	36
Mosaed et al. [16]	Prospective	290	20	16	23	0.85	12
Francis and Winarko [20]	Prospective	89	22	15	30	1	12
Ahuja et al. [17]	Retrospective	158	19	12	39	0.5	45
Klamann et al. [21]	Retrospective	27	23	14	40	0.29	12
Klamann et al. [22]	Retrospective	74	21	13	37.5	0.12	6
Francis [23]	Prospective	114	22	15	31	1	24

after the procedure and they still maintained a 38 % mean IOP decrease.

Studies reporting on the success of the trabectome procedure have used varying definitions of success, making it difficult to compare results. The only common definition of success was final IOP < 21 mmHg with a 20 % decrease in IOP from baseline. For standalone trabectome cases, the success rate using this definition ranged from 65 % [13] to 71 % [13] after 1 year, but then fell as low as 22 % after 2 years [14]. For cases combined with phacoemulsification, the success rate ranged from 87 % [16] to 95 % [20] after 1 year and 80 % at 2 years [23]. A series of 1,127 patients (738 cases of standalone trabectome and 366 cases of phaco-trabectome) found a 45 %

success rate after 4 years [12]. The same cohort was extended and analyzed success rates of 1,415 patients [25]. Using a less stringent definition of success as IOP < 21 or a 20 % IOP decrease from baseline, the success rate was approximately 95 % for combined cases after 3 years and approximately 52 % for standalone trabectome cases after 6 years.

3.4.2 Trabectome in Secondary Glaucomas

The realization that AIT with the trabectome works beyond primary open angle glaucoma (POAG) is relatively recent. Consequently, fewer

results have been reported for trabectome in secondary glaucomas specifically, although they may be included in outcomes without detailed subtype analysis. In fact, of all the published papers with nonoverlapping cohorts that detail the subtype of glaucoma, POAG alone accounts for two-thirds of the total reported cases. Pseudoexfoliation glaucoma (PXG) is the second largest subgroup and is detailed below. Numerous secondary glaucomas have been treated but in numbers too small for subgroup analysis and often with overlapping pathomechanisms. In order of prevalence in the reported literature of trabectome treatment, they are: pigment dispersion glaucoma, uveitic, steroid-induced, anti-VEGF agent-induced, postsurgical, and traumatic.

It was thought that trabectome may be more effective in PXG because in addition to removing the obstructed and dysfunctional TM, the irrigation, ablation, or resulting mild inflammatory response may help clear pseudoexfoliation material from the anterior chamber [13, 21]. Also, trabectome may deepen the angle, which could decrease iridolenticular touch and lead to decreased exfoliative material release [26]. Combining trabectome with phacoemulsification may be the most meaningful way to avoid the accumulation of pseudoexfoliative material produced primarily by the lens. Further, the combined treatment often allows for bypassing of highly difficult surgeries and complications from zonular dehiscence seen later in the course of the disease while preventing the unexpected, aggressively worsening IOP that may occur in some individuals.

There are three publications that investigated trabectome in secondary glaucomas. The first was a prospective study designed to compare the IOP outcomes in POAG versus PXG [13]. In the group that received standalone trabectome, the PXG group started from a significantly higher baseline IOP, at 29 mmHg, versus 26 mmHg in the POAG group. The mean decrease in IOP at 1 year was better for PXG (44 % versus 34 % in POAG). The success rate at 1 year (defined as a 20 % decrease in IOP from baseline without reoperation) was superior in PXG at 79 % versus 63 % in POAG and the reoperation rate was also

significantly lower in the PXG group. In the combined phaco-trabectome group, the baseline IOP of the two groups was statistically similar but the mean decrease in IOP was again superior for PXG at 35 % versus 22 % for POAG. The complication rates were non-visually threatening and similar in both groups.

The second, retrospective study investigated PXG only [21]. The study compared the results of 27 phaco-trabectomes to 28 cases of phaco-emulsification combined with trabecular aspiration. The baseline IOP was statistically equivalent at 23 mmHg in the phaco-trabectome group and 22 mmHg in the phaco-aspiration group. After 1 year, the IOP was 40 % lower in the phaco-trabectome group versus 23 % after phaco-aspiration. These outcomes are difficult to compare to other studies because according to the author's protocol, all of the patients had a target IOP below 16 mmHg and medications were used as needed to maintain the target IOP, even in the postoperative period. Strict adherence to this protocol would explain why there was no statistically significant decrease in medication in either group after 1 year.

The third study aimed to prospectively examine the outcome of trabectome in different types of glaucoma, although POAG alone still accounted for 45 % of the 557 cases [27]. The second largest subgroup was PXG, accounting for 30 % of cases, and was the only subtype besides POAG large enough for subgroup analysis with a short follow-up time of 7 months. Results were reported combining standalone trabectome with phaco-trabectome. The mean IOP in the POAG group decreased by 25 % from a baseline of 24 mmHg versus a 30 % decrease from a baseline of 25 mmHg in the PXG group. Although the final difference in IOP in PXG was not large (final IOP 17.6 mmHg in PXG versus 18.2 in POAG), the success rates were considerably higher in PXG. Defining success as a 20 % decrease in IOP, the rate after 2 years was 50 % for PXG and only 32 % for POAG. A fourth study found in their risk factor for failure analysis, that PXG was protective when compared to POAG since the hazard ratio was 0.43 [28].

However, there are several weaknesses in concluding that trabectome is more effective in PXG as compared to POAG. First, the number of studies is small. Second, in both comparative studies conducted to-date [13, 27], the POAG group had worse IOP outcomes and started from a lower baseline IOP. Lower baseline IOP has been consistently shown to have worse IOP outcomes with trabectome, including in multivariable analysis [14, 19, 29]. The lower baseline IOP in the POAG group would then be expected to have worse outcomes on that basis alone. Finally, in cases of pseudoexfoliation, simply increasing the volume of irrigation has been shown to be associated with a lower IOP for as long as 2 years [26]. Further, the possible IOP-lowering effect of washing out the exfoliation material (as may occur with almost any intraocular surgery) cannot be easily separated from the effects of TM ablation alone. Pigment dispersion glaucoma can continuously produce dispersed pigment until the burn-out phase (after an average of 10 years) [30] or resolution of the reverse pupillary block [31, 32]. We find that pigment dispersion glaucoma can be treated effectively, but patients have to be prepared to experience several months without compelling IOP reduction when massive pigment is liberated at the time of surgery. This freed material can obstruct collector intakes, but typically resolves eventually. Pigment dispersion eyes often have a high axial length that can lead to displacement of refluxed blood into the posterior chamber during abnormal iris lens diaphragm movement. It is plausible that POAG has a considerable outflow resistance component within the distal outflow tract [33], while PXG and possibly other types like steroid-induced glaucoma [34] primarily have a TM component and, therefore, have better results with ablation of the TM.

Several abstracts have also investigated the use of trabectome in secondary glaucomas. A small case series followed 15 eyes with complex glaucoma for one year after treatment with trabectome [35]. The IOP in five cases of retinal detachment repaired with scleral buckle fell 52 % from 31 ± 10 mmHg with a reduction of medications by 3.1. Three traumatic cases had a 55 % IOP

decrease from a baseline of 32 ± 9 mmHg on four fewer medications. In three cases with inactive, regressed neovascularization of the iris and angle after panretinal photocoagulation, the IOP fell 37 % from 46 ± 12 mmHg on 2.3 fewer medications, and the IOP of three cases of uveitic glaucoma decreased 60 % from a baseline of 30 ± 6 mmHg on 2.4 fewer medications. Only one patient (7 %) needed further surgery within 1 year and received cyclophotocoagulation. No other complications or vision loss occurred. A case series of 61 patients with uveitic glaucoma found a 32 % decrease from a baseline IOP of 32 mmHg after 1 year on 0.5 fewer medications with a 26 % reoperation rate [36]. Another abstract analyzed 12 cases of isolated anterior uveitis over 2 months and found that the IOP fell 43 % from a baseline of 31 mmHg on two fewer medications [37]. A small series of 15 cases of steroid-induced glaucoma found that IOP fell 47 % from a baseline of 31 mmHg on 1.5 fewer medications after 1 year [38].

3.4.3 Trabectome in Glaucomas with Narrow Angle as an Atypical Indication

A narrow anterior chamber angle has, in the past, been considered a relative contraindication because it was feared that in addition to poor visualization of the target structure during surgery, PAS, descemetization of the angle, and fibrosis may form more readily and hasten failure [39]. This has prevented a large number of glaucoma patients from taking advantage of the highly favorable risk profile of trabectome surgery compared to traditional filtering glaucoma surgery as angle-closure glaucoma contributes to approximately 70 % of glaucoma cases in women and to 87 % of cases in Asians [40].

In our prospective study of trabectome combined with phacoemulsification and trabectome-only in patients with narrow angles of Shaffer grade ≤ 2 ($SG \leq 2$) versus open angles with a Shaffer grade ≥ 3 ($SG \geq 3$), we analyzed outcomes that included IOP, medications, complications, secondary surgery, and success (IOP < 21 mmHg and > 20 % reduction without further surgery) [41].

Of 671 included cases with at least 1 year of follow-up, AIT patients with $SG \leq 2$ ($n=43$) had an IOP reduction of 42 % from 27.3 ± 7.4 to 15.7 ± 3.0 mmHg ($p < 0.01$) versus AIT $SG \geq 3$ ($n=271$) with an IOP reduction of 37 % from 26.1 ± 7.8 mmHg to 16.4 ± 3.9 ($p < 0.01$). In phaco-AIT with $SG \leq 2$ ($n=48$), IOP was reduced 24 % from 20.7 ± 7.0 mmHg to 15.7 ± 3.6 ($p < 0.01$) versus phaco-AIT with $SG \geq 3$ ($n=309$) with an IOP reduction of 25 % from 22.6 ± 6.4 mmHg to 17.0 ± 3.4 ($p < 0.01$). There was no significant difference between $SG \leq 2$ and $SG \geq 3$ in reduction of IOP or medications, complications, secondary surgery, and success rates (Fig. 3.2, $p > 0.05$).

These results indicate that both phaco-trabectome and standalone trabectome can significantly reduce the IOP and number of medications regardless of degree of angle opening. This suggests that indications for trabectome should be expanded to include narrow angles. The results show that trabectome can be considered in the relatively large population of patients with narrow angles who might have mixed mechanisms that lead to increased IOP. Phacoemulsification in itself can decrease IOP by 1.5–3 mmHg [42–44], via decompression or mechanical stretch of the TM and Schlemm's canal [45] or activation of a stress response pathway by ultrasound [46].

However, after TM ablation, this mechanism would not achieve additional IOP reduction via these mechanisms, disaffirming cataract surgery as a significant contributor.

3.4.4 Trabectome as a Secondary Procedure After Failed Trabeculectomy

Trabectome can be successfully used in cases following failed incisional surgery. We analyzed 73 patients with a minimum of 1 year of follow-up who were treated with trabectome following failed trabeculectomy (Fig. 3.3) [47]. In the standalone trabectome group, the mean IOP was reduced from 23.7 ± 5.5 mmHg to 16.2 ± 3.9 mmHg (28 % mean reduction, $p < 0.01$) on 0.8 fewer medications ($p < 0.01$) at 1 year. In the phaco-trabectome group, the mean IOP was reduced from 20.0 ± 5.9 mmHg to 15.6 ± 5.1 mmHg (19 % mean reduction, $p = 0.11$) on 0.9 fewer medications ($p = 0.24$). While 89 % of standalone trabectome and 92 % of phaco-trabectome cases finished with an IOP < 21 mmHg, defining success as IOP < 21 mmHg with a 20 % IOP decrease meant only 62 % of patients in both groups were successful at 1 year. There were no visually

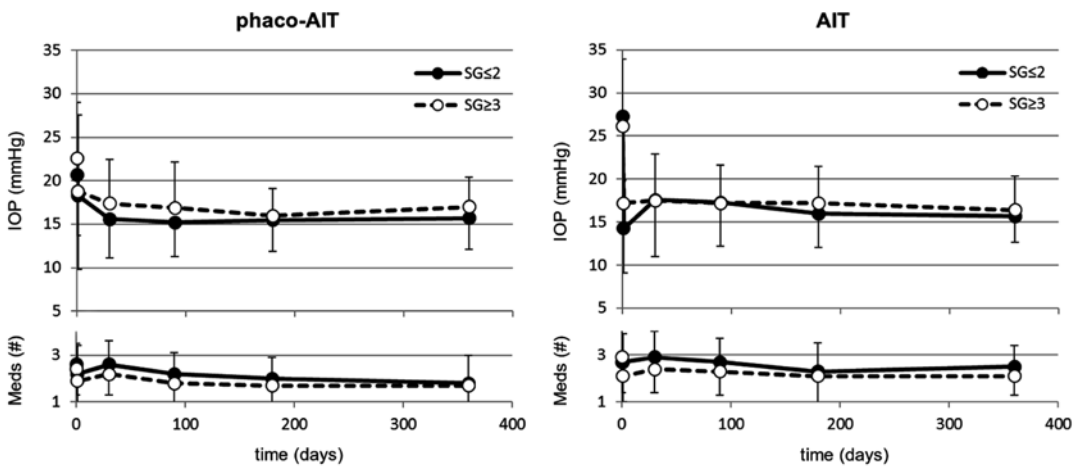


Fig. 3.2 In phaco-AIT (trabectome combined with phacoemulsification, *left*), no significant differences were found between IOP and glaucoma medication use in patients with a narrow anterior chamber angle ($SG \leq 2$, $n=48$) compared to those with an open angle ($SG \geq 3$,

$n=309$) over a 1-year period. Similarly, in AIT (trabectome, *right*), no significant differences were found in IOP and glaucoma medication use between patients with a narrow anterior chamber angle ($SG \leq 2$, $n=43$) and a wide angle ($SG \geq 3$, $n=271$) during 1-year period (all $p > 0.05$)

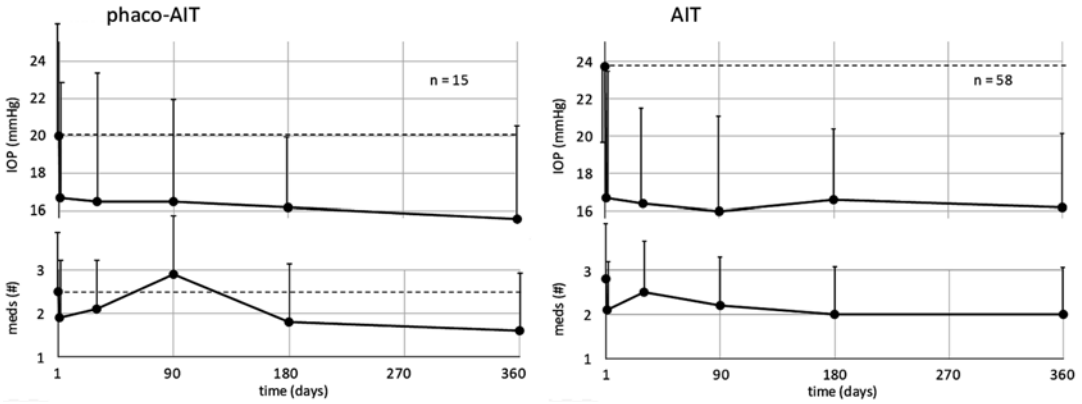


Fig. 3.3 One-year outcomes of trabectome-mediated ab interno trabeculectomy combined with phacoemulsifica-

tion (phaco-AIT, *left*) or trabectome surgery (AIT, *right*) after failed trabeculectomy

threatening complications. A recent abstract reported on 24 patients who had trabectome after failed aqueous shunt surgery [48]. The IOP fell 30 % from a baseline of 23 mmHg on 0.8 fewer medications after 1 year. 83 % of patients maintained an IOP < 21 mmHg with a 20 % decrease at 1 year. There were no visually threatening complications.

3.4.5 Trabectome as an Adjunctive Procedure

Trabectome can be used as an adjunctive procedure at the time of glaucoma drainage device implantation with a non-fenestrated tube that is completely tied off with a suture material that takes longer than two full months to dissolve (Video 3.2). Our preliminary data suggests that this prevents a hypertensive phase, achieves a lower final average IOP and reduces the need for topical medications. This approach is especially useful for advanced to end stage glaucoma and patients with poor compliance. For this reason, we prefer the 350 mm² Baerveldt implant (Abbott Medical Optics, Abbott Park, Illinois) and glue without tube fenestrations. This makes it also possible to treat thin-walled, high risk eyes where a scleral suture pass can risk perforation. The trabectome (or phaco-trabectome) is performed first to have the best possible view of the angle and chamber stability that a tight trabectome incision allows.

After trabectome and cataract surgery have concluded, the entire anterior chamber can be left filled with viscoelastic to facilitate tube shunt implantation and tube insertion. For the glaucoma drainage device implantation, an 8 mm long, limbus-parallel cut-down to the sclera is made either in the superotemporal or inferonasal position that is not more than 5 mm posterior to the limbus. The dissection is carried anterior to the limbus and posterior close to the recti muscles. The recti muscles and their insertions are visualized with muscle hooks. The tube of the tube shunt is tied with 6-0 chromic gut that has a longer absorption time of nearly 60 days compared to the commonly used threaded polyglactin 910 (coated Vicryl, Ethicon, Blue Ash, OH). After positioning the wings of the device under the muscles, the tube is placed on the cornea and cut with bevel up to allow positioning in the peripheral anterior chamber. The anterior chamber is entered with a 23 gauge needle 1.5 mm posterior to the limbus in an iris-parallel angle. The tip of the tube is guided into the eye to position flush on the iris with tube shunt insertion forceps, and the tube is secured to the sclera with 8-0 nylon in between the plate and the limbus to avoid displacement. A saline soaked, 5 mm by 8 mm long scleral patch graft is placed on the tube and nudged into the conjunctival pocket at the limbus. The thin component of fibrin glue is now applied in the sub-tenon space, around and on the scleral donor patch graft, followed by the more viscous, second glue component. The conjunctival lips are

approximated with forceps and held in place for 1 min. Conjunctival lips are secured with two interrupted vicryl sutures to the left and the right of the scleral flap to relieve tension on the incision. Some of the viscoelastic can be displaced by carefully gaping the main incision while injecting saline.

3.5 Surgical Failure

Possible reasons for failure to reach the target IOP following an apparently successful procedure may be inferred from preclinical studies on donor eyes [49]. At least one specimen showed that the TM was still intact, so the footplate likely never entered into Schlemm's canal. Another specimen revealed damage only to the superficial TM, suggesting incomplete penetrance of the handpiece. At least two specimens did show successful ablation of the TM, but the edges had re-approximated. Limbal corneal endothelial cells, particularly at Schwalbe's line [50], have been demonstrated to migrate and repair wounded TM and likely are capable of forming a membrane over the trabectome cleft [51]. Other cases demonstrate large PAS seen to directly block the trabectome cleft [52]. In cases with no visible blockage, there may be a transparent membrane or it may be that the downstream collector channels, plexi, or aqueous veins become more fibrosed or stenotic over time, decreasing outflow [52]. Fellman and Grover have proposed an intraoperative test of functional patency of the collector channels and downstream system following trabectome [52]. They suggest provoking an episcleral venous fluid wave by allowing the anterior chamber to decompress until blood reflux is noted through the trabectome cleft and then placing an irrigation/aspiration handpiece directly adjacent to the cleft and triggering irrigation. The surge of balanced salt solution can be seen to irrigate through (and blanch) episcleral, conjunctival, or aqueous veins and demonstrate functional patency of the distal collector system. They demonstrated a case of an absent fluid wave despite a visibly apparent trabectome cleft which suggested proximal intracanalicular stenosis. They

proceeded with a repeat trabectome in the same area which lead to successful IOP control. IOP failure with a visibly open cleft with a positive fluid wave may suggest damage to the collector channel orifices.

A common cause for failure and high pressures for new trabectome surgeons is wrong site ablation that injures the highly vascular ciliary body band when it is mistaken for the TM in the absence of TM pigmentation. Because the TM is still intact and the arterial hyphema cannot evacuate during the postoperative phase, pressures are very high yet wound burps in the clinic can lead to instant rebleeds. One way of addressing this is by evacuating the hyphema surgically and performing a proper TM ablation with a trabectome if there is no corneal edema that prevents ablation. Otherwise, tube shunt implantation, trabeculectomy, and cyclodestruction remain viable options. Wrong site ablation can also occur when the trabectome is inserted too anteriorly but the detaching Descemet is easily seen and the ablation can be reoriented. The postoperative course is marked by an absence of IOP drop if this is not recognized.

3.5.1 Risk Factors for Failure

The most established risk factor for failure of the surgery is a lower baseline IOP. This is primarily because IOP reduction is not a simple percentage of preoperative IOP but limited by the outflow resistance that remains downstream of the TM. The average postoperative IOP is somewhat higher than episcleral venous pressure (8 mmHg [53]) around 15–16 mmHg regardless of preoperative values. If a lower IOP is needed, phacotrabectome and trabectome still make good initial incisional therapy options as IOPs below 15 mmHg are achieved in up to 50 %, and they are safe and can improve vision where a cataract limits acuity. After multivariate Cox analysis, the hazard ratio of lower baseline IOP was calculated to be 0.96 per 1 mmHg [14]. One study ($n=304$) stratified IOP results after phaco-trabectome according to baseline IOP [19]. When baseline IOP was >25 mmHg, there was a 45 % IOP decrease at 12 months. For baseline IOP between

20 and 25 mmHg, there was a 28 % decrease, and for baseline IOP < 20, there was actually a 0.2 % IOP increase (although they were on 60 % fewer medications compared to baseline). A prospective study of 1,401 cases had a similar trend when stratifying results by baseline IOP [29]. From a baseline IOP below 17 mmHg, the decrease in IOP was only 7 %, whereas when the baseline IOP was between 23 and 29, the IOP decreased by 33 %. The superior IOP reduction reported in cases with higher baseline IOP may be due to the floor effect in that most successful cases will finish with an IOP in the low to mid teens, regardless of the baseline IOP. Another explanation may be different indications for surgery. With a high baseline IOP, the main goal of the procedure is to lower the IOP. Since trabectome has a relatively low side effect profile, with lower baseline IOPs, the procedure may be combined with phacoemulsification mainly to reduced the number of medications rather than significantly lower the IOP.

The second main risk factor is younger age (hazard ratio 0.98 per year of age) [14]. Other risk factors that have been investigated and determined not to increase the risk of failure include previous laser trabeculoplasty, although in that study the results were not stratified by type of laser [54]. The initial theory was that damage to the outflow pathway by the laser or resulting inflammation could lead to downstream scarring which would lower the efficacy of the trabectome procedure [54]. After reviewing 1,345 trabectome cases, 493 of whom had previous laser trabeculoplasty, the investigators found that despite starting from a similar baseline IOP, there was a larger mean IOP decrease at 36 months in the group who had previously undergone laser trabeculoplasty (39 % decrease versus 32 %), though the difference was not statistically significant. There was no statistically significant difference in the complication rate between the two groups. A second, smaller study found that previous argon laser trabeculoplasty (ALT) may be a risk factor for failure [28].

Previous selective laser trabeculoplasty (SLT) has also been analyzed separately as a risk factor for failure [22]. In fact, in patients with PXG, a

small retrospective comparative trial found that the group of patients who previously failed SLT (failure was defined as IOP > 16 mmHg) prior to combined phaco-trabectome actually had lower final IOP than patients with no history of SLT [22]. Starting from statistically equivalent baseline IOPs, the group of PXG patients who had failed SLT had a 46 % decrease in IOP 6 months after surgery, versus only a 35 % IOP decrease in the group of patients without a history of SLT. A similar but less significant outcome difference occurred in pigment dispersion glaucoma (PDG), again favoring patients with a history of failed SLT. The last group of patients in the study had POAG and there was no statistically significant difference in outcomes. The explanation for improved IOP outcome following previous SLT only in PXG and PDG but not in POAG is not immediately apparent.

A possible risk factor is phakic lens status, but results were conflicting. When analyzing their standalone trabectome cases, Ahuja et al. found no difference in IOP reduction between the phakic and pseudophakic cases [17]. Another study analyzed risk ratios for phaco-trabectome versus standalone trabectome and found a hazard ratio of 0.2 for the combined procedure, although it was not specified if they accounted for other contributing risk factors, mainly baseline IOP [27].

3.5.2 Timing of Surgical Failure

In studies that detail the timing of surgical failure and reoperation, it appears that most failures will occur before sixth months following trabectome. Over a five-year study period in a series of 738 standalone trabectomes, only 100 (14 %) required additional surgery [12]. Of these cases, 88 % required a second surgery by postoperative month 6. In a prospective study of standalone trabectome in 80 cases, 13 cases (16 %) went on to require reoperation within 1 year [18]. Of the 13, 77 % of them required reoperation before month 6. In another study, the range of time to reoperation following a failed trabectome was 3 days to 18 months, with an average of 4.9 months [55].

3.5.3 Reoperations

Following a failed trabectome surgery, every type of conventional surgery and laser has been reported to be used as a subsequent procedure, but the most common is advancing to trabeculectomy ab externo [14, 17, 27]. The IOP at the visit before reoperation is not detailed in most studies. In one study that did mention this (*n* = 246), the reoperation rate after 4 years was 27 % [17]. The mean IOP at the visit prior to reoperation was 26.2 mmHg, 21 % higher than the original IOP prior to the trabectome. In another study, the IOP in failed cases rose 33 % above pre-trabectome levels [10].

One study investigated the effect of SLT following failed phaco-trabectome in 14 patients [56]. Almost half of the patients had previously failed argon or SLT prior to the trabectome which was used for an average of only 89° of ablation arc. The mean IOP prior to the study SLT (mean 55 laser shots) was 18 mmHg which fell to an average of 13 mmHg (28 % decrease) on 0.8 fewer medications 6 months later. Success rates as defined by >20 % IOP decrease were only 57 % at 2 months and 0 % after 11 months, with a median time to failure of 3.8 months.

One study reports using Nd: YAG goniopuncture for 8 patients with post-trabectome IOP elevation [10]. Six of the eight patients had visible PAS lysis during the laser, while the other two were thought to have a membrane covering the trabectome cleft which was considered reopened upon blood reflux into the anterior chamber. Following goniopuncture, the IOP decreased 21 % 11 months later. The settings used were 0.2–0.6 mJ for 3–15 shots. This procedure offers an additional option, particularly in patients with uveitic glaucoma who are more prone to develop synechiae.

Repeat trabectome has been reported in small numbers [14]. The numbers are too small to be analyzed separately but the most common outcome is repeated failure, as happened in two of two cases [27]. It has been suggested that testing for an episcleral venous fluid wave (see above) can be used to distinguish between failure due to

fibrosis at the level of collector channel orifices versus more distal structures [52]. Repeat trabectome may be more successful in cases where the trabectome cleft is visibly patent but a fluid wave cannot be initiated, although this test requires a return to the operating room.

Outcomes of subsequent glaucoma procedures involving the conjunctiva are not affected by trabectome. One study compared the outcome of trabeculectomies in 34 patients who had failed trabectome surgery and 42 patients who underwent primary trabeculectomy [55]. Starting from a similar baseline IOP, the mean IOP was 11 mmHg in both groups after 24 months, with no statistically significant difference in IOP between the two groups at any time point. Success rates were also statistically equivalent. Finally, there was also no statistically significant difference in rates of complication between the two groups.

3.6 Complications

At this time, there is no evidence that the rate or type of intraoperative or postoperative complications is any different in primary versus secondary glaucoma, but further publications with subset analysis will be necessary to illuminate this issue. Table 3.3 below lists the published complications of trabectome. The most common complication is hyphema but given that blood refluxes into

Table 3.3 Complications reported after trabectome

Hyphema or microhyphema (nearly 100 % of 101 cases) [11]
PAS (14 % of 101 cases) [11]
Corneal injury (6 % of 101 cases) [11]
Transient IOP spike (6 % of 1,127 cases) [12]
Cyclodialysis cleft (two total cases) [14, 16]
Transient hypotony (1.5 % of 1,127 cases [12] no case reported to persist past 3 months)
Iris injury (1 % of 304 cases) [19]
Cystoid macular edema (1.6 % of 192 combined phaco-trabectomes) [27]
Cataract progression (1.2 % of 86 cases) [11]
Aqueous misdirection (four total cases) [12, 16, 17, 27]
Choroidal hemorrhage (1 total case) [15]

Schlemm's canal when episcleral pressure exceeds IOP, and Schlemm's canal is unroofed during this procedure, this can be an expected occurrence. There are only three published cases detailing surgical intervention for hyphema associated with an IOP spike [27, 28]. The vast majority are cleared by 1 week. In our experience, visual acuities of 20/30 can be expected if the anterior chamber is properly pressurized and maintained as described above.

A case series of 12 patients who complained of transient decrease in vision between 2 and 31 months following trabectome demonstrated a spontaneous rebleed associated with a mean IOP 12 mmHg higher than the preceding visit [28]. Knappe and Smith noted intraoperative hyphema during a trabeculectomy done 11 months after a failed trabectome surgery [57]. This led the authors to suggest avoiding hypotony during second surgeries following a trabectome. In the study by Jea et al. comparing trabeculectomy after failed trabectome to primary trabeculectomy, there was a higher incidence of postoperative hyphema in the group who had a previous trabectome surgery (20 % versus 7 %), but this difference was not statistically significant ($p=0.1$) [55].

In one study, the second-most common complication was formation of PAS, found in 24 % of patients [2]. Transient postoperative IOP spikes of at least 10 mmHg may be seen in 4 [58]–10 % [13]. It occurred in only 6 % of a series with 1,127 cases [12]. One study examined the time course and found that while 9 % had an IOP spike over 10 mmHg on post-op day 1, only 2 % still had an IOP spike at post-op day 7 [19]. One study compared corneal endothelial cell density before and 1 year after trabectome and showed that there was no decrease [18]. Doing trabectome-only in phakic eyes does not seem to have a large effect on cataract progression. After 30 months, only 1 of 86 cataracts (1.2 %) was noted to have significant progression [11].

Serious complications include a total of four cases of aqueous misdirection. Details were not given so it is not clear if chronic angle-closure, short axial length, other risk factors were present or if it was a combined procedure. In at least one of the four, it was a combined phaco-trabectome

case, and intracameral acetylcholine was used [27]. A single choroidal hemorrhage was reported without any further details [15]. A total of two cases with a cyclodialysis cleft were described but without additional details. In one of the two, it was noted that the cleft closed spontaneously [16]. A cyclodialysis cleft in trabectome is different from the deep and long clefts that trauma or surgical complications produce: [59] the tip can slip outward into the suprachoroidal space if undue outward pressure is applied leaving a small channel of 1 mm that tends to close on its own. Inadvertent traction and iris disinsertion along the scleral spur can also occur in fragile high myopic eyes when dragging is not noticed.

As of May 2014, no patient has been reported to have lost two lines of Snellen visual acuity that was directly attributed to the trabectome. Most of the literature directly specifies that no patient in the study lost two lines of vision. There is a single paper that notes that 13 patients (5 %) lost >2 lines of vision, but there is no clarification specifying if the vision loss was related to glaucoma or a comorbidity or whether those patients had received combined surgery [17].

3.7 Comparison to Other Surgeries

Unlike the iStent [60] (Glaukos, Laguna Hills, CA), trabectome has not been compared in a randomized trial to combined phaco-trabectome. It is doubtful that cataract surgery has an additional IOP-lowering effect when combined with trabectome because the effect of cataract is TM mediated that is here partially removed allowing to bypass the remaining TM along the nasal periphery [45, 46]. In one study, there was no regression of the success rate towards trabectome-only over time in a prospective study [19]. Also, previous studies suggest that standalone phacoemulsification usually only decreases the IOP by 1.5–2 mmHg in both healthy and glaucoma patients, even after 5 years [43]. There was one nonrandomized study that compared 145 cases of phacoemulsification in patients without glaucoma against 114 phaco-trabectomes [23].

Unfortunately, the baseline IOPs were too different (in favor of the phaco-trabectome group) to yield convincing conclusions. From a baseline IOP of 22 mmHg, the IOP fell by 31 % at 2 years after phaco-trabectome, while the nonglaucomatous phacoemulsification group only fell by 12 % from a baseline of 16 mmHg. Case matching by baseline IOP was done for only ten of the cases.

One of the main benefits of performing trabectome is that there is no bleb formation with the perpetual increased risk of infection nor is there any hardware left in the eye to erode or become infected. The conjunctiva is spared in case further surgery is needed. The main disadvantage is that trabectome should not be relied upon when the target IOP is in the low teens. Two studies compared the trabectome to trabeculectomy with mitomycin C but neither was randomized. The first was a prospective study that found a 52 % IOP decrease following trabeculectomy versus a 30 % decrease following trabectome [58]. Using the stringent success criteria of final IOP < 21 mmHg with a 20 % IOP decrease while avoiding hypotony and reoperation, the 12 month success rates were statistically similar at 95 % for trabectome and 83 % for trabeculectomy, $p=0.1$. The second (retrospective) study followed 217 patients for 2.5 years [14]. The reported success rate of trabectome after 2 years was only 43 % versus 76 % with trabeculectomy. At the same time, excluding hyphema (none of which required treatment), the complication rate was only 4 % with trabectome versus 35 % with trabeculectomy.

Since studies for different MIGS have different patient populations and different indications for surgery, the results cannot be directly compared. None of them have been compared to any other in a published randomized trial. To try to give some type of comparison from the available data, the iStent has been shown to reduce the IOP by 8 % [60]—27 % [61] with an overall mean final IOP of approximately 17 mmHg. In the multicenter, randomized Tube versus Trabeculectomy Study, a Baerveldt shunt lowered the IOP by 41 % (mean IOP at 5 years was 14.4 mmHg) and trabeculectomy by 50 % (mean IOP at 5 years was 12.6 mmHg) [62]. This compares well to other

large studies, including a national survey [63] as well as a meta-analysis which found that trabeculectomy lowered the IOP 3.8 mmHg more than aqueous shunts [64]. MIGS are designed to be highly standardized and should be performed significantly safer and faster than penetrating glaucoma surgery.

3.8 Conclusion

Trabectome-mediated AIT is a mature surgical technique with an extensive body of experience since 2004. On average, trabectome can be expected to lower the IOP by approximately 36 % to a final average IOP around 16 mmHg. Among secondary glaucomas, the most data is available for pseudoexfoliation glaucoma which may achieve even lower IOPs than in POAG. Comparable results may also be achieved with other secondary forms of glaucoma, including inactive neovascular, uveitic, traumatic, and post-surgical glaucoma. Trabectome as an adjunctive step in tube shunt implantation affords an effective way of achieving even lower IOPs safely over several months, avoiding the hypertensive phase and reducing drop dependence beyond regular tube shunt surgery. Vision-threatening complications are limited to case reports at the current time. Trabectome offers an effective and safe option for a wide range of glaucomas.

Acknowledgements Compliance with Ethical Requirements

Conflict of Interest: Kevin Kaplowitz declares no conflict of interest. Nils Loewen is a trabectome trainer for Neomedix.

Informed Consent: No human or animal studies were carried out by the authors for the writing of this chapter.

References

1. Food US (2012) FDA 510 (k) Database Entry Neomedix NMX-1000 (Trabectome). <http://www.accessdata.fda.gov/scripts/cdrh/cfdocs/cfPMN/pmn.cfm?ID=K040584>. Accessed 30 June 2014.
2. Minckler D, Baerveldt G, Alfaro M, Francis B. Clinical results with the trabectome for treatment of open-angle glaucoma. *Ophthalmology*. 2005;112:962–7.

3. Kahook MY, Lathrop KL, Noecker RJ. One-site versus two-site endoscopic cyclophotocoagulation. *J Glaucoma*. 2007;16:527–30.
4. Melamed S, Ben Simon GJ, Goldenfeld M, Simon G. Efficacy and safety of gold micro shunt implantation to the supraciliary space in patients with glaucoma: a pilot study. *Arch Ophthalmol*. 2009;127:264–9.
5. Ferrari E, Ortolani F, Petrelli L, et al. Ab interno trabeculectomy: ultrastructural evidence and early tissue response in a human eye. *J Cataract Refract Surg*. 2007;33:1750–3.
6. Seibold LK, Soohoo JR, Ammar DA, Kahook MY. Preclinical investigation of ab interno trabeculectomy using a novel dual-blade device. *Am J Ophthalmol*. 2013;155:524–9.
7. Singh D, Bundela DR, Agarwal DA, et al. Goniotomy ab interno “a glaucoma filtering surgery” using the fugo plasma blade. *Ann Ophthalmol*. 2006;38:213–7.
8. Rosenquist R, Epstein D, Melamed S, et al. Outflow resistance of enucleated human eyes at two different perfusion pressures and different extents of trabeculotomy. *Curr Eye Res*. 1989;8:1233–40.
9. Kaplowitz K, Schuman JS, Loewen NA. Techniques and outcomes of minimally invasive trabecular ablation and bypass surgery. *Br J Ophthalmol*. 2014;98:579–85.
10. Wang Q, Harasymowycz P. Goniopuncture in the treatment of short-term post-trabectome intraocular pressure elevation: a retrospective case series study. *J Glaucoma*. 2013;22(8):e17–20.
11. Minckler D, Baerveldt G, Ramirez MA, et al. Clinical results with the trabectome, a novel surgical device for treatment of open-angle glaucoma. *Trans Am Ophthalmol Soc*. 2006;104:40–50.
12. Minckler D, Mosaed S, Dustin L, Francis B. Trabectome (trabeculectomy—internal approach): additional experience and extended follow-up. *Trans Am Ophthalmol Soc*. 2008;106:149.
13. Ting J, Damji K, Stiles M. Ab interno trabeculectomy: outcomes in exfoliation versus primary open-angle glaucoma. *J Cataract Refract Surg*. 2012;38:315–23.
14. Jea SY, Francis BA, Vakili G, et al. Ab interno trabeculectomy versus trabeculectomy for open-angle glaucoma. *Ophthalmology*. 2012;119:36–42.
15. Minckler D, Dustin L, Mosaed S (2010) Trabectome update: 2004–2010. Poster, American Glaucoma Society, Naples, 2010.
16. Mosaed S, Rhee D, Filippopoulos T. Trabectome outcomes in adult open-angle glaucoma patients: one-year follow-up. *Clin Surg Ophthalmol*. 2010;28:5–9.
17. Ahuja Y, Ma Khin Pyi S, Malihi M, et al. Clinical results of ab interno trabeculotomy using the trabectome for open-angle glaucoma: the Mayo Clinic series in Rochester, Minnesota. *Am J Ophthalmol*. 2013;156:927–35.
18. Maeda M, Watanabe M, Ichikawa K. Evaluation of trabectome in open-angle glaucoma. *J Glaucoma*. 2013;22:205–8.
19. Francis BA, Minckler D, Dustin L, et al. Combined cataract extraction and trabeculotomy by the internal approach for coexisting cataract and open-angle glaucoma: initial results. *J Cataract Refract Surg*. 2008;34:1096–103.
20. Francis BA, Winarko J. Combined trabectome and cataract surgery versus combined trabeculectomy and cataract surgery in open-angle glaucoma. *Clin Surg Ophthalmol*. 2011;29:2–3.
21. Klamann M, Gonnermann J, Maier A, et al. Combined clear cornea phacoemulsification in the treatment of pseudoexfoliative glaucoma associated with cataract: significance of trabecular aspiration and ab interno trabeculectomy. *Graefes Arch Clin Exp Ophthalmol*. 2013;251(9):2195–9.
22. Klamann MKJ, Gonnermann J, Maier A-KB, et al. Influence of selective laser trabeculoplasty (SLT) on combined clear cornea phacoemulsification and trabectome outcomes. *Graefes Arch Clin Exp Ophthalmol*. 2014;252:627–31.
23. Francis BA. Trabectome combined with phacoemulsification versus phacoemulsification alone: a prospective, non-randomized controlled surgical trial. *Clin Surg J Ophthalmol*. 2010;28(10):1–7.
24. Vold SD. Ab interno trabeculotomy with the trabectome system: what does the data tell us? *Int Ophthalmol Clin*. 2011;51:65–81.
25. Mosaed S, Dustin L, Minckler D. Comparative outcomes between newer and older surgeries for glaucoma. *Trans Am Ophthalmol Soc*. 2009;107:127.
26. Damji KF, Konstas AGP, Liebmann JM, et al. Intraocular pressure following phacoemulsification in patients with and without exfoliation syndrome: a 2 year prospective study. *Br J Ophthalmol*. 2006;90:1014–8.
27. Jordan JF, Wecker T, van Oterendorp C, et al. Trabectome surgery for primary and secondary open angle glaucomas. *Graefes Arch Clin Exp Ophthalmol*. 2013;251:2753–60.
28. Ahuja Y, Malihi M, Sit A. Delayed-onset symptomatic hyphema after ab interno trabeculotomy surgery. *Am J Ophthalmol*. 2012;154:476–80.
29. Vold SD. Impact of preoperative intraocular pressure on trabectome outcomes: a prospective, non-randomized, observational, comparative cohort outcome study. *Clin Surg Ophthalmol*. 2010;28:11.
30. Speakman JS. Pigmentary dispersion. *Br J Ophthalmol*. 1981;65:249–51.
31. Campbell DG. Pigmentary dispersion and glaucoma. A new theory. *Arch Ophthalmol*. 1979;97:1667–72.
32. Campbell DG, Schertzer RM. Pathophysiology of pigment dispersion syndrome and pigmentary glaucoma: editorial review. *Curr Opin Ophthalmol*. 1995;6:96.
33. Grant WM. Experimental aqueous perfusion in enucleated human eyes. *Arch Ophthalmol*. 1963;69:783–801.
34. Polansky JR, Fauss DJ, Chen P, et al. Cellular pharmacology and molecular biology of the trabecular meshwork inducible glucocorticoid response gene product. *Ophthalmologica*. 1997;211:126–39.
35. Loewen R, Lagouros E, Loewen NA. Trabectome-mediated ab interno trabeculectomy in highly complex glaucomas. Paper presented at: Association for

- Research in Vision and Ophthalmology Annual Congress, Orlando, 2014.
36. Brown N, Jones L. Trabectome outcomes in uveitis patients. American Glaucoma Society Meeting; 2012.
 37. Arlene H, Rhee DH, Chen TC, et al. Trabectome in the surgical management of uveitic glaucoma. American Glaucoma Society Meeting; 2008.
 38. Chak G, Maeda M, Mosaed S. Trabectome outcome of glaucoma patients with steroid induced glaucoma. American Glaucoma Society Meeting; 2013.
 39. Liu J, Jung J, Francis BA. Ab interno trabeculotomy: trabectome™ surgical treatment for open-angle glaucoma. *Expert Rev Ophthalmol*. 2009;4:119–28.
 40. Quigley HA, Broman AT. The number of people with glaucoma worldwide in 2010 and 2020. *Br J Ophthalmol*. 2006;90:262–7.
 41. Bussel I, Kaplowitz K, Schuman JS, Loewen NA. Outcomes of ab interno trabeculectomy with the trabectome after failed trabeculectomy. *Br J Ophthalmol*. 2015;99:258–62.
 42. Mansberger SL, Gordon MO, Jampel H, et al. Reduction in intraocular pressure after cataract extraction: the Ocular Hypertension Treatment Study. *Ophthalmology*. 2012;119:1826–31.
 43. Shingleton BJ, Pasternack JJ, Hung JW, O'Donoghue MW. Three and five year changes in intraocular pressures after clear corneal phacoemulsification in open angle glaucoma patients, glaucoma suspects, and normal patients. *J Glaucoma*. 2006;15:494–8.
 44. Yang HS, Lee J, Choi S. Ocular biometric parameters associated with intraocular pressure reduction after cataract surgery in normal eyes. *Am J Ophthalmol*. 2013;156:89–94.
 45. Poley B, Lindstrom R, Samuelson T, et al. Intraocular pressure reduction after phacoemulsification with intraocular lens implantation in glaucomatous and nonglaucomatous eyes: evaluation of a causal relationship between the natural lens and open-angle glaucoma. *J Cataract Refract Surg*. 2009;35(11):1946–55.
 46. Wang N, Chintala SK, Fini ME, Schuman JS. Ultrasound activates the TM ELAM-1/IL-1/NF-kappaB response: a potential mechanism for intraocular pressure reduction after phacoemulsification. *Invest Ophthalmol Vis Sci*. 2003;44:1977–81.
 47. Bussel I, Kaplowitz K, Schuman JS, et al. Outcomes of ab interno trabeculectomy with the trabectome by degree of angle opening. *Br J Ophthalmol*. 2014; pii: [bjophthalmol-2014-305577](https://doi.org/10.1136/bjophthalmol-2014-305577). doi: [10.1136/bjophthalmol-2014-305577](https://doi.org/10.1136/bjophthalmol-2014-305577).
 48. Mosaed S. Effect of trabectome in patients with prior failed tube shunts surgery. San Francisco: American Glaucoma Society; 2014.
 49. Francis B, See R, Rao N, et al. Ab interno trabeculectomy: development of a novel device (Trabectome (TM)) and surgery for open-angle glaucoma. *J Glaucoma*. 2006;15:68–73.
 50. McGowan SL, Edelhauser HF, Pfister RR, Whitehart DR. Stem cell markers in the human posterior limbus and corneal endothelium of unwounded and wounded corneas. *Mol Vis*. 2007;13:1984–2000.
 51. Whitehart DR, Parikh CH, Vaughn AV, et al. Evidence suggesting the existence of stem cells for the human corneal endothelium. *Mol Vis*. 2005; 11:816–24.
 52. Fellman RL, Grover DS. Episcleral venous fluid wave: intraoperative evidence for patency of the conventional outflow system. *J Glaucoma*. 2014;23(6): 347–50.
 53. Sit AJ, Ekdawi NS, Malihi M, McLaren JW. A novel method for computerized measurement of episcleral venous pressure in humans. *Exp Eye Res*. 2011; 92:537–44.
 54. Vold SD, Dustin L. Impact of laser trabeculoplasty on Trabectome® outcomes. *Ophthalmic Surg Lasers Imaging*. 2010;41(4):443–51.
 55. Jea S, Mosaed S, Vold S, Rhee D. Effect of a failed trabectome on subsequent trabeculectomy. *J Glaucoma*. 2012;21:71.
 56. Töteberg-Harms M, Rhee DJ. Selective laser trabeculoplasty following failed combined phacoemulsification cataract extraction and ab interno trabeculectomy. *Am J Ophthalmol*. 2013;156:936–40.
 57. Knappe R, Smith M. Anterior chamber blood reflux during trabeculectomy in an eye with previous trabectome surgery. *J Glaucoma*. 2010;19:499–500.
 58. Francis BA, Winarko J. Ab interno Schlemm's canal surgery: trabectome and i-stent. *Dev Ophthalmol*. 2012;50:125–36.
 59. Joondeph HC. Management of postoperative and post-traumatic cyclodialysis clefts with argon laser photocoagulation. *Ophthalmic Surg*. 1980;11: 186–8.
 60. Craven ER, Katz LJ, Wells JM, et al. Cataract surgery with trabecular micro-bypass stent implantation in patients with mild-to-moderate open-angle glaucoma and cataract: two-year follow-up. *J Cataract Refract Surg*. 2012;38:1339–45.
 61. Fernández-Barrientos Y, García-Feijó J, Martínez-de-la-Casa JM, et al. Fluorophotometric study of the effect of the glaukos trabecular microbypass stent on aqueous humor dynamics. *Invest Ophthalmol Vis Sci*. 2010;51:3327–32.
 62. Gedde S, Schiffman J, Feuer W, et al. Treatment outcomes in the tube versus trabeculectomy (TVT) study after five years of follow-up. *Am J Ophthalmol*. 2012;29:2–3.
 63. Edmunds B, Thompson JR, Salmon JF, Wormald RP. The national survey of trabeculectomy. II. Variations in operative technique and outcome. *Eye (Lond)*. 2001;15:441–8.
 64. Minckler DS, Vedula SS, Li TJ, et al. Aqueous shunts for glaucoma (Cochrane review). *Cochrane Database Syst Rev*. 2006 Apr 19;(2):CD004918.

Lens Extraction in Angle Closure Glaucoma

4

Sameer Trikha, Shamira A. Perera, Rahat Husain,
and Tin Aung

4.1 Introduction

Angle closure originates from appositional closure of the drainage angle by the iris, which results in impaired aqueous outflow. This can progress to synechiae formation, an increase in intraocular pressure (IOP), and eventually, glaucomatous optic neuropathy. It is estimated that primary angle closure glaucoma (PACG) accounts for 26 % of all patients with glaucoma worldwide [1]. A number of mechanisms of PACG aetiology have been postulated, and an anatomical classification has been developed by Ritch and Lowe involving features at different levels within the eye: the pupil, the ciliary body (plateau iris), lens related phenomena, and forces posterior to the lens (e.g. malignant glaucoma) [2]. Of these, pupil block is the main

mechanism underlying PACG. Recent work has also identified iris volume, iris thickness, and choroidal expansion as factors potentially involved in PACG [3]. It is likely that the influence of these coexisting mechanistic factors, possibly coupled with physiological and dynamic factors, precipitates angle closure.

Research in the past 5 years has shed new light upon the management of PACG. The cornerstone of treatment is first relieving pupil block and then managing the IOP. Conventional management consists of topical and systemic IOP lowering medications, usually followed by laser peripheral iridotomy (LPI), with laser iridoplasty advocated for situations where there is a plateau iris configuration. Surgical management of PACG, in the form of cataract surgery, coupled with angle manipulation or filtration surgery, has been suggested as an alternative management strategy and may potentially offer advantages over the conventional approach.

In this chapter, we discuss the evidence for lens extraction in PACG, and follow this with aspects of preoperative counselling, surgical techniques, and suggestions for post-operative management.

4.2 Pathophysiology

The lens has long been thought to play a mechanical role in angle closure, and recent studies using imaging modalities such as anterior segment optical coherence tomography (AS-OCT) and ultra-

S. Trikha, B.Sc. (Hons). F.R.C.Ophth.
S.A. Perera, B.Sc. (Hons). F.R.C.Ophth.
R. Husain, M.D. Res., F.R.C.Ophth.
Singapore Eye Research Institute and Singapore
National Eye Centre, Singapore, Singapore
e-mail: sameer.trikha@seri.com.sg;
shamira.perera@sneec.com.sg;
rahat.husain@sneec.com.sg

T. Aung, F.R.C.Ophth., Ph.D. (✉)
Singapore Eye Research Institute and Singapore
National Eye Centre, Singapore, Singapore
Yong Loo Lin School of Medicine, National
University of Singapore, Singapore, Singapore
e-mail: aung.tin@sneec.com.sg

sound biomicroscopy (UBM) have demonstrated that spherophakic, swollen, or subluxed crystalline lenses may cause, or be a consequence of, angle closure glaucoma [4] (Fig. 4.1). Whilst an association between angle closure glaucoma and shallower anterior chamber depth and increased lens thickness has been established [5], more recently AS-OCT parameters such as lens vault (LV), the proportion of the lens anterior to the scleral spurs has been found to be a significant factor as well [6] (Fig. 4.2).

4.3 Reasons for Lens Extraction in Angle Closure Glaucoma

4.3.1 Evidence for Lens Extraction

Anatomical risk factors associated with PACG are primarily due to a crowded anterior chamber with iridotrabecular contact. Both can be relieved

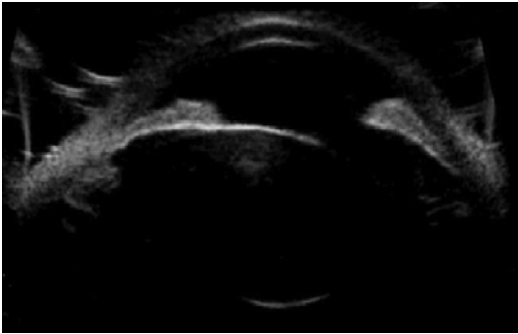


Fig. 4.1 AS-OCT demonstrating a subluxed crystalline lens causing angle closure

by lens extraction. A number of studies have advocated lens extraction in PACG, with the primary outcome measure being a sustained reduction in IOP. It has been postulated that the anterior chamber shallows with age due to an increase in lens thickness [7]. Consequently, deepening of the anterior chamber achieved by lens extraction may improve aqueous access to the angle, and therefore reduce the IOP [7] (Figs. 4.3a, b). Weak evidence exists as to whether patients without glaucoma receiving cataract surgery achieve any reduction in IOP. One study of 93 patients found an average of 1.5 mm reduction at 3 years [7]. IOP reductions of between 2–6 mmHg have been described following lens extraction in PACG eyes [8–11], notably greater in PACG compared to POAG eyes [12].

A recent randomized, controlled trial evaluated laser peripheral iridotomy (LPI) versus lens extraction in patients with acute primary angle closure (APAC), following emergency medical management to lower the IOP. Compared to the LPI group, the group receiving phacoemulsification demonstrated a greater IOP fall. Furthermore, when performed within 1 week of an acute angle closure attack, phacoemulsification was associated with reduced failure of IOP control at 2 years when compared to LPI [13]. A study performed by Lam et al. randomized 62 eyes to LPI or phaco/IOL after medical control of APAC and demonstrated a mean IOP of 12.6 mmHg in the phaco group versus 15.0 mmHg in the LPI group, after 18 months of follow-up [14].

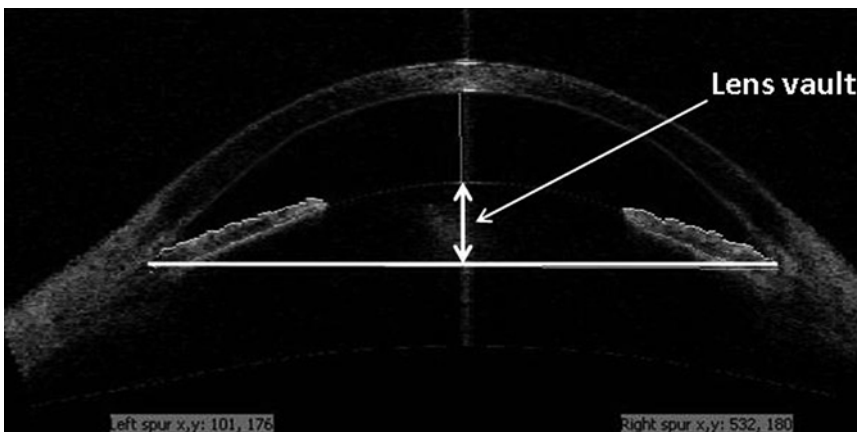


Fig. 4.2 AS-OCT depicting anterior lens vault which may contribute to angle crowding

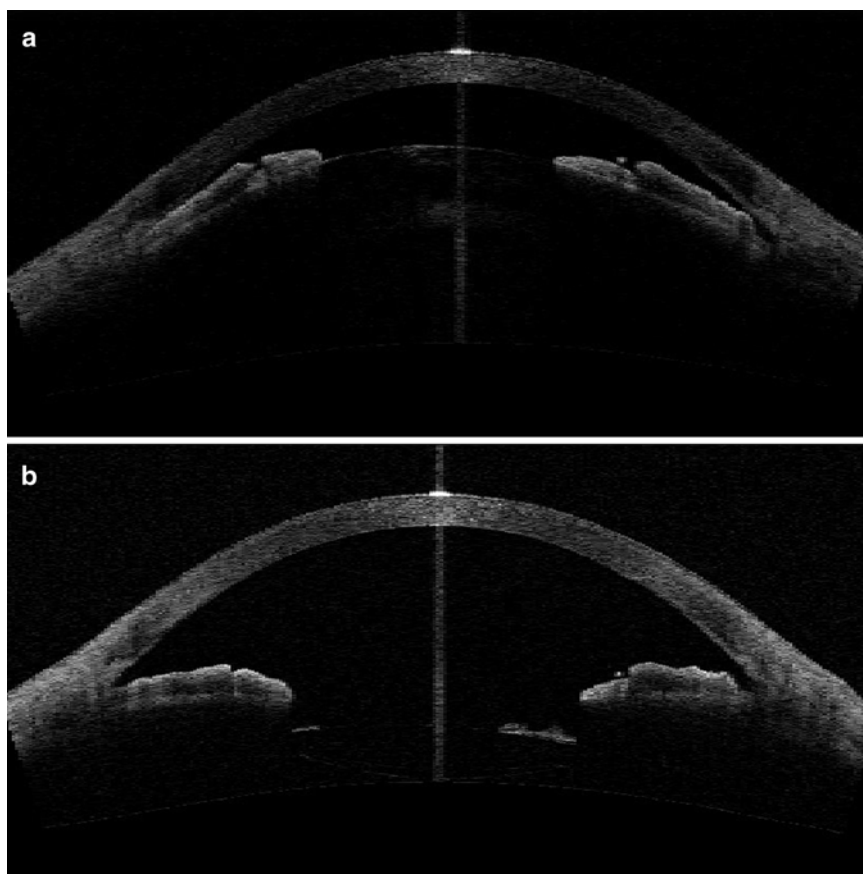


Fig. 4.3 (a) AS-OCT before phacoemulsification surgery showing a shallow anterior chamber and angle closure due to the presence of a cataract with large lens vault.

(b) AS-OCT of the same patient as in Fig. 4.3a after phacoemulsification surgery showing deepened anterior chamber with open angles

Whilst conventional LPI may open the drainage angle and reduce the IOP initially in APAC, a retrospective review of 65 subjects who had LPI followed up for 5 years revealed that 100 % required medications and 63 % surgery to lower the IOP [15]. Important mechanistic aspects of ACG, such as pupil block are relieved by lens extraction, reducing the risk of CACG. A case series of 21 eyes reported a 19 % reduction in PAS greater than 270° [16] and another purported that the degree of lens vault may be a positive predictor for IOP reduction and degree of angle widening following surgery [17].

Tham et al. [18, 19] performed two randomized studies comparing phacoemulsification alone to combined phaco-trabeculectomy in medically controlled and uncontrolled chronic PACG.

They assessed a number of factors including IOP control, post-operative complications, and the number of glaucoma drops. Combined phaco-trabeculectomy was associated with greater complications, with some necessitating additional surgery. The difference in glaucoma progression was not significant in both groups [19]. Interestingly improved IOP control in the phaco-trabeculectomy group was only marginal when compared to the phacoemulsification group across the 24 months of the study.

Whilst combined phaco-trabeculectomy surgery does offer a small benefit in terms of IOP control, there is little evidence to suggest that this improvement is associated with better long-term outcomes in terms of visual field progression. Therefore, primary lens extraction may be a

viable option in the management of angle closure glaucoma. In many circumstances, lens extraction may suffice for glaucoma control—only 2.9 % of patients with controlled PACG versus 14.8 % in uncontrolled PACG receiving lens extraction alone went on to require a trabeculectomy [18, 19].

4.3.2 Additional Considerations for Cataract Surgery in PACG

The patient pathway for conventional phacoemulsification surgery is well established. With infrequent post-operative visits compared to glaucoma filtration surgery, this option may appear more attractive to patients, particularly when the nature, demographics, and geographical setup of the clinical setting are considered. In a scenario where frequent and long-term patient follow-up may be difficult, the option of lens extraction may be favoured above other treatment modalities.

Furthermore, fluctuations in visual performance tend to be less frequent following cataract surgery when compared to glaucoma surgery, the latter often resulting in variations in IOP and blurred vision, which can persist for several weeks. Ocular surface discomfort and inflammation is less pronounced following phacoemulsification surgery [20], and studies have demonstrated improved patient satisfaction following this procedure [20, 21]. Glaucoma filtration surgery can potentially expose patients to long-term risks, including blebitis and bleb-related endophthalmitis which are circumvented by the choice of cataract surgery.

4.3.3 Combined Procedures

4.3.3.1 Lens Extraction with Goniosynechialysis/Viscogonioplasty

Whilst cataract surgery alone may deepen the anterior chamber and open the drainage angle, its effect on the presence of significant peripheral anterior synechiae (PAS) may be limited. PAS formation has been shown to occur even with the

presence of a patent PI [22]. In recent years, further evidence has emerged to incorporate goniosynechialysis (GSL) with cataract surgery [23]. In this procedure, PAS are stripped manually under gonioscopic view. This can be performed either directly, using a blunt spatula, or via the application of viscoelastic (also known as viscogonioplasty, VGP), delicately avoiding potential complications such as bleeding, iridodialysis, and fibrinous uveitis. GSL is thought to be most effective in patients where PAS has been present for less than 6–12 months [24].

Whilst the results of randomized controlled trials are awaited, there was a recent cohort study of 51 eyes (17 with APAC and 34 with chronic angle closure glaucoma) that underwent phacoemulsification surgery and GSL. At an average of 25 months follow-up, the mean IOP dropped by an average of 9.67 mmHg for both groups. The average number of medications used fell from 2.51 preoperatively to 0.67 post-operatively [25]. The GSL technique can contribute to deepening the anterior chamber angle [25]. Two retrospective case series have described the IOP effect of phaco-VGP. Varma et al. described, in 15 eyes of patients with refractory PACG, a mean IOP reduction from 27.4 mmHg (on medication) to 14.1 mmHg (off all medications in 14/15 eyes) at 6 months [26]. Another study, in 2008, of 11 patients (11 eyes) with PACG (all of whom had refractory control despite patent LPI) showed a reduction in IOP from 39.4 mmHg preoperatively to a mean of 13.4 mmHg after phaco-VGP at 7.8 months follow-up [27]. Intraoperative complications such as haemorrhage and iridocyclodialysis, previously described with GSL, were not observed in this series.

4.3.3.2 Phaco-Trabeculectomy

A combination of phacoemulsification surgery with trabeculectomy surgery with mitomycin-C should be considered in patients with cataract and advanced PACG or those with glaucomatous progression, with suboptimal IOP control, or those with extensive PAS. One benefit of this approach is that, in most cases, this will result in one visit to the operating room. However, trabeculectomy function may be compromised if

cataract surgery is complicated at the same sitting. Post-operative “spikes” in IOP are generally avoided with the combined procedure, and this may be advantageous particularly in advanced glaucoma to reduce the risk of “wipe out”. Tham et al. [19] have demonstrated lower mean IOP and medication use after phaco-trabeculectomy compared to phacoemulsification alone in medically uncontrolled CACG patients. However, the IOP findings were only significant at a few time points, and the increase in post-operative complications in the trabeculectomy group were due to the trabeculectomy part of the procedure [18]. Currently, the long-term results of phacoemulsification alone versus phaco-trabeculectomy are not known.

4.3.4 The Timing of Lens Extraction

Controversy surrounds the optimal timing of lens extraction in both acute and chronic PACG. Whilst some surgeons suggest primary lens extraction days after the resolution of the acute angle closure episode, surgery may be technically less challenging and safer once the corneal clarity and intraocular inflammation have settled after a few weeks. A study by Imaizumi on 18 eyes undergoing cataract surgery within 1 day of medical control of APAC demonstrated no difference in the endothelial cell count compared to a control group of conventional phacoemulsification in normal eyes [11]. Whilst the largest IOP reductions have been observed in medically uncontrolled APAC eyes undergoing phacoemulsification [28], Jacobi et al. demonstrated significantly better IOP control and reduced use of ocular hypotensive medications, at 10 months follow-up, in patients receiving phacoemulsification surgery within 4 days of APAC versus conventional surgical iridectomy [29]. Improved long-term results may be best if surgery is performed before PAS has had a chance to fully form. However, in cases where access to surgery is limited, preparative LPI may be a more viable option.

It has been suggested that 50 % of PACG patients are likely to go on and develop cataracts due to ageing and the effects of glaucoma

treatment, and the latter in fact may accelerate cataract progression [30]. However, by the time the cataracts have formed, glaucoma progression may be severe and irreversible. Higher rates of posterior capsule rupture have been associated with dense cataracts, suggesting surgeons may wish to intervene before this stage [31].

The exact timing of intervention will involve planning between the surgeon and patient. A detailed ocular examination, patient demographics, assessing visual symptoms, angle morphology (with the degree of appositional and synechial closure), along with IOP, and importantly, the rate of glaucoma progression, should determine when to consider phacoemulsification. In the presence of mild glaucoma and minimal PAS, phacoemulsification alone is preferred, whereas if extensive and relatively recent PAS is present, cataract surgery may be augmented by GSL or VGP. A cataract/filtration procedure (phaco-trabeculectomy) can be reserved for advanced glaucoma cases in which greater IOP lowering may be required.

4.4 Preparing for Surgery

4.4.1 Cataract Extraction in Angle Closure Glaucoma: Potential Risks

Phacoemulsification is not without its risks: Johnston et al. published an overall posterior capsule rupture rate of 1.92 % in the UK national cataract database of 55,297 cataract operations [32]. The risk of endophthalmitis varies between 0.014 and 0.048 % [33]. Risks associated with surgery may correlate with extreme refractive status, with a higher rate of complications associated with higher ametropia. Lens subluxation may be a precipitating factor for angle closure glaucoma in high myopes, whereas shallow anterior chamber depth may be a causative factor in high hyperopes.

Lens extraction in cases of angle closure glaucoma presents potential additional factors to consider aside from routine phacoemulsification surgery. Significant post-operative complications

have been reported. Technically, lens extraction post APAC may pose challenges involving a mid-dilated pupil. Iris atrophy and atonicity may increase the risk of iris prolapse, trauma, and bleeding. The eye itself may still be inflamed and the corneal clarity compromised, therefore obscuring the view. With APAC, inflammation may lead to zonular weakness and lens instability [13]. This may have secondary effects upon fluidic management and anterior chamber stability. In PACG, the lens itself may be bulky and cataractous, increasing the risk of sudden drop in IOP upon removal, and subsequent risk of suprachoroidal haemorrhage. Furthermore, the presence of a shallow anterior chamber may exacerbate endothelial damage, retard visual recovery, and occasionally lead to corneal decompensation. Additional risks in these PACG eyes include malignant glaucoma and post-operative IOP elevation, as well as prolonged post-operative inflammation [9]. Via risk stratification, these cases are therefore best reserved for more experienced surgeons.

In recent times, straightforward cataract surgery has received positive media coverage. However, the nuances and specific complications of lens extraction after APAC need to be carefully detailed to the patient and family members, to prevent potential medico-legal ramifications. Specifically, the patient may be required to modify their IOP medication regimen, use systemic medications, and be warned about the rare possibility of further procedures should the IOP become uncontrollable.

4.4.2 Lens Selection

Patients should be especially involved in the decision of lens selection. Some patients with angle closure may be of pre-presbyopic age and therefore should be warned of the potential loss of accommodation post-surgery and the possibility of spectacle dependence. Careful assessment involving focimetric analysis and manifest refraction should be performed, with a clear plan regarding the fellow eye also discussed. Patients need to be made aware of potential anisometropic symptoms and the possible commitment to second eye surgery.

4.4.3 Biometry Considerations

Myopic eyes with angle closure may have an elongated vitreous cavity in comparison to the anterior chamber depth, and this may result in inaccurate IOL calculations [24]. Furthermore, the subject of effective lens position (ELP) in cases of phacoemulsification post APAC has been subject to debate. It may be possible that the IOL actually moves anteriorly as the capsule contracts and fibroses, with subsequent effects upon IOL calculation. The Holladay IOL Consultant (Jack T. Holladay, Houston, Tex) is commonly used to optimize outcomes as the formula includes anterior chamber depth and corneal diameter measurements in the IOL calculation.

4.5 Surgical Technique

4.5.1 Choice of Anaesthesia

Ocular features that are likely to make surgery more challenging such as a small pupil, large bulky cataract, and reduced corneal clarity along with the presence of corneal guttata should be considered. Prior to surgery, the use of preoperative mannitol to shrink vitreous volume, or acetazolamide to reduce aqueous production, may be used. A detailed medical history should be available to prevent inadvertent use of these medications and subsequent cardiac, renal, or other systemic complications. Local anaesthetic, using topical and/or intracameral anaesthesia may be the first choice, as anterior sub-tenons or peribulbar block may increase orbital pressure. However, peribulbar anaesthesia may be more appropriate if the surgical time is likely to be extended, as this should reduce risk. The conversion of anaesthetic during surgery should be avoided, where possible, as this may exacerbate patient anxiety.

4.5.2 Anterior Chamber Management

Generally in eyes with angle closure, the anterior chamber is likely to be shallow, with little room for manoeuvring instruments. A small but long

side-port incision may be used first along with a highly retentive cohesive viscoelastic. Some surgeons may prefer DiscoVisc (Alcon, Fort Worth, Tex) and Healon GV or 5 (Advanced Medical Optics, Santa Ana, Calif) when AC stability and adequate pupil size is difficult to maintain. Protection of the corneal endothelium is of paramount importance, particularly as some patients with narrow angles may have coexisting corneal guttata or endothelial compromise, which may be exacerbated by the proximity to phacoemulsification and contact with lens fragments and instruments.

4.5.3 Surgical Steps

Due to the risk of iris prolapse, a three-step corneal incision should be considered. Any further sideport incision should be angled to prevent iris movement to the wound. The surgeon should be constantly aware of iris behaviour during surgery. In the case of iris movement, further viscoelastic can be used to tamponade the iris and prevent it from prolapsing. Failing this, the wound can be sutured and a new corneal main wound constructed.

The surgeon should anticipate any radial extension of the continuous curvilinear capsulorhexis (CCC) usually precipitated by a shallowing of the AC. If this occurs, the capsulorhexis should be temporarily aborted and the anterior chamber filled with viscoelastic. If the CCC continues to extend outwards despite a rescue technique, a second instrument may be placed on the lens to depress it. This will reduce the tendency for it to tear out and allow the capsulorhexis to be completed.

Hydrodissection should be performed with caution, to prevent inadvertent posterior capsule blowout in the presence of a small CCC. Furthermore, excessive hydrodissection should be avoided which can cause iris prolapse via a rapid increase in anterior chamber pressure. Gentle pressure on the posterior edge of the wounds can release viscoelastic in a controlled manner, decompressing the anterior chamber and permitting safe hydrodissection. A “phaco-chop”

or “stop and chop” technique is preferred, as this will result in lower overall energy and risk of endothelial cell loss, as well as minimize zonular stress. A continuous irrigation setting may help to provide further anterior chamber stability during this step and subsequent soft lens matter removal. Furthermore, the surgeon should be aware of aqueous misdirection and sudden changes in anterior chamber volume at all times.

Following soft lens matter removal and intraocular lens insertion, the surgeon should examine the anterior chamber for stability, and inspect the wounds for signs of a leak. Temporary 10-0 nylon sutures can be placed if a wound leak is suspected, and these can be removed after 4–6 weeks. Post-operatively, oral acetazolamide mitigates against transient IOP spikes, and close follow-up should be organized within the first week.

4.6 Conclusion

Increasing evidence suggests that lens extraction may be of benefit in cases of angle closure glaucoma, improving IOP control over the medium to long term, and thereby slowing glaucoma progression. However, detailed clinical evaluation is required to determine optimal surgical timing, in order to balance patient benefit with surgical risk and delay resulting in irreversible glaucomatous damage. In advanced cases of PACG, lens extraction may be combined with trabeculectomy. Patients need to be informed of the risks and benefits of lens extraction, with careful counselling. Furthermore, the surgical steps described should be considered to reduce the risk of complications, and ensure an optimal outcome.

Acknowledgements Financial disclosures: Nil.

Statement of informed consent: All imaging was recorded following informed consent from patients involved.

Statement on Conflict of interest: Sameer Trikha, Shamira Perera, Rahat Husain, and Tin Aung declare that they have no conflict of interest.

Ethical statement: No animal or human studies were carried out by the authors for this article. Furthermore, informed Consent and Animal Studies disclosures are not applicable to this review.

References

- Quigley HA, Broman AT. The number of people with glaucoma worldwide in 2010 and 2020. *Br J Ophthalmol*. 2006;90:262–7.
- Nogpiur M, Ku JY, Aung T. Angle closure glaucoma: a mechanistic review. *Curr Opin Ophthalmol*. 2011;22(2):96–101.
- Wang B, Sakata LM, Friedman DS. Quantitative iris parameters and association with narrow angles. *Ophthalmology*. 2010;118:474–9.
- Tsai A, Wong TT, Perera SA. The utility of anterior segment imaging in an atypical case of angle closure. In: *Proceedings of Singapore Health Care*, 2012. vol 21, p. 1.
- Tomlinson A, Leighton DA. Ocular dimensions in the heredity of angle closure glaucoma. *Br J Ophthalmol*. 1973;57:475–86.
- Nongpiur ME, He MG, Amerasinghe N, et al. Lens vault, thickness and position in chinese subjects with angle closure. *Ophthalmology*. 2011;118:474–9.
- Matsumura M, Mizoguchi T, Kuroda S, et al. Intraocular pressure decrease after phacoemulsification-aspiration+intraocular lens implantation in primary open angle glaucoma eyes. *Nihon Ganka Gakkai Zasshi*. 1996;100(11):885–9.
- Wishart PK, Atkinson PL. Extracapsular cataract extraction and posterior chamber lens implantation in patients with primary chronic angle-closure glaucoma: effect on intraocular pressure control. *Eye (Lond)*. 1989;3(Pt 6):706–12.
- Gunning FP, Greve EL. Lens extraction for uncontrolled angle-closure glaucoma: long-term follow-up. *J Cataract Refract Surg*. 1998;24(10):1347–56.
- Hayashi K, Hayashi H, Nakao F, et al. Effect of cataract surgery on intraocular pressure control in glaucoma patients. *J Cataract Refract Surg*. 2001;27(11):1779–86.
- Imaizumi M, Takaki Y, Yamashita H. Phacoemulsification and intraocular lens implantation for acute angle closure not treated or previously treated by laser iridotomy. *J Cataract Refract Surg*. 2006;32(1):85–90.
- Chan JCI, Lai JS, Tham CC. Comparison of postoperative refractive outcome in phacotrabeculectomy and phacoemulsification with posterior chamber intraocular lens implantation. *J Glaucoma*. 2006;15(1):26–9.
- Husain R, Gazzard G, Aung T, et al. Initial management of acute primary angle closure: a randomized trial comparing phacoemulsification with laser peripheral iridotomy. *Ophthalmology*. 2012;119(11):2274–81.
- Lam DS, Leung DY, Tham CC, et al. Randomized trial of early phacoemulsification versus peripheral iridotomy to prevent intraocular pressure rise after acute primary angle closure. *Ophthalmology*. 2008;115(7):1134–40.
- Alsagoff Z, Aung T, Ang LP, et al. Long-term clinical course of primary angle closure glaucoma in an Asian population. *Ophthalmology*. 2000;1074:2300–4.
- Lai JS, Tham CC, Chan JC. The clinical outcomes of cataract extraction by phacoemulsification in eyes with primary angle closure glaucoma. *J Glaucoma*. 2006;15(1):47–52.
- Huang G, Gonzalez E, Lee R, et al. Association of biometric factors with anterior chamber angle widening and intraocular pressure reduction after uneventful phacoemulsification for cataract. *J Cataract Refract Surg*. 2012;38(1):108–16.
- Tham CC, Kwong YY, Leung DY, et al. Phacoemulsification versus combined phacotrabeculectomy in medically uncontrolled chronic angle closure glaucoma with cataracts. *Ophthalmology*. 2009;116(4):725–31.
- Tham CC, Kwong YY, Leung DY, et al. Phacoemulsification versus combined phacotrabeculectomy in medically controlled chronic angle closure glaucoma with cataracts. *Ophthalmology*. 2008;115:2167–73.
- Colin J, El Kelbir S, Eydoux E, et al. Assessment of patient satisfaction with outcomes and ophthalmic care for cataract surgery. *J Cataract Refract Surg*. 2010;36(8):1373–9.
- Lundström M, Stenevi U, Thorburn W. Quality of life after first- and second-eye cataract surgery: five-year data collected by the Swedish National Cataract Register. *J Cataract Refract Surg*. 2001;27(10):1553–9.
- Nolan WP, Foster PJ, Devereux JG, et al. YAG laser iridotomy treatment for primary angle closure in East Asian eyes. *Br J Ophthalmol*. 2000;84:1255–9.
- Harasymowycz PJ, Papamatheakis DG, Ahmed I, et al. Phacoemulsification and goniosynechiolysis in the management of unresponsive primary angle closure. *J Glaucoma*. 2005;14:186–9.
- Campbell DG, Vela A. Modern goniosynechiolysis for the treatment of synechial angle-closure glaucoma. *Ophthalmology*. 1984;91:1052–60.
- Yu J, Sun M, Wei Y, et al. The timing of goniosynechiolysis in treatment of primary angle-closure glaucoma combined with cataract. *Mol Vis*. 2012;18:1074–82.
- Varma D, Baylis O, Wride N, et al. Viscogonioplasty: an effective procedure for lowering intraocular pressure in primary angle closure glaucoma. *Eye (Lond)*. 2007;21:472–5.
- Razeghinejad MR. Combined phacoemulsification and viscogoniolysis in patients with refractory acute-angle closure glaucoma. *J Cataract Refract Surg*. 2008;34:827–30.
- Roberts TV, Francis IC, Lertsumitkul S, et al. Primary phacoemulsification for uncontrolled angle-closure glaucoma. *J Cataract Refract Surg*. 2000;26:1012–6.
- Jacobi PC, Deitlein TS, Luke C, et al. Primary phacoemulsification and lens implantation for acute angle closure glaucoma. *Ophthalmology*. 2002;109(9):1597–603.
- Lim S, Husain R, Gazzard G, et al. Cataract progression after prophylactic laser iridotomy: potential implications for the prevention of glaucoma blindness. *Ophthalmology*. 2005;112:1355–9.

31. Zare M, Javadi M, Einollahi B, et al. Risk factors for posterior capsule rupture and vitreous loss during phacoemulsification. *J Ophthalmic Vis Res.* 2009;4(4):208–12.
32. Johnston RL, Taylor H, Smith R, et al. The Cataract National Dataset electronic multi-centre audit of 55,567 operations: variation in posterior capsule rupture rates between surgeons. *Eye (Lond).* 2010;24(5):888–93.
33. Barry P, Cordoves L, Gardner S. ESCRS treatment and prevention of endophthalmitis. European Society of Cataract and Refractive surgeons, Dublin, Ireland, 2013.
34. Yong KL, Gong T, Nongpiur ME, et al. Myopia in asian subjects with primary angle closure: implications for glaucoma trends in East Asia. *Ophthalmology.* 2014;121(8):1566–71.

Gonioscopy Assisted Transluminal Trabeculotomy (GATT) for the Treatment of Adult and Developmental Glaucomas

Davinder S. Grover and Ronald L. Fellman

5.1 Introduction

Lowering intraocular pressure (IOP) is the mainstay treatment option for preventing blindness due to glaucoma. Most commonly, this is accomplished with either medical and/or laser therapy. However, when the above modalities fail to control the disease, incisional surgery, a far more complicated process is necessary.

Historically, when incisional surgery is necessary, an alternative non-physiologic subconjunctival drainage space was created by the flow of aqueous through a guarded limbal fistula, or trabeculectomy. This labor-intensive procedure was the most common incisional surgery for failed medical/laser therapy. Trabeculectomy is a demanding procedure that requires intensive postoperative care. It remains a trying experience for both patients and physicians due to variability in wound healing and the long-term bleb vigilance for dysesthesia and blebitis.

Glaucoma drainage tubes are the other mainstay for non-physiologic surgical glaucoma management. Recent studies have provided more insight into their safety and efficacy [1–3]. While more and more surgeons are depending on glaucoma drainage tubes, they are not without risk. Following these surgeries, the patient is at risk for double vision, tube erosion, corneal failure, and/or poor IOP control.

Seeking a safer more predictable alternative, ophthalmologists are turning to simpler blebless procedures that reduce complications by improving flow into the eye's natural collector channels, commonly termed microinvasive glaucoma surgery (MIGS). These procedures enhance flow into the eye's natural collector channels instead of creating an artificial drain (bleb) that abandons the existing natural physiologic outflow channels (Fig. 5.1). Figure 5.2 outlines the general approach the authors follow when evaluating surgical glaucoma patients.

Trabeculotomy, a time honored blebless angle procedure, reduces IOP by increasing flow into the natural outflow pathway. It cleaves open a diseased glaucomatous outflow system and improves aqueous flow into Schlemm's canal and adjacent collector channels, thereby avoiding an artificial bleb drainage system. Trabeculotomy has evolved over the past 50 years from an ab externo metal segmental trabeculotome approach to a minimally invasive gonioscopy assisted ab interno microcatheter (iTrack, Ellex Medical

Electronic supplementary material The online version of this chapter (doi:[10.1007/978-3-319-18060-1_5](https://doi.org/10.1007/978-3-319-18060-1_5)) contains supplementary material, which is available to authorized users.

D.S. Grover, M.D., M.P.H. (✉) • R.L. Fellman, M.D.
Glaucoma Associates of Texas, Dallas, TX, USA
e-mail: dgrover@glaucomaassociates.com;
rfellman@glaucomaassociates.com

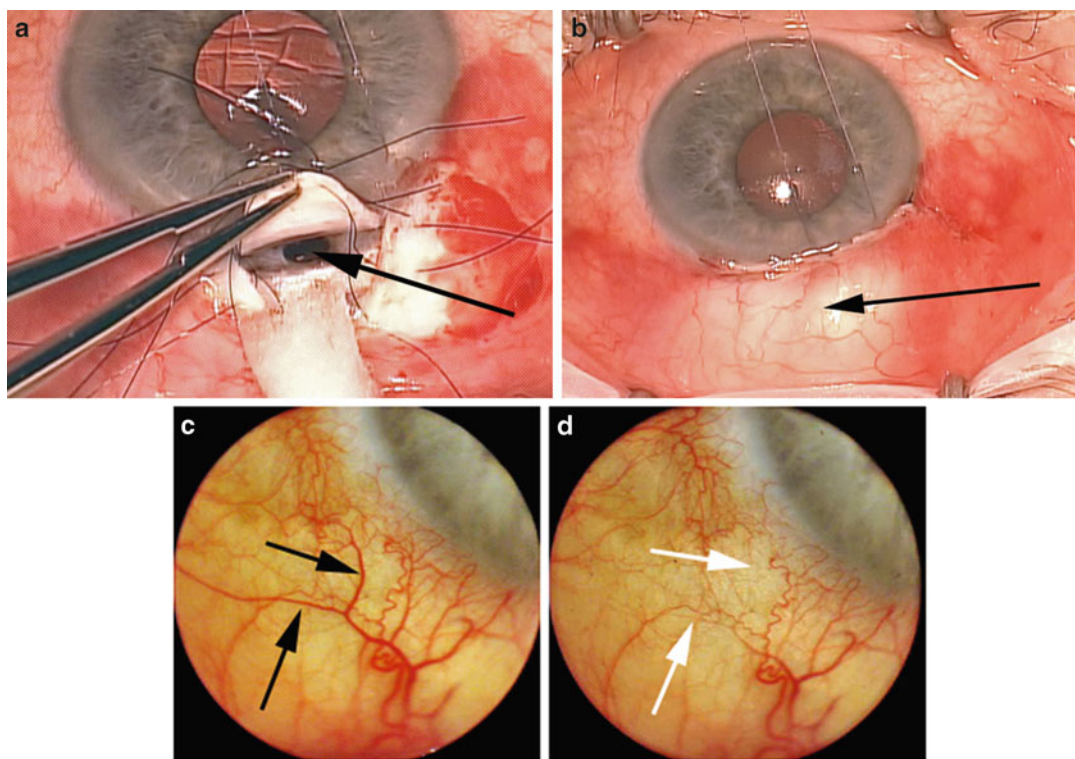


Fig. 5.1 Artificial subconjunctival drainage (trabeculectomy) versus physiologic canal-based collector channel outflow. **(a)** During trabeculectomy, a segment of tissue is removed at the limbus, creating a sclerostomy site (*arrow*). **(b)** This creates a pathway for aqueous to exit underneath the sclera (false passageway) into the subconjunctival space, creating a non-physiologic outflow pathway, seen as a bleb. **(c)** Improvement in physiologic outflow. Appearance of episcleral veins (*black arrow*) 1 week post-

canal-based surgery, IOP 12 mmHg. **(d)** When the patient looks slightly up, the IOP increases, forcing aqueous into recently cleaved open Schlemm's canal and out the adjacent veins causing a transient laminar washout of venous blood (*white arrows*). The *black* and *white arrows* are located in the same episcleral positions. This is similar to the phenomena of laminar flow in aqueous veins as described by Goldmann and Ascher

Lasers, Ltd.) circumferential approach [4–9]. In this chapter, the authors describe the Gonioscopy Assisted Transluminal Trabeculotomy (GATT) procedure, an ab interno suture-less circumferential MIGS for the treatment of adult and developmental open angle glaucomas [10].

5.2 Preoperative Evaluation

Prior to considering a GATT surgery, one must evaluate the drainage angle using a gonioscopic preoperatively. The patient must not only have an open angle with identifiable landmarks but the angle must also be free of extensive peripheral anterior synechiae (PAS) or neovascularization,

as this may result in extensive bleeding and inflammation and thus surgical failure. The cornea must also be sufficiently clear to allow for a proper view intraoperatively. If the patient has an unstable intraocular lens (IOL), one should consider an alternative surgery as the GATT surgery requires a moderate amount of intraocular manipulation.

5.3 Surgical Procedure

After a standard sterile preparation, the surgical eye is draped and an open wire nasal lid speculum inserted to hold the eyelids open. A 23-gauge needle paracentesis track, oriented tangentially, is

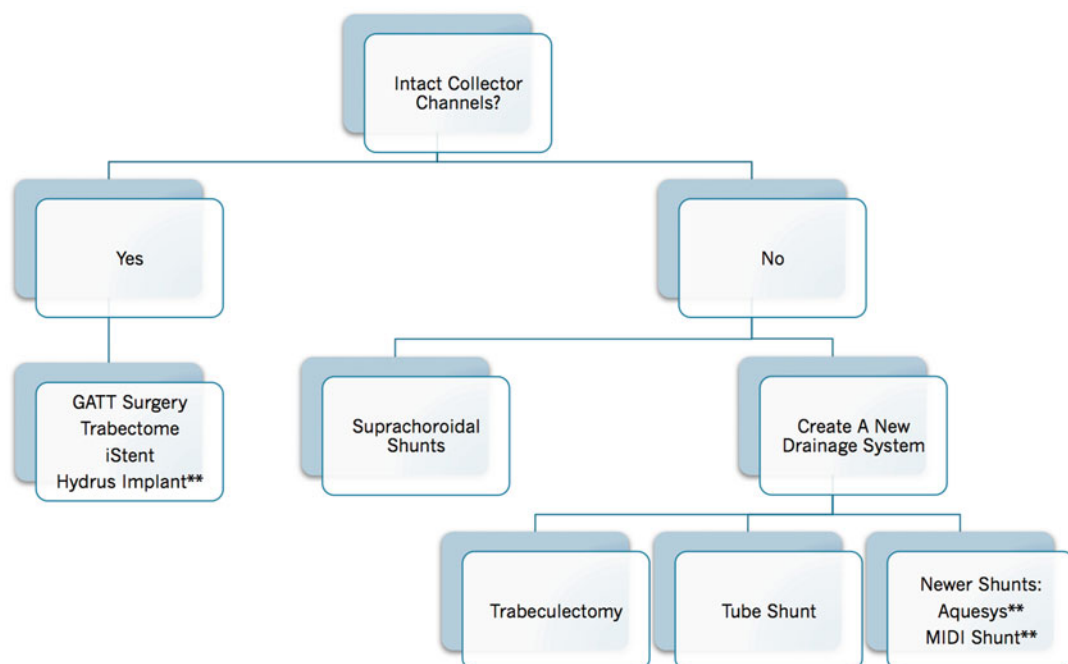


Fig. 5.2 Glaucoma surgery algorithm for physiologic restoration of outflow. It is no longer necessary to filter every glaucoma patient; the surgeon and patient now have the option to enhance flow into the patient's natural drainage system. Surgeons with experience in filtration and tube surgery along with canal-based techniques have greater options in order to tailor the surgery to the patient's

specific needs. In general, patients with earlier disease who have less damage to their natural collectors are good candidates for MIGS, while patients with advanced disease whose collectors are atrophic are better candidates for creation of a new drainage system as in filtration or tube shunt surgery. **indicates non-FDA approved devices/procedures

placed in either the supero-nasal or infero-nasal quadrant (Fig. 5.3a). This initial track serves as the entry site for the microcatheter or suture. A viscoelastic (sodium hyaluronate) is injected into the anterior chamber through this site. A temporal paracentesis is created (Fig. 5.3b). A suture (the authors prefer a 4.0 or 5.0 nylon suture, however, others prefer a 6.0 polypropylene suture) with a blunted tip or the microcatheter (iTrack, Ellex) is inserted into the anterior chamber through the entry site with the tip resting in the nasal angle (Fig. 5.3c). The microscope and the patient's head are then oriented to allow proper visualization of the nasal angle with a Swan-Jacob gonioscope. A 1–2 mm goniotomy of the anterior trabecular meshwork is created in the nasal angle with a microsurgical blade through the temporal site (Fig. 5.3d). Typically, upon decompression of the eye, blood will reflux into the canal, allowing for improved identification of angle structures. Microsurgical forceps are then

introduced through the temporal site and used to grasp the microcatheter or suture within the anterior chamber. The distal tip of the microcatheter is then inserted into Schlemm's canal at the goniotomy incision (Fig. 5.3e). Within the anterior chamber, the microsurgical forceps are used to advance the catheter through the canal circumferentially 360°. Viscoelastic is reinserted as needed to keep a clear medium for optimal viewing.

When using a microcatheter, the surgeon can visco-dilate the canal as the catheter is being passed as this may improve outcomes. If this is performed, one must keep the catheter moving for if the catheter stops, a Descemet's detachment can occur. The progress of the microcatheter is noted by observing the illuminated tip. When a suture is used, the progress of the suture can be appreciated through use of a gonioscope. Upon retrieving the distal tip, after the catheter has passed 360° around the canal, the catheter tip is externalized from the temporal corneal incision

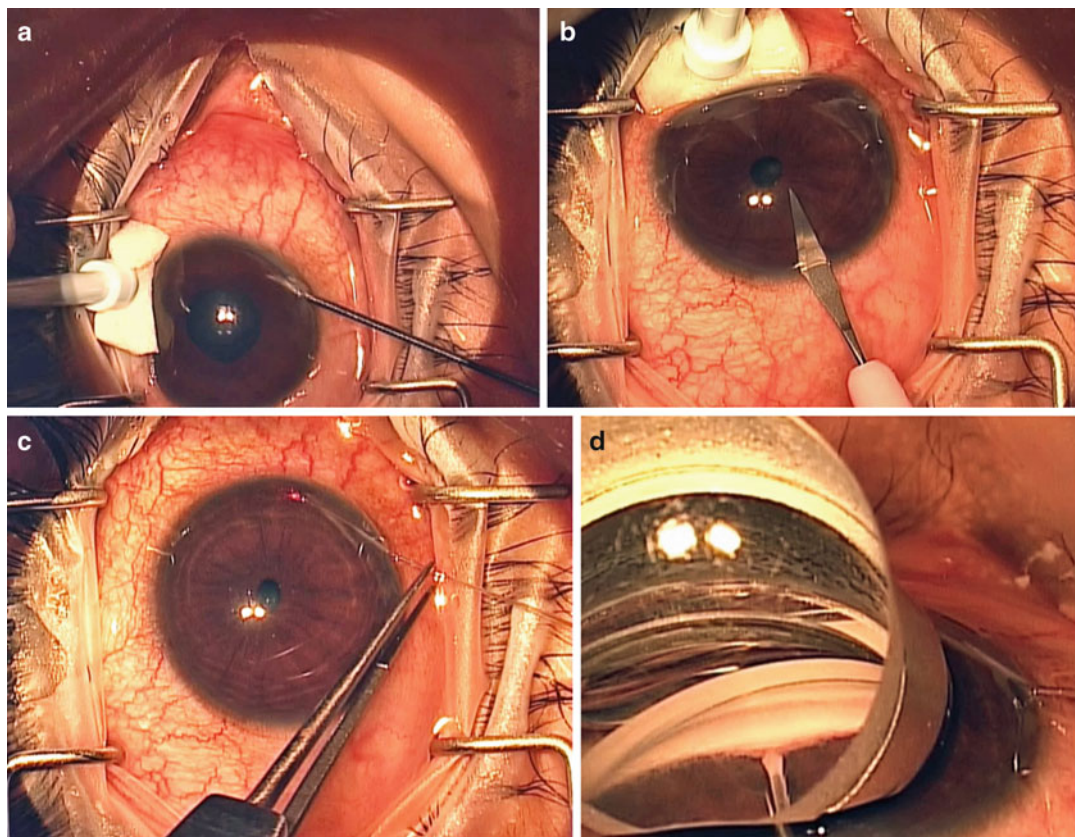


Fig. 5.3 GATT procedure. (a) tangential nasal paracentesis is made with a 23 gauge needle followed by mioclol and viscoelastic. (b) A larger temporal paracentesis is fashioned with a 15° blade; this site will accommodate entry for the microsurgical graspers. (c) The iTrack catheter is inserted into the anterior chamber. The distal tip rests above the iris in the nasal angle and the proximal portion is secured to the nearby drape for directional stability. (d) After appropriate tilting of the microscope and patient's head, the angle is viewed through the Swan-Jacob gonioscopes. An MVR blade is used to create a 1–2 mm goniotomy for access to the canal. Expose the canal as seen in the photo. (e) Insert the microcatheter into

the canal while visualizing the course of the illuminated tip. (f) Advance the tip for 360°, then retrieve the illuminated tip from the angle, pulling it towards and out the temporal paracentesis site. This initiates the circumferential trabeculotomy. (g) Stabilize the distal tip of the microcatheter as it exits from the temporal incision and pull the proximal portion of the catheter to complete the trabeculotomy. (h) Intraoperative gonioscopic photograph of angle immediately after trabeculotomy demonstrating an opened canal with blood reflux from adjacent collectors. At the end of the procedure, after AC washout, the wounds are hydrated with BSS until watertight

creating the first half of the 360° trabeculotomy (Fig. 5.3f). Then, traction is placed on the proximal aspect of the catheter, thus completing the 360° ab interno trabeculotomy (Fig. 5.3g). Intraoperative inspection of the anterior chamber angle immediately after performance of the trabeculotomy often reveals discrete areas of blood reflux from adjacent collector channels (Fig. 5.3h). The viscoelastic is then removed from the anterior chamber by a two-handed irrigation aspiration

system in order to wash the anterior chamber of blood. Near the end of the procedure, a 25 % anterior chamber fill with viscoelastic can be instilled to help tamponade bleeding from the canal. This may decrease the chance of a significant postoperative hyphema. The wounds are hydrated and checked to ensure a watertight closure. Postoperative steroid (sub-conjunctival or intracameral) and antibiotic drops are given per the surgeon's discretion.

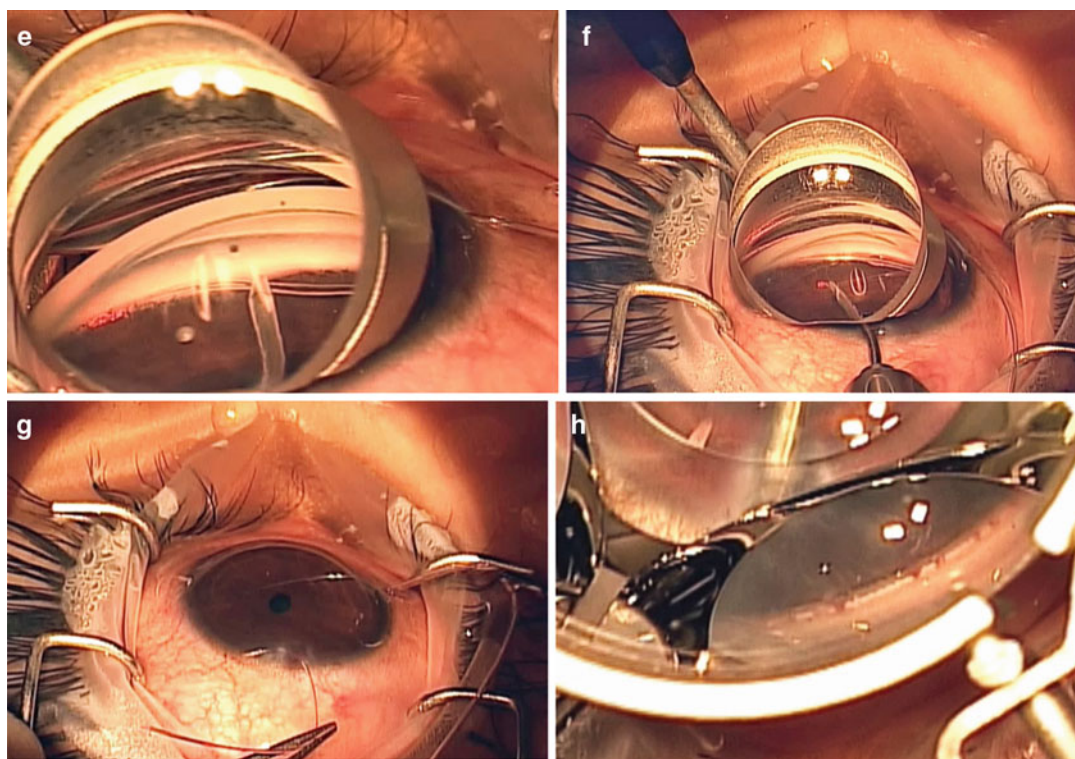


Fig. 5.3 (continued)

In certain cases, the suture or microcatheter cannot be passed 360° in one direction and stops at around 180–270°. In these limited trabeculotomy cases, create a new paracentesis site in order to better access the termination of the catheter or suture tip. Perform the goniotomy directly over the site where the probe stopped and retrieve the distal end from this location cleaving the cannulated part of the canal. A suture/microcatheter can then be passed in the opposite direction through an additional 23-gauge needle incision thus completing a 360° trabeculotomy.

5.4 Intraoperative Evaluation

During the irrigation/aspiration portion of this surgery, one can often appreciate an episcleral venous fluid wave [11]. The authors feel this is intraoperative evidence and confirmation of an intact collector system and is correlated with postoperative IOP control.

5.5 Postoperative Evaluation and Care

After surgery, all patients should be given topical broad-spectrum antibiotics and topical steroids. Pilocarpine can be used in the immediate postoperative period if the IOP is >15 mmHg; this may help keep the trabecular shelf open. The topical antibiotics should be stopped at postoperative week 1. The topical steroids (prednisolone acetate 1 %) should be tapered over 1–2 months, depending on the inflammation. Topical nonsteroidal anti-inflammatory (NSAID) drops can be used in addition to steroids to help control inflammation. Patients sometime have an IOP spike due to topical steroids. In these situations, the authors have used NSAIDS to control inflammation while rapidly tapering topical steroid drops. The patient's IOP should be treated during the postoperative period per the surgeons' discretion however, usually once steroid drops are eliminated, the IOP

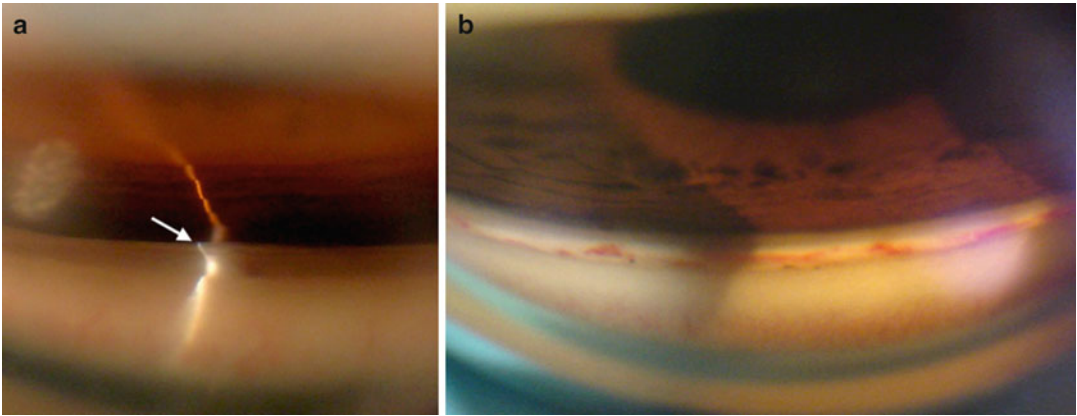


Fig. 5.4 Angle gonioscopy post-trabeculotomy. (a) Trabecular shelf. When the angle is successfully cleaved open, a large trabecular leaflet of tissue, termed the trabecular shelf, extends well over the iris. This is easily and consistently seen on gonioscopy within the superior angle. Filamentary cleavage of the canal creates this type of opening because the vector forces during cleavage of the suture or iTrack preferentially open first at Schwalbe's line. The large posterior leaflet then protrudes

over the iris and may attach to it, keeping the canal open. (b) Blood in angle post-trabeculotomy. Blood may be seen at various stages of healing in the angle post-trabeculotomy. Some of the blood appears to be in Schlemm's canal as expected. However, other vessels may represent undesirable or excessive scarring (wound healing) in the canal. At this time, our knowledge of wound healing in the canal after trabeculotomy is limited

will decrease. Typically, patients are seen on postoperative day 1, week 1, and then 2–3 weeks later. Afterwards, patients are then followed a month or two after and then every 3 months for a few visits before scheduling them out to every 6 months. Gonioscopy should be performed around the 1 month visit and then regularly afterwards to ensure that the trabecular shelf remains open and free of PAS (Fig. 5.4).

5.6 Outcomes

Several authors have reported on the success rates of circumferential ab externo trabeculotomy in various adult open angle glaucomas as well as pediatric glaucomas. Ikeda et al. reported nearly a 90 % success rate with a mean follow-up of 9.5 years, in patients diagnosed with developmental glaucoma that were treated with an ab externo trabeculotomy [12]. Similarly, Tanihara reported success rates in patients with primary open angle glaucoma (POAG) and pseudoexfoliation glaucoma (PXF) of 76.4 % and 83.6 %, respectively, at 1 year. After 5 years, the success rates dropped to 58 % and 73.5 % in POAG and PXF patients,

respectively [13]. Of note, there was substantial loss to follow up after 5 years in this study. Additionally, the success rates for trabeculotomy were similar to those reported at 5 years with the Tube versus Trabeculectomy (TVT) study [3]. Other authors have reported better long-term results. For example, Iwao et al. reported compared ab externo trabeculotomy with trabeculectomy in patients diagnosed with steroid-induced glaucoma [14]. These authors demonstrated that after 3 years, the trabeculotomy group had a success rate of 78.1 % versus 55.8 % in the trabeculectomy group.

Preliminary results with the GATT procedure are very similar (if not better) than the previously published results for ab externo trabeculotomy. The authors reviewed all cases that underwent a GATT surgery with at least 6 months of follow up (unpublished data). This study included 203 eyes of 177 patients, 66 % Caucasian, with an average age of 64.5 years, all of whom underwent the GATT procedure. The analysis was divided between a high pressure group (preoperative IOP \geq 18 mmHg) and a low pressure group (preoperative IOP < 18 mmHg). The “high pressure” group ($n=159$ eyes) had a

preoperative IOP averaging 26.7 ± 7.8 mmHg on 3.2 ± 1.1 medications. In eyes with ≥ 6 months follow-up ($n=92$ eyes), the mean IOP was reduced to 14.8 ± 5.6 mmHg on an average of 1.4 medications ($p < 0.001$). By 1 year, the cumulative proportion failing was 34.8 %. The “low pressure” group ($n=44$ eyes) had a preoperative IOP averaging 15.3 ± 2.1 mmHg on 2.6 ± 1.1 medications. In eyes with ≥ 6 months follow-up, the mean IOP was reduced to 13.5 ± 3.5 mmHg on $0.7 \pm .8$ medications ($p=0.010$). Overall, 38 of 203 eyes (18.7 %) were considered treatment failures, with 16 of the 38 eyes requiring further glaucoma surgery.

Grover et al. published on the initial results in POAG and secondary open angle glaucoma patients [10]. The group of patients was the same as the group reported above; however, the data was reported differently. Only one eye per patient was included (randomly selected). If an eye had a complication or failure from the surgery, they were also included in the study. This analysis strategy allowed for a more conservative approach to outcomes data analysis. Using this analysis, 85 patients with an age range of 24 to 88 years underwent GATT with at least 6 months of follow-up. In the 57 patients with POAG, the IOP decreased by an average of 7.7 mmHg [(SD,

6.2 mmHg) or 30.0 % (SD, 22.7 %)] with an average decrease in glaucoma medications of 0.9 (SD, 1.3) at 6 months. In this group, the IOP decreased by 11.1 mmHg (SD, 6.1 mmHg; 39.8 % [SD, 16.0 %]) with 1.1 fewer glaucoma medications at 12 months. In the secondary glaucoma group of 28 patients, IOP decreased by 17.2 mmHg (SD, 10.8 mmHg; 52.7 % [SD, 15.8 %]) with an average of 2.2 fewer glaucoma medications at 6 months. In this group, the IOP decreased by 19.9 mmHg (SD, 10.2 mmHg; 56.8 % [SD, 17.4 %]) with an average of 1.9 fewer medications (SD, 2.1) at 12 months. Failure was defined as postoperative IOP ≥ 21 mmHg and/or a drop in IOP < 20 % or need for further glaucoma surgery. Using this definition, treatment was considered to have failed in 9 % (8/85) of patients because of the need for further glaucoma surgery. The cumulative proportion of failure at 1 year ranged from 0.1 to 0.32, depending on the group. Lens status or concurrent cataract surgery did not have a statistically significant effect on IOP in eyes that underwent GATT at either 6 or 12 months ($P > 0.35$). The most common complication was transient hyphema, seen in 30 % of patients at the 1-week visit.

Table 5.1 describes the study groups, including number of eyes per group, mean age, gender,

Table 5.1 Demographic information separated by specific study groups

	POAG, GATT only	POAG, GATT+CE	POAG, prior CE, GATT only	Other glaucoma, GATT only	Other glaucoma, GATT+CE
N eyes (patients)	32 (29)	21 (17)	18 (17)	19 (18)	16 (15)
Age, Mean (SD) [range]	58.8 (10.2) [36–83]	74.4 (7.1) [60–86]	77.2 (6.6) [67–88]	47.8 (14.7) [24–68]	69.8 (14.5) [58–87]
N (%)					
Diagnosis					
POAG	32 (100 %)	21 (100 %)	18 (100 %)	2 (11 %)	3 (19 %)
CACG				4 (21 %)	9 (56 %)
PXF				4 (21 %)	0
Pigmentary				4 (21 %)	1 (6 %)
Uveitic/Infl				1 (5 %)	1 (6 %)
MMech				0	2 (13 %)
Other OAG				2 (11 %)	0
Trauma steroid				2 (11 %)	0

POAG Primary Open Angle Glaucoma, GATT Gonioscopy Assisted Transluminal Trabeculotomy, CE Cataract Extraction with Intraocular lens implantation, SD Standard Deviation, CACG Chronic Angle Closure Glaucoma, PXF Pseudoexfoliation Glaucoma, Infl Inflammatory, MMEch Mixed Mechanism, OAG Open Angle Glaucoma

Table 5.2 Efficacy data for all patients in the study, separated by different groups

	POAG, GATT only (N=25)	POAG, GATT+CE (N=16)	POAG, prior CE, GATT only (N=16)	Other glaucoma, GATT only (N=17)	Other glaucoma, GATT+CE (N=11)
Months followed, Mean (SD) [range]	11.4 (3.3) [6, 17]	9.2 (2.4) [6, 15]	10.7 (3.9) [6, 17]	12.4 (3.5) [6, 18]	10.5 (2.1) [7, 14]
N (%) patients requiring further IOP-lowering surgery	3 (12 %)	0	2 (13 %)	2 (12 %)	1 (9 %)
	7 weeks		7.6 months	2 weeks	4.2 months
	5.8 months		8.9 months	4.1 months	
	6.2 months				
<i>N (%) of patients at follow-up visit^a</i>					
3 months	24 (96 %)	16 (100 %)	16 (100 %)	16 (94 %)	11 (100 %)
6 months	24 (96 %)	16 (100 %)	16 (100 %)	15 (88 %)	10 (91 %)
12 months	12 (48 %)	4 (25 %)	5 (31 %)	10 (59 %)	5 (45 %)
<i>IOP, mean (SD)</i>					
Preoperative	25.6 (6.1)	23.9 (7.2)	23.8 (5.1)	31.8 (11.5)	27.6 (8.0)
Mo 3	16.8 (3.5)	12.5 (1.8)	16.8 (2.6)	14.2 (5.9)	15.1 (5.1)
Mo 6	18.5 (7.1)	16.9 (10.5)	17.4 (5.2)	13.6 (5.2)	13.4 (3.6)
Mo 12	15.7 (4.5)	15.5 (1.7)	16.2 (4.4)	12.4 (3.4)	13.8 (2.2)
<i>Postoperative IOP >21 mmHg</i>					
Mo 3	2 (8 %)	0	1 (8 %)	2 (13 %)	2 (18 %)
Mo 6	5 (28 %)	1 (13 %)	3 (30 %)	1 (10 %)	0
Mo 12	1 (8 %)	0	0	0	0
<i>Postoperative IOP >18 mmHg</i>					
Mo 3	6 (25 %)	0	2 (15 %)	3 (20 %)	2 (18 %)
Mo 6	6 (33 %)	1 (13 %)	4 (40 %)	2 (20 %)	1 (14 %)
Mo 12	4 (33 %)	0	2 (40 %)	0	0
<i>Num Meds</i>					
Preoperative	3.2 (0.9)	2.9 (1.1)	2.2 (1.0)	3.5 (1.0)	2.9 (1.3)
Mo 3	1.6 (1.1)	0.9 (1.0)	1.3 (1.2)	1.3 (1.4)	0.7 (1.1)
Mo 6	2.3 (1.5)	0.8 (1.1)	1.9 (1.3)	1.1 (1.3)	1.1 (1.2)
Mo 12	1.5 (1.2)	1.0 (1.4)	2.6 (1.5)	1.8 (2.0)	1.2 (1.3)
<i>Num Zero Meds</i>					
Mo 3	6 (25 %)	7 (47 %)	4 (31 %)	7 (47 %)	7 (64 %)
Mo 6	2 (11 %)	5 (56 %)	2 (20 %)	5 (50 %)	3 (43 %)
Mo 12	4 (33 %)	2 (50 %)	1 (20 %)	5 (50 %)	2 (40 %)

POAG Primary Open Angle Glaucoma, GATT Gonioscopy Assisted Transluminal Trabeculotomy, CE Cataract Extraction with Intraocular lens implantation, SD Standard Deviation, IOP Intraocular pressure, Num Meds Number of Glaucoma Medications, Num Zero Meds Number of eyes in which no Glaucoma Medications were required

^aFollow-up time censored after patient underwent glaucoma re-operation

and distributions of diagnoses per group. Efficacy data are reported in Table 5.2 for 85 eyes of 85 patients. There is a discrepancy in the number of study eyes between Tables 5.1 and 5.2. This difference is because we included both eyes of patients undergoing GATT as well as eyes with a short follow-up in assessing complications (Table 5.1), but only 1 eye of each patient and

none with follow-up of fewer than 6 months in assessing the outcomes (Table 5.2).

Table 5.3 represents the intraoperative and postoperative complications. Hyphema was a common occurrence within the first week, but nearly all cases resolved by the first postoperative month. Steroid-induced IOP spike did occur rarely at the first month postoperative visit.

Table 5.3 Intraoperative and postoperative complications, separated by group

	POAG, GATT only	POAG, GATT + CE	POAG, Prior CE, GATT only	Other glaucoma, GATT only	Other glaucoma, GATT + CE
Intraoperative complications	None	None	None	None	1 bag dehiscence/AV
<i>Hyphema</i>					
W1	7 (23 %)	6 (29 %)	5 (29 %)	7 (37 %)	5 (33 %)
M1	1 (3 %)	0	1 (6 %)	1 (5 %)	0
M3	1 (3 %)	0	0	0	0
M6	0	1 (5 %)	0	0	0
Other W1 complications	1 choroidal folds	0	0	2 IOP spike	0
Other M1 complications	2 steroid-induced IOP spike	0	2 steroid-induced IOP spike	1 steroid-induced spike 1 shallow AC	0
Other M3 complications	0	0	0	0	1 CME

POAG Primary Open Angle Glaucoma, GATT Gonioscopy Assisted Transluminal Trabeculotomy, CE Cataract Extraction with Intraocular lens implantation, AV Anterior Vitrectomy, W1 1st postoperative week, M1 1st postoperative month, M3 3rd postoperative month, M6 6th postoperative month, IOP Intraocular pressure, CME Cystoid Macular Edema

5.7 Conclusion

The GATT procedure is a safe, effective, and minimally invasive method for performing a circumferential, ab interno, 360° trabeculotomy. It is applicable to a wide variety of diagnoses and clinical situations. The ability to circumferentially open the majority of the trabecular meshwork without violating the conjunctiva is a major advancement, especially since it does not cause scarring of the conjunctiva and therefore should not interfere with future filtration surgery.

Our results with GATT in adults are similar to the previously published studies on trabeculotomies in adults. Gonioscopy revealed a number of pertinent findings. At the time of surgery, the entire trabecular meshwork was cleaved open. After the hyphema cleared, gonioscopy was carried out and most of the trabecular cleft remained open. In many patients, the posterior leaflet of the trabecular meshwork became tethered to a small area of the peripheral iris causing the leaflet of tissue to be easily seen protruding over the iris. Redmond Smith was the first to report on this suspension of tissue [15, 16] which we have termed a trabecular shelf (Fig. 5.4), a good indicator of an open cleaved

collector system typically associated with a good postoperative outcome. Using a novel trabeculotome, Lynn and Berry also commented on the importance of describing the type of trabecular leaflets or shelf produced by the cleavage of the particular trabeculotome [17].

Interestingly, there were a few patients who failed therapy even though their circumferential trabeculotomy site appeared open with a trabecular groove and shelf seen on gonioscopy. It is likely these patients have either a dysfunctional collector orifice or badly damaged distal collector system that is unable to accept the flow of aqueous. Currently, we have no way of clinically determining the function of one's collector system. There have been reports of determining the patency of the downstream collector system intraoperatively, however, the clinical utility of these techniques are yet to be determined [12]. In our recent analysis, we have found that POAG patients with a mean deviation worse than -15dB on Humphrey Visual Field tended to have a higher failure rate. These patients may be better treated with a trabeculectomy or a tube shunt.

Based on our initial experience, we feel there are absolute and relative contraindications for this procedure. Absolute contraindications include

an inability to stop anticoagulation medication, a bleeding diathesis, an unstable IOL, inability to identify angle structures (specifically the trabecular meshwork), a closed angle or severe endothelial compromise. Relative contraindications are a prior corneal transplant or inability to elevate the head 30° for the first postoperative week.

In conclusion, we introduce a minimally invasive, conjunctival sparing surgical technique (GATT procedure) that improves upon conventional ab externo trabeculotomy in adults and children. Success rates are at least equivalent to previously published studies of ab externo circumferential trabeculotomy. The procedure was safe and found to be effective in nearly 75 % of eyes in a variety of clinical settings.

Acknowledgements Compliance with Ethical Requirements

Drs. Davinder Grover and Ronald Fellman declare that they have no conflict of interest.

No human or animal studies were carried out by the authors for this article.

References

1. Christakis PG, Tsai JC, Kalenak JW, et al. The Ahmed versus Baerveldt study: three year treatment outcomes. *Ophthalmology*. 2013;120(11):2232–40.
2. Barton K, Feuer WJ, Budenz DL et al. Three-year treatment outcomes in the Ahmed Baerveldt comparison study. *Ophthalmology*. 2014 Apr 23. pii: S0161-6420(14)00204-8. doi: [10.1016/j.ophtha.2014.01.036](https://doi.org/10.1016/j.ophtha.2014.01.036).
3. Gedde SJ, Schifman JC, Feuer WJ, Herndon LW, Brandt JD, Budenz DL. Treatment outcomes in the Tube Versus Trabeculectomy (TVT) study after five years of follow-up. *Am J Ophthalmol*. 2012;153(5):789–803.
4. Allen L, Burian HM. Trabeculotomy ab externo. A new glaucoma operation: technique and results of experimental surgery. *Am J Ophthalmol*. 1962;53:19–26.
5. Harms H, Dannheim R. Epicritical consideration of 300 cases of trabeculotomy ‘ab externo’. *Trans Ophthalmol Soc U K*. 1970;89:491–9.
6. McPherson Jr SD, McFarland D. External trabeculotomy for developmental glaucoma. *Ophthalmology*. 1980;87:302–5.
7. Sarkisian Jr SR. An illuminated microcatheter for 360-degree trabeculotomy [corrected] in congenital glaucoma: a retrospective case series. *J AAPOS*. 2010;14:412–6.
8. Girkin CA, Marchase N, Cogen MS. Circumferential trabeculotomy with an illuminated microcatheter in congenital glaucomas. *J Glaucoma*. 2012;21:160–3.
9. Chin S, Nitta T, Shinmei Y, et al. Reduction of intraocular pressure using a modified 360-degree suture trabeculotomy technique in primary and secondary open-angle glaucoma: a pilot study. *J Glaucoma*. 2012;21:401–7.
10. Grover DS, Godfrey DG, Smith O, et al. Gonioscopy-assisted transluminal trabeculotomy, ab interno trabeculotomy: technique report and preliminary results. *Ophthalmology*. 2014;121(4):855–61.
11. Fellman RL, Grover DS. Episcleral venous fluid wave: intraoperative evidence for patency of the conventional outflow system. *J Glaucoma*. 2014;23(6):347–50.
12. Ikeda H, Ishigooka H, Muto T, et al. Long-term outcome of trabeculotomy for the treatment of developmental glaucoma. *Arch Ophthalmol*. 2004;122:1122–8.
13. Tanihara H, Negi A, Akimoto M, et al. Surgical effects of trabeculotomy ab externo on adult eyes with primary open angle glaucoma and pseudoexfoliation syndrome. *Arch Ophthalmol*. 1993;111(12):1653–61.
14. Iwao K, Inatani M, Tanihara H, Japanese Steroid-Induced Glaucoma Multicenter Study Group. Success rates of trabeculotomy for steroid-induced glaucoma: a comparative, multicenter, retrospective cohort study. *Am J Ophthalmol*. 2011;151:1047–56.
15. Smith R. A new technique for opening the canal of Schlemm: preliminary report. *Br J Ophthalmol*. 1960;44:370–3.
16. Smith R. Nylon filament trabeculotomy. Comparison with the results of conventional drainage operations in glaucoma simplex. *Trans Ophthalmol Soc N Z*. 1969;21:15–26.
17. Lynn JR, Berry PB. A New trabeculotome. *Am J Ophthalmol*. 1969;68:430–5.

Ab-Interno Subconjunctival Glaucoma Implant for Advanced Open-Angle Glaucomas

6

Alena Reznik and Rohit Varma

6.1 Introduction

Increasing aqueous outflow has been the goal of glaucoma surgery for decades. The most common strategy is to redirect the aqueous fluid into the subconjunctival space via sclerostomies or aqueous drainage devices. The final outcome relies on the patency of the sclerostomy, aqueous production, and the extent of conjunctival wound healing [1–5]. It is a fine balance between hypotony and hypertensive phase that has us searching for new alternatives and minimally invasive glaucoma surgery (MIGS). Most of these new technologies take advantage of an ab-interno approach to minimize the manipulation of the eye tissue. Most utilize other than subconjunctival drainage spaces such as Schlemm's canal and suprachoroidal space. However, those routes are dependent on the venous system and therefore cannot achieve an intraocular pressure (IOP) lower than the distal

outflow system. We argue that the superiority of subconjunctival space as a final drainage destination is important in the assessment of efficacy of the XEN Gel Stent (Aquesys, Inc.) [6].

6.2 Materials

The XEN Gel Stent is a 6 mm hydrophilic tube composed of a porcine gelatin cross-linked with glutaraldehyde. It is not degraded and is not rejected by the tissues. The stent is a rigid tube that becomes soft upon hydration. There are three models available based on lumen size: 140, 63, and 45 μm (Fig. 6.1). The final IOP control achieved with the device depends on the lumen size (larger lumen will produce a larger IOP decrease). The implantation is identical for all three models. Due to its flexibility the implant conforms to the tissue and there is less chance of migration and erosion.

6.2.1 Lumen Size and Flow

Laminar flow through a tube is calculated based on Hagen–Poiseuille equation (Eq. (6.1)). Outflow resistance depends on the tube geometry, flow rate, and viscosity of liquid. To avoid hypotony, the maximum flow rate should equal the maximum production of aqueous in the human eye (which is 2 $\mu\text{L}/\text{min}$ or 3 mL per day).

Electronic supplementary material The online version of this chapter (doi:[10.1007/978-3-319-18060-1_6](https://doi.org/10.1007/978-3-319-18060-1_6)) contains supplementary material, which is available to authorized users.

A. Reznik, M.D. (✉) • R. Varma, M.D., M.P.H.
Department of Ophthalmology, USC Eye Institute,
University of Southern California, Los Angeles,
CA, USA
e-mail: alena.reznik@med.usc.edu; rvarma@usc.edu

The resistance of outflow is a combination of outflow resistance of the tube and outflow resistance of the subconjunctival space. We all agree that outflow resistance of the subconjunctival space is minimal, therefore all outflow resistance has to come from the tube itself. In a glaucoma drainage device such as the Ahmed Glaucoma Valve (New World Medical, Inc.), outflow resistance comes from the valve mechanism; in Baerveldt Glaucoma Implants (Abbott Medical Optics, Inc.), the tube is initially ligated to allow a capsule to form around the plate to increase subconjunctival resistance. In the XEN 45 Gel Stent, the size of the lumen is small to allow enough flow resistance based on Hagen–Poiseuille equation to prevent hypotony. The size of XEN 45 Gel Stent reduces the risk of hypotony by providing 6–8 mmHg of flow resistance.

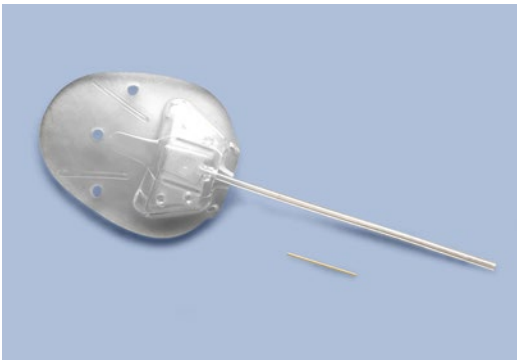


Fig. 6.1 Size comparison of glaucoma drainage device and XEN Gel Stent implant

6.3 Surgical Technique

A less invasive ab-interno approach is used. The injector is a single use 27 gauge needle with a preloaded XEN Gel Stent in a peel pack. The injector is designed to protect the XEN Gel Stent and to accurately deliver into the correct anatomical location. Placement is 1 mm posterior to limbus in the anterior chamber angle. During implantation, the stent will be hydrated and swell into place to decrease the risk of migration; the lumen diameter remains fixed.

Please refer to the accompanying Video for a step-by-step delivery technique.

1. Prep the eye in a standard fashion.
2. Intended placement quadrant is supero-nasal and 3 mm behind the limbus (marking pen used).
3. Corneal incision: main and sideport incisions are created.
4. A preloaded, single use injector is provided to the physician.
5. Viscoelastic is injected in the eye to allow better visualization and stability.
6. Optional gonioscope used. Placement is forgiving: anywhere from Schwalbe's line to scleral spur (Fig. 6.2a, b).
7. The needle is pushed to go through the sclera and into the subconjunctival space; bevel is visualized under the conjunctiva (Fig. 6.3a, b).
8. The XEN Gel Stent is deployed and visualized under the conjunctivae (Fig. 6.4a, b).
9. Procedure is complete by retracting the injector and disposing it (Fig. 6.5a, b).

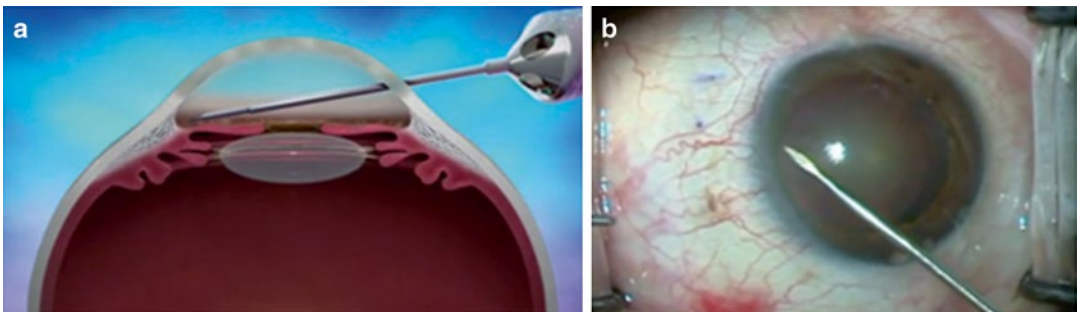


Fig. 6.2 Illustration (a) and surgical footage (b) of inserter passing across the anterior chamber to reach the angle

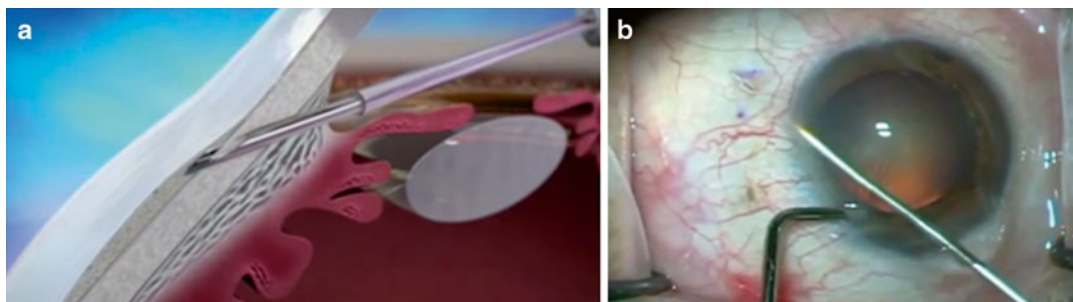


Fig. 6.3 Illustration (a) and surgical footage (b) of needle entering the angle and creating a ~3 mm scleral tunnel. Blue arrows pointing at the pre-marked target exit at 3 mm from the limbus

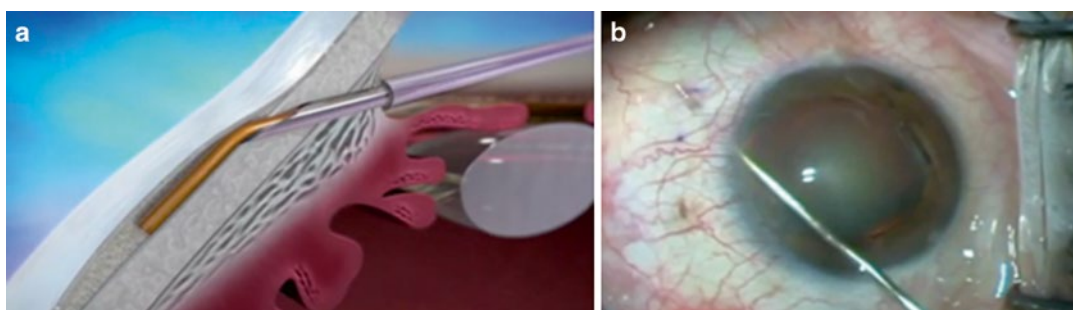


Fig. 6.4 Illustration (a) and surgical footage (b) of implant being deployed in position (blue arrow pointing at distal end of implant)

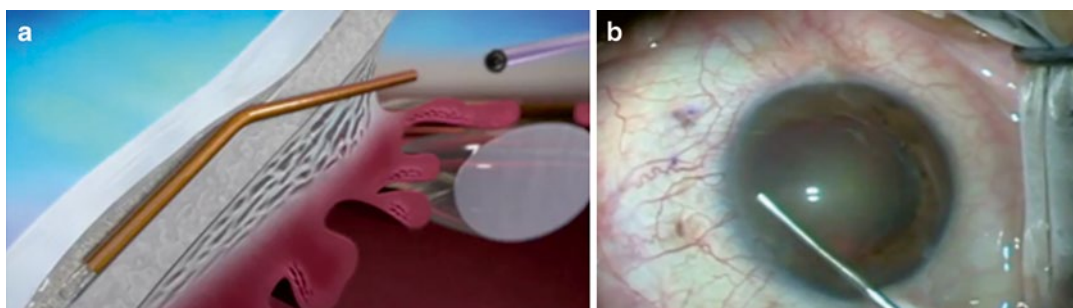


Fig. 6.5 Illustration (a) and surgical footage (b) of blunt sleeve being removed from eye

6.3.1 Postoperative Bleb Morphology

The presence of subconjunctival fluid marks a successful glaucoma surgery. There is an immediate bleb appearance with the XEN Gel Stent. From experience, during the first week this bleb will

gradually reduce and eventually subconjunctival fluid will disperse over wide areas, giving a much desired low-lying and diffuse appearance. These findings have been confirmed with anterior segment optical coherence tomography (AS-OCT). From our review of data, none of the patients received antimetabolites during the initial

implantation and most showed effective IOP lowering without the use of antimetabolites such as mitomycin C (MMC) at the time of surgery.

6.4 Clinical Results

6.4.1 Preclinical Testing

Several studies were performed in rabbits, primates, and canines with hundreds of XEN stents implanted that showed minimal inflammation and prolonged drainage time when compared to trabeculectomy in both rabbits and primates. No occlusion of lumen has been observed in these studies.

6.4.2 Clinical Testing

International and US studies are being held with the purpose of establishing the safety and effectiveness of the XEN Gel Stent in patients with primary open-angle glaucoma. In this multicentered, prospective, non-randomized, open label international study, 174 patients undergoing either primary or secondary surgery were followed for up to 36 months, and their outcomes for mean IOP, IOP change, and reduction of medications were recorded. Effectiveness was determined by comparing the baseline IOP and number of glaucoma medications taken with the postoperative values during a 3-year period. Safety parameters were evaluated such as loss of visual acuity and adverse side effects.

The study enrollment and follow-up is ongoing in Canada, Europe, Asia, Australia, and South America. Partial results are presented in Table 6.1. Mean preoperative IOP was 22.9 mmHg on 2.8 medications (no medication wash out). Mean postoperative IOP at 12 months was 15.6 mmHg on 1 medication. At 36 months mean IOP was at 13.9 and less than 1 medication was used. Please note that postoperative medication use was reduced by 82 %.

6.5 Conclusion

The XEN Gel Stent is an exciting conjunctiva-sparing ab-interno approach that promises an alternative initial treatment for open-angle glaucoma patients. The preliminary results are encouraging and the stent has been used in Europe for some time. XEN Gel Stent maintains a patent outflow pathway between the anterior chamber and subconjunctival space while tissues around heal naturally without surgical trauma or anti-scarring medication. Another advantage of this procedure is the simple and easy-to-perform surgical technique that does not require extensive training, surgical skills, or learning curve. More studies and follow-up are required to assess this procedure's effectiveness compared to standard trabeculectomies and glaucoma drainage devices. With FDA approval on the horizon, those studies will be possible in the near future.

Hagen Poiseuille Equation :

$$\Phi = \frac{dV}{dt} = v\pi R^2 = \frac{\pi R^4}{8\eta} \left(\frac{-\Delta P}{\Delta x} \right) = \frac{\pi R^4}{8\eta} \frac{|\Delta P|}{L} \quad (6.1)$$

Table 6.1 Efficacy results of a multicenter prospective non-randomized open-label study of the XEN Gel Implant (Aquesys, Inc.)

	12 months (N=111)	18 months (N=50)	24 months (N=41)	30 months (N=20)	36 months (N=10)
Mean IOP mm Hg (SD)	15.6 (4.5)	14.3 (3.7)	15.6 (4.9)	14.1 (3.9)	13.9 (4.0)
Mean post-op meds (mean % reduction in meds)	1.1 (61)	1.2 (57)	1.7 (39)	1.6 (43)	0.5 (82)
IOP reduction from medicated baseline (%)	30	38	30	36	37
IOP reduction from washout baseline (%)	48	52	48	53	53
≤21 mmHg and/or >20 reduction (%)	94	98	90	100	100
≤18 mmHg and/or >20 reduction (%)	86	92	88	100	90
<16 mmHg and/or >30 reduction (%)	66	86	71	85	70

IOP intraocular pressure, SD standard deviation

Acknowledgements Compliance with Ethical Requirements

Alena Reznik and Rohit Varma declare that they have no conflict of interest.

No human or animal studies were carried out by the authors for this chapter.

Conflicts of Interest: Alena Reznik and Rohit Varma declare that they have no conflict of interest.

Animal Studies: No human or animal studies were performed by the authors of this chapter.

References

1. The Advanced Glaucoma Intervention Study Investigators. The Advanced Glaucoma Intervention Study (AGIS). 4. Comparison of treatment outcomes within race. Seven-year results. *Ophthalmology*. 1998;105:1146–64.
2. Watson PG, Jakeman C, Ozturk M, Barnett MF, Barnett F, Khaw KT. Complications of trabeculectomy (a 20-year follow-up). *Eye*. 1990;4:425–38.
3. Nouri-Mahdavi K, Brigatti L, Weitzman M, Caprioli J. Outcomes of trabeculectomy for primary open-angle glaucoma. *Ophthalmology*. 1995;102:1760–9.
4. Ticho U, Ophir A. Late complications after glaucoma filtering surgery with adjunctive 5-fluorouracil. *Am J Ophthalmol*. 1993;115:506–10.
5. Costa VP, Wilson RP, Moster M, Schmidt CM, Gandham S. Hypotony maculopathy following the use of topical mitomycin C in glaucoma filtration surgery. *Ophthalmic Surg*. 1993;24:389–94.
6. Dao-Yi Y, et al. The critical role of the conjunctiva in glaucoma filtration surgery. *Prog Retin Eye Res*. 2009;28:303–28.

Ziad Khoueir and Tarek M. Shaarawy

7.1 Introduction

The concept of nonpenetrating glaucoma surgery (NPGS) evolved in a considerable manner during the last 50 years. The first published report goes back to 1964 when Krasnov published a paper on sinusotomy which consists of deroofting Schlemm's canal over 120°. This was done by removing a lamellar band of scleral tissue that was thought to be the main site of outflow resistance [1]. This technique fell relatively quickly out of favor because of its modest long-term results, as well as its technical difficulty in a time before the surgical microscope was widely used in ophthalmology [2].

In the same decade a new surgical technique called trabeculectomy was introduced and it

quickly became the standard of care for filtering procedures [3, 4]. However, despite numerous advances and modifications, reproducibility of trabeculectomy outcomes remained unsatisfactory when it came to intraocular pressure (IOP) lowering. Furthermore, sudden decompression of the eye occurs upon penetration of the anterior chamber which yields a relatively high risk of early postoperative complications such as overfiltration, hypotony, and choroidal detachment. The need to develop safer and more reliable surgical techniques led to a revival of Krasnov's concept of NPGS in light of a better understanding of the aqueous humor outflow.

It is now known that the primary resistance to outflow is located at the level of the juxtacanalicular trabeculum and the inner wall of Schlemm's canal. Zimmerman and colleagues proposed to target those two anatomical structures with a technique they termed nonpenetrating trabeculectomy [5]. The term ab-externo trabeculectomy was introduced in 1991 [6]. Fyodorov was the first to use the term deep sclerectomy [7] and later Kozlov suggested his version of the operation named "nonpenetrating deep sclerectomy," stressing the importance of removing corneal stroma behind the anterior trabeculum and Descemet's membrane [8]. A modification of NPGS was introduced by Stegmann in 1999, emphasizing the importance of dilating Schlemm's canal by injecting high-viscosity sodium hyaluronate into it in order to improve

Electronic supplementary material The online version of this chapter (doi:[10.1007/978-3-319-18060-1_7](https://doi.org/10.1007/978-3-319-18060-1_7)) contains supplementary material, which is available to authorized users.

Z. Khoueir, M.D., M.S.Ed. (✉)
Department of Glaucoma, Beirut Eye Specialist
Hospital, Mathaf Square, Hotel-Dieu Street,
Post Box 116-5311, Beirut, Lebanon
e-mail: ziad@khoeir.com

T.M. Shaarawy, M.D., M.Sc.
Department of Clinical Neurosciences,
Ophthalmology Service, University of Geneva,
Geneva, Switzerland
e-mail: tarek.shaarawy@hcuge.ch

aqueous outflow [9]. Currently deep sclerectomy, ab-externo trabeculectomy, and viscocanalostomy are the most commonly performed nonpenetrating techniques.

7.2 Surgical Technique

A deep sclerectomy can be broken down into several basic steps:

1. *Exposure*: A corneal limbal traction suture is used to rotate the globe down, providing good exposure of the superior sulcus and limbus, which can be very helpful for a limbus-based conjunctival flap. A superior bridle suture has the same purpose but with an increased risk of postoperative ptosis and subconjunctival hemorrhage. Care should be taken when adjusting the speculum to keep pressure off the globe. The Shaarawy Eye Speculum (Huco Vision SA, Saint-Blaise, Switzerland) facilitates this step since it has four knobs for attachment of corneal traction sutures.
2. *Conjunctival wound*: Usually, the deep sclerectomy is positioned at 12 o'clock or in either superior quadrant, depending on surgeon preference. A fornix-based or a limbus-based conjunctival flap can be used. Each technique has its pros and cons. The fornix-based is technically easier to realize but requires very careful suturing to avoid postoperative wound leak. The advantage of a fornix-based conjunctival flap is the creation of a subconjunctival scar anterior to the scleral flap, thereby facilitating posterior aqueous flow and a more posterior conjunctival bleb. The limbus-based conjunctival bleb is technically more challenging, but it offers the advantage of a secure closure well away from the limbus. The incision is done 8–10 mm posterior to the limbus while avoiding the superior rectus muscle. The limbus-based flap has a lower risk of leakage but with the disadvantage of a subconjunctival scar posterior to the scleral flap, impeding posterior flow with the resulting bleb closer to the limbus.
3. *Superficial scleral flap*: A 5 × 5 mm superficial rectangular scleral flap is created and it should include one-third of the scleral thickness (300 μm). The initial incisions are made with a No. 11 stainless steel blade while horizontal dissection is performed with a crescent knife. Anterior flap dissection 1–2 mm into clear cornea is essential to allow Descemet's membrane exposure during the next surgical step. Mitomycin 0.02 % soaked corneal shields may be placed in the scleral bed and under Tenon's capsule for 45 s or more in patients with a high risk of scar formation. This should be followed by thorough irrigation with balanced salt solution for 60 s to wash away the antifibrotic agent.
4. *Deep sclerokeratectomy and exposure of trabeculo-Descemet's membrane (TDM)*: A square of deep sclera measuring 4 × 4 mm is then dissected into the scleral bed leaving a margin of 0.5 mm on the three sides, allowing tight closure of the scleral flap in the setting of an intraoperative perforation of TDM. The initial incision is performed at the level of the lateral or posterior aspect of the flap down to the choroid to assess the depth of the remaining sclera and then deep sclerectomy is done slightly superficial to the choroidal plane leaving a residual layer of deep sclera that should be as thin as possible (50–100 μm) (Fig. 7.1a). In the posterior part of the dissection, the scleral fibers are arranged in a random pattern and they become organized and parallel to the limbus anteriorly to constitute the scleral spur which is the surgical landmark just posterior to Schlemm's canal. This canal is then unroofed and the dissection carefully continues further into clear corneal stroma to expose the anterior trabeculum and Descemet's membrane (Fig. 7.1b). Descemet's membrane dissection is the most critical and technically challenging step of the procedure. This membrane is very thin and is therefore prone to perforation. To expose Descemet's membrane, two radial corneal cuts are performed with a No. 11 steel blade with the bevel side up and out (Fig. 7.1c). The anterior trabeculum and Descemet's membrane are then gently

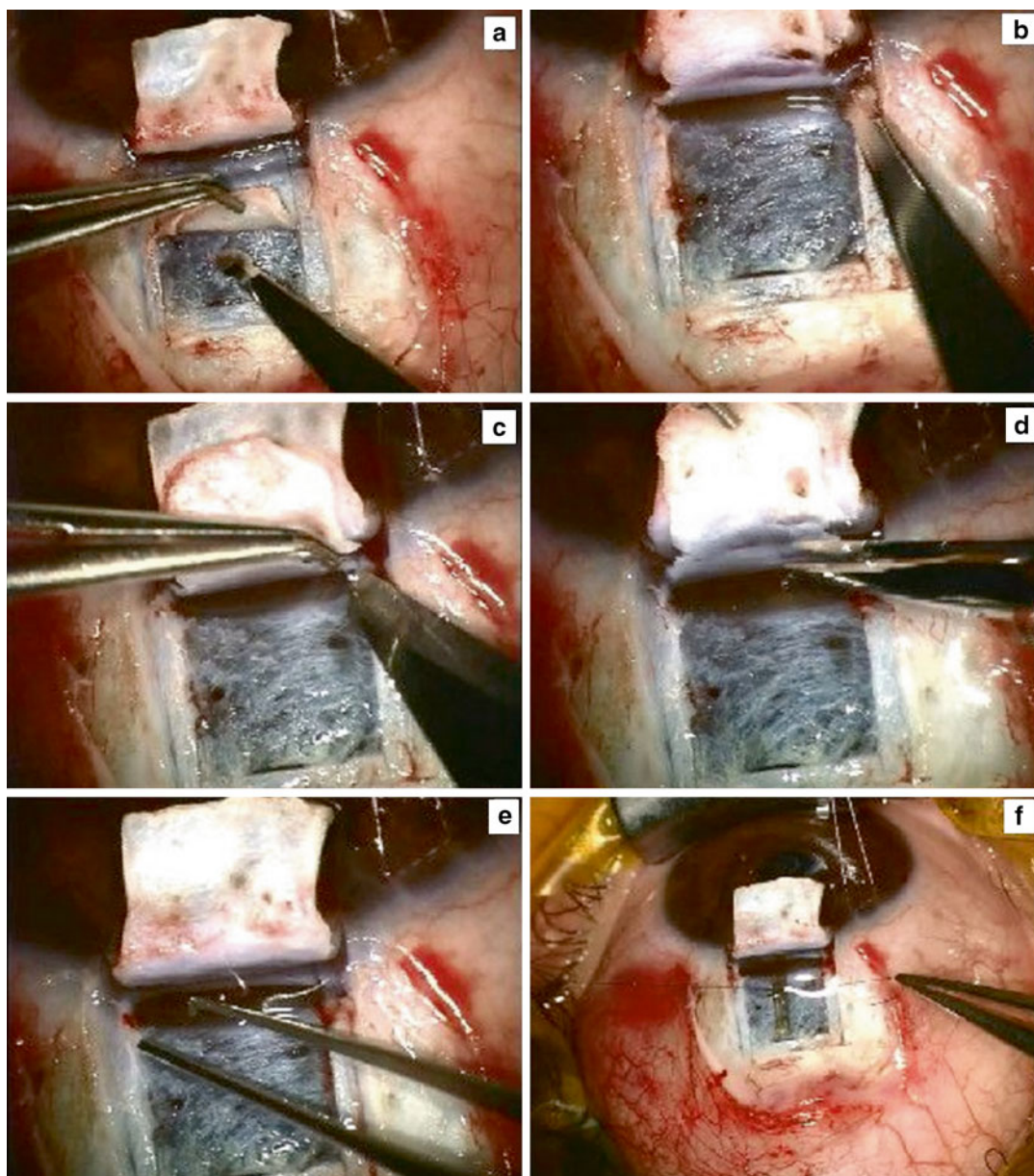


Fig. 7.1 Surgical footage demonstrating the stepwise performance of nonpenetrating glaucoma surgery. After creation of a 5×5 mm superficial scleral flap, a deep sclerokeratectomy is performed in order to expose the trabeculo-Descemet's membrane (a). Schlemm's canal is then unroofed (b) and dissection continues anteriorly into clear corneal stroma. Descemet's membrane is then exposed by creating two radial corneal cuts with a No. 11 steel blade with the bevel side up and out (c). The anterior

trabeculum and Descemet's membrane are then gently detached using a wet triangular sponge or a blunt metallic spatula. The deep scleral flap is then excised at the level of Descemet's membrane using microscissors (d). An ab-externo trabeculectomy is performed by grabbing and peeling away the Schlemm's canal endothelium and juxta-canalicular trabeculum (e). A space-maintaining implant may be sutured to the scleral bed (f)

detached from the overlying sclerocorneal tissue using a wet triangular sponge or a blunt metallic spatula. Upon completion of this anterior dissection the deep scleral flap is excised at the level of Descemet's membrane using microscissors (Fig. 7.1d). At this stage the ab-externo trabeculectomy is performed with a fine forceps after drying the exposed inner wall of Schlemm's canal with a sponge. It consists of grabbing and peeling away the thin Schlemm's canal endothelium and juxtacanalicular trabeculum (Fig. 7.1e). Aqueous humor is seen percolating through the remaining TDM in the scleral bed indicating a successful anatomical outcome. A space-maintaining implant can then be sutured to the scleral bed (Fig. 7.1f).

5. Closure of scleral flap and conjunctiva: The superficial scleral flap is then repositioned and closed with one or two 10.0 Nylon interrupted sutures. Conjunctiva and Tenon's capsule are closed separately or in a single layer using polyglactin 9.0 interrupted or running sutures.

7.3 Variations of Surgical Technique

7.3.1 The Use of Implants

Numerous space-maintaining implants have been developed to increase long-term success of NPGS by avoiding secondary collapse of the intrascleral space. They are placed in the scleral bed before suturing the superficial scleral flap. The first to be used was a highly purified lyophilized porcine collagen cylinder (Aquaflow, Staar Surgical AG, Mideau, Switzerland) [8, 10, 11]. It is placed radially at the center of the deep sclerectomy and secured with a single 10.0 Nylon suture to the scleral bed before closure of the superficial flap. It swells rapidly when exposed to aqueous humor and is progressively resorbed within 6–9 months after surgery [12, 13]. Another resorbable implant has been proposed in the form of a reticulated hyaluronic acid triangular implant (SK-GEL, Corneal, Paris, France) [14]. The advantage of this implant is that it does not need

to be sutured to the scleral bed and it can occupy a large volume in the intrascleral space given its rheological and physical characteristics [15–17]. Another hyaluronic acid device has been proposed in the form of a slowly resorbable viscoelastic implant that can be injected under the scleral flap and the conjunctiva to maintain both subconjunctival and intrascleral filtration routes (Healaflo, Anteis, Geneva, Switzerland) [18]. A nonresorbable hydrophilic implant has also been developed to maintain the intrascleral space (T-Flux, IOLTech laboratories, La Rochelle, France). Each arm of this T-shaped designed implant is inserted into one of the surgically created ostia of Schlemm's canal to increase aqueous outflow through this route [16, 19–21].

7.3.2 Trabeculectomy Ab-Externo

Once the conjunctiva is opened, a 4×4 mm superficial scleral flap is created with a depth corresponding to one-third of the scleral thickness. A radial cut is performed at the edge of the flap to localize Schlemm's canal. The change of orientation of the scleral fibers can be a good landmark for this step. Once Schlemm's canal is identified, it is unroofed. The inner wall of the canal is removed using fine forceps until percolation of aqueous humor occurs. This technique is similar to a sinusotomy except for the presence of a superficial scleral flap and the removal of the inner wall of Schlemm's canal [5, 22]. It differs from a deep sclerectomy since a deep scleral flap is not created and dissection of a TDM window is not performed.

7.3.3 Viscocanalostomy and Canaloplasty

In the 1990s Stegmann introduced a variant of NPGS consisting of injecting high-viscosity sodium hyaluronate (Healon GV) into Schlemm's canal to improve aqueous drainage through this pathway [9]. Injection of viscoelastic into the canal not only dilates the canal and associated collectors but also disrupts the internal and

external walls of Schlemm's canal and adjacent trabecular layers, thus increasing trabecular outflow facility and making the procedure act as a trabeculotomy [23]. Increased outflow occurs also at the TDM window into the scleral lake where it can diffuse into the subchoroidal and subconjunctival space. External filtration and filtering blebs are uncommon in viscocanalostomy because of tight suturing of the flap and can be detected only in up to one-third of the eyes [24], whereas a supraciliary hypoechoic area suggesting subchoroidal drainage has been shown in UBM studies [25]. The challenge in viscocanalostomy is to maximize circumferential outflow and this has been possible with the recent advances in cardiac stent technology. Canaloplasty consists of inserting a flexible catheter into Schlemm's canal (iTrack, iScience Interventional, Menlo Park, CA) [26]. This facilitates Healon GV injection followed by a 10.0 Prolene tensioning suture in the canal to enhance outflow [27, 28].

7.3.4 Laser-Assisted Sclerectomy

Numerous authors have reported the use of different kinds of lasers to facilitate the dissection of the deep corneoscleral flap. The use of erbium:Yag and excimer lasers for performing a deep sclerectomy have been described in the literature as relatively effective alternatives to the conventional surgical procedure [29–34]. More recently CO₂ Laser-assisted deep sclerectomy has been developed using an OT-135 beam manipulator system, conjugated with a CO₂ laser ("IOPtiMate"; IOPTima Ltd., Ramat Gan, Israel). This system, which was first described by Assia et al., enables deep tissue ablation with minimal risk of perforation [35, 36]. The far infrared radiation of this laser (wavelength of 10,600) is absorbed in water and thus is ineffective when applied over wet tissues [37]. Applying CO₂ laser energy on the dried scleral and trabecular tissue results in a localized ablation until the point at which fluid begins to percolate through the inner wall of Schlemm's canal. Once percolation occurs, further laser application is ineffec-

tive because of the wavelength characteristics. This technique offers a potential alternative to the manual NPGS, making the procedure simpler and less surgeon dependent [38].

7.4 Pathophysiology

Following NPGS, aqueous humor outflow is facilitated through two main pathways:

1. Anteriorly through the trabeculo-Descemet's membrane (TDM): the deep sclerokeratectomy performed during NPDS leaves a patent space behind the anterior trabeculum and Descemet's membrane. Tissue removal creates a gradient of pressure across the TDM allowing for aqueous humor percolation. In an *in vitro* model of aqueous dynamics after deep sclerectomy, Vaudaux et al. showed that ocular outflow resistance dropped for a mean of $5.34 \pm 0.19 \text{ ml min}^{-1} \text{ mmHg}^{-1}$ preoperatively to a mean of $0.41 \pm 0.16 \text{ ml min}^{-1} \text{ mmHg}^{-1}$ postoperatively while outflow facility increased from 0.19 ± 0.03 to $24.5 \pm 12.6 \text{ ml min}^{-1} \text{ mmHg}^{-1}$ [39]. Histological studies demonstrated that the main outflow through the TDM occurs at the level of the anterior trabeculum whereas some degree of outflow still occurs through the posterior trabeculum [40].
2. Posteriorly through the classical trabecular outflow. This pathway is considerably enhanced by ab-externo trabeculectomy [40] since it removes the external trabecular membrane which consists of the inner wall of Schlemm's canal and the cribriform juxtacanalicular trabeculum [41]. This membrane accounts for more than 50 % of outflow resistance in healthy human eyes and this percentage is suspected to be more important in glaucomatous eyes [42]. Rosier et al. studied aqueous dynamics in enucleated human eyes following ab-externo trabeculectomy. Outflow facility increased from 0.24 ± 0.08 preoperatively to $6.10 \pm 6.63 \text{ ml min}^{-1} \text{ mmHg}^{-1}$ which is still four times lower than after deep sclerectomy [40]. In ab-externo trabeculectomy the

filtration membrane is formed by the posterior trabeculum alone whereas in NPGS this membrane is larger since it encompasses the anterior trabeculum and Descemet's membrane.

Once it reaches the intrascleral space, aqueous humor resorption occurs through four hypothetical pathways:

1. *Subconjunctival bleb*: Similar to trabeculectomy, a conjunctival bleb is almost always obtained after NPGS on the first day postoperatively. However this bleb tends to be shallower and more diffuse than the one following trabeculectomy since aqueous resorption following NPGS does not rely solely on the subconjunctival route. UBM studies demonstrate the presence of a low and diffuse subconjunctival bleb even years after successful NPGS [43]. The presence of a subconjunctival bleb following viscocanalostomy (VCS) is still controversial. Some studies suggest that conjunctival blebs are associated with successful IOP control and that the subconjunctival route played a role in aqueous resorption after VCS [44]. Other reports demonstrated that blebs were rarely present following VCS and that a mechanism of filtration other than the subconjunctival one accounted for aqueous resorption [25, 45]. This probably is determined by the surgeons technique and the amount of diligence spent in suturing the scleral flap, with the aim of preventing subconjunctival filtration.
2. *Intrascleral bleb*: Approximately 5 to 8 mm³ of scleral tissue is removed during deep sclerectomy creating a patent space under the superficial scleral flap. This intrascleral volume represents a reservoir equivalent to a filtering bleb. Implants have been used in NPGS to preserve the patency of this space. UBM studies have demonstrated the presence of a scleral hyporeflexivity around the scleral lake in 45 % of patients where a reticulated hyaluronic acid implant was used as an adjunct to deep sclerectomy [43]. Similarly, Kzakova et al. observed an intrascleral bleb in more than 90 % of patients who received a collagen implant and the mean bleb volume was 1.8 mm³ [46]. New scleral drainage vessels develop after deep sclerectomy and are probably responsible for this intrascleral resorption route. Their presence has been demonstrated on animal models by optical microscopy [47] and anterior segment angiography using fluorescein and indocyanine green [48, 49].
3. *Suprachoroidal*: Aqueous humor outflow can occur into the suprachoroidal space through a 90 % thinned out sclera following deep sclerectomy. This can be demonstrated by the presence of a thin hyporeflexive suprachoroidal area in more than 45 % of cases [12, 43, 46]. On the other hand, the clinical significance of this suprachoroidal area is still quite controversial. Some studies suggest that its presence is associated with a statistically significantly lower IOP [12] whereas other reports find that it is not associated with surgical success [50]. One should keep in mind that this hyporeflexive area could also indicate a localized ciliary body detachment with a subsequent decrease in aqueous production and therefore further studies are needed to evaluate this resorption route.
4. *Schlemm's canal*: On either side of the deep sclerokeratectomy site lie the two surgically created sections of Schlemm's canal. Those two ostia may drain the aqueous humor through a "physiological" route into the episcleral veins. This mechanisms probably plays a more important role after VCS since viscoelastic substance is observed in the aqueous veins as blood is displaced [9]. The T-Flux implant takes advantage of its T-shaped design to keep the two ostia of Schlemm's canal open thus facilitating aqueous outflow through this route.

7.5 Indications

NPGS offers the advantage of slow postoperative decrease in IOP which helps prevent hypotony-related complications. There is also no need for iris tissue manipulation during the surgery which results in less postoperative inflammatory reaction [51]. In all types of open-angle glaucoma,

the main resistance to outflow is at the level of the trabecular meshwork. NPGS targets this specific aspect of the pathology by tackling the juxtacanalicular trabeculum and the inner wall of Schlemm's canal [42]. Because of its significant reduction in postoperative complications, NPGS can be proposed in early primary open-angle glaucoma (POAG) to preserve the conjunctiva from long periods of exposure to topical medication toxicity. Furthermore, it has the advantage of being less cataractogenic as compared to trabeculectomy and would be therefore the most suitable option for young patients with a clear lens [52]. It is also an efficient surgical alternative in advanced and medically uncontrolled POAG [53].

Pseudoexfoliative glaucoma (PEXG) is a challenging condition with high levels of IOP and an irregular pattern of fluctuations. Progression is difficult to halt with antiglaucoma medications and surgery is often needed. NPGS offers a safe surgical option in PEXG where the blood–aqueous barrier is altered and intraocular surgery such as trabeculectomy carries a high risk of complications [54]. Deep sclerectomy is a suitable option for PEXG patients with a high success rate that is maintained for a long period of time [55] with a need for more goniotomies [56]. NPGS is also an interesting option for pigmentary glaucoma since it targets the main site of pathology. This condition is more frequent in young patients and is often resistant to medical treatment. NPGS early in the course of the disease is a safe, lens-preserving option that is useful to avoid lifelong exposure to the noxious effects of topical medications on the ocular surface of those young patients.

Highly myopic eyes have an increased risk of complications with conventional glaucoma surgery because of their anatomical characteristics. NPGS could offer safer outcomes in those patients because of the gradual postoperative decrease in IOP [57]. On the other hand, highly myopic eyes are elongated with a lower scleral thickness and a modified limbal anatomy which makes flap dissection and identification of Schlemm's canal more challenging.

Uncontrolled aphakic glaucoma is one of the most difficult situations to manage when it comes to glaucoma surgery [58]. NPGS, unlike trabecu-

lectomy, does not require an iridectomy that would potentially disrupt the vitreous body stability. The vitreous base might migrate through the iridectomy and block the filtration site despite extensive peripheral vitrectomy that is often challenging in such cases. This instability carries an increased risk of traction retinal detachment. Aphakic glaucoma is also a serious complication in 14–45 % children who are left aphakic after congenital cataract extraction [59]. An early indication for NPGS instead of prolonged medical therapy would be beneficial in managing those cases. Zimmerman et al. performed nonpenetrating trabeculectomy in 28 aphakic eyes. The first group of 18 eyes had chronic open-angle glaucoma while the second group had secondary complicated glaucoma. At 1 year after surgery IOP was controlled in 89 % of eyes in the first group and 37.5 % in the second group. NPGS may be a good option in aphakic patients who require surgical management, at least in the setting of a chronic open-angle glaucoma [22].

NPGS has also been evaluated in congenital glaucoma. Tixier et al. were the first to report the results of deep sclerectomy in 12 eyes with juvenile glaucoma [60]. Success was achieved in 75 % of eyes (IOP < 16 mmHg under general anesthesia at final examination) with no intra- or early postoperative complications. Therefore deep sclerectomy is at least as effective as trabeculectomy in congenital glaucoma with a lower risk of complications. Other authors have drawn the same conclusions with deep sclerectomy and viscocanalostomy on congenital and juvenile glaucoma [61–63].

In open-angle uveitic glaucoma, inflammatory cells and mediators can activate fibroblasts and create excessive scarring that is detrimental for surgical success. Antimetabolites have been used to tackle the scarring cascade and increase the success rate but are also associated with an increased risk of late postoperative complications [64]. NPGS does not disrupt anterior chamber integrity and it does not require an iridectomy. It is indicated in uveitic cases because it is associated with less inflammation and targets the damaged trabeculum that is the site of resistance to aqueous outflow [12]. Both deep sclerectomy and viscocanalostomy have been reported to be safe

and effective in the setting of uncontrolled uveitic glaucoma [65, 66]. However, when extensive peripheral anterior synechiae (PAS) develop, NPGS is no longer a suitable option.

Sturge–Weber syndrome (SWS) is a neurocutaneous disorder with angiomas that involve the leptomeninges (leptomeningealangiomas) and the skin of the face, typically in the ophthalmic (V1) and maxillary (V2) distributions of the trigeminal nerve. Glaucoma occurs in 30–70 % of patients with SWS and is therefore the most common ophthalmic complication of this congenital disease [67]. Trabeculectomy offers good short-term results but with a risk of massive choroidal effusion or expulsive hemorrhage, which is already high in these patients because of the increased episcleral venous pressure [68, 69]. Few reports have been published on the use of NPGS in SWS [70, 71]. NPGS associated with laser and/or medical treatment is a safe and efficient alternative to trabeculectomy in SWS because it does not involve an abrupt peroperative drop of IOP that can be catastrophic in the setting of an elevated episcleral venous pressure [72]. Further studies of NPGS for glaucoma associated with thyroid orbitopathy, carotid-cavernous fistula, or SWS are warranted to explore the benefit of nonpenetrating procedures when glaucoma is caused by an increased episcleral venous pressure.

7.6 Relative Contraindications

NPGS relies on the integrity of the trabeculum for its outcomes and it works best when the angle structures are within limits of the normal anatomy and consequently when the cause of elevated IOP is structural rather than anatomical.

Most authors consider angle-closure glaucomas a relative contraindication to NPGS. Many therapeutic strategies have been proposed for angle-closure glaucoma. Laser peripheral iridotomy or surgical iridectomy is at best a temporary option to widen the angle configuration. Cataract surgery or clear lens extraction opens the angle too and helps deepens the chamber. When chronicity and progression occur, glaucoma surgery is indicated alone or in combina-

tion with lens extraction. NPGS can be attempted for these cases, even though the iris root is very close to the filtration window and may impede adequate outflow.

Eyes that have been treated with laser trabeculoplasty present ultrastructural and morphologic trabecular changes. The trabeculum may be more easily ruptured during surgery. In the setting of a perforation, an iridectomy is performed and NPGS can be then converted to trabeculectomy. Scarification of the trabeculum might also occur in posttraumatic angle-recession glaucoma. The damage of the trabeculum is not always complete and an attempt to perform NPGS can be made by trying to restore adequate outflow function. This is done by thoroughly scraping and peeling the posterior surface of the trabeculum during surgery [73].

7.7 Absolute Contraindications

NPGS is contraindicated in conditions when the angle is invaded by abnormal structures that will obstruct outflow. This is the case of neovascular glaucoma where rubeosis iridis extends to the iridocorneal angle. This is also the case of the iridocorneal endothelial syndrome (ICE syndrome). The trabeculum is obstructed and loses its function [74]. Neovascular glaucoma is a challenging condition and until now favorable outcomes have been reported only with drainage devices with or without the use of anti-VEGF injections [75, 76].

7.8 Complications

Various reports agree on the fact that NPGS offers the advantage of a low complication rate when compared to trabeculectomy. Visual acuity is also preserved after NPGS and quickly returns to the preoperative level within the first postoperative week [77]. This is mainly due to the fact that it is a closed-globe surgery that does not disrupt the anterior chamber structures. Inflammation and disturbance of the blood–aqueous barrier are minimal since there is no need for an iridectomy. Reduction of IOP is gradual because it relies on percolation through a membrane rather than the

Table 7.1 Complications of nonpenetrating glaucoma surgery according to the anatomical/functional structures involved

Structure/function involved	Intraoperative	Early postoperative	Late postoperative
TDM and iridocorneal angle	Perforation		PAS Iris Prolapse
Anterior chamber		Inflammation Hyphema Cataract progression	
Intraocular pressure		IOP spike Hypotony Hypotony maculopathy Choroidal effusion Suprachoroidal hemorrhage	
Sclerocorneal		Descemet's membrane detachment	Corneal steepening Corneal endothelial decompensation Scleral ectasia
Bleb		Wound leaks Blebitis	Bleb leaks Bleb fibrosis

TDM trabeculo-Descemet's membrane, *PAS* peripheral anterior synechiae, *IOP* intraocular pressure

creation of a hole, thus preventing complications related to sudden hypotony. We prefer to classify potential NPGS complications according to the anatomical or functional structures involved (Table 7.1).

7.8.1 TDM and Iridocorneal Angle Complications

Intraoperative perforation of the TDM is likely the most common complication of NPGS. It occurs during the anterior deep dissection, which is a delicate and complex technique resulting in the relatively flat learning curve of NPGS. It is not uncommon to encounter a 30 % perforation rate during the first 10–20 cases and this rate drops to 2–3 % after the learning phase [78]. Management of this complication depends on the magnitude of perforation, the depth of the anterior chamber, and the presence or absence of iris prolapse [79]. A small hole with a deep anterior chamber can be disregarded and the surgery is completed normally. These small perforations can be usually tamponaded by positioning the collagen implant next to the hole. If a larger crack in the membrane occurs upon deep

dissection with a flat or deep anterior chamber and no iris prolapse, viscoelastic can be injected through a paracentesis to restore a normal configuration. This prevents further iris prolapse or PAS. In the worst situation, transverse tears occur at the weakest point of the TDM which is the junction between the anterior trabeculum and Descemet's membrane. Such tears are immediately followed by iris prolapse. Protruding iris tissue must be excised by a peripheral iridectomy. NPGS is then converted to a trabeculectomy and the superficial scleral flap is tightly sutured with 6–8 10.0 Nylon sutures and outflow resistance is created by injecting viscoelastic into the intrascleral reservoir.

Late postoperative complications can also occur at the level of the TDM. PAS can develop late after intraoperative microperforations. They can also be caused by iris prolapse following goniotomy [80] or any other traumatic disruption of the TDM (e.g., blunt trauma, valsalva maneuver followed by corectopia and iris prolapse). PAS can disrupt aqueous outflow resulting in increased IOP. Failure of Nd:YAG laser synechiolysis to reposition the iris is an indication for medical or surgical treatment if the IOP is still high.

7.8.2 Anterior Chamber Complications

Early postoperative inflammation is relatively less common in NPGS compared to trabeculectomy. Chiou et al. compared flare levels after deep sclerectomy with collagen implant and conventional trabeculectomy [12]. Postoperative flare was significantly lower in the deep sclerectomy group and there was a quick return to the preoperative level within 1 week whereas the intense inflammation following trabeculectomy persisted for 1 month. Eyes with a compromised blood–aqueous barrier such as those with uveitic glaucoma or PEXG may benefit from this advantage that NPGS offers.

Early postoperative intraocular bleeding is a rare complication because the IOP is reduced gradually with nonpenetrating techniques. Hyphema has a low incidence after NPGS [79, 81] and does not require any particular treatment. It is usually due to a rupture of small iris vessels or leakage of red blood cells from the scleral bed or Schlemm's canal ostia through the TDM.

Cataract progression seems to be significantly reduced with NPGS. Cataract formation rate after trabeculectomy is 78 % at 5 years and the risk of cataract increases considerably in the setting of a flat anterior chamber or significant postoperative inflammation [51]. Shaarawy et al. followed 105 patients after deep sclerectomy and found no surgery-induced cataracts. The mean follow-up was 64 months and 25 % of eyes showed progression of a preexisting age-related cataract [13].

7.8.3 IOP Complications

Early postoperative IOP spikes have been described following trabeculectomy when the scleral flap has been too tightly sutured. This complication seldom occurs following NPGS if the dissection of the membrane has been done properly. Insufficient surgical dissection in the hands of an inexperienced surgeon can be a potential cause of hypertony. Hemorrhage in the scleral bed or even excessive viscoelastic in the anterior chamber can cause IOP spikes that are usually self-resolving in a few days. Hypertony

can also be caused by malignant glaucoma following NPGS as reported by Shaarawy et al. in a case that was successfully treated with cycloplegics [82]. Steroid response during the first postoperative weeks is also a potential cause of hypertony when other conditions have been ruled out. Iris prolapse and PAS should always be ruled out by gonioscopy in the setting of a postoperative IOP spikes and should be managed with laser synechiolysis or surgical management if the former doesn't work [80].

Hypotony occurs in 50 % of patients for some days following NPGS and the average IOP on the first postoperative day has been reported to be 5 mmHg [9, 82]. This indicates that the dissection was adequately performed and is generally considered as a favorable predictive factor for surgical success [13]. Prolonged hypotony should be carefully monitored to identify a cause such as wound leakage. The risk of prolonged hypotony remains minimal following NPGS [9, 82] but still can lead to hypotony maculopathy if left untreated [10, 83]. Choroidal effusion is a rare complication [9, 79, 84] and the incidence rate has been reported to be 5 % after NPGS which is four times lower than following trabeculectomy [85]. Suprachoroidal hemorrhage has been rarely reported after deep sclerectomy [86] or viscocanalostomy [87] and the main risk factor seems to be the occurrence of a prolonged hypotony [88]. Hypotony is more common in the first weeks following NPGS when compared to trabeculectomy but complications associated with prolonged hypotony are much less frequent in the former. The safer profile of NPGS is also due to the absence of an abrupt IOP decrease during the procedure [77].

7.8.4 Sclerocorneal Complications

Early postoperative Descemet's membrane detachment occurs in about one of 250–300 operated eyes after NPGS [77]. In viscocanalostomy, this complication is due to a misdirection of the viscoelastic canula during injection into Schlemm's ostia [89]. Descemet's membrane detachments are less frequent after deep sclerectomy and occur when the membrane is undermined by aqueous humor, viscoelastic, and/or

blood [77]. This can be seen several weeks after surgery as a bulla under the cornea at the level of the dissection site and the adjacent stroma becomes opalescent. Reflux of fluid in the sub-Descemet space can be caused by an elevation of intrableb pressure in the setting of a trauma or bleb fibrosis. Treatment consists of curing the cause if the problem is an encysted bleb or dealing with the detachment itself by descemetopexy.

Late postoperative corneal refractive and endothelial changes are uncommon following NPGS compared to trabeculectomy. NPGS induces less astigmatism and less endothelial cell loss than trabeculectomy [90, 91]. On the other hand, late postoperative scleral ectasia has been described in a single case after deep sclerectomy in a patient with chronic uveitic glaucoma secondary to juvenile arthritis [92]. The scleral bed in NPGS is thinner than the one created in trabeculectomy. The deep scleral dissection creates a zone of weakness that can lead to ectasia especially in patients with a thinner than usual scleral thickness (e.g., pathologic myopia, rheumatoid, or juvenile arthritis). The scleral bed in those patients is vulnerable and requires careful consideration when antimetabolites are used. Late scleral ectasia has also been reported in patients with no underlying predisposing conditions [93].

7.8.5 Bleb Complications

Early postoperative wound leaks are due to inadequate conjunctival closure and this complication occurs with the same frequency after trabeculectomy and NPGS [78, 79]. This condition should be carefully monitored and in most cases it resolves spontaneously with the use of ophthalmic ointments or a bandage contact lens. In some rare severe situations, surgical revision of the conjunctiva is mandatory to prevent prolonged hypotony and all related complications. Late postoperative bleb leaks are more frequently observed following Mitomycin C augmented glaucoma surgery in trabeculectomy when compared to deep sclerectomy (24.6 % vs. 3.1 %, respectively) [94]. Early postoperative blebitis has been well described after trabeculectomy and is a potentially dangerous complica-

tion that can lead to endophthalmitis [95]. Only two cases of blebitis have been reported in the literature to our knowledge [79, 96]. The TDM offers a natural barrier against the intraocular spread of bacteria and no cases of endophthalmitis following NPGS have been reported to date.

Late postoperative bleb fibrosis is due to episcleral or conjunctival fibrosis and is slightly more frequent after NPGS than after trabeculectomy [77]. If IOP increases, subconjunctival injections of antimetabolites are indicated to stop the scarring process. An encapsulated bleb or a Tenon's cyst is a thick-walled opalescent fibroblast overgrowth that traps aqueous in the subconjunctival process. Their incidence is comparable between trabeculectomy and sclerectomy. Needling of the cyst, with or without the use of antimetabolites, is indicated when IOP increases and surgical excision can be attempted in cases of recurrence. Shaarawy et al. reported that subconjunctival injections of 5FU were needed in 23 % of patients who underwent DSCI [13].

7.9 Goniopuncture Technique

Nd:Yag goniopuncture is indicated when filtration through the TDM is insufficient and IOP is not low enough. An insufficient surgical dissection or late postoperative TDM fibrosis can be the reason of insufficient percolation. A gonioscopic contact lens is used to visualize the TDM window and 2 to 15 shots are applied with a power of 5–10 mJ using the free-running and Q-switched mode [73]. The resulting microscopic holes allow aqueous outflow from the anterior chamber to the intrascleral space. Shaarawy et al. reported their goniopunctures rates following NPGS. The group reported that 42–46 % of their patients needed a goniopuncture after deep sclerectomy without collagen implant and this rate was 46–51 % when a collagen implant was used [13, 57, 97]. The immediate success rate of the laser procedure was 91.6 % [57]. In the group's study on viscocanalostomy, 37 % of the patients required goniopuncture and the mean time between surgery and laser treatment was 9.4 months with an immediate IOP reduction of 39.5 % on average [98].

7.10 The Learning Curve

NPGS is technically challenging and has a relatively long learning curve. One group compared viscocanalostomy to trabeculectomy in a randomized prospective study and reported a 50 % success rate for trabeculectomy vs. 0 % or total failure for canalostomy [99]. They presented a second study 1 year later with a new group of patients and success rates of 57 % with trabeculectomy and 30 % with viscocanalostomy [100]. Similarly, Gilmour et al. described how the procedure of viscocanalostomy required a learning curve and that this might have been relevant to their outcomes when compared to trabeculectomy [101]. This indicates the importance of the learning curve in NPGS, which should be taken into consideration when analyzing data concerning this kind of procedure. The same group also reported that their dissection depth was inadequate in 65 % of their cases (30 % too deeply and 35 % too superficial) [102]. When deep sclerectomy was performed they found that the dissection was performed too superficially in 48 % of cases [103]. The complication rate also tends to be higher among surgeons who have no prior experience in NPGS. Jehn et al. reported that half of their deep sclerectomy cases were followed by complications [104] and that surgical revision was required in 11 % of the eyes during that learning curve.

7.11 Outcomes

Trabeculectomy, as described by Sugar in 1961 and Cairns in 1968 remains the gold standard technique for filtering surgery [3, 4]. Therefore, all novel glaucoma procedures including NPGS are tested against it. Various studies comparing NPGS to trabeculectomy have a consensus on the superior safety of NPGS but controversy remains concerning efficacy [105–109]. This discrepancy can be attributed to a number of factors, including the fundamental differences between NPGS and penetrating filtering techniques, the long learning curve of NPGS, and the need to use goniotomy to achieve target IOPs [73]. It

should be kept in mind that goniotomy should not be considered a failure criterion in NPGS studies. This is based on the rationale that similar procedures like suture lysis and capsulotomy in glaucoma and cataract surgeries are not criteria of surgical failure in clinical trials.

In 2014, the Cochrane collaboration published a review comparing NPGS to trabeculectomy. This exhaustive review included relevant randomized controlled trials (RCTs) and quasi-RCTs that gave outcome data at a minimum of 12 months [110]. Only five trials met those criteria and were pooled in this review [107, 109, 111–113]. A total of 311 eyes from 247 participants were pooled in which 133 eyes (participants) were quasi-randomized. One hundred and fifty-one eyes had nonpenetrating glaucoma surgery (101 deep sclerectomy and 50 viscocanalostomy) while 160 eyes had trabeculectomy.

The odds of success in deep sclerectomy participants was no different than that in trabeculectomy participants (odds ratio (OR) 0.98, 95 % confidence interval (CI) 0.51–1.88) while the odds of success in viscocanalostomy participants was lower than in trabeculectomy participants (OR 0.33, 95 % CI 0.13–0.81). There was a trend toward better IOP outcomes with trabeculectomy which was statistically significant when comparing total success in participants with viscocanalostomy and trabeculectomy.

The rates of the reported adverse effects reported in this review were 26 complications with nonpenetrating surgeries (17 %), compared to 104 complications in the trabeculectomy group (65 %). This confirms that the justification for NPGS is based on greater safety with a lower risk of complications when compared to trabeculectomy [72, 114, 115].

7.12 Conclusion

NPGS encompasses various surgical techniques, including ab-externo trabeculectomy, nonpenetrating deep sclerectomy, and viscocanalostomy. All these variants require a long and flat learning curve that is still the main cause of its lack of popularity among eye surgeons. The main advan-

tage of NPGS is the superior safety profile when compared to conventional trabeculectomy. This low complication rate makes it the first choice in many indications especially in young patients. Primary and secondary angle-closure glaucomas are relative contraindications while neovascular glaucoma and ICE syndrome are absolute contraindications.

NPGS is efficient at lowering the IOP. Available data is not sufficient to draw a final conclusion compared to trabeculectomy which is still the gold standard and further multicenter prospective randomized trials are needed to draw final conclusions.

Acknowledgements Compliance with Ethical Requirements

Ziad Khoueir and Tarek Shaarawy declare that they have no conflict of interest.

No human or animal studies were carried out by the authors for this article.

References

1. Krasnov MM. Sinusotomy in glaucoma. *Vestn Oftalmol.* 1964;77:37–41.
2. Krasnov MM. Externalization of Schlemm's canal (sinusotomy) in glaucoma. *Br J Ophthalmol.* 1968;52:157.
3. Sugar HS. Experimental trabeculectomy in glaucoma. *Am J Ophthalmol.* 1961;51:623.
4. Cairns JE. Trabeculectomy. Preliminary report of a new method. *Am J Ophthalmol.* 1968;66:673–9.
5. Zimmerman TJ, Kooner KS, Ford VJ, et al. Trabeculectomy vs. nonpenetrating trabeculectomy: a retrospective study of two procedures in phakic patients with glaucoma. *Ophthalmic Surg.* 1984;15:734–40.
6. Arenas E. Trabeculectomy ab-externo. *Highlights Ophthalmol.* 1991;19:59–62.
7. Roy S, Mermoud A. Deep sclerectomy. In: Shaarawy T, Sherwood M, Hitchings R, Crowston J, editors. *Glaucoma, volume 2: surgical management—expert consult—online and print.* 1 Har/Pscth ed. Liverpool: Saunders; 2009. p. 295–313.
8. Kozlov V, Bagrov S, Anisimova S, et al. Nonpenetrating deep sclerectomy with collagen. *Eye Microsurg.* 1990;3:44–6.
9. Stegmann R, Pienaar A, Miller D. Viscocanalostomy for open-angle glaucoma in black African patients. *J Cataract Refract Surg.* 1999;25:316–22.
10. Sanchez E, Schnyder CC, Sickenberg M, et al. Deep sclerectomy: results with and without collagen implant. *Int Ophthalmol.* 1996;20:157–62.
11. Bissig A, Rivier D, Zaninetti M, et al. Ten years follow-up after deep sclerectomy with collagen implant. *J Glaucoma.* 2008;17:680–6. doi:10.1097/IJG.0b013e318182ed9e.
12. Chiou AG, Mermoud A, Underdahl JP, Schnyder CC. An ultrasound biomicroscopic study of eyes after deep sclerectomy with collagen implant. *Ophthalmology.* 1998;105:746–50. doi:10.1016/S0161-6420(98)94033-7.
13. Shaarawy T, Mansouri K, Schnyder C, et al. Long-term results of deep sclerectomy with collagen implant. *J Cataract Refract Surg.* 2004;30:1225–31. doi:10.1016/j.jcrs.2003.10.035.
14. Sourdille P, Santiago PY, Villain F, et al. Reticulated hyaluronic acid implant in nonpenetrating trabecular surgery. *J Cataract Refract Surg.* 1999;25:332–9.
15. Sourdille P, Santiago PY, Ducournau Y. Non-penetrating surgery of the trabeculum with reticulated hyaluronic acid implant: why, how, what results? *J Fr Ophtalmol.* 1999;22:794–7.
16. Wiermann A, Zeitz O, Jochim E, et al. A comparison between absorbable and non-resorbable scleral implants in deep sclerectomy (T-Flux and SK-Gel). *Ophthalmologie.* 2007;104:409–14. doi:10.1007/s00347-007-1520-2.
17. Galassi F, Giambene B. Deep sclerectomy with SkGel implant: 5-year results. *J Glaucoma.* 2008;17:52–6. doi:10.1097/IJG.0b013e3180d0a885.
18. Roy S, Thi HD, Feusier M, Mermoud A. Crosslinked sodium hyaluronate implant in deep sclerectomy for the surgical treatment of glaucoma. *Eur J Ophthalmol.* 2012;22:70–6. doi:10.5301/ejo.5000054.
19. Ateş H, Uretmen O, Andaç K, Azarsiz SS. Deep sclerectomy with a nonabsorbable implant (T-Flux): preliminary results. *Can J Ophthalmol.* 2003;38:482–8.
20. Ravinet E, Bovey E, Mermoud A. T-Flux implant versus Healon GV in deep sclerectomy. *J Glaucoma.* 2004;13:46–50.
21. Jungkim S, Gibran SK, Khan K, Murray A. External trabeculectomy with T-Flux implant. *Eur J Ophthalmol.* 2006;16:416–21.
22. Zimmerman TJ, Kooner KS, Ford VJ, et al. Effectiveness of nonpenetrating trabeculectomy in aphakic patients with glaucoma. *Ophthalmic Surg.* 1984;15:44–50.
23. Tamm ER, Carassa RG, Albert DM, et al. Viscocanalostomy in rhesus monkeys. *Arch Ophthalmol.* 2004;122:1826–38. doi:10.1001/archophth.122.12.1826.
24. Carassa RG, Bettin P, Fiori M, Brancato R. Viscocanalostomy: a pilot study. *Eur J Ophthalmol.* 1998;8:57–61.
25. Negri-Aranguren I, Croxatto O, Grigera DE. Midterm ultrasound biomicroscopy findings in eyes with successful viscocanalostomy. *J Cataract Refract Surg.* 2002;28:752–7.
26. Cameron B, Field M, Ball S, Kearney J. Circumferential viscodilation of Schlemm's canal with a flexible microcannula during non-penetrating glaucoma surgery. *Digit J Ophthalmol* 2006; 12

27. Lewis RA, von Wolff K, Tetz M, et al. Canaloplasty: circumferential viscodilation and tensioning of Schlemm's canal using a flexible microcatheter for the treatment of open-angle glaucoma in adults: interim clinical study analysis. *J Cataract Refract Surg.* 2007;33:1217–26. doi:[10.1016/j.jcrs.2007.03.051](https://doi.org/10.1016/j.jcrs.2007.03.051).
28. Grieshaber MC, Pienaar A, Olivier J, Stegmann R. Comparing two tensioning suture sizes for 360 degrees viscocanalostomy (canaloplasty): a randomized controlled trial. *Eye (Lond).* 2010;24:1220–6. doi:[10.1038/eye.2009.317](https://doi.org/10.1038/eye.2009.317).
29. Traverso CE, Murialdo U, Di Lorenzo G, et al. Photoablative filtration surgery with the excimer laser for primary open-angle glaucoma: a pilot study. *Int Ophthalmol.* 1992;16:363–5.
30. Argento C, Sanseau AC, Badoza D, Casiraghi J. Deep sclerectomy with a collagen implant using the excimer laser. *J Cataract Refract Surg.* 2001;27:504–6.
31. Maldonado-Bas A, Maldonado-Junyent A. Filtering glaucoma surgery using an excimer laser. *J Cataract Refract Surg.* 2001;27:1402–9.
32. Vergés C, Llevat E, Bardavio J. Laser-assisted deep sclerectomy. *J Cataract Refract Surg.* 2002;28:758–65.
33. Pallikaris IG, Kozobolis VP, Christodoulakis EV. Erbium:YAG laser deep sclerectomy: an alternative approach to glaucoma surgery. *Ophthalmic Surg Lasers Imaging.* 2003;34:375–80.
34. Klink T, Schlunck G, Lieb WE, et al. Long-term results of Erbium YAG-laser-assisted deep sclerectomy. *Eye (Lond).* 2008;22:370–4. doi:[10.1038/sj.eye.6702641](https://doi.org/10.1038/sj.eye.6702641).
35. Assia EI, Rotenstreich Y, Barequet IS, et al. Experimental studies on nonpenetrating filtration surgery using the CO₂ laser. *Graefes Arch Clin Exp Ophthalmol.* 2007;245:847–54. doi:[10.1007/s00417-006-0413-4](https://doi.org/10.1007/s00417-006-0413-4).
36. Ton Y, Geffen N, Kidron D, et al. CO₂ laser-assisted sclerectomy surgery part I: concept and experimental models. *J Glaucoma.* 2012;21:135–40. doi:[10.1097/IJG.0b013e31820e2ccd](https://doi.org/10.1097/IJG.0b013e31820e2ccd).
37. Skaat A, Goldenfeld M, Cotlear D, Melamed S. CO₂ laser-assisted deep sclerectomy in glaucoma patients. *J Glaucoma.* 2014;23:179–84. doi:[10.1097/IJG.0b013e3182707406](https://doi.org/10.1097/IJG.0b013e3182707406).
38. Geffen N, Ton Y, Degani J, Assia EI. CO₂ laser-assisted sclerectomy surgery, part II: multicenter clinical preliminary study. *J Glaucoma.* 2012;21:193–8. doi:[10.1097/IJG.0b013e3181f7b14f](https://doi.org/10.1097/IJG.0b013e3181f7b14f).
39. Vaudaux J, Uffer S, Mermoud A. Aqueous dynamics after deep sclerectomy: in vitro study. *Ophthalmic Pract.* 1998;16:204–9.
40. Rossier A, Uffer S, Mermoud A. Aqueous dynamics in experimental abexternotrabeculectomy. *Ophthalmic Res.* 2000;32:165–71.
41. Hamard P, Valtot F, Sourdille P, et al. Confocal microscopic examination of trabecular meshwork removed during abexternotrabeculectomy. *Br J Ophthalmol.* 2002;86:1046–52.
42. Johnson DH, Johnson M. How does nonpenetrating glaucoma surgery work? Aqueous outflow resistance and glaucoma surgery. *J Glaucoma.* 2001;10:55–67.
43. Marchini G, Marraffa M, Brunelli C, et al. Ultrasound biomicroscopy and intraocular-pressure-lowering mechanisms of deep sclerectomy with reticulated hyaluronic acid implant. *J Cataract Refract Surg.* 2001;27:507–17.
44. Yarangümelí A, Güreşer S, Köz ÖG, et al. Viscocanalostomy versus trabeculectomy in patients with bilateral high-tension glaucoma. *Int Ophthalmol.* 2004;25:207–13.
45. Park M, Tanito M, Nishikawa M, Chihara E. Ultrasound biomicroscopy of intrascleral lake after viscocanalostomy and cataract surgery. *J Glaucoma.* 2004;13:472–8.
46. Kazakova D, Roters S, Schnyder CC, et al. Ultrasound biomicroscopy images: long-term results after deep sclerectomy with collagen implant. *Graefes Arch Clin Exp Ophthalmol.* 2002;240:918–23. doi:[10.1007/s00417-002-0567-7](https://doi.org/10.1007/s00417-002-0567-7).
47. Delarive T, Rossier A, Rossier S, et al. Aqueous dynamic and histological findings after deep sclerectomy with collagen implant in an animal model. *Br J Ophthalmol.* 2003;87:1340–4.
48. Roy S, Boldea R, Perez D, et al. Aqueous outflow pathway imaging in the rabbit with fluorescein and indocyanine green. *Klin Monbl Augenheilkd.* 2000;216:305–8. doi:[10.1055/s-2000-10989](https://doi.org/10.1055/s-2000-10989).
49. Roy S, Boldea R, Nguyen C, et al. Analysis of filtration according to implant type after deep sclerectomy in the rabbit. *Klin Monbl Augenheilkd.* 2001;218:354–9. doi:[10.1055/s-2001-15899](https://doi.org/10.1055/s-2001-15899).
50. Roters S, Lücke K, Jonescu-Cuypers CP, et al. Ultrasound biomicroscopy and its value in predicting the long term outcome of viscocanalostomy. *Br J Ophthalmol.* 2002;86:997–1001. doi:[10.1136/bjo.86.9.997](https://doi.org/10.1136/bjo.86.9.997).
51. AGIS (Advanced Glaucoma Intervention Study) Investigators. The Advanced Glaucoma Intervention Study: 8. Risk of cataract formation after trabeculectomy. *Arch Ophthalmol.* 2001;119:1771–9.
52. Adelman RA, Brauner SC, Afshari NA, Grosskreutz CL. Cataract formation after initial trabeculectomy in young patients. *Ophthalmology.* 2003;110:625–9. doi:[10.1016/S0161-6420\(02\)01769-4](https://doi.org/10.1016/S0161-6420(02)01769-4).
53. Cheng J, Ma X, Wei R. Efficacy of non-penetrating trabecular surgery for open angle glaucoma: a meta-analysis. *Chin Med J.* 2004;117:1006–10.
54. Konstas AGP, Tsironi S, Ritch R. Current concepts in the pathogenesis and management of exfoliation syndrome and exfoliative glaucoma. *Compr Ophthalmol Update.* 2006;7:131–41.
55. Drolsum L. Longterm follow-up after deep sclerectomy in patients with pseudoexfoliative glaucoma. *Acta Ophthalmol Scand.* 2006;84:502–6. doi:[10.1111/j.1600-0420.2006.00674.x](https://doi.org/10.1111/j.1600-0420.2006.00674.x).
56. Mermoud A, Karlen ME, Schnyder CC, et al. Nd: yag-goniopuncture after deep sclerectomy with collagen implant. *Ophthalmic Surg Lasers.* 1999;30:120–5.

57. Hamel M, Shaarawy T, Mermoud A. Deep sclerectomy with collagen implant in patients with glaucoma and high myopia. *J Cataract Refract Surg.* 2001;27:1410–7.
58. Bellows AR, Johnstone MA. Surgical management of chronic glaucoma in aphakia. *Ophthalmology.* 1983;90:807–13.
59. Kirwan C, O’Keefe M. Paediatric aphakic glaucoma. *Acta Ophthalmol Scand.* 2006;84:734–9. doi:[10.1111/j.1600-0420.2006.00733.x](https://doi.org/10.1111/j.1600-0420.2006.00733.x).
60. Tixier J, Dureau P, Becquet F, Dufier JL. Deep sclerectomy in congenital glaucoma. Preliminary results. *J Fr Ophtalmol.* 1999;22:545–8.
61. Krzywicki S, Szała E. Non-perforating deep sclerectomy ab externo with intrascleral implant in juvenile glaucoma. *Klin Oczna.* 2002;104:222–5.
62. Nouredin BN, El-Haibi CP, Cheikha A, Bashshur ZF. Viscocanalostomy versus trabeculotomy ab externo in primary congenital glaucoma: 1-year follow-up of a prospective controlled pilot study. *Br J Ophthalmol.* 2006;90:1281–5. doi:[10.1136/bjo.2006.096388](https://doi.org/10.1136/bjo.2006.096388).
63. Stangos AN, Whatham AR, Sunaric-Megevand G. Primary viscocanalostomy for juvenile open-angle glaucoma. *Am J Ophthalmol.* 2005;140:490–6. doi:[10.1016/j.ajo.2005.04.038](https://doi.org/10.1016/j.ajo.2005.04.038).
64. Mearza AA, Aslanides IM. Uses and complications of mitomycin C in ophthalmology. *Expert Opin Drug Saf.* 2007;6:27–32. doi:[10.1517/14740338.6.1.27](https://doi.org/10.1517/14740338.6.1.27).
65. Miserocchi E, Carassa RG, Bettin P, Brancato R. Viscocanalostomy in patients with glaucoma secondary to uveitis: preliminary report. *J Cataract Refract Surg.* 2004;30:566–70. doi:[10.1016/j.jcrs.2003.10.029](https://doi.org/10.1016/j.jcrs.2003.10.029).
66. Souissi K, El Afrit MA, Trojet S, Kraiem A. Deep sclerectomy for the management of uveitic glaucoma. *J Fr Ophtalmol.* 2006;29:265–8.
67. Di Rocco C, Tamburrini G. Sturge-Weber syndrome. *Childs Nerv Syst.* 2006;22:909–21. doi:[10.1007/s00381-006-0143-2](https://doi.org/10.1007/s00381-006-0143-2).
68. Bellows AR, Chylack LT, Epstein DL, Hutchinson BT. Choroidal effusion during glaucoma surgery in patients with prominent episcleral vessels. *Arch Ophthalmol.* 1979;97:493–7.
69. Iwach AG, Hoskins HD, Hetherington J, Shaffer RN. Analysis of surgical and medical management of glaucoma in Sturge-Weber syndrome. *Ophthalmology.* 1990;97:904–9.
70. Audren F, Abitbol O, Dureau P, et al. Non-penetrating deep sclerectomy for glaucoma associated with Sturge-Weber syndrome. *Acta Ophthalmol Scand.* 2006;84:656–60. doi:[10.1111/j.1600-0420.2006.00723.x](https://doi.org/10.1111/j.1600-0420.2006.00723.x).
71. Rebolleda G, Muñoz-Negrete FJ. Nonpenetrating deep sclerectomy for Sturge-Weber syndrome. *Ophthalmology.* 2001;108:2152–3.
72. Mendrinos E, Mermoud A, Shaarawy T. Nonpenetrating glaucoma surgery. *Surv Ophthalmol.* 2008;53:592–630. doi:[10.1016/j.survophthal.2008.08.023](https://doi.org/10.1016/j.survophthal.2008.08.023).
73. Mendrinos E, Shaarawy T. Nonpenetrating glaucoma surgery. In: Stamper R, Grehn F, editors. *Glaucoma.* Berlin: Springer; 2009. p. 59–74.
74. Sharaawy T, Bhartiya S. Surgical management of glaucoma: evolving paradigms. *Indian J Ophthalmol.* 2011;59:S123–30. doi:[10.4103/0301-4738.73692](https://doi.org/10.4103/0301-4738.73692).
75. Schwartz KS, Lee RK, Gedde SJ. Glaucoma drainage implants: a critical comparison of types. *Curr Opin Ophthalmol.* 2006;17:181–9. doi:[10.1097/01.icu.0000193080.55240.7e](https://doi.org/10.1097/01.icu.0000193080.55240.7e).
76. Ma KT, Yang JY, Kim JH, et al. Surgical results of Ahmed valve implantation with intraoperative bevacizumab injection in patients with neovascular glaucoma. *J Glaucoma.* 2012;21:331–6. doi:[10.1097/IJG.0b013e31820e2fd0](https://doi.org/10.1097/IJG.0b013e31820e2fd0).
77. Ravinet E, Tritten JJ, Roy S, et al. Descemet membrane detachment after nonpenetrating filtering surgery. *J Glaucoma.* 2002;11:244–52.
78. Karlen ME, Sanchez E, Schnyder CC, et al. Deep sclerectomy with collagen implant: medium term results. *Br J Ophthalmol.* 1999;83:6–11.
79. Roy S, Mermoud A. Complications of deep non-penetrating sclerectomy. *J Fr Ophtalmol.* 2006;29:1180–97.
80. Kim CY, Hong YJ, Seong GJ, et al. Iris synechia after laser goniotomy in a patient having deep sclerectomy with a collagen implant. *J Cataract Refract Surg.* 2002;28:900–2.
81. Lachkar Y, Neverauskiene J, Jeanteur-Lunel MN, et al. Nonpenetrating deep sclerectomy: a 6-year retrospective study. *Eur J Ophthalmol.* 2004;14:26–36.
82. Shaarawy T, Karlen M, Schnyder C, et al. Five-year results of deep sclerectomy with collagen implant. *J Cataract Refract Surg.* 2001;27:1770–8.
83. Gavrilova B, Roters S, Engels BF, et al. Late hypotony as a complication of viscocanalostomy: a case report. *J Glaucoma.* 2004;13:263–7.
84. Guedes RAP, Guedes VMP. Nonpenetrating deep sclerectomy in Brazil: a 3-year retrospective study. *J Fr Ophtalmol.* 2005;28:191–6.
85. Brubaker RF, Pederson JE. Ciliochoroidal detachment. *Surv Ophthalmol.* 1983;27:281–9.
86. Neudorfer M, Sadetzki S, Anisimova S, Geyer O. Nonpenetrating deep sclerectomy with the use of adjunctive mitomycin C. *Ophthalmic Surg Lasers Imaging.* 2004;35:6–12.
87. Cheema RA, Choong YF, Algawi KD. Delayed suprachoroidal hemorrhage following viscocanalostomy. *Ophthalmic Surg Lasers Imaging.* 2003;34:209–11.
88. Tuli SS, WuDunn D, Ciulla TA, Cantor LB. Delayed suprachoroidal hemorrhage after glaucoma filtration procedures. *Ophthalmology.* 2001;108:1808–11.
89. Kim CY, Seong GJ, Koh HJ, et al. Descemet’s membrane detachment associated with inadvertent viscoelastic injection in viscocanalostomy. *Yonsei Med J.* 2002;43:279–81.
90. Arnavielle S, Lafontaine PO, Bidot S, et al. Corneal endothelial cell changes after trabeculotomy and deep sclerectomy. *J Glaucoma.* 2007;16:324–8. doi:[10.1097/IJG.0b013e3180391a04](https://doi.org/10.1097/IJG.0b013e3180391a04).

91. Egrilmez S, Ates H, Nalcaci S, et al. Surgically induced corneal refractive change following glaucoma surgery: nonpenetrating trabecular surgeries versus trabeculectomy. *J Cataract Refract Surg.* 2004;30:1232–9. doi:[10.1016/j.jcrs.2003.11.055](https://doi.org/10.1016/j.jcrs.2003.11.055).
92. Milazzo S, Turut P, Malthieu D, Levie MA. Scleral ectasia as a complication of deep sclerectomy. *J Cataract Refract Surg.* 2000;26:785–7.
93. Hyams M, Geyer O. Iris prolapse at the surgical site: a late complication of nonpenetrating deep sclerectomy. *Ophthalmic Surg Lasers Imaging.* 2003;34:132–5.
94. Anand N, Arora S, Clowes M. Mitomycin C augmented glaucoma surgery: evolution of filtering bleb avascularity, transconjunctival oozing, and leaks. *Br J Ophthalmol.* 2006;90:175–80. doi:[10.1136/bjo.2005.077800](https://doi.org/10.1136/bjo.2005.077800).
95. Tamcelik N, Ozdamar A, Kizilkaya M, et al. Fungal keratitis after nonpenetrating glaucoma surgery. *Cornea.* 2002;21:532–4.
96. Wallin OJ, Montan PG. Blebitis after deep sclerectomy. *Eye (Lond).* 2007;21:258–60.
97. Shaarawy T, Mermoud A. Deep sclerectomy in one eye vs deep sclerectomy with collagen implant in the contralateral eye of the same patient: long-term follow-up. *Eye (Lond).* 2005;19:298–302. doi:[10.1038/sj.eye.6701469](https://doi.org/10.1038/sj.eye.6701469).
98. Shaarawy T, Nguyen C, Schnyder C, Mermoud A. Five year results of viscocanalostomy. *Br J Ophthalmol.* 2003;87:441–5.
99. Jonescu-Cuyppers C, Jacobi P, Konen W, Kriegelstein G. Primary viscocanalostomy versus trabeculectomy in white patients with open-angle glaucoma: a randomized clinical trial. *Ophthalmology.* 2001;108:254–8.
100. Lüke C, Dietlein TS, Jacobi PC, et al. A prospective randomized trial of viscocanalostomy versus trabeculectomy in open-angle glaucoma: a 1-year follow-up study. *J Glaucoma.* 2002;11:294–9.
101. Gilmour DF, Manners TD, Devonport H, et al. Viscocanalostomy versus trabeculectomy for primary open angle glaucoma: 4-year prospective randomized clinical trial. *Eye (Lond).* 2009;23:1802–7. doi:[10.1038/sj.eye.6702726](https://doi.org/10.1038/sj.eye.6702726).
102. Dietlein TS, Lüke C, Jacobi PC, et al. Does the dissection depth and thickness of the deep scleral flap affect intraocular pressure after viscocanalostomy? A clinico-pathologic correlation. *Klin Monbl Augenheilkd.* 2001;218:168–73. doi:[10.1055/s-2001-13076](https://doi.org/10.1055/s-2001-13076).
103. Dietlein TS, Lüke C, Jacobi PC, et al. Variability of dissection depth in deep sclerectomy: morphological analysis of the deep scleral flap. *Graefes Arch Clin Exp Ophthalmol.* 2000;238:405–9.
104. Jehn AB, Bohnke M, Mojon DS. Deep sclerectomy with collagen implant: initial experience. *Ophthalmologica.* 2002;216:235–8.
105. Carassa RG, Bettin P, Fiori M, Brancato R. Viscocanalostomy versus trabeculectomy in white adults affected by open-angle glaucoma: a 2-year randomized, controlled trial. *Ophthalmology.* 2003;110:882–7. doi:[10.1016/S0161-6420\(03\)00081-2](https://doi.org/10.1016/S0161-6420(03)00081-2).
106. Chiselita D. Non-penetrating deep sclerectomy versus trabeculectomy in primary open-angle glaucoma surgery. *Eye (Lond).* 2001;15:197–201. doi:[10.1038/eye.2001.60](https://doi.org/10.1038/eye.2001.60).
107. El Sayyad F, Helal M, El-Kholify H, et al. Nonpenetrating deep sclerectomy versus trabeculectomy in bilateral primary open-angle glaucoma. *Ophthalmology.* 2000;107:1671–4.
108. Mermoud A, Schnyder CC, Sickenberg M, et al. Comparison of deep sclerectomy with collagen implant and trabeculectomy in open-angle glaucoma. *J Cataract Refract Surg.* 1999;25:323–31.
109. Yalvac IS, Sahin M, Eksioğlu U, et al. Primary viscocanalostomy versus trabeculectomy for primary open-angle glaucoma: three-year prospective randomized clinical trial. *J Cataract Refract Surg.* 2004;30:2050–7. doi:[10.1016/j.jcrs.2004.02.073](https://doi.org/10.1016/j.jcrs.2004.02.073).
110. Eldaly MA, Bunce C, Elsheikha OZ, Wormald R. Non-penetrating filtration surgery versus trabeculectomy for open-angle glaucoma. *Cochrane Database Syst Rev.* 2014;2, CD007059. doi:[10.1002/14651858.CD007059.pub2](https://doi.org/10.1002/14651858.CD007059.pub2).
111. Cillino S, Di Pace F, Casuccio A, et al. Deep sclerectomy versus trabeculectomy with low-dosage mitomycin C: four-year follow-up. *Ophthalmologica.* 2008;222:81–7. doi:[10.1159/000112623](https://doi.org/10.1159/000112623).
112. Kobayashi H, Kobayashi K, Okinami S. A comparison of the intraocular pressure-lowering effect and safety of viscocanalostomy and trabeculectomy with mitomycin C in bilateral open-angle glaucoma. *Graefes Arch Clin Exp Ophthalmol.* 2003;241:359–66. doi:[10.1007/s00417-003-0652-6](https://doi.org/10.1007/s00417-003-0652-6).
113. Russo V, Scott IU, Stella A, et al. Nonpenetrating deep sclerectomy with reticulated hyaluronic acid implant versus punch trabeculectomy: a prospective clinical trial. *Eur J Ophthalmol.* 2008;18:751–7.
114. Shaarawy T, Flammer J, Haefliger IO. Reducing intraocular pressure: is surgery better than drugs? *Eye (Lond).* 2004;18:1215–24. doi:[10.1038/sj.eye.6701374](https://doi.org/10.1038/sj.eye.6701374).
115. Tan JC, Hitchings RA. Non-penetrating glaucoma surgery: the state of play. *Br J Ophthalmol.* 2001;85:234–7.
116. Cameron B, Field M, Ball S, Kearney J. Circumferential viscodilation of Schlemm's canal with a flexible microcannula during non-penetrating glaucoma surgery. *Digital J Ophthalmol.* 2006;12(1).
117. Chiou AG, Mermoud A, Jewelewicz DA. Post-operative inflammation following deep sclerectomy with collagen implant versus standard trabeculectomy. *Graefes Arch Clin Exp Ophthalmol.* 1998;236:593–6.
118. Roy S, Mermoud A. Deep sclerectomy. In: Shaarawy T, Sherwood M, Hitchings R, Crowston J, editors. *Glaucoma volume 2: surgical management: expert consult—online and print, 1e.* 1 Har/Psc ed. Saunders Ltd; 2009. p. 295–313.
119. Shaarawy T, Flammer J, Smits G, Mermoud A. Low first postoperative day intraocular pressure as a positive prognostic indicator in deep sclerectomy. *Br J Ophthalmol.* 2004;88:658–61.

Endoscopic Cyclophotocoagulation in the Treatment of Plateau Iris and Angle-Closure Glaucomas

8

Robert Noecker and Shiyong Roh

8.1 Introduction

Over the past two decades, there have been advances in laser treatment for glaucoma that have improved glaucoma management and enhanced treatment options. One of these laser systems (Fig. 8.1) is Endoscopic Cyclophotocoagulation (ECP; Endo Optiks, Inc.), first made available in 1991. ECP uses a diode laser delivered through a 19–20 gauge fiberoptic probe and imaged via a video monitor that is integrated into the system (Fig. 8.2). The diode has a wavelength of 810 nm, a 175 W xenon light source, and a helium-neon aiming beam. The fiberoptic laser delivery system allows internal visualization (Fig. 8.3) and treatment of the ciliary body. In the United States, the FDA approved endoscopic laser system is the E4 laser system by Endoptiks.

ECP offers the advantage of being able to internally visualize the ciliary body and its processes, not visualized in transscleral cyclophotocoagulation procedures [1, 2]. The latter is not always effective and associated with side effects of pain, inflammation, choroidal effusions, and

hypotony. Thus, it is used to treat glaucoma in cases of failed conventional filtration surgery and in cases with poor predicted outcomes [3]. Studies of transscleral cyclophotocoagulation confirm extensive tissue damage compared to ECP-treated eyes, both in autopsy eyes and living human eyes that were subsequently enucleated for unrelated pathology [4, 5].

8.2 Indications

There are many studies pertaining to the use of ECP in open angle glaucoma and particularly in conjunction with phacoemulsification surgery [6, 7]. However, ECP has been found to be useful in other types of glaucoma as well [8]. Among these are plateau iris syndrome and angle-closure glaucomas.

Inherent in the treatment of angle-closure glaucomas with filtration surgery is the increased risk of aqueous misdirection or malignant glaucoma, choroidal effusions, and shallow anterior chambers. ECP is less invasive in reducing intraocular pressure (IOP) by reducing aqueous production. ECP combined with phacoemulsification to remove the natural lens and deepen the anterior chamber, provides an effective and safer IOP-lowering treatment option for angle-closure glaucomas [7, 9].

In plateau iris syndrome (PIS), ECP has been shown to help open the angles by shrinking the

R. Noecker, M.D., M.B.A. (✉)
Ophthalmic Consultants of Connecticut,
Fairfield, CT, USA
e-mail: noeckerrj@gmail.com

S. Roh, M.D.
Lahey Clinic, Peabody, MA

ciliary body and its processes away from the posterior iris and angle structures [10]. PIS is a condition characterized by narrow angles despite a patent iridotomy and may result in chronic

angle-closure glaucoma. The angle remains narrow due to ciliary processes that are anteriorly positioned and push forward the peripheral iris. Currently, the most common treatment is laser peripheral iridoplasty using argon laser [8]. The argon laser burns shrink the peripheral iris tissue away from the trabecular meshwork. ECP and variations of ECP, Endocycloplasty (ECPL) treatment, have recently been used in the management of this disorder and is done in conjunction with phacoemulsification [9–11]. ECP treats as much of the ciliary epithelium as possible, with the anterior processes being treated first and moving them anteriorly in order to treat more tissue [6, 7]. As opposed to ECP, ECPL treats the posterior processes first in order to shrink them away from the iris.



Fig. 8.1 The Endocyclophotocoagulation (ECP) unit (Image courtesy of Endo Optiks, Inc.)

8.3 Surgical Technique

The technique used by Francis in ECPL consists of performing cataract surgery first with phacoemulsification and implanting the intraocular lens implant (IOL). Following removal of viscoelastic from the capsular bag after IOL placement, viscoelastic is placed inside the anterior chamber and the ciliary sulcus, creating a space for the endoscope. The laser settings are similar to ECP, with a power setting of 300 mW on a continuous setting, 270° to 360° around the

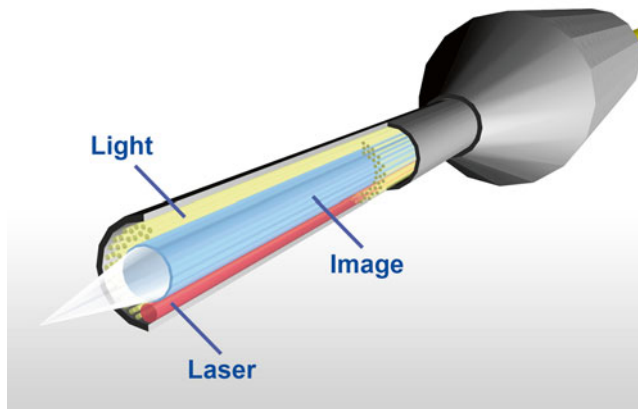


Fig. 8.2 The Endocyclophotocoagulation fiberoptic probe consisting of light, diode laser, and video sources (Image courtesy of Endo Optiks, Inc.)

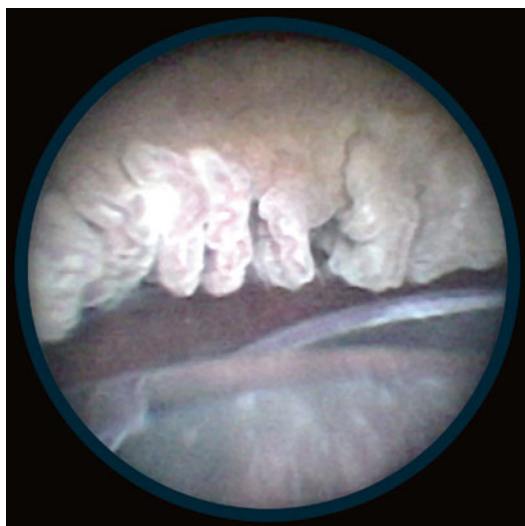

Fig. 8.3 In vivo image of the ciliary processes as captured by the Endocyclophotocoagulation (ECP) fiberoptic probe (Image courtesy of Endo Optiks, Inc.)

ciliary body. The spray-painting technique over the ciliary body is performed at the posterior or middle of the processes, thus pulling the anterior process posteriorly and away from the iris [12]. Steroid is injected subconjunctivally, and in cases where inflammation is an issue, an intracameral injection of 600 μg of preservative-free dexamethasone is recommended [12]. This technique is similar to others, whereby a 20-G curved ECP probe is used to deliver the diode laser 810 nm in a continuous delivery mode with power of 250–350 mW, targeting the posterior ciliary processes [13].

8.4 Outcomes

In the conventional management of PIS, laser iridoplasty does not always work, and its efficacy may not be long lasting [14]. Removing a cataract alone also does not change the anatomic configuration of PIS as previously thought. On ultrasound biomicroscopy evaluating the angle structures prior to cataract extraction and following cataract extraction, it has been shown that the angles were still narrow and the ciliary processes still touched the posterior iris in PIS [15]. The mainstay of treatment may thus lead to the need

for surgical intervention such as traditional trabeculectomy surgery or tube-shunt surgery.

ECPL offers a less invasive treatment option that actually targets the anatomic abnormality in PIS, with promising results. In a retrospective review of 58 patients treated with phacemulsification and ECPL for angle-closure glaucoma associated with plateau iris syndrome, Ahmed and colleagues [10] reported a mean IOP decrease from 17.3 to 13.3 mmHg with a corresponding decrease in IOP-lowering medications from 1.7 to 0.7. Widening of the anterior chamber angle was noted with gonioscopy, anterior segment optical coherence tomography, and ultrasound biomicroscopy. Adverse events included transient corneal edema ($n=3$), persistent anterior uveitis ($n=1$), and transient hyphema ($n=2$).

8.5 Conclusion

Angle-closure glaucoma encompasses an array of anatomic abnormalities that cause elevated IOP. Laser iridotomy is the first-line treatment for narrow angles at risk for angle closure, but often does not address the etiology of angle closure. In plateau iris syndrome, treatment with laser iridoplasty has its limitations. ECP and ECPL offer effective treatment options for these glaucoma cases that may be much less invasive and with fewer complications than traditional glaucoma surgeries.

Compliance with Ethical Requirements Robert Noecker is a consultant to EndoOptiks. No human or animal studies were carried out by the author for this article.

References

1. Beckman H, Waeltermann J. Transscleral ruby laser cyclodestruction. *Am J Ophthalmol.* 1984;98: 788–95.
2. Beckman H, Sugar HS. Neodymium laser cyclodestruction. *Arch Ophthalmol.* 1973;90:27–8.
3. Bietti G. Surgical intervention on the ciliary body: new trends for the relief of glaucoma. *JAMA.* 1950;142:889–97.
4. Pantcheva MB, Kahook MY, Schuman JS, et al. Comparison of acute structural and histopathological

- changes in human autopsy eyes after endoscopic cyclophotocoagulation and trans-scleral cyclophotocoagulation. *Br J Ophthalmol*. 2007;91:248–52.
5. Avarado J, Francis B. Characteristics of ciliary body lesions after endoscopic and transscleral laser cyclophotocoagulation. Poster presented at the American Academy of Ophthalmology Meeting, November 1998, New Orleans, LA.
 6. Uram M. Ophthalmic laser microendoscope endophotocoagulation. *Ophthalmology*. 1992;99:1829–32.
 7. Uram M. Combined phacoemulsification, endoscopic ciliary process photocoagulation and intraocular lens implantation in glaucoma management. *New Ideas*. 1995;26(4):346–52.
 8. Ritch R, Tham CC, Lam DS. Argon laser iridoplasty (ALPI): an update. *Surv Ophthalmol*. 2007;52:279–88.
 9. Francis BA, Kwon J, Fellman R, et al. Endoscopic ophthalmic surgery of the anterior segment. *Surv Ophthalmol*. 2014;59(2):217–31.
 10. Ahmed IK, Podbielski DW, Naqi A, et al. Endoscopic cycloplasty in angle closure glaucoma secondary to plateau iris. Poster presentation AGS Annual Meeting, March 5–8, 2009, San Diego, CA.
 11. Chen J, Cohn RA, Lin SC, et al. Endoscopic photocoagulation of the ciliary body for treatment of refractory glaucomas. *Am J Ophthalmol*. 1997;124:787–96.
 12. Francis BA. Endocycloplasty shows promise for treating plateau iris syndrome. *Ocular Surg News*. June 2012.
 13. Podbielski DW, Varma DK, Tam DY, et al. Endocycloplasty: a new technique for managing angle-closure glaucoma secondary to plateau iris syndrome. *Glaucoma Today*. October 2010.
 14. Ritch R, Tham CC, Lam DS. Long-term success of argon laser peripheral iridoplasty in the management of plateau iris syndrome. *Ophthalmology*. 2004;111(1):104–8.
 15. Tran HV, Liebmann JM, Ritch R. Iridoplasty apposition in plateau iris syndrome persists after cataract extraction. *Am J Ophthalmol*. 2003;135(1):40–3.

Ex-PRESS Miniature Glaucoma Shunt for the Treatment of Uveitic Glaucomas

9

Evan Allan and Steven R. Sarkisian Jr.

9.1 Introduction

Optonol Ltd. (Neve Ilan, Israel) first developed the Ex-PRESS device to shunt aqueous underneath the conjunctiva and reduce intraocular pressure (IOP). The device is a non-valved, stainless steel device. Once fixated, the device remains stable, even in the setting of magnetic resonance imaging [1]. At 3 mm in length and 400 μm external diameter, it remains one of the smallest implants being used in the human body. Models of the shunt are currently available in 50 or 200 μm internal lumen diameters (Fig. 9.1). In 2010, the device was acquired by Alcon Laboratories (Ft. Worth, Texas, USA) and it was felt confusion would be best avoided if the name was changed from Ex-PRESS Mini-Glaucoma Shunt to Ex-PRESS Mini-Glaucoma Device, thus separating the device from more traditional “shunt” implants. Originally, the rabbit models were used to prove biocompatibility [2].

Electronic supplementary material The online version of this chapter (doi:[10.1007/978-3-319-18060-1_9](https://doi.org/10.1007/978-3-319-18060-1_9)) contains supplementary material, which is available to authorized users.

E. Allan, M.D. (✉) • S.R. Sarkisian Jr., M.D.
Dean McGee Eye Institute, Oklahoma City, OK, USA
e-mail: evan-allan@dmei.org;
steven-sarkisian@dmei.org

Initially, the device was placed directly under the conjunctiva, full thickness through the sclera near the limbus. Unfortunately, implanting the Ex-PRESS in this manner was fraught with complications. Most worrisome were erosion, profound hypotony, and extrusion of the implant [3–6]. Endophthalmitis secondary to extrusion without a scleral flap was perhaps the most severe of complications [4]. Presentation of the above was typically initially seen as hypotony, followed by erosion of the conjunctiva at the outer flange of the device.

Typical to the innovative process, old surgical vision was melded with new surgical technology as Dahan and Carmichael became the first to recommend placement of the Ex-PRESS under a scleral flap [7]. Subsequently, erosion of the device was virtually eliminated. In addition, the scleral flap was found to reduce the risk of post-operative hypotony.

Initial reports were extremely favorable as the Ex-PRESS device surpassed trabeculectomy in almost every aspect. As longer follow-up time has accrued and further research performed, early excitement has been tempered. However, the Ex-PRESS still appears to be superior to trabeculectomy in visual recovery [8–10]. Some studies observed more favorable rates of hypotony and number of interventions due to hypotony [11, 12].

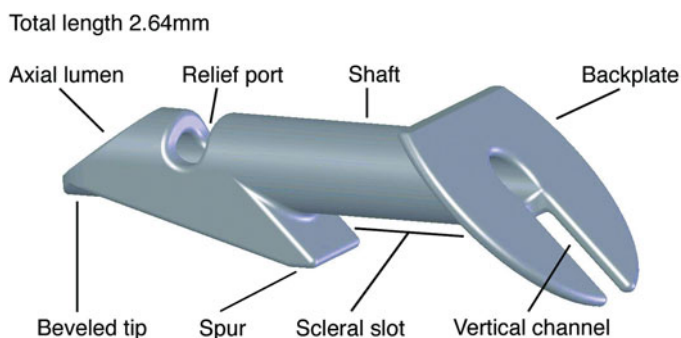


Fig. 9.1 Ex-PRESS mini-glaucoma device

9.2 Surgical Technique

The techniques used for Ex-PRESS implantation have many similarities to a traditional trabeculectomy. The Ex-PRESS device may be placed under topical, sub-tenon, or retrobulbar anesthesia. Choice of fornix- or limbal-based surgery is made according to surgeon preference. Careful cautery of the scleral bed is important for hemostasis prior to scleral flap creation. The shape of the scleral flap is not important as long as the flap has good 1 mm coverage of all sides of the device's outer flange. This requires at least a 2.5×2.5 mm flap. Anti-fibrotics are administered prior to or after scleral flap creation similar to the standard trabeculectomy. A clear corneal paracentesis allows for controlled lowering of the intraocular pressure and access for reformation of the anterior chamber if necessary. However, one advantage of the Ex-PRESS is that the anterior chamber typically stays extremely stable throughout the duration of the procedure. When anti-fibrotics have been administered, the non-dominant hand will lift the scleral flap with care so as to identify the trabecular meshwork at the "blue line" next to the cornea. Several different instruments can be used to enter the anterior chamber at the "blue line" including a 25-gauge needle or 25-gauge MVR blade. It is important to enter straight in at the iris plane and come straight out to ensure proper sizing of the ostium and avoid hypotony or device dislocation/instability in an ostium that is too large for the device.

The Ex-PRESS device comes on a preloaded injector. The injector has a metal shaft that holds the device at the lumen. The injector is then used to introduce the device via the created ostium. The ostium should be approached with the device's face plate rotated in a direction 90° from its final resting place. Care should also be taken to approach at the same angle as was used to fashion the ostium. Once the face plate is flush with the sclera, the device is rotated 90° so the flow is directed posteriorly and then released by pressing the button on the injector. The device should be centered at this time and checked for anterior chamber position. Of note, no sclerostomy or iridectomy is performed.

The scleral flap is closed in desired fashion with interrupted 10-0 nylon sutures. The number of sutures and tightness of sutures should be adjusted for proper flow. The previously created paracentesis can be utilized for injection of balanced salt solution to check flow. Conjunctiva is then closed in the surgeon's preferred technique and the wound checked with a fluorescein strip.

Several potential problems should be avoided during the Ex-PRESS implantation. Premature release of the device is possible and the provided injector is advertised as a single use system. Therefore, the assistant should be warned to not deploy the device. If it is inadvertently deployed, the surgeon can attempt to straighten the wire and reload the device.

At the time of scleral flap creation, the surgeon should be mindful of flap thickness as a thin flap could inadvertently be disinserted during

device implantation. A fair amount of counter-traction is needed to insert the Ex-PRESS through a properly sized ostium. Additionally, the flap should be dissected anterior into clear cornea to aid in proper device seating. If the device flange is immediately adjacent to the flap hinge, malrotation of the device and potential erosion, especially through a thin flap, may occur.

As discussed above, if the surgeon is not careful in using a properly sized needle for ostium creation, the resulting ostium can be larger than the device and lead to additional aqueous leakage around the device. Hypotony may be more likely in these cases. Also, creating the ostium and inserting the Ex-PRESS in the plane of the iris and at the “blue line” is important to avoid anterior or posterior positioning of the device. There is no evidence that anterior positioning results in endothelial cell loss. Posterior positioning may potentially result in cataract formation in phakic patients, increased inflammation due to iris chafing, and/or iris atrophy.

Subacute apparent failure of Ex-PRESS device implantation was observed in 1.7 % of patients in a large cohort [13]. These patients had flat blebs and elevated IOP during the late post-operative period. One eye had vitreous obstructing the Ex-PRESS tip. Four other patients had an inflammatory response in the anterior chamber. The Nd:YAG laser was utilized to treat the tip of these Ex-PRESS devices which resulted in an elevated bleb and lower IOP. Interestingly, the patients with the inflammatory response were not noted to have obstruction at the tip but were noted to have dispersal of white particles during the laser procedure. Before considering adding glaucoma medications, performing a bleb needling, or pursuing further glaucoma surgery, one should consider Nd:YAG to laser the tip of the Ex-PRESS, especially in patients that have had inflammation postoperatively.

Bleb needling with anti-fibrotics has become a frequently performed procedure in attempting to restore bleb function for trabeculectomy. It can be repeated as needed and there are a few sight-threatening complications reported with needle revision [14]. Unfortunately, there is no data that investigates this procedure in eyes after

Ex-PRESS shunt surgery, but anecdotally, needle revision is more difficult in these eyes [15]. Friedl concluded that bleb needling in an eye with an Ex-PRESS shunt is more difficult anecdotally than in an eye without the device. The authors state that one must take care to elevate the scleral flap parallel to the limbus and never in a radial fashion to prevent dislodging the Ex-PRESS shunt into the anterior chamber. Preliminary chart review from our institution (publication pending) has demonstrated efficacy results comparable to that of bleb needling for trabeculectomy. The safety of bleb needling after Ex-PRESS shunt surgery was also demonstrated. In contrast to Friedl and colleagues, we regularly approach the Ex-PRESS shunt radially at the time of needling procedures without dislodging the shunt. We regularly needle blebs after placement of the Ex-PRESS device and view it as a safe and efficacious procedure.

9.3 Outcomes

9.3.1 Ex-PRESS Versus Trabeculectomy

One of the first groups to study the Ex-PRESS was de Jong [16]. As mentioned, initial reports were extremely favorable with the Ex-PRESS being superior in almost every category. Long-term follow-up from this group showed equivalence of the Ex-PRESS and trabeculectomy in most areas [17]. Specifically, IOP results were favorable in both the Ex-PRESS and trabeculectomy groups, but better controlled in the Ex-PRESS group from years 1 to 3 (12 mmHg and 13.5 mmHg, respectively). Interestingly, although the Ex-PRESS group’s IOP remained stable through year 5 (11.5 mmHg), average IOP decreased to 11.3 mmHg at year 5. Complete success rates were significantly higher in the Ex-PRESS group through year 3 (66.7 % to 41 %, respectively). However, after year 1, there was no difference between the groups when placed on IOP lowering medications. By year 5, there was no difference between the groups in terms of complete or qualified success, albeit

with a substantial trend toward higher complete success rates in the Ex-PRESS group. Average number of medicines was similar between the two groups at year 5 (2.1 for Ex-PRESS and 2 for trabeculectomy). A smaller percentage of patients in the Ex-PRESS group required IOP lowering medicines when compared to the trabeculectomy group from years 1 to 5.

Studies have also investigated the P-200 Ex-PRESS model and specifically compared it to traditional trabeculectomy. Moisseiev and colleagues retrospectively reviewed 100 eyes, 39 of which had received the P-200 Ex-PRESS [18]. This study was particularly interesting as they did not exclude patients for “complex” glaucoma, a term they used for uveitic, neovascular, and chronic angle closure glaucomas (addressed below). Similar to de Jong et al. [17], success rates, whether complete (62.3 % for trabeculectomy and 66.6 % for Ex-PRESS) or qualified (86.9 % for trabeculectomy and 84.6 % for Ex-PRESS) were similar, as was postoperative IOP. The number of required medications, unlike the above study, was similar between the study groups. Overall complication and hypotony rates were similar (9.8 % for trabeculectomy and 7.7 % for Ex-PRESS). Four patients (two in each group) required reoperation for uncontrolled IOP. Interestingly, none of the four were from the complex glaucoma group.

9.3.2 Prospective Studies

Buys investigated the efficacy and safety of Ex-PRESS versus trabeculectomy procedures in a prospective, randomized fashion [8, 19]. The study was not masked and reported 1-year outcomes. This study again showed equivalence of trabeculectomy and the Ex-PRESS device in success rates (complete 57 % and 70 %, respectively, qualified 90 % and 83 %, respectively), postoperative IOP (11.6 and 11.3, respectively), number of medications (0.6 and 0.4, respectively), and complication rates. Postoperative hypotony rates were similar at 39 % in each group.

Two particularly interesting elements of the study were the endothelial cell counts and pachym-

etry readings, as this is the first information on the Ex-PRESS device’s effect on endothelial health. With the use of specular microscopy, it has been established that there is little to no endothelial cell loss especially when used prior to entry of the anterior chamber. Long-term study of the endothelium will be interesting and fortunately, at 1 year, there is no difference between trabeculectomy and Ex-PRESS groups (2,257 cells and 2,301 cells, respectively).

In both groups, vision was significantly reduced in the early postoperative period. However, the study reported that the Ex-PRESS group had faster visual recovery with no difference from preoperative acuity by postoperative month 1. In contrast, the trabeculectomy group never returned to baseline visual acuity even at last follow-up at 1 year. Median vision loss at the 6 month follow-up was 0 lines for the Ex-PRESS group and 1.5 lines for the trabeculectomy group. Forty-seven percent of patients treated with trabeculectomy experienced ≥ 2 Snellen lines of vision loss by their 6 month follow-up visit, whereas only 16 % of those treated with the Ex-PRESS device lost that level of vision.

It is important to pause and consider visual recovery. It is clear that transient vision loss is common after filtration surgery. Shallowing of the anterior chamber is thought to cause a myopic shift postoperatively. Tight flap suturing, scleral cautery, postoperative ptosis, and large filtration blebs may lead to changes in corneal curvature and subsequent astigmatism [20]. Other retrospective studies have been a mixed bag with differing definitions and analysis when considering visual recovery [7, 10, 16, 21–23]. However, both prospective studies that specifically analyzed visual recovery [8, 9] definitively demonstrated a quicker visual recovery in the Ex-PRESS group with Beltran-Agullo and colleagues reporting that the trabeculectomy group never returned to baseline visual acuity at 1 year follow-up. It would be interesting to understand the economic impact this has on patient job productivity as it has been previously unstudied in past economic analysis.

Perhaps one of the most important prospective, randomized trials is the XVT (Ex-PRESS versus trabeculectomy) study authored by

Netland et al. [9]. In that study, 59 patients received the Ex-PRESS device, whereas 61 underwent trabeculectomy. Mean IOP at 2 years was statistically equivalent (14.7 for Ex-PRESS and 14.6 for trabeculectomy, respectively). Mean number of medications was 0.9 for the Ex-PRESS group and 0.7 for the trabeculectomy group. Visual acuity was significantly reduced for both groups at the day 1 and week 1 postoperative visits. However, that reduction disappeared for the Ex-PRESS group at the 1 month visit and required an additional 2 months for the trabeculectomy group. Qualified success was 83 % at 2 years for the Ex-PRESS group and 79 % for patients undergoing trabeculectomy. Complication rates were higher in the trabeculectomy group (36.1 % versus 17 %).

Results from a recently performed meta-analysis of all randomized, prospective studies, excluding the XVT (not published at the time of the meta-analysis) [24] confirms most of the above conclusions. Qualified success rates, mean IOP, and number of medications are equivalent between both groups. However, the Ex-PRESS was more likely to have complete success at 1 year with fewer postoperative interventions. Hyphema was also found to be less common in the Ex-PRESS group.

9.3.3 Complex Glaucomas

Trabeculectomy was long the gold standard for any glaucoma. However in recent years, adoption of glaucoma drainage implants has increased for complex glaucomas. With the advent of the Ex-PRESS shunt, some are beginning to again switch back to filtering surgery for some complex glaucomas. Although no formal studies have been conducted investigating the outcomes in such cases with the Ex-PRESS shunt, there are some data to review.

9.3.3.1 Uveitic Glaucomas

Joseph Beer first described “arthritis iritis” in 1813 in a patient that developed glaucoma and blindness after a “gray-green” deep obscuration caused by vitreous opacification. Uveitic glaucoma

can be both open and closed angle with open angle being the more common. Etiology is varied. Inflammatory cells, proteins, debris, or fibrin can obstruct the trabecular meshwork. Resistance to flow can increase due to inflammatory precipitates on the meshwork and swelling or dysfunction of the trabeculum even from topical corticosteroid use. The biochemical milieu can also affect the IOP. Rho kinase can constrict the trabecular endothelium and cytokines can promote neovascularization. A fibrovascular membrane can eventually grow over the angle, fully obstructing flow. Secondary angle closure may occur in three instances: (1) pupillary block resulting in iris bombe because of posterior synechiae, (2) broad peripheral anterior synechiae, and (3) anterior rotation of the ciliary body secondary to edema and swelling.

Frequently, uveitic glaucoma can progress to the point of requiring surgical intervention. In the past, trabeculectomy was the procedure of choice. Ideally, good control of the intraocular inflammation is requisite prior to filtration surgery. Unfortunately, this is not always an option. Subconjunctival and intravitreal corticosteroid are other potential options in cases where inflammation is not optimally controlled prior to surgery. Antiproliferative agents have helped improve long-term outcomes, but compared to open angle glaucoma, outcomes with traditional trabeculectomy have not been excellent. Success rates with different definitions of success have ranged from 48 to 67 % [25–31]. One of the most difficult aspects of filtering surgery in uveitic glaucoma is hypotony. Ciliary body function may be tenuous. If ciliary body shutdown occurs, overfiltration can result even despite very minimal flow at the scleral flap. It has been recommended that loose sutures be avoided in these patients. Additionally, ciliary body shutdown can lead to scarring over the scleral flap due to absence of aqueous flow.

The Ex-PRESS shunt does not help the surgeon avoid potential ciliary body hyposecretion of aqueous, but it does have some potential advantages in these patients. Firstly, implantation of the Ex-PRESS device in uveitic individuals may decrease the risk of cataract progression due to relative maintenance of anterior chamber stability.

Additionally, implantation of the Ex-PRESS device may reduce the risk of increased postoperative intraocular inflammation, which can decrease success rates due to decreased flow secondary to ciliary body shutdown, a fibrovascular membrane forming across the sclerostomy site, or aggressive flap scarring. One advantage to the Ex-PRESS in these patients is there tends to be less postoperative inflammation due to the lack of iridectomy during surgery.

As mentioned, there are no formal published reports on the efficacy and safety of the Ex-PRESS device in uveitic glaucoma patients. However, few scientific abstracts have been presented and international ophthalmic society meetings. The first looked at 11 eyes of 10 patients, all of which had inactive disease and at least 6 months follow-up. Surgical success was defined as a 20 % or greater decrease in IOP and decrease in antiglaucoma medications at 6 months follow-up. Mean age was 66.7 years. Several of the patients had a history previous ocular surgery (three women had previous Ahmed valve implantation, three women and two men had selective laser trabeculoplasty (SLT), and one woman had trabeculectomy). The mean postoperative IOP was 12.2 mmHg with a mean number of postoperative medications of 1.2 at 6 months postoperatively. Complete surgical success (both a 20 % reduction in IOP and decrease in medications) was observed in 36.4 %. 72.7 % had 20 % or greater decrease in IOP with 63.6 % having a decrease in ocular hypotensive medication. Two eyes had no decrease in IOP, and only one eye had hypotony at 1 month that subsequently resolved.

A study from our group (Dean McGee Eye Institute) investigated the P-200 Ex-PRESS in various types of glaucoma (primary open angle, neovascular, uveitic, multiple mechanism, pigmentary, steroid response, pseudoexfoliation, aphakic, traumatic, chronic angle closure, and ICE syndrome). Sixty-eight percent of the eyes had a preoperative diagnosis of secondary glaucoma. Follow-up at the time of abstract presentation was relatively short with a mean of 9.6 months. Preoperative IOP was reduced from a mean of 31.5–14.7, resulting in an average IOP reduction

of >40 % at every time point. Medications were reduced from 3.1–0.3 at last follow-up. There were several failures with two patients requiring a glaucoma drainage device and four requiring subsequent cyclophotocoagulation. The patients requiring secondary procedures all had a preoperative diagnosis of neovascular glaucoma. One other patient required endocyclophotocoagulation, but it was not specified in the abstract what type of glaucoma this patient had. The study concluded that the Ex-PRESS can be safe and effective even in patients with high risk for failure. This may be in part due to the “shunt” aspect of the device. Failure from flap scarring is still possible, but fibrovascular or neovascular membranes may be less likely to obstruct the Ex-PRESS rather than a sclerostomy.

Lastly, Moisseiev and colleagues [18] did not exclude complex glaucomas in their study cohort when comparing trabeculectomy and Ex-PRESS procedures. They did not include specific success rates, IOP, or number of medications for these complex cases but did note that none of them required additional glaucoma surgery through last follow-up.

Our group tends to perform Ex-PRESS on most uveitic glaucoma patients as first-line surgical treatment for severe glaucoma when the patient's uveitis is quiet. However, some of our surgeons will perform aqueous shunt implantation in the setting of active uveitis.

9.3.3.2 Other Complex Glaucomas

Other complex glaucomas include neovascular, aphakic, Sturge–Weber, traumatic, anterior segment dysgenesis, congenital, and phakic primary angle closure entities. There are some considerations to address when using the Ex-PRESS in the above scenarios. First, neovascular glaucoma can result in brisk intraoperative bleeding and elicit a strong inflammatory response following surgery. For this reason, filtering surgery is often avoided. However, the absence of an iridectomy can limit some of the postoperative inflammation. Additionally, the Ex-PRESS device can function in a similar way to a shunting surgery, thus avoiding potential fibrovascular proliferation across a sclerostomy. One potential downside to

the Ex-PRESS in these patients is the potential for the device to become completely obstructed by blood clot with intraoperative bleeding. These patients may require anterior chamber washout if the blood does not clear on its own. We find it best if these cases can follow up with anti-vascular endothelial growth factor therapy within a few weeks, but this is not always possible.

In aphakic glaucoma patients, the device can become obstructed by vitreous. Thus, if any vitreous is presenting at the pupil or anterior chamber, it may be best to combine this surgery with a pars plana vitrectomy. However, if the vitreous is not presenting, the lack of an iridectomy may make the Ex-PRESS a great option.

Sturge–Weber patients are at especially high risk of suprachoroidal hemorrhage when IOP is acutely lowered. One advantage of the Ex-PRESS is the stability of the anterior chamber during placement. Although the IOP will still be lower following surgery, the stability of the anterior chamber allows for some control in this process. In a similar vein, traumatic glaucoma may benefit from minimal tissue manipulation that Ex-PRESS shunt surgery provides.

At this time, the long-term course of the device is unknown in congenital glaucoma or other patients with anterior segment dysgenesis. Often these patients benefit from primary trabeculotomy and we generally perform 360° trabeculotomy with the Itrack catheter (iScience Interventional, Menlo Park, CA) followed by aqueous shunt implantation if necessary. Some have advocated for not using the Ex-PRESS in phakic patients for fear of cataract formation. We have not observed this and will routinely place the device in phakic patients, who do not have cataract. We will not place the device in patients with narrow angles or angle closure glaucoma, in whom we leave phakic.

As mentioned, the effect of the Ex-PRESS on the corneal endothelium is mostly unknown at this time. It appears that endothelial cell count and pachymetry are stable at 1 year [19]. There is no data on outcomes of placing the Ex-PRESS in eyes with an anterior chamber intraocular lens; however, it is obvious that hypotony in these eyes could compromise the endothelium.

Patients with thin sclera should be approached with care as they may be especially at risk for device erosion depending on the thickness of the scleral flap. Additionally, there is no data in patients with microphthalmos or nanophthalmos and the general opinion is these eyes may not be good candidates for the Ex-PRESS.

9.4 Conclusion

It is clear that the Ex-PRESS is a safe and efficacious device. Although costly, it does afford patients with faster visual recovery and perhaps less hypotony or hypotony-related intervention. Additionally, the device should be considered in the treatment of complex glaucomas where in recent years, filtration surgery was unthinkable.

Fyodr Dostoevsky suggested that we tend toward stagnation in our lives when he wrote, “It seems, in fact, as though the second half of a man’s life is made up of nothing, but the habits he has accumulated during the first half.” May this idea of stagnancy not apply to the changing world of ophthalmology. Although not all new innovations are permanent fixtures in our armamentarium as glaucoma surgeons, an open mind is necessary to avoid making our life of work simply a habit.

Compliance with Ethical Requirements Dr. Allen had no conflict of interest. Dr. Sarkisian is a consultant to Alcon. All procedures followed were in accordance with the ethical standards of the responsible committee on human experimentation (institutional and national) and with the Helsinki Declaration of 1975, as revised in 2000. Informed consent was obtained from all patients for being included in the study.

References

1. Geffen N, Trope GE, Alasbali T, Salonen D, Crowley AP, Buys YM. Is the Ex-PRESS glaucoma shunt magnetic resonance imaging safe? *J Glaucoma*. 2010;19(2):116–8. doi:[10.1097/IJG.0b013e3181a98bda](https://doi.org/10.1097/IJG.0b013e3181a98bda).
2. Nyska A, Glovinsky Y, Belkin M, Epstein Y. Biocompatibility of the Ex-PRESS miniature glaucoma drainage implant. *J Glaucoma*. 2003;12(3):275–80.

3. Gandolfi S, Traverso CF, Bron A, Sellem E, Kaplan-Messas A, Belkin M. Short-term results of a miniature draining implant for glaucoma in combined surgery with phacoemulsification. *Acta Ophthalmol Scand Suppl.* 2002;236:66.
4. Stewart RM, Diamond JG, Ashmore ED, Ayyala RS. Complications following ex-press glaucoma shunt implantation. *Am J Ophthalmol.* 2005;140(2):340–1. doi:[10.1016/j.ajo.2005.02.033](https://doi.org/10.1016/j.ajo.2005.02.033).
5. Traverso CE, De Feo F, Messas-Kaplan A, Denis P, Levartovsky S, Sellem E, Badala F, Zagorski Z, Bron A, Gandolfi S, Belkin M. Long term effect on IOP of a stainless steel glaucoma drainage implant (Ex-PRESS) in combined surgery with phacoemulsification. *Br J Ophthalmol.* 2005;89(4):425–9. doi:[10.1136/bjo.2004.058032](https://doi.org/10.1136/bjo.2004.058032).
6. Wamsley S, Moster MR, Rai S, Alvim HS, Fontanarosa J. Results of the use of the Ex-PRESS miniature glaucoma implant in technically challenging, advanced glaucoma cases: a clinical pilot study. *Am J Ophthalmol.* 2004;138(6):1049–51. doi:[10.1016/j.ajo.2004.06.024](https://doi.org/10.1016/j.ajo.2004.06.024).
7. Dahan E, Carmichael TR. Implantation of a miniature glaucoma device under a scleral flap. *J Glaucoma.* 2005;14(2):98–102.
8. Beltran-Agullo L, Trope GE, Jin Y, Wagschal LD, Jinapriya D, Buys YM. Comparison of visual recovery following Ex-PRESS versus trabeculectomy: results of a prospective randomized controlled trial. *J Glaucoma.* 2013. doi:[10.1097/IJG.0b013e31829e1b68](https://doi.org/10.1097/IJG.0b013e31829e1b68).
9. Netland PA, Sarkisian Jr SR, Moster MR, Ahmed II, Condon G, Salim S, Sherwood MB, Siegfried CJ. Randomized, prospective, comparative trial of EX-PRESS glaucoma filtration device versus trabeculectomy (XVT study). *Am J Ophthalmol.* 2014;157(2):433–40. doi:[10.1016/j.ajo.2013.09.014](https://doi.org/10.1016/j.ajo.2013.09.014). e433.
10. Sugiyama T, Shibata M, Kojima S, Ueki M, Ikeda T. The first report on intermediate-term outcome of Ex-PRESS glaucoma filtration device implanted under scleral flap in Japanese patients. *Clin Ophthalmol.* 2011;5:1063–6. doi:[10.2147/OPHTH.S23129](https://doi.org/10.2147/OPHTH.S23129).
11. Dahan E, Ben Simon GJ, Lafuma A. Comparison of trabeculectomy and Ex-PRESS implantation in fellow eyes of the same patient: a prospective, randomised study. *Eye (Lond).* 2012;26(5):703–10. doi:[10.1038/eye.2012.13](https://doi.org/10.1038/eye.2012.13).
12. Wang W, Zhou M, Huang W, Zhang X. Ex-PRESS implantation versus trabeculectomy in uncontrolled glaucoma: a meta-analysis. *PLoS One.* 2013;8(5):e63591. doi:[10.1371/journal.pone.0063591](https://doi.org/10.1371/journal.pone.0063591).
13. Kanner EM, Netland PA, Sarkisian Jr SR, Du H. Ex-PRESS miniature glaucoma device implanted under a scleral flap alone or combined with phacoemulsification cataract surgery. *J Glaucoma.* 2009;18(6):488–91. doi:[10.1097/IJG.0b013e3181818fb4](https://doi.org/10.1097/IJG.0b013e3181818fb4).
14. Broadway DC, Bloom PA, Bunce C, Thiagarajan M, Khaw PT. Needle revision of failing and failed trabeculectomy blebs with adjunctive 5-fluorouracil: survival analysis. *Ophthalmology.* 2004;111(4):665–73. doi:[10.1016/j.ophtha.2003.07.009](https://doi.org/10.1016/j.ophtha.2003.07.009).
15. Freidl KB, Moster MR. ExPRESS shunt surgery: preferred glaucoma surgery in residency training? *Surv Ophthalmol.* 2012;57(4):372–5. doi:[10.1016/j.survophthal.2012.02.008](https://doi.org/10.1016/j.survophthal.2012.02.008).
16. de Jong LA. The Ex-PRESS glaucoma shunt versus trabeculectomy in open-angle glaucoma: a prospective randomized study. *Adv Ther.* 2009;26(3):336–45. doi:[10.1007/s12325-009-0017-6](https://doi.org/10.1007/s12325-009-0017-6).
17. de Jong L, Lafuma A, Aguade AS, Berdeaux G. Five-year extension of a clinical trial comparing the EX-PRESS glaucoma filtration device and trabeculectomy in primary open-angle glaucoma. *Clin Ophthalmol.* 2011;5:527–33. doi:[10.2147/OPHTH.S18565](https://doi.org/10.2147/OPHTH.S18565).
18. Moisseiev E, Zunz E, Tzur R, Kurtz S, Shemesh G. Standard trabeculectomy and Ex-PRESS miniature glaucoma shunt: a comparative study and literature review. *J Glaucoma.* 2014. doi:[10.1097/IJG.0000000000000047](https://doi.org/10.1097/IJG.0000000000000047).
19. Wagschal LD, Trope GE, Jinapriya D, Jin YP, Buys YM. Prospective randomized study comparing Ex-PRESS to trabeculectomy: 1-year results. *J Glaucoma.* 2013. doi:[10.1097/IJG.0000000000000029](https://doi.org/10.1097/IJG.0000000000000029).
20. Cunliffe IA, Dapling RB, West J, Longstaff S. A prospective study examining the changes in factors that affect visual acuity following trabeculectomy. *Eye (Lond).* 1992;6(Pt 6):618–22. doi:[10.1038/eye.1992.133](https://doi.org/10.1038/eye.1992.133).
21. Good TJ, Kahook MY. Assessment of bleb morphologic features and postoperative outcomes after Ex-PRESS drainage device implantation versus trabeculectomy. *Am J Ophthalmol.* 2011;151(3):507–13. doi:[10.1016/j.ajo.2010.09.004](https://doi.org/10.1016/j.ajo.2010.09.004). e501.
22. Maris Jr PJ, Ishida K, Netland PA. Comparison of trabeculectomy with Ex-PRESS miniature glaucoma device implanted under scleral flap. *J Glaucoma.* 2007;16(1):14–9. doi:[10.1097/01.ijg.0000243479.90403.cd](https://doi.org/10.1097/01.ijg.0000243479.90403.cd).
23. Seider MI, Rofagha S, Lin SC, Stamper RL. Resident-performed Ex-PRESS shunt implantation versus trabeculectomy. *J Glaucoma.* 2012;21(7):469–74. doi:[10.1097/IJG.0b013e3182182bfb](https://doi.org/10.1097/IJG.0b013e3182182bfb).
24. Chen G, Li W, Jiang F, Mao S, Tong Y. Ex-PRESS implantation versus trabeculectomy in open-angle glaucoma: a meta-analysis of randomized controlled clinical trials. *PLoS One.* 2014;9(1):e86045. doi:[10.1371/journal.pone.0086045](https://doi.org/10.1371/journal.pone.0086045).
25. Carreno E, Villaron S, Portero A, Herreras JM, Maquet JA, Calonge M. Surgical outcomes of uveitic glaucoma. *J ophthalmic inflamm infect.* 2011;1(2):43–53. doi:[10.1007/s12348-010-0012-8](https://doi.org/10.1007/s12348-010-0012-8).
26. Siddique SS, Selves AM, Baheti U, Foster CS. Glaucoma and uveitis. *Surv Ophthalmol.* 2013;58(1):1–10. doi:[10.1016/j.survophthal.2012.04.006](https://doi.org/10.1016/j.survophthal.2012.04.006).
27. Sung VC, Barton K. Management of inflammatory glaucomas. *Curr Opin Ophthalmol.* 2004;15(2):136–40.

28. Ceballos EM, Beck AD, Lynn MJ. Trabeculectomy with antiproliferative agents in uveitic glaucoma. *J Glaucoma*. 2002;11(3):189–96.
29. Kaburaki T, Koshino T, Kawashima H, Numaga J, Tomidokoro A, Shirato S, Araie M. Initial trabeculectomy with mitomycin C in eyes with uveitic glaucoma with inactive uveitis. *Eye (Lond)*. 2009;23(7):1509–17. doi:[10.1038/eye.2009.117-cme](https://doi.org/10.1038/eye.2009.117-cme).
30. Kok H, Barton K. Uveitic glaucoma. *Ophthalmol Clin North Am*. 2002;15(3):375–87. viii.
31. Moorthy RS, Mermoud A, Baerveldt G, Minckler DS, Lee PP, Rao NA. Glaucoma associated with uveitis. *Surv Ophthalmol*. 1997;41(5):361–94.

Sarah S. Khodadadeh and James C. Tsai

10.1 Introduction

Normal tension glaucoma (NTG), also called low-tension glaucoma, is clinically diagnosed as glaucomatous optic neuropathy with visual field damage and intraocular pressure (IOP) measurements documented at or below 21 mmHg [1]. The prevalence in large study populations is documented between 1 and 2 %; however, the percentage may be higher in specific demographics studied [2–4]. Patients typically have open normal-appearing anterior chamber angles. Prior to and in conjunction with initiation of treatment, patients with NTG should be evaluated, based on clinical decisions, for other conditions which can mimic NTG, such as primary open-angle glaucoma with diurnal IOP variation, causes of previously induced elevation of IOP (corticosteroid-induced glaucoma, uveitic glaucoma, previous trauma), and non-glaucomatous optic nerve head disease

(congenital disc anomalies, compressive lesions, acute episode of vascular insufficiency to the optic nerve shock and anterior ischemic optic nerve, and anterior ischemic optic neuropathy) with retrograde optic neuropathy, optic disc drusen, and toxic or nutritional optic neuropathy (methanol poisoning and tobacco/alcohol amblyopia) [5, 6].

It is debated whether NTG describes a disease spectrum of primary open-angle glaucoma with intraocular tension below 21 mmHg or, it is an entirely separate entity, with distinct structural difference from POAG. Our treatment options for lowering IOP to prevent devastating vision loss is in agreement with NTG being a continuum of the disease process of POAG. However, physiologic abnormalities of vascular flow have been postulated to play a causative role in the onset and progression of NTG. Vascular diseases including autoimmune diseases, coagulopathies, ischemic vascular disease, ocular migraine, Raynaud phenomenon, and sleep apnea have been documented with increased prevalence in NTG patients [7–10]. Modifications of any comorbid conditions may help to slow the progression of visual field loss in NTG patients, in association with topical and surgical glaucoma therapies.

Electronic supplementary material The online version of this chapter (doi:[10.1007/978-3-319-18060-1_10](https://doi.org/10.1007/978-3-319-18060-1_10)) contains supplementary material, which is available to authorized users.

S.S. Khodadadeh, M.D. (✉)
Center for Advanced Eye Care, Vero Beach, FL, USA
e-mail: sarah.khodadadeh@gmail.com

J.C. Tsai, M.D., M.B.A.
New York Eye and Ear Infirmary of Mount Sinai,
New York, NY, USA
e-mail: jtsai@nyee.edu; james.tsai@mssm.edu

10.2 Preoperative Considerations

The management of NTG requires a multifaceted approach to decrease the IOP and modify any accompanying systemic disease entities.

Identification of glaucomatous optic neuropathy and visual field change in the setting of “normal” tensions is key in allowing the physician to integrate the appropriate intervention and prevent blinding consequences. In patients with consistently stable intraocular tensions and repeatable visual fields without progression, monitoring, or continuation of current treatment is acceptable.

Automated visual field analysis on a regular basis is important in monitoring stability and progression in NTG. Patients who show advancing visual field defects and split fixation (Fig. 10.1) should be treated more aggressively to lower the intraocular pressure. However, these patients are also at increased risk for complete loss of vision with surgical intervention. Other risk factors for “snuff out” of the optic nerve include IOP spikes and hypotony postoperatively [11, 12].

10.2.1 Topical and Medication Therapy

Topical medical therapy is usually is the first line of treatment in NTG patients, especially in the pre-perimetric and early stages of NTG. If there are no contraindications to a specific topical drug class (allergic reactions, bronchospasm, cardiac disease, etc.), topical therapy is initiated with single or combination drugs. Typical maximum therapy is a combination medication (beta-blocker and alpha-agonist (timolol/brimonidine) or beta-blocker), combined with a third-line agent carbonic anhydrase inhibitor (CAI) (dorzolamide) and a prostaglandin analog at bedtime (latanoprost). Topical beta-blockers have been debated as a less efficacious first line of treatment in patients. A study conducted out of the Early Manifest Glaucoma

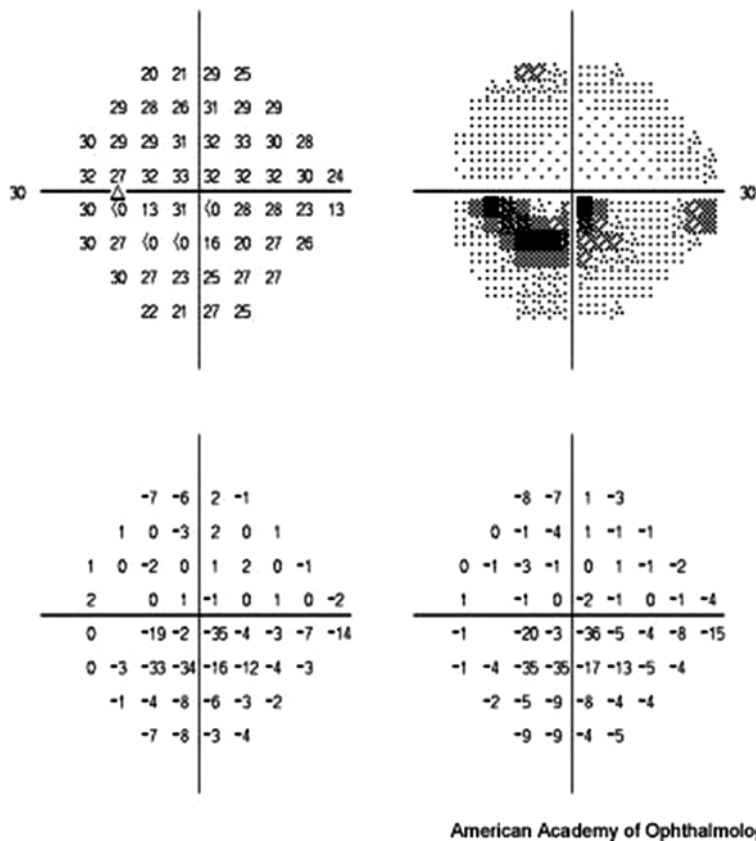


Fig. 10.1 Split fixation. Humphrey visual field (10-2) from a patient demonstrating inferior split fixation and inferior paracentral defect in the left eye. Reproduced

with permission from Practicing Ophthalmologists Learning System. American Academy of Ophthalmology, Copyright© 2014–2016

Trial showed that betaxolol combined with selective laser trabeculoplasty (SLT) had little reduction in IOP in patients with a baseline IOP of 15 mmHg or less [13]. In addition, oral beta-blockers may mask elevated IOP in true POAG patients. With the postulated vascular factors that may contribute to NTG, carbonic anhydrase inhibitors or alpha-agonists may be of increased benefit, especially with the postulated neuroprotective role of the latter [14, 15]. Miotic agents can be used as a last line of therapy; however, polypharmacy should be monitored in these patients as it may cause difficulty with compliance and surface irritation. Oral CAIs are rarely given to NTG patients, as IOP is relatively low even prior to surgical intervention. Oral medications can be reserved for further lowering of IOP prior to surgical intervention if necessary.

If topical or systemic IOP-lowering medications do not adequately control the IOP and risk of progressive visual field loss is imminent with advancing glaucomatous optic neuropathy, or difficulty with compliance of the medical regimen is documented, surgical intervention is pursued.

10.2.2 Intraocular Pressure Targeting

The acceptable and appropriate level of IOP varies from patient to patient. In most instances, target IOP is determined from the Collaborative Normal Tension Glaucoma Study Group finding that a reduction of visual field progression from 35 to 12 % was correlated with a decrease in IOP at least 30 % from baseline. Consideration of other risk factors such as thin central corneas and the presence of disc hemorrhages may lead the surgeon to consider earlier surgical intervention if progression is observed [16, 17]. In addition, women, older age, and history of migraine headaches showed increased progression, with two-thirds of all patients showing signs of progression after 7 years [2].

10.2.3 Preoperative Patient Considerations

As with any intraocular surgery, preoperative assessment of the well-being and life expectancy of the patient should be accounted for in the

decision to proceed with surgery. Since NTG patients often have vascular comorbidities, length of the surgery and anesthesia consideration should be discussed with the anesthesiologist and the patient prior to the intervention. Prior to proceeding with surgery, it is important to discuss with the patient goals, expectations of the surgery, complications, and importance of follow-up visits, as postoperative management of the surgical site is imperative and is not without failure.

10.3 Surgical Technique

10.3.1 Anesthesia

Topical anesthesia is a safe and effective alternative to retrobulbar anesthesia for glaucoma surgery and allows the surgeon to monitor a patient's pain response to rare but devastating complications, such as suprachoroidal hemorrhage [18–20]. Topical anesthesia is becoming more commonplace in anterior segment surgery, and the procedures discussed below can be routinely performed without retrobulbar injections, peribulbar injections or general anesthesia, which all carry significant potential risk (intra-arterial injection, intrathecal injection, globe perforation, extra-ocular muscle paralysis, atrophy, and retrobulbar hemorrhage).

Depending on surgeon preference and individual surgical efficiency, topical anesthesia can range from 15 to 60 min (Table 10.1) with additional re-administration to obtain an adequate desired effect. With the use of these analgesics, blitz anesthesia (topical plus intracameral and anterior subTenon locally administered anesthesia) has been proven to be safe and effective in anterior segment surgery [21].

Table 10.1 Topical anesthesia for anterior segment surgery

Agent (trade name)	Concentration (%)	Onset of action	Duration (min)
Lidocaine (xylocaine)	1, 2, 4	4–6 min	30–60
Proparacaine	0.5	30 s	15
Tetracaine	1	30 s	25

10.3.2 Trabeculectomy with Mitomycin-C for Normal Tension Glaucoma

The treatment of choice in NTG patients is trabeculectomy with adjunct mitomycin-C (MMC). Trabeculectomy alone has been shown to control IOP in primary open-angle glaucoma patients with ocular tensions only below 22 mmHg. In the same study, less than (1/5th) 17 % of patients with NTG treated with trabeculectomy and no adjunct antimetabolite therapy achieved a target IOP less than 30 % of baseline [22]. Patients with NTG require lower target IOPs and are at greater risk for failure; therefore, the use of intraoperative MMC should be considered for use in all cases for better long-term success [23].

10.3.3 Surgical Steps for Trabeculectomy with Adjunctive Mitomycin-C

1. Obtain informed consent.
2. Administer adequate anesthesia as appropriate for patient.
3. Preparation of the eye with 5 % betadine directly into the fornices.
4. Place eyelid speculum (preference to a temporal hinged-speculum, wire, or turn-knob).
5. Place and secure clear corneal traction suture 1 mm from limbus at the superior aspect of the cornea. (7-0 vicryl or 6-0 silk on a spatulated needle.)
6. Create a small opening in the conjunctiva and Tenon capsule at the limbus (in the presence of conjunctival scarring) or 1 mm posterior to the limbus.
7. Inject 1.5 cm³ of 2 % lidocaine with epinephrine beneath the conjunctiva and Tenon capsule to create a bleb of moderate size. (Preservative-free lidocaine can be used if there is concern for exposure to intraocular contents. Epinephrine provides a longer duration of action.)
8. Massage the subconjunctival anesthetic in a posterior direction, gently rolling a cotton swab from limbal edge toward the optic nerve posterior to disperse the agent of choice. (This also in creates a dissection plane for aqueous flow once the sclerostomy has been made and after conjunctival closure.)
9. Create a 5.5 mm superior (superotemporal or superonasal) fornix-based conjunctival peritomy. (In the absence of preexisting conjunctival scarring, create with a 1-mm conjunctival skirt of tissue remaining at the limbus; in the presence of preexisting conjunctival scarring, create the peritomy directly at the conjunctival/limbal junction.)
10. Gently dissect into sub-Tenon space toward the optic nerve, using a gentle spreading technique with blunt tip ophthalmic surgical scissors. Care should be taken when handling the conjunctiva to avoid fraying or button holes.
11. Obtain hemostasis with cautery if necessary.
12. Mark the eye for flap creation remove strikethrough with a caliper.
13. With a super sharp blade, create a 3 × 2.5 mm partial thickness rectangular scleral flap. The flap should be approximately 1/2 to 2/3 the thickness of the entirety of the sclera in that location.
14. Gently dissect anteriorly into clear cornea with a 57-blade (or flap/crescent blade of choice). Do NOT enter the anterior chamber at this point. Application of MMC may be compromised if this occurs.
15. Apply desired concentration of MMC directly to bare sclera. Take precaution to avoid medication exposure to epithelium.
16. Remove sponge(s) and copiously irrigate with balance salt solution.
17. Create a paracentesis.
18. Enter the anterior chamber within the previously made plane of the scleral flap.
19. Create a sclerostomy with a corneoscleral punch within the anterior base of the sclerostomy.
20. Perform a superior surgical peripheral iridectomy. (Cautery through the sclerostomy to the iris may be necessary.)
21. Ensure flow through the sclerostomy with irrigation of BSS from the temporal paracentesis.
22. Close the flap with 10-0 nylon suture to the desired flow rate. Recommended closure: single interrupted 10-0 nylon in an anatomical clockwise position of flap; releasable 10-0 nylon in an anatomical clockwise position of flap (see instructional Video 10.1).

23. In an alternating locking, non-locking fashion, create a water-tight conjunctival closure with a recommended 9-0 vicryl suture on a blood vascular needle.
24. Deepen the anterior chamber with BSS to create elevation of the bleb and to ensure that it is water-tight.
25. (Optional) Inject viscoelastic material into the anterior chamber to prevent postoperative hypotony. Step 25 is recommended in cases with previous longterm use of ocular hypotensive agents.

Table 10.2 outlines key surgical steps in the procedure. Modifications to the surgical procedure are adjusted based on patient-specific factors (Table 10.3).

10.3.4 Antimetabolites in Glaucoma Surgery

Antifibrotic agents have been used as adjunctive therapy for three decades to prevent fibrosis and scarring associated with glaucoma surgical failure.

Table 10.2 Key points for trabeculectomy surgery with mitomycin-C in normal tension glaucoma patients

• Use of topical/subconjunctival anesthesia
• Fornix-based conjunctival flap with 1 mm skirt at base (in the absence of previous conjunctival scarring)
• Adjunctive use of MMC: 0.4 mg/mL for 2 min
• Releasable flap suture (10-0 nylon)
• Running, interlocking closure of wound (9-0 vicryl on blood vascular (BV) needle)

In a meta-analysis of five studies comparing intraoperative use of MMC and 5-fluorouracil (5-FU), MMC adjunctive therapy reached target IOP of less than 30 % of baseline and sustained the IOP-lowering effect better than those treated with 5-FU [24].

Use of MMC and 5-FU in NTG patients can improve success of target IOP and delay visual field progression in NTG patients [25–27]. In most cases of NTG, the use of MMC is during surgical intervention with trabeculectomy, as these patients typically have endured multiple medications and are at risk of failure due to episcleral fibrosis, and require lower IOPs for control of progression [28].

5-Fluorouracil (5-FU) is reserved for postoperative subconjunctival injection and increases the success of trabeculectomy in patients who are at higher risk for fibrosis, as well as those requiring extremely low IOPs. Please see Table 10.4 for a comparison between 5-FU and MMC.

Table 10.3 Preoperative and intraoperative special considerations

Preoperative	Intraoperative
• Avoid uncontrolled IOP elevation	• Adjust scleral flap resistance precisely
• Avoid uncontrolled hypertension	• Avoid hypotony with viscoelastics
• Minimize blood pressure dips	• Consider placing a releasable suture
	• Check IOP in first few hours

These key items should be treated and employed to maximize successful outcomes and avoid during surgical and postoperative complication

Table 10.4 Dosage and frequency of common antimetabolites used in trabeculectomy surgery and postoperative period [8–10]

Antifibrotic agent	Mechanism of action	Delivery route	Dosage	Frequency	Side effects
MMC	Antineoplastic antibiotic (from <i>Streptomyces caespitosus</i>)	Intraoperative SubTenon's sponge	0.2–0.4 mg/mL	Varies based on patient; usually between 1 and 4 min	Hypotony maculopathy
5-FU	Pyrimidine analog; blocks DNA synthesis via inhibition of thymidylate synthesis in fibroblasts	Subconjunctival injection	5 mg in 0.1 mL	As needed, daily if necessary to prevent scarring	Corneal toxicity, bleb leak

MMC mitomycin-C, 5-FU 5-fluorouracil

However, adjunct therapy to increase success of surgery is not without risk. Postoperative hypotony and infection can ensue with the use of MMC, and 5-FU injections can induce corneal epithelial toxicity and wound leaks [29–31].

Topical nonsteroidal anti-inflammatory drops have shown an inhibitory effect on wound healing can be considered in patients intolerant to other anti-scarring postoperative therapies [32].

A newer alternative to antimetabolite treatment during surgery is placement of collagen material to promote structured fibroblast growth along a biodegradable matrix. Used in place of antimetabolites, the implant material has not yet been proven to be as effective in maintaining and achieving target IOP as previously discussed adjunctive agents with traditional trabeculectomy surgery [33].

10.4 Postoperative Management

Optimal postoperative care is key in helping to achieve success in filtering surgery. Achieving target IOP, preventing postoperative complications, and maintaining a viable filtering bleb requires frequent visits in the weeks after surgery. All topical tension-lowering medications should be discontinued after the filtering surgery to promote aqueous production. The eye should be treated with anti-inflammatory and antibiotic eye drops. Topical ointment can aid in patient comfort with suture irritation.

Steroid management (Table 10.5) should be based on clinical signs of inflammation. An ante-

Table 10.5 Steroid management in postoperative trabeculectomy for normal tension glaucoma

Steroid management in postoperative trabeculectomy with MMC for NTG
<ul style="list-style-type: none">• Taper based on clinical signs of inflammation• History of severe postoperative uveitis• Patient at high risk of bleb failure• Oral steroid use in patients with concurrent active uveitis• Alternative agents: topical nonsteroidal anti-inflammatory drops, immunosuppressive drugs

Key clinical considerations for aggressive steroid treatment early in the postoperative period

MMC mitomycin-C, NTG normal tension glaucoma

Table 10.6 Early bleb modulation and rescue techniques

Postoperative finding	Rescue treatment
1. Bleb encapsulation	<ul style="list-style-type: none">• Subconjunctival 5-FU or MMC injections• Bleb needling with or without anti-scarring adjuvant injections
2. Leaking bleb	<ul style="list-style-type: none">• Large diameter bandage contact lens• Surgical intervention
3. Flat bleb	<ul style="list-style-type: none">• Laser suture lysis• Pull releasable suture

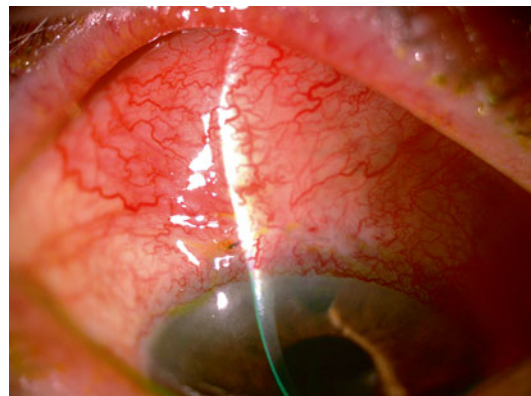


Fig. 10.2 Postoperative week 1 trabeculectomy with mitomycin-c adjunctive use. Note moderate elevation of the bleb, water-tight conjunctival closure, and mild to moderate vascularization of the conjunctiva. Releasable suture was pulled prior and injection of MMC given for hyperemia to prevent fibrosis

rior chamber reaction is generally present after surgery and typically resolves faster than injection of the conjunctiva at the surgical site. Steroid taper should be tailored to resolution of the conjunctival injection at the operative site to favor surgical success and help to decrease bleb fibrosis. If scarring develops despite aggressive steroid management, the bleb can be rescued with tailored treatment (Table 10.6; Fig. 10.2).

The risk and occurrence of late onset bleb leaks is increased with the use of MMC and 5 FU [34] (Fig. 10.3). Patients undergoing trabeculectomy with MMC carry a lifelong increased risk for infection. These patients should be monitored closely and treated empirically [35].

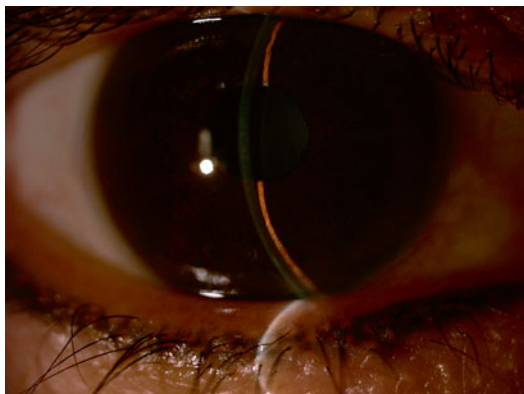

Fig. 10.3 Shallow anterior chamber after trabeculectomy with MMC. Anterior chamber is measured in comparison to the depth of the corneal light wedge

Other complications reported after incisional glaucoma surgery include hypotony, hypotony maculopathy, epithelial defect, conjunctival button hole, choroids detachment, and suprachoroidal hemorrhage [36].

10.5 Cataract Surgery in Normal Tension Glaucoma Patients

Cataract surgery can be performed as a standalone procedure or combined with filtering surgery for NTG patients, and can be executed from a one-site or two-sites. The one-site approach gains entry into the anterior chamber for phacoemulsification under the trabeculectomy flap before the punch sclerostomy is performed (see step #19 in Surgical Steps for Trabeculectomy with adjunctive MMC).

Numerous studies have concluded that cataract surgery alone can lower IOP in patients with a predisposition to glaucoma [37, 38]. However, cataract surgery can also induce an acute rise in intraocular tension postoperatively, one study noting an increase in as many as 17 % of patients [39]. Risk factors for IOP spikes include longer axial length, a higher number of preoperative medications and previous laser trabeculoplasty.

Cataract extraction with phacoemulsification after previous trabeculectomy may cause increased episcleral fibrosis and IOP elevation associated with changes in bleb morphology, and no studies to date recommend a timeline as to when post-trabeculectomy cataract extraction is recommended

to minimize bleb failure [40, 41]. Increases in intraocular inflammation with intraocular surgery can increase the risk of bleb failure secondary to fibrosis, leading to sustained increases in intraocular pressure [42]. Post-cataract subconjunctival injections of 5-FU may be administered to help prevent bleb failure [43]. Treatment of bleb failure related to cataract extraction, and cataract surgery itself in NTG patients should be considered on an individual clinical and pathologic basis.

10.6 Role of Laser Trabeculoplasty

Laser trabeculoplasty can be performed as a first-line treatment and as an adjunct to topical management of open-angle glaucomas. The intraocular tension reduction is thought to occur via increases in outflow of aqueous through the trabecular meshwork. While the procedure may be effective in some patients (pigmentary glaucoma, primary open-angle glaucoma, pseudoexfoliation glaucoma), it has a pressure-limited effect [44].

Different types of trabeculoplasty are available to treat patients with NTG: argon laser trabeculoplasty, SLT, and most recently, MicroPulse laser trabeculoplasty. ALT and SLT are the most widely performed laser procedures on NTG glaucoma patients [45]. SLT has shown to decrease IOP in NTG patients; however, an IOP reduction of 30 % of baseline is difficult to obtain, even with the additional topical medical therapy [46]. SLT laser is operator dependent and can be more effective in the hands of different surgeons. It has also been shown to have a greater IOP lowering effect if administered earlier in the treatment regimen when the number of topical medications is low, and in patients with higher pre-treatment intraocular tension [47–49]. In addition, laser trabeculoplasty may be considered prior to cataract extraction in NTG patients as phakic patients with higher intraocular tensions have the greatest response, historically; however, more recent studies note no statistically significant difference in reduction of IOP between phakic and pseudo-phakic individuals [50–55] (Table 10.7).

While laser trabeculoplasty studies show promise in the treatment of NTG in countries

Table 10.7 Settings for treatment of patients with argon laser trabeculoplasty and selective laser trabeculoplasty [8–10, 62]

Treatment	Size	Power	Duration	Laser	Lens	Treatment
ALT	50 μm	300–1,200 mW	0.10 s	Argon	Goniolens	Treat at junction of pigmented and nonpigmented TM. 50 spots in 180°; results in blanching
SLT	400 μm (fixed)	0.7–1.2 mJ	1 pulse/burst	SLT	SLT; goniolens	50 spots in 180°; results in tiny bubbles

ALT argon laser trabeculoplasty, SLT selective laser trabeculoplasty, mW milliwatts, mJ millijoules

where topical therapy is not readily available or cost-effective, surgical treatment of NTG with a 30 % reduction of IOP has been proven to be cost-effective in the United States [56]. SLT may decrease diurnal IOP variation in NTG patients, even if target reduction is not reached [46, 57]. In patients who cannot tolerate surgical intervention, laser trabeculoplasty is a viable option to help further reduce the intraocular tensions.

10.7 Role of Other Surgical Interventions

Novel techniques for treating glaucoma patients have flourished over the past decade. Microinvasive glaucoma surgery (MIGS; including canaloplasty, viscocanalostomy, trabectome, and iStent) are less invasive techniques entering the glaucoma circuit. They are not currently the gold standard for treating patients with NTG. Glaucoma drainage devices have also become common practice in a surgeon’s repertoire. While meta-analysis of both valved and non-valved surgical devices has shown similar long-term IOP reduction in primary open-angle glaucoma patients, IOP control below 10 mmHg is not theoretically attainable with the devices [58].

Endocyclophotocoagulation can be considered in the treatment of NTG; however, a sustained decrease in IOP is unlikely [59].

10.8 Future Treatments

The Collaborative Normal Tension Glaucoma Study showed that with aggressive reduction of IOP in NTG patients, visual field progression can be halted. However, 12 % of patients included

in the study continued to progress despite reaching target IOP. These calamitous findings are the focus of future of vascular, genetic, and neuro-protective research endeavors for NTG patients. Vascular dysregulation has been implicated in NTG patients, with clinical conditions such as migraine headaches and Raynaud phenomenon being linked with progression in NTG. Clinical studies have shown a difference in the vascular diameter in the central retinal artery in NTG patients who progressed compared to NTG patients who did not progress [47, 48]. Topical medical therapy may be of benefit in increasing ocular circulation and carry with it a decreased risk of optic nerve head and visual field progression [60]. Other studies have focused on modification of proteins in the aqueous and plasma (endothelin-1 and tumor necrosis factor- α) and research linking the possible association between cerebrospinal fluid and NTG [61].

Great successes and innovative research to develop key proteins and genes that potentially permit earlier detection or reversal of glaucomatous progression are the future of normal tension glaucoma therapy. Until these modern therapeutic additions are available to clinical practice, systemic control of risk factors and surgical intervention is needed to preserve vision in patients. Each patient should be approached with detail in history and examination. Surgical decisions should be made in conjunction with the patient to achieve success in lifestyle and surgical expectations.

10.9 Conclusion

The management of NTG can be challenging even for the most experienced and astute clinicians. A 30 % IOP reduction from baseline decreases

the risk of glaucomatous progression in NTG patients. Often, this degree of IOP lowering can only be achieved with trabeculectomy surgery. Trabeculectomy surgery in these cases often requires adjunctive antifibrotic therapy in order to increase the chances of success. Adjunctive medical and laser therapies also play a role in management of NTG patients. Neuroprotective, vascular, and gene therapies are on the horizon. These treatments show promise in the future of clinical practice for earlier detection and possible reversal of optic nerve damage.

Acknowledgments Conflict of interest: None to disclose

Compliance and ethical requirements: No animal or human studies were carried out by the authors for this article.

Compliance with ethical requirements: Dr. Khodadadeh and Dr. Tsai declare that they have no conflict of interest. No animal or human studies were carried out by the authors for this article.

References

1. Lee BL, Bathija R, Weinreb RN. The definition of normal-tension glaucoma. *J Glaucoma*. 1998;7(6):366–71.
2. Leske MC. Open-angle glaucoma—an epidemiologic overview (review). *Ophthalmic Epidemiol*. 2007;14(4):166–72.
3. Cedrone C, Mancino R, Cerulli A, et al. Epidemiology of primary glaucoma: prevalence, incidence, and blinding effects (review). *Prog Brain Res*. 2008;173:3–14.
4. Shiose Y, Kitazawa Y, Tsukahara S, et al. Epidemiology of glaucoma in Japan—a nationwide glaucoma survey. *Jpn J Ophthalmol*. 1991;35(2):133–55.
5. Drance SM, Sweeney VP, Morgan RW, et al. Studies of factors involved in the production of low tension glaucoma. *Arch Ophthalmol*. 1973;89(6):457–65.
6. Drance SM, Morgan RW, Sweeney VP. Shock-induced optic neuropathy: a cause of nonprogressive glaucoma. *N Engl J Med*. 1973;288(8):393–5.
7. Shields MB. Normal-tension glaucoma: is it different from primary open-angle glaucoma? *Curr Opin Ophthalmol*. 1991;19(2):85–8.
8. Allingham RR, Damji KF, Freedman S, Moroi SE, Shafranov G, editors. Chronic open-angle glaucoma and normal-tension glaucoma. In: Shields' textbook of glaucoma. 5th ed. Philadelphia: Lippincott Williams & Wilkins, 2005. p. 176–88.
9. Allingham RR, Damji KF, Freedman S, Moroi SE, Shafranov G, editors. Surgery of the anterior chamber angle and iris. In: Shields' textbook of glaucoma, 5th ed. 2005: Lippincott Williams & Wilkins, Philadelphia. p. 452–9.
10. Allingham RR, Damji KF, Freedman S, Moroi SE, Shafranov G, editors. Management of glaucoma. In: Shields' textbook of glaucoma, 5th ed. Philadelphia: Lippincott Williams & Wilkins, 2005. p. 483–523.
11. Francis BA, Hong B, Winarko J, et al. Vision loss and recovery after trabeculectomy: risk and associated risk factors. *Arch Ophthalmol*. 2011;129(8):1011–7.
12. Kolker AE. Visual prognosis in advanced glaucoma: a comparison of medical and surgical therapy for retention of vision in 101 eyes with advanced glaucoma. *Trans Am Ophthalmol Soc*. 1977;75:539–55.
13. Heijl A, Peters D, Leske MC, Bengtsson B. Effects of argon laser trabeculoplasty in the Early Manifest Glaucoma Trial. *Am J Ophthalmol*. 2011;152(2):842–8.
14. Schuman JS. Effects of systemic beta-blocker therapy on the efficacy and safety of topical brimonidine and timolol. Brimonidine Study Groups 1 and 2. *Ophthalmology*. 2000;108(6):1171–7.
15. Pfeiffer N, Lamparter J, Gericke A, et al. Neuroprotection of medical IOP-lowering therapy. *Cell Tissue Res*. 2013;353(2):245–51.
16. Collaborative Normal-Tension Glaucoma Study (CNTGS) Group. Comparison of glaucomatous progression between untreated patients with normal-tension glaucoma and patients with therapeutically reduced intraocular pressures. *Am J Ophthalmol*. 1998;126(4):487–505.
17. Kim M, Kim DM, Park KH, Kim TW, Jeoung JW, Kim SH. Intraocular pressure reduction with topical medications and progression of normal-tension glaucoma: a 12-year mean follow-up study. *Acta Ophthalmol*. 2013;91(4):e270–5.
18. Klink T, Grehn F. Modern filtration surgery. An update. *Ophthalmologe*. 2013;110(4):299–305. doi:10.1007/s00347-012-2710-0 [Article in German].
19. Page MA, Fraunfelder FW. Safety, efficacy, and patient acceptability of lidocaine hydrochloride ophthalmic gel as a topical anesthetic for use in ophthalmic procedures. *Clin Ophthalmol*. 2009;3:601–9.
20. Geffen N, Carrillo MM, Jin Y, Trope GE, Buys YM. Effect of local anesthesia on trabeculectomy success. *J Glaucoma*. 2008;17(8):658–61.
21. Kansal S, Moster MR, Gomes MC, et al. Patient comfort with combined anterior sub-Tenon's, topical and intracameral anesthesia versus retrobulbar anesthesia in trabeculectomy, phacotrabeculectomy and aqueous shunt surgery. *Ophthalmic Surg Lasers*. 2002;33:456–62.
22. Gyasi M, Amoaku W, Debrah O, et al. Outcome of trabeculectomies without adjunctive antimetabolites. *Ghana Med J*. 2006;40(2):39–44.
23. Jongsareejit B, Tomidokoro A, Mimura T, et al. Efficacy and complications after trabeculectomy with mitomycin C in normal-tension glaucoma. *Jpn J Ophthalmol*. 2005;49(3):223–7.
24. De Fendi LI, Arruda GV, Scott IU, et al. Mitomycin C versus 5-fluorouracil as an adjunctive treatment for trabeculectomy: a meta-analysis of randomized

- clinical trials. *Clin Experiment Ophthalmol*. 2013; 41(8):798–806.
25. Hagiwara Y, Yamamoto T, Kitazawa Y. The effect of mitomycin C trabeculectomy on the progression of visual field defect in normal-tension glaucoma. *Graefes Arch Clin Exp Ophthalmol*. 2000;238(3): 232–6.
26. Bhandari A, Crabb DP, Poinosawmy D, et al. Effect of surgery on visual field progression in normal-tension glaucoma. *Ophthalmology*. 1997;104(7):1131–7.
27. Koseki N, Araie M, Shirato S, et al. Effect of trabeculectomy on visual field performance in central 30 degrees field in progressive normal-tension glaucoma. *Ophthalmology*. 1997;104(2):197–201.
28. Mastropasqua L, Carpineto P, Ciancaglini M, et al. Delayed post-operative use of 5-fluorouracil as an adjunct in medically uncontrolled open angle glaucoma. *Eye (Lond)*. 1998;12(pt4):701–6.
29. Yamamoto T, Sawada A, Mayama C, et al. The 5-year incidence of bleb-related infection and its risk factors after filtering surgeries with adjunctive mitomycin C: collaborative bleb-related infection incidence and treatment study 2. *Ophthalmology*. 2014;121(5):1001–6.
30. Weinreb RN. Adjusting the dose of 5-fluorouracil after filtration surgery to minimize side effects. *Ophthalmology*. 1987;94(5):564–70.
31. Ruderman JM, Welch DB, Smith MF, et al. A randomized study of 5-fluorouracil and filtration surgery. *Am J Ophthalmol*. 1987;104(3):218–24.
32. Zhong H, Sun G, Lin X, et al. Evaluation of pirfenidone as a new postoperative antiscarring agent in experimental glaucoma surgery. *Invest Ophthalmol Vis Sci*. 2011;52(6):3136–42.
33. Menda SA, Lowry EA, Porco TC et al. Ex-PRESS outcomes using mitomycin-C, Ologen alone, Ologen with 5-fluorouracil. *Int Ophthalmol* 2014 [Epub ahead of print]
34. Membrey WL, Bunce C, Poinosawmy DP, et al. Glaucoma surgery with or without adjunctive antiproliferatives in normal tension glaucoma: 2 visual field progression. *Br J Ophthalmol*. 2001;85(6):696–701.
35. Wallin O, Al-ahramy AM, Lundstrom M, et al. Endophthalmitis and severe blebitis following trabeculectomy. Epidemiology and risk factors; a single-centre retrospective study. *Acta Ophthalmol*. 2014; 92(5):426–31.
36. Kirwan JF, Lockwood AJ, Shah P, et al. Trabeculectomy in the 21st century: a multicenter analysis. *Ophthalmology*. 2013;120(12):2532–9.
37. Shingleton BJ, Pasternack JJ, Hung JW, et al. Three and five year changes in intraocular pressures after clear corneal phacoemulsification in open angle glaucoma patients, glaucoma suspects, and normal patients. *J Glaucoma*. 2006;15(6):494–8.
38. Mansberger SL, Gordon MO, Jampel H, et al. Reduction in intraocular pressure after cataract extraction: the Ocular Hypertension Treatment Study. *Ophthalmology*. 2012;119(9):1826–31.
39. Salbaugh MA, Bojikian KD, Moore DB, et al. Risk factors for acute postoperative intraocular pressure elevation after phacoemulsification in glaucoma patients. *J Cataract Refract Surg*. 2014;40(4):528–44.
40. Salaga-Pylak M, Kowal M, Zamojski T. Deterioration of filtering bleb morphology and function after phacoemulsification. *BCM Ophthalmol*. 2013;13:17. doi:10.1186/1471-2415-13-17.
41. Peponis VG, Chalkiadakis SE, Katzakis MC, et al. The effect of phacoemulsification on late bleb failure or intraocular pressure in patients with glaucoma: a systematic review. *Clin Ophthalmol*. 2012;6:1045–9.
42. Augustinus CJ, Zeyen T. The effect of phacoemulsification and combined phaco/glaucoma procedures on the intraocular pressure in open-angle glaucoma. A review of the literature. *Bull Soc Belge Ophthalmol*. 2012;320:51–66.
43. Patel HY, Danesh-Meyer HV. Incidence and management of cataract after glaucoma surgery. *Curr Opin Ophthalmol*. 2013;24(1):15–20.
44. Shi JM, Jia SB. Selective laser trabeculoplasty. *Int J Ophthalmol*. 2012;5(6):742–9.
45. Schwartz AL, Perman KI, Whitten M. Argon laser trabeculoplasty in progressive low-tension glaucoma. *Ann Ophthalmol* 1984; 16(6):560–2, 566
46. Nitta K, Sugiyama K, Mawatari Y, et al. Results of selective laser trabeculoplasty (SLT) as initial treatment for normal tension glaucoma. *Nihon Ganka Gakkai Zasshi*. 2013;117(4):335–43 [Article in Japanese].
47. Lee JW, Liu CC, Chan JC, Lai JS. Predictors of success in selective laser trabeculoplasty for Chinese open-angle glaucoma. *J Glaucoma*. 2014;23(5): 321–5.
48. Lee TE, Kim YY, Yoo C. Retinal vessel diameter in normal-tension glaucoma patients with asymmetric progression. *Graefes Arch Clin Exp Ophthalmol*. 2014 [Epub ahead of print].
49. Tojo N, Oka M, Miyakoshi A, et al. Comparison of fluctuations of intraocular pressure before and after selective laser trabeculoplasty in normal-tension glaucoma patients. *J Glaucoma*. 2013 [Epub ahead of print].
50. Hirn C, Zweifel SA, Toteberg-Harms M, et al. Effectiveness of selective laser trabeculoplasty in patients with insufficient control of intraocular pressure despite maximum tolerated medical therapy. *Ophthalmologie*. 2012;109(7):683–90 [Article in German].
51. Lee LC, Pasquale LR. Surgical management of glaucoma in pseudophakic patients. *Semin Ophthalmol*. 2002;17(3–4):131–7.
52. Mahdavian S, Kitnarong N, Kropf JK, et al. Efficacy of laser trabeculoplasty in phakic and pseudophakic patients with primary open-angle glaucoma. *Ophthalmic Surg Lasers Imaging*. 2006;37(5):394–8.
53. Werner M, Smith MF, Doye JW. Selective laser trabeculoplasty in phakic and pseudophakic eyes. *Ophthalmic Surg Lasers Imaging*. 2007;38(3):182–8.

54. Shazly TA, Latina MA, Dagianis JJ, et al. Effect of prior cataract surgery on the long-term outcome of selective laser trabeculoplasty. *Clin Ophthalmol*. 2011;5:377–80.
55. Seymenoglu G, Baser EF. Efficacy of selective laser trabeculoplasty in phakic and pseudophakic eyes. *J Glaucoma*. 2015;24(2):105–10 [Epub ahead of print].
56. Li EY, Than CC, Chi SC, et al. Cost-effectiveness of treating normal tension glaucoma. *Invest Ophthalmol Vis Sci*. 2013;54(5):3394–9.
57. El Mallah MK, Walsh MM, Stinnett SS, et al. Selective laser trabeculoplasty reduces mean IOP and IOP variation in normal tension glaucoma patients. *Clin Ophthalmol*. 2010;4:889–93.
58. Minckler DS, Vedula SS, Li TJ, et al. Aqueous shunts for glaucoma. *Cochrane Database Syst Rev*. 2006; 19(2), CD004918.
59. Yip LW, Yong SO, Earnest A, et al. Endoscopic cyclophotocoagulation for the treatment of glaucoma: an Asian experience. *Clin Experiment Ophthalmol*. 2009;37(7):692–7.
60. Koseki N, Araie M, Tomidokoro A, et al. A placebo-controlled 3-year study of a calcium blocker on visual field and ocular circulation in glaucoma with low-normal pressure. *Ophthalmology*. 2008;115(11): 2049–57.
61. Song BJ, Caprioli J. New directions in the treatment of normal tension glaucoma. *Indian J Ophthalmol*. 2014;62(5):529–37.
62. Friedman NJ, Kaiser PK, Pineda R. Optic nerve and glaucoma. In: *The Massachusetts Eye and Ear Infirmary Illustrated Manual of Ophthalmology*, 3rd ed. China: Saunders Elsevier, 2009. p. 516

Glaucoma Drainage Implant Surgery Combined with Pars Plana Vitrectomy and KPro Implantation

11

Thasarat S. Vajaranant and Ahmad A. Aref

11.1 Indications and Contraindications

Glaucoma affects a majority of eyes undergoing Boston Type I Keratoprosthesis (KPro; Massachusetts Eye and Ear Infirmary, Boston, Massachusetts, USA) surgery and is associated with relatively poor postoperative outcomes [1, 2]. Glaucoma after KPro surgery most likely develops secondary to progressive, synechial angle closure [3]. Furthermore, a significant proportion of candidates for KPro surgery have a preexisting history of glaucoma [1–5]. For these reasons, many surgeons consider addressing long-term glaucoma therapy with incisional intervention at the time of initial KPro implantation. There are several advantages to this approach: (1) topical medical therapies may be inadequate due to diminished penetrance through the central polymethylmethacrylate KPro optic in the postoperative period, (2) an inability to monitor patients with accurate postoperative intraocular

pressure (IOP) measurements warrants interventions most likely to allow for long-term control, (3) glaucoma occurring after KPro surgery is characteristically aggressive in nature, and (4) surgical intervention in the setting of a preexisting KPro presents unique challenges potentially increasing the rate of postoperative complications. With regard to type of incisional surgery, glaucoma drainage implant (GDI) surgery is often preferred as trabeculectomy surgery may be prone to episcleral scarring and subsequent failure in the setting of previous or concurrent ophthalmic surgery [6]. Therefore, GDI surgery is indicated in individuals with corneal disease undergoing KPro surgery for visual rehabilitation. The optimal time for this intervention is at the time of initial KPro implantation. Contraindications to this approach include inadequate conjunctival tissue precluding placement of a GDI implant and also poor ability for patient follow-up in the postoperative period.

11.2 Preoperative Considerations

Given the complexity of combined glaucoma and KPro surgery, a host of medical, social, and anatomical factors must be considered during preoperative assessment. The relatively long operative time requires general anesthesia for most cases, so patient candidates must be deemed medically stable and consultation with experienced

Electronic supplementary material The online version of this chapter (doi:[10.1007/978-3-319-18060-1_11](https://doi.org/10.1007/978-3-319-18060-1_11)) contains supplementary material, which is available to authorized users.

T.S. Vajaranant, M.D. (✉) • A.A. Aref, M.D.
Illinois Eye and Ear Infirmary, University of Illinois
at Chicago School of Medicine, Chicago, IL, USA
e-mail: tvajaranant@yahoo.com; thasarat@uic.edu;
ahmadaref@gmail.com; aaref@uic.edu

anesthesiologists and/or primary care practitioners is often sought. The postoperative period requires several outpatient visits with multiple subspecialists for adequate monitoring and adjustment of medications. Therefore, a patient's ability for reliable follow-up in the setting of individual social circumstances must be ascertained and included in the consent process. Likewise, the potential need for further surgical intervention to address possible complications should be extensively discussed preoperatively.

Glaucoma and KPro surgeries are often combined with pars plana vitrectomy (PPV) to allow for posterior placement of the GDI tube. However, anterior chamber placement may be performed in select cases that demonstrate relatively deep anterior chambers. Preoperative anterior segment-optical coherence tomography (AS-OCT) is often very helpful in this regard (Fig. 11.1). On slit-lamp examination, the surgeon should carefully assess the conjunctival tissue for overall integrity and mobility. A cotton-swab may be used to mobilize conjunctiva under topical anesthesia for this purpose. However, even with astute preoperative clinical examination, adequacy of conjunctiva may not be fully realized until intraoperative assessment.

The preoperative assessment of candidates for combined glaucoma and KPro surgeries also requires coordination among multiple ophthalmic subspecialists including cornea, glaucoma, vitreoretinal, and contact lens specialists. Relevant medical, social, examination, and imaging data should be reviewed preoperatively among the various subspecialists in order to derive a surgical strategy specific to each individual patient to allow for the highest chance of success while minimizing the rate of complications.

11.3 Surgical Technique

This chapter focuses on two commonly used glaucoma drainage devices: the Baerveldt tube shunt (Abbott Medical Optics Inc., Santa Ana, CA) and the Ahmed Glaucoma Valve (New World Medical, Inc., Rancho Cucamonga, CA). Surgical steps with clinical pearls are as follows [7, 8].

1. Traction suture

A 7-0 Vicryl suture on a cutting needle is placed partial thickness through the superior cornea such that the superior temporal quadrant is exposed.

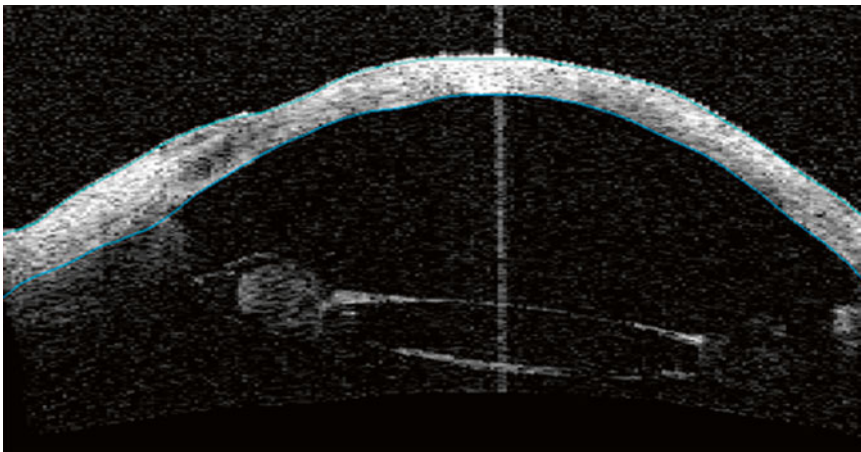


Fig. 11.1 Anterior segment-optical coherence tomography image corresponding to the right eye of a 58-year-old female undergoing preoperative assessment for combined glaucoma and KPro surgeries for a history aniridic

keratopathy. Anterior chamber depth is over 3.5 mm, indicating that sufficient space exists for anterior segment placement of glaucoma drainage implant tube

Clinical Pearl: The traction suture should be placed closer to the limbus to ensure that it will not interfere with subsequent trephination and suturing of the corneal button.

2. Conjunctival incision and subconjunctival/Tenon's dissection

After making a small opening of the conjunctiva at the limbus, lidocaine 2 %, with epinephrine is injected with a 30-gauge cannula to create a plane for subsequent conjunctival dissection. Conjunctival incision is made at the limbus with two relaxing incisions on either side. Dissection is carried through Tenon's capsule and down to bare sclera. The incision is extended for approximately 10–12 mm parallel to the limbus. Dissection at the level of bare sclera is carried posteriorly between the rectus muscles of the quadrant, first with Westcott scissors and then with curved Steven's scissors, to create an adequate pocket for the plate. Light hemostasis is performed to avoid bleeding when suturing the plate to the sclera.

Clinical Pearl: The authors prefer a peritomy at the limbus, especially in eye with extensive conjunctival scarring. In a primary surgery, some surgeons prefer a peritomy at 2–4 mm from the limbus.

3. Priming the tube

Ahmed Glaucoma Valve (New World Medical, Inc., Rancho Cucamonga, CA).

The Ahmed Glaucoma Valve is primed by cannulating the tube with a 30-gauge cannula on a Balanced Salt Solution (BSS)-filled syringe. BSS is slowly injected through the tube until a continuous stream of the fluid is demonstrated through valve.

Clinical Pearl: This step is crucial to ensure adequate functioning of the valve. If the initial opening pressure is extremely high, it will likely not be reached physiologically in the eye. Therefore, if this step is omitted, absolute flow restriction may occur postoperatively. Of note, forceful irrigation should be avoided.

Baerveldt Glaucoma Implant (Abbott Medical Optics Inc., Santa Ana, CA)

The tube is irrigated with a 30-gauge cannula on a BSS-filled syringe to ensure its patency. As the Baerveldt tube has no valve, it must be occluded to prevent early hypotony. A 7-0 Vicryl suture is then tied around the tube to occlude it at its base. The tube is then again cannulated with a 30-gauge cannula on a BSS-filled syringe. It is important to ensure that the tube is completely occluded to avoid immediate postoperative hypotony.

Clinical Pearl: A Vicryl absorbable suture will allow the tube to open around 5–6 weeks postoperatively. Some surgeons prefer placing a 5-0 Prolene suture in the tube lumen, as a stent or “ripcord.” A 7-0 Vicryl suture is then tied around the tube to occlude it at its base. As needed, the surgeon can then pull the ripcord in the office to allow earlier and/or more controlled opening of the tube.

4. Inserting and suturing the plate

Clinical Pearl: The authors prefer to place the plate before corneal and retinal procedures because it is easier to manipulate and move a closed and pressurized globe.

Ahmed Glaucoma Valve (New World Medical, Inc., Rancho Cucamonga, CA).

The Ahmed Valve plate is then inserted into the superotemporal (or other intended quadrant) sub-Tenon's pocket 8–10 mm posterior to the limbus. The valve portion of the plate should not be directly handled or it may be damaged. To fix the plate to the sclera, an 8-0 Nylon suture on a cutting needle is then placed through two fixing holes. Suture knots are rotated so they are buried.

Clinical Pearls: The plate should be at least 7 mm posterior to the limbus to decrease the risk of exposure or conjunctival erosion; however, it should not be much further back than 10 mm due to the risk of the end of the plate touching the optic nerve. In addition, caution should be used in eyes with short axial length. In general, axial length of more than 21 mm can accommodate the adult-size Ahmed. The posterior

end of the FP-7 plate can be trimmed if that is a concern. In the inferonasal quadrant, the plate should not be placed further than 8 mm from the limbus due to the proximity to the optic nerve in that quadrant. Lastly, the authors prefer not to use the Pars Plana Clip (New World Medical, Inc.), which has potential for exposure and requires a very relatively large bandage contact lens (ranging from 16 to 24 mm in diameter).

Baerveldt Glaucoma Implant (Abbott Medical Optics Inc., Santa Ana, CA)

In the selected quadrant, the two rectus muscles are carefully isolated to ensure that a clear space exists between the muscle belly and the underlying sclera. The wings of the Baerveldt plate are then placed under each muscle. To fix the plate to the sclera, an 8-0 Nylon suture on a cutting needle is then placed through two fixing holes. Suture knots are then rotated so they are buried.

Clinical Pearl: In most eyes, the suture eyelets should line up at 10 mm from the limbus if the plate is appropriately positioned behind the muscles.

5. Keratoprosthesis and Vitrectomy

Some retina surgeons prefer a view through a temporary KPro to ensure a complete shaving for the vitreous base in the desired quadrant. In this case, the steps will be temporary KPro, PPV, removal of the temporary KPro and then Boston KPro placement. Other retina surgeons may perform PPV through Boston KPro. In this case, the steps will be Boston KPro placement, and then PPV. This technique requires scleral depression for optimal visualization of the vitreous base.

Clinical Pearls: It is recommended to shave vitreous base 360° because many of these eyes may require a future second GDI. In many eyes that require KPro, a landmark for the limbus may be difficult to discern. In this case, transillumination and/or direct visualization will aid a safe introduction of a 23-gauge needle in the posterior part of the pars plana (approximately aiming for 4–5 mm from the limbus).

6. Inserting the tube into the anterior chamber

The tube is then trimmed to an appropriate length (approximately 4 mm from the entry to allow visualization of the tube behind the keratoprosthesis). The tube may be trimmed bevel down to decrease risk of contact/occlusion with the iris and/or KPro device. To avoid tube kinking, the tangential scleral entry for the tube (pointing slightly anteriorly) is created at 4–5 mm from the limbus using a 23-gauge needle. After the tube is inserted through the scleral entry, the tip of the tube should be visualized behind the KPro. The tube is secured to the sclera with a 10-0 Nylon mattress suture.

Clinical Pearl: Visualize the needle at all times. The authors prefer not to use the scleral entry from the vitrectomy port because most of them are too large for the tube causing excessive leakage around tube that may lead to early hypotony.

For a Baerveldt tube shunt, venting slits can be made proximal to the ligature to allow for early postoperative flow since the tube has been occluded. This is done by passing the needle of the 7-0 Vicryl suture through the side of the tube. Generally, three venting slits are placed. The authors prefer venting slits along the tube where the Nylon mattress suture is placed. Placing venting slits along a bent or curved tube may lead to less controlled flow and excessive leakage.

7. Scleral reinforcement

Common patch grafts used for scleral reinforcement include donor sclera, pericardium, and cornea. In a combined case, a corneo-scleral graft from the corneal rim can be used as a patch graft. The corneal rim is cut into an appropriate size about 3–4 mm. A partial thickness corneoscleral patch graft is prepared as follows. First, the corneal epithelium, Descemet membrane, and endothelium layers are removed. Second, a lamellar dissection of the corneal stroma is performed to create a partial-thickness corneal graft using a crescent blade. Third, the anterior edge of the graft is trimmed to create a gentle anterior slope.

The prepared corneoscleral patch graft is placed over the tube with the corneal side over the tube so that the tube entry can be visualized postoperatively. The graft can then be sutured to the sclera in the four quadrants with 7-0 Vicryl suture on a cutting needle.

Clinical Pearl: It is easier to suture while the vitrectomy infusion is on. The ports can be removed after the tube is secured to decrease a risk of significant intraoperative hypotony.

8. Conjunctival closure

The conjunctival incision is then closed using running 8-0 Vicryl on a non-cutting needle.

Clinical Pearls: To prevent early conjunctival dehiscence, the closure should include adequate Tenon's and excessive tension should be avoided. The wound should be checked to ensure that they are watertight.

11.4 Postoperative Care

Patients undergoing combined glaucoma, vitreo-retinal, and KPro surgery require close follow-up in the postoperative period. Several outpatient visits with multiple subspecialists are required for adequate monitoring and adjustment of medications. Patients are often fitted for a bandage contact lens to allow for adequate ocular surface hydration. Adequate fitting for each individual patient is critical to prevent rubbing of the lens edge against GDI tube-plate junction and/or the proximal aspect of the tube just posterior to the overlying patch graft. Friction in these areas may predispose to conjunctival erosion and subsequent tube exposure.

Given the aggressive nature of glaucoma occurring and/or potentially progressing after KPro surgery, frequent structural and functional testing of the optic nerve is required in the postoperative period. Once the initial postoperative course has stabilized, usually by 3 months, patients are followed on an outpatient basis at least every 3 months thereafter with serial structural and functional testing measures. A greater weight is often placed on structural measures such as optical coherence tomography of the

peripapillary retinal nerve fiber layer and stereoscopic disc photography as visual fields may be affected by coexisting corneal and retinal pathology. Postoperative slit-lamp examinations should be performed to carefully assess the status of conjunctival tissue overlying the GDI tube as conjunctival erosion may occur asymptotically in the postoperative period.

Unfortunately, after KPro surgery, current IOP measurement techniques are not possible through the central polymethylmethacrylate optic of the device. The current gold standard for postoperative IOP assessment in these cases involves finger palpation [9]. The clinician may perform this maneuver by alternately applying pressure adjacent to the 12 o'clock meridian of the globe with the index finger of each hand. The IOP can be estimated by the relative firmness of the globe or the amount of force needed to move fluid between the two fingers. Alternative techniques including scleral pneumatonometry may also be considered [10]. Novel methods for IOP measurement in these cases, including radio wave telemetry and implantable IOP sensors, are currently under investigation [11, 12].

Should structural/functional monitoring and/or IOP assessment in the postoperative period indicate persistently uncontrolled glaucoma, further surgical intervention may be warranted. A second GDI device may be considered (Fig. 11.2). External diode laser photocoagulation may also be an option in cases judged to be at high complication risk with a second GDI surgery [13].

11.5 Outcomes

Although the results of GDI surgery in the setting of a preexisting KPro have been described by several study groups, outcomes of combined GDI and KPro surgery are described mainly in two reports. Huh and colleagues described results with the aforementioned surgical technique in 20 eyes of 20 patients with average follow-up of 31.6 ± 17.4 months [14]. Patients who had preexisting GDI with subsequent tube repositioning to the pars plana were included in the analysis. On last follow-up in this series, 65 % and 95 % of

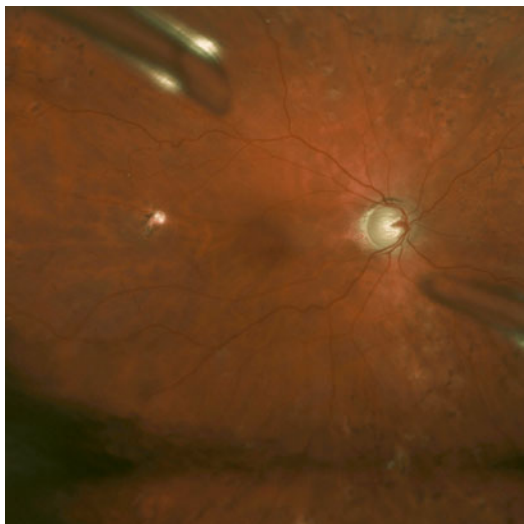


Fig. 11.2 Wide-field retinal photograph demonstrating superotemporal and inferonasal glaucoma drainage implant tubes in a patient with advanced glaucomatous optic neuropathy related to KPro implantation

patients had IOP measured less than 20 mmHg by scleral pneumatonometry and digital palpation, respectively. Four (20 %) of patients required additional procedures for adequate IOP control. Most patients (85 %) experienced an improvement in visual acuity from preoperative levels. Postoperative hypotony related to GDI surgery was not reported in the series. One patient experienced conjunctival erosion over a Pars Plana Clip (New World Medical Inc., Rancho Cucamonga, CA) and required revision surgery. Results of this study support a combined surgical approach for management of glaucoma at the time of initial KPro implantation with pars plana GDI tube insertion.

Law and colleagues separately described the results of 29 eyes of 29 patients that underwent combined GDI and KPro surgeries after a follow-up of 34.4 ± 17.7 months [15]. In contrast to the technique described by Huh et al., most of the GDI tubes in this series (91.3 %) were inserted into the anterior chamber or ciliary sulcus rather than the pars plana. By last follow-up, the majority of eyes (82.8 %) experienced the same or better final visual acuity compared with preoperative

levels. The investigators did not perform statistical analysis to compare pre- and postoperative IOPs. A single eye required additional surgical intervention for glaucoma in the series. The authors did not report any instances of conjunctival erosion and subsequent tube exposure. Similar to results reported by Huh et al., Law and colleagues present results supporting combined surgical techniques in the management of glaucoma associated with KPro implantation.

11.6 Complications

Indefinite contact lens wear is necessary to maintain adequate hydration of the donor tissue. This chapter focuses on two complications that related to KPro and contact lens wear: (1) GDI erosion secondary to contact lens wear and (2) hypotony that may potentially lead to poor contact lens fit, poor corneal hydration, and subsequent corneal melt.

11.6.1 Drainage Implant Erosion

Given the potential tube erosion secondary to contact lens wear, careful postoperative examinations of the GDI are recommended. A Seidel test should be performed to rule out any leakage of aqueous humor, and endophthalmitis needs to be excluded and treated accordingly. In cases of erosion without infection, the authors recommend a revision within 1 or 2 weeks, except urgently in children. In the meantime, antibiotic eye drops and/or ointment should be administered. Based on our experiences, if erosion involves the GDI plate, the success of revision surgery is relatively low. In these circumstances, it is best to explant the GDI and place a new GDI in a different quadrant, preferably inferonasally.

If the erosion involves only the tube portion of the GDI, revision can be performed successfully. The keys to the successful revision are as follows: First, determine if contact lens rubbing is a culprit and/or if a patch graft is too bulky. Then moving the tube to a more posterior position

and replacing an old patch graft with a new fresh corneal patch graft should be considered. Second, a complete removal of conjunctival epithelium around the exposed area is essential. This could be accomplished by scrapping, cauterization, and/or topical application of absolute alcohol in the exposed area. Third, tension along conjunctival suture lines should be avoided to prevent wound dehiscence. Several techniques such as a rotational conjunctival flap may be used. Lastly, to prevent recurrent erosion, contact lens fitting should be performed carefully.

11.6.2 Hypotony

Hypotony should be avoided in eyes with KPro because it could lead to poor contact lens fitting, poor corneal hydration, and sight-threatening corneal melt. Early postoperative hypotony may be avoided by using viscoelastics in Ahmed valve placement and a complete occlusion of the tube in Baerveldt Glaucoma Implant. In KPro eyes with chronic hypotony and poor fitting contact lens, a careful examination should be performed to ensure adequate hydration at the cornea donor-graft junction.

11.7 Conclusion

Glaucoma occurs with a relatively high frequency after KPro implantation. Disease course is often aggressive in nature and requires surgical intervention. Combined surgical techniques involving GDI surgery at the time of initial KPro implantation provide successful postoperative results. There is no consensus as to whether tube placement in the anterior versus posterior segments offers an enhanced rate of success. Patients require rigorous follow-up in the postoperative period with coordination of care among multiple ophthalmic subspecialists.

Compliance with Ethical Requirements Thasarat S. Vajaranant and Ahmed A. Aref declare that they have no conflict of interest. All procedures followed were in

accordance with the ethical standards of the responsible committee on human experimentation (institutional and national) and with the Helsinki Declaration of 1975, as revised in 2000. Informed consent was obtained from all patients for being included in the study. No animal studies were carried out by the authors for this article.

References

1. Netland PA, Scott ML, Boyle 4th JW, Lauderdale JD. Ocular and systemic findings in a survey of aniridia subjects. *J AAPOS*. 2011;15:562–6.
2. Talajic JC, Agoumi Y, Gagne S, Moussally K, Harissi-Dagher M. Prevalence, progression, and impact of glaucoma on vision after Boston type 1 KPro surgery. *Am J Ophthalmol*. 2012;153:267–74.
3. Panarelli JF, Ko A, Sidoti PA, Garcia JP, Banitt MR. Angle closure after Boston KPro. *J Glaucoma*. 2012;22:725–9.
4. Kamyar R, Weizer JS, de Paula FH, Stein JD, Moroi SE, John D, Musch DC, Mian SI. Glaucoma associated with Boston type 1 KPro. *Cornea*. 2012;31:134–9.
5. Chew HF, Ayers BD, Hammersmith KM, Rapuano CJ, Laibson PR, Myers JS, Jin YP, Cohen EJ. Boston KPro outcomes and complications. *Cornea*. 2009;28:989–96.
6. Gedde SJ, Schiffman JC, Feuer WJ, Herndon LW, Brandt JD, Budenz DL. Treatment outcomes in the Tube Versus Trabeculectomy (TVT) study after five years of follow-up. *Am J Ophthalmol*. 2012;153:789–803.
7. Vajaranant TS, Blair MP, McMahon T, Wilensky JT, de la Cruz J. Special considerations for pars plana tube-shunt placement in Boston type 1 keratoprosthesis. *Arch Ophthalmol*. 2010;128(11):1480–2.
8. El Mallah MK. Surgical management for glaucoma. Trabeculectomy and glaucoma drainage devices. In: Edward DP, Vajaranant TS, editors. *Glaucoma*. New York: Oxford University Press; 2013. p. 181–98.
9. Baum J, Chaturvedi N, Netland PA, Dreyer EB. Assessment of intraocular pressure by palpation. *Am J Ophthalmol*. 1995;119:650–1.
10. Kapamajian MA, de la Cruz J, Hallak JA, Vajaranant TS. Correlation between corneal and scleral pneumatonometry: an alternative method for intraocular pressure measurement. *Am J Ophthalmol*. 2013;156:902–6.
11. Todani A, Behlau I, Fava MA, Cade F, Cherfan DG, Zakka FR, Jakobiec FA, Gao Y, Dohlman CH, Melki SA. Intraocular pressure measurement by radio wave telemetry. *Invest Ophthalmol Vis Sci*. 2011;52:9573–80.
12. Rizq RN, Choi WH, Eilers D, Wright MM, Ziaie B. Intraocular pressure measurement at the choroid surface: a feasibility study with implications for

- implantable microsystems. *Br J Ophthalmol*. 2001; 85:868–71.
13. Rivier D, Paula JS, Kim E, Dohlman CH, Grosskreutz CL. Glaucoma and KPro: role of adjunctive cyclophotocoagulation. *J Glaucoma*. 2009;18:321–4.
14. Huh ES, Aref AA, Vajaranant TS, de la Cruz J, Chau FY, Cortina MS. Outcomes of pars plana glaucoma drainage implant in Boston type 1 KPro surgery. *J Glaucoma*. 2014;23:e39–44.
15. Law SK, Huang JS, Nassiri N, Moghimi S, Nilforushan N, Parham A, Moossai J, Kim M, Caprioli J, Aldave AJ. Technique of combined glaucoma tube shunt and KPro implantation. *J Glaucoma*. 2014;23(8): 501–7 [In Press].

Luis E. Vazquez and Steven J. Gedde

12.1 Introduction

Glaucoma is not infrequently associated with retinal detachment and retinal detachment surgery. The onset of glaucoma can sometimes precede that of retinal detachment. The prevalence of pre-existing open-angle glaucoma is about 4–12 times greater in eyes with a retinal detachment. Myopia, pigment dispersion, and the use of miotic eye drops are proposed risk factors for rhegmatogenous retinal detachment [1–5]. Neovascular glaucoma (NVG) and tractional retinal detachments are often found concurrently in advanced stages of diabetic retinopathy. Conversely, retinal detachment may precede glaucoma as seen in Schwartz-Matsuo syndrome, or NVG secondary to anterior segment neovascularization in chronic retinal detachments [6–8]. Nevertheless, glaucoma occurs subsequent to retinal detachment surgery in the majority of cases.

Retinal detachment surgery causes secondary glaucoma by a number of different mechanisms.

Electronic supplementary material The online version of this chapter (doi:[10.1007/978-3-319-18060-1_12](https://doi.org/10.1007/978-3-319-18060-1_12)) contains supplementary material, which is available to authorized users.

L.E. Vazquez, M.D. (✉) • S.J. Gedde, M.D.
Bascom Palmer Eye Institute, University of Miami,
Miami, FL, USA
e-mail: l.vazquez1@med.miami.edu;
sgedde@med.miami.edu

Vitrectomy itself is hypothesized to cause late-onset open-angle glaucoma from increased oxidative damage to the trabecular meshwork, especially in aphakic and pseudophakic eyes [9–11]. In addition, expansile gases and silicone oil overfill may anteriorly displace the lens-iris diaphragm resulting in secondary angle closure glaucoma with or without pupillary block [12]. Silicone oil may result in inflammation, synechial angle closure, rubeosis iridis, migration of oil to anterior chamber with obstruction of the angle, and idiopathic open-angle glaucoma [12]. Also, scleral buckling can result in decreased venous drainage from the vortex veins resulting in venous congestion and swelling of the ciliary body. This can lead to anterior rotation of the ciliary body shifting the lens-diaphragm forward and causing secondary angle closure glaucoma similar to that reported with sulfa medications, uveal effusion, choroidal hemorrhage, central retinal vein occlusion, and pan-retinal photocoagulation [13–19]. In sickle cell patients, retina surgery and encircling elements have also been reported to produce anterior segment ischemia and NVG [20]. Appropriate diagnosis and treatment of glaucoma after retinal detachment surgery is critical to prevent the deterioration of vision in postoperative patients.

Treatment of secondary glaucoma after retinal detachment surgery may be clinically challenging. The underlying problem must be recognized and addressed, and management may include

cycloplegic drops, anti-inflammatory drops, intravitreal anti-vascular endothelial growth factor (VEGF) injection, laser peripheral iridotomy, and/or silicone oil removal, among others, depending on the cause [12]. Treatment aimed at normalizing IOP is also critical. Conventional strategies include medical treatment with IOP-lowering drops or oral medications, cyclophoto-coagulation, incisional glaucoma surgery, or a combination of the above. Medical therapy is usually initiated first, but surgical intervention is often required for optimal long-term IOP control. The Tube Versus Trabeculectomy (TVT) Study demonstrated that glaucoma drainage device surgery is a more effective option than trabeculectomy in postsurgical eyes [21–23]. In addition, trabeculectomy has a particularly high failure rate in eyes with scleral buckles because significant conjunctival scarring does not allow bleb survival. Therefore, glaucoma drainage devices are generally the preferred option in the management of refractory glaucoma in eyes after retinal detachment surgery.

Eyes with preexisting scleral buckles pose additional challenges to glaucoma drainage device placement. The scleral buckles can sometimes be bulky, particularly in the area where the ends meet and are joined by the band. In addition, eyes with an encircling buckle have extensive scarring making conjunctival dissection difficult. This may result in postoperative conjunctival dehiscence, exposure of the tube or endplate of the drainage device, and wound leak. Scarring also limits the space available to fit a glaucoma drainage device endplate over a preexisting scleral buckle.

Sidoti and colleagues described a procedure in which aqueous is shunted to the capsule of a preexisting scleral buckle [24]. This procedure only requires the use of a piece of silicone tube similar to that of glaucoma drainage devices or a Crawford nasolacrimal stent, without the need for a plate. The tube is inserted into the fibrous capsule that forms around a preexisting scleral buckle at one end, and the other end is inserted into the anterior chamber as in routine glaucoma tube surgery. This is in sharp contrast to the original anterior chamber tube shunt to encircling

band (ACTSEB) surgery described by Schocket and colleagues in which an encircling band was used not for repair of a retinal detachment, but rather as the reservoir for aqueous humor [25]. The procedure described by Sidoti, commonly referred to as the modified Schocket procedure, is a useful tool to have in the armamentarium for treatment of refractory glaucoma in eyes with preexisting scleral buckles.

12.2 Surgical Technique

Schocket and colleagues were the first to describe an ACTSEB in which the tube drained aqueous to the cavity of a no. 20 scleral buckle [25, 26]. There have been several alterations to this procedure since its original publication [27–29, 24]. The procedure description below is based on the procedure described by Sidoti et al. in which aqueous is shunted to the fibrous capsule of a preexisting scleral buckle in eyes with a history of retinal detachment [24].

1. Anesthesia: A retrobulbar block consisting of a 50:50 mixture of lidocaine 2 % and bupivacaine 0.5 % is administered under monitored anesthesia care.
2. Exposure: The eyelids and ocular adnexae are sterilized in 5 % betadine solution and draped in the usual sterile manner for ophthalmic surgery. A lid speculum is placed and adjusted to keep pressure off the globe. A traction suture with 7-0 polyglactin is placed near the limbus to rotate the eye and improve exposure of the quadrant of planned surgery (usually superotemporal or inferonasal).
3. Conjunctival flap: A localized conjunctival peritomy is created in the surgical quadrant using blunt Westcott scissors, and the sub-Tenon's space is accessed and dissected posteriorly to expose the recti muscles and the fibrous capsule encasing the preexisting scleral buckle.
4. Cautery of the episcleral vessels is applied as needed to achieve hemostasis.
5. Capsule access: Sharp Vannas scissors are used to incise the top of the fibrous capsule

surrounding the scleral buckle. A blunt cyclodialysis spatula is inserted through this entry site over the scleral buckle to open the space between the implant and the capsule.

6. Tube placement into the capsule: A 30 mm piece of silicone tubing with 0.625 mm and 0.3 mm external and internal diameter respectively (Storz, St. Louis, MO, or FCI Ophthalmics, Pembroke, MA (Crawford nasolacrimal stent)) is obtained and one end is inserted through this incision. A 23-gauge needle is used to create an exit from the fibrous capsule at the anterior edge, and the proximal end of the tube is passed along this needle track aiming towards the limbus (Fig. 12.1). The incision on the top of the

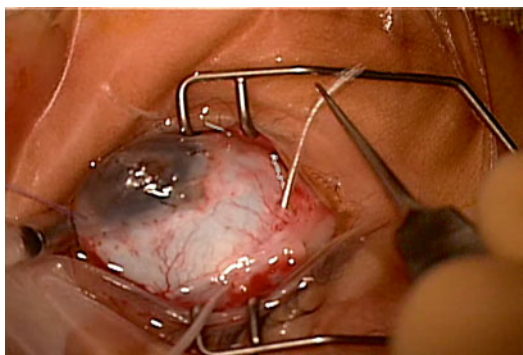


Fig. 12.1 The silicone tube is inserted into the fibrous capsule encasing the scleral buckle through a small incision on top of the scleral buckle. The tube exits the capsule through a 23-gauge needle anteriorly before scleral fistulization, anterior chamber insertion, and placement of a scleral patch graft

fibrous capsule may be closed with 8-0 polyglactin on a tapered needle in a watertight fashion.

7. Balanced salt solution on a blunt 27-gauge cannula is injected into the proximal end of the tube to test resistance and elevation of the fibrous capsule.
8. Tube ligation: The tube can be ligated with 7-0 polyglactin for early flow restriction and prevention of immediate postoperative hypotony (Fig. 12.2).
9. Sclerostomy: A sharp 23-gauge needle is used to enter the anterior chamber 1–2 mm posterior to the limbus and parallel to the iris plane. The tube is trimmed to the appropriate length with an anterior bevel, and is inserted into the anterior chamber through the needle tract. After ensuring that the tube is adequately positioned in the anterior chamber away from the corneal endothelium, it may be fixated to the sclera using a 9-0 nylon suture. Verify that the anterior chamber is holding stable depth.
10. Patch graft: To prevent erosion through the conjunctiva, cover the tube with a donor tissue patch graft (cornea, sclera, or pericardium), secured to the sclera using 7-0 polyglactin sutures.
11. Conjunctival closure: The conjunctiva is sutured using 8-0 polyglactin on a tapered needle in a watertight fashion.
12. Subconjunctival injections of an antibiotic and corticosteroid are administered and the traction suture, lid speculum, and drapes are removed.

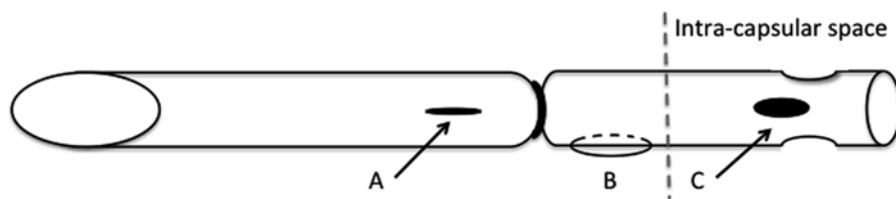


Fig. 12.2 Tube modifications include (A) fenestrations anterior to the ligature, (B) placing a securing suture to the sclera, and (C) side ports at the intracapsular end of the

tube. A 7-0 polyglactin cutting needle, a 9-0 nylon suture, and curved Westcott scissors can be used to perform these modifications, respectively. Modified from Lee et al. [27]

12.3 Procedure Modifications and Alternatives

1. Needle fenestrations may be placed across the tube anterior to the ligature using a 7-0 cutting needle to allow for early flow prior to dissolution of the ligature (Fig. 12.2) [27].
2. To decrease the risk of tube obstruction at the intracapsular end, side ports can be created on the tube using curved scissors (Fig. 12.2) [27].
3. To prevent the risk of tube migration, the tube can be secured to the sclera using a 9-0 nylon suture (Fig. 12.2) [27].
4. A Baerveldt glaucoma implant (or other glaucoma drainage devices) may be used [30, 31]. The device should be placed in the quadrant with least amount of hardware (away from the area where the ends of the scleral buckle are tied); adequate posterior dissection is needed to create enough space for the endplate. The endplate is positioned over the recti muscles and the encapsulated scleral buckle. The endplate can be secured to the sclera or buckle. Either 250 or 350 mm endplates may be used and trimmed to fit in tighter spaces if significant subconjunctival scarring is present.

12.4 Outcomes

The initial ACTSEB procedure described by Schocket and colleagues consisted of shunting aqueous to an encircling band in eyes with NVG [25, 26]. Final IOP in 18 of 19 eyes (95 %) was less than 20 mmHg (average IOP 16.2 mmHg, mean follow up 59 weeks). Of these 18 eyes, only 3 required IOP-lowering medications. The original Schocket fared well when compared to the initial data on the Krupin and Molteno glaucoma drainage devices [25]. The original Schocket was also compared to the double-plate Molteno in a randomized, prospective study in eyes with refractory glaucoma [32]. In this study, the final IOP was similar between groups (14.4 mmHg with Molteno and 15.1 mmHg with Schocket, mean follow up 26 months), although the

Schocket group required fewer medications (mean 0.95 vs. 0.43 number of medications for the Molteno and Schocket groups, respectively). Nevertheless, more frequent complications were encountered in the Schocket group. Also, newer glaucoma drainage devices, such as the Baerveldt and Ahmed implants, are similarly effective and do not require placement of a 360° encircling band, making them a more popular choice than the original Schocket procedure for treatment of refractory glaucoma.

The modified Schocket procedure originally described by Sidoti and colleagues—and discussed here—consists of shunting aqueous to the fibrous capsule of a previously existing scleral buckle in eyes with a history of retinal detachment [24]. Successful control of IOP (defined as IOP between 6 and 21 mmHg with or without IOP-lowering medications) after 1 year was achieved in about 85 % of the eyes in 2 independent small case series [27, 24]. Ten out of twenty-one eyes required at least one IOP-lowering medication, and vision improved in nineteen of twenty-one eyes in the two series combined. Thus, shunting aqueous to an encircling band placed at the time of surgery (original Schocket) or into the capsule surrounding a preexisting scleral buckle (modified Schocket) is similarly effective in lowering IOP.

Using glaucoma drainage devices in eyes with preexisting scleral buckle is also a good surgical option. Small retrospective case series have looked at outcomes of Baerveldt drainage implants in eyes with preexisting scleral buckle and found similar results compared to the modified Schocket procedure [30, 31]. Twenty-eight of thirty-three eyes (85 %) achieved successful control of IOP (defined as IOP between 6 and 21 mmHg with or without IOP-lowering medications) at last follow up in both studies combined. In one of the series, 7 of 16 eyes required at least one IOP-lowering medication. Of the 9 eyes that did not need postoperative IOP-lowering medications, 2 had a Baerveldt 250 mm and 7 had a Baerveldt 350 mm device [30]. In general, vision remained stable in both these studies at last follow up.

There is no prospective, randomized clinical trial to date to compare the safety and efficacy

between the modified Schocket procedure and glaucoma drainage implants in eyes with preexisting scleral buckles. Nevertheless, the outcomes reported for both procedures are comparable, and both are effective options in the treatment of refractory glaucoma in eyes with preexisting scleral buckles.

12.5 Complications

In the original series by Sidoti and colleagues, all complications related to the modified Schocket procedure were observed within 4 months postoperatively [24]. Complications included serous choroidal detachment, conjunctival dehiscence and wound leak, hyphema, and tube obstruction by lens, vitreous, or episcleral fibrous tissue. Interestingly, a more recent series by Lee et al. reports significantly fewer complications [27]. Lee et al. report tube exposure in one patient, and self-limited choroidal effusions in three eyes during the immediate postoperative period. They attribute the decreased rate of complications to securing the tube to the sclera, and creating side ports on the intracapsular end of the tube (Fig. 12.2). Indeed, intracapsular obstruction was the most common complication, and obstruction inside the eye could be attributed to tube migration. Thus, albeit limited evidence, these simple modifications appear to be beneficial in decreasing complications.

Placement of Baerveldt drainage implants in eyes with preexisting scleral buckle is associated with similar postoperative complications, including limited choroidal effusion, limited choroidal hemorrhage, hyphema, and conjunctival dehiscence and wound leak [30, 31]. Of note, there were more serious complications observed in these series, including retinal detachment recurrence, limited vitreous hemorrhage, and significant choroidal hemorrhage with subsequent phthisis.

Because these are small retrospective studies, it is difficult to estimate the exact frequency of complications associated with both these procedures. Similarly, one should consider the serious complications observed with the Baerveldt

implant surgery as possible complications for the modified Schocket procedure in eyes with a preexisting scleral buckle.

12.6 Conclusion

The modified Schocket procedure is an effective and relatively safe surgery for treatment of refractory glaucoma in eyes with preexisting scleral buckles. Placement of a glaucoma drainage device is an adequate alternative with comparable outcome and complication rates. There are no randomized, prospective clinical trials comparing the safety and efficacy between the modified Schocket procedure and glaucoma drainage implants in eyes with preexisting scleral buckles to date. The use of the modified Schocket procedure may be a better option in cases where significant conjunctival and subconjunctival scarring is present and placement of the plate of current glaucoma drainage devices may be difficult.

Compliance with Ethical Requirements Luis E. Vazquez and Steven J. Gedde declare that they have no conflict of interest. No human or animal studies were carried out by the authors for this article.

References

1. Beasley H, Fraunfelder FT. Retinal detachments and topical ocular miotics. *Ophthalmology*. 1979;86(1): 95–8.
2. Becker B, Podos SM. Krukenberg's spindles and primary open-angle glaucoma. *Arch Ophthalmol*. 1966; 76(5):635–9.
3. Pape LG, Forbes M. Retinal detachment and miotic therapy. *Am J Ophthalmol*. 1978;85(4):558–66.
4. Podos SM, Becker B, Morton WR. High myopia and primary open-angle glaucoma. *Am J Ophthalmol*. 1966;62(6):1038–43.
5. Scheie HG, Cameron JD. Pigment dispersion syndrome: a clinical study. *Br J Ophthalmol*. 1981; 65(4):264–9.
6. Barile GR, Chang S, Horowitz JD, Reppucci VS, Schiff WM, Wong DT. Neovascular complications associated with rubeosis iridis and peripheral retinal detachment after retinal detachment surgery. *Am J Ophthalmol*. 1998;126(3):379–89.
7. Matsuo N, Takabatake M, Ueno H, Nakayama T, Matsuo T. Photoreceptor outer segments in the

- aqueous humor in rhegmatogenous retinal detachment. *Am J Ophthalmol.* 1986;101(6):673–9.
8. van Meurs JC, Bolt BJ, Mertens DA, Peperkamp E, De Waard P. Rubeosis of the iris in proliferative vitreoretinopathy. *Retina.* 1996;16(4):292–5.
9. Chang S. LXII Edward Jackson lecture: open angle glaucoma after vitrectomy. *Am J Ophthalmol.* 2006;141(6):1033–43. doi:[10.1016/j.ajo.2006.02.014](https://doi.org/10.1016/j.ajo.2006.02.014).
10. Govetto A, Dominguez R, Landaluce ML, Alves MT, Lorente R. Prevalence of open angle glaucoma in vitrectomized eyes: a cross-sectional study. *Retina.* 2014;34(8):1623–9. doi:[10.1097/IAE.000000000000107](https://doi.org/10.1097/IAE.000000000000107).
11. Koreen L, Yoshida N, Escario P, Niziol LM, Koreen IV, Musch DC, Chang S. Incidence of, risk factors for, and combined mechanism of late-onset open-angle glaucoma after vitrectomy. *Retina.* 2012;32(1):160–7. doi:[10.1097/IAE.0b013e318217fffb](https://doi.org/10.1097/IAE.0b013e318217fffb).
12. Gedde SJ. Management of glaucoma after retinal detachment surgery. *Curr Opin Ophthalmol.* 2002;13(2):103–9.
13. Bloome MA. Transient angle-closure glaucoma in central retinal vein occlusion. *Ann Ophthalmol.* 1977;9(1):44–8.
14. Grant WM. Shallowing of the anterior chamber following occlusion of the central retinal vein. *Am J Ophthalmol.* 1973;75(3):384–7.
15. Hook SR, Holladay JT, Prager TC, Goosey JD. Transient myopia induced by sulfonamides. *Am J Ophthalmol.* 1986;101(4):495–6.
16. Hwang JC, Khine KT, Lee JC, Boyer DS, Francis BA. Methyl-sulfonyl-methane (MSM)-induced acute angle closure. *J Glaucoma.* 2013. doi:[10.1097/IJG.0000000000000027](https://doi.org/10.1097/IJG.0000000000000027).
17. Liang JC, Huamonte FU. Reduction of immediate complications after panretinal photocoagulation. *Retina.* 1984;4(3):166–70.
18. McDonald PR, Delapaz Jr V, Sarin LK. Nonrhegmatogenous retinal separation with choroidal detachment (uveal effusion). *Am J Ophthalmol.* 1965;59:820–7.
19. Mensher JH. Anterior chamber depth alteration after retinal photocoagulation. *Arch Ophthalmol.* 1977;95(1):113–6.
20. Ryan SJ, Goldberg MF. Anterior segment ischemia following scleral buckling in sickle cell hemoglobinopathy. *Am J Ophthalmol.* 1971;72(1):35–50.
21. Gedde SJ, Schiffman JC, Feuer WJ, Herndon LW, Brandt JD, Budenz DL. Treatment outcomes in the tube versus trabeculectomy study after one year of follow-up. *Am J Ophthalmol.* 2007;143(1):9–22. doi:[10.1016/j.ajo.2006.07.020](https://doi.org/10.1016/j.ajo.2006.07.020).
22. Gedde SJ, Schiffman JC, Feuer WJ, Herndon LW, Brandt JD, Budenz DL, Tube Versus Trabeculectomy Study Group. Three-year follow-up of the tube versus trabeculectomy study. *Am J Ophthalmol.* 2009;148(5):670–84. doi:[10.1016/j.ajo.2009.06.018](https://doi.org/10.1016/j.ajo.2009.06.018).
23. Gedde SJ, Schiffman JC, Feuer WJ, Herndon LW, Brandt JD, Budenz DL, Tube Versus Trabeculectomy Study Group. Treatment outcomes in the Tube Versus Trabeculectomy (TVT) study after five years of follow-up. *Am J Ophthalmol.* 2012;153(5):789–803. doi:[10.1016/j.ajo.2011.10.026](https://doi.org/10.1016/j.ajo.2011.10.026). e782.
24. Sidoti PA, Minckler DS, Baerveldt G, Lee PP, Heuer DK. Aqueous tube shunt to a preexisting episcleral encircling element in the treatment of complicated glaucomas. *Ophthalmology.* 1994;101(6):1036–43.
25. Schocket SS, Lakhanpal V, Richards RD. Anterior chamber tube shunt to an encircling band in the treatment of neovascular glaucoma. *Ophthalmology.* 1982;89(10):1188–94.
26. Schocket SS, Nirankari VS, Lakhanpal V, Richards RD, Lerner BC. Anterior chamber tube shunt to an encircling band in the treatment of neovascular glaucoma and other refractory glaucomas. A long-term study. *Ophthalmology.* 1985;92(4):553–62.
27. Lee KS, Sung KR, Na JH, Lee Y, Lee JY, Kim JG, Yoon YH. Clinical results of modified anterior chamber tube shunt to an encircling band surgery for uncontrolled intraocular pressure. *J Glaucoma.* 2013;22(2):140–4. doi:[10.1097/IJG.0b013e318225b428](https://doi.org/10.1097/IJG.0b013e318225b428).
28. Omi CA, De Almeida GV, Cohen R, Mandia Jr C, Kwitko S. Modified Schocket implant for refractory glaucoma. Experience of 55 cases. *Ophthalmology.* 1991;98(2):211–4.
29. Sherwood MB, Joseph NH, Hitchings RA. Surgery for refractory glaucoma. Results and complications with a modified Schocket technique. *Arch Ophthalmol.* 1987;105(4):562–9.
30. Scott IU, Gedde SJ, Budenz DL, Greenfield DS, Flynn Jr HW, Feuer WJ, Mello Jr MO, Krishna R, Godfrey DG. Baerveldt drainage implants in eyes with a preexisting scleral buckle. *Arch Ophthalmol.* 2000;118(11):1509–13.
31. Zhang L, Blachley TS, Weizer JS, Baerveldt 250 mm2 glaucoma drainage devices in eyes with preexisting scleral buckles. *J Glaucoma.* 2014. doi:[10.1097/IJG.0000000000000095](https://doi.org/10.1097/IJG.0000000000000095).
32. Smith MF, Sherwood MB, McGorray SP. Comparison of the double-plate Molteno drainage implant with the Schocket procedure. *Arch Ophthalmol.* 1992;110(9):1246–50.

Paul F. Palmberg

13.1 Introduction

The postoperative management in trabeculectomy plays a very important role in achieving success. One needs to maintain sufficient flow through the scleral flap to maintain the filtering bleb, working against the effects of fibrosis at the episcleral rim of the scleral incision and in the conjunctival-Tenons flap. Even with the use of anti-fibrosis agents at surgery, which have greatly reduced failure [1–4], about 20 % of patients require needling of the scleral flap [5]. Using the technique of Khaw [6] for applying Mitomycin-C in a wide area with thin sponges produces more diffuse blebs which are less prone to encapsulation, leakage or infection, but encapsulation can still occur.

Among the maneuvers that have been employed to deal with excessive fibrosis, especially in the early postoperative period, are laser

suture lysis of the scleral wound tensioning sutures [7], massage or mechanical distortion of the scleral wound edge to tear bridging fibrosis [8], trans-conjunctival needle revision (with or without adjacent subconjunctival injection of the anti-fibrosis agents Mitomycin-C or 5-Fluorouracil) [9, 10], YAG-laser treatment of the internal ostium [11] and/or external scleral wound [12, 13], and ab-interno revision with a cyclodialysis spatula [14, 15]. We describe here a new approach we have been using for several years, trans-corneal needling of the scleral wound and bleb, performed at the slit lamp.

13.2 Indications

The best indication for this procedure is a case in which clinical evaluation suggests that the site of excessive resistance is at the episcleral rim of the scleral incision, as indicated by an elevated intraocular pressure in the presence of a bleb that looks functional—that contains hydrated Tenons, is somewhat ischemic and has diffuse borders, and in which there is no blockage of the internal scleral ostium as determined by gonioscopy, and laser suture lysis has already been performed. However, the procedure can also be employed with reasonable success in any failing bleb in which the conjunctival flap has not become completely immobilized by fibrosis.

Electronic supplementary material The online version of this chapter (doi:[10.1007/978-3-319-18060-1_13](https://doi.org/10.1007/978-3-319-18060-1_13)) contains supplementary material, which is available to authorized users.

P.F. Palmberg, M.D., Ph.D. (✉)
Bascom Palmer Eye Institute, University of Miami,
Miami, FL, USA
e-mail: mitodoc@aol.com;
ppalmberg@med.miami.edu

13.3 Surgical Technique

The preparation for the procedure includes obtaining informed consent by discussion of the need for action, what is involved in the procedure, assurance that the procedure is almost always painless due to use of anesthetic drops and gel, and that we would stop if it became painful. One may also discuss options appropriate to the case, such as going to the operating room or resuming medical therapy, the risks and benefits of the procedure, and what the follow up will be. The eye is then prepped with drops (Fig. 13.1) of proparacaine for initial anesthesia (takes 20 s to work), apraclonidine for vasoconstriction (takes 60 s, and reduces not only bleeding, but also anterior chamber reaction and foreign body sensation postoperatively), a drop of 5 % povidone iodide applied to the cornea and conjunctiva for 2 min for anti-sepsis, a rinse with proparacaine, and application of 2 % xylocaine gel to the bleb area for 2 min, and a final rinse with saline or proparacaine (as xylocaine gel otherwise produces corneal epithelial toxicity).

The half-inch 30 g needle, mounted on a TB syringe, is bent into a “Z” shape (Fig. 13.2) [16]. This is done by holding the syringe upright with the needle bevel facing you, grasping the needle

3 mm from the hub with a blade-breaker or needle driver, bending the needle backwards at the needle hub and then twisting it forwards where it is being held by the blade-breaker. This makes an instrument that is held comfortably with the thumb and second and third fingers, and in which the tip of the needle can approach the eye parallel to the corneal surface.

After the patient has been seated comfortably at the slit lamp (sitting upright with good support of the chin and forehead) a solid bladed lid speculum is placed to isolate the lashes. The surgeon likewise must be seated comfortably in an

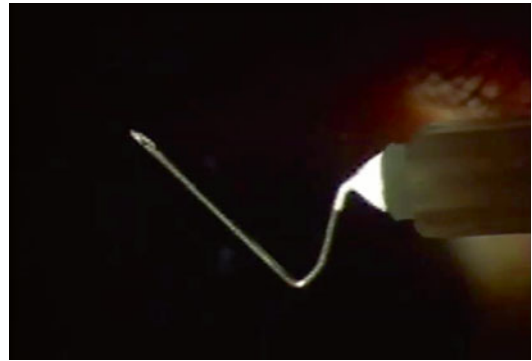


Fig. 13.2 Bent 30-gauge needle mounted on a tuberculin syringe

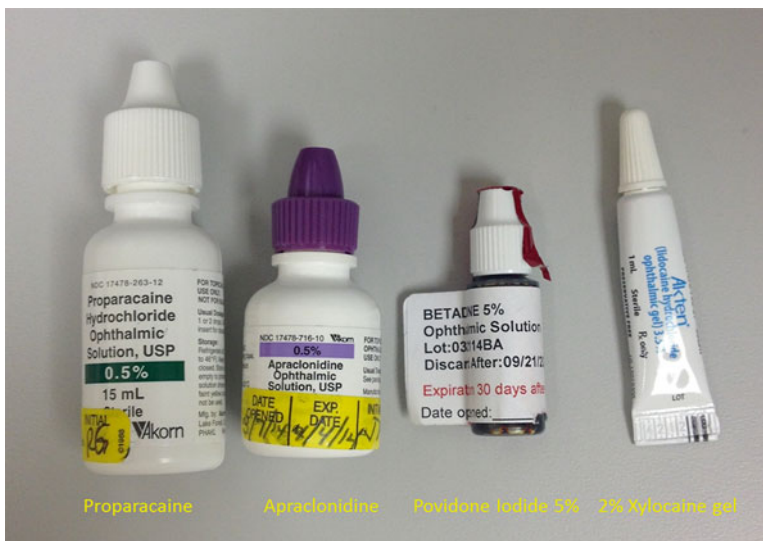

Fig. 13.1 The drops and gel to be applied before needling, proparacaine, apraclonidine, povidone iodide, and 3.5 % xylocaine gel

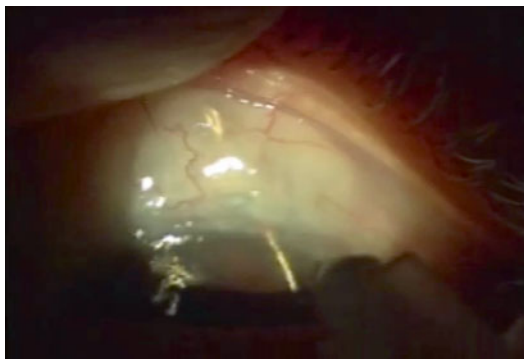


Fig. 13.3 Checking that the final portion of the needle will reach the bleb margins

upright position, have the elbows resting on either the slit lamp table or elbow supports, and the hand holding the TB syringe with needle stabilized by contact of the fourth and fifth fingers with the patient's cheek.

The needle is held over its intended path to be sure that there is sufficient length beyond the distal bend to pass through the internal ostium, out through the episcleral margin of the scleral wound and to the outer margins of the bleb (in case needling of the bleb itself is required) (Fig. 13.3).

The cornea is entered parallel to the surface and passed vertically and somewhat obliquely (so that the needle entry is not in the visual axis) aimed towards the internal ostium, with the bevel up, and until just the bevel is within the cornea. Then the syringe is tilted up so that the needle tip passes on a somewhat more perpendicular path to enter the anterior chamber. This is done so that the path in the cornea is not so long as to impede side to side and up and down manipulations of the needle tip. The needle is then advanced slowly by gentle wiggling of the syringe, so that it does not plunge too rapidly forwards. The needle tip must then pass through the internal wound of the trabeculectomy. This region is determined preoperatively with gonioscopy and noting any landmarks, such as an iridectomy or iris details. The needle should slide without significant resistance through to the scleral surface. This may require some gentle probing with retreat if resistance is encountered. One does not want to penetrate the sclera outside of the path of the trabeculectomy, as that does not restore aqueous flow and can

produce pain and bleeding. The procedure is far easier to perform in the eyes in which a short scleral tunnel or short scleral flap, with a wide internal entry, had been used in the trabeculectomy procedure [16].

Once the needle advances through the episcleral tissue to reach the interior of the bleb, the bleb may expand dramatically and that would indicate that the major unwanted resistance has been eliminated and that one may withdraw the needle. However, if the bleb does not expand, the needle may be advanced along the scleral surface to penetrate Tenons adhesions at the bleb margin, and the side of the 30 g needle used to slice such adhesions in one or a few places, until the bleb expands in size beyond its original margins.

13.4 Advantages of the Ab-interno Technique

There are several advantages of this procedure over trans-conjunctival needling, especially if the latter is done in an outpatient or hospital operating room. First, there are logistic advantages, as it is performed in the clinic at the time the patient is seen, with little cost and inconvenience, since no scheduling of the procedure and no hospital or outpatient facility paperwork and expense are involved. This is particularly advantageous to the practitioner within the global period, in which any postoperative interventions are not reimbursed, and in which returns to the hospital within the global period may be monitored. Second are the psychological advantages, in that one can explain to the patient that the operation they recently had has not "failed", but just needs adjustment, and deal with any anxiety by promptly dealing with the problem, rather than have it weigh on their mind until a revision could be scheduled and performed. Third, the procedure avoids several risks of trans-conjunctival needling.

With trans-corneal needling, the only entry into the eye is a self-sealing 30 g needle entry. To achieve a self-sealing wound, it is important that the bevel be parallel to the cornea so that a tunnel, and not a groove, is made. It is also important that the needle path be sufficiently long, and this is assured by having the bevel of

the needle fully in the cornea before turning the needle tip more perpendicularly for entry into the anterior chamber. In contrast, a trans-conjunctival needling by definition makes a hole in the conjunctiva, which can cause hypotony and can serve as an entry site for bacteria. For that reason, trans-conjunctival needling entry sites must always be Seidel tested and closed, if positive, with a suture or cautery.

With trans-corneal needling, especially if only an episcleral fibrosis at the scleral wound margin requires cutting, hypotony is unlikely to occur, as the outer margin of the bleb has usually formed by the time of the procedure. This is particularly true when a “safety-valve” trabeculectomy has been performed, in which the scleral wound has valve-like properties that provide about a 5 mmHg trans-scleral pressure gradient [17, 18]. With trans-scleral needling, especially if only an episcleral fibrosis at the scleral wound margin requires cutting, bleeding was usually not encountered, whereas trans-conjunctival needling often cuts vessels.

13.5 Results

Our clinical impression in about 20 cases performed has been that the success rate is somewhat better than trans-conjunctival needling, though favorable case selection likely played a role. The safety of trans-corneal needling appeared to be distinctly better, as no cases of hypotony, infection, or significant intra-bleb bleeding occurred. A formal retrospective analysis will be performed with Institutional Review Board approval and reported elsewhere.

Compliance with Ethical Requirements Dr. Palmberg declares no Conflict of Interest. This presentation is based upon a limited case series, does not constitute human subjects research and is exempt from Institutional Review Board review. No animal studies were performed by the author for this article.

References

1. Chen C-W. Enhanced intraocular pressure controlling effectiveness of trabeculectomy by local application of mitomycin-C. *Trans Asia-Pacific Acad Ophthalmol*. 1983;9:172–7.
2. Chen C-W, Huang HT, Bair JS, Lee CC. Trabeculectomy with simultaneous topical application of mitomycin-C in refractory glaucoma. *J Ocul Pharmacol*. 1990;3:175–82.
3. Heuer DK, Gressel MG, Parrish II RK, et al. 5-Fluorouracil and glaucoma filtering surgery. II. A pilot study. *Ophthalmology*. 1984;91(4):384–94.
4. The Fluorouracil Filtering Surgery Study Group. Five-year follow up of the fluorouracil filtering surgery study. *Am J Ophthalmol*. 1996;121:349–66.
5. Greenfield DS, Miller MP, Suner IJ, Palmberg PF. Needle elevation of the scleral flap for failing filtration blebs after trabeculectomy with mitomycin C. *Am J Ophthalmol*. 1996;122(2):195–204.
6. Wells AP, Cordeiro MF, Bunce C, Khaw PT. Cystic bleb formation and related complications in limbus-versus fornix-based conjunctival flaps in pediatric and young adult trabeculectomy with mitomycin C. *Ophthalmology*. 2003;110:2192–7.
7. Hoskins Jr HD, Miglizzo C. Management of failing filtering blebs with the argon laser. *Ophthalmic Surg*. 1984;15(9):731–3.
8. Traverso CE, et al. Focal pressure: a new method to encourage filtration after trabeculectomy. *Ophthalmic Surg*. 1984;15:62.
9. Ewing RH, Stamper RL. Needle revision with and without 5-fluorouracil for the treatment of failed filtering blebs. *Am J Ophthalmol*. 1990;110:254–9.
10. Mardelli PG, Lederer Jr CM, Murray PL, et al. Slit-lamp needle revision of failed filtering blebs using mitomycin C. *Ophthalmology*. 1996;103:1946–55.
11. Latina MA, Rankin GA. Internal and transconjunctival neodymium: YAG laser revision of late failing filters. *Ophthalmology*. 1991;98:215–21.
12. Rankin GA, Latina MA. Transconjunctival Nd-YAG laser revision of failing trabeculectomy. *Ophthalmic Surg*. 1990;21:365–7.
13. Weber PA, Jones JH, Kapetansky F. Neodymium: YAG transconjunctival laser revision of late-failing filtering blebs. *Ophthalmology*. 1999;106:2023–36.
14. Kasahara N, Sibayan SA, Montenegro MH, Simmons RB, Smith TJ. Corneal incision phacoemulsification and internal bleb revision. *Ophthalmic Surg Lasers*. 1996;27:361–6.
15. Pasternack JJ, Wand M, Shields MB, Abraham D. Needle revision of failed filtering blebs using 5-fluorouracil and a combined ab-externo and ab-interno approach. *J Glaucoma*. 2005;14:47–51.
16. Palmberg P. The failing filtering bleb. In: Liebmman JM, editor. *Glaucoma diagnosis and management*. *Ophthalmol Clin N Am* 2000;13(3): 517–29.
17. Palmberg P. Prevention and management of complicated hypotony in trabeculectomy with mitomycin. *Highlights Ophthalmol*. 1993;21(9):1. -67-77.
18. Suner IJ, Greenfield DS, Miller MP, et al. Hypotony maculopathy after filtering surgery with mitomycin C. Incidence and treatment. *Ophthalmology*. 1997; 104:207–14.

Kyla M. Teramoto and Troy M. Tanji

14.1 Introduction

14.1.1 Choroidal Anatomy

The choroid is a distinct component of uveal tissue that lies between sclera and the retinal pigment epithelium [28]. The suprachoroidal space (Fig. 14.1) is a potential space between the choroid and sclera. If fluid accumulates in that potential space, it becomes a true space of which the boundaries are the scleral spur anteriorly and the optic disc posteriorly. The choroid is also attached to the sclera at the ampullae of the four vortex veins. Normally there is a minimal amount of fluid in the suprachoroidal space that acts as a lubricant to allow the choroid to glide smoothly against the sclera. The outer surface of the ciliary body and the choroid are attached to the sclera by fine collagen fibrils arranged in tangential sheets. This arrangement also allows for movement of the choroid against the sclera. The optic nerve and perforating vessels and nerves limit the movement of the choroid during accommodation. The scleral openings created by these vessels and nerves can serve as emissarial channels or lymph-like spaces. They permit the slow drainage of fluid from the suprachoroidal space [3].

K.M. Teramoto, M.D. • T.M. Tanji, M.D. (✉)
University of Hawaii John A. Burns School of
Medicine, Honolulu, HI, USA
e-mail: ttanji@hawaii.edu

14.1.2 Choroidal Physiology

The choroid is highly vascularized and contains large capillaries that are 20–30 μm in diameter. It has been estimated that 70 % of the total blood supply to the eye is distributed to the choroid [21]. The choroidal circulation is designed to provide oxygen and metabolic support to the retina without obstructing vision at the fovea. Four to seven vortex veins provide venous drainage for the choroid [28]. Venous drainage and arterial supply are separated in the choroid, preventing thermal exchange between outgoing and incoming blood. This system suggests a role of the choroid as a temperature moderator for the neural retina.

The choroidal capillaries are fenestrated, allowing small and medium-sized molecules to traverse across. Intraocular pressure (IOP) opposes the outward osmotic pressure and maintains the steady state [2]. Under normal conditions, the albumin concentration of the interstitial space of the choroid is found to be less than 35 % of plasma [3].

The major arterial supply, together with the choriocapillaris, is functionally segmental with very little collateral flow [12]. This contributes to the pattern of large triangular lesions with the bases located anteriorly towards the equator if a vessel is occluded. Discrete lobular infarctions occur if a single end arteriole is blocked and can be associated with systemic hypertension, toxemia of pregnancy, disseminated intra-

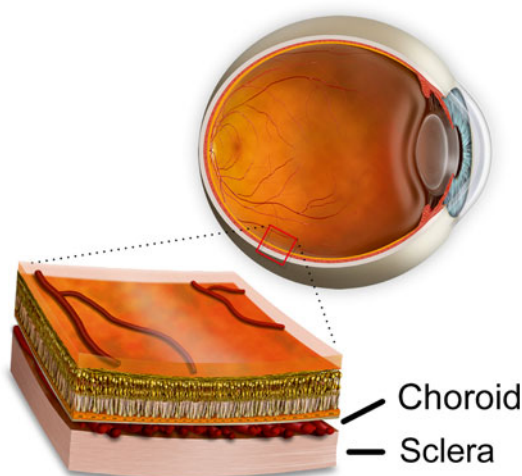


Fig. 14.1 Cross-section illustration of suprachoroidal potential space between the sclera and the vascular choroid. Copyright JirehDesign, reproduced with permission

vascular coagulopathy, acute posterior multifocal placoid pigment epitheliopathy, giant cell arteritis, Goodpasture's syndrome, and sickle cell anemia [28].

A conclusive relationship between glaucoma and the choroid has not been established. Numerous potential associations have been proposed, though studies have shown opposing results. Histologically, Yin et al. found a decrease in choroidal thickness in glaucomatous eyes when compared to eyes with optic atrophy of other causes and normal eyes [34]. Spraul et al. found increased choroidal thickness in eyes with a history of glaucoma compared to age-matched controls [31]. Of nine studies published using optical coherence tomography (OCT) measurements, six publications showed no significant difference between the macular choroidal thicknesses of glaucomatous eyes compared with controls [1, 14]. Choroid expansion may play a role in the anterior displacement of the lens in primary angle closure glaucoma according to Quigley [24].

14.2 Diagnosis

When choroidal effusions form, the abnormal accumulation of fluid in the suprachoroidal space can be seen as bullous, solid detachments, separated

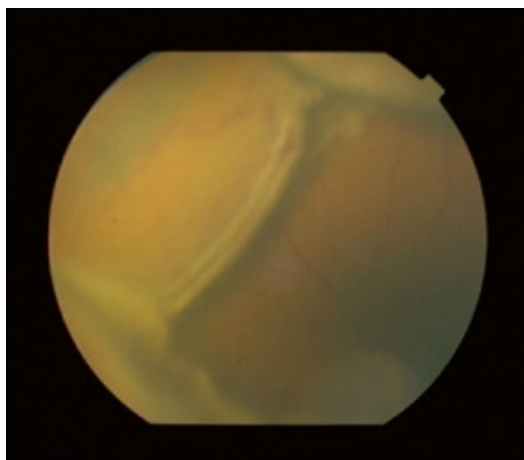


Fig. 14.2 Fundus photograph of choroidal effusions with associated exudative detachment

into quadrants [3]. The effusions usually appear as dome-shaped elevations in the posterior segment that are limited by fibrous adhesions concurrent with the vortex veins. Choroidal effusions may be associated with an exudative retinal detachment (Fig. 14.2). Funduscopic findings can usually differentiate a choroidal detachment from a retinal detachment, as choroidal detachments are solid dome-shaped elevation under the retina, which are relatively immobile, while retinal detachments are mobile detachments of the retina often with folds within the retina.

Ultrasonography can assist in the diagnosis of choroidals when there is a limited view of the posterior pole. B-scan ultrasonography will reveal dome-shaped elevations (Fig. 14.3) that do not cross from quadrant to quadrant [19]. Ultrasound imaging can also differentiate between serous effusions and hemorrhagic choroidals. Highly elevated choroidal detachments with opacities in the suprachoroidal space suggestive of clotted blood are typically noted with the hemorrhagic type. A-scan ultrasonography is also helpful and shows the steeply rising, double-peaked spike characteristic of choroidal effusion with lower reflective spikes from the clotted hemorrhage [5].

Small and peripheral choroidal effusions are usually asymptomatic with minimal vision loss and/or discomfort. Larger effusions can cause

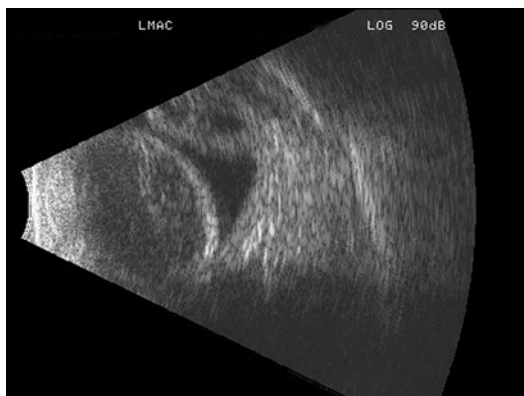


Fig. 14.3 Longitudinal sonographic section through the macula. Note the nasal and temporal bullous choroidal detachments which are not quite apposed to each other

decreased vision if the detachment involves the macula or if there is an anterior displacement of the lens-iris diaphragm causing a myopic shift [26]. Patients may notice an absolute scotoma corresponding to the site of the effusions. Sudden and severe pain with significant loss of vision is a feature of hemorrhagic choroidals. Hemorrhagic choroidals are often associated with headache, nausea and vomiting secondary to a sudden elevation in IOP [5].

14.3 Pathophysiology

The most common type of choroidal effusion is serous, with a protein concentration of approximately 67 % of serum protein. These effusions result from a decrease in IOP following intraocular surgery. This creates a pressure differential that allows small and medium-sized molecules, along with fluid, to traverse across the isoporous choroidal capillary membrane [2]. Normally when IOP is lowered, the hydrostatic pressure of the veins draining the choroid decreases and the hydrostatic pressure of choroid capillaries likely decreases, keeping the net hydrostatic pressure across capillary walls unchanged. However, with very low IOP or hypotony, the venous pressure outside of the eye limits venous pressure inside the eye so equilibrium shifts towards fluid accumulation. In addition, the pressure gradient across

the sclera is decreased, so fluid from the suprachoroidal space through the emissarial scleral openings is egressed at a slower rate. Fluid begins to accumulate and spontaneous detachment of the choroid from its scleral attachments occurs. If bulk outflow decreases and colloid accumulates in the suprachoroidal space, fluid will enter the space even more rapidly [3]. Although the degree of the detachment correlates to the degree of hypotony, inflammation is also thought to be an important facilitator [29]. Inflammation augments the above process by increasing the rate of colloid movement into the suprachoroidal space. It increases the permeability of choroidal capillaries [26]. Inflammation can also contribute to hypotony possibly by a prostaglandin-mediated decrease in aqueous production combined with an increase in uveoscleral outflow [29].

Bellows et al. described an additional mechanism for intraoperative choroidal effusion that occurs in eyes with prominent episcleral vessels and high episcleral venous pressure, as in patients with a carotid-cavernous fistula or Sturge-Weber syndrome. These effusions have a protein concentration that is 18 % of the serum and thought to be due to a process of molecular sieving. The elevated venous pressure creates a magnified pressure differential when IOP drops to zero, promoting the filtration of larger proteins as fluids flows into the extravascular space [2].

14.4 Sequelae

Persistent large choroidal effusions can result in a flat anterior chamber with corneal decompensation and cataract progression. Choroidal effusions can also turn into the hemorrhagic type with stretching and breaking of the choroidal arteries. This sequence of events may be especially pronounced if the patient is on anticoagulant treatment. Risk factors for hemorrhagic choroidals include older age, a history of glaucoma, previous ocular surgery, and long or very short axial length [19]. Hemorrhagic choroidal detachment is usually associated with severe pain, a flat anterior chamber and high IOP [13]. Liquefaction of

the hemorrhage must be considered before attempting drainage. B-scan echography can be used to follow progression of clot lysis that can take a variable amount of time [5]. Large “kissing” choroidals with prolonged retinal apposition may sometimes lead to retinal adherence and secondary retinal detachment, so earlier intervention is more highly considered in this scenario.

14.5 Etiology

14.5.1 Postoperative

The most common cause of choroidal effusions is intraocular surgery with the lowering of IOP. Intraoperative and postoperative hypotony with the inflammation associated with surgery is the proposed etiology with the pathophysiology previously discussed [3]. Associated risk factors for postoperative choroidals include systemic hypertension, older age, prior vitrectomy, nanophthalmos, and elevated episcleral venous pressure [19]. Effusions are commonly observed after panretinal photocoagulation [9]. The number of laser applications and increasing retinal surface treatment area are positively correlated with the development of effusions. Shorter eyes are also at higher risk. Self-limited choroidal effusions are often observed after scleral buckling procedures. The fluid accumulation is thought to be the result of compromised venous outflow at the vortex veins. Risk factors include the size of the buckle and its posterior location [22]. Choroidal effusions can also be found preoperatively in the setting of a rhegmatogenous retinal detachment. Several studies have found poor prognosis for these hypotonous eyes with a retinal detachment and choroidal effusions [29].

14.5.2 Inflammatory

Choroidal effusion can also be primarily associated with inflammatory disorders affecting the posterior pole, such as scleritis and Vogt–Koyanagi–Harada syndrome [15]. Orbital inflammation can also lead to choroidal effusions that are thought to be related to an associated scleritis

as well as congestion of the orbital cavity. Treatment of the underlying disease process with control of inflammation usually leads to reabsorption of the fluid.

14.5.3 Medical

Systemic medications such as sulfonamides, tetracycline, diuretics, topiramate and selective serotonin reuptake inhibitors have been reported to be associated with nonsurgical-related choroidal effusions. Discontinuation of the offending medication aids in the resolution of the effusion [26]. The intraoperative use of antifibrotic agents such as mitomycin-C or aqueous suppressants such as timolol or dorzolamide after trabeculectomy may be associated with prolonged hypotony and choroidal effusions [26].

14.5.4 Uveal Effusion Syndrome

Uveal effusion syndrome (UES) is a diagnosis of exclusion that is used to describe cases of uveal effusion with unknown etiology. It is characterized by uveal effusion and serous retinal detachment. UES can be distinguished from other causes of uveal effusion by normal IOP and the lack of significant inflammation. There are several proposed hypotheses for the pathogenesis of UES, with the most likely being reduced scleral protein permeability. It is felt to be related to scleral thickening and poor fluid outflow. UES is more common in males and generally follows a relapsing-remitting clinical course. Most patients with UES have bilateral involvement at some point in the disease process [7].

14.5.5 Choroidal Tumors

Primary or metastatic tumor, such as melanoma, may be associated with serous choroidal detachment. B-scan ultrasonography and transillumination may be helpful if tumor is suspected. Primary cancers that may metastasize to the choroid include breast, lung, prostate, kidney, gastrointestinal tract, lymphoma, and leukemia.

14.6 Medical Treatment

Suprachoroidal effusions are usually self-limited and resolve with supportive medical treatment. Resolution is generally expected within a few weeks if the underlying etiology is successfully addressed [19]. Inflammation should be aggressively treated with reversal of hypotony.

All patients with choroidal effusions are encouraged to avoid activities that increase venous pressure in the eye. Examples of such activities include lifting heavy objects, bending, coughing, and Valsalva maneuver. Any elevation in venous pressure increases the pressure differential and promotes movement of molecules and fluid into the suprachoroidal space. Increase in episcleral venous pressure also risks the rupture of these vessels and the occurrence of devastating hemorrhagic choroidals.

Cycloplegia with atropine 1 % or scopolamine 0.25 % is administered to relax an anteriorly rotated ciliary body and deepen a shallow anterior chamber [11]. The pupillary dilation with cycloplegic use also prevents posterior synechiae formation with a miotic pupil. Stabilization of the blood aqueous barrier is also thought to be a secondary action of these agents. Topical corticosteroids are the mainstay for control of inflammation. Frequent use of prednisolone acetate 1 % or difluprednate ophthalmic emulsification 0.05 % for a few weeks is recommended with dosing interval titrated to the inflammation present [11]. Peribulbar injections are effective for administration of steroids to the posterior segment. Sub-Tenon injection of triamcinolone acetonide has been shown to be effective in relieving inflammation in patients with scleritis before systemic corticosteroids take effect [18]. Systemic corticosteroids may be needed if local administration fails to control intraocular inflammation [8].

14.7 Hypotony Reversal

The goal of glaucoma surgery is to lower IOP; however if choroidal effusions are present with lower than desired pressure, a systematic approach to determine the etiology of the hypotony is undertaken. After filtering surgery, the integrity of

conjunctiva should be confirmed with Seidel testing. If a hole with leakage is found, a soft bandage contact lens may be used to cover the area of aqueous egress and promote closure. Daily pressure patching is an alternative treatment if contact lens use is not tolerated or unavailable. If overfiltration is present with a large Seidel negative bleb, steps to decrease aqueous flow should be attempted. Oversized bandage soft contact lenses can also be used to manage hypotony after filtration surgery. A thicker and larger custom-made lens compresses the bleb and underlying scleral flap to slow down filtration. Early application of the bandage soft contact lens can prevent progressive overfiltration that would require further surgical intervention [30]. Alternatively, torpedo patching with a fusiform-shaped cotton ball can be placed over the bleb area to slow down filtration. A shallow anterior chamber should deepen after about an hour as aqueous production inflates the globe. The patch is then left on until later in the evening or overnight [13]. Placement of a Simmons glaucoma shell under a patch has also found to be effective; however discomfort is always a consideration with this bulky apparatus [20].

Stopping medications that suppress aqueous production should be considered during treatment for hypotony. Beta-adrenergic blocking agents used systemically or to the contralateral eye can slow down aqueous production in the affected eye [33]. Systemic carbonic anhydrase inhibitors may also need to be withheld.

In the setting of ocular trauma or anterior segment surgery, chronic ocular hypotony can result from a cyclodialysis cleft. This is when there is disruption of the meridional ciliary muscle fiber insertion into the scleral spur and an abnormal secondary pathway of aqueous drainage into the suprachoroidal space is present. If there is associated corneal edema and a shallow anterior chamber, detection of the cyclodialysis cleft may be difficult. Treating the eye with a miotic and injecting a viscoelastic agent into the anterior chamber may facilitate detection with gonioscopy. Anterior segment OCT and/or ultrasound biomicroscopy may allow for enhanced visualization of the irido-corneal angle also in order to detect a cyclodialysis cleft [16].

However, Ioannidis et al. found that imaging was not sufficiently precise and viscoelastic-assisted gonioscopy was necessary for accurate diagnosis [17].

Retinal detachment can be associated with hypotony. It can be evaluated with indirect ophthalmoscopy with scleral decompression, slit lamp examination with contact lens, OCT, and/or B-scan ultrasonography. It is important to diagnose concurrent retinal detachment with choroidal effusion because it influences management and prognosis [10]. Prior cyclodestruction may be a risk factor for hypotony after installation of a glaucoma drainage device [27].

14.8 Surgical Indications

Suprachoroidal effusions are usually self-limited and resolve with treatment of the underlying cause. Resolution is generally expected within a few weeks with supportive treatment [19]. Drainage is also usually not necessary following retinal detachment buckling, as the fluid does not interfere with repair of the break and spontaneous resolution is expected.

Bellows et al. described a number of indications for surgical drainage of the suprachoroidal space: (1) a flat anterior chamber with lens-cornea touch for more than 12 h, (2) corneal edema with a shallow or flat anterior chamber, (3) a flat anterior chamber with an inflamed eye and apparent failing bleb, (4) suspicion of a hemorrhagic choroidal detachment with inflammation, (5) appositional “kissing” choroidal detachment for 48 h, (6) apposition of a combined choroidal-retinal detachment to the posterior lens surface, (7) persistent wound leak with choroidal detachment and flat anterior chamber, and (8) flat anterior chamber with choroidal detachment and concurrent pupillary block [2]. Brubaker also advocated immediate drainage of the detachment with anterior chamber reformation for phakic patients with lens corneal touch as well as for any signs of corneal decompensation or bleb failure [3]. In general, drainage is undertaken urgently for effusions that result in a flat anterior chamber

and electively for effusions causing a significant reduction in vision [34]. The exact timing for the latter surgical indication is an individualized clinical decision [34].

14.9 Surgical Technique

Drainage of choroidal effusions is performed in a surgical suite using the operating microscope. Topical anesthesia with supplemental intravenous sedation is usually sufficient for patient comfort. The operative eye is prepped and draped in the usual sterile fashion. A 6-0 traction suture on a spatula needle is placed through inferior peripheral cornea to allow exposure of the inferior globe where the drainage site(s) are usually placed. The inferior temporal quadrant between the rectus muscles is the usual preferred drainage site for ease of exposure. A temporal peripheral corneal paracentesis is created with a 15° blade to allow refilling of the anterior chamber. A circumferential conjunctival incision is placed approximately 4 mm from the limbus in the desired inferior quadrant(s) with the Wescott scissors. Hemostasis with the bipolar cautery before scleral incision placement prevents significant bleeding. The sharper tipped 15° blade is used to start the radially directed sclerotomy site starting and ending at approximately 4–7 mm from the limbus. When choroidal pigment is visualized, a rounded tip Beaver-type blade can be used to complete the penetrating scleral incision as to avoid injuring the underlying uveal tissue.

When the suprachoroidal space is entered, clear, xanthochromic fluid should readily flow from the drainage site. Fine-toothed forceps can be used to separate the wound edges to promote the drainage of the effusions. Application of cautery to the incision edges may facilitate drainage with the resultant scleral shrinkage. A scleral trabeculectomy punch can be placed to allow postoperative drainage. Flow of fluid may cease when the suprachoroidal space flattens with choroid against the scleral incision site. The cyclodialysis spatula can assist in additional drainage of

distal fluid by reopening the suprachoroidal space at the incision. The blunt tipped instrument is inserted between sclera and choroid with sclera lifted to create the space for additional flow of fluid.

Periodic monitoring and reinflation of the anterior chamber during the drainage procedure insures the eye maintains an adequate pressure that promotes the flattening of the effusions.

Various substances may be used for anterior chamber reformation, including balanced salt solution, a viscoelastic agent, air, or an expandable gas. Some have advocated the use of a cohesive viscoelastic agent to slow down filtration after glaucoma surgery. Intraocular gases have an expansile effect and persist longer, but may increase the risk of cataract formation in a phakic eye [13].

Intraoperative ophthalmoscopy can be used to confirm that adequate effusion removal was accomplished. An additional sclerotomy inferior nasally may be created if needed. The scleral incision is left open to allow additional drainage postoperatively with the conjunctival incision closed with an absorbable suture [2].

Hypotony contributing to the drained choroidal effusions should be addressed at the same time as the drainage procedure. Additional sutures may be placed across the scleral flap of an overfiltering trabeculectomy. Eha et al. recently reported long-term success in elevating pressure with placement of additional transconjunctival scleral flap sutures using 10-0 nylon on a longer cutting needle [6]. Opening of the bleb with scleral grafting may be necessary if the scleral flap appears inadequate [25]. In eyes with overfiltration after installation of a glaucoma drainage device, the tube may be ligated at the time of drainage with a nonabsorbable suture [32]. Removal of the tube with installation of a smaller or valved device is another option to consider. If a cyclodialysis cleft has been identified, direct repair under a scleral flap may be undertaken. There are multiple novel techniques for treatment of cyclodialysis cleft, but there are insufficient studies to determine efficacy and safety [4, 16].

14.10 Outcomes

When drainage of choroidal effusions is medically necessary, the eye's anatomy corrected with restoration of ocular physiology. Bellows reported good success with minimal intraoperative and postoperative complications [2]. A large retrospective study by WuDunn showed surgical drainage improved vision and reduced hypotony. Effusions associated with a flat anterior chamber took longer to resolve and multiple drainage procedures were required in a significant number of patients with 90 % of eyes achieving anatomic success [34]. When indicated, surgical drainage of choroidal effusions is an acceptable treatment option with good outcomes.

Compliance with Ethical Requirements Kyla M. Teramoto and Troy M. Tanji declare that they have no conflict of interest. No human or animal studies were carried out by the authors for this article.

References

1. Banitt M. The choroid in glaucoma. *Curr Opin Ophthalmol*. 2013;24:125–9.
2. Bellows AR, Chylack LT, Hutchinson BT. Choroidal detachment clinical manifestation, therapy, and mechanism of formation. *Ophthalmology*. 1981;88(11):1107–15.
3. Brubaker RF, Pederson JE. Ciliochoroidal detachment. *Surv Ophthalmol*. 1983;27:281–9.
4. Ceruti P, Tosi R, Marchini G. Gas tamponade and cyclocryotherapy of a chronic cyclodialysis cleft. *Br J Ophthalmol*. 2009;93:414–6.
5. Chu TG, Green RL. Suprachoroidal hemorrhage. *Surv Ophthalmol*. 1999;43(6):471–86.
6. Eha J, Hoffmann EM, Pfeiffer N. Long-term results after transconjunctival resuturing of the scleral flap in hypotony following trabeculectomy. *Am J Ophthalmol*. 2013;155(5):864–9.
7. Elagouz M, Stanescu-Segall D, Jackson TL. Uveal effusion syndrome. *Surv Ophthalmol*. 2010;55(2):134–45.
8. Erdol H, Kola M, Turk A. Optical coherence tomography findings in a child with posterior scleritis. *Eur J Ophthalmol*. 2008;18(6):1007–10.
9. Gentile RC, Stegman Z, Liebmman JM, Dayan AR, Tello C, Walsh JB, Ritch R. Risk factors for choroidal effusion after panretinal photocoagulation. *Ophthalmology*. 1996;103(5):827–32.
10. Gui JM, Jia LI, Liu L, Liu JD. Vitrectomy, lensectomy and silicone oil tamponade in the management of

- retinal detachment associated with choroidal detachment. *Int J Ophthalmol.* 2013;6(3):337–41.
11. Haynes WL, Alward WLM. Control of intraocular pressure after trabeculectomy. *Surv Ophthalmol.* 1999;43(4):345–55.
 12. Hayreh SS. In vivo choroidal circulation and its watershed zones. *Eye (Lond).* 1990;4(Pt 2):273–89.
 13. Herndon LW. Shallow or flat anterior chamber. In: Spaeth GL, editor. *Ophthalmic surgery principles and practice*. 3rd ed. Philadelphia: Saunders; 2003. p. 369–77.
 14. Hirooka K, Fujiwara A, Shiragami C, Baba T, Shiraga F. Relationship between progression of visual field damage and choroidal thickness in eyes with normal-tension glaucoma. *Clin Experiment Ophthalmol.* 2012;40:576–82.
 15. Ikeda N, Ikeda T, Nomura C, Mimura O. Ciliochoroidal effusion syndrome associated with posterior scleritis. *Jpn J Ophthalmol.* 2007;51:49–52.
 16. Ioannidis AS, Barton K. Cyclodialysis cleft: causes and repair. *Curr Opin Ophthalmol.* 2010;21:150–4.
 17. Ioannidis AS, Bunce C, Barton K. The evaluation and surgical management of cyclodialysis clefts that have failed to respond to conservative management. *Br J Ophthalmol.* 2014;98:544–9.
 18. Johnson KS, Chu DS. Evaluation of sub-Tenon triamcinolone acetate injections in the treatment of scleritis. *Am J Ophthalmol.* 2010;149(1):77–81.
 19. Kahook MY, Noecker RJ. Why do choroidals form, and how do you treat them? *Glaucoma Today.* Sept/Oct 2007: 36–8.
 20. Melamed S, Hersh P, Kersten D, Lee DA, Epstein DL. The use of glaucoma shell tamponade in leaking filtration blebs. *Ophthalmology.* 1986;93(6):839–42.
 21. Mrejen S, Spaide RF. Optical coherence tomography: imaging of the choroid and beyond. *Surv Ophthalmol.* 2013;58(5):387–429.
 22. Packer AJ, Maggiano JM, Aaberg TM, Meredith TA, Reeser FH, Kingham JD. Serous choroidal detachment after retinal detachment surgery. *Arch Ophthalmol.* 1983;101(8):1221–4.
 23. Parikh R, Parikh S, Das S, Thomas R. Choroidal drainage in the management of acute angle closure after topiramate toxicity. *J Glaucoma.* 2007;16(8): 691–3.
 24. Quigley HA, Freidman DS, Congdon NG. Possible mechanisms of primary angle-closure and malignant glaucoma. *J Glaucoma.* 2003;12:167–80.
 25. Radhakrishnan S, Quigley HA, Jampel HD, Friedman DS, Ahmad SI, Congdon NG, McKinnon S. Outcomes of surgical bleb revision for complications of trabeculectomy. *Ophthalmology.* 2009;116(9):1713–8.
 26. Reddy AC, Salim S. Diagnosis and management of choroidal effusions. *Eyenet.* Nov 2012:47–9.
 27. Rosentreter A, Gaki S, Lappas A, Cursiefen C, Dietlein TS. Previous cyclodestruction is a risk factor for late-onset hypotony and suprachoroidal haemorrhage after glaucoma drainage device surgery. *Br J Ophthalmol.* 2013;97:715–9.
 28. Scales DK, Fryczkowski AW, Opremcak EM. The choroid. In: Albert DM, Jakobiec FA, editors. *Principles and practice of ophthalmology*. Philadelphia: Saunders; 1994. p. 252–61.
 29. Schubert HD. Postsurgical hypotony: relationship to fistulization, inflammation, chorioretinal lesions, and the vitreous. *Surv Ophthalmol.* 1996;41:97–125.
 30. Smith MF, Doyle JW. Use of oversized bandage soft contact lenses in the management of early hypotony following glaucoma filtration surgery. *Ophthalmic Surg Lasers.* 1996;27(6):417–21.
 31. Spraul CW, Lang GE, Lang GK, Grossniklaus HE. Morphometric changes of the choriocapillaris and the choroidal vasculature in eyes with advanced glaucomatous changes. *Vision Res.* 2002;42:923–932.
 32. Stein JD, McCoy AN, Asrani S, Herndon LW, Lee PP, McKinnon SJ, Allingham RR, Challa P. Surgical management of hypotony owing to overfiltration in eyes receiving glaucoma drainage devices. *J Glaucoma.* 2009;18(8):638–41.
 33. Vela MA, Campbell DG. Hypotony and ciliochoroidal detachment following pharmacologic aqueous suppressant therapy in previously filtered patients. *Ophthalmology.* 1985;92:50–7.
 34. WuDunn D, Ryser D, Cantor LB. Surgical drainage of choroidal effusions following glaucoma surgery. *J Glaucoma.* 2005;14(2):103–8.
 35. Yin ZQ, Vaegan, Millar TJ, Beaumont P, Sarks S. Widespread choroidal insufficiency in primary open-angle glaucoma. *J Glaucoma.* 1997;6:23–32.

Devesh K. Varma and Iqbal Ike K. Ahmed

15.1 Introduction

Malignant glaucoma was first described in 1869 by Von Graefe, who noted anterior chamber shallowing with elevated intraocular pressure (IOP) following iridotomy. It was challenging to manage, and was therefore described as “malignant.” [1]. Often, the lens-iris diaphragm is displaced anteriorly during malignant glaucoma. It is most often seen following glaucoma surgery but can occur with any surgery, including iridotomy or even phacoemulsification alone in a susceptible eye [2].

The definition and understanding of malignant glaucoma has evolved over time. In the past, it has been called “aqueous misdirection syndrome” but, as no evidence of a “misdirected” aqueous mechanism has been found, many now prefer to avoid this term.

Electronic supplementary material The online version of this chapter (doi:[10.1007/978-3-319-18060-1_15](https://doi.org/10.1007/978-3-319-18060-1_15)) contains supplementary material, which is available to authorized users.

D.K. Varma, M.D., F.R.C.S.C. (✉)
I.I.K. Ahmed, M.D., F.R.C.S.C.
Department of Ophthalmology and Vision Sciences,
The University of Toronto, Toronto, ON, Canada

Trillium Health Partners, Mississauga, ON, Canada

Credit Valley Eyecare, Mississauga, ON, Canada
e-mail: devesh.varma@goeyecare.com;
ikeahmed@mac.com; ike.ahmed@utoronto.ca

15.2 Diagnosis

Typically, malignant glaucoma will present within the first few weeks following surgery with progressive anterior chamber shallowing accompanied by anterior shift of the lens-iris complex and progressively worsening myopia (Fig. 15.1). Angle closure with or without peripheral anterior synechia (PAS) and elevated IOP may be present and over time corneal decompensation can occur. In mild cases of malignant glaucoma, or in the presence of functioning filtering surgery, IOP may not be elevated.

Malignant glaucoma is a diagnosis of exclusion and it is important to rule out other causes of postoperative anterior chamber shallowing, including incision leakage, pupil block, capsular block syndrome, plateau iris, ciliary body cysts, zonulopathy-induced lens subluxation, and supraciliary or choroidal effusion/hemorrhage [3].

In some cases, malignant glaucoma may present intraoperatively and manifest as acute and marked anterior migration of capsule, lens, and iris following an intraoperative anterior chamber shallowing or decompression event. Iris often prolapses and it may not be possible to reposit despite decompressing the anterior chamber. The condition does not improve with usual maneuvers done for “positive pressure” such as relieving tension on the lid speculum or encouraging

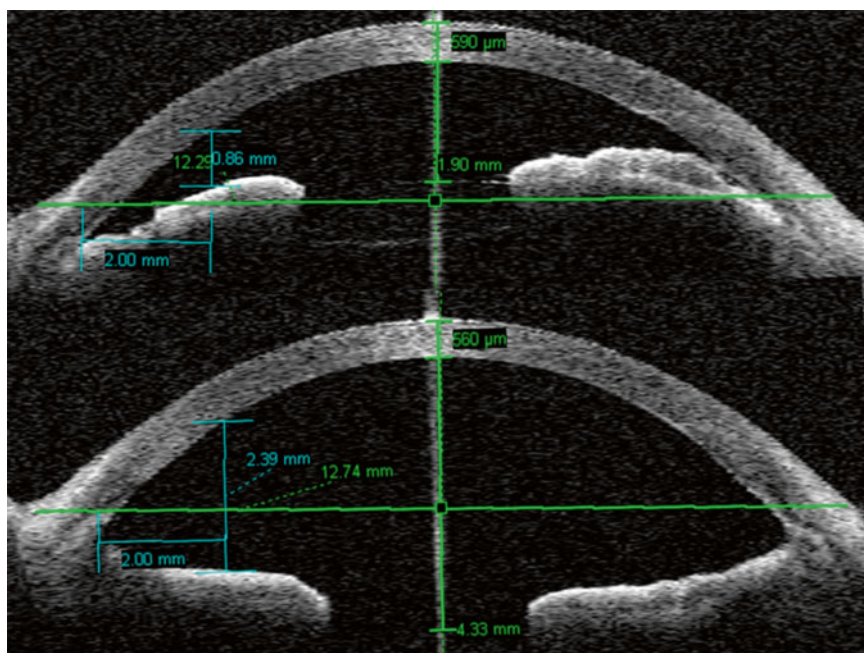


Fig. 15.1 Anterior segment OCT showing malignant glaucoma with anterior displacement of IOL and anterior chamber shallowing (*top*) and resolution of malignant

glaucoma and deepening of anterior chamber after treatment in the same eye (*bottom*)

the patient to avoid valsalva/strain. As well, unlike intraoperative suprachoroidal hemorrhage, pain is not a hallmark of this condition.

15.3 Pathophysiology

Decompression, or sudden drop in IOP, is thought to be the inciting event for malignant glaucoma. It is usually accompanied by anterior chamber shallowing. During surgery, decompression may occur during incision creation, while moving instruments in and out of the eye particularly larger ones like hand-pieces for phacoemulsification (phaco) or irrigation-aspiration, when creating openings for glaucoma filtration surgery or during wound closure if tissue apposition is insufficient. Following surgery, decompression can occur due to wound leak or excessive filtration from glaucoma surgery.

Reduced IOP from decompression may result in choroidal expansion as increased blood

volume rushes into the potential vascular space. The choroid covers a large surface area and a small increase in its thickness can add significant volume to the intraocular contents pushing other structures anteriorly. Normally, aqueous outflow either via trans-scleral drainage or anteriorly through the trabecular meshwork would compensate for this event. However, this may not occur in the susceptible eye due to a combination of factors. These include a reduced ability for fluid to transmit through vitreous due to poor conductivity, limited lens-iris channel area for anterior migration of aqueous, and reduced trans-scleral outflow due to thicker sclera. In eyes with these characteristics, a decompression event may result in anterior lens-iris movement and significant anterior chamber shallowing [4].

Risk factors for malignant glaucoma include shallow anterior chamber and shorter axial length. These conditions are more common in female hyperopes [5, 6].

15.4 Prevention

The risk of malignant glaucoma may be reduced, though not eliminated, by avoiding decompression during surgery.

During cataract surgery, when withdrawing the phaco hand piece after lens removal or when withdrawing the irrigation-aspiration hand piece after cortex or viscoelastic removal, the anterior chamber often shallows, signaling decompression. To avoid this, one can inject balanced salt solution (BSS) or viscoelastic through the paracentesis to maintain the anterior chamber pressure. The choice between BSS or viscoelastic would depend on the next step planned in surgery. Typically, the authors would inject BSS following phacoemulsification to prepare for cortex removal, viscoelastic following cortex removal to prepare for lens insertion, and BSS after viscoelastic removal to prepare for wound hydration. To reduce tremor, the surgeon can depress the plunger using the index finger while holding the syringe between the thumb and middle finger, rather than the traditional method of depressing the plunger with one's thumb. This technique takes practice and one can do so on routine cases so that the skill is honed for use when needed.

During filtration surgery, decompression can occur when creating an ostium as well as during closure. Viscoelastic can be used in the anterior chamber during ostium creation to avoid shallowing. As well, during closure of a trabeculectomy flap, periods of excessive aqueous egress can occur resulting in anterior chamber shallowing.

With the microscope centered on the flap and the surgeon's attention focused on suturing, this may go unnoticed. By periodically checking the anterior chamber status during this step, one can inject BSS or viscoelastic to help avoid excessive shallowing and decompression. Similarly, during tube shunt entry and manipulations, care in avoiding excessive anterior chamber shallowing may help reduce the risk of subsequent malignant glaucoma.

15.5 Medical Treatment

Definitive treatment for malignant glaucoma aims to restore the normal relationship between the anterior and posterior segments by establishing a unicameral eye. This can be achieved through a stepwise approach which begins with less invasive approaches and reserves more invasive strategies only for cases that do not resolve with earlier steps (Fig. 15.2).

Medical management consists of cycloplegics to help pull the lens-iris diaphragm posteriorly and aqueous suppressants to reduce intraocular volume as well as control pressure. Although traditionally this has been reported to be successful in up to 50 % of patients [7], more recent reports suggest this number may be as low as 10–14 % [8, 9]. Furthermore, since medical management does not address the underlying anatomic issue, cycloplegia often cannot be discontinued [2], suggesting a role for medications to help control but not necessarily cure malignant glaucoma.

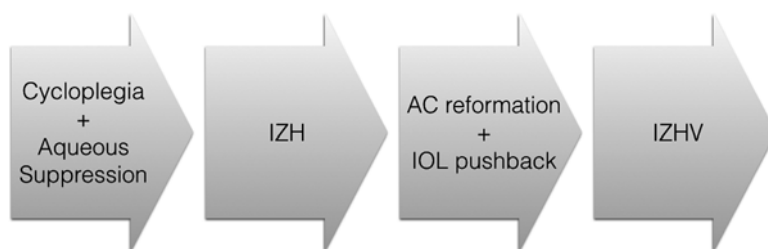


Fig. 15.2 Stepwise treatment approach beginning with medical therapy using cycloplegia and aqueous suppressants, then adding iridozonulohyaloidotomy (IZH) followed by anterior chamber (AC) reformation and IOL

pushback and ultimately moving to iridozonulohyaloidotomy with vitrectomy in those cases that do not resolve with the previous steps

15.6 Surgical Treatment

15.6.1 Iridozonulohyaloidotomy

Iridozonulohyaloidotomy (IZH) aims to create a channel for aqueous to pass through the iris, zonules, and anterior hyaloid effectively allowing aqueous to pass freely between the posterior and anterior segments. This is intended to equalize pressure between the two segments of the eye and if successful should result in a deepening of the anterior chamber within 24 h [10]. IZH can resolve malignant glaucoma in 35 % of cases [9].

An IZH may be performed using a YAG laser aimed at iris peripheral to the lens. A preexisting iridotomy is often a good starting point for this procedure and settings would mirror those used for a YAG laser iridotomy. Once through the iris, the laser is focused posteriorly to penetrate the zonules and hyaloid respectively. If necessary, the aperture can be enlarged to ensure adequate visualization of deeper structures. Often in malignant glaucoma, because the vitreous is compressed anteriorly, an IZH may pass through both anterior and posterior hyaloid.

In pseudophakic eyes with widely dilated pupils, one can aim the laser through anterior and posterior capsule leaflets peripheral to the lens edge rather than through iris performing a capsulohyaloidotomy rather than the traditional IZH.

15.6.2 Anterior Chamber Reformation and Intraocular Lens Pushback

In pseudophakic patients, once a patent IZH has been created, if malignant glaucoma persists or cycloplegia cannot be discontinued, it may help to reform the anterior chamber (AC) with viscoelastic and manually push the intraocular lens (IOL) posteriorly. The surgeon may note a palpable sense as anteriorly rotated ciliary processes “pop” back into place. As well, the posterior movement of the IOL can force fluid trapped in the posterior segment to migrate through the patent IZH into the anterior segment. This technique may resolve a further 30 % of malignant glaucoma cases [9].

This procedure can be done at the slit lamp or in an operating suite depending on the surgeon's comfort level. When performing this at the slit lamp, it is advisable to use iodine as well as a lid speculum to ensure sterility. A 30-gauge needle is placed on a viscoelastic syringe and introduced into the anterior chamber at the limbus. Viscoelastic is injected to maintain the anterior chamber and within this stable environment, the needle can be advanced over the IOL optic avoiding the visual axis. The needle is used to push the IOL posteriorly.

With viscoelastic stabilizing the anterior chamber during this procedure, there is an opportunity to perform other maneuvers. Specifically, the IZH can be enhanced by passing the needle 2 mm posteriorly through the IZH to penetrate through the hyaloid. If PAS have formed, one may also use the sharp needle tip to engage iris peripherally and then pull away from the angle thereby releasing synechiae. Successful release of PAS cannot be visualized during this procedure and should be confirmed on subsequent gonioscopic exam.

15.6.3 Surgical Iridozonulohyaloidotomy with Vitrectomy

Medical therapy, IZH and AC reformation with IOL pushback may not resolve malignant glaucoma in 25 % of cases [9]. When this occurs, a surgical iridozonulohyaloidotomy with vitrectomy (IZHV) provides a definitive treatment [11].

It is typically reserved for pseudophakic eyes or as part of a combined surgery in phakic patients. In the latter, phacoemulsification should be performed with insertion of an IOL prior to the IZHV. The procedure is performed in the operating room, typically under sedation with topical, intracameral, and possibly subconjunctival anesthesia. A retrobulbar or peribulbar block can be used though these may induce external pressure on the globe and make anterior chamber maneuvers more challenging.

The goal of an IZHV is to definitively create a unicameral eye by passing the vitrectomy cutter through peripheral iris, zonules, and hyaloid. It can be performed from an anterior limbal

approach or a posterior pars plana approach depending on the surgeon's comfort level. Bimanual vitrectomy separating the vitrectomy cutter from irrigation is highly recommended for this procedure and a high cut rate (at least 800 cuts/min) is helpful to ensure optimal control when removing tissue. Also, as a general rule, working through small incisions helps to maintain anterior chamber stability and is recommended.

To perform an IZHV from an anterior or limbal approach, the surgeon creates two small paracenteses—if sitting temporally one incision would be superotemporal and the other inferotemporal to allow easy manipulation of instruments held in both left and right hands. The surgeon would then form the anterior chamber with viscoelastic and following this, place the vitrectomy cutter through one incision. Use of the automated irrigation cannula can cause anterior chamber instability and iris prolapse. Therefore if a small amount of infusion is needed, this can be provided manually using a syringe with BSS. Alternatively, the vitrectomy can be performed under viscoelastic without infusion of BSS. The cutter can be extended across the anterior chamber and positioned over the iris with port facing down (Fig. 15.3a, b). Because the long ciliary arteries course at the 3:00 and 9:00 (horizontal) positions, these should be avoided to minimize risk of bleeding. The foot pedal is then depressed to position 3 (irrigation-cut-aspiration) and a controlled iris opening is created (Fig. 15.3c). One should be cautious to avoid excessive iris tissue removal as this may result in postoperative dysphotopsia or monocular diplopia. Once the iris opening has been created, the vitrectomy cutter port can be turned up to enable visualization. The shaft is then angled more posteriorly and passed through the iris opening in position 2 (irrigation-cut). Once through the foot pedal may again be advanced to position 3 to remove zonules and anterior hyaloid. The cutter need only be advanced 2 mm into the vitreous space to permit the hyaloidotomy. It may be kept for 1 or 2 s in the anterior vitreous space to ensure the IZHV path is adequately cleared (Fig. 15.3d). It is then withdrawn back into the anterior chamber and out of the eye on position 2 to avoid vitreous incarceration and prolapse. Throughout

this time, irrigation is maintained as needed through a separate cannula. The foot pedal is then moved to position 0 (no irrigation) leaving the irrigation cannula in the anterior chamber. Viscoelastic is injected to maintain the AC prior to removal of the irrigation cannula. Wounds are sutured to ensure AC stability postoperatively as any further decompression may result in vitreous prolapse into the IZHV, which could potentially block flow of aqueous and cause the procedure to fail. As viscoelastic will be left in the anterior chamber at the conclusion of the case, one must be prepared to manage IOP postoperatively. Medical therapy with topical agents and oral acetazolamide are generally adequate.

To perform an IZHV from a posterior or pars plana approach, the surgeon would inject subconjunctival lidocaine in a quadrant, then perform a limbal peritomy and conjunctival dissection in that quadrant. Caution is used for hemostasis and an MVR blade can be used to enter pars plana 3 mm from the limbus. Care must be taken to avoid the long ciliary arteries when choosing an entry site. The MVR blade should be angled toward the optic nerve, and it may be easier to visualize this angle if the eye is held in primary position rather than angled away. The tip of the MVR blade should be seen through the pupil before it is withdrawn. Alternatively, a sutureless trochar system can be used to create beveled pars plana access incisions. A paracentesis is then created at the limbus and can be used as needed to provide manual irrigation with BSS or viscoelastic. A second paracentesis is fashioned. The cutter is initially introduced into the anterior chamber through one paracentesis and with port facing posteriorly, is used to create a controlled opening in the iris peripherally, avoiding the long ciliary vessels at 3:00 and 9:00 (Fig. 15.4a). The vitrectomy cutter is then introduced into the anterior vitreous space with the port facing posteriorly such that it can be visualized through the pupil. The foot pedal is depressed to position 3 and the cutter is held stationary for 5–10 s to remove anterior vitreous (Fig. 15.4b). Once the local vitreous has been removed, the foot pedal can be withdrawn to position 2 and moved peripherally underlying the iris opening (Fig. 15.4c). The pedal is depressed to position 3 as the cutter is

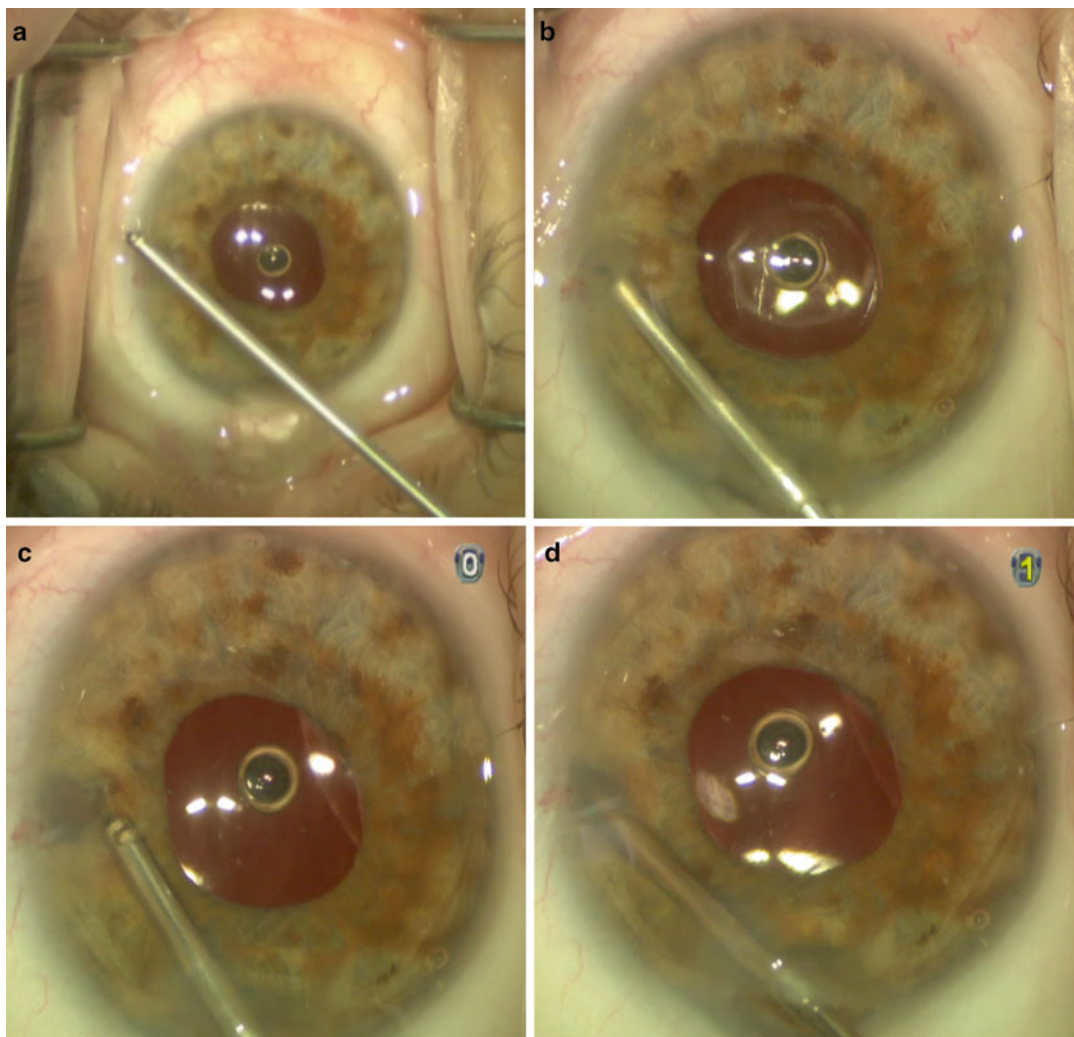


Fig. 15.3 Anterior approach IZHV. (a) A 23 gauge vitrectomy cutter shown outside the eye; (b) the cutter is with port down to remove a small amount of iris; (c) the port is then turned up to enable visualization; (d) the cutter is passed through the iris opening and anterior hyaloid and zonules are removed to create a unicameral eye

advanced anteriorly through hyaloid, zonules, and until it is passed through the iris opening into the anterior chamber (Fig. 15.4d). The pedal is then moved to position 2 (irrigation-cut) and withdrawn back into the posterior segment after which one can move the foot pedal to position 0 (no irrigation). If used, any irrigation is then stopped and while maintaining the cutter in the eye, viscoelastic can be injected into the anterior chamber, paying attention to tamponade the newly created IZHV pathway (Fig. 15.4e). This prevents vitreous prolapse through the

IZHV. Following this, the cutter is withdrawn from the pars plana incision site on position 2 (irrigation-cut) to avoid vitreous incarceration. Any vitreous at the pars plana incision site is cleaned by placing the cutter port down and returning to position 3 on the foot pedal. The pars plana incision is closed using an 8-0 vicryl suture (Ethicon Inc, Somerville NJ, USA) passed in a figure-8 pattern and the corneal incision can be sutured if needed. If a sutureless trochar system is used, the cutter and trochar can be removed using a toothed forceps then pressure is applied

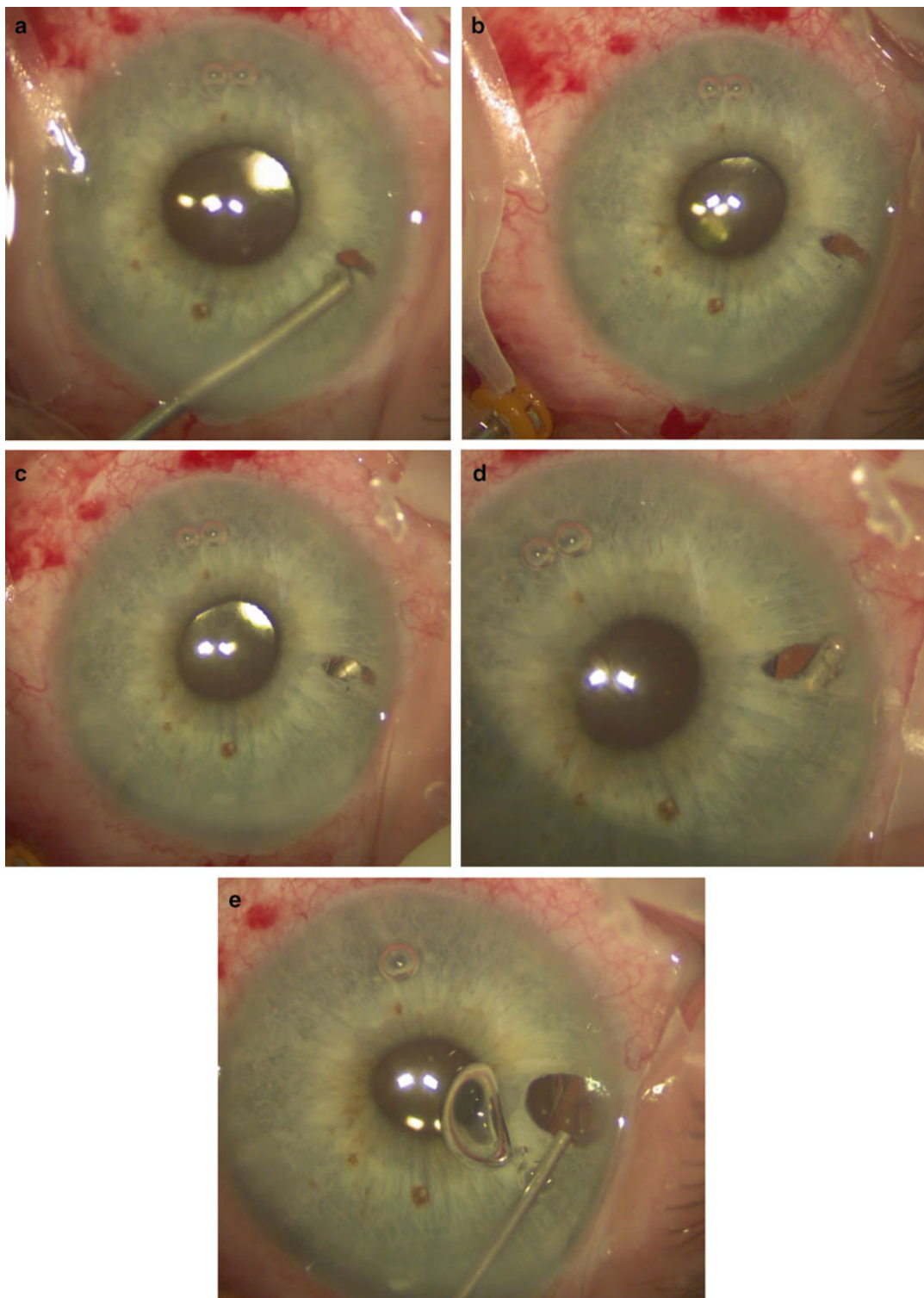


Fig. 15.4 Posterior approach IZHV. (a) A 23 gauge vitrectomy cutter in the anterior chamber with port down creating an iris opening at the intended IZHV site; (b) the cutter is introduced through pars plana and advanced until seen through the pupil where a limited anterior vitrectomy is carried out; (c) the cutter is

advanced until seen through the iris opening; (d) the cutter is advanced anteriorly through the iris opening while removing hyaloid and zonules to create a unicameral eye; (e) viscoelastic is used to tamponade the IZHV and maintain the AC prior to withdrawing the cutter and closing incisions

using a weck cell to limit fluid outflow and the possibility of vitreous incarceration.

A core vitrectomy alone will not resolve malignant glaucoma and when referring patients to a retina colleague for this procedure, it is imperative that they pass their cutter from the vitreous space, through the hyaloid and into the anterior chamber creating a unicameral eye.

When needed, surgical IZHV can be combined with goniosynechialysis to address PAS. In cases with underlying trabecular meshwork dysfunction, further IOP lowering therapy including medications or surgery may be required.

15.6.4 Additional Treatments

External cyclophotocoagulation (CPC) has been described as a potential treatment for malignant glaucoma [2]. While it may help to control IOP, it does not necessarily address the underlying progressive anterior chamber shallowing which results in myopia, PAS, and sometimes corneal decompensation. As well, in seeing eyes, it may be preferable to choose a nondestructive intervention. CPC may have a role in eyes that have failed IZH and for various reasons may not be amenable to an incisional approach.

Intraoperative malignant glaucoma can be challenging to manage. If mild, supercohesive viscoelastics such as Healon5 (Abbott Medical Optics, Abbot Park, IL, USA) can be helpful. In more severe cases, it may not be possible to reposit prolapsed iris. In such situations, the immediate goal is to decompress the vitreous allowing the surgeon to reposit iris and if possible complete the surgery. This can be achieved using the pars plana approach described previously to remove a small amount of vitreous. By decompressing the vitreous space, the surgery can be completed. At the conclusion of the surgery, the cutter can be reintroduced and used to perform the IZH. Alternatively, the eye can be closed and if malignant glaucoma occurs postoperatively, it can be managed using the stepwise approach described. For surgeons who are not comfortable with the pars plana approach,

intravenous Mannitol (500 mL of 20 % Mannitol given over 30–45 min) can be given to deturgesce the vitreous and allow iris to be repositioned.

15.7 Conclusion

Malignant glaucoma presents with progressive anterior chamber shallowing, myopia and may be accompanied by angle closure with elevated IOP. Decompression in a susceptible eye is thought to be the inciting event. It may be possible to prevent malignant glaucoma by avoiding anterior chamber shallowing during surgery through effective chamber maintenance during instrument changes and filtration ostium creation as well as judicious wound closure. Treatment of malignant glaucoma aims to create a unicameral eye and a stepwise approach can be followed. Medical therapy consisting of cycloplegics and aqueous suppressants may be adequate in 10 % of cases but typically are helpful to control but not resolve malignant glaucoma. IZH can resolve 35 % of cases and when combined with anterior chamber reformation and IOL pushback a further 30 % of cases can be addressed. 25 % of patients will go on to require surgical IZHV, which is a definitive treatment for malignant glaucoma.

Compliance with Ethical Requirements Devesh K Varma and Iqbal Ike K Ahmed declare that they have no conflict of interest. All procedures followed were in accordance with the ethical standards of the responsible committee on human experimentation (institutional and national) and with the Helsinki Declaration of 1975, as revised in 2000. Informed consent was obtained from all patients for being included in the study. No animal studies were carried out by the authors for this article.

References

1. Von Graefe A. Beitrage zur Pathologie und Therapie des Glaucomas. Albrecht Von Graefes Arch Ophthalmol. 1869;15(1):108–252.
2. Ruben S, Tsai J, Hitchings R. Malignant glaucoma and its management. Br J Ophthalmol. 1997;81(2):163–7.
3. Ahmed IK, Gagne S. Consultation section. Cataract surgical problem. J Cataract Refract Surg. 2009;35(8):1474–8.

4. Quigley HA, Friedman DS, Congdon NG. Possible mechanisms of primary angle-closure and malignant glaucoma. *J Glaucoma*. 2003;12(2):167–80.
5. Quigley HA, Broman AT. The number of people with glaucoma worldwide in 2010 and 2020. *Br J Ophthalmol*. 2006;90:262–7.
6. Foster PJ, Alsbirk PH, Baasanhu J, et al. Anterior chamber depth in Mongolians. Variation with age, sex and method of measurement. *Am J Ophthalmol*. 1997;124:40–53.
7. Trope GE, Pavlin CJ, Bau A, et al. Malignant glaucoma: clinical and ultrasound biomicroscopic features. *Ophthalmology*. 1994;101:1030–5.
8. Dave P, Senthil S, Rao HL, Garudadri CS. Treatment outcomes in malignant glaucoma. *Ophthalmology*. 2013;120(5):984–90. doi:[10.1016/j.ophtha.2012.10.024](https://doi.org/10.1016/j.ophtha.2012.10.024).
9. Varma DK, Belovay GW, Tam DY, Ahmed IK. Malignant glaucoma after cataract surgery. *J Cataract Refract Surg*. 2014;40(11):1843–9. doi:[10.1016/j.jcrs.2014.02.045](https://doi.org/10.1016/j.jcrs.2014.02.045).
10. Ching-Costa A, Chen TC. Malignant glaucoma. *Int Ophthalmol Clin*. 2000;40(1):117–27.
11. Lynch MG, Brown RH, Michels RG, et al. Surgical vitrectomy for pseudophakic malignant glaucoma. *Am J Ophthalmol*. 1986;102(2):149–53.

Index

A

- Ab-externo trabeculectomy, 5, 57
- Ab-interno bleb needling
 - clinical results, 116
 - indications, 113
 - logistic advantages, 115
 - psychological advantages, 115
 - surgical technique, 114–115
 - trans-corneal needling, 115–116
- Ab interno trabeculectomy (AIT)
 - adjunctive procedure, 22–23
 - benefits, 27
 - combined phaco-trabectome outcomes,
 - 17, 18
 - complications, 25–26
 - disadvantages, 27
 - failed incisional surgery, 21–22
 - Goniosynechiolysis technique, 17
 - indications, 15–16
 - narrow anterior chamber angle,
 - 20–21
 - prospective and retrospective studies, 27
 - in secondary glaucomas
 - failure analysis, 19
 - outcomes, 19
 - pigment dispersion glaucoma, 20
 - prospective study, 19
 - retrospective study, 19
 - weaknesses, 20
 - standalone trabectome outcomes, 17, 18
 - surgical failures
 - argon laser trabeculoplasty, 24
 - lower baseline IOP, 23–24
 - phakic lens status, 24
 - reoperation, 25
 - selective laser trabeculoplasty, 24
 - timing of, 24
 - wrong site ablation, 23
 - trabectome-mediated AIT, 16–17
- Ahmed, I.I.K., 10, 11, 75
- Ahuja, Y., 18, 24
- Anterior chamber tube shunt to encircling band (ACTSEB) surgery, 108

- Anterior segment optical coherence tomography (AS-OCT), 31
- Aqueous misdirection syndrome, 125
- Arriola-Villalobos, P., 10
- Assia, E.J., 61

B

- Bellows, A.R., 119, 122
- Belovay, G.W., 10
- Beltran-Agullo L., 80
- Bleb needling
 - clinical results, 116
 - ex-PRESS mini-glaucoma device, 79
 - indications, 113
 - logistic advantages, 115
 - NPGS, 67
 - psychological advantages, 115
 - surgical technique, 114–115
 - trans-corneal needling, 115–116

C

- Cataract surgery, NTG, 93
- Chiou, A.G., 66
- Choroidal effusions
 - anatomy, 117
 - diagnosis, 118–119
 - hypotony reversal, 121–122
 - inflammatory disorders, 120
 - medical treatment, 121
 - pathophysiology, 119
 - physiology, 117–118
 - postoperative choroidals, 120
 - primary/metastatic tumor, 120
 - sequelae, 119–120
 - surgical indications, 122
 - surgical outcomes, 123
 - surgical technique, 122–123
 - systemic medications, 120
 - uveal effusion syndrome, 120
- Craven, E.R., 9, 10
- Cyclophotocoagulation (CPC), 132

D

Deep sclerectomy, 57
de Jong, L.A., 79, 80

E

Eha, J., 123
Endocycloplasty (ECPL), 74
Endoscopic cyclophotocoagulation (ECP)
 advantages, 73
 indications, 73–74
 surgical outcomes, 75
 surgical technique, 74–75
Ex-PRESS mini-glaucoma device
 history, 77
 surgical outcomes
 aphakic glaucoma patients, 83
 Ex-PRESS vs. trabeculectomy, 79–80
 neovascular glaucoma, 82–83
 prospective studies, 80–81
 Sturge–Weber patients, 83
 uveitic glaucomas, 81–82
 surgical technique
 advantages, 78
 bleb needling, 79
 subacute apparent failure, 79

F

Fea, A.M., 9–11
Fernández-Barrientos, Y., 10
Francis, B.A., 18

G

Gilmour, 68
Glaucoma drainage implant (GDI) surgery
 advantages, 99
 complications
 drainage implant erosion, 104–105
 hypotony, 105
 contraindications, 99
 indications, 99
 postoperative care, 103
 preoperative assessment, 99–100
 surgical outcomes, 103–104
 surgical technique
 conjunctival closure, 103
 conjunctival incision, 101
 keratoprosthesis and vitrectomy, 102
 plate insertion and suturing, 101–102
 priming the tube, 101
 scleral reinforcement, 102–103
 subconjunctival/tenon's dissection, 101
 traction suture, 100–101
 tube insertion, 102
Glaucoma surgery algorithm, 43
Glaukos iStent® trabecular micro-bypass stent, 6
Gonioscopy assisted transluminal trabeculectomy (GATT)
 intraoperative evaluation, 45

 postoperative evaluation and care, 45–46
 preoperative evaluation, 42
 surgical outcomes
 complications, 48, 49
 efficacy data, 48
 POAG and PXF, 46
 study groups, demographic information, 47
 tube vs. trabeculectomy study, 46
 surgical procedure, 42–45
Goniosynechiolysis technique, 17
Grover, D.S., 47

H

Hagen Poiseuille Equation, 51, 54
Huh, E.S., 103, 104

I

Ikeda, T., 46
Ioannidis, A.S., 122
Iridocorneal endothelial (ICE)
 syndrome, 64
Iridozonulohyaloidotomy (IZH), 128
Iridozonulohyaloidotomy with vitrectomy (IZHV),
 128–132
Iwao, K., 46

J

Jacobi, P.C., 35
Jea, S.Y., 18, 26
Jehn, 68
Johnston, R.L., 35

K

Klamann, M., 18
Kobuch, K., 6
KPro surgery, 99. *See also* Glaucoma drainage
 implant (GDI) surgery
Kzakova, 62

L

Lam, D.S., 32
Laser assisted deep sclerectomy, 61
Laser trabeculoplasty, NTG, 93–94
Law, S.K., 104
Lee, K.S., 109, 111
Lens extraction in PACG
 anatomical risk factors, 32–34
 cataract surgery, 34
 with goniosynechiolysis/viscogonioplasty, 34
 pathophysiology, 31–32
 phaco-trabeculectomy, 34–35
 pre-operative complications
 biometry considerations, 36
 lens selection, 36
 potential risks, 35–36

surgical technique
 anaesthesia, 36
 anterior chamber, 36–37
 continuous curvilinear capsulorrhexis, 37
 hydrodissection, 37
 timing, 35
 Lowering intraocular pressure (IOP), 41
 Low-tension glaucoma. *See* Normal tension glaucoma (NTG)

M

Maeda, M., 18
 Malignant glaucoma
 anterior chamber reformation, 128
 diagnosis, 125–126
 external cyclophotocoagulation, 132
 intraocular lens pushback, 128
 iridopzonulohyaloidotomy, 128
 IZHV
 anterior approach, 129, 130
 automated irrigation cannula, 129
 goals, 128
 pars plana approach, 129
 phacoemulsification, 128
 posterior approach, 130, 131
 medical treatment, 127
 pathophysiology, 126
 prevention, 127
 Microinvasive glaucoma surgery (MIGS)
 ab externo glaucoma procedures, 5
 ab interno approach, 5
 Glaukos iStent® trabecular micro-bypass stent, 6
 NTG, 94
 reduce IOP, 5
 trabecular bypass stent, 6
 trabeculectomy vs. physiologic outflow, 42
 Minckler, D., 18
 Mitomycin C (MMC), 54
 Modified Schocket procedure, 108
 complications, 111
 modifications and alternatives, 110
 retinal detachment surgery, 107
 scleral buckling, 107, 108
 surgical outcomes, 110–111
 surgical technique, 108–110
 vitrectomy, 107
 Moisseiev, E., 80, 82
 Mosaed, S., 18

N

Netland, P.A., 81
 Nonpenetrating glaucoma surgery (NPGS)
 complications
 anterior chamber, 66
 bleb, 67
 intraocular pressure, 66
 sclerocorneal, 66–67
 TDM and iridocorneal angle, 65

congenital glaucoma, 63
 contraindications, 64
 goniotomy technique, 67
 indications, 62–64
 learning curve, 68
 modification of, 57
 open-angle uveitic glaucoma, 63
 pathophysiology, 61–62
 pseudoexfoliative glaucoma, 63
 Sturge–Weber syndrome, 64
 surgical outcomes, 68
 surgical technique
 canaloplasty, 61
 conjunctival wound, 58
 exposure, 58
 laser assisted deep sclerectomy, 61
 nonresorbable hydrophilic implants, 60
 resorbable implants, 60
 scleral flap and conjunctiva closure, 60
 space-maintaining implants, 60
 superficial rectangular scleral flap, 58
 trabeculectomy ab-externo, 60
 trabeculo–Descemet’s membrane, 58, 59, 61
 viscocanalostomy, 60–61
 uncontrolled aphakic glaucoma, 63
 Normal tension glaucoma (NTG)
 cataract surgery, 93
 endocyclophotocoagulation, 94
 future treatments, 94
 laser trabeculoplasty, 93–94
 microinvasive glaucoma surgery, 94
 postoperative management, 92–93
 preoperative considerations
 automated visual field analysis, 88
 glaucomatous optic neuropathy
 identification, 88
 intraocular pressure targeting, 89
 of patients, 89
 split fixation, 88
 topical medical therapy, 88–89
 surgical technique
 antimetabolites, 91–92
 topical anesthesia, 89
 trabeculectomy with MMC, 90–91
 vascular diseases, 87

O

Open-angle uveitic glaucoma, 63

P

Pars plana approach, 129. *See also* Glaucoma drainage implant (GDI) surgery
 Plateau iris syndrome (PIS), 73
 Pseudoexfoliative glaucoma (PEXG), 63

Q

Quigley, H.A., 118

R

Radcliffe, N.M., 11
Rosier, A., 61

S

Samuelson, T.W., 9, 10
Schocket, S.S., 108
Shaarawy, T., 66, 67
Sidoti, P.A., 108
Spiegel, D., 6, 9, 10
Spraul, C.W., 118
Sturge–Weber syndrome (SWS), 64

T

Tham, C.C., 33, 35
Ting, J., 18
Tixier, 63
Trabectome, 15
Trabectome-mediated AIT surgical technique,
 16–17
Trabecular bypass stent, 6
Trabeculotomy, 41
Tube vs. trabeculectomy study,
 GATT, 46

U

Uncontrolled aphakic glaucoma, 63
Uveal effusion syndrome (UES), 120

V

Varma, D., 34
Vaudaux, J., 61
Vitrectomy
 GDI surgery, 102
 iridopzonulohyaloidotomy, 128–132
 modified Schocket procedure, 107
Voskanyan, L., 10, 11

W

Winarko, J., 18

X

XEN Gel Stent
 advantages, 54
 clinical testing, 54
 Hagen Poiseuille Equation, 51, 54
 lumen size and flow, 51–52
 postoperative bleb morphology, 53–54
 preclinical testing, 54
 surgical technique, 52–53

Y

Yin, Z.Q., 118

Z

Zimmerman, T.J., 57, 63