


# Neurological Clinical Examination

John Morris  
Joseph Jankovic



FREE VIDEO LIBRARY



 **HODDER  
ARNOLD**

210

# Neurological Clinical Examination

*This page intentionally left blank*

# Neurological Clinical Examination

**Professor John GL Morris DM (OXON) FRACP FRCP**

Clinical Professor, University of Sydney

Past Chairman of the Education and Training Committee of the Australian and New Zealand Association of Neurologists

Past Examiner for the Royal Australasian College of Physicians

Past Head of the Neurology Department, Westmead Hospital, Past President of the Australian Association of Neurologists, Sydney, Australia

**Professor Joseph Jankovic MD**

Professor of Neurology

Distinguished Chair in Movement Disorders

Director, Parkinson's Disease Center and Movement Disorders Clinic

Co-Director, Parkinson's Disease Research Laboratory,

Past President of the Movement Disorders Society,

Department of Neurology, Baylor College of Medicine, Houston, Texas, USA



AN HACHETTE UK COMPANY

CRC Press  
Taylor & Francis Group  
6000 Broken Sound Parkway NW, Suite 300  
Boca Raton, FL 33487-2742

© 2012 by Taylor & Francis Group, LLC  
CRC Press is an imprint of Taylor & Francis Group, an Informa business

No claim to original U.S. Government works  
Version Date: 20150220

International Standard Book Number-13: 978-1-4441-4539-7 (eBook - PDF)

This book contains information obtained from authentic and highly regarded sources. While all reasonable efforts have been made to publish reliable data and information, neither the author[s] nor the publisher can accept any legal responsibility or liability for any errors or omissions that may be made. The publishers wish to make clear that any views or opinions expressed in this book by individual editors, authors or contributors are personal to them and do not necessarily reflect the views/opinions of the publishers. The information or guidance contained in this book is intended for use by medical, scientific or health-care professionals and is provided strictly as a supplement to the medical or other professional's own judgement, their knowledge of the patient's medical history, relevant manufacturer's instructions and the appropriate best practice guidelines. Because of the rapid advances in medical science, any information or advice on dosages, procedures or diagnoses should be independently verified. The reader is strongly urged to consult the relevant national drug formulary and the drug companies' and device or material manufacturers' printed instructions, and their websites, before administering or utilizing any of the drugs, devices or materials mentioned in this book. This book does not indicate whether a particular treatment is appropriate or suitable for a particular individual. Ultimately it is the sole responsibility of the medical professional to make his or her own professional judgements, so as to advise and treat patients appropriately. The authors and publishers have also attempted to trace the copyright holders of all material reproduced in this publication and apologize to copyright holders if permission to publish in this form has not been obtained. If any copyright material has not been acknowledged please write and let us know so we may rectify in any future reprint.

Except as permitted under U.S. Copyright Law, no part of this book may be reprinted, reproduced, transmitted, or utilized in any form by any electronic, mechanical, or other means, now known or hereafter invented, including photocopying, microfilming, and recording, or in any information storage or retrieval system, without written permission from the publishers.

For permission to photocopy or use material electronically from this work, please access [www.copyright.com](http://www.copyright.com) (<http://www.copyright.com/>) or contact the Copyright Clearance Center, Inc. (CCC), 222 Rosewood Drive, Danvers, MA 01923, 978-750-8400. CCC is a not-for-profit organization that provides licenses and registration for a variety of users. For organizations that have been granted a photocopy license by the CCC, a separate system of payment has been arranged.

**Trademark Notice:** Product or corporate names may be trademarks or registered trademarks, and are used only for identification and explanation without intent to infringe.

Visit the Taylor & Francis Web site at  
<http://www.taylorandfrancis.com>

and the CRC Press Web site at  
<http://www.crcpress.com>

To study ... disease without books is to sail an uncharted sea, while  
to study books without patients is not to go to sea at all.

*William Osler*

William B. Bean (ed.) (1950) *Sir William Osler Aphorisms*. Henny  
Schuman, Inc., New York. p.76.

*This page intentionally left blank*

# Contents

Foreword to the Third Edition	ix
Foreword to the First Edition	xi
Preface to the Third Edition	xiii
Preface to the First Edition	xv
Acknowledgements	xvii
Abbreviations	xix
Picture credits	xxi
Using this book	xxiii
Introduction	xxv
<b>1 The wasted hand</b>	<b>1</b>
<b>2 Wrist drop</b>	<b>9</b>
<b>3 Proximal weakness of the arm(s)</b>	<b>13</b>
<b>4 Proximal weakness of the leg(s)</b>	<b>20</b>
<b>5 Foot drop</b>	<b>24</b>
<b>6 Ataxia and gait disturbance</b>	<b>30</b>
<b>7 Facial palsy</b>	<b>40</b>
<b>8 Ptosis</b>	<b>48</b>
<b>9 Abnormalities of vision or eye movement</b>	<b>53</b>
<b>10 Tremor and cerebellar signs</b>	<b>67</b>
<b>11 Other abnormal involuntary movements</b>	<b>75</b>
<b>12 Speech disturbance</b>	<b>88</b>
<b>13 Higher function testing</b>	<b>95</b>
<b>14 Assessment of coma</b>	<b>103</b>
<b>15 Psychogenic disorders</b>	<b>109</b>
Index of videos	<b>115</b>
Index	<b>123</b>

This book includes QR codes which give you instant access to useful video clips. To use the QR codes you need to have a smartphone which has a camera and a QR code reader app installed.



*This page intentionally left blank*

# Foreword to the Third Edition

The rites of passage from student to graduation, acceptance as a physician and then neurologist, follow much the same pattern in Australia, the United Kingdom and the United States of America. Whereas in practice the history directs physical examination, candidates in a clinical examination may be confronted with a problem as a 'short case', perhaps a single physical sign, to interpret and present a spot diagnosis or a logical approach to investigations and management. Quick thinking is aided by a mental autocue to be rolled out of our brain when required.

In the many years I have known John Morris, he has assiduously recorded physical signs, the history and their significance. When the affected part was stationary, he photographed it. If it moved he took a video. In this way he has built up a collection of clinical signs that has added to his reputation as a teacher and examiner. Earlier editions of this book have proved popular as a supplement to practical work in the ward and clinic as well as being useful as a refresher course before clinical examinations.

John Morris' teaming with Joseph Jankovic in presenting this new edition is a particularly happy one because of their mutual interest in movement disorders which culminated in the video collection presented here.

James W Lance  
AO CBE MD FRCP FRACP FAA

Professor Emeritus of Neurology, University of New South Wales and Honorary Consultant Neurologist at the Prince of Wales Hospital, Sydney, Australia

Past president of the Australian Association of Neurologists is (now the Australian and New Zealand Association of Neurologists).

Fellow of the Australian Academy of Science

Past Vice President of the World Federation of Neurology

Honorary Member of the American Neurological Association and the Association of British Neurologists

Corresponding International Member of the European Federation of Neurological Societies

Regent Member of the American Headache Society, Past President of the International headache Society

# Foreword to the First Edition

If medical professional life were the Grand National, the MRCP (or FRACP) would be Beecher's Brook – a daunting obstacle approached with caution, attempted with panic and surmounted with relief. Anything which makes this barrier less formidable, even to those on their third or fourth circuit of the course, is to be welcomed.

Dr Morris is a master of the old-fashioned art of clinical observation and examination, and is renowned as a teacher of the subject. His wide experience both as practising clinician, instructor and examiner, makes him a particularly suitable choice as an author of a book of this kind.

It is clearly written, well-illustrated and full of sensible, practical guidance, not only to those taking examinations for whom the neurology case is a particular dread, but for general physicians faced with everyday clinical problems. Even professional neurologists could scan its pages with profit and enjoyment.

Dr RW Ross Russell

Past President of the Association of British Neurologists

*This page intentionally left blank*

# Preface to the Third Edition

Time is short and the neurological examination can be long. To make the best use of your time, you need to be able to tailor the examination to the problem in hand. That is what distinguishes the neurological examination from those involving the cardiovascular, respiratory or gastro-intestinal systems where the same general system of examination suffices in most cases. This book outlines an approach to seeking the key clinical signs relevant to those problems uncovered in the course of taking the history. This approach is based on the most likely diagnoses as well as neuro-anatomical considerations.

In its first two editions, the book was aimed primarily at candidates sitting for clinical examinations (in its other sense). It has now been broadened to provide guidance for anyone seeking to improve their skills in the neurological examination. Chapters on assessment of the comatose patient and on psychogenic disorders have been added. These changes have been made in collaboration with my distinguished colleague, Joseph Jankovic, of Baylor College of Medicine, Houston, Texas, who is known throughout the world as a master clinician, particularly in the field of movement disorders.

*This page intentionally left blank*

# Preface to the First Edition

Most people studying for clinical vivas in medicine dread the neurology case. Unlike cardiology, respiratory medicine or gastroenterology, there is no standard approach in neurology which is appropriate for most cases. In its entirety, the neurological examination is very time consuming; the skill lies in knowing which aspects of the examination deserve particular attention in a given case. This little book offers a simple approach to the assessment of a number of neurological problems which crop up in examinations and everyday practice.



*This page intentionally left blank*

# Acknowledgements

John Morris thanks his colleagues for their help in producing The Neurology Short Case, out of which this book has grown: Dr Elizabeth McCusker, Professor John King, Professor Christian Lueck, Dr Rick Boyle, Dr Mariese Hely, Dr Susie Tomlinson, Professor Philip Thompson, Dr Nicholas Cordato, Professor Victor Fung (who also helped greatly with the video material); Shanthi Graham (funded in part by the Westmead Charitable Trust), who worked with him over many years on the video database and produced the video clips; Dr Roly Bigg who, through his Movement Disorder Foundation, provided financial support and encouragement to build the video database; ANZAN for helping with the funding of the video database; Faith Oxley for the figures which she drew and the following colleagues for their comments and advice on the first edition: Dr Leo Davies, Dr Jonathon Ell, Dr Ron Joffe, Dr Michael Katekar, Dr Jonathon Leicester, Dr Ivan Lorentz, Professor James McLeod, Dr Dudley O'Sullivan, Dr Ralph Ross Russell, Dr Tom Robertson, Dr Raymond Schwartz, Dr Ernest Somerville and Dr Grant Walker.

Drs Grant Walker, Jon Leicester, Professors Alasdair Corbett, Yugan Mudaliar and Richard Stark provided helpful comments on the new chapter on coma.

Professor Jankovic thanks John Morris for inviting him to join in the writing of this guide to the clinical examination and to contribute additional illustrative and instructive videos. These videos were selected from a library of over 30 000 videos collected at the Parkinson's Disease Center and Movement Disorders Clinic, Baylor College of Medicine over more than three decades.

*This page intentionally left blank*

# Abbreviations

<b>ADM</b>	abductor digiti minimi
<b>ANA</b>	antinuclear antibody
<b>ANCA</b>	anti-neutrophil cytoplasmic autoantibodies
<b>ANF</b>	anti-nuclear factor
<b>APB</b>	abductor pollicis brevis
<b>A-R</b>	Argyll Robertson
<b>ASOT</b>	anti-streptolysin-O-antibody
<b>AVM</b>	arteriovenous malformation
<b>COMT</b>	catechol-ortho-methyltransferase
<b>CPAP</b>	continuous positive airway pressure
<b>CPK</b>	creatine phosphokinase
<b>CRP</b>	C-reactive protein
<b>CSF</b>	cerebrospinal fluid
<b>CT</b>	computed tomography
<b>DCI</b>	decarboxylase inhibitor
<b>DI</b>	dorsal interosseous
<b>DLBD</b>	diffuse Lewy body disease
<b>DVT</b>	deep vein thrombosis
<b>ECG</b>	electrocardiograph
<b>EEG</b>	electroencephalography
<b>EMG</b>	electromyography
<b>ENA</b>	extractable nuclear antigens
<b>ESR</b>	erythrocyte sedimentation rate
<b>FBP</b>	full blood picture
<b>HIV</b>	human immunodeficiency virus
<b>INO</b>	internuclear ophthalmoplegia
<b>LFTs</b>	liver function tests
<b>MND</b>	motor neurone disease
<b>MRA</b>	magnetic resonance angiography
<b>MRI</b>	magnetic resonance imaging
<b>MSA</b>	multiple system atrophy
<b>PEG</b>	percutaneous endoscopic gastrostomy
<b>PSP</b>	progressive supranuclear gaze palsy
<b>SCA</b>	spinocerebellar ataxia
<b>SLE</b>	systemic lupus erythematosus
<b>SPECT</b>	single-photon emission computed tomography
<b>SSEPs</b>	somatosensory evoked potentials
<b>SSPE</b>	subacute sclerosing panencephalitis
<b>SSRIs</b>	selective serotonin re-uptake inhibitors
<b>VDRL</b>	Venereal Disease Research Laboratories (test)

*This page intentionally left blank*

# Picture credits

- Fig. 1.6** Adapted with permission from Fig. 27 of *Aids to the Examination of the Peripheral Nervous System*, London, BaillièreTindall, 1986.
- Fig. 1.7** Adapted with permission from Fig. 4.78a of Spillane JD and Spillane JA, *An Atlas of Clinical Neurology*, 3rd edn, Oxford, OUP, 1982.
- Fig. 1.8** Adapted with permission from Fig. 76 of *Aids to the Examination of the Peripheral Nervous System*, London, BaillièreTindall, 1986.
- Fig. 1.9** Adapted with permission from Fig. 36 of *Aids to the Examination of the Peripheral Nervous System*, London, BaillièreTindall, 1986.
- Fig. 1.11** Adapted with permission from Fig. 87 of *Aids to the Examination of the Peripheral Nervous System*, London, BaillièreTindall, 1986.
- Fig. 2.1** Adapted with permission from Fig. 15 of *Aids to the Examination of the Peripheral Nervous System*, London, BaillièreTindall, 1986.
- Fig. 2.3** Adapted with permission from Fig. 72 of *Aids to the Examination of the Peripheral Nervous System*, London, BaillièreTindall, 1986.
- Fig. 3.1** Adapted with permission from Fig. 11 of Jamieson EB, *Illustration of Regional Anatomy*, Section VI, Edinburgh, E & S Livingston.
- Fig. 3.2** Adapted with permission from Fig. 1 of Jamieson EB, *Illustration of Regional Anatomy*, Section VI, Edinburgh, E & S Livingston.
- Fig. 4.1** Adapted with permission from Fig. 46 of *Aids to the Examination of the Peripheral Nervous System*, London, BaillièreTindall, 1986.
- Fig. 5.1** Adapted with permission from Fig. 4.34d of Spillane JD and Spillane JA, *An Atlas of Clinical Neurology*, 3rd edn, Oxford, OUP, 1982.
- Fig. 5.2** Adapted with permission from Fig. 47 of *Aids to the Examination of the Peripheral Nervous System*, London, BaillièreTindall, 1986.
- Fig. 5.3** Adapted with permission from Fig. 83 of *Aids to the Examination of the Peripheral Nervous System*, London, BaillièreTindall, 1986.
- Fig. 5.4** Adapted with permission from Fig. 84 of *Aids to the Examination of the Peripheral Nervous System*, London, BaillièreTindall, 1986.
- Fig. 5.5** Adapted with permission from Fig. 2.11 of Donaldson JO, *Neurology of Pregnancy*, 2nd edn, WB Saunders, 1989.
- Fig. 5.6** Adapted with permission from Fig. 89 of *Aids to the Examination of the Peripheral Nervous System*, London, BaillièreTindall, 1986.
- Fig. 5.7** Adapted with permission from Fig. 90 of *Aids to the Examination of the Peripheral Nervous System*, London, BaillièreTindall, 1986.
- Fig. 6.1** Adapted with permission from figures in Inman V, Human locomotion, *Canadian Medical Association Journal*, 1966;94: 1047–54.
- Fig. 6.3** Both adapted with permission from Fig. 18.2 of Mumenthaler M, *Neurological Differential Diagnosis*, New York, Thieme-Stratton, 1985.

- Fig. 7.1** Adapted with permission from Fig. 7.69 of Williams PL, Warwick R, *Functional Neuroanatomy of Man*, Edinburgh, Churchill Livingstone, 1986.
- Fig. 9.1** Adapted with permission from Fig. 8.3 of McLeod J, Munro J (eds), *Clinical Examination*, 7th edn, Edinburgh, Churchill Livingstone, 1986.
- Fig. 9.3** Adapted with permission from Fig. 3.9 of Duus P, *Topical Diagnosis in Neurology*, 2nd rev edn, Stuttgart, Georg ThiemeVerlag, 1983.
- Fig. 12.1** Adapted with permission from Goodglass H, Kaplan E, *The Boston Diagnostic Aphasia Examination Booklet*, Philadelphia, Lea and Febinger, 1983.

# Using this book

The boxes throughout this book alert you to the free-to-access accompanying video content available online.

You can view these through your usual internet browser by going to [www.hodderplus.com/nce](http://www.hodderplus.com/nce) and clicking on the video of your choice, or you can access the videos directly, using a QR Code reader.

There are many free QR Code readers available dependent on the smartphone/tablet you are using. We have supplied some suggestions below of well-known QR readers, but this is not an exhaustive list and you should only download software compatible with your device and operating system. We do not endorse any of the third-party products listed below and downloading them is at your own risk:

**iphone/ipad** Qrafter - <http://itunes.apple.com/app/qrafter-qr-code-reader-generator/id416098700>

**Android** QR Droid - <https://market.android.com/details?id=la.droid.qr&hl=en>

**Blackberry** QR Scanner Pro - <http://appworld.blackberry.com/webstore/content/13962>

**Windows/Symbian** Upcode - <http://www.upc.fi/en/upcode/download/>



*This page intentionally left blank*

# Introduction

In this age of ever more sophisticated technology, reliance is increasingly placed on imaging, laboratory tests and electrophysiology when making a diagnosis. Inevitably, less emphasis is placed on the old-fashioned skills of history taking and clinical examination. This is even the case in neurology, where the physical examination is widely regarded as time-consuming and laborious. Yet the foundation for a sound diagnosis in neurology remains, as it always has, on the clinical assessment. The physical examination does not need to be time-consuming and laborious. The secret of the effective neurological examination lies in the ability to select those aspects of it which are relevant to each patient. Neurology is unique among the various clinical specialities in that it relies on localization of the lesion or recognition of the phenomenology before arriving at the correct diagnosis and cause. To tailor the examination successfully to the problem at hand requires a careful and detailed present, past, family and social history from the patient and this, in most cases, will take up far more time than the physical examination. While the diagnosis is often apparent after eliciting the history, and the examination is merely confirmatory, the clinician must be familiar with and skilled in the art of examination as this is not only an essential element of the evaluation, but it also engenders confidence by the patient in the thoroughness of the physician.<sup>1</sup>

In the chapters that follow, a simple approach to the physical examination of patients with a number of common problems will be outlined.

## Technique

A brief examination can still be systematic and, as a rule, it is good to do things in the same order to lessen the chances of leaving something important out:

- **Inspection.** You can learn a great deal by observing patients as they enter the room and while you are taking the history. Note the gait, posture, demeanour, speech, facial expression, eye movements and speech. If involuntary movements are present, note their distribution and whether they are regular in timing and rhythm (tremor), rapid and irregular (chorea, tics, myoclonus) or more sustained and patterned (the same group of muscles is always involved as in dystonia).

1. Johnston SC, Hauser SL. The beautiful and ethereal neurological exam: an appeal for research. *Annals of Neurology* 2011; **70**(2): A9–A10.

- **Tone** refers to the resistance encountered in muscles when the limbs are put through a range of *passive* movements. Unfortunately, many patients try to make the doctor's task easier by actively moving their limbs during testing. Other patients resist the movements, particularly if they have not been put at ease. Active resistance against passive movement is also seen in patients with psychogenic dystonia. When testing the tone in the limbs, you should distract patients by talking to them for example about their social history. In order to elicit subtle arm rigidity in patients with suspected parkinsonism ask them to repeatedly extend and flex the opposite arm at the elbow while 'feeling' for increased resistance or cogwheeling in the tested arm. A slight increase in tone occurs with this manoeuvre in normal subjects, but in Parkinson's disease the increase may be striking and may bring out rigidity, cogwheeling or both that would not be otherwise appreciated. When testing for subtle rigidity in the legs, ask the patient to perform the repeated extension–flexion manoeuvre in the opposite arm. A useful technique in the lower limb is, with the patient lying, to roll the leg at the hip and, occasionally and without warning, to lift the knee off the bed. If the heel also lifts off the bed, tone is increased. Describe the tone as normal or increased. Hypotonia is probably not a valid term, for in a fully relaxed normal subject, no resistance is detectable to passive movement.
- **Muscle power** is tested using the techniques illustrated in *Aids to the Examination of the Peripheral Nervous System* (5th edn, WB Saunders, 2010) or *DeJong's The Neurologic Examination* (6th edn, Lippincott Williams and Wilkins, 2005). These are designed in such a way that, in most cases, you will overcome a particular muscle only if it is weak. This makes the assessment of muscle power more objective. Some muscles are more useful to test than others. Again, it is good to get into the habit of testing muscles in a certain order as this will lessen the risk of leaving an important one out. The most useful muscles to test in the limbs are:
  - *Arms*: deltoid, biceps, triceps, brachioradialis, wrist extensors, finger extensors and flexors, abductor pollicis brevis, abductor digiti minimi and first dorsal interosseous.
  - *Legs*: gluteus maximus, iliopsoas, quadriceps, hamstrings, anterior tibial group, gastrocnemius/soleus, tibialis posterior and the peroneal muscles.
- **Coordination**. In the upper limbs, the most sensitive way of demonstrating *cerebellar incoordination* is to get patients to try to slap their thigh alternately with the palm and back of the hand and listen to the rhythm. In cerebellar dysdiokokinesia, the rhythm is typically irregularly irregular. The finger-to-nose test may reveal ataxia as the finger approaches the target. Bradykinesia associated with Parkinson's disease or other parkinsonian disorders is best tested by asking the patient to repeatedly and in rapid succession tap the thumb with the tip of the index finger, flex and extend the fingers, pronate–supinate the hands, tap the heels when

the patient is seated and by repeatedly flexing–extending the hip, and tapping the toes with the heels resting on the floor. In contrast to weakness, which results in persistent slowness of rapid succession movements, patients with parkinsonian bradykinesia have a gradually decrementing amplitude with eventual complete cessation of movement (freezing) where there is more severe bradykinesia. Lower-limb coordination is tested by getting the patient to run the heel up and down the shin (heel-to-shin manoeuvre). Finally, observing the patient during normal walking and walking in tandem is a useful way of testing leg and axial coordination. For further information on how to test patients with parkinsonism using the Unified Parkinson's Disease Rating Scale and other rating scales to assess various movement disorders, visit [www.movementdisorders.org/publications/rating\\_scales/](http://www.movementdisorders.org/publications/rating_scales/).

- Be careful how you interpret incoordination in a patient in whom you have demonstrated muscle weakness. Patients with weak muscles find tests of coordination difficult to perform. As a rule, it is better to assume that incoordination, in the presence of muscle weakness, is due to that cause unless the weakness is minimal and the incoordination gross. Loss of proprioception may also cause incoordination.
- **Reflexes**, deep tendon, cutaneous and nociceptive, are crucial in determining the likely location of the lesion and the diagnosis. It is often difficult to elicit the ankle jerks in the elderly due to poor relaxation. Do not accept that a reflex is absent until you have tapped the Achilles tendon with the patient kneeling on a chair and done the Jendrassik reinforcement. For the upper-limb reflexes, get the patient to make a fist with the other hand, or clench the teeth; for the lower-limb reflexes, ask the patient to hook their hands together in a monkey grip and to try to pull them apart on command. The manoeuvre is most effective if the tendon is tapped immediately after the command to pull. In addition to the deep tendon reflexes, it is also important to try to elicit the Babinski sign or the extensor plantar response. When present, as evidenced by extension and fanning of the toes in response to nociceptive stimulation of the lateral aspect of the sole of the foot, the Babinski sign provides evidence for a lesion in the corticospinal or pyramidal tract. As some patients are unusually sensitive (ticklish) and have a nonspecific withdrawal response, it is helpful to use other supportive signs of corticospinal or pyramidal tract involvement. These include toe-extension signs, such as the Chaddock sign (elicited by stimulating the lateral aspect of the foot), Oppenheim sign (elicited by applying pressure to the anterior aspect of the tibia), or the Gordon sign (elicited by applying deep pressure to the calf muscles). In contrast, the Rossolimo sign (elicited by tapping the ball of the foot) and the Mendel–Bechterew sign (elicited by stroking the lateral aspect of the dorsum of the foot) result in a slightly delayed, quick plantar flexion of the toes in patients with pyramidal tract lesions.

- **Sensory testing** is the least reliable aspect of the examination and in most cases, not something on which to spend a great time of time. Minor differences in sensation between different parts of the body are common, and are usually of no significance. Perception of sensation is also affected by whether the part of the body being tested is painful or weak. Many patients with, for example, Bell's palsy or trigeminal neuralgia (disorders not usually associated with sensory loss) will say that the skin on the affected side feels different.
- More weight is given to a sensory disturbance if perception of a particular modality appears to be lost rather than altered. Ask the patient to say 'yes' each time the skin is lightly touched (with the eyes shut) and to distinguish between the blunt and sharp ends of a disposable pin applied repeatedly to an area of skin. In testing vibration, confirm that patients really can feel the sensation by asking them when it stops. After a suitable pause, terminate the vibration by touching the end of the tuning fork.
- There are certain circumstances in which you must make time to assess sensation:
  - In a patient with absent ankle jerks and bladder symptoms (suggesting a lesion of the cauda equina), it is essential to test sensation in the lower limbs and particularly in the buttocks.
  - In a patient with a spastic paraparesis, you must look for a sensory level. If there is impaired sensation in the legs, establish the level at which this occurs, moving the stimulus (pin [pain] or finger [touch]) repeatedly from the numb to the normal area. Test the front and back of the limbs and trunk. It is often useful to move a vibrating tuning fork (128 Hz) one segment at a time up the vertebral spines, or to drag the base up the legs and trunk and determine where it begins to feel cold. Cause the tuning fork to vibrate by plucking it between thumb and index finger. Banging it on the bed causes audible vibration and invalidates the test.
  - In a patient with suspected motor neurone disease, it is essential to show that sensation is normal.
- **Screening tests.** These are carried out in a few moments, and allow you to narrow down on a particular part or system for more detailed examination:
  - *Face.* Make a point of observing the patient's facial expressions as you take the history. Listen to their voice. Look particularly for facial asymmetry, craniotomy scars, ptosis, baldness, squint or loss of expression.
  - *Arms.* Ask patients to put their arms out in front of them in the supine position, to hold their arms there for a few moments with the eyes shut, and then to touch their nose with each index finger in turn. This simple manoeuvre will often reveal important clues such as weakness, sensory loss, intention tremor, postural tremor, wrist drop and dystonia.
  - *Legs.* Get the patient to walk in an open space. Observe the posture, arm swing and stride. Note whether the patient walks on a wide base or whether there is

unsteadiness on turning. Ask the patient to walk in tandem (heel to toe). In younger patients, you may ask them to rise from a squatting position (testing proximal power) and to stand on their toes and heels (testing distal power). You should also test balance using the *Romberg's sign* and the *pull test* (see below).

● **Formulation of a diagnosis.** By the time you have finished the examination you should have come to some conclusions on three questions: ‘*Where is the lesion?*’, ‘*What is the phenomenology?*’ and ‘*What is the likely underlying cause?*’ In the letter which you write to the referring doctor, you need to commit yourself to making a diagnosis with, in some cases, a short differential diagnosis. *Don't be a doctor who lists every possible cause and test for fear of being wrong. That helps no one. If you prove to be wrong, then you will have learned something.* Certain patterns of signs are useful in determining the site of the lesion:

- Generalized distal weakness is likely to be due to a peripheral neuropathy. Generalized proximal weakness is likely to be due to a myopathy.
- If a muscle is weak due to a peripheral nerve lesion, then all muscles innervated by that nerve below the site of the lesion will also be weak. For example, if brachioradialis is weak due to a lesion of the radial nerve in the spiral groove of the humerus, then extension of the fingers and wrist must also be weak. If they are not, then the problem must be elsewhere.
- In the case of an upper motor neurone disorder of the leg, the lesion must be above the level of the second lumbar vertebra. Whether the lesion is in the cord or above is determined by examining the upper limbs and cranial nerves.
- If you have decided that the signs suggest a lower motor neurone disorder, it is helpful to consider whether the lesion is likely to be in the anterior horn cell, root, plexus, peripheral nerve, neuromuscular junction or muscle.
- In a cord lesion, reflexes are lost at the level of the lesion and increased below the lesion.
- In a unilateral brainstem lesion above the medulla, there may be ‘crossed’ signs with a cranial nerve lesion ipsilateral to the lesion and hemiparesis contralateral to the lesion.

As students, we were drawn to neurology by the ability of our teachers to make a diagnosis relying almost entirely on their clinical skills. The neurological examination when conducted by a master of the art is a beautiful and ethereal experience.<sup>1</sup> We hope that through using the approaches outlined in the chapters ahead that your neurological examination will go some way to reaching that ideal.

*This page intentionally left blank*

# 1

## The wasted hand

### Inspection 01

### Distribution of wasting 02

### Power, coordination and reflexes 03

This is usually a chronic condition and patients present with weakness of the hand(s) or numbness/tingling. They may have noticed the muscle wasting.

The small muscles of the hand are supplied by the median and ulnar nerves and the C8/T1 roots. In a root lesion, all the small muscles are affected; in a single peripheral nerve lesion, wasting is selective.

## Inspection

Upon noting wasting of the small muscles of the hand, check:

- **The patient's age.** Some loss of muscle bulk is normal in the elderly, but this is symmetrical in the two hands and the wasted muscles are not weak.
- **Arthritis.** This also causes wasting with minimal weakness (allowing for the pain which testing power may induce). Subluxation of the metacarpal bone of the thumb causes selective wasting of the thenar eminence which may be mistaken for a median nerve lesion. Patients with parkinsonism often manifest 'striatal deformities' of the hands and feet which may be wrongly attributed to arthritis. The typical striatal hand deformity consists of flexion of the metacarpophalangeal joints, extension of the proximal interphalangeal joints and flexion of the distal interphalangeal joints without evidence of joint swelling or tenderness (see Fig. 1.1).
- **Pupils.** A smaller pupil with ptosis with lowering of upper eyelid and elevation of the lower eyelid due to weakness of the Müller orbital muscle (Horner's syndrome)<sup>1</sup> on the affected side suggests a C8/T1 root or cord lesion. Inequality of the pupils due to Horner's syndrome is most obvious in a dimly lit room.

1. Johann Friedrich Horner, Swiss ophthalmologist (1831–1886).





**Figure 1.1** Typical striatal hand deformity in a patient with Parkinson's disease, manifested by flexion of the metacarpophalangeal joints, extension of the proximal interphalangeal joints, and flexion of the distal interphalangeal joints. This deformity is often wrongly attributed to arthritis, but there is usually no painful swelling of the joints or other features of osteoarthritis or rheumatoid arthritis.

Because sympathetic innervation and medial longitudinal fasciculus extend caudally to the lower cervical and upper thoracic areas, Horner's syndrome and internuclear ophthalmoplegia are two neuro-ophthalmological signs that may accompany lesions in these anatomical areas.

- **Clawing** of the ring and little fingers (due to weakness of the lumbrical muscles) suggests an ulnar nerve lesion.
- **Fasciculations** suggest motor neurone disease.
- **Length of the two hands** and the size of the thumb nails. Hemi-atrophy (more accurately, hemi-smallness, as it reflects failure of growth rather than wasting) suggests injury to the nervous system in infancy (polio, birth trauma, stroke).
- **Scars** in the arms, especially over the elbow (ulnar nerve trauma).

## Distribution of wasting

Take particular note of three muscles: abductor digiti minimi (ADM); first dorsal interosseous (1st DI); and abductor pollicis brevis (APB) (see Figs 1.2 and 1.3). There are three common patterns of wasting:

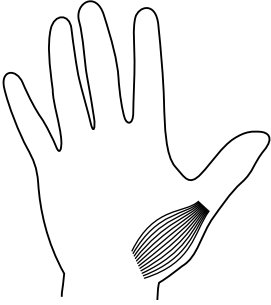


Figure 1.2 Abductor pollicis brevis.

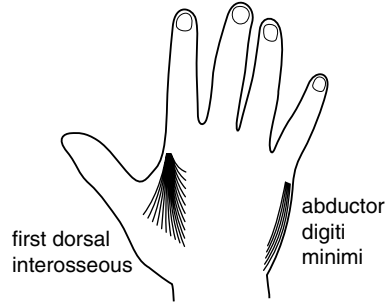


Figure 1.3 First dorsal interosseous and abductor digiti minimi.

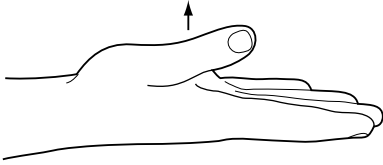


Figure 1.4 Abduction of the thumb.

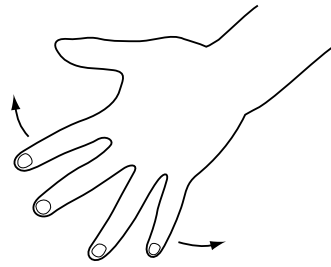


Figure 1.5 Abduction of the fingers.

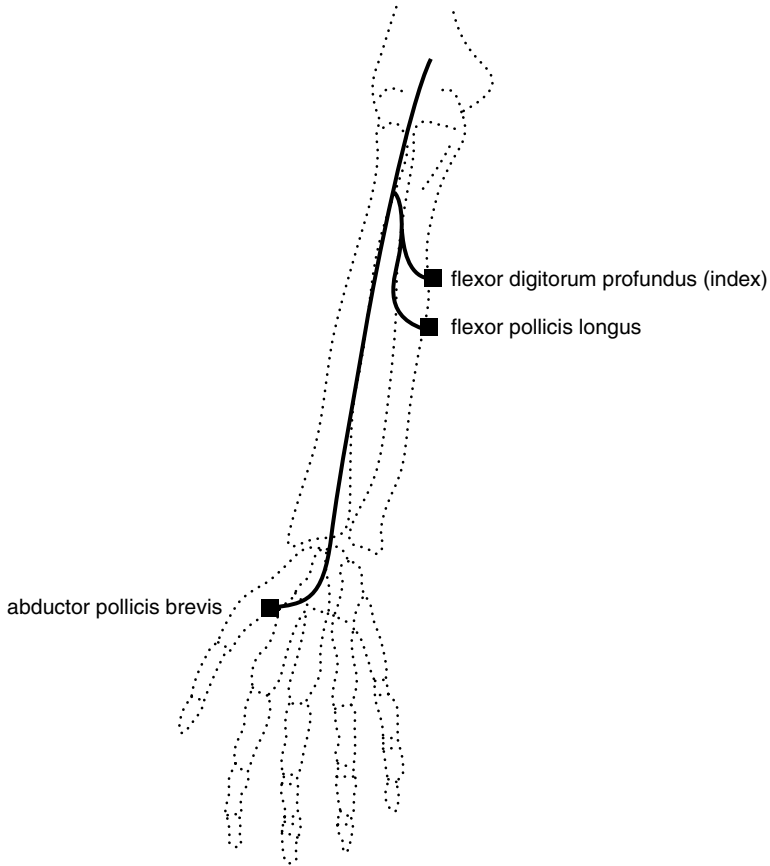
- *Wasting confined to APB.* Usually a median nerve lesion. Rarely due to cervical rib.
- *Wasting confined to ADM and 1st DI.* The patient has an ulnar nerve lesion.
- *Wasting of all three muscles.* Several possibilities (see below).

## Power, coordination and reflexes

After the arm raising screening test, test power in deltoid, biceps, triceps, brachioradialis, wrist extensors, finger extensors and then APB, ADM and 1st DI (Figs 1.4 and 1.5). Test coordination and all the reflexes in the upper limbs. There are three common patterns of weakness:

- Weakness confined to APB is usually due to entrapment of the median nerve at the wrist within the carpal tunnel. If it is due to a lesion at the elbow, there will also be weakness of the deep flexors of the index finger and of flexor pollicis longus (Fig. 1.6). Ask the patient to make a fist; he or she may have the ‘Benediction sign’<sup>2</sup> (Fig. 1.7a). Test power in the terminal phalanges of the index

2. Confusingly, the Benediction sign is also sometimes used to describe the posture in an ulnar nerve lesion where there is clawing of the ring and little fingers; in an ulnar nerve lesion, the ‘Benediction’ posture is seen at rest, in a median nerve lesion on attempting to make a fist.



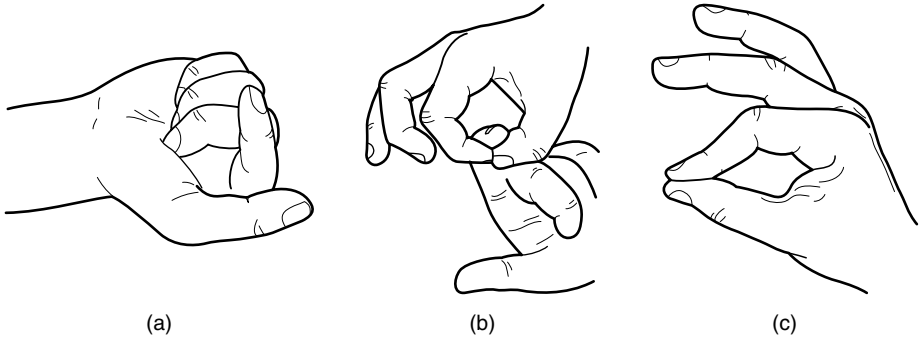
**Figure 1.6** Muscles supplied by the median nerve.

and thumb by getting the patient to form a figure 'O' with those digits (Fig. 1.7b). If those muscles are weak, the digits will assume the posture shown in Fig. 1.7c. Test whether there is a sensory loss in the distribution of the median nerve (Fig. 1.8).

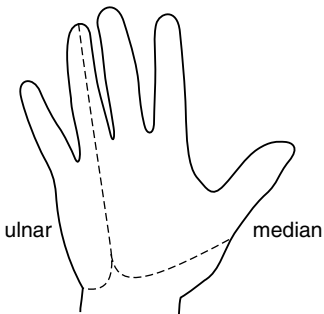


**See Video 1:** Benediction sign

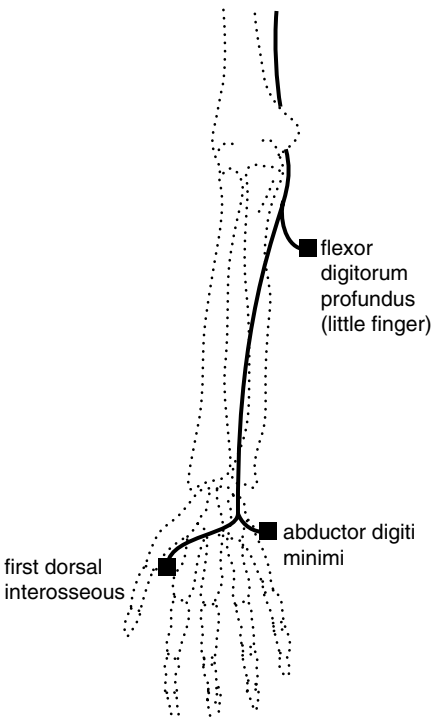
- Weakness confined to ADM and 1st DI is usually due to an ulnar nerve lesion at the elbow (see Fig. 1.9). In severe cases, there will also be weakness of the deep flexor of the little finger (see Fig. 1.10). Test for sensory loss in an ulnar distribution (Fig. 1.8).



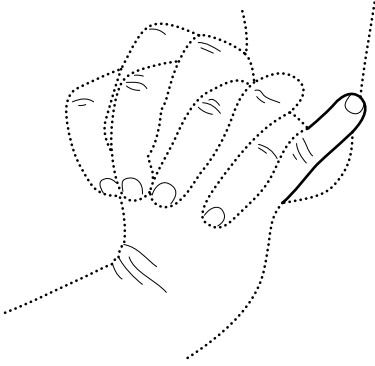
**Figure 1.7** (a) Benediction sign of a proximal lesion of the median nerve. (b) Testing flexor pollicis longus and the deep flexor of the index. (c) Posture adopted when flexor pollicis longus and the deep flexor of the index are weak.



**Figure 1.8** Sensory distribution of the median and ulnar nerves.



**Figure 1.9** Muscles supplied by the ulnar nerve.



**Figure 1.10** Weakness of flexor digitorum profundus of the little finger (proximal lesion of the ulnar nerve).

In the rare lesion of the deep palmar branch of the ulnar nerve, weakness is confined to abduction of the index and there is no sensory loss.

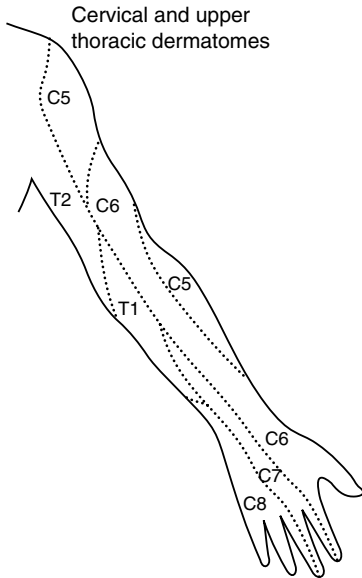


**See Video 2:** Ulnar nerve lesion

- Weakness of all three muscles has many causes, and it is not possible to make a definite diagnosis without performing a full neurological examination. In particular, it is important to check for:
  - Horner's syndrome
  - ptosis
  - facial weakness
  - wasting of the tongue
  - jaw jerk
  - wasting of the sternomastoids
  - wasting, weakness and reflex changes in all four limbs
  - sensory loss.

Certain patterns of neurological signs associated with wasting of the small muscles of the hand are characteristic:

- Wasting confined to one hand and weakness of the finger extensors, finger flexors and triceps. The triceps reflex is absent, and there is sensory loss on the ulnar aspect of the forearm and hand (see Fig. 1.11). The patient has a C7, C8, T1 root or plexus lesion. If this is due to a cervical rib, there may also be a subclavian bruit and



**Figure 1.11** Dermatomes of the arm.

diminished pulses in the arm. In a Pancoast tumour, there may be a Horner's syndrome, bovine cough, signs in the chest, lymphadenopathy and cachexia.

- 'Flail' arm with flaccid paralysis, wasting, areflexia and sensory loss confined to one arm. The most common cause of this is avulsion of all the roots of the brachial plexus from C5–T1, often resulting from a motorbike accident. Horner's syndrome is usually present.
- Wasting of one hand, loss of reflexes in the arm and a dissociated sensory loss (loss of pain with preserved touch sensation) in a half-cape distribution on the same side. The hands may be swollen, cold and blue with the skin shiny, atrophic and scarred from previous unnoticed injuries. These are signs of an intrinsic lesion of the cervical and upper thoracic cord. Syringomyelia and tumours, such as ependymoma, should be considered. The signs may be bilateral.
- Wasting of both hands and spastic weakness of the legs. The patient has a C8,T1 cord lesion. There will usually be sensory loss to the appropriate level. Causes of this include tumour and trauma.
- Generalized muscle weakness and wasting, fasciculations, hyper-reflexia and normal sensation. The patient has motor neurone disease. Check the tongue for wasting and fasciculations.
- Distal wasting and weakness of all four limbs, areflexia, and a glove and stocking sensory loss. The patient has a peripheral neuropathy.

- Distal wasting and weakness of all four limbs, hyporeflexia, baldness, ptosis and cataracts. The patient probably has dystrophia myotonica. Ask them to make a tight fist and then to open the fingers as rapidly as possible. If the fingers unfurl slowly, they have myotonia. Tap the thenar eminence. If the thumb slowly abducts and then falls back to its original position, they also have percussion myotonia.



See Video 3: Dystrophia myotonica

### Box 1.1

### Tips

- Cervical spondylosis is very common in older patients and, in most cases, is *not* the cause of marked muscle wasting in the hand; other causes should be considered.
- Generalized fasciculations are a key sign in the diagnosis of motor neurone disease. If you are considering this diagnosis, it is essential to disrobe the patient and to make a point of observing all parts of the musculature. Fasciculations are often best seen in triceps. Flickering movements of the calves and of the protruded tongue are common in normal individuals. They may also be seen in a generalized distribution in normal individuals. As a rule, fasciculations are rarely a matter of concern in the absence of muscle wasting, weakness and reflex changes.
- The most common cause of coldness in a wasted hand is not vascular occlusion, but disuse.
- The most common causes of wasting of the small muscles of the hands are old age and arthritis; in these conditions, muscle power in the wasted muscles is preserved.

# 2

## Wrist drop

**Inspection** 09

**Tone** 10

**Power, coordination and reflexes** 11

This is usually an acute phenomenon following compression of the radial nerve in the spiral groove of the humerus after falling asleep in a chair ('Saturday night palsy'). The nerve may also suffer infarction due to occlusion of the vasa nervorum in diabetes mellitus. Wrist extension is also weak in corticospinal lesions.

Wrist drop is due to weakness of extensor carpi radialis longus (supplied by C5/6 and the radial nerve) and extensor carpi ulnaris (supplied by C7/8 and the posterior interosseous branch of the radial nerve). It most commonly results from compression of the radial nerve in the spiral groove (Fig. 2.1).



**See Video 4:** Radial nerve lesion

### Inspection

Wrist drop is seen when the arms are held out during the screening examination. In a posterior interosseous nerve lesion or C7/8 root lesion, there will be radial deviation of the hand (Fig. 2.2). In a corticospinal lesion, the arm is slow to elevate and the elbow and wrist may remain a little flexed. Check for:

- bruising or scars, particularly over the spiral groove of the humerus in the posterior part of the upper arm (radial nerve palsy);
- facial asymmetry (hemiparesis); and/or



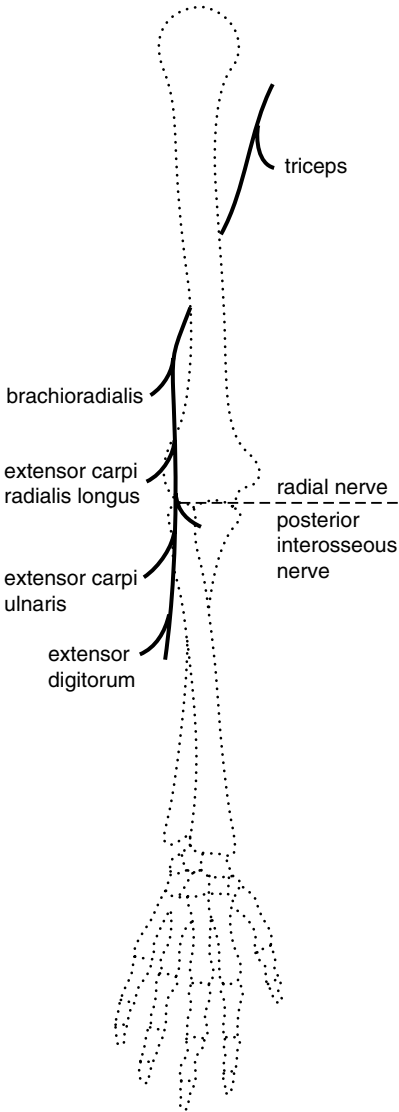
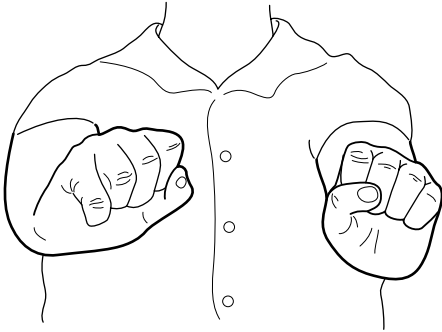


Figure 2.1 Muscles supplied by the radial nerve.

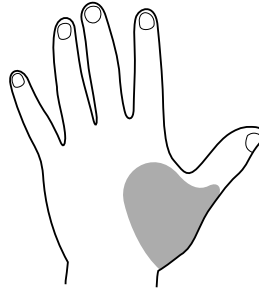
- muscle wasting, particularly in the extensor compartment of the forearm. Allow for the fact that the right forearm is usually thicker than the left in a right-handed person.

## Tone

Tone in the upper limbs will be normal in a lesion of the peripheral nerve or roots and usually increased in a corticospinal lesion.



**Figure 2.2** Radial deviation in wrist drop due to a posterior interosseous nerve lesion.



**Figure 2.3** Sensory loss over the snuff box in a radial nerve lesion.

## Power, coordination and reflexes

Test shoulder abduction, elbow flexion, elbow extension, brachioradialis, wrist extension, finger extension, finger flexion, finger abduction and thumb abduction. Test finger abduction with the hand resting on a surface. Check coordination and reflexes in the upper limbs.

You are likely to find one of four patterns of weakness:

- Weakness of brachioradialis, wrist extension and finger extension. The patient has a radial nerve lesion. As triceps is normal and brachioradialis is weak, the lesion is likely to be in the spiral groove. The brachioradialis reflex is reduced or absent. There may be sensory loss in the region of the snuff box (Fig. 2.3).
- Weakness of finger extension with radial deviation of the wrist on attempted extension (signifying weakness of extensor carpi ulnaris). There is no sensory loss and reflexes are normal. The patient has a posterior interosseous nerve lesion (rare). This may result from entrapment of the nerve or be part of a mononeuritis multiplex (or simplex) of any cause (e.g. diabetes, collagen disease).
- Weakness of triceps and finger extensors and flexors; radial deviation of the wrist on attempted extension. The triceps reflex is reduced or absent. The patient has a C7/8 root or plexus lesion. These signs may be seen in cervical spondylosis or a brachial plexus injury.
- Generalized weakness of the muscles of the upper limb which is most marked in deltoid, triceps, wrist extension and finger extension. The patient has a corticospinal lesion. Tone and reflexes are likely to be increased. Look for weakness in the face and leg on the same side (hemiparesis).

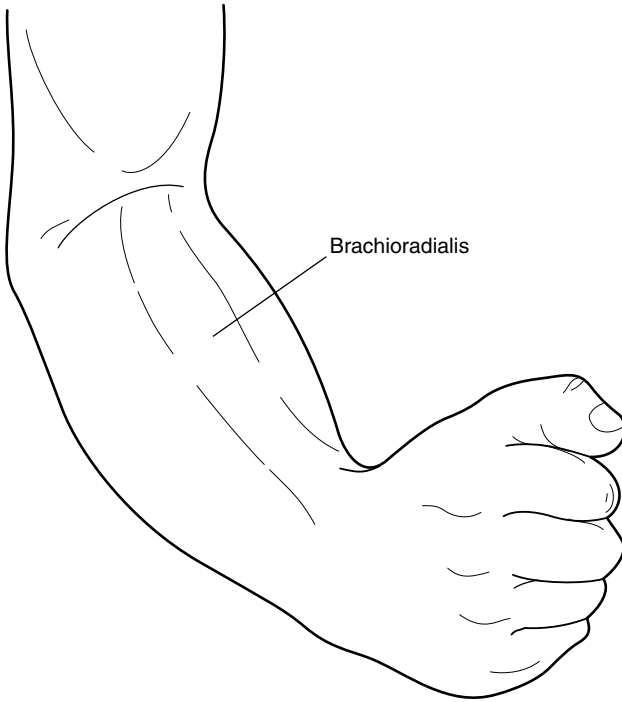


Figure 2.4 Brachioradialis.

### Box 2.1

### Tips

- It is almost impossible to abduct the fingers when they are flexed at the metacarpophalangeal joints. Try it yourself. In wrist drop, the fingers are also flexed and it is essential, therefore, for you to correct this before asking the patient to attempt to perform finger abduction. This is best done by resting the hand in the prone position on a flat surface.
- Brachioradialis is the key muscle to test in a suspected radial nerve palsy (Fig. 2.4).

# 3

## Proximal weakness of the arm(s)

**Inspection** 14

**Tone** 15

**Power, coordination and reflexes** 15

Here the patient may complain of difficulty putting clothes on the line or holding the arm up to use a screwdriver. The differential diagnosis very much depends on whether one arm or both are affected (see below).

The proximal muscles of the upper limb which are routinely tested are:

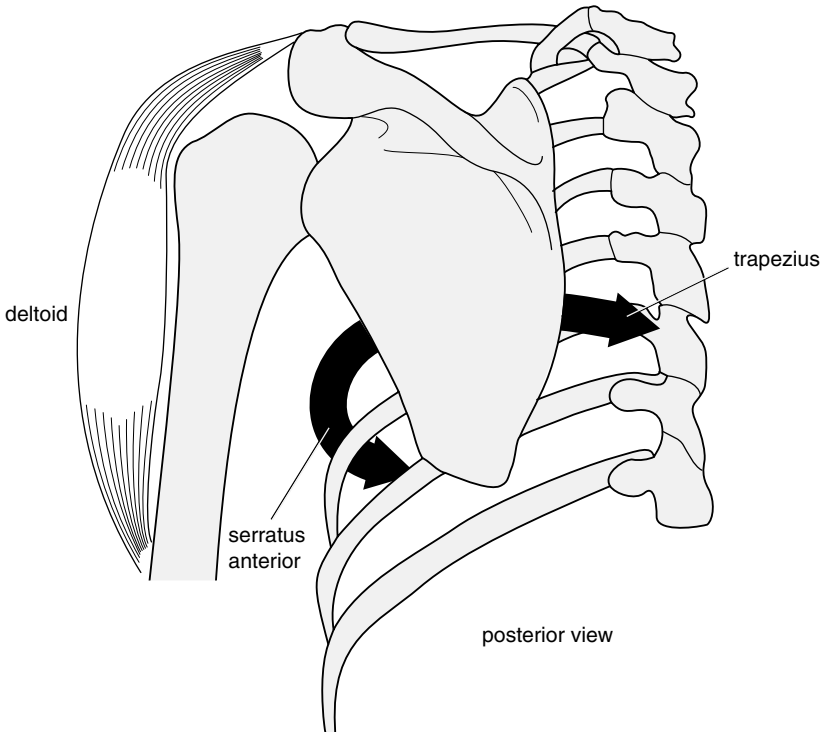
- deltoid: shoulder abduction; axillary nerve; C5/6 roots
- biceps: elbow flexion; musculocutaneous nerve; C5/6 roots
- triceps: elbow extension; radial nerve; C7/8 roots
- brachioradialis: elbow flexion with the thumb pointing to the shoulder; radial nerve; C5/6 roots

Under some circumstances, it is useful to test:

- supraspinatus: first 20° of shoulder abduction; suprascapular nerve; C5/6 roots
- infraspinatus: external rotation at the shoulder; suprascapular nerve; C5/6 roots
- trapezius: shoulder elevation; spinal accessory nerve (superior portion); C3/4 (inferior portion)
- serratus anterior: scapular fixation and rotation; long thoracic nerve; C5/6/7.

Deltoid can only function effectively if the scapula is firmly anchored by trapezius and serratus anterior (Fig. 3.1). Rotation of the scapula increases the range of abduction possible at the shoulder.

Unilateral weakness confined to the proximal upper limb is usually due to a lesion of the cervical roots, brachial plexus or peripheral nerves. In corticospinal lesions, all



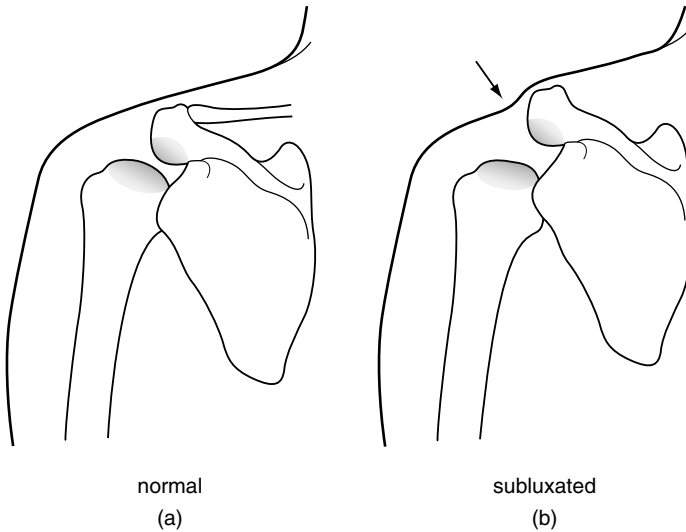
**Figure 3.1** Mode of action of trapezius and serratus anterior on the scapula.

the extensors of the upper limb, proximal and distal, are weak. Bilateral proximal weakness of the upper limbs raises the possibility of a myopathy.

## Inspection

Remove all garments from the patient's trunk and upper limbs and look for the following:

- **Skin.** A purple ('heliotrope') rash around the eyes and on the cheeks and a scaly erythema at the base of the finger nails and on the elbows and knees are features of dermatomyositis.
- **Joints.** Look for subluxation of the humerus (Fig. 3.2).
- **Wasting.** This is most obvious in deltoid. Look at the shoulder from the back as well as the front or you may miss winging of the scapula.
- **Face.** This may provide important clues: unilateral ptosis (Horner's syndrome with an avulsion injury of the cervical roots and T1); bilateral ptosis (dystrophia myotonica, myasthenia gravis, myopathy); facial droop (as part of a hemiparesis).
- **Fasciculations.** Motor neurone disease.



**Figure 3.2** (a) Profile of normal shoulder joint; (b) profile of shoulder in downward subluxation of the humerus.

## Tone

This will be normal in disorders of the peripheral nerves or muscle and may be increased in a corticospinal lesion.

## Power, coordination and reflexes

Test shoulder abduction, elbow flexion and extension, brachioradialis, wrist extension and flexion and finger extension, flexion and abduction. Check coordination and reflexes in the upper limbs. There are a number of characteristic patterns of weakness, each associated with other signs:

- Weakness confined to deltoid. This cannot be a C5/6 root lesion for biceps and brachioradialis are spared (Fig. 3.3). Make certain that the scapula does not move as the arm gives way when shoulder abduction is tested. If it does not, the patient has an axillary nerve lesion. Reflexes will be normal. There may be an area of sensory loss over the deltoid.
- Weakness of deltoid, biceps and brachioradialis, with normal power in the other muscles tested so far. This is a C5/6 cord, root or plexus lesion. To determine the level of the lesion, other signs need to be considered:
  - C5/6 cord lesion. Here, the reflexes at the level of the lesion – biceps and brachioradialis – are absent, while those below that level – triceps and the lower limb reflexes – are increased. The vibration caused by tapping the radius to elicit

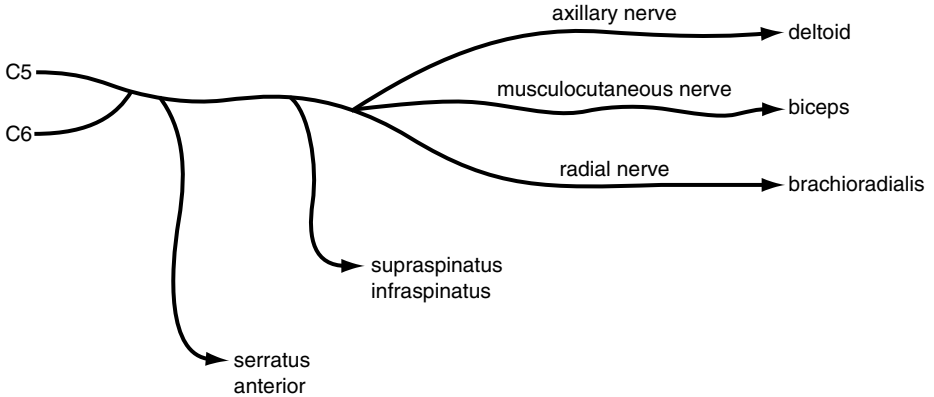




Figure 3.3 Muscles supplied by C5 and C6.

the brachioradialis reflex may cause the fingers to flex; the finger flexors arise below the site of the lesion (at C7/8) and are therefore more easily excited. Some flexion is common in normal individuals, but if flexion of the fingers occurs without contraction of the brachioradialis in response to tapping of the radius (the ‘inverted supinator’ reflex), a C5/6 cord lesion is probably present. Test tone and power in the lower limbs and look for a sensory level at C5.





**See Video 5:** Inverted supinator

- C5/6 root or plexus lesion. Here, the biceps and brachioradialis reflexes are absent, but the triceps reflex and leg reflexes are normal. The point at which these nerves have been damaged is determined by testing muscles, also supplied by the C5/6 roots, in the order in which they arise (Fig. 3.3). Thus, a very proximal lesion will involve all the C5/6 muscles. Further down, serratus anterior is spared and further down still, supraspinatus and infraspinatus will be spared. In a C5/6 root or plexus lesion, there is likely to be sensory loss in the same dermatomes (see Fig. 1.10).
- Weakness of all the muscles of one arm with:
  - Absence of reflexes in the arm. If the other limbs are normal, the patient probably has a brachial plexus lesion. Check for a Horner’s syndrome and a C5–T1 sensory

loss. If there is a dissociated sensory loss, consider intrinsic cord lesions such as syringomyelia.

- **Hyper-reflexia.** Use your screening tests on the face and legs to determine whether this is part of a hemiparesis. With a right hemiparesis, check for aphasia (see below). With a left hemiparesis, test for signs of neglect (sensory and visual), constructional apraxia and dressing apraxia.



**See Video 6:** Dressing apraxia

- Weakness of the proximal muscles of both arms. This is likely to be due to a disorder of muscle (myopathy) or neuromuscular junction. Test power and reflexes in the lower limbs. There are several characteristic patterns of signs:
  - Weakness of all the proximal muscles of the arms and legs. Reflexes are normal or reduced. Sensation is normal. Consider polymyositis, particularly in an older person, if there is muscle tenderness on palpation or if there is a skin rash (dermatomyositis). Myasthenia gravis is also a possibility. Check for fatigability by repeatedly pressing down on the arms held abducted and flexed at the elbows. Test for weakness of neck flexion (see Box 3.1).
  - Selective weakness and wasting of the proximal muscles of the arms and legs. Here, certain muscles are almost completely wasted while their neighbour, perhaps with the same root supply, is normal. Thus, brachioradialis (C5/6) may be wasted while deltoid (also C5/6) is spared. There may be winging of the scapula. These are the findings of muscular dystrophy, spinal muscular atrophy and inclusion body myositis. Test facial movements and eye closure. The patient could be of any age, but is more likely to be young. If the reflexes are lost, you should consider spinal muscular atrophy.
- Weakness of the muscles which fixate the scapula usually becomes apparent during testing of deltoid. You find weakness of shoulder abduction, but on careful inspection and palpation it becomes clear that you are not 'breaking' deltoid, rather you are forcing the scapula to rotate. The patient has weakness of trapezius, serratus anterior or both. Check the following:
  - Note the position of the shoulders. In weakness of trapezius, one shoulder will be lower than the other. Compare the muscle bulk of trapezius on the two sides. Wasting of trapezius is often visible and palpable.



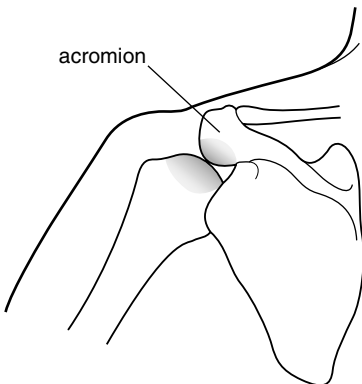


**See Video 7:** Weakness of trapezius

- Compare the sternocleidomastoids on both sides. Ask the patient to turn their head to either side and press their cheek against your hand. This will allow easy palpation of the sternocleidomastoid muscle and observation for hypotrophy, as seen in patients with dystonic torticollis, or hypotrophy, present with lesions of the accessory nerve. The accessory nerve supplies both trapezius and sternocleidomastoid.
- Ask the patient to push the extended arms against the wall. The vertebral border of the scapula lifts away from the thorax ('wings') if there is weakness of serratus anterior. Isolated weakness of serratus anterior is quite common. It follows injury to the long thoracic nerve by, for example, cervical gland biopsy. It is also one manifestation of neuralgic amyotrophy.



**See Video 8:** Weakness of serratus anterior



**Figure 3.4** Restriction of abduction of the humerus by the acromion in upward subluxation associated with a rotator cuff tear.

**Box 3.1**    **Tips**

- Weakness of shoulder abduction can be due to weakness of deltoid or failure of serratus anterior and trapezius to fixate the scapula. Feel the tip of the scapula with one hand as you test shoulder abduction with the other hand. If the scapula moves, the problem is at least in part due to weakness of serratus anterior or trapezius. The strength of deltoid can be tested separately by manually fixating the scapula as you test shoulder abduction.
- Brachioradialis is one of the most useful muscles to test. It is important in diagnosing C5/6 root lesions and in localizing the site of a radial nerve lesion. It is often selectively wasted in muscular dystrophy. Both biceps and brachioradialis flex the elbow; weakness of brachioradialis cannot be demonstrated by overcoming elbow flexion, for biceps is more than adequate for this task. Weakness in brachioradialis is detected by observing and feeling the muscle when elbow flexion is resisted with the forearm midway between pronation and supination (see Fig. 2.5): 'Pull your thumb towards your nose'. A weak brachioradialis remains soft during this procedure or fails to contract at all.
- Always test for weakness of neck flexion or extension when you find proximal weakness of the arms. This is characteristically present in myopathies and myasthenia gravis.



**See Video 9:** Severe head drop

- Patients with rotator cuff injuries of the shoulder can be confusing. When asked to abduct the shoulder they are only able to do so to a limited extent, and you may mistakenly diagnose an axillary nerve lesion. The following features should make you consider this possibility:
  - while abduction is limited, forward flexion of the elbow is normal. The reason for this is that the humerus subluxates upwards when the rotator cuff is ruptured and the coracoid bone prevents full abduction (Fig. 3.4).
  - the long head of biceps is ruptured, causing the biceps to 'bunch up' in elbow flexion.
  - on attempted abduction, the shoulder is elevated, giving it a characteristic shrugging appearance.
  - the range of passive movement of the shoulder is limited and sometimes painful.

# 4

## Proximal weakness of the leg(s)

**Inspection** 20

**Tone** 21

**Power, coordination and reflexes** 21

With proximal weakness of the lower limbs, the patient has difficulty getting out of a chair or climbing the stairs. Walking may also be affected.

The proximal muscles of the legs which are routinely tested are:

- Iliopsoas: hip flexion; femoral nerve; L1/2/3 roots.
- Quadriceps: knee extension; femoral nerve; L2/3/4 roots.
- Gluteus maximus: hip extension; inferior gluteal nerve; L5, S1/2 roots.
- Hamstrings: knee flexion; sciatic nerve; L5, S1/2 roots.
- Hip adductors: obturator nerve; L2/3/4.

Weakness which is confined to the proximal muscles of the legs is usually due to a disorder of muscle (e.g. myopathy) or neuromuscular junction (e.g. myasthenia gravis). Weakness of proximal and distal muscles is seen in Guillain–Barré<sup>1</sup> syndrome and motor neurone disease. Unilateral proximal weakness is often due to a femoral nerve lesion.

### Inspection

Observe the gait. This may be:

- waddling, with exaggerated shoulder sway, in any cause of proximal weakness or in hip joint disorders.
- antalgic, the stride when weight bearing on the painful side is faster and shorter than on the good side.
- hemiparetic (see section on gait).

1. Georges Guillain, French neurologist at the Salpêtrière, Paris (1876–1961); JA Barré, French neurologist (1880–1967).

Ask the patient to rise from a crouching position. Patients with proximal weakness of the lower limbs cannot get up. Children with muscular dystrophy may 'climb up' themselves, using their arms as levers (Gowers<sup>2</sup> sign).

- Look for wasting in quadriceps. This is most obvious with the patient standing. You may wish to compare the circumference of the thighs at a defined distance above the knee, but it is difficult to do this accurately.
- Look for fasciculations.
- Check the lower spine for scars and the buttocks for wasting.
- Note whether the hip remains flexed when the patient lies down: this may signify disease of the hip joint.

## Tone

Test tone in the lower limbs. This will be normal in lesions of the peripheral nerves and muscles and increased in corticospinal lesions. Internally and externally rotating the hip may reveal pain and limitation of movement due to hip disease.

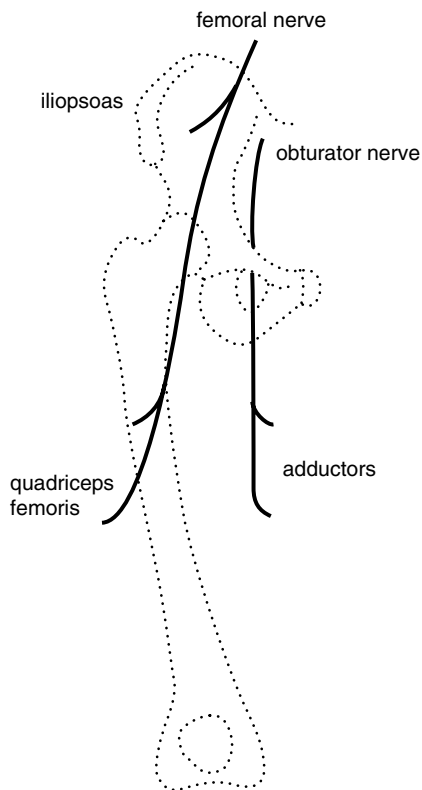
## Power, coordination and reflexes

Test hip flexion and extension, knee flexion and extension, ankle dorsiflexion and plantar flexion, eversion and inversion. Ask the patient to run the heel up and down the shin on each leg in turn. Test the knee, ankle and plantar reflexes.

You are likely to find one of the following patterns of abnormality:

- Weakness of iliopsoas and weakness and wasting of quadriceps. The knee jerk is reduced or absent. Power in the hip adductors is normal (see Box 4.1). The patient has a femoral nerve lesion (Fig. 4.1). There may also be sensory impairment over the thigh and medial aspect of the shin. An important cause of a painful femoral nerve lesion is adult-onset diabetes mellitus (diabetic amyotrophy). Haemorrhage into the psoas as a result of anticoagulant therapy and traction during hip surgery are other causes.
- Weakness of iliopsoas, quadriceps and hip adductors. The knee jerk is reduced or absent. The patient has an L2/3/4 root or plexus lesion. There is likely to be sensory loss in the equivalent dermatomes. If the lesion involves the cauda equina within the vertebral canal, both legs are likely to be involved. The most likely cause is a tumour, either primary or secondary. Prolapse of an intervertebral disc is uncommon at this spinal level. There are many causes of a femoral plexus lesion including pelvic malignancy, obstetric injury and neuralgic amyotrophy.

2. Sir William Gowers, Queen Square neurologist, author of *Diseases of the Nervous System*, the 'Bible' for neurologists for many years (1845–1915).



**Figure 4.1** Muscles supplied by the femoral and obturator nerves.

- Weakness of one leg, most marked in hip flexion, knee flexion, ankle dorsiflexion and eversion. Tone and reflexes are increased. The patient has a corticospinal lesion. Perform screening tests on the face and arm looking for evidence of a hemiparesis.
- Weakness of both legs, most marked in hip flexion, knee flexion, ankle dorsiflexion and eversion. Tone and reflexes are increased. The patient has a paraparesis. The lesion is likely to be in the spinal cord. Look for a motor and sensory level.
- Diffuse weakness of the proximal muscles of both legs. Check power and reflexes in the upper limbs. If there is also proximal weakness of the arms your assessment will largely hinge on the reflex findings:
  - Reflexes are preserved or reduced. Consider a myopathy (e.g. muscular dystrophy or polymyositis) or myasthenia gravis (check for fatigability).
  - Reflexes are lost. Consider spinal muscular atrophy or myasthenic syndrome (Eaton–Lambert<sup>3</sup> syndrome). The reflexes are also lost in Guillain–Barré syndrome, but here there is likely to be distal as well as proximal weakness.

- Reflexes are increased. Consider motor neurone disease (check for fasciculations; wasting and fasciculation of the tongue; sensation) or causes of a quadriparesis such as multilacunar state (check gait, jaw jerk, speech, mental state) or cervical myelopathy (normal cranial nerves; loss of some reflexes in the arms, depending on the level).
- Other patterns of proximal weakness are much less common. Weakness confined to hip adduction is seen with obturator nerve lesions (obstetric injury). Selective lesions of the superior gluteal nerve (which supplies gluteus medius and minimus and tensor fasciae latae) and of the inferior gluteal nerve (which supplies gluteus maximus) are very uncommon indeed. Sciatic nerve lesions are a cause of distal weakness of the leg, with or without weakness of hamstrings.

**Box 4.1****Tips**

- Arthritis of the hip or knee can cause wasting and weakness of quadriceps and diminution or loss of the knee jerk.
- Pain and wasting of quadriceps can be the presenting symptom of adult-onset diabetes mellitus.
- Weakness and wasting of quadriceps can be due to a femoral nerve lesion or an L2/3/4 root (or plexus) lesion. To distinguish between the two, you need to test a muscle which has the same root, but a different nerve supply. The hip adductors fulfil this requirement being supplied by L2/3/4 but via the obturator nerve.

# 5

## Foot drop

**Inspection** 24

**Tone** 26

**Power, coordination and reflexes** 26

Patients with foot drop often present with falls, as their toes fail to clear the ground.

Foot drop is due to weakness of tibialis anterior, a muscle supplied by the common peroneal nerve and L4/5 roots. The common peroneal nerve also supplies the peroneal muscles which evert the foot; the L4/5 roots also supply tibialis posterior which inverts the foot. Weakness of tibialis anterior can result from lesions of the corticospinal tract, as well as from lesions of the peripheral nerves or roots.

### Inspection

- **Gait.** Get the patient to walk in an open space where the arms can swing freely. The foot is plantar-flexed and inverted and the gait high-stepping in a common peroneal nerve lesion. In a corticospinal lesion, the foot is also inverted but the leg swings in an arc, allowing the toe to clear the ground (circumduction). In a patient with a stroke, the arm may fail to swing. Ask the patient to stand on their toes and then their heels.



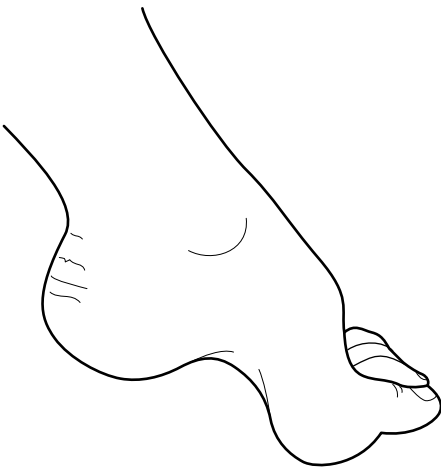**See Video 10:** Common peroneal nerve lesion



See Video 11: Hemiparetic gait following stroke

- **Wasting.** Remove all clothing from the patient's lower limbs after checking that they are wearing an undergarment. Observe the skin, joints and posture, and look for wasting. Wasting is most obvious in tibialis anterior in a common peroneal nerve lesion. This is seen as a loss of the normal convexity lateral to the ridge of the tibia, and is easily missed in a patient lying on a couch, if the knees are not lifted. If the calf muscles are also wasted, a number of conditions need to be considered (see below).
- **Pes cavus** (Fig. 5.1). This sign tells you that the lesion is long-standing. Causes include Charcot–Marie–Tooth<sup>1</sup> disease, Friedreich's<sup>2</sup> ataxia and spina bifida.
- **Fasciculations.**
- **The lower spine.** This should be inspected for evidence of spina bifida (lipoma or tuft of hair), spinal deformity or previous surgery.

Figure 5.1 Pes cavus.



1. Jean-Martin Charcot, French neurologist at the Salpêtrière, Paris, one of the founders of the discipline of neurology (1825–1893); Pierre Marie, French neurologist (1853–1940); Howard Henry Tooth, Queen Square neurologist (1856–1926).

2. Nikolaus Friedreich, German pathologist and physician (1825–1882).



- Ask the patient to lie on the couch and fully dorsiflex both feet. This is useful for detecting mild unilateral foot drop.
- Check the legs for scars or bruises, particularly over the head of the fibula in a patient with unilateral foot drop.

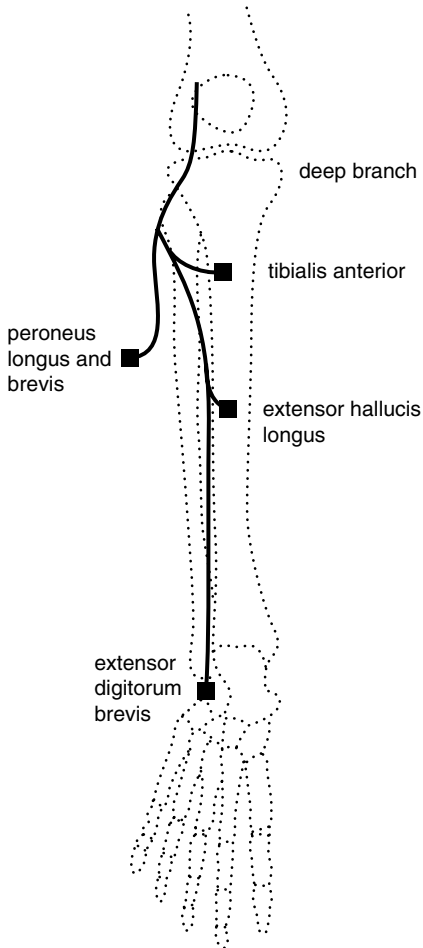
## Tone

Test tone at the knees and look for clonus at the ankles in both legs. Tone is normal in peripheral nerve and root lesions and increased in lesions of the corticospinal tract.

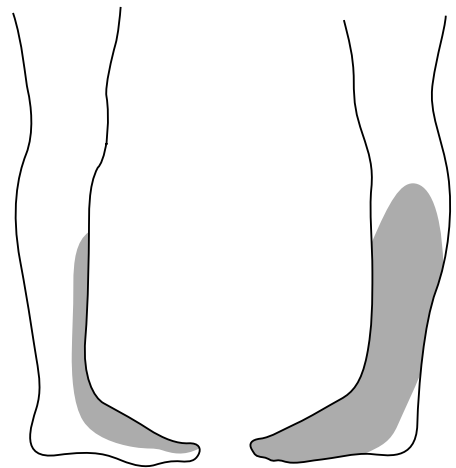
## Power, coordination and reflexes

Check hip flexion and extension, knee flexion and extension, ankle dorsiflexion, plantar flexion, and inversion and eversion in both legs. Get the patient to run each heel in turn up and down the shin. Test the knee, ankle and plantar reflexes. There are four common patterns of weakness:

- Weakness of dorsiflexion and eversion. The patient has a common peroneal nerve lesion (Fig. 5.2), and there will also be weakness of extensor hallucis longus. Reflexes in the leg will be normal, and there may be the typical sensory loss (Fig. 5.3). Look for scars or bruising over the head of the fibula. In the rare lesion of the deep peroneal nerve, eversion is normal and the area of sensory loss very small (Fig. 5.4).
- Weakness of dorsiflexion, eversion and inversion. The patient has an L4/5 root or plexus lesion. Causes of this include a prolapsed intervertebral disc, tumour of the cauda equina and obstetric injury to the lumbosacral trunk (Fig. 5.5). Reflexes in the leg are likely to be normal. There may also be weakness of hip abduction and sensory symptoms or signs in the L4/5 dermatomes (Fig. 5.6).
- Weakness of all movements of the foot with normal power at the knee and hip. There are several possibilities:
  - Peripheral neuropathy (with distal weakness of both legs, areflexia and glove and stocking sensory loss).
  - Sciatic nerve lesion (rare) due to pressure, trauma, vasculitis or tumour (with loss of the ankle jerk, extensive sensory loss and, depending on the site of the lesion, weakness of the hamstrings).
  - Root or plexus lesion (with loss of the ankle jerk and anal reflex, saddle anaesthesia (Fig. 5.7) and urinary incontinence). The cauda equina may be involved by tumour or prolapsed disc, the plexus by tumour or trauma.
  - Anterior horn cell disease due to motor neurone disease (with wasting, fasciculation, hyper-reflexia and normal sensation).

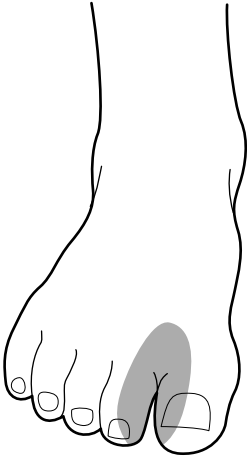


**Figure 5.2** Muscles supplied by the common peroneal nerve.

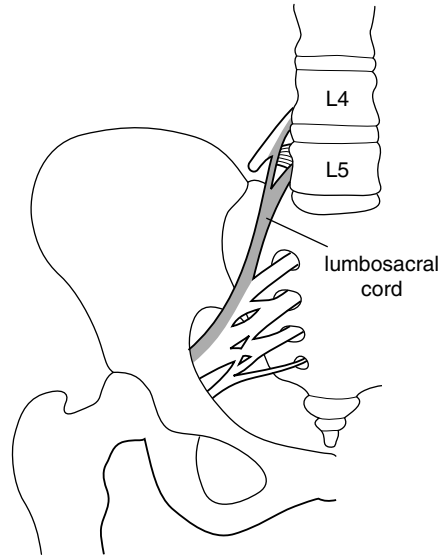


**Figure 5.3** Sensory loss in a common peroneal nerve lesion.

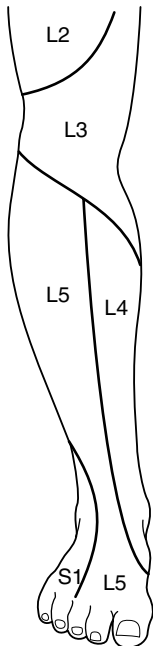
- Weakness of hip flexion, knee flexion, dorsiflexion and eversion. Tone in the leg is increased and the reflexes are brisk. The patient has a lesion of the cortico spinal tract. The following patterns of signs are useful in localizing the site of the lesion:
  - Both legs are weak (paraparesis). This is usually due to a spinal cord lesion. If this is in the thoracic cord (e.g. due to a meningioma), the arms will be spared and there will be a sensory level on the trunk. If it is due to a cervical cord lesion, there will be loss of reflexes at the appropriate level (C5/6: biceps and brachioradialis; C7/8: triceps). Parasagittal tumours pressing on the motor strips of the cerebral hemispheres are a rare cause of weakness of both legs.



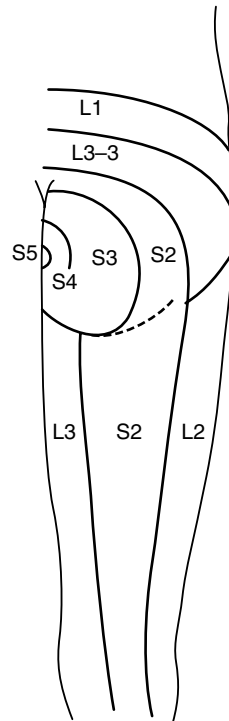
**Figure 5.4** Sensory loss in a lesion of the deep branch of the common peroneal nerve.



**Figure 5.5** The lumbosacral cord arising from the L4, L5 roots.



**Figure 5.6** Dermatomes of the lower leg.



**Figure 5.7** Dermatomes of the buttock.

- One leg is weak. Possibilities include: (1) Brown-Séguard<sup>3</sup> syndrome: check for dissociated sensory loss in the other leg (see Box 5.1); and (2) anterior cerebral artery occlusion: check for a grasp reflex in the hand on the same side. If it is the right leg which is weak, the patient may be aphasic.
- The arm and leg are weak on the same side (hemiparesis). The lesion is likely to be above the cervical cord. The most common causes are a stroke or tumour in the contralateral cerebral hemisphere.

### Box 5.1 Tips

- Pes cavus is a useful sign as long as it is not overdiagnosed. It is not enough to have a high arch. There should also be clawing of the toes and the foot should be thick (see Fig. 5.1). These signs are most apparent when the foot is dependent (hanging).
- In testing eversion and inversion of the foot, prevent the patient from rotating the hip by immobilizing the shin with one hand. With the other hand, move the foot into the required position, for example into the fully inverted position, and ask them to hold it there. Then attempt to evert the foot.
- In any patient with absent ankle jerks, it is important to test buttock sensation, as in lesions of the cauda equina sensation elsewhere may be normal.
- Absence of the ankle jerk is a key sign. Take time to put the patient at ease. Use the Jendrassik<sup>4</sup> manoeuvre. Sometimes, the reflex can be obtained more readily by tapping the sole of the foot than by tapping the Achilles tendon. If you are still in doubt, ask the patient to kneel on a chair and tap the tendon while gently dorsiflexing the foot.
- Remember: the spinal cord ends at the second lumbar vertebra. Lesions above this will cause increased tone and reflexes, below it decreased tone and areflexia.
- Selective nerve lesions often occur in the setting of a generalized peripheral neuropathy. In diabetes, for example, a patient may have a foot drop with the typical distribution of weakness of a common peroneal nerve lesion. In addition, the ankle jerk may be lost due to an underlying peripheral neuropathy. Peripheral neuropathy predisposes nerves to pressure palsy.
- A sign of particular importance is dissociated sensory loss where the patient can feel the lightest touch in the affected area, but is unable to distinguish one end of a pin from the other. Selective involvement of the pain pathways is a feature of syringomyelia, hemi-cord lesions (Brown-Séguard syndrome) and the lateral medullary syndrome.
- Wasting of extensor digitorum brevis is often found in peripheral neuropathies and in lesions of the common peroneal nerve. In a normal subject, the muscle stands out like a grape when the toes are dorsiflexed against resistance.
- Weakness of extension of the great toe may be the only motor sign of an L5 root lesion in a patient with sciatica.
- Spasticity of the legs (increased tone, hyper-reflexia, clonus) with well-preserved power (and no sensory loss or bladder involvement) is the characteristic finding in hereditary spastic paraplegia (rare in practice, common in examinations). Hydrocephalus may also cause spasticity of the legs.

3. Charles Edouard Brown-Séguard, Mauritian-born neurologist who practised at Queen Square and later Paris (1817–1894).

4. E Jendrassik, Hungarian neurologist (1858–1921).

# 6

## Ataxia and gait disturbance

**Observation** 30

**Further assessment** 31

The observation of gait is probably the single most informative part of the neurological examination. It provides you with an opportunity to see the patient as a whole. Muscle weakness, impairment of balance, sensory loss, involuntary movements, abnormalities of posture, even mood disturbance and dementia may all leave a distinctive imprint on the way we walk. Gait is sadly neglected, yet the extra few moments taken to observe it are rarely wasted. In some diseases, such as Parkinson's disease,<sup>1</sup> the gait is so distinctive that the diagnosis is clear as the patient walks into the room. To benefit from observing gait, you must train your eye to take a note of a number of key features (listed below). In this chapter, a number of gaits are described and illustrated on video.

The more you can learn from the gait, the more likely you are to direct the rest of the examination appropriately.

### Observation

- Never attempt to assess gait in a confined space such as a small examination room with a couch in it. You will not be able to judge stride length or arm swing under these conditions. Get the patient to walk in an open corridor.
- Don't stand too close.
- Don't base your assessment on a couple of strides. Get the patient to walk about 10 metres, turn and come back. In a difficult case you may want to repeat this.
- Make particular note of the following:
  - Posture of the head, trunk and limbs
  - Arm swing
  - Stride length
  - Base or stance (Fig. 6.1)
  - Involuntary movements.

1. James Parkinson, London physician and palaeontologist (1755–1824).

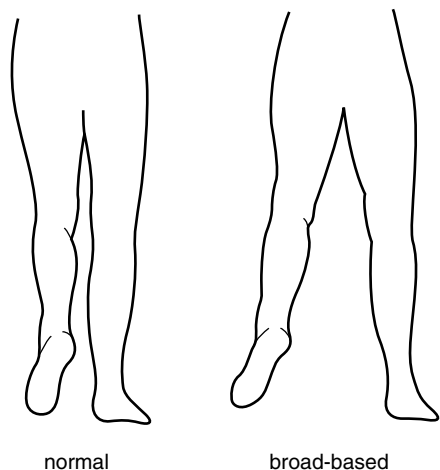


Figure 6.1 Normal and broad based gait (from behind).

- Ask the patient to stand on their toes. This is a sensitive test for weakness in gastrocnemius–soleus.
- Ask the patient to stand on their heels. Failure to do this will confirm the presence of foot drop.
- Do the Romberg test (see Box 6.1, page 39).
- If the patient appears to be parkinsonian, check the righting reflex (see below).

## Further assessment

There are a number of distinctive patterns of gait disturbance:

- One foot is lifted higher than the other during each stride. The affected foot hangs downwards while it is elevated. The patient has a *high-stepping gait* due to unilateral foot drop. This is usually caused by a common peroneal nerve lesion (see section on ‘Foot drop’). In such a case, the patient will be able to walk on their toes but not on their heel, on the affected side.



See Video 10: Common peroneal nerve lesion



**See Video 12:** Spastic gait

- Both feet are lifted higher than normal and may produce a slapping sound as they hit the ground. This type of high-stepping gait is most commonly due to bilateral foot drop due, for example, to a peripheral neuropathy such as Charcot–Marie–Tooth disease. Motor neurone disease is another cause. Such patients will have difficulty walking on their toes or heels.



**See Video 13:** Motor neurone disease

- A similar high-stepping gait is seen where there is impairment of sensation in the feet (sensory ataxia). The gait is wide-based and patients watch the ground and their feet intently. Test for Romberg's<sup>2</sup> sign (see Box 6.1, page 39). Place such patients between you and the wall, and ask them to put their feet together and to shut their eyes. In such a case, the patient may start to fall, without making any apparent attempt to stop themselves. You, of course, must prevent them from falling, but it may be difficult if the patient is very large. You will need to test position sense in the feet. Causes of sensory ataxia include sensory neuropathy, tabes dorsalis, spinocerebellar degeneration, subacute combined degeneration of the cord and multiple sclerosis.

2. Moritz Heinrich Romberg, German physician, author of one of the first textbooks in neurology (1795–1873).

- The shoulders sway from side to side in an exaggerated manner with each stride. The patient appears to be lifting the foot off the ground, not only by flexing the hip and knee but also by tilting the trunk. This is a *waddling gait*. It signifies weakness of hip abduction and can be demonstrated using Trendelenburg's<sup>3</sup> test (Fig. 6.2a,b). When the left foot is lifted off the ground, the pelvis is normally prevented from tilting downwards on the left side by the action of the right hip abductors. When these are weak, the buttock is seen to sag. It may take a number of seconds before this occurs. Weakness of hip abduction can result from muscle pathology, or from disturbance of the normal fulcrum provided by the hip joint. You will need to test proximal muscle power and put the hips through a full range of movements. A waddling gait in a child is likely to be due to muscular dystrophy or congenital dislocation of the hips. In an adult, consider a myopathy and osteoarthritis of the hips.

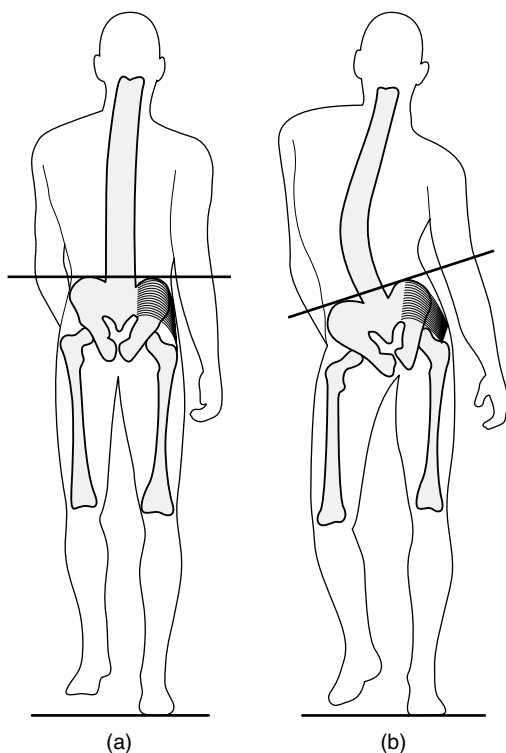


Figure 6.2 (a) Normal Trendelenburg test; (b) weakness of right hip abductors.

3. Friedrich Trendelenburg, German surgeon (1844–1924).





See Video 14: Antalgic gait

- One leg is held stiffly, and describes an arc around the other leg with each stride (circumduction). The foot scrapes the ground. The arm on the same side does not swing and is flexed at the elbow. This is a *hemiparetic gait*. There may be obvious facial weakness. You will need to test tone, power and reflexes in the limbs. The most common cause in an adult is stroke.
- Both legs are held stiffly and show circumduction. The steps are short and slow, as though the patient is wading through water. The feet are inverted and may cross ('scissor'). This is a spastic paraparetic or *scissoring gait*. It is seen in its most florid form in long-standing disorders, such as cerebral palsy and hereditary spastic paraplegia. Scissoring is less of a feature when paraparesis is acquired later in life, for example in association with cervical spondylosis or multiple sclerosis.



See Video 11: Hemiparetic gait



See Video 12: Spastic gait

- The patient fails to swing one arm as they walk. The gait is otherwise normal. The patient may have early Parkinson's disease (check for tremor, rigidity and akinesia). Test shoulder joint mobility; frozen shoulder can also interfere with the arm swing. Patients who have made an otherwise good recovery from stroke may also have reduced arm swing.

- The patient is flexed at the neck, elbows, hips and knees. The arms fail to swing. Steps are small and shuffling. Several steps are taken in turning. The base is normal. This is a *Parkinsonian gait*. Other features which may be present include: hand tremor; hurrying (festination); a tendency to run forwards (propulsion) or backwards (retropulsion); getting suddenly stuck and unable to go on, particularly when changing direction or going through a doorway (freezing).



**See Video 15:** Advanced Parkinson's disease



**See Video 16:** Freezing

- Patients with Parkinson's disease often have an impaired righting reflex. This is tested by using the "pull test": stand behind the patient, warn them that you are going to give their shoulders a tug ('don't let me get you off balance'), and then do so. If balance is normal, the patient takes one or two steps back and fully recovers. In mild impairment, the patient usually takes more than two steps back before recovering. In severe cases, the patient runs backwards uncontrollably (i.e. develops retropulsion) or begins to fall. As with Romberg's test, be careful with large patients. You are less likely to end up on the floor with the patient if you stand with your back close to the wall as you do the test.



**See Video 17:** Pull test

- The posture is upright, but the arms fail to swing and the steps are small and shuffling. Several steps are taken in turning. The appearance is similar to Parkinson's disease with one important difference: it is broad-based. This is called '*marche à petits pas*' (from the French, 'gait with small steps') and is seen particularly in multi-lacunar states (associated with emotional lability, dementia, generalized hyper-reflexia, positive jaw-jerk) and normal pressure hydrocephalus (associated with cognitive impairment and incontinence of urine).



See Video 18: Marche à petit pas



See Video 19: Marche à petit pas



See Video 20: Normal walking

- The gait is broad-based, with unsteady irregular steps. There is a tendency to veer to one side or the other and to stagger on turning. These are the features of a cerebellar or *ataxic gait*. See if the patient consistently staggers or turns to one side by asking them to march up and down on the spot with their eyes open and then shut. In Unterberger's test, the patient marches on the spot with the arms held out in front with the hands clasped; rotation is observed in a unilateral labyrinthine lesion. Get them to walk heel to toe and to walk round a chair, first one way and then the other. In a lesion of one cerebellar hemisphere, they will consistently stagger to the side of the lesion (look for intention tremor and incoordination in the limbs, nystagmus

and dysarthria). In midline cerebellar lesions, the patient will stagger in any direction. The trunk may tilt when the patient is seated. Often, there is no other evidence of cerebellar disturbance such as intention tremor, nystagmus or dysarthria.



**See Video 21:** Mild cerebellar ataxia



**See Video 22:** Progressive dysarthria

- Patients with involuntary movement disorders often have distinctive gaits:
  - The patient walks with the head twisted to one side (torticollis).



**See Video 23:** Cervical dystonia

- The head, trunk and limbs assume bizarre postures, often with associated abnormal movements (e.g. torsion dystonia).



**See Video 24:** Torsion dystonia

- Constant twitches in all parts of the body interrupt the normal smooth flow of movement, causing lurching and staggering. There may be facial grimacing and abnormal posturing of the limbs or trunk. These are features of the gait in Huntington's disease.



**See Video 25:** Huntington's disease



**See Video 26:** Dystonic camptocormia



**See Video 27:** Progressive generalized dystonia

- There are continuous writhing movements of the limbs during walking; one foot tends to invert, interfering with walking (e.g. 'dopa-induced dyskinesia' in a patient with Parkinson's disease).



**See Video 28:** Dopa-induced dyskinesia

- Patients who experience pain in the leg on bearing weight develop a very characteristic gait. You can see it for yourself by walking in front of a mirror with a pebble in your shoe. Each time you bear weight on the painful side, you hurry through the stride with the good leg to minimize the duration of the pain. The painful leg also buckles each time it bears weight in order to cushion the impact. This is called an *antalgic gait*. It is usually associated with arthritis of the hip, knee, ankle or foot joints.



See Video 14: Antalgic gait

#### Box 6.1

#### Tips

- A shuffling gait with small steps and loss of arm swing is likely to be due to idiopathic Parkinson's disease if the base is normal. A shuffling gait but with a widened base is seen in vascular parkinsonism and normal-pressure hydrocephalus and the multi-lacunar state. The base is often also widened in the parkinsonian disorder progressive supranuclear palsy (Steele Richardson syndrome).<sup>4</sup> In contrast to the narrow-base, shuffling gait of patients with Parkinson's disease, those with progressive supranuclear palsy tend to pivot on their toes rather than turn en bloc.
- Romberg observed that patients with loss of proprioception due to tabes dorsalis toppled when asked to stand with their feet together and eyes closed. An increase in body sway following closure of the eyes is often accepted as a positive Romberg's sign. Unfortunately, this can occur when balance is impaired for any reason, and even in normal, anxious individuals. The term 'positive Rombergism' is, therefore, better reserved for patients who can stand unassisted, but would fall on closing the eyes if you did not prevent them. Do not attempt this test on a patient who is larger than you are without assistance.
- Most patients who have difficulty in walking will have evidence, when you come to examine them on the couch, of weakness, spasticity, rigidity, akinesia, sensory loss, or ataxia. If none of these is present, consider the possibility of a truncal ataxia due to a midline cerebellar lesion; alcoholism is the most common cause of this. Another possibility is an apraxia of gait due to a frontal lobe lesion.

4. John Steele, Canadian neurologist at Toronto General Hospital then Guam; J Clifford Richardson, Canadian neurologist (1909–1986).

# 7

## Facial palsy

**Inspection** 41

**Distribution of weakness** 42

**Sensation on the face** 45

**Taste** 46

**Other important signs to look for** 46

The facial muscles are supplied by the VIIth cranial nerve, which arises from the facial nucleus in the pons (Fig. 7.1). The facial nerve is accompanied, for part of its course, by the chorda tympani, which innervates the taste receptors of the anterior two-thirds of the tongue. The muscles of the forehead are represented in the ipsilateral, as well as the contralateral, cerebral hemisphere (Fig. 7.2). Stroke is the most common cause of an upper motor neurone facial palsy, and Bell's<sup>1</sup> palsy the most common cause of a lower motor neurone palsy. Other causes of facial palsy are rare. The site of the lesion causing facial palsy is assessed by noting: (1) the pattern of facial weakness and (2) the presence of other signs.



**See Video 29:** Bell's palsy



**See Video 30:** Hemifacial spasm

1. Sir Charles Bell, Scottish anatomist and surgeon (1774–1842).

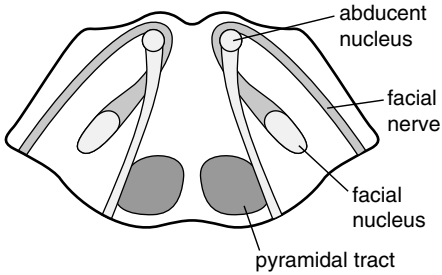


Figure 7.1 Transverse section of the pons.

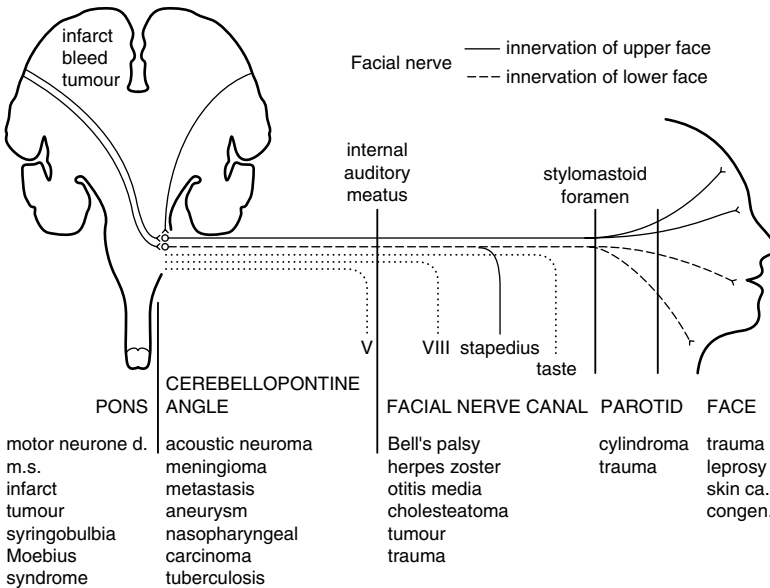


Figure 7.2 Schematic representation of the course and relations of the facial nerve.

## Inspection

- Are there vesicles behind the ear, within the external meatus, or on the palate (geniculate herpes, the Ramsay Hunt syndrome)?<sup>2</sup>
- Is there evidence of a parotid mass or swelling (cylindroma, sarcoidosis)?
- When the patient blinks, does the corner of the mouth twitch? When the patient smiles, does the eye close more on the affected side? These are features of synkinesis ('cross-talk' between axons within the facial nerve) and signify that the lesion is long-standing. Pouting is better than smiling for revealing eye closure due to synkinesis.

2. James Ramsay Hunt, American neurologist (1872–1937).



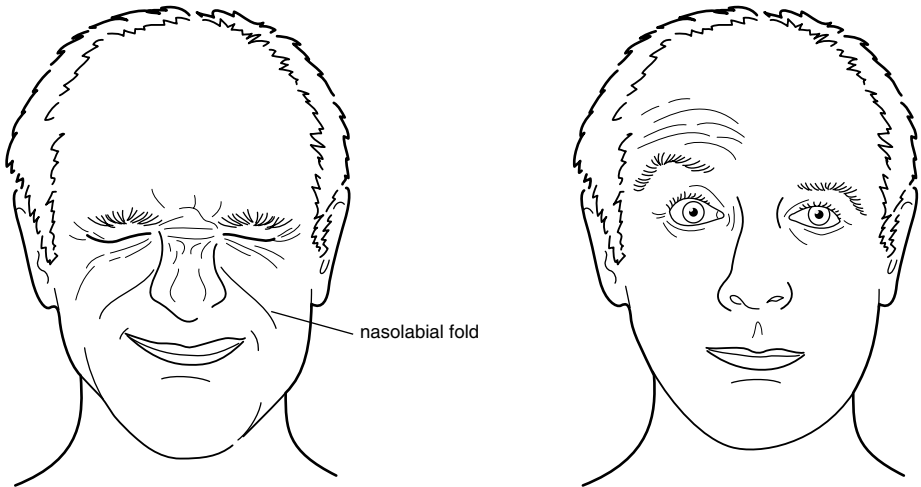


Figure 7.3 Raising the eyebrows: selective lesion of the temporal branch of the facial nerve.



See Video 31: Facial palsy

- Is the naso-labial fold (Fig. 7.3) lost (confirming weakness of the facial muscles) or deepened (signifying a long-standing weakness and associated with synkinesis)?
- Look for scars on the face (previous surgery for skin cancers) and over the occiput (previous surgery for acoustic neuroma).

## Distribution of weakness

Ask the patient to:

- Raise the eyebrows. Some patients have difficulty doing this voluntarily, but will do it involuntarily when asked to look up at the ceiling.
- Screw the eyes up tightly. Observe whether the eyelashes are buried.
- Show you their teeth.

- Blow the cheeks out. Air will escape from the mouth if there is weakness of orbicularis oris, and the cheek will blow out more on the side where there is weakness of buccinator.
- Turn the corners of their mouth down. This will also cause platysma to contract in many patients.

There are four main patterns of weakness:

- Weakness of all the muscles on one side of the face except frontalis and orbicularis oculi. The patient has an upper motor neurone lesion. This is most commonly due to a stroke involving the contralateral cerebral hemisphere and the facial weakness is but one part of a hemiparesis (detectable with your screening tests). Patients with this type of facial weakness often elevate the angle of the mouth involuntarily when smiling, but cannot do so on command.



**See Video 32:** Facial palsy

- Weakness of all the muscles on one side of the face. The patient has a lower motor neurone lesion, usually due to Bell's palsy. In Bell's palsy, there is often loss of taste and hyperacusis but no other signs. If it is due to a lesion of the facial nucleus, the patient may also have a CN VI nerve palsy or gaze palsy on the same side (see Fig. 7.2). If it is due to tumour – for example, acoustic neuroma – or infection within the facial nerve canal there may also be deafness or loss of taste.
- Bilateral facial weakness. When this occurs acutely, it is usually due to Guillain–Barré syndrome, and there may be associated generalized weakness and areflexia. Other causes of bilateral facial weakness or loss of facial movement include:
  - Sarcoidosis (with parotid swelling and fever).
  - Myopathies such as facio-scapulo-humeral dystrophy, oculopharyngeal dystrophy or mitochondrial myopathy.
  - Dystrophia myotonica (with ptosis, wasting of the masseters and sternomastoids, cataracts, frontal balding and inability to release the hand grip).



**See Video 3:** Dystrophia myotonica

- Myasthenia gravis (with ptosis and diplopia which worsen with sustained contraction and rapidly improve with rest. The pupils are spared. There may also be proximal weakness of the limbs).
  - Parkinson's disease. The 'frozen features' of the patient with Parkinson's disease are not due to weakness, but to facial akinesia and rigidity. These patients are able to bury their eyelashes and blow their cheeks out.
  - Bilateral upper motor neurone facial weakness occurs in multilacunar states (pseudobulbar palsy) and motor neurone disease. There is usually a brisk jaw jerk. While these patients have difficulty voluntarily contracting the facial muscles, their expressions may change in an exaggerated manner, and they may laugh or cry inappropriately.
- Weakness confined to one or two facial muscles on the same side (rare). In Figure 7.3, for example, weakness is confined to frontalis. This is never seen acutely in Bell's palsy; it may occur following incomplete recovery from a Bell's palsy and is then associated with synkinesis. Such a selective weakness is usually due to a lesion of the facial nerve after it has divided into its terminal branches in the parotid gland. Causes include facial trauma, parotid tumour, leprosy and perineural spread from a skin cancer.



**See Video 33:** Right facial weakness

Some patients who recover from Bell's palsy develop involuntary movements of the affected side of the face. This post-Bell's hemifacial spasm is usually associated with synkinesis due to aberrant regeneration of the facial nerve.



See Video 30: Hemifacial spasm

This form of hemifacial spasm should be differentiated from the more typical hemifacial spasm, usually caused by compression or irritation of the facial nerve by an artery in the posterior fossa.

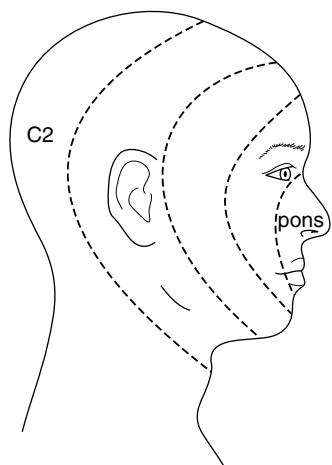


See Video 34: Hemifacial spasm

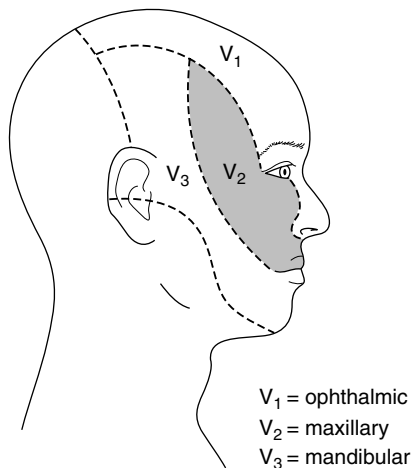
## Sensation on the face

Test touch and pin prick sensation on the forehead, cheek and chin on both sides of the face. Check corneal sensation. Several types of finding are worth considering:

- It is normal in Bell's palsy. Absence of the corneal reflex in Bell's palsy is due to interruption of the efferent limb of the reflex arc; the other eye blinks briskly when the cornea on the paralysed side is touched.
- In acoustic neuroma, there is usually loss of corneal sensation, and neither eye blinks when the cornea on the affected side is touched. Facial sensation is otherwise normal. Facial weakness is slight and there is deafness.
- Facial numbness, as part of a hemianaesthesia, is seen with strokes.
- Loss of sensation on the face, in the distribution of terminal branches of the trigeminal nerve, is a feature of perineural spread from skin cancers.
- Loss of sensation in the coolest parts of the face (nose and ears) is characteristic of leprosy (rare).
- Dissociated sensory loss on the face is seen in brainstem lesions, such as syringobulbia or glioma. Pain sensation is lost and touch sensation is preserved. The pattern of sensory loss with central lesions follows an 'onion-peel' pattern (Fig. 7.4), unlike sensory loss from peripheral lesions of the trigeminal nerve (Fig. 7.5).



**Figure 7.4** Onion-peel distribution of sensory loss associated with central lesions of the trigeminal nerve.



**Figure 7.5** Distribution of sensory loss associated with peripheral lesions of the trigeminal nerve.

## Taste

The testing of taste is time-consuming and for this reason often omitted. Taste sensation is normal in upper motor neurone facial weakness and in lesions of the facial nerve after it has left the facial canal. It is often lost in Bell's palsy and other lesions within the facial canal.

## Other important signs to look for

- **Ptosis.** The combination of weakness of orbicularis oculi and ptosis, with normal pupillary function, usually signifies that the problem involves muscle or neuromuscular function (see above).
- **Bilateral ophthalmoplegia.** This again usually signifies muscle disease or myasthenia gravis, the pupils being spared. Another cause of facial weakness and ophthalmoplegia is the Miller Fisher<sup>3</sup> variant of Guillain–Barré syndrome.
- **Hearing.** The combination of deafness and facial palsy is seen in lesions of the cerebello-pontine angle (e.g. acoustic neuroma) or of the facial canal (see Fig. 7.2). Hyperacusis often occurs in Bell's palsy due to paralysis of the nerve to stapedius.
- **Facial swelling** (rare) occurs in the Melkersson–Rosenthal<sup>4</sup> syndrome. Here, the facial palsy is often recurrent. Facial swelling also occurs in parotid tumours and parotitis due to sarcoid.

3 Charles Miller Fisher, Canadian neurologist at the Massachusetts General Hospital (1913–).

4 Ernst Gustaf Melkersson, Swedish physician, 1898–1932; Curt Rosenthal, German psychiatrist, twentieth century.

**Box 7.1**    **Tips**

- In an acute 'upper motor neurone' facial weakness, frontalis is often weak for a few days. At this time, it may be indistinguishable from a 'lower motor neurone' weakness.
- The elevators of the eyelids are not supplied by the facial nerve. Ptosis is not, therefore, a feature of a facial nerve lesion. A confusing sign is narrowing of the palpebral fissure due to over-activity of the orbicularis oculi muscle. This is seen in long-standing Bell's palsy and is associated with deepening of the naso-labial fold and a dimple in the chin.
- Facial palsy, occurring immediately after a fracture of the petrous part of the temporal bone, usually does not improve, as the nerve is severed. When it occurs several days after the head injury, recovery is the rule.
- In multiple sclerosis, facial palsy – unlike weakness in other muscle groups – is often 'lower motor neurone' in type. This may be due to demyelination of the nerve during its relatively long course within the pons, after leaving the facial nucleus (see Fig. 7.1).
- Many patients with Bell's palsy complain of a slight alteration of sensation on the affected side. This can be safely ignored, provided that the patient can feel the lightest touch, tell one end of the pin from the other, and has a normal consensual blink reflex.
- The affected eye sometimes brims with tears. This is due to separation of the punctum of the lacrimal duct from the conjunctival surface. It is not due to excessive production of tears. To the contrary, lacrimation is often reduced in Bell's palsy due to involvement of parasympathetic nerves.
- Bilateral facial weakness is easy to miss, as the patient's features are symmetrical. It should be suspected when, during the course of giving you the history, the patient is unblinking, expressionless, and smiles 'horizontally' – that is, they fail to elevate the angles of the mouth. Speech is often impaired – particularly labial sounds like 'puh' – and the patient cannot form a seal with the lips when asked to blow the cheeks out. In severe cases, the eyes are seen to roll up as the patient blinks (Bell's phenomenon).
- Bell's phenomenon is useful for determining whether a patient is really trying to screw the eyes up. Unless there is paralysis of the extra-ocular muscles, the eyes roll up when the orbicularis oculi muscles contract forcefully.
- Beware the child with an acute Bell's palsy where there is a recognized association with hypertension.
- Finally, do not overdiagnose facial palsy. Many patients have a lop-sided smile and they will soon tell you that this has always been the case, if you ask them. An old photograph is helpful.

# 8

# Ptosis

**Inspection 48**

**Distribution of weakness 49**

Drooping of the eyelids is common in the elderly, and results from dehiscence of the levator aponeurosis. Otherwise, it usually results from weakness of the levator palpebrae superioris muscle. This is innervated by the oculomotor (IIIrd) nerve. The under-surface of the levator muscles is connected to the tarsus by smooth muscle fibres, Müller's muscle, which is innervated by cervical sympathetic nerves. Ptosis results from damage to these nerves or to disorders of muscle or neuromuscular junction.

## Inspection

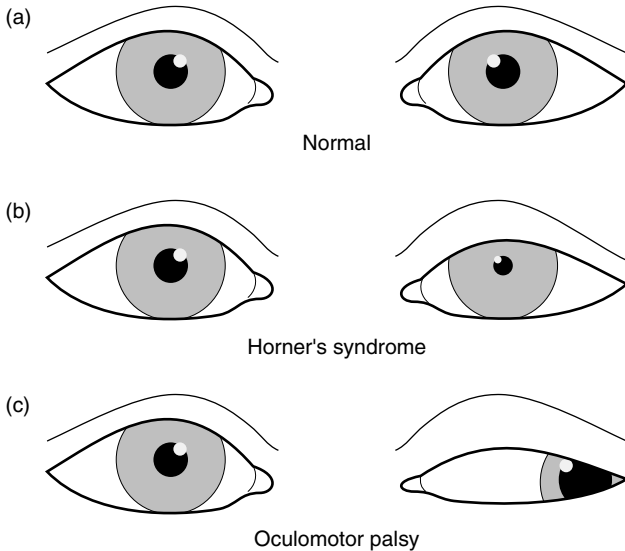
Give yourself a moment to take in the overall appearance of the patient. There are some characteristic presentations:

- One eye closed, the other normal (oculomotor palsy or myasthenia gravis).
- Ptosis with lowering of the upper eyelid due to weakness of the levator palpebrae on one side with the pupil larger on the same side (oculomotor palsy; Fig. 8.1).



**See Video 35:** Third nerve palsy

- Partial ptosis with lowering of upper eyelid and elevation of the lower eyelid due to weakness of the Müller's muscle on one side with the pupil smaller on the same side (Horner's syndrome; Fig. 8.1).



**Figure 8.1** The eyes in the primary position: (a) normal, (b) Horner's syndrome, (c) oculomotor nerve palsy.

- Bilateral ptosis (myopathy, such as dystrophia myotonica [drooping mouth, thin neck and frontal balding] or Kearns–Sayre<sup>1</sup> syndrome; or myasthenia gravis).
- Proptosis and ptosis in one eye (orbital tumour or vascular anomaly). Listen for a bruit over the eye.

## Distribution of weakness

In the first place, you need to:

- test visual acuity;
- examine the lens and fundi;
- test pupillary response to light and accommodation;
- test visual fields;
- test eye movements; and
- examine for weakness of the facial muscles (especially orbicularis oculi).

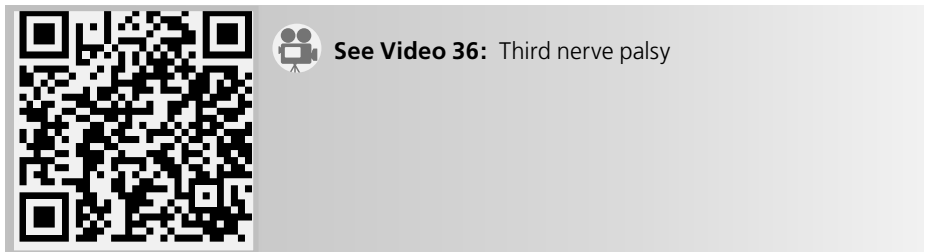
1. Thomas P Kearns, Mayo Clinic neuro-ophthalmologist (1922–); George Pomeroy Sayre, American ophthalmologist (1911–).



What you find will then lead you to other aspects of the examination. Certain patterns of weakness are characteristic:

● **Unilateral ptosis:**

- With the patient attempting to look straight ahead, the eye is ‘down and out’ (see Fig. 8.1c). There is weakness of adduction and vertical eye movements; the pupil is fixed and dilated. The patient has an oculomotor (IIIrd) nerve palsy (see Chapter 9).
- As for the previous case, but with pupillary sparing. Consider small-vessel disease due to diabetes mellitus and/or hypertension as a cause.



- With the pupil smaller on the same side but normally reactive to light, eye movements are full (see Fig. 8.1b). The patient has a Horner’s syndrome. If you look carefully, you may note that the lower lid is elevated on the affected side. Brush the back of your hand across the forehead. The skin may feel moist and sticky on the normal side, but smooth on the anhidrotic side. Horner’s syndrome is a good lateralizing but a poor localizing sign as the cervical sympathetic fibres run such a tortuous course. The following associated signs should be particularly looked for:
  - Loss of the corneal reflex in the same eye (orbital or retro-orbital lesion);
  - Weakness and loss of reflexes in the ipsilateral arm (avulsion injury to the brachial plexus; Pancoast<sup>2</sup> tumour of the lung apex);
  - Ipsilateral loss of facial pain and temperature sensation and contralateral loss of pain and temperature sensation in the trunk and limbs (brainstem lesion).
- With (or without) weakness of extra-ocular muscles and orbicularis oculi consider *myasthenia gravis*. Ask the patient to look up at the ceiling for about 2 minutes. The ptosis may worsen. After a brief rest, the eyelid will resume its original position. Look for evidence of weakness and fatigability in the limbs. Fatigability is most conveniently tested in the deltoid muscles. Sit the patient in a chair and ask them to abduct the arms at the shoulder, flex the elbows and to resist your attempts to press their arms down. It is easier for you to sustain this by pressing repetitively (about

2. Henry Khunrath Pancoast, American radiologist and radiotherapist (1875–1939).

once per second) rather than continuously. Within a minute or so, it becomes progressively easier to press the arms down if the patient has myasthenia gravis. Again, after a brief rest, the muscle strength returns. Triceps is often weak in myasthenia gravis.



**See Video 37:** Unilateral ptosis

### ● Bilateral ptosis

- With normal pupils. This usually signifies a disorder of muscle or neuromuscular junction. If there is weakness of the extra-ocular muscles and of orbicularis oculi, the following should be considered:
  - Senile ptosis (see Box 8.1).
  - Ocular myopathy. In Kearns–Sayre syndrome, there is complete or partial ophthalmoplegia with ptosis which may be unilateral or asymmetrical and the pupils are normal. In other myopathies, there may be generalized weakness. Perform an ECG to see if there is a conduction defect.



**See Video 38:** Ptosis

- Myasthenia gravis (see above).



**See Video 39:** Ocular myasthenia gravis

- Dystrophia myotonica. Supporting evidence will include frontal balding, cataracts, wasting of the masseters, sternomastoids and distal limb muscles. Again, check the ECG to see if there is a conduction defect. Test for myotonia (see section on Wasting of the hand).
- With unreactive dilated pupils. This uncommon finding is likely to be due to an abnormality of the oculomotor nerves (such as Miller Fisher syndrome) or their central connections in the midbrain.

**Box 8.1****Tips**

- Complete ptosis, where the pupil is covered by the lid, is unlikely to be due to Horner's syndrome.
- Pupillary inequality due to an oculomotor palsy is most obvious in a well-lit room; due to Horner's syndrome, is most obvious in a dimly lit room.
- Ptosis associated with weakness of orbicularis oculi is likely to be due to myasthenia gravis or to an ocular myopathy.
- Always consider myasthenia gravis when the pattern of weakness of eye movements cannot be readily fitted into a IIIrd, IVth or VIth cranial nerve palsy (and even when it can).
- In unilateral Horner's syndrome which has been present from birth, the iris of the affected eye may remain blue when the other becomes brown (heterochromia).
- In dysthyroid eye disease, ophthalmoplegia is usually associated with lid retraction, not ptosis.
- A common cause of bilateral ptosis is 'mechanical' ptosis where the levator palpebrae muscle dehisces from the tarsal plate. This condition is seen in elderly patients, and is often called 'senile ptosis'. There are no associated neurological signs.
- In ptosis associated with a complete IIIrd nerve palsy, there is often mild proptosis when the patient is examined sitting up. This is due to loss of tone in the extra-ocular muscles; it disappears when the patient lies down.

# 9

## Abnormalities of vision or eye movement

**Inspection** 53

**Testing vision** 53

**The remainder of the examination** 57

To see properly you need to have normal eyes, eye movements and central visual connections. Your approach to the examination thus involves determining which of these three components has failed. The range of possibilities with this introduction is wide and includes: blindness in one eye, bitemporal hemianopia, homonymous hemianopia and IIIrd, IVth or VIth nerve palsies. Patients with pupillary abnormalities and nystagmus will also be considered in this chapter. Many people experience difficulty in testing the eyes, and some time will be spent in describing techniques which are useful.

### Inspection

Step back and look at the patient as a whole. Certain features may be very revealing:

- Acromegaly or the smooth, soft, 'feminine' cheeks (in a man) signifying hypopituitarism. In such patients, you will be looking carefully for a bitemporal hemianopia.
- A patient with an obvious hemiparesis may also have a homonymous hemianopia, though this is only one of many associations.
- Loss of facial expression and ptosis raise the possibility of disorders of muscle or the neuromuscular junction (myopathy, myasthenia gravis, dystrophia myotonica).
- Look carefully at the eyes for nystagmus, inequality of the pupils, proptosis, cataracts and evidence of trauma.

### Testing vision

Test the following in every patient:

- **Acuity.** Carry a card with letters of different sizes which you give the patient to hold at a comfortable reading distance. See what the patient can read (with reading

glasses if they are normally used). Ask them if they wear reading glasses and to use them if they do. The aim of this part of the exercise is to make sure that the patient is not blind or near-blind in one or both eyes. Subtle abnormalities of visual acuity are not a concern.

- **Fundoscopy.** Maximize your chances of seeing something other than the reflection of the light from your ophthalmoscope by dimming the lights in the room, using a narrow beam and using, initially, a low light strength. Get as much practice as you can in using the instrument. The main abnormalities you are looking for include: papilloedema, optic atrophy, cataracts or retinal changes such as diabetic retinopathy, hypertensive retinopathy, haemorrhages and retinitis pigmentosa. If you are unable to visualize the retina, consider the possibility of cataracts or opacities in the cornea or vitreous humour.
- **Fields.** Visual field testing is often done badly and obvious abnormalities missed. The following approach may help:
  - *Peripheral field testing.* Sit in front of the patient, as shown in Fig. 9.1. The patient has both eyes open. Hold both of your hands in the upper fields and ask the patient to look at your eyes and to point to where your fingers are moving.

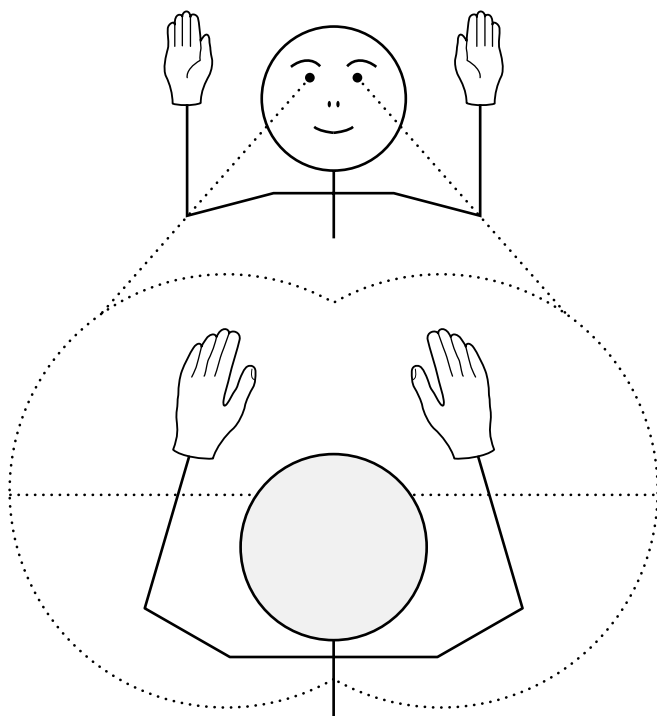
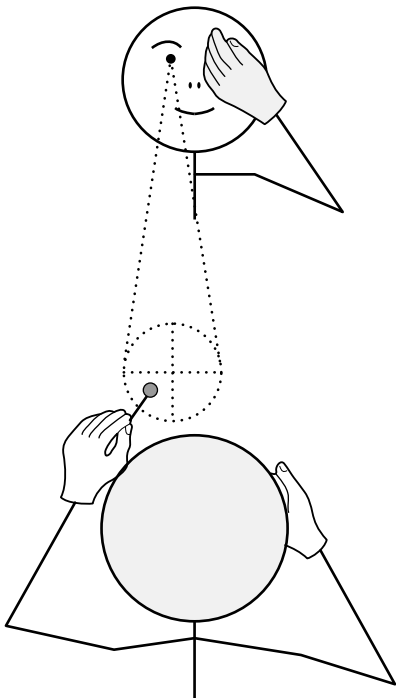


Figure 9.1 Testing the quadrants of the peripheral visual field.

Explain that sometimes you will move your fingers on both sides together. Move your fingers on one side, then the other, then both together. Repeat the procedure in the lower fields. This technique is good for detecting homonymous hemianopia and visual neglect. In the latter, the patient will miss the movements in the left visual field only when there are simultaneous movements in the right field. It is not good at detecting a blind eye for the field of a single eye is wide.

- **Central field testing** (Fig. 9.2). Cup your hand over your left eye and ask the patient to do the same with their right eye (warn the patient not to press on the eye or it will be untestable for the next few minutes). Ask the patient to look at your eye. Place a red pinhead in each of the four quadrants of the visual field, close to the centre. Ask the patient whether they can see the pin and whether the colour is the same in each quadrant. Don't stray far from the centre of the field; you will see yourself that the colour fades the further out you go. This is a sensitive test for optic nerve and chiasmal lesions; the patient will not see the pin on the affected side, or it will look grey. You can also assess the size of the blind spot in someone with papilloedema.
- **Pupillary responses.** See if the pupils are equal. Ask the patient to fixate on the wall opposite and test the direct and consensual light reflexes. An absent light reflex is a key sign and should be checked carefully. A common cause of failure to



**Figure 9.2** Testing the quadrants of the central visual field with a red pin.

induce a light reflex on the wards is a flat torch battery. Sometimes it is difficult to see the response in a brightly lit room because the pupils are so constricted. If in doubt, dim the lights. Use the swinging torch test to detect a relative afferent pupillary defect (the Marcus Gunn<sup>1</sup> response): shine the light in one eye and then quickly flick it across to the other eye, wait a second or two, then flick it back. Each time the light hits the eye with impaired vision, the pupil dilates. Test the near reflex.

- **Eye movements.** Observe the position of the eyes and look for evidence of strabismus (squint) or nystagmus in the primary position (looking straight ahead).

Here are some techniques which may prove useful:

- **Testing eye movements**

- *Pursuit gaze testing.* Ask the patient to follow your finger as you trace a large figure 'H'; this causes the eyes to move horizontally and then vertically in the abducted and adducted positions. Check the range of movement achieved by each eye and whether the movements are smooth as they follow your finger; in cerebellar disorders they are often jerky.
- *Voluntary gaze testing.* First, ask the patient to look to the left, then to the right, then up, then down. This will give you an idea of the range of eye movements. Note whether the patient blinks to initiate gaze or moves their head rather than their eyes. With practice, you may notice whether the saccades are slow. (Saccades are eye movements generated in voluntary gaze, and are so rapid that you cannot see them, only their start and finish.) These disorders of voluntary gaze are characteristic of certain diseases such as progressive supranuclear gaze palsy (PSP), Huntington's disease<sup>2</sup> and the rare spinocerebellar ataxias (SCA II, III and VII). Now, hold the thumb of your left hand and the index finger of your right hand about 50 cm apart in front of the patient. Ask the patient to look at your thumb when it moves and then your finger (again, when it moves). See if their eyes can go from one digit to the other in one clean sweep (saccade). The hallmark of motor dysfunction in Parkinson's disease is loss of amplitude of voluntary movements. In the eyes, this is reflected as hypometric saccades, with the eyes moving from thumb to finger in a series of bunny-hops rather than in one leap. In cerebellar disorders, the eyes may overshoot the target and then return (ocular dysmetria). In PSP, the patient may not be able to look down voluntarily and yet will achieve a full vertical excursion if the examiner passively flexes and extends the head as the patient fixates on a target (Doll's eye movement or oculocephalic manoeuvre induced by the vestibulo-ocular reflex).

1. Robert Marcus Gunn, Scottish ophthalmologist (1850–1909).

2. George Sumner Huntington, American neurologist (1851–1916).



See Video 40: Supranuclear gaze palsy

### ● The cover test:

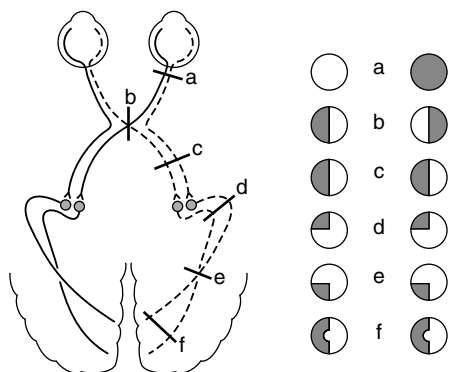
- *Objective confirmation of diplopia.* Failure of one or both eyes to move in a certain direction may be obvious. Often it is not, although the patient may complain of seeing double. You may confirm that the eyes are not aligned using the cover test. Ask the patient to fixate on your pin with both eyes open. Move the pin around until you find the position where the patient says that they are seeing double. Now cover each eye in turn. The eye that is fixating will not move when the other is covered. The other eye will move when the fixating eye is covered.
- The traditional method of determining which muscle is weak is to cover each eye in turn and to ask the patient which of the two images has disappeared. The outer image comes from the eye which has not moved fully. Unfortunately, patients often have difficulty with this test and report that it is the outer image which has gone when either eye is covered. It is more useful to determine from the patient whether the two images are separated in the vertical (e.g. IIIrd and IVth nerve palsies) or horizontal (e.g. VIth nerve palsy) planes.

## The remainder of the examination

You now have enough information to proceed with the remainder of the examination. What you do next will depend upon what you have found:

- **Abnormality of vision.** Here, you have found impairment of the visual fields or acuity. This might consist of:
  - **Impairment of acuity in one eye** (Fig. 9.3a). Cover the other eye and see if the patient can perceive hand movements or the light of your torch. The pupils are equal, but the affected eye has no response to light or has a relative afferent pupillary defect. The problem lies in the anterior visual system: the eye itself (e.g. central retinal artery occlusion, retinitis pigmentosa) or the optic nerve. If there is swelling of the optic disc, consider conditions such as optic neuritis or ischaemic optic neuropathy (see Box 9.1, page 65). If there is optic atrophy, a number of possibilities exist: subfrontal meningioma (test smell); pituitary tumour; carotid aneurysm;

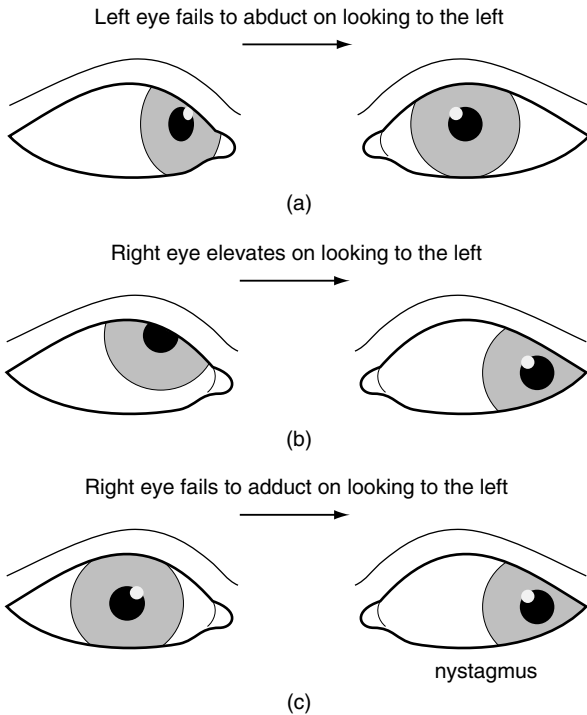




**Figure 9.3** Examples of visual field losses and their associated lesions.

anterior ischaemic optic neuropathy (feel the superficial temporal pulses and check the erythrocyte sedimentation rate [ESR] as temporal arteritis can cause this); multiple sclerosis; trauma; syphilis.

- **Bitemporal hemianopia** (Fig. 9.3b). This signifies a lesion of the optic chiasm, most commonly due to a pituitary tumour. You may have already observed the changes of hypopituitarism or acromegaly. Ask the patient if he/she has galactorrhoea (prolactinoma).
- **Homonymous hemianopia** (Fig. 9.3c and f). This signifies a lesion behind the optic chiasm – that is, involving the optic tract, radiation or visual cortex. In a left homonymous hemianopia, look for evidence of non-dominant parietal lobe function. Get the patient to draw a clock, put a cross in the middle of a line, and copy a cube. Test for sensory neglect. Use your screening tests to detect a hemiparesis. In a right homonymous hemianopia, look for evidence of aphasia and again for hemiparesis. Test reading. The most common causes of homonymous hemianopia with these signs are stroke and tumour.
- **Upper homonymous quadrantanopia** (see Fig. 9.3d). This signifies a temporal lobe lesion; a **lower homonymous quadrantanopia** signifies a parietal lobe lesion (Fig. 9.3e).
- **Abnormality of eye movements.** This is likely to be one of two types:
  - **Weak eye muscles.** Here, there is weakness of the ocular muscles of one or both eyes:
    - The patient fails to abduct one eye (Fig. 9.4). There are no other ocular findings. The patient has weakness of the lateral rectus muscle, most commonly due to an abducens (VIth) nerve palsy. The abducens nucleus is in the pons: check facial sensation and use the screening tests, looking for a contralateral hemiparesis (see Fig. 7.1). Causes of abducens palsy include microvascular occlusion of the vasa nervorum of the VIth nerve due to hypertension or diabetes, raised intracranial pressure, cavernous sinus lesions and nasopharyngeal carcinoma. Often, no cause is found.



**Figure 9.4** (a) Left abducens nerve palsy; (b) right trochlear nerve palsy; (c) right internuclear ophthalmoplegia.



**See Video 41:** Sixth nerve palsy

- In the primary position, one eye assumes an abducted and depressed position (see Fig. 8.1c). There is weakness of adduction, elevation and depression of the eye, and ptosis. The pupil is fixed and dilated. The patient has an oculomotor (IIIrd) nerve palsy. When this occurs acutely and there is a pain in the eye, it is a matter of some urgency to exclude a posterior communicating aneurysm (with a computed tomography [CT] angiogram, magnetic resonance angiogram [MRA] or spiral angiogram). Clipping the aneurysm before it has ruptured carries a much lower mortality than after. Chronic meningitis (e.g. tuberculosis), raised intracranial pressure or cavernous sinus lesions (check trigeminal nerve function) may also cause IIIrd nerve palsies. The pupil is

characteristically spared in a IIIrd nerve palsy associated with diabetes mellitus or hypertension.



**See Video 36:** Third nerve palsy

- On looking to the left, the right eye rides up (Fig. 9.4b). The head is tilted to the left. The patient has weakness of the right superior oblique muscle, usually due to a trochlear (IVth) nerve palsy. Attempts to demonstrate failure of the eye to depress in the adducted position are usually unrewarding. Often, it follows head injury, but diabetes is another cause.



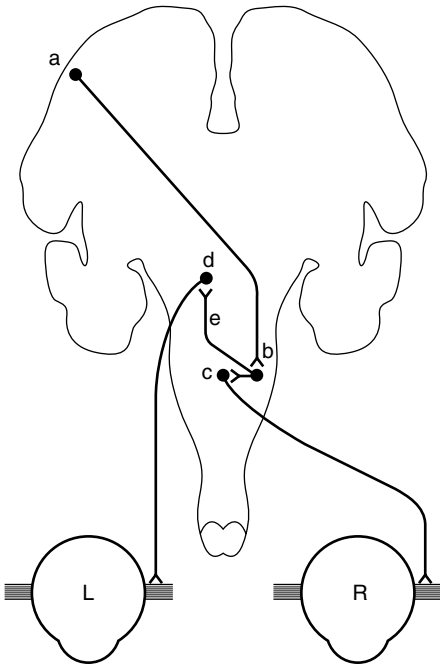
**See Video 42:** Fourth nerve palsy

- On lateral gaze, one eye fails to adduct (or adducts slowly) and the abducting eye overshoots and then corrects (Fig. 9.4c) or shows nystagmus. The affected eye may adduct fully on convergence testing. The patient has a unilateral internuclear ophthalmoplegia (INO). This signifies a lesion of the medial longitudinal fasciculus (Fig. 9.5). Unilateral INO is often due to stroke, and bilateral INO to multiple sclerosis.



**See Video 43:** Internuclear ophthalmoplegia

- Mild limitation of upward gaze is a common finding in otherwise normal elderly patients and in Parkinson's disease.



**Figure 9.5** Pathway for lateral gaze. (a) Frontal lobe eye field; (b) pontine lateral gaze centre; (c) abducens nucleus; (d) medial rectus nucleus of the oculomotor nerve; (e) medial longitudinal fasciculus.

- Both eyes fail to look to one side (conjugate gaze palsy). Loss of voluntary lateral gaze usually signifies a lesion of the contralateral frontal lobe or the ipsilateral pons (see Fig. 9.5).



**See Video 44:** Facial and gaze palsy

- On attempted upward gaze, the eyes develop a rapid flickering motion towards each other and retract rhythmically. This is convergence–retraction nystagmus, and is a feature of Parinaud’s syndrome.<sup>3</sup> The pupils may also become unreactive to light but not to accommodation. The usual underlying cause is compression of the midbrain by a pinealoma. Other causes include hydrocephalus and stroke.

3. Henri Parinaud, French neuro-ophthalmologist (1844–1905).



See Video 45: Parinaud's syndrome



See Video 46: Parinaud's syndrome

- **Loss of downward gaze.** In an elderly patient this is likely to be due to progressive supranuclear palsy (PSP; Steele Richardson syndrome), a type of parkinsonism. There is also loss of upward gaze. While the patient cannot look up or down voluntarily or with pursuit, reflex movement is preserved, showing that the lesion is above the nucleus of the oculomotor and trochlear nerves (i.e. it is 'supranuclear'). Ask the patient to look at a point on the wall opposite. Now, tilt the head back (this may be difficult as there is often marked neck rigidity in PSP, in itself a helpful sign). The eyes will depress.



See Video 40: Supranuclear gaze palsy

- **Nystagmus.** This refers to involuntary rhythmical movements of the eyes. In most cases, each movement has a fast and a slow phase ('jerk' nystagmus). Note whether the nystagmus is present in the primary position (looking straight ahead), on horizontal gaze, or on vertical gaze. Does it beat in a horizontal (left or right) or vertical plane (up or down)? By convention, the direction of nystagmus is defined by the direction of the fast phase. Vestibular nystagmus can be either 'peripheral' (labyrinth) or 'central' (vestibular nucleus/cerebellum), and is often induced by head movement. Patients with peripheral nystagmus may have

deafness and tinnitus, but usually no other signs. Gaze-evoked nystagmus is typically due to brainstem or cerebellar lesions. Several examples of nystagmus are worthy of mention.

- A few beats of horizontal nystagmus, only present at the extremes of lateral gaze. Unsustained nystagmus of this type is physiological. Avoid moving the eyes beyond the range of comfortable binocular vision.



**See Video 47:** Horizontal nystagmus

- Fine horizontal nystagmus with the fast component to one or other side, only present on deviation of the eyes to that side. This could be due to a peripheral or central lesion. Peripheral vestibular nystagmus beats away from the side of the lesion, whatever the direction of the gaze. Cerebellar nystagmus is gaze-evoked and typically beats to the side of the lesion if unilateral, but may also beat in whichever direction the patient looks. Central vestibular nystagmus, if purely horizontal, will usually beat away from the side of the lesion whichever way the patient looks. In such a patient you should:
  - Test hearing. Whisper a number on one side while masking the other ear by rubbing the tragus against the external meatus. Hearing might be impaired in a peripheral lesion as in Ménière's<sup>4</sup> disease. It might also be impaired in a cerebellopontine angle tumour. If hearing is impaired, you should do Rinné<sup>5</sup> and Weber<sup>6</sup> tests though, in the noisy environment of a ward or clinic, these are rarely helpful.
  - Test facial and corneal sensation and look for facial weakness (cerebellopontine angle tumour or pontine lesion).
  - Look for cerebellar signs: dysarthria, intention tremor, ataxic gait.
  - Perform screening tests for a hemiparesis.
- Sustained horizontal nystagmus on lateral gaze in both directions. This is seen in patients who are intoxicated with drugs, such as phenytoin, benzodiazepines and barbiturates. They may also have dysarthria and limb ataxia. It may also result from the lesions of the cerebellum and brainstem mentioned.

4. Prosper Ménière, French otologist (1799–1862).

5. Heinrich Adolf Rinné, German otolaryngologist (1819–1868).

6. Ernst Heinrich Weber, German anatomist and physiologist (1795–1878).

- Vertical nystagmus. This usually signifies a central lesion. It can be caused by the same drugs as horizontal nystagmus. There are two main types of vertical nystagmus:
  - Upbeat nystagmus, where the fast phase is upwards. Causes include multiple sclerosis, stroke, tumour and Wernicke's<sup>7</sup> encephalopathy. It is also seen in bilateral internuclear ophthalmoplegia.
  - Downbeat nystagmus, where the fast phase is downwards, is less common, and is particularly associated with lesions of the cervicomedullary junction, such as the Arnold–Chiari<sup>8</sup> malformation.



See Video 48: Vertical nystagmus

- Nystagmus confined to one eye ('ataxic' nystagmus) is seen in an internuclear ophthalmoplegia (see above).



See Video 43: Internuclear ophthalmoplegia

- Convergence–retraction nystagmus is seen in lesions of the tectal plate of the midbrain (see above).

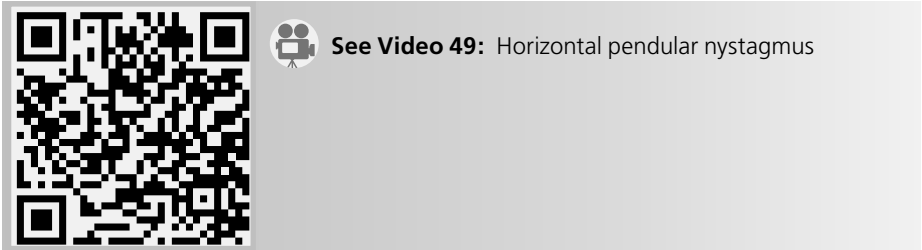


See Video 45: Parinaud's syndrome

7. Karl Wernicke, German neuropsychiatrist (1848–1905).

8. Julius Arnold, German physician (1835–1915); Hans Chiari, Austrian pathologist (1851–1916).

- In pendular nystagmus, there are no clearly recognizable fast and slow phases; the movements are sinusoidal. It is often long-standing and associated with failure of visual fixation or blindness. A common cause is multiple sclerosis.



- **Pupillary abnormality.** This is likely to be one of the following:
  - One pupil is smaller than the other. Both react briskly to light and accommodation. There is ptosis on the side of the small pupil. The patient has Horner's syndrome (see Fig 8.1b).
  - One pupil is smaller than the other. The larger pupil is unreactive to light or accommodation. There is ptosis and limitation of eye movements on the side with the larger pupil. The patient has a IIIrd nerve palsy (see Fig 8.1c).
  - One or both pupils are large, react poorly to light, but do constrict to a near stimulus. There is no ptosis; eye movements are full. This is likely to be an Adie<sup>9</sup> ('tonic') pupil; check for areflexia. Other possibilities include traumatic iridoplegia and the result of previous application of mydriatic eye drops.
  - Both pupils are small, irregular and unreactive to light. The response to accommodation is preserved. There is no ptosis. Eye movements are full. The patient may have Argyll Robertson<sup>10</sup> (A-R) pupils. A-R pupils are now rare and associated with diabetic autonomic neuropathy rather than neurosyphilis; more common is the long-standing Adie pupil which eventually becomes small. Like the A-R pupil, the response to accommodation is often brisk and, while the pupil does constrict to light, this may take so long as to be missed. The pupils of patients with glaucoma treated with pilocarpine eye drops are very small, and in these it may be difficult to see any response to light or accommodation.

### Box 9.1 Tips

- Optic nerve disease does not cause inequality of the pupils for the direct and consensual light reflexes are of equal strength. Thus, if the right optic nerve were transected, the size of the right pupil would remain the same as that of the left, by the action of the consensual reflex.
- The finding of an afferent pupillary defect usually indicates a lesion of the optic nerve, and is less common in retinal lesions.

9. William John Adie, Queen Square neurologist (1887–1935).

10. DMCL Argyll Robertson, Scottish ophthalmologist (1837–1909).



- Optic disc swelling may be due to optic neuritis or raised intracranial pressure. In optic neuritis, there is a central scotoma, impairment of colour vision (especially to red) and visual acuity is impaired; in raised intracranial pressure, the blind spots are enlarged and the visual acuity is usually normal in the early stages.
- Myasthenia gravis may mimic a IIIrd, IVth or VIth cranial nerve palsy, and even an internuclear ophthalmoplegia. The pupil is spared and there is often weakness of orbicularis oculi. The signs are usually bilateral and there is ptosis. Fatigability is the key sign.
- Dysthyroid eye disease should always be considered if the abnormality of eye movement does not readily conform to a IIIrd, IVth or VIth cranial nerve palsy. Associated features include proptosis, lid lag, lid retraction and conjunctival injection.
- You will miss the important sign of visual neglect, usually signifying a non-dominant parietal lesion, unless you routinely test the patient with simultaneous stimuli in each half field.
- The obliques elevate and depress the eyes in the adducted position, the recti in the abducted position.
- Abnormalities of conjugate horizontal gaze are seen in lesions of the pons, frontal or occipital lobes. Conjugate vertical gaze is impaired in lesions of the midbrain.
- Nystagmus is likely to be of central origin if it is vertical or involves only one eye.
- Nystagmus, dysarthria and tremor are some of the acute effects of alcohol. Often the only cerebellar sign in a chronic alcoholic is unsteadiness of gait.
- In a young woman, who looks well and has no ocular signs apart from a dilated, slowly reactive pupil, consider the Holmes–Adie syndrome.<sup>11</sup> Often, the pupil is oval. Both pupils may be involved. Check the tendon reflexes. In elderly patients with this syndrome, the pupils may become small.

11. Sir Gordon Holmes, Queen Square neurologist whose system of neurological examination forms the basis of what we all do to this day (1876–1965).

# 10

## Tremor and cerebellar signs

**Inspection** 67

**Examination of tremor** 68

**Other aspects** 70

Tremor is a rhythmical involuntary movement of any part of the body, but most commonly of the hands. It is convenient to divide tremors into three main categories: resting, postural and intention. The most common cause is physiological tremor which we all have at times. The patient whose tremor is severe enough to seek medical attention is most likely to have essential tremor or Parkinson's disease.

### Inspection

Step back and look at the patient as a whole. You should have two questions in your mind:

- Which parts of the body are shaking? Look particularly at the lips, tongue, chin, head and limbs. Also ask the patient to make the 'ahhh' sound to listen for any voice tremor, typically presents in patients with essential tremor. All patients with a history of tremor should be asked to write or perform other activities that typically trigger the tremor. Some patients with task-specific tremor shake only when writing (primary handwriting tremor), applying make-up, putting while playing golf, texting, or performing other activities that require fine coordinated movement.



**See Video 50:** Handwriting tremor

- Are there any signs of parkinsonism, such as rest tremor, hypomimia, bradykinesia, rigidity, decrementing amplitude on rapid succession movements, decreased arm swing, stooped posture, and other parkinsonian signs?

## Examination of tremor

The next step is to define the characteristics of the tremor. This is done on the basis of the observation of the tremor at rest, while the arms are outstretched in front of the body and in a wing-beating position, and in the finger-to-nose manoeuvre. Patients with essential tremor typically have hand action tremor (during movement) and postural tremor that is evident immediately after assuming an anti-gravity, horizontal, posture. In contrast, patients with Parkinson's disease typically have tremor at rest which, following a latency of several seconds or even a minute, may recur after assuming a horizontal position, the so-called re-emergent tremor.

- The circumstances in which it is maximal.
- Whether it is coarse (high amplitude, low frequency) or fine (low amplitude, high frequency).

Observe the tremor in the hands:

- with the patient sitting with their hands resting on their lap. A tremor that is maximal in this posture is called a **resting tremor** and is characteristic of Parkinson's disease. It is usually coarse and more marked in one hand than in the other. It pauses during movement of the affected hand yet, characteristically, persists or even increases during walking.



See Video 51: Resting tremor



See Video 52: Resting tremor

- with the arms outstretched in front, first with the elbows extended and then flexed with the fingers held in front of the nose. A tremor in this position is called a **postural tremor**. This may be of two types:
  - Physiological tremor: a fine tremor present equally in the two hands. It is enhanced by anxiety, thyrotoxicosis and adrenergic drugs.

- Essential tremor: this is also usually fine and symmetrical. It persists during movement.



See Video 53: Postural tremor

- as the patient repeatedly touches their nose and then your finger with each hand in turn. This manoeuvre elicits an **intention tremor**, a coarse tremor which appears and increases in amplitude as the hand approaches its target. Such a tremor signifies cerebellar dysfunction.



See Video 50: Handwriting tremor



See Video 54: Parkinson's disease



See Video 55: Intention tremor



See Video 56: Intention tremor

## Other aspects

What you do next will be determined by what you have found:

- **Resting tremor.** Your aim is to document and quantitate the parkinsonian features using the Unified Parkinson's Disease Rating Scale and confirm the diagnosis of Parkinson's disease:
  - *Tone.* Test tone in the arms (see Introduction). In Parkinson's disease, tone is increased throughout the range of movement. The tremor may also be felt as 'cogwheeling'.
  - *Akinesia.* This is tested by getting the patient to:
    - make piano-playing movements with the index and middle fingers of each hand in turn; or
    - open and close the hand repeatedly with the fingers extended. The amplitude of the movement decreases as the test continues.



See Video 57: Parkinson's disease

- If these tests are performed only with difficulty, make sure that the problem is not due to weakness. Rapid finger movements are also impaired in patients with hemiparesis but do not show the progressive decrement in amplitude which characterizes this activity in Parkinson's disease. Muscle strength is normal in Parkinson's disease.
- *Gait.* Check for: loss of arm swing, stooped posture, small steppage and stiffness or hesitation on turning. Eventually, there is loss of balance (demonstrated by performing the 'pull test') and freezing resulting in falls.



See Video 58: Parkinson's disease

- *Speech*. This will typically be of low volume with a tendency for words to run into each other or to stutter (palilalia).



See Video 59: Speech in Parkinson's disease

- **Postural tremor** (essential tremor or enhanced physiological tremor). The aim here is to exclude Parkinson's disease, which is not always easy as in many patients with severe, coarse essential tremor the tremor persists at rest and some patients have other overlapping features suggestive of co-existence of the two disorders, such as cogwheeling rigidity and bradykinesia. Conversely, postural tremor is common in Parkinson's disease. Distribution of the tremor, however, is often useful in differentiating the two disorders. Thus, head, voice and handwriting tremor are typically present in patients with essential tremor, but not in patients with Parkinson's disease. On the other hand, patients with Parkinson's disease, in addition to typical rest hand tremor, may also have leg and chin tremor. Another useful way of distinguishing between the two conditions is by observing the gait. In essential tremor, the gait is normal, although some patients may have difficulties with tandem gait. In contrast, in Parkinson's disease (unless in the very early stages or when they are receiving treatment), the gait is almost always abnormal. Furthermore, in essential tremor, the face is expressive and the patient gesticulates fluently in conversation, the tremor is longstanding, improves with alcohol, and there is usually a positive family history of tremor (or alcoholism).
  - If it is of recent onset, check for evidence of thyrotoxicosis: tachycardia, sweating, lid lag, exophthalmos, goitre, thyroid bruit, weight loss. Enquire about what drugs the patient is taking, particularly valproate, lithium and serotonin re-uptake inhibitors.
- **Intention tremor** (cerebellar dysfunction). Look for confirmatory signs of cerebellar dysfunction such as nystagmus, dysarthria, dysmetria, dyssynergia,

dysdiachokinesia, loss of check, and wide-based unsteady gait, and other evidence of ataxia. It is important not to confuse this tremor, which *only* appears as the hand or foot approaches its target during the finger-to-nose or the toe-to-finger manoeuvre ('terminal tremor'), with a kinetic tremor ('dynamic tremor'). The latter is present in patients with essential tremor, along with the more typical postural tremor, but patients with essential tremor usually do not have overt signs of ataxia except for difficulties with tandem gait.

Other signs of cerebellar dysfunction:

Eye movement abnormalities (see Chapter 9):

- Jerky pursuit
- Gaze-evoked nystagmus
- Square wave jerks

Dysarthria. Slurred or scanning ('robotic') speech (see Chapter 12)

Overshoot (dysmetria)

- Ballistic tracking test. Ask the patient to track your index finger with his own as you move it as rapidly as possible at various angles and to various distances. The patient's finger repeatedly overshoots the target.
- Loss of check. This is one of the most characteristic signs of cerebellar dysfunction. It is manifested by inability of the patient to stop a rapidly moving limb, often associated with "rebound", or an overshoot followed by an exaggerated movement in the opposite direction. There are two ways to elicit the sign. First, the patient is asked to raise his or her extended arms above the head and then instructed to rapidly lower the arms into a horizontal position. A patient with a unilateral cerebellar lesion will continue to move the ipsilateral arm below the horizontal position ("loss of check") and then often overcorrects by moving the arm above the horizontal position ("rebound"). Another way to elicit "loss of check" is to ask patients to forcefully flex their elbows against examiner's hand. When the examiner suddenly removes the hand the patient with cerebellar lesion will continue to flex the elbow and, if unprotected, could hit his own face. It is, therefore, very important to always protect the patient's face during this maneuver.

Dysrhythmia. Here the patient has difficulty sustaining a simple rhythm in, for example, patting the thigh with one hand.

Wide-based unsteady gait (see Chapter 6)

### ● Other tremors

- *Dystonic tremor*. Patients with dystonia, such as cervical dystonia (e.g. torticollis) or hand dystonia often have an associated tremor. This so-called 'dystonic tremor' has the same distribution as the dystonia (head or hand, respectively, in the

examples listed) and is manifested by irregular tremor that increases in amplitude as the patient tries to resist the abnormal pulling and may stop completely when the affected body part is allowed to assume the position to which it is pulled, the so-called ‘null point’. Patients with dystonia often also have a tremor in the body part otherwise unaffected by the dystonia. Thus, a patient with torticollis may have a marked tremor of the outstretched hands. Such tremors overlap phenomenologically with essential tremor.

- *Holmes (rubral, midbrain or cerebellar outflow) tremor*. This is a coarse, often proximal, tremor of the upper limb which may be present at rest, but which increases in amplitude with the arms outstretched and is maximal when approaching a target (‘terminal tremor’). It used to be called a ‘rubral tremor’ on the basis that it arose from the red nucleus of the midbrain, but this is no longer thought to be the case and it has been renamed the Holmes tremor after Gordon Holmes who wrote a definitive description of it. The presence of a contralateral oculomotor palsy in some cases points to the midbrain as the likely site of the lesion causing this tremor. The combination of cerebellar outflow tremor with or without ipsilateral hemiparesis and contralateral oculomotor palsy is referred to as the Benedikt syndrome.



See Video 60: Holmes tremor

- **Wing-beating tremor**. This refers to a striking, coarse tremor involving the proximal muscles of the upper limb. When this is seen in a young adult you should think of Wilson’s disease.<sup>1</sup> Carefully inspect the cornea, illuminated from the side with your flash light, for the characteristic brown rings (like a brown arcus senilis) described by Kayser<sup>2</sup> and Fleischer.<sup>3</sup>



See Video 61: Bat’s wing tremor

1. SA Kinnear Wilson, Queen Square neurologist (1874–1937).
2. Bernard Kayser, German ophthalmologist (1869–1954).
3. Richard Fleischer, German physician (1848–1909).





**See Video 62:** Slow tremor

### Box 10.1 Tips

- If you are wondering whether or not the patient has Parkinson's disease, get them to walk. Patients with Parkinson's disease nearly always fail to swing one or both arms fully. One exception to this is a patient who is so responsive to levodopa, that, while the drug is working, all signs of the disease disappear. Other characteristic features to observe are a slow, shuffling gait, intermittent freezing, particularly when walking through narrow passages such as the doorway, and turning en bloc. There are, of course, a number of atypical parkinsonian syndromes including progressive supranuclear palsy and multiple system atrophy, that are manifested by gait and balance difficulties, but in contrast to Parkinson's disease, these abnormalities occur relatively early in their course.



**See Video 63:** Progressive multiple system atrophy

- If you wish to enhance a resting or postural tremor, in order to observe its characteristics more easily, ask the patient to subtract 7 from 100 and go on subtracting 7s as fast as possible. The stress involved in doing this is guaranteed to increase the tremor. Parkinson's tremor is also exacerbated during walking.
- Chorea, most types of myoclonus, and tics differ from tremor in one major way. They are not rhythmical (regular in their timing).
- In Parkinson's disease, the amplitude of the tremor is often more marked in one hand than in the other.
- The tremor in essential tremor, while maximal on holding the arms out, persists during movement and often increases as the finger approaches the target (e.g. the nose).
- Isolated head tremor is never due to Parkinson's disease, but may be seen in essential tremor, cervical dystonia (dystonic tremor), and cerebellar pathology (titubation).

# 11

## Other abnormal involuntary movements

**Inspection** 75

**The movement** 75

**Drug-induced movement disorders** 83

Abnormal involuntary movements can be relatively easy to recognize if you have seen such a case before (pattern recognition). All is not lost if you have not, for more important than jumping to conclusions is your ability to carefully and accurately describe what you see and then, based on the observed phenomenology, come up with a reasonable differential diagnosis.

### Inspection

As always, step back and look at the patient as a whole. You have a number of questions in your mind:

- Which parts of the body are involved in the movements (focal, segmental, hemi-, generalized, symmetrical, asymmetrical)?
- What is the patient's posture (head, trunk, limbs)?
- What happens to the movements as the patient talks to you? Do they increase or lessen?
- Is the patient relating normally to you?

### The movement

In choosing the most appropriate term to describe the movement, it is useful to start off with a general category that does not commit you to a particular diagnosis. Broadly categorize it as rhythmical (e.g. tremor, segmental myoclonus) or irregular (e.g. dystonic tremor, chorea, tics), jerk-like (e.g. chorea, tics) or sustained and patterned (e.g. dystonia).

- **Chorea.** The hallmark of chorea is jerky, random movements that affect different parts of the body. In addition to the continuous movements of the limbs and trunk,

chorea may be manifested by dancing of the eyebrows due to irregular contractions of the frontalis muscles and a lurching stance and gait. Viewed as a whole, the patient with chorea appears to be in constant motion, restless, as you or I might be waiting for a bus with a full bladder. Yet, they usually do not feel restless and may not even be aware of the movements. Chorea can be generalized or confined to one side of the body (hemi-chorea). Chorea increases when the patient is talking or moving. There is often associated motor impersistence, such as milk-maid's grip and darting tongue (inability to sustain protrusion). There are many causes of chorea, including drugs (neuroleptics and levodopa), Huntington's disease and other genetic disorders, auto-immune disease such as systemic lupus erythematosus (SLE), anti-phospholipid syndrome and hyperglycemia.



See Video 64: Non-fluent aphasia



See Video 65: Diabetes mellitus

- **Hemiballismus.** This is a violent jerk-like, flinging, thrusting movement of the proximal arm and leg. So troublesome are the movements in some cases that the patient may sit on the hand to suppress them. This movement disorder usually comes on quite suddenly, often following a stroke involving the contralateral subthalamic nucleus or its connections.



See Video 66: Hemiballismus

- **Tics.** Motor tics most commonly involve the face and head, causing characteristic blinks, grimaces, poutings and head turns, but in some cases of Tourette's<sup>1</sup> syndrome, the whole body may be affected with violent jerks or complex, sequential movements. The movements tend to lessen with distraction, for example while talking, but they are voluntarily suppressed only with great difficulty. In addition to motor tics, patients with Tourette's syndrome also exhibit phonic tics, such as sniffing, grunting, squeaking and coughing. Sometimes, the involuntary sound resembles a loud bark or may present as a sudden scream. About 20 per cent of patients shout obscenities (swear words with sexual or racial connotation) or profanities (religious connotation), so-called coprolalia. This is often slipped in mid-sentence (like a tic, which of course it is) rather than delivered with the emphasis that is usually given to swearing. Obscene gestures (copropraxia) also commonly occur in the setting of Tourette's syndrome. One characteristic feature of tics, which helps differentiate this movement from other jerk-like movements, such as chorea or myoclonus, is the presence of a premonitory sensation that can occur in a crescendo before or during a tic or as more generalized urge to make the movement or sound. Patients often describe a need to make the movement and experience a sense of relief after its execution. Many patients with Tourette's syndrome also have obsessive compulsive disorder and attention deficit disorder with or without hyperactivity. Although the majority of children with Tourette's syndrome experience marked improvement or spontaneous remission in their tics by the time they reach their twenties, tics can persist into adulthood or can recur later in life.



See **Video 67:** Tourette's syndrome



See **Video 68:** Severe Tourette's syndrome

1. Gilles de la Tourette, French neurologist and pupil of Charcot (1857–1904).

- **Myoclonus.** This refers to sudden brief, shock-like, muscle twitches which can affect any part of the body. Depending on the setting, they may occur spontaneously or also in response to a stimulus such as a noise, visual threat, touch or pinprick (stimulus-sensitive myoclonus). Myoclonus often increases with voluntary movement (action or intention myoclonus). In some cases, the twitches are time-locked to an EEG event and may be regarded as a ‘fragment’ of an epileptic seizure. The movement is usually associated with a muscular contraction, but it can also be caused by gravity as the muscle momentarily loses tone. This is known as ‘**negative myoclonus**’ or, more commonly, ‘**asterixis**’ (or in the setting of hepatic failure, ‘**liver flap**’).



See Video 69: Reflex myoclonus



See Video 70: Post-hypoxic myoclonus

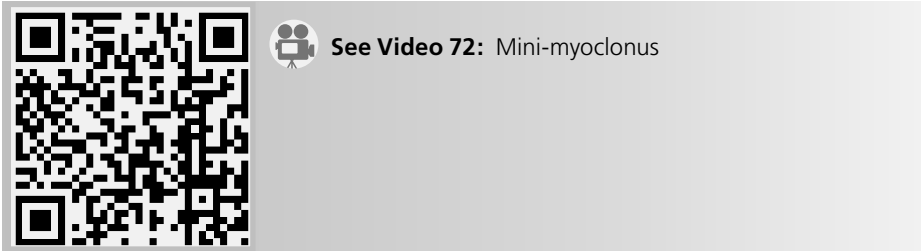


See Video 71: Asterixis

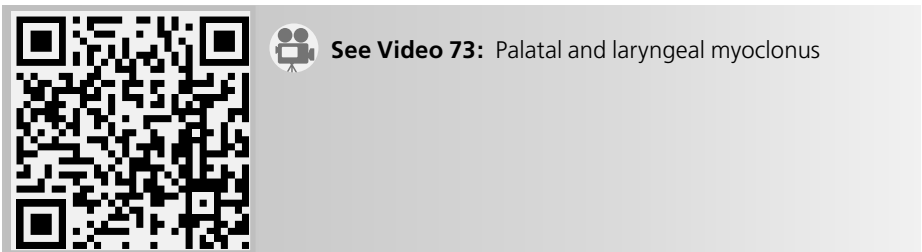
In hospital practice, myoclonus is seen most commonly in the setting of metabolic disturbance, such as diabetic ketoacidosis, post-hypoxic brain injury, epileptic syndromes and degenerative disease of the brain (e.g. multiple system atrophy). The site of origin of myoclonus determines, to some extent, its clinical features:

- *Cortical myoclonus*: low-amplitude, irregular twitches of individual fingers, induced by voluntary movement and sometimes touch, sudden perturbation,

or pinprick and associated with giant somatosensory evoked potentials (SSEPs).



- *Brainstem myoclonus*: generalized jerks, affecting the facial or bulbar musculature, or proximal limbs, and often triggered by noise or other stimuli.



- *Spinal myoclonus*: slow (about 1–2 Hz), rhythmical jerks of the trunk or limbs, often involving just a few adjacent spinal segments.
- *Dystonia*. In dystonia, body parts are twisted into odd *postures* due to abnormal contraction of opposing sets of muscles. In addition to abnormal postures, *dystonia* is often manifested by more or less regular or irregular and jerky movements (*dystonic tremor*). Dystonia may be *generalized* (involving the trunk and legs), *segmental* (involving two adjacent segments such as head and neck in cranial–cervical dystonia) or *focal* (e.g. blepharospasm, torticollis). It is usually induced or made worse by voluntary movement, and in some cases only appears with specific activities (e.g. writer’s cramp). A key feature in many cases is the presence of a *geste antagonistique* (‘sensory trick’), whereby, for example, the head posture of a patient with torticollis improves if the patient touches the cheek. (Interestingly, the correction has usually occurred before the hand reaches the face.) Although dystonia is often not disabling, it is usually troublesome and may interfere with activities of daily living or other activities, including chewing, swallowing and breathing; in rare instances it can be life-threatening (so-called status dystonius or dystonic storm). In some families, dystonia and myoclonus occur together. Rarely, dystonia can occur in paroxysms, either triggered by voluntary movement (kinesigenic paroxysmal dystonia) or occurring out of a background of rest or normal activity (non-kinesigenic paroxysmal dystonia). Task-specific dystonia occurs mainly or only with certain activities.



**See Video 74:** Athetosis



**See Video 75:** Generalized dystonia



**See Video 76:** Torticollis



**See Video 77:** Craniocervical dystonia



**See Video 78:** Myoclonus–dystonia syndrome



See Video 79: Myoclonus–dystonia syndrome



See Video 80: Paroxysmal kinesigenic dystonia



See Video 81: Task-specific dystonia

- Blepharospasm must be distinguished from apraxia of eyelid opening, where the eyes are not usually ‘screwed up’ due to forceful contraction of the orbicularis oculi, but instead the patient has trouble opening the eyes after they are closed.



See Video 82: Apraxia of eyelid opening

- **Athetosis.** This comprises slow, writhing, irregular movements of individual fingers and toes, and other parts of the limbs and sometimes the face, typically occurring in the setting of cerebral palsy.
- **Stereotypies.** These are repetitive movements, such as arm flapping, which can be normal in children but which are more marked and persistent in disorders such as autism.





See **Video 83**: Stereotypies



See **Video 84**: Progressive dysarthria




See **Video 85**: Dopa-induced dyskinesia



See **Video 86**: Chorea in Huntington's disease



See **Video 67**: Tourette's syndrome



See **Video 72:** Mini-myoclonus



See **Video 75:** Generalized dystonia



See **Video 76:** Torticollis



See **Video 87:** Blepharospasm/cranial dystonia

## Drug-induced movement disorders

Having been through the diagnostic process as described, there remains a group of conditions which do not fit readily into the schema above. These are the drug-induced movement disorders. They are more common than most of the conditions considered so far, and in some cases preventable, and for these reasons deserve special consideration.

● **Dopa-induced involuntary movements.** Most patients with Parkinson's disease who respond to levodopa eventually develop involuntary movements related to the drug regimen. This problem is most marked in younger-onset patients. There are two main types:

- *Peak-dose dyskinesia.* About an hour after taking a dose, the patient starts to make writhing twisting movements which are maximal in the head, trunk and proximal limbs. Often, the patient is unaware or untroubled by the movements. They last for an hour or two, but are made worse by taking another dose of levodopa while they are still present.



See Video 85: Dopa-induced dyskinesia

- *End-of-dose dystonia.* This occurs as the benefit from a dose of levodopa wears off, or in the early morning before the first dose, and comprises a painful cramping of the toes which makes walking difficult. It is relieved by taking another dose of levodopa.



See Video 88: End-of-dose dystonia

● **Tardive syndromes.** Nearly every known movement disorder can be encountered as a result of acute or chronic exposure to drugs, such as the dopamine-receptor blocking drugs (neuroleptics) and many other drugs. While the classic neuroleptic drugs prescribed for various psychiatric conditions, such as trifluoperazine, chlorpromazine and haloperidol, have been typically associated with tardive syndrome, anti-emetics, such as prochlorperazine and metoclopramide, can also do the same. Although the second- and third-generation neuroleptics have been thought to have a lower risk, all of them, with the possible exception of clozapine, can also cause tardive syndrome. Older patients, particularly women, are most

prone to develop this drug-induced movement disorder. There are many different types of tardive dyskinesia, defined as any involuntary movement that persists after the offending dopamine-receptor blocking drug is discontinued.

- *Akathisia*. This refers to a feeling of restlessness which is reflected in an inability to keep still for any length of time. The patient often paces the floor like a caged tiger. The movements themselves are stereotypic and are accompanied by a strong sensory component, an urge to move.



See Video 89: Tardive akathisia



See Video 90: Akathisia

- *Tardive dyskinesia*. This drug-induced movement disorder is characterized by continuous, stereotypic, movements of the mouth, tongue and jaw (bucco-lingual dyskinesia/oromandibular dystonia). They are often worse when the patient talks. In addition to oro-facial movements, patients with tardive dyskinesia may have involvement of other body parts and may also complain of sensory phenomena, such as burning pain or other discomfort in the mouth or genital area. Paradoxically, the movements initially get worse when the offending drug is withdrawn and may persist for years thereafter.



See Video 91: Tardive dyskinesia



See **Video 92:** Oramandibular dystonia



See **Video 93:** Tardive lingual dyskinesia



See **Video 77:** Craniocervical dystonia



See **Video 94:** Typical tardive dyskinesia

- *Tardive dystonia*. This is most commonly seen in young males treated with neuroleptics for schizophrenia. The typical posture is that of neck and trunk extension (retrocollis and opisthotonus) with arms extended and pronated. Again, the problem is made transiently worse by withdrawal of the drug which caused the problem.



See Video 95: Tardive dystonia

- *Drug-induced parkinsonism.* Neuroleptic drugs may produce a syndrome identical to idiopathic Parkinson's disease. This may persist for a year after the drugs are withdrawn.
- *Drug-induced tremors.* There are many drugs, such as lithium, valproate and serotonin-reuptake inhibitors, that can cause tremors, phenomenologically similar to parkinsonian or essential tremor.

#### Box 11.1 Tips

- With any involuntary movement, the first decision is whether the movement is rhythmical. If it is not rhythmical, it is better not to call it a tremor.
- The hallmark of chorea is that it is flitting and unpredictable.
- The key to understanding tics is the compulsion that the patient feels before the movement and relief when it is done – Kinnear Wilson likened it to a sneeze.
- The essence of myoclonus is its 'shock-like' or 'jerk-like' quality, that may be stimulus-induced, such as a loud noise and sudden visual threat, but not preceded by a premonitory sensation.
- Dystonia is characterized by patterned, repetitive contractions of muscles causing abnormal movements and postures.

# 12

## Speech disturbance

General approach 88

Dysarthria 89

Aphasia 91

Speech disturbance is usually one of two types: dysarthria or aphasia. When it is due to *dysarthria* – a problem of articulation – the patient will usually be acutely aware of the problem. With *aphasia* – a problem of language – the patient may not be aware of the problem or is unable to explain it. The term aphasia is usually reserved for patients with a focal lesion involving the dominant cerebral hemisphere (usually the left, even in left-handed patients) of the brain. Speech may also be impaired in dementia and many other neurodegenerative disorders where there is widespread disturbance of function in the cerebral hemispheres (see Chapter 13).

### General approach

- Patients with speech disturbance – particularly those with aphasia – find conversation an effort, and easily become distressed. It is important to make the patient feel at ease. Do not stand over them; sit with them. If it is clear that they are struggling, reassure them that you appreciate how upsetting it is not to be able to communicate.
- Engage them in conversation on a topic with which they are likely to feel comfortable: ‘Tell me about your job (family, holidays, hobbies, etc.)’. Your wish is to hear the patient forming sentences, so avoid questions to which the answer is likely to be ‘yes’ or ‘no’. It is often difficult to get a patient to speak freely. In this case, show them a picture (Fig. 12.1) and ask them to describe the scene. This approach has the advantage that you can tell what the patient is trying to say (see below). Do not rush this part of the examination for it forms the basis of your assessment. As the patient talks, pay particular attention to the following aspects of their speech:
  - Does the patient appear to have word-finding difficulties?
  - Are the words normally articulated?
  - Is the sentence structure normal?
  - Are they using words incorrectly?

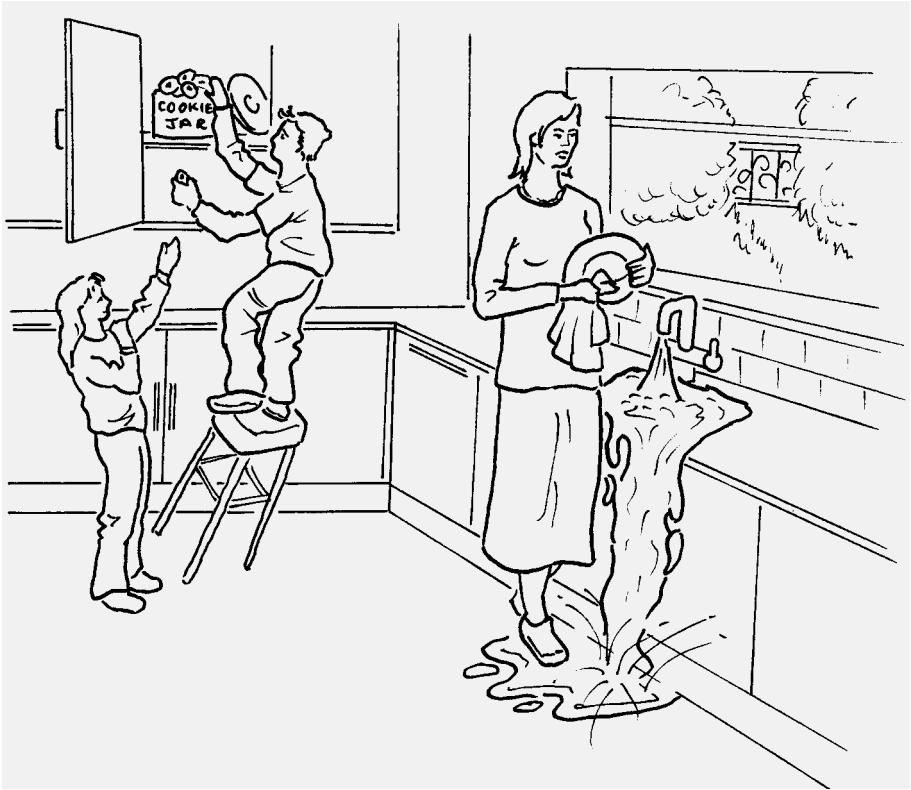


Figure 12.1 A picture which can be shown to an aphasic patient.

- Is there facial asymmetry? Is the right hand used as much as the left? A right hemiparesis often accompanies aphasia.
- Take note of the patient's 'body language'. Patients with non-fluent aphasia often have exaggerated body language. They sigh, gasp, roll their eyes and gesticulate, as they struggle to communicate with you. Sometimes they will burst into tears from sheer frustration. By contrast, patients who cannot communicate because of dementia may be unconcerned or unaware that there is a problem. Their body language is as impoverished as their speech.

Dealing with the two main patterns of abnormality, dysarthria and aphasia, in turn:

## Dysarthria

Here, the words are slurred but the language content – if you were to write it down – is normal. The problem is one of articulation. Slurring of speech signifies weakness or incoordination of the muscles involved in the production of sounds. Common causes are spasticity (e.g. pseudobulbar palsy, motor neurone disease), lower motor



neurone bulbar weakness (e.g. progressive bulbar palsy, a form of motor neurone disease) and cerebellar disorders (e.g. multiple sclerosis). With experience, one can confidently distinguish spastic from cerebellar dysarthria by the quality of speech. If you cannot, then you must rely on the neurological company which the dysarthria keeps.

Faint, quiet (dysphonic) speech is a feature of Parkinson's disease. The voice is also monotonous and the words tend to run into each other. Weakness of the diaphragm and of other respiratory muscles also causes the voice to be low in volume.

Assessment of dysarthria involves five steps:

- *Repetition of words or phrases* which are difficult to say. Examples of these include:
  - artillery, constitution, monotonous, autobiography
  - no ifs, ands, or buts.

Sometimes, a simple word can be correctly articulated but difficulty is encountered as the complexity of the word is progressively increased:

  - Zip, zipper, zippering
  - Please, pleasing, pleasingly
  - City, citizen, citizenship.
- *Repetition of sounds* which test the different muscles of articulation. Where there is weakness of the lips, the patient will have difficulty saying 'puh' or 'bah', of the tongue 'tuh' or 'lah', and of the palate 'kuh' or 'gah'.
- Ask the patient to *cough*. A hoarse cough is heard where there is paralysis of a vocal cord due to a recurrent laryngeal nerve palsy.
- Examination of the motor system, in order to determine whether the problem is due to:
  - a lower motor neurone lesion of the muscles of articulation (check for facial weakness; wasting, weakness or fasciculation of the tongue; loss of the gag reflex; palatal palsy).
  - an upper motor neurone lesion of the muscles of articulation (brisk jaw jerk, exaggerated gag reflex, hemiparesis).
  - a cerebellar disturbance (nystagmus, intention tremor of the arms, gait disturbance).
  - a hypokinetic dysarthria is typically seen in patients with Parkinson's disease, whereas hyperkinetic dysarthria is usually encountered in patients with involuntary movement disorders.
- Assessment of speech to determine whether patient has a language problem (aphasia) or slurring of speech (dysarthria), in which case the sentence structure, repetition and comprehension are usually normal (see below).

# Aphasia

This refers to a disturbance in the production or understanding of language, written, spoken and read. It occurs with lesions of the dominant cerebral hemisphere. The main areas of the brain involved in language are shown in Fig. 12.2. As a general rule, lesions of the frontal lobe ('anterior lesions') cause a non-fluent aphasia with preservation of comprehension. This is traditionally known as an 'expressive' or 'motor' aphasia. Lesions of the parietal and temporal lobes ('posterior lesions') cause a fluent aphasia and there is impairment of comprehension. The traditional term for this is 'receptive' or 'sensory' aphasia. Assessment of aphasia involves three steps.

## 1. Is the speech fluent, or non-fluent?

In a **non-fluent aphasia**, the patient's speech is effortful and may be slurred. Sentences are short and lack 'filler' words such as 'and', 'the', 'so' and 'to'. The information content is often high. If you write down what is said, the result looks like a telegram – for example, 'Come hospital get better'. The normal melody (prosody) of speech is lost, and the patient often appears to be making an exaggerated effort to get the words out.

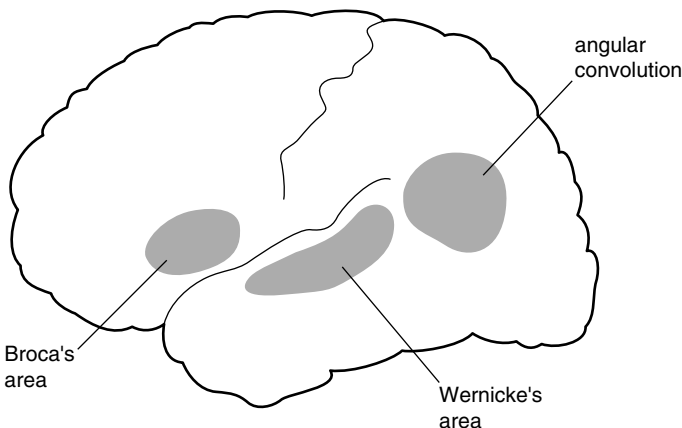
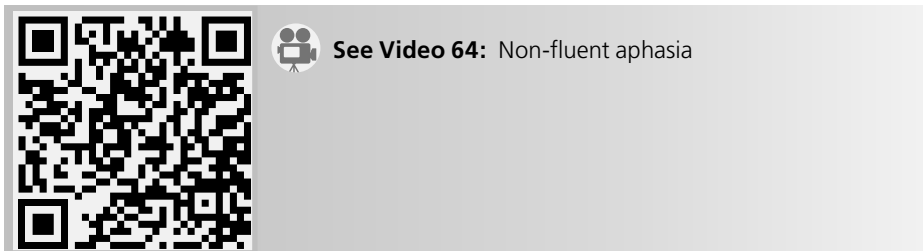


Figure 12.2 The main language areas.

In a **fluent aphasia**, words flow freely, sentences are of a normal length, the voice rises and falls melodiously, but the information content is low. What is said is difficult to understand and words are used wrongly. When shown Fig. 12.1, such a patient might say, 'The little boys and girls are getting up a stool and putting some cookies, right? Ah, this is the trouble the sing, the sing is overflowing, right?' Wrong words are known as paraphasias and are of three types:

- phonemic paraphasia: a consonant is substituted causing, for example, the patient to say 'sing' when they mean 'sink'.
- semantic paraphasia: a word is changed for another with an obvious association, e.g. a knife is called a fork.
- neologism: a non-existent word is substituted for the intended word, e.g. a 'room' is called a 'boof'. Paraphasic errors usually signify involvement of the posterior speech areas. In mild cases, speech may be normal for a few sentences and then the sentence structure breaks down and paraphasias appear.



**See Video 96:** Wernicke's aphasia



**See Video 97:** Fluent aphasia

## 2. Is the patient able to repeat?

Patients with aphasia often have difficulty repeating the phrase 'no ifs, ands or buts'. They will say 'no ands or buts' or 'no ifs and buts', but never the full phrase. Words which are readily linked to a visual image, such as house, ship, book, face and cigarettes, can often be repeated without difficulty. It is thought that the memory stores of these words have a wider distribution within the brain than non-picture words, and are therefore less likely to be affected by lesions confined to the speech area. The inability to repeat is used in some classifications of aphasia which attempt to relate the type of aphasia with the site of the lesion. In

practice, the main value of testing repetition is in confirming that the patient is aphasic.

### 3. Does the patient have normal comprehension?

Patients with severe disturbance of comprehension often give the appearance that they fully understand everything that is said to them and, indeed, may think that they do understand. They smile or nod when there is a pause in the conversation. They gesticulate so convincingly that their problem may initially go unnoticed by their own family. These patients have normal body language, taking their cues from the movements of those around them and responding appropriately. In testing their comprehension, one must make allowance for the fact that they may not be able to find the words to tell you that they understand what is being said to them. This is done in two ways:

- Reduce the amount of language that they need to use to the minimum: ‘yes’ or ‘no’. Ask a sequence of questions: ‘Are you in hospital?’; ‘Are we sitting in your house?’; ‘Have you got pyjamas on?’; ‘Have you got a coat on?’ Remember that the patient has an even chance, each time, of giving the correct response. Ask a number of questions, therefore, and vary them so that there are no sequences in which the same answer, ‘yes’ or ‘no’, would be correct. Perseveration is common in aphasia, causing the patient to repeat the same response several times. Subtle defects of comprehension may only be picked up by asking ‘double-barrelled’ questions: ‘Do you put your shoes on before your socks?’; ‘Do you put your socks on before your shoes?’; ‘Do you shut the car door before getting into the car?’; ‘If the lion ate the tiger, is the tiger alive?’
- Ask the patient to obey commands: ‘Touch your nose’ or ‘Touch your knee’. Many patients with aphasia can obey single commands, but cannot follow sequences: ‘Touch your chin, then your nose, then your ear’. Patients with normal comprehension are often unable to protrude the tongue on command due to an apraxia.

To summarize, in describing an aphasia you should state whether it was fluent or non-fluent, whether there were paraphasic errors, and whether repetition and comprehension were impaired. A description such as this is probably more useful than terms such as ‘nominal aphasia’ or ‘Wernicke’s aphasia’, which mean different things to different people. If you wish to use these terms, Table 12.1 provides a guide to their current usage.

To complete the examination, one should ask the patient to read and to write. The information obtained from doing this is similar to that gained from listening to the speech. Patients with non-fluent aphasias have great difficulty writing at all – even with the left hand. Patients with fluent aphasia make paraphasic errors in their reading and writing.

Table 12.1 Current definitions of aphasia.<sup>a</sup>

Speech type	Repetition	Comprehension	Associated signs
<b>Non-fluent</b>			
Broca's <sup>1</sup> aphasia	Impaired/normal	Normal	Weakness R arm
Global aphasia	Impaired	Impaired	R hemiparesis
<b>Fluent</b>			
Wernicke's aphasia	Impaired	Impaired	Homonymous hemianopia
Conduction aphasia	Impaired	Normal	
Isolation aphasia	Normal	Impaired	
Nominal aphasia	Normal	Normal	

<sup>a</sup>After Geschwind MD. Aphasia. *N Engl J Med* 1971; **284**: 654–6.

### Box 12.1 Tips

- The subdivisions of aphasia, outlined in Table 12.1, provide a useful approach to patients with speech and language problems, but many patients do not fit comfortably into this or any other system of classification. Thus, it is not uncommon for patients – for example with a posterior lesion – to have marked poverty of speech, albeit well articulated.
- The left hemisphere is dominant for language in the majority of individuals, regardless of their handedness.
- A fluent aphasia, with normal comprehension and repetition (nominal aphasia), is characteristically seen in metabolic encephalopathies.
- Gerstmann's<sup>2</sup> syndrome (finger agnosia, agraphia, acalculia and right–left disorientation), although a favourite diagnosis of many trainees faced with a patient with aphasia, is relatively rare and there is, of course, little point in testing for these features in a patient who has severely impaired comprehension.
- In children, aphasia is almost always non-fluent, regardless of the site of the lesion.
- How do you assess the quality of speech in a severely aphasic patient who is almost mute? Get the patient to count to 10, calling out the first few numbers with them and 'conducting' them through the remainder by hand signals, and using yes/no and multiple-choice questions.
- It is common for trainees to miss impairment of comprehension through inadequate testing. They will hurriedly ask the patient to point out different body parts (hand, foot, elbow) while looking at the part in question. This may give the patient who is relying solely on body language all the help they need to perform the task.

1. Pierre-Paul Broca, French anatomist and surgeon (1824–1880).  
 2. Josef Gerstmann, Austrian neuropsychiatrist (1887–1969).

# 13

## Higher function testing

General approach 95

Formal cognitive testing 98

Some syndromes of dementia 98

Patients presenting for the first time with dementia often have little insight into their problem and it is the relatives who make the appointment or bring them to Accident and Emergency. You will make the diagnosis mainly from the history that the relatives provide, but the neurological examination is important for confirming this.

### General approach

As with the aphasic patient, your approach to the patient with cognitive impairment will make allowance for the fact that there are problems of communication and the patient is anxious or alarmed. Sit beside the patient and make every effort by your manner to put them at their ease. If the answers they give are to questions you didn't ask, be patient and resist the temptation to be hectoring in your efforts to gain more information. Better still, have a relative or friend present who can provide moral support and fill in the aspects of the history which the patient is unable to provide; patients with dementia often lack insight into their problem.

- **Delirium versus dementia.** One of your first tasks is to determine whether this is an acute potentially reversible problem of delirium or a longer-term problem of dementia. Of course, the patient may have both: patients with dementia are more prone to delirium if they develop, for example, an infection. As you begin to examine the patient, make note of certain key findings:
  - *Grooming*: if the patient is unkempt with long unwashed hair and decayed teeth, the problem is likely to be long-standing, in keeping with a history of dementia.
  - *Bruising*: note any facial bruising or black eyes, feel over the scalp for boggy swelling (over a skull fracture), and look behind the ears for the tell-tale bruising of Battle sign (base of skull fracture). Any evidence of head trauma will encourage you to perform the computed tomography (CT) scan of the head earlier rather than later; you do not want delay diagnosing a subdural haematoma.

- *Level of consciousness*: dementia itself is not a cause of drowsiness. If the patient keeps falling asleep or is hard to rouse, you are dealing with delirium, most commonly due to *drug or alcohol overdose, infection or metabolic disturbance*. Delirious patients may go through periods of arousal in which they shout, moan or become aggressive. At these times, they may pluck restlessly at the sheets.
  - *Pulse, blood pressure, respiration*. Sweating, tachycardia, swings in blood pressure and altered breathing patterns are all common in delirium.
- **Behaviour**: patients with frontal dementia characteristically exhibit *abulia* (loss of will) and *apathy* (lack of feeling). They have no complaints and do not initiate conversation. They sit or lie for much of the day doing nothing and showing neither pleasure nor frustration. They are orientated, particularly for surroundings, and their responses to your questions may be sensible and appropriate, leading you to the erroneous conclusion that there is not much wrong with them. Such patients often show *environmental dependence*: they are unable to inhibit their innate or acquired responses to external stimuli. Exploratory behaviour with the hands and mouth (grasping and groping), visual fixation and following, using objects (utilization behaviour) and mimicry are behaviours which are controlled by the frontal lobes. When the frontal lobes are not functioning normally, such behaviours are exhibited indiscriminately. They can be readily tested:
- *Grasping and groping*. Hold your index and middle fingers in a vertical plane (i.e. not in a normal ‘hand-shaking’ posture) close to the patient’s hand. When they see the hand, they will reach out and grasp it.



See Video 98: Groping



See Video 99: Fronto-temporal dementia

- The grasp reflex is tested by sliding your index and middle fingers across the palm of the hand. This is sometimes distinguished from the traction reflex where you run your fingers along the length of the patient’s fingers – from base

to tip – again causing him or her to grasp them. The latter is said to induce the response by inducing a stretch reflex in the finger flexors and will be positive in a patient with hyper-reflexia of the upper limbs and no frontal lobe dysfunction. In practice, they provide very similar information. If the patient grips your fingers, ask them not to. Often, this will inhibit the response, but when you repeat the manoeuvre a few moments later, or after distraction, the grasping returns. A similar response is seen if you approach the patient's mouth with your index finger (after apologizing for the intrusion); the mouth opens and the patient may move the head forward to grasp the finger.



**See Video 100:** Mouth grasp

- Such patients may also have forced visual following; in contrast to their general lack of activity, their eyes follow you as you move around the room or bed. If you move your penlight in a circle in front of them, they will follow it, even when asked not to.



**See Video 101:** Visual grasping

- *Utilization behaviour.* Offer the patient your own or a colleague's glasses. The normal response is one of surprise. Patients with frontal lobe disinhibition will put them on, and a second and even a third pair if they are offered. If you give them your stethoscope they may attempt to use it. These patients tend to fiddle endlessly with whatever catches their attention: dressing gown cord, bed head, sheets.



**See Video 102:** Utilization behaviour



- *Imitation behaviour (mimicry)*. While conversing, put your arm out or up and hold it for a few seconds. The patient with frontal disinhibition will tend to copy you. This, incidentally, is not an aspect of the examination you will want to try on patients with normal cognition!



See Video 103: Forced mimicry

## Formal cognitive testing

The Mini-Mental State is now used routinely in most hospitals. With its emphasis on orientation and memory (it was designed as a screening test for Alzheimer's disease<sup>1</sup>), it is not a sensitive test of frontal lobe function. Evidence of frontal lobe dysfunction is best gained from the history given by the family: loss of insight, inappropriate behaviour, impairment of judgement in financial and personal matters, and loss of the ability to organize home or work activities. These are difficult things for the non-expert to gauge, particularly when there are time constraints. The features of abulia and release of behaviours outlined above only become apparent in moderately advanced cases of frontal dementia. What follows is an abbreviated and modified version of the Addenbrooke's Cognitive Examination (Fig. 13.1). In the short case examination, this will provide you with a flavour of the sort of problems the patient may be experiencing in orientation, memory, verbal fluency, language and visuospatial sense.

## Some syndromes of dementia

By definition, in dementia, there is impairment of memory and deficits in at least one other cognitive domain (speech, praxis, executive function or visuospatial function) sufficient to produce occupational or social disability. The pattern of abnormality varies according to which part of the brain is affected:

### ● Alzheimer's syndrome

- Initially, impairment of memory
- Later extends to all other domains: spatial sense, language, frontal executive function

1. Alois Alzheimer, German pathologist (1864–1915).

<b>Selected Tests modified from the Addenbrooke's Cognitive Examination</b>		<b>Patient's name</b> DOB MRN Date	
<b>ORIENTATION</b> Year? ..... Month? ..... Day of the week? .....		Country? ..... State/County? ..... Hospital? ..... Floor? .....	
<b>ANTEROGRADE MEMORY</b> Repeat this name and address and flower Peter Marshall 42 Market St Newcastle Daffodil (Test recall after 5 minutes)		<b>RETROGRADE MEMORY</b> Name of PM? USA President?	
		<b>ATTENTION</b> Say the months backwards	
<b>LANGUAGE</b> Ask the patient to: give the name for the hands of your watch, the sole of your shoe, the nib of your pen	Point to the door, floor and ceiling	Repeat 'No ifs, ands, or buts'	
<b>APRAXIA</b> Ask the patient to mime holding a piece of paper with the left hand and to cut it with a pair of scissors in the right hand. If he/she makes scissoring movements with the index and middle fingers, remind him that he/she is holding the scissors. If he/she has difficulty, repeat with real paper and scissors			
<b>VERBAL FLUENCY</b> Tell me as many words as you can think of beginning with the letter P, but not people or places. You have one minute to go (> 9)		Tell me the names of as many animals as you can think of in 1 minute, beginning with any letter of the alphabet (> 17)	
<b>VISUOSPATIAL ABILITIES</b> Ask the patient to copy your drawing of a cube		Draw a circle and ask the patient to fill in the numbers of the clock	

Figure 13.1 Modified version of the Addenbrooke's Cognitive Examination.

**● Dementia of frontal lobe type**

- Initially, change in behaviour with loss of social skills, loss of verbal fluency
- Later, loss of organizational skills, judgement
- Eventually, abulia and frontal release behaviour
- Three subtypes of frontal dementia are recognized:
  - Dorsolateral: executive dysfunction
  - Orbitofrontal: disinhibition
  - Medial: akinetic mutism

**● Dementia in parkinsonism**

- This occurs only after many years in idiopathic Parkinson's disease when it causes slowing of thinking, loss of verbal fluency, visual hallucinations and paranoid delusions (often at night) with good preservation of social skills. One of the clues that the patient is developing cognitive impairment is the appearance of apraxia of the hands. They cannot accurately copy the movement you demonstrate to test bradykinesia. They cannot copy you when you make a cut, fist and slap motion with one hand on the other (Luria test).<sup>2</sup> They cannot mime slicing a loaf of bread with a knife or cutting a piece of paper with a pair of scissors without using the hand as the tool (even when corrected) or making errors in the sequence of movements or position that the limbs adopt.



**See Video 104:** Apraxia in Parkinson's disease



**See Video 105:** Luria test

2. Aleksander Romanovich Luria, Russian aphasiologist (1902–1977).



**See Video 106:** Miming in apraxia

- Dementia with Lewy bodies. In contrast to Parkinson's disease dementia, where cognitive decline occurs in latter stages of the disease, patients with dementia with Lewy bodies often have cognitive decline, mental fluctuations and, most characteristically, visual hallucinations even before the onset of motor parkinsonian features.
- Dementia of frontal lobe type is prominent in progressive supranuclear palsy (PSP), although it may not be apparent until the latter stages of the disease.

#### ● **Vascular dementia**

- This is characterized by lower body parkinsonism, affecting mainly the legs with a broad-based shuffling gait occurring on a background of hypertension and other stroke risk factors. The course may have a stepwise progression and the examination may also reveal emotional lability and brisk jaw and other reflexes.

#### ● **Creutzfeldt–Jakob disease**

- This is a rare cause of dementia which has to be considered when the patient deteriorates over weeks rather than months or years and has prominent myoclonic jerks.



**See Video 107:** Creutzfeldt–Jakob disease

#### **Box 13.1** Tips

- If a confused patient is drowsy, the immediate problem is likely to be one of delirium, probably caused by some metabolic encephalopathy.
- The most useful aspect of the clinical assessment is the history obtained from the patient's relatives or spouse.
- The Mini-Mental State Examination does not adequately test frontal lobe function.

- The earliest feature of frontal lobe dysfunction which is readily tested is impairment of verbal fluency (generation of words).
- Signs of advanced frontal lobe dysfunction include abulia, grasping and groping, utilization behaviour and forced mimicry.
- The patient who is worried that he/she might have Alzheimer's disease rarely does: loss of insight is an early feature of dementia in Alzheimer's disease.
- Always run through the check list of reversible dementias:
  - 'Pseudo-dementia' due to depression
  - Hypothyroidism
  - Vitamin B<sub>12</sub> deficiency
  - Frontal meningioma.
- When discussing memory, the old classification of short- and long-term memory loss is no longer adequate. You should become familiar with the following terms:
  - *Declarative memory*: all the facts that you are able to recall, comprising:
    - *Episodic (autobiographical) memory*: events in your own life linked to a specific time and place.
    - *Semantic memory*: the body of general knowledge, linguistic skills and vocabulary which you have acquired.
  - *Procedural memory*: the memory of motor skills you have acquired.
  - *Working memory*: the ability to retain the information necessary to complete a task or to hold a conversation.

# 14

## Assessment of coma

**The Glasgow Coma Scale** 106

**Some distinctive types of coma** 106

Patients who are drowsy or comatose pose a particular problem as so much of the routine neurological examination relies on the ability of the patient to cooperate and follow instructions. A different approach is therefore required. Often the patient is already intubated, ventilated, sedated and even paralysed by the time you get the opportunity to examine them and some drugs may need to be temporarily withdrawn or reversed, under certain circumstances, to perform the neurological examination.

Coma results from impaired function of the brainstem reticular formation. The most common cause is drug overdose, but other causes include severe head injury, hypoxic brain injury, infections (like bacterial meningitis or viral encephalitis) metabolic disturbance like diabetic coma or hepatic failure, subarachnoid haemorrhage, exposure to toxins (e.g. carbon monoxide), encephalitis and severe raised intracranial pressure.

Lesions of the cerebral hemisphere do not cause coma unless they are very extensive and impinge, usually by mass effect, on brainstem function.

Watch your tongue when speaking at the bedside with colleagues, staff and relatives. Never assume the patient is not listening – they may be ‘locked in’ (see below).

The role of the neurological examination in coma is to assess its level, so that changes may be documented, and to determine which parts of the central nervous system (in particular, the brainstem and cerebral hemispheres) are still functioning. In deep coma, the question may arise as to whether brain death has occurred.

What follows is a list of examination techniques used in assessing coma. In the setting of the emergency situation, the immediate issues concern whether the patient:

- has an adequate airway;
- has an adequate blood pressure and circulatory perfusion;
- is breathing normally (or has Cheyne–Stokes waxing and waning breathing, hyperpnoea or hypopnoea);

- smells of acetone (diabetic coma) or alcohol or other toxic substances;
- has jaundice, cyanosis or pallor;
- has life-threatening issues, such as internal or external bleeding or major bony injuries;
- has signs of infection – check temperature and pulse rate.

Once these are attended to, attention can be directed to an examination of the nervous system:

- **Inspection.** The posture of the patient is noted, including asymmetry of the head or limbs. Are there spontaneous movements of the head or limbs and are they symmetrical? Are the eyes closed? Spontaneous blinking suggests that the pontine reticular formation is functioning. Is there bruising, particularly around the orbits or behind the ears (skull fracture)? Is there a boggy swelling on the scalp (skull fracture)?
- **Level of awareness.** Does the patient obey verbal commands? This test of cerebral hemisphere function may seem unnecessary in a patient who appears to be comatose but occasionally it turns out that they are ‘locked in’; their cerebral hemispheres are functioning normally, they are fully conscious but they cannot make any movements apart from raising and lowering their eyes. The lesion is in the pons. Ask them to try to look up and down.
- **Pupils.** Are the pupils of a normal size, for the degree of illumination in the room, symmetrical and responsive to light? Loss of the light reflex makes a metabolic cause for the coma unlikely. Unilateral loss of the light reflex suggests a structural lesion. Pin-point pupils most commonly are due to opiate overdose.
- **Fundi.** Look for papilloedema (raised intracranial pressure) and subhyaloid haemorrhages (subarachnoid haemorrhage).
- **Doll’s eye movements (oculocephalic reflex).** This is not something that can be done when the patient is first admitted as it is essential to establish first that there has been no neck injury or arterial dissection in the neck. This test is most useful later in the course of the admission to test brainstem function, particularly if brain death is a consideration. Roll the head briskly from side to side, pausing briefly at the end of each movement and observe whether the eyes, which you are holding open, rotate in the opposite direction. Flexing and extending the neck will induce vertical eye movements. Doll’s eye movements are also not usually affected by metabolic disorders.
- **Corneal reflex.** Touch their corneas in turn with cotton wool to see if the patient blinks and if the eyes roll up (Bell’s phenomenon). If they do, the pathways between the midbrain (IIIrd n. nuclei) and lower pons (VIIth n. nuclei) are intact.

- **Nose tickle.** Insert a piece of cotton wool into each nostril in turn and look for grimacing and limb movements. This is a neglected but most useful test. In a light coma, the patient will reach up and rub their nose. If there is a hemiparesis, only one hand will do this. If there is hemi-anaesthesia, tickling only one nostril will induce a response.
- **Cough reflex.** In an intubated patient, the cough reflex may be tested by suctioning with a catheter.
- **Gag reflex.** This is also not something that should be done in the initial assessment as it may induce vomiting and inhalation of vomitus. It is mostly used after the patient has been intubated and one is testing brainstem function, particularly when brain death is a consideration. Touch the back of the throat alternately, left and right sides with similar pressure, with a cotton-tipped probe, while the tongue is depressed with a wooden tongue depressor.
- Tone of neck and limbs
- Jaw jerk
- Limb reflexes
- Plantar responses
- Response to painful stimuli
  - Rub the sternum gently with your knuckle and press the nail beds of digits gently in all four limbs in turn with your tendon hammer. Several types of response may be observed. The normal response is to push the stimulus away, groan or grimace and withdraw the limb. With so-called *decorticate rigidity*, the arm slowly flexes and the leg extends. In *decerebrate rigidity*, which usually carries a worse prognosis than decorticate rigidity, the arms and legs extend, the back arches and the teeth clench. Both types of abnormal flexor and extensor response may be seen in structural, metabolic or toxic causes of coma. Sternal rub is valuable for comparing the two sides of the body to detect hemiparesis where one side fails to move, moves less than the other or postures abnormally (decorticate or decerebrate). Squeeze the medial side of the elbow, looking for abduction (good outcome) or adduction (bad outcome) of the shoulder; similarly, squeeze the medial side of the knee, where hip abduction with knee flexion is a good sign, while adduction of the ipsilateral or often both hips, with extension of knee, is a bad sign. In some patients, it is hard to get any response, or nothing but a minor change in breathing, signifying deep coma, perhaps due to drug overdose. Ice water caloric stimulation (see below) combined with the Doll's eye test may be used to demonstrate brainstem activity.



- The response of the pulse and blood pressure to painful stimuli may also be observed.
- **Caloric stimulation (oculovestibular reflex)**
  - This is usually done where brain death is suspected. The auditory canals are inspected (to exclude impacted wax or perforated drums), and the head elevated to 30 degrees above the horizontal. Then each external auditory canal is irrigated with iced water. In a normal conscious subject, this induces nystagmus with the fast component away from the ear. In coma, the fast component is lost and the eyes deviate towards the irrigated ear. In brain death, the reflex is lost. It may also be blocked by ototoxic drugs such as gentamycin, vestibulosuppressant drugs such as phenytoin, and phenobarbitone and neuromuscular blockers.

## The Glasgow Coma Scale

In the aftermath of a major neurological insult such as a head injury, it is important to monitor the level of coma as this will determine whether further medical or surgical intervention is required. The Glasgow Coma Scale scores the following items:

- Ability to open the eyes: 4, spontaneously; 3, to speech; 2, to pain; 1, none.
- Best motor response: 6, obeys commands; 5, localizes stimuli; 4, withdraws; 3, flexor posturing; 2, extensor posturing; 1, no movement.
- Best verbal response to stimulation: 5, orientated; 4, confused, inappropriate; 3, incomprehensible words; 2, sounds only; 1, none.

A comatose patient will have a score of 10 or less.

## Some distinctive types of coma

- **Coma with myoclonic jerks/tremor.** This is seen in metabolic disorders such as diabetic coma, uraemia, hepatic failure and hypoxia. Other causes include hypoxic encephalopathy after prolonged cardiac arrest, CO<sub>2</sub> narcosis, high-dose intravenous penicillin encephalopathy and overdosage with selective serotonin re-uptake inhibitors (SSRIs) causing serotonergic toxicity.
- **Coma with roving eye movements.** These slow random movements of the eyes are commonly seen in persisting coma after cerebral anoxia or cardiac arrest and indicate an intact brainstem with diffuse cortical damage.
- **Coma with ocular bobbing.** Brisk downward bobbing movements of the eyes in this setting is associated with severe caudal pontine injury.

- **Coma with eyes deviated to one side:**
  - With a destructive lesion of one frontal lobe, the eyes will be deviated towards the side of the lesion. With an irritative acute lesion of one frontal lobe, as occurs transiently with cerebral haemorrhage (or in an adverse epileptic seizure), the eyes will be deviated away from the side of the lesion.
  - With a destructive lesion of the pons, the eyes will be deviated away from the side of the lesion.
- **Coma with eyes deviated downwards.** This is seen with thalamic haemorrhage, with the patient often appearing to be ‘looking’ at the tip of his nose. It is also associated with compression of the midbrain tectum and has been described in hepatic coma.
- **Coma with bilateral fixed dilated pupils.** This is a grave sign if persistent, usually associated with brain death. Other causes include overdosage with atropine-like drugs, severe barbiturate intoxication, hypothermia, and transiently due to adrenalin injections during resuscitation.
- **Coma with one fixed dilated pupil.** In this setting, a fixed dilated pupil is due to a third nerve palsy resulting from coning or a ruptured posterior communicating aneurysm. If there is no ptosis or loss of eye movements, then it is more likely to be due to coning. Either way, this combination is an indication for urgent computed tomography (CT) scanning.
- **Coma with pin-point pupils.** Consider opiate overdosage or pontine haemorrhage.
- **Coma with unilateral Horner’s syndrome.** This is easily missed as the only sign of it will be inequality of the pupils (best seen in dim light). Brush the back of your hand over the forehead on each side. If one side offers less resistance (because it is dry), and the pupil is smaller on that side, the patient has a Horner’s syndrome. This is a good lateralizing but poor localizing sign. It is seen in hypothalamic and brainstem lesions. In a patient with a contralateral hemiplegia, dissection of the internal carotid is a consideration.
- **Coma with nystagmus.** Suspect epileptic activity – look for minor twitching of the corner of the mouth and perform an electroencephalograph (EEG).
- **Coma with hemiplegia.** Causes include: contralateral cerebral haemorrhage, massive cerebral hemisphere infarction (as with internal carotid artery occlusion), bleeding or swelling of a tumour and subdural haematoma. An important treatable cause of this picture is hypoglycaemia (usually in a diabetic patient on oral agents or insulin).
- **Apparent coma with no response of the face or limbs to pain, nose tickle or corneal stimulation.** Ask the patient to look up and down. If they respond, they have the ‘locked-in syndrome’ usually due to an infarct or haemorrhage involving the pons. Vertical eye movements, a function of the midbrain, are spared.

- **Coma with a stiff neck.** Patients with generalized hypertonia may also have a stiff neck. A good working rule is that if the neck stiffness is due to meningism, it will only be on neck flexion that resistance is felt, not on neck rotation. Causes include subarachnoid haemorrhage, meningoencephalitis and coning from a supratentorial mass.

**Box 14.1**   **Tips**

- Always consider the possibility of reversible coma: hypoglycaemia (check the blood glucose, give intravenous glucose), non-convulsive epileptic status (perform an EEG) and opiate overdosage, which usually responds to naloxone infusions.
- Small cerebral hemisphere lesions are not a cause of coma.
- Metabolic causes of coma usually do not affect the pupils or Doll's eye movements.
- Beware of performing a lumbar puncture in a comatose patient with a stiff neck – they may have raised intracranial pressure and be at risk of cerebral herniation. If bacterial meningitis is a serious consideration, start antibiotics while you conduct further tests, such as imaging.

## 15

# Psychogenic disorders

## 'Neurological' presentations of psychogenic disorders 110

It may seem surprising to be discussing psychogenic disorders in the context of the neurological examination. Surely, there will be no signs to find in a patient who does not have a neurological disease? Yet the difficulty of recognizing the signs of a psychogenic disorder should not be underestimated and psychogenic disorders account for perhaps 20 per cent of patients presenting to neurological clinics.

Some general points about psychogenic disorders need to be made. This is an area where both the clinical skills and wisdom of the physician are most tested. Patients who have difficulty coping emotionally with a physical illness or who have unusual even bizarre presentations are too readily dismissed by the inexperienced physician as having psychogenic disorders. The opinion of a senior colleague here is invaluable. The label of 'psychogenic' must be applied with great caution for thereafter they may be treated as time wasters by unenlightened staff. It is not uncommon for patients with neurological disorders to develop psychogenic symptoms in addition to the organic disorder, particularly at times of stress. Very few patients with psychogenic disorders are true malingerers and they deserve to be treated with kindness and compassion. These are the people in our society who are not coping with their lot.

Often the history, if the patient is willing to give it to you in full, is suggestive of a psychogenic disorder. Pointers include: a history of sudden onset, many years of mysterious illnesses for which no definite cause can be found, multiple symptoms which cannot readily be explained by any disease process (somatiform disorder), periods of severe disability alternating with periods of partial or complete spontaneous remissions or culminating in a sudden and dramatic 'cure' (as seen in 'faith healing'). It is the first psychogenic illness which poses the greatest diagnostic problem.

Until recently, neurologists were reluctant to make a firm diagnosis of psychogenicity for fear that eventually an organic basis for the symptoms would emerge. As a result, many patients were subjected to endless rounds of investigations, confirming their own worst fears about the nature of their illness, nor were they provided with the support and understanding which their condition required. Fortunately, the diagnosis

of a psychogenic disorder is now widely accepted and respectable. When made by an experienced clinician it is rarely proven to be wrong.

## 'Neurological' presentations of psychogenic disorders

### ● Gait

- Psychogenic gaits can come in many forms and include features such as knee-buckling, 'tight-rope' walking, 'collapses', convulsive shaking or extreme lurching and slowness. Many patients appear to be ataxic, but instead of compensating with a broad base, they walk with a narrow base and often even cross their feet while walking despite the appearance of extreme difficulties with balance ('astasia-abasia'). There may be emotive features such as exaggerated effort, sighing, groaning and gasping. Of course, all of these can happen in patients with a gait disturbance on an organic basis, but the difference is that in psychogenic gait there will be no relevant associated physical signs such as spasticity (increased tone and reflexes), clonus, rigidity, akinesia or intention tremor.

### ● Tremor

- Psychogenic tremor is often dramatic causing, for example, the arms to flap or the whole body to jig, and requiring so much exertion that the patient pants and sweats. As you watch, it may have a variable amplitude but also change its frequency, direction and distribution. If you engage the patient in conversation, it may momentarily cease altogether. Mentioning a particular limb may cause it to shake (*suggestibility*). Suggestibility may be also used to bring on a movement disorder that is paroxysmal and not present at the time of the evaluation. Thus, application of a tuning fork to the affected body part with the suggestion that 'vibration can cause an involuntary movement' often triggers the psychogenic movement. Likewise, a suggestion that 'vibration can stop an involuntary movement' often diminishes or completely suppresses the abnormal movement when a vibrating tuning fork is applied to the affected body part. Also, restraining the shaking limb may result in an emergence of shaking in contralateral limb or in another body part. Ask the patient to tap one hand in time with yours while you vary the frequency. If the tremor in the patient's other hand follows the pace that you are setting this is called *entrainment* and is a feature of a psychogenic tremor. Asking the patient to perform the 'serial sevens' test or other mental task will often reduce the amplitude of psychogenic tremor or the tremor may cease completely. Parkinsonian or essential tremor, by contrast, increases during the 'serial sevens' test. The best *distraction* manoeuvre is to ask the patient to perform a complicated, sequential task with the opposite limb, such as repetitively touching the thumb

with the second, fifth and then third finger of the same hand. These and other distraction manoeuvres will often cause psychogenic tremor to change its pattern or frequency, or cease. Unfortunately, some organic tremors may also be affected by distraction, so reliance should not be placed on this test alone.

### ● Jerks

- Excessive startle is usually psychogenic. All of us jump in response to a loud noise or an unexpected pain, perhaps from a pin jab. These patients will 'jump out of their skin' in response to a tendon tap or a slight touch. Often they can be distracted from doing this by engaging them in conversation or by getting them to perform the 'serial sevens' test. Psychogenic startle has to be distinguished from the rare hyperekplexia and stimulus-sensitive or reflex myoclonus. The pattern of recruitment when recorded neurophysiologically often occurs in an orderly sequence, consistent with the normal anatomical distribution, in organic myoclonus whereas it is quite haphazard in psychogenic myoclonus. Also, when neurophysiological techniques are employed, latency from the stimulus (sudden loud sound or a visual threat) to the onset of muscle contraction is usually longer than 100 msec in psychogenic jerks whereas organic reflex myoclonus usually has a latency between 40 and 100 msec.



See Video 108: Psychogenic tics

### ● 'Dystonia'

- Psychogenic dystonia, unlike most forms of dystonia, is usually manifested by fixed posture (i.e. cannot be overcome by passive movement). Although organic dystonia is rarely painful, patients with psychogenic dystonia often complain of painful spasms. When examining a patient with psychogenic dystonia, one often encounters resistance against passive movement. It may follow a minor injury and may be accompanied by discoloration of the skin and trophic changes, typically seen with reflex sympathetic dystrophy, now referred to as complex regional pain syndrome. Severe flexion of the spine (camptocormia) was first described in soldiers coming out of trenches during the First World War, and found to be a feature of post-traumatic stress disorder. Although camptocormia may be psychogenic, there are many organic causes of camptocormia, such as Parkinson's disease and axial (trunk) dystonia.

### ● Limb weakness

- Paralysis on a psychogenic basis often involves a single limb, or the arm and leg on the same side. Features suggestive of this include: excessive effort (grimacing, panting and gasping) when asked to move the affected limb(s); periods of days or weeks when power returns to normal; absence of objective signs such as changes in tone and reflexes; improvement with suggestion. A useful confirmatory sign in a patient with one 'paralysed' leg, is the 'Hoover sign'. While lying on their back on the couch, ask them to raise the 'good' leg off the bed after you have placed your hand under the heel of the paralysed leg. You will feel a downward pressure from the otherwise completely paralysed leg.

### ● Sensory loss

- This is very common, increasing in severity as the patient is subjected to repeated examinations in hospital. The key is that it does not conform to the anatomical boundaries of, say, a root or nerve. Rather, it will end at the top of the arm or top of the leg. With psychogenic 'hemisensory loss', the patient, unlike an organic hemisensory loss, will not be able to feel the vibration of a tuning fork held on one side of the sternum, but will be able to feel it on the other side (despite the fact that vibration is bilaterally conducted through the bone). Another test is to ask the patient to say 'yes' if they feel you touch them (with their eyes closed) or 'no' if they cannot. The timing of their response of 'no' after each touch tells you that they can feel it.

### ● Speech/voice

- Psychogenic speech disorders take a number of forms. One of the most common is *stutter* where whole words or phrases are repeated rather than the first sound, usually a consonant, of particular words, as occurs in organic stutter:
  - Psychogenic stutter: 'Drove drove drove down the road road road ...'.
  - Organic stutter: 'D-D-D-Drove d-d-down the r-r-r-road ...'.

In organic stutter, the main feature is often 'blocking' where the patient cannot begin a sentence or gets stuck in the middle.

- Another type is *aphonia* where the patient can make no sound at all, nor mouth the words. Periods of normality are reassuring and help to confirm the diagnosis of psychogenicity. Reversion to child-like speech, acquisition of a foreign accent, and the use of meaningless words ('neologism') are other examples of psychogenic speech.

### ● Eyes/vision

- A number of psychogenic disorders affecting the eyes and vision may be considered. Sudden complete *loss of all sight* including light perception is naturally very alarming – though often least so for the patient, who, paradoxically, may still be able to leave the house and go to work. Clues that this is psychogenic include the setting (often a young woman who is otherwise completely well); normal pupillary response to light (this, of course, can also occur with bilateral occipital infarction);

inability to move the eyes voluntarily but preserved doll's-eye movements; inability to point to where your voice is coming from (which can be readily done by hearing); preserved menace response. Often sight returns spontaneously after a few days or weeks. 'Tunnel vision' is manifested by markedly narrowed field of peripheral vision when tested close and also when far (several yards) from the patient.

- *Convergence spasm* is often misdiagnosed as bilateral abducens palsies. Each eye appears to fail to abduct on either lateral gaze, producing markedly dysconjugate gaze with or without diplopia, accompanied by miosis (pupillary constriction). Although brainstem lesions can result in convergence spasm, this sign is often seen in the setting of psychogenic disorders. See video 110.



**See Video 109:** Psychogenic nystagmus and opsoclonus



**See Video 110:** Psychogenic convergence spasm

- *Pseudoptosis*, where the patient screws one eye up. Here, the eyebrow on the affected side is lowered, unlike in true ptosis where it is usually elevated (in an attempt to raise the eyelid). One exception is hemifacial spasm in which the ipsilateral eyebrow is often elevated due to frontalis contraction. This sign is also known as 'the other Babinski sign', described by Babinski to differentiate hemifacial spasm from blepharospasm in which the eyebrow is usually lowered.

### Box 15.1 Tips

- Apparent indifference in the face of severe disability ('la belle indifference') is an unreliable marker of psychogenic disorders. It is, for example, commonly seen in the setting of multiple sclerosis.
- Psychogenic disorders are uncommon in children under the age of six years and should be diagnosed with caution when they occur for the first time in the elderly.



- The feature which often points to the possibility of a psychogenic disorder is the emotive, eye-catching quality of the presentation, sudden onset with spontaneous remissions, bizarre movement that is incongruous with organic movement disorder.
- The presence of undoubted psychogenic features does not exclude the possibility of an underlying physical illness.
- An absence of associated relevant objective physical signs, such as reflex changes, muscle wasting or cranial nerve lesions, is the starting point for making a diagnosis of a psychogenic disorder.
- Organic disorders where there are no associated signs accompanying the main feature are often misdiagnosed as psychogenic. These include dystonia, chorea and truncal ataxia (due to a midline cerebellar lesion where there may be no other cerebellar signs).
- The strongest evidence that a disorder has a psychogenic basis is a sudden onset, often triggered by recent stress, such as an argument, unresolved conflict or nonconsensual sexual encounter (e.g. rape or molestation). Lack of insight or denial of any stress prior to the onset of the symptoms is very frequent at the time of initial evaluation and the psychodynamic factors may not be apparent until subsequent interviews.
- Sudden 'cure' – often triggered by suggestion such as faith healing.
- The diagnosis of a psychogenic disorder must be based on 'positive' criteria, not merely the absence of organicity or negative investigation.

# Index of videos

- Video 1** **Benediction sign.** The patient fails to flex the terminal phalanx of the thumb and index. There is wasting of the thenar eminence. The patient has a proximal median nerve lesion.
- Video 2** **Deep branch lesion of the ulnar nerve.** The patient is unable to abduct the index finger on the right, and there is wasting of the first dorsal interosseous muscle.
- Video 3** **Dystrophia myotonica.** Frontal balding, ptosis, 'horizontal smile', failure to bury the eye lashes, myotonia causing slowing of fist opening, and percussion myotonia of thumb abduction.
- Video 4** **Radial nerve lesion.** Wrist drop on the right, failure to abduct the fingers in the flexed posture, failure to contract brachioradialis on wrist flexion against resistance.
- Video 5** **Inverted supinator.** The fingers flex when the radius is tapped, but there is no reflex contraction in brachioradialis. The triceps jerk is brisk.
- Video 6** **Dressing apraxia.** The patient gets into a tangle trying to put her jacket back on, having inadvertently pulled the left sleeve inside out.
- Video 7** **Weakness of trapezius.** The right shoulder is depressed, there is limitation of abduction of the right shoulder, the right scapula wings when the arms are pushed against the wall.
- Video 8** **Weakness of serratus anterior.** The right scapula lifts away from the chest wall when the arms are extended at the shoulder.
- Video 9** **Severe head drop as a result of neck extensor weakness due to acetylcholine receptor antibody-positive myasthenia gravis.**
- Video 10** **Common peroneal nerve lesion causing foot drop and high-stepping gait on left.**
- Video 11** **Hemiparetic gait following stroke.** Circumduction of the right leg and flexion of the right arm with loss of arm swing.
- Video 12** **Toe-walking spastic gait as a result of hereditary spastic paraparesis in a 21-year-old man.**
- Video 13** **Bilateral high-stepping gait and foot drop due to motor neurone disease.**
- Video 14** **Antalgic gait and positive Trendelenburg sign in a patient with left sacroileitis.** She minimizes the time that she bears weight on the painful left leg while walking by hurrying through with the stride on the right. When weight-bearing in the standing position, the pelvis momentarily sags on the right due to failure of the left hip abductors to hold the weight.

- Video 15 Gait in advanced Parkinson's disease.** Difficulty getting out of the chair; flexed at the hips; walks slowly with no arm swing; paradoxically, she can still run.
- Video 16 Marked freezing in Parkinson's disease overcome by using visual cues.**
- Video 17 Pull test with retropulsion in Parkinson's disease.** The patient walks well, though with absent arm swing. Runs backwards when pulled from behind.
- Video 18 Marche à petit pas due to multiple lacunes (seen on magnetic resonance imaging).** Small steps, festination (hurrying) when turning and negotiating the doorway. Like parkinsonism, but with a broadened base.
- Video 19 Marche à petit pas due to normal-pressure hydrocephalus.** Pre-shunt. The patient walks with small steps on a wide base with preserved arm swing and upright posture.
- Video 20 The same patient as in Video 14, walking normally after being shunted.**
- Video 21 Mild cerebellar ataxia.** Broad-based, unsteady on turning, uneven stride.
- Video 22 Dysarthria, ataxia and limitation of upgaze as a result of SCAIII (Machado–Joseph disease).**
- Video 23 Gait in cervical dystonia.** The head is tilted to the right as the patient walks.
- Video 24 Gait in torsion dystonia.** The patient walks awkwardly and hurriedly with the right arm internally rotated, the left arm flexed at the elbow, the right foot dorsiflexed and the head tilted to the right.
- Video 25 Gait in Huntington's disease.** The patient has a curious, untidy, mannered way of walking: bending the knees, pausing and making choreiform movements with his fingers.
- Video 26 Dystonic camptocormia (flexion of the trunk) with marked improvement following botulinum toxin injections into the rectus abdominus.**
- Video 27 Generalized dystonia secondary to DYT1 (TorsinA) mutation.**
- Video 28 Gait in dopa-induced dyskinesia.** As the patient walks, he makes continuous writhing twisting movements of his head, trunk and limbs.
- Video 29 Bell's palsy.** The patient is unable to raise the right eye brow (frontalis) or screw up the right eye (orbicularis oculi), or smile on the right, or purse his lips on the right (orbicularis oris) or contract the right platysma. When he screws the eyes up, the right eye is seen to roll up (Bell's sign).
- Video 30 Right hemifacial spasm in a patient with prior right Bell's palsy showing ipsilateral synkinesis of lower facial muscles when he voluntarily contracts right upper facial muscles.**
- Video 31 Long-standing right facial palsy.** Deepened right naso-labial fold; spontaneous blinking stronger on the normal (left) side; right corner of the

mouth twitches when he blinks; smiling, pouting or blowing his cheeks out all cause the right eye to close; right cheek blows out less than left (tighter right buccinator). All features of overactivity of surviving axons in the right facial nerve associated with synkinesis ('cross-talk' between axons). These signs are not due to contracture of the right facial muscles as they are lost if the nerve is severed by, for example, surgery for acoustic neuroma.

- Video 32 Left upper motor neurone facial palsy following stroke.** The patient's face is symmetrical at rest; on being asked to smile, he blinks and closes his eyes (apraxia of smiling) and then fails to elevate the right angle of the mouth fully; later, when amused, he smiles symmetrically.
- Video 33 Selective right facial weakness from skin cancer.** The right upper lip fails to purse, and the patient is unable to form a seal with his mouth when attempting to blow out his cheeks; he is able to raise his eyebrows and screw up his eyes normally; unable to flare the right nostril. The scar on the right cheek is from previous surgery for squamous cell carcinoma.
- Video 34 Right hemifacial spasm and elevation of ipsilateral eyebrow as a result of frontalis contraction, referred to as 'the other Babinski sign'.**
- Video 35 Trauma-induced left third nerve palsy manifested by ptosis and ophthalmoparesis and contralateral kinetic/postural tremor and ataxia (Benedict's syndrome).**
- Video 36 Left oculomotor (IIIrd) nerve palsy with pupillary sparing.** Complete ptosis; the patient is unable to fully adduct left eye on right lateral gaze; then fixates with left eye, causing right eye to abduct (Hering's law); normal abduction with left eye but limited elevation. Pupils equal.
- Video 37 Unilateral ptosis due to myasthenia gravis.** Ptosis increases with sustained upward gaze and improves after a brief rest.
- Video 38 Marked left ptosis, bilateral ophthalmoplegia and weakness of orbicularis oculi in Kearns–Sayre syndrome.**
- Video 39 Ocular myasthenia gravis.** Ptosis and divergent squint; on sustained upward gaze, the ptosis increases; later the ptosis is abolished by injection of edrophonium.
- Video 40 Early progressive supranuclear gaze palsy (Steele Richardson syndrome).** The patient's range of voluntary eye movements is good, but his vertical saccades, particularly when looking down, are slow.
- Video 41 Left abducens (VI) nerve palsy.** The left eye fails to abduct on left lateral gaze.
- Video 42 Right trochlear (IV) nerve palsy.** The head is tilted to the left; on left lateral gaze, the right eye rides up – this is more marked when the head is tilted to the right and corrected by tilting the head to the left.

- Video 43 Left internuclear ophthalmoplegia.** On right lateral gaze, the left eye fails to fully adduct and the right eye overshoots and then makes correcting nystagmoid movements.
- Video 44 Facial and gaze palsy due to pontine metastasis.** Widened left palpebral fissure; not blinking on left; loss of left naso-labial fold; unable to raise left eyebrow (frontalis); unable to screw up left eye (orbicularis oculi); left cheek blows out (buccinator weakness); able to look to the right but not the left (left gaze palsy). CT: multiple lesions including one in the left pons.
- Video 45 Parinaud's syndrome.** On attempted upward gaze, the eyes jerk rhythmically towards each other.
- Video 46 Parinaud's syndrome.** On attempted upward gaze, the eyes retract rhythmically into the orbits.
- Video 47 Horizontal nystagmus.** On left lateral gaze, there is horizontal nystagmus with the fast phase to the left; on right lateral gaze, there is horizontal nystagmus with the fast phase to the right.
- Video 48 Vertical nystagmus on downward gaze, fast phase down.**
- Video 49 Horizontal pendular nystagmus.** This is present continuously in the primary position and increases in amplitude on lateral gaze. No fast and slow phase.
- Video 50 Task-specific or task-exacerbated variant of essential tremor without postural tremor in an elderly woman with a 30-year history of handwriting tremor in the right hand that later spread to the left hand, with mild head tremor.**
- Video 51 Resting tremor in Parkinson's disease.** A highly coordinated synchronous rhythmical contraction in the plane of flexion and extension is seen in the fingers of the left hand. In the right hand, the tremor is pill-rolling, the thumb rubbing against the index. A side-to-side tremor of similar frequency is seen in the jaw.
- Video 52 Resting tremor in Parkinson's disease.** Coarse resting pill-rolling tremor in hands. Chin tremor.
- Video 53 Postural tremor in essential tremor.** Fine tremor of the outstretched arms; this goes when the arms are at rest and persists during movement; no akinesia of the hands.
- Video 54 Parkinson's disease and childhood-onset hereditary chin tremor.**
- Video 55 Intention tremor.** A coarse (high-amplitude, low-frequency) tremor is seen in the right hand as the index finger approaches the pointer and the patient's nose.
- Video 56 Intention tremor in cerebellar disease.** The patient develops a coarse tremor of the hand as her finger approaches her nose, especially on the right side; there is clumsiness (ataxia) of the hands when she slaps her thighs.

- Video 57 Tremor, akinesia and gait in Parkinson's disease.** While sitting, there is a coarse tremor of the right hand, causing flexion and extension at the wrist. The tremor pauses briefly when he raises the arms. There is slowing of voluntary flexion and extension of the hands (bradykinesia). The chin shakes. He does not swing the (tremulous) right arm on walking.
- Video 58 Falls in Parkinson's disease.** The patient walks cautiously with small steps and with a coarse tremor of the right hand. When he crosses the shadow thrown by light coming through the doorway, he freezes and falls to his knees.
- Video 59 Speech in Parkinson's disease.** A quiet voice with a tendency to stutter (pallialia).
- Video 60 Holmes tremor.** Coarse postural and intention tremor in a patient with midbrain lesion.
- Video 61 Bat's wing tremor in a patient with Wilson's disease.** At rest, he has a head tremor (titubation); with the arms abducted at the shoulder and flexed at the elbow, he develops a coarse asymmetrical proximal tremor of the arms.
- Video 62 Slow tremor (myorhythmia) in a patient with Wilson's disease.**
- Video 63 Progressive multiple system atrophy manifested by severe bradykinesia, dysarthria, dysautonomia with orthostatic hypotension, respiratory, gastrointestinal and urinary failure and marked sialorrhoea, precipitated by eating chocolate.**
- Video 64 Non-fluent aphasia following intracerebral haemorrhage from a left hemisphere arteriovenous malformation (AVM).** The patient exerts great effort to get any words out, and there are long pauses during which he gesticulates and appears to be frustrated; his sentences are short and easy to understand; his comprehension is normal.
- Video 65 Sudden onset of mild left hemiparesis and marked left hemichorea-hemiballismus in a woman with new-onset diabetes mellitus.** Brain computed tomography (CT) scan and magnetic resonance imaging showed T1W, T2W and DWI lesions in the right putamen and caudate, consistent with hyperglycaemia-induced hemichorea-hemiballismus. The involuntary movement almost completely resolved with tetrabenazine, a monoamine-depleting drug.
- Video 66 Hemiballismus.** There are almost continuous irregular coarse jerks of the proximal part of the left arm which persist/increase during hand movement and walking.
- Video 67 Tourette's syndrome.** Blinking, grimacing and platysma contraction are seen, particularly when the patient talks.
- Video 68 Severe Tourette's syndrome manifested by complex motor and blocking tics, as well as phonic tics associated with marked obsessive compulsive disorder and self-injurious behaviour.**

- Video 69 Reflex myoclonus.** Flicking the fingers of the right hand makes the arm jump. Pricking the fingers causes an exaggerated withdrawal reflex.
- Video 70 Post-hypoxic myoclonus.** At rest, this patient is still, but when she raises her arms or legs, large-amplitude, shock-like jerks are seen. The jerks interfere with her attempt to touch a pointer, but there is no true intention tremor.
- Video 71 Asterixis.** The outstretched hands and fingers repeatedly drop and then recover, reflecting a momentary loss of tone.
- Video 72 Mini-myoclonus.** There are fine, shock-like lateral movements of individual fingers.
- Video 73 Palatal and laryngeal myoclonus.**
- Video 74 Athetosis.** The fingers of the outstretched right hand make continuous writhing slow irregular movements, each finger moving independently. Similar, low-amplitude movements are seen in the face involving the mouth, eyelids and eyebrows.
- Video 75 Generalized dystonia.** The patient's head is turned to the right and the mouth pulls to the left as he talks. The fingers of the left hand are splayed, and the left elbow and wrist are flexed. All actions are interrupted by slow involuntary movements of his limbs and neck.
- Video 76 Torticollis.** The head is turned to the left and tilted to the right. The posture is corrected by touching the cheeks with either hand (even before the hand touches): geste antagonistique. Even imagining the geste temporarily corrects the posture.
- Video 77 Craniocervical dystonia and dystonic–respiratory dysregulation.**
- Video 78 Myoclonus–dystonia syndrome secondary to mutation in the gene coding for  $\epsilon$ -sarcoglycan.**
- Video 79 Myoclonus–dystonia syndrome secondary to mutation in the gene coding for  $\epsilon$ -sarcoglycan, father of the girl shown on video 78.**
- Video 80 Paroxysmal kinesigenic dystonia.**
- Video 81 Task-specific dystonia in a professional violinist manifested by involuntary left fifth finger flexion and compensatory extension.**
- Video 82 Marked apraxia of eyelid opening.**
- Video 83 Marked stereotypies associated with Rett syndrome.**
- Video 84 Stereotypic behaviour: repeatedly pushing a button on a remote control, and foot and finger tapping, in a right-handed man with progressive dysarthria, apathy, anxiety and mouth drooling.** His hand–face stereotypies markedly improved with tetrabenazine, a monoamine-depleting drug.

- Video 85 Dopa-induced peak dose dyskinesia.** The head tilts initially to the right and then the left. While seated, the patient's legs and feet move restlessly. While walking, the head tilts to the right and the fingers of the left hand writhe and posture.
- Video 86 Chorea in Huntington's disease.** This patient makes constant twitching movements of her hands and feet; she grimaces and her eyebrows dance. All this increases when she talks.
- Video 87 Blepharospasm/cranial dystonia.** The eyes keep screwing up and there are 'rabbit twitches' of the nose and upper lip.
- Video 88 End-of-dose dystonia.** The patient has a stiff upright posture with no arm swing, walking on the outside of the left foot, with the hallux dorsiflexed.
- Video 89 Tardive akathisia.** The patient has continuous restless movements of the limbs and is unable to keep still. He also has tardive dyskinesia, and repeatedly protrudes his tongue.
- Video 90 Akathisia induced by selective serotonin re-uptake inhibitor.**
- Video 91 Tardive dyskinesia.** This patient continually pouts her lips, protrudes her tongue and closes her eyes.
- Video 92 Severe oromandibular dystonia with bruxism (constant grinding of the teeth) resulting in extensive dental damage. The symptoms were subsequently controlled with botulinum toxin injections into the masseter and temporalis muscles.**
- Video 93 Tardive lingual dyskinesia (stereotypy).**
- Video 94 Typical tardive dyskinesia manifested by orofacial–lingual stereotypy.**
- Video 95 Tardive dystonia.** The neck and trunk are hyperextended, except when the patient clasps his hands behind his neck (*geste antagonistique*).
- Video 96 Wernicke's aphasia following a cardioembolic stroke.** The patient speaks freely, but what he says is so littered with paraphasias as to make it almost impossible to understand. His comprehension is poor.
- Video 97 Fluent aphasia in a man with a left parietal glioma.** He speaks freely with well-formed sentences and normal prosody (melody), at times making no mistakes; he then gets stuck '... and then for an extent for a week I was a problem with poisoning ... voicing'. He appears to understand what is said to him, but has great difficulty identifying and touching parts of his face in sequence. He is unable to repeat. In summary, he has a fluent aphasia with impaired comprehension and repetition and he makes paraphasic errors.



- Video 98 Groping.** The patient reaches out and grasps the hands which are offered to him (even though he has been asked not to) and is unable to let go. He also grasps with his feet.
- Video 99 Fronto-temporal dementia and marked grasp and snout reflexes, as well as foot stereotypies.**
- Video 100 Mouth grasp.** This patient flexes her head and opens her mouth to an approaching finger even when asked not to.
- Video 101 Forced visual following (visual grasping).** The patient follows the light with her eyes, even though it circles uncomfortably. She is unable to suppress the behaviour.
- Video 102 Utilization behaviour.** The patient stacks three pairs of spectacles on his nose, one at a time, as each is offered to him.
- Video 103 Forced mimicry.** When the examiner raises his hand with two fingers extended, the patient incorporates the posture into his own gestures. He also imitates left arm raising, both arm raising, right fist clenching and left leg raising, while continuing the conversation.
- Video 104 Apraxia in Parkinson's disease.** This patient is unable to copy accurately the akinesia test for Parkinsonism, flexing the interphalangeal joints, as well as the metacarpophalangeal joints.
- Video 105 Luria test.** The patient is not able to follow the sequence of fist, cut and slap.
- Video 106 Miming in apraxia.** The patient is able to obey a simple sequence of pointing commands (showing that her comprehension is reasonable), but is unable to mime cutting a loaf.
- Video 107 Rapidly progressive cognitive decline, apraxia, ataxia, myoclonus and spasticity secondary to Creutzfeldt–Jakob disease.**
- Video 108 Psychogenic, distractable tics, precipitated by severe life stressors and triggered by suggestion and application of a tuning fork.**
- Video 109 Intermittent tremor and intermittent multidirectional, conjugate gaze determined to be psychogenic nystagmus and opsoclonus.**
- Video 110 Psychogenic convergence spasm manifested by dysconjugate gaze and miosis and episodic left side 'involuntary' muscle contractions, triggered by a powerful suggestion and application of a vibrating tuning fork.**



# Neurological Clinical Examination

This book and extensive video library provide a practical guide to the clinical neurological examination, an essential tool in the diagnosis of common and unusual neurological conditions encountered in the outpatient clinic and hospital ward.

Each chapter covers a different condition and uses a step by step approach, selecting those aspects of the clinical examination which are most likely to lead you to the correct diagnosis.

- Gain instant access to over 100 free video clips from your desktop or via smart phone or tablet
- Generously illustrated with clear diagrams
- Tables are used to list the various causes of particular signs
- Key features of the neurological examination which help in reaching the correct conclusion are listed as Tips

Primary care physicians, neurologists and trainees preparing for certifying examinations will find this book an invaluable learning companion and essential tool for the diagnosis of neurological disorders.

## **John Morris** DM (OXON) FRACP FRCP

Clinical Professor, University of Sydney; Past Chairman of the Education and Training Committee of the Australian and New Zealand Association of Neurologists; Past Examiner for the Royal Australasian College of Physicians; Past Head of the Neurology Department, Westmead Hospital; Past President of the Australian Association of Neurologists, Sydney, Australia

## **Joseph Jankovic** MD

Professor of Neurology; Distinguished Chair in Movement Disorders; Director, Parkinson's Disease Center and Movement Disorders Clinic; Co-Director, Parkinson's Disease Research Laboratory; Past President of the Movement Disorders Society, Department of Neurology, Baylor College of Medicine, Houston, Texas, USA

### FREE VIDEO LIBRARY

- + 100 free-to-access video clips available at [www.hodderplus.com/nce](http://www.hodderplus.com/nce)
- + QR codes give you access to the video clips through smartphone or tablet
- + To use the QR codes your device must have a camera and a QR code reader app installed



**HODDER  
ARNOLD**

[www.hodderarnold.com](http://www.hodderarnold.com)

ISBN 978-1-4441-4538-0



9 781444 145380