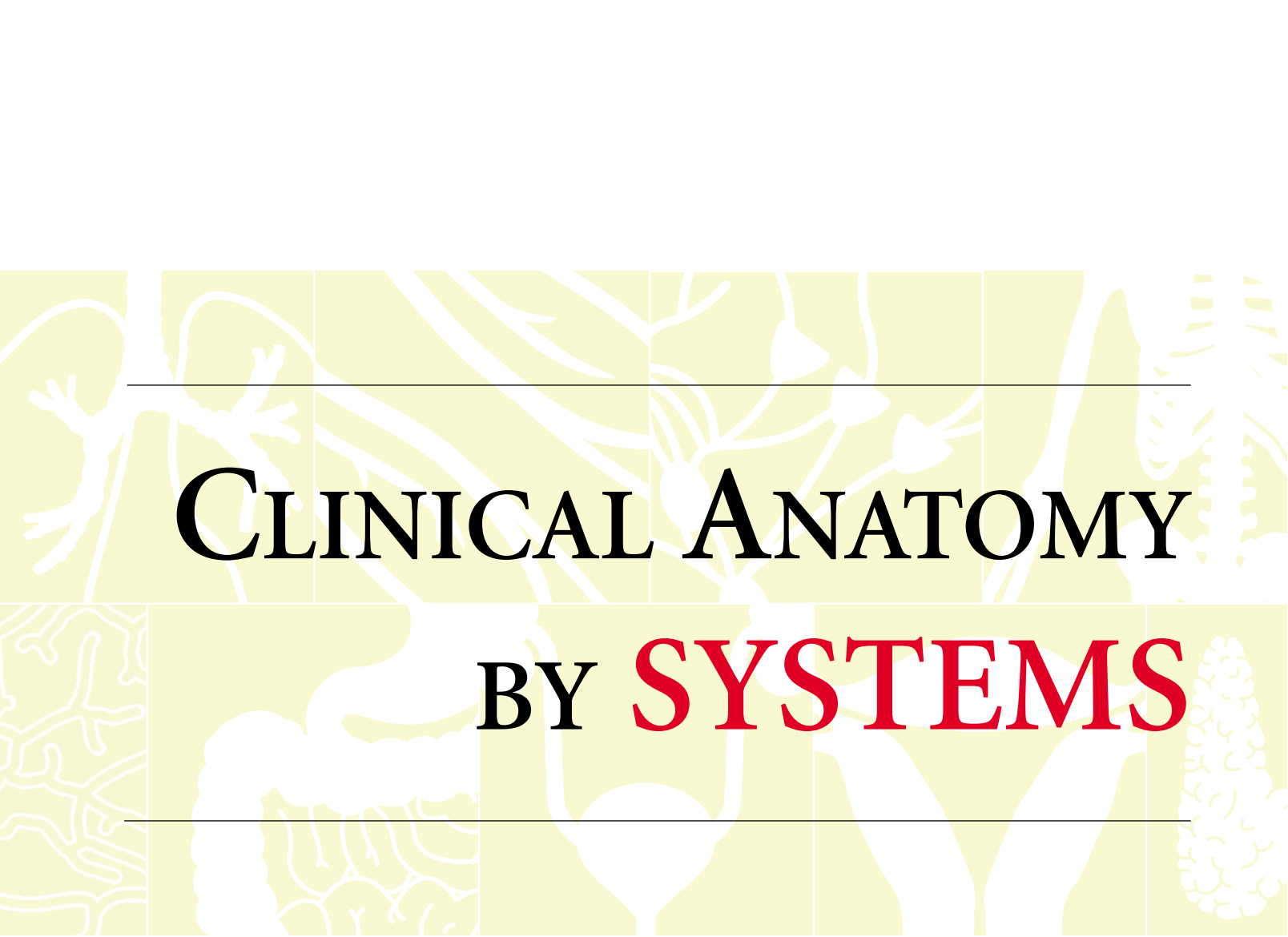


CLINICAL ANATOMY BY SYSTEMS

RICHARD S. SNELL, MD, PhD

 Lippincott Williams & Wilkins
a Wolters Kluwer business



CLINICAL ANATOMY

BY SYSTEMS

Richard S. Snell, MD, PhD

CD-ROM



LIPPINCOTT WILLIAMS & WILKINS
A Wolters Kluwer Company

Philadelphia • Baltimore • New York • London
Buenos Aires • Hong Kong • Sydney • Tokyo

Welcome to *Clinical Anatomy by Systems* by Richard S. Snell, MD, PhD. This CD-ROM is designed for medical students doing their clinical rotations, allied health students, dental students, nurses, and residents.

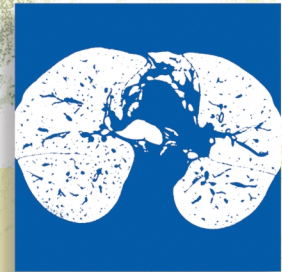The information provided is in the form of Clinical Notes, which are linked to the appropriate chapters of the main text. This gives students ready access to the basic anatomic and clinical material. Sections on Congenital Anomalies are also included.

The clinical material provides the medical professional with the practical application of anatomic facts that he or she will require when examining patients. It will also be of great assistance when interpreting the findings of techno-

logic investigations. The anatomy of Common Medical Procedures has also been included, and the complications caused by an ignorance of normal anatomy have been emphasized.

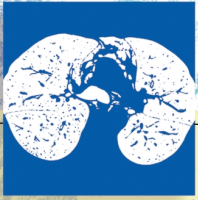Examples of clinical cases are given at the end of each group of Clinical Notes. Each clinical vignette is followed by multiple choice questions. Answers and explanations for the problems are given at the end of the section in the CD-ROM.

*No part of this CD-ROM may be reproduced in any form or by any means without written permission from the copyright owner.



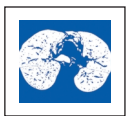I

Introduction to Clinical Anatomy



Chapter Outline

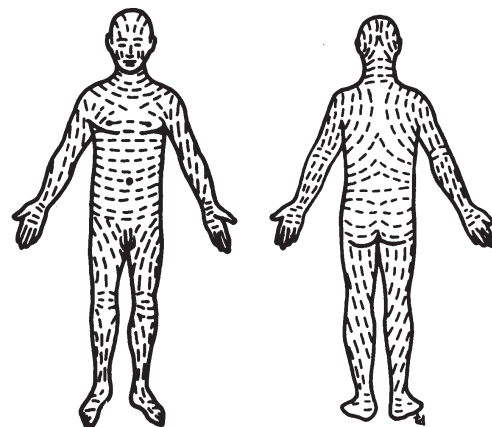
Skin	2	Blood Vessels	4
Lines of Cleavage	2	Diseases of Blood Vessels	4
Skin Infections	3	Lymphatic System	5
Sebaceous Cyst	3	Diseases of the Lymphatic System	5
Shock	3	Nervous System	5
Skin Burns	3	Segmental Innervation of Skin	5
Skin Grafting	3	Segmental Innervation of Muscle	5
Fasciae	3	Clinical Modification of the Activities of the Autonomic Nervous Systems	5
Fasciae and Infection	3	Mucous and Serous Membranes	5
Skeletal Muscle	3	Mucous and Serous Membranes and Inflammatory Disease	5
Muscle Attachments	3	Bones	6
Muscle Shape and Form	3	Bone Fractures	6
Cardiac Muscle	3	Rickets	7
Necrosis of Cardiac Muscle	3	Epiphyseal Plate Disorders	7
Joints	4	Clinical Significance of Sex, Race, and Age on Structure	9
Examination of Joints	4	Clinical Problem Solving Questions	9
Ligaments	4	Answers and Explanations	11
Damage to Ligaments	4		
Bursae and Synovial Sheaths	4		
Trauma and Infection of Bursae and Synovial Sheaths	4		



SKIN

Lines of Cleavage

In the dermis, the bundles of collagen fibers are mostly arranged in parallel rows. A surgical incision through the skin made along or between these rows causes the minimum of disruption of collagen, and the wound heals with minimal scar tissue. Conversely, an incision made across the rows of collagen disrupts and disturbs it, resulting in the massive production of fresh collagen and the formation of a broad, ugly scar. The direction of the rows of collagen is known as the **lines of cleavage** (Langer's lines), and they tend to run longitudinally in the limbs and circumferentially in the neck and trunk (CD Fig. 1-1).



CD Figure 1-1 Cleavage lines of the skin.

A general knowledge of the direction of the **lines of cleavage** greatly assists the surgeon in making incisions that result in cosmetically acceptable scars. This is particularly important in those areas of the body not normally covered by clothing. A salesperson, for example, may lose his or her job if an operation leaves a hideous facial scar.

Skin Infections

The nail folds, hair follicles, and sebaceous glands are common sites for entrance into the underlying tissues of pathogenic organisms such as *Staphylococcus aureus*. Infection occurring between the nail and the nail fold is called a **paronychia**. Infection of the hair follicle and sebaceous gland is responsible for the common **boil**. A **carbuncle** is a staphylococcal infection of the superficial fascia. It frequently occurs in the nape of the neck and usually starts as an infection of a hair follicle or a group of hair follicles.

Sebaceous Cyst

A sebaceous cyst is caused by obstruction of the mouth of a sebaceous duct and *may* be caused by damage from a comb or by infection. It occurs most frequently on the scalp.

Shock

A patient who is in a state of **shock** is pale and exhibits gooseflesh as a result of overactivity of the sympathetic system, which causes vasoconstriction of the dermal arterioles and contraction of the arrector pili muscles.

Skin Burns

The depth of a burn determines the method and rate of healing. A partial-skin-thickness burn heals from the cells of the hair follicles, sebaceous glands, and sweat glands as well as from the cells at the edge of the burn. A burn that extends deeper than the sweat glands heals slowly and from the edges only, and considerable contracture will be caused by fibrous tissue. To speed up healing and reduce the incidence of contracture, a deep burn should be grafted.

Skin Grafting

Skin grafting is of two main types: split-thickness grafting and full-thickness grafting. In a split-thickness graft the greater part of the epidermis, including the tips of the dermal papillae, are removed from the donor site and placed on the recipient site. This leaves at the donor site for repair purposes the epidermal cells on the sides of the dermal papillae and the cells of the hair follicles and sweat glands.

A full-thickness skin graft includes both the epidermis and dermis and, to survive, requires rapid establishment of a

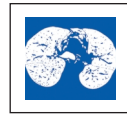
new circulation within it at the recipient site. The donor site is usually covered with a split-thickness graft. In certain circumstances the full-thickness graft is made in the form of a pedicle graft, in which a flap of full-thickness skin is turned and stitched in position at the recipient site, leaving the base of the flap with its blood supply intact at the donor site. Later, when the new blood supply to the graft has been established, the base of the graft is cut across.



FASCIAE

Fasciae and Infection

Knowledge of the arrangement of the deep fasciae often helps explain the path taken by an infection when it spreads from its primary site. In the neck, for example, the various fascial planes explain how infection can extend from the region of the floor of the mouth to the larynx.



SKELETAL MUSCLE

Muscle Attachments

The importance of knowing the main attachments of all the major muscles of the body need not be emphasized. Only with such knowledge is it possible to understand the normal and abnormal actions of individual muscles or muscle groups. How can one even attempt to analyze, for example, the abnormal gait of a patient without this information?

Muscle Shape and Form

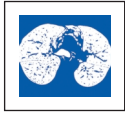The general shape and form of muscles should also be noted, since a paralyzed muscle or one that is not used (such as occurs when a limb is immobilized in a splint) quickly atrophies and changes shape. In the case of the limbs, it is always worth remembering that a muscle on the opposite side of the body can be used for comparison.



CARDIAC MUSCLE

Necrosis of Cardiac Muscle

The cardiac muscle receives its blood supply from the coronary arteries. A sudden block of one of the large branches of a coronary artery will inevitably lead to necrosis of the cardiac muscle and often to the death of the patient.



JOINTS

Examination of Joints

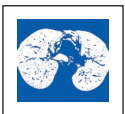When examining a patient, the clinician should assess the normal range of movement of all joints. When the bones of a joint are no longer in their normal anatomic relationship with one another, then the joint is said to be **dislocated**. Some joints are particularly susceptible to dislocation because of lack of support by ligaments, the poor shape of the articular surfaces, or the absence of adequate muscular support. The shoulder joint, temporomandibular joint, and acromioclavicular joints are good examples. Dislocation of the hip is usually congenital, being caused by inadequate development of the socket that normally holds the head of the femur firmly in position.

The presence of cartilaginous discs within joints, especially weightbearing joints, as in the case of the knee, makes them particularly susceptible to injury in sports. During a rapid movement the disc loses its normal relationship to the bones and becomes crushed between the weightbearing surfaces.

In certain diseases of the nervous system (e.g., syringomyelia), the sensation of pain in a joint is lost. This means that the warning sensations of pain felt when a joint moves beyond the normal range of movement are not experienced. This phenomenon results in the destruction of the joint.

Knowledge of the classification of joints is of great value because, for example, certain diseases affect only certain types of joints. Gonococcal arthritis affects large synovial joints such as the ankle, elbow, or wrist, whereas tuberculous arthritis also affects synovial joints and may start in the synovial membrane or in the bone.

Remember that more than one joint may receive the same nerve supply. For example, the hip and knee joints are both supplied by the obturator nerve. Thus, a patient with disease limited to one of these joints may experience pain in both.

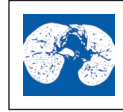

LIGAMENTS

Damage to Ligaments

Joint ligaments are very prone to excessive stretching and even tearing and rupture. If possible, the apposing damaged surfaces of the ligament are brought together by positioning and immobilizing the joint. In severe injuries, surgical approximation of the cut ends may be required. The blood

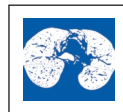
clot at the damaged site is invaded by blood vessels and fibroblasts. The fibroblasts lay down new collagen and elastic fibers, which become oriented along the lines of mechanical stress.



BURSAE AND SYNOVIAL SHEATHS

Trauma and Infection of Bursae and Synovial Sheaths

Bursae and synovial sheaths are commonly the site of traumatic or infectious disease. For example, the extensor tendon sheaths of the hand may become inflamed after excessive or unaccustomed use; an inflammation of the prepatellar bursa may occur as the result of trauma from repeated kneeling on a hard surface.



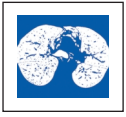BLOOD VESSELS

Diseases of Blood Vessels

Diseases of blood vessels are common. The surface anatomy of the main arteries, especially those of the limbs, is discussed in the appropriate sections of this book. The **collateral circulation** of most large arteries should be understood, and a distinction should be made between anatomic end arteries and functional end arteries.

All large arteries that cross over a joint are liable to be kinked during movements of the joint. However, the distal flow of blood is not interrupted because an adequate anastomosis is usually between branches of the artery that arise both proximal and distal to the joint. The alternative blood channels, which dilate under these circumstances, form the collateral circulation. Knowledge of the existence and position of such a circulation may be of vital importance should it be necessary to tie off a large artery that has been damaged by trauma or disease.

Coronary arteries are functional end arteries, and if they become blocked by disease (coronary arterial occlusion is common), the cardiac muscle normally supplied by that artery will receive insufficient blood and undergo necrosis. Blockage of a large coronary artery results in the death of the patient.



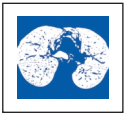LYMPHATIC SYSTEM

Diseases of the Lymphatic System

The lymphatic system is often de-emphasized by anatomists on the grounds that it is difficult to see on a cadaver. However, it is of vital importance to medical personnel, since lymph nodes may swell as the result of infection, metastases, or primary tumor. For this reason, the lymphatic drainage of all major organs of the body, including the skin, should be known.

A patient may complain of a swelling produced by the enlargement of a lymph node. A physician must know the areas of the body that drain lymph to a particular node if he or she is to be able to find the primary site of the disease. Often the patient ignores the primary disease, which may be a small, painless cancer of the skin.

Conversely, the patient may complain of a painful ulcer of the tongue, for example, and the physician must know the lymph drainage of the tongue to be able to determine whether the disease has spread beyond the limits of the tongue.



NERVOUS SYSTEM

Segmental Innervation of the Skin

The area of skin supplied by a single spinal nerve, and therefore a single segment of the spinal cord, is called a **dermatome**. On the trunk, adjacent dermatomes overlap considerably; to produce a region of complete anesthesia, at least three contiguous spinal nerves must be sectioned. Dermatomal charts for the anterior and posterior surfaces of the body are shown in CD Figs. 1-2 and 1-3.

In the limbs, arrangement of the dermatomes is more complicated because of the embryologic changes that take place as the limbs grow out from the body wall.

A physician should have a working knowledge of the segmental (dermatomal) innervation of skin, because with the help of a pin or a piece of cotton he or she can determine whether the sensory function of a particular spinal nerve or segment of the spinal cord is functioning normally.

Segmental Innervation of Muscle

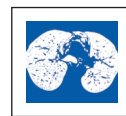
Skeletal muscle also receives a segmental innervation. Most of these muscles are innervated by two, three, or four spinal nerves and therefore by the same number of segments of the spinal cord. To paralyze a muscle completely, it is thus necessary to section several spinal nerves or to destroy several segments of the spinal cord.

Learning the segmental innervation of all the muscles of the body is an impossible task. Nevertheless, the segmental innervation of the following muscles should be known because they can be tested by eliciting simple muscle reflexes in the patient (CD Fig. 1-4):

- **Biceps brachii tendon reflex:** C5 and 6 (flexion of the elbow joint by tapping the biceps tendon)
- **Triceps tendon reflex:** C6, 7, and 8 (extension of the elbow joint by tapping the triceps tendon)
- **Brachioradialis tendon reflex:** C5, 6, and 7 (supination of the radioulnar joints by tapping the insertion of the brachioradialis tendon)
- **Abdominal superficial reflexes (contraction of underlying abdominal muscles by stroking the skin):** Upper abdominal skin T6–7, middle abdominal skin T8–9, and lower abdominal skin T10–12
- **Patellar tendon reflex (knee jerk):** L2, 3, and 4 (extension of the knee joint on tapping the patellar tendon)
- **Achilles tendon reflex (ankle jerk):** S1 and S2 (plantar flexion of the ankle joint on tapping the Achilles tendon)

Clinical Modification of the Activities of the Autonomic Nervous System

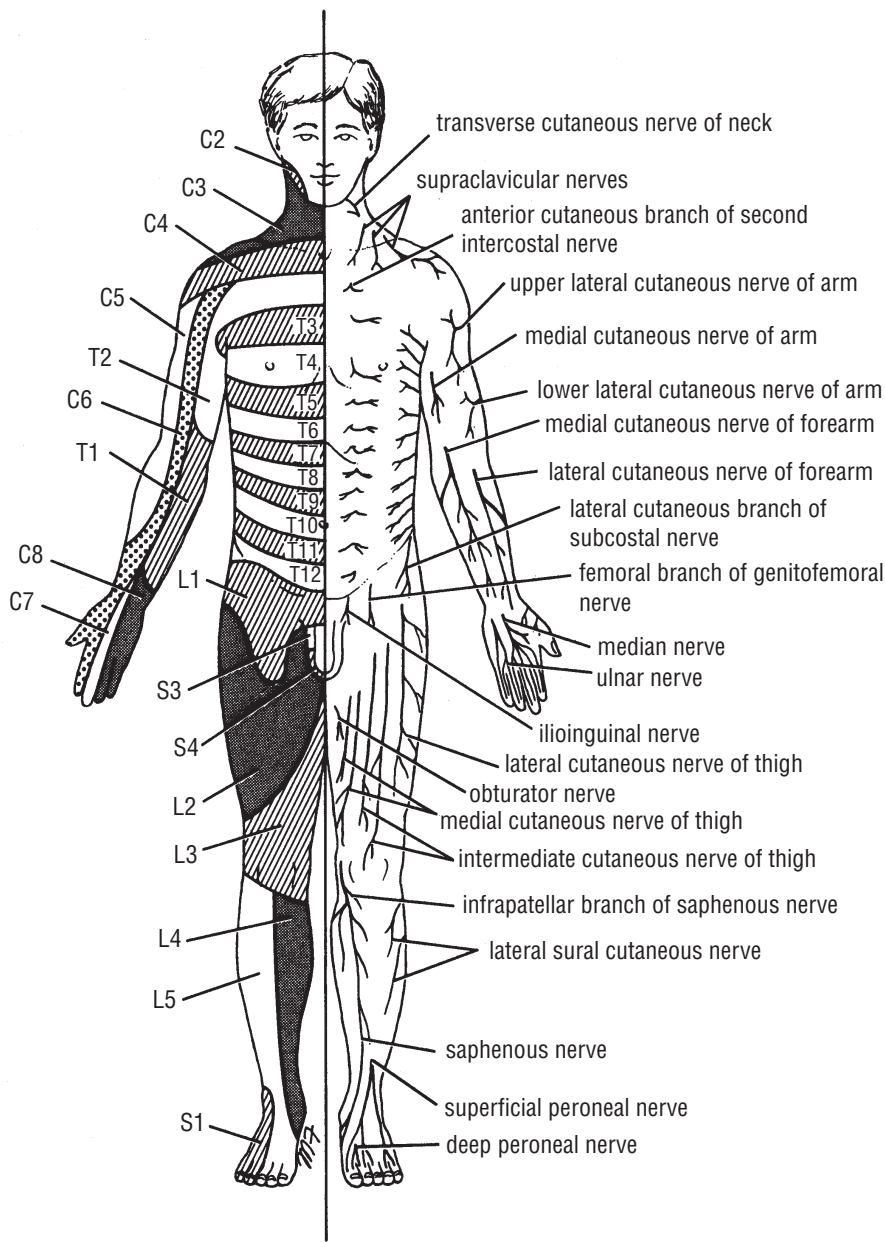
Many drugs and surgical procedures that can modify the activity of the autonomic nervous system are available. For example, drugs can be administered to lower the blood pressure by blocking sympathetic nerve endings and causing vasodilatation of peripheral blood vessels. In patients with severe arterial disease affecting the main arteries of the lower limb, the limb can sometimes be saved by sectioning the sympathetic innervation to the blood vessels. This produces a vasodilatation and enables an adequate amount of blood to flow through the collateral circulation, thus bypassing the obstruction.



MUCOUS AND SEROUS MEMBRANES

Mucous and Serous Membranes and Inflammatory Disease

Mucous and serous membranes are common sites for inflammatory disease. For example, **rhinitis**, or the common



CD Figure 1-2 Dermatomes and distribution of cutaneous nerves on the anterior aspect of the body.

cold, is an inflammation of the nasal mucous membrane, and **pleurisy** is an inflammation of the visceral and parietal layers of the pleura.



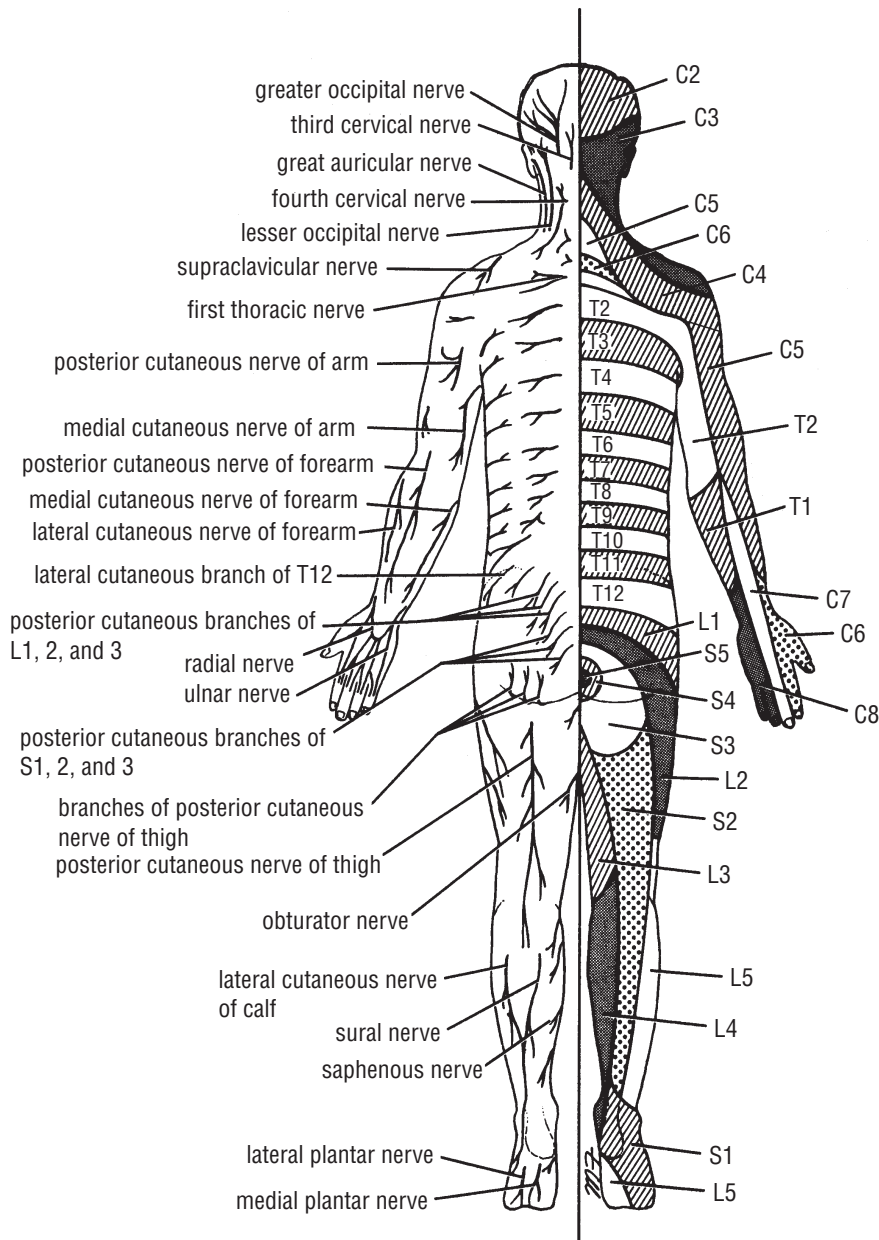
BONES

Bone Fractures

Immediately after a **fracture**, the patient suffers severe local pain and is not able to use the injured part. Deformity may be visible if the bone fragments have been displaced relative to each other. The degree of deformity and the di-

rections taken by the bony fragments depend not only on the mechanism of injury, but also on the pull of the muscles attached to the fragments. Ligamentous attachments also influence the deformity. In certain situations—for example, the ileum—fractures result in no deformity because the inner and outer surfaces of the bone are splinted by the extensive origins of muscles. In contrast, a fracture of the neck of the femur produces considerable displacement. The strong muscles of the thigh pull the distal fragment upward so that the leg is shortened. The very strong lateral rotators rotate the distal fragment laterally so that the foot points laterally.

Fracture of a bone is accompanied by a considerable hemorrhage of blood between the bone ends and into the



CD Figure 1-3 Dermatomes and distribution of cutaneous nerves on the posterior aspect of the body.

surrounding soft tissue. The blood vessels and the fibroblasts and osteoblasts from the periosteum and endosteum take part in the repair process.

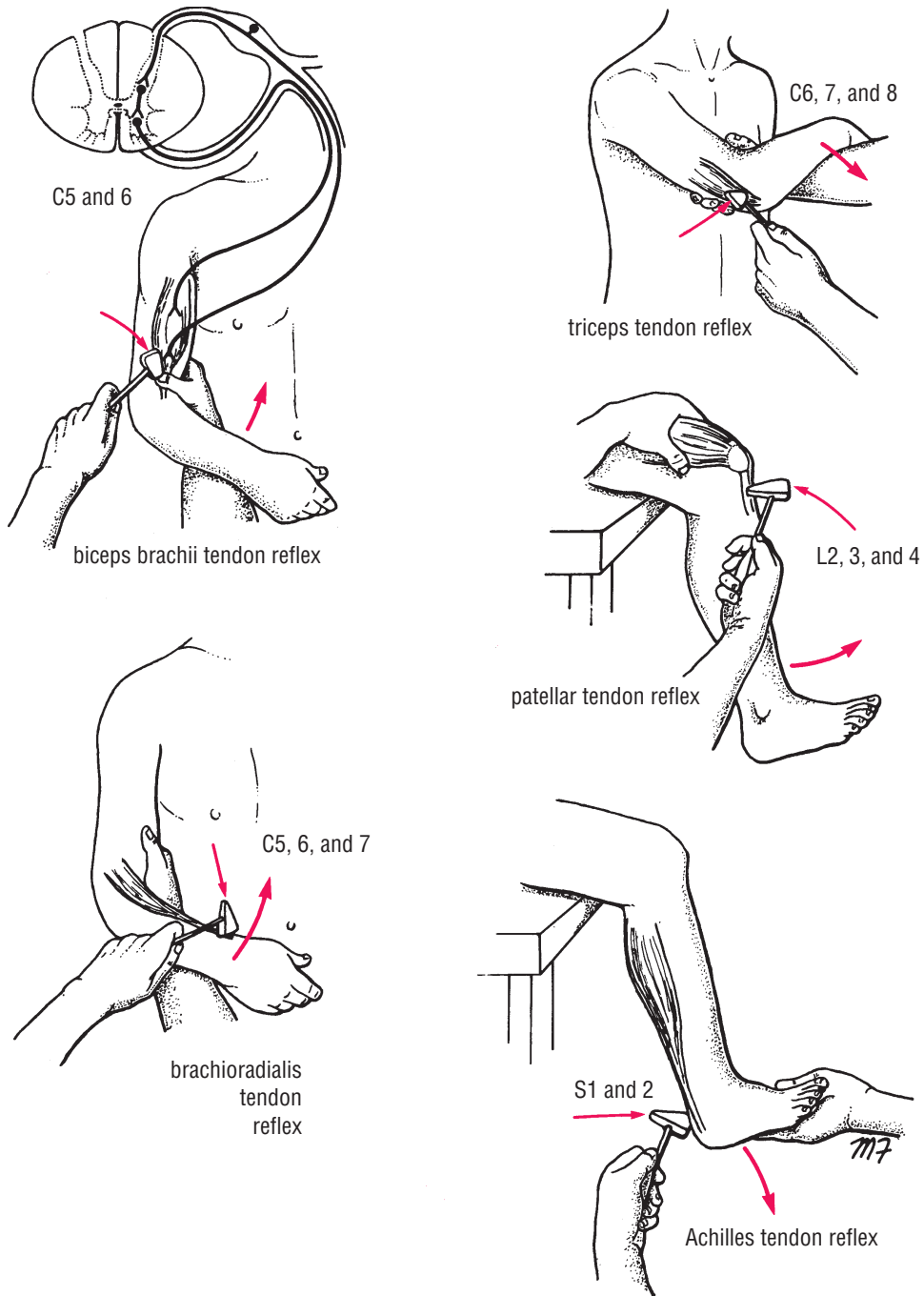
Rickets

Rickets is a defective mineralization of the cartilage matrix in growing bones. This produces a condition in which the cartilage cells continue to grow, resulting in excess cartilage and a widening of the epiphyseal plates. The poorly mineralized cartilaginous matrix and the osteoid matrix are soft, and they bend under the stress of bearing weight. The resulting deformities include enlarged costochondral junctions, bowing of the long bones of the lower limbs, and

bossing of the frontal bones of the skull. Deformities of the pelvis may also occur.

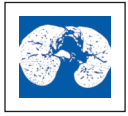Epiphyseal Plate Disorders

Epiphyseal plate disorders affect only children and adolescents. The epiphyseal plate is the part of a growing bone concerned primarily with growth in length. Trauma, infection, diet, exercise, and endocrine disorders can disturb the growth of the hyaline cartilaginous plate, leading to deformity and loss of function. In the femur, for example, the proximal epiphysis can slip because of mechanical stress or excessive loads. The length of the limbs can increase excessively because of increased vascularity in the region of the epiphyseal plate sec-



CD Figure 1-4 Some important tendon reflexes used in medical practice.

ondary to infection or in the presence of tumors. Shortening of a limb can follow trauma to the epiphyseal plate resulting from a diminished blood supply to the cartilage.



CLINICAL SIGNIFICANCE OF SEX, RACE, AND AGE ON STRUCTURE

The fact that the structure and function of the human body change with age may seem obvious, but it is often overlooked; a child is just not a small adult. A few examples of such changes are given here:

1. In the infant, the bones of the skull are more resilient than in the adult, and for this reason fractures of the skull are much more common in the adult than in the young child.
2. The liver is relatively much larger in the child than in the adult. In the infant, the lower margin of the liver extends inferiorly to a lower level than in the adult. This is an important consideration when making a diagnosis of hepatic enlargement.
3. The urinary bladder in the child cannot be accommodated entirely in the pelvis because of the small size of the pelvic cavity and thus is found in the lower part of the abdominal cavity. As the child grows, the pelvis enlarges and the bladder sinks down to become a true pelvic organ.
4. At birth, all bone marrow is of the red variety. With advancing age, the red marrow recedes up the bones of the limbs so that in the adult it is largely confined to the bones of the head, thorax, and abdomen.
5. Lymphatic tissues reach their maximum degree of development at puberty and thereafter atrophy, so the volume of lymphatic tissue in older persons is considerably reduced.

Clinical Problem Solving Questions

Read the following case histories/questions and give the best answer for each.

A 45-year-old patient has a small, firm, mobile tumor on the dorsum of the right foot just proximal to the base of the big toe and superficial to the bones and the long extensor tendon but deep to the superficial fascia. The patient has a neurofibroma of a digital nerve.

1. The following information concerning the tumor is **correct**:
 - A. It is situated on the lower surface of the foot close to the root of the big toe.
 - B. It is attached to the first metatarsal bone.
 - C. On palpation, it moves more freely from medial to lateral than from proximal to distal.
 - D. It lies deep to the tendon of the extensor hallucis longus muscle.
 - E. It is attached to the capsule of the metatarsophalangeal joint of the big toe.

A 31-year-old woman has a history of poliomyelitis affecting the anterior horn cells of the lower thoracic and lumbar segments of the spinal cord on the left side. On

examination, she has severe right lateral flexion deformity of the vertebral column.

2. The following statement is **correct** about this case:
 - A. The virus of poliomyelitis attacks and always destroys the motor anterior horn cells of the spinal cord.
 - B. The disease resulted in the paralysis of the muscles that normally laterally flex the vertebral column on the left side.
 - C. The muscles on the right side of the vertebral column are hyperactive.
 - D. The right lateral flexion deformity is caused by the slow degeneration of the sensory nerve fibers originating from the vertebral muscles on the right side.

A 20-year-old woman severely sprains her left ankle while playing tennis. When she tries to move the foot so that the sole faces medially, she experiences severe pain.

3. What is the **correct** anatomic term for the movement of the foot that produces the pain?
 - A. Pronation
 - B. Inversion
 - C. Supination
 - D. Eversion

A 25-year-old man has a deep-seated abscess in the posterior part of the neck.

4. The following statement is **correct** concerning the abscess:
 - A. The abscess probably lies superficial to the deep fascia.
 - B. The deep fascia does not determine the direction of spread of the abscess.
 - C. The abscess would be incised through a vertical skin incision.
 - D. The lines of cleavage are not important when considering the direction of skin incisions.
 - E. The abscess would be incised, if possible, through a horizontal skin incision.

A 40-year-old workman received a severe burn on the anterior aspect of his right forearm. The area of the burn exceeded 4 in.² (10 cm²). The greater part of the burn was superficial and extended only into the superficial part of the dermis.

5. In the superficially burned area, the epidermis cells would regenerate from the following sites **except** which?
 - A. The hair follicles
 - B. The sebaceous glands
 - C. The margins of the burn
 - D. The deepest ends of the sweat glands
6. In a small area the burn penetrated as far as the superficial fascia; in this region, the epidermal cells would regenerate from the following sites **except** which?
 - A. The ends of the sweat glands that lie in the superficial fascia
 - B. The margins of the burn
 - C. The sebaceous glands

In a 63-year-old man, a magnetic resonance imaging scan of the lower thoracic region of the vertebral column reveals the presence of a tumor pressing on the lumbar segments of the spinal cord. He has a loss of sensation in the skin over the anterior surface of the left thigh and is unable to extend his left knee joint. Examination reveals that the muscles of the front of the left thigh have atrophied and have no tone and that the left knee jerk is absent.

7. The following statements concerning this patient are correct **except** which?
 - A. The tumor is interrupting the normal function of the efferent motor fibers of the spinal cord on the left side.
 - B. The quadriceps femoris muscles on the front of the left thigh are atrophied.
 - C. The loss of skin sensation is confined to the dermatomes L1, 2, 3, and 4.
 - D. The absence of the left knee jerk is because of involvement of the first lumbar spinal segment.

A woman recently took up employment in a factory. She is a machinist, and for 6 hours a day she has to move a lever repeatedly, which requires that she extend and flex her right wrist joint. At the end of the second week of her employment, she began to experience pain over the posterior surface of her wrist and noticed a swelling in the area.

8. The following statements concerning this patient are correct **except** which?
 - A. Extension of the wrist joint is brought about by several muscles that include the extensor digitorum muscle.
 - B. The wrist joint is diseased.
 - C. Repeated unaccustomed movements of tendons through their synovial sheaths can produce traumatic inflammation of the sheaths.
 - D. The diagnosis is traumatic tenosynovitis of the long tendons of the extensor digitorum muscle.

A 19-year-old boy was suspected of having leukemia. It was decided to confirm the diagnosis by performing a bone marrow biopsy.

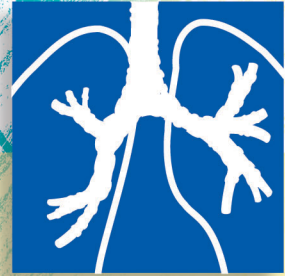9. The following statements concerning this procedure are correct **except** which?
 - A. The biopsy was taken from the lower end of the tibia.
 - B. Red bone marrow specimens can be obtained from the sternum or the iliac crests.
 - C. At birth, the marrow of all bones of the body is red and hematopoietic.
 - D. The blood-forming activity of bone marrow in many long bones gradually lessens with age, and the red marrow is gradually replaced by yellow marrow.

A 22-year-old woman had a severe infection under the lateral edge of the nail of her right index finger. On examination, a series of red lines were seen to extend up the back of the hand and around to the front of the forearm and arm, up to the armpit.

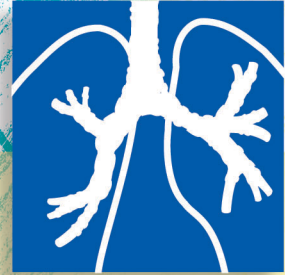10. The following statements concerning this patient are probably correct **except** which?
 - A. Palpation of the right armpit revealed the presence of several tender enlarged lymph nodes (lymphadenitis).
 - B. The red lines were caused by the superficial lymphatic vessels in the arm, which were red and inflamed (lymphangitis) and could be seen through the skin.
 - C. Lymph from the right arm entered the bloodstream through the thoracic duct.
 - D. Infected lymph entered the lymphatic capillaries from the tissue spaces.

Answers and Explanations

1. **C** is the correct answer. The tumor is a neurofibroma of a small digital nerve. This fact explains why the tumor is relatively superficial and moves with the digital nerve more freely from medial to lateral than from proximal to distal. **A**. The tumor is situated on the dorsum or upper surface of the foot. **B**. The tumor is mobile and not attached to the first metatarsal bone. **D**. The tumor lies superficial to the tendon of the extensor hallucis longus muscle. **E**. The tumor is mobile and is not attached to the capsule of the metatarsophalangeal joint.
2. **B** is the correct answer. The disease infected the anterior horn cells, whose axons supply the muscles that normally laterally flex the vertebral column on the left side. **A**. The virus of poliomyelitis attacks anterior horn cells in the spinal cord. The result may be death of the cells and muscle paralysis or, depending on the severity of the attack, the nerve cells may recover and the muscle paralysis may also recover. **C**. The muscles on the right side of the vertebral column are contracting normally against the paralyzed left-sided vertebral muscles. **D**. The sensory nerves of muscles are unaffected by the polio virus.
3. **B** is the correct answer. The movement of the foot so that the sole comes to face medially is called inversion (see text Fig. 1-3). For a full discussion of the movements of inversion and eversion of the foot at the subtalar and transverse joints of the foot, see text.
4. **E** is the correct answer. The abscess would be incised, if possible, through a horizontal skin incision along a line of cleavage (see CD Fig. 1-1). **A**. A deep-seated abscess in the neck usually lies deep to the superficial fascia and beneath the investing layer of deep cervical fascia. **B**. The arrangement of the deep fascia in the neck plays an important role in the direction of spread of a deep-seated abscess. **C**. The abscess would only be incised through a vertical incision if a horizontal incision along a line of cleavage was not possible. A vertical incision in the neck would result in an unsightly scar. **D**. The lines of cleavage (see CD Fig. 1-1) are very important when considering the direction of skin incisions. However, cosmetic concerns have to take second place in life-threatening situations.
5. **D** is the correct answer. In a superficial burn, the epidermal cells would regenerate from the hair follicles, the sebaceous glands, and the margins of the burn.
6. **C** is the correct answer. The sebaceous glands are located superficially (see text Fig. 1-4) and are destroyed in deep burns.
7. **D** is the correct answer. The patellar tendon reflex (knee jerk) involves L2, 3, and 4 segments of the spinal cord.
8. **B** is the correct answer. The wrist joint is not diseased in this patient. The swelling on the posterior surface of the wrist region was caused by the excessive production of fluid in the synovial sheaths of the extensor tendons secondary to repeated and excessive extensor movements, a condition called traumatic tenosynovitis.
9. **A** is the correct answer. In a 19-year-old boy, the bone marrow at the lower end of the tibia is yellow. A biopsy specimen of red marrow in an adult, who is suspected of suffering from leukemia, is easily obtained from the iliac crests or the sternum.
10. **C** is the correct answer. Lymph from the right upper limb enters the bloodstream through the right lymphatic duct.



The Respiratory System



2

The Upper and Lower Airway and Associated Structures



Chapter Outline

The Nose	17	Parotid Duct and Facial Injuries	22
Pupillodilatation	17	Submandibular Gland: Calculus Formation	22
Examination of the Nasal Cavity	17	Sublingual Gland and Cyst Formation	22
Infection of the Nasal Cavity	17	The Pharynx	22
Nasal Obstruction	18	Killian's Dehiscence and Foreign Bodies	22
Trauma to the Nose	18	The Piriform Fossa and Foreign Bodies	22
Nasal Fractures	18	The Process of Swallowing (Deglutition)	22
Skin Lacerations	18	Swallowing in Unconscious Individuals	22
Congenital Anomalies of the Nose	18	Pharyngeal Obstruction of the Upper Airway	22
Median Nasal Furrow	18	Loss of the Gag Reflex	22
Lateral Proboscis	18	Palatine Tonsils	23
The Paranasal Sinuses	18	Examination of the Tonsils	23
Sinusitis and the Examination of the Paranasal Sinuses	18	Tonsillitis	23
The Mouth	19	Quinsy	23
Examination of the Mouth	19	Adenoids	23
Lips and Vestibule and Facial Paralysis	20	The Larynx	23
Ranula	20	The Cricoid Cartilage and the Sellick Maneuver	23
The Tongue	20	Relationship between Vocal Folds and Cricothyroid Ligament	23
Laceration of the Tongue	20	Larynx in Children	23
Tongue and Airway Obstruction	20	Epiglottitis	23
Anatomy of Procedures	20	Foreign Bodies in the Airway	23
<i>Pulling the Tongue Forward in Airway Obstruction</i>	20	Anatomic Rationale for Differences in Procedures for Removing Foreign Bodies in Adults and Children	23
<i>Oral Endotracheal Intubation</i>	20	Lesions of the Laryngeal Nerves	24
Oral Endotracheal Intubation and the Incisor Teeth	20	Inspection of the Vocal Cords (Folds) with the Laryngeal Mirror and Laryngoscope	25
Oral Endotracheal Intubation and the Small Mandible	20	Important Anatomic Axes for Endotracheal Intubation	26
The Palate	20	Anatomy of the Visualization of the Vocal Cords with the Laryngoscope	27
Angioedema of the Uvula (Quincke's Uvula)	20	Reflex Activity Secondary to Endotracheal Intubation	28
Congenital Anomalies of the Palate	21	The Trachea	28
Cleft Palate	21	Palpation of the Trachea	28
The Salivary Glands	21		
Parotid Salivary Gland and Lesions of the Facial Nerve	21		
Parotid Gland Infections	21		

Compromised Airway	28	The Bronchi	32
Anatomy of Cricothyroidotomy	28	Aspiration of Foreign Bodies and Stomach Contents	32
<i>Complications</i>	29	Suction Catheters, Endotracheal Tubes, and the	
Anatomy of Tracheostomy	29	Bronchi	32
<i>Complications</i>	31	Bronchopulmonary Segments	32
Some Important Airway Distances	31	Clinical Problem Solving Questions	32
Changes in the Tracheal Length with		Answers and Explanations	33
Respiration and Position of the Head			
and Neck	31		



THE NOSE

Pupillodilatation

A vasoconstrictor sprayed into the nasal vestibule can ascend in the nasolacrimal duct to the conjunctival sac, where it is absorbed, and may produce pupillodilatation.

Examination of the Nasal Cavity

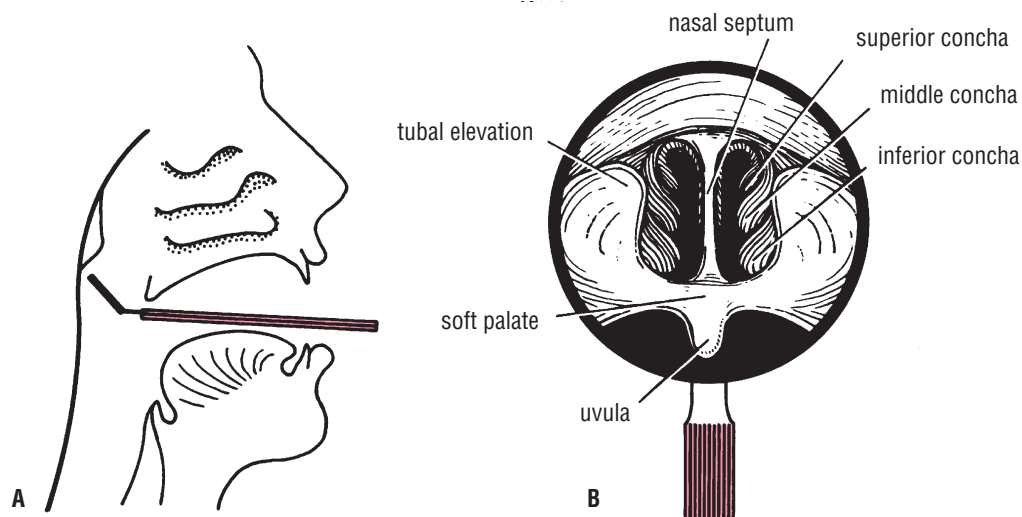
Examination of the nasal cavity may be carried out by inserting a speculum through the external nares or by means of a mirror in the pharynx. In the latter case, the choanae and the posterior border of the septum can be visualized (CD Fig. 2-1). It should be remembered that the nasal septum is rarely situated in the midline. A severely deviated septum may interfere with drainage of the nose and the paranasal sinuses.

Infection of the Nasal Cavity

Infection of the nasal cavity can spread in a variety of directions. The paranasal sinuses are especially prone to infection. Organisms may spread via the nasal part of the pharynx and the auditory tube to the middle ear. It is possible for organisms to ascend to the meninges of the anterior cranial fossa, along the sheaths of the olfactory nerves through the cribriform plate, and produce meningitis.

Epistaxis, or bleeding from the nose, is a frequent condition. The most common cause is nose picking. The bleeding may be arterial or venous, and most episodes occur on the anteroinferior portion of the septum and involve the septal branches of the sphenopalatine and facial vessels.

Beware of bilateral cauterization of the septal mucous membrane. It could compromise the blood supply to the perichondrium and cause necrosis of the cartilaginous part of the septum.



CD Figure 2-1 **A.** Position of the mirror in posterior rhinoscopy. **B.** Structures seen in posterior rhinoscopy.

Nasal Obstruction

Nasal obstruction can be caused by edema of the mucous membrane secondary to infection, or by foreign bodies lodged between the conchae. The shelf-like conchae make impaction and retention of balloons, peas, and small toys relatively easy in children. Other causes include tumors, polyps, and septal abscesses.

Deflection of the nasal septum is common. It is believed to occur most commonly in males because of trauma in childhood.

The most voluminous part of the nasal cavity is close to the floor, and it is usually possible to pass a well-lubricated tube through the nostril along the inferior meatus into the nasopharynx.

Trauma to the Nose

Nasal Fractures

Fractures involving the nasal bones are common. Blows directed from the front may cause one or both nasal bones to be displaced downward and inward.

Lateral fractures also occur in which one nasal bone is driven inward and the other outward; the nasal septum is usually involved.

Skin Lacerations

Lacerations are sutured in the usual way. Remember, however, that there is very little excess of skin so that the vascularity may be compromised if too much tension is placed on the sutures. Avoid making incisions across depressed areas on the side of the nose or at the junction of the nose and the

lip, or across the lower eyelid, since future scars tend to contract and distort the depression.



CONGENITAL ANOMALIES OF THE NOSE

Median Nasal Furrow

In median nasal furrow, the nasal septum is split, separating the two halves of the nose (CD Fig. 2-2A).

Lateral Proboscis

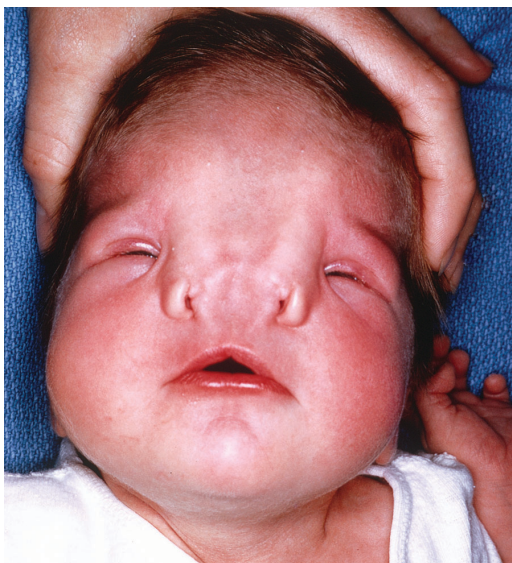In lateral proboscis, a skin-covered process develops, usually with a dimple at its lower end (CD Fig. 2-2B).



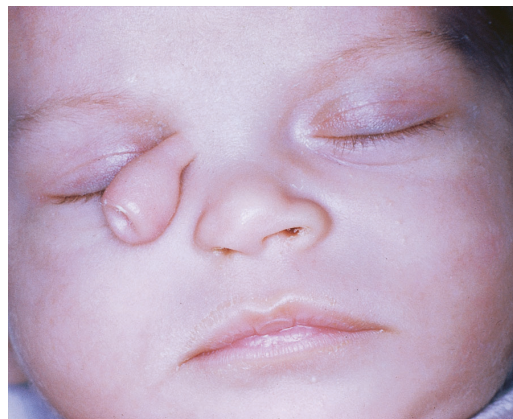THE PARANASAL SINUSES

Sinusitis and the Examination of the Paranasal Sinuses

Infection of the paranasal sinuses is a common complication of nasal infections. Rarely, the cause of maxillary sinusitis is

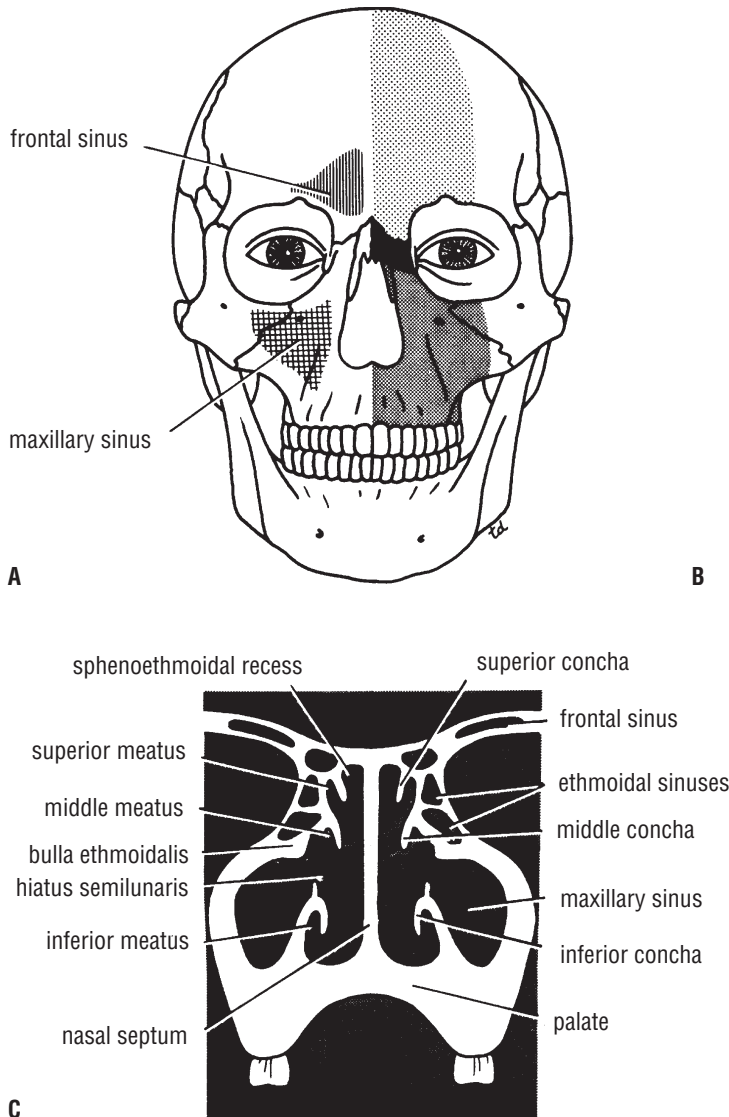


A



B

CD Figure 2-2 **A.** Median nasal furrow in which the nasal septum has completely split, separating the two halves of the nose. Note that the external nares are separated by a wide furrow. (Courtesy of L Thompson.) **B.** Lateral proboscis.



CD Figure 2-3 **A.** Bones of the face showing the positions of the frontal and maxillary sinuses. **B.** Regions where pain is experienced in sinusitis (lightly dotted area in frontal sinusitis; solid area in sphenoidal sinusitis; and heavily dotted area in maxillary sinusitis). **C.** Coronal section through the nasal cavity showing the frontal, ethmoidal, and maxillary sinuses.

extension from an apical dental abscess. The extreme thinness of the medial wall of the orbit relative to the ethmoidal air cells must be emphasized. Ethmoidal sinusitis is the most common cause of orbital cellulitis. The infection can easily spread through the paper-thin bone.

The frontal, ethmoidal, and maxillary sinuses can be palpated clinically for areas of tenderness (CD Fig. 2-3). The frontal sinus can be examined by pressing the finger upward beneath the medial end of the superior orbital margin. Here the floor of the frontal sinus is closest to the surface.

The ethmoidal sinuses can be palpated by pressing the finger medially against the medial wall of the orbit. The maxillary sinus can be examined for tenderness by pressing the finger against the anterior wall of the maxilla below the inferior orbital margin; pressure over the infraorbital nerve may reveal increased sensitivity.

The frontal sinus is supplied by the supraorbital nerve, which also supplies the skin of the forehead and scalp. It is not surprising, therefore, that patients with frontal sinusitis

have pain referred over this area (see CD Fig. 2-3). The maxillary sinus is innervated by the infraorbital nerve and, in this case, pain is referred to the upper jaw, including the teeth (see CD Fig. 2-3).



THE MOUTH

Examination of the Mouth

The mouth is one of the most important areas of the body that the medical professional is called on to examine. Needless to say, the health professional must be able to recognize all the structures visible in the mouth and be familiar with the normal variations in the color of the mucous membrane covering the underlying structures. The sensory nerve supply and lymph drainage of the mouth cavity should be known. The close relation of the lingual nerve to the lower

third molar tooth should be remembered. The close relation of the submandibular duct to the floor of the mouth may enable one to palpate a calculus in cases of periodic swelling of the submandibular salivary gland.

Lips and Vestibule and Facial Paralysis

Asymmetry of the lips and paralysis of the buccinator with a tendency to accumulate saliva and food in the vestibule indicate a lesion of the facial nerve on that side.

Ranula

Ranula is a cystic swelling arising in a distended mucous gland of the mucous membrane. It commonly occurs in the floor of the mouth, and because of its transparent covering, it resembles frog skin.



THE TONGUE

Laceration of the Tongue

A wound of the tongue is often caused by the patient's teeth following a blow on the chin when the tongue is partly protruded from the mouth. It can also occur when a patient accidentally bites the tongue while eating, during recovery from an anesthetic, or during an epileptic attack. Bleeding is halted by grasping the tongue between the finger and thumb posterior to the laceration, thus occluding the branches of the lingual artery.

Tongue and Airway Obstruction

In an unconscious patient, there is a tendency for the tongue to fall backward and obstruct the laryngeal opening. This is caused by the loss of tone of the extrinsic muscles and, unless quickly corrected "with a jaw thrust or chin lift maneuver," will lead to all of the signs and symptoms of airway obstruction.

Anatomy of Procedures

Pulling the Tongue Forward in Airway Obstruction

The head should be extended at the atlantooccipital joint and the neck flexed at the C4 to C7 joints. The extended head stretches the fascia and muscles of the front of the neck and causes a forward and downward movement of the mandible that is correctable by placing a finger below the symphysis menti and pulling the mandible forward and up.

Sometimes this is inadequate to relieve the obstruction and should be supplemented by placing the fingers behind the angles of the mandible and exerting forward pressure. This moves the mandible forward, causing displacement of the tongue away from the laryngeal opening, since the mandible is attached to the tongue by the genioglossus muscles.

Oral Endotracheal Intubation

Total visualization of the glottis with a laryngoscope is not necessary for endotracheal intubation. If the epiglottis is visible, the tube is laid on the laryngeal side of the epiglottis and advanced along its surface. Often this procedure alone will allow the tube to go into the trachea. If only the esophagus is visible and not the vocal cords, the endotracheal tube can be placed "blindly" just anterior to the esophageal opening. Occasionally when the tube is caught at the anterior glottic constriction, the head should be flexed slightly, allowing the pressure of the tongue to displace the endotracheal tube posteriorly and hence move it into the opening of the glottis. Frequently this maneuver has to be supplemented by turning the head slightly to one side or another. The use of styleted endotracheal tubes also may help in this situation. "Trigger tubes" may be used, which allow the tip to be manipulated from above.

When oral endotracheal intubation is impossible in the above situations, nasotracheal intubation may be successful, since the tube approaches the glottis slightly more posteriorly and is directed more toward it.

Oral Endotracheal Intubation and the Incisor Teeth

Interference with endotracheal intubation may be caused by the presence of protruding incisor teeth, often making it necessary to put the endotracheal tube in an extreme lateral position to approach the glottis.

Oral Endotracheal Intubation and the Small Mandible

Patients with receding jaws, secondary to a small mandible, often make intubation difficult, and in some cases the nasal route or a lighted stylet or digital intubation must be used. However, since this anatomic configuration approaches the picture seen in younger children, many times a small straight blade such as a Miller no. 2 or Miller no. 3 can overcome the visual difficulties noted when a curved blade of the Macintosh type is used.



THE PALATE

Angioedema of the Uvula (Quincke's Uvula)

The uvula has a core of voluntary muscle, the musculus uvulae, that is attached to the posterior border of the hard

palate. Surrounding the muscle is the loose connective tissue of the submucosa that is responsible for the great swelling of this structure secondary to angioedema.

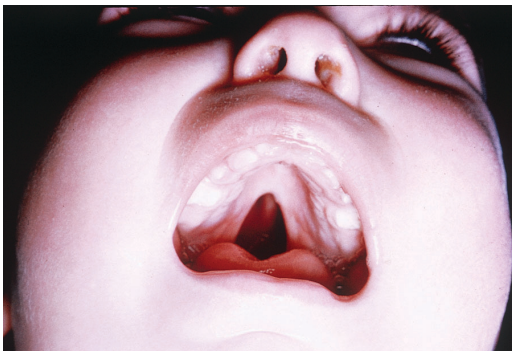

CONGENITAL ANOMALIES OF THE PALATE

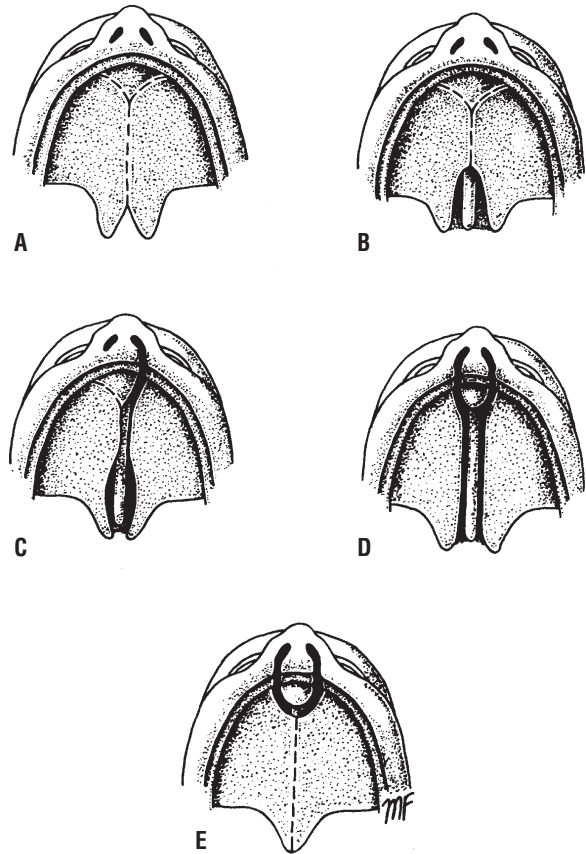
Cleft Palate

Cleft palate is commonly associated with cleft upper lip. All degrees of cleft palate occur and are caused by failure of the palatal processes of the maxilla to fuse with each other in the midline; in severe cases, these processes also fail to fuse with the primary palate (premaxilla) (CD Figs. 2-4 and 2-5). The first degree of severity is cleft uvula, and the second degree is ununited palatal processes. The third degree is ununited palatal processes and a cleft on one side of the primary palate. This type is usually associated with unilateral cleft lip. The fourth degree of severity, which is rare, consists of ununited palatal processes and a cleft on both sides of the primary palate. This type is usually associated with bilateral cleft lip. A rare form may occur in which a bilateral cleft lip and failure of the primary palate to fuse with the palatal processes of the maxilla on each side are present.

A baby born with a severe cleft palate presents a difficult feeding problem, since he or she is unable to suck efficiently. Such a baby often receives in the mouth some milk, which then is regurgitated through the nose or aspirated into the lungs, leading to respiratory infection. For this reason, careful artificial feeding is required until the baby is strong enough to undergo surgery. Plastic surgery is recommended usually between 1 and 2 years of age, before improper speech habits have been acquired.



CD Figure 2-4 Cleft hard and soft palate.



CD Figure 2-5 Different forms of cleft palate: cleft uvula (A), cleft soft and hard palate (B), total unilateral cleft palate and cleft lip (C), total bilateral cleft palate and cleft lip (D), and bilateral cleft lip and jaw (E).



THE SALIVARY GLANDS

Parotid Salivary Gland and Lesions of the Facial Nerve

The facial nerve lies in the interval between the superficial and deep parts of the gland. A benign parotid tumor rarely, if ever, causes facial palsy. A malignant tumor of the parotid is usually highly invasive and quickly involves the facial nerve, causing unilateral facial paralysis.

Parotid Gland Infections

The parotid gland may become acutely inflamed as a result of retrograde bacterial infection from the mouth via the parotid duct. The gland may also become infected via the bloodstream, as in mumps.

Parotid Duct and Facial Injuries

The parotid duct, which is a comparatively superficial structure on the face, runs forward from the parotid gland one fingerbreadth below the zygomatic arch (see text Fig. 2-18). It is about 2 in. (5 cm) long and can be rolled beneath the examining finger at the anterior border of the masseter as it turns medially and pierces the buccinator muscle; it then opens into the mouth opposite the upper second molar tooth (see text Fig. 2-8).

The parotid duct may be damaged in injuries to the face or may be inadvertently cut during surgical operations on the face. The integrity of the parotid duct can be established by wiping the inside of the cheek dry and then pressing on the parotid gland. Look for a drop of viscid saliva to appear on the tip of the papilla in the mouth.

Submandibular Gland: Calculus Formation

The submandibular salivary gland is a common site of calculus formation. The presence of a tense swelling below the body of the mandible, which is greatest before or during a meal and is reduced in size or absent between meals, is diagnostic of the condition. Examination of the floor of the mouth will reveal absence of ejection of saliva from the orifice of the duct of the affected gland. Frequently, the stone can be palpated in the duct, which lies below the mucous membrane of the floor of the mouth.

Sublingual Gland and Cyst Formation

Blockage of one of the ducts of the sublingual gland may cause cysts under the tongue.



THE PHARYNX

The Killian's Dehiscence and Foreign Bodies

Inverted foreign bodies tend to get snared in the region of Killian's dehiscence.

The Piriform Fossa and Foreign Bodies

The piriform fossa is a common site for fish bones or other foreign bodies to become lodged.



THE PROCESS OF SWALLOWING (DEGLUTITION)

Swallowing in Unconscious Individuals

During swallowing in conscious individuals, food and fluid cross naturally from the mouth to the esophagus, and movements of air from the nose to the larynx is momentarily stopped. In unconscious individuals, when the reflex mechanisms are not functioning, it is possible for food and fluid to enter the bronchial tree or air to enter the stomach. Moreover, should vomiting occur, the regurgitated gastric contents may be inhaled into the lungs (see below).

Pharyngeal Obstruction of the Upper Airway

This condition frequently occurs in patients during cardiopulmonary arrest or in the decreased level of consciousness that accompanies a major cerebrovascular accident or drug overdose. The obstruction is caused when the atonic tongue falls back and the pharyngeal wall caves in due to loss of tone of the pharyngeal muscles. The obstruction may clear if the patient is placed in the lateral decubitus position, with the neck extended and the jaw pulled forward (which pulls the tongue forward). If the patient must lie in a supine position, an oropharyngeal or nasopharyngeal airway may have to be inserted to counteract the flaccid pharyngeal walls.

Loss of the Gag Reflex

In conscious patients the airway is protected by a number of important reflexes, including the gag reflex, the laryngeal reflex, and the cough reflex. The gag or swallowing reflex occurs in response to stimulation of the pharyngeal mucous membrane, which is innervated by the glossopharyngeal nerve. The laryngeal and cough reflexes (trachea and bronchi) are mediated by the vagus nerve. These protective reflexes are lost in descending order as the patient becomes less and less responsive. In these circumstances the airway may be blocked by aspiration of vomit and gastric and pharyngeal secretions.



PALATINE TONSILS

Examination of the Tonsils

With the mouth wide open and with a good light shining into the mouth, the tongue is depressed with a spatula. The tonsils can be clearly seen on each side of the oral pharynx in the depression between the palatoglossal and palatopharyngeal folds. Note the size and color of the tonsil; a reddened tonsil covered with mucus or pus is a clear indication of tonsillitis.

Tonsillitis

The palatine tonsils reach their maximum normal size in early childhood. After puberty, together with other lymphoid tissues in the body, they gradually atrophy. The palatine tonsils are a common site of infection, producing the characteristic sore throat and pyrexia. The deep cervical lymph node situated below and behind the angle of the mandible, which drains lymph from this organ, is usually enlarged and tender.

Tonsillectomy, which is often the treatment for recurrent episodes of tonsillitis, is sometimes accompanied by troublesome postoperative bleeding from the external palatine vein.

Quinsy

A peritonsillar abscess, or quinsy, is caused by spread of infection from the palatine tonsil to the loose connective tissue outside the capsule (see text Fig. 2-24).

Adenoids

Adenoids are enlarged nasopharyngeal tonsils usually associated with infection. Excessive enlargement blocks the posterior nasal openings and causes the patient to snore loudly at night and to breathe through the open mouth. The close relationship of the infected lymphoid tissue to the auditory tube may be the cause of deafness and recurrent otitis media.



THE LARYNX

The Cricoid Cartilage and the Sellick Maneuver

The continuous ring structure of the cricoid cartilage is utilized when applying pressure on the cricoid to control regurgitation of stomach contents during the induction of anesthesia.

Relationship between Vocal Folds and Cricothyroid Ligament

Text Fig. 2-27 shows the relationship between the vocal folds and the cricothyroid ligament. It is clear that the folds may be damaged in puncture wounds in the front of the larynx.

Larynx in Children

In children the neck is shorter and the larynx is more cephalad than in adults (CD Fig. 2-6). At birth the cricoid cartilage lies at the level of the fourth cervical vertebra, and only at the age of 6 years does it lie opposite the sixth cervical vertebra. The glottis at birth lies opposite the second cervical vertebra.

The epiglottis is U-shaped and less flexible in children, which sometimes makes it difficult to line up the oral, pharyngeal, and tracheal axes when passing a laryngoscope.

The rima glottidis tends to be more anterior in children than in adults. The vocal folds in children have thicker submucosa, so that edema of the folds is more likely to occlude the glottis.

As mentioned previously, the cavity of the larynx is narrowest within the cricoid ring in children, whereas the glottis is the narrowest part of the cavity in adults.

Epiglottitis

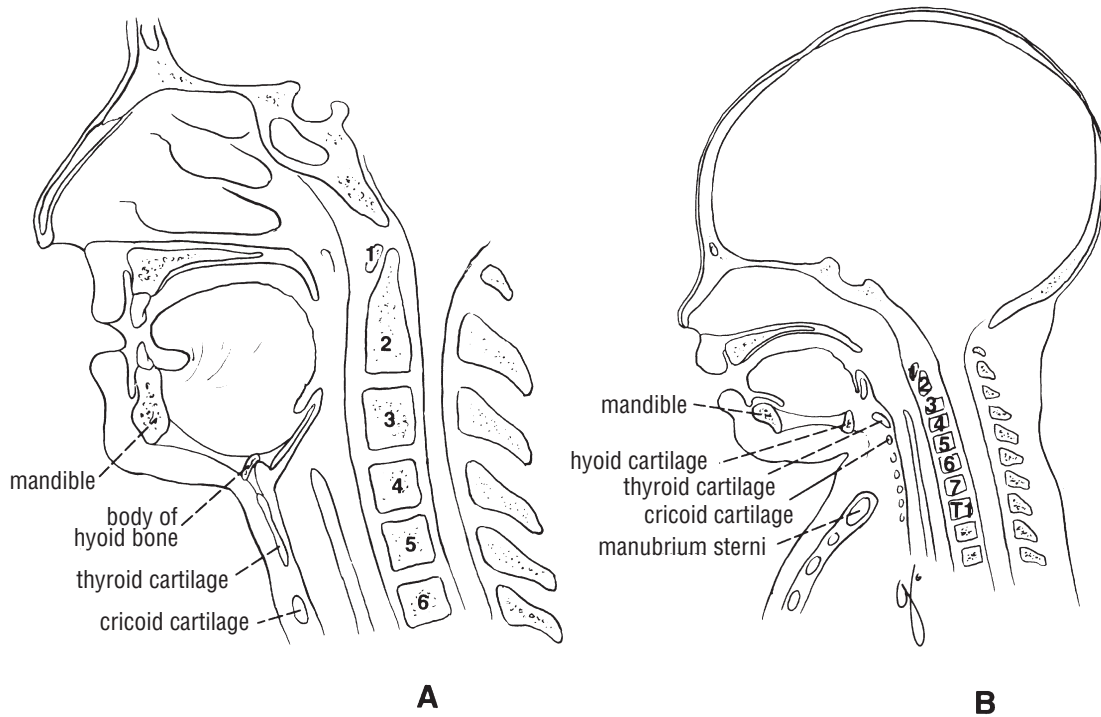
An acute inflammatory swelling of the mucous membrane of the epiglottis can compromise the upper airway. The inflammation may spread rapidly in the loosely arranged submucosa down to the vocal cords. Here the spreading stops because the mucosa is tightly adherent to the underlying vocal ligaments. The condition is most often seen in children where the narrow passageway quickly leads to upper airway obstruction.

Foreign Bodies in the Airway

The laryngeal and cough reflexes mediated through the vagus nerves are the natural defense mechanisms for expelling foreign bodies from the airway at all ages. If coughing is successfully freeing the obstruction, it should be encouraged to continue. If intervention is necessary, anatomic and physiologic age differences dictate treatment.

Anatomic Rationale for Differences in Procedures for Removing Foreign Bodies in Adults and Children

It is generally agreed that all maneuvers are directed toward the increase in intrathoracic pressure by compressing the



CD Figure 2-6 Sagittal sections of the neck of an adult (A) and an infant (B) shortly after birth. Different vertebral levels in these age groups are shown.

intrathoracic gas volume to expel the foreign body from the airway. For children older than 1 year and for adults, the abdominal thrust (Heimlich maneuver) should be used. The rapid compression of the abdominal viscera suddenly forces the diaphragm into the thoracic cavity. In infants, the relatively large size of the liver and the delicate structure of the abdominal viscera generally preclude its use. Children younger than 1 year should be placed face down over the rescuer's arm, with the head lower than the trunk, and measured back blows should be delivered between the scapulae. If this fails to open the airway, they should be rolled over, and four rapid sternal compressions should be administered.

It is now accepted that sudden blows to the back in the older age groups, especially in the standing or sitting position, extends the thoracic part of the vertebral column and may displace the foreign body further down the airway, leading to impaction or complete obstruction.

Lesions of the Laryngeal Nerves

The muscles of the larynx are innervated by the recurrent laryngeal nerves, with the exception of the cricothyroid muscle, which is supplied by the external laryngeal nerve. Both these nerves are vulnerable during operations on the thyroid gland because of the close relationship between them and the arteries of the gland. The left recurrent laryngeal nerve

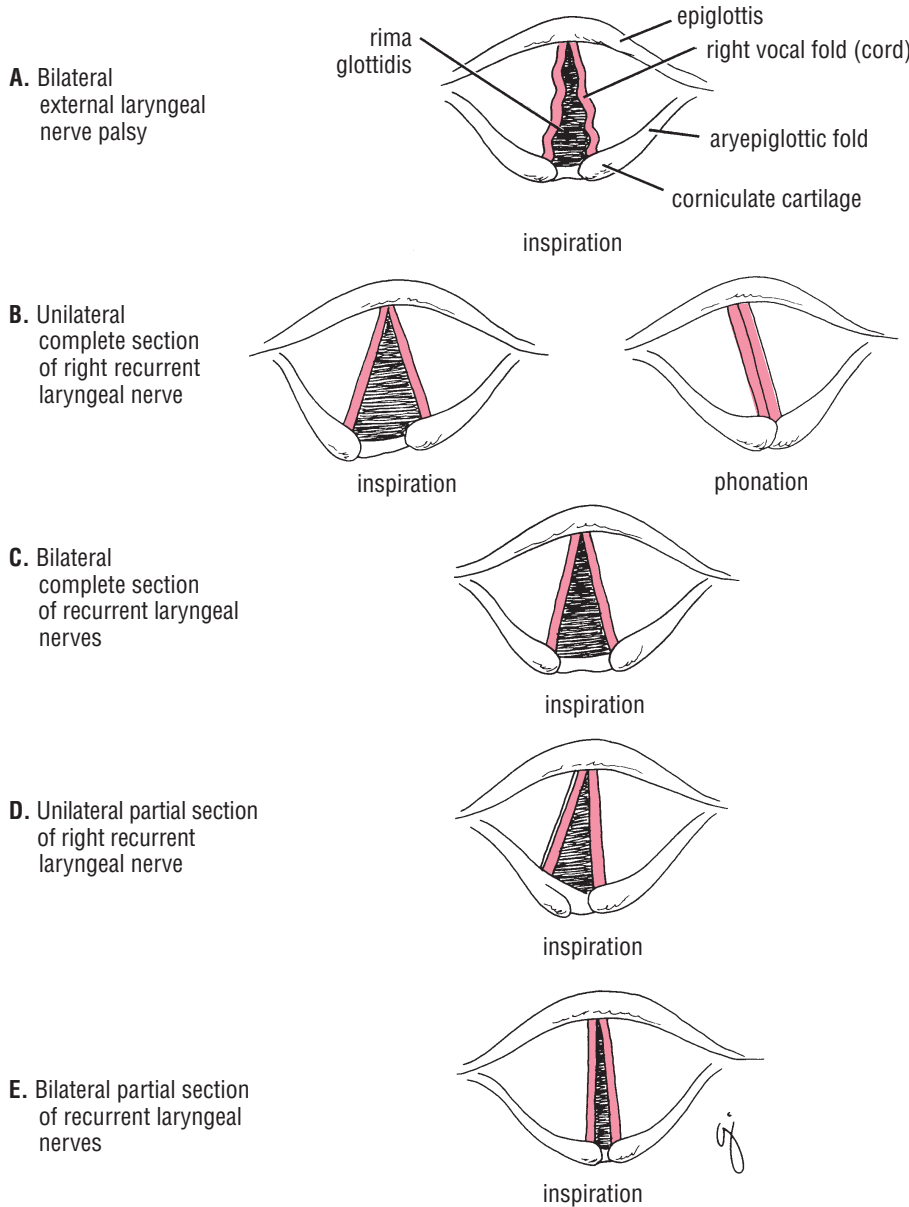
may be involved in a bronchial or esophageal carcinoma or in secondary metastatic deposits in the mediastinal lymph nodes. The right and left recurrent laryngeal nerves may be damaged by malignant involvement of the deep cervical lymph nodes.

Section of the external laryngeal nerve produces weakness of the voice because the vocal fold cannot be tensed. The cricothyroid muscle is paralyzed (CD Fig. 2-7).

Unilateral complete section of the recurrent laryngeal nerve results in the vocal fold on the affected side assuming the position midway between abduction and adduction. It lies just lateral to the midline. Speech is not greatly affected because the other vocal fold compensates to some extent and moves toward the affected vocal fold (CD Fig. 2-7).

Bilateral complete section of the recurrent laryngeal nerve results in both vocal folds assuming the position midway between abduction and adduction. Breathing is impaired because the rima glottidis is partially closed, and speech is lost (CD Fig. 2-7).

Unilateral partial section of the recurrent laryngeal nerve results in a greater degree of paralysis of the abductor muscles than of the adductor muscles. The affected vocal fold assumes the adducted midline position (CD Fig. 2-7). This phenomenon has not been explained satisfactorily. It must be assumed that the abductor muscles receive a



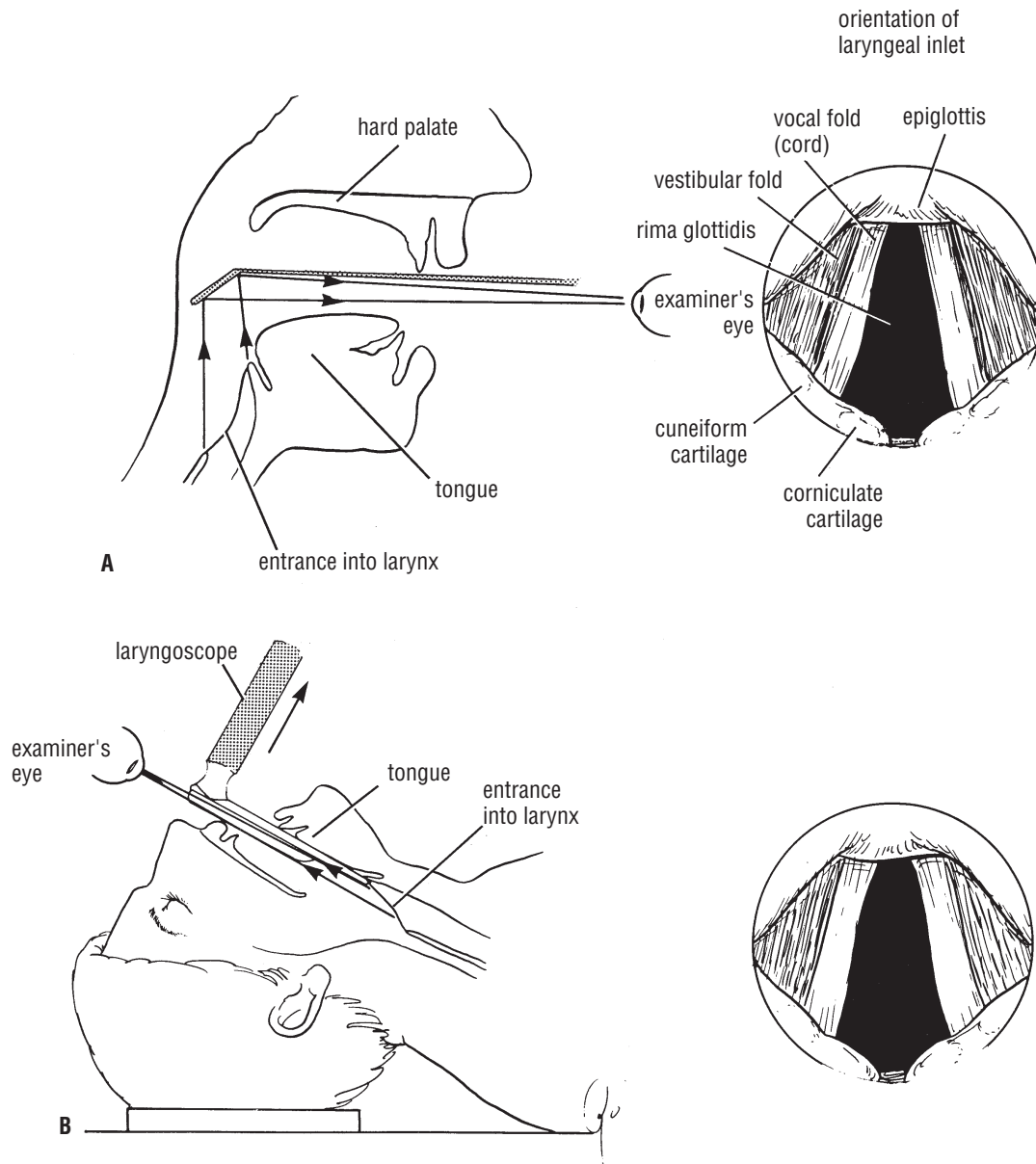
CD Figure 2-7 The position of the vocal folds (cords) after damage to the external and recurrent laryngeal nerves.

greater number of nerves than the adductor muscles, and thus partial damage of the recurrent laryngeal nerve results in damage to relatively more nerve fibers to the abductor muscles. Another possibility is that the nerve fibers to the abductor muscles are traveling in a more exposed position in the recurrent laryngeal nerve and are therefore more prone to be damaged.

Bilateral partial section of the recurrent laryngeal nerve results in bilateral paralysis of the abductor muscles and the drawing together of the vocal folds (CD Fig. 2-7). Acute breathlessness (dyspnea) and stridor follow, and cricothyroidotomy or tracheostomy is necessary.

Inspection of the Vocal Cords (Folds) with the Laryngeal Mirror and Laryngoscope

The interior of the larynx can be inspected indirectly through a laryngeal mirror passed through the open mouth into the oral pharynx (CD Fig. 2-8). A more satisfactory method is the direct method using the laryngoscope. The neck is brought forward on a pillow and the head is fully extended at the atlantooccipital joints. The illuminated



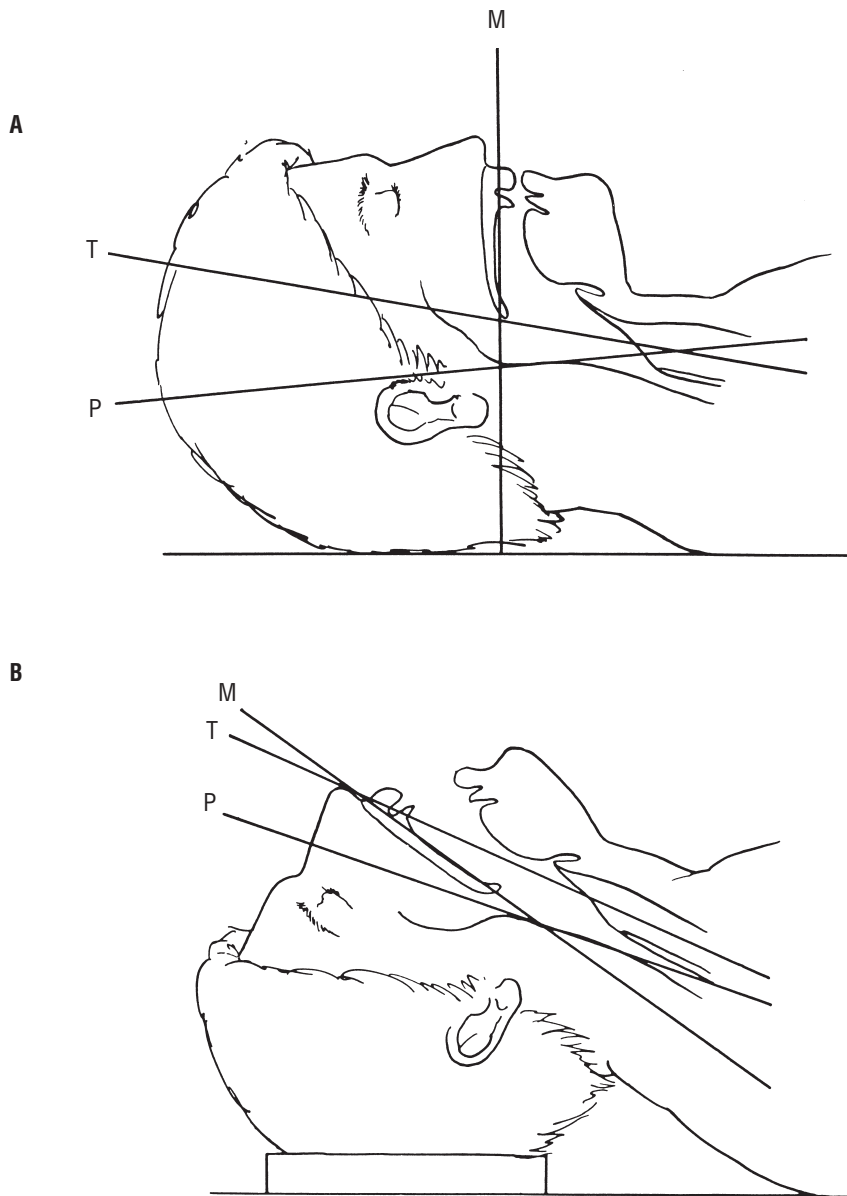
CD Figure 2-8 Inspection of the vocal folds (cords) indirectly through a laryngeal mirror (A) and through a laryngoscope (B). Note the orientation of the structures forming the laryngeal inlet.

instrument can then be introduced into the larynx over the back of the tongue (CD Fig. 2-8). The valleculae, the piriform fossae, the epiglottis, and the aryepiglottic folds are clearly seen. The two elevations produced by the corniculate and cuneiform cartilages can be recognized. Within the larynx, the vestibular folds and the vocal folds can be seen. The former are fixed, widely separated, and **reddish** in color; the latter move with respiration and are **white** in color. With quiet breathing, the rima glottidis is triangular, with the apex in front. With deep inspiration, the rima glottidis assumes a diamond shape because of the lateral rotation of the arytenoid cartilages.

If the patient is asked to breathe deeply, the vocal folds become widely abducted, and the inside of the trachea can be seen.

Important Anatomic Axes for Endotracheal Intubation

The upper airway has three axes that have to be brought into alignment if the glottis is to be viewed adequately through a laryngoscope—the axis of the mouth, the axis of the pharynx, and the axis of the trachea (CD Fig. 2-9).



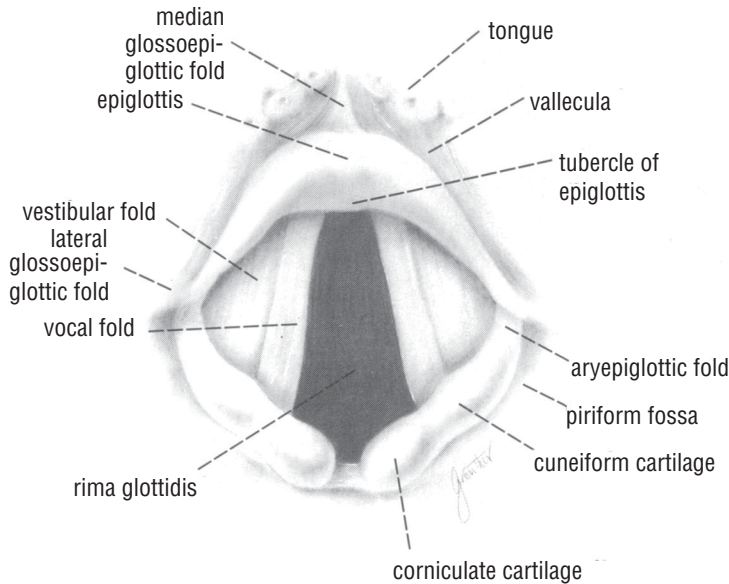
CD Figure 2-9 Anatomic axes for endotracheal intubation. **A.** With the head in the neutral position, the axis of the mouth (*M*), the axis of the trachea (*T*), and the axis of the pharynx (*P*) are not aligned with one another. **B.** If the head is extended at the atlantooccipital joints, the axis of the mouth is correctly placed. If the back of the head is raised off the table with a pillow, thus flexing the cervical vertebral column, the axes of the trachea and pharynx are brought in line with the axis of the mouth.

The following procedures are necessary: First the head is extended at the atlantooccipital joints. This brings the axis of the mouth into the correct position. Then the neck is flexed at cervical vertebrae C4 to C7 by elevating the back of the head off the table, often with the help of a pillow. This brings the axes of the pharynx and the trachea in line with the axis of the mouth.

Anatomy of the Visualization of the Vocal Cords with the Laryngoscope

1. The pear-shaped epiglottis is attached by its stalk at its lower end to the interior of the thyroid cartilage (see text Fig. 2-26).
2. The vocal cords (ligaments) are attached at their anterior ends to the thyroid cartilage just below the attachment of the epiglottis (see text Fig. 2-26).
3. Because of the above two facts, it follows that manipulation of the epiglottis and possibly the thyroid cartilage will greatly assist the operator in visualizing the cords and the glottis.

The patient's head and neck are correctly positioned so that the three axes of the airway (noted above) have been established and the patient has assumed the "sniffing" position. The laryngoscope is inserted into the patient's mouth, and the blade is correctly placed alongside the right mandibular molar teeth. The blade can then be passed over the tongue and down into the esophagus. The tip of the



CD Figure 2-10 The laryngeal inlet as seen from above.

blade must be fully inserted into the esophagus (so that you know where it is anatomically). The blade should by now have moved toward the midline and followed the anatomic curvature on the posterior surface of the tongue.

The laryngoscopic blade is then gently and slowly withdrawn. The tip of the blade is kept under direct vision at all times and is permitted to rise up out of the esophagus. Remember that the tip of the blade is at first in the esophagus and therefore distal to the level of the vocal cords. Once the blade tip has left the esophagus, it is in the laryngeal part of the pharynx, and a view of the glottis should immediately be apparent (CD Fig. 2-10). This is the critical stage. If the glottis is not visualized, then the operator is viewing the posterior surface of the epiglottis. **Now use your anatomic knowledge.**

With the tip of the blade of the laryngoscope applied to the posterior surface of the epiglottis, gently lift up and elevate the epiglottis to expose the glottis. If the glottis is still not in view, **do not panic!** Again use your knowledge of anatomy. With the right free hand grasp the thyroid cartilage (to which the cords and the epiglottis are attached) between your finger and thumb and apply firm backward, upward, rightward pressure (**BURP**). This maneuver realigns the box of the larynx relative to the laryngoscopic blade, and the visual axis of the operator and the glottis should immediately be seen.

Reflex Activity Secondary to Endotracheal Intubation

Stimulation of the mucous membrane of the upper airway during the process of intubation may produce cardiovascular changes such as bradycardia and hypertension. These

changes are largely mediated through the branches of the vagus nerves.



THE TRACHEA

Palpation of the Trachea

The trachea can be readily felt below the larynx. As it descends, it becomes deeply placed and may lie as much as 1.5 in. (4 cm) from the surface at the suprasternal notch. Remember that in the adult it may measure as much as 1 in. (2.5 cm) in diameter, but in a 3-year-old child it may measure only 0.5 in. in diameter. The trachea is a mobile elastic tube and is easily displaced by the enlargement of adjacent organs or the presence of tumors. Remember also that lateral displacement of the cervical part of the trachea may be caused by a pathologic lesion in the thorax.

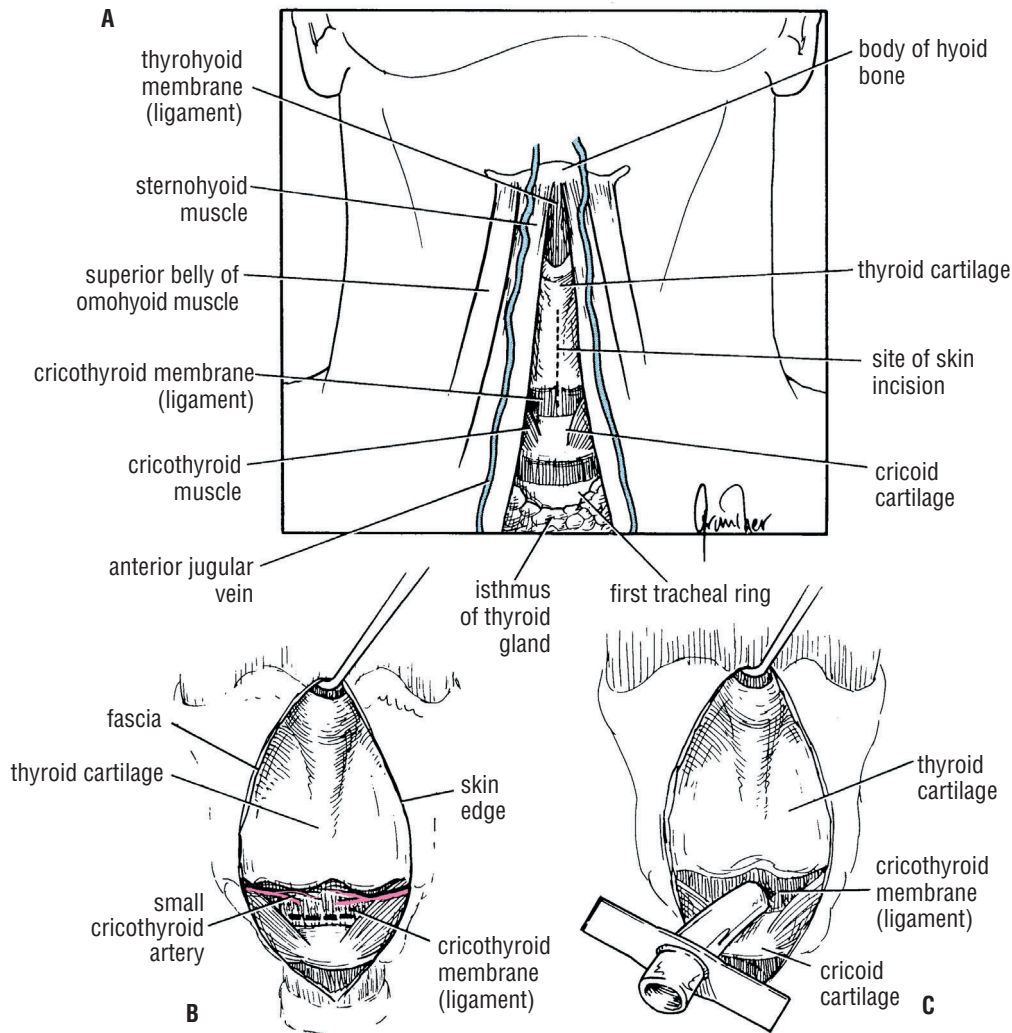
Compromised Airway

In a medical emergency immediate treatment is necessary.

Anatomy of Cricothyroidotomy

In cricothyroidotomy, a tube is inserted in the interval between the cricoid cartilage and the thyroid cartilage. The trachea and larynx are steadied by extending the neck over a sandbag.

A vertical or transverse incision is made in the skin in the interval between the cartilages (CD Fig. 2-11). The incision is made through the following structures: the skin, the superficial fascia (beware of the anterior jugular veins, which lie close together on either side of the midline), the



CD Figure 2-11 The anatomy of cricothyroidotomy. **A.** A vertical incision is made through the skin and superficial and deep cervical fasciae. **B.** The cricothyroid membrane (ligament) is incised through a horizontal incision close to the upper border of the cricoid cartilage. **C.** Insertion of the tube.

investing layer of deep cervical fascia, the pretracheal fascia (separate the sternohyoid muscles and incise the fascia), and the larynx. The larynx is incised through a horizontal incision through the cricothyroid ligament and the tube inserted (CD Fig. 2-12).

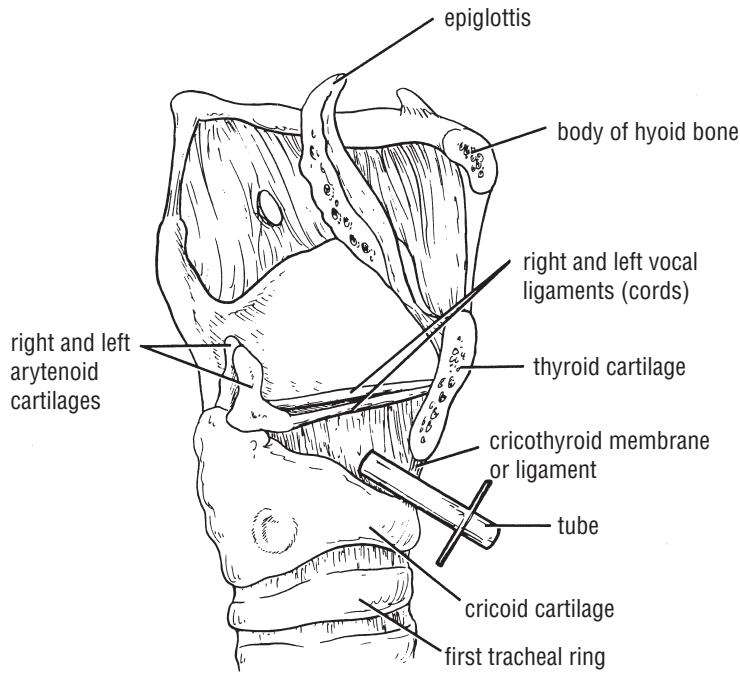
Complications

1. Esophageal perforation: Because the lower end of the pharynx and the beginning of the esophagus lie directly behind the cricoid cartilage, it is imperative that the scalpel incision through the cricothyroid membrane not be carried too far posteriorly. This is particularly important in young children, in whom the cross diameter of the larynx is so small.

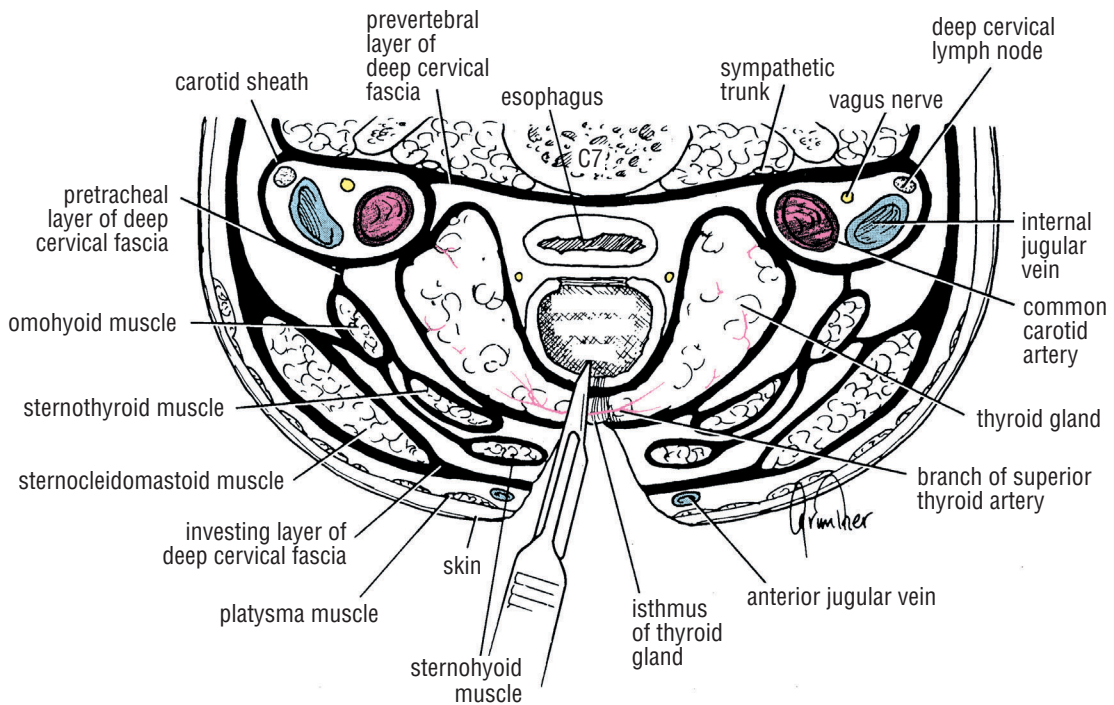
2. Hemorrhage: The small branches of the superior thyroid artery that occasionally cross the front of the cricothyroid membrane to anastomose with one another should be avoided.

Anatomy of Tracheostomy

Tracheostomy is rarely performed and is limited to patients with extensive laryngeal damage and infants with severe airway obstruction. Because of the presence of major vascular structures (carotid arteries and internal jugular vein), the thyroid gland, nerves (recurrent laryngeal branch of vagus and vagus nerve), the pleural cavities, and esophagus, meticulous attention to anatomic detail has to be observed (CD Fig. 2-13).



CD Figure 2-12 View of the interior of the larynx as seen from the right side (the right lamina of the thyroid cartilage has been removed). Note the closeness of the deep end of the cricothyroidotomy tube to the vocal cords, especially if the tube is directed upward.



CD Figure 2-13 Cross section of the neck at the level of the second tracheal ring. A vertical incision is made through the ring, and the tracheostomy tube is inserted.

The procedure is as follows:

1. The thyroid and cricoid cartilages are identified and the neck is extended to bring the trachea forward.
2. A vertical midline skin incision is made from the region of the cricothyroid membrane inferiorly toward the suprasternal notch.
3. The incision is carried through the superficial fascia and the fibers of the platysma muscle. The anterior jugular veins in the superficial fascia are avoided by maintaining a midline position.
4. The investing layer of deep cervical fascia is incised.
5. The pretracheal muscles embedded in the pretracheal fascia are split in the midline two fingerbreadths superior to the sternal notch.
6. The tracheal rings are then palpable in the midline, or the isthmus of the thyroid gland is visible. If a hook is placed under the lower border of the cricoid cartilage and traction is applied upward, the slack is taken out of the elastic trachea; this stops it from slipping from side to side.
7. A decision is then made as to whether to enter the trachea through the second ring above the isthmus of the thyroid gland; through the third, fourth, or fifth ring by first dividing the vascular isthmus of the thyroid gland; or through the lower tracheal rings below the thyroid isthmus. At the latter site, the trachea is receding from the surface of the neck, and the pretracheal fascia contains the inferior thyroid veins and possibly the thyroidea ima artery.
8. The preferred site is through the second ring of the trachea in the midline, with the thyroid isthmus retracted inferiorly. A vertical tracheal incision is made, and the tracheostomy tube is inserted.

3. Pneumothorax: The cervical dome of the pleura may be pierced. This is especially common in children because of the high level of the pleura in the neck.
4. Esophageal injury: Damage to the esophagus, which is located immediately posterior to the trachea, occurs most commonly in infants; it follows penetration of the small-diameter trachea by the point of the scalpel blade.



SOME IMPORTANT AIRWAY DISTANCES

CD Table 2-1 shows some important distances between the incisor teeth or nostrils to anatomic landmarks in the airway in the adult. These approximate figures are helpful in determining the correct placement of an endotracheal tube.



CHANGES IN THE TRACHEAL LENGTH WITH RESPIRATION AND POSITION OF THE HEAD AND NECK

On deep inspiration the carina may descend by as much as 3 cm. Extension of the head and neck, as when maintaining an airway in an anesthetized patient, may stretch the trachea and increase its length by 25%.

Complications

Most complications result from not adequately palpating and recognizing the thyroid, cricoid, and tracheal cartilages and not confining the incision strictly to the midline.

1. Hemorrhage: The anterior jugular veins located in the superficial fascia close to the midline should be avoided. If the isthmus of the thyroid gland is transected, secure the anastomosing branches of the superior and inferior thyroid arteries that cross the midline on the isthmus.
2. Nerve paralysis: The recurrent laryngeal nerves may be damaged as they ascend the neck in the groove between the trachea and the esophagus.

CD Table 2-1 Important Airway Distances (Adult)^a

Airway	Distances (approximate)
Incisor teeth to the vocal cords	5.9 in. (15 cm)
Incisor teeth to the carina	7.9 in. (20 cm)
External nares to the carina	11.8 in. (30 cm)

^aAverage figures given ± 1–2 cm.



THE BRONCHI

Aspiration of Foreign Bodies and Stomach Contents

In adults, foreign bodies and stomach contents tend to be aspirated into the right principal bronchus, since this is more in line with the trachea than the left bronchus. In young babies, since both bronchi arise from the trachea at equal angles, no predilection for the right bronchus exists.

Suction Catheters, Endotracheal Tubes, and the Bronchi

Suction catheters and endotracheal tubes are more likely to enter the right more vertical principal bronchus than the obliquely positioned left principal bronchus in adults and older children.



BRONCHOPULMONARY SEGMENTS

See CD-ROM Chapter 3.

Clinical Problem Solving Questions

Read the following case histories/questions and give the best answer for each.

1. A 36-year-old man was taken to the emergency department after having been found lying unresponsive in a local park with an empty whisky bottle nearby. He was given oxygen by an open face mask during the 15-minute ride in the ambulance. The paramedic decided to improve the airway by passing a soft nasal tube. On attempting to pass the well-lubricated tube into the patient's nose, the paramedic found it impossible to push it much beyond the nasal vestibule on either side. What are the common anatomic causes of obstruction of the nasal airway?
2. A 12-year-old girl was brought to the hospital with a history of fever, malaise, anorexia, and a sore throat. She also had hoarseness, a cough, and rhinitis. On examination there was erythema of the posterior pharyngeal wall, with small ulcers on the palatoglossal folds and soft palate. The tonsils were seen to be red and enlarged, and an obvious white-yellow exudate was seen on the surface of the left tonsil. Examination of the deep cervical lymph nodes showed enlargement and tenderness of the node below and behind the angle of the mandible; the enlargement was greatest on the left side. A diagnosis of viral pharyngitis was made. List the various lymphoid organs found in the nasal and oral parts of the pharynx. Explain Waldeyer's ring.
3. A 3-year-old boy was playing with his toys on the floor when his sister decided to share some peanuts with him. A few minutes later he started to cough and gave a hoarse cry. The cough then became croupy, and aphonia occurred. The mother, hearing the commotion, rushed into the room and quickly realized what had happened. She turned the child upside down and hit his back several times, but with no effect. The child, now in obvious respiratory distress, was rushed to the local emergency department. On examination, he was tachypneic, with suprasternal retractions. He was not coughing, and although he attempted to cry, there was no sound. He would not tolerate being laid down. On the basis of your knowledge of the anatomy of the airway, where do you think the foreign body was lodged? Describe the normal protective reflexes that exist in the airway to *prevent* the inhalation of a foreign body. What is the anatomic and physiologic rationale behind the use of back blows, chest thrusts, and abdominal thrusts (Heimlich procedure) in the management of upper airway obstruction? Which of these procedures is most appropriate for a 3-year-old child?
4. A 17-year-old boy was driving his minibike at high speed along a country lane, when he suddenly saw what he thought was a shortcut through a gap in a hedge. He did not see that the gap was closed by a strand of barbed wire. He struck the wire with his neck and was thrown from the bicycle. On arrival at the emergency department, he had all the signs and symptoms of upper airway obstruction. Using your knowledge of the anatomy of the neck, explain the type of injury that could have occurred in this case. Does the position of the vocal cords at the time of impact influence the type of injury that occurs? What anatomic factors normally protect

the upper airway from serious blunt injuries? Does age play a role in the severity of the injury?

5. A 39-year-old man with extensive maxillofacial injuries following an automobile accident was brought to the hospital. Evaluation of the airway revealed partial obstruction. Despite an obvious fractured mandible, an attempt was made to move the tongue forward from the posterior pharyngeal wall by pushing the angles of the mandible forward. This maneuver failed to move the tongue, and it became necessary to hold the tongue forward directly in order to pull it away from the poste-
- rior pharyngeal wall. At times, why is it not possible to pull the tongue forward in the presence of a fractured mandible?
6. When a laryngoscope is passed it is important to align the mouth, the oropharynx, and the larynx into one plane. How do you bring the axes of the oropharynx and the larynx in line? How do you bring the axis of the mouth in line with the other axes? Describe the structures in the order that you can view them through a laryngoscope from the base of the tongue down to the trachea.

Answers and Explanations

1. The most common cause for difficulty in passing a nasal tube is a deflected nasal septum. This occurs more commonly in the male, and is thought to be due to previous trauma to the septum during the period of active growth. Nasal spurs and polyps may cause difficulty and swelling of the mucous membrane secondary to infection or chemical irritation, and can also cause blockage. The widest part of the nasal cavity is near the floor.
2. The lymphoid tissue around the openings of the mouth and nasal cavities into the pharynx include (1) the palatine tonsil, (2) the lingual tonsil, (3) the tubal tonsils, and (4) the pharyngeal tonsil. For details of Waldeyer's ring, see text Chapter 2.
3. The presence of severe respiratory distress with suprasternal retractions and aphonia indicates the presence of upper airway obstruction, probably located within the larynx. The airway is protected by a number of important reflexes, including the gag reflex, the laryngeal reflex, and the cough reflex. The gag reflex occurs in response to stimulation of the pharyngeal mucous membrane innervated by the glossopharyngeal nerve. The laryngeal and the cough reflexes are mediated via the vagus nerve. These protective reflexes are lost in descending order as a patient loses consciousness.

All maneuvers that are directed toward freeing an obstruction of the airway by an inhaled foreign body are based on an attempt to increase the intrathoracic pressure by compressing the intrathoracic gas volume, so that the foreign body is expressed from the mouth. The underlying mechanisms involved in the use of back blows, chest thrusts, and abdominal thrusts are discussed in this CD chapter. It is now generally agreed that the best and safest method to use on a 3-year-old child is the abdominal thrust.

4. The impact of the wire to the front of the neck caused hyperextension of the cervical part of the vertebral column with stretching of the larynx and trachea. This effectively fixed the airway structures in the midline so that they were not deflected laterally at the moment of impact. Under these circumstances the cartilages of the larynx are fractured or crushed. Depending on the speed of the impact, the larynx could be completely avulsed from the trachea. In this situation the tone of the suprahyoid muscles would cause the larynx to be retracted superiorly and the elasticity of the trachea would cause it to retract inferiorly to the root of the neck or behind the sternum.

If the glottis were closed at the time of impact, the raised intraluminal pressure within the upper airway may contribute to the severity of the injury. The upper airway receives a considerable amount of protection from blows to the front of the neck and chest because of the presence of the mandible and manubrium sterni. With the head and neck in the flexed position, the larynx and trachea are remarkably mobile and often deflected laterally by an anterior blow to the neck.

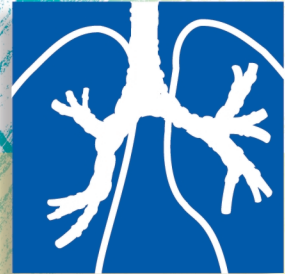In children, the very flexible nature of the laryngeal and tracheal cartilages and looseness of the supporting connective tissue reduce the likelihood of severe damage to these structures.

5. The root of the tongue is attached anteriorly to the mental spines on the posterior surface of the symphysis menti of the mandible by the right and left genioglossus muscles. If this bony origin were floating because of fractures on both sides of the body of the mandible, pulling the angles of the mandible forward would have no effect on the position of the tongue.

6. The axis of the oropharynx and the larynx are brought into direct line by flexing the cervical part of the vertebral column. The axis of the mouth is brought in line with the oropharynx by extending the atlantooccipital joints.

The following structures may be viewed: (1) the base of the tongue; (2) the median glossoepiglottic fold, the two lateral glossoepiglottic folds, and the valleculae on each

side of the median fold; (3) the upper edge of the epiglottis and the opening into the larynx, bounded in front by the epiglottis with its tubercle and laterally by the aryepiglottic folds—the rounded elevations of the cuneiform and corniculate cartilages in the folds can be recognized; (4) the reddish fixed vestibular folds; (5) the whitish mobile vocal cords; and (6) below the glottis the interior of the trachea with the upper two or three rings.



3

The Chest Wall, Chest Cavity, Lungs, and Pleural Cavities



Chapter Outline

The Chest Wall	37	Lymph Drainage of the Thoracic Wall	43
Sternum and Marrow Biopsy	37	The Breasts	43
The Ribs	37	Witch's Milk in the Newborn	43
Cervical Rib	37	Breast Examination	43
Rib Excision	37	Mammography	43
The Intercostal Nerves	37	Supernumerary and Retracted Nipples	44
Skin Innervation of the Chest Wall and Referred Pain	37	The Importance of Fibrous Septa	44
Herpes Zoster	38	Lymph Drainage and Carcinoma of the Breast	45
Anatomy of Intercostal Nerve Block	38	Congenital Anomalies of the Breast	45
Area of Anesthesia	38	Polythelia	45
Indications	38	Retracted Nipple or Inverted Nipple	45
Procedure	38	Micromastia	45
Anatomy of Complications	39	Macromastia	45
The Sternum, Ribs, and Costal Cartilages	39	Gynecomastia	46
Chest Cage Distortion	39	The Mediastinum	46
Chest Trauma	39	Deflection of Mediastinum	46
Mechanics of Chest Trauma	39	Mediastinitis	46
Rib Contusion	39	Mediastinal Tumors or Cysts	46
Rib Fractures	39	Mediastinoscopy	46
Flail Chest	39	The Pleura	46
Fractured Sternum	39	Pleural Fluid	46
Traumatic Injury to the Back of the Chest	40	Pleurisy	46
Traumatic Injury to the Chest and Abdominal Viscera	40	Pneumothorax	46
The Diaphragm	40	Spontaneous Pneumothorax	46
Hiccup	40	Open Pneumothorax	47
Paralysis of the Diaphragm	40	Tension Pneumothorax	47
Penetrating Injuries of the Diaphragm	40	Fluid in the Pleural Cavity	47
Rupture of the Diaphragm	41	Pleural Effusion	47
Congenital Anomalies of the Diaphragm	41	Hydropneumothorax	47
Congenital Herniae	41	Pyopneumothorax	47
Acquired Herniae	41	Hemopneumothorax	48
Internal Thoracic Artery in the Treatment of Coronary Artery Disease	41	Empyema	48
The Clavicle and Its Relationship with the Thoracic Outlet	41	Position of Thoracic and Upper Abdominal Viscera during Different Phases of Respiration	49
The Thoracic Outlet Syndromes	41	Root of the Neck Injuries	49
The Adson Maneuver	42	Traumatic Asphyxia	49
		Cardiopulmonary Resuscitation	49

The Chest Wall	49	Segmental Resection of the Lung	54
Thoracocentesis	49	Pulmonary Contusion	54
Needle Thoracostomy	49	Tracheobronchial Injury	54
Anterior Approach	49	Bronchogenic Carcinoma	54
Lateral Approach	49	Conditions That Decrease Respiratory Efficiency	54
Tube Thoracostomy	50	Constriction of the Bronchi (Bronchial Asthma)	54
Thoracotomy	50	Loss of Lung Elasticity	54
The Trachea and Principal Bronchi	51	Loss of Lung Distensibility	54
Compression of the Trachea	51	Postural Drainage	54
Tracheitis or Bronchitis	51	Congenital Anomalies of the Trachea and Lungs	55
Inhaled Foreign Bodies	51	Esophageal Atresia and Tracheoesophageal Fistula	55
Bronchoscopy	51	Neonatal Lobar Emphysema	55
The Lungs	51	Congenital Cysts of the Lung	55
Clinical Examination of the Chest	51	Clinical Problem Solving Questions	56
Trauma to the Lungs	53	Answers and Explanations	58
Fractured Ribs and the Lungs	53		
Pain and Lung Disease	53		
Surgical Access to the Lungs	54		



THE CHEST WALL

Sternum and Marrow Biopsy

Since the sternum possesses red hematopoietic marrow throughout life, it is a common site for **marrow biopsy**. Under a local anesthetic, a wide-bore needle is introduced into the marrow cavity through the anterior surface of the bone. The sternum may also be split at operation to allow the surgeon to gain easy access to the heart, great vessels, and thymus.



THE RIBS

Cervical Rib

A cervical rib (i.e., a rib arising from the anterior tubercle of the transverse process of the seventh cervical vertebra) occurs in about 0.5% of humans (CD Fig. 3-1). It may have a free anterior end, may be connected to the first rib by a fibrous band, or may articulate with the first rib. The importance of a cervical rib is that it can cause pressure on the lower trunk of the brachial plexus in some patients, producing pain down the medial side of the forearm and hand and wasting of the small muscles of the hand. It can

also exert pressure on the overlying subclavian artery and interfere with the circulation of the upper limb.

Rib Excision

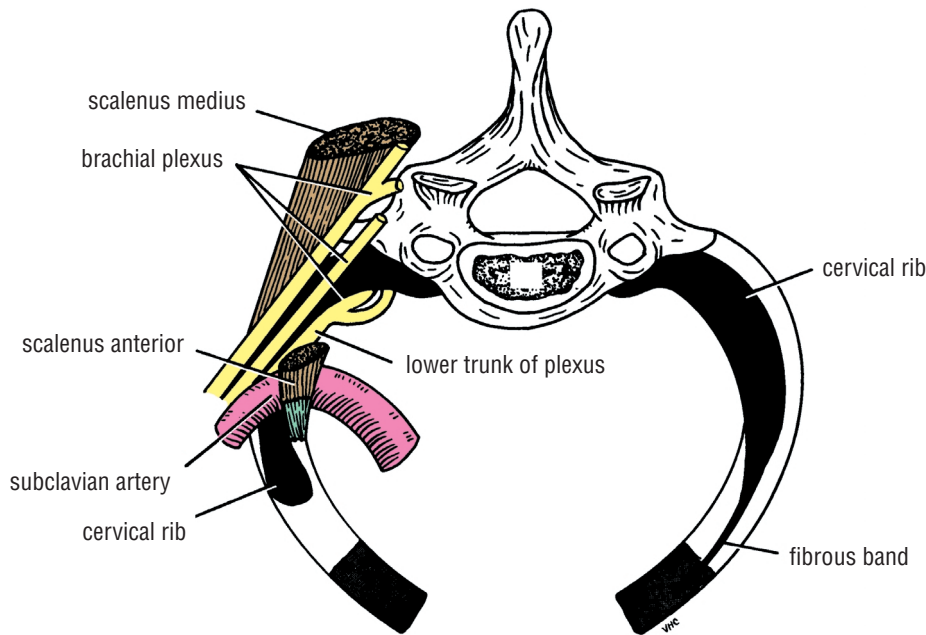
Rib excision is commonly performed by thoracic surgeons wishing to gain entrance to the thoracic cavity. A longitudinal incision is made through the periosteum on the outer surface of the rib and a segment of the rib is removed. A second longitudinal incision is then made through the bed of the rib, which is the inner covering of periosteum. After the operation, the rib regenerates from the osteogenetic layer of the periosteum.



THE INTERCOSTAL NERVES

Skin Innervation of the Chest Wall and Referred Pain

Above the level of the sternal angle, the cutaneous innervation of the anterior chest wall is derived from the **supraclavicular nerves** (C3 and 4). Below this level, the anterior and lateral cutaneous branches of the intercostal nerves supply



CD Figure 3-1 Thoracic outlet as seen from above. Note the presence of the cervical ribs (*black*) on both sides. On the right side of the thorax, the rib is almost complete and articulates anteriorly with the first rib. On the left side of the thorax, the rib is rudimentary but is continued forward as a fibrous band that is attached to the first costal cartilage. Note that the cervical rib may exert pressure on the lower trunk of the brachial plexus and may kink the subclavian artery.

oblique bands of skin in regular sequence. The skin on the posterior surface of the chest wall is supplied by the posterior rami of the spinal nerves. The arrangement of the dermatomes is shown in CD Figures 1-2 and 1-3.

An intercostal nerve supplies not only areas of skin but also the ribs, costal cartilages, intercostal muscles, and the parietal pleura lining the intercostal space. Furthermore, the seventh to eleventh intercostal nerves leave the thoracic wall and enter the anterior abdominal wall so that they, in addition, supply dermatomes on the anterior abdominal wall, muscles of the anterior abdominal wall, and parietal peritoneum. This latter fact is of great clinical importance because it means that disease in the thoracic wall may be revealed as pain in a dermatome that extends across the costal margin into the anterior abdominal wall. For example, a pulmonary thromboembolism or pneumonia with pleurisy involving the costal parietal pleura could give rise to abdominal pain and tenderness and rigidity of the abdominal musculature. The abdominal pain in these instances is called **referred pain**.

Herpes Zoster

Herpes zoster, or shingles, is a relatively common condition caused by the reactivation of the latent varicella-zoster virus in a patient who has previously had chickenpox. The lesion is seen as an inflammation and degeneration of the sensory neuron in a cranial or spinal nerve with the formation of vesicles and inflammation of the skin. In the thorax, the first symptom is a band of dermatomal pain in

the distribution of the sensory neuron in a thoracic spinal nerve, followed in a few days by a skin eruption. The condition occurs most frequently in patients older than 50 years.

Anatomy of Intercostal Nerve Block

Area of Anesthesia

The skin and the parietal pleura cover the outer and inner surfaces of each intercostal space, respectively; the seventh to eleventh intercostal nerves supply the skin and the parietal peritoneum covering the outer and inner surfaces of the abdominal wall, respectively. Therefore, an intercostal nerve block will also anesthetize these areas. In addition, the periosteum of the adjacent ribs is anesthetized.

Indications

Intercostal nerve block is indicated for repair of lacerations of the thoracic and abdominal walls, for relief of pain in rib fractures, and to allow pain-free respiratory movements.

Procedure

To produce analgesia of the anterior and lateral thoracic and abdominal walls, the intercostal nerve should be blocked before the lateral cutaneous branch arises at the midaxillary line. The ribs may be identified by counting down from the second (opposite sternal angle) or up from the twelfth. The needle is directed toward the rib

near the lower border (Text Fig. 3-4) and the tip comes to rest near the subcostal groove, where the local anesthetic is infiltrated around the nerve. Remember that the order of structures lying in the neurovascular bundle from above downward is intercostal vein, artery, and nerve and that these structures are situated between the posterior intercostal membrane of the internal intercostal muscle and the parietal pleura. Furthermore, laterally the nerve lies between the internal intercostal muscle and the innermost intercostal muscle.

Anatomy of Complications

Complications include pneumothorax and hemorrhage.

Pneumothorax can occur if the needle point misses the subcostal groove and penetrates too deeply through the parietal pleura.

Hemorrhage is caused by the puncture of the intercostal blood vessels. This is a common complication, so aspiration should always be performed before injecting the anesthetic. A small hematoma may result.



THE STERNUM, RIBS, AND COSTAL CARTILAGES

Chest Cage Distortion

The shape of the thorax can be distorted by congenital anomalies of the vertebral column or by the ribs. Destructive disease of the vertebral column that produces lateral flexion or scoliosis results in marked distortion of the thoracic cage.

Chest Trauma

Traumatic injury to the thorax is common, especially as a result of automobile accidents.

Mechanics of Chest Trauma

Chest organ injuries from blunt trauma occur as the result of rapid acceleration or deceleration, by compression, or by a sudden increase in intrathoracic or intraabdominal pressure. A knife wound piercing the chest wall injures the organs along its path. A bullet wound does not follow a straight path but yaws, tumbles, and may fragment, causing widespread tissue damage. In addition, the kinetic energy generated by a speeding bullet may damage tissue that is distant from the actual path of the bullet.

Rib Contusion

Bruising of a rib, secondary to trauma, is the most common rib injury. In this painful condition, a small hemorrhage occurs beneath the periosteum.

Rib Fractures

Fractures of the ribs are common chest injuries. In children, the ribs are highly elastic, and fractures in this age group are therefore rare. Unfortunately, the pliable chest wall in the young can be easily compressed so that the underlying lungs and heart may be injured. With increasing age, the rib cage becomes more rigid, owing to the deposit of calcium in the costal cartilages, and the ribs become brittle. The ribs then tend to break at their weakest part, their angles.

The ribs prone to fracture are those that are exposed or relatively fixed. Ribs five through 10 are the most commonly fractured ribs. The first four ribs are protected by the clavicle and pectoral muscles anteriorly and by the scapula and its associated muscles posteriorly. The eleventh and twelfth ribs float and move with the force of impact.

Because the rib is sandwiched between the skin externally and the delicate pleura internally, it is not surprising that the jagged ends of a fractured rib may penetrate the lungs and present as a **pneumothorax**.

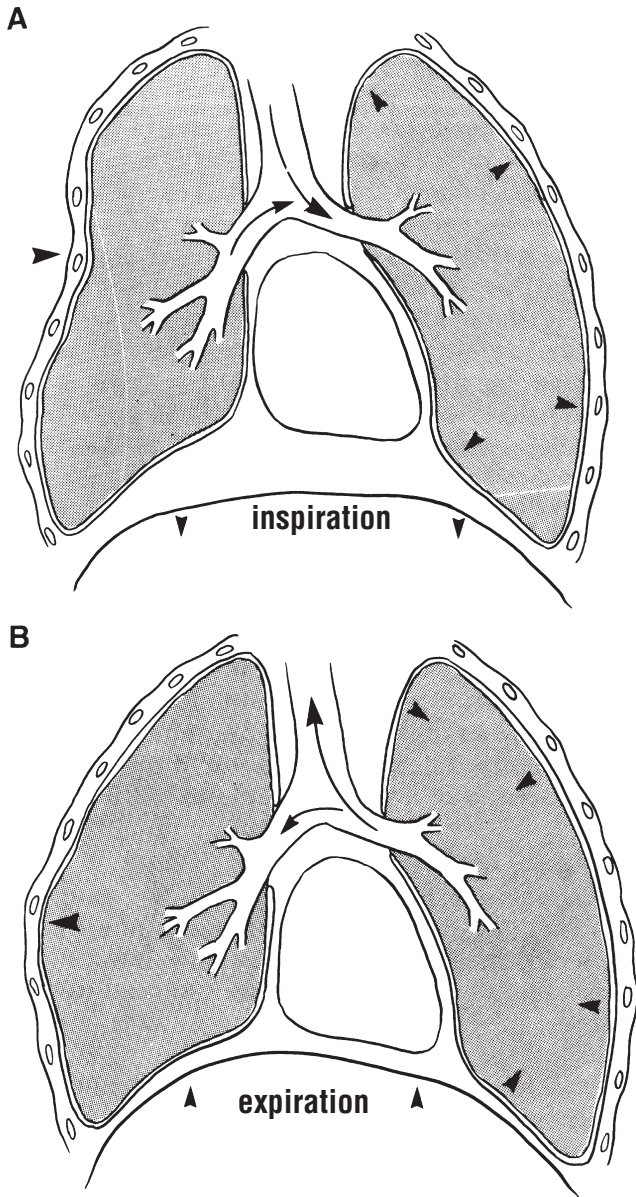
Severe localized pain is usually the most important symptom of a fractured rib. The periosteum of each rib is innervated by the intercostal nerves above and below the rib. To encourage the patient to breathe adequately, it may be necessary to relieve the pain by performing an intercostal nerve block.

Flail Chest

In severe crush injuries, a number of ribs may break. If limited to one side, the fractures may occur near the rib angles and anteriorly near the costochondral junctions. This causes flail chest, in which a section of the chest wall is disconnected to the rest of the thoracic wall. If the fractures occur on either side of the sternum, the sternum may be flail. In either case, the stability of the chest wall is lost, and the flail segment is sucked in during inspiration and driven out during expiration, producing paradoxical and ineffective respiratory movements (CD Fig. 3-2).

Fractured Sternum

The sternum is a resilient structure that is held in position by relatively pliable costal cartilages and bendable ribs. For these reasons, fracture of the sternum is not common; however, it does occur in high-speed motor vehicle accidents. Remember that the heart lies posterior to the sternum and may be severely contused by the sternum on impact.



CD Figure 3-2 Flail chest is a condition in which a portion of the chest wall is drawn inward during inspiration and bulges outward during expiration; it occurs when several ribs are fractured in two or more places. **A.** On inspiration the fractured ribs are pulled inward as the pressure within the chest decreases. The inspired air passing down the trachea tends to be drawn into the lung on the unaffected side. **B.** On expiration the fractured ribs are pushed outward as the pressure within the chest rises. Note that some of the air in the bronchi tends to enter the lung on the affected side as well as passing up the trachea.

Traumatic Injury to the Back of the Chest

The posterior wall of the chest in the midline is formed by the vertebral column. In severe posterior chest injuries, the possibility of a vertebral fracture with associated injury to the

spinal cord should be considered. Remember also the presence of the scapula, which overlies the upper seven ribs. This bone is covered with muscles and is fractured only in cases of severe trauma.

Traumatic Injury to the Chest and Abdominal Viscera

When the anatomy of the thorax is reviewed, it is important to remember that the upper abdominal organs—namely, the liver, stomach, and spleen—may be injured by trauma to the rib cage. In fact, any injury to the chest below the level of the nipple line may involve abdominal organs as well as chest organs.



THE DIAPHRAGM

Hiccup

Hiccup is the involuntary spasmodic contraction of the diaphragm accompanied by the approximation of the vocal folds and closure of the glottis of the larynx. It is a common condition in normal individuals and occurs after eating or drinking as a result of gastric irritation of the vagus nerve endings. It may, however, be a symptom of disease such as pleurisy, peritonitis, pericarditis, or uremia.

Paralysis of the Diaphragm

A single dome of the diaphragm may be paralyzed by crushing or sectioning of the phrenic nerve in the neck. This may be necessary in the treatment of certain forms of lung tuberculosis, when the physician wishes to rest the lower lobe of the lung on one side. Occasionally, the contribution from the fifth cervical spinal nerve joins the phrenic nerve late as a branch from the nerve to the subclavius muscle. To obtain complete paralysis under these circumstances, the nerve to the subclavius muscle must also be sectioned.

Penetrating Injuries of the Diaphragm

Penetrating injuries can result from stab or bullet wounds to the chest or abdomen. Any penetrating wound to the chest below the level of the nipples should be suspected of causing damage to the diaphragm until proved otherwise. The arching domes of the diaphragm can reach the level of the fifth rib (the right dome can reach a higher level).

Rupture of the Diaphragm

In severe crushing injuries to the chest or abdomen, the diaphragm may rupture, usually through the central tendon. Herniation of abdominal viscera into the thorax may occur, especially if the left dome of the diaphragm is the site of the rupture. The rupture of the right dome or the central tendon is usually plugged by the large right lobe of the liver, unless the opening is very great. A ruptured diaphragm, if not repaired, may result in a delayed herniation of abdominal contents.



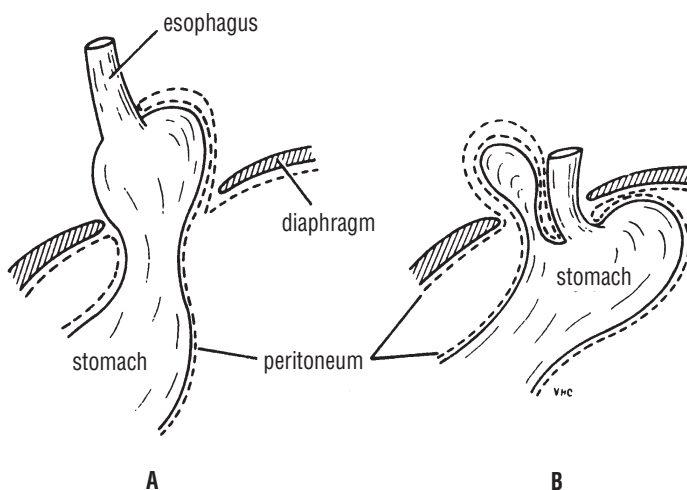
CONGENITAL ANOMALIES OF THE DIAPHRAGM

Congenital Herniae

Congenital herniae may occur as the result of incomplete fusion of the septum transversum, the dorsal mesentery, and the pleuroperitoneal membranes from the body wall. The herniae occur at the following sites: (1) the pleuroperitoneal canal (more common on the left side; caused by failure of fusion of the septum transversum with the pleuroperitoneal membrane), (2) the opening between the xiphoid and costal origins of the diaphragm, and (3) the esophageal hiatus.

Acquired Herniae

Acquired herniae may occur in middle-aged people with weak musculature around the esophageal opening in the diaphragm. These herniae may be either sliding or paraesophageal (CD Fig. 3-3).



INTERNAL THORACIC ARTERY IN THE TREATMENT OF CORONARY ARTERY DISEASE

In patients with occlusive coronary disease caused by atherosclerosis, the diseased arterial segment can be bypassed by inserting a graft. The graft most commonly used is the great saphenous vein of the leg. In some patients, the myocardium can be revascularized by surgically mobilizing one of the internal thoracic arteries and joining its distal cut end to a coronary artery.

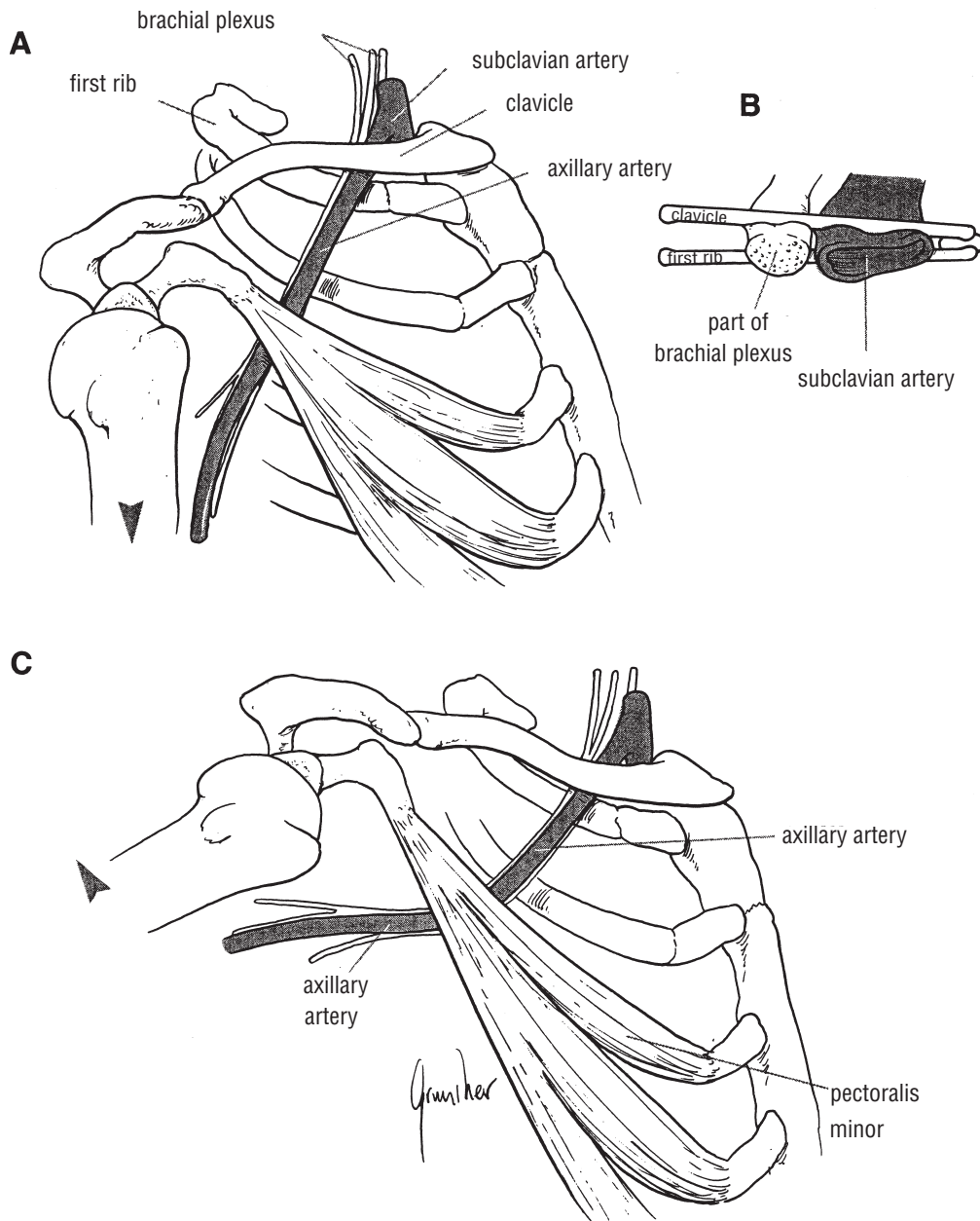


THE CLAVICLE AND ITS RELATIONSHIP WITH THE THORACIC OUTLET

The Thoracic Outlet Syndromes

The brachial plexus of nerves (C5, 6, 7, and 8 and T1) and the subclavian artery and vein are closely related to the upper surface of the first rib and the clavicle as they enter the upper limb (see CD Fig. 3-4). It is here that the

CD Figure 3-3 **A.** Sliding esophageal hernia. **B.** Paraesophageal hernia.



CD Figure 3-4 Examples of thoracic outlet syndrome. **A.** The relationship between the brachial plexus, the subclavian and axillary arteries, the clavicle, the first rib, and the pectoralis minor tendon. **B.** How the cords of the brachial plexus and the subclavian artery can be squeezed between the clavicle and the first rib in some individuals. **C.** How the axillary artery and the branches of the brachial plexus might be pressed upon by the pectoralis minor tendon when the arm is abducted at the shoulder joint.

nerves or blood vessels may be compressed between the bones. Most of the symptoms are caused by pressure on the lower trunk of the plexus producing pain down the medial side of the forearm and hand and wasting of the small muscles of the hand. Pressure on the blood vessels may compromise the circulation of the upper limb. Examples of the thoracic outlet syndromes are shown in CD Fig. 3-4.

The Adson Maneuver

This maneuver was commonly used in making the diagnosis of thoracic outlet syndrome; recently the reliability of the test has been questioned. The patient takes a deep breath (raises the first rib), extends the neck (takes up the slack of the brachial nerve plexus and subclavian vessels), and turns

his or her chin to the side being examined (narrows the interval between the scalene muscles); at the same time the pulse of the radial artery is palpated. Disappearance or reduction of the pulse, and possibly coldness and paleness of the hand, would indicate that the subclavian artery is being compressed by the scalene muscles and/or the first (or cervical) rib. In addition to looking for vascular compromise, the physician should also look for replication of the nerve symptoms down the arm.



LYMPH DRAINAGE OF THE THORACIC WALL

The lymph drainage of the skin of the anterior chest wall passes to the anterior axillary lymph nodes; that from the posterior chest wall passes to the posterior axillary nodes (CD Fig. 3-5). The lymph drainage of the intercostal spaces passes forward to the internal thoracic nodes, situated along the internal thoracic artery, and posteriorly to the posterior intercostal nodes and the paraaortic nodes in the posterior mediastinum. The lymphatic drainage of the breast is described in the next section.



THE BREASTS

Witch's Milk in the Newborn

While the fetus is in the uterus, the maternal and placental hormones cross the placental barrier and cause proliferation

of the duct epithelium and the surrounding connective tissue. This proliferation may cause swelling of the mammary glands in both sexes during the first week of life; in some cases a milky fluid, called witch's milk, may be expressed from the nipples. The condition is resolved spontaneously as the maternal hormone levels in the child fall.

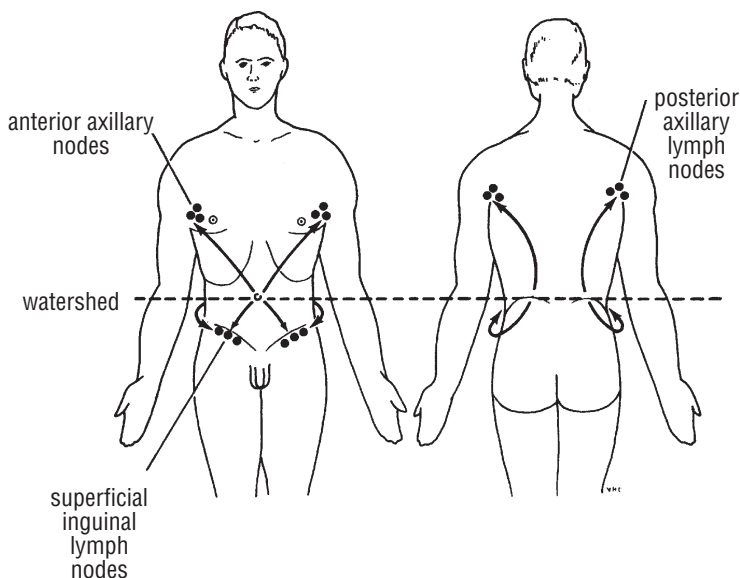
Breast Examination

The breast is one of the common sites of cancer in women. It is also the site of different types of benign tumors and may be subject to acute inflammation and abscess formation. For these reasons, clinical personnel must be familiar with the development, structure, and lymph drainage of this organ.

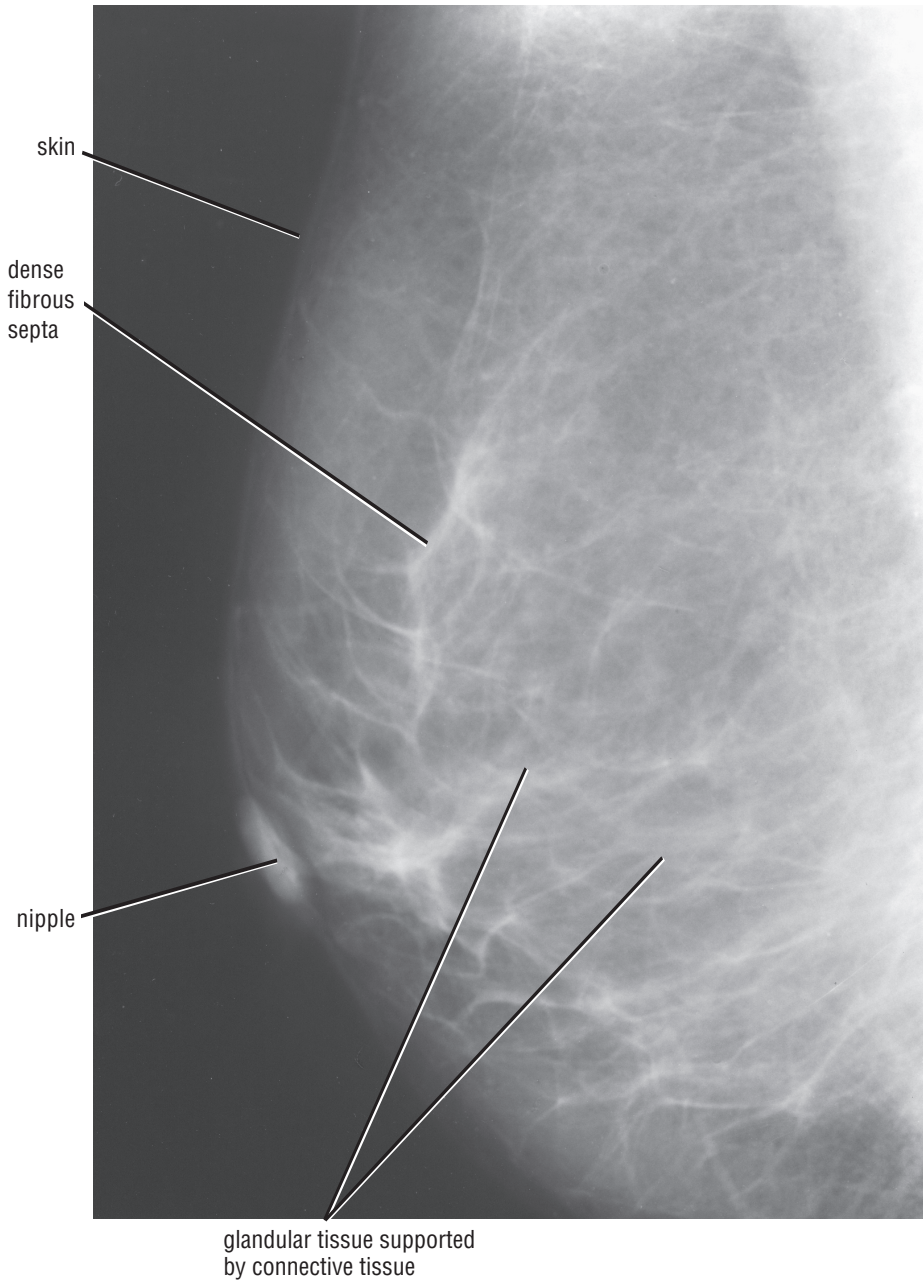
With the patient undressed to the waist and sitting upright, the breasts are first inspected for symmetry. Some degree of asymmetry is common and is the result of unequal breast development. Any swelling should be noted. A swelling can be caused by an underlying tumor, cyst, or abscess formation. The nipples should be carefully examined for evidence of retraction. A carcinoma within the breast substance can cause retraction of the nipple by pulling on the lactiferous ducts. The patient is then asked to lie down so that the breasts can be palpated against the underlying thoracic wall. Finally, the patient is asked to sit up again and raise both arms above her head. With this maneuver, a carcinoma tethered to the skin, the suspensory ligaments, or the lactiferous ducts produces dimpling of the skin or retraction of the nipple.

Mammography

Mammography is a radiographic examination of the breast (CD Fig. 3-6). This technique is extensively used for screening the breasts for benign and malignant tumors and cysts.



CD Figure 3-5 Lymph drainage of the skin of the thorax and abdomen. Note that levels of the umbilicus anteriorly and iliac crests posteriorly may be regarded as watersheds for lymph flow.



CD Figure 3-6 Mediolateral mammogram showing the glandular tissue supported by the connective tissue septa.

Extremely low doses of x-rays are used so that the dangers are minimal and the examination can be repeated often. Its success is based on the fact that a lesion measuring only a few millimeters in diameter can be detected long before it is felt by clinical examination.

Supernumerary and Retracted Nipples

Supernumerary nipples occasionally occur along a line extending from the axilla to the groin; they may or may not be associated with breast tissue. This minor congenital anomaly

may result in a mistaken diagnosis of warts or moles. A long-standing retracted nipple is a congenital deformity caused by a failure in the complete development of the nipple. A retracted nipple of recent occurrence is usually caused by an underlying carcinoma pulling on the lactiferous ducts.

The Importance of Fibrous Septa

The interior of the breast is divided into 15 to 20 compartments that radiate from the nipple by fibrous septa that extend from the deep surface of the skin. Each compartment contains a lobe of the gland. Normally, the skin feels completely mobile over the breast substance. However,

should the fibrous septa become involved in a scirrhous carcinoma or in a disease such as a breast abscess, which results in the production of contracting fibrous tissue, the septa will be pulled on, causing dimpling of the skin. The fibrous septa are sometimes referred to as the suspensory ligaments of the mammary gland.

An acute infection of the mammary gland may occur during lactation. Pathogenic bacteria gain entrance to the breast tissue through a crack in the nipple. Because of the presence of the fibrous septa, the infection remains localized to one compartment or lobe in the beginning. Abscesses should be drained through a radial incision to avoid spreading of the infection into neighboring compartments; a radial incision also minimizes the damage to the radially arranged ducts.

Lymph Drainage and Carcinoma of the Breast

The importance of knowing the lymph drainage of the breast in relation to the spread of cancer from that organ cannot be overemphasized. The lymph vessels from the medial quadrants of the breast pierce the second, third, and fourth intercostal spaces and enter the thorax to drain into the lymph nodes alongside the internal thoracic artery. The lymph vessels from the lateral quadrants of the breast drain into the anterior or pectoral group of axillary nodes. It follows, therefore, that a cancer occurring in the lateral quadrants of the breast tends to spread to the axillary nodes. Thoracic metastases are difficult or impossible to treat, but the lymph nodes of the axilla can be removed surgically.

Approximately 60% of carcinomas of the breast occur in the upper lateral quadrant. The lymphatic spread of cancer to the opposite breast, to the abdominal cavity, or into lymph nodes in the root of the neck is caused by obstruction of the normal lymphatic pathways by malignant cells or destruction of lymph vessels by surgery or radiotherapy. The cancer cells are swept along the lymph vessels and follow the lymph stream. The entrance of cancer cells into the blood vessels accounts for the metastases in distant bones.

In patients with localized cancer of the breast, most surgeons do a simple mastectomy or a lumpectomy, followed by radiotherapy to the axillary lymph nodes and/or hormone therapy. In patients with localized cancer of the breast with early metastases in the axillary lymph nodes, most authorities agree that radical mastectomy offers the best chance of cure. In patients in whom the disease has already spread beyond these areas (e.g., into the thorax), simple mastectomy, followed by radiotherapy or hormone therapy, is the treatment of choice.

Radical mastectomy is designed to remove the primary tumor and the lymph vessels and nodes that drain the area.

This means that the breast and the associated structures containing the lymph vessels and nodes must be removed en bloc. The excised mass is therefore made up of the following: a large area of skin overlying the tumor and including the nipple; all the breast tissue; the pectoralis major and associated fascia through which the lymph vessels pass to the internal thoracic nodes; the pectoralis minor and associated fascia related to the lymph vessels passing to the axilla; all the fat, fascia, and lymph nodes in the axilla; and the fascia covering the upper part of the rectus sheath, the serratus anterior, the subscapularis, and the latissimus dorsi muscles. The axillary blood vessels, the brachial plexus, and the nerves to the serratus anterior and the latissimus dorsi are preserved. Some degree of postoperative edema of the arm is likely to follow such a radical removal of the lymph vessels draining the upper limb.

A modified form of radical mastectomy for patients with clinically localized cancer is also a common procedure and consists of a simple mastectomy in which the pectoral muscles are left intact. The axillary lymph nodes, fat, and fascia are removed. This procedure removes the primary tumor and permits pathologic examination of the lymph nodes for possible metastases.



CONGENITAL ANOMALIES OF THE BREAST

Polythelia

Supernumerary nipples occasionally occur along a line corresponding to the position of the milk ridge. They are liable to be mistaken for moles.

Retracted Nipple or Inverted Nipple

Retracted nipple is a failure in the development of the nipple during its later stages. It is important clinically, because normal suckling of an infant cannot take place, and the nipple is prone to infection.

Micromastia

An excessively small breast on one side occasionally occurs, resulting from lack of development.

Macromastia

Diffuse hypertrophy of one or both breasts occasionally occurs at puberty in otherwise normal girls.

Gynecomastia

Unilateral or bilateral enlargement of the male breast occasionally occurs, usually at puberty. The cause is unknown, but the condition is probably related to some form of hormonal imbalance.



THE MEDIASTINUM

Deflection of Mediastinum

In the cadaver, the mediastinum, as the result of the hardening effect of the preserving fluids, is an inflexible, fixed structure. In the living, it is very mobile; the lungs, heart, and large arteries are in rhythmic pulsation, and the esophagus distends as each bolus of food passes through it.

If air enters the pleural cavity (a condition called **pneumothorax**), the lung on that side immediately collapses and the mediastinum is displaced to the opposite side. This condition reveals itself by the patient's being breathless and in a state of shock; on examination, the trachea and the heart are found to be displaced to the opposite side.

Mediastinitis

The structures that make up the mediastinum are embedded in loose connective tissue that is continuous with that of the root of the neck. Thus, it is possible for a deep infection of the neck to spread readily into the thorax, producing a mediastinitis. Penetrating wounds of the chest involving the esophagus may produce a mediastinitis. In esophageal perforations, air escapes into the connective tissue spaces and ascends beneath the fascia to the root of the neck, producing **subcutaneous emphysema**.

Mediastinal Tumors or Cysts

Because many vital structures are crowded together within the mediastinum, their functions can be interfered with by an enlarging tumor or organ. A tumor of the left lung can rapidly spread to involve the mediastinal lymph nodes, which on enlargement may compress the left recurrent laryngeal nerve, producing paralysis of the left vocal fold. An expanding cyst or tumor can partially occlude the superior vena cava, causing severe congestion of the veins of the upper part of the body. Other pressure effects can be seen on the sympathetic trunks, phrenic nerves, and sometimes the trachea, main bronchi, and esophagus.

Mediastinoscopy

Mediastinoscopy is a diagnostic procedure whereby specimens of tracheobronchial lymph nodes are obtained without

opening the pleural cavities. A small incision is made in the midline in the neck just above the suprasternal notch, and the superior mediastinum is explored down to the region of the bifurcation of the trachea. The procedure can be used to determine the diagnosis and degree of spread of carcinoma of the bronchus.



THE PLEURA

Pleural Fluid

The pleural space normally contains 5 to 10 mL of clear fluid, which lubricates the apposing surfaces of the visceral and parietal pleurae during respiratory movements. The formation of the fluid results from hydrostatic and osmotic pressures. Since the hydrostatic pressures are greater in the capillaries of the parietal pleura than in the capillaries of the visceral pleura (pulmonary circulation), the pleural fluid is normally absorbed into the capillaries of the visceral pleura. Any condition that increases the production of the fluid (e.g., inflammation, malignancy, congestive heart disease) or impairs the drainage of the fluid (e.g., collapsed lung) results in the abnormal accumulation of fluid, called a **pleural effusion**. The presence of 300 mL of fluid in the costodiaphragmatic recess in an adult is sufficient to enable its clinical detection. The clinical signs include decreased lung expansion on the side of the effusion, with decreased breath sounds and dullness on percussion over the effusion.

Pleurisy

Inflammation of the pleura (**pleuritis** or **pleurisy**), secondary to inflammation of the lung (e.g., **pneumonia**), results in the pleural surfaces becoming coated with inflammatory exudate, causing the surfaces to be roughened. This roughening produces friction, and a **pleural rub** can be heard with the stethoscope on inspiration and expiration. Often the exudate becomes invaded by fibroblasts, which lay down collagen and bind the visceral pleura to the parietal pleura, forming **pleural adhesions**.

Pneumothorax

As a result of disease or injury (stab or gunshot wounds), air can enter the pleural cavity from the lungs or through the chest wall (pneumothorax).

Spontaneous Pneumothorax

A spontaneous pneumothorax is a condition in which air enters the pleural cavity suddenly without its cause being immediately apparent. After investigation, it is usually found that air has entered from a diseased lung and a bulla (bleb)

has ruptured. The resulting signs of pneumothorax are absent or diminished breath sounds over the affected lung and deflection of the trachea to the opposite side.

Open Pneumothorax

Open pneumothorax occurs when the air enters the pleural cavity through an opening in the chest wall and may result from stab or bullet wounds (CD Fig. 3-7). **Sucking pneumothorax** occurs when the hole in the chest wall is larger than the glottis. With each inspiration the negative pressure created is more effective at sucking air in through the chest wound than air entering through the glottis; this produces a sucking sound. The lung cannot be expanded, and respiration is compromised.

Tension Pneumothorax

Tension pneumothorax occurs when air is sucked into the pleural cavity through a chest wound with each inspiration but does not escape (CD Fig. 3-8). This can occur as the result of clothing and/or the layers of the chest wall combining to form a valve so that air enters on inspiration but cannot exit through the wound. In these circumstances, the air pressure builds up on the wounded side and pushes the mediastinum progressively over to the opposite side. Because of the anatomic thin walls of the great veins (vena cavae) and the atria of the heart, the increase in air pressure within the chest cavity interferes with blood return to the heart; the patient may die because of lack of venous return. The clinical signs are hypertension, hyperresonance to percussion on the affected side, the engorgement of the neck veins, and the evidence of mediastinal deflection. Eventually, hypotension (secondary to lack of venous return) results. The treatment is immediate decompression of the affected side by the insertion of a needle thoracostomy.

Fluid in the Pleural Cavity

Pleural Effusion

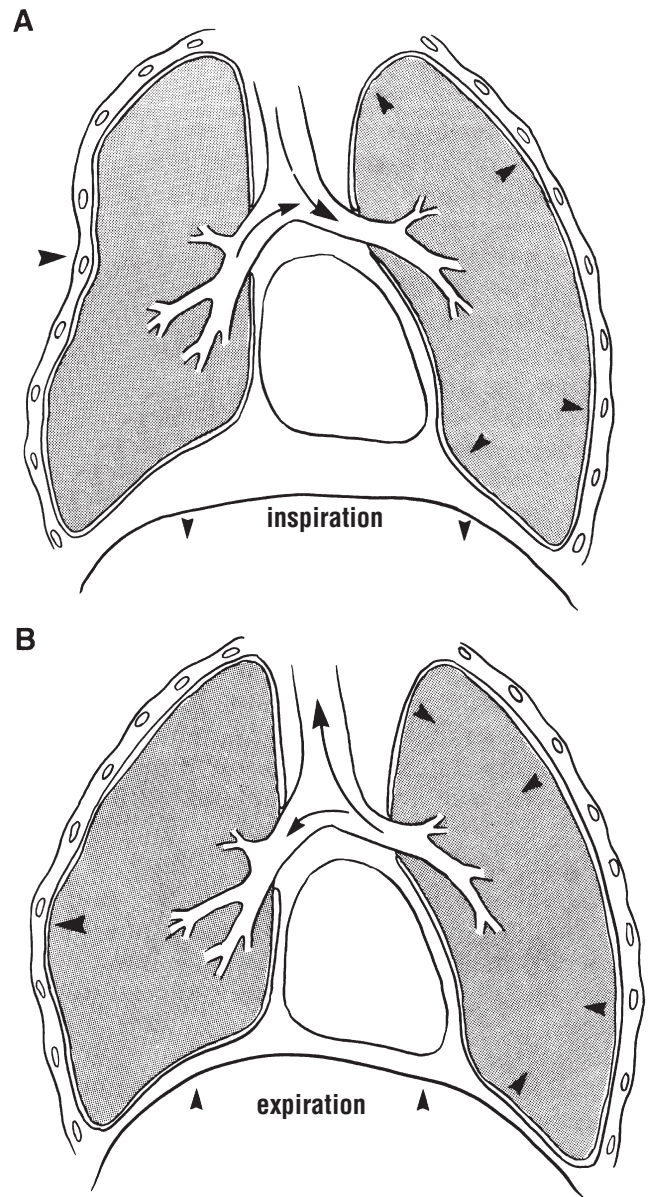
The presence of fluid in the cavity is referred to as a pleural effusion. Fluid (serous, blood, or pus) can be drained from the pleural cavity through a wide-bore needle, as described later in this section.

Hydropneumothorax

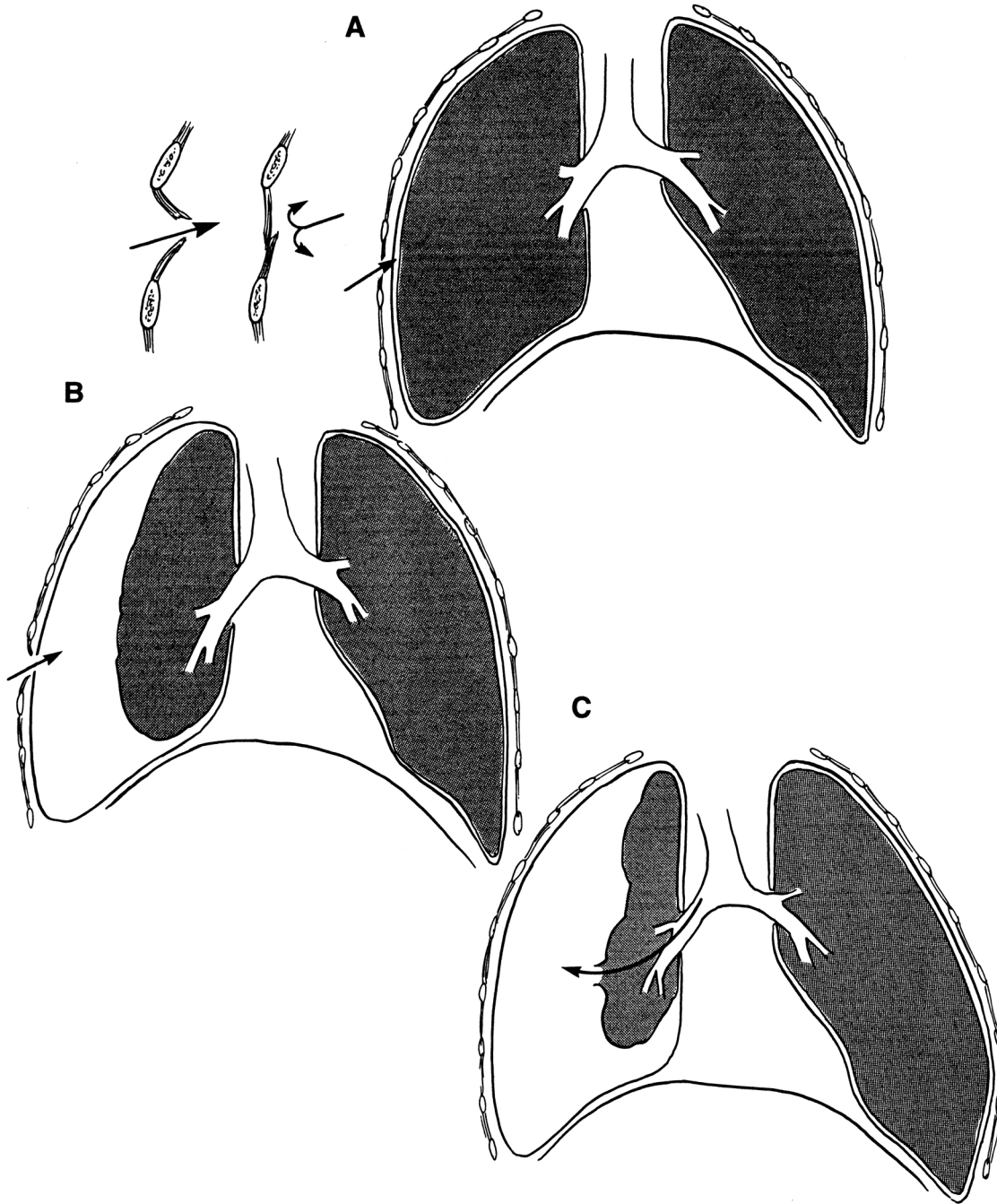
Air in the pleural cavity associated with serous fluid is known as hydropneumothorax.

Pyopneumothorax

Air in the pleural cavity associated with pus is known as pyopneumothorax.



CD Figure 3-7 Open pneumothorax without tension. **A.** On inspiration air is drawn in through the wound in the chest wall at atmospheric pressure, and the lung partially or completely collapses (depending on the size of the hole in the chest wall) from its own inherent elasticity; the mediastinum is deflected to the opposite side. **B.** On expiration air passes out of the chest wound as the diaphragm rises and the mediastinum is deflected to the same side. With large chest openings (larger than the cross-sectional area of trachea), air will preferentially use the hole in the chest wall rather than passing up and down the trachea, and respiratory ventilation will cease.



CD Figure 3-8 Tension pneumothorax. **A.** Following penetration of the chest wall, clothing and/or tissue create a valve-like mechanism that permits air entry into the pleural space during inspiration but prevents exit during expiration. **B.** The lung collapses on the wounded side and the buildup of air pressure with each respiration causes severe deflection of the mediastinum to the opposite side. **C.** Spontaneous pneumothorax with air entering the pleural space through a ruptured bulla; the lung collapses and the mediastinum is deflected to the opposite side.

Hemopneumothorax

Air in the pleural cavity associated with blood is known as hemopneumothorax.

Empyema

A collection of pus (without air) within the pleural cavity is called an empyema.



POSITION OF THORACIC AND UPPER ABDOMINAL VISCERA DURING DIFFERENT PHASES OF RESPIRATION

It is important to remember that the pleura, lungs, and heart in the chest cavity, and the upper abdominal viscera in the abdominal cavity, move extensively during the different phases of respiration. This movement largely results from the rising and falling of the diaphragm. It is particularly important when trying to work out the path taken by a sharp instrument or bullet following penetrating wounds to the lower chest.



ROOT OF THE NECK INJURIES

The cervical dome of the parietal pleura and the apex of the lungs extend into the neck so that at their highest point they lie about 1 in. (2.5 cm) above the clavicles (see text Fig. 3-51). Consequently, they are vulnerable to stab wounds in the root of the neck.



TRAUMATIC ASPHYXIA

The sudden caving in of the anterior chest wall associated with fractures of the sternum and ribs causes a dramatic rise in intrathoracic pressure. Apart from the immediate evidence of respiratory distress, the anatomy of the venous system plays a significant role in the production of the characteristic vascular signs of traumatic asphyxia. The thinness of the walls of the thoracic veins and the right atrium of the heart causes their collapse under the raised intrathoracic pressure, and venous blood is dammed back in the veins of the neck and head. This produces venous congestion; bulging of the eyes, which become injected; and swelling of the lips and tongue, which become cyanotic. The skin of the face, neck, and shoulders becomes purple.



CARDIOPULMONARY RESUSCITATION

Cardiopulmonary resuscitation (CPR), achieved by compression of the chest, was originally believed to succeed because of the compression of the heart between the sternum and the vertebral column. Now it is recognized that the blood flows in CPR because the whole thoracic cage is the pump; the heart functions merely as a conduit for blood. An extrathoracic pressure gradient is created by external chest compressions. The pressure in all chambers and locations within the chest cavity is the same. With compression, blood is forced out of the thoracic cage. The blood preferentially flows out the arterial side of the circulation and back down the venous side because the venous valves in the internal jugular system prevent a useless oscillatory movement. With the release of compression, blood enters the thoracic cage, preferentially down the venous side of the systemic circulation.



THE CHEST WALL

Thoracocentesis

Needle Thoracostomy

A needle thoracostomy is necessary in patients with tension pneumothorax (air in the pleural cavity under pressure) or to drain fluid (blood or pus) away from the pleural cavity to allow the lung to reexpand. It may also be necessary to withdraw a sample of pleural fluid for microbiologic examination.

Anterior Approach

For the anterior approach, the patient is in the supine position. The sternal angle is identified, and then the second costal cartilage, the second rib, and the second intercostal space are found in the midclavicular line.

Lateral Approach

For the lateral approach, the patient is lying on the lateral side. The second intercostal space is identified as above, but the anterior axillary line is used.

The skin is prepared in the usual way, and a local anesthetic is introduced along the course of the needle above the upper border of the third rib. The thoracostomy needle will pierce the following structures as it passes through the chest wall (see text Fig. 3-4): (a) skin, (b) superficial fascia (in the anterior approach the pectoral muscles are then penetrated), (c) serratus anterior muscle, (d) external intercostal muscle, (e) internal intercostal muscle, (f) innermost intercostal muscle, (g) endothoracic fascia, and (h) parietal pleura.

The needle should be kept close to the upper border of the third rib to avoid injuring the intercostal vessels and nerve in the subcostal groove.

Tube Thoracostomy

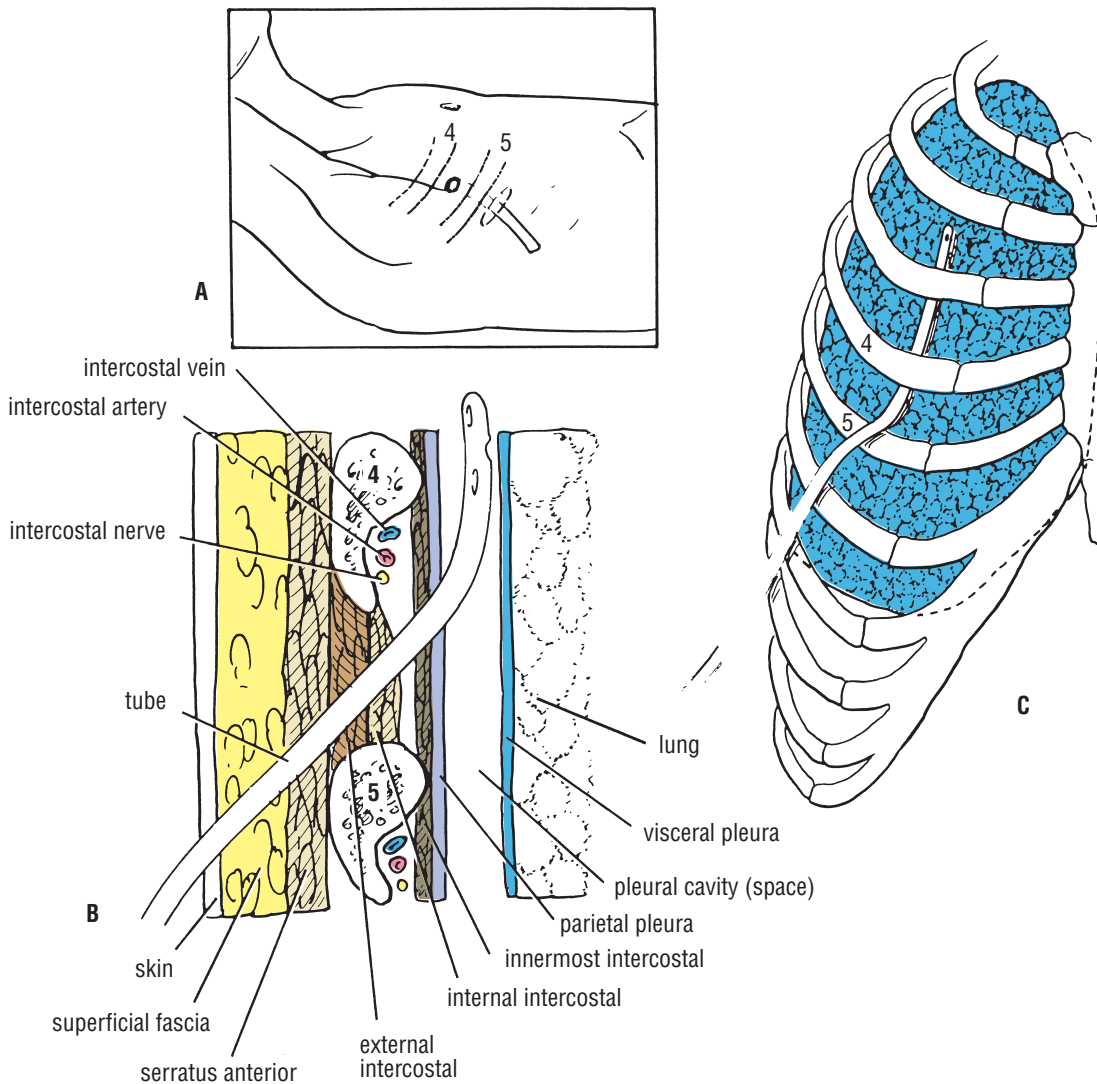
The preferred insertion site for a tube thoracostomy is the fourth or fifth intercostal space at the anterior axillary line (CD Fig. 3-9). The tube is introduced through a small incision. The neurovascular bundle changes its relationship to the ribs as it passes forward in the intercostal space. In the most posterior part of the space, the bundle lies in the middle of the intercostal space. As the bundle passes forward to the rib angle, it becomes closely related to the lower border

of the rib above and maintains that position as it courses forward.

The introduction of a thoracostomy tube or needle through the lower intercostal spaces is possible provided that the presence of the domes of the diaphragm is remembered as they curve upward into the rib cage as far as the fifth rib (higher on the right). Avoid damaging the diaphragm and entering the peritoneal cavity and injuring the liver, spleen, or stomach.

Thoracotomy

In patients with penetrating chest wounds with uncontrolled intrathoracic hemorrhage, thoracotomy may be a



CD Figure 3-9 Tube thoracostomy. **A.** The site for insertion of the tube at the anterior axillary line. The skin incision is usually made over the intercostal space one below the space to be pierced. **B.** The various layers of tissue penetrated by the scalpel and later the tube as they pass through the chest wall to enter the pleural cavity (space). The incision through the intercostal space is kept close to the upper border of the rib to avoid injuring the intercostal vessels and nerve. **C.** The tube advancing superiorly and posteriorly in the pleural space.

life-saving procedure. After preparing the skin in the usual way, the physician makes an incision over the fourth or fifth intercostal space, extending from the lateral margin of the sternum to the anterior axillary line (CD Fig. 3-10). Whether to make a right or left incision depends on the site of the injury. For access to the heart and aorta, the chest should be entered from the left side. The following tissues will be incised (see CD Fig. 3-9): (a) skin, (b) subcutaneous tissue, (c) serratus anterior and pectoral muscles, (d) external intercostal muscle and anterior intercostal membrane, (e) internal intercostal muscle, (f) innermost intercostal muscle, (g) endothoracic fascia, and (h) parietal pleura.

Avoid the **internal thoracic artery**, which runs vertically downward behind the costal cartilages about a fingerbreadth lateral to the margin of the sternum, and the **intercostal vessels** and **nerve**, which extend forward in the subcostal groove in the upper part of the intercostal space (see CD Fig. 3-9).



THE TRACHEA AND PRINCIPAL BRONCHI

Compression of the Trachea

The trachea is a membranous tube kept patent under normal conditions by U-shaped bars of cartilage. In the neck, a unilateral or bilateral enlargement of the thyroid gland can cause gross displacement or compression of the trachea. A dilatation of the aortic arch (**aneurysm**) can compress the trachea. With each cardiac systole the pulsating aneurysm may tug at the trachea and left bronchus, a clinical sign that can be felt by palpating the trachea in the suprasternal notch.

Tracheitis or Bronchitis

The mucosa lining the trachea is innervated by the recurrent laryngeal nerve and, in the region of its bifurcation, by the pulmonary plexus. A tracheitis or bronchitis gives rise to a raw, burning sensation felt deep to the sternum instead of actual pain. Many thoracic and abdominal viscera, when diseased, give rise to discomfort that is felt in the midline. It seems that organs possessing a sensory innervation that is not under normal conditions directly relayed to consciousness display this phenomenon. The afferent fibers from these organs traveling to the central nervous system accompany autonomic nerves.

Inhaled Foreign Bodies

Inhalation of foreign bodies into the lower respiratory tract is common, especially in children. Pins, screws, nuts, bolts,

peanuts, and parts of chicken bones and toys have all found their way into the bronchi. Parts of teeth may be inhaled while a patient is under anesthesia during a difficult dental extraction. Because the right bronchus is the wider and more direct continuation of the trachea (see text Fig. 3-22), foreign bodies tend to enter the right instead of the left bronchus. From there, they usually pass into the middle or lower lobe bronchi.

Bronchoscopy

Bronchoscopy enables a physician to examine the interior of the trachea; its bifurcation, called the **carina**; and the main bronchi (CD Figs. 3-11 and 3-12). With experience, it is possible to examine the interior of the lobar bronchi and the beginning of the first segmental bronchi. By means of this procedure, it is also possible to obtain biopsy specimens of mucous membranes and to remove inhaled foreign bodies (even an open safety pin).



THE LUNGS

Clinical Examination of the Chest

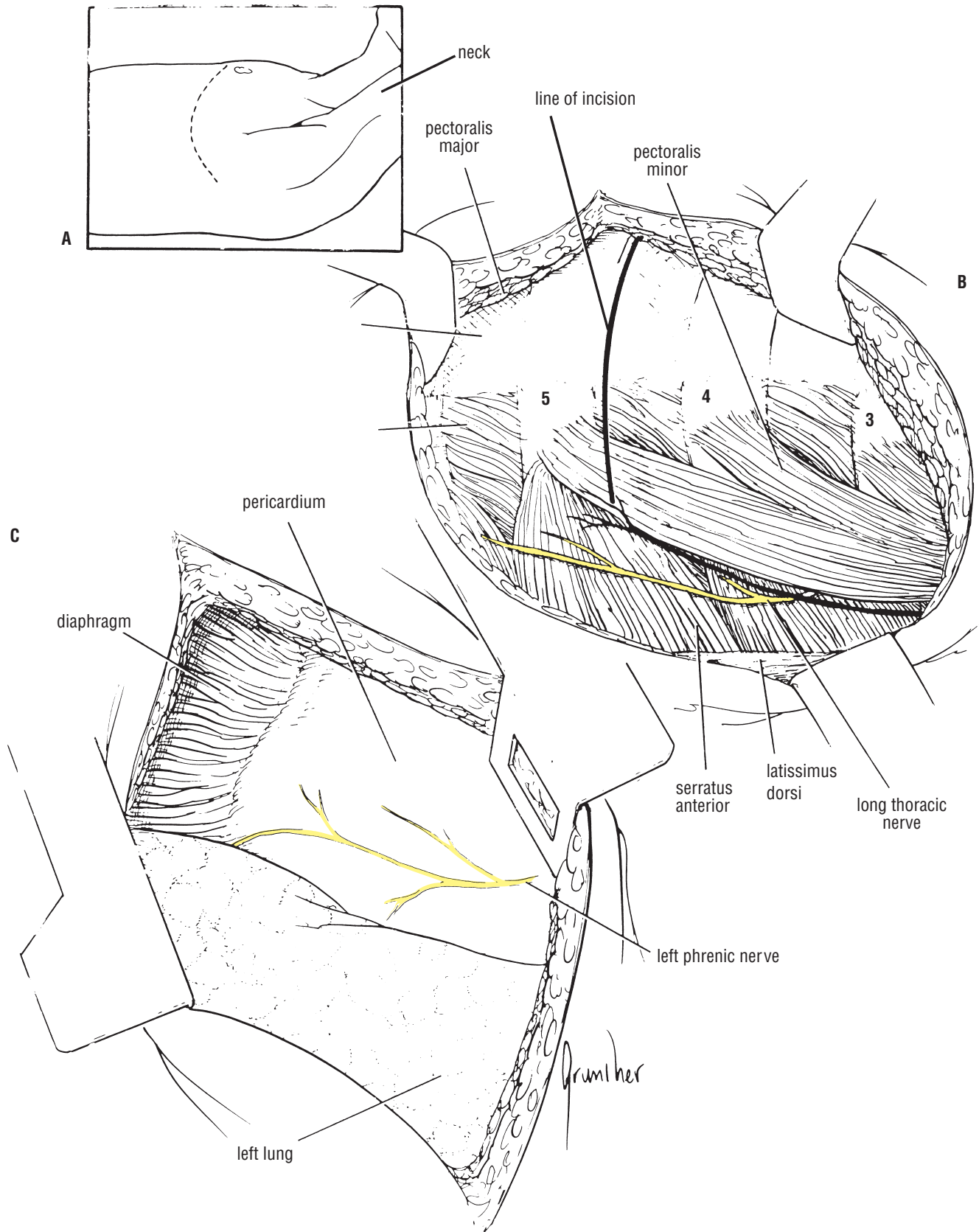
As medical personnel, you will be examining the chest to detect evidence of disease. Your examination consists of inspection, palpation, percussion, and auscultation.

Inspection shows the configuration of the chest, the range of respiratory movement, and any inequalities on the two sides. The type and rate of respiration are also noted.

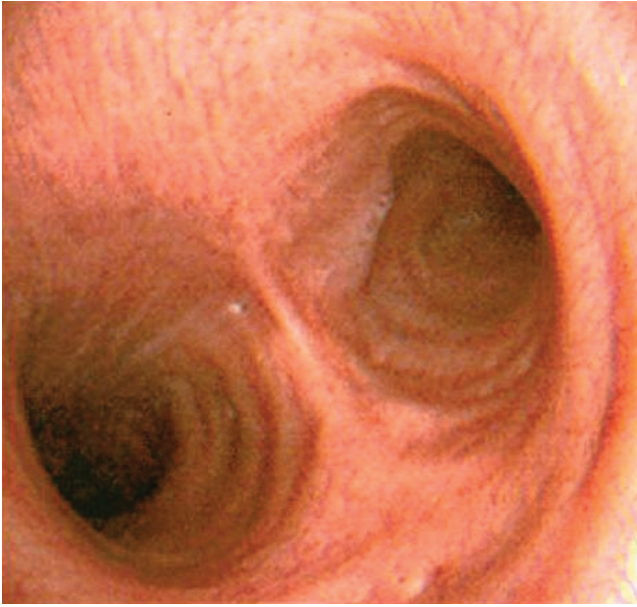
Palpation enables the physician to confirm the impressions gained by inspection, especially of the respiratory movements of the chest wall. Abnormal protuberances or recession of part of the chest wall is noted. Abnormal pulsations are felt and tender areas detected.

Percussion is a sharp tapping of the chest wall with the fingers. This produces vibrations that extend through the tissues of the thorax. Air-containing organs such as the lungs produce a resonant note; conversely, a more solid viscus such as the heart produces a dull note. With practice, it is possible to distinguish the lungs from the heart or liver by percussion.

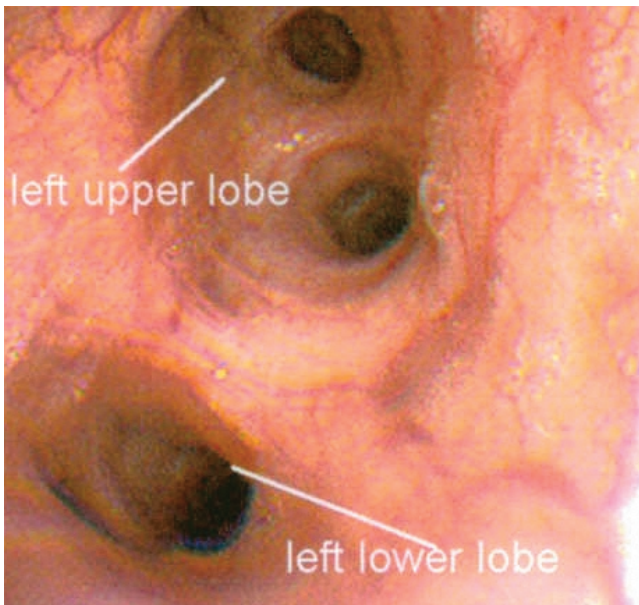
Auscultation enables the physician to listen to the breath sounds as the air enters and leaves the respiratory passages. Should the alveoli or bronchi be diseased and filled with fluid, the nature of the breath sounds will be altered. The rate and rhythm of the heart can be confirmed by auscultation, and the various sounds produced by the heart and its valves during the different phases of the cardiac cycle can be heard. It may be possible to detect friction sounds produced by the rubbing together of diseased layers of pleura or pericardium.



CD Figure 3-10 Left thoracotomy. **A.** Site of skin incision over fourth or fifth intercostal space. **B.** The exposed ribs and associated muscles. The line of incision through the intercostal space should be placed close to the upper border of the rib to avoid injuring the intercostal vessels and nerve. **C.** The pleural space opened and the left side of the mediastinum exposed. The left phrenic nerve descends over the pericardium beneath the mediastinal pleura. The collapsed left lung must be pushed out of the way to visualize the mediastinum.



CD Figure 3-11 The bifurcation of the trachea as seen through an operating bronchoscope. Note the ridge of the carina seen in the center and the opening into the right main bronchus on the right, which is a more direct continuation of the trachea. (Courtesy of E.D. Andersen.)



CD Figure 3-12 The interior of the left main bronchus as seen through an operating bronchoscope. The openings into the left upper lobe bronchus and its division and the left lower lobe bronchus are indicated. (Courtesy of E. D. Andersen.)

To make these examinations, the physician must be familiar with the normal structure of the thorax and must have a mental image of the normal position of the lungs and heart in relation to identifiable surface landmarks. Furthermore, it is essential that the physician be able to relate any abnormal findings to easily identifiable bony landmarks so that he or she can accurately record and communicate them to colleagues.

Since the thoracic wall actively participates in the movements of respiration, many bony landmarks change their levels with each phase of respiration. In practice, to simplify matters, the levels given are those usually found at about midway between full inspiration and full expiration.

For physical examination of the patient, it is good to remember that the upper lobe of the lungs is most easily examined from the front of the chest and the lower lobe from the back. In the axilla, areas of all three lobes can be examined (see text Fig. 3-53).

Trauma to the Lungs

A physician must always remember that the apex of the lung projects up into the neck (1 in. [2.5 cm] above the clavicle) and can be damaged by stab or bullet wounds in this area.

Fractured Ribs and the Lungs

Although the lungs are well protected by the bony thoracic cage, a splinter from a fractured rib can nevertheless penetrate the lung, and air can escape into the pleural cavity, causing a pneumothorax and collapse of the lung. It can also find its way into the lung connective tissue. From there, the air moves under the visceral pleura until it reaches the lung root. It then passes into the mediastinum and up to the neck. Here, it may distend the subcutaneous tissue, a condition known as **subcutaneous emphysema**.

The changes in the position of the thoracic and upper abdominal viscera and the level of the diaphragm during different phases of respiration relative to the chest wall are of considerable clinical importance. A penetrating wound in the lower part of the chest may or may not damage abdominal viscera, depending on the phase of respiration at the time of injury.

Pain and Lung Disease

Lung tissue and the visceral pleura are devoid of pain-sensitive nerve endings, so that pain in the chest is always the result of conditions affecting the surrounding structures. In tuberculosis or pneumonia, for example, pain may never be experienced.

Once lung disease crosses the visceral pleura and the pleural cavity to involve the parietal pleura, pain becomes a prominent feature. Lobar pneumonia with pleurisy, for example, produces a severe tearing pain, accentuated by inspiring deeply or coughing. Because the lower part of the

costal parietal pleura receives its sensory innervation from the lower five intercostal nerves, which also innervate the skin of the anterior abdominal wall, pleurisy in this area commonly produces pain that is referred to the abdomen. This has sometimes resulted in a mistaken diagnosis of an acute abdominal lesion.

In a similar manner, pleurisy of the central part of the diaphragmatic pleura, which receives sensory innervation from the phrenic nerve (C3, 4, and 5), can lead to referred pain over the shoulder because the skin of this region is supplied by the supraclavicular nerves (C3 and 4).

Surgical Access to the Lungs

Surgical access to the lungs or mediastinum is commonly undertaken through an intercostal space. Special rib retractors that allow the ribs to be widely separated are used. The costal cartilages are sufficiently elastic to permit considerable bending. Good exposure of the lungs is obtained by this method.

Segmental Resection of the Lung

A localized chronic lesion such as that of tuberculosis or a benign neoplasm may require surgical removal. If it is restricted to a bronchopulmonary segment, it is possible to carefully dissect out a particular segment and remove it, leaving the surrounding lung intact. Segmental resection requires that the radiologist and thoracic surgeon have a sound knowledge of the bronchopulmonary segments and that they cooperate fully to localize the lesion accurately before operation.

Pulmonary Contusion

This condition is caused by a sudden rapid compression of the chest wall and underlying lung. It may be produced by blunt trauma or gunshot wounds. Because of the pliability of the chest wall in children, lung contusion is often present in the absence of rib fractures. The localized endothelial damage to the capillaries results in the transudation of fluid into the lung parenchyma, thus compromising lung function. In cases of blunt trauma, the area of damage to the lung will depend on the site of impact and will not be determined by anatomic subdivisions of the lung.

Tracheobronchial Injury

The lung root is the site where the mobile lung is connected by the main bronchi to the relatively fixed lower end of the trachea. It is not surprising, therefore, to find that when a rapid deceleration or shearing force is applied to the lungs, injuries occur to the bronchi. In the majority of patients, the tear occurs within 1 in. of the carina.

Bronchogenic Carcinoma

Bronchogenic carcinoma accounts for about one third of all cancer deaths in men and is becoming increasingly common in women. It commences in most patients in the mucous membrane lining the larger bronchi and is therefore situated close to the hilum of the lung. The neoplasm rapidly spreads to the tracheobronchial and bronchomediastinal nodes and may involve the recurrent laryngeal nerves, leading to hoarseness of the voice. Lymphatic spread via the bronchomediastinal trunks may result in early involvement in the lower deep cervical nodes just above the level of the clavicle. Hematogenous spread to bones and the brain commonly occurs.

Conditions That Decrease Respiratory Efficiency

Constriction of the Bronchi (Bronchial Asthma)

One of the problems associated with bronchial asthma is the spasm of the smooth muscle in the wall of the bronchioles. This particularly reduces the diameter of the bronchioles during expiration, usually causing the asthmatic patient to experience great difficulty in expiring, although inspiration is accomplished normally. The lungs consequently become greatly distended and the thoracic cage becomes permanently enlarged, forming the so-called **barrel chest**. In addition, the air flow through the bronchioles is further impeded by the presence of excess mucus, which the patient is unable to clear because an effective cough cannot be produced.

Loss of Lung Elasticity

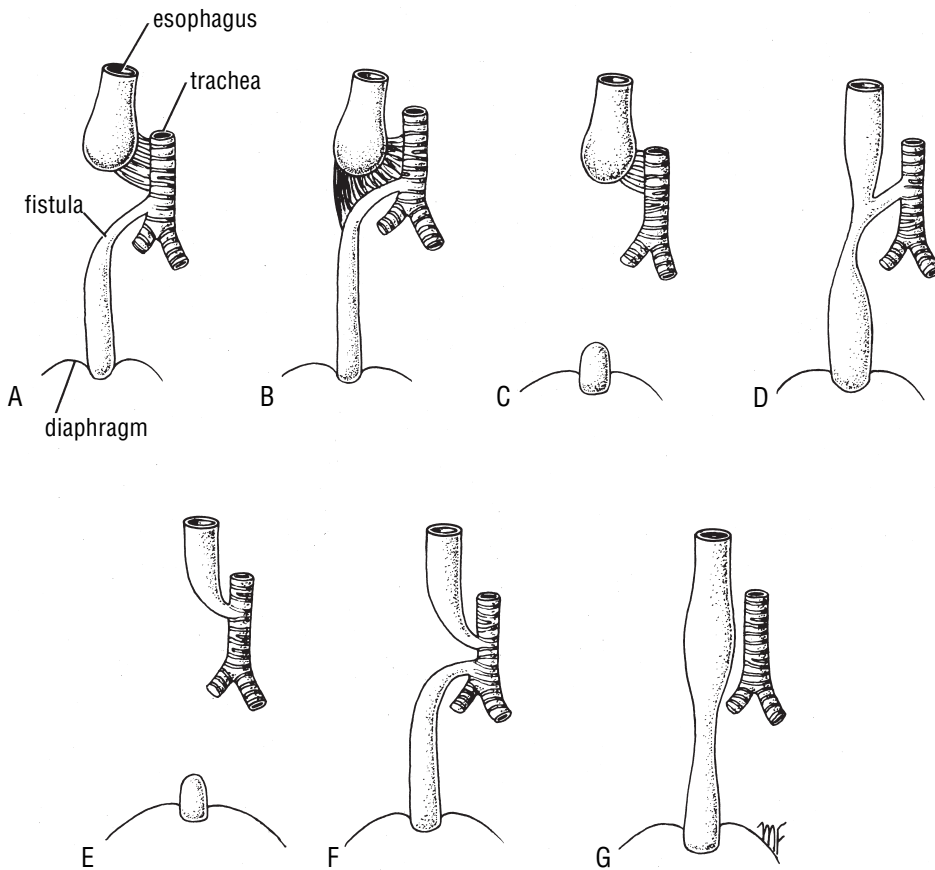
Many diseases of the lungs, such as **emphysema** and **pulmonary fibrosis**, destroy the elasticity of the lungs, and thus the lungs are unable to recoil adequately, causing incomplete expiration. The respiratory muscles in these patients have to assist in expiration, which no longer is a passive phenomenon.

Loss of Lung Distensibility

Diseases such as **silicosis**, **asbestosis**, **cancer**, and **pneumonia** interfere with the process of expanding the lung in inspiration. A decrease in the compliance of the lungs and the chest wall then occurs, and a greater effort has to be undertaken by the inspiratory muscles to inflate the lungs.

Postural Drainage

Excessive accumulation of bronchial secretions in a lobe or segment of a lung can seriously interfere with the normal



CD Figure 3-13 Different types of esophageal atresia and tracheoesophageal fistula. **A.** Complete blockage of the esophagus with a tracheoesophageal fistula. **B.** Similar to type A, but the two parts of the esophagus are joined together by fibrous tissue. **C.** Complete blockage of the esophagus; the distal end is rudimentary. **D.** A tracheoesophageal fistula with narrowing of the esophagus. **E.** An esophagotracheal fistula; the esophagus is not connected with the distal end, which is rudimentary. **F.** Separate esophagotracheal and tracheoesophageal fistulas. **G.** Narrowing of the esophagus without a fistula. In most cases, the lower esophageal segment communicates with the trachea, and types A and B occur more commonly.

flow of air into the alveoli. Furthermore, the stagnation of such secretions is often quickly followed by infection. To aid in the normal drainage of a bronchial segment, a physiotherapist often alters the position of the patient so that gravity assists in the process of drainage. Sound knowledge of the bronchial tree is necessary to determine the optimum position of the patient for good postural drainage.



CONGENITAL ANOMALIES OF THE TRACHEA AND LUNGS

Esophageal Atresia and Tracheoesophageal Fistula

If the margins of the laryngotracheal groove fail to fuse adequately, an abnormal opening may be left between the laryngotracheal tube and the esophagus. If the tracheoesophageal

septum formed by the fusion of the margins of the laryngotracheal groove should be deviated posteriorly, the lumen of the esophagus would be much reduced in diameter. The different types of atresia, with and without fistula, are shown in CD Fig. 3-13). Obstruction of the esophagus prevents the child from swallowing saliva and milk, and this leads to aspiration into the larynx and trachea, which usually results in pneumonia. With early diagnosis, it is often possible to correct this serious anomaly surgically.

Neonatal Lobar Emphysema

This condition occurs shortly after birth and is an overdistention of one or more lobes of the lung. It is a result, in many cases, of a failure of development of bronchial cartilage, which causes the bronchi to collapse. Air is inspired through the collapsed bronchi, but it is trapped during expiration.

Congenital Cysts of the Lung

Lung cysts may be solitary or may form multiple honeycomb-like masses. They are believed to be caused by separation of lung tissue occurring during development. Prompt surgical removal of the cysts is necessary to prevent compression and collapse of surrounding lung and infectious complications.

Clinical Problem Solving Questions

Read the following case histories/questions and give the best answer for each.

A 31-year-old soldier received a shrapnel wound in the neck during the Persian Gulf War. Recently, during a physical examination, it was noticed that when he blew his nose or sneezed, the skin above the right clavicle bulged upward.

1. The upward bulging of the skin could be explained by
 - A. injury to the cervical pleura.
 - B. damage to the suprapleural membrane.
 - C. damage to the deep fascia in the root of the neck.
 - D. ununited fracture of the first rib.

A 52-year-old woman was admitted to the hospital with a diagnosis of right-sided pleurisy with pneumonia. It was decided to remove a sample of pleural fluid from her pleural cavity. The resident inserted the needle close to the lower border of the eighth rib in the anterior axillary line. The next morning he was surprised to hear that the patient had complained of altered skin sensation extending from the point where the needle was inserted downward and forward to the midline of the abdominal wall above the umbilicus.

2. The altered skin sensation in this patient after the needle thoracostomy could be explained by which of the following?
 - A. The needle was inserted too low down in the intercostal space.
 - B. The needle was inserted too close to the lower border of the eighth rib and damaged the eighth intercostal nerve.
 - C. The needle had impaled the eighth rib.
 - D. The needle had penetrated too deeply and pierced the lung.

A 68-year-old man complained of a swelling in the skin on the back of the chest. He had noticed it for the last 3 years and was concerned because it was rapidly enlarging. On examination, a hard lump was found in the skin in the right scapula line opposite the seventh thoracic vertebra. A biopsy revealed that the lump was malignant.

3. Because of the rapid increase in the size of the tumor, the following lymph nodes were examined for metastases:
 - A. Superficial inguinal nodes
 - B. Anterior axillary nodes
 - C. Posterior axillary nodes
 - D. External iliac nodes
 - E. Deep cervical nodes

A 65-year-old man and a 10-year-old boy were involved in a severe automobile accident. In both patients the thorax had been badly crushed. Radiographic examination revealed that the man had five fractured ribs but the boy had no fractures.

4. What is the most likely explanation for this difference in medical findings?
 - A. The patients were in different seats in the vehicle.
 - B. The boy was wearing his seat belt and the man was not.
 - C. The chest wall of a child is very elastic, and fractures of ribs in children are rare.
 - D. The man anticipated the impact and tensed his muscles, including those of the shoulder girdle and abdomen.

On examination of a posteroanterior chest radiograph of an 18-year-old woman, it was seen that the left dome of the diaphragm was higher than the right dome and reached to the upper border of the fourth rib.

5. The position of the left dome of the diaphragm could be explained by the following conditions **except** which?
 - A. The left lung could be collapsed.
 - B. There is a collection of blood under the diaphragm on the left side.
 - C. There is an amoebic abscess in the left lobe of the liver.
 - D. The left dome of the diaphragm is normally higher than the right dome.
 - E. There is a peritoneal abscess beneath the diaphragm on the left side.

A 43-year-old man was involved in a violent quarrel with his wife over another woman. In a fit of rage, the wife picked up a carving knife and lunged forward at her husband, striking his anterior neck over the left clavicle. The husband collapsed on the kitchen floor, bleeding profusely from the wound. The distraught wife called for an ambulance.

6. On examination in the emergency department of the hospital the following conditions were found **except** which?
 - A. A wound was seen about 1 in. (2.5 cm) wide over the left clavicle.
 - B. Auscultation revealed diminished breath sounds over the left hemithorax.
 - C. The trachea was deflected to the left.
 - D. The left upper limb was lying stationary on the table, and active movement of the small muscles of the left hand was absent.

E. The patient was insensitive to pin prick along the lateral side of the left arm, forearm, and hand.

A 72-year-old man complaining of burning pain on the right side of his chest was seen by his physician. On examination the patient indicated that the pain passed forward over the right sixth intercostal space from the posterior axillary line forward as far as the midline over the sternum. The physician noted that there were several watery blebs on the skin in the painful area.

7. The following statements are correct **except** which?
- This patient has herpes zoster.
 - A virus descends along the cutaneous nerves, causing dermatomal pain and the eruption of vesicles.
 - The sixth right intercostal nerve was involved.
 - The condition was confined to the anterior cutaneous branch of the sixth intercostal nerve.

An 18-year-old woman was thrown from a horse while attempting to jump a fence. She landed heavily on the ground, striking the lower part of her chest on the left side. On examination in the emergency department she was conscious but breathless. The lower left side of her chest was badly bruised, and the ninth and tenth ribs were extremely tender to touch. She had severe tachycardia, and her systolic blood pressure was low.

8. The following statements are possibly correct **except** which?
- There was evidence of tenderness and muscle spasm in the left upper quadrant of the anterior abdominal wall.
 - A posteroanterior radiograph of the chest revealed fractures of the left ninth and tenth ribs near their angles.
 - The blunt trauma to the ribs had resulted in a tear of the underlying spleen.
 - The presence of blood in the peritoneal cavity had irritated the parietal peritoneum, producing reflex spasm of the upper abdominal muscles.
 - The muscles of the anterior abdominal wall are not supplied by thoracic spinal nerves.

A 55-year-old man states that he has noticed an alteration in his voice. He has lost 40 lb (18 kg) and has a persistent cough with blood-stained sputum. He smokes 50 cigarettes a day. On examination, the left vocal fold is immobile and lies in the adducted position. A posteroanterior chest radiograph reveals a large mass in the upper lobe of the left lung with an increase in width of the mediastinal shadow on the left side.

9. The symptoms and signs displayed by this patient can be explained by the following statements **except** which?
- This patient has advanced carcinoma of the bronchus in the upper lobe of the left lung, which was seen as a mass on the chest radiograph.

- The carcinoma had metastasized to the bronchomediastinal lymph nodes, causing their enlargement and producing a widening of the mediastinal shadow seen on the chest radiograph.
- The enlarged lymph nodes had pressed on the left recurrent laryngeal nerve.
- Partial injury to the recurrent laryngeal nerve resulted in paralysis of the abductor muscles of the vocal cords, leaving the adductor muscles unopposed.
- The enlarged lymph nodes pressed on the left recurrent nerve as it ascended to the neck anterior to the arch of the aorta.

A 35-year-old woman had difficulty breathing and sleeping at night. She says she falls asleep only to wake up with a choking sensation. She finds that she has to sleep propped up in bed on pillows with her neck flexed to the right.

10. The following statements concerning this case are correct **except** which?
- Veins in the skin at the root of the neck are congested.
 - The U-shaped cartilaginous rings in the wall of the trachea prevent it from being kinked or compressed.
 - The left lobe of the thyroid gland is larger than the right lobe.
 - On falling asleep, the patient tends to flex her neck laterally over the enlarged left thyroid lobe.
 - The enlarged thyroid gland extends down the neck into the superior mediastinum.
 - The brachiocephalic veins in the superior mediastinum were partially obstructed by the enlarged thyroid gland.

A 15-year-old boy was rescued from a lake after falling through thin ice. The next day, he developed a severe cold, and 3 days later his general condition deteriorated. He became febrile and started to cough up blood-stained sputum. At first, he had no chest pain, but later, when he coughed, he experienced severe pain over the right fifth intercostal space in the midclavicular line.

11. The following statements would explain the patient's signs and symptoms **except** which?
- The patient had developed lobar pneumonia and pleurisy in the right lung.
 - Disease of the lung does not cause pain until the parietal pleura is involved.
 - The pneumonia was located in the right middle lobe.
 - The visceral pleura is innervated by autonomic nerves that contain pain fibers.
 - Pain associated with the pleurisy was accentuated when movement of the visceral and parietal pleurae occurred, for example, on deep inspiration or coughing.

A 2-year-old boy was playing with his toy car when his baby-sitter noticed that a small metal nut was missing from the car. Two days later the child developed a cough and became febrile.

12. This child's illness could be explained by the following statements **except** which?
- The child had inhaled the nut.
 - The metal nut could easily be seen on posteroanterior and right oblique radiographs.
 - The left principal bronchus is the more vertical and wider of the two principal bronchi, and inhaled foreign bodies tend to become lodged in it.
 - The nut was successfully removed through a bronchoscope.
 - Children who are teething tend to suck on hard toys.

A 23-year-old woman was examined in the emergency department because of the sudden onset of respiratory distress. The physician was listening to breath sounds over the right hemithorax and was concerned when no sounds were heard on the front of the chest at the level of the tenth rib in the midclavicular line.

13. The following comments concerning this patient are correct **except** which?
- In a healthy individual, the lower border of the right lung in the midclavicular line in the midrespiratory position is at the level of the sixth rib.
 - The parietal pleura in the midclavicular line crosses the tenth rib.

- The costodiaphragmatic recess is situated between the lower border of the lung and the parietal pleura.
- The lung on extreme inspiration could descend in the costodiaphragmatic recess only as far as the eighth rib.
- No breath sounds were heard because the stethoscope was located over the liver.

A 36-year-old woman with a known history of emphysema (dilatation of alveoli and destruction of alveolar walls with a tendency to form cystic spaces) suddenly experiences a severe pain in the left side of her chest, is breathless, and is obviously in a state of shock.

14. Examination of this patient reveals the following findings **except** which?
- The trachea is displaced to the right in the suprasternal notch.
 - The apex beat of the heart can be felt in the fifth left intercostal space just lateral to the sternum.
 - The right lung is collapsed.
 - The air pressure in the left pleural cavity is at atmospheric pressure.
 - The air has entered the left pleural cavity as the result of rupture of one of the emphysematous cysts of the left lung (left-sided pneumothorax).
 - The elastic recoil of the lung tissue caused the lung to collapse.

Answers and Explanations

- B** is the correct answer. The shrapnel had torn the suprapleural membrane, which normally prevents the cervical dome of the pleura from bulging up into the neck.
- B** is the correct answer. The intercostal nerve is located in the subcostal groove on the lower border of the rib (see text Fig. 3-4).
- C** is the correct answer. The lymphatic drainage of the skin of the back above the level of the iliac crests is upward and forward into the posterior axillary lymph nodes.
- C** is the correct answer. The chest wall of a child is very elastic, and fractures of ribs in children are rare.
- D** is the correct answer. The right dome of the diaphragm is normally higher than the left dome due to the large size of the right lobe of the underlying liver.
- E** is the correct answer. The lower trunk of the brachial plexus was cut by the knife. This would explain the loss of movement of the small muscles of the left hand. It would also explain the loss of skin sensation that occurred in the C8 and T1 dermatomes on the *medial*, not on the lateral, side of the left forearm and hand. The knife had also pierced the left dome of the cervical pleura, causing a left pneumothorax with left-sided diminished breath sounds and a deflection of the trachea to the left.
- D** is the correct answer. The skin over the sixth intercostal space is innervated by the lateral cutaneous branch as well as the anterior cutaneous branch of the sixth intercostal nerve.
- E** is the correct answer. The seventh to the eleventh intercostal nerves supply the muscles of the anterior abdominal wall.

9. **E** is the correct answer. The left recurrent laryngeal nerve ascends to the neck by passing under the arch of the aorta; it ascends in the groove between the trachea and the esophagus.
10. **B** is the correct answer. The trachea is a mobile, fibro-elastic tube that can be kinked or compressed despite the presence of the cartilaginous rings.
11. **D** is the correct answer. Lung tissue and the visceral pleura are not innervated with pain fibers. The costal parietal pleura is innervated by the intercostal nerves, which have pain endings in the pleura.
12. **C** is the correct answer. The right principal (main) bronchus is the more vertical and wider of the two principal bronchi, and for this reason an inhaled foreign body passes down the trachea and tends to enter the right main bronchus, where it was lodged in this patient.
13. **B** is the correct answer. The parietal pleura in the mid-clavicular line only extends down as far as the eighth rib (see text Fig. 3-51).
14. **C** is the correct answer. The left lung collapsed immediately when air entered the left pleural cavity because the air pressures within the bronchial tree and in the pleural cavity were then equal.



The Cardiovascular System



4

The Heart, Coronary Vessels, and Pericardium



Chapter Outline

The Heart	64	Cardiac Injuries	68
Chordae Tendineae and Papillary Muscle Rupture	64	Cardiac Contusion	68
Mitral Valve Prolapse	64	Valve and Septal Injuries	69
Accessory Atrioventricular Bundles	64	Penetrating Injuries to the Heart	69
Circus Movement	64	Congenital Anomalies	69
Failure of Conduction System	65	Atrial Septal Defects	69
Coronary Angiography	65	Ventricular Septal Defects	69
Coronary Artery Disease	65	Tetralogy of Fallot	69
Myocardial Infarction and Papillary Muscle Rupture	66	Mitral Valve Prolapse	69
Chest Pain	66	Bicuspid Aortic Valve	70
Somatic Pain	66	Persistent Truncus Arteriosus	70
Visceral Pain	67	Patent Ductus Arteriosus	71
Referred Pain	67	The Pericardium	71
Clinical Significance of Thoracic Dermatomes		Traumatic Injury to the Pericardium	71
Relative to Chest Pain	67	Pericardial Disruption	71
Cardiac Pain	67	Hemopericardium	71
Auscultation of Heart Valves	68	Pericardiocentesis	71
Valvular Disease of the Heart	68	Anatomy of Complications	72
Valvular Heart Murmurs	68	Clinical Problem Solving Questions	72
		Answers and Explanations	74



THE HEART

Chordae Tendineae and Papillary Muscle Rupture

Rupture of the chordae tendineae by disease, such as acute bacterial endocarditis, may cause sudden valvular insufficiency and cardiac decompensation. Rupture of a papillary muscle, since each has many chordae attached to its apex, is much more serious. Rupture of a papillary muscle may occur in penetrating wounds of the heart.

Mitral Valve Prolapse

In this condition, one or both mitral valve cusps balloon up into the left atrium during ventricular systole. The valve cusps are larger than normal and the chordae tendineae may be excessively long. The posterior cusp is always involved; the anterior cusp is involved less frequently.

Accessory Atrioventricular Bundles

Accessory atrioventricular bundles are thought to exist. They are believed to be slender and normally have no functional significance. However, in the condition of accelerated atrioventricular conduction, the aberrant connection (bundle of Kent) permits one ventricle to be excited early. In this condition the PR interval is shortened and a delta wave appears on the initial part of the QRS complex. Another aberrant connection (bundle of Mahaim) bypasses the atrioventricular node and inserts just distal to the node. In this condition, known as the Lown-Ganong-Levine syndrome, the PR interval is short but the QRS complex is normal.

Circus Movement

This abnormal form of conduction allows a wave of excitation to travel continuously in a circle. This ring may occur in the atrioventricular node, causing abnormal atrial contractions and paroxysmal nodal tachycardia. If the individual has an accessory atrioventricular bundle, the circus

movement may pass in one direction through the atrioventricular node and in the opposite direction through the bundle of Kent.

Failure of Conduction System

The sinoatrial node is the spontaneous source of the cardiac impulse. The atrioventricular node is responsible for picking up the cardiac impulse from the atria. The atrioventricular bundle is the only route by which the cardiac impulse can spread from the atria to the ventricles. Failure of the bundle to conduct the normal impulses results in alteration in the rhythmic contraction of the ventricles (arrhythmias) or, if complete bundle block occurs, complete dissociation between the atria and ventricular rates of contraction. The common cause of defective conduction through the bundle or its branches is atherosclerosis of the coronary arteries, which results in a diminished blood supply to the conducting system.

Coronary Angiography

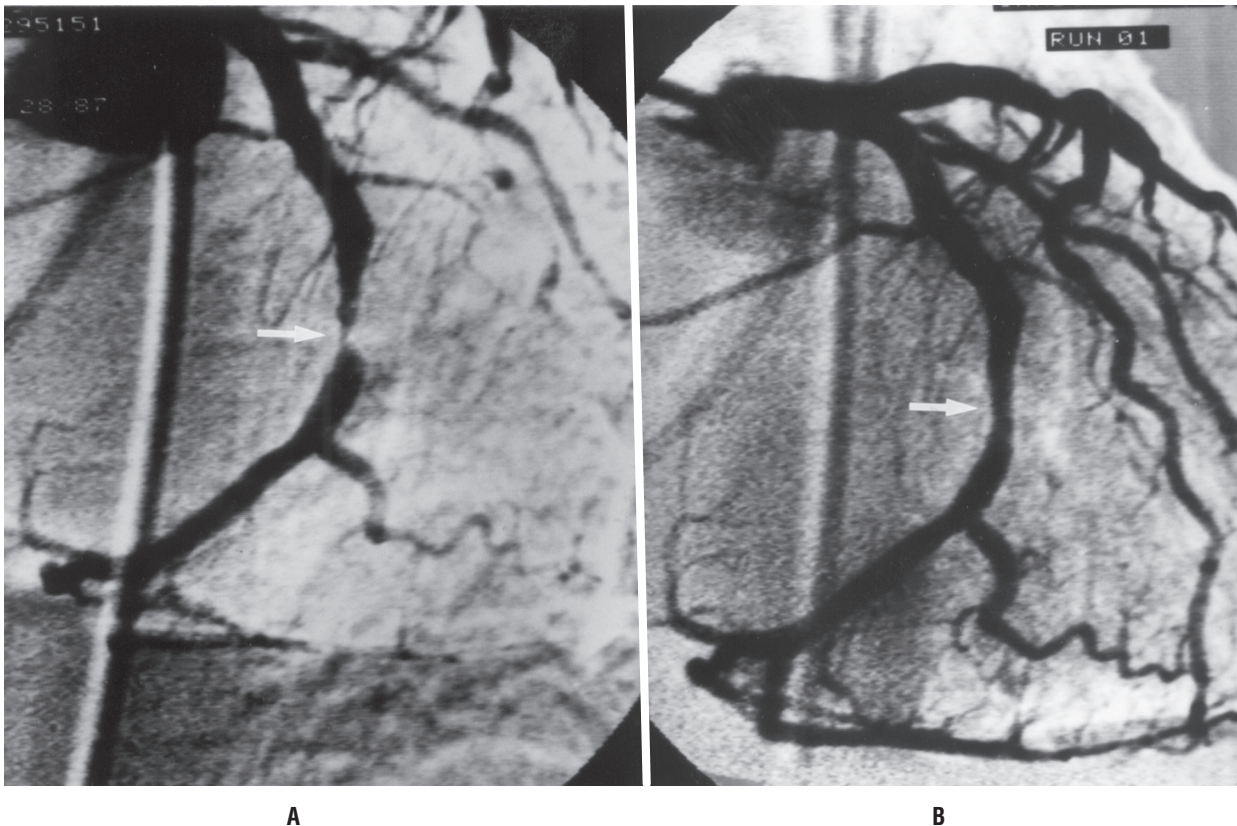
The coronary arteries can be visualized by the introduction of radiopaque material into their lumen. Under fluoro-

scopic control, a long narrow catheter is passed into the ascending aorta via the femoral artery in the leg. The tip of the catheter is carefully guided into the orifice of a coronary artery and a small amount of radiopaque material is injected to reveal the lumen of the artery and its branches. The information can be recorded on radiographs (CD Fig. 4-1) or by cineradiography. Using this technique, pathologic narrowing or blockage of a coronary artery can be identified.

Coronary Artery Disease

The myocardium receives its blood supply through the right and left coronary arteries. Although the coronary arteries have numerous anastomoses at the arteriolar level, they are essentially functional end arteries. A sudden block of one of the large branches of either coronary artery will usually lead to necrosis of the cardiac muscle (myocardial infarction) in that vascular area, and often the patient dies. Most cases of coronary artery blockage are caused by an acute thrombosis on top of a chronic atherosclerotic narrowing of the lumen.

Arteriosclerotic disease of the coronary arteries may present in three ways, depending on the rate of narrowing of the lumina of the arteries: (1) General degeneration and fibrosis



CD Figure 4-1 Coronary angiograms. **A.** An area of extreme narrowing of the circumflex branch of the left coronary artery (white arrow). **B.** The same artery after percutaneous transluminal coronary angioplasty. Inflation of the luminal balloon has dramatically improved the area of stenosis (white arrow).

CD Table 4-1 Coronary Artery Lesions, Infarct Location, and ECG Signature

Coronary Artery	Infarct Location	ECG Signature
Proximal LAD More distal LAD	Large anterior wall Anteroapical Inferior wall if wraparound LAD	ST elevation: I, L, V1–V6 ST elevation: V2–V4 ST elevation: II, III, F
Distal LAD Early obtuse, marginal More distal marginal branch, circumflex Circumflex	Anteroseptal High lateral wall Small lateral wall	ST elevation: V1–V3 ST elevation: I, L, V4–V6 ST elevation: I, L, or V4–V6, or no abnormality
Distal RCA Proximal RCA	Posterolateral Small inferior wall Large inferior wall and posterior wall Some lateral wall	ST elevation: V4–V6; ST depression: V1–V2 ST elevation: II, III, F; ST depression: I, L ST elevation: II, III, F; ST depression: I, L, V1–V3 ST elevation: V5–V6
RCA	Right ventricular Usually inferior	ST elevation: V2R–V4R; some ST elevation: V1, or ST depression: V2–V3 ST elevation: II, III, F

ECG, electrocardiographic; LAD, left anterior descending (interventricular); RCA, right coronary artery.

of the myocardium occur over many years and are caused by a gradual narrowing of the coronary arteries. (2) Angina pectoris is cardiac pain that occurs on exertion and is relieved by rest. In this condition, the coronary arteries are so narrowed that myocardial ischemia occurs on exertion but not at rest. (3) Myocardial infarction occurs when coronary flow is suddenly reduced or stopped and the cardiac muscle undergoes necrosis. Myocardial infarction is the major cause of death in industrialized nations.

CD Table 4-1 shows the different coronary arteries that supply the different areas of the myocardium. This information can be helpful when attempting to correlate the site of myocardial infarction, the artery involved, and the electrocardiographic signature.

Because coronary bypass surgery, coronary angioplasty, and coronary artery stenting are now commonly accepted methods of treating coronary artery disease, it is incumbent on the student to be prepared to interpret still- and motion-picture angiograms that have been carried out before treatment. For this reason, a working knowledge of the origin, course, and distribution of the coronary arteries should be memorized.

Myocardial Infarction and Papillary Muscle Rupture

Rarely, in acute myocardial infarction involving the left ventricle, a papillary muscle may rupture. Rupture of the posteromedial papillary muscle is more common since it is

supplied by a single artery, the right coronary artery. The anterolateral papillary muscle is less likely to rupture since it has a dual blood supply from the anterior interventricular and circumflex branches of the left coronary artery.

Chest Pain

The presenting symptom of chest pain is a common and classic problem in medicine. Unfortunately, chest pain is a symptom common to a large number of conditions and may be caused by disease in the thoracic and abdominal walls or in many different chest or abdominal viscera. The severity of the pain is often unrelated to the seriousness of the cause. Myocardial pain may mimic esophagitis, musculoskeletal chest wall pain, and other non-life-threatening causes. Unless medical personnel are astute, a patient may be discharged from the hospital with a more serious condition than the symptoms indicate. It is not good enough to have a correct diagnosis only 99% of the time with chest pain. An understanding of the anatomy of chest pain will help the physician in the systematic consideration of the differential diagnosis.

Somatic Pain

Pain arising from the chest or abdominal walls is intense and discretely localized. Somatic pain arises in sensory nerve endings in these structures and is conducted to the central nervous system by somatic segmental spinal nerves.

Visceral Pain

Visceral pain is diffuse and poorly localized. It is conducted to the central nervous system along afferent autonomic nerves. Most visceral pain fibers ascend to the spinal cord along sympathetic nerves and enter the cord through the posterior nerve roots of segmental spinal nerves. Some pain fibers from the pharynx and upper part of the esophagus and the trachea enter the central nervous system through the parasympathetic nerves via the glossopharyngeal and vagus nerves. The descending colon, the pelvic colon and rectum, and the bladder reach the sacral spinal cord through the parasympathetic nerves.

Referred Pain

Visceral pain frequently is referred to skin areas that are innervated by the same segment of the spinal cord as is the painful viscus. The explanation for referred pain is not known. One theory is that the nerve fibers from the viscus and the dermatome ascend in the central nervous system along a common pathway and the cerebral cortex is incapable of distinguishing between the sites of origin. Another theory is that under normal conditions the viscus does not give rise to painful stimuli, whereas the skin area repeatedly receives noxious stimuli. Because both afferent fibers enter the spinal cord at the same segment, the brain interprets the information as coming from the skin rather than the viscus. Pain arising from the gastrointestinal tract is referred to the midline. This can probably be explained since the tract arises embryologically as a midline structure and receives a bilateral nerve supply.

Clinical Significance of Thoracic Dermatomes Relative to Chest Pain

The dermatomes on the anterior and posterior chest walls are shown in CD Figs. 1-2 and 1-3. A dermatome is an area of skin supplied by a single spinal nerve and, therefore, a single segment of the spinal cord. On the trunk, adjacent dermatomes overlap considerably and a given area of skin is innervated by three adjacent spinal nerves.

Each thoracic spinal nerve innervates a large number of structures, including the vertebrae; the ribs and costal cartilages and their joints; the postvertebral, intercostal, and abdominal muscles; and the costal parietal pleura and parietal peritoneum. Any one of these structures could be the source of chest pain.

The skin of the anterior and posterior chest walls, down as far as the sternal angle in front and the spine of the scapula behind, is supplied by the supraclavicular nerves (C3 and C4). The phrenic nerves (C3, C4, and C5) supply the parietal pleura over the central part of the diaphragm and a corresponding area of parietal peritoneum over the lower surface of the diaphragm. Irritation of these areas by

disease of neighboring viscera, such as the gallbladder, liver, or stomach, could send afferent impulses up to the central nervous system. Because of the phenomenon of referred pain, the patient would presume that the cause of the pain was located over the upper part of the chest wall or shoulder.

Below the level of the sternal angle and the spine of the scapula, the chest skin is innervated by the thoracic segments of the spinal cord. The anterior chest wall is supplied by the intercostal nerves T2 through T6; the seventh intercostal nerve enters the anterior abdominal wall to supply the skin in the xiphoid area. The posterior chest wall is supplied by the posterior primary rami of the thoracic spinal nerves T2 through T11. Remember that the seventh to the eleventh intercostal nerves cross the costal margin and innervate the full thickness of the anterior abdominal wall including the parietal peritoneum. This would explain how irritation of the parietal peritoneum caused by disease of abdominal viscera could give rise to pain referred to the chest wall.

Note also the distribution of the T1 and T2 dermatomes; they extend down the medial side of the upper limbs. The second thoracic nerve reaches the skin of the axilla and the medial (ulnar) side of the arm via the intercostobrachial nerve (a branch of the second intercostal nerves). T1 reaches the ulnar side of the forearm via the medial cutaneous nerve of the forearm from the brachial plexus.

Cardiac Pain

Pain originating in the heart as the result of acute myocardial ischemia is assumed to be caused by oxygen deficiency and the accumulation of metabolites, which stimulate the sensory nerve endings in the myocardium. The afferent nerve fibers ascend to the central nervous system through the cardiac branches of the sympathetic trunk and enter the spinal cord through the posterior roots of the upper four thoracic nerves. The nature of the pain varies considerably, from a severe crushing pain to nothing more than mild discomfort.

The pain is not felt in the heart, but is referred to the skin areas supplied by the corresponding spinal nerves. The skin areas supplied by the upper four intercostal nerves and by the intercostobrachial nerve (T2) are therefore affected. The intercostobrachial nerve communicates with the medial cutaneous nerve of the arm and is distributed to skin on the medial side of the upper part of the arm. A certain amount of spread of nervous information must occur within the central nervous system, for the pain is sometimes felt in the neck and the jaw.

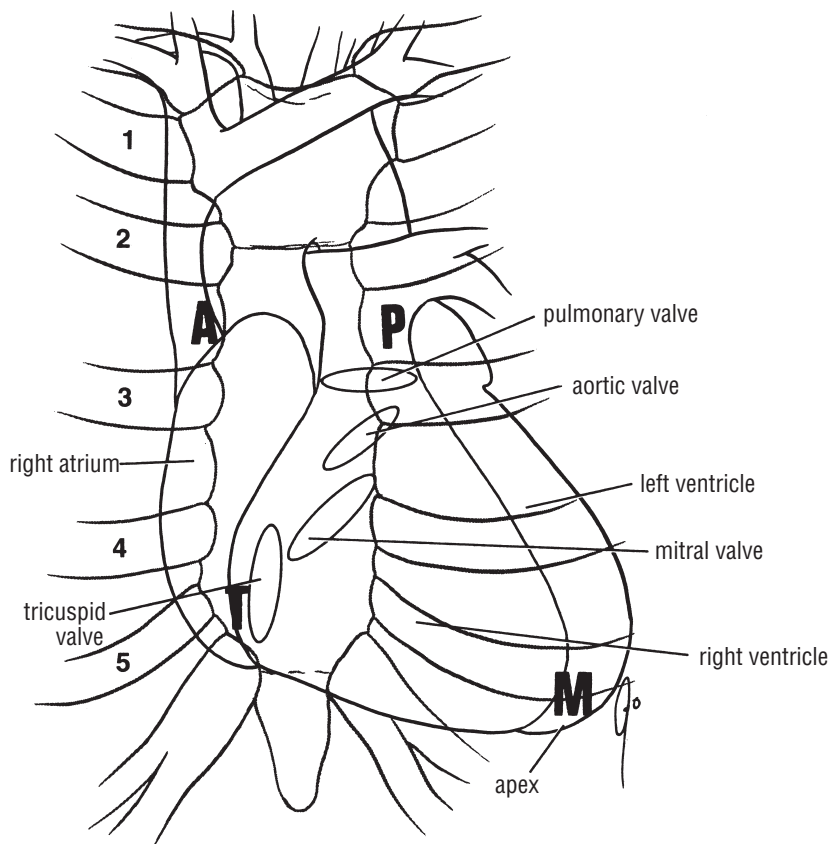
Myocardial infarction involving the inferior wall or diaphragmatic surface of the heart often gives rise to discomfort in the epigastrium. One must assume that the afferent pain fibers from the heart ascend in the sympathetic nerves and enter the spinal cord in the posterior roots of the seventh, eighth, and ninth thoracic spinal nerves and give rise to referred pain in the T7, T8, and T9 thoracic dermatomes in the epigastrium.

Because the heart and the thoracic part of the esophagus probably have similar afferent pain pathways, it is not surprising that painful acute esophagitis can mimic the pain of myocardial infarction.

Auscultation of Heart Valves

On listening to the heart with a stethoscope, one can hear two sounds: *lūb-dūp*. The first sound is produced by the contraction of the ventricles and the closure of the tricuspid and mitral valves. The second sound is produced by the sharp closure of the aortic and pulmonary valves. It is important for a physician to know where to place the stethoscope on the chest wall so that he or she will be able to hear sounds produced at each valve with the minimal distraction or interference (CD Fig. 4-2).

- The **tricuspid valve** is best heard over the right half of the lower end of the body of the sternum.
- The **mitral valve** is best heard over the apex beat, that is, at the level of the fifth left intercostal space, 3.5 in. (9 cm) from the midline.
- The **pulmonary valve** is heard with least interference over the medial end of the second left intercostal space.
- The **aortic valve** is best heard over the medial end of the second right intercostal space.



CD Figure 4-2 Surface anatomy of the heart and great blood vessels. Note the position of the heart valves relative to the chest wall. The bold letters indicate positions where valves may be heard with least interference. A = aortic valve, M = mitral valve, P = pulmonary valve, T = tricuspid valve.

Valvular Disease of the Heart

Inflammation of a valve can cause the edges of the valve cusps to stick together. Later, fibrous thickening occurs, followed by loss of flexibility and shrinkage. Narrowing (stenosis) and valvular incompetence (regurgitation) result, and the heart ceases to function as an efficient pump. In rheumatic disease of the mitral valve, for example, not only do the cusps undergo fibrosis and shrink, but also the chordae tendineae shorten, preventing closure of the cusps during ventricular systole.

Valvular Heart Murmurs

Apart from the sounds of the valves closing, *lūb-dūp*, the blood passes through the normal heart silently. Should the valve orifices become narrowed or the valve cusps distorted and shrunken by disease, however, a rippling effect would be set up, leading to turbulence and vibrations that are heard as heart murmurs.

Cardiac Injuries

Cardiac Contusion

The heart, although protected by the thoracic cage, can be squeezed between the sternum and the vertebral column

(see text Fig. 4-8) when the thorax is subjected to a severe frontal impact. Moreover, if the force is also applied to the anterior abdominal wall, the diaphragm is thrust upward, impinging on the heart from below. The highly flexible rib cage present in children makes myocardial contusion a common occurrence in this age group. The result of heart muscle damage is precordial pain, similar in nature to a myocardial infarction. Tachycardia often occurs and, if enough cardiac muscle is contused, cardiac output may decrease. Depending on the severity of the injury, there may be arrhythmias and evidence of heart block.

Valve and Septal Injuries

In both blunt and penetrating injuries to the heart, the valve cusps, the papillary muscles, and the chordae tendineae can be damaged. The incidence of valve involvement is in the following order: aortic, mitral, and pulmonary. Acute valvular insufficiency can be diagnosed clinically, but it should be confirmed by cardiac catheterization. In severe cases prompt surgical repair may be necessary.

Penetrating Injuries to the Heart

The anatomy of the heart relative to the front of the thoracic cage determines the common sites of injury. The anterior surface of the heart is formed largely by the right ventricle; the left border is formed by the left ventricle and the right border is formed by the right atrium. The right ventricle is most commonly injured, followed by the left ventricle and the right atrium. The anterior interventricular branch of the left coronary artery is the most common artery to be damaged.

Since the pericardium has to be penetrated for the heart to be injured, cardiac tamponade is often present. The hemopericardium quickly presses on the thin-walled atria and large veins and compromises the venous return. The classic triad of (1) distension of the jugular veins of the neck, (2) faint heart sounds (damped down by blood in the pericardial sac), and (3) hypotension may all be present. If there is substantial concomitant blood loss or volume depletion, the jugular veins may not be enlarged. Do not expect to see a greatly enlarged heart shadow on a chest radiograph. Even though the blood in the pericardial sac may be under high pressure caused by a ventricular leak, the tough fibrous tissue in the wall of the fibrous pericardium prevents its undue distension. Hemopericardium must be relieved surgically.

Congenital Anomalies

Atrial Septal Defects

After birth, the foramen ovale becomes completely closed as the result of the fusion of the septum primum with the septum secundum. In 25% of hearts, a small opening persists, but this is usually of such a minor nature that it has no clinical significance. Occasionally, the opening is much larger

and results in oxygenated blood from the left atrium passing over into the right atrium (CD Fig. 4-3).

Ventricular Septal Defects

The ventricular septum is formed in a complicated manner and is complete only when the membranous part fuses with the muscular part. Ventricular septal defects are less frequent than atrial septal defects. They are found in the membranous part of the septum and can measure 1 to 2 cm in diameter. Blood under high pressure passes through the defect from left to right, causing enlargement of the right ventricle. Large defects are serious and can shorten life if surgery is not performed.

Tetralogy of Fallot

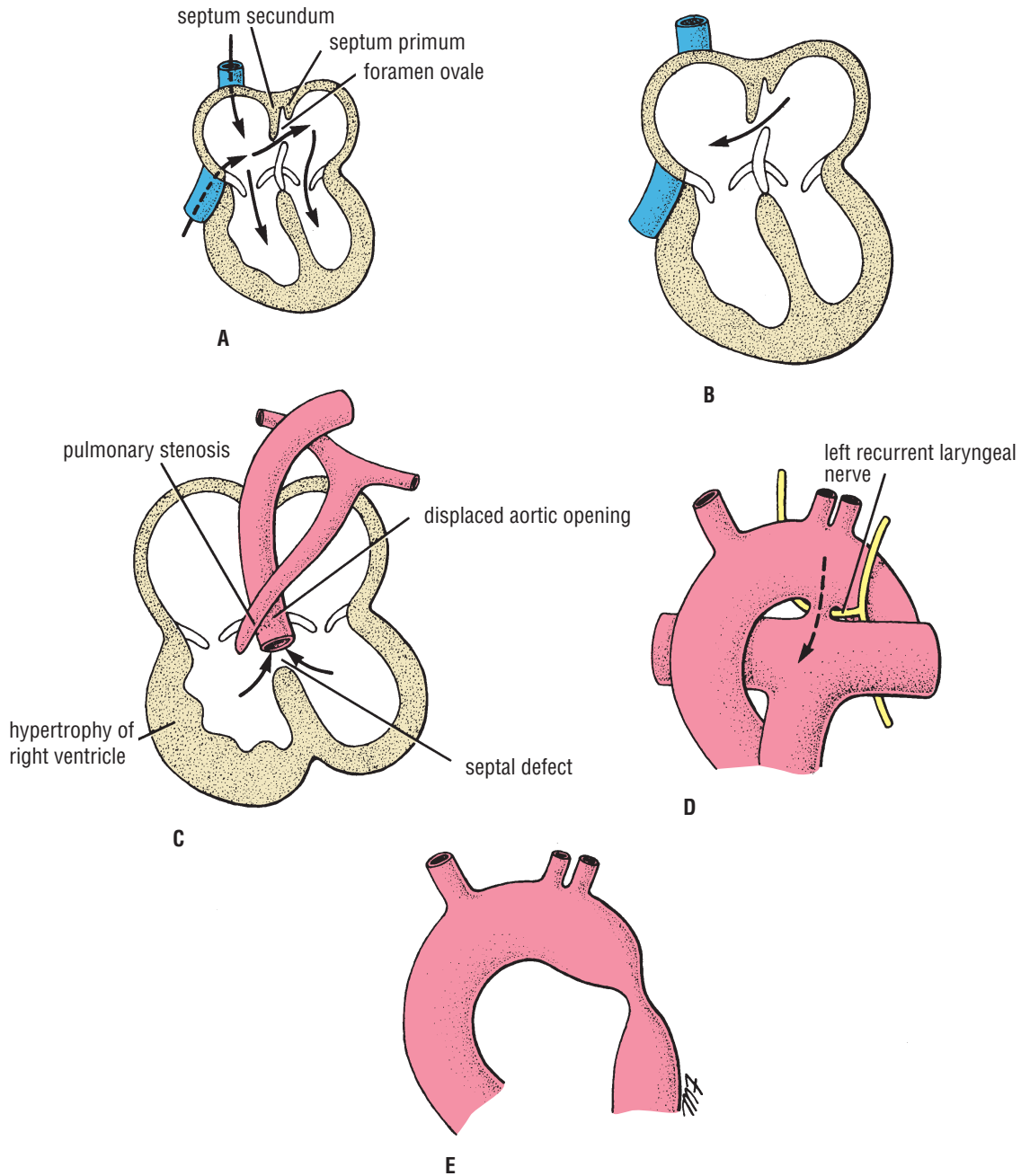
Normally, the bulbus cordis becomes divided into the aorta and pulmonary trunk by the formation of the spiral aortopulmonary septum. This septum is formed by the fusion of the bulbar ridges. If the bulbar ridges fail to fuse correctly, unequal division of the bulbus cordis may occur, with consequent narrowing of the pulmonary trunk and resulting in interference with the right ventricular outflow.

This congenital anomaly is responsible for about 9% of all congenital heart disease (see CD Fig. 4-3). The anatomic abnormalities include large ventricular septal defect; stenosis of the pulmonary trunk, which can occur at the infundibulum of the right ventricle or at the pulmonary valve; exit of the aorta immediately above the ventricular septal defect (instead of from the left ventricular cavity only); and severe hypertrophy of the right ventricle, because of the high blood pressure in the right ventricle. The defects cause congenital cyanosis and considerably limit activity; patients with severe untreated abnormalities die. Once the diagnosis has been made, most children can be successfully treated surgically.

Most children find that assuming the squatting position after physical activity relieves their breathlessness. This happens because squatting reduces the venous return by compressing the abdominal veins and increasing the systemic arterial resistance by kinking the femoral and popliteal arteries in the legs; both these mechanisms tend to decrease the right-to-left shunt through the ventricular septal defect and improve the pulmonary circulation.

Mitral Valve Prolapse

In this condition, one or both mitral valve cusps balloon up into the left atrium during ventricular systole. The valve cusps are larger than normal and the chordae tendineae may be excessively long. The posterior cusp is always involved; the anterior cusp is involved less frequently. The majority of the patients are female, and there may be a familial incidence of the syndrome. The typical symptoms are chest pain and palpitations, and dysrhythmias may occur.



CD Figure 4-3 **A.** Normal fetal heart. **B.** Atrial septal defect. **C.** Tetralogy of Fallot. **D.** Patent ductus arteriosus (note the close relationship to the left recurrent laryngeal nerve). **E.** Coarctation of the aorta.

Bicuspid Aortic Valve

This is a congenital anomaly occurring in 1% to 2% of the population. At first it causes no functional problems. However, with advancing years and continued wear and tear, the valve cusps become damaged and undergo fibrosing stenosis and calcification. The valve is also prone to the development of infective endocarditis.

Persistent Truncus Arteriosus

This condition represents about 1% of all congenital heart defects. Only one artery arises from the heart, the pulmonary artery and aorta sharing a common trunk. A large ventricular septal defect is usually present. The child exhibits mild cyanosis and heart failure. Surgical correction of the ventricular septal defect and the

establishment of a separate pulmonary and aortic outflow are necessary.

Patent Ductus Arteriosus

The ductus arteriosus represents the distal portion of the sixth left aortic arch and connects the left pulmonary artery to the beginning of the descending aorta (see CD Fig. 4-3). During fetal life, blood passes through it from the pulmonary artery to the aorta, thus bypassing the lungs. After birth, it normally constricts, later closes, and becomes the ligamentum arteriosum.

Failure of the ductus arteriosus to close may occur as an isolated congenital abnormality or may be associated with congenital heart disease. A persistent patent ductus arteriosus results in high-pressure aortic blood passing into the pulmonary artery, which raises the pressure in the pulmonary circulation. A patent ductus arteriosus is life threatening and should be ligated and divided surgically.

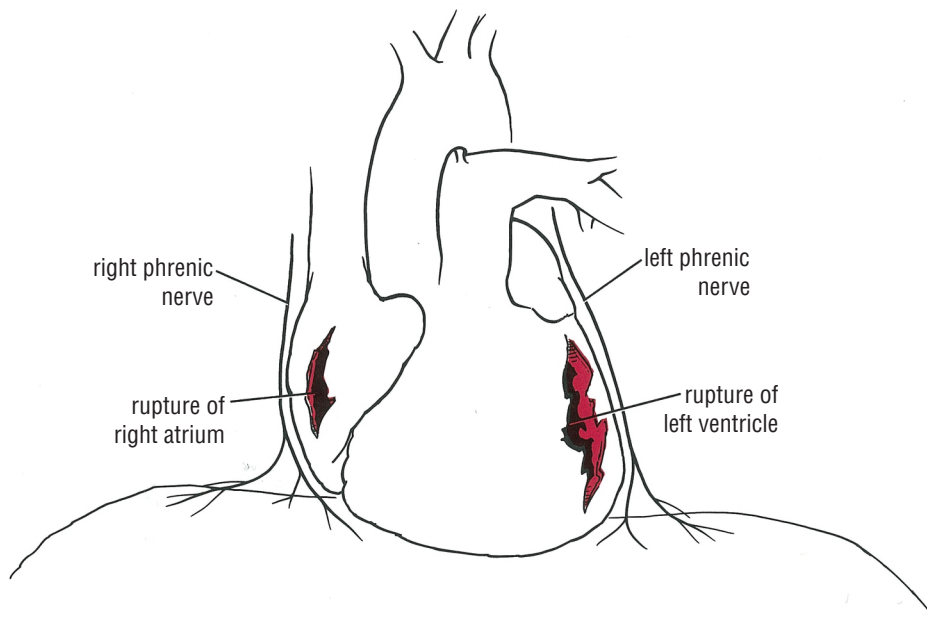


THE PERICARDIUM

Traumatic Injury to the Pericardium

Pericardial Disruption

This may occur from blunt trauma from a puncture following penetration by a fractured rib and rupture from a sudden increase in pressure. The most common location of rupture is along the lateral margins, especially on the left side. The phrenic nerve may be involved, as it is situated between the mediastinal parietal pleura and the pericardium (CD Fig. 4-4)



CD Figure 4-4 Anterior view of the heart showing common sites for rupture of the pericardium on the anterior surface. Note the position of the right and left phrenic nerves.

Hemopericardium

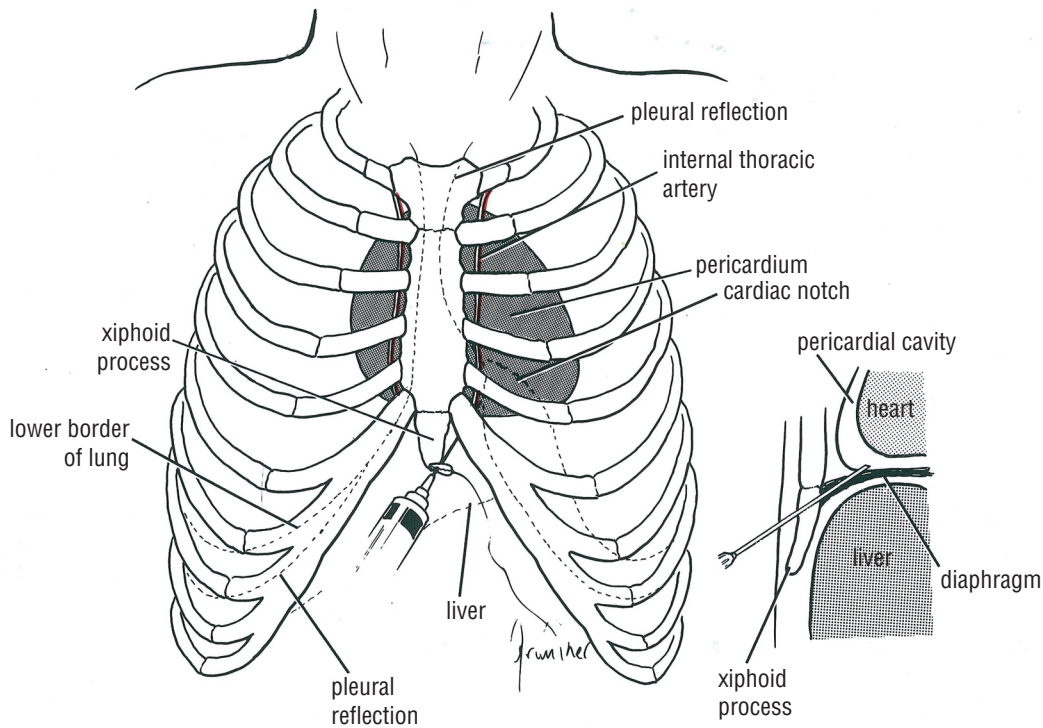
With blunt or penetrating injuries to the heart, blood can escape into the pericardial cavity. The normal volume of pericardial fluid, about 50 mL, is used to lubricate the apposing surfaces of the serous pericardium during heart movements. Once the fluid in the cavity exceeds about 250 mL, the diastolic filling is compromised, a condition known as **cardiac tamponade**.

Pericardiocentesis

This procedure is used in the treatment of cardiac tamponade.

The patient is placed in a supine position with the shoulders raised 60° from the horizontal position. The usual skin preparation is now completed. The needle is inserted in the angle between the xiphoid process and the left costal margin. With the positions of the cardiac notches of the lungs and pleura in mind (CD Fig. 4-5), the tip of the needle is directed upward, backward, and to the left in the left xiphocostal angle, that is, toward the left shoulder. The following structures will be penetrated by the needle:

1. Skin
2. Subcutaneous tissue
3. Aponeurosis of the external oblique muscle of the abdomen
4. Anterior lamina of the aponeurosis of the internal oblique muscle of the abdomen
5. Rectus abdominis muscle



CD Figure 4-5 A and B. The xiphisternal approach for pericardiocentesis. Note that the needle is aimed upward and backward in the direction of the left shoulder.

6. Posterior lamina of the aponeurosis of the internal oblique and the transversus abdominis muscles
7. Extraperitoneal fat; avoid entering the peritoneal cavity
8. Diaphragm
9. Pericardium (fibrous pericardium and parietal serous pericardium)

The long large-bore needle is advanced through the above structures and when pericardial penetration is achieved there is a sudden “give.” The needle is connected to a 20-mL syringe with a three-way stopcock to permit aspiration of the fluid.

Anatomy of Complications

1. The needle is advanced too far and enters the myocardium of the right ventricle.
2. The needle pierces the anterior descending branch of the left coronary artery.
3. The needle enters the pleural cavity, producing a pneumothorax or a hydropneumothorax.
4. The needle pierces the liver.

Clinical Problem Solving Questions

Read the following case histories/questions and give the best answer for each.

A 61-year-old man was seen in the emergency department complaining of a feeling of pressure within his chest. On questioning, he said that he had several attacks before and that they had always occurred when he was climbing stairs or digging in the garden. He found that

the discomfort disappeared with rest after about 5 minutes. The reason he came to the emergency department was that the chest discomfort had occurred with much less exertion.

1. The following comments concerning this case are correct **except** which?
 - A. The diagnosis is a classic case of angina pectoris.

- B. The sudden change in history, that is, pain caused by less exertion, should cause the physician concern that the patient now has unstable angina or an actual myocardial infarction.
- C. The afferent pain fibers from the heart ascend to the central nervous system through the cardiac branches of the sympathetic trunk to enter the spinal cord.
- D. The afferent pain fibers enter the spinal cord via the posterior roots of the tenth to the twelfth thoracic nerves.
- E. Pain is referred to dermatomes supplied by the upper four intercostal nerves and the intercostal brachial nerve.

A 55-year-old woman has severe aortic incompetence, with the blood returning to the cavity of the left ventricle during ventricular diastole.

- 2. To hear the aortic valve with the least interference from the other heart sounds, the best place to place your stethoscope on the chest wall is
 - A. the right half of the lower end of the body of the sternum.
 - B. the medial end of the second right intercostal space.
 - C. the medial end of the second left intercostal space.
 - D. the apex of the heart.
 - E. the fifth left intercostal space 3.5 in. (9 cm) from the midline.

A 33-year-old woman was jogging across the park at 11 PM when she was attacked by a gang of youths. After she was brutally mugged and raped, one of the youths decided to stab her in the heart to keep her silent. Later in the emergency department she was unconscious and in extremely poor shape. A small wound about 0.5 in. in diameter was present in the left fifth intercostal space about 0.5 in. from the lateral sternal margin. Her carotid pulse was rapid and weak, and her neck veins were distended. No evidence of a left-sided pneumothorax existed. A diagnosis of cardiac tamponade was made.

- 3. The following observations are in agreement with the diagnosis **except** which?
 - A. The tip of the knife had pierced the pericardium.
 - B. The knife had pierced the anterior wall of the left ventricle.
 - C. The blood in the pericardial cavity was under right ventricular pressure.
 - D. The blood in the pericardial cavity pressed on the thin-walled atria and large veins as they traversed the pericardium to enter the heart.
 - E. The backed-up venous blood caused congestion of the veins seen in the neck.
 - F. The poor venous return severely compromised the cardiac output.
 - G. A left-sided pneumothorax did not occur because the knife passed through the cardiac notch.

A 38-year-old woman was taken from the scene of an automobile accident to the local hospital. She had been driving her car without a seat belt on and had hit a utility pole head on. On examination she was conscious and alert but had sustained severe facial and chest injuries. A careful examination of the chest cage revealed the presence of a sternal fracture (middle of the body) and fractures of the third and fourth left ribs near their costochondral junctions. After an extensive workup it was decided that the patient had a ruptured pericardium.

- 4. The following observations are in agreement with the diagnosis **except** which?
 - A. Blunt trauma had been applied to the anterior chest wall.
 - B. The fractures of the third and fourth left ribs were situated over the anterior surface of the heart.
 - C. The left dome of the diaphragm was paralyzed.
 - D. The patient had tachycardia.
 - E. The right lateral margin of the pericardium was the site of the rupture.
 - F. There were diminished breath sounds over the lower lobe of the left lung.

A 21-year-old man was walking along a city street when suddenly a burst of automatic gunfire came from a passing car. The man, who was an innocent bystander, was struck in the front of the chest by a stray bullet. He was rushed to the emergency department by an ambulance. The position of the entry wound was the fourth left intercostal space about 3 in. from the midline.

- 5. The following observations are in agreement with the findings in this patient **except** which?
 - A. The right ventricle is the most likely chamber of the heart to be injured should a bullet enter the frontal surface of the chest.
 - B. If the bullet continues on its path, the left ventricle is also damaged, since the left ventricle lies posterior to the right ventricle.
 - C. The circumflex branch of the left coronary artery may be damaged by the bullet as it runs down the anterior surface of the heart.
 - D. The chordae tendineae of the anterior cusp of the tricuspid valve could be injured.

A 5-year-old boy was seen in the emergency room following an attack of breathlessness during which he had lost consciousness. The mother, on questioning, said that her child had had several such attacks before and sometimes his skin had become bluish. Recently she had noticed that he breathed more easily when he was playing in a squatting position; he also seemed to sleep more easily with his knees drawn up. On physical examination, the child was found to be thinner and shorter than normal. His lips were cyanotic, and his fingers and toes were clubbed. A systolic murmur was

present along the left border of the sternum, and the heart was considerably enlarged to the right. An extensive workup, including angiography, demonstrated tetralogy of Fallot.

6. Using your knowledge of cardiac development, critically read the following observations made in this case and determine the one that is **incorrect**.
 - A. The systolic murmur heard along the left border of the sternum was caused by the pulmonary stenosis.
 - B. A right-to-left shunt of blood occurs through the large ventricular septal defect.
 - C. The aortic blood is poorly oxygenated resulting in the impaired growth of the child, the cyanosis of the lips, and the clubbing of the fingers and toes
 - D. Maintaining the squatting position during play and sleeping with the knees drawn up increases the peripheral resistance in the systemic circulation and decreases the right-to-left shunt through the ventricular septum.
 - E. If the patient had a large ductus arteriosus as well as the tetralogy of Fallot, the cyanosis would be much worse.

A 43-year-old woman was seen in the emergency department complaining of a severe localized pain over the left side of the chest. She stated that the pain started quite suddenly, about 1 hour previously, when she was reaching for a book on a high shelf. On further questioning she disclosed that she had been sailing with her

husband the previous day and that they had been caught in a storm. She described the pain as a continuous dull ache that was made worse by taking deep breaths and using the left arm. She indicated that the pain was localized over the sixth left costal cartilage about 2 in. to the left of the sternum, which corresponded to an area of tenderness over the sixth left costochondral junction.

7. The following possible conditions could explain the severe chest pain. Choose the **most likely** diagnosis based on your knowledge of anatomy.
 - A. Myocardial infarction
 - B. Lobar pneumonia of the left lung
 - C. Tearing of muscle fibers in the chest wall, possibly the serratus anterior muscle
 - D. Separation of the sixth left costochondral joint or an acute costochondritis
 - E. Left-sided pleurisy
8. The following anatomic structures are penetrated by a needle when performing a pericardiocentesis **except** which?
 - A. Skin and subcutaneous tissue
 - B. The aponeuroses of the external and internal oblique muscles
 - C. The left parietal and visceral layers of pleura
 - D. The rectus abdominis muscle
 - E. The diaphragm and fibrous pericardium

Answers and Explanations

1. **D** is the correct answer. The afferent pain fibers from the heart enter the spinal cord via the posterior nerve roots of the upper four thoracic spinal nerves.
2. **B** is the correct answer. The best location to place your stethoscope on the chest wall to hear the aortic valve is the medial end of the second right intercostal space (see CD Fig. 4-2).
3. **B** is the correct answer. The knife had pierced the anterior wall of the right ventricle.
4. **E** is the correct answer. The left lateral margin of the pericardium had ruptured, injuring the left phrenic nerve; this resulted in the paralysis of the left dome of the diaphragm and the diminished breathing heard over the lower lobe of the left lung.
5. **C** is the correct answer. The anterior interventricular (descending) branch of the left coronary artery is the most likely artery to be damaged in such a wound through the frontal surface of the chest.
6. **E** is the correct answer. The tetralogy of Fallot consists of the following: (1) a large ventricular septal defect, (2) a stenosis of the pulmonary trunk or the pulmonary valve, (3) an exit of the aorta that lies immediately above the ventricular septal defect and thus communicates with both ventricles, and (4) a right ventricular hypertrophy secondary to the ventricular septal defect and pulmonary stenosis. Should the child have a large patent ductus arteriosus, cyanosis is reduced to a minimum. This is because a large patent ductus allows aortic blood to enter the pulmonary trunk distal to the stenosis of the pulmonary artery or valve and, in this way, enables the blood to enter the pulmonary circulation for oxygenation.
7. **D** is the correct answer. Separation of the sixth left costochondral joint or an acute costochondritis can be extremely painful conditions. The injury must have occurred when the patient was pulling on the ropes of the sailing boat during the storm on the previous day. The

joint is innervated by the sixth intercostal nerve and the pain is localized over the affected joint. This case is a good example of somatic pain that may be intense and localized, in contradistinction to visceral pain, which is diffuse and poorly localized.

8. C is the correct answer. By placing the needle correctly in the angle between the xiphoid process and the left

costal margin and directing the tip of the needle upward, backward, and to the left toward the left shoulder, the left pleura is not pierced. By passing the needle through the cardiac notches of the left lungs and pleura both these structures are avoided (see CD Fig. 4-5). Entry of the needle into the pleural cavity produces a pneumothorax or hydropneumothorax.



5

The Blood Vessels of the Thorax



Chapter Outline

Large Arteries of the Thorax	78	Coarctation of the Aorta	82
The Aorta	78	Double Aorta and Right Aortic Arch	82
Ascending Aorta and the Pericardium	78	Large Veins of the Thorax	83
Aneurysm of the Arch of the Aorta	78	Penetrating Injuries	83
Coarctation of the Aorta	78	Migrating Bullets	83
Trauma to the Aorta in the Thorax	78	Superior Vena Cava or Brachiocephalic Vein Thrombosis	83
<i>Deceleration Injuries</i>	78	Important Connections between the Superior and Inferior Venae Cavae	83
<i>Penetrating Injuries of the Aorta</i>	79	Embryologic Note: Fetal Circulation and Changes in Fetal Circulation at Birth	83
<i>The Descending Thoracic Aorta and the Esophagus in Posterior Thoracotomy</i>	79	Fetal Circulation	83
The Descending Thoracic Aorta and Left Hemothorax	79	Changes in the Fetal Circulation at Birth	84
Aortic Dissection	79	Physiologic Note: Blood Flow in the Umbilical Cord after Delivery	84
The Pulmonary Trunk	80	Physiologic Note: The Heart in the Newborn	87
Penetrating Injuries of the Pulmonary Trunk	80	Clinical Problem Solving Questions	87
Pulmonary Artery (Swan-Ganz) Catheterization	80	Answers and Explanations	87
Pulmonary Embolism	80		
Embryologic Note: Detailed Development of the Large Arteries of the Thorax and the Ductus Arteriosus	81		
Congenital Anomalies	82		
Patent Ductus Arteriosus	82		



LARGE ARTERIES OF THE THORAX

The Aorta

Ascending Aorta and the Pericardium

The entire ascending aorta lies within the pericardial sac. Consequently, tear or rupture of this part of the aorta results in a massive outpouring of blood into the pericardial cavity, producing cardiac tamponade.

Aneurysm of the Arch of the Aorta

The arch of the aorta lies behind the manubrium sterni. A gross dilatation of the aorta (aneurysm) may show itself as a pulsatile swelling in the suprasternal notch.

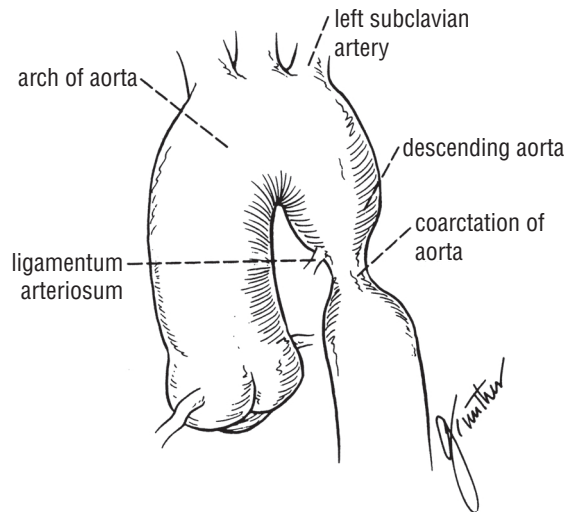
Coarctation of the Aorta

Coarctation of the aorta is a congenital narrowing of the aorta just proximal, opposite, or distal to the site of attachment of the ligamentum arteriosum (CD Fig. 5-1). Clinically, the cardinal sign of aortic coarctation is absent or diminished pulses in the femoral arteries of both lower limbs. To compensate for the diminished volume of blood reaching the lower part of the body, an enormous collateral circulation develops, with dilatation of the internal thoracic, subclavian, and posterior intercostal arteries. The dilated intercostal arteries erode the lower borders of the ribs, producing characteristic notching, which is seen on radiographic examination. The condition should be treated surgically.

Trauma to the Aorta in the Thorax

Deceleration Injuries

The heart is suspended from the aorta much like a weight attached to the end of a curved piece of flexible tubing.



CD Figure 5-1 Coarctation of the aorta.

In **horizontal deceleration injuries** the movement of the body is suddenly stopped and the heart continues to move forward within the pericardial sac. The descending thoracic aorta from the point of origin of the left subclavian artery onward is firmly attached to the vertebral column by connective tissue and pleura. As the heart continues to move forward on body impact, the curve of the arch of the aorta is slightly straightened and the vessel shears just distal to the origin of the left subclavian artery. The aorta may be completely transected and be accompanied by a massive hemorrhage. If the trauma to the aorta is less, a tear may occur in the aortic wall, leaving the more resilient outer connective tissue coat intact. Blood then dissects between the layers of the aortic wall, producing a **false aneurysm**.

In **vertical deceleration injuries**, as in falls from a height, the violent pull of the heart on the end of the aortic arch causes a tear in the inner coat of the aortic wall at the root of the ascending aorta. If rupture of the ascending aorta should ensue, the aortic blood would burst into the pericardial sac, causing immediate cardiac tamponade. The ascending aorta together with the pulmonary trunk is surrounded only by a thin sleeve of serous pericardium and by the fibrous pericardium. Once the sleeve of serous pericardium gives way, the blood enters the pericardial cavity, causing cardiac tamponade. Most of these injuries are fatal.

Penetrating Injuries of the Aorta

Penetrating vascular injuries are likely to occur when the entrance and exit wounds are on opposite sides of the chest, indicating that the bullet has crossed the midline of the chest. Penetrating injuries involving blood vessels and not the heart have the highest mortality when they occur in the superior mediastinum; here the aortic arch gives rise to its major branches, and the superior vena cava and brachiocephalic veins are present.

The Descending Thoracic Aorta and the Esophagus in Posterior Thoracotomy

The relationship of the aorta and the esophagus in the posterior mediastinum is important when distinguishing between these structures when performing an emergency thoracotomy.

The Descending Thoracic Aorta and Left Hemothorax

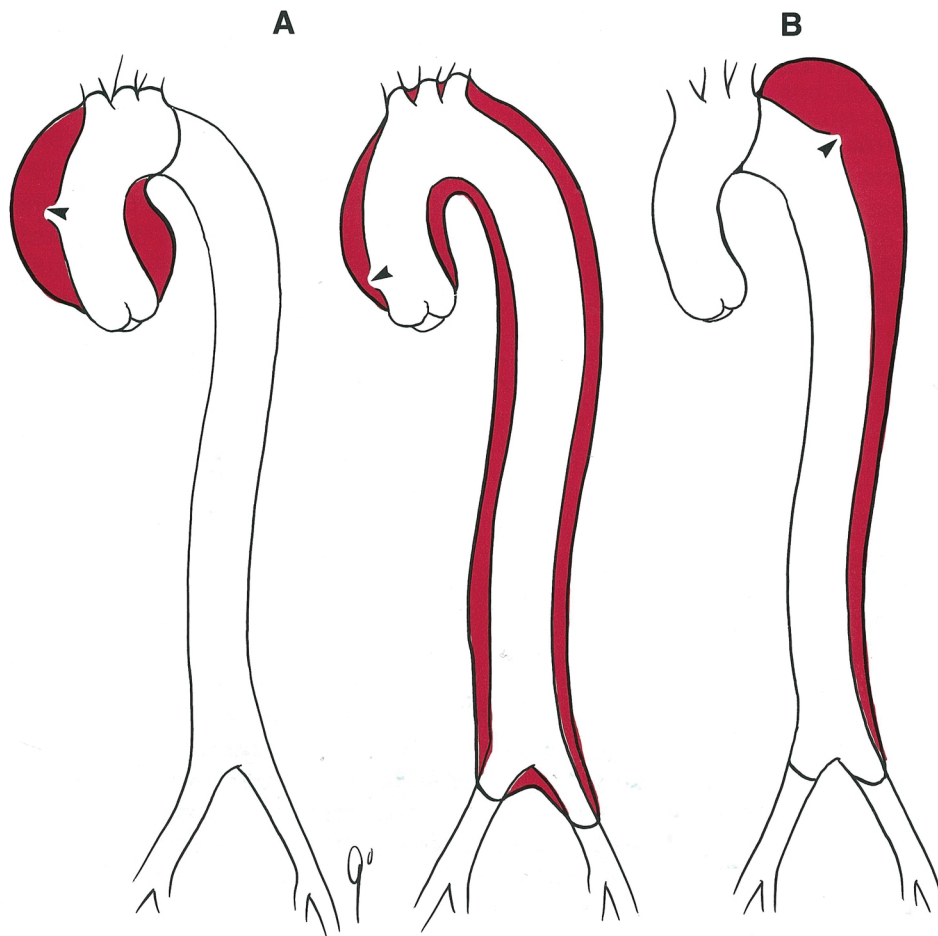
The close relationship of the descending thoracic aorta to the left pleura and lung means that rupture of the aorta may occur into the left pleural cavity, producing a massive hemothorax.

Aortic Dissection

This is the most serious and difficult form of aortic disease to treat (CD Fig. 5-2). Degeneration of the tunica media of the aortic wall is believed to be the basic cause, and the condition is associated with a history of hypertension in the majority of patients. Marfan's disease can also be responsible for the degeneration. Hemorrhage occurs through the tunical intima and extends as an expanding hematoma between the middle and outer thirds of the tunica media. The initial tear may occur anywhere along the thoracic aorta. **Type A (proximal dissection)** involves the ascending aorta or ascending and descending aorta (see CD Fig. 5-2). **Type B (distal dissection)** does not involve the ascending aorta and usually begins distal to the left subclavian artery. The clinical signs and symptoms will depend on the type of aneurysm present and the extent of distal propagation.

The sudden onset of excruciating, sharp, tearing pain localized to the front or the back of the chest and back is a typical presenting symptom. It must be assumed that the pain impulses originate in the aortic wall, ascend to the central nervous system along with the sympathetic nerves, and enter the spinal cord through the posterior roots of the segmental spinal nerves. The pain is then referred along the somatic spinal nerves of the same segments. The number of dermatomes involved will depend on the extent of the dissection. If the dissection continues to spread distally, the pain may be felt segmentally in the abdomen, lower back, and legs.

An aneurysm of the ascending aorta has the highest mortality since it may rupture into the pericardial cavity, producing immediate cardiac tamponade; it may rupture into the mediastinum or pleural cavities; it may extend into the coronary arteries, causing occlusion; or it may extend to the aortic valve, producing acute aortic incompetence. Involvement of the brachiocephalic, left common carotid, or left subclavian arteries at their origin from the aortic arch may give rise to symptoms of cerebral ischemia or upper limb ischemia.



CD Figure 5-2 Aortic dissection. Type A (proximal dissection) involves the ascending aorta or ascending and descending aorta. Type B (distal dissection) does not involve the ascending aorta.

An aneurysm of the descending thoracic aorta can rupture into the pleural cavity on the left side. If the dissection progresses distally to involve the abdominal aorta, occlusion of the mesenteric arteries could result in bowel infarction, and occlusion of the renal arteries could result in renal failure. Ischemic necrosis of the spinal cord resulting in paraplegia could follow blockage of the posterior intercostal arteries arising from the thoracic aorta or the lumbar arteries arising from the abdominal aorta.

Rupture of the aneurysm below the diaphragm may produce catastrophic retroperitoneal hemorrhage.

The Pulmonary Trunk

Penetrating Injuries of the Pulmonary Trunk

Any missile injury with entry or exit wounds close to the manubrium sterni may damage the pulmonary trunk or any other vessel in the superior mediastinum. Remember that the pulmonary trunk and the ascending aorta together are surrounded by a sheath of serous pericardium within the fibrous pericardium (see text Fig. 4-21), so that hemorrhage

into the pericardial cavity from either of these vessels could result in cardiac tamponade.

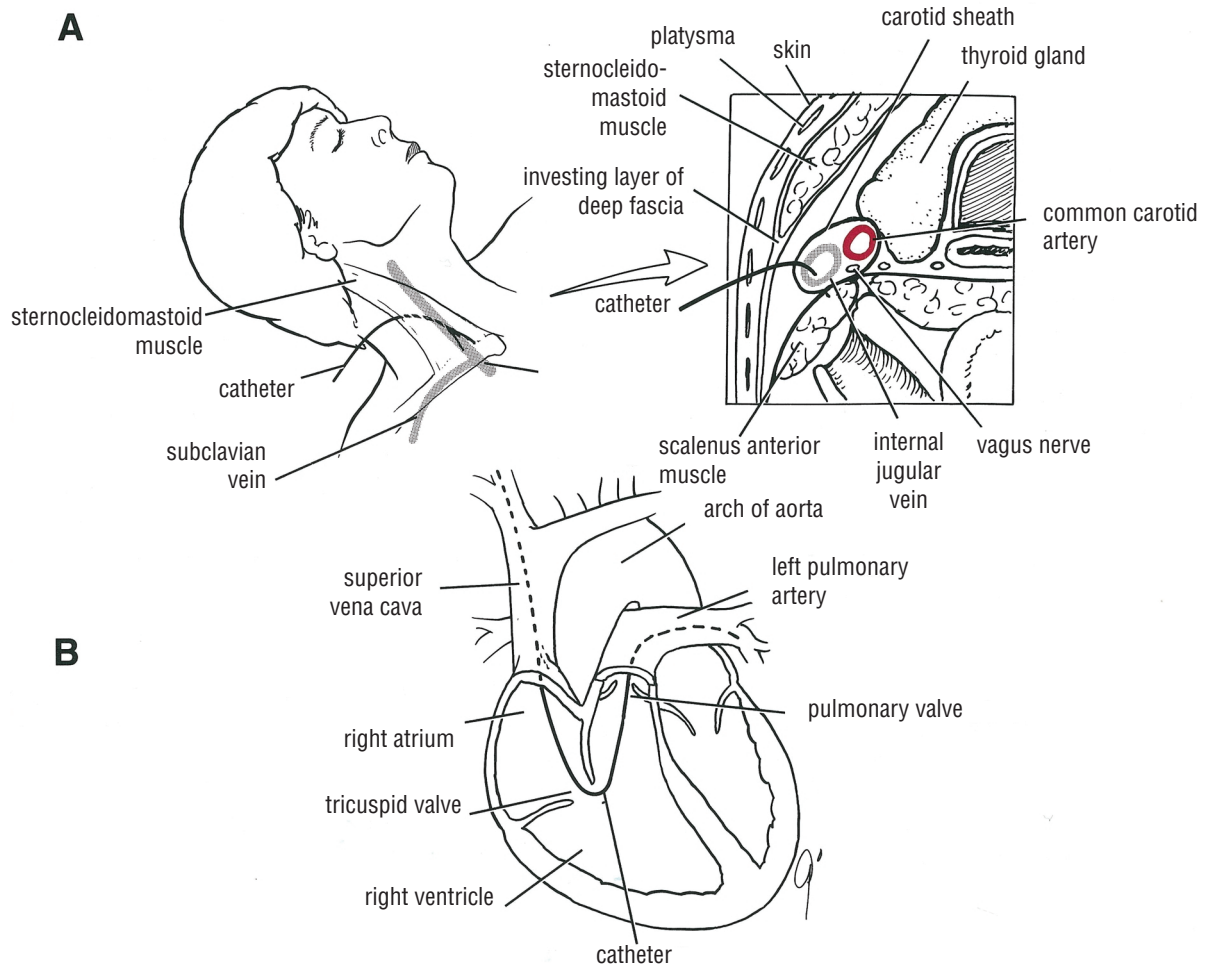
Pulmonary Artery (Swan-Ganz) Catheterization

The pulmonary artery catheter is used to assess left and right ventricular function, measure pulmonary artery and right and left atrial pressures, measure cardiac output, and take samples of right atrial and pulmonary arterial blood.

The catheter is introduced through the right internal jugular vein, right subclavian vein, right basilic vein, or the femoral vein. The catheter is advanced into the right atrium through the tricuspid valve into the right ventricle (CD Fig. 5-3). The balloon is advanced into the pulmonary trunk and then into the left pulmonary artery.

Pulmonary Embolism

In the great majority of patients, the pulmonary emboli arise from a thrombosis in the large deep veins of the lower extremity, especially from the femoral veins, and from the internal iliac veins in the pelvis. Thromboses in the veins of the calf muscles following prolonged immobility, such as



CD Figure 5-3 Pulmonary artery (Swan-Ganz) catheterization. **A.** The catheter has been introduced through the right internal jugular vein (posterior approach). **B.** Diagram showing the course taken by the catheter through the right side of the heart into the pulmonary trunk and the left pulmonary artery.

commonly occurs in long-distance plane flights, may be the origin of pulmonary emboli.

EMBRYOLOGIC NOTE

Detailed Development of the Large Arteries of the Thorax and the Ductus Arteriosus

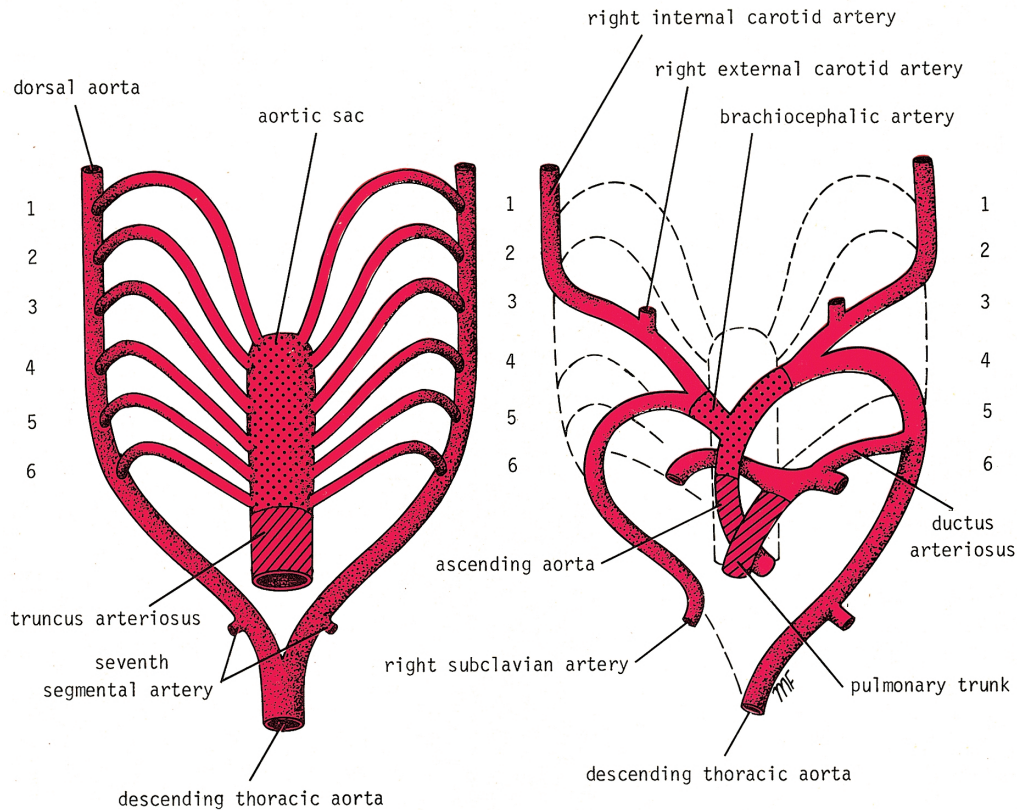
The truncus arteriosus, which is the distal part of the bulbus cordis (CD Fig. 5-4) is continuous beyond the pericardium with a large vessel called the **aortic sac**. This sac gives off two branches, each of which runs dorsally in the first pharyngeal arch on each side in the developing embryo. The branches then pass caudally in the posterior wall of the embryo as the two **dorsal aortae**. Five additional arteries now join the aortic sac to the dorsal aortae (see CD Fig. 5-4). Meanwhile, the two dorsal aortae fuse throughout much of their lengths to form the **descending thoracic aorta** and the **abdominal aorta**.

The **ascending aorta** below the right pulmonary artery and the main pulmonary trunk are derived from the truncus arteriosus (see CD Fig. 5-4). The aorta, from the level of the right pulmonary artery up to the level of the left common carotid artery, is derived from the aortic sac.

The **brachiocephalic artery** also is formed from the aortic sac. The remainder of the **arch of the aorta** is formed from the left fourth aortic arch artery and the left dorsal aorta (see CD Fig. 5-4).

The fourth right aortic arch artery becomes the root of the **right subclavian artery**, which also is derived in sequence from a small part of the right dorsal aorta and the right seventh segmental artery.

The third aortic arch artery on both sides becomes the **common carotid artery**; this sends off a bud of mesenchyme that becomes the **external carotid artery**. The remainder of the third aortic arch artery and part of the dorsal aorta form the **internal carotid artery** on each side.



CD Figure 5-4 The formation and fate of the aortic arch arteries.

The first, second, and fifth aortic arch arteries disappear completely. The **right and left pulmonary arteries** are formed from the sixth aortic arch arteries. The distal part of the right sixth aortic arch artery disappears, while the remainder of the left sixth aortic arch artery becomes the important **ductus arteriosus**, which after birth becomes the **ligamentum arteriosum**.

The **descending thoracic aorta** below the level of the fourth thoracic vertebra is formed from the fusion of the dorsal aortae (see CD Fig. 5-4).

Congenital Anomalies

Patent Ductus Arteriosus

The ductus arteriosus represents the distal portion of the sixth left aortic arch and connects the left pulmonary artery to the beginning of the descending aorta (see CD Fig. 5-4). During fetal life, blood passes through it from the pulmonary artery to the aorta, thus bypassing the lungs. After birth, it normally constricts, later closes, and becomes the **ligamentum arteriosum**.

Failure of the ductus arteriosus to close may occur as an isolated congenital abnormality or may be associated

with congenital heart disease. A persistent patent ductus arteriosus results in high-pressure aortic blood passing into the pulmonary artery, which raises the pressure in the pulmonary circulation. A patent ductus arteriosus is life threatening and should be ligated and divided surgically.

Coarctation of the Aorta

Coarctation of the aorta is a congenital narrowing of the aorta just proximal, opposite, or distal to the site of attachment of the ligamentum arteriosum (see CD Fig. 5-1). This condition is believed to result from an unusual quantity of ductus arteriosus muscle tissue in the wall of the aorta. When the ductus arteriosus contracts, the ductal muscle in the aortic wall also contracts, and the aortic lumen becomes narrowed. Later, when fibrosis takes place, the aortic wall also is involved, and permanent narrowing occurs.

Double Aorta and Right Aortic Arch

Anomalies involving double parts of the arterial system are rare conditions that result from the persistence of aortic arch arteries, which normally disappear. In the case of the right aortic arch, the development of the left arch does not take place.



LARGE VEINS OF THE THORAX

Penetrating Injuries

As has been emphasized before with arterial injuries, the highest mortality can occur in penetrating injuries in the region of the superior mediastinum. Behind the manubrium sterni lie not only the aortic arch and its large branches but also the right and left brachiocephalic veins and the superior vena cava. Moreover, the thoracic cage may hide the extent of the bleeding, which may take place entirely within the thoracic cavity. The cage also renders the veins relatively inaccessible to the operating physician.

Migrating Bullets

Bullets entering a large artery or vein may migrate with the blood from their site of entrance. Bullets in the aorta can migrate to the distal branches until they become wedged, causing blockage and ischemia. In the same manner, a bullet entering a pulmonary vein can migrate to the left atrium and left ventricle and enter the systemic circulation. A bullet entering the superior vena cava can migrate into the right atrium and right ventricle and enter the pulmonary circulation. Paradoxical movement of bullets through a patent atrial septum has been reported.

Superior Vena Cava or Brachiocephalic Vein Thrombosis

This condition usually results from compression of the veins by tumors in the superior mediastinum; enlarging lymph node metastases secondary to a bronchial carcinoma is a common cause. Venous blockage results in engorgement of the veins of the head and neck.

Important Connections between the Superior and Inferior Venae Cavae

In obstruction of the superior or inferior venae cavae, the azygos veins provide an alternative pathway for the return of venous blood to the right atrium of the heart. This is possible since these veins and their tributaries connect the superior and inferior venae cavae (CD Fig. 5-5).

EMBRYOLOGIC NOTE

Fetal Circulation and Changes in Fetal Circulation at Birth

Fetal Circulation

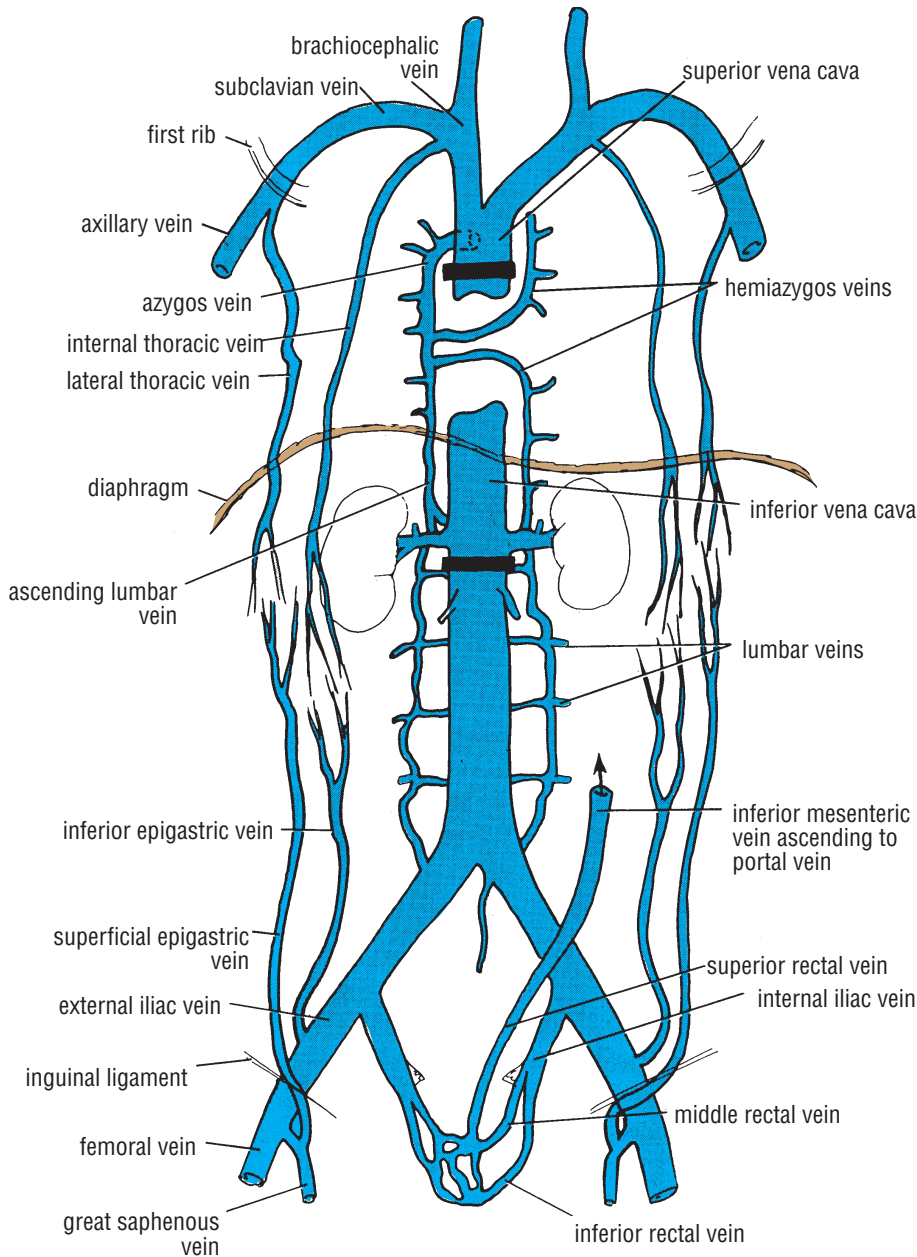
Starting at the placenta, the fetal blood may be traced in the circulation as follows:

Having circulated through the capillaries of the placental villi, the fetal blood returns through the umbilical vein to the fetus about 80% saturated with oxygen and containing many important nutrients, antibodies, and hormones (CD Fig. 5-6). The oxygenated blood then passes toward the liver. However, the greater volume of it bypasses the liver, since this organ is not fully functioning, and travels to the inferior vena cava by way of the **ductus venosus**. The remainder is distributed to the liver sinusoids by offshoots of the umbilical vein, and this in turn passes to the inferior vena cava by the hepatic veins. At the same time, the ductus venosus receives poorly oxygenated blood from the gut by way of the left branch of the portal vein. In addition, the inferior vena cava already contains venous blood from the lower part of the trunk and the lower limbs of the fetus. As a consequence of this admixture of blood from these various sources, the inferior vena cava contains blood about 67% saturated with oxygen.

Before considering the further passage of the fetal blood, it is necessary to examine the anatomic arrangement of the inferior vena cava and its relationship with the right and left atria in the fetal heart (CD Fig. 5-7). In the fetus, the opening of the inferior vena cava into the right atrium lies directly opposite the **foramen ovale**. Thus, blood entering the heart through the inferior vena cava is directed through the foramen ovale and enters the left atrium. This process is assisted by the presence of the **valve of the inferior vena cava**.

The nutritious oxygenated fetal blood, on reaching the foramen ovale, is divided into two streams by the **crista dividens**, which is the lower margin of the **septum secundum**. The greater volume of blood enters the left atrium, and the remainder, joined by venous blood from the superior vena cava and coronary sinus, passes from the right atrium into the right ventricle.

The oxygenated blood in the left atrium is joined by a relatively small volume of blood from the nonaerated fetal lungs. The left atrial blood then passes into the left ventricle and out into the aorta. The oxygen saturation of this blood is about 62%. This is distributed chiefly to the arteries of the head, neck, and upper extremities. Thus, it is apparent that blood that is richer in oxygen and nutrients is transported to the cephalic region rather than the caudal regions of the fetus.



CD Figure 5-5 The possible collateral circulations of the superior and inferior venae cavae. Note the alternative pathways that exist for blood to return to the right atrium of the heart if the superior vena cava becomes blocked below the entrance of the azygos vein (*upper black bar*). Similar pathways exist if the inferior vena cava becomes blocked below the renal veins (*lower black bar*). Note also the connections that exist between the portal circulation and systemic veins in the anal canal.

Meanwhile, the right ventricular blood passes into the pulmonary trunk. Only a small portion of this passes into the unexpanded lungs, since the vascular resistance is high. Most of the blood bypasses the lungs by being directed through the wide channel, the **ductus arteriosus**, into the descending thoracic aorta (see CD Fig. 5-6).

The now relatively poor oxygenated blood passes down the descending thoracic and abdominal aortae and supplies the thoracic and abdominal viscera and lower limbs. The fetal blood, which by this time is loaded with waste products of metabolism and carbon dioxide, then returns to the placenta through the right and left umbilical arteries, where the waste products and carbon dioxide are eliminated and oxygen is picked up. The circulatory cycle then is repeated.

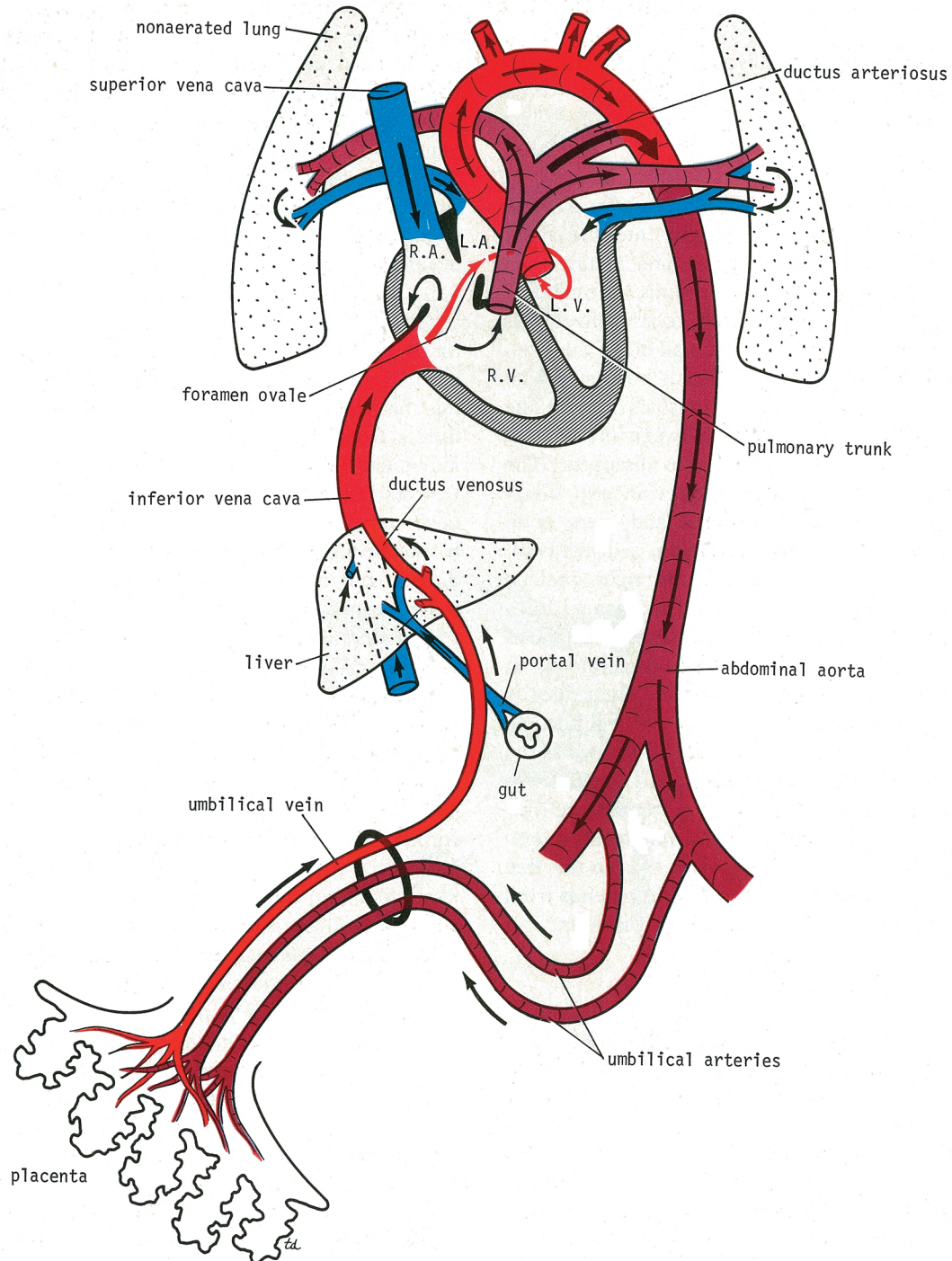
Changes in Fetal Circulation at Birth

Immediately after birth the umbilical cord is tied, thus severing the placental extension of the fetal circulation.

PHYSIOLOGIC NOTE

Blood Flow in the Umbilical Cord after Delivery

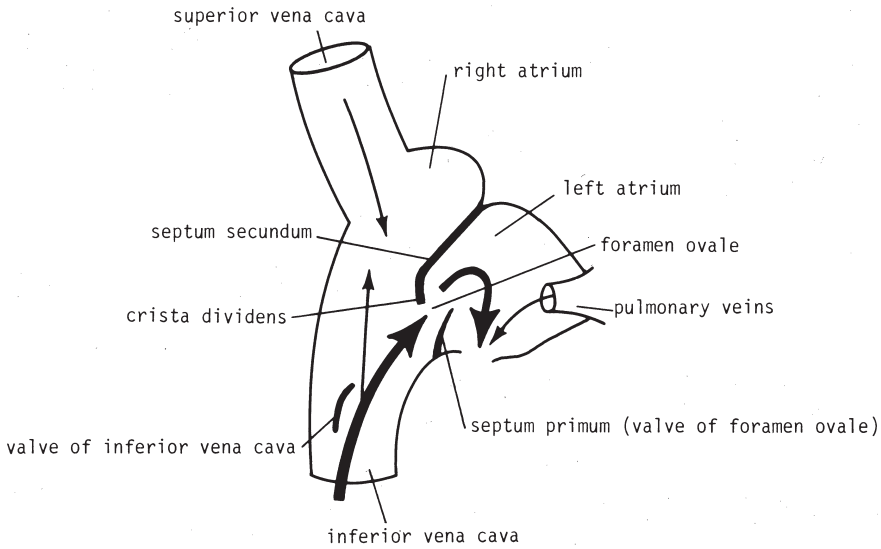
In cases in which the umbilical cord is not tied, the blood flow may continue for several minutes after delivery, although at a rapidly decreasing rate. A number of factors may contribute to this diminishing flow, including (1)



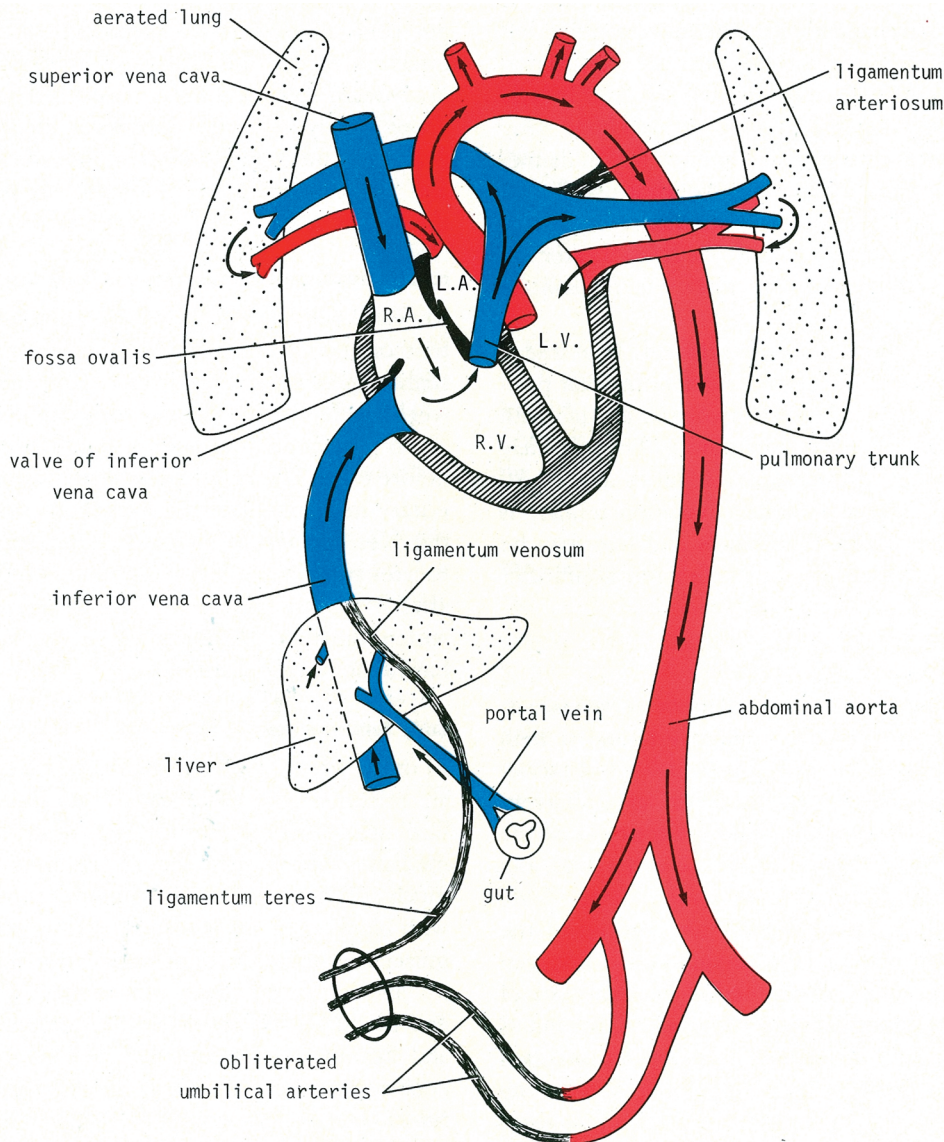
CD Figure 5-6 Fetal circulation. R.A. = right atrium, R.V. = right ventricle, L.A. = left atrium, L.V. = left ventricle.

the contraction of the uterus and the effect of this on the placental attachment and (2) constriction of the umbilical vessels as the result of mechanical stimulation or the presence in the fetal circulation of catecholamines. The fetal blood volume may be increased by as much as 100 mL if the tying of the cord is delayed. However, it generally is agreed that there is no advantage in delaying the tying beyond a minute after delivery.

The interruption of umbilical flow when the cord is tied results in an immediate fall in blood pressure in the inferior vena cava. This fact, coupled with the increased left atrial pressure from the increased pulmonary blood flow, causes the foramen ovale to close (CD Fig. 5-8). From that moment onward the valve of the foramen ovale is kept closed by the hemodynamic changes, and within a few days of birth the valve becomes attached to the edge of the foramen ovale.



CD Figure 5-7 Relationship between the opening of the inferior vena cava and the foramen ovale.



CD Figure 5-8 The circulatory system after birth. Compare this with the circulation in the fetus (CD Fig. 5-6). R.A. = right atrium, R.V. = right ventricle, L.A. = left atrium, L.V. = left ventricle.

The diminished pulmonary vascular resistance associated with inflation of the lungs cause the direction of flow (**from right to left**) through the ductus arteriosus to be changed to the neonatal route of **left to right**. The **ductus arteriosus** constricts as a reaction of its muscle to the raised oxygen tension. It later closes and becomes the **ligamentum arteriosum**. One week after birth its lumen is 2 mm or less in diameter, and by the end of the first month it usually has closed (see CD Fig. 5-8). In addition, the wall of the ductus venosus contracts and the lumen is closed. Later the ductus becomes fibrosed to form the **ligamentum venosum**.

PHYSIOLOGIC NOTE

The Heart in the Newborn

The heart in the newborn is relatively large and is higher in the thorax and in a more horizontal position than it is in later life. The pulse rate is rapid, with an average of 130 beats per minute. The rate may rise considerably with crying and fall to around 80 during sleep. The peripheral circulation initially is slow in the newborn. The hands and feet may be cold and slightly cyanotic for the first few hours after birth.

Clinical Problem Solving Questions

Read the following case histories/questions and give the best answer for each.

1. A 16-year-old girl, on examination in the doctor's office, was found to have absent pulses in both femoral arteries. In addition, her blood pressure was higher in both upper limbs than in both lower limbs. An anteroposterior radiograph of the chest showed notching of the necks of the upper ribs on both sides. What is your diagnosis? Why is there notching of the ribs?
2. Name the common sites on the thoracic aorta where damage occurs in blunt trauma. Between 80% and 90% of such injuries result in immediate death. Explain in anatomic terms the path commonly taken by the escaping blood in cases of traumatic rupture of the thoracic aorta. Name the tissues that can sometimes temporarily control the leak, thus permitting the patients to be taken to the emergency department alive.
3. A 56-year-old man was seen in the emergency department complaining of swelling of both arms. On questioning, he said that he first noticed that his hands were swollen 3 weeks earlier. He admitted being a heavy smoker and had on several occasions coughed up blood-stained sputum. On examination, his face looked puffy, especially around the eyes. Pitting edema was present in both the upper limbs, the face, and the neck. With the patient in the recumbent position, numerous dilated superficial veins were seen over the chest wall and abdomen. Later a chest radiograph revealed a large opacity in the upper lobe of the right lung. A diagnosis of advanced bronchogenic carcinoma of the right upper lobe was made. Can you explain the presence of edema in both the upper limbs, the face, and the neck? What is the cause of the dilated superficial veins of the chest and abdominal walls? Is there normally communication between the main veins draining the upper part of the body and those draining the lower half of the body?
4. A fourth-year medical student was asked by a pediatrician what factors are responsible for the closure of the foramen ovale in the atrial septum at birth. The student also was asked if oxygenated or deoxygenated blood normally passes through the foramen ovale during fetal life. How would you answer these questions?

Answers and Explanations

1. Coarctation of the aorta is a narrowing of the aorta just proximal, opposite, or distal to the site of attachment of the ligamentum arteriosum. It is believed to result from the presence of an unusual quantity of ductus arteriosus muscle tissue incorporated in the wall of the aorta. When the ductus arteriosus contracts after birth, the ductus muscle in the aortic wall also contracts and the aortic lumen becomes narrowed. Later, fibrosis occurs and permanent narrowing takes place. The notching of the lower borders of the ribs is caused by the opening up of the collateral circulation through the subclavian, internal thoracic, and posterior intercostal arteries to carry

blood from above the coarctation to the distal part of the aorta ; it is the dilated posterior intercostal arteries that notch the ribs.

2. Blunt traumatic injury to the thoracic aorta involving horizontal deceleration occurs most commonly just distal to the origin of the left subclavian artery. This site is vulnerable since the heart and the aortic arch are mobile and the descending aorta is fixed. Sudden vertical deceleration, as in a fall, may result in an intimal tear at the root of the ascending aorta; the momentum of the heart filled with blood is sufficient to produce the tear.

Rupture of the ascending aorta occurs into the pericardial cavity, producing immediate cardiac tamponade and death. Rupture of the descending thoracic aorta frequently occurs into the left pleural cavity. The tear initially occurs in the tunica intima; the tunica media and adventitia and the surrounding connective tissue and the pleura may delay the complete rupture or temporarily control the leak. If untreated, delayed rupture and death usually occur in these cases within 2 weeks.

3. The swelling of both upper extremities and the head and neck, caused by edema, and the engorgement of the superficial veins of the chest and abdominal walls

clearly indicate the presence of a superior vena caval obstruction. This obstruction was caused by the expanding metastases in the mediastinal lymph nodes secondary to the bronchogenic carcinoma. The dilated superficial veins included the lateral thoracic vein, a tributary of the axillary vein; lumbar veins, tributaries of the inferior vena cava; and the superficial epigastric vein, a tributary of the great saphenous vein of the leg that drains into the femoral vein. These venous channels provide an alternative pathway in superior vena caval obstruction, permitting superior vena caval blood to return to the heart via the inferior vena cava. The superior vena cava normally communicates with the inferior vena cava through the azygos veins. However, in this case the tumor was pressing on the superior vena cava proximal to the entrance of the azygos vein.

4. The foramen ovale is closed after birth by the valve-like flap formed by the lower part of the septum primum pressing against the septum secundum and fusing with it. This takes place as a result of a rise in blood pressure in the left atrium, which occurs once the child takes a deep breath and the pulmonary circulation is established. During fetal life, oxygenated blood passes through the foramen ovale from the right atrium to the left atrium..



6

The Blood Vessels of the Head and Neck



Chapter Outline

Large Arteries of the Head and Neck	90	Cavernous Sinus Thrombosis and Facial Infection	93
Taking the Carotid Pulse	90	Spread of Infection and the Emissary Veins	93
Carotid Sinus Sensitivity	90	Visibility of the External Jugular Vein	94
Facial Artery Pulse	90	The External Jugular Vein as Venous Manometer	94
Temporal Artery Pulse	91	External Jugular Vein Catheterization	94
Middle Meningeal Artery and Extradural Hemorrhage	91	Penetrating Wounds of the Internal Jugular Vein	94
Atherosclerosis of the Carotid Arteries and Neurologic Injury	91	Internal Jugular Vein Catheterization	94
Penetrating Neck Injuries to the Carotid Arteries	92	Subclavian Vein Thrombosis	94
Aneurysms of the Carotid Arteries	92	Subclavian Vein Catheterization	94
Cerebral Circulation and the Circle of Willis	93	Infraclavicular Approach	95
Compression of the Subclavian Artery and the Brachial Plexus at the Root of the Neck	93	<i>Anatomy of the Procedure</i>	95
Cerebrovascular Disease	93	Anatomy of Problems	96
Cerebral Ischemia	93	Anatomy of Complications	96
Internal Thoracic Artery and Coronary Bypass Operations	93	The Procedure in Children	97
Palpation and Compression of the Subclavian Artery in Patients with Upper Limb Hemorrhage	93	<i>Supraclavicular Approach</i>	97
Veins of the Head and Neck	93	Anatomy of the Procedure	98
The Sigmoid Sinus and Infection from the Mastoid Antrum	93	Anatomy of Complications	98
		Clinical Problem Solving Questions	98
		Answers and Explanations	100



LARGE ARTERIES OF THE HEAD AND NECK

Taking the Carotid Pulse

The bifurcation of the common carotid artery into the internal and external carotid arteries (see text Figs. 6-1 and 6-3) can be easily palpated just beneath the anterior border of the sternocleidomastoid muscle at the level of the supe-

rior border of the thyroid cartilage. This is a convenient site to take the carotid pulse.

Carotid Sinus Sensitivity

In cases of carotid sinus hypersensitivity, pressure on one or both carotid sinuses can cause excessive slowing of the heart rate, a fall in blood pressure, and cerebral ischemia with fainting.

Facial Artery Pulse

The facial artery (see text Fig. 6-1), as it winds around the lower margin of the mandible level with the anterior border

of the masseter, is commonly used by the anesthetist to take the patient's pulse.

Temporal Artery Pulse

The superficial temporal artery, as it crosses the zygomatic arch in front of the ear (see text Fig. 6-1), can also be used by the anesthetist to take the patient's pulse.

Middle Meningeal Artery and Extradural Hemorrhage

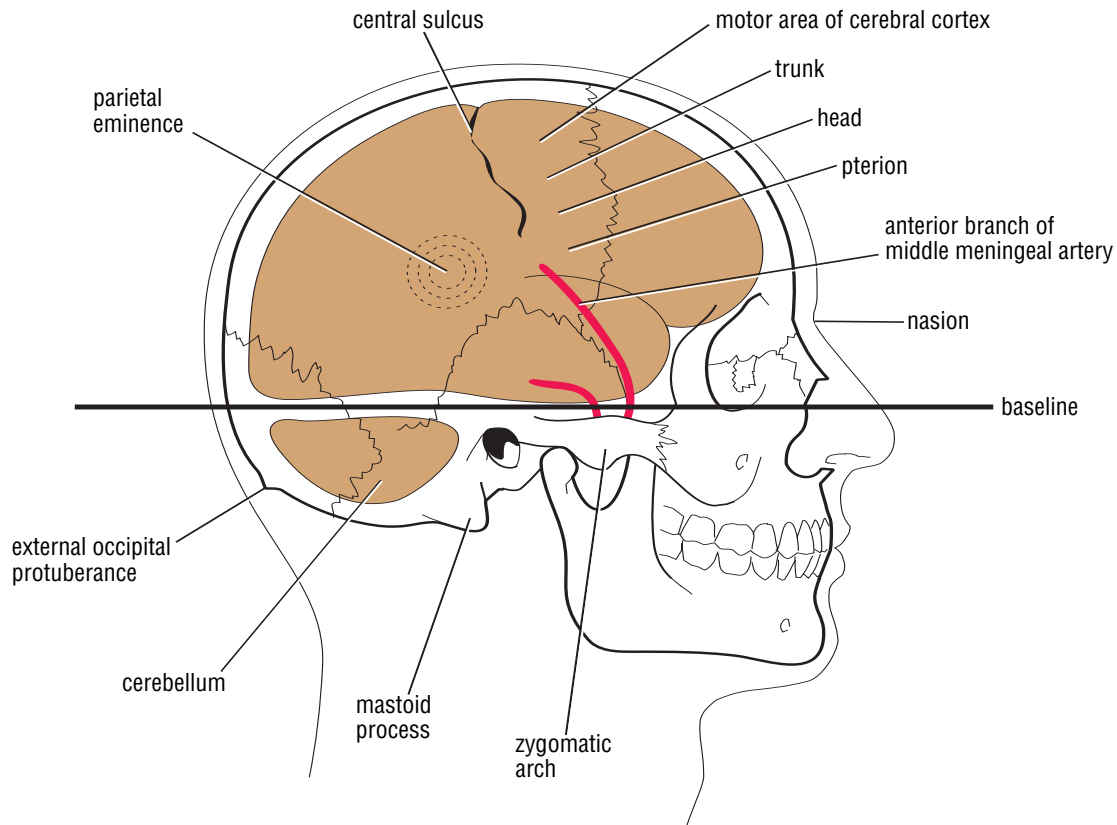
Extradural hemorrhage results from injuries to the meningeal arteries or veins. The most common artery to be damaged is the anterior division of the middle meningeal artery (CD Fig. 6-1). A comparatively minor blow to the side of the head, resulting in fracture of the skull in the region of the anteroinferior portion of the parietal bone, may sever the artery. The arterial or venous injury is especially liable to occur if the artery and vein enter a bony canal in this region. Bleeding occurs and strips up the meningeal layer of dura from the internal surface of the skull. The intracranial pressure rises, and the enlarging blood clot exerts local

pressure on the underlying motor area in the precentral gyrus. Blood may also pass outward through the fracture line to form a soft swelling under the temporalis muscle.

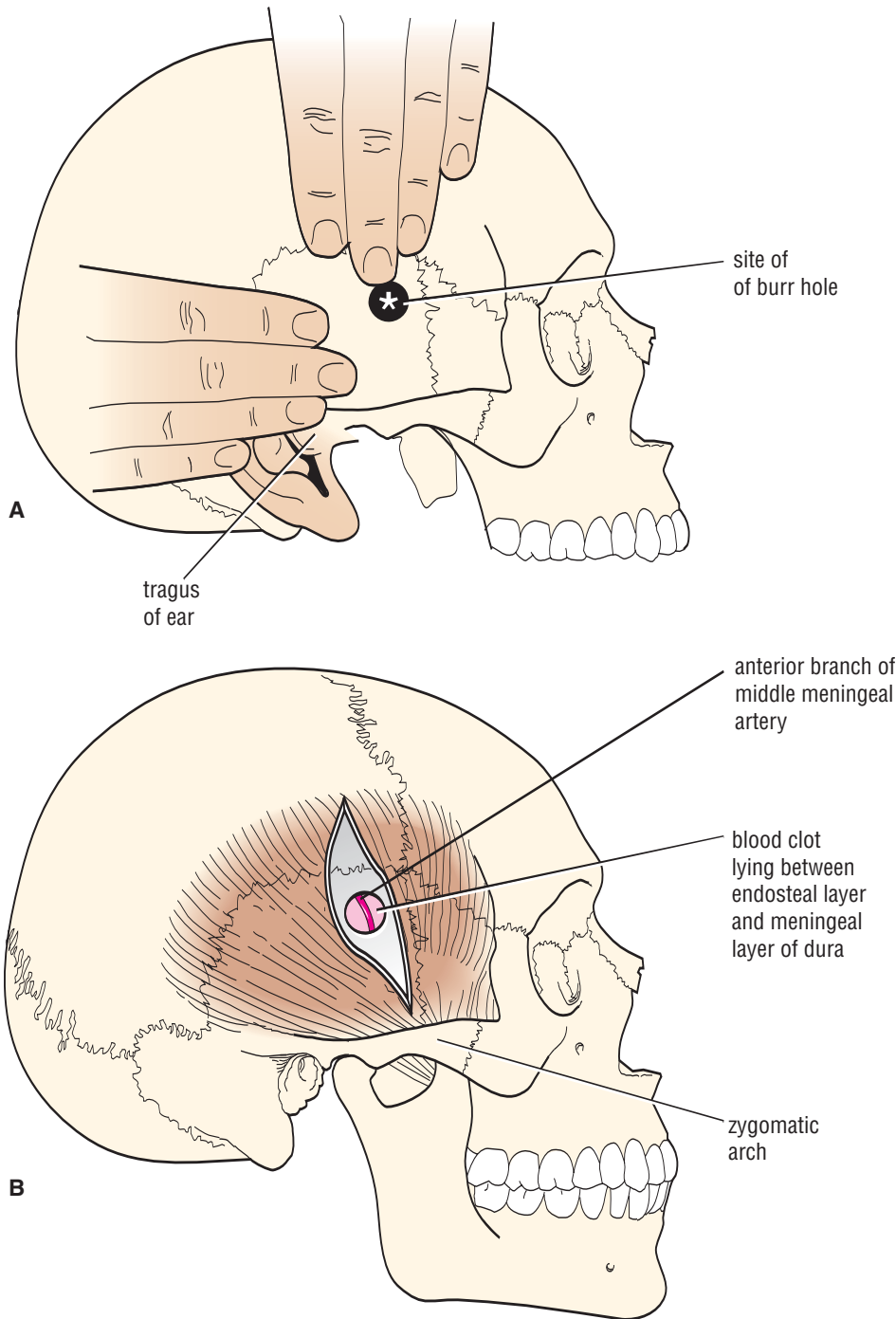
To stop the hemorrhage, the torn artery or vein must be ligated or plugged. The burr hole through the skull wall should be placed about 1 to 1.5 in. (2.5 to 4 cm) above the midpoint of the zygomatic arch (CD Fig. 6-2).

Atherosclerosis of the Carotid Arteries and Neurologic Injury

Approximately 70% of strokes are caused by extracranial arteriosclerosis of the carotid and/or vertebral arteries. In the carotid arteries the atherosclerotic thromboses usually form slowly in the distal part of the common carotid and the first parts of the external and internal carotid arteries. The result is a diminished blood flow to the central nervous system. Less commonly, emboli, formed of fragments of plaques or blood clots, are carried distally to lodge in the ipsilateral central artery of the retina or in the smaller branches of the middle cerebral artery. Such a situation could produce the classic syndrome of ipsilateral blindness and contralateral hemiplegia, although it is unusual to have both at the same time.



CD Figure 6-1 Surface landmarks on the right side of the head. The relations of the middle meningeal artery and the brain to the surface of the skull are shown.



CD Figure 6-2 **A.** Surface landmarks for a temporal burr hole. **B.** The vertical incision passes through the temporalis muscle down to bone. The middle meningeal artery lies between the endosteal and meningeal layers of dura and is embedded in the endosteal layer of dura or lies in a bony tunnel.

Penetrating Neck Injuries to the Carotid Arteries

Hemorrhage may be severe, with consequent hypotension or shock. An enlarging hematoma may press on the larynx or trachea, compromising the airway. Injuries to the internal carotid artery are usually associated with a central neurologic deficit. Injuries to the common carotid arteries are less

likely to cause neurologic problems, provided there is adequate collateral circulation through the external carotid arteries and their branches.

Aneurysms of the Carotid Arteries

Aneurysms of the carotid arteries in the neck are rare and are usually caused by arteriosclerosis. They are commonly located at the bifurcation of the common carotid artery. Expansion of

the aneurysm may create pressure on the vagus nerve (causing hoarseness), glossopharyngeal nerve (causing dysphagia), or hypoglossal nerve (causing weakness of the tongue); pressure on the sympathetic trunk as it lies behind the carotid sheath may cause Horner's syndrome. Rupture of the aneurysm resulting in hemorrhage may exert pressure on surrounding structures and compromise the airway (see text Fig. 6-5).

Cerebral Circulation and the Circle of Willis

The circle of Willis allows blood that enters by either internal carotid or vertebral arteries to be distributed to any part of both cerebral hemispheres. The arterial circle permits the blood to flow across the midline, as shown when the internal carotid or vertebral artery on one side is blocked by disease.

Compression of the Subclavian Artery and the Brachial Plexus at the Root of the Neck

At the root of the neck, the brachial plexus and the subclavian artery enter the posterior triangle through a narrow muscular-bony triangle (see text Fig. 6-2). The boundaries of the narrow triangle are formed in front by the scalenus anterior, behind by the scalenus medius, and below by the first rib. In the presence of a cervical rib, the first thoracic nerve and the subclavian artery are raised and angulated as they pass over the rib. Partial or complete occlusion of the artery causes ischemic muscle pain in the arm, which is worsened by exercise. Rarely, pressure on the first thoracic nerve causes symptoms of pain in the forearm and hand and wasting of the small muscles of the hand.

Cerebrovascular Disease

Cerebral Ischemia

Unconsciousness occurs in 5 to 10 seconds if the blood flow to the brain is completely cut off. Irreversible brain damage with death of nervous tissue rapidly follows complete arrest of cerebral blood flow. It has been estimated that neuronal function ceases after about 1 minute and that irreversible changes start to occur after about 4 minutes, although this time may be longer if the patient's body has been cooled.

Internal Thoracic Artery and Coronary Bypass Operations

In patients with occlusive coronary disease caused by atherosclerosis, the diseased arterial segment can be bypassed by

inserting a graft. The graft most commonly used is the great saphenous vein of the leg. In some patients, the myocardium can be revascularized by surgically mobilizing one of the internal thoracic arteries (see text Fig. 6-2) and joining its distal cut end to a coronary artery.

Palpation and Compression of the Subclavian Artery in Patients with Upper Limb Hemorrhage

In severe traumatic accidents to the upper limb involving laceration of the brachial or axillary arteries, it is important to remember that the hemorrhage can be stopped by exerting strong pressure downward and backward on the third part of the subclavian artery (see text Fig. 6-2). The use of a blunt object to exert the pressure is of great help, and the artery is compressed against the upper surface of the first rib.



VEINS OF THE HEAD AND NECK

The Sigmoid Sinus and Infection from the Mastoid Antrum

Infection of the mastoid antrum of the ear may spread to the sigmoid venous sinus, causing thrombosis and septicemia.

Cavernous Sinus Thrombosis and Facial Infection

The area of facial skin bounded by the nose, the eye, and the upper lip is a potentially dangerous zone to have an infection. For example, a boil in this region can cause thrombosis of the facial vein, with spread of organisms through the inferior ophthalmic veins to the cavernous sinus. The resulting cavernous sinus thrombosis may be fatal unless adequately treated with antibiotics.

Spread of Scalp Infections and the Emissary Veins

Infections of the scalp tend to remain localized and are usually painful because of the fibrous tissue in the subcutaneous layer. Occasionally, an infection of the scalp

spreads by the emissary veins (see text Fig. 6-8), which are valveless, to the skull bones, causing osteomyelitis. Infected blood in the diploic veins may travel by the emissary veins farther into the venous sinuses and produce venous sinus thrombosis.

Visibility of the External Jugular Vein

The external jugular vein is less obvious in children and women because their subcutaneous tissue tends to be thicker than the tissue of men. In obese individuals, the vein may be difficult to identify even when they are asked to hold their breath, which impedes the venous return to the right side of the heart and distends the vein.

The superficial veins of the neck tend to be enlarged and often tortuous in professional singers because of prolonged periods of raised intrathoracic pressure.

The External Jugular Vein as a Venous Manometer

The external jugular vein serves as a useful venous manometer. Normally, when the patient is lying at a horizontal angle of 30°, the level of the blood in the external jugular veins reaches about one third of the way up the neck. As the patient sits up, the blood level falls until it is no longer visible behind the clavicle.

External Jugular Vein Catheterization

The external jugular vein can be used for catheterization, but the presence of valves or tortuosity may make the passage of the catheter difficult. Because the right external jugular vein is in the most direct line with the superior vena cava, it is the one most commonly used (CD Fig. 6-3).

The vein is catheterized about halfway between the level of the cricoid cartilage and the clavicle. The passage of the catheter should be performed during inspiration when the valves are open.

Penetrating Wounds of the Internal Jugular Vein

The hemorrhage of low-pressure venous blood into the loose connective tissue beneath the investing layer of deep cervical fascia may present as a large, slowly expanding hematoma. Air embolism is a serious complication of a

lacerated wall of the internal jugular vein. Because the wall of this large vein contains little smooth muscle, its injury is not followed by contraction and retraction (as occurs with arterial injuries). Moreover, the adventitia of the vein wall is attached to the deep fascia of the carotid sheath, which hinders the collapse of the vein. Blind clamping of the vein is prohibited because the vagus and hypoglossal nerves are in the vicinity.

Internal Jugular Vein Catheterization

The internal jugular vein is remarkably constant in position. It descends through the neck from a point halfway between the tip of the mastoid process and the angle of the jaw to the sternoclavicular joint. Above, it is overlapped by the anterior border of the sternocleidomastoid muscle, and below, it is covered laterally by this muscle. Just above the sternoclavicular joint the vein lies beneath a skin depression between the sternal and clavicular heads of the sternocleidomastoid muscle. In the **posterior approach**, the tip of the needle and the catheter are introduced into the vein about two fingerbreadths above the clavicle at the posterior border of the sternocleidomastoid muscle (CD Fig. 6-4). In the **anterior approach**, with the patient's head turned to the opposite side, the triangle formed by the sternal and clavicular heads of the sternocleidomastoid muscle and the medial end of the clavicle are identified. A shallow skin depression usually overlies the triangle. The needle and catheter are inserted into the vein at the apex of the triangle in a caudal direction (see CD Fig. 6-4).

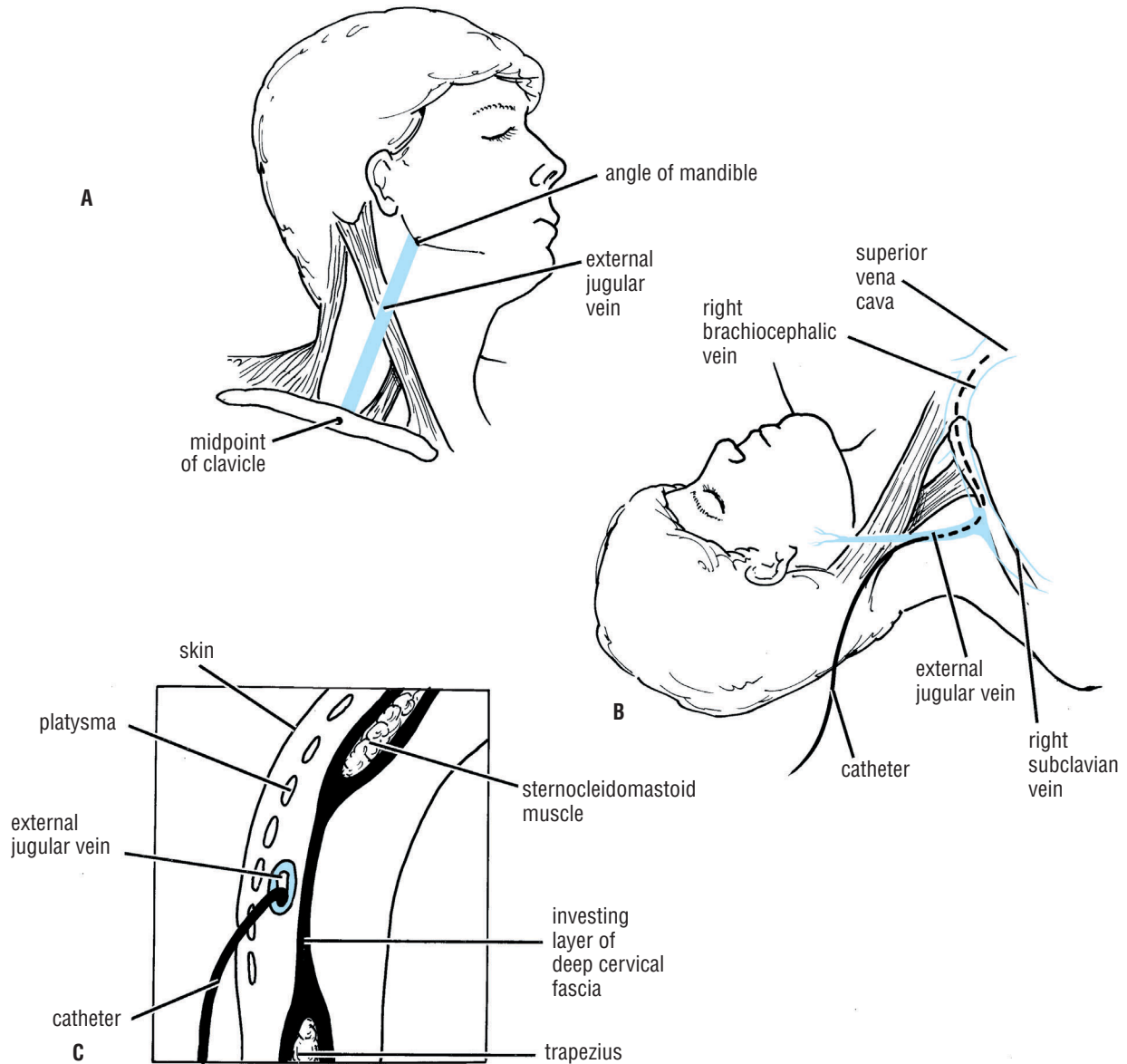
Subclavian Vein Thrombosis

Spontaneous thrombosis of the subclavian and/or axillary veins occasionally occurs after excessive and unaccustomed use of the arm at the shoulder joint. The close relationship of these veins to the first rib and the clavicle and the possibility of repeated minor trauma from these structures is probably a factor in its development.

Secondary thrombosis of subclavian and/or axillary veins is a common complication of an indwelling venous catheter. Rarely, the condition may follow a radical mastectomy with a block dissection of the lymph nodes of the axilla. Persistent pain, heaviness, or edema of the upper limb, especially after exercise, is a complication of this condition.

Subclavian Vein Catheterization

The subclavian vein is located in the lower anterior corner of the posterior triangle of the neck (CD Fig. 6-5), where it lies immediately posterior to the medial third of the clavicle.



CD Figure 6-3 Catheterization of the right external jugular vein. **A.** Surface marking of the vein. **B.** Site of catheterization. Note how the external jugular vein joins the subclavian vein at a right angle. **C.** Cross section of the neck showing the relationships of the external jugular vein as it crosses the posterior triangle of the neck.

Infraclavicular Approach

Since the subclavian vein lies close to the undersurface of the medial third of the clavicle (see CD Fig. 6-5), this is a relatively safe site for catheterization. The vein is slightly more medially placed on the left side than on the right side.

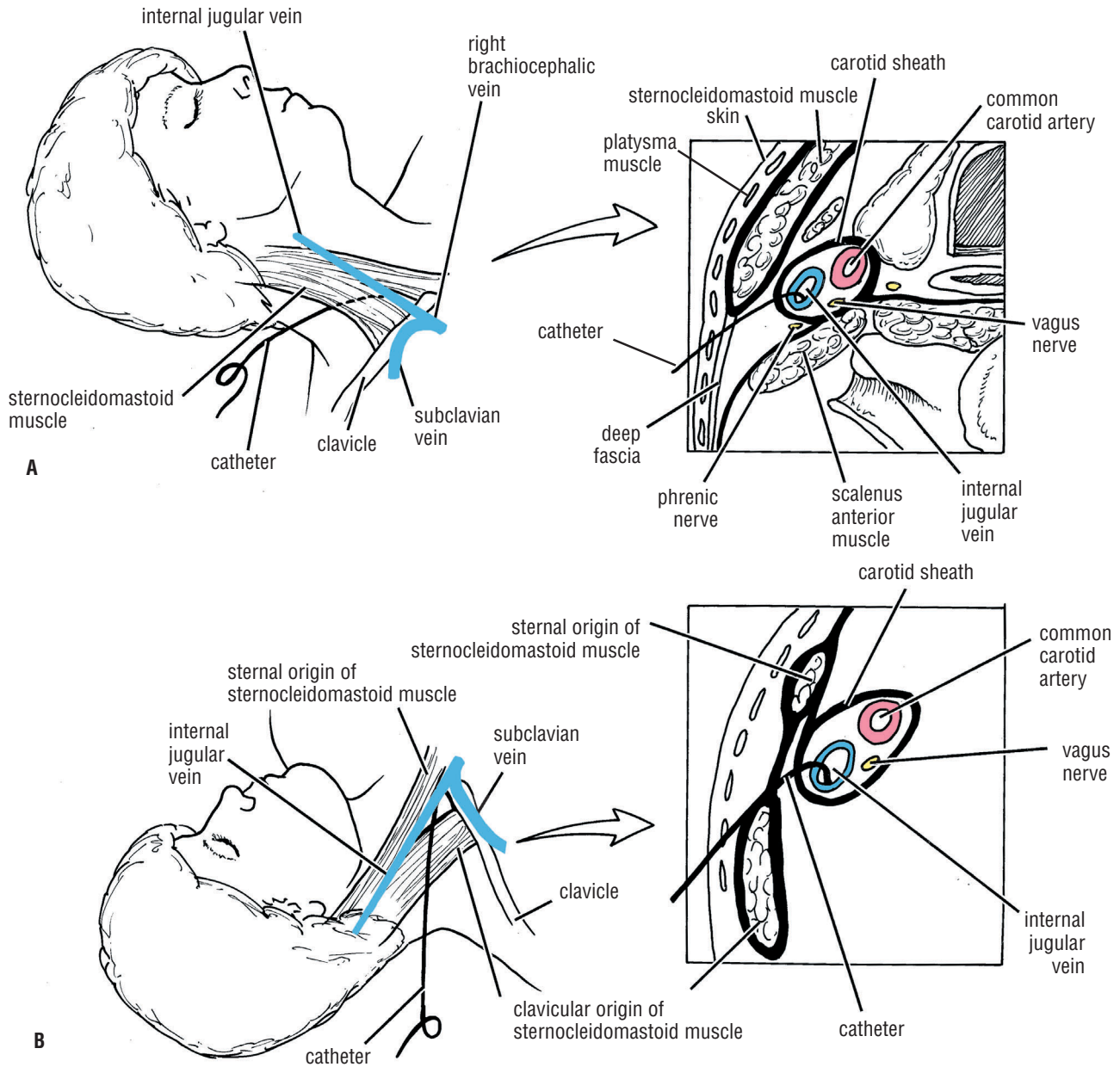
Anatomy of the Procedure

The needle should be inserted through the skin just below the lower border of the clavicle at the junction of the medial third and outer two thirds, coinciding with the posterior

border of the origin of the clavicular head of the sternocleidomastoid muscle on the upper border of the clavicle (see CD Fig. 6-5). The needle pierces the following structures:

- Skin
- Superficial fascia
- Pectoralis major muscle (clavicular head)
- Clavipectoral fascia and subclavius muscle
- Wall of subclavian vein

The needle is pointed upward and posteriorly toward the middle of the suprasternal notch.



CD Figure 6-4 Catheterization of the right internal jugular vein. **A.** Posterior approach. Note the position of the catheter relative to the sternocleidomastoid muscle and the common carotid artery. **B.** Anterior approach. Note that the catheter is inserted into the vein close to the apex of the triangle formed by the sternal and clavicular heads of the sternocleidomastoid muscle and the clavicle.

Anatomy of Problems

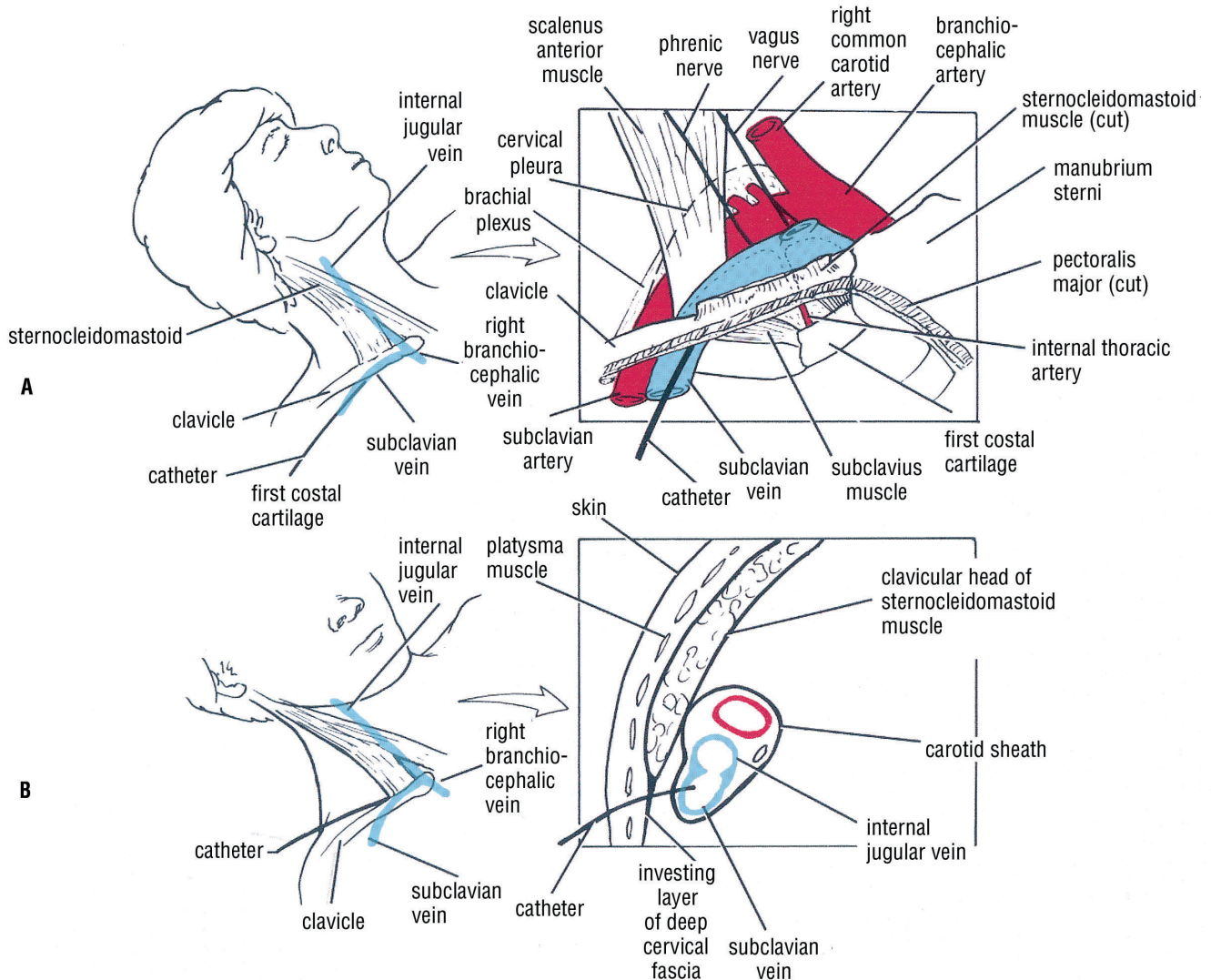
- **Hitting the clavicle:** The needle may be “walked” along the lower surface of the clavicle until its posterior edge is reached.
- **Hitting the first rib:** The needle may hit the first rib if it is pointed downward and not upward.
- **Hitting the subclavian artery:** A pulsatile resistance and bright red blood flow indicates that the needle has passed

posterior to the scalenus anterior muscle and perforated the subclavian artery.

Anatomy of Complications

Refer to CD Fig. 6-5.

- **Pneumothorax:** The needle may pierce the cervical dome of the pleura, permitting air to enter the pleural cavity. This complication is more common in



CD Figure 6-5 Subclavian vein catheterization. **A.** Infraclavicular approach. Note the many important anatomic structures located in this region. **B.** Supraclavicular approach. The catheter enters the subclavian vein close to its junction with the internal jugular vein to form the brachiocephalic vein.

children, in whom the pleural reflection is higher than in adults.

- **Hemothorax:** The catheter may pierce the posterior wall of the subclavian vein and the pleura.
- **Subclavian artery puncture:** The needle pierces the wall of the artery during its insertion.
- **Internal thoracic artery injury:** Hemorrhage may occur into the superior mediastinum.
- **Diaphragmatic paralysis:** This occurs when the needle damages the phrenic nerve.

The Procedure in Children

The needle pierces the skin in the deltopectoral groove about 2 cm from the clavicle. The catheter is tunneled

beneath the skin to enter the subclavian vein at the point where the clavicle and the first rib cross.

The more oblique approach in children minimizes the possibility of entering the subclavian artery.

Supraclavicular Approach

This approach (see CD Fig. 6-5) is preferred by many for the following anatomic reasons:

- The site of penetration of the vein wall is larger, since it lies at the junction of the internal jugular vein and the subclavian vein, which makes the procedure easier.
- The needle is pointed downward and medially toward the mediastinum, away from the pleura, avoiding the complication of pneumothorax.

- The catheter is inserted along a more direct course into the brachiocephalic vein and superior vena cava.

Anatomy of the Procedure

With the patient in the Trendelenburg position (patient supine with head tilted downward) or simple supine position and the head turned to the opposite side, the posterior border of the clavicular origin of the sternocleidomastoid muscle is palpated (see CD Fig. 6-5). The needle is inserted through the skin at the site where the posterior border of the clavicular origin of sternocleidomastoid is attached to the upper border of the clavicle. At this point, the needle lies lateral to the lateral border of scalenus anterior muscle and above the first rib. The needle pierces the following structures (see CD Fig. 6-5):

- Skin
- Superficial fascia and platysma
- Investing layer of deep cervical fascia
- Wall of the subclavian vein

The needle is directed downward in the direction of the opposite nipple. The needle enters the junction of the internal jugular vein and the subclavian vein. It is important that the operator understands that the pleura is not being penetrated and that it is possible for the needle to lie in a zone between the chest wall and the cervical dome of the parietal pleura but outside the pleural space (cavity).

Anatomy of Complications

The following complications may occur as the result of damage to neighboring anatomic structures (see CD Fig. 6-5):

- **Paralysis of the diaphragm:** This is caused by injury to the phrenic nerve as it descends posterior to the internal jugular vein on the surface of the scalenus anterior muscle.
- **Pneumothorax or hemothorax:** This is caused by damage to the pleura and/or internal thoracic artery by the needle passing posteriorly and downward.
- **Brachial plexus injury:** This is caused by the needle passing posteriorly into the roots or trunks of the plexus.

Clinical Problem Solving Questions

Read the following case histories/questions and give the best answer for each.

A 40-year-old man mentioned to his physician during a medical checkup that on four occasions during the past 5 months he had fainted at work. On each occasion the fainting attack occurred while he was sitting at his desk. He said that the attack took place when he turned his face to the left and bent down to open a bottom drawer. He also complained that he first felt dizzy before he fainted. The physician noted that the patient was rather formally dressed with a stiff collar and a regimental tie. When the physician commented on his collar, the patient stated that he always wore this type of collar to work. On careful examination of the patient no abnormal physical signs were found. In fact, the man looked very fit.

1. Using your knowledge of anatomy and physiology, make the **most likely** diagnosis.
 - A. Atrial fibrillation
 - B. Cardiac ischemia
 - C. Carotid sinus syndrome
 - D. Anemia
 - E. Petit mal (a form of epilepsy)

Two sisters were playing in their bedroom having a pillow fight, when one of them tripped and fell head first

against a window. The glass was shattered and a knife-like piece became impaled in her neck. Within seconds the wound spurted bright red blood and she ran screaming to her parents. In the emergency department of the local hospital it was immediately apparent that a large artery in the front of the neck had been pierced by the glass.

2. The examining physician made the following observations and comments, all of which were correct **except** which?
 - A. The entry wound was situated along the anterior border of the sternocleidomastoid muscle at about the level of the upper border of the thyroid cartilage.
 - B. The artery involved could be either the terminal part of the common carotid artery or the beginning of the external or internal carotid arteries.
 - C. The arteries were situated beneath the investing layer of deep cervical fascia within the carotid fascial sheath.
 - D. The internal jugular vein, which is also located within the carotid sheath, is not involved because the blood was bright red in color and spurted from the wound on removing the pressure gauze pad.
 - E. Branches of the trigeminal nerve lie in the sheath at this level and are likely to have been damaged.

A 7-year-old boy was playing in his grandparents' garden when he suddenly disappeared from view. His grandfather rushed over to see what had happened to his grandson when he heard muffled crying coming from a hole in the ground. On peering into the hole, the child's head was just visible about five feet from the surface. The local rescue team determined that the child had fallen down a disused well. Fortunately, the opening of the hole was large enough to allow the emergency physician to be lowered to the child. Having reassured the child, it was necessary to check his vital signs. The only arteries that could be palpated were restricted to the head and neck.

3. Name sites in the head and neck where the arterial pulse can be felt.
 - A. On the upper surface of the head in the midline
 - B. Just in front of the auricle of the ear, the lower margin of the mandible, or the anterior border of the sternocleidomastoid muscle at the level of the upper margin of the thyroid cartilage
 - C. Behind the ear over the mastoid process or at the root of the nose
 - D. In the midline of the front of the neck in the suprasternal notch or just below the mandible
 - E. At the apex of the posterior triangle of the neck or halfway down the posterior border of the sternocleidomastoid muscle

A 53-year-old man was admitted to the emergency room unconscious. Apparently he had attempted to cross the road on crutches when he was hit on the side of the head by a car. On examination he was found to have a large swelling over the left side of the head in the temporal region. The neurologic findings included a right-sided hemiplegia. A lateral radiograph of the skull showed a fracture line across the region of the lower anterior end of the right parietal bone.

4. Name the artery that was most likely to have been damaged in the accident.
 - A. The left middle cerebral artery
 - B. The right posterior cerebral artery
 - C. The anterior division of the left middle meningeal artery
 - D. The posterior division of the left middle meningeal artery
 - E. The left superficial temporal artery

A 42-year-old workman was cutting down a tree. During the cleanup of the site, he was feeding the cut branches into a large wood chipping machine and the sleeve of his shirt on his right arm became caught in the machinery. Within seconds his arm was dragged into the cutters. The man attempted to turn off the machine but could not reach the switch. His right upper limb was

cut to pieces and he fell to the ground in agony and quickly lost consciousness. When the emergency personnel arrived on the scene they found the man to be still alive but unconscious and lying in a pool of blood. They had to stop the bleeding immediately.

5. Using your knowledge of anatomy, where would you apply pressure at the root of the limb to stop the bleeding?
 - A. Just above the manubrium sterni in the midline to compress the right brachiocephalic artery
 - B. Above the right sternoclavicular joint to compress the right subclavian artery
 - C. Behind the medial part of the right clavicle, applying pressure downward and backward on the right subclavian artery as it lies on the upper surface of the first rib
 - D. High up in the right armpit to compress the axillary artery
 - E. Behind the lateral part of the right clavicle, applying pressure backward to compress the right subclavian artery as it becomes the axillary artery

A 45-year-old man was rushed to hospital complaining of cardiac pain referred to the root of his neck. After a thorough workup, including a coronary arteriogram, which showed extensive blockage of the coronary arteries, it was decided to do an immediate triple bypass operation. At operation, because of the poor condition of his superficial leg veins, an artery rather than a vein was selected to perform the bypass.

6. From the list of arteries given below, choose an artery in the chest cavity that could be used to perform a coronary bypass.
 - A. Right superior intercostal artery
 - B. Right and left anterior thoracic arteries
 - C. Phrenic arteries
 - D. Musculophrenic artery
 - E. Superior epigastric artery

A patient with a malignant melanoma in the left temporal region was told that because of the seriousness of the condition and the likelihood of metastases, an extensive operation was required including the removal of the deep cervical lymph nodes in the neck.

7. Using your knowledge of anatomy, explain why it is necessary to remove the internal jugular vein in the neck as well as the deep cervical lymph nodes.
 - A. The deep cervical lymph nodes lie deep to the internal jugular vein, and it is necessary to remove the vein to get at the lymph nodes.
 - B. Damage to the internal jugular vein would result in serious air embolism.
 - C. The numerous tributaries of the internal jugular vein would complicate the procedure

- D. The deep cervical lymph nodes are embedded in the carotid sheath and the tunica adventitia of the internal jugular vein.
- E. Metastases of the melanoma commonly invade the internal jugular vein.

A 57-year-old woman was examined by her physician and found to have right-sided heart failure. As the patient lay propped up on pillows in bed, her physician noticed that the blood in a superficial vein on the side of the neck (in the posterior triangle) could be easily seen.

8. From the list of veins in the neck given below, select the **most likely** one that the physician could see.
- Anterior jugular vein
 - Suprascapular vein
 - Superficial cervical vein
 - Internal jugular vein
 - External jugular vein
9. The jugular veins are commonly used to establish a central venous line. Why is it sometimes difficult to pass a catheter from the external jugular vein into the right atrium?
- The catheter tip may catch in the valves.
 - The vein turns at a right angle before it drains into the subclavian vein.

- The catheter tip may enter the mouth of the anterior division of the retromandibular vein.
- The vein may be very small in professional singers.
- The vein is normally constricted as it passes behind the clavicle.

10. In deep penetrating injuries of the neck involving the common carotid artery, the status of the collateral circulation determines the feasibility of ligation versus a reconstructive procedure. Describe the collateral circulation of the common carotid artery. How may injury to the artery produce loss of sight on the same side and contralateral hemiplegia? How may a carotid artery injury produce airway obstruction?
11. Why is air embolism a complication of a lacerated wall of the internal jugular vein?
12. In subclavian vein catheterization using the infraclavicular approach, the following problems may occur, even when great care is exercised: (a) The needle may hit the clavicle; (b) the needle may hit the first rib; (c) the needle may hit the subclavian artery. How would you deal with these problems?

Answers and Explanations

1. **C** is the correct answer. The carotid sinus syndrome is a condition in which the carotid sinus reflex is hypersensitive. Pressure on one or both carotid sinuses can cause excessive slowing of the heart, a fall in blood pressure, and cerebral ischemia with fainting. In this patient the pressure of the stiff collar on the carotid sinuses, caused by bending over to gain access to the bottom desk drawer, was sufficient to cause the episodes of fainting and loss of consciousness.
2. **E** is the correct answer. The trigeminal nerve is not related to the carotid arteries in the neck. However, the hypoglossal nerve crosses the external carotid artery opposite the level of the tip of the greater cornu of the hyoid bone. The glossopharyngeal nerve is related to the internal and external carotid arteries high up in the neck (see text Fig. 6-4). The vagus nerve lies within the carotid sheath and accompanies the internal jugular vein and common and internal carotid arteries down the neck. The sympathetic trunk lies behind the common and internal carotid arteries (see text Fig. 6-4).
3. **B** is the correct answer. In a difficult situation, when the patient's head and neck are the only accessible parts of

the body for taking the pulse, the following arteries are easily palpable: The pulsating facial artery can be felt as it winds around the lower margin of the mandible in line with the anterior border of the masseter muscle (see text Fig. 6-10). The superficial temporal artery may be palpated in front of the auricle of the ear as it ascends over the zygomatic arch (see text Fig. 6-1). The classical site for feeling the pulse in the neck is along the anterior border of the sternocleidomastoid muscle at the level of the upper border of the thyroid cartilage (see text Fig. 6-3). Here, the common carotid artery divides into the external carotid and internal carotid arteries, and all three are quite superficial at this location.

4. **C** is the correct answer. The anterior division of the middle meningeal artery is the most common artery to be damaged after a blow to the lateral side of the head. The arterial or venous injury is especially liable to occur if the artery and vein enter a bony canal in the region of the anterior inferior angle of the parietal bone (see CD Fig. 6-1).
5. **C** is the correct answer. The arterial supply to the upper limb can be cut off by applying deep pressure to the

third part of the subclavian artery, as it lies on the upper surface of the first rib. Here, the subclavian artery lies behind the medial part of the clavicle and becomes continuous with the axillary artery (see text Fig. 6-10).

6. **B** is the correct answer. The anterior thoracic artery, which is a branch of the first part of the subclavian artery, can be used in coronary bypass operations.
7. **D** is the correct answer. The deep cervical lymph nodes are embedded in the carotid sheath and in the tunica adventitia of the internal jugular vein. The aim of the operation is to remove all the lymph nodes on the affected side of the neck.
8. **E** is the correct answer. The external jugular vein lies superficially beneath the platysma muscle and can be easily seen in a good light (in an obese patient it may be difficult to see). The vein serves as a useful venous manometer. It runs from the angle of the jaw to the midpoint of the clavicle (see text Fig. 6-10). The level of the blood in the vein normally reaches about one third of the way up the neck when the patient is lying at a horizontal angle of 30° . As the patient sits up, the blood level falls until the vein is no longer visible behind the clavicle.
9. **A** is the correct answer. The catheter tip may catch in the valves. The external jugular vein has two sets of valves: One pair lies at its entrance into the subclavian vein and the other pair lies about 4 cm superior to the clavicle. The valves are usually incompetent.
10. The common carotid artery has no branches in the neck except for its terminal branches, the internal and external carotid arteries. The internal carotid artery has no branches in the neck, but at the base of the brain it takes part in the arterial circle of Willis, where it anastomoses with the branches of the vertebral arteries and the internal carotid artery of the opposite side. The

external carotid artery, however, gives off numerous important branches in the neck that anastomose with the fellow branches from the opposite side.

Since the internal carotid artery gives off the ophthalmic artery and the middle cerebral artery, severe damage or blockage of the common carotid artery could cause ipsilateral blindness and contralateral hemiplegia.

The common carotid artery is contained within the carotid sheath beneath the investing and pretracheal layers of deep cervical fascia. Hemorrhage beneath the deep fascia could spread medially and compress the larynx or the trachea, thus compromising the airway.

11. Air embolism is a serious complication of a lacerated wall of the internal jugular vein. Because the wall of this large vein contains very little smooth muscle, its injury is not followed by contraction and retraction (as occurs with arterial injuries). Moreover, the outer coat of the vein is attached to the fascia of the carotid sheath, which hinders the collapse of the vein.
12. When performing a subclavian vein catheterization using the infraclavicular approach, the clavicle may be hit by the advancing needle. The needle may then be "walked" along the lower surface of the clavicle until its posterior edge is reached and then inserted into the subclavian vein. The needle may hit the first rib. This is due to the fact that the needle is pointing downward and not upward. The needle may hit the subclavian artery. This is recognized by feeling the pulsatile resistance to the advancing needle and the presence of bright red blood in the catheter. It indicates that the needle has passed too deeply posterior to the scalenus anterior muscle and perforated the wall of the subclavian artery (see CD Fig. 6-5). The needle should be partially withdrawn and the vein approached again.



7

The Blood Vessels of the Upper Extremity



Chapter Outline

Arteries of the Upper Extremity	104	Finding the Superficial Veins of the Upper Extremity	106
The Importance of the Collateral Circulation when Ligating Arteries of the Upper Extremity	104	Anatomy of Basilic and Cephalic Vein Catheterization	106
Anatomy of Arterial Injuries in the Upper Extremity	104	Thrombosis of the Superficial Veins	106
Penetrating Arterial Injuries	104	Anatomy of Arteriovenous Shunts and Fistulas in the Upper Limb for Hemodialysis	106
Injuries to the Axillary Artery	105	External Arteriovenous Shunt	106
Injuries to the Brachial Artery	105	Internal Arteriovenous Fistula	108
Allen Test	105	Deep Veins of the Upper Extremity	108
Injuries to the Radial Artery	105	Axillary-Subclavian Vein Thrombosis	108
Injuries to the Ulnar Artery	105	Anatomy of Subclavian Vein Catheterization	108
Intraarterial Injections by Drug Users	105	Venous Tone and Hypovolemic Shock	108
Arterial Venous Fistulas	105	Clinical Problem Solving Questions	108
Anatomy of the Procedure of Arterial Puncture	105	Answers and Explanations	110
Brachial Artery	106		
Radial Artery	106		
Needle Approach	106		
Cutdown Approach	106		
Superficial Veins of the Upper Extremity	106		



ARTERIES OF THE UPPER EXTREMITY

The Importance of the Collateral Circulation when Ligating Arteries of the Upper Extremity

The arteries of the upper limb may be damaged by penetrating wounds or may require ligation in amputation operations. Because of adequate collateral circulation around the shoulder, elbow, and wrist joints, ligation of the main arteries of the upper limb is not followed by tissue necrosis or gangrene, provided, of course, that the arteries forming the collateral circulation are not diseased and that the patient's general circulation is satisfactory. Nevertheless, it may take days or weeks for the collateral vessels to open up sufficiently to provide the distal part of the limb with the same volume of blood as previously provided by the main artery.

At the time of the injury, where there is a complete interruption of the main arterial supply, the collateral flow

may be sufficient to prevent the signs of ischemia; it is rare, however, for the physician to be able to palpate the distal pulse at the initial examination.

Anatomy of Arterial Injuries in the Upper Extremity

Many of the injuries are directly related to the anatomy of the upper limb. The extreme mobility of the limb at the shoulder joint permits the forearm and hand to be raised as a shield to ward off an attack. This position of the arm commonly results in laceration of the blood vessels.

Penetrating Arterial Injuries

Arterial injuries of the upper limb are common and may occur from guns, knives, automobile accidents, and iatrogenic causes. Basically, three types of arterial injury are possible, and the structure of the artery determines the signs and symptoms as well as the type of treatment instituted.

1. In a **completely severed artery** the circular smooth-muscle fibers of the tunica media contract, immediately slowing the bleeding. In addition, the elastic fibers and longitudinal smooth-muscle fibers of the media contract,

causing the ends of the artery to retract. The contraction and retraction of the arterial ends usually slow the blood flow to such an extent that bleeding ceases spontaneously, and a firm blood clot plugs both ends of the severed artery. The loss of distal pulses is immediate.

2. In a **partially severed artery** the vessel is unable to contract and retract; in fact, any retraction that does occur causes the arterial wound to gape, resulting in serious bleeding. Hemorrhage into the surrounding tissues may produce an enlarging pulsatile hematoma that may slowly expand along fascial planes to reach the surface and cause a severe hemorrhage. Another possibility is that the damaged arterial wall gives way, leaving only the tunica adventitial intact. In these circumstances, a **pseudoaneurysm** is formed.

Since with partial arterial injury the arterial wall is still intact, blood flow continues into the distal end, and a distal pulse is usually recognizable.

3. In an artery with **intimal damage only** secondary to external blunt trauma, excessive stretching, or internal damage from a catheter, there is a reduction in blood flow and an absence of external hemorrhage. Later, as a result of progressive thrombosis or bleeding into the wall at the site of injury, the blood flow becomes diminished and the distal pulses disappear.

Injuries to the Axillary Artery

These are often caused by penetrating wounds in the pectoral region, fractures of the surgical neck of the humerus, or excessive stretching following anterior dislocations of the shoulder joint (see text Fig. 7-7). Damage to the branches of the brachial plexus may be an added complication.

Injuries to the Brachial Artery

These may follow supracondylar fractures of the lower end of the humerus (especially in children), a site where the artery is close to the shaft of the humerus as it lies on the brachialis muscle (see text, Fig. 7-9). Damage to the adjacent median nerve may also occur. Severe dislocations of the elbow joint may damage the artery in the cubital fossa. Since the brachial artery is located superficially in the upper part of the arm, it is a common site for arterial catheterization. Frequently the tunical intima is damaged on the wall opposite the penetration site, and arterial thrombosis may follow.

Allen Test

This test may be used to determine the patency of the ulnar and radial arteries. With the patient's hands resting in his or her lap, the radial arteries are compressed against the anterior surface of each radius. The patient then tightly clenches his or her fists, which closes off the superficial and deep palmar arterial arches. When he or she opens his or her hands,

the skin of the palms is at first white, and then normally the blood quickly flows into the arches through the ulnar arteries, causing the palms to promptly turn pink. This establishes that the ulnar arteries are patent. The patency of the radial arteries can be established by repeating the test, only with the ulnar arteries compressed where they lie lateral to the pisiform bone

Injuries to the Radial Artery

These are common and occur in the lacerations of the front of the forearm. The close relation of the artery to the radial nerve and the forearm tendons means that these structures are also commonly damaged (see text Figs. 7-12 and 7-13). Catheter injuries are also common just proximal to the wrist joint.

Injuries to the Ulnar Artery

These are relatively common and occur in lacerations in the front of the wrist and flexor retinaculum. Here the artery is superficial and easily cut in glass or knife wounds (see text Figs. 7-12 and 7-13). The closely related ulnar nerve is frequently involved also.

Intraarterial Injections by Drug Users

In cases of intraarterial injection by drug abusers, the patient presents with a swollen and extremely painful hand. The drug is often injected into the radial or ulnar arteries. The pharmacologic agent and its diluent causes damage at the arteriole level as the result of blockage by crystal, chemical necrosis of the tunica intima, or vasospasm of the smooth muscle in the tunica media. Extensive tissue necrosis or gangrene may occur in the area of anatomic distribution of the artery injected.

Arterial Venous Fistulas

Arteriovenous fistulas are common complications of arterial injuries in the upper limbs. This results from the close relationship that exists between the arteries and veins in the limbs. The axillary artery has the axillary vein on its medial side; the brachial, radial, and ulnar arteries have venae comitantes running alongside.

Arteriovenous fistulas occur when the penetrating arterial injury also perforates the accompanying vein. Bleeding from the artery follows the path of least resistance, and therefore an arteriovenous communication is established with resulting venous hypertension, varicosities, and edema distal to the communication site.

Anatomy of the Procedure of Arterial Puncture

The brachial, radial, and ulnar arteries are commonly used for arterial puncture.

Brachial Artery

The brachial artery is usually cannulated as it descends into the cubital fossa on the medial border of the biceps brachii muscle (see text Fig. 7-11). Unfortunately, the brachial artery has been associated with a higher incidence of post-catheterization thrombosis than the radial artery. This is probably because of the motility of the brachial artery associated with movements at the elbow joint.

Radial Artery

With the radial artery it is first essential to determine the adequacy of the collateral circulation of the hand by performing the Allen test. This precaution is necessary in case thromboid occurs during or after cannulation. The forearm is then supinated and the wrist joint is extended to an approximately 50° angle (CD Fig. 7-1). The radial artery can then easily be palpated as it lies anterior to the distal end of the radius.

Needle Approach

The needle is passed through the arterial wall at an angle of about 25° to the anterior surface of the wrist (see CD Fig. 7-1). The catheter can then be advanced into the arterial lumen and the needle withdrawn.

Cutdown Approach

A transverse incision is made over the radial artery just above the proximal transverse skin crease at the wrist. The artery is gently mobilized on the anterior surface of the radius and the cannula is introduced.

Some physicians make a vertical incision for the radial artery cutdown to lessen the risk of cutting a nerve and also to avoid giving the patient a horizontal cut that could potentially be misinterpreted (as a suicide attempt) on the anterior surface of the forearm.



SUPERFICIAL VEINS OF THE UPPER EXTREMITY

Finding the Superficial Veins of the Upper Extremity

The cephalic, basilic, median cubital, median cephalic, median basilic, and median veins of the forearm can all be used for venipuncture and blood transfusion. These veins are fairly large and relatively constant in position. Unfortunately, in

obese persons the veins cannot always be seen. The surface anatomy of the superficial veins is given on text page 209.

Anatomy of Basilic and Cephalic Vein Catheterization

The median basilic or basilic veins are the veins of choice for central venous catheterization, because from the cubital fossa until the basilic vein reaches the axillary vein, the basilic vein increases in diameter and is in direct line with the axillary vein (see text Fig. 7-19). The valves in the axillary vein may be troublesome, but abduction of the shoulder joint may permit the catheter to move past the obstruction.

The cephalic vein does not increase in size as it ascends the arm, and it frequently divides into small branches as it lies within the deltopectoral triangle. One or more of these branches may ascend over the clavicle and join the external jugular vein. In its usual method of termination, the cephalic vein joins the axillary vein at a right angle. It may be difficult to maneuver the catheter around this angle.

Thrombosis of the Superficial Veins

Prolonged intravenous infusion and, rarely, bacterial cellulitis of the superficial fascia can produce thrombosis of the superficial veins. In both cases injury to the tunical intima is the initiating factor.

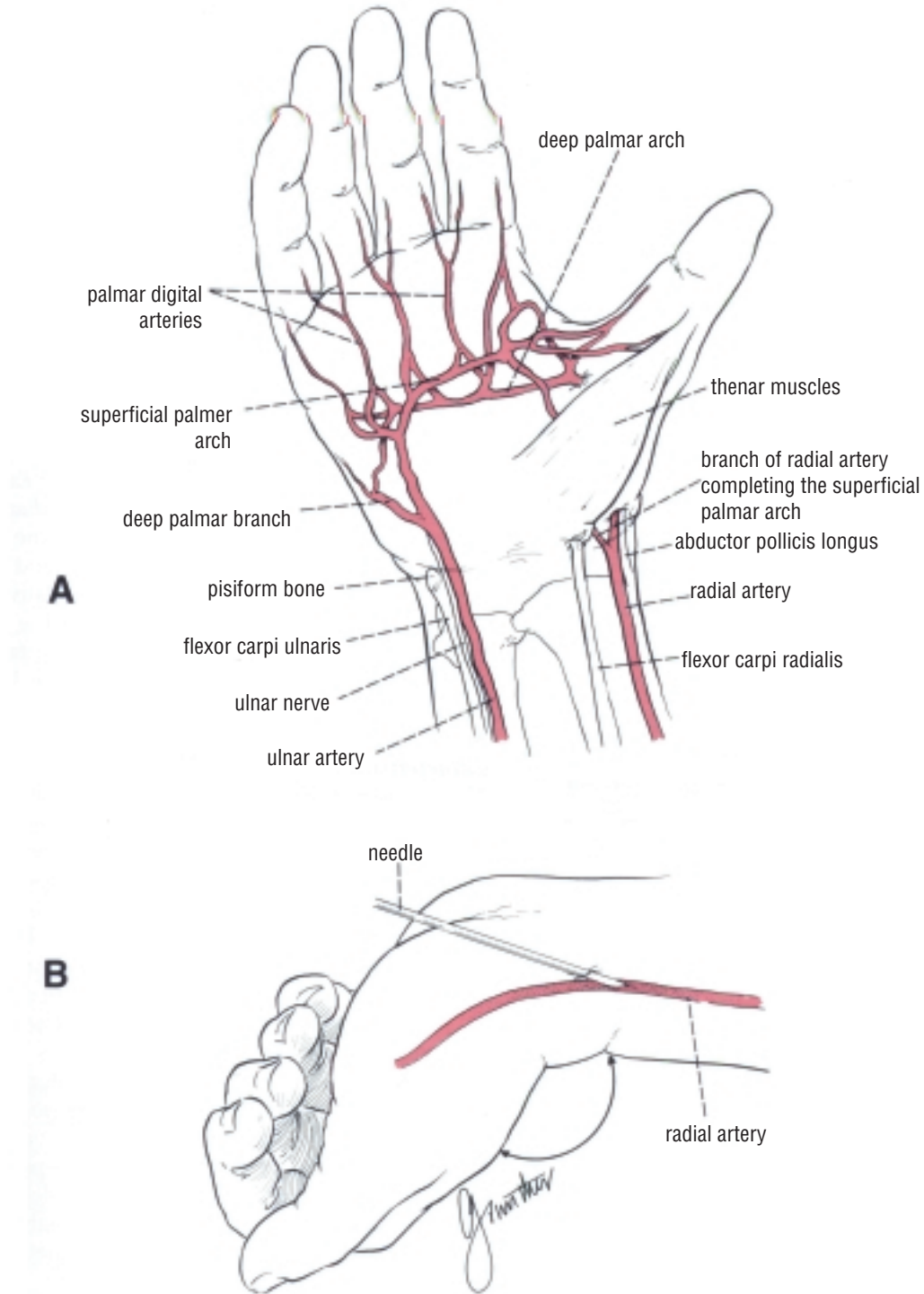
Anatomy of Arteriovenous Shunts and Fistulas in the Upper Limb for Hemodialysis

Vascular access for hemodialysis can be provided by the construction of an external arteriovenous shunt or an internal arteriovenous fistula. Most methods can be performed under local anesthesia.

External Arteriovenous Shunt

This is commonly used when a short period of treatment is required. The shunt is constructed if possible in the non-dominant limb. The radial artery or the ulnar artery, and the cephalic vein or the basilic vein may be used. The procedure is as follows:

- The branches of the lateral and medial cutaneous nerves of the forearm are blocked with a local anesthetic.
- A midline incision is made on the anterior surface of the distal part of the forearm.
- The cephalic vein or the basilic vein is located in the superficial fascia as it winds around from the dorsum of the



CD Figure 7-1 **A.** The positions of the radial and ulnar arteries in front of the wrist. Note that the superficial palmar arch is formed mainly from the ulnar artery and the deep palmar arch receives its major contribution from the radial artery. **B.** The wrist joint is extended during cannulation of the radial artery.

hand to ascend the front of the forearm (see text Figs. 7-18 and 7-19).

- The deep fascia is incised and the artery is located. The radial artery can be palpated (see text Fig. 7-13) as it lies anterior to the distal third of the radius and between the tendons of flexor carpi radialis (medially) and the brachioradialis (laterally). The ulnar artery can be felt just lateral to the pisiform bone and can be traced proximally into the forearm (see text Fig. 7-13).
- The appropriate artery and vein are then connected to the dialyzer.

In those patients in whom the distal vessels have been previously used, the same vessels can be cannulated at a more proximal site.

In children, if the distal arteries and veins are too small, a shunt can be constructed between the brachial artery and cephalic vein just proximal to the cubital fossa.

Internal Arteriovenous Fistula

This procedure is most often used when it is necessary to have a prolonged period of hemodialysis. The procedure is as follows:

- The branches of the lateral and medial cutaneous nerves of the forearm are blocked with a local anesthetic.
- A midline incision is made on the anterior surface of the distal part of the forearm.
- The cephalic vein is located in the superficial fascia.
- The deep fascia is incised and the radial artery is located in front of the distal end of the radius, as described in the previous section.
- A side-to-side anastomosis is performed between the radial artery and the cephalic vein. Alternatively, an end-to-end or end of vein-to-side of artery anastomosis can be constructed. The peripheral circulation is maintained by the extensive anastomoses from the ulnar artery around the wrist and through the palmar arches.
- The vein quickly becomes arterialized and distended and can be easily punctured with a cannula. The cannula

from the dialyzer is inserted into the distended vein, and the cannula to the dialyzer is inserted into the fistula to enter the radial artery.

A similar arrangement can be made using the ulnar artery and the basilic vein.



DEEP VEINS OF THE UPPER EXTREMITY

Axillary-Subclavian Vein Thrombosis

Spontaneous thrombosis of the axillary and or subclavian veins occasionally occurs following excessive and unaccustomed use of the arm at the shoulder joint. The close relationship of these veins to the first rib and the clavicle and the possibility of repeated minor trauma from these structures is probably a factor in its development.

Secondary thrombosis of axillary and/or subclavian veins is a common complication of an indwelling venous catheter.

Anatomy of Subclavian Vein Catheterization

Venous Tone and Hypovolemic Shock

In extreme hypovolemic shock, excessive venous tone may inhibit venous blood flow and thus delay the introduction of intravenous blood into the vascular system.

Clinical Problem Solving Questions

Read the following case histories/questions and give the best answer for each.

A young secretary, running from her office, had a glass door swing back in her face. To protect herself, she held out her left hand, which smashed through the glass. On admission to the hospital, she was bleeding profusely

from a superficial laceration in front of her left wrist. She had sensory loss over the palmar aspect of the medial one and a half fingers but normal sensation of the back of these fingers over the middle and proximal phalanges. She had difficulty in grasping a piece of paper between her left index and middle fingers. All her long flexor tendons were intact.

1. The following statements concerning this patient are correct **except** which?
 - A. The radial artery was cut in front of the flexor retinaculum, and this accounted for the profuse bleeding.
 - B. The loss of skin sensation on the palmar aspect of the medial one and a half fingers was caused by the severance of the ulnar nerve as it crossed in front of the flexor retinaculum.
 - C. The normal sensation on the back of the medial one and a half fingers over the proximal phalanges was caused by the fact that the posterior cutaneous branch of the ulnar nerve arises about 2.5 in. (6.25 cm) proximal to the flexor retinaculum and was spared.
 - D. The inability to hold the piece of paper was caused by the paralysis of the second palmar interosseous muscle, which is supplied by the deep branch of the ulnar nerve.
 - E. There was no sensory loss on the palm of the hand because the palmar cutaneous branch of the ulnar nerve was not cut.
2. A middle-aged man with a history of chronic duodenal ulcer was seen in the emergency department in a state of severe shock. He was pale, restless, and sweating, and his blood pressure was 80/60 mm Hg. The resident made a diagnosis of internal hemorrhage, probably due to the erosion of the gastroduodenal artery or one of its branches, and decided to set up a blood transfusion immediately. Based on your knowledge of anatomy, into which superficial vein of the upper limb would you perform the transfusion: in the elbow region or in the forearm? If the veins were too collapsed to be identified, where, in an emergency, could you cut down on a superficial vein in the upper limb?
3. Palpation of the radial artery at the wrist can provide the experienced medical professional with considerable insight into the state of the patient's circulatory system. The degree of hardness of the arterial wall can be appreciated by the examining finger; the pulse rate and quality of the rhythm can be determined; and the amount of pressure required to occlude the vessel can be used to assess the blood pressure. What are the relations of the radial artery at this site where the pulse is taken?
4. An 8-year-old boy fell off a swing and sustained a supracondylar fracture of his left humerus. Following the reduction of the fracture, a suitable splint was applied and the child was sent home. A few hours later, the child complained of pain in the forearm, which persisted. Four hours later, the parents decided to return to the hospital, since the child's left hand looked dusky white and the pain in the forearm was still present. On examination, there was found to be a complete loss of skin sensation of the hand. After removal of the splint, the pulse of the radial and ulnar arteries could not be felt. Every possible effort was made to restore the circulation of the forearm, without avail. What has happened to this child's circulation in the forearm? What deformity would you expect this child to have 1 year later?
5. Why is the radial artery chosen in preference to the ulnar artery or brachial artery for direct blood pressure monitoring? Why are the upper limb arteries used in preference to the dorsalis pedis artery of the foot? What are the important anatomic relations of the radial artery at the site of cannulation? Why is it necessary to extend the wrist joint when the canula is introduced?
6. During an emergency procedure it is sometimes necessary to monitor central venous pressure via peripheral access. Why is the basilic vein more often used to establish a central venous pressure line than the cephalic vein?
7. A 29-year-old woman was seen in the emergency department complaining of severe pain and discoloration of the fourth and fifth fingers of both hands. She said that she had had similar symptoms before and that they always occurred in very cold weather. Initially, her fingers turned white on exposure to cold and then became deep blue in color. The color change was confined to the distal half of each finger and was accompanied by an aching pain. Placing her hands in hot water was the only treatment that relieved the pain. As the pain disappeared, she said, her fingers became red and swollen. Using your knowledge of anatomy, make the diagnosis.
8. A 23-year-old medical student decided to assist his father in building a garden shed. Unfortunately, much of the wood had to be cut to length by using a hand saw. He noticed on the third day that his right arm felt heavy and that his right hand was swollen. At the emergency department, a diagnosis of right subclavian vein thrombosis was made. Can you explain the possible anatomic reasons why thrombosis occurred in this vein in a healthy individual?

Answers and Explanations

1. **A** is the correct answer. The radial artery does not enter the palm by passing in front of the flexor retinaculum; it does so by passing forward between the two heads of the first dorsal interosseous muscles between the first and second metacarpal bones (see text Fig. 7-14). It was the ulnar artery that was cut with the ulnar nerve in front of the flexor retinaculum.
2. The cephalic, basilic, and median cubital veins, and their tributaries, are located in front of the cubital fossa and may be used for transfusion (see text Fig. 7-19). In the forearm, the cephalic and basilic veins can be seen as they wind around the lateral and medial borders of the forearm, respectively. The cephalic vein lies in a constant position behind the styloid process of the radius (see text Fig. 7-18), and it is here that it may be exposed through a small skin incision.
3. The radial artery lies in front of the distal third of the shaft of the radius; it is directly in contact with the front of the bone (see text Fig. 7-11). On its lateral side lies the tendon of the brachioradialis, and on its medial side is the tendon of the flexor carpi radialis muscle. The artery is covered anteriorly by skin and fascia.
4. At the time of sustaining the supracondylar fracture of the humerus or the application of the splint, the brachial artery went into spasm in the distal third of the upper arm. This effectively shut off the blood flow through the radial and ulnar arteries, including the collateral circulation around the elbow joint (see text Fig. 7-8). During the following hours, when the child was complaining of severe pain, avascular necrosis of the tissues of the forearm was taking place. Later this was followed by Volkmann's contracture.
5. The radial artery has a lower incidence of arterial thrombosis than the brachial artery, possibly because the tunica intima of the brachial artery is more likely to be damaged by the point of the catheter, since the brachial artery is more difficult to immobilize because of the movements at the elbow joint. The dorsalis pedis artery can be easily cannulated. It has a higher incidence of thrombosis, however, and sometimes the circulation of the foot is compromised by the inadequate collateral circulation. The radial artery is usually cannulated 2 to 3 cm proximal to the distal transverse crease of the wrist. Here the artery lies anterior to the distal third of the shaft of the radius, medial to the tendon of the brachioradialis and lateral to the tendon of flexor carpi radialis. It is covered anteriorly by skin and fascia. The forearm is supinated, and the wrist is extended to an approximately 50° angle (see CD Fig. 7-1). Extension stretches and stabilizes the artery during the process of introducing the needle and the catheter.
6. The basilic vein is used more often than the cephalic vein for the following reasons: (a) The basilic vein increases progressively in diameter from the cubital fossa to the axillary and subclavian veins, whereas the diameter of the cephalic vein increases only slightly as it ascends the upper extremity; (b) the basilic vein is in line with the axillary vein (see text Figs. 7-19, 7-22, and 7-23), whereas the cephalic vein opens into the axillary vein at a right angle; and (c) the basilic vein is directly continuous with the end of the axillary vein, whereas the cephalic vein may bifurcate into several small veins near its termination or may join the external jugular vein.
7. This patient had Raynaud's disease. The initial pallor of the fingers is due to spasm of the digital arterioles. The cyanosis that follows is due to local capillary dilatation caused by an accumulation of metabolites. Since there is no blood flow through the capillaries, blue deoxygenated hemoglobin accumulates within them. It is during this period of prolonged cyanosis that the patient experiences severe aching pain. On exposing the fingers to warmth, the vasospasm disappears, and oxygenated blood flows back into the very dilated capillaries. Reactive hyperemia is responsible for the swelling of the affected fingers.
8. The subclavian vein is closely related to the upper surface of the first rib and to the posterior surface of the medial third of the clavicle (see text Fig. 7-3). Repeated minor trauma to the vein wall by these bones during the movements of the right shoulder while sawing resulted in damage to the tunica intima, followed by thrombosis. This problem is particularly likely to occur in an individual who is not used to this type of excessive movement of the shoulder. Usually there is some preexisting compression.



8

The Blood Vessels of the Abdomen, Pelvis, and Perineum



Chapter Outline

The Abdominal Aorta	112	The Portal Vein	115
Traumatic Injury to the Abdominal Aorta	112	Portal–Systemic Anastomoses	115
Aortic Aneurysm	112	Portal Hypertension	117
Gradual Occlusion of the Abdominal Aorta	113	Blood Flow in the Portal Vein and Malignant Disease	117
Embolus Blockage of the Abdominal Aorta	113	Penetrating Injuries to the Portal Vein	117
Mesenteric Artery Occlusion	113	Clinical Problem Solving Questions	117
The Inferior Vena Cava	113	Answers and Explanations	119
Caval–Caval Anastomosis	113		
Compression of the Inferior Vena Cava	114		
Trauma to the Inferior Vena Cava	115		



THE ABDOMINAL AORTA

Traumatic Injury to the Abdominal Aorta

Because of the deep position of the aorta on the posterior abdominal wall behind the peritoneum (see text Figs. 8-1 and 8-2), **blunt injuries** to the aorta are relatively rare. In children the elasticity of the aortic wall and the usual absence of atherosclerosis make the condition even more rare.

In blunt trauma from an automobile accident, the abdominal aorta can be injured by the crossing band of a seat belt. The tunical intima is commonly damaged just distal to the origin of the inferior mesenteric artery at the level of the third lumbar vertebra. The diagnosis is difficult since occlusion due to thrombosis may occur at the time of the trauma or be delayed for several months. In the presence of complete occlusion, the femoral pulses are absent, and motor and sensory deficits may be present in the lower limbs due to ischemia of the peripheral nerves.

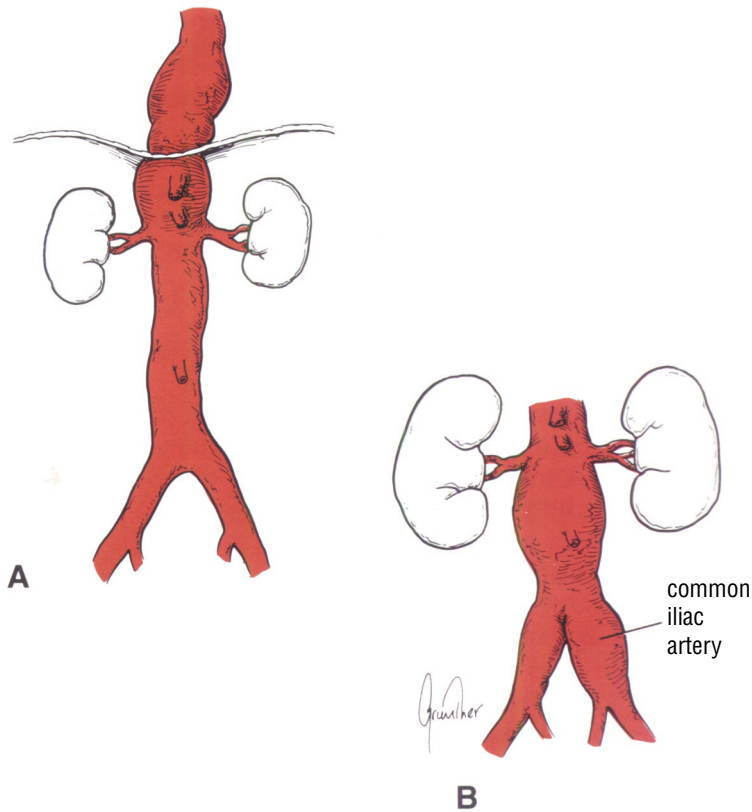
Deceleration injuries to the renal vessels may occur as the body stops its forward motion. The abdominal aorta, like the descending thoracic aorta, is tightly attached to the vertebral column by connective tissue. The kidney,

however, is relatively mobile and continues to move forward after body impact, being finally restrained by the attachment of the renal artery to the aorta. Excessive stretching of the renal artery may cause intimal damage with clot formation. The renal vessels may be avulsed from the hilum of the kidney, or the renal artery may be torn free from the aorta. The hemorrhage may be contained in the retroperitoneal space, and hypovolemic shock may not immediately occur.

Penetrating injuries to the abdominal aorta are common and are usually associated with multiple intraabdominal injuries. The peritoneum has been violated, and hemorrhage occurs directly into the peritoneal cavity. The signs of a distended abdomen associated with those of hypovolemic shock make the diagnosis relatively simple. However, when the arterial leak is small, peritoneal lavage may be necessary to confirm the diagnosis. Penetrating injuries through the back or flank (especially when directed from the left) may cause a retroperitoneal injury to the aorta; the blood may be contained within the retroperitoneal space and delay the onset of hypovolemic shock.

Aortic Aneurysms

Localized or diffuse dilatations of the abdominal part of the aorta (aneurysms) usually occur below the origin of the renal arteries (CD Fig. 8-1). Most result from atherosclerosis, which causes weakening of the arterial wall, and occur most commonly in elderly men. Large aneurysms should be surgically excised and replaced with a prosthetic graft.



CD Figure 8-1 Aneurysms of the abdominal aorta. **A.** Above the origin of the renal arteries. **B.** Below the level of the renal arteries. The latter aneurysms, which are the most common, may extend inferiorly to involve the common iliac arteries.

Gradual Occlusion of the Abdominal Aorta

Gradual occlusion of the aorta may occur due to atherosclerosis. Intermittent claudication in both legs may be present due to insufficient arterial blood reaching the muscles of the lower limbs. If the progress of the atherosclerosis is slow, an adequate collateral circulation may become established (CD Fig. 8-2).

Embolic Blockage of the Abdominal Aorta

The bifurcation of the abdominal aorta where the lumen suddenly narrows may be a lodging site for an embolus discharged from the heart. Severe ischemia of the lower limbs results.

Mesenteric Artery Occlusion

Occlusion of the superior or inferior mesenteric arteries with intestinal ischemia is discussed in CD Chapter 19. The occlusive process commonly occurs at the origin of the artery or in the proximal 1 to 2 cm of the artery and may be caused by an embolus, a thrombus, or trauma. Oc-

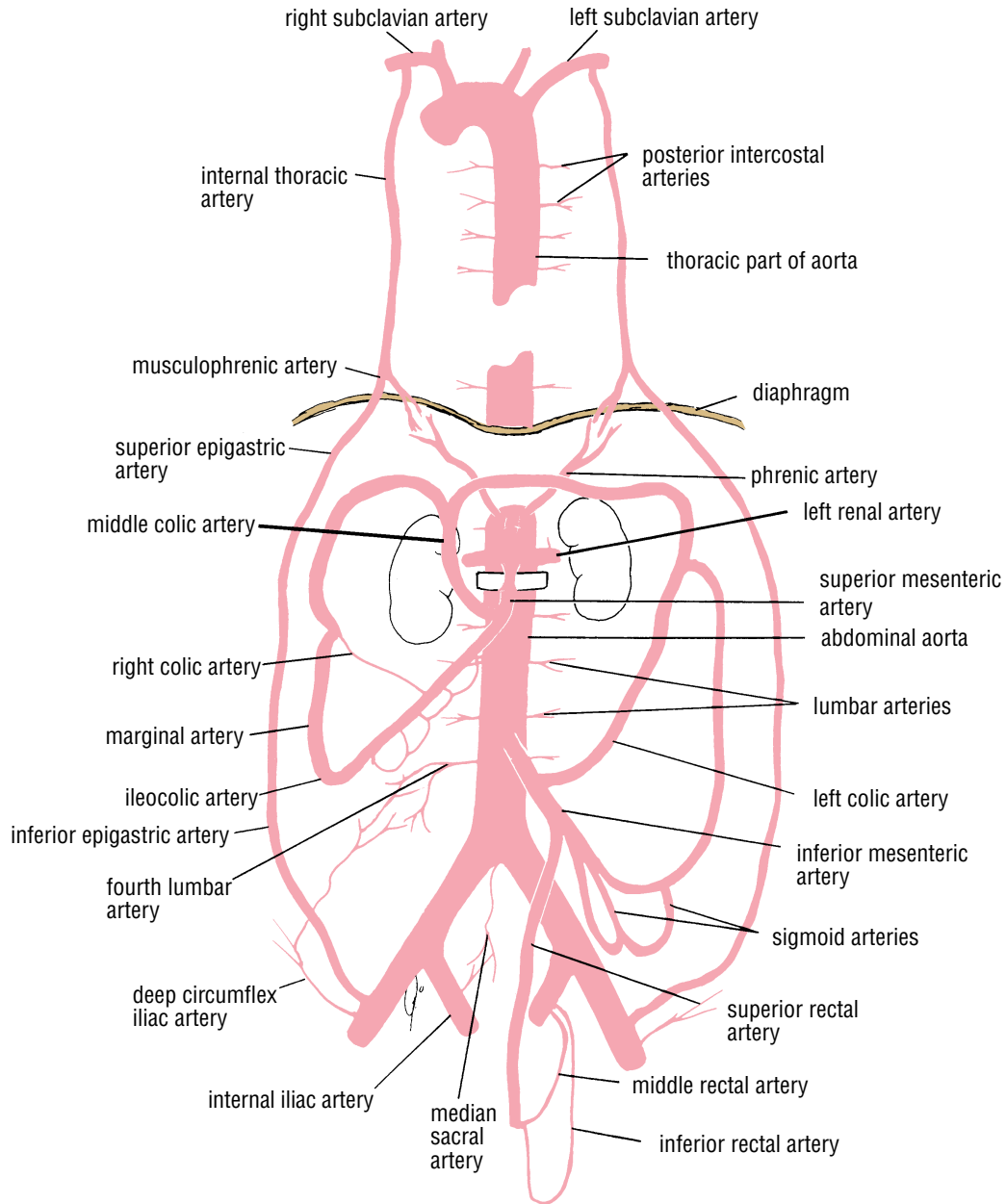
clusive disease of the superior mesenteric artery is much more common than that of the inferior mesenteric artery, which may be explained by the angle of takeoff of the superior artery from the aorta. In cases of embolus of the superior mesenteric artery, the embolus usually lodges in the region of the middle colic artery so that the jejunum may be spared.



THE INFERIOR VENA CAVA

Caval-Caval Anastomosis

A caval-caval shunt is the opening up of an alternative venous pathway should the superior or inferior vena cava become blocked by disease. The anastomoses of the vena cava are as follows (CD Fig. 8-3): The lumbar veins, which are tributaries of the inferior vena cava, anastomose behind the diaphragm with the azygos and hemiazygos veins, which are tributaries of the superior vena cava. The lumbar veins also anastomose with the superficial veins of the trunk, which eventually drain into the superior vena cava via the lateral thoracic veins, tributaries of the axillary veins.



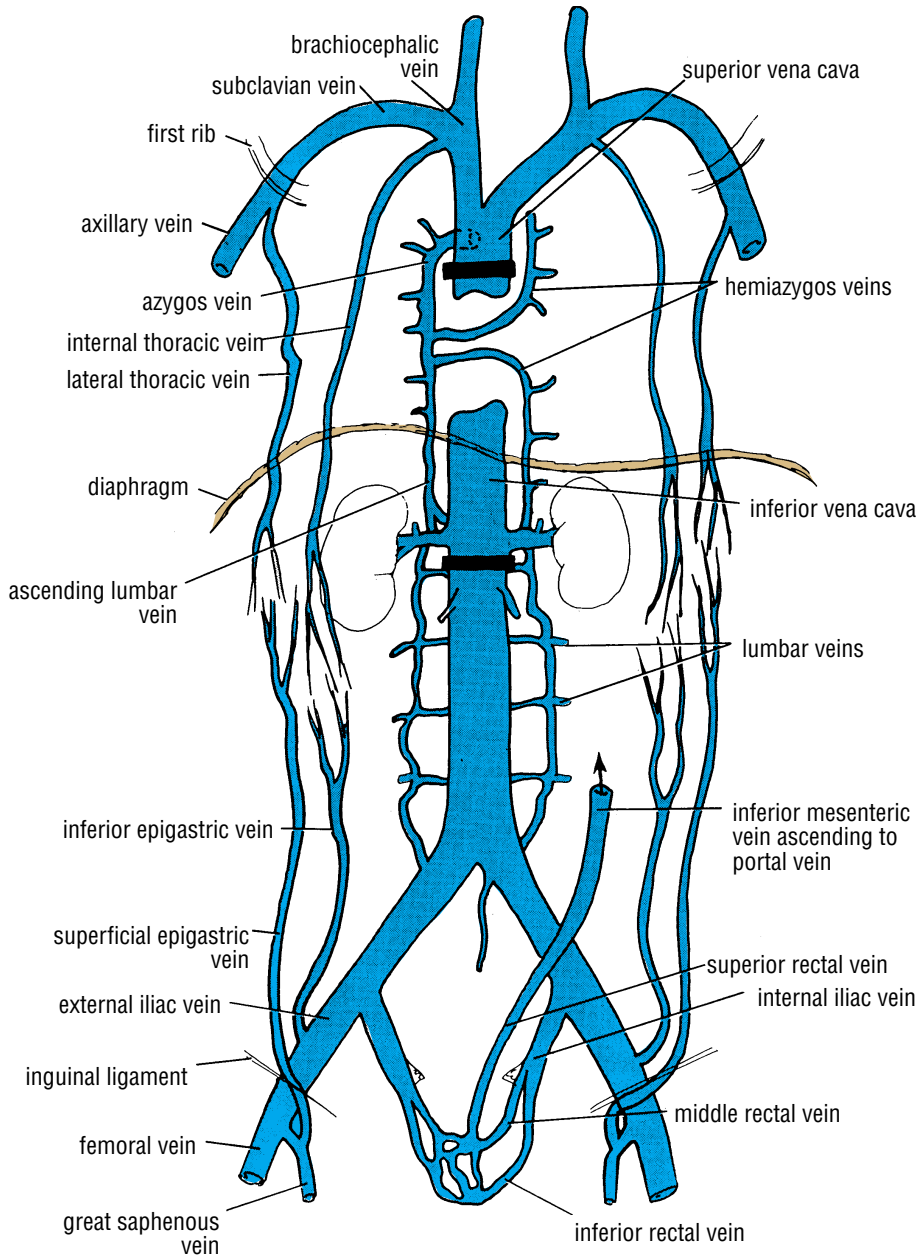
CD Figure 8-2 The possible collateral circulations of the abdominal aorta. Note the great dilatation of the mesenteric arteries and their branches, which occurs if the aorta is slowly blocked just below the level of the renal arteries (*white bar*).

Compression of the Inferior Vena Cava

The inferior vena cava is commonly compressed by the enlarged uterus during the later stages of pregnancy. This produces edema of the ankles and feet and temporary varicose veins.

Malignant retroperitoneal tumors can cause severe compression and eventual blockage of the inferior vena cava. This results in the dilatation of the extensive anastomoses of the tributaries (see CD Fig. 8-3).

This alternative pathway for the blood to return to the right atrium of the heart is commonly referred to as the **caval-caval shunt**. The same pathway comes into effect in patients with a superior mediastinal tumor compressing the superior vena cava. Clinically, the enlarged subcutaneous anastomosis between the lateral thoracic vein, a tributary of the axillary vein, and the superficial epigastric vein, a tributary of the femoral vein, may be seen on the thoracoabdominal wall (see CD Fig. 8-3).



CD Figure 8-3 The possible collateral circulations of the superior and inferior venae cavae. Note the alternative pathways that exist for blood to return to the right atrium of the heart if the superior vena cava becomes blocked below the entrance of the azygos vein (*upper black bar*). Similar pathways exist if the inferior vena cava becomes blocked below the renal veins (*lower black bar*). Note also the connections that exist between the portal circulation and the systemic veins in the anal canal.

Trauma to the Inferior Vena Cava

Injuries to the inferior vena cava are commonly lethal, despite the fact that the contained blood is under low pressure. The anatomic inaccessibility of the vessel behind the liver, duodenum, and mesentery of the small intestine and the blocking presence of the right costal margin make a surgical approach difficult. Moreover, the thin wall of the vena cava makes it prone to extensive tears.

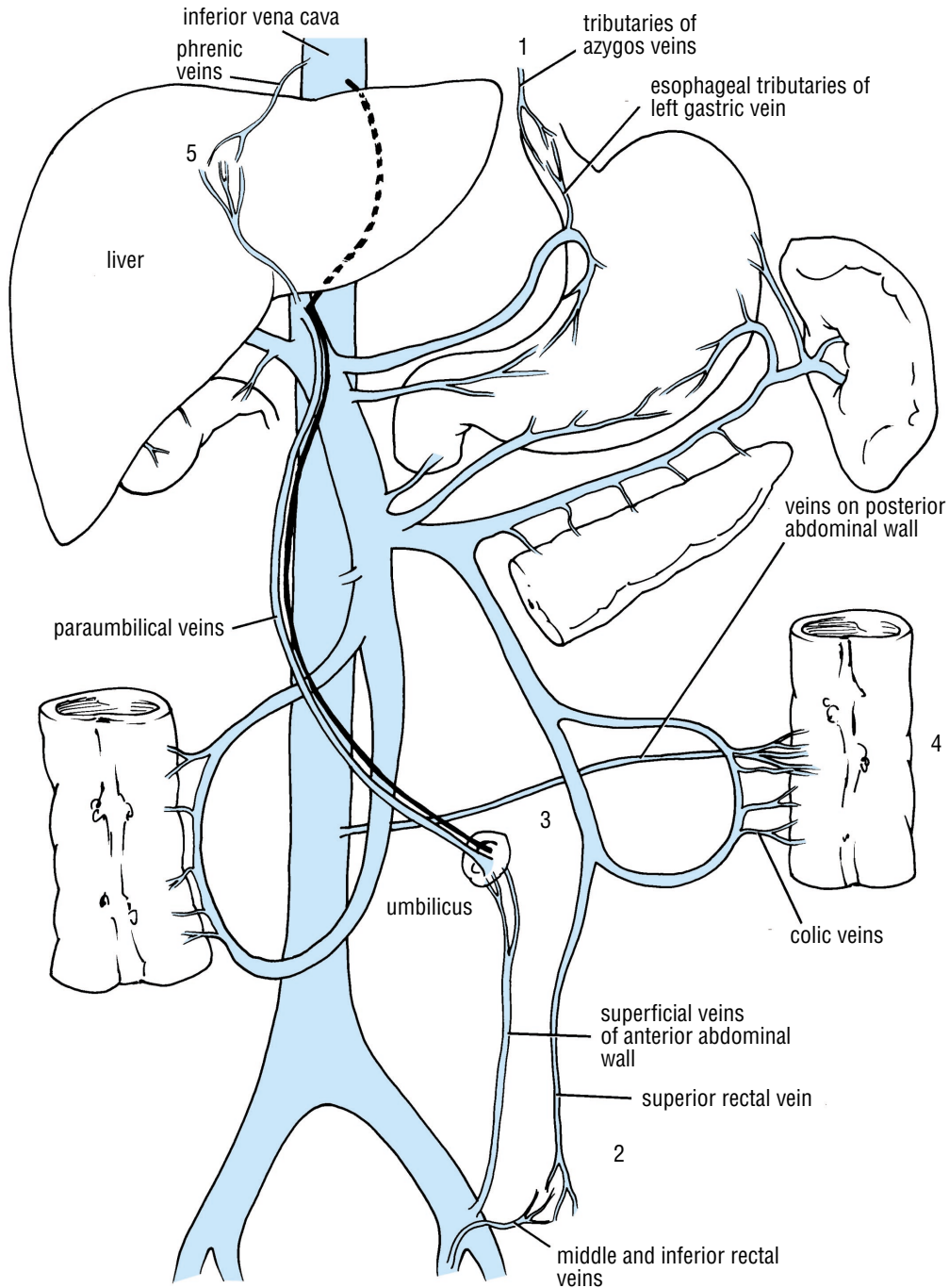
Because of the multiple anastomoses of the tributaries of the inferior vena cava (see CD Fig. 8-3), it is possible in an emergency to ligate the vessel. Most patients have venous congestion of the lower limbs.



THE PORTAL VEIN

Portal-Systemic Anastomoses

Under normal conditions, the portal venous blood traverses the liver and drains into the inferior vena cava of the systemic venous circulation by way of the hepatic veins. This is the direct route (see text Fig. 8-19). However, other, smaller communications exist between the portal and systemic systems, and they become important when the direct route becomes blocked (CD Fig. 8-4).



CD Figure 8-4 Important portal–systemic anastomoses.

These communications are as follows:

- **At the lower third of the esophagus**, the esophageal branches of the left gastric vein (portal tributary) anastomose with the esophageal veins draining the middle third of the esophagus into the azygos veins (systemic tributary).
- **Halfway down the anal canal**, the superior rectal veins (portal tributary) draining the upper half of the anal canal anastomose with the middle and inferior rectal veins (systemic tributaries), which are tributaries of the internal iliac and internal pudendal veins, respectively.
- The **paraumbilical veins** connect the left branch of the portal vein with the superficial veins of the anterior abdominal wall (systemic tributaries). The paraumbilical veins travel in the falciform ligament and accompany the ligamentum teres.
- The **veins of the ascending colon, descending colon, duodenum, pancreas, and liver** (portal tributary) anastomose with the renal, lumbar, and phrenic veins (systemic tributaries).

Portal Hypertension

Portal hypertension is a common clinical condition; thus, the list of portal–systemic anastomoses should be remembered. Enlargement of the portal–systemic connections is frequently accompanied by congestive enlargement of the spleen. Portacaval shunts for the treatment of portal hypertension may involve the anastomosis of the portal vein, because it lies within the lesser omentum, to the anterior wall of the inferior vena cava behind the entrance into the lesser sac. The splenic vein may be anastomosed to the left renal vein after removing the spleen.

Blood Flow in the Portal Vein and Malignant Disease

The portal vein conveys about 70% of the blood to the liver. The remaining 30% is oxygenated blood, which passes to

the liver via the hepatic artery. The wide angle of union of the splenic vein with the superior mesenteric vein to form the portal vein leads to streaming of the blood flow in the portal vein. The right lobe of the liver receives blood mainly from the intestine, whereas the left lobe plus the quadrate and caudate lobes receive blood from the stomach and the spleen. This distribution of blood may explain the distribution of secondary malignant deposits in the liver.

Penetrating Injuries to the Portal Vein

Penetrating injuries to the portal vein are life threatening and are usually associated with multiple abdominal injuries. A deep penetrating abdominal wound on the transpyloric plane, about two fingerbreadths to the right of the midline, could easily penetrate the liver and perforate the first part of the duodenum, the portal vein, and the inferior vena cava.

Clinical Problem Solving Questions

Read the following case histories/questions and give the best answer for each.

1. A 59-year-old man was involved in a head-on automobile accident. When seen in the emergency department, he was in hypovolemic shock and showed signs of extensive bruising on the lower part of the anterior abdominal wall. He was wearing a seat belt at the time of the accident. On examination, his abdomen was distended and tense; he had hypotension and tachycardia. A diagnosis of ruptured abdominal aorta was made during an emergency laparotomy. In cases of blunt traumatic injury to the abdominal aorta, do all patients become hypotensive immediately? Explain the possible role that the kidneys may play in causing damage to the aorta in deceleration injuries.
2. A 74-year-old man was seen in the emergency department complaining of the sudden onset of severe lumbar back pain. Three years previously he had had a myocardial infarction. On questioning, the patient admitted that he often experienced mild back and hip pains on getting up in the morning, but never had he experienced such a severe back pain. On examination, a somewhat tender pulsatile swelling could be felt in the abdomen at the level of the umbilicus. Both femoral pulses were present. A diagnosis of abdominal aortic aneurysm was made. What is the surface marking of the abdominal aorta? Explain why the back pain had started so suddenly and its significance. When an abdominal aneurysm ruptures, does an immediate fatal outcome always occur?

Into which hollow viscera or blood vessels may an aortic aneurysm rarely rupture into?

3. Explain in anatomic terms why penetrating injuries to the inferior vena cava are commonly fatal. Explain how it is possible to ligate the inferior vena cava below the level of the renal veins without adverse effects.

A 63-year-old man with a long history of a duodenal ulcer was seen in the emergency department after vomiting blood-stained fluid and exhibiting all the signs and symptoms of severe hypovolemic shock.

4. The following statements concerning duodenal ulcers could apply to the patient's condition **except** which?
 - A. Hemorrhage from a duodenal ulcer often reveals itself by the passage of black stools on defecation.
 - B. The pyloric sphincter prevents most of the blood from the duodenal lumen from passing up into the stomach.
 - C. The gastroduodenal artery lies behind the first part of the duodenum and was probably eroded by the ulcer.
 - D. The gastroduodenal artery is a small branch of the hepatic artery.
 - E. The duodenal ulcer was most likely to be situated on the posterior wall of the first part of the duodenum.

A 58-year-old man was in a restaurant when he suddenly started to vomit blood. He was taken unconscious to the emergency department of a local hospital. On examination, he had all the signs of severe hypovolemic shock. On palpation of the anterior abdominal wall, the right

lobe of the liver was felt three fingerbreadths below the costal margin. Several enlarged superficial veins could be seen around the umbilicus. His wife said that he had vomited blood 3 months previously and had nearly died. She admitted that he was a chronic alcoholic. The diagnosis was cirrhosis of the liver secondary to chronic alcoholism.

5. The symptoms and signs displayed by this patient can be explained by the following statements **except** which?
 - A. The normal flow of portal blood through the liver is impaired by cirrhosis of the liver.
 - B. The portal–systemic anastomoses become enlarged in this condition.
 - C. At the lower end of the esophagus, a branch from the right gastric vein anastomoses with an esophageal tributary of the azygos vein.
 - D. Rupture of a varicose esophageal vein could produce a severe hemorrhage so that the patient would vomit up blood.
 - E. With portal hypertension the paraumbilical veins linking the superficial veins of the skin (systemic veins) to the portal vein become congested and visible.

A 56-year-old man visited his physician complaining that he experiences severe pain in both legs when taking long walks. He noticed recently that the cramp-like pain occurs after walking only a hundred yards. On questioning, he said that the pain quickly disappears on rest only to return after he walks the same distance. When the physician asked about his sex life the patient admitted that he was experiencing difficulty with erection.

6. The symptoms and signs displayed by this patient can be explained by the following statements **except** which?
 - A. Arteriography of the abdominal aorta revealed blockage in the region of the bifurcation.
 - B. Only the right common iliac artery was involved by disease.
 - C. The gradual blockage of the aorta was caused by advanced arteriosclerosis.
 - D. An insufficient amount of blood was reaching both legs, causing pain (claudication) on walking.
 - E. The lack of blood entering both internal iliac arteries was responsible for the difficulty with erection.

A 23-year-old woman, who was 8 months pregnant, told her obstetrician that she had recently noticed that her feet and ankles were swollen at the end of the day. She said that the swelling was worse if she had been standing for long periods. She also noticed that the veins around her ankles were becoming prominent.

7. The symptoms and signs displayed by this patient can be explained by the following statements **except** which?
 - A. The enlarged uterus is an abdominal organ and often compresses the inferior vena cava.
 - B. Venous back pressure causes the tissue fluid to accumulate in the subcutaneous tissues of the feet and ankles.
 - C. Venous back pressure impairs the venous return in the superficial veins in both the legs, leading to varicose veins.
 - D. High levels of progesterone in the blood during pregnancy cause the smooth muscle in the wall of the veins to relax, thus permitting the veins to dilate.
 - E. The pregnant uterus presses on the sympathetic trunks, causing vasodilatation of the blood vessels of the legs.
8. After complete occlusion of the origin of the inferior mesenteric artery with a blood clot, the blood supply of the left portion of the colon is maintained by the following arteries **except** which?
 - A. The marginal artery
 - B. The middle colic artery
 - C. The left lumbar arteries
 - D. Anastomoses between the superior, middle, and inferior hemorrhoidal arteries
 - E. Sigmoid arteries
9. In patients with an obstruction of the superior vena cava, blood may return to the right atrium through the following anastomotic channels **except** which?
 - A. The lateral thoracic, lumbar, and superficial epigastric veins
 - B. The superior and inferior epigastric veins
 - C. The lateral thoracic, paraumbilical, and portal veins
 - D. The posterior intercostal and lumbar veins
 - E. The lateral thoracic veins alone
10. If the common hepatic artery is unavoidably ligated during surgery, the arterial supply to the liver is maintained by the following anastomotic connections **except** which?
 - A. The superior pancreaticoduodenal artery anastomosing with the inferior pancreaticoduodenal artery
 - B. The right gastric artery anastomosing with the left gastric artery
 - C. The gastroduodenal artery anastomosing with the splenic artery
 - D. The esophageal arteries anastomosing with the inferior phrenic arteries
 - E. The right gastroepiploic artery anastomosing with the left gastroepiploic artery

Answers and Explanations

1. Frequently, patients with blunt rupture to the abdominal aorta may not immediately show signs of hypovolemic shock because the aorta is situated behind the peritoneum in the retroperitoneal space and the blood may not escape immediately into the peritoneal cavity (see text Fig. 5-62).

On impact, the patient may be held stationary by the seat belt, but the kidneys may continue forward until restrained by the vascular pedicles. Avulsion of the renal artery from the side of the aorta may take place under these circumstances.

2. The abdominal aorta is a midline structure that enters the abdomen at the level of the twelfth thoracic vertebra, and its entrance may be projected onto the anterior abdominal wall just above the transpyloric plane (see text Fig. 8-3). The vessel extends downward to its bifurcation into the common iliac arteries at the level of the summit of the iliac crests.

The sudden onset of severe back pain can be explained by the aneurysm suddenly expanding or rupturing and pressing on the vertebral column, which lies immediately posterior to the aorta.

Death does not always immediately follow an abdominal aneurysm rupture. This can be explained by the fact that the hemorrhage may be initially confined to the retroperitoneal space, and a tamponade effect may temporarily prevent further bleeding.

The abdominal aorta is crossed by the third part of the duodenum, and cases have been reported of an aneurysm rupturing into the duodenal lumen. The inferior vena cava lies along the right side of the aorta, and an aneurysm has been known to rupture into it, producing a massive arteriovenous fistula.

3. Penetrating injuries of the upper part of the inferior vena cava are commonly fatal because (a) the

site of the injury is inaccessible behind the liver, duodenum, and the mesentery of the small intestine; (b) the presence of the right costal margin makes surgical access difficult; (c) the thin walls of the vena cava are likely to tear extensively and make repair difficult; and (d) the almost certain possibility that the liver is also damaged.

The extensive anastomosis of the lumbar veins with other retroperitoneal veins ensures that the blood is able to bypass the obstruction should the inferior vena cava be ligated below the level of the renal veins (see CD Fig. 8-3).

4. **D** is the correct answer. The gastroduodenal artery is a large branch of the hepatic artery.
5. **C** is the correct answer. At the lower end of the esophagus, a branch from the left gastric vein anastomoses with an esophageal tributary of the azygos vein.
6. **B** is the correct answer. The blockage of the aorta in the region of the bifurcation had effectively blocked the entrances into both common iliac arteries.
7. **E** is the correct answer. The sympathetic trunks are not pressed on by the pregnant uterus.
8. **C** is the correct answer. The left lumbar arteries do not significantly contribute to the left portion of the colon. The middle colic artery from the superior mesenteric artery, the sigmoid arteries, and the marginal artery, as well as the hemorrhoidal arteries, will maintain the blood supply to the left portion of the colon.
9. **E** is the correct answer. The lateral thoracic and the superior epigastric veins are directly or indirectly connected with the superior vena cava only.
10. **C** is the correct answer. The gastroduodenal artery does not directly anastomose with the splenic artery.



9

The Blood Vessels of the Lower Extremity



Chapter Outline

The Arteries	122	Great Saphenous Vein Cutdown	125
Collateral Circulation	122	Anatomy of Ankle Vein Cutdown	126
Femoral Artery Catheterization	122	Anatomy of Groin Vein Cutdown	126
Anatomy of Technique	123	The Great Saphenous Vein in Coronary Bypass Surgery	126
Anatomy of Complications	123	Intraosseous Infusion in the Infant	126
Traumatic Injury to Arteries of the Lower Limb	124	Varicose Veins	126
Anatomy of Complications of Arterial Injury	124	Varicose Leg Ulcers	126
Compartmental Syndromes	124	Traumatic Bleeding from a Varicosed Vein	127
Occlusion of the Popliteal, Anterior, and Posterior Tibial Arteries	124	Superficial Thrombophlebitis	127
Intermittent Claudication and Arterial Occlusive Disease of the Lower Extremity	124	Deep Thrombophlebitis	127
Femoropopliteal and Femorotibial Bypass for Lower Extremity Vascular Insufficiency	124	Deep Vein Thrombosis and Long-Distance Air Travel	127
Lumbar Sympathectomy and Occlusive Arterial Disease	124	Femoral Vein Catheterization	127
Aneurysms of the Lower Extremity	124	Anatomy of the Procedure	127
The Veins	125	Doppler Ultrasound Examination of Venous Flow in the Lower Extremity	127
Great Saphenous Vein Variations and Venous Vein Cutdown	125	Venous Tone in Hypovolemic Shock	128
		Arterial Palpation	128
		Clinical Problem Solving Questions	129
		Answers and Explanations	130



THE ARTERIES

Collateral Circulation

If the arterial supply to the leg is occluded, necrosis or gangrene will follow unless an adequate bypass to the obstruction is present—that is, a collateral circulation. Sudden occlusion of the femoral artery by ligature or embolism, for example, is usually followed by gangrene. However, gradual occlusion such as occurs in atherosclerosis is less likely to be followed by necrosis because the collateral blood vessels have time to dilate fully. The collateral circulation for the proximal part of the femoral artery is through the cruciate and trochanteric anastomoses; for the femoral artery in the adductor canal, it is through the perforating

branches of the profunda femoris artery and the articular and muscular branches of the femoral and popliteal arteries.

Femoral Artery Catheterization

A long, fine catheter can be inserted into the femoral artery as it descends through the femoral triangle. The catheter is guided under fluoroscopic view along the external and common iliac arteries into the aorta. The catheter can then be passed into the inferior mesenteric, superior mesenteric, celiac, or renal arteries. Contrast medium can then be injected into the artery under examination and a permanent record obtained by taking a radiograph. Pressure records can also be obtained by guiding the catheter through the aortic valve into the left ventricle.

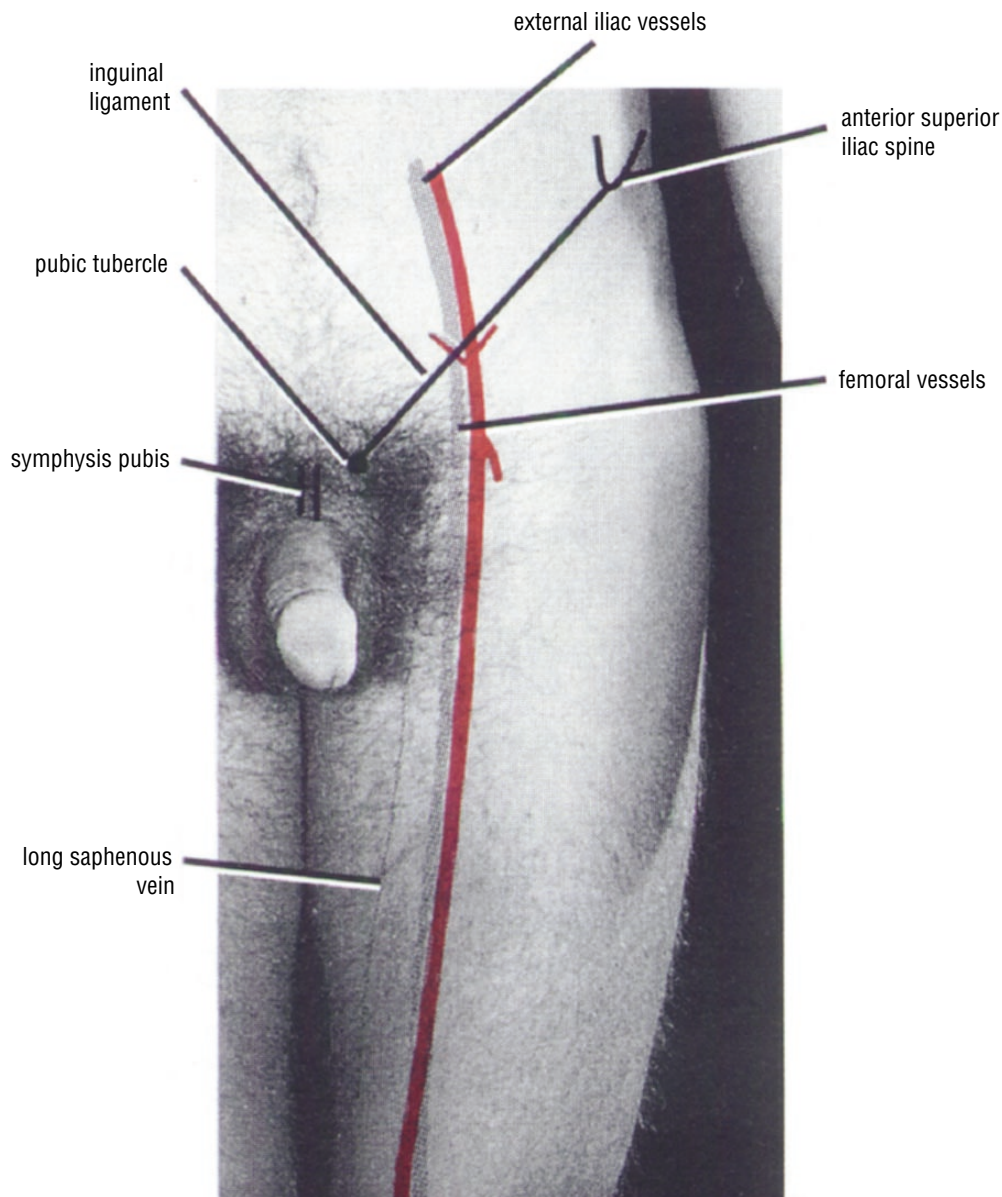
Anatomy of Technique

The femoral artery is first located just below the inguinal ligament midway between the symphysis pubis and the anterior superior iliac spine (CD Fig. 9-1). The needle or catheter is then inserted into the artery. The following structures are pierced:

- Skin
- Superficial fascia
- Deep fascia
- Anterior layer of the femoral sheath

Anatomy of Complications

The femoral vein lies immediately medial to the artery and may be entered in error. The nonpulsatile nature of the vein on palpation should exclude this possibility. Since the hip joint lies posterior to the femoral artery, the erroneous passage of the needle through the posterior arterial wall may cause it to pierce the psoas muscle and enter the joint cavity. Some difficulty may be experienced in passing the catheter up the femoral artery if the artery is tortuous or if there is extensive atherosclerosis of the arterial wall.



CD Figure 9-1 Surface markings of the major blood vessels on the anterior surface of the left thigh.

Traumatic Injury to Arteries of the Lower Limb

Injury to the large femoral artery can cause rapid exsanguination of the patient. Unlike in the upper extremity, arterial injuries of the lower limb do not have a good prognosis. The collateral circulations around the hip and knee joints, although present, are not as adequate as that around the shoulder and elbow. Damage to a neighboring large vein can further complicate the situation and causes further impairment of the circulation to the distal part of the limb.

Anatomy of Complications of Arterial Injury

A single perforating injury to an artery in the lower limb may also perforate an accompanying vein and establish an acute **arteriovenous fistula**. This complication is common in regions where large vessels run close together, such as the femoral artery and vein in the femoral triangle and the subartorial canal, and the popliteal artery and vein behind the knee. Such a shunt produces a continuous machinery-like murmur over the fistula with the later development of varicosities and edema of the distal part of the limb.

Anatomically, a true aneurysm is one whose wall contains all three layers of the arterial wall, namely, the intima, media, and adventitia. A **false aneurysm**, sometimes called a **pulsating hematoma**, is one whose wall contains only the tunica adventitia. An arterial perforation may lead to a false aneurysm that becomes walled off by the adventitia and surrounding tissues. Pressure on neighboring nerves may give rise to neurologic symptoms.

Compartmental Syndromes

Delay in the diagnosis and repair of injured arteries, especially when accompanied by vein damage, may lead to muscle necrosis and compartmental edema. The compartment syndromes are discussed on CD Chapter 13.

Occlusions of the Popliteal, Anterior, and Posterior Tibial Arteries

Popliteal artery occlusion occurs just below the beginning of the artery (just below the opening in the adductor magnus muscle). In some cases the occlusion extends distally to involve the origins of the anterior and posterior tibial arteries and even the peroneal artery. Symptoms include intermittent claudication, night cramps, and rest pain caused by ischemic neuritis. Signs include impaired or absent arterial pulses, lowered skin temperature, color changes, muscle weakness, and trophic changes.

Intermittent Claudication and Arterial Occlusive Disease of the Lower Extremity

Atherosclerosis of the lower limb arteries is common in men. Ischemia of the muscles produces a cramp-like pain with exercise. **Intermittent claudication** is a condition characterized by calf muscle cramping pain on exertion that is relieved by rest. Thrombosis in a diseased segment of the artery may lead to a sudden worsening of the symptoms and even cause nocturnal ischemic pain. The common sites for occlusion are the femoral, popliteal, and tibioperoneal arteries. If the obstruction occurs more proximally in the aorta or iliac arteries, impotence is common.

Femoropopliteal and Femorotibial Bypass for Lower Extremity Vascular Insufficiency

Bypasses have been used with success in patients with severe distal extremity ischemia. In the presence of gangrene or severe rest pain, the distal limb has been successfully salvaged. A reversed ipsilateral autogenous saphenous vein, a contralateral saphenous vein, or a cephalic vein graft has been used to connect the proximal femoral artery or popliteal artery to the distal popliteal or tibial or peroneal arteries.

Lumbar Sympathectomy and Occlusive Arterial Disease

Lumbar sympathectomy may be advocated as a form of treatment in occlusive arterial disease of the lower extremity to increase the blood flow through the collateral circulation. Preganglionic sympathectomy is performed by removing the upper three lumbar ganglia and the intervening parts of the sympathetic trunk.

Aneurysms of the Lower Extremity

These occur much less frequently than abdominal aortic aneurysms and are usually caused by atherosclerosis. Most patients are over 50 years of age, and the common sites are the femoral and popliteal arteries. The diagnosis is usually made by finding an expansile swelling along the course of the artery. Patients may present in the emergency department with complications, which include sudden embolic obstruction to arteries distal to the aneurysm or sudden thrombotic occlusion of the aneurysm. Pressure on neighboring nerves may give rise to symptoms; for example, an enlarging popliteal aneurysm may press on the tibial nerve,

causing pain in the foot. Rupture of femoral or popliteal aneurysms is rare.



THE VEINS

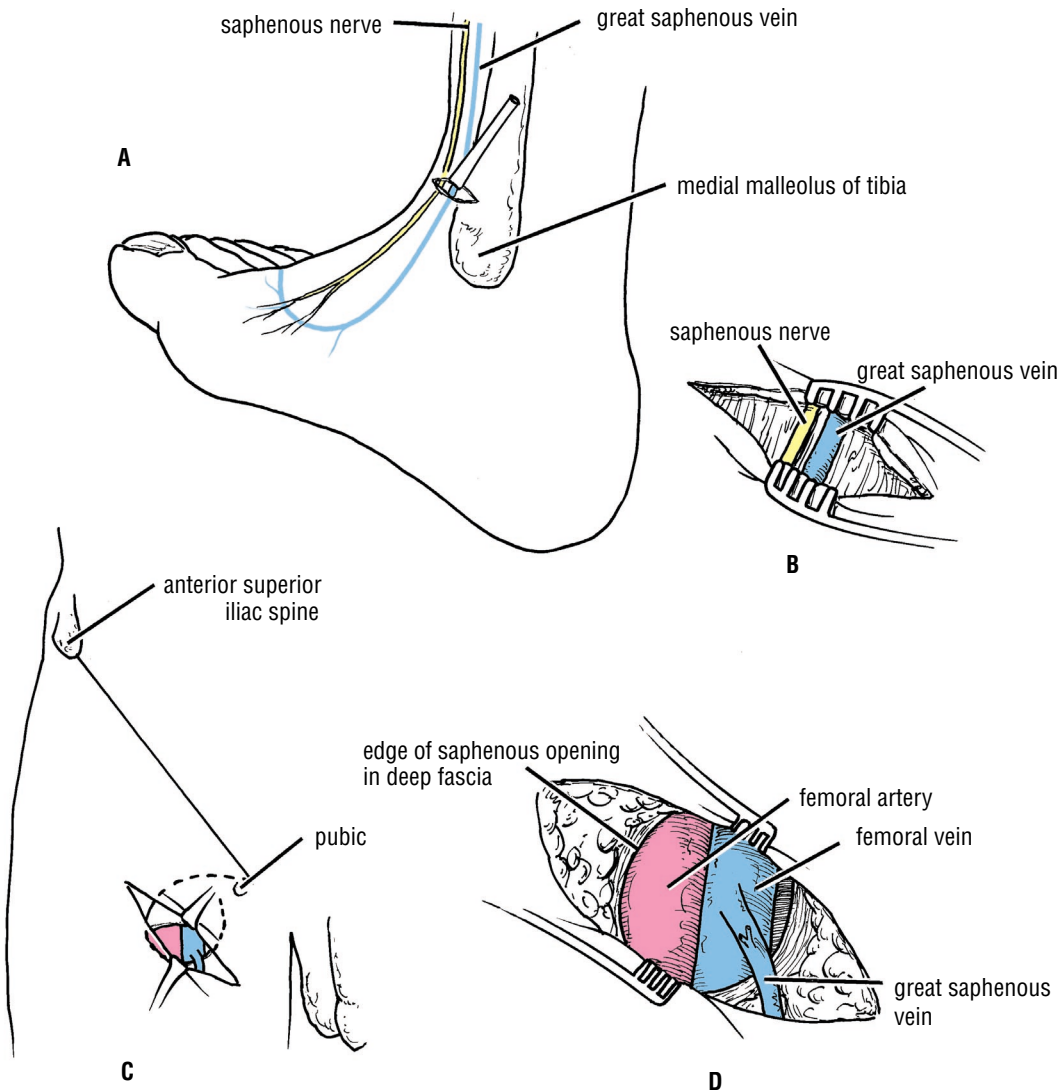
Great Saphenous Vein Variation and Venous Vein Cutdown

Occasionally the great saphenous vein at the medial malleolus is replaced by several small veins instead of a single

large one. This possibility is of great clinical importance when performing a venous cutdown

Great Saphenous Vein Cutdown

Exposure of the great saphenous vein through a skin incision (a “cutdown”) is usually performed at the ankle (CD Fig. 9-2). This site has the disadvantage that phlebitis (inflammation of the vein wall) is a potential complication. The great saphenous vein also can be entered at the groin in the femoral triangle, where phlebitis is relatively rare; the larger diameter of the vein at this site permits the use of large-diameter catheters and the rapid infusion of large volumes of fluids.



CD Figure 9-2 Great saphenous vein cutdown. **A and B.** At the ankle. The great saphenous vein is constantly found in front of the medial malleolus of the tibia. **C and D.** At the groin. The great saphenous vein drains into the femoral vein two fingerbreadths below and lateral to the pubic tubercle.

Anatomy of Ankle Vein Cutdown

The procedure is as follows:

1. The sensory nerve supply to the skin immediately in front of the medial malleolus of the tibia is from branches of the saphenous nerve, a branch of the femoral nerve. The saphenous nerve branches are blocked with local anesthetic.
2. A transverse incision is made through the skin and subcutaneous tissue across the long axis of the vein just anterior and superior to the medial malleolus (see CD Fig. 9-2). Although the vein may not be visible through the skin, it is **constantly** found at this site.
3. The vein is easily identified, and the **saphenous nerve** should be recognized; the nerve usually lies just anterior to the vein (see CD Fig. 9-2).

Anatomy of Groin Vein Cutdown

1. The area of thigh skin below and lateral to the scrotum or labium majus is supplied by branches of the ilioinguinal nerve and the intermediate cutaneous nerve of the thigh. The branches of these nerves are blocked with local anesthetic.
2. A transverse incision is made through the skin and subcutaneous tissue centered on a point about 1.5 in. (4 cm) below and lateral to the pubic tubercle (see CD Fig. 9-2). If the femoral pulse can be felt (may be absent in patients with severe shock), the incision is carried medially just medial to the pulse.
3. The great saphenous vein lies in the subcutaneous fat and passes posteriorly through the saphenous opening in the deep fascia to join the femoral vein about 1.5 in. (4 cm), or two fingerbreadths, below and lateral to the pubic tubercle. It is important to understand that the great saphenous vein passes through the saphenous opening to gain entrance to the femoral vein. However, the size and shape of the opening are subject to variation.

The Great Saphenous Vein in Coronary Bypass Surgery

In patients with occlusive coronary disease caused by atherosclerosis, the diseased arterial segment can be bypassed by inserting a graft consisting of a portion of the great saphenous vein. The venous segment is reversed so that its valves do not obstruct the arterial flow. Following removal of the great saphenous vein at the donor site, the superficial venous blood ascends the lower limb by passing through perforating veins and entering the deep veins.

The great saphenous vein can also be used to bypass obstructions of the brachial or femoral arteries.

Intraosseous Infusion in the Infant

This technique may be used for the infusion of fluids and blood when it has been found impossible to obtain an intravenous line. The procedure is easy and rapid to perform as follows:

- With the distal leg adequately supported, the anterior subcutaneous surface of the tibia is palpated.
- The skin is anesthetized about 1 in. (2.5 cm) distal to the tibial tuberosity, thus blocking the infrapatellar branch of the saphenous nerve.
- The bone marrow needle is directed at right angles through the skin, superficial fascia, deep fascia, and tibial periosteum and the cortex of the tibia. Once the needle tip reaches the medulla and bone marrow, the operator senses a feeling of “give.” The position of the needle in the marrow can be confirmed by aspiration. The needle should be directed slightly caudad to avoid injury to the epiphyseal plate of the proximal end of the tibia. The transfusion may then commence.

Varicose Veins

A varicosed vein is one that has a larger diameter than normal and is elongated and tortuous. Varicosity of the esophageal and rectal veins is described elsewhere. This condition commonly occurs in the superficial veins of the lower limb and, although not life threatening, is responsible for considerable discomfort and pain.

Varicose veins have many causes, including hereditary weakness of the vein walls and incompetent valves; elevated intraabdominal pressure as a result of multiple pregnancies or abdominal tumors; and thrombophlebitis of the deep veins, which results in the superficial veins becoming the main venous pathway for the lower limb. It is easy to understand how this condition can be produced by incompetence of a valve in a perforating vein. Every time the patient exercises, high-pressure venous blood escapes from the deep veins into the superficial veins and produces a varicosity, which might be localized to begin with but becomes more extensive later.

The successful operative treatment of varicose veins depends on the ligation and division of all the main tributaries of the great or small saphenous veins, to prevent a collateral venous circulation from developing, and the ligation and division of all the perforating veins responsible for the leakage of high-pressure blood from the deep to the superficial veins. It is now common practice to also remove or strip the superficial veins. Needless to say, it is imperative to ascertain that the deep veins are patent before operative measures are taken.

Varicose Leg Ulcers

These occur in the region of the medial malleolus, are caused by venous skin stasis, and may be a complication of

varicose veins; many are caused by postthrombotic incompetent perforating veins in the region.

A venous ulcer must be distinguished from an **arterial ulcer** caused by atherosclerosis of the skin arteries. An arterial ulcer tends to occur on the lateral side of the distal leg, and the leg is often pulseless and cool. A venous ulcer occurs on the medial side of the distal leg because skin venous stasis tends to be more severe on the medial side in the presence of varicose veins. The explanation for the laterally placed arterial ulcer is that the skin over the lateral malleolus receives a poorer arterial supply than that over the medial malleolus.

Traumatic Bleeding from a Varicosed Vein

Profuse bleeding from a pierced varicosed vein may cause a patient to seek medical treatment. Pressure over the vein, proximal to the injury, should stop the blood escaping. The varicosed veins have incompetent valves and venous blood is merely draining downward by gravity from the abdominal veins. Raising the leg to a level above the heart should also stop the bleeding.

Superficial Thrombophlebitis

Thrombosis of the superficial veins of the lower limb is often associated with varicose veins. The condition is painful, and the thrombosed vein is tender to touch; the overlying skin is reddened and edematous. The thrombus is usually strongly adherent to the wall of the vein so that emboli are rarely formed. However, should the thrombosis extend to the deep veins through a perforating vein, embolic formation in the deep vein can be a serious, although rare, complication.

Deep Thrombophlebitis

Thrombosis of the deep veins can occur at any time, but significant predisposition is immobility of the lower limbs in bed or in a splint. The common site where the process starts is the veins draining the soleus muscle in the calf. It must be assumed that the pressure of the bed on the calf veins damages the tunica intima, and this together with certain predisposing factors, such as surgical trauma, malignant disease, pregnancy, or estrogen therapy, initiates thrombus formation. Once formed, the thrombus may extend proximally into the popliteal and femoral veins and even higher into the iliac veins. The symptoms include discomfort and tightness in the calf, especially when the patient is using the calf muscles, as in standing and walking. Tenderness of the calf muscles may be apparent, and edema of the ankles, pretibial area, or thigh may be present. The superficial veins may be dilated and more obvious than normal. The great danger of deep vein thrombosis is the high incidence of pulmonary embolism. A secondary problem is residual chronic venous insufficiency of the lower extremities.

Deep Vein Thrombosis and Long-Distance Air Travel

Passengers who sit immobile for hours on long-distance flights are very prone to deep vein thrombosis in the legs. Preventative measures include stretching of the legs every hour to improve the venous circulation.

Femoral Vein Catheterization

Femoral vein catheterization is used when rapid access to a large vein is needed. The femoral vein has a constant relationship to the medial side of the femoral artery just below the inguinal ligament and is easily cannulated. However, because of the high incidence of thrombosis with the possibility of fatal pulmonary embolism, the catheter should be removed once the patient is stabilized.

Anatomy of the Procedure

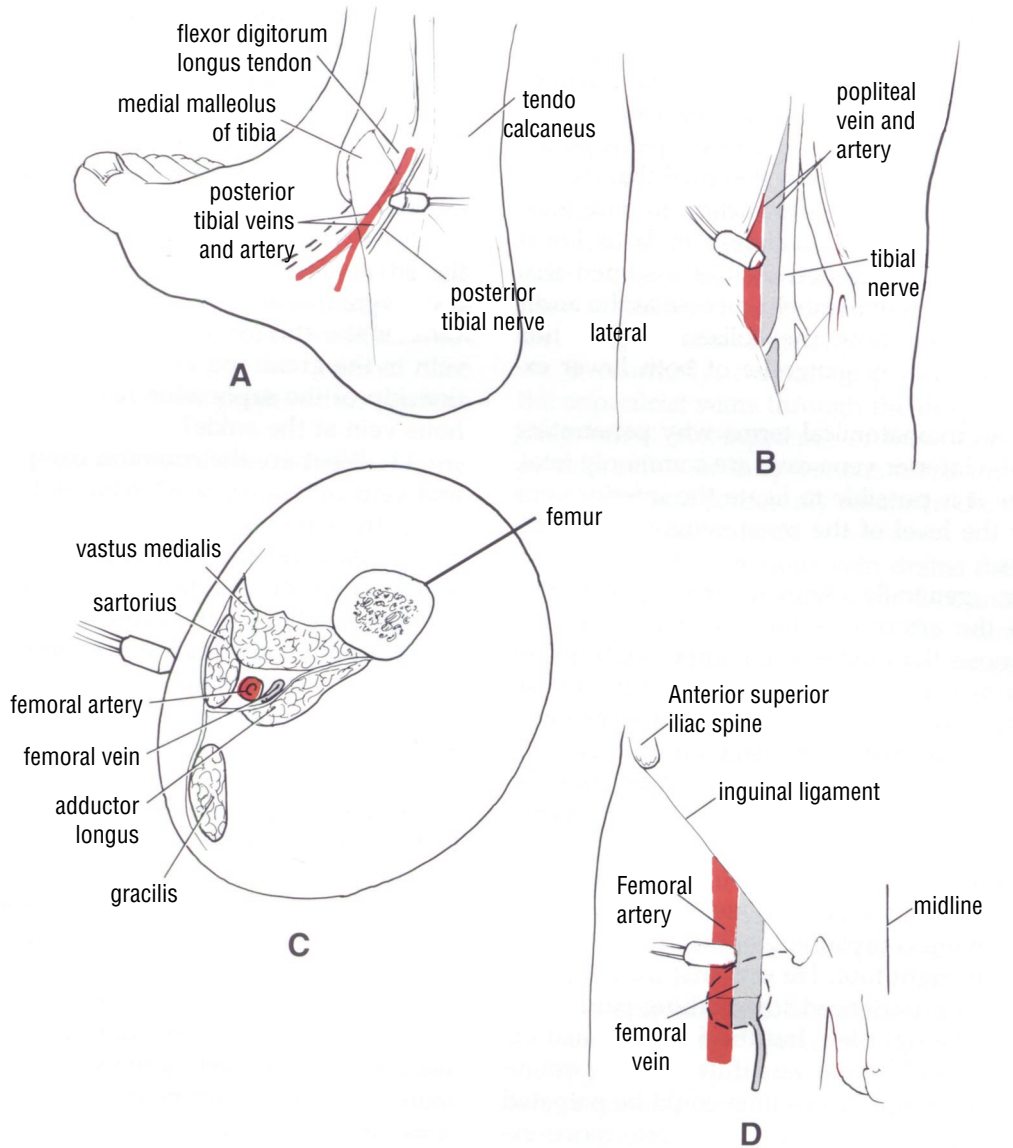
1. The skin of the thigh below the inguinal ligament is supplied by the genitofemoral nerve; this nerve is blocked with a local anesthetic.
2. The femoral pulse is palpated midway between the anterior superior iliac spine and the symphysis pubis, and the femoral vein lies immediately medial to it.
3. At a site about two fingerbreadths below the inguinal ligament, the needle is inserted into the femoral vein.

Doppler Ultrasound Examination of Venous Flow in the Lower Extremity

Posterior tibial veins: The probe is applied to the skin just posterior to the medial malleolus of the tibia. Here the posterior tibial veins accompany the posterior tibial artery between the tendon of the flexor digitorum longus and the posterior tibial nerve (CD Fig. 9-3).

Popliteal vein: The probe is applied to the skin over the popliteal space with the knee partly flexed to relax the deep fascia. The flow signal is best heard over the vein just lateral to the popliteal artery (see CD Fig. 9-3).

Femoral vein: The probe is placed over the vein at midthigh as it lies in the subsartorial canal with the femoral artery (see CD Fig. 9-3). The probe can also be applied higher up on the skin covering the femoral triangle just below the inguinal ligament. Here the femoral vein lies medial to the femoral artery (see CD Fig. 9-3). The pulse of the femoral artery can easily be felt at the midpoint between the anterior superior iliac spine and the symphysis pubis.



CD Figure 9-3 Doppler ultrasound of venous blood flow in the lower limb. **A.** Posterior tibial veins at the ankle. **B.** Popliteal vein behind the knee. **C.** Femoral vein and the subsartorial (adductor) canal in the midthigh. **D.** Femoral vein just below the inguinal ligament.

Venous Tone in Hypovolemic Shock

In extreme hypovolemic shock, excessive venous tone caused by the contraction of the smooth muscle in the vein walls may inhibit the venous flow and thus delay the introduction of intravenous blood into the vascular system.

Arterial Palpation

Every health professional should know the precise position of the main arteries within the lower limb, for he or she

may be called on to arrest a severe hemorrhage or palpate different parts of the arterial tree in patients with arterial occlusion.

The **femoral artery** enters the thigh behind the inguinal ligament at a point midway between the anterosuperior iliac spine and the symphysis pubis (see text Fig. 9-2 and CD Fig. 9-1). The artery is easily palpated here because it can be pressed backward against the pectineus and the superior ramus of the pubis.

The **popliteal artery** can be felt by gentle palpation in the depths of the popliteal space provided that the deep fascia is fully relaxed by passively flexing the knee joint (see text Fig. 9-7).

The **dorsalis pedis artery** lies between the tendons of extensor hallucis longus and extensor digitorum longus, midway between the medial and lateral malleoli on the front of the ankle (see text Fig. 9-9).

The **posterior tibial artery** passes behind the medial malleolus and beneath the flexor retinaculum; it lies between the tendons of flexor digitorum longus and flexor hallucis

longus. The pulsations of the artery can be felt midway between the medial malleolus and the heel (see text Fig. 9-14).

It should be remembered that the dorsalis pedis artery is sometimes absent and is replaced by a large perforating branch of the peroneal artery. In the same manner, the peroneal artery may be larger than normal and replace the posterior tibial artery in the lower part of the leg.

Clinical Problem Solving Questions

Read the following case histories/questions and give the best answer for each.

A 47-year-old woman complaining of a dull, aching pain in the lower part of both legs visited her physician. She stated that the pain was particularly severe at the end of a long day of standing at her work. On examination, the patient was found to have widespread varicose veins in both legs.

- The following symptoms and signs supported the diagnosis **except** which?
 - The patient stated that the skin down the medial side of the leg was irritated especially in dry weather.
 - If the patient coughed in the standing position, a fluid thrill was transmitted from the abdomen to the hand palpating the veins.
 - The skin showed marked discoloration over the medial malleoli and was dry and scaly.
 - The patient had a large family of six children and the varicose veins showed improvement during each pregnancy.
 - The great and small saphenous veins in both legs were enlarged and elongated.

A 65-year-old man told his physician that he could walk only about 50 yd (46 m) before a cramp-like pain in his left leg forced him to rest. After a thorough physical examination, a diagnosis of severe intermittent claudication of the left leg was made.

- The following findings in this patient supported the diagnosis **except** which?
 - His femoral pulses were normal in both legs.
 - The popliteal, posterior tibial, and dorsalis pedis pulses were present in the right leg and completely absent in the left leg.
 - Arteriography revealed a blockage of the left femoral artery at the level of the adductor tubercle.
 - The lower part of the left leg was receiving its blood supply through the muscular and genicular

branches of the femoral artery and the muscular and genicular branches of the popliteal artery.

- The collateral circulation in the left leg was adequate to prevent gangrene but was insufficient to supply oxygen to the active leg muscles.
- The perforating branches of the profunda femoris artery did not participate in the collateral circulation around the blocked femoral artery.

A 58-year-old businessman flew to Korea from New York by plane. Except for infrequent visits to the toilet, he remained in his seat sleeping or reading. Toward the end of the long flight, he experienced mild cramp-like pain in his right calf. On feeling his leg, he found it to be tender but thought nothing more about it. On reaching his destination, he was walking down the ramp from the plane when he suddenly collapsed with severe pain in his left chest and was experiencing extreme respiratory distress. The airport physician made the diagnosis of pulmonary embolism, secondary to deep vein thrombosis of the right calf.

- The blood clot (embolus) reached the left lung via the following blood vessels **except** which?
 - The right popliteal vein
 - The right common iliac vein
 - The inferior vena cava
 - The pulmonary trunk
 - The left pulmonary vein
- A 65-year-old man was seen in the emergency department complaining of the onset of a sudden pain in his right foot. He said that for the past 6 months he had experienced some aching pain in the lower part of the right leg, but the foot pain had occurred quite suddenly and was different. On examination, a tender pulsatile swelling could be palpated in the right popliteal space. In anatomic terms explain the chronic aching pain in the right lower leg. What is your explanation for the sudden onset of pain in the right foot?

5. Explain the significance of the valved perforating veins of the lower limbs. What is the surface marking of the small saphenous vein at the ankle?
6. What is the surface marking of the femoral artery? Name the structures that are pierced by the insertion of a catheter into the femoral artery. What is the relationship of the femoral artery to the femoral vein and the hip joint?
7. Compare in anatomic and practical terms the advantages and disadvantages of cutting down on the great saphenous vein at the groin and ankle. What is the surface marking of the great saphenous vein in the groin and at the ankle? What is the relationship of the saphenous nerve to the great saphenous vein at the ankle?
8. What are the common complications of femoral vein catheterization? What is the surface marking of the femoral vein?

Answers and Explanations

1. **D** is the correct answer. During the later months of pregnancy, the enlarged uterus presses on the inferior vena cava and impedes the venous return from the lower limbs. This condition results in a worsening of preexisting varicose veins.
2. **F** is the correct answer. The profunda femoris artery arises from the femoral artery about 1.5 in. (3.8 cm) below the inguinal ligament. It plays a major role in the formation of the collateral circulation around the knee joint.
3. **E** is the correct answer. The embolus does not enter the left pulmonary vein. The embolus ascends the venous system via the popliteal, femoral, external iliac, and common iliac veins and inferior vena cava to reach the right atrium of the heart. It then passes into the right ventricle, pulmonary trunk, and left pulmonary artery to finally reach the small or medium-sized branches of the left pulmonary artery, where it becomes lodged and obstructs the circulation.
4. The chronic aching pain in the right lower leg could be explained by the pressure of the expanding popliteal aneurysm on the tibial nerve (see text Fig. 9-7) in the popliteal space. The sudden onset of severe pain in the foot could be explained by the lodging of an embolus in one of the arteries in the foot. The embolus could have originated as a thrombus in the wall of the popliteal aneurysm.
5. Normally, the valved perforating veins drain the superficial veins through the deep fascia into the deep veins. Incompetence of these important veins permits reflux of deep venous blood into the superficial veins and commonly results in the formation of local superficial varices.

The small saphenous vein drains the lateral end of the dorsal venous arch of the foot and ascends in the superficial fascia **posterior** to the lateral malleolus of the

fibula. Here the position is constant and it can be readily seen.

6. The femoral artery enters the thigh beneath the inguinal ligament at a point midway between the anterior superior iliac spine and the symphysis pubis (see CD Fig. 9-1).

The following structures are pierced by a catheter entering the femoral artery in the thigh just below the inguinal ligament: (a) skin, (b) superficial fascia, (c) deep fascia, and (d) anterior layer of femoral sheath.

The femoral vein lies along the medial side of the femoral artery within the femoral sheath. The cavity of the hip joint lies posterior to the femoral artery, separated by the psoas muscle and the fibrous joint capsule.

7. The advantages of great saphenous vein cutdown at the ankle are (a) the position of the vein in front of the medial malleolus is constant, and (b) apart from the presence of the saphenous nerve, there are no other anatomic structures to damage—the cutdown is made over bone. The disadvantages are (a) phlebitis is a common complication, and (b) the small diameter precludes the rapid instillation of large volumes of fluid; in young children the small diameter of the vein sometimes make it difficult to identify.

The advantages of great saphenous cutdown in the groin are (a) the larger diameter of the vein at this site permits the rapid instillation of large volumes of fluid, and (b) there is easier recognition of the vein at this site. The disadvantages of the groin site are (a) the great saphenous vein lies in thick subcutaneous fat about 1 1/2 in. below and lateral to the pubic tubercle; its identification may prove difficult in obese patients; and (b) other important structures may be damaged, including the femoral artery and vein, if the procedure is carried out by an inexperienced individual.

The saphenous nerve usually lies just anterior to the great saphenous vein as it ascends anterior to the medial malleolus of the tibia (see CD Fig. 9-2).

8. The common complications of femoral vein catheterization are (a) thrombophlebitis of the femoral vein, especially if the catheterization is prolonged (since the catheter entering the saphenous vein at the groin also goes into the femoral vein, there is risk of phlebitis with saphenous catheterization as well); (b) hematoma formation if the procedure is poorly carried out and the vein wall is torn; (c) infection of the hip joint if an infected catheter pierces the femoral vein completely

or misses the vein and traverses the psoas muscle and the anterior part of the capsule of the hip joint; and (d) damage to the femoral nerve, which normally lies some distance laterally to the femoral artery (midpoint between the anterior superior iliac spine and the pubic tubercle).

The surface marking of the femoral vein is just medial to the pulsating femoral artery below the inguinal ligament. If the artery is pulseless, the position of the artery may be determined as being midway between the anterior superior iliac spine and the symphysis pubis; the vein lies just medial to it (see text Fig. 9-1).



The Lymphatic System



10

The Lymph Vessels and Lymph Tissue



Chapter Outline

The Lymph Vessels and Lymph Tissue	136	Examination of the Axillary Lymph Nodes	137
Edema and Lymphatic Obstruction	136	Carcinoma of the Breast and the Axillary Lymph Nodes	138
Lymphangitis and Lymphadenitis	136	Mediastinoscopy and the Tracheobronchial Lymph Nodes	138
Lymph Flow in Clinical Medicine	136	Lymphatics of the Lower Limb	138
Lymph Vessels and the Spread of Malignant Disease	137	The Thymus	139
Enlargement of the Submandibular Lymph Nodes and Swelling of the Submandibular Salivary Gland	137	Allograft Rejection	139
Clinical Significance of the Cervical Lymph Nodes	137	Tumors of the Thymus	139
Examination of the Deep Cervical Lymph Nodes	137	Clinical Problem Solving Questions	139
Carcinoma Metastases in the Deep Cervical Lymph Nodes	137	Answers and Explanations	141



THE LYMPH VESSELS AND LYMPH TISSUE

Edema and Lymphatic Obstruction

An inability to absorb protein from the tissue fluid into the lymphatic capillary will result in an accumulation of protein in the tissue fluid outside the capillary and cause **edema**. This occurs in several conditions:

- **Congenital lymphatic obstruction (Milroy's disease):** In this condition the lymphatic vessels, especially those of the lower limbs, fail to develop.
- **Surgical removal of lymph nodes and lymph vessels:** This occurs when an attempt is made to completely remove cancer cells that may have spread from their primary locus. This form of edema commonly occurs in the upper limbs following a radical mastectomy for carcinoma of the breast.
- **Filariasis:** In this mosquito-spread disease, common in the tropics, the worm larvae enter the lymphatic vessels and progressively block the lymph nodes. After a number of years, the lymphatic drainage of the leg may become totally obstructed and the grossly edematous lower limb

may resemble that of an elephant, hence the name **elephantiasis**.

- **Malignant metastases in lymph nodes and lymphatic vessels:** This condition may cause edema of the skin of the breast or arm in advanced carcinoma of the breast.

Lymphangitis and Lymphadenitis

Lymphangitis is an infection of the lymphatic vessels and is a common occurrence. Red streaks along the course of the lymphatic vessels are characteristic of the condition. For example, a severe infection of the thumb may be followed by the spread of the bacteria into the lymphatic vessels draining the area. Red streaks may be seen on the anterior aspect of the forearm, following the course of the cephalic vein.

Once the infection reaches the lymph nodes, the nodes become enlarged and tender, a condition known as lymphadenitis.

Lymph Flow in Clinical Medicine

The factors responsible for normal lymph flow in lymphatic vessels include muscle activity, local arterial pulsation, valves in lymphatic vessels, tissue fluid pressure, and gravity. There are clinical situations in which it is important to diminish the speed of lymph flow. For example, a patient who has a severe bacterial infection of the hand may have the arm immobilized in a sling as an important part of the treatment. This procedure reduces the muscular activity of the

limb and, consequently, the lymph flow, lessening the possibility of bacterial spread via the lymphatic vessels and diminishing the rate of entry of toxins into the blood stream via the lymph. In some conditions, it may be necessary to have the patient rest in bed to reduce lymph flow.

Other clinical conditions may require an increase in the flow of lymph in lymphatic vessels. In postural edema, an individual who has been standing in one position for hours may experience swelling of the ankles and feet. Increasing lymph flow also may be important in someone who has had a limb immobilized for a long period in a splint. Muscular exercises, raising the limb to use the force of gravity, or massage applied to the area will aid the flow of lymph along the valved lymphatic vessels.

Lymph Vessels and the Spread of Malignant Disease

Lymphatic vessels provide a pathway for the spread of certain types of malignant tumors from their site of origin. When the cancer cells reach a lymph node, they may be temporarily stopped by the network of reticular fibers. However, the cancer cells may continue to multiply in situ, leading to the formation of a secondary growth or metastasis.

Enlargement of the Submandibular Lymph Nodes and Swelling of the Submandibular Salivary Gland

The submandibular lymph nodes are commonly enlarged as a result of a pathologic condition of the scalp, face, maxillary sinus, or mouth cavity. One of the most common causes of painful enlargement of these nodes is acute infection of the teeth. Enlargement of these nodes should not be confused with pathologic swelling of the submandibular salivary gland.

Clinical Significance of the Cervical Lymph Nodes

Knowledge of the lymph drainage of an organ or region is of great clinical importance. Examination of a patient may reveal an enlarged lymph node. It is the physician's responsibility to determine the cause and be knowledgeable about the area of the body that drains its lymph into a particular node. For example, an enlarged submandibular node can be caused by a pathologic condition in the scalp, the face, the maxillary sinus, or the tongue. An infected tooth of the upper or lower jaw may be responsible. Often a physician has to search systematically the various areas known to drain into a node to discover the cause.

Examination of the Deep Cervical Lymph Nodes

Lymph nodes in the neck should be examined from behind the patient. The examination is made easier by asking the patient to flex the neck slightly to reduce the tension of the muscles. The groups of nodes should be examined in a definite order to avoid omitting any.

After the identification of enlarged lymph nodes, possible sites of infection or neoplastic growth should be examined, including the face, scalp, tongue, mouth, tonsil, and pharynx.

Carcinoma Metastases in the Deep Cervical Lymph Nodes

In the head and neck, all the lymph ultimately drains into the **deep cervical group of nodes**. Secondary carcinoma deposits in these nodes are common. The primary growth may be easy to find. On the other hand, at certain anatomic sites the primary growth may be small and overlooked, for example, in the larynx, the pharynx, the cervical part of the esophagus, and the external auditory meatus. The bronchi, breast, and stomach are sometimes the site of the primary tumor. In these cases, the secondary growth has spread far beyond the local lymph nodes.

When cervical metastases occur, the surgeon usually decides to perform a **block dissection of the cervical nodes**. This procedure involves the removal en bloc of the internal jugular vein, the fascia, the lymph nodes, and the submandibular salivary gland. The aim of the operation is removal of all the lymph tissues on the affected side of the neck. The carotid arteries and the vagus nerve are carefully preserved. It is often necessary to sacrifice the hypoglossal and vagus nerves, which may be involved in the cancerous deposits. In patients with bilateral spread, a bilateral block dissection may be necessary. An interval of 3 to 4 weeks is necessary before removing the second internal jugular vein.

Examination of the Axillary Lymph Nodes

With the patient standing or sitting, he or she is asked to place the hand of the side to be examined on the hip and push hard medially. This action of adduction of the shoulder joint causes the pectoralis major muscle to contract maximally so that it becomes hard like a board. The examiner then palpates the axillary nodes (see text Fig. 10-3) as follows:

- The **anterior (pectoral) nodes** may be palpated by pressing forward against the posterior surface of the pectoralis major muscle on the anterior wall of the axilla.

- The **posterior (subscapular) nodes** may be palpated by pressing backward against the anterior surface of the subscapularis muscle on the posterior wall of the axilla.
- The **lateral nodes** may be palpated against the medial side of the axillary vein. The examiner's fingers are pressed laterally against the subclavian vein and the pulsating axillary artery.
- The **central nodes** may be palpated in the center of the axilla between the pectoralis major (anterior wall) and the subscapularis (posterior wall).
- For the **apical nodes**, the patient is asked to relax the shoulder muscles and let the upper limb hang down at the side. The examiner then gently places the tips of the fingers of the examining hand high up in the axilla to the outer border of the first rib. If the nodes are enlarged they can be felt.

The examination of the axillary lymph nodes always forms part of the clinical examination of the breast.

Carcinoma of the Breast and the Axillary Lymph Nodes

The importance of knowing the lymph drainage of the breast in relation to the spread of cancer from that organ cannot be overemphasized. The lymph vessels from the medial quadrants of the breast pierce the second, third, and fourth intercostal spaces and enter the thorax to drain into the lymph nodes alongside the internal thoracic artery. The lymph vessels from the lateral quadrants of the breast drain into the anterior or pectoral group of axillary nodes. It follows, therefore, that a cancer occurring in the lateral quadrants of the breast tends to spread to the axillary nodes. Thoracic metastases are difficult or impossible to treat, but the lymph nodes of the axilla can be removed surgically.

Approximately 60% of carcinomas of the breast occur in the upper lateral quadrant. The lymphatic spread of cancer to the opposite breast, to the abdominal cavity, or into lymph nodes in the root of the neck is caused by obstruction of the normal lymphatic pathways by malignant cells or destruction of lymph vessels by surgery or radiotherapy. The cancer cells are swept along the lymph vessels and follow the lymph stream. The entrance of cancer cells into the blood vessels accounts for the metastases in distant bones.

In patients with localized cancer of the breast, most surgeons do a simple mastectomy or a lumpectomy, followed by radiotherapy to the axillary lymph nodes and/or hormone therapy. In patients with localized cancer of the breast with early metastases in the axillary lymph nodes, most authorities agree that radical mastectomy offers the best chance of cure. In patients in whom the disease has already spread beyond these areas (e.g., into the thorax), simple mastectomy, followed by radiotherapy or hormone therapy, is the treatment of choice.

Radical mastectomy is designed to remove the primary tumor and the lymph vessels and nodes that drain the area. This means that the breast and the associated structures containing the lymph vessels and nodes must be removed en bloc. The excised mass is therefore made up of the following: a large area of skin overlying the tumor and including the nipple; all the breast tissue; the pectoralis major and associated fascia through which the lymph vessels pass to the internal thoracic nodes; the pectoralis minor and associated fascia related to the lymph vessels passing to the axilla; all the fat, fascia, and lymph nodes in the axilla; and the fascia covering the upper part of the rectus sheath, the serratus anterior, the subscapularis, and the latissimus dorsi muscles. The axillary blood vessels, the brachial plexus, and the nerves to the serratus anterior and the latissimus dorsi are preserved. Some degree of postoperative edema of the arm is likely to follow such a radical removal of the lymph vessels draining the upper limb.

A modified form of radical mastectomy for patients with clinically localized cancer is also a common procedure and consists of a simple mastectomy in which the pectoral muscles are left intact. The axillary lymph nodes, fat, and fascia are removed. This procedure removes the primary tumor and permits pathologic examination of the lymph nodes for possible metastases.

Mediastinoscopy and the Tracheobronchial Lymph Nodes

Mediastinoscopy is a diagnostic procedure whereby specimens of tracheobronchial lymph nodes are obtained without opening the pleural cavities. A small incision is made in the midline in the neck just above the suprasternal notch, and the superior mediastinum is explored down to the region of the bifurcation of the trachea. The procedure can be used to determine the diagnosis and degree of spread of carcinoma of the bronchus.

Lymphatics of the Lower Limb

The superficial and deep inguinal lymph nodes not only drain all the lymph from the lower limb, but also drain lymph from the skin and superficial fascia of the anterior and posterior abdominal walls below the level of the umbilicus; lymph from the external genitalia and the mucous membrane of the lower half of the anal canal also drains into these nodes. Remember the large distances the lymph has had to travel in some instances before it reaches the inguinal nodes. For example, a patient may present with an enlarged, painful inguinal lymph node caused by lymphatic spread of pathogenic organisms that entered the body through a small scratch on the undersurface of the big toe.



THE THYMUS

Allograft Rejection

At about the time of birth, T lymphocytes leave the thymus and populate the peripheral lymphatic tissue; it is these cells that will bring about rejection of an allograft. Grafts between identical twins or from an individual to himself or herself will survive indefinitely, because there is no antigenic response. Although the thymus in the adult continues to influence the activities of the T lymphocytes, possibly by means of **thymosin**, thymectomy has been unsuccessful in preventing the rejection of allografts. Attempts to suppress

the immunocompetent lymphocytes with drugs have been moderately successful.

Tumors of the Thymus

Thymomas are tumors of the thymus and are some of the most common tumors found in the anterior mediastinum. Many of the tumors are associated with myasthenia gravis and aplasia of blood cells. It is thought that these diseases are autoimmune in origin and may develop as a result of the formation of T lymphocytes that react to the individual's own tissues. Myasthenia gravis is a disease in which there is a possible reduction of acetylcholine receptors at the motor end-plates of skeletal muscle. Thymomas may be benign or malignant.

Clinical Problem Solving Questions

Read the following case histories/questions and give the best answer for each.

1. A 23-year-old woman is treated in the emergency department for an infected right index finger. Three days previously, she had got a rose thorn in her finger while gardening. On examination, the finger is red, tender, and very swollen. After removing the thorn and applying a dressing, the physician prescribes a course of antibiotics. He asks the nurse to put the patient's right arm in a sling, and warns the patient not to move the arm excessively. Explain why the patient's arm has been placed in a sling.
2. A 54-year-old man visits his doctor complaining of a skin infection of the auricle of the right ear. The patient had scratched his ear 4 days previously and since then his ear has become greatly swollen, and his wife has noted that the right side of his neck is also swollen. The physician's assistant made the diagnosis of impetigo and gave the patient an antibiotic to be taken orally. She advised the patient to place a warm compress over the ear twice daily to reduce the auricular swelling. Using your knowledge of anatomy and physiology, explain the following: (a) Why is the ear swollen? (b) Why is the right side of the neck swollen? and (c) Why will the application of a warm compress to the ear reduce the swelling?
3. A 58-year-old woman following a right radical mastectomy (which involves the removal of the right breast and the right axillary lymph nodes) has lymphatic edema of the right arm because of obstruction of the

normal lymph flow. Describe the main factors responsible for lymph flow.

4. Explain the mechanism of allograft rejection. What form of immunity is lacking in a patient who has a congenital absence of the thymus?

A 70-year-old man complaining of a small painless swelling below his chin visited his physician. On questioning, he said that he had first noticed the swelling 4 months earlier and that it was gradually increasing in size. Because it had not caused any discomfort, he had chosen to ignore it. On examination, a single, small, hard swelling could be palpated in the submental triangle. It was mobile on the deep tissues and not attached to the skin.

5. The following statements suggest that the hard swelling is a secondary malignant deposit in a lymph node **except** which?
 - A. The submental lymph nodes are located in the submental triangle just below the chin.
 - B. The submental lymph nodes drain the tip of the tongue, the floor of the mouth in the region of the frenulum of the tongue, the gums and incisor teeth, the middle third of the lower lip, and the skin over the chin.
 - C. A small, hard-based carcinomatous ulcer was found on the right side of the tongue near the tip.
 - D. The deep cervical group of lymph nodes beneath the sternocleidomastoid muscle receive lymph from the submental lymph nodes.

E. The submental lymph nodes lie deep to the superficial part of the submandibular salivary gland.

An 8-year-old boy was examined by a pediatrician and found to have a painful swelling below and behind the angle of the jaw on the left side. The skin over the swelling was red and hot. Palpation of the neck revealed a tender firm swelling beneath the anterior border of the sternocleidomastoid muscle on the left side. The right side of the neck was normal. Examination of the pharynx and palatine tonsils showed marked redness of the mucous membrane and enlargement of both tonsils, especially the one on the left. The left tonsil also showed a yellow exudate draining from the tonsillar crypts.

6. Using your knowledge of anatomy, name the group of lymph nodes involved in the disease.

An 18-year-old woman complaining of severe pain and redness around the base of the nail of the right thumb visited her physician. She stated that she had trimmed the cuticle (eponychium) of her nail with scissors, and the following day the pain commenced. On examination, the skin folds around the root of the nail were red, swollen, and extremely tender. The thumb was swollen, and red streaks were seen coursing up the front of the forearm.

7. The following symptoms and signs in this patient were consistent with a diagnosis of an acute bacterial infection under the nail folds (paronychia) of the right thumb **except** which?
- Some tender lymph nodes could be palpated in the infraclavicular fossa.
 - The patient's temperature was raised.
 - The infection had spread into the lymph vessels draining the finger.
 - The red streaks on the front of the forearm were caused by the local vasodilatation of the blood vessels along the course of the lymph vessels.
 - The lymph vessels from the thumb drain into the supratrochlear node, which was inflamed and enlarged.

A 45-year-old woman having her yearly physical examination was found to have a hard, painless lump in the upper lateral quadrant of the left breast. On examination with her arms at her sides, the left nipple was seen to be higher than the right, and a small dimple of skin was noted over the lump. On examination of the left axilla, three small, hard discrete nodules could be palpated below the lower border of the pectoralis major muscle. The right breast was normal. A diagnosis of

carcinoma of the left breast was made, with secondary deposits in the axilla.

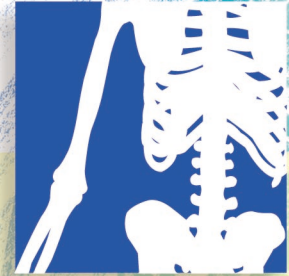8. The following statements concerning this patient are correct **except** which?
- The contracting fibrous tissue of the malignant tumor had pulled on the lactiferous ducts of the nipple, raising it above the level of the opposite nipple.
 - The dimpling of the skin was caused by the fibrous tissue pulling on the suspensory ligaments of the breast.
 - The upper lateral quadrant of the breast is drained into the pectoral or anterior axillary lymph nodes.
 - The enlarged pectoral lymph nodes could be palpated against the surgical neck of the humerus.
 - The malignant tumor had spread by way of the lymph vessels to the pectoral lymph nodes.

A 45-year-old man complaining of a lump in the groin was seen by his physician. The lump, which caused him no pain or discomfort, was first recognized 3 months previously. On examination, a large discrete hard lump was found about 2 in. (5 cm) below and lateral to the pubic tubercle on the front of the right thigh.

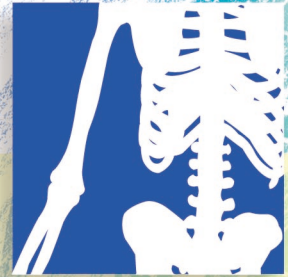9. The following signs indicated that this patient had a melanoma of the right big toe with secondaries in the inguinal lymph nodes **except** which?
- Two smaller hard swellings were found immediately below the large swelling.
 - On flexing the right knee joint, three small hard swellings could be palpated in the popliteal fossa.
 - The external genitalia were found to be normal.
 - Examination of the anal canal revealed nothing abnormal.
 - A small pigmented mole was discovered beneath the nail of the right big toe.
10. A senior medical student taking a surgical examination was asked to look at a 55-year-old man. On examination of the abdomen, he found a hard, fixed mass in the midline, about 4 in. (10 cm) in diameter, lying on the transpyloric plane. On questioning, the patient said that he had recently lost 20 lb and had a poor appetite. The student told the examiner that the patient was suffering from a carcinoma of the stomach and should have an immediate gastrectomy. The examiner then asked the student if he had examined the patient's scrotum, and the student admitted he had not. On examination, the scrotum was found to contain a large, hard mass on the right side that was not tethered to the skin. The inguinal lymph nodes on the right side were normal. Explain the connection between the abdominal swelling and the scrotal swelling. Why were the inguinal lymph nodes normal?

Answers and Explanations

1. The immobilization of the patient's arm in a sling reduces the muscular activity and, thus, the rate of lymph flow from the limb. This serves to limit the spread of toxins and bacteria from the site of infection.
2. (a) The auricle of the ear is swollen by inflammatory edema. Edema is an abnormal accumulation of tissue fluid in the intercellular spaces. The fluid dynamics of inflammatory edema includes the vasodilatation of the arterioles and capillaries at the site of infection with an outpouring of protein-rich plasma into the tissue spaces along with the outpouring of neutrophils. (b) The right side of the neck is swollen because the bacteria have spread from the right auricle via the lymphatic vessels to the right superficial and deep cervical lymph nodes, which are enlarged as a result of the proliferation of the contained lymphocytes. (c) In the early stages of infection, heat causes arteriolar vasodilatation, which in turn raises blood flow through the infected skin, hastening the arrival of neutrophils, antibodies, and antibiotics to the site of infection. Once the infection is controlled, the increased vascular and lymphatic flow will help reduce the local accumulation of tissue fluid and cause the swelling of the ear to diminish.
3. The factors responsible for lymph flow are summarized in the CD paragraph under Lymph Flow in Clinical Medicine.
4. The mechanism of allograft rejection is summarized in the CD paragraph under Allograft Rejection. In congenital absence of the thymus, the patient lacks T lymphocytes and, therefore, cellular immunity.
5. E is the correct answer. The submental lymph nodes are not covered by the superficial parts of the submandibular salivary gland (see text Fig. 10-2).
6. This patient had a streptococcal pharyngitis with involvement of the palatine tonsils, especially the one on the left. The infection had spread on the left side to involve the jugulodigastric member of the deep cervical lymph nodes (see text Fig. 10-2). This node had enlarged due to the inflammatory process and was responsible for the tender swelling on the left side of the neck.
7. E is the correct answer. The lymph vessels from the index finger drain into the deltopectoral nodes (see text Fig. 10-1).
8. D is the correct answer. The enlarged pectoral lymph nodes can be palpated against the posterior surface of the contracted pectoralis major muscle (see text Fig. 10-4).
9. B is the correct answer. Melanomas, which are highly malignant tumors, tend to initially spread via the lymph vessels to the local lymph nodes. These become enlarged and firm on palpation. The lymphatic drainage of the big toe is into the vertical group of superficial inguinal lymph nodes (see text Fig. 10-7).
10. The student failed to examine the entire patient and made an erroneous diagnosis. He may have been sidetracked in his thoughts by the patient stating that he had a poor appetite. One thing is certain—the student had forgotten his anatomy! (a) Malignant disease of the testis metastasizes to the lateral aortic nodes lying on the side of the body of the first lumbar vertebra in the abdomen (on the transpyloric plane). This is the normal lymph drainage of the testis. (b) The inguinal lymph nodes are only involved if the tumor spreads locally into the tissues of the scrotum outside the testis.

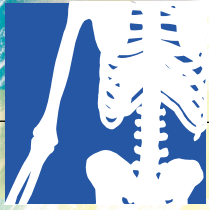


The Musculoskeletal System



11

Bones and Cartilage



Chapter Outline

Bones	147		
Bone Fractures	147	Greater Tuberosity Fractures	152
Rickets	147	Lesser Tuberosity Fractures	152
Epiphyseal Plate Disorders	147	Surgical Neck Fractures	152
Skull	147	<i>Fractures of the Shaft of the Humerus</i>	152
Clinical Features of the Neonatal Skull	147	<i>Fractures of the Distal End of the Humerus</i>	152
Fontanelles	147	Bones of the Forearm	152
Tympanic Membrane	147	<i>Fractures of the Radius and Ulna</i>	152
Forceps Delivery and the Facial Nerve	147	<i>Olecranon Bursitis</i>	154
Fractures of the Skull	147	Bones of the Hand	154
<i>Fractures of the Anterior Cranial Fossa</i>	148	<i>Injuries to the Bones of the Hand</i>	154
<i>Fractures of the Middle Cranial Fossa</i>	148	Bones of the Lower Limb	154
<i>Fractures of the Posterior Cranial Fossa</i>	148	Bones of the Pelvic Girdle	154
<i>Bone Injuries of the Skull and Skeletal Development</i>	148	<i>Clinical Concept: The Pelvis is a Basin with Holes in its Walls</i>	154
Anatomy of Common Facial Fractures	148	<i>Pelvic Measurements in Obstetrics</i>	155
<i>Nasal Fractures</i>	148	Internal Pelvic Assessments	155
<i>Maxillofacial Fractures</i>	148	<i>The Female Pelvis</i>	155
<i>Blowout Fractures of the Maxilla</i>	148	<i>Fractures of the Pelvis</i>	156
<i>Fractures of the Zygoma or Zygomatic Arch</i>	149	Fractures of the False Pelvis	156
Mandible	149	Fractures of the True Pelvis	156
Fractures of the Mandible	149	Fractures of the Sacrum and Coccyx	158
Vertebral Column	149	Minor Fractures of the Pelvis	158
Examination of the Back	149	Anatomy of Complications of Pelvic Fractures	158
Abnormal Curves of the Vertebral Column	150	Bones of the Thigh	158
Partial Fusion of the Sacral Vertebrae	150	<i>Tenderness of the Head of the Femur and Arthritis of the Hip Joint</i>	158
Fracture of the Sacrum in Trauma of the Pelvis	150	<i>Blood Supply to the Femoral Head and Neck Fractures</i>	159
Fractures of the Coccyx and Coccydynia	150	<i>The Neck of the Femur and Coxa Valga and Coxa Vara</i>	159
Thoracic Bones	150	<i>Fractures of the Femur</i>	159
Clinical Importance of the Sternal Angle (Angle of Louis)	150	<i>Patellar Dislocations</i>	161
Sternum and Marrow Biopsy	150	<i>Patellar Fractures</i>	161
Cervical Rib	150	Bones of the Leg	161
Rib Excision	151	<i>Fractures of the Tibia and Fibula</i>	161
Bones of the Upper Limb	151	<i>Interosseous Infusion of the Tibia in the Infant</i>	161
Bones of the Shoulder Girdle	151	Bones of the Foot	161
<i>Fractures of the Clavicle</i>	151	<i>Fractures of the Calcaneum</i>	161
<i>Compression of the Brachial Plexus, Subclavian Artery, and Subclavian Vein by the Clavicle</i>	151	<i>Fractures of the Talus</i>	161
<i>Fractures of the Scapula</i>	151	<i>Fractures of the Metatarsal Bones</i>	162
<i>Dropped Shoulder and Winged Scapula</i>	151		
Bones of the Arm	152	Clinical Problem Solving Questions	162
<i>Fractures of the Proximal End of the Humerus</i>	152	Answers and Explanations	165
Humeral Head Fractures	152		



BONES

Bone Fractures

Immediately after a fracture, the patient suffers severe local pain and is not able to use the injured part. Deformity may be visible if the bone fragments have been displaced relative to each other. The degree of deformity and the directions taken by the bony fragments depend not only on the mechanism of injury but also on the pull of the muscles attached to the fragments. Ligamentous attachments also influence the deformity. In certain situations—for example, the ileum—fractures result in no deformity because the inner and outer surfaces of the bone are splinted by the extensive origins of muscles. In contrast, a fracture of the neck of the femur produces considerable displacement. The strong muscles of the thigh pull the distal fragment upward so that the leg is shortened. The very strong lateral rotators rotate the distal fragment laterally so that the foot points laterally.

Fracture of a bone is accompanied by a considerable hemorrhage of blood between the bone ends and into the surrounding soft tissue. The blood vessels and the fibroblasts and osteoblasts from the periosteum and endosteum take part in the repair process.

Rickets

Rickets is a defective mineralization of the cartilage matrix in growing bones. This produces a condition in which the cartilage cells continue to grow, resulting in excess cartilage and a widening of the epiphyseal plates. The poorly mineralized cartilaginous matrix and the osteoid matrix are soft, and they bend under the stress of bearing weight. The resulting deformities include enlarged costochondral junctions, bowing of the long bones of the lower limbs, and bossing of the frontal bones of the skull. Deformities of the pelvis may also occur.

Epiphyseal Plate Disorders

Epiphyseal plate disorders affect only children and adolescents. The epiphyseal plate is the part of a growing bone concerned primarily with growth in length. Trauma, infection, diet, exercise, and endocrine disorders can disturb the growth of the hyaline cartilaginous plate, leading to deformity and loss of function. In the femur, for example, the proximal epiphysis can slip because of mechanical stress or excessive loads. The length of the limbs can increase excessively because of increased vascularity in the region of the epiphyseal plate secondary to infection or in the presence of tumors. Shortening of a limb can follow trauma to the epiphyseal plate resulting from a diminished blood supply to the cartilage.

Skull

Clinical Features of the Neonatal Skull

Fontanelles

Palpation of the fontanelles enables the physician to determine the progress of growth in the surrounding bones, the degree of hydration of the baby (e.g., if the fontanelles are depressed below the surface, the baby is dehydrated), and the state of the intracranial pressure (a bulging fontanelle indicates raised intracranial pressure).

Samples of cerebrospinal fluid can be obtained by passing a long needle obliquely through the anterior fontanelle into the subarachnoid space or even into the lateral ventricle.

Clinically, it is usually not possible to palpate the anterior fontanelle after 18 months, because the frontal and parietal bones have enlarged to close the gap.

Tympanic Membrane

At birth, the tympanic membrane faces more downward and less laterally than in maturity; when examined with the otoscope, it therefore lies more obliquely in the infant than in the adult.

Forceps Delivery and the Facial Nerve

In the newborn infant, the mastoid process is not developed, and the facial nerve, as it emerges from the stylomastoid foramen, is close to the surface. Thus, it can be damaged by forceps in a difficult delivery.

Fractures of the Skull

Fractures of the skull are common in the adult but much less so in the young child. In the infant skull, the bones are more resilient than in the adult skull, and they are separated by fibrous sutural ligaments. In the adult, the inner table of the skull is particularly brittle. Moreover, the sutural ligaments begin to ossify during middle age.

The type of fracture that occurs in the skull depends on the age of the patient, the severity of the blow, and the area of skull receiving the trauma. The **adult skull** may be likened to an eggshell in that it possesses a certain limited resilience beyond which it splinters. A severe, localized blow produces a local indentation, often accompanied by splintering of the bone. Blows to the vault often result in a series of linear fractures, which radiate out through the thin areas of bone. The petrous parts of the temporal bones and the occipital crests strongly reinforce the base of the skull and tend to deflect linear fractures.

In the **young child**, the skull may be likened to a table-tennis ball in that a localized blow produces a depression without splintering. This common type of circumscribed lesion is referred to as a “**pond**” fracture.

Fractures of the Anterior Cranial Fossa

In fractures of the anterior cranial fossa, the cribriform plate of the ethmoid bone may be damaged. This usually results in tearing of the overlying meninges and underlying mucoperiosteum. The patient will have bleeding from the nose (**epistaxis**) and leakage of cerebrospinal fluid into the nose (**cerebrospinal rhinorrhea**). Fractures involving the orbital plate of the frontal bone result in hemorrhage beneath the conjunctiva and into the orbital cavity, causing **exophthalmos**. The frontal air sinus may be involved, with hemorrhage into the nose.

Fractures of the Middle Cranial Fossa

Fractures of the middle cranial fossa are common, because this is the weakest part of the base of the skull. Anatomically, this weakness is caused by the presence of numerous foramina and canals in this region; the cavities of the middle ear and the sphenoidal air sinuses are particularly vulnerable. The leakage of cerebrospinal fluid and blood from the external auditory meatus is common. The seventh and eighth cranial nerves may be involved as they pass through the petrous part of the temporal bone. The third, fourth, and sixth cranial nerves may be damaged if the lateral wall of the cavernous sinus is torn. Blood and cerebrospinal fluid may leak into the sphenoidal air sinuses and then into the nose.

Fractures of the Posterior Cranial Fossa

In fractures of the posterior cranial fossa, blood may escape into the nape of the neck deep to the postvertebral muscles. Some days later, it tracks between the muscles and appears in the posterior triangle, close to the mastoid process. The mucous membrane of the roof of the nasopharynx may be torn, and blood may escape there. In fractures involving the jugular foramen, the ninth, tenth, and eleventh cranial nerves may be damaged. The strong bony walls of the hypoglossal canal usually protect the hypoglossal nerve from injury.

Bone Injuries of the Skull and Skeletal Development

The developing bones of a child's face are more pliable than an adult's, and fractures may be incomplete or greenstick. In adults, the presence of well-developed, air-filled sinuses and the mucoperiosteal surfaces of the alveolar parts of the upper and lower jaws means that most facial fractures should be considered to be open fractures, susceptible to infection and requiring antibiotic therapy.

Anatomy of Common Facial Fractures

Automobile accidents, fisticuffs, and falls are common causes of facial fractures. Fortunately, the upper part of the

skull is developed from membrane (whereas the remainder is developed from cartilage); therefore, this part of the skull in children is relatively flexible and can absorb considerable force without resulting in a fracture.

Signs of fractures of the facial bones include deformity, ocular displacement, or abnormal movement accompanied by crepitation and malocclusion of the teeth. Anesthesia or paresthesia of the facial skin will follow fracture of bones through which branches of the trigeminal nerve pass to the skin.

The muscles of the face are thin and weak and cause little displacement of the bone fragments. Once a fracture of the maxilla has been reduced, for example, prolonged fixation is not needed. However, in the case of the mandible, the strong muscles of mastication can create considerable displacement, requiring long periods of fixation.

The most common facial fractures involve the nasal bones, followed by the zygomatic bone and then the mandible. To fracture the maxillary bones and the supra-orbital ridges of the frontal bones, an enormous force is required.

Nasal Fractures

Fractures of the nasal bones, because of the prominence of the nose, are the most common facial fractures. Because the bones are lined with mucoperiosteum, the fracture is considered open; the overlying skin may also be lacerated. Although most are simple fractures and are reduced under local anesthesia, some are associated with severe injuries to the nasal septum and require careful treatment under general anesthesia.

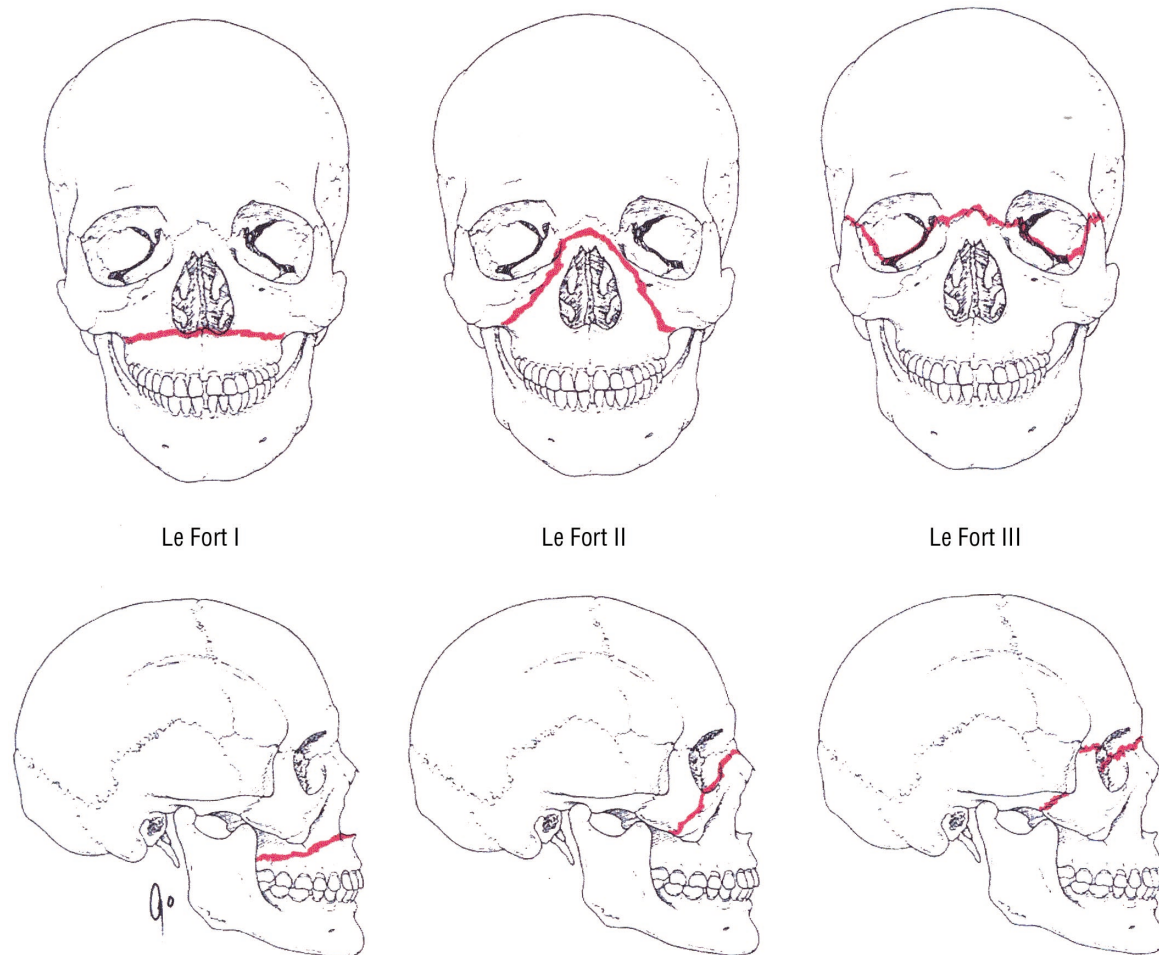
Maxillofacial Fractures

Maxillofacial fractures usually occur as the result of massive facial trauma. There is extensive facial swelling, midface mobility of the underlying bone on palpation, malocclusion of the teeth with anterior open bite, and possibly leakage of cerebrospinal fluid (cerebrospinal rhinorrhea) secondary to fracture of the cribriform plate of the ethmoid bone. Double vision (diplopia) may be present, owing to orbital wall damage. Involvement of the infra-orbital nerve with anesthesia or paresthesia of the skin of the cheek and upper gum may occur in fractures of the body of the maxilla. Nose bleeding may also occur in maxillary fractures. Blood enters the maxillary air sinus and then leaks into the nasal cavity.

The sites of the fractures were classified by Le Fort as type I, II, or III; these fractures are summarized in CD Fig. 11-1.

Blowout Fractures of the Maxilla

A severe blow to the orbit (as from a baseball) may cause the contents of the orbital cavity to explode downward through



CD Figure 11-1 Le Fort classification of maxillofacial fractures. The red line denotes the fracture line.

the floor of the orbit into the maxillary sinus. Damage to the infraorbital nerve, resulting in altered sensation to the skin of the cheek, upper lip, and gum, may occur.

Fractures of the Zygoma or Zygomatic Arch

The zygoma or zygomatic arch can be fractured by a blow to the side of the face. Although it can occur as an isolated fracture, as from a blow from a clenched fist, it may be associated with multiple other fractures of the face, as often seen in automobile accidents.

Mandible

Fractures of the Mandible

The mandible is horseshoe shaped and forms part of a bony ring with the two temporomandibular joints and the base of the skull. Traumatic impact is transmitted around

the ring, causing a single fracture or multiple fractures of the mandible, often far removed from the point of impact.

Vertebral Column

Examination of the Back

It is important that the whole area of the back and legs be examined and that the shoes be removed. Unequal length of the legs or disease of the hip joints can lead to abnormal curvatures of the vertebral column. The patient should be asked to walk up and down the examination room so that the normal tilting movement of the pelvis can be observed. As one side of the pelvis is raised, a coronal lumbar convexity develops on the opposite side, with a compensatory thoracic convexity on the same side. When a person assumes the sitting position, it will be noted that the normal lumbar curvature becomes flattened, with an increase in the interval between the lumbar spines.

The normal range of movement of the different parts of the vertebral column should be tested. In the cervical region, flexion, extension, lateral rotation, and lateral flexion are possible. Remember that about half of the movement referred to as flexion is carried out at the atlantooccipital joints. In flexion, the patient should be able to touch his or her chest with the chin, and in extension he or she should be able to look directly upward. In lateral rotation the patient should be able to place the chin nearly in line with the shoulder. Half of lateral rotation occurs between the atlas and the axis. In lateral flexion the head can normally be tilted 45° to each shoulder. It is important that the shoulder is not raised when this movement is being tested.

In the thoracic region the movements are limited by the presence of the ribs and sternum. When testing for rotation, make sure that the patient does not rotate the pelvis.

In the lumbar region, flexion, extension, lateral rotation, and lateral flexion are possible. Flexion and extension are fairly free. Lateral rotation, however, is limited by the interlocking of the articular processes. Lateral flexion in the thoracic and lumbar regions is tested by asking the patient to slide, in turn, each hand down the lateral side of the thigh.

Abnormal Curves of the Vertebral Column

Kyphosis is an exaggeration in the sagittal curvature present in the thoracic part of the vertebral column. It can be caused by muscular weakness or by structural changes in the vertebral bodies or by intervertebral discs. In sickly adolescents, for example, where the muscle tone is poor, long hours of study or work over a low desk can lead to a gently curved kyphosis of the upper thoracic region. The person is said to be “round-shouldered.” Crush fractures or tuberculous destruction of the vertebral bodies leads to acute angular kyphosis of the vertebral column. In the aged, **osteoporosis** (abnormal rarefaction of bone) and/or degeneration of the intervertebral discs leads to **senile kyphosis**, involving the cervical, thoracic, and lumbar regions of the column.

Lordosis is an exaggeration in the sagittal curvature present in the lumbar region. Lordosis may be caused by an increase in the weight of the abdominal contents, as with the gravid uterus or a large ovarian tumor, or it may be caused by disease of the vertebral column such as spondylolisthesis. The possibility that it is a postural compensation for a kyphosis in the thoracic region or a disease of the hip joint (congenital dislocation) must not be overlooked.

Scoliosis is a lateral deviation of the vertebral column. This is most commonly found in the thoracic region and may be caused by muscular or vertebral defects. Paralysis of muscles caused by poliomyelitis can cause severe scoliosis. The presence of a congenital hemivertebra can cause scoliosis. Often scoliosis is compensatory and may be caused by a short leg or hip disease.

Partial Fusion of the Sacral Vertebrae

The first sacral vertebra can be partly or completely separated from the second sacral vertebra. Occasionally, on radiographs of the vertebral column, examples are seen in which the fifth lumbar vertebra has fused with the first sacral vertebra.

Fracture of the Sacrum in Trauma of the Pelvis

Trauma to the true pelvis can result in fracture of the lateral mass of the sacrum.

Fractures of the Coccyx and Coccydynia

Fractures of the coccyx are rare. However, **coccydynia** is common and is usually caused by direct trauma to the coccyx, as in falling down a flight of concrete steps. The anterior surface of the coccyx can be palpated with a rectal examination.

Thoracic Bones

Clinical Importance of the Sternal Angle (Angle of Louis)

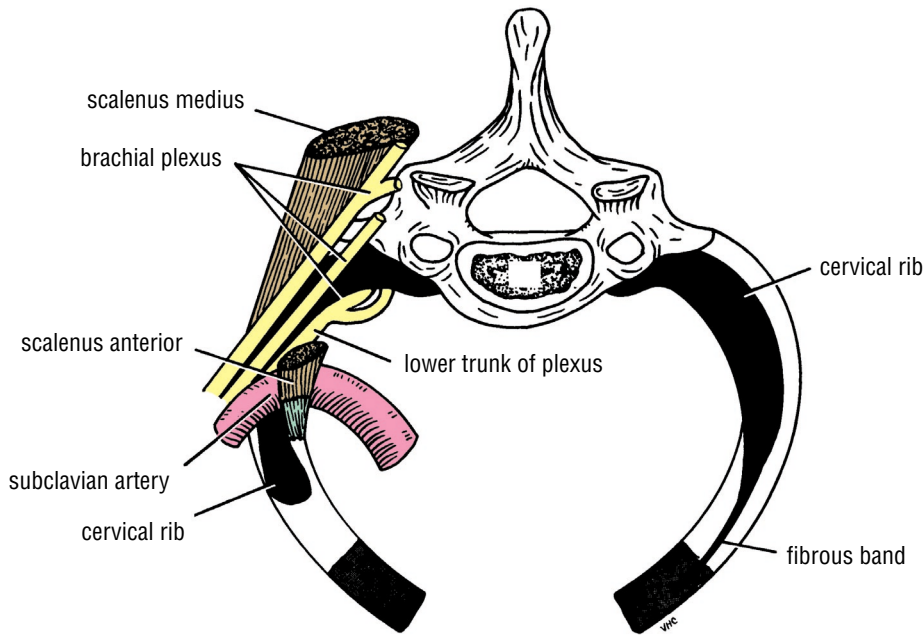
When one is examining the chest from the front, the **sternal angle (angle of Louis)** is an important landmark. Its position can easily be felt and can often be seen by the presence of a transverse ridge. The finger moved to the right or to the left passes directly onto the second costal cartilage and then the second rib. All other ribs can be counted from this point. The twelfth rib can usually be felt from behind, but in some obese persons this may prove difficult.

Sternum and Marrow Biopsy

Since the sternum possesses red hematopoietic marrow throughout life, it is a common site for **marrow biopsy**. Under a local anesthetic, a wide-bore needle is introduced into the marrow cavity through the anterior surface of the bone. The sternum may also be split at operation to allow the surgeon to gain easy access to the heart, great vessels, and thymus.

Cervical Rib

A cervical rib (i.e., a rib arising from the anterior tubercle of the transverse process of the seventh cervical vertebra) occurs in about 0.5% of humans (CD Fig. 11-2). It may have a free anterior end, may be connected to the first rib by a fibrous band, or may articulate with the first rib. The importance of a cervical rib is that it can cause pressure on the lower trunk of the brachial plexus in some patients, producing pain down



CD Figure 11-2 Thoracic outlet as seen from above. Note the presence of the cervical ribs (*black*) on both sides. On the right side of the thorax, the rib is almost complete and articulates anteriorly with the first rib. On the left side of the thorax, the rib is rudimentary but is continued forward as a fibrous band that is attached to the first costal cartilage. Note that the cervical rib may exert pressure on the lower trunk of the brachial plexus and may kink the subclavian artery.

the medial side of the forearm and hand and wasting of the small muscles of the hand. It can also exert pressure on the overlying subclavian artery and interfere with the circulation of the upper limb.

Rib Excision

Rib excision is commonly performed by thoracic surgeons wishing to gain entrance to the thoracic cavity. A longitudinal incision is made through the periosteum on the outer surface of the rib and a segment of the rib is removed. A second longitudinal incision is then made through the bed of the rib, which is the inner covering of periosteum. After the operation, the rib regenerates from the osteogenetic layer of the periosteum.

Bones of the Upper Limb

Bones of the Shoulder Girdle

Fractures of the Clavicle

The clavicle is a strut that holds the arm laterally so that it can move freely on the trunk. Unfortunately, because of its position, it is exposed to trauma and transmits forces from the upper limb to the trunk. *It is the most commonly fractured bone in the body.* The fracture usually occurs as a result of a fall on the shoulder or outstretched hand. The force is transmitted along the clavicle, which breaks at its weakest point, the junction of the middle and outer thirds. After the fracture, the lateral fragment is depressed by the weight of the arm, and it is pulled medially and forward by the strong adductor muscles of the shoulder joint, especially the

pectoralis major. The medial end is tilted upward by the sternocleidomastoid muscle.

The close relationship of the supraclavicular nerves to the clavicle may result in their involvement in callus formation after fracture of the bone. This may be the cause of persistent pain over the side of the neck.

Compression of the Brachial Plexus, Subclavian Artery, and Subclavian Vein by the Clavicle

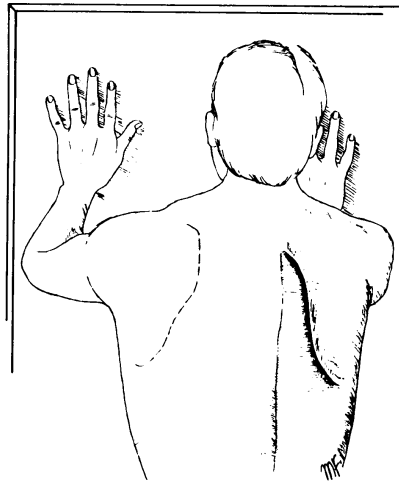
The interval between the clavicle and the first rib in some patients may become narrowed and thus is responsible for compression of nerves and blood vessels.

Fractures of the Scapula

Fractures of the scapula are usually the result of severe trauma, such as occurs in run-over accident victims or in occupants of automobiles involved in crashes. Injuries are usually associated with fractured ribs. Most fractures of the scapula require little treatment because the muscles on the anterior and posterior surfaces adequately splint the fragments.

Dropped Shoulder and Winged Scapula

The position of the scapula on the posterior wall of the thorax is maintained by the tone and balance of the muscles attached to it. If one of these muscles is paralyzed, the balance is upset, as in dropped shoulder, which occurs with paralysis of the trapezius, or winged scapula (CD Fig. 11-3), caused by paralysis of the serratus anterior. Such imbalance can be detected by careful physical examination.



CD Figure 11-3 Winging of the right scapula.

Bones of the Arm

Fractures of the Proximal End of the Humerus

Humeral Head Fractures

Fractures of the humeral head (CD Fig. 11-4) can occur during the process of anterior and posterior dislocations of the shoulder joint. The fibrocartilaginous glenoid labrum of the scapula produces the fracture, and the labrum can become jammed in the defect, making reduction of the shoulder joint difficult.

Greater Tuberosity Fractures

The greater tuberosity of the humerus can be fractured by direct trauma, displaced by the glenoid labrum during dislocation of the shoulder joint, or avulsed by violent contractions of the supraspinatus muscle. The bone fragment will have the attachments of the supraspinatus, teres minor, and infraspinatus muscles, whose tendons form part of the rotator cuff. When associated with a shoulder dislocation, severe tearing of the cuff with the fracture can result in the greater tuberosity remaining displaced posteriorly after the shoulder joint has been reduced. In this situation, open reduction of the fracture is necessary to attach the rotator cuff back into place.

Lesser Tuberosity Fractures

Occasionally, a lesser tuberosity fracture accompanies posterior dislocation of the shoulder joint. The bone fragment receives the insertion of the subscapularis tendon (see CD Fig. 11-4), a part of the rotator cuff.

Surgical Neck Fractures

The surgical neck of the humerus (see CD Fig. 11-4), which lies immediately distal to the lesser tuberosity, can be fractured by a direct blow on the lateral aspect of the shoulder or in an indirect manner by falling on the outstretched hand.

Fractures of the Shaft of the Humerus

Fractures of the humeral shaft are common; displacement of the fragments depends on the relation of the site of the fracture to the insertion of the deltoid muscle (see CD Fig. 11-4). When the fracture line is proximal to the deltoid insertion, the proximal fragment is adducted by the pectoralis major, latissimus dorsi, and teres major muscles; the distal fragment is pulled proximally by the deltoid, biceps, and triceps. When the fracture is distal to the deltoid insertion, the proximal fragment is abducted by the deltoid, and the distal fragment is pulled proximally by the biceps and triceps. The radial nerve can be damaged where it lies in the spiral groove on the posterior surface of the humerus under cover of the triceps muscle.

Fractures of the Distal End of the Humerus

Supracondylar fractures (see CD Fig. 11-4) are common in children and occur when the child falls on the outstretched hand with the elbow partially flexed. Injuries to the medial, radial, and ulnar nerves are not uncommon, although function usually quickly returns after reduction of the fracture. Damage to or pressure on the brachial artery can occur at the time of the fracture or from swelling of the surrounding tissues; the circulation to the forearm may be interfered with, leading to Volkmann's ischemic contracture.

The medial epicondyle (see CD Fig. 11-4) can be avulsed by the medial collateral ligament of the elbow joint if the forearm is forcibly abducted. The ulnar nerve can be injured at the time of the fracture, can become involved later in the repair process of the fracture (in the callus), or can undergo irritation on the irregular bony surface after the bone fragments are reunited.

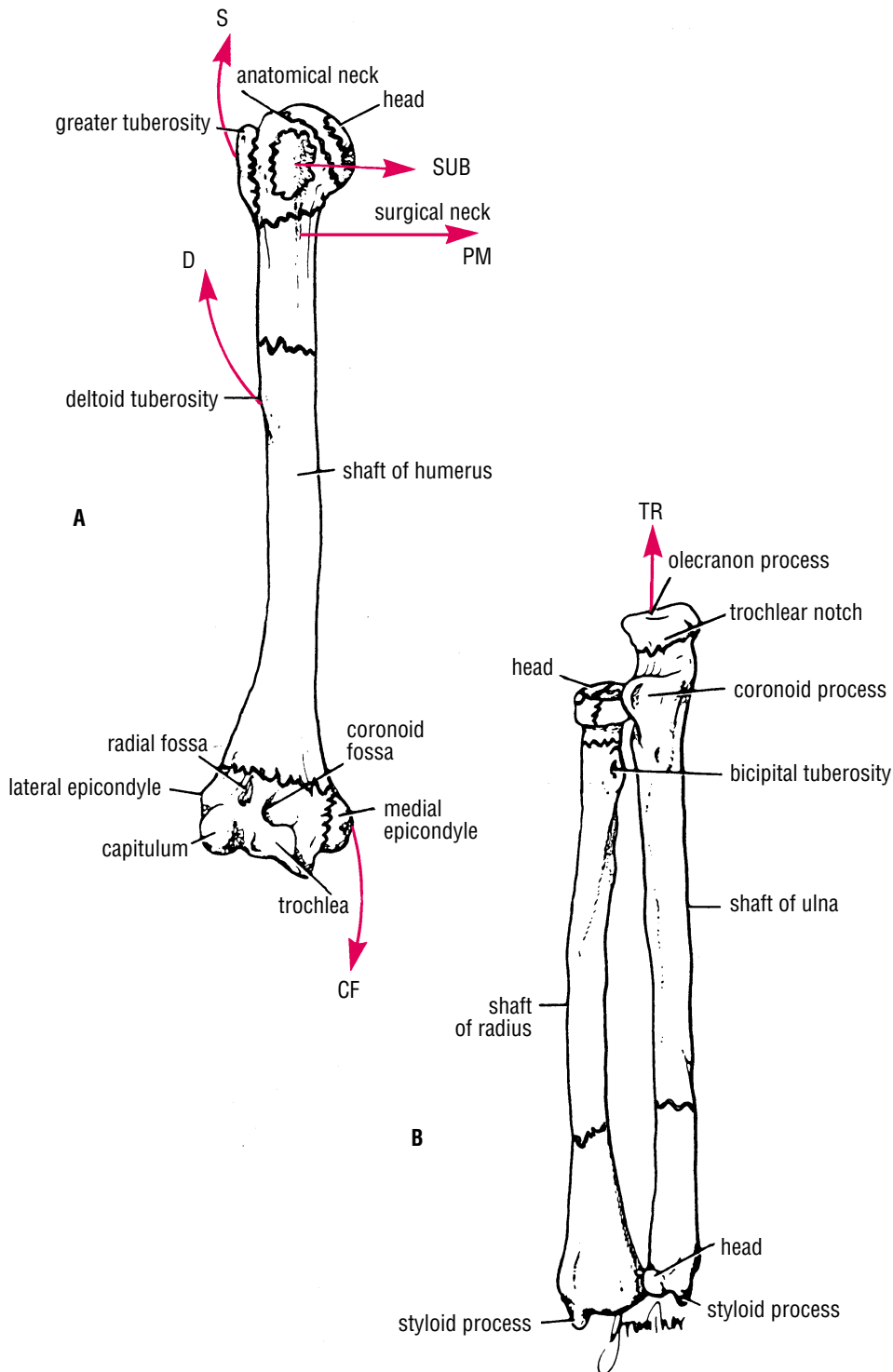
Bones of the Forearm

Fractures of the Radius and Ulna

Fractures of the head of the radius can occur from falls on the outstretched hand. As the force is transmitted along the radius, the head of the radius is driven sharply against the capitulum, splitting or splintering the head (see CD Fig. 11-4).

Fractures of the neck of the radius occur in young children from falls on the outstretched hand (see CD Fig. 11-4).

Fractures of the shafts of the radius and ulna may or may not occur together (see CD Fig. 11-4). Displacement of the fragments is usually considerable and depends on the pull of the attached muscles. The proximal fragment of the radius is supinated by the supinator and the biceps brachii muscles (see CD Fig. 11-4). The distal fragment of the radius is pronated and pulled medially by the pronator quadratus muscle. The strength of the brachioradialis and extensor carpi radialis longus and brevis shortens and angulates the forearm. In fractures of the ulna, the ulna angulates



CD Figure 11-4 **A.** Common fractures of the humerus. **B.** Common fractures of the radius and ulna. The displacement of the bony fragments on the site of the fracture line and the pull of the muscles. CF = pull of common flexure muscles, D = deltoid, PM = pectoralis major, S = supraspinatus, SUB = subscapularis, and TR = triceps.

posteriorly. To restore the normal movements of pronation and supination, the normal anatomic relationship of the radius, ulna, and interosseous membrane must be regained.

A fracture of one forearm bone may be associated with a dislocation of the other bone. In **Monteggia's fracture**, for example, the shaft of the ulna is fractured by a force applied from behind. There is a bowing forward of the ulnar shaft

and an anterior dislocation of the radial head with rupture of the annular ligament. In **Galeazzi's fracture**, the proximal third of the radius is fractured and the distal end of the ulna is dislocated at the distal radioulnar joint.

Fractures of the olecranon process can result from a fall on the flexed elbow or from a direct blow. Depending on the location of the fracture line, the bony fragment may be

displaced by the pull of the triceps muscle, which is inserted on the olecranon process (see CD Fig. 11-4). Avulsion fractures of part of the olecranon process can be produced by the pull of the triceps muscle. Good functional return after any of these fractures depends on the accurate anatomic reduction of the fragment.

Colles' fracture is a fracture of the distal end of the radius resulting from a fall on the outstretched hand. It commonly occurs in patients older than 50 years. The force drives the distal fragment posteriorly and superiorly, and the distal articular surface is inclined posteriorly (CD Fig. 11-5). This posterior displacement produces a posterior bump, sometimes referred to as the "dinner-fork deformity" because the forearm and wrist resemble the shape of that eating utensil. Failure to restore the distal articular surface to its normal position will severely limit the range of flexion of the wrist joint.

Smith's fracture is a fracture of the distal end of the radius and occurs from a fall on the back of the hand. It is a reversed Colles' fracture because the distal fragment is displaced anteriorly (see CD Fig. 11-5).

Olecranon Bursitis

A small subcutaneous bursa is present over the olecranon process of the ulna, and repeated trauma often produces chronic bursitis.

Bones of the Hand

Injuries to the Bones of the Hand

Fracture of the scaphoid bone is common in young adults; unless treated effectively, the fragments will not unite, and permanent weakness and pain of the wrist will result, with the subsequent development of osteoarthritis. The fracture line usually goes through the narrowest part of the bone, which because of its location is bathed in synovial fluid.

The blood vessels to the scaphoid enter its proximal and distal ends, although the blood supply is occasionally confined to its distal end. If the latter occurs, a fracture deprives the proximal fragment of its arterial supply, and this fragment undergoes avascular necrosis. Deep tenderness in the anatomic snuffbox after a fall on the outstretched hand in a young adult makes one suspicious of a fractured scaphoid.

Dislocation of the lunate bone occasionally occurs in young adults who fall on the outstretched hand in a way that causes hyperextension of the wrist joint. Involvement of the median nerve is common.

Fractures of the metacarpal bones can occur as a result of direct violence, such as the clenched fist striking a hard object. The fracture always angulates dorsally. The "boxer's fracture" commonly produces an oblique fracture of the neck of the fifth and sometimes the fourth metacarpal bones. The distal fragment is commonly displaced proximally, thus shortening the finger posteriorly.

Bennett's fracture is a fracture of the base of the metacarpal of the thumb caused when violence is applied along the long axis of the thumb or the thumb is forcefully abducted. The fracture is oblique and enters the carpometacarpal joint of the thumb, causing joint instability.

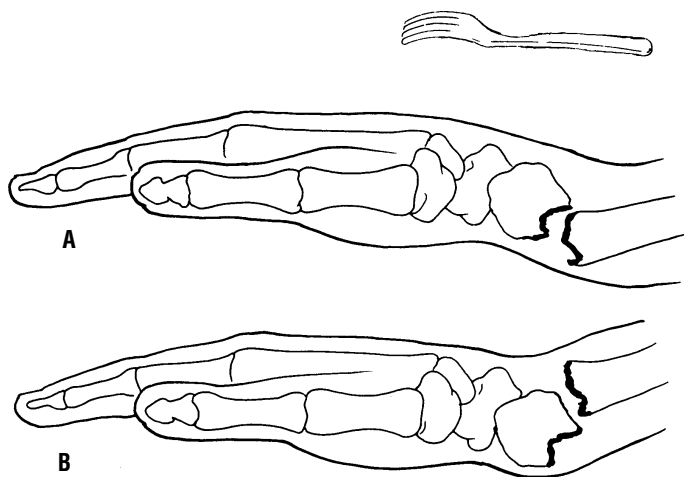
Fractures of the phalanges are common and usually follow direct injury.

Bones of the Lower Limb

Bones of the Pelvic Girdle

Clinical Concept: The Pelvis Is a Basin with Holes in Its Walls

The walls of the pelvis are formed by bones and ligaments; these are partly lined with muscles (obturator internus and piriformis) covered with fascia and parietal peritoneum. On



CD Figure 11-5 Fractures of the distal end of the radius. **A.** Colles' fracture. **B.** Smith's fracture.

the outside of the pelvis are the attachments of the gluteal muscles and the obturator externus muscle. The greater part of the bony pelvis is thus sandwiched between inner and outer muscles.

The basin has anterior, posterior, and lateral walls and an inferior wall or floor formed by the important levator ani and coccygeus muscles and their covering fascia.

The basin has many holes: The posterior wall has holes on the anterior surface of the sacrum, the **anterior sacral foramina**, for the passage of the anterior rami of the sacral spinal nerves. The **sacrospinous** and **sacrotuberous ligaments** convert the greater and lesser sciatic notches into the **greater and lesser sciatic foramina**. The greater sciatic foramen provides an exit from the true pelvis into the gluteal region for the sciatic nerve, the pudendal nerve, and the gluteal nerves and vessels; the lesser sciatic foramen provides an entrance into the perineum from the gluteal region for the pudendal nerve and the internal pudendal vessels. (One can make a further analogy here: For the wires to gain entrance to the apartment below, without going through the floor, they have to pierce the wall [greater sciatic foramen] to get outside the building and then return through a second hole [lesser sciatic foramen]. In the case of the human body, the pudendal nerve and internal pudendal vessels are the wires and the levator ani and the coccygeus muscles are the floor.)

The lateral pelvic wall has a large hole, the **obturator foramen**, which is closed by the **obturator membrane**, except for a small opening that permits the obturator nerve to leave the pelvis and enter the thigh.

Pelvic Measurements in Obstetrics

The capacity and shape of the female pelvis are of fundamental importance in obstetrics. The female pelvis is well adapted for the process of childbirth. The pelvis is shallower and the bones are smoother than in the male. The size of the pelvic inlet is similar in the two sexes, but in the female, the cavity is larger and cylindrical and the pelvic outlet is wider in both the anteroposterior and the transverse diameters.

Four terms relating to areas of the pelvis are commonly used in clinical practice:

- The **pelvic inlet** or **brim** of the true pelvis (CD Fig. 11-6) is bounded anteriorly by the symphysis pubis, laterally by the iliopectineal lines, and posteriorly by the sacral promontory.
- The **pelvic outlet** of the true pelvis (see CD Fig. 11-6) is bounded in front by the pubic arch, laterally by the ischial tuberosities, and posteriorly by the coccyx. The sacrotuberous ligaments also form part of the margin of the outlet.
- The **pelvic cavity** is the space between the inlet and the outlet (see CD Fig. 11-6).
- The **axis of the pelvis** is an imaginary line joining the central points of the anteroposterior diameters from the inlet to the outlet and is the curved course taken by

the baby's head as it descends through the pelvis during childbirth (CD Figs. 11-6 and 11-7A).

Internal Pelvic Assessments

Internal pelvic assessments are made by vaginal examination during the later weeks of pregnancy, when the pelvic tissues are softer and more yielding than in the newly pregnant condition.

- **Pubic arch:** Spread the fingers under the pubic arch and examine its shape. Is it broad or angular? The examiner's four fingers should be able to rest comfortably in the angle below the symphysis.
- **Lateral walls:** Palpate the lateral walls and determine whether they are concave, straight, or converging. The prominence of the ischial spines and the position of the sacrospinous ligaments are noted.
- **Posterior wall:** The sacrum is palpated to determine whether it is straight or well curved. Finally, if the patient has relaxed the perineum sufficiently, an attempt is made to palpate the promontory of the sacrum. The second finger of the examining hand is placed on the promontory, and the index finger of the free hand, outside the vagina, is placed at the point on the examining hand where it makes contact with the lower border of the symphysis. The fingers are then withdrawn and the distance measured (CD Fig. 11-7B), providing the measurement of the **diagonal conjugate**, which is normally about 5 in. (13 cm). The anteroposterior diameter from the sacrococcygeal joint to the lower border of the symphysis is then estimated.
- **Ischial tuberosities:** The distance between the ischial tuberosities may be estimated by using the closed fist (CD Fig. 11-7D). It measures about 4 in. (10 cm), but it is difficult to measure exactly.

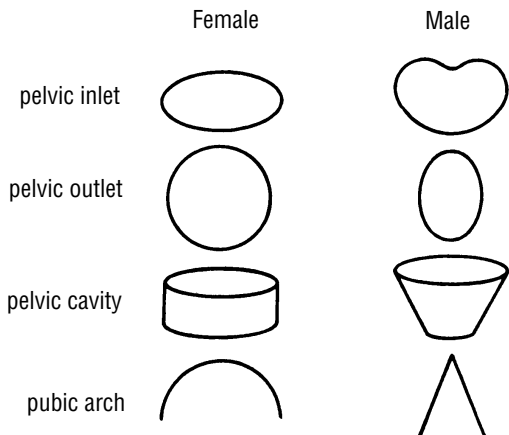
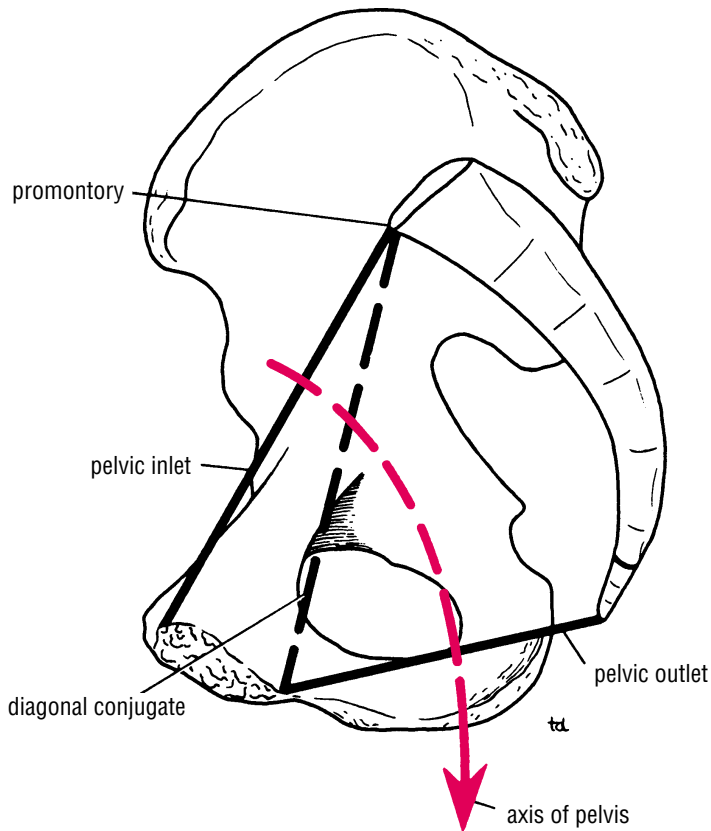
Needless to say, considerable clinical experience is required to be able to assess the shape and size of the pelvis by vaginal examination.

The Female Pelvis

Deformities of the pelvis may be responsible for **dystocia** (difficult labor). A contracted pelvis may obstruct the normal passage of the fetus. It may be indirectly responsible for dystocia by causing conditions such as malpresentation or malposition of the fetus, premature rupture of the fetal membranes, and uterine inertia.

The cause of pelvic deformities may be congenital (rare) or acquired from disease, poor posture, or fractures caused by injury. Pelvic deformities are more common in women who have grown up in a poor environment and are undernourished. It is probable that these women suffered in their youth from minor degrees of rickets.

In 1933, Caldwell and Moloy classified pelvises into four groups: gynecoid, android, anthropoid, and platypelloid



CD Figure 11-6 Pelvic inlet, pelvic outlet, diagonal conjugate, and axis of the pelvis. Some of the main differences between the female and the male pelvis are also shown.

(CD. Fig. 11-7C). The **gynecoid** type, present in about 41% of women, is the typical female pelvis, which was previously described.

The **android** type, present in about 33% of white females and 16% of black females, is the male or funnel-shaped pelvis with a contracted outlet.

The **anthropoid** type, present in about 24% of white females and 41% of black females, is long, narrow, and oval shaped.

The **platypelloid** type, present in only about 2% of women, is a wide pelvis flattened at the brim, with the promontory of the sacrum pushed forward.

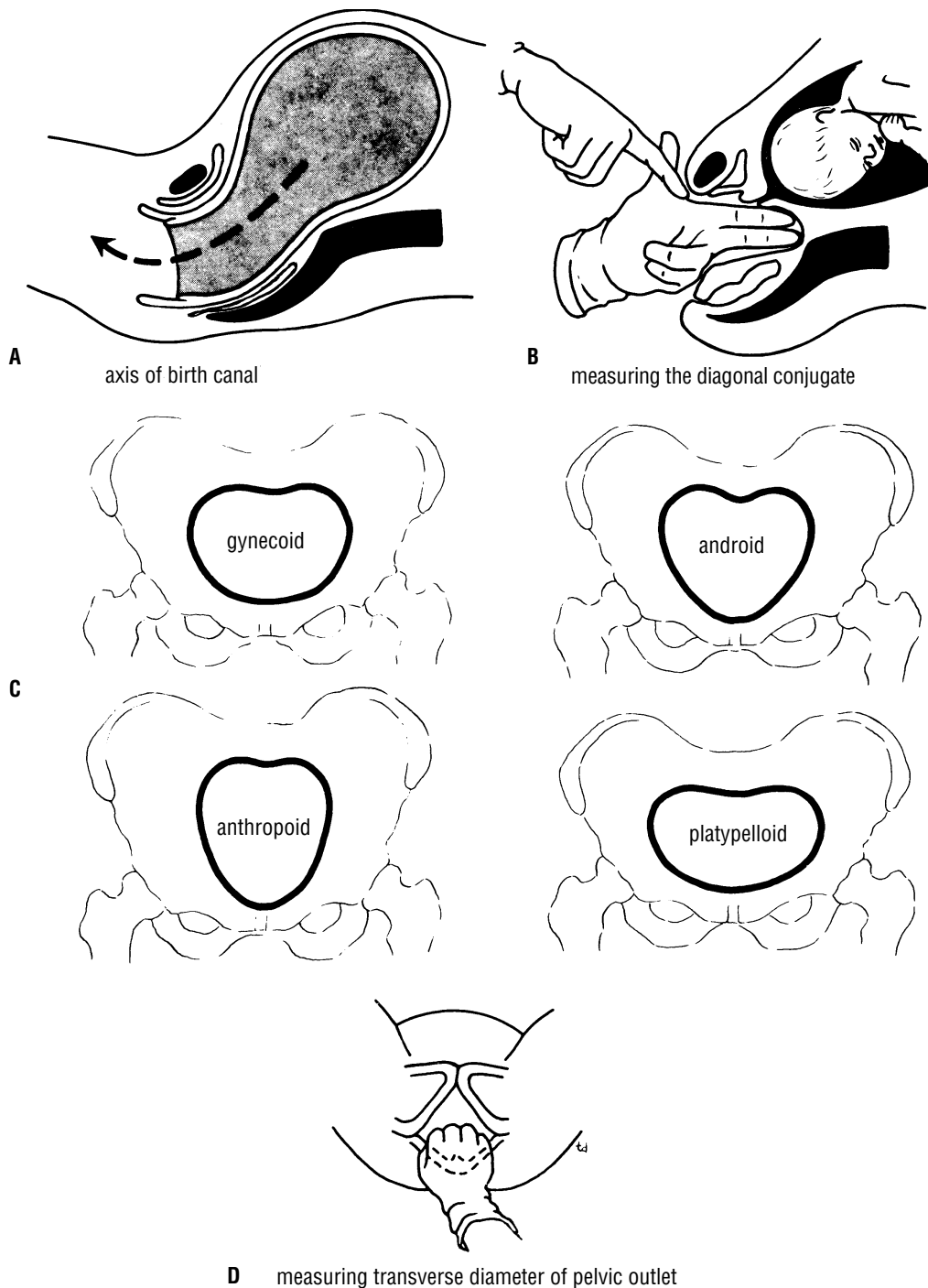
Fractures of the Pelvis

Fractures of the False Pelvis

Fractures of the false pelvis caused by direct trauma occasionally occur. The upper part of the ilium is seldom displaced because of the attachment of the iliacus muscle on the inside and the gluteal muscles on the outside.

Fractures of the True Pelvis

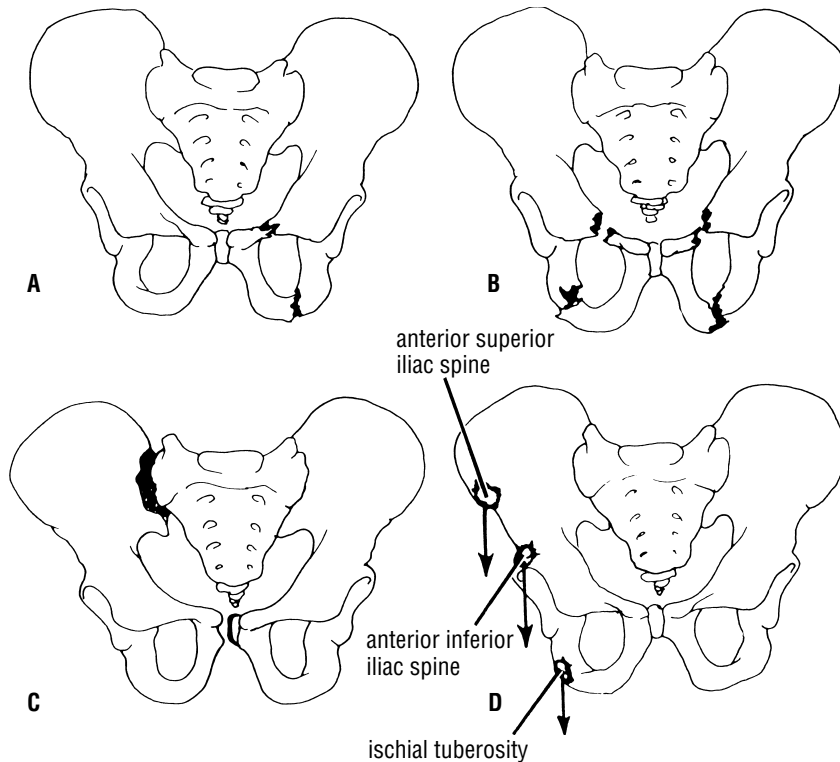
The mechanism of fractures of the true pelvis can be better understood if the pelvis is regarded not only as a basin but also as a rigid ring (see CD Fig. 11-8). The ring is made up



CD Figure 11-7 **A.** Birth canal. *Interrupted line* indicates the axis of the canal. **B.** Procedure used in measuring the diagonal conjugate. **C.** Different types of pelvic inlets, according to Caldwell and Moley. **D.** Estimation of the width of the pelvic outlet by means of a closed fist.

of the pubic rami, the ischium, the acetabulum, the ilium, and the sacrum, joined by strong ligaments at the sacroiliac and symphyseal joints. If the ring breaks at any one point, the fracture will be stable and no displacement will occur. However, if two breaks occur in the ring, the fracture will be

unstable and displacement will occur, because the postvertebral and abdominal muscles will shorten and elevate the lateral part of the pelvis (see CD Fig. 11-8). The break in the ring may occur not as the result of a fracture but as the result of disruption of the sacroiliac or symphyseal joints. Fracture



CD Figure 11-8 A–C. Different types of fractures of the pelvic basin. **D.** Avulsion fractures of the pelvis. The sartorius muscle is responsible for the avulsion of the anterior superior iliac spine; the straight head of the rectus femoris muscle, for the avulsion of the anterior inferior iliac spine; and the hamstring muscles, for the avulsion of the ischial tuberosity.

of bone on either side of the joint is more common than disruption of the joint.

The forces responsible for the disruption of the bony ring may be anteroposterior compression, lateral compression, or shearing.

A heavy fall on the greater trochanter of the femur may drive the head of the femur through the floor of the acetabulum into the pelvic cavity.

Fractures of the Sacrum and Coccyx

Fractures of the lateral mass of the sacrum may occur as part of a pelvic fracture. Fractures of the coccyx are rare.

Minor Fractures of the Pelvis

The anterior superior iliac spine may be pulled off by the forcible contraction of the sartorius muscle in athletes (see CD Fig. 11-8). In a similar manner the anterior inferior iliac spine may be avulsed by the contraction of the rectus femoris muscle (origin of the straight head). The ischial tuberosity can be avulsed by the contraction of the hamstring muscles. Healing may occur by fibrous union, possibly resulting in elongation of the muscle unit and some reduction in muscular efficiency.

Anatomy of Complications of Pelvic Fractures

Fractures of the true pelvis are commonly associated with injuries to the soft pelvic tissues.

If damaged, the thin pelvic veins—namely, the internal iliac veins and their tributaries—that lie in the parietal pelvic

fascial beneath the parietal peritoneum can be the source of a massive hemorrhage, which may be life threatening.

The male urethra is often damaged, especially in vertical shear fractures that may disrupt the urogenital diaphragm.

The bladder, which lies immediately behind the pubis in both sexes, is occasionally damaged by spicules of bone; a full bladder is more likely to be injured than is an empty bladder.

The rectum lies within the concavity of the sacrum and is protected and rarely damaged. Fractures of the sacrum or ischial spine may be thrust into the pelvic cavity, tearing the rectum.

Nerve injuries can follow sacral fractures; the laying down of fibrous tissue around the anterior or posterior nerve roots or the branches of the sacral spinal nerves can result in persistent pain.

Damage to the sciatic nerve may occur in fractures involving the boundaries of the greater sciatic notch. The peroneal part of the sciatic nerve is most often involved, resulting in the inability of a conscious patient to dorsiflex the ankle joint or failure of an unconscious patient to reflexly plantar-flex (ankle jerk) the foot.

Bones of the Thigh

Tenderness of the Head of the Femur and Arthritis of the Hip Joint

The head of the femur—that is, that part that is not intraacetabular—can be palpated on the anterior aspect of the thigh

just inferior to the inguinal ligament and just lateral to the pulsating femoral artery. Tenderness over the head of the femur usually indicates the presence of arthritis of the hip joint.

Blood Supply to the Femoral Head and Neck Fractures

Anatomic knowledge of the blood supply to the femoral head explains why avascular necrosis of the head can occur after fractures of the neck of the femur. In the young, the epiphysis of the head is supplied by a small branch of the obturator artery, which passes to the head along the ligament of the femoral head. The upper part of the neck of the femur receives a profuse blood supply from the medial femoral circumflex artery (see text Fig. 12-25). These branches pierce the capsule and ascend the neck deep to the synovial membrane. As long as the epiphyseal cartilage remains, no communication occurs between the two sources of blood. In the adult, after the epiphyseal cartilage disappears, an anastomosis between the two sources of blood supply is established. Fractures of the femoral neck interfere with or completely interrupt the blood supply from the root of the femoral neck to the femoral head. The scant blood flow along the small artery that accompanies the round ligament may be insufficient to sustain the viability of the femoral head, and ischemic necrosis gradually takes place.

The Neck of the Femur and Coxa Valga and Coxa Vara

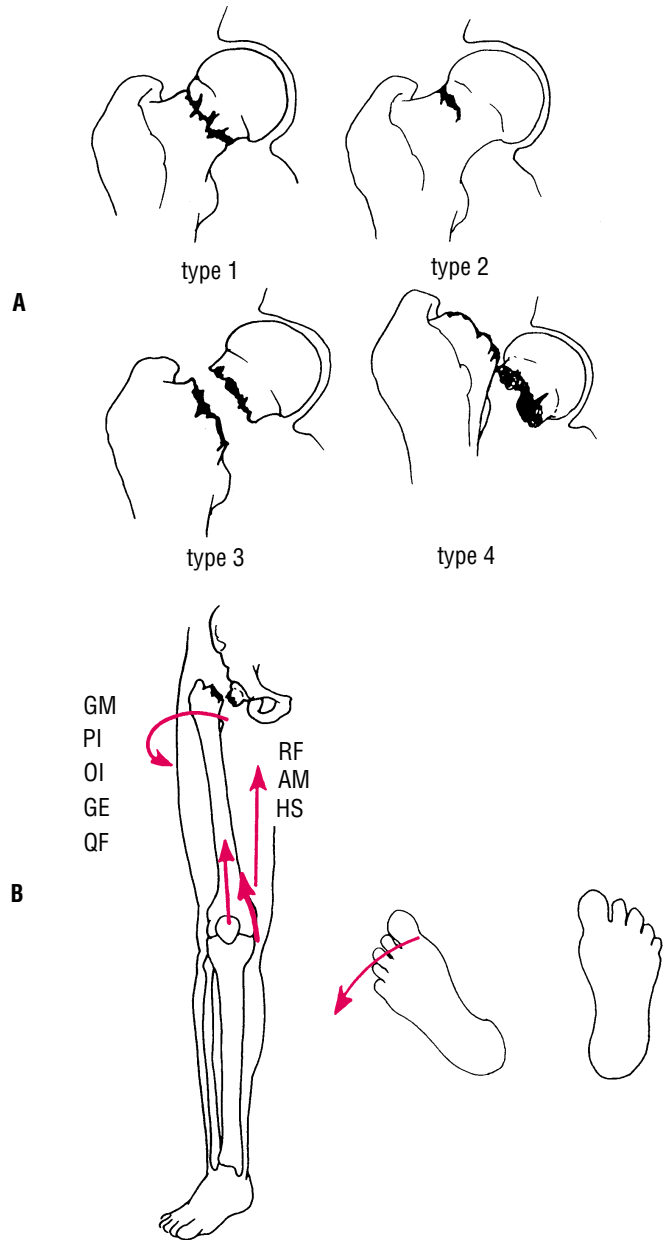
The neck of the femur is inclined at an angle with the shaft; the angle is about 160° in the young child and about 125° in the adult. An increase in this angle is referred to as **coxa valga**, and it occurs, for example, in cases of congenital dislocation of the hip. In this condition, adduction of the hip joint is limited. A decrease in this angle is referred to as **coxa vara**, and it occurs in fractures of the neck of the femur and in slipping of the femoral epiphysis. In this condition, abduction of the hip joint is limited. Shenton's line is a useful means of assessing the angle of the femoral neck on a radiograph of the hip region (see text Fig. 11-66).

Fractures of the Femur

Fractures of the neck of the femur are common and are of two types, subcapital and trochanteric. The **subcapital fracture** occurs in the elderly and is usually produced by a minor trip or stumble. Subcapital femoral neck fractures are particularly common in women after menopause. This gender predisposition is because of a thinning of the cortical and trabecular bone caused by estrogen deficiency. Avascular necrosis of the head is a common complication. If the fragments are not impacted, considerable displacement occurs. The strong muscles of the thigh (CD Fig. 11-9), including the rectus femoris, the adductor muscles, and the hamstring muscles, pull the distal fragment upward, so that

the leg is shortened (as measured from the anterior superior iliac spine to the adductor tubercle or medial malleolus). The gluteus maximus, the piriformis, the obturator internus, the gemelli, and the quadratus femoris rotate the distal fragment laterally, as seen by the toes pointing laterally.

Trochanteric fractures commonly occur in the young and middle-aged as a result of direct trauma. The fracture



CD Figure 11-9 **A.** Fractures of the neck of the femur. **B.** Displacement of the lower bone fragment caused by the pull of the powerful muscles. Note in particular the outward rotation of the leg so that the foot characteristically points laterally. GM = gluteus maximus, AM = adductor muscles, GE = gemelli, HS = hamstring muscles, OI = obturator internus, PI = piriformis, QF = quadratus femoris, RF = rectus femoris.

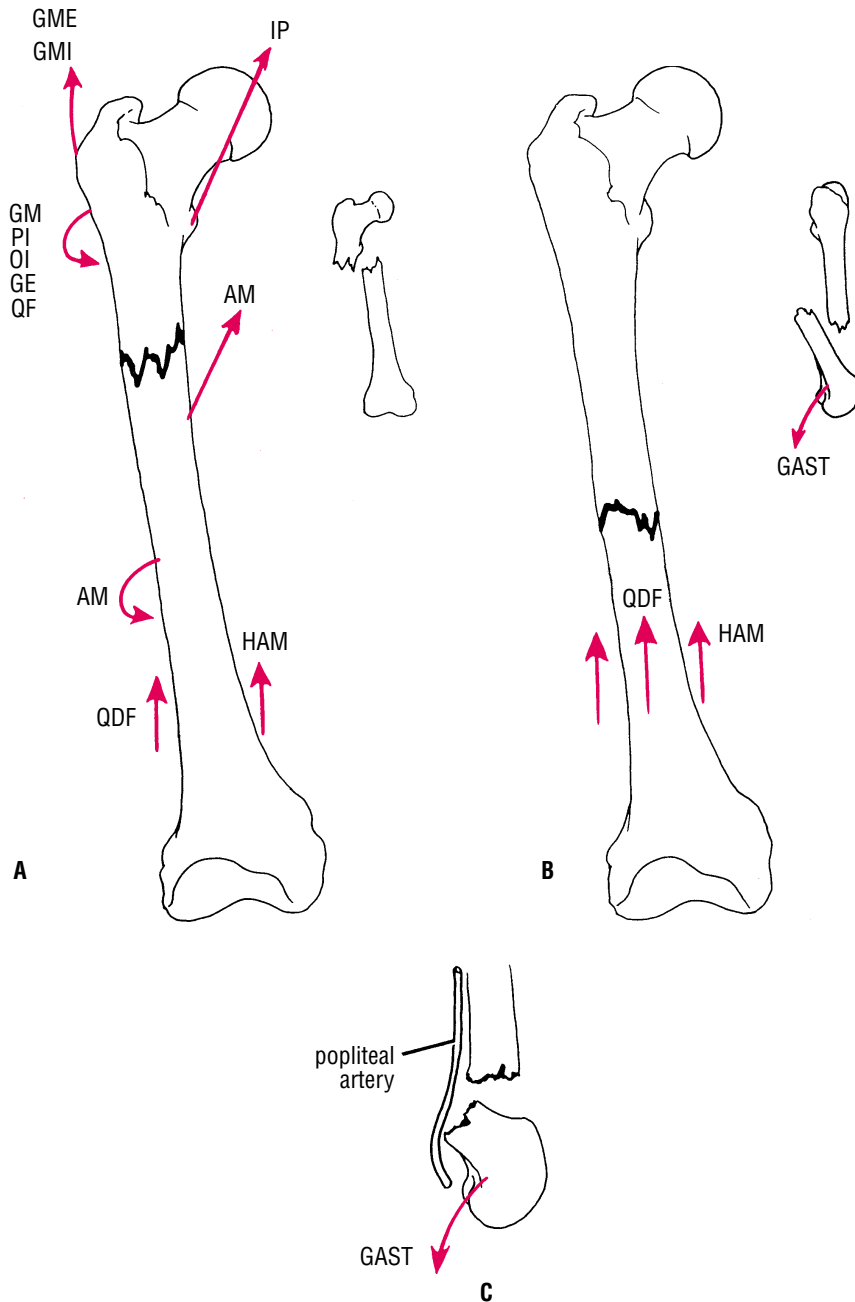
line is extracapsular, and both fragments have a profuse blood supply. If the bone fragments are not impacted, the pull of the strong muscles will produce shortening and lateral rotation of the leg, as previously explained.

Fractures of the shaft of the femur usually occur in young and healthy persons. In **fractures of the upper third of the shaft** of the femur, the proximal fragment is flexed by the iliopsoas; abducted by the gluteus medius and minimus; and laterally rotated by the gluteus maximus, the piriformis, the obturator internus, the gemelli, and the quadratus femoris (CD Fig. 11-10). The lower fragment is adducted by the adductor muscles, pulled upward by the hamstrings and

quadriceps, and laterally rotated by the adductors and the weight of the foot (see CD Fig. 11-10).

In **fractures of the middle third of the shaft** of the femur, the distal fragment is pulled upward by the hamstrings and the quadriceps (see CD Fig. 11-10), resulting in considerable shortening. The distal fragment is also rotated backward by the pull of the two heads of the gastrocnemius (see CD Fig. 11-10).

In **fractures of the distal third of the shaft** of the femur, the same displacement of the distal fragment occurs as seen in fractures of the middle third of the shaft. However, the distal fragment is smaller and is rotated backward by the



CD Figure 11-10 Fractures of the shaft of the femur. **A.** Upper third of the femoral shaft. Note the displacement caused by the pull of the powerful muscles. **B.** Middle third of the femoral shaft. Note the posterior displacement of the lower fragment caused by the gastrocnemius muscle. **C.** Lower third of the femoral shaft. Note the excessive displacement of the lower fragment caused by the pull of the gastrocnemius muscle, threatening the integrity of the popliteal artery. AM = adductor muscles, GAST = gastrocnemius, GE = gemelli, GM = gluteus maximus, GME = gluteus medius, GMI = gluteus minimus, HAM = hamstrings, IP = iliopsoas, OI = obturator internus, PI = piriformis, QDF = quadriceps femoris, QF = quadratus femoris.

gastrocnemius muscle (see CD Fig. 11-10) to a greater degree and may exert pressure on the popliteal artery and interfere with the blood flow through the leg and foot.

From these accounts it is clear that knowledge of the different actions of the muscles of the leg is necessary to understand the displacement of the fragments of a fractured femur. Considerable traction on the distal fragment is usually required to overcome the powerful muscles and restore the limb to its correct length before manipulation and operative therapy to bring the proximal and distal fragments into correct alignment.

Patellar Dislocations

The patella is a sesamoid bone lying within the quadriceps tendon. The importance of the lower horizontal fibers of the vastus medialis and the large size of the lateral condyle of the femur in preventing lateral displacement of the patella have been emphasized. Congenital recurrent dislocations of the patella are caused by underdevelopment of the lateral femoral condyle. Traumatic dislocation of the patella results from direct trauma to the quadriceps attachments of the patella (especially the vastus medialis), with or without fracture of the patella.

Patellar Fractures

A patella fractured as a result of direct violence, as in an automobile accident, is broken into several small fragments. Because the bone lies within the quadriceps femoris tendon, little separation of the fragments takes place. The close relationship of the patella to the overlying skin may result in the fracture being open. Fracture of the patella as a result of indirect violence is caused by the sudden contraction of the quadriceps snapping the patella across the front of the femoral condyles. The knee is in the semiflexed position, and the fracture line is transverse. Separation of the fragments usually occurs.

Bones of the Leg

Fractures of the Tibia and Fibula

Fractures of the tibia and fibula are common. If only one bone is fractured, the other acts as a splint and displacement is minimal. Fractures of the shaft of the tibia are often open because the entire length of the medial surface is covered only by skin and superficial fascia. Fractures of the distal third of the shaft of the tibia are prone to delayed union or nonunion. This can be because the nutrient artery is torn at the fracture line, with a consequent reduction in blood flow to the distal fragment; it is also possible that the splint-like action of the intact fibula prevents the proximal and distal fragments from coming into apposition.

Fractures of the **proximal end of the tibia**, at the tibial condyles (tibial plateau), are common in the middle-

aged and elderly; they usually result from direct violence to the lateral side of the knee joint, as when a person is hit by the bumper of an automobile. The tibial condyle may show a split fracture or be broken up, or the fracture line may pass between both condyles in the region of the intercondylar eminence. As a result of forced abduction of the knee joint, the medial collateral ligament can also be torn or ruptured.

Fractures of the **distal end of the tibia** are considered with the ankle joint.

Intraosseous Infusion of the Tibia in the Infant

The technique may be used for the infusion of fluids and blood when it has been found impossible to obtain an intravenous line. The procedure is easy and rapid to perform, as follows:

1. With the distal leg adequately supported, the anterior subcutaneous surface of the tibia is palpated.
2. The skin is anesthetized about 1 in. (2.5 cm) distal to the tibial tuberosity, thus blocking the infrapatellar branch of the saphenous nerve.
3. The bone marrow needle is directed at right angles through the skin, superficial fascia, deep fascia, and tibial periosteum and the cortex of the tibia. Once the needle tip reaches the medulla and bone marrow, the operator senses a feeling of "give." The position of the needle in the marrow can be confirmed by aspiration. The needle should be directed slightly caudad to avoid injury to the epiphyseal plate of the proximal end of the tibia. The transfusion may then commence.

Bones of the Foot

Fractures of the Calcaneum

Compression fractures of the calcaneum result from falls from a height. The weight of the body drives the talus downward into the calcaneum, crushing it in such a way that it loses vertical height and becomes wider laterally. The posterior portion of the calcaneum above the insertion of the tendo calcaneus can be fractured by posterior displacement of the talus. The sustentaculum tali can be fractured by forced inversion of the foot.

Fractures of the Talus

Fractures occur at the neck or body of the talus. Neck fractures occur during violent dorsiflexion of the ankle joint when the neck is driven against the anterior edge of the distal end of the tibia. The body of the talus can be fractured by jumping from a height, although the two malleoli prevent displacement of the fragments.

Fractures of the Metatarsal Bones

The base of the fifth metatarsal can be fractured during forced inversion of the foot, at which time the tendon of insertion of the peroneus brevis muscle pulls off the base of the metatarsal.

Stress fracture of a metatarsal bone is common in joggers and in soldiers after long marches; it can also occur in nurses and hikers. It occurs most frequently in the distal third of the second, third, or fourth metatarsal bone. Minimal displacement occurs because of the attachment of the interosseous muscles.

Clinical Problem Solving Questions

Read the following case histories/questions and give the best answer for each.

A 19-year-old boy was suspected of having leukemia. It was decided to confirm the diagnosis by performing a bone marrow biopsy.

- The following statements concerning this procedure are correct **except** which?
 - The biopsy was taken from the lower end of the tibia.
 - Red bone marrow specimens can be obtained from the sternum or the iliac crests.
 - At birth, the marrow of all bones of the body is red and hematopoietic.
 - The blood-forming activity of bone marrow in many long bones gradually lessens with age, and the red marrow is gradually replaced by yellow marrow.

A 45-year-old man with extensive maxillofacial injuries after an automobile accident was brought to the emergency department. Evaluation of the airway revealed partial obstruction. Despite an obvious fractured mandible, an attempt was made to move the tongue forward from the posterior pharyngeal wall by pushing the angles of the mandible forward. This maneuver failed to move the tongue, and it became necessary to hold the tongue forward directly to pull it away from the posterior pharyngeal wall.

- The **most likely** reason the physician was unable to pull the tongue forward in this patient is which?
 - The hypoglossal nerves were damaged on both sides of the neck.
 - Spasm of the styloglossus muscles
 - The mandibular origin of the genioglossus muscles was floating because of bilateral fractures of the body of the mandible.
 - The presence of a blood clot in the mouth
 - The resistance of the patient

A 46-year-old man was seen in the emergency department after being knocked down in a street brawl. He

had received a blow on the head with an empty bottle. On examination, the patient was conscious and had a large dough-like swelling over the back of the head that was restricted to the area over the occipital bone. The skin was intact, and the swelling fluctuated on palpation.

- The following statements concerning this patient are correct **except** which?
 - The hematoma, although large, did not extend forward to the orbital margins and did not extend laterally as far as the temporal lines.
 - The hematoma was located just beneath the scalp and was superficial to the periosteum of the occipital bone.
 - The swelling did not occupy the subcutaneous tissue of the scalp.
 - The hematoma was restricted to one skull bone and was situated beneath the periosteum.

A 45-year-old woman visited her physician because of a low back pain of 3 months' duration. She was otherwise very fit. On examination of her back, nothing abnormal was discovered. The physician then listened to her chest, examined her thyroid gland, and finally examined both breasts. A large, hard mass was found in the left breast.

- The following facts supported the diagnosis of carcinoma of the left breast with secondaries in the vertebral column **except** which?
 - The lump in the breast was painless and the patient had noticed it while showering 6 months previously.
 - Several large, hard, pectoral lymph nodes were found in the left axilla.
 - A lateral radiograph of the lumbar vertebral column showed extensive metastases in the bodies of the second and third lumbar vertebrae.
 - The lump was situated in the upper outer quadrant of the left breast and was fixed to surrounding tissues.

E. Although the cancer had spread by the lymph vessels, no evidence of spread via the bloodstream was present.

A 65-year-old man and a 10-year-old boy were involved in a severe automobile accident. In both patients the thorax had been badly crushed. Radiographic examination revealed that the man had five fractured ribs but the boy had no fractures.

5. What is the **most likely** explanation for this difference in medical findings?
- The patients were in different seats in the vehicle.
 - The boy was wearing his seat belt and the man was not.
 - The chest wall of a child is very elastic, and fractures of ribs in children are rare.
 - The man anticipated the impact and tensed his muscles, including those of the shoulder girdle and abdomen.

An 18-year-old woman was thrown from a horse while attempting to jump a fence. She landed heavily on the ground, striking the lower part of her chest on the left side. On examination in the emergency department she was conscious but breathless. The lower left side of her chest was badly bruised, and the ninth and tenth ribs were extremely tender to touch. She had severe tachycardia, and her systolic blood pressure was low.

6. The following statements are possibly correct **except** which?
- There was evidence of tenderness and muscle spasm in the left upper quadrant of the anterior abdominal wall.
 - A posteroanterior radiograph of the chest revealed fractures of the left ninth and tenth ribs near their angles.
 - The blunt trauma to the ribs could not result in injury to the underlying spleen.
 - The presence of blood in the peritoneal cavity had irritated the parietal peritoneum, producing reflex spasm of the upper abdominal muscles.
 - The muscles of the anterior abdominal wall are supplied by thoracic spinal nerves.

A 15-year-old girl, while demonstrating to her friends her proficiency at standing on her hands, suddenly went off balance and put all her body weight on her left outstretched hand. A distinctive cracking noise was heard, and she felt a sudden pain in her left shoulder region. On examination in the emergency department, the smooth contour of her left shoulder was absent. The clavicle was obviously fractured, and the edges of the bony fragments could be palpated.

7. The following statements concerning this case are correct **except** which?
- The clavicle is one of the most common bones in the body to be fractured.
 - Anatomically, the weakest part of the clavicle is the junction of the medial and middle thirds, and this is where the fracture commonly occurs.
 - The lateral bony fragment is depressed downward by the weight of the arm.
 - The lateral fragment is pulled forward and medially by the pectoral muscles.
 - The medial fragment is elevated by the sternocleidomastoid muscle.
 - The supraclavicular nerves or a communicating vein between the cephalic and internal jugular vein may be damaged by the bone fragments.

A 22-year-old medical student fell off her bicycle onto her outstretched hand. She thought she had sprained her right wrist joint and treated herself by binding her wrist with an elastic bandage. Three weeks later, however, she was still experiencing pain on moving her wrist and so decided to visit the emergency department. On examination of the dorsal surfaces of both hands, with the fingers and thumbs fully extended, a localized tenderness could be felt in the anatomic snuffbox of her right hand. A diagnosis of fracture of the right scaphoid bone was made.

8. The following statements concerning this patient are correct **except** which?
- The fracture line on the scaphoid bone may deprive the proximal fragment of its arterial supply.
 - A bony fragment deprived of its blood supply may undergo ischemic necrosis.
 - Because the scaphoid bone articulates with other bones, the fracture line may enter a joint cavity and become bathed in synovial fluid, which would inhibit repair.
 - The scaphoid bone is an easy bone to immobilize because of its small size.
 - Fractures of the scaphoid bone have a high incidence of nonunion.

A heavily built, middle-aged man running down a flight of stone steps misjudged the position of one of the steps and fell suddenly onto his buttocks. Following the fall, he complained of severe bruising of the area of the cleft between the buttocks and persistent pain in this area.

9. The following statements concerning this patient are correct **except** which?
- The lower end of the vertebral column was traumatized by the stone step.
 - The coccyx can be palpated beneath the skin in the natal cleft.

- C. The anterior surface of the coccyx cannot be felt clinically.
- D. The coccyx is usually severely bruised or fractured.
- E. The pain is felt in the distribution of dermatomes S4 and S5.

An elderly woman was run over by an automobile as she was crossing the road. Radiographic examination of the pelvis in the emergency department of the local hospital revealed a fracture of the ilium and iliac crest on the left side.

10. The following statements about fractures of the pelvis are correct **except** which?
- A. Fractures of the ilium have little displacement.
 - B. Displacement is prevented by the presence of the iliacus and the gluteal muscles on the inner and outer surfaces of this bone, respectively.
 - C. If two fractures occur in the ring forming the true pelvis, the fracture will be unstable and displacement will occur.
 - D. Fractures of the true pelvis do not cause injury to the pelvic viscera.
 - E. The postvertebral and abdominal muscles are responsible for elevating the lateral part of the pelvis should two fractures occur.
 - F. A heavy fall on the greater trochanter of the femur may drive the head of the femur through the floor of the acetabulum and into the pelvic cavity.

A pregnant woman visited an antenatal clinic. A vaginal examination revealed that the sacral promontory could be easily palpated and that the diagonal conjugate measured less than 4 in. (10 cm).

11. The following statements concerning this examination are correct **except** which?
- A. Normally it is difficult or impossible to feel the sacral promontory by means of a vaginal examination.
 - B. The normal diagonal conjugate measures about 10 in. (25 cm).
 - C. This patient's pelvis was flattened anteroposteriorly, and the sacral promontory projected too far forward.
 - D. It is likely that this patient would have an obstructed labor.
 - E. This patient was advised to have a cesarean section.

On a routine anteroposterior radiographic examination of a patient's right hip joint, the long axis of the neck of the femur was found to be at an angle of 160° with the long axis of the femoral shaft.

12. Is this angle normal in a 5-year-old child? In a 35-year-old man? What is the clinical condition called in which the angle is smaller than normal? Which movement of the hip joint is limited by this condition?

13. Fracture of the neck of the femur in the adult commonly results in avascular necrosis of part of the femoral head. Can you explain this on anatomic grounds? Trochanteric fractures are never accompanied by avascular necrosis. Why?

A 37-year-old woman was involved in a light plane accident. She and her husband were flying home from a business trip when they had to make a forced landing in a field due to fog. On landing, the plane hit a tree and came to rest on its nose. Her husband was killed on impact and she was thrown from the cockpit. She was evaluated in the emergency department with multiple injuries. Radiographic examination of her pelvis showed a fracture of her left ilium and iliac crest.

14. From your knowledge of anatomy, would you expect much displacement of the bony fragments?

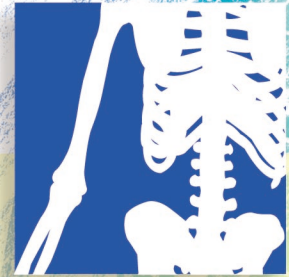A 25-year-old man was running across a field when he caught his right foot in a rabbit hole. As he fell, the right foot was violently rotated laterally and oververted. On attempting to stand, he could place no weight on his right foot. On examination by a physician, the right ankle was considerably swollen, especially on the lateral side. After further examination, including a radiograph of the ankle, a diagnosis of severe fracture dislocation of the ankle joint was made.

15. The following statements concerning this patient are correct **except** which?
- A. This type of fracture dislocation is caused by forced external rotation and overversion of the foot.
 - B. The talus is externally rotated against the lateral malleolus of the fibula, causing it to fracture.
 - C. The torsion effect on the lateral malleolus produces a spiral fracture.
 - D. The medial ligament of the ankle joint is strong and never ruptures.
 - E. If the talus is forced to move farther laterally and continues to rotate, the posterior inferior margin of the tibia will be sheared off.

16. A 32-year-old woman was rock climbing when she decided to jump from a ledge down to a flat rock some five feet below. On landing she maintained her balance but experienced a severe pain in her right foot in the region of the heel. On examination later in the emergency department of the local hospital, the physician's assistant noted the extreme tenderness felt over the sides and inferior surface of the right calcaneum. She also noted that the right calcaneum appeared wider than the one on the left. Using your knowledge of anatomy, make the diagnosis.

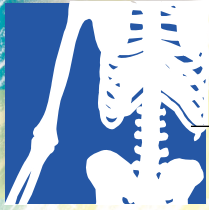
Answers and Explanations

1. **A** is the correct answer. In a 19-year-old boy, the bone marrow at the lower end of the tibia is yellow.
2. **C** is the correct answer. The genioglossus muscle arises from the superior mental spines behind the symphysis menti of the mandible (see text Fig. 11-10).
3. **B** is the correct answer. The hematoma was located deep to the periosteum of the occipital bone.
4. **E** is the correct answer. The carcinoma of the left breast was in an advanced stage and had spread by way of the lymph vessels to the axillary lymph nodes and by the bloodstream to the bodies of the second and third lumbar vertebrae. Carcinoma of the thyroid, bronchus, breast, kidney, and prostate tend to metastasize via the bloodstream to bones.
5. **C** is the correct answer. The chest wall of a child is very elastic, and fractures of ribs in children are rare.
6. **C** is the correct answer. Trauma to the lower part of the woman's left chest could easily severely damage the spleen in the abdomen, resulting in hemorrhage into the peritoneal cavity.
7. **B** is the correct answer. Anatomically, the weakest part of the clavicle is the junction of the middle and lateral thirds, and that is where the fracture occurred in this patient.
8. **D** is the correct answer. The scaphoid bone is a difficult bone to immobilize because of its position and small size.
9. **C** is the correct answer. The anterior surface of the coccyx can be palpated with a gloved finger placed in the anal canal.
10. **D** is the correct answer. Fractures of the true pelvis are commonly associated with injuries to the soft pelvic viscera, especially the bladder and the urethra.
11. **B** is the correct answer. The normal diagonal conjugate measures about 5 in. (11.5 cm) (see CD Fig. 11-6).
12. This angle is within normal limits in a 5-year-old child. It is too great in a 35-year-old man; the condition is called coxa valga, in which adduction of the hip joint is limited. When the angle of the femoral neck is smaller than normal (coxa vara), abduction of the hip joint is limited.
13. Fractures of the neck of the femur in the adult commonly result in avascular necrosis of part of the femoral head. The femoral head receives its blood supply from two sources—a small artery, a branch of the obturator artery, that runs with the round ligament of the femoral head and a profuse blood supply from the medial femoral circumflex femoral artery, branches that ascend the femoral neck beneath the synovial membrane. Fracture of the femoral neck may deprive the femoral head of part or all of the blood from the medial femoral circumflex femoral artery, and avascular necrosis will occur. In trochanteric fractures, both fragments have a profuse blood supply.
14. Most fractures of the upper part of the ilium have little displacement of the bone fragments. This is because the iliacus muscle is attached to the inner surface and the gluteal muscles are attached to the outer surface (see text Fig. 11-54). Splinting the bones is unnecessary because of the attachment of these muscles.
15. **D** is the correct answer. Although the medial ligament of the ankle joint is strong, extreme force can result in rupture of the ligament, or the ligament can be torn from the medial malleolus, or the pull on the ligament can fracture the medial malleolus.
16. This woman had suffered a compression fracture of the right calcaneum as a result of the fall from a height. The weight of the body drives the talus downward into the calcaneum, crushing it in such a way that it loses vertical height and becomes wider laterally. The diagnosis was confirmed on an anteroposterior and a lateral radiograph of the right ankle.



12

Joints



Chapter Outline

General Clinical Features Concerning Joints	169	Radioulnar Joint	174
Examination of Joints	169	Radioulnar Joint Disease	174
Dislocation of Joints	169	Wrist Joint	174
Presence of Cartilaginous Discs within Joints	169	Wrist Joint Injuries	174
Loss of Joint Innervation	169	Falls on the Outstretched Hand	174
Value of Joint Classification	169	Joints of the Pelvis	174
Joint Pain and Joint Innervation	169	Changes in the Pelvic Joints with Pregnancy	174
Temporomandibular Joint	169	Changes in the Pelvic Joints with Age	174
Clinical Significance of the Temporomandibular Joint	169	Sacroiliac Joint Disease	175
Dislocation of the Temporomandibular Joint	169	Joints of the Lower Limb	175
Joints of the Vertebral Column	170	Hip Joint	175
Abnormal Curves of the Vertebral Column	170	Referred Pain from the Hip Joint	175
Dislocations of the Vertebral Column	170	Congenital Dislocation of the Hip	175
Fractures of the Vertebral Column	170	Traumatic Dislocation of the Hip	175
Fractures of the Spinous Processes, Transverse Processes, or Laminae	170	Hip Joint Stability and Trendelenburg's Sign	175
Anterior and Lateral Compression Fractures	170	Arthritis of the Hip Joint	175
Fracture Dislocations	170	Knee Joint	175
Vertical Compression Fractures	170	Strength of the Knee Joint	175
Fractures of the Odontoid Process of the Axis	172	Knee Injury and the Synovial Membrane	176
Fractures of the Pedicles of the Axis (Hangman's Fracture)	172	Ligamentous Injury of the Knee Joint	176
Spondylolisthesis	172	<i>Medial Collateral Ligament</i>	176
Joints of the Upper Limb	172	<i>Lateral Collateral Ligament</i>	176
Sternoclavicular Joint	172	<i>Cruciate Ligaments</i>	176
Sternoclavicular Joint Injuries	172	Meniscal Injury of the Knee Joint	178
Acromioclavicular Joint	172	Pneumoarthrography of the Knee Joint	178
Acromioclavicular Joint Injuries	172	Arthroscopy of the Knee Joint	179
<i>Acromioclavicular Joint Dislocation</i>	172	Ankle Joint	179
Shoulder Joint	173	Ankle Joint Stability	179
Stability of the Shoulder Joint	173	Acute Sprains of the "Lateral Ankle"	179
Dislocations of the Shoulder Joint	173	Acute Sprains of the "Medial Ankle"	179
<i>Anterior-Inferior Dislocations</i>	173	Fracture Dislocations of the Ankle Joint	179
<i>Posterior Dislocations</i>	173	Joints of the Foot	179
Shoulder Pain	173	Metatarsophalangeal Joint of the Big Toe	179
Elbow Joint	173	Clinical Examination of the Arches of the Foot	179
Stability of the Elbow Joint	173	The "Stone Bridge" Mechanisms for Arch Support	179
Dislocations of the Elbow Joint	173	Maintenance of the Medial Longitudinal Arch	181
Arthrocentesis of the Elbow Joint	173	Maintenance of the Lateral Longitudinal Arch	181
Damage to the Ulnar Nerve with Elbow Joint Injuries	173	Maintenance of the Transverse Arch	181
Radiology of the Elbow Region after Injury	174	Physiologic Note: Muscle Tone and the Arches of the Foot	181
		Clinical Problems Associated with the Arches of the Foot	181
		Clinical Problem Solving Questions	182
		Answers and Explanations	185



GENERAL CLINICAL FEATURES CONCERNING JOINTS

Examination of Joints

When examining a patient, the clinician should assess the normal range of movement of all joints. When the bones of a joint are no longer in their normal anatomic relationship with one another, then the joint is said to be **dislocated**.

Dislocation of Joints

Some joints are particularly susceptible to dislocation because of lack of support by ligaments, the poor shape of the articular surfaces, or the absence of adequate muscular support. The shoulder joint, temporomandibular joint, and acromioclavicular joints are good examples. Dislocation of the hip is usually congenital, being caused by inadequate development of the socket that normally holds the head of the femur firmly in position.

Presence of Cartilaginous Discs within Joints

The presence of cartilaginous discs within joints, especially weightbearing joints, as in the case of the knee, makes them particularly susceptible to injury in sports. During a rapid movement the disc loses its normal relationship to the bones and becomes crushed between the weightbearing surfaces.

Loss of Joint Innervation

In certain diseases of the nervous system (e.g., **syringomyelia**), the sensation of pain in a joint is lost. This means that the warning sensations of pain felt when a joint moves beyond the normal range of movement are not experienced. This phenomenon results in the destruction of the joint.

Value of Joint Classification

Knowledge of the classification of joints is of great value because, for example, certain diseases affect only certain types of joints. **Gonococcal arthritis** affects large synovial joints

such as the ankle, elbow, or wrist, whereas **tuberculous arthritis** also affects synovial joints and may start in the synovial membrane or in the bone.

Joint Pain and Joint Innervation

Remember that more than one joint may receive the same nerve supply. For example, the hip and knee joints are both supplied by the obturator nerve. Thus, a patient with disease limited to one of these joints may experience pain in both.



TEMPOROMANDIBULAR JOINT

Clinical Significance of the Temporomandibular Joint

The temporomandibular joint lies immediately in front of the external auditory meatus. The great strength of the lateral temporomandibular ligament prevents the head of the mandible from passing backward and fracturing the tympanic plate when a severe blow falls on the chin.

The **articular disc** of the temporomandibular joint may become partially detached from the capsule, and this results in its movement becoming noisy and producing an audible click during movements at the joint.

Dislocation of the Temporomandibular Joint

Dislocation sometimes occurs when the mandible is depressed. In this movement, the head of the mandible and the articular disc both move forward until they reach the summit of the articular tubercle. In this position, the joint is unstable, and a minor blow on the chin or a sudden contraction of the lateral pterygoid muscles, as in yawning, may be sufficient to pull the disc forward beyond the summit. In bilateral cases the mouth is fixed in an open position, and both heads of the mandible lie in front of the articular tubercles. Reduction of the dislocation is easily achieved by pressing the gloved thumbs downward on the lower molar teeth and pushing the jaw backward. The downward pressure overcomes the tension of the temporalis and masseter muscles, and the backward pressure overcomes the spasm of the lateral pterygoid muscles.



JOINTS OF THE VERTEBRAL COLUMN

Abnormal Curves of the Vertebral Column

Kyphosis is an exaggeration in the sagittal curvature present in the thoracic part of the vertebral column. It can be caused by muscular weakness, by structural changes in the vertebral bodies, or by intervertebral discs. In sickly adolescents, for example, where the muscle tone is poor, long hours of study or work over a low desk can lead to a gently curved kyphosis of the upper thoracic region. The person is said to be “round-shouldered.” Crush fractures or tuberculous destruction of the vertebral bodies leads to acute angular kyphosis of the vertebral column. In the aged, **osteoporosis** (abnormal rarefaction of bone) and/or degeneration of the intervertebral discs leads to **senile kyphosis**, involving the cervical, thoracic, and lumbar regions of the column.

Lordosis is an exaggeration in the sagittal curvature present in the lumbar region. Lordosis may be caused by an increase in the weight of the abdominal contents, as with the gravid uterus or a large ovarian tumor, or it may be caused by disease of the vertebral column such as spondylolisthesis. The possibility that it is a postural compensation for a kyphosis in the thoracic region or a disease of the hip joint (congenital dislocation) must not be overlooked.

Scoliosis is a lateral deviation of the vertebral column. This is most commonly found in the thoracic region and may be caused by muscular or vertebral defects. Paralysis of muscles caused by poliomyelitis can cause severe scoliosis. The presence of a congenital hemivertebra can cause scoliosis. Often scoliosis is compensatory and may be caused by a short leg or hip disease.

Dislocations of the Vertebral Column

Dislocations without fracture occur only in the cervical region because the inclination of the articular processes of the cervical vertebrae permits dislocation to take place without fracture of the processes. In the thoracic and lumbar regions, dislocations can occur only if the vertically placed articular processes are fractured.

Dislocations commonly occur between the fourth and fifth or fifth and sixth cervical vertebrae, where mobility is

greatest. In unilateral dislocations the inferior articular process of one vertebra is forced forward over the anterior margin of the superior articular process of the vertebra below. Because the articular processes normally overlap, they become locked in the dislocated position. The spinal nerve on the same side is usually nipped in the intervertebral foramen, producing severe pain. Fortunately, the large size of the vertebral canal allows the spinal cord to escape damage in most cases.

Bilateral cervical dislocations are almost always associated with severe injury to the spinal cord. Death occurs immediately if the upper cervical vertebrae are involved because the respiratory muscles, including the diaphragm (phrenic nerves C3 to C5), are paralyzed.

Fractures of the Vertebral Column

Fractures of the Spinous Processes, Transverse Processes, or Laminae

Fractures of the spinous processes, transverse processes, or laminae are caused by direct injury or, in rare cases, by severe muscular activity.

Anterior and Lateral Compression Fractures

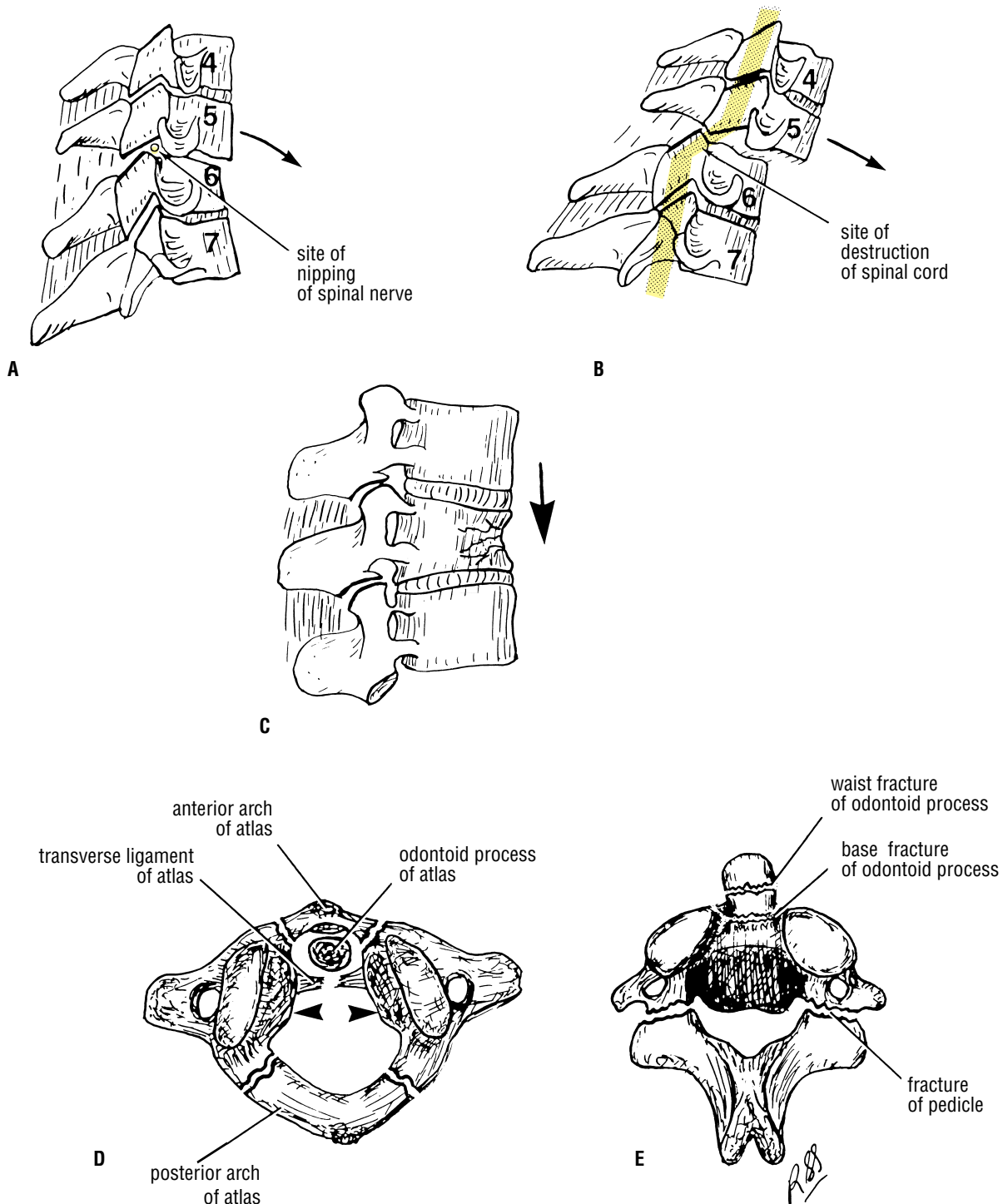
Anterior compression fractures of the vertebral bodies are usually caused by an excessive flexion compression type of injury and take place at the sites of maximum mobility or at the junction of the mobile and fixed regions of the column. It is interesting to note that the body of a vertebra in such a fracture is crushed, whereas the strong posterior longitudinal ligament remains intact. The vertebral arches remain unbroken and the intervertebral ligaments remain intact so that vertebral displacement and spinal cord injury do not occur. When injury causes excessive lateral flexion in addition to excessive flexion, the lateral part of the body is also crushed.

Fracture Dislocations

Fracture dislocations are usually caused by a combination of a flexion and rotation type of injury; the upper vertebra is excessively flexed and twisted on the lower vertebra. Here again, the site is usually where maximum mobility occurs, as in the lumbar region, or at the junction of the mobile and fixed region of the column, as in the lower lumbar vertebrae. Because the articular processes are fractured and the ligaments are torn, the vertebrae involved are unstable, and the spinal cord is usually severely damaged or severed, with accompanying paraplegia.

Vertical Compression Fractures

Vertical compression fractures occur in the cervical and lumbar regions, where it is possible to fully straighten the



CD Figure 12-1 Dislocations and fractures of the vertebral column. **A.** Unilateral dislocation of the fifth or the sixth cervical vertebra. Note the forward displacement of the inferior articular process over the superior articular process of the vertebra below. **B.** Bilateral dislocation of the fifth on the sixth cervical vertebra. Note that 50% of the vertebral body width has moved forward on the vertebra below. **C.** Flexion compression-type fracture of the vertebral body in the lumbar region. **D.** Jefferson's-type fracture of the atlas. **E.** Fractures of the odontoid process and the pedicles (hangman's fracture) of the axis.

vertebral column (CD Fig. 12-1). In the cervical region, with the neck straight, an excessive vertical force applied from above will cause the ring of the atlas to be disrupted and the lateral masses to be displaced laterally (**Jefferson's fracture**). If the neck is slightly flexed, the lower cervical vertebrae remain in a straight line and the compression load is transmitted to the lower vertebrae, causing disruption of the intervertebral disc and breakup of the vertebral body. Pieces of the vertebral body are commonly forced back into the spinal cord.

It is possible for nontraumatic compression fractures to occur in severe cases of osteoporosis and for pathologic fractures to take place.

In the straightened lumbar region, an excessive force from below can cause the vertebral body to break up, with protrusion of fragments posteriorly into the spinal canal.

Fractures of the Odontoid Process of the Axis

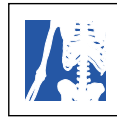Fractures of the odontoid process are relatively common and result from falls or blows on the head (see CD Fig. 12-1). Excessive mobility of the odontoid fragment or rupture of the transverse ligament can result in compression injury to the spinal cord.

Fracture of the Pedicles of the Axis (Hangman's Fracture)

Severe extension injury of the neck, such as might occur in an automobile accident or a fall, is the usual cause of hangman's fracture. Sudden overextension of the neck, as produced by the knot of a hangman's rope beneath the chin, is the reason for the common name. Because the vertebral canal is enlarged by the forward displacement of the vertebral body of the axis, the spinal cord is rarely compressed (see CD Fig. 12-1).

Spondylolisthesis

In spondylolisthesis, the body of a lower lumbar vertebra, usually the fifth, moves forward on the body of the vertebra below and carries with it the whole of the upper portion of the vertebral column. The essential defect is in the pedicles of the migrating vertebra. It is now generally believed that, in this condition, the pedicles are abnormally formed and accessory centers of ossification are present and fail to unite. The spine, laminae, and inferior articular processes remain in position, whereas the remainder of the vertebra, having lost the restraining influence of the inferior articular processes, slips forward. Because the laminae are left behind, the vertebral canal is not narrowed, but the nerve roots may be pressed on, causing low backache and sciatica. In severe cases the trunk becomes shortened, and the lower ribs contact the iliac crest.



JOINTS OF THE UPPER LIMB

Sternoclavicular Joint

Sternoclavicular Joint Injuries

The strong costoclavicular ligament firmly holds the medial end of the clavicle to the first costal cartilage. Violent forces directed along the long axis of the clavicle usually result in fracture of that bone, but dislocation of the sternoclavicular joint takes place occasionally.

Anterior dislocation results in the medial end of the clavicle projecting forward beneath the skin; it may also be pulled upward by the sternocleidomastoid muscle.

Posterior dislocation usually follows direct trauma applied to the front of the joint that drives the clavicle backward. This type is the more serious because the displaced clavicle may press on the trachea, esophagus, and major blood vessels in the root of the neck.

If the costoclavicular ligament ruptures completely, it is difficult to maintain the normal position of the clavicle once reduction has been accomplished.

Acromioclavicular Joint

Acromioclavicular Joint Injuries

The plane of the articular surfaces of the acromioclavicular joint passes downward and medially so that there is a tendency for the lateral end of the clavicle to ride up over the upper surface of the acromion. The strength of the joint depends on the strong coracoclavicular ligament, which binds the coracoid process to the undersurface of the lateral part of the clavicle. The greater part of the weight of the upper limb is transmitted to the clavicle through this ligament, and rotary movements of the scapula occur at this important ligament.

Acromioclavicular Joint Dislocation

A severe blow on the point of the shoulder, as is incurred during blocking or tackling in football or any severe fall, can result in the acromion being thrust beneath the lateral end of the clavicle, tearing the coracoclavicular ligament. This condition is known as **shoulder separation**. The displaced outer end of the clavicle is easily palpable. As in the case of the sternoclavicular joint, the dislocation is easily reduced, but withdrawal of support results in immediate re-dislocation.

Shoulder Joint

Stability of the Shoulder Joint

The shallowness of the glenoid fossa of the scapula and the lack of support provided by weak ligaments make this joint an unstable structure. Its strength almost entirely depends on the tone of the short muscles that bind the upper end of the humerus to the scapula—namely, the subscapularis in front, the supraspinatus above, and the infraspinatus and teres minor behind. The tendons of these muscles are fused to the underlying capsule of the shoulder joint. Together, these tendons form the rotator cuff.

The least supported part of the joint lies in the inferior location, where it is unprotected by muscles.

Dislocations of the Shoulder Joint

The shoulder joint is the most commonly dislocated large joint.

Anterior–Inferior Dislocations

Sudden violence applied to the humerus with the joint fully abducted tilts the humeral head downward onto the inferior weak part of the capsule, which tears, and the humeral head comes to lie inferior to the glenoid fossa. During this movement, the acromion has acted as a fulcrum. The strong flexors and adductors of the shoulder joint now usually pull the humeral head forward and upward into the subcoracoid position.

Posterior Dislocations

Posterior dislocations are rare and are usually caused by direct violence to the front of the joint.

On inspection of the patient with shoulder dislocation, the rounded appearance of the shoulder is seen to be lost because the greater tuberosity of the humerus is no longer bulging laterally beneath the deltoid muscle. A subglenoid displacement of the head of the humerus into the quadrangular space can cause damage to the axillary nerve, as indicated by paralysis of the deltoid muscle and loss of skin sensation over the lower half of the deltoid. Downward displacement of the humerus can also stretch and damage the radial nerve.

Shoulder Pain

The synovial membrane, capsule, and ligaments of the shoulder joint are innervated by the axillary nerve and the suprascapular nerve. The joint is sensitive to pain, pressure, excessive traction, and distension. The muscles surrounding the joint undergo reflex spasm in response to pain originating in the joint, which in turn serves to immobilize the joint and thus reduce the pain.

Injury to the shoulder joint is followed by pain, limitation of movement, and muscle atrophy owing to disuse. It is important to appreciate that pain in the shoulder region can be caused by disease elsewhere and that the shoulder joint may be normal; for example, diseases of the spinal cord and vertebral column and the pressure of a cervical rib can cause shoulder pain. Irritation of the diaphragmatic pleura or peritoneum can produce referred pain via the phrenic and supraclavicular nerves.

Elbow Joint

Stability of the Elbow Joint

The elbow joint is stable because of the wrench-shaped articular surface of the olecranon and the pulley-shaped trochlea of the humerus; it also has strong medial and lateral ligaments. When examining the elbow joint, the physician must remember the normal relations of the bony points. In extension, the medial and lateral epicondyles and the top of the olecranon process are in a straight line; in flexion, the bony points form the boundaries of an equilateral triangle.

Dislocations of the Elbow Joint

Elbow dislocations are common, and most are posterior. Posterior dislocation usually follows falling on the outstretched hand. Posterior dislocations of the joint are common in children because the parts of the bones that stabilize the joint are incompletely developed. Avulsion of the epiphysis of the medial epicondyle is also common in childhood because then the medial ligament is much stronger than the bond of union between the epiphysis and the diaphysis.

Arthrocentesis of the Elbow Joint

The anterior and posterior walls of the capsule are weak, and when the joint is distended with fluid, the posterior aspect of the joint becomes swollen. Aspiration of joint fluid can easily be performed through the back of the joint on either side of the olecranon process.

Damage to the Ulnar Nerve with Elbow Joint Injuries

The close relationship of the ulnar nerve to the medial side of the joint often results in its becoming damaged in dislocations of the joint or in fracture dislocations in this region. The nerve lesion can occur at the time of injury or weeks, months, or years later. The nerve can be involved in scar tissue formation or can become stretched owing to lateral deviation of the forearm in a badly reduced supracondylar fracture of the humerus. During movements of the elbow joint, the continued friction between the medial epicondyle and the stretched ulnar nerve eventually results in ulnar palsy.

Radiology of the Elbow Region after Injury

In examining lateral radiographs of the elbow region, it is important to remember that the lower end of the humerus is normally angulated forward 45° on the shaft; when examining a patient, the physician should see that the medial epicondyle, in the anatomic position, is directed medially and posteriorly and faces in the same direction as the head of the humerus.

Radioulnar Joint

Radioulnar Joint Disease

The proximal radioulnar joint communicates with the elbow joint, whereas the distal radioulnar joint does not communicate with the wrist joint. In practical terms, this means that infection of the elbow joint invariably involves the proximal radioulnar joint. The strength of the proximal radioulnar joint depends on the integrity of the strong anular ligament. Rupture of this ligament occurs in cases of anterior dislocation of the head of the radius on the capitulum of the humerus. In young children, in whom the head of the radius is still small and undeveloped, a sudden jerk on the arm can pull the radial head down through the anular ligament.

Wrist Joint

Wrist Joint Injuries

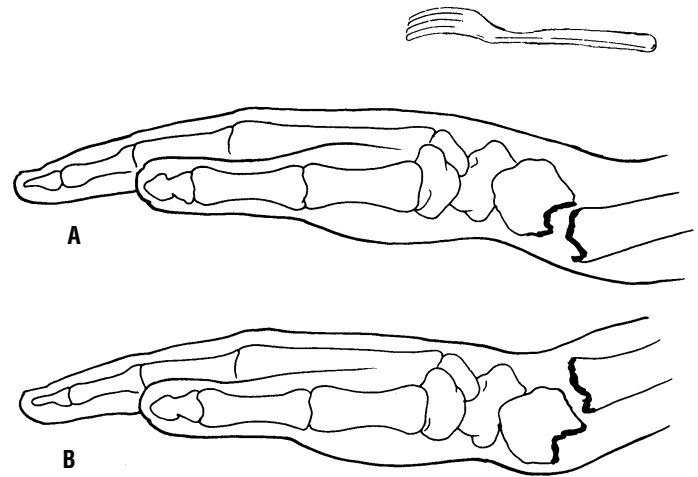
The wrist joint is essentially a synovial joint between the distal end of the radius and the proximal row of carpal bones. The head of the ulna is separated from the carpal bones by the strong triangular fibrocartilaginous ligament, which separates the wrist joint from the distal radioulnar joint. The joint is stabilized by the strong medial and lateral ligaments.

Because the styloid process of the radius is longer than that of the ulna, abduction of the wrist joint is less extensive than adduction. In flexion–extension movements, the hand can be flexed about 80° but extended to only about 45° . The range of flexion is increased by movement at the midcarpal joint.

A fall on the outstretched hand can strain the anterior ligament of the wrist joint, producing synovial effusion, joint pain, and limitation of movement. These symptoms and signs must not be confused with those produced by a fractured scaphoid or dislocation of the lunate bone, which are similar.

Falls on the Outstretched Hand

In falls on the outstretched hand, forces are transmitted from the scaphoid to the distal end of the radius, from the radius across the interosseous membrane to the ulna, and from the ulna to the humerus; thence, through the glenoid fossa of the scapula to the coracoclavicular ligament and



CD Figure 12-2 Fractures of the distal end of the radius. **A.** Colles' fracture. **B.** Smith's fracture.

the clavicle, and finally, to the sternum. If the forces are excessive, different parts of the upper limb give way under the strain. The area affected seems to be related to age. In a young child, for example, there may be a posterior displacement of the distal radial epiphysis; in the teenager the clavicle might fracture; in the young adult the scaphoid is commonly fractured; and in the elderly the distal end of the radius is fractured about 1 in. (2.5 cm) proximal to the wrist joint (Colles' fracture) (CD Fig. 12-2).



JOINTS OF THE PELVIS

Changes in the Pelvic Joints with Pregnancy

During pregnancy, the symphysis pubis and the ligaments of the sacroiliac and sacrococcygeal joints undergo softening in response to hormones, thus increasing the mobility and increasing the potential size of the pelvis during childbirth. The hormones responsible are estrogen and progesterone produced by the ovary and the placenta. An additional hormone, called relaxin, produced by these organs can also have a relaxing effect on the pelvic ligaments.

Changes in the Pelvic Joints with Age

Obliteration of the cavity in the sacroiliac joint occurs in both sexes after middle age.

Sacroiliac Joint Disease

The sacroiliac joint is innervated by the lower lumbar and sacral nerves so that disease in the joint can produce low back pain and pain referred along the sciatic nerve (sciatica).

The sacroiliac joint is inaccessible to clinical examination. However, a small area located just medial to and below the posterior superior iliac spine is where the joint comes closest to the surface. In disease of the lumbosacral region, movements of the vertebral column in any direction cause pain in the lumbosacral part of the column. In sacroiliac disease, pain is extreme on rotation of the vertebral column and is worst at the end of forward flexion. The latter movement causes pain because the hamstring muscles hold the hip bones in position while the sacrum is rotating forward as the vertebral column is flexed.



JOINTS OF THE LOWER LIMB

Hip Joint

Referred Pain from the Hip Joint

The femoral nerve not only supplies the hip joint but, via the intermediate and medial cutaneous nerves of the thigh, also supplies the skin of the front and medial side of the thigh. It is not surprising, therefore, for pain originating in the hip joint to be referred to the front and medial side of the thigh. The posterior division of the obturator nerve supplies both the hip and knee joints. This would explain why hip joint disease sometimes gives rise to pain in the knee joint.

Congenital Dislocation of the Hip

The stability of the hip joint depends on the ball-and-socket arrangement of the articular surfaces and the strong ligaments. In congenital dislocation of the hip, the upper lip of the acetabulum fails to develop adequately, and the head of the femur, having no stable platform under which it can lodge, rides up out of the acetabulum onto the gluteal surface of the ilium.

Traumatic Dislocation of the Hip

Traumatic dislocation of the hip is rare because of its strength; it is usually caused by motor vehicle accidents. However, should it occur, it usually does so when the joint is flexed and adducted. The head of the femur is displaced posteriorly out of the acetabulum, and it comes to rest on the gluteal surface of the ilium (posterior dislocation). The close relation of the sciatic nerve to the posterior surface of the joint makes it prone to injury in posterior dislocations.

Hip Joint Stability and Trendelenburg's Sign

The stability of the hip joint when a person stands on one leg with the foot of the opposite leg raised above the ground depends on three factors:

- The gluteus medius and minimus must be functioning normally.
- The head of the femur must be located normally within the acetabulum.
- The neck of the femur must be intact and must have a normal angle with the shaft of the femur.

If any one of these factors is defective, then the pelvis will sink downward on the opposite, unsupported side. The patient is then said to exhibit a positive **Trendelenburg's sign** (CD Fig. 12-3).

Normally, when walking, a person alternately contracts the gluteus medius and minimus, first on one side and then on the other. By this means he or she is able to raise the pelvis first on one side and then on the other, allowing the leg to be flexed at the hip joint and moved forward—that is, the leg is raised clear of the ground before it is thrust forward in taking the forward step. A patient with a right-sided congenital dislocation of the hip, when asked to stand on the right leg and raise the opposite leg clear of the ground, will exhibit a positive Trendelenburg's sign, and the unsupported side of the pelvis will sink below the horizontal. If the patient is asked to walk, he or she will show the characteristic “dipping” gait. In patients with bilateral congenital dislocation of the hip, the gait is typically “waddling” in nature.

Arthritis of the Hip Joint

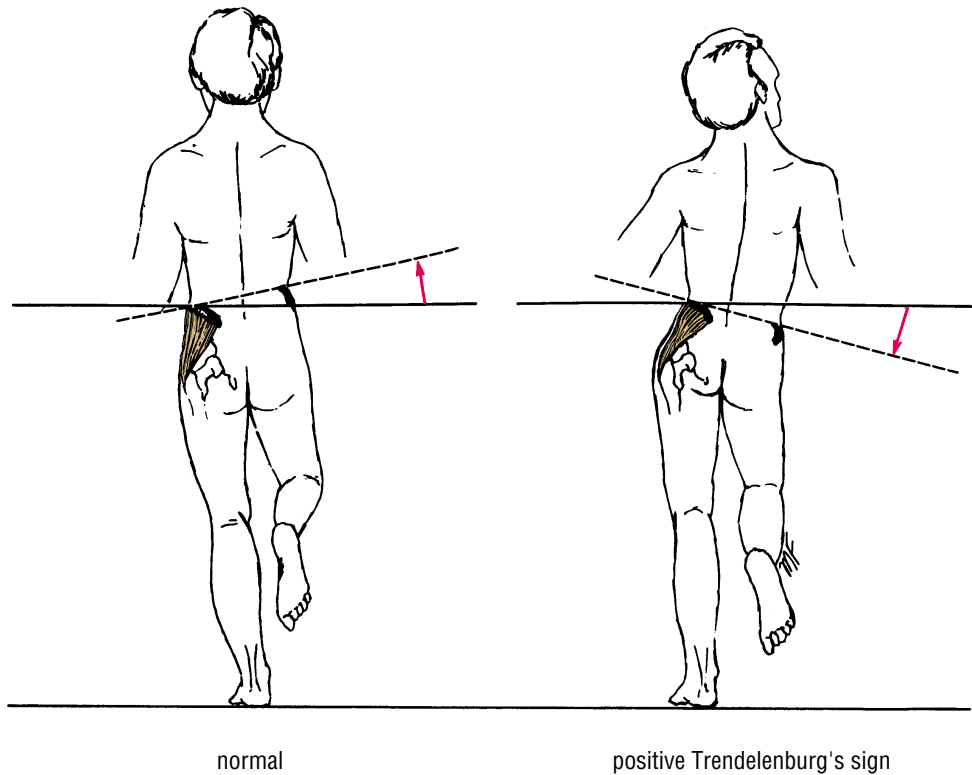
A patient with an inflamed hip joint will place the femur in the position that gives minimum discomfort—that is, the position in which the joint cavity has the greatest capacity to contain the increased amount of synovial fluid secreted. The hip joint is partially flexed, abducted, and externally rotated.

Osteoarthritis, the most common disease of the hip joint in the adult, causes pain, stiffness, and deformity. The pain may be in the hip joint itself or referred to the knee (the obturator nerve supplies both joints). The stiffness is caused by the pain and reflex spasm of the surrounding muscles. The deformity is flexion, adduction, and external rotation and is produced initially by muscle spasm and later by muscle contracture.

Knee Joint

Strength of the Knee Joint

The strength of the knee joint depends on the strength of the ligaments that bind the femur to the tibia and on the tone of the muscles acting on the joint. The most important muscle group is the quadriceps femoris; provided that this is well



CD Figure 12-3 Trendelenburg's test.

developed, it is capable of stabilizing the knee in the presence of torn ligaments.

Knee Injury and the Synovial Membrane

The synovial membrane of the knee joint is extensive, and if the articular surfaces, menisci, or ligaments of the joint are damaged, the large synovial cavity becomes distended with fluid. The wide communication between the suprapatellar bursa and the joint cavity results in this structure becoming distended also. The swelling of the knee extends three or four fingerbreadths above the patella and laterally and medially beneath the aponeuroses of insertion of the vastus lateralis and medialis, respectively.

Ligamentous Injury of the Knee Joint

Four ligaments—the medial collateral ligament, the lateral collateral ligament, the anterior cruciate ligament, and the posterior cruciate ligament—are commonly injured in the knee. Sprains or tears occur depending on the degree of force applied.

Medial Collateral Ligament

Forced abduction of the tibia on the femur can result in partial tearing of the medial collateral ligament, which can

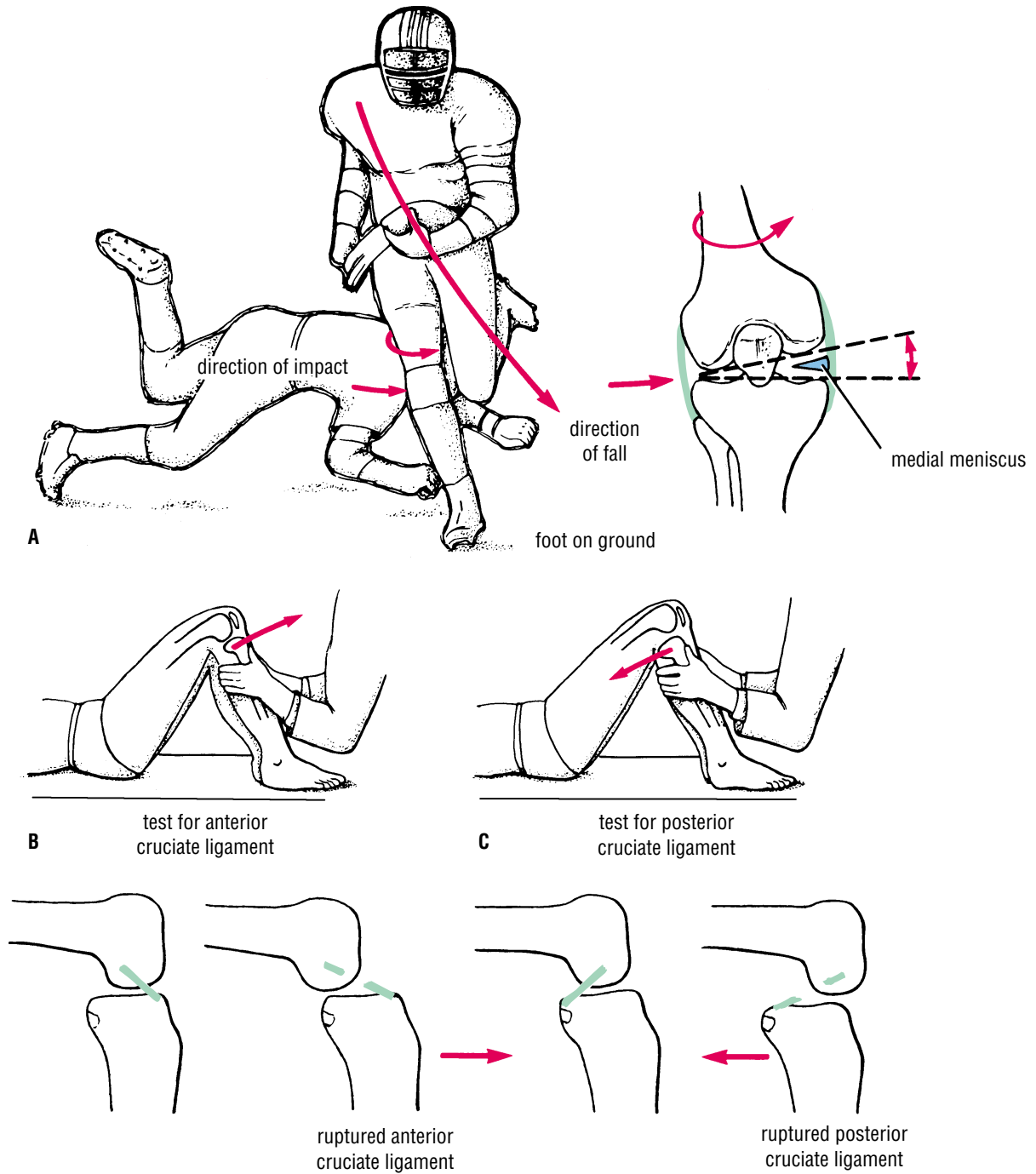
occur at its femoral or tibial attachments. It is useful to remember that tears of the menisci result in localized tenderness on the joint line, whereas sprains of the medial collateral ligament result in tenderness over the femoral or tibial attachments of the ligament.

Lateral Collateral Ligament

Forced adduction of the tibia on the femur can result in injury to the lateral collateral ligament (less common than medial ligament injury).

Cruciate Ligaments

Injury to the cruciate ligaments can occur when excessive force is applied to the knee joint. Tears of the anterior cruciate ligament are common; tears of the posterior cruciate ligament are rare. The injury is always accompanied by damage to other knee structures; the collateral ligaments are commonly torn or the capsule may be damaged. The joint cavity quickly fills with blood (hemarthrosis) so that the joint is swollen. Examination of patients with a ruptured anterior cruciate ligament shows that the tibia can be pulled excessively forward on the femur; with rupture of the posterior cruciate ligament, the tibia can be made to move excessively backward on the femur (CD Fig. 12-4). Because the stability of the knee joint depends largely on the tone of the quadriceps femoris muscle and the integrity



CD Figure 12-4 **A.** Mechanism involved in damage to the medial meniscus of the knee joint from playing football. Note that the right knee joint is semiflexed and that medial rotation of the femur on the tibia occurs. The impact causes forced abduction of the tibia on the femur, and the medial meniscus is pulled into an abnormal position. The cartilaginous meniscus is then ground between the femur and the tibia. **B.** Test for integrity of the anterior cruciate ligament. **C.** Test for integrity of the posterior cruciate ligament.

of the collateral ligaments, operative repair of isolated torn cruciate ligaments is not always attempted. The knee is immobilized in slight flexion in a cast, and active physiotherapy on the quadriceps femoris muscle is begun at once. Should, however, the capsule of the joint and the collateral ligaments be torn in addition, early operative repair is essential.

Meniscal Injury of the Knee Joint

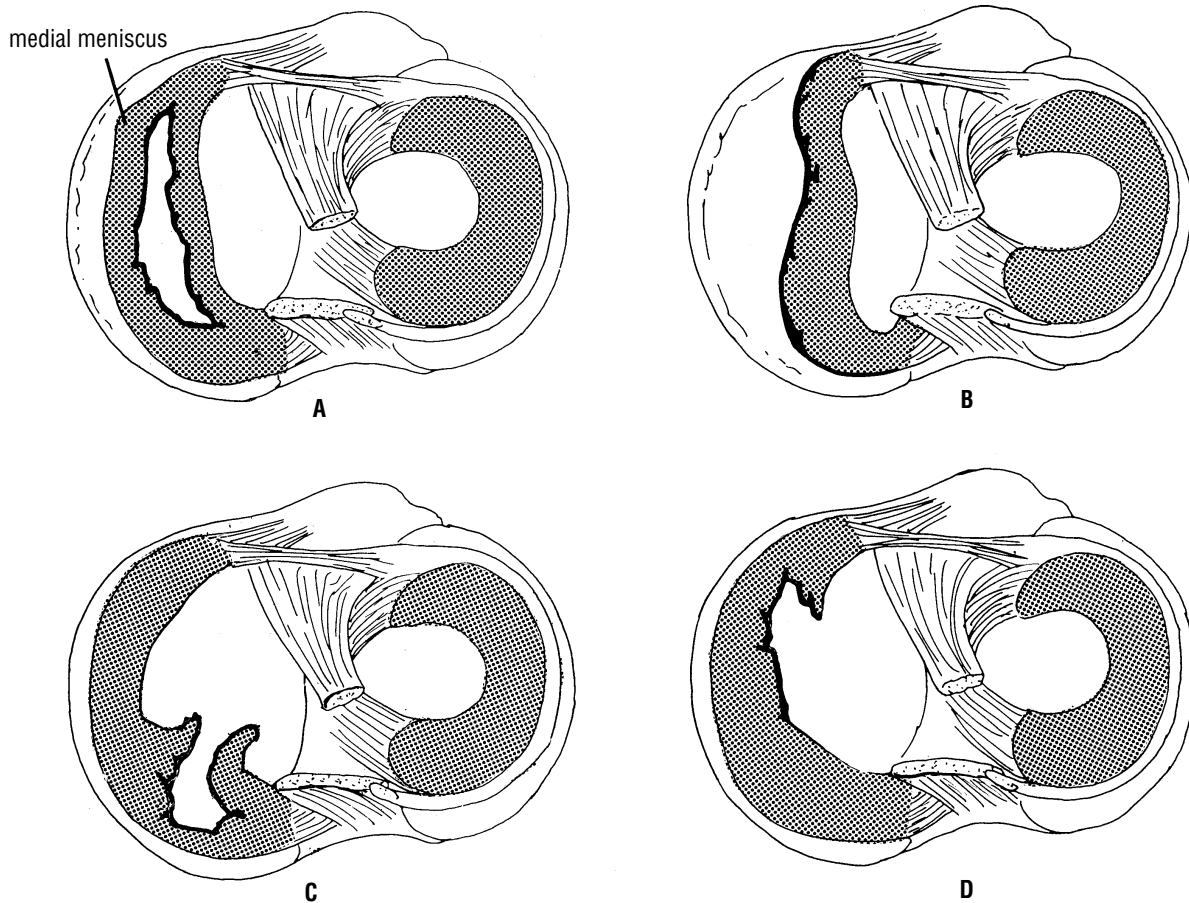
Injuries of the menisci are common. The medial meniscus is damaged much more frequently than the lateral, and this is probably because of its strong attachment to the medial collateral ligament of the knee joint, which restricts its mobility. The injury occurs when the femur is rotated on the tibia, or the tibia is rotated on the femur, with the knee joint partially flexed and taking the weight of the body. The tibia is usually abducted on the femur, and the medial meniscus is pulled into an abnormal position between the femoral and tibial condyles (CD Fig. 12-4A). A sudden movement between the condyles results in the meniscus

being subjected to a severe grinding force, and it splits along its length (CD Fig. 12-5). When the torn part of the meniscus becomes wedged between the articular surfaces, further movement is impossible, and the joint is said to “lock.”

Injury to the lateral meniscus is less common, probably because it is not attached to the lateral collateral ligament of the knee joint and is consequently more mobile. The popliteus muscle sends a few of its fibers into the lateral meniscus, and these can pull the meniscus into a more favorable position during sudden movements of the knee joint.

Pneumoarthrography of the Knee Joint

Air can be injected into the synovial cavity of the knee joint so that soft tissues can be studied. This technique is based on the fact that air is less radiopaque than structures such as the medial and lateral menisci, so their outline can be visualized on a radiograph (see text Fig. 12-43).



CD Figure 12-5 Tears of the medial meniscus of the knee joint. **A.** Complete bucket handle tear. **B.** The meniscus is torn from its peripheral attachment. **C.** Tear of the posterior portion of the meniscus. **D.** Tear of the anterior portion of the meniscus.

Arthroscopy of the Knee Joint

Arthroscopy involves the introduction of a lighted instrument into the synovial cavity of the knee joint through a small incision. This technique permits the direct visualization of structures, such as the cruciate ligaments and the menisci, for diagnostic purposes.

Ankle Joint

Ankle Joint Stability

The ankle joint is a hinge joint possessing great stability. The deep mortise formed by the lower end of the tibia and the medial and lateral malleoli securely holds the talus in position.

Acute Sprains of the “Lateral Ankle”

Acute sprains of the lateral ankle are usually caused by excessive inversion of the foot with plantar flexion of the ankle. The anterior talofibular ligament and the calcaneofibular ligament are partially torn, giving rise to great pain and local swelling.

Acute Sprains of the “Medial Ankle”

Acute sprains of the medial ankle are similar to but less common than those of the lateral ankle. They may occur to the medial or deltoid ligament as a result of excessive eversion. The great strength of the medial ligament usually results in the ligament pulling off the tip of the medial malleolus.

Fracture Dislocations of the Ankle Joint

Fracture dislocations of the ankle are common and are caused by forced external rotation and overversion of the foot. The talus is externally rotated forcibly against the lateral malleolus of the fibula. The torsion effect on the lateral malleolus causes it to fracture spirally. If the force continues, the talus moves laterally, and the medial ligament of the ankle joint becomes taut and pulls off the tip of the medial malleolus. If the talus is forced to move still farther, its rotary movement results in its violent contact with the posterior inferior margin of the tibia, which shears off.

Other less common types of fracture dislocation are caused by forced overversion (without rotation), in which the talus presses the lateral malleolus laterally and causes it to fracture transversely. Overinversion (without rotation), in which the talus presses against the medial malleolus, produces a vertical fracture through the base of the medial malleolus.

Joints of the Foot

Metatarsophalangeal Joint of the Big Toe

Hallux valgus, which is a lateral deviation of the great toe at the metatarsophalangeal joint, is a common condition. Its incidence is greater in women than in men and is associated with badly fitting shoes. It is often accompanied by the presence of a short first metatarsal bone. Once the deformity is established, it is progressively worsened by the pull of the flexor hallucis longus and extensor hallucis longus muscles. Later, osteoarthritic changes occur in the metatarsophalangeal joint, which then becomes stiff and painful; the condition is then known as **hallux rigidus**.

Clinical Examination of the Arches of the Foot

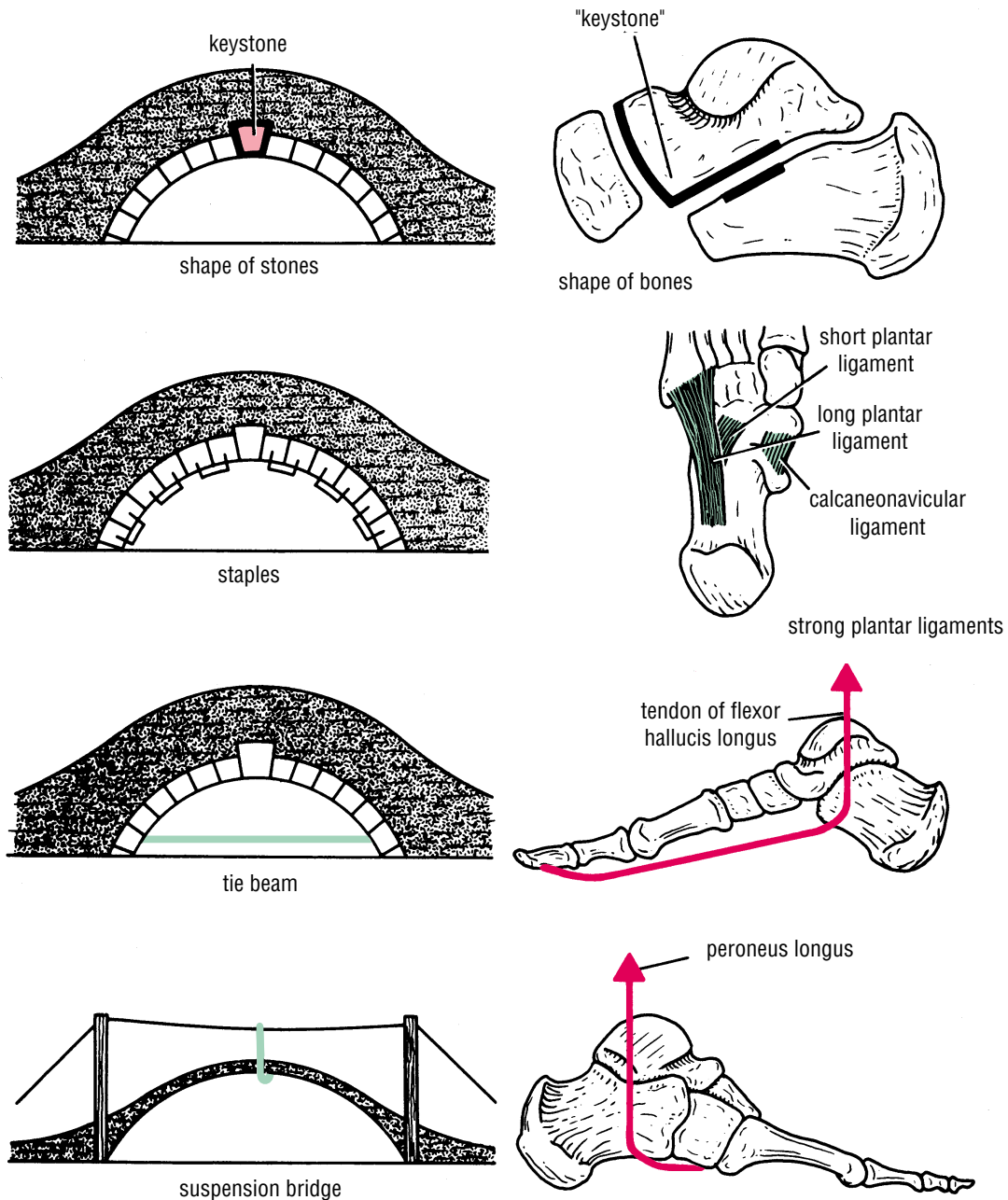
On examination of the imprint of a wet foot on the floor made with the person in the standing position, one can see that the heel, the lateral margin of the foot, the pad under the metatarsal heads, and the pads of the distal phalanges are in contact with the ground (see text Figs. 12-41 and 12-42). The medial margin of the foot, from the heel to the first metatarsal head, is arched above the ground because of the important medial longitudinal arch. The pressure exerted on the ground by the lateral margin of the foot is greatest at the heel and the fifth metatarsal head and least between these areas because of the presence of the low-lying lateral longitudinal arch. The transverse arch involves the bases of the five metatarsals and the cuboid and cuneiform bones. This is, in fact, only half an arch, with its base on the lateral border of the foot and its summit on the foot's medial border. The foot has been likened to a half-dome, so that when the medial borders of the two feet are placed together, a complete dome is formed.

From this description, it can be understood that the body weight on standing is distributed through a foot via the heel behind and six points of contact with the ground in front, namely, the two sesamoid bones under the head of the first metatarsal and the heads of the remaining four metatarsals.

The “Stone Bridge” Mechanisms for Arch Support

Examination of the design of any stone bridge reveals the following engineering methods used for its support (CD Fig. 12-6).

- **The shape of the stones:** The most effective way of supporting the arch is to make the stones wedge shaped, with the thin edge of the wedge lying inferiorly. This applies particularly to the important stone that occupies



CD Figure 12-6 Different methods by which the arches of the foot may be supported.

the center of the arch and is referred to as the “keystone.”

- **The inferior edges of the stones are tied together:** This is accomplished by interlocking the stones or binding their lower edges together with metal staples. This method effectively counteracts the tendency of the lower edges of the stones to separate when the arch is weightbearing.
- **The use of the tie beams:** When the span of the bridge is large and the foundations at either end are insecure, a tie

beam connecting the ends effectively prevents separation of the pillars and consequent sagging of the arch.

- **A suspension bridge:** Here, the maintenance of the arch depends on multiple supports suspending the arch from a cable above the level of the bridge.

Using the bridge analogy, one can now examine the methods used to support the arches of the feet (see CD Fig. 12-6).

Maintenance of the Medial Longitudinal Arch

- **Shape of the bones:** The sustentaculum tali hold up the talus; the concave proximal surface of the navicular bone receives the rounded head of the talus; the slight concavity of the proximal surface of the medial cuneiform bone receives the navicular. The rounded head of the talus is the keystone in the center of the arch (see CD Fig. 12-6).
- **The inferior edges of the bones are tied together** by the plantar ligaments, which are larger and stronger than the dorsal ligaments. The most important ligament is the plantar calcaneonavicular ligament (see CD Fig. 12-6). The tendinous extensions of the insertion of the tibialis posterior muscle play an important role in this respect.
- **Tying the ends of the arch together** are the plantar aponeurosis, the medial part of the flexor digitorum brevis, the abductor hallucis, the flexor hallucis longus, the medial part of the flexor digitorum longus, and the flexor hallucis brevis (see CD Fig. 12-6).
- **Suspending the arch from above** are the tibialis anterior and posterior and the medial ligament of the ankle joint.

Maintenance of the Lateral Longitudinal Arch

- **Shape of the bones:** Minimal shaping of the distal end of the calcaneum and the proximal end of the cuboid. The cuboid is the keystone.
- **The inferior edges of the bones are tied together** by the long and short plantar ligaments and the origins of the short muscles from the forepart of the foot (see CD Fig. 12-6).
- **Tying the ends of the arch together** are the plantar aponeurosis, the abductor digiti minimi, and the lateral part of the flexor digitorum longus and brevis.
- **Suspending the arch from above** are the peroneus longus and the brevis (see CD Fig. 12-6).

Maintenance of the Transverse Arch

- **Shape of the bones:** The marked wedge shaping of the cuneiform bones and the bases of the metatarsal bones (see text Fig. 12-42)
- **The inferior edges of the bones are tied together** by the deep transverse ligaments, the strong plantar ligaments, and the origins of the plantar muscles from the forepart of the foot; the dorsal interossei and the transverse head of the adductor hallucis are particularly important in this respect.
- **Tying the ends of the arch together** is the peroneus longus tendon.

- Suspending the arch from above are the peroneus longus tendon and the peroneus brevis.

PHYSIOLOGIC NOTE

Muscle Tone and the Arches of the Foot

The arches of the feet are maintained by the shape of the bones, strong ligaments, and muscle tone. Which of these factors is the most important? Basmajian and Stecko demonstrated electromyographically that the tibialis anterior, the peroneus longus, and the small muscles of the foot play no important role in the normal static support of the arches. They are commonly totally inactive. However, during walking and running, all these muscles become active. Standing immobile for long periods, especially if the person is overweight, places excessive strain on the bones and ligaments of the feet and results in fallen arches or flat feet. Athletes, route-marching soldiers, and nurses are able to sustain their arches provided that they receive adequate training to develop their muscle tone.

Clinical Problems Associated with the Arches of the Foot

Of the three arches, the medial longitudinal is the largest and clinically the most important. The shape of the bones, the strong ligaments, especially those on the plantar surface of the foot, and the tone of muscles all play an important role in supporting the arches. It has been shown that in the active foot the tone of muscles is an important factor in arch support. When the muscles are fatigued by excessive exercise (a long-route march by an army recruit), by standing for long periods (waitress or nurse), by being overweight, or by illness, the muscular support gives way, the ligaments are stretched, and pain is produced.

Pes planus (flat foot) is a condition in which the medial longitudinal arch is depressed or collapsed. As a result, the forefoot is displaced laterally and everted. The head of the talus is no longer supported, and the body weight forces it downward and medially between the calcaneum and the navicular bone. When the deformity has existed for some time, the plantar, calcaneonavicular, and medial ligaments of the ankle joint become permanently stretched, and the bones change shape. The muscles and tendons are also permanently stretched. The causes of flat foot are both congenital and acquired.

Pes cavus (clawfoot) is a condition in which the medial longitudinal arch is unduly high. Most cases are caused by muscle imbalance, in many instances resulting from poliomyelitis.

Clinical Problem Solving Questions

Read the following case histories/questions and give the best answer for each.

General Joint Questions

A 31-year-old woman has a history of poliomyelitis affecting the anterior horn cells of the lower thoracic and lumbar segments of the spinal cord on the left side. On examination, she has severe right lateral flexion deformity of the vertebral column.

- The following statements are true about this case **except** which?
 - The virus of poliomyelitis attacks and destroys the motor anterior horn cells of the spinal cord.
 - The disease resulted in the paralysis of the muscles that normally laterally flex the vertebral column on the left side.
 - The muscles on the right side of the vertebral column are unapposed.
 - The right lateral flexion deformity is caused by the slow degeneration of the sensory nerve fibers originating from the vertebral muscles on the right side.

A 20-year-old woman severely sprains her left ankle while playing tennis. When she tries to move the foot so that the sole faces medially, she experiences severe pain.

- What is the correct anatomic term for the movement of the foot that produces the pain?
 - Pronation
 - Inversion
 - Supination
 - Eversion

Joints of the Skull

- An exhausted medical student decided to brush up on gross anatomy by attending a lecture given by an old and revered visiting professor. After 45 minutes the lecture began to bore him, and his mind began to wander. He could not forget the attractive brunette nurse in the surgical clinic whom he had dated the previous evening. After 5 more minutes he found he just could not keep his eyes open. When would this lecture end? Just then, he involuntarily opened his mouth wide and yawned. To his great consternation he could not close his mouth. His jaw was stuck in the open position. What is your diagnosis?

Joints of the Vertebral Column

An 11-year-old boy was showing off in front of friends by diving into the shallow end of a swimming pool. After one

particularly daring dive, he surfaced quickly and climbed out of the pool, holding his head between his hands. He said that he had hit the bottom of the pool with his head and now had severe pain in the root of the neck, which was made worse when he tried to move his neck. A lateral radiograph revealed that the right inferior articular process of the fifth cervical vertebra was forced over the anterior margin of the right superior articular process of the sixth cervical vertebra, producing a unilateral dislocation with nipping of the right sixth cervical nerve.

- The following symptoms and signs confirmed the diagnosis **except** which?
 - The head was rotated to the right.
 - There was spasm of the deep neck muscles on the right side of the neck, which were tender to touch.
 - The patient complained of severe pain in the region of the back of the neck and right shoulder.
 - The slightest movement produced severe pain in the right sixth cervical dermatome.
 - The large size of the vertebral canal in the cervical region permitted the spinal cord to escape injury.

A 50-year-old coal miner was crouching at the mine face when a large rock suddenly became dislodged from the roof of the mine shaft and struck him on the upper part of his back. The emergency department physician suspected a displacement of the upper thoracic spines on the sixth thoracic spine.

- The following physical signs confirmed a diagnosis of fracture dislocation between the fifth and sixth thoracic vertebrae **except** which?
 - A lateral radiograph revealed fractures involving the superior articular processes of the sixth thoracic vertebra and the inferior articular processes of the fifth thoracic vertebra.
 - Considerable forward displacement of the body of the fifth thoracic vertebra on the sixth thoracic vertebra occurred.
 - The patient had signs and symptoms of spinal shock.
 - The large size of the vertebral canal in the thoracic region leaves plenty of space around the spinal cord for bony displacement.
 - The patient later showed signs and symptoms of paraplegia.

A 66-year-old woman was seen in the emergency department complaining of a burning pain over the upper part of her right arm. The pain had started 2 days previously and had progressively worsened. Physical examination revealed weakness and wasting of the right

deltoid and biceps brachii muscles. The patient also had hyperesthesia in the skin over the lower part of the right deltoid and down the lateral side of the arm. Radiologic examination showed extensive spur formation on the bodies of the fourth, fifth, and sixth cervical vertebrae. These signs and symptoms suggested severe osteoarthritis of the cervical vertebral column.

6. This disease produced the following changes in the vertebrae and related structures **except** which?
 - A. Repeated trauma and aging had resulted in degenerative changes at the articulating surfaces of the fourth, fifth, and sixth cervical vertebrae.
 - B. Extensive spur formation resulted in narrowing of the intervertebral foramina with pressure on the nerve roots.
 - C. The burning pain and hyperesthesia were caused by pressure on the third and fourth cervical posterior roots.
 - D. The weakness and wasting of the deltoid and biceps brachii muscles were caused by pressure on the fifth and sixth cervical anterior roots.
 - E. Movements of the neck intensified the symptoms by exerting further pressure on the nerve roots.
 - F. Coughing or sneezing raised the pressure within the vertebral canal and resulted in further pressure on the roots.

A medical student offered to move a grand piano for his landlady. He had just finished his final examinations in anatomy and was in poor physical shape. He struggled with the antique monstrosity and suddenly experienced an acute pain in the back, which extended down the back and outer side of his left leg. On examination in the emergency department, he was found to have a slight scoliosis with the convexity on the right side. The deep muscles of the back in the left lumbar region felt firmer than normal. No evidence of muscle weakness was present, but the left ankle jerk was diminished.

7. The symptoms and signs of this patient strongly suggest a diagnosis of prolapsed intervertebral disc **except** which?
 - A. The pain was the worst over the left lumbar region opposite the fifth lumbar spine.
 - B. The pain was accentuated by coughing.
 - C. With the patient supine, flexing the left hip joint with the knee extended caused a marked increase in the pain.
 - D. A lateral radiograph of the lumbar vertebral column revealed nothing abnormal.
 - E. A magnetic resonance imaging study revealed the presence of small fragments of the nucleus pulposus that had herniated outside the anulus in the disc between the fifth lumbar vertebra and the sacrum.
 - F. The pain occurred in the dermatomes of the third and fourth lumbar segments on the left side.

A 22-year-old student was driving home from a party and crashed his car head on into a brick wall. On examination in the emergency department, he was found to have a fracture dislocation of the seventh thoracic vertebra, with signs and symptoms of severe damage to the spinal cord.

8. On recovery from spinal shock, he was found to have the following signs and symptoms **except** which?
 - A. Fracture dislocation of the seventh thoracic vertebra, which would result in severe damage to the seventh thoracic segment of the spinal cord
 - B. A band of cutaneous hyperesthesia extending around the abdominal wall on the left side at the level of the umbilicus that was caused by the irritation of the cord immediately above the site of the lesion
 - C. On the right side, total analgesia, thermoanesthesia, and partial loss of tactile sense of the skin of the abdominal wall below the level of the umbilicus involving the whole of the right leg
 - D. Upper motor neuron paralysis of his left leg
 - E. Unequal sensory and motor losses on the two sides, which indicate a left hemisection of the spinal cord

Joints of the Ribs

9. A 36-year-old woman went sailing with her husband and they were caught in a severe gale. While the husband at the helm desperately managed to keep the boat under control, the wife tried to get the sails down. Eventually the squall died down and they were able to return safely to port. The next morning, the woman woke up with severe pain over the left side of her chest. On being examined in the emergency department of the local hospital for a suspected myocardial infarction, the physician found that the patient was acutely tender over her left costal margin, which was made worse on taking a deep breath. What is the possible diagnosis?

Joints of the Upper Extremity

10. Separation of the acromioclavicular joint is common in football and soccer players. Explain why such separations are unstable after reduction.

A father, seeing his 3-year-old son playing in the garden, ran up and picked him up by both hands and swung him around in a circle. The child's enjoyment suddenly turned to tears, and he said his left elbow hurt. On examination, the child held his left elbow joint semiflexed and his forearm pronated.

11. The following statements concerning this case are consistent with the diagnosis of dislocation of the superior radioulnar joint **except** which?
 - A. The head of the radius was pulled out of the annular ligament.

- B. At age 3 years, the child's anular ligament has a large diameter and the head of the radius can easily be pulled out of the ligament by traction.
- C. The incidence of this condition is equal in both sexes.
- D. The pain from the joint caused reflex contraction of the surrounding muscles to protect the joint from further movement.
- E. The subluxation of the joint can be treated by pulling downward on the forearm and at the same time performing the movement of pronation and supination. Finally, the elbow joint is flexed and held in that position.

A 60-year-old woman fell down the stairs and was admitted to the emergency department with severe right shoulder pain. On examination, the patient was sitting up with her right arm by her side and her right elbow joint supported by the left hand. Inspection of the right shoulder showed loss of the normal rounded curvature and evidence of a slight swelling below the right clavicle. Any attempt at active or passive movement of the shoulder joint was stopped by severe pain in the shoulder. A diagnosis of dislocation of the right shoulder joint was made.

12. The following statements concerning this patient are consistent with the diagnosis **except** which?
- A. This patient had a subcoracoid dislocation of the right shoulder joint.
 - B. The head of the humerus was dislocated downward through the weakest part of the capsule of the joint.
 - C. The pull of the pectoralis major and subscapularis muscles had displaced the upper end of the humerus medially.
 - D. The greater tuberosity of the humerus no longer displaced the deltoid muscle laterally, and the curve of the shoulder was lost.
 - E. The integrity of the axillary nerve should always be tested by touching the skin over the upper half of the deltoid muscle.

A 63-year-old man fell down a flight of stairs and sustained a fracture of the lower end of the left radius. On examination the distal end of the radius was displaced posteriorly. This patient had sustained a Colles' fracture.

13. The following statements concerning this case are correct **except** which?
- A. Occasionally the styloid process of the ulna is also fractured.
 - B. The median nerve may be injured at the time of the fall.
 - C. When the fracture is reduced, the styloid process of the radius should come to lie about 0.75 in. (1.9 cm) proximal to that of the ulna.
 - D. The fracture produces posterior angulation of the distal fragment of the radius.

- E. On reduction of the fracture the distal end of the radius should lie at an angle of 15° anteriorly.
- F. The hand should always be splinted in the position of function.

A 22-year-old medical student fell off her bicycle onto her outstretched hand. She thought she had sprained her right wrist joint and treated herself by binding her wrist with an elastic bandage. Three weeks later, however, she was still experiencing pain on moving her wrist and so decided to visit the emergency department. On examination of the dorsal surfaces of both hands, with the fingers and thumbs fully extended, a localized tenderness could be felt in the anatomic snuffbox of her right hand. A diagnosis of fracture of the right scaphoid bone was made.

14. The following statements concerning this patient are correct **except** which?
- A. The scaphoid bone is an easy bone to immobilize because of its small size.
 - B. A bony fragment deprived of its blood supply may undergo ischemic necrosis.
 - C. Because the scaphoid bone articulates with other bones, the fracture line may enter a joint cavity and become bathed in synovial fluid, which would inhibit repair.
 - D. The fracture line on the scaphoid bone may deprive the proximal fragment of its arterial supply.
 - E. Fractures of the scaphoid bone have a high incidence of nonunion.
15. A 46-year-old woman slipped on a shiny floor and sustained a fracture of the fifth metacarpal bone on her left hand. What type of angulation of the fragments is commonly found in fractures at this site? When a splint is applied with the little finger flexed, in which direction should the little finger be pointing?

Joints of the Lower Extremity

A medical student, while playing football, collided with another player and fell to the ground. As he fell, the right knee, which was taking the weight of his body, was partially flexed; the femur was rotated medially; and the leg was abducted on the thigh. A sudden pain was felt in the right knee joint, and he was unable to extend it. The student was diagnosed as having a torn medial meniscus of the knee joint.

16. The following statements concerning this case confirmed the diagnosis **except** which?
- A. The right knee joint quickly became swollen.
 - B. Severe local tenderness was felt along the medial side of the joint line.
 - C. The medial meniscus split along part of its length, and the detached portion became jammed between the articular surfaces, limiting further extension.

- D. The trauma stimulated the production of synovial fluid, which filled the joint cavity.
- E. The distension of the suprapatellar bursa was responsible for the large amount of swelling above the injured knee.
- F. The pain sensation from the injured knee was confined to the femoral nerve as it ascended to the central nervous system.

A 27-year-old woman was found to have an unstable right knee joint following a severe automobile accident. On examination it was possible to pull the tibia excessively forward on the femur. A diagnosis of ruptured anterior cruciate ligament was made.

17. The following statements concerning this patient are correct **except** which?
- A. The anterior cruciate ligament is attached to the tibia in the anterior part of the intercondylar area.
 - B. The anterior cruciate ligament passes upward, backward, and laterally from its tibial attachment.
 - C. The anterior cruciate ligament is attached above to the posterior part of the medial surface of the lateral femoral condyle.
 - D. The anterior cruciate ligament is more commonly torn than is the posterior cruciate ligament.
- E. Because the cruciate ligaments are located outside the synovial membrane, bleeding from a torn ligament does not enter the joint cavity.
- A 25-year-old man was running across a field when he caught his right foot in a rabbit hole. As he fell, the right foot was violently rotated laterally and oververted. On attempting to stand, he could place no weight on his right foot. On examination by a physician, the right ankle was considerably swollen, especially on the lateral side. After further examination, including a radiograph of the ankle, a diagnosis of severe fracture dislocation of the ankle joint was made.
18. The following statements concerning this patient are correct **except** which?
- A. This type of fracture dislocation is caused by forced external rotation and overversion of the foot.
 - B. The talus is externally rotated against the lateral malleolus of the fibula, causing it to fracture.
 - C. The medial ligament of the ankle joint is strong and never ruptures.
 - D. The torsion effect on the lateral malleolus produces a spiral fracture.
 - E. If the talus is forced to move farther laterally and continues to rotate, the posterior inferior margin of the tibia will be sheared off.

Answers and Explanations

1. **D** is the correct answer. The right lateral flexion deformity is not caused by the slow degeneration of the sensory nerve fibers originating from the vertebral muscle on the right side. It is the motor nerves supplying the vertebral muscles on the left side that are affected in this patient.
2. **B** is the correct answer. Moving the foot at the subtalar and midtarsal joints so that the sole faces medially is called inversion.
3. The student had dislocated his temporomandibular joints on both sides. When he yawned, his lateral pterygoid muscles reflexly contracted forcibly and pulled the head of the mandible and the articular disc forward over the summit of the articular tubercle in each joint. Reduction is easily performed by pressing gloved thumbs downward and backward on the last molar teeth. The lateral pterygoid, the temporalis, and the masseter muscle tension is overcome and the head of the mandible snaps back over the articular tubercle to assume its normal anatomical position.
4. **A** is the correct answer. The right inferior articular process of the fifth cervical vertebra was forced over the anterior margin of the right superior articular process of the sixth cervical vertebra, causing the head of the patient to be rotated to the left.
5. **D** is the correct answer. The vertebral canal in the thoracic region is small and round and little space is around the spinal cord for bony displacement to occur without causing severe damage to the cord.
6. **C** is the correct answer. The burning pain and hyperesthesia were caused by pressure on the fifth and sixth cervical posterior roots.
7. **F** is the correct answer. The pain occurred in the dermatomes of the fifth lumbar and first sacral segments on the left side.
8. **A** is the correct answer. Fracture dislocation of the seventh thoracic vertebra would result in severe damage to the tenth thoracic segment of the spinal cord.

9. The localized tenderness over the left costal margin is strongly suggestive of subluxation of one of the interchondral joints on the costal margin. Subluxation of a joint implies that the ligaments and capsule are stretched or torn but the damage is not so severe that the articulating surfaces lose contact with one another. This condition can be extremely painful and in this patient was secondary to trauma caused by excessive pulling of the muscles connecting the thoracic cage to the upper limb. The sixth, seventh, eighth, ninth, and tenth costal cartilages articulate with each other along their borders by small synovial joints.
10. In subluxation of the acromioclavicular joint, the lateral end of the clavicle elevates and becomes more prominent than normal; there is a definite step down onto the acromion. A dislocation occurs when the damage to the restraining structures is more severe and the articulating surfaces lose contact with one another. In the case of the acromioclavicular joint, the clavicle rises above the acromion and the joint is very unstable.

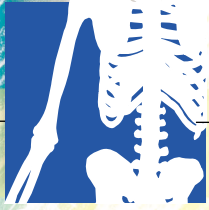
The main strength of the acromioclavicular joint depends on the integrity of the strong coracoclavicular ligament (see text Fig. 12-14). Should this ligament be disrupted, the acromioclavicular joint dislocates; the lateral end of the clavicle rides over the acromion and the upper limb is depressed.

11. **B** is the correct answer. Under age 6 years, the child's head of the radius is of a relatively small size and may easily be pulled out of the annular ligament by traction on the forearm.
12. **E** is the correct answer. The integrity of the axillary nerve is tested by touching the skin over the lower half of the deltoid muscle. The skin of the curve of the shoulder, including the skin covering the upper half of the deltoid muscle, is supplied by the supraclavicular nerves.
13. **C** is the correct answer. The normal position of the tip of the styloid process of the radius is about 0.75 in. (1.9 cm) distal to that of the ulna.
14. **A** is the correct answer. The scaphoid bone is a difficult bone to immobilize because of its position and small size.
15. Fractured metacarpal bones show dorsal angulation caused by the forward pull of the long flexor tendons and the lumbricals and interossei on the distal fragment. When flexed individually, all fingers (excluding the thumb) point toward the tubercle of the scaphoid. When a finger is unstable following a fracture, it should be aligned so that its tip points to the scaphoid tubercle; failure to achieve this will result in malfunction.
16. **F** is the correct answer. The sensation of pain from the knee joint ascends to the central nervous system via the femoral, obturator, common peroneal, and tibial nerves.
17. **E** is the correct answer. The synovial membrane covering the cruciate ligaments (see text Fig. 12-31) is torn along with the ligaments, and the joint cavity quickly fills with blood.
18. **C** is the correct answer. Although the medial ligament of the ankle joint is strong, extreme force can result in rupture of the ligament, the ligament can be torn from the medial malleolus, or the pull on the ligament can fracture the medial malleolus.



13

Skeletal Muscles



Chapter Outline

General Clinical Features Concerning Muscles	189	Rupture of the Supraspinatus Tendon	195
Muscle Tone	189	Axillary Nerve and the Quadrangular Space	196
Muscle Attachments	189	Carpal Tunnel Syndrome	196
Muscle Shape and Form	189	Tenosynovitis of the Synovial Sheaths of the Flexor Tendons	196
Segmental Innervation of Muscle	189	Trigger Finger	198
Muscles of the Head	189	Mallet Finger	198
Lacerations of the Scalp	189	Boutonniere Deformity	198
Facial Muscle Paralysis	189	Dupuytren's Contracture	198
Muscles of the Neck	191	Muscles of the Lower Limb	199
Sternocleidomastoid Muscle and Protection from Trauma	191	Gluteus Maximus and Intramuscular Injections	199
Congenital Torticollis	191	Gluteus Maximus and Bursitis	199
Spasmodic Torticollis	191	Gluteus Medius and Minimus and Poliomyelitis	199
Clinical Significance of the Deep Fascia of the Neck	191	Quadriceps Femoris as a Knee-Joint Stabilizer	200
Fascial Spaces	191	Rupture of the Rectus Femoris	200
<i>Acute Infections of the Fascial Spaces of the Neck</i>	191	Rupture of the Ligamentum Patellae	200
<i>Chronic Infection of the Fascial Spaces of the Neck</i>	191	Femoral Sheath and Femoral Hernia	200
Clinical Significance of the Triangles of the Neck	191	Adductor Muscles and Cerebral Palsy	201
Muscles of the Abdominal Wall	192	The Adductor Magnus and Popliteal Aneurysms	202
Hematoma of the Rectus Sheath	192	Semimembranosus Bursa Swelling	202
Abdominal Muscles, Abdominothoracic Rhythm, and Visceroptosis	192	Anterior Compartment of the Leg Syndrome	202
Muscle Rigidity and Referred Pain	193	Tenosynovitis and Dislocation of the Peroneus Longus and Brevis Tendons	202
Surgery and the Tendinous Intersections of the Rectus Abdominis Muscle	193	Gastrocnemius and Soleus Muscle Tears	202
Psoas Abscess	193	Ruptured Tendo Calcaneus	202
Muscles of the Pelvis	193	Rupture of the Plantaris Tendon	202
Pelvic Floor	193	Plantaris Tendon and Autografts	202
Functional Significance of the Pelvic Floor in the Female	193	Plantar Fasciitis	202
Injury to the Pelvic Floor	194	Clinical Problems Associated with the Arches of the Foot	203
Muscles of the Upper Limb	194	Bursae and Bursitis in the Lower Limb	203
Rotator Cuff Tendinitis	194	Clinical Problem Solving Questions	203
		Answers and Explanations	206



GENERAL CLINICAL FEATURES CONCERNING MUSCLES

Muscle Tone

Determination of the **tone** of a muscle is an important clinical examination. If a muscle is **flaccid**, then either the afferent, the efferent, or both neurons involved in the reflex arc necessary for the production of muscle tone have been interrupted. For example, if the nerve trunk to a muscle is severed, both neurons will have been interrupted. If poliomyelitis has involved the motor anterior horn cells at a level in the spinal cord that innervates the muscle, the efferent motor neurons will not function. If, conversely, the muscle is found to be hypertonic, the possibility exists of a lesion involving higher motor neurons in the spinal cord or brain.

Muscle Attachments

The importance of knowing the main attachments of all the major muscles of the body need not be emphasized. Only with such knowledge is it possible to understand the normal and abnormal actions of individual muscles or muscle groups. How can one even attempt to analyze, for example, the abnormal gait of a patient without this information?

Muscle Shape and Form

The general shape and form of muscles should also be noted, since a paralyzed muscle or one that is not used (such as occurs when a limb is immobilized in a cast) quickly atrophies and changes shape. In the case of the limbs, it is always worth remembering that a muscle on the opposite side of the body can be used for comparison.

Segmental Innervation of Muscle

Skeletal muscle receives a segmental innervation. Most of these muscles are innervated by two, three, or four spinal nerves and therefore by the same number of segments of the spinal cord. To paralyze a muscle completely, it is thus necessary to section several spinal nerves or to destroy several segments of the spinal cord.

Learning the segmental innervation of all the muscles of the body is an impossible task. Nevertheless, the segmen-

tal innervation of the following muscles should be known because they can be tested by eliciting simple muscle reflexes in the patient (CD Fig. 13-1).

- **Biceps brachii tendon reflex:** C5 and 6 (flexion of the elbow joint by tapping the biceps tendon)
- **Triceps tendon reflex:** C6, 7, and 8 (extension of the elbow joint by tapping the triceps tendon)
- **Brachioradialis tendon reflex:** C5, 6, and 7 (supination of the radioulnar joints by tapping the insertion of the brachioradialis tendon)
- **Abdominal superficial reflexes (contraction of underlying abdominal muscles by stroking the skin):** Upper abdominal skin T6–7, middle abdominal skin T8–9, and lower abdominal skin T10–12
- **Patellar tendon reflex (knee jerk):** L2, 3, and 4 (extension of the knee joint on tapping the patellar tendon)
- **Achilles tendon reflex (ankle jerk):** S1 and S2 (plantar flexion of the ankle joint on tapping the Achilles tendon)



MUSCLES OF THE HEAD

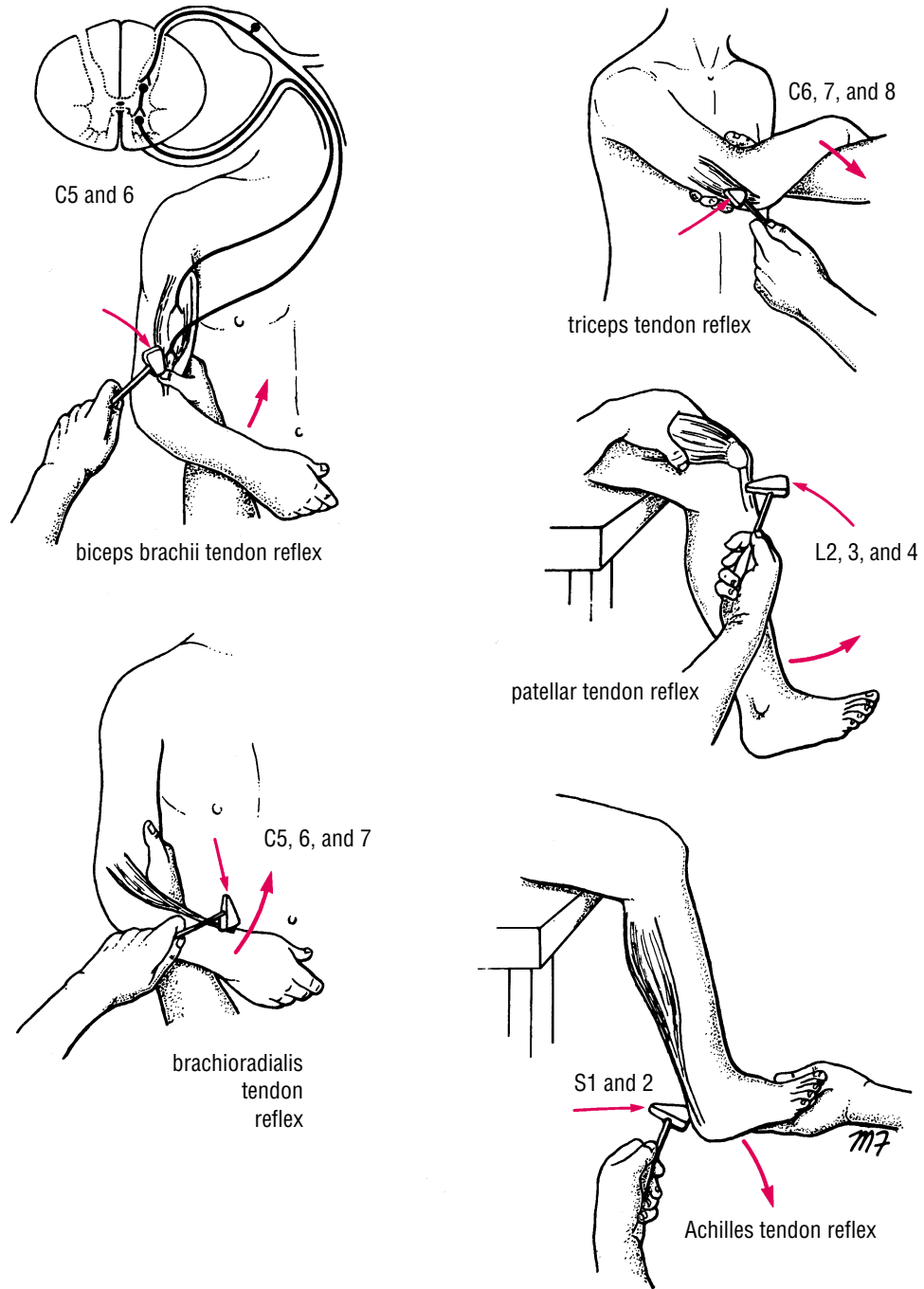
Lacerations of the Scalp

The tension of the **epicranial aponeurosis** (see text Fig. 13-6), produced by the tone of the occipitofrontalis muscles, is important in all deep wounds of the scalp. If the aponeurosis has been divided, the wound will gape open. For satisfactory healing to take place, the opening in the aponeurosis must be closed with sutures.

Often a wound caused by a blunt object such as a baseball bat closely resembles an incised wound. This is because the scalp is split against the unyielding skull, and the pull of the occipitofrontalis muscles causes a gaping wound. This anatomic fact may be of considerable forensic importance.

Facial Muscle Paralysis

The facial muscles are innervated by the facial nerve. Damage to the facial nerve in the internal acoustic meatus (by a tumor), in the middle ear (by infection or operation), in the facial nerve canal (perineuritis, **Bell's palsy**), or in the parotid gland (by a tumor) or caused by lacerations of the face will cause distortion of the face, with drooping of the lower eyelid, and the angle of the mouth will sag on the affected side. This is essentially a lower motor neuron lesion. An upper motor neuron lesion (involvement of the pyramidal tracts) will leave the upper part of the face normal because the neurons supplying this part of the face receive corticobulbar fibers from both cerebral cortices.



CD Figure 13-1 Some important tendon reflexes used in medical practice.



MUSCLES OF THE NECK

Sternocleidomastoid Muscle and Protection from Trauma

The sternocleidomastoid, a strong, thick muscle crossing the side of the neck (see text Fig. 13-9), protects the underlying soft structures from blunt trauma. Suicide attempts by cutting one's throat often fail because the individual first extends the neck before making several horizontal cuts with a knife. Extension of the cervical part of the vertebral column and extension of the head at the atlantooccipital joint cause the carotid sheath with its contained large blood vessels to slide posteriorly beneath the sternocleidomastoid muscle. To achieve the desired result with the head and neck fully extended, some individuals have to make several attempts and only succeed when the larynx and the greater part of the sternocleidomastoid muscles have been severed. The common sites for the wounds are immediately above and below the hyoid bone.

Congenital Torticollis

Most cases of congenital torticollis are a result of excessive stretching of the sternocleidomastoid muscle during a difficult labor. Hemorrhage occurs into the muscle and may be detected as a small, rounded "tumor" during the early weeks after birth. Later, this becomes invaded by fibrous tissue, which contracts and shortens the muscle. The mastoid process is thus pulled down toward the sternoclavicular joint of the same side, the cervical spine is flexed, and the face looks upward to the opposite side. If left untreated, asymmetrical growth changes occur in the face, and the cervical vertebrae may become wedge shaped.

Spasmodic Torticollis

Spasmodic torticollis, which results from repeated chronic contractions of the sternocleidomastoid and trapezius muscles, is usually psychogenic in origin. Section of the spinal part of the accessory nerve may be necessary in severe cases.

Clinical Significance of the Deep Fascia of the Neck

The deep fascia in certain areas of the neck forms distinct sheets called the investing, pretracheal, and prevertebral

layers (see text Fig. 13-11). These fascial layers are easily recognizable to the surgeon at operation.

Fascial Spaces

Between the more dense layers of deep fascia in the neck is loose connective tissue that forms potential spaces that are clinically important. Among the more important spaces are the visceral, retropharyngeal, submandibular, and masticatory spaces (CD Fig. 13-2).

The deep fascia and the fascial spaces are important because organisms originating in the mouth, teeth, pharynx, and esophagus can spread among the fascial planes and spaces, and the tough fascia can determine the direction of spread of infection and the path taken by pus. It is possible for blood, pus, or air in the retropharyngeal space to spread downward into the superior mediastinum of the thorax.

Acute Infections of the Fascial Spaces of the Neck

Dental infections most commonly involve the lower molar teeth. The infection spreads medially from the mandible into the submandibular and masticatory spaces and pushes the tongue forward and upward. Further spread downward may involve the visceral space and lead to edema of the vocal cords and airway obstruction.

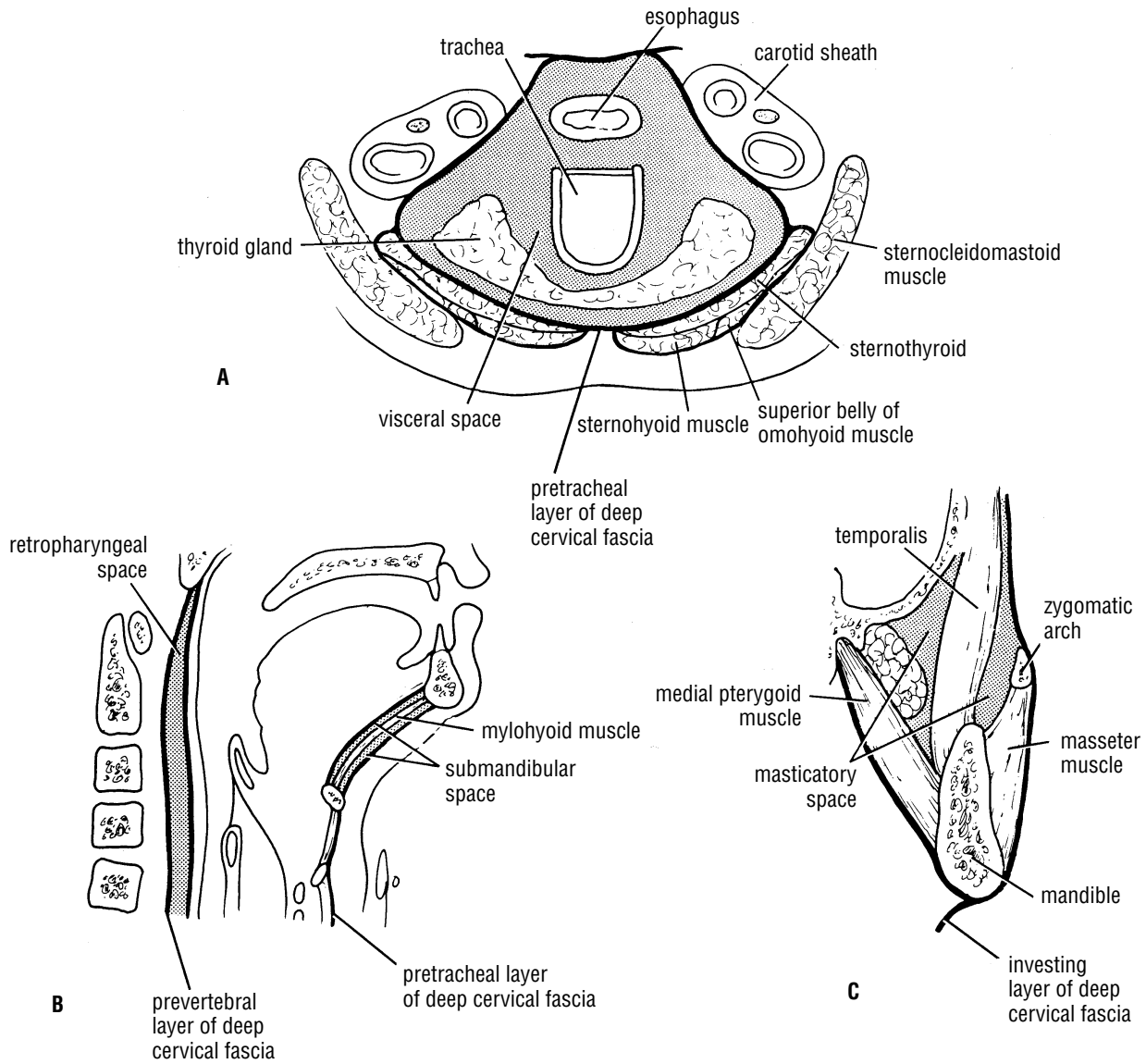
Ludwig's angina is an acute infection of the submandibular fascial space and is commonly secondary to dental infection.

Chronic Infection of the Fascial Spaces of the Neck

Tuberculous infection of the deep cervical lymph nodes can result in liquefaction and destruction of one or more of the nodes. The pus is at first limited by the investing layer of the deep fascia. Later, this becomes eroded at one point, and the pus passes into the less restricted superficial fascia. A dumbbell-shaped abscess is now present. The clinician is aware of the superficial abscess but must not forget the existence of the deeply placed abscess.

Clinical Significance of the Triangles of the Neck

The triangles of the neck (see text Fig. 13-12) assist the medical examiner in accurately localizing a wound, tumor, or swelling. Commit to memory the boundaries and make a list of the important contents of each triangle.



CD Figure 13-2 **A.** Cross section of the neck showing the visceral space. **B.** Sagittal section of the neck showing the positions of the retropharyngeal and submandibular spaces. **C.** Vertical section of the body of the mandible close to the angle showing the masticatory space.



MUSCLES OF THE ABDOMINAL WALL

Hematoma of the Rectus Sheath

Hematoma of the rectus sheath is uncommon but important, since it is often overlooked. It occurs most often on the right side below the level of the umbilicus. The source of the bleeding is the inferior epigastric vein or, more rarely, the inferior epigastric artery (see text Fig. 19-7). These

vessels may be stretched during a severe bout of coughing or in the later months of pregnancy, which may predispose to the condition. The cause is usually blunt trauma to the abdominal wall, such as a fall or a kick. The symptoms that follow the trauma include midline abdominal pain. An acutely tender mass confined to one rectus sheath is diagnostic.

Abdominal Muscles, Abdominothoracic Rhythm, and Visceroptosis

The abdominal muscles contract and relax with respiration, and the abdominal wall conforms to the volume of the abdominal viscera. There is an **abdominothoracic rhythm**.

Normally, during inspiration, when the sternum moves forward and the chest expands, the anterior abdominal wall also moves forward. If, when the chest expands the anterior abdominal wall remains stationary or contracts inward, it is highly probable that the parietal peritoneum is inflamed and has caused a reflex contraction of the abdominal muscles.

The shape of the anterior abdominal wall depends on the tone of its muscles. A middle-aged woman with poor abdominal muscles who has had multiple pregnancies is often incapable of supporting her abdominal viscera. The lower part of the anterior abdominal wall protrudes forward, a condition known as **visceroptosis**. This should not be confused with an abdominal tumor such as an ovarian cyst or with the excessive accumulation of fat in the fatty layer of the superficial fascia.

Muscle Rigidity and Referred Pain

Sometimes it is difficult for a physician to decide whether the muscles of the anterior abdominal wall of a patient are rigid because of underlying inflammation of the parietal peritoneum or whether the patient is voluntarily contracting the muscles because he or she resents being examined or because the physician's hand is cold. This problem is usually easily solved by asking the patient, who is lying supine on the examination table, to rest the arms by the sides and draw up the knees to flex the hip joints. It is practically impossible for a patient to keep the abdominal musculature tensed when the thighs are flexed. Needless to say, the examiner's hand should be warm.

A pleurisy involving the lower costal parietal pleura causes pain in the overlying skin that may radiate down into the abdomen. Although it is unlikely to cause rigidity of the abdominal muscles, it may cause confusion in making a diagnosis unless these anatomic facts are remembered:

- The xiphoid process—T7
- The umbilicus—T10
- The pubis—L1

Surgery and the Tendinous Intersections of the Rectus Abdominis Muscle

Note that the anterior wall of the rectus sheath is firmly attached to the tendinous intersections of the rectus abdominis muscle. The posterior wall of the sheath, however, has no attachment to the muscle.

Psoas Abscess

The psoas fascia covers the anterior surface of the psoas muscle and can influence the direction taken by a tuber-

culous abscess. Tuberculous disease of the thoracolumbar region of the vertebral column results in the destruction of the vertebral bodies, with possible extension of pus laterally under the psoas fascia (CD Fig. 13-3). From there, the pus tracks downward, following the course of the psoas muscle, and appears as a swelling in the upper part of the thigh below the inguinal ligament. It may be mistaken for a femoral hernia.



MUSCLES OF THE PELVIS

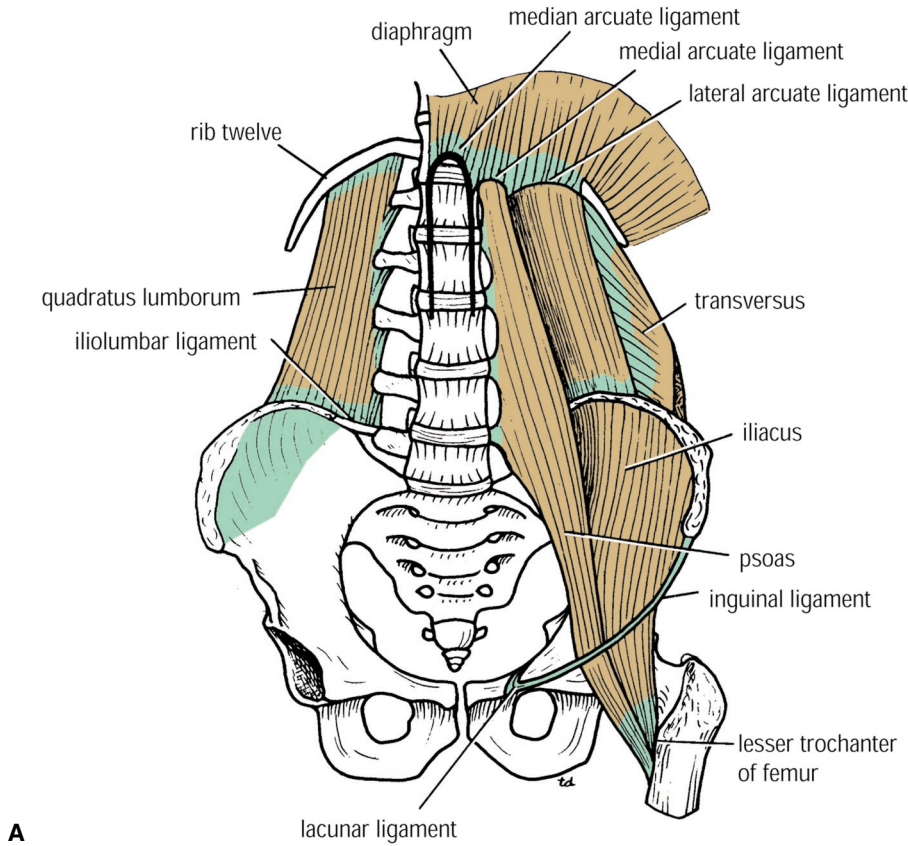
Pelvic Floor

The pelvic diaphragm is a gutter-shaped sheet of muscle formed by the levatores ani and coccygeus muscles and their covering fasciae (see text Figs. 13-19 and 13-20). From their origin, the muscle fibers on the two sides slope downward and backward to the midline, producing a gutter that slopes downward and forward.

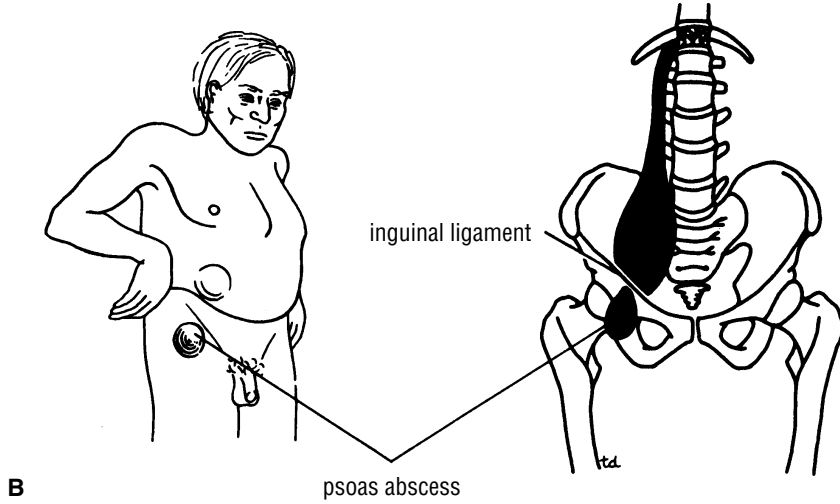
A rise in the intraabdominal pressure, caused by the contraction of the diaphragm and the muscles of the anterior and lateral abdominal walls, is counteracted by the contraction of the muscles forming the pelvic floor. By this means, the pelvic viscera are supported and do not “drop out” through the pelvic outlet. Contraction of the puborectalis fibers greatly assists the anal sphincters in maintaining continence under these conditions by pulling the anorectal junction upward and forward. During the act of defecation, however, the levator ani continues to support the pelvic viscera but the puborectalis fibers relax with the anal sphincters.

Functional Significance of the Pelvic Floor in the Female

The female pelvic floor serves an important function during the second stage of labor (CD Fig. 13-4). At the pelvic inlet, the widest diameter is transverse so that the longest axis of the baby's head (anteroposterior) takes up the transverse position. When the head reaches the pelvic floor, the gutter shape of the floor tends to cause the baby's head to rotate so that its long axis comes to lie in the anteroposterior position. The occipital part of the head now moves downward and forward along the gutter until it lies under the pubic arch. As the baby's head passes through the lower part of the birth canal, the small gap that exists in the anterior part of the pelvic diaphragm becomes enormously enlarged so that the head may slip through into the perineum. Once the baby has passed through the perineum, the levatores ani muscles recoil and take up their previous position.



A



B

CD Figure 13-3 A. Muscles and bones forming the posterior abdominal wall. B. Case of advanced tuberculous disease of the thoracolumbar region of the vertebral column. A psoas abscess is present, and swellings occur in the right groin above and below the right inguinal ligament.

Injury to the Pelvic Floor

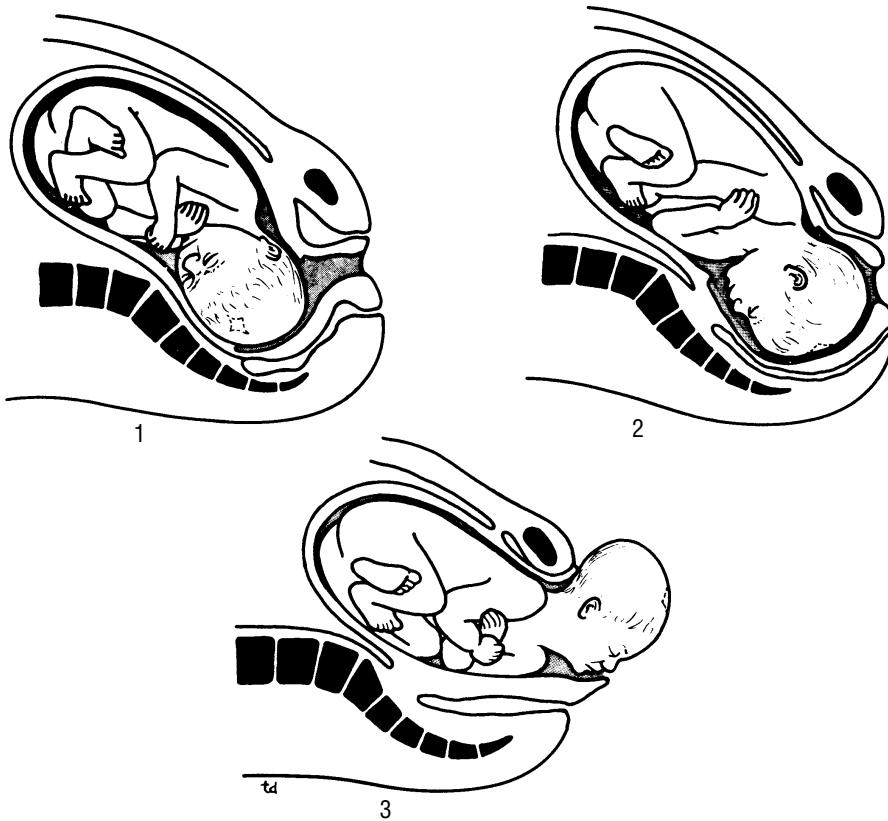
Injury to the pelvic floor during a difficult childbirth can result in the loss of support for the pelvic viscera leading to **uterine** and **vaginal prolapse**, herniation of the bladder (**cystocele**), and alteration in the position of the bladder neck and urethra, leading to **stress incontinence**. In the latter condition, the patient dribbles urine whenever the intraabdominal pressure is raised, as in coughing. **Prolapse of the rectum** may also occur.



MUSCLES OF THE UPPER LIMB

Rotator Cuff Tendinitis

The rotator cuff, consisting of the tendons of the subscapularis, supraspinatus, infraspinatus, and teres minor muscles,

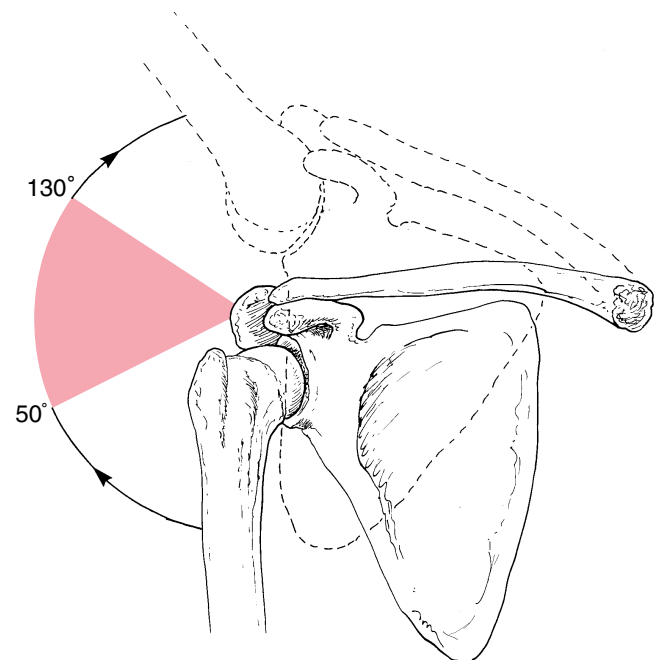


CD Figure 13-4 Stages in rotation of the baby's head during the second stage of labor. The shape of the pelvic floor plays an important part in this process.

which are fused to the underlying capsule of the shoulder joint, plays an important role in stabilizing the shoulder joint. Lesions of the cuff are a common cause of pain in the shoulder region. Excessive overhead activity of the upper limb may be the cause of tendinitis, although many cases appear spontaneously. During abduction of the shoulder joint, the supraspinatus tendon is exposed to friction against the acromion (CD Fig. 13-5). Under normal conditions, the amount of friction is reduced to a minimum by the large subacromial bursa, which extends laterally beneath the deltoid. Degenerative changes in the bursa are followed by degenerative changes in the underlying supraspinatus tendon, and these may extend into the other tendons of the rotator cuff. Clinically, the condition is known as **subacromial bursitis**, **supraspinatus tendinitis**, or **pericapsulitis**. It is characterized by the presence of a spasm of pain in the middle range of abduction (CD Fig. 13-5), when the diseased area impinges on the acromion.

Rupture of the Supraspinatus Tendon

In advanced cases of rotator cuff tendinitis, the necrotic supraspinatus tendon can become calcified or rupture. Rupture of the tendon seriously interferes with the normal



CD Figure 13-5 Subacromial bursitis, supraspinatus tendinitis, or pericapsulitis showing the painful arc in the middle range of abduction, when the diseased area impinges on the lateral edge of the acromion.

abduction movement of the shoulder joint. It will be remembered that the main function of the supraspinatus muscle is to hold the head of the humerus in the glenoid fossa at the commencement of abduction. The patient with a ruptured supraspinatus tendon is unable to initiate abduction of the arm. However, if the arm is passively assisted for the first 15° of abduction, the deltoid can then take over and complete the movement to a right angle.

Axillary Nerve and the Quadrangular Space

A subglenoid dislocation of the head of the humerus into the quadrangular space (see text Fig. 13-24) can cause damage to the axillary nerve, as indicated by paralysis of the deltoid muscle and loss of skin sensation over the lower half of the deltoid muscle.

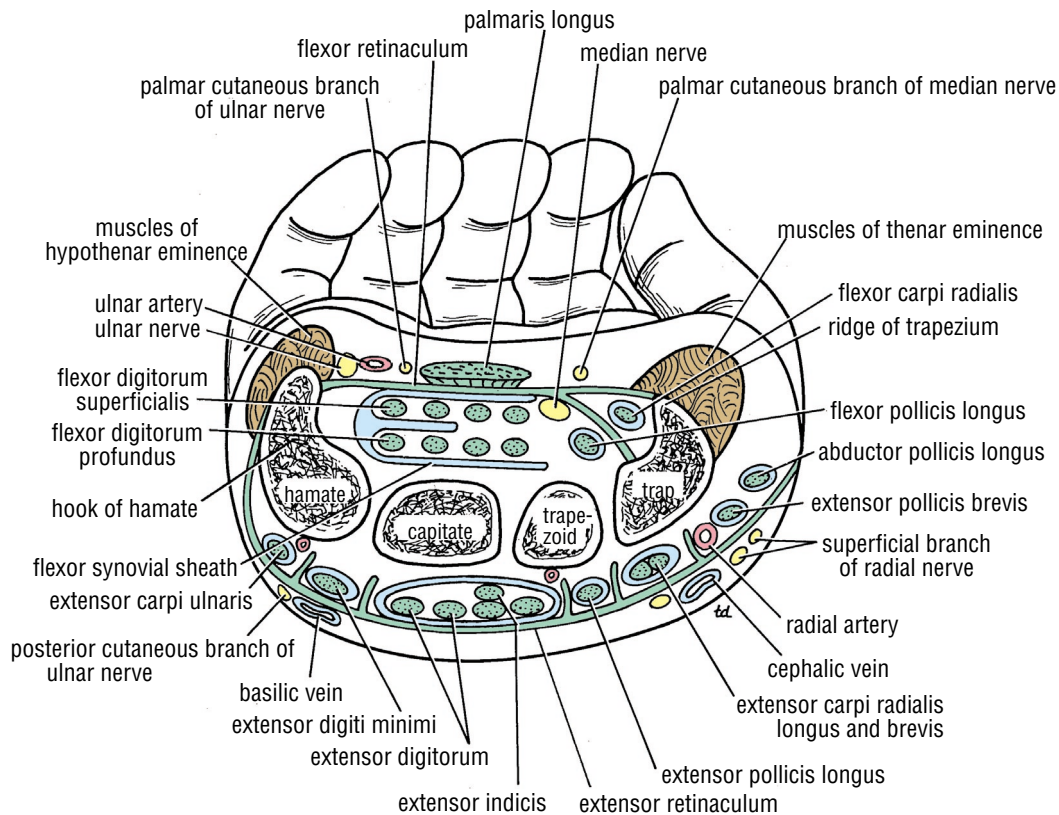
Carpal Tunnel Syndrome

The carpal tunnel, formed by the concave anterior surface of the carpal bones and closed by the flexor retinaculum, is tightly packed with the long flexor tendons of the fingers, their surrounding synovial sheaths, and the median nerve

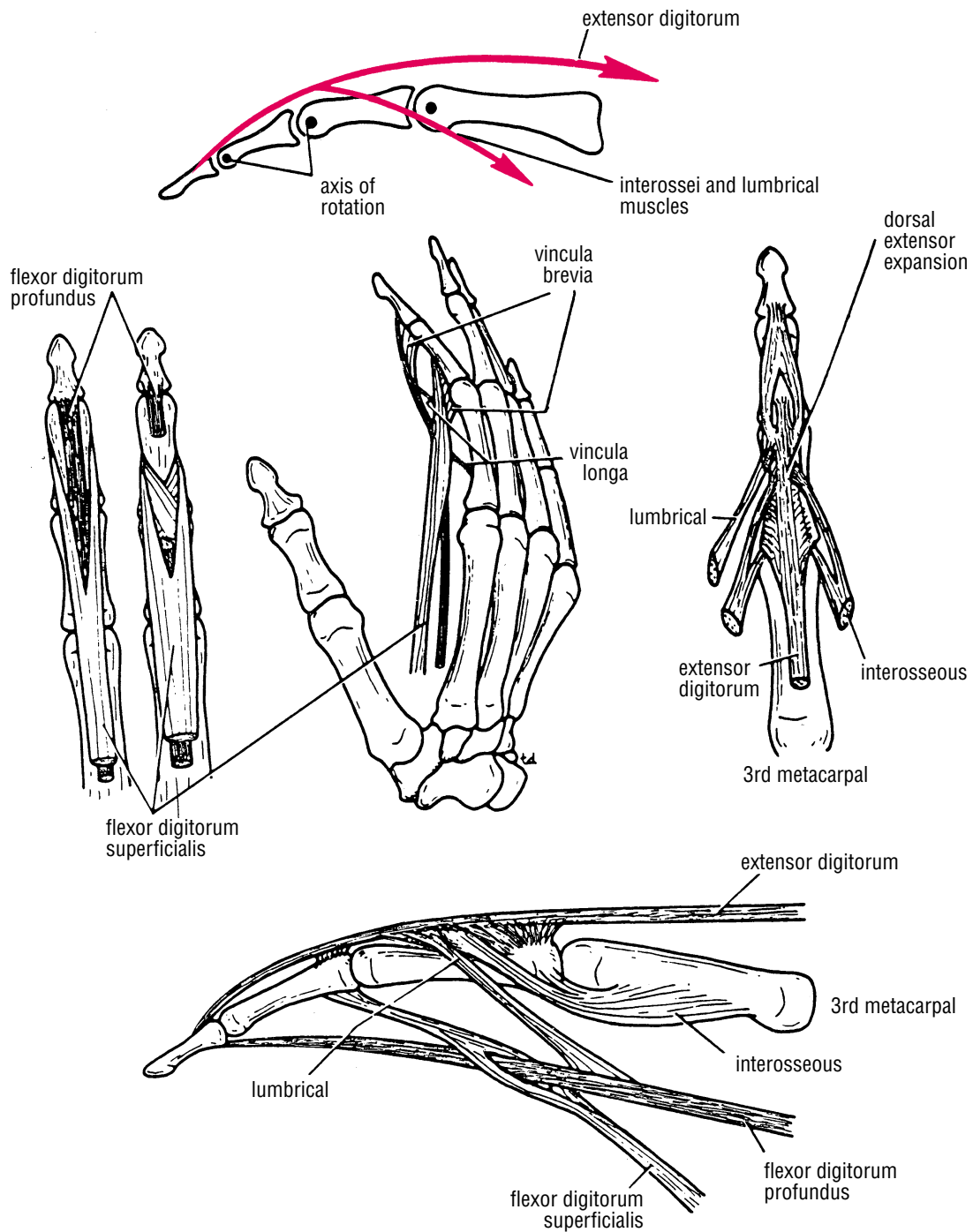
(CD Fig. 13-6). Clinically, the syndrome consists of a burning pain or “pins and needles” along the distribution of the median nerve to the lateral three and a half fingers and weakness of the thenar muscles. It is produced by compression of the median nerve within the tunnel. The exact cause of the compression is difficult to determine, but thickening of the synovial sheaths of the flexor tendons or arthritic changes in the carpal bones are thought to be responsible in many cases. As you would expect, no paresthesia occurs over the thenar eminence because this area of skin is supplied by the palmar cutaneous branch of the median nerve, which passes superficially to the flexor retinaculum. The condition is dramatically relieved by decompressing the tunnel by making a longitudinal incision through the flexor retinaculum.

Tenosynovitis of the Synovial Sheaths of the Flexor Tendons

Tenosynovitis is an infection of a synovial sheath. It most commonly results from the introduction of bacteria into a sheath through a small penetrating wound, such as that made by the point of a needle or thorn. Rarely, the sheath may become infected by extension of a pulp-space infection.



CD Figure 13-6 Cross section of the hand showing the relation of the tendons, nerves, and arteries to the flexor and extensor retinacula.



CD Figure 13-7 Insertions of long flexor and extensor tendons in the fingers. Insertions of the lumbrical and interossei muscles are also shown. The uppermost figure illustrates the action of the lumbrical and interossei muscles in flexing the metacarpophalangeal joints and extending the interphalangeal joints.

Infection of a digital sheath results in distension of the sheath with pus; the finger is held semiflexed and is swollen. Any attempt to extend the finger is accompanied by extreme pain because the distended sheath is stretched. As the inflammatory process continues, the pressure within the sheath rises

and may compress the blood supply to the tendons that travel in the vincula longa and brevia (CD Fig. 13-7). Rupture or later severe scarring of the tendons may follow.

A further increase in pressure can cause the sheath to rupture at its proximal end. Anatomically, the digital sheath

of the index finger is related to the thenar space, whereas that of the ring finger is related to the midpalmar space. The sheath for the middle finger is related to both the thenar and midpalmar spaces. These relationships explain how infection can extend from the digital synovial sheaths and involve the palmar fascial spaces.

In the case of infection of the digital sheaths of the little finger and thumb, the ulnar and radial bursae are quickly involved. Should such an infection be neglected, pus may burst through the proximal ends of these bursae and enter the fascial space of the forearm between the flexor digitorum profundus anteriorly and the pronator quadratus and the interosseous membrane posteriorly. This fascial space in the forearm is commonly referred to clinically as the **space of Parona**.

Trigger Finger

In trigger finger, there is a palpable and even audible snapping when a patient is asked to flex and extend the fingers. It is caused by the presence of a localized swelling of one of the long flexor tendons that catches on a narrowing of the fibrous flexor sheath anterior to the metacarpophalangeal joint. It may take place either in flexion or in extension. A similar condition occurring in the thumb is called trigger thumb. The situation can be relieved surgically by incising the fibrous flexor sheath.

Mallet Finger

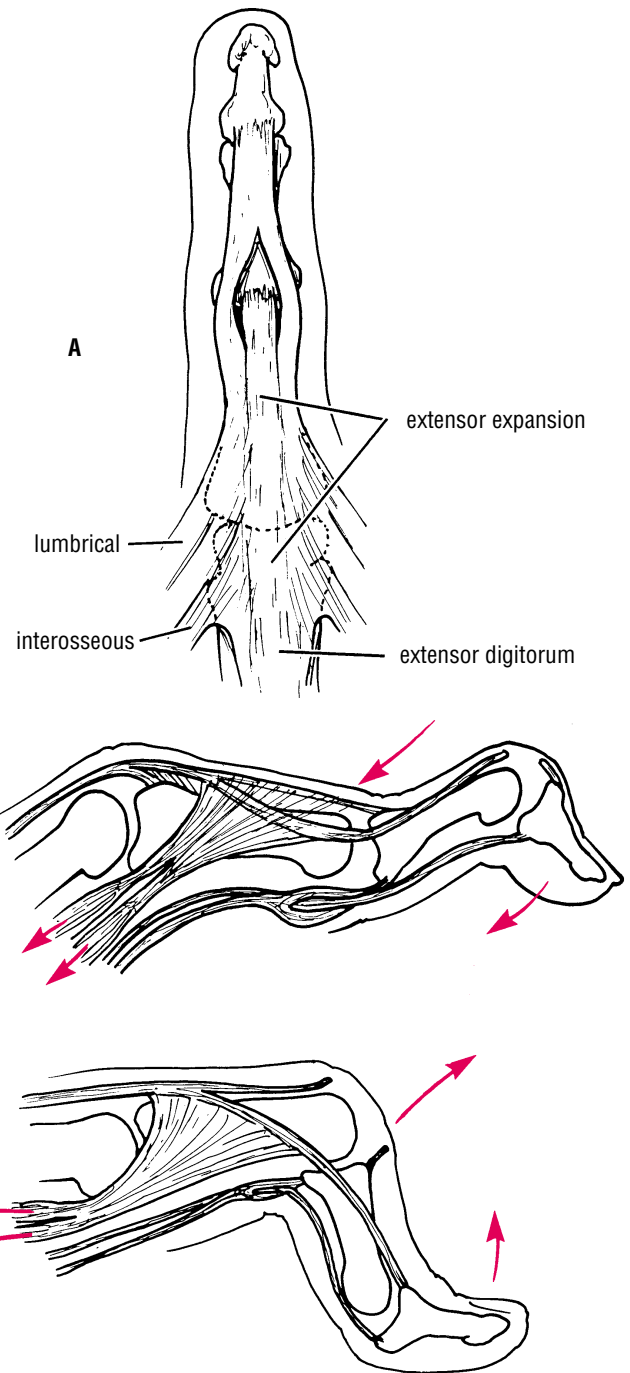
Avulsion of the insertion of one of the extensor tendons into the distal phalanges can occur if the distal phalanx is forcibly flexed when the extensor tendon is taut. The last 20° of active extension is lost, resulting in a condition known as mallet finger (CD Fig. 13-8).

Boutonnière Deformity

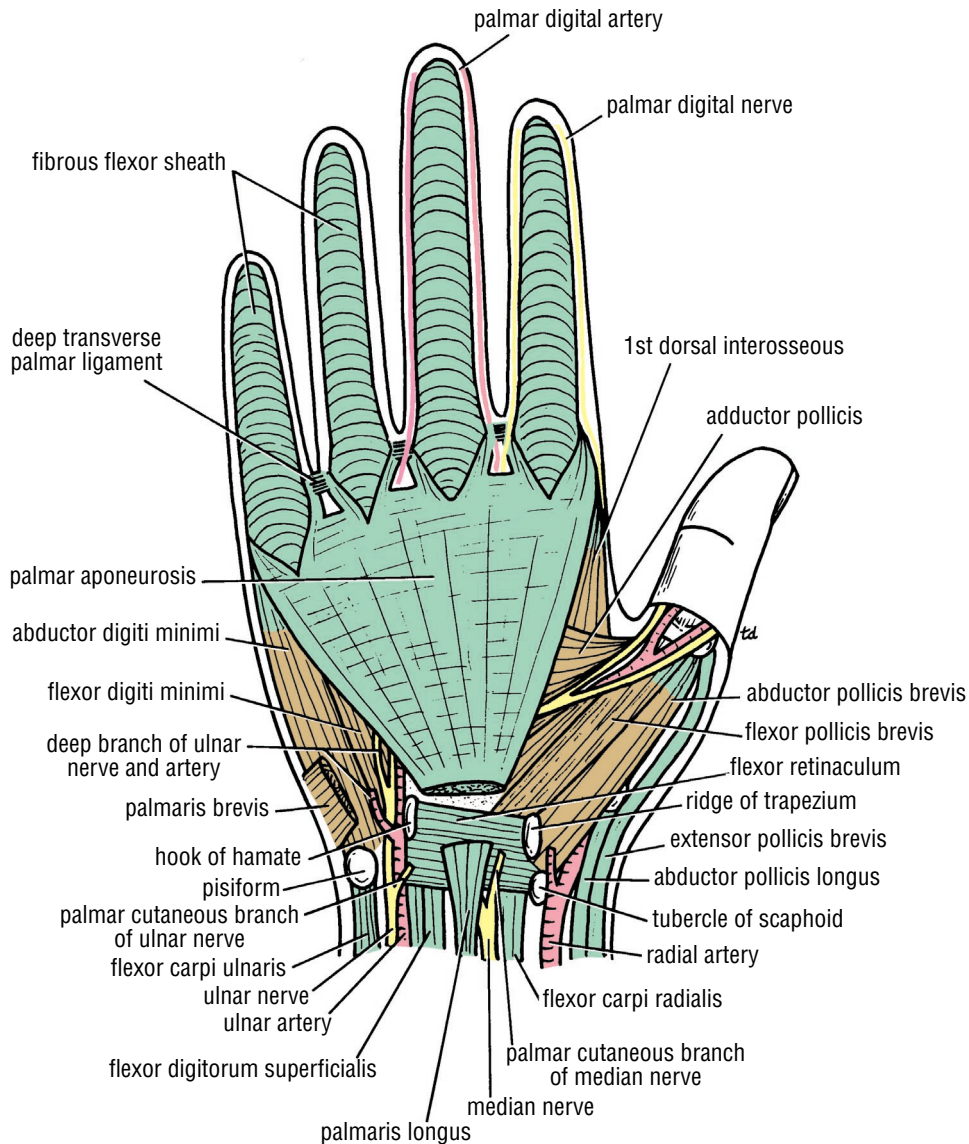
Avulsion of the central slip of the extensor tendon proximal to its insertion into the base of the middle phalanx results in a characteristic deformity (CD Fig. 13-8C). The deformity results from flexing of the proximal interphalangeal joint and hyperextension of the distal interphalangeal joint. This injury can result from direct end-on trauma to the finger, direct trauma over the back of the proximal interphalangeal joint, or laceration of the dorsum of the finger.

Dupuytren's Contracture

Dupuytren's contracture is a localized thickening and contracture of the palmar aponeurosis (CD Fig. 13-9). It commonly starts near the root of the ring finger and draws that finger into the palm, flexing it at the metacarpophalangeal joint. Later, the condition involves the little finger in the same manner. In long-standing cases, the pull on the fibrous sheaths of these fingers results in flexion of the proximal



CD Figure 13-8 **A.** Posterior view of normal dorsal extensor expansion. The extensor expansion near the proximal interphalangeal joint splits into three parts: a central part, which is inserted into the base of the middle phalanx, and two lateral parts, which converge to be inserted into the base of the distal phalanx. **B.** Mallet or baseball finger. The insertion of the extensor expansion into the base of the distal phalanx ruptured; sometimes a flake of bone on the base of the phalanx is pulled off. **C.** Boutonnière deformity. The insertion of the extensor expansion into the base of the middle phalanx is ruptured. The *arrows* indicate the direction of the pull of the muscles and the deformity.



CD Figure 13-9 Anterior view of the palm of the hand. The palmar aponeurosis has been left in position.

interphalangeal joints. The distal interphalangeal joints are not involved and are actually extended by the pressure of the fingers against the palm.



MUSCLES OF THE LOWER LIMB

Gluteus Maximus and Intramuscular Injections

The gluteus maximus is a large, thick muscle with coarse fasciculi that can be easily separated without damage. The great thickness of this muscle makes it ideal for intramuscu-

lar injections. To avoid injury to the underlying sciatic nerve, the injection should be given well forward on the **upper outer quadrant of the buttock**.

Bursitis, or inflammation of a bursa, can be caused by acute or chronic trauma.

Gluteus Maximus and Bursitis

An inflamed bursa becomes distended with excessive amounts of fluid and can be extremely painful. The bursae associated with the gluteus maximus are prone to inflammation.

Gluteus Medius and Minimus and Poliomyelitis

The gluteus medius and minimus muscles may be paralyzed when poliomyelitis involves the lower lumbar and

sacral segments of the spinal cord. They are supplied by the superior gluteal nerve (L4 and 5 and S1). Paralysis of these muscles seriously interferes with the ability of the patient to tilt the pelvis when walking.

Quadriceps Femoris as a Knee-Joint Stabilizer

The quadriceps femoris is an important extensor muscle for the knee joint. Its tone greatly strengthens the joint; therefore, this muscle mass must be carefully examined when disease of the knee joint is suspected. Both thighs should be examined, and the size, consistency, and strength of the quadriceps muscles should be tested. Reduction in size caused by muscle atrophy can be tested by measuring the circumference of each thigh a fixed distance above the superior border of the patella.

The vastus medialis muscle extends farther distally than the vastus lateralis. Remember that the vastus medialis is the first part of the quadriceps muscle to atrophy in knee-joint disease and the last to recover.

Rupture of the Rectus Femoris

The rectus femoris muscle can rupture in sudden violent extension movements of the knee joint. The muscle belly retracts proximally, leaving a gap that may be palpable on the anterior surface of the thigh. In complete rupture of the muscle, surgical repair is indicated.

Rupture of the Ligamentum Patellae

This can occur when a sudden flexing force is applied to the knee joint when the quadriceps femoris muscle is actively contracting.

Femoral Sheath and Femoral Hernia

The hernial sac descends through the femoral canal within the femoral sheath.

The femoral sheath is a prolongation downward into the thigh of the fascial lining of the abdomen. It surrounds the femoral vessels and lymphatic vessels for about 1 in. (2.5 cm) below the inguinal ligament (CD Fig. 13-10). The **femoral artery**, as it enters the thigh below the inguinal ligament, occupies the lateral compartment of the sheath. The **femoral vein**, which lies on its medial side and is separated from it by a fibrous septum, occupies the intermediate compartment. The **lymphatics**, which are separated from the vein by a fibrous septum, occupy the most medial compartment.

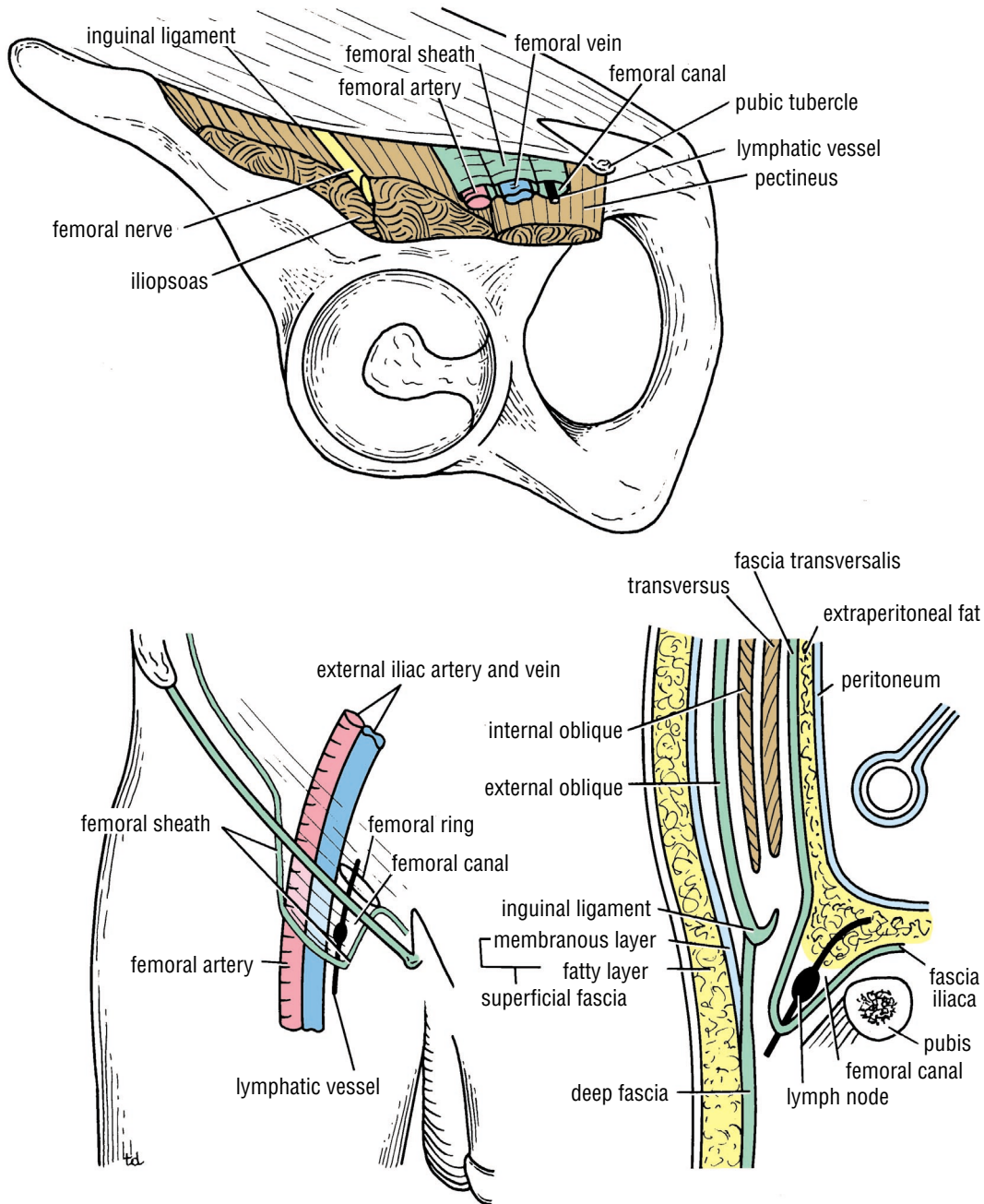
The **femoral canal**, the compartment for the lymphatic vessels, occupies the medial part of the sheath. It is about 0.5 in. (1.3 cm) long, and its upper opening is referred to as the **femoral ring**. The **femoral septum**, which is a condensation of extraperitoneal tissue, plugs the opening of the femoral ring.

A **femoral hernia** is more common in women than in men (possibly because of their wider pelvis and femoral canal). The hernial sac passes down the femoral canal, pushing the femoral septum before it. On escaping through the lower end of the femoral canal, it expands to form a swelling in the upper part of the thigh deep to the deep fascia. With further expansion, the hernial sac may turn upward to cross the anterior surface of the inguinal ligament.

The neck of the sac always lies **below and lateral to the pubic tubercle**. This serves to distinguish it from an inguinal hernia, which lies above and medial to the pubic tubercle. The neck of the sac is narrow and lies at the femoral ring. The ring is related anteriorly to the inguinal ligament, posteriorly to the pectineal ligament and the superior ramus of the pubis, medially to the sharp free edge of the lacunar ligament, and laterally to the femoral vein. Because of these anatomic structures, the neck of the sac is unable to expand. Once an abdominal viscus has passed through the neck into the body of the sac, it may be difficult to push it up and return it to the abdominal cavity (**irreducible hernia**). Furthermore, after the patient strains or coughs, a piece of bowel may be forced through the neck, and its blood vessels may be compressed by the femoral ring, seriously impairing its blood supply (**strangulated hernia**). A femoral hernia is a dangerous condition and should always be treated surgically.

When considering the differential diagnosis of a femoral hernia, it is important to consider diseases that may involve other anatomic structures close to the inguinal ligament. For example:

- **Inguinal canal:** The swelling of an inguinal hernia lies above the medial end of the inguinal ligament. Should the hernial sac emerge through the superficial inguinal ring to start its descent into the scrotum, the swelling will lie above and medial to the pubic tubercle. The sac of a femoral hernia lies below and lateral to the pubic tubercle.
- **Superficial inguinal lymph nodes:** Usually, more than one lymph node is enlarged. In patients with inflammation of the nodes (**lymphadenitis**), carefully examine the entire area of the body that drains its lymph into these nodes. A small, unnoticed skin abrasion may be found. Never forget the mucous membrane of the lower half of the anal canal—it may have an undiscovered carcinoma.
- **Great saphenous vein:** A localized dilatation of the terminal part of the great saphenous vein, a **saphenous varix**, can cause confusion, especially because a hernia



CD Figure 13-10 Right femoral sheath and its contents.

and a varix increase in size when the patient is asked to cough. (Elevated intraabdominal pressure drives the blood downward.) The presence of varicose veins elsewhere in the leg should help in the diagnosis.

- **Psoas sheath:** Tuberculous infection of a lumbar vertebra can result in the extravasation of pus down the psoas sheath into the thigh (CD Fig. 13-3). The presence of a swelling above and below the inguinal ligament, together with clinical signs and symptoms referred to the vertebral column, should make the diagnosis obvious.

- **Femoral artery:** An expansile swelling lying along the course of the femoral artery that fluctuates in time with the pulse rate should make the diagnosis of **aneurysm of the femoral artery** certain.

Adductor Muscles and Cerebral Palsy

In patients with cerebral palsy who have marked spasticity of the adductor group of muscles, it is common practice to

perform a tenotomy of the adductor longus tendon and to divide the anterior division of the obturator nerve. In addition, in some severe cases the posterior division of the obturator nerve is crushed. This operation overcomes the spasm of the adductor group of muscles and permits slow recovery of the muscles supplied by the posterior division of the obturator nerve.

The Adductor Magnus and Popliteal Aneurysms

The pulsations of the wall of the femoral artery against the tendon of adductor magnus at the opening of the adductor magnus is thought to contribute to the cause of popliteal aneurysms.

Semimembranosus Bursa Swelling

Semimembranosus bursa swelling is the most common swelling found in the popliteal space. It is made tense by extending the knee joint and becomes flaccid when the joint is flexed. It should be distinguished from a Baker's cyst, which is centrally located and arises as a pathologic (osteoarthritis) diverticulum of the synovial membrane through a hole in the back of the capsule of the knee joint.

Anterior Compartment of the Leg Syndrome

The anterior compartment syndrome is produced by an increase in the intracompartmental pressure that results from an increased production of tissue fluid. Soft tissue injury associated with bone fractures is a common cause, and early diagnosis is critical. The deep, aching pain in the anterior compartment of the leg that is characteristic of this syndrome can become severe. Dorsiflexion of the foot at the ankle joint increases the severity of the pain. Stretching of the muscles that pass through the compartment by passive plantar flexion of the ankle also increases the pain. As the pressure rises, the venous return is diminished, thus producing a further rise in pressure. In severe cases, the arterial supply is eventually cut off by compression, and the dorsalis pedis arterial pulse disappears. The tibialis anterior, the extensor digitorum longus, and the extensor hallucis longus muscles are paralyzed. Loss of sensation is limited to the area supplied by the deep peroneal nerve—that is, the skin cleft between the first and second toes. The surgeon can open the anterior compartment of the leg by making a longitudinal incision through the deep fascia and thus decompress the area and prevent anoxic necrosis of the muscles.

Tenosynovitis and Dislocation of the Peroneus Longus and Brevis Tendons

Tenosynovitis (inflammation of the synovial sheaths) can affect the tendon sheaths of the peroneus longus and brevis muscles as they pass posterior to the lateral malleolus. Treatment consists of immobilization, heat, and physiotherapy. Tendon dislocation can occur when the tendons of peroneus longus and brevis dislocate forward from behind the lateral malleolus. For this condition to occur, the superior peroneal retinaculum must be torn. It usually occurs in older children and is caused by trauma.

Gastrocnemius and Soleus Muscle Tears

Tearing of the gastrocnemius or soleus muscles will produce severe localized pain over the damaged muscle. Swelling may be present.

Ruptured Tendo Calcaneus

Rupture of the tendo calcaneus is common in middle-aged men and frequently occurs in tennis players. The rupture occurs at its narrowest part, about 2 in. (5 cm) above its insertion. A sudden, sharp pain is felt, with immediate disability. The gastrocnemius and soleus muscles retract proximally, leaving a palpable gap in the tendon. It is impossible for the patient to actively plantar flex the foot. The tendon should be sutured as soon as possible and the leg immobilized with the ankle joint plantar flexed and the knee joint flexed.

Rupture of the Plantaris Tendon

Rupture of the plantaris tendon is rare, although tearing of the fibers of the soleus or partial tearing of the tendo calcaneus is frequently diagnosed as such a rupture.

Plantaris Tendon and Autografts

The plantaris muscle, which is often missing, can be used for tendon autografts in repairing severed flexor tendons to the fingers; the tendon of the palmaris longus muscle can also be used for this purpose.

Plantar Fasciitis

Plantar fasciitis, which occurs in individuals who do a great deal of standing or walking, causes pain and tenderness of the sole of the foot. It is believed to be caused by repeated

minor trauma. Repeated attacks of this condition induce ossification in the posterior attachment of the aponeurosis, forming a **calcaneal spur**.

Clinical Problems Associated with the Arches of the Foot

See CD Chapter 12.

Bursae and Bursitis in the Lower Limb

A variety of bursae are found in the lower limb where skin, tendons, ligaments, or muscles repeatedly rub against bony points or ridges.

Bursitis, or inflammation of a bursa, can be caused by acute or chronic trauma, crystal disease, infection, or disease of a neighboring joint that communicates with the bursa. An inflamed bursa becomes distended with excessive amounts of fluid. The following bursae are prone to

inflammation: the bursa over the ischial tuberosity; the greater trochanter bursa; the prepatellar and superficial infrapatellar bursae; the bursa between the tendons of insertion of the sartorius, gracilis, and semitendinosus muscles on the medial proximal aspect of the tibia; and the bursa between the tendo calcaneus and the upper part of the calcaneum (long-distance runner's ankle).

Two important bursae communicate with the knee joint, and they can become distended if excessive amounts of synovial fluid accumulate within the joint. The suprapatellar bursa extends proximally about three fingerbreadths above the patella beneath the quadriceps femoris muscle. The bursa, which is associated with the insertion of the semimembranosus muscle, may enlarge in patients with osteoarthritis of the knee joint.

The anatomic bursae described should not be confused with **adventitious bursae**, which develop in response to abnormal and excessive friction. For example, a subcutaneous bursa sometimes develops over the tendo calcaneus in response to badly fitting shoes. A **bunion** is an adventitious bursa located over the medial side of the head of the first metatarsal bone.

Clinical Problem Solving Questions

Read the following case histories/questions and give the best answer for each.

General Muscle Information

In a 63-year-old man, a magnetic resonance imaging scan of the lower thoracic region of the vertebral column reveals the presence of a tumor pressing on the lumbar segments of the spinal cord. He has a loss of sensation in the skin over the anterior surface of the left thigh and is unable to extend his left knee joint. Examination reveals that the muscles of the front of the left thigh have atrophied and have no tone and that the left knee jerk is absent.

- The following statements concerning this patient are correct **except** which?
 - The tumor is interrupting the normal function of the efferent motor fibers of the spinal cord on the left side.
 - The quadriceps femoris muscles on the front of the left thigh are atrophied.
 - The loss of skin sensation is confined to the dermatomes L1, 2, 3, and 4.
 - The absence of the left knee jerk is because of involvement of the first lumbar spinal segment.

- The loss of muscle tone is caused by interruption of a nervous reflex arc.

A woman recently took up employment in a factory. She is a machinist, and for 6 hours a day she has to move a lever repeatedly, which requires that she extend and flex her right wrist joint. At the end of the second week of her employment, she began to experience pain over the posterior surface of her wrist and noticed a swelling in the area.

- The following statements concerning this patient are correct **except** which?
 - Extension of the wrist joint is brought about by several muscles that include the extensor digitorum muscle.
 - The wrist joint is diseased.
 - Repeated unaccustomed movements of tendons through their synovial sheaths can produce traumatic inflammation of the sheaths.
 - The diagnosis is traumatic tenosynovitis of the long tendons of the extensor digitorum muscle.

Head and Neck Muscles

A 43-year-old woman was seen in the emergency department with a large abscess in the middle of the right

posterior triangle of the neck. The abscess was red, hot, and fluctuant. The abscess showed evidence that it was pointing and about to rupture. The physician decided to incise the abscess and insert a drain. The patient returned to the department for the dressings to be changed 5 days later. She stated that she felt much better and that her neck was no longer painful. However, there was one thing that she could not understand. She could no longer raise her right hand above her head to brush her hair.

3. The following statements explain the signs and symptoms in this case, suggesting that the spinal part of the accessory nerve had been incised, **except** which?
 - A. To raise the hand above the head, it is necessary for the trapezius muscle, assisted by the serratus anterior, to contract and rotate the scapula so that the glenoid cavity faces upward.
 - B. The trapezius muscle is innervated by the spinal part of the accessory nerve.
 - C. As the spinal part of the accessory nerve crosses the posterior triangle of the neck, it is deeply placed, being covered by the skin, the superficial fascia, the investing layer of deep cervical fascia, and the levator scapulae muscle.
 - D. The surface marking of the spinal part of the accessory nerve is as follows: Bisect at right angles a line joining the angle of the jaw to the tip of the mastoid process. Continue the second line downward and backward across the posterior triangle.
 - E. The knife opening the abscess had cut the accessory nerve.

A 46-year-old man was seen in the emergency department after being knocked down in a street brawl. He had received a blow on the head with an empty bottle. On examination, the patient was conscious and had a large gaping wound on the top of the head.

4. Why did the wound in this patient gape wide open when he was hit with a blunt object and not a knife?
 - A. The skin on the top of the head was excessively tight.
 - B. The blow of the bottle had split the epicranial aponeurosis against the underlying skull and the tone of the occipitofrontalis muscle had pulled the skin wound open.
 - C. The subcutaneous tissue of the scalp contains smooth muscle, which pulled the wound open.
 - D. A hematoma was formed beneath the scalp and forced the wound open.
 - E. The underlying parietal bone of the skull was fractured and forced the wound open.

Muscles of the Back

A 75-year-old woman was dusting the top of a high closet while balanced on a chair. She lost her balance

and fell to the floor, catching her right lumbar region on the edge of the chair.

5. The following statements about this patient are correct **except** which?
 - A. A lumbar puncture (spinal tap) should always be performed in back injuries to exclude damage to the spinal cord.
 - B. Anteroposterior and lateral radiographs exclude the presence of a fracture, especially of a transverse process.
 - C. A 24-hour specimen of urine should be examined for blood to exclude or confirm injury to the right kidney.
 - D. Careful examination of the erector spinae muscles or quadratus lumborum muscle may reveal extreme tenderness and therefore injury to these muscles.
 - E. Examination of the back revealed a large bruised area in the right lumbar region, which was extremely tender to touch.

Muscles of the Thoracic Wall

A resident obtained a sample of pleural fluid from a patient's right pleural cavity. He inserted the needle close to the upper border of the sixth rib in the anterior axillary line.

6. Name the muscles that the needle pierced in order to enter the pleural cavity.
 - A. Trapezius and latissimus dorsi
 - B. Trapezius and serratus anterior
 - C. Serratus anterior, external intercostal, internal intercostal, and innermost intercostal
 - D. External intercostal and internal intercostal
 - E. Latissimus dorsi, serratus anterior, and external intercostal

Abdominal Muscles

A 75-year-old man with chronic bronchitis noticed that a bulge was developing in his left groin. On examination, an elongated swelling was seen above the medial end of the left inguinal ligament. When the patient coughed, the swelling enlarged but did not descend into the scrotum. The patient had weak abdominal muscles.

7. The symptoms and signs displayed by this patient can be explained by the following statements **except** which?
 - A. The inguinal swelling was a direct inguinal hernia.
 - B. The cause of the hernia was weak abdominal muscles.
 - C. The hernial sac was wide and in direct communication with the peritoneal cavity.
 - D. A rise in intraabdominal pressure on coughing caused the hernial swelling to expand.
 - E. The swelling did not involve the conjoint tendon.

A 40-year-old woman noticed a painful swelling in her right groin after helping her husband move some heavy furniture. On examination, a small tender swelling was noted in the right groin.

8. The symptoms and signs displayed by this patient can be explained by the following statements **except** which?
 - A. The neck of a femoral hernial sac is situated below and medial to the pubic tubercle.
 - B. A hernial sac formed of parietal peritoneum was forced downward.
 - C. The peritoneum was forced through the right femoral canal.
 - D. The patient had a right-sided femoral hernia.
 - E. The excessive exertion caused a rise in intraabdominal pressure.
9. Following a sudden severe blow on the anterior abdominal wall from the hind leg of a horse, a patient complained of pain and swelling below the umbilicus. On examination, extensive bruising of the skin was observed over the lower part of the right rectus muscle. On gentle palpation, a deep swelling confined to the right rectus sheath was felt. Given that the deep swelling was due to a collection of blood (hematoma), which blood vessels were likely to have been ruptured?
10. In a patient with a history of tuberculosis, an angular kyphosis of the lumbar vertebral column suddenly developed. On examination, a swelling was found in the groin, just below the right inguinal ligament. On deep palpation of the anterior abdominal wall above the right inguinal ligament, a further swelling could be felt. Digital pressure on the first swelling caused expansion of the second swelling and vice versa. What is the diagnosis? Explain the swelling in anatomical terms.
11. The following statements concerning this patient are correct **except** which?
 - A. Altered skin sensation was felt in the skin areas supplied by the digital branches of the median nerve.
 - B. The muscles of the thenar eminence showed some evidence of wasting as seen by flattening of the thenar eminence.
 - C. The muscles of the thenar eminence are supplied by the recurrent muscular branch of the median nerve.
 - D. The median nerve enters the palm through the carpal tunnel.
 - E. The median nerve occupies a large space between the tendons behind the flexor retinaculum.
 - F. This patient has carpal tunnel syndrome.
12. The following statements concerning this patient are correct **except** which?
 - A. Altered skin sensation was felt in the skin areas supplied by the digital branches of the median nerve.
 - B. The muscles of the thenar eminence showed some evidence of wasting as seen by flattening of the thenar eminence.
 - C. The muscles of the thenar eminence are supplied by the recurrent muscular branch of the median nerve.
 - D. The median nerve enters the palm through the carpal tunnel.
 - E. The median nerve occupies a large space between the tendons behind the flexor retinaculum.
 - F. This patient has carpal tunnel syndrome.
13. Following a radical mastectomy operation a woman noticed that her right shoulder blade projected backwards. Can you explain this deformity?
14. A 40-year-old man visited his physician complaining of pain of 3 weeks' duration in his right shoulder. On examination, the patient could actively abduct his right shoulder to 50°; thereafter, he experienced severe pain that prevented further movement. If the arm was then passively raised above a right angle, it could be held actively without pain in that position. If the patient attempted to lower the arm, he again experienced severe pain in the middle range of abduction. What is your diagnosis?

A 64-year-old man consulted his physician because he had noticed during the past 6 months a thickening of the skin at the base of his left ring finger. As he described it: "There appears to be a band of tissue that is pulling my ring finger into the palm." On examination of the palms of both hands, a localized thickening of subcutaneous tissue could be felt at the base of the left ring and little fingers. The metacarpophalangeal joint of the ring finger could not be fully extended, either actively or passively.

15. The following statements concerning this patient are correct **except** which?
 - A. The deep fascia beneath the skin of the palm is thickened to form the palmar aponeurosis.
 - B. The distal end of the aponeurosis gives rise to five slips to the five fingers.
 - C. Each slip is attached to the base of the proximal phalanx and to the fibrous flexor sheath of each finger.
 - D. Fibrous contraction of the slip to the ring finger resulted in permanent flexion of the metacarpophalangeal joint.
 - E. The patient had Dupuytren's contracture.

Pelvic Muscles

11. A multiparous 57-year-old woman visited her gynecologist complaining of a "bearing-down" feeling in the pelvis and of low backache, both of which were worse when she was tired. On vaginal examination, the external os of the cervix was found to be located just within the vaginal orifice. A diagnosis of uterine prolapse was made. What are the main supports of the uterus?

Muscles of the Upper Limb

A 50-year-old woman complaining of severe "pins and needles" in her right hand and lateral fingers visited her physician. She said that she had experienced difficulty in buttoning up her clothes when dressing. On physical examination the patient pointed to her thumb and index, middle, and ring fingers as the areas where she felt discomfort. No objective impairment of sensation was found in these areas. The muscles of the thenar

Muscles of the Lower Limb

A 54-year-old man was told by his physician to reduce his weight. He was prescribed a diet and was advised to exercise more. One morning while jogging, he heard a sharp snap and felt a sudden pain in his right lower calf. On examination in the emergency department, the physician noted that the upper part of the right calf was swollen and a gap was apparent between the swelling and the heel. A diagnosis of rupture of the right Achilles tendon was made.

16. The following statements concerning this patient are correct **except** which?
- With the patient supine, gentle squeezing of the upper part of the right calf did not produce plantar flexion of the ankle joint.
 - The Achilles tendon is the tendon of insertion of the gastrocnemius and soleus muscles.
 - The Achilles tendon is inserted into the posterior surface of the talus.
 - Rupture of the Achilles tendon results in the bellies of the gastrocnemius and soleus muscles retracting upward, leaving a gap between the divided ends of the tendon.
 - Normally, the gastrocnemius and soleus muscles are the main muscles responsible for plantar flexion of the ankle joint.

A 25-year-old man was admitted to the emergency department after an automobile accident. Apart from other superficial injuries, he was found to have a fracture of the middle third of the right femur.

17. The following statements concerning this patient are possible **except** which?
- The soleus muscle was responsible for the backward rotation of the distal fragment.
 - A lateral radiograph showed overlap of the fragments, with the distal fragment rotated backward.

- A large amount of force would be necessary to restore the leg to its original length.
- The hamstrings and quadriceps femoris muscles were responsible for the leg shortening.
- The right leg was 2 in. (5 cm) shorter than the left leg.

18. A 42-year-old woman was seen in the emergency department after slipping on some ice on the way to work. She complained of pain on movement of her right ankle joint. The physician asked the patient to evert her right foot. Which of the following muscles everts the foot?
- The tibialis anterior muscle
 - The flexor hallucis longus muscle
 - The peroneus longus muscle
 - The tibialis anterior muscle
 - The flexor digitorum longus muscle
19. A 61-year-old woman was being examined for osteoarthritis of the left hip joint by an orthopedic surgeon. He flexed the left hip joint with the knee flexed. What structure normally limits the flexion of this joint with the knee flexed?
- The hamstring muscles
 - The iliofemoral ligament
 - The adductor magnus muscle
 - The anterior abdominal wall
 - The ischiofemoral ligament
20. A physician's assistant asked a patient to walk up and down the examining room so that she might study his gait. Which of the following muscles plays an important role in lifting the left foot off the ground while walking?
- The left gluteus medius muscle
 - The left gluteus maximus muscle
 - The right adductor longus muscle
 - The right gluteus medius muscle
 - None of the above


Answers and Explanations

- D** is the correct answer. The patellar tendon reflex (knee jerk) involves L2, 3, and 4 segments of the spinal cord.
- B** is the correct answer. The wrist joint is not diseased. This patient has traumatic tenosynovitis of the long tendons of the extensor digitorum muscle.
- C** is the correct answer. The spinal part of the accessory nerve, which supplies the sternocleidomastoid and the trapezius muscles, lies superficial to the levator

scapulae muscle as it crosses the posterior triangle of the neck (see text Fig. 13-9).

- B** is the correct answer. A blunt object forcibly striking the head often splits the epicranial aponeurosis against the underlying skull, causing the skin wound to gape open as if incised by a knife.
- A** is the correct answer. A lumbar puncture (spinal tap) is not required in cases of simple trauma to the back.

6. **C** is the correct answer. On the anterior axillary line (a line extending vertically downward from the lower border of the pectoralis major muscle) at the level of the upper border of the sixth rib, the needle would pierce the skin, fascia, the serratus anterior muscle, the external intercostal muscle, the internal intercostal muscle, the innermost intercostal muscle, and the parietal pleura (see text Fig. 3-4).
7. **E** is the correct answer. The conjoint tendon, formed by the fusion of the tendons of the internal oblique and transversus abdominis muscles, greatly strengthens the posterior wall of the inguinal canal. A weakness of the conjoint tendon and the lower abdominal musculature was responsible for the bulge, which constitutes a direct inguinal hernia.
8. **A** is the correct answer. The neck of the femoral hernial sac is situated below and lateral to the pubic tubercle (see CD Fig. 13-10).
9. A sudden unexpected blow on the anterior abdominal wall causes excessive stretching of this structure. In this case the right inferior epigastric artery, which lies within the rectus sheath, was ruptured and the bleeding occurred into the sheath. If a person is expecting a blow, he or she automatically contracts his abdominal muscles and protects the underlying structures.
10. The patient had a tuberculous infection of the lumbar vertebral column with destruction of the bodies of the vertebrae, hence the kyphosis. The tuberculous pus extended laterally and to the right and entered the right psoas fascial sheath. From there, it extended downward into the thigh, producing a swelling above and below the inguinal ligament. Since the pus in each swelling was continuous, pressure could be transmitted from one swelling to the other (see CD Fig. 13-3).
11. The uterus is mainly supported by the tone of the levatores ani muscles. In addition, the ligaments of the visceral layer of pelvic fascia, namely, the transverse cervical, sacrocervical, and pubocervical ligaments, play an important role.
12. **E** is the correct answer. The median nerve occupies a small restricted space in the carpal (see CD Fig. 13-6).
13. This patient has a winged scapula caused by the paralysis of the serratus anterior muscle. The nerve supply to the serratus anterior muscle is the thoracodorsal nerve, a branch of the posterior cord of the brachial plexus. Sometimes during a radical mastectomy operation, which involves the clearing out of the lymph nodes and fat in the axilla, the nerve is sacrificed since it may be involved in malignant disease (see text Fig. 13-23).
14. This patient had supraspinatus tendinitis. During the middle range of abduction, the tendon of the supraspinatus impinges against the outer border of the acromion. Normally, the larger subacromial bursa intervenes and ensures that the movement is relatively free of friction and is painless. In this condition, the bursa has degenerated and the supraspinatus tendon exhibits a localized area of collagen degeneration (see CD Fig. 13-5).
15. **B** is the correct answer. The distal end of the palmar aponeurosis gives rise to four slips, which pass to the four medial fingers (see CD Fig. 13-9).
16. **C** is the correct answer. The Achilles tendon is inserted into the posterior surface of the calcaneum (see text Fig. 13-55).
17. **A** is the correct answer. The gastrocnemius muscle is responsible for the backward rotation of the distal fragment of the fractured femur.
18. **C** is the correct answer. The peroneus longus everts the foot.
19. **D** is the correct answer. Flexion of the hip joint (with the knee flexed) is limited by the thigh coming in contact with the anterior abdominal wall.
20. **D** is the correct answer. The right gluteus medius and the right gluteus minimus tilt the pelvis so that the left lower limb is raised, thus permitting the left foot to be advanced forward clear of the ground.



The Nervous System

14

The Skull, the Brain, the
Meninges, and the Blood
Supply of the Brain Relative
to Trauma and Intracranial
Hemorrhage



Chapter Outline

The Skull	213	Cerebral Artery Occlusion	219
The Thinnest Part of the Lateral Wall of the Skull	213	Anterior Cerebral Artery Occlusion	219
Fractures of the Skull	213	Middle Cerebral Artery Occlusion	221
Fractures of the Facial Bones	213	Internal Carotid Artery Occlusion	221
Rises in Supratentorial Pressure	213	Vertebral Artery Occlusion	221
Rises in Subtentorial Pressure	213	Basilar Artery Occlusion	222
Movements of the Brain Relative to the Skull and Meninges in Head Injuries	214	Central Branch Artery Occlusion	222
Intracranial Hemorrhage	215	Transient Ischemic Attacks	222
Computed Tomography Scans of Extradural and Subdural Hematomas	215	Hydrocephalus	222
Cerebral Arteriography	216	Hydrocephalus Resulting from Excessive Formation of Cerebrospinal Fluid	222
Congenital Aneurysms	217	Hydrocephalus Resulting from Blockage of Cerebrospinal Fluid Circulation	222
Subarachnoid Hemorrhage	217	Hydrocephalus Resulting from Diminished Absorption of Cerebrospinal Fluid	222
Cerebral Hemorrhage	217	Clinical Problem Solving Questions	222
Cerebral Ischemia	219	Answers and Explanations	223



THE SKULL

The Thinnest Part of the Lateral Wall of the Skull

The thinnest part of the lateral wall of the skull is where the anteroinferior corner of the parietal bone articulates with the greater wing of the sphenoid; this point is known as the **pterion**. This is a very important area since it overlies the anterior division of the middle meningeal artery and vein.

Fractures of the Skull

See Chapter 11 of the CD-ROM.

Fractures of the Facial Bones

See Chapter 11 of the CD-ROM.

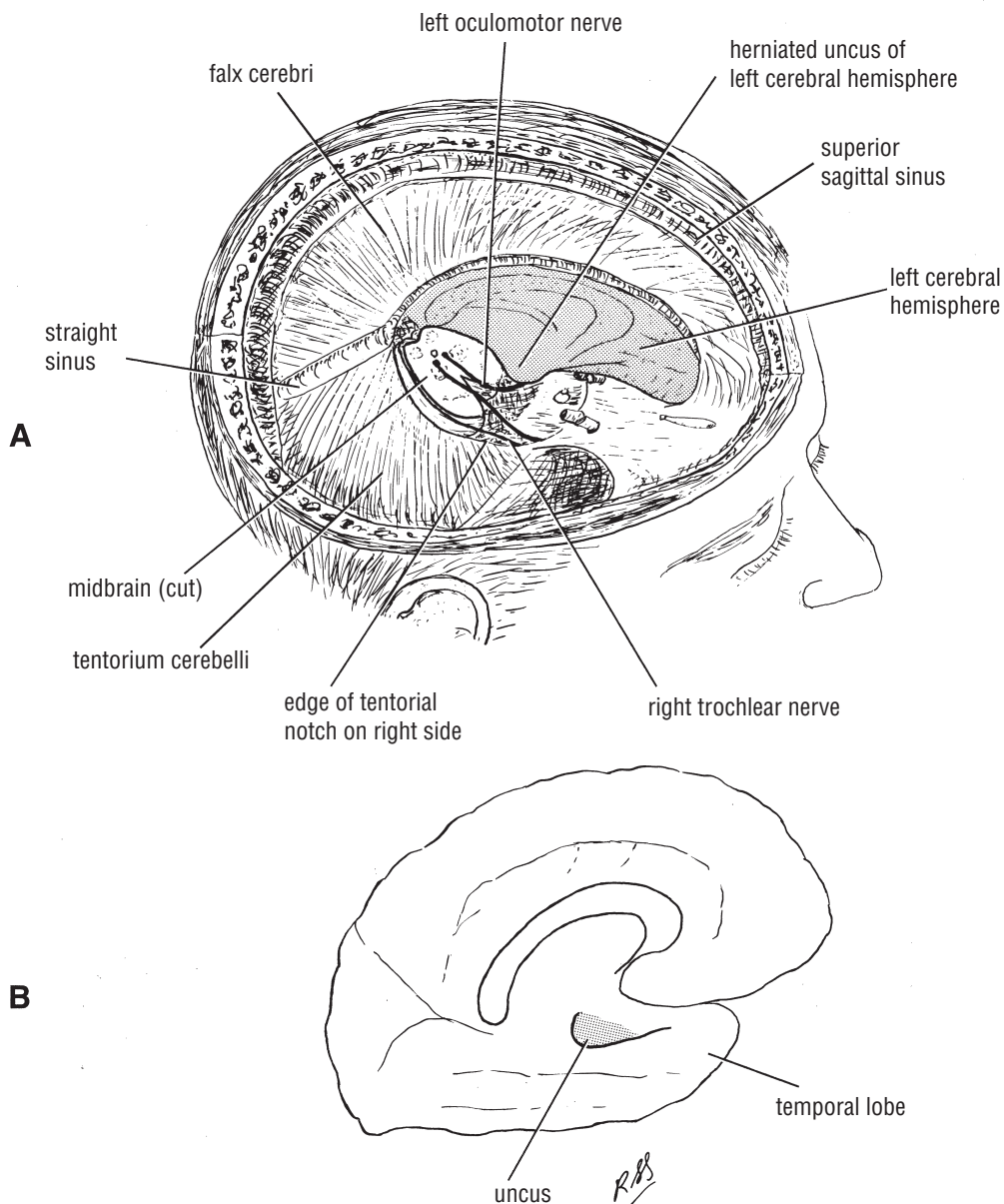
Rises in Supratentorial Pressure

The common causes of a rise in supratentorial pressure are intracerebral hemorrhage, subarachnoid hemorrhage, subdural hemorrhage, epidural hemorrhage, and cerebral edema. Two forms of caudal herniation of the brain through the tentorial notch of the tentorium cerebelli can occur as a result of the raised supratentorial pressure:

- **Central herniation syndrome:** In this syndrome the thalamus and midbrain are pushed caudally through the tentorial notch.
- **Uncal herniation syndrome:** In this syndrome the uncus of the temporal lobe is displaced medially and pushes the midbrain against the opposite sharp edge of the tentorial notch. At the same time, the displaced uncus presses on the ipsilateral oculomotor nerve at the notch, resulting in a sluggishly reactive and dilated pupil (CD Fig. 14-1).

Rises in Subtentorial Pressure

Posterior cranial fossa lesions such as those in cerebellar hemorrhage cause a rise in pressure that can directly com-

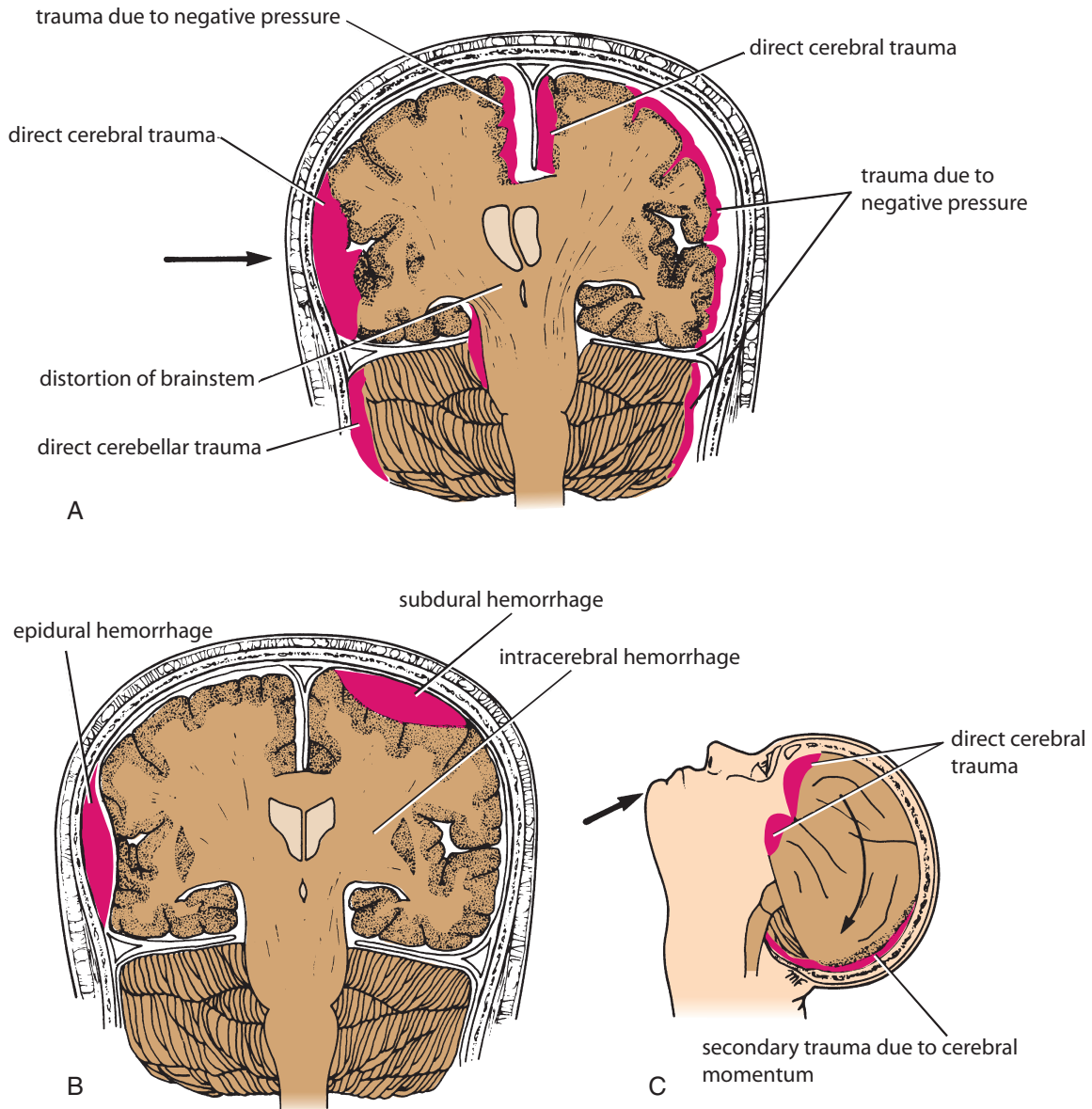


CD Figure 14-1 **A.** Lateral view of the interior of the skull showing the falx cerebri, tentorium cerebelli, and brainstem. As the result of abnormal supratentorial pressure, the uncus of the left cerebral hemisphere has herniated down through the tentorial notch of the tentorium cerebelli and is pressing on the left oculomotor nerve. **B.** The position of the uncus on the temporal lobe of the left cerebral hemisphere in a normal brain.

press the brainstem or its blood supply. Indirect compression can follow upward herniation of the cerebellum through the tentorial notch or downward herniation of the cerebellar tonsils through the foramen magnum. In the latter instance the medulla will also be displaced and pressed upon. The problem can be compounded by pressure on the cerebral aqueduct in the midbrain or the roof of the fourth ventricle, producing an acute obstructive hydrocephalus.

Movements of the Brain Relative to the Skull and Meninges in Head Injuries

Brain injuries are produced by displacement and distortion of the neuronal tissues at the moment of impact (CD Fig. 14-2).



CD Figure 14-2 **A.** Mechanisms of acute cerebral injury when a blow is applied to the lateral side of the head. **B.** Varieties of intracranial hemorrhage. **C.** Mechanism of cerebral trauma following a blow on the chin. The movement of the brain within the skull can also tear the cerebral veins.

The brain, which is incompressible, may be likened to a log soaked with water floating in water. The brain is floating in the cerebrospinal fluid in the subarachnoid space and is capable of a certain amount of anteroposterior and lateral gliding movement. The anteroposterior movement is limited by the attachment of the superior cerebral veins to the superior sagittal sinus. In lateral movements, the lateral surface of one hemisphere hits the side of the skull, and the medial surface of the opposite hemisphere hits the side of the falx cerebri (see CD Fig. 14-2). In superior movements, the superior surfaces of the cerebral hemispheres hit the vault of the skull, and the superior surface of the corpus callosum may hit the sharp free

edge of the falx cerebri; the superior surface of the cerebellum presses against the inferior surface of the tentorium cerebelli.

It follows from these anatomic facts that blows on the front or back of the head lead to displacement of the brain, which may produce severe cerebral damage, stretching and distortion of the brainstem, and stretching and even tearing of the commissures of the brain. Blows to the side of the head produce less cerebral displacement, and the injuries to the brain consequently tend to be less severe. The falx cerebri, however, is a tough structure and may cause considerable damage to the softer brain tissue in cases where there has been a severe blow to the side of the head (see CD Fig.

14-2). Furthermore, glancing blows to the head may result in considerable rotation of the brain, causing shearing strains and distortion, particularly in areas where further rotation is prevented by bony prominences in the anterior and middle cranial fossae. Brain lacerations are likely to occur when the brain is forcibly thrown against the sharp edges of bone within the skull—the lesser wing of the sphenoid, for example.

When the brain is suddenly given momentum within the skull, the part of the brain that moves away from the skull wall is subjected to diminished pressure, because the cerebrospinal fluid has not had time to accommodate the brain movement (see CD Fig. 14-2). This results in a suction effect on the brain surface, with rupture of surface blood vessels.

A sudden severe blow to the head, as in an automobile accident, may result in damage to the brain at the following two sites: (1) at the point of impact and (2) at the pole of the brain opposite the point of impact, where the brain is thrown against the skull wall. This is referred to as **contre-coup injury**.

Movements of the brain relative to the skull and dural septa may seriously injure the cranial nerves that are tethered as they pass through the various foramina. This particularly applies to the long, slender nerves, such as the trochlear, abducent, and oculomotor nerves. Furthermore, the fragile cortical veins that tether the brain and drain into the dural sinuses may be torn, resulting in severe subdural or subarachnoid hemorrhage. The large arteries found at the base of the brain are tortuous, and this, coupled with their strong walls, explains why they are seldom damaged.

Intracranial Hemorrhage

Intracranial hemorrhage may result from trauma or cerebral vascular lesions. Four varieties are considered here: extradural, subdural, subarachnoid, and cerebral.

Extradural hemorrhage results from injuries to the meningeal arteries or veins. The most common artery to be damaged is the anterior division of the middle meningeal artery. A comparatively minor blow to the side of the head, resulting in fracture of the skull in the region of the anteroinferior portion of the parietal bone, may sever the artery. The arterial or venous injury is especially liable to occur if the artery and vein enter a bony canal in this region. Bleeding occurs and strips the meningeal layer of dura from the internal surface of the skull. The intracranial pressure rises, and the enlarging blood clot exerts local pressure on the underlying motor area in the precentral gyrus. Blood may also pass outward through the fracture line to form a soft swelling under the temporalis muscle.

To stop the hemorrhage, the torn artery or vein must be ligated or plugged. The burr hole through the skull wall should be placed about 1 to 1.5 in. (2.5 to 4 cm) above the midpoint of the zygomatic arch.

Subdural hemorrhage results from tearing of the superior cerebral veins at their point of entrance into the superior sagittal sinus. The cause is usually a blow on the front or the back of the head, causing excessive anteroposterior displacement of the brain within the skull.

This condition, which is much more common than middle meningeal hemorrhage, can be produced by a sudden minor blow. Once the vein is torn, blood under low pressure begins to accumulate in the potential space between the dura and the arachnoid. In about half the cases the condition is bilateral.

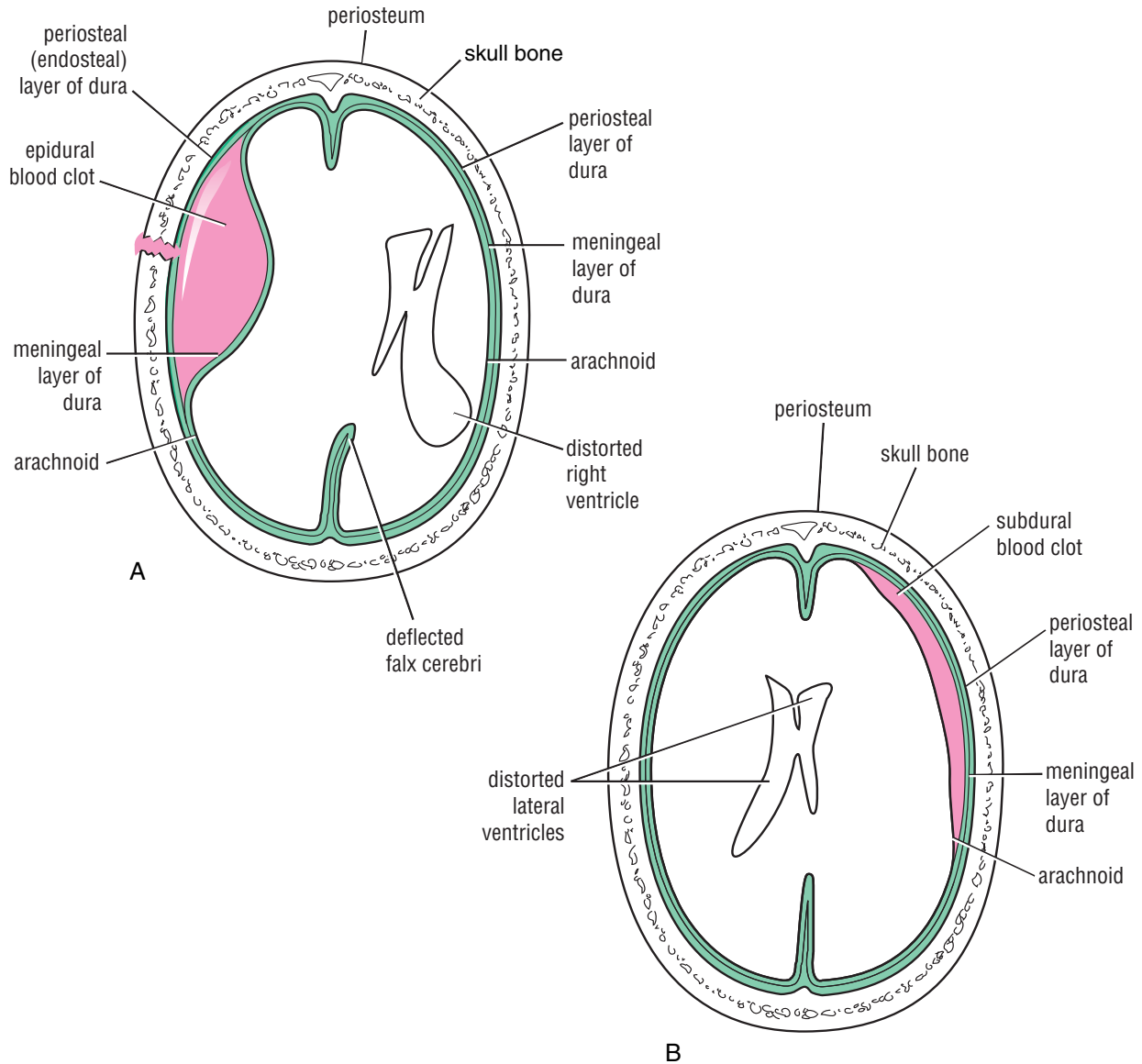
Acute and chronic forms of the clinical condition occur, depending on the speed of accumulation of fluid in the subdural space. For example, if the patient starts to vomit, the venous pressure will rise as a result of a rise in the intrathoracic pressure. Under these circumstances, the subdural blood clot will increase rapidly in size and produce acute symptoms. In the chronic form, over a course of several months the small blood clot will attract fluid by osmosis so that a hemorrhagic cyst is formed, which gradually expands and produces pressure symptoms. In both forms the blood clot must be removed through burr holes in the skull.



COMPUTED TOMOGRAPHY SCANS OF EXTRADURAL AND SUBDURAL HEMATOMAS

The different appearances of blood clots in these two conditions as seen on computed tomography (CT) scans is related to the anatomy of the area (CD Fig. 14-3). In an extradural hemorrhage the blood strips the meningeal layer of the dura from the endosteal layer of dura (periosteum of the skull), producing a lens-shaped hyperdense collection of blood that compresses the brain and displaces the midline structures to the opposite side. The shape of the blood clot is determined by the adherence of the meningeal layer of dura to the periosteal layer of dura.

In patients with subdural hematoma the blood accumulates in the extensive potential space between the meningeal layer of dura and the arachnoid, producing a long, crescent-shaped, hyperdense rim of blood that extends from anterior to posterior along the inner surface of the skull. With a large hematoma, the brain sulci are obliterated, and the midline structures are displaced to the opposite side.



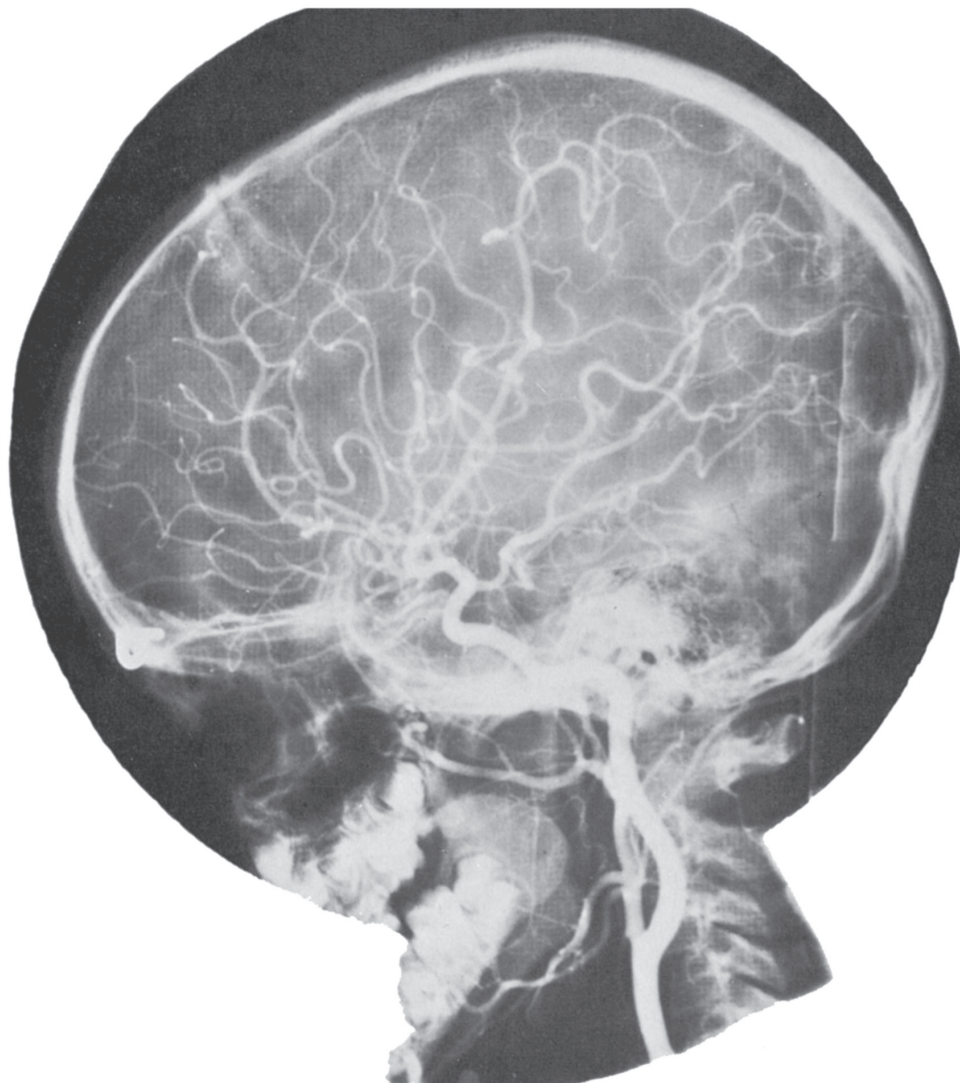
CD Figure 14-3 Diagrammatic representation of an extradural hemorrhage and a subdural hemorrhage. **A.** Extradural hemorrhage from the middle meningeal artery or vein on the left side. The hematoma is lens-shaped and occupies the space between the endosteal layer of dura (periosteum of the skull) and the meningeal layer of dura (true dura, hence the name extradural). **B.** Subdural hemorrhage from the cerebral veins at the site of entrance into the venous sinus on the right side. The hematoma is crescent-shaped and occupies the space between the meningeal layer of dura and the arachnoid, (i.e., beneath the dura).



CEREBRAL ARTERIOGRAPHY

The technique of cerebral arteriography is used to detect abnormalities of the cerebral arteries and localization of space-occupying lesions such as tumors, blood clots, or abscesses.

With the patient under general anesthesia and in the supine position, the head is centered on a radiographic apparatus that will take repeated radiographs at 2-second intervals. Both anteroposterior and lateral projections are obtained. A radiopaque medium is rapidly injected into the lumen of the common carotid or vertebral arteries. As the radiopaque material is introduced, a series of films are exposed. By this means the cerebral arteries can be demonstrated and their position and patency determined (CD Figs. 14-4 to 14-7).



CD Figure 14-4 Lateral internal carotid arteriogram.

This technique is not without risk because the insertion of a needle through the wall of an artery or the manipulation of a catheter within its lumen may dislodge an atheromatous plaque, leading to cerebral embolism.

Congenital Aneurysms

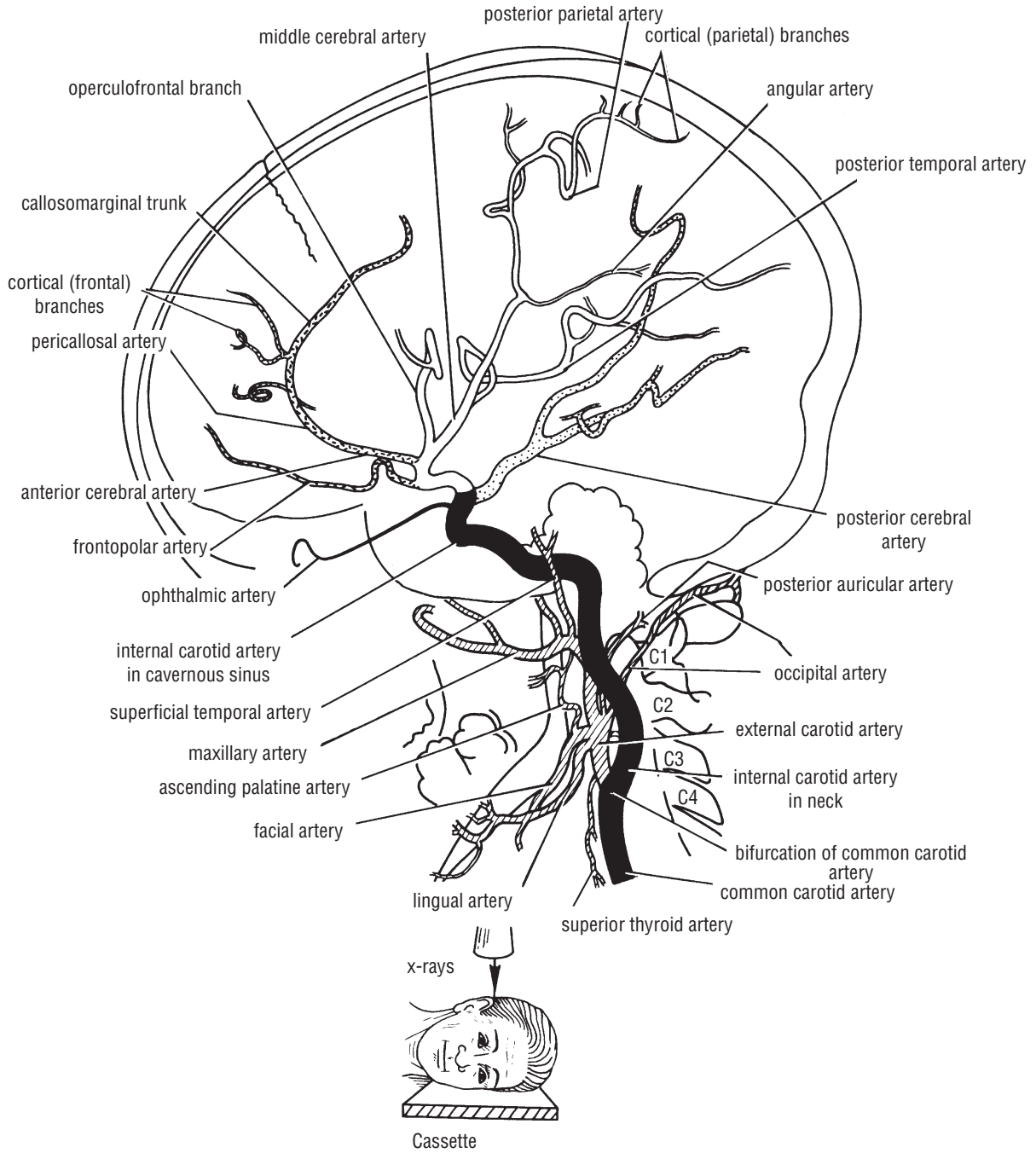
Congenital aneurysms occur most commonly at the site where two arteries join in the formation of the circle of Willis (CD Fig. 14-8). At this point, there is a deficiency in the tunica media that so weakens the arterial wall that an aneurysm develops. The enlarging aneurysm may press on neighboring structures, such as the optic, oculomotor, trochlear, and abducent nerves, and produce signs and symptoms or may suddenly rupture into the subarachnoid space.

Subarachnoid Hemorrhage

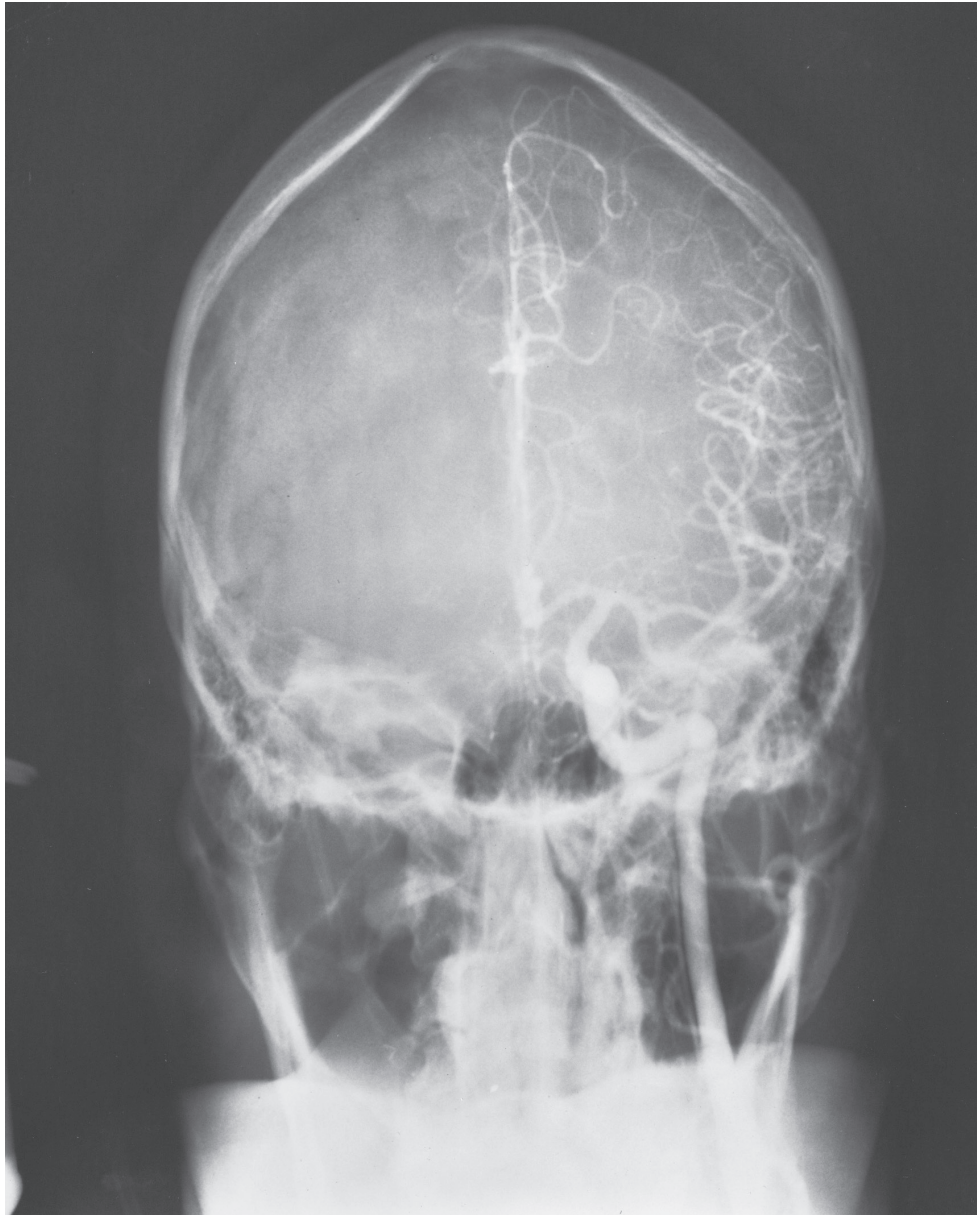
Subarachnoid hemorrhage results from leakage or rupture of a congenital aneurysm on the circle of Willis or, less commonly, from an angioma. The symptoms, which are sudden in onset, include severe headache, stiffness of the neck, and loss of consciousness. The diagnosis is established by withdrawing heavily blood-stained cerebrospinal fluid through a lumbar puncture (spinal tap).

Cerebral Hemorrhage

Cerebral hemorrhage is generally caused by rupture of the thin-walled lenticulostriate artery, a branch of the middle



CD Figure 14-5 Main features that can be seen in the arteriogram in CD Fig. 14-4.



CD Figure 14-6 Anteroposterior internal carotid arteriogram.

cerebral artery. The hemorrhage involves the vital corticobulbar and corticospinal fibers in the internal capsule and produces hemiplegia on the opposite side of the body. The patient immediately loses consciousness, and the paralysis is evident when consciousness is regained.

Cerebral Ischemia

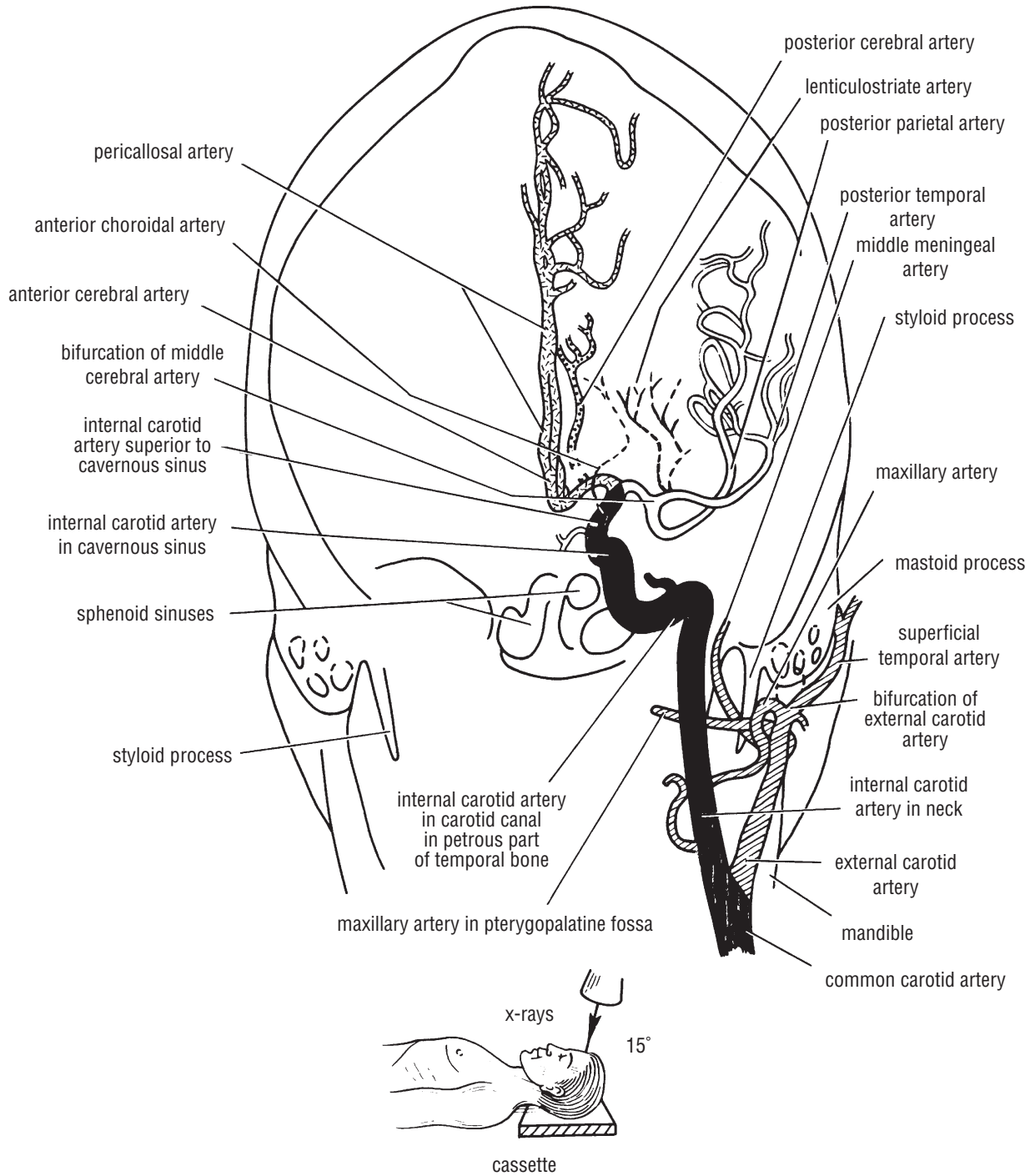
It has been pointed out that there are two distinct yet interconnected vascular systems supplying the brain. The carotid arteries are the major suppliers of the cerebral hemispheres, and the basilar and vertebral arteries are the major suppliers of the brainstem and cerebellum. The neurologic deficit fol-

lowing blockage of one of the intracranial vessels will depend on the location of the blockage and the status of the collateral circulation. The blood supply to the functional areas of the cerebral cortex is shown in text Fig. 14-17.

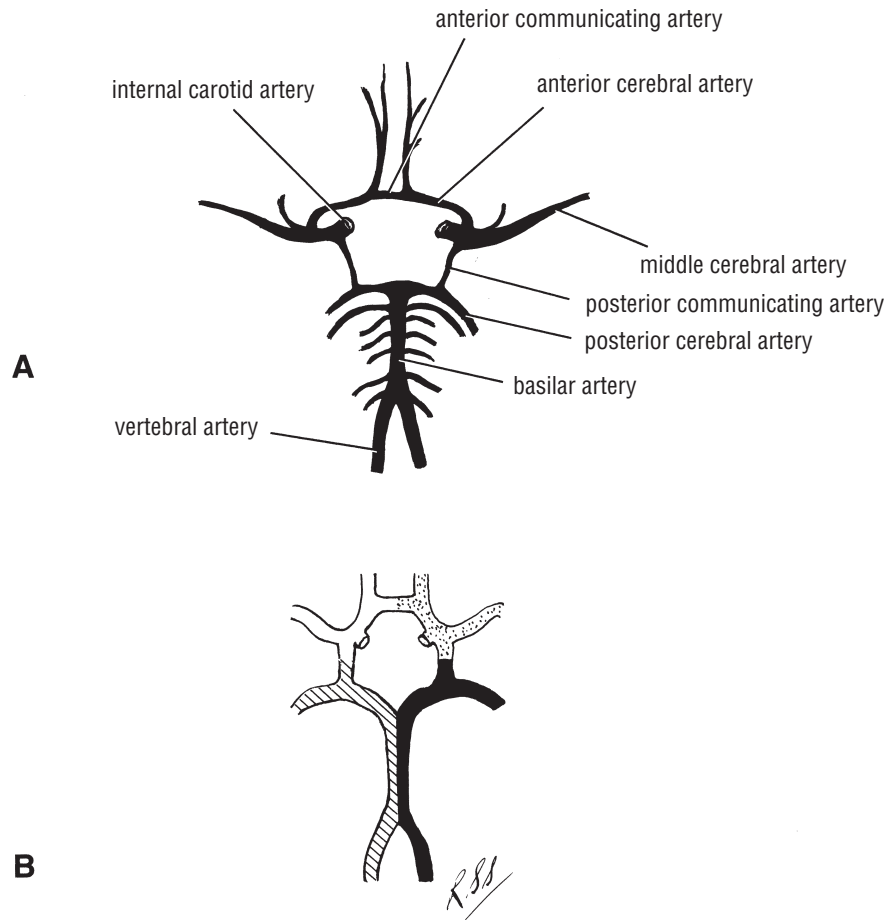
Cerebral Artery Occlusion

Anterior Cerebral Artery Occlusion

If the occlusion of the artery is proximal to the anterior communicating artery, the collateral circulation is usually adequate to preserve the circulation. Occlusion distal to the communicating artery may produce the following signs and



CD Figure 14-7 Main features that can be seen in the arteriogram in CD Fig. 14-6.



CD Figure 14-8 **A.** The formation of the circle of Willis from the two internal carotid and two vertebral arteries. **B.** The distribution of blood from the four main arteries.

symptoms:

- Contralateral hemiparesis and hemisensory loss involving mainly the leg and foot
- Inability to identify objects correctly, apathy, and personality changes

Middle Cerebral Artery Occlusion

Occlusion of the artery may produce the following signs and symptoms.

- Contralateral hemiparesis and hemisensory loss
- Aphasia if the left hemisphere is affected (rarely if the right hemisphere is affected)
- Homonymous hemianopia
- Anosognosia if the right hemisphere is affected (rarely if the left hemisphere is affected)

Internal Carotid Artery Occlusion

This may produce all the symptoms and signs of anterior and middle cerebral artery occlusion, depending on the degree of collateral circulation at the circle of Willis; in addition,

the following may be seen:

- Loss of vision on the same side as the internal carotid artery occlusion due to blockage of the ophthalmic artery
- Decreased level of consciousness

Vertebral Artery Occlusion

This produces a variable clinical picture and may include the following signs and symptoms:

- Ipsilateral pain and temperature sensory loss of the face and contralateral pain and temperature sensory loss of the body
- Ipsilateral loss of the gag reflex, dysphagia, and hoarseness as the result of lesions of the nuclei of the glossopharyngeal and vagus nerves
- Vertigo, nystagmus, nausea, and vomiting
- Ipsilateral Horner's syndrome
- Ipsilateral ataxia

If the lesion is more extensive, the corticospinal tracts may be involved, producing contralateral hemiparesis of the body. Contralateral loss of position and vibration sense may also be lost due to damage to the medial lemniscus.

Basilar Artery Occlusion

Since this artery gives off numerous branches to the pons, cerebellar peduncles, and cerebellum, total blockage of this artery can produce lesions of the trigeminal, abducent, and facial nerve nuclei, quadriplegia, and coma (reticular formation). If occlusion is restricted to branches of the basilar artery, there may be contralateral hemiparesis, contralateral sensory loss, or evidence of cerebellar dysfunction.

Central Branch Artery Occlusion

Small artery occlusion will cause discrete areas of brain necrosis. The signs and symptoms produced will obviously depend on the area involved. For example, a lesion of the internal capsule may result in contralateral hemiplegia.

Transient Ischemic Attacks

These are brief, self-limited focal neurologic deficits caused by embolic or thrombotic occlusion of arteries supplying the brain. The signs and symptoms will depend on the area of brain involved.

For further information on the clinical neuroanatomy of this area, please consult *Clinical Neuroanatomy*, 6th ed., by R.S. Snell, Lippincott Williams & Wilkins.

Hydrocephalus

Hydrocephalus is an abnormal increase in the volume of the cerebrospinal fluid within the skull. If hydrocephalus is accompanied by raised cerebrospinal fluid pressure, it is caused by either (1) an abnormal increase in fluid formation, (2) blockage of the fluid circulation, or (3) diminished absorption of the fluid. Rarely, hydrocephalus occurs with normal cerebrospinal fluid pressure, and in these patients compensatory hypoplasia or atrophy of the brain substance exists.

When the block of the movement of cerebrospinal fluid lies within the brain, the hydrocephalus is the **noncommunicating** type (i.e., the cerebrospinal fluid inside the brain does not communicate with that on the outside). If the fluid is able to pass through the roof of the fourth ventricle into

the subarachnoid space and cannot be absorbed by the arachnoid villi, the hydrocephalus is the **communicating** type (i.e., the cerebrospinal fluid inside the brain communicates with that on the outside).

Hydrocephalus Resulting from Excessive Formation of Cerebrospinal Fluid

This condition is rare and may occur when there is a tumor of the choroid plexuses.

Hydrocephalus Resulting from Blockage of Cerebrospinal Fluid Circulation

An obstruction of the interventricular foramen by a tumor will block the drainage of the lateral ventricle on that side. The continued production of cerebrospinal fluid by the choroid plexus of that ventricle will cause distention of that ventricle and atrophy of the surrounding neural tissue.

An obstruction in the cerebral aqueduct in the mid-brain may be congenital or result from inflammation or pressure from a tumor. This causes a symmetrical distension of both lateral ventricles and distension of the third ventricle.

Obstruction of the foramina in the roof of the fourth ventricle by inflammatory exudate, or by tumor growth, will produce symmetrical dilatation of both lateral ventricles and the third and fourth ventricle.

Sometimes inflammatory exudate secondary to meningitis will block the subarachnoid space and obstruct the flow of cerebrospinal fluid over the outer surface of the cerebral hemispheres. Here, again, the entire ventricular system of the brain will become distended.

Hydrocephalus Resulting from Diminished Absorption of Cerebrospinal Fluid

Interference with the absorption of cerebrospinal fluid at the arachnoid granulations can be caused by inflammatory exudate, venous thrombosis or pressure on the venous sinuses, or obstruction of the internal jugular vein.

Clinical Problem Solving Questions

Read the following case histories/questions and give the best answer for each.

1. A 36-year-old man was admitted to the emergency department unconscious. He had been hit on the side of the head by a taxi while crossing the road. On examina-

tion, he was found to have a dough-like swelling over the right temporalis muscle. He also had the signs of right-sided hemiplegia. Later, a right-sided, fixed, dilated pupil developed. **A lateral radiograph of the skull showed** a linear fracture running downward and forward across the right pterion. His coma deepened, and he died 6 hours

- after the accident. Using your knowledge of anatomy, make the diagnosis. Explain the clinical findings. How would you explain the homolateral hemiplegia?
2. Severe injury to the soft structures within the skull may follow head trauma. What structures exist within the skull to limit damage to the cerebral hemispheres and other parts of the brain? Which blood vessels are damaged more commonly, the cerebral arteries or the cerebral veins? Which cranial nerves are likely to be damaged in head injuries? What is the reason for their susceptibility?
 3. A 51-year-old woman was examined in the emergency department complaining of a severe headache. She said that the headache had started about 1 hour after she had hit her head on the mantle piece of a fireplace after bending down to poke the fire. Four hours later it was noticed that she was becoming mentally confused and was developing a left-sided hemiplegia on the side opposite the head injury. Her deep reflexes were exaggerated, and she had a positive Babinski response on the left side. A CT scan demonstrated a right subdural hematoma. Explain in anatomic terms the development of a subdural hematoma.
 4. Which part of the base of the skull is most prone to fracture? Can you give an anatomic reason for this answer?
 5. It is not uncommon to read in newspapers of the survival of a baby that has fallen from a great height, such as a third-floor window, and yet it is known that if an adult falls from a similar height, it would be fatal. Can you give an anatomic explanation, based on age, for this difference in survival?
 6. Using your knowledge of the anatomic pathways along which the cerebrospinal fluid flows, name the sites at which pathologic blockage may occur.
 7. There are no anastomoses of clinical importance between the terminal end arteries within the brain substance, but there are many important anastomoses between the large arteries, both within and outside the skull, and these may play a major role in determining the extent of brain damage in cerebral vascular disease. Name the sites at which important arterial anastomoses take place.
 8. A 35-year-old man was seen in the emergency department with a history of sudden excruciating, generalized headache while gardening. Ten minutes later the patient collapsed to the ground in a state of unconsciousness. After being carried indoors and placed on a settee, he regained consciousness but appeared confused. He complained of a severe headache and a stiff neck. Physical examination revealed some rigidity of the neck but nothing further. A careful neurologic examination 4 days later revealed some loss of tone of the muscles of the left leg. Using your knowledge of anatomy, make a diagnosis. What caused the neck rigidity?

Answers and Explanations


1. The initial loss of consciousness was due to cerebral trauma. The swelling over the right temporalis muscle and the radiographic finding of a linear fracture over the anterior inferior angle of the right parietal bone (pterion) would suggest that the right middle meningeal artery had been damaged and an extradural hemorrhage had occurred. Blood had extravasated through the fracture line into the overlying temporalis muscle and soft tissue. **The right homolateral hemiplegia was due to** the compression of the left cerebral peduncle against the edge of the tentorial notch of the tentorium cerebelli. This is unusual. A left hemiplegia due to pressure on the right precentral gyrus is more common.
The right-sided, fixed, dilated pupil was due to the pressure on the right oculomotor nerve by the hippocampal gyrus, which had herniated through the tentorial notch.
2. The meninges and the cerebrospinal fluid afford a remarkable degree of protection to the brain tissue. The dural partitions limit the extent of side-to-side, forward and backward, and rotation movements of the brain within the skull.

The thin-walled cerebral veins are liable to be damaged during excessive movements of the brain relative to the skull, especially at the point where the veins join the dural venous sinuses. The thick-walled cerebral arteries are rarely damaged.

The small-diameter cranial nerves of long length are particularly prone to damage during head injuries. The trochlear, abducent, and oculomotor nerves are commonly injured.
3. A subdural hematoma is an accumulation of blood clot in the interval between the meningeal layer of dura and the arachnoid mater. It results from tearing of the supe-

rior cerebral veins at their point of entrance into the superior sagittal sinus. The cause is usually a blow to the front or the back of the head (which may be minor), resulting in excessive anteroposterior displacement of the brain within the skull.

4. The middle cranial fossa is the part of the skull most prone to fracture, since it possesses numerous foramina and canals and has air spaces, namely, the sphenoid air sinus and the tympanic cavity. The foramen magnum in the posterior cranial fossa is very large but its boundaries are extremely thick.
5. In infants the skull bones are more resilient than in adults, and they are separated by fibrous sutural ligaments. In adults the inner table of the skull is particularly brittle and the sutural ligaments begin to ossify during middle age.
6. The common sites for blockage of the flow of cerebrospinal fluid are where the passages are narrowest, namely, the interventricular foramina (between the lateral and third ventricles), the cerebral aqueduct of the midbrain, the median aperture, and the lateral apertures in the roof of the fourth ventricle. It is possible for inflammatory exudate secondary to meningitis or a cerebral tumor to narrow down or even obliterate the opening in the tentorial notch so that the passage of the cerebrospinal fluid to the outer surface of the cerebral hemisphere is impeded or stopped. Inflammatory exudate may also block the drainage of the fluid into the superior sagittal sinus at the arachnoid villi.
7. Once the terminal branches of the cerebral arteries enter the brain substance, no further anastomoses occur. Blockage of such end arteries by disease is quickly followed by neuronal death and necrosis. The following important anastomoses exist between the cerebral arteries: (1) the circle of Willis, (2) anastomoses between the branches of the cerebral arteries on the surface of the cerebral hemispheres and the cerebellar hemispheres, and (3) anastomoses between the branches of the internal and external carotid arteries at their origin at the common carotid artery, at the anastomosis between the branches of the ophthalmic artery within the orbit and the facial and maxillary arteries, and between the meningeal branches of the internal carotid artery and the middle meningeal artery.
8. This patient had a congenital aneurysm of the anterior communicating artery. The sudden onset of a severe headache, which is often so dramatic that the patient feels as though he has been hit on the head, is characteristic of rupture of a congenital aneurysm into the subarachnoid space. The stiff or rigid neck is due to meningeal irritation caused by the presence of blood in the subarachnoid space. This patient had no evidence of previous pressure on the optic nerve leading to unilateral visual defect, which sometimes occurs when the aneurysm is situated on the anterior part of the circle of Willis. The loss of tone in the left leg muscles is difficult to explain, although it may be due to penetration of the hemorrhage into the right cerebral hemisphere.




15

The Cranial Nerves and Trigeminal Nerve Blocks



Chapter Outline

Clinical Testing of the Cranial Nerves	227		
Testing the Integrity of the Olfactory Nerve	227		
Testing the Integrity of the Optic Nerve	227		
Testing the Integrity of the Oculomotor, Trochlear, and Abducent Nerves	227		
Testing the Integrity of the Trigeminal Nerve	227		
Testing the Integrity of the Facial Nerve	228		
Testing the Integrity of the Vestibulocochlear Nerve	229		
Testing the Integrity of the Glossopharyngeal Nerve	229		
Testing the Integrity of the Vagus Nerve	229		
Testing the Integrity of the Accessory Nerve	229		
Testing the Integrity of the Hypoglossal Nerve	229		
Clinical Anatomy of Trigeminal Nerve Blocks	229		
Ophthalmic Nerve Block	229		
Supraorbital Nerve Block	230		
<i>Area of Anesthesia</i>	230		
<i>Indications</i>	230		
<i>Procedure</i>	230		
Supratrochlear Nerve Block	231		
<i>Area of Anesthesia</i>	231		
<i>Indications</i>	231		
<i>Procedure</i>	231		
Infratrochlear Nerve Block	232		
<i>Area of Anesthesia</i>	232		
<i>Indications</i>	232		
<i>Procedure</i>	232		
External Nasal Nerve Block	232		
<i>Area of Anesthesia</i>	232		
<i>Indications</i>	232		
<i>Procedure</i>	232		
Maxillary Nerve Block	232		
Infraorbital Nerve Block	232		
<i>Area of Anesthesia</i>	232		
<i>Indications</i>	232		
<i>Procedure</i>	233		
Intraoral Method	233		
Extraoral Method	233		
Pterygopalatine Ganglion Block	233		
<i>Area of Anesthesia</i>	233		
<i>Indications</i>	233		
<i>Procedure</i>	234		
Mandibular Nerve Block	234		
Auriculotemporal Nerve Block	234		
<i>Area of Anesthesia</i>	234		
<i>Indications</i>	234		
<i>Procedure</i>	234		
Anatomy of Complications	235		
Lingual Nerve and Inferior Alveolar Nerve Blocks	235		
<i>Area of Anesthesia</i>	235		
<i>Indications</i>	235		
<i>Procedure</i>	235		
Mental Nerve Block	236		
<i>Area of Anesthesia</i>	236		
<i>Indications</i>	236		
<i>Procedure</i>	236		
Intraoral Method	236		
Extraoral Method	237		
Special Areas for Nerve Blocks	237		
Tooth Nerve Blocks	237		
<i>Supraperiosteal Infiltration</i>	237		
<i>Dental Nerve Blocks</i>	238		
Anesthesia of the Nose	238		
<i>Nasal Interior</i>	238		
<i>Nasal Exterior</i>	238		
Anesthesia of the Ear	240		
Anesthesia of the Scalp	240		
Clinical Problem Solving Questions	240		
Answers and Explanations	242		



CLINICAL TESTING OF THE CRANIAL NERVES

Systematic examination of the 12 cranial nerves is an important part of the examination of every neurologic patient. It may reveal a lesion of a cranial nerve nucleus or its central connections, or it may show an interruption of the lower motor neurons.

The letter symbols commonly used to indicate the functional components of each cranial nerve are shown in text Table 15-1. The different components of the cranial nerves, their functions, and the openings in the skull through which the nerves leave the cranial cavity are summarized in text Table 15-2.

Testing the Integrity of the Olfactory Nerve

The olfactory nerve can be tested by applying substances with different odors to each nostril in turn. It should be remembered that food flavors depend on the sense of smell and not on the sense of taste. Fractures of the anterior cranial fossa or cerebral tumors of the frontal lobes may produce lesions of the olfactory nerves, with consequent loss of the sense of smell (anosmia).

Testing the Integrity of the Optic Nerve

The optic nerve is evaluated by first asking the patient whether any changes in eyesight have been noted. The acuity of vision is then tested by using charts with lines of print of varying size. The retinas and optic discs should then be examined with an ophthalmoscope. When examining the optic disc, it should be remembered that the intracranial subarachnoid space extends forward around the optic nerve to the back of the eyeball. The retinal artery and vein run in the optic nerve and cross the subarachnoid space of the nerve sheath a short distance behind the eyeball. A rise in cerebrospinal fluid pressure in the subarachnoid space will compress the thin walls of the retinal vein as it crosses the space, resulting in congestion of the retinal veins, edema of the retina, and bulging of the optic disc (papilledema).

The visual fields should then be tested. The patient is asked to gaze straight ahead at a fixed object with the eye being tested, with the opposite eye covered. A small object is then moved in an arc around the periphery of the field of vision, and the patient is asked whether he or she can see the

object. It is important not to miss loss or impairment of vision in the central area of the field (central scotoma).

Blindness in one half of each visual field is called hemianopia. Lesions of the optic tract and optic radiation produce the same hemianopia for both eyes, that is, homonymous hemianopia. Bitemporal hemianopia is a loss of the lateral halves of the fields of vision of both eyes (i.e., loss of function of the medial half of both retinas). This condition is most commonly produced by a tumor of the pituitary gland exerting pressure on the optic chiasma.

Testing the Integrity of the Oculomotor, Trochlear, and Abducent Nerves

The oculomotor, trochlear, and abducent nerves innervate the muscles that move the eyeball. The oculomotor nerve supplies all the orbital muscles except the superior oblique and the lateral rectus. It also supplies the levator palpebrae superioris and the smooth muscles concerned with accommodation—namely, the sphincter pupillae and the ciliary muscle. The trochlear nerve supplies the superior oblique muscle, and the abducent nerve supplies the lateral rectus.

To examine the ocular muscles, the patient's head is fixed and he or she is asked to move the eyes in turn to the left, to the right, upward, and downward, as far as possible in each direction.

In complete third-nerve paralysis the eye cannot be moved upward, downward, or inward. At rest the eye looks laterally (external strabismus) because of the activity of the lateral rectus and downward because of the activity of the superior oblique. The patient sees double (diplopia). Drooping of the upper eyelid (ptosis) occurs because of paralysis of the levator palpebrae superioris. The pupil is widely dilated and nonreactive to light because of the paralysis of the sphincter pupillae and the unopposed action of the dilator pupillae (supplied by the sympathetic). Accommodation of the eye is paralyzed.

In fourth-nerve paralysis the patient complains of double vision on looking straight downward. This is because the superior oblique is paralyzed and the eye turns medially as the inferior rectus pulls the eye downward.

In sixth-nerve paralysis the patient cannot turn the eyeball laterally. When looking straight ahead, the lateral rectus is paralyzed, and the unopposed medial rectus pulls the eyeball medially, causing internal strabismus.

Testing the Integrity of the Trigeminal Nerve

The trigeminal nerve has sensory and motor roots. The sensory root passes to the trigeminal ganglion, from which

emerge the ophthalmic (V1), maxillary (V2), and mandibular (V3) divisions. The motor root joins the mandibular division.

The sensory function can be tested by using a cotton wisp over each area of the face supplied by the divisions of the trigeminal nerve (CD Fig. 15-1).

The motor function can be tested by asking the patient to clench the teeth. The masseter and the temporalis muscles, which are innervated by the mandibular division of the trigeminal nerve, can be palpated and felt to harden as they contract.

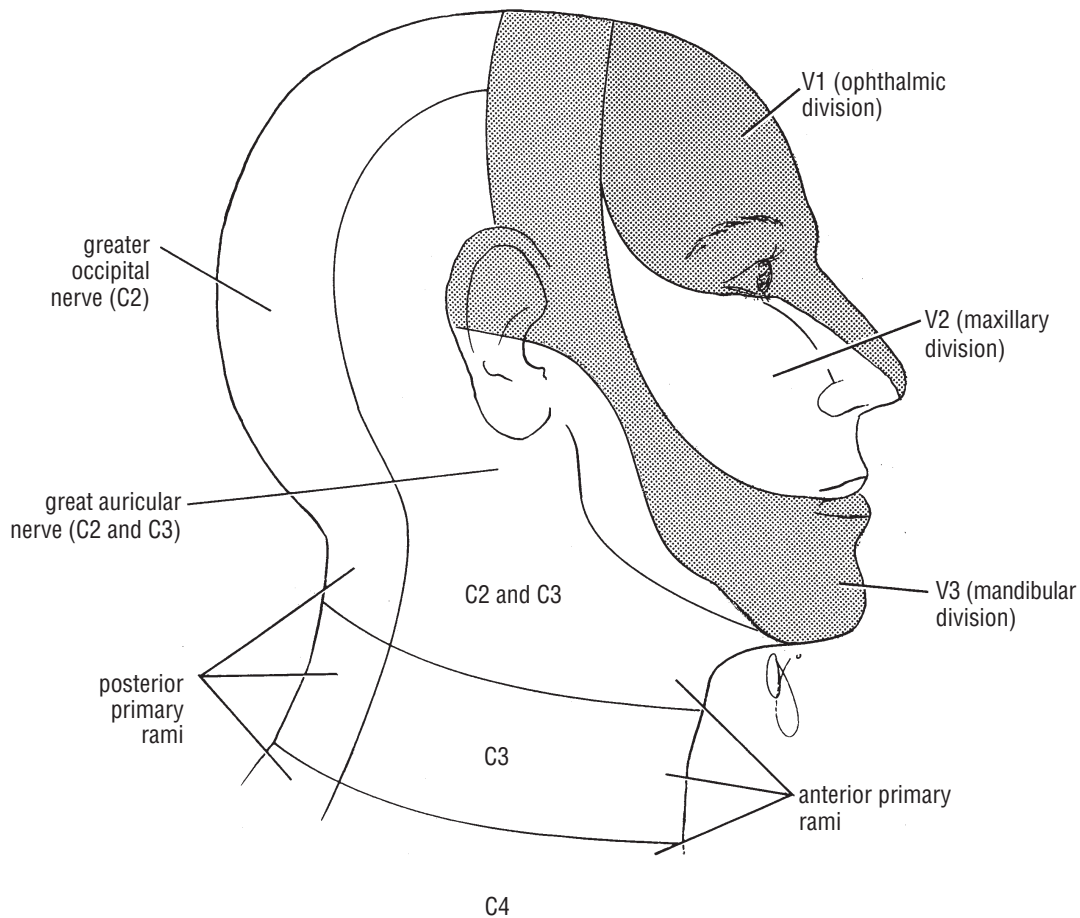
Testing the Integrity of the Facial Nerve

The facial nerve supplies the muscles of facial expression; supplies the anterior two thirds of the tongue with taste fibers; and is secretomotor to the lacrimal, submandibular, and sublingual glands.

The anatomic relationship of this nerve to other structures enables a physician to localize lesions of the nerve accurately. If the sixth and seventh nerves are not functioning, this would suggest a lesion within the pons of the brain. If the eighth and seventh nerves are not functioning, this would suggest a lesion in the internal acoustic meatus. If the patient is excessively sensitive to sound in one ear, the lesion probably involves the nerve to the stapedius. Loss of taste over the anterior two thirds of the tongue implies that the seventh nerve is damaged proximal to the point where it gives off the chorda tympani.

To test the facial nerve, the patient is asked to show the teeth by separating the lips with the teeth clenched, and then to close the eyes. Taste on each half of the anterior two thirds of the tongue can be tested with sugar, salt, vinegar, and quinine for the sweet, salty, sour, and bitter sensations, respectively.

It should be remembered that the part of the facial nerve nucleus that controls the muscles of the upper part of the face receives corticobulbar fibers from both cerebral



CD Figure 15-1 The facial cutaneous distribution of the ophthalmic (V1), maxillary (V2), and mandibular (V3) divisions of the trigeminal nerve. Note that the skin over the angle of the jaw is supplied by the great auricular nerve (C2 and C3 segments of the spinal cord).

cortices. Therefore, in patients with an upper motor neuron lesion, only the muscles of the lower part of the face will be paralyzed. However, in patients with a lower motor neuron lesion, all the muscles on the affected side of the face will be paralyzed. The lower eyelid will droop, and the angle of the mouth will sag. Tears will flow over the lower eyelid, and saliva will dribble from the corner of the mouth. The patient will be unable to close the eye and cannot expose the teeth fully on the affected side.

Testing the Integrity of the Vestibulocochlear Nerve

The vestibulocochlear nerve innervates the utricle and saccule, which are sensitive to static changes in equilibrium; the semicircular canals, which are sensitive to changes in dynamic equilibrium; and the cochlea, which is sensitive to sound.

Disturbances of vestibular function include dizziness (vertigo) and nystagmus. The latter is an uncontrollable pendular movement of the eyes. Disturbances of cochlear function reveal themselves as deafness and ringing in the ears (tinnitus). The patient's ability to hear a voice or a tuning fork should be tested, with each ear tested separately.

Testing the Integrity of the Glossopharyngeal Nerve

The glossopharyngeal nerve supplies the stylopharyngeus muscle and sends secretomotor fibers to the parotid gland. Sensory fibers innervate the posterior one third of the tongue.

The integrity of this nerve may be evaluated by testing the patient's general sensation and that of taste on the posterior third of the tongue.

Testing the Integrity of the Vagus Nerve

The vagus nerve innervates many important organs, but the examination of this nerve depends on testing the function of the branches to the pharynx, soft palate, and larynx. The pharyngeal reflex may be tested by touching the lateral wall of the pharynx with a spatula. This should immediately cause the patient to gag—that is, the pharyngeal muscles will contract.

The innervation of the soft palate can be tested by asking the patient to say “ah.” Normally, the soft palate rises and the uvula moves backward in the midline.

All the muscles of the larynx are supplied by the recurrent laryngeal branch of the vagus, except the cricothyroid

muscle, which is supplied by the external laryngeal branch of the superior laryngeal branch of the vagus. Hoarseness or absence of the voice may occur. Laryngoscopic examination may reveal abductor paralysis.

Testing the Integrity of the Accessory Nerve

The accessory nerve supplies the sternocleidomastoid and the trapezius muscles by means of its spinal part. The patient should be asked to rotate the head to one side against resistance, causing the sternocleidomastoid of the opposite side to come into action. Then the patient should be asked to shrug the shoulders, causing the trapezius muscles to come into action.

Testing the Integrity of the Hypoglossal Nerve

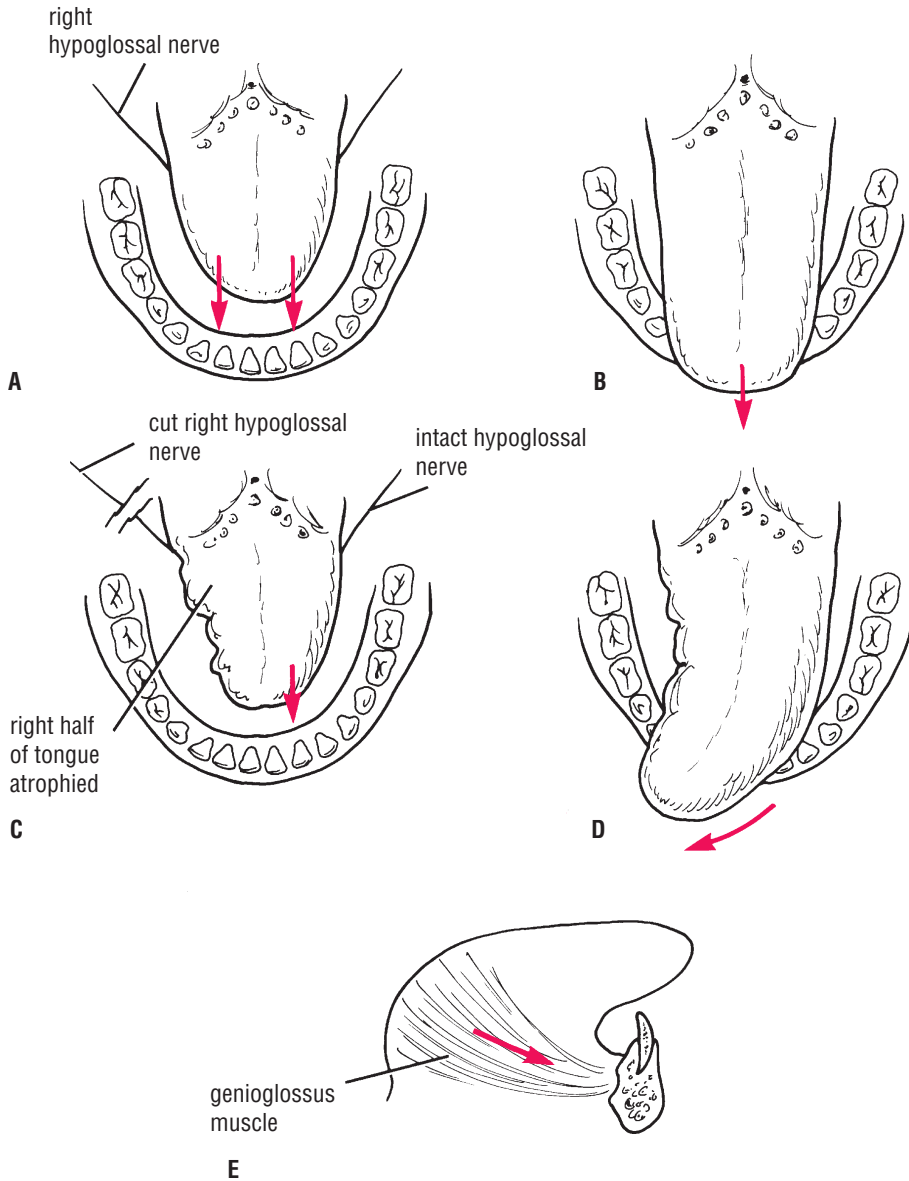
The hypoglossal nerve supplies the muscles of the tongue. The patient is asked to put out the tongue, and if a lesion of the nerve is present, it will be noted that the tongue deviates toward the paralyzed side (CD Fig. 15-2). This can be explained as follows. One of the genioglossus muscles, which pull the tongue forward, is paralyzed on the affected side. The other, normal genioglossus muscle pulls the unaffected side of the tongue forward, leaving the paralyzed side of the tongue stationary. The result is the tip of the tongue's deviation toward the paralyzed side. In patients with long-standing paralysis, the muscles on the affected side are wasted, and the tongue is wrinkled on that side.



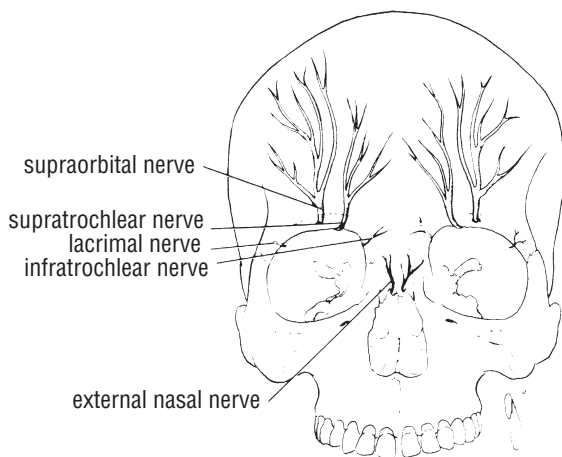
CLINICAL ANATOMY OF TRIGEMINAL NERVE BLOCKS

Ophthalmic Nerve Block

The terminal branches of the ophthalmic division of the trigeminal nerve that emerge onto the face and nose include the supraorbital, supratrochlear, infratrochlear, external nasal, and lacrimal nerves (CD Fig. 15-3). The latter nerve gives off only a few branches to the skin and is seldom blocked.



CD Figure 15-2 Diagrammatic representation of the action of the right and left genioglossus muscles of the tongue. **A.** The right and left muscles contract equally together and as a result **(B)** the tip of the tongue is protruded in the midline. **C.** The right hypoglossal nerve (which innervates the genioglossus muscle and the intrinsic tongue muscles on the same side) is cut and as a result the right side of the tongue is atrophied and wrinkled. **D.** When the patient is asked to protrude the tongue, the tip points to the side of the nerve lesion. **E.** The origin and insertion and direction of pull of the genioglossus muscle.



CD Figure 15-3 Anterior view of the skull showing the branches of the ophthalmic (V1) division of the trigeminal nerve emerging onto the face.

Supraorbital Nerve Block

This involves the following:

Area of Anesthesia

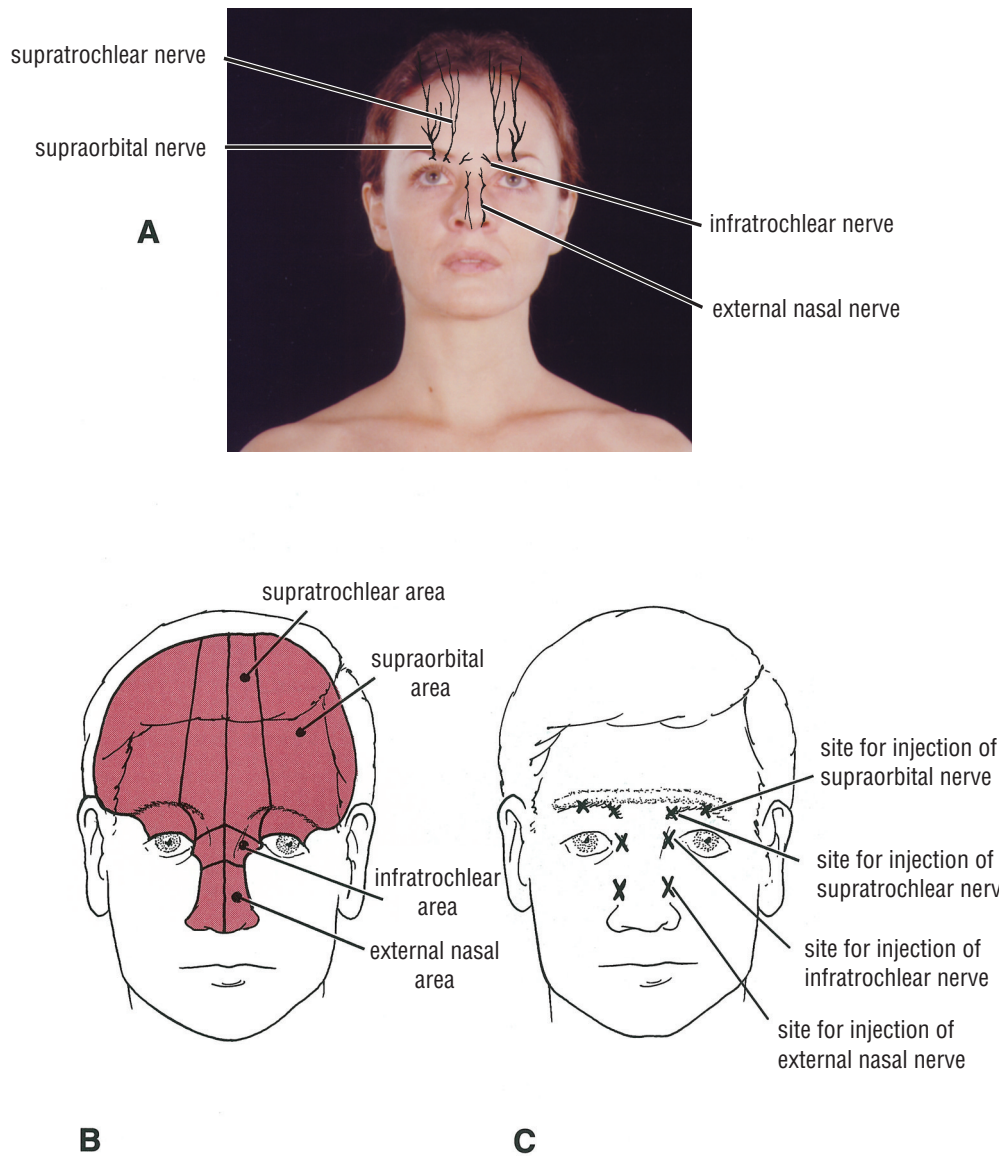
Skin of the upper eyelid, the forehead, and the scalp as far back as the vertex (CD Fig. 15-4)

Indications

Repair of lacerations of the upper eyelid, forehead, and scalp

Procedure

The supraorbital nerve emerges from the orbital cavity in the same vertical plane as the pupil when the patient is looking straight ahead (see CD Fig. 15-4). If the nerve passes through the supraorbital notch, this can easily be palpated on the



CD Figure 15-4 Supraorbital, supratrochlear, infratrochlear, and external nasal nerve blocks. **A.** The positions of the nerves on the face; the supraorbital nerve emerging from the orbital cavity in the same vertical plane as the pupil. **B.** The areas of skin anesthetized by blocking these nerves. **C.** Sites where the nerves may be blocked. The supraorbital and supratrochlear nerves may be blocked by raising a horizontal wheal of anesthetic solution above the orbital margin.

supraorbital margin, which is the site for injection. If the notch is a foramen, however, it is small and difficult to feel, and the needle is inserted into the skin over the supraorbital margin in line with the pupil.

Supratrochlear Nerve Block

This involves the following:

Area of Anesthesia

Skin of the upper eyelid and the lower forehead close to the midline (see CD Fig. 15-4)

Indications

Repair of lacerations of the medial end of the eyelid and the forehead close to the midline

Procedure

The supratrochlear nerve winds around the supraorbital margin about a fingerbreadth medial to the supraorbital nerve. The needle is inserted at the point where the bridge of the nose meets the supraorbital margin (see CD Fig. 15-4).

Infratrochlear Nerve Block

This involves the following:

Area of Anesthesia

Skin of the medial ends of the eyelids and the side of the root of the nose (see CD Fig. 15-4)

Indications

Repair of lacerations of the medial eyelids and the root of the nose

Procedure

The infratrochlear nerve emerges from the orbital cavity at the junction of the superior and medial walls, which is the site for injection (see CD Fig. 15-4).

External Nasal Nerve Block

This involves the following:

Area of Anesthesia

Skin of the side of the nose down as far as the tip (see CD Fig. 15-4)

Indications

Repair of lacerations of the skin of the nose

Procedure

The external nasal nerve is blocked at the point where it emerges between the nasal bone and the upper lateral nasal cartilage (see CD Fig. 15-4).

Maxillary Nerve Block

This block is not used in emergency medicine. The infraorbital nerve, which is a continuation of the maxillary nerve onto the face, is commonly blocked. Occasionally, the pterygopalatine ganglion is blocked.

Infraorbital Nerve Block

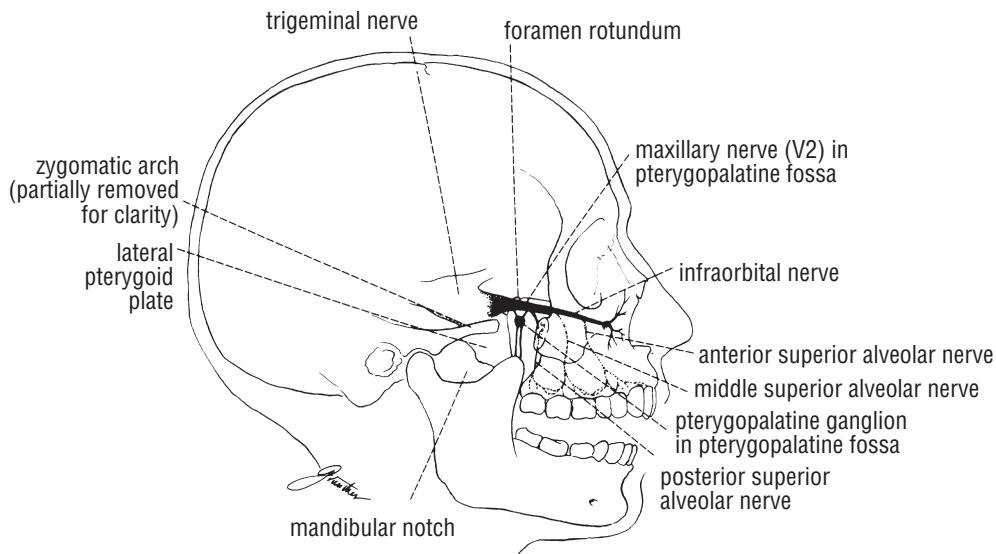
This involves the following:

Area of Anesthesia

Skin of the lower eyelid, the lateral nose, the cheek, and the skin and mucous membrane of the upper lip and the upper gingiva. Since the anesthetic agent also blocks the anterior and middle superior alveolar nerves, the upper incisor, canine, and premolar teeth are also affected (CD Fig. 15-5).

Indications

Lacerations of the cheek, side of the nose, and the upper lip



CD Figure 15-5 Lateral view of the skull showing the maxillary (V2) division of the trigeminal nerve leaving the trigeminal ganglion and passing forward to become the infraorbital nerve, which emerges on the face. Note the location of the pterygopalatine ganglion (parasympathetic) in the pterygopalatine fossa. Note also the sensory innervation of the teeth of the upper jaw.

Procedure

The infraorbital nerve emerges from the infraorbital foramen as a direct continuation of the maxillary nerve (CD Fig. 15-6). The opening of the foramen is situated about 1 cm below the midpoint of the lower border of the orbit and faces downward and medially.

Intraoral Method

With the index finger of the left hand palpating the infraorbital foramen through the skin of the cheek and serving as a guide, the needle is inserted into the reflection of the mucous membrane from the upper lip onto the gingiva (see CD Fig. 15-6). The site for the needle insertion is just posterior to the canine tooth and is directed upward to the infraorbital foramen.

Extraoral Method

The infraorbital foramen is palpated below the lower margin of the orbit, and the needle is inserted through the skin

and is directed upward and outward toward the foramen (see CD Fig. 15-6).

Pterygopalatine Ganglion Block

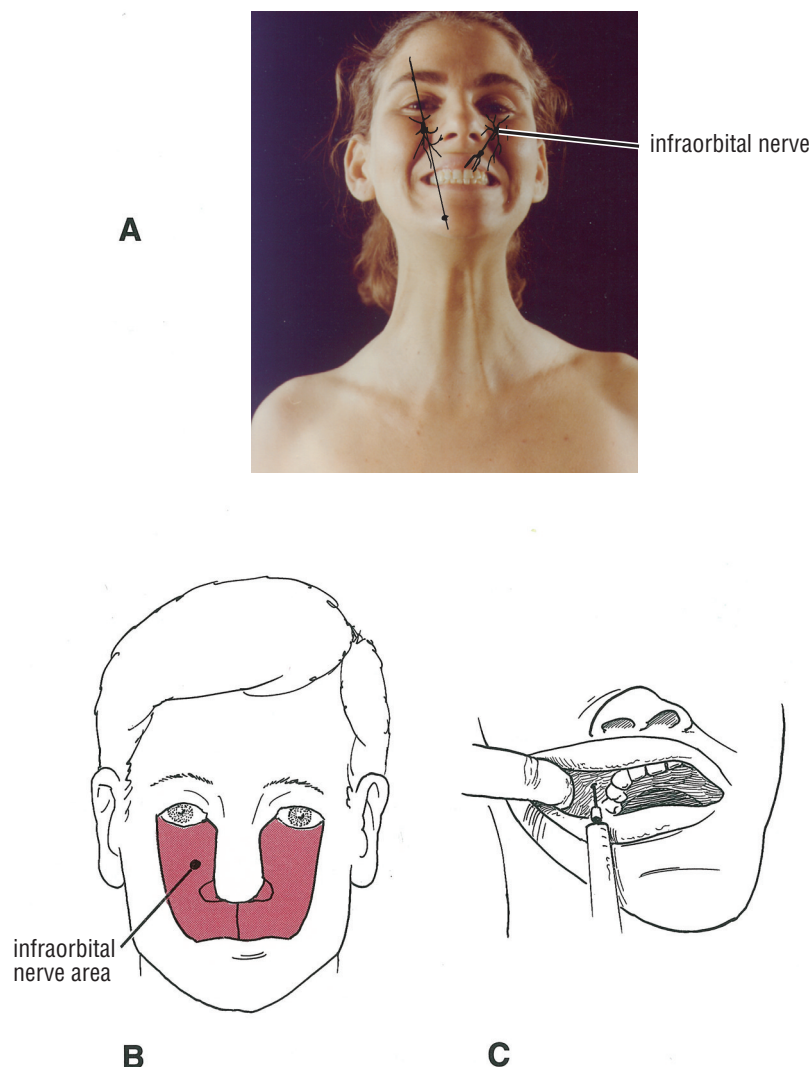
The pterygopalatine ganglion is a small parasympathetic ganglion and is suspended from the lower border of the maxillary nerve in the pterygopalatine fossa (CD Fig. 15-7). Passing through the ganglion without interruption are the sensory fibers from the orbit, the nose, the hard and soft palate, the gums, and the tonsillar region of the pharynx.

Area of Anesthesia

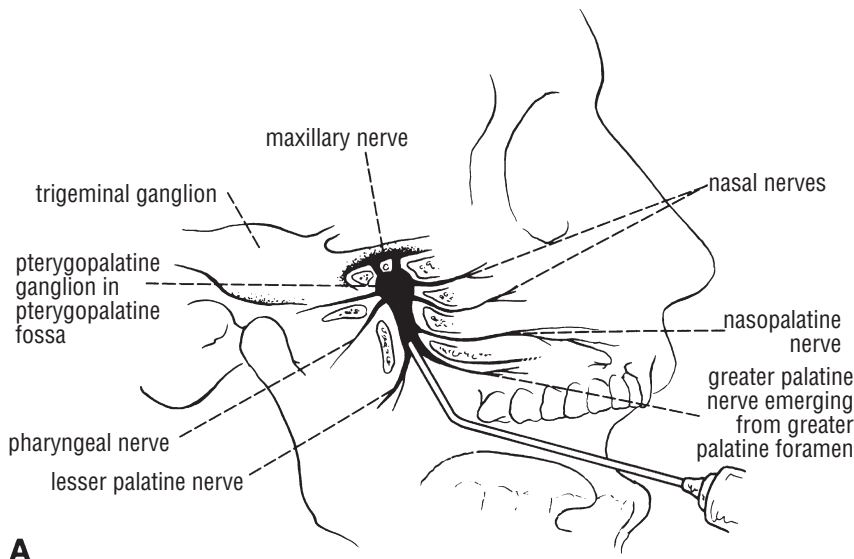
The lower nasal cavity, hard and soft palates, the upper gum, the teeth of the upper jaw, and the tonsillar region of the pharynx

Indications

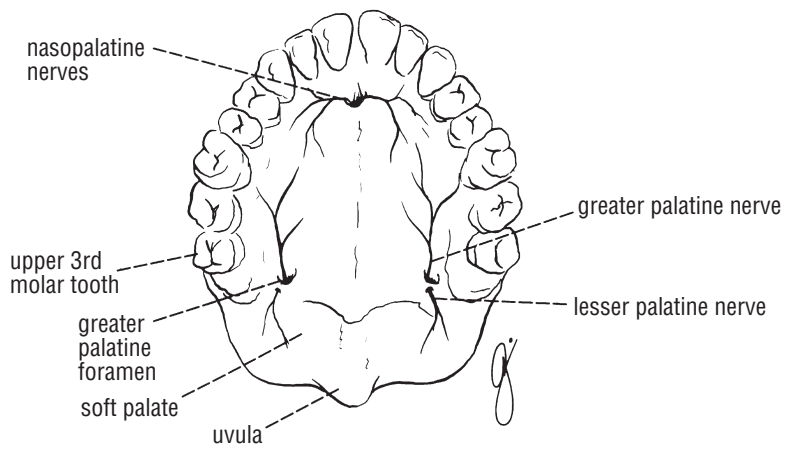
Repair of lacerations involving the palate



CD Figure 15-6 Infraorbital nerve block. **A.** Extraoral method shows the infraorbital nerve emerging from the infraorbital foramen. The infraorbital foramen lies on the same vertical line that passes through the supraorbital notch, the mental foramen, and the first premolar tooth. The blocking needle is inserted in the direction of the infraorbital foramen just below the lower margin of the orbit. **B.** The area of skin anesthetized by blocking the infraorbital nerve. **C.** Intraoral method. The needle is inserted into the reflection of the mucous membrane from the upper lip onto the gingiva just posterior to the canine tooth and is directed toward the infraorbital foramen.



A



B

CD Figure 15-7 Blocking the pterygopalatine ganglion. **A.** Lateral view of the skull showing the insertion of the needle into the greater palatine foramen in order to block the ganglion. **B.** The undersurface of the palate showing the position of the greater palatine foramen in relation to the upper third molar tooth and the soft palate. Note the distribution of the branches of the maxillary nerve through the ganglion to the walls of the nose and the palate.

Procedure

The ganglion and, therefore, the sensory fibers may be blocked by inserting a long-angled needle into the greater palatine foramen with the mouth wide open (see CD Fig. 15-7). The foramen is located at the posterior portion of the hard palate just medial to the gumline of the third molar tooth. The greater palatine foramen leads superiorly into the pterygopalatine fossa. Injection of the anesthetic blocks the greater and lesser palatine nerves, the orbital nerves, the nasal nerves, and the pharyngeal nerves.

Mandibular Nerve Block

This block is rarely used. However, the auriculotemporal nerve, the lingual nerve, and the inferior alveolar nerve, which are branches of the mandibular nerve, are commonly blocked.

Auriculotemporal Nerve Block

This involves the following:

Area of Anesthesia

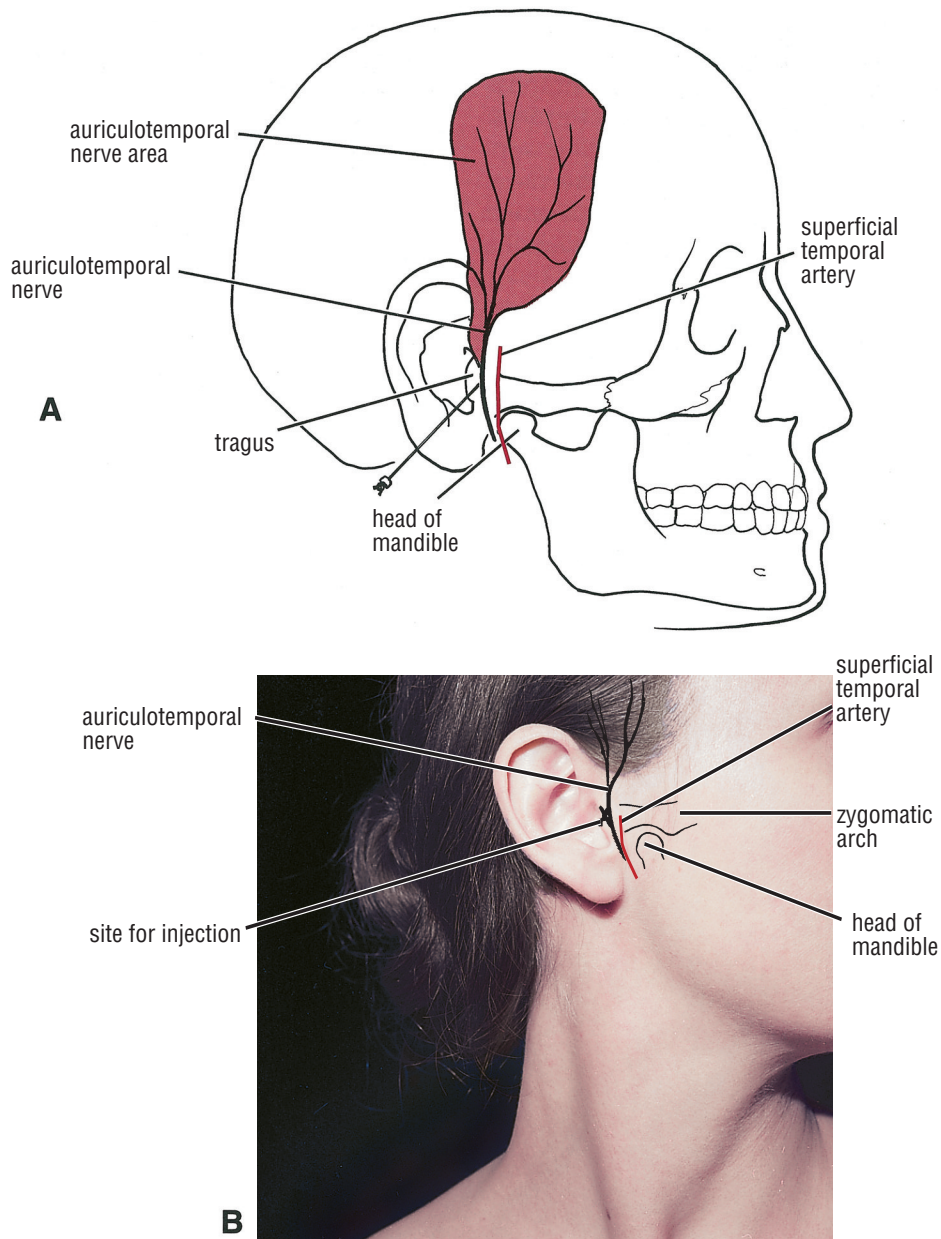
The external auditory meatus, the tympanic membrane, the upper part of the auricle, and the scalp in the temporal region (CD Fig. 15-8)

Indications

Repair of lacerations of the auricle and scalp

Procedure

The auriculotemporal nerve is easily blocked as it ascends in front of the auricle over the posterior root of the zygoma, behind the superficial temporal artery (see CD Fig. 15-8).



CD Figure 15-8 Blocking the auriculotemporal nerve. **A.** The relationship of the auriculotemporal nerve to the superficial temporal artery and the tragus of the ear. Note the area of skin supplied by this sensory nerve. The needle is inserted just behind the pulsating superficial temporal artery and in front of the tragus; the needle is directed horizontally medially. **B.** The surface marking of the auriculotemporal nerve and its relationship to the superficial temporal artery and the temporomandibular joint. **X** marks the site for injection.

Anatomy of Complications

The superficial temporal artery may be pierced if the needle is inserted too far anteriorly.

Lingual Nerve and Inferior Alveolar Nerve Blocks

These involve the following:

Area of Anesthesia

The lingual nerve supplies the mucous membrane of the anterior two thirds of the tongue and the floor of the mouth (taste is supplied by the chorda tympani branch of the facial nerve),

and the lower gums. The inferior alveolar nerve supplies the lower teeth and gums and the skin of the lower lip and chin.

Indications

Repair of lacerations of the tongue, floor of the mouth, and lower lip and chin

Procedure

Both the lingual and inferior alveolar nerves may be blocked as they pass downward and forward in the infratemporal fossa on the lateral surface of the medial pterygoid muscle and on the medial surface of the ramus of the mandible

(CD Fig. 15-9). With the patient's mouth wide open, the anterior border of the ramus of the mandible is palpated just above the third molar tooth. The blocking needle is inserted above the palpating finger and between the mucosa and the inner surface of the ramus of the mandible, and the barrel of the syringe lies in line with the interval between the bicuspids on the opposite side of the mandible (see CD Fig. 15-9). The needle is advanced posteriorly and slightly superiorly until the tip lies in close proximity to the mandibular foramen. The anesthetic solution will infiltrate around the nerves.

Mental Nerve Block

This involves the following:

Area of Anesthesia

The lower lip and gums

Indications

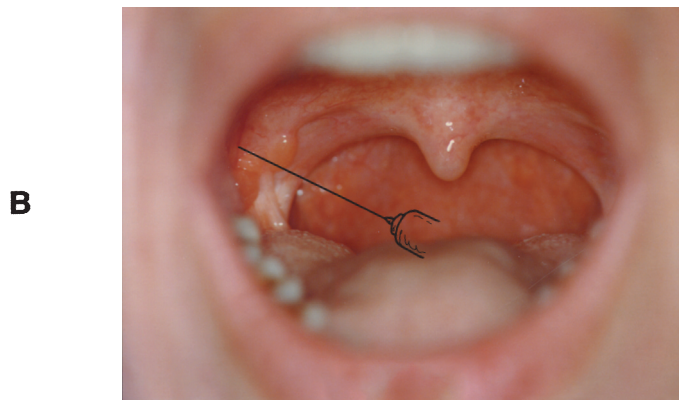
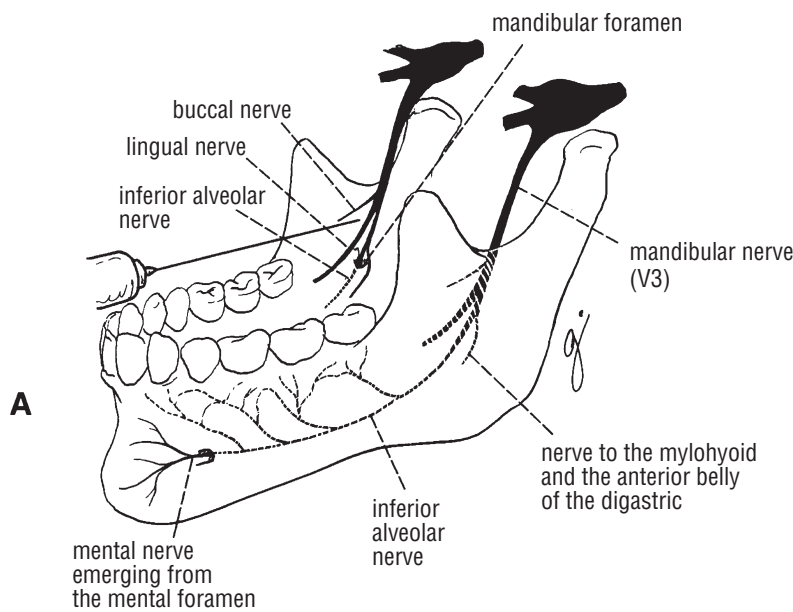
Repair of lacerations of the lower lip

Procedure

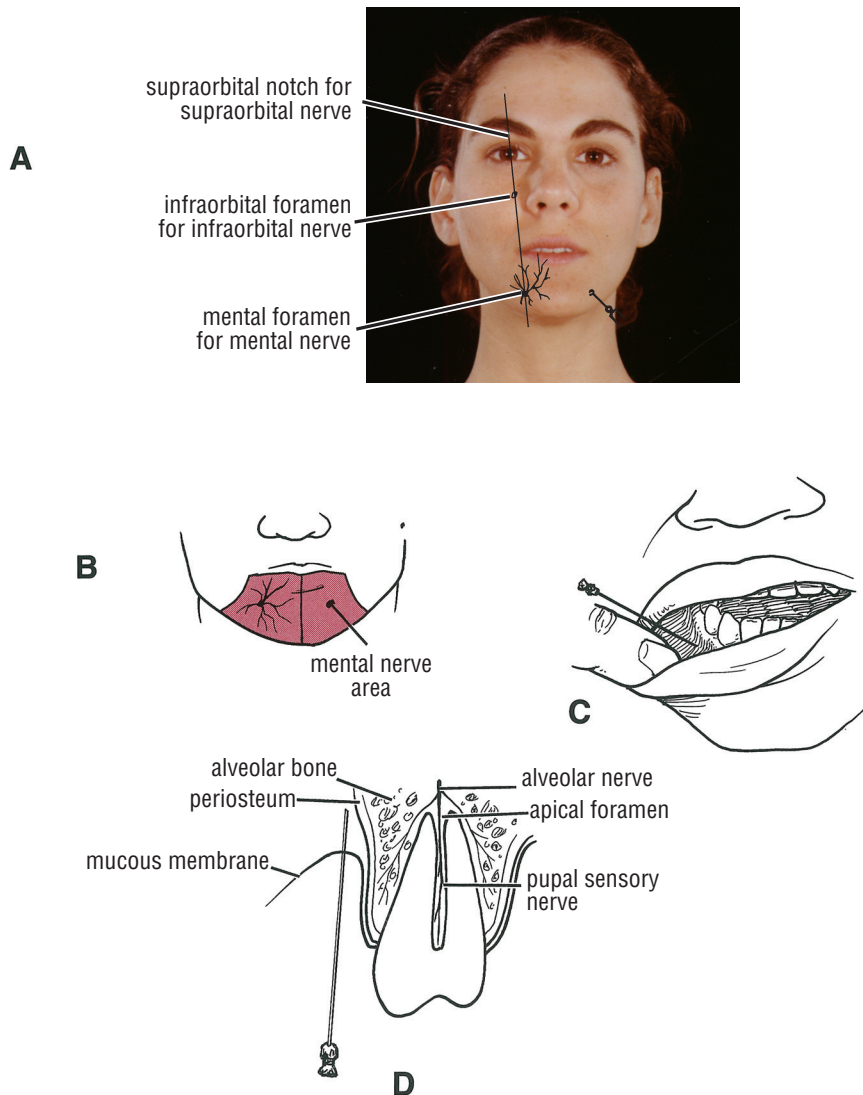
The mental nerve may be blocked as it emerges from the mental foramen on the body of the mandible (CD Fig. 15-10). The foramen lies on the same vertical line that passes through the supraorbital notch, the infraorbital foramen, and the first premolar tooth.

Intraoral Method

The left index finger palpates the position of the mental foramen. The needle is inserted through the reflexion of the mucous membrane from the lower lip onto the gum between the apices of the premolar teeth (see CD Fig. 15-10). The point of the needle is directed toward the mental foramen.



CD Figure 15-9 Lingual and inferior alveolar nerve blocks. **A.** The location of the buccal, lingual, and inferior alveolar nerves in relation to the mandible. **B.** The needle is inserted just above the lower third molar tooth and directed between the mucosa and the inner surface of the ramus of the mandible; the barrel of the syringe lies in line with the interval between the bicuspids on the opposite side of the mandible. The needle is advanced posteriorly and slightly superiorly until the tip lies in close proximity to the mandibular foramen.



CD Figure 15-10 Mental nerve and tooth nerve blocks. **A.** Extraoral mental nerve block. The surface marking of the mental nerve as it emerges from the mental foramen. The mental foramen lies on the same vertical plane as the supraorbital notch, the pupil (when the patient is looking straight ahead), the infraorbital foramen, and the first premolar tooth. The mental foramen is palpated, and the needle is inserted through the skin and is directed toward the foramen. **B.** Area of skin anesthesia produced by blocking the mental nerve. **C.** Intraoral mental nerve block. The needle is inserted through the reflection of the mucous membrane between the apices of the premolar teeth and is directed toward the mental foramen. **D.** Suprape-riosteal infiltration. Needle is inserted through the mucous membrane with the bevel against the periosteum and is advanced until it reaches the level of the apex of the tooth.

Extraoral Method

The mental foramen is palpated, and the needle is inserted through the skin. When the mandible is contacted with the needle, the point is directed toward the mental foramen (see CD Fig. 15-10).

Special Areas for Nerve Blocks

Tooth Nerve Blocks

Two techniques are commonly used—suprape-riosteal infiltration and dental nerve blocks.

Suprape-riosteal Infiltration

This technique is commonly used in an emergency for the relief of toothache. The anesthetic solution is applied directly to the outer surface of the periosteum opposite the apices of the roots of the teeth (see CD Fig. 15-10). The

anesthetic diffuses through the periosteum and the alveolar bone to reach the dental nerve fibers entering the apices of the dental roots; it also reaches the nerves supplying the mucoperiosteum of the gums and the periodontal membrane.

The labiogingival or buccogingival folds, where the mucous membrane lining the lips or cheek are reflected onto the gums, are identified. This may be accomplished in the maxilla by pulling the upper lip downward, and in the case of the mandible by pulling the lower lip upward. At the point where the mucous membrane becomes fused with the periosteum to form the mucoperiosteum of the gum, the needle is inserted with the bevel against the periosteum (see CD Fig. 15-10). The needle is advanced until it reaches the level of the apex of the root of the tooth, and the anesthetic solution is injected. If anesthesia is not produced, it may be necessary to repeat the injection on the palatal surface of the gums. Failure to produce an adequate nerve block may be due to the needle tip being inserted too far away from the

apex of the tooth—that is, too far away from the periosteum or too far above or below the tooth apex. The technique is less successful for mandibular teeth because of the density of the bone structure of the mandible.

The upper teeth are innervated by the anterior, middle, and superior alveolar branches of the maxillary division of the trigeminal nerve. The buccal nerve, a branch of the mandibular division of the trigeminal nerve, supplies the lateral surface of the gum and the greater palatine and the nasopalatine nerves, from the maxillary nerve, supply the medial surface of the gum.

The lower teeth are innervated by the inferior alveolar nerve, a branch of the mandibular division of the trigeminal nerve. The buccal nerve supplies the lateral surface of the gums, and the lingual nerve, a branch of the mandibular nerve, supplies the medial surface.

Dental Nerve Blocks

For the maxillary teeth, the anterior and middle superior alveolar nerves are blocked along with the infraorbital nerve as described on page 232 of the CD. For the mandibular teeth, the inferior alveolar nerve is blocked as described on page 235 of the CD.

Anesthesia of the Nose

This involves the following:

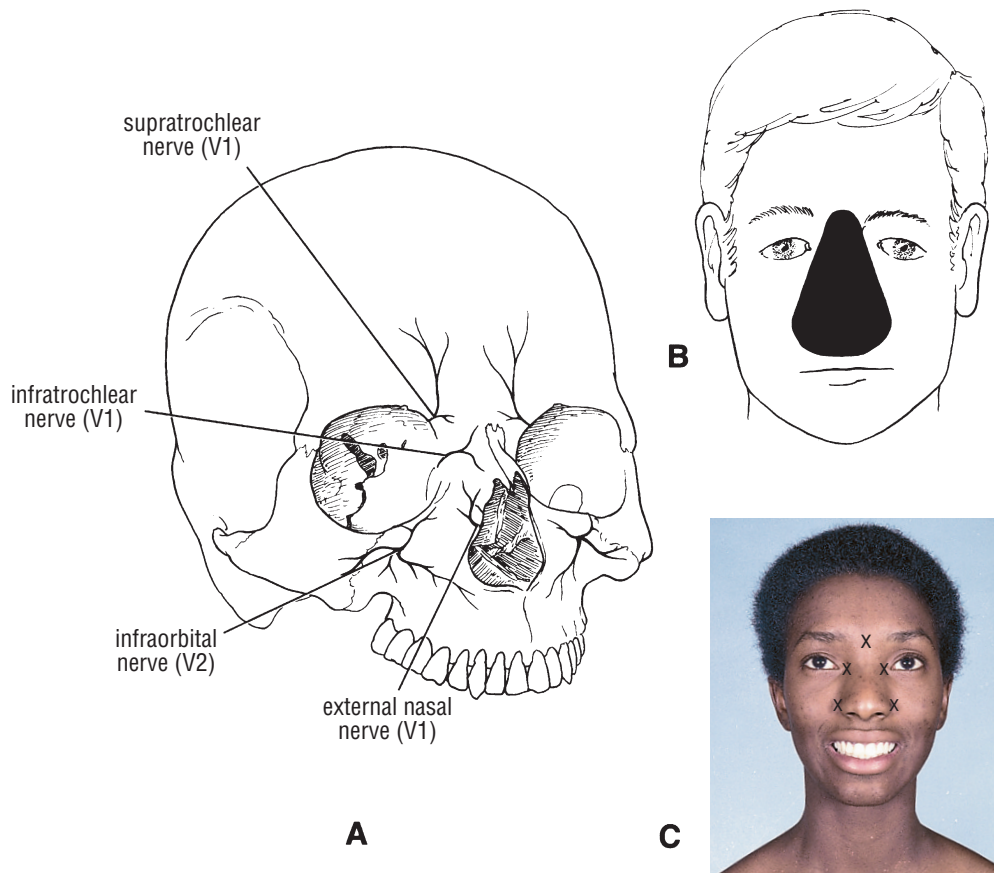
Nasal Interior

The lateral wall of the nose is innervated by the anterior ethmoidal branch of the nasociliary branch of the ophthalmic division of the trigeminal nerve, from branches of the maxillary division of the trigeminal nerve, and from the olfactory nerve. The nasal septum is innervated by branches of the anterior ethmoidal nerve, by branches of the maxillary nerve, and from the olfactory nerve.

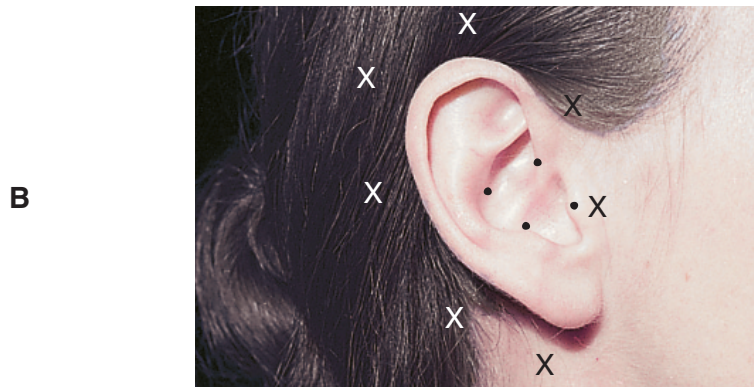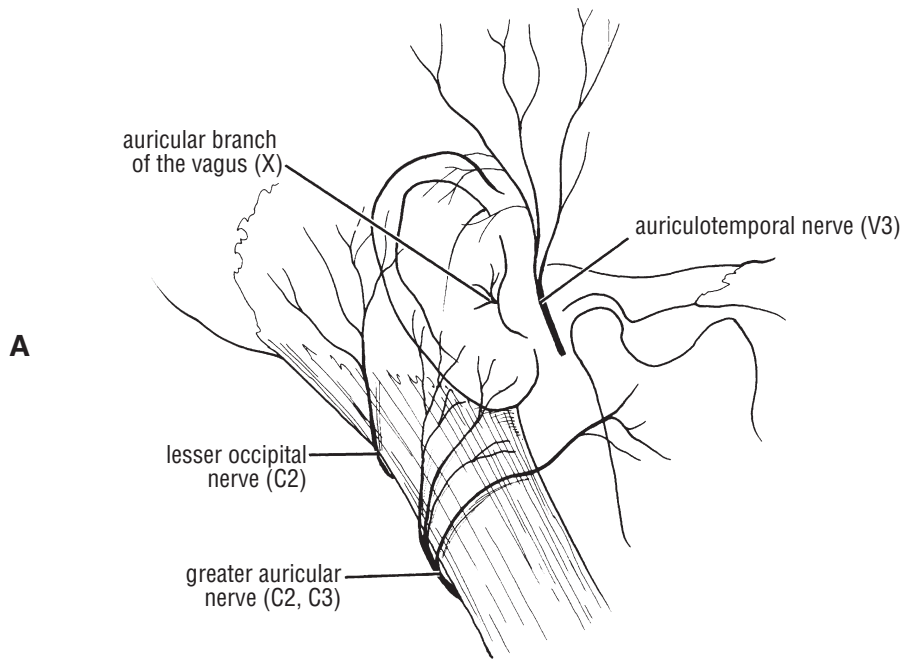
Analgesia of the mucous membrane can easily be obtained by placing pledgets soaked in local anesthetic in the nose between the conchae and the septum for 5 to 10 minutes.

Nasal Exterior

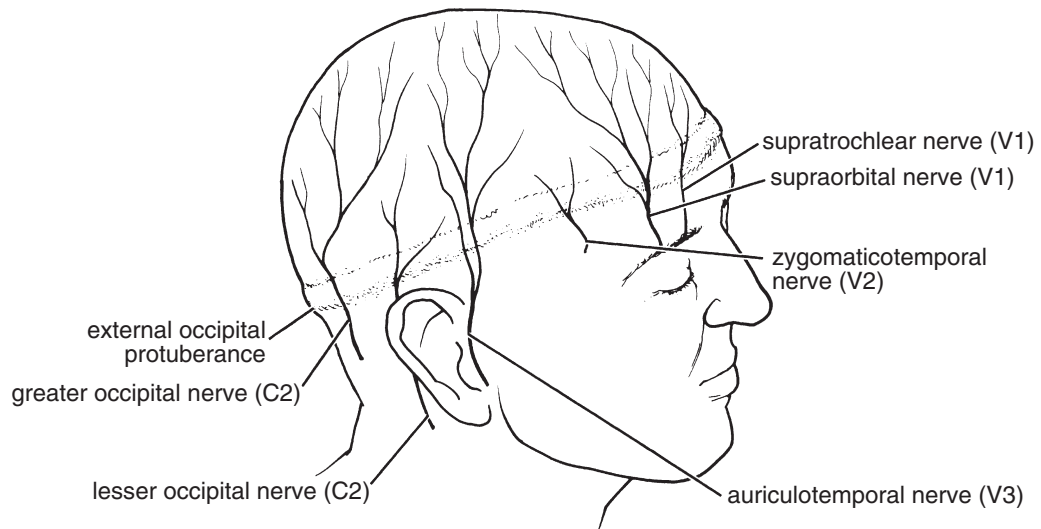
The skin of the nose is innervated by the supratrochlear and infratrochlear branches of the ophthalmic division of the trigeminal nerve and the infraorbital nerve, a continuation of the maxillary division of the trigeminal nerve (CD Fig. 15-11). Skin analgesia is obtained by infiltrating first the base of the nose and then the nasofacial groove, thus



CD Figure 15-11 Anesthesia of the external nose. **A.** The sensory nerves that supply the skin of the nose emerging from the skull. **B.** The extent of the skin supplied by these nerves. **C.** The sites (X) where the needle is introduced to produce anesthesia over the area shown in **B.**



CD Figure 15-12 Ear nerve blocks. **A.** The sensory innervation of the auricle; note the auricular branch of the vagus nerve that supplies part of the external auditory meatus. **B.** The sites (X) at which multiple subcutaneous injections may be made circumferentially around the auricle to block the sensory nerves. The external auditory meatus may be anesthetized by using a four-quadrant block (dots).



CD Figure 15-13 Scalp nerve block. A subcutaneous infiltration with anesthetic solution is made around the circumference of the head from just above the eyebrows to the region of the external occipital protuberance.

blocking the terminal branches of the ophthalmic and maxillary nerves (see CD Fig. 15-11).

Anesthesia of the Ear

The auricle is innervated by the greater auricular nerve (C2 and C3), a branch of the cervical plexus (CD Fig. 15-12). This nerve mainly supplies the skin on the medial and lateral surfaces of the inferior part of the auricle. The auriculotemporal branch of the mandibular division of the trigeminal nerve supplies the lateral and upper part of the auricle. The lesser occipital nerve (C2) may also supply a small area on the medial surface. The external auditory meatus is also innervated by the auricular branch of the vagus nerve.

Anesthesia of the skin is obtained by multiple subcutaneous injections along a line that is continued circumferentially around the auricle (see CD Fig. 15-12). The external auditory meatus may be anesthetized by using a four-quadrant block of the canal; in addition, several drops of anesthetic solution may be instilled into the canal to anesthetize the tympanic membrane.

Anesthesia of the Scalp

The anterior part of the scalp extending back as far as the vertex is innervated by the supraorbital and supratrochlear branches of the ophthalmic division of the trigeminal nerve (CD Fig. 15-13). The posterior part of the scalp is innervated by the greater occipital nerve (C2) and the lesser occipital nerve (C2). The lateral part of the scalp is supplied by the auriculotemporal branch of the mandibular division of the trigeminal nerve. A small area over the temple is supplied by the zygomaticotemporal nerve from the maxillary division of the trigeminal nerve.

A subcutaneous infiltration with anesthetic solution is made around the circumference of the head from just above the nose and eyebrows to the ear and back to the external occipital protuberance (see CD Fig. 15-13). A large volume of anesthetic is required to completely anesthetize the scalp.

Clinical Problem Solving Questions

Read the following case histories/questions and give the best answer for each.

A 73-year-old woman visited her physician because she had noticed that the right side of her face was sagging downward. She first noticed the condition on waking up two mornings ago. Otherwise she felt very well. On examination the patient had a complete right-sided facial paralysis, the right lower eyelid was drooping, and the right angle of the mouth was sagging. A diagnosis of Bell's palsy was made.

- Further examination of this patient demonstrated the following signs and symptoms **except** which?
 - Tears tended to flow easily over the right lower eyelid.
 - Saliva dribbled from the right corner of her mouth.
 - The patient was unable to close her right eye completely.
 - The patient was unable to expose the teeth fully on the right side of her mouth.
 - The muscles on the right side of her forehead worked perfectly normally when she was asked to raise her right eyebrow.

A 17-year-old boy was seen in the emergency department after receiving a stab wound at the front of the neck. The knife entrance wound was located on the left side of the neck just lateral to the tip of the greater cornu of the hyoid bone. Dur-

ing the physical examination the patient was asked to protrude his tongue, which deviated to the left.

- The following statements would explain the physical signs in this patient **except** which?
 - The genioglossus muscles are responsible for protruding the tongue.
 - The genioglossus muscle is supplied by the glossopharyngeal nerve.
 - Paralysis of the left genioglossus muscle permitted the right genioglossus to pull the tongue forward and turned the tip to the left side.
 - The hypoglossal nerve descends in the neck between the internal carotid artery and the internal jugular vein.
 - At about the level of the tip of the greater cornu of the hyoid bone the hypoglossal nerve turns forward and crosses the internal and external carotid arteries and the lingual artery to enter the tongue.
 - The point of the knife blade severed the left hypoglossal nerve.

A 43-year-old woman was seen in the emergency department with a large abscess in the middle of the right posterior triangle of the neck. The abscess was red, hot, and fluctuant. The abscess showed evidence that it was pointing and about to rupture. The physician decided to incise the abscess and

insert a drain. The patient returned to the department for the dressings to be changed 5 days later. She stated that she felt much better and that her neck was no longer painful. However, there was one thing that she could not understand. She could no longer raise her right hand above her head to brush her hair.

3. The following statements explain the signs and symptoms in this case, suggesting that the spinal part of the accessory nerve had been incised, **except** which?
 - A. To raise the hand above the head, it is necessary for the trapezius muscle, assisted by the serratus anterior, to contract and rotate the scapula so that the glenoid cavity faces upward.
 - B. The trapezius muscle is innervated by the spinal part of the accessory nerve.
 - C. As the spinal part of the accessory nerve crosses the posterior triangle of the neck, it is deeply placed, being covered by the skin, the superficial fascia, the investing layer of deep cervical fascia, and the levator scapulae muscle.
 - D. The surface marking of the spinal part of the accessory nerve is as follows: Bisect at right angles a line joining the angle of the jaw to the tip of the mastoid process. Continue the second line downward and backward across the posterior triangle.
 - E. The knife opening the abscess had cut the accessory nerve.

A 35-year-old woman had a partial thyroidectomy for the treatment of thyrotoxicosis. During the operation a ligature slipped off the right superior thyroid artery. To stop the hemorrhage, the surgeon blindly grabbed for the artery with artery forceps. The operation was completed without further incident. The following morning the patient spoke with a husky voice.

4. The following statements about this patient would explain the husky voice **except** which?
 - A. Laryngoscopic examination revealed that the right vocal cord was slack, causing the huskiness of the voice.
 - B. The vocal cord is tensed by the contraction of the cricothyroid muscle.
 - C. The cricothyroid muscle tilts back the cricoid cartilage and pulls forward the thyroid cartilage.
 - D. The cricothyroid muscle is innervated by the recurrent laryngeal nerve.
 - E. The superior thyroid artery is closely related to the external laryngeal nerve.

A 43-year-old woman visited her physician complaining of severe intermittent pain on the right side of her face. The pain was precipitated by exposing the right side of her face to a draft of cold air. The pain was stabbing in nature and lasted about 12 hours before finally disappearing. When asked to point out on her face the area where the pain was

experienced, the patient mapped out the skin area over the right side of the lower jaw extending backward and upward over the side of the head to the vertex.

5. The following signs and symptoms in this patient strongly suggest a diagnosis of trigeminal neuralgia **except** which?
 - A. The skin area where the patient experienced the pain was innervated by the mandibular division of the trigeminal nerve.
 - B. The stabbing nature of the pain is characteristic of the disease.
 - C. The trigger mechanism, stimulation of an area that received its sensory innervation from the trigeminal nerve, is characteristic of trigeminal neuralgia.
 - D. Examination of the actions of the masseter and the temporalis muscles showed evidence of weakness on the right side.
 - E. The patient experienced hyperesthesia in the distribution of the right auriculotemporal nerve.

A 10-year-old boy was playing darts with his friends. He bent down to pick up a fallen dart when another dart fell from the dart board and hit him on the side of his face. On examination in the emergency department a small skin wound was found over the right parotid salivary gland. Then, 6 months later, the boy's mother noticed that before mealtimes the boy began to sweat profusely on the facial skin close to the healed dart wound.

6. The following statements can explain this phenomenon **except** which?
 - A. The point of the dart had entered the parotid salivary gland and damaged the parasympathetic secretomotor fibers to the gland.
 - B. The secretomotor fibers to the parotid gland arise in the otic ganglion.
 - C. The preganglionic parasympathetic fibers originate in the superior salivatory nucleus of the facial nerve.
 - D. The skin over the parotid salivary gland is innervated by the great auricular nerve, which was also damaged by the dart.
 - E. On regeneration of the damaged nerves some of the parasympathetic nerves to the parotid salivary gland had crossed over and joined the sympathetic secretomotor nerves to the sweat glands in the distal end of the great auricular nerve.
 - F. The patient has Frey's syndrome.

A 31-year-old woman fell off her bicycle and lacerated the skin of her forehead just above the left eyebrow.

7. What is the sensory innervation of the skin of the forehead? Where may these nerves be blocked?

A 27-year-old man was involved in a motorcycle accident and was seen in the emergency department with

extensive lacerations of the right ear. It was decided to suture the skin lesions under local anesthesia.

8. How would you anesthetize the ear?

A 63-year-old woman visited her physician with a swelling over the parotid gland on the right side. She stated that she had first noticed the swelling 3 months previously, and since that time it had rapidly increased in size. Recently, she had noticed that the right side of her face “felt weak” and she could no longer whistle for her dog. On examination, a hard swelling deeply attached to the parotid gland was found. On testing the facial muscles, it was found that the muscles on the right side were weaker than those on the left side.

9. What is the connection between the parotid swelling and the right-sided facial weakness?

10. On examination, a patient is found to have a bitemporal hemianopia. An enlargement of which anatomic structure is likely to cause this condition?

11. A patient is suspected of having a lesion of the glossopharyngeal nerve. How would you test the integrity of this cranial nerve?

12. A 47-year-old woman is seen by a neurologist because of trouble reading the newspaper. She said that the print starts to tilt and she begins to see double. She also stated that she has difficulty walking down steps because she cannot easily look downward with her right eye. On physical examination, the patient was found to have weakness of the movement of the right eye, both downward and laterally. Using your knowledge of anatomy, explain the signs and symptoms.


Answers and Explanations

- E** is the correct answer. In this patient all the facial muscles on the right side were paralyzed. When making the diagnosis of Bell's palsy, it is imperative that one makes the distinction between an upper motor neuron palsy and a lower motor neuron palsy. The part of the facial nucleus of the facial nerve that controls the muscles of the upper part of the face receives corticonuclear fibers from both cerebral hemispheres. Therefore, it follows that with a lesion involving the upper motor neurons, only the muscles of the lower part of the face will be paralyzed. In this patient all the facial muscles on the affected side were paralyzed, indicating that the lesion was confined to the facial nerve.
- B** is the correct answer. The genioglossus muscle is supplied by the hypoglossal nerve.
- C** is the correct answer. The spinal part of the accessory nerve lies superficial to the levator scapulae muscle in the posterior triangle of the neck.
- D** is the correct answer. The cricothyroid muscle is innervated by the external laryngeal nerve, which was damaged in this patient.
- D** is the correct answer. The motor portion of the trigeminal nerve is unaffected in patients with trigeminal neuralgia.
- C** is the correct answer. The secretomotor fibers to the parotid salivary gland originate in the inferior salivatory nucleus of the glossopharyngeal nerve.

- The skin of the forehead is innervated by the supra-orbital and supratrochlear branches of the frontal nerve, a branch of the ophthalmic division of the trigeminal nerve. The nerves may be blocked as they emerge onto the forehead around the superior margin of the orbital cavity.
- The auricle receives its sensory innervation from the greater auricular nerve (C2 and C3), the auriculotemporal nerve (mandibular division of the trigeminal nerve), and the auricular branch of the vagus nerve. Analgesia of the skin can be obtained by multiple subcutaneous injections that are continued circumferentially around the auricle.
- The facial nerve, the retromandibular vein, and the external carotid artery lie within the parotid salivary gland. This patient had a highly invasive carcinoma of the right parotid gland, which quickly involved the right facial nerve, with consequent weakness of the right facial muscles. The method used clinically to test the integrity of the facial nerve is fully described on CD p. 228. A benign tumor of the parotid gland tends not to damage the facial nerve.
- Bitemporal hemianopia is a loss of both temporal fields of vision and is due to the interruption of the optic nerve fibers derived from the medial halves of both retinae. Pressure on the optic chiasma by a tumor of the pituitary gland is the most common cause of the condition.

11. The glossopharyngeal nerve supplies the mucous membrane of the posterior third of the tongue with taste fibers and those for common sensation. These sensations can easily be tested by using appropriate stimuli.
12. The difficulty with reading and the diplopia can be explained by paralysis of the right superior oblique muscle. When a patient with paralysis of the superior oblique muscle looks straight downward, the affected eye turns medially as well as downward. Moreover, the patient has great difficulty turning that eye downward

and laterally. This abnormality can be explained as follows: Contraction of the inferior rectus muscle rotates the eyeball so that the cornea is depressed downward. Because of the manner of its insertion, the inferior rectus muscle also rotates the eyeball medially. This tendency to rotate the eyeball medially is normally neutralized by simultaneous contraction of the superior oblique muscle, whose action is to rotate the eyeball laterally as well as to depress the cornea downward.



16

The Vertebral Column, the Spinal Cord, and the Meninges



Chapter Outline

Vertebral Column	246	Subarachnoid Space	250
Examination of the Back	246	Spinal Tap (Lumbar Puncture)	250
Abnormal Curves of the Vertebral Column	246	Anatomy of "Not Getting In"	253
Dislocations of the Vertebral Column	246	Anatomy of Complications of Lumbar Puncture	253
Fractures of the Vertebral Column	246	Block of the Subarachnoid Space	253
Spinal Nerve Root Pain	246	Caudal Anesthesia	253
Herniated Intervertebral Discs	247	Congenital Anomalies	255
Disease and the Intervertebral Foramina	247	Scoliosis	255
Narrowing of the Spinal Canal	249	Spina Bifida	255
Sacroiliac Joint Disease	249	Relationship of the Vertebral Body to the Spinal Nerve	255
Spinal Cord	250	Clinical Problem Solving Questions	257
Spinal Cord Ischemia	250	Answers and Explanations	259
Spinal Cord Injuries	250		
Relationship of Spinal Cord Segments to Vertebral Numbers	250		



VERTEBRAL COLUMN

Examination of the Back

See Chapter 11, CD-ROM.

Abnormal Curves of the Vertebral Column

See Chapter 11, CD-ROM.

Dislocations of the Vertebral Column

See Chapter 12, CD-ROM.

Fractures of the Vertebral Column

See Chapter 12, CD-ROM.

Spinal Nerve Root Pain

Spinal nerve roots exit from the vertebral canal through the intervertebral foramina. Each foramen is bounded superiorly and inferiorly by the pedicles, anteriorly by the intervertebral disc and the vertebral body, and posteriorly by the articular processes and joints (see text Fig. 16-3). In the lumbar region, the largest foramen is between the first and second lumbar vertebrae and the smallest is between the fifth lumbar and first sacral vertebra.

One of the complications of osteoarthritis of the vertebral column is the growth of osteophytes, which commonly encroach on the intervertebral foramina, causing pain along the distribution of the segmental nerve. The fifth lumbar spinal nerve is the largest of the lumbar spinal nerves, and it exits from the vertebral column through the smallest intervertebral foramen. For this reason, it is the most vulnerable.

Osteoarthritis as a cause of root pain is suggested by the patient's age, its insidious onset, and a history of back pain of long duration; this diagnosis is made only when all other causes have been excluded. For example, a prolapsed disc usually occurs in a younger age group and often has an acute onset.

Herniated Intervertebral Discs

The structure and function of the intervertebral disc is described on text page 581. The resistance of these discs to compression forces is substantial, as seen, for example, in circus acrobats who can support four or more of their colleagues on their shoulders. Nevertheless, the discs are vulnerable to sudden shocks, particularly if the vertebral column is flexed and the disc is undergoing degenerative changes, that result in herniation of the nucleus pulposus.

The discs most commonly affected are those in areas where a mobile part of the column joins a relatively immobile part—that is, the cervicothoracic junction and the lumbosacral junction. In these areas, the posterior part of the anulus fibrosus ruptures, and the nucleus pulposus is forced posteriorly like toothpaste out of a tube. This is referred to as a **herniation of the nucleus pulposus**. This herniation can result either in a central protrusion in the midline under the posterior longitudinal ligament of the vertebrae or in a lateral protrusion at the side of the posterior ligament close to the intervertebral foramen (CD Fig. 16-1). The escape of the nucleus pulposus will produce narrowing of the space between the vertebral bodies, which may be visible on radiographs. Slackening of the anterior and posterior longitudinal ligaments results in abnormal mobility of the vertebral bodies, producing local pain and subsequent development of osteoarthritis.

Cervical disc herniations are less common than herniations in the lumbar region (see text Fig. 16-21). The discs most susceptible to this condition are those between the fifth and sixth or sixth and seventh vertebrae. Lateral protrusions cause pressure on a spinal nerve or its roots. Each spinal nerve emerges above the corresponding vertebra; thus, protrusion of the disc between the fifth and sixth cervical vertebrae can cause compression of the C6 spinal nerve or its roots (see CD Fig. 16-1). Pain is felt near the lower part of the back of the neck and shoulder and along the area in the distribution of the spinal nerve involved. Central protrusions may press on the spinal cord and the anterior spinal artery and involve the various nerve tracts of the spinal cord.

Lumbar disc herniations are more common than cervical disc herniations (see CD Fig. 16-1). The discs usually affected are those between the fourth and fifth lumbar vertebrae and between the fifth lumbar vertebra and the sacrum. In the lumbar region the roots of the cauda equina run posteriorly over several intervertebral discs (see CD Fig. 16-1B).

A lateral herniation may press on one or two roots and often involves the nerve root going to the intervertebral foramen just below. However, because C8 nerve roots exist and an eighth cervical vertebral body does not, the thoracic and lumbar roots exit below the vertebra of the corresponding number. Thus, the L5 nerve root exits between the fifth lumbar and first sacral vertebrae. Moreover, because the nerve roots move laterally as they pass toward their exit, the root corresponding to that disc space (L4 in the case of the L4–5 disc) is already too lateral to be pressed on by the herniated disc. Herniation of the L4–5 disc usually gives rise to symptoms referable to the L5 nerve roots, even though the L5 root exits between L5 and S1 vertebrae. The nucleus pulposus occasionally herniates directly backward, and if it is a large herniation, the whole cauda equina may be compressed, producing paraplegia.

An initial period of back pain is usually caused by the injury to the disc. The back muscles show spasm, especially on the side of the herniation, because of pressure on the spinal nerve root. As a consequence, the vertebral column shows a scoliosis, with its concavity on the side of the lesion. Pain is referred down the leg and foot in the distribution of the affected nerve. Since the sensory posterior roots most commonly pressed on are the fifth lumbar and the first sacral, pain is usually felt down the back and lateral side of the leg, radiating to the sole of the foot. This condition is often called **sciatica**. In severe cases paresthesia or actual sensory loss may be present.

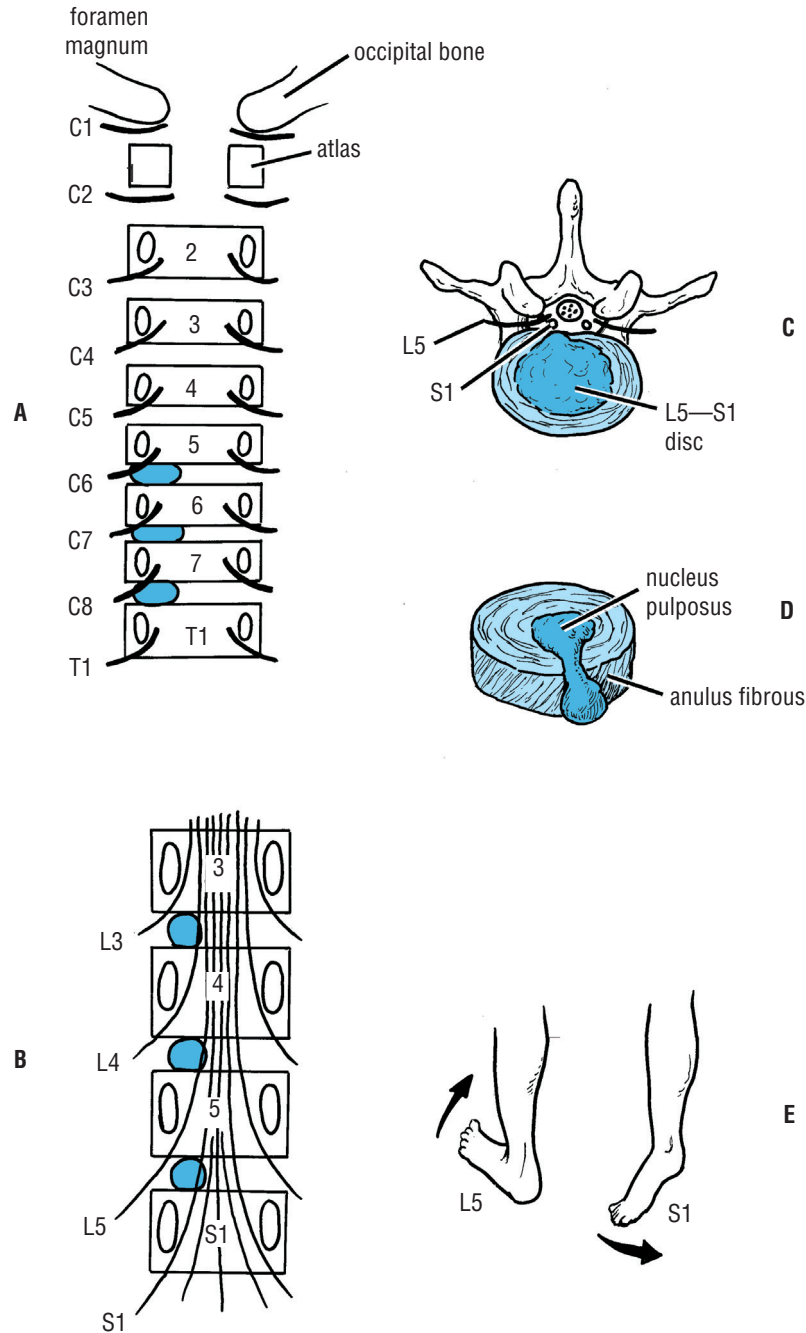
Pressure on the anterior motor roots causes muscle weakness. Involvement of the fifth lumbar motor root produces weakness of dorsiflexion of the ankle, whereas pressure on the first sacral motor root causes weakness of plantar flexion, and the ankle jerk may be diminished or absent (see CD Fig. 16-1).

A large, centrally placed protrusion may give rise to bilateral pain and muscle weakness in both legs. Acute retention of urine may also occur.

A correlation between the disc lesion, the nerve roots involved, the pain dermatome, the muscle weakness, and the missing or diminished reflex is shown in CD Table 16-1.

Disease and the Intervertebral Foramina

The intervertebral foramina (see text Fig. 16-3) transmit the spinal nerves and the small segmental arteries and veins, all of which are embedded in areolar tissue. Each foramen is bounded above and below by the pedicles of adjacent vertebrae, in front by the lower part of the vertebral body and by the intervertebral disc, and behind by the articular processes and the joint between them. In this situation, the spinal nerve is vulnerable and may be pressed on or irritated by disease of the surrounding structures. Her-



CD Figure 16-1 **A** and **B**. Posterior views of vertebral bodies in the cervical and lumbar regions showing the relationship that might exist between the herniated nucleus pulposus and the spinal nerve roots. Note that there are eight cervical spinal nerves but only seven cervical vertebrae. In the lumbar region, for example, the emerging L4 nerve roots pass out laterally close to the pedicle of the fourth lumbar vertebra and are not related to the intervertebral disc between the fourth and fifth lumbar vertebrae. **C**. Posterolateral herniation of the nucleus pulposus of the intervertebral disc between the fifth lumbar vertebra and the first sacral vertebra showing pressure on the S1 nerve root. **D**. An intervertebral disc that has herniated its nucleus pulposus posteriorly. **E**. Pressure on the L5 motor nerve root produces weakness of dorsiflexion of the ankle; pressure on the S1 motor nerve root produces weakness of plantar flexion of the ankle joint.

CD Table 16-1 Summary of Important Features Found in Cervical and Lumbosacral Root Syndromes

Root Injury	Dermatome Pain	Muscle Supplied	Movement Weakness	Reflex Involved
C5	Lower lateral aspect of upper arm	Deltoid and biceps	Shoulder abduction, elbow flexion	Biceps
C6	Lateral aspect of forearm	Extensor carpi radialis longus and brevis	Wrist extensors	Brachioradialis
C7	Middle finger	Triceps and flexor carpi radialis	Extension of elbow and flexion of wrist	Triceps
C8	Medial aspect of forearm	Flexor digitorum superficialis and profundus	Finger flexion	None
L1	Groin	Iliopsoas	Hip flexion	Cremaster
L2	Anterior aspect of thigh	Iliopsoas, sartorius, hip adductors	Hip flexion, hip adduction	Cremaster
L3	Medial aspect of knee	Iliopsoas, sartorius, quadriceps, hip adductors	Hip flexion, knee extension, hip adduction	Patellar
L4	Medial aspect of calf	Tibialis anterior, quadriceps	Foot inversion, knee extension	Patellar
L5	Lateral part of lower leg and dorsum of foot	Extensor hallucis longus, extensor digitorum longus	Toe extension, ankle dorsiflexion	None
S1	Lateral edge of foot	Gastrocnemius, soleus	Ankle plantar flexion	Ankle jerk
S2	Posterior part of thigh	Flexor digitorum longus, flexor hallucis longus	Ankle plantar flexion, toe flexion	None

niation of the intervertebral disc, fractures of the vertebral bodies, and osteoarthritis involving the joints of the articular processes or the joints between the vertebral bodies can all result in pressure, stretching, or edema of the emerging spinal nerve. Such pressure would give rise to dermatomal pain, muscle weakness, and diminished or absent reflexes.

Narrowing of the Spinal Canal

After about the fourth decade of life the spinal canal becomes narrowed by aging. Osteoarthritic changes in the joints of the articular processes with the formation of osteophytes, together with degenerative changes in the intervertebral discs and the formation of large osteophytes between the vertebral bodies, can lead to narrowing of the spinal canal and intervertebral foramina. In persons in whom the spinal canal was originally small, significant

stenosis in the cauda equina area can lead to neurologic compression. Symptoms vary from mild discomfort in the lower back to severe pain radiating down the leg with the inability to walk.

Sacroiliac Joint Disease

The clinical aspects of this joint are referred to again because disease of this joint can cause low back pain and may be confused with disease of the lumbosacral joints. Essentially, the sacroiliac joint is a synovial joint that has irregular elevations on one articular surface that fit into corresponding depressions on the other articular surface. It is a strong joint and is responsible for the transfer of weight from the vertebral column to the hip bones. The joint is innervated by the lower lumbar and sacral nerves so that disease in the joint may produce low back pain and sciatica.

The sacroiliac joint is inaccessible to clinical examination. However, a small area located just medial to and below the posterosuperior iliac spine is where the joint comes closest to the surface. In disease of the lumbosacral region, movements of the vertebral column in any direction cause pain in the lumbosacral part of the column. In sacroiliac disease, pain is extreme on rotation of the vertebral column and is worst at the end of forward flexion. The latter movement causes pain because the hamstring muscles hold the hip bones in position while the sacrum is rotating forward as the vertebral column is flexed.



SPINAL CORD

Spinal Cord Ischemia

The blood supply to the spinal cord is surprisingly meager, considering the importance of this nervous tissue. The longitudinally running anterior and posterior spinal arteries are of small and variable diameter, and the reinforcing segmental arteries vary in number and in size. Ischemia of the spinal cord can easily follow minor damage to the arterial supply as a result of regional anesthesia, pain block procedures, or aortic surgery.

Spinal Cord Injuries

The degree of spinal cord injury at different vertebral levels is largely governed by anatomic factors. In the cervical region, dislocation or fracture dislocation is common, but the large size of the vertebral canal often results in the spinal cord escaping severe injury. However, when considerable displacement occurs, the cord is sectioned and death occurs immediately. Respiration ceases if the lesion occurs above the segmental origin of the phrenic nerves (C3, 4, and 5).

In fracture dislocations of the thoracic region, displacement is often considerable, and the small size of the vertebral canal results in severe injury to the spinal cord.

In fracture dislocations of the lumbar region, two anatomic facts aid the patient. First, the spinal cord in the adult extends only down as far as the level of the lower border of the first lumbar vertebra. Second, the large size of the vertebral foramen in this region gives the roots of the cauda equina ample room. Nerve injury may therefore be minimal in this region.

Injury to the spinal cord can produce partial or complete loss of function at the level of the lesion and partial or complete loss of function of afferent and efferent nerve tracts

below the level of the lesion. The symptoms and signs of spinal shock and paraplegia in flexion and extension are beyond the scope of this book. For further information, a textbook of neurology should be consulted.

Relationships of Spinal Cord Segments to Vertebral Numbers

Because the spinal cord is shorter than the vertebral column, the spinal cord segments do not correspond numerically with the vertebrae that lie at the same level (CD Fig. 16-2). The following list helps determine which spinal segment is contiguous with a given vertebral body:

Vertebrae	Spinal Segment
Cervical	Add 1
Upper thoracic	Add 2
Lower thoracic (T7–9)	Add 3
Tenth thoracic	L1 and 2 cord segments
Eleventh thoracic	L3 and 4 cord segments
Twelfth thoracic	L5 cord segment
First lumbar	Sacral and coccygeal cord segments

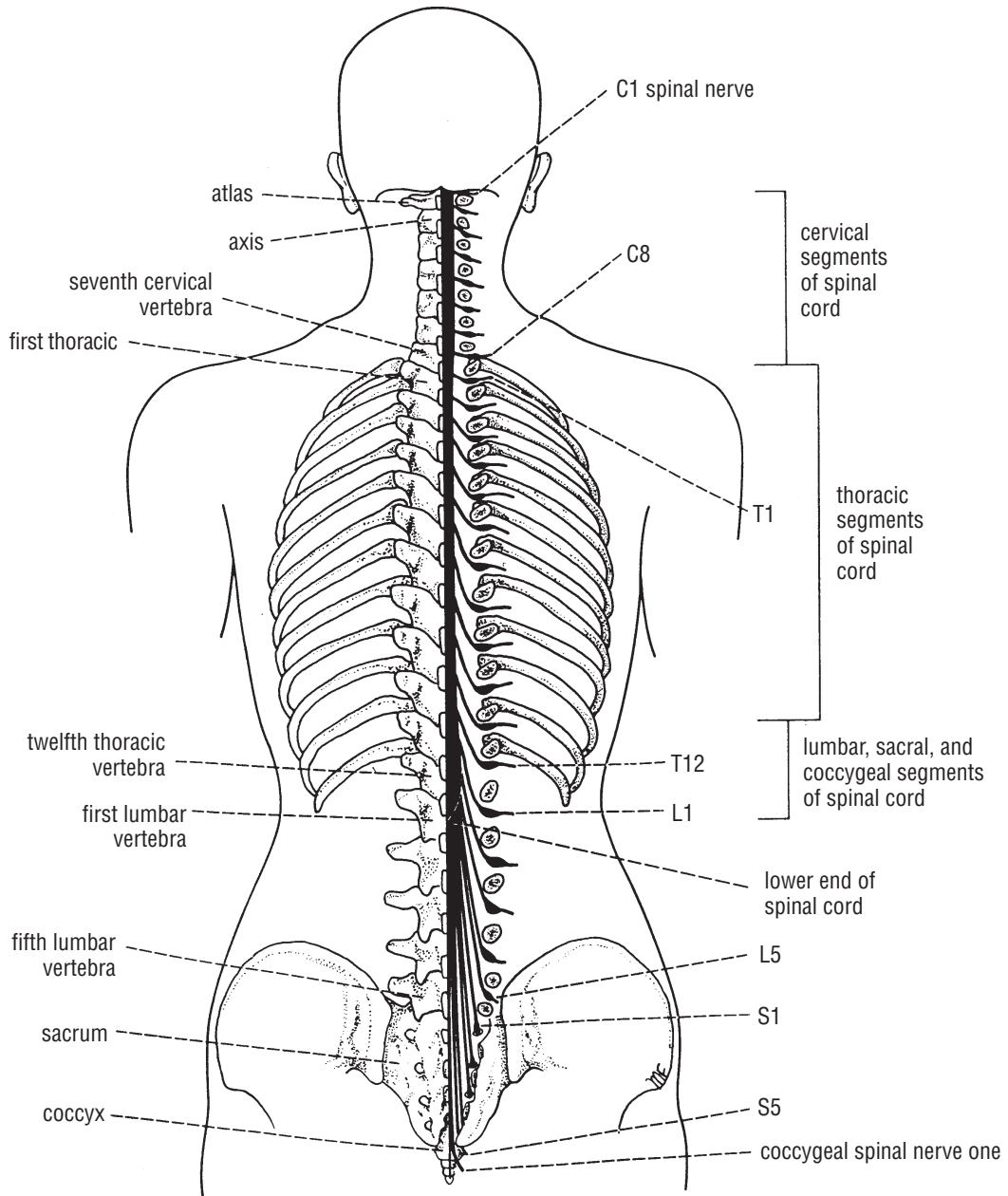


SUBARACHNOID SPACE

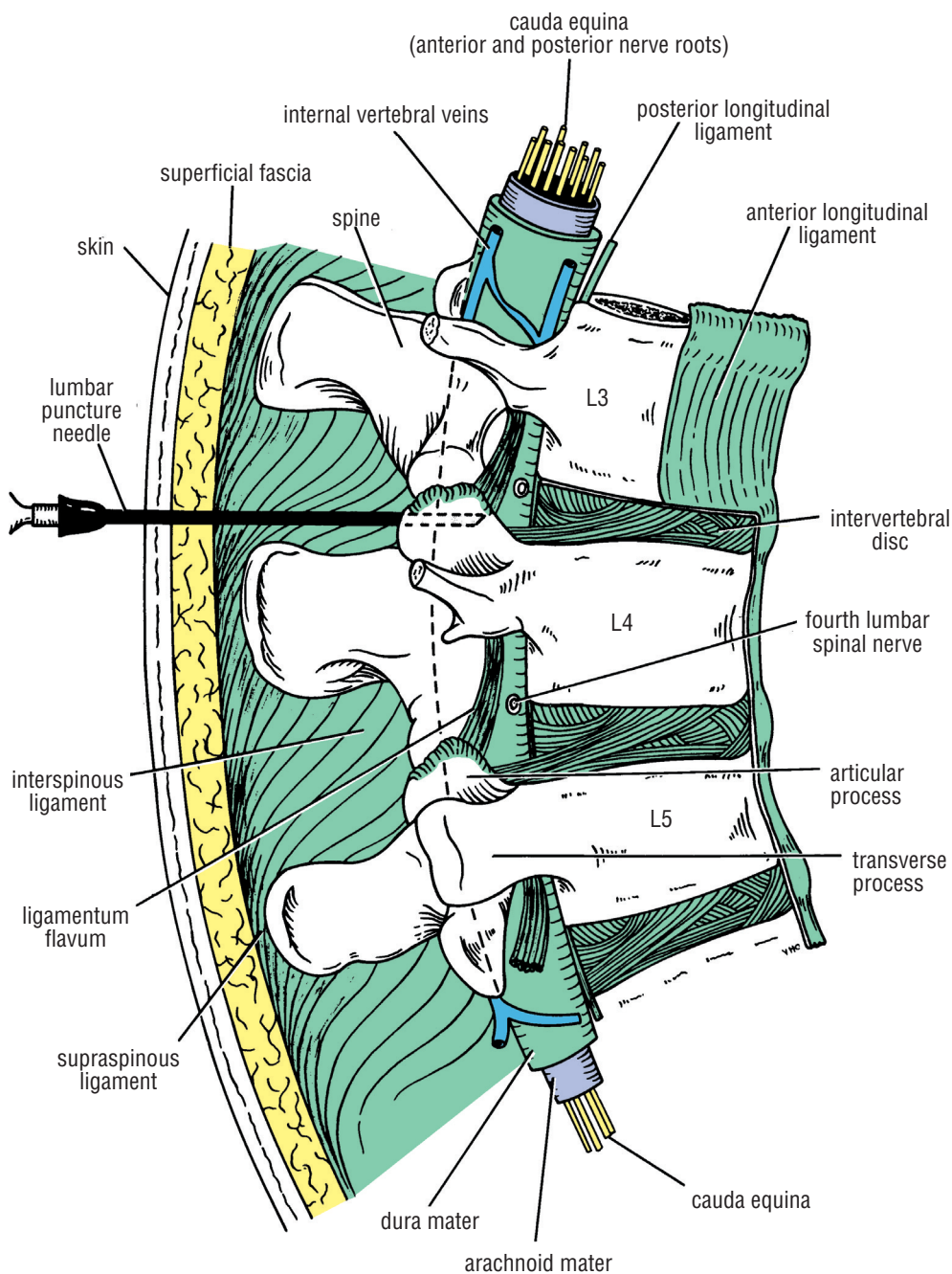
Spinal Tap (Lumbar Puncture)

Lumbar puncture may be performed to withdraw a sample of cerebrospinal fluid for examination. Fortunately, the spinal cord terminates below at the level of the lower border of the first lumbar vertebra in the adult. (In the infant, it may reach as low as the third lumbar vertebra.) The subarachnoid space extends down as far as the lower border of the second sacral vertebra. The lower lumbar part of the vertebral canal is thus occupied by the subarachnoid space, which contains the cauda equina—that is, the lumbar and sacral nerve roots and the filum terminale. A needle introduced into the subarachnoid space in this region usually pushes the nerve roots to one side without causing damage.

With the patient lying on the side with the vertebral column well flexed, the space between adjoining laminae in the lumbar region is opened to a maximum (CD Fig. 16-3). An imaginary line joining the highest points on the iliac crests passes over the fourth lumbar spine (see text Fig. 16-22). With a careful aseptic technique and under local anesthesia, the lumbar puncture needle, fitted with a stylet, is



CD Figure 16-2 Posterior view of the spinal cord showing the origins of the roots of the spinal nerves and their relationship to the different vertebrae. On the right, the laminae have been removed to expose the right half of the spinal cord and the nerve roots.



CD Figure 16-3 Sagittal section through the lumbar part of the vertebral column in flexion. Note that the spines and laminae are well separated in this position, enabling one to introduce a lumbar puncture needle into the subarachnoid space.

passed into the vertebral canal above or below the fourth lumbar spine (see CD Fig. 16-3). The needle will pass through the following anatomic structures before it enters the subarachnoid space: skin, superficial fascia, supraspinous ligament, interspinous ligament, ligamentum flavum, areolar tissue (containing the internal vertebral venous plexus in the epidural space), dura mater, and arachnoid mater. The depth to which the needle will have to pass varies from 1 in. (2.5 cm) or less in a child to as much as 4 in. (10 cm) in obese adults.

As the stylet is withdrawn, a few drops of blood commonly escape. This usually indicates that the point of the needle is situated in one of the veins of the internal vertebral plexus and has not yet reached the subarachnoid space. If the entering needle should stimulate one of the nerve roots of the cauda equina, the patient will experience a fleeting discomfort in one of the dermatomes, or a muscle will twitch, depending on whether a sensory or a motor root was impaled. If the needle is pushed too far anteriorly, it may hit the body of the third or fourth lumbar vertebra (see CD Fig. 16-3).

The cerebrospinal fluid pressure can be measured by attaching a manometer to the needle. In the recumbent position, the normal pressure is about 60–150 mm H₂O. It is interesting to note that the cerebrospinal fluid pressure normally fluctuates slightly with the heart beat and with each phase of respiration.

Anatomy of “Not Getting In”

If bone is encountered, the needle should be withdrawn as far as the subcutaneous tissue, and the angle of insertion should be changed. The most common bone encountered is the spinous process of the vertebra above or below the path of insertion. If the needle is directed laterally rather than in the midline, it may hit the lamina or an articular process.

Anatomy of Complications of Lumbar Puncture

- **Postlumbar puncture headache:** This headache starts after the procedure and lasts 24 to 48 hours. The cause is a leak of cerebrospinal fluid through the dural puncture, and it usually follows the use of a wide-bore needle. The leak reduces the volume of cerebrospinal fluid, which, in turn, causes a downward displacement of the brain and stretches the nerve-sensitive meninges—a headache follows. The headache is relieved by assuming the recumbent position. Using small-gauge stylet needles and avoiding multiple dural holes reduce the incidence of headache.
- **Brain herniation:** Lumbar puncture is contraindicated in cases in which intracranial pressure is significantly raised. A large tumor, for example, above the tentorium cerebelli with a high intracranial pressure may result in a

caudal displacement of the uncus through the tentorial notch or a dangerous displacement of the medulla through the foramen magnum, when the lumbar cerebrospinal fluid pressure is reduced.

Block of the Subarachnoid Space

A block of the subarachnoid space in the vertebral canal, which may be caused by a tumor of the spinal cord or the meninges, can be detected by compressing the internal jugular veins in the neck. This raises the cerebral venous pressure and inhibits the absorption of cerebrospinal fluid in the arachnoid granulations, thus producing a rise in the manometric reading of the cerebrospinal fluid pressure. If this rise fails to occur, the subarachnoid space is blocked and the patient is said to exhibit a positive Queckenstedt’s sign.



CAUDAL ANESTHESIA

Solutions of anesthetics may be injected into the sacral canal through the sacral hiatus. The solutions pass upward in the loose connective tissue and bathe the spinal nerves as they emerge from the dural sheath. Caudal anesthesia is used in operations in the sacral region, including anorectal surgery and culdoscopy. Obstetricians use this method of nerve block to relieve the pains during the first and second stages of labor. Its advantage is that, administered by this method, the anesthetic does not affect the infant.

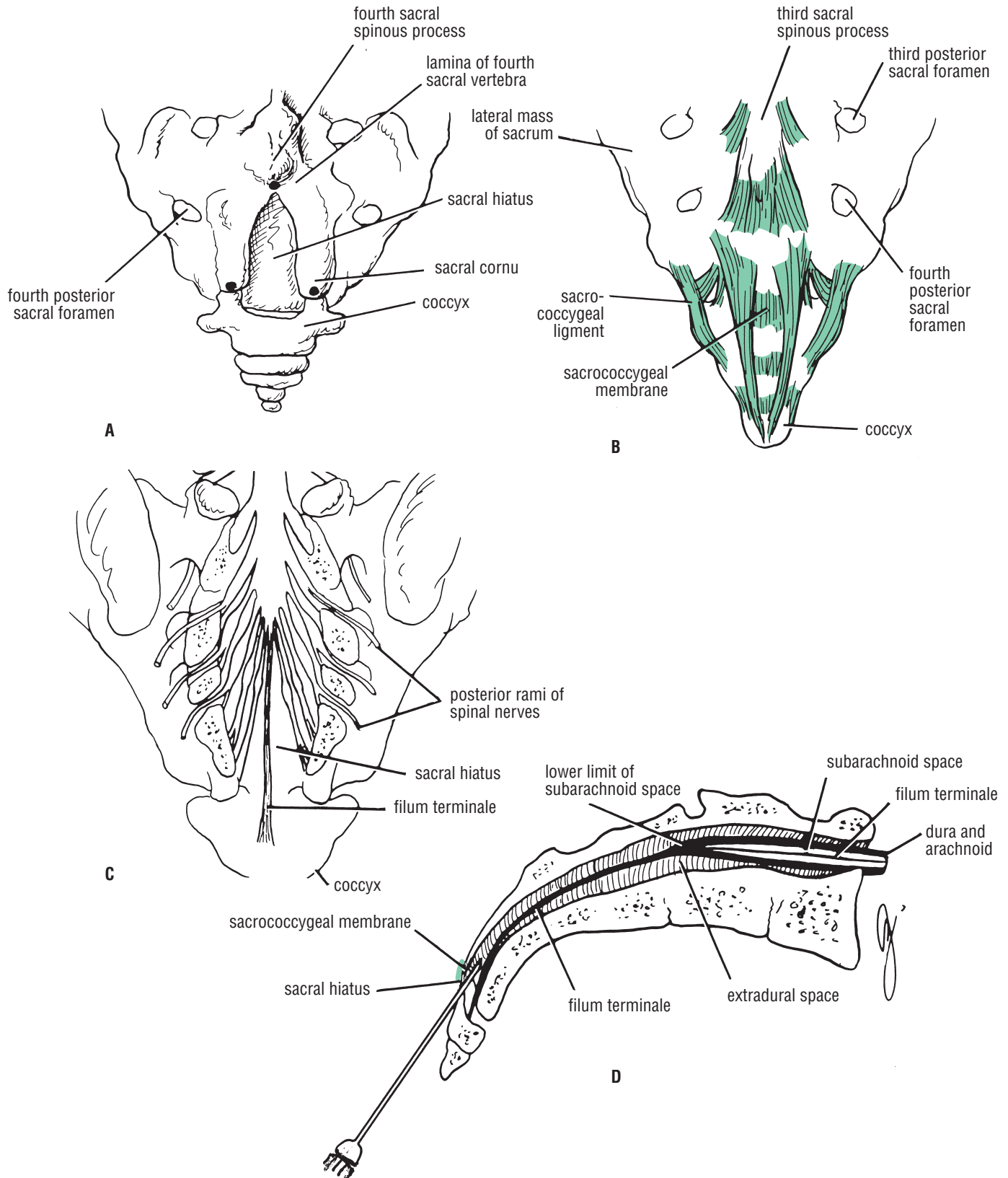
The sacral hiatus is palpated as a distinct depression in the midline about 1.6 in. (4 cm) above the tip of the coccyx in the upper part of the cleft between the buttocks. The hiatus is triangular or U shaped and is bounded laterally by the sacral cornua (CD Fig. 16-4).

The size and shape of the hiatus depend on the number of laminae that fail to fuse in the midline posteriorly. The common arrangement is for the hiatus to be formed by the nonfusion of the fifth and sometimes the fourth sacral vertebrae.

With a careful aseptic technique and under local anesthesia, the needle, fitted with a stylet, is passed into the vertebral (sacral) canal through the sacral hiatus.

The needle pierces the skin and fascia and the sacrococcygeal membrane that fills in the sacral hiatus (see CD Fig. 16-4). The membrane is formed of dense fibrous tissue and represents the fused supraspinous and interspinous ligaments as well as the ligamentum flavum. A distinct feeling of “give” is felt when the ligament is penetrated.


Note that the sacral canal is curved and follows the general curve of the sacrum (see CD Fig. 16-4). The anterior



CD Figure 16-4 **A.** The sacral hiatus. *Black dots* indicate the position of important bony landmarks. **B.** Posterior surface of the lower end of the sacrum and the coccyx showing the sacrococcygeal membrane covering the sacral hiatus. **C.** The dural sheath (thecal sac) around the lower end of the spinal cord and spinal nerves in the sacral canal; the laminae have been removed. **D.** Longitudinal section through the sacrum showing the anatomy of caudal anesthesia.

wall, formed by the fusion of the bodies of the sacral vertebrae, is rough and ridged. The posterior wall, formed by the fusion of the laminae, is smooth. The average distance between the sacral hiatus and the lower end of the subarachnoid space at the second sacral vertebra is about 2 in. (5 cm) in adults.

Note also that the sacral canal contains the dural sac (containing the cauda equina), which is tethered to the coccyx by the filum terminale; the sacral and coccygeal nerves as they emerge from the dural sac surrounded by their dural sheath; and the thin-walled veins of the internal vertebral venous plexus.



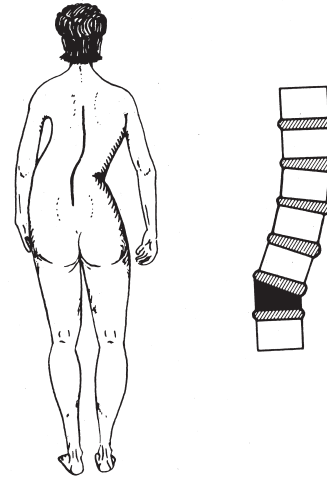
CONGENITAL ANOMALIES

Scoliosis

Scoliosis results from a congenital hemivertebra. A hemivertebra is caused by a failure in development of one of the two ossification centers that appear in the centrum of the body of each vertebra (CD Fig. 16-5).

Spina Bifida

In spina bifida, the spines and arches of one or more adjacent vertebrae fail to develop. The condition occurs most frequently in the lower thoracic, lumbar, and sacral regions. Beneath this defect, the meninges and spinal cord may or may not be involved in varying degrees. This condition is a result of failure of the mesenchyme, which grows in between the neural tube and the surface ectoderm, to form the vertebral arches in the affected region. The types of spina bifida are shown in CD Figs. 16-6 and 16-7.

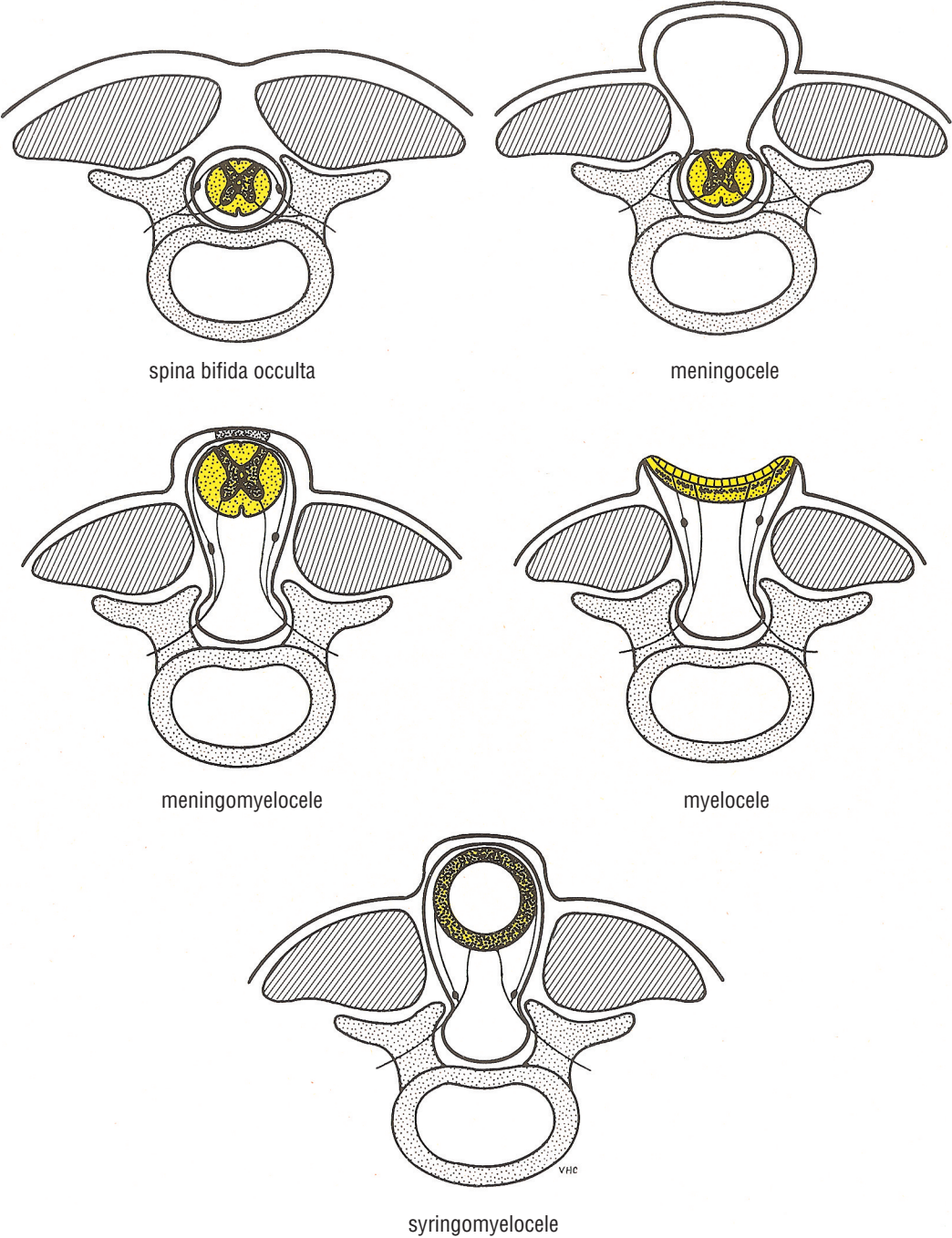


CD Figure 16-5 Posterior view of a woman with scoliosis resulting from a congenital hemivertebra in the lower thoracic region.

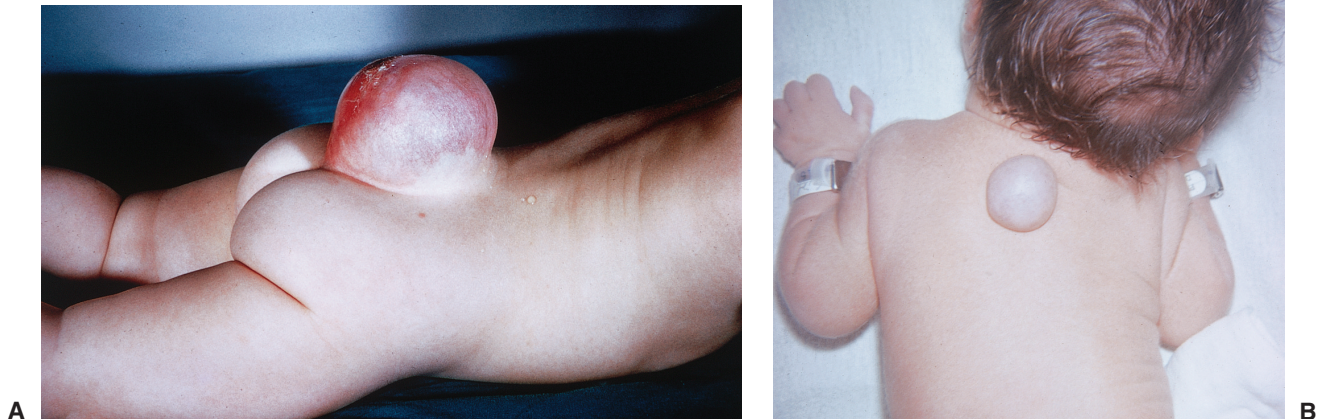


RELATIONSHIP OF THE VERTEBRAL BODY TO THE SPINAL NERVE

Since the fully developed vertebral body is intersegmental in position, each spinal nerve leaves the vertebral canal through the intervertebral foramen and is closely related to the intervertebral disc. This fact is of great clinical significance in cases with prolapse of an intervertebral disc (see CD Fig. 16-1).



CD Figure 16-6 Different types of spina bifida.



CD Figure 16-7 A. Meningocele in the lumbosacral region. (Courtesy of L. Thompson.)
 B. Meningomyelocele in the upper thoracic region. (Courtesy of G. Avery.)

Clinical Problem Solving Questions

Read the following case histories/questions and give the best answer for each.

An 11-year-old boy was showing off in front of friends by diving into the shallow end of a swimming pool. After one particularly daring dive, he surfaced quickly and climbed out of the pool, holding his head between his hands. He said that he had hit the bottom of the pool with his head and now had severe pain in the root of the neck, which was made worse when he tried to move his neck. A lateral radiograph revealed that the right inferior articular process of the fifth cervical vertebra was forced over the anterior margin of the right superior articular process of the sixth cervical vertebra, producing a unilateral dislocation with nipping of the right sixth cervical nerve.

- The following symptoms and signs confirmed the diagnosis **except** which?
 - The head was rotated to the right.
 - There was spasm of the deep neck muscles on the right side of the neck, which were tender to touch.
 - The patient complained of severe pain in the region of the back of the neck and right shoulder.
 - The slightest movement produced severe pain in the right sixth cervical dermatome.
 - The large size of the vertebral canal in the cervical region permitted the spinal cord to escape injury.

A 50-year-old coal miner was crouching at the mine face when a large rock suddenly became dislodged from the roof of the mine shaft and struck him on the upper part of his back. The emergency department

physician suspected a displacement of the upper thoracic spines on the sixth thoracic spine.

- The following physical signs confirmed a diagnosis of fracture dislocation between the fifth and sixth thoracic vertebrae **except** which?
 - A lateral radiograph revealed fractures involving the superior articular processes of the sixth thoracic vertebra and the inferior articular processes of the fifth thoracic vertebra.
 - Considerable forward displacement of the body of the fifth thoracic vertebra on the sixth thoracic vertebra occurred.
 - The patient had signs and symptoms of spinal shock.
 - The large size of the vertebral canal in the thoracic region leaves plenty of space around the spinal cord for bony displacement.
 - The patient later showed signs and symptoms of paraplegia.

A 66-year-old woman was seen in the emergency department complaining of a burning pain over the upper part of her right arm. The pain had started 2 days previously and had progressively worsened. Physical examination revealed weakness and wasting of the right deltoid and biceps brachii muscles. The patient also had hyperesthesia in the skin over the lower part of the right deltoid and down the lateral side of the arm. Radiologic examination showed extensive spur formation on the bodies of the fourth, fifth, and sixth cervical vertebrae. These signs and symptoms suggested severe osteoarthritis of the cervical vertebral column.

3. This disease produced the following changes in the vertebrae and related structures **except** which?
- Repeated trauma and aging had resulted in degenerative changes at the articulating surfaces of the fourth, fifth, and sixth cervical vertebrae.
 - Extensive spur formation resulted in narrowing of the intervertebral foramina with pressure on the nerve roots.
 - The burning pain and hyperesthesia were caused by pressure on the third and fourth cervical posterior roots.
 - The weakness and wasting of the deltoid and biceps brachii muscles were caused by pressure on the fifth and sixth cervical anterior roots.
 - Movements of the neck intensified the symptoms by exerting further pressure on the nerve roots.
 - Coughing or sneezing raised the pressure within the vertebral canal and resulted in further pressure on the roots.

A medical student offered to move a grand piano for his landlady. He had just finished his final examinations in anatomy and was in poor physical shape. He struggled with the antique monstrosity and suddenly experienced an acute pain in the back, which extended down the back and outer side of his left leg. On examination in the emergency department, he was found to have a slight scoliosis with the convexity on the right side. The deep muscles of the back in the left lumbar region felt firmer than normal. No evidence of muscle weakness was present, but the left ankle jerk was diminished.

4. The symptoms and signs of this patient strongly suggest a diagnosis of prolapsed intervertebral disc **except** which?
- The pain was the worst over the left lumbar region opposite the fifth lumbar spine.
 - The pain was accentuated by coughing.
 - With the patient supine, flexing the left hip joint with the knee extended caused a marked increase in the pain.
 - A lateral radiograph of the lumbar vertebral column revealed nothing abnormal.
 - A magnetic resonance imaging study revealed the presence of small fragments of the nucleus pulposus that had herniated outside the anulus in the disc between the fifth lumbar vertebra and the sacrum.
 - The pain occurred in the dermatomes of the third and fourth lumbar segments on the left side.
5. When performing a lumbar puncture (spinal tap) on an adult, the following anatomic facts have to be taken into consideration **except** which?
- With the patient in the lateral prone or upright sitting position, the vertebral column should be well flexed to separate the spines and laminae of adjacent vertebrae.

- An imaginary line joining the anterior superior iliac spines passes over the fourth lumbar spine.
- The needle should be inserted above or below the fourth lumbar spine.
- To enter the subarachnoid space, the needle will pass through the skin, superficial fascia, supraspinous ligament, interspinous ligament, ligamentum flavum, areolar tissue (containing the internal vertebral venous plexus), dura mater, and arachnoid mater.
- The spinal cord ends below in the adult at the level of the lower border of the first lumbar vertebra.
- With the patient in the lateral prone position, the normal cerebrospinal fluid pressure is about 60–150 mm H₂O.

A 22-year-old student was driving home from a party and crashed his car head on into a brick wall. On examination in the emergency department, he was found to have a fracture dislocation of the seventh thoracic vertebra, with signs and symptoms of severe damage to the spinal cord.

6. On recovery from spinal shock he was found to have the following signs and symptoms **except** which?
- Upper motor neuron paralysis of his left leg
 - A band of cutaneous hyperesthesia extending around the abdominal wall on the left side at the level of the umbilicus, which was caused by the irritation of the cord immediately above the site of the lesion
 - On the right side, total analgesia, thermoanesthesia, and partial loss of tactile sense of the skin of the abdominal wall below the level of the umbilicus involving the whole of the right leg
 - Fracture dislocation of the seventh thoracic vertebra, which would result in severe damage to the seventh thoracic segment of the spinal cord
 - Unequal sensory and motor losses on the two sides, which indicate a left hemisection of the spinal cord

A 45-year-old woman visited her physician because of a low back pain of 3 months' duration. She was otherwise very fit. On examination of her back, nothing abnormal was discovered. The physician then listened to her chest, examined her thyroid gland, and finally examined both breasts. A large, hard mass was found in the left breast.

7. The following facts support the diagnosis of carcinoma of the left breast with secondaries in the vertebral column **except** which?
- The lump in the breast was painless and the patient had noticed it while showering 6 months previously.
 - Several large, hard, pectoral lymph nodes were found in the left axilla.
 - A lateral radiograph of the lumbar vertebral column showed extensive metastases in the bodies of the second and third lumbar vertebrae.
 - The lump was situated in the upper outer quadrant of the left breast and was fixed to surrounding tissues.

E. Although the cancer had spread by the lymph vessels, no evidence of spread via the bloodstream was present.

A 75-year-old woman was dusting the top of a high closet while balanced on a chair. She lost her balance and fell to the floor, catching her right lumbar region on the edge of the chair.

8. The following statements about this patient are correct **except** which?
- A. Examination of the back revealed a large bruised area in the right lumbar region, which was extremely tender to touch.

B. Anteroposterior and lateral radiographs exclude the presence of a fracture, especially of a transverse process.


C. A 24-hour specimen of urine should be examined for blood to exclude or confirm injury to the right kidney.

D. Careful examination of the erector spinae muscles or quadratus lumborum muscle may reveal extreme tenderness and therefore injury to these muscles.

E. A lumbar puncture (spinal tap) should always be performed in back injuries to exclude damage to the spinal cord.

Answers and Explanations

- A** is the correct answer. The right inferior articular process of the fifth cervical vertebra was forced over the anterior margin of the right superior articular process of the sixth cervical vertebra, causing the head of the patient to be rotated to the left.
- D** is the correct answer. The vertebral canal in the thoracic region is small and round and little space is around the spinal cord for bony displacement to occur without causing severe damage to the cord.
- C** is the correct answer. The burning pain and hyperesthesia were caused by pressure on the fifth and sixth cervical posterior roots.
- F** is the correct answer. The pain occurred in the dermatomes of the fifth lumbar and first sacral segments on the left side.
- B** is the correct answer. An imaginary line joining the highest points of the iliac crests passes over the fourth lumbar spine.
- D** is the correct answer. Fracture dislocation of the seventh thoracic vertebra would result in severe damage to the tenth thoracic segment of the spinal cord.
- E** is the correct answer. The carcinoma of the left breast was in an advanced stage and had spread by way of the lymph vessels to the axillary lymph nodes and by the bloodstream to the bodies of the second and third lumbar vertebrae. Carcinoma of the thyroid, bronchus, breast, kidney, and prostate tend to metastasize via the bloodstream to bones.
- E** is the correct answer. A lumbar puncture (spinal tap) is not required in cases of simple trauma to the back.



17

The Spinal Nerves and Spinal Nerve Blocks



Chapter Outline

Cervical Plexus	263	Arterial Innervation and Raynaud's Disease	271
Lesions of the Phrenic Nerve and Paralysis of the Diaphragm	263	Intercostal Nerves	272
Brachial Plexus	263	Skin Innervation of the Chest Wall and Referred Pain	272
Clinical Notes on the Nerves of the Upper Limb	263	Herpes Zoster	272
Dermatomes and Cutaneous Nerves of the Upper Limb	263	Lumbar Plexus	272
Tendon Reflexes and the Segmental Innervation of Muscles of the Upper Limb	263	Clinical Notes on the Nerves of the Lower Limb	272
Brachial Plexus Injuries	263	Tendon Reflexes of the Lower Limb	272
Upper Lesions of the Brachial Plexus (Erb-Duchenne Palsy)	264	Femoral Nerve Injury	272
Lower Lesions of the Brachial Plexus (Klumpke Palsy)	265	Sciatic Nerve Injury	272
Compression of the Brachial Plexus, Subclavian Artery, and Subclavian Vein by the Clavicle	265	Trauma to the Sciatic Nerve	273
Long Thoracic Nerve Injuries	266	Sciatica	273
Axillary Nerve Injuries	266	Common Peroneal Nerve Injury	273
Radial Nerve Injuries	266	Tibial Nerve Injury	273
Injuries to the Radial Nerve in the Axilla	268	Obturator Nerve Injury	274
<i>Motor</i>	268	Referred Pain from the Hip Joint	274
<i>Sensory</i>	268	Sacral Plexus	274
<i>Trophic Changes</i>	268	Pressure from the Fetal Head on the Sacral Plexus	274
Injuries to the Radial Nerve in the Spiral Groove of the Humerus	268	Invasion of the Sacral Plexus by Malignant Tumors	274
Injuries to the Deep Branch of the Radial Nerve	268	Referred Pain from the Obturator Nerve	274
Injuries to the Superficial Radial Nerve	268	Clinical Anatomy of Spinal Nerve Blocks	274
Musculocutaneous Nerve Injuries	269	Brachial Plexus Block	274
Median Nerve Injuries	269	Interscalene Block	274
Injuries to the Median Nerve at the Elbow	269	Supraclavicular Block	276
<i>Motor</i>	269	Infraclavicular Block	276
<i>Sensory</i>	269	Axillary Block	276
<i>Vasomotor Changes</i>	269	Musculocutaneous Nerve Block	276
<i>Trophic Changes</i>	269	Median Nerve Block	276
Injuries to the Median Nerve at the Wrist	270	Ulnar Nerve Block	277
Carpal Tunnel Syndrome	270	Radial Nerve Block	278
Ulnar Nerve Injuries	270	Digital Nerve Blocks	278
Injuries to the Ulnar Nerve at the Elbow	270	Thoracic Spinal Nerve Blocks	280
<i>Motor</i>	270	Intercostal Nerve Block	280
<i>Sensory</i>	271	Anterior Abdominal Nerve Blocks	282
<i>Vasomotor Changes</i>	271	Lumbar Spinal Nerve Blocks	283
Injuries to the Ulnar Nerve at the Wrist	271	Ilioinguinal and Iliohypogastric Nerve Blocks	283
		Genitofemoral Nerve Block	283

Femoral Nerve Block	283	Superficial Peroneal Nerve Block	287
Saphenous Nerve Block	284	Deep Peroneal Nerve Block	288
Lateral Cutaneous Nerve of the Thigh Block	284	Toe Nerve Blocks	289
Sacral Spinal Nerve Blocks	285	Pudendal Nerve Blocks	290
Tibial Nerve Block	285	Clinical Problem Solving Questions	290
Sural Nerve Block	286	Answers and Explanations	293
Common Peroneal Nerve Block	287		



CERVICAL PLEXUS

Lesions of the Phrenic Nerve and Paralysis of the Diaphragm

The diaphragm may be paralyzed because of pressure from malignant tumors in the mediastinum on the phrenic nerve. Surgical crushing or sectioning of the phrenic nerve in the neck, producing paralysis of the diaphragm on one side, was once used as part of the treatment of lung tuberculosis, especially of the lower lobes. The immobile dome of the diaphragm rests the lung.



BRACHIAL PLEXUS



CLINICAL NOTES ON THE NERVES OF THE UPPER LIMB

Dermatomes and Cutaneous Nerves of the Upper Limb

It may be necessary for a physician to test the integrity of the spinal cord segments of C3 through T1. The diagrams in CD Figs. 17-1 and 17-2 show the arrangement of the dermatomes of the upper limb. It is seen that the dermatomes for the upper cervical segments C3 to 6 are located along the lateral margin of the upper limb; the C7 dermatome is situated on the middle finger; and the dermatomes for C8, T1, and T2 are along the medial margin of the limb. The nerve fibers from a particular segment of the spinal cord, although

they exit from the cord in a spinal nerve of the same segment, pass to the skin in two or more different cutaneous nerves.

The skin over the point of the shoulder and halfway down the lateral surface of the deltoid muscle is supplied by the supraclavicular nerves (C3 and 4). Pain may be referred to this region as a result of inflammatory lesions involving the diaphragmatic pleura or peritoneum. The afferent stimuli reach the spinal cord via the phrenic nerves (C3, 4, and 5). Pleurisy, peritonitis, subphrenic abscess, or gallbladder disease may therefore be responsible for shoulder pain.

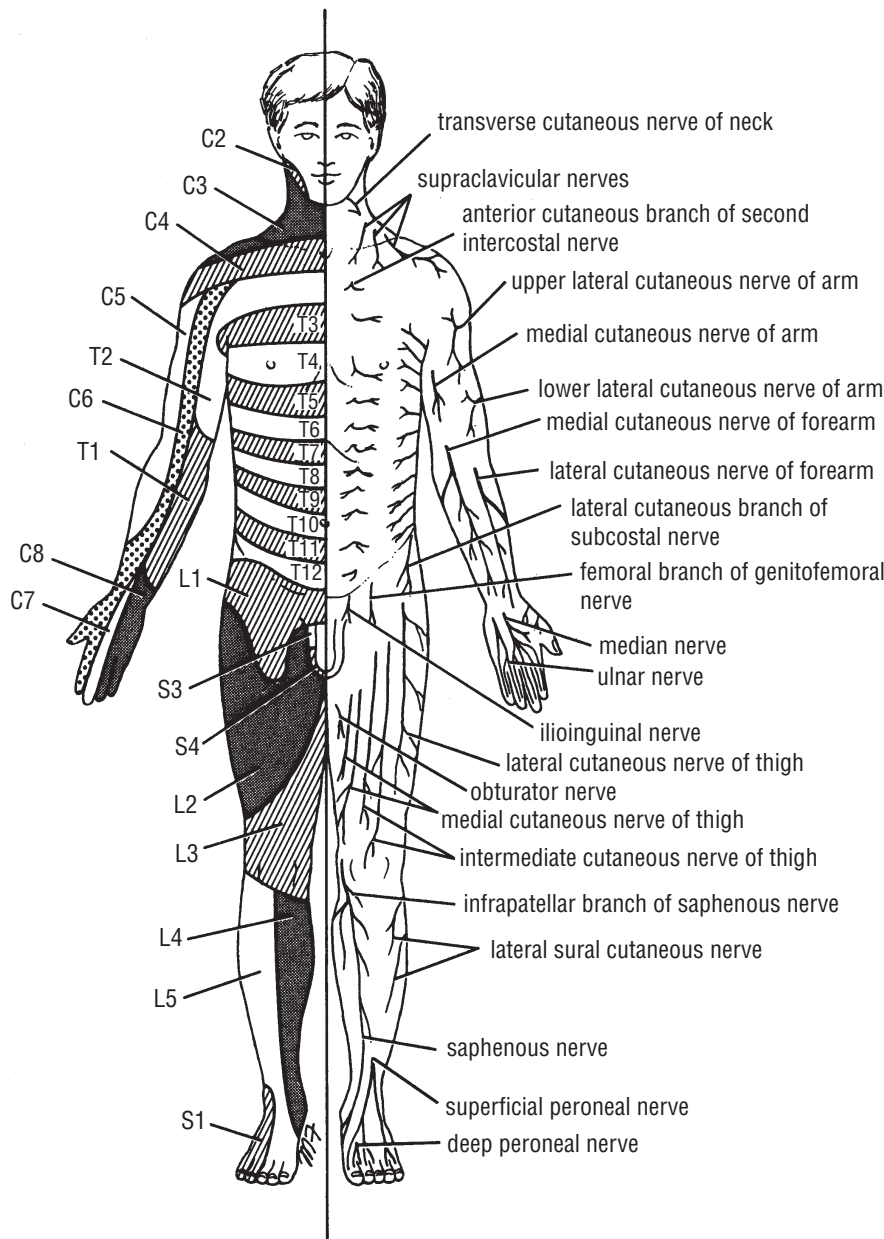
Tendon Reflexes and the Segmental Innervation of Muscles of the Upper Limb

The skeletal muscle receives a segmental innervation. Most muscles are innervated by several spinal nerves and therefore by several segments of the spinal cord. A physician should know the segmental innervation of the following muscles because it is possible to test them by eliciting simple muscle reflexes in the patient:

- **Biceps brachii tendon reflex:** C5 and 6 (flexion of the elbow joint by tapping the biceps tendon)
- **Triceps tendon reflex:** C6, 7, and 8 (extension of the elbow joint by tapping the triceps tendon)
- **Brachioradialis tendon reflex:** C5, 6, and 7 (supination of the radioulnar joints by tapping the insertion of the brachioradialis tendon)

Brachial Plexus Injuries

The roots, trunks, and divisions of the brachial plexus reside in the lower part of the posterior triangle of the neck, whereas the cords and most of the branches of the plexus lie in the axilla. Complete lesions involving all the roots of the plexus are rare. Incomplete injuries are common and are usually caused by traction or pressure; individual nerves can be divided by stab wounds.

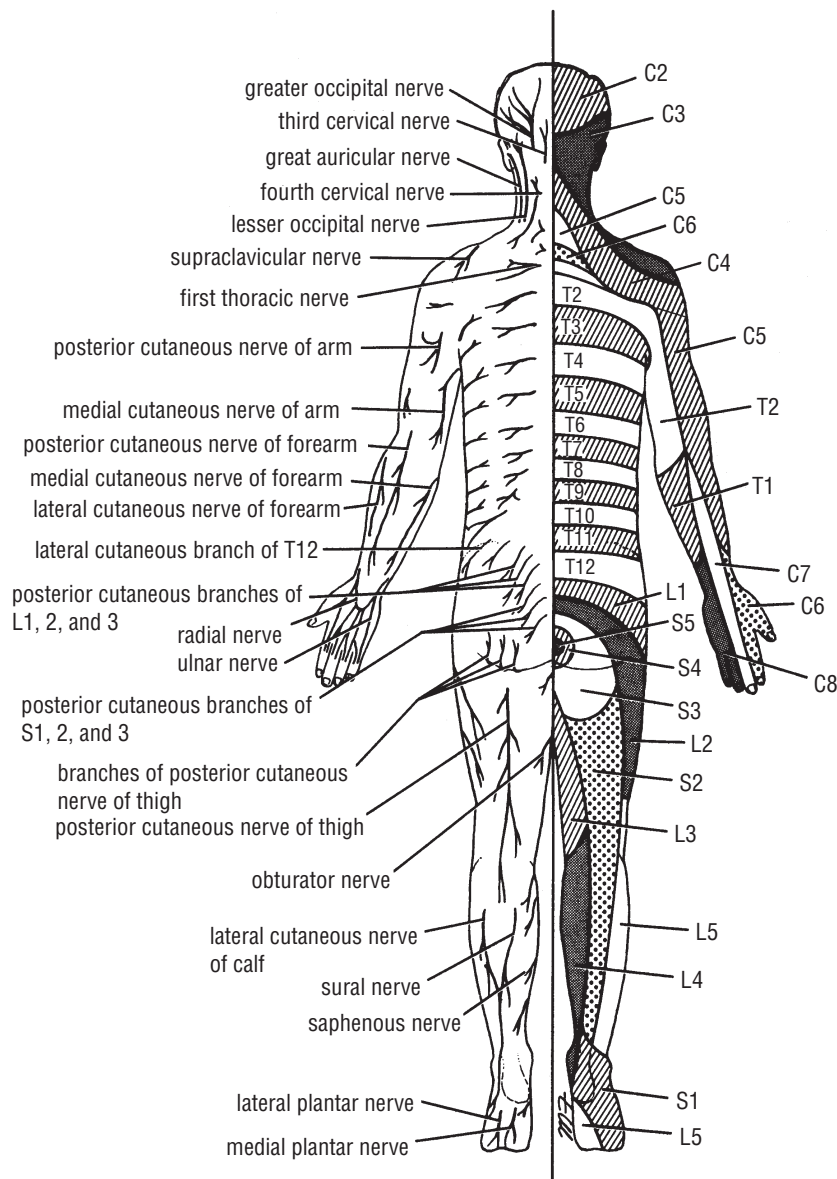


CD Figure 17-1 Dermatomes and distribution of cutaneous nerves on the anterior aspect of the body.

Upper Lesions of the Brachial Plexus (Erb-Duchenne Palsy)

Upper lesions of the brachial plexus are injuries resulting from excessive displacement of the head to the opposite side and depression of the shoulder on the same side. This causes excessive traction or even tearing of C5 and 6 roots of the plexus. It occurs in infants during a difficult delivery or in adults after a blow to or fall on the shoulder. The suprascapular nerve, the nerve to the subclavius, and the musculocutaneous and axillary nerves all possess nerve fibers derived from C5 and 6 roots and will therefore be functionless. The following muscles will consequently be paralyzed: the supraspinatus (abductor of the shoulder)

and infraspinatus (lateral rotator of the shoulder); the subclavius (depresses the clavicle); the biceps brachii (supinator of the forearm, flexor of the elbow, weak flexor of the shoulder), and the greater part of the brachialis (flexor of the elbow), and the coracobrachialis (flexor of the shoulder); and the deltoid (abductor of the shoulder) and the teres minor (lateral rotator of the shoulder). Thus, the limb will hang limply by the side, medially rotated by the unopposed sternocostal part of the pectoralis major; the forearm will be pronated because of loss of the action of the biceps. The position of the upper limb in this condition has been likened to that of a porter or waiter hinting for a tip (CD Fig.17-3). In addition, there will be a loss of sensation down the lateral side of the arm.



CD Figure 17-2 Dermatomes and distribution of cutaneous nerves on the posterior aspect of the body.

Lower Lesions of the Brachial Plexus (Klumpke Palsy)

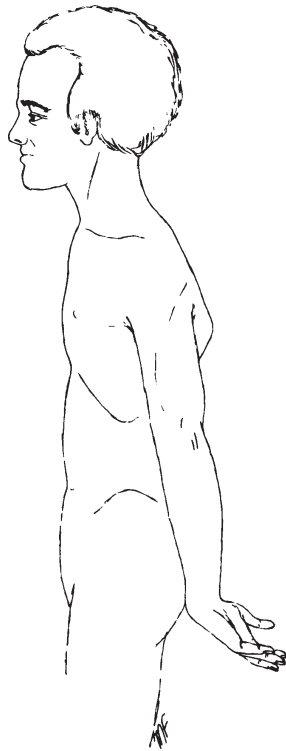Lower lesions of the brachial plexus are usually traction injuries caused by excessive abduction of the arm, as occurs in the case of a person falling from a height clutching at an object to save himself or herself. The first thoracic nerve is usually torn. The nerve fibers from this segment run in the ulnar and median nerves to supply **all the small muscles of the hand**. The hand has a clawed appearance caused by hyperextension of the metacarpophalangeal joints and flexion of the interphalangeal joints. The extensor digitorum is unopposed by the lumbricals and interossei and extends the metacarpophalangeal joints; the flexor digitorum superficialis and profundus are unopposed by the lumbricals and interossei and flex the middle and terminal phalanges, respectively. In addition, loss of sensation will occur along the medial side

of the arm. If the eighth cervical nerve is also damaged, the extent of anesthesia will be greater and will involve the medial side of the forearm, hand, and medial two fingers.

Lower lesions of the brachial plexus can also be produced by the presence of a cervical rib or malignant metastases from the lungs in the lower deep cervical lymph nodes.

Compression of the Brachial Plexus, Subclavian Artery, and Subclavian Vein by the Clavicle

The interval between the clavicle and the first rib in some patients may become narrowed and thus is responsible for compression of nerves and blood vessels.



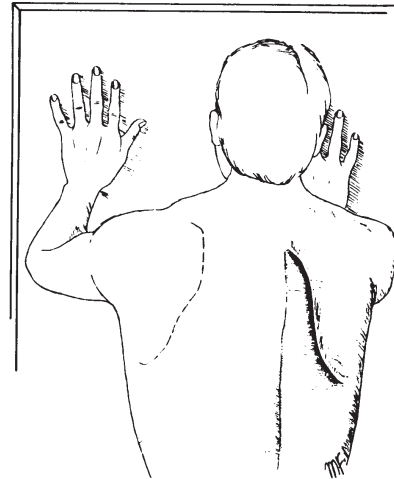
CD Figure 17-3 Erb-Duchenne palsy (waiter's tip).

Long Thoracic Nerve Injuries

The long thoracic nerve, which arises from C5, 6, and 7 and supplies the serratus anterior muscle, can be injured by blows to or pressure on the posterior triangle of the neck or during the surgical procedure of radical mastectomy. Paralysis of the serratus anterior results in the inability to rotate the scapula during the movement of abduction of the arm above a right angle. The patient therefore experiences difficulty in raising the arm above the head. The vertebral border and inferior angle of the scapula will no longer be kept closely applied to the chest wall and will protrude posteriorly, a condition known as “winging scapula” (CD Fig. 17-4).

Axillary Nerve Injuries

The axillary nerve (see text Fig. 17-20B), which arises from the posterior cord of the brachial plexus (C5 and 6), can be injured by the pressure of a badly adjusted crutch pressing upward into the armpit. The passage of the axillary nerve backward from the axilla through the quadrangular space makes it particularly vulnerable here to downward displacement of the humeral head in shoulder dislocations or fractures of the surgical neck of the humerus. Paralysis of the deltoid and teres minor muscles results. The cutaneous branches of the axillary nerve, including the upper lateral cutaneous nerve of the arm, are functionless, and consequently there is a loss of skin sensation over the **lower half** of the deltoid muscle. The paralyzed deltoid wastes rapidly,



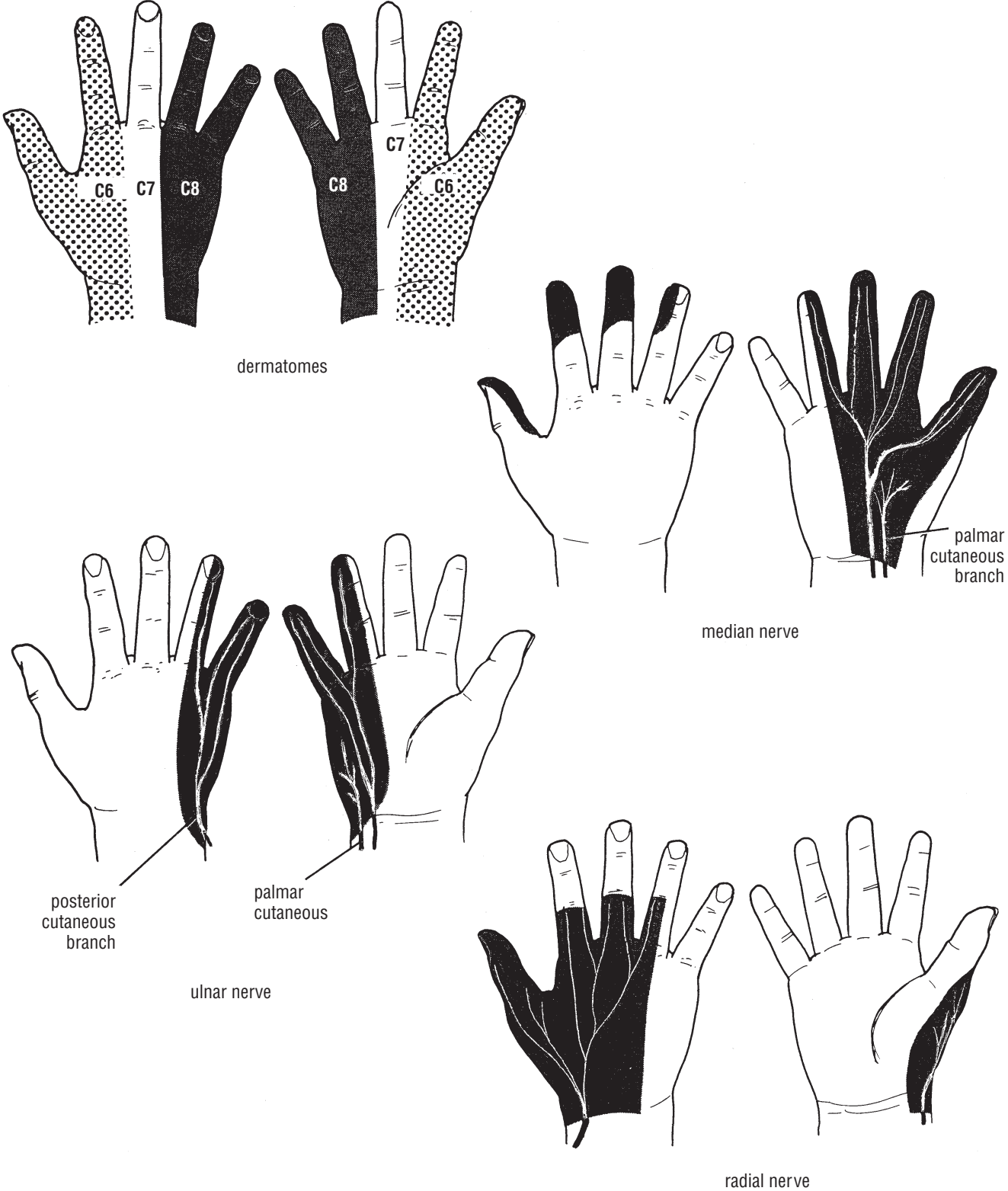
CD Figure 17-4 Winging of the right scapula.

and the underlying greater tuberosity can be readily palpated. Because the supraspinatus is the only other abductor of the shoulder, this movement is much impaired. Paralysis of the teres minor is not recognizable clinically.

Radial Nerve Injuries

The radial nerve (see text Fig. 17-21), which arises from the posterior cord of the brachial plexus, characteristically gives off its branches some distance proximal to the part to be innervated.

- **In the axilla** it gives off three branches: the posterior cutaneous nerve of the arm, which supplies the skin on the back of the arm down to the elbow; the nerve to the long head of the triceps; and the nerve to the medial head of the triceps.
- **In the spiral groove** of the humerus it gives off four branches: the lower lateral cutaneous nerve of the arm, which supplies the lateral surface of the arm down to the elbow; the posterior cutaneous nerve of the forearm, which supplies the skin down the middle of the back of the forearm as far as the wrist; the nerve to the lateral head of the triceps; and the nerve to the medial head of the triceps and the anconeus.
- **In the anterior compartment of the arm** above the lateral epicondyle it gives off three branches: the nerve to a small part of the brachialis, the nerve to the brachioradialis, and the nerve to the extensor carpi radialis longus.
- **In the cubital fossa** it gives off the deep branch of the radial nerve and continues as the superficial radial nerve. The deep branch supplies the extensor carpi radialis brevis and the supinator in the cubital fossa and all the extensor muscles in the posterior compartment of the forearm. The superficial radial nerve is sensory and supplies the skin over the lateral part of the dorsum of the hand and the dorsal surface of the lateral three and a half fingers proximal to the nail beds (CD Fig. 17-5).



CD Figure 17-5 Sensory innervation of the skin of the volar (palmar) and dorsal aspects of the hand; the arrangement of the dermatomes is also shown.

(The ulnar nerve supplies the medial part of the dorsum of the hand and the dorsal surface of the medial one and a half fingers; the exact cutaneous areas innervated by the radial and ulnar nerves on the hand are subject to variation.)

The radial nerve is commonly damaged in the axilla and in the spiral groove.

Injuries to the Radial Nerve in the Axilla

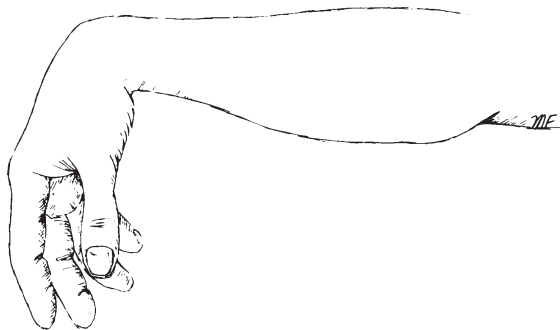
In the axilla the nerve can be injured by the pressure of the upper end of a badly fitting crutch pressing up into the armpit or by a drunkard falling asleep with one arm over the back of a chair. It can also be badly damaged in the axilla by fractures and dislocations of the proximal end of the humerus. When the humerus is displaced downward in dislocations of the shoulder, the radial nerve, which is wrapped around the back of the shaft of the bone, is pulled downward, stretching the nerve in the axilla excessively.

The clinical findings in injury to the radial nerve in the axilla are as follows.

Motor

The triceps, the anconeus, and the long extensors of the wrist are paralyzed. The patient is unable to extend the elbow joint, the wrist joint, and the fingers. Wristdrop, or flexion of the wrist (CD Fig. 17-6), occurs as a result of the action of the unopposed flexor muscles of the wrist. Wristdrop is very disabling because one is unable to flex the fingers strongly for the purpose of firmly gripping an object with the wrist fully flexed. (Try it on yourself.) If the wrist and proximal phalanges are passively extended by holding them in position with the opposite hand, the middle and distal phalanges of the fingers can be extended by the action of the lumbricals and interossei, which are inserted into the extensor expansions.

The brachioradialis and supinator muscles are also paralyzed, but supination is still performed well by the biceps brachii.



CD Figure 17-6 Wristdrop.

Sensory

A small loss of skin sensation occurs down the posterior surface of the lower part of the arm and down a narrow strip on the back of the forearm. A variable area of sensory loss is present on the lateral part of the dorsum of the hand and on the dorsal surface of the roots of the lateral three and a half fingers. The area of total anesthesia is relatively small because of the overlap of sensory innervation by adjacent nerves.

Trophic Changes

Trophic changes are slight.

Injuries to the Radial Nerve in the Spiral Groove of the Humerus

In the spiral groove of the humerus, the radial nerve can be injured at the time of fracture of the shaft of the humerus or subsequently involved during the formation of the callus. The pressure of the back of the arm on the edge of the operating table in an unconscious patient has also been known to injure the nerve at this site. The prolonged application of a tourniquet to the arm in a person with a slender triceps muscle is often followed by temporary radial palsy.

The clinical findings in injury to the radial nerve in the spiral groove are as follows:

The injury to the radial nerve occurs most commonly in the distal part of the groove, beyond the origin of the nerves to the triceps and the anconeus and beyond the origin of the cutaneous nerves.

- **Motor:** The patient is unable to extend the wrist and the fingers, and wristdrop occurs.
- **Sensory:** A variable small area of anesthesia is present over the dorsal surface of the hand and the dorsal surface of the roots of the lateral three and a half fingers.
- **Trophic changes:** These are very slight or absent.

Injuries to the Deep Branch of the Radial Nerve

The deep branch of the radial nerve is a motor nerve to the extensor muscles in the posterior compartment of the forearm. It can be damaged in fractures of the proximal end of the radius or during dislocation of the radial head. The nerve supply to the supinator and the extensor carpi radialis longus will be undamaged, and because the latter muscle is powerful, it will keep the wrist joint extended, and wristdrop will not occur. No sensory loss occurs because this is a motor nerve.

Injuries to the Superficial Radial Nerve

Division of the superficial radial nerve, which is sensory, as in a stab wound, results in a variable small area of anesthesia over the dorsum of the hand and the dorsal surface of the roots of the lateral three and a half fingers.

Musculocutaneous Nerve Injuries

The musculocutaneous nerve (see text Fig. 17-9) is rarely injured because of its protected position beneath the biceps brachii muscle. If it is injured high up in the arm, the biceps and coracobrachialis are paralyzed and the brachialis muscle is weakened (the latter muscle is also supplied by the radial nerve). Flexion of the forearm at the elbow joint is then produced by the remainder of the brachialis muscle and the flexors of the forearm. When the forearm is in the prone position, the extensor carpi radialis longus and the brachioradialis muscles assist in flexion of the forearm. There is also sensory loss along the lateral side of the forearm. Wounds or cuts of the forearm can sever the lateral cutaneous nerve of the forearm, a continuation of the musculocutaneous nerve beyond the cubital fossa, resulting in sensory loss along the lateral side of the forearm.

Median Nerve Injuries

The median nerve (see text Fig. 17-9), which arises from the medial and lateral cords of the brachial plexus, gives off no cutaneous or motor branches in the axilla or in the arm. In the proximal third of the front of the forearm, by unnamed branches or by its anterior interosseous branch, it supplies all the muscles of the front of the forearm except the flexor carpi ulnaris and the medial half of the flexor digitorum profundus, which are supplied by the ulnar nerve. In the distal third of the forearm, it gives rise to a palmar cutaneous branch, which crosses in front of the flexor retinaculum and supplies the skin on the lateral half of the palm (see CD Fig. 17-5). In the palm the median nerve supplies the muscles of the thenar eminence and the first two lumbricals and gives sensory innervation to the skin of the palmar aspect of the lateral three and a half fingers, including the nail beds on the dorsum.

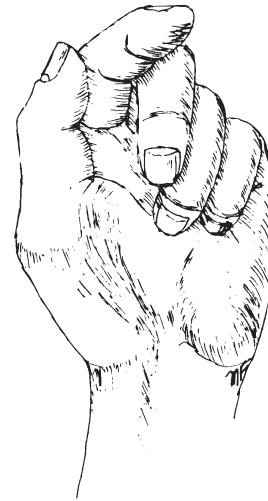
From a clinical standpoint, the median nerve is injured occasionally in the elbow region in supracondylar fractures of the humerus. It is most commonly injured by stab wounds or broken glass just proximal to the flexor retinaculum; here it lies in the interval between the tendons of the flexor carpi radialis and flexor digitorum superficialis, overlapped by the palmaris longus.

The clinical findings in injury to the median nerve are as follows.

Injuries to the Median Nerve at the Elbow

Motor

The pronator muscles of the forearm and the long flexor muscles of the wrist and fingers, with the exception of the flexor carpi ulnaris and the medial half of the flexor digitorum profundus, will be paralyzed. As a result, the forearm is kept in the supine position; wrist flexion is weak and is



CD Figure 17-7 Median nerve palsy.

accompanied by adduction. The latter deviation is caused by the paralysis of the flexor carpi radialis and the strength of the flexor carpi ulnaris and the medial half of the flexor digitorum profundus. No flexion is possible at the interphalangeal joints of the index and middle fingers, although weak flexion of the metacarpophalangeal joints of these fingers is attempted by the interossei. When the patient tries to make a fist, the index and to a lesser extent the middle fingers tend to remain straight, whereas the ring and little fingers flex (CD Fig. 17-7). The latter two fingers are, however, weakened by the loss of the flexor digitorum superficialis.

Flexion of the terminal phalanx of the thumb is lost because of paralysis of the flexor pollicis longus. The muscles of the thenar eminence are paralyzed and wasted so that the eminence is flattened. The thumb is laterally rotated and adducted. The hand looks flattened and “ape-like.”

Sensory

Skin sensation is lost on the lateral half or less of the palm of the hand and the palmar aspect of the lateral three and a half fingers. Sensory loss also occurs on the skin of the distal part of the dorsal surfaces of the lateral three and a half fingers. The area of total anesthesia is considerably less because of the overlap of adjacent nerves.

Vasomotor Changes

The skin areas involved in sensory loss are warmer and drier than normal because of the arteriolar dilatation and absence of sweating resulting from loss of sympathetic control.

Trophic Changes

In long-standing cases, changes are found in the hand and fingers. The skin is dry and scaly, the nails crack easily, and atrophy of the pulp of the fingers is present.

Injuries to the Median Nerve at the Wrist

- **Motor:** The muscles of the thenar eminence are paralyzed and wasted so that the eminence becomes flattened. The thumb is laterally rotated and adducted. The hand looks flattened and “ape-like.” Opposition movement of the thumb is impossible. The first two lumbricals are paralyzed, which can be recognized clinically when the patient is asked to make a fist slowly, and the index and middle fingers tend to lag behind the ring and little fingers.
- **Sensory, vasomotor, and trophic changes:** These changes are identical to those found in the elbow lesions.

Perhaps the most serious disability of all in median nerve injuries is the loss of ability to oppose the thumb to the other fingers and the loss of sensation over the lateral fingers. The delicate pincer-like action of the hand is no longer possible.

Carpal Tunnel Syndrome

The carpal tunnel, formed by the concave anterior surface of the carpal bones and closed by the flexor retinaculum, is tightly packed with the long flexor tendons of the fingers, their surrounding synovial sheaths, and the median nerve. Clinically, the syndrome consists of a burning pain or “pins and needles” along the distribution of the median nerve to the lateral three and a half fingers and weakness of the thenar muscles. It is produced by compression of the median nerve within the tunnel. The exact cause of the compression is difficult to determine, but thickening of the synovial sheaths of the flexor tendons or arthritic changes in the carpal bones are thought to be responsible in many cases. As would be expected, no paresthesia occurs over the thenar eminence because this area of skin is supplied by the palmar cutaneous branch of the median nerve, which passes superficially to the flexor retinaculum. The condition is dramatically relieved by decompressing the tunnel by making a longitudinal incision through the flexor retinaculum.

Ulnar Nerve Injuries

The ulnar nerve (see text Fig. 17-20A), which arises from the medial cord of the brachial plexus (C8 and T1), gives off no cutaneous or motor branches in the axilla or in the arm. As it enters the forearm from behind the medial epicondyle, it supplies the flexor carpi ulnaris and the medial half of the flexor digitorum profundus. In the distal third of the forearm, it gives off its palmar and posterior cutaneous branches. The palmar cutaneous branch supplies the skin over the hypothenar eminence; the posterior branch supplies the skin over the medial third of the dorsum of the hand and the medial one and a half fingers. Not uncommonly, the posterior branch supplies two and a half instead of one and a half fingers. It does not supply the skin over the distal part of the dorsum of these fingers.

Having entered the palm by passing in front of the flexor retinaculum, the superficial branch of the ulnar nerve supplies the skin of the palmar surface of the medial one and a half fingers (see CD Fig. 17-5), including their nail beds; it also supplies the palmaris brevis muscle. The deep branch supplies all the small muscles of the hand except the muscles of the thenar eminence and the first two lumbricals, which are supplied by the median nerve.

The ulnar nerve is most commonly injured at the elbow, where it lies behind the medial epicondyle, and at the wrist, where it lies with the ulnar artery in front of the flexor retinaculum. The injuries at the elbow are usually associated with fractures of the medial epicondyle. The superficial position of the nerve at the wrist makes it vulnerable to damage from cuts and stab wounds.

The clinical findings in injury to the ulnar nerve are as follows.

Injuries to the Ulnar Nerve at the Elbow

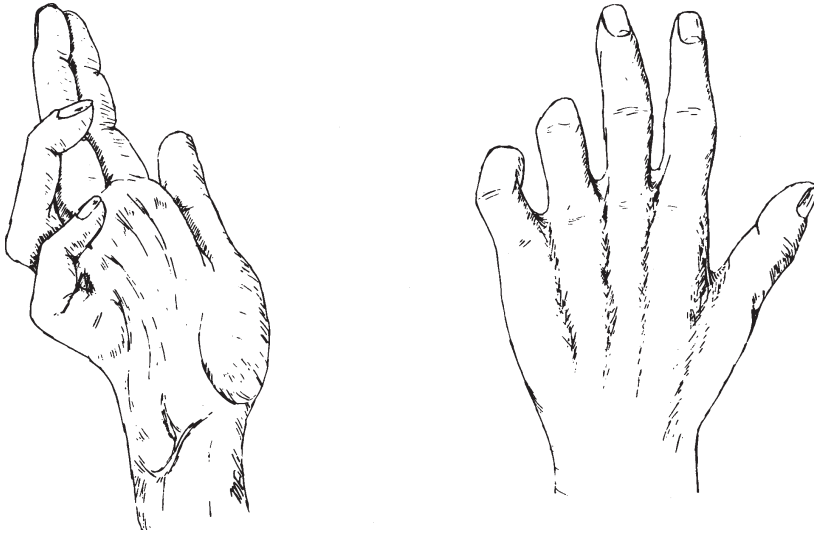
Motor

The flexor carpi ulnaris and the medial half of the flexor digitorum profundus muscles are paralyzed. The paralysis of the flexor carpi ulnaris can be observed by asking the patient to make a tightly clenched fist. Normally, the synergistic action of the flexor carpi ulnaris tendon can be observed as it passes to the pisiform bone; the tightening of the tendon will be absent if the muscle is paralyzed. The profundus tendons to the ring and little fingers will be functionless, and the terminal phalanges of these fingers are therefore not capable of being markedly flexed. Flexion of the wrist joint will result in abduction, owing to paralysis of the flexor carpi ulnaris. The medial border of the front of the forearm will show flattening, owing to the wasting of the underlying ulnaris and profundus muscles.

The small muscles of the hand will be paralyzed, except the muscles of the thenar eminence and the first two lumbricals, which are supplied by the median nerve. The patient is unable to adduct and abduct the fingers and consequently is unable to grip a piece of paper placed between the fingers. Remember that the extensor digitorum can abduct the fingers to a small extent, but only when the metacarpophalangeal joints are hyperextended.

It is impossible to adduct the thumb because the adductor pollicis muscle is paralyzed. If the patient is asked to grip a piece of paper between the thumb and the index finger, he or she does so by strongly contracting the flexor pollicis longus and flexing the terminal phalanx (Froment’s sign).

The metacarpophalangeal joints become hyperextended because of the paralysis of the lumbrical and interosseous muscles, which normally flex these joints. Because the first and second lumbricals are not paralyzed (they



CD Figure 17-8 Ulnar nerve palsy.

are supplied by the median nerve), the hyperextension of the metacarpophalangeal joints is most prominent in the fourth and fifth fingers. The interphalangeal joints are flexed, owing again to the paralysis of the lumbrical and interosseous muscles, which normally extend these joints through the extensor expansion. The flexion deformity at the interphalangeal joints of the fourth and fifth fingers is obvious because the first and second lumbrical muscles of the index and middle fingers are not paralyzed. In long-standing cases the hand assumes the characteristic “claw” deformity (*main en griffe*). Wasting of the paralyzed muscles results in flattening of the hypothenar eminence and loss of the convex curve to the medial border of the hand. Examination of the dorsum of the hand will show hollowing between the metacarpal bones caused by wasting of the dorsal interosseous muscles (CD Fig. 17-8).

Sensory

Loss of skin sensation will be observed over the anterior and posterior surfaces of the medial third of the hand and the medial one and a half fingers.

Vasomotor Changes

The skin areas involved in sensory loss are warmer and drier than normal because of the arteriolar dilatation and absence of sweating resulting from loss of sympathetic control.

Injuries to the Ulnar Nerve at the Wrist

- **Motor:** The small muscles of the hand will be paralyzed and show wasting, except for the muscles of the thenar eminence and the first two lumbricals, as described (see previous page). The clawhand is much more obvious in wrist lesions because the flexor digitorum profundus

muscle is not paralyzed, and marked flexion of the terminal phalanges occurs.


- **Sensory:** The main ulnar nerve and its palmar cutaneous branch are usually severed; the posterior cutaneous branch, which arises from the ulnar nerve trunk about 2.5 in. (6.25 cm) above the pisiform bone, is usually unaffected. The sensory loss will therefore be confined to the palmar surface of the medial third of the hand and the medial one and a half fingers and to the dorsal aspects of the middle and distal phalanges of the same fingers.
- **Vasomotor and trophic changes:** These are the same as those described for injuries at the elbow. It is important to remember that with ulnar nerve injuries, the higher the lesion is, the less obvious is the clawing deformity of the hand.

Unlike median nerve injuries, lesions of the ulnar nerve leave a relatively efficient hand. The sensation over the lateral part of the hand is intact, and the pincer-like action of the thumb and index finger is reasonably good, although there is some weakness, owing to loss of the adductor pollicis.

Arterial Innervation and Raynaud's Disease

The arteries of the upper limb are innervated by sympathetic nerves. The preganglionic fibers originate from cell bodies in the second to eighth thoracic segments of the spinal cord. They ascend in the sympathetic trunk and synapse in the middle cervical, inferior cervical, first thoracic, or stellate ganglia. The postganglionic fibers join the nerves that form the brachial plexus and are distributed to the arteries within the branches of the plexus. For example, the digital arteries of the fingers are supplied by postgan-

glionic sympathetic fibers that run in the digital nerves. Vasospastic diseases involving digital arterioles, such as **Raynaud's disease**, may require a cervicodorsal preganglionic sympathectomy to prevent necrosis of the fingers. The operation is followed by arterial vasodilatation, with consequent increased blood flow to the upper limb.



INTERCOSTAL NERVES


Skin Innervation of the Chest Wall and Referred Pain

Above the level of the sternal angle, the cutaneous innervation of the anterior chest wall is derived from the **supraclavicular nerves** (C3 and 4). Below this level, the anterior and lateral cutaneous branches of the intercostal nerves supply oblique bands of skin in regular sequence. The skin on the posterior surface of the chest wall is supplied by the posterior rami of the spinal nerves. The arrangement of the dermatomes is shown in CD Figs. 17-1 and 17-2.


An intercostal nerve not only supplies areas of skin but also supplies the ribs, costal cartilages, intercostal muscles, and parietal pleura lining the intercostal space. Furthermore, the seventh to eleventh intercostal nerves leave the thoracic wall and enter the anterior abdominal wall so that they, in addition, supply dermatomes on the anterior abdominal wall, muscles of the anterior abdominal wall, and parietal peritoneum. This latter fact is of great clinical importance because it means that disease in the thoracic wall may be revealed as pain in a dermatome that extends across the costal margin into the anterior abdominal wall. For example, a pulmonary thromboembolism or a pneumonia with pleurisy involving the costal parietal pleura could give rise to abdominal pain and tenderness and rigidity of the abdominal musculature. The abdominal pain in these instances is called **referred pain**.

Herpes Zoster

Herpes zoster, or shingles, is a relatively common condition caused by the reactivation of the latent varicella-zoster virus in a patient who has previously had chickenpox. The lesion is seen as an inflammation and degeneration of the sensory neuron in a cranial or spinal nerve with the formation of vesicles with inflammation of the skin. In the thorax the first symptom is a band of dermatomal pain in the distribution of the sensory neuron in a thoracic spinal nerve, followed in a few days by a skin eruption. The condition occurs most frequently in patients older than 50 years.



LUMBAR PLEXUS



CLINICAL NOTES ON THE NERVES OF THE LOWER LIMB

Tendon Reflexes of the Lower Limb

Skeletal muscles receive a segmental innervation. Most muscles are innervated by two, three, or four spinal nerves and therefore by the same number of segments of the spinal cord. The segmental innervation of the following muscles in the lower limb should be known because it is possible to test them by eliciting simple muscle reflexes in the patient:

- **Patellar tendon reflex** (knee jerk): L2, 3, and 4 (extension of the knee joint on tapping the patellar tendon)
- **Achilles tendon reflex** (ankle jerk): S1 and S2 (plantar flexion of the ankle joint on tapping the Achilles tendon)

Femoral Nerve Injury

The femoral nerve (L2, 3, and 4) enters the thigh from behind the inguinal ligament, at a point midway between the anterior superior iliac spine and the pubic tubercle; it lies about a fingerbreadth lateral to the femoral pulse. About 2 in. (5 cm) below the inguinal ligament, the nerve splits into its terminal branches (see text Fig. 17-29).

The femoral nerve can be injured in stab or gunshot wounds, but a complete division of the nerve is rare. The following clinical features are present when the nerve is completely divided:

- **Motor:** The quadriceps femoris muscle is paralyzed, and the knee cannot be extended. In walking, this is compensated for to some extent by use of the adductor muscles.
- **Sensory:** Skin sensation is lost over the anterior and medial sides of the thigh, over the medial side of the lower part of the leg, and along the medial border of the foot as far as the ball of the big toe; this area is normally supplied by the saphenous nerve.

Sciatic Nerve Injury

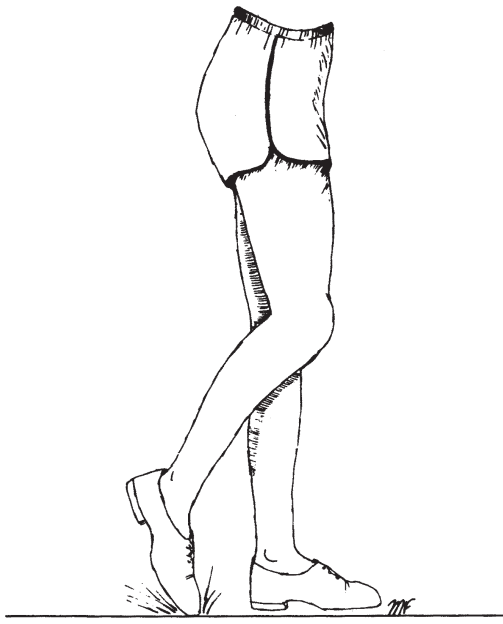
The sciatic nerve (L4 and 5 and S1, 2, and 3) curves laterally and downward through the gluteal region, situated at

first midway between the posterosuperior iliac spine and the ischial tuberosity, and lower down, midway between the tip of the greater trochanter and the ischial tuberosity. The nerve then passes downward in the midline on the posterior aspect of the thigh and divides into the common peroneal and tibial nerves, at a variable site above the popliteal fossa (see text Figs. 17-42 and 17-46).

Trauma to the Sciatic Nerve

The nerve is sometimes injured by penetrating wounds, fractures of the pelvis, or dislocations of the hip joint. It is most frequently injured by badly placed intramuscular injections in the gluteal region. To avoid this injury, injections into the gluteus maximus or the gluteus medius should be made well forward on the upper outer quadrant of the buttock. Most nerve lesions are incomplete, and in 90% of injuries, the common peroneal part of the nerve is the most affected. This can probably be explained by the fact that the common peroneal nerve fibers lie most superficial in the sciatic nerve. The following clinical features are present:

- **Motor:** The hamstring muscles are paralyzed, but weak flexion of the knee is possible because of the action of the sartorius (femoral nerve) and gracilis (obturator nerve). All the muscles below the knee are paralyzed, and the weight of the foot causes it to assume the plantar-flexed position, or **foot drop** (CD Fig. 17-9).
- **Sensory:** Sensation is lost below the knee, except for a narrow area down the medial side of the lower part of the leg and along the medial border of the foot as far as the ball of the big toe, which is supplied by the saphenous nerve (femoral nerve).



CD Figure 17-9 Foot drop. With this condition, the individual catches his or her toes on the ground when walking.

The result of operative repair of a sciatic nerve injury is poor. It is rare for active movement to return to the small muscles of the foot, and sensory recovery is rarely complete. Loss of sensation in the sole of the foot makes the development of trophic ulcers inevitable.

Sciatica

Sciatica describes the condition in which patients have pain along the sensory distribution of the sciatic nerve. Thus, the pain is experienced in the posterior aspect of the thigh, the posterior and lateral sides of the leg, and the lateral part of the foot. Sciatica can be caused by prolapse of an intervertebral disc with pressure on one or more roots of the lower lumbar and sacral spinal nerves, pressure on the sacral plexus or sciatic nerve by an intrapelvic tumor, or inflammation of the sciatic nerve or its terminal branches.

Common Peroneal Nerve Injury

The common peroneal nerve (see text Fig. 17-38) is in an exposed position as it leaves the popliteal fossa and winds around the neck of the fibula to enter the peroneus longus muscle.

It is commonly injured in fractures of the neck of the fibula and by pressure from casts or splints. The following clinical features are present:

- **Motor:** The muscles of the anterior and lateral compartments of the leg are paralyzed, namely, the tibialis anterior, the extensor digitorum longus and brevis, the peroneus tertius, the extensor hallucis longus (supplied by the deep peroneal nerve), and the peroneus longus and brevis (supplied by the superficial peroneal nerve). As a result, the opposing muscles, the plantar flexors of the ankle joint and the invertors of the subtalar and transverse tarsal joints, cause the foot to be plantar flexed (foot drop) and inverted, an attitude referred to as **equinovarus**.
- **Sensory:** Loss of sensation occurs down the anterior and lateral sides of the leg and dorsum of the foot and toes, including the medial side of the big toe. The lateral border of the foot and the lateral side of the little toe are virtually unaffected (sural nerve, mainly formed from tibial nerve). The medial border of the foot as far as the ball of the big toe is completely unaffected (saphenous nerve, a branch of the femoral nerve).

When the injury occurs distal to the site of origin of the lateral cutaneous nerve of the calf, the loss of sensibility is confined to the area of the foot and toes.

Tibial Nerve Injury

The tibial nerve (see text Fig. 17-42) leaves the popliteal fossa by passing deep to the gastrocnemius and soleus muscles. Because of its deep and protected position, it is rarely

injured. Complete division results in the following clinical features:

- **Motor:** All the muscles in the back of the leg and the sole of the foot are paralyzed. The opposing muscles dorsiflex the foot at the ankle joint and evert the foot at the subtalar and transverse tarsal joints, an attitude referred to as **calcaneovalgus**.
- **Sensory:** Sensation is lost on the sole of the foot; later, trophic ulcers develop.

Obturator Nerve Injury

The obturator nerve (L2, 3, and 4) enters the thigh as anterior and posterior divisions through the upper part of the obturator foramen. The anterior division descends in front of the obturator externus and the adductor brevis, deep to the floor of the femoral triangle. The posterior division descends behind the adductor brevis and in front of the adductor magnus (see text Fig. 17-33).

It is rarely injured in penetrating wounds, in anterior dislocations of the hip joint, or in abdominal herniae through the obturator foramen. It may be pressed on by the fetal head during parturition. The following clinical features occur:

- **Motor:** All the adductor muscles are paralyzed except the hamstring part of the adductor magnus, which is supplied by the sciatic nerve.
- **Sensory:** The cutaneous sensory loss is minimal on the medial aspect of the thigh.

Referred Pain from the Hip Joint

The femoral nerve not only supplies the hip joint but, via the intermediate and medial cutaneous nerves of the thigh, also supplies the skin of the front and medial side of the thigh. It is not surprising, therefore, for pain originating in the hip joint to be referred to the front and medial side of the thigh. The posterior division of the obturator nerve supplies both the hip and knee joints. This would explain why hip joint disease sometimes gives rise to pain in the knee joint.



SACRAL PLEXUS

Pressure from the Fetal Head on the Sacral Plexus

During the later stages of pregnancy, when the fetal head has descended into the pelvis, the mother often complains of discomfort or aching pain extending down one of the lower limbs. The discomfort, caused by pressure from the fetal head, is often relieved by changing position, such as lying on the side in bed.

Invasion of the Sacral Plexus by Malignant Tumors

The nerves of the sacral plexus can become invaded by malignant tumors extending from neighboring viscera. A carcinoma of the rectum, for example, can cause severe intractable pain down the lower limbs.

Referred Pain from the Obturator Nerve

The obturator nerve lies on the lateral wall of the pelvis and supplies the parietal peritoneum. An inflamed appendix hanging down into the pelvic cavity could cause irritation of the obturator nerve endings, leading to referred pain down the inner side of the right thigh. Inflammation of the ovaries can produce similar symptoms.



CLINICAL ANATOMY OF SPINAL NERVE BLOCKS

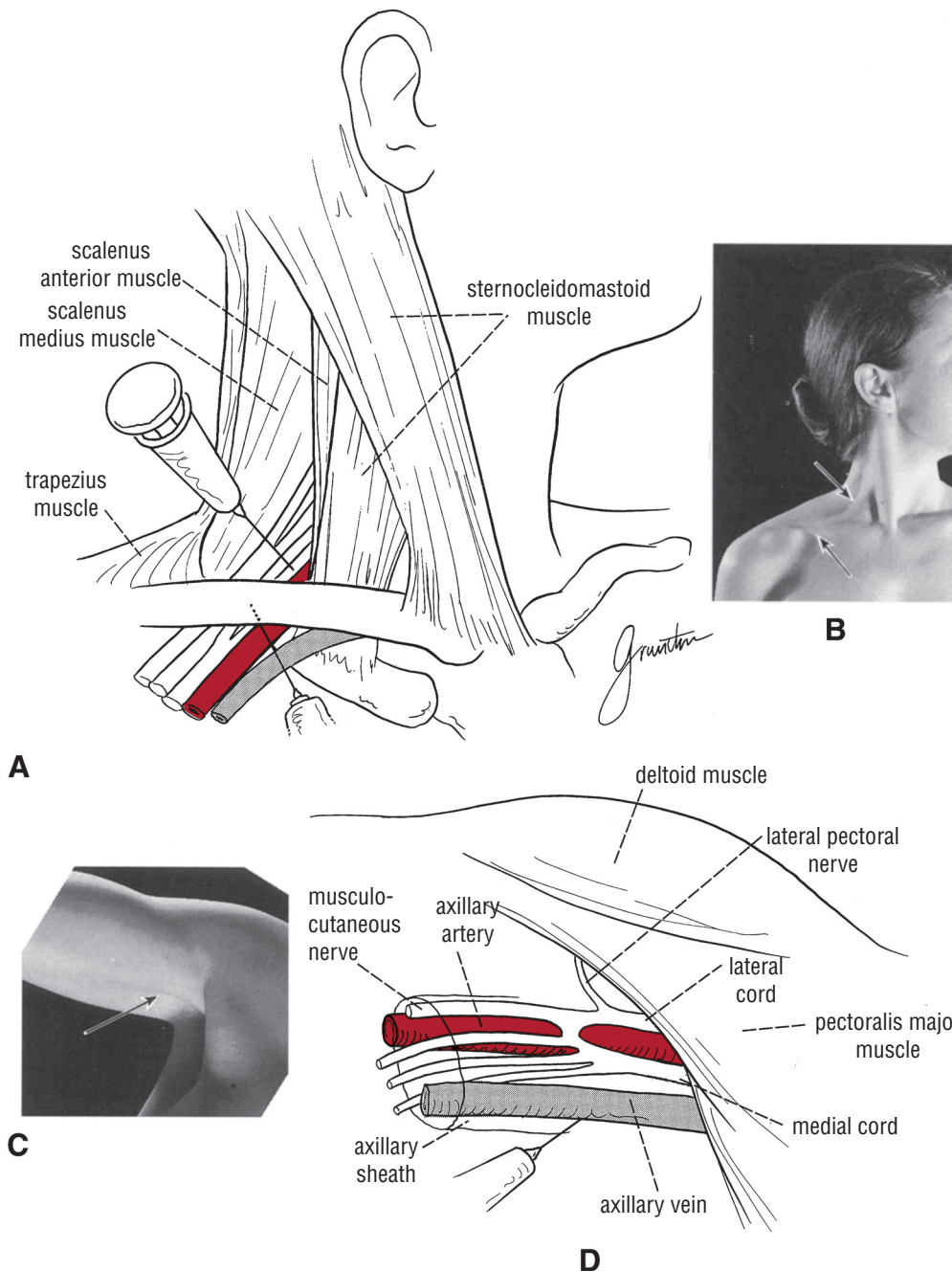
Brachial Plexus Block

In the neck, the brachial plexus occupies the lower part of the posterior triangle (CD Fig. 17-10). It lies below and anterior to a line connecting the cricoid cartilage of the larynx to the midpoint of the clavicle. In the axilla, the brachial plexus and its branches are arranged within the axillary sheath around the axillary artery, which can be palpated.

Four techniques can be used—interscalene block, supraclavicular block, infraclavicular block, and axillary block.

Interscalene Block

Procedure: At the level of the cricoid cartilage (C6) the posterior border of the sternocleidomastoid muscle can be palpated. With the head turned laterally and upward from the side of the block, the palpating finger can feel the groove between the scalenus anterior and the scalenus medius muscles just lateral to the sternocleidomastoid muscle (see CD Fig. 17-10). The blocking needle is inserted into the interval between the scalene muscles, and the roots of the upper part of the brachial plexus can be blocked.



CD Figure 17-10 **A.** Brachial plexus block. Supraclavicular block. The needle is inserted just posterior to the posterior border of the sternocleidomastoid muscle at the level of the cricoid cartilage at the lower anterior corner of the posterior triangle. The needle is directed caudally behind the palpable subclavian artery. In an infraclavicular block, the needle is inserted inferior to the midpoint of the clavicle and is directed laterally in the direction of the head of the humerus and toward the subclavian artery. **B.** Sites of supraclavicular and infraclavicular brachial plexus blocks. **C.** Axillary nerve block. The axillary artery is palpated and the needle is inserted into the axillary sheath (see text). **D.** Site of the axillary brachial plexus block.

Supraclavicular Block

Procedure: The trunks of the brachial plexus can be blocked as they cross the first rib and enter the axilla (see CD Fig. 17-10). The third part of the subclavian artery is first palpated in the lower anterior corner of the posterior triangle of the neck. The posterior border of the sternocleidomastoid muscle is then felt. A blocking needle is inserted at the level of the cricoid cartilage between the scalenus anterior and the scalenus medius muscles and directed caudally behind the subclavian artery toward the upper surface of the first rib (see CD Fig. 17-10). It is here that the brachial plexus is very compact, consisting of the upper middle and lower trunks.

Anatomy of complications: The subclavian artery lies between the scalenus anterior and scalenus medius muscles just behind the clavicle and may be pierced by the needle. The cervical dome of parietal pleura is situated close to the brachial plexus, and a pneumothorax can be caused if the needle enters the pleural cavity.

Infraclavicular Block

Procedure: The middle of the clavicle is identified. A blocking needle is inserted 1 in. (2.5 cm) inferior to it and directed laterally in the direction of the head of the humerus and toward the subclavian artery. The anesthetic solution is infiltrated around the trunks of the brachial plexus (see CD Fig. 17-10).

Anatomy of complications: The close relationship of the axillary vessels to the brachial plexus within the axillary sheath means that vessel puncture and hematoma formation may occur. Frequent aspirations are necessary before the anesthetic agent is injected.

Axillary Block

Procedure: With the arm abducted to an angle greater than 90°, the axillary artery within the axillary sheath may be palpated high up in the axilla (see CD Fig. 17-10). The artery is compressed, and a blocking needle is inserted just proximal to the point of compression into the axillary sheath. The cords and branches of the plexus lie within the sheath along with the artery. The disadvantage of this approach is the difficulty in blocking the musculocutaneous nerve. The object of compressing the artery distal to the point of injection is to close off the axillary sheath distally so that the anesthetic agent may rise in the sheath to the musculocutaneous nerve.

Anatomy of complications: The close relationship of the axillary vessels to the brachial plexus within the axillary sheath means that vessel puncture and hematoma formation may occur. Frequent aspirations are necessary before the anesthetic agent is injected.

Musculocutaneous Nerve Block

Area of anesthesia: The anterior and posterior surfaces of the lateral border of the forearm down as far as the thenar eminence (see CD Figs. 17-1 and 17-2)

Indications: Repair of lacerations on the lateral border of the forearm

Procedure: These include the following:

- **Brachial plexus approach:** The musculocutaneous nerve trunk may be blocked with the rest of the brachial plexus (see CD Fig. 17-10). The infraclavicular or axillary approach is used; in the axillary approach great care has to be taken to ensure that the anesthetic agent rises sufficiently high in the axillary sheath to block the musculocutaneous nerve.
- **Lateral cutaneous nerve of the forearm approach:** The musculocutaneous nerve may also be blocked as it emerges between the biceps and the brachialis muscles just above the lateral epicondyle of the humerus, where it becomes the lateral cutaneous nerve of the forearm (CD Fig. 17-11). The needle is inserted just lateral to the tendon of the biceps muscle on a line between the two epicondyles of the humerus.

Median Nerve Block

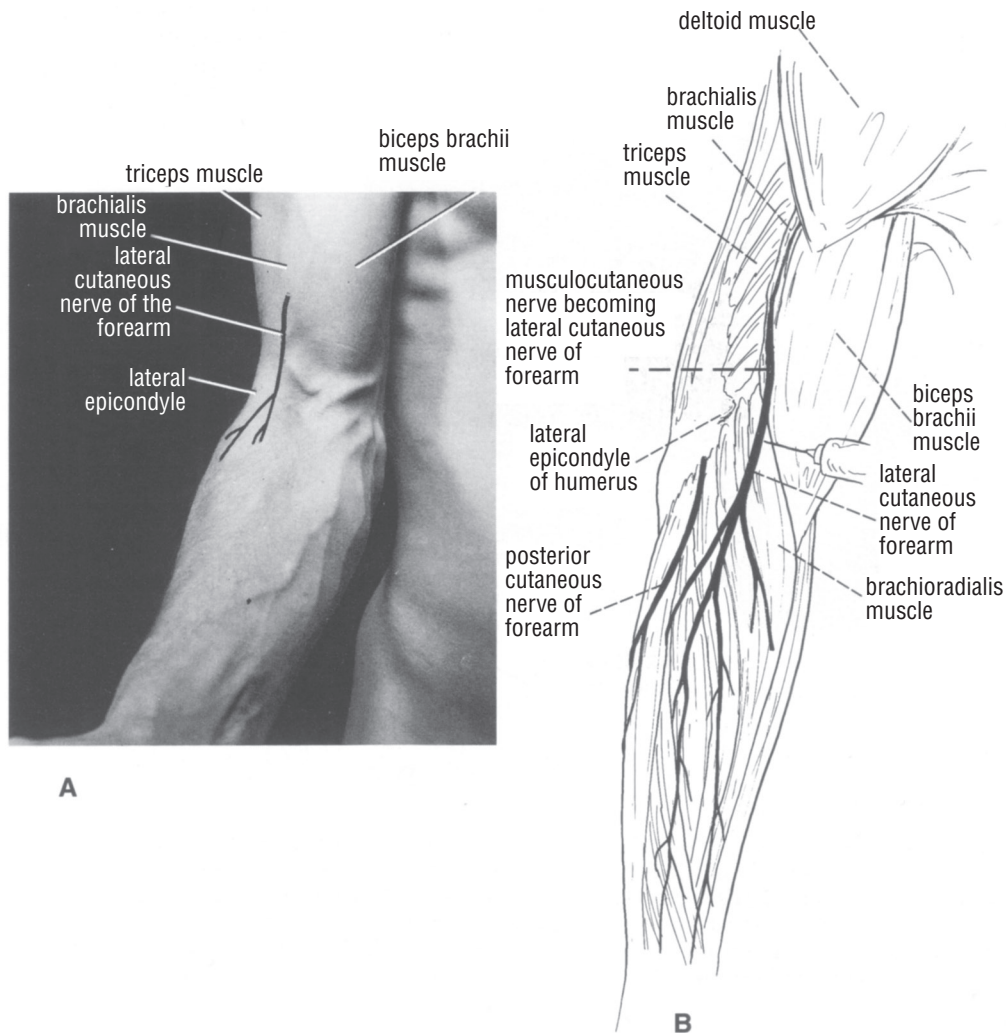
Area of anesthesia: The skin on the lateral half of the palm, the palmar aspect of the lateral three and a half fingers, including the nail beds on the dorsum (see CD Fig. 17-16)

Indications: Repair of lacerations of the palm and fingers

Procedures: These include the following:

- **Block at the elbow:** With the elbow joint extended, the brachial artery can easily be palpated in the cubital fossa on the medial side of the tendon of the biceps muscle. The needle is inserted on the medial side of the brachial artery (CD Fig. 17-12).
- **Block at the wrist:** Here the median nerve lies on the medial side of the tendons of the flexor carpi radialis and to the lateral side of the flexor digitorum superficialis (CD Fig. 17-13); it usually lies posterior to the tendon of the palmaris longus muscle (sometimes absent). The nerve may be infiltrated here with local anesthetic just proximal to the flexor retinaculum (i.e., just proximal to the distal transverse crease in front of the wrist). The needle is inserted for 3/8 in. between the tendons of flexor carpi radialis and the palmaris longus.

The palmar cutaneous branch of the median nerve leaves the main trunk just proximal to the distal transverse crease of the palm, and, unless this nerve is also blocked, the sensation to the skin on the lateral part of the palm will remain intact.



CD Figure 17-11 Lateral cutaneous nerve of the forearm block. **A** and **B** show the musculocutaneous nerve becoming the lateral cutaneous nerve of the forearm. The nerve is blocked just lateral to the tendon of the biceps brachii muscle on a line between the two epicondyles of the humerus.

Ulnar Nerve Block

Area of anesthesia: The skin of the medial one third of the palmar and dorsal surfaces of the hand and the palmar and dorsal surfaces of the medial one and a half fingers (see CD Fig. 17-16)

Indications: Repair of lacerations of the hand and fingers

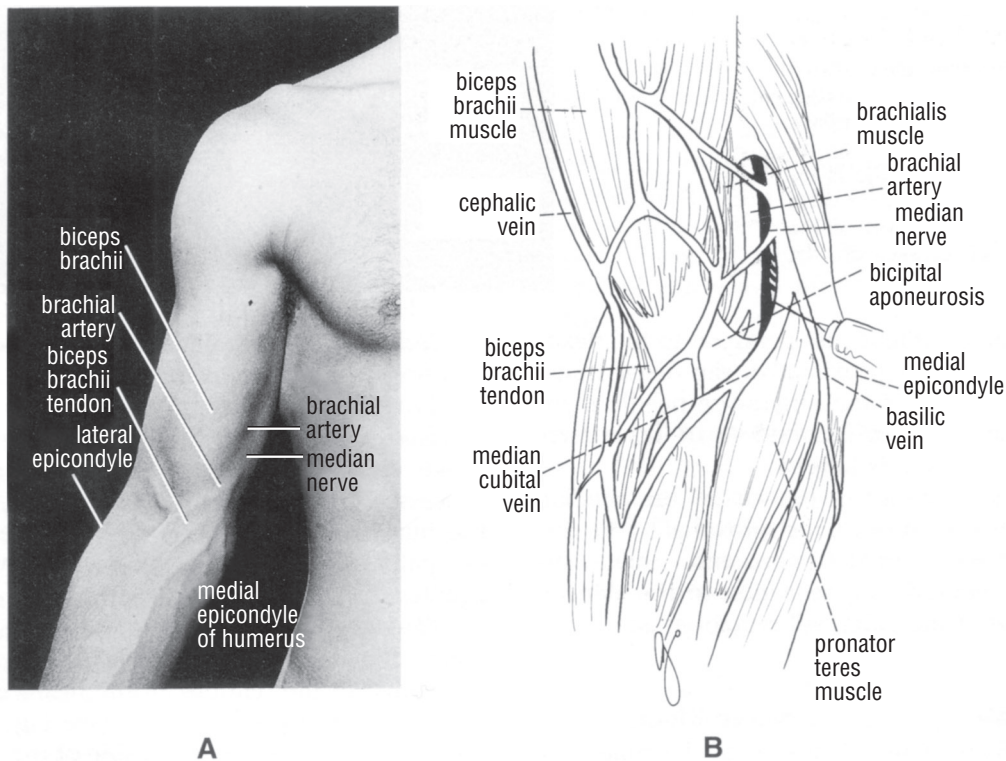
Procedures: These involve the following:

- **Block at the elbow:** At the elbow, the ulnar nerve enters the forearm between the olecranon process of the ulna and the medial epicondyle of the humerus (CD Fig. 17-14). Here the nerve may be palpated and infiltrated with an anesthetic agent.
- **Block at the wrist:** At the wrist, the ulnar nerve enters the hand anterior to the flexor retinaculum and

lateral to the tendons of the flexor carpi ulnaris muscle and the pisiform bone (see CD Fig. 17-13). The ulnar artery lies on the lateral side of the ulnar nerve. The needle is inserted just lateral to the flexor carpi ulnaris tendon at the level of the distal transverse crease of the wrist.

Note that the dorsal cutaneous branch of the ulnar nerve (see CD Fig. 17-16) leaves the main trunk about 2 in. (5 cm) proximal to the wrist; an ulnar nerve block at the wrist will therefore leave the skin sensation on the dorsum of the hand and fingers intact.

Also, the superficially placed palmar cutaneous branch of the ulnar nerve leaves the nerve trunk a variable distance proximal to the transverse crease of the wrist; unless this nerve is also infiltrated with anesthetic, the ulnar block at



CD Figure 17-12 **A** and **B**. Median nerve block at the elbow. The brachial artery is identified in the cubital fossa, and the needle is inserted on the medial side of the artery.

the wrist will leave the sensory nerve supply to the medial part of the palm intact.

Radial Nerve Block

Area of anesthesia: The skin of the back of the arm down as far as the elbow, the skin of the lower lateral surface of the arm down to the elbow, the skin down the middle of the posterior surface of the forearm as far as the wrist, the skin of the lateral half of the dorsal surface of the hand, and the dorsal surface of the lateral three and a half fingers proximal to the nail beds (see CD Figs. 17-1 and 17-2)

Indications: Repair of lacerations of the hand:

Procedures: These involve the following:

- **Block at the elbow:** At the elbow, the radial nerve descends anterior to the lateral epicondyle of the humerus in the interval between the brachialis and the brachioradialis muscles (CD Fig.17-15). With the elbow joint extended, the lateral edge of the biceps tendon is easily palpated. The needle is inserted halfway between the tendon and the tip of the lateral epicondyle, and the local anesthetic is injected at this point.
- **Block at the wrist:** Just proximal to the wrist, the superficial branch of the radial nerve lies lateral to the radial artery. The nerve leaves the artery and passes laterally and backward under the tendon of brachioradialis to reach the posterior surface of the wrist (see CD Fig. 17-15). At

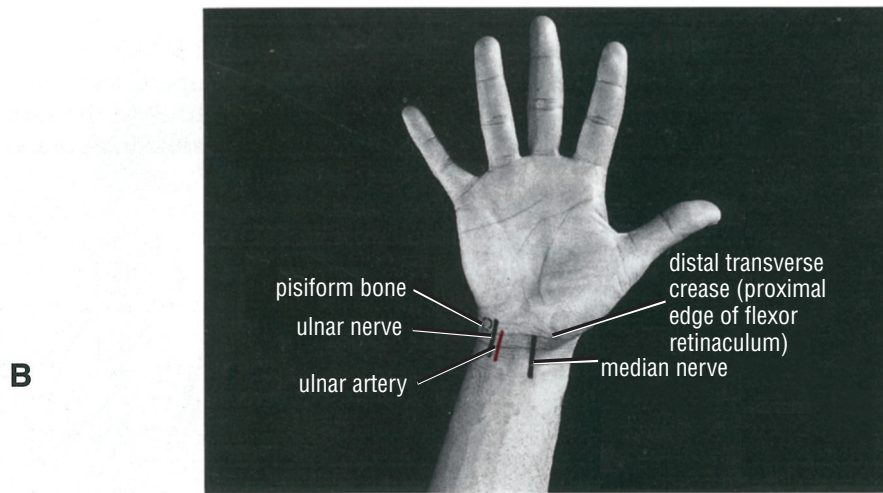
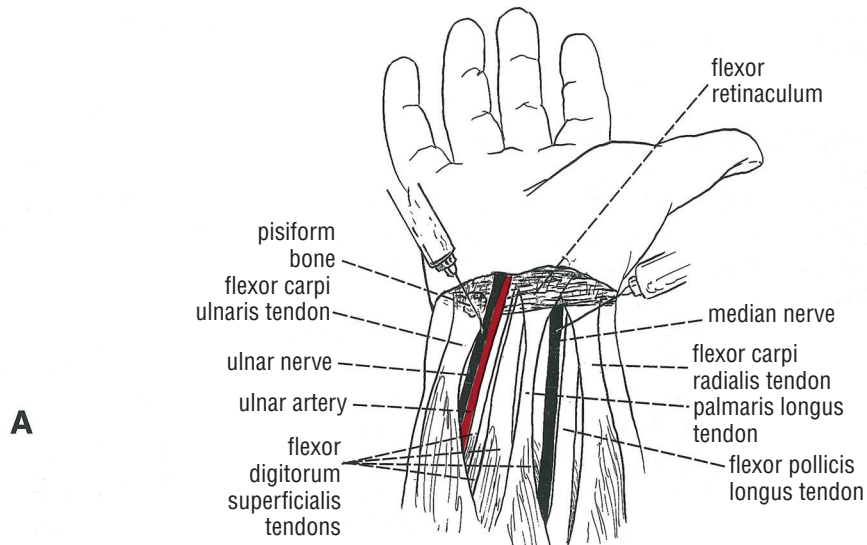
the level of the proximal transverse flexor crease on the lateral side of the radial artery, the nerve may be infiltrated with an anesthetic solution. Since other terminal branches of the radial nerve run in the subcutaneous tissue on the dorsum of the wrist, a subcutaneous wheal of local anesthetic is necessary; this should run across the lateral half of the dorsum of the wrist.

Digital Nerve Blocks

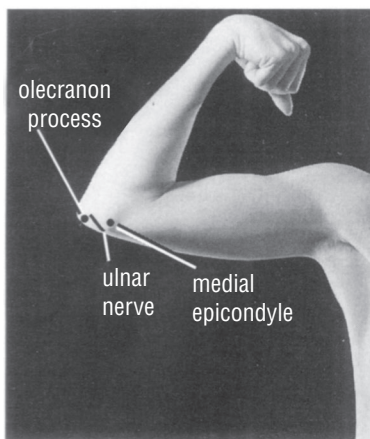
Area of anesthesia: Skin of the fingers. Each finger is supplied by four digital nerves at the 2 o'clock, 5 o'clock, 7 o'clock, and 10 o'clock positions. The palmar digital nerves are derived from the ulnar and median nerves; the dorsal digital nerves are derived from the ulnar and radial nerves (CD Fig.17-16).

The palmar digital nerves, which arise from the superficial terminal branch of the ulnar nerve in the hand, supply the palmar surface of the medial one and a half fingers, including their nail beds. The dorsal digital nerves, which arise from the dorsal cutaneous branch of the ulnar nerve in the forearm, supply the dorsal surface of the proximal parts of the medial one and a half fingers (see CD Fig. 17-16).

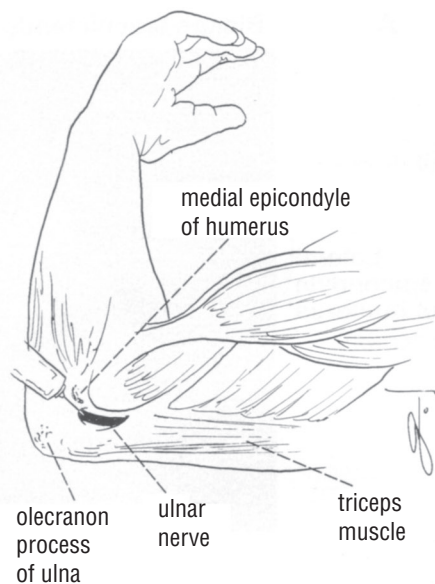
The palmar digital nerves, which arise from the median nerve in the palm, supply the palmar surface of the lateral three and a half fingers, including their nail beds.



CD Figure 17-13 A and B. Median and ulnar nerve blocks at the wrist. In a median nerve block, the needle is inserted just proximal to the distal transverse crease of the wrist between the tendons of flexor carpi radialis and the palmaris longus. In an ulnar nerve block, the needle is inserted just lateral to the flexor carpi ulnaris tendon at the level of the distal transverse crease of the wrist.

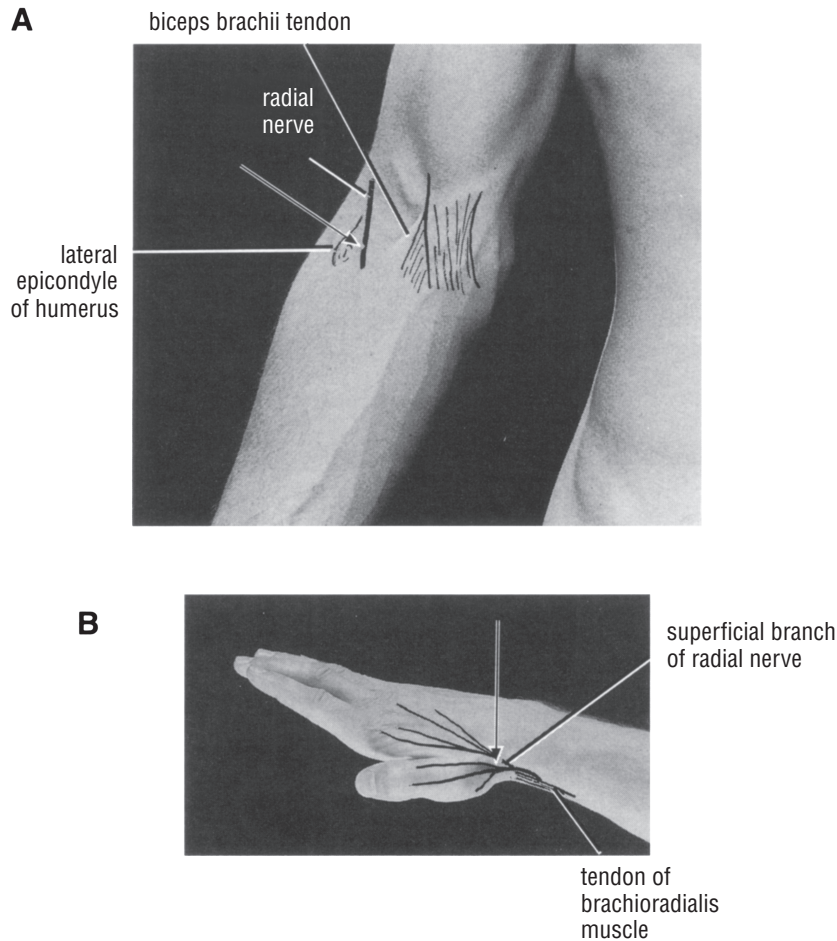


A



B

CD Figure 17-14 A and B. Ulnar nerve block at the elbow. The ulnar nerve may be palpated between the olecranon process of the ulna and the medial epicondyle of the humerus, where it may be infiltrated with anesthetic.



CD Figure 17-15 **A.** Radial nerve block at the elbow. The needle is inserted halfway between the tendon of the biceps brachii and the tip of the lateral epicondyle of the humerus. **B.** Radial nerve block at the wrist. The needle is inserted into the subcutaneous tissue on the dorsum of the hand, and a wheal of anesthetic is placed across the lateral half of the dorsum of the wrist.

The dorsal digital nerves, which arise from the superficial branch of the radial nerve, supply the dorsal surface of the proximal parts of the lateral three and a half fingers (see CD Fig. 17-16).

Note that the origins of the dorsal digital nerves from the ulnar and radial nerves are subject to variation.

Indications: Repair of lacerations involving individual fingers; removal of nails

Procedures: These involve the following:

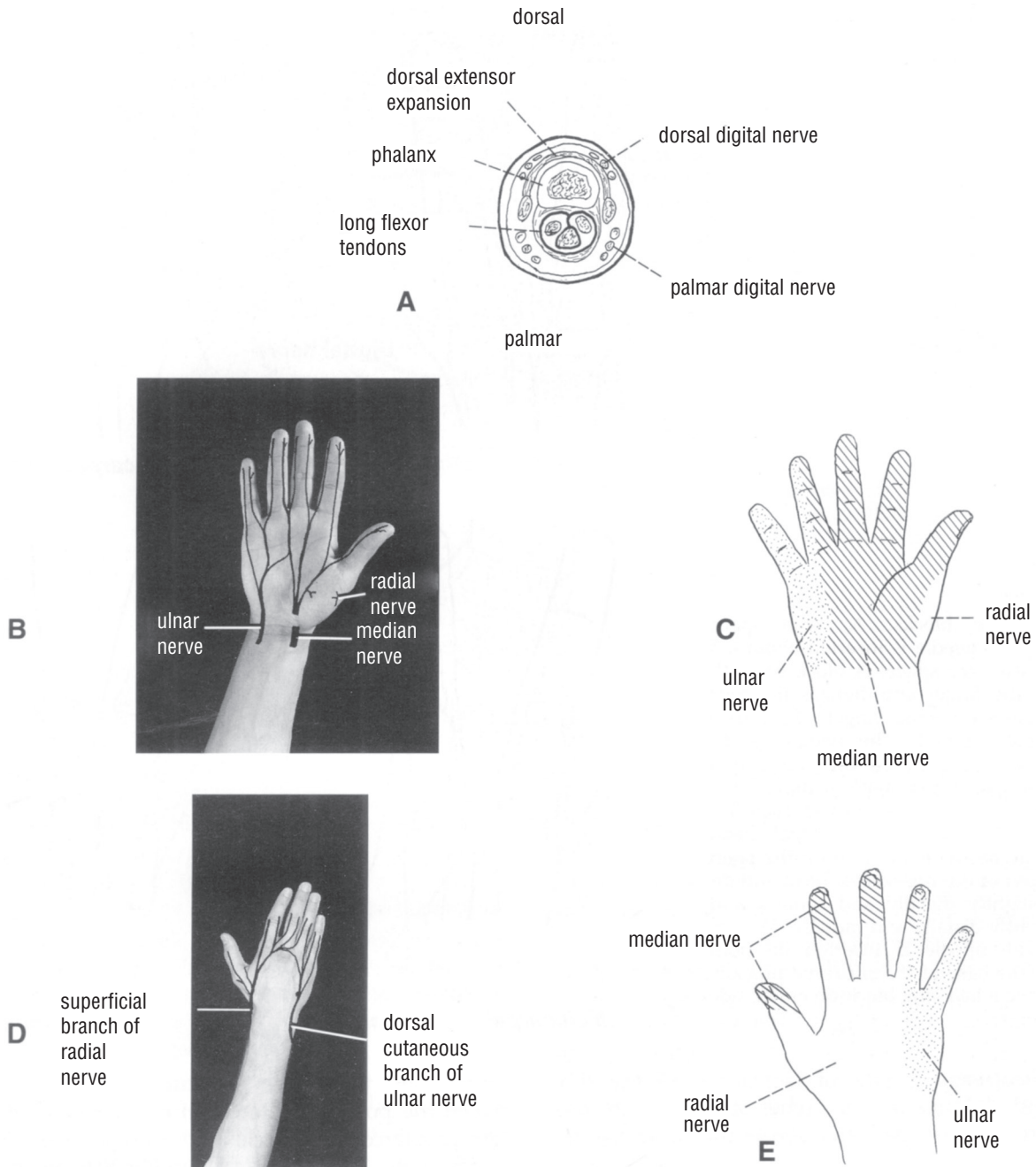
- **Web space method:** At the web space, the digital nerves are about to enter the fingers (CD Fig. 17-17). The needle is inserted about 0.5 cm, and the nerves are infiltrated with the anesthetic agent. A block on both sides of the finger adequately deals with the four digital nerves supplying the finger. When blocking the digital nerves of the index and little fingers, a subcutaneous wheal of anesthetic solution must be deposited on the lateral side of the index finger and the medial side of the little finger.
- **Dorsal metacarpal method:** A skin wheal of anesthetic is raised between the metacarpal bones on the dorsum of the hand (see CD Fig. 17-17). The needle is inserted through the wheal and advanced slowly forward between the metacarpal bones, stopping just short of the palmar skin. The anesthetic solution will block the common palmar and dorsal digital nerves.

- **Metacarpal head block:** The needle is inserted in the palm at the metacarpal head and directed slightly distally and medially and then slightly distally and laterally to block the palmar digital nerves (see CD Fig. 17-17). The dorsal digital nerves, if they remain unblocked, are handled with an injection across the base of the dorsum of the proximal phalanx.
- **Ring block:** Since the digital nerves lie in pairs on either side of the proximal phalanges, they are easily blocked at the base of the digit (see CD Fig. 17-16). The needle is inserted on both sides of the base of the proximal phalanx, and the anesthetic agent is infiltrated around the nerves between the bone and the skin; this produces a half-ring block on either side of the finger (see CD Fig. 17-17).

Thoracic Spinal Nerve Blocks

Intercostal Nerve Block

Area of anesthesia: The skin and the parietal pleura covering the outer and inner surfaces of each intercostal space respectively; the seventh to the eleventh intercostal nerves supply the skin and the parietal peritoneum

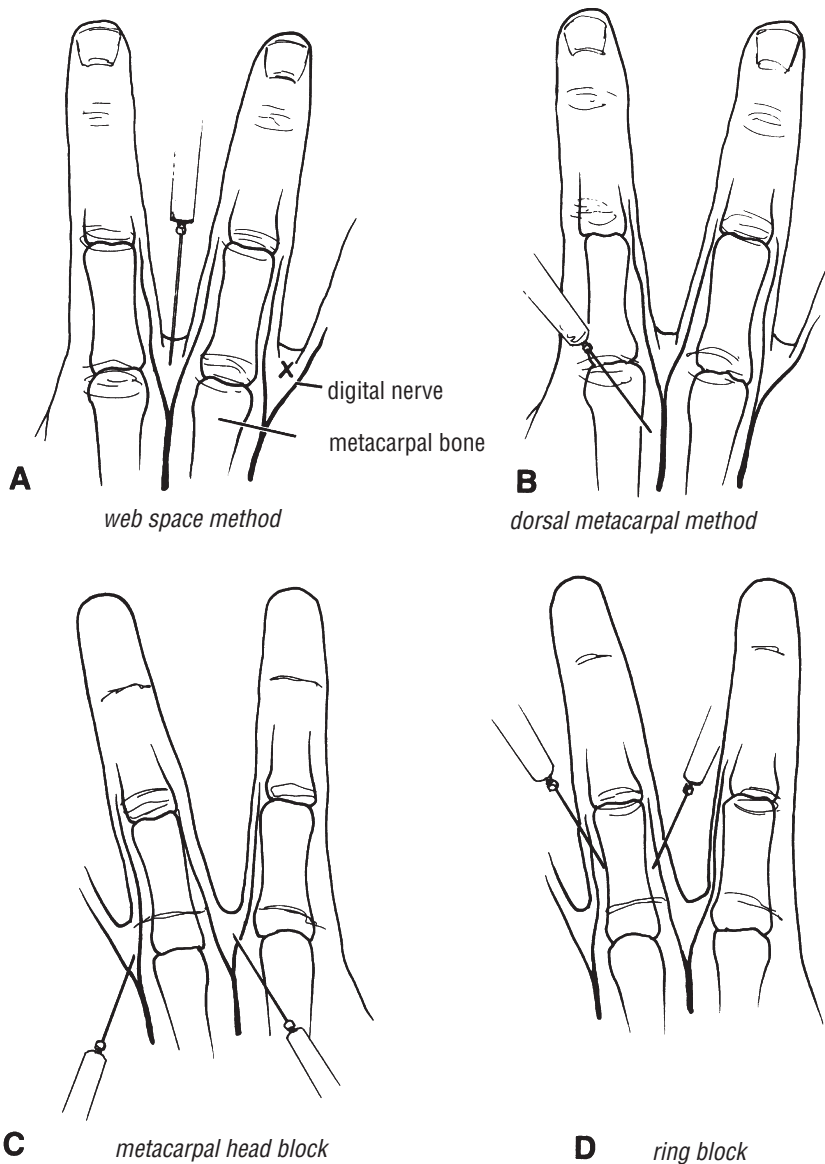


CD Figure 17-16 **A.** Transverse section of the finger showing the location of the dorsal and palmar digital nerves. **B.** Palmar surface of hand and fingers showing the origin of the palmar digital nerves. **C.** Palmar surface of the hand and fingers showing the areas of skin supplied by the ulnar, median, and radial nerves. **D.** Dorsal surface of the hand and fingers showing the origin of the dorsal digital nerves. **E.** Dorsal surface of the hand and fingers showing the areas of skin supplied by the radial, ulnar, and median nerves.

covering the outer and inner surfaces of the abdominal wall, respectively; therefore, these areas will also be anesthetized. In addition, the periosteum of the adjacent ribs is anesthetized.

Indications: Repair of lacerations of the thoracic and abdominal walls; relief of pain in rib fractures and to allow pain-free respiratory movements

Procedure: To produce analgesia of the anterior and lateral thoracic and abdominal walls, the intercostal nerve should be blocked before the lateral cutaneous branch arises at the midaxillary line. The ribs may be identified by counting up from the twelfth or down from the second (opposite sternal angle). The needle is directed toward the rib near the lower border (CD Fig. 17-18), and the tip



CD Figure 17-17 Digital nerve blocks. **A.** Web space method. The needle is inserted about 0.5 cm into the web space. A block on both sides of the finger anesthetizes the four digital nerves to the finger. **B.** Dorsal metacarpal method. The needle is directed forward between the metacarpal bones, stopping just short of the palmar skin. The four digital nerves to each finger are blocked. **C.** Metacarpal head block. The needle is inserted in the palm at the level of the metacarpal head and directed slightly distally and medially and then slightly distally and laterally. **D.** Ring block. The needle is inserted on both sides of the base of the proximal phalanx to produce a half-ring block on either side of the finger.

comes to rest near the subcostal groove, where the local anesthetic is infiltrated around the nerve. Remember that the order of structures lying in the neurovascular bundle from above downward is intercostal vein, artery, and nerve, and that these structures are situated between the posterior intercostal membrane of the internal intercostal muscle and the parietal pleura. Furthermore, laterally the nerve lies between the internal intercostal muscle and the subcostals and the innermost intercostals (i.e., transverse thoracic muscle).

Anatomy of complications: These include the following:

- **Pneumothorax:** This complication can occur if the needle point misses the subcostal groove and penetrates too deeply through the parietal pleura.
- **Hemorrhage:** Puncture of the intercostal blood vessels. This is a common complication so that aspiration should

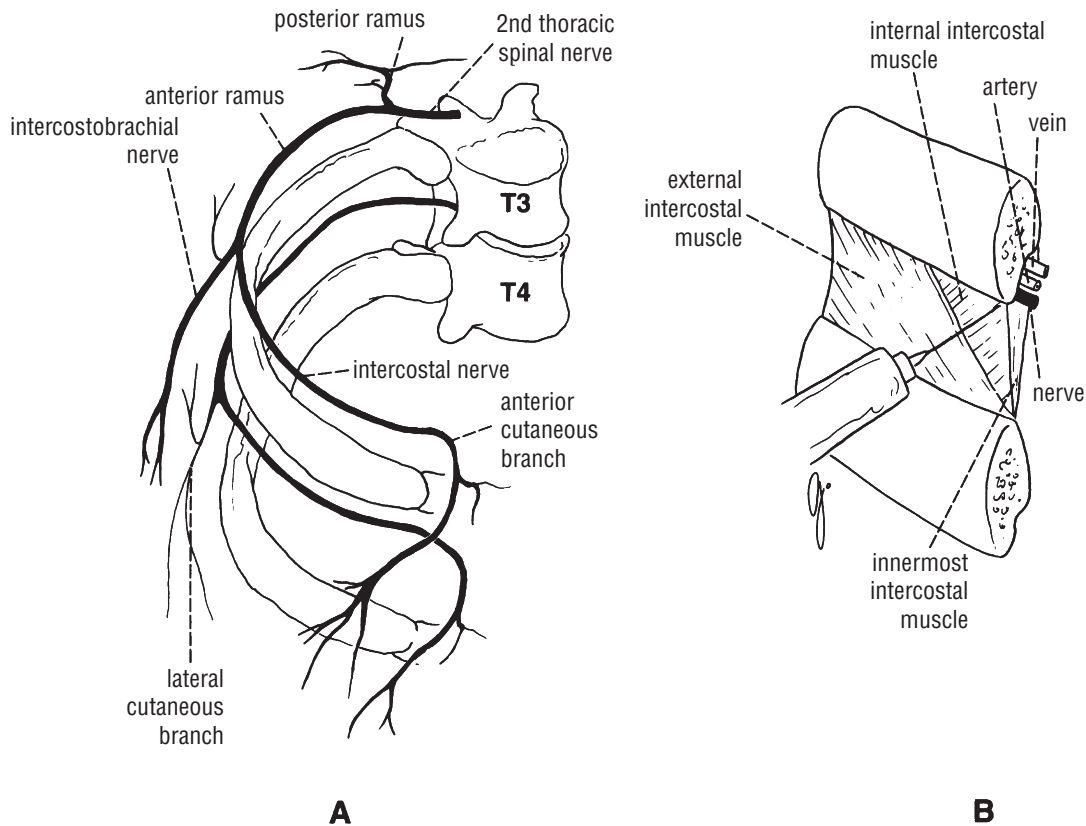
always be performed before injecting the anesthetic. A small hematoma may result.

Anterior Abdominal Nerve Blocks

Area of anesthesia: Skin of the anterior abdominal wall. The nerves of the anterior and lateral abdominal walls are the anterior rami of the seventh through the twelfth thoracic nerves and the first lumbar nerve.

Indications: Repair of lacerations of the anterior abdominal wall

Procedure: The anterior ends of the intercostal nerves T7 through T11 enter the abdominal wall by leaving the intercostal spaces and passing posterior to the costal cartilages (CD Fig. 17-19). An abdominal field block is most easily carried out along the lower border of the costal



CD Figure 17-18 Intercostal nerve block. **A.** The distribution of two intercostal nerves relative to the rib cage. **B.** Section through an intercostal space showing the positions of the intercostal nerve, artery, and vein relative to the intercostal muscles. The needle is directed toward the rib near the lower border, and the tip comes to rest near the subcostal groove.

margin and then infiltrating the nerves as they emerge between the xiphoid process and the tenth or eleventh rib along the costal margin.

Lumbar Spinal Nerve Blocks

Ilioinguinal and Iliohypogastric Nerve Blocks

Area of anesthesia: Skin of the lower part of the anterior abdominal wall

Indications: Repair of lacerations on the anterior abdominal wall

Procedure: The ilioinguinal nerve (L1) passes forward around the anterior abdominal wall, through the inguinal canal, and emerges through the superficial inguinal ring to supply the skin of the groin and part of the scrotum or labium majus. The iliohypogastric nerve (L1) passes around the abdominal wall and pierces the external oblique aponeurosis above the superficial inguinal ring to supply the skin (see CD Fig. 17-19).

The two nerves are easily blocked by inserting the anesthetic needle 1 in. (2.5 cm) above the anterior superior iliac spine on the spinoumbilical line (see CD Fig. 17-19).

Genitofemoral Nerve Block

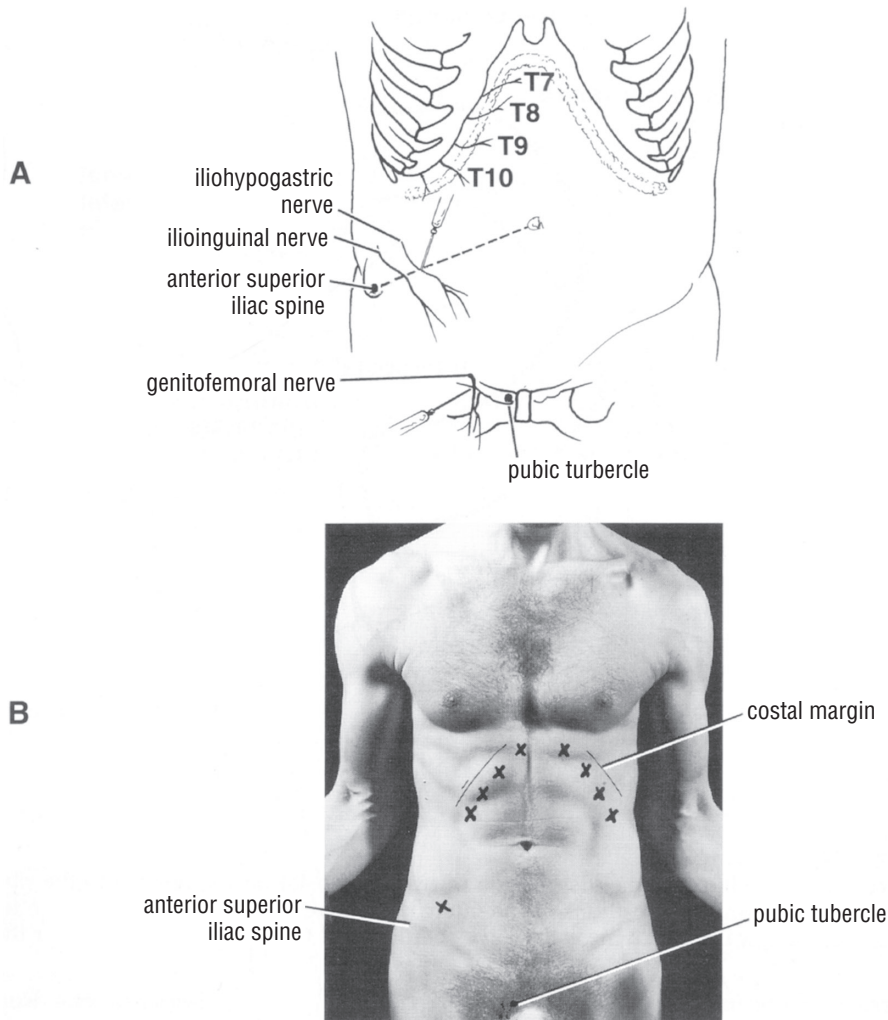
Area of anesthesia: Small area of skin of the thigh below the inguinal ligament and adjacent part of the scrotum or labium majus

Indications: Repair of lacerations in the thigh and genital area

Procedure: The genitofemoral nerve (L1 and L2) runs downward under the inguinal ligament at a point halfway between the anterior superior iliac spine and the symphysis pubis. The terminal branches are most easily blocked by infiltrating the subcutaneous tissue through a needle inserted through the skin lateral to the pubic tubercle (see CD Fig. 17-19).

Femoral Nerve Block

Area of anesthesia: Skin of the front and medial side of the thigh, extending down the medial side of the knee



CD Figure 17-19 Anterior abdominal wall nerve blocks. **A** and **B**. T7 through T11 intercostal nerves are blocked (x) as they emerge from beneath the costal margin. The iliohypogastric and ilioinguinal nerves are blocked by inserting the needle about 1 in. above the anterior superior iliac spine on the spinoumbilical line (x). The terminal branches of the genitofemoral nerve are blocked by inserting the needle through the skin just lateral to the pubic tubercle and infiltrating the subcutaneous tissue with anesthetic solution (x).

and leg, and along the medial border of the foot as far as the ball of the big toe

Indications: Repair of lacerations of the thigh, medial side of the leg, and medial side of the foot

Procedure: The femoral nerve (L2 through L 4) enters the thigh beneath the inguinal ligament at a point midway between the anterior superior iliac spine and the pubic tubercle (CD Fig. 17-20). Here it lies lateral to the femoral artery.

The nerve may be blocked by introducing the anesthetic needle just below the midpoint of the inguinal ligament and lateral to the femoral artery (see CD Fig. 17-20).

Saphenous Nerve Block

Area of anesthesia: Skin of the medial side of the leg and the medial border of the foot down as far as the ball of the big toe

Indications: Repair of lacerations on the medial side of the leg and the medial side of the foot

Procedure: The saphenous nerve is a continuation of the femoral nerve and becomes superficial on the

medial side of the knee after emerging between the tendons of sartorius and gracilis muscles (CD Fig. 17-21).

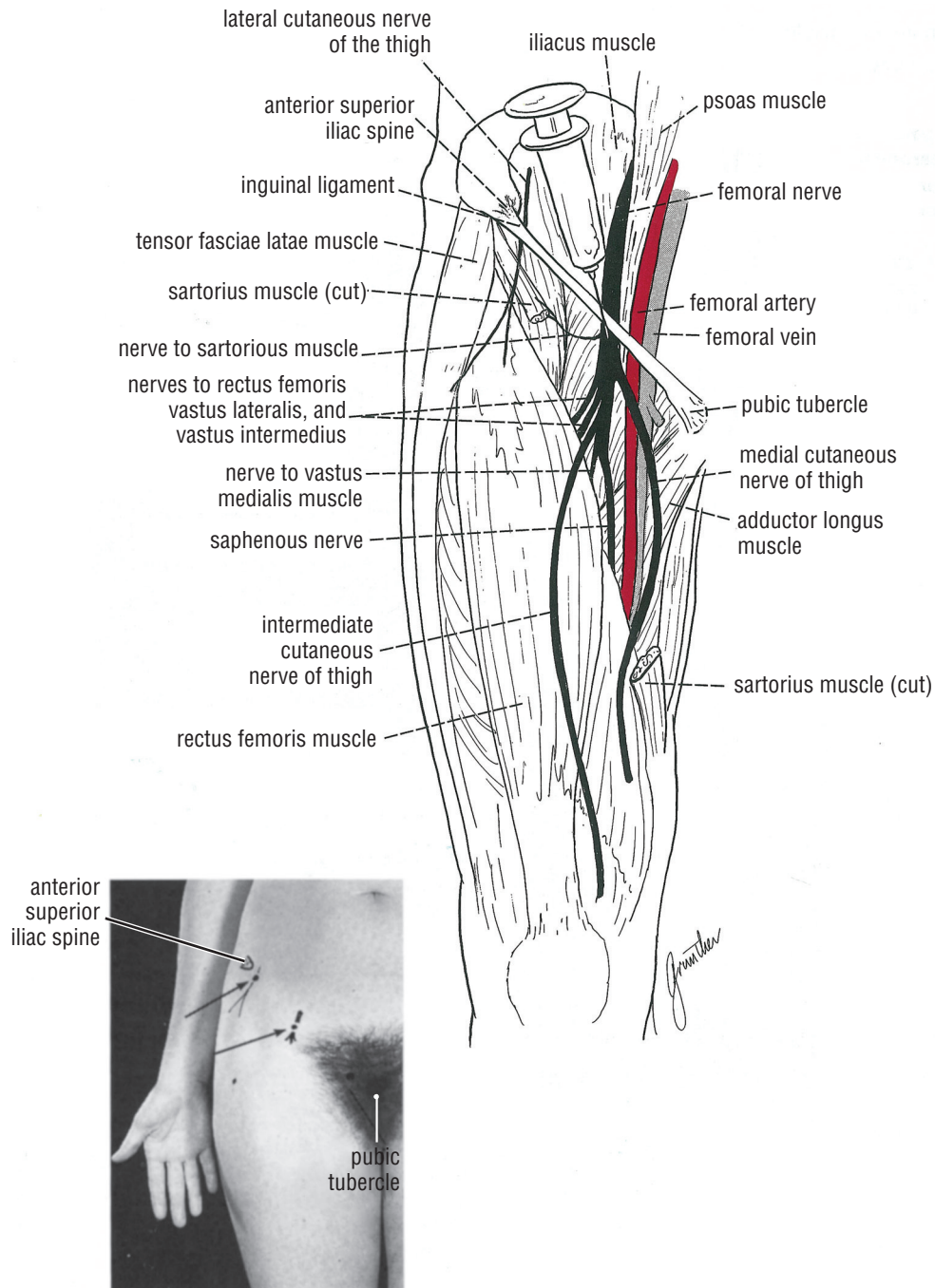
The nerve may be blocked by inserting the anesthetic needle on the medial side of the knee joint either over the medial femoral condyle or lower down over the condyle of the tibia (see CD Fig. 17-21). Care should be taken to avoid the great saphenous vein. The nerve may also be blocked at the ankle where it passes anterior to the medial malleolus (see CD Fig. 17-21).

Lateral Cutaneous Nerve of the Thigh Block

Area of anesthesia: Skin of the anterolateral surface of the thigh down to the lateral side of the knee

Indications: Repair of lacerations on the anterolateral surface of the thigh

Procedure: The lateral cutaneous nerve of the thigh (L2 and L3) enters the thigh behind (or through) the lateral end of the inguinal ligament just medial to



CD Figure 17-20 Femoral nerve block. The needle is directed posteriorly just below the midpoint of the inguinal ligament and lateral to the femoral artery. In a lateral cutaneous nerve of the thigh block, the needle is directed posteriorly just inferior to the inguinal ligament about 0.5 in. (1.3 cm) medial to the anterior superior iliac spine.

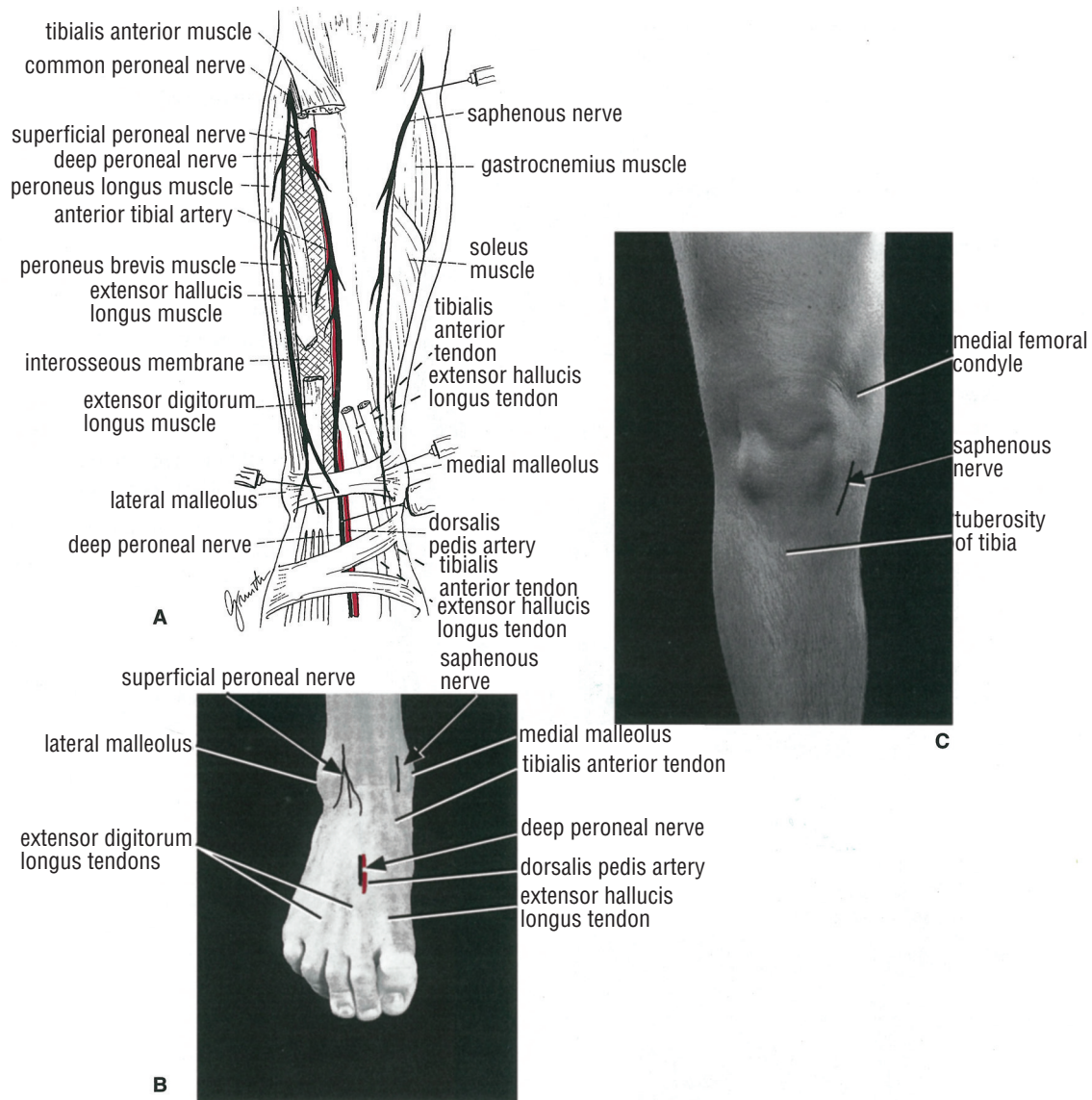
the anterior superior iliac spine (see CD Fig. 17-20). It then descends anterior or through the sartorius muscle and divides into terminal anterior and posterior branches.

The nerve may be blocked by inserting the anesthetic needle just inferior to the inguinal ligament about 0.5 in. (1.3 cm) medial to the anterior superior iliac spine.

Sacral Spinal Nerve Blocks

Tibial Nerve Block

Area of anesthesia: Skin of the sole of the foot (medial and lateral plantar nerves)



CD Figure 17-21 Nerve blocks on the front of the lower part of the leg and dorsum of foot. **A.** The saphenous nerve, the superficial peroneal nerve, and the deep peroneal nerve in relation to other important anatomic structures. **B.** The surface landmarks in the ankle region and on the dorsum of the foot necessary for performing superficial peroneal nerve block, saphenous nerve block, and deep peroneal nerve block. **C.** The surface landmarks used for performing saphenous nerve block on the medial side of the knee.

Indications: Repair of lacerations on the sole of foot

Procedure: The tibial nerve (L4 and L5 and S1 through S3) is the largest terminal branch of the sciatic nerve. At the ankle, the nerve, accompanied by the posterior tibial artery, becomes superficial. It lies behind the medial malleolus, between the tendons of the flexor digitorum longus and the flexor hallucis longus muscles, and is covered by the flexor retinaculum (CD Fig. 17-22).

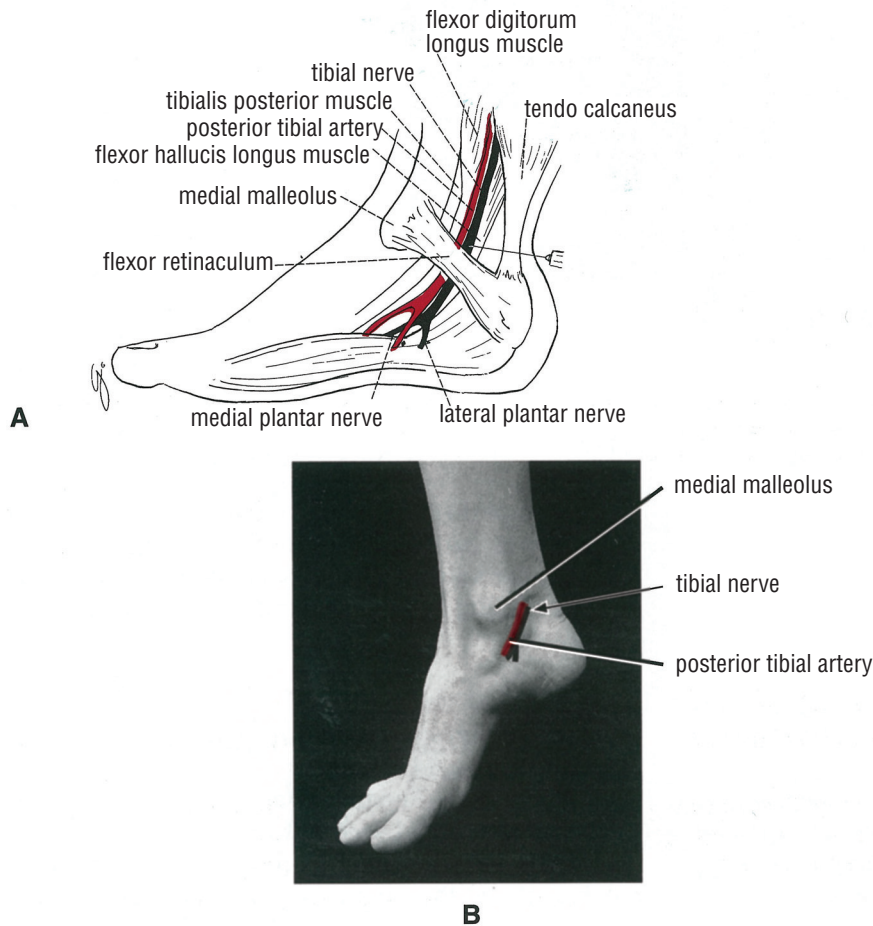
The tibial nerve may be blocked as it lies behind the medial malleolus. By careful palpation, the pulsations of the

posterior tibial artery can be felt midway between the medial malleolus and the heel. The nerve lies immediately posterior to the artery, and the anesthetic needle can be inserted at this location (see CD Fig. 17-22).

Sural Nerve Block

Area of anesthesia: Skin of the lateral border of foot and lateral side of the little toe

Indications: Repair of lacerations on the lateral side of the foot and little toe



CD Figure 17-22 Tibial nerve block. **A.** The tibial nerve and its relationships as it passes behind the medial malleolus of the tibia. **B.** The important surface landmarks used when blocking the tibial nerve at the ankle.

Procedure: The sural nerve is a branch of the tibial nerve in the popliteal space. It descends superficially in the calf accompanied by the small saphenous vein. It courses behind the lateral malleolus and passes to its distribution along the lateral border of the foot and little toe (CD Fig. 17-23).

The sural nerve may be blocked by inserting the anesthetic needle midway between the lateral malleolus and the tendo calcaneus (Achilles) and infiltrating the subcutaneous tissue with anesthetic solution (see CD Fig. 17-23).

Common Peroneal Nerve Block

Area of anesthesia: Skin on the anterior and lateral sides of the leg and the dorsum of the foot and toes, including the medial side of the big toe

Indications: Repair of lacerations on the anterior and lateral sides of the leg and the dorsum of the foot and toes

Procedure: The common peroneal nerve (L4 and L5 and S1 and S2) is the smaller of the terminal branches of the sciatic nerve. It winds laterally around the neck of the fibula to pierce the peroneus longus muscle (see CD Fig. 17-23). As the nerve lies on the lateral side of the neck of

the fibula, it is subcutaneous and can easily be rolled against the bone.

The common peroneal nerve can be blocked by first palpating the nerve below the head of the fibula and infiltrating the tissue around the nerve with a local anesthetic solution.

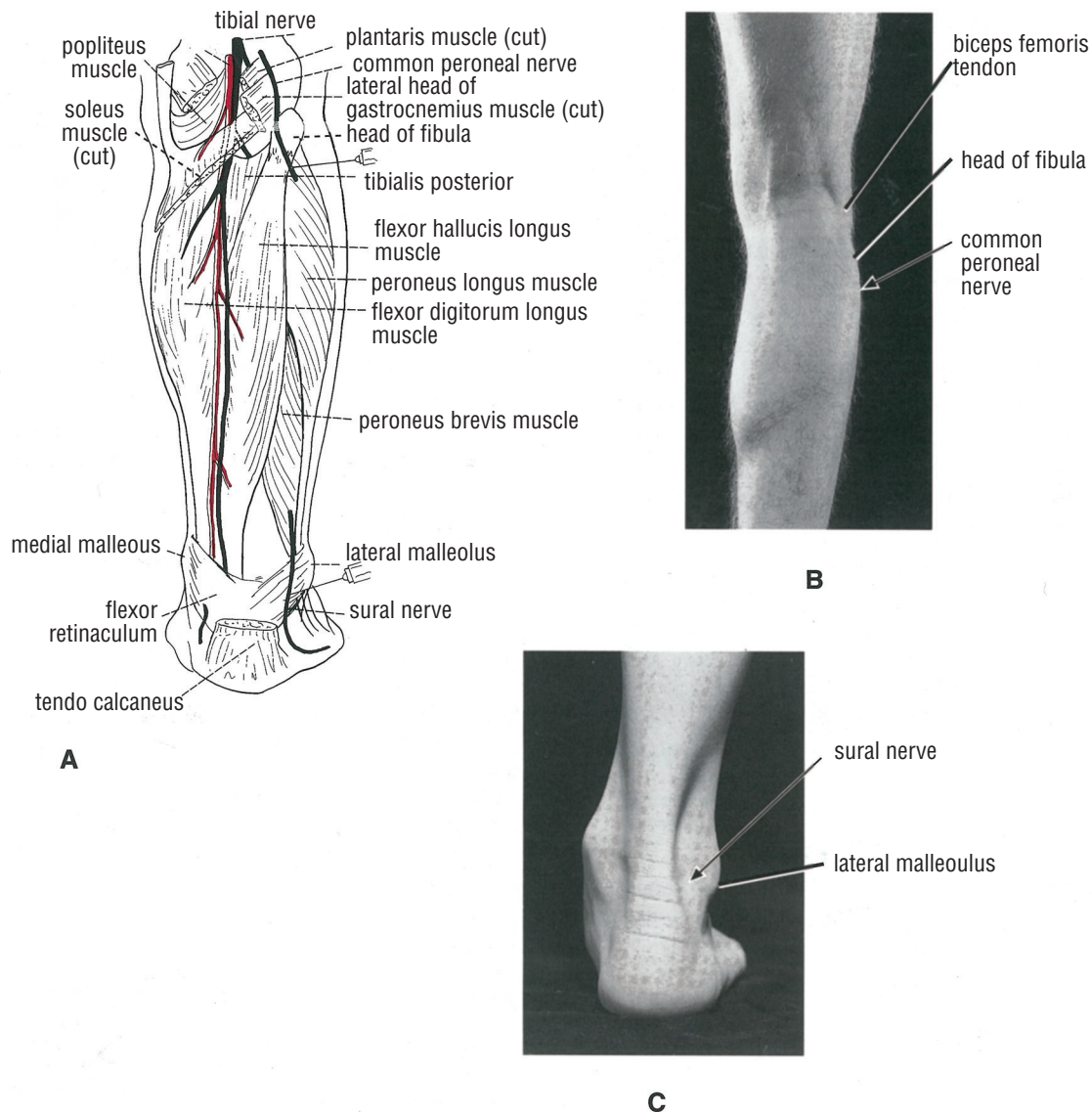
Superficial Peroneal Nerve Block

Area of anesthesia: Skin on the lower anterior and lateral sides of the leg and the dorsum of the foot and toes (except the cleft between the first and second toes, which is innervated by the deep peroneal nerve and the lateral side of the little toe, which is supplied by the sural nerve)

Indications: Repair of lacerations in the area of its cutaneous distribution

Procedure: The superficial peroneal nerve is a branch of the common peroneal nerve. In the lower third of the leg it becomes superficial and its terminal branches pass to their distribution on the dorsum of the foot and toes (see CD Fig. 17-21).

The superficial peroneal nerve is easily blocked in the lower part of the leg by infiltrating the anesthetic in the



CD Figure 17-23 **A.** The important anatomic relationships of the common peroneal nerve at the back of the knee joint and the sural nerve behind the lateral malleolus of the fibula. **B.** The surface landmarks used for performing a common peroneal nerve block at the knee. **C.** The surface landmarks used for performing a sural nerve block at the ankle.

subcutaneous tissue along a transverse line connecting the medial and lateral malleoli (see CD Fig. 17-21).

Deep Peroneal Nerve Block

Area of anesthesia: Skin in the cleft between the big and second toes

Indications: Repair of lacerations in the cleft between the big and second toes

Procedure: The deep peroneal nerve is a terminal branch of the common peroneal nerve. It descends in the anterior compartment of the leg and at the ankle it passes onto the dorsum of the foot. Here the nerve lies

on the lateral side of the dorsalis pedis artery and is superficially placed between the tendons of extensor digitorum longus and the extensor hallucis longus muscles (see CD Fig. 17-21).

First, the dorsalis pedis artery is palpated midway between the medial and lateral malleoli. With the foot actively dorsiflexed, the tendons of the extensor digitorum longus and extensor hallucis longus muscles can be seen. The nerve lies on the lateral side of the artery between these tendons (see CD Fig. 17-21). The needle is then inserted over the nerve, and the surrounding tissues are infiltrated with anesthetic.

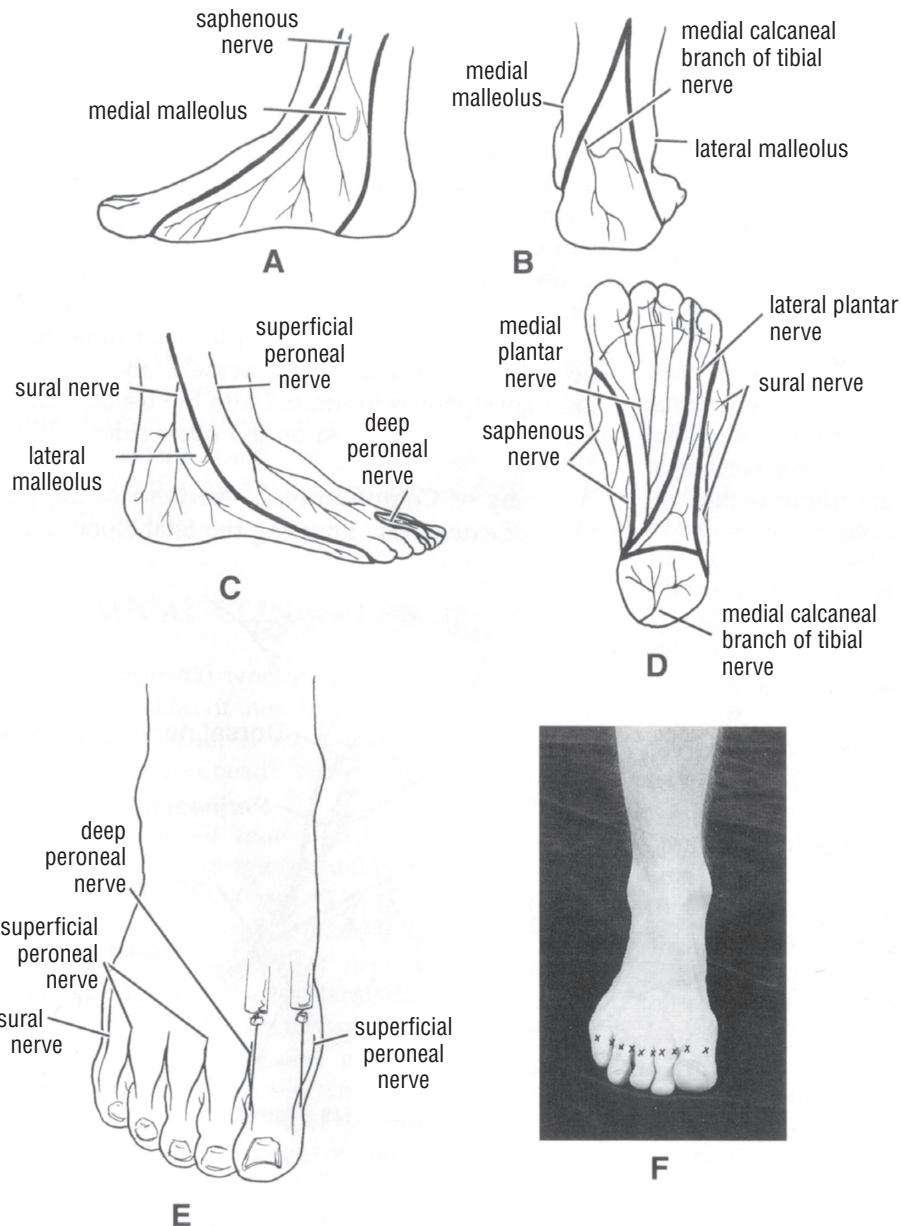
Toe Nerve Blocks

Area of anesthesia. Skin of the toes. Each toe is supplied by four digital nerves at the 2 o'clock, 5 o'clock, 7 o'clock, and 10 o'clock positions. The plantar digital nerves are derived from the medial and lateral plantar nerves (CD Fig. 17-24); the dorsal digital nerves are from the superfi-

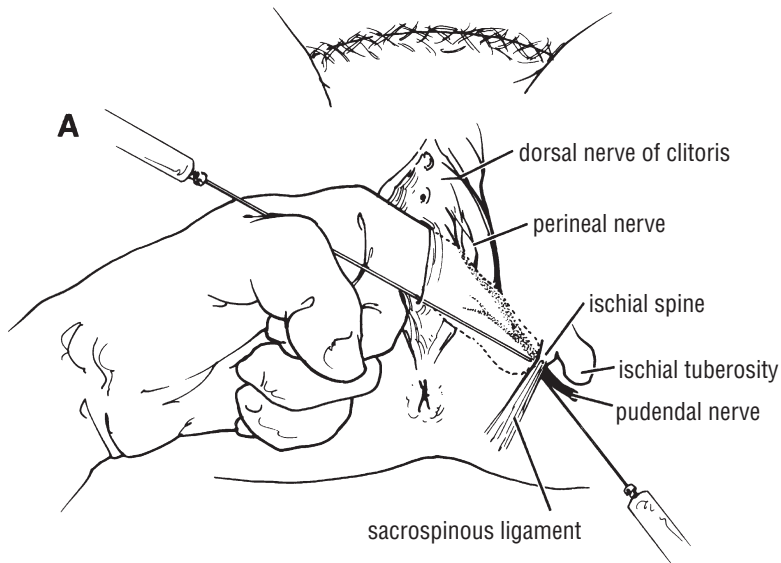
cial peroneal nerve (except the cleft between the big toe and second toe, which is supplied by the deep peroneal nerve, and the lateral side of the little toe, which is supplied by the sural nerve).

Indications: Repair of lacerations of the toes, removal of foreign bodies, and removal of nails

Procedure: The nerves are easily blocked with small volumes of anesthetic solution injected subcutaneously and



CD Figure 17-24 Toe nerve blocks. **A, B, C,** and **D.** The sensory nerve supply to the foot and toes; the heavy lines indicate the boundaries between the different areas of innervation. The plantar digital nerves are derived from the medial and lateral plantar nerves; the dorsal digital nerves are from the superficial peroneal nerve (except the cleft between the big and second toes, which are supplied by the deep peroneal nerve, and the lateral side of the little toe, which is supplied by the sural nerve). **E** and **F.** The sites at the base of each toe (x) where the anesthetic solution may be injected subcutaneously.



CD Figure 17-25 Pudendal nerve blocks. **A.** Transvaginal method. The needle is passed through the vaginal mucous membrane toward the ischial spine. On passing through the sacrospinous ligament the anesthetic solution is infiltrated around the pudendal nerve. **B.** Perineal method. The ischial tuberosity is palpated subcutaneously through the buttock. The needle is inserted on the medial side of the ischial tuberosity to a depth of about 1 in. from the free surface of the tuberosity. The anesthetic is infiltrated around the pudendal nerve.

circumferentially around the base of each toe (see CD Fig. 17-24).

Pudendal Nerve Block

Area of anesthesia: Skin of the perineum; it does not, however, abolish sensation from the anterior part of the perineum, which is innervated by terminal branches of the ilioinguinal nerve and genitofemoral nerve. Needless to say, it does not abolish pain from uterine contractions that ascend to the spinal cord via the sympathetic afferent nerves.

Indications: Forceps delivery and episiotomy repair

Procedures: These involve the following:

- **Transvaginal method:** The bony landmark used is the ischial spine (CD Fig. 17-25). The index finger is

inserted through the vagina to palpate the ischial spine. The needle of the syringe is then passed through the vaginal mucous membrane toward the ischial spine. On passing through the sacrospinous ligament there is a feeling of “give.” The anesthetic solution is then infiltrated into the tissues around the pudendal nerve (see CD Fig. 17-25).

- **Perineal method:** The bony landmark is the ischial tuberosity (see CD Fig. 17-25). The tuberosity is palpated subcutaneously through the buttock, and the needle is introduced into the pudendal canal along the medial side of the tuberosity. The canal lies about 1 in. (2.5 cm) deep to the free surface of the ischial tuberosity. The local anesthetic is then infiltrated around the pudendal nerve.

Clinical Problem Solving Questions

Read the following case histories/questions and give the best answer for each.

A 60-year-old woman fell down the stairs and was admitted to the emergency department with severe right shoulder pain. On examination, the patient was sitting up with her right arm by her side and her right elbow joint supported by her left hand. Inspection of the right shoulder showed loss of the normal rounded curvature and evidence of a slight swelling below the right clavicle. Any attempt at active or passive movement of the shoulder joint was stopped by severe pain in the shoulder. A

diagnosis of dislocation of the right shoulder joint was made.

1. The following statements concerning this patient are consistent with the diagnosis **except** which?
 - A. This patient had a subcoracoid dislocation of the right shoulder joint.
 - B. The head of the humerus was dislocated downward through the weakest part of the capsule of the joint.
 - C. The pull of the pectoralis major and subscapularis muscles had displaced the upper end of the humerus medially.

- D. The greater tuberosity of the humerus no longer displaced the deltoid muscle laterally, and the curve of the shoulder was lost.
- E. The integrity of the axillary nerve should always be tested by touching the skin over the upper half of the deltoid muscle.

A young housewife was on a ladder cleaning a window in her home, when she lost her balance and started to fall. To protect herself, she held out her right hand, which smashed through the glass. On admission to the hospital, she was bleeding profusely from a superficial laceration in front of her right wrist. She had sensory loss over the palmar aspect of the medial one and a half fingers but normal sensation of the back of these fingers over the middle and proximal phalanges. She had difficulty in grasping a piece of paper between her right index and middle fingers. All her long flexor tendons were intact.

2. The following statements concerning this patient are correct **except** which?
 - A. The ulnar artery was cut in front of the flexor retinaculum, and this accounted for the profuse bleeding.
 - B. The loss of skin sensation on the palmar aspect of the medial one and a half fingers was caused by the severance of the median nerve as it crossed in front of the flexor retinaculum.
 - C. The normal sensation on the back of the medial one and a half fingers over the proximal phalanges was caused by the fact that the posterior cutaneous branch of the ulnar nerve arises about 2.5 in. (6.25 cm) proximal to the flexor retinaculum and was spared.
 - D. The inability to hold the piece of paper was caused by the paralysis of the second palmar interosseous muscle, which is supplied by the deep branch of the ulnar nerve.
 - E. There was no sensory loss on the palm of the hand because the palmar cutaneous branch of the ulnar nerve was not cut.

A 50-year-old woman complaining of severe “pins and needles” in her right hand and lateral fingers visited her physician. She said that she had experienced difficulty in buttoning up her clothes when dressing. On physical examination the patient pointed to her thumb and index, middle, and ring fingers as the areas where she felt discomfort. No objective impairment of sensation was found in these areas. The muscles of the thenar eminence appeared to be functioning normally, although there was some loss of power compared with the activity of the muscles of the left thenar eminence.

3. The following statements concerning this patient are correct **except** which?
 - A. Altered skin sensation was felt in the skin areas supplied by the digital branches of the median nerve.

- B. The muscles of the thenar eminence showed some evidence of wasting as seen by flattening of the thenar eminence.
- C. The muscles of the thenar eminence are supplied by the recurrent muscular branch of the median nerve.
- D. The median nerve enters the palm through the carpal tunnel.
- E. The median nerve occupies a large space between the tendons behind the flexor retinaculum.
- F. This patient has carpal tunnel syndrome.

A 6-year-old boy, running along a concrete path with a glass jam jar in his hand, slipped and fell. The glass from the broken jar pierced the skin on the front of his left wrist. On examination a small wound was present on the front of the left wrist and the palmaris longus tendon had been severed. The thumb was laterally rotated and adducted, and the boy was unable to oppose his thumb to the other fingers. There was loss of skin sensation over the lateral half of the palm and the palmar aspect of the lateral three and a half fingers.

4. The following facts concerning this patient are correct **except** which?
 - A. Sensory loss of the distal part of the dorsal surfaces of the lateral three and a half fingers was experienced.
 - B. The median nerve lies superficial to the palmaris longus proximal to the flexor retinaculum and was severed by the piece of glass.
 - C. The median nerve lies in the interval between the tendons of the flexor digitorum superficialis and the flexor carpi radialis muscles just proximal to the wrist joint.
 - D. Adduction of the thumb was produced by the contraction of the adductor pollicis muscle, which is supplied by the ulnar nerve.
 - E. The palmar cutaneous branch of the median nerve had been severed.

A 52-year-old woman was admitted to the hospital with a diagnosis of right-sided pleurisy with pneumonia. It was decided to remove a sample of pleural fluid from her pleural cavity. The resident inserted the needle close to the lower border of the eighth rib in the anterior axillary line. The next morning he was surprised to hear that the patient had complained of altered skin sensation extending from the point where the needle was inserted downward and forward to the midline of the abdominal wall above the umbilicus.

5. The altered skin sensation in this patient after the needle thoracostomy could be explained by **which**?
 - A. The needle was inserted too low down in the intercostal space.
 - B. The needle was inserted too close to the lower border of the eighth rib and damaged the eighth intercostal nerve.

- C. The needle had impaled the eighth rib.
- D. The needle had penetrated too deeply and pierced the lung.
- E. There is a peritoneal abscess beneath the diaphragm on the left side.

A 43-year-old man was involved in a violent quarrel with his wife over another woman. In a fit of rage, the wife picked up a carving knife and lunged forward at her husband, striking his anterior neck over the left clavicle. The husband collapsed on the kitchen floor, bleeding profusely from the wound. The distraught wife called an ambulance.

6. On examination in the emergency department of the hospital, the following conditions were found **except** which?
 - A. A wound was seen about 1 in. (2.5 cm) wide over the left clavicle.
 - B. Auscultation revealed diminished breath sounds over the left hemithorax.
 - C. The trachea was deflected to the left.
 - D. The left upper limb was lying stationary on the table, and active movement of the small muscles of the left hand was absent.
 - E. The patient was insensitive to pin prick along the lateral side of the left arm, forearm, and hand.

A 72-year-old man complaining of burning pain on the right side of his chest was seen by his physician. On examination the patient indicated that the pain passed forward over the right sixth intercostal space from the posterior axillary line forward as far as the midline over the sternum. The physician noted that there were several watery blebs on the skin in the painful area.

7. The following statements are correct **except** which?
 - A. This patient has herpes zoster.
 - B. A virus descends along the cutaneous nerves, causing dermatomal pain and the eruption of vesicles.
 - C. The sixth right intercostal nerve was involved.
 - D. The condition was confined to the anterior cutaneous branch of the sixth intercostal nerve.

An obese 40-year-old woman was seen in the emergency department complaining of a severe pain over the right shoulder and in her right side and back below the shoulder blade. She said that she had experienced the pain on several occasions before and that when she ate fatty foods it seemed to make the pain worse. Ultrasound demonstrated the presence of gallstones. Her condition was diagnosed as cholelithiasis, and the pain was attributed to gallstone colic.

8. The symptoms and signs displayed by this patient can be explained by the following statement **except** which?
 - A. The fundus of the gallbladder lies against the anterior abdominal wall next to the tip of the right ninth costal cartilage.

- B. The parietal peritoneum in this area is innervated by the tenth and eleventh intercostal nerves, which give rise to referred pain in the tenth and eleventh dermatomes on the side and back.
- C. The parietal peritoneum on the central part of the undersurface of the diaphragm is supplied by the phrenic nerve.
- D. The spinal segmental nerves within the phrenic nerve are C3, C4, and C5.
- E. The pain was referred to the shoulder along the supraclavicular nerves (C3 and C4).

An 8-year-old boy was admitted to the hospital with a temperature of 101°F, a furred tongue, and pain in the right lower quadrant. On examination, the skin on the right lower quadrant was tender to the touch, and the abdominal muscles were contracted and rigid. A diagnosis of acute appendicitis was made.

9. The symptoms and signs displayed by this patient can be explained by the following statements **except** which?
 - A. An acutely inflamed appendix produces an inflammation of the peritoneal coat covering it.
 - B. Should the inflammatory process spread, for example, if the appendix should rupture, the parietal peritoneum would become involved.
 - C. The parietal peritoneum, the abdominal muscles, and the overlying skin are supplied by the same segmental spinal nerves.
 - D. The segmental nerves supplying the right lower quadrant of the abdominal wall are T7, T8, and T9.
 - E. The pain in the right lower quadrant and the regional contraction of the abdominal muscles are attempts by the body to keep the inflamed appendix immobile so that the inflammatory process remains localized.

A 45-year-old woman was shopping in a liquor store when an armed robbery took place. A shoot-out occurred and a bullet ricocheted off the wall and entered her left side. Fortunately, the bullet did not enter the peritoneal cavity. One year later, in addition to diminished skin sensation over the left lumbar region and umbilicus, she noticed a bulging forward of the left side of her anterior abdominal wall.

10. The symptoms and signs displayed by this patient can be explained by the following statements **except** which?
 - A. The bullet cut the ninth and tenth intercostal nerves just below the costal margin on the left side.
 - B. The diminished skin sensation was caused by the loss of the sensory nerve supply to the ninth and tenth thoracic dermatomes.
 - C. Portions of the oblique, transversus, and rectus abdominis muscles on the left side were paralyzed.
 - D. Atrophy of the pyramidalis muscle resulted in loss of support to the abdominal viscera, which then sagged forward.

After a major abdominal operation, a patient was given a course of antibiotics by intramuscular injection. The nurse was instructed to give the injections into the right buttock. Later, when the patient left the hospital, he developed several symptoms and signs that suggested that the injections into the gluteus maximus muscle had been given over the course of the sciatic nerve and had caused a lesion of the common peroneal nerve.

11. The symptoms and signs displayed by this patient included the following **except** which?
 - A. He experienced numbness and tingling sensations down the anterior and lateral sides of the right leg and the dorsum of the foot.
 - B. His right foot tended to catch on steps and on the edges of the carpet.
 - C. On testing, he had impaired skin sensation on the lateral side of the right thigh.
 - D. The patient tended to hold the foot plantar flexed and slightly inverted.
 - E. Dorsiflexion of the right ankle joint was weaker than the same movement of the left ankle.
 - F. The evertor muscles of the right midtarsal joints were weaker than those of the opposite side.

A 17-year-old girl was dealing drugs on a street corner when she became involved in a fight. During the brawl she received a deep knife wound to the front of her right thigh. After a thorough examination in the emergency department of the local hospital, it was determined that the knife point had severed the trunk of the right femoral nerve just below the inguinal ligament.

12. This patient had the following signs and symptoms **except** which?
 - A. The right quadriceps femoris muscle failed to contract when the patient was asked to extend her right knee joint.

- B. Skin sensation was lost over the anterior and medial sides of the thigh.
- C. Skin sensation was lost along the medial border of the big toe.
- D. Skin sensation was lost on the lower part of the leg and the medial border of the foot as far as the ball of the big toe.
- E. Weak extension of the knee was possible when walking because of the use of the adductor muscles.


13. A patient was seen in the emergency department with a laceration of the skin over the middle phalanx of the left index finger. What is the sensory nerve supply of that finger? Where is it possible to perform a nerve block so that the wound could be sutured?
14. A 37-year-old woman was involved in an automobile accident and sustained a fracture of her sixth right rib. It was decided to relieve her acute pain caused by the broken rib by performing an intercostal nerve block. Which intercostal nerve innervates the sixth rib? What is the course taken by an intercostal nerve in an intercostal space? From what part of a spinal nerve is an intercostal nerve formed? Name the order of structures forming the neurovascular bundle in an intercostal space from above downward.
15. A 17-year-old boy received a knife wound on the lateral side of his right thigh. What is the sensory nerve supply to this region of the thigh? Which important surface landmarks would you use when blocking the nerves?
16. What is the sensory nerve supply to the skin on the dorsum of the foot? Where would you block these nerves?

Answers and Explanations

1. **E** is the correct answer. The integrity of the axillary nerve is tested by touching the skin over the lower half of the deltoid muscle. The skin of the curve of the shoulder, including the skin covering the upper half of the deltoid muscle, is supplied by the supraclavicular nerves.
2. **B** is the correct answer. The loss of skin sensation of the palmar aspect of the medial one and a half fingers was caused by the severance of the ulnar nerve as it crossed in front of the flexor retinaculum with the ulnar artery, which was also cut (see text Fig. 17-14).
3. **E** is the correct answer. The median nerve occupies a small restricted space in the carpal tunnel (see text Fig. 17-14).
4. **B** is the correct answer. The median nerve lies deep to the palmaris longus tendon proximal to the flexor retinaculum (see text Fig. 17-12).

5. **B** is the correct answer. The needle was inserted too close to the lower border of the eighth rib and damaged the eighth intercostal nerve (see CD Fig. 17-18).
6. **E** is the correct answer. The lower trunk of the brachial plexus was cut by the knife. This would explain the loss of movement of the small muscles of the left hand. It would also explain the loss of skin sensation that occurred in the C8 and T1 dermatomes on the **medial** not on the lateral side of the left forearm and hand. The knife had also pierced the left dome of the cervical pleura, causing a left pneumothorax with left-sided diminished breath sounds and a deflection of the trachea to the left.
7. **D** is the correct answer. The skin over the sixth intercostal space is innervated by the lateral cutaneous branch as well as the anterior cutaneous branch of the sixth intercostal nerve.
8. **B** is the correct answer. The parietal peritoneum in the region of the fundus of the gallbladder is innervated by the eighth and ninth intercostal nerves, which give rise to referred pain in the eighth and ninth thoracic dermatomes on the side and back.
9. **D** is the correct answer. The segmental nerves supplying the right lower quadrant of the abdominal wall are T11, T12, and L1 (see CD Fig. 17-1).
10. **D** is the correct answer. The pyramidalis muscle (if present) is innervated by the twelfth thoracic nerve.
11. **C** is the correct answer. The skin on the lateral side of the thigh is innervated by the lateral cutaneous nerve of the thigh (L2 and L3), a branch of the lumbar plexus (see CD Fig. 17-1).
12. **C** is the correct answer. The skin covering the medial border of the big toe is innervated by the superficial peroneal nerve (see CD Fig. 17-1).
13. The index finger receives the following sensory innervation: anterior aspect, two digital branches of the median nerve; posterior aspect, two digital branches of the superficial radial nerve. The nerves are easily blocked by injecting small volumes of anesthetic solution around the base of the finger (see CD Fig. 17-17).
14. The periosteum of the sixth rib is innervated by the sixth intercostal nerve. (It is conceivable that in the individual who has a collateral branch of the fifth intercostal nerve, the periosteum of the sixth is also innervated by this nerve.) Intercostal nerves are formed from the anterior rami of T1 through T11 spinal nerves. An intercostal nerve passes forward around the chest wall first, between the posterior intercostal membrane and the parietal pleura, then between the internal intercostal muscle and the innermost intercostal muscle (part of the transversus thoracis). The nerve lies in the subcostal groove of the rib of its own number. The intercostal vein, the intercostal artery, and the intercostal nerve lie within the subcostal groove in that order from above downward.
15. The sensory innervation of the skin on the lateral surface of the thigh is the lateral cutaneous nerve of the thigh, a branch of the lumbar plexus (L2 and L3). The nerve may be blocked by inserting an anesthetic needle just inferior to the inguinal ligament about 0.5 in. (1.3 cm) medial to the anterior superior iliac spine.
16. The sensory nerve supply to the skin on the dorsum of the foot is from the superficial peroneal nerve. The cleft between the first and second toes is from the deep peroneal nerve.

The superficial peroneal nerve can be blocked by infiltrating the anesthetic in the subcutaneous tissue along a transverse line connecting the medial and lateral malleoli (see CD Fig. 17-21). The deep peroneal nerve is blocked by first palpating the dorsalis pedis artery as it lies between the tendons of the extensor hallucis longus and the extensor digitorum longus. The nerve lies on the lateral side of the artery between these tendons. The needle is then inserted over the nerve, and the surrounding tissue is infiltrated with anesthetic.



18

The Eye and the Ear



Chapter Outline

The Eye	296		
Eyelids	296		
Clinical Examination of the Eyelids	296		
Hordeolum (Stye)	296		
Chalazion	297		
Edema of the Eyelids	297		
Subtarsal Sulcus and Foreign Bodies	297		
Ptosis (Drooping of the Upper Lid)	297		
Lacrimal Apparatus	297		
Inflammation of the Lacrimal Sac	297		
Probing the Nasolacrimal Duct	298		
Eye Trauma	298		
Blowout Fractures of the Maxilla	298		
Movements of the Eye	298		
Clinical Testing for the Actions of the Superior and Inferior Recti and the Superior and Inferior Oblique Muscles	298		
Lesions of the Cranial Nerves that Control the Eye			
Movements	298		
Strabismus	298		
Eye Structure	298		
Sclera	298		
<i>The Lamina Cribrosa, the Cerebrospinal Fluid, and the Aqueous Humor Pressure</i>	298		
Cornea	298		
<i>Aging Changes in the Cornea</i>	298		
<i>Astigmatism</i>	299		
		<i>Trauma and the Cornea</i>	299
		<i>Corneal Ulcers</i>	299
		Pupil	300
		<i>Flashlight Examination of the Pupil</i>	300
		<i>Pupillary Reflexes</i>	300
		Retina	300
		<i>Detachment of the Retina</i>	300
		<i>Central Retinal Artery Occlusion</i>	300
		<i>Papilledema, the Central Vein, and Increased Cerebrospinal Fluid Pressure</i>	300
		Lens	300
		<i>Cataract</i>	300
		Examination of the Eye as Seen with the Direct Ophthalmoscope	300
		The Ear	303
		External Ear	303
		Tympanic Membrane Examination	303
		Middle Ear	303
		Infections and Otitis Media	303
		<i>Complications of Otitis Media</i>	303
		Clinical Problem Solving Questions	303
		Answers and Explanations	305



THE EYE

Eyelids

Clinical Examination of the Eyelids

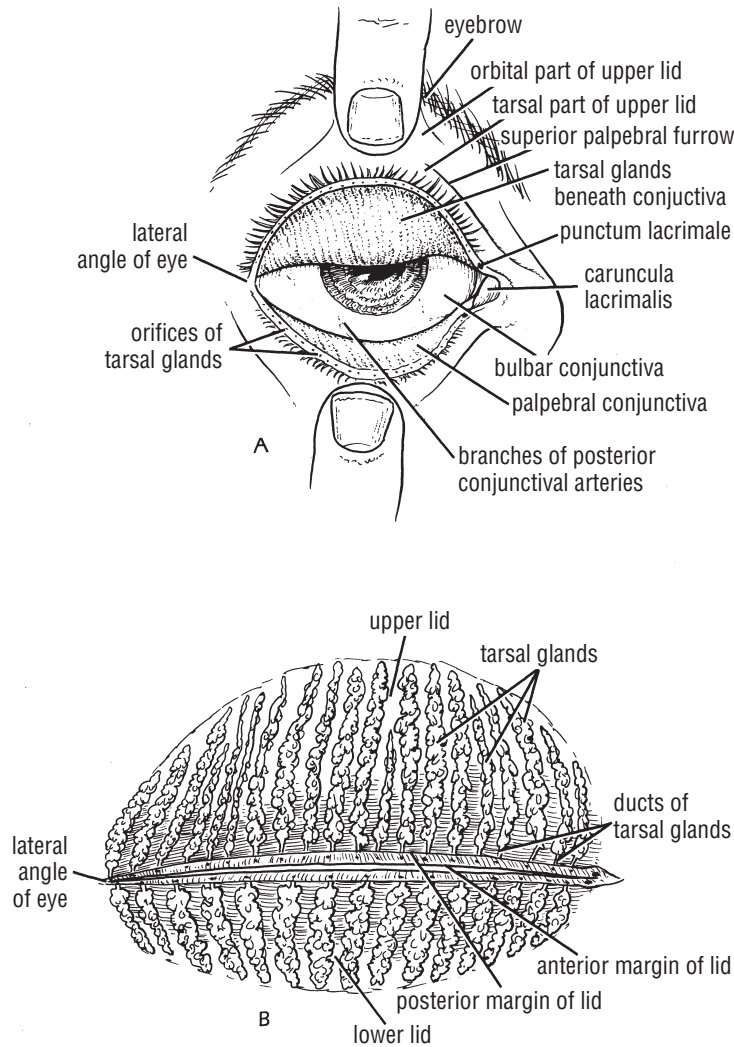
Retraction of the eyelids: Both the upper and lower lids can be retracted by applying the thumbs to the patient's forehead and the cheek just above and below the orbital margins. The lids are then gently retracted away from the eyeball, and the lower lid may be easily everted (CD Fig. 18-1).

Eversion of the upper lid: Eversion of the upper lid is more difficult than that of the lower lid because of its size

and muscular attachments. It is performed for purposes of inspection of the eye and removing a superficial conjunctival foreign body. With the patient looking downward, the upper lid is grasped by the central eyelashes and pulled downward while a cotton-tipped applicator is applied centrally to the skin on the upper surface of the upper lid. With the superior tarsal plate serving to stiffen the upper lid, the upper lid is gently flipped upward over the applicator tip so that the conjunctival surface is fully exposed (see CD Fig. 18-1).

Hordeolum (Stye)

An external hordeolum is an acute infection of a lash follicle or a sebaceous gland (of Zeis) or a ciliary sweat gland (of Moll); all drain externally to the skin surface of the lid.



CD Figure 18-1 **A.** Complete eversion of the upper eyelid of the right eye made possible by stiffness of the superior tarsal plate; the lower eyelid is pulled downward. Note the orifices of the tarsal glands and the puncta lacrimalia. **B.** Posterior view of the eyelids with the upper and lower lids nearly closed. Note the tarsal glands with their short ducts and orifices. In this diagram the conjunctiva has been removed from the back of the eyelids to reveal the tarsal glands in situ.

An internal hordeolum is an acute infection of a tarsal gland (of Meibom). The tarsal glands drain onto the conjunctival surface of the lid.

Chalazion

This is a localized, painless swelling of the lid resulting from chronic inflammation of a tarsal gland. Since the gland lies on the conjunctival surface of the tarsal plate, the swelling should be incised through the conjunctival surface of the lid.

Edema of the Eyelids

The looseness of the subcutaneous tissue of the eyelids explains why edema fluid secondary to renal failure or insect bites can rapidly accumulate, causing extensive swelling of the lids.

Subtarsal Sulcus and Foreign Bodies

Foreign bodies in the conjunctival sac produce severe pain and reflex tearing. The superior and inferior fornices can be examined for the foreign bodies by everting the eyelids as

described previously. Small particles often migrate and become lodged in the subtarsal sulcus (see text Fig. 18-1). Corneal abrasions may occur as the result of the foreign body being carried across the cornea with the movement of the eyelids.

Ptosis (Drooping of the Upper Lid)

In Horner's syndrome, ptosis is caused by loss of sympathetic innervation of the smooth muscle component of the levator palpebrae superioris muscle. In third cranial nerve dysfunction, ptosis is due to paralysis of the striated muscle of the levator palpebrae superioris.

Lacrimal Apparatus

Inflammation of the Lacrimal Sac

This presents as a tender swelling above the upper margin of the medial palpebral ligament. Gentle pressure on the sac may result in a yellowish discharge emerging from the puncta lacrimalia.

Probing the Nasolacrimal Duct

Congenital or acquired blockage of the duct may occur. To relieve the blockage, a probe is passed downward starting at the punctum lacrimale of the upper eyelid. The probe is first directed vertically upward and then medially into the lacrimal sac. It is then turned downward at right angles in the nasolacrimal duct to reach the inferior meatus in the nose. The end of the probe should then be visible within the nose. Remember that the nasolacrimal duct inclines downward, backward, and laterally as it descends to the nose.

Eye Trauma

Although the eyeball is well protected by the surrounding bony orbit, it is protected anteriorly only from large objects, such as tennis balls, which tend to strike the orbital margin but not the globe. The bony orbit provides no protection from small objects, such as golf balls, which can cause severe damage to the eye. Careful examination of the eyeball relative to the orbital margins shows that it is least protected from the lateral side.

Blowout Fractures of the Maxilla

Blowout fractures of the orbital floor involving the maxillary sinus commonly occur as a result of blunt force to the face. If the force is applied to the eye, the orbital fat explodes inferiorly into the maxillary sinus, fracturing the orbital floor. Not only can blowout fractures cause displacement of the eyeball, with resulting symptoms of double vision (diplopia), but also the fracture can injure the infraorbital nerve, producing loss of sensation of the skin of the cheek and the gum on that side. Entrapment of the inferior rectus muscle in the fracture may limit upward gaze.

Movements of the Eye

Clinical Testing for the Actions of the Superior and Inferior Recti and the Superior and Inferior Oblique Muscles

Since the actions of the superior and inferior recti and the superior and inferior oblique muscles are complicated when a patient is asked to look vertically upward or vertically downward, the examiner tests the eye movements in which the single action of each muscle predominates.

The origins of the superior and inferior recti are situated about 23° medial to their insertion and, therefore, when the patient is asked to turn the cornea laterally, these muscles are placed in the optimum position to raise the cornea (superior rectus) or lower it (inferior rectus). To test the superior rectus, have the patient look up and laterally; to test the inferior rectus, have the patient look down and out.

Using the same rationale, the examiner tests the superior and the inferior oblique muscles. The pulley of the superior

oblique and the origin of the inferior oblique muscles lie medial and anterior to their insertions. The ophthalmologist tests the action of these muscles by asking the patient first to look medially, thus placing these muscles in the optimum position to lower the cornea (superior oblique) or to raise it (inferior oblique). In other words, when you ask a patient to look medially and downward at the tip of his nose, you are testing the superior oblique at its best position. Conversely, by asking the patient to look medially and upward, you are testing the inferior oblique at its best position.

Because the lateral and medial recti are neutrally placed relative to the axes of the eyeball, asking the patient to turn his or her cornea directly laterally tests the lateral rectus, and turning the cornea directly medially tests the medial rectus.

The cardinal positions of the eye and the actions of the recti and oblique muscles are shown in CD Fig. 18-2.

Lesions of the Cranial Nerves that Control the Eye Movements

Lesions of the oculomotor, trochlear, and abducent nerves are described on CD page 227.

Strabismus

Many cases of strabismus are nonparalytic and are caused by an imbalance in the action of opposing muscles. This type of strabismus is known as **concomitant strabismus** and is common in infancy.

Eye Structure

Sclera

The Lamina Cribrosa, the Cerebrospinal Fluid, and the Aqueous Humor Pressure

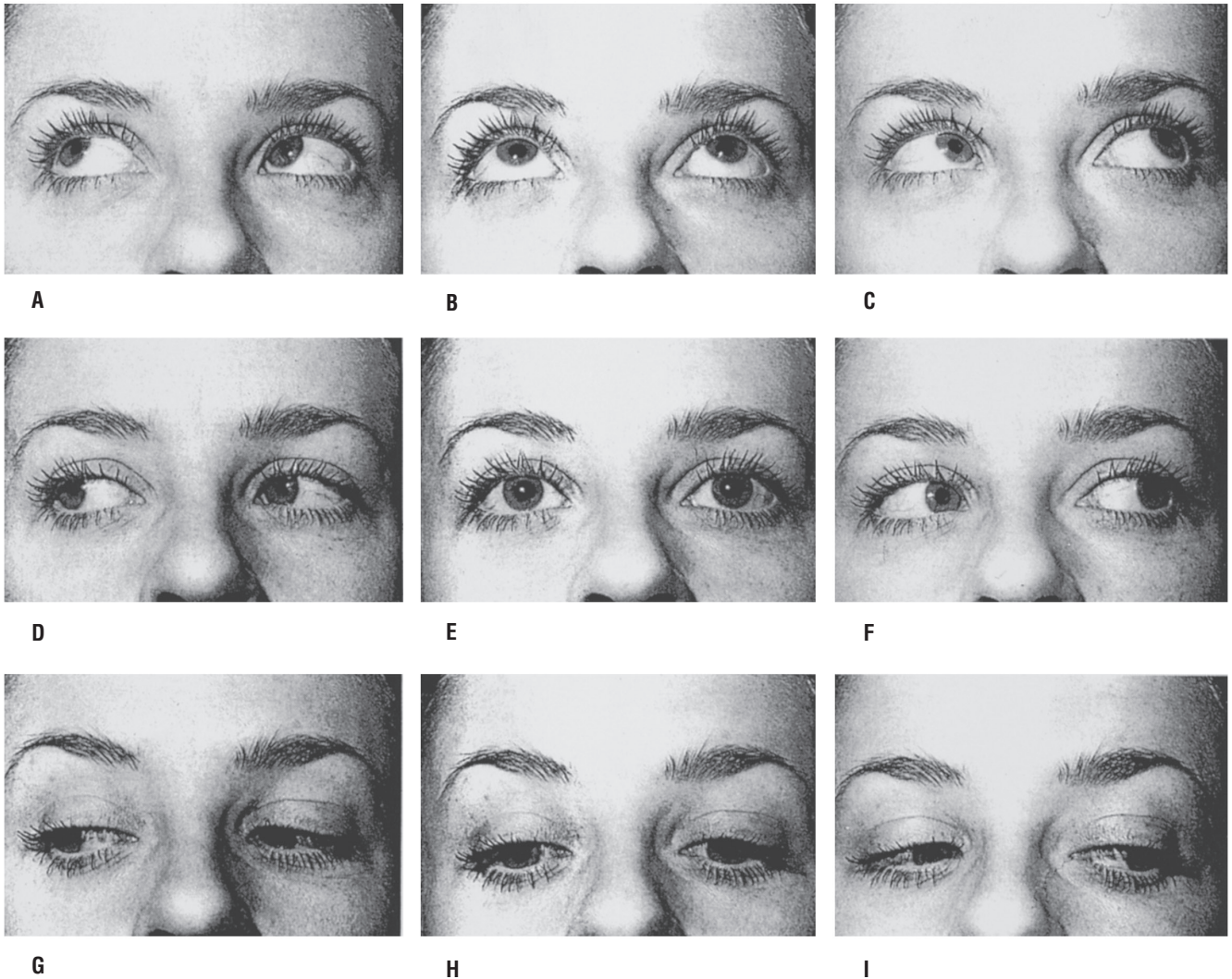The lamina cribrosa is the area of the sclera that is pierced by the nerve fibers of the optic nerve. It is a relatively weak area and can be made to bulge into the eyeball by a rise of cerebrospinal fluid pressure in the tubular extension of the subarachnoid space, which surrounds the optic nerve.

If the intraocular pressure rises, due to blockage in the drainage of aqueous humor, as in glaucoma, the lamina cribrosa will bulge outward, producing a cupped disc, as seen through the ophthalmoscope.

Cornea

Aging Changes in the Cornea

With advancing years, the cornea becomes less translucent, and dust-like opacities may occur in the deeper parts of the substantia propria. **Arcus senilis** appears as white arcs near the edge of the cornea and is caused by an extracellular infiltration of lipid; it is present in almost every person over 60 years old.



CD Figure 18-2 The cardinal positions of the right and left eyes and the actions of the recti and oblique muscles *principally* responsible for the movements of the eyes. **A.** Right eye, superior rectus muscle; left eye, inferior oblique muscle. **B.** Both eyes, superior recti and inferior oblique muscles. **C.** Right eye, inferior oblique muscle; left eye, superior rectus muscle. **D.** Right eye, lateral rectus muscle; left eye, medial rectus muscle. **E.** Primary position, with the eyes fixed on a distant fixation point. **F.** Right eye, medial rectus muscle; left eye, lateral rectus muscle. **G.** Right eye, inferior rectus muscle; left eye, superior oblique muscle. **H.** Both eyes, inferior recti and superior oblique muscles. **I.** Right eye, superior oblique muscle; left eye, inferior rectus muscle.

Astigmatism

Often the cornea is not the section of a perfect sphere so that the refractive power is not the same in all directions, a condition known as astigmatism.

Trauma and the Cornea

Because a portion of the cornea is exposed between the eyelids, injuries from foreign bodies or abrasions are very common. Damage to the corneal epithelium causes considerable pain, reflex tearing, and vasodilatation of the conjunctival capillaries. Later, edema of the lids will be apparent.

Fortunately, the stratified squamous epithelium covering the anterior surface of the cornea is capable of rapid regeneration after an abrasion.

Foreign bodies driven with great force may penetrate the cornea and enter the anterior chamber or even the deepest parts of the eyeball.

Corneal Ulcers

Corneal ulcers are caused by a bacterial invasion of the cornea with the formation of a stromal abscess. The ability of the cornea to resist bacterial invasion depends on the cleansing action of the tears and their normal circulation and the

integrity of the corneal epithelium. A breakdown of this mechanism can occur as the result of mild trauma, such as that which occurs when soft corneal lenses are worn for an excessive period of time, or in the presence of chronic disease.

Pupil

Flashlight Examination of the Pupil

Normally, the pupils should be of equal or nearly equal diameter (within 1 to 2 mm in diameter is normal). They should be round and react to light and accommodation.

Pupillary Reflexes

The pupillary reflexes—that is, the reaction of the pupils to light and accommodation—depend on the integrity of nervous pathways. In the **direct light reflex**, the normal pupil reflexly contracts when a light is shone into the patient's eye. The nervous impulses pass from the retina along the optic nerve to the optic chiasma and then along the optic tract. Before reaching the lateral geniculate body, the fibers concerned with this reflex leave the tract and pass to the oculomotor nuclei on both sides via the pretectal nuclei. From the parasympathetic part of the nucleus, efferent fibers leave the midbrain in the oculomotor nerve and reach the ciliary ganglion via the nerve to the inferior oblique. Postganglionic fibers pass to the constrictor pupillae muscles via the short ciliary nerves.

The **consensual light reflex** is tested by shining the light in one eye and noting the contraction of the pupil in the opposite eye. This reflex is possible because the afferent pathway just described travels to the parasympathetic nuclei of both oculomotor nerves.

The **accommodation reflex** is the contraction of the pupil that occurs when a person suddenly focuses on a near object after having focused on a distant object. The nervous impulses pass from the retina via the optic nerve, the optic chiasma, the optic tract, the lateral geniculate body, the optic radiation, and the cerebral cortex of the occipital lobe of the brain. The visual cortex is connected to the eye field of the frontal cortex. From here, efferent pathways pass to the parasympathetic nucleus of the oculomotor nerve. From there, the efferent impulses reach the constrictor pupillae via the oculomotor nerve, the ciliary ganglion, and the short ciliary nerves.

Retina

Detachment of the Retina

The neural retina is firmly attached to the underlying pigment epithelium at the optic disc and the ora serrata.

Pathologic separation of the two layers of the retina may follow trauma to the eyeball or degeneration of the neural retina. Vitreous traction of the retina, or the presence of a

hole or tear, allows accumulation of fluid between the pigment epithelium and the neural retina, causing the layers to separate or become detached.

Central Retinal Artery Occlusion

At the point where the central artery pierces the lamina cribrosa (CD Fig. 18-3), it is subject to atherosclerosis and can undergo complete or partial occlusion. Disease changes in the arteriolar wall can be seen with the ophthalmoscope where the arteries cross the veins as a nicking or narrowing of the venous blood column.

In complete central artery occlusion there is a sudden onset of unilateral blindness. In branch arteriole occlusion there is a partial loss of sight corresponding to the sector supplied by the arteriole. Total arterial occlusion lasting longer than 1½ hours can produce irreversible retinal degeneration.

Papilledema, the Central Vein, and Increased Cerebrospinal Fluid Pressure

Since the optic nerve is surrounded by the dura and arachnoid sheaths, an increase in the intracranial pressure is transmitted through the cerebrospinal fluid along the extension of the subarachnoid space to the lamina cribrosa of the eyeball. Because the central artery and vein of the retina cross the subarachnoid space to enter or leave the optic nerve, they will be subject to a rise in cerebrospinal fluid pressure. The thick-walled artery is unaffected, but the thin-walled vein may be compressed, causing congestion of the retinal veins and edema of the retina; bulging of the disc may also occur.

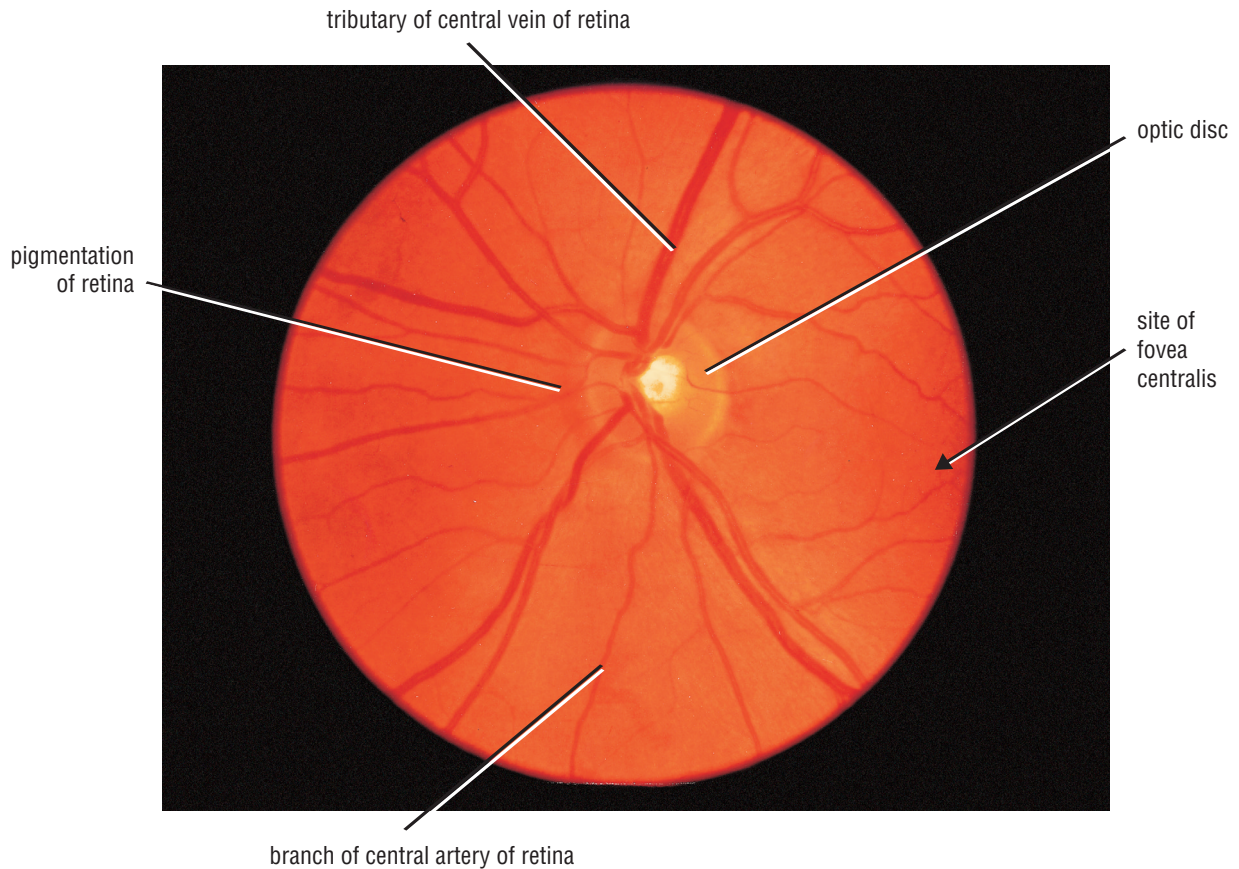
Lens

Cataract

In this condition the lens becomes opaque. Metabolic products accumulate within the lens fibers. Senile cataract is the most common form; its cause is unknown.

Examination of the Eye as Seen with the Direct Ophthalmoscope

Red reflex: On looking through the ophthalmoscope, holding it about 1 ft away from the patient, the examiner notes that the fundus appears red (see CD Fig. 18-3). The fundus shows red because the light is being reflected back from the blood in the choroidal blood vessels, with the intervening retina being transparent. An **absent red reflex** means that either there is an opacity in the refractive media or the retina is not against the choroid. The possible opacities include a cataract, a vitreous hemorrhage, and a detached retina.



CD Figure 18-3 The left ocular fundus as seen with an ophthalmoscope.

Fundus examination: Without pupillary dilatation, only about 15% of the fundus can be seen. With full pupillary dilatation, about 50% of the fundus can be viewed, but the area between the equator of the eyeball and the ora serrata cannot be seen.

Optic disc: This structure is circular or oval with a vertical orientation (see CD Fig. 18-3). It is pink, with the temporal side slightly lighter than the nasal side. The disc measures about 1.5 mm in diameter and can be used as a unit of measurement. The center of the disc has a pale, almost white, depression called the **physiologic cup**. The edge of the disc is usually flat and sharply defined. In some individuals in whom the retina does not quite reach the margin of the disc, an arc of choroid pigment may be visible.

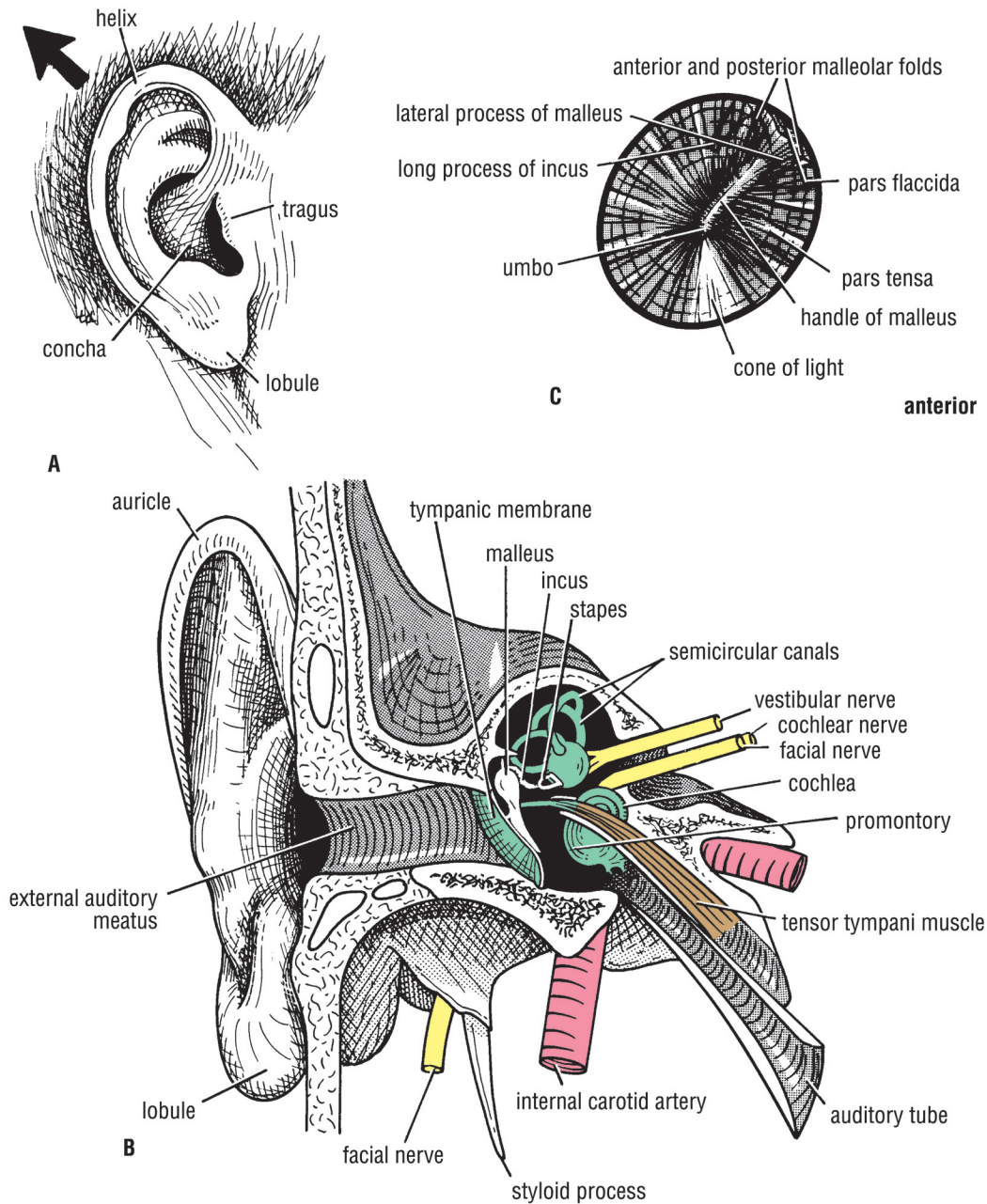
The bright red central artery of the retina becomes visible on the disc surface emerging from the optic cup, where it divides into its superior and inferior branches. The arteries do not normally pulsate. The darker red main tributaries of the central vein of the retina pass into the cup and unite in the cup or deeper out of site within the optic nerve.

In glaucoma, the increase in intraocular pressure leads to atrophy of the optic nerve and defects in the visual field. Since the lamina cribrosa of the sclera at the


optic disc is a weak area, a rise in intraocular pressure can cause it to bulge outward, producing a cupped disc that can be seen with the ophthalmoscope.

Retinal arteries and veins: The arteries are bright red; the veins are darker red (see CD Fig. 18-3). The arteries are smaller than the veins (about a 3:4 ratio). The arteries have thicker walls, which reflect the light as a shiny central reflex stripe. The walls of the arteries and the veins are transparent, so that the examiner observes a moving column of blood. The arteries usually cross the veins on their superficial or vitreal surface, and normally the arteries do not compress or nick the veins at the site of crossing. The branching of the vessels is variable.

Macula: The macula area lies about two disc diameters on the lateral side of the optic disc (see CD Fig. 18-3). It is darker than the surrounding retina. The superior and inferior temporal blood vessels arch above and below the macular area, and no blood vessels are visible in the center of the macula. The center of the macula shows a small, dark red area called the **fovea centralis**. A small white-yellow light reflex can be detected at the center of the fovea, caused by the reflection of the ophthalmoscope light from the concavity of the fovea.



CD Figure 18-4 **A.** Different parts of the auricle of the external ear. The *arrow* indicates the direction that the auricle should be pulled to straighten the external auditory meatus before insertion of the otoscope in the adult. **B.** External and middle portions of the right ear viewed from in front. **C.** The right tympanic membrane as seen through the otoscope.



THE EAR

External Ear

Tympanic Membrane Examination

Otoscopic examination of the tympanic membrane is facilitated by first straightening the external auditory meatus by gently pulling the auricle upward and backward in the adult (CD Fig. 18-4), and straight backward or backward and downward in the infant. Normally, the tympanic membrane is pearly gray and concave. Remember that in the adult the external meatus is about 1 in. (2.5 cm) long and is narrowest about 0.2 in. (5 mm) from the tympanic membrane.

Middle Ear

Infections and Otitis Media

Pathogenic organisms can gain entrance to the middle ear by ascending through the auditory tube from the nasal part

of the pharynx. Acute infection of the middle ear (otitis media) produces bulging and redness of the tympanic membrane.

Complications of Otitis Media

Inadequate treatment of otitis media can result in the spread of the infection into the mastoid antrum and the mastoid air cells (acute mastoiditis). Acute mastoiditis may be followed by the further spread of the organisms beyond the confines of the middle ear. The meninges and the temporal lobe of the brain lie superiorly. A spread of the infection in this direction could produce a meningitis and a cerebral abscess in the temporal lobe. Beyond the medial wall of the middle ear lie the facial nerve and the internal ear. A spread of the infection in this direction can cause a facial nerve palsy and labyrinthitis with vertigo. The posterior wall of the mastoid antrum is related to the sigmoid venous sinus. If the infection spreads in this direction, a thrombosis in the sigmoid sinus may well take place. These various complications emphasize the importance of knowing the anatomy of this region.

Clinical Problem Solving Questions

Read the following case histories/questions and give the best answer for each.

A 49-year-old woman was found on ophthalmoscopic examination to have edema of both optic discs (bilateral papilledema) and congestion of both retinal veins. The cause of the condition was found to be a rapidly expanding intracranial tumor.

- The following statements concerning this patient are correct **except** which?
 - An intracranial tumor causes a rise in cerebrospinal fluid pressure.
 - The optic nerves are surrounded by sheaths derived from the pia mater, arachnoid mater, and dura mater.
 - The intracranial subarachnoid space extends forward around the optic nerve for about half its length.
 - The thin walls of the retinal vein will be compressed as the vein crosses the extension of the subarachnoid space around the optic nerve.
 - Because both subarachnoid extensions are continuous with the intracranial subarachnoid space, both eyes will exhibit papilledema and congestion of the retinal veins.

A 33-year-old woman was riding her bicycle when she swerved to avoid a pothole and lost her balance. She then crashed and hit her head hard on the sidewalk. When she regained consciousness in the hospital, it was immediately noted that she had medial strabismus (squint) of her left eye.

- Which eye muscle was paralyzed in this injury?
 - The medial rectus muscle
 - The inferior rectus muscle
 - The superior rectus muscle
 - The lateral rectus muscle
 - The superior obliques muscle
- An 18-year-old student went to the clinic complaining of an acute tender area on the middle of his right upper eyelid. Examination revealed a localized red, indurated area on the eyelid margin. Close inspection showed a yellowish spot in the center of the swelling. Gentle eversion of the lid showed no evidence of swelling on its posterior surface. What is the diagnosis? Which anatomic structure(s) is (are) involved in the inflammatory process? On which part of the eyelid does the abscess tend to point?

4. A 13-year-old schoolboy was hit in the left eye by another boy during recess. During the next hour, both the eyelids of the victim swelled up until he could barely see. Examination in the emergency department revealed a bluish-red discoloration of both eyelids of his left eye with narrowing of the palpebral fissure. The discoloration extended to the forehead and the left cheek. Careful separation of the eyelids showed a localized hemorrhage of the inferolateral part of the bulbar conjunctiva (part of the conjunctiva adherent to the sclera of the eyeball). When the conjunctiva was gently moved with the tip of the examiner's little finger, the hemorrhage moved also.

When the patient was asked to look medially, the physician could clearly see the posterior limit of the conjunctival hemorrhage. Does this patient have a simple "black eye," or is this a fracture of the anterior cranial fossa of the skull? What role does the orbital septum play in enabling one to distinguish between these lesions? Is the appearance of the conjunctival hemorrhage important in making the diagnosis?

5. A 6-month-old girl was seen in the emergency department because her mother had noticed a yellow, sticky discharge from the baby's left eye. On questioning, the mother said that she had first noticed the condition that morning when her daughter woke up. She also said that she had noticed that her daughter's left eye watered excessively when she cried ever since birth. The physician confirmed the epiphora of the left eye and noted the emergence of yellow pus into the lacus lacrimalis from the puncta when gentle pressure was exerted over the medial palpebral ligament. What is the diagnosis? What is the most likely cause in a child of this age? What are the posterior relations of the medial palpebral ligament? Describe the anatomy of the drainage passages of the conjunctival sac and give the direction of each of the tubes.

A 7-year-old boy with right-sided otitis media was treated with antibiotics. The organisms did not respond to the treatment, and the infection spread to the mastoid antrum and the mastoid air cells. The surgeon decided to perform a radical mastoid operation. After the operation, it was noticed that the boy's face was distorted.

6. The following signs and symptoms suggest that the right facial nerve had been damaged during the operation **except** which?
- The mouth was drawn upward to the right.
 - He was unable to close his right eye.

- Saliva tended to accumulate in his right cheek.
- The saliva tended to dribble from the corner of his mouth.
- All the muscles of the right side of his face were paralyzed.

7. A 3-year-old boy was playing with his friend when they decided to see how many peas they could stick into each others ears. Later, the babysitter noticed that one of the boys had become completely deaf in his left ear. On examination in the emergency department of the local hospital, the physician's assistant noticed what appeared to be several peas deeply embedded in the left external auditory meatus. She decided to attempt the removal of the peas through an otoscope. Which direction should the auricle be pulled in a child to straighten the meatus and assist in the operation? How does this change in the adult?
8. Following a severe cold, a 10-year-old girl complained of severe right-sided earache. On examination by her pediatrician, the tympanic membrane looked reddened and bulged laterally. A diagnosis of otitis media was made. A yellowish area was apparent close to the umbo and it appeared that perforation of the tympanic membrane was about to take place. It was decided to do a myringotomy (incise the tympanic membrane). Where would you do a myringotomy? What structures do you have to avoid in this operation? What are the features normally seen on the tympanic membrane with an otoscope?
9. A 13-year-old boy was struck on his right ear by another boy's fist during a fight. By the time the boy was examined, the ear was extremely swollen and bluish and very painful. Explain in anatomic terms where the blood and edema fluid collect in such a case. Can the ear be treated conservatively or should the hematoma be drained? What is a cauliflower ear?
10. A 45-year-old woman with a severe cold had to make a business trip by plane. On takeoff she noticed that her hearing became impaired and she experienced acute pain in her right ear. She told the stewardess about her problem and asked for an aspirin. The stewardess advised the patient to relax and swallow hard several times. On reaching the cruising altitude the right ear suddenly popped and the deafness and pain disappeared. In anatomic terms explain this patient's condition.

Answers and Explanations

1. **C** is the correct answer. The intracranial subarachnoid space extends forward through the optic canal around the optic nerve as far as the back of the eyeball (see text Fig. 18-9).
2. **D** is the correct answer. The left abducent nerve was damaged by the head trauma and resulted in paralysis of the left lateral rectus muscle. As a consequence, the medial rectus muscle was unopposed and turned the eye medially (medial strabismus).
3. The student had a hordeolum or sty in his right eye. The usual cause is a staphylococcal infection of the eyelash follicle, the sebaceous gland of Zeis, or the ciliary gland of Moll. The suppurative infection tends to point on the anterior part of the lid margin. Repeated multiple styes tend to occur as the result of spread of infection along the eyelid margin.
4. This schoolboy has a severe "black eye." In this patient the contusion involved not only the eyelids but the skin of the cheek and forehead. In anterior cranial fossa fractures, the hemorrhage occurs into the orbital cavity and is limited anteriorly by the attachment of the orbital septum to the orbital margin. In such cases the discoloration tends to be circular. In fractures of the anterior cranial fossa, because the bleeding is deeply placed, it tends to be purplish from the start, whereas with a black eye the color is initially red.
5. This girl was suffering from chronic dacryocystitis secondary to congenital obstruction of the nasolacrimal duct. The obstruction results from failure of the nasolacrimal duct to open up and drain into the inferior meatus of the nose. The posterior relation of the medial palpebral ligament is the lacrimal sac. The drainage passages start at the puncta on the tip of the lacrimal papilla. The canaliculi first pass vertically in the eyelids for about 2 mm and then turn sharply at right angles and run medially for about 8 mm to enter the lacrimal sac. The lower end of the lacrimal sac is connected to the inferior meatus of the nose by the nasolacrimal duct, which is about 15 mm long. The duct passes downward, backward, and laterally.
6. **A** is the correct answer. The facial muscles on the left side of the mouth on contraction pull the mouth upward and to the left because the muscles on the right side were paralyzed.
7. In a young child, the external auditory meatus may be straightened by pulling the auricle directly backward. In an adult, the meatus is straightened by pulling the auricle backward and upward (see CD Fig. 18-4).
8. A myringotomy is performed through the lower quadrants of the tympanic membrane to avoid damaging the chorda tympani nerve that crosses the tympanic membrane on the medial side of the upper quadrants (see text Fig. 18-15A). The features seen on a normal tympanic membrane with an otoscope with a good light include (1) the long process of the malleus with the umbo; (2) the anterior and posterior malleolar folds with the pars flaccida; (3) the cone of light produced by light reflection on the concave tympanic membrane; (4) the tympanic membrane is pearl colored with no evidence of dilated blood vessels; (5) sometimes when the tympanic membrane is translucent, as in a young child, the long process of the incus and the promontory on the medial wall of the middle ear can be seen (see CD Fig. 18-4).
9. In auricular hematomas the blood tends to accumulate between the perichondrium and the underlying cartilage. The edema fluid has little room to spread since the skin is tightly bound down to the perichondrium; moreover, the pressure of the fluid causes extreme pain. Failure to aspirate the hematoma may lead to necrosis of the cartilage, since it has been deprived of its blood supply due to separation of the perichondrium from the cartilage. If cartilaginous necrosis takes place, fibrous replacement occurs followed by contraction and deformity, the so-called cauliflower ear.
10. Inflammation of the mucous membrane of the pharynx tends to spread upward to the middle ear via the auditory tube. The swelling of the mucous membrane lining the stiff wall of the tube results in blockage of the passageway. Very quickly, the trapped air in the middle ear becomes absorbed into the bloodstream, creating a vacuum. As a result, the tympanic membrane is pulled inward and causes deafness and acute pain. In a plane that is taking off and climbing quickly, the cabin pressures are subject to changes and this augments the pressure differences on the two sides of the tympanic membrane. Repeated swallowing causes the contraction of the salpingopharyngeus muscle and often allows sufficient air into the tympanic cavity through the auditory tube, thus relieving the problem.



The Digestive System



19

The Abdominal Wall,
the Peritoneal Cavity,
the Retroperitoneal Space,
and the Alimentary Tract



Chapter Outline

Abdominal Wall	312	Abdominal Stab Wounds	326
General Appearances of the Abdominal Wall	312	Abdominal Gun Shot Wounds	327
Infection of the Umbilicus	312	Tying the Umbilical Cord	327
Surgical Incisions and Lines of Cleavage	312	Patent Urachus	327
Caval Obstruction	312	Vitellointestinal Duct	327
Portal Vein Obstruction and Caput Medusae	312	Umbilical Vessel Catheterization	327
Skin and Its Regional Lymph Nodes	312	Indications for Umbilical Artery	
Membranous Layer of the Superficial Fascia		Catheterization	327
and a Healing Skin Wound	313	<i>Anatomy of Procedure</i>	327
Membranous Layer of Superficial Fascia and the		<i>Anatomy of Complications</i>	327
Extravasation of Urine	313	Indications for Umbilical Vein Catheterization	328
Hematoma of the Rectus Sheath	313	<i>Anatomy of Procedure</i>	328
Abdominal Muscles, Abdominothoracic Rhythm,		<i>Anatomy of Complications</i>	329
and Visceroptosis	313	Peritoneum and Peritoneal Cavity	329
Muscle Rigidity and Referred Pain	313	Movement of Peritoneal Fluid	329
Surgery and Tendinous Intersections of the		Peritoneal Infection	329
Rectus Abdominis Muscle	314	Greater Omentum and the Localization of	
Fate of the Processus Vaginalis	314	Infection	329
Abdominal Herniae	314	Greater Omentum as a Hernial Plug	329
Indirect Inguinal Hernia	314	Greater Omentum in Surgery	329
Direct Inguinal Hernia	315	Torsion of the Greater Omentum	329
Femoral Hernia	316	Ascites	329
Umbilical Herniae	319	Peritoneal Pain	330
Epigastric Hernia	320	From the Parietal Peritoneum	330
Separation of the Recti Abdominis	320	From the Visceral Peritoneum	331
Incisional Hernia	320	Peritoneal Dialysis	331
Hernia of the Linea Semilunaris		Internal Abdominal Hernia	331
(Spigelian Hernia)	320	Retroperitoneal Space	331
Lumbar Hernia	320	Trauma to Organs in the Retroperitoneal Space	331
Internal Hernia	320	Abscess Formation	332
Abdominal Pain	320	Leaking Aortic Aneurysm	332
Somatic Abdominal Pain	320	The Alimentary Tract	332
Visceral Abdominal Pain	320	Esophagus	332
Referred Abdominal Pain	321	Narrow Areas of the Esophageal Lumen	332
Anterior Abdominal Nerve Block	322	Achalasia of the Cardia (Esophagogastric	
Surgical Incisions	322	Junction)	332
Endoscopic Surgery	323	Bleeding Esophageal Varices	332
Paracentesis of the Abdomen	323	Anatomy of the Insertion of the	
Anatomy of Peritoneal Lavage	324	Sengstaken-Blakemore Balloon for	
Midline Incision Technique	324	Esophageal Hemorrhage	332
Paraumbilical Incision Technique	325	<i>Anatomy of Complications</i>	332
Anatomy of the Complications of			
Peritoneal Lavage	326		

Stomach	332	Cancer of the Rectum	341
Nausea	332	Rectal Injuries	341
Vomiting	332	Anal Canal	341
Trauma to the Stomach	333	Internal Hemorrhoids (Piles)	341
Gastric Ulcer	334	External Hemorrhoids	342
Gastric Pain	334	Perianal Hematoma	343
Cancer of the Stomach	334	Anal Fissure	343
Gastroscopy	334	Perianal Abscesses	345
Nasogastric Intubation	334	Removal of Anorectal Foreign Bodies	345
<i>Anatomic Structures that May Impede</i>		Anal Sphincter Nerve Block and Anesthetizing	
<i>the Passage of the Nasogastric Tube</i>	335	the Perianal Skin	345
<i>Anatomy of Complications</i>	335	Incontinence Associated with Rectal	
Duodenum	335	Prolapse	345
Trauma to the Duodenum	335	Incontinence after Trauma	345
Duodenal Ulcer	335	Incontinence after Spinal Cord Injury	345
Duodenal Recesses	335	Rectal Examination	346
Important Duodenal Relations	335	Cancer and Lymph Drainage of the	
Jejunum and Ileum	335	Anal Canal	347
Trauma to the Jejunum and Ileum	335	Ischiorectal Fossa	347
Recognition of the Jejunum and Ileum	335	The Ischiorectal Fossa and Infection	347
Tumors and Cysts of the Mesentery of the		Congenital Anomalies of the Esophagus	347
Small Intestine	335	Atresia of the Esophagus	347
Pain Fibers from the Jejunum and Ileum	336	Esophageal Stenosis	347
Mesenteric Arterial Occlusion	336	Congenital Short Esophagus	347
Mesenteric Vein Thrombosis	336	Congenital Anomalies of the Stomach	347
Appendix	336	Congenital Hypertrophic Pyloric Stenosis	347
Variability of Position of the Appendix	336	Congenital Anomalies of the Small	
Pelvic Appendix	336	and Large Intestines	347
Predisposition of the Appendix to Infection	336	Diverticula of the Intestine	347
Predisposition of the Appendix to Perforation	336	Atresia and Stenosis of the Small Intestine	348
Pain of Appendicitis	336	Duplication of the Digestive System	348
Colon and Cecum	336	Arrested Rotation or Malrotation of the	
Colonoscopy	336	Midgut Loop	349
Trauma of the Cecum and Colon	338	Complete Absence of Rotation or Incomplete	
Cancer of the Large Bowel	338	Rotation	349
Diverticulosis	338	Malrotation of the Midgut Loop	349
Cecostomy and Colostomy	338	Persistence of the Vitellointestinal Duct	349
Volvulus	338	Meckel's Diverticulum	349
Intussusception	338	Undescended Cecum and Appendix	349
Sigmoid Colon	339	Anomalies of the Appendix	349
Variations in the Length and Location of the		Anomalies of the Colon	349
Sigmoid Colon	339	Primary Megacolon (Hirschsprung Disease)	349
Cancer of the Sigmoid Colon	339	Imperforate Anus	349
Volvulus	339	Clinical Problem Solving Questions	350
Diverticula	339	Answers and Explanations	355
Sigmoidoscopy	339		
<i>Anatomic Facts Relative to</i>			
<i>Sigmoidoscopy</i>	339		
<i>Anatomy of Complications of</i>			
<i>Sigmoidoscopy</i>	339		
Colostomy	339		
Rectum	340		
Rectal Curves and Mucosal Folds	340		
Blood Supply and Internal Hemorrhoids	340		
Partial and Complete Prolapse of the Rectum	340		



ABDOMINAL WALL

General Appearances of the Abdominal Wall

The normal abdominal wall is soft and pliable and undergoes inward and outward excursion with respiration. The contour is subject to considerable variation and depends on the tone of its muscles and the amount of fat in the subcutaneous tissue. Well-developed muscles or an abundance of fat can prove to be a severe obstacle to the palpation of the abdominal viscera.

Infection of the Umbilicus

In the adult, the umbilicus often receives scant attention in the shower and is consequently a common site of infection.

Surgical Incisions and Lines of Cleavage

If possible, all surgical incisions should be made in the lines of cleavage where the bundles of collagen fibers in the dermis run in parallel rows. An incision along a cleavage

line will heal as a narrow scar, whereas one that crosses the lines will heal as wide or heaped-up scars.

Caval Obstruction

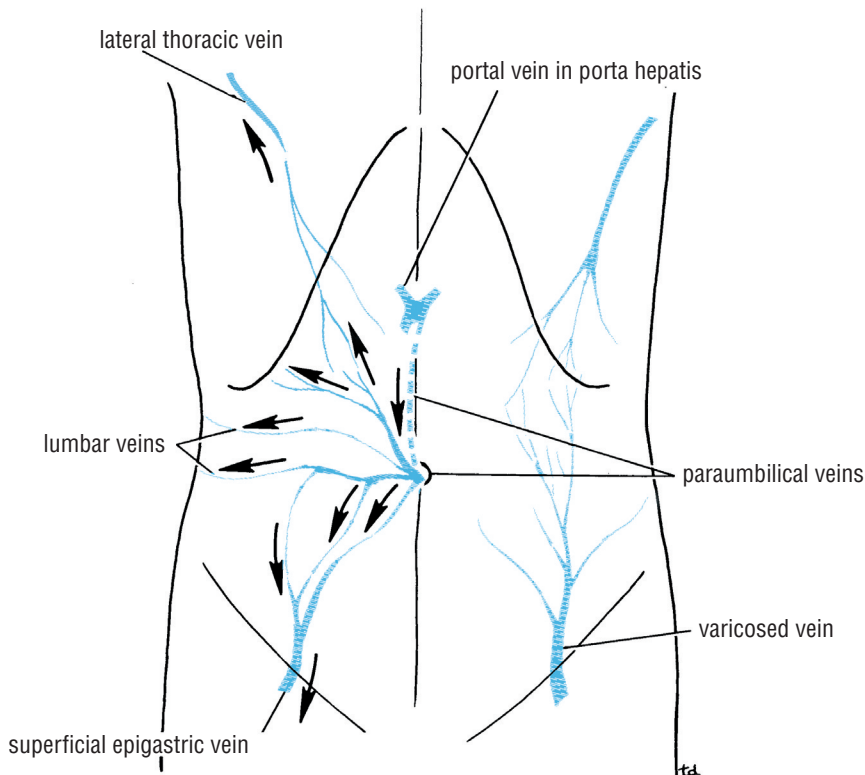
If the superior or inferior vena cava is obstructed, the venous blood causes distension of the veins running from the anterior chest wall to the thigh. The lateral thoracic vein anastomoses with the superficial epigastric vein, a tributary of the great saphenous vein of the leg. In these circumstances, a tortuous varicose vein may extend from the axilla to the lower abdomen (CD Fig. 19-1).

Portal Vein Obstruction and Caput Medusae

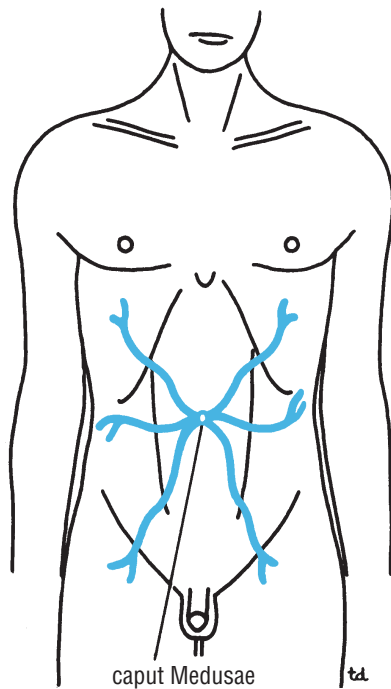
In cases of portal vein obstruction (CD Fig. 19-2), the superficial veins around the umbilicus and the paraumbilical veins become grossly distended. The distended subcutaneous veins radiate out from the umbilicus, producing in severe cases the clinical picture referred to as **caput medusae**.

Skin and Its Regional Lymph Nodes

Knowledge of the areas of the skin that drain into a particular group of lymph nodes is clinically important (see text Fig. 19-3). For example, it is possible to find a swelling in the



CD Figure 19-1 Superficial veins of the anterior abdominal wall. On the left are anastomoses between systemic veins and the portal vein via paraumbilical veins. *Arrows* indicate the direction taken by venous blood when the portal vein is obstructed. On the right is an enlarged anastomosis between the lateral thoracic vein and the superficial epigastric vein. This occurs if either the superior or the inferior vena cava is obstructed.



CD Figure 19-2 An example of caput Medusae in a case of portal obstruction caused by cirrhosis of the liver.

groin (enlarged superficial inguinal node) caused by an infection or malignant tumor of the skin of the lower part of the anterior abdominal wall or that of the buttock.

Membranous Layer of the Superficial Fascia and a Healing Skin Wound

When closing abdominal wounds, it is usual for a surgeon to put in a continuous suture uniting the divided membranous layer of superficial fascia. This strengthens the healing wound, prevents stretching of the skin scar, and makes for a more cosmetically acceptable result.

Membranous Layer of Superficial Fascia and the Extravasation of Urine

The membranous layer of the superficial fascia is important clinically because beneath it is a potential closed space that does not open into the thigh but is continuous with the superficial perineal pouch via the penis and scrotum. Rupture of the penile urethra may be followed by extravasation of urine into the scrotum, perineum, and penis and then up

into the lower part of the anterior abdominal wall deep to the membranous layer of fascia. The urine is excluded from the thigh because of the attachment of the fascia to the fascia lata (see text Fig. 19-4).

Hematoma of the Rectus Sheath

Hematoma of the rectus sheath is uncommon but important, since it is often overlooked. It occurs most often on the right side below the level of the umbilicus. The source of the bleeding is the inferior epigastric vein or, more rarely, the inferior epigastric artery. These vessels may be stretched during a severe bout of coughing or in the later months of pregnancy, which may predispose to the condition. The cause is usually blunt trauma to the abdominal wall, such as a fall or a kick. The symptoms that follow the trauma include midline abdominal pain. An acutely tender mass confined to one rectus sheath is diagnostic.

Abdominal Muscles, Abdominothoracic Rhythm, and Visceroptosis

The abdominal muscles contract and relax with respiration, and the abdominal wall conforms to the volume of the abdominal viscera. There is an **abdominothoracic rhythm**. Normally, during inspiration, when the sternum moves forward and the chest expands, the anterior abdominal wall also moves forward. If, when the chest expands, the anterior abdominal wall remains stationary or contracts inward, it is highly probable that the parietal peritoneum is inflamed and has caused a reflex contraction of the abdominal muscles.

The shape of the anterior abdominal wall depends on the tone of its muscles. A middle-aged woman with poor abdominal muscles who has had multiple pregnancies is often incapable of supporting her abdominal viscera. The lower part of the anterior abdominal wall protrudes forward, a condition known as **visceroptosis**. This should not be confused with an abdominal tumor such as an ovarian cyst or with the excessive accumulation of fat in the fatty layer of the superficial fascia.

Muscle Rigidity and Referred Pain

Sometimes it is difficult for a physician to decide whether the muscles of the anterior abdominal wall of a patient are rigid because of underlying inflammation of the parietal peritoneum or whether the patient is voluntarily contracting the muscles because he or she resents being examined or because the physician's hand is cold. This problem is usually easily solved by asking the patient, who is lying supine on the examination table, to rest the arms by the sides and draw up the knees to flex the hip joints. It is practically impossible for a patient to keep the abdominal musculature tensed when the thighs are flexed. Needless to say, the examiner's hand should be warm.

A pleurisy involving the lower costal parietal pleura causes pain in the overlying skin that may radiate down into the abdomen. Although it is unlikely to cause rigidity of the abdominal muscles, it may cause confusion in making a diagnosis unless these anatomic facts are remembered.

It is useful to remember the following:

Dermatomes over:

- The xiphoid process—T7
- The umbilicus—T10
- The pubis—L1

See text Figure 19-1.

Surgery and Tendinous Intersections of the Rectus Abdominis Muscle

Transverse tendinous intersections that divide the rectus abdominis muscle into distinct segments are firmly attached to the anterior wall of the rectus sheath, whereas the posterior wall of the sheath is not attached. This information is of great value to the surgeon when entering the abdominal cavity through the anterior abdominal wall.

Fate of the Processus Vaginalis

The formation of the processus vaginalis and its passage through the lower part of the anterior abdominal wall with the formation of the inguinal canal in both sexes were described in text Chapter 19. Normally, the upper part becomes obliterated just before birth and the lower part remains as the tunica vaginalis.

The processus is subject to the following common congenital anomalies:

- It may persist partially or in its entirety as a **preformed hernial sac** for an indirect inguinal hernia (CD Fig. 19-3).
- It may become very much narrowed, but its lumen remains in communication with the abdominal cavity. Peritoneal fluid accumulates in it, forming a **congenital hydrocele** (see CD Fig. 19-3).
- The upper and lower ends of the processus may become obliterated, leaving a small intermediate cystic area referred to as an **encysted hydrocele of the cord** (see CD Fig. 19-3).

The tunica vaginalis is closely related to the front and sides of the testis. It is therefore not surprising to find that inflammation of the testis can cause an accumulation of fluid within the tunica vaginalis. This is referred to simply as a **hydrocele** (CD Fig. 19-4). Most hydroceles are idiopathic.

To remove excess fluid from the tunica vaginalis, a procedure termed **tapping a hydrocele**, a fine trocar and

cannula are inserted through the scrotal skin (see CD Fig. 19-4). The following anatomic structures are traversed by the cannula: skin, dartos muscle and membranous layer of fascia (Colles' fascia), external spermatic fascia, cremasteric fascia, internal spermatic fascia, and parietal layer of the tunica vaginalis.

Abdominal Herniae

A hernia is the protrusion of part of the abdominal contents beyond the normal confines of the abdominal wall (CD Fig. 19-5). It consists of three parts: the sac, the contents of the sac, and the coverings of the sac. The **hernial sac** is a pouch (diverticulum) of peritoneum and has a neck and a body. The **hernial contents** may consist of any structure found within the abdominal cavity and may vary from a small piece of omentum to a large viscus such as the kidney. The **hernial coverings** are formed from the layers of the abdominal wall through which the hernial sac passes.

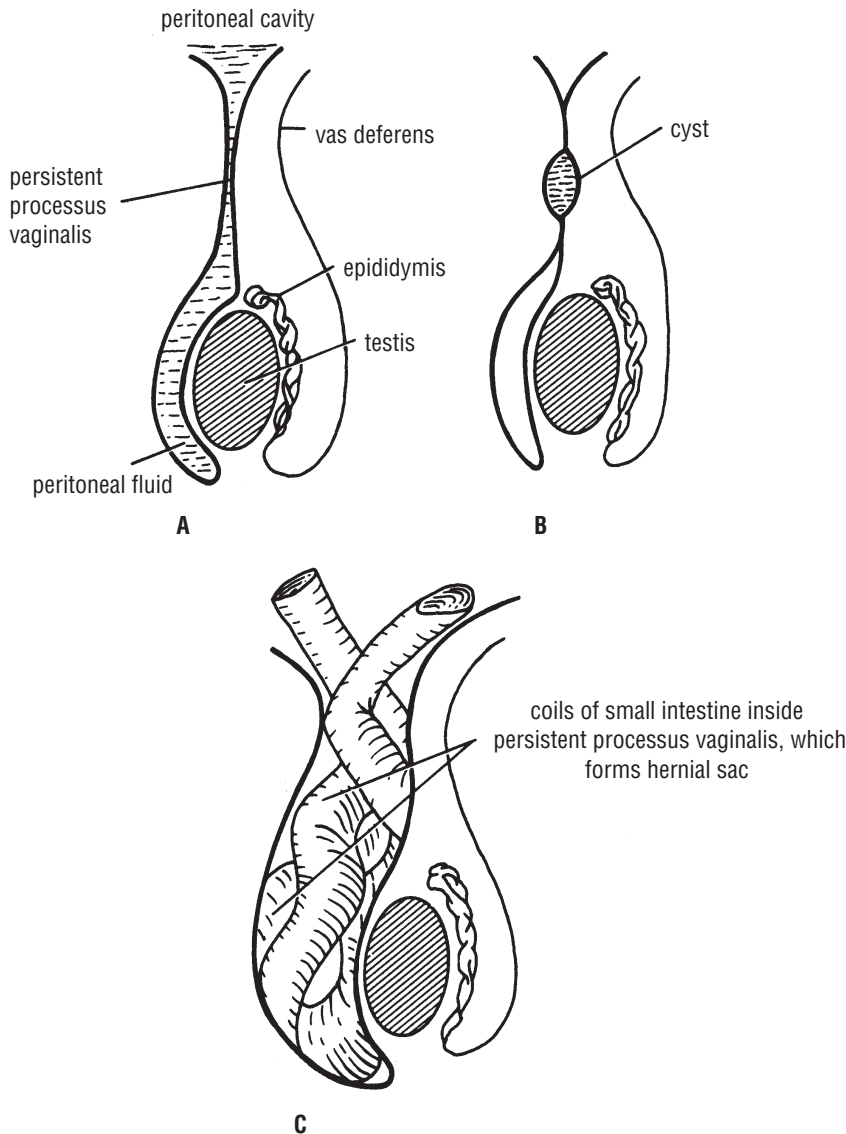
Abdominal herniae are of the following common types:

- Inguinal (indirect or direct)
- Femoral
- Umbilical (congenital or acquired)
- Epigastric
- Separation of the recti abdominis
- Incisional hernia
- Hernia of the linea semilunaris (Spigelian hernia)
- Lumbar hernia (Petit's triangle hernia)
- Internal hernia

Indirect Inguinal Hernia

The indirect inguinal hernia is the most common form of hernia and is believed to be congenital in origin (CD Fig. 19-6A). The hernial sac is the remains of the processus vaginalis (an outpouching of peritoneum that in the fetus is responsible for the formation of the inguinal canal). It follows that the sac enters the inguinal canal through the deep inguinal ring **lateral to the inferior epigastric vessels** (CD Fig. 19-6). It may extend part of the way along the canal or the full length, as far as the superficial inguinal ring. If the processus vaginalis has undergone no obliteration, then the hernia is complete and extends through the superficial inguinal ring down into the scrotum or labium majus. Under these circumstances the neck of the hernial sac lies at the deep inguinal ring lateral to the inferior epigastric vessels, and the body of the sac resides in the inguinal canal and scrotum (or base of labium majus).

An indirect inguinal hernia is about 20 times more common in males than in females, and nearly one third are bilateral. It is more common on the right (normally, the right processus vaginalis becomes obliterated after the left; the right testis descends later than the left). It is most common in children and young adults.



CD Figure 19-3 Common congenital anomalies of the processus vaginalis. **A.** Congenital hydrocele. **B.** Encysted hydrocele of the cord. **C.** Preformed hernial sac for indirect inguinal hernia.

The indirect inguinal hernia can be summarized as follows:

- It is the remains of the processus vaginalis and therefore is congenital in origin.
- It is more common than a direct inguinal hernia.
- It is much more common in males than in females.
- It is more common on the right side.
- It is most common in children and young adults.
- The hernial sac enters the inguinal canal through the deep inguinal ring and **lateral** to the inferior epigastric vessels. The neck of the sac is narrow.
- The hernial sac may extend through the superficial inguinal ring above and **medial** to the pubic tubercle. (Femoral hernia is located below and lateral to the pubic tubercle.)
- The hernial sac may extend down into the scrotum or labium majus.

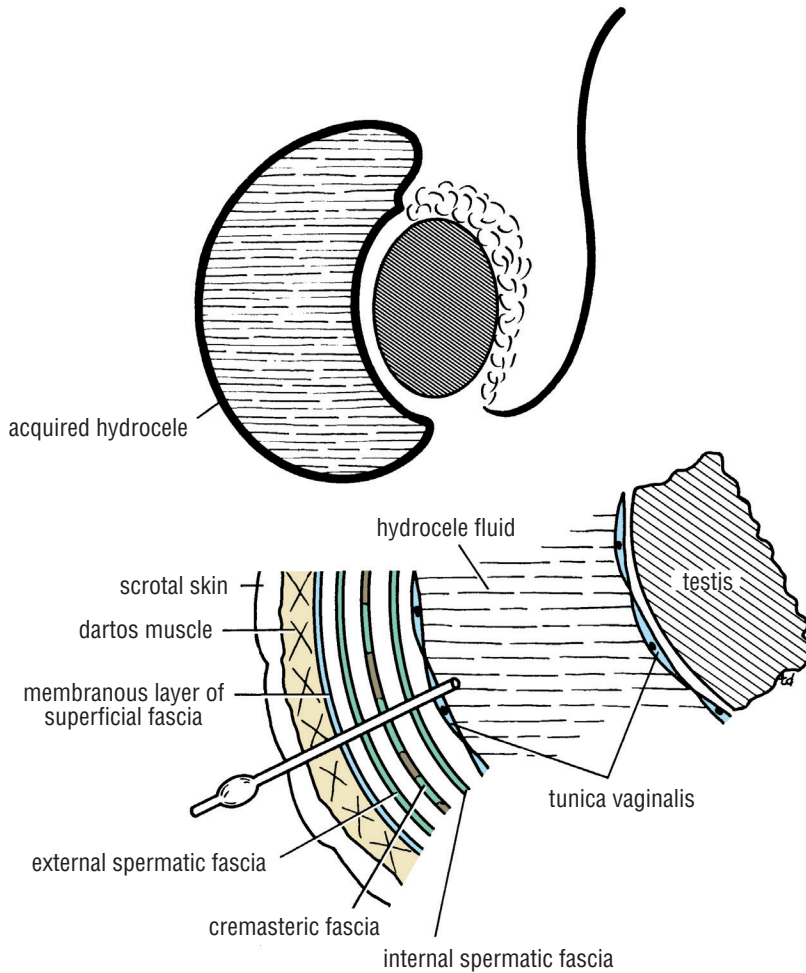
Direct Inguinal Hernia

The direct inguinal hernia makes up about 15% of all inguinal hernias. The sac of a direct hernia bulges directly anteriorly through the posterior wall of the inguinal canal **medial to the inferior epigastric vessels** (CD Fig. 19-6B). Because of the presence of the strong conjoint tendon (combined tendons of insertion of the internal oblique and transversus muscles), this hernia is usually nothing more than a generalized bulge; therefore, the neck of the hernial sac is wide.

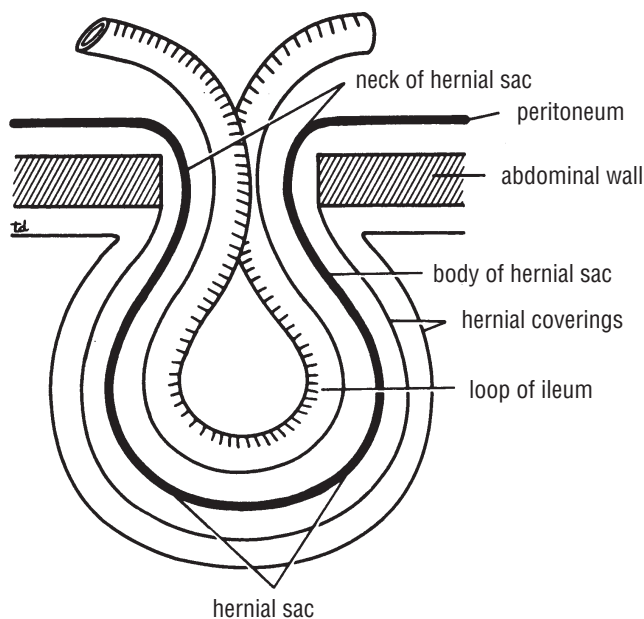
Direct inguinal hernias are rare in women and most are bilateral. It is a disease of old men with weak abdominal muscles.

A direct inguinal hernia can be summarized as follows:

- It is common in old men with weak abdominal muscles and is rare in women.



CD Figure 19-4 The tunica vaginalis distended with fluid (hydrocele). Also shown are the various anatomic layers traversed by a trocar and cannula when a hydrocele is tapped.



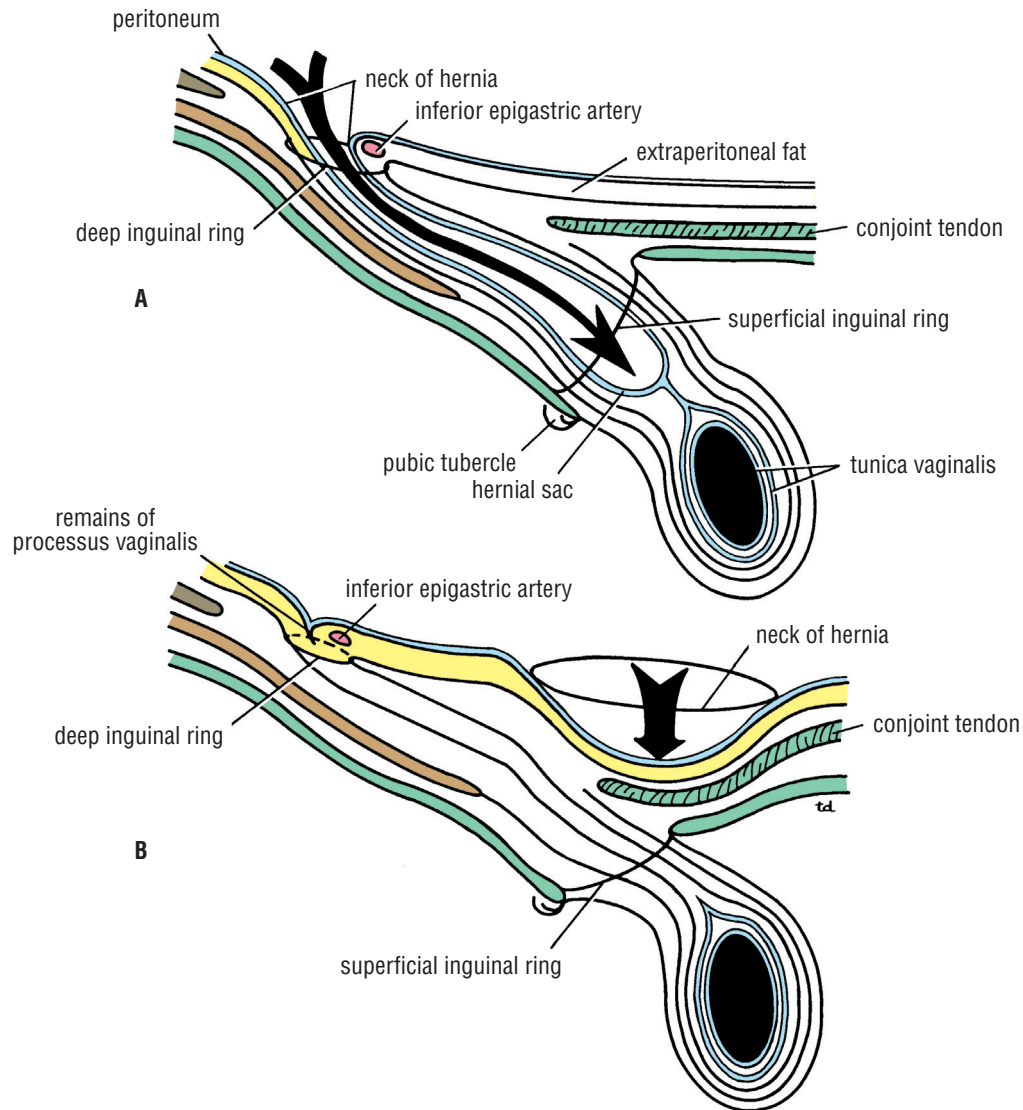
CD Figure 19-5 Different parts of a hernia.

- The hernial sac bulges forward through the posterior wall of the inguinal canal **medial** to the inferior epigastric vessels.
- The neck of the hernial sac is wide.

An inguinal hernia can be distinguished from a femoral hernia by the fact that the sac, as it emerges through the superficial inguinal ring, lies above and medial to the pubic tubercle, whereas that of a femoral hernia lies below and lateral to the tubercle (CD Fig. 19-7).

Femoral Hernia

The hernial sac descends through the femoral canal within the femoral sheath, creating a femoral hernia. The femoral sheath is a protrusion of the fascial envelope lining the abdominal walls and surrounds the femoral vessels and lymphatics for about 1 in. (2.5 cm) below the inguinal ligament (CD Fig. 19-8). The **femoral artery**, as it enters the thigh below the inguinal ligament, occupies the lateral compartment of the sheath. The **femoral vein**, which lies on its medial side and is separated from it by a fibrous



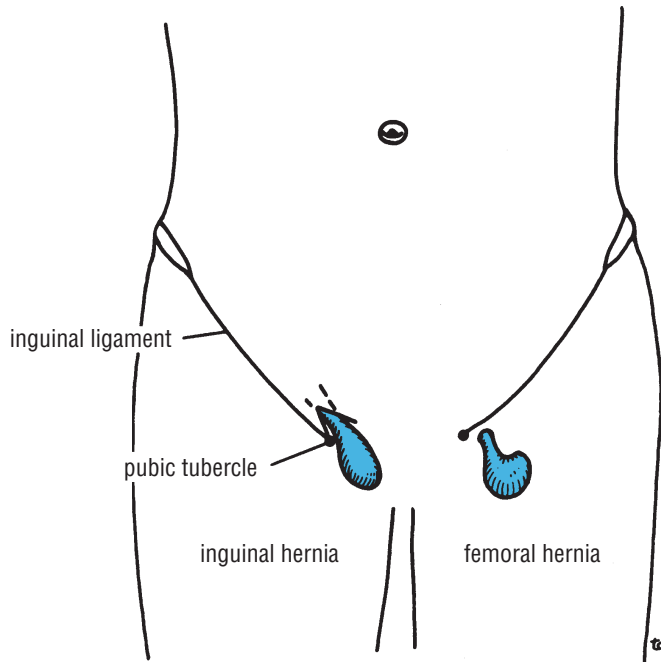
CD Figure 19-6 **A.** Indirect inguinal hernia. **B.** Direct inguinal hernia. Note that the neck of the indirect inguinal hernia lies lateral to the inferior epigastric artery, and the neck of the direct inguinal hernia lies medial to the inferior epigastric artery.

septum, occupies the intermediate compartment. The **lymph vessels**, which are separated from the vein by a fibrous septum, occupy the most medial compartment. The **femoral canal**, the compartment for the lymphatics, occupies the medial part of the sheath. It is about 0.5 in. (1.3 cm) long, and its upper opening is referred to as the **femoral ring**. The **femoral septum**, which is a condensation of extraperitoneal tissue, plugs the opening of the femoral ring.

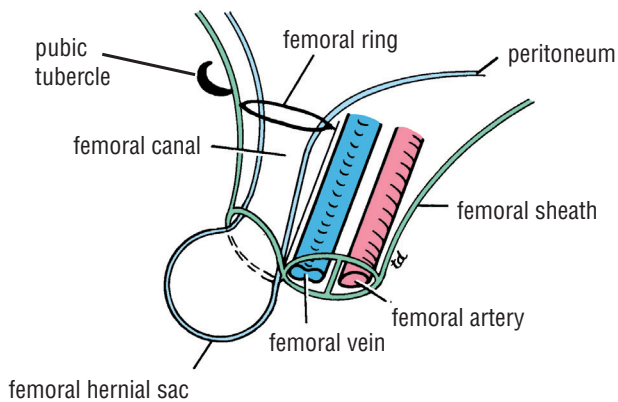
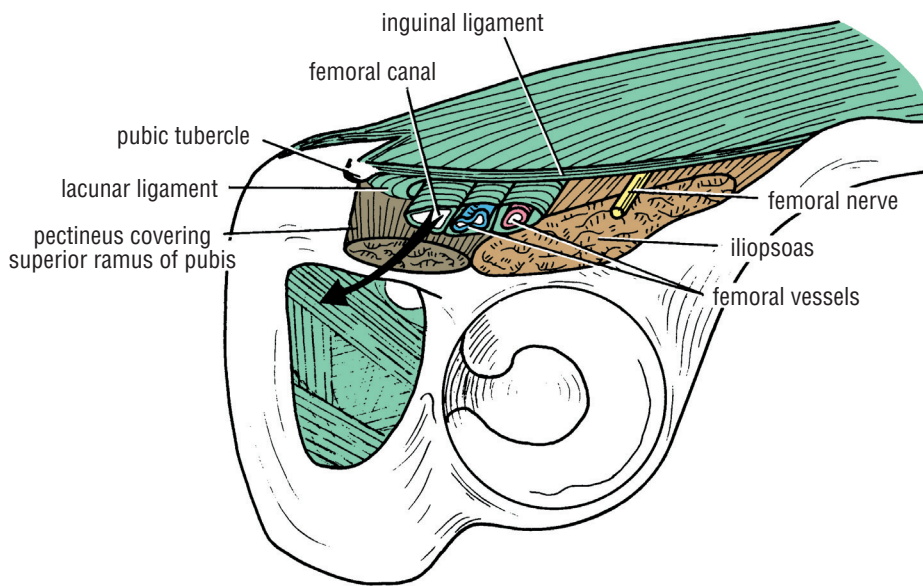
A femoral hernia is more common in women than in men (possibly because of a wider pelvis and femoral canal). The hernial sac passes down the femoral canal, pushing the femoral septum before it. On escaping through the lower

end, it expands to form a swelling in the upper part of the thigh deep to the deep fascia (see CD Fig. 19-8). With further expansion, the hernial sac may turn upward to cross the anterior surface of the inguinal ligament.

The neck of the sac always lies below and lateral to the **pubic tubercle** (see CD Fig. 19-7), which serves to distinguish it from an inguinal hernia. The neck of the sac is narrow and lies at the femoral ring. The ring is related anteriorly to the inguinal ligament, posteriorly to the pectineal ligament and the pubis, medially to the sharp free edge of the lacunar ligament, and laterally to the femoral vein. Because of the presence of these anatomic structures, the neck of the sac is unable to expand. Once



CD Figure 19-7 Relation of inguinal and femoral hernial sacs to the pubic tubercle.



CD Figure 19-8 The femoral sheath as seen from below. *Arrow* emerging from the femoral canal indicates the path taken by the femoral hernial sac. Note relations of the femoral ring.

an abdominal viscus has passed through the neck into the body of the sac, it may be difficult to push it up and return it to the abdominal cavity (**irreducible hernia**). Furthermore, after straining or coughing, a piece of bowel may be forced through the neck and its blood vessels may be compressed by the femoral ring, seriously impairing its blood supply (**strangulated hernia**). A femoral hernia is a dangerous disease and should always be treated surgically.

A femoral hernia can be summarized as follows:

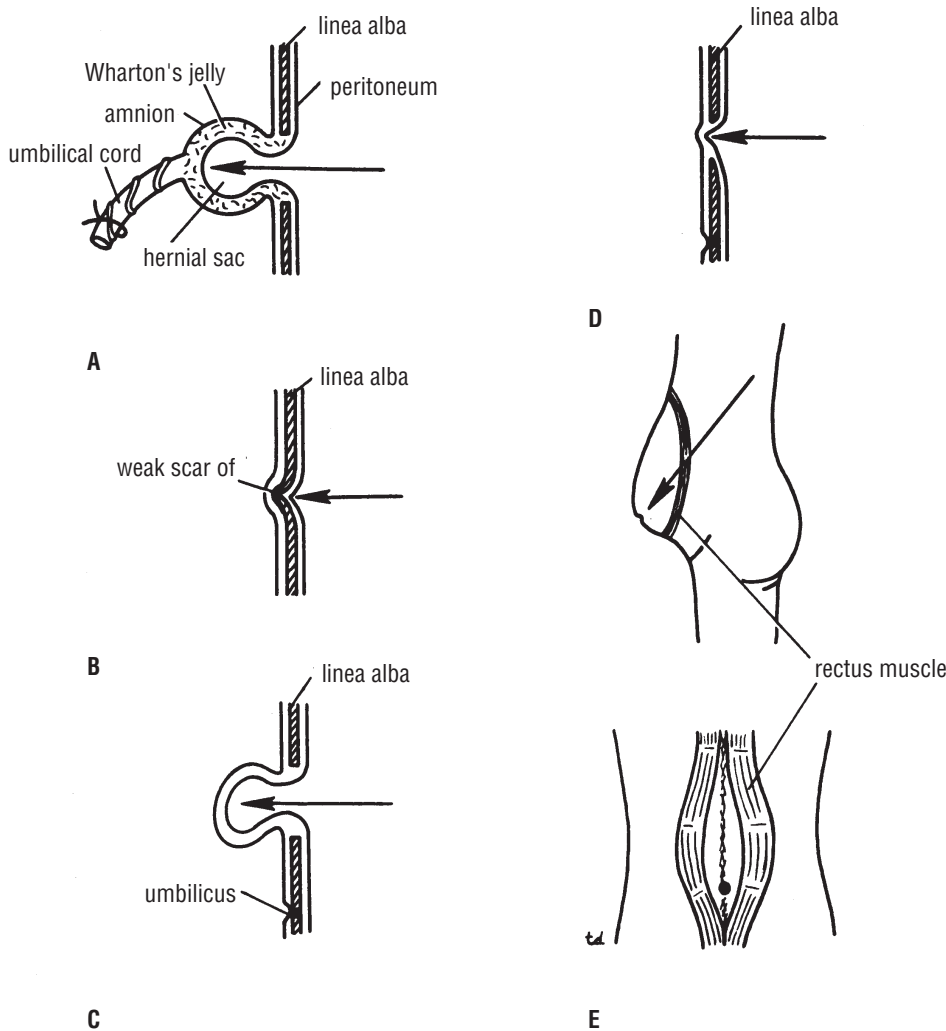
- A protrusion of abdominal parietal peritoneum down through the femoral canal forms the hernial sac.
- It is more common in women than in men.
- The neck of the hernial sac lies below and lateral to the pubic tubercle.
- The neck of the hernial sac lies at the femoral ring and at that point is related anteriorly to the inguinal ligament, posteriorly to the pectineal ligament and the pubis, laterally to the femoral vein, and medially to the sharp free edge of the lacunar ligament.

Umbilical Herniae

Congenital umbilical hernia, or exomphalos (omphalocele), is caused by a failure of part of the midgut to return to the abdominal cavity from the extraembryonic coelom during fetal life. The hernial sac and its relationship to the umbilical cord are shown in CD Fig. 19-9.

Acquired infantile umbilical hernia is a small hernia that sometimes occurs in children and is caused by a weakness in the scar of the umbilicus in the linea alba (see CD Fig. 19-9). Most become smaller and disappear without treatment as the abdominal cavity enlarges.

Acquired umbilical hernia of adults is more correctly referred to as a **paraumbilical hernia**. The hernial sac does not protrude through the umbilical scar, but through the linea alba in the region of the umbilicus (see CD Fig. 19-9). Paraumbilical herniae gradually increase in size and hang downward. The neck of the sac may be narrow, but the body of the sac often contains coils of small and large intestine and omentum. Paraumbilical herniae are much more common in women than in men.



CD Figure 19-9 A. Congenital umbilical hernia. B. Infantile umbilical hernia. C. Paraumbilical hernia. D. Epigastric hernia. E. Separation of recti abdominis.

Epigastric Hernia

Epigastric hernia occurs through the widest part of the linea alba, anywhere between the xiphoid process and the umbilicus. The hernia is usually small and starts off as a small protrusion of extraperitoneal fat between the fibers of the linea alba. During the following months or years the fat is forced farther through the linea alba and eventually drags behind it a small peritoneal sac. The body of the sac often contains a small piece of greater omentum. It is common in middle-aged manual workers.

Separation of the Recti Abdominis

Separation of the recti abdominis occurs in elderly multiparous women with weak abdominal muscles (see CD Fig. 19-9). In this condition, the aponeuroses forming the rectus sheath become excessively stretched. When the patient coughs or strains, the recti separate widely, and a large hernial sac, containing abdominal viscera, bulges forward between the medial margins of the recti. This can be corrected by wearing a suitable abdominal belt.

Incisional Hernia

A postoperative incisional hernia is most likely to occur in patients in whom it was necessary to cut one of the segmental nerves supplying the muscles of the anterior abdominal wall; postoperative wound infection with death (necrosis) of the abdominal musculature is also a common cause. The neck of the sac is usually large, and adhesion and strangulation of its contents are rare complications. In very obese individuals the extent of the abdominal wall weakness is often difficult to assess.

Hernia of the Linea Semilunaris (Spigelian Hernia)

The uncommon hernia of the linea semilunaris occurs through the aponeurosis of the transversus abdominis just lateral to the lateral edge of the rectus sheath. It usually occurs just below the level of the umbilicus. The neck of the sac is narrow, so that adhesion and strangulation of its contents are common complications.

Lumbar Hernia

The lumbar hernia occurs through the lumbar triangle and is rare. The lumbar triangle (**Petit's triangle**) is a weak area in the posterior part of the abdominal wall. It is bounded anteriorly by the posterior margin of the external oblique muscle, posteriorly by the anterior border of the latissimus dorsi muscle, and inferiorly by the iliac crest. The floor of the triangle is formed by the internal oblique and the transversus abdominis muscles. The neck of the hernia is usually large, and the incidence of strangulation is low.

Internal Hernia

Occasionally, a loop of intestine enters a peritoneal recess (e.g., the lesser sac or the duodenal recesses) and becomes strangulated at the edges of the recess.

Abdominal Pain

Abdominal pain is one of the most important problems facing the physician. This section provides an anatomic basis for the different forms of abdominal pain found in clinical practice.

Three distinct forms of pain exist: somatic, visceral, and referred pain.

Somatic Abdominal Pain

Somatic abdominal pain in the abdominal wall can arise from the skin, fascia, muscles, and parietal peritoneum. It can be severe and precisely localized. When the origin is on one side of the midline, the pain is also lateralized. The somatic pain impulses from the abdomen reach the central nervous system in the following segmental spinal nerves:

- **Central part of the diaphragm:** phrenic nerve (C3, 4, and 5)
- **Peripheral part of the diaphragm:** intercostal nerves (T7–11)
- **Anterior abdominal wall:** thoracic nerves (T7–12) and the first lumbar nerve
- **Pelvic wall:** obturator nerve (L2, 3, and 4)

The inflamed parietal peritoneum is extremely sensitive, and because the full thickness of the abdominal wall is innervated by the same nerves, it is not surprising to find cutaneous hypersensitivity (hyperesthesia) and tenderness. Local reflexes involving the same nerves bring about a protective phenomenon in which the abdominal muscles increase in tone. This increased tone or rigidity, sometimes called **guarding**, is an attempt to rest and localize the inflammatory process.

Rebound tenderness occurs when the parietal peritoneum is inflamed. Any movement of that inflamed peritoneum, even when that movement is elicited by removing the examining hand from a site distant from the inflamed peritoneum, brings about tenderness.

Examples of acute, severe, localized pain originating in the parietal peritoneum are seen in the later stages of appendicitis. Cutaneous hyperesthesia, tenderness, and muscular spasm or rigidity occur in the lower right quadrant of the anterior abdominal wall. A perforated peptic ulcer, in which the parietal peritoneum is chemically irritated, produces the same symptoms and signs but involves the right upper and lower quadrants.

Visceral Abdominal Pain

Visceral abdominal pain arises in abdominal organs, visceral peritoneum, and the mesenteries. The causes of visceral pain

include stretching of a viscus or mesentery, distension of a hollow viscus, impaired blood supply (ischemia) to a viscus, and chemical damage (e.g., acid gastric juice) to a viscus or its covering peritoneum. Pain arising from an abdominal viscus is dull and poorly localized. Visceral pain is referred to the midline, probably because the viscera develop embryologically as midline structures and receive a bilateral nerve supply; many viscera later move laterally as development proceeds, taking their nerve supply with them.

Colic is a form of visceral pain produced by the violent contraction of smooth muscle; it is commonly caused by luminal obstruction as in intestinal obstruction, in the passage of a gallstone in the biliary ducts, or in the passage of a stone in the ureters.

Many visceral afferent fibers that enter the spinal cord participate in reflex activity. Reflex sweating, salivation, nausea, vomiting, and increased heart rate may accompany visceral pain.

The sensations that arise in viscera reach the central nervous system in afferent nerves that accompany the sympathetic nerves and enter the spinal cord through the posterior roots. The significance of this pathway is better understood in the following discussion on referred visceral pain.

Referred Abdominal Pain

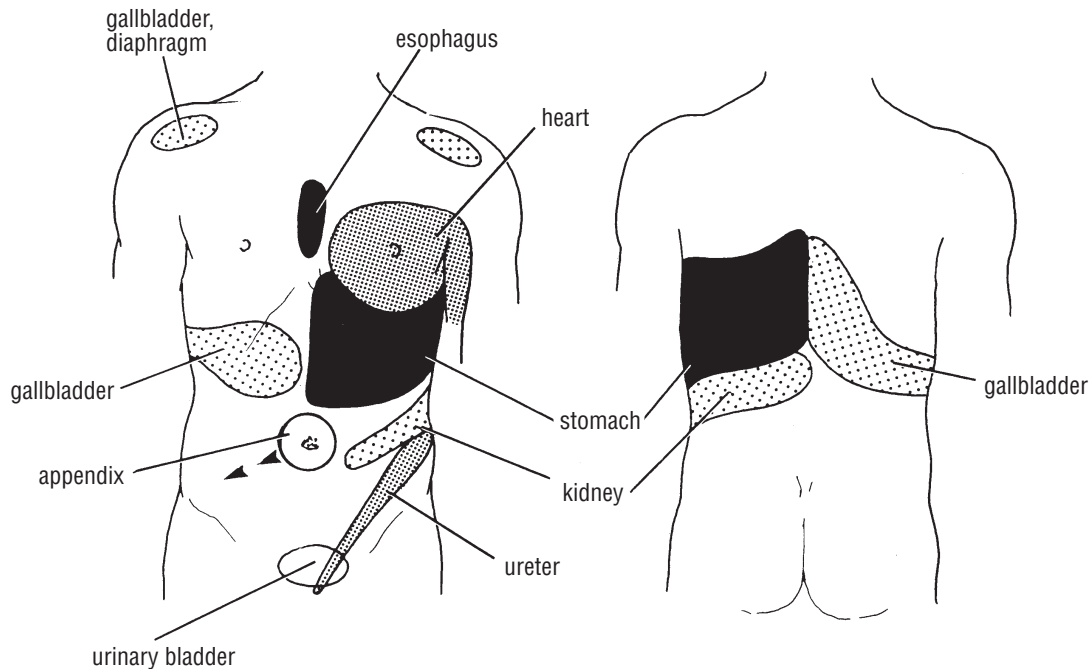
Referred abdominal pain is the feeling of pain at a location other than the site of origin of the stimulus but in an area supplied by the same or adjacent segments of the spinal

cord. Both somatic and visceral structures can produce referred pain.

In the case of referred somatic pain, the possible explanation is that the nerve fibers from the diseased structure and the area where the pain is felt ascend in the central nervous system along a common pathway, and the cerebral cortex is incapable of distinguishing between the sites. Examples of referred somatic pain follow. Pleurisy involving the lower part of the costal parietal pleura can give rise to referred pain in the abdomen because the lower parietal pleura receives its sensory innervation from the lower five intercostal nerves, which also innervate the skin and muscles of the anterior abdominal wall.

Visceral pain from the stomach is commonly referred to the epigastrium (CD Fig. 19-10). The afferent pain fibers from the stomach ascend in company with the sympathetic nerves and pass through the celiac plexus and the greater splanchnic nerves. The sensory fibers enter the spinal cord at segments T5–9 and give rise to referred pain in dermatomes T5–9 on the lower chest and abdominal walls.

Visceral pain from the appendix (see CD Fig. 19-10), which is produced by distension of its lumen or spasm of its smooth muscle coat, travels in nerve fibers that accompany sympathetic nerves through the superior mesenteric plexus and the lesser splanchnic nerve to the spinal cord (T10 segment). The vague referred pain is felt in the region of the umbilicus (T10 dermatome). Later, if the inflammatory process involves the parietal peritoneum, the severe somatic pain dominates the clinical picture and is localized precisely in the right lower quadrant.



CD Figure 19-10 Some important skin areas involved in referred pain.

Visceral pain from the gallbladder, as occurs in patients with cholecystitis or gallstone colic, travels in nerve fibers that accompany sympathetic nerves. They pass through the celiac plexus and greater splanchnic nerves to the spinal cord (segments T5–9). The vague referred pain is felt in the dermatomes (T5–9) on the lower chest and upper abdominal walls (see CD Fig. 19-10). If the inflammatory process spreads to involve the parietal peritoneum of the anterior abdominal wall or peripheral diaphragm, the severe somatic pain is felt in the right upper quadrant and through to the back below the inferior angle of the scapula. Involvement of the central diaphragmatic parietal peritoneum, which is innervated by the phrenic nerve (C3, 4, and 5), can give rise to referred pain over the shoulder because the skin in this area is innervated by the supraclavicular nerves (C3 and 4).

Anterior Abdominal Nerve Block

See CD Chapter 17.

Surgical Incisions

The length and direction of surgical incisions through the anterior abdominal wall to expose the underlying viscera are largely governed by the position and direction of the nerves of the abdominal wall, the direction of the muscle fibers, and the arrangement of the aponeuroses forming the rectus sheath. Ideally, the incision should be made in the direction of the lines of cleavage in the skin so that a hairline scar is produced. The surgeon usually has to compromise, placing the safety of the patient first and the cosmetic result second.

Incisions that necessitate the division of one of the main segmental nerves lying within the abdominal wall result in paralysis of part of the anterior abdominal musculature and a segment of the rectus abdominis. The consequent weakness of the abdominal musculature causes an unsightly bulging forward of the abdominal wall and visceroptosis; extreme cases may require a surgical belt for support.

If the incision can be made in the line of the muscle fibers or aponeurotic fibers as each layer is traversed, on closing the incision the fibers fall back into position and function normally.

Incisions through the rectus sheath are widely used, provided that the rectus abdominis muscle and its nerve supply are kept intact. On closure of the incisions, the anterior and posterior walls of the sheath are sutured separately, and the rectus muscle springs back into position between the suture lines. The result is a very strong repair, with minimum interference with function.

The following incisions are commonly used:

- **Paramedian incision:** This may be supraumbilical, for exposure of the upper part of the abdominal cavity, or infraumbilical, for the lower abdomen and pelvis. In

extensive operations in which a large exposure is required, the incision can run the full length of the rectus sheath. The anterior wall of the rectus sheath is exposed and incised about 1 in. (2.5 cm) from the midline. The medial edge of the incision is dissected medially, freeing the anterior wall of the sheath from the tendinous intersections of the rectus muscle. The rectus abdominis muscle is retracted laterally with its nerve supply intact, and the posterior wall of the sheath is exposed. The posterior wall is then incised, together with the fascia transversalis and the peritoneum. The wound is closed in layers.

- **Pararectus incision:** The anterior wall of the rectus sheath is incised medially and parallel to the lateral margin of the rectus muscle. The rectus is freed and retracted medially, exposing the segmental nerves entering its posterior surface. If the opening into the abdominal cavity is to be small, these nerves may be retracted upward and downward. The posterior wall of the sheath is then incised, as in the paramedian incision. The great disadvantage of this incision is that the opening is small, and any longitudinal extension requires that one or more segmental nerves to the rectus abdominis be divided, with resultant postoperative rectus muscle weakness.
- **Midline incision:** This incision is made through the linea alba. The fascia transversalis, the extraperitoneal connective tissue, and the peritoneum are then incised. It is easier to perform above the umbilicus because the linea alba is wider in that region. It is a rapid method of gaining entrance to the abdomen and has the obvious advantage that it does not damage muscles or their nerve and blood supplies. Midline incision has the additional advantage that it may be converted into a T-shaped incision for greater exposure. The anterior and posterior walls of the rectus sheath are then cut across transversely, and the rectus muscle is retracted laterally.
- **Transrectus incision:** The technique of making and closing this incision is the same as that used in the paramedian incision, except that the rectus abdominis muscle is incised longitudinally and not retracted laterally from the midline. This incision has the great disadvantage of sectioning the nerve supply to that part of the muscle that lies medial to the muscle incision.
- **Transverse incision:** This can be made above or below the umbilicus and can be small or so large that it extends from flank to flank. It can be made through the rectus sheath and the rectus abdominis muscles and through the oblique and transversus abdominis muscles laterally. It is rare to damage more than one segmental nerve so that postoperative abdominal weakness is minimal. The incision gives good exposure and is well tolerated by the patient. Closure of the wound is made in layers. It is unnecessary to suture the cut ends of the rectus muscles, provided that the sheaths are carefully repaired.

- **Muscle splitting, or McBurney's incision:** This is chiefly used for cecostomy and appendectomy. It gives a limited exposure only, and should any doubt arise about the diagnosis, an infraumbilical right paramedian incision should be used instead. An oblique skin incision is made in the right iliac region about 2 in. (5 cm) above and medial to the anterior superior iliac spine. The external and internal oblique and transversus muscles are incised or split in the line of their fibers and retracted to expose the fascia transversalis and the peritoneum. The latter are now incised and the abdominal cavity is opened. The incision is closed in layers, with no postoperative weakness.
- **Abdominothoracic incision:** This is used to expose the lower end of the esophagus, as, for example, in esophagogastric resection for carcinoma of this region. An upper oblique or paramedian abdominal incision is extended upward and laterally into the seventh, eighth, or ninth intercostal space, the costal arch is transected, and the diaphragm is incised. Wide exposure of the upper abdomen and thorax is then obtained by the use of a rib-spreading retractor.

On completion of the operation, the diaphragm is repaired with nonabsorbable sutures, the costal margin is reconstructed, and the abdominal and thoracic wounds are closed.

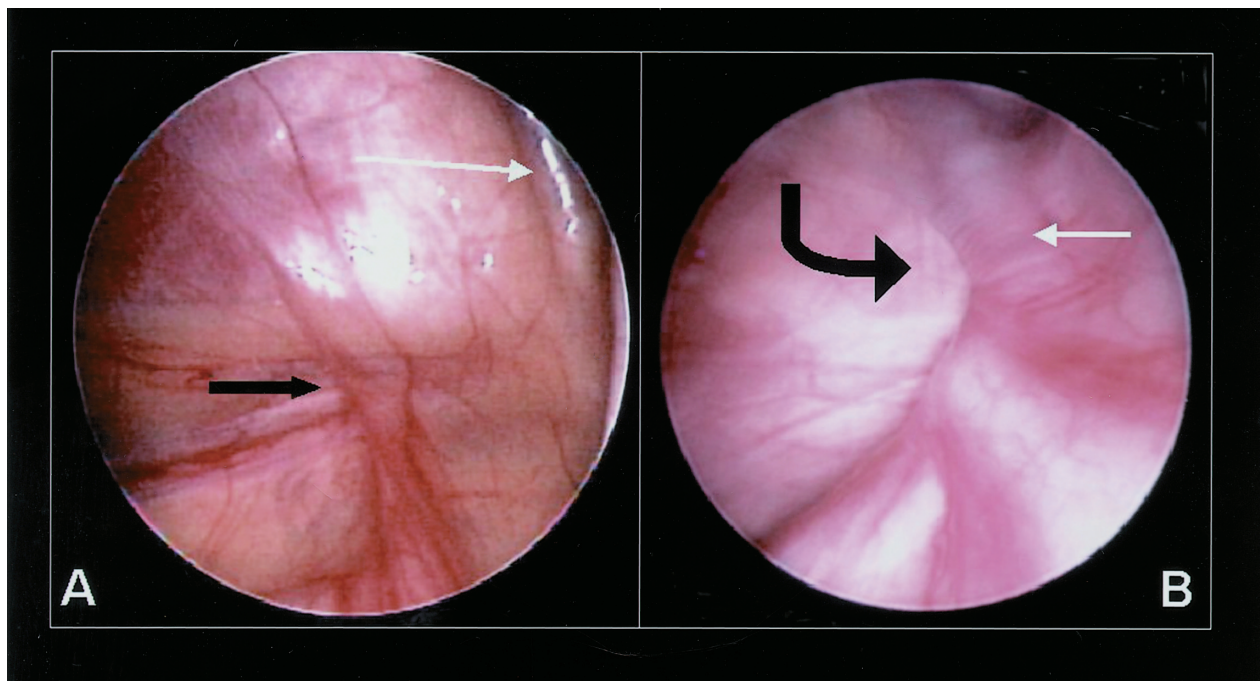
Endoscopic Surgery

Endoscopic surgery on the gallbladder, bile ducts, and appendix has become a common procedure. It involves the passage of the endoscope into the peritoneal cavity through small incisions in the anterior abdominal wall. The anatomic structures traversed by the instruments are similar to those enumerated for peritoneal lavage. Great care must be taken to preserve the integrity of the segmental nerves as they course down from the costal margin to supply the abdominal musculature.

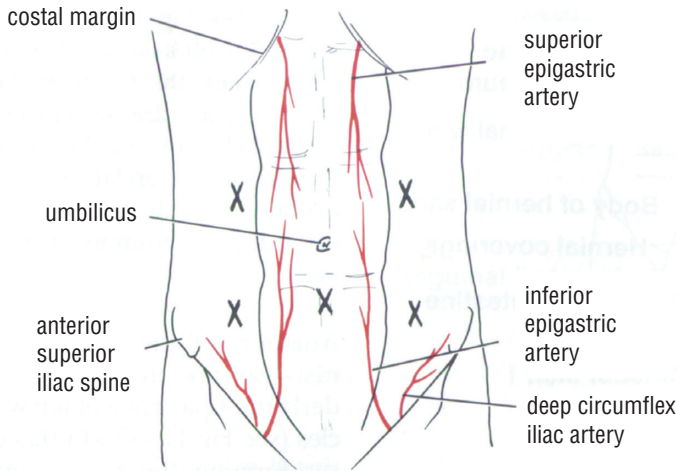
The advantages of this surgical technique are that the anatomic and physiologic features of the anterior abdominal wall are disrupted only minimally and, consequently, convalescence is brief. The great disadvantages are that the surgical field is small and the surgeon is limited in the extent of the operation (CD Fig. 19-11).

Paracentesis of the Abdomen

Paracentesis of the abdomen may be necessary to withdraw excessive collections of peritoneal fluid, as in ascites secondary to cirrhosis of the liver or malignant ascites secondary to advanced ovarian cancer. Under a local anesthetic, a needle or catheter is inserted through the anterior abdominal wall. The underlying coils of intestine are not



CD Figure 19-11 Inguinal canal anatomy as viewed during laparoscopic exploration of the peritoneal cavity. **A.** The normal anatomy of the inguinal region from within the peritoneal cavity. *Black arrow* indicates the closed deep inguinal ring; *white arrow*, the inferior epigastric vessels. **B.** An indirect inguinal hernia. *Curved black arrow* indicates the mouth of the hernial sac; *white arrow*, the inferior epigastric vessels. (Courtesy of N.S. Adzick.)



CD Figure 19-12 Common sites used in abdominal paracentesis. Note the position of the superior and inferior epigastric arteries in the rectus sheath and the deep circumflex iliac arteries.

damaged because they are mobile and are pushed away by the cannula.

If the cannula is inserted in the midline (CD Figs. 19-12 and 19-13), it will pass through the following anatomic structures: skin, superficial fascia, deep fascia (very thin), linea alba (virtually bloodless), fascia transversalis, extraperitoneal connective tissue (fatty), and parietal peritoneum.

If the cannula is inserted in the flank (see CD Figs. 19-12 and 19-13) lateral to the inferior epigastric artery and above the deep circumflex artery, it will pass through the following: skin, superficial fascia, deep fascia (very thin), aponeurosis or muscle of external oblique, internal oblique muscle, transversus abdominis muscle, fascia transversalis, extraperitoneal connective tissue (fatty), and parietal peritoneum.

Anatomy of Peritoneal Lavage

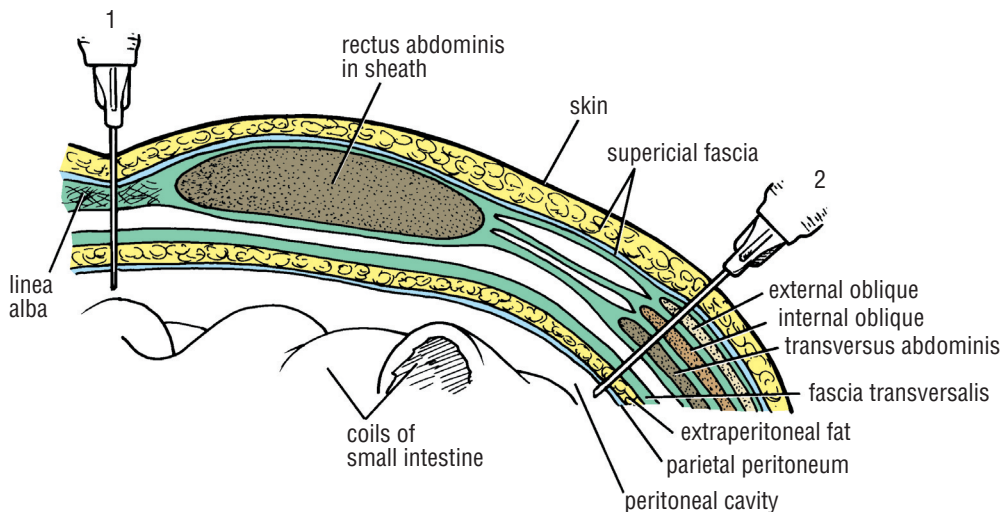
Peritoneal lavage is used to sample the intraperitoneal space for evidence of damage to viscera and blood vessels (CD

Fig. 19-14). It is generally employed as a diagnostic technique in certain cases of blunt abdominal trauma. In non-trauma situations, peritoneal lavage has been used to confirm the diagnosis of acute pancreatitis and primary peritonitis, to correct hypothermia, and to conduct dialysis.

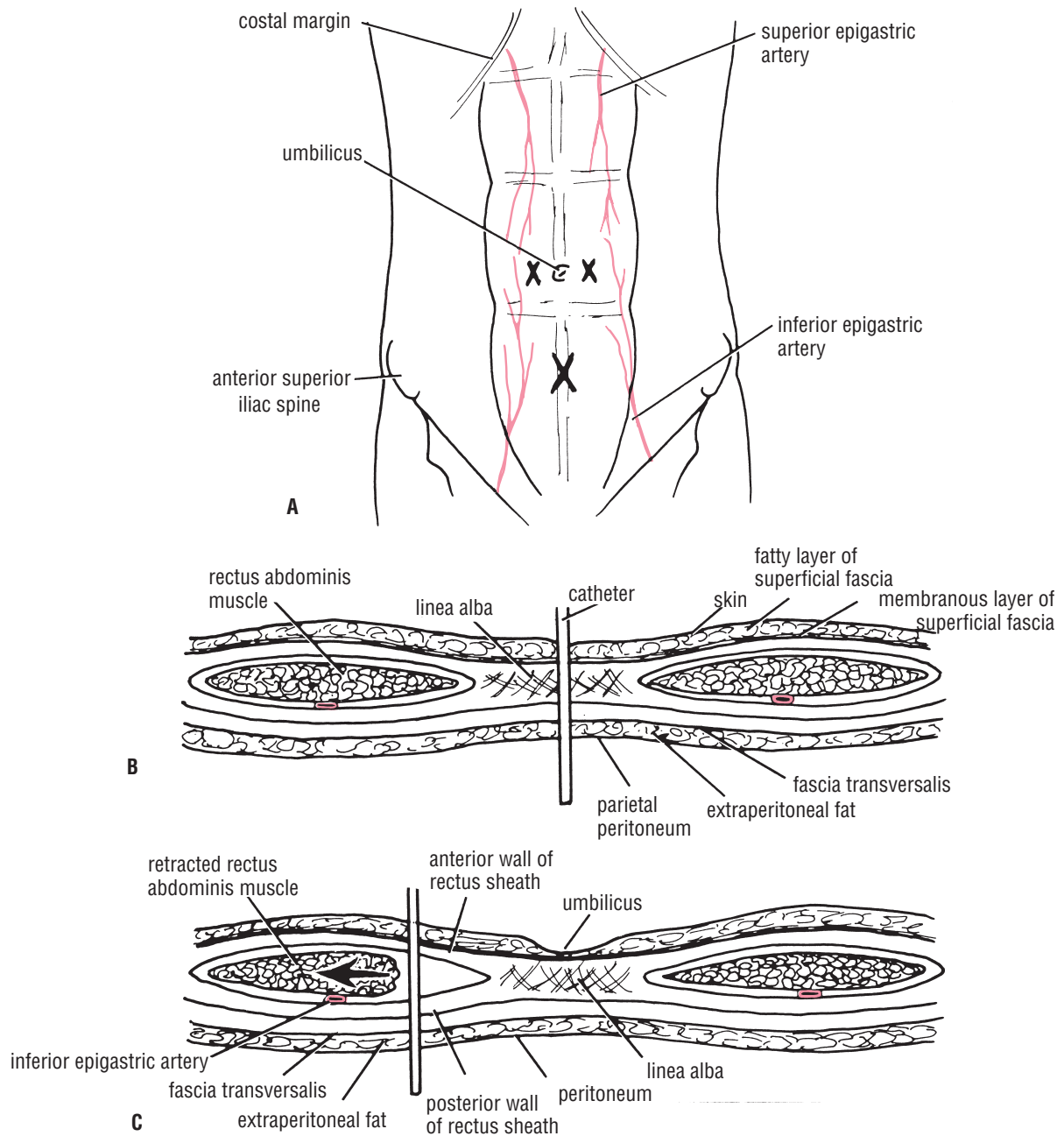
The patient is placed in the supine position and the urinary bladder is emptied by catheterization. In small children the bladder is an abdominal organ; in adults, the full bladder may rise out of the pelvis and reach as high as the umbilicus. The stomach is emptied by a nasogastric tube because a distended stomach may extend to the anterior abdominal wall. The skin is anesthetized and a 2.25 in. (3-cm) vertical incision is made.

Midline Incision Technique

The following anatomic structures are penetrated, in order, to reach the parietal peritoneum (CD Fig. 19-14): skin, fatty layer of superficial fascia, membranous layer of superficial



CD Figure 19-13 Paracentesis of the abdominal cavity in midline (1) and laterally (2).



CD Figure 19-14 Peritoneal lavage. **A.** The two common sites used in this procedure. Note the positions of the superior and inferior epigastric arteries in the rectus sheath. **B.** Cross section of the anterior abdominal wall in the midline. Note the structures pierced by the catheter. **C.** Cross section of the anterior abdominal wall just lateral to the umbilicus. Note the structures pierced by the catheter. The rectus muscle has been retracted laterally.

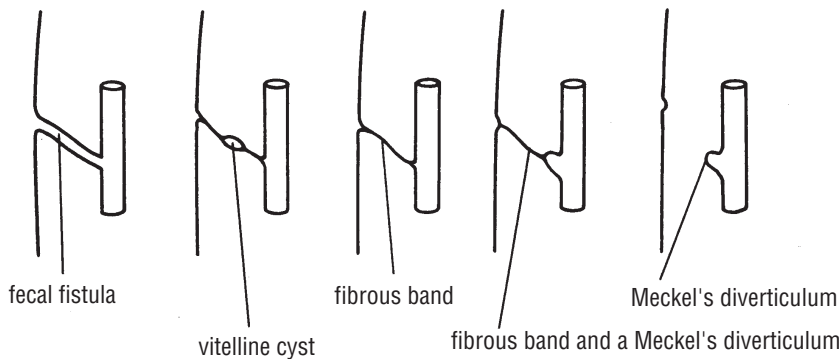
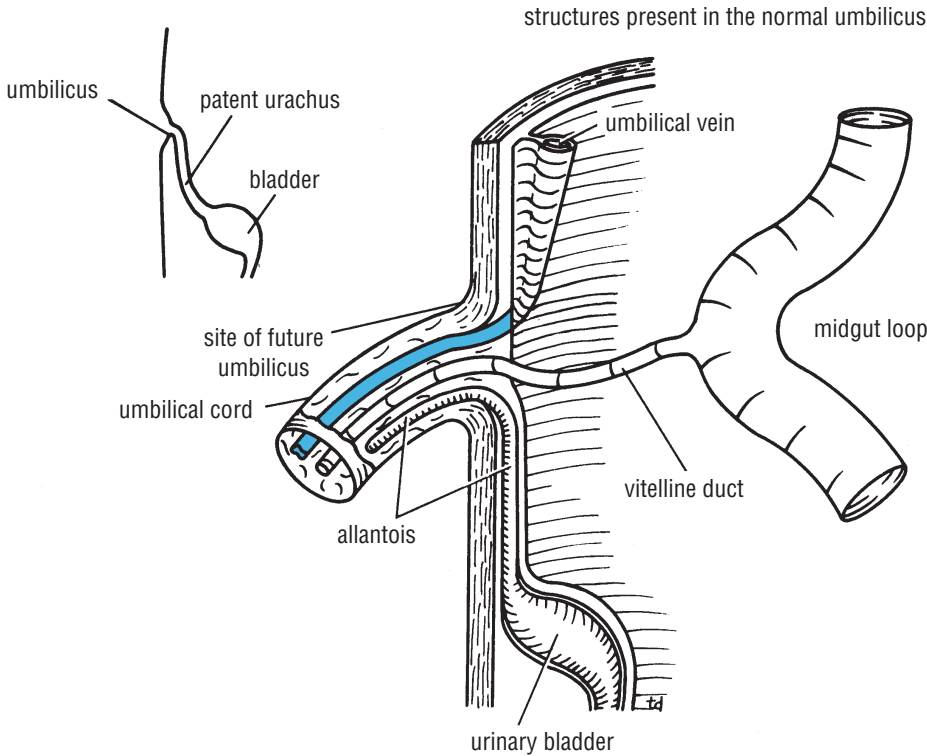
fascia, thin layer of deep fascia, linea alba, fascia transversalis, extraperitoneal fat, and parietal peritoneum.

Paraumbilical Incision Technique

The following anatomic structures are penetrated, in order, to reach the parietal peritoneum (see CD Fig. 19-14): skin,

fatty layer of superficial fascia, membranous layer of superficial fascia, thin layer of deep fascia, anterior wall of rectus sheath, the rectus abdominis muscle is retracted, posterior wall of the rectus sheath, fascia transversalis, extraperitoneal fat, and parietal peritoneum.

It is important that all the small blood vessels in the superficial fascia be secured, because bleeding into the



CD Figure 19-15 Umbilicus and some common congenital defects.

peritoneal cavity might produce a false-positive result. These vessels are the terminal branches of the superficial and deep epigastric arteries and veins.

Anatomy of the Complications of Peritoneal Lavage

- In the midline technique, the incision or trocar may miss the linea alba and enter the rectus sheath and traverse the vascular rectus abdominis muscle and encounter branches of the epigastric vessels. Bleeding from this source could produce a false-positive result.
- Perforation of the gut by the scalpel or trocar
- Perforation of the mesenteric blood vessels or vessels on the posterior abdominal wall or pelvic walls

- Perforation of a full bladder
- Wound infection

Abdominal Stab Wounds

Abdominal stab wounds may or may not penetrate the parietal peritoneum and violate the peritoneal cavity, and consequently may or may not significantly damage the abdominal viscera. The structures in the various layers through which an abdominal stab wound penetrates will depend on the anatomic location.

Lateral to the rectus sheath (see CD Fig. 19-13) are the following: skin, fatty layer of superficial fascia, membranous layer of superficial fascia, thin layer of deep fascia, external oblique muscle or aponeurosis, internal oblique muscle or

aponeurosis, transversus abdominis muscle or aponeurosis, fascia transversalis, extraperitoneal connective tissue (often fatty), and parietal peritoneum.

Anterior to the rectus sheath (see CD Fig. 19-13) are the following: skin; fatty layer of superficial fascia; membranous layer of superficial fascia; thin layer of deep fascia; anterior wall of rectus sheath; rectus abdominis muscle, with segmental nerves and epigastric vessels lying behind the muscle; posterior wall of rectus sheath; fascia transversalis; extraperitoneal connective tissue (often fatty); and parietal peritoneum.

In the midline (see CD Fig. 19-13) are the following: skin, fatty layer of superficial fascia, membranous layer of superficial fascia, thin layer of deep fascia, linea alba, fascia transversalis, extraperitoneal connective tissue (often fatty), and parietal peritoneum.

In a stab wound, peritoneal lavage may be used to determine whether any damage to viscera or vasculature has occurred.

Abdominal Gunshot Wounds

Gunshot wounds are much more serious than stab wounds; in most patients, the peritoneal cavity has been entered, and significant visceral damage has ensued.

Tying the Umbilical Cord

At birth, the cord is tied off close to the umbilicus. About 2 in. (5 cm) of cord is left between the umbilicus and the ligature, since a piece of intestine may be present as an **umbilical hernia** in the remains of the extraembryonic coelom. After application of the ligature, the umbilical vessels constrict and thrombose. Later, the stump of the cord is shed and the umbilical scar tissue becomes retracted and assumes the shape of the **umbilicus**, or **navel**.

Patent Urachus

The urachus is the remains of the allantois of the fetus and normally persists as a fibrous cord that runs from the apex of the bladder to the umbilicus. Occasionally, the cavity of the allantois persists, and urine passes from the bladder through the umbilicus. In newborns, it usually reveals itself when a congenital urethral obstruction is present. More often, it remains undiscovered until old age, when enlargement of the prostate may obstruct the urethra (see CD Fig. 19-15).

Vitellointestinal Duct

The vitelline duct in the early embryo connects the developing gut to the yolk sac. Normally, as development proceeds, the duct is obliterated, severs its connection with the small intestine, and disappears. Persistence of the vitel-

lointestinal duct can result in an umbilical fecal fistula (see CD Fig. 19-15). If the duct remains as a fibrous band, a loop of bowel can become wrapped around it, causing intestinal obstruction (see CD Fig. 19-15).

Meckel's diverticulum is a congenital anomaly representing a persistent portion of the vitellointestinal duct. It occurs in 2% of patients (see CD Fig. 19-15), is located about 2 ft (61 cm) from the ileocolic junction, and is about 2 in. (5 cm) long. It can become ulcerated or cause intestinal obstruction.

Umbilical Vessel Catheterization

The umbilical cord is surrounded by the fetal membrane, **amnion**, and contains **Wharton's jelly**. Embedded in this jelly are the remains of the vitellointestinal duct and the allantois, and the single umbilical vein and the two umbilical arteries (CD Fig. 19-16). The vein is a larger thin-walled vessel and is located at the 12 o'clock position when facing the umbilicus; the two arteries, which lie adjacent to one another and are located at the 4 and 8 o'clock positions when facing the umbilicus, are smaller and thick walled.

Indications for Umbilical Artery Catheterization

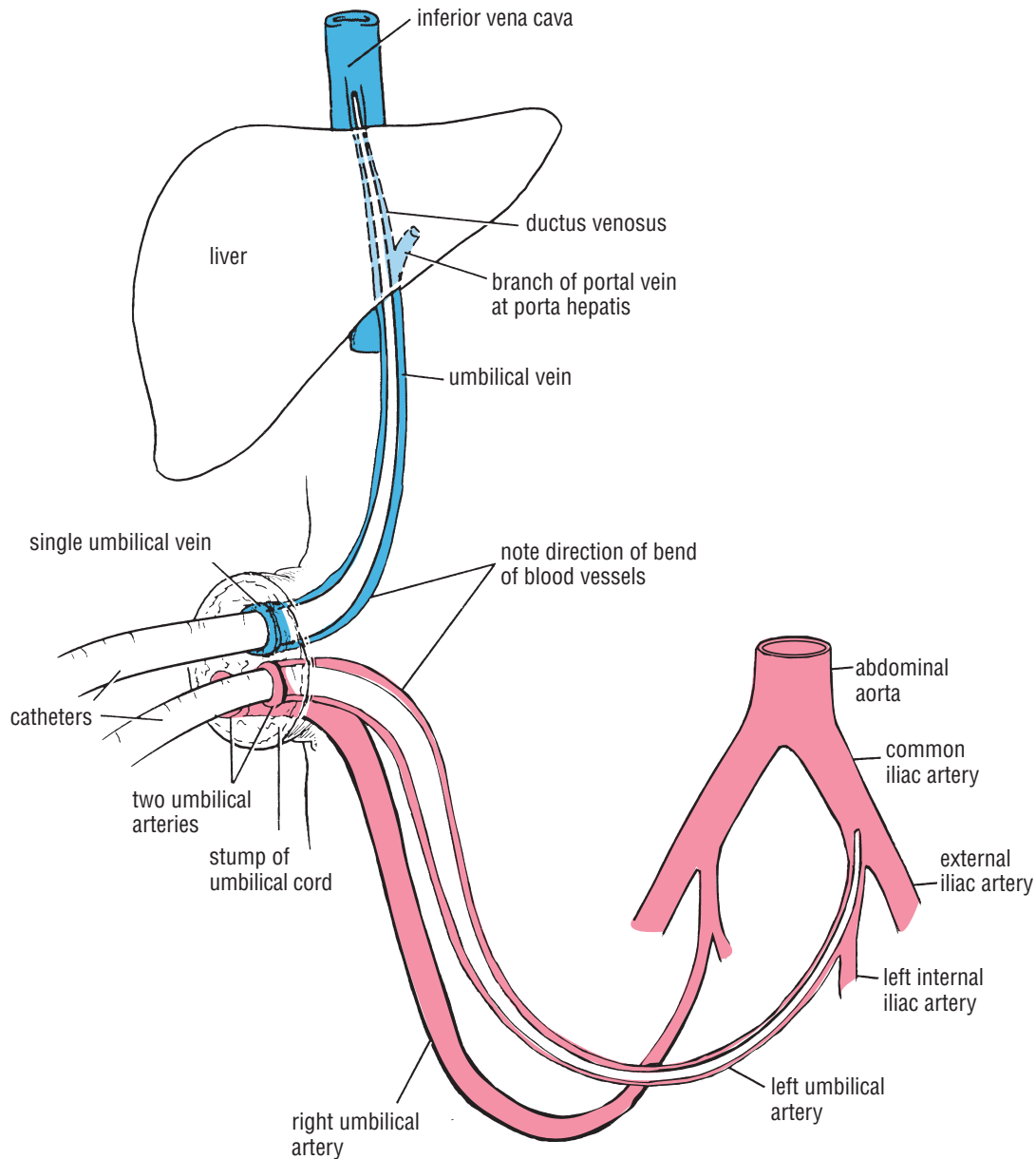
1. Administration of fluids or blood for resuscitation purposes
2. Arterial blood gas and blood pressure monitoring. The umbilical arteries may be cannulated most easily during the first few hours after birth, but they may be cannulated up to 6 days after delivery.

Anatomy of Procedure

One of the small, thick-walled arteries is identified in the Wharton's jelly in the umbilical stump. Because the umbilical arteries are branches of the internal iliac arteries in the pelvis, the catheter is introduced and advanced slowly in the direction of the feet. The catheter can be inserted for about 2.75 in. (7 cm) in a premature infant and 4.75 in. (12 cm) in a full-term infant. The course of the catheter can be confirmed on a radiograph and is as follows: (1) umbilical artery (directed downward into the pelvis), (2) internal iliac artery (acute turn into this artery), and (3) common iliac artery and the aorta.

Anatomy of Complications

- Catheter perforates arterial wall at a point where the artery turns downward toward the pelvis at the anterior abdominal wall.
- Catheter enters the thin-walled wider umbilical vein instead of the thick-walled smaller artery.
- Catheter enters the thin-walled persistent urachus (urine is returned into catheter).



CD Figure 19-16 Catheterization of the umbilical blood vessels. Arrangement of the single umbilical vein and the two umbilical arteries in the umbilical cord and the paths taken by the catheter in the umbilical vein and the umbilical artery.

- Vasospasm of the umbilical and the iliac arteries causing blanching of the leg
- Perforation of arteries distal to the umbilical artery, for example, the iliac arteries or even the aorta
- Other complications include thrombosis, emboli, and infection of the umbilical stump.

Indications for Umbilical Vein Catheterization

1. Administration of fluids or blood for resuscitation purposes

2. Exchange transfusions; the umbilical vein may be cannulated up to 7 days after birth.

Anatomy of Procedure

The umbilical vein is located in the cord stump at the 12 o'clock position (see CD Fig. 19-16), as described previously, and is easily recognized because of its thin wall and large lumen. The catheter is advanced gently and is directed toward the head, because the vein runs in the free margin of the falciform ligament to join the ductus venosus at the porta hepatis. The catheter may be advanced about 2 in. (5 cm) in a full-term infant. The course of the catheter may

be confirmed by radiography and is as follows: (1) the umbilical vein, (2) the ductus venosus, and (3) the inferior vena cava (4 to 4.75 in.; 10 to 12 cm).

Anatomy of Complications

- Catheter may perforate the venous wall. This is most likely to occur where the vein turns cranially at the abdominal wall.
- Other complications include liver necrosis, hemorrhage, and infection.



PERITONEUM AND PERITONEAL CAVITY

Movement of Peritoneal Fluid

The peritoneal cavity is divided into an upper part within the abdomen and a lower part in the pelvis. The abdominal part is further subdivided by the many peritoneal reflections into important recesses and spaces, which, in turn, are continued into the paracolic gutters (CD Fig. 19-17). The attachment of the transverse mesocolon and the mesentery of the small intestine to the posterior abdominal wall provides natural peritoneal barriers that may hinder the movement of infected peritoneal fluid from the upper part to the lower part of the peritoneal cavity.

It is interesting to note that when the patient is in the supine position the right subphrenic peritoneal space and the pelvic cavity are the lowest areas of the peritoneal cavity and the region of the pelvic brim is the highest area (see CD Fig. 19-17).

Peritoneal Infection

Infection may gain entrance to the peritoneal cavity through several routes: from the interior of the gastrointestinal tract and gallbladder, through the anterior abdominal wall, via the uterine tubes in females (gonococcal peritonitis in adults and pneumococcal peritonitis in children occur through this route), and from the blood.

Collection of infected peritoneal fluid in one of the **subphrenic spaces** is often accompanied by infection of the pleural cavity. It is common to find a localized empyema in a patient with a subphrenic abscess. It is believed that the infection spreads from the peritoneum to the pleura via the diaphragmatic lymph vessels. A patient with a subphrenic abscess may complain of pain over the shoulder. (This also holds true for collections of blood under the diaphragm, which irritate the parietal diaphrag-

matic peritoneum.) The skin of the shoulder is supplied by the supraclavicular nerves (C3 and 4), which have the same segmental origin as the phrenic nerve, which supplies the peritoneum in the center of the undersurface of the diaphragm.

To avoid the accumulation of infected fluid in the subphrenic spaces and to delay the absorption of toxins from intraperitoneal infections, it is common nursing practice to sit a patient up in bed with the back at an angle of 45°. In this position, the infected peritoneal fluid tends to gravitate downward into the pelvic cavity, where the rate of toxin absorption is slow (see CD Fig. 19-17).

Greater Omentum and the Localization of Infection

The greater omentum is often referred to by the surgeons as the **abdominal policeman**. The lower and the right and left margins are free, and it moves about the peritoneal cavity in response to the peristaltic movements of the neighboring gut. In the first 2 years of life it is poorly developed and thus is less protective in a young child. Later, however, in an acutely inflamed appendix, for example, the inflammatory exudate causes the omentum to adhere to the appendix and wrap itself around the infected organ (CD Fig. 19-18). By this means, the infection is often localized to a small area of the peritoneal cavity, thus saving the patient from a serious diffuse peritonitis.

Greater Omentum as a Hernial Plug

The greater omentum has been found to plug the neck of a hernial sac and prevent the entrance of coils of small intestine.

Greater Omentum in Surgery

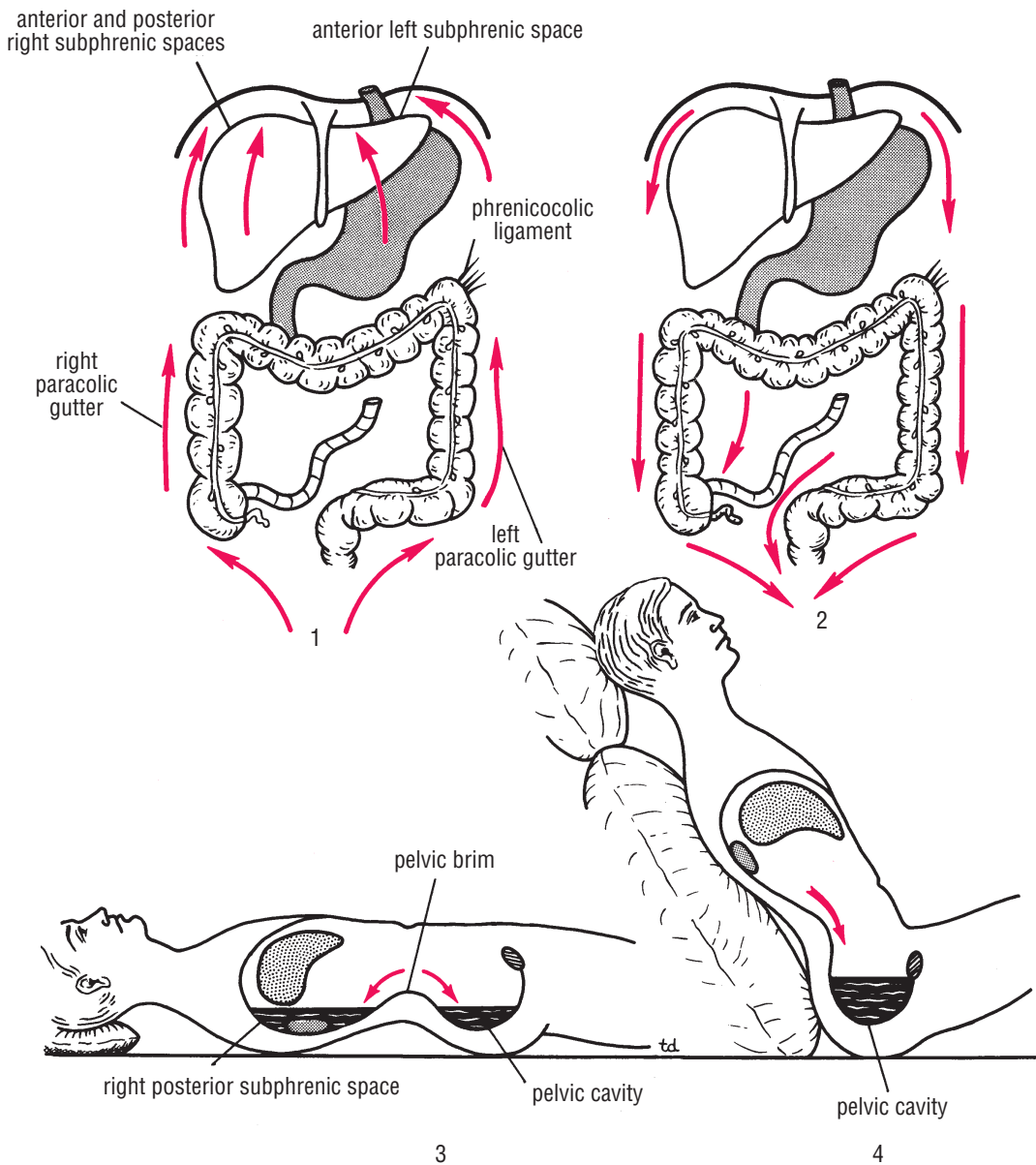
Surgeons sometimes use the omentum to buttress an intestinal anastomosis or in the closure of a perforated gastric or duodenal ulcer.

Torsion of the Greater Omentum

The greater omentum may undergo torsion, and if extensive, the blood supply to a part of it may be cut off, causing necrosis.

Ascites

Ascites is essentially an excessive accumulation of peritoneal fluid within the peritoneal cavity. Ascites can occur secondary to hepatic cirrhosis (portal venous congestion), malignant disease (e.g., cancer of the ovary), or congestive heart failure (systemic venous congestion). In a thin patient,



CD Figure 19-17 Direction of flow of the peritoneal fluid. **1.** Normal flow upward to the subphrenic spaces. **2.** Flow of inflammatory exudate in peritonitis. **3.** The two sites where inflammatory exudate tends to collect when the patient is nursed in the supine position. **4.** Accumulation of inflammatory exudate in the pelvis when the patient is nursed in the inclined position.

as much as 1,500 mL has to accumulate before ascites can be recognized clinically. In obese individuals, a far greater amount has to collect before it can be detected.

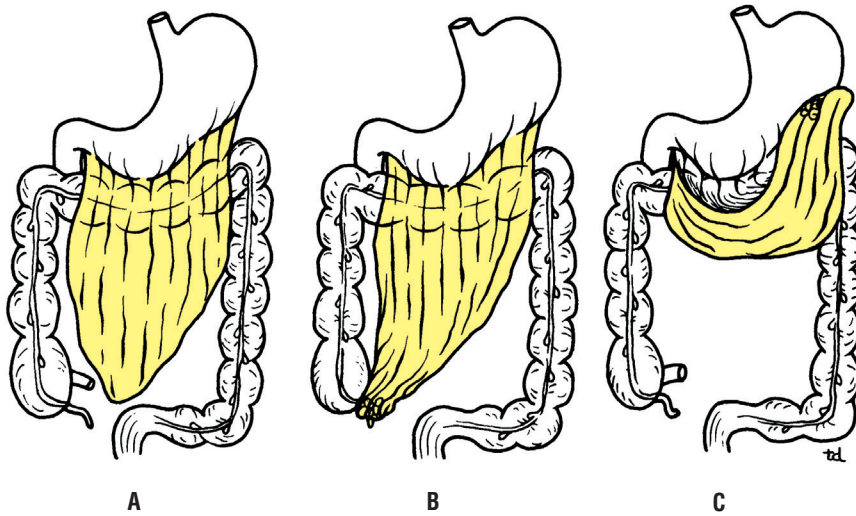
Peritoneal Pain

From the Parietal Peritoneum

The parietal peritoneum lining the anterior abdominal wall is supplied by the lower six thoracic nerves and the

first lumbar nerve. Abdominal pain originating from the parietal peritoneum is therefore of the somatic type, can be precisely localized, and is usually severe (see Abdominal Pain).

An inflamed parietal peritoneum is extremely sensitive to stretching. This fact is made use of clinically in diagnosing peritonitis. Pressure is applied to the abdominal wall with a single finger over the site of the inflammation. The pressure is then removed by suddenly withdrawing the finger. The abdominal wall rebounds,



CD Figure 19-18 **A.** The normal greater omentum. **B.** The greater omentum wrapped around an inflamed appendix. **C.** Greater omentum adherent to the base of a gastric ulcer. One important function of the greater omentum is to attempt to limit the spread of intraperitoneal infections.

resulting in extreme local pain, which is known as **rebound tenderness**.

It should always be remembered that the parietal peritoneum in the pelvis is innervated by the obturator nerve and can be palpated by means of a rectal or vaginal examination. An inflamed appendix may hang down into the pelvis and irritate the parietal peritoneum. A pelvic examination can detect extreme tenderness of the parietal peritoneum on the right side.

From the Visceral Peritoneum

The visceral peritoneum, including the mesenteries, is innervated by autonomic afferent nerves. Stretch caused by overdistension of a viscus or pulling on a mesentery gives rise to the sensation of pain. The sites of origin of visceral pain are shown in CD Fig. 19-10.

Because the gastrointestinal tract arises embryologically as a midline structure and receives a bilateral nerve supply, pain is referred to the midline. Pain arising from an abdominal viscus is dull and poorly localized (see Abdominal Pain).

Peritoneal Dialysis

Because the peritoneum is a semipermeable membrane, it allows rapid bidirectional transfer of substances across itself. Because the surface area of the peritoneum is enormous, this transfer property has been made use of in patients with acute renal insufficiency. The efficiency of this method is only a fraction of that achieved by hemodialysis.

A watery solution, the dialysate, is introduced through a catheter through a small midline incision through the anterior abdominal wall below the umbilicus. The technique is

the same as peritoneal lavage. The products of metabolism, such as urea, diffuse through the peritoneal lining cells from the blood vessels into the dialysate and are removed from the patient.

Internal Abdominal Hernia

Occasionally, a loop of intestine enters a peritoneal pouch or recess (e.g., the lesser sac or the duodenal recesses) and becomes strangulated at the edges of the recess. Remember that important structures form the boundaries of the entrance into the lesser sac and that the inferior mesenteric vein often lies in the anterior wall of the paraduodenal recess.



RETROPERITONEAL SPACE

Trauma to Organs in the Retroperitoneal Space

Palpation of the anterior abdominal wall in the lumbar and iliac regions may give rise to signs indicative of peritoneal irritation (the peritoneum forms the anterior boundary of the space; see text Fig. 19-30). In other words, tenderness and muscle spasm (rigidity) may be present. Palpation of the back in the interval between the twelfth rib and the vertebral column may reveal tenderness suggestive of kidney disease.

Abdominal radiographs may reveal air in the extraperitoneal tissues, indicating perforation of a viscus (e.g., ascending or descending colon). Computed tomography scans can often accurately define the extent of the injury to the extraperitoneal organs.

Abscess Formation

Infection originating in retroperitoneal organs, such as the kidneys, lymph nodes, and retrocecal appendix, may extend widely into the retroperitoneal space.

Leaking Aortic Aneurysm

The blood may first be confined to the retroperitoneal space before rupturing into the peritoneal cavity.



THE ALIMENTARY TRACT

Esophagus

Narrow Areas of the Esophageal Lumen

The esophagus is narrowed at three sites: at the beginning, behind the cricoid cartilage of the larynx; where the left bronchus and the arch of the aorta cross the front of the esophagus; and where the esophagus enters the stomach. These three sites may offer resistance to the passage of a tube down the esophagus into the stomach (CD Fig. 19-19).

Achalasia of the Cardia (Esophagogastric Junction)

The cause of achalasia is unknown, but it is associated with a degeneration of the parasympathetic plexus (Auerbach's plexus) in the wall of the esophagus. The primary site of the disorder may be in the innervation of the cardioesophageal sphincter by the vagus nerves. Dysphagia (difficulty in swallowing) and regurgitation are common symptoms that are later accompanied by proximal dilatation and distal narrowing of the esophagus.

Bleeding Esophageal Varices

At the lower third of the esophagus is an important portal–systemic venous anastomosis. Here, the esophageal tributaries of the left gastric vein (which drains into the portal vein) anastomose with the esophageal tributaries of the azygos veins (systemic veins). Should the portal vein become obstructed, as, for example, in cirrhosis of the liver,

portal hypertension develops, resulting in dilatation and varicosity of the portal–systemic anastomoses. Varicose esophageal veins may rupture, causing severe vomiting of blood (hematemesis).

Anatomy of the Insertion of the Sengstaken-Blakemore Balloon for Esophageal Hemorrhage

The Sengstaken-Blakemore balloon is used for the control of massive esophageal hemorrhage from esophageal varices. A gastric balloon anchors the tube against the esophageal–gastric junction. An esophageal balloon occludes the esophageal varices by counterpressure. The tube is inserted through the nose or by using the oral route.

The lubricated tube is passed down into the stomach, and the gastric balloon is inflated. In the average adult the distance between the external orifices of the nose and the stomach is 17.2 in. (44 cm), and the distance between the incisor teeth and the stomach is 16 in. (41 cm).

Anatomy of the Complications

- Difficulty in passing the tube through the nose
- Damage to the esophagus from overinflation of the esophageal tube
- Pressure on neighboring mediastinal structures as the esophagus is expanded by the balloon within its lumen
- Persistent hiccups caused by irritation of the diaphragm by the distended esophagus and irritation of the stomach by the blood

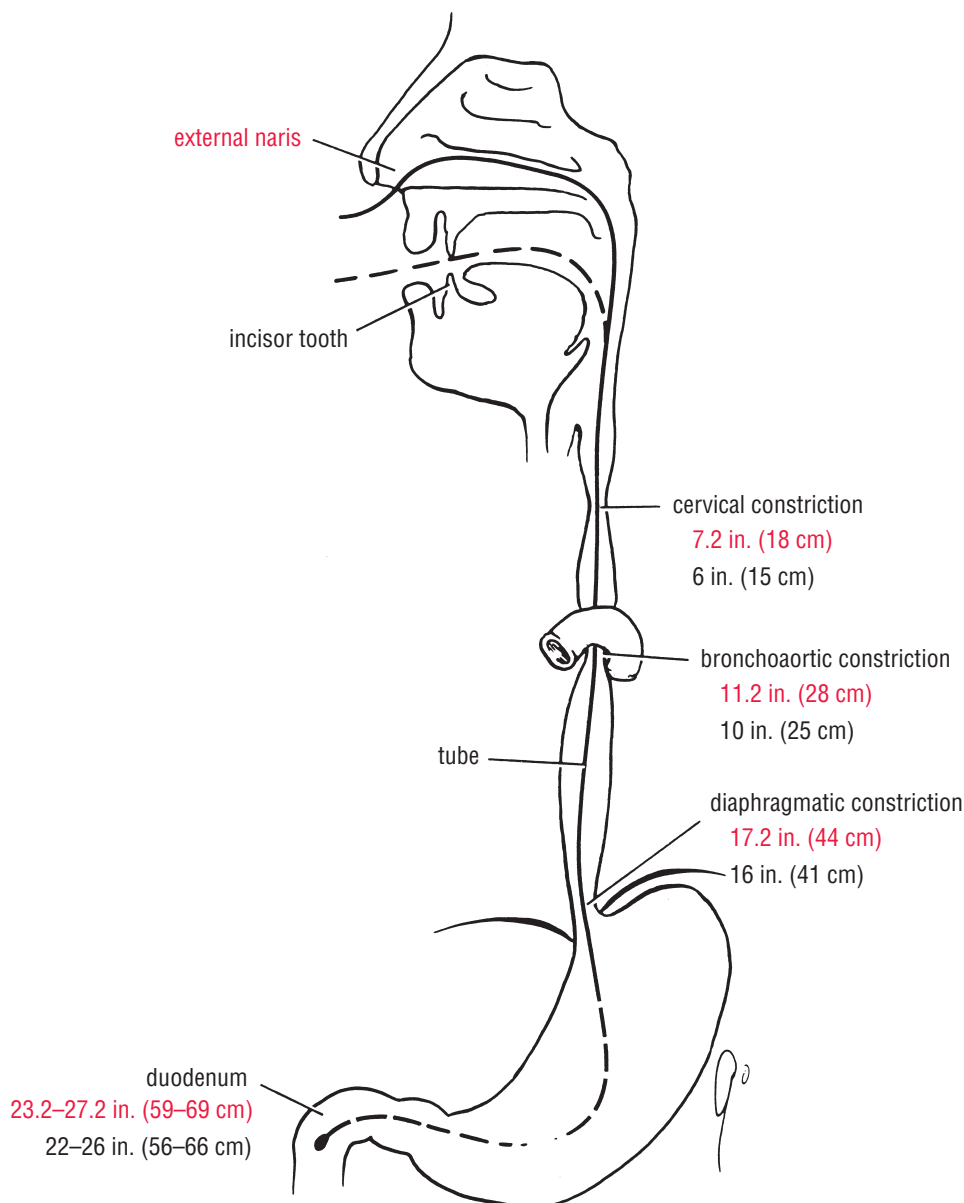
Stomach

Nausea

Nausea is a very common symptom and may occur as the result of drugs, such as anesthetics and apomorphine, pregnancy, motion sickness, and chemotherapy. It often precedes vomiting. Nausea is the recognition that the vomiting center in the medulla oblongata is being stimulated by afferent impulses derived from the stomach and intestines, or in the case of motion sickness, impulses derived from the semicircular canals of the inner ear. It is well known that certain offensive odors can initiate nausea and vomiting and this is presumably due to the direct stimulation of the vomiting center by nerve impulses from the cerebral cortex.

Vomiting

Vomiting is the process by which the stomach and upper intestinal tract empties itself of its contents. It is caused by the presence in the upper gastrointestinal tract of some substance, chemical, bacterial, or viral, that excessively irritates



CD Figure 19-19 The approximate respective distances from the incisor teeth (*black*) and the nostrils (*red*) to the normal three constrictions of the esophagus. To assist in the passage of a tube to the duodenum, the distances to the first part of the duodenum are also included.

the gut wall and results in overdistension of the upper part of the gastrointestinal tract. The act of vomiting is preceded by excessive salivation (presumably an attempt to dilute the irritant). This is followed by stimulation of the sympathetic system resulting in dilatation of the pupils, an increase in the heart rate, facial pallor (due to vasoconstriction of the blood vessels), cold sweating, fatigue, and drowsiness. Nerve impulses travel to the vomiting center from the gastrointestinal tract via the vagi and sympathetic afferent fibers. Once the nerve stimulation of the vomiting center reaches a certain level, the vomiting act takes place.

The act of vomiting has two phases. The retching phase is nonproductive and involves one or two rounds of the coordinated contraction of the diaphragm, the anterior abdominal wall muscles, and the muscles of inspiration. In

the expulsive phase a deep breath is taken and the larynx is raised to close the inlet; the nasopharynx is also closed by the raising of the soft palate. This is quickly followed by the massive coordinated contraction of the diaphragm and abdominal muscles exerting intense squeezing pressure on the stomach. Suddenly the gastroesophageal sphincter relaxes and the stomach contents are ejected through the esophagus and the mouth. The act of vomiting usually makes the patient feel better, but it may be repeated if the irritant has not been expelled or the drug action persists.

Trauma to the Stomach

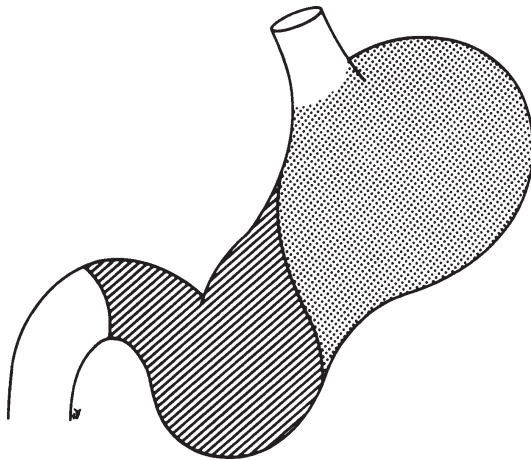
Apart from its attachment to the esophagus at the cardiac orifice and its continuity with the duodenum at the

pylorus, the stomach is relatively mobile. It is protected on the left by the lower part of the rib cage. These factors greatly protect the stomach from blunt trauma to the abdomen. However, its large size makes it vulnerable to gunshot wounds.

Gastric Ulcer

The mucous membrane of the body of the stomach and, to a lesser extent, that of the fundus produce acid and pepsin. The secretion of the antrum and pyloric canal is mucous and weakly alkaline (CD Fig. 19-20). The secretion of acid and pepsin is controlled by two mechanisms: nervous and hormonal. The vagus nerves are responsible for the nervous control, and the hormone **gastrin**, produced by the antral mucosa, is responsible for the hormonal control. In the surgical treatment of chronic gastric and duodenal ulcers, attempts are made to reduce the amount of acid secretion by sectioning the vagus nerves (vagotomy) and by removing the gastrin-bearing area of mucosa, the antrum (partial gastrectomy).

Gastric ulcers occur in the alkaline-producing mucosa of the stomach, usually on or close to the lesser curvature. A chronic ulcer invades the muscular coats and, in time, involves the peritoneum so that the stomach adheres to neighboring structures. An ulcer situated on the posterior wall of the stomach may perforate into the lesser sac or become adherent to the pancreas. Erosion of the pancreas produces pain referred to the back. The splenic artery runs along the upper border of the pancreas, and erosion of this artery may produce fatal hemorrhage. A penetrating ulcer of the anterior stomach wall may result in the escape of stomach contents into the greater sac, producing diffuse peritonitis. The anterior stomach wall may, however, adhere to the liver, and the chronic ulcer may penetrate the liver substance.



CD Figure 19-20 Areas of the stomach that produce acid and pepsin (*stippled*) and alkali and gastrin (*diagonal lines*).

Gastric Pain

The sensation of pain in the stomach is caused by the stretching or spasmodic contraction of the smooth muscle in its walls and is referred to the epigastrium. It is believed that the pain-transmitting fibers leave the stomach in company with the sympathetic nerves. They pass through the celiac ganglia and reach the spinal cord via the greater splanchnic nerves.

Cancer of the Stomach

Because the lymphatic vessels of the mucous membrane and submucosa of the stomach are in continuity, it is possible for cancer cells to travel to different parts of the stomach, some distance away from the primary site. Cancer cells also often pass through or bypass the local lymph nodes and are held up in the regional nodes. For these reasons, malignant disease of the stomach is treated by total gastrectomy, which includes the removal of the lower end of the esophagus and the first part of the duodenum; the spleen and the gastrosplenic and splenicorenal ligaments and their associated lymph nodes; the splenic vessels; the tail and body of the pancreas and their associated nodes; the nodes along the lesser curvature of the stomach; and the nodes along the greater curvature, along with the greater omentum. This radical operation is a desperate attempt to remove the stomach en bloc and, with it, its lymphatic field. The continuity of the gut is restored by anastomosing the esophagus with the jejunum.

Gastroscopy

Gastroscopy is the viewing of the mucous membrane of the stomach through an illuminated tube fitted with a lens system. The patient is anesthetized and the gastroscope is passed into the stomach, which is then inflated with air. With a flexible fiberoptic instrument, direct visualization of different parts of the gastric mucous membrane is possible. It is also possible to perform a mucosal biopsy through a gastroscope.

Nasogastric Intubation

Nasogastric intubation is a common procedure and is performed to empty the stomach, to decompress the stomach in cases of intestinal obstruction, or before operations on the gastrointestinal tract; it may also be performed to obtain a sample of gastric juice for biochemical analysis.

1. The patient is placed in the semiupright position or left lateral position to avoid aspiration.
2. The well-lubricated tube is inserted through the wider nostril and is directed backward along the nasal floor.
3. Once the tube has passed the soft palate and entered the oral pharynx, decreased resistance is felt, and the conscious patient will feel like gagging.

4. Some important distances in the adult may be useful. From the nostril (external nares) to the cardiac orifice of the stomach is about 17.2 in. (44 cm), and from the cardiac orifice to the pylorus of the stomach is 4.8 to 5.6 in. (12 to 14 cm). The curved course taken by the tube from the cardiac orifice to the pylorus is usually longer, 6.0 to 10.0 in. (15 to 25 cm) (see CD Fig. 19-19).

Anatomic Structures that May Impede the Passage of the Nasogastric Tube

- Deviated nasal septum, making the passage of the tube difficult on the narrower side
- Three sites of esophageal narrowing may offer resistance to the nasogastric tube—at the beginning of the esophagus behind the cricoid cartilage (7.2 in.; 18 cm), where the left bronchus and the arch of the aorta cross the front of the esophagus (11.2 in.; 28 cm), and where the esophagus enters the stomach (17.2 in.; 44 cm). The upper esophageal narrowing may be overcome by gently grasping the wings of the thyroid cartilage and pulling the larynx forward. This maneuver opens the normally collapsed esophagus and permits the tube to pass down without further delay.

Anatomy of Complications

- The nasogastric tube enters the larynx instead of the esophagus.
- Rough insertion of the tube into the nose will cause nasal bleeding from the mucous membrane.
- Penetration of the wall of the esophagus or stomach. **Always aspirate tube for gastric contents to confirm successful entrance into stomach.**

Duodenum

Trauma to the Duodenum

Apart from the first inch, the duodenum is rigidly fixed to the posterior abdominal wall by peritoneum and therefore cannot move away from crush injuries. In severe crush injuries to the anterior abdominal wall, the third part of the duodenum may be severely crushed or torn against the third lumbar vertebra.

Duodenal Ulcer

As the stomach empties its contents into the duodenum, the acid chyme is squirted against the anterolateral wall of the first part of the duodenum. This is thought to be an important factor in the production of a duodenal ulcer at this site. An ulcer of the anterior wall of the first inch of the duodenum may perforate into the upper part of the greater sac, above the transverse colon. The transverse colon directs

the escaping fluid into the right lateral paracolic gutter and thus down to the right iliac fossa. The differential diagnosis between a perforated duodenal ulcer and a perforated appendix may be difficult.

An ulcer of the posterior wall of the first part of the duodenum may penetrate the wall and erode the relatively large gastroduodenal artery, causing a severe hemorrhage.

The gastroduodenal artery is a branch of the hepatic artery, a branch of the celiac trunk (see text Fig. 19-38).

Duodenal Recesses

The importance of the duodenal recesses and the occurrence of herniae of the intestine were already alluded to in this chapter.

Important Duodenal Relations

The relation to the duodenum of the gallbladder, the transverse colon, and the right kidney should be remembered. Cases have been reported in which a large gallstone ulcerated through the gallbladder wall into the duodenum. Operations on the colon and right kidney have resulted in damage to the duodenum.

Jejunum and Ileum

Trauma to the Jejunum and Ileum

Because of its extent and position, the small intestine is commonly damaged by trauma. The extreme mobility and elasticity permit the coils to move freely over one another in instances of blunt trauma. Small, penetrating injuries may self-seal as a result of the mucosa plugging up the hole and the contraction of the smooth muscle wall. Material from large wounds leaks freely into the peritoneal cavity. The presence of the vertebral column and the prominent anterior margin of the first sacral vertebra may provide a firm background for intestinal crushing in cases of midline crush injuries.

Small-bowel contents have nearly a neutral pH and produce only slight chemical irritation to the peritoneum.

Recognition of the Jejunum and Ileum

A physician should be able to distinguish between the large and small intestine. He or she may be called on to examine a case of postoperative burst abdomen, where coils of gut are lying free in the bed. The macroscopic differences are described on text page 738.

Tumors and Cysts of the Mesentery of the Small Intestine

The line of attachment of the small intestine to the posterior abdominal wall should be remembered. It extends from a point just to the left of the midline about 2 in. (5 cm) below the transpyloric plane (L1) downward to the right iliac fossa.

A tumor or cyst of the mesentery, when palpated through the anterior abdominal wall, is more mobile in a direction at right angles to the line of attachment than along the line of attachment.

Pain Fibers from the Jejunum and Ileum

Pain fibers traverse the superior mesenteric sympathetic plexus and pass to the spinal cord via the splanchnic nerves. Referred pain from this segment of the gastrointestinal tract is felt in the dermatomes supplied by the ninth, tenth, and eleventh thoracic nerves. Strangulation of a coil of small intestine in an inguinal hernia first gives rise to pain in the region of the umbilicus. Only later, when the parietal peritoneum of the hernial sac becomes inflamed, does the pain become more intense and localized to the inguinal region (see Abdominal Pain).

Mesenteric Arterial Occlusion

The superior mesenteric artery, a branch of the abdominal aorta, supplies an extensive territory of the gut, from halfway down the second part of the duodenum to the left colic flexure. Occlusion of the artery or one of its branches results in death of all or part of this segment of the gut. The occlusion may occur as the result of an embolus, a thrombus, an aortic dissection, or an abdominal aneurysm.

Mesenteric Vein Thrombosis

The superior mesenteric vein, which drains the same area of the gut supplied by the superior mesenteric artery, may undergo thrombosis after stasis of the venous bed. Cirrhosis of the liver with portal hypertension may predispose to this condition.

Appendix

Variability of Position of the Appendix

The inconstancy of the position of the appendix should be borne in mind when attempting to diagnose appendicitis. A retrocecal appendix, for example, may lie behind a cecum distended with gas, and thus it may be difficult to elicit tenderness on palpation in the right iliac region. Irritation of the psoas muscle, conversely, may cause the patient to keep the right hip joint flexed.

Pelvic Appendix

An appendix hanging down in the pelvis may result in absent abdominal tenderness in the right lower quadrant, but deep tenderness may be experienced just above the symphysis pubis. Rectal or vaginal examination may reveal tenderness of the peritoneum in the pelvis on the right side.

Predisposition of the Appendix to Infection

The following factors contribute to the appendix's predilection to infection:

- It is a long, narrow, blind-ended tube, which encourages stasis of large-bowel contents.
- It has a large amount of lymphoid tissue in its wall.
- The lumen has a tendency to become obstructed by hardened intestinal contents (enteroliths), which leads to further stagnation of its contents.

Predisposition of the Appendix to Perforation

The appendix is supplied by a long small artery that does not anastomose with other arteries. The blind end of the appendix is supplied by the terminal branches of the appendicular artery. Inflammatory edema of the appendicular wall compresses the blood supply to the appendix and often leads to thrombosis of the appendicular artery. These conditions commonly result in necrosis or gangrene of the appendicular wall, with perforation.

Perforation of the appendix or transmigration of bacteria through the inflamed appendicular wall results in infection of the peritoneum of the greater sac. The part that the greater omentum may play in arresting the spread of the peritoneal infection is described on CD page 329.

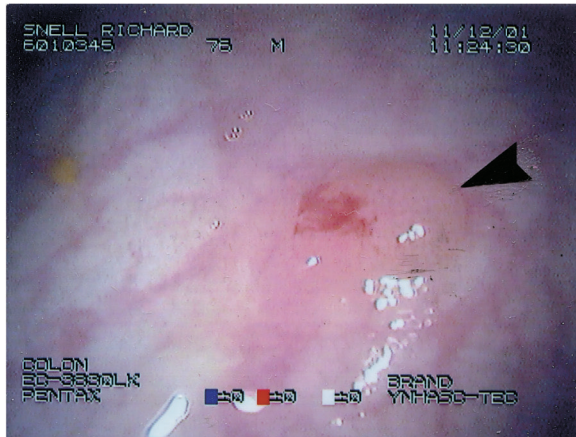
Pain of Appendicitis

Visceral pain in the appendix is produced by distention of its lumen or spasm of its muscle. The afferent pain fibers enter the spinal cord at the level of the tenth thoracic segment, and a **vague referred pain** is felt in the region of the umbilicus. Later, the pain shifts to where the inflamed appendix irritates the parietal peritoneum. Here the pain is **precise, severe, and localized**.

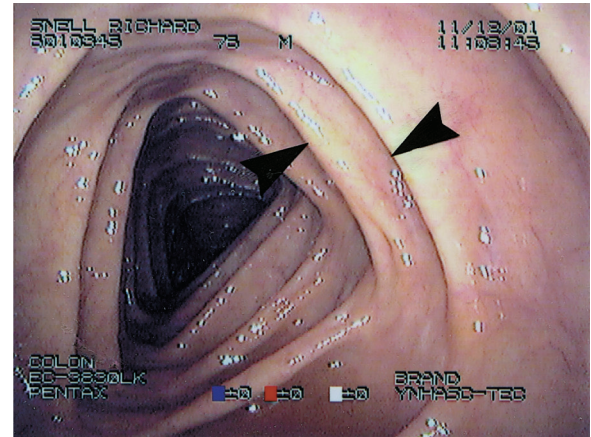
Colon and Cecum

Colonoscopy

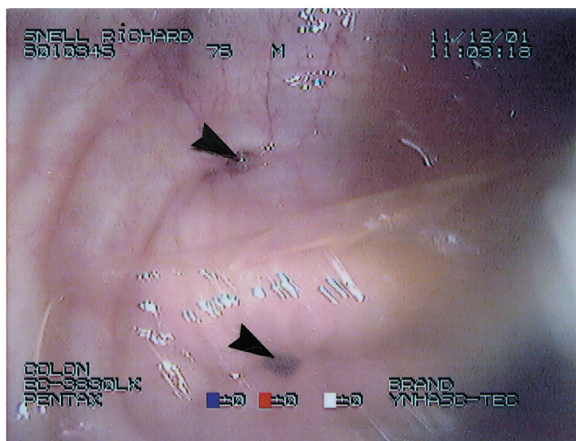
Since colorectal cancer is a leading cause of death in the Western world, colonoscopy is now being extensively used for early detection of malignant tumors. In this procedure, the mucous membrane of the colon can be directly visualized through an elongated flexible tube, or endoscope. Following a thorough washing out of the large bowel, the patient is sedated, and the tube is gently inserted into the anal canal. The interior of the large bowel can be observed from the anus to the cecum (CD Fig. 19-21). Photographs of suspicious areas, such as polyps, can be taken and biopsy specimens can be removed for pathologic examination. Although a relatively expensive procedure, it provides a



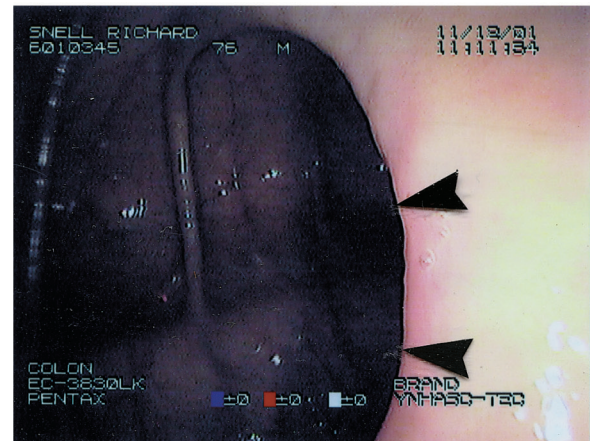A



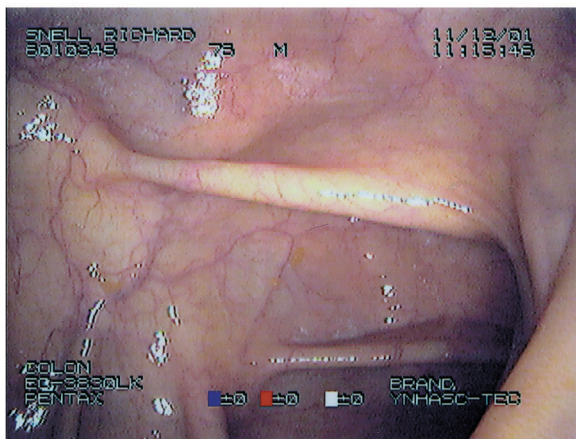
D



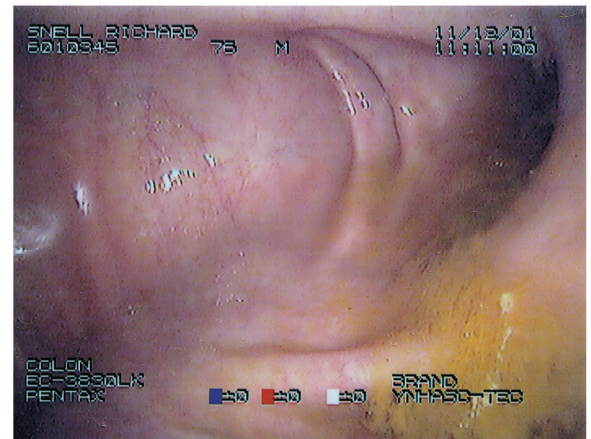B



E



C



F

CD Figure 19-21 Series of the interior of the large bowel taken during a colonoscopy procedure. **A.** The rectal mucosa shows a small benign polyp (*arrowhead*). **B.** The sigmoid mucous membrane shows evidence of a mild diverticulosis. *Arrowheads* indicate the entrances into the mucosal pouches. **C.** The splenic flexure is normal. Note the light reflections from the drops of mucus on the mucous membrane. **D.** The transverse colon shows the characteristic normal folds or ridges (*arrowheads*) between the sacculations of the wall of the colon. **E.** The ileocecal valve shows the upper lip (*arrowheads*) of the valve, which has a normal appearance. **F.** Finally, the mucous membrane lining the inferior wall or floor of the cecum looks normal. (Courtesy of M.H. Brand.)

more complete screening examination for colorectal cancer than combined fecal occult blood testing and the examination of the distal colon with sigmoidoscopy.

Trauma of the Cecum and Colon

Blunt or penetrating injuries to the colon occur. Blunt injuries most commonly occur where mobile parts of the colon (transverse and sigmoid) join the fixed parts (ascending and descending).

Penetrating injuries following stab wounds are common. The multiple anatomic relationships of the different parts of the colon explain why isolated colonic trauma is unusual.

Cancer of the Large Bowel

Cancer of the large bowel is relatively common in persons older than 50 years. The growth is restricted to the bowel wall for a considerable time before it spreads via the lymphatics. Bloodstream spread via the portal circulation to the liver occurs late. If a diagnosis is made early and a partial colectomy is performed, accompanied by removal of the lymph vessels and lymph nodes draining the area, then a cure can be anticipated.

Diverticulosis

Diverticulosis of the colon is a common clinical condition. It consists of a herniation of the lining mucosa through the circular muscle between the teniae coli and occurs at points where the circular muscle is weakest—that is, where the blood vessels pierce the muscle (CD Fig. 19-22). The common site for herniation is shown in CD Fig. 19-22.

Cecostomy and Colostomy

Because of the anatomic mobility of the cecum, transverse colon, and sigmoid colon, they may be brought to the surface through a small opening in the anterior abdominal wall. If the cecum or transverse colon is then opened, the bowel contents may be allowed to drain by this route. These procedures are referred to as **cecostomy** or **colostomy**, respectively, and are used to relieve large-bowel obstructions.

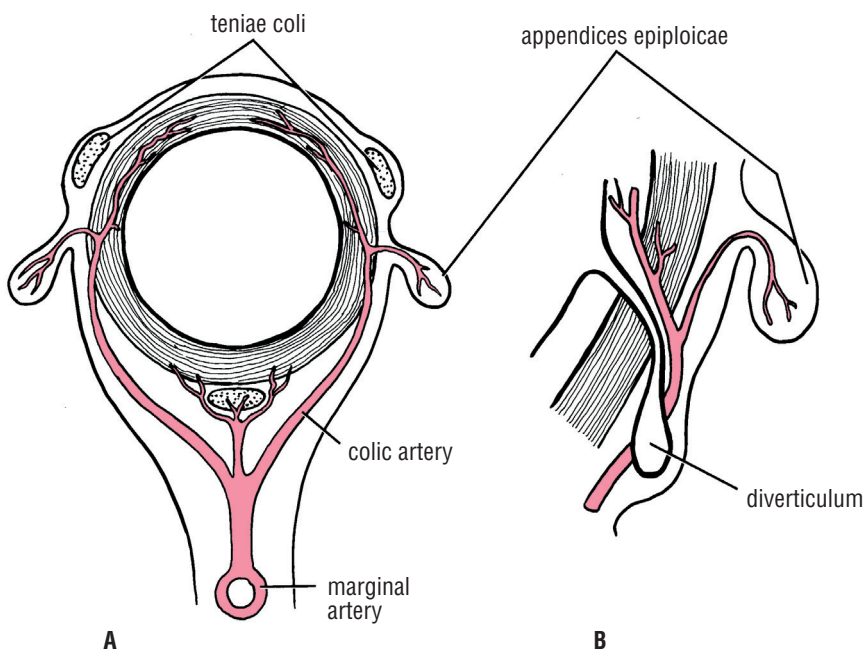
Volvulus

Because of its extreme mobility, the sigmoid colon sometimes rotates around its mesentery. This may correct itself spontaneously or the rotation may continue until the blood supply of the gut is cut off completely.

Intussusception

Intussusception is the telescoping of a proximal segment of the bowel into the lumen of an adjoining distal segment. Needless to say, there is a grave risk of cutting off the blood supply to the gut and developing gangrene. It is common in children. Ileocolic, colocolic, and ileoileal forms do occur, but ileocolic is the most common.

The high incidence in children may be caused by the relatively large size of the large bowel compared with the small intestine at this time of life. Another factor may be the possible swelling of Peyer's patches secondary to infection. In the latter case, the swollen patch protrudes into the lumen and violent peristalsis of the ileal wall tries to pass it distally along the gut lumen.



CD Figure 19-22 Blood supply to the colon (**A**) and formation of the diverticulum (**B**). Note the passage of the mucosal diverticulum through the muscle coat along the course of the artery.

Sigmoid Colon

Variation in the Length and Location of the Sigmoid Colon

The sigmoid colon shows great variation in length and may measure as much as 36 in. (91 cm). In the young child, because the pelvis is small, this segment of the colon may lie mainly in the abdomen.

Cancer of the Sigmoid Colon

The sigmoid colon is a common site for cancer of the large bowel. Because the lymphatic vessels of this segment of the colon drain ultimately into the inferior mesenteric nodes, it follows that an extensive resection of the gut and its associated lymphatic field is necessary to extirpate the growth and its local lymphatic metastases. The colon is removed from the left colic flexure to the distal end of the sigmoid colon, and the transverse colon is anastomosed to the rectum.

Volvulus

Because of its extreme mobility, the sigmoid colon sometimes rotates around its mesentery. This may correct itself spontaneously, or the rotation may continue until the blood supply of the gut is cut off completely. The rotation commonly occurs in a counterclockwise direction and is referred to as volvulus.

Diverticula

Diverticula of the mucous membrane along the course of the arteries supplying the sigmoid colon is a common clinical condition and is described on page 338. In patients with diverticulitis or ulcerative colitis, the sigmoid colon may become adherent to the bladder, rectum, ileum, or ureter and produce an internal fistula.

Sigmoidoscopy

Because the sigmoid colon lies only a short distance from the anus (6.5 in. [17 cm]) it is possible to examine the mucous membrane under direct vision for pathologic conditions. A flexible tube fitted with lenses and illuminated internally is introduced through the anus and carefully passed up through the anal canal, rectum, sigmoid colon, and descending colon. This examination, called sigmoidoscopy, can be carried out without an anesthetic in an outpatient clinic. Biopsy specimens of the mucous membrane can be obtained through this instrument.

Anatomic Facts Relative to Sigmoidoscopy

- The patient is placed in the left lateral position with the left knee flexed and the right knee extended (CD Fig. 19-23). Alternatively, the patient is placed kneeling in the knee–chest position.

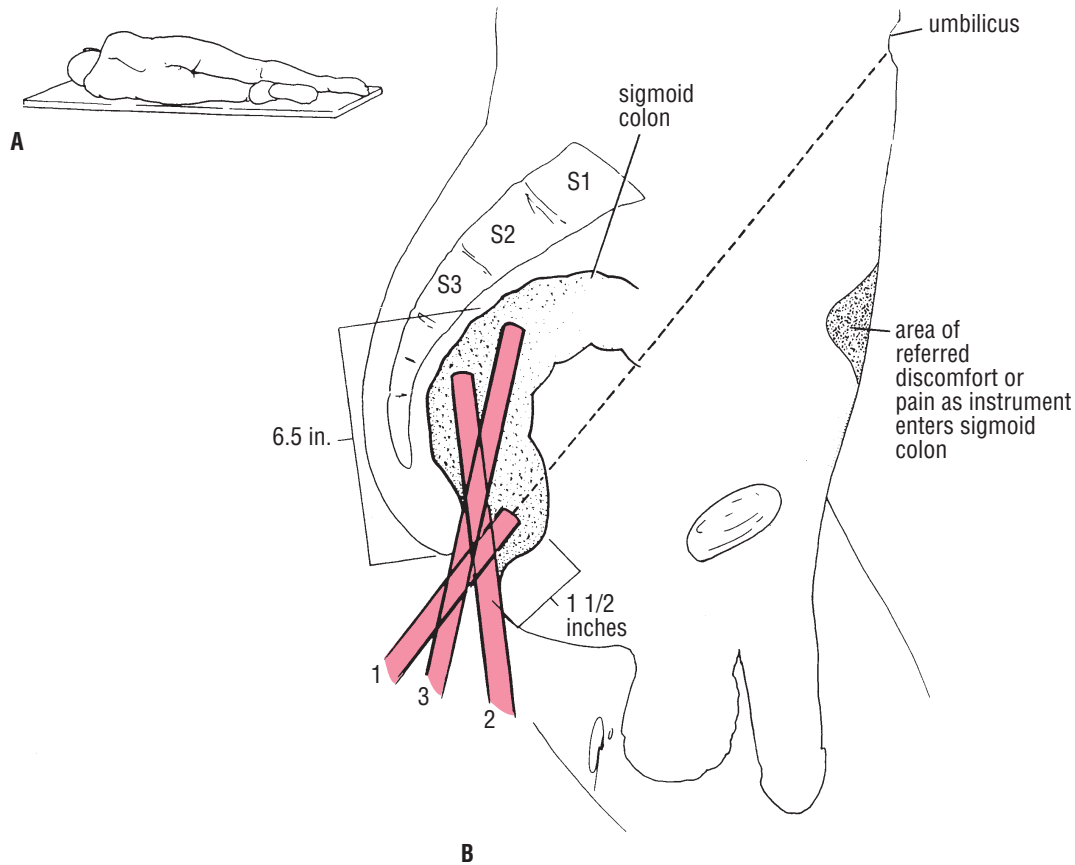
- The sigmoidoscope is gently inserted into the anus and anal canal in the direction of the umbilicus to ensure that the instrument passes along the long axis of the canal. Gentle but firm pressure is applied to overcome the resistance of the anal sphincters (see text Fig. 19-68).
- After a distance of about 1.5 in. (4 cm), the instrument enters the ampulla of the rectum. At this point, the tip of the sigmoidoscope should be directed posteriorly in the midline to follow the sacral curve of the rectum (see CD Fig. 19-23).
- Slow advancement is made under direct vision. Some slight side-to-side movement may be necessary to bypass the **transverse rectal folds**.
- At approximately 6.5 in. (16.25 cm) from the anal margin, the rectosigmoid junction will be reached. The sigmoid colon here bends forward and to the left, and the lumen appears to end in a blind cul-de-sac. To negotiate this angulation, the tip of the sigmoidoscope must be directed anteriorly and to the patient's left side. This maneuver can cause some discomfort in the anal canal from distortion of the anal sphincters by the shaft of the sigmoidoscope. Another possibility is that the point of the instrument may stretch the wall of the colon, giving rise to colicky pain in the lower abdomen.
- Once the instrument has entered the sigmoid colon, it should be possible to pass it smoothly along its full extent and, using the full length of the sigmoidoscope, enter the descending colon.
- The sigmoidoscope may now be slowly withdrawn, carefully inspecting the mucous membrane. The normal rectal and colonic mucous membrane is smooth and glistening and pale pink with an orange tinge, and blood vessels in the submucosa can be clearly seen. The mucous membrane is supple and moves easily over the end of the sigmoidoscope.

Anatomy of Complications of Sigmoidoscopy

Perforation of the bowel at the rectosigmoid junction can occur. This is almost invariably caused by the operator failing to negotiate carefully the curve between the rectum and the sigmoid colon. In some patients, the curve is in the form of an acute angulation, which may frustrate the overzealous advancement of the sigmoidoscope. Perforation of the sigmoid colon results in the escape of colonic contents into the peritoneal cavity.

Colostomy

The sigmoid colon is often selected as a site for performing a colostomy in patients with carcinoma of the rectum. Its mobility allows the surgeon to bring out a loop of colon, with its blood supply intact, through a small incision in the left iliac region of the anterior abdominal wall. Its mobility also makes it suitable for implantation of the ureters after surgical removal of the bladder.



CD Figure 19-23 Sigmoidoscopy. **A.** Patient in the left lateral position with the left knee flexed and the right knee extended. **B.** Sagittal section of the male pelvis showing the positions (1, 2, and 3) of the tube of the sigmoidoscope relative to the patient as it ascends the anal canal and rectum. The area of discomfort or pain experienced by the patient as the tube is negotiated around the bend into the sigmoid colon is referred to the skin of the anterior abdominal wall below the umbilicus.

Rectum

Rectal Curves and Mucosal Folds

The anteroposterior flexure of the rectum, as it follows the curvature of the sacrum and coccyx, and the lateral flexures must be remembered when one is passing a sigmoidoscope to avoid causing the patient unnecessary discomfort.

The crescentic transverse mucosal folds of the rectum must also be borne in mind when passing an instrument into the rectum. It is thought that these folds serve to support the weight of the feces and to prevent excessive distension of the rectal ampulla.

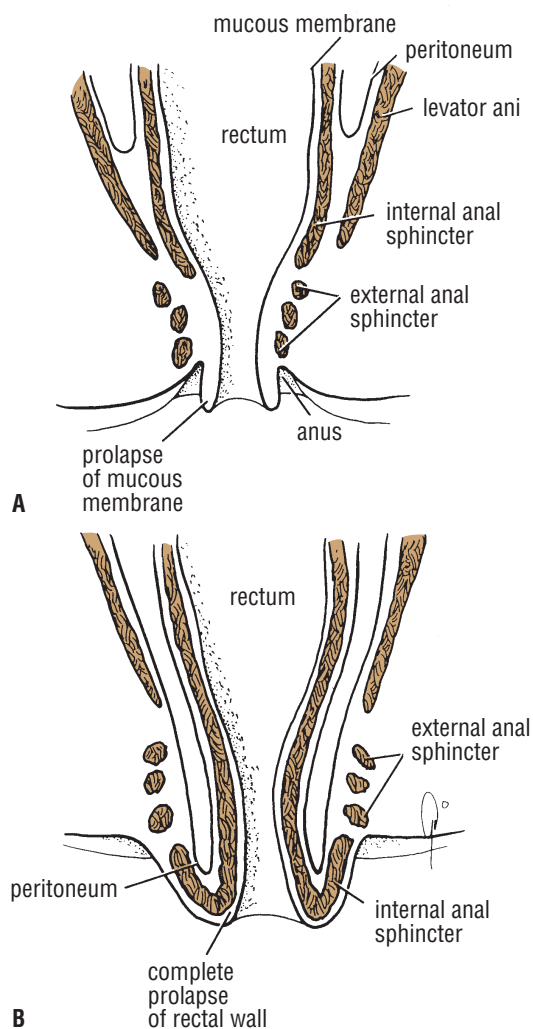
Blood Supply and Internal Hemorrhoids

The chief arterial supply to the rectum is from the superior rectal artery, a continuation of the inferior mesenteric artery. In front of the third sacral vertebra, the artery divides into right and left branches. Halfway down the rectum, the right

branch divides into an anterior and a posterior branch. The tributaries of the superior rectal vein are arranged in a similar manner, so that it is not surprising to find that **internal hemorrhoids** are arranged in three groups (see CD p. 341): two on the right side of the lower rectum and anal canal and one on the left.

Partial and Complete Prolapse of the Rectum

Partial and complete prolapses of the rectum through the anus are relatively common clinical conditions. In partial prolapse, the rectal mucous membrane and submucous coat protrude for a short distance outside the anus (CD Fig. 19-24). In complete prolapse, the whole thickness of the rectal wall protrudes through the anus. In both conditions, many causative factors may be involved. However, damage to the levatores ani muscles as the result of childbirth and poor muscle tone in the aged are important contributing factors. A complete rectal prolapse may be regarded as a sliding hernia through the pelvic diaphragm.



CD Figure 19-24 Coronal section of the rectum and anal canal. **A.** Incomplete rectal (mucosal) prolapse. **B.** Complete rectal prolapse.

Cancer of the Rectum

Cancer (carcinoma) of the rectum is a common clinical finding that remains localized to the rectal wall for a considerable time. At first, it tends to spread locally in the lymphatics around the circumference of the bowel. Later, it spreads upward and laterally along the lymph vessels, following the superior rectal and middle rectal arteries. Venous spread occurs late, and because the superior rectal vein is a tributary of the portal vein, the liver is a common site for secondary deposits.

Once the malignant tumor has extended beyond the confines of the rectal wall, knowledge of the anatomic relations of the rectum will enable a physician to assess the structures and organs likely to be involved. In both sexes, a posterior penetration involves the sacral plexus and can cause severe intractable pain down the leg in the distribution of the sciatic nerve. A lateral penetration may

involve the ureter. An anterior penetration in the male may involve the prostate, seminal vesicles, or bladder; in the female, the vagina and uterus may be invaded.

It is clear from the anatomic features of the rectum and its lymph drainage that a wide resection of the rectum with its lymphatic field offers the best chance of cure. When the tumor has spread to contiguous organs and is of a low grade of malignancy, some form of pelvic evisceration may be justifiable.

It is most important for a medical student to remember that the interior of the lower part of the rectum can be examined by a gloved index finger introduced through the anal canal. The anal canal is about 1.5 in. (4 cm) long so that the pulp of the index finger can easily feel the mucous membrane lining the lower end of the rectum. Most cancers of the rectum can be diagnosed by this means. This examination can be extended in both sexes by placing the other hand on the lower part of the anterior abdominal wall. With the bladder empty, the anterior rectal wall can be examined bimanually. In the female, the placing of one finger in the vagina and another in the rectum may enable the physician to make a thorough examination of the lower part of the anterior rectal wall.

Rectal Injuries

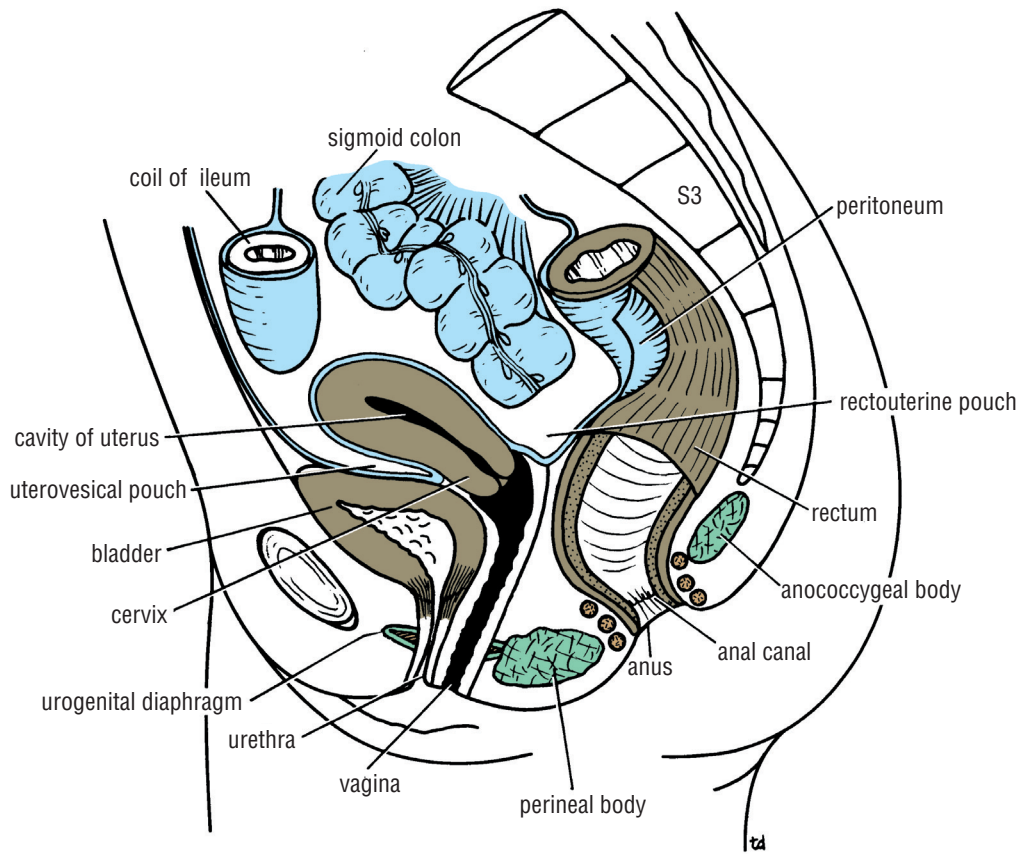
The management of penetrating rectal injuries will be determined by the site of penetration relative to the peritoneal covering. The upper third of the rectum is covered on the anterior and lateral surfaces by peritoneum, the middle third is covered only on its anterior surface, and the lower third is devoid of a peritoneal covering (CD Fig. 19-25). The treatment of penetration of the intraperitoneal portion of the rectum is identical to that of the colon, because the peritoneal cavity has been violated. In the case of penetration of the extraperitoneal portion, the rectum is treated by diverting the feces through a temporary abdominal colostomy, administering antibiotics, and repairing and draining the tissue in front of the sacrum.

Anal Canal

Internal Hemorrhoids (Piles)

Internal hemorrhoids are varicosities of the tributaries of the superior rectal (hemorrhoidal) vein and are covered by mucous membranes (CD Fig. 19-26). The tributaries of the vein, which lie in the anal columns at the 3, 7, and 11 o'clock positions when the patient is viewed in the lithotomy position,^{*} are particularly liable to become varicose. Anatomically, a hemorrhoid is therefore a fold of mucous

^{*}The patient is in the supine position with both hip joints flexed and abducted; the feet are held in position by stirrups. The position is commonly used for pelvic examinations of the female.



CD Figure 19-25 Sagittal section of the female pelvis.

membrane and submucosa containing a varicosed tributary of the superior rectal vein and a terminal branch of the superior rectal artery. Internal hemorrhoids are initially contained within the anal canal (first degree). As they enlarge, they extrude from the canal on defecation but return at the end of the act (second degree). With further elongation, they prolapse on defecation and remain outside the anus (third degree).

Because internal hemorrhoids occur in the upper half of the anal canal, where the mucous membrane is innervated by autonomic afferent nerves, they are painless and are sensitive only to stretch. This may explain why large internal hemorrhoids give rise to an aching sensation rather than acute pain.

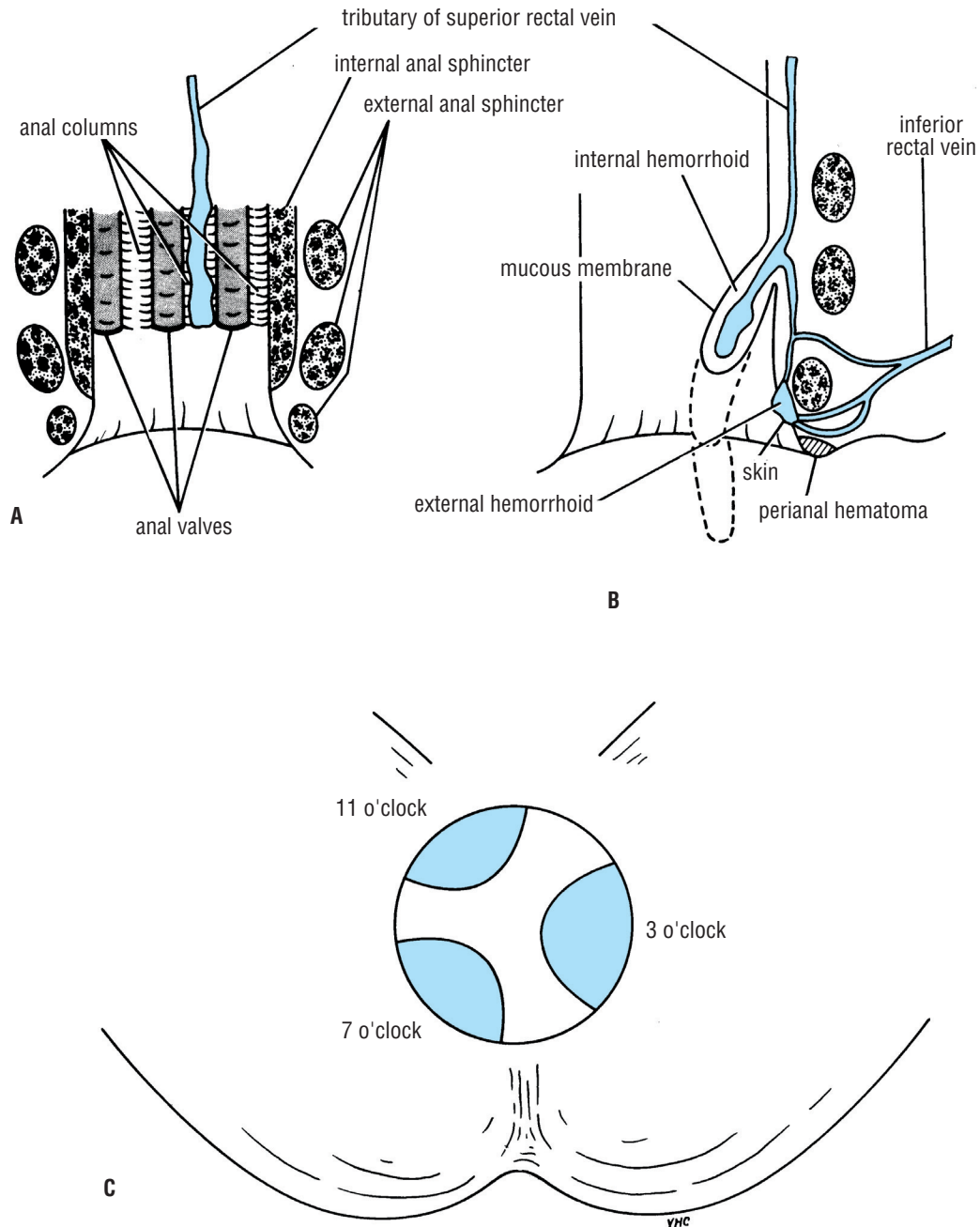
The causes of internal hemorrhoids are many. They frequently occur in members of the same family, which suggests a congenital weakness of the vein walls. Varicose veins of the legs and hemorrhoids often go together. The superior rectal vein is the most dependent part of the portal circulation and is valveless. The weight of the column of venous blood is thus greatest in the veins in the upper half of the anal canal. Here, the loose connective tissue of the submucosa gives little support to the walls of the veins. Moreover, the venous return is interrupted by the contraction of the

muscular coat of the rectal wall during defecation. Chronic constipation, associated with prolonged straining at stool, is a common predisposing factor. Pregnancy hemorrhoids are common owing to pressure on the superior rectal veins by the gravid uterus. Portal hypertension as a result of cirrhosis of the liver can also cause hemorrhoids. The possibility that cancerous tumors of the rectum are blocking the superior rectal vein must never be overlooked.

External Hemorrhoids

External hemorrhoids are varicosities of the tributaries of the inferior rectal (hemorrhoidal) vein as they run laterally from the anal margin. They are covered by skin (see CD Fig. 19-26) and are commonly associated with well-established internal hemorrhoids.

External hemorrhoids are covered by the mucous membrane of the lower half of the anal canal or the skin, and they are innervated by the inferior rectal nerves. They are sensitive to pain, temperature, touch, and pressure, which explains why external hemorrhoids tend to be painful. Thrombosis of an external hemorrhoid is common. Its cause is unknown, although coughing or straining may produce distension of the hemorrhoid followed by stasis.



CD Figure 19-26 **A.** Normal tributary of the superior rectal vein within the anal column. **B.** Varicosed tributary of the superior rectal vein forming the internal hemorrhoid. *Dotted lines* indicate degrees of severity of condition. **C.** Positions of three internal hemorrhoids as seen through a proctoscope with the patient in the lithotomy position.

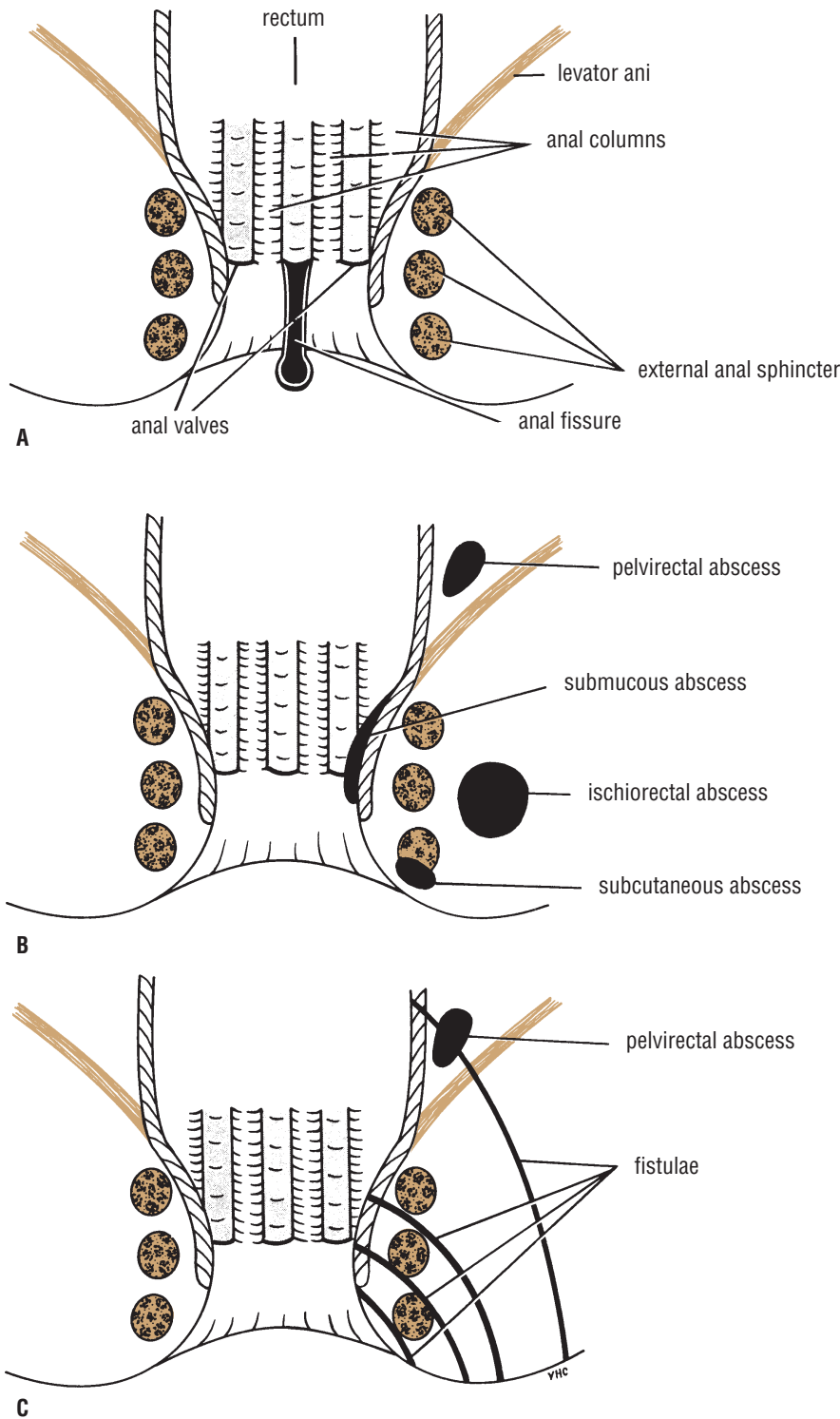
The presence of a small, acutely tender swelling at the anal margin is immediately recognized by the patient.

Perianal Hematoma

A perianal hematoma is a small collection of blood beneath the perianal skin (see CD Fig. 19-26). It is caused by a rupture of a small subcutaneous vein, possibly an external hemorrhoid, and is extremely painful.

Anal Fissure

The lower ends of the anal columns are connected by small folds called **anal valves** (CD Fig. 19-26A). In people suffering from chronic constipation, the anal valves may be torn down to the anus as the result of the edge of the fecal mass catching on the fold of mucous membrane. The elongated ulcer so formed, known as an **anal fissure** (CD Fig. 19-27), is extremely painful. The fissure occurs most



CD Figure 19-27 **A.** Tearing downward of the anal valve to form an anal fissure. **B.** Common locations of perianal abscesses. **C.** Common positions of perianal fistulae.

commonly in the midline posteriorly or, less commonly, anteriorly, and this may be caused by the lack of support provided by the superficial part of the external sphincter in these areas. (The superficial part of the external sphincter does not encircle the anal canal, but sweeps past its lateral sides.)

The site of the anal fissure in the sensitive lower half of the anal canal, which is innervated by the inferior rectal nerve, results in reflex spasm of the external anal sphincter, aggravating the condition. Because of the intense pain, anal fissures may have to be examined under local anesthesia.

Perianal Abscesses

Perianal abscesses are produced by fecal trauma to the anal mucosa (see CD Fig. 19-27). Infection may gain entrance to the submucosa through a small mucosal lesion, or the abscess may complicate an anal fissure or the infection of an anal mucosal gland. The abscess may be localized to the submucosa (submucous abscess), may occur beneath the perianal skin (subcutaneous abscess), or may occupy the ischiorectal fossa (ischiorectal abscess). Large ischiorectal abscesses sometimes extend posteriorly around the side of the anal canal to invade the ischiorectal fossa of the opposite side (horseshoe abscess). An abscess may be found in the space between the ampulla of the rectum and the upper surface of the levator ani (pelvirectal abscess). Anatomically, these abscesses are closely related to the different parts of the external sphincter and levator ani muscles, as seen in CD Fig. 19-27.

Anal fistulae develop as the result of spread or inadequate treatment of anal abscesses. The fistula opens at one end at the lumen of the anal canal or lower rectum and at the other end on the skin surface close to the anus (see CD Fig. 19-27). If the abscess opens onto only one surface, it is known as a **sinus**, not a fistula. The high-level fistulae are rare and run from the rectum to the perianal skin. They are located above the anorectal ring; as a result, fecal material constantly soils the clothes. The low-level fistulae occur below the level of the anorectal ring, as shown in CD Fig. 19-27.

The most important part of the sphincteric mechanism of the anal canal is the **anorectal ring**. It consists of the deep part of the external sphincter, the internal sphincter, and the puborectalis part of the levator ani. Surgical operations on the anal canal that result in damage to the anorectal ring will produce fecal incontinence.

Removal of Anorectal Foreign Bodies

Normally, the anal canal is kept closed by the tone of the internal and external anal sphincters and the tone of the puborectalis part of the levator ani muscles. The rectal contents are supported by the levator ani muscles, possibly assisted by the transverse rectal mucosal folds. For these reasons, the removal of a large foreign body, such as a vase or electric light bulb, from the rectum may be a formidable problem.

The following procedure is usually successful:

1. The foreign body must first be fixed so that the sphincteric tone, together with external attempts to grab the object, do not displace the object farther up the rectum.
2. Large, irregular, or fragile foreign bodies may not be removed so easily, and it may be necessary to paralyze the anal sphincter by giving the patient a general anesthetic or by performing an anal sphincter nerve block.

Anal Sphincter Nerve Block and Anesthetizing the Perianal Skin

By blocking the branches of the inferior rectal nerve and the perineal branch of the fourth sacral nerve, the anal sphincters will be relaxed and the perianal skin anesthetized.

The procedure is as follows:

1. An intradermal wheal is produced by injecting a small amount of anesthetic solution behind the anus in the midline.
2. A gloved index finger is inserted into the anal canal to serve as a guide.
3. A long needle attached to a syringe filled with anesthetic solution is inserted through the cutaneous wheal into the sphincter muscles along the posterior and lateral surfaces of the anal canal. The procedure is repeated on the opposite side. The purpose of the finger in the anal canal is to guide the needle and to prevent penetration of the anal mucous membrane.

Incontinence Associated with Rectal Prolapse

Fecal incontinence can accompany severe rectal prolapse of long duration. It is thought that the prolonged and excessive stretching of the anal sphincters is the cause of the condition. The condition can be treated by restoring the anorectal angle by tightening the puborectalis part of the levator ani muscles and the external anal sphincters behind the anorectal junction.

Incontinence after Trauma

Trauma, such as childbirth, or damage to the sphincters during surgery or perianal abscesses or fistulae can be responsible for incontinence after trauma.

Incontinence after Spinal Cord Injury

After severe spinal cord injuries, the patient is not aware of rectal distension. Moreover, the parasympathetic influence on the peristaltic activity of the descending colon, sigmoid colon, and rectum is lost. In addition, control over the abdominal musculature and sphincters of the anal canal may be severely impaired. The rectum, now an isolated structure, responds by contracting when the pressure within its lumen rises. This local reflex response is much more efficient if the sacral segments of the spinal cord are spared. At best, however, the force of the contractions of the rectal wall is small, and constipation and impaction of feces are the usual outcome.

Rectal Examination

The following structures can be palpated by the gloved index finger inserted into the anal canal and rectum in the normal patient.

Anteriorly

In the male:

- **Opposite the terminal phalanx** are the contents of the rectovesical pouch, the posterior surface of the bladder, the seminal vesicles, and the vasa deferentia (CD Fig. 19-28).
- **Opposite the middle phalanx** are the rectoprostatic fascia and the prostate.

- **Opposite the proximal phalanx** are the perineal body, the urogenital diaphragm, and the bulb of the penis.

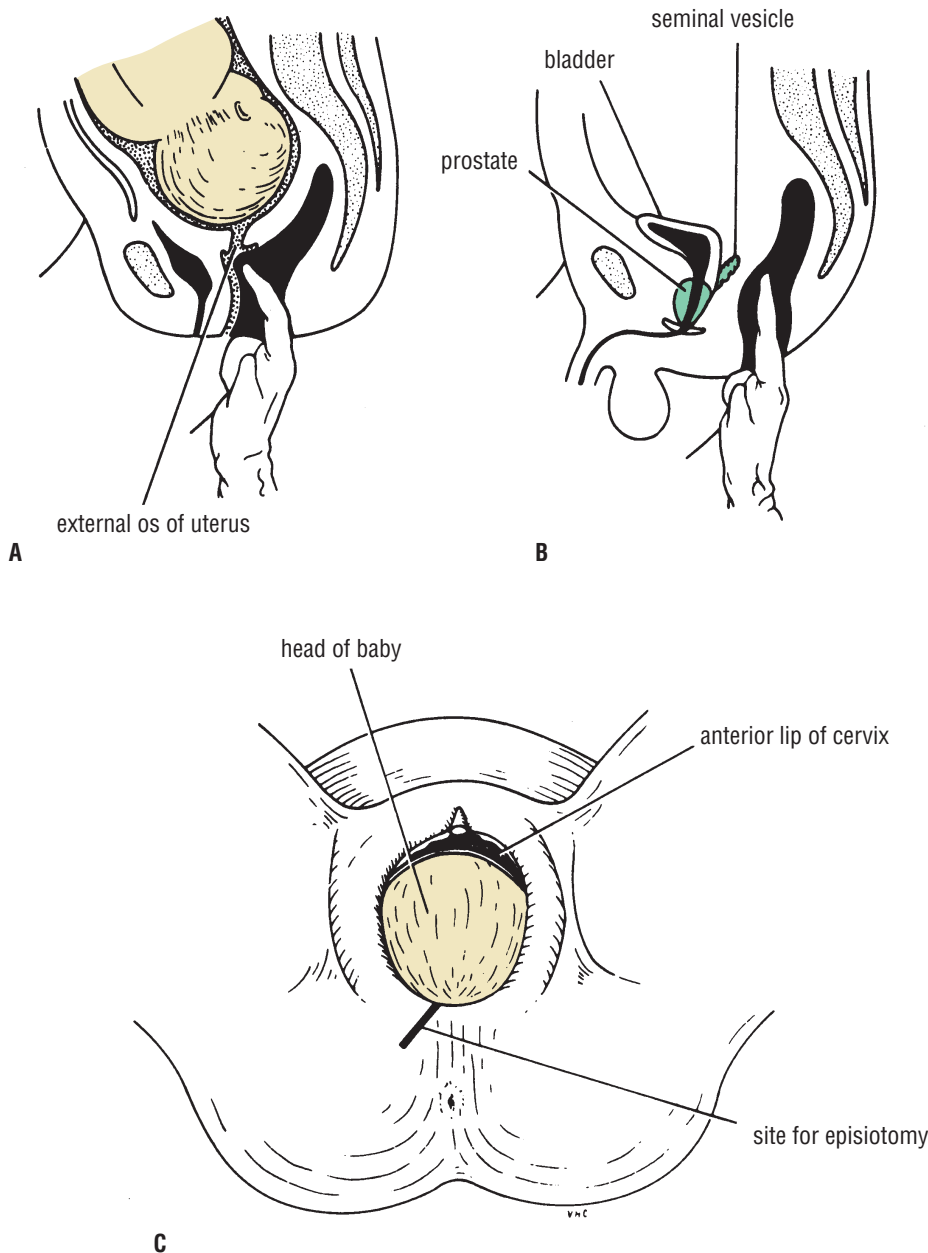
In the female:

- **Opposite the terminal phalanx** are the rectouterine pouch, the vagina, and the cervix (CD Fig. 19-25).
- **Opposite the middle phalanx** are the urogenital diaphragm and the vagina.
- **Opposite the proximal phalanx** are the perineal body and the lower part of the vagina.

Posteriorly

The sacrum, coccyx, and anococcygeal body can be felt.

Laterally



CD Figure 19-28 **A.** Rectal examination in a pregnant woman showing how it is possible to palpate the cervix through the anterior rectal wall. **B.** Rectal examination in the male showing how it is possible to palpate the prostate and the seminal vesicles through the anterior rectal wall. **C.** Position of the episiotomy incision in a woman during the second stage of labor. The baby's head is presenting at the vaginal orifice.

The ischiorectal fossae and ischial spines can be palpated.

Cancer and the Lymph Drainage of the Anal Canal

The upper half of the mucous membrane of the anal canal is drained upward to lymph nodes along the course of the superior rectal artery. The lower half of the mucous membrane is drained downward to the medial group of superficial inguinal nodes. Many patients have thought they had an inguinal hernia, and the physician has found a cancer of the lower half of the anal canal, with secondary deposits in the inguinal lymph nodes.



ISCHIORECTAL FOSSA

The Ischiorectal Fossa and Infection

The ischiorectal fossae (ischioanal fossae) are filled with fat that is poorly vascularized. The close proximity to the anal canal makes them particularly vulnerable to infection. Infection commonly tracks laterally from the anal mucosa through the external anal sphincter. Infection of the perianal hair follicles or sweat glands may also be the cause of infection in the fossae. Rarely, a perirectal abscess bursts downward through the levator ani muscle. An ischiorectal abscess may involve the opposite fossa by the spread of infection across the midline behind the anal canal.



CONGENITAL ANOMALIES OF THE ESOPHAGUS

Atresia of the Esophagus

Atresia of the esophagus, with and without fistula, with the trachea is considered in detail on CD Chapter 3.

Esophageal Stenosis

Esophageal stenosis is a narrowing of the lumen of the esophagus, which commonly occurs in the lower part. It is treated by dilatation.

Congenital Short Esophagus

Abnormal shortness of the esophagus is caused by an esophageal hiatus hernia in the diaphragm. Stomach contents flow into the esophagus, resulting in esophagitis.



CONGENITAL ANOMALIES OF THE STOMACH

Congenital Hypertrophic Pyloric Stenosis

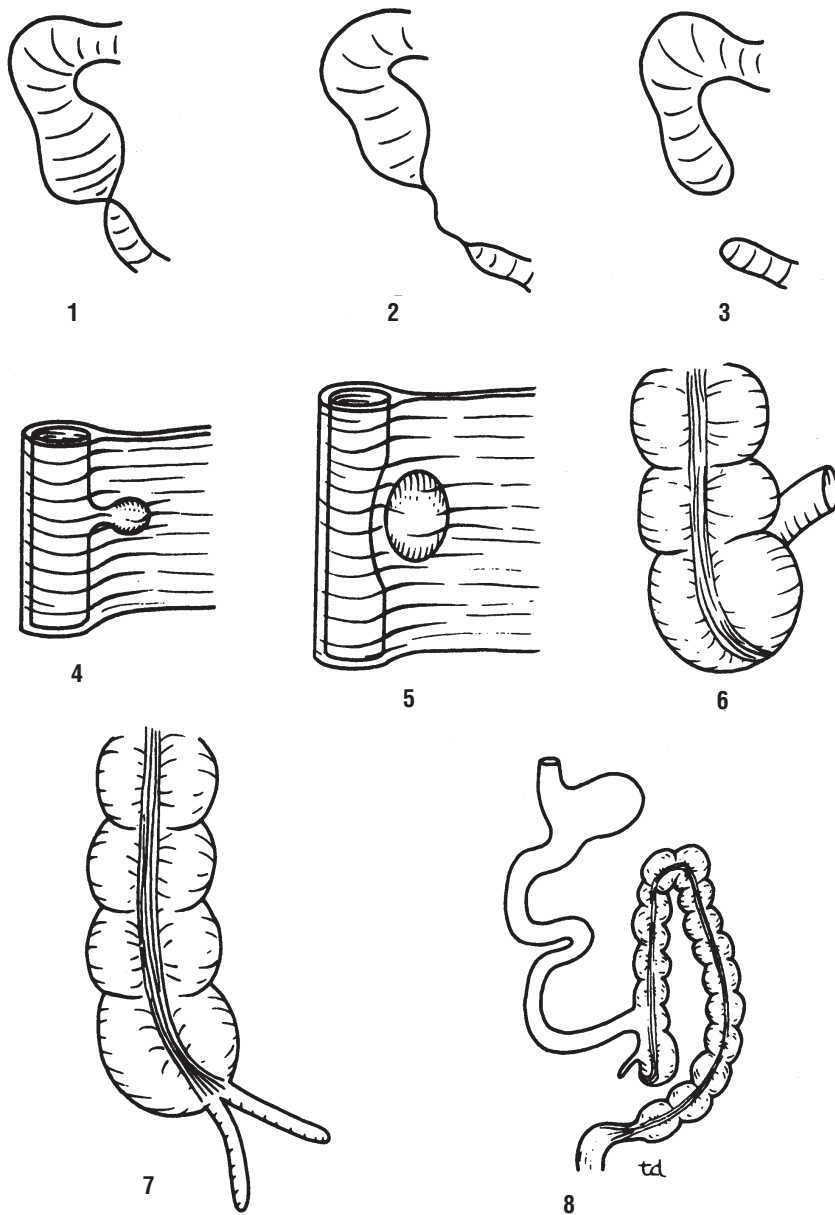
Hypertrophic pyloric stenosis is a relatively common emergency in infants between the ages of 3 and 6 weeks. The child ejects the stomach contents with considerable force. The exact cause of the stenosis is unknown, although evidence suggests that the number of autonomic ganglion cells in the stomach wall is fewer than normal. This possibility leads to prenatal neuromuscular incoordination and localized muscular hypertrophy and hyperplasia of the pyloric sphincter. It is much more common in male children.



CONGENITAL ANOMALIES OF THE SMALL AND LARGE INTESTINES

Diverticula of the Intestine

All coats of the intestinal wall are found in the wall of a congenital diverticulum. In the duodenum, diverticula are found on the medial wall of the second and third parts (CD Fig. 19-29). Usually, these are symptomless. Jejunal diverticula occasionally occur and usually give rise to no symptoms. For Meckel's diverticulum of the ileum, see CD page 327. A diverticulum of the cecum is commonly situated on the medial side of the cecum close to the ileocecal valve. It may be subject to acute inflammation and then is confused with appendicitis. Diverticula of the colon are acquired, not congenital (see CD p. 338).



CD Figure 19-29 Some common congenital anomalies of the intestinal tract. **1-3.** Congenital atresias of the small intestine. **4.** Diverticulum of the duodenum or jejunum. **5.** Mesenteric cyst of the small intestine. **6.** Absence of the appendix. **7.** Double appendix. **8.** Malrotation of the gut, with the appendix lying in the left iliac fossa. For Meckel's diverticulum, see CD Fig. 19-15.

Atresia and Stenosis of the Small Intestine

The most common site of an atretic or stenotic obstruction is in the duodenum. During the development of the duodenum, the lining cells proliferate at such a rate that the lumen becomes completely obliterated. Later, as a result of degeneration of these cells, the gut becomes recanalized. Failure of recanalization could produce atresia or stenosis. Different forms of duodenal atresia and stenosis are shown in CD Fig. 19-29. Vomiting is the most common presenting symptom, and the vomitus usually is bile stained. Surgical treatment during the first few days of life is essential.

The next most common sites are the ileum and jejunum, respectively (see CD Fig. 19-29). Frequently, the

obstruction occurs at multiple sites. The cause is possibly the failure of the lumen to become recanalized after it has been blocked by epithelial proliferation of the cells of the mucous membrane. Other causes have been suggested, such as vascular damage associated with twisting or volvulus of the intestine. Persistent bile-stained vomiting occurs from birth. Surgical relief of the obstruction should be carried out as soon as possible.

Duplication of the Digestive System

In duplication of the digestive system, the normal degeneration of the mucous membrane cells, which have proliferated to temporarily block the lumen, occurs at two sites simultaneously instead of at one. In this way, two lumina are formed side by side. The additional segment of bowel

should be removed as soon as possible, since it may cause obstruction or be the site of hemorrhage or perforation.

Arrested Rotation or Malrotation of the Midgut Loop

Complete Absence of Rotation or Incomplete Rotation

Complete absence of rotation is rare. In cases of incomplete rotation, no further rotation occurs after the initial counterclockwise rotation of 90° in the umbilical cord. Thus, the duodenum, jejunum, and ileum remain on the right side of the abdomen, and the cecum and colon are on the left side of the abdomen (see CD Fig. 19-29). In other cases, a counterclockwise rotation of 180° occurs, and although the duodenum may take up its correct position posterior to the superior mesenteric artery, the cecum comes to lie anterior and to the left of the duodenum. Abnormal adhesions form, which run across the anterior surface of the duodenum and cause obstruction to its second part.

Malrotation of the Midgut Loop

Counterclockwise rotation of 90° followed by clockwise rotation of 90° or 180° may occur. In these cases, the duodenum comes to lie anterior to the superior mesenteric artery, and the colon may come to lie anterior to the mesentery of the small intestine. Repeated vomiting is usually the presenting symptom and is caused by duodenal obstruction. Surgical correction of the incomplete rotation or malrotation of the gut is performed, and all adhesions are divided.

Persistence of the Vitellointestinal Duct

The vitelline duct in the early embryo connects the developing gut to the yolk sac (see text Fig. 19-78). Normally, as development proceeds, the duct is obliterated, severs its connection with the intestine, and disappears. Persistence of the vitellointestinal duct can result in an umbilical fistula (see CD Fig. 19-15). If the duct remains as a fibrous band, a loop of small intestine can become wrapped around it, causing intestinal obstruction (see CD Fig. 19-15).

Meckel's Diverticulum

Meckel's diverticulum, a congenital anomaly, represents a persistent portion of the vitellointestinal duct (see CD Fig. 19-15). The diverticulum is located on the antimesenteric border of the ileum about 2 ft (61 cm) from the ileocecal junction. It is about 2 in. (5 cm) long and occurs in about

2% of individuals. The diverticulum is important clinically, since it may possess a small area of gastric mucosa, and bleeding may occur from a "gastric" ulcer in its mucous membrane. Moreover, the pain from this ulcer may be confused with the pain from appendicitis. Should a fibrous band connect the diverticulum to the umbilicus, a loop of small bowel may become wrapped around it, causing intestinal obstruction.

Undescended Cecum and Appendix

In cases of undescended cecum and appendix, an inflammation of the appendix would give rise to tenderness in the right hypochondrium, which may lead to a mistaken diagnosis of inflammation of the gallbladder.

Anomalies of the Appendix

Agensis of the appendix (failure to develop) is extremely rare; however, a few examples of double appendix have been reported (see CD Fig. 19-29). The possibility of left-sided appendix in individuals with transposition of thoracic and abdominal viscera or in cases of arrested rotation of the midgut should always be remembered (see CD Fig. 19-29).

Anomalies of the Colon

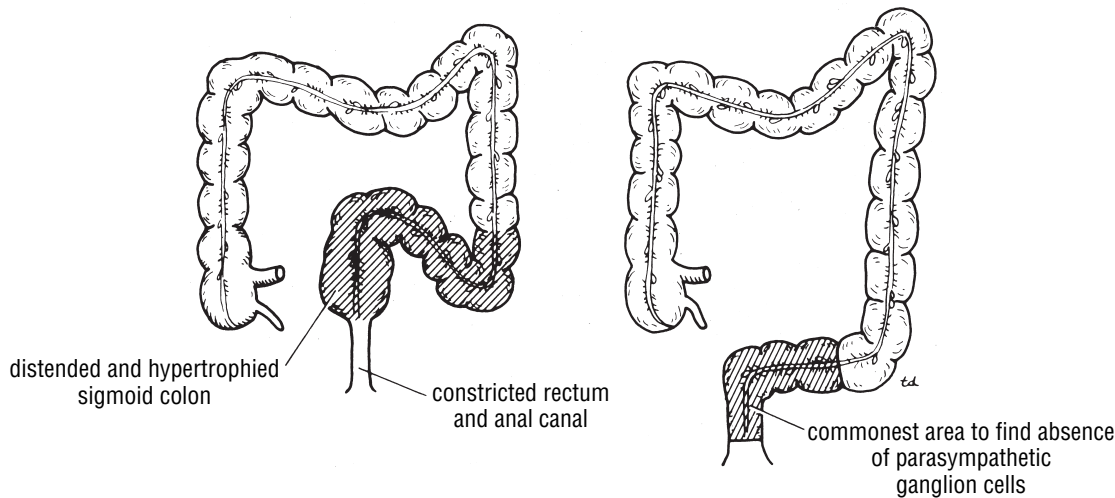
The congenital anomaly of undescended cecum or failure of rotation of the gut so that the cecum lies in the left iliac fossa may give rise to confusion in diagnosis. The pain of appendicitis, for example, although initially starting in the umbilical region, may shift not to the right iliac fossa but to the right upper quadrant or to the left lower quadrant.

Primary Megacolon (Hirschsprung Disease)

Hirschsprung disease shows a familial tendency and is more common in males than in females. Symptoms usually appear during the first few days after birth. The child fails to pass meconium, and the abdomen becomes enormously distended. The sigmoid colon is greatly distended and hypertrophied, while the rectum and anal canal are constricted (CD Fig. 19-30). It is the constricted segment of the bowel that causes the obstruction, and histologic examination reveals a complete failure of development of the parasympathetic ganglion cells in this region. The treatment is operative excision of the aganglionic segment of the bowel.

Imperforate Anus

About 1 child in 4,000 is born with imperforate anus caused by an imperfect fusion of the entodermal cloaca with the proctodeum (see text Fig. 19-77).



CD Figure 19-30 Main characteristics of primary megacolon (Hirschsprung disease).

Clinical Problem Solving Questions

Read the following case histories/questions and give the best answer for each.

An 8-year-old boy was admitted to the hospital with a temperature of 101°F, a furred tongue, and pain in the right lower quadrant. On examination, the skin on the right lower quadrant was tender to the touch, and the abdominal muscles were contracted and rigid. A diagnosis of acute appendicitis was made.

- The symptoms and signs displayed by this patient can be explained by the following statements **except** which?
 - An acutely inflamed appendix produces an inflammation of the peritoneal coat covering it.
 - Should the inflammatory process spread, for example, if the appendix should rupture, the parietal peritoneum would become involved.
 - The parietal peritoneum, the abdominal muscles, and the overlying skin are supplied by the same segmental spinal nerves.
 - The segmental nerves supplying the right lower quadrant of the abdominal wall are T7, T8, and T9.
 - The pain in the right lower quadrant and the regional contraction of the abdominal muscles is an attempt by the body to keep the inflamed appendix immobile so that the inflammatory process remains localized.

A workman engaged in demolishing a building lost his balance and fell astride a girder on the floor below. On examination, he was found to have extensive swelling of

his perineum, scrotum, and penis. He was unable to urinate normally, passing only a few drops of blood-stained urine. The lower part of the anterior abdominal wall was also swollen, but his thighs were normal.

- The symptoms and signs displayed by this patient can be explained by the following statements **except** which?
 - The patient's fall ruptured the urethra in the perineum.
 - When the patient attempted to micturate, the urine extravasated beneath Colles' fascia.
 - The urine passed over the scrotum and penis under the membranous layer of superficial fascia.
 - The urine passed upward beneath the membranous layer of superficial fascia on the anterior abdominal wall.
 - The urine could not extend posteriorly because of the attachment of Colles' fascia to the tip of the coccyx.
 - The urine did not extend into the thigh because of the attachment of the membranous layer of superficial fascia to the fascia lata, just below the inguinal ligament.

A 45-year-old woman was shopping in a liquor store when an armed robbery took place. A shootout occurred and a bullet ricocheted off the wall and entered her left side. Fortunately, the bullet did not enter the peritoneal cavity. One year later, in addition to diminished skin sensation over the left lumbar region and umbilicus, she noticed a bulging forward of the left side of her anterior abdominal wall.

3. The symptoms and signs displayed by this patient can be explained by the following statements **except** which?
- The bullet cut the ninth and tenth intercostal nerves just below the costal margin on the left side.
 - The diminished skin sensation was caused by the loss of the sensory nerve supply to the ninth and tenth thoracic dermatomes.
 - Portions of the oblique, transversus, and rectus abdominis muscles on the left side were paralyzed.
 - Atrophy of the pyramidalis muscle resulted in loss of support to the abdominal viscera, which then sagged forward.

A 9-week-old boy was admitted to the hospital with a swelling in the right groin that extended down into the upper part of the scrotum. When he cried, the swelling enlarged. On careful palpation it was possible to reduce the size of the swelling, and this procedure was accompanied by a gurgling noise.

4. The symptoms and signs displayed by this patient can be explained by the following statements **except** which?
- The swelling was situated above and medial to the pubic tubercle on the right side.
 - The child had a right indirect inguinal hernia.
 - The processus vaginalis in its upper part had failed to become obliterated before birth.
 - The hernial sac in an indirect inguinal hernia emerges from the superficial inguinal ring.
 - The superficial inguinal ring lies above and medial to the pubic tubercle.
 - The contents of the hernial sac consisted only of the greater omentum.

A 75-year-old man with chronic bronchitis noticed that a bulge was developing in his left groin. On examination, an elongated swelling was seen above the medial end of the left inguinal ligament. When the patient coughed, the swelling enlarged but did not descend into the scrotum. The patient had weak abdominal muscles.

5. The symptoms and signs displayed by this patient can be explained by the following statements **except** which?
- The inguinal swelling was a direct inguinal hernia.
 - The cause of the hernia was weak abdominal muscles.
 - The hernial sac was wide and in direct communication with the peritoneal cavity.
 - A rise in intraabdominal pressure on coughing caused the hernial swelling to expand.
 - The swelling occurred lateral to the inferior epigastric artery.

A 40-year-old woman noticed a painful swelling in her right groin after helping her husband move some heavy furniture. On examination, a small tender swelling was noted in the right groin.

6. The symptoms and signs displayed by this patient can be explained by the following statements **except** which?
- The excessive exertion caused a rise in intraabdominal pressure.
 - A hernial sac formed of parietal peritoneum was forced downward.
 - The peritoneum was forced through the right femoral canal.
 - The patient had a right-sided femoral hernia.
 - The neck of a femoral hernial sac is situated below and medial to the pubic tubercle.

A 55-year-old man was admitted to the hospital with a large hard, fixed, intraabdominal mass. On examination of the abdomen, the mass was situated on the transpyloric plane. The inguinal lymph nodes were normal.

7. The symptoms and signs displayed by this patient can be explained by the following statements **except** which?
- Radiologic examination of the stomach showed nothing abnormal.
 - The right testicle was enlarged and was much harder than normal.
 - A diagnosis of malignant disease of the right testis was made.
 - The malignant tumor had metastasized to the lumbar lymph nodes lying on the transpyloric plane on the posterior abdominal wall, which is the normal lymphatic drainage of the testis.
 - In malignant disease of the testis the superficial inguinal lymph nodes only become involved if the tumor spreads to involve the scrotal skin.
 - The normal testis is tethered to the skin of the scrotum.

A 25-year-old man involved in purchasing drugs was knifed in the abdomen in the left upper quadrant. On examination in the emergency department, it was difficult to determine whether the knife had penetrated the peritoneal cavity. It was decided to do a midline peritoneal lavage below the umbilicus to see if there was any free blood in the peritoneal cavity.

8. The following layers of tissue were penetrated by the trocar and cannula to enter the peritoneal cavity **except** which?
- Skin
 - Fatty and membranous layers of superficial fascia
 - Rectus sheath and rectus abdominis muscle
 - Deep fascia
 - Fascia transversalis
 - Extraperitoneal tissue and parietal peritoneum

A 45-year-old man was admitted to the emergency department complaining of severe pain in the right lower quadrant of the anterior abdominal wall. He had repeatedly vomited, and his temperature and pulse rate were elevated.

His history indicated that he had acute appendicitis and that the pain had suddenly increased. On examination, the muscles of the lower part of the anterior abdominal wall in the right lower quadrant showed rigidity. The diagnosis of peritonitis after perforation of the appendix was made.

9. The symptoms and signs displayed by this patient can be explained by the following statements **except** which?
 - A. The perforation of the appendix had resulted in the spread of the infection from the appendix to involve the parietal peritoneum.
 - B. The parietal peritoneum in the right iliac region, the muscles of the anterior abdominal wall, and the overlying skin are all supplied by the segmental nerves T12 and L1.
 - C. Irritation of the parietal peritoneum reflexly increases the tone of the abdominal muscles, causing rigidity.
 - D. The greater omentum tends to become stuck down to the appendix and restricts the spread of infection.
 - E. The pain was intensified after perforation of the appendix because of stimulation of the autonomic pain endings in the parietal peritoneum.

A 63-year-old man with a long history of a duodenal ulcer was seen in the emergency department after vomiting blood-stained fluid and exhibiting all the signs and symptoms of severe hypovolemic shock.

10. The following statements concerning duodenal ulcers could apply to the patient's condition **except** which?
 - A. Hemorrhage from a duodenal ulcer often reveals itself by the passage of black stools on defecation.
 - B. The pyloric sphincter prevents most of the blood from the duodenal lumen from passing up into the stomach.
 - C. The gastroduodenal artery lies behind the first part of the duodenum and was probably eroded by the ulcer.
 - D. The gastroduodenal artery is a small branch of the hepatic artery.
 - E. The duodenal ulcer was most likely to be situated on the posterior wall of the first part of the duodenum.

A 47-year-old woman was operated on for the treatment of a chronic gastric ulcer that had not responded to medical treatment. At operation for partial gastrectomy, it was found that the posterior wall of the stomach was stuck down to the posterior abdominal wall. The surgeon had to proceed with great care to avoid damaging important structures lying on the posterior abdominal wall.

11. The following structures located on the posterior abdominal wall were possibly involved in the disease process **except** which?
 - A. The right kidney
 - B. The pancreas
 - C. The left suprarenal gland
 - D. The left kidney

- E. The lesser sac of peritoneum
- F. The splenic artery

A 58-year-old man was in a restaurant when he suddenly started to vomit blood. He was taken unconscious to the emergency department of a local hospital. On examination, he had all the signs of severe hypovolemic shock. On palpation of the anterior abdominal wall, the right lobe of the liver was felt three fingerbreadths below the costal margin. Several enlarged superficial veins could be seen around the umbilicus. His wife said that he had vomited blood 3 months previously and had nearly died. She admitted that he was a chronic alcoholic. The diagnosis was cirrhosis of the liver secondary to chronic alcoholism.

12. The symptoms and signs displayed by this patient can be explained by the following statements **except** which?
 - A. The normal flow of portal blood through the liver is impaired by cirrhosis of the liver.
 - B. The portal–systemic anastomoses become enlarged in this condition.
 - C. At the lower end of the esophagus, a branch from the right gastric vein anastomoses with an esophageal tributary of the azygos vein.
 - D. Rupture of a varicose esophageal vein could produce a severe hemorrhage so that the patient would vomit up blood.
 - E. With portal hypertension the paraumbilical veins linking the superficial veins of the skin (systemic veins) to the portal vein become congested and visible.

A 48-year-old woman with a history of repeated vomiting was admitted to the hospital with a diagnosis of large bowel obstruction. To decompress the stomach a nasogastric tube was passed.

13. When passing a nasogastric tube some important anatomic facts should be considered **except** which?
 - A. The well-lubricated tube is inserted through the wider nostril.
 - B. The tube is directed backward along the nasal floor and not upward because it may become caught on the nasal choanae.
 - C. The distance between the nostril and the cardiac orifice of the stomach is about 23 in. (57.5 cm).
 - D. The distance between the cardiac orifice and the pylorus is 4.8 to 5.6 in. (12 to 14 cm).
 - E. Esophageal narrowing may offer resistance to the tube behind the cricoid cartilage, 7.2 in. (18 cm) from the nostril.
 - F. The left bronchus and the arch of the aorta cross in front of the esophagus and may impede the descent of the tube, 11.2 in. (28 cm) from the nostril.
 - G. Where the esophagus enters the stomach there is a slight resistance to the descent of the tube.

14. The following statements concerning an indirect inguinal hernia are correct **except** which?
- It is the most common form of abdominal hernia.
 - The neck of the hernial sac lies medial to the inferior epigastric artery.
 - The sac is the remains of the processus vaginalis.
 - The hernial sac can extend into the scrotum.
 - At the superficial inguinal ring, the hernial sac lies above and medial to the pubic tubercle.

A mother took her 20-day-old baby boy to a pediatrician because he had started to vomit after his feeds. The baby was breast-fed. For the first 15 days after birth, the baby had taken his feeds very well and had slept contentedly in his crib following the normal after-feed burp. However, in the previous 5 days, the baby had begun to vomit toward the end of each feed, shooting the milk out of his mouth for a distance of 1 to 2 ft. After carefully questioning the mother and after a physical examination of the boy, the pediatrician made the diagnosis of congenital hypertrophic pyloric stenosis.

15. He was able to ascertain the following additional signs and symptoms **except** which?
- Once the milk had been vomited, the child immediately would feed again, only to repeat the same performance.
 - On gentle palpation of the anterior abdominal wall, a small firm swelling was felt just below and medial to the tip of the left eighth costal cartilage.
 - On observing the anterior abdominal wall, an occasional wave of gastric peristalsis was seen traveling across the epigastrium from left to right.
 - The stools were small in quantity and infrequent.
 - The child showed signs of dehydration as evidenced by a depressed anterior fontanelle of the skull.

A 6-year-old girl was examined by a pediatrician because she had a history of recurrent pain in the region of the umbilicus. The pain was dull and aching in nature and lasted for about 1 week. It had recurred on four occasions in the previous 2 years. Then 2 days before the examination, the child had severe rectal bleeding and had fainted.

16. On examination of the child, the pediatrician found the following signs and symptoms consistent with the diagnosis of Meckel's diverticulum **except** which?
- Tenderness of the anterior abdominal wall in the right iliac region
 - Anemia
 - Stools streaked with dark red blood
 - Pyrexia of 102°F

A 30-year-old man involved in a barroom brawl was seen in the emergency department. He was found to have a blood-stained tear on the seat of his trousers and lacerations of the anal margin. During the fight he was knocked down and fell

in the sitting position on the leg of an upturned bar stool. While under observation he developed the signs and symptoms of peritonitis.

17. The signs and symptoms displayed by this patient could be explained by the following anatomic statements **except** which?
- The patient had impaled his rectum on the leg of the upturned bar stool.
 - At operation, a laceration of the anterior wall of the middle of the rectum was found.
 - The leg of the bar stool had entered the rectovesical pouch.
 - The rectal contents had contaminated the peritoneal cavity and were responsible for the development of peritonitis.
 - The anterior surface of the middle third of the rectum has no peritoneal covering.

A 46-year-old man had been treating himself for hemorrhoids for the past 3 years. He had noticed that his feces were often slightly blood stained. For the past 12 months, he had noticed that when he had his bowels open, he always felt that more was to come. Sometimes he went to the toilet several times a day but was only able to pass flatus and blood-stained mucus. Recently, pain had developed down the outside of his right leg. Digital examination of the rectum revealed a large, hard-based ulcer on the posterior wall of the rectum with extensive induration of the pararectal tissues. A diagnosis of advanced carcinoma of the rectum was made.

18. The following statements about this patient are probably correct **except** which?
- Some of the bleeding was from the carcinomatous ulcer of the rectum as well as from the hemorrhoids.
 - The lymphatic drainage of the rectum takes place first into the pararectal lymph nodes.
 - Carcinoma of the rectum never metastasizes to the liver.
 - Examination of the right leg revealed some weakness of the muscles supplied by the sciatic nerve.
 - The carcinoma had extended posteriorly to involve the sacral plexus.
 - The patient indicated that the leg pain was felt in skin areas supplied by branches of the sciatic nerve.

A 72-year-old woman was suspected of having a tumor of the sigmoid colon. The physician decided to confirm the diagnosis by performing a sigmoidoscopy.

19. The following anatomic statements are correct concerning the procedure of sigmoidoscopy **except** which?
- After inserting the instrument into the anus, the lighted end enters the ampulla of the rectum after a distance of about 1.5 in. (4 cm).
 - Some side-to-side movement may be necessary to avoid the transverse rectal folds.

- C. The rectosigmoid junction will be reached approximately 6.5 in. (16.25 cm) from the anal margin.
- D. To negotiate the rectosigmoid junction, the tip of the sigmoidoscope should be directed anteriorly and to the patient's left.
- E. Stretching of the colonic wall may give rise to colicky pain in the upper part of the abdomen in the region of the xiphoid process.

A 3-week-old boy was taken to a pediatrician because of repeated vomiting and reluctance to feed. On questioning, the mother said the child had started to vomit on the first day of life and has vomited at least once a day since then. Early on, the mother had been reassured and told that the baby was taking his feedings too quickly and that the vomiting eventually would cease. While initially accepting this reassurance, the mother now noticed that the child did not seem hungry at feeding time; moreover, she could see that the abdomen was becoming distended. She added that the child definitely was constipated; very occasionally, hard meconium was passed. After a thorough physical examination of the child, the pediatrician made the diagnosis of primary megacolon (Hirschsprung disease).

20. The examination of the child revealed the following possible signs **except** which?
- A. The abdomen was found to be distended.
 - B. A rectal examination with the gloved little finger resulted in the passage of a large amount of flatus and the abdominal distension became visibly less.
 - C. A low barium enema followed by an X-ray examination showed a normal rectum.
 - D. On the radiograph, above the rectum, a narrowed part of the colon led to a funnel-shaped expansion, which in turn led to a greatly dilated descending colon and transverse colon.
 - E. On placing a stethoscope on the abdominal wall, the physician could not hear sounds of peristalsis.

A 53-year-old man complained that for the past 4 years he had frequently passed blood-stained stools. Recently, he had noticed that his "bowel" protruded from his anus after defecation, and this caused him considerable discomfort.

21. The following symptoms and signs in this patient were consistent with a diagnosis of third-degree internal hemorrhoids **except** which?
- A. The patient suffered from intense perianal irritation caused by the mucous secretions from the prolapsed mucous membrane.
 - B. Proctoscopic examination revealed three pink swellings of mucous membrane at the level of the anal valves.
 - C. The swellings were situated at the 1, 4, and 9 o'clock positions with the patient in the lithotomy position.

- D. The swellings bulged downward when the patient was asked to strain.
- E. Large, congested veins were seen in the swellings.
- F. The swellings remained outside the anus after defecation.
- G. Abrasion of the mucous membrane was responsible for the bleeding.

A 42-year-old woman visited her physician because she experienced an agonizing pain in the rectum, which occurred on defecation. She had first noticed the pain a week before when she tried to defecate. The pain lasted for about an hour, then passed off, only to return with the next bowel movement. She said that she suffered from constipation and admitted that sometimes her stools were streaked with blood. After a careful examination, a diagnosis of anal fissure was made.

22. The following statements concerning this case are correct **except** which?
- A. Examination of the anal canal was difficult because any attempt to insert a gloved finger into the canal caused severe pain.
 - B. The anus was kept tightly closed by the spasm of the external anal sphincter.
 - C. Gentle eversion of the anal margin under local anesthesia revealed the lower edge of a linear tear in the posterior wall of the anal canal; a small tag of skin projected from the lower end of the tear.
 - D. The forward edge of a hard fecal mass may have caught one of the anal valves and torn it downward as it descended.
 - E. Anal fissures tend to occur on the anterior and posterior walls of the anal canal because the mucous membrane is poorly supported in this region by the superficial external sphincter muscle.
 - F. The mucous membrane of the lower half of the anal canal is innervated by autonomic afferent nerves and is sensitive only to stretch.

A 41-year-old woman was seen in the emergency department complaining of a painful swelling in the region of the anus. On examination, a hot, red, tender swelling was found on the right side of the anal margin. A diagnosis of ischiorectal abscess was made.

23. The following statements concerning this case are probably correct **except** which?
- A. An ischiorectal abscess is a common complication of anal fissure.
 - B. The fat in the ischiorectal fossa is prone to infection that might extend laterally through the base of the anal fissure.
 - C. The fat in the ischiorectal fossa has a profuse blood supply.
 - D. A surgical incision of the abscess should provide adequate drainage of the pus.

- E. The surgeon should avoid the inferior rectal nerve and vessels that cross the ischiorectal fossa from the lateral to the medial side.
24. The differential diagnosis between a perforated duodenal ulcer and a perforated appendix may prove difficult. Can you explain this in anatomic terms?
25. The pain of acute appendicitis is commonly first felt in the umbilical region and later in the right iliac region. Can you explain this in anatomic terms?
26. Following a terrorist bomb attack, a young child was seen in the emergency department with a gaping hole in the anterior abdominal wall, and coils of gut were exposed on the surface. How would you determine by inspection whether the gut was small or large intestine?

Answers and Explanations

1. **D** is the correct answer. The segmental nerves supplying the right lower quadrant of the abdominal wall are T11, T12, and L1.
2. **E** is the correct answer. The urine could not extend posteriorly because of the attachment of the Colles' fascia to the posterior edge of the perineal membrane.
3. **D** is the correct answer. The pyramidalis muscle (if present) is innervated by the twelfth thoracic nerve.
4. **F** is the correct answer. The contents of this hernial sac included coils of small intestine, which were responsible for the gurgling noises that occurred as the hernia was reduced.
5. **E** is the correct answer. The swelling occurs medial to the inferior epigastric artery (see CD Fig. 19-6).
6. **E** is the correct answer. The neck of a femoral hernial sac is situated below and lateral to the pubic tubercle (see CD Fig. 19-7).
7. **F** is the correct answer. The normal testis is freely mobile within the scrotum and is not tethered to the subcutaneous tissue or skin.
8. **C** is the correct answer. The linea alba lies in the midline; the rectus sheath lies lateral to the linea alba.
9. **E** is the correct answer. In the parietal peritoneum lining the anterior abdominal wall in the right iliac fossa, the sensation of pain originates in the nerve endings of somatic spinal nerves (T12 and L1).
10. **D** is the correct answer. The gastroduodenal artery is a large branch of the hepatic artery.
11. **A** is the correct answer. The right kidney does not lie behind the stomach (see text Fig. 19-38)
12. **C** is the correct answer. At the lower end of the esophagus, a branch from the left gastric vein anastomoses with an esophageal tributary of the azygos vein.
13. **C** is the correct answer. The distance between the nostril and the cardiac orifice of the stomach is about 17.2 in. (44 cm).
14. **B** is the correct answer. The neck of the hernial sac in an indirect inguinal hernia lies lateral to the inferior epigastric artery (see CD Fig. 19-6).
15. **B** is the correct answer. In congenital hypertrophic pyloric stenosis, there is a localized muscular hypertrophy and hyperplasia of the pyloric sphincter, which is larger than normal and can usually be palpated just below and medial to the tip of the right ninth costal cartilage.
16. **D** is the correct answer. In many cases of Meckel's diverticulum, a small area of ectopic gastric mucosa is present, which is capable of producing hydrochloric acid and pepsin. In the adjoining mucous membrane, this child had a chronic ulcer that was responsible for the umbilical pain. Sudden severe hemorrhage from an artery in the floor of the ulcer was the cause of the rectal bleeding and fainting attack. The condition is not associated with pyrexia. After restoration of the blood volume and hemoglobin to a normal level, a child with this condition should be operated on and the diverticulum should be widely excised. The cut ends of the ileum then are joined by an end-to-end anastomosis.
17. **E** is the correct answer. The upper third of the rectum has peritoneum on its anterior and lateral surfaces; the middle third has peritoneum on its anterior surface; and the lower third has no peritoneal covering (see text Fig. 19-64).

18. **C** is the correct answer. Advanced carcinoma of the rectum not only extends to the pararectal and inferior mesenteric nodes but may also spread via the superior rectal, inferior mesenteric, splenic, and portal veins to the liver.
19. **E** is the correct answer. Colicky pain from the colon is referred to the lower part of the anterior abdominal wall above the symphysis pubis (see CD Fig. 19-23).
20. **E** is the correct answer. In patients with primary megacolon, the muscle of the colon immediately proximal to the obstruction is hypertrophied as the result of attempting to force the meconium and feces onward. Usually very active peristalsis is heard on listening to the abdomen with a stethoscope.
21. **C** is the correct answer. The swellings of internal hemorrhoids are situated at the 3, 7, and 11 o'clock positions with the patient in the lithotomy position. These swellings are caused by a dilatation of the three main tributaries of the superior rectal vein (see CD Fig. 19-26).
22. **F** is the correct answer. The mucous membrane of the lower half of the anal canal is innervated by the inferior rectal nerve and is very sensitive to pain, temperature, touch, and pressure.
23. **C** is the correct answer. The fat in the ischioanal fossa has a poor blood supply.
24. A small perforation of the first part of the duodenum may result in the contents of the duodenum running down the right paracolic gutter to the right iliac fossa. The signs then closely resemble those of a perforated appendix.
25. The initial pain of acute appendicitis is a vague discomfort and is referred to the umbilical region. The afferent nerve fibers from the appendix accompany the sympathetic nerves to the superior mesenteric plexus. They enter the thorax via the splanchnic nerves and enter the spinal cord at the level of the tenth thoracic segment. The tenth thoracic intercostal nerve supplies the skin of the umbilicus, and for this reason pain is commonly referred to the umbilicus. Once the inflammatory process has extended beyond the confines of the appendix and has involved the parietal peritoneum, a severe localized pain is felt in the right iliac region. The parietal peritoneum, the overlying muscles of the anterior abdominal wall, and the covering skin are all supplied by the first lumbar nerve.
26. A list of naked-eye differences between the small and large intestine are given on text page 751.



20

The Viscera Associated
with the Alimentary
Tract: The Liver, the
Pancreas, and the Spleen



Chapter Outline

The Liver	358	Accessory Bile Duct	361
Liver Supports and Surgery	358	Congenital Choledochal Cyst	361
Liver Trauma	358	The Pancreas	362
Liver Biopsy	358	Diagnosis of Pancreatic Disease	362
Subphrenic Spaces	359	Trauma of the Pancreas	362
Portal–Systemic Anastomoses	359	Cancer of the Head of the Pancreas and the Bile Duct	362
Portal Hypertension	359	The Pancreatic Tail and Splenectomy	362
Blood Flow in the Portal Vein and Malignant Disease	359	Congenital Anomalies of the Pancreas	362
Gallstones	359	Anular Pancreas	362
Biliary Colic	359	Ectopic Pancreas	363
Acute Cholecystitis	359	Congenital Fibrocystic Disease	363
Cholecystectomy and the Arterial Supply to the Gallbladder	359	The Spleen	363
Gangrene of the Gallbladder	359	Splenic Enlargement	363
Congenital Anomalies of the Gallbladder	359	Trauma to the Spleen	363
Biliary Atresia	359	Congenital Anomalies of the Spleen	363
Absence of the Gallbladder	361	Supernumerary Spleens	363
Double Gallbladder	361	Clinical Problem Solving Questions	363
Absence of the Cystic Duct	361	Answers and Explanations	364



THE LIVER

Liver Supports and Surgery

The liver is held in position in the upper part of the abdominal cavity by the attachment of the hepatic veins to the inferior vena cava. The peritoneal ligaments and the tone of the abdominal muscles play a minor role in its support. This fact is important surgically because even if the peritoneal ligaments are cut, the liver can be only slightly rotated.

Liver Trauma

The liver is a soft, friable structure enclosed in a fibrous capsule. Its close relationship to the lower ribs must be emphasized. Fractures of the lower ribs or penetrating wounds of

the thorax or upper abdomen are common causes of liver injury. Blunt traumatic injuries from automobile accidents are also common, and severe hemorrhage accompanies tears of this organ.

Because anatomic research has shown that the bile ducts, hepatic arteries, and portal vein are distributed in a segmental manner, appropriate ligation of these structures allows the surgeon to remove large portions of the liver in patients with severe traumatic lacerations of the liver or with a liver tumor. (Even large, localized carcinomatous metastatic tumors have been successfully removed.)

Liver Biopsy

Liver biopsy is a common diagnostic procedure. With the patient holding his or her breath in full expiration—to reduce the size of the costodiaphragmatic recess and the likelihood of damage to the lung—a needle is inserted through

the right eighth or ninth intercostal space in the midaxillary line. The needle passes through the diaphragm into the liver, and a small specimen of liver tissue is removed for microscopic examination.

Subphrenic Spaces

The important subphrenic spaces and their relationship to the liver are described on text page 713. Under normal conditions these are potential spaces only, and the peritoneal surfaces are in contact. An abnormal accumulation of gas or fluid is necessary for separation of the peritoneal surfaces. The anterior surface of the liver is normally dull on percussion. Perforation of a gastric ulcer is often accompanied by a loss of liver dullness caused by the accumulation of gas over the anterior surface of the liver and in the subphrenic spaces.

Portal-Systemic Anastomoses

See CD Chapter 8.

Portal Hypertension

See CD Chapter 8.

Blood Flow in the Portal Vein and Malignant Disease

See CD Chapter 8.

Gallstones

Gallstones are usually asymptomatic; however, they can give rise to gallstone colic or produce acute cholecystitis.

Biliary Colic

Biliary colic is usually caused by spasm of the smooth muscle of the wall of the gallbladder in an attempt to expel a gallstone. Afferent nerve fibers ascend through the celiac plexus and the greater splanchnic nerves to the thoracic segments of the spinal cord. Referred pain is felt in the right upper quadrant or the epigastrium (T7, 8, and 9 dermatomes).

Obstruction of the biliary ducts with a gallstone or by compression by a tumor of the pancreas results in backup of bile in the ducts and development of jaundice. The impaction of a stone in the ampulla of Vater may result in the passage of infected bile into the pancreatic duct, producing pancreatitis. The anatomic arrangement of the terminal part of the bile duct and the main pancreatic duct is subject to considerable variation. The type of duct system present

determines whether infected bile is likely to enter the pancreatic duct.

Gallstones have been known to ulcerate through the gallbladder wall into the transverse colon or the duodenum. In the former case, they are passed naturally per the rectum, but in the latter case, they may be held up at the ileocecal junction, producing intestinal obstruction.

Acute Cholecystitis

Acute cholecystitis produces discomfort in the right upper quadrant or epigastrium. Inflammation of the gallbladder may cause irritation of the subdiaphragmatic parietal peritoneum, which is supplied in part by the phrenic nerve (C3, 4, and 5). This may give rise to referred pain over the shoulder, because the skin in this area is supplied by the supraclavicular nerves (C3 and 4).

Cholecystectomy and the Arterial Supply to the Gallbladder

Before attempting a cholecystectomy operation, the surgeon must be aware of the many variations in the arterial supply to the gallbladder and the relationship of the vessels to the bile ducts (CD Fig. 20-1). Unfortunately, there have been several reported cases in which the common hepatic duct or the main bile duct has been included in the arterial ligature with disastrous consequences.

Gangrene of the Gallbladder

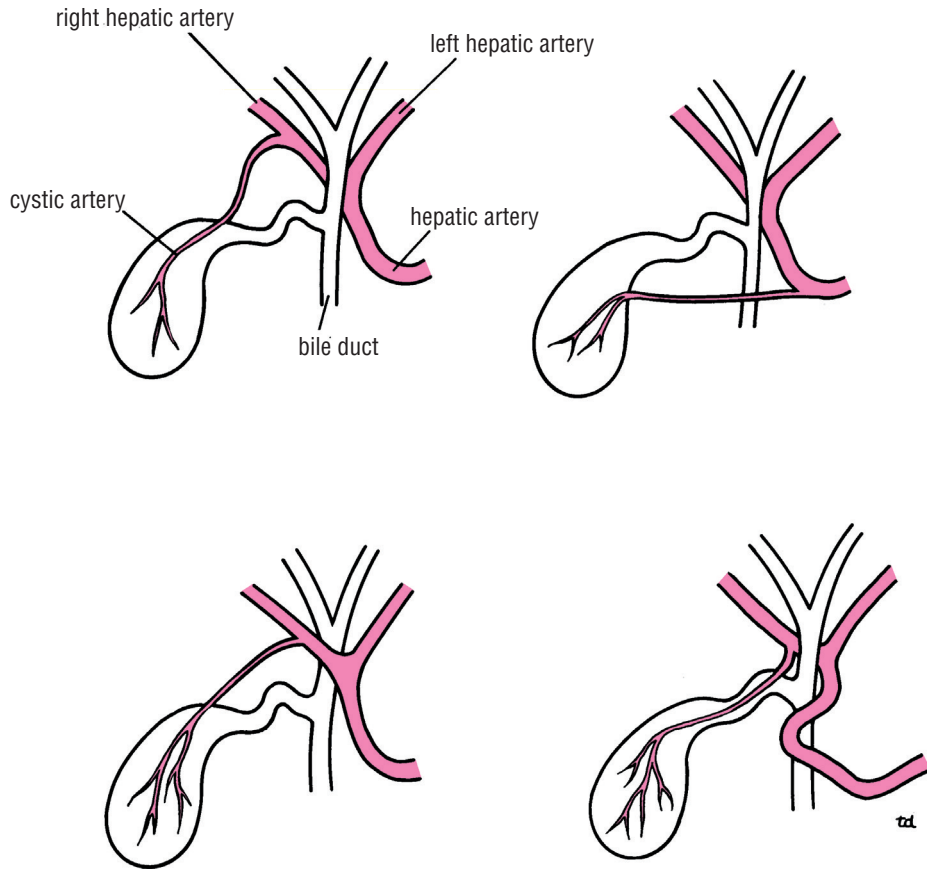
Unlike the appendix, which has a single arterial supply, the gallbladder rarely becomes gangrenous. In addition to the cystic artery, the gallbladder also receives small vessels from the visceral surface of the liver.



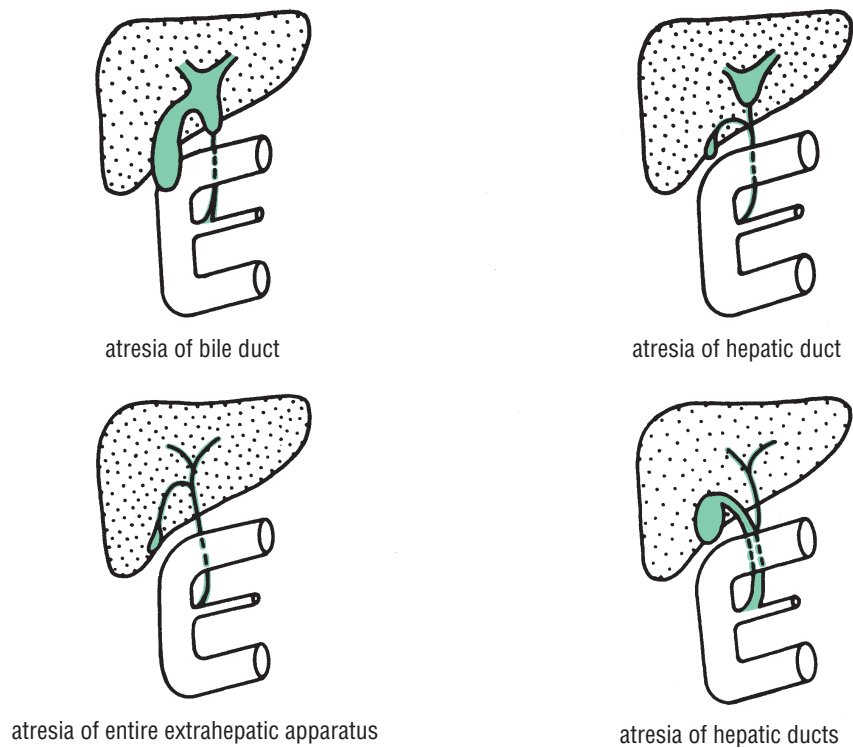
CONGENITAL ANOMALIES OF THE GALLBLADDER

Biliary Atresia

Failure of the bile ducts to canalize during development causes atresia. The various forms of atresia are shown in CD Fig. 20-2. Jaundice appears soon after birth; clay-colored stools and very dark colored urine are also present. Surgical correction of the atresia should be attempted when possible. If the atresia cannot be corrected, the child will die of liver failure.



CD Figure 20-1 Some common variations of blood supply to the gallbladder.



CD Figure 20-2 Some common congenital anomalies of the biliary ducts.

Absence of the Gallbladder

Occasionally, the outgrowth of cells from the hepatic bud fails to develop. In these cases, there is no gallbladder and no cystic duct (CD Fig. 20-3).

Double Gallbladder

Rarely, the outgrowth of cells from the hepatic bud bifurcates so that two gallbladders are formed (see CD Fig. 20-3).

Absence of the Cystic Duct

In absence of the cystic duct, the entire outgrowth of cells from the hepatic bud develops into the gallbladder and fails to leave the narrow stem that would normally form the cystic

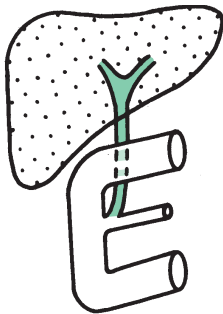
duct. The gallbladder drains directly into the bile duct. The condition may not be recognized when performing a cholecystectomy, and the bile duct may be seriously damaged by the surgeon (see CD Fig. 20-3).

Accessory Bile Duct

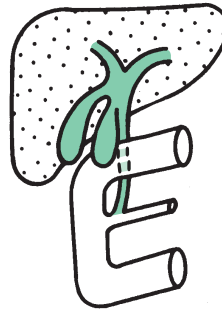
A small accessory bile duct may open directly from the liver into the gallbladder, which may cause leakage of bile into the peritoneal cavity after cholecystectomy if it is not recognized at the time of surgery (see CD Fig. 20-3).

Congenital Choledochal Cyst

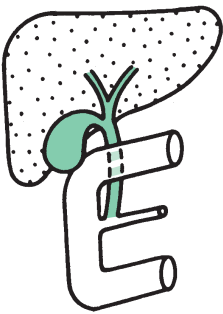
Rarely, a choledochal cyst develops because of an area of weakness in the wall of the bile duct. A cyst can contain 1 to 2 L of bile. The anomaly is important in that it may press



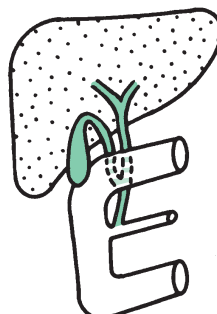
congenital absence of gallbladder



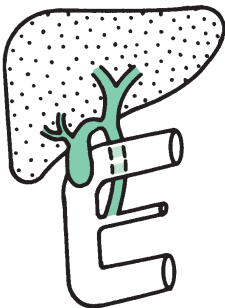
double gallbladder



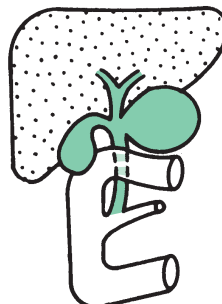
absence of cystic duct



abnormally long cystic duct



accessory bile duct



choledochal cyst

CD Figure 20-3 Some common congenital anomalies of the gallbladder.

on the bile duct and cause obstructive jaundice (see CD Fig. 20-3).



THE PANCREAS

Diagnosis of Pancreatic Disease

The deep location of the pancreas sometimes gives rise to problems of diagnosis for the following reasons:

- Pain from the pancreas is commonly referred to the back.
- Because the pancreas lies behind the stomach and transverse colon, disease of the gland can be confused with that of the stomach or transverse colon.
- Inflammation of the pancreas can spread to the peritoneum, forming the posterior wall of the lesser sac. This in turn can lead to adhesions and the closing off of the lesser sac to form a pseudocyst.

Trauma of the Pancreas

The pancreas is deeply placed within the abdomen and is well protected by the costal margin and the anterior abdominal wall. However, blunt trauma, such as in a sports injury when a sudden blow to the abdomen occurs, can compress and tear the pancreas against the vertebral column. The pancreas is most commonly damaged by gunshot or stab wounds.

Damaged pancreatic tissue releases activated pancreatic enzymes that produce the signs and symptoms of acute peritonitis.

Cancer of the Head of the Pancreas and the Bile Duct

Because of the close relation of the head of the pancreas to the bile duct, cancer of the head of the pancreas often causes obstructive jaundice.

The Pancreatic Tail and Splenectomy

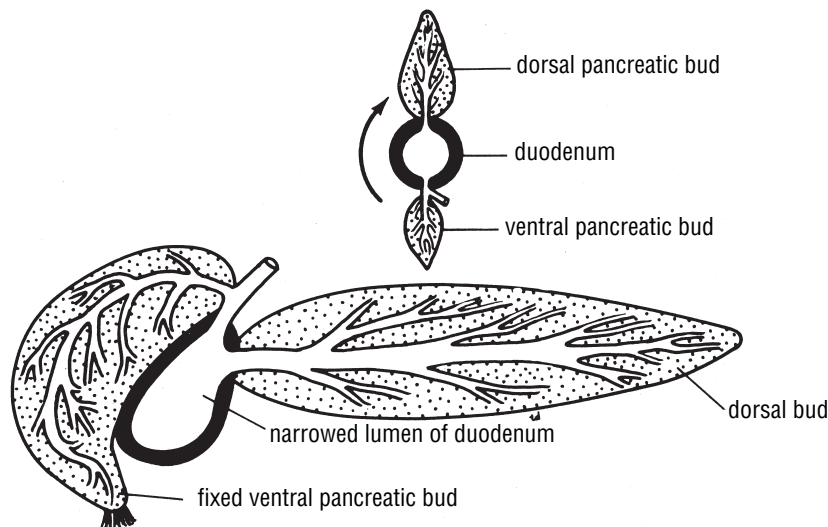
The presence of the tail of the pancreas in the splenicorenal ligament sometimes results in its damage during splenectomy. The damaged pancreas releases enzymes that start to digest surrounding tissues, with serious consequences.



CONGENITAL ANOMALIES OF THE PANCREAS

Anular Pancreas

In anular pancreas, the ventral pancreatic bud becomes fixed so that, when the stomach and duodenum rotate, the ventral bud is pulled around the right side of the duodenum to fuse with the dorsal bud of the pancreas, thus encircling the duodenum (CD Fig. 20-4). This may cause obstruction of the duodenum, and vomiting may start a few hours after birth. Early surgical relief of the obstruction is necessary.



CD Figure 20-4 Formation of the anular pancreas, producing duodenal obstruction. Note the narrowing of the duodenum.

Ectopic Pancreas

Ectopic pancreatic tissue may be found in the submucosa of the stomach, duodenum, small intestine (including Meckel's diverticulum), and gallbladder and in the spleen. It is important in that it may protrude into the lumen of the gut and be responsible for causing intussusception.

Congenital Fibrocystic Disease

Basically, congenital fibrocystic disease in the pancreas is caused by an abnormality in the secretion of mucus. The mucus produced is excessively viscid and obstructs the pancreatic duct, which leads to pancreatitis with subsequent fibrosis. The condition also involves the lungs, kidneys, and liver.



THE SPLEEN

Splenic Enlargement

A pathologically enlarged spleen extends downward and medially. The left colic flexure and the phrenicocolic ligament prevent a direct downward enlargement of the organ. As the enlarged spleen projects below the left costal margin, its notched anterior border can be recognized by palpation through the anterior abdominal wall.

The spleen is situated at the beginning of the splenic vein, and in cases of portal hypertension it often enlarges from venous congestion.

Trauma to the Spleen

Although anatomically the spleen gives the appearance of being well protected, automobile accidents of the crushing or run-over type commonly produce laceration of the spleen. Penetrating wounds of the lower left thorax can also damage the spleen.



CONGENITAL ANOMALIES OF THE SPLEEN

Supernumerary Spleens

In 10% of people, one or more supernumerary spleens may be present, either in the gastrosplenic omentum or in the splenicorenal ligament. Their clinical importance is that they may hypertrophy after removal of the major spleen and be responsible for a recurrence of symptoms of the disease for which splenectomy was initially performed.

Clinical Problem Solving Questions

Read the following case histories/questions and give the best answer for each.

A 55-year-old woman with a history of flatulent dyspepsia suddenly experienced an excruciating colicky pain across the upper part of the abdomen. On examination in the emergency department, she was found to have some rigidity and tenderness in the right upper quadrant. A diagnosis of biliary colic was made.

- The following statements would explain this patient's symptoms **except** which?
 - The pain of gallstone colic is caused by spasm of the smooth muscle in the wall of the gallbladder and distension of the bile ducts by the stones.
 - The pain fibers from the gallbladder and bile ducts ascend through the superior mesenteric plexus and the greater splanchnic nerves to enter the thoracic segments of the spinal cord.

- Referred pain is felt in the right upper quadrant or the epigastrium.
- T7 through T9 dermatomes are involved.
- The violent contractions of the gallbladder wall are attempts to expel the gallstones.

On examination of the abdomen of a 31-year-old woman, a large swelling was found to extend downward and medially below the left costal margin. On percussion, a continuous band of dullness was noted to extend upward from the left of the umbilicus to the left axillary region. On palpation, a notch was felt along the anterior border of the swelling. A diagnosis of splenic enlargement was made.

- The signs displayed by this patient can be explained by the following statements **except** which?
 - The spleen has a notched anterior border caused by incomplete fusion of its parts during development.

- B. Because of the presence of the left colic flexure and the phrenicocolic ligament, the spleen is unable to expand vertically downward.
 - C. A pathologically enlarged spleen extends downward and forward, toward the umbilicus.
 - D. The spleen is situated in the upper left quadrant of the abdomen beneath the diaphragm.
 - E. The long axis of the spleen lies along the twelfth rib.
3. A 19-year-old football player was accidentally kicked on the left side of his chest. On returning to the locker room he said he felt faint and collapsed to the floor. On examination in the emergency department, he was found to be in hypovolemic shock. He had tenderness and guarding in the left upper quadrant of his abdomen. He also had extreme local tenderness over his left tenth rib in the midaxillary line. A diagnosis of a ruptured spleen and the possibility of a fractured tenth rib was made. Explain the tenderness and guarding in the abdomen in this patient.

A 40-year-old obese woman complaining of indigestion was admitted to the hospital for investigation. She had a past history of gallstones and transient attacks of jaundice. Large gallstones have been known to erode through the posterior wall of the gallbladder and enter the intestinal tract.

- 4. Which part of the intestinal tract is likely to initially contain the stone?
 - A. The sigmoid colon
 - B. The descending colon
 - C. The transverse colon
 - D. The ascending colon
 - E. The jejunum
- 5. A 50-year-old woman with a history of flatulent dyspepsia suddenly experienced an excruciating colicky pain

across the upper part of the abdomen. On examination after the attack, some rigidity and tenderness was noted in the right hypochondrium. Two days later the patient became jaundiced, and it was noticed that the degree of jaundice varied from day to day. The diagnosis of biliary colic was made. Why should a person passing a gallstone experience pain? Why is the pain experienced in the area described above? Why does the jaundice vary in intensity?

- 6. A 65-year-old woman was admitted to the hospital with progressive jaundice of three months' duration and weight loss. She had not experienced any colicky pain. On examination, a soft swelling could be felt in the abdomen in the region of the tip of the right ninth costal cartilage. A diagnosis of cancer of the head of the pancreas was made. What anatomic structure is responsible for the swelling?
- 7. A patient with thrombocytopenic purpura was advised to have a splenectomy to stop the episodes of bleeding from the gums and gastrointestinal tract. The operation was successful. Eighteen months later the clinical features returned. Can you explain in anatomic terms the recurrence of the bleeding after the condition had apparently been cured by splenectomy?
- 8. Following a splenectomy, it was noticed that pancreatic juice was exuding through the patient's abdominal wound. Is the pancreas likely to be damaged during splenectomy? Which part of the pancreas?
- 9. The anatomic arrangement of the terminal part of the bile duct and the main pancreatic duct is subject to considerable variation. Which variations are likely to be associated with a pancreatitis should a gallstone become impacted at the lower end of the bile duct?

Answers and Explanations

- 1. **B** is the correct answer. The pain fibers from the gallbladder and bile ducts ascend through the celiac plexus.
- 2. **E** is the correct answer. The long axis of the spleen lies along the tenth rib (see text Fig. 20-27).
- 3. Initially in this patient, the spleen underwent a subcapsular hemorrhage, and later, in the locker room, the capsule gave way, allowing the blood to escape into the peritoneal cavity. The presence of blood in the peritoneal cavity irritated the parietal peritoneum, causing tenderness in the left upper quadrant and reflex guarding of the muscles in the same area.
- 4. **C** is the correct answer. The transverse colon is in close posterior relation to the gallbladder.
- 5. The pain is due to the spastic contraction of the muscle of the gallbladder attempting to flush the stone down the bile ducts and to the distension of the ducts by the stone. The afferent pain fibers from the gallbladder and bile ducts enter the spinal cord between segments T5 and T9. Pain is referred to the epigastrium via the sev-

- enth to the ninth intercostal nerves. A variable amount of bile gets past the stone.
6. A small carcinoma of the head of the pancreas was found at operation to be compressing the bile duct. Back pressure along the bile ducts produced dilatation of the gallbladder, which could be felt in the region of the tip of the right ninth costal cartilage.
 7. About 10% of persons have accessory spleens. These should always be looked for when performing a splenectomy for such conditions as thrombocytopenic purpura. If an accessory spleen is missed, it will enlarge and take over the functions of the main spleen.
 8. The tail of the pancreas lies within the splenicorenal ligament, and its tip is related to the hilus of the spleen. The surgeon has to take extreme care not to damage the tail of the pancreas during a splenectomy.
 9. Any variation in which the bile duct and the pancreatic duct open by a common orifice into the duodenum is likely to cause this problem (see text Fig. 20-26). Gallstones are usually associated with infected bile. A stone impacted at the orifice into the duodenum will allow reflux of infected bile along the main pancreatic duct, and pancreatitis will occur.



The Urinary System



21

The Kidneys, the Ureters, the Bladder, and the Urethra



Chapter Outline

The Kidneys	370	Bladder Distension	375
Renal Mobility	370	Urinary Retention	375
Kidney Trauma	370	Suprapubic Aspiration	375
Kidney Tumors	371	Cystoscopy	375
Renal Pain	371	Bladder Injuries	375
Transplanted Kidneys	371	Difficulty with Micturition after Spinal Cord Injury	375
The Ureters	371	The Male Urethra	377
Traumatic Ureteral Injuries	371	Urethral Infections	377
Ureteric Stones	372	Injuries to the Penis	377
Renal Colic	372	Rupture of the Urethra	377
Congenital Anomalies of the Kidneys	372	Catheterization	377
Polycystic Kidney	372	Anatomy of the Procedure of Catheterization	377
Pelvic Kidney	372	The Female Urethra	378
Horseshoe Kidney	372	Urethral Infections	378
Unilateral Double Kidney	373	Urethral Injuries	378
Rosette Kidney	373	Catheterization	378
Supernumerary Renal Arteries	373	Congenital Anomalies of the Bladder	378
Congenital Anomalies of the Ureters	374	Exstrophy of the Bladder (Ectopia Vesicae)	378
Double Pelvis	374	Congenital Anomalies of the Urethra	378
Bifid Ureter	374	Meatal Stenosis	378
Megaloureter	374	Hypospadias	378
Postcaval Ureter	375	Epispadias	378
The Urinary Bladder	375	Clinical Problem Solving Questions	380
Palpation of the Urinary Bladder	375	Answers and Explanations	382



THE KIDNEYS

Renal Mobility

The kidneys are maintained in their normal position by intraabdominal pressure and by their connections with the perirenal fat and renal fascia. Each kidney moves slightly with respiration. The right kidney lies at a slightly lower level than the left kidney, and the lower pole may be palpated in the right lumbar region at the end of deep inspiration in a person with

poorly developed abdominal musculature. Should the amount of perirenal fat be reduced, the mobility of the kidney may become excessive and produce symptoms of renal colic caused by kinking of the ureter. Excessive mobility of the kidney leaves the suprarenal gland undisturbed because the latter occupies a separate compartment in the renal fascia.

Kidney Trauma

The kidneys are well protected by the lower ribs, the lumbar muscles, and the vertebral column. However, a severe blunt

injury applied to the abdomen may crush the kidney against the last rib and the vertebral column. Depending on the severity of the blow, the injury varies from a mild bruising to a complete laceration of the organ. Penetrating injuries are usually caused by stab wounds or gunshot wounds and often involve other viscera. Because 25% of the cardiac outflow passes through the kidneys, renal injury can result in rapid blood loss. A summary of the injuries to the kidneys is shown in CD Fig. 21-1.

Kidney Tumors

Malignant tumors of the kidney have a strong tendency to spread along the renal vein. The left renal vein receives the left testicular vein in the male, and this may rarely become blocked, producing left-sided **varicocele**.

Renal Pain

Renal pain varies from a dull ache to a severe pain in the flank that may radiate downward into the lower abdomen. Renal pain can result from stretching of the kidney capsule or spasm of the smooth muscle in the renal pelvis. The afferent nerve fibers pass through the renal plexus around the renal artery and ascend to the spinal cord through the lowest splanchnic nerve in the thorax and the sympathetic trunk. They enter the spinal cord at the level of T12. Pain is commonly referred along the distribution of the

subcostal nerve (T12) to the flank and the anterior abdominal wall.

Transplanted Kidneys

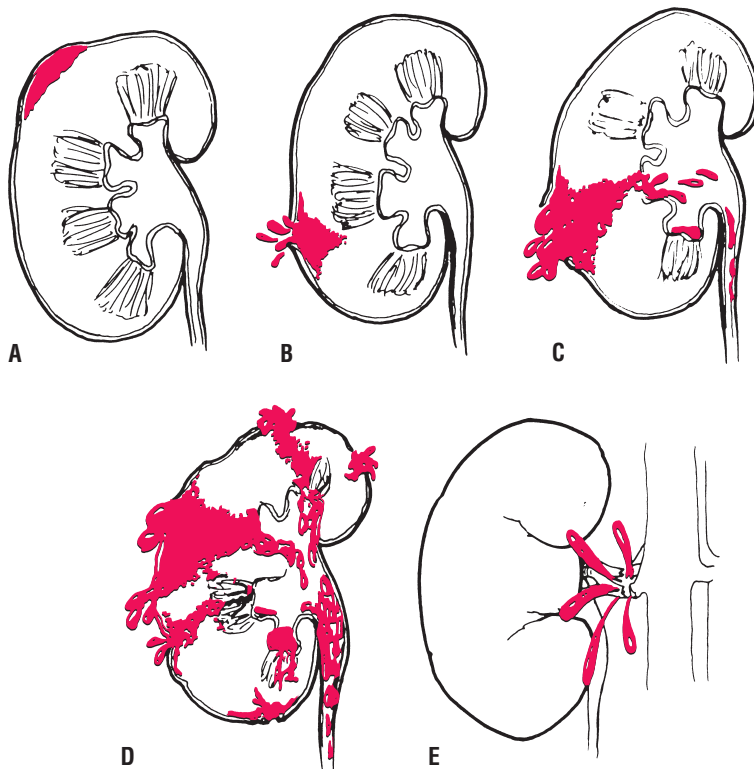
The iliac fossa on the posterior abdominal wall is the usual site chosen for transplantation of the kidney. The fossa is exposed through an incision in the anterior abdominal wall just above the inguinal ligament. The iliac fossa in front of the iliacus muscle is approached retroperitoneally. The kidney is positioned and the vascular anastomosis constructed. The renal artery is anastomosed end to end to the internal iliac artery and the renal vein is anastomosed end to side to the external iliac vein (CD Fig. 21-2). Anastomosis of the branches of the internal iliac arteries on the two sides is sufficient so that the pelvic viscera on the side of the renal arterial anastomosis are not at risk. Ureterocystostomy is then performed by opening the bladder and providing a wide entrance of the ureter through the bladder wall.



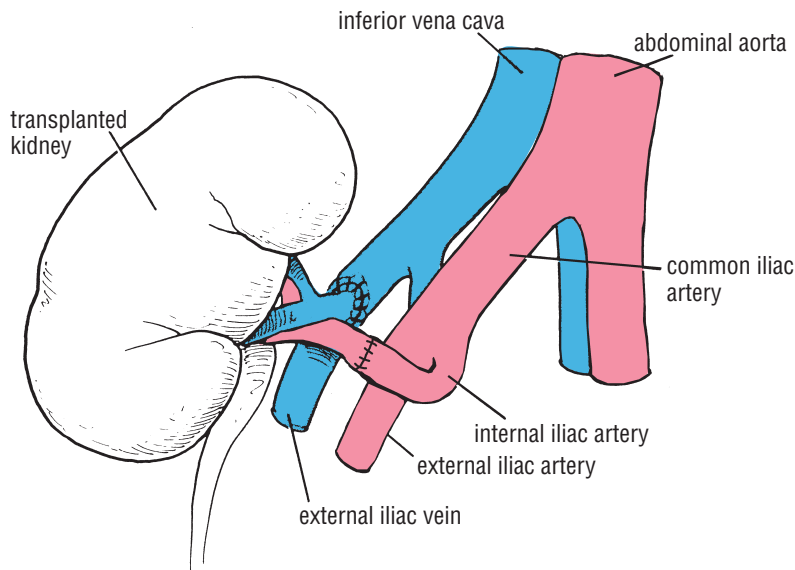
THE URETERS

Traumatic Ureteral Injuries

Because of its protected position and small size, injuries to the ureter are rare. Most injuries are caused by gunshot



CD Figure 21-1 Injuries to the kidney. **A.** Contusion, with hemorrhage confined to the cortex beneath the intact fibrous capsule. **B.** Tearing of the capsule and cortex with bleeding occurring into the perirenal fat. **C.** Tearing of the capsule, the cortex, and the medulla. Note the escape of blood into the calyces and therefore the urine. Urine as well as blood may extravasate into the perirenal and pararenal fat and into the peritoneal cavity. **D.** Shattered kidney with extensive hemorrhage and extravasation of blood and urine into the perirenal and pararenal fat; blood also enters the calyces and appears in the urine. **E.** Injury to the renal pedicle involving the renal vessels and possibly the renal pelvis.



CD Figure 21-2 The transplanted kidney.

wounds and, in a few individuals, penetrating stab wounds. Because the ureters are retroperitoneal in position, urine may escape into the retroperitoneal tissues on the posterior abdominal wall.

Ureteric Stones

There are three sites of anatomic narrowing of the ureter where stones may be arrested, namely, the pelviureteral junction, the pelvic brim, and where the ureter enters the bladder. Most stones, although radiopaque, are small enough to be impossible to see definitely along the course of the ureter on plain radiographic examination. An intravenous pyelogram is usually necessary. The ureter runs down in front of the tips of the transverse processes of the lumbar vertebrae, crosses the region of the sacroiliac joint, swings out to the ischial spine, and then turns medially to the bladder.

Renal Colic

The renal pelvis and the ureter send their afferent nerves into the spinal cord at segments T11 and 12 and L1 and 2. In renal colic, strong peristaltic waves of contraction pass down the ureter in an attempt to pass the stone onward. The spasm of the smooth muscle causes an agonizing colicky pain, which is referred to the skin areas that are supplied by these segments of the spinal cord, namely, the flank, loin, and groin.

When a stone enters the low part of the ureter, the pain is felt at a lower level and is often referred to the testis or the tip of the penis in the male and the labium majus in the female. Sometimes ureteral pain is referred along the femoral branch of the genitofemoral nerve (L1 and 2) so that pain is experienced in the front of the thigh. The pain is often so severe that afferent pain impulses spread within the central nervous system, giving rise to nausea.



CONGENITAL ANOMALIES OF THE KIDNEYS

Polycystic Kidney

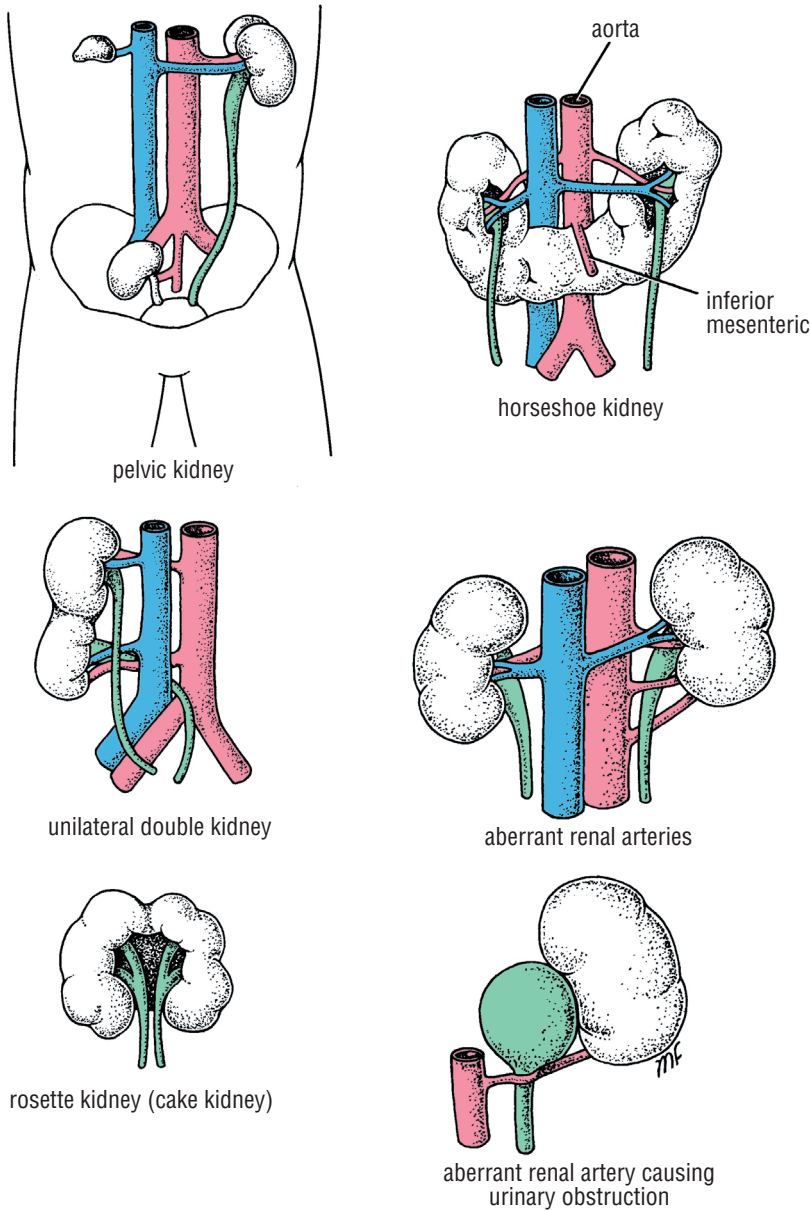
A hereditary disease, polycystic kidney can be transmitted by either parent. It may be associated with congenital cysts of the liver, pancreas, and lung. Both kidneys are enormously enlarged and riddled with cysts. Polycystic kidney is thought to be caused by a failure of union between the developing convoluted tubules and collecting tubules. The accumulation of urine in the proximal tubules results in the formation of retention cysts.

Pelvic Kidney

In pelvic kidney, the kidney is arrested in some part of its normal ascent; it usually is found at the brim of the pelvis (CD Fig. 21-3). Such a kidney may present with no signs or symptoms and may function normally. However, should an ectopic kidney become inflamed, it may—because of its unusual position—give rise to a mistaken diagnosis.

Horseshoe Kidney

When the caudal ends of both kidneys fuse as they develop, the result is horseshoe kidney (see CD Fig. 21-3). Both kidneys commence to ascend from the pelvis, but the interconnecting bridge becomes trapped behind the



CD Figure 21-3 Some common congenital anomalies of the kidney.

inferior mesenteric artery so that the kidneys come to rest in the low lumbar region. Both ureters are kinked as they pass inferiorly over the bridge of renal tissue, producing urinary stasis, which may result in infection and stone formation. Surgical division of the bridge corrects the condition.

Unilateral Double Kidney

The kidney on one side may be double, with separate ureters and blood vessels. In unilateral double kidney, the ureteric bud on one side crosses the midline as it ascends, and its upper pole fuses with the lower pole of the normally placed kidney (see CD Fig. 21-3). Here again, angulation of

the ureter may result in stasis of the urine and may require surgical treatment.

Rosette Kidney

Both kidneys may fuse together at their hila, and they usually remain in the pelvis. The two kidneys together form a rosette (see CD Fig. 21-3). This is the result of the early fusion of the two ureteric buds in the pelvis.

Supernumerary Renal Arteries

Supernumerary renal arteries are relatively common. They represent persistent fetal renal arteries, which grow in

sequence from the aorta to supply the kidney as it ascends from the pelvis. Their occurrence is clinically important because a supernumerary artery may cross the pelviureteral junction and obstruct the outflow of urine, producing dilation of the calyces and pelvis, a condition known as **hydronephrosis** (see CD Fig. 21-3).



CONGENITAL ANOMALIES OF THE URETERS

Double Pelvis

Double pelvis of the ureter is usually unilateral (CD Fig. 21-4). The upper pelvis is small and drains the upper group of calyces; the larger lower pelvis drains the middle and

lower groups of calyces. The cause is a premature division of the ureteric bud near its termination.

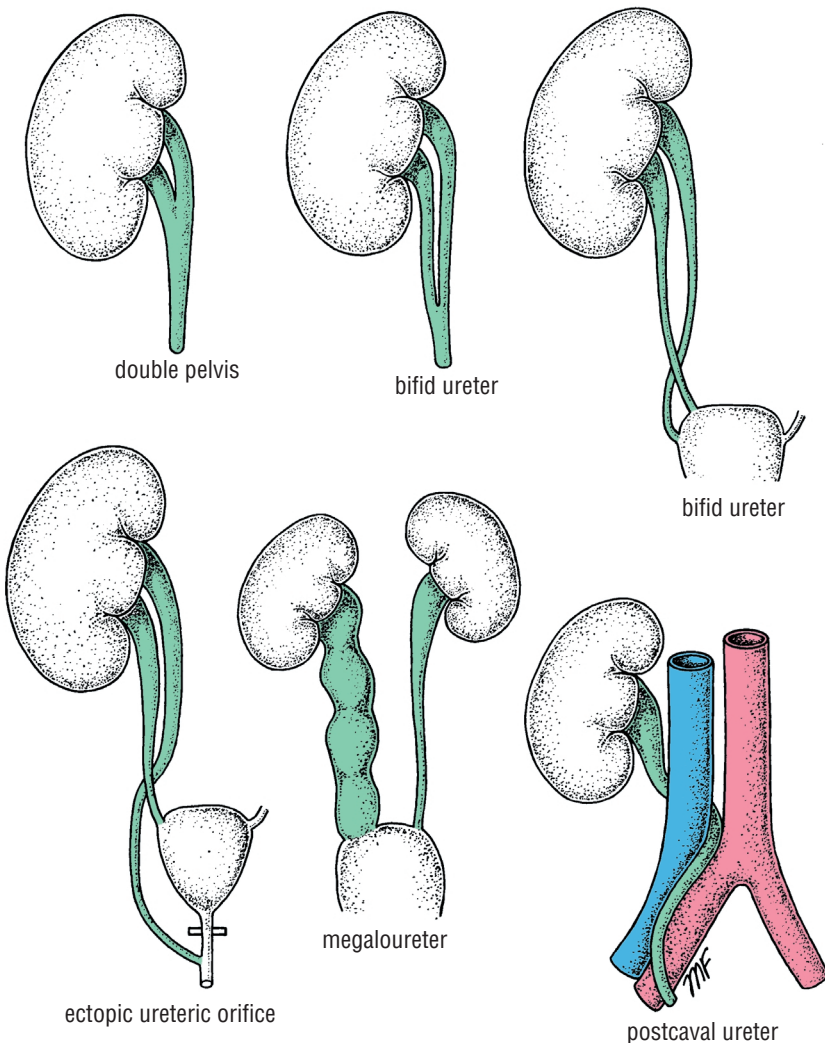
Bifid Ureter

In bifid ureter, the ureters may join in the lower third of their course, may open through a common orifice into the bladder, or may open independently into the bladder (see CD Fig. 21-4). In the latter case, one ureter crosses its fellow and may produce urinary obstruction. The cause of bifid ureter is a premature division of the ureteric bud.

Cases of double pelvis and double ureters may be found by chance on radiologic investigation of the urinary tract. They are more liable to become infected or to be the seat of calculus formation than is a normal ureter.

Megaloureter

Megaloureter may be unilateral or bilateral and shows complete absence of motility (see CD Fig. 21-4). The cause is unknown. Because of the urinary stasis, the ureter is prone



CD Figure 21-4 Some common congenital anomalies of the ureter.

to infection. Plastic surgery is required to improve the rate of drainage.

Postcaval Ureter

The right ureter may ascend posterior to the inferior vena cava and may be obstructed by it (see CD Fig. 21-4). Surgical rerouting of the ureter with reimplantation of the distal end into the bladder is the treatment of choice.



THE URINARY BLADDER

Palpation of the Urinary Bladder

The full bladder in the adult projects up into the abdomen and may be palpated through the anterior abdominal wall above the symphysis pubis.

Bimanual palpation of the empty bladder with or without a general anesthetic is an important method of examining the bladder. In the male, one hand is placed on the anterior abdominal wall above the symphysis pubis, and the gloved index finger of the other hand is inserted into the rectum. From their knowledge of anatomy, students can see that the bladder wall can be palpated between the examining fingers. In the female, an abdominovaginal examination can be similarly made. In the child, the bladder is in a higher position than in the adult because of the relatively smaller size of the pelvis.

Bladder Distension

The normal adult bladder has a capacity of about 500 mL. In the presence of urinary obstruction in males, the bladder may become greatly distended without permanent damage to the bladder wall; in such cases, it is routinely possible to drain 1,000 to 1,200 mL of urine through a catheter.

Urinary Retention

In adult males, urinary retention is commonly caused by obstruction to the urethra by a benign or malignant enlargement of the prostate. An acute urethritis or prostatitis can also be responsible. Acute retention occurs much less frequently in females. The only anatomic cause of urinary retention in females is acute inflammation around the urethra (e.g., from herpes).

Suprapubic Aspiration

As the bladder fills, the superior wall rises out of the pelvis and peels the peritoneum off the posterior surface of the

anterior abdominal wall. In cases of acute retention of urine, when catheterization has failed, it is possible to pass a needle into the bladder through the anterior abdominal wall above the symphysis pubis, without entering the peritoneal cavity. This is a simple method of draining off the urine in an emergency.

Cystoscopy

The mucous membrane of the bladder, the two ureteric orifices, and the urethral meatus can easily be observed by means of a cystoscope. With the bladder distended with fluid, an illuminated tube fitted with lenses is introduced into the bladder through the urethra. Over the trigone, the mucous membrane is pink and smooth. If the bladder is partially emptied, the mucous membrane over the trigone remains smooth, but it is thrown into folds elsewhere. The ureteric orifices are slit-like and eject a drop of urine at intervals of about 1 minute. The interureteric ridge and the uvula vesicae can easily be recognized.

Bladder Injuries

The bladder may rupture intraperitoneally or extraperitoneally. Intraperitoneal rupture usually involves the superior wall of the bladder and occurs most commonly when the bladder is full and has extended up into the abdomen. Urine and blood escape freely into the peritoneal cavity. Extraperitoneal rupture involves the anterior part of the bladder wall below the level of the peritoneal reflection; it most commonly occurs in fractures of the pelvis when bony fragments pierce the bladder wall. Lower abdominal pain and blood in the urine (hematuria) are found in most patients.

In young children, the bladder is an abdominal organ, so abdominal trauma can injure the empty bladder.

Difficulty with Micturition after Spinal Cord Injury

After injuries to the spinal cord, the nervous control of micturition is disrupted.

The **normal bladder** is innervated as follows:

- **Sympathetic outflow** is from the first and second lumbar segments of the spinal cord. The sympathetic nerves (see the footnote on text p. 819) inhibit contraction of the detrusor muscle of the bladder wall and stimulate closure of the sphincter vesicae.
- **Parasympathetic outflow** is from the second, third, and fourth sacral segments of the spinal cord. The parasympathetic nerves stimulate the contraction of the detrusor muscle of the bladder wall and inhibit the action of the sphincter vesicae.

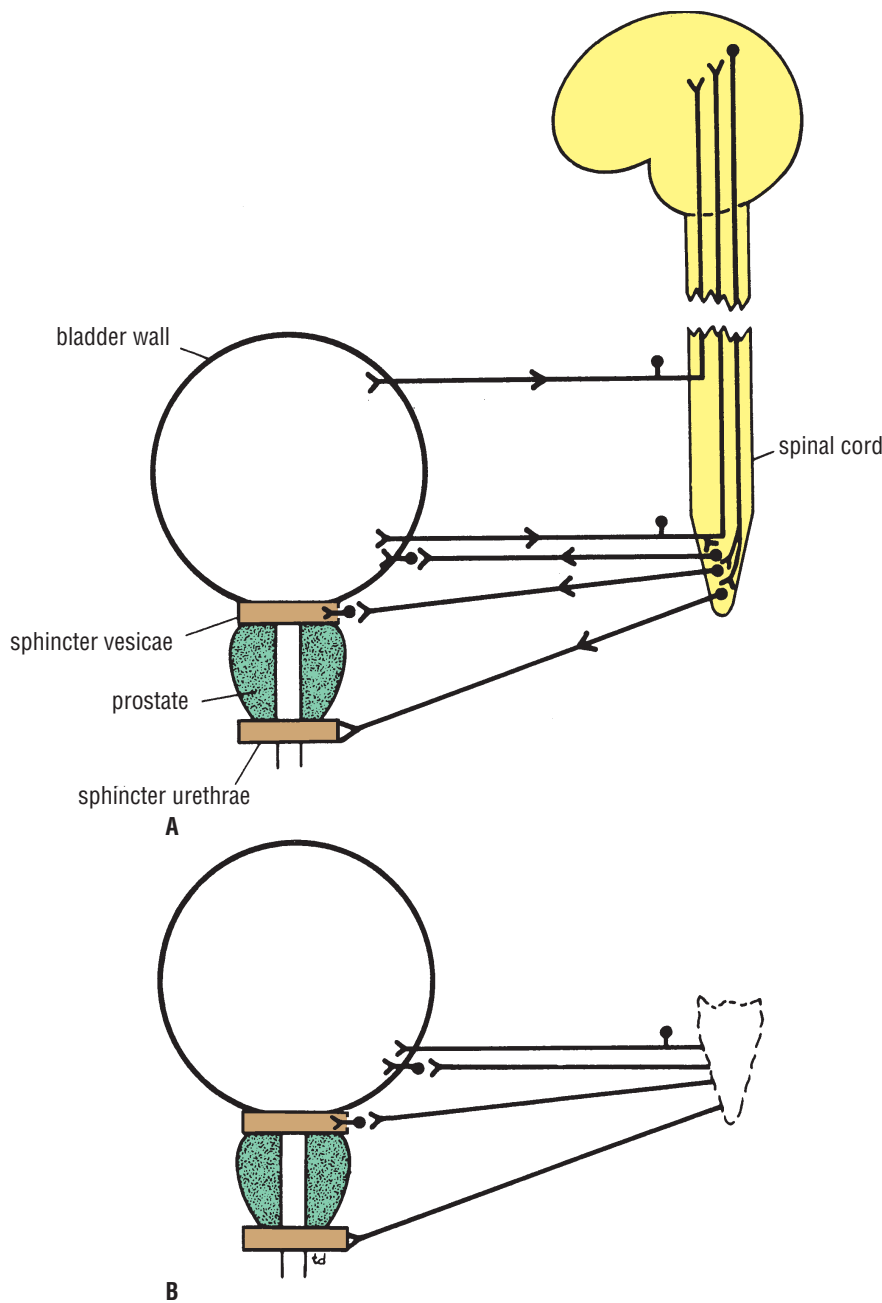
■ **Sensory nerve fibers** enter the spinal cord at the above segments. The normal process of micturition is described on text page 819.

Disruption of the process of micturition by spinal cord injuries may produce the following types of bladder:

■ The **atonic bladder** occurs during the phase of spinal shock, immediately after the injury, and may last for a few days to several weeks. The bladder wall muscle is relaxed, the sphincter vesicae tightly contracted, and the sphincter urethrae relaxed. The bladder becomes greatly distended and finally overflows. Depending on the level of the cord injury, the patient either is or is not aware that the bladder is full.

■ The **automatic reflex bladder** (CD Fig. 21-5) occurs after the patient has recovered from spinal shock, provided that the cord lesion lies above the level of the parasympathetic outflow (S2, 3, and 4). It is the type of bladder normally found in infancy. The bladder fills and empties reflexly. Stretch receptors in the bladder wall are stimulated as the bladder fills, and the afferent impulses pass to the spinal cord (segments S2, 3, and 4). Efferent impulses pass down to the bladder muscle, which contracts; the sphincter vesicae and the urethral sphincter both relax. This simple reflex occurs every 1 to 4 hours.

■ The **autonomous bladder** (see CD Fig. 21-5) is the condition that occurs if the sacral segments of the spinal cord are destroyed. The sacral segments of the spinal cord are



CD Figure 21-5 **A.** Nervous control of the bladder after section of the spinal cord in the upper thoracic region. Destruction of the sacral segments of the spinal cord. **B.** The afferent sensory fibers from the bladder entering the central nervous system and the parasympathetic efferent fibers passing to the bladder are shown; the sympathetic fibers have been omitted for clarity.

situated in the upper part of the lumbar region of the vertebral column. The bladder is without any external reflex control. The bladder wall is flaccid, and the capacity of the bladder is greatly increased. It merely fills to capacity and overflows; continual dribbling is the result. The bladder may be partially emptied by manual compression of the lower part of the anterior abdominal wall, but infection of the urine and backpressure effects on the ureters and kidneys are inevitable.



THE MALE URETHRA

Urethral Infections

The most dependent part of the male urethra is that which lies within the bulb. Here, it is subject to chronic inflammation and stricture formation.

The many glands that open into the urethra—including those of the prostate, the bulbourethral glands, and many small penile urethral glands—are commonly the site of chronic gonococcal infection.

Injuries to the Penis

Injuries to the penis may occur as the result of blunt trauma, penetrating trauma, or strangulation. Amputation of the entire penis should be repaired by anastomosis using microsurgical techniques to restore continuity of the main blood vessels.

Rupture of the Urethra

Rupture of the urethra may complicate a severe blow on the perineum. The common site of rupture is within the bulb of the penis, just below the perineal membrane. The urine extravasates into the superficial perineal pouch and then

passes forward over the scrotum beneath the membranous layer of the superficial fascia, as described on CD page 313. If the membranous part of the urethra is ruptured, urine escapes into the deep perineal pouch and can extravasate upward around the prostate and bladder or downward into the superficial perineal pouch.

Catheterization

The following anatomic facts should be remembered before passing a catheter or other instrument along the male urethra:

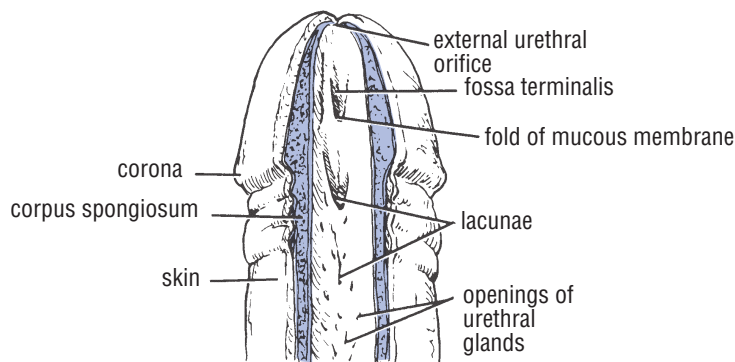
- The external orifice at the glans penis is the narrowest part of the entire urethra.
- Within the glans, the urethra dilates to form the **fossa terminalis** (navicular fossa).
- Near the posterior end of the fossa, a fold of mucous membrane projects into the lumen from the roof (CD Fig. 21-6).
- The membranous part of the urethra is narrow and fixed.
- The prostatic part of the urethra is the widest and most dilatable part of the urethra.
- By holding the penis upward, the S-shaped curve to the urethra is converted into a J-shaped curve.

If the point of the catheter passes through the external orifice and is then directed toward the urethral floor until it has passed the mucosal fold, it should easily pass along a normal urethra into the bladder.

Anatomy of the Procedure of Catheterization

The procedure is as follows:

1. The patient lies in a supine position.
2. With gentle traction, the penis is held erect at right angles to the anterior abdominal wall. The lubricated catheter is passed through the narrow external urethral meatus. The catheter should pass easily along the penile urethra. On reaching the membranous part of the



CD Figure 21-6 The penile urethra slit open to show the folds of mucous membrane and glandular orifices in the roof of the urethra.

urethra, a slight resistance is felt because of the tone of the urethral sphincter and the surrounding rigid perineal membrane.

3. The penis is then lowered toward the thighs, and the catheter is gently pushed through the sphincter.
4. Passage of the catheter through the prostatic urethra and bladder neck should not present any difficulty.



THE FEMALE URETHRA

Urethral Infections

The short length of the female urethra predisposes to ascending infection; consequently, **cystitis** is more common in females than in males.

Urethral Injuries

Because of the short length of the urethra, injuries are rare. In fractures of the pelvis, the urethra may be damaged by shearing forces as it emerges from the fixed urogenital diaphragm.

Catheterization

Because the female urethra is shorter, wider, and more dilatable, catheterization is much easier than in males. Moreover, the urethra is straight, and only minor resistance is felt as the catheter passes through the urethral sphincter.

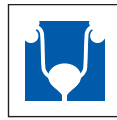

CONGENITAL ANOMALIES OF THE BLADDER

Exstrophy of the Bladder (Ectopia Vesicae)

Exstrophy of the bladder occurs three times more commonly in males than in females. The posterior bladder wall protrudes through a defect in the anterior abdominal wall below the umbilicus (CD Fig. 21-7). The condition is caused by a failure of the embryonic mesenchyme to invade the embryonic disc caudal to the cloacal membrane (CD Fig. 21-7). The absence of intervening mesenchyme between the ectoderm and entoderm produces an unstable state, which is followed by breakdown of this area.

Because of the urinary incontinence and almost certain occurrence of ascending urinary infection, surgical reconstruction of the bladder is attempted.



CONGENITAL ANOMALIES OF THE URETHRA

Meatal Stenosis

The external urinary meatus normally is the narrowest part of the male urethra, but occasionally the opening is excessively small and may cause back pressure effect on the entire urinary system. In severe cases, dilatation of the orifice by incision is necessary.

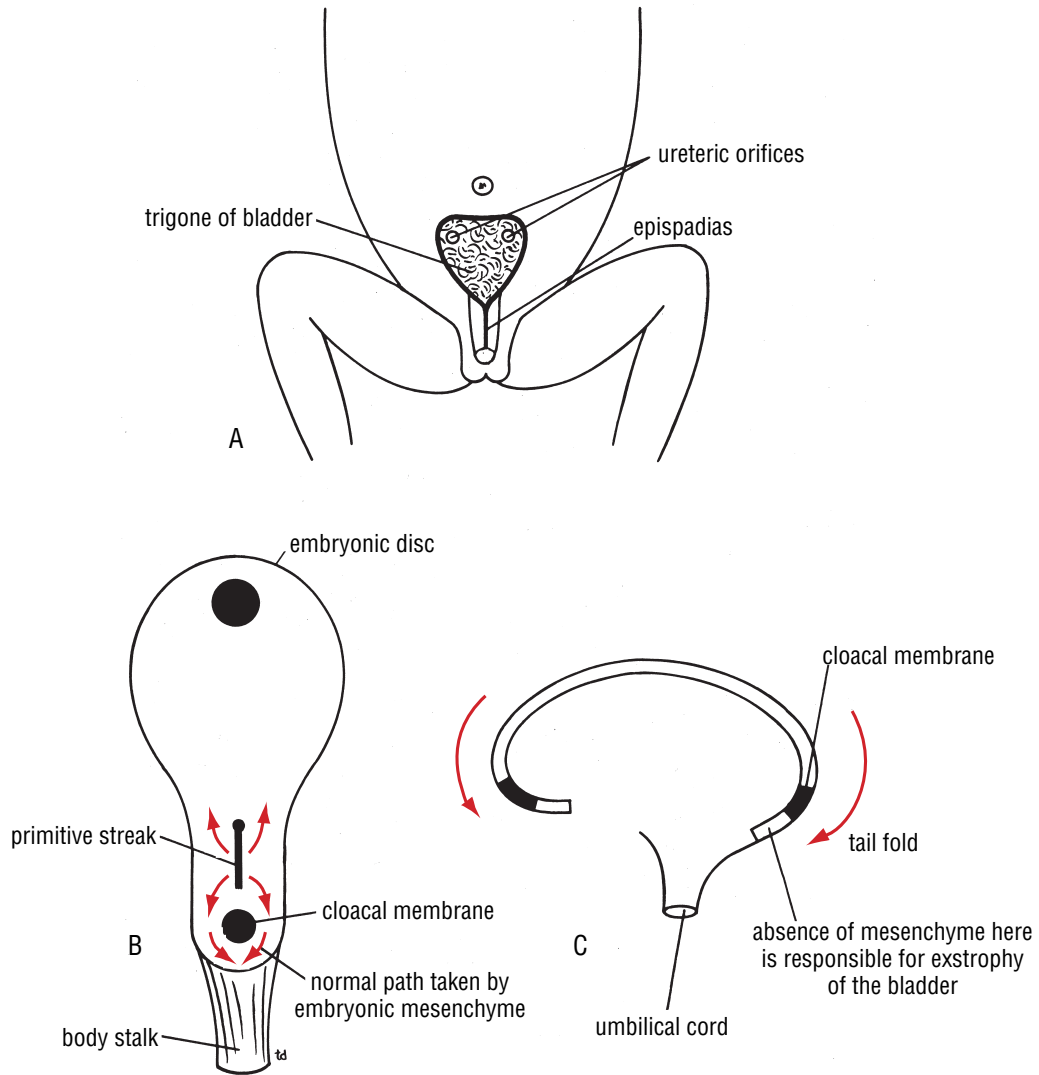
Hypospadias

Hypospadias is the most common congenital anomaly affecting the male urethra. The external meatus is situated on the ventral or undersurface of the penis anywhere between the glans and the perineum. Five degrees of severity may occur, the first of which is the most common: (1) glandular, (2) coronal, (3) penile, (4) penoscrotal, and (5) perineal (CD Fig. 21-8). In all except the first type, the penis is curved in a downward or ventral direction, a condition referred to as **chordee**.

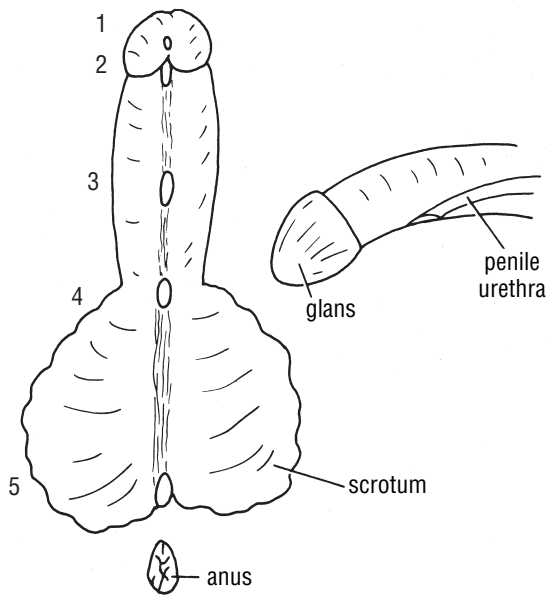
Types 1 and 2 are caused by a failure of the bud of ectodermal cells from the tip of the glans to grow into the substance of the glans and join the entodermal cells lining the penile urethra. Types 3, 4, and 5 are caused by a failure of the genital folds to unite on the undersurface of the developing penis and convert the urethral groove into the penile urethra. In the penoscrotal variety, the genital swellings fail to fuse completely, so that the meatal orifice occurs in the midline of the scrotum. Type 1 requires no treatment; for the remainder, plastic surgery is necessary.

Epispadias

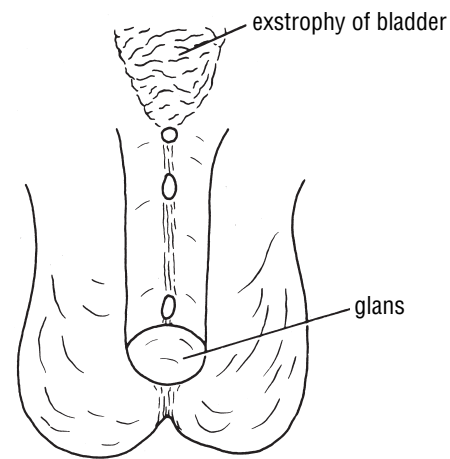
Epispadias is a relatively rare condition and is more commonly found in the male. In the male, the external meatus is situated on the dorsal or upper surface of the penis between the glans and the anterior abdominal wall (CD Fig. 21-9). The most severe type is associated with exstrophy of the bladder. In the female, the urethra is split dorsally and is associated with a double clitoris. It is thought that epispadias is caused by failure of the embryonic mesenchyme to develop in the lower part of the anterior abdominal wall, so that when the cloacal membrane breaks down, the urogenital sinus opens onto the surface of the cranial aspect of the penis. Plastic surgery is the required treatment.



CD Figure 21-7 **A.** Exstrophy of the bladder. **B.** Dorsal view of the embryonic disc. The normal path taken by the growing embryonic mesenchyme in the region of the cloaca is shown. **C.** Fetus as seen from the side. The head and tail folds have developed, but the mesenchyme has failed to enter the ventral body wall between the cloaca and the umbilical cord.



CD Figure 21-8 Types of hypospadias: (1) glandular, (2) coronal, (3) penile, (4) penoscrotal, and (5) perineal. Ventral flexion (chordee) of the penis also is present.



CD Figure 21-9 Types of epispadias.

Clinical Problem Solving Questions

Read the following case histories/questions and give the best answer for each.

A 16-year-old boy received a severe kick in the right flank while playing football at school. On examination in the emergency department, his right flank was severely bruised, and his right costovertebral angle was extremely tender on palpation. A specimen of urine showed microscopic hematuria. A diagnosis of damage to the right kidney was made.

- The following statements concerning blunt trauma to the kidney are correct **except** which?
 - The kidney tends to be crushed between the twelfth rib and the vertebral column.
 - The kidney can be injured by fractures of the twelfth rib (right kidney) or eleventh and twelfth ribs (left kidney).
 - In most patients the kidney damage is mild and results in nothing more than microscopic hematuria, as in this patient.
 - In severe kidney lacerations, extensive hemorrhage and extravasation of blood and urine into the pararenal fat occurs.
 - In severe kidney lacerations, a mass caused by extravasated blood and urine behind the peritoneum may be palpated, especially on the right side.

F. Both kidneys lie on the posterior abdominal wall and are at the same vertebral level.

A 19-year-old boy was involved in a gang fight. It started as an argument but quickly worsened into a street brawl with the use of knives. He was examined in the emergency department and found to have a bleeding stab wound in his left flank. A urine specimen revealed frank blood.

- Stab wounds of the kidneys involve other abdominal organs in a high percentage of cases. Of the organs listed, which one is least likely to be damaged in this patient?
 - Stomach
 - Spleen
 - Inferior vena cava
 - Left colic flexure
 - Left suprarenal gland
 - Coils of jejunum
 - Body of the pancreas

An inebriated 40-year-old man was involved in a fight over a woman. The woman's husband gave the man a severe blow to the lower part of the anterior abdominal wall, whereupon he doubled up with pain and collapsed on the floor. On admission to the emergency department of the local hospital, the man was in a state of shock and

complaining of severe pain in the lower abdominal region. He was unable to pass urine since the fight. A diagnosis of ruptured urinary bladder was made.

3. The following statements concerning this patient are correct **except** which?
 - A. Rectal examination revealed a bulging backward of the rectovesical fossa.
 - B. Although the patient had consumed a considerable volume of liquor, dullness was not present on percussion of the anterior abdominal wall above the symphysis pubis.
 - C. The urine accumulated in the rectovesical pouch.
 - D. A full bladder is more likely to be ruptured by a blow to the anterior abdominal wall than an empty bladder.
 - E. In the adult, as the normal bladder fills, its superior wall extends upward into the abdomen, leaving the covering of parietal peritoneum behind.

A 39-year-old woman was admitted to the local hospital after experiencing a gunshot wound to the lower part of her back. Radiographic examination revealed that the bullet was lodged in the vertebral canal at the level of the third lumbar vertebra. A comprehensive neurologic examination indicated that a complete lesion of the cauda equina had occurred.

4. The following statements concerning this patient are likely to be true **except** which?
 - A. The cauda equina, which consists of anterior and posterior nerve roots below the level of the first lumbar segment, was sectioned at the level of the third lumbar vertebra.
 - B. The preganglionic sympathetic nerve fibers to the vesical sphincter that descend in the anterior roots of the fourth and fifth lumbar nerves were sectioned.
 - C. The preganglionic parasympathetic fibers to the detrusor muscle that descend in the anterior roots of the second, third, and fourth sacral nerves were sectioned.
 - D. The patient would have an autonomous bladder.
 - E. The bladder would fill to capacity and then overflow.
 - F. Micturition could be activated by powerful contraction of the abdominal muscles and manual pressure on the anterior abdominal wall in the suprapubic region.

A 15-year-old boy was taking part in a bicycle race when, on approaching a steep hill, he stood up on the pedals to increase the speed. His right foot slipped off the pedal and he fell violently, his perineum hitting the bar of the bicycle. Several hours later he was admitted to the hospital unable to micturate. On examination, he was found to have extensive swelling of the penis and scrotum. A diagnosis of ruptured urethra was made.

5. The following statements concerning this case are correct **except** which?
 - A. Rupture of the bulbous part of the urethra had taken place.
 - B. The urine had escaped from the urethra and extravasated into the superficial perineal pouch.
 - C. The urine had passed forward over the scrotum and penis to enter the anterior abdominal wall.
 - D. The urine had extended posteriorly into the ischioanal fossae.
 - E. The urine was located beneath the membranous layer of superficial fascia.

A 34-year-old man was suffering from postoperative retention of urine after an appendectomy. The patient's urinary tract was otherwise normal. Because the patient was in considerable discomfort, the resident decided to pass a catheter.

6. The following statements concerning the catheterization of a male patient are correct **except** which?
 - A. Because the external urethral orifice is the narrowest part of the urethra, once the tip of the catheter has passed this point, further passage should be easy.
 - B. Near the posterior end of the fossa terminalis, a fold of mucous membrane projects from the roof and may catch the end of the catheter.
 - C. The membranous part of the urethra is narrow and fixed and may produce some resistance to the passage of the catheter.
 - D. The prostatic part of the urethra is the widest and most easily dilated part of the urethra and should cause no difficulty to the passage of the catheter.
 - E. The bladder neck is surrounded by the sphincter vesicae and always strongly resists the passage of the tip of the catheter.
7. An explorer in the Amazon jungle was found alive after having lost contact with the outside world for 6 months. On physical examination, he was found to be in an emaciated condition. On palpation of the abdomen, a rounded, smooth swelling appeared in the right loin at the end of inspiration. On expiration, the swelling moved upward and could no longer be felt. What anatomic structure could produce such a swelling?
8. An intravenous pyelogram revealed that a patient's left kidney was in its normal position, but the right kidney was situated in front of the right sacroiliac joint. Can you explain this on embryologic grounds?
9. An examination of a patient revealed that she had a horseshoe kidney. What anatomic structure prevents a horseshoe kidney from ascending to a level above the umbilicus?

10. An intravenous pyelogram revealed that the calyces and pelvis of a patient's right kidney were grossly dilated (a condition known as hydronephrosis). What embryologic anomaly may be responsible for this condition?
11. A 55-year-old woman was found rolling on her kitchen floor, crying out from agonizing pain in her abdomen. The pain came in waves and extended from the right loin to the groin and to the front of the right thigh. An anteroposterior radiograph of the abdomen revealed a calculus in the right ureter. What causes the pain when a ureteral calculus is present? Why is the pain felt in such an extensive area? Where does one look for the course of the ureter in a radiograph? Where along the ureter is a calculus likely to be held up?
12. Which congenital anomaly of the ureter is likely to present as a case of urinary incontinence?
13. Renal pain is a common symptom faced by medical professionals. Describe the course taken by pain nerve fibers from the kidneys. In which regions of the body is pain commonly referred to?
14. In relation to abdominal trauma, can you explain the differences between the bladder position in a child compared with that of an adult? Does the degree of filling of the adult bladder affect the signs and symptoms presented by the patient with a ruptured bladder? Can you explain how it is possible to pass an aspirating needle through the anterior abdominal wall into the full bladder in an adult without entering the peritoneal cavity?
15. Why is acute cystitis more common in females than in males? In anatomic terms explain stress incontinence.

Answers and Explanations

1. **F** is the correct answer. Because of the large size of the right lobe of the liver, the right kidney lies at a lower level than the left kidney.
2. **C** is the correct answer. The inferior vena cava lies at some distance from the left flank.
3. **E** is the correct answer. In the adult, as the normal bladder fills, its superior wall bulges upward into the abdomen, peeling off the peritoneum from the posterior surface of the anterior abdominal wall (see text Fig. 21-17).
4. **B** is the correct answer. The preganglionic sympathetic nerve fibers to the vesical sphincter descend in the anterior roots of the first and second lumbar nerves and were left intact.
5. **D** is the correct answer. The superficial perineal pouch is closed off posteriorly by the attachment of the membranous layer of superficial fascia to the posterior margin of the urogenital diaphragm (see text Fig. 21-15). Because of this attachment, the extravasated urine cannot enter the ischiorectal fossae.
6. **E** is the correct answer. The bladder neck does not cause obstruction to the passage of the catheter. In this patient, the sphincter may provide some minor resistance that is easily overcome.
7. The right kidney was felt. It is the only normal kidney that can be palpated. The lower pole may be felt in a thin person at the end of inspiration, when the contracted diaphragm has pushed it down to its lowest level. When the diaphragm relaxes on expiration, the kidney returns to its original position.
8. Both kidneys originate in the pelvis and with development rise up on the posterior abdominal wall until the hili lie opposite the second lumbar vertebra. Occasionally, one of the kidneys fails to reach its normal position.
9. The bridge of renal tissue, which unites the lower poles of the two kidneys to form the horseshoe, becomes trapped behind the inferior mesenteric artery (see CD Fig. 21-3). The artery arrests the ascent of the kidneys.
10. An aberrant renal artery may cross the pelviureteric junction and obstruct the flow of urine (see CD Fig. 21-3).
11. Spasm of the smooth muscle in the wall of the pelvis and ureter occurs as it attempts to move the calculus down the urinary tract. Afferent pain nerve fibers enter the spinal cord in the first and second lumbar segments. The anterior rami of the first lumbar nerves are distributed in the skin in the lumbar region and groin as the iliohypogastric and ilioinguinal nerves. The pain experienced in the front of the thigh was referred along the femoral branch of the genitofemoral nerve (L1 and 2). One could look for the course of the ureter in front of the tips of the transverse processes of the lumbar vertebrae, in front of the sacroiliac joint, and in the region of the spine of the ischium. A calculus is likely to be held up at the pelviureteric junction, where the ureter crosses the pelvic brim and where it enters the bladder.

12. The congenital anomaly is a case of bifid ureters in which one ureter opens into the urinary tract below the bladder sphincter in the male, or into the vagina in the female (see CD Fig. 21-4).
13. Renal pain may result from stretching the renal capsule or spasm of the smooth muscle in the pelvis or the ureter. The afferent nerve fibers pass through the renal plexus around the renal artery and ascend to the spinal cord through the lowest thoracic splanchnic nerve and the sympathetic trunk. They enter the twelfth thoracic spinal nerve through the white rami communicantes and the twelfth thoracic segment of the spinal cord through the posterior root of the spinal nerve. The pain fibers are then believed to ascend to the brain in the lateral spinal thalamic tracts. The pain is referred along the distribution of the subcostal nerve (T12) to the flank and the anterior abdominal wall.
14. In young children, the empty bladder lies in the abdomen; later, as the pelvis enlarges, the bladder sinks to become a pelvic organ.

In adults, the full bladder lies behind the lower part of the anterior abdominal wall. Severe trauma to the lower abdomen in patients with a full bladder may cause the superior wall of the bladder to rupture into the peritoneal cavity. The blood and urine irritates the peritoneum, causing lower abdominal tenderness and later muscle rigidity.

When the bladder is empty, the anterior wall of the bladder lies behind the symphysis pubis. Trauma to the lower abdomen in these circumstances may not damage the bladder. However, if the pubic bones are fractured, the anterior wall of the bladder may be damaged by bone fragments, and urine escapes below the reflection of the peritoneum and does not enter the peritoneal cavity. Lower abdominal pain and hematuria are present in the majority of such patients.

It is possible to pass an aspirating needle through the lower part of the anterior abdominal wall into the full bladder in an adult without entering the peritoneal cavity. This can be explained because as the bladder fills, the superior wall rises and strips the peritoneum off the lower part of the anterior abdominal wall. Thus, the aspirating needle will enter the bladder below the peritoneal reflection and avoid the peritoneal cavity.

15. Acute cystitis is much more common in females than males because the urethra is much shorter. In females the urethra measures 1.5 in. long, whereas in males the urethra measures about 8 in. long, and thus bacteria have a shorter distance to travel in the female.

Stress incontinence usually follows a difficult childbirth, where there has been injury to the pelvic floor. This results in an alteration in the position of the bladder neck relative to the urethra.



The Reproductive System



22

The Male Genital
Organs, the Penis, and
the Scrotum



Chapter Outline

The Scrotum	388	The Bulbourethral Glands	391
Lymph Drainage of the Scrotum	388	Infection of the Bulbourethral Glands	391
Hydrocele	388	The Penis	391
The Testis and the Epididymis	388	Circumcision	391
Varicocele	388	Urethral Infection	391
Malignant Tumor of the Testis	389	Catheterization	391
Torsion of the Testis	389	Blunt Trauma to the Penis	391
Congenital Anomalies of the Testis	389	Penetrating Trauma to the Penis	391
Appendix of the Testis and Appendix of the Epididymis	389	Strangulation of the Penis	391
The Vas Deferens	390	Phimosis	392
Vasectomy	390	Erection and Ejaculation after Spinal Cord Injuries	392
The Prostate	390	Congenital Anomalies of the Penis	392
Prostate Examination	390	Meatal Stenosis	392
Prostate Activity and Disease	390	Hypospadias	392
Benign Enlargement of the Prostate	390	Epispadias	392
Prostate Cancer and the Prostatic Venous Plexus	390	Clinical Problem Solving Questions	392
		Answers and Explanations	393



THE SCROTUM

Lymph Drainage of the Scrotum

It is important to remember that the lymph drainage of the scrotal wall, including the fascia and tunica vaginalis, is into the superficial inguinal nodes. The lymph drainage of the testis and epididymis (which develop on the posterior abdominal wall) is into the lumbar or paraaortic nodes at the level of the first lumbar vertebra.

Hydrocele

This is an accumulation of fluid within the tunica vaginalis. Most hydroceles are idiopathic, but some may be caused by spread of infection from the testis or epididymis. Tapping a hydrocele is described on CD page 314.



THE TESTIS AND THE EPIDIDYMIS

Varicocele

A varicocele is a condition in which the veins of the pampiniform plexus are elongated and dilated. It is a common disorder in adolescents and young adults, with most occurring on the left side. This is thought to be because the right testicular vein joins the low-pressure inferior vena cava, whereas the left vein joins the left renal vein, in which the venous pressure is higher. Rarely, malignant disease of the left kidney extends along the renal vein and blocks the exit of the testicular vein. A rapidly developing left-sided varicocele should therefore always lead one to examine the left kidney.

Malignant Tumor of the Testis

A malignant tumor of the testis spreads upward via the lymph vessels to the lumbar (paraaortic) lymph nodes at the level of the first lumbar vertebra. It is only later, when the tumor spreads locally to involve the tissues and skin of the scrotum, that the superficial inguinal lymph nodes are involved.

Torsion of the Testis

Torsion of the testes is a rotation of the testis around the spermatic cord within the scrotum. It is often associated with an excessively large tunica vaginalis. Torsion commonly occurs in active young men and children and is accompanied by severe pain. If not treated quickly, the testicular artery may be occluded, followed by necrosis of the testis.



CONGENITAL ANOMALIES OF THE TESTIS

The testis may be subject to the following congenital anomalies:

- **Anterior inversion**, in which the epididymis lies anteriorly and the testis and the tunica vaginalis lie posteriorly
- **Polar inversion**, in which the testis and epididymis are completely inverted

■ Imperfect descent (cryptorchidism):

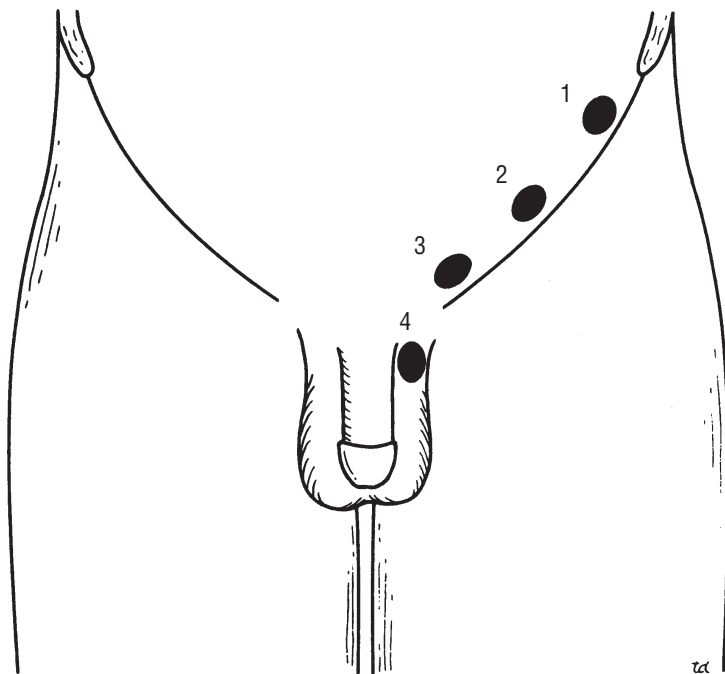
Incomplete descent (CD Fig. 22-1), in which the testis, although traveling down its normal path, fails to reach the floor of the scrotum. It may be found within the abdomen, within the inguinal canal, at the superficial inguinal ring, or high up in the scrotum.

Maldescent (CD Fig. 22-2), in which the testis travels down an abnormal path and fails to reach the scrotum. It may be found in the superficial fascia of the anterior abdominal wall above the inguinal ligament, in front of the pubis, in the perineum, or in the thigh.

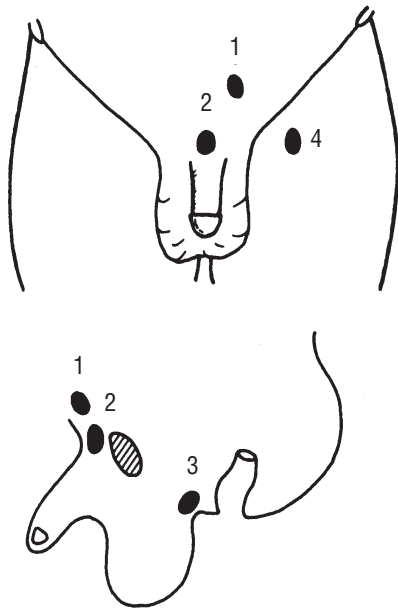
It is necessary for the testes to leave the abdominal cavity because the temperature there retards the normal process of spermatogenesis. If an incompletely descended testis is brought down into the scrotum by surgery before puberty, it will develop and function normally. A maldescended testis, although often developing normally, is susceptible to traumatic injury and, for this reason, should be placed in the scrotum. Many authorities believe that the incidence of tumor formation is greater in testes that have not descended into the scrotum.

Appendix of the Testis and Appendix of the Epididymis

These are embryologic remnants found at the upper poles of these organs that may become cystic. The appendix of the testis is derived from the paramesonephric ducts, and the appendix of the epididymis is a remnant of the mesonephric tubules.



CD Figure 22-1 Four degrees of incomplete descent of the testis. **1.** In the abdominal cavity close to the deep inguinal ring. **2.** In the inguinal canal. **3.** At the superficial inguinal ring. **4.** In the upper part of scrotum.



CD Figure 22-2 Four types of maldescent of the testis. **1.** In the superficial fascia of the anterior abdominal wall, above the superficial inguinal ring. **2.** At the root of the penis. **3.** In the perineum. **4.** In the thigh.



THE VAS DEFERENS

Vasectomy

Bilateral vasectomy is a simple operation performed to produce infertility. Under local anesthesia, a small incision is made in the upper part of the scrotal wall, and the vas deferens is divided between ligatures. Spermatozoa may be present in the first few postoperative ejaculations, but that is simply an emptying process. Now only the secretions of the seminal vesicles and prostate constitute the seminal fluid, which can be ejaculated as before.



THE PROSTATE

Prostate Examination

The prostate can be examined clinically by palpation by performing a rectal examination (see CD Chapter 19). The examiner's gloved finger can feel the posterior surface of the prostate through the anterior rectal wall.

Prostate Activity and Disease

It is now generally believed that the normal glandular activity of the prostate is controlled by the androgens and

estrogens circulating in the bloodstream. The secretions of the prostate are poured into the urethra during ejaculation and are added to the seminal fluid. Acid phosphatase is an important enzyme present in the secretion in large amounts. When the glandular cells producing this enzyme cannot discharge their secretion into the ducts, as in carcinoma of the prostate, the serum acid phosphatase level of the blood rises.

It has been shown that trace amounts of proteins produced specifically by prostatic epithelial cells are found in peripheral blood. In certain prostatic diseases, notably cancer of the prostate, this protein appears in the blood in increased amounts. The specific protein level can be measured by a simple laboratory test called the **PSA** (prostatic-specific antigen) test.

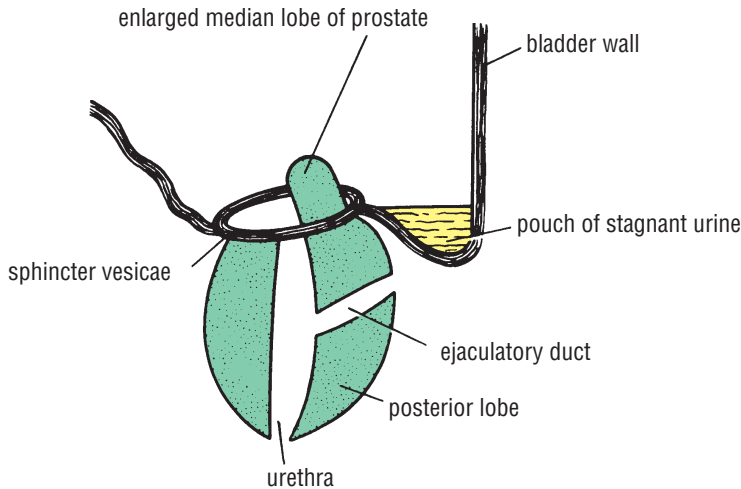
Benign Enlargement of the Prostate

Benign enlargement of the prostate is common in men older than 50 years. The cause is possibly an imbalance in the hormonal control of the gland. The median lobe of the gland enlarges upward and encroaches within the sphincter vesicae, located at the neck of the bladder. The leakage of urine into the prostatic urethra causes an intense reflex desire to micturate. The enlargement of the median and lateral lobes of the gland produces elongation and lateral compression and distortion of the urethra so that the patient experiences difficulty in passing urine and the stream is weak. Backpressure effects on the ureters and both kidneys are a common complication. The enlargement of the uvula vesicae (owing to the enlarged median lobe) results in the formation of a pouch of stagnant urine behind the urethral orifice within the bladder (CD Fig. 22-3). The stagnant urine frequently becomes infected, and the inflamed bladder (**cystitis**) adds to the patient's symptoms.

In all operations on the prostate, the surgeon regards the prostatic venous plexus with respect. The veins have thin walls, are valveless, and are drained by several large trunks directly into the internal iliac veins. Damage to these veins can result in a severe hemorrhage.

Prostate Cancer and the Prostatic Venous Plexus

Many connections between the prostatic venous plexus and the vertebral veins exist. During coughing and sneezing or abdominal straining, it is possible for prostatic venous blood to flow in a reverse direction and enter the vertebral veins. This explains the frequent occurrence of skeletal metastases in the lower vertebral column and pelvic bones of patients with carcinoma of the prostate. Cancer cells enter the skull via this route by floating up the valveless prostatic and vertebral veins.



CD Figure 22-3 Sagittal section of a prostate that had undergone benign enlargement of the median lobe. Note the bladder pouch filled with stagnant urine behind the prostate.



THE BULBOURETHRAL GLANDS

Infection of the Bulbourethral Glands

The bulbourethral glands are the common sites for chronic venereal infection (e.g., gonorrhoea). The organisms reach the gland by ascending from the bulbous part of the urethra along the duct of the gland.



THE PENIS

Circumcision

Circumcision is the operation of removing the greater part of the prepuce, or foreskin. In many newborn males, the prepuce cannot be retracted over the glans. This can result in infection of the secretions beneath the prepuce, leading to inflammation, swelling, and fibrosis of the prepuce. Repeated inflammation leads to constriction of the orifice of the prepuce (**phimosis**) with obstruction to urination. It is now generally believed that chronic inflammation of the prepuce predisposes to carcinoma of the glans penis. For

these reasons, prophylactic circumcision is commonly practiced. For Jews, it is a religious rite.

Urethral Infection

See CD Chapter 21.

Catheterization

See CD Chapter 21.

Blunt Trauma to the Penis

This may cause penile fracture when it is in the erect state. A transverse laceration of the fibrous envelopes of the erectile tissue of the penis occurs followed by the formation of a large hematoma; the base of the penis is the common site of injury. Rupture of the penile urethra may also occur and is accompanied by a bloody urethral discharge.

Penetrating Trauma to the Penis

This may injure the skin, fascia, erectile tissue, and urethra. Amputation of the entire penis should be repaired by anastomosis using microsurgical techniques to restore continuity of the main blood vessels.

Strangulation of the Penis

Strangulation of the penis by means of a ring or ligature may cause ischemia of the entire penis. It is imperative that the constriction be removed without delay to avoid compromising the blood supply.

Phimosis

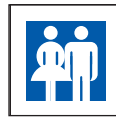In this condition the opening in the prepuce is narrowed so that it is impossible to retract the prepuce over the glans penis. Occasionally the narrowing is so extreme that the urinary flow is obstructed. The usual cause of the condition is infection under the prepuce, causing fibrosis and subsequent contraction of the prepuce.

Erection and Ejaculation after Spinal Cord Injuries

Erection of the penis is controlled by the parasympathetic nerves that originate from the second, third, and fourth sacral segments of the spinal cord. Bilateral damage to the reticulospinal nerve tracts in the spinal cord will result in loss of erection. Later, when the effects of spinal shock have disappeared, spontaneous or reflex erection may occur if the sacral segments of the spinal cord are intact.

Ejaculation is controlled by sympathetic nerves that originate in the first and second lumbar segments of the spinal cord. As in the case of erection, severe bilateral

damage to the spinal cord results in loss of ejaculation. Later, reflex ejaculation may be possible in patients with spinal cord transections in the thoracic or cervical regions.



CONGENITAL ANOMALIES OF THE PENIS

Meatal Stenosis

See CD Chapter 21.

Hypospadias

See CD Chapter 21.

Epispadias

See CD Chapter 21.

Clinical Problem Solving Questions

Read the following case histories/questions and give the best answer for each.

A 55-year-old man was admitted to the hospital with a large hard, fixed, intraabdominal mass. On examination of the abdomen, the mass was situated on the transpyloric plane and appeared to be attached to the posterior abdominal wall. The inguinal lymph nodes were normal.

- The symptoms and signs displayed by this patient can be explained by the following statements **except** which?
 - Radiologic examination of the stomach showed nothing abnormal.
 - The right testicle was enlarged and was much harder than normal.
 - A diagnosis of malignant disease of the right testis was made.
 - The malignant tumor had metastasized to the lumbar lymph nodes lying on the transpyloric plane on the posterior abdominal wall, which is the normal lymphatic drainage of the testis.
 - In malignant disease of the testis the superficial inguinal lymph nodes only become involved if the tumor spreads to involve the scrotal skin.
 - The normal testis is tethered to the skin of the scrotum.

While bathing her 5-month-old boy, a mother noticed that his penis tended to curve downward. She decided to seek advice from a pediatrician.

- The pediatrician examined the child and made the following possible correct observations and statements **except** which?
 - The penis had a definite downward curvature (chordee).
 - Both testes were in the scrotum.
 - The external urethral meatus opened halfway along the undersurface of the penis.
 - The fusion of the genital folds on the ventral or undersurface of the shaft of the penis was incomplete so that the urethra opened on the ventral surface.
 - The condition is a rare congenital anomaly.
- The pediatrician made the following possible correct statements to the mother regarding the diagnosis and treatment **except** which?
 - The child had hypospadias associated with chordee.
 - The proximal portion of the penile urethra had developed normally but was incomplete.
 - The bud of cells (ectodermal) on the tip of the glans penis had failed to grow into the substance of the

- glans and join with the cells (entodermal cells) of the penile urethra.
- D. The treatment is the surgical correction of the chordee, which is followed by the plastic reconstruction of the penile urethra.
- E. In view of the delicate tissues involved, the treatment should be delayed until the child is at least 10 years old.
4. A 65-year-old man with a history of prostatic disease was found on radiographic examination of his skeleton to have extensive carcinomatous metastases in his skull and lumbar vertebrae. His PAS levels in his blood were very much higher than normal. Using your knowledge of anatomy, can you suggest a possible route taken by the cancer cells as they migrated from the prostate to (1) the lumbar vertebrae and (2) the skull?
 5. An 88-year-old man had a history of prostatic disease. His latest symptoms included difficulty in starting to micturate, a poor urinary stream, and difficulty in stopping the flow of urine. Which lobe or lobes of the prostate are related to the sphincter vesicae? The enlargement of which lobe is likely to interfere with the sphincter's function?
 6. A 6-year-old boy was examined by a pediatrician and found to have no testicle present in the right side of his scrotum. On careful palpation, a deep, firm ovoid structure could be felt above the medial part of the inguinal ligament. What is the diagnosis? Is surgical treatment necessary?
 7. An 18-year-old boy, at a medical examination for admission to the army, was found to have no testis in the left side of the scrotum. Nothing abnormal could be palpated in the inguinal canal, but a small, firm ovoid structure could be felt in front of the upper part of the left thigh. What is the diagnosis? Is surgical treatment required?
 8. A 25-year-old man developed a swelling above the medial end of the right inguinal ligament. It was associated with a dull, aching pain, but it did not expand on coughing. On palpation, the swelling appeared to fluctuate, and on grasping the right testis through the scrotal wall and gently pulling it inferiorly, the swelling moved medially along the inguinal canal. What was the swelling? Why did it move with the testis?
 9. A patient suffering from tuberculosis of the left epididymis was found to have an ulcer on the posterior surface of the scrotum. Which group of lymph nodes would you examine for local spread of the disease?
 10. A resident was asked to examine the vas deferens of a patient. Where would you examine the vas deferens and what does a normal vas feel like?
 11. In a patient with a history of venereal disease, a large, fluctuant swelling developed in front of the left testis. From your knowledge of anatomy, and given that there is fluid present in the scrotum, where in the scrotum is the fluid likely to collect?
 12. A 50-year-old man was found on examination to have a small cystic swelling above his right testis. What anatomic structure is likely to be involved? Can you explain the presence of this structure embryologically?
 13. A 25-year-old man was found, during a physical examination, to have an abnormal scrotum. On feeling the scrotum with the palm of the hand, it felt like a bag of worms. This situation was caused by an enlargement of the pampiniform plexus on the left side. The physician examined the scrotum and then the left kidney. Can you explain why he should examine the left kidney?

Answers and Explanations

1. **F** is the correct answer. The normal testis is freely mobile within the scrotum and is not tethered to the subcutaneous tissue or skin.
2. **E** is the correct answer. The condition is one of the most common congenital anomalies affecting the male urethra.
3. **E** is the correct answer. The surgical treatment should start at about the age of 2 years and be complete before the child goes to school. Little boys like to look the same as other little boys.
4. The prostatic venous plexus is drained into the internal iliac veins. Large valveless veins also connect the plexus to the valveless vertebral veins. On coughing or sneezing, the blood may be forced from the prostatic plexus in the pelvis into the vertebral veins. Dislodged prostatic cancer cells may be carried along this route to the vertebral column. They may also pass up the vertebral plexus to enter the veins of the skull.
5. The median (middle) lobe of the prostate is located between the prostatic urethra and the ejaculatory ducts,

just inferior to the sphincter vesicae. Benign hypertrophy of the median lobe results in its upward expansion within the sphincter vesicae. The sphincter can no longer function effectively, and urine continues to dribble into the urethra, giving the patient an intense desire to continue to micturate.

6. The boy had an incompletely descended testis on the right side. The right testis was situated in the inguinal canal. Spontaneous descent of the testis usually occurs without treatment. The injection of gonadotropic hormone can be used to speed up the descent. However, if the descent has not occurred by the age of 10 years, surgical treatment is necessary to place the testis in the scrotum. The high temperature of the abdominal cavity and inguinal canal inhibits normal spermatogenesis.
7. The boy had a maldescended testis on the left side. Instead of following the gubernaculum down into the scrotum, it passed laterally and came to rest in the superficial fascia in the upper part of the left thigh. A maldescended testis is very prone to injury and should be placed in the scrotum by surgical means.
8. The patient had a right encysted hydrocele of the spermatic cord. This is a cyst in the remnant of the upper part of the processus vaginalis and is connected to the tunica vaginalis by a fibrous strand (a further remnant of the processus). On pulling down the testis and the tunica vaginalis, the cyst was pulled medially by the fibrous strand.
9. The skin of the scrotum, the fascia, and the tunica vaginalis drain their lymph into the superficial inguinal lymph nodes.
10. Palpate the upper part of the scrotum between finger and thumb, and you can roll the vas deferens as a cord-like structure. It has a smooth external wall and is firm in consistency. Remember there are two sides and to always compare the two.
11. The tunica vaginalis covers the front and sides of the testis, and the visceral layer is in direct contact with the tunica albuginea of the testis. Infection causes an excessive production and accumulation of fluid within the tunica, a condition known as hydrocele.
12. The patient has a cyst of the appendix of the testis, a structure that is derived embryologically from the paramesonephric duct.
13. The left pampiniform plexus is drained by the left testicular vein, which is drained into the left renal vein. A malignant tumor of the left kidney could spread along the left renal vein, blocking the exit of the left testicular vein and causing congestion and varicosity of the left pampiniform plexus. This is a rare cause. The majority of varicoceles are idiopathic.



23

The Perineum, the
Female Genital Organs,
and Childbirth



Chapter Outline

The Vulva	397	The Anatomy of Emergency Cesarean Section	403
Vulval Infection	397	The Anatomy of the Technique	403
The Vulva and Pregnancy	397	Prolapse of the Uterus	403
The Urethra	397	Hysterectomy and Damage to the Ureter	404
Urethral Infection	397	Congenital Anomalies of the Uterus	404
Urethral Injuries	397	Agnesis of the Uterus	404
Catheterization	397	Infantile Uterus	404
The Ovary	397	Failure of Fusion of the Paramesonephric Ducts	404
Position of the Ovary	397	The Placenta	404
Cysts of the Ovary	397	The Placenta and Bleeding in Late Pregnancy	404
Congenital Anomalies of the Ovary	397	Placenta Previa	404
Ovarian Dysgenesis	397	Placental Abruption	405
Imperfect Descent of the Ovary	397	The Vagina	405
The Uterine Tube	397	Vaginal Examination	405
The Uterine Tube as a Conduit for Infection	397	Prolapse of the Vagina	406
Pelvic Inflammatory Disease	397	Culdocentesis	406
Ectopic Pregnancy	398	Anatomic Structures through which the Needle Passes	406
Tubal Ligation	398	Anatomic Features of the Complications of Culdocentesis	406
The Uterus	398	Vaginal Trauma	406
Rectal Examination	398	Congenital Anomalies of the Vagina	406
Bimanual Pelvic Examination of the Uterus	398	Vaginal Agnesis	406
Basic Anatomy of a Normal Pregnancy	399	Double Vagina	406
Ultrasound Anatomy of the Developing Fetus	400	Imperforate Vagina and Imperforate Hymen	406
Anatomy of Childbirth	400	Visceral Pelvic Fascia	406
Labor Pains	400	Visceral Pelvic Fascia and Infection	406
Labor	400	The Pelvic Peritoneum	406
The Uterus in Pregnancy	401	The Rectouterine Pouch and Disease	406
The Role of the Uterus in the Onset of Labor	401	Clinical Problem Solving Questions	407
Injury to the Perineum during Childbirth	402	Answers and Explanations	408
Varicose Veins and Hemorrhoids in Pregnancy	403		



THE VULVA

Vulval Infection

In the region of the vulva, the presence of numerous glands and ducts opening onto the surface makes this area prone to infection (see text Fig. 23-7). The sebaceous glands of the labia majora, the ducts of the greater vestibular glands, the vagina (with its indirect communication with the peritoneal cavity), the urethra, and the paraurethral glands can all become infected. The vagina itself has no glands and is lined with stratified squamous epithelium. Provided that the pH of its interior is kept low, it is capable of resisting infection to a remarkable degree.

The Vulva and Pregnancy

An important sign in the **diagnosis of pregnancy** is the appearance of a bluish discoloration of the vulva and vagina as a result of venous congestion. It appears at the eighth to twelfth week and increases as the pregnancy progresses.



THE URETHRA

Urethral Infection

The short length of the female urethra predisposes to ascending infection; consequently, **cystitis** is more common in females than in males.

Urethral Injuries

Because of the short length of the urethra, injuries are rare. In fractures of the pelvis, the urethra may be damaged by shearing forces as it emerges from the fixed urogenital diaphragm.

Catheterization

Because the female urethra is shorter, wider, and more dilatable, catheterization is much easier than in males. Moreover, the urethra is straight, and only minor resistance is felt as the catheter passes through the urethral sphincter.



THE OVARY

Position of the Ovary

The ovary is kept in position by the broad ligament and the mesovarium (see text Fig. 23-10). After pregnancy, the

broad ligament is lax, and the ovaries may prolapse into the rectouterine pouch (pouch of Douglas). In these circumstances, the ovary may be tender and cause discomfort on sexual intercourse (dyspareunia). An ovary situated in the rectouterine pouch may be palpated through the posterior fornix of the vagina.

Cysts of the Ovary

Follicular cysts are common and originate in unruptured graafian follicles; they rarely exceed 0.6 in. (1.5 cm) in diameter. **Luteal cysts** are formed in the corpus luteum. Fluid is retained, and the corpus luteum cannot become fibrosed. Luteal cysts rarely exceed 1.2 in. (3 cm) in diameter.

Congenital Anomalies of the Ovary

Ovarian Dysgenesis

Complete failure of both ovaries to develop is found in Turner's syndrome. The classic features of this syndrome are webbed neck, short stocky build, increased carrying angle of the elbows, lack of secondary sex characteristics, and amenorrhea.

Imperfect Descent of the Ovary

The ovary may fail to descend into the pelvis or very rarely may be drawn downward with the round ligament of the uterus into the inguinal canal or even into the labium majus.



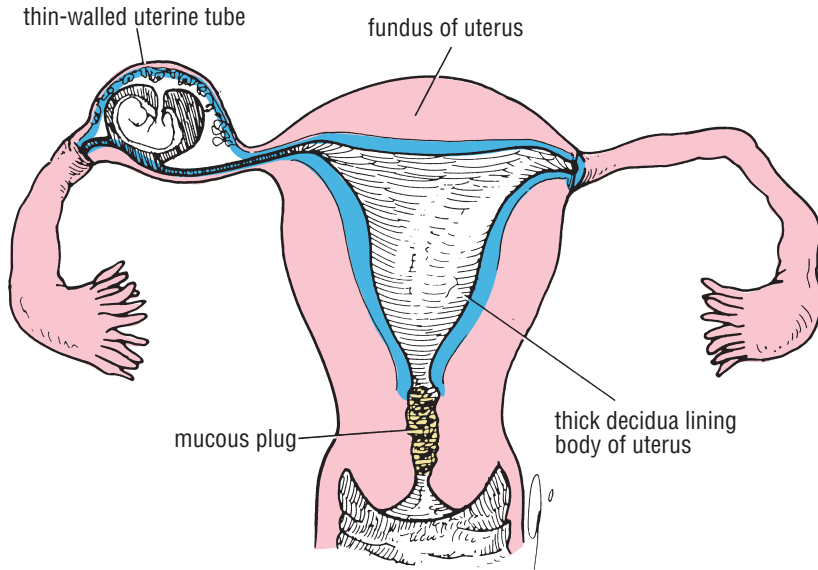
THE UTERINE TUBE

The Uterine Tube as a Conduit for Infection

The uterine tube lies in the upper free border of the broad ligament (see text Fig. 23-10) and is a direct route of communication from the vulva through the vagina and uterine cavity to the peritoneal cavity.

Pelvic Inflammatory Disease

The pathogenic organism(s) enter the body through sexual contact and ascend through the uterus and enter the uterine tubes. **Salpingitis** may follow, with leakage of pus into the peritoneal cavity, causing pelvic peritonitis. A pelvic abscess usually follows, or the infection spreads farther, causing general peritonitis.



CD Figure 23-1 An ectopic pregnancy located where the ampulla of the uterine tube narrows down to join the isthmus. Note the thin tubal wall compared to the thick decidua that lines the body of the uterus.

Ectopic Pregnancy

Implantation and growth of a fertilized ovum may occur outside the uterine cavity in the wall of the uterine tube (CD Fig. 23-1). This is a variety of **ectopic pregnancy**. There being no decidua formation in the tube, the eroding action of the trophoblast quickly destroys the wall of the tube. Tubal abortion or rupture of the tube, with the effusion of a large quantity of blood into the peritoneal cavity, is the common result.

The blood pours down into the rectouterine pouch (pouch of Douglas) or into the uterovesical pouch. The blood may quickly ascend into the general peritoneal cavity, giving rise to severe abdominal pain, tenderness, and guarding. Irritation of the subdiaphragmatic peritoneum (supplied by phrenic nerves C3, C4, and C5) may give rise to referred pain to the shoulder skin (supraclavicular nerves C3 and C4).

Tubal Ligation

Ligation and division of the uterine tubes is a method of obtaining permanent birth control and is usually restricted to women who already have children. The ova that are discharged from the ovarian follicles degenerate in the tube proximal to the obstruction. If, later, the woman wishes to have an additional child, restoration of the continuity of the uterine tubes can be attempted, and, in about 20% of women, fertilization occurs.



THE UTERUS

Rectal Examination

The following structures can be palpated by the gloved index finger inserted into the anal canal and rectum in the healthy patient (CD Fig. 23-2 and see CD Fig. 23-8).

Anteriorly: The anterior structures include the following:

1. Opposite the terminal phalanx are the rectouterine pouch of Douglas, the vagina, and the cervix.
2. Opposite the middle phalanx are the urogenital diaphragm and the vagina.
3. Opposite the proximal phalanx are the perineal body and the lower part of the vagina.

Posteriorly: The posterior structures include the following:

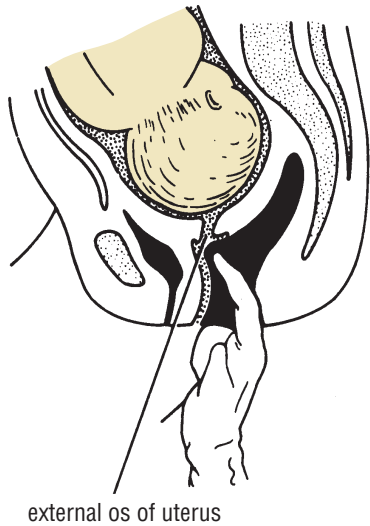
1. The sacrum, coccyx, and anococcygeal body

Laterally: The lateral structures include the following:

1. The ischiorectal fossae and ischial spines

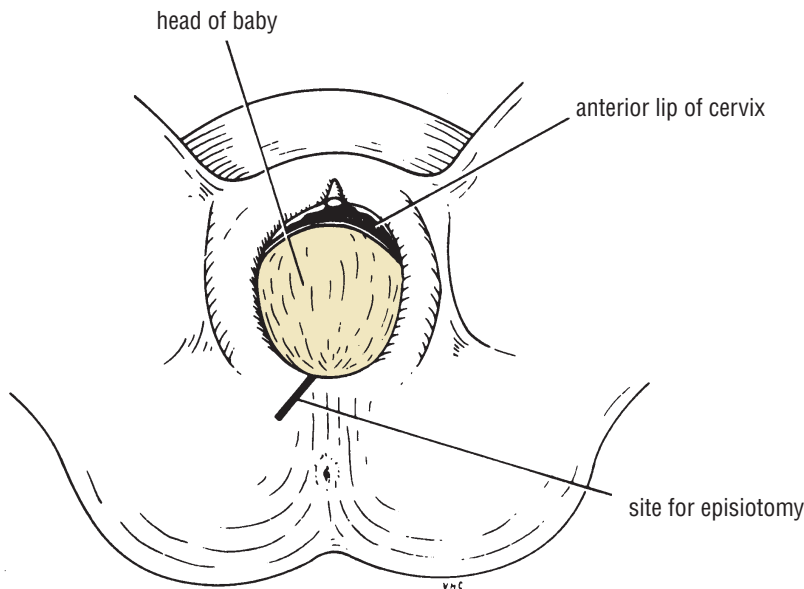
Bimanual Pelvic Examination of the Uterus

A great deal of useful clinical information can be obtained about the state of the uterus, uterine tubes, and ovaries from a bimanual examination. The examination is easiest in parous women who are able to relax while the examination is in progress. In patients in whom it causes distress, the examination may be performed under an anesthetic. With the bladder empty, the vaginal portion of the cervix is first palpated with the index finger of the right hand. The external os is circular in the nulliparous woman but has anterior and posterior lips in the multiparous woman. The cervix normally has the consistency of the end of the nose, but in the pregnant uterus it is soft and vascular and has the consistency of the lips. The left hand is then placed gently on the anterior abdominal wall above the symphysis pubis, and the fundus and body of the uterus may be palpated between the abdominal and vaginal



A

external os of uterus



B

CD Figure 23-2 **A.** Rectal examination in a pregnant woman showing how it is possible to palpate the cervix through the anterior rectal wall. **B.** Position of the episiotomy incision in a woman during the second stage of labor. The baby's head is presenting at the vaginal orifice.

fingers situated in the anterior fornix. The size, shape, and mobility of the uterus can then be ascertained.

In most women, the uterus is anteverted and anteflexed. A retroverted, retroflexed uterus can be palpated through the posterior vaginal fornix.

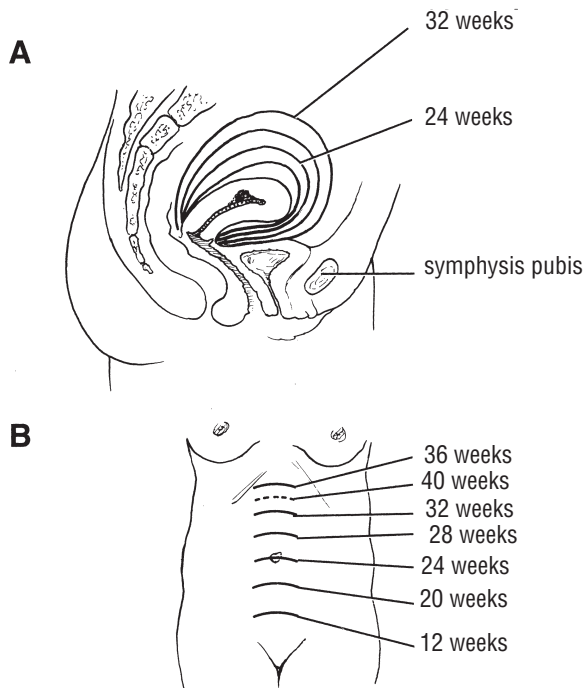


BASIC ANATOMY OF A NORMAL PREGNANCY

As the fetus enlarges, the uterus increases in size, and the fundus gradually rises out of the pelvic cavity (CD Fig.

23-3). The ascent of the fundus is fairly uniform. At 12 weeks, it lies just above the symphysis pubis; at 20 weeks, it lies about halfway between the symphysis pubis and the umbilicus; at 24 weeks, it is level with the umbilicus; at 32 weeks, it lies halfway between the umbilicus and the xiphoid process; at 36 weeks, it has reached the xiphoid process; and at 40 weeks; in the first pregnancy, the fetus sinks downward as the presenting part enters the pelvic cavity and the fundus again takes up the position halfway between the xiphoid and the umbilicus. In multipara, the presenting part of the fetus descends at a later date.

Further evidence of fetal growth can be determined by the mother first recognizing movements of the fetus (quickening), which usually occurs between the sixteenth and twentieth weeks of pregnancy. Fetal heart sounds may be heard as early as the twelfth week, when a Doppler stethoscope is used.



CD Figure 23-3 The height of the fundus of the uterus at various weeks of pregnancy. **A.** As seen in sagittal section. **B.** As felt through the anterior abdominal wall.

Ultrasound Anatomy of the Developing Fetus

With sequential longitudinal and transverse scans of the uterus, the developing fetus, amniotic fluid, and placenta can be studied. The gestational sac can be recognized at about 5 weeks after the first day of the last menstrual period. By 6 to 7 weeks the fetal pole (extreme end or ends of fetus) can be visualized, and the beating heart can be seen. Later, the fetal head, trunk, and limbs can be identified (see text Fig. 23-30).

Anatomy of Childbirth

Labor Pains

The underlying cause of labor pains is believed to be the anoxia of the uterine muscle brought about by the uterine contractions. Afferent pain fibers from the fundus and body of the uterus ascend to the spinal cord through the hypogastric plexuses, entering the cord through the posterior roots of the tenth, eleventh, and twelfth thoracic spinal nerves. Sensory fibers from the cervix run in the pelvic splanchnic nerves and enter the spinal cord through the posterior roots of the second, third, and fourth sacral nerves. Contraction pains from the fundus and body are referred to the lower

part of the anterior abdominal wall and the lower part of the back (dermatomes T10 through T12).

Labor

Labor, or parturition, is the series of processes by which the baby, the fetal membranes, and the placenta are expelled from the genital tract of the mother. Forceful uterine contractions occurring at regular intervals indicate the onset of labor. The **first stage** is dilatation of the cervix. The **second stage** is expulsion of the fetus. The **third stage** begins immediately following the delivery of the baby and ends with expulsion of the placenta and fetal membranes.

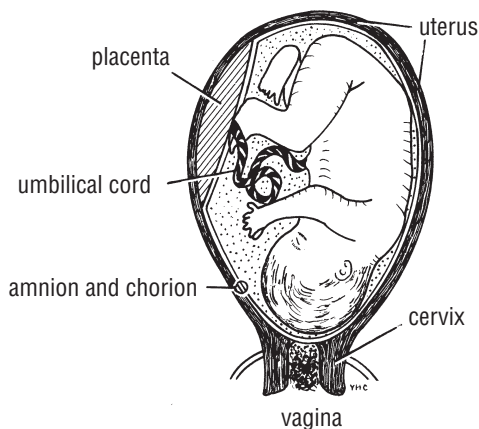
Duration of labor: This depends on (1) the strength and frequency of the uterine contractions and (2) the resistance offered to the passage of the baby by the bony pelvis and the soft tissues of the lower part of the genital tract, namely, the cervix, the vagina, the pelvic floor, and the perineum. The approximate length of each stage is as follows: first stage, 9 1/2 hours; second stage, 50 minutes; and third stage, 10 minutes. In multigravida the duration of the first and second stages is shorter because of the reduced resistance offered by the maternal soft tissues.

Processes of Labor: During the first stage of labor, the liquor amnii and the fetal membranes are forced down into the cervical canal as a hydrostatic wedge, and the cervix slowly dilates (CD Fig. 23-4). The pulling away of the membranes from the uterine wall in the region of the internal os of the cervix causes a little bleeding, and this, together with the cervical plug of mucus that fills the canal of the cervix, forms the so-called **bloody show**. The rupture of the membranes and the escape of the liquor amnii usually occur when the first stage of labor is well advanced. The escape of the liquor amnii allow the uterus to exert pressure directly on the baby and force it down.

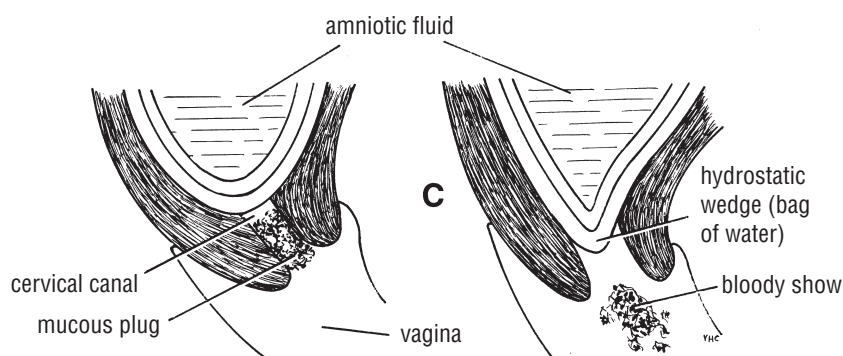
During the second stage of labor, the combined actions of the very strong uterine contractions and the reflex and voluntary contractions of the abdominal muscles force the baby through the maternal passages (CD Fig. 23-5).

The pelvic floor, formed by the levatores ani and coccygeus muscles, serves an important function during the second stage of labor. From their origin on the two sides of the pelvis, the muscle fibers slope downward and backward in the midline, producing a gutter that slopes downward and forward. To begin with, the long axis of the baby's head is transversely positioned at the pelvic inlet. When the head reaches the pelvic floor, the gutter shape of the floor tends to cause the baby's head to rotate, so that its long axis comes to lie in the anteroposterior position, with the occiput anteriorly in the majority. The occipital part of the head now moves downward and forward along the gutter until it lies under the pubic arch. As the baby's head passes through the lower part of the birth canal, the small

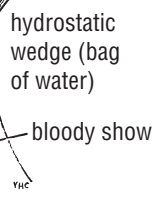
A



B



C



CD Figure 23-4 **A.** The relation of the fetus to the uterus, placenta, and the fetal membranes at the fortieth week of pregnancy. **B** and **C.** The cervix dilating during the first stage of labor as the result of the fetal membranes being forced down into the cervical canal as a hydrostatic wedge. The bloody show consists of the mucous plug from the cervical canal mixed with the small amount of bleeding that occurs following separation of the fetal membrane from the uterine wall in the region of the internal os.

gap that exists in the anterior part of the pelvic floor becomes enormously enlarged, so that the head may slip through into the perineum. Once the baby has passed through the perineum, the levatores ani muscles recoil and take up their previous position.

The third stage of labor then commences, and the uterus contracts downward so that the fundus lies at the level of the umbilicus. Rhythmic uterine contractions continue, as in the second stage, but they are painless. Separation of the placenta from the uterine wall takes place. As the uterus diminishes in size, there is a decrease in the surface area at the site of placental attachment. The placenta, being unable to accommodate itself to the decreased area, begins to fold up and is squeezed off the uterine wall (CD Fig. 23-6). Separation takes place at the spongy layer of the decidua, and some bleeding occurs. In a similar manner, the fetal membranes and the remains of the decidua are squeezed from the remainder of the uterine wall. As the placenta is finally expelled from the uterus by the uterine contractions, the membranes that are attached to it are dragged after it and peeled off from the inner surface of the uterus. The expelled placenta and fetal membranes are often referred to as

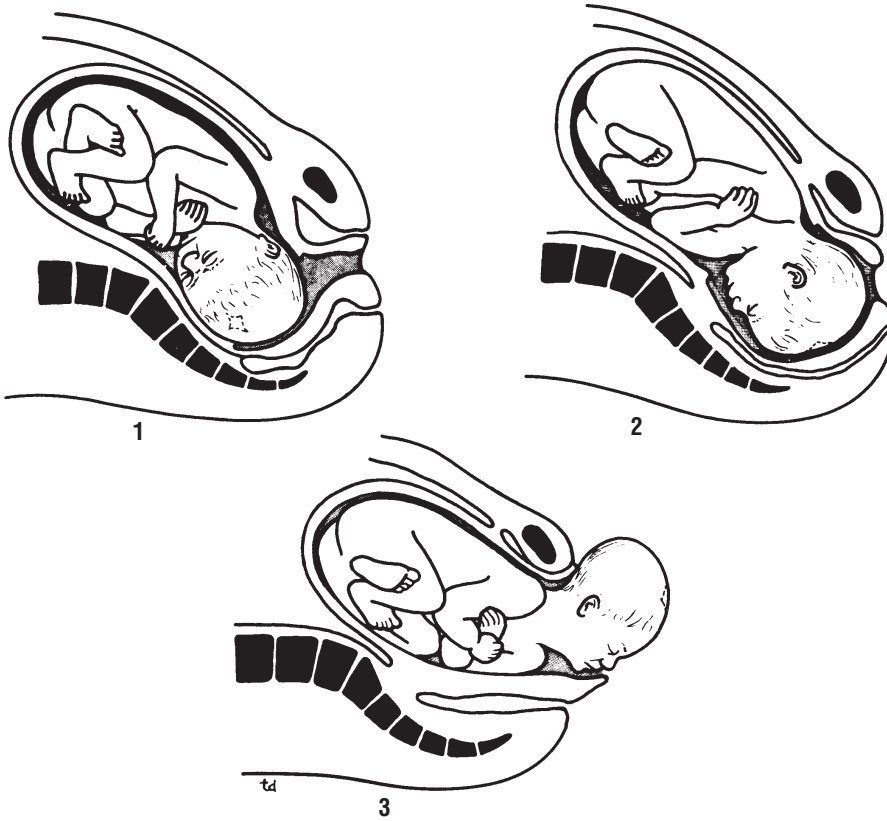
the **afterbirth**. The uterine muscle becomes firmly contracted and little bleeding occurs.

The Uterus in Pregnancy

During pregnancy, the uterus becomes greatly enlarged as a result of the increasing production of estrogens and progesterone, first by the corpus luteum of the ovary and later by the placenta. At first it remains as a pelvic organ, but by the third month the fundus rises out of the pelvis, and by the ninth month it has reached the xiphoid process (see CD Fig. 23-3). The increase in size is largely a result of hypertrophy of the smooth muscle fibers of the myometrium, although some hyperplasia takes place.

Role of the Uterus in the Onset of Labor

Normally labor takes place at the end of the tenth lunar month, at which time the pregnancy is said to be at term. The cause of the onset of labor is not definitely known. By



CD Figure 23-5 Stages in rotation of the baby's head during the second stage of labor. The shape of the pelvic floor plays an important part in this process.

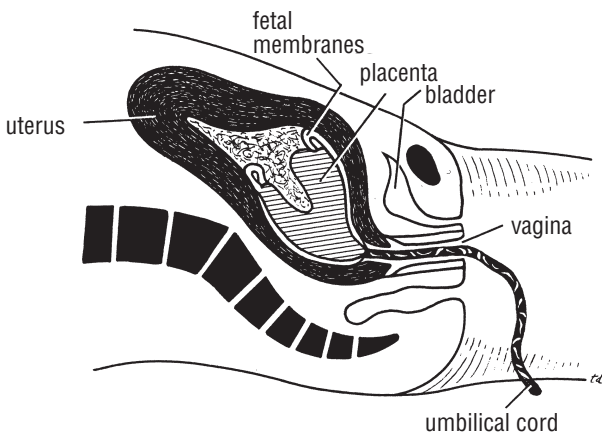
the end of pregnancy, the contractility of the uterus has been fully developed in response to estrogen, and it is particularly sensitive to the actions of oxytocin at this time. It is possible that the onset of labor is triggered by the sudden withdrawal of progesterone. Once the presenting part (usually the fetal head) starts to stretch the cervix, it is thought that a nervous reflex mechanism is initiated and increases the force of the contractions of the uterine body.

The uterine muscular activity is largely independent of the extrinsic innervation. In women in labor, spinal anesthesia does not interfere with the normal uterine contractions. Severe emotional disturbance, however, can cause premature parturition.

Injury to the Perineum during Childbirth

The perineal body is a wedge of fibromuscular tissue that lies between the lower part of the vagina and the anal canal. It is held in position by the insertion of the perineal muscles and by the attachment of the levatores ani muscles. In the female, it is a much larger structure than in the male, and it serves to support the posterior wall of the vagina. Damage by laceration during childbirth can be followed by permanent weakness of the pelvic floor.

Few women escape some injury to the birth canal during delivery. In most, this is little more than an abrasion of the posterior vaginal wall. Spontaneous delivery of the child with the patient unattended can result in a severe tear of the lower third of the posterior wall of the vagina, the perineal body, and overlying skin. In severe tears, the lacerations may extend backward into the anal canal and damage the external sphincter. In these cases, it is imperative that an accurate



CD Figure 23-6 The third stage of labor showing the separated placenta with the attached fetal membranes about to be expelled through the vagina.

repair of the walls of the anal canal, vagina, and perineal body be undertaken as soon as possible.

In the management of childbirth, when it is obvious to the obstetrician that the perineum will tear before the baby's head emerges through the vaginal orifice, a planned surgical incision is made through the perineal skin in a posterolateral direction to avoid the anal sphincters. This procedure is known as an **episiotomy** (see CD Fig. 23-2). Breech deliveries and forceps deliveries are usually preceded by an episiotomy.

Varicosed Veins and Hemorrhoids in Pregnancy

Varicosed veins and hemorrhoids are common conditions in pregnancy. The following factors probably contribute to their cause: pressure of the gravid uterus on the inferior vena cava and the inferior mesenteric vein, impairing venous return, and increased progesterone levels in the blood, leading to relaxation of the smooth muscle in the walls of the veins and venous dilatation.



THE ANATOMY OF EMERGENCY CESAREAN SECTION

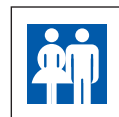An emergency cesarean section is rarely performed. However, a physician may need to perform this surgery in cases in which the mother may die after suffering a severe traumatic incident. Following maternal death, placental circulation ceases, and the child must be delivered within 10 minutes; after a delay of more than 20 minutes, neonatal survival is rare.

The Anatomy of the Technique

1. The bladder is emptied, and an indwelling catheter is left in position. This allows the empty bladder to sink down away from the operating field.
2. A midline skin incision is made that extends from just below the umbilicus to just above the symphysis pubis. The following structures are then incised: superficial fascia, fatty layer, and membranous layer; deep fascia (thin layer); linear alba; fascia transversalis; extraperitoneal fatty layer; and parietal peritoneum. To avoid damaging loops of the small intestine or the greater omentum, which might be lying beneath the parietal peritoneum, a fold of peritoneum is raised between

two hemostats; an incision is then made between the hemostats.

3. The bladder is identified, and a cut is made in the floor of the uterovesical pouch. The bladder is then separated from the lower part of the body of the uterus and depressed downward into the pelvis.
4. The uterus is palpated to identify the presenting part of the fetus.
5. A transverse incision about 1 in. (2.5 cm) long is made into the exposed lower segment of the body of the uterus. Care is taken that the uterine wall is not immediately penetrated and the fetus injured.
6. When the uterine cavity is entered, the amniotic cavity is opened, and amniotic fluid spurts. The uterine incision is then enlarged sufficiently to deliver the head and trunk of the fetus. When possible, the large tributaries and branches of the uterine vessels in the myometrial wall are avoided. Great care has to be taken to avoid the large uterine arteries that course along the lateral margin of the uterus.
7. Once the fetus is delivered, the umbilical cord is clamped and divided.
8. The contracting uterus will cause the placenta to bulge through the uterine incision. The placenta and fetal membranes are then delivered.
9. The uterine incision is closed with a full-thickness continuous suture. The peritoneum over the bladder and lower part of the uterine body is then repaired to restore the integrity of the uterovesical pouch. Finally, the abdominal wall incision is closed in layers.



PROLAPSE OF THE UTERUS

The great importance of the tone of the levatores ani muscles in supporting the uterus has already been emphasized. The importance of the transverse cervical, pubocervical, and sacrocervical ligaments in positioning the cervix within the pelvic cavity has been considered. Damage to these structures during childbirth or general poor body muscular tone may result in downward displacement of the uterus called **uterine prolapse**. It most commonly reveals itself after menopause, when the visceral pelvic fascia tends to atrophy along with the pelvic organs. In advanced cases, the cervix descends the length of the vagina and may protrude through the orifice.

Because of the attachment of the cervix to the vaginal vault, it follows that prolapse of the uterus is always accompanied by some prolapse of the vagina.



HYSTERECTOMY AND DAMAGE TO THE URETER

During the surgical procedure of hysterectomy, great care must be exercised to not damage the ureters. When the surgeon is looking for the uterine artery on each side at the base of the broad ligament (see text Fig. 23-10), it is essential that he or she first identifies the ureter before clamping and tying off the artery. The uterine artery passes forward from the internal iliac artery and crosses the ureter at right angles to reach the cervix at the level of the internal os.



CONGENITAL ANOMALIES OF THE UTERUS

Agensis of the Uterus

Rarely the uterus will be absent as the result of a failure of the paramesonephric ducts to develop.

Infantile Uterus

Some adults may have an infantile uterus, a condition in which the uterus is much smaller than normal and resembles that present before puberty. Amenorrhea is present, but the vagina and ovaries may be normal.

Failure of Fusion of the Paramesonephric Ducts

Failure of the paramesonephric ducts to fuse may cause a variety of uterine defects: (1) The uterus may be duplicated with two bodies and two cervixes; (2) there may be a complete septum through the uterus, making two uterine cavities and two cervixes; (3) there may be two separate uterine bodies with one cervix; (4) one paramesonephric duct may fail to develop, leaving one uterine tube and half of the body of the uterus. Clinically, the main problems with a double uterus may be seen when pregnancy occurs. Abortion is frequent, and the nonpregnant half of the uterus may cause obstruction at labor.



THE PLACENTA

The Placenta and Bleeding in Late Pregnancy

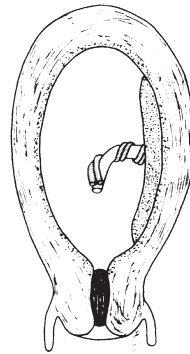
The common causes of substantial vaginal bleeding in the third trimester are placenta previa and placental abruption.

Placenta Previa

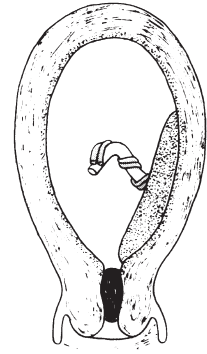
Placenta previa occurs in about 1 of every 200 pregnancies. It is more common in multiparous women and in those who have had surgery on the lower part of the uterus. Normally, the placenta is situated in the upper half of the uterus. Should implantation occur in the lower half of the body of the uterus, the condition is called placenta previa.

Three types of placenta previa may be recognized (CD Fig. 23-7): **central placenta previa**, in which the

Type 1

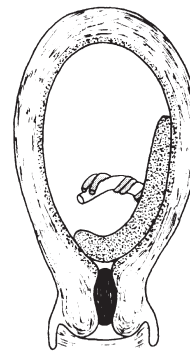


lateral placenta previa



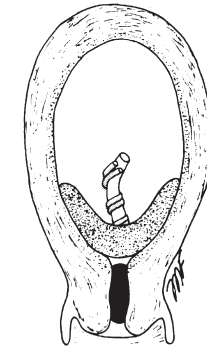
lateral placenta previa

Type 2



marginal placenta previa

Type 3



central placenta previa

CD Figure 23-7 The different types of placenta previa.

entire internal os is covered by placental tissue; **marginal placenta previa**, when the edge of the placenta is encroaching on the internal os; and a low-lying **lateral placenta previa**, when the placenta lies low down in the uterus, lateral to the internal os. Severe, painless hemorrhage occurring from the twenty-eighth week onward is the clinical sign of placenta previa and is caused by expansion of the lower half of the uterine wall at this time and by its tearing away from the placenta.

Placental Abruption

Placental abruption is the premature separation of the placenta in which normal implantation has occurred. It occurs in about 1% of pregnancies. It is more common in multiparous women and in women with hypertension in pregnancy. As the placenta separates, hemorrhage occurs; the blood clot dissects the fetal membranes away from the uterine wall. The blood usually escapes through the cervix or ruptures into the amniotic cavity. The blood irritates the myometrium, and uterine muscle tone is increased, which results in contractions. The placental circulation is

compromised by the placental separation and the increased pressure on the placenta by the increased uterine tone.



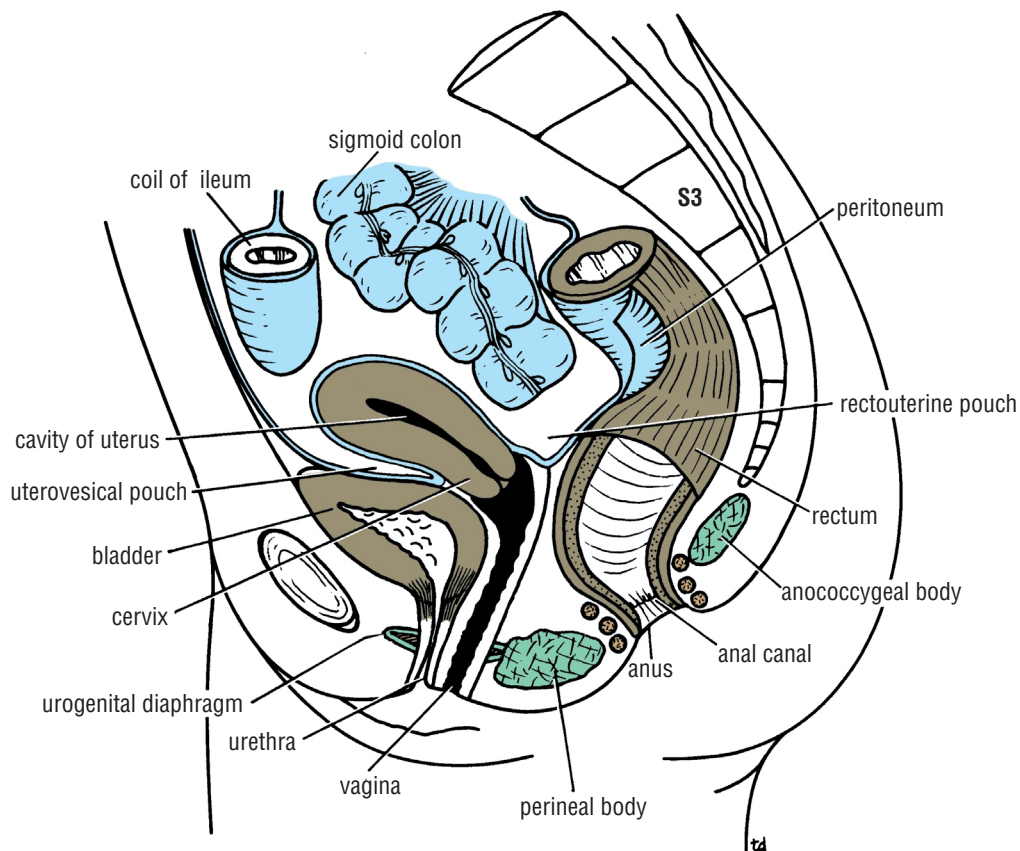
THE VAGINA

Vaginal Examination

The anatomic relations of the vagina are of great clinical importance. Many pathologic conditions occurring in the female pelvis may be diagnosed using a simple vaginal examination.

The following structures can be palpated through the vaginal walls from above downward:

- **Anteriorly:** The bladder and the urethra (CD Fig. 23-8)
- **Posteriorly:** Loops of ileum and the sigmoid colon in the rectouterine peritoneal pouch (pouch of Douglas), the rectal ampulla, and the perineal body (see CD Fig. 23-8)



CD Figure 23-8 Sagittal section of the female pelvis.

- **Laterally:** The ureters, the pelvic fascia and the anterior fibers of the levatores ani muscles, and the urogenital diaphragm

Prolapse of the Vagina

The vaginal vault is supported by the same structures that support the uterine cervix. Prolapse of the uterus is necessarily associated with some degree of sagging of the vaginal walls. However, if the supports of the bladder, urethra, or anterior rectal wall are damaged in childbirth, prolapse of the vaginal walls occurs, with the uterus remaining in its correct position.

Sagging of the bladder results in the bulging of the anterior wall of the vagina, a condition known as a **cystocele**. When the ampulla of the rectum sags against the posterior vaginal wall, the bulge is called a **rectocele**.

Culdocentesis

The closeness of the peritoneal cavity to the posterior vaginal fornix enables the physician to drain a pelvic abscess through the vagina without performing a major operation. It is also possible to identify blood or pus in the peritoneal cavity by the passage of a needle through the posterior fornix.

Anatomic Structures through which the Needle Passes

The needle passes through the mucous membrane of the vagina, muscular coat of the vagina, connective tissue coat of the vagina, visceral layer of pelvic fascia, and visceral layer of peritoneum.

Anatomic Features of the Complications of Culdocentesis

Complications are as follows: (1) The loops of ileum and the sigmoid colon, structures that are normally present within the pouch of Douglas, could be impaled by the needle. However, the presence of blood or pus within the pouch tends to deflect the viscera superiorly. (2) Occasionally, when the uterus is somewhat retroflexed, the needle may enter the posterior wall of the body of the uterus.

Vaginal Trauma

Coital injury, picket fence–type of impalement injury, and vaginal perforation caused by water under pressure, as occurs in water skiing, are common injuries. Lacerations of the vaginal wall involving the posterior fornix may violate the pouch of Douglas of the peritoneal cavity and cause prolapse of the small intestine into the vagina.

Congenital Anomalies of the Vagina

Vaginal Agenesis

If the paramesonephric ducts fail to develop, the wall of the urogenital sinus will fail to form the vaginal plate. In these patients, there is an absence of the vagina, uterus, and uterine tubes. Plastic surgical construction of a vagina should be attempted.

Double Vagina

A double vagina is caused by incomplete canalization of the vaginal plate.

Imperforate Vagina and Imperforate Hymen

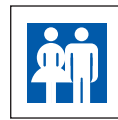Imperforate vagina is caused by a failure of the cells to degenerate in the center of the vaginal plate. Imperforate hymen is caused by a failure of the cells of the lower part of the vaginal plate and wall of the urogenital sinus to degenerate. These conditions lead to retention of the menstrual flow, a clinical condition called **hematocolpos**. Surgical incision of the obstruction, followed by dilatation, relieves the condition.



THE VISCERAL PELVIC FASCIA

Visceral Pelvic Fascia and Infection

Clinically, the pelvic fascia in the region of the uterine cervix is often referred to as the **parametrium**. It is a common site for the spread of acute infections from the uterus and vagina, and here the infection often becomes chronic (pelvic inflammatory disease).



THE PELVIC PERITONEUM

The Rectouterine Pouch and Disease

Since the rectouterine pouch (pouch of Douglas) is the most dependent part of the entire peritoneal cavity (see CD Fig. 23-8) (when the patient is in the standing position), it frequently becomes the site for the accumulation of blood

(from a ruptured ectopic pregnancy) or pus (from a ruptured pelvic appendicitis or in gonococcal peritonitis).

Because the pouch lies directly behind the posterior fornix of the vagina, it is commonly violated by misguided nonsterile instruments, which pierce the wall of the posterior fornix in a failed attempt at an illegal abortion. Pelvic peritonitis, often with fatal consequences, is the almost certain result.

A needle may be passed into the pouch through the posterior fornix in the procedure known as **culdocentesis** (see CD p. 406). Surgically, the pouch may be entered in **posterior colpotomy**.

The interior of the female pelvic peritoneal cavity may be viewed for evidence of disease through an endoscope; the instrument is introduced through a small colpotomy incision.

Clinical Problem Solving Questions

Read the following case histories/questions and give the best answer for each.

- The following anatomic statements concerning uterine prolapse are correct **except** which?
 - The most important support to the uterus is the tone of the levatores ani muscles.
 - The transverse cervical, pubocervical, and sacrocervical ligaments play an important role in supporting the uterus.
 - Damage to the levatores ani and the cervical ligaments during childbirth can be responsible for prolapse of the uterus.
 - Prolapse most commonly reveals itself before menopause.
 - Prolapse of the uterus is always accompanied by some prolapse of the vagina.

A 25-year-old woman was seen in the emergency department complaining of severe pain in the right iliac region. Just before admission she had fainted. On physical examination, her abdominal wall was extremely tender on palpation in the lower right quadrant, and some rigidity and guarding of the lower abdominal muscles were noticed. A vaginal examination revealed a rather soft cervix with a circular external os. A tender "dough-like" mass could be felt through the posterior fornix. The patient had missed her last period.

- The following statements concerning this patient are correct **except** which?
 - A diagnosis of ruptured ectopic pregnancy was made.
 - Tubal pregnancies commonly occur where the ampulla narrows to join the isthmus.
 - Each uterine tube is situated in the base of the broad ligament.
 - An ectopic tubal pregnancy almost invariably results in rupture of the tube with severe intraperitoneal hemorrhage.

- Tubal rupture occurs as a result of the eroding action of the trophoblast.
- Once a tubal pregnancy dies the decidual lining of the uterus begins to be shed because of lack of hormonal support, and this causes vaginal bleeding.
- The dough-like mass is produced by the accumulation of blood in the pouch of Douglas.

A 35-year-old woman was seen by her gynecologist complaining of a swelling in the genital region. On examination, a tense cystic swelling was found beneath the posterior two thirds of the right labium majus and minus. A diagnosis of a cyst of the right greater vestibular gland (Bartholin's cyst) was made.

- The following statements concerning this case are probably correct **except** which?
 - The cyst of the greater vestibular gland is produced by the retention of secretion caused by the blockage of the duct.
 - Infection of the duct by the gonococcus is a common cause of the blockage.
 - Infection of the cyst may occur, forming a painful abscess.
 - The lymphatic drainage of this area is into the lateral group of superficial inguinal nodes.
 - A small tender swelling was detected below and medial to the inguinal ligament.
- In anatomic terms explain the procedure of culdocentesis.
- A 23-year-old woman was seen in the emergency department with severe vaginal bleeding. She was 35 weeks pregnant. On questioning she stated that she had slight bleeding a week previously but this had stopped spontaneously. There was absolutely no pain associated with the bleeding. On examining the abdomen, it was found that the fetal head was high, and it was not possible to make it enter the pelvis. The

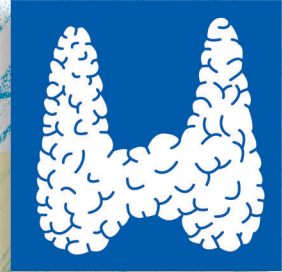
uterus had a normal consistency and was not tender. On examination of the genital organs, no cause for the bleeding could be determined. A diagnosis of placenta previa was made. What is placenta previa? What is the cause of the bleeding? Why is the bleeding painless?

6. What is believed to be the cause of pain in labor? Describe the pathways taken by the afferent pain fibers in labor and explain the distribution of the areas of referred pain.
7. The postnatal vaginal examination of a young woman revealed that the fundus and body of the uterus could be palpated in the rectouterine pouch (pouch of Douglas). What is the normal position of the uterus?
8. A multiparous 57-year-old woman visited her physician complaining of a “bearing-down” feeling in the pelvis and of low backache, both of which were worse when she was tired. On vaginal examination, the external os of the cervix was found to be located just within the vaginal orifice. A diagnosis of uterine prolapse was made. What are the main supports of the uterus?
9. During the vaginal examination of a multiparous woman, she was asked to strain downward. The anterior wall of the vagina was found to sag downward. A diagnosis of prolapsed anterior vaginal wall was made. What structures lie anterior to the vagina and will sag downward with the vaginal wall?
10. A 65-year-old woman went to her physician complaining of irritation, discharge, and bleeding of the genital region. On physical examination, a hard-based ulcer was found on the medial aspect of the right labium majus. A diagnosis of squamous cell carcinoma of the skin was made. What is the lymphatic drainage of this region, and which group of lymph nodes would you therefore examine for evidence of metastases?
11. A mother took her 15-year-old daughter to a physician because she had failed to start to menstruate. On examination the child was noted to be short and stocky with a webbed neck. She had an abnormally large carrying angle of the elbow (cubitus valgus), a broad chest with lack of breast development, and an absence of pubic and axillary hair. No further abnormalities were found on physical examination. What is your diagnosis? What investigations would you undertake to confirm your diagnosis? How would you treat this patient?
12. During the third stage of labor, the placenta and fetal membranes are expelled from the uterus. The obstetrician or midwife must carefully examine the placenta and the membranes to make sure that no part of them has been retained in the uterus. What is the approximate diameter and thickness of a normal placenta? Describe the appearance of the maternal and fetal surfaces of a full-term placenta. Is it possible to separate the amnion from the chorion?
13. A 12-year-old girl was taken to a pediatrician because she experienced cyclic monthly pain, but there was no actual menstrual flow. On physical examination of the vulva, the hymen was seen as a bulging septum. No vaginal orifice could be detected. What is your diagnosis? How would you explain this condition embryologically? How would you treat this patient?

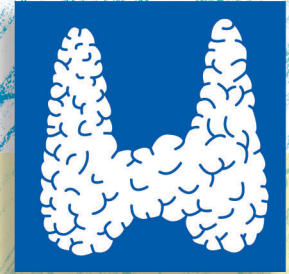
Answers and Explanations

1. **D** is the correct answer. Prolapse of the uterus most often reveals itself after menopause, when the pelvic fascia tends to atrophy.
2. **C** is the correct answer. Each uterine tube is situated in the upper free margin of the broad ligament (see text Fig. 23-10).
3. **D** is the correct answer. The lymphatic drainage of this area is into the medial group of superficial inguinal nodes situated below the inguinal ligament. The spread of infection can result in an enlargement of one of the nodes, as in this case, which becomes tender to palpation.
4. See discussion of culdocentesis in this chapter.
5. Normally the placenta is situated in the upper half of the uterus. Should implantation occur in the lower half of the body of the uterus, the condition is called placenta previa. As the lower half of the body of the uterus dilates toward the end of pregnancy, the placenta is separated from the uterine wall and hemorrhage occurs. The bleeding is painless since the blood escapes through the cervix, and the uterus does not contract and is not distended.
6. The cause of labor pains has been fully discussed in this chapter, as have the path taken by the afferent pain fibers from the uterus and the areas of the body to which labor pains are referred.

7. The long axis of a normal uterus usually lies at right angles to the long axis of the vagina (anteverted); the body of the uterus is also bent forward on the cervix at the internal os (anteflexion).
8. The uterus is mainly supported by the tone of the levatores ani muscles and the ligaments of the visceral layer of pelvic fascia, namely, the transverse cervical, sacrocervical, and pubocervical ligaments.
9. The urethra lies directly in contact with the lower half of the anterior vaginal wall, and the bladder lies in contact with the upper half of the vaginal wall. The bulging downward of the bladder with the anterior vaginal wall is referred to as a cystocele.
10. The vulva is drained into the medial group of horizontal superficial inguinal nodes.
11. This case is a typical example of Turner's syndrome, in which there is complete failure of both ovaries to develop. In Turner's syndrome the cells have only 45 chromosomes because one X chromosome is missing (XO). In this case the clinical signs and symptoms make the diagnosis obvious. A simple buccal smear and the finding of absent nuclear sex chromatin make the diagnosis absolute. In difficult cases, where the diagnosis is in doubt, culdoscopy shows the absence of ovaries in the pelvis. Since these individuals are females in appearance and psychological outlook, they should be brought up as females. The cyclic administration of estrogen and progesterone in this case will bring about the development of normal female secondary sexual characteristics and cyclic menstrual function.
12. The normal placenta is flattened and circular in shape, with a diameter of about 8 in. (20 cm) and a thickness of about 1 in. (2.5 cm). The maternal surface is dark red in color and oozes blood from the torn maternal vessels. It has a sponge-like consistency. The outer surface is rough, and the margins of the lobules or cotyledons may be recognized. The fetal surface is smooth and shining and is covered by amnion, which is fused with the underlying chorion. The umbilical cord is attached near its center, and the umbilical vessels radiate out under the amnion from the point of attachment. The amnion may be peeled from the chorion up to the umbilical cord. This procedure should always be carried out following delivery to determine if the chorion is complete and to make sure that some part has not been retained in the uterus adherent to the decidua.
13. This girl has an imperforate hymen. The pelvic discomfort and the absence of menstrual flow are due to the accumulation of blood and old menstrual secretions (hematocolpos) above the intact hymen. This condition is caused by a failure of the cells of the lower part of the vaginal plate and the wall of the urogenital sinus to degenerate. Surgical incision of the hymen, followed by dilatation, cures the condition.

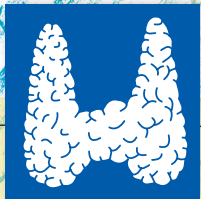

The Endocrine System



24

The Endocrine Glands



Chapter Outline

Endocrine Glands in the Head and Neck	414	Hypoparathyroidism	418
Pituitary Gland (Hypophysis Cerebri)	414	Congenital Anomalies of the Parathyroid Glands	418
Pituitary Enlargement and the Optic Chiasma	414	<i>Absence and Hypoplasia of the Parathyroid Glands</i>	418
Gigantism and Acromegaly	414	<i>Ectopic Parathyroid Glands</i>	418
Dwarfism	415	Endocrine Glands in the Abdomen and Pelvis	419
Diabetes Insipidus	415	Suprarenal Glands	419
Pineal Gland	415	Cushing's Syndrome	419
Pineal Calcification	415	Addison's Disease	419
Pineal Tumors and Reproductive Function	415	Pheochromocytoma	419
Thyroid Gland	415	Surgical Significance of the Renal Fascia	419
Swellings of the Thyroid Gland and Movement on Swallowing	415	Suprarenal Susceptibility to Trauma at Birth	419
The Thyroid Gland and the Airway	415	Islets of Langerhans of the Pancreas	419
Retrosternal Goiter	415	Islets of Langerhans and Diabetes Mellitus	419
Thyroid Arteries and Important Nerves	415	Interstitial Cells of the Testis	419
Thyroidectomy and the Parathyroid Glands	415	Testosterone Deficiency	419
Hyperthyroidism	416	Ovaries	420
Hypothyroidism	416	Menopause	420
Thyroid Tumors	417	Hypogonadism	420
Congenital Anomalies of the Thyroid Gland	417	Placenta	420
<i>Agensis of the Thyroid</i>	417	Hydatidiform Mole	420
<i>Incomplete Descent of the Thyroid</i>	417	Clinical Problem Solving Questions	420
<i>Ectopic Thyroid Tissue</i>	418	Answers and Explanations	422
<i>Persistent Thyroglossal Duct</i>	418		
<i>Thyroglossal Cyst</i>	418		
<i>Thyroglossal Sinus (Fistula)</i>	418		
Parathyroid Glands	418		
Thyroidectomy and the Parathyroid Glands	418		
Hyperparathyroidism	418		



ENDOCRINE GLANDS IN THE HEAD AND NECK

Pituitary Gland (Hypophysis Cerebri)

Pituitary Enlargement and the Optic Chiasma

Since the pituitary is located in the bony sella turcica, enlargement causes it to expand superiorly (see text Fig. 24-2).

A pituitary tumor classically pushes the diaphragma sellae upward and causes pressure on the optic chiasma. This results in interference with the function of the nerve fibers crossing in the chiasma (from the inner quadrants of the retina), and the patient presents with **bitemporal hemianopia** (see text Fig. 15-1B). Further expansion of the pituitary tumor causes erosion of the body of the sphenoid bone.

Gigantism and Acromegaly

Excessive production of the growth hormone by the somatotrope cells of the pars anterior or by tumors of these cells can produce abnormal growth of the skeleton. Gigantism occurs in the young before the epiphyses in long bones fuse with the diaphysis. The growth hormone stimulates the cartilage cells of the epiphyseal cartilage to continue laying

down new matrix, so that fusion of the epiphyses with the shaft of long bones is delayed and the bones lengthen enormously. In this way, giants 9 ft tall have been produced before the epiphyseal cartilage finally stops growing.

Acromegaly is a form of abnormal skeletal and soft tissue growth that occurs after adolescence, following the fusion of the epiphyses in long bones with the diaphysis. In this disease, the individual cannot grow taller, but overgrowth occurs in the bones and soft tissues of the forehead, nose, lower jaw, hands, and feet. In the fully developed syndrome, the prominent supraorbital ridges and mandible, the very large nose, and the very large, thick hands and feet make the diagnosis relatively easy.

Dwarfism

A deficiency in the growth hormone secreted by the somatotrope cells of the pars anterior during childhood leads to pituitary dwarfism. Growth does not stop entirely, and the different parts of the body are in relatively normal proportions. The person is of normal intelligence, but the facial skin is often wrinkled and sexual maturation is delayed.

Diabetes Insipidus

This syndrome results from a lesion of the supraoptic and paraventricular nuclei of the hypothalamus and a failure of these cells to synthesize the antidiuretic hormone, or from destruction of the hypothalamohypophysial tract. There are many causes of this syndrome, including cerebral tumors, cerebral abscesses, surgical or radiation damage, and head injuries.

Characteristically, the patient passes large volumes of urine (polyuria) of low specific gravity. The absence of antidiuretic hormone results in a failure to conserve water, which is not reabsorbed in the collecting tubules of the kidneys. As a result, the patient is extremely thirsty (polydipsia) and drinks large quantities of fluids. The condition must be distinguished from diabetes mellitus, in which there is glucosuria.

Pineal Gland

Pineal Calcification

With age, the pineal gland accumulates magnesium phosphate and carbonate within the glial cells and connective tissue. These deposits are useful to radiologists, because they serve as a landmark and assist in determining whether the pineal gland has been displaced laterally by a space-occupying lesion within the skull.

Pineal Tumors and Reproductive Function

Pineal tumors may have an antigonadotropic effect. As they increase in size, they may obstruct the cerebral aqueduct of

the midbrain, producing **hydrocephalus**. Occasionally, the tumor destroys the pineal gland and causes precocious puberty.

Thyroid Gland

Swellings of the Thyroid Gland and Movement on Swallowing

The thyroid gland is invested in a sheath derived from the pretracheal fascia (see text Fig. 24-10). This tethers the gland to the larynx and the trachea and explains why the thyroid gland follows the movements of the larynx in swallowing. This information is important because any pathologic neck swelling that is part of the thyroid gland will move upward when the patient is asked to swallow.

The Thyroid Gland and the Airway

The close relationship between the trachea and the lobes of the thyroid gland commonly results in pressure on the trachea in patients with pathologic enlargement of the thyroid.

Retrosternal Goiter

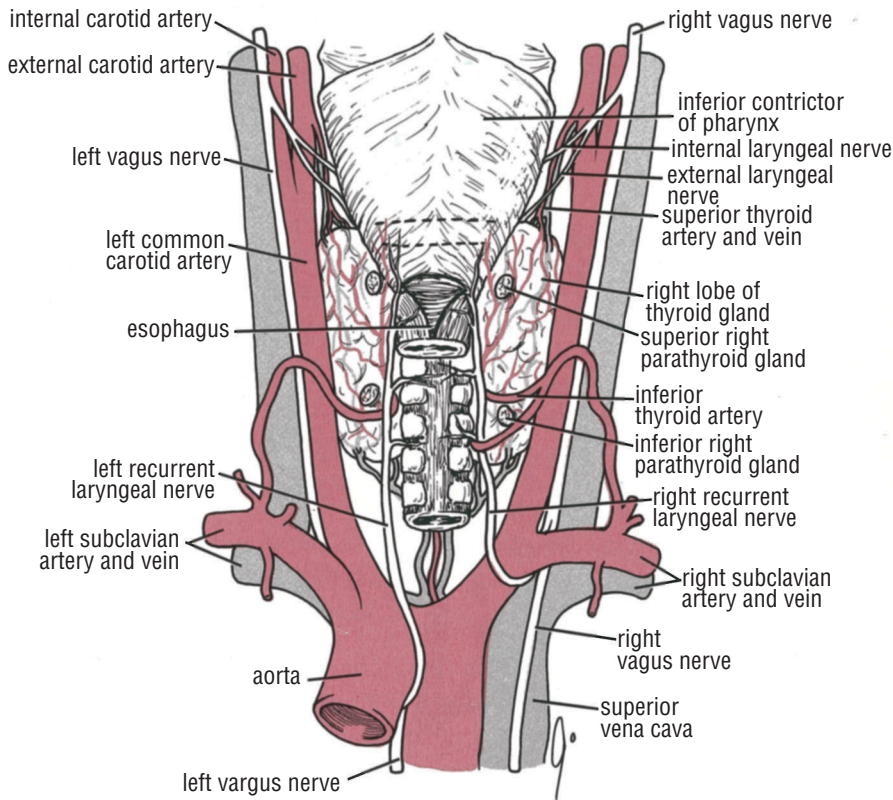
The attachment of the sternothyroid muscles to the thyroid cartilage effectively binds down the thyroid gland to the larynx and limits upward expansion of the gland. There being no limitation to downward expansion, it is not uncommon for a pathologically enlarged thyroid gland to extend downward behind the sternum. A retrosternal goiter (any abnormal enlargement of the thyroid gland) can compress the trachea and cause dangerous dyspnea; it can also cause severe venous compression.

Thyroid Arteries and Important Nerves

It should be remembered that the two main arteries supplying the thyroid gland are closely related to important nerves that can be damaged during thyroidectomy operations (CD Fig. 24-1). The **superior thyroid artery** on each side is related to the external laryngeal nerve, which supplies the cricothyroid muscle. The terminal branches of the **inferior thyroid artery** on each side are related to the recurrent laryngeal nerve. Damage to the external laryngeal nerve results in an inability to tense the vocal folds and in hoarseness. For the results of damage to the recurrent laryngeal nerve, see CD page 24.

Thyroidectomy and The Parathyroid Glands

The parathyroid glands are usually four in number and are closely related to the posterior surface of the thyroid gland



CD Figure 24-1 The pharynx, esophagus, and trachea as seen from the posterior aspect. Note the positions of the thyroid and parathyroid glands and the relationships of the large blood vessels and nerves. The dotted lines indicate the level of the cricothyroid membrane.

(see CD Fig. 24-1). In partial thyroidectomy, the posterior part of the thyroid gland is left undisturbed so that the parathyroid glands are not damaged. The development of the inferior parathyroid glands is closely associated with the thymus. For this reason it is not uncommon for the surgeon to find the inferior parathyroid glands in the superior mediastinum because they have been pulled down into the thorax by the thymus.

Hyperthyroidism

In hyperthyroidism (thyrotoxicosis, Grave's disease), which is common in middle-aged women, the thyroid gland is diffusely enlarged. The walls of the thyroid follicles are much infolded, and the epithelial cells lining the follicular walls are taller than normal. Production of the thyroid hormones is greatly increased, and the colloid present is usually reduced in volume. The serum thyroid-stimulating hormone level is normal or below normal. In most patients, there is a thyroid-stimulating immunoglobulin in the blood that is capable of stimulating increased thyroid activity.

The symptoms of hyperthyroidism are caused by the excessive stimulation of the tissues by the thyroid hormones. There is excessive sweating and loss of weight; increased nervousness, with fine tremor of the extended fingers; intolerance to heat; and muscular weakness.

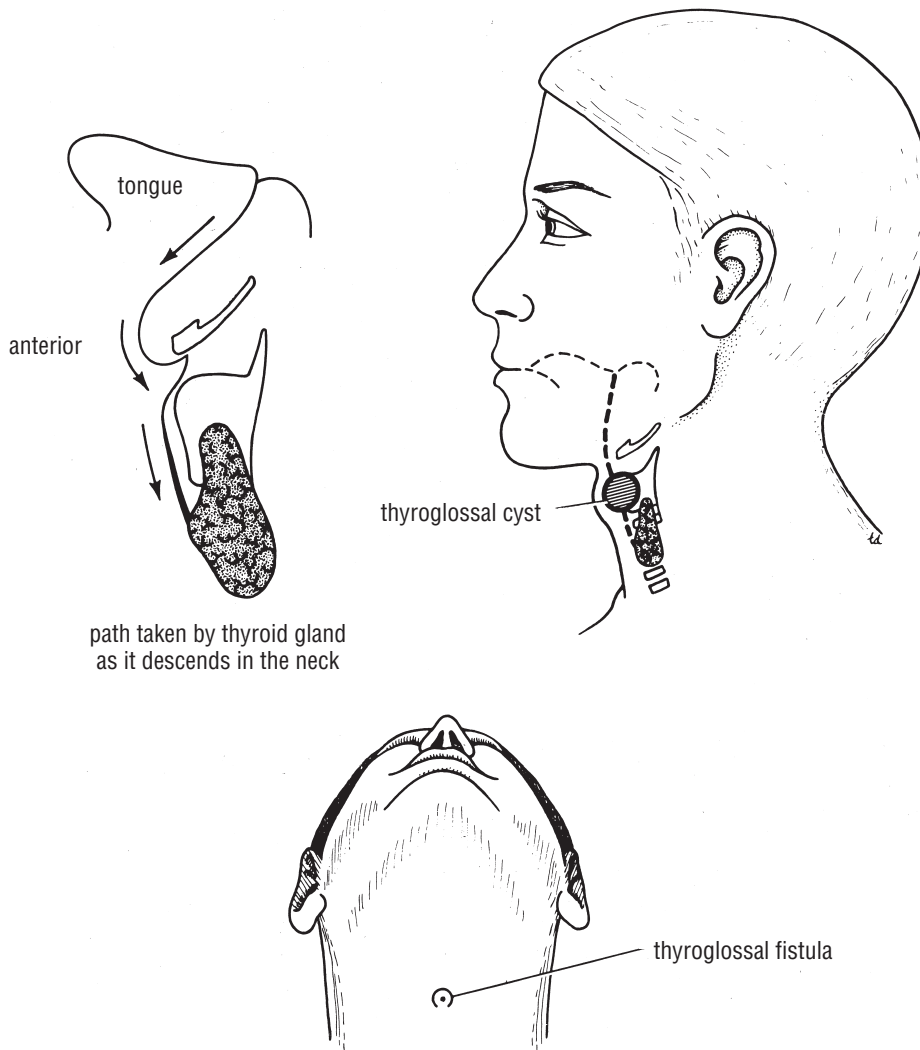
The hair thins, and the eyes may protrude (exophthalmos). The heart rate is increased and frequent bowel movements may occur; the menstrual periods may be missed or scanty. Three forms of therapy are available for the treatment of hyperthyroidism: (1) surgical excision of thyroid tissue, (2) antithyroid drugs, and (3) radioactive iodine.

Hypothyroidism

Hypothyroidism occurs in two forms: cretinism in infants and myxedema in adults.

Cretinism can occur as a result of a failure in the development of the thyroid gland. The child is born with a normal appearance, caused by the mother's thyroid hormones having crossed the placenta. Soon after birth, the child shows signs of retarded mental and physical growth. If cretinism is diagnosed early and the child is given adequate, lifelong thyroid hormone therapy, he or she will develop normally and live a normal life.

Myxedema may be caused in adults by many conditions ranging from spontaneous degeneration of the thyroid gland to hypopituitarism or hypothalamic failure. Excessive treatment of hyperthyroidism with drugs or surgery is another possible cause. The majority of the patients are female. The symptoms include the slowing of mental and physical processes of the individual. There is an increase in body weight and a preference for a warm environment.



CD Figure 24-2 A thyroglossal cyst in the midline in the neck and a thyroglossal fistula.

Constipation is present, and the heart rate is slowed. The skin is dry and cold, and the hair is dry and brittle and tends to fall out. Libido is diminished in both sexes, and menorrhagia is common in the female. The condition can be successfully treated by the daily oral administration of the thyroid hormones.

Thyroid Tumors

Benign thyroid tumors occur in the form of adenomas. Carcinoma of the thyroid gland is relatively rare.

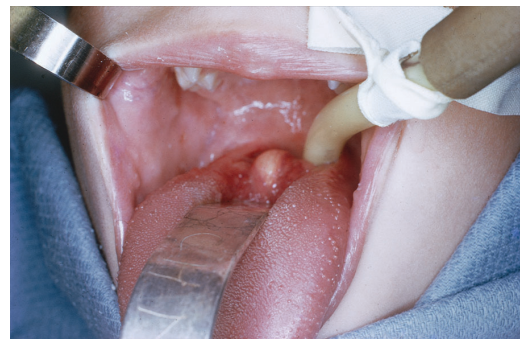
Congenital Anomalies of the Thyroid Gland

Agenesis of the Thyroid

Failure of development of the thyroid gland may occur and is the commonest cause of **cretinism**.

Incomplete Descent of the Thyroid

The descent of the thyroid may be arrested at any point between the base of the tongue and the trachea (CD Fig. 24-2). **Lingual thyroid** is the most common form of incomplete descent (CD Fig. 24-3). The mass of tissue



CD Figure 24-3 Lingual thyroid. (Courtesy of J. Randolph.)

found just beneath the foramen cecum may be sufficiently large to obstruct swallowing in the infant.

Ectopic Thyroid Tissue

Ectopic thyroid tissue is occasionally found in the thorax in relation to the trachea or bronchi or even the esophagus. It is assumed that this thyroid tissue arises from entodermal cells displaced during the formation of the laryngotracheal tube or from entodermal cells of the developing esophagus.

Persistent Thyroglossal Duct

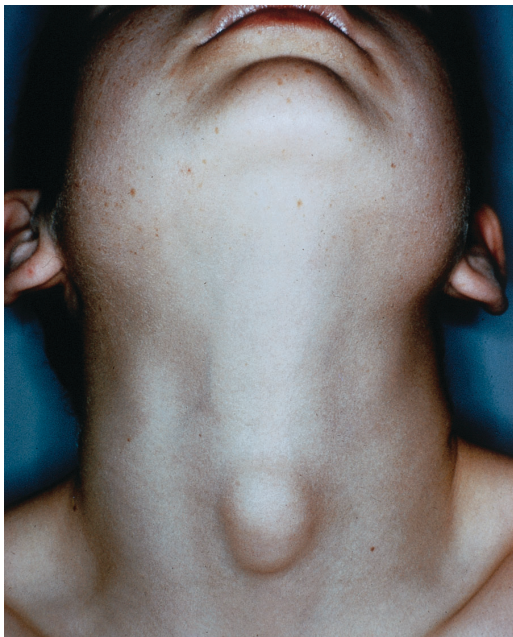
Conditions related to a persistence of the thyroglossal duct usually appear in childhood, in adolescence, or in young adulthood.

Thyroglossal Cyst

Cysts may occur at any point along the thyroglossal tract (see CD Fig. 24-2 and CD Fig. 24-4). They occur most commonly in the region below the hyoid bone. Such a cyst occupies the midline and develops as a result of persistence of a small amount of epithelium that continues to secrete mucus. As the cyst enlarges, it is prone to infection and so it should be removed surgically. Since remnants of the duct often traverse the body of the hyoid bone, this may have to be excised also to prevent recurrence.

Thyroglossal Sinus (Fistula)

Occasionally, a thyroglossal cyst ruptures spontaneously, producing a sinus (see CD Fig. 24-2). Usually, this is a result



CD Figure 24-4 A thyroglossal cyst. (Courtesy of L. Thompson.)

of an infection of a cyst. All remnants of the thyroglossal duct should be removed surgically.

Parathyroid Glands

Thyroidectomy and the Parathyroid Glands

See previous section of this CD chapter.

Hyperparathyroidism

This condition is caused by a benign adenoma or hyperplasia of the parathyroid glands. As a result, there is an excessive secretion of the parathyroid hormone, and the blood calcium level rises to as much as 15 mg/100 mL from the normal level of 10 mg/100 mL. The raised levels of blood calcium in this disease may cause the repeated occurrence of renal stones as the result of the spilling over of the calcium salts into the urine. The high blood calcium levels also affect the central and peripheral nervous systems. Neurologic abnormalities include emotional instability, memory loss, and muscular weakness. The treatment is surgical removal of the diseased gland.

Hypoparathyroidism

This condition is most commonly caused by injury to or removal of the glands during surgical procedures on the thyroid gland.

The main symptoms and signs of low blood calcium are numbness and tingling in the fingers and toes and cramps of the muscles in the hands and feet. These cramps are called **carpopedal spasms**. The spasm, or tetany, of muscles may also involve the facial or laryngeal muscles. The central nervous system may also be involved, as evidenced by signs of mental confusion and loss of memory.

The condition is treated by giving the patient calcium gluconate and large quantities of vitamin D by mouth.

Congenital Anomalies of the Parathyroid Glands

Absence and Hypoplasia of the Parathyroid Glands

Agensis or incomplete development of the parathyroid glands has been demonstrated in individuals with idiopathic hypoparathyroidism.

Ectopic Parathyroid Glands

The close relationship between the parathyroids III and the developing thymus explains the frequent finding of parathyroid tissue in the superior mediastinum of the thorax (see text Fig. 24-14). If the parathyroid glands remain attached to

the thymus, they may be pulled inferiorly into the lower part of the neck or thoracic cavity. Moreover, this also explains the variable position of the inferior parathyroid glands in relation to the lower poles of the lateral lobes of the thyroid gland.



ENDOCRINE GLANDS IN THE ABDOMEN AND PELVIS

Suprarenal Glands

Cushing's Syndrome

Suprarenal cortical hyperplasia is the most common cause of Cushing's syndrome, the clinical manifestations of which include moon-shaped face, truncal obesity, abnormal hairiness (hirsutism), and hypertension; if the syndrome occurs later in life, it may result from an adenoma or carcinoma of the cortex.

Addison's Disease

Adrenocortical insufficiency (Addison's disease), which is characterized clinically by increased pigmentation, muscular weakness, weight loss, and hypotension, may be caused by tuberculous destruction or bilateral atrophy of both cortices.

Pheochromocytoma

Pheochromocytoma, a tumor of the medulla, produces a paroxysmal or sustained hypertension. The symptoms and signs result from the production of a large amount of catecholamines, which are then poured into the bloodstream.

Because of their position on the posterior abdominal wall, few tumors of the suprarenal glands can be palpated. Computed tomography (CT) scans can be used to visualize the glandular enlargement; however, when interpreting CT scans, remember the close relationship of the suprarenal glands to the crura of the diaphragm.

Surgical Significance of the Renal Fascia

The suprarenal glands, together with the kidneys, are enclosed within the renal fascia; the suprarenal glands, however, lie in a separate compartment, which allows the two organs to be separated easily at operation.

Suprarenal Susceptibility to Trauma at Birth

At birth, the suprarenal glands are relatively large because of the presence of the fetal cortex; later, when this part of the cortex involutes, the gland becomes reduced in size. During the process of involution, the cortex is friable and susceptible to damage and severe hemorrhage.

Islets of Langerhans of the Pancreas

Islets of Langerhans and Diabetes Mellitus

In diabetes mellitus, the beta cells of the islets of Langerhans lose their ability to secrete insulin or the target cells of the tissues become insensitive to circulating insulin. In juvenile diabetes, there is total absence of insulin, but when the onset of diabetes occurs in adulthood, the plasma levels of insulin may be normal or only slightly below normal. The exact cause of diabetes mellitus is not known. Genetic, metabolic, and autoimmune factors, as well as viral infections, are thought to play an important causative role in many patients.

In all patients with diabetes mellitus, the blood glucose level is above normal (hyperglycemia). Once the blood glucose level reaches a certain threshold value, approximately 180 mg/100 mL, the glucose spills over into the urine (glucosuria). The osmotic pressure exerted by the high concentration of glucose in the urine inhibits the reabsorption of water in the kidney tubules, causing excessive urination (polyuria). The patient becomes thirsty and dehydration may occur. There is an upset in the carbohydrate, fat, and protein metabolism in these patients that leads to loss of weight and lack of energy.

The treatment of patients with diabetes mellitus includes giving sufficient insulin and a special diet so that the carbohydrate metabolism returns to normal. In those patients with the less severe type of diabetes, the hyperglycemia often can be treated with a low-calorie, low-carbohydrate diet without the administration of insulin.

Interstitial Cells of the Testis

Testosterone Deficiency

The function of the testes is the production of spermatozoa and the secretion of the male sex hormones, particularly testosterone, by the interstitial cells. The two functions may be interfered with simultaneously by a severe acute infection or by the occlusion of the blood supply during a repair operation for inguinal hernia. Total absence of testosterone follows surgical castration, which may be necessary following severe trauma to the perineum. Testosterone deficiency

is not present in patients with incompletely descended or maldescended testes. If testosterone deficiency occurs before puberty, the accessory organs of reproduction do not develop; the penis, scrotum, seminal vesicles, and prostate remain small. The secondary sexual characteristics do not appear. There is no growth of the hair on the face or trunk or in the axillae. The pubic hair is of the female distribution and develops in response to the suprarenal androgens. The larynx fails to enlarge, and the voice remains high pitched and infantile. The muscles are poorly developed. There is delay in the fusion of the epiphyses in the long bones with the diaphysis. Excessive fat deposits may occur in the pectoral region, abdomen, and buttocks, and on the hips.

Testosterone deficiency after puberty causes the accessory sex organs to atrophy and the secondary sexual characteristics to regress. Those organs and structures that do not require testosterone for their maintenance are unaffected, however. Thus, the penis remains of normal size, the voice remains unchanged, and facial hair growth may be affected only slightly. Sexual desire and erection may be absent.

Ovaries

Menopause

Menopause is the period of life when the ovaries normally cease to respond to the gonadotropic hormones of the anterior lobe of the pituitary. Menopause occurs on average between ages 45 and 50. The ovaries become smaller, and the graafian follicles atrophy and are replaced by fibrous tissue. The tunica albuginea thickens. The corpora lutea and the ovarian hormones are no longer produced.

As a result of the cessation of the production of ovarian estrogens and progesterone, menstruation ceases and the genital organs atrophy to some extent. Vasomotor changes, in the form of hot flashes, occur in the skin of the face, neck, and chest. The vaginal mucous membrane thins and atrophies. The breasts may enlarge, because of the deposition of

fat, or shrink, because of atrophy of the glandular ducts. The patient usually gains weight from a diffuse deposition of fat. The patient often complains of pains in the joints, fatigue, and insomnia. Anxiety, depression, and emotional instability may also be present.

The lack of estrogen also increases protein catabolism. This change reveals itself by an alteration in the texture of the hair and nails, wrinkling of the skin, and osteoporosis.

In the great majority of women, the symptoms of the menopause are slight, but for some, the body changes and emotional disturbances are very severe, requiring considerable patience and understanding from the husband and relatives.

Hypogonadism

Ovarian hypofunction may be associated with lesions of the hypothalamus that impair the release of the gonadotropic-releasing hormone. Via a similar mechanism, emotional strain, such as leaving home and attending college, may change the afferent nervous input of the hypothalamus, causing amenorrhea. Hypopituitarism with a failure of follicle-stimulating hormone and luteinizing hormone secretion caused by a pituitary tumor may also cause ovarian hypofunction. Removal of the ovaries in the adult results in a premature, artificial menopause.

Placenta

Hydatidiform Mole

Excessive proliferation of the trophoblast during the early stages of placenta formation may lead to the condition of hydatidiform mole. The uterus may become filled with vesicular structures, which may be the size of grapes, and the fetus dies. Very large quantities of chorionic gonadotropin are produced by the trophoblast, and the hormone appears in the urine.

Clinical Problem Solving Questions

Read the following case histories/questions and give the best answer for each.

1. On examination, a patient is found to have a bitemporal hemianopia. An enlargement of which anatomic structure is likely to cause this condition?
2. A 40-year-old woman was involved in an automobile accident in which she sustained severe head injuries. Following a slow but uneventful recovery, she was released from the hospital without any residual signs or symptoms. Six months later, the patient started to complain of frequency of micturition and was passing very large quantities of pale urine. She also said that she always seemed thirsty and would often drink 10 glasses of water in one morning. Using your knowledge of anatomy and physiology, do you think there is any connection between the urinary symptoms and her automobile accident?
3. A 17-year-old boy is taken by his parents to a pediatrician because the parents are concerned about his

excessive height and his complaints of fatigue and general lassitude. His standing height is 84 in. Questioning reveals that the boy has grown very rapidly since his thirteenth birthday. As a young child, he excelled in competitive sports, but for the past 3 years, he has experienced weakness and fatigue and has ceased to compete. His nose is broad, and his mandible and facial features appear larger than normal. He has large hands and feet and takes a size 18 shoe. There is no family history of unusual tallness. The patient is of normal intelligence, and the size of his external genitalia is normal for his age. His secondary sexual characteristics are normal. Using your knowledge of anatomy and physiology, make a diagnosis. Which cell groups are likely to have undergone pathologic changes? How do you account for the excessive tallness and the presence of a large mandible, hands, and feet in the same individual?

4. A 25-year-old woman has been in labor for several hours. Her uterine contractions are weak, and her labor is not progressing. The obstetrician decides to give her some Pitocin, a synthetic oxytocin hormone. What is the effect of oxytocin on the uterus? In which part of the pituitary is this hormone normally released into the bloodstream?
5. A 45-year-old woman visits her physician for a medical checkup. The woman has no complaints, but her husband has noted the following changes in her appearance during the previous year: She has gained a considerable amount of weight and is becoming mentally and physically slow, often falling asleep while talking to friends. Her face is puffy, and her hair is dry and has developed a tendency to fall out. The lateral third of her eyebrows is missing. Her skin is pale and dry, and her voice is becoming deep and her articulation slow. She frequently complains of the cold when others feel warm. Using your knowledge anatomy and physiology, what do you think is wrong with this patient? What do you think would be the appropriate treatment?

A 25-year-old woman complaining of a swelling on the front of the neck and breathlessness visited her physician. On examination, a small, solitary swelling of firm consistency was found to the left of the midline of the neck below the thyroid cartilage of the larynx. The swelling was not attached to the skin but moved upward on swallowing. About 2 weeks previously the swelling had suddenly increased in size and had become tender to touch; following this increase in size the patient became breathless.

6. The following statements concerning this case would suggest a diagnosis of adenoma of the thyroid gland **except** which?
 - A. The pretracheal layer of deep cervical fascia binds the thyroid gland to the larynx, which moves upward on swallowing.

- B. Each lobe of the thyroid gland is closely related to the sides of the trachea.
- C. The isthmus of the thyroid gland was found to cross in front of the third, fourth, and fifth rings of the trachea.
- D. The sudden increase in the size of the swelling can be explained by a hemorrhage into the adenoma.
- E. The swelling was located superficial to the left sternothyroid muscle.
- F. The breathlessness was caused by the adenoma pressing on the trachea, partially occluding the lumen.

A 35-year-old woman had a partial thyroidectomy for the treatment of thyrotoxicosis. During the operation a ligature slipped off the right superior thyroid artery. To stop the hemorrhage, the surgeon blindly grabbed for the artery with artery forceps. The operation was completed without further incident. The following morning the patient spoke with a husky voice.

7. The following statements about this patient would explain the husky voice **except** which?
 - A. Laryngoscopic examination revealed that the right vocal cord was slack, causing the huskiness of the voice.
 - B. The vocal cord is tensed by the contraction of the cricothyroid muscle.
 - C. The cricothyroid muscle tilts back the cricoid cartilage and pulls forward the thyroid cartilage.
 - D. The cricothyroid muscle is innervated by the recurrent laryngeal nerve.
 - E. The superior thyroid artery is closely related to the external laryngeal nerve.
8. Following a total thyroidectomy for carcinoma of the thyroid gland, a 55-year-old man noticed tingling and numbness of the fingers, toes, and lips. Painful cramps of the hands and feet were also experienced. Strong muscle spasms producing adduction of the thumb, flexion of the wrist and metacarpophalangeal joints, and plantar flexion of the feet also occurred. Laboratory examination of the blood revealed a blood calcium level of 4 mg/100 mL. Which organ was damaged during the total thyroidectomy?

An 18-year-old woman went to her physician because she had noticed a swelling in the midline of her neck. She said she had first noticed this swelling 3 years previously, and it had gradually increased in size. On physical examination, a small swelling was found in the midline of the neck; it measured about 0.5 in. (1.25 cm) in diameter. It was situated just below the body of the hyoid bone, was soft and fluctuant, and moved upward on swallowing. Nothing else abnormal was discovered.

9. The physician made the diagnosis of thyroglossal cyst based on the following symptoms and signs **except** which?
 - A. The swelling was not hard.
 - B. The swelling was fluctuant.

- C. The swelling was located in the midline of the neck.
- D. It moved upward on swallowing, which indicated that it was tethered to tissue associated with the thyroid gland.
- E. A thyroglossal cyst is always found below the hyoid bone.
- A 38-year-old man is admitted to the hospital for laboratory tests. When seen by his physician, he complains of increasing tiredness and muscular weakness over the previous year. He has experienced five attacks of nausea and vomiting, and diarrhea during this period. His reason for visiting his physician is that his friends have noticed that his skin is becoming darker. After a complete physical examination, a diagnosis of Addison's disease is made, and it is confirmed by laboratory tests. What is the cause of Addison's disease? The secretions of which hormones are defective in this disease? What is responsible for the weakness and increased pigmentation of the skin in this condition?
 - A 29-year-old man recently experienced what he describes as severe pounding palpitations. The attacks had lasted about 20 minutes each and had been accompanied by severe sweating, headache, and paleness and coldness of the skin. While in the hospital clinic he has another attack. His pulse rate is 120 beats per minute, and his blood pressure is 240/140 mm Hg. A preliminary diagnosis of pheochromocytoma is made, which is later confirmed by analysis of the urinary content of catecholamines. What hormones are secreted by the cells of the suprarenal medulla, and what is their action?
 - A 51-year-old man is concerned because he has noticed during the past few weeks that he has started to urinate more frequently and is always hungry and thirsty. He is also worried because he has been treated for skin infections on six occasions during the past year. The fasting blood glucose level is measured, and a glucose tolerance test is performed. The results show that the patient has diabetes mellitus. What is the normal fasting blood glucose level? Why does glucose appear in the urine in diabetes mellitus? What is the underlying cause of diabetes mellitus?
 - A 21-year-old man sustains a severe injury to the perineum following an explosion of a road-side bomb by a terrorist. The surgeon is forced to amputate the scrotum and remove both testes. Using your knowledge of physiology, describe the changes that will take place because of the absence of testosterone. Is testosterone produced in patients with bilateral undescended testicles?
 - What are the clinical signs and symptoms of menopause? What is responsible for menopause? Is it caused by a cessation of the activity of the hypothalamus, a cessation of the activity of the pars anterior, or a failure of the ovary to respond to hormonal stimulation from the pituitary?

Answers and Explanations

- Bitemporal hemianopia is a loss of both temporal fields of vision and is due to the interruption of the optic nerve fibers derived from the medial halves of both retinæ. Pressure on the optic chiasma by a tumor of the pituitary gland is the most common cause of the condition.
- Yes, there is a connection between the accident and the urinary symptoms. This patient is suffering from diabetes insipidus caused by traumatic damage either to the posterior lobe of the pituitary gland or to the supraoptic or paraventricular nuclei of the hypothalamus. In any event, production of vasopressin was inhibited. It should be pointed out that a lesion of the posterior lobe of the pituitary is usually not followed by diabetes insipidus, since the vasopressin (antidiuretic hormone) produced by the neurons of the supraoptic and paraventricular nuclei escapes directly into the bloodstream. The action of vasopressin is to increase the absorption of water in the distal convoluted tubules and collecting tubules of the kidney.
- This patient has the signs and symptoms of gigantism and acromegaly caused by the excessive secretion of growth hormone by the acidophil cells of the anterior lobe of the pituitary gland. The condition started before the epiphyses of the long bones fused with the diaphysis, hence the gigantism, and continued growth after the fusion had taken place, hence the acromegalic changes.
- Oxytocin stimulates the smooth muscle of the uterus to contract. Normally, it plays an important role in labor and delivery. During the third stage of labor, when the placenta and the fetal membranes have been delivered, it stimulates the uterine muscle to contract and prevents excessive bleeding. In this patient the obstetrician was supplementing the patient's own oxytocin with

synthetic hormone to increase the force of the uterine contractions.

Oxytocin is produced by the nerve cells in the hypothalamus. The hormone reaches the posterior lobe of the pituitary via the hypothalamohypophysial tract, where it is stored and later released from the nerve endings.

5. This patient has the signs and symptoms of hypothyroidism and myxedema. After confirming the diagnosis by estimating the PBI (protein-bound iodine concentration) and serum T₄ levels, which are low in this disease, the doctor should prescribe daily doses of thyroid hormone, and this treatment should be continued indefinitely.
6. E is the correct answer. The thyroid gland lies deep to the sternothyroid muscle (see text Fig. 24-10).
7. D is the correct answer. The cricothyroid muscle of the larynx is innervated by the external laryngeal nerve, which was damaged in this patient.
8. The patient is suffering from parathyroid tetany due to accidental removal of one or more of the parathyroid glands during the operation of total thyroidectomy. Sometimes the condition occurs following interference with the blood supply to these glands. The function of the parathyroid gland is to secrete a hormone that regulates calcium metabolism and plasma calcium concentration. A low level of plasma calcium results in increased neuromuscular excitability and the clinical syndrome known as tetany.
9. E is the correct answer. A thyroglossal cyst occurs most commonly in the midline of the neck below the hyoid bone and above the isthmus of the thyroid gland. It should be emphasized that it can occur anywhere along the path of the thyroglossal tract, even as far superiorly as the foramen cecum of the tongue. As the cyst enlarges it is prone to infection, so it should be removed surgically.
10. Addison's disease occurs as a result of the destruction of the suprarenal cortex by tuberculosis or idiopathic atrophy; it may also occur secondary to a failure of elaboration of adrenocorticotrophic hormone (ACTH) from the pars anterior of the pituitary, which results in atrophy of the suprarenal cortex. Cortisol and aldosterone are the two hormones that are lacking in this disease. The weakness is caused by the absence of cortisol secretion, which causes a fall in the level of blood glucose. The increased melanin pigmentation in the skin and buccal mucous membrane is caused by the increased secretion of ACTH from the pars anterior of the pituitary. (The increased pigmentation does not occur in patients in whom the disease is caused by hypopituitarism.) ACTH stimulates the melanocytes in the skin to increase their production of melanin.
11. The epithelial cells of the suprarenal medulla synthesize and secrete norepinephrine and epinephrine.
12. The normal fasting blood glucose level is about 110 mg/100 mL. Once the blood glucose level in diabetes mellitus reaches a certain threshold value, approximately 180 mg/100 mL, the glucose spills out into the urine. The exact cause of diabetes mellitus is not known. Genetic, metabolic, and autoimmune factors, as well as viral infections, are thought to play an important causative role in many patients. Excessive glucagon secretion combined with insulin deficiency has been suggested as a contributing cause of the high levels of blood glucose. It should be remembered that insulin stimulates the uptake and storage of glucose in the liver and muscle, whereas glucagon inhibits this process.
13. Because the testes were removed after puberty, many of the accessory sex organs of this patient will atrophy and the secondary sexual characteristics will regress. Testosterone is produced in individuals with undescended testes because the interstitial cells are not as sensitive to heat as are the germinal epithelium of the seminiferous tubules.
14. A summary of the clinical signs and symptoms of menopause are given on CD page 420. At menopause, the few remaining graafian follicles of the ovary cease to be sensitive to stimulation by the gonadotropic hormones of the pars anterior of the pituitary, even though the blood levels of these hormones rise after menopause. The hypothalamus–pituitary–ovary hormonal mechanism thus ceases to operate.

Appendix

Useful Anatomical Data of Clinical Significance

Appendix Outline

Respiratory System	426	Table VII. Summary of the Movements of the Knee Joint and the Muscles Producing Those Movements	434
Table I. Important Airway Distances (Adult)	426		
Table II. Important Data Concerning the Trachea	426	Table VIII. Summary of the Movements of the Ankle Joint and the Muscles Producing Those Movements	435
Musculoskeletal System	427	Digestive System	436
Table III. Summary of the Movements of the Shoulder Joint and the Muscles Producing Those Movements	427	Table IX. Lengths and Capacities	436
Table IV. Summary of the Movements of the Elbow Joint and the Muscles Producing Those Movements	429	Urinary System	436
Table V. Summary of the Movements of the Wrist Joint and the Muscles Producing Those Movements	430	Table X. Lengths and Capacities	436
Table VI. Summary of the Movements of the Hip Joint and the Muscles Producing Those Movements	432	Reproductive System	436
		Table XI. Dimensions	436
		Embryology	437
		Table XII. The Size and Weight of the Developing Human Embryo and Fetus	437

Respiratory System

Table I Important Airway Distances (Adult) ^a	
Airway	Distances (approx.)
Incisor teeth to the vocal cords	5.9 in. (15 cm)
Incisor teeth to the carina	7.9 in. (20 cm)
External nares to the carina	11.8 in. (30 cm)

^a Average figures given \pm 1–2 cm.

Table II Important Data Concerning the Trachea ^a		
	Length (approx.)	Diameter (approx.)
Adults	4.5 in. (11.4 cm)	1 in. (2.5 cm)
Infants	1.6–2 in. (4–5 cm)	As small as 3 mm ^b

^a Extension of the head and neck, as when maintaining an airway in an anesthetized patient, may stretch the trachea and increase its length by 25%. In the adult, the carina may descend by as much as 3 cm on deep inspiration. At the carina, the right bronchus leaves the trachea at an angle of 25° from the vertical and the left bronchus leaves the trachea at an angle of 45° from the vertical. In children younger than 3 years, both bronchi arise from the trachea at equal angles.

^b As children grow, the diameter in millimeters corresponds approximately to their age in years.

Musculoskeletal System

Table III Summary of the Movements of the Shoulder Joint and the Muscles Producing Those Movements^a

Movements	Muscles	Origin	Insertion	Nerve Supply	Segmental Nerve ^b
Flexion	Deltoid (anterior fibers)	Clavicle	Middle of lateral surface of shaft of humerus	Axillary nerve	C5, 6
	Pectoralis major (clavicular part)	Clavicle	Lateral lip bicipital groove of humerus	Medial and lateral pectoral nerves from brachial plexus	C5, 6
	Biceps brachii Long head	Supraglenoid tubercle of scapula	Tuberosity of radius, deep fascia of forearm	Musculocutaneous nerve	C5, 6
	Short head	Coracoid process of scapula			
	Coraco-brachialis	Coracoid process of scapula	Medial aspect of shaft of humerus	Musculocutaneous nerve	C5, 6, 7
Extension	Deltoid (posterior fibers)	Spine of scapula	Middle of lateral surface of shaft of humerus	Axillary nerve	C5, 6
	Latissimus dorsi	Iliac crest, lumbar fascia, spines of lower six thoracic vertebrae, lower three or four ribs, and inferior angle of scapula	Floor of bicipital groove of humerus	Thoracodorsal nerve	C6, 7, 8
	Teres major	Lower third lateral border of scapula	Medial lip of bicipital groove of humerus	Lower subscapular nerve	C6, 7
Abduction	Middle fibers of deltoid	Acromion process of scapula	Middle of lateral surface of shaft of humerus	Axillary nerve	C5, 6
	Supraspinatus	Supraspinous fossa of scapula	Greater tuberosity of humerus	Suprascapular nerve	C4, 5, 6
Adduction	Pectoralis major (sternal part)	Sternum and upper six costal cartilages	Lateral lip of bicipital groove of humerus	Medial and lateral pectoral nerves	C7, 8; T1
	Latissimus dorsi	Iliac crest, lumbar fascia, spines of lower six thoracic vertebrae, lower three or four ribs, inferior angle of scapula	Floor of bicipital groove of humerus	Thoracodorsal nerve	C6, 7, 8

Table III (continued)

Movements	Muscles	Origin	Insertion	Nerve Supply	Segmental Nerve ^b
Lateral rotation	Teres major	Lower third lateral border of scapula	Medial lip of bicipital groove of humerus	Lower subscapular nerve	C6, 7
	Teres minor	Upper two thirds lateral border of scapula	Greater tuberosity of humerus	Axillary nerve	C5, 6
	Infraspinatus	Infraspinous fossa of scapula	Greater tuberosity of humerus	Suprascapular nerve	C5, 6
	Teres minor	Upper two thirds lateral border of scapula	Greater tuberosity of humerus	Axillary nerve	C5, 6
	Deltoid (posterior fibers)	Spine of scapula	Middle of lateral surface of shaft of humerus	Axillary nerve	C5, 6
Medial rotation	Subscapularis	Subscapular fossa	Lesser tuberosity of humerus	Upper and lower subscapular nerves	C5, 6
	Latissimus dorsi	Iliac crest, lumbar fascia, spines of lower three or four ribs, inferior angle of scapula	Floor of bicipital groove of humerus	Thoracodorsal nerve	C6, 7, 8
	Teres major	Lower third lateral border of scapula	Medial lip bicipital groove of humerus	Lower subscapular nerve	C6, 7
	Deltoid (anterior fibers)	Clavicle	Middle of lateral surface of shaft of humerus	Axillary nerve	C5, 6

^a Circumduction is a combination of all the movements described.

^b The predominant segmental nerve supply is indicated by boldface type.

Musculoskeletal System

Table IV

Summary of the Movements of the Elbow Joint and the Muscles Producing Those Movements

Movements	Muscles	Origin	Insertion	Nerve Supply	Segmental Nerve ^a
Flexion	Brachialis	Front of lower half of humerus	Coronoid process of ulna	Musculocutaneous nerve	C5, 6
	Biceps brachii Long head	Supraglenoid tubercle of scapula	Tuberosity of radius, deep fascia of forearm	Musculocutaneous nerve	C5, 6
	Short head	Coracoid process of scapula			
	Brachioradialis	Lateral supracondylar ridge of humerus	Styloid process of radius	Radial nerve	C5, 6 , 7
	Pronator teres Humeral head	Medial epicondyle of humerus	Lateral aspect of shaft of radius	Median nerve	C6, 7
Extension	Ulnar head	Coronoid process of ulna			
	Triceps Long head	Infraglenoid tubercle of scapula	Olecranon process of ulna	Radial nerve	C6, 7 , 8
	Lateral head	Posterior surface of shaft of humerus			
	Medial head	Lower half of posterior surface of shaft of humerus			
	Anconeus	Lateral epicondyle of humerus	Olecranon process of ulna	Radial nerve	C7, 8; T1

^aThe predominant segmental nerve supply is indicated by boldface type.

Musculoskeletal System

Table V

Summary of the Movements of the Wrist Joint and the Muscles Producing Those Movements

Movements	Muscles	Origin	Insertion	Nerve Supply	Segmental Nerve ^a	
Flexion	Flexor carpi radialis	Medial epicondyle of humerus	Bases of second and third metacarpal bones	Median nerve	C6, 7	
	Flexor carpi ulnaris	Humeral head	Pisiform bone, hook of hamate, base of fifth metacarpal bone	Ulnar nerve	C7, 8	
		Ulnar head				Olecranon process, posterior border of ulna
	Palmaris longus	Medial epicondyle of humerus	Flexor retinaculum, palmar aponeurosis	Median nerve	C7, 8	
	Flexor digitorum superficialis	Humero-ulnar head	Medial epicondyle of humerus, coronoid process of ulna	Middle phalanx of medial four fingers	Median nerve	C7, 8; T1
		Radial head	Oblique line anterior surface shaft of radius			
		Flexor digitorum profundus	Anterior surface shaft of ulna, interosseous membrane	Distal phalanx of medial four fingers	Ulnar half—ulnar nerve, radial half—median nerve	C8; T1
		Flexor pollicis longus	Anterior surface shaft of radius	Distal phalanx of thumb	Anterior interosseous branch of median nerve	C8; T1
Extension	Extensor carpi radialis longus	Lateral supracondylar ridge of humerus	Base of second metacarpal bone	Radial nerve	C6, 7	
	Extensor carpi radialis brevis	Lateral epicondyle of humerus	Base of third metacarpal bone	Deep branch of radial nerve	C7, 8	
	Extensor carpi ulnaris	Lateral epicondyle of humerus	Base of fifth metacarpal bone	Deep branch of radial nerve	C7, 8	
	Extensor digitorum	Lateral epicondyle of humerus	Middle and distal phalanges of medial four fingers	Deep branch of radial nerve	C7, 8	

Table V (continued)

Movements	Muscles	Origin	Insertion	Nerve Supply	Segmental Nerve ^a
Abduction	Extensor indicis	Shaft of ulna and interosseous membrane	Extensor expansion of index finger	Deep branch of radial nerve	C7, 8
	Extensor digiti minimi	Lateral epicondyle of humerus	Extensor expansion of little finger	Deep branch of radial nerve	C7, 8
	Extensor pollicis longus	Shaft of ulna and interosseous membrane	Base of distal phalanx of thumb	Deep branch of radial nerve	C7, 8
	Flexor carpi radialis	Medial epicondyle of humerus	Bases of second and third metacarpal bones	Median nerve	C6, 7
	Extensor carpi radialis longus	Lateral supracondylar ridge of humerus	Base of second metacarpal bone	Radial nerve	C6, 7
	Extensor carpi radialis brevis	Lateral epicondyle of humerus	Bases of third metacarpal bone	Deep branch of radial nerve	C7, 8
	Abductor pollicis longus	Shafts of radius and ulna	Base of first metacarpal bone	Deep branch of radial nerve	C7, 8
	Extensor pollicis longus	Shaft of ulna and interosseous membrane	Base of distal phalanx of thumb	Deep branch of radial nerve	C7, 8
Adduction	Extensor pollicis brevis	Shaft of radius and interosseous membrane	Base of proximal phalanx of thumb	Deep branch of radial nerve	C7, 8
	Flexor carpi ulnaris Humeral head	Medial epicondyle of humerus	Pisiform bone, hook of hamate, base of fifth metacarpal bone	Ulnar nerve	C7, 8
	Ulnar head	Olecranon process of ulna			
	Extensor carpi ulnaris	Lateral epicondyle of humerus	Base of fifth metacarpal bone	Deep branch of radial nerve	C7, 8

^a The predominant segmental nerve supply is indicated by boldface type.

Musculoskeletal System

Table VI Summary of the Movements of the Hip Joint and the Muscles Producing Those Movements^a

Movements	Muscles	Origin	Insertion	Nerve Supply	Segmental Nerve ^b	
Flexion	Iliacus	Iliac fossa	Lesser trochanter of femur	Femoral nerve	L2, 3	
	Psoas	Body of twelfth thoracic vertebra, transverse processes, bodies and intervertebral discs of the five lumbar vertebrae	Lesser trochanter of femur	Lumbar plexus	L1, 2, 3	
	Rectus femoris	Straight head	Anterior inferior iliac spine	Patella	Femoral nerve	L2, 3, 4
		Reflected head	Ilium above acetabulum			
	Sartorius	Anterior superior iliac spine	Upper medial surface of shaft of tibia	Femoral nerve	L2, 3	
Extension (a posterior movement of the flexed thigh)	Gluteus maximus	Outer surface of ilium, sacrum, coccyx, sacrotuberous ligament	Iliotibial tract, gluteal tuberosity of femur	Inferior gluteal nerve	L5; S1, 2	
		Biceps femoris	Long head: ischial tuberosity	Head of fibula	Tibial nerve (sciatic nerve)	L5; S1, 2
	Semitendinosus	Ischial tuberosity	Upper part of medial surface of shaft of tibia	Tibial nerve (sciatic nerve)	L5; S1, 2	
	Semimembranosus	Ischial tuberosity	Medial condyle of tibia	Tibial nerve (sciatic nerve)	L5; S1, 2	
	Adductor magnus	Ischial tuberosity	Adductor tubercle of femur	Tibial nerve (sciatic nerve)	L2, 3, 4	
Abduction	Gluteus medius	Outer surface of ilium	Greater trochanter of femur	Superior gluteal nerve	L5; S1	
	Gluteus minimus	Outer surface of ilium	Greater trochanter of femur	Superior gluteal nerve	L5; S1	
	Sartorius	Anterior superior iliac spine	Upper medial surface of shaft of tibia	Femoral nerve	L2, 3	
	Tensor fasciae latae	Iliac crest	Iliotibial tract	Superior gluteal nerve	L4, 5	
	Piriformis	Anterior surface of sacrum	Greater trochanter of femur	Sacral plexus	L5; S1, 2	

Table VI (continued)

Movements	Muscles	Origin	Insertion	Nerve Supply	Segmental Nerve ^a
Adduction	Adductor longus	Body of pubis	Posterior surface of shaft of femur	Obturator nerve	L2, 3 , 4
	Adductor brevis	Inferior ramus of pubis	Posterior surface of shaft of femur	Obturator nerve	L2, 3, 4
	Adductor magnus (adductor fibers)	Inferior ramus of pubis, ramus of ischium, ischial tuberosity	Posterior surface of shaft of femur, adductor tubercle of femur	Obturator nerve	L2, 3 , 4
	Pectineus	Superior ramus of pubis	Upper end of shaft of femur	Femoral nerve	L2, 3
	Gracilis	Inferior ramus of pubis, ramus of ischium	Upper part of shaft of tibia on medial surface	Obturator nerve	L2 , 3
Lateral rotation	Piriformis	Anterior surface of sacrum	Greater trochanter of femur	Sacral plexus	L5; S1 , 2
	Obturator internus	Inner surface of obturator membrane	Greater trochanter of femur	Sacral plexus	L5; S1
	Obturator externus	Outer surface of obturator membrane	Greater trochanter of femur	Obturator nerve	L3, 4
	Superior gemellus	Spine of ischium	Greater trochanter of femur	Sacral plexus	L5; S1
	Inferior gemellus	Ischial tuberosity	Greater trochanter of femur	Sacral plexus	L5; S1
	Quadratus femoris	Ischial tuberosity	Quadratus tubercle on upper end of posterior surface of femur	Sacral plexus	L5; S1
	Gluteus maximus	Outer surface of ilium, sacrum, coccyx, sacrotuberous ligament	Iliotibial tract, gluteal tuberosity of femur	Inferior gluteal nerve	L5; S1 , 2
Medial rotation	Gluteus medius	Outer surface of ilium	Greater trochanter of femur	Superior gluteal nerve	L5 ; S1
	Gluteus minimus	Outer surface of ilium	Greater trochanter of femur	Superior gluteal nerve	L5 ; S1
	Tensor fasciae latae	Iliac crest	Iliotibial tract	Superior gluteal nerve	L4, 5

^a Circumduction is a combination of all the movements described.

^b The predominant segmental nerve supply is indicated by boldface type.

Musculoskeletal System

Table VII

Summary of the Movements of the Knee Joint and the Muscles Producing Those Movements

Movements	Muscles	Origin	Insertion	Nerve Supply	Segmental Nerve ^a
Flexion	Biceps femoris Long head Short head	Ischial tuberosity Shaft of femur	Head of fibula	Tibial nerve Common peroneal nerve	L5; S1, 2
	Semitendinosus	Ischial tuberosity	Upper part of medial surface of shaft of tibia	Tibial nerve	L5; S1, 2
	Semimembranosus	Ischial tuberosity	Medial condyle of tibia	Tibial nerve	L5; S1, 2
	Gastrocnemius	Medial, lateral condyles of femur	Via Achilles tendon into calcaneum	Tibial nerve	S1, 2
Extension	Quadriceps femoris: rectus femoris Straight head Reflected head	Anterior inferior iliac spine Ilium above acetabulum	Patella	Femoral nerve	L2, 3, 4
	Vastus lateralis	Upper end and shaft of femur	Patella	Femoral nerve	L2, 3, 4
	Vastus medialis	Upper end and shaft of femur	Patella	Femoral nerve	L2, 3, 4
	Vastus intermedius	Shaft of femur	Patella	Femoral nerve	L2, 3, 4
Medial rotation	Sartorius	Anterior superior iliac spine	Upper medial surface of shaft of tibia	Femoral nerve	L2, 3
	Gracilis	Interior ramus of pubis, ramus of ischium	Upper part of shaft of tibia on medial surface	Obturator nerve	L2, 3
Lateral rotation	Biceps femoris Long head Short head	Ischial tuberosity Shaft of femur	Head of fibula —	Tibial nerve Common peroneal nerve	L5; S1, 2 L5; S1, 2

^a The predominant segmental nerve supply is indicated by boldface type.

Musculoskeletal System

Table VIII
Summary of the Movements of the Ankle Joint and the Muscles Producing Those Movements

Movements	Muscles	Origin	Insertion	Nerve Supply	Segmental Nerve ^a
Dorsiflexion	Tibialis anterior	Shaft of tibia, interosseous membrane	Medial cuneiform, base of first metatarsal bone	Deep peroneal nerve	L4,5
	Extensor hallucis longus	Shaft of fibula, interosseous membrane	Base of distal phalanx of great toe	Deep peroneal nerve	L5, S1
	Extensor digitorum longus	Shaft of fibula, interosseous membrane	Dorsal extensor expansion of lateral four toes	Deep peroneal nerve	L5, S1
	Peroneus tertius	Shaft of fibula, interosseous membrane	Base of fifth metatarsal bone	Deep peroneal nerve	L5, S1
Plantar-flexion	Gastrocnemius	Medial, lateral condyles of femur	Via Achilles tendon into calcaneum	Tibial nerve	S1,2
	Soleus	Shaft of tibia and fibula	Via Achilles tendon into calcaneum	Tibial nerve	S1,2
	Plantaria	Lateral supracondylar ridge of femur	Calcaneum	Tibial nerve	S1,2
	Peroneus longus	Shaft of fibula	Base of first metatarsal and medial cuneiform	Superficial peroneal nerve	L5; S1,2
	Peroneus brevis	Shaft of fibula	Base of fifth metatarsal bone	Superficial peroneal nerve	L5; S1,2
	Tibialis posterior	Shaft of tibia, fibula, interosseous membrane	Tuberosity of navicular	Tibial nerve	L4,5
	Flexor digitorum longus	Shaft of tibia	Distal phalanges of lateral four toes	Tibial nerve	S2,3
	Flexor hallucis longus	Shaft of fibula	Base of distal phalanx of big toe	Tibial nerve	S2,3

^a The predominant segmental nerve supply is indicated by boldface type.

Digestive System

Table IX Lengths and Capacities

Region (approx.)	Lengths (approx.)	Capacities (Approx.)
Esophagus	10 in. (25 cm)	—
Stomach ^a	Lesser curvature 4.8–5.6 in. (12–14 cm)	1,500 mL
Duodenum	10 in. (25 cm)	—
Jejunum	8 ft (2.4 M)	—
Ileum	12 ft (3.7 M)	—
Appendix	3–5 in. (8–13 cm)	—
Ascending colon	5 in. (13 cm)	—
Transverse colon	15 in. (38 cm)	—
Descending colon	10 in. (25 cm)	—
Sigmoid colon	10–15 in. (25–38 cm)	—
Rectum	5 in. (13 cm)	—
Anal canal	1.5 in. (4 cm)	—
Gallbladder	2.8–3.9 in. (7–10 cm)	30–50 mL
Cystic duct	1.5 in. (3.8 cm)	—
Bile duct	3 in. (8 cm)	—

^a The curved course taken by a nasogastric tube from the cardiac orifice to the pylorus is usually longer, 6–10 in. (15–25 cm).

Urinary System

Table X Lengths and Capacities

Organ	Lengths (approx.)	Capacity (approx.)
Ureter	10 in. (25 cm)	—
Bladder	—	500 mL
Male urethra	8 in. (20 cm)	—
Penile	6 in. (15.7 cm)	—
Membranous	0.5 in. (1.25 cm)	—
Prostatic	1.25 in. (3 cm)	—
Female urethra	1.5 in. (3.8 cm)	—

Reproductive System

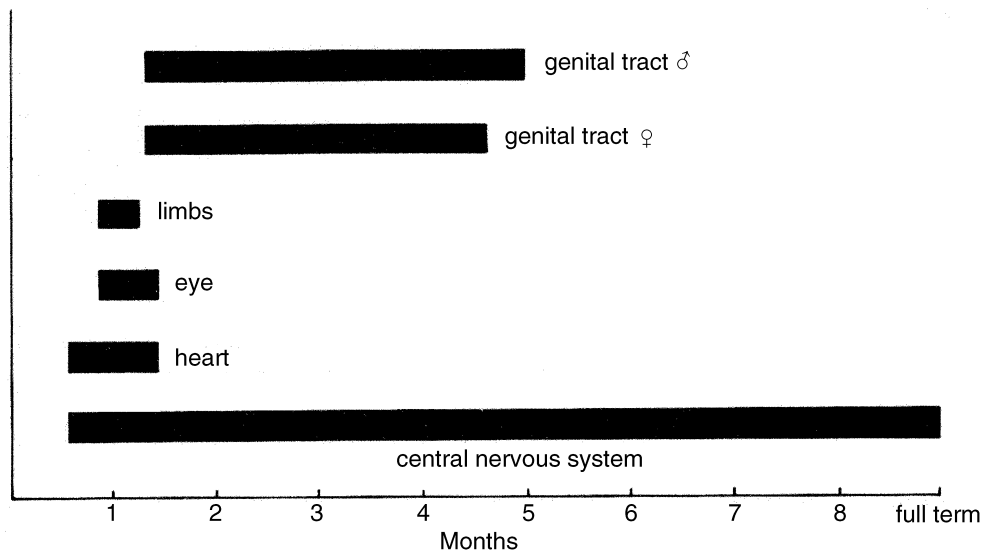
Table XI Dimensions

Organ	Dimensions (approx.)
Male	
Testis	2 × 1 in. (5 × 2.5 cm)
Vas deferens	18 in. (45 cm)
Penis (erect)	6 in. (15 cm)
Female	
Ovary	1.5 × 0.75 in. (4 × 2 cm)
Uterine tube	4 in. (10 cm)
Uterus	3 × 2 × 1 in. (8 × 5 × 2.5 cm)
Vagina	3 in. (8 cm)

Embryology

Table XII The Size and Weight of the Developing Human Embryo and Fetus		
Age of Conception (weeks)	Crown-Rump Length (mm)	Weight (g)
4	5	0.02
5	8	—
8	23	1
12	56	14
16	112	105
20	160	310
24	203	640
28	242	1,080
32	277	1,670
36	313	2,400
Full term	350	3,300

Reprinted with permission, Arey 1966.



CD Figure APP-1 Critical times in the maturation of the human fetus during which mutant genes, drugs, or environmental factors may alter normal development of specific structures.