

Richard R. Gacek

Ear Surgery

DVD-VIDEO



INCLUDED

 Springer

Richard R. Gacek

Ear Surgery

Richard R. Gacek

Ear Surgery

With 186 Figures, 1 Table and 6 DVDs

 Springer

Richard R. Gacek, MD

University of Massachusetts Medical Center
Department of Otolaryngology
Head and Neck Surgery
55 Lake Avenue North
Worcester MA 01655
USA

ISBN 978-3-540-77411-2

e-ISBN 978-3-540-77412-9

DOI 10.1007/978-3-540-77412-9

Library of Congress Control Number: 2007942202

© 2008 Springer-Verlag Berlin Heidelberg

This work is subject to copyright. All rights are reserved, whether the whole or part of the material is concerned, specifically the rights of translation, reprinting, reuse of illustrations, recitation, broadcasting, reproduction on microfilm or in any other way, and storage in data banks. Duplication of this publication or parts thereof is permitted only under the provisions of the German Copyright Law of September 9, 1965, in its current version, and permission for use must always be obtained from Springer. Violations are liable to prosecution under the German Copyright Law.

The use of general descriptive names, registered names, trademarks, etc. in this publication does not imply, even in the absence of a specific statement, that such names are exempt from the relevant protective laws and regulations and therefore free for general use.

Product liability: the publishers cannot guarantee the accuracy of any information about dosage and application contained in this book. In every individual case the user must check such information by consulting the relevant literature.

Cover design: Frido Steinen-Broo, eStudio Calamar, Spain

Production & Typesetting: le-tex publishing services oHG, Leipzig, Germany

Printed on acid-free paper

9 8 7 6 5 4 3 2 1

springer.com



Acknowledgement

The author is grateful to Linda Barnes for excellent secretarial assistance in manuscript preparation. The professional expertise in DVD production by Thomas Delaney, Luigi Piarulli, and Tony Maciag is much appreciated.



Preface

Otologic procedures that endure are based on a detailed knowledge of the anatomy, physiology, and pathology of the temporal bone. Several excellent texts on surgery of the temporal bone are available, which comprehensibly describe surgical techniques and instrumentation in otologic surgery. Pictorials used in these renditions live up to the adage that a “picture is worth a thousand words.” Building on that principle, videos of otologic surgery and pathology can complete the presentation of temporal bone surgery. This mode of illustration can convey subtleties such as the use of instruments and the management of adverse events during surgery. The present book uses narrated and edited surgical clips to illustrate this perspective of otologic practice.

Each chapter begins with a basic text to introduce a particular area of pathology responsible for clinical symptoms. Knowledge of the microscopic anatomy and pathology in the temporal bone provides the surgeon with an incomparable ability to manage successfully expected as well as unexpected problems encountered during otologic surgery. Photomicrographs are utilized extensively in this book to illustrate this dimension of surgery on the temporal bone. The book is intentionally not comprehensive, but a brief description of major otologic procedures and their indications. The emphasis on video description and histopathology is intended for surgeons in training as well as those beginning practice.

*Richard R. Gacek, M.D.
University of Massachusetts Medical School
Worcester, Massachusetts
December 2007*

Contents

1 Otosclerosis Surgery Complications

| | | |
|-----|---------------------------|----|
| 1.1 | Preoperative Phase | 1 |
| 1.2 | Operative Phase | 4 |
| 1.3 | Postoperative Phase | 5 |
| | References | 12 |

2 Tympanoplasty/Ossiculoplasty

| | | |
|-----|--|----|
| 2.1 | Evaluation of the Patient | 13 |
| 2.2 | Eustachian Tube Function | 13 |
| 2.3 | Control of Disease | 13 |
| 2.4 | Repair of the Sound-Conduction Mechanism | 16 |
| 2.5 | Postoperative Care | 24 |
| | References | 26 |

3 Surgery for Chronic Otitis Media

| | | |
|--|------------------|----|
| | References | 31 |
|--|------------------|----|

4 Complications of Chronic Otitis Media

| | | |
|-------|---|----|
| 4.1 | Extracranial Complication | 33 |
| 4.1.1 | Labyrinthitis | 33 |
| 4.1.2 | Facial Paralysis | 38 |
| 4.2 | Intracranial Complications | 39 |
| 4.2.1 | Intradural Extension of Cholesteatoma | 39 |
| 4.2.2 | Meningitis | 40 |
| 4.2.3 | Brain Abscess | 40 |
| 4.2.4 | Lateral Sinus Thrombosis | 40 |
| | References | 42 |

5 Petrous Apex Lesions

| | | |
|-------|----------------------|----|
| 5.1 | Diagnosis | 43 |
| 5.2 | Management | 44 |
| 5.2.1 | Solid Tumors | 44 |
| 5.2.2 | Cystic Lesions | 45 |
| 5.2.3 | Petrositis | 46 |

| | | |
|-------|--|----|
| 5.2.4 | Congenital Epidermoid Cyst | 48 |
| 5.2.5 | Cholesterol Granuloma (Mucocele, Cholesterol Cyst) | 49 |
| | References | 53 |

6 Cholesteatoma

| | | |
|-----|--------------------------------|----|
| 6.1 | Acquired Cholesteatoma | 55 |
| 6.2 | Congenital Cholesteatoma | 56 |
| | References | 60 |

7 External Auditory Canal Lesions

| | | |
|-----|---|----|
| 7.1 | Bony Lesions | 61 |
| 7.2 | Congenital Aural Atresia | 62 |
| 7.3 | Stenosing Chronic External Otitis | 63 |
| 7.4 | Necrotizing External Otitis | 63 |
| | References | 64 |

8 Spontaneous Cerebral Spinal Fluid Otorrhea

| | | |
|--|------------------|----|
| | References | 74 |
|--|------------------|----|

9 Facial Nerve Surgery

| | | |
|---------|--|----|
| 9.1 | Anatomy of the Facial Nerve | 77 |
| 9.1.1 | Organization of the Facial Nerve | 77 |
| 9.1.2 | Sheath of the Facial Nerve | 81 |
| 9.2 | Surgery of the Facial Nerve | 83 |
| 9.2.1 | Idiopathic Facial Paralysis (Bell's Palsy) | 83 |
| 9.2.2 | Chronic Otitis Media | 83 |
| 9.2.3 | Trauma: Temporal Bone | 85 |
| 9.2.3.1 | Longitudinal Fracture | 85 |
| 9.2.3.2 | Transverse Fracture | 85 |
| 9.2.4 | Neoplasia | 86 |
| 9.2.5 | Pseudotumor of the Facial Nerve | 86 |
| | References | 87 |

10 Surgery for Vertigo

| | | |
|------|---------------------------------------|----|
| 10.1 | Antiviral Therapy | 89 |
| 10.2 | Vestibular Neurectomy | 93 |
| 10.3 | Labyrinthectomy | 95 |
| 10.4 | Singular Neurectomy | 95 |
| 10.5 | Endolymphatic Sac Decompression | 97 |
| | References | 98 |

11 Tumor Surgery

| | | |
|------|--|-----|
| 11.1 | Internal Auditory Canal and Cerebellopontine Angle | 99 |
| 11.2 | Intralabyrinthine Vestibular/Cochlear Schwannoma | 102 |
| 11.3 | Benign Tumors of the Middle Ear and Mastoid | 102 |
| 11.4 | Malignant Tumors of the TB | 105 |
| 11.5 | Pseudoepithelial Hyperplasia of External Ear Canal | 108 |
| | References | 109 |

12 Cochlear Implant Surgery

| | | |
|------|---|-----|
| 12.1 | Surgery for Cochlear Implantation | 113 |
| 12.2 | Transcanal Approach to Round Window Niche (Veria Operation) | 114 |
| 12.3 | Cochlear Implantation in Canal Wall Down Mastoidectomy | 114 |
| | References | 115 |

13 Differential Diagnosis of Unilateral Serous Otitis Media

| | | |
|------|------------------|-----|
| 13.1 | Level 1 | 118 |
| 13.2 | Level 2 | 118 |
| 13.3 | Level 3 | 118 |
| 13.4 | Level 4 | 119 |
| 13.5 | Level 5 | 119 |
| | References | 120 |

| | |
|----------------------------|-----|
| Subject Index | 121 |
|----------------------------|-----|

Core Messages

- Confirm audiometric results with tuning fork (512 cycles per second) and speech reception using Barany masker in contralateral ear.
- Manage anatomical and pathologic conditions of the external ear canal before the stapedotomy.
- In unilateral conductive hearing loss, consider malleus and/or incus fixation.
- Stapedotomy is preferred to stapedectomy in otosclerosis surgery.
- Prosthesis length must be carefully assessed.
- In sensorineural hearing loss after stapedotomy suspect reparative granuloma.

The surgical treatment for the conductive hearing loss in otosclerosis over the past 50 years required replacement of the stapedial footplate, with a prosthesis anchored to the long process of the incus. Although total stapedectomy with tissue-wire replacement had been the initial choice for this procedure [11], the preferred choice is a small fenestra stapedotomy, limiting exposure of the vestibule, which accepts a piston like prosthesis [4, 7, 12]. Several varieties of prostheses and techniques exist for fenestrating the stapes footplate. The goal is to atraumatically create a fenestra in the footplate and replace the crural arch with a piston prosthesis of appropriate size and length for the fenestra. The universal employment of this procedure for over 50 years has been associated with one of the most predictable and successful hearing levels in all surgery. However, some minor and a few major complications may result during evaluation of a patient preoperatively, the conduct of the surgical procedure, and in the postoperative period.

This chapter focuses on adverse events that may occur intraoperatively and perioperatively in surgery for otosclerosis. The discussion is followed by a videotape of the stapedotomy procedure and some of the complications described in the text.

1.1 Preoperative Phase

Preoperative evaluation concerns the patient's age, medical status, and expectations. The hearing loss in otosclerosis usually is brought to the attention of the otologist in patients from the second to the fourth or fifth decade, when the progressive loss has stabilized, and the patient is able to give informed consent [6]. Patients in the second decade of life are encouraged to delay operative intervention until the beginning or middle of the third decade, allowing for a slowing in the activity of the otosclerotic bone and its tendency for regeneration. However, younger patients with a disabling magnitude of conductive hearing loss or aversion to the use of amplification may be acceptable candidates for surgery. The upper end of the age scale is more arbitrary. Since the surgical procedure may be performed under local anesthesia with sedation, it can be safely employed in the older patient. An associated existing sensorineural hearing loss component may limit the restoration of hearing even in the best surgical result, leaving the patient still dependent on amplification. However, patients with a severe, mixed hearing loss pattern receiving limited improvement with maximal electronic amplification may benefit from elimination of the conductive component by successful stapedotomy. Such patients are uncommon but do represent an exception to the rule.

Although 10–15% of clinical otosclerosis presents with a unilateral conductive loss [6], this audiometric pattern should raise suspicion of a cause other than otosclerosis. Fixation of the malleus head in the attic typically presents with a predominant low-frequency conductive hearing loss [5]. Mobility of the manubrium can be assessed by pneumatic otoscopy or palpation with an instrument. The possibility of a “shadow” threshold curve caused by transmitted bone conduction to an inadequately masked contralateral normal ear should also receive serious consideration in the assessment of a unilateral hearing loss. The use of 100+ decibels (dB) white noise masking delivered by a Bárány noise box to the contralateral ear while

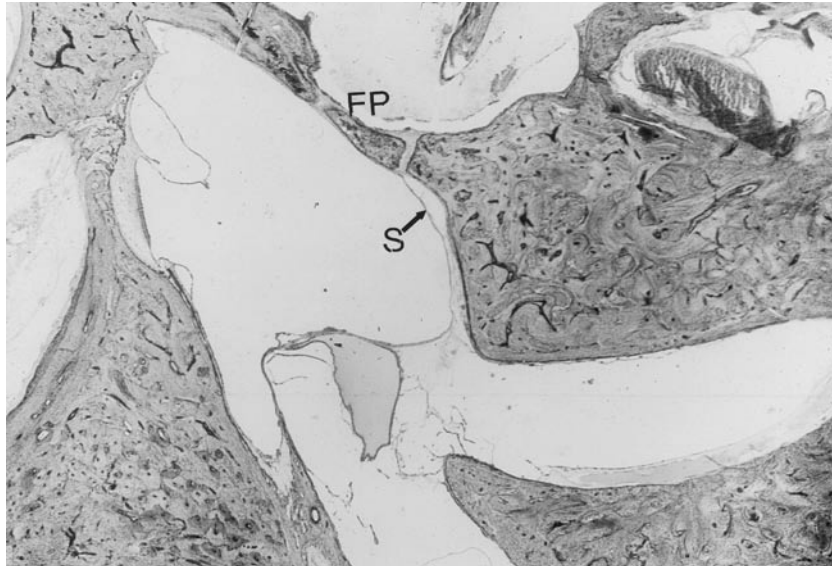


Fig. 1.1 This photomicrograph illustrates the vulnerability of a dilated saccule(s) to fenestration of the stapes footplate (FP)

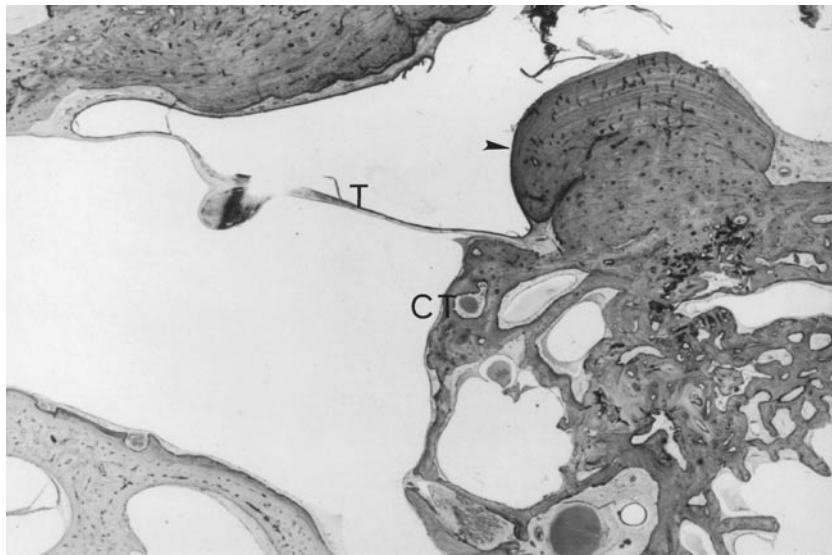


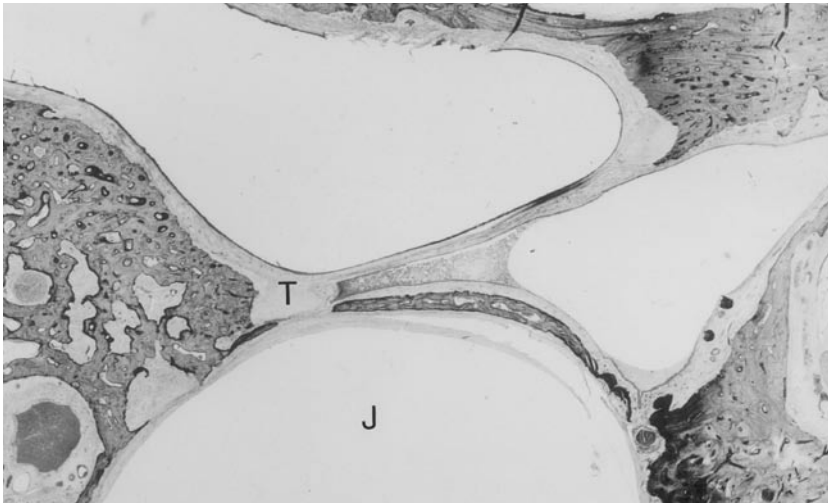
Fig. 1.2 A small exostosis such as this (arrow) on the posterior ear canal wall can be removed with curettage to allow exposure of the middle ear. TM tympanic membrane, CT chorda tympani nerve

speech reception is tested in the affected ear will effectively identify an unsuspected “dead” ear.

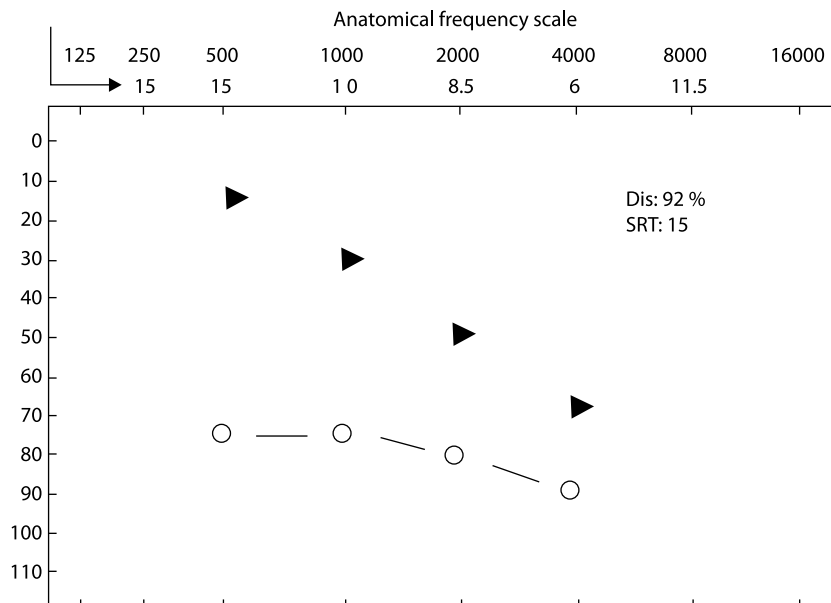
Coexistent retrolabyrinthine or labyrinthine disease may exist in patients with atypical symptoms and clinical findings. A conductive hearing loss with a sensorineural component and discrimination score that is significantly lower than that of the contralateral ear should raise the suspicion of a retrocochlear lesion (i.e., acoustic neuroma), while severe vertigo associated with a low-frequency sensorineural hearing loss suggests endolymphatic hydrops, which would be de-

compressed at stapedotomy, leading to sensorineural hearing loss postoperatively (Fig. 1.1).

Local conditions in the ear canal may adversely affect the performance of the stapedotomy procedure. Small exostoses on the posterior canal wall can be removed by curettage after elevation of the tympanomeatal flap, permitting completion of the stapedotomy procedure (Fig. 1.2). However, if the exostoses are large enough to require canaloplasty with a motorized drill, then the stapedotomy should be performed as a staged procedure.



■ **Fig. 1.3** A large partially dehiscant jugular bulb (*J*) could be injured during elevation of the tympanic annulus (*T*). *F* facial nerve



■ **Fig. 1.4** Closure of this air-bone gap with stapedectomy could result in a loss in speech discrimination because of the descending bone conduction curve

The presence of external otitis should be controlled medically prior to performing the surgery in order to avoid contamination of the middle and inner ear. If the external otitis is chronic, and not responsive to chemotherapeutic drugs, then resection of the infected skin with replacement by split thickness skin grafts, followed by a sufficiently long waiting period for healing, should precede the stapedotomy. Anatomical anomalies such as a dehiscant jugular bulb adjacent to the eardrum inferiorly (Fig. 1.3) should be recognized by preoperative otoscopy as a vascular blush in the hy-

potympanum [9]. Avoidance of such anatomical variants during flap elevation is mandatory.

Recognition of a descending bone conduction curve in the ear with a conductive loss should be carefully evaluated in anticipation of the postoperative result (Fig. 1.4). Tilting the audiogram by closing the air bone gap may result in a decreased discrimination score, without injury to the sensory or neural elements in the cochlea. The patient should be aware of this possible loss of word discrimination before the stapedotomy procedure.

1.2 Operative Phase

The following group of complications may occur and be recognized intraoperatively.

Tears of the tympanic membrane occur because of either a thin atrophic tympanic membrane or inattention to elevation of the fibrous annulus from its sulcus when raising a tympanomeatal flap. Simple tears without a loss of tympanic membrane tissue may be reapproximated by advancing the tympanomeatal flap when it is returned to its anatomical position. Gelfoam may be used in the middle ear for temporary support. A large defect in the drum that cannot be closed by meatal flap advancement should be repaired with adipose tissue from the earlobe.

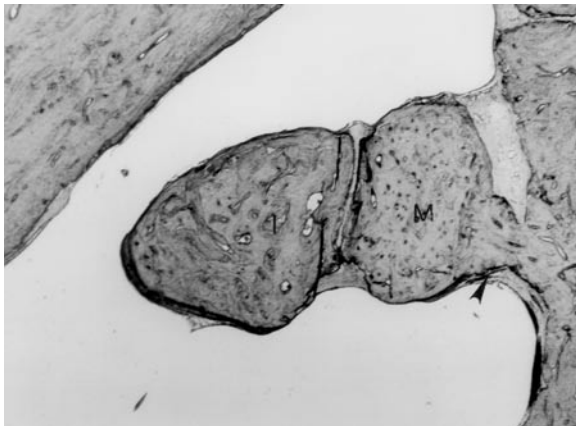
The chorda tympani nerve should be preserved when curetting the posterior/superior canal wall. However, in a small number of cases, probably less than 20%, the chorda tympani nerve may be stretched or dried out in order to achieve adequate exposure of the oval window. Resection of the nerve segment will avoid aberrant neural regeneration responsible for a troublesome taste response postoperatively.

Associated fixation of the malleus or incus should be suspected in middle ear exploration [5]. It is routine during any stapedectomy procedure that all ossicles be individually palpated for mobility [6]. Palpation of the malleus by delicate displacement of the manubrium and of the incus by displacement of its long process after removal of the stapedial arch is a routine step in the procedure. Malleus ankylosis

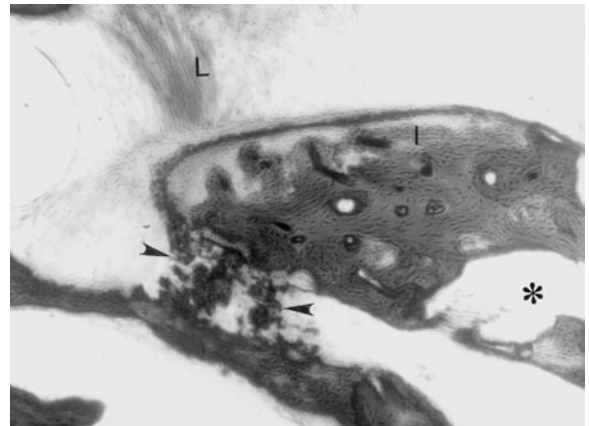
may be congenital or acquired and be obscured from visualization because of its location in the epitympanum (Fig. 1.5). Fixation of the incus may be caused by ossification of the posterior incudal ligaments, in the incudal recess (Fig. 1.6). Unrecognized ossicular fixation may be responsible for failure to close the air bone gap postoperatively.

Rarely, the incus may be dislocated during the stapedectomy procedure. The initial maneuver is to replace the incus into its anatomical position, relying on healing of the ligaments to retain it [6]. However, if the dislocation is severe, and the incus does not retain its relocated position, then malleus attachment for the prosthesis is the most reliable solution for a satisfactory result. Occasionally pneumatization of the long process of the incus may be responsible for fracture after crimping of the wire prosthesis. This event requires that an appropriately long new prosthesis be applied to the manubrium of the malleus.

The critical part of the stapedotomy procedure concerns fenestration of the ankylosed footplate. The accompanying figures demonstrate some of the anatomical variations in oval window pathology that affect the surgical technique. In the case of a thin footplate in an oval window niche with overhanging bone (Fig. 1.7), removal of the overhanging bone with a rotating burr will provide complete visualization of the annular ligament. Such overhanging bone may compromise the ability to retrieve a floating or depressed footplate. A thick footplate with marginal fixation will require careful pressure with the drill to avoid a floating foot-



■ Fig. 1.5 Anterior malleus head ankylosis may be congenital (arrow). *I* incus body



■ Fig. 1.6 Fixation of the short process of incus (*I*) may be acquired by calcification in its ligaments (arrow). * air cell in the incus, *L* normal ligament

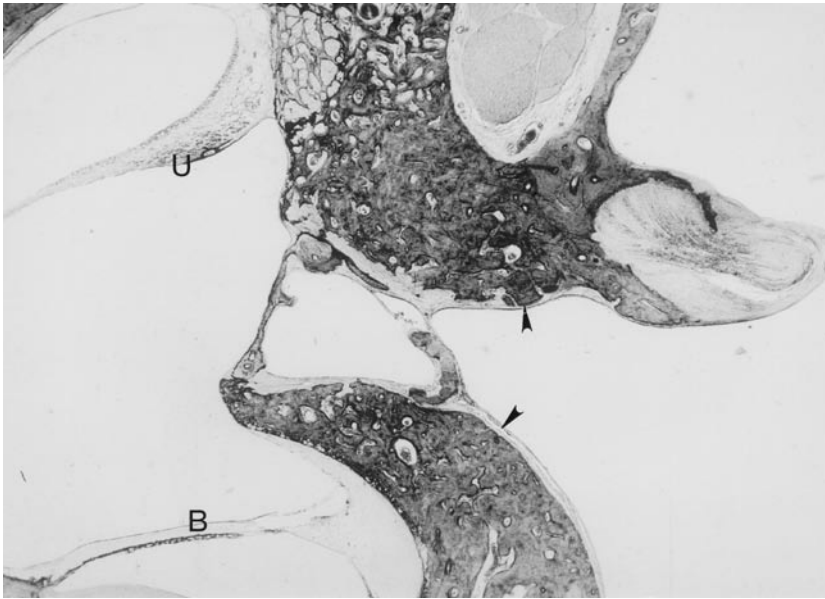


Fig. 1.7 This oval window niche is narrowed by overhanging otosclerotic bone (*arrows*) although the thin footplate is marginally fixed. *U* utricular nerve, *F* facial nerve, *B* basal turn of the cochlea

plate (Fig. 1.8). The end result to be avoided with the floating footplate is depression of the footplate into the vestibule, where it cannot be retrieved (Fig. 1.9). If this occurs, then the depressed footplate should be left in the vestibule, and a shorter-than-required prosthesis be inserted in the oval window. The technique for safe removal of the floating footplate, avoiding subluxation, is insertion of a small hook into the cleft between the margin of the footplate and the oval window [6]. Rotation of the hook 90° can bring it under the edge of the footplate for extraction by tilting. If this cannot be accomplished, then a 1-mm drill hole is made just outside the stapedio-vestibular joint for insertion of a small hook to lift the footplate [5]. The technique for removal of floating footplate is demonstrated in an accompanying video.

Dehiscence of the fallopian canal most frequently occurs in its tympanic segment (Fig. 1.10). Since this portion of the bony canal is formed by periosteal bone enveloping the facial nerve superior to the oval window, the extent of dehiscence may vary from very small to complete absence of bone with prolapse of the facial nerve. Usually stapedectomy or stapedotomy can be performed, avoiding trauma or impingement of the prosthesis on the nerve. In the rare instance where a prolapsed facial nerve completely obscures a view of the footplate, the procedure should be aborted and amplification recommended.

A persistent stapedia artery may be dealt with in various ways depending on the size of the vessel [3]. If the vessel is represented by a small mucosal vessel crossing the footplate, then bipolar cautery or laser obliteration can be performed, allowing for a routine stapedotomy procedure. However, if large, the vessel can be circumvented by a stapedotomy and insertion of a piston prosthesis adjacent to the vessel.

The presence of round window involvement by otosclerosis should be routinely recorded to explain an unsatisfactory hearing result after stapedotomy [6]. As long as a dimple can be recognized in the round window niche, it is generally felt that the round window niche and membrane have not been immobilized (Fig. 1.11). Even without the presence of a dimple, there may be a microscopic opening into the niche, which is responsible for satisfactory hearing result. In no case should the bone around the round window niche be drilled out, as it is prone to regeneration, and the procedure may violate the round window membrane, causing sensorineural hearing loss (Fig. 1.12).

1.3 Postoperative Phase

The postoperative complications of stapedectomy/stapedotomy are usually related to the prosthesis [1]. The most common of these is incomplete tightening

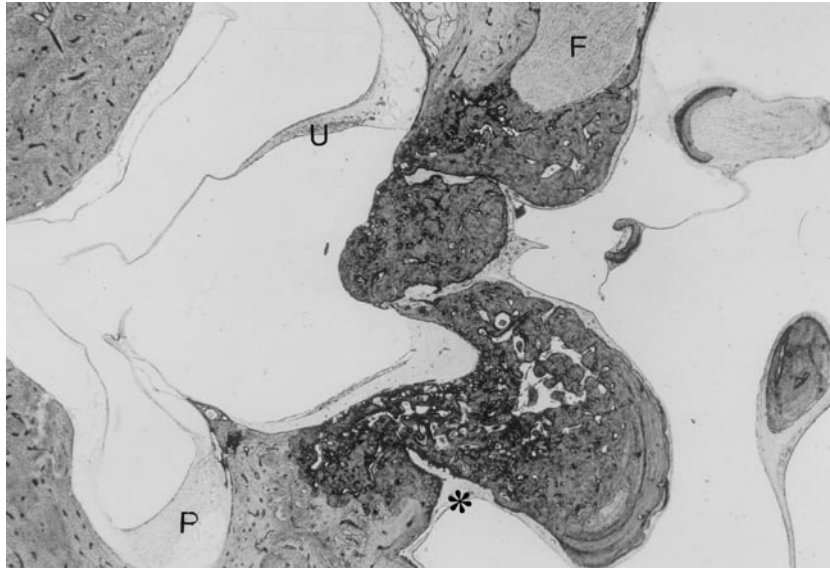


Fig. 1.8 This thick footplate is marginally fixed in a narrow oval window niche. This can be suspected at surgery by a cleavage plane around the footplate (*arrow*). The round window niche is obliterated by otosclerotic bone (*)

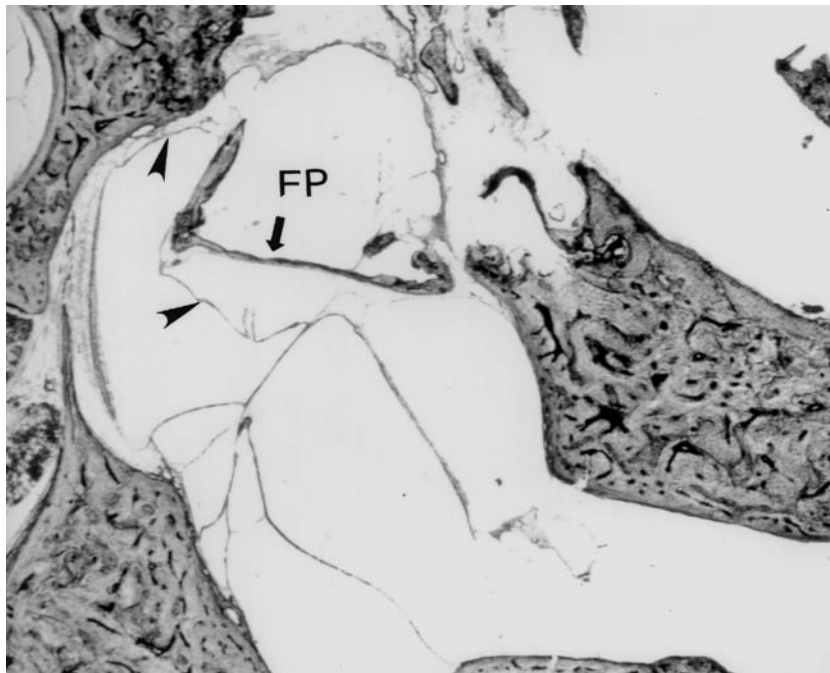
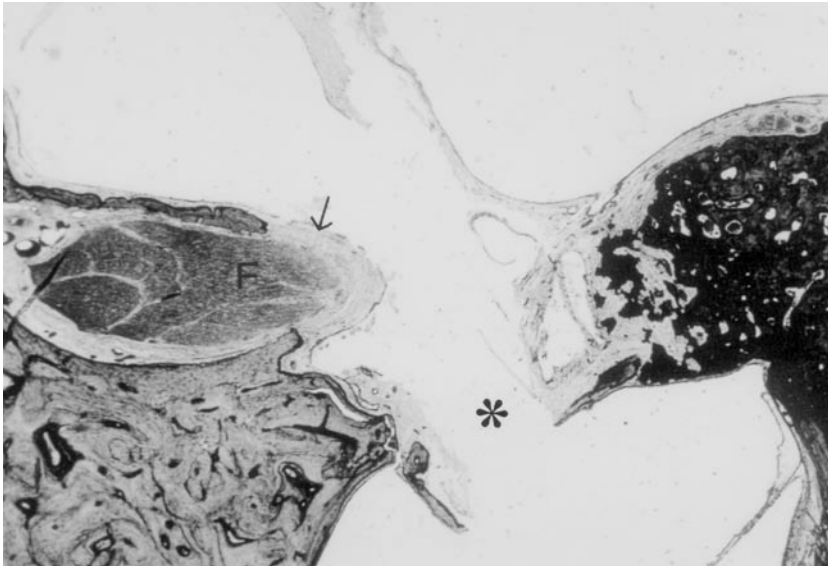


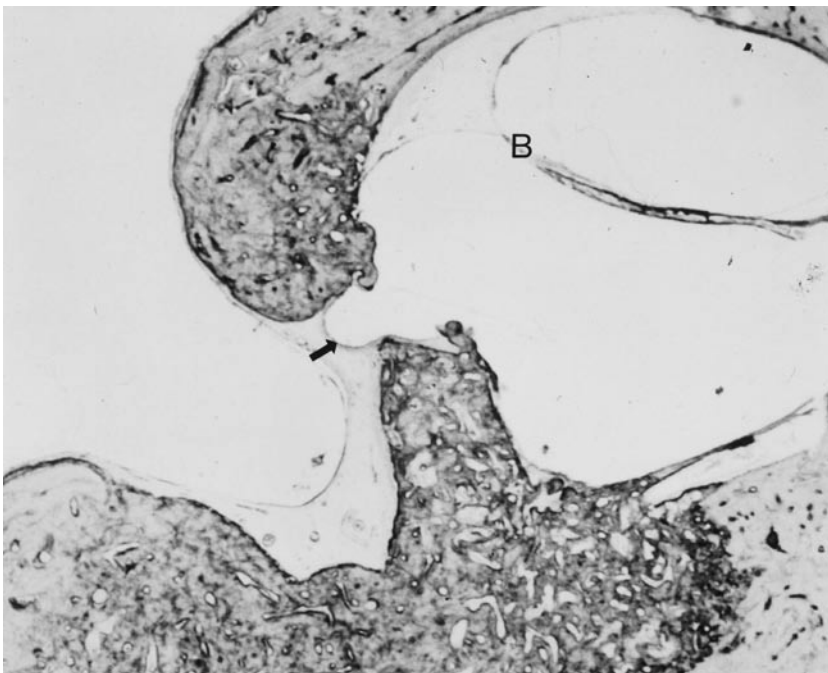
Fig. 1.9 Subluxation of the floating footplate (FP) can cause a traumatic labyrinthitis manifested by endolymphatic hydrops (*arrowheads*)

of the wire loop around the long process of the incus, which gradually leads to bone erosion and the development of fluctuating conductive hearing loss. Auto-inflation of the middle ear improves hearing, and as the middle ear air volume is released by the Eustachian tube, the contact between the incus and the prosthesis is lost leading to a conductive loss. Erosion of the bone of the incus long process is the result of loosely applied

wire prosthesis, and when it occurs, it should be revised by replacement of the prosthesis in a more superior position on the long process of the incus or to the manubrium of the malleus. Revision surgery after total stapedectomy is aided by lateral displacement of the membrane seal in the oval window (Fig. 1.13). Such displacement produced by the pressure in the perilymphatic compartment offers counterpressure to a sharp



■ **Fig. 1.10** Dehiscence (*arrow*) of the fallopian canal is most common in the oval window niche. This partial stapedectomy (*) was performed without injury to the facial nerve (*F*)

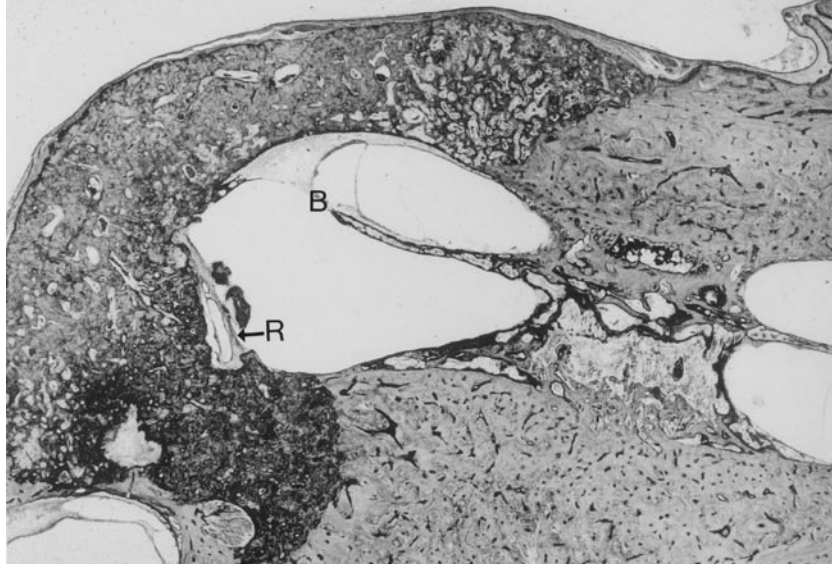


■ **Fig. 1.11** Extensive round window otosclerosis may not completely obliterate the round window membrane (*arrow*), allowing satisfactory activation of the basilar membrane (*B*)

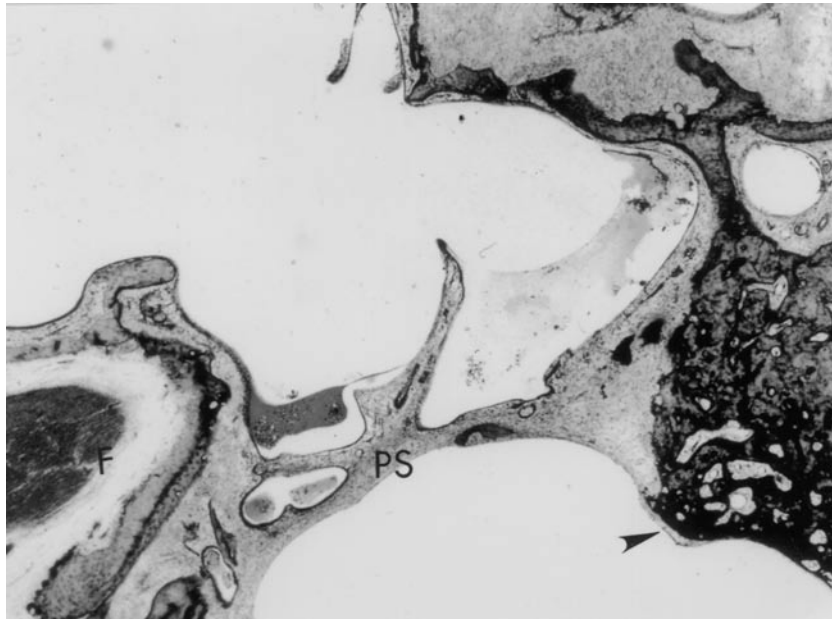
instrument in the creation of a fenestra small enough to accept piston prosthesis.

The prosthesis may be too short or too long. If it is too short, as shown in a celloidin-embedded temporal bone (Fig. 1.14a) with the histopathology of the bone and soft tissue deep to the oval window (Fig. 1.14b), then the prosthesis will be ankylosed, recreating a conductive hearing loss (Fig. 1.15). Therefore, meas-

urement of the depth of the space to be bridged by the prosthesis (the undersurface of the footplate to the under surface of the long process) must be carefully assessed with a measuring instrument. The desired arrangement is represented by a prosthesis, which extends slightly beyond the fenestra. If the prosthesis is too long, then it may contact the utricular nerve and macula in the vestibule (Fig. 1.16). This contact can be



■ **Fig. 1.12** Complete obliteration of the round window niche with immobilization of the round window membrane (*R*)



■ **Fig. 1.13** The pressure of perilymph creates lateral displacement of the post stapedectomy membrane (*PS*). *Arrowhead* indicates level of the oval window. This displacement facilitates revision with a small fenestra in the membrane

detected intraoperatively by the patient's response to depression of the incus under local anesthesia.

The most serious postoperative complication of stapedotomy/stapedectomy surgery is the formation of post-stapedectomy granuloma [2]. The granuloma may form in the oval window after the use of Gelfoam, adipose tissue, or other connective tissues. Although it had been reported more often with the use of Gelfoam than with connective tissue, it is generally

felt to be a reparative granuloma to surgical trauma in the oval window region. It probably accounts for most unexplained sensorineural hearing losses after stapedotomy. The presence of a granuloma affecting labyrinthine function is usually detected within the first 2 weeks postsurgery by the appearance of a sensorineural hearing loss, with a reduced word discrimination score and vertigo (Fig. 1.17). Sensorineural hearing loss with vertigo as a manifestation of mild

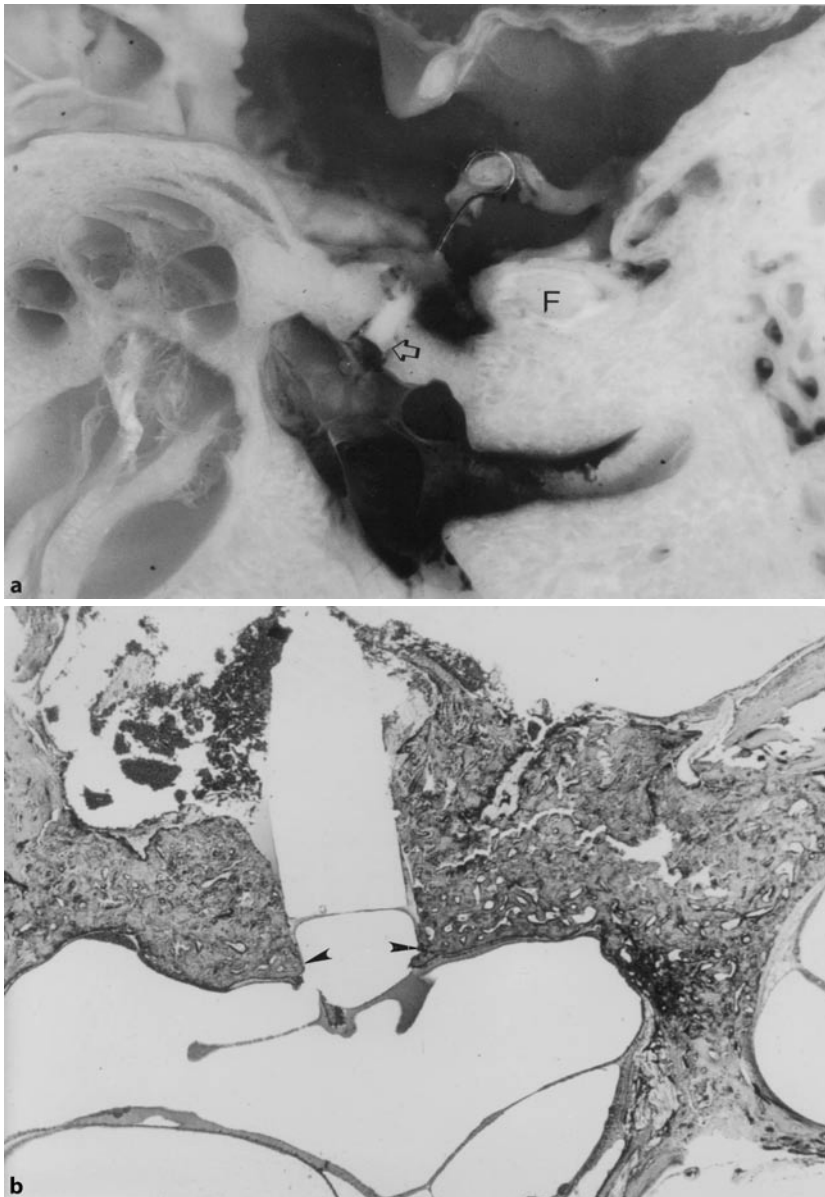
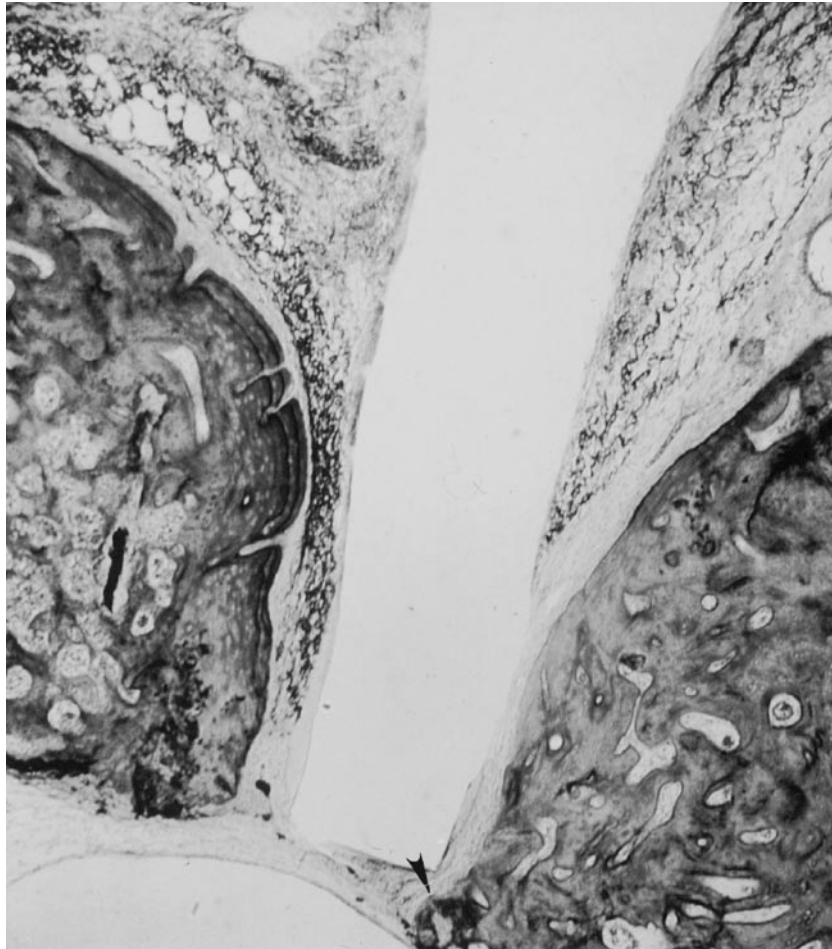


Fig. 1.14 **a** This photograph taken during sectioning of a celloidin embedded temporal bone specimen demonstrates a Teflon-wire piston, which falls short of extending into the vestibular cistern (*arrow*). **b** Histological preparation demonstrates early regeneration of otosclerotic bone deep to the Teflon piston (*arrowhead*)

surgical serous labyrinthitis improves with postoperative time. If these symptoms persist or worsen with time after surgery, then they indicate a progressive labyrinthitis. Careful otoscopy at 1 week will reveal eardrum changes (edema, erythema) indicative of middle ear inflammation. However, audiologic demonstration of a significant loss in word discrimination is key to confirming the progressive nature of the labyrinthitis. Early recognition is important as surgical exploration

and complete removal of the granuloma may salvage labyrinthine function (Fig. 1.18).

A perilymph fistula may occur along the prosthesis in the stapedotomy fenestra [8, 10]. The larger the space around the prosthesis in the fenestra, the greater the incidence for nonhealing of this space and leakage of perilymph, manifested by fluctuating sensorineural hearing loss and vertigo. This may occur at any time in the postoperative phase and is an indication for early



■ Fig. 1.15 Another temporal bone specimen shows piston prosthesis ankylosis by regeneration of otosclerotic bone (*arrowhead*)

re-exploration with tissue repair of the fistula. The use of tissue (adipose, perichondrium, vein) to seal the perilymphatic compartment will reduce the incidence of oval window fistulae.

Experience with these complications allows the otologic surgeon to develop the ability to recognize and avoid them. It is hoped that this description of otosclerosis surgery will aid in prevention of these complications.

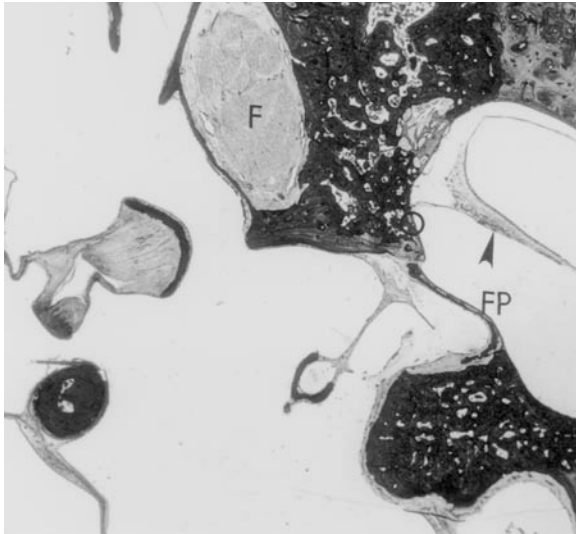
COMPLICATIONS TO AVOID

1. Avoid eardrum tears by elevation of the tympanic annulus.
2. Avoid incus dislocation by careful curettage of bony ear canal.

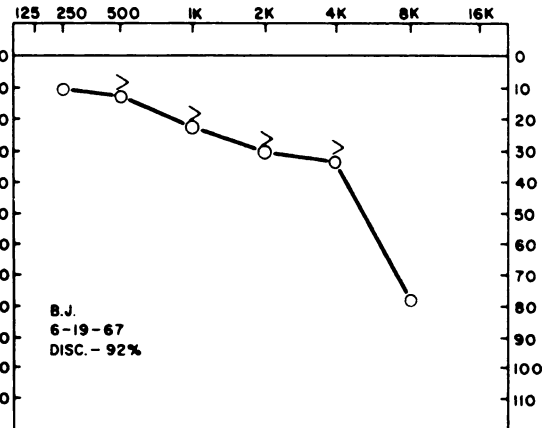
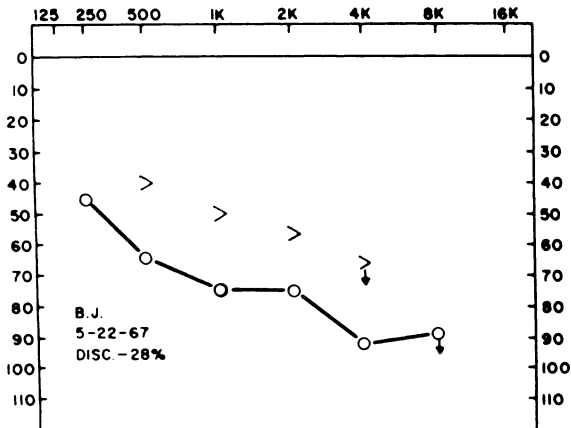
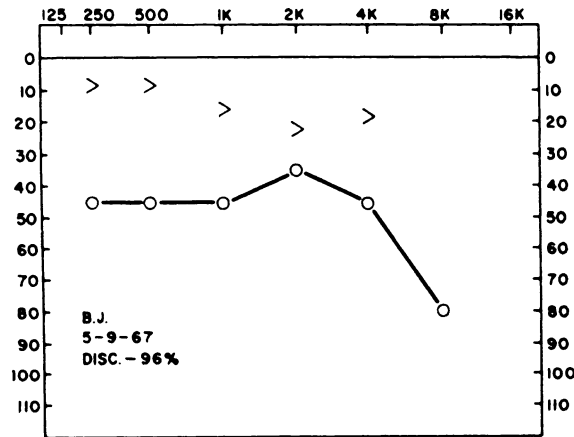
3. Avoid floating footplate when fracturing crural arch.
4. Precise measurement of footplate to incus distance to determine prosthesis length.
5. Seal large defects around piston with soft tissue to avoid perilymph fistula.
6. Prevent sensorineural hearing from granuloma by careful monitoring of hearing postoperatively.

● Pearl

- Small fenestra stapedotomy is preferable to total stapedectomy.



■ Fig. 1.16 This vertical section through the oval window region demonstrates the proximity of the utricular nerve and macula (arrowhead) to the stapes footplate (FP). O otosclerotic bone, F facial nerve



■ Fig. 1.17 This series of audiograms document the preoperative (9 May 1967), 13 days post-stapedectomy (22 May 1967), and 1-month post-revision surgery (19 June 1967) of patient B.J., who underwent surgery for removal of a post-stapedectomy (granuloma) on 22 May 1967

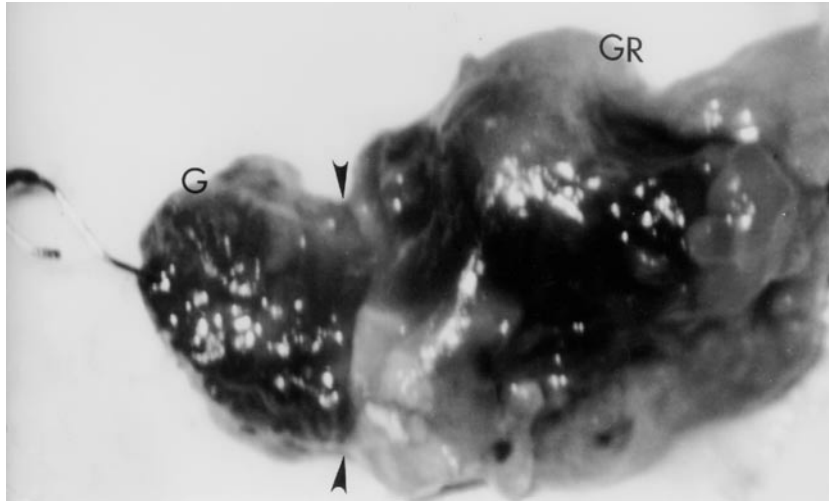


Fig. 1.18 Photograph of the specimen removed from patient B.J. *Arrowhead* marks the interface between gel foam (G) and granuloma (GR)

References

1. Feldman BA, Schuknecht HF (1970) Experiences with revision stapedectomy procedures. *Laryngoscope* 80:1281–1291
2. Gacek RR (1970) The diagnosis and treatment of post stapedectomy granuloma. *Ann Otol Rhinol Laryngol* 79:970–975
3. House HP, Patterson MD (1964) Persistent stapedia artery: a report of two cases. *Trans Am Acad Ophthalmol Otolaryngol* 68:644–646F
4. McGee TM (1965) The stainless steel piston: surgical indications and results. *Arch Otolaryngol* 81:34–40
5. Tabb HG (1976) Epitympanic fixation of incus and malleus. *Laryngoscope* 82:243–246
6. Schuknecht HF (1971) *Stapedectomy*. Brown, Boston
7. Schuknecht HF (1987) Current method of stapes surgery. *Adv Otorhinolaryngol* 37:101–103
8. Schuknecht HF, Bentkover SH (1980) Partial stapedectomy and piston prosthesis. In: Snow JB Jr (ed) *Controversy in otolaryngology*. Saunders, Philadelphia, pp 281–291
9. Schuknecht HF, Gulya AJ (1986) *Anatomy of the temporal bone with surgical implications*. Lea & Febiger, Philadelphia, p 196
10. Schuknecht HF, Reisser C (1988) The morphologic basis for perilymphatic gushers and oozers. *Adv Otorhinolaryngol* 39:1–12
11. Schuknecht HF, McGee TM, Colman BH (1960) Stapedectomy. *Ann Otol Rhinol Laryngol* 69:597–609
12. Shea JJ, Sanabria F, Smyth GDL (1962) Teflon piston operation for otosclerosis. *Arch Otolaryngol* 76:516–521

Core Messages

- Preoperative assessment of the patient as well as the hearing loss is important to determine the need for surgery.
- Control of the disease process is necessary before reconstruction of the sound transmission system.
- Medial onlay grafting of the tympanic membrane is preferable to lateral onlay techniques.
- Reconstruction of the middle ear is based on ossicular or acoustic coupling.
- Bone is preferred as a graft in ossicular coupling.

Numerous techniques have been described for repair of the sound conducting mechanism. However varied these techniques are, those that are successful adhere to certain basic principles. These principles are outlined in this chapter and the surgical technique illustrated with videos.

The principles of tympanoplasty/ossiculoplasty can be divided into five sections: (1) evaluation of the patient, (2) Eustachian tube function, (3) control of middle ear and mastoid disease, (4) repair of the sound-conducting mechanism, and (5) postoperative care.

2.1 Evaluation of the Patient

For patients who are over the age of 65–70 years, medical status is of prime importance. The presence of coexistent disease such as diabetes mellitus, cardiovascular disease, neurologic disease, etc., would affect the feasibility of elective tympanoplasty. A patient who represents an anesthesia risk is not a candidate for elective surgery. Medical conditions associated with small-vessel compromise may deter healing and the functional result. The coexistence of a significant sensorineural hearing loss component, with the conductive compo-

nent caused by the middle ear pathology, limits the auditory rehabilitation provided by successful middle ear reconstruction. This leaves a patient still dependent on amplification for communication purposes. A decision to perform elective surgery is an individual consideration between the patient and surgeon, and the patient's expectations should be based on an honest and realistic presentation of the proposed surgery and what it can provide.

2.2 Eustachian Tube Function

Since a practical reliable test of Eustachian tube function is not available [7, 12, 20], one must rely on other factors such as history and the ability of the patient to autoinflate the middle ear space to gain insight to this important factor. In patients with a repaired cleft palate, the likelihood of poor Eustachian tube function usually represents a contraindication to elective surgery. In patients with normal palatal anatomy—the ability to autoinflate the middle ear—may indicate a patent Eustachian tube, which can maintain an aerated middle ear space. The response to autoinflation by the patient may be detected by the use of an ear insert connected by an auditory tube to the examiner's ear, or may be visible movement of a residual tympanic membrane segment. Although the ability to autoinflate the middle ear does not imply normal Eustachian tube function, the failure to detect such a response should be a contraindication to elective surgery.

2.3 Control of Disease

The most common disease entity requiring control before reconstruction of the middle ear sound-conducting mechanism is chronic inflammatory disease of the middle ear and mastoid. This may be caused by a cholesteatoma or irreversible mucosal disease, represented by granulation tissue filling the middle ear and mastoid compartments. It must be emphasized that the primary goal of surgery is to eradicate disease

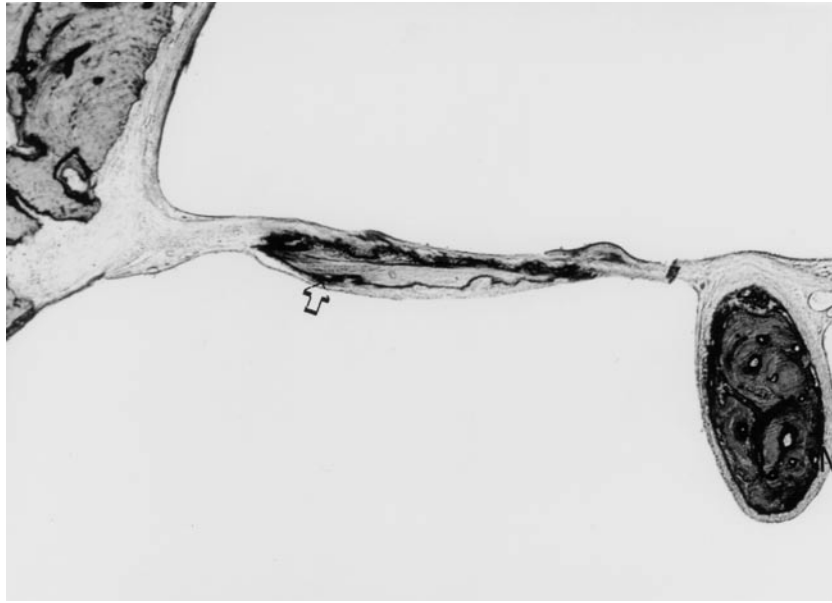


Fig. 2.1 Photomicrograph of tympanosclerotic plaque in the lamina propria of the tympanic membrane (*arrow*). *M* manubrium of malleus

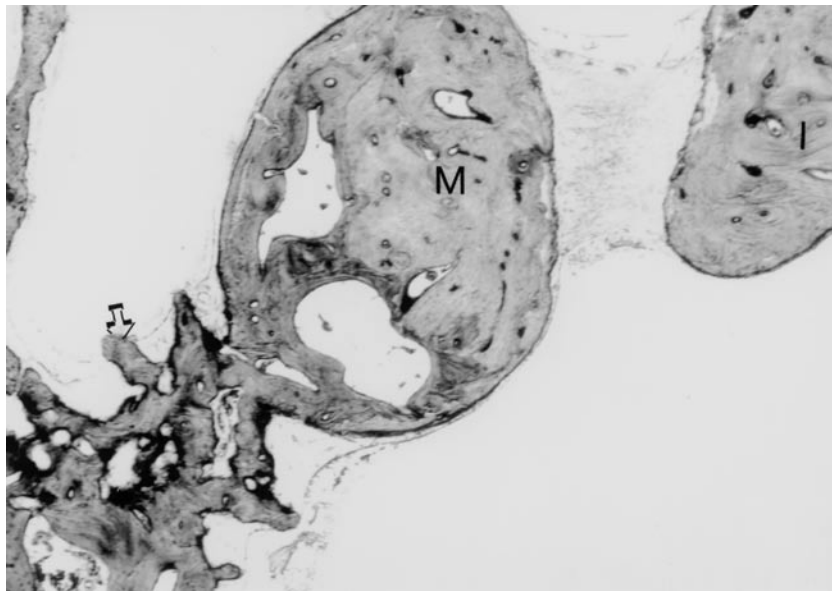
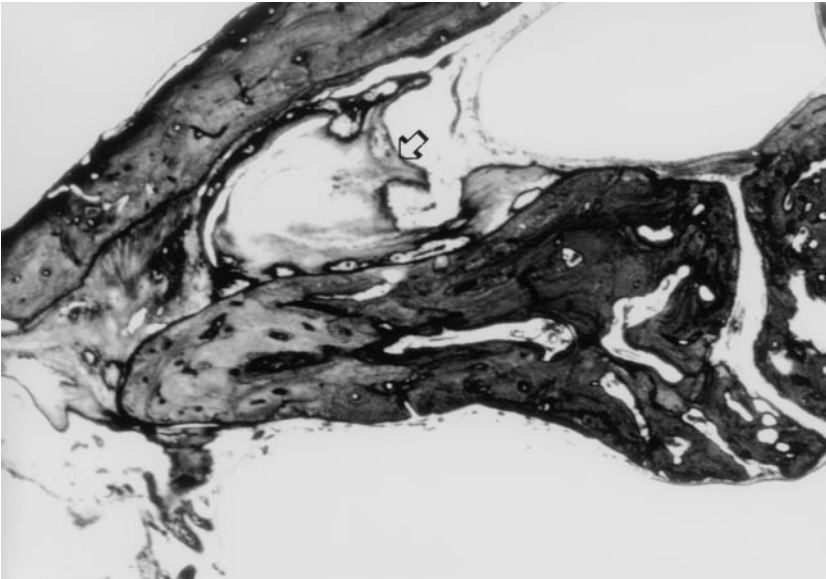


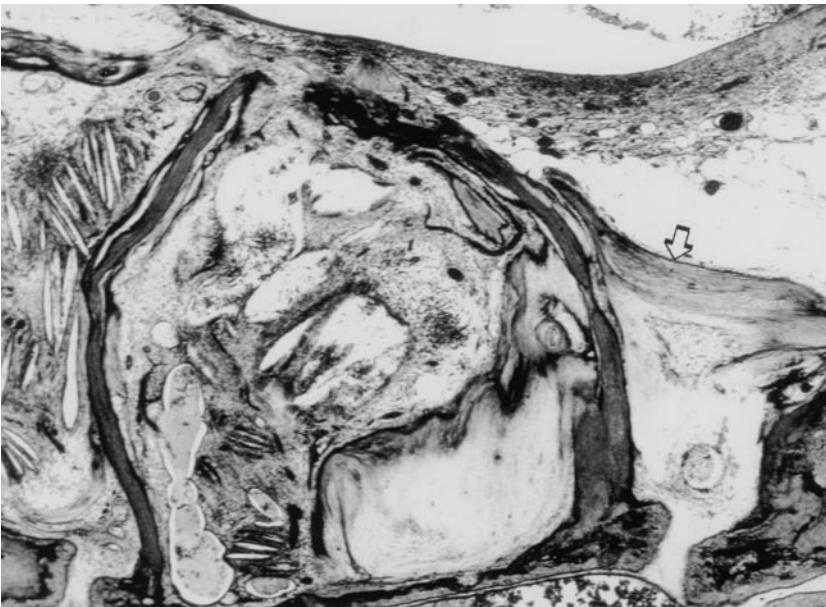
Fig. 2.2 Acquired anterior malleus head bony ankylosis (*arrow*). Compare to Fig. 1.5. *I* body of incus

and secondarily to correct the defect in the sound conducting mechanism that results after exenteration of disease [4, 18, 21]. On occasion, benign neoplasia of the middle ear (i.e., glomus tumor, glandular tumors of the middle ear) may represent pathology adequately controlled before reconstruction. Direct (penetrating injury) or indirect (temporal bone fracture) trauma may also be responsible for disruption of the ossicular chain [10].

Inactive inflammatory disease of the middle ear and tympanic membrane may also present pathology requiring excision prior to tympanoplasty. Extensive tympanosclerosis of the tympanic membrane (Fig. 2.1) represents an avascular change in the lamina propria of the pars tensa, and should be removed to provide a vascular bed in the tympanic membrane remnant for graft survival [1]. Tympanosclerotic ankylosis of the ossicles must also be suspected, and removed to



■ **Fig. 2.3** Tympanosclerotic replacement of posterior incudal ligament (*arrow*)



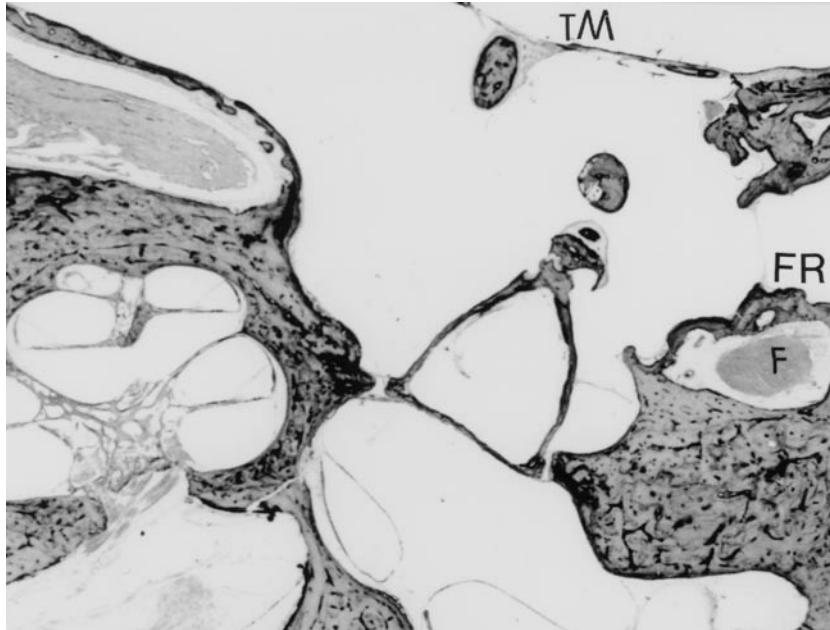■ **Fig. 2.4** Extensive tympanosclerosis of stapes arch (*arrow*)

ensure a satisfactory functional result (Figs. 2.2, 2.3, 2.4).

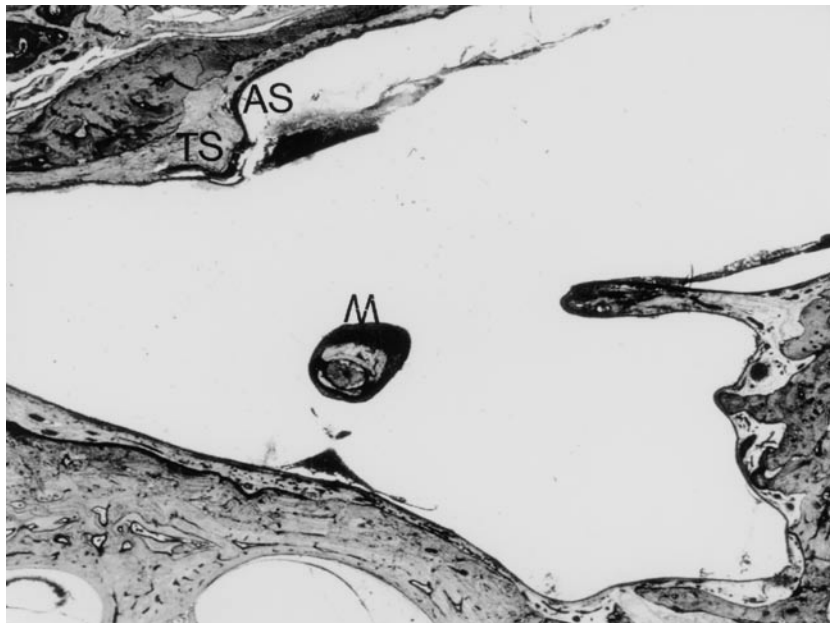Since control of disease is a primary consideration before reconstruction of the middle ear can be carried out, the surgical approach has a direct bearing on the form of reconstruction selected. In those surgical procedures such as tympanotomy and/or canaloplasty, atticotomy, or canal wall up mastoidectomy, the posterior bony canal wall remains in an an-

atomical position, which preserves the middle ear space (Fig. 2.5). Therefore, reconstituting the ossicular chain [2, 3, 8] is selected as the mechanism to effectively transmit the traveling wave along the basilar membrane by preserving the lever and areal ratio features of the ossicles [13].

On the other hand, when the posterior canal wall is taken down, as in mastoid surgery for extensive disease (cholesteatoma) or revision mastoidectomy, the



■ **Fig. 2.5** This horizontal temporal bone section illustrates the level of stapes head to the drum level (*TM*) and the vertical fallopian canal (*F*). When the posterior ear canal wall is preserved, ossiculoplasty is indicated for sound transmission. When the canal wall is removed to the level of the facial recess (*FR*), type III or IV tympanoplasty is recommended

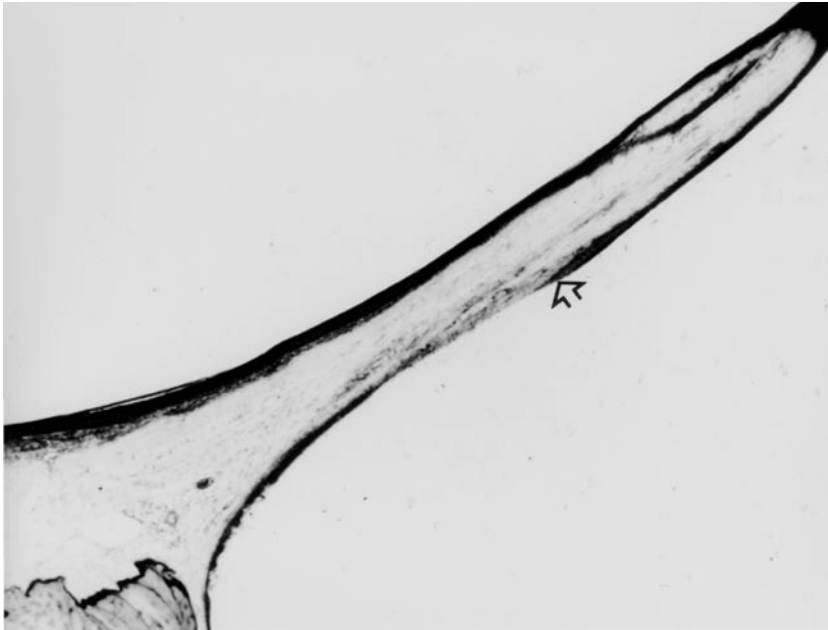


■ **Fig. 2.6** A horizontal temporal bone section demonstrates the need for medial onlay graft placement to prevent lateralization of the graft and anterior sulcus (*AS*) blunting. *M* manubrium of malleus, *TS* tympanic annulus

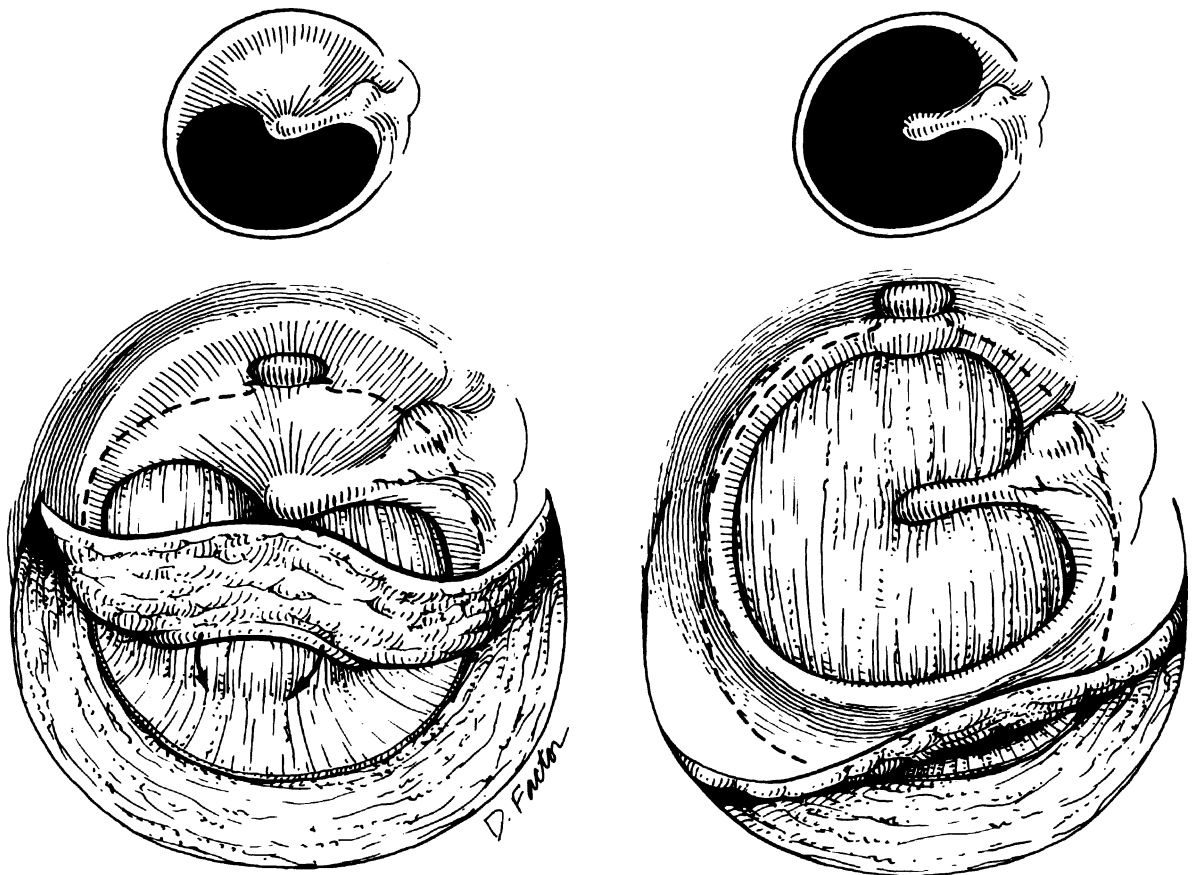
lowered drum remnant narrows the middle ear space to the level of the promontory and fallopian canal (Fig. 2.5). The effective force of the sound pressure wave directly contacts the stapes head or footplate, but is enhanced by a small air compartment shielding the round window membrane [11, 14, 19] (acoustic coupling).

2.4 Repair of the Sound-Conduction Mechanism

Repair of the sound transmission system consists of (1) repair of the tympanic membrane and (2) reconfiguring the ossicles to transmit effectively the sound pressure energy to the cochlea by ossicular or acoustic coupling.



■ Fig. 2.7 This drum remnant surrounding a central perforation demonstrates the migration of squamous epithelium around the margin of the perforation to the medial surface of the drum (*arrow*)



■ Fig. 2.8 The medial on lay technique of drum repair consists of graft stabilization by buttonhole pull through maneuvers anteriorly and meatal skin overlay techniques posteriorly

Repair of a tympanic membrane defect utilizes basic principles of tissue grafting. The technique favored is the medial onlay method for several reasons. The first, placing the graft on the medial surface of the tympanic membrane remnant, prevents lateralization (Fig. 2.6). Second, healing is more rapid since the squamous epithelial covering of the tympanic membrane is not sacrificed as it is with lateral onlay grafts. Third, in order to prepare the medial surface of the tympanic membrane for receiving the graft, it is necessary to remove epithelium from the medial surface of the drum, which may include occult squamous epithelium that

has migrated around the edge of the tympanic membrane defect (Fig. 2.7). Although lateral onlay grafting is attractive technically, it carries a risk of lateralization, blunting of the anterior sulcus angle, and may bury squamous epithelium on the medial surface of the drum remnant. The medial onlay graft is stabilized by pulling a tag of graft through a buttonhole incision in the tympanic membrane remnant anteriorly, and sandwiched under the fibrous annulus of the canal skin flap and the bony canal wall posteriorly (Fig. 2.8). This method of graft security avoids the use of absorbable synthetic material (Gelfoam) in the middle ear

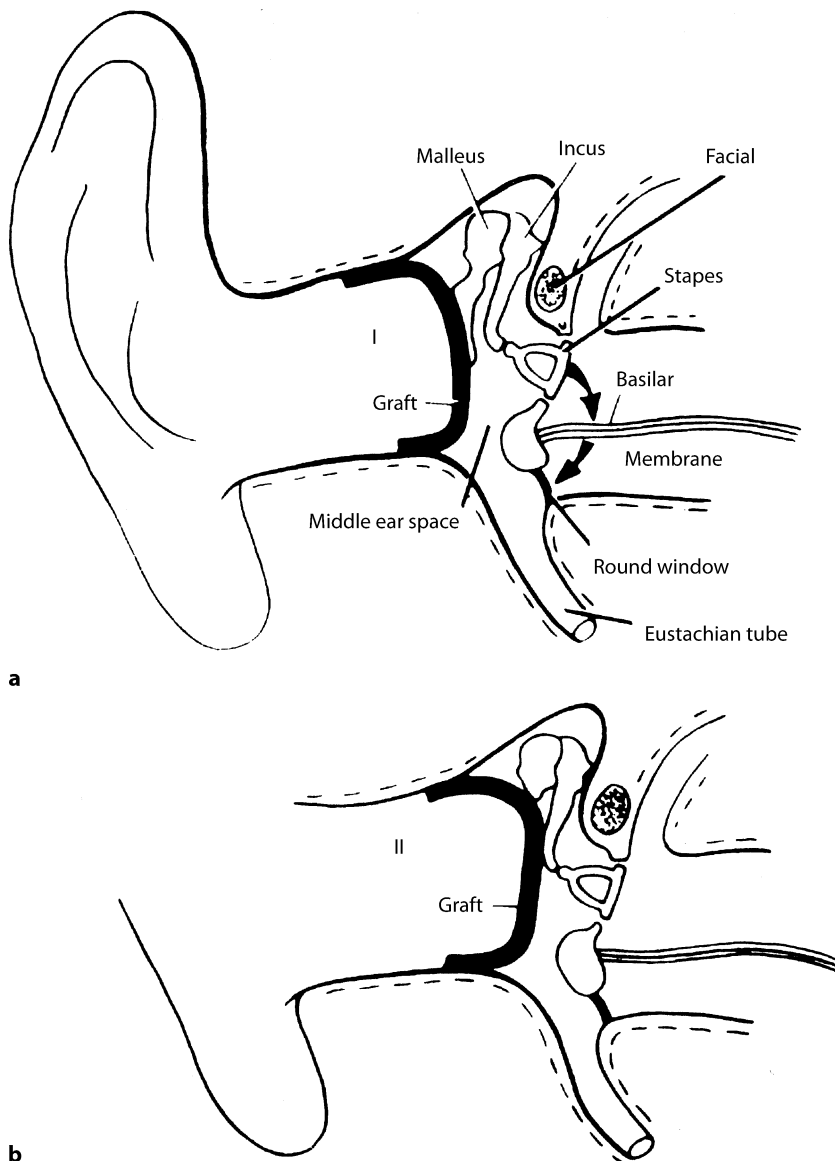


Fig. 2.9 Schematically type I and II tympanoplasty rely on an intact (a) or partially deficient (b) ossicular chain, which retains the areal and lever mechanisms of the middle ear

space, which may give rise to a granuloma, posing a threat to cochlear function through the round window membrane. Finally, firm packing to compress the graft onto its recipient bed prevents blood products from causing graft separation.

Repair of the sound-conduction mechanism, which transmits energy of the sound pressure wave to the cochlea where movement of the basilar membrane activates the neural response, must follow one of two principal modes of sound transmission [13]:

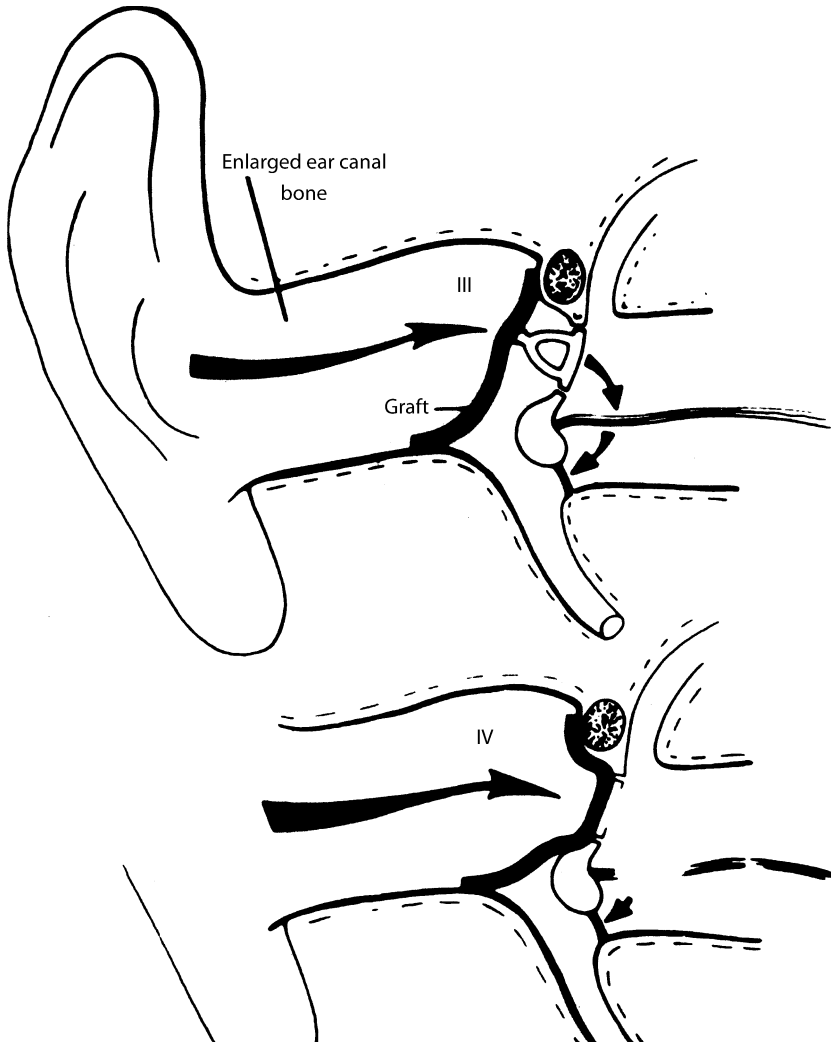
1. Ossicular coupling

- a. Ossicular coupling utilizes the lever and a real ratio features of drumhead to oval window to activate the basilar membrane (Fig. 2.9).

2. Acoustic coupling

- a. Acoustic coupling activates the basilar membrane by shielding the round window membrane and exposing the oval window footplate to the sound pressure wave (Fig. 2.10). In general, ossicular coupling will be employed when the posterior ear canal is intact, the middle ear space is not reduced, and portions of the ossicular chain are in place. Some of the interposition techniques used without atticotomy defect and with repair of the lateral attic wall are illustrated in Fig. 2.11a,b.

Although many preformed implants made of artificial



■ **Fig. 2.10** Type III tympanoplasty utilizes the areal ratio of drum to oval window (*upper diagram*), while type IV activates the basilar membrane by acoustic coupling (*lower diagram*)

material have been suggested to reconstitute an ossicular defect, our preference is for autogenous tissue because most synthetic implants are eventually extruded [9, 17]. Of the two major choices of autograft material (cartilage, bone), bone is preferable because it is plentiful (ossicles, cortical bone), rigid, and lends itself to precise shaping and sizing. These features are

important, as the defect to be bridged must be filled by an insert that is slightly larger so that it maintains its position without the need of support material. Angulation of the interposed custom-fitted insert should be avoided in order to provide maximal transmission of sound pressure energy from drumhead to the oval window.

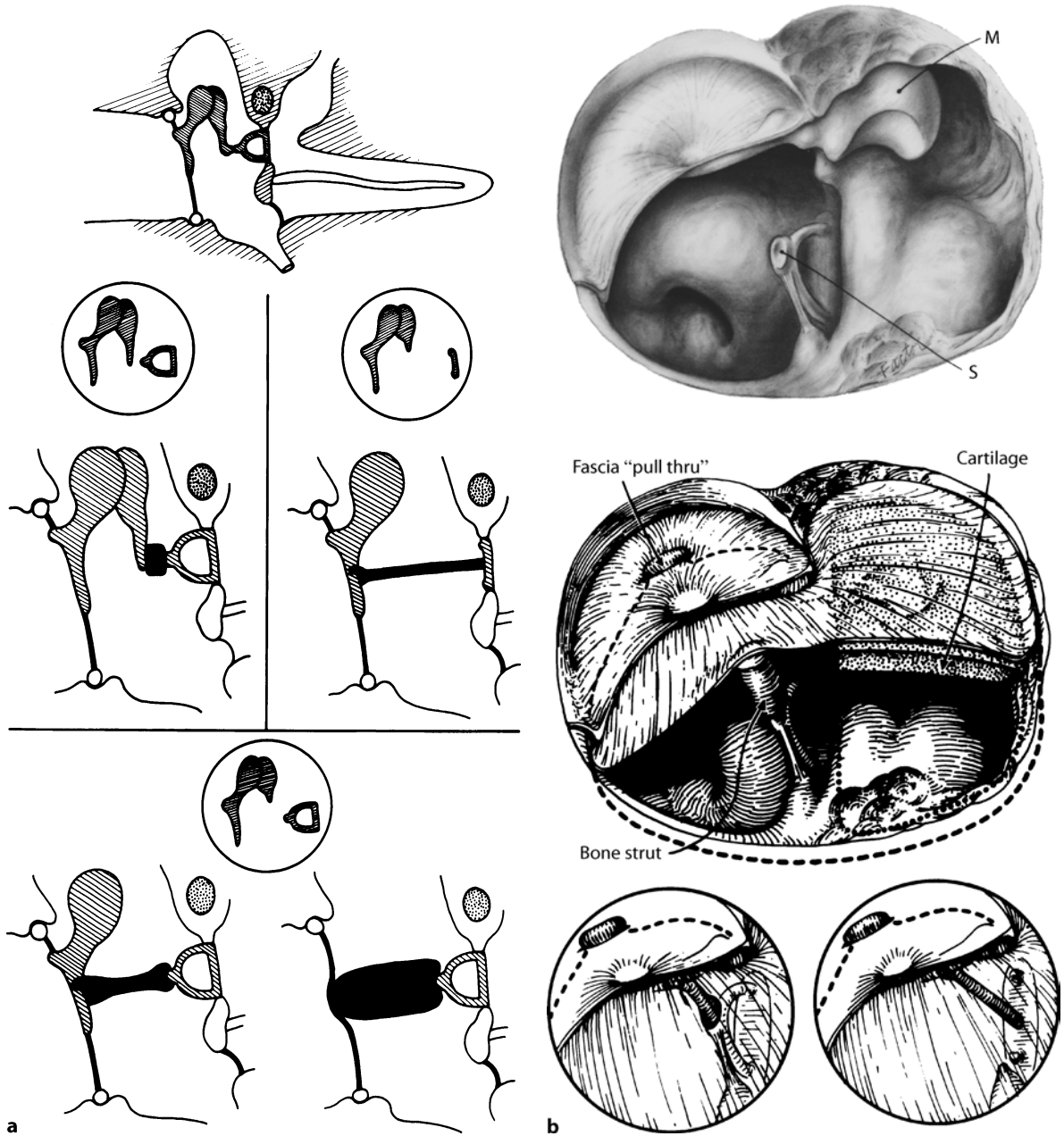
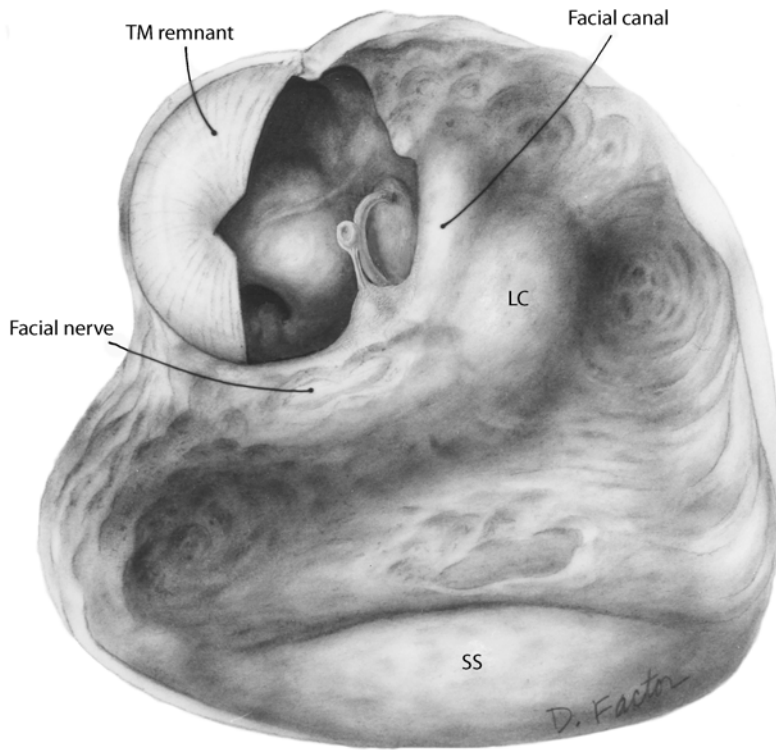
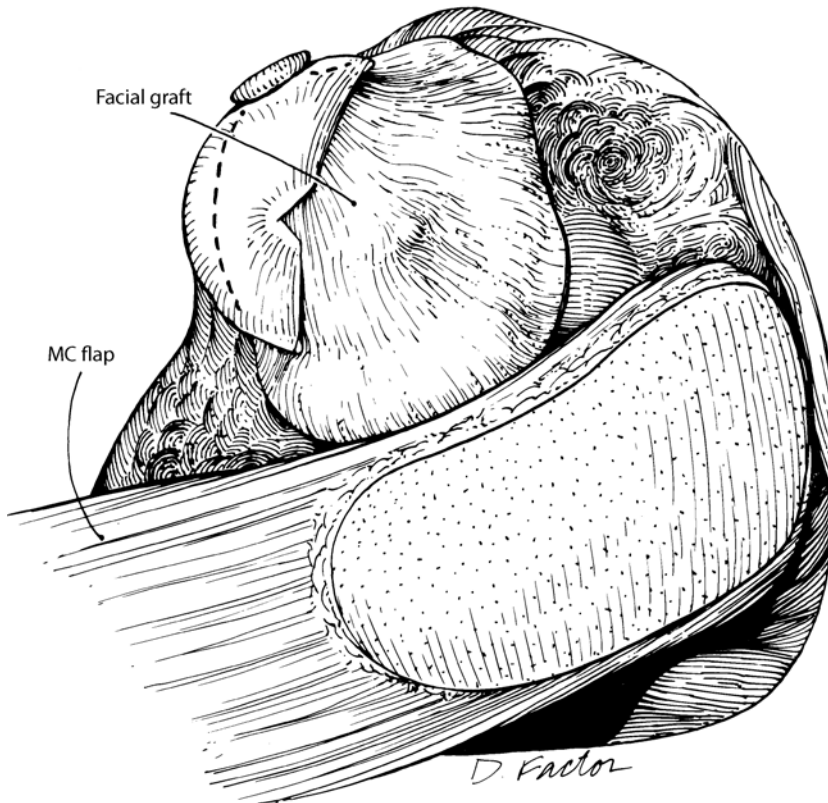


Fig. 2.11 a Interposition techniques used for ossicular coupling when no atticotomy is required. b Various techniques for ossicular coupling are utilized after atticotomy depending on the anatomical relationships of the middle ear structures



■ **Fig. 2.12** Canal wall down mastoidectomy requires a type III tympanoplasty with fascial graft contacting stapes head. Postauricular myocutaneous flap (*MC flap*) obliteration of a large mastoid cavity is recommended. *SS* sigmoid sinus plate, *LC* lateral canal prominence



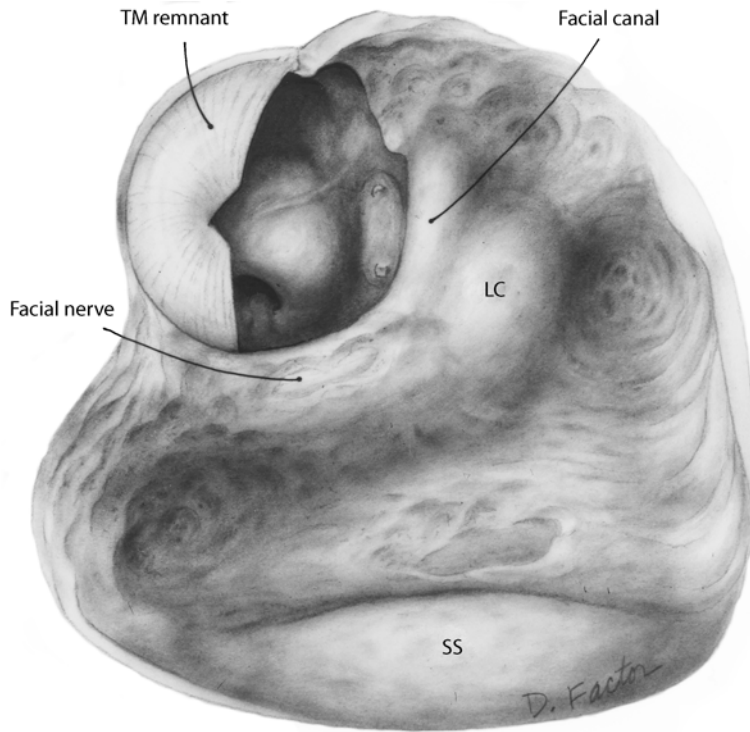
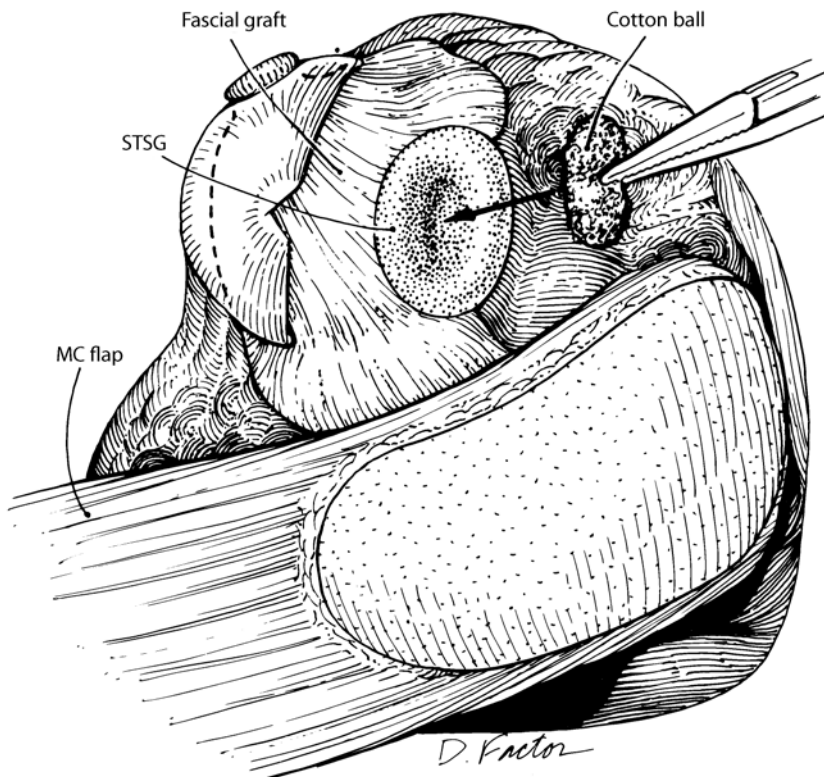


Fig. 2.13 The technique for type IV tympanoplasty includes a cavum minor to shield the round window membrane and exteriorization of the stapes footplate by application of a skin graft (STSG) to the oval window



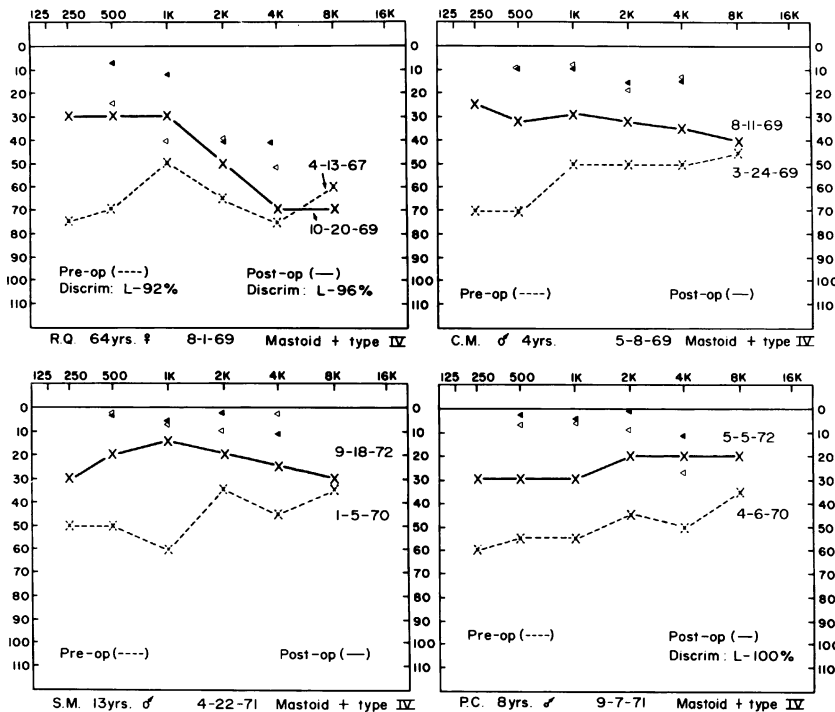
The expected postoperative hearing level with types I and II tympanoplasty is significantly better than with types III and IV reconstruction. This is largely due to loss of the lever mechanism and some of the areal ratio of drumhead to oval window associated with type III and IV tympanoplasty. The average conductive component produced with type III is 15 dB, while type IV gives a 20- to 25-dB conductive loss. These functional results assume a ventilated middle ear space and mobile stapes footplate. Less-than-satisfactory hearing levels in the presence of normal Eustachian tube function imply fibrous or bony ankylosis of ossicles including the stapedio-vestibular joint.

When the posterior canal wall has been lowered to the facial recess in open mastoidectomy for extensive cholesteatoma or revision surgery for recurrent disease, the middle ear space is narrowed, and only the stapes with or without its crural arch is available for rebuilding a sound-conduction mechanism. Lowering the drumhead to the stapes head (type III) is the logical choice when the crural arch is intact (Fig. 2.12). When the arch is absent, leaving a footplate in the oval window, acoustic coupling is the reliable method chosen for sound transmission to the cochlea. The key features of an effective type IV tympanoplasty are [13]:

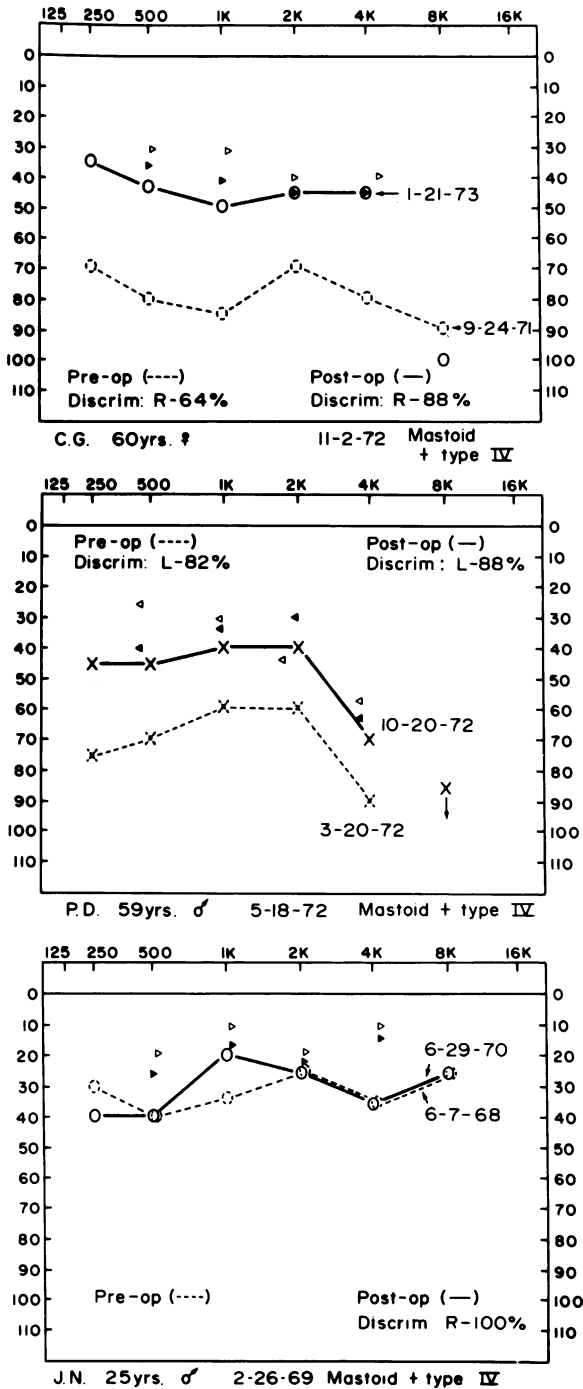
effective shielding of the round window membrane in an aerated cavum minor, and exteriorization of the footplate in the oval window by the application of a thin split thickness skin graft (taken with a razor blade) to a denuded footplate and held in place with firm packing (Fig. 2.13).

Properly performed in the presence of a functioning Eustachian tube, acoustic coupling with type IV tympanoplasty can provide satisfactory hearing results, as shown in the accompanying audiograms (Figs. 2.14, 2.15). Key to a successful type IV tympanoplasty is the removal of mucosa from the footplate and surrounding bone of the oval window, followed by a very thin split-thickness skin graft held in the oval window by a small cotton ball.

If the anatomical requirements for a successful type IV tympanoplasty are present, (i.e., an air-containing hypotympanum and a well-epithelialized oval window), and a greater than 25-dB conductive hearing loss is present postoperatively, then ankylosis of the stapes footplate by tympanosclerosis (Fig. 2.16) should be suspected. Removal of the fixed footplate at a second stage, replacing it with an adipose tissue graft (Fig. 2.17) will provide successful acoustic coupling (modified type V) [5, 15], (Fig. 2.18).



■ Fig. 2.14 The expected hearing result from type IV Tympanoplasty with an aerated cavum minor is approximately 15–20 dB



■ Fig. 2.15 Unusually, after type IV tympanoplasty almost no air-bone gap may be achieved by an increase in bone conduction thresholds

2.5 Postoperative Care

Postoperative care, although usually not emphasized in discussions of ear surgery, may make the difference between success and failure of tympanoplasty surgery. Proper visualization of the reconstructed drumhead is dependent on an adequate meatoplasty formed by removal of sufficient conchal cartilage. This is a key element to a satisfactory external auditory meatus postoperatively. A small external auditory meatus not only makes examination and cleaning of the ear difficult, but also may lead to canal cholesteatoma in some cases.

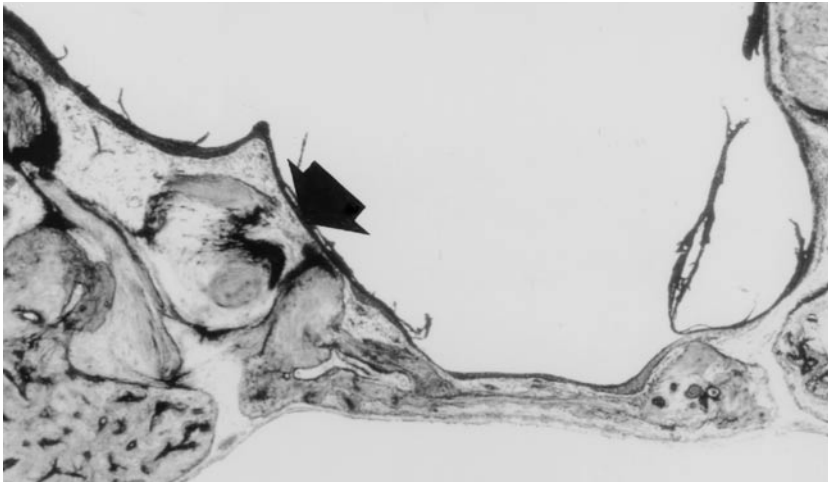Good, postoperative care consists of frequent and thorough cleaning of the ear canal along with the application of a topical antibiotic/steroid drops to the ear. Frequent visits weekly or biweekly, with examination and cleaning under binocular microscopy are crucial to a successful postoperative course. If the postoperative antibiotics appear not to be effective, then it may be necessary to instill the antibiotics on expandable ear wicks so that the entire surface of the canal and mastoid bowl are adequately bathed in the antibiotic solution. Ultimately, the goal of healing is to promote and allow the epidermalization of the ear canal, mastoid cavity, and tympanic eardrum to prevent stenosis of the ear canal. Excessive formation of granulation tissue is kept to a minimum by curettage and cautery. Delayed healing of the surgical cavity should be corrected by the application of split thickness skin grafts in order to prevent stenosis [16].

COMPLICATIONS TO AVOID

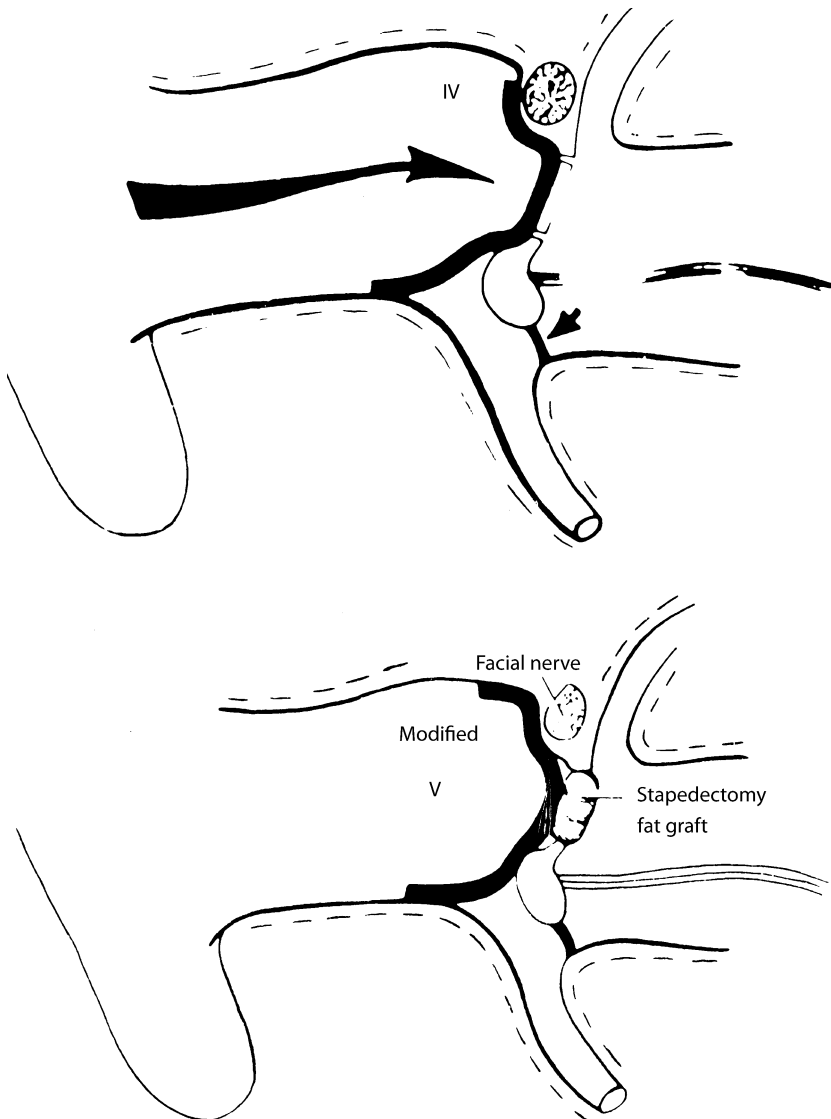
1. Firm compressive packing of graft to avoid separation.
2. Medial onlay graft, application to avoid lateralization and entrapment of epithelial remnants.
3. Use homograft bone or fascia for reconstruction of sound-conduction mechanism to avoid extrusion.

● Pearl

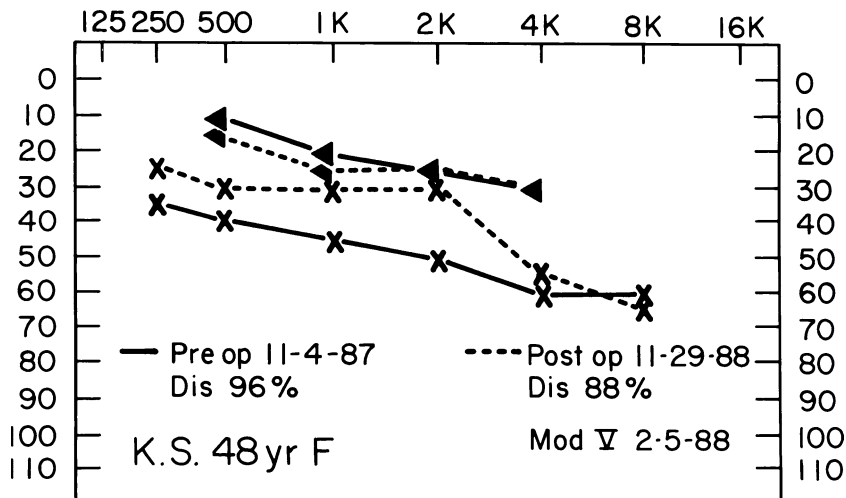
- Medial onlay grafting is responsible for better graft positioning and more rapid healing.



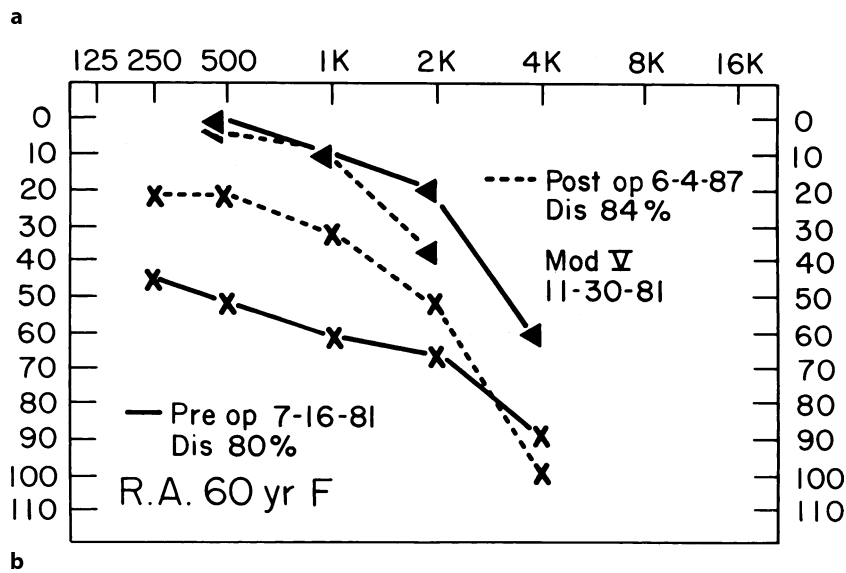
■ **Fig. 2.16** Tympanosclerotic fixation (*arrow*) of the stapes footplate may account for unsuccessful hearing results after type IV tympanoplasty



■ **Fig. 2.17** Modified type V tympanoplasty is accomplished by stapedectomy in acoustic coupling



■ Fig. 2.18a,b Examples of sound transmission results after modified type V tympanoplasty



References

- Austin DF (1988) Reconstructive techniques for tympanosclerosis. *Ann Otol Rhinol Laryngol* 97:670-674
- Chiossone E (1987) Homograft ossiculoplasty: long-term results. *Am J Otol* 8:545-550
- Crabtree JA (1982) Tympanoplasty and ossicular reconstruction: the last four years. *Am J Otol* 4:172-176
- Edelstein DR, Parisier SC (1989) Surgical techniques and recidivism in cholesteatoma. *Otolaryngol Clin North Am* 22:1029-1040
- Gacek R. Symposium on tympanoplasty. 1. Results of modified type V tympanoplasty. *Laryngoscope* 83:437-447
- Glasscock ME, Jackson CG, Nissen AJ et al (1982) Postauricular undersurface tympanic membrane grafting: a follow-up report. *Laryngoscope* 92:718-727
- Holmquist J, Lindeman P (1987) Eustachian tube function and healing after myringoplasty. *Otolaryngol Head Neck Surg* 96:80-82
- Hughes GB (1987) Ossicular reconstruction: a comparison of reported results. *Am J Otol* 8:371-374
- Jahnke K (1987) Extrusion of middle ear implants. *Clin Otolaryngol* 12:227-232
- Kristen S, Juul A, Gammelgaard NP, Rasmussen OR (1989) Traumatic tympanic membrane perforations: complications and management. *Ear Nose Throat J* 68:503-514
- Lee K, Schuknecht HF (1971) Results of tympanoplasty and mastoidectomy at the Massachusetts Eye and Ear Infirmary. *Laryngoscope* 81:529-543
- Magnuson B, Falk B (1984) Diagnosis and management of Eustachian tube malfunction. *Otolaryngol Clin North Am* 17:659-671
- Merchant SN (2005) Ossiculoplasty and tympanoplasty in chronic otitis media. In: Nadol JB, McKenna MJ (eds) *Surgery of the ear and temporal bone*. Lippincott, Williams & Wilkins, Philadelphia, pp 305-324

14. McEivieen JT, Goode RL, Miller C, Falk SA (1982) Effect of mastoid cavity modification on middle ear sound transmission. *Ann Otol Rhinol Laryngol* 91:526–532
15. Montandon P, Chatelain C (1991) Restoration of hearing with type V tympanoplasty. *ORL* 53:342–345
16. Nadol JB, Schuknecht HF (2005) Skin grafting in otologic surgery. In: Nadol JB, McKenna MJ (eds) *Surgery of the ear and temporal bone*. Lippincott, Williams & Wilkins, Philadelphia, pp 115–120
17. Palva T, Mäkinen J (1983) Histopathological observations on polyethylene-type materials in chronic ear surgery. *Acta Otolaryngol (Stockh)* 95:139–146
18. Ragheb SM, Gantz BJ, McCabe BF (1987) Hearing results after cholesteatoma surgery: the Iowa experience. *Laryngoscope* 97:1254–1263
19. Schuknecht HF (1979) The surgical management of hearing impairment. In: Bradford LJ, Hardy WG (eds) *Hearing and hearing impairment*. Grune & Stratton, New York, pp 67–74
20. Shanks JE (1984) Tympanometry. *Ear Hear* 5:268–280
21. Tos M, Lau T (1989) Late results of surgery in different cholesteatoma types. *ORL* 51:33–49

Core Messages

- The endaural approach is recommended for the control of inactive or active chronic middle ear and mastoid disease. This approach offers the flexibility of limited bone removal to match the extent of disease.
- The endaural approach enhances cosmesis and reduces postoperative care.
- A postauricular approach is recommended for intact canal wall mastoidectomy, revision mastoidectomy, and total middle ear/mastoid obliteration.
- Meatoplasty with conchal cartilage removal is an important step in chronic ear surgery.
- Postoperative care including the use of antibiotic steroid solutions and frequent cleaning are important to a successful operation.
- Thin split-thickness skin grafts are effective in the control of postoperative healing.

Chronic inflammatory disease of the middle ear and the mastoid compartments (COM) can be classified as *active* or *inactive*. Inactive COM describes those ears in which past infection has resulted in tissue damage in the middle ear and/or mastoid compartments of the temporal bone, but without otorrhea. These changes are (1) tympanosclerosis, (2) eardrum defects consisting of perforations or retraction pockets, and (3) ossicular necrosis or ankylosis. Since retraction pockets usually reflect inadequate Eustachian tube (ET) function, surgery to correct these drum deformations is unlikely to be effective in restoring hearing. However, demonstration of ET patency (absence of effusion, middle ear inflation on Valsalva) may be sufficient to permit successful ossiculoplasty. Perforations of the drum and/or tympanosclerosis are the usual surgical indications for restoration of a conductive hearing loss or prevention of recurrent acute otitis media. Repair of the tympanic membrane perforation was discussed in a previous chapter. Tympanosclerosis refers to hya-

linized collagen, which replaces tissue damage from infection and is most commonly located in the lamina propria of the tympanic membrane [10]. Deposition of tympanosclerosis may also occur in the middle ear mucosa, causing fixation of the auditory ossicles. The clinical indication for removal of tympanosclerosis with repair occurs when the tympanosclerosis is extensive enough to cause a significant conductive hearing loss. Resection of tympanosclerotic plaques in the tympanic membrane and from around ossicles constitutes a valid approach to this problem. Tympanosclerotic fixation of the stapes footplate usually represents an indication for staging. A transcanal or endaural approach with or without atticotomy provides sufficient exposure to accomplish this result. An accompanying video demonstrates the removal of extensive tympanosclerosis of the tympanic membrane, and ossicles responsible for a bilateral conductive hearing loss in a middle-aged patient. Two types of ossicular chain reconstruction were employed in the two ears to achieve hearing improvement. These were based primarily on the extent of involvement of the ossicular chain.

The surgical management of active chronic otitis media (mastoiditis) requires a more aggressive approach. These may be divided into patients that have cholesteatoma responsible for the chronic inflammatory disease and those in whom mucosal disease with granulation tissue is the pathological correlate [6]. Except for the unusual case where age or coexistent morbid medical conditions may contraindicate a surgical procedure under general anesthesia, the cholesteatoma ear is virtually always an indication for surgical removal [6, 7]. Control of mucosal disease without cholesteatoma should be given a serious trial of local and systemic medical therapy to control the chronic infection. Failing medical control or reversibility of the inflammatory tissue response, surgical eradication of the chronically diseased tissue is necessary. In addition to deleterious effects on labyrinthine function, uncontrolled chronic infection in either the external or middle ear compartments is a risk factor for malignant change in the epithelial lining of these compartments.

Since chronic middle ear disease usually originates in the middle ear and epitympanic compartments, with subsequent extension to the sub compartments of the middle ear and/or the mastoid antrum, it is logical to initiate surgical removal of the disease in the middle ear, extending bone removal posteriorly to permit exenteration of disease extension. The recommended approach is an endaural one, which provides the flexibility of performing limited bone removal (i.e., atticotomy) as well as canaloplasty for disease limited to the epitympanum and the middle ear space, frequently avoiding an unnecessary mastoidectomy [5]. With extension of disease into the mastoid antrum or central mastoid tract, cholesteatoma can still be removed with confidence, minimizing the bony defect in the posterior ear canal wall. This defect can be reconstructed using cartilage taken from the conchal region during the meatoplasty portion of the procedure [8]. Should a canal wall down mastoidectomy be required for adequate control of the disease, this can still be accomplished through the endaural approach even with a pneumatized mastoid. If a small sclerotic mastoid defect is created, then often no soft tissue obliteration is necessary. If a large cavity is created, then partial obliteration of the cavity with bone pate or free muscle/fascial graft is effective in reducing cavity size. The endaural approach also provides the view that one will use in the postoperative period for examining the patient's ear and monitoring the healing process. By avoiding a postauricular incision, postoperative care is simplified and cosmesis is enhanced. Finally, the postoperative care of the ear with a minimal suprameatal incision, requiring no sutures minimizes wound care for the patient.

The postauricular approach is utilized for: (1) canal wall up mastoidectomy when dealing with benign neoplastic disease (i.e., advanced glomus tympanicum tumors), noncholesteatoma chronic infection (mucosal disease), facial nerve exploration, or exploration for cerebrospinal fluid otorrhea; (2) revision canal wall down mastoidectomy following failed surgery for cholesteatoma removal; and (3) obliteration procedures (partial or total) on the mastoid compartment [1, 4].

The postauricular approach is utilized for canal wall down mastoidectomy in which revision of a previous mastoidectomy is required and obliteration of the mastoid compartment with an inferiorly based myocutaneous muscle flap will promote controlled healing. A modification of the inferiorly based fibro-

muscular flap used to reduce the size of a large mastoid cavity can be advantageous, especially in revision of a canal wall down mastoidectomy. Incorporation of the non-hair bearing skin between the postauricular crease and the hairline as part of the inferiorly based muscle flap can effectually replace the sacrificed posterior canal wall skin (Koerner flap) and enhance the viability of the soft tissue obliteration of a large cavity (see Chap. 2, Figs. 2.12, 2.13). The postauricular approach is also used in those cases where total obliteration of the middle ear and mastoid is planned. Total obliteration is indicated for a chronically infected ear when the ear has no useful auditory function or the patient is unable to adequately care for a mastoid cavity [2, 3, 9]. Requirements for total obliteration include (1) absolute control of disease, (2) complete obliteration with soft tissue of the middle ear and mastoid compartments, (3) removal of all epithelial remnants of the ear canal and middle ear, and (4) suture closure of the external auditory meatus.

In all procedures performed for the control of active chronic middle ear mastoid disease, it is imperative that all cell tracts that are involved in the process are exenterated. Special consideration is given to: (1) the sinodural angle, (2) the anterior epitympanic cell, (3) the facial recess and the sinus tympani, (4) the infralabyrinthine cell tracts, and (5) retrofacial cell tracts. As indicated earlier, the primary goal of chronic ear surgery is to control the disease process by adequate surgical exenteration of compartments and cells containing diseased tissue.

COMPLICATIONS TO AVOID

1. Adequate removal of conchal cartilage is necessary to prevent meatal stenosis.
2. Thorough removal of mastoid cells to prevent recurrence of cholesteatoma.
3. Removal of epithelial lining of the external ear canal as well as the middle ear mastoid system is necessary in total obliteration procedures to prevent recurrent cholesteatoma.
4. Regular careful postoperative visits are important to prevent canal stenosis.

Pearl

- The endaural approach allows bone remove in parallel with the chronic disease.

References

1. Austin DF (1989) Single-stage surgery for cholesteatoma: an actuarial analysis. *Am J Otol* 10:419–425
2. Bartels LJ, Sheehy JL (1981) Total obliteration of the mastoid, middle ear, and external auditory canal: a review of 27 cases. *Laryngoscope* 91:1100–1108
3. Gacek RR (1976) Mastoid and middle ear cavity obliteration for control of otitis media. *Ann Otol Rhinol Laryngol* 85:305–309
4. Glasscock ME, Miller GW (1976) Intact canal wall tympanoplasty in the management of cholesteatoma. *Laryngoscope* 86:1639–1657
5. McCabe BF (1982) Atticotomy results. In: Sade J (ed) *Cholesteatoma and mastoid surgery*. Kugler and Ghedini, Amsterdam, pp 553–535
6. Nadol JB Jr (1987) The chronic draining ear. In: Gates GA (ed) *Current therapy in otolaryngology—head and neck surgery*, 3. Decker, Philadelphia, pp 18–22
7. Nadol JB Jr, Arnold WJ (1987) Ear. In: Arnold WJ, Laissue JA, Friedmann I, Naumann HH et al (eds) *Disease of the head and neck. An atlas of histopathology*. Thieme Medical, pp 22–54
8. Nadol JB, Schuknecht HF (1993). *Surgery of the ear and temporal bone*. Raven, New York., pp 115
9. Rambo JHT (1958) Primary closure of the radical mastoidectomy wound: a technique to eliminate postoperative care. *Laryngoscope* 68:1216–1227
10. Schuknecht HF (1974) *Pathology of the ear*. Harvard University Press, Cambridge, Mass.

Core Messages

- The most common extracranial complications of chronic otitis media (COM) are labyrinthitis and facial nerve paralysis.
- Labyrinthitis associated with COM occurs through fistulization of the otic capsule or invasion through the oval and round windows.
- Removal of cholesteatoma membrane from the endosteal membrane is recommended.
- Repair of oval or round window defects with soft tissue is an effective technique to preserve labyrinth function.
- Facial nerve paralysis in COM requires early surgery to remove chronic disease and preserve facial function.
- Intracranial complications from COM include meningitis, brain abscess, epidural/subdural abscess, and sigmoid sinus thrombophlebitis.
- Meningitis and brain abscess from COM may occur through a preformed pathway or by retrograde thrombophlebitis.

The most serious complications of untreated COM and mastoiditis are labyrinthitis, facial paralysis, and various intracranial complications. The main intracranial complications are meningitis, brain abscess, subdural or epidural abscess, and lateral/sigmoid sinus thrombophlebitis.

4.1 Extracranial Complication

4.1.1 Labyrinthitis

Labyrinthitis or invasion of the perilymphatic space by chronic middle ear and mastoid disease occur over three pathways. These are (1) fistulization of the bony labyrinth, (2) round window, and (3) oval window. The most common of the pathways is bony erosion of the labyrinthine capsule, usually of the semicircular canals but less often of the bony wall of the cochlea. This bone erosion occurs as a result of the effects of pressure from an enlarging cholesteatoma and/or the chemical breakdown of collagen by collagenase enzymes in the cholesteatoma membrane [1] (Fig. 4.1).

Diagram of Erosion and Fistula of Bony Semicircular Canal

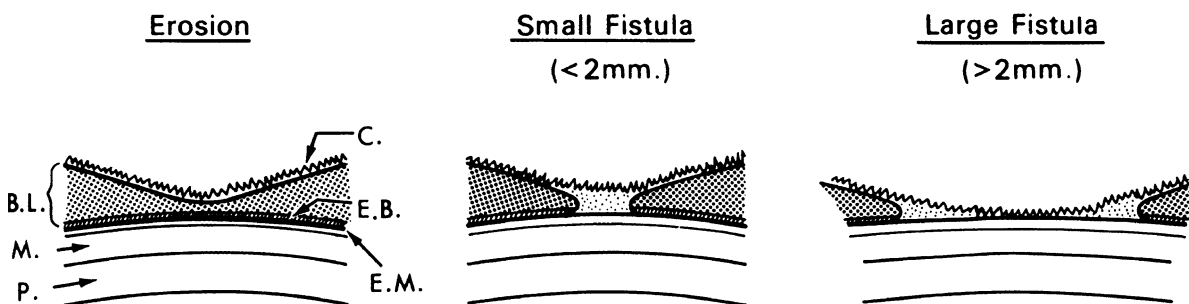
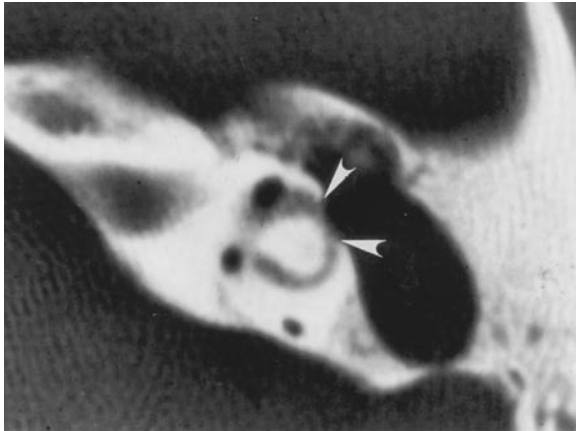
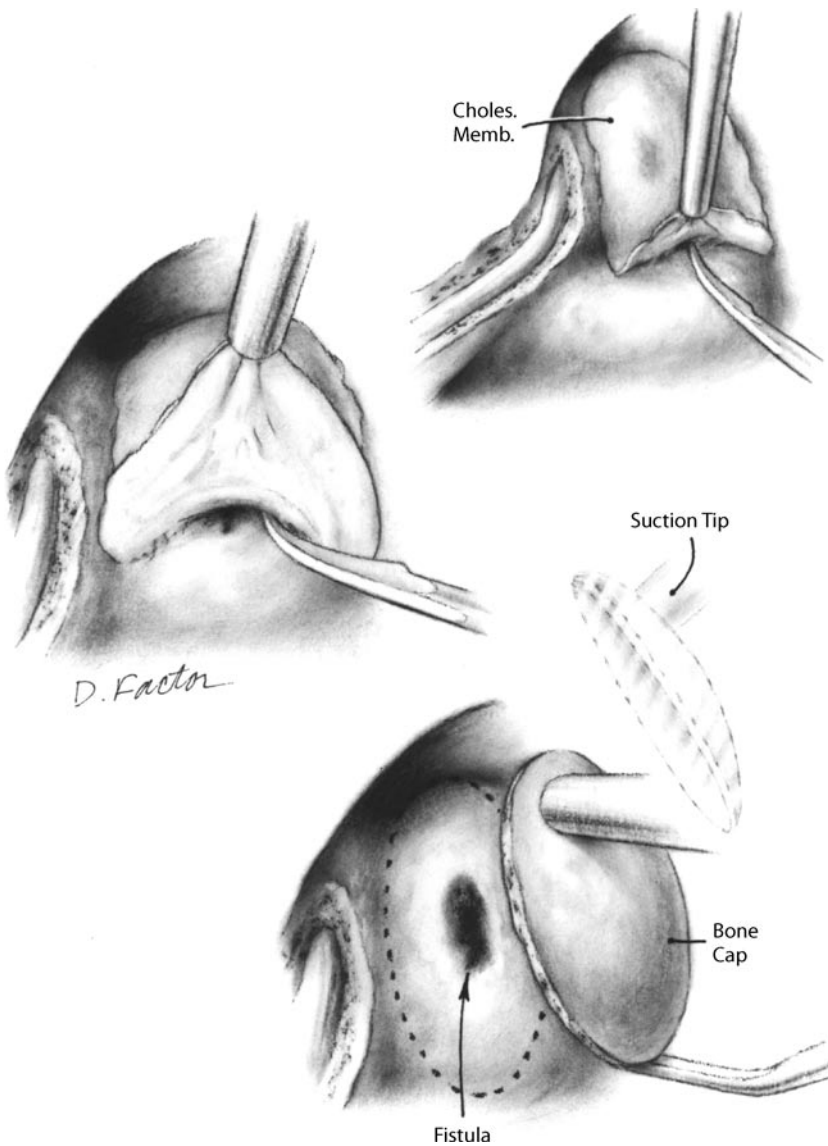


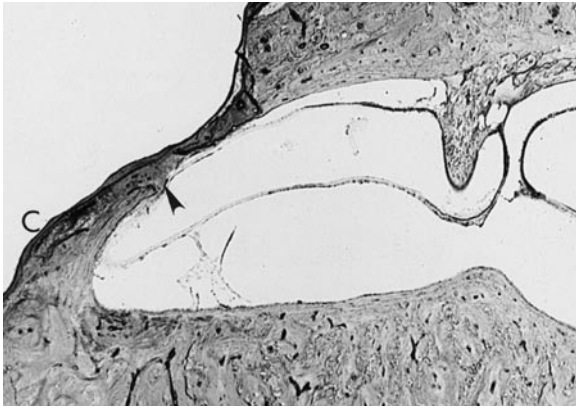
Fig. 4.1 A schematic demonstration of stages in bone erosion by cholesteatoma. *BL* bony labyrinth, *EB* endosteal bone, *M* membranous canal, *EM* endosteal membrane, *P* perilymph



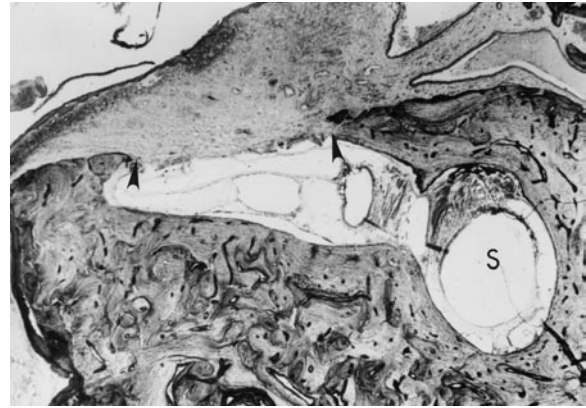■ Fig. 4.2 Axial CT of a temporal bone with large cholesteatoma of the mastoid and erosion of the lateral canal (arrows)



■ Fig. 4.3 Surgical technique for removal of cholesteatoma membrane from lateral canal fistula



■ **Fig. 4.4** Histopathology of a small fistula (*arrowhead*) of the lateral canal. C cholesteatoma membrane



■ **Fig. 4.5** A large bony fistula (*arrowhead*) of the lateral canal covered by cholesteatoma membrane is illustrated in this photomicrograph. S superior canal ampulla

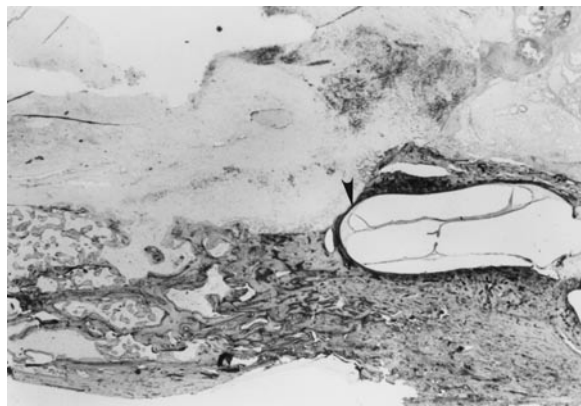
When bony fistulization over the vestibular labyrinth occurs, recurrent vertigo on compression of air in the ear canal is the signal symptom heralding its presence. Confirmation by the fistula test with or without CT (Fig. 4.2) will provide some guidance as to which of the semicircular canals is involved. A horizontally directed nystagmus in the fistula test indicates the lateral canal as the site of the fistula; a vertical nystagmus points to the posterior canal as the site of involvement, and a vertical/rotatory nystagmus identifies the superior canal as the site of fistulization. If uncontrolled, such bony fistulae will eventually lead to inflammatory invasion of the labyrinth with loss of vestibular and auditory function, emphasizing the need for early surgical correction.

The technique for surgical management of a bony fistula consists of sharp dissection of the cholesteatoma membrane from the endosteal membrane in the area of bone defect (Fig. 4.3). The guidelines for removal of cholesteatoma membrane depend on the surgeon's experience, the size and location of the fistula, and the function of the involved ear and uninvolved ears [2]. Small fistulae (2 mm or less) of the bony semicircular canal lend themselves to safe removal of the lining membrane, which does not adhere to the underlying endosteal membrane (Fig. 4.4). Bony fistulae larger than 2 mm are managed on an individual basis. Adherence of the matrix to the underlying endosteal membrane at surgery is determined by sharp dissection (Fig. 4.5). After the cholesteatoma membrane has been removed from the endosteal membrane, the bony defect may be covered by a precisely sculpted cortical bone graft held in place by a temporalis fascia free graft.

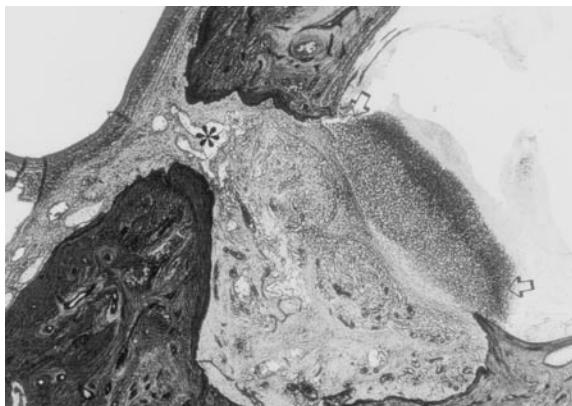
This will provide immediate relief of pressure-induced symptoms of vertigo. Alternatively, if vestibular symptoms are not severe, a temporalis fascia graft may be laid over the fistula allowing eventual periosteal bone regeneration to obliterate the bony defect. The removal of cholesteatoma from a fistula in an only hearing ear is dependent on these guidelines, and if the foregoing previous factors cannot provide guidance, it is best to leave the matrix undisturbed in the only hearing ear. In rare instances where cholesteatoma membrane invades the bony semicircular canal and removal is not possible without disruption of the membranous contents, enlarging the bony fistula to allow eradication of cholesteatoma matrix is necessary. Obliteration of the defect with bone wax may preserve residual labyrinthine function by sealing off the endolymphatic and perilymphatic compartments [2].

Fistulization of the otic capsule surrounding the cochlea [2] is usually located over the promontory and basal turn (Fig. 4.6). A sensorineural hearing loss should alert the surgeon to its presence, which may be confirmed on CT of the temporal bone. Even atraumatic removal of cholesteatoma matrix from a cochlear fistula will result in profound loss of function [2, 9]. Therefore, removal is not recommended, and the residual cholesteatoma membrane is exteriorized surrounded by a fascial graft.

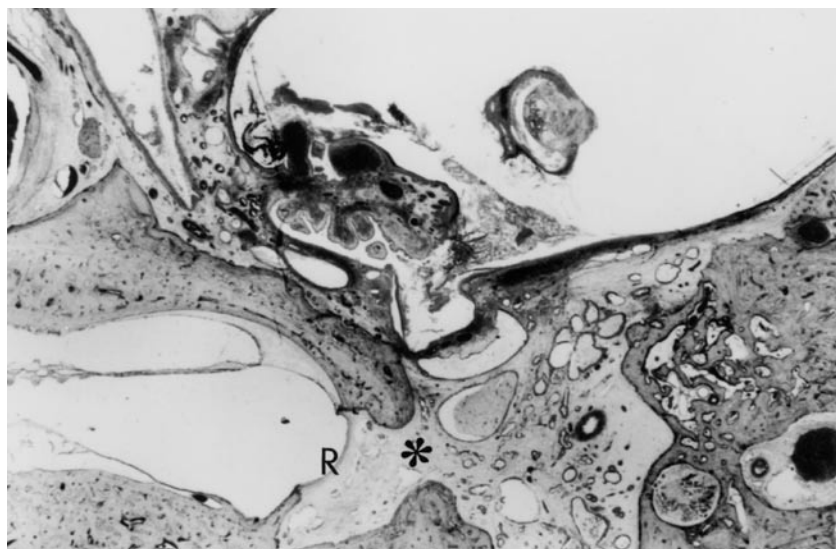
It is possible for recurrent cholesteatoma to invade the cochlea and the internal auditory canal. This unusual extension of cholesteatoma is associated with a severe sensorineural hearing loss in combination with additional neural deficits in the temporal bone (e.g., facial paralysis). A case illustrated in the video



■ **Fig. 4.6** Erosion of bone over the cochlea by chronic osteitis is indicated by the *arrowhead*. The endosteal bone layer is intact



■ **Fig. 4.7** Extension of chronic infection through the round window membrane (*arrow*) is often associated with inflammatory changes locked in a small round window niche (*)

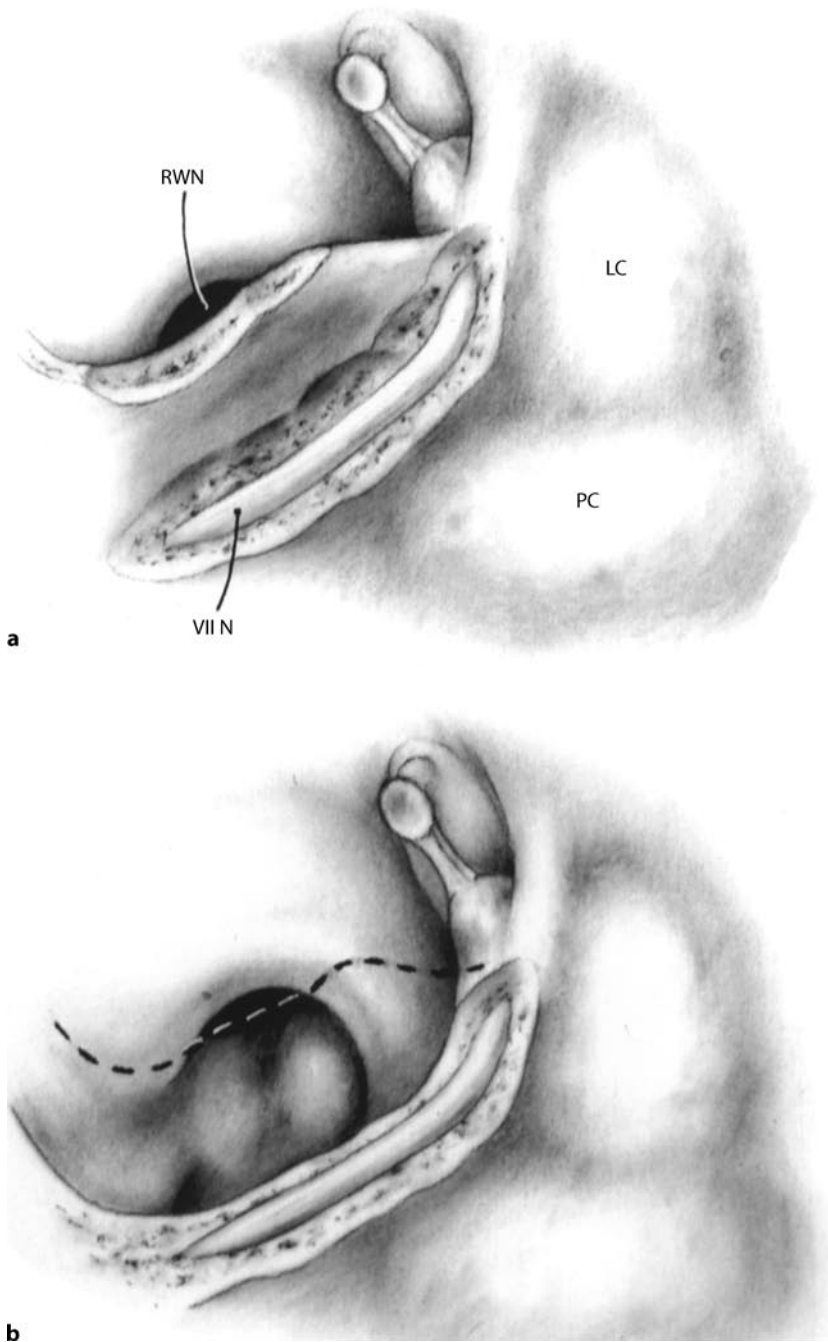


■ **Fig. 4.8** Chronic inflammatory tissue may be sequestered in a round window niche with a narrow aperture (*). *R* round window membrane

presented with facial paralysis along with loss of labyrinthine function. Imaging studies demonstrated erosion of the internal auditory canal and cochlea. Cholesteatoma membrane had extended in to the internal auditory canal by way of the fallopian canal in its tympanic and labyrinthine segments. Resection of the seventh and eighth nerves was necessary for control of cholesteatoma. A hypoglossal-to-facial nerve anastomosis was used to rehabilitate the facial muscles.

Labyrinthine extension from inflammatory middle ear disease may also occur through the round and oval windows [12]. The round window membrane forming the sole membranous barrier between middle

ear and the labyrinthine space is the next most vulnerable location for the spread of toxic inflammatory changes (Fig. 4.7). The anatomy of the round window niche may have bearing on the severity of inflammatory tissue response on the membrane. Niches with a narrow bony aperture may isolate inflamed middle ear mucosa with an increased potential for creating a destructive effect on the membrane (Fig. 4.8). Auditory deficits out of proportion to function of the contralateral ear are a clinical indication of invasion through this site. The auditory threshold deficit may assume various patterns but characteristic is a loss in speech discrimination.



■ **Fig. 4.9** Exposure of the round window niche (*RWN*) for removal of disease requires identification of the facial nerve (**a**), followed by removal of bone in the facial recess (**b**). *LC* bone of lateral semicircular canal

Adequate removal of inflammatory tissue and cholesteatoma requires exposure of the round window niche and adjacent sinus tympani. A reliable surgical step is to identify the descending (mastoid) segment of the facial nerve, followed by removal of the bony

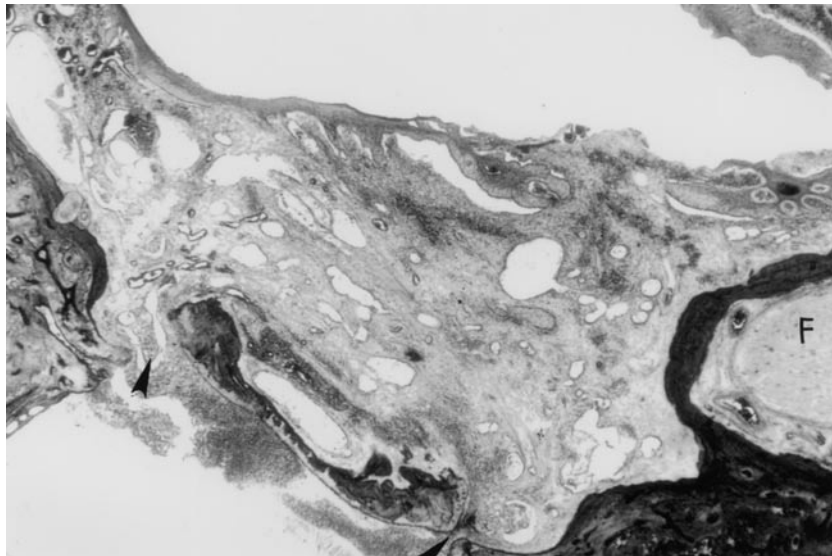
floor of the facial recess (Fig. 4.9). A small diamond burr can then be used to remove the overhang of the round window niche sufficiently to allow sharp dissection of pathological tissue from the round window membrane [3].

Less common is invasion through the oval window where the footplate forms a thin bony barrier between the middle ear and labyrinthine fluids (Fig. 4.10). However, with chronic inflammatory disease, decalcification, and erosion of the footplate may allow the inflammatory process to affect the perilymphatic space in the vestibule. Since the vestibular sense organs are nearby, dizziness of varying severity and forms, rather than an auditory deficit, is a common early clinical indicator of extension through this pathway. Control of extension of disease through these natural windows is accomplished with adipose tissue graft replacement of the footplate (modified type V tympanoplasty) and with tissue repair of round window membrane defects. The effect of inflammation in the perilymphatic space (labyrinthitis) is generally divided into two stages, serous labyrinthitis and suppurative (destructive) labyrinthitis [14]. The two forms are defined by the recovery of function (serous) or by the loss of function (suppurative). An intermediate stage (serofibrinous) has been suggested for partial loss of function and an end stage type included which refers to a histological change resulting from labyrinthine suppuration (labyrinthitis ossificans) (Fig. 4.11).

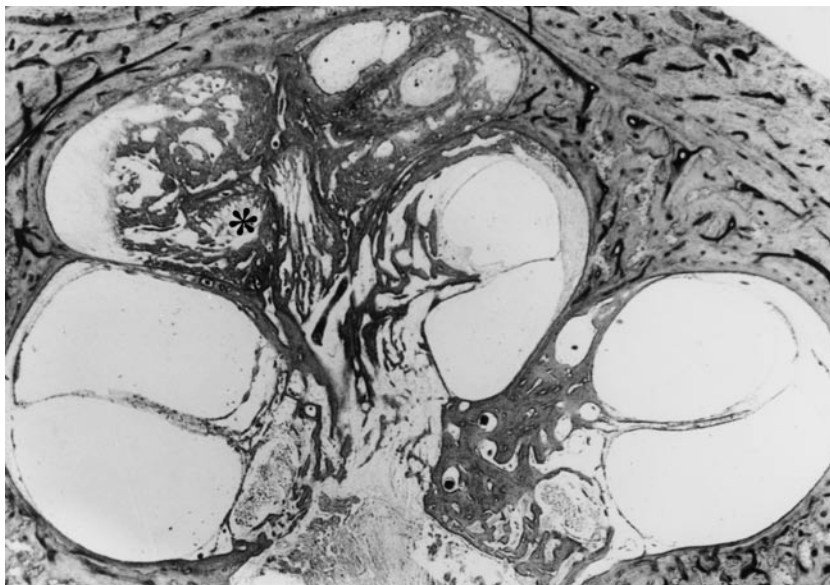
Serous labyrinthitis can be eradicated by timely surgery to remove the source of the inflammation (bony fistula, round or oval window infection) while suppurative labyrinthitis must be exenterated surgically together with sense organs to prevent spread to the subarachnoid space and promote central compensation for vestibular ablation. The techniques for this surgical intervention are described elsewhere.

4.1.2 Facial Paralysis

Facial paralysis is a serious neural complication of chronic middle ear and mastoid disease, particularly from cholesteatoma [6, 11, 16]. In the presence of active chronic middle ear disease, this complication should be dealt with urgently. Exposure of the facial nerve and its sheath proximal and distal to the area of involvement by chronic inflammatory tissue must be reached by careful removal of soft tissue and bone. Removal of disease from the facial nerve and release of nerve edema is then provided by incising the nerve sheath.



■ Fig. 4.10 Chronic infection may also extend through the oval window by extension through the stapedio vestibular ligament (*arrowheads*) or the stapedial footplate. *F* facial nerve



■ Fig. 4.11 The end stage in suppurative labyrinthitis is ossification (*)

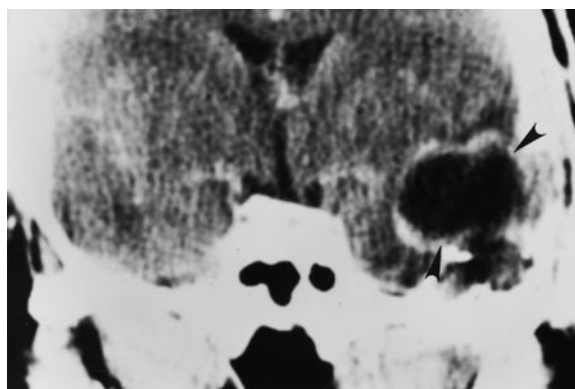
4.2 Intracranial Complications

4.2.1 Intradural Extension of Cholesteatoma

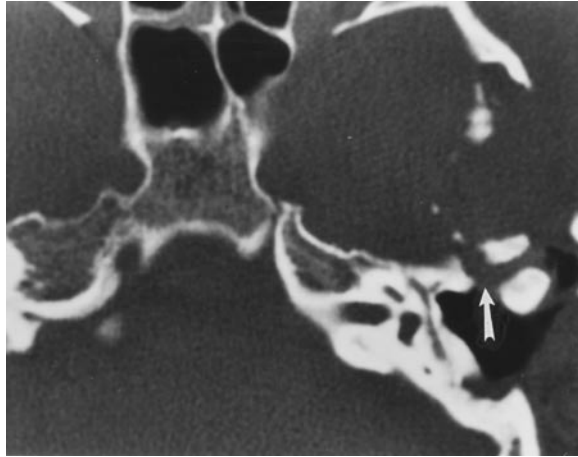
The extension of cholesteatoma membrane beyond the confines of the mastoid and middle ear compartment may occur through a preformed defect in the dura. These dural defects are not a result of cholesteatoma-induced breakdown of dura, but rather represent congenital defects through which arachnoid granulations (AG) herniate and come to lie in apposition with the temporal bone (see Chap. 8, Fig. 8.4). Invasion of the subdural space by cholesteatoma occurs by invagination of the AG, which then allows a subdural collection of cholesteatoma. We have experience with one patient who underwent several mastoid explorations for recurrent cholesteatoma that was found to be extensive in the subdural space. Severe pain was the patient's primary symptom. Complete removal of the subdural cholesteatoma would require a neurosurgical approach, but the neurosurgical consult deferred until neurological deficits appeared.

The intradural invasion by cholesteatoma may not be limited to the subdural space. The accompanying figures demonstrate a case of a middle-aged man who had successful surgical control of mastoid cholesteatoma, but many years later presented with a tempo-

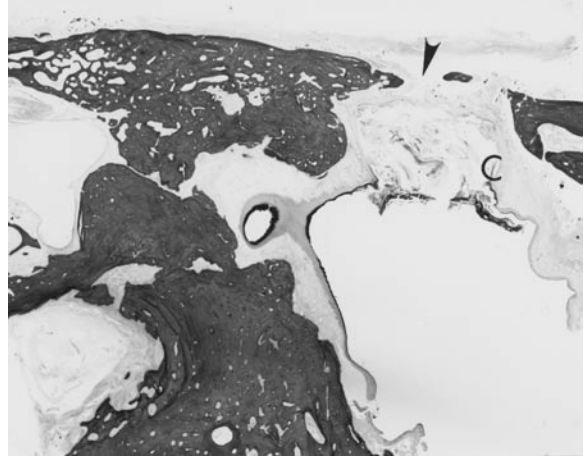
ral lobe abscess (Fig. 4.12). A neurosurgical approach confirmed that the cholesteatoma membrane had extended through a defect in the tegmen and middle fossa dura into the temporal lobe cortex (Fig. 4.13). The patient survived a short period because of the chemical meningitis associated with the surgical excision of cholesteatoma. The postmortem examination of the temporal bone in this patient revealed the bony and dural defect, which permitted such intracranial extension of cholesteatoma (Fig. 4.14).



■ Fig. 4.12 A ring enhancing temporal lobe brain abscess (arrowheads) proved to be cholesteatoma extension from the epitympanum



■ Fig. 4.13 The cholesteatoma extended from a bone defect in the tegmen (arrow)



■ Fig. 4.14 Temporal bone specimen from deceased patient in Figs. 4.12 and 4.13 shows the epitympanic bony defect (arrowhead). C cholesteatoma membrane

4.2.2 Meningitis

Recurrent meningitis may result from extension of disease through an AG [4, 15]. The accompanying video demonstrates a patient with a history of recurring episodes of meningitis with each episode of otitis media. CT scan of the temporal bones revealed a bony defect in the tegmen mastoidea with opacification of the mastoid compartment and middle ear (Fig. 4.15). The surgical exploration revealed a mass of tissue protruding from a defect in the dura, which consisted of a granulation tissue mass with a transition from granuloma to normal temporal lobe white matter. The surgical procedure accomplished removal of the AG and herniated temporal lobe, suture closure of the dural defect, and adipose tissue obliteration of the intact canal wall mastoidectomy defect.

Meningitis as an extension of suppurative labyrinthitis may occur as a result of progressive infection along branches of the eighth cranial nerve or through preformed pathways (i.e., cochlear aqueduct).

4.2.3 Brain Abscess

Brain abscess secondary to acute or chronic mastoiditis may develop directly through a preformed defect in the dura (AG) or indirectly as a retrograde thrombophlebitis of the small dural vessels that permeate overlying bony surfaces of the temporal bone [5, 13,

16]. The intracranial accumulation formed through a dural defect usually appears earlier (almost immediate) after acute suppurative otitis media and mastoiditis than does an abscess that develops by retrograde vascular spread. The development of temporal lobe or cerebellar abscess is usually determined by the responsible method of spread in either the tegmen or posterior fossa surfaces of the temporal bone. The clinical signs of intracerebral infection in these locations are well known and not reviewed here. CT and MRI imaging provide early confirmation of this intracranial complication.

4.2.4 Lateral Sinus Thrombosis

Spread of infection to the intracranial venous system may occur from untreated or undertreated acute mastoiditis or active chronic otitis media and mastoiditis [5, 17, 18]. Infection with thrombus formation may occur in the lateral venous sinus because of exposure in the sigmoid segment within the mastoid compartment. Infection usually spreads directly through the sinus wall or by way of retrograde thrombophlebitis when there is osteitic bone of the sinus plate.

Although typical clinical findings associated with this sequela are spiking high temperatures, headache, drowsiness, and indications of hydrocephalus, the full clinical picture is not usually seen in the present era of antibiotic therapy. Therefore, the diagnosis should be

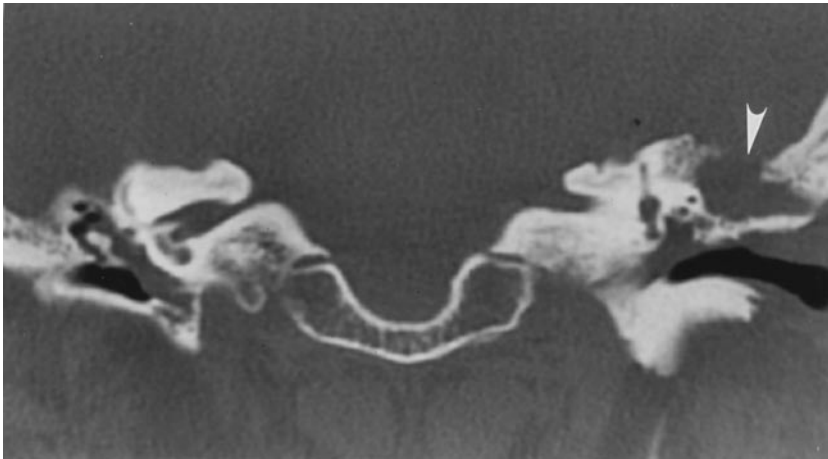


Fig. 4.15 Coronal CT scan of temporal bones in a patient with recurrent meningitis. The tegmen defect (*arrow*) was filled with an arachnoid granulation adherent to the temporal lobe

suspected in any patient with constant mastoid infection, persistent intermittent fever, and headaches. CT and MRI imaging of the temporal bone are essential to provide clues for bone demineralization and interruption of venous flow [7, 8, 10]. Vascular studies such as the venous phase of an arteriogram are mandatory to make the diagnosis (Fig. 4.16).

Surgical treatment of sinus thrombosis consists of exposure of the sigmoid segment in a wide-field

mastoidectomy. If ballotement reveals a patent sinus, then no further treatment of the sinus except thorough curettage of granulation tissue from the surrounding dura. A firm sinus segment requires needling first with fine- then a large-gauge needle. No venous return requires opening the sinus while compressing its lumen proximal and distal to the segment filled with thrombus. Evacuation of the thrombus can then be carried out. Intensive antibiotic and anticoagulant management is necessary for at least 6–8 weeks.

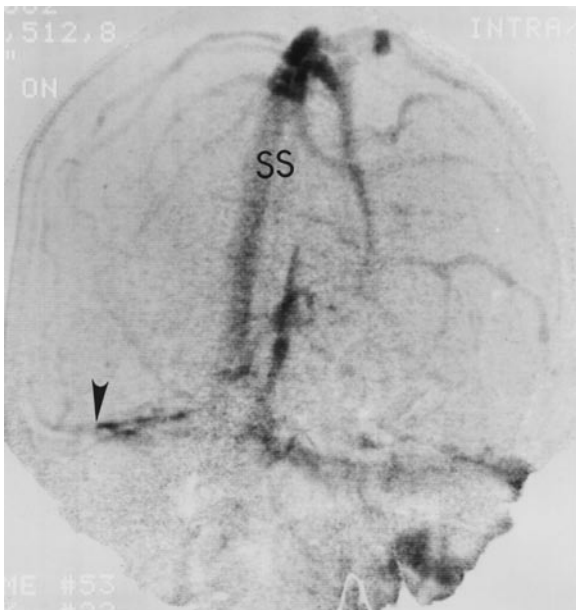


Fig. 4.16 Venogram in a patient with sigmoid and lateral sinus thrombosis demonstrates obstruction in venous flow (*arrow*). SS superior sagittal venous sinus

COMPLICATIONS TO AVOID

1. Avoid injury to the facial nerve in chronic OM surgery by exposing nerve in intact part of the fallopian canal.
2. Remove cholesteatoma membrane from the endosteal lining of a bony fistula in the semi-circular canals to avoid injury to the membranous canal.
3. Avoid removal of cholesteatoma membrane from bony fistulas of the cochlea to prevent sensorineural hearing loss.

Pearl

- It is safe to remove cholesteatoma lining from a bony fistula of the vestibular labyrinth but not the cochlea.
- Repair of fistula of the oval window with adipose tissue to preserve cochlear function.

References

1. Abramson M (1969) Collagenolytic activity in middle ear cholesteatoma. *Ann Otol Rhinol Laryngol* 78:112–124
2. Gacek R (1974) The surgical management of labyrinthine fistulae in chronic otitis media with cholesteatoma. *Ann Otol Rhinol Laryngol* 83:(Suppl):1–19
3. Gacek RR (1993) Surgery of the vestibular system. In: Cummings C, Schuller DE (eds) *Otolaryngology—head and neck surgery*. Mosby, St. Louis, pp 3199–3216
4. Gacek RR (1990) Arachnoid granulation cerebrospinal otorrhea. *Ann Otol Rhinol Laryngol* 99:854–862
5. Glasscock ME III, Shambaugh GE Jr (1990) Intracranial complications of otitis media. In: Glasscock ME III, Shambaugh GE Jr (eds) *Surgery of the ear*, 4th edn. Saunders, Philadelphia, pp 249–275
6. Ludman H (1987) Complications of suppurative otitis media. In: Kerr AG (ed) *Scott-Brown's otolaryngology*, 5th edn. Butterworth, London, pp 264–291
7. Macchi PJ, Grossman RI, Gomori JM, Goldberg HI, Zimmerman RA, Bilaniuk LT (1986) High-field MR imaging of cerebral venous thrombosis. *J Comp Assist Tomogr* 10:10–15
8. McArdle CB, Mirfakhraee M, Amparo EG, Kulkarni MV (1987) MR imaging of transverse/sigmoid dural sinus and jugular vein thrombosis. *J Comp Assist Tomogr* 11:831–838
9. McCabe BF (1984) Labyrinthine fistula in chronic mastoiditis. *Ann Otol Rhinol Laryngol* 93:(Suppl):138–141
10. McMurdo SK Jr, Brant-Zawadzki M, Bradley WG Jr, Chang GY, Berg BO (1986) Dural sinus thrombosis: study using intermediate field strength MR imaging. *Radiology* 161:83–86
11. Neely JG (1986) Complications of temporal bone infection. In: Cummings C, Schuller DE (eds) *Otolaryngology—head and neck surgery*. Mosby, St. Louis, pp 2988–3015
12. Paparella MM, Sugiura S (1967) The pathology of suppurative labyrinthitis. *Ann Otol Rhinol Laryngol* 76:554–586
13. Quijano M, Schuknecht HF (1988) Temporal bone pathology associated with intracranial abscess. *ORL* 50:2–31
14. Schuknecht HF (1974) *Pathology of the ear*. Harvard University Press Cambridge, Mass.
15. Schuknecht HF (1970), Montandon P. Pathology of the ear in pneumococcal meningitis. *Arch Klin Exp Ohr Nas Kehlkheilk* 195:207–225
16. Snow JB (1989) Cranial and intracranial complications of otitis media. In: English GM (ed) *Otolaryngology*. Lippincott, Philadelphia
17. Southwick FS, Richardson EP Jr, Swartz MN (1986) Septic thrombosis of the dural venous sinuses. *Medicine* 65:82–106
18. Teichgraeber JF, Per-Lee JH, Turner JS Jr (1982) Lateral sinus thrombosis: a modern perspective. *Laryngoscope* 92:744–751

Core Messages

- The petrous apex may be affected by cystic and solid lesions. Cystic lesions are more common and are benign. Solid lesions are less common and may be benign or malignant.
- Clinical signs and symptoms of expanding lesions of the petrous apex include Eustachian tube compression, third and sixth nerve deficits, and headache.
- Both magnetic resonance imaging and computerized tomography are recommended in the diagnosis and management of petrous apex lesions.
- Surgical approaches to biopsy or fistulize petrous apex lesions include perilyabyrinthine cell tracts, sphenoid sinus, middle cranial fossa, transcochlear.

The subtle clinical presentations of petrous apex lesions are related to the regional anatomy of the apical segment of the temporal bone (Fig. 5.1). Prior to 1975, the major lesion of the petrous apex described in the literature was infection, causing epidural abscess formation responsible for a classic triad of symptoms (Gradenigo's syndrome). These were diplopia, deep pain, and facial hypoesthesia. Nearby structures in the petrous apex (fifth and sixth cranial nerves) provided logical explanation of the clinical findings in this potentially lethal sequela of middle ear infection. Radiologic techniques (plain x-rays, polytomography) were capable of demonstrating only the most advanced osteolytic lesions in this area [3, 7]. Using these methods, a series of solid and cystic lesions primary in the petrous apex were demonstrated and managed in a monograph publication [3, 7]. These lesions are a manifestation of the complex anatomical composition of the petrous apex, consisting of air cells, bone marrow, cartilage, nerves, and vascular structures (internal carotid artery, jugular bulb). This report of petrous apex cases and their management unlocked the many

pathologies located in this obscure region of the skull base. Sophisticated imaging techniques (CT, MRI) now permit early recognition of a petrous apex lesion.

The usual presenting symptoms of an expanding lesion in the petrous apex are a conductive hearing loss from the serous effusion caused by Eustachian tube obstruction, headache from pressure on the dural covering, diplopia related to involvement of the third and sixth cranial nerves, facial hypoesthesia caused by compression of the fifth cranial nerve, and varying degrees of faintness or vertigo probably caused by changes in the labyrinthine blood supply. The pathologies involving the petrous apex may be divided into solid and cystic lesions (Table 5.1).

Table 5.1 Petrous apex pathologies categorized by lesion type

| | |
|----------------|---|
| Solid lesions | |
| Benign | |
| | Neurofibroma or schwannoma |
| | Chondroma |
| | Meningioma |
| | Paraganglioma |
| Malignant | |
| | Chondrosarcoma |
| | Eosinophilic granuloma |
| | Lymphoma |
| | Metastatic malignancies (breast, lung, kidney, prostate) |
| Cystic lesions | |
| Vascular | |
| | Internal carotid aneurysm |
| | Venous lake |
| Nonvascular | |
| | Apicitis (abscess) |
| | Congenital epidermoid cyst |
| | Cholesterol granuloma (mucocele) |

5.1 Diagnosis

The clinical suspicion of a progressive lesion in the petrous apex is based on recognition of one or more of the signs and symptoms related to adjacent anatomical

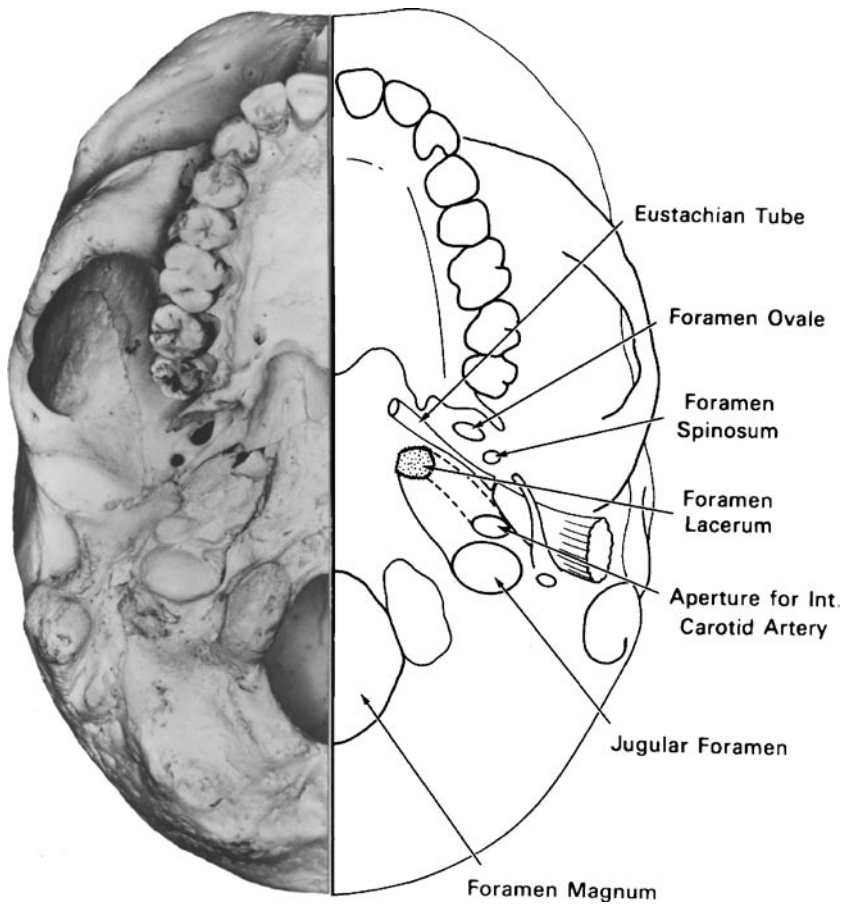


Fig. 5.1 Diagram of the skull base with anatomical structures related to the petrous apex and foramen lacerum

structures (Eustachian tube, cranial nerves III through VIII, dura, and internal carotid artery).

Presently, thin-section (1–1.5 mm) CT scanning and MRI are capable of identifying such lesions in the petrous apex much earlier in their development, with minimal risk. The evaluation of a suspected lesion in the petrous apex should require CT scanning and MRI [15, 16]. The nature of a lesion as solid or cystic is usually revealed by the enhancement on CT and signal picture on T_1 and T_2 images with MRI. Arteriography may be added to define a vascular lesion or to locate displacement of the internal carotid artery.

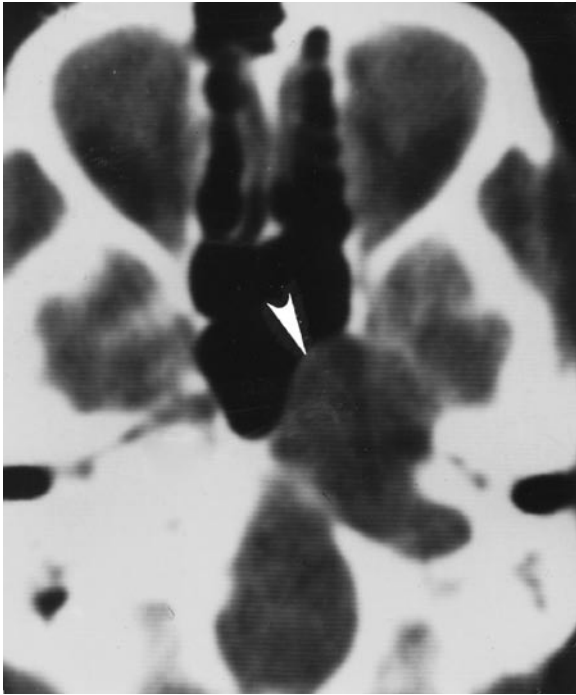
5.2 Management

5.2.1 Solid Tumors

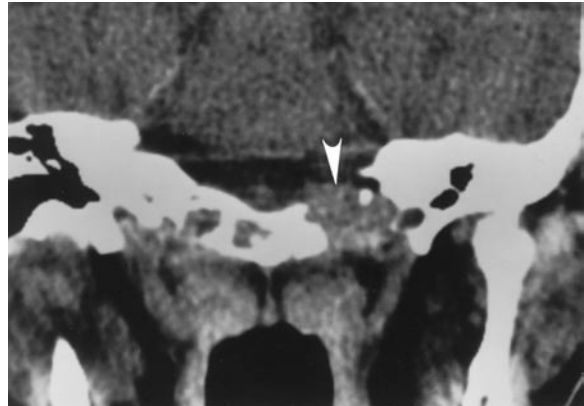
The management of solid tumors requires identification of the histopathology prior to definitive treatment [7]. Several factors determine the approach to biopsy

of solid petrous apex lesions. If the tumor has extended into an area that is easily accessible without risk to labyrinthine function such as the infralabyrinthine and hypotympanic cell tracts or into the sphenoid sinus, then these compartments should be accessed for sampling the tumor (Fig. 5.2.). However, if the tumor is contained within the petrous apex and labyrinth function is normal, then a middle cranial fossa extradural approach skirting the temporal bone is the most direct approach to the tumor while preserving seventh and eighth cranial nerve functions.

Definitive management is guided by the histologic nature of the lesion. A benign lesion may be excised totally or subtotally, depending on the progressive nature of the clinical symptoms and the patient's age and medical status. Postoperative surveillance of the petrous apex tumor may be carried out with imaging studies to determine possible recurrence and progression. A malignant tumor will require nonsurgical management (radiation therapy, chemotherapy) since en bloc resection of this portion of the temporal bone



■ **Fig. 5.2** Axial CT demonstrating a solid lesion (schwannoma) arising from the petrous apex (*arrowhead*) and presenting into the sphenoid sinus, where it was biopsied through an ethmoid-sphenoid approach. Presenting signs were Eustachian tube obstruction and sixth cranial nerve palsy in a 60-year-old female. Observation with CT scanning was recommended



■ **Fig. 5.3** Metastatic breast carcinoma in the bone marrow of the petrous apex presented with a fifth-nerve deficit (*arrowhead*)

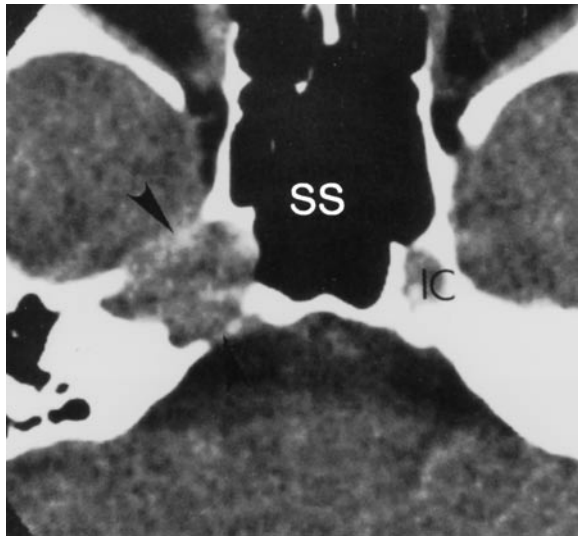
is not feasible for cure, particularly if one considers the morbidity associated with the surgery (Fig. 5.3). However, low-grade malignancy such as eosinophilic granuloma may be treated more effectively by extensive subtotal removal using curettage, followed by radiation therapy.

5.2.2 Cystic Lesions

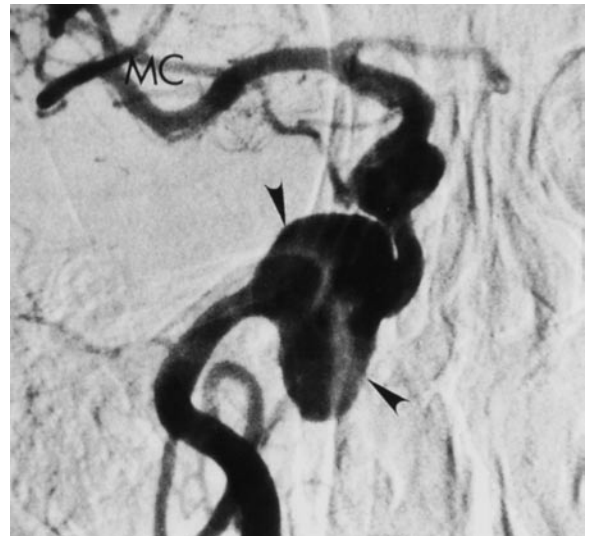
Cystic lesions may be vascular or nonvascular, and their management will vary from case to case. If imaging studies are not able to demonstrate the vascular nature of a lesion with certainty, then arteriography is required. The major vascular lesion of the petrous apex is an internal carotid aneurysm (Figs. 5.4, 5.5). If the lesion is causing minimal nonprogressive clinical symptoms, then the aneurysm should be conservatively followed clinically and neuroradiologically. If the aneurysm becomes progressive and is responsible for significant neurologic symptoms, then a team ap-

proach (neurosurgery and otolaryngology) to management of the aneurysm is necessary. Progressive preoperative occlusion followed by resection is one method of management if the patient tolerates the occlusive maneuver.

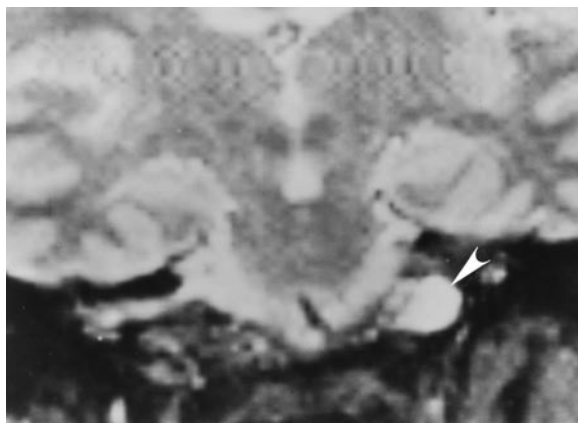
Occasionally, imaging studies are misleading. We have seen two patients presenting with episodic vertigo that revealed on MRI a high-signal-intensity mass resembling a cholesterol cyst in the petrous apex (Fig. 5.6). However, CT scan did not reveal bone erosion, but rather a compartment in the petrous apex was present (Fig. 5.7). It has been suggested that this may represent bone marrow. However, exploration of the petrous apex in these cases with severe sensorineural hearing loss in the involved ear revealed a thin-walled space with brisk venous bleeding requiring firm packing control. It is possible that these lesions represent venous anomalies (venous lakes). The sigmoid sinus and the jugular bulb were anatomically separated from this vascular compartment. The importance of this entity is that if it is properly recognized with the posi-



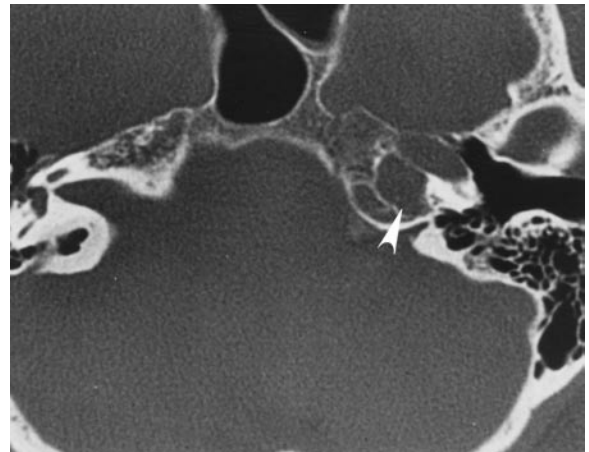
■ Fig. 5.4 A CT scan in a middle-aged woman with recurrent vertigo revealed an osteolytic lesion (*arrowhead*) in the petrous apex



■ Fig. 5.5 Arteriogram in the same patient as Fig 5.4 demonstrated an aneurysm of the internal carotid artery. Since neurological deficits were absent, observation was recommended. MC middle cerebral artery



■ Fig. 5.6 Coronal MRI demonstrates a localized enhancement (*arrowhead*) in the petrous apex of a middle-aged female with recurrent vertigo and normal labyrinthine function



■ Fig. 5.7 Axial CT scan demonstrated a cavity with intact bone trabeculae in the petrous apex (*arrowhead*). Transmastoid exploration revealed a venous lake

tive MRI but with no evidence of bone erosion on CT scanning, then surgical exploration should be withheld and the patients only followed with clinical and radiologic methods to detect the possibility of a progressive lesion. Documentation of progression justifies surgical exploration.

5.2.3 Petrositis

In the preantibiotic era, the most common cystic lesion of the petrous apex was infection, either chronic or acute, as a result of extension of the inflammatory process from the middle ear and mastoid compartments [11]. Progression of an epidural abscess in

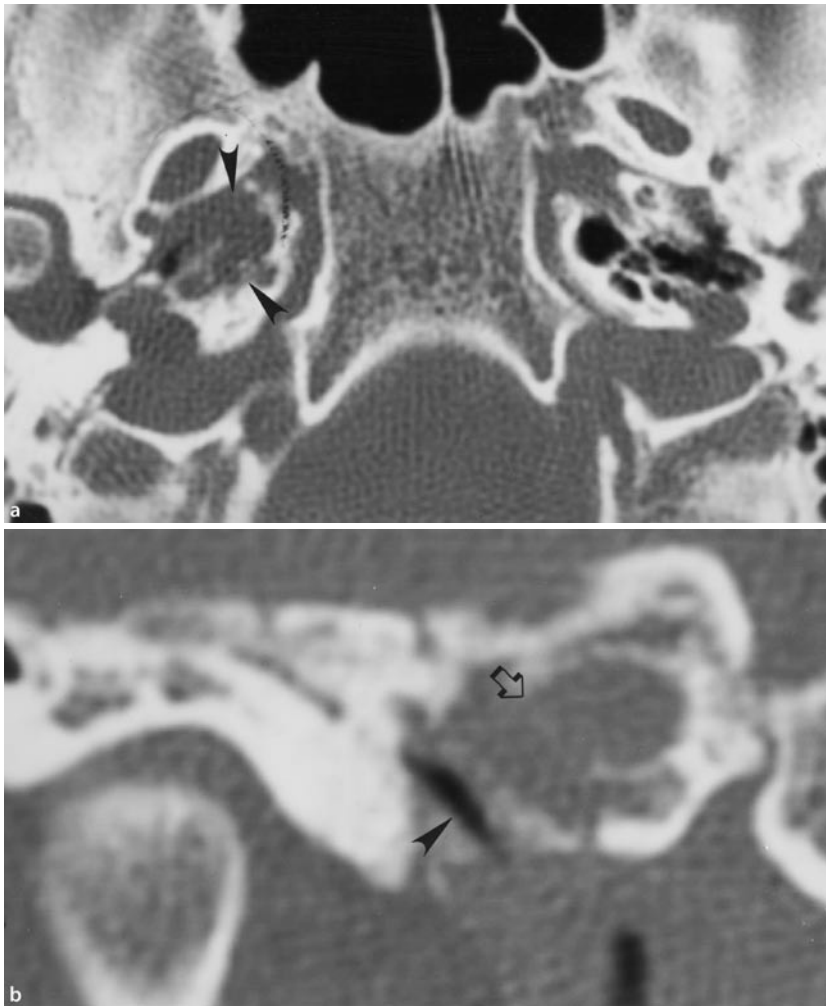
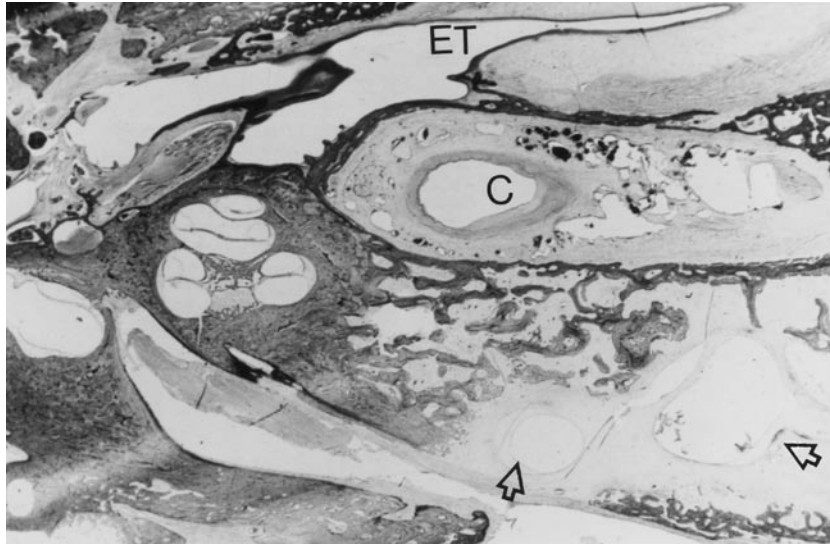

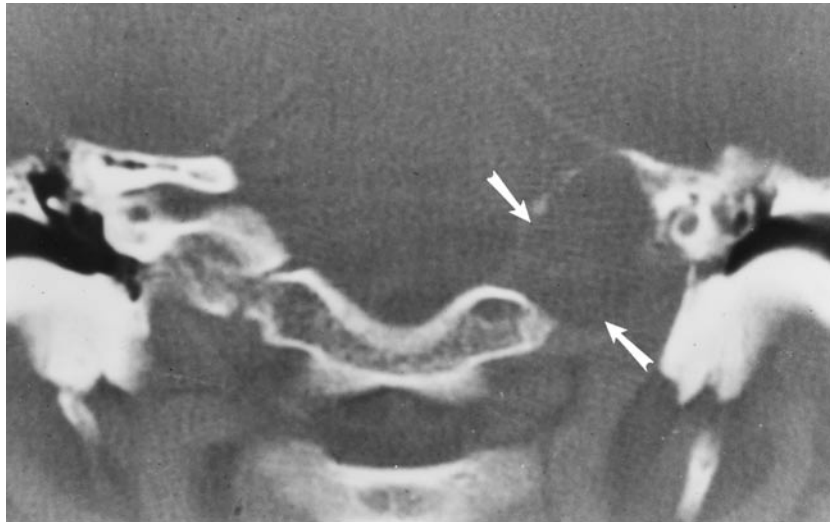
Fig. 5.8 **a** Patient with chronic otitis media and retro-orbital pain. Axial CT scan demonstrates opacification of petrous apex air cells with decalcification of bony trabeculae (*arrow*). The contralateral petrous apex is normal. **b** Coronal CT of same patient shows erosion of the carotid canal (*arrow*) and air in the Eustachian tube (*arrowhead*)

the air cell system of the petrous apex, resulting in bone destruction with dural irritation and involvement of the cranial nerves adjacent to the petrous apex represent Gradenigo's syndrome (Figs. 5.8, 5.9). The advent of antibiotics and thorough mastoid surgery has virtually eliminated this complication of suppurative otitis media. Nevertheless, this complication does occasionally occur and presents a similar constellation of cranial nerve deficits and symptoms (pain) associated with signs of infection. Surgical exenteration and drainage of the epidural petrous apex abscess cavity is urgently indicated. Wide-field mastoid and middle ear exploration with identification of the cell tract leading to the apex is necessary to correctly locate and manage the abscess cavity. Most frequently,

this tract will be located in the infra- or perilyabyrinthine cell groups (posteromedial, posterosuperior). The extent of bone removal required to expose the cavity will depend on the presence or absence of function in the involved ear. If labyrinthine function is normal, then exenteration of the diseased air cells should be performed with preservation of the otic capsule. Insertion of drainage tube for the instillation of antibiotics into the abscess cavity is recommended for complete treatment of the infected cavity. Resolution of the inflammatory process results in obliteration of the defect with fibrous and osseous tissue. If labyrinthine function is significantly depressed, then a transcochlear translabyrinthine approach to the petrous apex abscess is chosen [7, 8].



■ **Fig. 5.9** Horizontal temporal bone specimen illustrates the histopathology of a petrous apicitis (*arrow*). C internal carotid artery, ET Eustachian tube

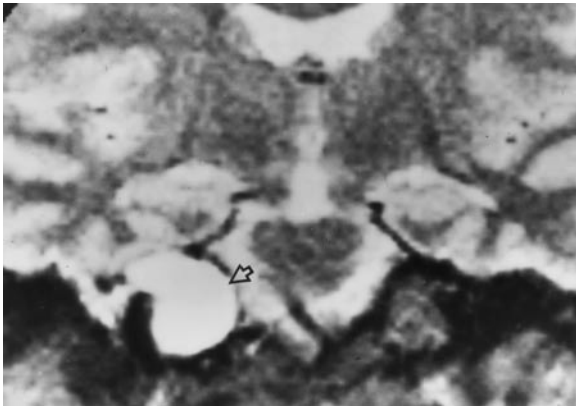


■ **Fig. 5.10** Coronal CT scan of a primary epidermoid in the petrous apex (*arrow*)

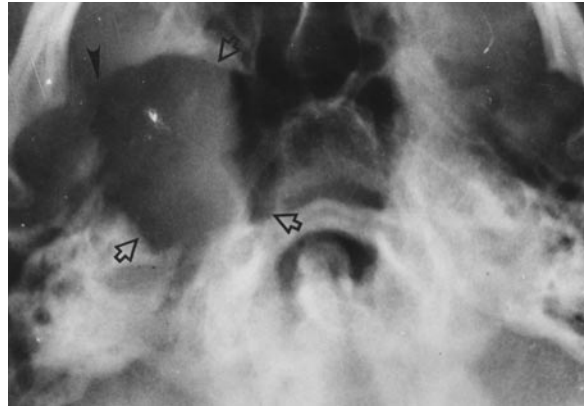
5.2.4 Congenital Epidermoid Cyst

Although the petrous apex may be invaded by extension of acquired cholesteatoma arising in the middle ear, a congenital epidermoid cyst limited to the petrous apex is a cystic lesion caused by retention of epithelial remnants embryonically in the region of the foramen lacerum [2, 8]. The cartilage in this space is a remnant of the embryonic mesenchyme in the cephalic flexure, which may entrap epithelial remnants from the foregut as they recede before the shrinking cephalic flexure during development. The pattern of growth and clinical symptoms are similar to that of the pro-

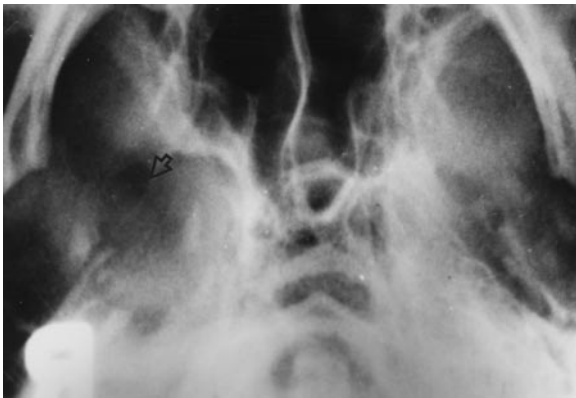gressive petrous apex lesions. Congenital epidermoid cysts of the petrous apex usually become manifest in young adulthood or early middle age [2, 13]. At this point the epidermoid has reached a size where surrounding structures are affected, and significant bone loss permits identification with modern CT and MRI techniques. The expanding pattern of bone erosion typical of a congenital cystic lesion is demonstrated best with CT scanning (Fig. 5.10). An MRI study showing a low-to-medium signal intensity on the T_1 image and high signal intensity on the T_2 image is characteristic of an epidermoid cyst [16] (Fig. 5.11). Because of the progressive pressure exerted by retained kera-



■ Fig. 5.11 MRI demonstrates enhancing cystic lesion of the petrous apex consistent with primary epidermoid (arrow)



■ Fig. 5.12 Base of skull x-ray demonstrates a large cystic lesion of the petrous apex (arrow), with compression of the Eustachian tube and V₃ nerve in the foramen ovale (arrowhead)



■ Fig. 5.13 Six months after transmastoid fistulization of the cyst, recalcification of bone around the foramen ovale can be seen (arrow)

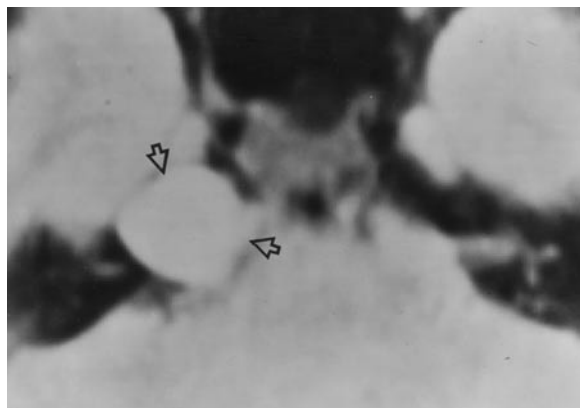
tin within a stratified squamous epithelial cyst wall, compression of the cranial nerves and vascular and ventilatory structures of the temporal bone eventually requires surgical treatment of this epidural tumor. Since removal of the stratified squamous epithelial lining from the surrounding structures (internal carotid artery, dura, jugular bulb, cranial nerves) is not possible without significant morbidity, the recommended management is decompression and exteriorization of the epidermoid cyst [7, 8, 13, 14]. The surgical considerations of this maneuver are essentially the same as with other nonvascular cystic lesions of the petrous apex such as cholesterol cyst (granuloma). Therefore,

the technical considerations will be discussed together with management of cholesterol cysts or granuloma of the petrous apex.

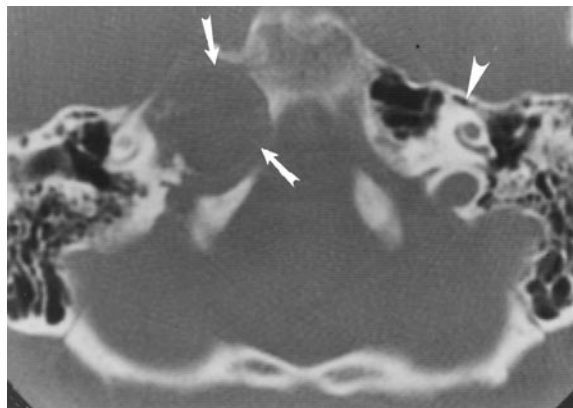
Extension of cholesteatoma toward the petrous apex through perilyabyrinthine cell tracts or through the labyrinth is managed by surgical removal of the cholesteatoma membrane after wide exposure of the extension through an open mastoidectomy approach. The epithelial membrane responsible for congenital cholesteatoma (epidermoid) cysts of the petrous apex, however, is firmly adherent to the dura, internal carotid artery, and nerve bundles, requiring an extraordinary surgical exposure associated with significant morbidity. It is questionable whether this membrane can be completely excised in order to safely permit a closed technique for repair (obliteration) [5]. However, it has been suggested that once a congenital epidermoid cyst has been evacuated, it may require 10–20 years for sufficient reaccumulation to produce clinical symptoms [10]. Nevertheless, the technique of decompression and exteriorization is favored because it has proven to carry low morbidity and mortality while restricting enlargement of the cyst [7, 8, 14]. There is evidence that such decompression leads to decrease in cyst size [7] (Figs. 5.12, 5.13).

5.2.5 Cholesterol Granuloma (Mucocele, Cholesterol Cyst)

Cholesterol granuloma is the most common cystic lesion of the petrous apex and represents the end result of complete obstruction of an air cell tract to the



■ **Fig. 5.14** Typical appearance on MRI of a petrous apex cholesterol cyst (*arrow*)



■ **Fig. 5.15** Axial CT of the petrous apex shows an osteolytic expanding lesion with dural exposure (*arrows*). Note pneumatization of contralateral petrous apex with narrow cell tract (*arrowhead*) to the middle ear

petrous apex early in life [3]. The contralateral petrous apex in patients with cholesterol cysts of the petrous apex is usually well pneumatized, suggesting that the involved petrous apex was similarly pneumatized early in development. MRI characteristically demonstrates a high signal lesion on both T_1 and T_2 images (Fig. 5.14). A fibrous and bony obliteration occurs in a narrow cell tract, which provides the pneumatization to the apex [3]. Complete obstruction leads to the sequence of events that is responsible for mucocele formation in aerated compartments of the paranasal sinuses as well as in the temporal bone [4, 6, 12]. Resorption of the normal gas component leads to obliteration of the space with mucoid fluid and breakdown products of blood from the capillary network of the mucoperiosteal lining. The breakdown products of hemoglobin (hemosiderin, cholesterol) eventually produce a foreign body reaction with macrophage accumulation, giant cells, and the distribution of cholesterol crystals within the soft tissue lining of the cyst. The continued accumulation of fluid is responsible for progressively increased pressure on the bony walls of the space, resulting in breakdown of bone composition and compression of the adjacent soft tissue structures (Fig. 5.15). This lesion has been referred to in various terms that reflect either the mechanisms of the lesion or the various stages of reaction to the obstruction. Mucocele, cholesterol granuloma, and cholesterol cyst have been used synonymously for this lesion. Since this lesion has been documented with increased frequency by the new imaging techniques, it is surprising that it was not described in early literature. Petrous apex cystic le-

sions fitting this description were reported in 1975 [7] and 1979 [3], although the true nature of pathogenesis was not appreciated. The 1979 report described a cystic petrous apex lesion demonstrated by polytomography in a young man that was shown at surgery to be a mucocele. It was suggested that this lesion resulted from an obstructed air cell tract in the petrous apex since the contralateral petrous apex was well pneumatized.

Since it is unlikely that this is a new form of pathology in the petrous apex, it is reasonable to assume that it has been overlooked in the past, eluding diagnosis and treatment. Radiologic techniques prior to the modern era of temporal bone imaging failed to detect bone erosion in the petrous apex unless it reached extensive proportions. The fate of patients with undiagnosed congenital epidermoids or cholesterol cysts of the petrous apex can only be guessed. It is possible that untreated progressive enlargement of these lesions resulted in a defect of thinned dura, with communication into the adjoining intracranial space at the base of the skull. Leakage of the cyst contents could produce a chemical and/or bacterial meningitis and unexplained death. The temporal bone and the paranasal sinuses are often overlooked in routine postmortem examination of such cases unless that portion of the skull is examined carefully after brain removal. This scenario is suggested in the report of Canfield [1] describing a young man with a chronically retracted tympanic membrane, several episodes of unexplained coma, somnolence, and fatal meningitis. Despite drainage and treatment of the meningitis, the patient died and postmortem examination revealed a large cystic space

in the petrous apex with a dural defect near the middle fossa.

Therefore, decompression and permanent exteriorization is recommended for cystic lesions in the petrous apex region that manifest progression by: (1) bone erosion and exposed dura, (2) unresolved or recurrent cranial nerve deficits, and (3) persistent or recurrent headache. The justification for surgical decompression is the prevention of a lethal complication into the subarachnoid space. If the cystic lesion demonstrates bone erosion short of dural exposure, then observation with monitoring by CT scan periodically (every 1 to 2 years) is permissible.

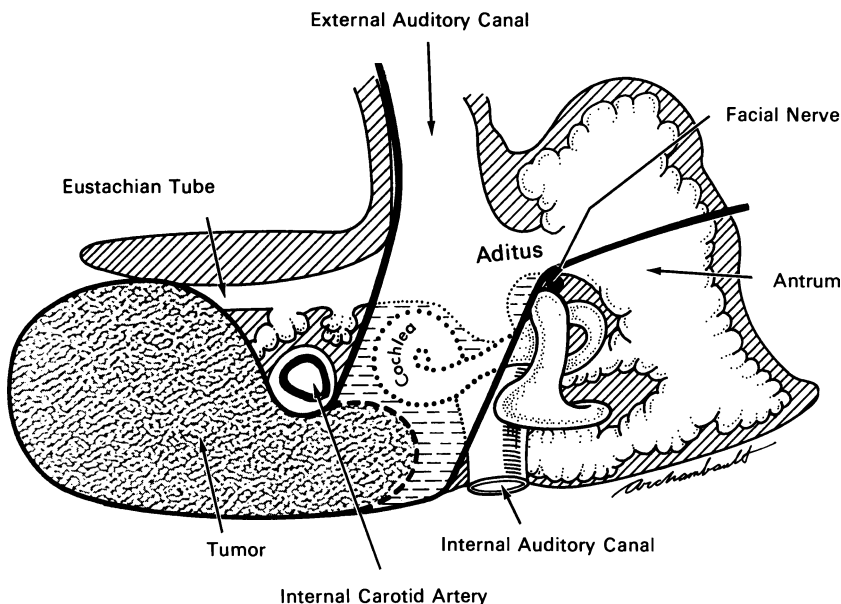
The technique of fistulization of the cystic lesion in the petrous apex depends on: (1) pneumatization of the temporal bone and surrounding pneumatized structures such as the sphenoid sinus, (2) the function of the labyrinth in the involved and uninvolved ears, and (3) the presence of infection in spaces that may be used to approach the lesion such as in the paranasal sinuses.

If the involved ear has severely depressed auditory function, then the transcochlear approach with or without mastoidectomy, depending on the presence of mastoid disease, is recommended (Fig. 5.16). Removal of bone between the internal carotid artery, jugular bulb, and middle fossa will permit the largest exposure of the petrous apex cyst. Bone should be removed anteriorly as far as the internal carotid artery, superi-

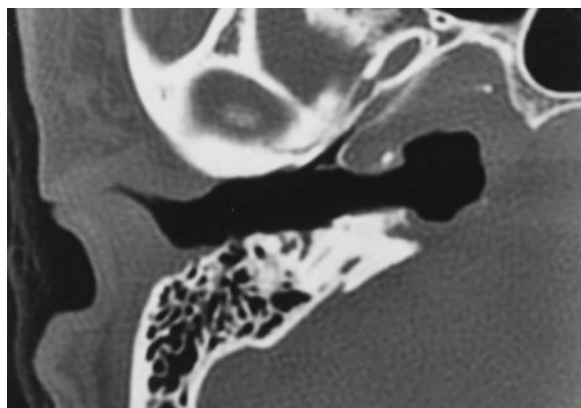
orly to the dura of the floor of the middle cranial fossa and/or fallopian canal, inferiorly to the dome of the jugular bulb, and posteriorly to the level of the vertical portion of the facial canal and cribose portion of the cochlea. Excision of all vestibular sense organs should be completed so that optimal recovery from the labyrinthectomy is permitted.

Wide fistulization of the petrous apex may require skin grafts and/or stents to insure patency. Split-thickness skin grafts should be applied to the surfaces of the bony tract leading from the cystic space to the skin of the external auditory canal. Such skin grafts should be maintained in place with packing for at least 10 days, until a proper vascular bed has provided viability for the grafts. An additional measure that may be used to fistulize the cyst is use of a large-bore soft stent (Silastic) that may be used over the long term until patency of the fistulous tract has been achieved. The transcochlear approach for fistulization of the petrous apex has the advantage of low risk from a potentially contaminated area such as the paranasal sinuses and a short working distance for periodic aspiration and debridement of the cystic space (Fig. 5.17).

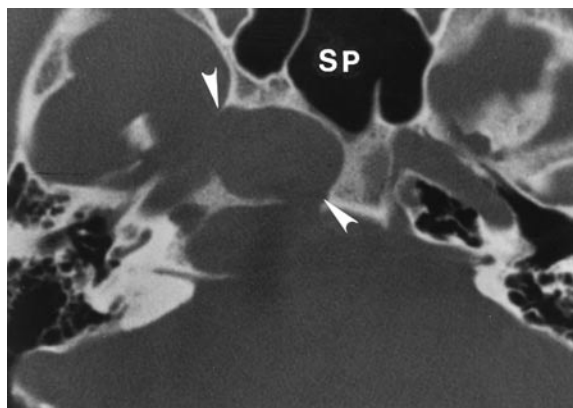
If labyrinthine function is normal in both ears, then consideration should be given to other anatomical routes for establishing a fistulous tract into the petrous apex cyst. If the sphenoid sinus is extensively pneumatized and the cystic lesion encroaches upon its posterior wall, then transthemoidal sphenoidotomy with



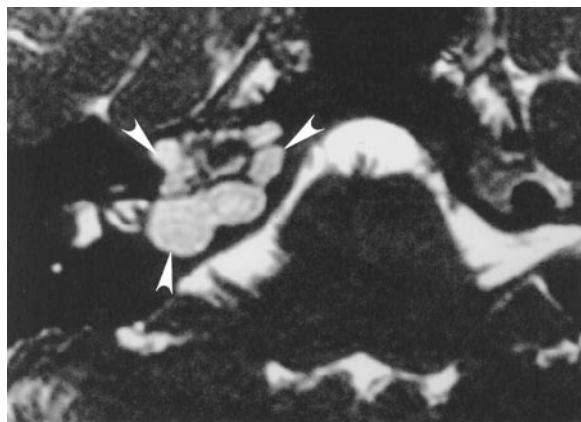
■ Fig. 5.16 Diagram of the transcochlear approach to permanent fistulization of cystic lesions in the petrous apex



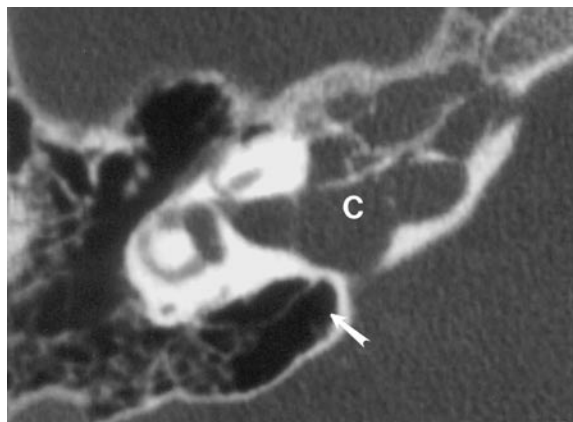
■ Fig. 5.17 Axial CT scan of a fistulized petrous apex cyst. The wall of the cyst reflects collapse



■ Fig. 5.18 Axial CT shows a cholesterol cyst (arrowhead), which was fistulized into the sphenoid sinus (SP) because of its anatomical presentation



■ Fig. 5.19 MRI of a cholesterol cyst in the petrous apex of a 26-year-old male shows the typical multilocular composition of the cyst (arrowhead)



■ Fig. 5.20 This axial CT of same patient demonstrates the proximity of the cyst (C) to a wide posteromedial cell tract (arrows). The cyst was fistulized into this cell tract via intact canal wall mastoidectomy

fistulization of the cyst is favored (Fig. 5.18). Insertion of a Silastic stent in the form of a collar button may be used to maintain patency of this method of fistulization [8]. A second route for perilabyrinthine fistulization of the petrous apex may utilize a well-developed infralabyrinthine cell tract [9] posterior to the internal carotid artery canal, inferior to the basal turn of the cochlea, and superior to the jugular bulb. However, the size of the infralabyrinthine tract depends on the location of the jugular bulb. Frequently, the diameter that is permitted by this cell tract is limited and requires long-term or permanent stenting to achieve successful

fistulization. If neither of these two routes is an available option in a patient with bilateral normal labyrinth function, then it is justified to destroy labyrinthine function in one ear by a transcochlear approach in order to limit progressive enlargement of cystic lesions, which is responsible for clinical deficits. Unusually a well-pneumatized mastoid compartment with a wide posteromedial cell tract will allow creation of a communication from the cyst into the mastoid compartment (Figs. 5.19, 5.20).

In the rare instance where there is no function in the contralateral ear, and the involved ear is an only

hearing ear, an approach should be selected that allows preservation of that function. Fistulization through an infralabyrinthine cell tract or sphenoid sinus carried out with permanent stenting should be used to maintain decompression of the cysts.

COMPLICATIONS TO AVOID

1. Expose the carotid artery and jugular bulb in the middle ear before approaching the petrous apex to avoid injury to these vessels.
2. Create as large a bony fistula as possible to the petrous apex with a skin-grafted lining to avoid stenosis of the fistula.

Pearl

- Cystic lesions of the petrous apex are controlled by fistulization.

References

1. Canfield RB (1913) Some conditions associated with the loss of cerebrospinal fluid. *Ann Otol Rhinol Laryngol* 22:604–622
2. Cole TB, McCoy G (1968) Congenital cholesteatoma of temporal bone and sphenoid sinus. *Arch Otolaryngol* 87:576–579
3. DeLozier HL, Parkins CW, Gacek RR (1979) Mucocele of the petrous apex. *J Laryngol Otol* 93:177–180
4. Dota T, Nakamura K, Shaheki M, Sasaki Y (1963) Cholesterol granuloma: experimental observations. *Ann Otol Rhinol Laryngol* 72:346–356
5. Franklin DJ, Jenkins HA, Horowitz BL, Coker NJ (1989) Management of petrous apex lesions. *Arch Otolaryngol* 115:1121–1125
6. Friedman I (1959) Epidermoid cholesteatoma and cholesterol granuloma: experimental and human. *Ann Otol Rhinol Laryngol* 68:57–79
7. Gacek RR (1975) Diagnosis and management of primary tumors of the petrous apex. *Ann Otol Rhinol Laryngol* 84(Suppl):1–20
8. Gacek RR (1980) Evaluation and management of primary petrous apex cholesteatoma. *Otolaryngol Head Neck Surg.* 88:519–523
9. Gherini SG, Brackmann DE, Lo WWM, Solti-Bohman LG (1985) Cholesterol granuloma of the petrous apex. *Laryngoscope* 95:659–664
10. House WF, Doyle JB Jr (1962) Early diagnosis and removal of primary cholesteatoma causing pressure to the 8th nerve. *Laryngoscope* 72:1053–1063
11. Kopetzky SJ, Almour R (1931) The suppuration of the petrous pyramid: pathology, symptomatology and surgical treatment. Part III. *Ann Otol Rhinol Laryngol* 40:396–414
12. Manin TS, Shimada T, Lim DJ (1970) Experimental cholesterol granuloma. *Arch Otolaryngol* 91:356–359
13. Montgomery WW (1977) Cystic lesions of the petrous apex: trans-sphenoid approach. *Ann Otol Rhinol Laryngol* 86:429–435
14. Sataloff RT, Myers DL, Roberts B-R, Feldman MD, Mayer DP, Choi HY (1988) Giant cholesterol cysts of the petrous apex. *Arch Otolaryngol* 144:451–453
15. Valvassori GE (1988) Diagnosis of retrocochlear and central vestibular disease by magnetic resonance imaging. *Ann Otol Rhinol Laryngol* 97:19–22
16. Valvassori GE, Guzman M (1988) Magnetic resonance imaging of the posterior cranial fossa. *Ann Otol Rhinol Laryngol* 97:594–598

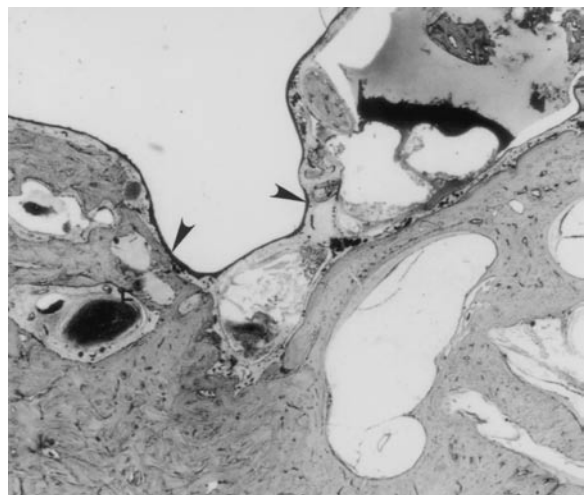
Core Messages

- Cholesteatoma may be acquired or congenital.
- Acquired cholesteatoma is the result of retraction pocket extension, invasion through a perforation, or trapped epithelium from a temporal bone fracture.
- Congenital cholesteatoma represents the isolation of squamous epithelial elements in the temporal bone during development. These are located in the middle ear, petrous apex, or mastoid compartment.
- As a rule, the cholesteatoma epithelial lining should be surgically removed although instances exist where marsupialization may prevent enlargement.

The term *cholesteatoma* implies the formation of a cystic lesion lined with keratinizing or exfoliating stratified squamous epithelium. These are generally classified into *acquired* or *congenital*. The acquired cholesteatoma is by far the more common seen in practice responsible for chronic otitis media and mastoiditis with drainage. Acquired cholesteatoma may result from a deepening retraction pocket usually in the pars flaccida region of the tympanic membrane, which extends into the epitympanum and further into the central mastoid tract [10]. Other regions of the middle ear space (hypotympanum, mesotympanum, sinus tympani, and facial recess) may also be invaded by extension of a cholesteatoma mass. The retraction pocket may also arise from the pars tensa, with extension into the mesotympanum or epitympanic space. The invasion of stratified squamous epithelium directly through a perforation in the pars tensa portion of the tympanic membrane may also result in middle ear and epitympanic cholesteatoma.

6.1 Acquired Cholesteatoma

Since a shallow retraction pocket lined with stratified squamous epithelium is not classified as cholesteatoma (Fig. 6.1), when the pocket deepens to the point where the aperture with which it communicates to the ear canal is small, a cholesteatoma is formed causing the accumulation of keratinaceous debris of stratified squamous epithelium [9, 10] (Fig. 6.2). The bone-erosive properties of cholesteatoma are generally thought to result from pressure exerted by the wall of the cholesteatoma with accumulated debris and/or by enzymatic compounds in the lining membrane that breaks down bone, particularly the collagen component [1, 7]. Secondary infection of the cholesteatoma debris may be responsible for chronic inflammatory changes in the surrounding tissues, as well as for the osteolytic properties of cholesteatoma. The acquired forms of cholesteatoma are well known to otologists and are covered in the section on surgery for chronic otitis media with cholesteatoma (Chap. 4).



■ Fig. 6.1 Photomicrograph of a retraction pocket (arrowheads) lined with stratified squamous epithelium. Note absence of keratin debris. F facial nerve

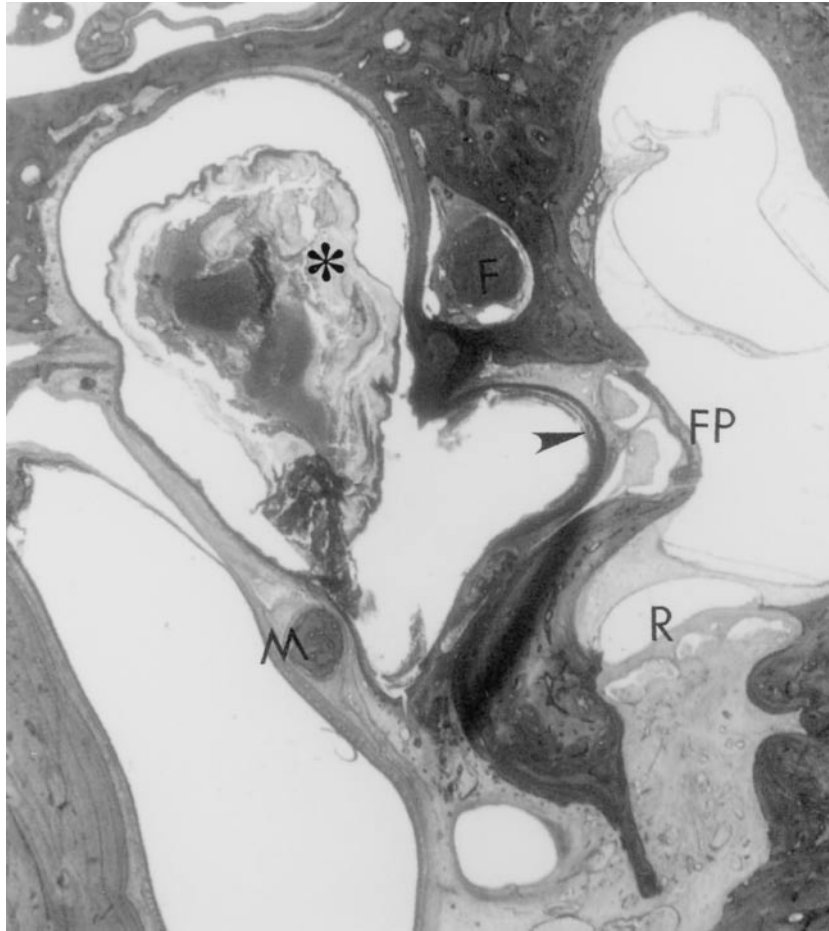


Fig. 6.2 Keratinaceous debris (*) fills this middle ear cholesteatoma, which has caused erosion of the crural arch of the stapes bone (arrowhead). FP stapes footplate, F facial nerve, M manubrium of the malleus, R round window membrane

6.2 Congenital Cholesteatoma

Congenital cholesteatoma on the other hand, is a cyst that forms as a result of misplaced squamous epithelial cells during development of the temporal bone, which later give rise clinically to a cholesteatoma cyst [6]. These have been described in the middle ear, in the petrous apex of the temporal bone, and in the mastoid compartment. Of these locations, the middle ear congenital cholesteatoma is by far the most frequent. It is thought that these middle ear cholesteatomas arise from remnants of epithelial tissue displaced in the embryonic development of the middle ear [6]. They are usually located in the anterior part of the middle ear and are not recognized until they are large enough to be visible on otoscopic examination. The temporal bone slide in Fig. 6.3 shows a fetal temporal bone in which an epithelial rest in the middle ear could give rise to a congenital cholesteatoma of the middle ear.

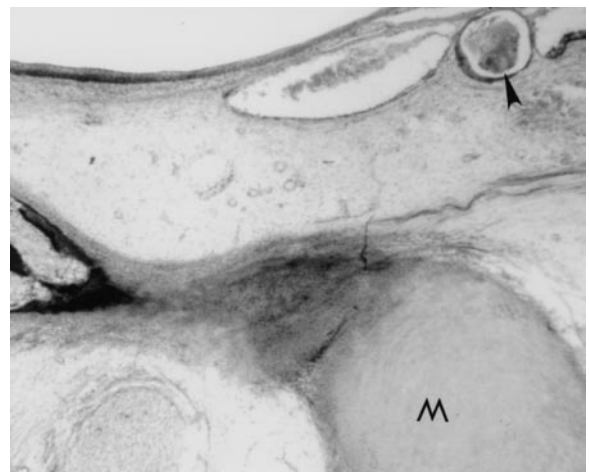
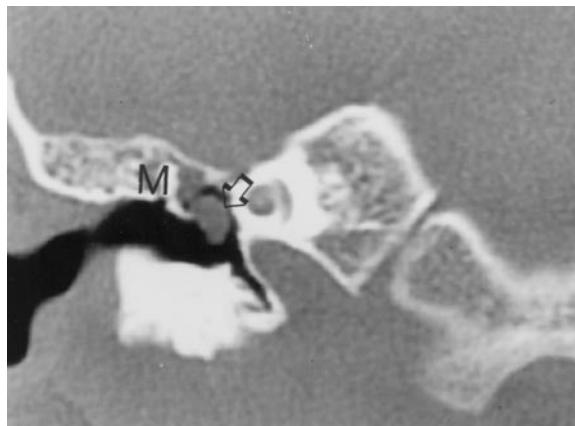


Fig. 6.3 Arrow points out small epidermal cyst in the middle ear mucosa of a fetal temporal bone. M Malleus

These congenital cholesteatomas are frequently recognized on routine examination by astute examiners in the pediatric or medical specialties. The appearance of a whitish mass usually associated with the manubrium of the malleus behind an intact tympanic membrane without middle ear effusion is the typical clinical presentation. CT of the temporal bone confirms the middle ear location of such a mass (Fig. 6.4). Since these congenital cholesteatomas are destined to enlarge risking involvement (necrosis) of middle ear structures, removal is recommended by an extended tympanotomy approach [5]. Video demonstrates the surgical removal of a congenital middle ear cholesteatoma. Because of the close attachment to the manubrium of the malleus, it is often necessary to transect and resect a portion of the manubrium while retaining the lever properties of the ossicular chain. Despite complete removal by the surgical approach, follow-up examinations should be maintained for at least 5–10 years after surgery.

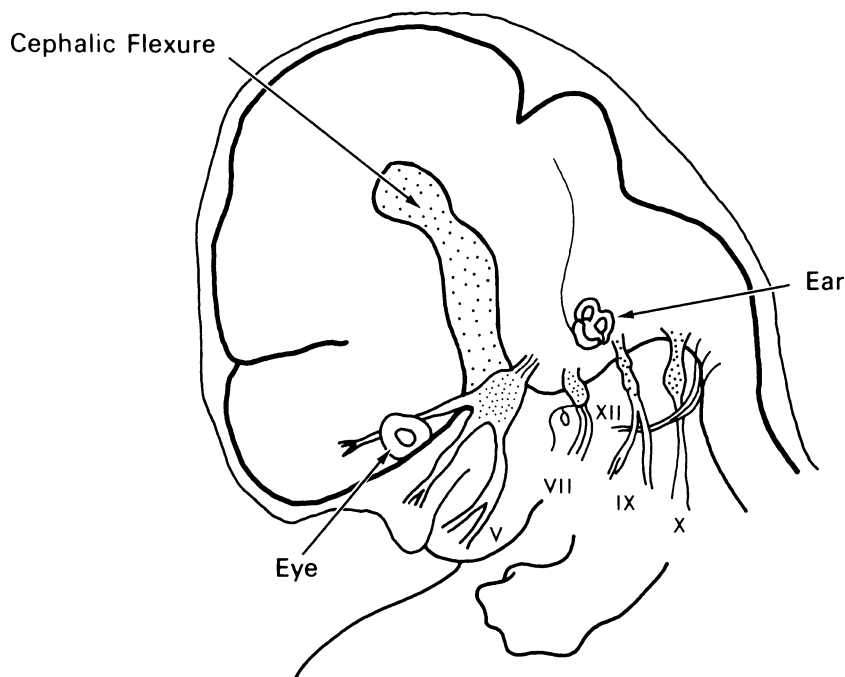
Congenital cholesteatoma in the petrous apex is reflected in clinical symptoms related to an expanding petrous apex lesion, as discussed in Chap. [3]. These symptoms are compression of the Eustachian tube with serous otitis media, deficits of cranial nerves V,

VI and rarely, of the nerves related to the jugular foramen. Pain is another symptom associated with an expanding lesion in this area, which is best demonstrated by imaging techniques including CT and MRI. Anatomical features of a cystic lesion in this area are covered in the previous chapter.

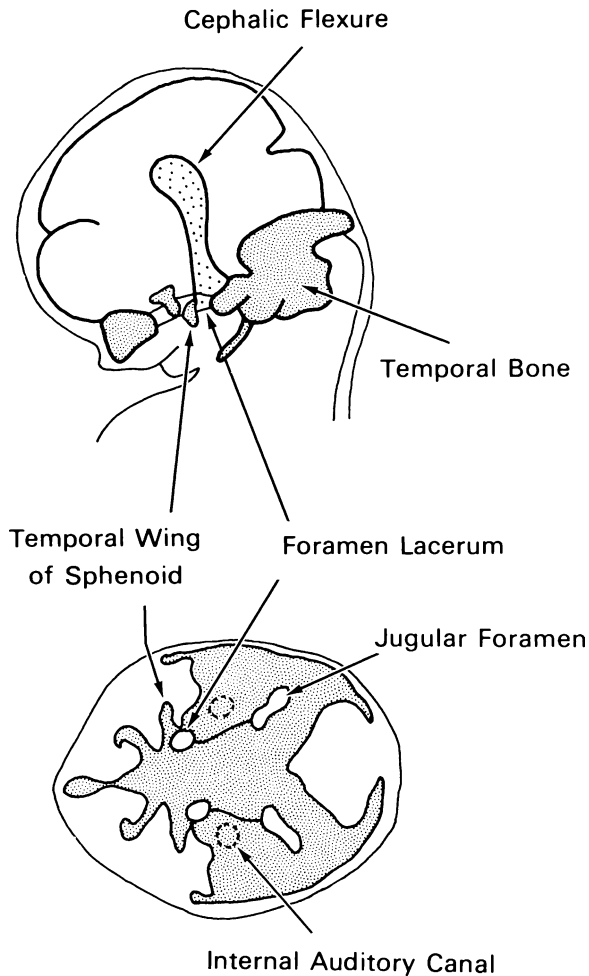


■ Fig. 6.4 Coronal CT confirms a congenital cholesteatoma (arrow) attached to the malleus

Drawing of Trigeminal ganglion and relationship to Cephalic Flexure, eye and ear



■ Fig. 6.5 The base of the cephalic flexure is located medial to the trigeminal nerve ganglion



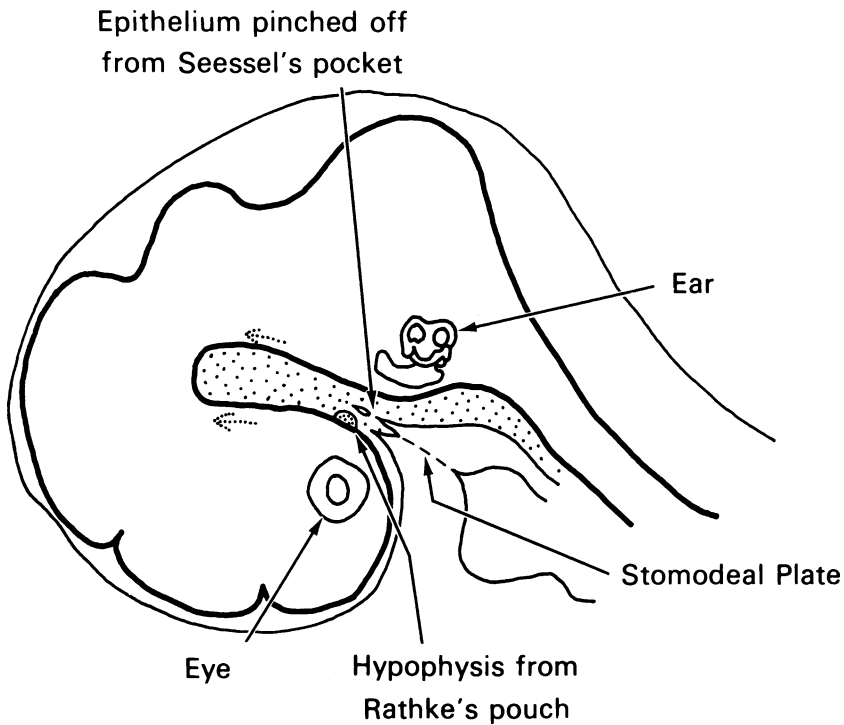
■ Fig. 6.6 As ossification forms the skull base, the foramen lacerum is filled with cartilage as the remnant of mesenchyme in the cephalic flexure

It is thought that the epithelial rests responsible for a primary epidermoid in the petrous apex are located in the foramen lacerum, which is filled with embryonic mesenchyme of the cephalic flexure [2] (Figs. 6.5, 6.6), eventually filling the foramen with cartilage. Epithelial remnants separated from invaginations at the stomodeal plate region near Rathke's pouch and Seessel's pocket maybe responsible for these cell rests (Fig. 6.7). Congenital epidermoids in the petrous apex usually present clinically in patients in the third and fourth decades. It is at this point that the cystic lesions acquire significant size to cause deficits by compression of the structures in the petrous apex.

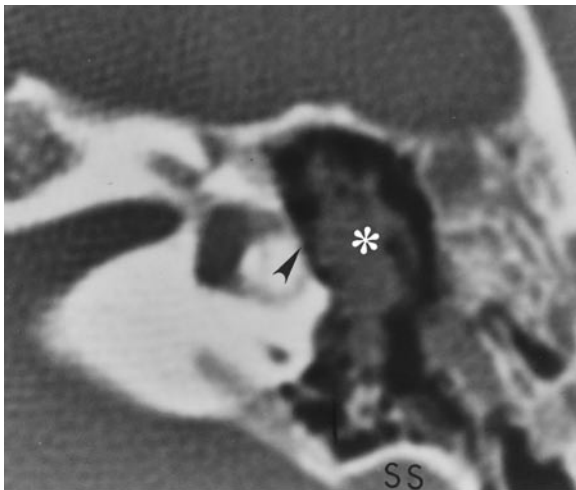
Since the lining of the primary epidermoid is virtually unresectable at the skull base because of adherence to important structures such as the middle and posterior fossa dura, and the internal carotid artery wall, the recommended treatment of the petrous apex epidermoid is permanent fistulization to the middle ear and ear canal through an epithelial lined tract.

A third location for primary epidermoid, much less common than the previous two, is in the mastoid compartment. These have been reported usually in adults, with symptoms related to mastoiditis without involvement of the middle ear compartment [4]. It is typical of these patients to present with recurrent vertigo because of fistulization of the lateral semicircular canal but with a normal middle ear and normal hearing (Fig. 6.8). After CT of a temporal bone demonstrates lateral canal fistula, cholesteatoma can be confirmed by surgical exploration, which is clearly separated from the middle ear or epitympanic space. These patients have been described as representing a primary cholesteatoma from epithelial remnants in the mastoid compartment. However, there is a subset of such patients where a defect in the posterior bony ear canal wall can be identified near the tympanomastoid suture (Fig. 6.9). A history of head injury earlier in life in these suggests that the primary epidermoid may be secondary to entrapment of stratified squamous epithelium in the tympanomastoid suture line. Therefore, although primary epidermoid in the mastoid compartment is possible, isolated mastoid cholesteatomas may be more likely the result of posttraumatic entrapment of squamous epithelium of ear canal skin in the tympanomastoid suture line.

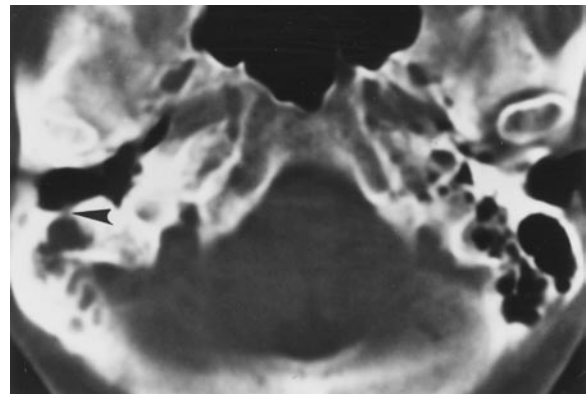
An unusual type of cholesteatoma is that related to the size of the ear canal [8]. In ear canals with a congenitally small external meatus and a normal size bony ear canal, or in patients where the external auditory meatus has become stenosed as a result of an inflammatory or traumatic lesion, the stratified squamous epithelium of the bony ear canal skin may accumulate keratin, forming a canal cholesteatoma (Fig. 6.10). Such a canal cholesteatoma may have the same bone erosive properties as middle ear cholesteatoma and produce medial displacement of the tympanic membrane with subsequent atelectasis of the middle ear. Ossicular chain discontinuity can also be an end result of a canal cholesteatoma. This cholesteatoma (keratoma obturans) is formed because of a congenital anatomical basis, but can be controlled by surgical enlargement (canalplasty) of the cartilaginous canal and external auditory meatus.



■ **Fig. 6.7** Epithelial remnants from Seessel's pocket may become isolated in the mesenchyme of the cephalic flexure, giving rise to congenital epidermoids of the petrous apex



■ **Fig. 6.8** Congenital cholesteatoma (*) in the mastoid of a 25-year-old female presented with recurrent vertigo and a normal-hearing middle ear. *Arrowhead* points to fistula of lateral semicircular canal. *SS* sigmoid sinus



■ **Fig. 6.9** This cholesteatoma of the mastoid in a 90-year-old female also presented with recurrent vertigo and a normal drum. There was a history of head injury more than 30 years previously. A large lateral canal fistula was found at surgery, and cholesteatoma was limited to the mastoid. *Arrowhead* points to a defect in the posterior wall of ear canal representing separation of the tympanomastoid suture

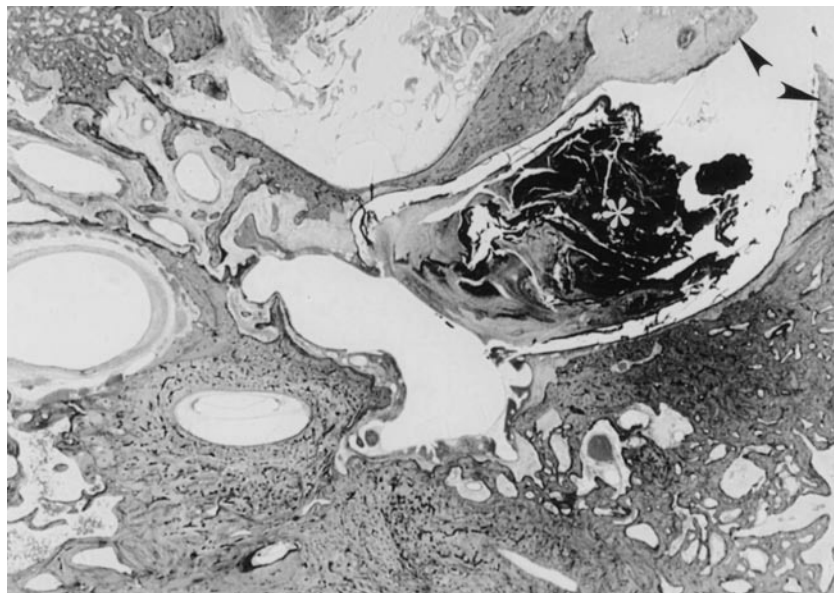


Fig. 6.10 Horizontal temporal bone section demonstrates a canal cholesteatoma (*) secondary to stenosis of the cartilaginous external auditory canal (arrowheads)

COMPLICATIONS TO AVOID

1. Remove cholesteatoma membrane completely to avoid recurrence.
2. Avoid exposing the subarachnoid space to cholesteatoma prevents a chemical meningitis.

Pearl

- After removal of cholesteatoma from the mastoid, drill the bony surfaces lightly to eliminate microscopic foci of squamous epithelium.

References

1. Chole RA (1984) Cellular and subcellular events of bone resorption in human and experimental cholesteatoma: the role of osteoclasts. *Laryngoscope* 94:76–95
2. Gacek RR (1975) Diagnosis and management of primary tumors of the petrous apex. *Ann Otol Rhinol Laryngol* 84:1–20
3. Gacek RR (1980) Evaluation and management of primary petrous apex cholesteatoma. *Otolaryngol Head Neck Surg* 88:519–523
4. Gacek RR (2005) Unpublished observation.
5. Heumann H (1989) Cholesteatoma in childhood, surgical treatment and results. In: Tos M, Thomsen J, Peiterson E (eds) *Cholesteatoma and mastoid surgery*. Kugler & Ghedini, Amsterdam, pp 671–676
6. Levenson MJ, Michaels L, Parisier SC, Juarbe C (1988) Congenital cholesteatoma in children: an embryological correlation. *Laryngoscope* 98:949–955
7. Morigama H, Huang CC, Abramson M, Kato M (1984) Bone resorption factors in chronic otitis media. *Otolaryngol Head Neck Surg* 92:322–328
8. Piepergerdes MC, Kramer BM, Behnke EE (1980) Keratosis obturans and external auditory canal cholesteatoma. *Laryngoscope* 90:383–391
9. Portmann M (1982) Surgery of retraction pockets versus attic cholesteatoma. In: Sade J (ed) *Cholesteatoma and mastoid surgery*. Kugler & Ghedini, Amsterdam, pp 509–510
10. Sade J (1982) Treatment of retraction pockets and cholesteatoma. In: Sade J, ed. *Cholesteatoma and mastoid surgery*. Kugler & Ghedini, Amsterdam, pp 511–525

Core Messages

- Obstructive lesions of the external auditory canal require surgical management when conductive hearing loss, retained epithelial debris, and recurrent canal infection is present.
- Surgical method requires adequate enlargement of the bony and cartilaginous segments with re-epithelialization employing skin flaps or split thickness skin grafts.

Obstructive lesions of the external auditory canal, requiring surgical correction, are primarily of three types.

7.1 Bony Lesions

Bony lesions of the ear canal (osteoma, exostosis) are the most common of these obstructive lesions. Os-

teoma, usually solitary, has the normal structure of periosteal bone and is uncommonly large enough to cause obstruction of the ear canal, leading to accumulation of debris and/or cholesteatoma in the deep ear canal [5, 7]. Exostosis on the other hand, are more common, represent the formation of usually three locations of laminated periosteal bone in the external auditory canal. The histologic make up of exostoses is shown in Fig. 7.1. It is thought that since these occur in patients who have the practice of swimming in very cold water that the periosteal irritation from such a cold stimulus promotes the laying down of periosteal bone matrix in a repeated fashion leading to the gradual enlargement of bony lesions in the ear canal [21]. While of no clinical significance when they are small, as they become large enough to cause recurrent entrapment of cerumen and/or debris in the deep ear canal, repeated external canal infection occurs (Fig. 7.2). Rarely, they may cause complete obstruction of the lumen of the bony ear canal and a conductive hearing loss. These are the primary indications for surgical removal.

Removal is performed through an endaural approach under general anesthesia, with preservation

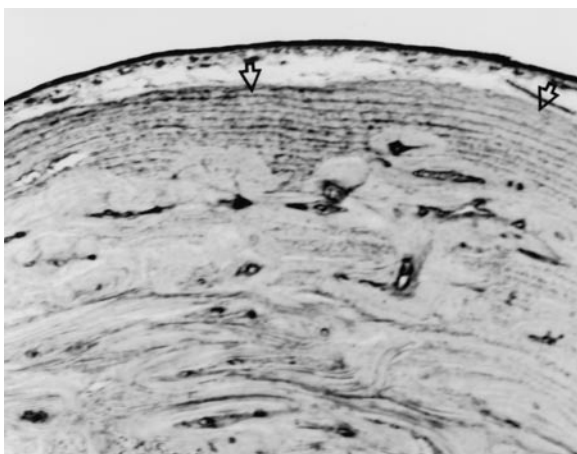


Fig. 7.1 The histological composition of external canal exostosis reflects multiple periosteal bone insults with the deposition of bone matrix (*arrows*)

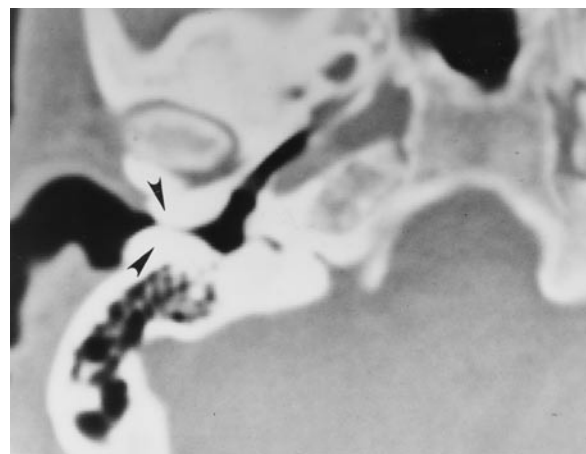


Fig. 7.2 Axial CT scan demonstrates near obstruction of the external canal lumen by exostosis (*arrowheads*)

of as much ear canal skin both laterally and medially to the location of the exostoses. The exostoses are removed with a rotating burr, first with a cutting burr, and finally with a diamond burr when nearing the tympanic membrane. The diamond burr is used to hollow out the rounded exostosis, leaving a shell-like cover. These thin bony portions of the exostoses can then be removed with a curette and/or small diamond burrs. It is important to avoid contact with the manubrium or the lateral process of the malleus when drilling in the deep ear canal to avoid transmitted energy to the labyrinth causing sensorineural hearing loss [18]. Sufficiently large canal wall skin flaps can be preserved to allow for adequate coverage of the exposed canal bone. If this is not possible, then the application of split-thickness skin grafts to bone, held in place with packing for at least 1 week to 10 days is effective. This surgical exercise is demonstrated in accompanying video.

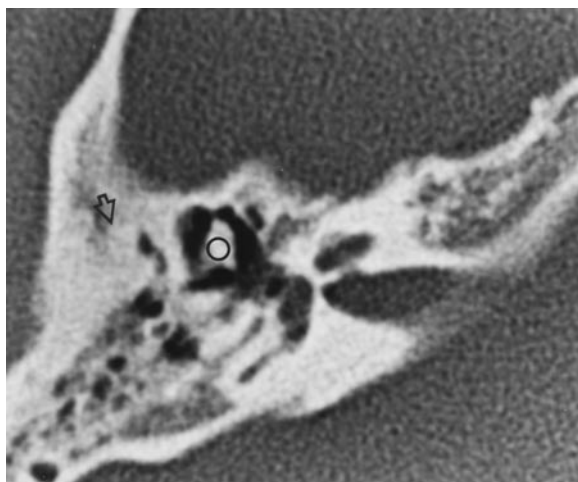
7.2 Congenital Aural Atresia

Congenital aural atresia may affect the external auditory canal by merely causing a narrow canal with a small external meatus, a normal bony canal with a small external meatus, or in its fullest expression, complete absence of the bony and cartilaginous canal. This congenital lesion may occur unilaterally or bilaterally [8, 9, 14, 20]. When it is bilateral, the indications for surgical correction are clear-cut and are usually carried out at the age of 5 or 6 years, when the

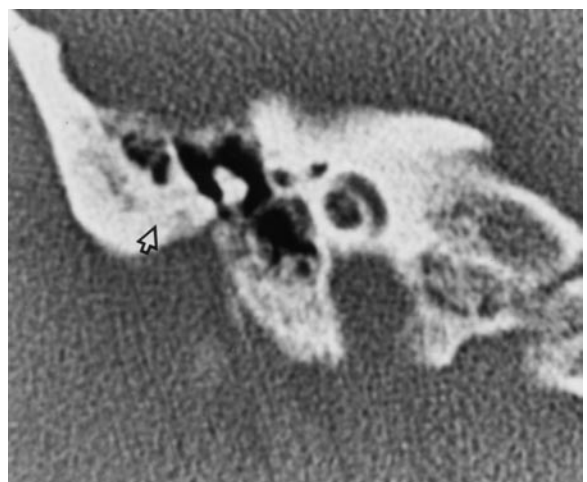patient is more capable of tolerating the postoperative care involved and the mastoid compartment has been fully pneumatized. The usual criteria in a candidate for this surgery is that they have a pneumatized middle ear and mastoid compartment, that there is a normally developed labyrinth with evidence of normal bone conduction, and that parts of the ossicular chain, that is the malleus and the incus are visible on CT scanning [10] (Fig. 7.3).

Generally, two approaches have been used to correct the congenital atresia. One is a posterior approach through the mastoid compartment, identifying the central mastoid tract and then performing a canal wall down mastoidectomy with the middle ear [20]. However, this surgical approach, while offering a wide exposure of possible anomalous middle ear and facial nerve structures, leaves a patient with a mastoid cavity to care for with attendant water precautions and potential for recurrent infection.

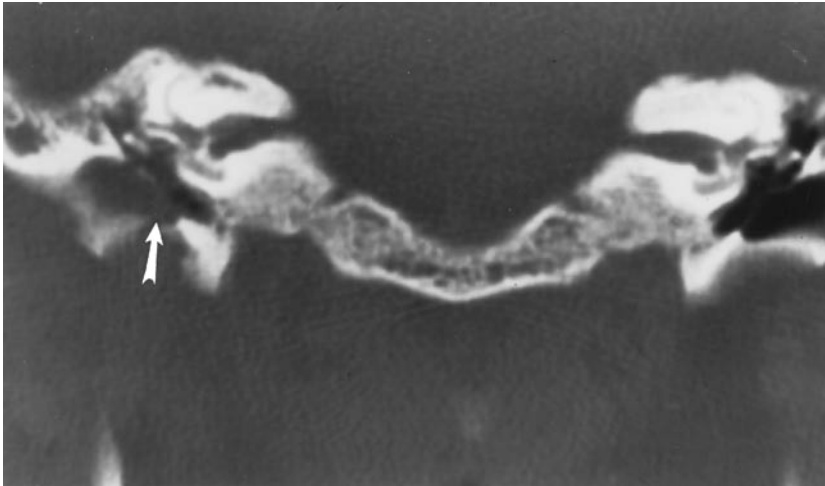
A preferred approach is the anterior one, following the middle fossa dura medially to the epitympanic recess of the middle ear (Fig. 7.4). An endaural soft tissue approach is used [10]. The head of the malleus and the body of the incus are identified in the epitympanum, and the new ear canal is created by drilling bone from the epitympanum anteriorly and inferiorly. With this approach, the facial nerve is not at any increased risk, and a satisfactory bony ear canal can be created in an orderly fashion. Split-thickness skin grafts are used to line the newly created ear canal, and temporalis fascia is used as grafting material for a new tympanic mem-



■ Fig. 7.3 Axial CT of external canal bony atresia (arrow), with pneumatized middle ear and mastoid. O ossicles



■ Fig. 7.4 Coronal CT demonstrates absence of the tympanic bone (arrow)



■ **Fig. 7.5** Coronal CT in a patient with necrotizing external otitis and facial paralysis demonstrates erosion of the floor of the osseous external canal (*arrow*)

brane. The ossiculoplasty is dependent on the presence of usable ossicles in the middle ear [4]. If a malleus is present along with the incus, then releasing the manubrium of the malleus from the bony ear canal will mobilize the ossicular chain and provide an effective way of providing good hearing by way of a type II tympanoplasty. It is crucial that skin grafts be applied to all surfaces in the bony and cartilaginous canal as well as the lateral surface of the tympanic membrane fascial graft to prevent fibrous stenosis of the newly created ear canal. The issue of reconstruction of the auricle is dependent on the degree of aplasia or hypoplasia of the auricle and of the willingness of the patient and family to undergo the multiple procedures necessary to recreate a cosmetically acceptable auricle [10].

7.3 Stenosing Chronic External Otitis

An obstructive lesion of the ear canal not usually recognized as a surgical condition is the fibrosing chronic external otitis [17, 22]. A chronic inflammatory process in the ear canal skin may be responsible for not only pain and discharge refractory to medical treatment, but also for a conductive hearing loss. Recognition of canal stenosis as a result of recurrent or chronic external otitis as well as hearing loss from thickening of the tympanic membrane can be confirmed with CT. The anatomical structures responsible for the retention of offending organisms are hair follicles and ceruminous glands located in the cartilaginous segment of the ear canal. The definitive recommended treatment is excision of the involved skin and soft tissue

of not only the external cartilaginous canal, but also of the bony canal and the lateral surface of the tympanic membrane. This procedure is shown in an accompanying video. Following removal of the fibrous and epithelial components of the ear canal, the application of split-thickness skin grafts held in place with a bolus-type dressing (rosebud dressing) is effective in not only controlling the symptoms of external otitis, but also in correction of the conductive hearing loss caused by this ear canal lesion.

7.4 Necrotizing External Otitis

Necrotizing or malignant external otitis is a potentially lethal form of osteitis of the ear canal, which occurs in immunocompromised patients, particularly elderly diabetics, by the organism *Pseudomonas aeruginosa*. This pathologic entity first described by Keleman and Meltzer [13] was more fully described with effective management by Chandler [1, 3] in the 1960s. Although the progressive osteitis responsible for this ear canal infection occurs in the floor of the bony ear canal with the capability of extension to the base of the skull, its lethal nature results from involvement of the major vascular and neural structures in this area [6, 16]. The primary treatment is by effective antibiotics delivered intravenously as well as topically. Gentamycin has been shown to be an effective topical antibiotic in the area of involvement in the ear canal while the preferred systemic antibiotic is ciprofloxacin [11, 12, 15, 19]. Gentamycin used systemically is held in reserve if ciprofloxacin is ineffective because of the

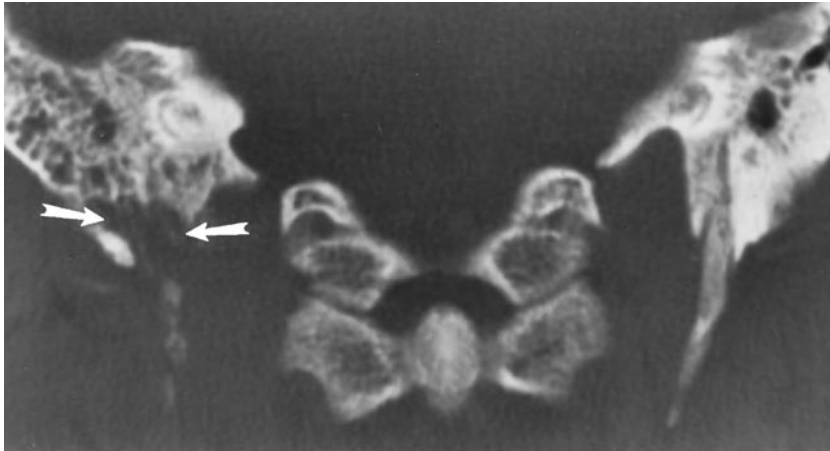


Fig. 7.6 A more posterior view through the temporal bone revealed erosion of bone around the fallopian canal (arrows)

potential ototoxic properties of gentamycin. The CT image in Fig. 7.5 demonstrates bony destruction in the floor of the external ear canal of a patient with malignant external otitis and facial paralysis caused by involvement of the descending fallopian canal near the stylomastoid foramen (Fig. 7.6). When a cranial nerve such as the facial nerve is involved by the process, surgical curettage of diseased bone and removal of granulation tissue is helpful for the resolution of this most serious of external ear infections [2].

COMPLICATIONS TO AVOID

1. In the removal of exostoses of the external ear canal, avoid contact of the lateral process of the malleus with the drill to prevent sensorineural hearing loss.
2. Use split-thickness skin grafts to re-line the enlarged bony ear canal following canalplasty to prevent stenosis.
3. Surgery to correct congenital aural atresia should follow the level of the middle cranial floor to avoid facial nerve injury.
4. Avoid drill contact of the malleus fused to the atresia plate to prevent sensorineural hearing loss.

Pearl

- Canalplasty with split-thickness skin grafting is useful in the treatment of ear canal lesions.

References

1. Chandler JR (1968) Malignant external otitis. *Laryngoscope* 78:1257–1294
2. Chandler JR (1972) Pathogenesis and treatment of facial paralysis due to malignant external otitis. *Ann Otol Rhinol Laryngol* 81:648–658
3. Chandler JR (1977) Malignant external otitis: further considerations. *Ann Otol Rhinol Laryngol* 86:417–428
4. Crabtree JA (1968) Tympanoplastic techniques in congenital atresia. *Arch Otolaryngol* 88:63–70
5. DiBartolomeo JR (1979) Exostoses of the external auditory canal. *Ann Otol Rhinol Laryngol* 88(Suppl):1–20
6. Faden A (1975) Neurological sequelae of malignant external otitis. *Arch Neurol*. 32:204–205
7. Graham MD (1979) Osteomas and exostoses of the external auditory canal: a clinical, histopathologic and scanning electron microscopic study. *Ann Otol Rhinol Laryngol* 88:556–572
8. House HP (1953) Management of congenital ear canal atresia. *Laryngoscope* 63:916–946
9. Jafek BW, Nager GT, Strife J, Gayler RW (1975) Congenital aural atresia: an analysis of 311 cases. *Trans Am Acad Ophthalmol Otolaryngol* 80:588–595
10. Jahrsdoerfer RA, Hall JW III (1986) Congenital malformations of the ear. *Am J Otol* 7:267–269
11. Levy R, Shpitzer T, Shvero J, Pitlik SD (1990) Oral ciprofloxacin as treatment of malignant external otitis: a study of 17 cases. *Laryngoscope* 100:548–551
12. Mader JT, Love JT (1982) Malignant external otitis—cure with adjunctive hyperbaric oxygen therapy. *Arch Otolaryngol* 108:38–40
13. Meltzer PE, Kelemen G (1959) Pyocyanous osteomyelitis of the temporal bone, mandible and zygoma. *Laryngoscope* 69:1300–1316
14. Meurman Y (1957) Congenital microtia and meatal atresia: observations and aspects of treatment. *Arch Otolaryngol* 66:443–463
15. Meyer BR, Mendelson MH, Parisier SC, Hirschman SZ (1987) Malignant external otitis—comparison of monotherapy vs. combination therapy. *Arch Otolaryngol Head Neck Surg* 113:974–978

16. Nadol JB Jr (1980) Histopathology of *Pseudomonas* osteomyelitis of the temporal bone starting as malignant external otitis. Am J Otolaryngol 1:359–371
17. Nadol JB, Schuknecht HF (1993) Surgery of the ear and temporal bone. Raven, New York
18. Paparella MM (1962) Acoustic trauma from the bone cutting bur. Laryngoscope 72:116–26
19. Raines JM, Schindler RA (1980) The surgical management of recalcitrant malignant external otitis. Laryngoscope 90:369–378
20. Schuknecht HF (1989) Congenital aural atresia. Laryngoscope 99:908–917
21. Schuknecht HF (1993) Pathology of the ear. In: Disorders of the bone. Lea & Febiger, Philadelphia
22. Tos M, Balle V (1986) Post inflammatory acquired atresia of the external auditory canal: late results of surgery. Am J Otol 7:365–370

Core Messages

- Two categories of spontaneous cerebral spinal fluid otorrhea: (1) pediatric: ages 1–5 years, (2) adult: over 50 years of age
- Pediatric preformed pathways are:
 - Enlarged fallopian canal
 - Patent tympanomeningeal (Hyrtrl's) fissure
 - Mondini dysplasia with communication to internal auditory canal
- The adult form is caused by enlarging arachnoid granulations through the middle fossa or posterior fossa surfaces of the temporal bone.
- CT (1-mm cuts) of the temporal bone in both axial and coronal planes is best to demonstrate the bony defect and associated soft tissue mass.
- Surgical repair (middle fossa approach for tegmen defects; mastoidectomy for posterior fossa defects) with soft tissue repair is recommended.

While cerebral spinal fluid otorrhea (CSFO) secondary to head trauma and surgery is usually expectant and obvious, spontaneous cerebral spinal fluid otorrhea (SCSFO) is frequently overlooked because it may be subtle and intermittent. Both types require a defect in dura mater that normally represents a substantial barrier to the spread of inflammatory and neoplastic disease from the middle ear and mastoid compartments. Traumatic tears in the dura mater are responsible for the former type, but the latter are caused by congenital dural defects that may be divided into two groups. In one type, a preformed bony pathway around or through the bony labyrinth allows the higher subarachnoid pressure to communicate with the middle ear as a result of herniation of dura (meningocele) or erosion through the labyrinthine windows because of an absent or thin bony barrier to the middle ear [8, 13,

16, 18, 26]. This form of SCSFO usually presents early in life, from the ages of 1 to 5 years.

The clinical presentation is usually meningitis after acute otitis media or as serous otitis media (SOM), which is resistant to medical treatment. The presence of CSF in the middle ear is often first recognized after myringotomy. Three such preformed pathways have been described [8, 13, 16, 18, 26]: (1) enlarged petrosal fallopian canal (Fig. 8.1); (2) patent tympanomeningeal (Hyrtrl's) fissure (Fig. 8.2); and (3) communication of the internal auditory canal with the vestibule (Mondini dysplasia) (Fig. 8.3). The fallopian canal herniation of the subarachnoid space may be responsible for SCSFO in the adult, while all three pathways have been shown to cause SCSFO in the pediatric age group. A contrast CT examination is an effective technique to document a preformed pathway for CSF leak into the temporal bone (TB).

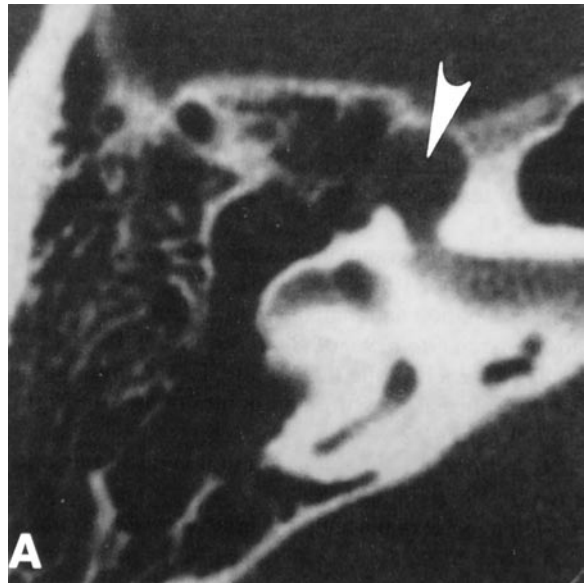


Fig. 8.1 Axial CT scan of enlarged fallopian canal in the epitympanum (*arrowhead*) representing the potential for spontaneous cerebral spinal fluid leak into the middle ear

The second type of congenital defect manifests itself clinically later in life (after age 50 years) because the congenital structures (arachnoid villi) carrying CSF enlarge with increased age and physical activity as a result of intermittent subarachnoid pressure [7, 9, 10, 12, 22]. This pulsatile pressure is capable of bone erosion over the course of many years [10, 11]. If the bone erosion occurs over a pneumatized part of the skull such as the TB or paranasal sinuses, then CSF otorrhea or rhinorrhea may develop [9, 10]. The clinical presentation is usually unilateral SOM, which at first is recurrent but eventually is persistent [1, 20, 23, 24].

SCSFO in the adult age group may be frequently overlooked when the CSF leak is slow and intermittent.

The reports of surgically repaired adult SCSFO have described a tissue mass as glioma, meningomyelocele, or encephalocele [17, 23, 25] at the site of leak, which was controlled with surgical excision and repair. On the basis of TB review and histopathologic examination of surgical specimens removed from patients with adult onset SCSFO [9], we have concluded that the responsible congenital structures are arachnoid granulations (AG), which, in development, are aberrantly located over a pneumatized part of the skull (TB, paranasal sinuses) rather than invaginated in the intracranial venous system enclosed in dura (lateral, sigmoid sinus, petrosal, and sagittal).

AGs are formed during development of the subarachnoid space as the primary method of CSF resorption into the venous system [6, 19, 21, 27, 31]. They normally penetrate the dural wall of venous sinuses to lie within the vessel lumen. Forming a sponge-like arrangement of channels lined by arachnoid cell processes, AGs carry CSF driven by a higher pressure in the subarachnoid space to the lower intraluminal venous pressure [15, 31]. Passage of CSF into the venous lumen occurs through gaps between endothelial cells covering the AG and by pinocytosis through this cell layer [14, 30, 32].

It has been known for more than 70 years that a variable number of AGs do not find a venous termination in development, and after penetrating dura mater they come to lie against the bony surface of the skull where they may produce pitholes over a period of years [4, 11] (Fig. 8.4). Some AGs are surrounded by ossifying mesenchyme and become separated from

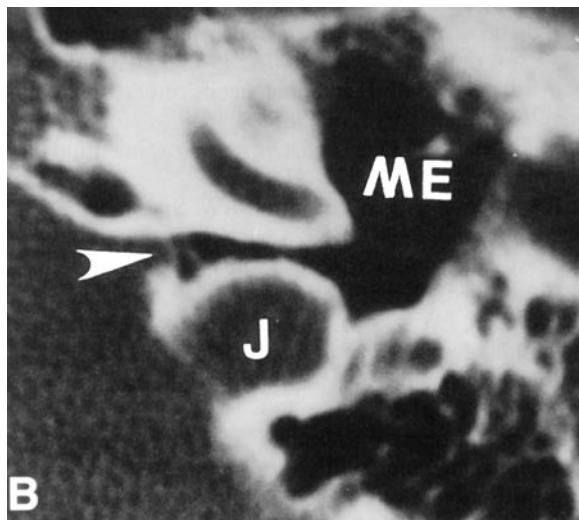
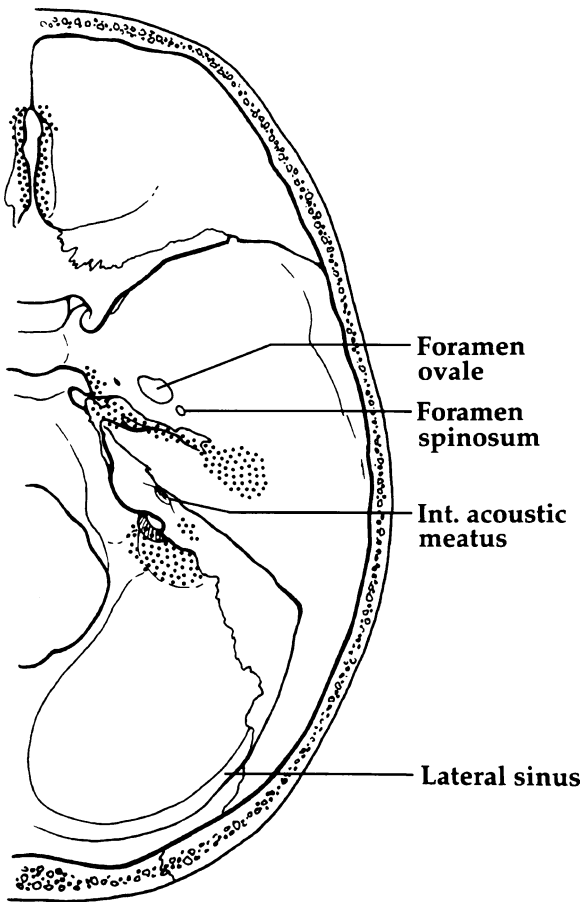


Fig. 8.2 Axial CT of the tympanomeningeal (Hyrtl's) fissure (arrowhead) between the jugular bulb (J) and the basal turn of the cochlea. ME middle ear

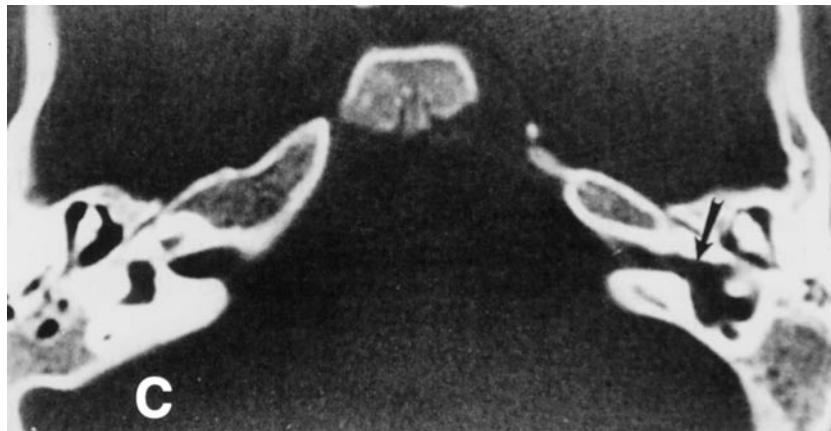

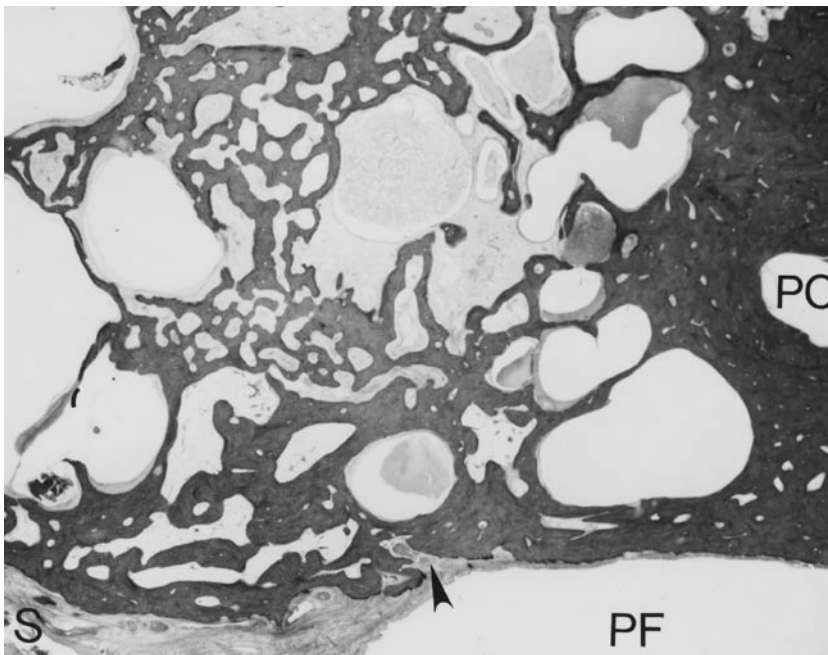
Fig. 8.3 Axial CT of Mondini malformation of the temporal bone in a 2-year-old boy with recurrent meningitis and CSF in the middle ear. Arrow points to defect between the internal auditory canal and the vestibule



the dural defect by a narrow stalk that passes through bone. The most common locations [4] for aberrant AGs are lateral to the cribriform plate in the anterior cranial fossa, and along the floor of the middle fossa from the tegmen tympani to the lateral surface of the sella turcica. Aberrant AGs may be infrequently located in the posterior fossa plate of the TB between the sigmoid sinus and bony labyrinth (Fig. 8.5) and in the region of the jugular foramen. There may be an increased incidence of the AG on the right side of the skull, which reflects a right side predominance of the venous system.

It is well known that AGs become larger and more complex with time. At least part of the reason for this change is the pulsation of CSF pressure that is increased in the upright position and with physical activity [14, 30]. The pressure from CSF pulsation over a long time is capable of eroding bone. Erosion of bone is not clinically significant unless it is located near a pneumatized part of the skull, such as the middle ear/mastoid (Fig. 8.6) or the paranasal sinuses (ethmoid and sphenoid) (Figs. 8.7, 8.8).

■ Fig. 8.4 Drawing of the inside of the skull base shows the location of aberrant arachnoid villi in the anterior, middle, and posterior cranial fossa (*stippled areas*)



■ Fig. 8.5 Horizontal temporal bone section shows the typical location for an arachnoid villus (*arrowhead*) in the posterior fossa surface of the mastoid. *PF* posterior fossa, *PC* posterior semicircular canal

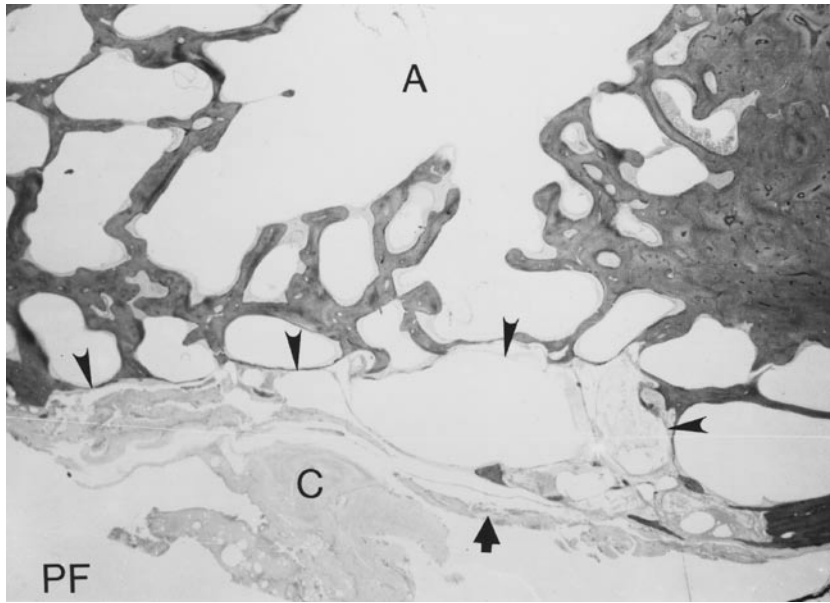


Fig. 8.6 This horizontal TB section shows a large cystic arachnoid granulation (C) that has eroded the bone of the mastoid cortex and trabeculae (arrowheads). PF posterior fossa, A mastoid antrum

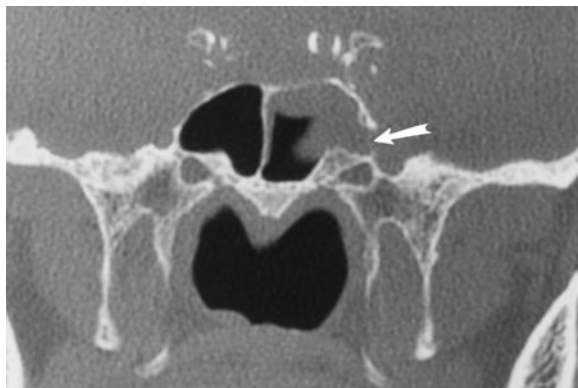


Fig. 8.7 Coronal CT through sphenoid sinus demonstrates herniation of an arachnoid granulation (arrow) responsible for cerebrospinal fluid rhinorrhea

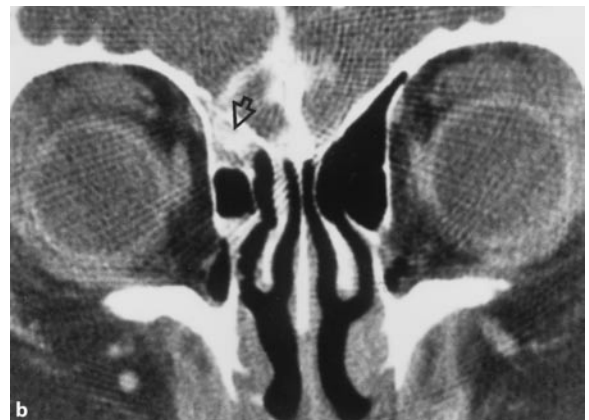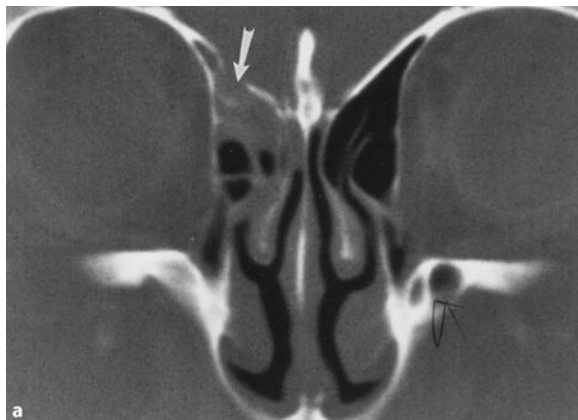
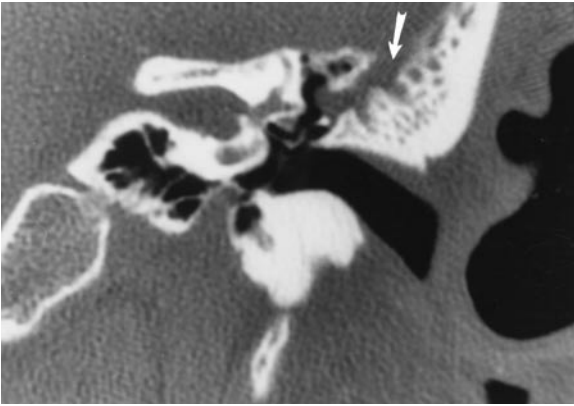


Fig. 8.8 a Herniation of arachnoid granulation (arrow) through the roof of ethmoid responsible for cerebrospinal fluid rhinorrhea. **b** Metrizamide contrast CT of patient in a demonstrates continuity of the subarachnoid space with the arachnoid granulation (arrow)



■ **Fig. 8.9** Coronal CT demonstrates soft tissue herniation into the mastoid antrum through a bony defect in the tegmen mastoidea (arrow)

CSF flow from such an AG may be slow and intermittent initially, presenting clinically as recurrent SOM. The CSF may dissect submucosally and distend mucosa, enhancing the appearance of a tissue mass (Fig. 8.9). Initially, perforation of the mucosa may intermittently leak CSF into the middle ear. If the bone erosion is extensive, reflecting a large AG, then the CSF leakage may be copious. Although the SOM is usually unilateral, bilaterality is possible because aberrant AGs are frequently symmetrical. Because AGs are far more numerous in the floor of the middle fossa [4] and the bony tegmen plate is usually thin [3], most reported cases of adult SCSFO are associated with an AG located in the roof of the epitympanum or mastoid compartment. Reports of a posterior fossa source for SCSFO are uncommon [10].

The diagnosis of SCSFO in the adult depends on a high index of suspicion. The late age at presentation supports the contention that AG enlarges with time to the point where they cause SCSFO in the adult. Every adult older than 50 years with a negative history of otologic disease who has refractory or recurrent SOM should be evaluated for SCSFO [11].

Undetected AGs in the TB may be partly responsible for an increased incidence of intracranial infection, particularly meningitis in patients older than age 60 years. A bimodal incidence of bacterial meningitis, one with a peak between 1 and 10 years and a second older than 50 years, has been demonstrated in several studies [28, 29]. In the series ($n = 164$) reported by Rasmussen et al. [29], more than half ($n = 88$) of the patients were older than 50 years, with 32 older

than 70 years. The most common source of infection in meningitis is the ear, with paranasal sinus infection second [2, 5]. An unrecognized AG may be responsible for bacterial meningitis in the elderly patient. This portal of entry in the TB has been documented histopathologically [10].

After elimination of neoplastic causes of unilateral SOM, a search for CSFO should be made. A flow of clear watery fluid after myringotomy is a strong indicator of subarachnoid communication to the middle ear cleft. A small amount of aspirate from myringotomy may be misleading, but should be considered as CSF if it recurs. Analysis of the aspirate for beta-2-transferrin will support a suspicion of CSFO. However, this test is an added expense and may be falsely negative.

A time and cost-efficient approach is to proceed with imaging of the TB or paranasal sinuses. CT (1-mm slices) of the TB or paranasal sinuses in coronal and axial planes is the most helpful study in locating the lesion responsible for SCSFO. CT is superior to MRI for the detection of bone erosion, which is the primary mechanism by which AG reach the middle ear cleft. CT is also sensitive in demonstrating the presence of a soft tissue mass in the middle ear or mastoid. Because AGs are most commonly located in the middle fossa, examination of the tegmen tympani and mastoid with coronal CT is most likely to reveal the source of CSF communication. The presence of a soft tissue mass near a dehiscence in the bony tegmen is strong evidence of AG CSFO (Fig. 8.10). If a dehiscence in bone is present but no tissue mass can be demonstrated on CT, then a repeat CT after intrathecal administration of contrast is useful to demonstrate an AG responsible for CSFO. Symptomatic AG located in the posterior fossa plate of the TB are uncommon (Figs. 8.11, 8.12). A TB review [10] found AGs, many of them small and asymptomatic, in 9% of TB. The cortical bone of the posterior fossa surface of the TB is thick and does not contain developmental dehiscences as in the tegmen. Localized erosion of cortical and trabecular bone in the posterior mastoid compartment indicates posterior fossa AGs.

Early diagnosis of AG CSFO is important to prevent the morbidity and mortality associated with bacterial meningitis (Fig. 8.13). Surgical repair is recommended regardless of age. The approach and method of repair of middle fossa and posterior fossa AG differs. Middle fossa craniotomy with extradural elevation of the temporal lobe avoids the sound transmission system and permits complete exposure and closure of the dural defect. Furthermore, additional asymptomatic AG in

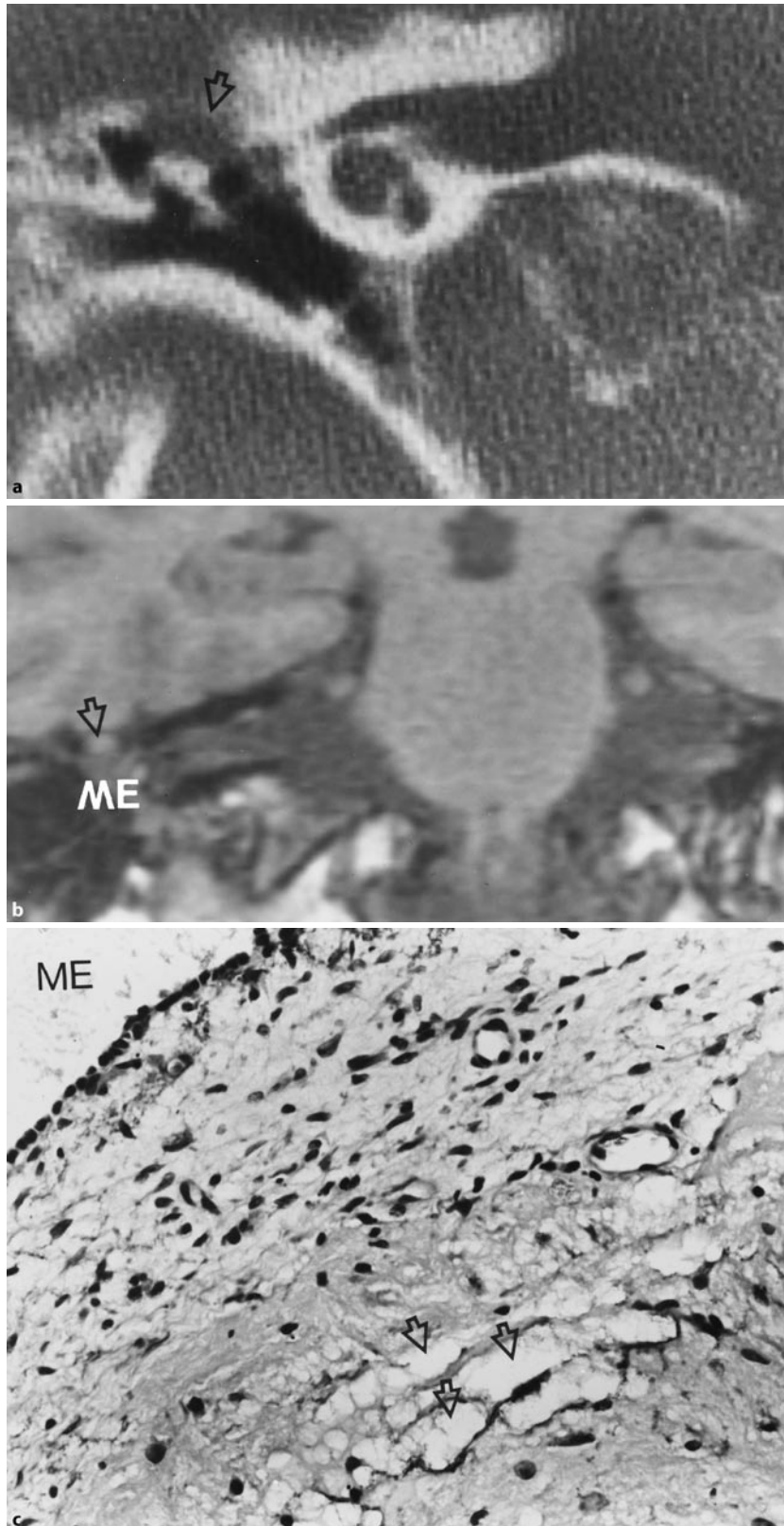
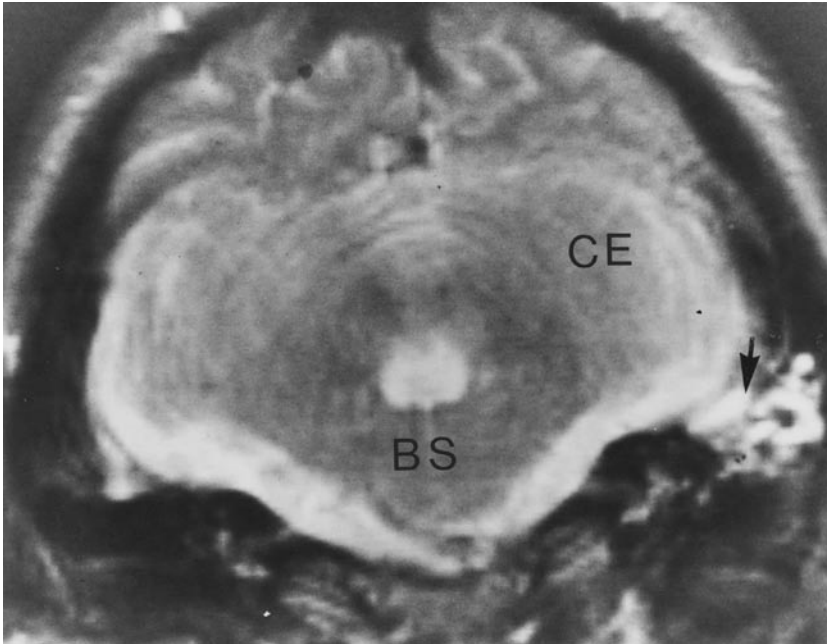
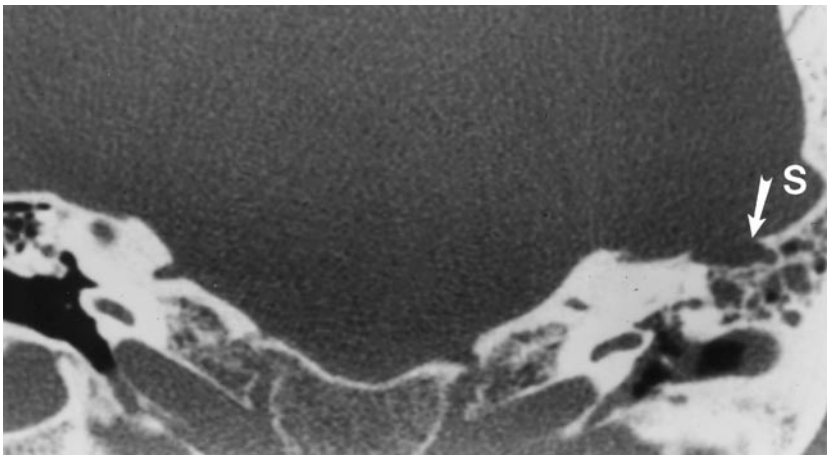


Fig. 8.10 **a** Coronal CT shows a soft tissue mass (*arrow*) adjacent to a bony defect in the tegmen of a 57-year-old male with recurrent serous otitis media. **b** MRI in same patient demonstrates a soft tissue mass (*arrow*) separate from temporal lobe. *ME* middle ear space. **c** Tissue mass removed via a middle fossa craniotomy illustrates the histological features of an arachnoid granulation. *Arrows* indicate tubules with CSF



■ **Fig. 8.11** MRI in a 64-year-old male with CSF otorrhea after myringotomy for conductive hearing loss. Arrow points to collection of CSF in a mastoid defect and air cells. CE cerebellum, BS brainstem



■ **Fig. 8.12** Axial CT shows the bony defect (arrow) from a large arachnoid granulation on the posterior fossa surface of the temporal bone. S sigmoid sinus

the middle fossa floor can be excised prophylactically. If the dural defect is small (1–2 mm), then closure may be accomplished with a suture ligature and coverage, using temporalis fascia held in place by absorbable packing, and the reexpanded temporal lobe. A larger dural defect is covered with a thick temporal fascia graft secured in place with absorbable packing.

The posterior fossa AG is usually solitary and best managed through an intact canal wall mastoidectomy. After thorough exenteration of mastoid air cells and mucosa, the dural defect is widely exposed by removal

of the surrounding posterior fossa bony plate. The mastoid defect is obliterated generously with a free adipose tissue graft.

Many minor CSF leaks in the adult age group are overlooked and treated as recurrent SOM. Observation of these patients, particularly where the SOM is preceded by a negative otologic history, should include analysis of middle ear aspirate for beta-2-transferrin. If the aspirate is positive for this protein, then the initial examination is made with CT (1-mm slices) of the TB (coronal and axial).

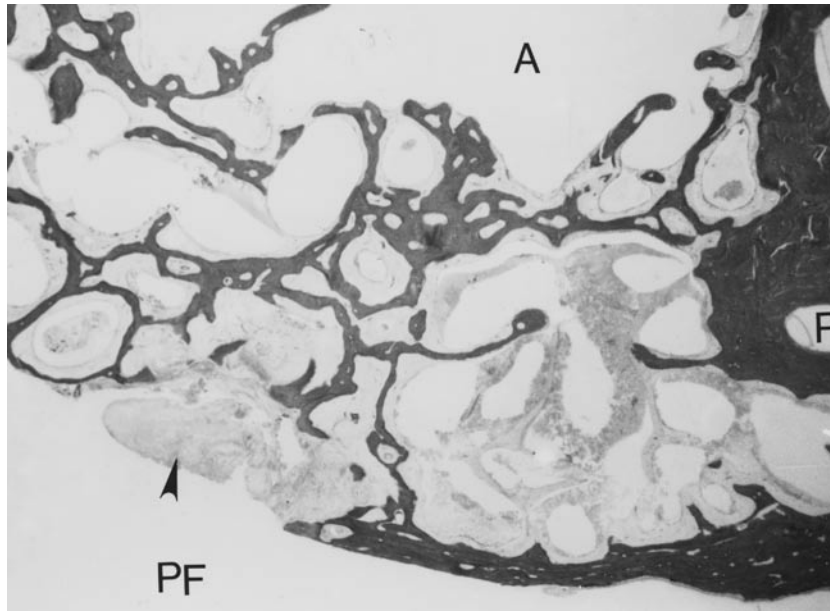


Fig. 8.13 This horizontal temporal bone section from an elderly man who died from meningitis secondary to acute pneumococcal otitis media. *Arrowhead* points to arachnoid granulation responsible for the extension of infection into the posterior fossa (*PF*). *A* mastoid antrum, *P* posterior semicircular canal

COMPLICATIONS TO AVOID

1. Secure an early diagnosis of CSF dural defect with CT and MRI to avoid delay in diagnosis.
2. The middle cranial fossa approach to the repair of dural defects in the tegmen is best to avoid damage to the sound transmission system.
3. Dural defects should be repaired as soon as diagnosis made to prevent intracranial complications.

Pearl

- Arachnoid granulations in the temporal bone should be considered in the differential diagnosis of refractory unilateral serous otitis media in an adult.

References

1. Adams GL, McCoid G, Weisbeski D (1982) Cerebrospinal fluid otorrhea presenting as serous otitis media. *Minn Med* 65:410–415
2. Anderson J, Backer V, Jensen E, Voldsgaard P, Wandall JH (1995) Acute meningitis of unknown aetiology: analysis of 219 cases admitted to hospital between 1977 and 1990. *J Infect* 31:115–122
3. Ahren C, Thulin CA (1965) Lethal intracranial complications following inflation in treatment of serous otitis media and due to defects in the petrous bone. *Acta Otolaryngol (Stockh)* 60:407–421
4. Brunner H (1946) Intracranial complications of ear, nose, and throat infections. Year Book, Chicago, pp 32–33
5. Bruyn GA, Kremer HP, deMarie S, Padberg GW, Hermans J, Van Furth R (1989) Clinical evaluation of pneumococcal meningitis in adults over a twelve year period. *Eur J Clin Microbiol Infect Dis* 8:695–700
6. D'Avella D, Baroni A, Mingrino S, Scanarini M (1980) An electron microscope study of human arachnoid villi. *Surg Neurol* 14:41–47
7. Dysart BR (1959) Spontaneous cerebrospinal otorrhea. *Laryngoscope* 69:935–939
8. Elverland HH, Mair IWS (1983) Recurrent meningitis, congenital anacusis and Mondini anomaly. *Acta Otolaryngol (Stockh)* 95:147–151
9. Ferguson BJ, Wilkins RH, Hudson W, Farmer J Jr (1986) Spontaneous CSF otorrhea from tegmen and posterior fossa defects. *Laryngoscope* 96:635–644
10. Gacek RR (1990) Arachnoid granulation cerebrospinal fluid otorrhea. *Ann Otol Rhinol Laryngol* 99:854–862
11. Gacek RR (1992) Evaluation and management of temporal bone arachnoid granulations. *Arch Otolaryngol Head Neck Surg* 118:327–332
12. Gacek RR (1992) A differential diagnosis of unilateral serous otitis media. *Laryngoscope* 102:461–468
13. Gacek R, Leipzig B (1979) Congenital cerebrospinal otorrhea. *Ann Otol Rhinol Laryngol* 88:358–365
14. Gomez DG, Potts DG, Deonaraine RT, Reilly KF (1973) Effects of pressure gradient changes on the morphology of arachnoid villi and granulations of the monkey. *Lab Invest* 28:648–657
15. Gomez DG, Di Benedetto AT, Pavese AM, Firpo A, Herscham DB, Potts DG (1981) Development of arachnoid villi and granulations in man. *Acta Anat (Basel)* 111:247–258
16. Guindi GM (1981) Congenital labyrintho-tympanic fistula—a recently recognized entity in children. *J Otolaryngol* 10:67–71

17. Hall GM, Pulec JL, Hallberg OE (1967) Persistent cerebrospinal fluid otorrhea. *Arch Otolaryngol* 86:377–381
18. Hirakawa K, Kurokawa M, Yajin K, Harada Y (1983) Recurrent meningitis due to a congenital fistula in the stapedia footplate. *Arch Otolaryngol* 109:697–700
19. Jayatilaka AD (1967) An electron microscopic study of sheep arachnoid granulations. *J Anat* 99:635–649
20. Kaufman B, Yonas H, White RJ, Miller CF (1979) Acquired middle cranial fossa fistulas: normal pressure and nontraumatic in origin. *Neurosurgery* 5:466–472
21. Kido DK, Gomez DG, Pavese AM, Potts DG (1976) Human spinal arachnoid villi and granulations. *Neuroradiology* 11:221–228
22. Kline OR (1933) Spontaneous cerebrospinal otorrhea. *Arch Otolaryngol* 18:34–39
23. Koch H (1950) Meningocele of the temporal bone. *Acta Otolaryngol (Stockh)* 38:59–61
24. Kramer SA, Yanagisawa E, Smith HW (1971) Spontaneous cerebrospinal fluid otorrhea simulating serous otitis media. *Laryngoscope* 81:1083–1089
25. Myer CM III, Miller GW, Ball JB Jr (1985) Spontaneous cerebrospinal fluid otorrhea. *Ann Otol Rhinol Laryngol* 94:96–97
26. Neely JG (1985) Classification of spontaneous cerebrospinal fluid middle ear effusion: review of forty-nine cases. *Otolaryngol Head Neck Surg* 93:625–634
27. Potts DG, Reilly KF, Deonaine RT (1972) Morphology of the arachnoid villi and granulations. *Radiology* 105:333–341
28. Rasmussen N, Johnsen NJ, Bohr VA (1991) Otologic sequelae after pneumococcal meningitis: a survey of 164 consecutive cases with a follow-up of 94 survivors. *Laryngoscope* 101:876–882
29. Small M, Dale BAB (1984) Intracranial suppuration 1968–1982: a 15-year review. *Clin Otolaryngol* 9:315–321
30. Upton ML, Weller RO (1985) The morphology of cerebrospinal fluid drainage pathways in human arachnoid granulations. *J Neurosurg* 63:867–875
31. Weed LH (1923) The absorption of cerebrospinal fluid into the venous system. *Am J Anat* 31:191–221
32. Yamashima T (1986) Ultrastructural study of the final cerebrospinal fluid pathway. *Brain Res* 384:68–76

Core Messages

- Functional components of the facial nerve include:
 - General efferents to facial muscles
 - Secretomotor preganglionic efferents to the submandibular, lacrimal, and nasal glands
 - Special sensory to taste receptors in the tongue and palate/nasal pharynx
 - Somatic sensory to the skin of external auditory canal and concha
- The motor axons to regional facial muscle groups are mixed, not compartmentalized, through the temporal course of the facial nerve.
- The sensory ganglia of the facial nerve are the geniculate and meatal ganglia.
- Surgery is usually indicated for facial nerve paralysis secondary to chronic otitis media, transverse TB fracture, neoplasia, ear surgery, and pseudotumor.
- Surgery is usually not indicated in idiopathic facial paralysis (Bell's palsy) and longitudinal TB fracture.

9.1 Anatomy of the Facial Nerve

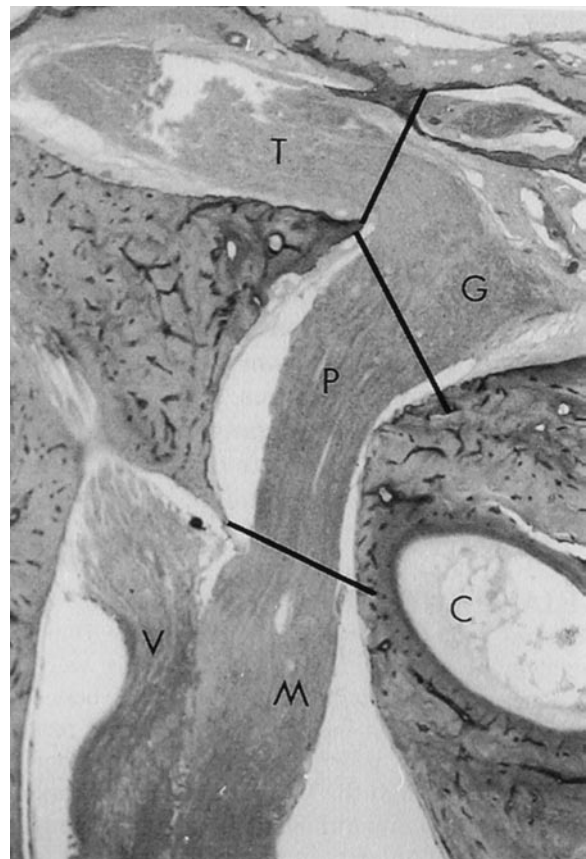
The gross anatomy and functional components of the facial nerve in its intratemporal course have been extensively described in texts of anatomy and otologic surgery. Recent additions to facial nerve anatomy and their impact on disorders of the nerve are briefly reviewed in this chapter.

9.1.1 Organization of the Facial Nerve

After emerging from the brainstem, the facial nerve (FN) travels with the vestibular division of the eighth cranial nerve the length of the internal auditory canal

(Fig. 9.1). The FN then enters the labyrinthine segment of the fallopian canal, which conveys it throughout a tortuous course in the TB. The FN is derived from the second branchial arch and innervates structures that are derived from Reichert's cartilage. Four groups of functional neurons constitute the FN complex [15]:

1. The *special efferent* FN axons supply the striated muscles of facial expression, as well as the stapedius muscle, the stylohyoid muscle, and the posterior belly of the digastric muscle.



■ **Fig. 9.1** Division of the FN as it enters the fallopian canal. *M* meatal, *P* petrosal, *T* tympanic, *G* geniculate ganglion, *V* vestibular nerve (superior division), *C* basal turn of cochlea

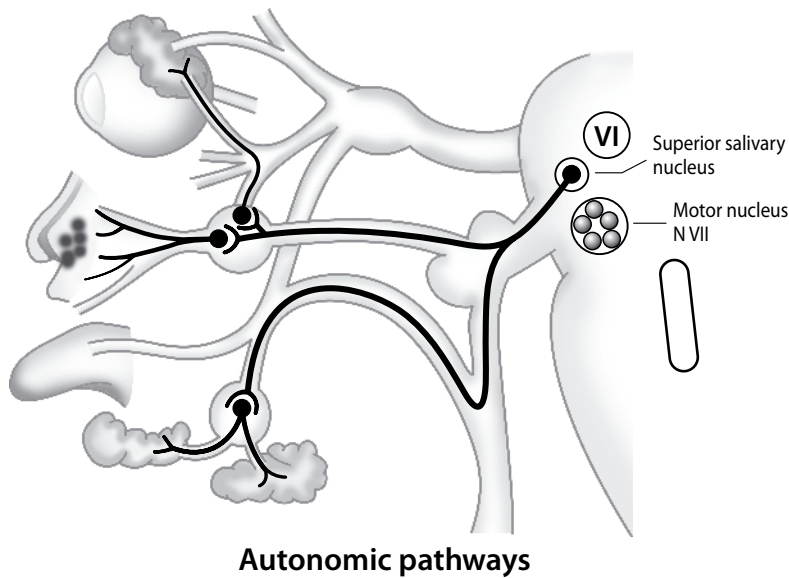


Fig. 9.2 Schematic of the efferent secretomotor pathways in the nervus intermedius

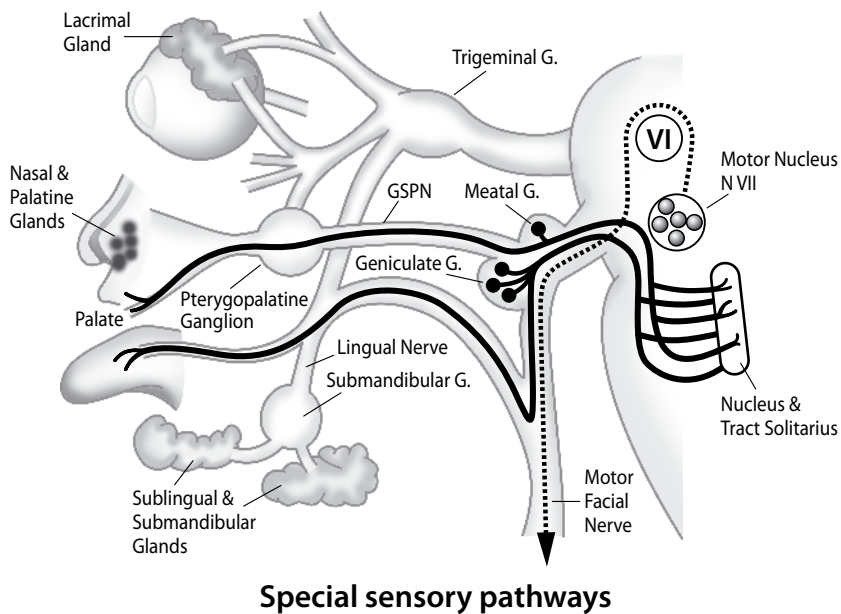


Fig. 9.3 Schema of the special sensory neural pathways serving gustatory function in the FN

2. *General visceral efferent fibers* represent the pre-ganglionic portion of the autonomic pathway to glandular and vascular structures (Fig. 9.2). The main glandular structures are the submandibular, lacrimal gland, and the seromucinous glands in the nasal cavity. Some of these fibers travel in the greater superficial petrosal nerve (GSPN) to synapse in the sphenopalatine ganglion, which contains the postganglionic neurons providing secreto-

motor function. Secretory fibers are also carried by the chorda tympani nerve and synapse with post-ganglionic neurons in the submandibular ganglion innervating the submandibular and sublingual salivary glands.

3. *Special sensory fibers* (taste; Fig. 9.3) are carried over two pathways. The majority of the taste receptors inputting to the FN are located in the anterior two thirds of the tongue. Peripheral dendrites sup-

plying these sensory receptors in the chorda tympani nerve join their cell bodies in the geniculate ganglion (GG). A second group of taste receptors is located in the soft palate and nasopharyngeal mucosa and is innervated by fibers in the GSPN, which belong to ganglion cells (meatal ganglion [MG]) located in the meatal segment of the FN.

4. *Somatic sensory neurons* supply the skin of the external auditory canal and the concha.

The brainstem nuclei that give rise to FN axons are:

- a. The motor nucleus of the FN, which is located in the caudal brainstem adjacent to the superior olivary nucleus of the auditory system; just caudal to the facial nucleus is the rostral limit of the nucleus ambiguus, which provides motor innervation to the intrinsic laryngeal musculature; the number of facial motor neurons has been estimated at approximately 10,000–20,000; the motor neurons for various facial muscle groups are topographically arranged in subnuclei within the facial nucleus [25]; however, the axons from these subnuclei intermix as they leave the facial nucleus in a dorsal direction to loop around the abducens nucleus near the floor of the fourth ventricle [13]; the axons converge at this point and then bend in a ventrolateral direction just medial to the vestibular nerve (VN) root before exiting the brainstem
- b. The location of motor neurons for the stapedius muscle and the posterior belly of the digastric muscle are separately clustered in the brainstem; stapedius motor neurons are located in the interface between the facial nucleus and the superior olivary nucleus, where they are strategically located to receive stimuli from the afferent auditory pathway and carry out reflex contraction of the stapedius muscle (stapedius reflex) [19]; the motor neurons for the posterior belly of the digastric muscle are located along the course of the emerging FN root in the lateral brainstem region
- c. The superior salivary nucleus is responsible for secretomotor (autonomic) neurons in the FN system; this nucleus is located dorsally to the motor facial nucleus and gives rise to the preganglionic parasympathetic secretomotor neurons entering the submandibular and the sphenopalatine ganglia
- d. The nucleus of the solitary tract, also located in the medulla, receives taste input over sensory fibers of the FN.

The major portion of the FN is composed of motor axons to the facial musculature. Although arising

from regional groups of motor neurons in the facial nucleus, these fibers intermix throughout the course of the FN in its intracranial and intratemporal segments [13]. After exiting the stylomastoid foramen, the motor axons gather in functional groups before forming the four to five branches that supply the regional facial muscle groups. For purposes of this discussion, the important divisions of the FN trunk are the meatal segment, the labyrinthine (petrosal) portion, the geniculate portion, and the tympanic part (Fig. 9.1). Except for the meatal portion that lies free in the internal auditory canal, the remaining segments of the FN are contained within a bony canal (fallopian). Accompanying the FN trunk is the nervus intermedius, which carries secretomotor of the preganglionic neurons in the superior salivary nucleus, as well as proximal axons of sensory neurons in the FN ganglia (geniculate and meatal), traveling to the nucleus solitarius in the brainstem.

The sensory ganglia of the FN (geniculate and meatal) are important to the subject of virus-mediated neuropathy (Fig. 9.4). A quantitative study [11] of 100 TB described these ganglionic masses (Fig. 9.5).

- e. These two ganglia are derived from different embryologic anlagen, the GG from epibranchial placode (second branchial arch), while the MG develops from the neural crest primordium. In most TB (88%), the GG contains most of the sensory neurons in the FN, while the MG is very small (Fig. 9.6). In approximately 12% of FN, the MG may equal or exceed the number of ganglion cells in the GG. The study found that the number of neurons in the GG ranged from 66 to 4,017 (mean 1,713) while the MG contained from zero to 2,764 cells (448). Fourteen percent of the GG contained less than 1,000 cells, while 88% of the MG contained fewer than 1,000 cells. Sixty-four percent of the MG held fewer than 500 cells, and 34% had less than 200. In approximately 2% of the TB, the MG represents the entire ganglion associated with the FN.

In instances where the GG is absent and the MG represents the only sensory ganglion of the FN [11], TB specimens indicate that the GSPN inputs to the MG. This observation supports a conclusion that the afferent input from taste receptors in the soft palate and nasopharynx is carried over the GSPN to the MG, while the GG contains sensory neurons for taste receptors in the anterior two thirds of the tongue [6]. Furthermore, the MG loca-

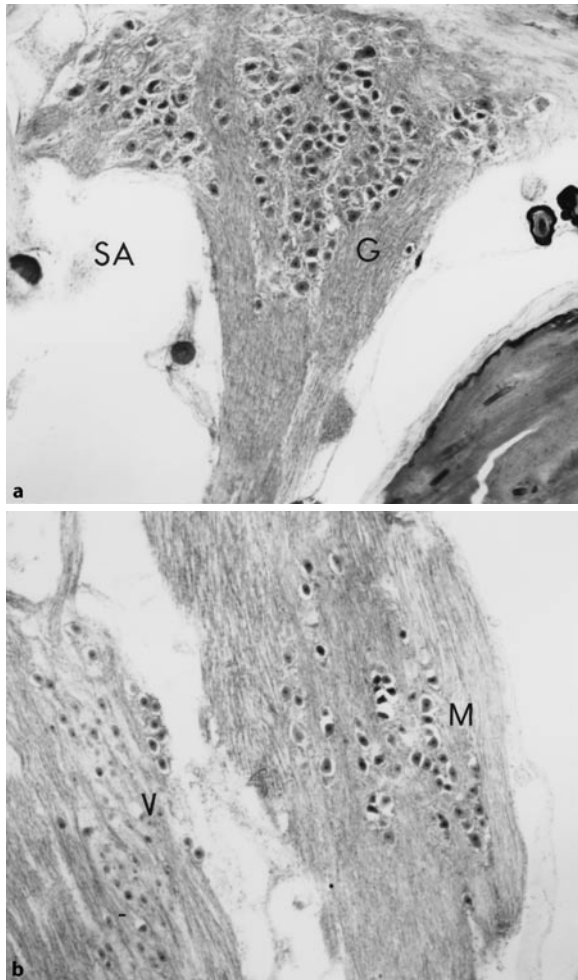


Fig. 9.4 **a** Photomicrograph of a horizontal TB section shows the GG (G) and a lateral extension of the subarachnoid space (SA). **b** Same TB section shows the facial and vestibular nerves in the internal auditory canal. V vestibular ganglion, M meatal ganglion

9

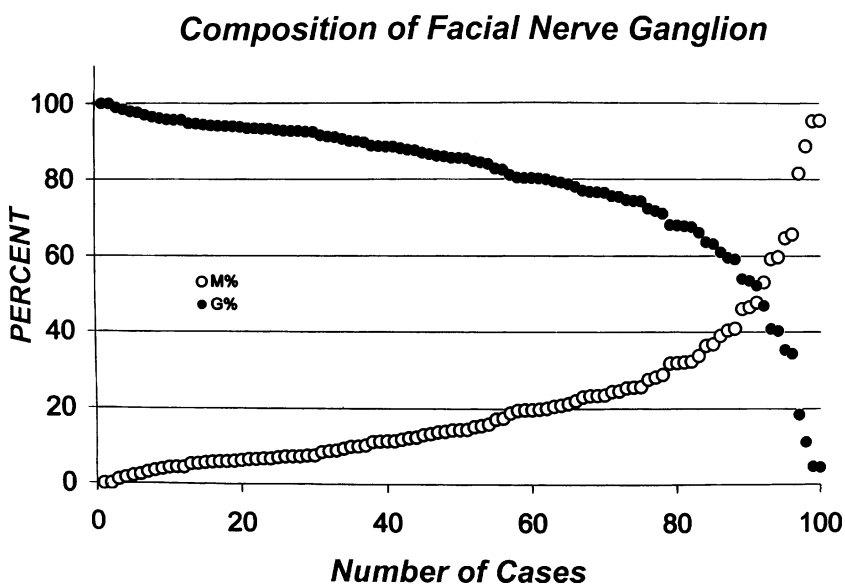
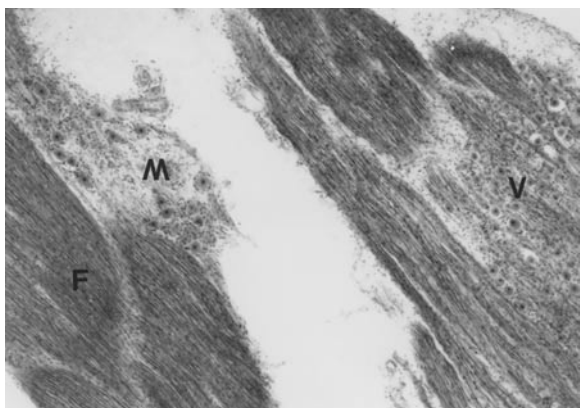
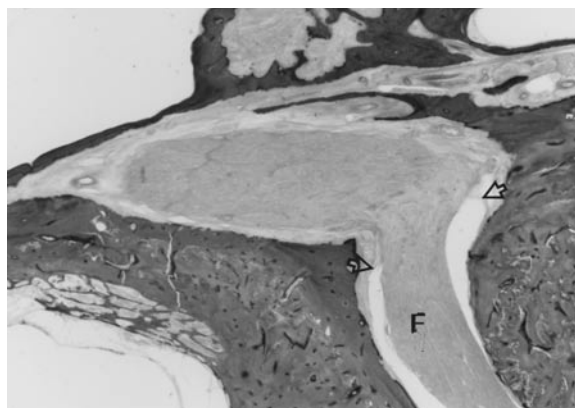


Fig. 9.5 Graph of 100 normal TBs, ordering the percentage composition of geniculate and meatal (M) ganglion cells in the FN (G)



■ **Fig. 9.6** The meatal ganglion (*M*) is usually small as shown in this photomicrograph. *V* vestibular ganglion, *F* FN



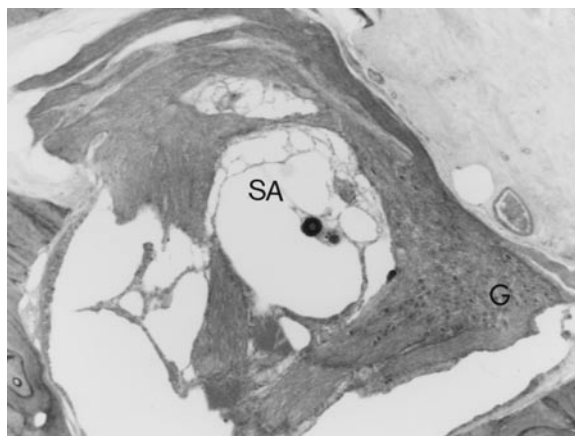
■ **Fig. 9.7** The subarachnoid space in the petrosal facial canal usually is limited at the GG (*arrows*)

tion in the internal auditory canal portion of the FN is juxtaposed to the vestibular ganglion (Scarpa's ganglion). It is well known that part of the nervus intermedius travels within the vestibular nerve trunk before leaving by way of the vestibulofacial anastomosis. In this way, the nervus intermedius is collected before entering the FN trunk. The significance of this inclusion of a part of the nervus intermedius is that some MG cells are incorporated into the vestibular ganglion. Although these two ganglionic masses are derived from two separate embryologic sources, their intimate anatomic association permits a common involvement in inflammatory processes [12].

9.1.2 Sheath of the Facial Nerve

The FN benefits from having a dense, collagenous sheath surrounding it throughout its course through the TB. Since the dural lining of the internal auditory canal blends with the perineurium of the FN at the GG, the subarachnoid space extends to the ganglion in the majority of TB (Fig. 9.7). Thus, in most TB, the dural lining of the labyrinthine (petrosal) fallopian canal permits an extension of the subarachnoid space to the GG [10]. Here the dural sheath becomes closely applied to the perineurium of the main nerve trunk. This dense nerve sheath extends throughout the temporal course and joins the periosteum at the stylomastoid foramen. The extra temporal FN is surrounded by a

normal epineurium. However, various factors in development such as increased subarachnoid pressure may displace the lateral extent of the cerebrospinal fluid space into or distal to the GG (Fig. 9.8). Therefore, in a small number of TB the subarachnoid space may extend beyond the GG and into the tympanic segment of the fallopian canal. With continuous pulsatile subarachnoid pressure, such extension may fistulize into the middle ear space (Fig. 9.9). Such a preformed pathway may be responsible for spontaneous CSF otorrhea.



■ **Fig. 9.8** Extension of the subarachnoid space (*SA*) into the GG (*G*) may displace the FN laterally

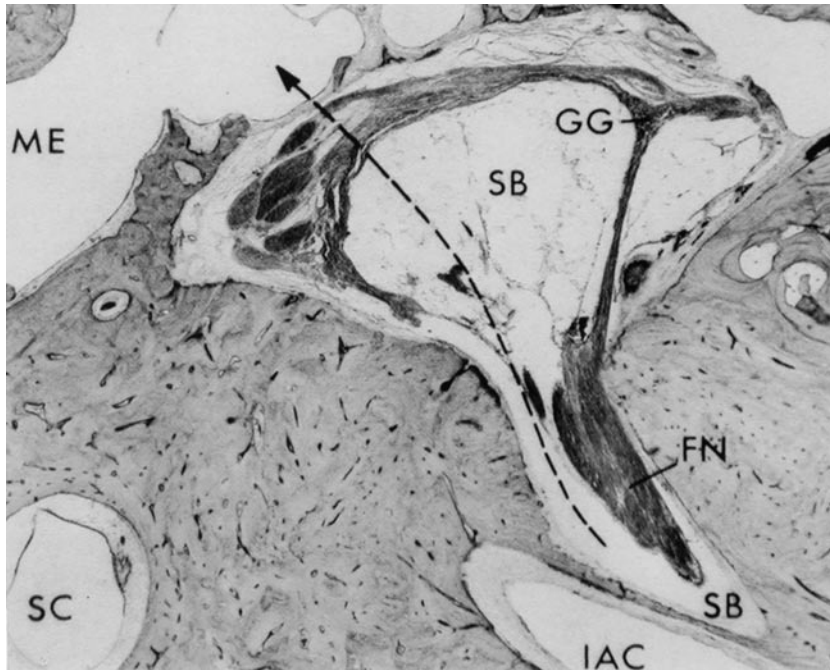


Fig. 9.9 Horizontal temporal bone section demonstrates near fistulization (*dashed line*) of the subarachnoid space (SB) into the middle ear (ME). Compare with Fig. 8.1 (Chap. 8). IAC internal auditory canal, SC superior semicircular canal ampulla

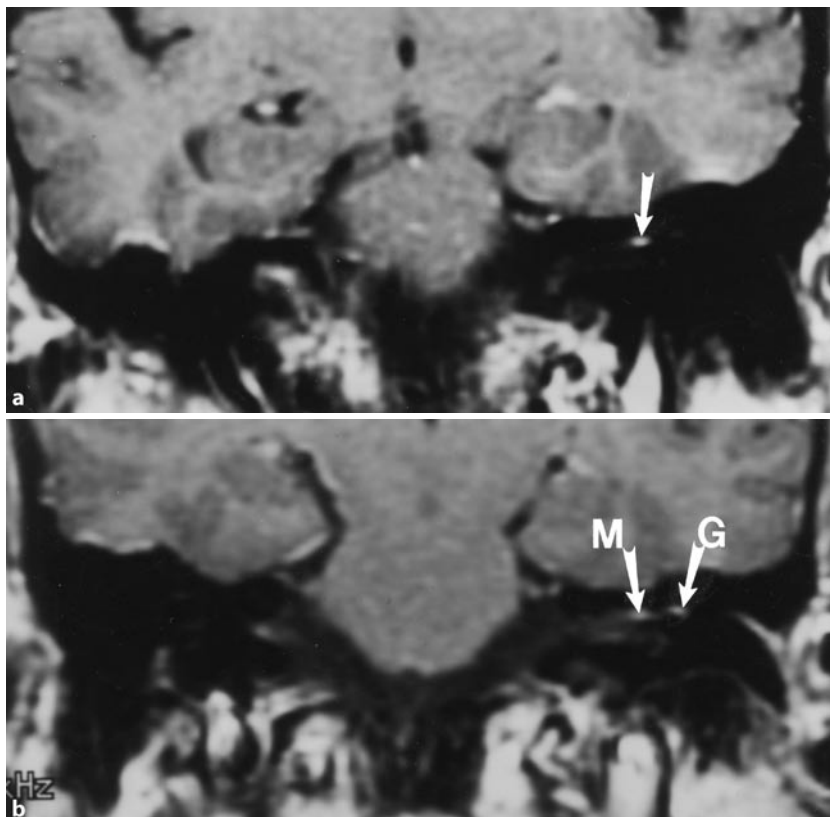


Fig. 9.10 a Idiopathic facial paralysis (Bell's palsy) shows enhancement of the meatal ganglion (*arrow*) early. **b** Later in IFP enhancement is seen in the geniculate (G) as well as the meatal (M) ganglion

9.2 Surgery of the Facial Nerve

9.2.1 Idiopathic Facial Paralysis (Bell's Palsy)

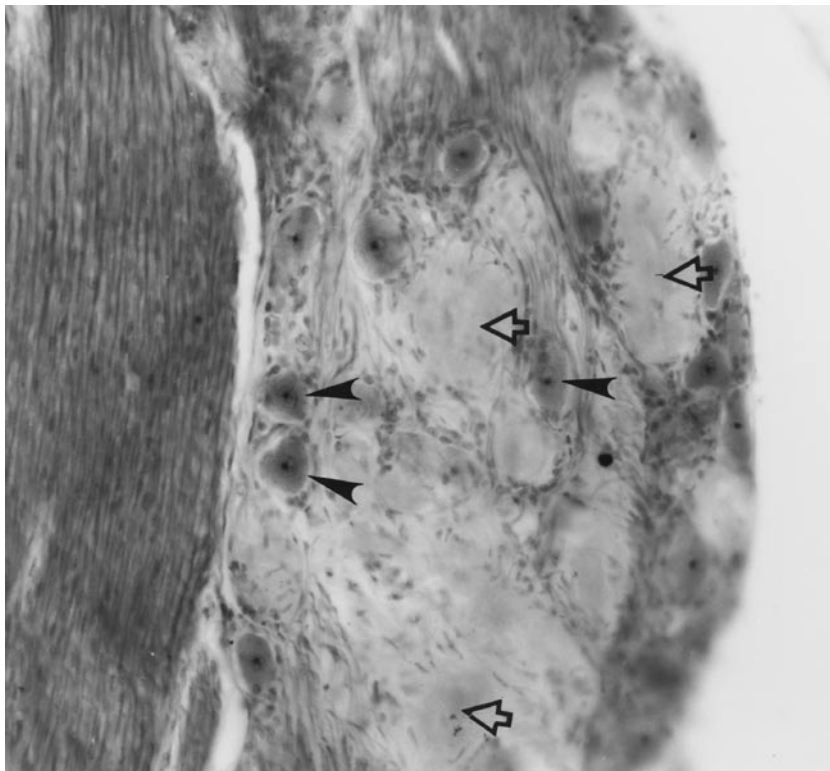
Idiopathic facial paralysis (IFP) is by far the most common cause for peripheral facial paralysis (>70%). Clinical and experimental evidence supports a viral neuritis caused by reactivation of neurotropic viral agents (HSV I and HZV) as the responsible pathology [1, 3, 17, 20–22, 27]. Other viral agents such as mumps, Epstein Barr, and Cytomegalo-inclusion virus as well as Lyme disease have been reported as causative factors. The treatment therefore is primarily—if not entirely—medical, not surgical. Excellent spontaneous resolution can be expected in >85% of patients with IFP [23]. Resolution with minimal-to-moderate residual deficit can account for all but a few percent of the remainder. Oral administration of steroids and antivirals has been shown to significantly improve the quality of return in IFP [2].

Surgery has been advocated in a small number of patients with electrical monitoring signs of impending nerve axonal degeneration [7]. Such surgical interven-

tion is based on FN swelling proximal to the meatal foramen in the internal auditory canal. Swelling in this segment of the FN can be explained by virus reactivation in the meatal ganglion. Numerous reports describing early enhancement with contrast MRI [4, 5, 14, 18, 26], agree that the lateral end (fundus) of the internal auditory canal is characteristic in this viral neuropathy (Fig. 9.10). Histopathology in TBs from patients with a history of IFP revealed degenerated ganglion cells in the meatal ganglion but not the GG (Fig. 9.11) [14]. However, decompression of the meatal foramen may pose a risk of further reactivation of latent virus in the meatal ganglion by virtue of surgical stress, thus aggravating the pathogenesis of IFP. Therefore, the benefits of such surgical intervention must be balanced against the risk of worsening the end result by virus reactivation.

9.2.2 Chronic Otitis Media

Facial neuritis as a complication of chronic middle ear infection with or without cholesteatoma is the next most common cause of facial paralysis. Although



■ **Fig. 9.11** Photomicrograph of the meatal ganglion in a case of IFP shows many degenerated (arrows) and a few intact ganglion cells (arrowheads)

the inflammatory effect of cholesteatoma membrane is the usual pathology responsible, chronic mucous membrane disease with granuloma formation may also cause FN neuritis. This complication represents an urgent indication for surgical intervention to ensure a satisfactory recovery of FN function. Thorough exenteration of mastoid and middle ear disease with exposure of the FN proximal and distal to the location of nerve disease interface is necessary.

Since chronic inflammatory changes camouflage the bony structures in the middle ear, the fallopian canal may be difficult to identify in surgery for this complication. A reliable landmark to the location of the FN canal in the epitympanum is the shelf of bone that separates the epitympanum from the anterior epitympanic space [8] (Fig. 9.12). This partition, located anterior to the head of malleus, may be entirely bony or have a membranous portion (Fig. 9.13). It is a reliable structure for the FN canal because it develops from the bony partition that envelops the FN, forming the fallopian canal (Fig. 9.14).

Incision of the sheath with release of edematous nerve is controversial because even atraumatic incising of the sheath is accompanied by axonal degeneration. However, when herniation of nerve tissue has already occurred through the sheath, incision of the sheath is recommended. Preservation of motor axons by incision of the lateral aspect of the sheath is favored by the lateral location of the sensory component in the temporal course of the FN.

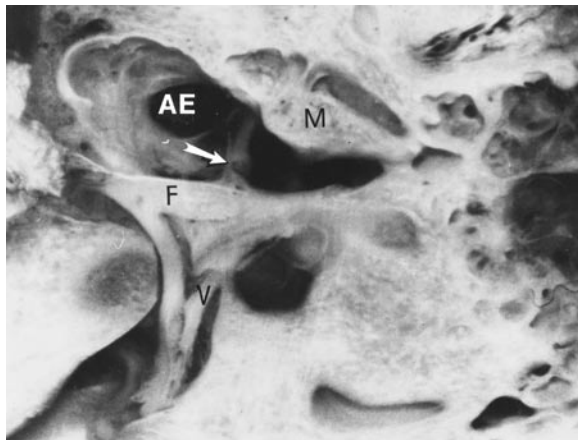


Fig. 9.12 Celloidin embedded TB demonstrates the FN (F) in the anterior epitympanum. The partition separating the anterior epitympanic cell (AE) from the epitympanum is indicated by arrow. M head of malleus and body of incus, V vestibular nerve (superior division), P petrosal segment of FN

Facial paralysis in acute middle ear infection requires a staged approach. Generally, intravenous antibiotic administration with sustained drainage of the middle ear (tube) is sufficient to reverse the middle ear infection responsible for FN neuritis. However, poor response of the infection to such treatment supported by radiologic evidence of mastoid bone demineralization mandates surgical exploration with decompression of the fallopian canal (tympanic and mastoid).

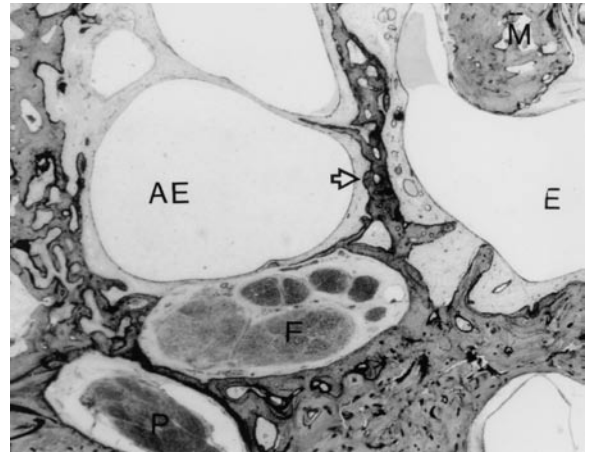


Fig. 9.13 Photomicrograph of the same area as in Fig. 9.12. The bony partition (arrow) forms part of the fallopian canal by enveloping the FN (F). AE anterior epitympanum, E epitympanum, M head of malleus, P petrosal segment of the FN

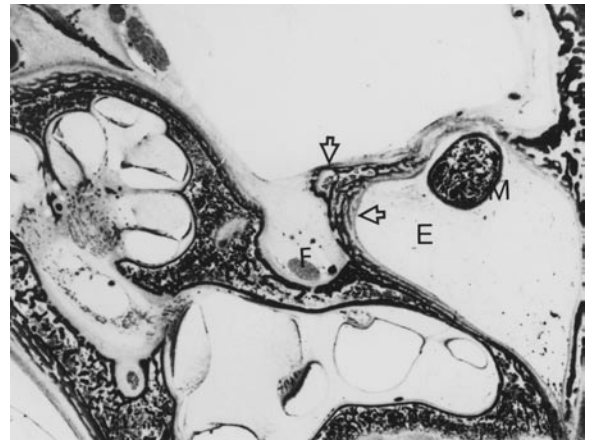

Fig. 9.14 Similar section through a fetal TB shows development of the fallopian canal in the epitympanum (arrow). M head of malleus, F FN

9.2.3 Trauma: Temporal Bone

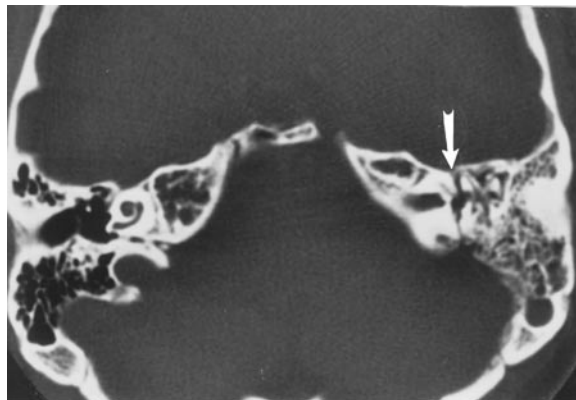
9.2.3.1 Longitudinal Fracture

TB fractures represent another common cause for facial paralysis. Longitudinal fracture of the TB results from a force to the lateral aspect (squamous) of the TB. In such injury, the fracture line passes through the juncture of petrous bone with the floor of middle cranial fossa, injuring the FN at the GG [28]. The type of injury produced is contusion without transection of nerve. Surgical exploration is not usually indicated as nerve function recovers with observation. Rarely, the fracture may be complex and shear the vertical segment of the nerve near the bony external auditory canal. CT scan of the TB will reveal such involvement and prompt surgical exploration. A conductive hearing loss (hemotympanum) also usually improves with time. A residual conductive loss when the ear has returned to a normal state suggests ossicular dislocation. Cerebrospinal leak may occur with this injury, but usually resolves spontaneously.

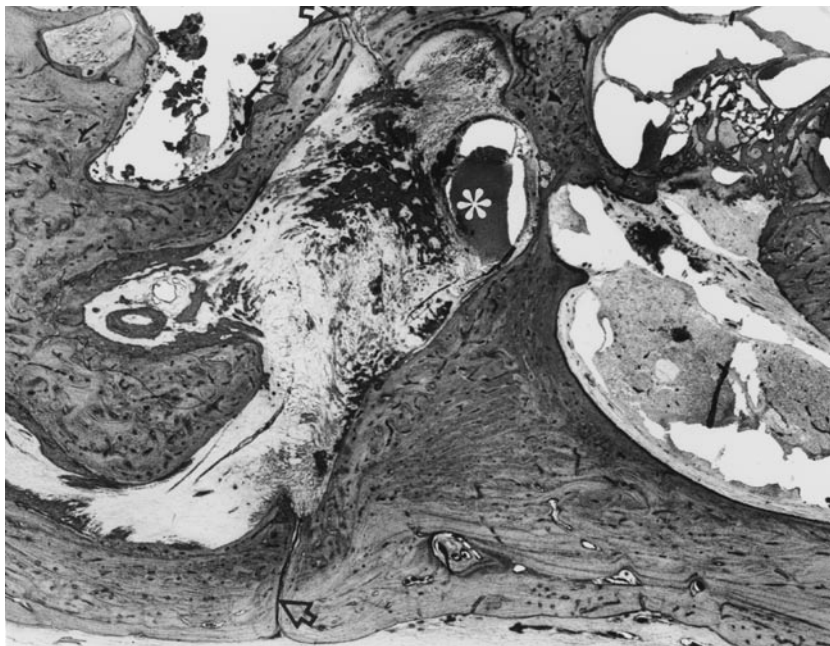9.2.3.2 Transverse Fracture

The fracture line here results from a blow to the occiput and passes through petrous bone where the labyrinth and the internal auditory canal (IAC) rep-

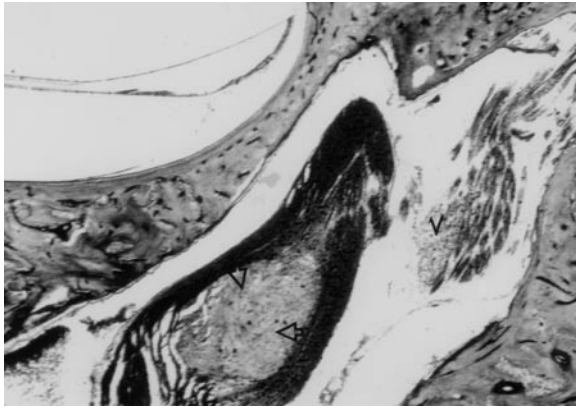
resent a weakness (Fig. 9.15). The marked displacement of fracture fragments frequently disrupts the FN, which is securely anchored in its bony canal. Surgical exploration is indicated when the patient's neurological status permits [6]. Because of the loss of labyrinth function, there is opportunity for rerouting of FN segments through the vestibule and repair with primary anastomosis (Fig. 9.16). Total obliteration of the ear to control CSF leak is used for closure of the defect.



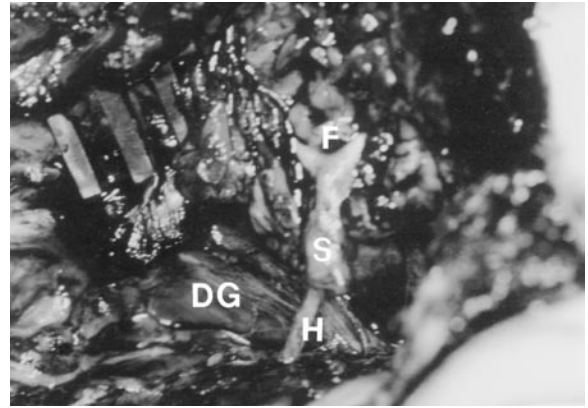
■ Fig. 9.15 CT scan of a transverse TB fracture (*arrow*) shows wide separation of the bone fragments of the petrous bone



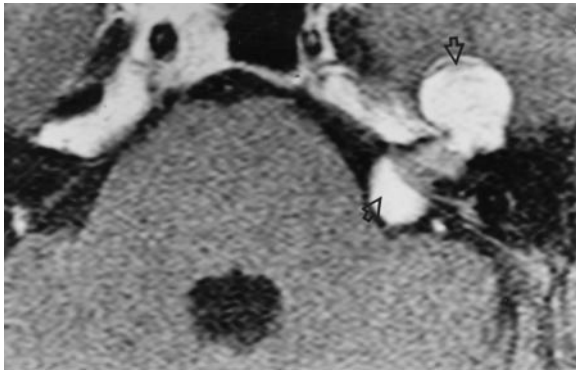
■ Fig. 9.16 The histological changes produced by a transverse TB fracture (*arrow*) are shown in the photomicrograph. Replacement by fibrous and osseous tissue is seen in the labyrinth (*)



■ Fig. 9.17 Photomicrograph of a small FN schwannoma (arrow) shows displacement of adjacent FN axons. V vestibular nerve



■ Fig. 9.19 Photo of hypoglossal (H)-to-facial (F) nerve anastomosis in the neck. A vein sleeve (S) covers the anastomosis. DG posterior belly of digastric muscle



■ Fig. 9.18 MRI demonstrates the middle and posterior fossa extension of a large FN schwannoma (arrows)

9.2.4 Neoplasia

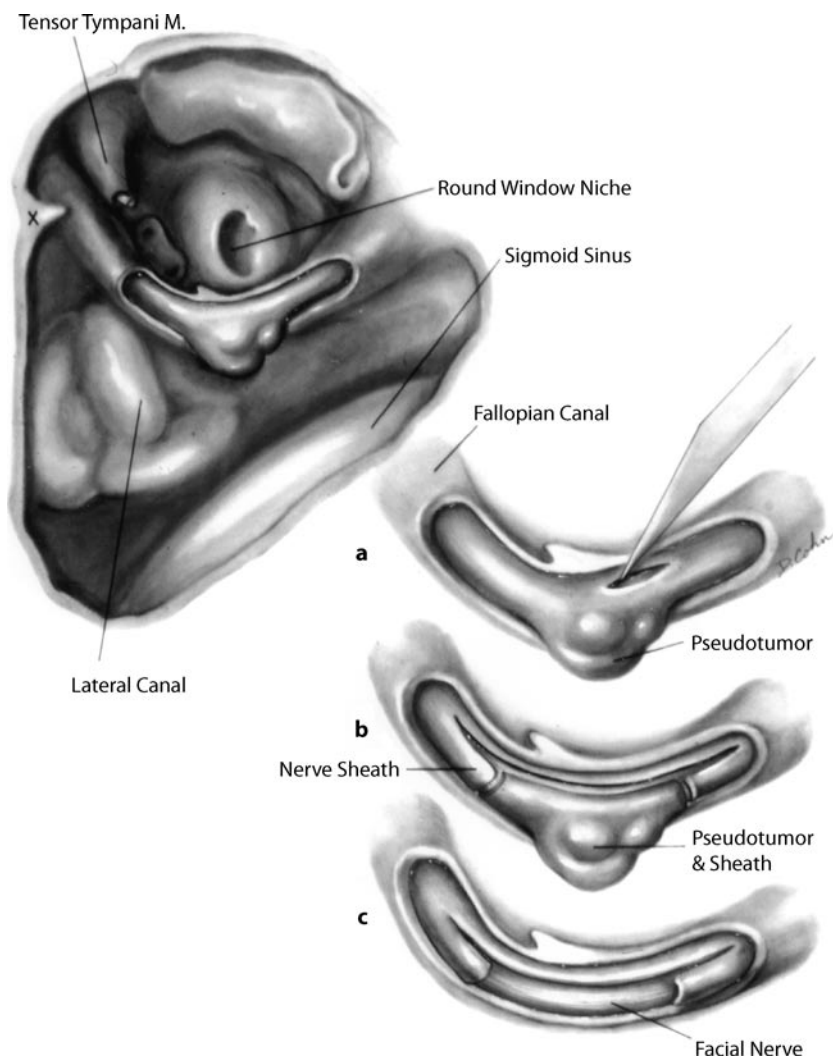
Benign tumors arising in the FN present clinically as progressive facial weakness. The most common tumors are hemangioma and schwannoma. Hemangiomas are usually found at the geniculate bend or in the meatal segment of the FN where the sensory ganglia are located [24]. These tumors are thought to arise from the vascular plexus associated with sensory ganglia. Schwann cell tumors may arise at any level distal to the glial-Schwann cell interface of the nerve near the porus acousticus in the internal auditory canal.

Hemangiomas have an expansile growth from within the ganglionic mass to engulf the nerve. Complete removal requires resection of the segment of nerve containing the neoplasm. Repair with a free

nerve graft is necessary. Schwann cell tumors arise from a discrete group of sensory axons and displace intact fascicles of motor nerve fibers as they enlarge (Fig. 9.17). Frequently they may be removed while preserving some intact FN bundles [16]. However, when they reach large dimensions, the nerve segment must be resected and repaired with a free nerve graft (Fig. 9.18). Malignant tumors involve the FN secondarily as spread from a nearby primary. Typical primary tumors are squamous cell carcinoma of the ear canal or middle ear, and parotid gland carcinoma. Resection of the FN with serial frozen sections taken proximally is necessary for tumor control. Facial rehabilitation may be achieved with a cable graft to peripheral main branches or facial-hypoglossal nerve anastomosis depending on the length of remaining nerve segments distally (Fig. 9.19).

9.2.5 Pseudotumor of the Facial Nerve

Pseudotumor refers to an exuberant hyperplasia of the dural sheath surrounding the FN in the TB, simulating a neoplasm of the nerve [9]. Since the usual preceding history includes multiple mastoid surgeries, the stimulus for this hyperplastic response is likely an inflammatory one. Characteristically FN function is normal, and the pseudotumor is encountered at revision surgery for recurrent chronic infection. These signs indicate that the mass represents a pathologic alteration of the sheath rather than the nerve bundles. The mass is resected by excision of the FN sheath with preservation of the FN (Fig. 9.20).



■ **Fig. 9.20** Drawing of the surgical management of FN pseudotumor

COMPLICATIONS TO AVOID

1. Identification of the FN in chronic otitis media starts with exposure of the nerve in a normal segment of the fallopian canal to avoid injury to the nerve.
2. Pseudotumor of the FN sheath requires sharp dissection of the sheath to avoid nerve injury.
3. Cable nerve grafts in FN surgery should be longer than the defect to avoid poor regeneration of nerve fibers.

Pearl

- The meatal ganglion of the FN is equal to or larger than the GG in 15% of TBs.

References

1. Adour K, Bell DN, Hilsinger R (1975) Herpes simplex virus in idiopathic facial paralysis (Bell's palsy) JAMA 233:527-530
2. Adour K, Ruboyanes JM, Von Doersten PG et al (1996) Bell's palsy treatment with acyclovir and prednisone compared with prednisone alone: a double-blind randomized controlled trial. Ann Otol Rhinol Laryngol 105:371-378

3. Burgess RC, Michaels L, Bale JF, Smith RH (1994) Polymerase chain reaction amplification of herpes simplex viral DNA from the geniculate ganglion of a patient with Bell's palsy. *Ann Otol Rhinol Laryngol* 103:775-779
4. Engstrom M, Thomas K-A, Naeser P, Stalberg R, Jonsson L (1993) Facial nerve enhancement by different gadolinium-enhanced magnetic resonance imaging techniques. *Arch Otolaryngol Head Neck Surg* 119:221-225
5. Engstrom M, Abdsaleh S, Ahlstrom H, Johnansson L, Stalberg E, Jonsson L (1997) Serial gadolinium-enhanced magnetic resonance imaging and assessment of facial nerve function in Bell's palsy. *Otolaryngol Head Neck Surg* 117:559-566
6. Fisch U (1974) Facial paralysis in fractures of the petrous bone. *Laryngoscope* 84:2141-2154
7. Fisch U, Esslen E (1972) Total intratemporal exposure of the facial nerve. *Arch Otolaryngol* 95:335-341
8. Gacek R (1980) A surgical landmark for the facial nerve in the epitympanum. *Ann Otol Rhinol Laryngol* 89:249-250
9. Gacek R (1982) Dissection of the facial nerve in chronic otitis media. *Laryngoscope* 92:108-109
10. Gacek R (1998) Anatomy and significance of the subarachnoid space in the fallopian canal. *Am J Otolaryngol* 19:358-365
11. Gacek RR (1998) On the duality of the facial nerve ganglion. *Laryngoscope* 108:1077-1086
12. Gacek RR (1999) The pathology of facial and vestibular neuronitis. *Am J Otolaryngol* 20:202-210
13. Gacek R, Radpour S (1982) Fiber orientation of the facial nerve: an experimental study in the cat. *Laryngoscope* 92:547-556
14. Gacek R, Gacek M (1999) Meatal ganglionitis: clinical pathologic correlation in idiopathic facial paralysis (Bell's palsy) *Otorhinolaryngol Nova* 9:229-238
15. Gacek R, Gacek M (2003) Anatomy of the auditory and vestibular systems. In: Ballenger J, Snow J (eds) *Ballenger's otorhinolaryngology, head, and neck surgery*, 16th edn. Singular, San Diego
16. Hanurka C, Ugar Y, Acaro O, Yaman H, Avunduk M (2004) Facial nerve schwannomas: a report of four cases and review of the literature. *Am J Otolaryngol* 25:426-431
17. Ishii K, Kurata T, Sata T, Hao M, Nomura Y (1988) An animal model of type I herpes simplex virus infection of facial nerve. *Acta Otolaryngol Suppl (Stockh)* 446:157-164
18. Kohsyu H, Aoyagi M, Tojima H, Tada Y, Inamura H, Ikarishi T, Koike Y (1994) Facial nerve enhancement in Gd-MRI in patients with Bell's palsy. *Acta Otolaryngol (Stockh)* 511:165-169
19. Lyon M (1978) The central location of the motor neuron to the stapedius motor muscle in the cat. *Brain Res* 143:437-444
20. McCormick DP (1972) Herpes simplex virus as a cause of Bell's palsy. *Lancet* i:937-939
21. Murakami S, Mizobuchi M, Nakashino Y, Doi T, Hato N, Yanagihara N (1996) Bell's palsy and herpes simplex virus: identification of viral DNA in endoneural fluid and muscle. *Ann Intern Med* 124:27-30
22. Nakamura K, Yanagihara N (1988) Neutralization antibody to herpes simplex virus type I in Bell's palsy. *Ann Otol Rhinol Laryngol* 37:18-21
23. Peitersen E, Andersen P (1967) Spontaneous course of 220 peripheral non-traumatic facial palsies. *Acta Otolaryngol (Stockh)* 224:296-300
24. Piccirillo E, Agarwal M, Rohit T, Khrais T, Sanna M (2004) Management of TB hemangiomas. *Ann Otol Rhinol Laryngol* 113 431-437
25. Radpour S, Gacek R (1980) Further observations on the organization of the facial nucleus. *Laryngoscope* 90:685-692
26. Schwaber M, Larson T, Zealar D, Creasy J (1990) Gadolinium enhanced MRI in Bell's palsy. *Laryngoscope* 100:1264-1269
27. Sugita T, Murakami S, Yanagihara N, Fukiwara Y, Hirata Y, Kurata T (1995) Facial nerve paralysis induced by herpes simplex virus in mice: an animal model of acute and transient facial paralysis. *Ann Otol Rhinol Laryngol* 104:574-581
28. Ulug T, Ulubil S (2005) Management of facial paralysis in temporal bone fractures: a prospective study analyzing 11 operated fractures. *Am J Otolaryngol* 26:230-238

Core Messages

- The cause of most recurrent vestibulopathies is viral. The syndromes known as vestibular neuronitis, Ménière's disease, and benign paroxysmal positional vertigo account for the majority of these presentations. Others that do not fulfill the criteria for these three account for the remainder.
- These recurrent vestibulopathies are viral neuropathies caused by neurotropic viruses (e.g., Herpesviridae family).
- Initial treatment of these vestibulopathies is the use of antiviral agents orally or by intratympanic administration.
- Ablation therapy is used when the antiviral approach fails to control vertigo.
- Selective vestibular ablation of one ear may be accomplished by intratympanic gentamycin or selective vestibular nerve transaction.
- Selective bilateral vestibular ablation is best achieved by parenteral administration of streptomycin sulfate.
- Nonselective ablation of vestibular function is achieved by labyrinthectomy.
- Refractory benign paroxysmal positional vertigo (posterior canal) is relieved by singular neurectomy.

The diagnosis and treatment of recurrent vertigo has changed significantly over the past several years, primarily because the etiology of disorders presenting as recurrent vertigo has been clarified. Occasionally a patient experiences a solitary episode of acute vertigo, with or without hearing loss, then compensates or recovers vestibular function and is no longer troubled by recurrent vestibular symptoms [5, 9, 12, 22]. However, the majority of patients encountered in clinical practice complain of recurrent vertigo with or without hearing loss. In the past, approximately 40–50% of patients seen for recurrent vertigo have been classified

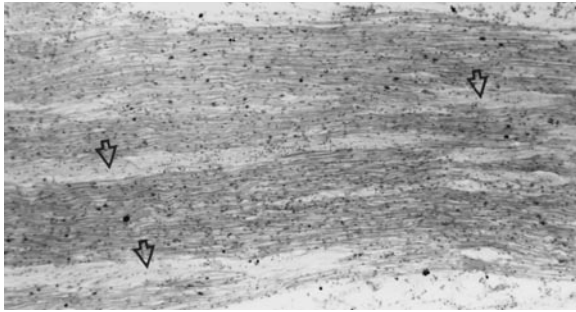
into Ménière's disease, vestibular neuronitis, or benign paroxysmal positional vertigo. An additional number of patients do not fill the criteria required for these diagnoses [9]. Many of these patients experience recurrent vertigo without hearing loss, but do not exhibit a reduction in vestibular function. Since these patients lack the reduced vestibular response required for a diagnosis of vestibular neuronitis, they have been called by various terms such as recurrent vestibulopathy, vestibular Ménière's disease, or psychogenic in nature [19].

Several reports have documented fluctuating levels of vestibular function in vestibular neuronitis [24, 27]. As many as 40% of patients presenting as vestibular neuronitis with a reduced vestibular response eventually demonstrate recovery of vestibular sensitivity to a normal level [27, 28]. Such reversibility is best explained by vestibular ganglion changes incurred by an alteration in the internal or external environment of the vestibular neuron. Histopathological, neuroradiological, and molecular evidence supports a ganglionic cell inflammation produced by reactivation of latent neurotropic virus.

10.1 Antiviral Therapy

The histopathologic changes consist of tightly grouped clusters of ganglion cells with changes varying from degenerated cells to others surrounded by satellite and inflammatory cells in the vestibular ganglion of patients with vestibular neuronitis, Ménière's disease, and benign paroxysmal positional vertigo [19]. The vestibular nerve trunk in these temporal bones contained numerous fascicles of degenerated axons (Fig. 10.1). These fascicles may represent several [11, 19] degenerated neurons or only a few [5, 12]. This variation may be related to the virulence of individual virus types or strains. These neuronal changes have been described in nerves of patients with trigeminal nerve zoster [11].

Neuroradiological evidence of inflammatory vestibular ganglion changes in vestibular neuronitis [13]



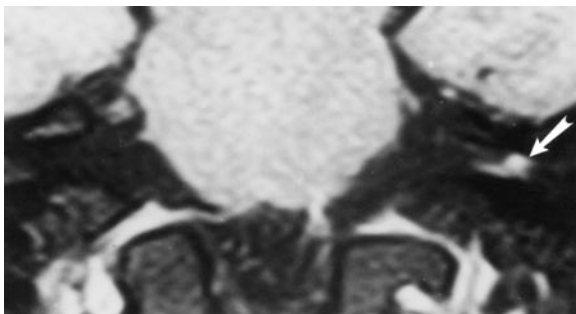
■ **Fig. 10.1** The vestibular nerve of a 62-year-old man with vestibular neuronitis contained several similar-sized fascicles of degenerated axons (arrows)



■ **Fig. 10.2** Contrast enhanced MRI in a 52-year-old female with Ménière's disease showed an enhancing mass in the internal auditory canal (arrow). Excision of the mass through a middle cranial fossa approach revealed inflammatory changes in the vestibular ganglion, with focal degeneration of axons

and Ménière's disease [19] has been demonstrated with enhanced MRI (Figs. 10.2, 10.3). Excision of the vestibular ganglion in patients with Ménière's disease has revealed inflammatory changes surrounding ganglion cells, with focal axonal degeneration passing through the ganglion [19]. Contrast enhancement of the ganglion in these neuropathies may be caused by vascular dilatation or edema in the region of the vestibular ganglion.

Polymerase chain reaction has amplified *HSV-1* gene products of active infection in vestibular nerves removed from patients with Ménière's disease [29, 31] and in temporal bones of patients with vestibular neuronitis [3]. In addition, HSV-I antibodies have been found in the perilymph of patients with Ménière's disease [6]. *HSV-1* DNA has also been detected in the

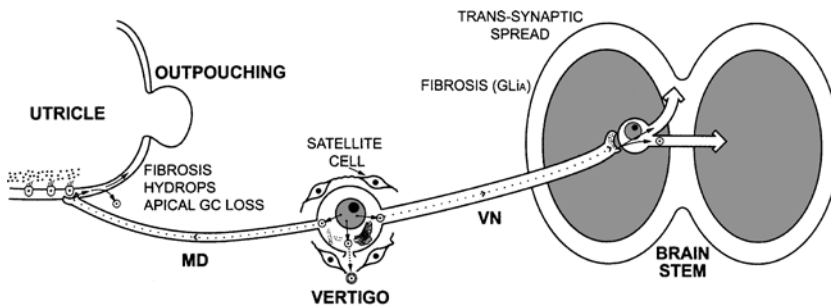


■ **Fig. 10.3** Contrast enhanced MRI in a 45-year-old male with vestibular neuronitis revealed this enhanced mass in the internal auditory canal (arrow). Subsequent MRI revealed diminished enhancement after antiviral treatment

vestibular nuclei of patients demonstrating vestibular neuronitis [4]. This gives support to clinical reports of central nervous system involvement in patients with vestibular neuronitis [35]. These observations together with clinical observations of the recurrent vestibulopathies support the role of neurotropic (NT) viruses in the vestibular ganglionitis, which accounts for clinical signs and symptoms [1, 19]. The diagram in Fig. 10.4 summarizes this concept.

The NT viruses of the alpha-Herpesviridae subfamily (herpes simplex I, herpes zoster) have the propensity to invade sensory neurons and their ganglion cells, eventually establishing a permanent latency in the DNA of the nucleus of these ganglion cells [2, 7, 26]. In the head and neck the fifth, seventh (sensory), eighth, and ninth cranial nerves are most commonly involved [20]. Vulnerability of individuals to invasion of these nerves by NT viruses is dependent on the presence of heparan sulfate receptors in the neuron's cell membrane, which combine with glycoproteins in the virus envelop [36]. Presence of these receptors is determined by heredity [24].

When the patient's immune system is downregulated by increased age or disease and a stressful period is encountered (i.e., surgery, trauma, divorce, death of family member, or a spouse, etc.), the latent virus may be reactivated [32]. Two levels of virus reactivation are possible (Fig. 10.4). In the first, virus core breaks through the nuclear membrane acquiring a temporary envelop. In this form, the nucleocapsid has infectivity but only flows within cisternae of the ganglion cell cytoplasm. The directionality of this flow, i.e., antero- (toward the brain) or retrograde (toward the



■ **Fig. 10.4** Diagram that summarizes how neurotrophic virus reactivation in the vestibular ganglion is responsible for the signs and symptoms of recurrent vestibulopathy. *MD* Ménière's disease, *VN* vestibular neuronitis

VESTIBULAR GANGLION (SCARPA)

ear) is dependent on the strain of virus [37]. Anterograde flow allows the virus to travel trans-synaptically to second-order neurons in the vestibular nuclei and cerebellum. Retrograde flow results in the release of viral nucleic acids from branches of the vestibular nerve. Since the utricular nerve is most exposed to the perilymphatic compartment, these toxic viral products are released into the vestibular cistern, where a labyrinthitis is produced. A fibrous tissue response in the vestibular cistern and scala vestibule causes the displacement of yielding membranes (i.e., saccular wall, Reissner's membrane) referred to as endolymphatic hydrops.

Most members of the Herpesviridae family are beyond the resolution power of the light microscope. However, the inclusion body of one member in this group of neurotropic viruses is large enough to be visualized by light microscopy. The intranuclear inclusion body of cytomegalovirus (CMV) has been identified in epithelial cells surrounding the utricular nerve and vestibular cistern of a TB from a patient with a clinical history and morphologic changes of delayed endolymphatic hydrops. Morphological findings such as these strengthen the concept that endolymphatic hydrops is the result of the pathophysiology of Ménière's disease not the causative mechanism of this common vestibulopathy.

In the second form of virus reactivation, the temporary envelop is lost when the virus capsid breaks through the ganglion cell membrane and is surrounded by a double-layered permanent envelope acquired from lipoproteins in the nerve cell membrane [10]. This break in the cell membrane results in loss of

the ionic gradient between the intra- and extra-cellular environments of the cell, causing loss of the normal electric potential of the cell [25]. The resulting asymmetry in the vestibular system is manifested as vertigo. The severity of vertigo is dependent on the number of ganglion cells disrupted or degenerated. The form of the vertigo (rotatory, drop attacks, position induced) depends on the ganglion cell's location in the vestibular ganglion. Since NT viruses tend to affect clusters of adjacent ganglion cells, they produce a pattern of focal axonal degeneration in the vestibular nerve (Fig. 10.1). However, it is not known that all ganglion cells degenerate after the initial disruption. They may require repeated disruptions of the cell membrane to result in a degenerated ganglion cell. Therefore, fluctuations in the level of vestibular sensitivity when tested by caloric stimulation are commonly seen in the recurrent vestibulopathies [30].

Vestibular sensitivity may return to a normal level or may reflect a reduced response, depending on the number and location of degenerated neurons in the vestibular ganglion. Therefore, although a vestibular test (electronystagmography [ENG]) is helpful as a baseline in the patient's course, it is not necessary for diagnosis. Occasionally, MRI with contrast is helpful in confirming the diagnosis of vestibular ganglionitis and identifying the side responsible for symptom (Figs. 10.2, 10.3). The optimal timing for MRI to demonstrate this inflammation is not known.

Based on this viral concept, the initial treatment of the recurrent vestibulopathies is antiviral. Although the recommended antiviral treatment for sensory nerve zoster (shingles) is 800 mg of acyclovir three times a

day for 1 week, we have elected to use a longer period because many patients notice relief of vertigo after 2 weeks of treatment. This longer period of antiviral administration may be necessary to reach an effective level in perilymph for uptake by vestibular neurons. The antiviral approach utilized is a course of oral antivirals for a three week period in doses of either 800 mg of acyclovir three times a day, or Valtrex (valacyclovir) 1 g three times a day. A maintenance dose of acyclovir 800 mg or Valtrex 1 g daily may be continued to prevent relapse. If the initial approach is not successful in relief of patient symptoms, (primarily vertigo) then the intratympanic application of an antiviral (ganciclovir) is chosen. Under local anesthesia, a tympanomeatal flap is elevated to provide access to the round window niche. After exposure of the round window membrane by taking down mucous membrane folds, the round window niche is filled with dry Gelfoam. Ganciclovir (500 mg/10 ml sterile water) is then injected into the Gelfoam until saturated. The tympanomeatal flap is then allowed to return to its anatomical position. Using this approach, we have been able to control most of the disabling vestibular symptoms in patients with vestibular neuronitis (89%), Ménière's disease (90%), and benign paroxysmal positional vertigo (70%). There have been no complications associated with this approach used in 200 patients over the past 4 years. Failure to respond to the antiviral treatment represents a resistant virus strain because of thymidine kinase (TK)-deficient mutants. Other mutant strains may be TK gene altered or DNA polymerase deficient. The antiviral action of acyclovir is based on its affinity for the TK encoded by HSV and HZV. This enzyme converts acyclovir into acyclovir monophosphate, which is further converted into di- and triphosphate by other cellular enzymes. Acyclovir triphosphate stops replication of viral DNA by inhibition and inactivation of viral DNA polymerase.

Patients who fail to respond to an antiviral approach may be candidates for ablation of vestibular system function. Ablation of peripheral vestibular function has been the most effective means for the relief of recurrent vertigo. Techniques for ablation may be nonsurgical [8, 23] or surgical [14–18]. However, the vestibular deficit created by ablation stimulates a permanent alteration in central vestibular pathways bilaterally guided by neurotrophins [20, 21]. These protein substances are responsible for the development of vestibular pathways early in life and for the adjustment of perturbations in the system for the lifetime of an individual. Therefore, the effectiveness of this neural

adjustment is dependent on the presence of these important neurochemicals, which are genetically determined. The unpredictability of this central nervous system adjustment supports an approach to recurrent vestibulopathies, which preserves the integrity of this neural system.

As a nonsurgical approach to vestibular ablation, intratympanic gentamycin offers the advantage of an outpatient procedure that can be used to achieve unilateral ablation in a staged or titrated manner. The risk of sensorineural hearing loss can be minimized by limiting the total dose of drug administered to the amount necessary for ablation of the vestibulo-ocular reflex [8]. Bilateral vestibular ablation can be accomplished safely and effectively by parenteral administration of streptomycin sulfate monitored by serially testing the vestibulo-ocular reflex [33]. The antiviral approach has the advantages of an outpatient nonsurgical technique that preserves both vestibular and auditory function. Furthermore, it carries a 50% chance of relieving tinnitus and otalgia associated with the vestibular ganglionitis. Since morphologic evidence indicates vestibular ganglion cell changes in the asymptomatic contralateral ears of patients with active Ménière's disease, the use of acyclovir as a maintenance dose may prevent the progression to bilaterality.

Using these two nonsurgical approaches for relief of recurrent vestibulopathies, the need for ablation surgery, is rarely necessary. There remains a group of patients with troublesome vestibular symptoms refractory to either of these two treatments, who may be candidates for the ablation procedures. Furthermore, there are other pathologies responsible for vertigo such as temporal bone trauma (fracture), chronic ear disease, and failed oval window surgery that may require surgical ablation. The ablation procedures described in this chapter have specific indications and features that are necessary for successful results. The procedures to be described are:

1. Selective vestibular nerve section for hearing preservation through a middle cranial fossa approach and nonselective, vestibular nerve section where residual hearing is sacrificed via a transmastoid approach
2. Labyrinthectomy performed through a transcanal approach
3. Singular neurectomy for chronic benign paroxysmal positional vertigo of the posterior semicircular canal
4. Endolymphatic sac decompression

10.2 Vestibular Neurectomy

Selective vestibular neurectomy (VN) is used to ablate vestibular function unilaterally in the ear with normal or near normal hearing. It may be performed in the older patient (>65 years) as well as the young provided health is good and vision as well as proprioception are intact. Compensation for the unilateral vestibular deficit is comparable to that after labyrinthectomy [18]. The procedure may be performed by way of a middle cranial fossa (MF) extradural exposure of the IAC or via a suboccipital retrolabyrinthine approach to the cerebellopontine angle [17], (CPA). Our preference is for the MF approach for several reasons (Fig. 10.5):

1. The extradural exposure is less risky for subarachnoid space complications (i.e., bleeding or infection)
2. The separation between the vestibular nerve and the cochlear nerve permits complete vestibular ablation and hearing preservation

3. The vestibular ganglion is excised preventing regeneration and permitting histological examination
4. Less chance for headache

The approach to selective VN in the CPA must contend with an unnatural (surgical) separation of the vestibular and cochlear divisions of the eighth cranial nerve (Fig. 10.6). This may lead to incomplete vestibular ablation or risk some loss of cochlear neurons. Transection of vestibular axons in the CPA leaves the vestibular ganglion in the IAC with a potential for regeneration of axons. Finally, postoperative headache is more likely with the posterior fossa approach.

Nonselective VN is usually indicated in those patients with severe or profound loss of hearing who have failed labyrinthectomy, survived transverse temporal bone fracture, or demonstrated amputation neuroma after labyrinthectomy (Fig. 10.7). The exposure of the internal auditory canal and its contents is achieved by way of an intact canal wall mastoidectomy

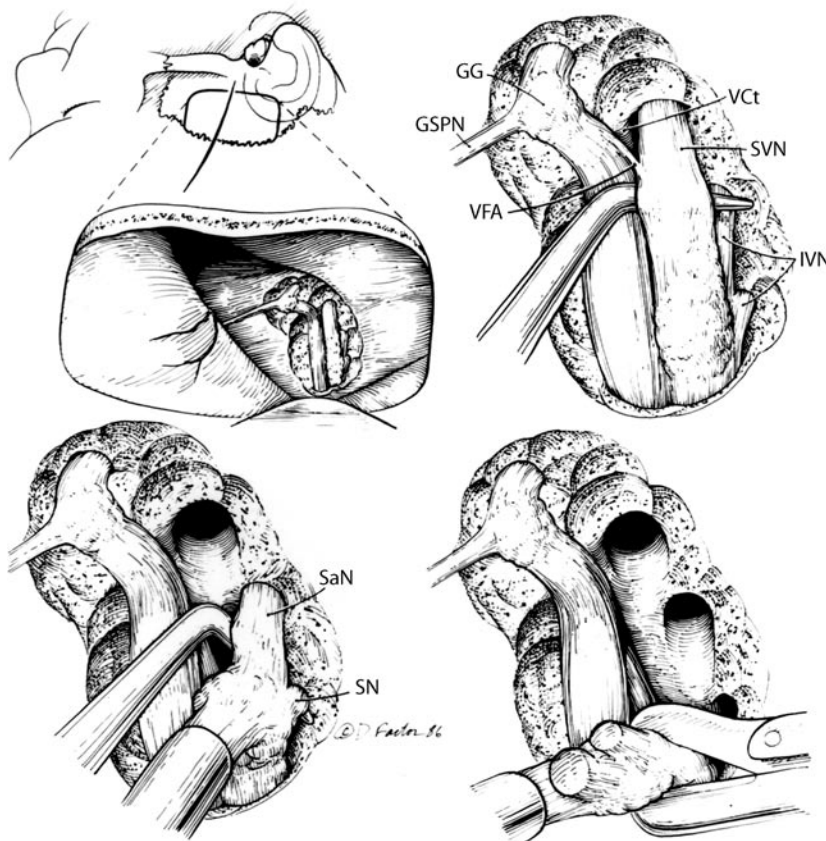


Fig. 10.5 Diagram of the main steps in the middle fossa approach to vestibular neurectomy. *SVN* superior vestibular nerve, *IVN* inferior vestibular nerve, *GSPN* greater superficial petrosal nerve, *SaN* saccular nerve, *SN* singular nerve, *VCT* vertical crest in the internal auditory canal

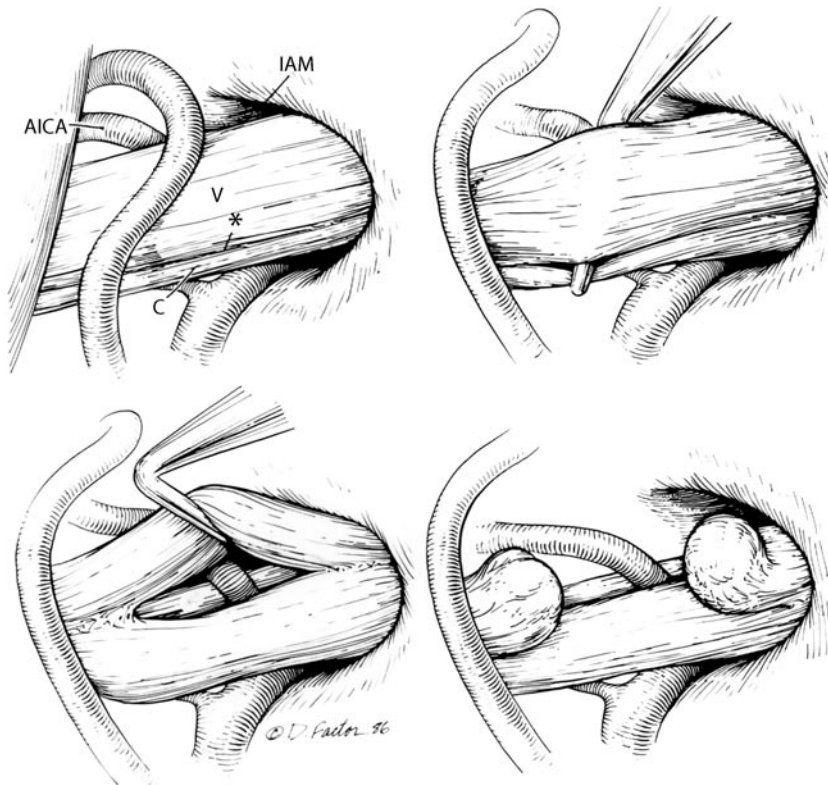


Fig. 10.6 When vestibular neurectomy is performed in the cerebellopontine angle, the cleavage plane (*) between the vestibular, and cochlear (C) divisions is developed with hooks before transection (D). Note that the ganglion remains in the internal auditory canal. *F FN, AICA anterior inferior cerebellar artery*

10

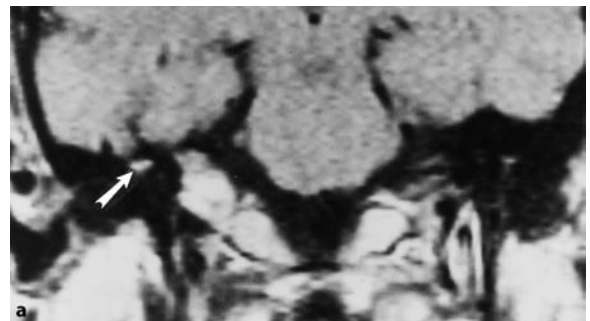
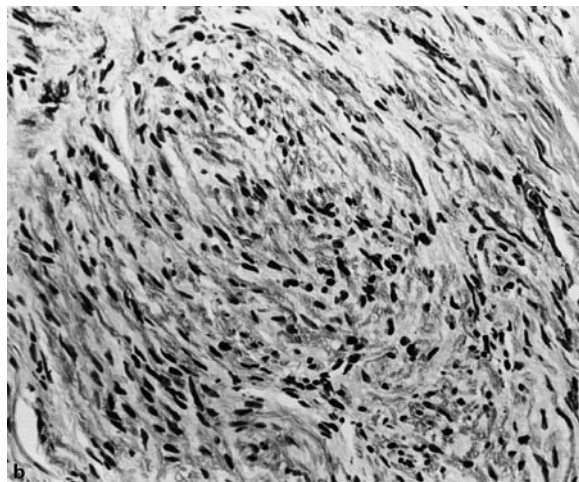


Fig. 10.7 **a** Contrast MRI in a patient with recurrent vertigo 6 months after a successful labyrinthectomy for Ménière's disease. There is enhancement in the region of the vestibule (arrow). **b** Removal of the mass by intact canal wall mastoidectomy revealed disorganized myelinated and unmyelinated nerve fibers

tomy and translabyrinthine decompression of the IAC (Fig. 10.8).

The VN branches and nerve trunk along with its ganglion is excised after separation from the facial and

cochlear nerves. The cochlear nerve is usually atrophic after severe peripheral injury to the labyrinth and need not be excised. Tran section of the cochlear nerve has not been shown to have a beneficial effect in tinnitus.

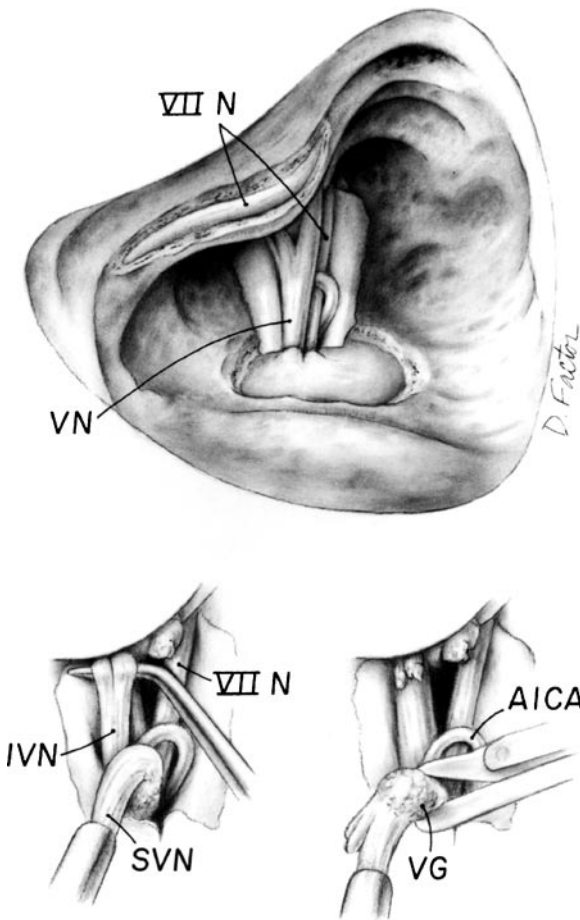


Fig. 10.8 Exposure of the nerves in the internal auditory canal (VN vestibular nerve, VII N FN) via transmastoid translabyrinthine approach. The superior (SVN) and inferior (VN) vestibular divisions are excised with the vestibular ganglion (VG). AICA anterior inferior cerebellar artery

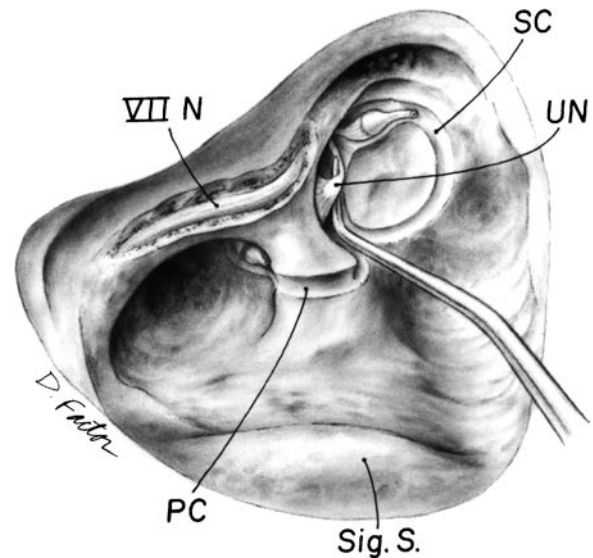


Fig. 10.9 Transmastoid exposure of the vestibular sense organs (VN utricular nerve, SC, PC superior and posterior semicircular canals and cristae ampullaris, respectively). Frequently, the FN (VII N) must be exposed in this procedure

gans are located is through the middle ear (Fig. 10.10). Removal of the promontory, connecting the oval and round windows, aids the removal of vestibular sense organs with long hooks. Transection of the posterior ampullary nerve in the singular canal assures ablation of the posterior semicircular crista, which is located in its ampullary recess.

The recovery of balance after labyrinthectomy is dependent on the level of vestibular sensitivity preoperatively and the completeness of vestibular sense organ ablation [18]. Patients usually leave the hospital 1–2 days post surgery.

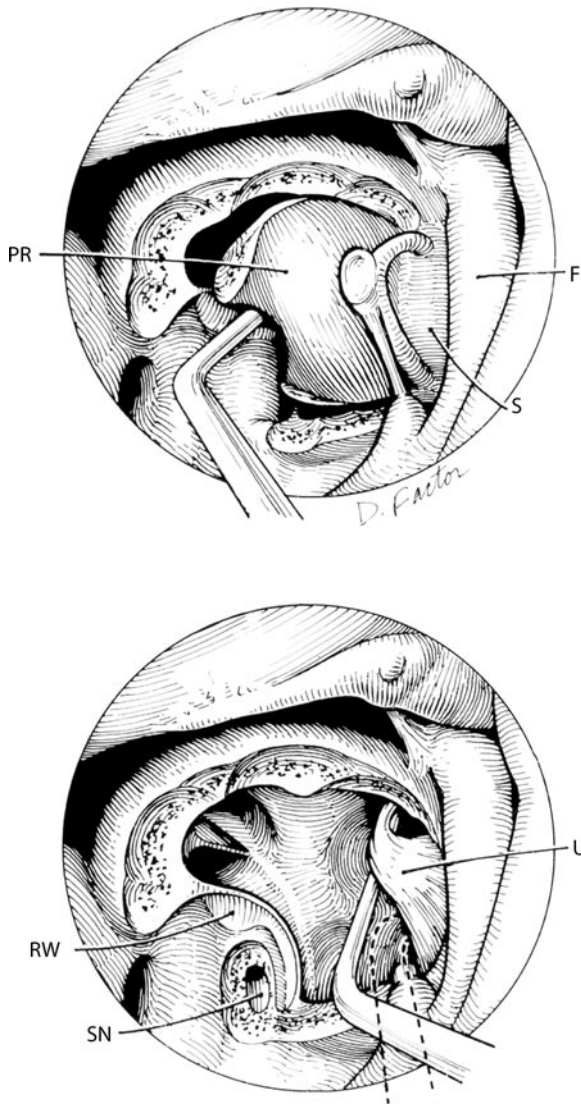
10.3 Labyrinthectomy

Labyrinthectomy is very effective (>95%) in the relief of peripherally induced recurrent vertigo in the non-hearing ear [18]. Key to the success of this procedure is the complete removal of all vestibular sense organ tissue. This removal can be accomplished via a transcanal [14] or a transmastoid [15] approach.

While the posterior approach (mastoid) to the vestibular labyrinth is suitable when the labyrinthectomy is performed in the course of exenteration of chronic otitis media and mastoiditis (Fig. 10.9), the most direct approach to the vestibule where the vestibular sense or-

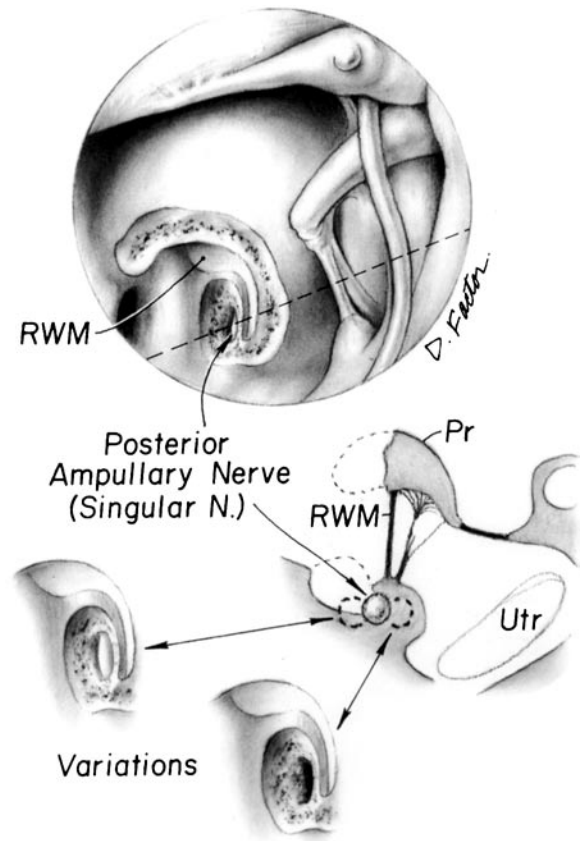
10.4 Singular Neurectomy

Singular neurectomy (SN) is specifically indicated in the patient with chronic (>1 year) benign paroxysmal positional vertigo provoked by activation of the posterior semicircular canal [16]. In such patients where hearing is normal, the Hallpike provocative maneuver elicits a brief (10–20 s) rotatory nystagmus after a short latency period of 1–2 s, and is fatigable on repeated provocation. If the patient is significantly disabled by the positional vertigo despite conservative measures (i.e., repositioning maneuvers, antiviral medication,



■ Fig. 10.10 Steps in transcanal labyrinthectomy. The promontory (PR) is removed to provide wide exposure of the vestibular cistern. F FN, S stapes

avoidance of provocative position), then SN can offer a >95% chance of complete relief of vertigo, with a < 3% risk of sensorineural hearing loss [16]. Patients with benign paroxysmal positional vertigo accompanied by a horizontal or purely vertical nystagmus with the same features of latency, duration, and fatigability represent findings associated with the lateral and superior canal cristae. The ablation procedure required for vertigo relief in these patients is selective vestibular nerve transaction.



■ Fig. 10.11 Selective transaction of the singular nerve for benign paroxysmal positional vertigo. After exposure of the RWM, the floor of the RW niche is drilled to a depth of 2–3 mm to identify the singular nerve. The bottom diagram shows the various locations of the singular canal in a cross section location through the round and oval windows (dashed line)

The procedure is performed under local anesthesia with added sedation. The round window niche is exposed via a tympanotomy approach (Fig. 10.11). The most important landmark for the singular canal is the round window membrane (RWM), which must be identified fully by removal of the bony overhang with a small diamond burr. Drilling the cavity for the approach to the singular canal, is located inferior to the posterosuperior end of the RWM. The SN is encountered at a depth of 2–3 mm as a white myelinated nerve bundle. The nerve bundle can vary in its superior to inferior location. Approximately 30% of the time, the nerve is easily identified in the floor of the niche, usually (50%), it is partially exposed inferior to the RWM, and uncommonly (10–15%), it is hidden under the

RWM. In this latter location, it must be approached by undercutting the RWM and reliance on the patient's response to probing of the canal (vertigo or pain). In a few (<5%) of patients, the nerve cannot be exposed safely in this location without risk to hearing. In a few of these patients, posterior semicircular canal occlusion in the mastoid has been successfully used. The main anatomical variation that has prevented SN is a superiorly located jugular bulb, which may occupy the RWN.

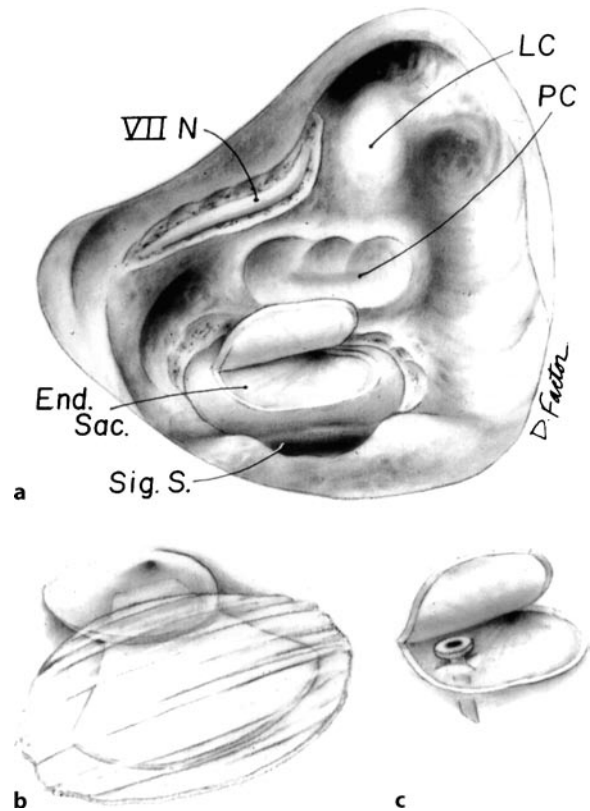
10.5 Endolymphatic Sac Decompression

Patients disabled by recurrent vertigo in the clinical syndrome of Ménière's disease, who are unwilling to undergo selective VN or risk the hearing loss from intratympanic gentamycin, may be offered a single procedure: shunting of the endolymphatic sac into the mastoid compartments [33], for relief of vertigo with preservation of hearing (Fig. 10.12).

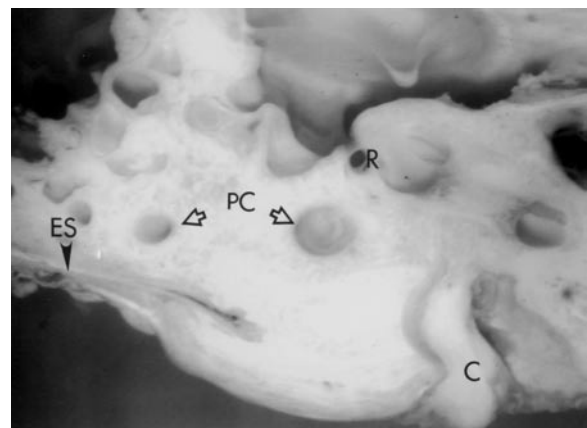
This procedure may be performed under light general anesthesia or local anesthesia with added sedation. The duration of the procedure is one hour or less and is outpatient surgery. The important landmark for locating the endolymphatic sac is the posterior semicircular canal in the bony labyrinth (Fig. 10.13). When this procedure is performed under local anesthesia, it is possible to record a paralytic nystagmus response with eyes closed, recording leads when the sac is opened. Measurement of vestibular sensitivity 1–2 months after surgery reveals a reduced vestibular response compared to presurgery assessment. These objective measures suggest a reduction in vestibular sensitivity secondary to a surgical labyrinthitis in the endolymph compartment (and fluid) as the mechanism responsible for relief of vestibular symptoms [15].

COMPLICATIONS TO AVOID

1. FN monitoring is useful in vestibular nerve transection to avoid facial paralysis.
2. In transcanal labyrinthectomy, excision of the saccular macula should be performed carefully to avoid cerebrospinal fluid leak.
3. The RWM should be fully exposed in singular neurectomy to avoid sensorineural hearing loss.
4. Gray lining the bony posterior semicircular canal is useful to locate the endolymphatic sac.



■ Fig. 10.12 Surgical exposure of the endolymphatic sac (*End. Sac.*) in the mastoid compartment requires removal of bone over the posterior fossa dura and sigmoid sinus at the level of the posterior semicircular canal (*PC*). *LC* lateral canal prominence, *VII N* FN



■ Fig. 10.13 This horizontal section through the temporal bone demonstrates the relationship of the endolymphatic sac (*ES*) to the posterior semicircular canal (*PC*). *C* cochlear nerve, *R* round window niche

Pearl

- The vertigo in a majority of patients with Ménière's disease or vestibular neuronitis can be controlled on antiviral medication (acyclovir).

References

1. Adour KK, Byle FM, Hilsinger R (1980): Ménière's disease as a form of cranial polyneuritis. *Laryngoscope* 90:392–398
2. Adour KK, Hilsinger R, Byl FM (1980) Herpes simplex polyganglionitis. *Otolaryngol Head Neck Surg* 88:270–274
3. Arbusow V, Schutz P, Strupp M, Dieterich M et al (1999) Distribution of herpes simplex virus type I in human geniculate and vestibular ganglion: implications for vestibular neuritis. *Ann Neurol* 46:416–419
4. Arbusow V, Strupp M, Wasicky R, Horn AKE, Schultz P, Brandt T (2000) Detection of herpes simplex virus type I in human vestibular nuclei. *Neurology* 55:880–882
5. Aschan G, Stahle J (1956) Vestibular neuritis. *J Laryngol Otol* 70:497–511
6. Arnold W, Niedermeyer HP (1997) Herpes simplex virus antibodies in the perilymph of patients with Ménière's disease. *Arch Otolaryngol Head Neck Surg* 123:53–56
7. Baringer JR, Swoveland P (1973) Recovery of herpes simplex virus from human trigeminal ganglions. *N Engl J Med* 288:648–650
8. Carey J (2004) Intratympanic gentamycin for the treatment of Ménière's disease and other forms of peripheral vertigo. *Otolaryngol Clin N Am* 37:1075–1090
9. Coats A (1969) Vestibular neuronitis. *Acta Otolaryngol (Stockh)* 251:1–32
10. Cook ML, Stevens JG (1973) Pathogenesis of herpetic neuritis and ganglionitis in mice: evidence for intra-axonal transport of infection. *Infect Immun* 7:272–288
11. Denny-Brown D, Adams RD, Fitzgerald PJ (1949) Pathologic features of herpes zoster: a note on geniculate herpes. *Arch Neurol Psychiatry* 51:216–231
12. Dix M, Hallpike C (1952) The pathology, symptomatology, and diagnosis of certain common disorders of the vestibular system. *Ann Otol Rhinol Laryngol* 61:987–1016
13. Fenton JE, Shirazi A, Turner J, Fagan P (1995) Atypical vestibular neuritis: a case report. *Otolaryngol Head Neck Surg* 112:738–741
14. Gacek R. (1978) "How I do it": transcanal labyrinthectomy. *Laryngoscope* 88:1707–1708
15. Gacek R (1993) Surgery of the vestibular system. In: Cummings CW et al (eds) *Head and neck surgery*, vol. 4. Mosby, St. Louis, pp 3199–3216
16. Gacek R (1996) Technique and results of singular neurectomy for the management of benign paroxysmal positional vertigo. *Acta Otolaryngol (Stockh)* 115:154–157
17. Gacek R (1998) Selective vestibular nerve section of Ménière's disease. In: Schmidek HH, Sweet WH (eds) *Operative neurosurgical techniques: indications, methods, and results*. Grune & Stratton, New York
18. Gacek R, Gacek M (1996) Comparison of labyrinthectomy and vestibular neurectomy in control of vertigo. *Laryngoscope* 106:225–230
19. Gacek R, Gacek M (2002) The three faces of vestibular ganglionitis. *Ann Otol Rhinol Laryngol* 111:103–114
20. Gacek R, Schoonmaker J (1997) Morphologic changes in the vestibular nerves and nuclei following labyrinthectomy in the cat: a case for the neurotrophin hypothesis in vestibular compensation. *Acta Otolaryngol (Stockh)* 117:244–249
21. Gacek R, Khetarpal U (1998) NT3, not BDNF and NT4, knockout mice have delay in compensation after unilateral labyrinthectomy. *Laryngoscope* 108:671–678
22. Hart C (1965) Vestibular paralysis of sudden onset and probably viral etiology. *Ann Otol Rhinol Laryngol* 74:33–47
23. Kaplan DM, Nedzelski JM, AL Abidi A (2002) Hearing loss following intratympanic instillation of gentamycin for the treatment of unilateral Ménière's disease. *J Otolaryngol* 31:106–111
24. Laquerre S, Argnani R, Anderson D, Zucchini S, Manservigi R, Gloriosio J (1998) Heparan sulfate proteoglycan binding by herpes simplex type I glycoproteins B and C attachment, which differ in their contributions to virus penetration and cell to cell spread. *J Virol* 72:6119–6130
25. Lehninger AL (1968) The neuronal membrane. *NAS Symp* 60:1069–1080
26. Meier JL, Straus SE (1992) Comparative biology of latent varicella zoster virus and herpes simplex virus infections. *J Infect Dis* 166(Suppl):S13–S23
27. Nadol JB (1995) Vestibular neuritis. *Otolaryngol Head Neck Surg* 112:162–172
28. Ohbayashi S, Oda M, Yamamoto M et al (1993) Recovery of vestibular function after vestibular neuronitis. *Acta Otolaryngol (Stockh)* 503:31–34
29. Pitovski DZ, Robinson AM, Garcia-Ibanez E, Wiet R (1999) Presence of *HSV-1* gene products characteristic of active infection in the vestibular ganglia of patients diagnosed with acute Ménière's disease (abstract 457). 22nd Annual Midwinter Research Meeting of the Associates for Research in Otolaryngology, St. Petersburg Beach, February 1999
30. Proctor LR (2000) Results of serial vestibular testing in unilateral Ménière's disease. *Am J Otol* 21:522–558
31. Rosenstein, Pitovski D (1998) Detection of herpes simplex virus type I latency associated DNA in human vestibular ganglion by in situ polymerase chain reaction (abstract 261) 21st Annual Midwinter Research Meeting of the Associates for Research in Otolaryngology, St. Petersburg Beach, February 1998
32. Schmidt J, Rasmussen AF (1960) Activation of latent herpes simplex encephalitis by chemical means. *J Infect Dis* 106:154–158
33. Schuknecht HF (1957) Ablation therapy in the management of Ménière's disease. *Acta Otolaryngol (Stockh)* 132:1–42
34. Schuknecht HF, Kitamura K (1981) Vestibular neuritis. *Ann Otol Rhinol Laryngol* 90(Suppl):1–19
35. Silvoniemi P (1988) Vestibular neuronitis: An otoneurological evaluation. *Acta Otolaryngol (Stockh)* 453:1–72
36. Wu Dunn D, Spear PG (1989) Initial interaction of herpes simplex virus with cells is binding to heparan sulfate. *J Virol* 63:52–58
37. Zemanick MC, Strick PL, Dix RD (1991) Direction of transneuronal transport of herpes simplex virus I in the primate motor system is strain-dependent. *Proc Natl Acad Sci USA* 88:8048–8051

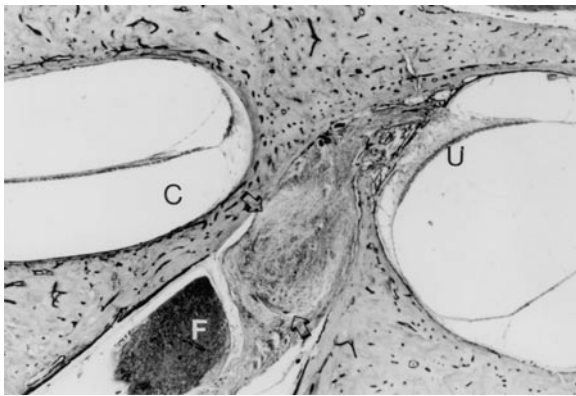Core Messages

- The most common benign tumors in the TB are the vestibular schwannoma (acoustic neuroma) and the paraganglioma (glomus tumor).
- Other benign tumors of the internal auditory canal include meningioma, epidermoid, lipoma, and arachnoid cyst. Additional benign tumors in the middle ear include adenoma, carcinoid, chondroma, and schwannoma.
- Treatment of vestibular schwannoma may be nonsurgical (irradiation) or surgical. In the medically stable young patient, surgery is preferred, while irradiation is effective in the elderly or medically compromised patient.
- Surgical approach to vestibular schwannoma may utilize either the posterior or middle cranial fossa. Posterior fossa approach may be transmastoid translabyrinthine (no hearing) or suboccipital (hearing preservation). The middle fossa approach is employed for tumors limited to the internal auditory canal, where hearing is to be preserved.
- Glomus tumors may be limited to the middle ear space (glomus tympanicum) or arise in the jugular bulb and extend to the middle ear, mastoid, neck and other perilyabyrinthine compartments (glomus jugulare).
- Glomus tympanicum tumors are best removed through an endaural surgical approach.
- Glomus jugulare tumors require an extended lateral skull base approach including the neck and wide TB exenteration. Preoperative endovascular embolization is not effective in reducing blood loss.
- Partial (lateral) TB resection is an effective surgical procedure for carcinoma limited to the external auditory canal.
- Pseudoepithelial hyperplasia may simulate squamous cell carcinoma of the ear canal clinically and histopathologically.

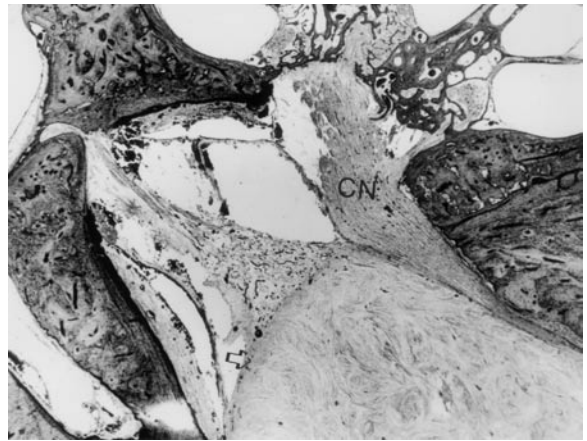
Most neoplasms of the cerebellopontine angle, middle ear, and jugular foramen are benign and require removal because of potential cranial nerve deficits or risk to intracranial structures from uncontrolled progressive growth. Representative surgical approaches to tumors in these locations of the TB are discussed.

11.1 Internal Auditory Canal and Cerebellopontine Angle

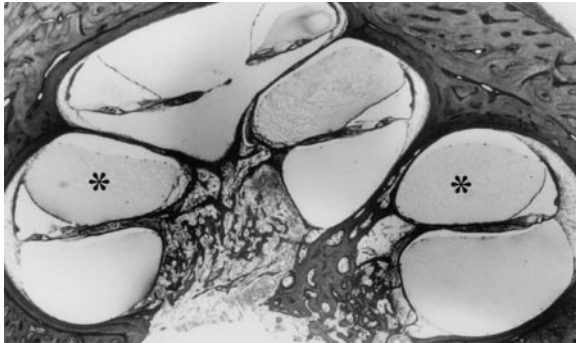
The most common retrocochlear neoplasm is the vestibular schwannoma (VS), also referred to as acoustic neuroma. Second in frequency in this location is meningioma, followed by several other benign tumors (lipoma, epidermoid, dermoid, and arachnoid cyst). Since Schwann cells are responsible for the myelin component of nerve fibers [16, 18, 19], these tumors may arise from any location distal to the glial-Schwann sheath junction of the VIII cranial nerve (Fig. 11.1). Since this segment of the eighth nerve is located within the internal auditory canal, filling of the canal on contrast neuroimaging (MRI) helps to differentiate VS from other retrocochlear lesions, i.e., meningioma, epidermoid. The vestibular, rather than the cochlear nerve, usually gives rise to these schwannomas. In this bony compartment, the tumors slowly enlarge, causing minimal vestibular symptoms as the vestibular neurons are gradually replaced. However, if labyrinthine blood supply is suddenly compromised by tumor growth, then acute vertigo and hearing loss may occur. As compression of adjacent cochlear neurons is reached, auditory symptoms (sensorineural hearing loss and tinnitus) appear (Fig. 11.2). The accumulation of tumor specific proteins in the perilymphatic space may also play a role in the sensorineural hearing loss (Fig. 11.3). Even maximal displacement of the FN with loss of motor nerve fibers fails to manifest as facial paralysis because of peripheral re-innervation of denervated muscle units by adjacent surviving FN axons. Of course, with uninterrupted growth, the VS spills out into the cerebellopontine angle and may compress other nerves (trigeminal, vagus, glossopharyngeal) and neural structures (brainstem, cer-



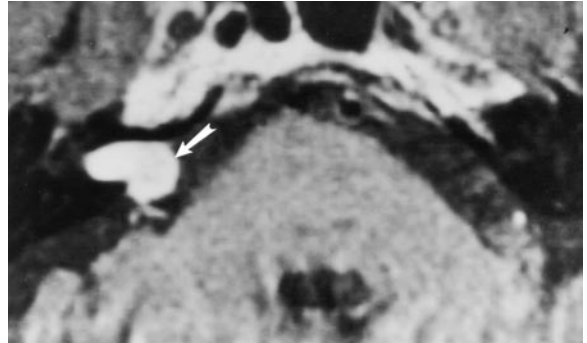
■ **Fig. 11.1** Photomicrograph of an early asymptomatic vestibular schwannoma (*arrow*) arising in the distal end of the internal auditory canal. *FN*, *C* cochlea, *U* utricular macula



■ **Fig. 11.2** When the vestibular schwannoma (*arrow*) enlarges in the internal auditory canal, it compresses the cochlear nerve (*CN*), resulting in sensorineural hearing loss



■ **Fig. 11.3** This photomicrograph demonstrates the increased tumor protein (*) in the perilymph of the cochlea in the TB of a patient with a vestibular schwannoma



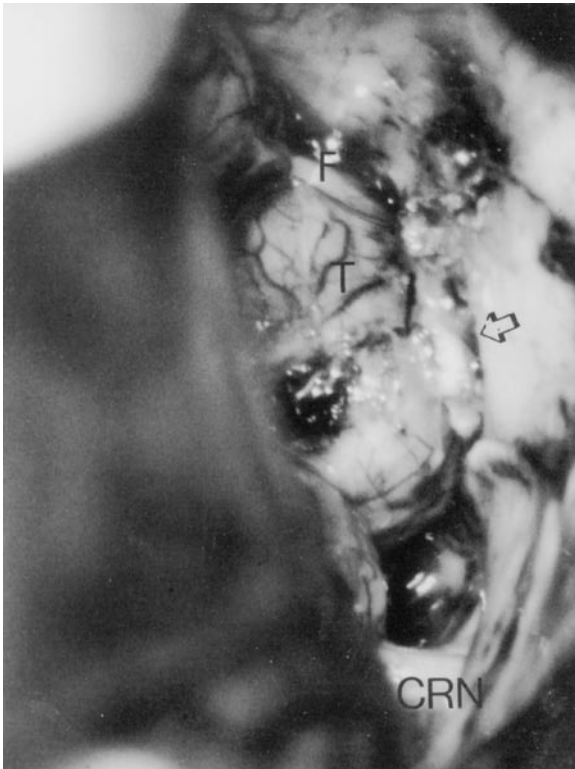■ **Fig. 11.4** Gadolinium-enhanced MRI is the standard test for tumor demonstration (*arrow*)

ebellum). Greater diagnostic suspicion and sensitive neuroimaging techniques [7] have all but eliminated the large VS with central neural signs and symptoms (Fig. 11.4). The treatment of the various retrocochlear neoplasms are similar to that employed for VS.

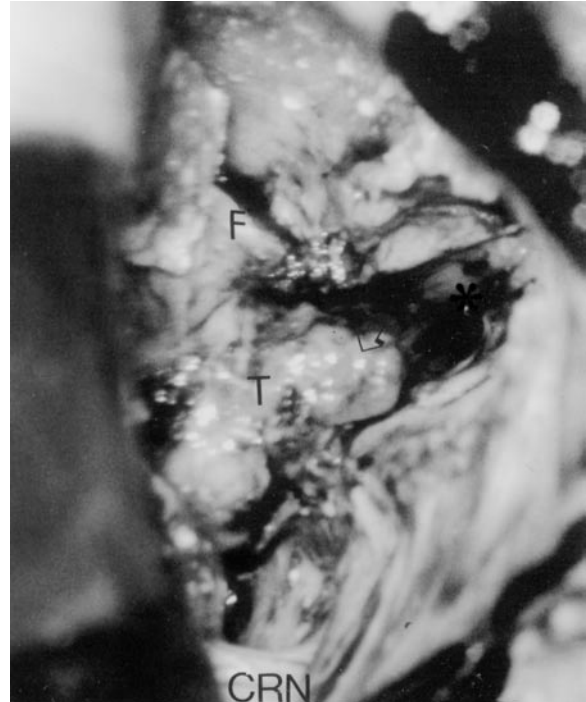
Surgical removal of VS may be accomplished via a transmastoid translabyrinthine approach or by through a posterior fossa craniotomy. In general, otologists prefer the former while the latter is used neurosurgically. The transmastoid approach is utilized in ears where hearing has been lost as a result of tumor [10] progression. Advantages are better control of tumor removal within the IAC, early identification and preservation of the FN, minimal craniotomy, and cerebellar retraction. This approach can be used for small and large tumors.

The posterior fossa approach is used when hearing preservation is desired [15] and with very large tumors causing brainstem and cerebellar compression [17]. A disadvantage is uncertainty about residual tumor in the most lateral end (fundus) of the IAC, and more difficult identification of the FN (Fig. 11.5, 11.6). There are individual cases where more than one approach is used in a staged fashion [17]. The techniques for these procedures have been described thoroughly in texts of otologic surgery.

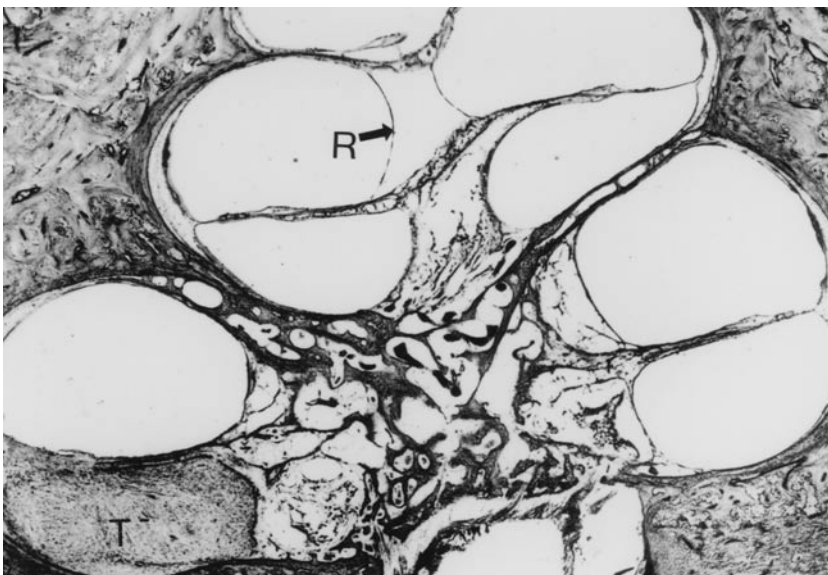
Small VS limited to the IAC in ears with normal or near normal hearing may also be excised via a middle cranial fossa approach [9]. This approach carries a slightly higher risk to FN function because of the nerve's location in the superior compartment of the



■ **Fig. 11.5** The posterior fossa approach for hearing preservation in vestibular schwannoma removal requires exposure of the internal auditory meatus (*arrow*). *T* tumor, *F* FN, *CRN* lower cranial nerves



■ **Fig. 11.6** The canalicular portion of tumor (*arrow*) has been dissected from the internal canal (*), with preservation of the facial (*F*) and cochlear (*C*) nerves



■ **Fig. 11.7** Photomicrograph of an intralabyrinthine cochlear nerve schwannoma (*T*). The endolymphatic hydrops (*arrows*) is caused by tumor compression of the ductus reuniens. *R* Reissner's membrane

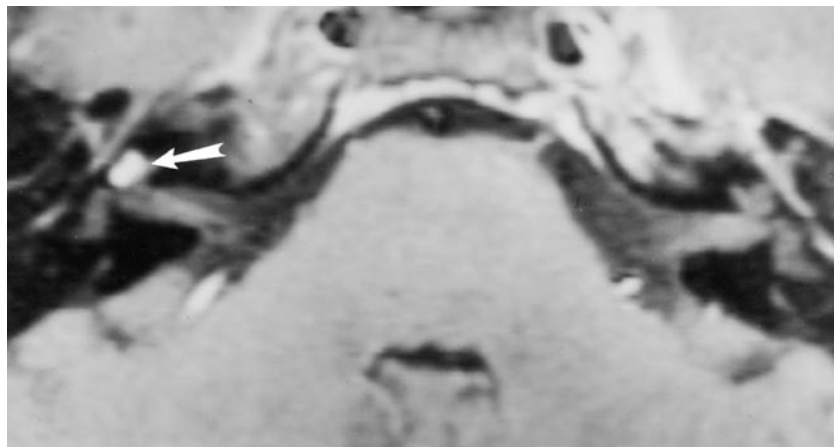


Fig. 11.8 Gadolinium-enhanced MRI demonstrates an intralabyrinthine cochlear schwannoma (arrow) in a patient with the audiogram in Fig. 11.9

IAC. In this location, the nerve is encountered before tumor dissection is initiated. The results with hearing preservation, however, are better than with other approaches because the labyrinthine blood supply is remotely located inferiorly in the IAC and can be avoided.

11.2 Intralabyrinthine Vestibular/ Cochlear Schwannoma

The proliferation of Schwann cell neoplasms may be limited to the bony labyrinth [1, 12, 22]. These tumors arise from the peripheral vestibular nerve branches, after leaving the cribrose portions of the otic capsule and before supplying the vestibular sense organs. In the cochlea, they arise from the dendrites of spiral ganglion cells adjacent to the scala tympani (Fig. 11.7). These tumors are usually limited to the bony labyrinth and are referred to as intralabyrinthine schwannomas. The clinical presentation of the vestibular variety is frequent recurrent vertigo, while the cochlear nerve type is associated with sensorineural hearing loss, usually in the low frequencies. If an intracanalicular component has been excluded by imaging studies, then excision of the intralabyrinthine schwannoma may be accomplished through the middle ear after removal of the promontory.

In the past, most cases of intralabyrinthine schwannoma have been recognized during labyrinthectomy surgery for severe Ménière's disease [12]. Now they may be diagnosed preoperatively by MRI (Fig. 11.8). The most common sensorineural hearing loss pattern

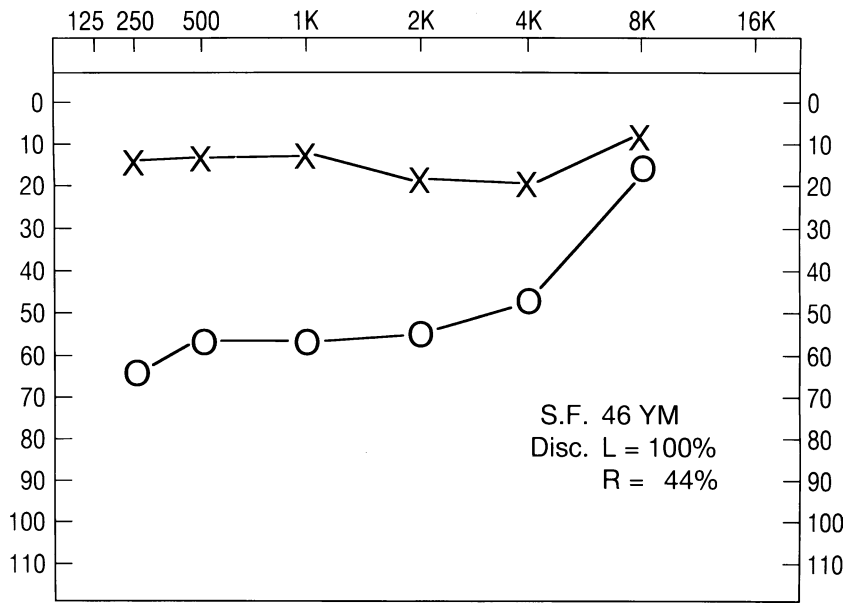
associated with the intralabyrinthine tumor is the ascending threshold pattern, seen with endolymphatic hydrops [1], (Fig. 11.9). The most effective surgical approach to the detection and removal of these neural tumors is by transcanal middle ear exposure of the vestibule and cochlea after removal of the promontory.

11.3 Benign Tumors of the Middle Ear and Mastoid

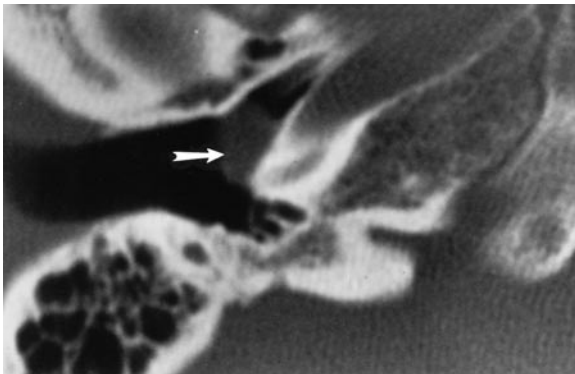
Examples of these are glomus tumors, adenoma, low-grade adenocarcinoma, and neurogenic tumors of the middle ear. Clinical presentation is heralded by a progressive conductive hearing loss, pulsatile tinnitus, and a mass in the middle ear confirmed by neuroimaging of the TB. Computed tomography of the TB is recommended to compliment MRI by evaluating bony confines of the middle ear, especially the jugular foramen (JF).

Paraganglioma tumors that arise from glomus bodies located along the course of the tympanic branch of cranial nerve IX (Jacobsen's) in the middle ear are classified as glomus tympanicum tumors. Those paraganglioma tumors that arise from glomus bodies located in the adventia of the jugular bulb are classified as glomus jugulare tumors. When these tumors are large enough to be visible in the hypotympanum, the bony margins of the jugular foramen have been eroded with or without deficits of the nerves passing through the foramen.

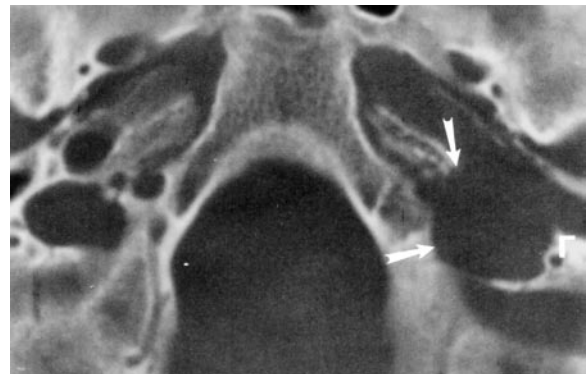
Small glomus tympanicum tumors can be excised through a tympanotomy approach (Fig. 11.10). Larger



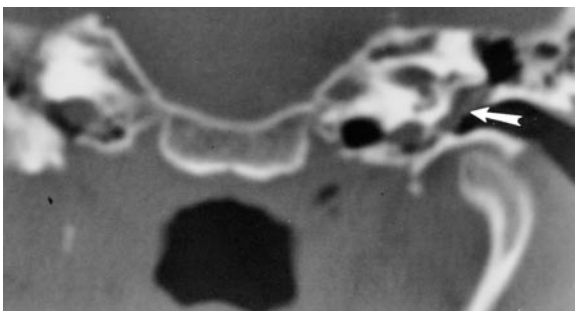
■ Fig. 11.9 Low-frequency sensorineural hearing associated with intralabyrinthine cochlear schwannoma



■ Fig. 11.10 Axial CT scan demonstrates a small glomus tympanicum tumor (arrow)



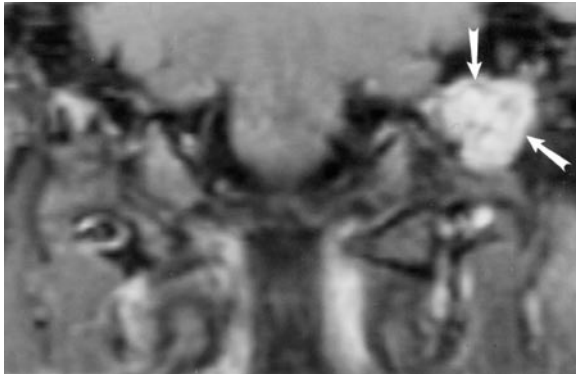
■ Fig. 11.12 Axial CT scan of skull base demonstrates erosion of the jugular foramen (arrows) in a patient with a glomus jugulare tumor. F FN canal (mastoid)



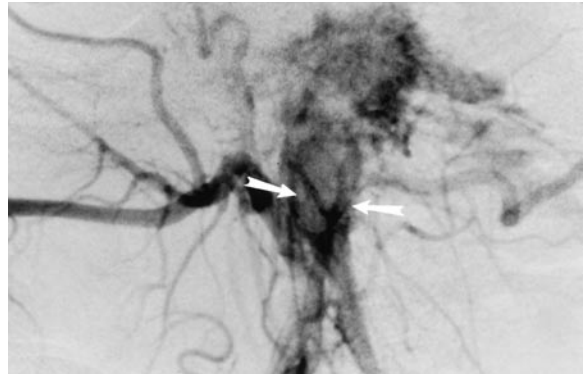
■ Fig. 11.11 Coronal CT of a patient with larger glomus tympanicum filling the middle ear space (arrow)

tumors filling the middle ear space require more exposure provided by atticotomy and canaloplasty in order to accomplish tumor removal with preservation of the sound transmission system (20), (Fig. 11.11).

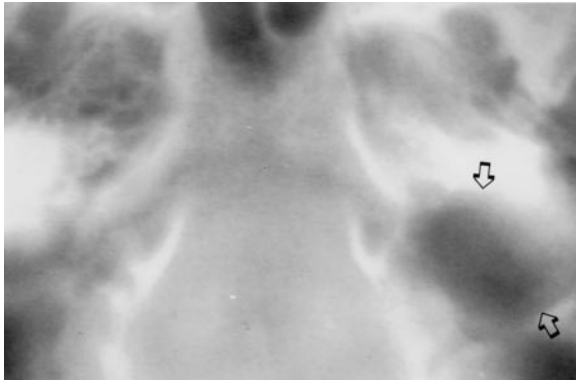
If CT indicates erosion of the bony limits of the jugular foramen [21], then the presence of tumor (glomus jugulare) arising in the JF with extension into the middle ear must be assumed (Fig. 11.12). Additional neuroradiological studies are necessary to determine the size of tumor [11]. These include MRI (Fig. 11.13) and arteriography (Fig. 11.14). Lateral skull base approaches to the JF and middle ear are necessary to control major vessels supplying the tumor, be-



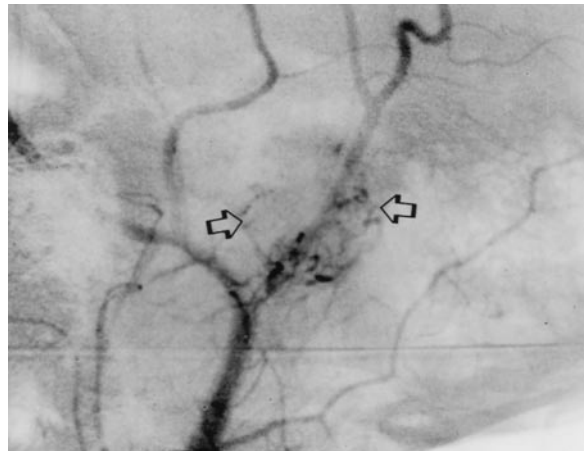
■ Fig. 11.13 Gadolinium-enhanced coronal MRI of the glomus jugulare tumor (arrow)



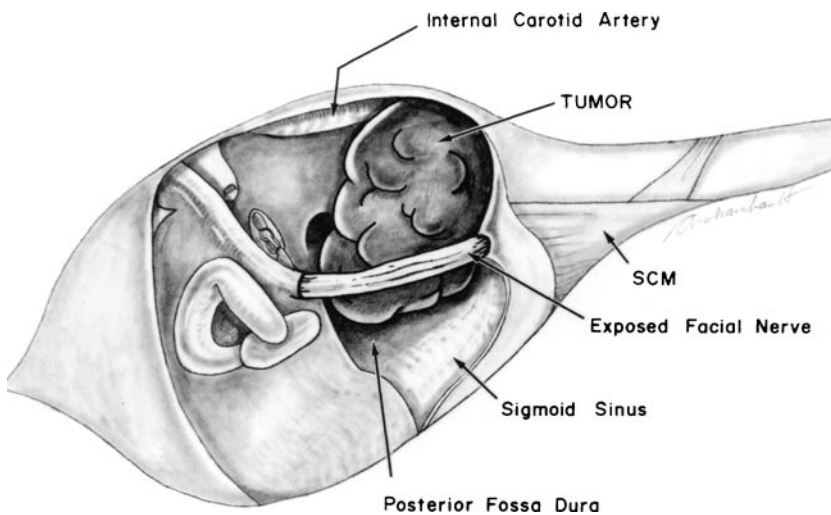
■ Fig. 11.14 Venous phase of arteriogram shows the intraluminal extension of glomus jugulare tumor into the internal jugular vein (arrow)



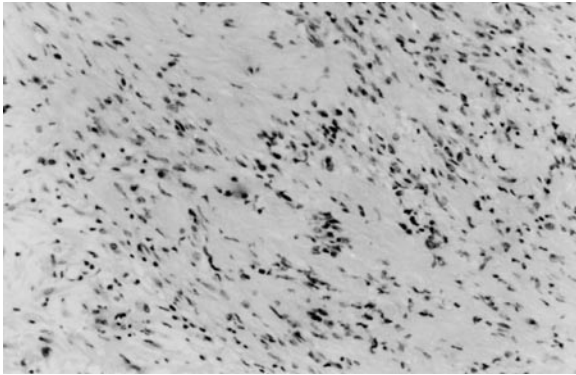
■ Fig. 11.15 Axial CT of an enlarged jugular foramen (arrows) in a young woman with a red mass in the hypotympanum



■ Fig. 11.16 Arteriogram in same patient as in Fig. 11.15 shows a spherical mass with mild vascular blush (arrows)



■ Fig. 11.17 Drawing of the findings at surgery in same patient. The tumor was completely removed



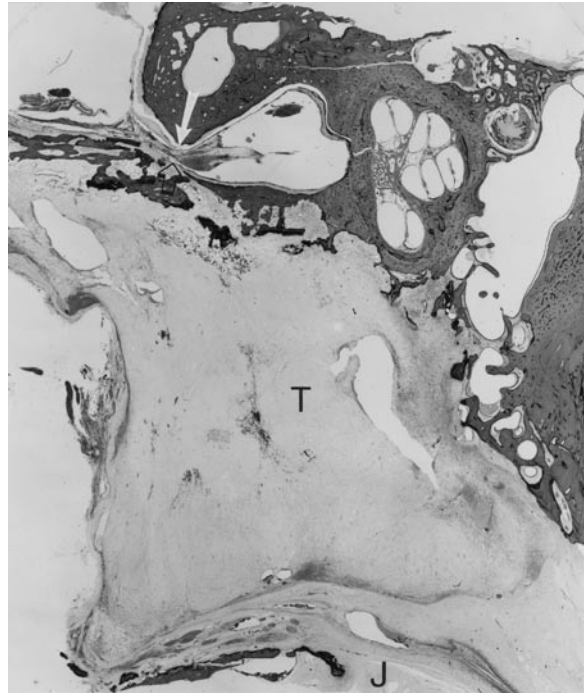
■ **Fig. 11.18** Histopathologically the tumor was classified as schwannoma

fore tumor resection. Transposition of the FN may or may not be required for exposure of the JF and venous structures [8]. Embolization of the tumor through the external carotid system has not been effective in reducing intraoperative bleeding, probably because of significant flow from tumor vessels arising from the internal carotid artery. Preoperative assessment for a catecholamine secreting paraganglioma should be performed especially in the patient with a history of elevated blood pressure.

Neurogenic (schwannomas) tumors arising from nerves in the jugular foramen may closely mimic the more vascular glomus jugulare tumor (Fig. 11.15). Arteriography is the definitive study for this differentiation [2]. The vascular supply in the neurogenic tumor is far less prominent (Fig. 11.16) than it is in the glomus (paraganglioma) tumor. Accordingly, the surgical approach need not control the major vascular supply (ascending pharyngeal) in the neck when dealing with neurogenic tumors in this location (Figs. 11.17, 11.18).

The histopathologic demonstration of neurofibroma arising from the jugular foramen is shown in Fig. 11.19. This 89-year-old female was diagnosed with a glomus jugulare tumor causing deficits of cranial nerves VII, VIII, and X, and erosion of the jugular foramen [3]. She received low-dose radiation therapy recommended by Dr. Harvey Cushing and lived for over 50 years with the tumor (shown in Fig. 11.19.)

Careful interpretation of CT, MRI, with arteriography should be employed to eliminate false-positive radiologic findings in the skull base by imaging techniques. Figure 11.20 is an MRI taken of a patient with a 6-month history of pulsatile tinnitus in the right ear.



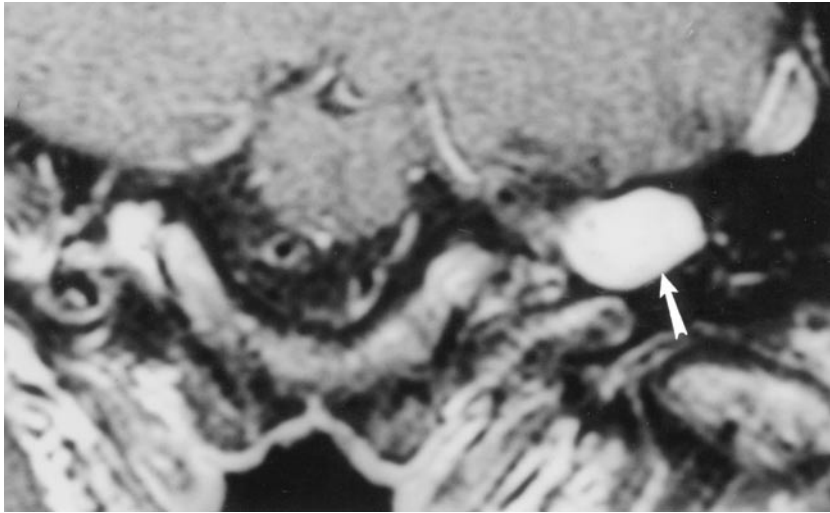
■ **Fig. 11.19** This vertical section through the TB of an 89-year-old female with a jugular foramen schwannoma (T) that was treated with radiation therapy over 50 years before her death. The tumor arose from nerves of the jugular foramen (J) and compressed the seventh and eighth nerves in the internal auditory canal (arrow)

CT confirmed a large right jugular foramen with an intact cortical rim (Fig. 11.21). Recommended vascular studies failed to demonstrate neoplasm (Fig. 11.22).

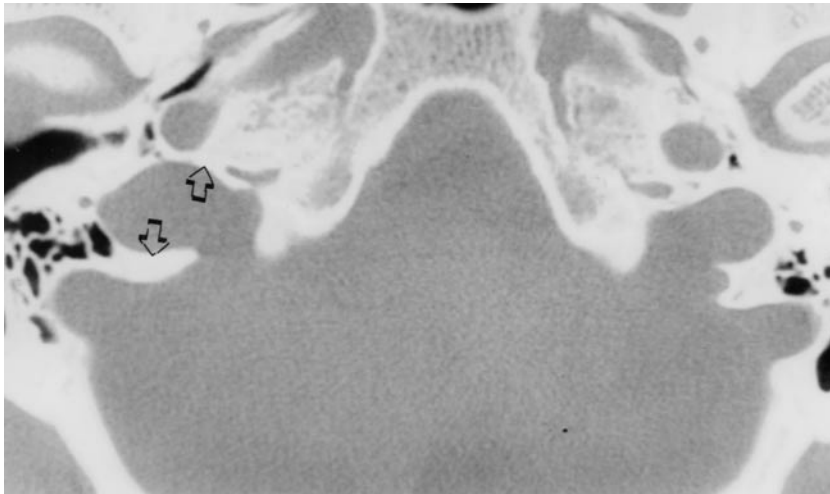
11.4 Malignant Tumors of the TB

Malignant tumors of the outer ear (auricle and external auditory meatus) are common (60%) and usually of squamous cell, basal cell, and melanoma types [13]. These are recognized early and resected completely with generous margins, allowing for high curability. Rarely regional node dissection is required unless surrounding soft tissue structures (i.e., parotid gland, auricle) are involved.

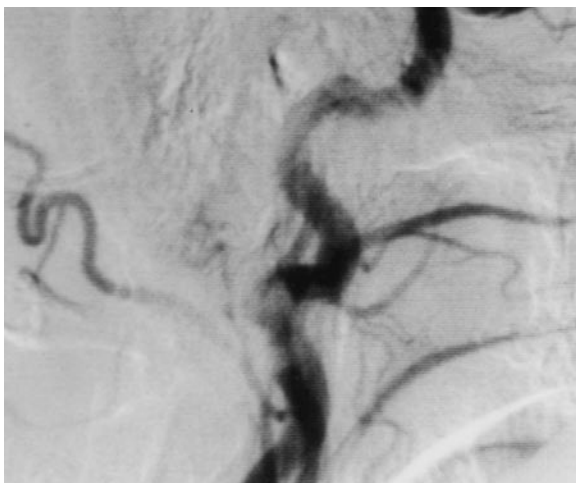Carcinoma (usually squamous cell) of the external auditory canal is next in frequency (30% of malignant ear neoplasms) and is causally related to chronic irritation (external otitis). The bony and cartilaginous canal forms a compartment with the tympanic membrane as



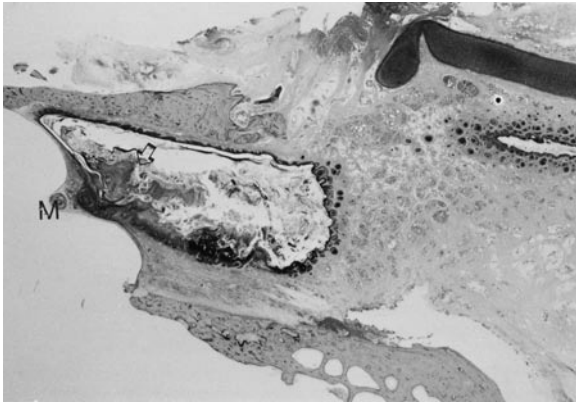
■ **Fig. 11.20** This gadolinium-enhanced jugular foramen (*arrow*) resembles a neoplasm



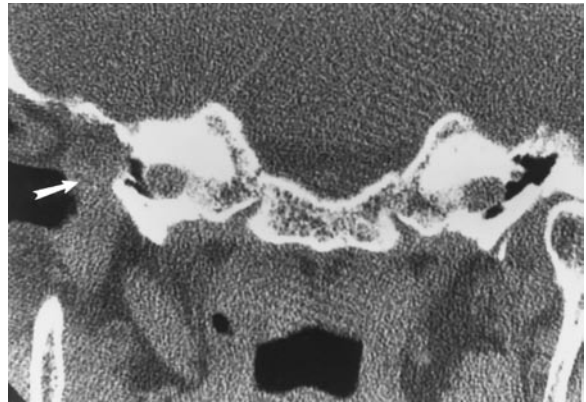■ **Fig. 11.21** Axial CT in same patient in Fig. 11.20 shows intact cortical rim of the jugular foramen (*arrow*)



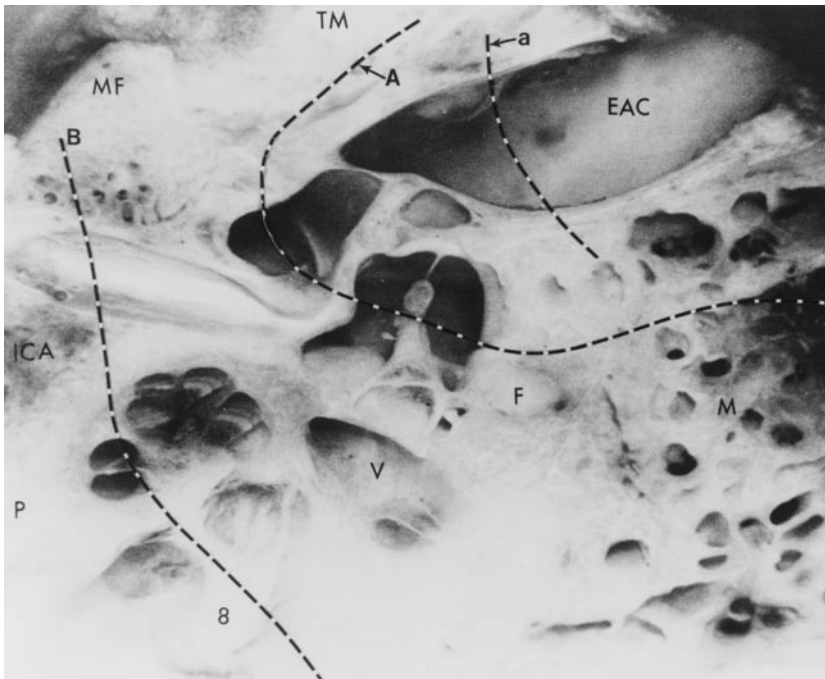
■ **Fig. 11.22** Arteriogram confirms no neoplasm in jugular foramen



■ **Fig. 11.23** Specimen removed with partial TB resection demonstrates carcinoma in deep external auditory canal (*arrow*). *M* manubrium of malleus



■ **Fig. 11.24** Coronal CT of patient after partial TB resection demonstrates muscle flap obliteration of the defect (*arrow*)

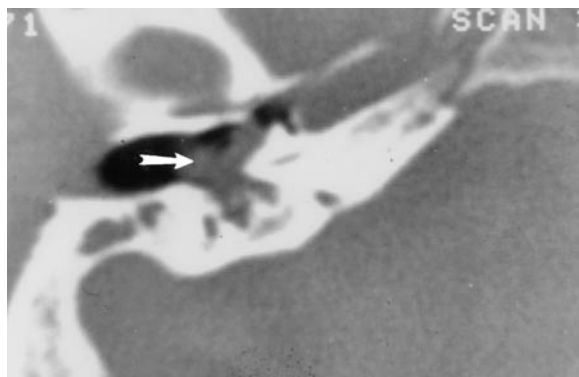


■ **Fig. 11.25** Section through a celloidin-embedded TB demonstrates the medial resection plane from subtotal (*B*) and lateral TB resection. *A* plane for partial resection of the external ear canal. *M* mastoid compartment, *P* PA, *ICA* internal carotid artery, *F* FN, *TM* temporomandibular joint, *8* eighth nerve

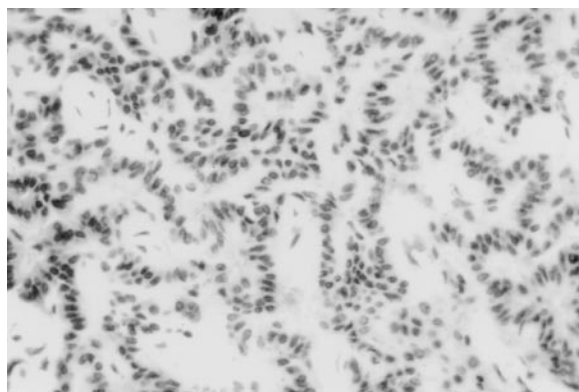
its medial boundary, and has sparse lymphatic drainage. These anatomical features tend to restrict tumor growth, allow for en bloc surgical resection, and lead to very good curability (80%) (Fig. 11.23).

Resection of the external ear canal compartment is referred to as lateral or partial TB resection. The key to successful en bloc extirpation is identification of the intratemporal course of the FN and completion

of appropriate bone cuts lateral to the fallopian canal through the facial recess, tympanic bone, and epitympanum [5]. Vascularized muscle flap coverage of the mastoid cavity is appropriate for postoperative radiation therapy (Fig. 11.24). Occasionally tumor involvement of the lateral half of the external ear canal may be encompassed by transection of the bony canal lateral to the tympanic membrane (Fig. 11.25).



■ Fig. 11.26 Low-grade malignancy of the middle ear (arrow), with no evidence of bone erosion on CT scan



■ Fig. 11.27 Histopathologically the tumor was classified as carcinoid tumor

Malignancy arising in or extending into the middle ear spreads through preformed bony pathways to deeper portions of the TB, into vascular and neural structures, and intracranially. Subtotal TB resection carries risk to major vascular structures (internal carotid artery), brain injury, and intracranial infection (Fig. 11.25). Cure rates of squamous cell carcinoma of the middle ear by subtotal TB resection average 30% [13, 14]. Similar cure rates have been reported with radical mastoid–middle ear exenteration, followed by radiation therapy. Therefore, a clear case for the en bloc approach to treatment of carcinoma in the middle ear has not been made. The management of such cases is best decided on case-by-case basis.

An exception in the treatment of malignancy in the middle ear is the management of low-grade adenocarcinoma or adenoma of the middle ear [4]. These

neoplasms cause a conductive hearing loss and present as a middle ear mass behind an intact tympanic membrane. Complete piecemeal removal of these tumors from the middle ear and its recesses is sufficient for cure with low morbidity (Figs. 11.26, 11.27).

11.5 Pseudoepithelial Hyperplasia of External Ear Canal

The importance of recognizing pseudoepithelial hyperplasia (PH) is that, although it is a benign lesion, it can, on clinical and histopathologic examination, simulate an epithelial malignancy of the external auditory canal (EAC) [6]. It is important to correlate the clinical history and findings with the histopathologic presentation of lesions in the EAC. These features are important in differentiating benign from malignant lesions of the EAC. Malignancy of the EAC usually has a preceding history of chronic inflammation and irritation of the ear canal (external otitis) or chronic otitis media. A long history (years) of symptoms is usually present before the development of malignancy. Clinical symptoms usually consist of bloody discharge from the ulcerated lesion of the EAC and pain in the ear with or without radiation locally. Examination of the ear usually reveals an ulcerated lesion in the EAC and/or middle ear. On histologic examination, malignancies are usually of the squamous cell type (SCC). Basal cell carcinoma, adenocystic carcinoma, and melanoma are less frequent lesions of the ear canal. On radiologic examination, malignancy of the EAC may be associated with evidence of destruction of the bony ear canal initially and with neural deficits (i.e., facial) in advanced lesions.

Benign lesions of the EAC, on the other hand, are not usually associated with a bloody discharge from the ear canal or otalgia. These superficial lesions are usually covered with intact epithelium, although ulceration may be present. However, such ulceration often resolves with conservative measures employing antibiotic and steroidal eardrops. The discharge from the ear canal is usually of a much shorter duration than found with malignancy. PH represents a reaction of the epithelium of the ear canal to chronic irritation and may clinically and histopathologically simulate SCC (Fig. 11.28).

Since malignancy involving the EAC represents a grave prognosis that justifies aggressive surgical and nonsurgical (radiation therapy) treatment, it is essential that histologic confirmation of epithelial malig-

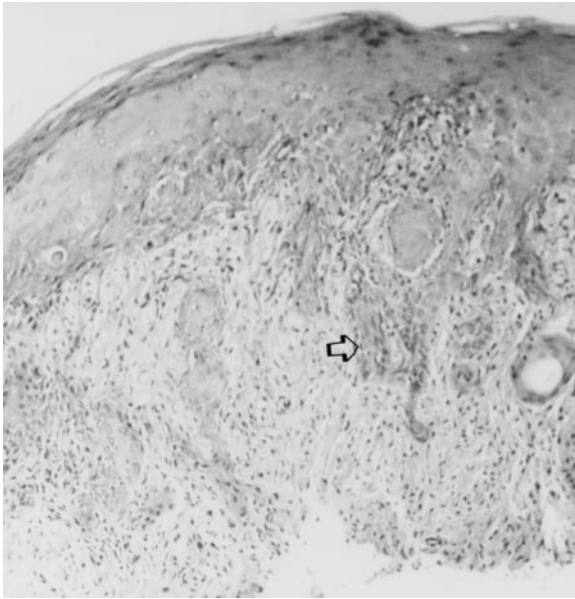


Fig. 11.28 Histopathologically, pseudoepithelial hyperplasia can resemble squamous cell carcinoma. *Arrow* points to areas of squamous cell breakthrough into subepithelial tissue layers

nancy be ensured before such treatment be initiated. The distinction between PH and SCC may be difficult to make with certainty. The surgeon should provide the pathologist with a favorable opportunity to make this distinction by supplying a sufficiently large tissue sample that includes the transition from normal to abnormal squamous epithelium. Generally, this means total or subtotal excision of the granular lesion with some surrounding epithelium. In addition, the clinical response to a course of conservative treatment designed to eliminate the irritative stimulus may help to support the diagnosis of PH.

COMPLICATIONS TO AVOID

1. FN monitoring is essential in vestibular schwannoma surgery to avoid FN injury.
2. Soft tissue obliteration of the dural defect following translabyrinthine removal of vestibular schwannoma will prevent cerebrospinal fluid leak.
3. When the facial nerve is resected in large vestibular schwannoma, facial–hypoglossal nerve anastomosis will prevent significant facial disfigurement.

4. Blood loss can be minimized during glomus tumor surgery by the use of minipacks to compress the tumor.
5. Ligation of the internal jugular vein and the sigmoid sinus will greatly reduce blood loss in glomus jugulare surgery.

Pearl

- Microscopic diagnosis of squamous cell carcinoma of the external ear canal should be carefully assessed and consistent with the clinical presentation.

References

1. DeLozier H, Gacek R, Dana S (1979) Intralabyrinthine schwannoma. *Ann Otol Rhinol Laryngol* 88:187–191
2. Gacek RR (1976) Schwannoma of the jugular foramen. *Ann Otol Rhinol Laryngol* 85:215–224
3. Gacek RR (1983) Pathology of jugular foramen neurofibroma. *Ann Otol Rhinol Laryngol* 92:128–133
4. Gacek RR (1992) Management of malignancy in the temporal bone. In: Nadol JB, Schuknecht HF (eds) *Surgery of the ear and temporal bone*. Raven, New York
5. Gacek RR, Goodman M (1977) Management of malignancy of the temporal bone. *Laryngoscope* 87:1622–1634
6. Gacek M, Gacek R, Gantz B, McKenna M, Goodman M (1998) Pseudoepithelial hyperplasia versus squamous cell carcinoma of the external canal. *Laryngoscope* 108:620–623
7. Glasscock ME III (1968) Acoustic neuroma: recent advances in the diagnosis and treatment. *Rev Laryngol Otol Rhinol* 89:28–42
8. Glasscock ME, Kveton JF (1987) Therapy of glomus tumors of the ear and skull base. In: Thawley S, Panje W, Batsakis J, Lindberg R (eds) *Comprehensive management of head and neck tumors*. Saunders, Philadelphia, pp 222–246
9. House WF (1961) Surgical exposure of the internal auditory canal and its contents through the middle cranial fossa. *Laryngoscope* 71:1363–1385
10. House WF (1968) Monograph II acoustic neuroma. *Arch Otolaryngol* 88:576–715
11. Jackson CG, Glasscock ME, Nissen AJ, Schwaber MK (1982) Glomus tumor surgery: the approach, results, and problems. *Otolaryngology Clin North Am* 15:897–916
12. Karlan MS, Basek M, Potter GB (1972) Intracochlear neurilemma. *Arch Otolaryngol* 96:573–575
13. Lewis JS (1960) Cancer of the ear: a report of 150 cases. *Laryngoscope* 70:551–579
14. Lewis JS (1983) Surgical management of tumors of the middle ear and mastoid. *J Laryngol Otol*. 97:299–311
15. Nadol JB Jr, Levine R, Ojemann RG, Martuza RL, Montgomery WW, Kleivins de Sandolval P (1987) Preservation of hearing in surgical removal of acoustic neuromas of the internal auditory canal and cerebellopontine angle. *Laryngoscope* 97:1287–1294
16. Nager GT (1985) Acoustic neuromas. *Acta Otolaryngol (Stockh)* 99:245–261

17. Ojemann RG, Montgomery WW, Weiss AD (1972) Evaluation and surgical treatment of acoustic neuroma. *N Engl J Med* 287:895–899
18. Schuknecht HF (1977) Pathology of vestibular schwannoma (acoustic neurinoma) In: Silverstein H, Norrell H (eds) *Neurological surgery of the ear*. Aesculapius, Birmingham, Ala., pp 193–197
19. Skinner H (1929) Origin of acoustic nerve tumors. *Br J Surg* 16:440
20. Spector GJ, Maisel RH, Ogura JH (1973) Glomus tumors in the middle ear. I. An analysis of 46 patients. *Laryngoscope* 83:1652–1672
21. Spector GJ, Compagno J, Perez CA, Maisel RH, Ogura JH (1975) Glomus jugulare tumors: effects of radiotherapy. *Cancer* 35:1316–1321
22. Wanamaker H (1972) Acoustic neuroma: primary arising in the vestibule. *Laryngoscope* 82:1040–1044

Core Messages

- Implantation of a multiple-channel electrode prosthesis has proven to be a successful approach to the profoundly deafened patient, acquired or congenital.
- The results in the post lingual deafened patient are superior to those in the patients with congenital forms of profound hearing loss.
- Insertion of the prosthesis close to spiral ganglion cells in Rosenthal's canal (scala tympani is the desired location).
- The intracochlear prosthesis may be introduced via a transmastoid approach through the facial recess or a transcanal approach through the posterior epitympanic space.

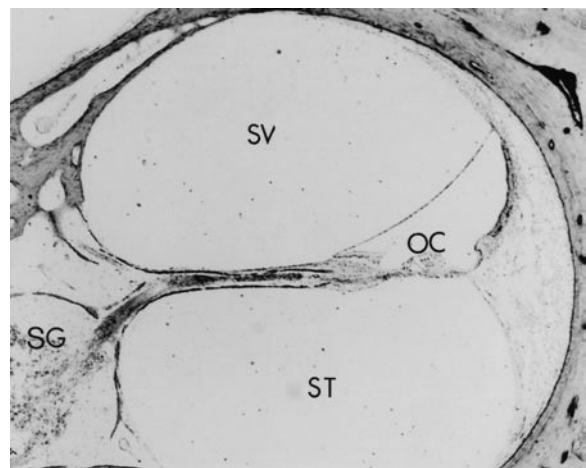
Cochlear implantation (CI) has been a relatively new addition to the realm of otologic surgery over the past 20–25 years [1, 4, 9]. Its intent is to produce meaningful electrical stimulation of the auditory nerve in those individuals where degeneration of the sense organ has progressed to the point where the external stimulation (amplification) provided by hearing aids is no longer effective.

The details of the evaluation process used to identify candidates for this form of auditory rehabilitation are not covered in this section. The criteria for the postlingually deafened individual are the clearest. Bilateral profound sensorineural hearing loss that is no longer aidable represents the indication for CI consideration. The longer the time from reaching this level of SNHL to the evaluation for implantation, the greater the chance for auditory nerve degeneration and fewer neurons available for stimulation. Protocols for this evaluation process vary among institutions. Commonly they include careful audiometric assessment of the hearing loss, psychologic evaluation of the patients and their expectations, radiologic (CT) evaluation of the middle ear, mastoid, and inner ears, and some es-

timination of auditory nerve reserve [5]. A well-trained team of audiologists, speech pathologists, and social workers are vital to the success of the cochlear implantation project. Implantation in the congenitally deaf child is more controversial but the centers performing CI in this group report encouraging results.

Although extracochlear implantation has been used early in the development of this concept, intracochlear implantation is the preferred method of stimulation used. Extracochlear implantation avoids the trauma of intracochlear insertion and allows for stimulation sites in the upper turns, but it has a major disadvantage in a greater distance of electrodes from auditory neurons requiring elevated thresholds for stimulation.

Although several variations of the surgical approach for intra cochlear implantation have been described, there are anatomical and neuropathological issues that are crucial to this method of auditory rehabilitation. The scala tympani is chosen for CI because it is the larger of the two perilymphatic compartments in the cochlea and allows the stimulating bipolar electrodes of the prosthesis to be in close proximity to



■ Fig. 12.1 Photomicrograph of cross section through a cochlear turn shows the proximity of the scala tympani (ST) to spiral ganglion cells (SG) in Rosenthal's canal. SV scala vestibuli, OC organ of Corti

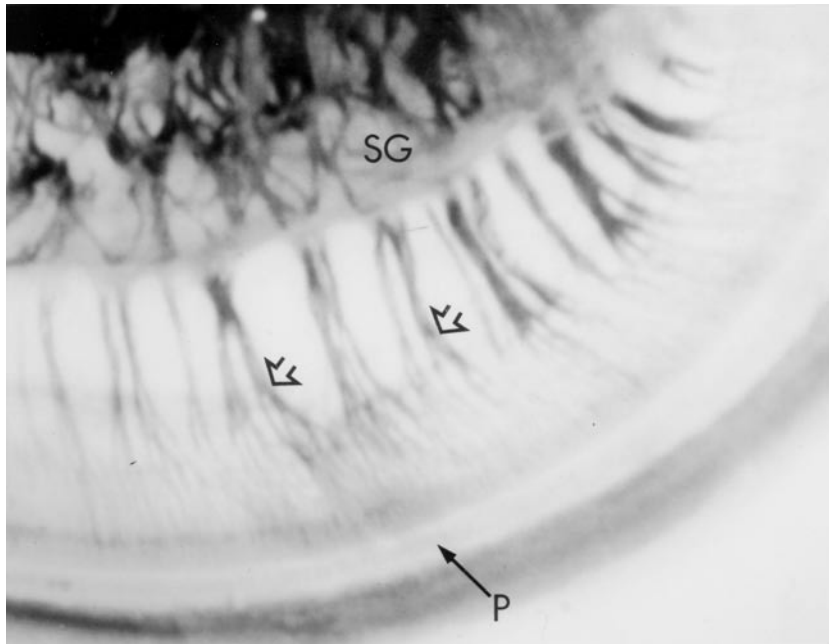


Fig. 12.2 The myelinated dendrites (*arrows*) travel in bundles within the osseous spiral lamina to innervate inner hair cells located in discrete segments of the organ of Corti. *P* heads of pillar cells in organ of Corti, *SG* spiral ganglion

spiral ganglion cells and dendrites (Fig. 12.1). Furthermore, the ionic composition of perilymph (high Na^+ , low K^+) is favorable for neural impulse generation. This requires low stimulation thresholds, with little risk of spread to adjacent neurons. The dendrites of spiral ganglion cells travel within the osseous spiral lamina as bundles of myelinated nerve fibers to discrete areas of the basilar membrane (Fig. 12.2). Since these nerve fibers supply inner hair cells in these discrete locations, frequency localization is maintained. These anatomical features allow for selective activation of remaining auditory neurons.

The lesser curvature and diameter of the cochlear basal turn permits insertion of present-day prostheses up to a distance of 20–21 mm from the RWM. This permits stimulation of two thirds of spiral ganglion cells including some at the speech frequencies. The minimum number of surviving neurons necessary for successful stimulation is not known. However, some histopathological studies have indicated that a third (approximately 10,000) of the normal complement of cochlear neurons is necessary for successful reactivation [6, 7]. When technological changes in the prosthesis permit further insertion of the scala tympani into the middle and apical turns, it may be possible to stimulate a greater number of ganglion cells.

Although insertion of the prosthesis through a co-

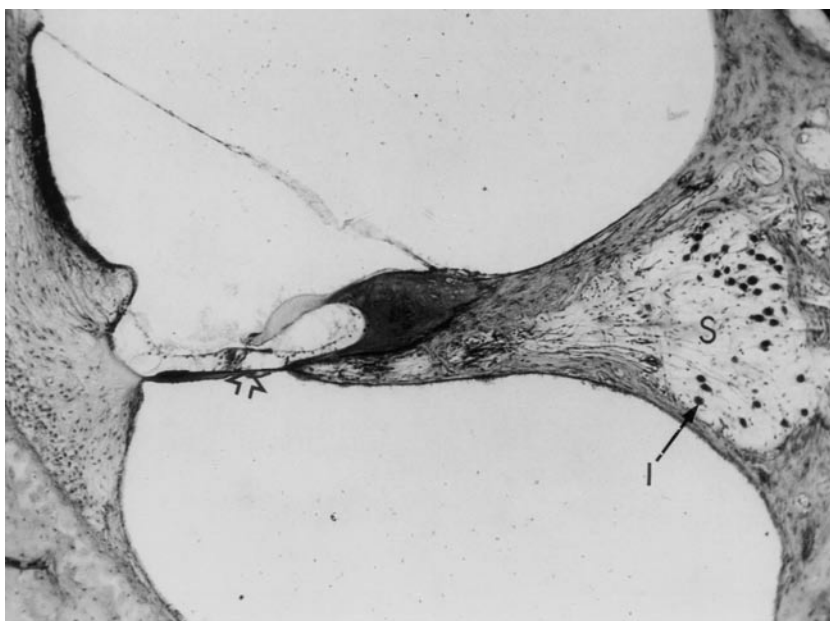
chleostomy in the round window niche was originally selected for CI, many surgeons have favored a cochleostomy site further up the basal turn (away from the round window niche). This location avoids the curvature of the hook portion of the basal turn, allowing for a straightforward insertion into the upper basal turn. Such a higher cochleostomy location permits a fuller insertion of the prosthesis, reaching the location for speech frequencies and bypassing little-used and often-degenerated neurons in the hook region of the basal turn (Fig. 12.3).

The histopathological correlate of profound sensorineural hearing loss is based on the behavior of the auditory nerve to the sensory hair cells in the organ of Corti. When the hair cells (inner) in the organ of Corti degenerate because of peripheral pathology (ototoxicity, infection, trauma, heredity, immunology) a secondary degeneration of type I spiral ganglion cells, (90% of auditory nerve) follows in time [6]. This degeneration process is dependent on the loss of peripheral trophic factors, which may have a variable loss after hair cell loss. At least a part of this trophic factor loss may depend on the integrity of supporting elements [8] in the organ of Corti (Fig. 12.4).

Therefore, CI should be planned as soon as possible after the hearing impairment has reached a profound level. This reduces the risk of further secondary neu-



■ **Fig. 12.3** The *solid line* shows the location of the RWM facing the basal end of the scala tympani in the human cochlea. There is degeneration of myelinated dendrites in the hook portion of the basal turn (*B*). Note the sharper curvature of the middle (*M*) and apical (*A*) turns, which prevent insertion of present day prosthesis.



■ **Fig. 12.4** Cochlea of cat subjected to excessive acoustic trauma shows degeneration of over 50% of type I spiral ganglion cells (*I*) secondary to the loss of sensory and supporting cells in the organ of Corti (*arrow*). *S* Rosenthal's canal

ronal loss by providing electrical stimulation. On the other hand, primary neuronal degeneration (neoplastic, surgical transection) with preservation of labyrinthine blood supply preserves the structural integrity of the organ of Corti (Fig. 12.5). This form of profound sensorineural hearing loss is not amendable to CI.

12.1 Surgery for Cochlear Implantation

The transmastoid approach utilizes a canal wall up mastoidectomy to expose the facial recess (FR) approach to the round window niche (RWN). Exposure of RWN is dependent on size of FR. If the FR cell is

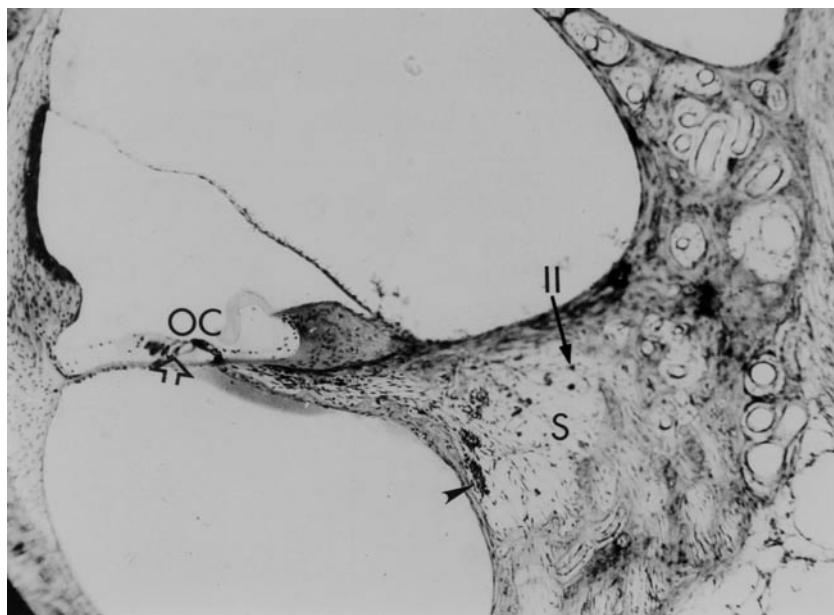


Fig. 12.5 Cochlea of cat after intracranial transection of the cochlear nerve. There is total loss of type I spiral ganglion cells leaving only type II ganglion cells (II) and efferent fibers (arrowhead) in Rosenthal's canals. The organ of Corti (OC) has normal complement of sensory and supporting cells

large, then the exposure is generous and removal of the fallopian canal wall is not necessary. However, with small FR, removal of fallopian canal wall and the posterior bony ear canal may be required to gain exposure of the RWN. The FN is at some risk but should be preserved using careful surgical technique. If the exposure of the RWN still not possible using the above modifications in FR exposure, then the cochleostomy may be created further up the basal turn of cochlea for insertion of the prosthesis. The implanted cochlea is x-rayed after surgery and before discharge to confirm the depth of insertion and the absence of kinking, which may negatively affect activation of the prosthesis.

In the rare instance where the scala tympani cannot be accessed because of anatomical or pathological (ossification) reasons, the prosthesis may be inserted through the oval window into the scala vestibuli. There is a greater incidence of vestibular labyrinth trauma with the latter. However, if vestibular symptoms persist and are disabling postoperatively, then ablation of residual vestibular function with intratympanic gentamycin may be effective.

12.2 Transcanal Approach to Round Window Niche (Veria Operation)

Insertion of the CI prosthesis may be accomplished without mastoidectomy and posterior tympanotomy

[2, 3]. In this procedure, an endaural exposure of the middle ear is provided with tympanomeatal flap to permit the cochleostomy. A bony tunnel is drilled from a recess in the outer cortex above the suprameatal spine. This tunnel takes a direct path just beneath the surface of the posterior bony ear canal into the epitympanum.

The prosthesis is then guided through this bony tunnel across the middle ear, into the cochleostomy, and up the basal turn. The receiver is secured in a spherical recess that has been drilled in the suprameatal cortex. This approach may be used to decrease the time from surgery to prosthesis activation in young children with an underdeveloped mastoid compartment, and in some revision cases where the mastoid compartment is to be avoided. We have no experience with this technique.

12.3 Cochlear Implantation in Canal Wall Down Mastoidectomy

Profound cochlear deafness may occur in patients with asymptomatic or minimally symptomatic open mastoid cavities. The hearing loss may be a coincident deficit or be a sequela of chronic middle ear infection. If there is significant active chronic inflammatory disease present, then surgical control of the infection should be completed and the ear allowed to heal before the cochlear implantation procedure to minimize

the risk of ascending infection (meningitis) via the cochleostomy site.

All soft tissue and epithelium of the external ear canal (bony), middle ear, and mastoid (including the anterior and posterior epitympanum, perilyabyrinthine cells, and Eustachian tube orifice) must be removed with sharp dissection and bony surfaces drilled down. After the preparation of a bony recess for housing the receiver, the cochleostomy is made in the basal turn and the prosthesis inserted in the standard fashion. With the prosthesis secured in position and the cochleostomy site sealed with fascial tissue, the middle ear, mastoid, and ear canal space are abundantly obliterated with a freshly obtained autogenous adipose tissue graft and the external meatal flaps everted with buried absorbable sutures. The postauricular flap incision is closed in the standard fashion.

COMPLICATIONS TO AVOID

1. FN injury in the facial recess approach to the round window can be prevented by monitoring and use of diamond burrs.
2. Leakage of perilymph is prevented by connective tissue packing around the implant in the cochleostomy.
3. Necrosis of the skin flap covering the receiver can be prevented by the use of a sigmoid skin incision.

Pearl

- Locate the cochleostomy in an apical direction from the round window to facilitate prosthesis insertion.

References

1. House WM, Berliner K, Crary W et al (1976) Cochlear implants. *Ann Otol Rhinol Laryngol* 85(Suppl):1–6
2. Kiratzidis T, Arnold W, Iliades T (2002) Veria operation updated. *ORL* 64:406–412
3. Kronenberg J, Miginov L, Baumgartner WD (2003) The suprameatal approach in cochlear implant surgery: experience with 80 patients. *ORL* 64:403–406
4. Michelson RP (1971) Electrical stimulation of the human cochlea. *Arch Otolaryngol* 93:317–323
5. Nadol JB, McKenna M (eds) (2005) *Surgery of the ear and temporal bone*. Lippincott Williams & Wilkins, New York
6. Nadol JB Jr, Young Y-S, Glynn RJ (1988) Survival of spiral ganglion cells in profound sensorineural hearing loss: implications for cochlear implantation. *Ann Otol Rhinol Laryngol* 98:411–416
7. Otte Garcia J, Schuknecht HF, Kerr AG (1978) Ganglion cell populations in normal and pathological human cochlear. Implications for cochlear implantation. *Laryngoscope* 88:1231–1246
8. Schuknecht HF (1993) *Pathology of the ear*, 2nd edn. Lea & Febiger, Philadelphia, pp 77–113
9. Simmons FB, Mongeon CJ, Lewis WR, Huntington DA (1964) Electrical stimulation of the acoustical nerve and inferior colliculus: results in man. *Arch Otolaryngol* 79:559–567

Differential Diagnosis of Unilateral Serous Otitis Media

Core Messages

- The cause of unilateral serous otitis media should be investigated at five levels of the temporal bone.
- The most common level for Eustachian tube obstruction is by edema in the nasopharynx.
- Neoplastic causes for serous otitis media may be in the nasopharynx, infratemporal fossa or the petrous apex.
- A nonobstructive cause of serous otitis media is spontaneous cerebrospinal fluid leak.
- Pediatric preformed pathways for cerebrospinal fluid are:
 - Enlarged fallopian canal
 - Tympanomeningeal (Hyrtil's) fissure
 - Mondini dysplasia
- Adult preformed dural defects are caused by AGs.

The most frequently performed surgical procedure in otolaryngology is myringotomy with insertion of

a middle ear ventilation tube. While it is not the intent here to describe surgical technique, it seems appropriate to review the possible causes for serous otitis media (SOM). Although bilateral SOM usually reflects Eustachian tube (ET) obstruction from edema, it is unilateral chronic SOM that invokes a differential diagnosis.

Although SOM is usually reversible, potentially serious neoplastic and congenital disorders may cause persistent unilateral SOM in both the pediatric and the adult age groups. There are several levels of ET obstruction with middle ear effusion that may produce a unilateral SOM.

The anatomical relationships of the ET illustrated in Fig. 13.1 summarize the location for five levels at which pathology may cause SOM. Although it is generally regarded that a third of the ET length is osseous and the other two thirds is cartilaginous [7], it is apparent from Fig. 13.1 that the osseous segment probably represents only a fourth of the overall length of the ET while the cartilaginous portion composes three fourths. Furthermore, the diameter of the lumen in the ET is narrowest at the isthmus. The various levels at

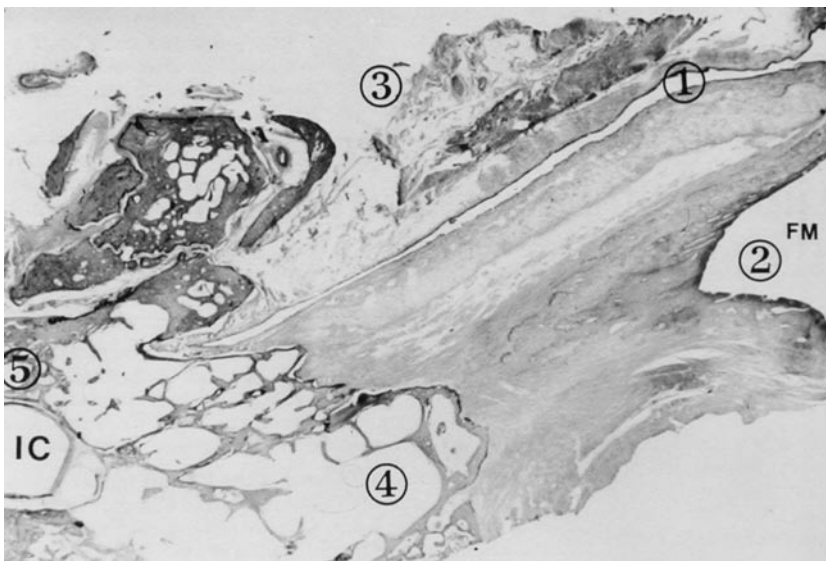


Fig. 13.1 Histological section through the bony and cartilaginous portions of the Eustachian tube. Numbers 1–5 refer to levels discussed in the text. *FM* fossa of Rosenmüller, *IC* internal carotid artery

which ET patency may be compromised are indicated by the numbers 1–4 on the diagram. A serous middle ear effusion may also be produced by communication with the subarachnoid compartment (level 5).

SOM caused by mechanical obstruction of the Eustachian tube or by leakage of cerebrospinal fluid (CSF) into the middle ear compartment may occur in both pediatric and adult age groups.

13.1 Level 1

Mucosal edema from inflammatory or allergic disorders is the most common site for obstruction of the ET in both the pediatric and adult age groups. Tubal malfunction that improves with age in the pediatric population may be caused by deficiency in size and composition of tubal musculoskeletal structures [12]. The obstruction is usually bilateral but, occasionally, it may be predominantly unilateral. Examples of this form of obstruction are so common that discussion is not necessary.

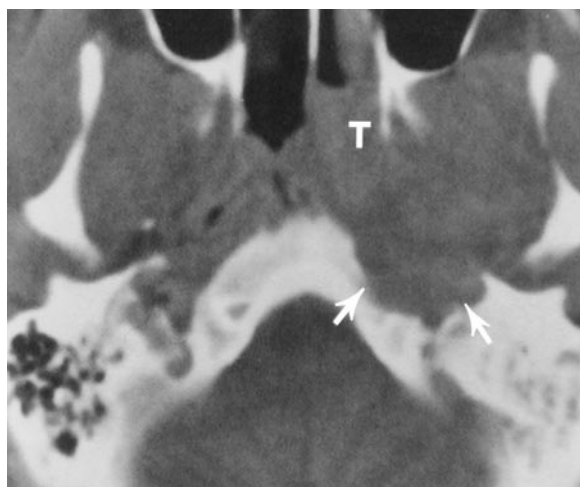
13.2 Level 2

It is well known that benign and malignant neoplasms in the nasopharynx may cause unilateral obstruction of the ET [1]. The best-known example of this level

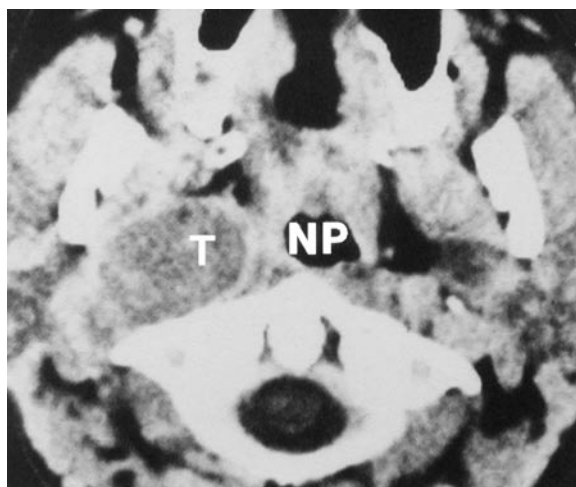
of obstruction is a malignancy in the lateral recess of the nasopharynx (fossa of Rosenmüller) in adult patients (Fig. 13.2). This form of neoplasm may or may not be detected by clinical examination and may require random biopsies of the nasopharynx for detection. Benign neoplasms such as juvenile angiofibroma, extensive allergic polyposis, and large adenoid masses may also be responsible for obstruction at this level. These neoplasms usually are detected by clinical or radiological examination.

13.3 Level 3

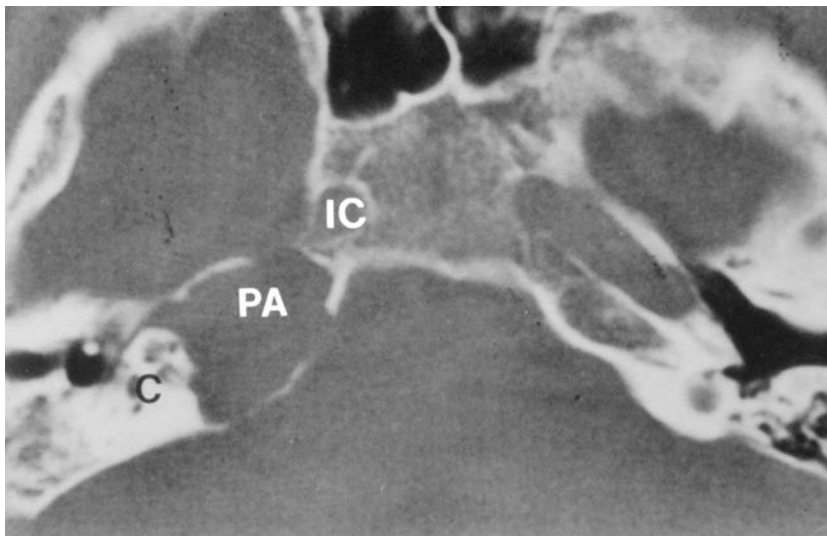
A space-occupying lesion extending to the skull base in the infratemporal fossa may be responsible for obstruction of the ET from a lateral direction (Fig. 13.3). Although such neoplasms usually produce lateral displacement of neck tissues or medial displacement of the pharyngeal wall, they may occasionally cause tubal obstruction without obvious clinical signs. Examples of such tumors of the parapharyngeal space are chemodectoma, neurofibroma, and neoplasms in the deep lobe of the parotid gland. Malignant neoplasms such as adenoid cystic carcinoma, mucoepidermoid carcinoma, or lymphoma in this space may also obstruct the tube at this level. CT scanning is an informative, noninvasive technique for the detection of pathology in this location.



■ **Fig. 13.2** Axial CT scan in a 32-year-old man demonstrates Eustachian tube obstruction and bone erosion (arrows) by nasopharyngeal carcinoma (T) in Rosenmüller's fossa



■ **Fig. 13.3** Axial CT scan in a 48-year-old woman shows an encapsulated tumor mass (T) in the parapharyngeal space. IC internal carotid artery, NP nasopharynx



■ **Fig. 13.4** Axial CT scan in a 39-year-old man with an expanding cystic lesion in the PA with erosion of the bony labyrinth (C). IC internal carotid artery

13.4 Level 4

Solid and cystic lesions of the petrous apex may occlude the ET lumen from a medial direction (Fig. 13.4). The most common of these lesions are congenital epidermoid, cholesterol granuloma, neurofibroma, and chondrosarcoma [2]. Rare lesions include eosinophilic granuloma, lymphoma, metastatic carcinoma, and chemodectoma. In addition to producing ET obstruction, these lesions may involve cranial nerves III, IV, V, VI, and VII and may produce headache associated with dural stretching. As a group, these are lesions of the young adult and middle-aged adult group; they are not seen in the pediatric age group. CT scanning and MRI are the most informative imaging studies for demonstration of pathology in this region.

13.5 Level 5

Level 5 represents the effusion of CSF into the middle ear and mastoid compartment. The most common cause of CSF otorrhea is TB trauma. Spontaneous CSF otorrhea is produced by uncommon congenital defects in the posterior or middle fossa dura [3, 5, 8, 9, 11]. Neely has classified these congenital defects into three types [10].

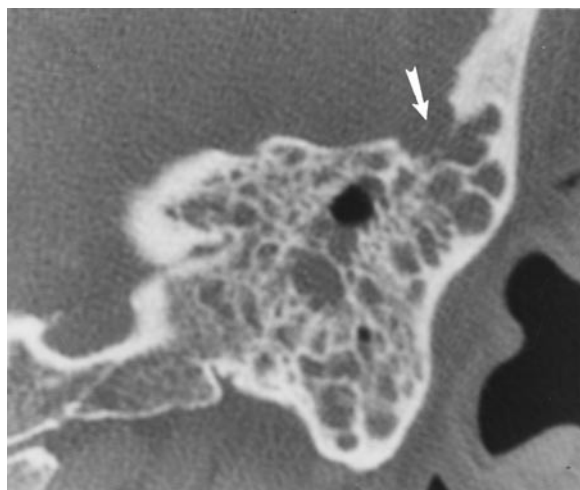
Type 1 represents a CSF communication through a congenital dysplasia (Mondini syndrome) of the labyrinth, which eventually erodes through the stapes footplate or RWM into the middle ear space. Clinically,

this is manifested as an SOM in a young child (less than 10 years old) with a profound hearing loss in the affected ear.

Type 2, which also occurs in children less than 10 years old, is a CSF leak through a preformed bony pathway around a normal labyrinth. This rarest form of communication may occur through two pathways: (1) the tympanomeningeal fissure (Hyrtl's fissure), which is located inferior to the basal turn of the cochlea; and (2) the fallopian canal near the geniculate ganglion. CSF leaks through these pathways are seen in young patients with normal cochlear function and a conductive hearing loss.

Type 3 spontaneous CSF otorrhea occurs in adults, especially in those over 50 years old. The congenital defect in this group is a dural defect associated with AG that are formed embryologically in the TB [6] and enlarge with increasing age and physical activity. The increased intermittent pressure from the AG causes bone erosion, which may ultimately communicate with a pneumatized mastoid or middle ear compartment. These occur on both the middle fossa and posterior fossa surfaces of the temporal bone (Fig. 13.5). Their recognition and management has been discussed elsewhere (Chap. 8).

Consideration of the various levels responsible for SOM should be given in any pediatric or adult patient with unilateral recurrent or persistent SOM without an obvious explanation for ET obstruction [4]. Clinical examination, CT scan of the head including the upper neck, and myringotomy should constitute the



■ **Fig. 13.5** Coronal CT in a 45-year-old woman with recurrent serous otitis media demonstrates bony erosion from an AG in the floor of middle cranial fossa (*arrow*)

minimum work-up in such a patient. History, age of the patient, and a thorough head and neck examination will help to initially differentiate levels of ET involvement. In the pediatric patient, levels 1 and 2 are most frequently responsible for ET obstruction, but congenital CSF leaks (level 5) should be considered either if the fluid aspirated at myringotomy resembles CSF or if there has been a history of meningitis. CT scanning of the temporal bones is an essential diagnostic study in level 5.

In the adult patient, all five levels should be considered as sites of pathology. The clinical examination should include fiber optic evaluation of the nasopharynx and random biopsy if a mass is suspected on clinical or CT examination. Examination of the fluid aspirate at myringotomy is a simple and informative office procedure. If the fluid is amber colored and does not reaccumulate with a ventilating tube in place, then an obstructive mechanism can be assumed. CT imaging in the axial plane can provide evidence of a lesion at levels 2 through 4. If the myringotomy aspirate is watery clear and reforms despite a ventilation tube, CT scanning (1.5-mm cuts) of the TBs in both the axial and coronal planes should be performed to detect a site of CSF leak through a middle or posterior fossa AG. Should this examination be inconclusive,

then special studies (metrizamide, radionuclide) can be used to document a communication with the subarachnoid space.

COMPLICATIONS TO AVOID

1. A full otolaryngologic examination is necessary in the patient with unilateral SOM to prevent delay in diagnosis.
2. Avoid myringotomy in a young child with severe sensorineural hearing loss in an ear with SOM to prevent cerebrospinal fluid otorrhea.

Pearl

- MRI and CT scanning are essential to the diagnosis of occult lesions that cause SOM.

References

1. Batsakis JG (1979) Carcinoma of the nasopharynx. In: Pathology of head and neck neoplasm. Williams & Wilkins, Baltimore, p 128
2. Gacek RR (1975) Diagnosis and management of primary tumors of petrous apex. *Ann Otol Rhino Laryngol* 184 (Suppl):1-20
3. Gacek RR (1990) Arachnoid granulation cerebrospinal fluid otorrhea. *Ann Otol Rhinol Laryngol* 99:854-862
4. Gacek RR (1992) Evaluation and management of temporal bone arachnoid granulation. *Arch Otolaryngol Head Neck Surg* 118:327-332
5. Gacek R, Leipzig B (1979) Congenital cerebrospinal otorrhea. *Ann Otol Rhinol Laryngol* 88:358-365
6. Gomez DG, DiBenedetto AT, Pavese AM et al (1981) Development of arachnoid villi and granulations in man. *Acta Anat (Basel)* 111:247-258
7. Graves G, Edwards L (1944) The Eustachian tube: a review of its descriptive, microscopic, topographic and clinical anatomy. *Arch Otolaryngol* 39:359
8. Guindi GM (1981) Congenital labyrinth-tympanic fistula—a recently recognized entity in children. *J Otolaryngol* 10:67-71
9. Hirakawa K, Kurskawa M, Yajim K et al (1983) Recurrent meningitis due to a congenital fistula in the stapedial footplate. *Arch Otolaryngol* 190:697-700
10. Neely JG (1985) Classification of spontaneous cerebrospinal fluid middle ear effusion: review of forty-nine cases. *Otolaryngol Head Neck Surg* 93:625-634
11. Parisier SC, Birken EA (1976) Recurrent meningitis secondary to idiopathic oval window CSF leak. *Laryngoscope* 86:1503-1515
12. Silverstein H, Miller GF, Lindeman RC (1966) Eustachian tube dysfunction as a cause for chronic secretory otitis in children. *Laryngoscope* 76:259-273

Subject Index

A

- anatomy 77
 - functional neuron 77
 - general visceral efferent 78
 - somatic sensory 79
 - special efferent 77
 - special sensory 78
- approach 30
 - endaural 30
 - postauricular 30
- arachnoid villi 68
 - development 68
 - mastoidectomy 73
 - posterior fossa 73
 - surgical repair 71
- atresia 62
 - approach 62
 - skin graft 63

B

- benign paroxysmal positional vertigo 89
- benign tumors 86, 102
 - adenoma 102
 - glomus 102
 - hemangioma 86
 - neurogenic 102
 - schwannoma 86
- bony lesion 61
 - exostosis 61
 - removal 61
- brain abscess 40
 - mastoiditis 40
- brainstem nuclei 79
 - motor neurons 79
 - digastric 79
 - stapedius 79
 - motor nucleus 79
 - solitary tract 79
 - superior salivary nucleus 79

C

- canal cholesteatoma 58
- canal wall down mastoidectomy 114
 - cochlear implantation 114

- cerebral spinal fluid otorrhea 67
 - presentation 67
- cholesteatoma 55
 - acquired 55
 - congenital 55
- cholesterol granuloma 49
- chronic inflammation 29, 84
 - active 29
 - inactive 29
 - surgery 84
- chronic middle ear infection 83
- cochlear fistula 35
- cochlear implantation 111
 - criteria 111
- cochleostomy 112
- coexistent disease 2
- complication 4
 - dislocation 4
 - incus 4
 - fallopian canal dehiscence 5
 - floating footplate 5
 - intraoperative 4
 - postoperative 5
- complications (poststop)
 - granuloma 8
 - perilymph fistula 9
- congenital cholesteatoma 56
 - mastoid 56
 - middle ear 56
 - petrous apex 56
- congenital epidermoid 48
- CSF 119
 - Type 1 119
 - Type 2 119
 - Type 3 119
- cytomegalovirus 91

D

- diagnosis 43
- diagnosis SCSFO 71
 - CT 71
- differential diagnosis
 - CSF in middle ear 119
 - edema 118

- infratemporal fossa 118
- nasopharynx 118
- neoplasm 118
- petrous apex 119
- disease control 13
- surgery 15
- tympanosclerosis 14

E

- embryology 58
- endolymphatic sac 97
- decompression 97
- eustachian tube function 13
- evaluation of the patient 13
- exposure of the round window 37
- external otitis 63
- removal 63

F

- facial musculature 79
- facial paralysis 38, 84
- acute infection 84
- cholesteat 38
- fixation 4
- incus 4
- malleus 4

G

- guideline 35
- removal 35

H

- hearing level 23
- types I and II 23
- types III and IV 23

I

- idiopathic facial paralysis 83
- histopathology 83
- treatment 83
- viral neuritis 83
- implant 20
- bone 20
- cartilage 20
- intradural extension 39
- cholesteatoma 39
- intralabyrinthine schwannoma 102
- labyrinthectomy 102
- presentation 102

L

- labyrinthectomy 95
- transcanal 95
- transmastoid 95
- labyrinthitis 33, 38
- fistulization 33
- oval window 33
- round window 33
- stage 38
- landmark 84
- epitympanum 84
- lateral sinus thrombosis 40

M

- malignant external otitis 63
- curettage 64
- treatment 63
- malignant tumor 86, 105
- adenocarcinoma 108
- carcinoma 105
- parotid 86
- partial TB resection 107
- squamous cell 86
- management 29, 44
- cholesteatoma mucosal disease 29
- cystic lesion 45
- solid tumor 44
- medical therapy 29
- Ménière's disease 89
- meningitis 40
- middle ear 119

O

- obliteration 30
- myocutaneous muscle flap 30
- otosclerosis 5
- oval window 38

P

- paraganglioma 102
- glomus jugulare 102
- glomus tympanicum 102
- permanent exteriorization 51
- cystic 51
- technique 51
- petrositis 46
- Gradenigo's syndrome 47
- petrous apex 43
- cystic 43
- presenting symptom 43

- solid 43
- polymerase chain reaction 90
 - HSV-I 90
- postoperative care 24
- preformed pathway 67
 - Mondini dysplasia 67
 - petrosal fallopian canal 67
 - tympanomeningeal fissure 67
- preoperative evaluation 1
 - age 1
 - descending bone conduction 3
 - malleus fixation 1
 - tilting audiogram 3
 - unsuspected dead ear 2
- profound sensorineural hearing loss 112
 - histopathology 112
- prosthesis 7
 - long 7
 - short 7
- pseudoepithelial hyperplasia 108
- pseudotumor 86

R

- retraction pocket 55
- retrocochlear neoplasm 99
 - meningioma 99
 - vestibular schwannoma 99
- round window 5
- round window membrane 36

S

- scala tympani 111
- sensory ganglia 79
 - geniculate 79
 - meatal 79
- serous otitis media 117
 - differential diagnosis 117
- sheath 81
 - subarachnoid space 81

- singular neurectomy 95
 - Hallpike maneuver 95
- sound-conduction mechanism 16, 19
 - acoustic 16
 - acoustic coupling 19
 - ossicular 16
 - ossicular coupling 19
- stapedial artery 5
- surgery 113
 - endaural 114
 - facial recess 113
 - scala vestibuli 114
 - transmastoid 113
 - veria 114

T

- TB fracture 85
 - longitudinal 85
 - transverse 85
- treatment 91
 - antiviral 91
- tympanic membrane defect 18
 - lateral onlay 18
 - medial onlay 18
- Type V 23

V

- vestibular ablation 92
 - gentamycin 92
- vestibular neurectomy 93
 - nonselective 93
 - selective 93
- vestibular neuronitis 89
- vestibular schwannoma
 - middle fossa 100
 - posterior fossa 100
 - surgical removal 100
 - translabyrinthine 100
- vestibular sensitivity 91